Fitzpatrick's Dermatology In General Medicine (Two Vol. Set) 6th edition (May 23, 2003): by Irwin M. Freedberg (Editor), Arthur Z. Eisen (Editor), Klauss Wolff (Editor), K. Frank Austen (Editor), Lowell A. Goldsmith (Editor), Stephen Katz (Editor) By McGraw-Hill Professional

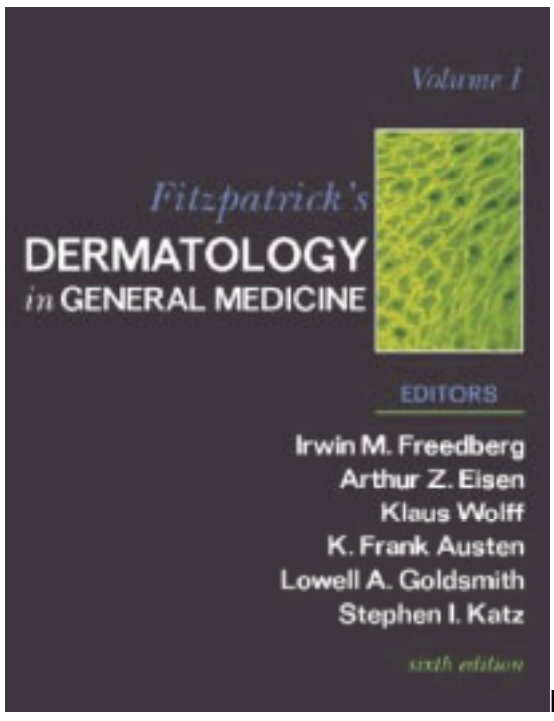

By OkDoKeY

Fitzpatrick's Dermatology In General Medicine

CONTENTS

Editors

Contributors

Preface

Notice

Part One: Introduction
Part Two: Biology and Development of Skin
Part Three: Disorders Presenting in the Skin and Mucous Membranes
Part Four: Dermatology and Medicine
Part Five: Diseases Due to Microbial Agents, Infestations, Bites, and Stings
Part Six: Therapeutics

PART ONE

Introduction

Top

SECTION 1 GENERAL CONSIDERATIONS

Chapter 1 Where Have We Come From?
Karl Holubar and Stella Fatovic-Ferencic

Chapter 2 The Epidemiology and Burden of Skin Diseases
Martin A. Weinstock and Mary-Margaret Chren

SECTION 2 CLINICAL-PATHOLOGIC CORRELATIONS OF SKIN LESIONS: APPROACH TO DIAGNOSIS

Chapter 3 The Structure of Skin Lesions and Fundamentals of Diagnosis
Margaret I. Stewart, Jeffrey D. Bernhard, Thomas G. Cropley, and Thomas B. Fitzpatrick

Chapter 4 Basic Pathologic Reactions of the Skin
Klaus Wolff, Abdul-Ghani Kibbi, and Martin C. Mihm

PART TWO

Biology and Development of Skin

Top

SECTION 3 STRUCTURE AND DEVELOPMENT OF SKIN

Chapter 5 Genetics in Relation to the Skin
Lowell A. Goldsmith and Ervin H. Epstein, Jr.

Chapter 6 The Structure and Development of Skin
David H. Chu, Anne R. Haake, Karen Holbrook, and Cynthia A. Loomis

SECTION 4 BIOLOGY AND FUNCTION OF EPIDERMIS AND APPENDAGES

Chapter 7 Epidermal Cell Kinetics, Epidermal Differentiation, and Keratinization
Arash Kimyai-Asadi, Ming H. Jih, and Irwin M. Freedberg

Chapter 8 Biology of Eccrine and Apocrine Sweat Glands
Lowell A. Goldsmith

Chapter 9 Skin As an Organ of Protection
Peter M. Elias, Kenneth R. Feingold, and Joachim W. Fluhr

Chapter 10 Thermoregulation
C. Bruce Wenger

Chapter 11 Biology of Melanocytes
Ruth Halaban, Daniel N. Hebert, and David E. Fisher

Chapter 12 Biology of Hair Follicles
Robert M. Lavker, Arthur P. Bertolino, and Tung-Tien Sun

Chapter 13 Biology of Nails
Antonella Tosti and Bianca Maria Piraccini

SECTION 5 BIOLOGY OF EXTRACELLULAR MATRIX, BLOOD VESSELS, AND NERVES

Chapter 14 Collagen
Jouni Uitto, Leena Pulkkinen, and Mon-Li Chu

Chapter 15 Elastic Fibers
Jouni Uitto and Mon-Li Chu

Chapter 16 Basement Membranes
Leena Bruckner-Tuderman

Chapter 17 The Role of Extracellular Matrix Metalloproteinases in Connective Tissue Remodeling
Jo L. Seltzer and Arthur Z. Eisen

Chapter 18 Proteoglycans and Glycosaminoglycans of Skin
Richard L. Gallo and Janet M. Trowbridge

Chapter 19 Endothelium
Peter Petzelbauer, Jeffrey S. Schechner, and Jordan S. Pober

Chapter 20 Neurobiology of the Skin
Franz J. Legat, Cheryl A. Armstrong, Thomas Scholzen, John E. Olerud, Nigel W. Bunnett, Thomas A. Luger, and John C. Ansel

Chapter 21 Mechanisms of Cutaneous Wound Repair
Vincent Falanga

SECTION 6 CELLULAR AND MOLECULAR BIOLOGY OF INFLAMMATION, REPAIR, AND CARCINOGENESIS

Chapter 22 Innate Immunity and the Skin
Jenny Kim and Robert L. Modlin

Chapter 23 The Skin: An Immunologic Barrier
Georg Stingl, Dieter Maurer, Conrad Hauser, and Klaus Wolff

Chapter 24 Influence of the HLA System on Disease Susceptibility
Madeleine Duvic

Chapter 25 Immunoglobulin Structure and Function
Lela A. Lee

Chapter 26 Cytokines
Ifor R. Williams, Benjamin E. Rich, and Thomas S. Kupper

Chapter 27 Chemokines
Sam T. Hwang

Chapter 28 Lymphocytes
Robert L. Modlin

Chapter 29 Regulation of the Production and Activation of Neutrophils
Shireen V. Guide and Steven M. Holland

Chapter 30 Regulation of the Production and Activation of Eosinophils
Adrienne Rencic and Lisa A. Beck

Chapter 31 Regulation of the Production and Activation of Basophils
John T. Schroeder

Chapter 32 The Molecular and Cellular Biology of the Mast Cell
Fred H. Hsieh, Clifton O. Bingham, III, and K. Frank Austen

Chapter 33 Human Complement System
Irma Gigli

Chapter 34 Eicosanoids
Alice P. Pentland

Chapter 35 Cellular Hypersensitivity and DNA Repair
Kenneth H. Kraemer

Chapter 36 Carcinogenesis: Chemical
Andrzej Dlugosz and Stuart H. Yuspa

Chapter 37 Oncogenes and Viral Carcinogenesis
Douglas R. Lowy

Chapter 38 Carcinogenesis: Ultraviolet Radiation
Margaret L. Kripke and Honnavara N. Ananthaswamy

Chapter 39 Photoimmunology
Richard D. Granstein

PART THREE

Disorders Presenting in the Skin and Mucous Membranes

Top

SECTION 7 NONCUTANEOUS MANIFESTATIONS OF SKIN DISEASES

Chapter 40 Psychological Aspects of Skin Diseases
Thomas W. Koenig, Sylvia Garnis-Jones, Adrienne Rencic, and Francisco A. Tausk

Chapter 41 Pathophysiology and Clinical Aspects of Pruritus
Malcolm W. Greaves

SECTION 8 EPIDERMIS: DISORDERS OF PERSISTENT INFLAMMATION, CELL KINETICS, AND DIFFERENTIATION

Chapter 42 Psoriasis
Enno Christophers and Ulrich Mrowietz

Chapter 43 Psoriatic Arthritis
Robert Winchester

Chapter 44 Exfoliative Dermatitis
Ming H. Jih, Arash Kimyai-Asadi, and Irwin M. Freedberg

Chapter 45 Pityriasis Rubra Pilaris
Lowell A. Goldsmith and Howard P. Baden

Chapter 46 Pityriasis Rosea
Alf Björnberg and Eva Tegner

Chapter 47 Parapsoriasis
Gary S. Wood and Chung-Hong Hu

Chapter 48 Pityriasis Lichenoides
Mazen S. Daoud and Mark R. Pittelkow

Chapter 49 Lichen Planus
Mazen S. Daoud and Mark R. Pittelkow

Chapter 50 Lichen Nitidus
Mazen S. Daoud and Mark R. Pittelkow

Chapter 51 Ichthyosiform Dermatoses
John J. DiGiovanna

Chapter 52 The Inherited Keratodermas of Palms and Soles
Howard P. Stevens, David P. Kelsell, and Irene M. Leigh

Chapter 53 Ectodermal Dysplasias
Virginia P. Sybert

Chapter 54 Darier-White Disease (Keratosis Follicularis) and Acrokeratosis Verruciformis
Lowell A. Goldsmith and Howard P. Baden

Chapter 55 Transient Acantholytic Dermatosis (Grover Disease)
Peter J. Heenan and Christopher J. Quirk

Chapter 56 Porokeratosis
Elisabeth Ch. Wolff-Schreiner

Chapter 57 Kyrle Disease and Other Perforating Disorders
Elisabeth Ch. Wolff-Schreiner

SECTION 9 EPIDERMIS: DISORDERS OF EPIDERMAL COHESION—VESICULAR AND BULLOUS DISORDERS

Chapter 58 Erythema Multiforme, Stevens-Johnson Syndrome, and Toxic Epidermal Necrolysis
Peter O. Fritsch and Ramon Ruiz-Maldonado

Chapter 59 Pemphigus
John R. Stanley

Chapter 60 Paraneoplastic Pemphigus
Grant J. Anhalt and H. Carlos Nousari

Chapter 61 Bullous Pemphigoid
John R. Stanley

Chapter 62 Cicatricial Pemphigoid
Kim B. Yancey

Chapter 63 Linear IgA Dermatosis and Chronic Bullous Disease of Childhood
Caroline L. Rao and Russell P. Hall, III

Chapter 64 Pemphigoid Gestationis (Herpes Gestationis)
Stephen I. Katz

Chapter 65 Inherited Epidermolysis Bullosa
M. Peter Marinkovich, Paul A. Khavari, G. Scott Herron, and Eugene A. Bauer

Chapter 66 Epidermolysis Bullosa Acquisita
David T. Woodley, Mei Chen, W. Ray Gammon, and Robert A. Briggaman

Chapter 67 Dermatitis Herpetiformis
Stephen I. Katz

Chapter 68 Familial Benign Pemphigus (Hailey-Hailey Disease)
Robin A.C. Graham-Brown

Chapter 69 Subcorneal Pustular Dermatosis (Sneddon-Wilkinson Disease)
Herbert Hönigsmann, Franz Trautinger, and Klaus Wolff

Chapter 70 Pustular Eruptions of Palms and Soles
Enno Christophers and Ulrich Mrowietz

SECTION 10 DISORDERS OF EPIDERMAL APPENDAGES AND RELATED DISORDERS

Chapter 71 Hair
Elise A. Olsen

Chapter 72 Nails
Robert Baran and Antonella Tosti

Chapter 73 Diseases of the Sebaceous Glands
Diane M. Thiboutot and John S. Strauss

Chapter 74 Rosacea
Gerd Plewig and Thomas Jansen

Chapter 75 Perioral Dermatitis
Ronald Marks

Chapter 76 Disorders of the Eccrine Sweat Glands
Lowell A. Goldsmith

Chapter 77 Disorders of the Apocrine Sweat Glands
Mazen S. Daoud and Charles H. Dicken

Chapter 78 Follicular Syndromes with Inflammation and Atrophy
Peter Fritsch

SECTION 11 EPIDERMAL AND APPENDAGEAL TUMORS

Chapter 79 Epithelial Precancerous Lesions
Karynne O. Duncan and David J. Leffell

Chapter 80 Squamous Cell Carcinoma
Douglas Grossman and David J. Leffell

Chapter 81 Basal Cell Carcinoma
John A. Carucci and David J. Leffell

Chapter 82 Basal Cell Nevus Syndrome
Ervin Epstein, Jr.

Chapter 83 Keratoacanthoma
Lorenzo Cerroni and Helmut Kerl

Chapter 84 Benign Epithelial Tumors
Shane G. Silver and Vincent C.Y. Ho

Chapter 85 Appendage Tumors of the Skin
Steven Kaddu and Helmut Kerl

Chapter 86 Cutaneous Neuroendocrine Carcinoma: Merkel Cell Carcinoma
Helmut Kerl and Rainer Hofmann-Wellenhof

Chapter 87 Mammary and Extramammary Paget's Disease
S. M. Connolly

SECTION 12 DISORDERS OF MELANOCYTES

Chapter 88 Normal Skin Color and General Considerations of Pigmentary Disorders
Thomas B. Fitzpatrick and Jean-Paul Ortonne

Chapter 89 Albinism
Philippe Bahadoran, Jean-Paul Ortonne, Richard A. King, and William S. Oetting

Chapter 90 Hypomelanoses and Hypermelanoses
Jean-Paul Ortonne, Philippe Bahadoran, Thomas B. Fitzpatrick, David B. Mosher, and Yoshiaki Hori

Chapter 91 Benign Hyperplasias and Neoplasias of Melanocytes
James M. Grichnik, Arthur R. Rhodes, and Arthur J. Sober

Chapter 92 Atypical Melanocytic Nevi
Hensin Tsao and Arthur J. Sober

Chapter 93 Neoplasms: Cutaneous Melanoma
Richard G.B. Langley, Raymond L. Barnhill, Martin C. Mihm, Jr., Thomas B. Fitzpatrick, and Arthur J. Sober

SECTION 13 INFLAMMATORY AND NEOPLASTIC DISORDERS OF THE DERMIS

Chapter 94 Acute Febrile Neutrophilic Dermatosis (Sweet's Syndrome)
Herbert Hönigsmann, Philip R. Cohen, and Klaus Wolff

Chapter 95 Erythema Elevatum Diutinum
Stephen I. Katz

Chapter 96 Eosinophils in Cutaneous Diseases
Kristin M. Leiferman, Margot S. Peters, and Gerald J. Gleich

Chapter 97 Granuloma Faciale
Walter H.C. Burgdorf

Chapter 98 Pyoderma Gangrenosum
Klaus Wolff and Georg Stingl

Chapter 99 Erythema Annulare Centrifugum and Other Figurate Erythemas
Walter H.C. Burgdorf

Chapter 100 Granuloma Annulare
Mark V. Dahl

Chapter 101 Malignant Atrophic Papulosis (Degos' Disease)
Louis Dubertret

Chapter 102 Fibrous Lesions of Dermis and Soft Tissue
Christopher R. Shea and Victor G. Prieto

Chapter 103 Vascular Anomalies and Tumors of Skin and Subcutaneous Tissues
Suzanne Virnelli Grevelink and John Butler Mulliken

Chapter 104 Kaposi's Sarcoma
Klemens Rappersberger, Georg Stingl, and Klaus Wolff

Chapter 105 Anetoderma and Other Atrophic Disorders of the Skin
Walter H.C. Burgdorf

Chapter 106 Ainhum and Pseudoainhum
Walter H.C. Burgdorf

Chapter 107 Neoplasias and Hyperplasias of Neural and Muscular Origin
Steffen Albrecht

Chapter 108 Acquired Perforating Disorders
Mark Lebwohl

SECTION 14 DISORDERS OF SUBCUTANEOUS TISSUE

Chapter 109 Panniculitis
Michael J. Camilleri and W.P. Daniel Su

Chapter 110 Lipodystrophy
Ervin H. Epstein, Jr.

Chapter 111 Neoplasms of the Subcutaneous Fat
Karl H. Anders

SECTION 15 DISORDERS OF THE MUCOCUTANEOUS INTEGUMENT

Chapter 112 Biology and Pathology of the Oral Mucosa
Jonathan A. Ship, Joan Phelan, and A. Ross Kerr

Chapter 113 Diseases and Disorders of the Male Genitalia
Richard Allen Johnson

Chapter 114 Diseases and Disorders of the Anogenitalia of Females
Libby Edwards

SECTION 16 CUTANEOUS CHANGES IN DISORDERS OF ALTERED REACTIVITY

Chapter 115 Genetic Immunodeficiency Diseases
Amy S. Paller

Chapter 116 Urticaria and Angioedema
Nicholas A. Soter and Allen P. Kaplan

Chapter 117 Angioedema Associated with Complement Abnormalities
Irma Gigli and Fred S. Rosen

Chapter 118 Graft-versus-Host Disease
Thomas D. Horn

Chapter 119 Mucocutaneous Manifestations of the Non-HIV-Infected Immunosuppressed Host
Andrew Blauvelt

Chapter 120 Allergic Contact Dermatitis
Donald V. Belsito

Chapter 121 Autosensitization Dermatitis
Donald V. Belsito

Chapter 122 Atopic Dermatitis (Atopic Eczema)
Donald Y.M. Leung, Lawrence F. Eichenfield, and Mark Boguniewicz

Chapter 123 Nummular Eczema and Lichen Simplex Chronicus/Prurigo Nodularis
Nicholas A. Soter

Chapter 124 Seborrheic Dermatitis
Gerd Plewig and Thomas Jansen

Chapter 125 Vesicular Palmoplantar Eczema
Alexa Boer Kimball

SECTION 17 SKIN CHANGES DUE TO MECHANICAL AND PHYSICAL FACTORS

Chapter 126 Cold Injuries
Gérald Piérard, Isabelle Fumal, and Claudine Piérard-Franchimont

Chapter 127 Evaluation and Management of the Thermally Injured Patient
Robert Sheridan

Chapter 128 Radiobiology and Radiotherapy of Skin Diseases
Frederick D. Malkinson and Renato G. Panizzon

Chapter 129 Skin Problems in Amputees and Ostomates
Calum C. Lyon and Michael H. Beck

Chapter 130 Corns and Calluses
Thomas M. DeLauro

Chapter 131 Sports Dermatology
Dirk M. Elston

Chapter 132 Decubitus (Pressure) Ulcers and Venous Ulcers
Joel M. Gelfand and David J. Margolis

SECTION 18 PHOTOMEDICINE

Chapter 133 Photophysics, Photochemistry, and Photobiology
Irene E. Kochevar and Charles R. Taylor

Chapter 134 Acute and Chronic Effects of Ultraviolet Radiation on the Skin
Susan L. Walker, John L.M. Hawk, and Antony R. Young

Chapter 135 Abnormal Responses to Ultraviolet Radiation: Idiopathic, Probably Immunologic, and Photoexacerbated
John L.M. Hawk, Paul G. Norris, and Herbert Hönigsmann

Chapter 136 Abnormal Responses to Ultraviolet Radiation: Photosensitivity Induced by Exogenous Agents
Henry W. Lim

SECTION 19 DISORDERS DUE TO DRUGS AND CHEMICAL AGENTS

Chapter 137 Occupational Skin Diseases
James S. Taylor and Apra Sood

Chapter 138 Cutaneous Reactions to Drugs
Neil H. Shear, Sandra R. Knowles, John R. Sullivan, and Lori Shapiro

Chapter 139 Mucocutaneous Complications of Antineoplastic Therapy
James E. Fitzpatrick

Chapter 140 Cutaneous Reactions to Cytokines and Growth Factors
Maria L. Chanco Turner

Chapter 141 Cutaneous Manifestations of Drug Abuse
Miguel Sanchez

PART FOUR

Dermatology and Medicine

Top

SECTION 20 SKIN CHANGES ACROSS THE SPAN OF LIFE

Chapter 142 Skin Changes and Diseases in Pregnancy
Thomas J. Lawley and Kim B. Yancey

Chapter 143 Neonatal, Pediatric, and Adolescent Dermatology
Mary Wu Chang and Seth J. Orlow

Chapter 144 Aging of Skin
Mina Yaar and Barbara A. Gilchrest

SECTION 21 SKIN LESIONS IN NUTRITIONAL, METABOLIC, AND HERITABLE DISORDERS

Chapter 145 Cutaneous Changes in Nutritional Diseases
David S. Nieves and Lowell A. Goldsmith

Chapter 146 Acrodermatitis Enteropathica and Other Zinc-Deficiency Disorders
Kenneth H. Neldner

Chapter 147 Cutaneous Changes in Errors of Amino Acid Metabolism: Tyrosinemia II, Phenylketonuria, Argininosuccinic Aciduria, and Alkaptonuria
Lowell A. Goldsmith

Chapter 148 Amyloidosis of the Skin
Stephen Michael Breathnach

Chapter 149 The Porphyrias
David R. Bickers and Jorge Frank

Chapter 150 Xanthomatoses and Lipoprotein Disorders
Lowell A. Goldsmith

Chapter 151 Fabry Disease: a-Galactosidase A Deficiency (Angiokeratoma Corporis Diffusum Universale)
Robert J. Desnick and Maryam Banikazemi

Chapter 152 Lipoid Proteinosis
Ch. M. Lapière

Chapter 153 Cutaneous Mineralization and Ossification
John S. Walsh and Janet A. Fairley

Chapter 154 Heritable Disorders of Connective Tissue with Skin Changes
Richard J. Wenstrup and Huiquan Zhao

Chapter 155 Heritable Diseases with Increased Sensitivity to Cellular Injury
Kenneth H. Kraemer

SECTION 22 SKIN MANIFESTATIONS OF BONE MARROW OR BLOOD ELEMENT DISORDERS

Chapter 156 Hematologic Diseases
Warren W. Piette

Chapter 157 Cutaneous T Cell Lymphomas
Jo-Ann Latkowski and Peter Heald

Chapter 158 Other Systemic Lymphomas with Skin Infiltration
Wolfram Sterry and J. Marcus Muche

Chapter 159 Inflammatory Diseases That Simulate Lymphomas: Cutaneous Pseudolymphomas
Gary S. Wood

Chapter 160 Langerhans Cell Histiocytosis
Ruggero Caputo

Chapter 161 Cutaneous Nonhistiocytoses X
Ruggero Caputo

Chapter 162 Multicentric Reticulohistiocytosis
Karl Holubar

Chapter 163 The Mastocytosis Syndrome
Dean D. Metcalfe

SECTION 23 SKIN MANIFESTATIONS OF GASTROINTESTINAL AND RENAL DISORDERS

Chapter 164 The Skin and Disorders of the Alimentary Tract and the Hepatobiliary System
Graham A. Johnston and Robin A.C. Graham-Brown

Chapter 165 Cutaneous Changes in Renal Disorders
Susan Sweeney and Thomas G. Cropley

SECTION 24 SKIN MANIFESTATIONS OF DISORDERS OF THE CARDIOVASCULAR AND PULMONARY SYSTEMS

Chapter 166 Cutaneous Aspects of Cardiopulmonary Disease
Andrew G. Franks, Jr. and Victoria P. Werth

Chapter 167 Cutaneous Changes in Peripheral Vascular Disease
Jay D. Coffman and Robert T. Eberhardt

SECTION 25 SKIN MANIFESTATIONS OF ALTERATIONS AND DISORDERS OF THE ENDOCRINE SYSTEM

Chapter 168 Diabetes Mellitus
Jennifer L. Bub and John E. Olerud

Chapter 169 Cutaneous Manifestations of Other Endocrine Diseases
Janie M. Leonhardt and Warren R. Heymann

Chapter 170 Cutaneous Changes in the Flushing Disorders and the Carcinoid Syndrome
Eva A. Hurst and Michael P. Heffernan

SECTION 26 SKIN MANIFESTATIONS OF RHEUMATOLOGIC MULTISYSTEM DISEASES

Chapter 171 Lupus Erythematosus
Melissa I. Costner and Richard D. Sontheimer

Chapter 172 Dermatomyositis
Richard D. Sontheimer and Melissa I. Costner

Chapter 173 Scleroderma
Benjamin D. Yu and Arthur Z. Eisen

Chapter 174 Systemic Necrotizing Arteritis
Brian F. Mandell and Gary S. Hoffman

Chapter 175 Cutaneous Necrotizing Venulitis
Nicholas A. Soter

Chapter 176 Pigmented Purpuric Dermatoses
Theresa Schroeder

Chapter 177 Cryoglobulinemia and Cryofibrinogenemia
Lynn A. Cornelius and Thomas J. Lawley

Chapter 178 Relapsing Polychondritis
Stephen I. Katz

Chapter 179 Rheumatoid Arthritis, Rheumatic Fever, and Gout
Carlin B. Hollar and Joseph L. Jorizzo

Chapter 180 Sjögren's Syndrome
H. Carlos Nousari and Thomas T. Provost

Chapter 181 Raynaud's Phenomenon
John H. Klippel

Chapter 182 Reiter's Syndrome
Robert Winchester

SECTION 27 SKIN MANIFESTATIONS OF DISEASES IN OTHER ORGAN SYSTEMS

Chapter 183 Sarcoidosis
Irwin M. Braverman

Chapter 184 Cutaneous Manifestations of Internal Malignant Disease: Cutaneous Paraneoplastic Syndromes
David I. McLean and Harley A. Haynes

Chapter 185 Acanthosis Nigricans
Karen R. Houpt and Ponciano D. Cruz, Jr.

Chapter 186 Scleredema
Raul Fleischmajer

Chapter 187 Papular Mucinosis
Raul Fleischmajer

Chapter 188 Neurocutaneous Diseases
Rudolf Happle

Chapter 189 Tuberous Sclerosis Complex
Amy S. Paller and Lowell A. Goldsmith

Chapter 190 Neurofibromatoses
Eniko K. Pivnick and Vincent M. Riccardi

Chapter 191 Ataxia-Telangiectasia
Amy S. Paller

Chapter 192 Behçet's Disease
Rachel A. Garton and Joseph L. Jorizzo

PART FIVE

Diseases Due to Microbial Agents, Infestations, Bites, and Stings

Top

SECTION 28 BACTERIAL DISEASES WITH CUTANEOUS INVOLVEMENT

Chapter 193 General Considerations of Bacterial Diseases
Morton N. Swartz and Arnold N. Weinberg

Chapter 194 Pyodermas: Staphylococcus aureus, Streptococcus, and Other Gram-Positive Bacteria
Peter K. Lee, Matthew T. Zipoli, Arnold N. Weinberg, Morton N. Swartz, and Richard A. Johnson

Chapter 195 Staphylococcal Scalded Skin Syndrome
Steven D. Resnick and Peter M. Elias

Chapter 196 Soft-Tissue Infections: Erysipelas, Cellulitis, Gangrenous Cellulitis, and Myonecrosis
Arnold N. Weinberg, Morton N. Swartz, Hensin Tsao, and Richard A. Johnson

Chapter 197 Gram-Negative Coccal and Bacillary Infections
Arnold N. Weinberg and Morton N. Swartz

Chapter 198 Bartonellosis
Timothy G. Berger and Francisco Bravo

Chapter 199 Miscellaneous Bacterial Infections with Cutaneous Manifestations
Morton N. Swartz and Arnold N. Weinberg

Chapter 200 Tuberculosis and Other Mycobacterial Infections
Gerhard Tappeiner and Klaus Wolff

Chapter 201 Actinomycosis, Nocardiosis, and Actinomycetoma
Mauricio Goihman-Yahr, Michael M. McNeil, and June M. Brown

Chapter 202 Leprosy
Thomas H. Rea and Robert L. Modlin

Chapter 203 Lyme Borreliosis
Eva Åsbrink and Anders Hovmark

Chapter 204 Kawasaki Syndrome
Donald Y.M. Leung and Anne W. Lucky

SECTION 29 FUNGAL DISEASES WITH CUTANEOUS INVOLVEMENT

Chapter 205 Superficial Fungal Infections: Dermatophytosis, Onychomycosis, Tinea Nigra, Piedra
Michael M. Nelson, Ann G. Martin, and Michael P. Heffernan

Chapter 206 Yeast Infections: Candidiasis, Pityriasis (Tinea) Versicolor
Alison S. Klenk, Ann G. Martin, and Michael P. Heffernan

Chapter 207 Deep Fungal Infections
R. J. Hay

SECTION 30 VIRAL AND RICKETTSIAL DISEASES

Chapter 208 Viral Diseases: General Considerations
Douglas R. Lowy

Chapter 209 Rubella (German Measles)
Stephen E. Gellis

Chapter 210 Measles
Louis Z. Cooper

Chapter 211 Hand-Foot-and-Mouth Disease
Raphael Dolin

Chapter 212 Herpangina
David A. Sirois

Chapter 213 Erythema Infectiosum and Parvovirus B19 Infection
Karen Wiss

Chapter 214 Herpes Simplex
Adriana R. Marques and Stephen E. Straus

Chapter 215 Varicella and Herpes Zoster
Stephen E. Straus, Kenneth E. Schmader, and Michael N. Oxman

Chapter 216 Cytomegalovirus Infection
Francesco Drago and Alfredo Rebora

Chapter 217 Epstein-Barr Virus Infections
Jeffrey I. Cohen

Chapter 218 Human Herpesvirus 6 and 7 Infections and Exanthem Subitum (Roseola Infantum or Sixth Disease)
Sandy Tsao

Chapter 219 Smallpox and Complications of Smallpox Vaccination
Vincent A. Fulginiti

Chapter 220 Orf (Contagious Pustular Dermatitis, Contagious Ecthyma)
Renee R. Snyder and Dayna G. Diven

Chapter 221 Molluscum Contagiosum
Douglas R. Lowy and Elliot J. Androphy

Chapter 222 Milker's Nodules
Douglas R. Lowy

Chapter 223 Warts
Douglas R. Lowy and Elliot J. Androphy

Chapter 224 Human Retroviral Disease: Human T-Lymphotropic Viruses
Erwin Tschachler, Marvin S. Reitz, Jr., and Genoveffa Franchini

Chapter 225 Cutaneous Manifestations of Human Immunodeficiency Virus Disease
Richard Allen Johnson

Chapter 226 Prions and the Skin
Johannes Pammer and Erwin Tschachler

Chapter 227 The Rickettsioses and Ehrlichioses
Justin J. Green and Warren R. Heymann

SECTION 31 SEXUALLY TRANSMITTED DISEASES

Chapter 228 Syphilis
Miguel R. Sanchez

Chapter 229 Endemic (Nonvenereal) Treponematoses
Miguel R. Sanchez

Chapter 230 Chancroid
Stephan Lautenschlager and Alfred R. Eichmann

Chapter 231 Lymphogranuloma Venereum
Richard Rothenberg

Chapter 232 Granuloma Inguinale
Richard Rothenberg

Chapter 233 Gonorrhea
David S. Feingold and Claire P. Mansur

Chapter 234 Other Venereal Diseases
Alfred R. Eichmann and Stephan Lautenschlager

SECTION 32 INFESTATIONS

Chapter 235 Leishmaniasis and Other Protozoan Infections
Sidney N. Klaus, Shoshana Frankenburg, and A. Damian Dhar

Chapter 236 Cysticercosis and Other Helminthic Infections
Leslie C. Lucchina and Mary E. Wilson

SECTION 33 BITES AND STINGS

Chapter 237 Bites and Stings of Terrestrial and Aquatic Life
Mark Jordan Scharf and Jennifer Susan Daly

Chapter 238 Scabies and Pediculosis
Stephen P. Stone

Chapter 239 Arthropod Bites and Stings
David C. Wilson, Michael L. Smith, and Lloyd E. King, Jr.

PART SIX

Therapeutics

Top

SECTION 34 EVIDENCE-BASED DERMATOLOGY

Chapter 240 Evidence-Based Dermatology
Michael Bigby and Moyses Szklo

SECTION 35 TOPICAL THERAPY

Chapter 241 Pharmacokinetics and Topical Applications of Drugs
Hans Schaefer, Thomas E. Redelmeier, and Gerhard J. Nohynek

Chapter 242 Principles of Topical Therapy
Bruce E. Strober, Ken Washenik, and Jerome L. Shupack

Chapter 243 Topical Glucocorticoids
Isabel C. Valencia and Francisco A. Kerdel

Chapter 244 Topical Retinoids
Sewon Kang and John J. Voorhees

Chapter 245 Topical Antibiotics
Mark W. Bonner, Paul M. Benson, and William D. James

Chapter 246 Topical Antifungal Agents
James E. Fitzpatrick

Chapter 247 Sun Protective Agents: Formulations, Effects, and Side Effects
Francis P. Gasparro, Douglas Brown, Brian L. Diffey, John S. Knowland, and Vivienne Reeve

Chapter 248 Keratolytic Agents
Howard P. Baden and Lynn A. Baden

Chapter 249 Topical Cytotoxic Agents
Lesley Clark-Loeser, Ken Washenik, and Jerome L. Shupack

Chapter 250 Topical Immunomodulators
Robert Sidbury and Jon M. Hanifin

Chapter 251 Other Topical Medications
Adam I. Rubin, Nicole LaNatra, and Matthew J. Stiller

Chapter 252 Cosmetics and Skin Care in Dermatologic Practice
Patricia G. Engasser and Howard I. Maibach

SECTION 36 SYSTEMIC THERAPY

Chapter 253 Systemic Glucocorticoids
Victoria P. Werth

Chapter 254 Sulfones
Stephen I. Katz

Chapter 255 Aminoquinolines
Jeffrey R. LaDuca and Anthony A. Gaspari

Chapter 256 Cytotoxic and Antimetabolic Agents
Christopher T. Cassetty, Jerome L. Shupack, and Ken Washenik

Chapter 257 The Retinoids
Stéphane Kuenzli and Jean-Hilaire Saurat

Chapter 258 Antihistamines
Nicholas A. Soter

Chapter 259 Overview of Antibiotics
Jan V. Hirschmann

Chapter 260 Antiviral Drugs
Raphael Dolin

Chapter 261 Oral Antifungal Agents
Nellie Konnikov and Helen Raynham

Chapter 262 Immunosuppressive and Immunomodulatory Drugs
H. Carlos Nousari and Grant J. Anhalt

Chapter 263 Immunobiologicals in Dermatology
James G. Krueger and Alice B. Gottlieb

Chapter 264 Thalidomide
Gerhard Tappeiner and Klaus Wolff

Chapter 265 Therapeutic Photomedicine: Phototherapy
Jean Krutmann and Akimichi Morita

Chapter 266 Photochemotherapy and Photodynamic Therapy
Herbert Hönigsmann, Rolf-Markus Szeimies, Robert Knobler, Thomas B. Fitzpatrick, Madhukar A. Pathak, and Klaus Wolff

Chapter 267 Lasers in Dermatology
Graeme M. Lipper and R. Rox Anderson

SECTION 37 SURGERY IN DERMATOLOGY

Chapter 268 Dermatologic Surgery: Introduction and Approach
June K. Robinson and George J. Hruza

Chapter 269 Skin Resurfacing: Chemical Peels
Harold J. Brody

Chapter 270 Skin Resurfacing: Dermabrasion
Christopher B. Harmon and John M. Yarborough, Jr.

Chapter 271 Skin Resurfacing: Laser
George J. Hruza, Jeffrey S. Dover, and Kenneth A. Arndt

Chapter 272 Wound Dressings
Michelle M. Choucair, Ysabel M. Bello, and Tania J. Phillips

Chapter 273 Treatment of Varicose and Telangiectatic Veins
Robert A. Weiss and Margaret A. Weiss

Chapter 274 Tumescent Liposuction
Rhoda S. Narins, Arnold William Klein, and Jeffrey A. Klein

Chapter 275 Substances for Soft-Tissue Augmentation
Arnold William Klein

Chapter 276 Botulinum Toxin
Richard G. Glogau

Chapter 277 Hair Transplantation and Alopecia Reduction
Walter Unger and Robin Unger

Chapter 278 Cryosurgery
Gloria F. Graham, K. Andrew Cerveny, Jr., and James SanFilippo

Chapter 279 Mohs Micrographic Surgery
Ken K. Lee and Neil A. Swanson

Chapter 280 Nail Surgery
Robert Baran

EDITORS

IRWIN M. FREEDBERG, MD
George Miller MacKee Professor and Chairman
The Ronald O. Perelman Department of Dermatology
New York University Medical Center
New York, New York

ARTHUR Z. EISEN, MD
The Emma Showman Professor of Dermatology; Program Director; Chief Emeritus
Division of Dermatology
Washington University School of Medicine
St. Louis, Missouri

KLAUS WOLFF, MD, FRCP
Professor and Chairman
Department of Dermatology
University of Vienna Medical School
Vienna General Hospital, Vienna
Austria

K. FRANK AUSTEN, MD
AstraZeneca Professor of Respiratory and Inflammatory Diseases
Department of Medicine, Harvard Medical School
Brigham and Women's Hospital, Boston
Massachusetts

LOWELL A. GOLDSMITH, MD
Professor of Dermatology
University of North Carolina School of Medicine
Chapel Hill, North Carolina; Dean Emeritus
University of Rochester School of Medicine and Dentistry
Rochester, New York

STEPHEN I. KATZ, MD, PHD
Director
National Institute of Arthritis and Musculoskeletal and Skin Diseases
National Institutes of Health, Bethesda
Maryland

CONTRIBUTORS

Steffen Albrecht, MD, FRCPC
Department of Pathology, The Sir Mortimer B. Davis—Jewish General Hospital and McGill University, Montreal, Quebec, Canada (107)

Honnavara N. Ananthaswamy, PhD
Ashbel Smith Professor and Deputy Chairman, Department of Immunology, The University of Texas M.D. Anderson Cancer, Center, Houston, Texas (38)

Karl H. Anders, MD
Chief of Pathology and Director of Laboratories, Department of Pathology, Southern California Permanente Medical Group; Associate Clinical Professor of Pathology and Laboratory Medicine, UCLA School of Medicine, Woodland Hills, California (111)

Richard Rox Anderson, MD
Associate Professor of Dermatology, Harvard Medical School, Massachusetts General Hospital, Boston, Massachusetts (267)

Elliot J. Androphy, MD
Professor and Vice Chair of Research; Barbara and Nathan Greenberg Chair in Biomedical Research, University of Massachusetts Medical School, Worcester, Massachusetts (221, 223)

Grant J. Anhalt, MD
Professor of Dermatology and Pathology, Johns Hopkins Medical Institutions, Baltimore, Maryland (60, 262)

John C. Ansel, MD
Professor and Chairman, Department of Dermatology, Northwestern University Medical School, Chicago, Illinois (20)

Cheryl A. Armstrong, MD
Associate Professor, Department of Dermatology, Northwestern University Medical School, Chicago, Illinois (20)

Kenneth A. Arndt, MD
Professor of Dermatology, Harvard Medical School; Adjunct Professor of Medicine, Dartmouth Medical School, SkinCare Physicians of Chestnut Hill, Chestnut Hill, Massachusetts (271)

Eva Åsbrink, MD, PhD
Associate Professor of Dermatology, Karolinska Institutet at Stockholm Soder Hospital, Stockholm, Sweden (203)

K. Frank Austen, MD
AstraZeneca Professor of Respiratory and Inflammatory Diseases, Department of Medicine, Harvard Medical School, Brigham and Women's Hospital, Boston, Massachusetts (32)

Howard P. Baden, MD
Professor of Dermatology, Department of Dermatology, Cutaneous Biology Research Center, Harvard Medical School, Massachusetts General Hospital, Charlestown, Massachusetts (45, 54, 248)

Lynn A. Baden, MD
Clinical Instructor in Dermatology, Harvard Medical School, Boston, Massachusetts (248)

Philippe Bahadoran, MD
Assistant Professor of Dermatology, Nice University School of Medicine, Nice, France (89, 90)

Maryam Banikazemi, MD
Assistant Professor, Department of Human Genetics, Mount Sinai School of Medicine, New York, New York (151)

Robert Baran, MD
Nail Disease Center, Cannes, France (72, 280)

Raymond L. Barnhill, MD
Chair and Professor of Dermatology and Pathology, Division of Dermatology, The George Washington University School of Medicine, Washington, District of Columbia (93)

Eugene A. Bauer, MD
Department of Dermatology, Stanford University School of Medicine, Stanford, California, (65)

Lisa A. Beck, MD
Assistant Professor of Dermatology and Medicine, Department of Dermatology, Johns Hopkins Medical Institutions; Johns Hopkins Asthma and Allergy Center, Baltimore, Maryland (30)

Michael H. Beck, MD

Honorary Associate Lecturer in Dermatology in the Department of Medicine, University of Manchester School of Medicine, Hope Hospital, Salford, Lancs, England (129)

Ysabel M. Bello, MD
Dermatology Resident, Department of Dermatology and Cutaneous Surgery, University of Miami School of Medicine, Miami, Florida (272)

Donald V. Belsito, MD
Professor and Director, Division of Dermatology, University of Kansas Medical Center, Kansas City, Kansas (120, 121)

Col. Paul M. Benson, MD
Associate Professor, Uniformed Services University of the Health Sciences; Walter Reed Army Medical Center, Washington, District of Columbia (245)

Timothy G. Berger, MD
Professor of Clinical Dermatology, Department of Dermatology, University of California, San Francisco, San Francisco, California (198)

Jeffrey D. Bernhard, MD
Professor of Medicine; Chief, Division of Dermatology, UMass Memorial Medical Center, Worcester, Massachusetts (3)

Arthur P. Bertolino, MD, PhD
Professor and Director, Division of Dermatology, Ohio State University Medical Center, Columbus, Ohio (12)

David R. Bickers, MD
Carl Truman Nelson Professor and Chair, Department of Dermatology, Columbia University, College of Physicians and Surgeons, New York, New York (149)

Michael Bigby, MD
Assistant Professor of Dermatology, Harvard Medical School, Beth Israel Deaconess Medical Center, Boston, Massachusetts (240)

Clifton O. Bingham, III, MD
Assistant Professor of Medicine, New York University School of Medicine; Director, Ambulatory Clinical Research Center, New York, New York (32)

Alf Björnberg, MD
Associate Professor of Dermatology, Department of Dermatology, University of Lund, University Hospital, Lund, Sweden (46)

Andrew Blauvelt, MD
Investigator, Dermatology Branch, Center for Cancer Research, National Cancer Institute, National Institutes of Health, Bethesda, Maryland (119)

Mark Boguniewicz, MD
Division of Pediatric Allergy/Immunology National Jewish Medical and Research Center, Department of Pediatrics, University of Colorado Health Sciences Center, Denver, Colorado (122)

Mark W. Bonner, MD
Staff Dermatologist, Dermatology Clinic, Womack Army Medical Center, Fort Bragg, North Carolina (245)

Irwin M. Braverman, MD
Professor of Dermatology, Yale University School of Medicine, New Haven, Connecticut (183)

Francisco Bravo, MD
Auxiliary Professor of Dermatology and Pathology, Universidad Peruana Cayetano Heredia, Miraflores, Lima, Peru (198)

Stephen Michael Breathnach, MD, PhD, FRCP
Consultant Dermatologist and Senior Lecturer, St. John's Institute of Dermatology, St. Thomas's Hospital, London, United Kingdom (148)

Robert A. Briggaman, MD
Professor and Chair Emeritus, Department of Dermatology, University of North Carolina at Chapel Hill, Chapel Hill, North Carolina (66)

Harold J. Brody, MD
Clinical Professor of Dermatology, Emory University School of Medicine, Atlanta, Georgia (269)

Douglas B. Brown, PhD
Research Scientist, DakDak Photoaging Technologies Division, Charles River Laboratories, Elkins Park, Pennsylvania (247)

June M. Brown, BS
Meningitis and Special Pathogens Branch, Division of Bacterial and Mycotic Diseases, National Center for Infectious

Diseases, Centers for Disease Control and Prevention, Atlanta, Georgia (201)

Leena Bruckner-Tuderman, MD
Professor of Dermatology, Department of Dermatology, University Hospital Muenster, Muenster, Germany (16)

Jennifer L. Bub, MD
Dermatology Resident, Division of Dermatology, Department of Medicine, University of Washington School of Medicine, Seattle, Washington (168)

Nigel W. Bunnett, PhD
Professor, Departments of Surgery and Physiology, University of California San Francisco, San Francisco, California (20)

Walter H.C. Burgdorf, MD
Clinical Lecturer, Department of Dermatology, Ludwig Maximilian University, Munich, Tutzing, Germany (97, 99, 105, 106)

Michael J. Camilleri, MD MRCP
Senior Resident Consultant, Department of Dermatology, Mayo Clinic, Rochester, Minnesota (109)

Ruggero Caputo, MD
Professor and Chairman; Director of the School of Specialization in Dermatology and Venereology, Institute of Dermatological Sciences, Milan, Italy (160, 161)

John A. Carucci, MD, PhD
Assistant Professor of Dermatology, Section of Dermatologic Surgery, Weill Medical College of Cornell University, New York, New York (81)

Christopher T. Cassetty, MD
Fellow, Dermatopharmacology, Department of Dermatology, New York University School of Medicine, New York, New York (256)

Lorenzo Cerroni, MD
Professor of Dermatology, University of Graz, Graz, Austria (83)

K. Andrew Cerveny, Jr., MD
Northeastern Ohio Universities College of Medicine, Wadsworth, Ohio (278)

Mary Wu Chang, MD
Assistant Professor of Dermatology, The Ronald O. Perelman Department of Dermatology, New York University School of Medicine, New York, New York (143)

Mei Chen, MD
Division of Dermatology, LAC and USC Medical Center, Los Angeles, California (66)

Michelle M. Choucair, MD
Assistant Professor, Department of Dermatology, University of Cincinnatti, West Chester, Ohio (272)

Mary-Margaret Chren, MD
Staff Dermatologist, San Francisco VA Medical Center; Associate Professor, UCSF Comprehensive Cancer Care Center, San Francisco, California (2)

Prof. Dr. Enno Christophers
Professor and Chairman of Dermatology, University of Kiel, Kiel, Germany (42, 70)

David H. Chu, MD, PhD
Department of Dermatology, New York University School of Medicine, New York, New York (6)

Mon-Li Chu, PhD
Professor of Dermatology and Cutaneous Biology; Professor of Biochemistry and Molecular Pharmacology, Thomas Jefferson University, Philadelphia, Pennsylvania (14, 15)

Lesley Clark-Loeser, MD
Department of Dermatology, New York University School of Medicine, New York, New York (249)

Jay D. Coffman, MD
Professor of Medicine; Chief, Section of Vascular Medicine, Boston University School of Medicine, Boston Medical Center, Boston, Massachusetts (167)

Jeffrey I. Cohen, MD
Head, Medical Virology Section, Laboratory of Clinical Investigation, National Institutes of Health, Bethesda, Maryland (217)

Philip R. Cohen, MD
Clinical Associate Professor, Department of Dermatology, University of Texas-Houston Medical School, Bellaire, Texas

(94)

Suzanne M. Connolly, MD
Associate Professor, Mayo Clinic, Scottsdale, Arizona (87)

Louis Z. Cooper, MD
Professor of Pediatrics, Columbia College of Physicians and Surgeons, New York, New York (210)

Lynn A. Cornelius, MD
Chief, Division of Dermatology, Washington University School of Medicine, St. Louis, Missouri (177)

Melissa I. Costner, MD
Assistant Professor of Dermatology, UT Southwestern Medical Center at Dallas, Dallas, Texas (171, 172)

Thomas G. Cropley, MD
Associate Professor of Medicine, Division of Dermatology, University of Massachusetts Memorial Medical Center, Worcester, Massachusetts (3, 165)

Ponciano D. Cruz, Jr., MD
Professor of Dermatology, University of Texas Southwestern Medical Center, Dallas, Texas (185)

Mark V. Dahl, MD
Professor, Department of Dermatology, Mayo Clinic, Arizona (100)

Jennifer Susan Daly, MD
Associate Professor of Medicine; Clinical Chief, Infectious Disease and Immunology, UMass Memorial Medical Center, Worcester, Massachusetts (237)

Mazen S. Daoud, MD
Fort Myers Dermatopathology, Fort Myers, Florida (48, 49, 50, 77)

Thomas M. DeLauro, DPM
New York College of Podiatric Medicine, Hospital for Joint Diseases-Orthopaedic Institute, Diabetic Foot and Ankle Center, New York, New York (130)

Robert J. Desnick, MD, PhD
Professor and Chairman, Department of Human Genetics, Mount Sinai School of Medicine, New York, New York (151)

A. Damian Dhar, JD, MD
Instructor in Medicine; Chief Resident, Dermatology, Department of Dermatology, Dartmouth-Hitchcock Medical Center, Lebanon, New Hampshire (235)

Charles H. Dicken, MD
Department of Dermatology, Olmstead Medical Center, Rochester, Minnesota (77)

Brian L. Diffey, PhD, DSc
Professor of Photobiology and Medical Physics, Regional Medical Physics Department, Newcastle General Hospital, Newcastle, United Kingdom (247)

John J. DiGiovanna, MD
Director, Division of Dermatopharmacology; Professor, Department of Dermatology, Brown University Medical School, Providence, Rhode Island (51)

Dayna G. Diven, MD
Clinical Associate Professor, University of Texas Medical Branch, Galveston, Texas (220)

Andrzej Dlugosz, MD
Associate Professor, Department of Dermatology and Comprehensive Cancer Center, University of Michigan, Ann Arbor, Michigan (36)

Raphael Dolin, MD
Maxwell Finland Professor of Medicine; Dean for Clinical Programs, Harvard Medical School, Boston, Massachusetts (211, 260)

Jeffrey S. Dover, MD, FRCPC
SkinCare Physicians of Chestnut Hill, Chestnut Hill, Massachusetts (271)

Francesco Drago, MD
Professor of Dermatology, Department of Endocrinology and Metabolic Diseases; Section of Dermatology, University of Genoa, Genova, Italy (216)

Louis Dubertret, MD
Professeur de le Clinique de Maladies Cutania, Universite Paris VII, Paris, France (101)

Karynne O. Duncan, MD
Assistant Professor of Internal Medicine and Dermatology, Department of Dermatology, University of Colorado Health Sciences Center, Denver, Colorado (79)

Madeleine Duvic, MD
Professor; Section Chief, Section of Dermatology, M.D. Anderson Cancer Center, University of Texas Medical School, Houston, Texas (24)

Robert T. Eberhardt, MD
Assistant Professor of Medicine; Director, Vascular Diagnostic Laboratory, Boston University School of Medicine, Boston Medical Center, Boston, Massachusetts (167)

Libby Edwards, MD
Associate Clinical Professor of Dermatology, Wake, Forest University School of Medicine, Charlotte, North Carolina (114)

Lawrence F. Eichenfield, MD
Chief of Pediatric and Adolescent Dermatology, Children's Hospital and Health Center; Clinical Professor of Pediatrics and Medicine (Dermatology), UC San Diego School of Medicine, San Diego, California (122)

Alfred R. Eichmann, MD
Associate Professor, Outpatient Clinic of Dermatology and Venereology, Triemli Hospital, Zurich, Switzerland (230, 234)

Arthur Z. Eisen, MD
The Emma Showman Professor of Dermatology; Program Director; Chief Emeritus, Division of Dermatology, Washington University School of Medicine, St. Louis, Missouri (17, 173)

Peter M. Elias, MD
Professor of Dermatology, Department of Dermatology, UC San Francisco, Dermatology Service, Veteran's Affairs Medical Center, San Francisco, California (9, 195)

Dirk M. Elston, MD
Departments of Dermatology and Pathology, Geisinger Medical Center, Danville, Pennsylvania (131)

Patricia G. Engasser, MD
Clinical Professor of Dermatology, University of California, San Francisco School of Medicine and Stanford University School of Medicine, Atherton, California (252)

Ervin H. Epstein, Jr., MD
Research Dermatologist, San Francisco General Hospital, San Francisco, California (5, 82, 110)

Janet A. Fairley, MD
Professor of Dermatology, Medical College of Wisconsin, Milwaukee, Wisconsin (153)

Vincent Falanga, MD
Professor of Dermatology and Biochemistry, Department of Dermatology, Boston University School of Medicine, Roger Williams Medical Center, Providence, Rhode Island (21)

Stella Fatović-Ferenčić, MD, PhD
Institute for the History of Medicine, Croatian Academy of Arts and Sciences, Zagreb, Croatia (1)

David S. Feingold, MD
Professor of Dermatology, Tufts University School of Medicine, Boston, Massachusetts (233)

Kenneth R. Feingold, MD
Professor of Medicine and Dermatology, University of California, San Francisco; Staff Physician, Veterans Affairs Medical Center, San Francisco, California (9)

David E. Fisher, MD, PhD
Associate Professor, Division of Pediatric Hematology/Oncology, Dana Farber Cancer Institute, Harvard Medical School, Boston, Massachusetts (11)

James E. Fitzpatrick, MD
Associate Professor, Department of Dermatology, University of Colorado Health Sciences Center, Aurora, Colorado (139, 246)

Thomas B. Fitzpatrick, MD, PhD, DSc(Hon)
Edward C. Wigglesworth Professor of Dermatology, Emeritus; Chairman Emeritus, Department of Dermatology, Harvard Medical School, Massachusetts General Hospital, Boston, Massachusetts (3, 88, 90, 93, 266)

Raul Fleischmajer, MD
Professor Emeritus, Department of Dermatology, Mount Sinai School of Medicine, New York, New York (186, 187)

Joachim W. Fluhr, MD
Consultant Dermatologist, Head Skin Physiology Laboratory, Dept. of Dermatology and Allergy, Friedrich Schiller University Jena, Jena, Germany (9)

Genoveffa Franchini, MD
Basic Research Laboratory, Division of Basic Sciences, National Cancer Institute, National Institutes of Health, Bethesda, Maryland (224)

Priv.-Doz. Dr. med. Jorge Frank
Dept. of Dermatology and Allergy, University Clinic of the RWTH, Aachen, Germany (149)

Shoshana Frankenburg, PhD
Department of Dermatology and Sharett Institute of Oncology, Hadassah Medical Organization, Jerusalem, Israel (235)

Andrew G. Franks, Jr., MD
Associate Professor of Dermatology, New York University Medical Center, New York, New York (166)

Irwin M. Freedberg, MD
George Miller MacKee Professor and Chairman, The Ronald O. Perelman Department of Dermatology, New York University Medical Center, New York, New York (7, 12, 44)

Peter O. Fritsch, MD
Department of Dermatology and Venereology, University of Innsbruck, Innsbruck, Austria (58, 78)

Vincent A. Fulginiti, MD
Professor Emeritus, University of Arizona Health Sciences Center, Tucson, Arizona (219)

Isabelle Fumal, MD
Department of Dermatopathology, CHU Sart Tilman, University Medical Centre, Liege, Belgium (126)

Richard L. Gallo, MD, PhD
Chief, Dermatology; Associate Professor of Medicine and Pediatrics, VA Medical Center/UCSD, San Diego, California (18)

W. Ray Gammon, MD
Eastern Dermatology, Greenville, North Carolina (66)

Sylvia Garnis-Jones, MSc, MDCM, FRCPC
Clinical Assistant Professor and Director of the Psychodermatology Clinic, Division of Dermatology, Department of Medicine, McMaster University, Oakville, Ontario, Canada (40)

Rachel A. Garton, MD
Department of Dermatology, Wake Forest University School of Medicine, Winston-Salem, North Carolina (192)

Anthony A. Gaspari, MD
Shapiro Professor of Dermatology, University of Maryland, Baltimore, Maryland (255)

Francis P. Gasparro, PhD
Adjunct Research Professor of Dermatology, Thomas Jefferson University, Hamden, Connecticut (247)

Joel M. Gelfand, MD
Department of Dermatology, Hospital of the University of Pennsylvania, Philadelphia, Pennsylvania (132)

Stephen E. Gellis, MD
Assistant Professor of Dermatology (Pediatrics), Harvard Medical School, Boston, Massachusetts (209)

Irma Gigli, MD
The Walter and Mary Mischer Professor in Molecular Medicine; Associate Director, Institute of Molecular Medicine, The University of Texas-Houston, Houston, Texas (117)

Barbara A. Gilchrest, MD
Chief of Dermatology, Boston University School of Medicine, Boston, Massachusetts (33, 144)

Gerald J. Gleich, MD
Professor, Department of Dermatology, University of Utah Health Sciences Center, Salt Lake City, Utah (96)

Richard G. Glogau, MD
Clinical Professor of Dermatology, University of California, San Francisco, San Francisco, California (276)

Mauricio Goihman-Yahr, MD, PhD
Professor of Dermatology, Instituto de Biomedicina, Faculty of Medicine, Central University of Venezuela, Caracas,

Venezuela (201)

Lowell A. Goldsmith, MD, MPH
Professor of Dermatology, University of North Carolina School of Medicine, Chapel Hill, North Carolina, Dean Emeritus; University of Rochester School of Medicine and Dentistry, Rochester, New York (5, 8, 45, 54, 76, 145, 147, 150, 189)

Alice B. Gottlieb, MD, PhD
Professor of Medicine; W. H. Conzen Chairman of Clinical Pharmacology; Director, Clinical Research Center, Robert Wood Johnson Medical School, University of Medicine and Dentistry of New Jersey, New Brunswick, New Jersey (263)

Gloria F. Graham, MD
Associate Clinical Professor of Dermatology, Wake Forest University School of Medicine, Winston-Salem, North Carolina (278)

Robin A.C. Graham-Brown, BSc MB FRCP
Consultant Dermatologist; Honorary Senior Lecturer in Dermatology, University of Leicester, The Leicester Royal Infirmary, Leicester, United Kingdom (68, 164)

Richard D. Granstein, MD
George W. Hambrick, Jr. Professor of Dermatology; Chairman, Department of Dermatology, Joan and Sanford I. Weill Medical College of Cornell University, New York, New York (39)

Malcolm W. Greaves, MD, PhD, FRCP
Emeritus Professor of Dermatology, St. Johns Institute of Dermatology, St. Thomas' Hospital, London; Senior Consultant Dermatologist, Singapore General Hospital, Singapore (41)

Justin J. Green, MD
Clinical Instructor of Medicine, Division of Dermatology, UMDNJ, Robert Wood Johnson Medical School at Camden, Marlton, New Jersey (227)

Suzanne Virnelli Grevelink, MD
Department of Dermatology, Children's Hospital Medical Center, Boston, Massachusetts (103)

James M. Grichnik, MD, PhD
Associate Professor; Director Melanocytic Diseases Section, Department of Medicine, Division of Dermatology, Duke University Medical Center, Durham, North Carolina (91)

Douglas Grossman, MD, PhD
Assistant Professor, Departments of Dermatology and Oncological Sciences, Huntsman Cancer Institute, University of Utah, Salt Lake City, Utah (80)

Shireen V. Guide, MD
Stanford University Medical Center, Stanford, California (29)

Anne R. Haake, PhD
Assistant Professor, Information Technology and Bioinformatics, Rochester Institute of Technology, Rochester, New York (6)

Ruth Halaban, PhD
Senior Research Scientist, Department of Dermatology, Yale University School of Medicine, New Haven, Connecticut (11)

Russell P. Hall, III, MD
J. Lamar Callaway Professor of Dermatology, Duke University Medical Center, Durham, North Carolina (63)

Jon M. Hanifin, MD
Professor of Dermatology, Department of Dermatology, Oregon Health and Science University, Portland, Oregon (250)

Rudolf Happle, MD
Professor and Chairman, Department of Dermatology and Allergy, Philipp University of Marburg, Marburg, Germany (188)

Christopher B. Harmon, MD
University of Alabama at Birmingham, Birmingham, Alabama (270)

Conrad Hauser, MD
Associate Professor, Allergy Unit and Department of Dermatology, University Hospital, Geneva, Switzerland (23)

John L.M. Hawk, MD
Professor, Photobiology Unit, St. Thomas' Hospital, London, United Kingdom (134, 135)

Roderick J. Hay, MD
Dean; Faculty of Medicine and Health Sciences, Queens University Belfast, Belfast, Northern Ireland (207)

Harley A. Haynes, MD
Vice Chairman, Department of Dermatology, Brigham and Women's Hospital, Boston, Massachusetts (184)

Peter W. Heald, MD
Professor of Dermatology, Yale School of Medicine, New Haven, Connecticut (157)

Daniel N. Hebert, PhD
Assistant Professor, Department of Biochemistry and Molecular Biology, University of Massachusetts, Amherst, Massachusetts (11)

Peter J. Heenan, MD
Clinical Associate Professor, Department of Pathology, The University of Western Australia, Nedlands, Western Australia (55)

Michael P. Heffernan, MD
Assistant Professor, Division of Dermatology, Washington University School of Medicine, St. Louis, Missouri (170, 205, 206)

G. Scott Herron, MD, PhD
Department of Dermatology, Stanford University School of Medicine, Stanford, California (65)

Warren R. Heymann, MD
Professor of Medicine; Head, Division of Dermatology, UMDNJ-Robert Wood Johnson Medical School at Camden, Marlton, New Jersey (169, 227)

Jan V. Hirschmann, MD
Professor of Medicine, University of Washington School of Medicine, Puget Sound VA Medical Center, Seattle, Washington (259)

Vincent C.Y. Ho, MD
Professor, Skin Care Center, Vancouver, British Columbia, Canada (84)

Gary S. Hoffman, MD
Chair, Department of Rheumatic and Immunologic Disease, The Cleveland Clinic Foundation, Cleveland, Ohio (174)

Rainer Hofmann-Wellenhof, MD
Professor of Dermatology, Department of Dermatology, University of Graz, Graz, Austria (86)

Karen A. Holbrook, PhD
President, Ohio State University, Columbus, Ohio (6)

Steven M. Holland, MD
Senior Clinical Investigator, Laboratory of Host Defenses, NIAID, National Institutes of Health, Bethesda, Maryland (29)

Carlin B. Hollar, MD
Resident, Department of Dermatology, Wake Forest University School of Medicine, Wake Forest University Baptist Medical Center, Winston-Salem, North Carolina (179)

Karl Holubar, MD, FRCP
Professor of Dermatology and Venereology and of the History of Medicine; Chairman, Institute for the History of Medicine, University of Vienna, Vienna, Austria (1, 162)

Herbert Hönigsmann, MD
Professor and Chairman, Division of Special and Environmental Dermatology, Department of Dermatology, University of Vienna Medical School, Vienna, Austria (69, 94, 135, 266)

Yoshiaki Hori, MD (deceased)
Professor and Chairman Emeritus, Department of Dermatology, Yamanashi Medical College, Yamanashi, Japan (90)

Thomas D. Horn, MD
Professor of Dermatology and Pathology; Chair, Department of Dermatology, University of Arkansas for Medical Sciences, Central Arkansas Veterans Healthcare System, Little Rock, Arkansas (118)

Karen R. Houpt, MD
Clinical Associate Professor of Dermatology, Southwestern Medical School, University of Texas Southwestern Medical Center, Dallas, Texas (185)

Anders Hovmark, MD, PhD
Associate Professor of Dermatology, Karolinska Institutet at Stockholm Soder Hospital, Stockholm, Sweden (203)

George J. Hruza, MD
Clinical Associate Professor of Dermatology and Otolaryngology/Head and Neck Surgery, St. Louis University School of

Medicine, Town and Country, Missouri (268, 271)

Fred H. Hsieh, MD
Section of Allergy and Immunology, Department of Pulmonary and Critical Care Medicine, Cleveland Clinic Foundation, Cleveland, Ohio (32)

Chung-Hong Hu, MD
Professor of Dermatology and President, Taipei Medical College, Taipei, Japan (47)

Eva A. Hurst, MD
Dermatology Department, Washington University School of Medicine, St. Louis, Missouri (170)

Sam T. Hwang, MD, PhD
Tenure-Track Investigator, Dermatology Branch, Center for Cancer Research, National Cancer Institute, Bethesda, Maryland (27)

William D. James, MD
Vice Chairman and Residency Program Director; Albert M. Kligman Professor, Department of Dermatology, University of Pennsylvania School of Medicine, Philadelphia, Pennsylvania (245)

Prof. Dr. Thomas Jansen
Department of Dermatology and Allergy, Ruhr-University Bochum, Bochum, Germany (74, 124)

Ming H. Jih, MD, PhD
The Ronald O. Perelman Department of Dermatology, New York University Medical Center, New York, New York (7, 44)

Richard Allen Johnson, MDCM
Clinical Associate in Dermatology, Department of Dermatology, Massachusetts General Hospital, Boston, Massachusetts (196, 113, 194, 225)

Graham A. Johnston, MB ChB MRCP
Consultant Dermatologist, Department of Dermatology, The Leicester Royal Infirmary, Leicester, United Kingdom (164)

Joseph L. Jorizzo, MD
Professor and Former (Founding) Chair, Department of Dermatology, Wake Forest University School of Medicine, Wake Forest University Baptist Medical Center, Winston-Salem, North Carolina (179, 192)

Steven Kaddu, MD
Associate Professor, Department of Dermatology, University of Graz, Graz, Austria (85)

Sewon Kang, MD
Associate Professor; Director of Clinical Research Unit, Department of Dermatology, University of Michigan Medical School, Ann Arbor, Michigan (244)

Allen P. Kaplan, MD
Professor of Medicine, Division of Pulmonary, Allergy, and Critical Care; Department of Medicine, Medical University of South Carolina, Charleston, South Carolina (116)

Stephen I. Katz, MD, PhD
Director, National Institute of Arthritis and Musculoskeletal and Skin Diseases, National Institutes of Health, Bethesda, Maryland (64, 67, 95, 178, 254)

David P. Kelsell, MD
Centre for Cutaneous Research, Bart's and The London, Queen Mary's School of Medicine and Dentistry, University of London, London, England (52)

Francisco A. Kerdel, MD
Professor, Department of Dermatology and Cutaneous Surgery, University of Miami School of Medicine, Cedars Medical Center, Miami, Florida (243)

Helmut Kerl, MD
Professor and Chairman, Department of Dermatology, University of Graz, Graz, Austria (83, 85, 86)

A. Ross Kerr, DDS, MSD
Assistant Professor, Department of Oral Medicine, New York University College of Dentistry, New York, New York (112)

Paul A. Khavari, MD, PhD
Department of Dermatology, Stanford University School of Medicine, Stanford, California (65)

Abdul-Ghani Kibbi, MD, FACP
Professor and Chairman, Department of Dermatology, American University of Beirut Medical Center, Beirut, Lebanon (4)

Jenny Kim, MD, PhD
Assistant Clinical Professor of Medicine/Dermatology, Division of Dermatology, UCLA, Geffen School of Medicine, Los

Angeles, California (22)

Alexa Boer Kimball, MD, MPH
Assistant Professor, Department of Dermatology, Stanford University School of Medicine, Stanford, California (125)

Arash Kimyai-Asadi, MD
The Ronald O. Perelman Department of Dermatology, New York University Medical Center, New York, New York (7, 44)

Lloyd E. King, Jr., MD, PhD
Professor and Chairman, Division of Dermatology, Department of Medicine, Vanderbilt University Medical Center, Nashville, Tennessee (239)

Richard A. King, MD, PhD
Professor of Medicine and Pediatrics, Institute of Human Genetics, University of Minnesota, Minneapolis, Minnesota (89)

Sidney N. Klaus, MD
Professor of Medicine; Staff Dermatologist, Department of Dermatology, Darmouth Medical School, Dartmouth-Hitchcock Medical Center, Lebanon, New Hampshire (235)

Arnold William Klein, MD
Professor of Medicine/Dermatology, UCLA Geffen School of Medicine, Los Angeles, California (274, 275)

Jeffrey A. Klein, MD
Associate Clinical Professor of Medicine/Dermatology, UCLA Geffen School of Medicine, Los Angeles, California (274)

Alison S. Klenk, MD
Washington University School of Medicine, St. Louis, Missouri (206)

John H. Klippel, MD
Medical Director, Arthritis Foundation, Washington, District of Columbia (181)

Robert Knobler, MD
Associate Professor of Dermatology, Division of Special and Environmental Dermatology, Department of Dermatology, University of Vienna Medical School, Vienna, Austria (266)

John S. Knowland, PhD
Department of Biochemistry, Brasenose College, University of Oxford, Oxford, United Kingdom (247)

Sandra R. Knowles, BScPhm
Lecturer, University of Toronto, Sunnybrook and Women's College Health Sciences Centre, Toronto, Ontario, Canada (138)

Irene E. Kochevar, PhD
Professor, Wellman Laboratories of Photomedicine Department of Dermatology, Massachusetts General Hospital, Harvard Medical School, Boston, Massachusetts (133)

Thomas W. Koenig, MD
Assistant Professor of Psychiatry and Behavioral Sciences, Johns Hopkins Medical Institutions, Baltimore, Maryland (40)

Nellie Konnikov, MD
Professor of Dermatology, Boston University School of Medicine, Boston, Massachusetts (261)

Kenneth H. Kraemer, MD
Chief, DNA Repair Section, Basic Research Laboratory, National Cancer Institute, Bethesda, Maryland (35, 155)

Margaret L. Kripke, PhD
Professor of Immunology; Executive Vice President and Chief Academic Officer, The University of Texas M.D. Anderson Cancer Center, Houston, Texas (38)

James G. Krueger, MD
The Rockefeller University, New York, New York (263)

Jean Krutmann, MD
Professor of Dermatology and Environmental Health; Director, Research Institute for Environmental Health, Heinrich-Heine University, Düsseldorf, Germany (265)

Stephane Kuenzli, MD
Department of Dermatology, Geneva University Medical School, University Hospital, Geneva, Switzerland (257)

Thomas S. Kupper, MD
Chairman, Department of Dermatology, Brigham and Women's Hospital, Boston, Massachusetts (26)

Jeffrey R. LaDuca, PhD, MD

University of Rochester, School of Medicine and Dentistry, Rochester, New York (255)

Nicole LaNatra
Medical Student, New York Medical College, New York, New York (251)

Richard G.B. Langley, MD
Assistant Professor of Dermatology, Dalhousie University, Halifax, Nova Scotia, Canada (93)

Charles M. Lapiere
Emeritus Professor of Dermatology, Universite de Liege, Liege, Belgium (152)

Jo-Ann M. Latkowski, MD
Assistant Professor, Department of Dermatology, New York University School of Medicine, New York, New York (157)

Stephan Lautenschlager, MD
Clinical Lecturer; Staff Physician, Outpatient Clinic of Dermatology and Venereology, Triemli Hospital, Zurich, Switzerland (230, 234)

Robert M. Lavker, PhD
Professor of Dermatology, The Feinberg School of Medicine, Northwestern University, Chicago, Illinois (12)

Thomas J. Lawley, MD
Dean; Professor of Dermatology, Emory University School of Medicine, Atlanta, Georgia (142, 177)

Mark Lebwohl, MD
Professor and Chairman, Department of Dermatology, Mount Sinai School of Medicine, New York, New York (108)

Ken K. Lee, MD
Assistant Professor of Dermatology, Otolaryngology/Head and Neck Surgery, Oregon Health and Science University, Portland, Oregon (279)

Lela A. Lee, MD
Professor of Dermatology and Medicine, University of Colorado School of Medicine; Chief of Dermatology, Denver Health Medical Center, Denver, Colorado (25)

Peter K. Lee, MD
Assistant Professor, Department of Dermatology, University of Minnesota, Minneapolis, Minnesota (194)

David J. Leffell, MD
Professor of Dermatology and Surgery, Department of Dermatology, Yale University School of Medicine, Yale-New Haven Hospital, New Haven, Connecticut (79, 80, 81)

Franz J. Legat, MD
Assistant Professor, Department of Dermatology, Kral-Sranzens-University Graz, School of Medicine, Graz, Austria (20)

Kristin M. Leiferman, MD
Professor, Department of Dermatology, University of Utah Health Sciences Center, Salt Lake City, Utah (96)

Irene M. Leigh, MD, FRCP
Centre for Cutaneous Research, Bart's and The London, Queen Mary's School of Medicine and Dentistry, University of London, London, England (52)

Janie M. Leonhardt, MD
Division of Dermatology, UMDNJ—Robert Wood Johnson Medical School at Camden, Marlton, New Jersey (169)

Donald Y.M. Leung, MD, PhD
Head, Division of Pediatric Allergy/Immunology, National Jewish Medical and Research Center; Professor of Pediatrics, University of Colorado Health Sciences Center, Denver, Colorado (122, 204)

Henry W. Lim, MD
Chairman and C.S. Livingood Chair Department of Dermatology; Director, Academic Programs, Henry Ford Hospital, Detroit, Michigan (136)

Graeme M. Lipper, MD
Research Fellow, Wellman Laboratories of Photomedicine, Department of Dermatology, Massachusetts General Hospital, Boston, Massachusetts (267)

Cynthia A. Loomis, MD, PhD
Assistant Professor, Departments of Cell Biology and Dermatology, New York University School of Medicine, New York, New York (6)

Douglas R. Lowy, MD
Deputy Director, Center for Cancer Research, National Cancer Institute, National Institutes of Health, Bethesda,

Maryland (37, 208, 221, 222, 223)

Leslie C. Lucchina, MD
Director of Aesthetic Dermatology, Department of Dermatology, Brigham and Women's Hospital, Boston, Massachusetts (236)

Anne W. Lucky, MD
Department of Pediatrics, Division of Dermatology, Children's Hospital Medical Center of Cincinnati, Cincinnati, Ohio (204)

Thomas A. Luger, MD
Professor and Chairman, Department of Dermatology, University of Munster, Munster, Germany (20)

Calum C. Lyon, MA, MRCP
Clinical Lecturer, Section of Dermatology, University of Manchester/Hope Hospital, Manchester, England (129)

Howard I. Maibach, MD
Professor of Dermatology, Department of Dermatology, University of California, San Francisco School of Medicine, San Francisco, California (252)

Frederick D. Malkinson, MD
Clark W. Finnerud Professor Emeritus, Department of Dermatology, Rush Medical College, Rush-Presbyterian-St. Luke's Medical Center, Chicago, Illinois (128)

Brian F. Mandell, MD, PhD
Clinical Professor of Medicine, Pennsylvania State College of Medicine, Hershey, Pennsylvania (174)

Claire P. Mansur, MD
Assistant Professor of Dermatology, Tufts University School of Medicine; Chair of Dermatology, Tufts-New England Medical Center, Boston, Massachusetts (233)

David J. Margolis, MD, PhD
Associate Professor; Director, Cutaneous Ulcer Center, University of Pennsylvania/ CCEB, Philadelphia, Pennsylvania (132)

M. Peter Marinkovich, MD
Assistant Professor; Director, Bullous Disease Clinic, Department of Dermatology and Program in Epithelial Biology, Stanford University School of Medicine, Stanford, California (65)

Ronald Marks, MD
Emeritus Professor, University of Wales, Cardiff, Penylan, Cardiff, United Kingdom (75)

Adriana R. Marques, MD
Head, Clinical Studies Unit, Laboratory of Clinical Investigation, National Institute of Allergy and Infectious Diseases, National Institutes of Health, Bethesda, Maryland (214)

Ann G. Martin, MD
Assistant Professor of Medicine, Division of Dermatology, Washington University School of Medicine, St. Louis, Missouri (205, 206)

Dieter Maurer, MD
Associate Professor; Director of Immunology, Allergy and Infectious Diseases, Department of Dermatology, University of Vienna Medical School, Vienna, Austria (23)

David I. McLean, MD, FRCP
Professor of Dermatology; Associate Dean, Health Care Systems and Planning, University of British Columbia, Vancouver, British Columbia, Canada (184)

Michael M. McNeil, MD, MPH
Epidemiology and Surveillance Division, National Immunization Program, Centers for Disease Control and Prevention, Atlanta, Georgia (201)

Dean D. Metcalfe, MD
Laboratory of Allergic Diseases, National Institute of Allergy and Infectious Diseases, National Institutes of Health, Bethesda, Maryland (163)

Martin C. Mihm, Jr., MD, FACP
Senior Dermatopathologist; Associate Dermatologist; Pathologist; Clinical Professor of Pathology, Massachusetts General Hospital, Harvard Medical School, Boston, Massachusetts (4, 93)

Robert L. Modlin, MD
Professor of Dermatology and Microbiology and Immunology, Division of Dermatology, David Geffen School of Medicine at UCLA, Los Angeles, California (22, 28, 202)

Akimichi Morita, MD
Associate Professor, Department of Dermatology, Nagoya City University Medical School, Nagoya, Japan (265)

David B. Mosher, MD (deceased)
Department of Dermatology, Harvard Medical School, Massachusetts General Hospital, Boston, Massachusetts (90)

Prof. Dr. Ulrich Mrowietz
Associate Professor of Dermatology, University of Kiel, Kiel, Germany (42, 70)

J. Marcus Muche, MD
Department of Dermatology and Allergy, Humboldt University, Charite Berlin, Berlin, Germany (158)

John Butler Mulliken, MD
Professor of Surgery, Harvard Medical School, Children's Hospital, Boston, Massachusetts (103)

Rhoda S. Narins, MD
Clinical Professor in Dermatology, New York University Medical Center, New York, New York (274)

Kenneth H. Neldner, MD
Professor and Chairman Emeritus, Department of Dermatology, Texas Tech University Health Sciences Center, Lubbock, Texas (146)

Michael M. Nelson, MD
Clinical Research Fellow, Division of Dermatology, Washington University School of Medicine, St. Louis, Missouri (205)

David S. Nieves, MD
Resident in Dermatology, Department of Dermatology, University of Rochester Medical Center, Rochester, New York (145)

Gerhard J. Nohynek, MSc, PhD, DABT
Centre Charles Zviak, L'Oreal Life Sciences Research, Clichy, France (241)

Paul G. Norris, MA, MB
Consultant Dermatologist, Department of Dermatology, Addenbrookes Hospital, Cambridge, United Kingdom (135)

H. Carlos Nousari, MD
Chairman, Department of Dermatology, Cleveland Clinic Florida, Weston, Florida (60, 180, 262)

William S. Oetting, MD
Assistant Professor, Medicine Genetics Office, University of Minnesota, Minneapolis, Minnesota (89)

John E. Olerud, MD
Professor and Chairman, Division of Dermatology, University of Washington Medical School, Seattle, Washington (20, 168)

Elise A. Olsen, MD
Professor of Medicine, Division of Dermatology, Duke University Medical Center, Durham, North Carolina (71)

Seth J. Orlow, MD, PhD
Samuel Weinberg Professor of Dermatology, New York University School of Medicine, New York, New York (143)

Jean-Paul Ortonne, MD
Chief, Department of Dermatology, Hospital Pasteur; Professor of Dermatology, Nice University School of Medicine, Nice, France (88, 89, 90)

Michael N. Oxman, MD
Professor of Medicine and Pathology, University of California at San Diego; Chief, Infectious Diseases and Clinical Virology Sections, VA Medical Center, San Diego, California (215)

Amy S. Paller, MD
Professor of Pediatrics and Dermatology, Northwestern University Medical School; Head, Division of Dermatology, Children's Memorial Hospital, Chicago, Illinois (115, 189, 191)

Johannes Pammer, MD
Associate Professor of Pathology, Clinical Institute for Pathology, University of Vienna Medical School, Vienna, Austria (226)

Renato G. Panizzon, MD
Professor and Chairman, Department of Dermatology, University Hospital CHUV, Lausanne, Switzerland (128)

Madhukar A. Pathak, PhD

Department of Dermatology, Massachusetts General Hospital, Boston, Massachusetts (266)

Alice P. Pentland, MD
Professor and chair, Department of Dermatology, University of Rochester, Rochester, New York (34)

Margot S. Peters, MD
Rochester, Minnesota (96)

Peter Petzelbauer, MD
Department of Dermatology, University of Vienna Medical School, Vienna, Austria (19)

Joan A. Phelan, DDS
Professor and Chair, Department of Oral Pathology, New York University College of Dentistry, New York, New York (112)

Tania J. Phillips, MD
Professor of Dermatology, Boston University School of Medicine, Boston, Massachusetts (272)

Gérald Piérard, MD, PhD
Department of Dermatopathology, CHU Sart Tilman, University Medical Centre, Liege, Belgium (126)

Claudine Piérard-Franchimont, MD, PhD
Department of Dermatopathology, CHU Sart Tilman, University Medical Centre, Liege, Belgium (126)

Warren W. Piette, MD
Professor, Department of Dermatology, University of Iowa College of Medicine, Iowa City, Iowa (156)

Bianca Maria Piraccini, MD, PhD
Department of Dermatology, University of Bologna, Bologna, Italy (13)

Mark R. Pittelkow, MD
Professor, Departments of Dermatology and Biochemistry and Molecular Biology, Mayo Medical School, Rochester, Minnesota (48, 49, 50)

Eniko K. Pivnik, MD
Associate Professor, Department of Pediatrics, University of Tennessee Health Science Center, Memphis, Tennessee (190)

Prof. Dr. Dr. h.c. Gerd Plewig
Department of Dermatology and Allergy, Ludwig-Maximilians-University, Munich, Germany (74, 124)

Jordan S. Pober, MD, PhD
Professor of Pathology, Immunobiology and Dermatology; Director, Interdepartmental Program in Vascular Biology and Transplantation, Boyer Center for Molecular Medicine, Yale University School of Medicine, New Haven, Connecticut (19)

Victor G. Prieto, MD, PhD
Associate Professor of Pathology and Dermatology; Chief of Dermatopathology, Department of Pathology, M.D. Anderson Cancer Center, Houston, Texas (102)

Thomas T. Provost, MD
Distinguished Service Professor, Department of Dermatology, Johns Hopkins Medical Institutions, Baltimore, Maryland (180)

Leena Pulkkinen, PhD
Department of Dermatology and Cutaneous Biology, Thomas Jefferson University, Philadelphia, Pennsylvania (14)

Christopher J. Quirk, MBBS, FACD
Part-time Senior Lecturer, Department of Dermatology, Royal Perth Hospital, Fremantle, Western Australia (55)

Caroline L. Rao, MD
Assistant Professor of Medicine, Duke University Medical Center, Durham, North Carolina (63)

Univ. Prof. Dr. Klemens Rappersberger
Head, Department of Dermatology, Hospital Rudolfstiftung, Vienna, Austria (104)

Helen Raynham, MD
Boston University School of Medicine, Boston, Massachusetts (261)

Thomas H. Rea, MD
Emeritus Professor, Division of Dermatology, LAC/USC Medical Center, Los Angeles, California (202)

Alfredo Rebora, MD
Professor and Director, Department of Endocrinology and Metabolic Diseases, Section of Dermatology, University of

Genoa, Genoa, Italy (216)

Thomas E. Redelmeier, PhD
President, Northern Lipids, Inc., Vancouver, British Columbia, Canada (241)

Vivienne Reeve, PhD
Senior Research Fellow; Faculty of Veterinary Science, University of Sydney, New South Wales, Australia (247)

Marvin S. Reitz, Jr., PhD
Institute of Human Virology, University of Maryland Biotechnology Institute, Baltimore, Maryland (224)

Adrienne Rencic, MD, PhD
Department of Dermatology, Johns Hopkins Outpatient Center, Baltimore, Maryland (30, 40)

Steven D. Resnick, MD
Chief, Division of Dermatology, Bassett Healthcare, Cooperstown, New York (195)

Arthur R. Rhodes, MD, MPH
Professor, Department of Dermatology, Rush University, Rush Medical College, Chicago, Illinois (91)

Vincent M. Riccardi, MD
Clinical Professor of Pediatrics (Genetics), The NF Institute, La Crescenta, California (190)

Benjamin E. Rich, PhD
Instructor in Dermatology, Harvard Medical School; Brigham and Women's Hospital, Boston, Massachusetts (26)

June K. Robinson, MD
Director, Division of Dermatology, Loyola University Chicago Stritch School of Medicine; Program Leader of the Skin Cancer Clinical Program, Cardinal Bernardin Cancer Center, Maywood, Illinois (268)

Fred S. Rosen, MD
James L. Gamble Professor of Pediatrics, Center for Blood Research, Harvard Medical School, Boston, Massachusetts (117)

Richard Rothenberg, MD, MPH
Professor, Department of Family and Preventive Medicine, Emory University School of Medicine, Atlanta, Georgia (231, 232)

Adam I. Rubin, MD
Post-Doctoral Residency Fellow, Department of Dermatology, Columbia University College of Physicians and Surgeons; Columbia Presbyterian Medical Center, New York, New York (251)

Ramon Ruiz-Maldonado, MD
Professor, Instituto Nacional de Pediatria, Insurgentes Sur, Mexico City, Mexico (58)

Miguel R. Sanchez, MD
Associate Professor, Ronald O. Perelman Department of Dermatology, New York University School of Medicine, Bellevue Hospital Center, New York, New York (141, 228, 229)

James SanFilippo, MD
Northeastern Ohio Universities College of Medicine, Tallmadge, Ohio (278)

Jean-Hilaire Saurat, MD
Department of Dermatology, Geneva University Medical School, University Hospital, Geneva, Switzerland (257)

Hans Schaefer, PhD
Professor Emeritus; Advisor to the Center of Experimental and Applied Cutaneous Physiology, Department of Dermatology, Charite Hospital, Humboldt-University, Berlin, Germany (241)

Mark Jordan Scharf, MD
Associate Professor, Division of Dermatology, University of Massachusetts Medical School, Worcester, Massachusetts (237)

Jeffrey S. Schechner, MD
Assistant Professor, Department of Dermatology, Yale University School of Medicine, New Haven, Connecticut (19)

Kenneth E. Schmader, MD
Associate Professor of Medicine and Geriatrics, Duke and Durham VA Medical Centers, Durham, North Carolina (215)

Thomas Scholzen, PhD
Department of Dermatology, Ludwig Boltzmann Institute, University Clinical Center of Munster, Munster, Germany (20)

John T. Schroeder, PhD

Assistant Professor of Medicine, Johns Hopkins Asthma and Allergy Center, Baltimore, Maryland (31)

Theresa Schroeder, MD
Assistant Professor, Department of Dermatology, Oregon Health and Science University, Portland, Oregon (176)

Jo L. Seltzer, PhD
Division of Dermatology, Washington University School of Medicine, St. Louis, Missouri (17)

Lori Shapiro, MD, FRCP
Assistant Professor, Departments of Medicine, Dermatology, and Clinical Pharmacology, Sunnybrook and Women's College Health Sciences Centre, Toronto, Ontario, Canada (138)

Christopher R. Shea, MD
Professor of Medicine; Chief, Section of Dermatology, University of Chicago Medical Center, Chicago, Illinois (102)

Neil H. Shear, MD, FRCP
Professor and Chief of Dermatology, University of Toronto, Sunnybrook and Women's Health Sciences Centre, Toronto, Ontario, Canada (138)

Robert L. Sheridan, MD
Assistant Chief of Staff, Shriners Burns Hospital, Boston, Massachusetts (127)

Jonathan A. Ship, DMD
Director, Bluestone Center for Clinical Research; Professor, Department of Oral Medicine, New York University College of Dentistry, New York, New York (112)

Jerome L. Shupack, MD
Professor of Dermatology, The Ronald O. Perelman Department of Dermatology, New York University Medical Center, New York, New York (242, 249, 256)

Robert Sidbury, MD
Assistant Professor, Departments of Pediatrics and Dermatology, University of Washington School of Medicine, Seattle, Washington (250)

Shane G. Silver, MD
The Skin Care Center, University of British Columbia, Vancouver, British Columbia, Canada (84)

David A. Sirois, DMD, PhD
Professor and Chairman, Department of Oral Medicine, New York University College of Dentistry, New York, New York (212)

Michael L. Smith, MD
Assistant Professor of Medicine and Pediatrics, Division of Dermatology, Vanderbilt University Medical Center, Nashville, Tennessee (239)

Renee R. Snyder, MD
Department of Dermatology, University of Texas Medical Branch, Galveston, Texas (220)

Arthur J. Sober, MD
Professor of Dermatology; Associate Chief of Dermatology, Harvard Medical School, Massachusetts General Hospital, Boston, Massachusetts (91, 92, 93)

Richard D. Sontheimer, MD
John S. Strauss Endowed Chair in Dermatology; Professor and Head, Department of Dermatology, University of Iowa College of Medicine/University of Iowa Health Care, Iowa City, Iowa (171, 172)

Apra Sood, MD
Fellow, Contact Dermatitis and Environmental Skin Disease, Department of Dermatology, Cleveland Clinic Foundation, Cleveland, Ohio (137)

Nicholas A. Soter, MD
Professor, The Ronald O. Perelman Department of Dermatology, New York University Medical Center, Tisch Hospital, New York, New York (116, 123, 175, 258)

John R. Stanley, MD
Milton B. Hartzell Professor and Chairman, Department of Dermatology, Hospital of the University of Pennsylvania, Philadelphia, Pennsylvania (59, 61)

Wolfram Sterry, MD
Department of Dermatology and Allergy, Humboldt University, Charite Berlin, Berlin, Germany (158)

Howard P. Stevens, MD
Department of Dermatology, Barnet General Hospital, Barnet, Hertfordshire, United Kingdom (52)

Margaret I. Stewart, MD
Assistant Professor of Medicine, Division of Dermatology, University of Massachusetts Memorial Medical Center, Worcester, Massachusetts (3)

Matthew J. Stiller, MD
Associate Professor of Clinical Dermatology; Director, Clinical Pharmacology Unit, Columbia University College of Physicians and Surgeons; Columbia Presbyterian Medical Center, New York, New York (251)

Georg Stingl, MD
Professor of Dermatology; Head, Division of Immunology, Allergy and Infectious Diseases, Department of Dermatology, University of Vienna Medical School, Vienna, Austria (23, 98, 104)

Stephen P. Stone, MD
Professor of Clinical Medicine, Division of Dermatology, Southern Illinois University School of Medicine, Springfield, Illinois (238)

Stephen E. Straus, MD
Chief, Laboratory of Clinical Investigation, National Institute of Allergy and Infectious Diseases, Director, National Center for Complementary and Alternative Medicine, National Institutes for Health, Bethesda, Maryland (214, 215)

John S. Strauss, MD
Emeritus Professor of Dermatology, University of Iowa College of Medicine/University of Iowa Health Care, Iowa City, Iowa (73)

Bruce E. Strober, MD, PhD
Assistant Professor of Dermatology, The Ronald O. Perelman Department of Dermatology, New York University Medical Center, New York, New York (242)

W.P. Daniel Su, MD
Professor, Department of Dermatology, Mayo Clinic, Rochester, Minnesota (109)

John R. Sullivan, MB, BS, FACD
Director, Centre for Product Testing, Skin and Cancer Foundation, Liverpool and Westmead Hospital, Westmead, New South Wales, Australia (138)

Tung-Tien Sun, PhD
Rudolf A. Baer Professor of Dermatology; Professor of Pharmacology and Urology, New York University School of Medicine, New York, New York (12)

Neil A. Swanson, MD
Professor and Chair of Dermatology; Professor of Otolaryngology/Head and Neck Surgery, Department of Dermatology, Oregon Health and Science University, Portland, Oregon (279)

Morton N. Swartz, MD
Professor of Medicine; Chief, Jackson Firm of Medical Service, Harvard Medical School, Massachusetts General Hospital, Boston, Massachusetts (193, 194, 196, 197, 199)

Susan Sweeney, MD
Chief Resident, Division of Dermatology, University of Massachusetts Medical School, Worcester, Massachusetts (165)

Virginia P. Sybert, MD
Professor, Division of Dermatology, Department of Medicine, University of Washington School of Medicine, Seattle, Washington (53)

Rolf-Markus Szeimies, MD
Assistant Professor, Department of Dermatology, University of Regensburg, Regensburg, Germany (266)

Moyses Szklo, MD, MPH, DrPH
Professor of Chronic Disease Epidemiology, Johns Hopkins University, Bloomberg School of Hygiene and Public Health, Baltimore, Maryland (240)

Gerhard Tappeiner, MD
Associate Professor, Department of Dermatology, University of Vienna Medical School, Vienna, Austria (200, 264)

Francisco A. Tausk, MD
Associate Professor of Dermatology, Johns Hopkins Medical Institutions, Baltimore, Maryland (40)

Charles R. Taylor, MD
Associate Professor of Dermatology, Wellman Laboratories of Photomedicine, Department of Dermatology, Massachusetts General Hospital, Harvard Medical School, Boston, Massachusetts (133)

James S. Taylor, MD
Head, Section of Industrial Dermatology, Department of Dermatology, Cleveland Clinic Foundation, Cleveland, Ohio

(137)

Eva Tegner, MD
Associate Professor of Dermatology, University of Lund, University Hospital, Lund, Sweden (46)

Diane M. Thiboutot, MD
Associate Professor of Dermatology, The Pennsylvania State University, The Milton S. Hershey Medical Center, Hershey, Pennsylvania (73)

Antonella Tosti, MD
Associate Professor, Department of Dermatology, University of Bologna, Bologna, Italy (13, 72)

Franz Trautinger, MD
Associate Professor of Dermatology, Division of Special and Environmental Dermatology, Department of Dermatology, University of Vienna Medical School, Vienna, Austria (69)

Janet M. Trowbridge, MD, PhD
Division of Dermatology/Department of Medicine, VA Medical Center/UCSD, San Diego, California (18)

Hensin Tsao, MD
Assistant Professor, Department of Dermatology, Harvard Medical School/Massachusetts General Hospital, Boston, Massachusetts (92, 196)

Sandy Tsao, MD
Instructor in Dermatology, MGH Dermatology Laser Center, Massachusetts General Hospital, Harvard Medical School, Boston, Massachusetts (218)

Erwin Tschachler, MD
Professor of Dermatology, Ludwig Boltzmann Institute for Venero-Dermatological Infections/Department of Dermatology, University of Vienna Medical School, Vienna, Austria (224, 226)

Maria L. Chanco Turner, MD
Dermatology Branch, National Cancer Institute, Bethesda, Maryland (140)

Jouni Uitto, MD, PhD
Professor and Chairman, Department of Dermatology and Cutaneous Biology, Director, Jefferson Institute of Molecular Medicine, Jefferson Medical College, Philadelphia, Pennsylvania (14, 15)

Robin Unger, MD
New York, New York (277)

Walter Unger, MD
Clinical Professor of Dermatology, Mt. Sinai School of Medicine, New York, New York (277)

Isabel C. Valencia, MD
Dermatology Fellow, Department of Dermatology and Cutaneous Surgery, University of Miami School of Medicine, Miami, Florida (243)

John J. Voorhees, MD
Duncan and Ella Poth Distinguished Professor and Chair, Department of Dermatology, University of Michigan Medical Center, Ann Arbor, Michigan (244)

Susan L. Walker, PhD
Department of Environmental Dermatology, Guy's, King's and St. Thomas' School of Medicine, London, England (134)

John S. Walsh, MD
Assistant Professor of Dermatology, Mayo Clinic Jacksonville, Jacksonville, Florida (153)

Ken Washenik, MD, PhD
Clinical Assistant Professor of Dermatology; Director of Dermatopharmacology, The Ronald O. Perelman Department of Dermatology, New York University Medical Center, New York, New York (242, 249, 256)

Arnold N. Weinberg, MD
Professor of Medicine, Infectious Disease Unit, Massachusetts General Hospital, Boston, Massachusetts (193, 194, 196, 197, 199)

Martin A. Weinstock, MD, PhD
Dermatoepidemiology Unit, VA Medical Center, Providence, Rhode Island (2)

Margaret A. Weiss, MD
Assistant Professor, Department of Dermatology, Johns Hopkins University School of Medicine, Hunt Valley, Maryland (273)

Robert A. Weiss, MD

Assistant Professor, Department of Dermatology, Johns Hopkins University School of Medicine, Hunt Valley, Maryland (273)

C. Bruce Wenger, MD, PhD
Research Pharmacologist, Military Performance Division, US Army Research Institute of Environmental Medicine, Natick, Massachusetts (10)

Richard J. Wenstrup, MD
Professor of Pediatrics, Division of Human Genetics, Cincinnati Children's Hospital Medical Center, Cincinatti, Ohio (154)

Victoria P. Werth, MD
Associate Professor of Dermatology, University of Pennsylvania, Chief, VA Dermatology, Philadelphia, Pennsylvania (166, 253)

Ifor R. Williams, MD, PhD
Assistant Professor of Pathology, Emory University School of Medicine, Atlanta, Georgia (26)

David C. Wilson, MD
Central Virginia Dermatology, Inc., Forest, Virginia (239)

Mary E. Wilson, MD
Chief of Infectious Diseases; Director, Travel Resource Center, Division of Infectious Diseases, Mount Auburn Hospital, Cambridge, Massachusetts (236)

Robert J. Winchester, MD
Director, Division of Autoimmune and Molecular Diseases, Professor of Pediatrics, Medicine and Pathology, Columbia University College of Physicians and Surgeons, New York, New York (43, 182)

Karen Wiss, MD
Associate Professor of Dermatology and Pediatrics; Director, Pediatric Dermatology, University of Massachusetts Memorial Medical Center, Worcester, Massachusetts (213)

Klaus Wolff, MD, FRCP
Professor and Chairman, Department of Dermatology, University of Vienna Medical School, Vienna General Hospital, Vienna, Austria (4, 23, 69, 94, 98, 104, 200, 264, 266)

Elizabeth Ch. Wolff-Schreiner, MD
Associate Professor of Dermatology, University of Vienna, Vienna, Austria (56, 57)

Gary S. Wood, MD
Geneva F. and Sture Johnson Professor; Chairman, Department of Dermatology, University of Wisconsin Medical School, Madison, Wisconsin (47, 159)

David T. Woodley, MD
Division of Dermatology, LAC and USC Medical Center, Los Angeles, California (66)

Mina Yaar, MD
Professor of Dermatology, Department of Dermatology, Boston University School of Medicine, Boston, Massachusetts (144)

Kim B. Yancey, MD
Professor and Chair, Department of Dermatology, Medical College of Wisonsin, Milwaukee, Wisconsin (62, 142)

John M. Yarborough, Jr., MD
Tulane University School of Medicine, New Orleans, Louisiana (270)

Antony R. Young, PhD
Department of Environmental Dermatology, Guy's, King's and St. Thomas' School of Medicine, London, England (134)

Benjamin D. Yu, MD
Instructor in Dermatology, Department of Dermatology, University of California San Francisco, San Francisco, California (173)

Stuart H. Yuspa, MD
Chief, Laboratory of Cellular Carcinogenesis and Tumor Promotion; Deputy Director, Center for Cancer Research, National Cancer Institute, Bethesda, Maryland (36)

Huiquan Zhao, MD, PhD
Clinical Geneticist and Pediatrician, Department of Pediatrics, Kaiser Permanente Fontana Medical Center, Fontana, California (154)

Matthew T. Zipoli, MD
Department of Dermatology, University of Minnesota, Minneapolis, Minnesota (194)

PREFACE

The editors and contributors are proud to present to our readers this sixth edition of *Fitzpatrick's Dermatology in General Medicine (DIGM),* a work that has become recognized as a classic medical textbook. Classics often are known by the name of the person most instrumental in their development, and through its past five editions *Fitzpatrick's* (or just *Fitz,* as the text is often called) has become a worldwide resource for physicians, scientists, students, and, in increasing numbers, patients interested in the skin and its diseases. Although the excellence for which *DIGM* is known has come from the input of many clinicians and investigators throughout the world, the driving force for the initial development of the concept and the person who brought *DIGM* to fruition was Thomas B. Fitzpatrick, MD, PhD, Wigglesworth Professor of Dermatology Emeritus at Harvard Medical School. Dr. Fitzpatrick has devoted almost all of his professional energy to bringing dermatology and cutaneous biology into the center of medicine and science throughout the world. He has worked diligently to ensure that the medical and scientific progress made since he first conceived the idea of *DIGM* more than four decades ago was translated rapidly to dermatology. This work remains a testament to his vision.

During the second half of the twentieth century, the period of dermatologic progress covered by the six editions of *DIGM,* great strides have been made in clinical dermatology. It has been our intent to define and document those advances in this sixth edition for our dermatologic colleagues, as well as for the physicians and surgeons of other specialties for whom changes on the skin of their patients are important. Although much has changed over the past decades, the concept for and the purpose of the book remain the same—to provide an all-encompassing, state-of-the-art review of dermatology and to describe the biologic basis for diseases of the skin. Although *DIGM* is truly encyclopedic, it has been edited with the goal of making the entire text easily readable and useful.

The 280 chapters are grouped into 37 sections covering all aspects of the science and clinical care of the skin in health and disease. Fifty new contributors have participated in this edition, many of the chapters are completely new, and a large number of the others have been completely rewritten. Disorders thought to be of only historic importance, such as anthrax and variola, are now central to our twenty-first century world; they are discussed both as dermatologic diseases and as potential agents of mass destruction. Our understanding of disease and pathophysiology has led to novel therapeutic agents such as botulinum toxin, which has proven to be of value in many diverse situations. Thus, the sixth edition of *Dermatology in General Medicine* clearly reflects the complexities and the great potential of our age.

Since complete integration of the basic and clinical sciences is the *DIGM* signature, many new approaches to the biology, structure, and function of the skin are offered in detail. We have introduced a new section on evidence-based dermatology and have expanded the portion of the text dealing with dermatologic changes through the stages of life. Essentially all of the illustrative material is now in full color, and charts and diagrams have been redrawn for ease of interpretation. The therapeutic sections have all been updated to encompass the most recently introduced types of biologic therapy. The progress that has been made in dealing with HIV infection, the scourge of our generation, is clearly described.

We are indebted to the members of our families for their support and for the time with us that they gave up so that *DIGM* could reach all of you. Our thanks to the dedicated staff members at our institutions who helped so much with this edition, to the skilled professionals who participated in the process, including Arlene Stolper Simon, who has assisted in editing the last four editions, and to the McGraw-Hill team, especially Darlene Cooke and Peter Boyle.

Irwin M. Freedberg
Arthur Z. Eisen
Klaus Wolff
K. Frank Austen
Lowell A. Goldsmith
Stephen I. Katz

March 2003

NOTICE

Medicine is an ever-changing science. As new research and clinical experience broaden our knowledge, changes in treatment and drug therapy are required. The editors and the publisher of this work have checked with sources believed to be reliable in their efforts to provide information that is complete and generally in accord with the standards accepted at the time of publication. However, in view of the possibility of human error or changes in medical sciences, neither the editors nor the publisher nor any other party who has been involved in the preparation or publication of this work warrants that the information contained herein is in every respect accurate or complete, and they disclaim all responsibility for any errors or omissions or for the results obtained from use of the information contained in this work. Readers are encouraged to confirm the information contained herein with other sources. For example and in particular, readers are advised to check the product information sheet included in the package of each drug they plan to administer to be certain that the information contained in this work is accurate and that changes have not been made in the recommended dose or in the contraindications for administration. This recommendation is of particular importance in connection with new or infrequently used drugs.

Chapter 1

Karl Holubar Stella Fatovic-Ferencic

Where Have We Come From?

REFERENCES

Readily visible alterations of the skin surface have been recognized since the dawn of history. Some were treated; some were not. The equilibrium of the body's humors was considered routinely; the skin was seen as an excretory organ through which bad humors became visible and were drained to the outside world, purifying the body. Skin lesions were believed to have social or even religious significance. Egyptian papyri, Biblical sources, mummies, and classical antiquity attest to this view. *Itching* and changes in *skin color* rank prominently among the abnormalities described. Modern attempts to identify such abnormalities as those representing eczema, leprosy, psoriasis, and similar diseases inevitably fail because the changes represent *inclusive* terms into which half of our latter-day dermatology might well fit. Twenty-five centuries have passed since the apogee of the Hippocratic school, and only very slowly have clinical descriptions improved to the point where they can be identified with disease entities as we know them. Over these many years, medicine and its underlying theories have changed considerably, and yet skin diseases continue to be attributed to divine punishment or personal or ancestral sin.

Little by little, the concepts of *holistic* medicine and *humoral* pathology gave way to organ pathology; the first disease entities were considered, and clinical bedside teaching became a compulsory program in medical school curricula. The enlightenment period eventually brought about the first attempts to systematize and categorize diseases. Clinical observation triumphed, the first therapeutic trials were conducted, scientific periodicals sprang up, and regular exchanges between scientists developed at national and international levels. Balloons lifted humans into the air, ships sailed to the remotest corners of the earth, and good maps became available. The French Revolution was the cogent harbinger of change, and the Napoleonic wars washed away much of the old and opened avenues for medicine as we know it. *Percussion, auscultation,* and local and general *anesthesia* made their appearance, and surgery and “medicine” slowly merged, only to be split up later into the so-called specialty disciplines, dermatology being among the first. It is 200 years since the *first great school of dermatology* became a physical reality and Alibert was entrusted with the directorship of the famous Hôpital Saint-Louis in Paris (1801). The *first textbooks* (Willan's, 1798–1808) and *atlases* (Alibert's, 1806–1814) appeared in print at that time. Skin diseases were described by *individual lesions* (Plenck, 1776), and skin was considered to be an *organ* (Lorry, 1777). Special skin clinics and hospitals were opened.

The *name of the specialty* originated in the form of the (semantically wrong) words *dermologie* (in French, 1764) and, a little later, *dermatologia* (in Latin, 1777). Almost a full century passed before the term *dermatology* was integrated into the various national languages of Europe and was used to identify appointments, departments, and university chairs. Earlier, *diseases of the skin, maladies de la peau, Haut-Krankheiten, malattie della pelle,* and the like were standard. *Dermatopathologia* appeared in 1792 but found its proper use only one century later (Unna's book, 1894). Many journals were founded before the mid-nineteenth century but did not survive. The oldest to continue into our time is the Italian journal, founded in 1866. *Dermatologic societies* began in 1869 (New York Dermatological Society). The American Dermatological Association (ADA) followed in 1876. The first *International Congress of Dermatology* was held in Paris in 1889. The *International League of Dermatological Societies* was formed in Budapest in 1935 and serves as the governing body of world dermatology.

The history of dermatopathology is a century-long story from the early and prophetic thoughts of Henry Seguin Jackson to the first textbook by Unna. The first forays into skin pathology, albeit largely conceptual and semantic, were conducted by Jackson (1792), Gilbert Breschet (1835), and Julius Rosenbaum (1839). Their efforts stalled; both the optical instruments and the cutting and staining techniques were not yet sufficiently developed. Full fruition required several more generations and the hard work and talents of Auspitz, Brocq, Darier, Gans, and Lever.

In the 1930s, two lines of development interacted, one *political*—political on the level of dermatologic organizations and political on the world level—and the other *conceptual*—a shift in emphasis from the purely clinical to investigative dermatology. The interaction, which Rudolf Baer called “revolutionary,” began in the United States with three important events that occurred in close succession—the formation of the *American Board of Dermatology* (1932), the foundation of the *Society of Investigative Dermatology* (SID, 1937), and founding of the *American Academy of Dermatology* (AAD, 1938). “Giants” (Baer's word again) like Donald Pillbury, Stephen Rothman, and Marion Sulzberger guaranteed success. On the world scene, and as a consequence of racism, fascism, and Nazism in Europe, Jewish doctors were eliminated—particularly dermatologists, because they constituted the highest percentage in the field and were at the heart and helm of the specialty. Thousands were forced to leave or were killed. This enormous brain drain deprived Europe and dermatology of great strength and enriched the transatlantic regions. The dermatologic center of gravity shifted to America, where this enormous injection of brain power soon made itself felt. Immigrants seldom come with the legal right to practice medicine, a fact that resulted in concentration of the talents of the new arrivals in research areas. American dermatology up to then had concerned itself largely with the clinical, but henceforth the *functional aspect* came to the fore, and *investigative dermatology* was born. From the late 1930s to Stephen Rothman and his classic textbook in 1954 and the contributions of Montagna, the disciplines of histochemistry and cytochemistry were applied to dermatology, and eventually cutaneous immunopathology and molecular biology came into their own.

Meanwhile, Europe took decades to recover. In 1973, the *European Society for Dermatological Research* (ESDR) was

founded as a counterpart to the SID, and the *Japanese Society for Investigative Dermatology*(JSID) was founded in 1975. Slowly, a triumverate of research centers emerged—the United States, Europe, and Japan—and regular tricontinental meetings were instituted in support of their dermatologic investigational activities.

The revelation of the function of the Langerhans cell illustrates extremely well the change in the direction of dermatology that took place within the last quarter of the twentieth century. An erstwhile “effete” melanocyte destined to be shed as a useless pensioner within the epidermis, the Langerhans cell moved to the center stage in the research arena with the discovery of its role as the key figure in the elicitation of skin sensitization and immunization. With proper identification of the antigens on “our” cells, dermatology moved to the very center of tissue typing, confirming at last the conviction of Leon Battista Alberti, Donatello, and other humanists of fourteenth and fifteenth century Italy that every individual is singular and special.

Genetics and the human genome, the background for all that we are and stand for, constitute the latest areas of investigation, inseparably linked to the potential capability of altering the preceding singularity, for better or for worse. Many investigators have provided us with discoveries and revelations that are overwhelming. What genetics and genetic engineering have in store for us remains shrouded in the mist of the future.

REFERENCES

The following references are general treatises on the history of dermatology in English, French, German, and Spanish, plus the chapter of the preceding edition of *Dermatology in General Medicine* and the semicentennial issue of the *Journal of Investigative Dermatology* (for the convenience of readers of different ethnic backgrounds and maternal languages). For more specific references and information, we encourage readers to turn to the Web sites of the American History of Dermatology Society (HDS, http://www.dermato.med.br/hds/) and the French Society for the History of Dermatology (SFHD, http://www.bium.univ-paris5.fr/histmed/debut.htm), which also leads to the European Society for the History of Dermatology and Venereology (ESHDV).

1. Crissey JT, Parish LC: *The Dermatology and Syphilology of the Nineteenth Century.* New York, Praeger, 1981

2. Crissey JT et al: *An Historical Atlas of Dermatology and Dermatologists.* Park Ridge, NJ, Parthenon, 2002

3. Beerman H, Lazarus GS: *The Tradition of Excellence.* Philadelphia, Beerman & Lazarus, 1986

4. Shelly W, Shelley DE: *CMD Congressus Mundi Dermatologiae.* Park Ridge, NJ, Parthenon, 1992

5. Tilles G: *La naissance de la dermatologie (1776–1980).* Paris, éditions Roger Dacosta, 1989 (in French)

6. Scholz A: *Geschichte der Dermatologie in Deutschland.* Berlin, Springer, 1999 (in German)

7. Sierra Valentí X: *Cien años de dermatología 1900–2000.* Madrid, Biblioteca Aula Medica, 2001 (in Spanish)

8. Fifty years of investigative dermatology (semi-centennial issue). *J Invest Dermatol* **92**(suppl):1S–198S, 1989.

9. The Editors: Dermatology in the perspective of general medicine, in *Dermatology in General Medicine,* 5th ed. New York, McGraw-Hill, 1999, pp 3–5

10. Holubar K, Wallach D: History of dermatology: A bicentennial perspective, in *Dermatology in General Medicine,* 5th ed. New York, McGraw-Hill, 1999, pp 5–7

T>

Chapter 2

Martin Weinstock Mary-Margaret Chren

The Epidemiology and Burden of Skin Disease

TYPES OF EPIDEMIOLOGIC STUDIES
BIAS AND CONFOUNDING
CAUSAL INFERENCE
INVESTIGATION OF DISEASE OUTBREAKS
DESCRIPTIONS OF DISEASE IN POPULATIONS: MEASURES OF DISEASE BURDEN
Other Measures of Morbidity: Conceptual Issues
Other Measures of Morbidity: Issues in Quantification
Impairment
Disability
Handicap and Quality of Life
Utilities
Costs
QUALITY OF CARE IN DERMATOLOGY

REFERENCES

Scientists in health-related fields may focus on different levels. For laboratory scientists, the focus is on phenomena at the molecular, cellular, or organ-system level; for clinical scientists, the focus is on the patient; and for public health practitioners, the focus is on the population. Epidemiology is the basic science of public health.

Epidemiology has many subdivisions and offshoots. Often the *epidemiology of a disease* in a clinical review refers primarily to its frequency and distribution in the population and estimates of the morbidity and mortality of that disease. These data are derived by *descriptive* epidemiology. Case-control, cohort, and cross-sectional studies may seek to identify risk factors and causes of disease and form the core of *analytical* epidemiology. Evaluations of public health interventions (*experimental* epidemiology) constitute the third major branch of *classic epidemiology*. The basic principles of epidemiology have found broad application in many areas, including understanding the public health implications of naturally occurring and synthetic compounds (*molecular epidemiology*), the complex interactions of genetic and environmental factors in disease (*genetic epidemiology*), the formulation of better diagnostic and treatment strategies for patients based on available evidence (*clinical epidemiology*), and the structuring of health care delivery for better outcomes and greater efficiency (*health services research*). The reader is referred to other volumes for a more detailed discussion of dermatoepidemiology. [1], [2]

TYPES OF EPIDEMIOLOGIC STUDIES

Three of the many types of epidemiologic studies are mentioned here because of their prominence in epidemiologic research. The randomized, controlled trial is a particularly rigorous type of study appropriate to the evaluation of public health interventions. In general, the intervention is performed on a random sample of the study population, and the entire study population is then observed for the occurrence of the outcome in question. The random assignment of intervention allows the more rigorous application of many statistical techniques and reduces the potential for bias. It is the elimination of many biases that particularly supports the general assumption that these studies more accurately evaluate the efficacy and impact of the intervention than trials that do not assign the intervention condition randomly. Standards have been published [3] and adopted by leading dermatology journals to improve assessment of their validity and their use in subsequent systematic reviews [4] (see Chap. 240).

When evaluating risk factors for disease, it is frequently impossible to assign the risk factor randomly. Hence inference is based on observational studies. In classical cohort studies, a group with exposure to the risk factor and a group without are chosen and observed over time. Occurrences of the study outcome are counted and compared between groups. Although more vulnerable to bias than randomized trials, in cohort studies exposure to the risk factor is known well before the study outcome is knowable, so some potentially serious biases are avoided. In a cohort study, the incidence of the study outcome can be measured directly in each group, and the relative risk can be measured directly as the ratio of the incidence between the two groups.

Cohort studies often are quite expensive to conduct because they require following a large population over time and may be impossible if the outcome being studied is uncommon. Hence observational studies often use the case-control approach, where cases with the outcome being studied and appropriate controls are investigated to determine their past exposure to the risk factor. Relative risks generally can be estimated by this approach, although incidence of the disorder cannot. Readers are referred to standard texts for more detail regarding epidemiologic study designs. [5] Case-control and cohort study methods in dermatology also have been reviewed. [6], [7] and [8]

BIAS AND CONFOUNDING

The problem with inference from observational studies is that one may be led to draw erroneous conclusions. In particular, an association that is found between an exposure and a disease may be an artifact due to one or more of the many forms of bias or confounding. Proper inference regarding cause and effect requires understanding of these possible artifacts and their potential impacts. [9]

Selection bias occurs when factors that lead to selection of the study population affect the likelihood of the outcomes or exposures evaluated. For example, a case-control study of cutaneous lymphoma may recruit its cases from sources that typically include a high proportion of referred patients. If controls are recruited from a local clinic population, their socioeconomic status and location of residence may be substantially different from those of the cases simply due to the method of recruitment. Under these circumstances, an association of cutaneous lymphoma with occupation may be noted. It then becomes important to note that the observed association may be due not to a carcinogenic chemical in the workplace but rather to the method by which cases and controls were selected. Similarly, if one were conducting a cohort study of the effect of breast feeding on the risk of atopic dermatitis, it would be important to select breast-fed and bottle-fed infants from similar environments.

Information bias occurs when the assessment of exposure or outcome may differ between the groups being compared. People who were exposed to a publicized environmental toxin may be more likely to seek care for minor symptoms or signs (and hence be more likely to be diagnosed and treated) than those who were not so exposed, even if the exposure had no biologic effect. Similarly, people who are diagnosed with a disease may be more likely to recall past exposures than healthy controls.

Confounding occurs when an observed association (or lack thereof) between exposure and disease is due to the influence of a third factor on both the exposure and the disease. For example, people who use sunscreens may be the ones who have the most intense sun exposures, and intense sun exposure is one cause of melanoma. Hence observational studies may mistakenly conclude that sunscreen use is a cause of melanoma when the observed association is due to sunscreen use serving as an indicator of a lifestyle involving intense sun exposure.

CAUSAL INFERENCE

Key issues in the public health arena often must rely on observational data for inferring cause and effect. The criteria for assessment in these circumstances require careful examination of both the validity and generalizability of the individual studies and of the totality of the evidence. The following criteria generally are applied for causal inference when an association is found. Although they are described for inferring causality between an exposure and a disease, they are more generally applicable to epidemiologic causal inference.

Time sequence. The exposure must precede the disease. This is simple and obvious in the abstract but sometimes difficult to establish in practice because the onset of disease may precede the diagnosis of disease by years, and the timing of exposure is often not well defined.
Consistency on replication. Replication of the observed association is key and provides the strongest evidence if the replications are many and diverse and with consistent results. The diversity of the replications refers to varied contexts as well as to study designs with different potential weaknesses and strengths.
Strength of association. True causal relationships may be strong (i.e., high relative risk) or weak, but artifactual associations are unlikely to have a high relative risk. If the association between factors x and y is due to the association of both with confounding variable z, the magnitude of the association between x and y always will be less than the magnitude of the association of either with z.
Graded association. Also described as *biologic gradient,* this criterion refers to an association of the degree of exposure with occurrence of disease, in addition to an overall association of presence of exposure with disease. This dose-response relation may take many forms, since degree of exposure may, for example, refer to intensity, duration, frequency, or latency of exposure.
Coherence. Coherence refers to plausibility based on evidence other than the existence of an association between this exposure and this disease in epidemiologic studies. Coherence with existing epidemiologic knowledge of the disease in question (e.g., other risk factors for the disease and population trends in its occurrence) and other disorders (including but not limited to related disorders) supports inference. Coherence with existing knowledge from other fields, particularly those relevant to pathogenesis, is critically important when those fields are well developed. It may involve direct links, which are preferred, or analogy. Just as observations in the laboratory assume greater significance when their relevance is supported by epidemiologic data, the reverse is equally true.
Experiment. Experimental support is critical when feasible. The strongest inferences derive from results of randomized trials, although other experimental designs and quasi-experimental designs may contribute useful evidence.

More detailed discussions of these issues are available. [10], [11]

INVESTIGATION OF DISEASE OUTBREAKS

Although outbreaks of disease vary tremendously, use of a standard framework for investigation is important to address the public health issues efficiently. The Centers for Disease Control and Prevention has described this framework as a series of 10 steps, which are described in more detail elsewhere. [12]

1. *Preparation*. Before initiating fieldwork, background information on the disease must be gathered, and appropriate interinstitutional and interpersonal contacts should be made.
2. *Confirm the outbreak*. Publicity, population changes, or other circumstances may lead to an inaccurate perception that more cases than expected have occurred. Hence local or regional data should be sought to confirm the existence of an increased frequency of disease.
3. *Confirm the diagnosis.* Symptoms and signs of persons affected should be determined and laboratory findings confirmed, perhaps with the assistance of reference laboratories.
4. *Establish a case definition, and find cases.* Careful epidemiologic investigation will involve precise and simple case definitions that can be applied in the field. Efforts to find and count additional cases beyond those reported initially is key to defining the scope of the outbreak.
5. *Establish the descriptive epidemiology.* The cases can now be characterized in terms of *time,* including development of an epidemic curve that describes the changes in magnitude of the outbreak; *place,* including

mapping the distribution of cases; and *person,* the demographic and potential exposure characteristics of cases.

6. *Develop hypotheses.* On the basis of the data gathered in steps 1 through 5 and the input of other individuals, plausible hypotheses can be developed for further evaluation.
7. *Conduct analytical epidemiologic investigations.* If the data gathered do not yet clearly prove a hypothesis, cohort and case-control investigations can be conducted to verify or disprove the hypotheses.
8. *Revise hypotheses and obtain additional evidence as needed.* Steps 6 and 7 are repeated, each building on prior iterations, in order to establish the causal chain of events.
9. *Implement control measures.* As soon as the causal chain of events is understood, prevention and control measures are initiated.
10. *Communicate results.* An outbreak investigation is not complete until the results have been appropriately communicated to the relevant communities.

DESCRIPTIONS OF DISEASE IN POPULATIONS: MEASURES OF DISEASE BURDEN

No single number can describe the burden of skin disease because that burden has many dimensions and because the term *skin disease* itself is rather ambiguous. Many disorders with substantial morbidity or mortality, such as melanoma or lupus erythematosus, affect multiple organ systems. The degree of skin involvement may vary widely from patient to patient and within the same patient from time to time. Diseases not typically treated by dermatologists, such as the thermal burns, often are excluded from estimates of the burden of skin disease even though they primarily involve the skin. In addition, some diseases treated most often by dermatologists may be classified in a different category by funding agencies or others [e.g., melanoma is classified as an oncologic disorder as opposed to dermatologic disorder by the National Institutes of Health and by the *International Classification of Diseases,* 9th revision (ICD-9), even though it almost always arises in the skin]. Organ systems are interrelated, and the overlap is sufficiently great that any definition of skin disease is necessarily arbitrary, and any estimate of the public health burden of these diseases is therefore open to challenge.

Mortality is a critical measure of disease impact. Death certification is universal in the United States, and the ICD code of the underlying cause of each death is recorded. For the year 1998, there were 14,080 deaths reported as due to “skin disease” in the United States, of which most were due to melanoma (Table 2-1). Additional major causes included other skin cancers (primarily keratinocyte carcinomas), infections of the skin, and skin ulcers (primarily decubitus ulcers). Bullous disorders represented about 1 percent of these deaths. The total number of skin disease deaths, of course, depends critically on the definition of skin disease, as noted earlier.

Cancers	10,740
Melanoma	7,431
Genital	1,040
Lymphoma	122
Other cancers (primarily basal and squamous cell carcinoma)	2,059*
Ulcers	1,851
Bacterial infections	985
Bullous disorders	122
Other causes	420
TOTAL	14,080

*We estimate that approximately half of these are misclassified squamous cell carcinomas arising from mucosal surfaces in the head and neck.**

SOURCE: Centers for Disease Control Web site. Available at: www.cdc.gov (verified January 15, 2001).

TABLE 2-1 **Skin Disease Deaths, United States, 1998**

In addition to the total number of deaths, mortality typically is expressed as an age-adjusted rate to facilitate comparisons among populations with different age distributions. Statements of age-adjusted rates of mortality (or anything else that is standardized by age) should be accompanied by an indication of the standard used in the adjustment to avoid potentially misleading inferences. For example, when 1998 melanoma mortality rates are estimated using the 2000 U.S. population standard, the result is 50 percent higher than if the 1940 U.S. standard population is used (1.8 versus 1.2 per 100,000 per year for women and 4.1 versus 2.7 per 100,000 per year for men). Sometimes *years of potential life lost* (YPLL) is also measured, and here again, the reader must be wary of different definitions that may be applied. In one analysis, a decline in mortality from melanoma was noted by one definition that was not observed with another. [13]

Careful analyses of mortality include assessment of the validity of the data. Melanoma mortality statistics appear to be reasonably accurate. [14], [15] However, deaths from keratinocyte carcinomas are overestimated by a factor of 2 (mostly due to the erroneous inclusion of mucosal squamous cell carcinomas of the head and neck region), [16] and deaths from cutaneous lymphoma are underestimated by about 40 percent. [14]

Incidence refers to the number of new cases of a disorder. Mortality is low for most skin diseases; hence incidence may be a more useful measure for the assessment of burden of disease. However, many features of skin diseases make their incidence difficult to measure. For example, for many skin disorders there are no diagnostic laboratory tests, and in fact, some disorders may evade physician diagnosis (e.g., allergic reactions). Incidence for reportable communicable diseases in the United States is published periodically based on reports to health departments, although underreporting of skin diseases due to failure to present for medical care or to misdiagnosis is a concern (Table 2-2). Incidences of melanoma and cutaneous lymphoma also have been published based on data from a system of nationwide cancer registries, yet underreporting remains a potential concern with these data. [17], [18] Special surveys have been conducted to estimate incidence of other disorders such as keratinocyte carcinomas, although a system of sentinel registries would be required for nationwide assessment. [19] For some diseases unlikely to evade medical detection due to their severity, such as toxic epidermal necrolysis, efforts to estimate incidence have met with considerable success. [20], [21] Specific contexts that permit more accurate incidence estimates include the workplace, for example, where occupational skin disease is a prevalent problem. [22]



TABLE 2-2 **New Cases of Selected Reportable Diseases in the United States**

Cohort patterns of changes in mortality or incidence typically are observed when exposures determined in childhood predict frequency of disease throughout the life span. A classic example is melanoma mortality, for which sun exposure in childhood is an important determinant. A birth cohort is defined as the group of individuals born within a defined (e.g., 10-year) period. Melanoma mortality generally increases as a power function of age within a birth cohort. Until recent decades, each successive birth cohort had higher risk than its predecessor; hence the curves of mortality versus age were shifted upward. Thus the cross-sectional relationship of mortality versus age and the increase in mortality risk during most of the twentieth century followed a cohort pattern. For many countries in the past several decades we have seen a decline in melanoma mortality in the younger age groups despite an increase in older age groups, suggesting a lower baseline in these mortality versus age curves for recent cohorts and hence a likely future decline in overall melanoma mortality.

Prevalence refers to the proportion of the population affected by a disorder. Since many skin diseases are nonlethal yet chronic, prevalence is a particularly important measure of frequency in dermatology. Population-based data on prevalence of skin disease for the United States were obtained in the first Health and Nutrition Examination Survey, which was conducted in the early 1970s. [23] Despite its limitations, this study was notable because the sample was representative of the general U.S. population, the number surveyed was large (over 20,000), and the entire surveyed population was examined by physicians (primarily dermatology residents), so the resulting estimates were not dependent on patients' ability or inclination to seek medical care. Indeed, one of the findings of the survey was that nearly one-third of those examined had one or more skin conditions judged to be significant enough to merit a visit to a physician. The most common conditions and their age- and gender-specific prevalences are indicated in Table 2-3 and Fig. 2-1. A similar survey in the United Kingdom of over 2000 Lodoners in 1975 noted that almost one-quarter of adults had a skin condition serious enough to warrant medical care. [24] Other efforts have focused on obtaining prevalence estimates of specific conditions with special surveys (e.g., see refs. [25] and [26]).

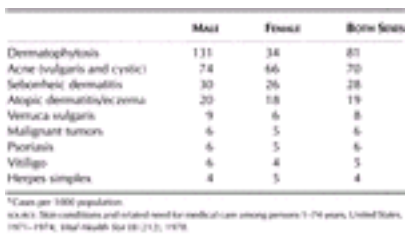

	Male	Female	Both Sexes
Dermatophytosis	131	34	81
Acne (vulgaris and cystic)	74	66	70
Seborrheic dermatitis	30	26	28
Atopic dermatitis/eczema	20	18	19
Verruca vulgaris	9	6	8
Malignant tumors	6	5	6
Psoriasis	6	5	6
Vitiligo	6	4	5
Herpes simplex	4	5	4

*Cases per 1000 population.
SOURCE: Skin conditions and related need for medical care among persons 1–74 years, United States, 1971–1974, Vital Health Stat 11(213), 1978.

TABLE 2-3 **Prevalence of Skin Conditions—United States, 1971–1974***

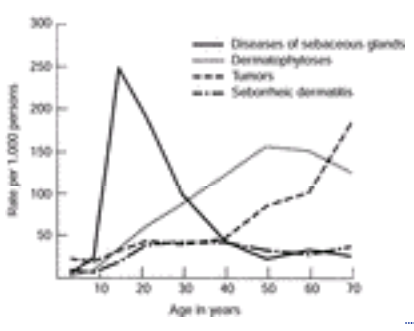

FIGURE 2-1 Prevalence rates for the four leading types of significant pathology among persons 1 to 74 years, by age, in the United States, 1971–1974.

Lifetime risks for certain disorders are quoted commonly, although their validity can be questioned. Lifetime risk can be measured only in retrospect, and even then it reflects competing causes of mortality in addition to incidence. It is commonly quoted for disorders such as cutaneous malignancies that are changing substantially in incidence, yet those changes are frequently ignored in its calculation, and in any case, projections of future changes are quite speculative and may be quite misleading.

Number of physician visits for a condition is one practical measure of its frequency that may reflect its incidence, prevalence, and severity, as well as access to health care. Table 2-4 lists frequencies of dermatologist and other physician outpatient visits for some of the most common skin conditions. A feature of using this measure of disease frequency is its direct relation to expenditures for care of the disease.



TABLE 2-4 **Visits to Nonfederal Office-Based Physicians in the United States, 1998**

Other Measures of Morbidity: Conceptual Issues

The consequences of skin disease for a population may be difficult to describe because these conditions most often do not affect survival, and the most important gauges of disease status and progression are the physical examination and patients' reports, which are difficult to measure and compile. The World Health Organization has classified the effects on patients of nonfatal diseases into three dimensions. [27] *Impairment* due to disease refers to loss of an anatomic structure or of a physiologic or psychological function. For example, psoriasis can cause thickening and scaling of the palms. *Disability* is restriction on normal performance of an activity due to impairment. Disability from psoriasis may include the loss of ability to use one's hands easily because of skin thickening and scale. Disability may lead to *handicap,* which refers to its consequences for an individual; for example, loss of hand function from psoriasis may render a pianist or dishwasher unable to perform his or her livelihood.

Interpreting and using measures of handicap for groups of persons is complex due to differences in perceptions, expectations, and values. These differences may be related to sociodemographic variables such as age, access to health care, and cultural conceptions of health. For this reason, some have argued that for assessing burden of disease, disability is a more appropriate construct to measure than handicap because it is less prone to cultural differences that might lead to inequities in allocation of resources. [27] A crucial point for skin diseases is that a patient's experiences other than disability are important to a determination of the value patients place on disease effects. For example, experiences such as social stigma and effects of disease on mood may be significant effects of skin diseases that are visible and affect appearance. [28] Thus the measurement and in particular the comparative valuation of nonfatal consequences of disease—and their significance for national policymaking—are controversial. This debate has important implications for dermatology as global health needs, resource allocation, and cost-effectiveness are assessed with single-item metrics that are used for empirical ranking of disease burden. [29], [30]

Related to these effects of diseases on patients is the concept of *quality of life,* which refers to the physical, functional, psychological, and social health of the individual. [31] As defined, quality of life includes disability and handicap from a disease and is an important measure of the morbidity of skin conditions, which may cause disfigurement and thus affect patients emotionally as well as physically. Finally, *utility* is a numeric measure of the value a patient attaches to a given health state compared with other health states. This metric is important for the calculation of cost-effectiveness, in which the costs of treatments are compared with the values of the health states they make possible.

Other Measures of Morbidity: Issues in Quantification

Like all assays, measures of the nonfatal consequences of diseases must have certain characteristics of accuracy. [32] For example, they must be *reliable* in that the variability in results among subjects who truly differ should be greater than the variability when a stable subject is examined repeatedly. The measures must have evidence of *validity,* which refers to the extent to which an instrument measures what it is supposed to measure and does not measure something else. Finally, health outcome measures also must demonstrate *responsiveness,* the ability to detect clinical change. In general, the accuracy of measures of disease status and morbidity in dermatology has not been evaluated adequately. [33], [34] Furthermore, even when a validated instrument exists, the clinical significance of scores or changes in scores often cannot be judged until the tool is used widely and scores are available for many patients with disease of varying severity. Finally, a significant challenge is developing a consensus among dermatologists about the specific clinical features of an individual disease that are important to include in such measures. For example, criteria for clinically important improvement have been developed for some rheumatologic conditions [35] that, like skin diseases, are chronic and are best assessed using clinical rather than laboratory criteria.

Impairment

The extent to which a specific skin disease disrupts the skin itself is related both to the percentage of body surface area involved and to physical signs of the eruption such as the amount of induration and the degree of scale. Given the pleomorphism of skin eruptions and lesions, most dermatologic severity-of-disease measures are disease-specific. Among the most studied instruments to measure clinical severity of disease are the Psoriasis Area and Severity Index (PASI) [36] and the Severity Scoring of Atopic Dermatitis (SCORAD) index. [37] With the PASI, severity of disease is assessed by judgment of the degree of involvement of four body regions with signs of erythema, induration, and desquamation. The SCORAD index combines an assessment of disease area with six clinical signs of disease intensity (scales to measure pruritus and sleep loss also can be included). These instruments share certain problems; for example, estimates of body surface area are often unreliable, [38] and many investigators (and patients) may not agree that the selected clinical signs represent the important features of disease severity.

Disability

Disease-induced restrictions in the ability of a patient to perform normal activities have been measured for specific skin diseases such as psoriasis. A prototypical instrument is the Psoriasis Disability Index (PDI). [39] The PDI asks patients to rate the effects of their psoriasis on specific aspects of their functioning (e.g., daily activities, work or school, personal

relationships, leisure). The PDI has important measurement properties such as validity and responsiveness to change and has been used not only as an outcomes measure in clinical trials but also as a model for measuring disability from other conditions.

Handicap and Quality of Life

Substantial progress has been made in the development and testing of quality-of-life instruments for patients with skin diseases. Several generic instruments exist that are applicable to patients with dermatologic disease of any sort. [40], [41] and [42] Data continue to be accumulated about the performance of these instruments and the interpretation of their scores. An important conclusion from these studies is that correlations between the quality-of-life effects of skin diseases and their clinical severity as assessed by physicians are modest at best and may in fact be quite low. This finding is also typical of many nondermatologic diseases and implies that a comprehensive assessment of patients with skin disease should include measurement of clinical severity as well as its effects on quality of life. [43]

Utilities

In the measurement of utilities, a variety of procedures are used (such as visual analogue scales and time tradeoff exercises) to assign a numerical value (or utility) to health states. This value reflects patients' preferences for the health states, where 1.0 represents perfect health and 0.0 represents death. With utilities, improvements in morbidity and mortality can be combined into a single weighted metric. Few studies have formally measured utilities of patients with skin diseases, although the approach is feasible [44], [45] and has been used for comparing cost-effectiveness of therapies for psoriasis. [46]

Costs

Measurement of costs of skin disease depends on the perspective from which they are measured, since the costs to insurers and patients may be quite different from the overall cost to society. Because most skin diseases are chronic and are cared for in the outpatient setting, estimation of both their monetary and intangible costs is difficult. There are no recent studies of the direct or indirect cost of dermatologic diseases and their care overall. Costs have been estimated, however, for individual diseases. The treatment costs to Medicare of keratinocyte carcinoma (basal cell and squamous cell carcinomas of the skin) in 1995 were estimated to be approximately $285 million, which represented 0.7 percent of the Medicare budget. [47] The direct costs of treating newly diagnosed melanoma in 1997 were estimated at $563 million. [48] The costs of diseases not treated surgically are even more difficult to estimate because valid estimates of drug costs are not widely available. For example, the treatment of acne in the United States generates over 6 million prescriptions annually for oral medications alone, and the total yearly cost of acne likely exceeds $1 billion. [49] /SUP>Costs also depend on the processes of delivering health care and the technology used. For example, the trend toward increased use of sentinel lymph node biopsies and adjuvant chemotherapy for localized melanoma may increase the costs associated with this disease substantially.

QUALITY OF CARE IN DERMATOLOGY

Health services research uses many of the scientific methods from epidemiology, clinical epidemiology, and the quantitative social sciences to study and improve the quality of health care. From the perspective of health services research, the processes involved in the provision of health care, as well as the particular therapeutic interventions and patient and provider characteristics, are all potentially important determinants of the results (*outcomes* in terms of mortality, morbidity, and cost) of the provision of health care. Dermatologic health services research is still new; much attention has focused on improved outcomes of health care, [50] although the results of well-done clinical trials should inform the process of care as well. [51] Many of the examples cited earlier demonstrate a sharpened focus in dermatology on accurate measurement of the clinical encounter. This capacity to measure the progress of chronic diseases and their care will permit rigorous efforts to evaluate and improve the quality of that care.

REFERENCES

1. Williams HC, Strachan DP, eds: *The Challenge of Dermatoepidemiolog* Boca Raton, FL, CRC Press, 1997
2. Weinstock MA, ed: *Dermatoepidemiolog*. Philadelphia, Saunders, 1995
3. Begg C et al: Improving the quality of reporting of randomized controlled trials: The CONSORT statem *JAMA* **276**:637, 1996
4. Weinstock MA: The JAAD adopts the CONSORT statement *J Am Acad Dermato* **41**:1045, 1999
5. Gordis L: *Epidemiology* Philadelphia, Saunders, 2000
6. Karagas MR: When subjects are not randomly assigned: The cohort approac *J Cutan Med Surg* **2**:90, 1997
7. Heacock HJ, Rivers JK: Assessing scientific data: The case-control study as it applies to dermatology. Part I. The case-control metl *J Cutan Med Surg* **1**:151, 1997
8. Heacock HJ, Rivers JK: Assessing scientific data: The case-control study as it applies to dermatology. Part 2. Interpreting the res *J Cutan Med Surg* **2**:35, 1997
9. Sackett DL: Bias in analytic research *J Chron Dis* **32**:51, 1979
10. Susser M: *Causal Thinking in the Health Sciences: Concepts and Strategies of Epidemiolo* New York, Oxford University Press, 1973
11. Hill AB: Environment and disease: Association or causatior *Proc R Soc Med* **58**:295, 1965

12. Centers for Disease Control Web site. Available a http://www.cdc.gov/excite/classroom/outbreak_steps.htm#ste. Accessed January 15, 2003

13. Weinstock MA: Epidemiology of melanoma, i *Current Research and Clinical Management of Melanom* edited by L Nathanson Boston, Kluwer Academic, 1993, pp 29–56

14. Weinstock MA, Reynes JF: Validation of cause of death certification for outpatient cancers: The contrasting cases of melanoma and mycosis fungo *Am J Epidemio* **148**:1184, 1998

15. Percy C et al: Accuracy of cancer death certificates and its effect on cancer mortality statisti *Am J Public Healtl* **71**:242, 1981

16. Weinstock MA et al: Inaccuracies in certification of nonmelanoma skin cancer deatl *Am J Public Healtl* **82**:278, 1992

17. Jemal A et al: Recent trends in cutaneous melanoma incidence among whites in the United Sta *J Natl Cancer Ins* **93**:678, 2001

18. Weinstock MA, Gardstein BA: Twenty-year trends in the reported incidence of mycosis fungoides and associated mort *Am J Public Healtl* **89**:1240, 1999

19. Weinstock MA: Overview of ultraviolet radiation and cancer: What is the link? How are we doi *Environ Health Perspec* **103**(suppl 8):251, 1995

20. Roujeau JC et al: Toxic epidemiomal necrolysis (Lyell syndrome): Incidence and drug etiology in France, 1981–1 *Arch Dermato* **126**:37, 1990

21. Rzany B et al: Epidemiology of erythema exsudativum multiforme majus, Stevens-Johnson syndrome, and toxic epidermal necrolysis in Germany (1990–1992): Structure and results of a population-based registry *J Clin Epidemio* **49**:769, 1996

22. Dickel H et al: Occupational skin diseases in Northern Bavaria between 1990 and 1999: A population-based stu *Br J Dermato* **145**:453, 2001

23. Johnson M-LT, Roberts J: *Skin Conditions and Related Need for Medical Care Among Persons 1–74 Years, United States, 1971–* (DHEW Publication No. PHS 79-1660). Hyattsville, MD, National Center for Health Statistics, 1978

24. Rea JN et al: Skin disease in Lambeth: A community study of prevalence and use of medical c *Br J Prevent Soc Mea* **30**:107, 1976

25. Foley P et al: The frequency of common skin conditions in preschool-age children in Australia: Atopic dermat *Arch Dermato* **137**:293, 2001

26. Brandrup F, Green A: The prevalence of psoriasis in Denmar *Acta Derm Venereo* **61**:344, 1981

27. Murray CJL: *The Global Burden of Disease: A Comprehensive Assessment of Mortality and Disability from Diseases, Injuries, and Risk Factors in 1990 and Projected to 2 020.* Cambridge, MA, Harvard University Press, 1996

28. Ustun TB et al: Multiple-informant ranking of the disabling effects of different health conditions in 14 countries. WHO/NIH Joint Project CAR Study Gr *Lancet* **354**:111, 1999

29. Arnesen T, Nord E: The value of DALY life: Problems with ethics and validity of disability adjusted life ye *Br Med J* **319**:1423, 1999

30. Gross CP et al: The relation between funding by the National Institutes of Health and the burden of disea *N Engl J Mea* **340**:1881, 1999

31. Testa MA, Simonson DC: Assessment of quality-of-life outcome *N Engl J Mea* **334**:835, 1996

32. Chren MM: Giving “scale” new meaning in dermatology: Measurement matte *Arch Dermato* **136**:788, 2000

33. Marks R et al: Assessment of disease progress in psoriasis *Arch Dermato* **125**:235, 1989

34. Charman C, Williams H: Outcome measures of disease severity in atopic eczem *Arch Dermato* **136**:763, 2000

35. Ward MM: Response criteria and criteria for clinically important improvement: Separate and equ *Arthritis Rheum* **44**:1728, 2001

36. Fredriksson T, Pettersson U: Severe psoriasis: Oral therapy with a new retinc *Dermatologica* **157**:238, 1978

37. Kunz B et al: Clinical validation and guidelines for the SCORAD index: Consensus report of the European Task Force on Atopic Derma *Dermatology* **195**:10, 1997

38. Tiling-Grosse S, Rees J: Assessment of area of involvement in skin disease: A study using schematic figure outlir *Br J Dermato* **128**:69, 1993

39. Finlay AY, Kelley SE: Psoriasis: An index of disabilit *Clin Exp Dermato* **12**:8, 1987

40. Finlay AY, Khan GK: Dermatology life quality index (DLQI): A simple practical measure for routine clinical u *Clin Exp Dermato* **19**:210, 1994

41. Chren MM et al: Improved discriminative and evaluative capability of a refined version of Skindex, a quality-of-life instrument for patients with skin dise *Arch Dermato* **133**:1433, 1997

42. Chren MM et al: Measurement properties of Skindex-16: A brief quality-of-life measure for patients with skin disea *J Cutan Med Surg* **5**:105, 2001

43. Kirby B et al: Physical and psychologic measures are necessary to assess overall psoriasis seve *J Am Acad Dermato* **45**:72, 2001

44. Lundberg L et al: Quality of life, health-state utilities and willingness to pay in patients with psoriasis and atopic ecze *Br J Dermato* **141**:1067, 1999

45. Zug KA et al: Assessing the preferences of patients with psoriasis: A quantitative, utility approa *Arch Dermato* **131**:561, 1995

46. Chen S et al: Cost-effectiveness and cost-benefit analysis of using methotrexate versus Goeckerman therapy for psori *Arch Dermato* **134**:1602, 1998

47. Joseph AK et al: The period prevalence and costs of treating nonmelanoma skin cancers in patients over 65 years of age covered by Med *Dermatol Surg* **27**:955, 2001

48. Tsao H et al: An estimate of the annual direct cost of treating cutaneous melanon *J Am Acad Dermato* **38**:669, 1998

49. Stern RS: Medication and medical service utilization for acne 1995–19 *J Am Acad Dermato* **43**:1042, 2000

50. Chren MM: Quality of care in dermatology: The state of (measuring) the ε *Arch Dermatol* **133**:1349, 1997

51. Bigby M: Challenges to the hierarchy of evidence: Does the emperor have no cloth *Arch Dermatol* **137**:345, 2001

T>

Chapter 3

Margaret Stewart Jeffrey Bernhard Thomas Cropley Thomas Fitzpatrick

The Structure of Skin Lesions and Fundamentals of Diagnosis

APPROACH TO THE PATIENT
EXAMINATION OF THE SKIN, HAIR, NAILS, AND MUCOUS MEMBRANES
General Features of the Skin
General Features of the Hair and Nails
General Features of the Mucous Membranes
SKIN LESIONS
Types of Skin Lesions
Shape and Arrangement of Lesions
Distribution of Skin Lesions
PHYSIOLOGIC ABNORMALITIES
PRURITUS
INSTRUMENTAL AND LABORATORY PROCEDURES IN DERMATOLOGIC DIAGNOSIS
Aids to Dermatologic Diagnosis: Clinical, Instrumental, and Laboratory
Clinical Signs
Clinical Tests
Microscope Examination of Scales, Crusts, Serum, and Hair
Biopsy of the Skin

REFERENCES

> What is most difficult of all? It is what appears most simple: To see with your eyes what lies in front of your eyes. *
>
> **Goethe**

The diagnosis and treatment of diseases that affect the skin rest upon the physician's ability to use the lexicon of dermatology, to recognize the basic and sequential lesions of the skin, and to recognize the various patterns in which they occur in a large variety of diseases and syndromes. [1] The physician who recognizes a malignant melanoma, the rash of Rocky Mountain spotted fever, or the lesions of cutaneous vasculitis will save lives. The physician who fails to perceive cutaneous markers of systemic diseases, or who fails to recognize inconsequential or normal skin lesions for what they are, may fail to make an important diagnosis or subject patients to unwarranted, expensive, and potentially harmful diagnostic procedures.

The visibility and accessibility of the skin are at the root of the challenge and satisfaction of dermatologic diagnosis: there are a myriad of visible lesions and, consequently, a large number of recognizable syndromes and diseases. The general physical examination provides an opportunity to screen for cutaneous markers of systemic disease as well as for skin tumors, and in particular for malignant melanomas at their earliest—and curable—stages. [2], [3] Physicians, therefore, must learn to “read” the skin. Certain cutaneous markers, such as the hypomelanotic ash-leaf spot in tuberous sclerosis or necrolytic migratory erythema in glucagonoma syndrome, are signs as sensitive and specific as those seen in an ECG or an x-ray film of the chest.

Individual skin lesions (see Table 3-1 and Fig. 3-1, Fig. 3-2, Fig. 3-3, Fig. 3-4, Fig. 3-5, Fig. 3-6, Fig. 3-7, Fig. 3-8, Fig. 3-9, Fig. 3-10, Fig. 3-11, Fig. 3-12, Fig. 3-13, Fig. 3-14, Fig. 3-15 and Fig. 3-16) are analogous to the letters of the alphabet, and groups of lesions can be analogous to words or phrases. Pathologic changes affect various components of the skin (namely, epidermis, dermis, panniculus, and blood vessels). It is helpful to estimate the component of the skin that is *primarily* affected inasmuch as there is a finite number of disorders that produce pathologic changes in the various individual components.

Flat Lesion (Usually in the Plane of the Skin)	Elevated Lesion (Above the Plane of the Skin)	Depressed Lesion (Below the Plane of the Skin)
Macule	Papule	Atrophy
Infarct	Plaque	Sclerosis
Sclerosis	Nodule	Erosion
Telangiectasia	Wheal	Excoriation
	Vesicle and bulla	Scar
	Pustule	Ulcer
	Abscess	Sinus
	Cyst	Gangrene
	Exudate (crusts)	
	Scales	
	Scar	
	Lichenification	

TABLE 3-1 **Types of Skin Lesions**

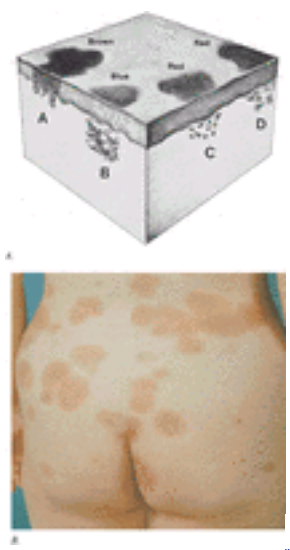

FIGURE 3-1 Macule. A macule is a circumscribed, flat lesion that differs from surrounding skin because of its color. Macules may have any size or shape. *A*. They may be the result of hyperpigmentation (A), hypopigmentation, dermal pigmentation (B), vascular abnormalities, capillary dilatation (erythema) (C), or purpura (D). Macules with very-fine scaling are called *maculosquamous,* as in tinea versicolor. *B*. The clinical appearance of an eruption that consists of multiple, well-defined red macules of varying size that blanch upon pressure (diascopy) and are thus due to inflammatory vasodilatation. This eruption represents a drug reaction.

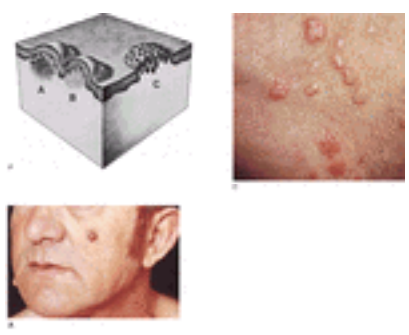

FIGURE 3-2 Papule. A papule is a small, solid, elevated lesion. Papules are generally smaller than 1 cm in diameter, and the major portion of a papule projects above the plane of the surrounding skin. *A*. Papules may result, for example, from metabolic deposits in the dermis (A), from localized dermal cellular infiltrates (B), and from localized hyperplasia of cellular elements in the dermis or epidermis (vegetation) (C). Papules with scaling are referred to as *papulosquamous* lesions, as in psoriasis. Clinical examples of papules are shown in: *B*. Two well-defined and dome-shaped papules of firm consistency and brownish color, which are dermal melanocytic nevi; *C*. multiple, well-defined, and coalescing papules of varying size are seen. Their violaceous color, glistening surface, and flat tops are characteristic of lichen planus.

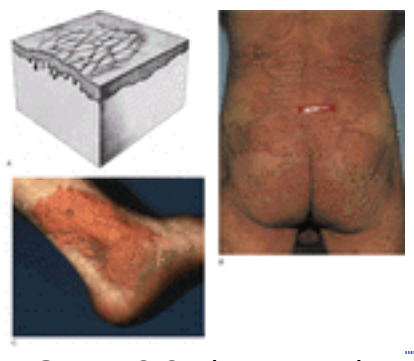

FIGURE 3-3 Plaque. A plaque, shown in the drawing (*A*), is a mesa-like elevation that occupies a relatively large surface area in comparison with its height above the skin surface. Well-defined, reddish, scaling plaques that coalesce to cover large areas of the back and buttocks are seen in (*B*). There is some regression in the center, as is typical for psoriasis. *Lichenification* (*C*) represents thickening of skin and accentuation of skin markings. The process results from repeated rubbing and frequently develops in persons with atopy; it can occur in eczematous dermatitis or other conditions associated with pruritus. Lesions of lichenification are not as well defined as most plaques are and often show signs of scratching, such as excoriations and crusts.

FIGURE 3-4 Nodule. A nodule is a palpable, solid, round or ellipsoidal lesion. Depth of involvement and/or substantive palpability rather than diameter differentiate a nodule from a papule. *A*. Nodules may be located in the epidermis (B) or extend into the dermis or subcutaneous tissue (A). *B*. This photograph shows a well-defined, firm nodule with a smooth and glistening surface through which telangiectasia (dilated capillaries) can be seen; there is central crusting indicating tissue breakdown and thus incipient ulceration (nodular basal cell carcinoma). *C*. Multiple nodules of varying size can be seen (melanoma metastases).

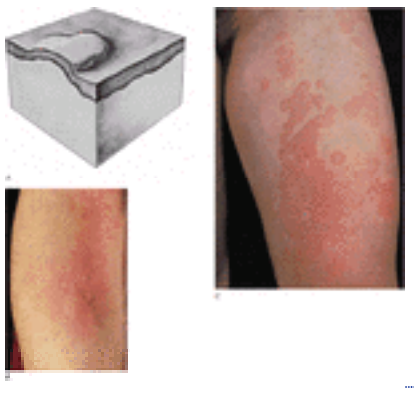

FIGURE 3-5 Wheal. A wheal (*A*) is a rounded or flat-topped papule or plaque that is characteristically evanescent, disappearing within hours. Wheals may be tiny papules 3 to 4 mm in diameter, as in cholinergic urticaria [shown in the clinical photograph (*B*)]. They may be large, coalescing plaques, as in allergic reactions to penicillin, other drugs, or alimentary allergens, as shown in (*C*). An eruption consisting of wheals is termed *urticaria* and usually itches.

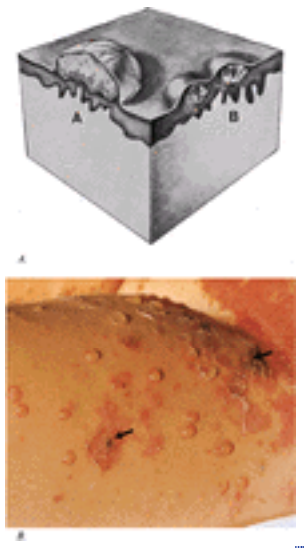

FIGURE 3-6 Vesicles and bullae are the technical terms for blisters. A vesicle is a circumscribed lesion that contains fluid. Shown in the drawing (*A*), subcorneal vesicles (A) result from fluid accumulation just below the stratum corneum. Spongiotic vesicles (B) result from intercellular edema. A bulla is a vesicle larger than 0.5 cm. The clinical photograph (*B*) shows multiple translucent subcorneal vesicles that are extremely fragile, collapse easily, and thus lead to crusting (*arrows*). These lesions represent staphylococcal impetigo. Leukocytes present within the vesicles sediment to the lowest portion of the subcorneal cavity when the patient is in an upright position.

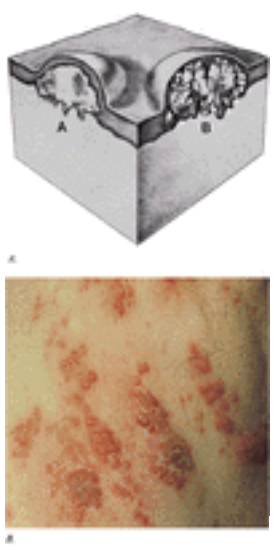

FIGURE 3-7 Vesicle. Shown in the drawing (*A*), acantholytic vesicles (A) result from cleavage within the epidermis due to loss of intercellular attachments. Balloon degeneration of epidermal cells leads to the formation of vesicles in certain viral infections (B), such as varicella-zoster. Vesicles characteristic of herpes zoster are shown in (*B*). They appear in crops and are grouped. Central umbilication can be seen in some of them.

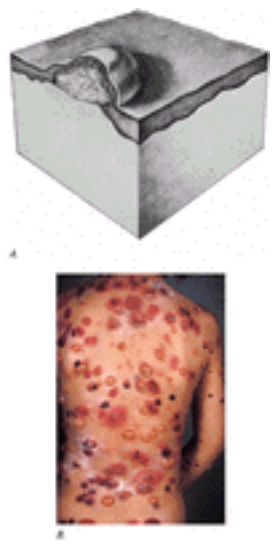

FIGURE 3-8 Vesicle. Subepidermal vesicles, as shown in the drawing (*A*), occur as a consequence of pathologic changes in the region of the dermal-epidermal junction. Subepidermal vesicles and bullae are seen in bullous erythema multiforme, porphyria cutanea tarda, epidermolysis bullosa, dermatitis herpetiformis, and bullous pemphigoid. The clinical photograph (*B*) demonstrates bullae in the latter condition. Some of them arise on normal and some on erythematous skin. Most of them are tense and filled with a serous or hemorrhagic fluid; some have collapsed and crusted.

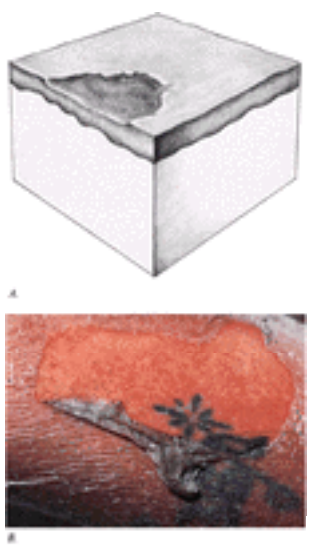

FIGURE 3-9 Erosion. An erosion, as shown in the drawing (*A*), is a moist, circumscribed, usually depressed lesion that results from loss of all or a portion of the viable epidermis. Erosions remain after the roofs of vesicles and bullae become detached. Erosions also develop after epidermal necrosis as in toxic epidermal necrolysis, shown in the photograph (*B*). They usually heal without scarring.



FIGURE 3-10 Pustule. A pustule is a papule that contains purulent exudate (*A*). Primary, nonfollicular pustules occur in pustular psoriasis (*B*). These very superficial, subcorneal pustules may coalesce to form lakes of pus.

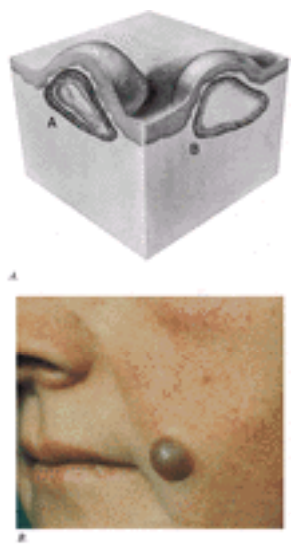

FIGURE 3-11 Cyst. A cyst is a sac that contains liquid or semisolid material (fluid, cells, cell products). A spherical or oval nodule or papule may clinically be suspected of being a cyst if, on palpation, it is resilient; the eyeball, for example, feels like a cyst. The most common cysts, shown in the drawing (*A*), are epidermal cysts (A), which are lined with squamous epithelium and produce keratinous material. Cysts of pilar origin that are lined with multilayered epithelium, which does not mature through a granular layer, are pilar cysts (B). The bluish, resilient cyst, shown in (*B*), represents a cystic adnexal tumor (cystic hidradenoma), which is filled with a mucus-like material.



FIGURE 3-12 Atrophy. Atrophy refers to a diminution or thinning of the skin. It may be limited to the epidermis or the dermis or may occur simultaneously in both. As shown in the drawing (*A*), epidermal atrophy (B) is manifested by a thin, almost transparent epidermis. Atrophic epidermis may or may not retain the normal skin lines. Dermal atrophy (A) results from a decrease in the papillary or reticular dermal connective tissue and is manifested as a depression in the skin. Atrophy of subcutaneous tissue may also lead to depressions in the skin surface. Marked dermal and epidermal atrophy is shown in the photograph (*B*). Loss of normal skin texture, thinning, and wrinkling are present.

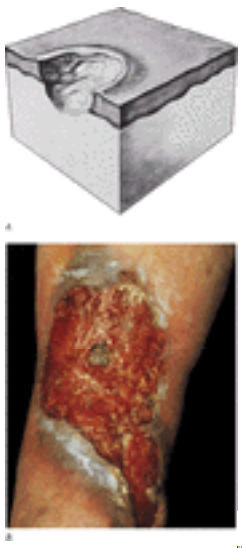

FIGURE 3-13 Ulcer. An ulcer, shown in (*A*), is the hole or defect that remains after an area of epidermis and at least part of the dermis have been destroyed or removed. Because the dermis is involved, ulcers heal with scarring. The clinical photograph (*B*) shows a gigantic ulcer with a red, granulating base and well-defined, punched-out borders.



FIGURE 3-14 Scar. A scar is the fibrous tissue replacement that develops as a consequence of healing at the site of a prior ulcer or wound. A scar may be hypertrophic (A) or atrophic (B), as shown in the drawing (*A*). A typical clinical example of a hypertrophic scar is shown in the photograph (*B*).

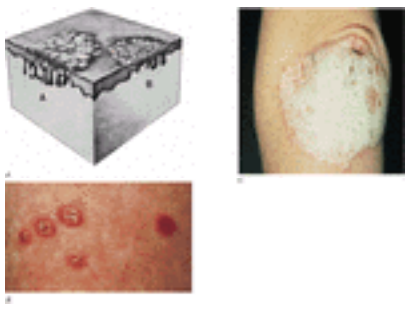

FIGURE 3-15 Desquamation. Abnormal shedding or accumulation of stratum corneum in perceptible flakes is called scaling and is shown in the drawing (*A*). Parakeratotic scale (with retained nuclei) may be seen surmounting psoriasiform epidermal hyperplasia (A). Densely adherent scale with a gritty feel from a localized increase in the stratum corneum is seen in actinic keratoses (B). Typical psoriatic scaling is shown in the photograph (*B*). Scales that adhere tightly to the underlying epidermis may build up to form an asbestos-like layer that obscures the underlying lesion, as in the psoriatic plaque shown in (*C*).

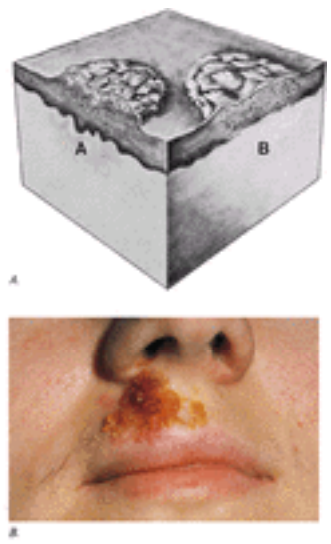

FIGURE 3-16 Crusts (encrusted exudates). Crusts result when serum, blood, or purulent exudate dries on the skin surface and are characteristic of injury and pyogenic infections. Crusts may be thin, delicate, and friable (A) or thick and adherent (B), as shown in the drawing (*A*). Crusts are yellow when formed from dried serum, green or yellow-green when formed from purulent exudate, or brown or dark red when formed from blood. Superficial crusts that occur as honey-colored, delicate, glistening particulates on the surface are typical of impetigo and are illustrated in the photograph (*B*).

Once the component of the skin affected by a pathologic process is determined to the extent possible by clinical examination, the lesion or lesions should be assessed in terms of their type, shape, arrangement, and distribution. These attributes are discussed fully later in this chapter. Furthermore, as in all other diseases, many skin conditions undergo a characteristic evolution: in many cases, definitive diagnosis may not be possible without the benefit of observation on more than one occasion. Finally, definitive diagnosis may require the information provided by a complete history, physical examination, laboratory tests, and histopathologic analysis.

APPROACH TO THE PATIENT

Dermatologists often prefer to examine the patient *before* obtaining the history and review of systems. [4] This preference is based on three important points. First, that diagnostic accuracy may be higher when visual examination is approached without preconceived ideas. [5], [6] This is also true in radiology. [7] Second, that preconceived notions have the power to truncate thinking and to eliminate important considerations from differential diagnosis (the “white bear syndrome”: when someone is told not to think about a white bear it is difficult to think about anything else). [8] The third is that some dermatologic lesions and eruptions are so distinctive that a history is not required to make a diagnosis. Some history must always be obtained, however, as misdiagnosis will certainly occur if the opportunity for corroboration of a clinical diagnosis is missed. In many instances, as in the case of a patient with fever and a rash, the complete history is obviously of major importance, but findings from the initial physical examination can be utilized to shape the way the history is obtained. The history, in turn, should provide direction for a subsequent and refined reexamination. In practice, many skilled clinicians obtain much of the history during the clinical examination of the patient.

In patients who present with a skin problem as the chief complaint, the cutaneous process is commonly so readily apparent that the physician's attention is easily diverted from the patient as a whole. This mistake must be avoided; the majority of patients with a “rash” should be approached in the same manner as a patient with a chief complaint of arthralgia or weight loss or dyspnea, when a general medical history is always essential.

The history of a dermatologic illness should include an exact description of the onset, a careful description of the first lesions, and the details of the development and extension of the lesions. In obtaining the history, careful questioning by the examiner is necessary to elucidate the relationship of the onset of the initial eruption or of recurrences to (1) the patient's *occupation;* (2) *treatment* obtained from a previous physician or self-administered; (3) the *diagnosis* such treatment was based on and how it was established; (4) the patient's experience with prescription and nonprescription *drugs;* (5) exposure to *sunlight* and *seasonal variations* (especially in temperate latitudes); (6) the *immediate environment,* including contact with plants, animals, chemicals, metal, and the like; (7) physiologic states such as

menses or *pregnancy;* and (8) *foods*.

Drugs, given orally or parenterally, are frequent causes of skin eruptions, and therefore the search for a history of drug ingestion or injection must be persistent and detailed (see Chap. 138). The importance of obtaining and recording an accurate medication history cannot be overstated. Drug eruptions usually develop rapidly, so recollection is often not that difficult.

Patients who complain about skin symptoms but who have no visible abnormality of the skin may fall into several categories. Some patients may have genuine organic disease with skin symptoms such as itching or pain. [9] For example, the so-called nonrash of pruritus (itching without visible skin lesions) may be an important sign of an underlying disorder such as thyrotoxicosis. [10] Other "nonrashes," which may range from delusions to dirt accumulated on the skin, have also been described. [11] Cotterill has described the syndrome of dermatologic nondisease, in which patients complain of symptoms such as itching, sweating, burning, excessive hair, or pain in localized areas such as the face, scalp, mouth, or perineum. Some of these patients have deranged body images (dysmorphophobia) and severe, potentially dangerous psychological disturbances. [12], [13] Cutaneous artifactual disease is another point at which dermatology and psychiatry intersect. [14] Also in the realm of "invisible dermatoses" are physiologic or pathologic abnormalities of the skin that may not be grossly apparent on clinical examination. [16]

EXAMINATION OF THE SKIN, HAIR, NAILS, AND MUCOUS MEMBRANES

The skin functions as a sensory organ; as an organ of metabolism that has synthesizing, excretory, and absorptive functions; as a protective barrier against the external environment; and as an important factor in temperature regulation. The clinical examination of the skin is partly an appraisal of these particular functions. In addition, however, the skin is synergistic with internal organ systems, and therefore, it reflects pathologic processes that are either primary elsewhere or shared in common with other tissues. The history of medicine suggests that diseases initially characterized as solely cutaneous (e.g., lupus erythematosus, dermatitis herpetiformis, and urticaria pigmentosa) have often subsequently been found to involve several systems.

Inasmuch as visual appreciation of skin lesions is the sine qua non of dermatologic diagnosis, the examiner's eye is undoubtedly the most important instrument at his or her disposal. Yet the standardization of this instrument is a subject that receives scant attention, even though there are surprising variations in physicians' reports of what has been seen. Furthermore, variability persists at every step of the diagnostic process, from description to differential diagnosis. The chances for correct recognition improve, of course, as the examiner gains familiarity with the various disorders of the skin. Even with experience, however, the greatest difficulty in diagnosis is often because of a failure to notice pertinent details from the available evidence.

Feinstein has challenged the tendency to favor laboratory tests that give numerical values as opposed to clinical observations. [17] He wrote that clinicians try to be scientific in the use of inanimate objects but not in the use of their own sensory organs and brain. They often believe that their own human equipment is a hindrance instead of an advantage, an apology rather than an incentive for science in clinical work. Feinstein emphasized the need for more attention to sick people and the human methods of evaluating them, not to inanimate technology. Furthermore, the ability to arrive at a diagnosis through the history and physical examination is probably the most ancient, perhaps defining, and often—from an intellectual point of view—most satisfying attribute of being a physician. Physical diagnosis *is an art, but no less a science because of it,* and nowhere is the *skill* of physical examination more crucial to accurate diagnosis than it is in dermatology.

The examination of the skin should be made in a well-lighted room with natural light, if possible, or a "daylight" type of lamp. When feasible, the patient should be gowned, and examined completely and systematically in sections or quadrants. Articles of clothing are hindrances during the examination and may even be responsible for the inadvertent concealment of large areas of the skin.

The examination should commence with a general assessment of the patient as a whole—a "low-power" scan of the skin surface, during which rapid stock is taken of the skin, nails, and mucous membranes. The survey should include an appreciation of the color, moisture, the turgor, odor and the texture of the skin. Clothing may give clues to the cause of a suspected contact dermatitis or parasitic infestation (e.g., pediculosis).

General Features of the Skin

COLOR Skin color represents an aggregate of the remitted and reflected light, the wavelengths of which depend largely on the presence of four biochromes. Two biochromes are in the epidermis: *melanin* (see discussion in Chap. 11), which is brown and has a broad absorption in the ultraviolet and visible light ranges, and *carotenoids,* which are yellow. Two other biochromes are in the dermis: *oxyhemoglobin,* which is bright red and is found largely in the arterioles and capillaries of the papillary layer, and *reduced hemoglobin,* which is bluish red and is found in the subpapillary venous plexus. The dermal connective tissue may also contribute to the "whiteness" of the skin in lightly pigmented persons. Greater detail on the role of carotenoids in the skin, as well as an in-depth discussion of ceruloderma (blue skin), can be found in Chap. 145 and Chap. 91, respectively.

General Features of the Hair and Nails

The distribution of the body hair, its texture, and amount should be noted as a part of the initial overall survey of the patient's skin, as should examination of the nails. The nails (see Chap. 72) can provide evidence of latent skin disease (psoriasis, lichen planus, alopecia areata, congenital ectodermal defect), as well as suggest the presence of renal or liver disease. Beau's lines (transverse indentations of the nails) and other variations on the theme of transverse white lines across the nails may be associated with a recent febrile or systemic illness, especially a renal or hepatic one.

Telangiectasia in the periungual skin is a frequent and important diagnostic finding in systemic lupus erythematosus and dermatomyositis. The hair and nails are discussed in greater detail in Chap. 71 and Chap. 72.

General Features of the Mucous Membranes (See Chap. 112, Chap. 113 and Chap. 114)

The initial general assessment of the patient must also include the oral, genital, and anal regions. The oral mucous membranes indicate the state of hydration and show pigmentary changes that can be racial traits or that may be helpful in the diagnosis of Peutz-Jeghers syndrome and Addison's disease. Among the many skin diseases that have mucous membrane manifestations are lichen planus, pemphigus, pemphigoid, herpes simplex, and erythema multiforme. The tongue may be red and smooth in various states of vitamin B deficiency. Soreness, as well as a beefy-red tongue, may be present as an initial complaint in pernicious anemia. The so-called black hairy tongue may be present as a relatively trivial problem, consisting of darkened, elongate filiform papillae that appear after the use of orally administered antibiotics or without any antecedent cause. The so-called geographic tongue consists of an irregular pattern of areas exhibiting absence of papillae; it may be associated with pustular and other varieties of psoriasis or it may be idiopathic. Lichen planus may be found on the tongue as linear white markings, sometimes in a netlike pattern. Oral thrush (moniliasis) occurs in diseases of altered immunity. Generalized monilial infections involving axillary, oral, periungual, and vaginal areas occur in the syndrome of mucocutaneous candidiasis and the syndrome of Addison's disease with hypoparathyroidism. Oral hairy leukoplakia occurs in HIV infection, often as an early sign.

SKIN LESIONS

Types of Skin Lesions (See Table 3-1)

The basic skin lesions (macules, papules, vesicles, plaques, etc.) are the essential elements upon which clinical diagnosis rests. To read words, one must recognize letters; to read the skin, one must recognize the basic lesions. To understand a paragraph, one must know how words are put together; to arrive at a differential diagnosis, one must know what the basic lesions represent and how they behave, how they are arranged and distributed, when they occur together, and how they evolve. To establish the diagnosis, one must be able to obtain the appropriate history and know when and how to perform appropriate diagnostic tests, such as a biopsy or cytologic preparation.

The lack of standardization of basic terminology has been one of the principal barriers to successful communication among physicians in describing skin lesions. For example, in standard dermatologic texts, the papule is variously described as no greater than 1 cm in size, less than 0.5 cm, smaller than a pea, or ranging from the size of a pinhead to that of a split pea; a nodule is designated as larger than a papule. These are, at best, haphazard standards of measurement, and until there is a more precise system the situation is likely to remain confusing. The International League of Dermatologic Societies has published a glossary of basic lesions that provides a helpful step in this direction. [18] At the very least, the metric ruler must be part of the standard examining apparatus for the skin so that accurate documentation of lesion size will be possible.

Often, identification of the *type* of primary lesion is enough to establish a diagnosis. In many instances, however, it is necessary to observe the evolution of individual lesions or of the eruption as a whole before a diagnostic pattern manifests itself. The evolution of individual lesions results in the formation of *sequential lesions.* Occasionally sequential lesions can be seen at the same time as primary ones. In chickenpox, for example, where new lesions occur in crops, erosions and crusted papules can be seen at the same time as new vesicles: this was helpful in the clinical differentiation of chickenpox from smallpox, in which lesions evolve simultaneously (see Chap. 219). Acral, tender erythematous papules that evolve into purpuric pustules are seen in disseminated gonococcemia. The evolution of an eruption results in a *pattern of spread*. In rubella, the rash involves the entire body within 1 day; in measles (rubeola), the rash takes 3 days to spread from the forehead and behind the ears to the rest of the body. In Rocky Mountain spotted fever, the pattern of spread is from the ankles and wrists, and then to the palms, soles, face, and center of the body surface.

The following *visual glossary* of current descriptive nomenclature is presented with some examples. No attempt has been made to make the examples exhaustive because more comprehensive guides are available. [19], [20] Table 3-1 lists the types of lesions to be discussed. A number of infrequently used terms are also defined within this section; others may be found in Leider and Rosenblum. [21]

MACULES (See Fig. 3-1) A *macule* is a circumscribed, flat lesion that differs from the surrounding skin because of its color. Macules may have any size or shape. They may be the result of hyperpigmentation, hypopigmentation, vascular abnormalities, capillary dilatation (*erythema*), or *purpura* (extravasated red blood cells). Some macular lesions are associated with fine scaling. Such scaling may become apparent only after *grattinage,* a combination of light scraping and scratching. We call some such lesions *maculosquamous:* they are not perceptibly raised and therefore cannot be considered plaques (see below). *Telangiectases* are permanent dilatations of capillaries that may or may not disappear with application of pressure. They form nonpulsatile, fine, bright red lines or netlike patterns on the skin. Telangiectases are commonly observed on faces of persons chronically exposed to the wind and sun. They are a prominent feature of the erythematous color noted in cutaneous lupus erythematosus. In addition, periungual telangiectases are an important marker for collagen vascular disorders such as lupus erythematosus and dermatomyositis. In hereditary hemorrhagic telangiectasia, the lesions are usually nonpulsatile, dull red, sharply outlined macules or papules, most commonly present on the tongue, lips, face, and fingers. Telangiectases are also a prominent feature of rosacea. Lesions caused by extravasated red blood cells are included under the term *purpura. Petechiae* are small, pinpoint purpuric spots that are often seen in thrombocytopenic states. *Ecchymoses* are larger, bruiselike purpuric lesions. *Suggillations* are swollen “black and blue” marks that are often the consequence of bruising or other injury. The application of pressure with two glass slides or an unbreakable clear lens (*diascopy*) on a red lesion is a simple and reliable method for differentiating redness due to vascular dilatation (erythema) from redness due to extravasated erythrocytes or erythrocyte products (purpura). If the redness remains under the pressure of the slide, the lesion is purpuric. An *infarct* is an area of cutaneous necrosis resulting from occlusion of blood vessels, as in vasculitis and bacterial embolism. Cutaneous infarcts have a variegated, dusky-red, grayish hue. They are irregularly shaped macules, sometimes depressed slightly below the plane

of the skin and often surrounded by a pink zone of hyperemia. They may be tender.

PAPULES A *papule* is a small, solid, elevated lesion (Fig. 3-2) generally smaller than a centimeter or so, and the major portion of a papule projects above the plane of the surrounding skin. *Oblique lighting with a flashlight in a darkened room is often necessary to detect slight elevation*. Papules may have a variety of shapes. They may be acuminate (pointed), as in miliaria rubra (prickly heat rash); surmounted with scale, as in secondary syphilis; dome-shaped, as in molluscum contagiosum; or flat-topped, as in lichen planus. Other features, such as color, are also important in the identification of papular lesions. Red papules are seen in psoriasis, often with a superimposed scale that produces bleeding when removed (Auspitz's sign). Papules with scaling are referred to as *papulosquamous lesions*. A copper color is noted in the lesions of secondary syphilis. Flat-topped papules with a violaceous hue are characteristic of lichen planus. The presence of fine, netlike white markings, called Wickham's striae, on the surface of the lesion provides further evidence for the diagnosis of lichen planus. Yellow papules are seen in xanthomatosis. Hemorrhagic or necrotic papules are noted in cutaneous vasculitis and meningococcemia. Purpuric papules— *palpable purpura*—are indicative of vasculitis until proved otherwise. Nevi and melanomas are often characterized by varying shades of red, brown, and black and must be differentiated from pigmented basal cell carcinomas, which often have a somewhat similar appearance. Basal cell carcinomas are waxy-smooth with raised, rolled telangiectatic borders. Rounded, skin-colored papules may be seen in adenoma sebaceum and amyloidosis. Molluscum contagiosum may be identified as a rounded, translucent papule with a central umbilication; when the papule is punctured, a rounded central “molluscum body” is noted. Pedunculated papules, darker than or the same color as normal skin, occur in neurofibromatosis. A papule or plaque may consist of multiple, small closely packed, projected elevations that are known as a *vegetation* (Fig. 3-2). Vegetations may be covered with thick dry scales, described as *keratotic* (as in verruca vulgaris), or may be soft and smooth (as in condyloma acuminatum). Seborrheic keratoses are common vegetative lesions, especially in older age groups. They may be yellowish, tan, brown, or black and often have a soft greasy surface. Dry, scaly vegetations occur in actinic keratoses. All erythematous papules should be examined by diascopy (discussed later in this chapter), inasmuch as a yellow-brown color appears in the papules found in a number of granulomatous disorders, and an erythematous papule that does not blanch on diascopy may be a sign of vasculitis (palpable purpura). Although certain eruptions may have both macular and papular components, we believe that the abused term *maculopapular* is a non sequitur, or, at best, an oxymoron, and we avoid using it for the sake of clear thinking and communication. [22]

PLAQUES A *plaque* is a mesalike elevation that occupies a relatively large surface area in comparison with its height above skin level (Fig. 3-3). Plaques are often formed by a confluence of papules, as in psoriasis. The typical psoriatic lesion is a raised, erythematous plaque with layers of silvery scale, often described as micaceous. Repeated rubbing, especially in people with chronic eczema, leads to areas of *lichenification*. Proliferation of keratinocytes and stratum corneum, in combination with changes in the collagen of the underlying dermis, causes lichenified areas of skin to appear as thickened plaques with accentuated skin markings (Fig. 3-3C). The lesions may resemble tree bark. The presence of atrophy, especially in the presence of erythema, scales, pigmentary changes, and follicular plugging, may suggest the diagnosis of cutaneous lupus erythematosus.

“PATCH” According to the *Oxford English Dictionary,* a patch is “a portion of any surface markedly different in appearance or character from what is around it.” The *O.E.D*. also states that a patch may be “a small well-defined area of the kin, etc. distinct in color or appearance.” Dermatologists have used this term in different ways: some restrict its use to the description of very large macules; others use it to refer to relatively thin but large plaques. In general, we feel that accurate description can almost always be better served by more precise terminology, such as large macule, thin and scaling plaque, etc.

NODULES (See Fig. 3-4) A *nodule* is a palpable, solid, round or ellipsoidal lesion. Depth of involvement and/or substantive palpability, rather than diameter, differentiate a nodule from a papule. Depending upon the anatomic component(s) primarily involved, nodules are of five main types: (1) epidermal, (2) epidermal-dermal, (3) dermal, (4) dermal-subdermal, and (5) subcutaneous. Epidermal nodules include, for example, keratoacanthoma, verruca vulgaris, and basal cell carcinoma. Epidermal-dermal nodules include certain compound nevi, malignant melanomas, invasive squamous cell carcinomas, and some lesions of mycosis fungoides. Examples of dermal nodules are lesions of granuloma annulare and dermatofibromas. Erythema nodosum and superficial thrombophlebitis are examples of dermal-subdermal nodules. Lipomas are subcutaneous nodules of adipose tissue. Nodules in the dermis and subcutis may indicate systemic disease and result from inflammation, neoplasms, or metabolic deposits in the dermis or subcutaneous tissue. For example, late syphilis, tuberculosis, the deep mycoses, xanthomatosis, lymphoma, and metastatic neoplasms all can present as cutaneous nodules. Erythema nodosum presents with tender, subcutaneous nodules on the legs, often as a manifestation of hypersensitivity. Foreign-body reactions, insect bites, and viral and bacterial infections are among other causes of nodular lesions. Because nodules may represent serious systemic disease, unidentified persistent nodules should always be biopsied and cultured. The terms *tuber* and *phyma* are less often applied and are synonyms for nodule. *Tumor* is a general term for any mass, benign or malignant, and is sometimes used to indicate a large nodule. A *gumma* is, specifically, the granulomatous nodular lesion of tertiary syphilis. It is always helpful to describe a nodule with measurements and with modifying adjectives such as hard, firm, soft, fleshy, warm, movable, fixed, painless. The surface of a nodule should also be described as, for example, smooth, keratotic, ulcerated, fungating. There has been some semantic confusion in distinguishing nodules from large papules and small tumors. Size is not a major consideration in the definition of nodule. For example, rheumatoid nodules, which are usually located over bony prominences, may be as small as 1 or 2 mm, or as large as several centimeters. In certain instances, more than one term may be satisfactory. In most cases, it is simply best to include measurements and descriptive terms that convey the important features of the lesion in question.

WHEALS A *wheal* is a rounded or flat-topped papule or plaque that is characteristically evanescent, disappearing within hours (Fig. 3-5). The epidermis is not affected: there is no scaling. The borders of a wheal, although sharp, are not stable and in fact move from involved to adjacent uninvolved areas over a period of hours. These lesions, also known as hives or urticaria, are the result of edema in the upper portion of the dermis. Wheals are pale red in color, but if the amount of edema is sufficient to compress superficial vessels, they may be white, especially in the center. Wheals may be tiny papules 3 to 4 mm in diameter, as in cholinergic urticaria, or giant erythematous plaques of 10 to 12 cm, as in some cases of urticaria caused by penicillin hypersensitivity. Wheals occur in many shapes: round, oval, serpiginous, annular (ring-shaped). Wheals can be seen as an allergic response to innumerable initiating agents, such as drugs and insect bites. Wheal-like lesions occur occasionally in dermatitis herpetiformis and bullous pemphigoid. The wheal produced in response to the stroking of a reddish-brown or brownish macule (Darier's sign) is pathognomonic of urticaria pigmentosa (mastocytosis). Stroking of the skin may produce wheals in some normal persons; this phenomenon is called *dermographism,* classified as one of the physical urticarias. When it is associated with significant itching, it is called *symptomatic* dermographism (see Chap. 116). *Angioedema* is a deep, edematous urticarial reaction that occurs in areas

with very loose dermis and subcutaneous tissue, such as the lip or scrotum. It may occur on the hands and feet as well, and may cause grotesque deformity. A careful search should be made for laryngeal edema, which may cause airway obstruction (see Chap. 117).

VESICLES AND BULLAE A *vesicle* is a circumscribed, elevated lesion that contains fluid (Fig. 3-6). Often the vesicle walls are so thin that they are translucent and the serum, lymph, blood, or extracellular fluid is visible. A vesicle with a diameter greater than 0.5 cm is a *bulla*. Vesicles and bullae arise from cleavage at various levels of the skin; the cleavage may be within the epidermis (i.e., intraepidermal vesication) (Fig. 3-6), or at or below the dermal-epidermal interface (i.e., subepidermal). Cleavage just beneath the stratum corneum produces a subcorneal vesicle or bulla (A in Fig. 3-6A), as in impetigo. Intraepidermal vesication may result from intercellular edema (spongiosis), as characteristically seen in delayed hypersensitivity reactions of the epidermis (e.g., in contact eczematous dermatitis) and in pompholyx. *Spongiotic vesicles* (B in Fig. 3-6A) may be detectable microscopically but may not be clinically apparent as vesicles. Loss of intercellular bridges, or desmosomes, is known as *acantholysis,* and this type of intraepidermal vesication (A in Fig. 3-7A) is seen in pemphigus vulgaris, where the cleavage is usually just above the basal layer. In pemphigus foliaceus, the cleavage occurs just below the subcorneal layer. Viruses cause a curious “ballooning degeneration” of epidermal cells (B in Fig. 3-7A), as in herpes zoster, herpes simplex, variola, and varicella. Viral bullae often have a depressed (“umbilicated”) center. Pathologic changes at the dermal-epidermal junction may lead to subepidermal vesicles and bullae (Fig. 3-8), as are seen in pemphigoid, bullous erythema multiforme, porphyria cutanea tarda, dermatitis herpetiformis, and some forms of epidermolysis bullosa. The thickness of the wall of a bulla may be estimated by its translucency and flaccidity. The amount of pressure required to collapse the lesion may help predict whether the bulla is intraepidermal or subepidermal. It has been said that a relatively large, tense bulla suggests pemphigoid, whereas a flaccid bulla suggests pemphigus. There is, however, no reliable means of distinguishing these two diseases except by histologic examination of the lesion and immunofluorescence.

EROSIONS An *erosion* is a moist, circumscribed, usually depressed lesion that results from loss of all or a portion of the viable epidermis (Fig. 3-9). After the rupture of vesicles or bullae, the moist areas remaining at the base are called erosions. Extensive areas of denudation due to erosions may be seen in bullous diseases such as pemphigus. Unless they become secondarily infected, erosions usually do not scar. If inflammation extends into the papillary dermis, an ulcer is present and scarring results, as in vaccinia and variola, and less often in herpes zoster and varicella.

PUSTULES AND OTHER PYODERMATOSES A *pustule* is a circumscribed, raised lesion that contains a purulent exudate (Fig. 3-10). Pus, composed of leukocytes with or without cellular debris, may contain bacteria or may be sterile, as in the lesions of pustular psoriasis. Pustules may vary in size and shape and, depending on the color of the exudate, may appear white, yellow, or greenish yellow. Follicular pustules are conical, usually contain a hair in the center, and generally heal without scarring. Pustules are characteristic of rosacea, pustular psoriasis, Reiter's disease, and some drug eruptions, especially those due to bromide or iodide. Vesicular lesions of some viral diseases (varicella, variola, vaccinia, herpes simplex, and herpes zoster), as well as the lesions of dermatophytosis, may become pustular. A Gram's stain and culture of the exudate from pustules should always be performed. A *furuncle* is a deep necrotizing form of folliculitis, with pus accumulation. Several furuncles may coalesce to form a *carbuncle*. An *abscess* is a localized accumulation of purulent material so deep in the dermis or subcutaneous tissue that the pus is usually not visible on the surface of the skin. It is red, warm, and tender. An abscess frequently begins as a folliculitis and is commonly a manifestation of cutaneous streptococcal or *Staphylococcus aureus* infection. A *sinus* is a tract leading from a suppurative cavity to the skin surface or between cystic or abscess cavities. A sinus near the rectum may be seen in rectal abscess, carcinoma of the bowel, or inflammatory bowel disease. Sinuses of the neck suggest actinomycosis, scrofula, branchial pouch, or dental sinus. Deep sinus tracts may occur in hidradenitis suppurativa and acne conglobata.

CYSTS A *cyst* is a sac that contains liquid or semisolid material (fluid, cells, and cell products). A spherical or oval nodule or papule may be suspected of being a cyst if, on palpation, it is resilient; the eyeball, for example, feels like a cyst. The most common cysts are *epidermal (keratinous) cysts* (A in Fig. 3-11A), which are lined with squamous epithelium and produce keratinous material. Cysts of pilar (hair follicle) origin that are lined with multilayered epithelium that does not mature through a granular layer are called *pilar cysts* (B in Fig. 3-11A).

ATROPHY *Atrophy* refers to a diminution in the size of a cell, tissue, organ, or part of the body. Epidermal atrophy refers to thinning of the epidermis and is associated with a decrease in the number of epidermal cells (B in Fig. 3-12A). Atrophic epidermis may be almost transparent and may or may not retain the normal skin lines. Epidermal atrophy is often associated with alterations in the dermis as well. Senile skin, especially in sun-exposed areas, retains its normal skin lines, exhibits a fine wrinkling, and is somewhat transparent; the deep veins and yellow tendons are easily discernible. Preceding injury or inflammation (e.g., discoid lupus erythematosus) may also cause epidermal atrophy with an “ironed out” appearance and loss of the skin markings. Dermal atrophy results from a decrease in the papillary or reticular dermal connective tissue and is usually manifested as a depression of the skin (A in Fig. 3-12A). Dermal atrophy may follow inflammation or trauma with or without ulceration and is also seen after chronic application of fluorinated topical steroids. In dermal atrophy occurring without epidermal atrophy, the area of skin is normal in color and markings because the circumscribed depression is produced only by the decrease in dermal tissue. Dermal atrophy may occur with epidermal atrophy, as in the striae of pregnancy, Cushing's disease, or necrobiosis lipoidica; in the latter condition, there are loss of skin markings, increased translucence, and localized depression of the skin. Atrophy is noted in morphea-like basal cell carcinoma, chronic discoid lupus erythematosus, scleroderma, dermatomyositis, and chronic radiodermatitis. If atrophy takes place in the panniculus, depressions of the skin may occur, as in liquefying panniculitis, lipogranulomatosis, progressive lipodystrophy, and poststeroid injections.

ULCERS An *ulcer* is a “hole in the skin” in which there has been destruction of the epidermis and at least the upper (papillary) dermis (Fig. 3-13). Features that are helpful in determining the cause of ulcers and that must be considered in describing them include location, borders, base, discharge, and any associated topographic features of the lesion or surrounding skin, such as nodules, excoriations, varicosities, hair distribution, presence or absence of sweating, and adjacent pulses (see Chap. 167). Stasis ulcers are accompanied by pigmentation and, occasionally, by edema or sclerosis. They most commonly begin on the medial aspect of the ankle or lower leg. Hypertensive or ischemic ulcers tend to start on the lateral aspect of the ankle or foot. Factitial ulcerations often have “artificial” shapes, including straight, angular borders. Excoriations that have enlarged into ulcers give a similar appearance but may show the residua of an underlying dermatosis (e.g., eczematous dermatitis associated with chronic venous insufficiency). Pyoderma gangrenosum has purplish, raised, and undermined ragged borders and may be associated with ulcerative colitis or a number of other internal disorders. Decubitus ulcers occur at pressure points. Ulceration can occur as a result of tissue infarction in areas of large- or small-vessel occlusion or constriction due to various etiologic factors: embolus; thrombosis; ergot poisoning; cryoagglutinins, cryofibrinogenemia, or cryoglobulinemia; polyarteritis; macroglobulinemia; thrombotic thrombocytopenic purpura; polycythemia; generalized Arthus' reaction (purpura fulminans); sepsis; Raynaud's

phenomenon; arteriosclerosis obliterans; Wegener's granulomatosis; [23] and calciphylaxis. [24] Ulceration occurs in granulomatous nodules of various types due to deep fungi, tuberculosis, syphilis, and yaws, as well as in a variety of parasitic and bacteriologic disorders. Nodules adjacent to ulcerations suggest granulomatous or neoplastic disease. Neoplasms may become necrotic and ulcerated, generally as a result of small-vessel obliteration by the proliferating tumor.

SCAR A *scar* occurs wherever a wound or ulceration has taken place and reflects the pattern of healing in the affected area. Scars may be hypertrophic (A in Fig. 3-14A) or atrophic (B in Fig. 3-14A). They may be sclerotic, or hard, as a consequence of collagen proliferation. The scarred epidermis is thin, generally without normal skin lines and without appendages (B in Fig. 3-14A). A depressed scar may resemble a primary atrophic process (see Chap. 105). Scars may occur in the course of acne, some porphyrias, herpes zoster, and varicella. Raynaud's disease, syphilis, tuberculosis (especially on the face), leprosy, or carcinoma may produce *mutilations,* or a loss of tissue that alters major anatomic structures.

SCLEROSIS *Sclerosis* refers to a circumscribed or diffuse hardening or induration in the skin; it is detected more easily by palpation than by inspection. Sclerosis is a component of morphea, linear scleroderma, systemic scleroderma, and porphyria cutanea tarda. It often occurs in chronic stasis dermatitis and chronic lymphedema. Sclerosis may result from dermal or subcutaneous edema, cellular infiltration, or collagen proliferation.

CALCINOSIS *Calcinosis* of the dermis or subcutaneous tissue (e.g., in dermatomyositis and scleroderma) may be felt as *hard* nodules or plaques, with or without visible alteration of the skin surface.

SCALE, DESQUAMATION (SCALING) (See Fig. 3-15) Abnormal shedding or accumulation of stratum corneum in perceptible flakes is called scaling. Under normal circumstances the epidermis is completely replaced approximately every 27 days. The end product of this holocrine process of keratinization is the cornified cell of the outermost layer of the skin—the stratum corneum. The cornified cell is packed with filamentous proteins, normally does not contain a nucleus, and is usually lost imperceptibly. When keratinocyte production occurs at an increased rate, as in psoriasis, immature keratinocytes that retain nuclei reach the skin surface—this is called *parakeratosis*. Parakeratotic cells may pile up and contribute to the formation of *scales*. In psoriasis, scales may appear in thin, mica-like (micaceous) sheets, or accumulate massively, suggesting the appearance of an oyster shell (ostraceous scale). Densely adherent scales that have a gritty feel like sandpaper are typically seen in solar keratosis. Fishlike scale occurs in a group of disorders known as *ichthyoses,* in some of which prolonged retention of the stratum corneum occurs, even though it is produced at a normal rate. Scaling lesions also occur in dermatophyte infections, pityriasis rosea, secondary and tertiary syphilis, and in a large number of conditions in which abnormal keratinization and/or exfoliation of epithelial cells occur. To the well-trained eye, not all scales are equal, and the expert dermatologist will often obtain diagnostically useful information from close examinations of the type of scale present. Siemens [4] describes the following types of scale: pityriasiform (branny); psoriasiform (brittle platelets of several loose layers); ichthyosiform (like fish scales); cuticular and lamellar (thin, relatively large flakes); membranous or exfoliative (large sheets, peeling); keratotic (composed of horny masses); granular (like small grains); hystrix-like (from the Greek for porcupine); scale formations that appear as little horns; and follicular scale, which may occur as keratotic plugs, spines, filaments, or lichenoid scales. Siemens also points out that scale formation can sometimes be observed only after scratching the lesion, and notes that this phenomenon—latent desquamation—may be found in the early stages of pityriasis rosea as well as in tinea versicolor, parapsoriasis, and psoriasis. Large, heaped-up scale accumulations in psoriasis may be described as ostraceous (oyster-like). Cracklike desquamation can be seen in scabetic burrows and eczema craquelé. Collarettes of scale are seen in pityriasis rosea, superficial mycoses, secondary syphilis, and erythema annulare centrifugum. Seborrheic desquamation refers to the yellow-to-brown, waxy, or greasy scales characteristically seen in seborrheic dermatitis. When exudates such as serum or pus mix with scale, crusts are formed. Eruptions that consist of scaling papules are referred to as *papulosquamous*. Psoriasis, in which scaling papules coalesce to form plaques, is the classic example of a papulosquamous eruption. *Maculosquamous* refers to flat lesions with fine scaling such as those that can be seen in tinea versicolor and erythrasma. Pityriasis rosea may have papulosquamous, maculosquamous, and even papulovesicular lesions.

CRUSTS (ENCRUSTED EXUDATES) *Crusts* are hardened deposits that result when serum, blood, or purulent exudate dries on the skin surface, and they are characteristic of pyogenic infections. Crusts may be thin, delicate, and friable (A in Fig. 3-16A), or thick and adherent (B in Fig. 3-16A). Crusts are yellow when formed from dried serum, green or yellow-green when formed from purulent exudate, or when formed from blood. Crusts may be present in acute eczematous dermatitis and impetigo (honey-colored, glistening crusts). When the exudate or crust involves the entire thickness of the epidermis, the crusts may be thick and adherent; this condition is known as *ecthyma*. A *scutula* is a small, yellowish, cup-shaped crust especially characteristic of superficial fungal infection of the scalp caused by *Trichophyton schoenleinii*.

GANGRENE AND SPHACELUS *Gangrene* refers to a severe necrotizing and sloughing process. Gangrene that results from arterial occlusion is characterized by a sharply demarcated blue-black color. Gangrene from streptococcal or clostridial infection may begin with vesicles that become purplish black followed by rapid necrosis of whole segments of skin. A *sphacelus* is a densely adherent, dry, necrotic membrane occurring in the floor of an ulcer. It is seen in decubitus ulcers, chronic ulcers due to x-ray damage, diphtheritic or anthrax ulcers, any ischemic ulcer, or factitial dermatosis.

EXCORIATIONS *Excoriations* are superficial excavations of epidermis that may be linear or punctate and result from scratching. They are frequent findings in all types of pruritus and are concomitants of pruritic skin disease, such as atopic eczema, dermatitis herpetiforms, or infestations.

FISSURES *Fissures* are linear cleavages or cracks in the skin and may be painful. They occur particularly in palmar/plantar psoriasis and in chronic eczematous dermatitis of the hands and feet, especially after therapy that has caused excessive drying of the skin. Fissures are frequently noted in perianal psoriasis or at the angles of the mouth (perlèche). Perlèche may be caused by avitaminosis, moniliasis, ill-fitting dentures, or unknown factors.

POIKILODERMA As a morphologic descriptive term, *poikiloderma* refers to the combination of atrophy, telangiectasia, and pigmentary changes (hyper- and hypo-). Poikilodermatous lesions can be seen in radiodermatitis, dermatomyositis, mycosis fungoides, and lupus erythematosus. Because of some confusion stemming from the use of the word poikiloderma in the naming of specific syndromes in the past, it is probably best to restrict it to use as a descriptive, morphologic term and to so indicate when using it.

Shape and Arrangement of Lesions

After the type or types of lesion have been identified, it is necessary to consider their *shape, arrangement* in relation to each other, the pattern of their *distribution,* and their *extent*. The shape, arrangement, and distribution are often helpful

and sometimes a key to the diagnosis. The following descriptions of the shape and arrangement of lesions can apply to single or multiple lesions. For example, an annular shape can occur in a single lesion or be derived from the annular arrangement of a number of vesicles, papules, and the like. A single lesion may assume a linear shape, or a number of lesions may be arranged in a linear pattern.

LINEAR LESIONS AND LINEAR ARRANGEMENT Linearity is a simple but important feature of skin lesions because it often indicates an exogenous cause (Fig. 3-17A). Vesicles on the leg may convey no particular meaning until a linear arrangement is observed; this type of arrangement occurs after a vesicant or allergen has been drawn across the skin, as, for example, when there has been contact with *Rhus* leaves. Erythema in linear streaks over an extremity brings to mind the possibility of lymphangitis.

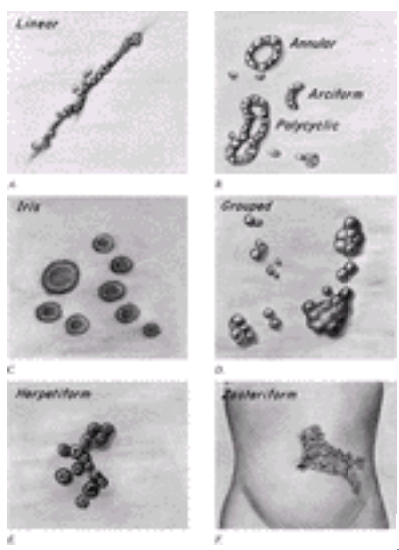

FIGURE 3-17 Shape and arrangement of lesions (see text for descriptions).

The *Koebner (isomorphic) phenomenon* refers to the fact that in persons with certain skin diseases, especially psoriasis, trauma is followed by new lesions in the traumatized but otherwise normal skin, and these new lesions are identical to those in the diseased skin. [25] The Koebner reaction occurs in traumatized normal skin in vitiligo, psoriasis, and lichen planus, among other conditions. The Koebner phenomenon may occur in recent scars or at pressure points. Nodules may be linear, inasmuch as they occur along the course of a vein in superficial thrombophlebitis or along an artery in temporal arteritis or polyarteritis nodosa. Deep mycoses (sporotrichosis and coccidioidomycosis) may present as granulomatous nodules along the course of the lymphatics. Vesicles arranged linearly occur in localized herpes zoster (and rarely in herpes simplex) with a distribution that follows a dermatome. Epidermal nevi (nevus unius lateris) may have a striking linear pattern that extends along an entire extremity. Such nevi, as well as a number of other nevoid and acquired skin diseases, may follow the curious *Blaschko's lines,* which do not follow any known vascular or nervous structures in the skin. [26], [27] The lesions of factitial dermatosis, which include ulcers, atrophy, scars, or all three, frequently occur in a linear pattern. Linear scleroderma may be recognized by its bands of induration or atrophy that extend along an upper or lower extremity or the midline of the forehead (*coup de sabre*).

ANNULAR AND ARCIFORM LESIONS AND ANNULAR AND ARCIFORM ARRANGEMENTS In most acute erythemas associated with inflammation, the macules are round or oval; Siemens [4] attempted to explain this on the basis of the blood supply, stating that each individual erythematous spot represents the territory of direct blood supply from an individual arteriole. An *annular* (Latin *annulus,* a ring) (Fig. 3-17B) lesion may result when the pathologic process in a round lesion spreads peripherally and recedes in the center or when individual lesions occur in a ring-shaped arrangement. A special and important type of annular lesion, the *iris* (Fig. 3-17C) or *bull's-eye* lesion, consists of an erythematous annular macule or papule with a purplish or dusky, papular or vesicular center. Iris-type lesions are characteristic of the erythema multiforme syndrome. *Annular* and *round* should not be used interchangeably: annular lesions have clear or contrasting centers, round ones do not. *Nummular* (coin-shaped) and *discoid* (like a disc) are used to describe distinctive round lesions that occur in eczema and cutaneous lupus erythematosus, respectively. Annular lesions that may be macular or slightly raised occur in erythema marginatum and other figurate erythemas (see Chap. 99), drug eruptions, mycosis fungoides, secondary syphilis, or lupus erythematosus. Annular lesions with scales suggest pityriasis rosea, dermatophytosis, psoriasis, or seborrheic dermatitis. The individual papules of psoriasis often occur in an annular, polycyclic, or arciform arrangement (Fig. 3-17B). Lupus vulgaris, sarcoid, granuloma annulare, mycosis fungoides, and tertiary syphilis may exhibit annular or arciform patterns of papules or nodules. As a rule, however, the lesions of tertiary syphilis are arranged in incomplete or broken rings. Secondary syphilis, erythema multiforme, lichen planus, urticaria, lupus erythematosus, dermatophytosis, Lyme borreliosis (erythema migrans), or the figurate erythemas (see Chap. 99) may produce annular papules. A *serpiginous* (snakelike) arrangement of lesions is seen in the wheals of creeping eruptions (larva migrans) and in the papules and nodules of late syphilis and lupus vulgaris.

GROUPED LESIONS Papules, wheals, nodules, and vesicles may occur in groups (Fig. 3-17D). These groupings are of little diagnostic value unless they assume a pattern. Clusters or groups of vesicles may occur anywhere on the skin surface, and this arrangement is so characteristic of herpes simplex and herpes zoster that it is termed *herpetiform* (Fig. 3-17E). When vesicles or bullae of herpes zoster occur in a bandlike pattern following a dermatome, the arrangement is termed *zosteriform* (Fig. 3-17F). A zosteriform or dermatomal arrangement of cutaneous nodules is occasionally observed in metastatic carcinoma of the breast. Nevoid conditions such as melanocytic nevi or epidermal nevi (ichthyosis hystrix) may occur in a zosteriform pattern. *Corymbiform* refers to a grouped arrangement that consists of a central cluster of lesions beyond which are scattered individual lesions. The picture is reminiscent of an explosion, or cluster of flowers, and can be seen in verruca vulgaris. Unpatterned, grouped lesions are noted in verruca plana, lichen planus, urticaria, insect bites (often in groups of three), leiomyoma, and lymphangioma circumscriptum.

RETICULAR ARRANGEMENT A netlike, lacy, or retiform (Latin *reticulum,* “little net”) pattern occurs in a number of conditions, the prototype of which is livedo reticularis. Such reticular arrangements also occur in cutis marmorata and erythema ab igne. Individual lesions may also have reticular or lacy components, as, for example, the *Wickham's striae* in lichen planus (see Chap. 49).

Distribution of Skin Lesions

Although it is possible to recognize some skin eruptions by their *patterns of distribution,* the type and shape of the lesion, which have already been discussed, are much more reliable criteria in diagnosis. Inasmuch as the type, shape, and arrangement of lesions and their distribution pattern constitute the important tetrad in dermatologic diagnosis, it is important that the physician be acquainted with some of the more characteristic distribution patterns that are presented in the discussions of individual diseases throughout this book. Skin disorders can be classified as *localized (isolated), regional,* or *generalized;* the term *total (universal)* denotes involvement of the entire skin, the hair, and the nails.

As a first step in the examination of the skin, the physician should view the disrobed patient from a distance. After a survey of the entire skin surface and a close-up inspection of the type and shape of lesions, the distribution pattern can be put in perspective. For example, if eczematous patches are found on the wrist, earlobes, and neck, there is a clue to a metal contact dermatitis from a metal watchband, metal earrings, and a metal necklace.

When an eruption occurs in a bilateral and symmetric distribution, the cause is often endogenous or systemic. This pattern suggests hematogenous dissemination of the pathologic stimulus and is most often indicative of hypersensitivity reactions (e.g., drug sensitization and “allergic” vasculitis), viral exanthems, and certain other skin disorders, such as atopic eczema, dermatitis herpetiformis, etc.

In most cases, the reason for the localization of skin lesions to certain areas is unknown. A few factors, however, account for sites of predilection. Diseases caused or exacerbated by exposure to sunlight are localized to exposed areas such as the dorsa of the hands and arms, the neck, and face, a so-called “photo-distribution.” Areas of the face that are usually spared include the skin of the top part of the upper eyelids and the skin of the hair-covered scalp. Cutaneous (discoid) and systemic lupus erythematosus are predominantly localized in exposed areas but may also appear in completely light-shielded areas, such as the skin of the hair-covered scalp, ears, mouth, and feet.

Areas of minor and repeated trauma and areas where skin rubs against skin account for the distribution of lesions of epidermolysis bullosa and some of the lesions in vitiligo and psoriasis. Trauma in combination with light exposure accounts for the skin fragility and bullae localized to the backs of the hands and the face in porphyria cutanea tarda.

Hidradenitis suppurativa consists of abscesses of apocrine sweat glands and is therefore localized to axillae, nipples (in females), and anogenital areas.

Rosacea is usually confined to the “blush” area of the face, and factors that induce blushing are thought to be precipitative; these include alcoholic beverages, certain spicy condiments, hot beverages, and possibly emotional stress.

Candidiasis (moniliasis) is predominantly localized to areas where the skin is warm and moist (axillary, inframammary, and inguinal regions, the intergluteal cleft, the vaginal area, and the mouth). *Candida albicans* is a frequent resident of the gastrointestinal tract and reaches some of these sites by direct contact.

Herpes zoster occurs in a dermatomal pattern because the virus moves along the sensory nerves to the skin.

Lesions may be associated with openings of follicles, as in the follicular keratoses of keratosis pilaris, pityriasis rubra pilaris, and vitamin A deficiency. There is a follicular pattern of involvement in acne, lichen planopilaris, psoriasis, some drug eruptions, fungal infections (particularly *Trichophyton rubrum* and *Trichophyton verrucosum*), various forms of bacterial folliculitis, and some cases of atopic eczema.

During the time taken to survey the distribution pattern of the dermatosis, it is pertinent to review the history, occupation, various forms of exposure (e.g., to light or to airborne and contact allergens), and history of drug ingestion.

PHYSIOLOGIC ABNORMALITIES

Some of the most common disorders in dermatology are basically functional abnormalities of the skin, which include dryness, seborrhea, hyperhidrosis and anhidrosis. These entities are covered in detail in Chap. 76.

PRURITUS

Itching may be a cardinal symptom of general medical significance, the earliest sign of Hodgkin's disease, occult carcinoma, and primary biliary cirrhosis. [10] It is a critical feature of dermatologic disorders such as atopic eczema, dermatitis herpetiformis, and often psoriasis. On the other hand, severe itching can occur as a consequence of mere dryness of the skin. The pathophysiology and clinical aspects of pruritus are discussed in Chap. 41.

INSTRUMENTAL AND LABORATORY PROCEDURES IN DERMATOLOGIC DIAGNOSIS

Aids to Dermatologic Diagnosis: Clinical, Instrumental, and Laboratory

Magnification: To examine the skin surface critically and to detect the fine morphologic detail of skin lesions it is necessary to use a hand lens magnifier (preferably 7×); also, a better image is obtained following application of a drop of mineral oil to the lesion. Magnification is especially helpful in the diagnosis of lupus erythematosus (follicular plugging and atrophy), lichen planus (Wickham's striae), basal cell carcinomas (translucence and delicate telangiectasia), and early malignant melanoma (subtle changes in color, especially gray, slate, or blue). Hand-held magnifying instruments with built-in lighting and a magnification of 10× to 30× have recently become available and these permit better

visualization of lesions when used with a drop of oil. Using this small optical instrument or the larger binocular microscope—this technique is called *epiluminescence microscopy*—facilitates the distinction of benign and malignant pigmented neoplasms. [28], [29] and [30]

Wood's lamp (longwave ultraviolet light, “black” light) is essential for the clinical diagnosis of certain skin and hair diseases and of porphyria. Longwave ultraviolet radiation is obtained by fitting a high-pressure mercury lamp with a specially compounded filter made of nickel oxide and silica (Wood's filter); this filter is opaque to all light except for a band between 320 and 400 nm. When using the Wood's lamp, it is essential for the examiner to become dark-adapted in order to see the contrasts clearly. When the ultraviolet waves emitted by Wood's lamp impinge on the skin, a visible fluorescence occurs. Wood's lamp is particularly useful in the detection of the fluorescence of dermatophytosis (*Microsporum*) in the hair shaft (green) and of erythrasma (coral red) on the skin. Wood's lamp also helps to estimate the variation in the “whiteness” of lesions in relation to the normal skin color, in dark-skinned and especially in fair-skinned persons; for example, the lesions seen in hypomelanotic macules in tuberous sclerosis and in tinea versicolor are not as white as the macules present in vitiligo, which are typically amelanotic. Circumscribed hypermelanosis, such as ephelides and melasma, is much more evident under Wood's lamp, and in lentigo maligna melanoma and acrolentiginous melanoma the Wood's lamp can be used to detect the total extent of the lesion as a guide to total excision. Melanin in the dermis, as in a Mongolian sacral spot, does not become accentuated under Wood's lamp. [31] Therefore, it is possible to localize the site of melanin (epidermal or dermal) by use of the Wood's lamp; this phenomenon is not evident in patients with brown or black skin. The technique is as follows: a grading (minimal, moderate, marked) of the degree of pigmentation is made with visible light and compared with a grading of the degree of color change when examined with Wood's lamp. In epidermal melanin pigmentation the pigment grade increases from minimal to marked, but dermal melanin has the same degree of pigment in both visible light and Wood's lamp illumination.

Diascopy consists of firmly pressing a transparent, hard, flat object (such as a hand lens or *two* microscope slides) over the surface of a skin lesion. The examiner will find this procedure of special value in determining whether the red color of a macule or papule is due to capillary dilatation (erythema) or to extravasation of blood (purpura). Diascopy is also useful for the detection of the hyaline yellowish-brown color of papules or nodules in sarcoidosis, tuberculosis of the skin, lymphoma, and granuloma annulare.

Clinical Signs

The *dimple sign* is a useful maneuver in differentiating dermatofibromas (benign, firm, nodular lesions that are often pigmented) from malignant melanoma. Application of lateral pressure with the thumb and index finger results in the formation of a depression (dimple) in a dermatofibroma, whereas melanoma and melanocytic nevi protrude above their initial plane (become elevated), as does the normal skin when this maneuver is performed. [32]

Nikolsky's sign refers to the sheetlike removal of epidermis (Fig. 3-18) by gentle traction that can be observed in several diseases, the most important of which are pemphigus vulgaris and toxic epidermal necrolysis. [33]

FIGURE 3-18 Pemphigus vulgaris. The bulla has been extended by applying pressure with the finger (Nikolsky's sign).

Darier's sign refers to the development of an urticarial wheal in the lesions of urticaria pigmentosa (a brown macule or a slightly elevated papule) after they are rubbed with the rounded end of a pen. The wheal, which is strictly confined to the borders of the lesion, may not appear for 5 to 10 min.

Auspitz's sign refers to the appearance of pinpoint dots of blood at the tops of ruptured capillaries when scale is forcibly removed from psoriatic plaques. [33]

Clinical Tests

Patch testing is used to document and validate a diagnosis of allergic contact sensitization and to identify the causative agent. It may also be of value as a screening procedure in some patients with chronic or bizarre eczematous eruptions (e.g., hand and foot dermatoses). It is a unique means of in vivo reproduction of disease in diminutive proportions, for sensitization affects all the skin and may therefore be elicited at any cutaneous site. The patch test is easier and safer than a “use test” with a questionable allergen, for test items can be applied in low concentrations in small areas of skin for short periods of time. Textbooks on contact dermatitis contain complete lists of antigens used in patch testing. [35]

Photopatch testing is a combination of patch testing and ultraviolet irradiation of the test site and is used to detect photoallergy.

Phototesting is done to determine the patient's sensitivity to various wavelengths of ultraviolet radiation. This is useful in

the diagnosis of certain photosensitivities (see Chap. 135 and Chap. 136).

Microscope Examination of Scales, Crusts, Serum, and Hair

Gram's stain and cultures of exudates should be made in lesions suspected of being a bacterial or a yeast (*C. albicans*) infection. Ulcers and nodules require a scalpel biopsy in which a wedge of tissue consisting of all three layers of skin is obtained; the biopsy specimen is minced in a sterile mortar, and the tissue is then cultured for bacteria (including typical and atypical mycobacteria) and fungi.

Microscope examination for mycelia should be made of the roofs of vesicles or of the scales (the advancing borders are preferable) or of the hair and of nails. The tissue is cleared with 10% KOH (20% KOH for nails) and warmed gently. Fungal cultures with Sabouraud's or other appropriate medium should be made. The specifics of dermatophyte and other fungal infections are covered in Chap. 205 to Chap. 207.

Microscope examination of cells obtained from the base of vesicles and bullae (*Tzanck test*) may reveal the presence of giant epithelial cells and multinucleated giant cells (containing 10 to 12 nuclei) in herpes simplex, herpes zoster, and varicella. Material from the base of a vesicle obtained by gentle (do not produce bleeding!) curettage with a scalpel is smeared on a glass slide, stained with Giemsa's (Fig. 3-19) or Wright's stain, and examined for the presence of giant epithelial cells, which are diagnostic. Cultures and rapid immunofluorescent diagnosis for herpes simplex and varicella-zoster are now easily and rapidly available and are more specific than the Tzanck test.

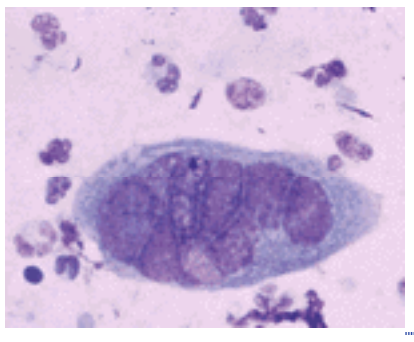

FIGURE 3-19 Tzanck preparation showing multinucleate giant epidermal cell (Giemsa's stain). (*Courtesy of Arthur R. Rhodes, M.D.*)

Biopsy of the Skin

Biopsy of the skin is a rewarding diagnostic technique because of the easy accessibility of the skin and the variety of techniques that can be used for the study of the excised specimen, such as immunofluorescence, immunoperoxidase, electron microscopy, and the polymerase chain reaction. In many instances the correlation of the clinical and histologic findings is mandatory, as the histologic diagnosis, especially in noninfectious inflammatory disease, may be nonspecific. A good general rule is that when the histopathology and the clinical findings do not agree, count on the clinical diagnosis, get another biopsy, and see the patient again after a few days or weeks.

The selection of the site of the biopsy is important and is based primarily on the stage of the eruption. Early lesions are usually more typical in vesiculobullous eruptions in which the lesion should be no more than 24 h old. In all other eruptions, older, fully developed lesions are often more characteristic. More than one biopsy may be necessary, especially if the eruption is polymorphous.

A common technique for diagnostic biopsy using local anesthesia is the use of a 4-mm “punch”—a small disposable tubular knife. Immunofluorescence analysis may be done with similar specimens from bullous diseases or lupus erythematosus. For nodules and tumors and, especially, nodules on the leg, a large wedge scalpel biopsy or generous, deep punch biopsy should be obtained including the subcutaneous tissue. Furthermore, all inflammatory nodules suspected of being infectious granulomas should be bisected—one-half for histology, the other half sent in a sterile container for bacterial and mycotic cultures using a tissue mince. Specimens for light microscopy should be fixed immediately in 10% aqueous formalin. A brief but detailed and specific summary of the clinical history and lesions should accompany the specimen. Biopsy is indicated in all suspected neoplasms, in all bullous disorders using immunofluorescence simultaneously, and in all dermatologic disorders in which a specific diagnosis is not possible by clinical examination alone.

More specifics on histology in general and on immunofluorescent and immunoperoxidase techniques in particular, are best described in dermatopathology texts. [36], [37]

In summary, dermatologists are physicians who can diagnose a rash! They may also be internists, surgeons, biochemists, or immunologists; but without competency in dermatologic diagnosis they cannot qualify as dermatologists. The sine qua non of the dermatologist is a trained clinical eye for morphologic diagnosis. This diagnostic eye can be acquired only by endlessly repeated encounters in which the physician is forced not only to look at but to observe the rash, while an *experienced mentor points the way.* The most common error in dermatologic diagnosis is to regard the lesions as nonspecific “rashes” rather than as aggregates of specific individual lesions. As in surveying a blood smear, a “general impression” is not enough: the morphologic aspects of each individual cell must be carefully scrutinized and judged to be normal or abnormal. Too often, physicians adopt a speedy, superficial approach to the skin that they would not apply to any other organ that they examine. See Table 3-2.

1. Do not remove tissue without sending a portion for histologic examination.
2. If the dermatopathologic findings are at odds with the clinical diagnosis, obtain another biopsy. If disagreement presists, follow the clinical lead (cautiously).
3. Generalized pruritus of more than 1 month's duration and without an obvious cause needs investigation with history, search for lymph nodes (including the supraclavicular nodes), laboratory studies, chest x-ray, and, if indicated, imaging studies.
4. A new or changing mole should be carefully evaluated and excised for diagnosis if it has suspicious features.
5. Examine the entire skin and mucous membranes whenever possible and always in patients presenting with a personal or family history of melanoma or with multiple "moles."
6. Medications can cause almost every type of dermatologic lesion and are always in the list of possible diagnoses. Drug reactions often appear suddenly and are usually symmetric in distribution.
7. A diagnosis of factitial (self-induced) dermatosis can be made only after all other reasonable possibilities are considered. A nervous, strange, or "crazy" affect can be the consequence or the cause of a terrible skin problem.
8. Beware of "snap," "curbside," or "doorway" diagnoses. No other medical specialty engages in this hazardous practice.
9. Be wary of the "atypical" diagnosis. Atypical "this" may be typical "that" to someone who has seen it before.

TABLE 3-2 **Pointers and Pitfalls in Dermatologic Diagnosis**

Lewis Thomas has said that "Medicine is no longer the laying on of hands, it is more like the reading of signals from machines." [37] In dermatology there can be no replacement for the laying on of hands, and the physician is repeatedly gratified by reading signals not from machines, but from people.

*Was ist das Schwerste von allem? Was du das Leichteste dünket: Mit den Augen zu *sehn* was vor den Augen dir liegt.

REFERENCES

1. Jackson R: *Morphological Diagnosis of Skin Disease.* Ontario, Grimsby, 1998

2. Mihm MC Jr et al: Early detection of primary cutaneous malignant melanoma: A color atlas. *N Engl J Med* **289**:989, 1973

3. Boyce JA, Bernhard JD: Total skin examination should be part of routine health maintenance screening. *J Gen Intern Med* **2**:59, 1987

4. Siemens HW: *General Diagnosis and Therapy of Skin Diseases: An Introduction to Dermatology for Students and Physicians* translated by K Wiener. Chicago, Univ of Chicago Press, 1958

5. Haxthausen H: How are dermatological diagnoses made? *Trans St Johns Hosp Dermatol Soc* **30**:3, 1951

6. Jackson R: The importance of being visually literate. *Arch Dermatol* **111**:632, 1975

7. Kundel HL, Wright DJ: The influence of prior knowledge on visual search strategies during the viewing of chest radiographs. *Radiology* **93**:315, 1969

8. Hurst JW: *Notes from a Chairman*. Chicago, Year Book Medical, 1987, p 46

9. Bernhard JD, Haynes HA: Nonrashes 1. The Koebner non-reaction. *Cutis* **29**:158, 1982

10. Bernhard JD (ed): *Itch: Mechanisms and Management of Pruritus.* New York, McGraw-Hill, 1994

11. Brownstein MH: Invisible dermatoses versus nonrashes. *J Am Acad Dermatol* **9**:599, 1983

12. Phillips KA et al: Rate of body dysmorphic disorder in dermatology patients. *J Am Acad Dermatol* **42**:436, 2000

13. Cotterill JA: Clinical features of patients with dermatologic nondisease. *Semin Dermatol* **2**:203, 1983

14. Koblenzer CS: *Psychocutaneous Disease*. Orlando, Grune & Stratton, 1987

15. Gougerot MH: Dermatoses invisibles, leur fréquence, leur intérêt doctrinal et pratique. *Bull Soc Dermatol Syphilol* **47**:361, 1940

16. Requena L, Yus ES: Invisible dermatoses: Additional findings. *Int J Dermatol* **30**:552, 1991

17. Feinstein AR: *Clinical Judgment*. Baltimore, Williams & Wilkins, 1967

18. Winkelmann RK (chairman): The International League of Dermatologic Societies Committee on Nomenclature. Glossary of basic dermatologic lesions. *Acta Derm Venereol Suppl* 130, *(Stockh)*, 1987

19. Fitzpatrick TB, Walker SA: *Dermatologic Differential Diagnosis.* Chicago, Year Book, 1962

20. Goldsmith LA et al: *Adult and Pediatric Dermatology: A Color Guide to Diagnosis and Treatment.* Philadelphia, FA Davis, 1997

21. Leider M, Rosenblum M: *A Dictionary of Dermatological Words, Terms, and Phrases*. New York, McGraw-Hill, 1968, or West Haven, CT, Dome Laboratories, 1976

22. Bernhard JD et al: Maculopapularism. *Am J Dermatopathol* **8**:173, 1986

23. Bernhard JD, Marks EJ: Case records of the Massachusetts General Hospital. Case 17-1986. An 18-year-old man with cutaneous ulcers and bilateral pulmonary infiltrates [Wegener's granulomatosis]. *N Engl J Med* **314**:1170, 1986

24. Oh DH et al: Five cases of calciphylaxis and a review of the literature. *J Am Acad Dermatol* **40**:979, 1999

25. Melski JW et al: The Koebner (isomorphic) response in psoriasis. *Arch Dermatol* **119**:655, 1983

26. Bolognia JL et al: Lines of Blaschko. *J Am Acad Dermatol* **31**:157, 1994

27. Happle R, Assim A: The lines of Blaschko on the head and neck. *J Am Acad Dermatol* **44**:612, 2001

28. Menzies SW et al: *An Atlas of Surface Microscopy of Pigmented Skin Lesions*. New York, McGraw-Hill, 1996

29. Stolz W et al: *Color Atlas of Dermatoscopy*. Germany, Blackwell Science, 1994

30. Kittler H et al: Morphologic changes of pigmented skin lesions: A useful extension of the ABCD rule for dermatoscopy. *J Am Acad Dermatol* **40:**558, 1999

31. Gilchrest BA et al: Localization of melanin pigment on the skin with Wood's lamp. *Br J Dermatol* **96**:245, 1977

32. Fitzpatrick TB, Gilchrest BA: Dimple sign to differentiate benign from malignant pigmented cutaneous lesions. *N Engl J Med* **296**:1518, 1977

33. Goodman H: Nikolsky sign. *Arch Derm Syphilol* **68**:334, 1953

34. Bernhard JD: Auspitz sign is not sensitive or specific for psoriasis. *J Am Acad Dermatol* **22**:1079, 1990

35. Rietschel RL, Fowler JF: *Fisher's Contact Dermatitis*. Philadelphia, Williams & Wilkins, 2001

36. Elder D et al: *Lever's Histopathology of the Skin*. Philadelphia, Lippincott-Raven, 1997

37. Weedon D: *Skin Pathology*. Edinburgh, Churchill Livingstone, 1997

38. Thomas L: *The Youngest Science. Notes of a Medicine-Watcher.* New York, Viking Press, 1983, p 58

T>

Chapter 4

Klaus Wolff Abdul-Ghani Kibbi Martin Mihm

Basic Pathologic Reactions of the Skin

SUPERFICIAL REACTIVE UNIT
Epidermis
The Dermal-Epidermal Junction
Pathologic Reactions of the Entire Superficial Reactive Unit
THE DERMIS
Pathologic Reactions of the Dermal Vasculature
Lymphocytic Infiltrates
Polymorphonuclear Leukocytic Infiltrates
Granulomatous Reactions
The Fibrous Dermis and Extracellular Matrix
SUBCUTANEOUS FAT

SUGGESTED READINGS

The skin is composed of various tissue compartments that interconnect anatomically and interact functionally. It is difficult to envisage epidermal function without signals from the dermis; in fact, there are only a few pathologic processes that relate solely to the epidermis without involving or being involved by the underlying papillary body or passenger leukocytes traveling to and from the skin. Epidermis, dermis, and subcutaneous tissue by themselves are heterogeneous in nature (see Chap. 6). An analysis of pathologic processes involving the skin should therefore consider both the heterogeneity and the interactions of the individual cutaneous compartments, because only then will it be understood why a few basic reactions lead to a multiplicity of reaction patterns within this tissue.

Pathophysiologically, the skin can be subdivided into three reactive units that extend beyond anatomic boundaries; they overlap and can be divided into different subunits (Table 4-1). These units respond to pathologic stimuli according to their inherent reaction capacities in a coordinated pattern.

I Superficial reactive unit
A Epidermis
B Junction zone (dermal-epidermal junction)
C Papillary body
D Superficial microvascular plexus
II Reticular dermis
A Connective tissue
B Appendages (hair follicles, sweat glands, sebaceous glands)
C Deep vascular plexus
III Subcutis
A Lobules
B Septae

TABLE 4-1 **Reactive Units of the Skin**

The *superficial reactive unit* comprises the epidermis, the subjacent loose connective tissue of the papillary body and its capillary network, and the superficial venular plexus embedded in this connective tissue. The *reticular layer of the dermis* represents another reactive unit and is composed of subunits—hair follicles, glands, and the surrounding connective tissue. The above subunits may respond individually or jointly to pathologic stimuli. Finally, the third reactive unit, the *subcutaneous tissue,* is functionally also heterogeneous; septal and lobular compartments may be involved either alone or together.

SUPERFICIAL REACTIVE UNIT

Epidermis

Keratinocytes, which have the capacity to keratinize, represent the bulk of the epidermis. The epidermis, an ectodermal epithelium, also harbors a number of other cell populations such as melanocytes, Langerhans cells, Merkel cells, and other cellular migrants. The basal cells of the epidermis undergo proliferation cycles that provide for the renewal of the epidermis and, as they move toward the surface of the skin, undergo a differentiation process that results in keratinization (Chap. 7). The epidermis is thus a dynamic tissue in which cells are constantly in nonsynchronized motion; the proliferation kinetics and the direction and speed of migration of the individual cell populations differ from each other, so that keratinocytes not only pass each other but also pass melanocytes or Langerhans cells as they move toward the surface of the skin. At the same time they are interconnected through forces of coherence that guarantee the continuity of the epithelium. Stability for this directional cellular flow is provided by the basal membrane complex, which anchors the epidermis to the dermis, and the stratum corneum. It is here that individual cell migration ceases as the keratinizing cells are firmly interconnected by an intercellular cement-like substance (Chap. 9). These forces of cohesion are finally lost at the surface of the epidermis where the individual cornified cells are desquamated. Pathologic changes within the epidermis may therefore relate to the kinetics of epidermal cells or their differentiation and may involve transepidermal migration and intraepidermal cohesion; they also relate to peripatetic leukocytes trafficking to and from the epidermis and adhesion molecules facilitating and directing such cellular movements; and they relate to cytokines and hormones generated by keratinocytes, Langerhans cells, melanocytes, and peripatetic leukocytes. They may affect the entire cell population or individual cells, may be primarily targeted on keratinocytes, or may encompass the other epidermal cell populations. All these processes may occur in an isolated fashion or represent combined phenomena involving all

epidermal functions.

DISTURBANCES OF EPIDERMAL CELL KINETICS The mitotic rate of germinative cells, the desquamation rate of corneocytes, and the generation time of epidermal cells determine the homeostasis of the epidermis. Under physiologic conditions, there is a balance among proliferation, differentiation, and desquamation. Enhanced cell proliferation accompanied by an enlargement of the germinative cell pool and increased mitotic rates lead to an increase of the epidermal cell population and thus to a broadening of the epidermis (*acanthosis*) (Fig. 4-1). The causes for acanthosis may reside within the epidermis, as is the case in acanthotic conditions due to epidermotropic viruses, or represent signals that reach the epidermis from the dermis or vasculature. Thus, a shift in the ratio of proliferating to resting cell pools, for example, by a release of the G_1 or G_2 block as in psoriasis (see Chap. 7 and Chap. 42), will lead to both an increase in the turnover of the entire epidermis and to a considerable increase of the volume of germinative cells that have to be accommodated at the dermal-epidermal junction.

FIGURE 4-1 Acanthosis. This sign of increased epidermal kinetics is illustrated in this photomicrograph of psoriasis. Parakeratosis, the retention of nuclei in the horny layer, is evident.

The interactions of epidermis and subjacent connective tissue are best illustrated by the process of acanthosis, because thickening of the epidermis and elongation of the rete ridges are usually accompanied by an elongation of the connective tissue papillae, which extend far into the epithelium. This results in an enlargement of the dermal-epidermal interface and, consequently, in an increased area for dermal-epidermal interactions (see Fig. 4-1). A slowing of epidermal cell kinetics results in a reduction of the epidermal cell turnover. This, in turn, leads to a diminution of the germinative cell volume and a flattening of the rete ridges; the epidermis becomes thinner and epidermal *atrophy* results. Disturbances of epidermal cell kinetics are also reflected in the architecture and composition of the stratum corneum. A simple example is *hyperkeratosis,* where thickening of the stratum corneum may be caused by increased production or a reduced desquamation of corneocytes. In *orthohyperkeratosis,* the stratum corneum may appear qualitatively similar to the normal horny layer, but there may be differences in the packing and cohesion of horny cells. A thickened stratum corneum may occur in an epidermis exhibiting a rudimentary or a pronounced stratum granulosum.

DISTURBANCES OF EPIDERMAL CELL DIFFERENTIATION A simple example of disturbed epidermal differentiation is parakeratosis, in which faulty and accelerated cornification leads to a retention of pyknotic nuclei of epidermal cells (see Fig. 4-1). In parakeratosis, the stratum granulosum is only rudimentary or may not be present at all, but at the ultrastructural level small keratohyaline granules can be detected. A parakeratotic stratum corneum is not a compact sheet of cornified cells but a loose structure with gaps between cells; these gaps lead to a loss of the barrier function of the epidermis. Parakeratosis can be the result of incomplete differentiation in postmitotic germinative cells that will become visible morphologically only much later in that layer of the epidermis where keratinization is normally complete, e.g., the stratum corneum. Considering a transit time of 14 days for a postmitotic epidermal cell, a pathologic signal inducing parakeratosis in a cell early in differentiation requires 2 weeks to appear histologically in the stratum corneum. Alternatively, parakeratosis can also be the result of reduced transit time, which does not permit epidermal cells to complete the whole differentiation process. However, “parakeratosis” of cellophane-stripped epidermis becomes microscopically visible as early as 1 h after trauma; here, parakeratosis does not represent disturbed differentiation; rather, it results from direct cellular injury. Finally, in some skin diseases in which the pathology resides in and around the superficial blood vessels of the dermis, parakeratosis can appear as a secondary epidermal phenomenon 24 h after the eruption. In this case, parakeratosis is the result of a signal delivered to upper epidermal cells already far advanced in differentiation. Therefore, the morphologic term *parakeratosis* signifies both a programmed disturbance of differentiation and maturation and a direct cellular injury. *Dyskeratosis* is a term used for premature cornification of individual cells within the viable layers of the epidermis. Dyskeratotic cells have an eosinophilic cytoplasm and a pyknotic nucleus and are packed with keratin filaments arranged in perinuclear aggregates. This leads to a breakdown of the cytoplasmic skeleton of the cell, which loses its ability to adjust its shape and form according to the requirements of adjacent keratinocytes. Such a cell will tend to round up and lose its attachments to the surrounding cells. Dyskeratosis is therefore often associated with acantholysis (see below) but not vice versa (Fig. 4-2).

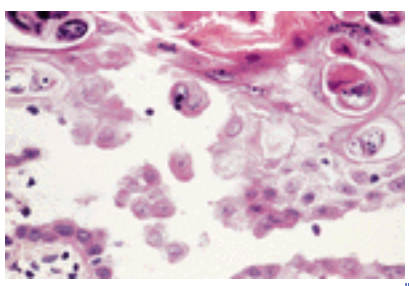

FIGURE 4-2 The association of dyskeratosis and acantholysis is seen in this high-power view of Darier's disease, which also demonstrates the intraepidermal cleft formation resulting from these phenomena.

Dyskeratosis may also signify irreversible cellular damage. In some diseases, it is the expression of a genetically programmed disturbance of keratinization, with keratin filaments detaching from their desmosomal anchoring sites and

aggregating in the perinuclear cytoplasm. This is the case in Darier's disease, where keratin filament–desmosome detachments occur in the suprabasal layers, resulting in acantholysis, and only later, as the cell matures, is dyskeratosis apparent. Dyskeratosis may occur in actinic keratosis and squamous cell carcinoma. The morphologic phenomenon of dyskeratosis may also be the result of *apoptosis* (programmed cell death) and may be caused by direct physical and chemical injury. In the sunburn reaction, eosinophilic, apoptotic cells—so-called sunburn cells—are found within the epidermis within the first 24 h after irradiation with UVB (290 to 320 nm), and similar "dyskeratotic," i.e., apoptotic, cells may occur after massive systemic cytotoxic treatment. Individual cell death within the epidermis due to cytotoxic lymphocytes is a regular phenomenon in graft-versus-host reactions of the skin and in erythema multiforme.

DISTURBANCES OF EPIDERMAL COHERENCE Epidermal coherence is the result of a dynamic equilibrium of forming and dissociating intercellular contacts. Epidermal cohesion must permit epidermal cell motion. Both specific intercellular attachment devices (desmosomes) and the intercellular substance are responsible for intercellular cohesion. Desmosomes dissociate and re-form at new sites of intercellular contact as cells migrate through the epidermis, and this requires a functional integrity of epidermal cells. Intercellular cohesion forces are strong enough to guarantee the continuity of the epidermis as an uninterrupted epithelium but, on the other hand, are adaptable enough to permit locomotion, permeability of the intercellular space, and intercellular interactions. The most common result of disturbed epidermal cohesion is the intraepidermal vesicle, a small cavity filled with fluid. Only rarely, however, is fluid the pathogenetically relevant factor for vesicle formation; loss of cohesion between epidermal cells and the secondary influx of fluid from the dermis is more often responsible for vesiculation. Cell death and lysis of epidermal cells are a third possible cause of the formation of intraepidermal cavities. Despite the multitude of causes and possible pathomechanisms leading to intraepidermal blister formation, distinction can be made on the basis of their anatomic site of origin (see Table 4-2).

Granular layer	Suprabasal
Friction blister	Pemphigus vulgaris
Pemphigus foliaceus	Darier's disease
Subcorneal pustular dermatosis	Basal layer
Staphylococcal scalded-skin syndrome/bullous impetigo	Erythema multiforme
	Lupus erythematosus
Spinous layer	Lichen planus
Eczematous dermatitis	Epidermolysis bullosa simplex
Herpesvirus infection	
Familial benign pemphigus	

TABLE 4-2 **Classification of Intraepidermal Blisters by Anatomic Level with Clinical Examples**

Three basic morphologic patterns of intraepidermal vesicle formation are classically recognized. *Spongiosis* is an example of the secondary loss of cohesion between epidermal cells due to the influx of tissue fluid into the epidermis. Serous exudate may extend from the dermis into the intercellular compartment of the epidermis; as it expands, epidermal cells remain in contact with each other only at the sites of desmosomes, acquiring a stellate appearance and giving the epidermis a spongelike morphology (spongiosis). As the intercellular edema increases, individual cells rupture and lyse, and microcavities (*spongiotic vesicles*) result (Fig. 4-3). Confluence of such microcavities leads to larger blisters. Epidermal cells may also be separated by leukocytes, disturbing intraepidermal coherence; thus, the migration of leukocytes into the epidermis and spongiotic edema are often a combined phenomenon. The accumulation of polymorphonuclear leukocytes within the epidermis, the resulting separation of epidermal cells, and their subsequent destruction eventually lead to the formation of a *spongiform pustule*.

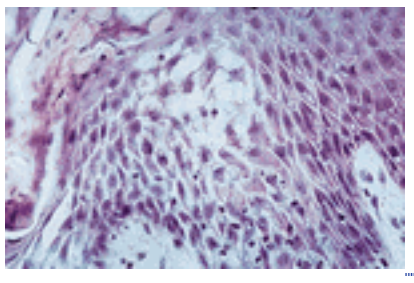

FIGURE 4-3 Spongiform vesicle resulting from edematous separation of keratinocytes. These are still partially attached to each other by desmosomes and have thus acquired a stellate appearance.

Acantholysis is a primary loss of cohesion of epidermal cells. This is initially characterized by a separation of the interdesmosomal regions of the cell membranes of keratinocytes, followed by splitting and a disappearance of desmosomes (see Chap. 59). The cells are intact but are no longer attached; they acquire their smallest possible surface and round up (Fig. 4-2 and Fig. 4-4). Intercellular gaps and slits result, and the influx of fluid from the dermis leads to a cavity, which may form in a suprabasal, midepidermal, or even subcorneal location (Fig. 4-5). Keratin filaments within acantholytic cells acquire a perinuclear orientation because they are no longer anchored to desmosomes. However, the cells remain metabolically active (at least for some time) and retain their capacity for DNA synthesis. Degeneration and cell death represent only secondary phenomena. Acantholytic cells can easily be demonstrated in cytologic smears (see Fig. 4-4) and in some conditions have diagnostic significance.

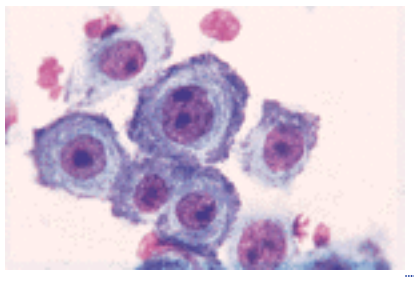

FIGURE 4-4 Acantholysis. Single as well as clusters of acantholytic cells are seen. The round shapes result from the loss of intercellular connections. Cytologic smear preparation.

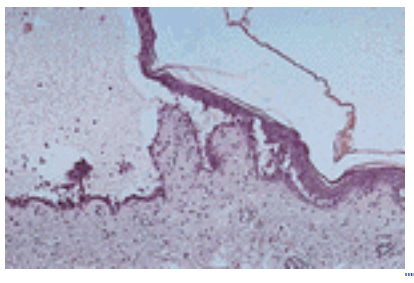

FIGURE 4-5 Pemphigus vulgaris. An intraepidermal suprabasal cleft is visible that has resulted from suprabasal acantholysis. It contains acantholytic and inflammatory cells.

Acantholysis occurs in a number of different pathologic processes that do not have a uniform etiology and pathogenesis. It is important to distinguish between diseases in which acantholysis is the primary event and leads to intraepidermal cavitation (primary acantholysis) and those conditions where epidermal cells are secondarily shed from the walls of established intraepidermal blisters (secondary acantholysis). Primary acantholysis is a pathogenetically relevant event in diseases belonging to the pemphigus group, where it results from the interaction of autoantibodies and antigenic determinants on the keratinocyte membranes (see Fig. 4-5) and is mediated by epidermal proteases (see Chap. 59). This type of acantholysis can also be produced by pemphigus autoantibodies in vitro. Primary acantholysis also occurs in the staphylococcal scalded-skin syndrome, where it is caused by a staphylococcal exotoxin (epidermolysin) that leads to the loss of cohesion of epidermal cells of the subcorneal epidermal layers without impairing cellular integrity (see Chap. 195). Acantholysis in familial benign pemphigus results from the combination of a genetically determined defect of the keratinocyte cell membrane and exogenous factors such as bacterial toxins, trauma, or maceration. In this condition, the loss of intercellular cohesion leads to compensatory development of microvilli on the cell surfaces and an acantholytic separation of cells throughout the whole width of the epidermis (see Chap. 68). A similar phenomenon, albeit more confined to the suprabasal epidermis, occurs in Darier's disease, in which it is combined with dyskeratosis in the upper epidermal layers (see Fig. 4-2) and a compensatory proliferation of basal cells into the papillary body (see Chap. 54). Finally, acantholysis can result from viral infection, but here it is usually combined with other cellular phenomena such as ballooning giant cells and cytolysis (Fig. 4-6) (see Chap. 214).

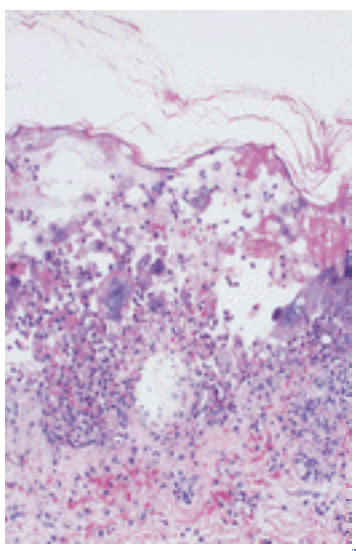

FIGURE 4-6 Herpes simplex infection. The epidermis shows marked ballooning degeneration, cytolysis, and intraepidermal vesiculation. Acantholytic and multinucleated epidermal giant cells are a clue to herpetic infection.

A loss of epidermal cohesion can result from a dissolution of cells. In the epidermolytic forms of epidermolysis bullosa, basal cells rupture as a result of trauma so that the cleft forms through the basal cell layer independently from preexisting anatomic boundaries (see Chap. 65). Cytolytic phenomena in the stratum granulosum, as are characteristic for epidermolytic hyperkeratosis, result from disturbed differentiation and are the cause of intraepidermal blister formation in bullous congenital ichthyosiform erythroderma, ichthyosis hystrix, and some forms of hereditary palmoplantar hyperkeratosis (see Chap. 51 and Chap. 52).

The Dermal-Epidermal Junction

Epidermis and dermis are interlocked by means of the epidermal rete ridges and the corresponding dermal papillae and footlike cytoplasmic microprocesses of basal cells that extend into corresponding indentations of the dermis. Dermal-epidermal attachment is enforced by hemidesmosomes that anchor basal cells on the basal lamina; this, in turn, is attached to the dermis by means of anchoring filaments and microfibrils (see Chap. 6, Chap. 16, and Chap. 65). The basal lamina is not a rigid structure because leukocytes, Langerhans cells, or other migratory cells pass through it without causing a permanent breach in the junction. After being destroyed by pathologic processes, the basal lamina is reconstituted; this represents an important phenomenon in wound healing and other reparative processes. Functionally, the basal lamina is part of a unit that, by light microscopy, appears as the PAS-positive basal membrane and, in fact, represents the entire junction zone. This consists of the lamina lucida, spanned by anchoring fibrils, and subjacent microfibrils, small collagen fibers, and extracellular matrix (see Chap. 6, Chap. 16, and Chap. 65). The junction zone is a functional complex that is primarily affected in a number of pathologic processes.

DISTURBANCES OF DERMAL-EPIDERMAL COHESION The destruction of the junction zone or its components usually manifests as disturbance of dermal-epidermal cohesion and leads to blister formation. These blisters appear to be subepidermal by light microscopy (Fig. 4-7) but in reality may be localized at different levels and result from pathogenetically heterogeneous processes. Subepidermal blister formation can be epidermal (cytolysis of basal cells), as is the case in epidermolysis bullosa simplex (*epidermolytic blistering*) (see Chap. 65). Cytolysis of basal cells can also be the result of a complex inflammatory process that involves the entire junction zone, as is the case in lupus erythematosus, erythema multiforme, or lichen planus; therefore, it may be a phenomenon occurring in a group of etiologically and pathogenetically heterogeneous conditions. In bullous pemphigoid (see Fig. 4-7), cleft formation runs through the lamina lucida of the basal membrane and is caused by autoantibodies directed against specific antigens on the cytomembrane of basal cells (see Chap. 61). The accompanying inflammation and the hydrodynamic pressure of

plasma released from the superficial dermal vessels will eventually lead to a lifting of the basal cells from the basal lamina at the level of injury and thus to blister formation (*junctional blistering*) (see Fig. 4-7). In cicatricial pemphigoid and herpes gestationis, similar mechanisms lead to clefting at the same level, but in the latter there is also destruction of the lamina densa (see Chap. 62 and Chap. 64). Junctional blistering also occurs in the junctional forms of epidermolysis bullosa, but here it is due to the impairment or absence of molecules important for epidermal-dermal cohesion (see Chap. 65) (Table 4-3).

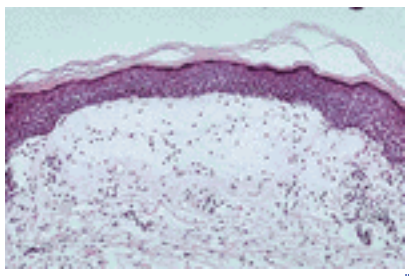

FIGURE 4-7 Bullous pemphigoid. Subepidermal (junctional) cleft formation and a perivascular and interstitial lymphoeosinophilic infiltrate are characteristic.

Junctional (at the lamina lucida)
Junctional epidermolysis bullosa
Bullous pemphigoid
Dermolytic (below basal lamina)
Epidermolysis bullosa dystrophicans
Epidermolysis bullosa acquisita
Porphyria cutanea tarda
Dermatitis herpetiformis

TABLE 4-3 **Classification of Blisters at the Dermal-Epidermal Junction by Anatomic Level With Clinical Examples**

In genuine subepidermal blistering, the target of the pathologic process is below the basal lamina (dermolytic blistering) (see Table 4-3). Reduced anchoring filaments and increased collagenase production result in dermolytic dermal-epidermal separation in recessive epidermolysis bullosa (see Chap. 65); circulating autoantibodies directed against type VII collagen in anchoring fibrils are the cause of dermolytic blistering in acquired epidermolysis bullosa (see Chap. 66). Other immunologically mediated inflammatory mechanisms result in dermolytic blistering in dermatitis herpetiformis (see below and Chap. 67), and physical and chemical changes in the junction zone and papillary body are the cause for a dermolytic cleft formation after trauma in porphyria cutanea tarda (see Chap. 149).

Pathologic Reactions of the Entire Superficial Reactive Unit

The papillary body represents a loose connective tissue matrix that supports the epidermis and contains the superficial vascular plexus, the common site of cutaneous inflammatory disease.

As mentioned above, the individual subunits of the superficial reactive unit are only rarely the isolated target of a pathologic process. Examples of isolated reaction patterns are the hyperkeratosis in ichthyosis vulgaris, the hyperproliferative acanthosis, and hyperkeratosis in lamellar ichthyosis. On the ther hand, some reaction patterns in the epidermis, such as acantholysis in pemphigus or acantholysis and dyskeratosis in Hailey-Hailey disease, are accompanied by involvement of the superficial papillary dermis. Thus, most pathologic reactions of the superficial skin involve the subunits of the superficial reactive unit jointly. However, the prominence of involvement of one of the components over the other leads to the development of certain clinical pictures. For example, the prominent involvement of the epidermis with hyperplasia leads to psoriatic plaques. Interface dermatitis can result in blister formation as in erythema multiforme. In most cases of bullous diseases dominated by inflammation, different types of inflammatory cells may be characteristic, such as eosinophils in bullous pemphigoid or neutrophils in dermatitis herpetiformis. Interestingly enough, although the transient vasodilatation of urticaria that results in dermal edema and clinical wheal formation affects the dermis predominantly, spongiosis, and even subepidermal blister formation, can occur in severe cases. A few examples of such interactions are detailed below.

CONTACT DERMATITIS (See Chap. 120) In allergic contact dermatitis, there are an inflammatory reaction of the papillary body and superficial microvascular plexus and spongiosis of the epidermis (see Fig. 4-3) with signs of cellular injury and parakeratosis. Lymphocytes infiltrate the epidermis early in the process and aggregate around Langerhans cells, and this is followed by spongiotic vesiculation (Fig. 4-8). Parakeratosis develops as a consequence of epidermal injury, and the inflammation in the papillary body and around the superficial venular plexus stimulates mitotic processes within the epidermis, which, in turn, result in acanthosis and epidermal hyperplasia.

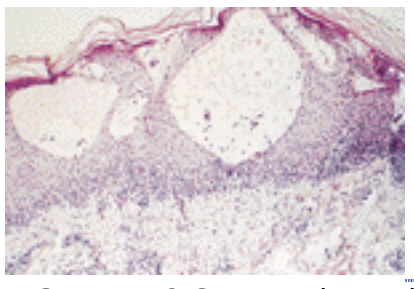

FIGURE 4-8 Contact dermatitis. Intraepidermal spongiotic vesicles and pronounced intercellular edema are present in the epidermis. The dermis contains perivascular aggregates of lymphocytes and histiocytes admixed with occasional eosinophils.

PSORIASIS (See Chap. 42) The initial lesion of psoriatic lesions appears to be the perivascular accumulation of lymphocytes and monocytoid elements within the papillary body and superficial venules and focal migration of polymorphonuclear leukocytes into the epidermis. The molecular basis for the sequence of these events is now being clarified. Acanthosis caused by increased epidermal proliferation, papillomatosis, and edema of the elongated dermal papillae together with vasodilatation of the papillary capillary loops and a denser perivascular infiltrate develop almost

simultaneously (see Fig. 4-1); the disturbed differentiation of the epidermal cells results in parakeratosis, and neutrophils infiltrating the epithelium from tortuous capillaries (squirting capillaries) lead to spongiform pustules and, in the parakeratotic stratum corneum, to *Munro's abscesses*. It appears that the stimulus for increased epidermal proliferation follows signals released from T cells that are attracted to the epidermis by the expression of adhesion molecules at the keratinocyte surface and are maintained by cytokines released by keratinocytes (see Chap. 42). It is important to note, however, that inflammation of the papillary body and superficial venules, increased epidermal proliferation resulting in acanthosis, disturbance of differentiation leading to parakeratosis, and the infiltration of neutrophils, which, in turn, also disturb the architecture of the epidermis, all result in the composite picture characteristic of psoriasis. The lesion, therefore, results from a combined pathology of the papillary body, superficial venules, the epidermis, and circulating cells. Psoriasis is a good example of the limited specificity of histopathologic reaction patterns within the skin because psoriasiform histologic features occur in a number of diseases unrelated to psoriasis.

INTERFACE DERMATITIS Inflammation along the dermal-epidermal junction associated with vacuolation characterizes interface dermatitis. This common type of reaction may lead to papules or plaques in some skin diseases and bullae on others.

ERYTHEMA MULTIFORME (See Chap. 58) Two types of reaction occur. In both there is interface dermatitis characterized by lymphocytes scattered along a vacuolated dermal-epidermal junction.

LUPUS ERYTHEMATOSUS (See Chap. 171) Inflammation, edema, and a dense lymphocytic infiltrate in the papillary body and superficial venular plexus, as well as in the deeper layers of the dermis, are a hallmark of this disorder. The main target is the dermal-epidermal junction, where immune complex deposition leads to broadening of the PAS-positive basement membrane zone, accompanied by hydropic degeneration and destruction of basal cells (Fig. 4-9). Scattered inflammatory cells also often appear along the junction. Cytoid bodies result from apoptosis of individual epidermal cells that are infiltrated and coated by immunoglobulins. The changes in the junctional zone reflect on epidermal differentiation resulting in increased orthokeratosis and parakeratosis. Lupus erythematosus readily illustrates the heterogeneity, as well as the lack of specificity, of cutaneous reaction patterns: histologically, it is possible to distinguish between acute and chronic lesions but not between cutaneous and systemic lupus erythematosus. In chronic persisting lesions, the changes in the junctional zone secondarily result in hyperplasia, hyperkeratosis, and an increased interdigitation between epidermis and connective tissue, whereas in acute cases, the destruction of the basal cell layer may lead to subepidermal blistering. Although immune complexes are primarily found within and underneath the basal lamina, blister formation within lupus lesions occurs above the lamina densa; this is in contrast to the situation in the syndrome of “bullous eruptions in lupus erythematosus” in which blister formation is due to collagen type VII autoantibodies and occurs in the dermis.

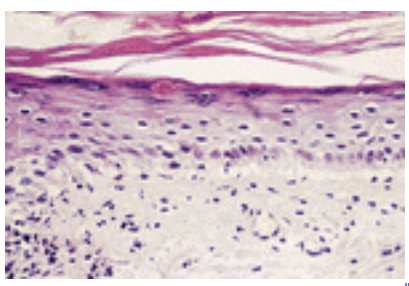

FIGURE 4-9 Lupus erythematosus. Hyperkeratosis, thinned epidermis devoid of rete ridges, and vacuolization of the basement membrane zone are present.

LICHEN PLANUS (See Chap. 49) This disease also exhibits a primarily junctional reaction pattern with accumulation of a dense lymphocytic infiltrate in the subepidermal tissue and cytoid bodies at the junction (Fig. 4-10). Lymphocytes encroach upon the epidermis, destroying the basal cells, but they do not infiltrate the suprabasal layers and blister formation only rarely ensues. The destruction of the junctional zone is compensated by a repopulation of the germinative epidermal cell layers through lateral migration from the periphery of the lesion; these alterations are accompanied by changes of epidermal differentiation—there is a widening of the stratum granulosum (*hypergranulosis*) and hyperkeratosis. Identical changes can be seen in graft-versus-host disease (see Chap. 118).

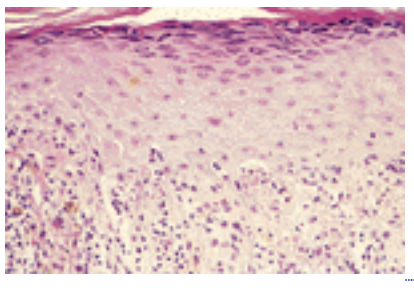

FIGURE 4-10 Lichen planus. There is hyperkeratosis, wedge-shaped hypergranulosis, basal cell vacuolization, and a lymphocytic infiltrate at the dermal-epidermal junction. This infiltrate “hugs” the basal cell layer and is associated with many cytoid bodies.

DERMATITIS HERPETIFORMIS (See Chap. 67) This condition is usually included among the classic bullous dermatoses; however, it illustrates that the preponderance of one or several pathologic reaction patterns may obscure the true pathogenesis of the condition. The deposition of IgA and complement or fibrillar and nonfibrillar sites within the tips of the dermal papillae represents the primary pathogenic phenomenon. Probably through the activation of the alternative pathway of the complement cascade, there is an influx of leukocytes, which form small abscesses at the tips of the dermal papillae, as well as inflammation and edema (Fig. 4-11). This explains why the primary lesion in dermatitis herpetiformis is urticarial or papular in nature, because only in the case of massive neutrophil infiltration will there be tissue destruction and cleft formation below the lamina densa that results in clinically visible vesiculation.

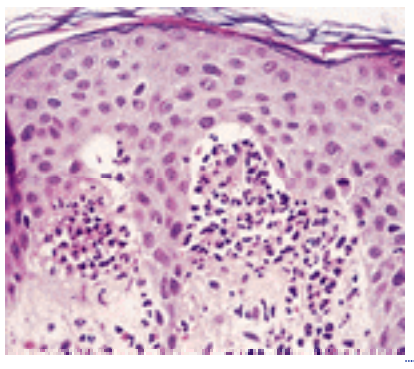

FIGURE 4-11 Dermatitis herpetiformis. Two papillae show microabscesses composed of neutrophils. Vacuolization and early cleft formation are evident in both papillae.

THE DERMIS

The dermis represents a strong fibroelastic tissue with a network of collagen and elastic fibers embedded in an extracellular matrix with a high water-binding capacity (see Chap. 6 and Chap. 14). In contrast to the tightly interwoven fibrous components of the reticular layer of the dermis, the fibrous texture of the papillary body and the perifollicular and perivascular compartments is loose, and the orientation of the collagen bundles here follows the structures they surround.

The dermis contains vascular networks situated parallel to the skin surface at various levels and connected by vertical communicating vessels. In the upper dermis, they form the superficial plexus that supplies individual vascular districts consisting of several dermal papillae. Superficial and deep networks are connected so intimately that the entire dermal vascular system represents a single three-dimensional unit consisting of vessels of different sizes and dimensions (see Chap. 19). Vascular reaction patterns of the skin should therefore not be viewed too schematically because the vessels are not as regular and geometrically arranged as may appear from schematic drawings. On the other hand, there are profound functional differences between superficial and deep dermal vascular networks, which explains the differences of homing patterns of inflammatory cells to these sites. The architecture of the vascular system is subject to regional modifications because it also depends on the thickness of the subcutaneous fat, which varies from one region to another. Blood vessels and the surrounding loose periadventitial connective tissue represent reaction units embedded three-dimensionally in the connective tissue matrix.

The papillary body with its capillaries and superficial venular plexus represents one functional unit of the dermis. It reacts rather uniformly to a wide spectrum of stimuli, and in a large number of dermatoses it represents the primary target tissue. However, as stated above, the close anatomic and functional relationship to the junctional zone and the epidermis explains why this tissue is affected only rarely in an isolated fashion. Principally, two reaction patterns occur: (1) acute inflammatory processes in which the epidermis and junctional zone are often involved together with the vascular system, and (2) more chronic processes that often remain confined to the perivascular compartment. In this context, it should be noted that the cytologic composition of an inflammatory infiltrate within the skin does not always mirror the acuity of an inflammatory process. Polymorphonuclear leukocytic infiltrates are not always synonymous with an acute process; conversely, chronic processes are not always represented by a lymphohistiocytic infiltrate.

Inflammation confined to the superficial connective tissue–vascular unit is characterized by vascular dilatation, increased permeability, edema, a reduction of intravascular blood flow, and accumulation of red blood cells in the capillary loops. Also, cellular infiltration of the perivascular tissue and an activation of preexisting perivascular histiocytic and connective tissue cells occur. Depending on the degree of vasodilatation, edema, and cellular infiltration, the macroscopic corollary of the histologic changes represents erythematous, urticarial, and infiltrative lesions (wheals, redness, papules). The release of mediators from IgE-laden mast cells in type I immune reactions is histologically manifested primarily as vasodilatation, edema of the papillary body, and a rather sparse infiltrate of leukocytes and histiocytic elements around the superficial venules (Fig. 4-12). These lesions usually resolve relatively rapidly without any residual pathology. The most characteristic example of this type of inflammation is urticaria. More massive reactions, however, lead to a dense perivascular infiltrate (Fig. 4-13A), and this may represent a transition to those processes where edema is less pronounced and where dense lymphocytic infiltrates surround the vessels in a sleevelike fashion, as is the case in some cutaneous drug eruptions (Fig. 4-13B). More dramatic alterations occur when the vascular system itself is the target of the inflammatory process, which results in a destruction of the vascular channels with all its sequelae, as is the case in necrotizing vasculitis (Fig. 4-14).

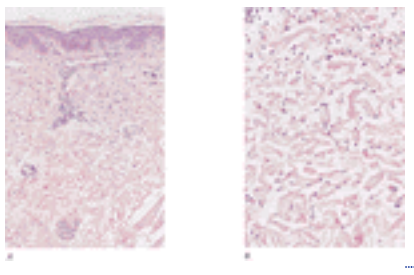

FIGURE 4-12 Urticaria. *A*. Characteristic of this reaction is a sparse, perivascular lymphocytic infiltrate with few eosinophils. Note the slight edema in the dermis and around the postcapillary venules. *B*. Higher magnification reveals separation of collagen bundles by edema and sparse interstitial inflammatory infiltrate with eosinophils.

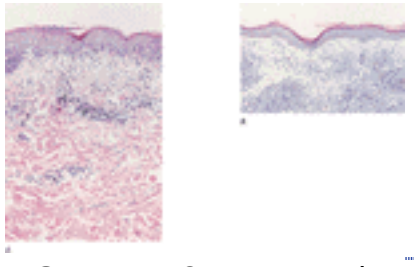

FIGURE 4-13 Drug eruption. *A*. Throughout the dermis, perivascular sleeves of mononuclear cells, mainly lymphocytes, are present about superficial and deep venules. There is slight edema in the papillary body and minimal interface dermatitis in this reaction to nifedipine. *B*. More pronounced, even nodular, mononuclear cell infiltrates around vessels in a drug reaction to a beta-blocker.

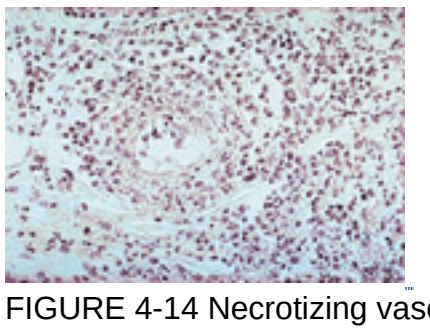

FIGURE 4-14 Necrotizing vasculitis. An inflammatory infiltrate composed mostly of neutrophils and nuclear dust is present both around and in the wall of a venule where fibrin is also deposited.

Pathologic Reactions of the Dermal Vasculature

Cutaneous necrotizing vasculitis (see Chap. 175) is an inflammatory process that involves vessels of all sizes and, depending on the caliber of vessel and the type of inflammatory reaction, it may lead to clinically and histopathologically different disease patterns. The sequence of pathologic events in vasculitis is best illustrated in necrotizing venulitis of the superficial dermal plexus, where fibrillar and amorphous eosinophilic material is deposited within the vessel wall, which is infiltrated by polymorphonuclear leukocytes and becomes anuclear and necrotic. As leukocytoclasia occurs, nuclear dust is found both within the vessels and in the tissue surrounding the vascular channels. Red blood cells and plasma appear within the perivascular tissue, and these changes give the histologic impression of an “exploded vessel” (see Fig. 4-14). Later, there will also be lymphocytes and histiocytic cells as the tissue damage is repaired. Infiltration of the vascular wall by circulating immune complexes, the activation of the complement cascade, the release of leukotactic factors that attract neutrophils, phagocytosis of immune complexes by leukocytes, and the release of hydrolytic enzymes are the pathogenic background for these massive and destructive vascular changes.

Chronic inflammatory reactions of the superficial plexus usually reveal lymphocytic infiltrates in close association with the vascular walls. An example is the superficial erythema occurring with the lymphocytic infiltrates. Also, in purpura simplex (see Chap. 176), damage to the vessel wall is much less evident than in necrotizing vasculitis, but the integrity of the vessels is also impaired as is evidenced by hemorrhage into the tissue. Lymphocytes and, as a secondary reaction, histiocytic elements partly laden with phagocytosed material constitute the inflammatory infiltrate.

The superficial venules can also be the target of cytolytic processes, with inflammation playing only a secondary role. In erythropoietic protoporphyria (see Chap. 149), endothelial cells are lysed by the phototoxic reaction; plasma, red blood cells, and cellular debris are deposited in the perivascular tissue, causing a massive inflammatory reaction. It is not known whether circulating protoporphyrins sensitize endothelial cells, which are then directly destroyed by a phototoxic reaction, or whether the phototoxic reaction is mediated by the complement system, which has been shown to be activated by porphyrins and light. Regenerating endothelial cells, which use the basal lamina of the destroyed vessel as scaffold, produce new basal lamina material so that after multiple consecutive phototoxic reactions, concentrically arranged basal laminae surround the vascular channels. This basal lamina material and serum proteins that are deposited around the vessels represent the submicroscopic substrate of the massive perivascular hyalinization that is so characteristic of this disease.

The reaction patterns described for the vascular system of the papillary body and the superficial venular plexus also occur in the deep dermis, but there are morphologic and functional differences because here larger vessels are involved. Lymphocytic infiltrates surrounding the vessels in a sleevelike fashion lead to clinical signs only when they are substantial, and then they represent the histopathologic substrate for papular or nodular lesions. This is the case with drug eruptions (see Chap. 138 and Fig. 4-13B) and it is also true for deep-seated infiltrates in lupus erythematosus. In the case of necrotizing vasculitis of the medium-sized and larger vessels, there is usually a much more pronounced inflammatory infiltrate, clinically appearing as papular and nodular lesions. Secondary changes due to the interruption of the vascular flow are more pronounced; there may be necrosis and blistering as well as ulceration. Such reactions occur in cutaneous panarteritis nodosa (see Chap. 174), where a total or partial necrosis of the vascular wall is followed by a massive inflammatory reaction, intravascular thrombosis, and hemorrhage. Granulomatous vasculitis also leads to nodular lesions, whereas the hyalinizing vascular changes and vascular occlusion in livedoid vasculitis result in ischemic necrosis (see Chap. 167).

Lymphocytic Infiltrates

Although lymphocytic infiltrates occur in the majority of inflammatory dermatoses, there are a number of pathologic processes in which such infiltrates are the most prominent feature and thus determine the histologic picture. The analysis of these infiltrates is one of the more difficult areas of cutaneous pathology. Lymphocytic infiltrates are formed in inflammatory or proliferative conditions and in the latter may represent a benign or malignant process. They may differ in

their cytologic appearance and distribution, may be confined to the periadventitial compartments of the vascular system, or may occur diffusely throughout the collagenous tissue. They may be confined almost exclusively to the reticular dermis and spare the subepidermal compartment or may exhibit pronounced epidermotropism. Because lymphocytes are a heterogeneous population of cells, the analysis of such infiltrates should take into account not only the cytomorphology and distribution pattern but also histochemical properties and immunologic markers. The analysis of round cell infiltrates by monoclonal antibodies (immunophenotyping) and determination of their clonality are at present some of the most important aspects of dermatopathology (see Chap. 157, Chap. 158, and Chap. 159).

The distribution pattern of lymphocytic infiltrates can be perivascular, diffuse, or nodular. With superficial localization, secondary involvement of the epidermis may occur and may be of importance: circumscribed parakeratosis occurs, for instance, in the figurate erythemas; pronounced acanthosis often follows inflammatory reactions following insect bites; and massive epidermotropism of lymphocytes occurs in cutaneous T cell lymphoma (see Chap. 157). Vascular involvement, such as hyperplasia of the vessel walls in angiolymphoid hyperplasia (Fig. 4-15), or vasculitis, as in lymphomatoid papulosis, is as important a diagnostic feature as is the involvement of collagen and ground substance by the myxoid changes in lupus erythematosus (Fig. 4-16), lymphocytic infiltration of Jessner-Kanof, and reticular erythematous mucinosis. Extension of the infiltrate into the fat is often a sign of a malignant lymphoma, and the development of lymphoid follicles may either indicate a lymphocytoma or be a sign of centrocytic or centroblastic lymphoma (see Chap. 158). Cytologic examination must include careful determination of whether an infiltrate is monomorphous or polymorphous. In polymorphic infiltrations, the nature of individual cells, such as eosinophils, histiocytes, or other cells, is of importance, as is the consideration of secondary alterations, such as hemorrhage and phagocytosis of cells or cell debris, melanin, or fat, by histiocytic or other mononuclear cells.

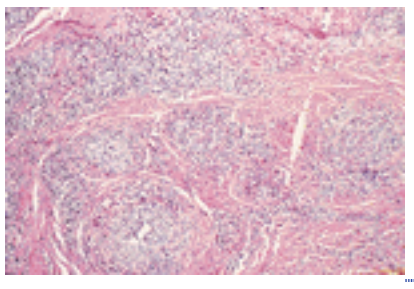

FIGURE 4-15 Angiolymphoid hyperplasia. Numerous vascular channels are surrounded by aggregates of inflammatory cells made up of lymphocytes and eosinophils. Note the protrusion of endothelial cells into the lamina of these vessels.

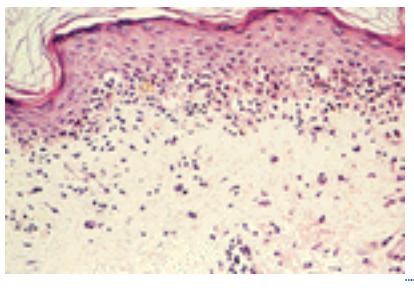

FIGURE 4-16 Mucinosis in lupus erythematosus. All the histologic features of lupus erythematosus are illustrated in this photomicrograph (see also Fig. 4-9). Another feature shown is abundant mucin in the superficial dermis, resulting in widely separated collagen bundles.

Among the many possible reaction patterns characterized by lymphocytic infiltrates, several typical patterns can be distinguished.

1. Superficial perivascular infiltrates involve the papillary body and superficial venular plexus and are often accompanied by secondary reactions of the epidermis. Lymphoid cells surround the vascular channels in a sleevelike fashion but often extend diffusely to the epidermis, which may reveal focal parakeratosis in these areas. Clinically, these changes are often characterized as palpable figurate erythemas such as erythema annulare centrifugum, but polymorphic light eruption, drug eruptions (see Fig. 4-13A), or insect bites can produce a similar histopathologic picture.
2. Lymphocytic cuffing of venules without involvement of the papillary body and the epidermis may occur in figurate erythemas but also in drug eruptions (see Fig. 4-13B). The infiltrates of chronic lymphatic leukemia show a similar distribution pattern but are usually more pronounced.
3. Perivascular lymphocytic infiltrates with a mucinous infiltration of the nonperivascular connective tissue may be found in lymphocytic infiltration of Jessner-Kanof, reticular erythematous mucinosis, or in lupus erythematosus (see Fig. 4-16) and dermatomyositis. In the latter, it may be accompanied by the epidermal changes discussed above and similar alterations in the hair follicles.
4. Nodular lymphocytic infiltrates, which extend throughout the dermis exhibiting focal accumulations of histiocytic cells and thus acquiring the appearance of lymphoid follicles, are typical of lymphocytoma cutis (see Chap. 159 and Chap. 203). Phagocytosed polychrome bodies in histiocytic cells, mitoses in the center of these infiltrates, and an admixture of eosinophils are characteristic features, as is the fact that the papillary body is usually spared so that a conspicuous Grenz zone is found between the infiltrate and the epidermis.
5. Nonfollicular lymphocytic infiltrates sparing the superficial reactive unit may also occur in benign lymphoid hyperplasias, but in these cases, the differentiation from malignant lymphoma is very difficult. Polymorphic infiltrates showing histiocytes, plasma cells, and occasional eosinophils are usually benign, whereas most malignant non-Hodgkin's lymphomas exhibit a more monomorphous picture.
6. Nodular accumulations of lymphocytes with an admixture of plasma cells and eosinophils accompanied by vascular hyperplasia are characteristic of angiolymphoid hyperplasia (see Fig. 4-15), in which blood vessel walls are

thickened and the endothelial cells appear proliferated, swollen, and enlarged. Clinical manifestations also depend on the type and extent of the histopathologic substrate. Involvement of the deep dermis may lead to the inclusion of the subcutaneous tissue into the pathologic process and may thus be manifest clinically as diffuse swelling resembling cellulitis; identical infiltrates and vascular changes confined to the upper dermis clinically lead to well-defined papular and nodular lesions.

7. Atypical lymphocytic infiltrates involving both the superficial and deeper dermis, and cytologically characterized by pronounced pleomorphism of the cellular infiltrate, are characteristic of lymphomatoid papulosis (see Chap. 159). This pseudolymphoma exemplifies the problems that arise when the histopathology of a lesion is used alone to determine whether a process is benign or malignant. Without knowledge of the clinical features and the course of disease, a definite diagnosis is extremely difficult.

Polymorphonuclear Leukocytic Infiltrates

Although neutrophils are the classic inflammatory cells of acute bacterial infections, there are diseases in which neutrophils dominate the histopathology, even in the absence of a bacterial cause. In pyoderma gangrenosum, massive neutrophilic infiltration leads to sterile abscesses, breakdown of the tissue, and ulceration (see Chap. 98). In dermatitis herpetiformis, neutrophils accumulate in the tips of dermal papillae and form papillary abscesses (see Fig. 4-11) that precede the dermolytic blister formation described earlier in this chapter (see also Chap. 67). In erythema elevatum diutinum, neutrophils are the predominant cells centering around superficial and mid-dermal vessels, which exhibit fibrinoid homogenization of their walls (toxic hyalin) and signs of vasculitis (see Chap. 95). The neutrophil is also the predominant cell in the early stages of the more common necrotizing vasculitis (see Fig. 4-14). Neutrophils also represent the majority of the often massive inflammatory infiltrate in acute febrile neutrophilic dermatosis, which is accompanied by pronounced subepidermal edema (see Chap. 94).

Granulomatous Reactions

Skin is an ideal tissue for granuloma formation in which histiocytes play a key role. Although these cells are involved at one time or another in practically all inflammatory processes, it is only the proliferation and focal aggregation of histiocytic cells that may be termed a *granuloma*. When such cells are closely clustered they resemble epithelial tissue, hence the designation *epithelioid cells*. Development of giant cells, storage of phagocytosed material, and the admixture of inflammatory cells such as lymphocytes, plasma cells, and eosinophils may render the histologic picture of a granulomatous reaction more complex. To these have to be added vascular changes and alterations in the fibrous structure of the connective tissue. Granulomas almost always lead to destruction of preexisting tissue, particularly elastic fibers, and in such instances result in atrophy, fibrosis, or scarring. Tissue damage or destruction manifests either as necrobiosis or fibrinoid or caseous necrosis, or it may result from liquefaction and abscess formation or from replacement of preexisting tissue by the histiocytic infiltrate and fibrosis.

Granulomatous reactions of the skin comprise a large spectrum of histopathologic features. Palisading granulomas surround necrobiotic areas of the connective tissue with histiocytes in radial alignment (Fig. 4-17). Granuloma annulare, necrobiosis lipoidica, rheumatoid nodules, and he juxtaarticular nodules of syphilis belong to this group. Necrosis can also develop within the granuloma proper, as is the case for fibrinoid necrosis in sarcoidosis, caseation in tuberculosis, or the necrosis developing in mycotic granulomas.

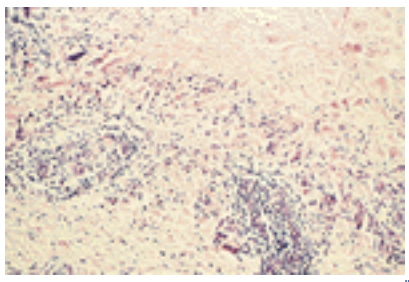

FIGURE 4-17 Granuloma annulare. A well-circumscribed palisading granuloma is seen in the dermis. The necrobiotic collagen shown on top is surrounded by histiocytes, lymphocytes, and a few scattered multinucleated giant cells.

Sarcoidal granulomas are typically characterized by naked nodules consisting of epithelioid cells, occasional Langhans' giant cells, and only a small number of lymphocytes (Fig. 4-18). In larger infiltrates, there is often fibrinoid necrosis in the center, the elastic fibers are destroyed, and healing results in atrophy. Silica, zirconium, and beryllium granulomas and a number of foreign-body granulomas may have similar histopathologic features. Consequently, the diagnosis of sarcoidosis should never be made from the histologic appearance of a skin lesion alone; instead, the diagnosis must rely on a combination of the clinical and histopathologic manifestations, the state of cellular immunity, and other symptoms (see Chap. 183). Infectious granulomas with a sarcoidal appearance may occur in tuberculosis, syphilis, leishmaniasis, Hansen's disease, or fungal infections. It is often difficult to classify granulomatous reactions within the skin by the histopathology alone, for even completely different etiologic conditions such as immunopathies and some forms of vasculitis may develop granulomas.

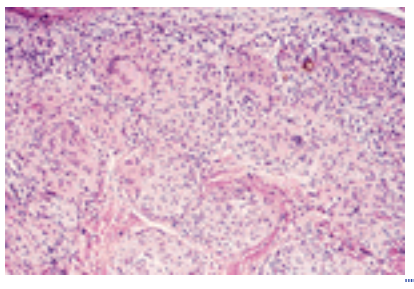

FIGURE 4-18 Sarcoidal granuloma. In the dermis numerous “naked” tubercles consisting of epithelioid cells and scant lymphocytes are seen. The overlying epidermis is atrophic.

Granulomatous reactions may either extend into the subcutaneous fat or include the superficial reactive unit. In the latter, there is a concomitant reaction of the epidermis, which responds with acanthosis or pseudoepitheliomatous hyperplasia with hyperkeratosis and intraepithelial neutrophilic abscesses, as in bromoderma, or blastomycosis.

A specific form of granulomatous reaction results when the cellular infiltrate consists almost exclusively of the key granuloma cell, the transformed monocyte, commonly referred to as a *histiocyte*. One property of this cell is its capacity to store phagocytosed material. In xanthomatous reaction patterns, histiocytes take up and store fat and are thus transformed into foam cells. They are distributed either diffusely within the dermis with the infiltrate between the collagen bundles, as is the case in diffuse normolipemic xanthomatosis, or as an aggregate infiltrate mimicking a tumor, as is present in the xanthomas occurring in the hyperlipoproteinemias and xanthelasma (see Chap. 150). Less pronounced phagocytosis of fat and giant cells is found in juvenile xanthogranuloma (see Chap. 161); this is mainly located in the upper portions of the reticular dermis and the papillary body and may also acquire a more polymorphous appearance by the admixture of lymphocytes and eosinophils and secondary acanthotic elongations of the rete ridges extending into the granuloma.

An entirely different condition with granulomatous features, in which epidermotropism of histiocytes is a diagnostic sign, is histiocytosis X, or Langerhans cell histiocytosis (see Chap. 160). Depending on the stage and the clinical type, the infiltrate may be predominantly histiocytic or mixed with eosinophils. It may be characterized by phagocytosis of finely dispersed lipid within the histiocytes. Common to all forms is the involvement of the epidermis, into which histiocytic and monocytic cells migrate, which may thus be included in the pathologic process with practically all the reaction patterns it can muster: spongiosis, acanthosis, parakeratosis, spongiotic vesiculation, subepidermal blistering, and necrosis. The identity of histiocytosis X cells with Langerhans cells explains the epidermotropism of the infiltrate in this syndrome.

Reactive proliferative processes of the histiocytic system of the skin include dermatofibroma (Fig. 4-19). There is evidence in some cases that these histiocytic nodules represent a response to insect bites. When dermatofibromas extend into the deep dermis, they may involve the superficial fat by inducing fibrosis; a superficial location involving the papillary body induces a reactive response of the epidermis. Acanthosis, proliferation of the rete ridges, and a pseudobasal cell carcinoma type of epidermal hyperplasia accompany such processes (see Chap. 102).

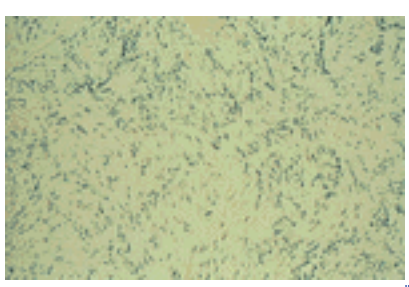

FIGURE 4-19 Dermatofibroma. The dermis exhibits spindle cell proliferations that wrap around thickened collagen bundles.

The Fibrous Dermis and Extracellular Matrix

Sclerosing processes of the skin usually reflect dynamic changes of structure and function that involve practically all compartments of this organ. The hallmark of scleroderma (see Chap. 173) is the homogenization and dense packing of the collagen bundles, a narrowing of the interfascicular clefts within the reticular dermis, and the disappearance of the boundary between this portion of the dermis and the papillary body. There is also a diminution of the small papillary and subpapillary vessels, which appear narrowed, and, in the early stages, a perivascular lymphocytic infiltrate and edema of the tissue are constant histopathologic phenomena (Fig. 4-20). The impressive thickening of the dermis not only results from an increase of its fibrous components but is also caused by the fibrosis of the superficial layers of the subcutaneous fat that follows lymphocytic infiltration and a histiocytic reaction.

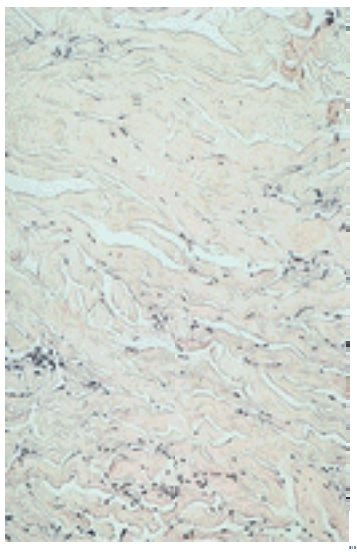

FIGURE 4-20 Scleroderma. Extensive homogenization and dense packing of the collagen bundles are seen in the dermis and extending to the subcutis. A sparse inflammatory cell infiltrate is present.

Sclerodermoid changes may be found in the toxic oil syndrome and L-tryptophan disease, eosinophilic fasciitis (see Chap. 173), and mixed connective tissue disease; they also occur in pachydermoperiostosis, where an increase of fibroblasts and ground substance accompany the sclerotic changes, and in porphyria cutanea tarda, which does not involve the subcutaneous fat and shows typical hyalinization of the papillary vessels. In lichen sclerosus et atrophicus, there is a massive edema of the papillary body and a dense lymphocytic infiltrate that initially hugs the epidermis and later separates the edematous papillary body from the reticular dermis (see Chap. 113 and Chap. 114). As sclerosis sets in, there is also a disappearance of elastic tissue from the papillary body; the concomitant involvement of the epidermis includes hydropic degeneration of basal cells, atrophy, and, at the same time, hyperkeratosis. Changes in the junctional zone in this condition may occasionally lead to a separation of the epidermis from the dermis and thus to blister formation.

Faulty synthesis or cross-linking of collagen results in a number of well-defined diseases or syndromes but leads to relatively few characteristic histopathologic changes. In the different types of the Ehlers-Danlos syndrome (see Chap. 154), the faulty collagen cannot be recognized histopathologically, and only the relative increase of elastic tissue may indicate that something abnormal has occurred in the dermis. On the other hand, pathologic changes of the elastic tissue can be recognized more easily either because elastic fibers have lost their characteristic staining properties or because they appear different with special staining techniques. In generalized elastolysis, a fragmentation of elastic fibers is the histopathologic substrate of the clinical appearance of cutis laxa, and the fragmentation and curled and clumped appearance of elastic fibers are similarly diagnostic in pseudoxanthoma elasticum (see Chap. 154). On the other hand, in actinic elastosis, the histologic substrate of dermatoheliosis, all components of the superficial connective tissue are involved (see Chap. 134). The papillary body, except for a narrow Grenz zone between it and the epidermis, and the superficial layers of the reticular dermis are filled with clumped and curled fibers that progressively become homogenized and basophilic. They are stained by dyes that have an affinity for elastic tissue and thus histochemically behave like elastic fibers; however, there is no doubt that collagen is also involved in this process.

It is not surprising that such profound changes of skin architecture are clinically apparent: the taut and firm connective tissue in scleroderma reflects the sclerotic texture and homogenization of the collagen bundles seen histologically; the loose folds of cutis laxa are a result of the fragmentation of elastic fibers; the cobblestone-like papules in pseudoxanthoma elasticum correspond to the focal aggregation of the pathologically altered elastic material; and the coarseness of skin lines and surface profile in dermatoheliosis are the clinical manifestations of the focal aggregation of elastotic material.

Changes in the extracellular matrix may occur in practically all pathologic processes of an inflammatory or a neoplastic nature. Pronounced accumulation of glycosaminoglycans occurs in inflammatory conditions such as lupus erythematosus, dermatomyositis, or granuloma annulare. In other diseases such as pretibial myxedema and scleredema adultorum (see Chap. 169 and Chap. 186), the accumulation of mucin-like material within the ground substance is the leading alteration. In scleromyxedema (see Chap. 187), similar changes may occur, but a proliferation of fibroblasts may dominate the picture and this is also reflected by the clinical appearance of the skin, which is thickened and hardened.

SUBCUTANEOUS FAT

Inflammatory processes in the subcutaneous adipose tissue take a slightly different course than in the connective tissue of the dermis because of the specific anatomy of the subcutis (see Chap. 6 and Chap. 109). Inflammation of subcutaneous fat reflects either an inflammatory process of the adipose tissue proper or a process arising in the septa; it can involve small venules and capillaries or arise from the larger muscular vessels. The histopathologic manifestations may vary accordingly. Small-vessel pathology is usually manifested locally, involving the neighboring fat lobules, while the destruction or occlusion of a larger vessel will influence the entire tissue segment supplied or drained by this vessel, possibly including even the overlying dermis. Destruction of fat, be it of a traumatic or inflammatory nature, leads to the release of fatty acids that by themselves are strong inflammatory stimuli, attracting neutrophils and scavenger histiocytes and macrophages; phagocytosis of destroyed fat usually results in lipogranuloma formation.

Septal processes that follow inflammatory changes of the trabecular vessels are usually accompanied by massive edema, infiltration of inflammatory cells, and a histiocytic reaction. This is the classic appearance in erythema nodosum (Fig. 4-21); recurring septal inflammation may lead to a broadening of the interlobular septa, fibrosis, and the accumulation of histiocytes and giant cells and may result in vascular proliferation. By contrast, in nodular vasculitis (Fig. 4-22), large-vessel vasculitis in the septal area is accompanied by necrosis of the fat, followed by massive histiocytic reactions and epithelioid cell granulomas within the fat lobules, which often result in a massive fibrotic reaction sclerosing

the entire subcutaneous fat layer, Lobular panniculitis, however, results from the necrosis of fat lobules as the primary event, as is the case in idiopathic nodular panniculitis (see Chap. 109), followed by an accumulation of neutrophils and leukocytoclasia. The lipid material derived from necrotic adipocytes contains free and esterified cholesterol, neutral fats, soaps, and free fatty acids, which, in turn, exert an inflammatory stimulus. Histiocytic cells migrate into the inflamed fat, and phagocytosis leads to foam cell formation. Epithelioid granulomas with giant cells may also result, and all types of fibrosis may develop. Fat necrosis is therefore the primary, and inflammation the secondary, event in this type of panniculitis.

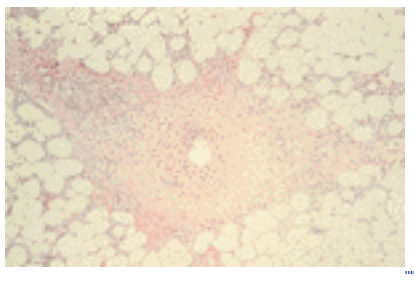

FIGURE 4-21 Erythema nodosum. A chronic granulomatous inflammatory infiltrate extends from a septal vessel along the thickened septum into the adjacent fat lobule.

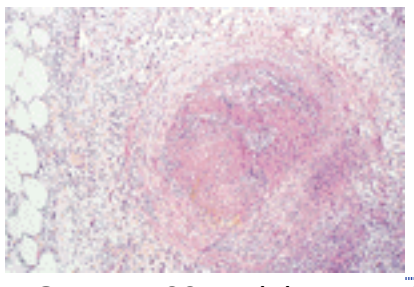

FIGURE 4-22 Nodular vasculitis. The characteristic features illustrated are severe vasculitis with necrosis of the large vessel wall and occlusion of the lumen. Necrosis of the fat lobules is present along with an acute and chronic inflammatory cell infiltrate.

The inherent capacity of the adipose tissue to respond characteristically to pathologic stimuli with necrosis, inflammation, and lipogranuloma formation also holds true for disease conditions that affect the subcutaneous tissue only secondarily or result from exogenous factors. Traumatic panniculitis also leads to necrosis of fat lobules and a reactive inflammatory and granulomatous tissue response. After the injection of oils or silicone, large cystic cavities may be formed (Fig. 4-23), whereas after the injection of pentazocine, for instance, fibrosis and sclerosis dominate the histopathologic picture. Oily substances may remain within the adipose tissue for long periods without causing a significant tissue reaction; oil cysts evolve that are surrounded by multiple layers of residual connective tissue, so that the tissue acquires a “Swiss cheese” appearance (Fig. 4-23). Animal or vegetable oils often lead to tuberculoid or lipophagic granulomas with massive histiocytic reactions, foam cells, and secondary fibrosis.

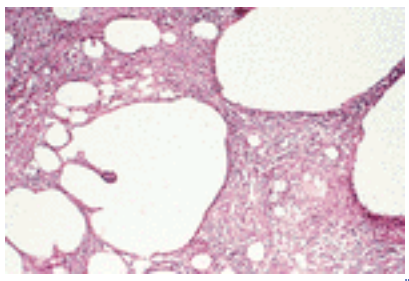

FIGURE 4-23 Injection granuloma. The architecture of the panniculus has been obliterated by acute and chronic inflammation in response to fat necrosis with resultant irregular spaces or micropseudocysts.

Panniculitis also occurs as a result of infectious agents or specific disease processes. Inflammation, necrosis, and granuloma result from infections by cocci, mycobacteria, and other bacterial organisms and also from mycotic infections where the grade of acuity of the infection and the type of organism determine whether more inflammatory and necrotizing or granulomatous processes result. On the other hand, in sarcoidosis, fat is gradually replaced by epithelioid cell nodules and, in lymphoma, by specific lymphomatous infiltrates. In lupus panniculitis, a dense lymphocytic infiltrate of the septal and lobular tissue determines the histopathologic picture, as does involvement of vessels manifesting as vasculitis. However, destruction of fat, liquefaction, and lipogranuloma may be so pronounced that the vascular component can hardly be recognized, and the histopathologic picture may resemble idiopathic nodular panniculitis.

SUGGESTED READINGS

Ackerman AB et al: *Histologic Diagnosis of Inflammatory Skin Diseases: An Algorithmic Method Based on Pattern Analysis,* 2d ed. Baltimore, Williams & Wilkins, 1997

Ackerman AB: *Resolving Quandaries in Dermatopathology.* New York, Promethean Medical, 1995

Bos JD (ed): *Skin Immune System,* 2d ed. Boca Raton, FL, CRC Press, 1997

Cerroni L et al: An Illustrated Guide to Skin Lymphoma. Oxford, Blackwell Sciences Ltd, 1998

Caputo R et al: *Pediatric Dermatology and Dermatopathology: A Text and Atlas,* vols 1–4. Philadelphia, Lea & Febiger, 1990, 1992, 1997

Crowson A et al: The Melanocytic Proliferations. A Comprehensive Textbook of Pigmented Lesions. Wiley-Liss, Inc, 2001

Elder DE et al: *Lever's Histopathology of the Skin,* 8th ed. Philadelphia, Lippincott, 1997

Farmer ER, Hood AF: *Pathology of the Skin.* 2nd ed, New York, McGraw-Hill Co Inc, 2000

Hood AF et al: A Primer of Dermatopathology, 3rd ed, Norwalk, CT, Appleton & Lange, 2002

Murphy GF et al: Inflammatory Diseases of the Skin, AFIP Fascicle, third series, AFIP September 2002

T>

Chapter 5

Lowell Goldsmith Ervin Epstein

Genetics in Relation to the Skin

PEDIGREE PATTERNS
Autosomal Dominant
Autosomal Recessive
X-Linked Recessive
VARIABILITY OF GENETIC DISEASES
PENETRANCE
EXPRESSIVITY
Complex Phenotypes
MUTATION
TRIPLET REPEATS
GENE LOCALIZATION AND IDENTIFICATION
CHROMOSOMES AND CHROMOSOMAL DISORDERS
GENETIC COUNSELING
PRENATAL DIAGNOSIS

REFERENCES

An understanding of genetic principles and methods and the special terminology of genetics is essential for the comprehension of the molecular basis, the familial clustering, and in the not too distant future, the genetic treatment of many skin diseases. [1], [2], [3], [4] and [5] Important and sometimes confusing terms are defined throughout this chapter. Patients often present with a disease in which the pattern of inheritance (e.g., autosomal dominant) is clear, and penetrance of the gene is high [i.e., those who carry the abnormal gene(s) nearly always have resulting clinical abnormalities, such as X-linked ichthyosis, xeroderma pigmentosum, epidermolysis bullosa simplex]. Individually, these diseases are uncommon; but in aggregate, they comprise a significant fraction of the more severe skin problems.

A second group of patients has diseases with familial clustering (e.g., 25 percent of patients with psoriasis may have an affected first-degree relative), but the pattern of inheritance is uncertain. This group includes very common skin problems—psoriasis, atopic dermatitis, and androgenetic alopecia.

We are now in the midst of an explosion of unprecedented accrual of precise and detailed genetic information about many of the inherited disorders of the skin—partly because of an increased awareness of familial clustering of disease but mostly because of the opportunity to apply knowledge of the sequenced human genome. This precise molecular information will make gene therapy a reality within this decade. Although eventual cures of genetic diseases by gene replacement or modification are as of yet still hoped for, there are now satisfactory treatments aimed at preventing or modifying the deleterious effects of some defective genes. Examples include zinc supplementation to treat acrodermatitis enteropathica, a low-tyrosine and low-phenylalanine diet to treat tyrosinemia II (Richner-Hanhart syndrome), the administration of oral beta-carotene for erythropoietic protoporphyria, and the avoidance of gluten in the treatment of dermatitis herpetiformis.

When the mutant gene in a single dose (or heterozygous state) results in the particular clinical phenotype, the condition is said to be *dominant;* when the mutant gene must be present in double dose (or homozygous state) to produce disease, the resulting disorder is said to be *recessive.* When the mutant gene is on the X chromosome, the condition produced thereby is called *sex-linked* or, more precisely, *X-linked*. X-linked conditions also may be dominant or recessive, depending on whether the heterozygous female does or does not show the phenotype. When the mutant gene is on one of the 22 pairs of autosomes (nonsex chromosomes), the disorder is referred to as *autosomal*.

PEDIGREE PATTERNS

An understanding of the characteristic pedigree patterns of rare, simple inherited (*Mendelizing*) disorders is essential for counseling prospective parents about the risk of having affected children. The three main patterns of inheritance are *autosomal dominant, autosomal recessive,* and *X-linked recessive*.

Autosomal Dominant

Apart from the recipients of new mutations, persons affected with autosomal dominant disorders have one affected parent, and the condition is transmitted from generation to generation. Males and females are affected in approximately equal numbers, and both can transmit the disorder. On average, when an affected person is married to an unaffected person, half the children will have the condition. Figure 5-1 illustrates an idealized autosomal dominant pedigree pattern. Figure 5-2 shows the pedigree of a kindred with monilethrix. It must be emphasized that the exact expected 50:50 ratio probably is found only when many pedigrees (or an exceptionally extensive single pedigree) are available for analysis.

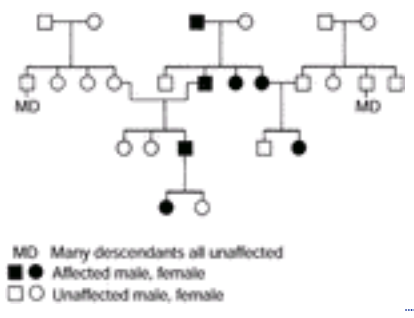

FIGURE 5-1 Idealized autosomal dominant pedigree pattern. The condition is transmitted from generation to generation by affected males or females to males or females.


FIGURE 5-2 Monilethrix. Although the degree of alopecia was highly variable, all affected persons had an affected parent. (*From McKusick VA:* Medical Genetics 1961–1963: An Annotated Review. *Oxford, England, Pergamon, 1966.*)

Autosomal Recessive

Typically, rare autosomal recessive disorders occur in siblings, both of whose parents are unaffected. The parents are related to each other more often than the average, and the rarer the condition, the more likely is such parental consanguinity. Provided that affected individuals do not marry a relative, their children are unlikely to manifest the condition. Figure 5-3 shows an idealized pedigree. Figure 5-4 illustrates a kindred with a junctional form of epidermolysis bullosa. Both parents of all the individuals marked as affected could be traced back to one common ancestral couple, one of whom presumably was heterozygous for the mutant gene. This family belonged to the Old Order Amish, where exact pedigree data are available for many generations. This is an example of inbreeding that per se does not alter significantly the frequency of genes in a population. What it does is increase homozygosity and therefore the appearance of undesirable recessive traits. If a person who is homozygous for a particular recessive gene, and therefore affected, does not reproduce because of the grave nature of the hereditary ailment, inbreeding actually may lead to a small decline of the frequency of the gene in the given population. Consanguinity plays little part in rare X-linked recessive and/or autosomal dominant disorders. Carriers of a recessive gene are usually clinically normal; a notable exception is that carriers of the gene for Fanconi's anemia have an increased incidence of skin and mucosal malignancies.

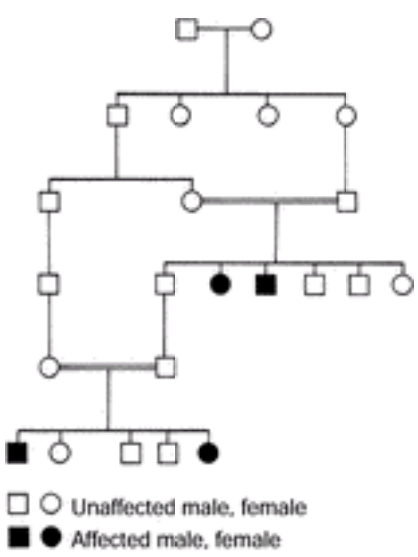

FIGURE 5-3 Idealized autosomal recessive pedigree pattern. The parents are unaffected, and consanguinity is common.

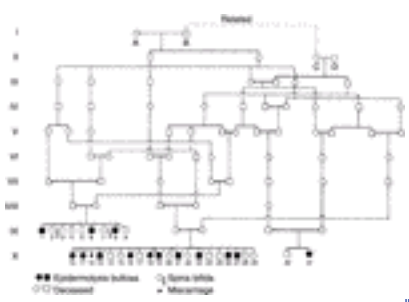
FIGURE 5-4 A junctional form of epidermolysis bullosa in a pedigree from the Old Order Amish showing considerable consanguinity.

X-Linked Recessive

These conditions occur almost exclusively in males, but the gene is transmitted by carrier females, who have the gene only in single dose (heterozygous state). The sons of an affected male all will be normal (since their single X

chromosome comes from their clinically unaffected mother). The daughters of an affected male all will be carriers (since all had to have received the single X chromosome that their father had, and that X chromosome carries the mutant copy of the relevant gene). Occasionally, some females show clinical abnormalities as evidence of the carrier state; this phenomenon can be explained by the *Lyon hypothesis.*

Dr. Mary Lyon suggested that (1) early in embryogenesis one X chromosome in each cell of the normal XX female becomes genetically inactive, (2) which X chromosome is inactive is a random matter, and (3) once it had been “decided” whether the X chromosome from the female's mother or that from her father will be the active one in a given cell, all descendants of that cell “abide by the decision.” Thus the adult female is a mosaic of two populations of cells, those with the paternal X as the active one and those with the maternal X as the active one. The inactive X chromosome forms the Barr body, or sex chromatin.

The Lyon hypothesis provides an explanation for an intermediate level of gene effect in the heterozygous female and for its rather wide variability. By chance alone, rare individuals may have all cells of a particular type with the mutant X chromosome as the inactive one, in which case no phenotypic abnormality is detectable by even the most sensitive methods. However, in many X-linked conditions, such as anhidrotic ectodermal dysplasia, some carrier females demonstrate abnormal features, suggesting that the X chromosome carrying the mutant gene is active in many cells and that the X chromosome carrying the normal gene is active in relatively few cells. Indeed, patchy abnormalities, such as the Lyon principle would predict, have been observed in females heterozygous for this gene. An idealized pedigree of X-linked inheritance is given in Fig. 5-5, and an example of a family with X-linked ichthyosis is shown in Fig. 5-6. Several individual genes, such as those for steroid sulfatase, abnormalities of which cause X-linked ichthyosis, and those for the Xg^{a} blood group, do not undergo complete inactivation, but they are the exceptions.

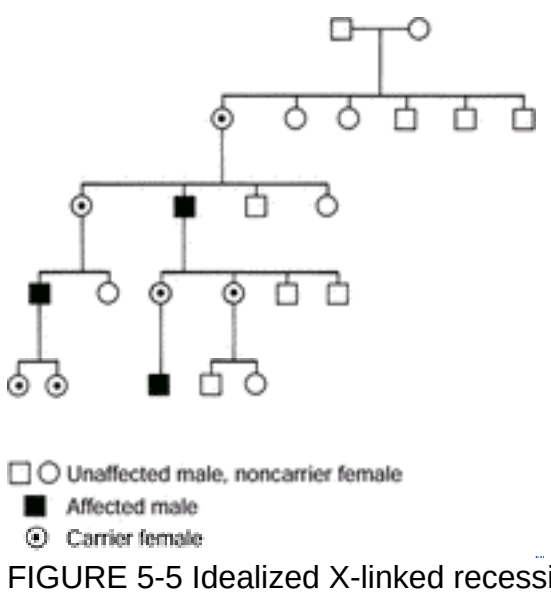

FIGURE 5-5 Idealized X-linked recessive pedigree pattern. Only males are affected, and the gene is transmitted by carrier females.

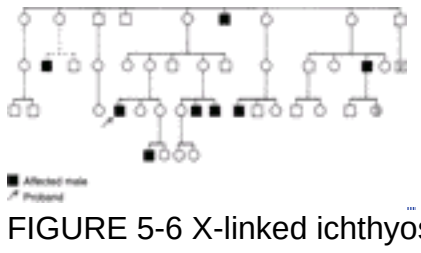
FIGURE 5-6 X-linked ichthyosis. No evidence of ichthyosis in the heterozygous females. (Dotted lines are a convention for extramarital relationships.)

In X-linked dominant inheritance, both males and females are affected, and the pedigree pattern superficially may resemble that of autosomal dominant inheritance. There is, however, one important difference. An affected male transmits the disorder to all his daughters and to none of his sons. X-linked dominant inheritance, lethal in males (Fig. 5-7), has been postulated as a mechanism in incontinentia pigmenti, a condition almost always limited to females. Affected males may be aborted spontaneously or die before implantation.

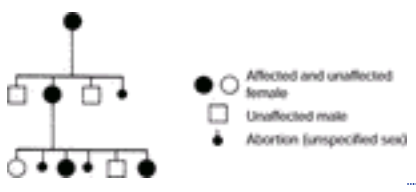

FIGURE 5-7 Idealized pedigree pattern of an X-linked dominant trait that is lethal in the male.

The term *sex-linked* is used if an autosomal disorder is confined to one sex. Such conditions may be seen in either males or females, and a definite mode of inheritance is not implied by the use of this term. When only males or females in a given family are affected with a condition, this may be an example of *sex limitation,* but it is more likely the result of chance. Sex linkage, better called *X-linkage,* results in a specific pedigree pattern, as described earlier. True sex-limited conditions—that is, disorders that have manifestations in one sex only—are rare. *Sex-influenced* is the term used when

an autosomal trait occurs more often but not exclusively in one sex.

A second possible type of sex-linked transmission is that observed with genes carried on the Y chromosome. Since this chromosome determines the maleness of an individual and must be inherited from the father, all the sons and none of the daughters of the affected person will manifest the disorder. There is some evidence that hairy ears (Fig. 5-8), a trait seen more frequently in some areas of India than elsewhere, may be transmitted in this way. An illustrative pedigree is given in Fig. 5-9. The Y chromosome codes for a variety of genes, including genes specifying a testis-specific protein, cytokine receptors, factors whose deficiency leads to azospermia, and other genes. The exact gene causing hairy ears remains to be elucidated.

FIGURE 5-8 Hairy ear rims in a male.

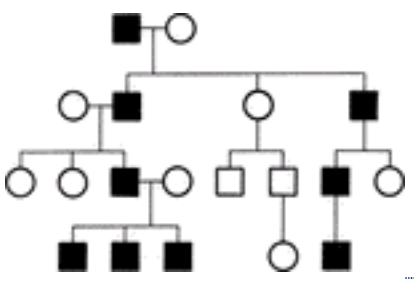

FIGURE 5-9 Idealized Y-linked pedigree pattern. All the sons of an affected male must be affected.

These disorders are examples of inheritance related to nuclear DNA, but there is also DNA in the mitochondria (mtDNA). Mitochondrial disorders frequently involve the function of the respiratory chain and oxidative metabolism, and the nervous system often is severely affected. The mitochondria in a fertilized ovum are derived from the mother, and the inheritance pattern is maternal. There is no male-to-male transmission (which by itself is characteristic of X-linked inheritance), and *all* the children of an affected woman are affected, although there may be a variation in phenotype. An idealized pedigree of this type of inheritance is illustrated in Fig. 5-10. There often is a mixture of wild-type and mutated mtDNA (defined as *heteroplasmy*) that can lead to random variation in the degree of phenotypic expression. A review of 140 children with mtDNA disease showed that 10 percent of them have skin disorders, including alopecia, pili torti, trichothiodystrophy, hypertrichosis, and hypo- and reticulated hyperpigmentation on sun-exposed areas. [6] Most of these traits are nonspecific but should be looked for in the appropriate clinical setting.

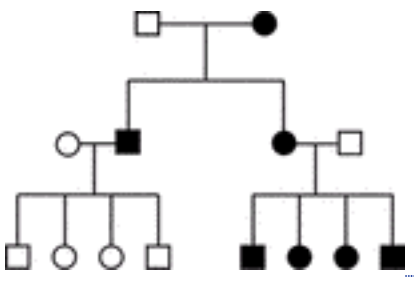

FIGURE 5-10 Idealized pedigree demonstrating mitochondrial inheritance. All the children of an affected female are affected, and there is no male-to-male inheritance.

VARIABILITY OF GENETIC DISEASES

The physician must deal with the problem of marked variability in the expression of abnormal genotypes, especially when deciding whether a new mutation has occurred and whether manifestations of a deleterious gene are present in a carrier of that gene who may be asymptomatic. In those cases in which specific quantitative biochemical tests are available, the presence of an abnormal gene, even in a completely asymptomatic carrier, can be determined.

Several terms are used to describe phenotypic (clinically appreciated) variability; their use often is confused, and a brief discussion of these terms is in order. These terms were in use before the molecular bases of the phenomena were established. They can now be reinterpreted through modern insights.

PENETRANCE

Penetrance is the presence of any detectable manifestation of an abnormal genotype. If no phenotypic manifestations of a genotype are discernible, the gene is *nonpenetrant.* Thus *penetrance* is an operational term depending on how well one can analyze for evidence of the abnormal genotype. If one can determine detailed DNA sequences of the gene determining the disease, an abnormal genotype always can be detected. If a trait is not penetrant, its expressivity must be none.

EXPRESSIVITY

Expressivity defines the degree of expression (severity) of a trait. It is a designation of the qualitative and quantitative manifestations of a specific genotype and is the variability in phenotype produced by a given genotype. Low levels of disease expression may cause familial cases of disease to appear sporadically and complicate genetic analysis. [7]

HETEROGENEITY Many diseases called by a single name have greatly disparate phenotypic abnormalities: Patients have heterogeneity in the clinical manifestations of their disease. There are several genetic reasons for such heterogeneity. First, the “disease” actually may be a collection of distinct diseases with only enough similarities to cause them to be lumped together in past classifications. For example, epidermolysis bullosa and ichthyosis today are viewed as groups of clinically distinct diseases, and the genes whose mutations cause these differing diseases themselves are distinct. Thus the gene that is mutant in epidermolysis bullosa simplex causes a defective intracellular protein, and the split is within the basal cells of the epidermis, whereas the clinically quite different junctional epidermolysis bullosa is due to mutations in genes that encode proteins that help to hold the epidermis and dermis together. It is likely that in the future the very definitions of diseases in at least some instances will move from those of a typical constellation of clinical abnormalities to those of a specific mutant gene. This change would mirror the switch of the definition of the clinical entity “consumption” to the definition of the disease tuberculosis, irrespective of whether the disease manifestations are, for example, pulmonary or cutaneous. Second, even within more narrowly defined diseases, the clinical abnormalities may be caused by mutations in different genes. Such heterogeneity is termed *locus heterogeneity* because the causative mutation may occur at differing genetic loci. This may occur because the differing genes affect independent proteins that function in the same pathway, and it is the abnormality of the pathway that causes the disease manifestations (e.g., the abnormal behavior of basal cell carcinomas may be driven by mutations in either of two interacting proteins in the same pathway—PTCH1 or SMO). Alternatively, the two different genes may encode proteins that actually act together to produce a protein complex (e.g., mutations of either the keratin-5 or the keratin-14 gene may cause epidermolysis bullosa simplex, which is caused by dysfunction of the keratin-5–keratin-14 protein complex). Third, in most genetic diseases, even those in which there is locus homogeneity—in which the clinical abnormalities are always produced by mutations of the same gene—different patients generally have mutations at different sites of the same gene. These different alleles may produce proteins that are more or less impaired in their functioning and hence may produce clinical abnormalities that are more or less severe. For example, within the spectrum of epidermolysis bullosa simplex, mutations at certain regions of keratin-14 may cause the relatively mild Weber-Cockayne type in which blisters are limited to the hands and feet and appear only with friction, whereas mutations at other sites of the same gene cause the much more severe Dowling-Meara type in which blisters are generalized and appear spontaneously. Thus, different patients have disease of differing clinical severity because they have different versions (alleles) of the gene—there is *allelic heterogeneity.* If the disease is recessive, there is a further opportunity for heterogeneity in that different patients may have different combinations of two mutant alleles—i.e., they are *compound heterozygotes.* However, patients with the very same mutation (e.g., within a single kindred) still may have disease of differing severity (expressivity). This variation may be due to different external environmental influences (e.g., it is possible to reduce markedly the severity of disease in xeroderma pigmentosum by meticulous avoidance of ultraviolet radiation exposure). In addition, no gene or encoded protein functions in isolation. Rather, they function in the context of an internal environment that varies among patients because they have different versions of other genes (*background-modifying genes*), and these versions may be relatively effective or relatively ineffective at opposing the deleterious effects of the mutant gene. As a mechanistically trivial but heuristically useful example, the development of basal cell carcinomas in patients with the basal cell nevus syndrome may be influenced greatly by skin pigmentation. Patients of African descent and dark skin color have few to no basal cell carcinomas, whereas patients of northern European descent and poor skin melanization have many more of these skin tumors.

Complex Phenotypes

PLEIOTROPY The multiple phenotypic effects due to the primary actions of an abnormal genotype are referred to as *pleiotropy*. Single autosomal genes such as those for Gardner's syndrome, pachyonychia congenita, neurofibromatosis, and basal cell nevus syndrome or the X-linked gene for Menkes' disease cause multiple phenotypic effects in several organ systems. Defining the basic molecular defect in each of these diseases leads to the physiologically based explanation of the complex phenotype. The expressivity or even the penetrance of these traits may differ in individuals in the same family or between families. The elucidation of the basic defects in these diseases allows understanding of the multiple manifestations of an abnormal genotype. In most cases, pleiotropy is not due to the close linkage of several genes on a chromosome. Those few diseases caused by deletions that remove several adjacent genes on one chromosome are termed *contiguous-gene syndromes*. For example, X-linked ichthyosis in association with Kallman's syndrome is caused by an X-chromosome deletion large enough to delete more than one gene. The Prader-Willi syndrome and the Langer-Giedion syndrome, which may have dermatologic manifestations of hypopigmentation and sparse hair, respectively, often are associated with small chromosomal deletions. In these cases, loss of activity of a portion of a chromosome containing the normal allele of a gene may “uncover” an otherwise silent mutation in a gene on the active chromosome. Epigenetic phenomena are gene-regulating activities that can persist through one or more generations and *do not* change the basic genetic code. [8], [9] Cytosine methylation and histone acetylation or methylation are the basis of imprinting. Over 40 genes are already known to be subject to imprinting. Imprinted genes “remember” the parent of origin and hence may complicate the interpretation of pedigree-derived data. The genes responsible for the Angelman syndrome (maternally derived genes expressed) and the Prader-Willi syndrome (paternally derived genes

expressed) are at the same chromosomal location and have hypopigmentation in addition to other phenotypic features. Two other terms that are useful in a discussion of some genetic diseases but that often lead to confusion are *phenocopy* and *congenital*.

PHENOCOPY Phenocopy in its broadest sense describes an individual who has the manifestations (phenotype) of a genetic disease but does not have a mutation in the putative gene (e.g., a patient with a-fucosidase deficiency has skin lesions that mimic those of Fabry's disease). Phenocopy is also used to describe those cases in which environmental (nongenetic) causes may mimic inherited diseases. The vascular lesions of the CREST (calcinosis, Raynaud's phenomenon, esophageal motility disorders, sclerodactyly, and telangiectasia) form of systemic sclerosis mimic very closely the telangiectatic lesions of Osler-Rendu-Weber disease. The recognition of phenocopies is of importance for prognosis and counseling for individual patients.

CONGENITAL The words *congenital* ("present at birth") and *familial* do not necessarily imply that a condition is genetically determined. For instance, the developmental abnormalities of newborns due to maternal ingestion of thalidomide during pregnancy are congenital but not, at least as a prime cause, "genetic," and the familial clustering of the ability to use chopsticks or to play basketball with dexterity does not necessarily imply a genetic trait.

MUTATION

A central dogma is that hereditary diseases are caused by abnormalities of DNA sequence, that is, by mutations. DNA in the region of a gene is functionally arranged in alternating blocks of sequences called *exons* and *introns.* All these sequences are transcribed into RNA, and then the introns ("intervening sequences") are spliced out to leave behind the sequences derived from the exons. This process generates the mature messenger RNA (mRNA). The DNA sequences transcribed into mRNA encode the information (three bases per amino acid) that will direct the translation from the nucleic acid "language" to the protein "language" plus regions upstream *(5-prime)* and downstream *(3-prime)* that are important in the metabolism and action of the mRNA. Mutations of a single base pair in an exon may be neutral (may leave unchanged the amino acid that is encoded, may change the amino acid that is incorporated (which may or may not affect the functioning of the encoded protein and may or may not cause phenotypic changes) or may cause premature termination or abnormal elongation of the growing protein chain (which generally abrogates the function of the protein and perhaps even its very presence in the cell). Alternatively, a single base change in an intron, especially if it is at a base adjacent to the start or end of an exon, may cause changes in the splicing—so that an intron is not removed or perhaps an exon is skipped—and thus give rise to a severely abnormal message and hence to a severely abnormal, often truncated protein. Instead of a single base change, mutations may delete or add one or more bases. These commonly lead to premature termination of translation.

TRIPLET REPEATS

Several neurologic diseases are caused by expansions of trinucleotide repeats—"runs" of three base pairs that can mutate to form longer and longer such runs. Once some expansion has occurred, further expansion appears to become more likely. Severity of disease often is related to the number of triplets in the expansion. Thus these diseases often show "anticipation," with the onset of clinical disease at progressively younger ages in succeeding generations of a kindred. The mechanisms by which these expanded repeats cause disease are incompletely understood and probably vary in different diseases. Examples of diseases caused by these expansions include Huntington's disease and myotonic dystrophy (which has early-onset androgenetic alopecia).

GENE LOCALIZATION AND IDENTIFICATION

Currently, there are two main strategies for identifying disease-causing mutations. The historical approach was to use knowledge of the manifestations of the disease and of biochemistry and cell biology to hypothesize about what the underlying defect might be. Thus several decades ago Cleaver and colleagues hypothesized that the fundamental defect underlying the extreme sensitivity to ultraviolet (UV) radiation–induced skin cancer in patients with xeroderma pigmentosum might be a failure to repair UV radiation–induced damage to the DNA. Indeed, they were able to demonstrate that repair of DNA was faulty in these patients. Progress in developing this hypothesis is discussed in Chap. 155. Similarly, when enough knowledge was accrued about the mechanisms by which skin pigment is formed normally (when there was clear knowledge of melanocytes, melanosomes, and tyrosinase as the essential enzymatic step), it was not difficult to discover that tyrosinase enzyme activity is lacking in many patients with albinism.

As another example, in the 1970s, groups in Los Angeles and Holland serendipitously found that patients with X-linked ichthyosis lack the enzyme steroid sulfatase. They and others proceeded to isolate that enzyme, to isolate the gene that carries the information for production of steroid sulfatase, to demonstrate that the disease generally arises because of a large deletion of DNA that includes the whole steroid sulfatase gene, and to learn that the failure of normal desulfation of cholesterol sulfate in the stratum corneum underlies the impaired desquamation. Thus, if the correct guess can be made or if by luck a correlation can be detected, the strategies and technologies for investigation are relatively well marked.

However, no one has made such a correct guess or has been the lucky recipient of such serendipitous correlation for most inherited disorders, including psoriasis and atopic dermatitis. For these diseases, a second strategy, that of linkage analysis, is used, and this is the most common approach for disease gene identification today. Linkage analysis has been spectacularly successful during the past 1 1/2 decades in all medical specialties, including dermatology. *Linkage* refers to the occurrence of two loci on one chromosome at sites sufficiently close together that something less than completely independent assortment takes place; that is, they tend to be inherited together. Therefore, conversely, if traits specified by two genes are inherited together all or most of the time, then the two genes probably are located near one another on the same chromosome. This principle underlies the strategy of positional cloning, that is, of identifying a gene whose abnormality causes a disease by finding its chromosomal location rather than by guessing which abnormal biochemical function might cause the disease. Thus the inheritance of the disease is compared with the inheritance of a polymorphic marker at a known chromosomal location (i.e., a "mapped" DNA polymorphism). The raw materials of such an analysis are samples of DNA from multiple members of kindreds in which the disease is inherited and probes that recognize DNA polymorphisms at specific sites. One type of polymorphism commonly studied today is that of different

length DNA fragments produced by polymerase chain reaction (PCR) amplification of specific sites with differing numbers of repeated elements, e.g., di- or tetranucleotide repeats. Once the general region of the gene has been identified, careful study of that region can identify sequences that are parts of expressed genes and eventually can identify the actual mutation underlying the disease. This process already has been performed for the whole genome. Such “careful study” has become remarkably easier with the publication of the sequence of the entire human genome—the sequence of nucleic acid bases that comprise the complete genetic information of at least a prototype of our species. Thus, once the candidate chromosomal region has been identified, it no longer is necessary to sequence the region and then identify the genes among these sequences. It is now possible to localize the gene causing the disease, even by a semiautomated genome-wide scan, and then to search the Web to identify candidate genes that can be tested for mutations in the patients. This strategy of positional cloning does not rely at all on knowledge or prescient guessing of the nature of a deranged biochemical pathway. Its power has been amply demonstrated by identification of previously unknown genes, such as those responsible for extracutaneous diseases such as Huntington's disease, Duchenne muscular dystrophy, hereditary retinoblastoma, and cystic fibrosis. These strategies have been applied to heritable Mendelian skin diseases as well, and numerous examples of successful disease gene identification are found in many chapters of this book.

With the great success of identification of genes whose mutations underlie Mendelian diseases, the field is turning now to study of non-Mendelian diseases. These diseases cluster in families, but the clustering fails to follow Mendelian inheritance rules; that is, the relationships among affected individuals cannot be explained by autosomal or X-linked dominant or recessive mechanisms. Such diseases include psoriasis and atopic dermatitis. The risk of psoriasis is markedly increased to 25 percent for those with a first-degree relative from the 2 to 5 percent risk in the general population. Evidence that much of this increase is due to shared genes rather than to shared environment comes from the study of twins. If one twin has psoriasis, the chance of a fraternal twin also having psoriasis is 25 percent, which is about the same as if the siblings were products of separate pregnancies. By contrast, the risk to an identical twin of a sibling with psoriasis is approximately 70 percent. This difference between 25 percent concordance for fraternal twins and 70 percent concordance for identical twins is taken as good evidence that the shared genes are of extreme importance in producing a susceptibility to psoriasis.

The current best-accepted hypothesis to account for this complex inheritance pattern is that susceptibility is controlled by several genes; to be susceptible, individuals must carry susceptibility alleles at more than one gene. It may be that susceptibility alleles at a small number of genes (e.g., three or four) will suffice and that each locus contributes a significant amount to the overall genetic susceptibility. However, it is not formally disproven that susceptibility may be controlled by a much larger number of genes and that susceptibility alleles at each contribute a relatively small amount of the overall genetic susceptibility. If susceptibility to the disease requires susceptibility alleles at more than a few genes, then for diseases that are relatively common (e.g., 2–5 percent for psoriasis in the European population), susceptibility alleles at the relevant genes also must be common. At this writing, the search for loci controlling susceptibility to this group of diseases has been frustratingly unsuccessful. The hope is that it may be possible to identify these genes by looking for polymorphisms at yet smaller intervals. Thus, after the initial sequencing of the genome, there followed immediately the effort to identify single-nucleotide polymorphisms (SNPs). SNPs are specific sites at which alternative bases are found in fairly high incidence (e.g., more than 5–10 percent of the alleles in a given population are the base of minor frequency—the less common allele, and the rest are the more common base—the common allele). SNPs occur as often as every 500 to 1000 bases across the genome, and millions of SNPs have been identified in the hope that they will allow finer-scale mapping of disease-associated genes. Testing of these polymorphisms in thousands of individuals at perhaps hundreds of thousands of sites seems a daunting task and must await the development of cheaper, faster, and more reliable techniques for gathering these data. The importance of these efforts is readily apparent because the diseases of complex inheritance appear to include much of the disease burden, particularly of the populations living in the industrialized parts of the world. However, beyond those diseases such as diabetes, atherosclerosis, asthma, and cancers, it also is hoped that successful unraveling of the genetic bases of complex diseases will lead to significantly improved understanding of diseases in which there is a large environmental component. These diseases include infectious diseases such as tuberculosis or leishmaniasis, in which many are infected, some have clinically apparent disease, and fewer suffer disastrous sequelae. Although environmental factors (e.g., general nutrition) surely help to control these differing responses, currently it is believed that a significant portion of the differential response to infectious diseases is controlled by genetic factors. As examples of genetic influences on the response to infectious disease, the protection afforded against malaria by heterozygosity for sickle hemoglobin has been appreciated for years, whereas the resistance to HIV infection conferred by variant chemokine receptors is a more recent finding. Linkage studies with the HLA locus have determined that celiac disease is an important model disorder because it has a very specific HLA type. HLA type HLA-DQ2 (A1*0501/B1*0201) and/or HLA-DQ8 (A1*0301/B1*0302) heterodimers are associated with the ability to form a pathogenic immune response to diet-derived gluten and provide an example of how a gene predisposes to an immune reaction to a common environmental antigen. [10] This association, however, does not explain all the susceptibility factors in celiac disease, and other genetic factors seem to be more important than environmental factors except for dietary gluten.

A potential complication in linkage studies is *linkage disequilibrium,* when there is nonrandom association between alleles at different loci. The HLA locus is the classic location that shows linkage disequilibrium, which can complicate gene identification and recombination frequency interpretation. *Haplotypes* are contiguous regions of a chromosome that have a low frequency of recombination and can be used as markers for an adjacent gene of interest. Haplotype analysis can be used to establish ancestral relations between mutant loci that may be in individuals at different geographic locations, as was done for xeroderma pigmentosum loci in families in Turkey and Italy. [11] There are now efforts to apply related strategies to genetically complex skin diseases, and several loci believed to harbor genes important in determining susceptibility (e.g., to psoriasis and atopy) have been found. A distinction is often made between *multifactorial inheritance,* the effect of several genes and the environment, and *multigenic inheritance,* the genetic component of multifactorial inheritance. In such instances, these traits will establish several characteristics: Risk to relatives will be greater than to the general population; the incidence of disease will decrease with increasing distance of genetic relationship; the risk to relatives will increase with the number of affected relatives in the pedigree; and the incidence in first-degree relatives will be greater than the incidence of the disease in the general population. Between typical one-locus (biallelic) inheritance and polygenic inheritance is an example of triallelic recesssive inheritance in the

Bardet-Biedl syndrome. [12]

One other technical innovation in the study of hereditary disorders is the insertion into an animal genome of a gene whose abnormality underlies a human disease in order to produce a transgenic animal (e.g., mouse) with the human disease. Such production of a hereditary disease by transferring a mutant gene is analogous to the production of an infectious disease by transferring the causative microbe. Similarly, both approaches allow confirmation of the etiologic role of transferred material, and both offer the possibility of testing experimental therapies in animals instead of humans. For example, insertion of a mutant keratin gene can produce murine epidermolysis bullosa simplex, and insertion of the HLA-B27 gene can produce rat psoriasiform dermatitis and ankylosing spondylitis. Alternatively, mouse DNA sequences coding for specific proteins can be deleted, and these “knockout” mice can be studied as models for human diseases caused by defects in the homologous gene.

For many disorders, it is probably valid to assume genetic equilibrium; the loss of genes from the population, due to failure of the affected individuals to have as many children as the population as a whole, is balanced by the addition of new mutant genes through the process of mutation. The lower the fertility of affected persons, the higher will be the proportion of all cases that are new mutants as opposed to familial cases. For instance, probably about 15 percent of cases of Marfan's syndrome are new mutants. In X-linked recessive conditions such as Duchenne muscular dystrophy or agammaglobulinemia, in which the affected males do not survive to have children, one-third of the cases are new mutants, and two-thirds have a carrier mother and therefore are inherited. In epidermolytic hyperkeratosis, new mutations are common.

Thus sporadic cases of hereditary disease may represent new-dominant or X-linked mutants. Another frequent mechanism for sporadic cases is the chance occurrence of only one case of a recessive disorder in the family. Human families are small, and a family may have only one child affected by a given recessive disorder. In fact, it can be calculated that of all two-child families with one child affected by a given recessive disorder, the other child will be normal in 86 percent of instances; in three-child families, only one child will be affected in 73 percent of instances; and so on.

For the sporadic cases of most autosomal dominant disorders studied from this point of view, it has been possible to demonstrate an effect of paternal age. For example, fathers of children with sporadic cases of achondroplastic dwarfism are, on average, about 7 years older than fathers of children without the disease. By contrast, for new mutations affecting a single gene, maternal age per se probably is not a factor, although a maternal age effect is well known in certain chromosomal aberrations, notably Down's syndrome.

CHROMOSOMES AND CHROMOSOMAL DISORDERS

Genes are arranged and organized in supramolecular groups, the chromosomes. Techniques for the culture of cells and analysis of their chromosomes allowed the definition of the chromosomal basis of several diseases. The use of fluorescent dyes and special staining techniques (banding) has increased the resolution of the cytogenetic techniques possible with the light microscope. Besides a large number of congenital diseases diagnosable by chromosomal analysis, acquired diseases, such as chronic myelogenous leukemia, some T cell lymphomas (mycosis fungoides), and retinoblastoma, also have characteristic chromosomal alterations.

In clinical practice, lymphocytes are stimulated to divide by phytohemagglutinin, and their chromosomes are then studied. The chromosomes of a single such cell are examined with light microscopy at a magnification of about 1800×, and the 46 chromosomes are arranged in what is known as a *karyotype.* The autosomes occur in 22 pairs; the sex chromosomes are X and Y in the male and two X's in the female. Each of the 46 chromosomes consists, at this state of cell division (metaphase), of two chromatids attached at what is called the *centromere.* Each chromatid is destined to form the particular chromosome in one of the two daughter cells.

Abnormalities of chromosome number include trisomy (three of a particular chromosome rather than two), monosomy (absence of an autosome), deletion of a long or a short arm of a chromosome, and the presence of an additional portion of a chromosome (often because of translocation). Since multiple genes will be lost or increased due to a chromosomal aberration, the disorders associated with chromosomes often are serious (or even lethal) and may involve malformations of many organ systems. Skin tumors may lose portions of chromosomes and exhibit *loss of heterozygosity* after one of the two alleles of a gene (the normal allele) is altered or “lost.” Such deletion is the “signature” of a nearby tumor-suppressor gene that also is lost along with one allele of the polymorphic marker being assessed.

In certain of the chromosomal disorders, the skin manifestations of the disease are prominent. The prominent skin manifestations are grouped in Table 5-1. The complete phenotypes of many of these syndromes are discussed in other sections of this book.



TABLE 5-1 **Skin Manifestations Associated with Chromosomal Defects (and Frequency of Traits)**

Several disorders with prominent skin manifestations have evidence of chromosomal instability that is detectable by karyotypic analysis of the cultured cells (Table 5-2). Detailed descriptions of these disorders are given elsewhere in this book. Malignancies of various types are increased in these diseases. In ataxia-telangiectasia and Fanconi's anemia, there is evidence that heterozygotes have an increased incidence of cancer.

TABLE 5-2 **Genetic Diseases with Skin Manifestations, Neoplasia, and Chromosomal Instability**

GENETIC COUNSELING

Genetic counseling is an integral part of the practice of medicine and usually requires the services of a specialist in medical genetics. Once the diagnosis is established beyond doubt and the mode of inheritance is known, every dermatologist should be able to advise patients correctly and sympathetically. Familiarity with the disease in question allows the dermatologist to discuss with assurance the disease, its various manifestations, and its degree of variability. Genetic counseling must be based on an understanding of genetic principles and on a familiarity with the usual behavior of hereditary and congenital abnormalities not only in terms of mode of inheritance but also in terms of range of severity, social consequences of the disorder, and the availability of therapy.

Counseling should include an explanation of the nature of the defect, the likelihood of recurrence, and what recurrence would entail. Besides being preventive medicine, counseling often relieves parental guilt and can allay rather than increase anxiety. For example, it may not be clear to the person that he or she cannot transmit the given disorder. The unaffected brother of a patient with Fabry's disease or with X-linked ichthyosis need not worry about his children being affected or even carrying the abnormal allele, but he may not know this. The adult unaffected son of a patient with epidermolytic hyperkeratosis (a condition inherited as a dominant) also will not transmit the condition to his children. A person with the recessively inherited form of pseudoxanthoma elasticum (PXE), which leads to serious visual impairment and vascular disease, will have children who will all be clinically normal, provided that he or she does not marry a person who is heterozygous for the PXE gene. In many congenital malformations, such as congenital heart disease and harelip–cleft palate syndrome, and in disorders such as epilepsy, the risk is of the order of a few percent, but the patient often has an exaggerated impression of the risk in future pregnancies.

Generally, unaffected parents who give birth to one child affected with a rare autosomal dominant disorder (e.g., epidermolytic hyperkeratosis) have a negligible chance of having a second affected child. However, such a happy prognosis requires some qualification because the mutation may have occurred not during the development of the sperm or ovum from which the affected child developed but rather during development of the parent so that the parent actually is a mosaic of normal and mutant cells. If the testes or ovaries contain some of the mutant cells, a condition termed *germ-line mosaicism,* then, for counseling purposes, the clinically unaffected parents must be considered as affected; therefore, as many as half the children also will be affected. Of particular interest to dermatologists are instances in which patients with localized lesions with histology resembling that found in generalized disease (e.g., nevoid, localized Darier's disease, or epidermolytic hyperkeratosis) may be such mosaics who carry the mutation in a small population of skin cells as well as in some germinal cells. Their children then may carry the mutation in all skin cells and have the generalized condition, such as Darier's disease or epidermolytic hyperkeratosis. Hence it is worthwhile (if not necessary) to examine carefully the parents of a child with apparently new mutations causing generalized disease for the presence of localized disease of the same type as that of their child because such a finding would greatly change the estimate of the likelihood of subsequent children being affected.

Special problems that arise during nondirective counseling include the fact that the parents and patients often have a limited knowledge of biology, genetics, and probability. The burden imposed by a disease rather than the strict mathematical risk of recurrence often determines the decision about reproduction. Physicians must be sensitive to cultural and religious beliefs that often determine the attitude of the parents and family to the concept of risk and to the significance and burden associated with disease. It must be remembered that if a couple has three children with a given recessive disorder, then the chance of a fourth being affected is still 1:4. “Chance has no memory,” and even if the couple has 10 children, the chance with each succeeding pregnancy remains 1:4. Similarly, with autosomal dominant

conditions, with one parent affected, the chance of each child having the same condition is 1:2.

The prevailing philosophy in giving genetic counseling is that the counselor states the risk in as precise mathematical terms as possible (with ancillary information on the range of severity that can be expected, the prospects for treatment, and so on) and leaves the decision about the course of action to the prospective parents. Contact information for patient advocacy groups, many of which provide further information for patients and families, is listed in individual chapters and is available online (http://www.aad.org/patientadvocacy.htlm).

Prognosis and counseling for those conditions in which the genetic basis is still unclear is more difficult. In such circumstances, empirical data should be used. Persons can be advised, for example, that if both parents have psoriasis, the probability is 60 to 75 percent that a child will have psoriasis; if one parent and a child of that union have psoriasis, then the chance is 30 percent that another child will have psoriasis; and if two normal parents have produced a child with psoriasis, the probability is 15 to 20 percent for another child with psoriasis.

PRENATAL DIAGNOSIS

Molecular diagnoses (identification of specific mutations in individual patients/families) are available for a fee through several laboratories. One company focused on molecular diagnosis of genetic skin diseases is GeneDx (www.genedx.com/240-453-6285). In the current absence of effective treatment for many hereditary skin diseases, prenatal diagnosis can provide much appreciated information to couples at risk of having affected children. Three strategies are available.

First, the abnormal genotype may be demonstrable. This soon will become the predominant method of disease detection. Thus identification of the defect of genomic DNA in specific families (e.g., with tyrosinase-negative albinism, most types of epidermolysis bullosa, some severe forms of ichthyosis, and neurofibromatosis) allows analysis of the DNA of noncutaneous fetal cells, generally rapidly and efficiently.

Second, simple karyotyping of fetal cells obtained by chorionic villous sampling or amniocentesis can establish a diagnosis of chromosomal abnormalities and can establish fetal sex, which may indicate the presence of an unaffected fetus should it be a girl and the disease be a recessive X-linked trait.

Third, the phenotype of the disease may be demonstrable. Fetoscopy—direct visualization of the fetus—and skin biopsy in utero allow nearly routinely the prenatal diagnosis of harlequin fetus and some other types of ichthyosis, some forms of epidermolysis bullosa, and albinism. Alternatively, the enzyme deficiency (e.g., steroid sulfatase in kindreds with recessive X-linked ichthyosis) may be demonstrable in noncutaneous fetal cells.

Some dermatologic disorders for which the pattern of inheritance has been established are listed in Table 5-3 and Table 5-4. They are separated into groups on the basis of their major phenotypic features. For more detail, [12], [13], [14], [15], [16] and [17]) *McKusick's Catalog of Inherited Diseases,* which is on line (http://www3.ncbi.nlm.nih.gov/omim/), has an exhaustive listing of diseases, is continually updated, and is very well referenced.

TABLE 5-3 **Autosomal Dominant Skin Diseases (Classified According to Major Skin Phenotypic Features)**

Blistering	Hyperkeratosis (cont'd)
Acrodermatitis enteropathica	Mal de Meleda
Congenital erythropoietic porphyria	Refsum's syndrome
Epidermolysis bullosa dystrophica	Sjögren-Larsson syndrome
Epidermolysis bullosa lethalis	Tyrosinemia II (Richner-Hanhart syndrome)
Tyrosinemia II	Hypopigmentation
Connective tissue abnormalities	Fanconi's syndrome
Alkaptonuria	Gaucher's disease
Cockayne's syndrome	Niemann-Pick disease
Conradi's disease	Wilson's disease
Cutis laxa	Hypopigmentation
Ehlers-Danlos syndrome	Albinism
Homocystinuria	Chediak-Higashi syndrome
Lipoid proteinosis	Phenylketonuria
Mucopolysaccharidoses	Light sensitivity
Progeria	Albinism
Pseudoxanthoma elasticum	Aspartylglucosaminuria
Seip-Lawrence syndrome	Cockayne's syndrome
Werner's syndrome	Congenital erythropoietic porphyria
Hair abnormalities	Hartnup's disease
Argininosuccinic aciduria	Phenylketonuria
Biotin-responsive carboxylase deficiency	Xeroderma pigmentosum
Cartilage-hair hypoplasia	Multiple skin papules
Chediak-Higashi disease	Epidermodysplasia verruciformis
Cornelia de Lange syndrome	Farber's lipogranulomatosis
Hallermann-Streiff syndrome	Hunter's syndrome
Homocystinuria	Juvenile fibromatosis
Marinesco-Sjögren syndrome	Lipoid proteinosis
Mucopolysaccharidoses	Pseudoxanthoma elasticum
Low-sulfur hair syndrome (trichothiodystrophy)	Skin ulcers
Phenylketonuria	Prolidase deficiency
Vitamin D-resistant rickets (type II) with alopecia	Werner's syndrome
Werner's syndrome (premature graying)	Tumors
Hyperkeratosis	Xeroderma pigmentosum
Conradi's syndrome	Vascular skin lesions
Harlequin fetus	Acro-telangiectasia
Ichthyosiform erythroderma (nonbullous)	Bloom's syndrome
Ichthyosis, lamellar, of the newborn	Fucosidosis type II
Keratoderma palmaris et plantaris with corneal dystrophy	Rothmund-Thomson syndrome
Keratoderma palmaris et plantaris with periodontopathia (Papillon-Lefèvre syndrome)	Sialidosis, juvenile type II

TABLE 5-4 **Autosomal Recessive Skin Diseases (Classified According to Major Skin Features)**

In summary, for a large number of conditions seen in dermatologic practice, exact information is available about their mode of inheritance, and the basic principles of genetic counseling have been established. With some common disorders such as atopic eczema and psoriasis, the inheritance has, however, not been established beyond doubt, and the etiology is probably multifactorial. In these circumstances, counseling necessarily is more indefinite, but the chance of an affected person having affected children or of unaffected parents with one affected child having other children with the disorder is less than in single-gene conditions and should not be exaggerated.

REFERENCES

1. Genomics Issue. *Arch Dermatol* **137**: 11 (November) [entire issue], 2001

2. Collins F, Guttmacher A: Genetics moves into the medical mainstream. *JAMA* **286**:2322, 2001

3. McKusick V: The anatomy of the human genome: A neo-Vesalian basis for medicine in the 21st century. *JAMA* **286**:2289, 2001

4. Subramanian G et al: Implications of the human genome for understanding human biology and medicine. *JAMA* **286**:2296, 2001

5. Emery A, Rimon D: *Principles and Practice of Medical Genetics,* 3d ed. Edinburgh, Churchill Livingstone, 1996

6. Bodemer C et al: Hair and skin disorders as signs of mitochondrial disease. *Pediatrics* **103**:428, 1999

7. Newman J et al: Mutation in the gene for bone morphogenetic protein receptor II as a cause of primary pulmonary hypertension in a large kindred. *N Engl J Med* **345**:319, 2001

8. Ferguson-Smith A, Surani M: Imprinting and the epigenetic asymmetry between parental genomes. *Science* **293**:1086, 2001

9. Jones P, Takai D: The role of DNA methylation in mammalian epigenetics. *Science* **293**:1068, 2001

10. Papadopoulos G et al: Interplay between genetics and the environment in the development of celiac disease: Perspectives for a healthy life. *J Clin Invest* **108**:1261, 2001

11. Gozukara EM et al: A stop codon in xeroderma pigmentosum group C families in Turkey and Italy: Molecular genetic evidence for a common ancestor. *J Invest Dermatol* **117**:197, 2001

12. Katsanis N et al: Triallelic inheritance in Bardet-Biedl syndrome, a Mendelian recessive disorder. *Science* **293**:2256, 2001

13. Moss C, Savin J: *Dermatology and the New Genetics*. Oxford, Blackwell, 1995

14. Novice F et al: *Handbook of Genetic Skin Disorders*. Philadelphia, Saunders, 1994

15. Scriver CR et al: *The Metabolic and Molecular Bases of Inherited Disease,* 8th ed. New York, McGraw-Hill, 2001

16. Spitz J: *Genodermatosis: A Full-Color Guide to Genetic Skin Disorders*. Baltimore, Williams & Wilkins, 1996

17. Sybert V: *Genetic Skin Disorders*. New York, Oxford University Press, 1997

T>

Chapter 6

David Chu Anne Haake Karen Holbrook Cynthia Loomis

The Structure and Development of Skin

THE EPIDERMIS
Overview
The Keratinocyte
Layers of the Epidermis
Regulation of Epidermal Proliferation and Differentiation
Integrins
Growth Factors
Cytokines
Retinoids
Calcium
Apoptosis
NONKERATINOCYTES OF THE EPIDERMIS
Melanocytes
Merkel Cells
The Langerhans Cell: A Nonkeratinocyte Localized in Suprabasal Epidermal Layers
THE DERMAL–EPIDERMAL JUNCTION
THE DERMIS
Connective Tissue Matrix of the Dermis
The Diffuse and Filamentous Dermal Matrix
Organization of the Dermis: Major Regions of the Dermis55
The Cutaneous Vasculature
Nerves and Receptors of the Skin
THE HYPODERMIS
DEVELOPMENT OF SKIN
Overview
Epidermis
Specialized Components of the Dermis
SUBCUTIS
DERMAL–EPIDERMAL JUNCTION
DEVELOPMENT OF SKIN APPENDAGES
Hair
Sebaceous Glands
Nail Development
Eccrine and Apocrine Sweat Gland Development
PRENATAL TESTING OF CONGENITAL SKIN DISORDERS

REFERENCES

Much of the complex structure of skin can be explained in terms of the function of its component cells, cellular organelles, and biochemical composition. This broad image has resulted from the application of immunology, biochemistry, physiology, transgenic models, biophysics, and molecular biology often used in combination with various forms of microscopy, and from alterations in structural and regulatory proteins that are the molecular basis of genodermatoses and skin tumors. This chapter presents a unified concept of structure and function of skin organized according to skin region. These divisions are not independent—they are interdependent, functional units; each region of the skin relies upon and is integrated with the surrounding tissue for regulation and modulation of normal structure and functions at molecular, cellular, and tissue levels of organization.

THE EPIDERMIS

Overview

The epidermis is a continually renewing, stratified, squamous epithelium that keratinizes and gives rise to derivative structures (pilosebaceous units, nails, and sweat glands) called appendages (Fig. 6-1, Fig. 6-2, and Fig. 6-3). It is approximately 0.4 to 1.5 mm in thickness, as compared to the 1.5- to 4-mm full-thickness skin. The majority of cells in the epidermis are keratinocytes that are organized into four layers named for either their position or a structural property of the cells. Viable cells move outwardly from the basal layer to form layers of progressively more differentiated cells; terminally differentiated (keratinized) keratinocytes are found in the stratum corneum. Intercalated among the keratinocytes at various levels in the epidermis are the immigrant cells—melanocytes and Langerhans cells—and Merkel cells. The melanocytes and Langerhans cells migrate into the epidermis during embryonic development while Merkel cells probably differentiate in situ. Other cells, such as lymphocytes, are transient inhabitants of the epidermis and are extremely sparse in normal skin. The epidermis rests on, and is attached to, a basal lamina that separates epidermis and dermis and mediates their attachment. There are many regional variations in the structure and properties of the epidermis and its appendages; some are apparent grossly, such as thickness (e.g., comparing palm with flexor forearm); other regional differences are microscopic.

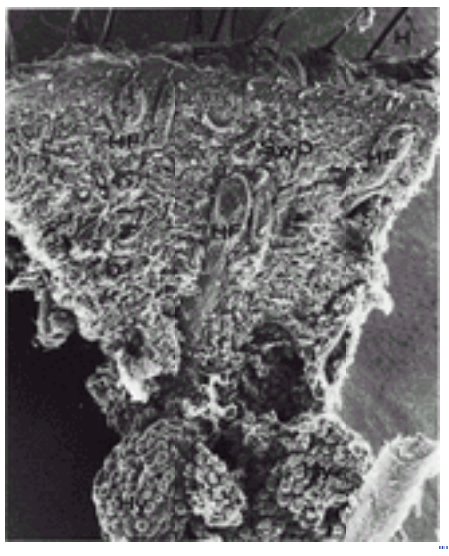

FIGURE 6-1 Scanning electron micrograph of full-thickness skin from a newborn infant illustrating all regions of the skin and the appendages. D, dermis; E, epidermis; H, hair; HF, hair follicle; Hy, hypodermis; and SwD, sweat duct. (*From Holbrook KA: An histological comparison of infant and adult skin, in Neonatal Skin Structure and Function, edited by H Maibach, EK Boisits. New York, Marcel Dekker, 1982, p 3, by courtesy of Marcel Dekker.*)

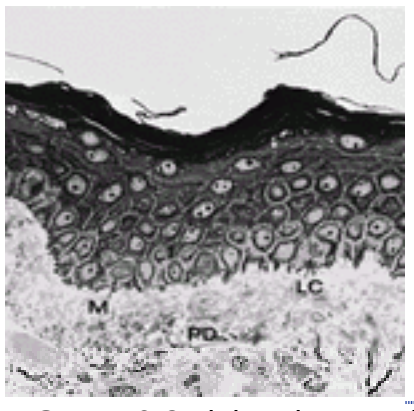

FIGURE 6-2 Light micrograph of adult epidermis and papillary dermis (PD). Note the shapes of the cells in each layer. A melanocyte (M) and Langerhans cells (LC) are present among keratinocytes of the basal layer. (*From Holbrook K: Structure and Development of the Skin, in Pathophysiology of Dermatologic Disease, edited by NA Soter, HP Baden. New York, McGraw-Hill, 1991, 2nd edition, p 5, with permission.*)

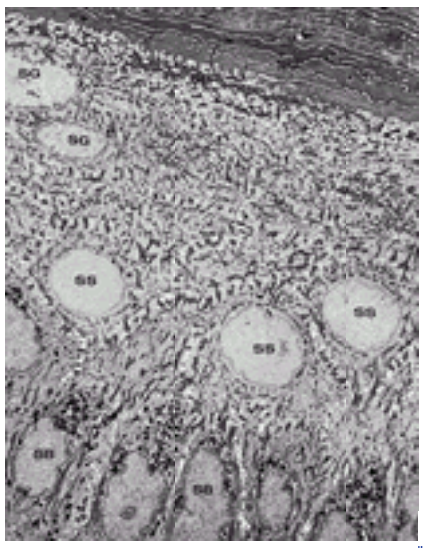

FIGURE 6-3 Full-thickness adult epidermis from a black individual. Basal (SB), spinous (SS), granular (SG), and cornified (SC) layers are shown. Melanosomes (*arrows*) are evident in cells of all layers. Note the changes in distribution and organization of keratin filaments. (*From Holbrook K: Structure and Development of the Skin in Pathophysiology of Dermatologic Disease, edited by NA Soter, HP Baden. New York, McGraw-Hill, 1991, 2nd edition, p 4, with permission.*)

The Keratinocyte

The keratinocyte is an ectodermally derived cell that constitutes at least 80 percent of the epidermal cells. All keratinocytes contain cytoplasmic keratin intermediate filaments in their cytoplasm and form desmosomes or modified desmosomal junctions with adjacent cells. Other features of keratinocytes depend upon their location within the epidermis.

Keratin filaments are a hallmark of the keratinocyte and other epithelial cells (reviewed in Refs. [1] and [2]). Predominantly, they serve a structural (cytoskeletal) role in the cells. More than 30 different keratins—approximately 20 epithelial and 10 hair keratins, all within a range of 40- to 70-kDa molecular mass—have been identified in epithelial cells, catalogued, and assigned a number. The keratins are separated into acidic (type I; cytokeratins K10 to K20) and basic-to-neutral (type II; cytokeratins K1 to K9) subfamilies based on their isoelectric points, immunoreactivity, and sequence homologies with type I and type II wool keratins. Keratins assemble into filaments both within cells and when reconstituted in vitro as “obligate heteropolymers,” meaning that a member of each family (acidic and basic) must be coexpressed in order to form the filament structure. The coexpression of specific keratin pairs is dependent on cell type, tissue type, developmental stage, differentiation stage, and disease condition. Thus, understanding how keratin expression is

regulated provides insight into epidermal differentiation.

Layers of the Epidermis

EPIDERMAL DIFFERENTIATION DEFINES THE CHARACTERISTICS OF THE EPIDERMAL LAYERS The characteristics of each epidermal layer reflect the mitotic and synthetic properties of the keratinocytes and their state of differentiation. Keratinization is a genetically programmed, carefully regulated, complex series of morphologic changes and metabolic events that occur progressively in postmitotic keratinocytes and involve (1) an increase in cell size and flattening of cell shape; (2) the appearance of new cellular organelles and the structural reorganization of those present; (3) change from a generalized cellular metabolism to a more “focused” metabolism associated with the synthesis and modification of molecules (structural proteins and lipids) related to keratinization; (4) alterations in the properties of the plasma membrane, cell surface antigens, and receptors; (5) the eventual degradation of cellular organelles including internucleosomal chromatin fragmentation characteristic of apoptosis; and (6) dehydration. Each stage of differentiation becomes more specialized in cell structure and function. The end point of keratinization is a terminally differentiated, dead keratinocyte (corneocyte) that contains keratin filaments, matrix protein, and a protein-reinforced plasma membrane with surface-associated lipids. Differentiation is a controlled series of events regulated by both extrinsic (environmental) and intrinsic (systemic and genetic) factors; thus it is vulnerable to alteration at different levels in the keratinization pathway. For many genetic diseases of keratinization, it has been possible to identify a specific defect in an enzyme, the synthesis of a structural protein, or an alteration in lipid metabolism. Understanding this process provides a rational basis for pharmacologic management of some of these disorders.
THE BASAL LAYER The basal layer or stratum germinativum contains mitotically active, columnar-shaped keratinocytes that attach to the basement membrane zone and give rise to cells of the more superficial epidermal layers (Fig. 6-2 and Fig. 6-3). Basal cells contain a large nucleus with little marginated heterochromatin and a prominent nucleolus. The typical “housekeeping” organelles, Golgi, rough endoplasmic reticulum, mitochondria, lysosomes, and ribosomes are present in the cytoplasm; in addition, there are membrane-bound vacuoles that contain pigmented melanosomes transferred from melanocytes by phagocytosis (Fig. 6-3 and Fig. 6-4).

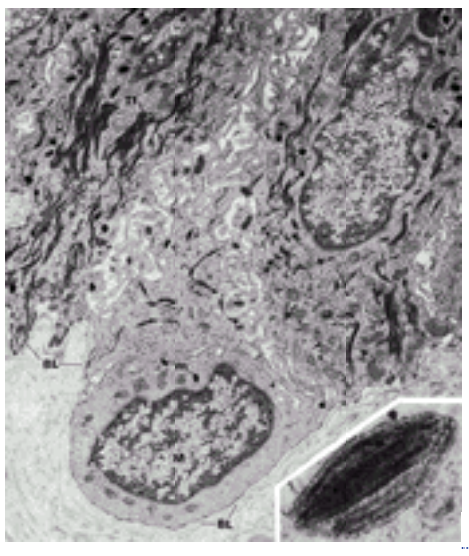

FIGURE 6-4 Basal layer of the epidermis. Melanocyte (M) is present at the dermal–epidermal junction protruding into the dermis, still above the basal lamina (BL). It can be distinguished from the keratinocytes by the absence of keratin filaments (Tf) and the presence of melanosomes (m). ×10,000. Inset: Melanosome, ×130,000.

The keratin filaments in basal cells are in fine bundles organized around the nucleus, and they insert into desmosomes and hemidesmosomes. The K5 and K14 (approximately 58 kDa/50 kDa) pair of keratins are expressed in the basal layer of the epidermis and other stratifying epithelia. Other keratins are expressed in small subpopulations of basal keratinocytes, including K15 and K19, which are associated with putative stem cells. [3], [4] Microfilaments (actin, myosin, and a-actinin) and microtubules are other cytoskeletal elements present in basal cells. Some of the microfilamentous components of the cytoskeleton are also important links with the external environment via their association with the integrin receptors present on basal keratinocytes. Integrins are a large family of cell surface molecules involved in cell-cell and cell-matrix interactions, including adhesion and initiation of terminal differentiation. The basal layer is the primary location of mitotically active cells of the epidermis. Not all basal cells, however, display equal proliferative potential. Based on cell kinetic studies, three populations coexist within this layer: stem cells, transient amplifying cells, and postmitotic cells. Functional evidence for the existence of long-lived epidermal stem cells comes from both in vivo and in vitro studies. [5], [6] Because epidermal cells isolated from small biopsy specimens can be expanded in tissue culture and can be used to reconstitute sufficient epidermis to cover the entire skin surface of burn patients, such a starting population must contain long-lived stem cells with extensive proliferative potential. The tissue localization of putative epidermal stem cells has been based in part on stem cell characteristics defined in other self-renewing systems, such as bone marrow and fetal liver. Under stable conditions, stem cells cycle slowly; only under conditions requiring more extensive proliferative activity, such as during wound healing or after exposure to exogenous growth factors, do stem cells undergo multiple, rapid cell divisions. A large amount of data supports the existence of multipotent epidermal stem cells within the bulge region of the hair follicle based on these traits. Additional evidence suggests that a subpopulation of surface epidermal basal cells also possesses stem cell characteristics. These basal stem cells appear to be clonogenic, progress rapidly through S-phase of the cell cycle, and divide infrequently during stable self-renewal (retaining ^{3}H-thymidine label over long periods). Additionally, they are capable of cell division in response to exogenous and endogenous agents. The second type of cell, the transient amplifying cells of the stratum germinativum, arise as a subset of daughter cells produced by the infrequent division of stem cells. These transient amplifying cells provide the bulk of the cell divisions needed for stable self-renewal and are the most common cells in the basal compartment. After undergoing several cell divisions, these cells give rise to the third class of epidermal basal cells, the postmitotic cells. It is the postmitotic cells that undergo terminal differentiation, detaching from the basal lamina and migrating superficially, ultimately differentiating into a corneocyte. In humans, the normal transit time for a basal cell, from the time it detaches from the basal layer to the time it enters the stratum corneum, is at least 14 days. Transit through the stratum corneum and desquamation require another 14 days. These three functional classes of epidermal basal cells (stem cells, transient

amplifying cells and postmitotic cells) are difficult to distinguish in situ based solely on morphology or protein expression. The term *epidermal proliferative unit* has been used to describe vertical columns of progressively differentiating cells in the epidermis (see Chap. 7). Evidence for such columns has come from cell lineage studies and the preferential tracking of a fluorescent dye across gap junctions joining cells within vertical columns rather than laterally within a horizontal plane of cells. Integrin immunolocalization studies, however, suggest that stem cells are largely concentrated in focal areas of the epidermis, such as the deep rete ridges of human palm skin and over the dermal papillae of both scalp and foreskin. The functional significance of these integrin localization patterns is supported by the observations that stem cells can be enriched in culture on the basis of high levels of $ß_1$-integrin expression in vivo and the rapid adhesion of these cells to relevant extracellular matrix proteins. Cells enriched in this manner appear to be clonogenic and suitable for long-term expression of transfected genes.

THE SPINOUS LAYERS The shape, structure, and subcellular properties of spinous cells correlate with their position within the mid-epidermis. They are named for the spine-like appearance of the cell margins in histologic sections (Fig. 6-2). Suprabasal spinous cells are polyhedral in shape and have a rounded nucleus. Cells of the upper spinous layers are larger, more flattened, and contain organelles called “lamellar granules.” The cells of all spinous layers contain large and conspicuous bundles of keratin filaments. As in basal cells, the filaments are organized concentrically around the nucleus and insert into desmosomes peripherally. The K5/K14 keratins present in basal cells are stable and thus remain in the cytoplasm of the spinous cells. In situ hybridization studies show that, except in hyperproliferative disorders where a low level of expression is sustained, the mRNAs for these keratins are not synthesized by suprabasal cells. New synthesis of the K1/K10 (56.5 and 67 kDa) keratin pair occurs in spinous cells. These keratins are characteristic of an epidermal-type pattern of differentiation and thus are referred to as the differentiation- or keratinization-specific keratins. Although this pattern of differentiation is the rule for normal epidermis, the suprabasal keratinocytes in hyperproliferative epidermis (e.g., psoriasis, actinic keratoses, and wound healing) switch to an alternative pathway of differentiation in which the synthesis of K1 and K10 mRNA and protein is downregulated and the synthesis and translation of the messages for K6 and K16 (48- and 56-kDa keratins) are favored. Correlated with this change in keratin expression is a loss of normal phenotypic differentiation in granular and cornified cell layers (see below). The mRNAs for K6 and K16 normally are present in all layers of the epidermis, but the message is translated only when proliferation is stimulated. The “spines” of spinous cells are the abundant desmosomes, calcium-dependent cell surface modifications that promote adhesion of epidermal cells and resistance to mechanical stresses (Fig. 6-3). The molecular components of the desmosome have been well characterized. [7] Within each cell there is a desmosomal plaque (Fig. 6-5A) associated with the internal surface of the plasma membrane that is composed of six polypeptides: plakoglobin, desmoplakins I and II, keratocalmin, desmoyokin, and band 6 protein (plakophilin). Transmembrane glycoproteins of the cadherin family provide the adhesive properties on the external surface or core of the desmosome. These glycoproteins include desmogleins 1 and 3 and desmocollins I and II. The extracellular domains of these proteins form part of the core. The intracellular domains insert into the plaque, linking them to the intermediate filament (keratin) cytoskeleton. E-cadherins, which are characteristic of adherens junctions, are associated with actin filaments via interaction with catenins, [8] and may regulate the organization of adherens junctions and influence epidermal stratification. The differences in the proteins in the two types of cell attachment structure may be related to specific requirements for the adherens junction–actin relationship as compared with the association of the desmosome proteins and keratin intermediate filaments. A central density/plate bisects the intercellular space between desmosomes (Fig. 6-5A).

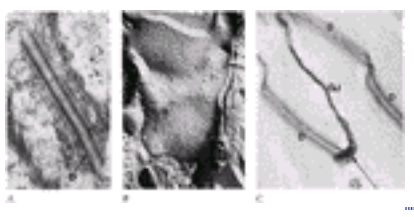

FIGURE 6-5 Desmosomes (D) as they appear in skin observed with transmission electron microscopy (*A*) and in the plane of the plasma membrane of tissue prepared by freeze-fracture techniques (*B*). Desmosomes (*arrow*) and a gap junction (GJ) as revealed by aldehyde-potassium ferrocyanide-osmium fixation (*C*). *A Trends in Electron Microscopy of Skin* and *C* ×94,000; *B*×61,700. (*Part C from Wolff K, Wolff-Schreiner EC: J Invest Dermatol 67:39, 1976, with permission.*)

Abnormal desmosomal structure or disruption of desmosomes causes cells to round, separate (acantholysis), and form blisters and vesicles within the epidermis, and may lead to exfoliation of several epidermal layers. These changes occur in autoimmune diseases such as pemphigus foliaceus and pemphigus vulgaris, in which patients produce antibodies that specifically bind to the extracellular domain of desmogleins 1 and 3, respectively, [9] or in staphylococcal scalded skin syndrome, in which the bacterial exotoxin is a protease that cleaves the extracellular domain of desmoglein 1. [10] In these examples, the desmosomes either disappear entirely or the intercellular association site is destroyed. While desmosomes provide a mechanical coupling between epidermal cells, gap junctions between keratinocytes [11] are sites of physiologic communication (Fig. 6-5C). As with desmosomes, gap junctions are more abundant in more differentiated keratinocytes, correlating with the observation that dye is transferred more efficiently among cells of the suprabasal compartment than among basal cells. Communication by means of these junctions is undoubtedly important in the regulation of cell metabolism, growth, and differentiation. Lamellar granules deliver precursors of stratum corneum lipids into the intercellular space. The granules are first evident in the cytoplasm of the upper spinous cells even though the primary site of their activity is at the granular–cornified layer interface (Fig. 6-6). They are 0.2- to 0.3-µm in diameter, membrane-bound, secretory organelles that contain a series of alternating thick and thin lamellae; these are folded sheets or disk- or liposome-like structures. Lamellar granules contain glycoproteins, glycolipids, phospholipids, free sterols, and a number of acid hydrolases, including lipases, proteases, acid phosphatase, and glycosidases. Glucosylceramides, the precursors to ceramides and the dominant component of the stratum corneum lipids, are found in lamellar granules. These enzymes indicate that lamellar granules are a type of lysosome with characteristics of both secretory granules and lysosomes. Roles for the lamellar granule in providing the epidermal lipids responsible for the barrier properties of the stratum corneum, synthesis and storage of cholesterol, and adhesion/desquamation of cornified cells have been hypothesized. These conclusions are based on known defects in structure and composition of lamellar granules and deficits in function of the tissue. Several genodermatoses, including recessive X-linked ichthyosis, involve mutations in genes critical for steroid and lipid metabolism and are characterized by a failure of cornified cells to slough, the result being a retention hyperkeratosis. [12]

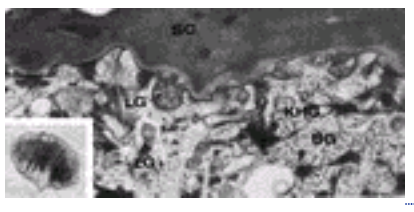

FIGURE 6-6 Junction of the stratum granulosum (SG) and stratum corneum (SC). Lamellar granules (LG) are in the intercellular space and cytoplasm of the granular cell. Keratohyalin granules (KHG) are also evident. *Inset:* Lamellar granule, ×28,750. (*From Holbrook K: Structure and Development of the Skin in Pathophysiology of Dermatologic Di sease, edited by NA Soter, HP Baden. New York, McGraw-Hill, l991, 2nd edition, p 7, with permission. Inset courtesy of EC Wolff-Schreiner, MD.*)

THE GRANULAR LAYER This layer is characterized by the build-up of components necessary for the process of programmed cell death and formation of a superficial water-impermeable barrier. [13], [14] and [15] The typical cytoplasmic organelles associated with an active synthetic metabolism are still evident within cells of the stratum granulosum, but the most apparent structures within these cells are the basophilic, keratohyalin granules (Fig. 6-3 and Fig. 6-6). Keratohyalin granules are composed primarily of an electron-dense protein, profilaggrin, and keratin intermediate filaments (Fig. 6-6). Loricrin, a protein of the cornified cell envelope (see below), is also found within the keratohyalin granule. Processing of the high-molecular-weight keratins by proteolysis and phosphorylation occurs in the granular layer, thus modifying K1 to K2 (65 kDa) and K10 to K11 (56 kDa). Profilaggrin is a high molecular mass (>400 kDa), histidine-rich, polyphosphorylated intermediate filament-associated protein made up of tandem repeats of filaggrin monomers joined by small linker peptides. In humans, the 10 to 12 tandem repeats are polymorphic. Although in normal epidermis profilaggrin mRNA is evident only in the granular cell layer and mRNAs for the differentiation-specific keratins are expressed first in the spinous cells, in certain disease states the expression of these two sets of differentiation markers is similarly altered, suggesting some means of coordinate regulation. For example, in some forms of harlequin ichthyosis, there is a low level of expression of K1/K10 and an absence of filaggrin expression. In the restrictive dermopathies, there is similar downregulation of K1/K10 and abnormal structure of the keratohyalin granules. Conversion of the profilaggrin precursor to oligomeric then monomeric filaggrin subunits occurs stepwise during the transition of a granular cell to a cornified cell by site-specific proteolysis, which involves at least three proteases, and by dephosphorylation. Final proteolysis of filaggrin monomers to free amino acids occurs in the outer layers of the stratum corneum (see below). This is thought to be important for regulation of epidermal osmolarity and flexibility. The function of filaggrin in the granular cell is uncertain, but in the cornified cell it is thought to serve as the matrix protein that embeds and promotes the aggregation and disulfide bonding of keratin filaments (hence, the name “filaggrin” from *fil*ament *aggr*egation prote *in*) producing the “keratin pattern” structure of the lower cornified cells. The conversion of profilaggrin into its monomeric subunits must be carefully controlled to prevent premature intermediate filament aggregation. Structural abnormalities in the keratohyalin granule, or the absence of the granules altogether, are histopathologic features of several keratinization disorders; these morphologic changes correlate with abnormalities in filaggrin expression. In many patients with ichthyosis vulgaris there is a marked reduction or an absence of keratohyalin granules, and filaggrin is correspondingly reduced or absent. The effect of this alteration on the organization of the stratum corneum is not substantial, suggesting that even minor amounts of filaggrin can promote keratin filament aggregation. Other protein markers of keratinization are components of the cornified cell envelope (CE), a 7- to 15-nm thick, dense, protein layer deposited beneath the plasma membrane of cornified cells. Proteins of the CE constitute a significant fraction of the protein in the granular cell and are rendered insoluble by cross-linking via disulfide bonds and N ^{e}-(?-glutamyl) lysine isopeptide bonds formed by transglutaminases. Involucrin, keratolinin (cystatin-a), loricrin, small proline-rich proteins (cornifin, SPR1, and SPR2), the serine proteinase inhibitor elafin (SKALP), filaggrin linker–segment peptide, and envoplakin have all been found as components of the CE. Involucrin is an insoluble, 70- to 80-kDa, cysteine-rich protein, first synthesized in the cytoplasm of spinous cells; it becomes cross-linked by transglutaminase(s) in the granular layer into an insoluble cell boundary that is resistant to denaturing and reducing chemicals. Loricrin, a highly insoluble, sulfur- and glycine/serine-rich protein, is a later differentiation product; its mRNA is transcribed only in the uppermost spinous layer and throughout the granular layers. Loricrin is the major CE protein comprising approximately 75 percent of the total CE protein mass. Envoplakin, homologous to desmoplakin, may link the CE to desmosomes and to keratin filaments. The genes encoding loricrin, involucrin, and cornifin have been localized along with profilaggrin and trichohyalin genes to chromosome region 1q21, which may act as a functional cluster of genes. Although the envelope precursors are first synthesized in the spinous and/or granular layers, where they can be recognized biochemically and immunohistochemically, the CE is evident morphologically only in cornified cells. Current models propose that TGase 1 (see below) catalyzes cross-linking of involucrin at the plasma membrane and that less-abundant precursors such as cornifin, elafin, and the SPR proteins are added subsequently. The cytoplasmic surface of the CE is composed primarily of loricrin. The calcium-requiring transglutaminases are present in all stratified epithelia and in hair follicles. There are three transglutaminases in the epidermis. TGase 1 (keratinocyte TGase) exists in membrane-associated, as well as soluble, full-length proteolytically processed, activated forms. Some TGase 1 activity is present in basal cells, but enzyme activity is especially prevalent in the granular layer of the epidermis. Its membrane-bound, processed form accounts for most of the activity in differentiating keratinocytes. TGase 2 is present in fetal epidermis and in the basal layer of the adult. Soluble TGase 2 appears to be similar to tissue transglutaminase found in other cells and appears to play a role in apoptosis; it is an autoantigen reacting with dermatitis herpetiformis serum. TGase 3 (epidermal TGase) is expressed after early differentiation markers (e.g., K1 and K10) and coincident with loricrin and profilaggrin. It is less abundant than TGase 1 on the basis of mRNA levels but accounts for a relatively high proportion of epidermal TGase activity. It is clear that the soluble and particulate TGases in the epidermis are distinct, but their independent or coordinated roles in cross-linking the CE have not been fully resolved. How the various components of the CE interact and possibly cross-link with one another is a major area of investigation. Mutations in the TGM1 gene have been shown to be the genetic basis of some cases of lamellar ichthyosis, an autosomal recessive genodermatosis characterized by large scales and a disruption in the uppermost differentiating layers of the epidermis. These findings underscore the importance of CE formation to the normal process of epidermal keratinization. As described previously, lamellar granules are first evident in upper spinous layer cells, although their primary site of action is at the interface between the granular and cornified cell layers. In this position they aggregate in clusters, fuse with the plasma membrane, and release their contents into the intercellular space (see Fig. 6-6). The extruded material is stacked into discs, similar to the internal organization of the granule, and is rearranged in various stages, leading to the formation of sheets. The hydrolytic enzymes of the granules are released

with the lipids and are involved in their reorganization and subsequent assembly into the intercellular lamellae. The change in morphology corresponds to the remodeling of the “probarrier” lipids (glycolipids, free sterols, and phospholipids) to “barrier” lipids (e.g., sphingolipids that create a hydrophobic seal at the interface between the granular and cornified layers). Epidermis treated with lipid solvents loses its barrier properties. This barrier reduces water loss from the skin and impedes the movement of polar compounds. Animals with an essential fatty acid deficiency have reduced numbers of lamellar granules, lack the barrier lipids, and demonstrate increased water loss from the skin. What triggers exocytosis of the lamellar granules at the granular-cornified interface or what prevents them from discharging their contents within the cell is not understood.

THE TRANSITION FROM A GRANULAR TO A CORNIFIED CELL The granular cell not only synthesizes, modifies, and/or cross-links new proteins involved in keratinization, it also plays a role in its own programmed destruction. This occurs during the abrupt transition from a granular cell to a terminally differentiated cornified cell. The change involves the loss of the nucleus and virtually all of the cellular contents with the exception of the keratin filaments and filaggrin matrix. DNAse, RNAse, acid hydrolases, esterases, phosphatases, proteases, and plasminogen activator have been identified in the granular cell and implicated in degradation. Morphologic stages of nuclear destruction have been described and occur by an apoptotic mechanism. Individual cells that have characteristics of both granular and cornified cells are identified occasionally within the granular layer. The mechanism for the final dissolution of organelles and disposition of the degraded components is not yet understood, although it is apparent that nucleotides, some amino acids, ions, and trace elements are recovered and reutilized within the epidermis.

THE STRATUM CORNEUM Complete transition from a granular to a cornified cell is accompanied by a 45 to 86 percent loss in dry weight. The layers of resultant cornified, or horny, cells provide mechanical protection to the skin and a barrier to water loss and permeation of soluble substances from the environment (Fig. 6-2, Fig. 6-3, and Fig. 6-7). [13], [14], [15] and [16] The stratum corneum barrier is formed by a two-compartment system of lipid-depleted protein-enriched corneocytes surrounded by a continuous extracellular lipid matrix. The flattened, polyhedral-shaped, horny cell is the largest cell of the epidermis (Fig. 6-7B). Its shape and surface features are adapted to maintain the integrity of the stratum corneum yet allow for desquamation (Fig. 6-7). High molecular mass keratins (>60 kDa), stabilized by intermolecular disulfide bonds, account for up to 80 percent of the cornified cell. The remainder of the cell content appears limited to an electron-dense matrix material, probably filaggrin, surrounding the filaments (Fig. 6-7B). The nucleus is lost from normal stratum corneum cells but it persists in incompletely keratinized cells (parakeratosis), as seen in psoriasis. Remnants of organelles, especially profiles of membranes and melanin pigment, are occasionally present within the normal cell. Membrane profiles can be particularly abundant in the stratum corneum of patients with excessive numbers of cornified layers, as seen in some of the ichthyoses and in acne. The lipid enrichment results from the deposition of lamellar body contents. Three key lipid types—cholesterol, ceramides, and free fatty acids—form the lamellar bilayers. Lamellar bodies are enriched with glycosphingolipids, phospholipids, cholesterol, and hydrolases. The metabolism and secretion of these contents results in the formation of the lamellar unit structure in the mid-stratum corneum.



FIGURE 6-7 Stratum corneum. Note the closely associated cell layers in the stratum corneum (*A*); the surface markings, thin and flattened shape, and overlapping margins of individual stratum corneum “squames” (*B*); and the interlocking contours of thickly sectioned frozen cornified cells (*C*). *A*, ×5050; *B*, ×450; *C*, ×15,000 in the original magnifications.

Changes in the structure, composition, and function of cornified cells accompany their movement toward the outer surface of the skin. Cells of the deeper layers of the stratum corneum, sometimes called the stratum compactum, are thicker and have more densely packed, organized parallel arrays of keratin filaments, a more fragile cornified CE, and a greater variety of modifications for lateral cell-to-cell attachment [modified desmosomes (Fig. 6-7A)], as well as superior–inferior interlocking ridges and villi (Fig. 6-7B and *C*), when compared to cells of the outer cornified layers. The latter cell layers are prone to desquamation and thus are referred to as the stratum disjunctum (Fig. 6-7). Cells of the deeper cornified layers have less capacity for water-binding than the mid- and upper regions. Cells in the mid-stratum corneum have the highest concentration of free amino acids and, correspondingly, are able to bind water with greater efficiency. A rigid CE borders the outer stratum corneum cells. The protein composition of the fragile and rigid envelopes is identical; thus differences in the physical properties must reflect maturation of the envelope or perhaps a different association with membrane lipids. The desmosomes undergo proteolytic degradation in the outermost stratum corneum cells, which is one factor that allows individual corneocytes to be shed. The stratum corneum cell retains some metabolic functions and thus is not the inert covering it has been previously considered. Lipid extraction or metabolic imbalances such as fatty acid deficiency perturb the barrier as well as resulting in epidermal hyperproliferation, scaling, and inflammation. Thus, aberrations in the stratum corneum may initiate skin diseases rather than be the end result of processes in subjacent cell layers.

Regulation of Epidermal Proliferation and Differentiation

Because the epidermis is a continually renewing tissue, its structure and function depend on several processes that must be initiated during development and continue throughout life. These processes include establishment and maintenance of relatively constant cell numbers; interactions between keratinocytes and immigrant cells; adhesion among neighboring keratinocytes, among basal keratinocytes and the basal lamina, among basal lamina and underlying dermis; and keratinocyte terminal differentiation to produce functional corneocytes. Many of the genes and regulatory pathways involved in these processes have been elucidated through tissue culture studies of human and mouse epidermal cells, in vivo studies, and, more recently, transgenic and gene-targeting studies in mice.

The dermis has well-known regulatory influences over epidermal morphogenesis and differentiation. [17] This was determined from studies using tissue recombinants prepared by annealing the epidermis from one source with specific characteristics (e.g., age, species, region) with dermis from another and evaluating the outcome of the recombined skin

after it has been grafted to a nude mouse or allowed to differentiate in organ culture. Such experiments, typically performed with embryonic tissues, demonstrate that the thickness, architecture, and pattern of differentiation of the epidermis, and the pattern of the epidermally derived appendages that are formed, conform to the region of the body from which the dermis was obtained. Epidermal–dermal interactions are also critical for the maintenance of postnatal skin structure and function. This can be demonstrated directly and can be observed indirectly in pathologic skin. For example, hyperproliferative keratins are expressed in epidermis that is superficial to a dermal tumor; the extent of K6 and K16 expression correlates with the proximity of the epidermis to the tumor and the degree of tumor cellularity. The products of normal keratinocytes and fibroblasts are also modulated by their interactions. A mutual induction of paracrine growth factor gene expression is induced by coculture of epidermal and dermal cells. The epidermis and dermis also collaborate in the development of the epidermal appendages and in the dermal–epidermal junction (see below).

Integrins

Growth factors, cytokines, and neuropeptides act in concert with cell-cell and extracellular matrix influences to control epidermal homeostasis. An association of matrix molecules with basal keratinocytes through integrin receptors, a family of transmembrane glycoprotein matrix receptors, [18] is important. More than 20 integrin receptors are assembled as heterodimers from one a and one ß subunit. The combination of the subunits generally specifies the binding ligand. In keratinocytes, integrins are most evident on basal cells where they are found typically at the sites of focal adhesions and hemidesmosomes. Keratinocytes express several integrins and they have been shown to be involved in a variety of functions important to skin homeostasis. [19], [20] The predominant integrins are a $_6$ß $_4$, a $_2$ß $_1$, and a $_3$ß $_1$. The ß $_1$ integrins are found concentrated around the lateral borders between neighboring keratinocytes, whereas a $_6$ß $_4$ is found on the basal surface associated with hemidesmosomes. During wound healing, de novo expression of a $_5$ß $_1$ and a $_v$ß $_6$ integrins, together with a redistribution of ß $_1$ integrins, promotes keratinocyte migration on matrix molecules such as fibronectin. The integrins serve as a physical link and route of communication between matrix molecules, such as collagen, laminin, fibronectin, thrombospondin, and vitronectin, through the plasma membrane to the cytoskeleton of the keratinocyte. What was once thought to be a mechanism for cell anchorage has now been shown to be a route of bidirectional communication that can result in changes, for example, in gene expression, pH, and calcium fluxes. The physical association of basal keratinocytes with the basement membrane is thought to be important in maintaining the phenotype of the cell; separation of the cells from this substrate, the change of cell shape, and relationship to extracellular matrix molecules can induce the onset of terminal differentiation. In culture, it has been demonstrated that differentiating keratinocytes lose adhesiveness to types I and IV collagen, laminin, and fibronectin. Loss of adhesion to fibronectin per se precedes the loss of the integrin receptors for fibronectin. The signal that triggers the decline in ability of an integrin to bind ligand, and hence perhaps an early signal for keratinocyte differentiation, is not yet understood.

Growth Factors

As mentioned above, growth factors regulate epidermal growth and proliferation by autocrine and paracrine mechanisms. [21], [22] Much of this evidence comes from studies of transgenic mice that overexpress various factors in the epidermis. Epidermal growth factor (EGF) and transforming growth factor (TGF)-a bind to the same tyrosine kinase activatable receptors on basal and immediately suprabasal epidermal cells to stimulate proliferation. [23] TGF-a is produced by keratinocytes, whereas EGF is synthesized elsewhere in the body. TGF-a is overexpressed in psoriasis and may contribute to the hyperproliferative component of the disease. Targeted overexpression of TGF-a in the mouse epidermis results in a phenotype of hyperplasia, hyperkeratosis, and the formation of spontaneous papillomas, suggesting a potential role of TGF-a in hyperproliferative disorders. Keratinocyte growth factor (KGF), a member of the fibroblast growth factor family, is a potent mitogen for keratinocytes and other epithelia. Although the transcripts for KGF in skin are found only in the dermis, the receptor for KGF is expressed on keratinocytes. Ectopic expression of KGF in the epidermis of transgenic mice results in epidermal thickening as well as regional loss of hair follicles. [24] Other growth factors suppress DNA synthesis and mitosis of keratinocytes and promote differentiation. Among these is TGF-ß. The messages for TGF-ß $_1$ and -ß $_2$ are present in low levels in the keratinocytes of the upper epidermal layers but can be upregulated by TGF-ß itself and by agents that promote differentiation, such as calcium and phorbol esters. TGF-ß requires activation to be effective. Abnormal skin phenotypes in transgenic mice with either increased or decreased levels of functional TGF-ß demonstrate that this pathway is part of the endogenous homeostatic regulatory machinery of the epidermis. [25] Keratinocytes produce other growth factors and cytokines, some of which affect their own proliferation and migration and others of which act on other cells in the epidermis [e.g., basic fibroblast growth factor (bFGF) influences proliferation of melanocytes] and in the dermis [e.g., platelet-derived growth factor (PDGF) produced by keratinocytes is active only on cells in the dermis that bear PDGF receptors]. Dermal cells, in turn, synthesize products that act synergistically with molecules in the epidermis to promote or retard growth.

Cytokines (See Chap. 26)

Keratinocyte-derived cytokines, interleukin (IL)-1a, IL-6, IL-8, and granulocyte-macrophage colony-stimulating factor (GM-CSF) play a role in normal regulation of the epidermis, inflammatory processes, and wound repair in the skin. [26] IL-1a may also promote growth of cultured keratinocytes, an effect that is not implausible because keratinocytes express high affinity IL-1 receptors and thus are a target for autocrine regulation by this molecule.

Retinoids (See Chap. 244 and Chap. 257)

Epidermal homeostasis is dependent on the interaction of several hormones and factors that control the balance between keratinocyte proliferation, differentiation, and apoptosis. One such factor is vitamin A and its derivative compounds and drugs (retinoids). [27] Retinoic acid (RA) can modulate the response of keratinocytes to mitogens and is a pleiotropic regulator of epidermal morphogenesis and differentiation. In the skin, a critical level of RA is necessary for normal morphogenesis and differentiation. The effects of retinoids on the skin in vivo can be appreciated from their use in treating disorders of keratinization and acne.

The diverse cellular effects of retinoids, in the skin and other tissues, result primarily from activation of different sets of responsive genes mediated by specific subtypes of receptors, the retinoic acid receptors (RARs) and retinoid X receptors (RXRs). RA has both positive and negative influences on keratinocyte differentiation that appear to be mediated primarily through the RAR?1 receptor, which is the major RAR subtype of the epidermis. Moreover, the effects of RA on keratinocytes depend on the RA concentration and on the state of the target cell. Micromolar concentrations of RA stimulate slowly growing keratinocytes and act as a mitogen for growth-arrested cells but inhibit proliferation of rapidly proliferating cells in vitro. There is also suppression of genes for differentiation-specific proteins such as K1/K10, filaggrin, and proteins of the cornified envelope when keratinocytes are treated in vitro. Consistent with the finding that the concentration of retinoids in the skin must be tightly controlled, both increased and decreased retinoid signaling can lead to aberrant differentiation in vivo. Long-term RA treatment in vivo results in epidermal hyperproliferation and a modified program of terminal differentiation, [28] whereas formation of an epidermis with compromised barrier function can also result from inactivation of retinoid signaling through expression of a dominant negative receptor.

Vitamin D_3 is another important factor that regulates keratinocyte homeostasis because the skin is both a synthetic and a target organ for vitamin D_3. [27], [29] A specific receptor [vitamin D_3 receptor (VDR)], belonging to the same superfamily of nuclear hormone receptors as the retinoid receptors, has been identified in human skin. VDR forms heterodimers with RXR, allowing for crosstalk between these two signaling pathways. The active form of vitamin D_3, 1a,25$(OH)_2D_3$, regulates a decrease in keratinocyte proliferation and an increase in morphologic differentiation of cultured keratinocytes. These effects appear to occur through both changes in gene expression and nongenomic events such as increases in cytosolic calcium. Vitamin D_3 and synthetic analogs are being developed as new clinical tools. Calcipotriene has been studied most extensively and has been shown to be effective in the treatment of psoriasis.

Calcium

The role of calcium in regulating epidermal proliferation and differentiation [29], [30] /SUP>was revealed when it was shown that keratinocytes grown in a low-calcium medium (0.002 to 0.1 mmol Ca^{2+} failed to stratify and differentiate. There is evidence for a profound effect of calcium on keratinocyte growth and differentiation both in vitro and in vivo. Low calcium stimulates proliferation, which is inhibited by high calcium concentrations in vitro. There is a calcium gradient in native epidermis, increasing from the basal to the upper granular layer. Calcium is required by the epidermis for desmosome formation and activation of enzymes such as transglutaminase. Its effect on differentiation appears to be more related to the block it creates to the establishment of normal tissue architecture than to the regulation of gene expression because a number of differentiation-specific markers are still expressed in cells grown in low-calcium medium. Changes in extracellular calcium levels have a profound and sustained effect on the intracellular calcium levels in normal cultured keratinocytes. The recent discovery that the molecular defects in Hailey-Hailey and Darier diseases are in calcium transporters also suggests that calcium homeostasis plays an important role in maintaining the structural integrity of keratinocytes and the epidermis. [31], [32]

The complex interplay of extrinsic and intrinsic factors that regulates the proportion of proliferating and differentiating cells to maintain a constant epidermal thickness as cells desquamate is often perturbed in disease, such as psoriasis or carcinoma. In wound healing, an alteration in the various regulatory factors is essential and advantageous to bringing about enhanced proliferation for epithelial repair.

Apoptosis

Apoptosis, or programmed cell death, is a major cellular homeostatic mechanism in the skin that is affected by the hormones, growth factors, cytokines, and other factors discussed above. Apoptosis is a gene-directed, single-cell death that follows an orderly pattern of morphologic and biochemical changes. [33] Apoptosis functions in the skin in developmental remodeling, regulation of cell numbers, and defense against damaged, virus-infected, or transformed cells. There is evidence that terminal differentiation of the epidermal keratinocyte occurs by a modified apoptotic program that has evolved to adapt the keratinocyte to its specialized functions. As would be predicted for an important homeostatic mechanism, dysregulation of apoptosis has been documented in several diseases of the skin, both immune mediated and genetic, and in skin tumors. Another well-documented occurrence of apoptosis is the formation of the sunburn cell, a typical apoptotic keratinocyte that can be detected in the epidermis following exposure to ultraviolet light. Apoptosis also plays an important role in the hair follicle growth cycle. The mechanism of catagen appears to be related to the onset of apoptosis in the proliferative cells of the hair bulb.

Many studies have focused on the regulatory mechanism of apoptosis because of the obvious significance of the existence of a genetically controlled form of cell death. The skin promises to be one of the primary targets for the generation of new therapeutic strategies to regulate apoptosis because of its widespread occurrence in the skin and the already well-defined pathways controlling epidermal homeostasis.

NONKERATINOCYTES OF THE EPIDERMIS

Melanocytes (See Chap. 11)

The melanocyte is a dendritic, pigment-synthesizing cell derived from neural crest that is confined mainly to the basal layer. [34] In postnatal skin, the cell body of the melanocyte often extends toward the dermis below the level of the basal cell, but always superior to the lamina densa (see Fig. 6-4). Melanocyte processes contact keratinocytes in basal and more superficial layers but do not form junctions with them at any level. Melanocytes are recognized light microscopically by their pale-staining cytoplasm, ovoid nucleus, and the intrinsic color of the pigment-containing melanosomes. Differentiation of the melanocyte correlates with the acquisition of its primary functions: melanogenesis, arborization, and transfer of pigment to keratinocytes.

The melanosome is the distinctive organelle of the melanocyte (Fig. 6-4, inset). It is resolved at the ultrastructural level as an ovoid, membrane-bound structure within which a series of receptor-mediated, hormone-stimulated, enzyme-catalyzed reactions produce melanin. Four

different stages (I to IV) of melanosome structure correlate with the degree of melanization. Melanosomes that are involved in the synthesis of brown or black eumelanin are elliptical and have an internal organization of longitudinally-oriented, concentric lamellae; melanosomes that synthesize red or yellow pheomelanin pigments have a spheroidal shape and a microvesicular internal structure. The size of melanosomes is determined genetically; black skin typically contains larger melanosomes than more lightly pigmented skins.

There are important organizational relationships and functional interactions between keratinocytes and melanocytes that the melanocyte depends on for differentiation and function. [35] Approximately 36 basal and suprabasal keratinocytes are thought to coexist functionally with each melanocyte in an epidermal melanin unit, an organizational system that is mimicked in vitro when the two cell types are cocultured. Within this aggregate, melanocytes transfer pigment to associated keratinocytes. As a result, pigment is distributed throughout the basal layer and, to a lesser extent, the more superficial layers where it protects the skin by absorbing and scattering potentially harmful radiation. Once within the keratinocyte, melanosomes exist either individually or in membrane-bound aggregates (melanosome complexes). The distribution of melanosomes within the keratinocyte varies with race (see Chap. 11). Melanosomes within keratinocytes are degraded by lysosomal enzymes as the cells differentiate and move upward. A few melanosomes may still be recognized in the stratum corneum, but these are usually no longer enclosed by a membrane.

The keratinocytes produce soluble factors that regulate melanocyte proliferation, dendricity, and melanization. These phenomena have been observed in cocultures in vitro where undifferentiated and proliferating keratinocytes maintain continuous growth control over melanocytes. Keratinocytes produce growth factors that are mitogenic for melanocytes (e.g., bFGF and TGF-a), but also produce growth inhibitory factors (IL-1, IL-6, TGF-ß. Keratinocytes, but not keratinocyte-conditioned medium, induce a dendritic phenotype in melanocytes. The balance between negative and positive regulatory mechanisms involving the keratinocyte requires further investigation. Proliferation of melanocytes and their dendrites, melanogenesis, as well as transfer of pigment also rely on hormonal control (melanocyte-stimulating hormone, agouti signal protein, sex hormones), inflammatory mediators, and vitamin D_3 synthesized within the epidermis.

Merkel Cells

Merkel cells are slow-adapting, type I mechanoreceptors located in sites of high tactile sensitivity. They are present among basal keratinocytes in particular regions of the body [36], [37] (Fig. 6-8), and join with them by desmosomal junctions. Merkel cells receive stimuli as keratinocytes are deformed and respond by secretion of chemical transmitters. They are found both in hairy skin and in the glabrous skin of the digits, lips, regions of the oral cavity, and the outer root sheath of the hair follicle. In some of these sites, they are assembled in specialized structures called tactile discs or touch domes. Like other nonkeratinocytes, Merkel cells have a pale-staining cytoplasm. The nucleus is lobulated, and the margins of cells project cytoplasmic “spines” toward keratinocytes. Immunohistochemical markers of the Merkel cell include K18, K8, K19, and K20 keratin peptides. Keratin 20 is restricted to Merkel cells in the skin and thus may be the most reliable marker.

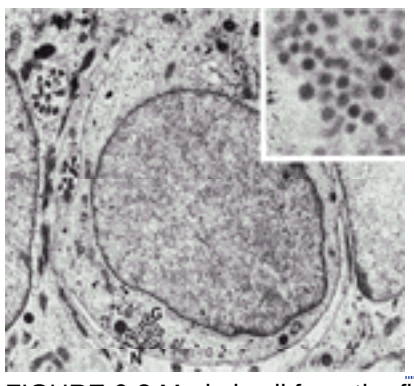

FIGURE 6-8 Merkel cell from the finger of a 130-mm CR (crown-rump) 21-week human fetus. Note nerve (N) in direct contact with the lateral and basal of the cell and dense core cytoplasmic granules (G). ×13,925. *Inset:* Merkel cell granules, ×61,450.

Merkel cells make synaptic contacts with nerve endings to form the Merkel cell–neurite complex. The cells are easily identified at the ultrastructural level by the 80- to 200-nm diameter, membrane-bounded, dense-core granules that collect opposite the Golgi and proximal to an unmyelinated neurite (Fig. 6-8); the granules are a constant feature of the cell, but the neurite is not always present. The structure of the granule is similar to neurosecretory granules in neurons; they form in the Golgi in the manner of a secretory granule and contain neurotransmitter-like substances and markers of neuroendocrine cells, including metenkephalin, vasoactive intestinal peptide, chromogranin A, acetylcholine, calcitonin gene-related peptide, neuron-specific enolase, and synaptophysin. The granules are also stained positively with the uranaffin reaction, which recognizes amine-storing granules in other neuroendocrine cells, as well as the Merkel cell.

New evidence suggests that Merkel cells are the mechanoreceptors while the nerve terminals transduce the transient phase. The morphology of the contacting membranes of both the Merkel cell and neurite are similar to the pre- and postsynaptic modifications that are characteristic of a synapse. Moreover the presence of neurotransmitter-like substances in the dense core granules suggests that the Merkel cell is the receptor that transmits a stimulus to the neurite ia a chemical synapse. Merkel cells may function as targets for the anchorage of nerve endings during embryonic and fetal development, as a stimulus for such fibers to branch or they may participate in induction or alignment of the arrector pili muscles associated with the pilosebaceous unit. Merkel cell neoplasms are discussed in Chap. 86.

The Langerhans Cell: A Nonkeratinocyte Localized in Suprabasal Epidermal Layers (See Chap. 23)

Langerhans cells are bone marrow–derived, antigen-processing and -presenting cells that are involved in a variety of T cell responses. [38] The Langerhans cell is not unique to the epidermis; it is found in other squamous epithelia, including the oral cavity, esophagus, and vagina; in

lymphoid organs such as the spleen, thymus, and lymph node; and in the normal dermis.

The life cycle of the Langerhans cells is characterized by two distinct stages. Langerhans cells in the epidermis can ingest and process antigens efficiently but are weak stimulators of unprimed T cells. Activated Langerhans cells that have been induced to migrate after contact with antigen are not phagocytic but are potent stimulators of naïve T cells. They account for 2 to 8 percent of the total epidermal cell population. Like melanocytes, Langerhans cells are dendritic and do not form junctions with any of the cells they appose (Fig. 6-9 and Fig. 6-10). They are distributed in the basal, spinous, and granular layers, showing a preference for a suprabasal position. In histologic preparations, Langerhans cells are pale-staining and have convoluted nuclei.

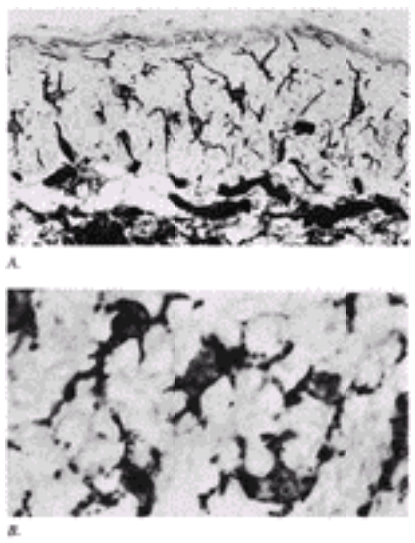

FIGURE 6-9 *A*. Light micrographs of Langerhans cells, as revealed by ATPase staining, in vertical section of epidermis. *B*. Langerhans cells are seen at higher magnification in an isolated epidermal sheet viewed from the dermal side. Note the density and dendritic shape of this nonkeratinocyte population within the epithelium.

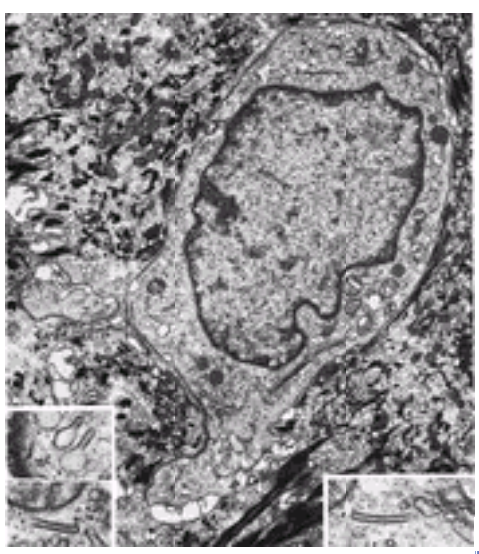

FIGURE 6-10 Langerhans cell. Note indented nucleus, rod- and racket-shaped cytoplasmic granules (see also insets), lysosomes, and absence of keratin filaments characteristic of surrounding keratinocytes. ×13,200. *Inset:* Birbeck granules, ×88,000. (*Courtesy of N. Romani, MD.*)

The cytoplasm of the Langerhans cells, as seen by electron microscopy, contains dispersed vimentin intermediate filaments, and small rod- or racket-shaped structures called Langerhans cell granules or Birbeck granules (Fig. 6-10). Serial reconstruction of the Langerhans cell granule shows that it is a cup-shaped disc. The Langerhans cell granule forms when membrane-bound antigen is internalized by endocytosis. Phagolysosomes are common in the cytoplasm of the Langerhans cell. They contain enzymes similar to those of the macrophage and often include particulate material such as melanosomes.

Langerhans cells migrate from the bone marrow to the circulation into the epidermis early in embryonic development and continue to repopulate the epidermis throughout life. A number of the markers expressed by the Langerhans cell are characteristic for other cells of the monocyte–macrophage lineage and provide some insight into their function. In vitro studies demonstrate that dendritic cells can differentiate from a number of progenitor cells. Their maturation can be followed by measuring the expression of certain cell-surface molecules, such as cutaneous lymphocyte-associated antigen (CLA), E-cadherin, $a_6ß_4$ integrin, very-late-activation antigens (VLAs), CD44, integrins of the CD11/CD18 class, as well as intercellular adhesion molecule (ICAM)-1, ICAM-3, and LFA-3. These molecules serve not only as markers of differentiation, but also have a role in Langerhans cell trafficking, adhesion, and costimulation.

Langerhans cells are the primary cells in the epidermis responsible for the recognition, uptake, processing, and presentation of soluble antigen and haptens to sensitized T lymphocytes, and are implicated in the pathologic mechanisms underlying allergic contact dermatitis, cutaneous leishmaniasis, and human immunodeficiency virus infection. They are reduced in the epidermis of patients with certain skin diseases (e.g., psoriasis, sarcoidosis, contact dermatitis) and are impaired functionally by ultraviolet radiation; following UVB irradiation, there is a decrease in the ability of Langerhans cells to present antigen, a decreased production of cytokines (e.g., IL-10 and *cis*-urocanic acid) by keratinocytes, and a

depletion in Langerhans cell numbers. Thus, UVB irradiation results in an overall diminished capacity for immune surveillance.

Because of their effectiveness in antigen presentation and lymphocyte stimulation, dendritic cells and Langerhans cells have become prospective vehicles for tumor therapy and tumor vaccines. The principle behind such strategies is to load dendritic cells with tumor-specific antigens, which will then stimulate the host immune response to mount an antigen-specific (and therefore tumor-specific response).

THE DERMAL–EPIDERMAL JUNCTION (See Chap. 16)

The dermal–epidermal junction (DEJ) is a basement membrane zone that forms the interface between the epidermis and dermis (Fig. 6-11). [39], [40] The major function of the DEJ is to attach the epidermis and dermis to each other and to provide resistance against external shearing forces. It serves as a support for the epidermis, determines the polarity of growth, directs the organization of the cytoskeleton in basal cells, provides developmental signals, and serves as a semipenetrable barrier. The structures of the DEJ are almost entirely products of basal keratinocytes, with minor contributions from dermal fibroblasts.

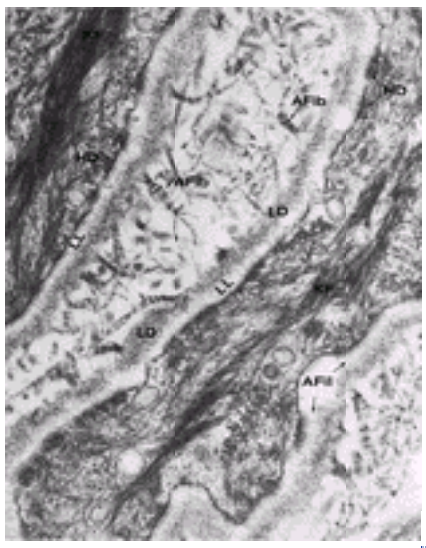

FIGURE 6-11 Structure of the dermal-epidermal junction. Tongues of basal keratinocytes contain keratin filaments (KFs). Some of them insert into hemidesmosomes (HD). The lamina lucida (LL) is spanned by anchoring filaments (AFil). Banded anchoring fibrils (AFib) extend into the papillary dermis from the lamina densa (LD). ×71,250 in the original magnification.

The DEJ can be subdivided into three supramolecular networks: the hemidesmosome–anchoring filament complex, the basement membrane itself, and the anchoring fibrils. The localization of antigens, determination of composition, and the known affinities of some of the matrix molecules present in the basement membrane zone for other matrix molecules (e.g., laminin, entactin/nidogen, and type IV collagen) are the basis for the structural models of this region of the skin and define its function and physical properties. The subdivisions coincide with areas of weakness that can result in dermal–epidermal separation under circumstances of physical stress, genetic disease, an autoimmune process, or trauma.

The hemidesmosome–anchoring filament complex binds basal keratinocytes to the basement membrane. The hemidesmosome has cytoplasmic, membranous, and extracellular components, which have been well characterized. Keratin intermediate filaments insert into the plaque portion (Fig. 6-11), which consists of bullous pemphigoid antigen 230 (BP230; BPAg-1) and plectin. The transmembrane component consists of bullous pemphigoid antigen 180 (BP180; BPAg-2; collagen XVII) and a $_6ß_4$ integrin. The extracellular domain of BP180 has been localized to the extracellular space beneath the hemidesmosome—the lamina lucida—and has been identified as a type XVII collagen. The intracellular domain of BP180 is localized in the hemidesmosomal plaque. The extracellular matrix components of the hemidesmosome are the subbasal dense plate (Fig. 6-11) and the anchoring filaments. Anchoring filaments originate at hemidesmosomes and insert into the lamina densa. The major component of these filaments is laminin 5 (previously referred to as GB3 antigen, nicein, BM600, kalinin, and epiligrin), which is localized mainly to the lamina densa and the lower lamina lucida and is associated with a $_6ß_4$ in hemidesmosomes. Laminin-5 consists of three subunits encoded by the genes LAMA3, LAMB3, and LAMC2.

The importance of these structures and molecules in maintaining the integrity of the skin can be surmised from inherited and acquired diseases of the skin in which they are either destroyed, altered, or absent, thereby resulting in dermal–epidermal separation. [41] A similar, although more superficial blistering within the plane of the basal epidermal layer, occurs in patients with the various forms of epidermolysis bullosa simplex caused by mutations in genes that code for the K5 and/or K14 basal cell keratins or other structural proteins specific for this layer (see Chap. 65 and Chap. 66).

The lamina lucida (Fig. 6-11) is the primary location of several noncollagenous glycoproteins: laminins, entactin/nidogen, and fibronectin. [39] Because these molecules self-aggregate (e.g., entactin/nidogen), bind to other matrix molecules (e.g., laminin–entactin/ nidogen, laminin-type IV collagen, and laminin-perlecan) and to cells (e.g., fibronectin, laminin, entactin/nidogen), they are all important in promoting adhesion between the epidermal cell and the lamina densa. Based on structural analysis of the component proteins, a scheme for the supramolecular assembly of the basement membrane has been put forth. This model integrates the role of laminins and their interactions with nidogen, perlecan, and type IV collagen. The lamina lucida appears to be the weakest zone of the DEJ. It separates easily with heat and suction, with treatment with salt solutions and proteolytic enzymes, and in disease.

Type IV collagen is the primary component of the lamina densa. It is a nonbanded, network-forming collagen synthesized by keratinocytes that

provides structural support and flexibility to this layer. Type V collagen is codistributed with type IV collagen in the DEJ but not in all basement membranes. Sulfated proteoglycans associated with the lamina densa probably assist in regulating permeability by restricting the passage of cationic macromolecules. Laminin is also within the lamina densa.

The lamina densa functions as a barrier/filter that restricts passage of molecules with a molecular mass =40 kDa, but it is penetrated by melanocytes and Langerhans cells during development and, postnatally, by large molecules such as type VII collagen and by neurites associated with Merkel cells; lymphocytes also enter the epidermis in certain inflammatory conditions. It is not clear how penetration occurs in these instances, although cells of invasive carcinomas appear capable of local proteolysis of the lamina densa, in some situations through the production of a type IV collagenase. Repair and remodeling of the DEJ occurs at sites of tissue damage, often in an overly compensated manner recognized ultrastructurally as reduplicated regions of lamina densa. The cause for this excessive synthesis of lamina densa is unclear but probably relates to the stimulatory role of cytokines in promoting synthesis by the epidermis in inflammatory situations.

Anchoring fibrils are broad (20 to 60 nm), elongated (200 to 800 nm), flexible, banded, fibrillar structures that originate at the lamina densa and extend into the dermis. The fibrillar portions of anchoring fibrils have the morphologic appearance of collagen fibrils and have been shown to be composed of parallel bundles of end-to-end dimers of type VII collagen molecules, which have the longest helical domains of all collagen molecules and are synthesized primarily by the epidermal keratinocyte.

The anchoring fibrils penetrate into the deepest zone of the DEJ, the sublamina densa region or reticular lamina. Interstitial collagens (types I, III, V, and VI) and procollagens (types I and III) are present in this zone. In addition, the first fibers of the elastic fiber system are organized and probably form part of the complex that anchors the epidermis to the dermis through the basement membrane zone. The oxytalan fibers are bundles of the microfibrillary components of the elastic fibers. They originate from the lamina densa and insert into the planar networks of elaunin elastic fibers organized at the junction between papillary and reticular dermis. Oxytalan fibers are coated with soluble elastin (rather than the cross-linked, insoluble elastin of the mature elastic fibers); they are flexible integrating elements that accommodate deformation of the skin without compromise to structural integrity. The appearance of these fibers in electron micrographs suggests that they can exert tension on the epidermis.

THE DERMIS (See Chap. 14 and Chap. 15)

The dermis is an integrated system of fibrous, filamentous, and amorphous connective tissue that accommodates nerve and vascular networks, epidermally derived appendages, fibroblasts, macrophages, and mast cells, and other blood-borne cells, including lymphocytes, plasma cells, and other leukocytes, that enter the dermis in response to various stimuli. The dermis makes up the bulk of the skin and provides its pliability, elasticity, and tensile strength. It protects the body from mechanical injury, binds water, aids in thermal regulation, and includes receptors of sensory stimuli. The dermis interacts with the epidermis in maintaining the properties of both tissues, [42] collaborates during development in the morphogenesis of the DEJ and epidermal appendages (teeth, nails, pilosebaceous structures, and sweat glands) and interacts in repairing and remodeling the skin as wounds are healed.

Connective Tissue Matrix of the Dermis

Collagen and elastic connective tissue are the main types of fibrous connective tissue of the dermis (Fig. 6-12). The properties of the matrix molecules themselves and their supramolecular organization into fibrous elements and assembly and integration into an interwoven fabric provide the mechanical properties of the dermis. Other nonfibrous, connective tissue molecules include finely filamentous glycoproteins and the proteoglycans (PGs) and glycosaminoglycans (GAGs) of the “ground substance.” The biochemistry of these connective tissue molecules is the topic of subsequent chapters, but each matrix component is introduced in the present chapter in order to reveal the properties and interactions that regulate normal dermal architecture.

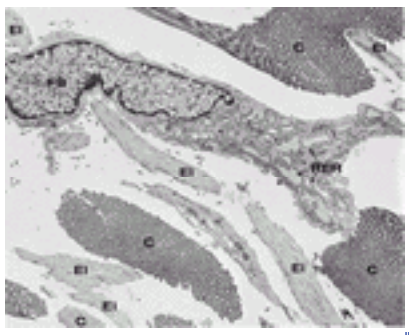

FIGURE 6-12 Human dermal fibroblast (FB) and collagen (C) and elastic (EI) connective extracellular connective tissue of the extracellular matrix. Note dilation of the rough endoplasmic reticulum (RER). ×5500 in the original magnification. (*From Smith et al., Structure of the dermal matrix during development and in the adult. J. Invest Dermatol 79:93s, 1982, with permission.*)

COLLAGENOUS CONNECTIVE TISSUE Collagen is the major dermal constituent. [43] It accounts for approximately 75 percent of the dry weight of the skin, and provides both tensile strength and elasticity. The periodically banded, interstitial collagens (types I, III, and V) account for the greatest proportion of the collagen in adult dermis (Fig. 6-12). Approximately 80 to 90 percent of the collagen is type I collagen and 8 to 12 percent is type III collagen. Type V collagen, although less than 5 percent, codistributes and assembles into fibrils with both types I and III collagen in which it is believed to assist in regulating fibril diameter. Type V collagen is polymorphic in structure (granules, filaments) and has been immunolocalized primarily to the papillary dermis and the matrix surrounding basement membranes of vessels, nerves, and epidermal appendages, and at the DEJ. Type VI collagen is abundant throughout the dermis, associated with fibrils and in the interfibrillar spaces, where it can organize into a variety of forms including fine, beaded filaments. Because of its early appearance during development, it is thought to

organize the matrix as it is becoming established. Type IV collagen in the skin is confined to the basal lamina of the DEJ, vessels, and epidermal appendages. Type VII collagen forms anchoring fibrils at the DEJ (see above) that interdigitate with the interstitial collagen fibrils in the papillary dermis. Types I and III procollagen molecules and minor collagens, such as a1(I) trimer, are also present in normal dermis. More than 20 genetically distinct collagens exist in animal tissues. These molecules are composed of three chains that vary according to the collagen type; all chains have a helical domain consisting of $(Gly\text{-}X\text{-}Y)_n$ repeats, where X and Y are typically proline and hydroxyproline, and globular terminal domains. The chains are glycosylated, assemble into soluble procollagen molecules, and undergo interchain bonding within the rough endoplasmic reticulum. They are then secreted into the extracellular space. Outside of the cell, the amino and carboxyl termini are cleaved proteolytically by collagen metalloproteinases, the molecules align in various patterns (e.g., a staggered array for types I and III collagen molecules, a chicken wire–like network for type IV collagen molecules, and antiparallel dimers for type VII collagen molecules), and are cross-linked. The result is the formation of banded collagen fibrils, filaments, and networks visible by light and electron microscopy. A number of factors such as the physical and chemical properties of the collagen molecules themselves and the interaction in the extracellular space of collagen molecules with proteoglycans and other proteins, including other collagens, influence the assembly of the molecules into fibrils.

ELASTIC CONNECTIVE TISSUE The elastic connective tissue is a complex macromolecular mesh, [44], [45] assembled in a continuous network that extends from the lamina densa of the DEJ throughout the dermis and into the connective tissue of the hypodermis. Its organization and importance in the dermis is best appreciated when examining samples of skin that have been digested to remove the collagen and other structures of the dermis, but retain the extraordinarily stable elastic fibers. Elastic fibers return the skin to its normal configuration after being stretched or deformed. Elastic fibers are also present in the walls of cutaneous blood vessels and lymphatics and in the sheaths of hair follicles. By dry weight, elastic connective tissue accounts for approximately 4 percent of the dermal matrix protein. The sequence of elastogenesis is initiated with the synthesis and deposition of microfibrils in a pattern that establishes the position of the elastic fibers. Elastin is then deposited, in variable quantities, on the microfibrillar framework according to the region of the dermis. Mature elastic fibers contain as much as 90 percent elastin; microfibrils are embedded within and collected on the surface of the elastin matrix. Elaunin fibers have an intermediate amount of insoluble, cross-linked elastin (Fig. 6-13). Oxytalan, elaunin, and mature elastic fibers occur in order progressively beginning at the DEJ.

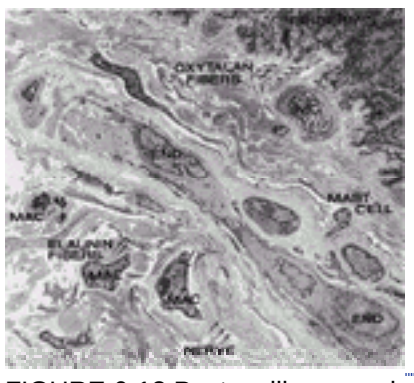

FIGURE 6-13 Postcapillary venule of the subpapillary plexus. Note the characteristic rings of basal lamina. Immature elastic fibers (oxytalan and elaunin) are seen above and below the vessel respectively; a melanocyte (MC) bulges down from the epidermis, and a small unmyelinated nerve is subjacent to the vessel. Macrophages (MAC) are seen between the fibrous components. END, endothelial cell. ×3950 in the original magnification.

Elastic fibers have microfibrillar and amorphous matrix components (see Fig. 6-12). Several glycoproteins have been identified as constituents of the microfibrils. Among the most characterized of these molecules is fibrillin, a 350-kDa molecule. Mutations in fibrillin have been identified in patients with Marfan's syndrome, an inherited connective-tissue disease in which patients frequently die of an aneurysm in the aorta. Aberrant elastic laminae in the vessel wall may not provide sufficient strength to support the vessel. Elastin, the elastic fiber matrix component, is processed from a secreted, soluble, precursor tropoelastin molecule that is rich in hydrophobic amino acids. Intermolecular, covalent, desmosine cross-links form between four lysyl residues of the tropoelastin molecules to provide exceptional stability and insolubility to the molecule. The oxytalan fibers extend perpendicularly from the DEJ to the junction between the papillary and reticular dermis, where they merge with the horizontal network of elaunin fibers. Oxytalan fibers are flexible integrating elements that accommodate deformation of the skin without compromise to structural integrity. In turn, the elaunin fibers evolve into the network of mature elastic fibers that extends throughout the reticular dermis. Elastic fibers are positioned between bundles of collagen fibers (Fig. 6-14C) except in certain pathologic conditions (e.g., the Buschke-Ollendorff syndrome) where both elastic and collagen fibers are assembled within the same bundle. Cloning and molecular analyses have demonstrated that a variety of well-characterized syndromes involving the skin, as well as cardiovascular, nervous, and/or musculoskeletal systems, result from mutations in genes encoding components of the elastic fiber network. Elastic fibers, which turn over very slowly in the skin, are also damaged by solar radiation and become dysmorphic with aging. [46]

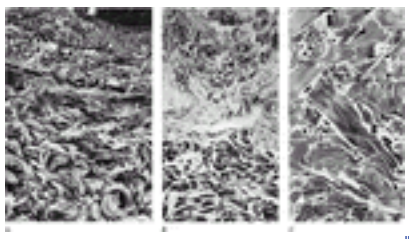

FIGURE 6-14 Papillary (PD) and reticular (RD) dermis shown in scanning electron (*A*) and light (*B,C*) micrographs. In *A*, the fine PD network is seen beneath the epidermis (E) extending to a vascular boundary created by vessels of the subpapillary plexus (SPP) as shown in *B*. The upper portion of the reticular dermis (RD1) has smaller collagen bundles than the deep reticular dermis. Elastic fibers (E1) border the collagen bundles. *A*, ×525; *B*, ×300; *C*, ×700 in the original magnifications.

The Diffuse and Filamentous Dermal Matrix (See Chap. 18)

Several filamentous or amorphous matrix components are present in the dermis between the fibrous matrix elements, associated with the fibers themselves, organized on the surfaces of cells, and in basement membranes. PGs and glycosaminoglycans are the molecules of the “ground substance” that surrounds and embeds the fibrous components. [47], [48] They can account for up to 0.2 percent dry weight of the dermis. PGs are unusually large molecules (100 to 2500 kDa) consisting of a core protein that is specific for the molecule and that determines which GAGs will be incorporated into the molecule. Hyaluronic acid (hyaluronan) usually binds to the core protein. The PGs/GAGs can bind up to 1000 times their own volume and thus regulate the water-binding capabilities of the dermis and influence dermal volume and compressibility; they also bind growth factors (e.g., bFGF) and link cells with the fibrillar and filamentous matrix, thereby influencing proliferation, differentiation, tissue repair, and morphogenesis. They are components of basement membranes and are present on surfaces of mesenchymal and epithelial cells.

The major PGs in the adult dermis are chondroitin sulfates/dermatan sulfate (biglycan, decorin, versican), heparan/heparan sulfate proteoglycans (HSPGs; perlecan, syndecan), and chondroitin-6 sulfate proteoglycans (CSPGs; components of the DEJ). The small dermatan sulfate molecule called PGII, or decorin, is more abundant in the papillary layer of the dermis than the reticular layer. It binds through its core protein to type I collagen where it may influence the lateral growth of fibrils. Versican is a large CSPG found in both papillary and reticular layers of the dermis and is thought to be associated with the microfilaments of the elastic network. HSPGs bind and influence the function of multiple effector molecules (growth factors, cytokines, extracellular matrix, proteases). Syndecan-4, induced in neonatal but not fetal wounds, may be responsible for inflammation and fibrosis. [49] Hyaluronan exists in the dermis as a free GAG and as a component of PGs, although it is much more abundant in fetal dermis where its presence is associated with a more watery, less stable matrix that permits cells to move freely within the tissue. As the dermis matures, the matrix is stabilized by a greater predominance of sulfated GAGs, although rises in hyaluronan are seen in wound healing and other situations analogous to development in which migration of cells is essential to the repair process. Age-related changes in proteoglycan composition of the adult dermis typically occur after age 40 years and involve increases in dermatan sulfate, but decreases in chondroitin-6 sulfate from the basal lamina and native chondroitin sulfate from the dermis.

Fibronectin (in the matrix), laminin (restricted to basement membranes), thrombospondin, vitronectin, and tenascin are glycoproteins found in the dermis and, like the PGs/GAGs, they interact with other matrix components and with cells through specific integrin receptors. [50], [51], [52], [53] and [54] As a consequence of their binding to other glycoproteins, collagen and elastic fibers, PGs, and to cells, glycoproteins are involved in—in some cases mediate—cell attachment (adhesion), migration, spreading in vitro, morphogenesis (epithelial–mesenchymal interactions, e.g., in follicle development), and differentiation.

Fibronectin is an insoluble, filamentous glycoprotein synthesized in the skin by both epithelial and mesenchymal cells; it ensheathes collagen fiber bundles and the elastic network, is associated with basal laminae, and appears on the surfaces of cells where it is bound to the cell through one of multiple integrin receptors that mediate cell-matrix adhesion. Fibronectin also binds platelets to collagen, is found in fibrin-fibrinogen complexes, and plays a role in organizing the extracellular matrix. Vitronectin is present throughout the dermis in association with the surfaces of all elastic fibers except for oxytalan. Tenascin is a large hexameric extracellular matrix glycoprotein. Minimal quantities of tenascin are present in adult dermis in a distribution restricted to the subepidermal reticular lamina and surrounding smooth muscle of blood vessels, arrector pili muscles, and sweat glands, but expression is strongly upregulated in the papillary dermis in conditions of epidermal hyperproliferation. Epidermal keratinocytes appear to be the primary source. In general, cell adhesion molecules are upregulated during wound healing, in tumors, and during developmental morphogenesis.

Organization of the Dermis: Major Regions of the Dermis [55]

The dermis is organized into papillary and reticular regions (Fig. 6-14); the distinction of the two zones is based largely on their differences in connective tissue organization, cell density, and nerve and vascular patterns. Subdivisions of each of these regions are more or less apparent in mature skin, depending upon the individual. The papillary dermis is proximal to the epidermis, molds to its contours, and is usually no more than twice its thickness. The reticular dermis is the dominant region of the dermis and of the skin as a whole. A horizontal plane of vessels, the subpapillary plexus, marks the boundary between the papillary and reticular dermis. The deep boundary between the dermis and the hypodermis is defined by the transition from fibrous to adipose connective tissue.

PAPILLARY DERMIS The papillary dermis is characterized by small bundles of small-diameter collagen fibrils and oxytalan elastic fibers (Fig. 6-14A, Fig. 6-14B). Mature elastic fibers are usually not found in the normal papillary dermis, but they are common in the skin of patients with certain inherited connective tissue diseases (e.g., dominantly inherited forms of the Ehlers-Danlos syndrome), in aging skin, and in actinically damaged skin. Large, dense, elastic fibers with abnormal structure are the hallmark of sun-damaged skin. The structural characteristics of the matrix in the papillary dermis permit the skin to accommodate to impact. The papillary dermis also has a high density of fibroblastic cells that proliferate more rapidly, have a higher rate of metabolic activity, and synthesize different species of PGs, as compared to those of the reticular dermis. Capillaries extending from the subpapillary plexus project toward the epidermis within the dermal papillae, fingerlike projections of papillary dermis that interdigitate with the rete pegs that project from the epidermis into the dermis (Fig. 6-15).

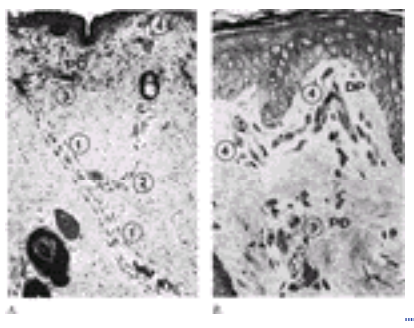

FIGURE 6-15 Light micrographs showing the pattern of dermal vasculature seen in the skin of a third trimester fetus (*A*) and an adult (*B*). Ascending/descending vessels pass vertically through the reticular dermis (1) and give off branches to epidermal appendages (2). The ascending vessels terminate at the border between the papillary dermis (PD) and reticular dermis where they form the horizontal subpapillary plexus (3).

Capillary loops (4) extend from the plexus into the dermal papillae (*left*). *B*. Enlarged regions of the papillary dermis showing vessels of the subpapillary plexus in cross section (e) and capillary loops in dermal papillae (4) (DP). ×300 in the original magnification. *(Courtesy of LT Smith, PhD.)*

The papillary dermis is generally less involved in pathologic change than the reticular dermis in patients with inherited disorders involving the connective tissue matrix. This suggests that factors other than the connective tissue itself may have a significant role in modulating the structure and function of that tissue. The epidermis and proximal dermis exchange a number of cytokines and growth factors, and matrix components of the dermis are linked to the cytoskeleton of the epidermis through transmembrane receptors; it is possible, therefore, that the organization and composition of the papillary dermis reflect the zone of influence of the epidermis through its soluble and diffusible factors. Connective tissue with the same organization and composition as the papillary dermis ("adventitial dermis") surrounds hair follicles and vessels—situations where matrix also underlies an epithelium. The sublamina densa region, or reticular lamina, can be identified in some individuals as a subdivision of the papillary dermis. It stains selectively with antibodies to type I procollagen and is characterized by a fine but dense organization of fibrils. Because of this, the structure is sometimes called a *compact zone*. It is a region that is particularly rich in cells that bear receptors for growth factors produced by the epidermis (e.g., PDGF) and it has an abundance of molecules that have adhesive properties (e.g., tenascin). This is also the region containing the ends of anchoring fibrils and related anchoring plaques. This region is more prominent and often thickened in pathologic skin.

RETICULAR DERMIS The reticular dermis is composed primarily of large-diameter collagen fibrils organized into large, interwoven fiber bundles. Mature, bandlike, branching elastic fibers form a superstructure around the collagen fiber bundles (Fig. 6-14C). In sectioned specimens of skin, these appear as fine bands at the periphery of the bundles, but scanning electron microscopy provides a more accurate impression of how the two fiber systems are integrated and can interact to provide the dermis with strong and resilient mechanical properties (Fig. 6-14A). In normal individuals, the elastic fibers and collagen bundles of the reticular dermis increase in size progressively toward the hypodermis. Subdivision of the reticular dermis into an upper intermediate zone and a deeper zone is possible because of graded differences in the size and character of the fibrous connective tissue. Intermediate-sized collagen fibrils and fiber bundles and horizontally oriented elaunin elastic fibers characterize the upper zone of the reticular dermis. This zone also has distinct mechanical properties compared with the deeper dermis; it is particularly susceptible to cleavage following trauma, and it may be involved in disease processes (e.g., selective loss of elastic fibers) when other regions are not. Compared to the deeper reticular dermis, the intermediate dermis is also enriched in fibroblastic cells and other connective tissue cells and in inflammatory cells that migrate into the tissue from the subpapillary plexus located in the region.

CELLS OF THE DERMIS Fibroblasts, macrophages, and mast cells are regular residents of the dermis (Fig. 6-12, Fig. 6-13, and Fig. 6-15 to Fig. 6-17). They are found in greatest density in normal skin in the papillary region and surrounding vessels of the subpapillary plexus, but they also occur in the reticular dermis where they are found in the interstices between collagen fiber bundles. Small numbers of lymphocytes collect around blood vessels in normal skin, and, at a site of inflammation, lymphocytes and other leukocytes from the blood are prominent. Pericytes and veil cells ensheathe the walls of blood vessels, and Schwann cells encompass nerve fibers (Fig. 6-13 and Fig. 6-15). Once viewed as distinct populations, the separation between fibroblasts, macrophages, and monocytes is no longer clear-cut. Moreover, there is significant heterogeneity among populations of each type based on criteria of structure, function, differentiation, and immunophenotype. Many cells in the dermis previously described as fibroblasts are probably cells with functions different from those of the typical fibroblast.

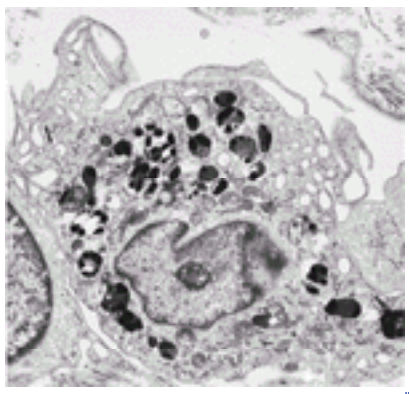

FIGURE 6-17 Macrophage. Note melanosomes within the phagosomes. ×15,950.

The *fibroblast* is a mesenchymally derived cell that migrates through the tissue and is responsible for the synthesis and degradation of fibrous and nonfibrous connective tissue matrix proteins and a number of soluble factors (Fig. 6-12). Thus, the function of fibroblasts is to provide a structural extracellular matrix framework as well as to promote interaction between epidermis and dermis by the synthesis of soluble mediators. [42] The same fibroblast is capable of synthesizing more than one type of matrix protein simultaneously. The morphology of the fibroblast often suggests active synthetic activity; the cytoplasm includes multiple profiles of dilated rough endoplasmic reticulum and typically more than one Golgi complex. Focal densities along the plasma membrane are identified as sites where there is communication between the cytoskeleton, transmembrane proteins of the plasma membrane (integrin receptors), and a variety of matrix proteins including laminin, fibronectin, vitronectin, thrombospondin, and collagens. Fibroblasts migrate between and on the surface of fiber bundles in the tissue but rarely do they invade or become trapped within them. Studies of human fibroblast cell lines indicate that they are a highly diverse population and within a single tissue phenotypically distinct populations exist. [56] There is great interest in fibroblast regulation because of increased proliferative and synthetic activity in wound healing and during formation of hypertrophic scars. Resting and proliferating fibroblasts respond to immune mediators, including IL-1a and IL-1ß, by increasing their production of KGF, hepatocyte growth factor (HGF), IL-1a, -1ß, and -8. Fibroblasts from hypertrophic scars upregulate and appear abnormally sensitive to TGF-ß, whereas interferon (IFN)-1a can decrease their proliferation and collagen production. [57]

Monocytes, macrophages, and dermal dendrocytes The monocytes, macrophages, and dermal dendrocytes are a heterogeneous collection of cells that constitute the mononuclear phagocytic system of cells in the skin. They can be distinguished into the monocyte–macrophage lineage and the dendritic cell lineage on the basis of ultrastructure, histochemistry, and immunocytochemistry. The latter series of cells includes Langerhans cells, indeterminant cells, interdigitating cells, and dermal dendrocytes. *Macrophages* [58] are derived from precursor cells of the bone

marrow that differentiate into monocytes in the blood, then migrate into the dermis where they differentiate (see Fig. 6-13 and Fig. 6-17). Macrophages are difficult to distinguish morphologically from fibroblasts if they do not contain lysosomes and phagocytic vacuoles because both cell types can have well-developed rough endoplasmic reticulum and Golgi, cytoplasmic intermediate filaments, and they occupy similar locations in the tissue. Several antigenic and enzymatic markers, considered macrophage differentiation antigens, characterize the macrophages and distinguish them from fibroblasts (MAC387, RFD7; KiM8, RFDR); other markers expressed by dermal macrophages are common among tissue macrophages and other cells derived from the monocyte-macrophage lineage. Subsets of macrophages that differ in structure, maturation, function, and position exist in the skin, although all phagocytic skin macrophages appear to coexpress CD11c (KiM1), CD6 (KiM6), and KiM8 antigens. [59] Macrophages have an expansive list of functions. They are phagocytic; they process and present antigen to immunocompetent lymphoid cells; they are microbicidal (through the production of lysozyme, peroxide, and superoxide), tumoricidal, secretory (growth factors, cytokines, and other immunomodulatory molecules), and hematopoietic; and they are involved in coagulation, atherogenesis, wound healing, and tissue remodeling. *Mast cells* (see Chap. 32) are specialized secretory cells distributed in connective tissues throughout the body, typically at sites adjacent to the interface of an organ and the environment. [60] In the skin, mast cells are present in greatest density in the papillary dermis, near the DEJ, in sheaths of epidermal appendages, and around blood vessels and nerves of the subpapillary plexus. They are also common in the subcutaneous fat (see Fig. 6-16 and Fig. 6-18). A close association of mast cells with neuropeptide-containing sensory nerves has been found in psoriatic lesional skin. Mast cells are easily identified histologically by a round or oval nucleus and abundant, darkly staining cytoplasmic granules. At the ultrastructural level the granules can be separated into populations of secretory and lysosomal granules. The surface of dermal mast cells is modified by microvilli and, like fibroblasts, they are coated with fibronectin, which probably assists in securing the cells within the connective tissue matrix. The cells are larger in the adult than in the child and contain a greater volume of cytoplasm. Mast cells can become hyperplastic in mastocytosis, a pleomorphic disease that varies with the organ involved.

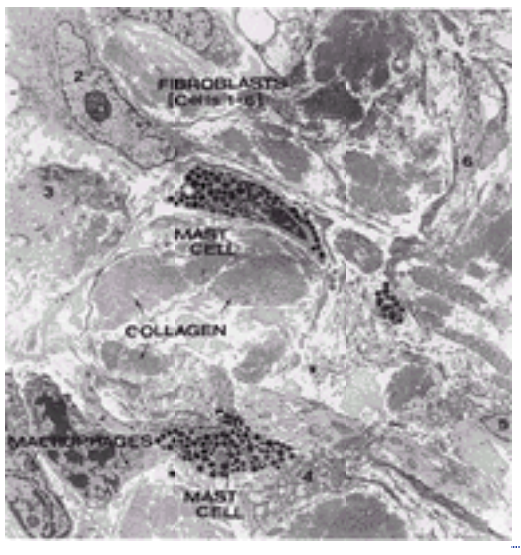

FIGURE 6-16 Typical cells of the dermis photographed at the level of the intermediate reticular dermis. ×35,000 in the original magnification. (*Courtesy of SK Anderson.*)

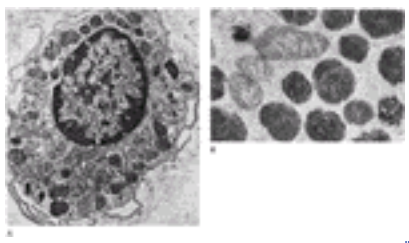

FIGURE 6-18 *A.* Mast cell with cytoplasmic granules and villous projections from the cell surface. ×19,000 in the original magnification. *B.* Secretory granules from another cell. ×43,700 in the original magnification.

Mast cells originate in the bone marrow from CD34+ stem cells. Mast cell proliferation depends on the *c-kit* receptor and its ligand, SCF. Mutations in *c-kit* have been documented in patients with mastocytosis. [61] Like basophils, mast cells also contain metachromatic granules and stores of histamine; both cells synthesize eosinophilic chemotactic factor and have IgE antibodies bound to their plasma membranes. Differentiation of the mast cell occurs in the tissue under the influence of factors produced by other cells and extracellular matrix. IL-3 is one of the factors required for this process to occur In rodents, which are frequently used as an animal model system, mast cells can be divided into two distinct subclasses based on their location, content of histamine and T cell responsiveness; this subdivision in humans is far less rigid, however. Mast cells synthesize an impressive repertoire of mediators. Some of them are preformed and stored in the granules. Histamine, heparin, tryptase, chymase, carboxypeptidase, neutrophil chemotactic factor, and eosinophilic chemotactic factor of anaphylaxis are organized in the predominantly proteoglycan milieu of the granule in a manner that is suggested to retain the enzymes in an inactive state prior to release. The mast cell synthesizes and releases other molecules, without storage, including a number of growth factors, cytokines (IL-1, -3, -4, -5, GM-CSF, and TNF-a), leukotrienes, and platelet-activating factors. Lysosomal granules in the cell contain acid hydrolases that degrade glycosaminoglycans, PGs, and complex glycolipids intracellularly. Several additional enzymes are present in both the lysosomal and the secretory granules. These may be important in initiating the repair of damaged tissue, and/or may help in degrading foreign material. Various stimuli can trigger release of the contents of the secretory granules. The process of degranulation occurs in the same manner regardless of the type of stimulus. The granules swell and their contents become lucent and disorganized. They fuse with one another and with the plasma membrane, opening channels through which the contents can be released. Release of the mediators into the tissue provokes contraction of vascular smooth muscle and increases vascular permeability, tissue edema, and the recruitment of inflammatory cells into the site. Mast cells are responsible for immediate-type hypersensitivity reactions in the skin and are involved in the production of subacute and chronic inflammatory disease. The *dermal dendrocyte* is a stellate, dendritic, or sometimes spindle-shaped, highly phagocytic fixed connective tissue cell in the dermis

of normal skin. Dermal dendrocytes are not specialized fibroblasts, but rather represent a subset of antigen-presenting macrophages or a distinct lineage that originates in the bone marrow. Similar to many other bone marrow–derived cells, dermal dendrocytes express factor XIIIa and the HLe-1 (CD45) antigen [62] and they lack typical markers of the fibroblastic cell (e.g., Te-7). These cells are particularly abundant in the papillary dermis and upper reticular dermis, frequently in the proximity of vessels of the subpapillary plexus. Dermal dendrocytes are also present around vessels in the reticular dermis and in the subcutaneous fat. The number of dermal dendrocytes is elevated in fetal, infant, photoaged, and certain pathologic adult skin and in association with sites of angiogenesis. Dermal dendrocytes are immunologically competent cells that function as effector cells in the afferent limb of an immune response. They are also highly phagocytic; they can be recognized as melanophages in the dermis or containing other exogenous pigment and iron. They are likely the cell of origin of a number of benign fibrotic proliferative conditions in the skin (e.g., dermatofibromas and fibroxanthomas).

The Cutaneous Vasculature

THE CUTANEOUS BLOOD VESSELS The skin is richly supplied with a vascular network consisting of distributing and collecting channels and horizontal plexuses located at boundaries within the dermis and supplying the epidermal appendages (see Fig. 6-15). [63] The microcirculatory beds in skin include arterioles/terminal arterioles, precapillary sphincters, arterial and venous capillaries, postcapillary venules, and collecting venules. The vessels provide nutrition for the tissues, but for the skin as a whole, the abundance of vessels is more than is needed to meet its metabolic needs. The vasculature is also involved in the regulation of temperature, blood pressure, wound repair, and numerous immunologic events. By comparison with the vasculature of other organs, the vessels of the skin have thick walls supported by connective tissue and smooth muscle cells. This structure is advantageous to an organ that is regularly subjected to shearing forces. All vessels of the cutaneous microcirculation are surrounded by veil cells. These cells are not part of the vessel wall but appear to define a domain for the vessel within the dermis. The vessels that supply the dermis are small branches from musculocutaneous arteries that penetrate the subcutaneous fat and enter the deep reticular dermis where they are organized into a horizontal, arteriolar plexus. Ascending arterioles extend vertically from the plexus toward the epidermis (see Fig. 6-15). These arterioles have two layers of smooth muscle cells, a discontinuous internal elastic lamina, and pericytes, a second type of contractile cell of the vessel wall. Three-dimensional reconstruction of the smooth muscle reveals an organization of the vessel wall that suggests they are the resistance vessels of the microcirculation. Ascending arterioles may join with one another through vascular arcades. At the junction between the papillary and reticular dermis, terminal arterioles form the subpapillary plexus (see Fig. 6-14, Fig. 6-15, and Fig. 6-19). The arterioles at this level lack the elastic fibers of the previous segment and have a single layer of smooth muscle cells that is organized in a manner to suggest the vessels' function as precapillary sphincters. Capillary loops extend from the terminal arterioles of the plexus into the papillary dermis, typically one per dermal papilla, but more in areas where the rete ridges are highly developed (see Fig. 6-15). The ascending limb of the loop and all of its intrapapillary portion consist of arterial capillaries that have a continuous endothelium, basal lamina, and a few pericytes that lie external to the subendothelial basal lamina. Pericytes may project through the basal lamina to contact and form tight junctions with endothelial cells. In the thinnest portion of the loop, at its apex, both the endothelium and basal lamina are attenuated, permitting transport of material out of the capillary.

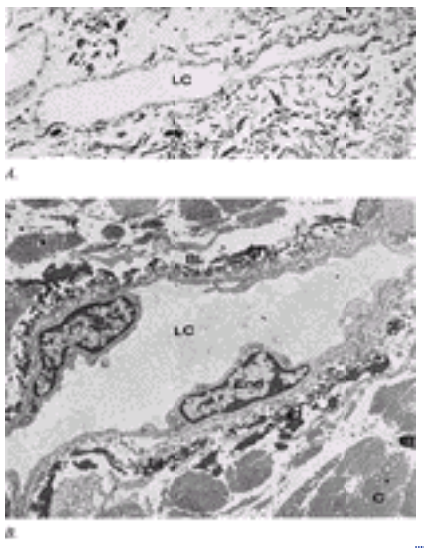

FIGURE 6-19 Lymph channels (LC) in adult dermis. Note the valves (*arrows*) (*A*) and that the wall of the channel consists of an endothelium (End), basal lamina (BL), and elastic connective tissue (El). Collagen (C) and elastic fibers of the dermis are also shown (*B*). *A*, ×400; *B*, ×42,000 in the original magnifications.

The extrapapillary, descending limb of the loop is a venous capillary. It drains into venous channels of the subpapillary plexus that lie above and below the arteriolar vascular plexus. The venous capillaries and the larger diameter postcapillary venules of the plexus have multiple layers of basal lamina separated by intervening collagen fibrils and a loosely organized sheath of pericytes and veil cells. These elements are more abundant than those of the arterial capillaries. The pericyte–endothelial cell contacts are also enhanced over those that occur in arterial capillaries. The walls of postcapillary venules can become significantly thickened by actinic damage and in metabolic diseases such as diabetes. The postcapillary venules of the subpapillary plexus are physiologically important components of the microcirculation. They respond to mediators such as histamine by developing gaps between adjacent endothelial cells that allow for the extravasation of fluid and escape of cells from the lumen of the vessel and thus are often the site of inflammatory cells in the tissue. The postcapillary venules empty into venous channels, parallel to the ascending arterioles, that carry blood to the deep horizontal plexus and then away from the skin. Venules in this location also have the laminated basement membrane structure characteristic of postcapillary venules in the subpapillary plexus. Valves present in the collecting venules exiting the plexus at the junction of the dermis and hypodermis appear to be advantageously placed to insure propulsion of the blood from the skin. Direct connections exist between arterial and venous circulation in certain regions of the skin (e.g., palms and soles) as alternative bypass routes that shunt blood around congested capillary beds. These sites consist of an ascending arteriole (called a *glomus body*), which is modified by three to six layers of smooth muscle cells and has associated sympathetic nerve fibers and venules. The glomus can close completely when the blood pressure is below a critical level. In the adult, cutaneous vasculature is normally quiescent with the exception of some angiogenesis related to anagen of the hair cycle. This quiescent state is maintained by inhibition of angiogenesis in the normal dermal matrix, by

factors such as thrombospondin. Secondary angiogenesis occurs in response to pathogenic stimuli. The major factor stimulated appears to be vascular permeability factor [VPF; vascular endothelial growth factor (VEGF)] secreted by keratinocytes. [64]

THE CUTANEOUS LYMPHATICS The lymph channels of the skin are important in regulating pressure of the interstitial fluid by resorption of fluid released from vessels and in clearing the tissue of cells, proteins, lipids, bacteria, and degraded substances. [65] Lymph flow within the skin depends upon movements of the tissue caused by arterial pulsations and larger-scale muscle contractions and movement of the body. Bicuspid-like valves within the lymphatic vessels may help prevent backflow and stasis of fluid in the vessels. Dissolved substances, debris, and cells to be removed by lymphatic tissue are collected in blind-ending initial lymphatics (also called lymphatic capillaries, prelymphatic tubules, and terminal or peripheral lymphatics) in the papillary dermis. [65] These vessels are sparse and do not extend as close to the epidermis as the capillary loops. Melanoma cells destroy the endothelial cells of the initial lymphatics to gain entry to the lymph circulation. [66] The lymph capillaries drain into a horizontal plexus of larger lymph vessels located deep to the subpapillary venous plexus. Lymph vessels can be distinguished from blood vessels in the same position by a larger luminal diameter (often difficult to see in their normally collapsed state in the skin) and thinner wall that consists of an endothelium, discontinuous basal lamina, and elastic fibers (Fig. 6-20 and Fig. 6-21). Integration of the elastic fibers of the vessel wall with those of the dermal connective tissue matrix has been suggested to serve as a conduit along which fluid can track toward the collecting channels. [65] The endothelial cells are typically flattened and attenuated and either abut one another or overlap; gaps are evident between adjacent endothelial cells in the subpapillary plexus lymphatic vessels in normal and damaged tissue. Gaps are observed less frequently in the vertical lymphatics that carry fluid and debris through the reticular dermis to the deeper collecting plexus at the reticular dermis–hypodermis border. The presence and location of this plexus is more variable in the skin. Smooth muscle cells are present in the walls of lymphatics only at the level of the hypodermis.

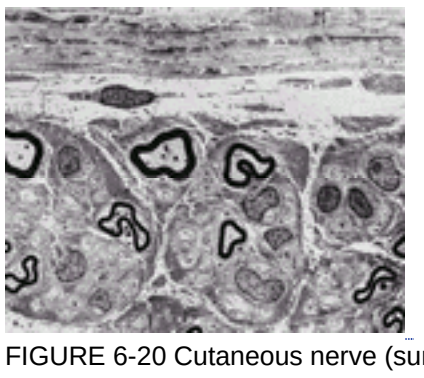

FIGURE 6-20 Cutaneous nerve (sural). At the top is the multilayered perineurium consisting of flattened cells interspaced with collagen fibers. This encloses the endoneurial compartment containing bundles of myelinated and unmyelinated axons embedded in collagen. The nuclei seen are those of Schwann cells. ×3350.

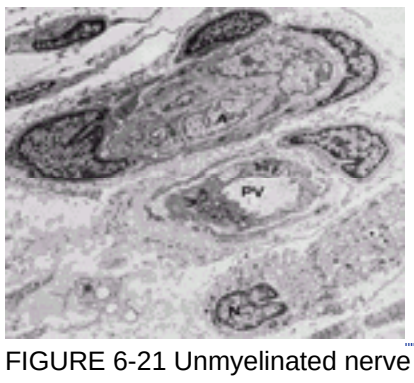

FIGURE 6-21 Unmyelinated nerve (N), arteriole (A), and postcapillary venule (PV) of the subpapillary plexus. Note the difference in wall structure of the A and PV. ×4400 in the original magnification.

Nerves and Receptors of the Skin

OVERVIEW The nerve networks of the skin contain somatic sensory and sympathetic autonomic fibers. [67] The sensory fibers alone (free nerve endings) or in conjunction with specialized structures (corpuscular receptors) function at every point of the body as receptors of touch, pain, temperature, itch, and mechanical stimuli. The density and types of receptors are regionally variable and specific, thus accounting for the variation in acuity at different sites of the body. Receptors are particularly dense in hairless areas such as the areola, labia, and glans penis. Sympathetic motor fibers are codistributed with the sensory nerves in the dermis until they branch to innervate the sweat glands, vascular smooth muscle, the arrector pili muscle of hair follicles, and sebaceous glands. The skin is innervated by large, myelinated cutaneous branches of musculocutaneous nerves that arise segmentally from spinal nerves (see Fig. 6-20). Small branches that enter the deep dermis are surrounded by an epineurial sheath; perineurial and endoneurial sheaths and Schwann cells envelop fiber bundles and individual fibers, respectively. The pattern of nerve fibers in the skin is similar to the vascular patterns. Nerve fibers form a deep plexus, then ascend to a superficial, subpapillary plexus (see Fig. 6-13). Branches leave both plexuses to supply various regions and structures of the skin. The extent to which fibers retain their sheaths depends upon their terminal distribution.

ANATOMIC DISTRIBUTION OF NERVES AND RECEPTORS IN THE SKIN The sensory nerves, in general, supply the skin segmentally (dermatomes), but the boundaries are imprecise and there is overlapping innervation to any given area. Autonomic innervation does not follow exactly the same pattern because the postganglionic fibers distributed in the skin originate in sympathetic chain ganglia where preganglionic fibers of several different spinal nerves synapse.

FREE NERVE ENDINGS Free nerve endings are the most widespread and undoubtedly the most important sensory receptors of the body (Fig. 6-21, Fig. 6-22). In humans, they are always ensheathed by Schwann cells and a basal lamina. Free nerve endings are particularly common in the papillary dermis just beneath the epidermis (see Fig. 6-13, Fig. 6-21, and Fig. 6-22); the basal lamina of the fiber may merge with the lamina densa of the basement membrane zone.

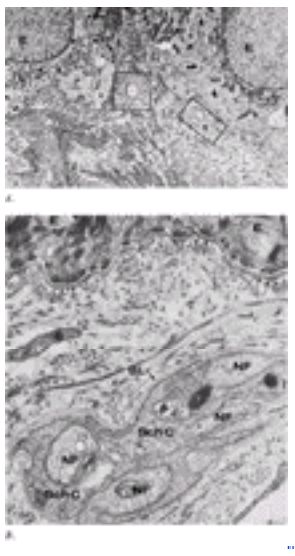

FIGURE 6-22 *A*. Free nerve endings in the papillary dermis. Note the close proximity of these endings (enclosed). E, epidermis. *B*. Nerve fibers (NF) surrounded by a Schwann cell (SchC) are shown in an ending that lies near to the dermal–epidermal junction (*arrows*). *A*, ×6850; *B*, ×20,000 in the original magnifications. (*From Holbrook K: Structure and Development of the Skin. in Pathophysiology of Dermatologic Disease, edited by NA Soter, HP Baden. New York, McGraw-Hill, 1991, 2nd edition, p 15, with permission.*)

The *penicillate fibers* are the primary nerve fibers found subepidermally in hairy skin. Separate, unmyelinated branches from one or more myelinated stem axons are ensheathed collectively by the processes of a single Schwann cell (see Fig. 6-22). The basal lamina of the Schwann cell and longitudinally-oriented collagen fibrils surround each branch to its termination. The penicillate nerve endings are rapidly adapting receptors and function in the perception of touch, temperature, pain, and itch. Discrimination is somewhat generalized (as opposed to punctate) because of the overlapping innervation to any given region. On the other hand, free nerve endings present in nonhairy, ridged skin (palms and soles) have a more precise distribution and project individually and vertically into a dermal papilla without overlapping distribution. These receptors probably function in fine discrimination and are only one of many types of receptors in this tissue, which is richly supplied with encapsulated nerve endings. *Papillary nerve endings* are found at the orifice of a follicle. They are branches from nerves that innervate the follicle at a deeper level in the skin. These terminals, in comparison with the penicillate endings, contain more mitochondria and vesicles and are believed to be particularly receptive to cold sensation. Other free nerve endings of the skin are associated with specific structures. Hair follicles, for example, are innervated by fibers that arise from myelinated stem axons in the deep dermal plexus, and they are thought to be slow-adapting receptors that respond to the bending or movement of hairs. Cholinergic sympathetic fibers en route to the eccrine sweat gland and adrenergic and cholinergic fibers to the arrector pili muscle are carried along with the sensory fibers in the hair basket. Free nerve endings are also associated with individual Merkel cells. As they penetrate the epidermis, they lose all of their sheaths. Complex receptors, described by a number of names (touch domes, Hederiform endings, Iggo's capsule, Pinkus corpuscles, Haarscheibe, etc.), containing as many as 50 Merkel cells, and supplied by a single arborizing nerve, are also present in the skin. In hairy skin, touch domes are associated with certain follicles, particularly those on the neck and dorsal surface of the forearm. In ridged palmar and plantar skin, Merkel cell–neurite assemblies collect at the site where the eccrine sweat duct penetrates a glandular epidermal papilla.

CORPUSCULAR RECEPTORS Corpuscular receptors have a capsule and an inner core and contain both neural and nonneural components. The capsule is a continuation of the perineurium, and the core includes preterminal and terminal portions of the fiber surrounded by lamellated wrappings of Schwann cells. The size of these receptors depends upon their position within the skin (the deeper structures being larger) and, for certain types, upon the age of the individual. Remodeling of the corpuscular receptors occurs throughout life. Corpuscular receptors express neuron-specific enolase, neurofilaments, calbindin D28K and other calcium-binding proteins, S-100, and p75 neurotrophin receptor. The *Meissner's corpuscle* is an elongated or ovoid mechanoreceptor located in the dermal papillae of digital skin and oriented vertically toward the epidermal surface (Fig. 6-23). One to six myelinated axons enter the base of the corpuscle, lose their myelin coverings, ramify extensively, and terminate in bulboid endings that are surrounded by lamellae.

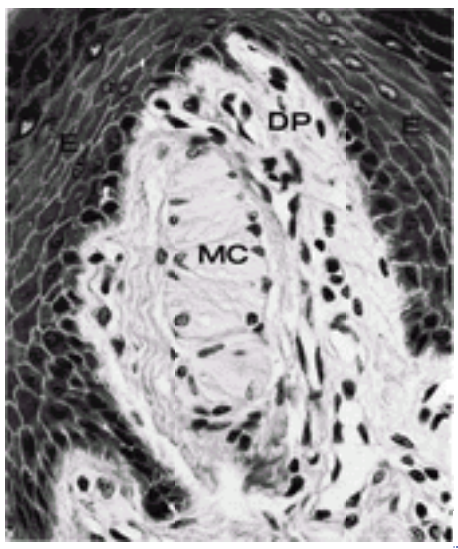

FIGURE 6-23 Meissner's corpuscle (MC) within the connective tissue of a dermal papilla (DP) from the sole of the foot. Note the many vessels also in the papilla and the layers of the epidermis (E). ×600.

The *Pacinian corpuscle* lies in the deep dermis and subcutaneous tissue of skin that covers weight-bearing surfaces of the body (Fig. 6-24). It is distinguished by the structure of its capsule and lamellar wrappings. The perineurium (capsule) is organized into 30 or more concentric layers of cells and fibrous connective tissue. A middle subcapsular zone is composed of collagen and fibroblasts, and the inner core consists of Schwann

cell–derived hemilamellae—flattened semicircles that alternate with those of the opposite side. The hemilamellae are packed closely around the nerve fiber and terminals. Pacinian corpuscles serve as rapidly adapting mechanoreceptors responding to vibrational stimuli.

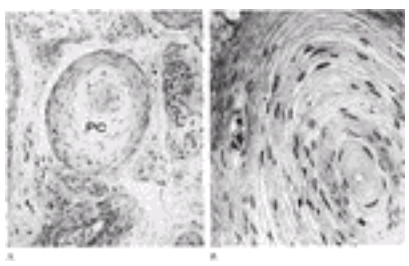

FIGURE 6-24 Pacinian corpuscle (PC) in the subcutaneous plantar tissue. Note the lamellated wrappings and the small vessels interspersed among the layers. A large myelinated nerve is also shown on the right-hand side of *A*. *A*, ×580; *B*, ×1050 in the original magnifications.

FUNCTIONAL DISTRIBUTION OF NERVES IN THE SKIN Immunohistochemical staining of nerve fibers in the skin has provided new understanding of the diversity of nerve fibers and complexity of innervation to the skin. The work has demonstrated that nerve fibers have overlapping characteristics. The structures are provided with fibers that release a variety of neurotransmitter substances that may affect their activity. Even though the chemical properties of fibers are recognized, the function of the innervation is not always apparent. Moreover, the distribution of specific types of fibers to zones and structures of the skin from one region of the body may not reflect the innervation for another region of the skin, and the effect of the neurotransmitters may be different among organs. There are pronounced efferent activities of the cutaneous neurologic system. Neuropeptides released by sensory neurons activate cutaneous target cells to induce inflammatory activities. Neuropeptide receptors and enzymes are expressed by nonneuronal skin cells. Sensory nerve fibers of the skin have been found to synthesize and release calcitonin gene– related peptide, somatostatin, substance P, neurokinin A, vasoactive intestinal peptide (VIP), and melanocyte-stimulating hormone (MSH)-? or MSH-?–like peptide. Autonomic nerve fibers that supply large vessels and sweat glands in the skin produce the vasoconstrictor neuropeptide Y, tyrosine hydroxylase that is used in the synthesis of catecholamines, VIP, neuron-specific enolase, myelin basic protein, S-100, and possibly somatostatin. Fibers to sweat glands are particularly immunoreactive with antibodies to antinatriuretic peptide, a substance that can function as a diuretic and promote vasodilation, thus possibly assisting the sweat gland in regulating water and electrolyte balance.

THE HYPODERMIS

The boundary between the deep reticular dermis and the hypodermis is an abrupt transition between a predominantly fibrous dermal connective tissue to an adipose tissue–rich subcutaneous region (see Fig. 6-1). Nonetheless, the two regions are structurally and functionally well integrated through nerve and vascular networks and the continuity of epidermal appendages. Actively growing hair follicles extend into the subcutaneous fat, and the apocrine and eccrine sweat glands are normally confined to this depth of the skin.

Mesenchymally derived adipocytes are the primary cells in the hypodermis. They are organized into lobules defined by septa of fibrous connective tissue. Nerves, vessels, and lymphatics are located within the septa and richly supply the region. Subcutaneous fat deposits begin to form in the midtrimester fetus and are already well developed in the newborn infant. The synthesis and storage of fat continues throughout life by enhanced accumulation of lipid within fat cells, proliferation of existing adipocytes, or by recruitment of new cells from undifferentiated mesenchyme. [68], [69] The hormone leptin, secreted by adipocytes, appears to provide a long-term feedback signal regulating fat mass. Leptin levels are higher in subcutaneous than omental adipose, suggesting a role for leptin in control of adipose distribution as well. The tissue of the hypodermis insulates the body, serves as a reserve energy supply, cushions and protects the skin, and allows for its mobility over underlying structures. It has a cosmetic effect in molding body contours. The importance of the subcutaneous tissue is apparent in patients with Werner's syndrome, in which subcutaneous fat is absent in lesional areas over bone, or with scleroderma where the subcutaneous fat is replaced with dense fibrous connective tissue. Such regions in Werner's patients ulcerate and heal poorly. The skin of patients with scleroderma is taut and painful. In the hereditary and acquired lipodystrophies, loss of subcutaneous fat is of concern not only cosmetically, but in terms of glucose, triglyceride, and cholesterol regulation as well.

DEVELOPMENT OF SKIN

Overview

Significant advances in the understanding of the molecular processes responsible for the development of the skin have been made over the last several years. Such advances increase the understanding of clinicopathologic correlation among some inherited disorders of the skin, and allow for the early diagnosis of such diseases. [70], [71] The developmental progression of various components of the skin is well-documented, and a timeline indicating the events that occur during embryonic and fetal development is provided (Table 6-1). [72], [73] Of note, the estimated gestational age (EGA) is used throughout this chapter; this system refers to the age of the fetus, with fertilization occurring on day 1. To avoid confusion, it should be pointed out that obstetricians and most clinicians define day 1 as the first day of the last menstrual period (menstrual age), in which fertilization occurs on approximately day 14. Thus, the two dating systems differ by approximately 2 weeks, such that a woman who is 14 weeks pregnant (menstrual age) is carrying a 12-week-old fetus (EGA).

TABLE 6-1 **Timing of the Major Events in the Embryogenesis of Human Skin***

Conceptually, fetal skin development can be divided into three distinct but temporally overlapping stages, those of specification, morphogenesis, and differentiation. These stages roughly correspond to the embryonic period (0 to 60 days), the early fetal period (2 to 5 months), and the late fetal period (5 to 9 months) of development. The earliest stage, specification, refers to the process by which the ectoderm lateral to the neural plate is committed to become epidermis, and subsets of mesenchymal and neural crest cells are committed to form the dermis. It is at this time that patterning of the future layers and specialized structures of the skin occurs, often via a combination of gradients of proteins and cell-cell signals. The second stage, morphogenesis, is the process by which these committed tissues begin to form their specialized structures, including epidermal stratification, epidermal appendage formation, subdivision between the dermis and subcutis, and vascular formation. The last stage, differentiation, denotes the process by which these newly specialized tissues further develop and assume their mature forms. Table 6-2 integrates specification, morphogenesis, and differentiation with skin morphology and genetic diseases.

TABLE 6-2 **Proteins Involved in Cutaneous Development and Differentiation**

For simplification and greater clarity, the stages of development of the epidermis—dermis and hypodermis, dermal–epidermal junction, and epidermal appendages—are presented sequentially.

Epidermis

EMBRYONIC DEVELOPMENT During the third week after fertilization, the human embryo undergoes gastrulation, a complex process of involution and cell redistribution that results in the formation of the three primary embryonic germ layers: ectoderm, mesoderm, and endoderm. Shortly after gastrulation, ectoderm further subdivides into neuroectoderm and presumptive epidermis. The specification of the presumptive epidermis is believed to be mediated by the bone morphogenetic proteins (BMPs). Later during this period, BMPs again appear to play a critical role, along with Engrailed-1 (En1), in specifying the volar versus interfollicular skin. [74], [75] and [76] By 6 weeks EGA, the ectoderm that covers the body consists of basal cells and superficial periderm cells (Fig. 6-25).

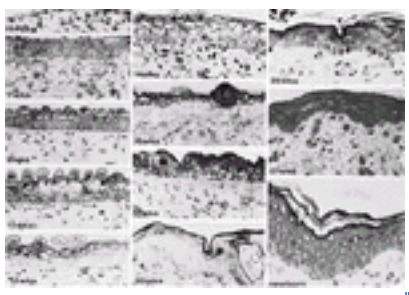

FIGURE 6-25 Epidermis and papillary dermis of human embryonic and fetal skin at progressive stages of development. Left column, first trimester; middle column, second trimester; right column, third trimester and newborn. ×120 in the original magnification.

The basal cells of the embryonic epidermis differ from those of later developmental stages. Embryonic basal cells are more columnar than fetal basal cells, and they have not yet formed hemidesmosomes (see below). Although certain integrins (e.g., $a_6ß_4$ are expressed in these cells, they are not yet localized to the basal pole of the cells. Prior to the formation of hemidesmosomes and desmosomes, intercellular attachment between individual basal cells appears to be medicated by adhesion molecules such as E- and P-cadherin, which have been detected on basal cells as early as 6 weeks EGA. Keratins K5 and K14, proteins restricted to definitive stratified epithelia, are expressed even at these early stages of

epidermal formation. At this stage, periderm cells form a “pavement epithelium.” These cells are embryonic epidermal cells that are larger and flatter than the underlying basal cells (Fig. 6-26). Apical surfaces contact the amniotic fluid and are studded with microvilli. Connections between periderm cells are sealed with tight junctions rather than desmosomes. By the end of the second trimester, these cells are sloughed and eventually form part of the vernix caseosa. Like stratified epithelial cells, periderm cells express K5 and K14, but they also express simple epithelial keratins K8, K18, and K19.

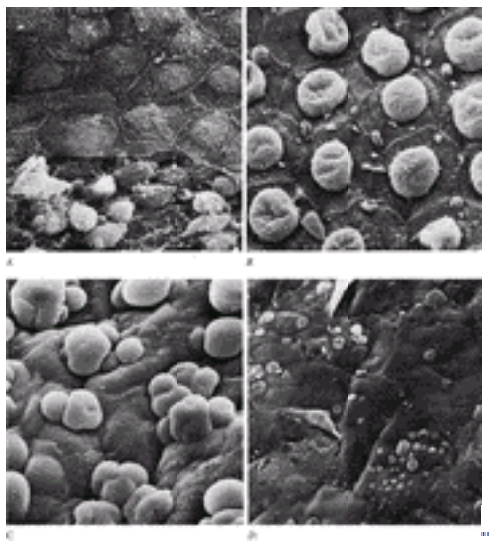

TABLE cellSpacing=0 cellPadding=0 align=left border=0 hspace="10" vspace="5"> FIGURE 6-26 Scanning electron micrographs of the periderm (epidermal surface) of embryonic and fetal skin at progressive stages of development. Cells of the basal layer are revealed where the periderm is torn (*A*). *A*, ×1885; *B* and *C*, ×1450; *D*, ×400.

Aplasia cutis may reflect focal defects in either epidermal specification or development caused by somatic mosaicism, or mutations that occur postzygotically. The molecular defect for this disorder is not known, however. The fact that few genetic diseases have been described in which epidermal specification or morphogenesis are defective likely reflects the fact that such defects would be incompatible with survival.

EARLY FETAL DEVELOPMENT (MORPHOGENESIS) By the end of 8 weeks' gestation, hematopoiesis has switched from the extraembryonic yolk sac to the bone marrow, the classical division between embryonic and fetal development. By this time, the epidermis begins its stratification and formation of an intermediate layer between the two preexisting cell layers. The cells in this new layer are similar to the cells of the spinous layer in mature epidermis. Like spinous cells, they express keratins K1/K10 and the desmosomal protein desmoglein-3 (pemphigus vulgaris antigen). The cells are still highly proliferative, and during this period of development they evolve into a multilayer structure that will eventually replace the degenerating periderm. Expression of the p63 gene plays a critical role in the proliferation and maintenance of the basal layer cells. Epidermal stratification does not occur in mice deficient for p63. [77], [78] In humans, although no null mutations have been isolated, partial loss of p63 function mutations have been identified in ankyloblepharon, ectodermal dysplasia, and cleft lip/palate syndrome (AEC, Hay-Wells syndrome) as well as ectrodactyly, ectodermal dysplasia, and cleft lip/palate syndrome (EEC). [79], [80] and [81] The preexisting basal cell layer also undergoes morphologic changes at this time, becoming more cuboidal and expressing new keratin genes, K6, K8, K19, and K6/K16, that are usually expressed in hyperproliferative tissues. The basal layer also begins to elaborate proteins that will ultimately anchor them to the developing basal lamina (see below), including hemidesmosomal proteins bullous pemphigoid antigen 1 (BPAG1), BPAG2, and collagens V and VII.

LATE FETAL DEVELOPMENT (DIFFERENTIATION) Late fetal development reveals the further specialization and differentiation of keratinocytes in the epidermis. It is at this time that the granular and stratum corneal layers are formed, and the rudimentary periderm is sloughed (see Fig. 6-25 and Fig. 6-26). Keratinization of the surface epidermis is a process of keratinocyte terminal differentiation which begins at 15 weeks EGA. The granular layer becomes prominent, and important structural proteins are elaborated in the basal layer cells. The hemidesmosomal proteins plectin and $a_6ß_4$ integrin are expressed and correctly localized at this time. Mutations in these genes result in various bullous genodermatoses (reviewed in more detail in Chap. 65). The more superficial cells undergo further terminal differentiation, and the keratin-aggregating protein filaggrin is expressed at this time. The formation of the cornified envelope is a late feature of differentiating keratinocytes, and it relies on a number of different modifications to create an impermeable barrier. Enzymes such as transglutaminase, LEKTI (encoded by the gene SPINK-5), phytanoyl CoA reductase, fatty aldehyde dehydrogenase, and steroid sulfatase are all important in the elaboration of the cornified envelope and mature lipid barrier, and defects in these enzymes can lead to abnormal epidermal barrier formation (see Table 6-2).

SPECIALIZED CELLS WITHIN THE EPIDERMIS The three major nonepidermal cell types—melanocytes, Langerhans cells, and Merkel cells—can be detected within the epidermis by the end of the embryonic period. Melanocytes are derived from the neural crest, a subset of neuroectoderm cells. The migratory paths of melanoblast clones are revealed as “Blaschko's lines” in banded pigmentary dyscrasias such as hypomelanosis of Ito and linear and whorled hypermelanosis. The founders of each melanoblast clone originate at distinct points along the dorsal midline, traversing ventrally and distally to take up residence in the epidermis. Melanocytes are first seen within the epidermis at 50 days EGA. Melanocytes express integrin receptors in vivo and in vitro and may use these to migrate to the epidermis during embryonic development. Migration, colonization, proliferation, and survival of melanocytes in developing skin depend on the cell surface tyrosine kinase receptor, *c-kit,* and its ligand, stem cell factor. [82] Melanin becomes detectable between 3 and 4 months EGA, and by 5 months, melanosomes begin to transfer pigment to keratinocytes. Many genetic disorders of pigmentation have been characterized and are presented in detail in Chaps. 89 and 90. Langerhans' cells, another immigrant population, are detectable by 40 days EGA. They begin to express CD1 on their surface and to produce their characteristic Birbeck granules by the embryonic–fetal transition. By the third trimester, most of the adult numbers of Langerhans' cells will have been produced. Merkel cells, as described earlier in the chapter, reside in the epidermis. They are first detectable in the volar epidermis of the 11- to 12-week EGA human fetus. The embryonic derivation of this population of cells is controversial. The strongest evidence thus far for in situ differentiation of Merkel cells from epidermal ectoderm versus immigration of Merkel cells, perhaps from neural crest, comes from studies in which 8- and 11-week EGA fetal volar skin that lacked Merkel cells was transplanted to the nude mouse. Tissue harvested 8 weeks later contained an abundance of human K18-positive Merkel cells within the epidermis, suggesting that the cells differentiated within the grafted tissue. [83] Recent studies show that Merkel cells do not proliferate in the epidermis. This can be interpreted as further evidence that Merkel cells arise

from an epidermal stem cell. [84]

DERMAL AND SUBCUTICULAR DEVELOPMENT The origin of the dermis and subcutaneous tissue is more diverse than that of the epidermis, which is exclusively ectodermally derived. The embryonic tissue that forms the dermis depends on the specific body site. [85], [86] Dermal mesenchyme of the face and anterior scalp is derived from neural crest ectoderm. The limb and ventral body wall mesenchyme is derived from the lateral plate mesoderm. The dorsal body wall mesenchyme derives from the dermomyotomes of the embryonic somite. Lmx-1B and Wnt7a are important in the specification of the dorsal limb. [87], [88] and [89] En-1 and BMPs, on the other hand, specify the volar (ventral) limb mesenchyme (see Table 6-2). [78], [89] The embryonic dermis, in contrast to the mature dermis, is cellular and amorphous, with few organized fibers. The mature dermis contains a complex mesh of collagen and elastic fibers embedded in a matrix of proteoglycans, whereas the embryonic mesenchyme contains a large variety of pluripotent cells in a hydrated gel that is rich in hyaluronic acid. These mesenchymal cells are thought to be the progenitors of cartilage-producing cells, adipose tissue, dermal fibroblasts, and intramembranous bone. Dermal fibers exist as fine filaments, but not thick fibers. The protein components of the future elastin and collagen fibers are synthesized during this period but not assembled. At this point, there is no obvious separation between cells that will become musculoskeletal elements and those that will give rise to the skin dermis. Although there is no known inherited disorder of dermal development, certain conditions such as restrictive dermopathy, focal dermal hypoplasia (Goltz's syndrome), and Proteus syndrome exhibit focal defects, probably a result of genetic mosaicism affecting genes important in this process. Mutations causing a global defect in this process would likely be incompatible with life. The superficial mesenchyme becomes distinct from the underlying tissue by the embryonic–fetal transition (about 60 days EGA). By 12 to 15 weeks, the reticular dermis begins to take on its characteristic fibrillar appearance in contrast to the papillary dermis, which is more finely woven. Large collagen fibers continue to accumulate in the reticular dermis, as well as elastin fibers, beginning around mid-gestation and continuing until birth. By the end of the second trimester, the dermis has changed from a nonscarring tissue to a scarring one. As the dermis matures, it also becomes thicker and well-organized, such that at birth, it resembles the dermis of the adult, although it is still more cellular. Many well-known clinical syndromes and molecules have been discovered that affect this final stage of dermal differentiation. These diseases include dystrophic epidermolysis bullosa (EB) (a collagen VII defect), Marfan syndrome (a defect in fibrillin), Ehlers-Danlos syndrome, cutis laxa (elastin), pseudoxanthoma elasticum (PXE), hereditary hemorrhagic telangiectasia (HHT, or Osler-Weber-Rendu syndrome), and osteogenesis imperfecta (OI) (see Table 6-2). In many of these cases, the specific genetic defect helps to define the many different manifestations of these diseases, although in certain cases (e.g. PXE), the identity of the gene does not readily explain the mechanism of disease.

Specialized Components of the Dermis

BLOOD VESSELS AND NERVES Cutaneous nerves and vessels begin to form early during gestation, but they do not evolve into those of the adult until a few months after birth. The process of vasculogenesis requires the in situ differentiation of the endothelial cells at the endoderm–mesoderm interface. Originally, horizontal plexuses are formed within the subpapillary and deep reticular dermis, which are interconnected by groups of vertical vessels. This lattice of vessels is in place by 45 to 50 days EGA. At 9 weeks EGA, blood vessels are seen at the dermal–hypodermal junction. By 3 months, the distinct networks of horizontal and vertical vessels have formed. By the fifth month, further changes in the vasculature derive from budding and migration of endothelium from preexisting vessels, the process of angiogenesis. Depending on the body region, gestational age, presence of hair follicles and glands, this pattern can vary with blood supply requirements. Defects in vascular development have been described, as in the Klippel-Trenaunay and Sturge-Weber syndromes (see Chap. 103). In the Klippel-Trenaunay syndrome, unilateral cutaneous vascular malformations develop, with associated venous varicosities, edema, and hypertrophy of associated soft tissue and bone. In Sturge-Weber syndrome, many cutaneous capillary malformations are seen in the lips, tongue, nasal, and buccal mucosae. Some familial defects in vascular formation result from mutations in the gene encoding TIE2 receptor tyrosine kinase. Capillary malformations seen in hereditary hemorrhagic telangiectasia have been linked to mutations in TGF-ß binding proteins, endoglin and activin receptor-like kinase 1.

LYMPHATICS Accumulating evidence suggests that lymphatics originate from endothelial cells that bud off from veins. The pattern of embryonic lymphatic vessel development parallels that of blood vessels. Detailed molecular studies into the development of lymphatics during embryogenesis and fetal development have long been hampered by the lack of lymphatic-specific markers. However, recent studies have identified new genes that appear to be specific for some of the earliest lymphatic precursors. LYVE-1 and Prox-1 are genes considered to be critical for earliest lymphatic specification, whereas VEGF-R3 and SLC may be important in later lymphatic differentiation. Supporting the assertion that VEGF-3 is a critical component of lymphatic formation, some patients with hereditary lymphedema have been found to have defects in the VEGF-3 gene. [90]

NERVES The development of cutaneous nerves parallels that of the vascular system in terms of patterning, maturation, and organization. Nerves of the skin consist of somatic sensory and sympathetic autonomic fibers, which are predominantly small and unmyelinated. As these nerves develop, they become myelinated, with associated decrease in the number of axons. This process may continue as long as puberty.

SUBCUTIS

As mentioned above, by 50 to 60 days EGA, the hypodermis is separated from the overlying dermis by a plane of thin-walled vessels. Toward the end of the first trimester, the matrix of the hypodermis can be distinguished from the more fibrous matrix of the dermis. By the second trimester, adipocyte precursors begin to differentiate and accumulate lipids. By the third trimester, fat lobules and fibrous septae are found to separate the mature adipocytes. The molecular pathways that define this process are currently an area of intense investigation. Although few regulators important in embryonic adipose specification and development have identified, several factors critical for preadipocyte differentiation have been demonstrated, including leptin, a hormone important in fat regulation, and the PPAR family of transcription factors. [69], [91]

DERMAL–EPIDERMAL JUNCTION

The dermal–epidermal junction is an interface where many inductive interactions occur that result in the specification or differentiation of the characteristics of the dermis and epidermis. This zone includes specialized basement membrane, basal cell extracellular matrix, the basal-most portion of the basal cells, and the superficial-most fibrillar structures of the papillary dermis. Both the epidermis and dermis contribute to this

region.

P>As early as 8 weeks EGA, a simple basement membrane separates the dermis from the epidermis and contains many of the major protein elements common to all basement membranes, including laminin 1, collagen IV, heparin sulfate, and proteoglycans. Components specific to the cutaneous basement membrane zone, such as proteins of the hemidesmosome and anchoring filaments, are first detected at the embryonic–fetal transition. By the end of the first trimester, or around the time of late embryonic development, all basement membrane proteins are in place. The a_6 and $ß_4$ integrin subunits are expressed earlier than most of the other basement membrane components. However, they are not localized to the basal surface until 9.5 weeks EGA, coincident with the time that the hemidesmosomal proteins are expressed and hemidesmosomes are first observed. At the same time, anchoring filaments (laminin 5) and anchoring fibrils (collagen VII) begin to be assembled. The actual synthesis of collagen VII can be detected slightly earlier, at 8 weeks EGA.

Many congenital blistering disorders have been demonstrated to be a result of defects in proteins of the DEJ (for details, see Chap. 65). The severity of the disease, plane of tissue separation, and involvement of nonskin tissues depend on the proteins involved and the specific mutations. These genes are important candidates for prenatal testing.

DEVELOPMENT OF SKIN APPENDAGES

Skin appendages, which include hair, nails, sweat and mammary glands, are composed of two distinct components: an epidermal portion, which produces the differentiated product, and the dermal component, which regulates differentiation of the appendage. During embryonic development, dermal–epidermal interactions are critical for the induction and differentiation of these structures. Disruption of these signals often has profound influences on development of skin appendages. Our discussion focuses on hair differentiation as a paradigm for appendageal development, because it is the appendage that has been studied most intensely. [92]

Hair

Dermal signals are initially responsible for instructing the basal cells of the epidermis to begin to crowd at regularly spaced intervals, starting between days 75 and 80 on the scalp. This initial grouping is known as the follicular placode or anlage. Based on molecular localization of ß-catenin, it has been implicated as a candidate for one of the effectors of this “dermal signal.”

From the scalp, follicular placode formation spreads ventrally and caudally, eventually covering the skin. The placodes then signal back to the underlying dermis to form a “dermal condensate,” which occurs at 12 to 14 weeks EGA. This process is thought to be a balance of placode promoters and placode inhibitors. [92] Wnt family signaling molecules are proposed to mediate placode promoting effects via the molecules LEF and ß-catenin, as well as FGF, TGF-$ß_2$, Msx1 and 2, ectodysplasin A (EDA), and EDAR (EDA receptor). BMP family molecules, on the other hand, act as inhibitors of follicle formation. In model systems, ectopic expression of this family of molecules tends to suppress the formation of follicles. In mice, EDAR and ß-catenin expression are required for expression of BMP4 and Sonic hedgehog (Shh), implicating these molecules in early follicular morphogenesis. Furthermore, EDAR may be important for lateral inhibition of cells surrounding the follicles.

Formation of the dermal papilla is thought to be initiated by the “first epithelial signal” that gets transmitted from the follicle epithelium to the underlying mesenchyme. Molecules proposed to be involved in this signaling process include PDGF-A and Shh. After the follicular differentiation process begins, the dermis sends another signal to the epithelial placode cells to proliferate and invade the dermis. The dermal cells associated with the follicle then develop into the dermal papilla. The epithelial cells go on to form the inner root sheath and hair shaft of the mature hair follicle.

In addition to the widened bulge at the base, two other bulges form along the length of the developing follicle, termed the *bulbous hair peg*. The uppermost bulge is the presumptive sebaceous gland, whereas the middle bulge serves as the site for insertion of the arrector pili muscle. This middle bulge is also the location of the multipotent hair stem cells, which are capable of differentiating into any of the cells of the hair follicle, and also have the potential to replenish the entire epidermis, as has seen in cases of extensive surface wounds or burns.

By 19 to 21 weeks EGA, the hair canal has completely formed and the hairs on the scalp are visible above the surface of the fetal epidermis. They continue to lengthen until 24 to 28 weeks, at which time they shift from the active growth (anagen) phase to the degenerative phase (catagen), then to the resting phase (telogen). This completes the first hair cycle. With subsequent hair cycles, hairs increase in diameter and coarseness. During adolescence, vellus hairs of androgen-sensitive areas mature to terminal-type hair follicles.

Sebaceous Glands

Sebaceous glands mature during the course of follicular differentiation. This process begins between 13 and 16 weeks EGA, at which point the presumptive sebaceous gland is first visible as the most superficial bulge of the maturing hair follicle. The outer proliferative cells of the gland give rise to the differentiated cells that accumulate lipid and sebum. After they terminally differentiate, these cells disintegrate and release their products into the upper portion of the hair canal. Sebum production is accelerated in the second and third trimesters, during which time maternal steroids cause stimulation of the sebaceous glands. Hormonal activity is once again thought to influence the production of increased sebum during adolescence, resulting in the increased incidence in acne at this age.

Nail Development

Presumptive nail structures begin to appear on the dorsal digit tip at 8 to 10 weeks EGA, slightly earlier than the initiation of hair follicle development. The first sign is the delineation of the flat surface of the future nail bed. A portion of ectoderm buds inward at the proximal boundary of the early nail field, and gives rise to the proximal nail fold. The presumptive nail matrix cells, which differentiate to become the nail plate, are present on the ventral side of the proximal invagination. At 11 weeks, the dorsal nail bed surface begins to keratinize. By the fourth

month of gestation, the nail plate grows out from the proximal nail fold, completely covering the nail bed by the fifth month. Mutations in p63 affect nail development in syndromes such as AEC, as well as EEC. Functional p63 is required for the formation and maintenance of the apical ectodermal ridge, an embryonic signaling center essential for limb outgrowth and hand plate formation. Wnt 7a is thought to be important for dorsal limb patterning, and thus nail formation. In contrast to follicular development, Shh is not required for nail plate formation. Also similar to follicular differentiation, LMX1b and MSX1 are important for nail specification; LMX1b & MSX1 are mutated in nail-patella syndrome and Witkop syndrome respectively. [93], [94] and [95] Hoxc13 appears to be an important homeodomain-containing gene for both follicular and nail appendages, at least in murine models. [96]

Eccrine and Apocrine Sweat Gland Development

Eccrine glands begin to develop on the volar surfaces of the hands and feet, beginning as mesenchymal pads between 55 and 65 days EGA. By 12 to 14 weeks EGA, parallel ectodermal ridges are induced, which overly these pads. The eccrine glands arise from the ectodermal ridge. By 16 weeks EGA, the secretory portion of the gland becomes detectable. The dermal duct begins around week 16, but the epidermal portion of the duct and opening are not complete until 2 weeks EGA.

Interfollicular eccrine and apocrine glands, in contrast, do not begin to bud until the fifth month of gestation. Apocrine sweat glands usually bud from the upper portion of the hair follicle. By 7 months EGA, the cells of the apocrine glands become distinguishable.

Although not much is known with regard to the molecular signals responsible for the differentiation of these structures, the EDA, EDAR, En1, and Wnt10b genes have been implicated.

PRENATAL TESTING OF CONGENITAL SKIN DISORDERS

The identification of the genes involved in early cutaneous differentiation and development, as well as some of their associated mutations in disease, have made it possible for prenatal testing to diagnose fetuses with life-threatening or debilitating disorders. [97] Candidates for prenatal testing include those fetuses with an affected sibling or family member. A number of techniques have been developed for evaluation of involved genes. For example, chorionic villous sampling (CVS) can be undertaken at 8 to 10 weeks EGA or amniocentesis at 16 to 18 weeks EGA (see Table 6-2). These techniques are associated with less morbidity and mortality to the fetus than the only previously available method, fetal skin biopsy, performed between 19 and 22 weeks EGA. Although these recent advances in prenatal diagnosis allow for the early detection of many severe genodermatoses, certain syndromes, such as harlequin fetus, still require fetal biopsy for diagnosis. Resources for health care providers, including currently available laboratory tests, as well as reviews regarding some of these congenital disorders, can be found at GeneTest (http://www.genetests.org/).

REFERENCES

1. Fuchs E: Keratins and the skin. *Annu Rev Cell Dev Biol* **11**:123, 1995

2. Freedberg IM et al: Keratins and the keratinocyte activation cycle. *J Invest Dermatol* **116**:633, 2001

3. Michel M et al: Keratin 19 as a biochemical marker of skin stem cells in vivo and in vitro: Keratin 19 expressing cells are differentially localized in function of anatomic sites, and their number varies with donor age and culture stage. *J Cell Sci* **109**:1017, 1996

4. Lyle S et al: The C8/144B monoclonal antibody recognizes cytokeratin 15 and defines the location of human hair follicle stem cells. *J Cell Sci* **111**:3179, 1998

5. Watt FM: Stem cell fate and patterning in mammalian epidermis. *Curr Opin Genet Dev* **11**:410, 2001

6. Fuchs E et al: At the roots of a never-ending cycle. *Dev Cell* **1**:13, 2001

7. Kowalczyk AP et al: Desmosomes: Intercellular adhesive junctions specialized for attachment of intermediate filaments. *Int Rev Cytol* **185**:237, 1999

8. Yap AS et al: Molecular and functional analysis of cadherin-based adherens junctions. *Annu Rev Cell Dev Biol* **13**:119, 1997

9. Lin MS et al: The desmosome and hemidesmosome in cutaneous autoimmunity. *Clin Exp Immunol* **107**(Suppl 1):9, 1997

10. Hanakawa Y et al: Molecular mechanisms of blister formation in bullous impetigo and staphylococcal scalded skin syndrome. *J Clin Invest* **110**:53, 2002

11. Richard G: Connexins: A connection with the skin. *Exp Dermatol* **9**:77, 2000

12. Herman GE: X-Linked dominant disorders of cholesterol biosynthesis in man and mouse. *Biochim Biophys Acta* **1529**:357, 2000

13. Holbrook KA: Biologic structure and function: Perspectives on morphologic approaches to the study of the granular layer keratinocyte. *J Invest Dermatol* **92**:84S, 1989

14. Nemes Z, Steinert PM: Bricks and mortar of the epidermal barrier. *Exp Mol Med* **31**:5, 1999

15. Presland RB, Dale BA: Epithelial structural proteins of the skin and oral cavity: Function in health and disease. *Crit Rev Oral Biol Med* **11**:383, 2000

16. Elias PM, Feingold KR: Coordinate regulation of epidermal differentiation and barrier homeostasis. *Skin Pharmacol Appl Skin Physiol* **14**(Suppl 1):28, 2001

17. Sengel P: Epidermal–dermal interaction, in *Biology of the Integument* vol. 2, *Vertebrates,* edited by J Bereiter-Hahn, AG Matoltsy, KS Richards. Berlin, Springer-Verlag, 1986, p 374

18. Hynes RO: Cell adhesion: Old and new questions. *Trends Cell Biol* **9**:M33, 1999

19. Tennenbaum T et al: Differential regulation of integrins and extracellular matrix binding in epidermal differentiation and squamous tumor progression. *J Investig Dermatol Symp Proc* **1**:157, 1996

20. Fuchs E et al: Integrators of epidermal growth and differentiation: Distinct functions for beta 1 and beta 4 integr *Curr Opin Genet Dev* **7**:672, 1997

21. Tomic-Canic M et al: Epidermal signal transduction and transcription factor activation in activated keratinocy *J Dermatol Sc* **17**:167, 1998

22. Fuchs E, Byrne C: The epidermis: Rising to the surface *Curr Opin Genet Dev* **4**:725, 1994

23. Jost M et al: The EGF receptor—An essential regulator of multiple epidermal functio *Eur J Dermato* **10**:505, 2000

24. Beer HD et al: Expression and function of keratinocyte growth factor and activin in skin morphogenesis and cutaneous wound re *J Investig Dermatol Symp Pro* **5**:34, 2000

25. Ito Y et al: Overexpression of Smad2 reveals its concerted action with Smad4 in regulating TGF-beta-mediated epidermal homeos *Dev Bio* **236**:181, 2001

26. Steinhoff M et al: Keratinocytes in epidermal immune response *Curr Opin Allergy Clin Immun* **1**:469, 2001

27. Kang S et al: Pharmacology and molecular action of retinoids and vitamin D in sl *J Investig Dermatol Symp Pro* **1**:15, 1996

28. Eichner R et al: Effects of long-term retinoic acid treatment on epidermal differentiation in vivo: specific modifications in the programme of terminal differenti *Br J Dermato* **135**:687, 1996

29. Bikle DD et al: Calcium- and vitamin D-regulated keratinocyte differentiati *Mol Cell Endocrino* **177**:161, 2001

30. Missiaen L et al: Abnormal intracellular Ca(+) homeostasis and disease *Cell Calciun* **28**:1, 2000

31. Sakuntabhai A et al: Spectrum of novel ATP2A2 mutations in patients with Darier's disea *Hum Mol Genei* **8**:1611, 1999

32. Hu Z et al: Mutations in ATP2C1, encoding a calcium pump, cause Hailey-Hailey disea *Nat Genet* **24**:61, 2000

33. Nickoloff BJ, Denning M: Life and death signaling in epidermis: Following a planned cell death pathway involving a trail that does not lead to skin c *J Invest Dermato* **117**:1, 2001

34. Vancoillie G et al: Melanocyte biology and its implications for the clinici *Eur J Dermato* **9**:241, 1999

35. Seiberg M: Keratinocyte-melanocyte interactions during melanosome transf *Pigment Cell Res* **14**:236, 2001

36. Ogawa H: The Merkel cell as a possible mechanoreceptor c *Prog Neurobio* **49**:317, 1996

37. Johnson KO: The roles and functions of cutaneous mechanoreceptor *Curr Opin Neurobio* **11**:455, 2001

38. Jakob T, Udey MC: Epidermal Langerhans cells: From neurons to nature's adjuvar *Adv Dermato* **14**:209, 1999

39. Ghohestani RF et al: Molecular organization of the cutaneous basement membrane zo *Clin Dermato* **19**:551, 2001

40. Burgeson RE, Christiano AM: The dermal–epidermal junctio *Curr Opin Cell Bio* **9**:651, 1997

41. Uitto J, Pulkkinen L: Molecular genetics of heritable blistering disorde *Arch Dermato* **137**:1458, 2001

42. Werner S, Smola H: Paracrine regulation of keratinocyte proliferation and differentiati *Trends Cell Bio* **11**:143, 2001

43. Burgeson RE, Nimni ME: Collagen types. Molecular structure and tissue distributio *Clin Orthop* **282**:250, 1992

44. Christiano AM, Uitto J: Molecular pathology of the elastic fiber *J Invest Dermato* **103**:53S, 1994

45. Kielty CM, Shuttleworth CA: Microfibrillar elements of the dermal matr *Microsc Res Tech* **38**:413, 1997

46. Uitto J, Bernstein EF: Molecular mechanisms of cutaneous aging: Connective tissue alterations in the derr *J Investig Dermatol Symp Pro* **3**:41, 1998

47. Iozzo RV: Matrix proteoglycans: From molecular design to cellular functi *Annu Rev Biochem* **67**:609, 1998

48. Scott JE: Supramolecular organization of extracellular matrix glycosaminoglycans in vitro and in the tissu *FASEB J* **6**:2639, 1992

49. Gallo R et al: Syndecans-1 and -4 are induced during wound repair of neonatal but not fetal s *J Invest Dermato* **107**:676, 1996

50. Schwarzbauer JE, Sechler JL: Fibronectin fibrillogenesis: A paradigm for extracellular matrix assem *Curr Opin Cell Bio* **11**:622, 1999

51. Aumailley M, Rousselle P: Laminins of the dermo-epidermal junctio *Matrix Bio* **18**:19, 1999

52. Adams JC: Thrombospondins: Multifunctional regulators of cell interaction *Annu Rev Cell Dev Bio* **17**:25, 2001

53. Schvartz I et al: Vitronectin *Int J Biochem Cell Bio* **31**:539, 1999

54. Jones FS, Jones PL: The tenascin family of ECM glycoproteins: Structure, function, and regulation during embryonic development and tissue remod *Dev Dyn* **218**:235, 2000

55. Holbrook KA, Byers PH: Diseases of the extracellular matrix: Structural alterations of collagen fibrils in skir *Connective Tissue Disease: Molecular Pathology of the Extracellular Matrix,* edited by J Uitto and A Perejda. New York, Marcel Dekker, 1987, p 10

56. Falanga V et al: Human dermal fibroblast clones derived from single cells are heterogeneous in the production of mRNAs for alpha 1(I) procollagen and transforming growth factor-beta 1. *J Invest Dermato* **105**:27, 1995

57. Wang R et al: Hypertrophic scar tissues and fibroblasts produce more transforming growth factor-beta1 mRNA and protein than normal skin and c *Wound Repair Reger* **8**:128, 2000

58. Cline MJ: Monocytes, macrophages, and their diseases in ma *J Invest Dermato* **71**:56, 1978

59. Weber-Matthiesen K, Sterry W: Organization of the monocyte/macrophage system of normal human s *J Invest Dermato* **95**:83, 1990

60. Church MK, Clough GF: Human skin mast cells: in vitro and in vivo studie *Ann Allergy Asthma Immunc* **83**:471, 1999

61. Nagata H et al *c-Kit* mutation in a population of patients with mastocytosi *Int Arch Allergy Immunc* **113**:184, 1997

62. Nemes Z et al: Identification of histiocytic reticulum cells by the immunohistochemical demonstration of factor XIII (F-XIIIa) in human lymph n *J Patho* **149**:121, 1986

63. Braverman IM: The cutaneous microcirculatior *J Investig Dermatol Symp Pro* **5**:3, 2000

64. Detmar M: Molecular regulation of angiogenesis in the ski *J Invest Dermato* **106**:207, 1996

65. Ryan TJ: Structure and function of lymphatics *J Invest Dermato* **93**:18S, 1989

66. Deutsch A et al: Ultrastructural studies on the invasion of melanomas in initial lymphatics of human s *J Invest Dermato* **98**:64, 1992

67. Johansson O: The innervation of the human epidermi *J Neurol Sc* **130**:228, 1995

68. Holst D, Grimaldi PA: New factors in the regulation of adipose differentiation and metabolis *Curr Opin Lipidc* **13**:241, 2002

69. Koutnikova H, Auwerx J: Regulation of adipocyte differentiatic *Ann Mec* **33**:556, 2001

70. Online Mendelian Inheritance in Man, OMIN http://www.ncbi.nlm.nih.gov/omin. 2001.

71. Novice FM, Collison DW, Burgdorf WHC, Esterly NB *Handbook of Genetic Skin Disorders* Philadelphia, W.B. Saunders, 1994.

72. Holbrook KA: Structure and function of the developing human skin, *Physiology, Biochemistry, and Molecular Biology of the Ski* edited by LA Goldsmith. New York, Oxford Press, 1991, p 63

73. Loomis CA: Development and morphogenesis of the ski *Adv Dermato* **17**:183, 2001

74. Loomis CA et al: The mouse Engrailed-1 gene and ventral limb patternir *Nature* **382**:360, 1996

75. Ahn K et al: BMPR-IA signaling is required for the formation of the apical ectodermal ridge and dorsal-ventral patterning of the *Developmen* **128**:4449, 2001

76. Pizette S, Niswander L: Early steps in limb patterning and chondrogenes *Novartis Found Sym* **232**:23, 2001

77. Yang A et al: p63 is essential for regenerative proliferation in limb, craniofacial and epithelial developn *Nature* **398**:714, 1999

78. Mills A et al: p63 is a p53 homologue required for limb and epidermal morphogene *Nature* **398**:708, 1999

79. Celli J et al: Heterozygous germline mutations in the p53 homolog p63 are the cause of EEC syndro *Cell* **99**:143, 1999

80. McGrath JA et al: Hay-Wells syndrome is caused by heterozygous missense mutations in the SAM domain of p *Hum Mol Gene* **10**:221, 2001

81. Wessagowit V et al: Heterozygous germline missense mutation in the p63 gene underlying EEC syndro *Clin Exp Dermato* **25**:441, 2000

82. Okura M et al: Effects of monoclonal anti-*c-ki* antibody (ACK2) on melanocytes in newborn mic *J Invest Dermato* **105**:322, 1995

83. Moll I et al: Intraepidermal formation of Merkel cells in xenografts of human fetal sl *J Invest Dermato* **94**:359, 1990

84. Moll I et al: Proliferative Merkel cells were not detected in human sk *Arch Dermatol Res* **288**:184, 1996

85. Christ B et al: Differentiating abilities of avian somatopleural mesoder *Experientia* **35**:1376, 1979

86. Noden DM: Vertebrate craniofacial development: Novel approaches and new dilemr *Curr Opin Genet Dev* **2**:576, 1992

87. Parr BA, McMahon AP: Dorsalizing signal Wnt-7a required for normal polarity of D-V and A-P axes of mouse lir *Nature* **374**:350, 1995

88. Cygan JA et al: Novel regulatory interactions revealed by studies of murine limb pattern in Wnt-7a and En-1 mut *Developmen* **124**:5021, 1997

89. Loomis CA et al: Analysis of the genetic pathway leading to formation of ectopic apical ectodermal ridges in mouse Engrailed-1 mutant l *Developmen* **125**:1137, 1998

90. Oliver G, Detmar M: The rediscovery of the lymphatic system: Old and new insights into the development and biological function of the lymphatic vascul *Genes Dev* **16**:773, 2002

91. Rosen ED, Spiegelman BM: Molecular regulation of adipogenes *Annu Rev Cell Dev Bio* **16**:145, 2000

92. Millar SE: Molecular mechanisms regulating hair follicle developme *J Invest Dermato* **118**:216, 2002

93. Dreyer SD, et al: Mutations in LMX1B cause abnormal skeletal patterning and renal dysplasia in nail patella syndr *Nature Gene* **19**:47,1998

94. Vollrath D, et al: Loss-of-function mutations in the LIM-homeodomain gene, LMX1B, in nail-patella syndro *Hum Mol Gene* **7**:1091, 1998

95. Jumlongras D et al: A nonsense mutation in MSX1 causes Witkop syndrom *Am J Hum Gene* **69**:67, 2001

96. Godwin AR, Capecchi MR: Hoxc13 mutant mice lack external ha *Genes Dev* **12**:11, 1998

97. Ashton GH et al: Prenatal diagnosis for inherited skin disease *Clin Dermato* **18**:643, 2000

T>

Chapter 7

Arash Kimyai-Asadi Ming Jih Irwin Freedberg

Epidermal Cell Kinetics, Epidermal Differentiation, and Keratinization

EPIDERMAL CELL KINETICS
THE CONCEPTS OF STEM CELLS, TRANSIENT AMPLIFYING CELLS, AND DIFFERENTIATED CELLS IN THE EPIDERMIS
EPIDERMAL DIFFERENTIATION
Basal Cell Layer
Spinous Cell Layer
Granular Cell Layer
Stratum Corneum and the Cornified Cell Envelope
Corneocyte Shedding
INTERMEDIATE FILAMENT PROTEINS
Keratins

REFERENCES

The epidermis is the prototype of keratinizing squamous epithelia, also present in the esophagus, vagina, and oral mucosa. The stratified squamous epidermis is composed of a proliferative basal layer containing the self-sustaining stem cell component and spinous and granular cells that express a tightly regulated set of proteins and lipids that are eventually woven into the cornified cell envelope of the corneocyte, providing the skin with its mechanical and chemical barrier. The ability to culture keratinocytes in vitro has provided the opportunity to study many aspects of epidermal proliferation and differentiation. Moreover, a variety of techniques can be used to isolate and characterize the structural and functional proteins of the epidermis and to identify and clone many of the genes responsible for normal epidermal function and for an increasing number of hereditary skin disorders (Table 7-1 and Table 7-2). Information about other cells in the epidermis, including melanocytes and Langerhans cells, is found in Chapter 11 and Chapter 23, respectively. Hair follicles are considered in Chapter 12, nails in Chapter 13, and sweat glands in Chapter 8. The epidermal barrier is discussed in Chapter 9, and skin structure and development are analyzed in Chapter 6.



TABLE 7-1 **Hereditary Diseases Associated with Abnormalities in Epidermal Proteins**

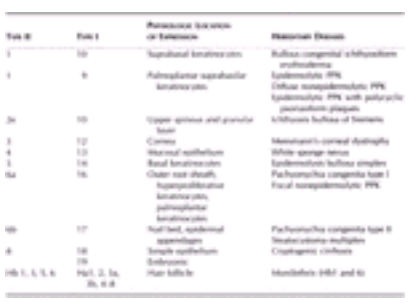

TABLE 7-2 **Keratin Expression Patterns and Keratin-Associated Diseases**

EPIDERMAL CELL KINETICS

From a cell kinetic viewpoint, tissues can be divided into three types: (1) static tissues, such as the adult CNS, in which cells do not divide, (2) normally nonproliferative tissues, such as the liver, which retain the ability to divide in response to injury, and (3) constantly renewing tissues, such as the epidermis and gastrointestinal mucosa.

The cell cycle itself is divided into four stages (Fig. 7-1). Mitosis (M) is followed by a resting stage called *gap 1* (G_1). This stage is both the longest and most variable in duration. From G_1, in response to signals that have not been completely defined, cells enter the stage of DNA replication, which is called the *synthesis* (S) stage. The duration of the S phase is relatively constant in mammalian tissues and lasts approximately 7 to 16 h in dividing keratinocytes. During this phase, duplication of the DNA content occurs in anticipation of cell division. During the second gap phase (G_2), which lasts 6 to 8 h, cells complete final preparation for cell division. During the mitotic phase (M), which is the shortest segment of cell division (1–2 h), two daughter cells are produced. There is an additional stage, termed G_0, that some cells may enter during G_1 or possibly G_2. During G_0, cells do not progress through the cell cycle, although they retain the potential to return to the active cell cycle in response to appropriate signals. Progression of the cell through G_1 is controlled by cyclin-dependent kinases, and increases in their inhibitors play a role in the induction of irreversible growth

arrest, which is an early and integral step in keratinocyte differentiation. [1]

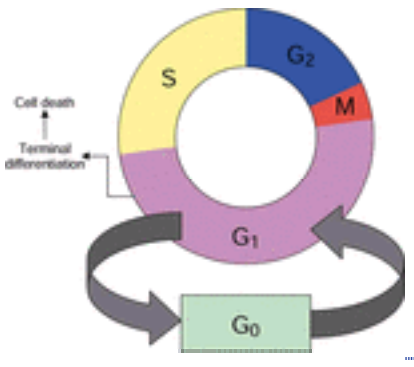

FIGURE 7-1 A diagram of the cell cycle. The cycling component starts with cells in the G_1 phase, the most variable part of the cycle. Cells then move into the S phase, during which the DNA content of the cell is doubled. Subsequently, cells enter the second gap phase (G_2), which leads to mitosis and the production of two daughter cells. The daughter cells may proceed through another replicative cycle, enter the differentiation pathway, or enter a resting phase (G_0).

Measurements related to the cell cycle were of particular focus in the past but today have little direct in vivo physiologic or pathologic significance. The cell cycle time is the time it takes a cell to move from any given point in one cycle to the corresponding point in the next cycle, and in proliferating keratinocytes, it is between 60 and 450 h. The growth fraction is the ratio of proliferating to nonproliferating cells in a given tissue. The mitotic index is the percentage of cells that are in the M phase of the cell cycle. This value is approximately 5 percent in the basal layer and can be determined histologically. The flash-labeling index determines the fraction of cells that take up tritiated thymidine and represents cells in the S phase when thymidine is incorporated into elongating DNA molecules. Thymidine analogues such as bromodeoxyuridine, which can be detected immunologically, as well as fluorescent dyes, which bind stoichiometrically to DNA or other molecules, also can be used to label cells in S phase. Both the mitotic index and the flash-labeling index should include only the proliferative compartment as the denominator and generally are determined as a fraction of the population of basal layer cells. The turnover time is the time required to replace the number of cells of a given tissue compartment, and the transit time is the time between a cell entering and leaving a given tissue compartment. Distinguishing these latter two values from the cell cycle time in the basal layer has been difficult. Moreover, these two values are conceptually identical in the spinous cells and stratum corneum and last approximately 14 days for each. [2] The decreased cell cycle time and increased growth fraction in psoriatic epidermis result in a shorter transit time (see Chap. 42).

THE CONCEPTS OF STEM CELLS, TRANSIENT AMPLIFYING CELLS, AND DIFFERENTIATED CELLS IN THE EPIDERMIS

In the adult epidermis, cell division is necessary to replace the cells lost through apoptosis or injury in order to maintain cell numbers at a relatively constant level. In stratified epithelia, differentiated cells have a relatively short lifespan. Therefore, throughout adult life, a population of cells is required that is capable of both self-renewal and the formation of cells destined for terminal differentiation. These are the stem cells. In normal skin, two populations of stem cells have been described: those which contribute epidermal keratinocytes destined to become cornified cells and those which contribute cells to the hair follicle and are destined to become the hair shaft. Recent studies have shown that the bulge cells of the hair follicle are at least bipotential, possessing the ability to give rise to both a stratum corneum and a hair shaft [3] (see Chap. 12). Although follicular stem cells are recruited during epidermal wound repair, long-term maintenance of the interfollicular keratinocyte population in adults is thought to be independent of follicular stem cells. [4]

Evidence for the existence of slow-cycling epidermal stem cells initially came from several sources. First, the fact that cultured basal keratinocytes from non-hair-bearing skin can last many years on burn patients suggested a source of self-renewing keratinocytes. [5] In addition, the presence of radio-resistant epidermal cells capable of repopulating the epidermis suggested the presence of a population of cells with prolonged cell cycle times. [6] This has been confirmed by tritiated thymidine labeling of keratinocytes, demonstrating a subpopulation of basal cells with retention of the label for up to 14 months. [7] These stem cells tend to be concentrated in the bulge region of the hair follicle, above the dermal papillae in nonacral skin, and at the deep portion of epidermal rete ridges on acral skin. The bulge is located below the opening of the sebaceous duct and is at the anchoring site of the arrector pili muscle; it is also the deepest part of the permanent portion of the hair follicle. [8] Whereas the bulge is histologically visible in rodent and human fetal hair follicles, it is difficult to visualize in adult hair follicles. Stem cells are relatively small, undifferentiated cells with few organelles and with strong attachments to the basement membrane zone. [8]

Whereas stem cells have an indefinite capacity for self-renewal, transient amplifying cells are defined as proliferating keratinocytes that have limited capacity for self-renewal and will, after a few rounds of mitosis, terminally differentiate. [9] Both stem cells and transient amplifying cells are located within the basal layer, although a third of the latter may be found in the lower spinous layer. That transient amplifying cells divide rapidly is reflected in their avid uptake but short retention of tritiated thymidine, since the marker is diluted with each round of cell division. This is in contrast to prolonged retention of tritiated thymidine by stem cells, reflecting their slow rate of cell division, which serves to protect them from the acquisition of genetic mutations.

Keratinocyte cell cultures, when seeded at low density, demonstrate that some colonies will contain several thousand cells by 2 weeks, whereas others will consist of a small number of terminally differentiated cells. [10] The cells forming the large colonies have the ability to both self-renew and generate daughter cells capable of terminal differentiation and are believed to represent stem cells. The smaller colonies are formed by cells that undergo only a few rounds of mitosis,

representing transient amplifying cells. Terminally differentiated keratinocytes lack the ability to divide and thus will not yield clonal colonies in culture, although individual keratinocytes often reassociate in culture, forming colonies composed of a few cells. Thus, each stem cell gives rise to a number of transient amplifying cells that, after a few rounds of mitosis, become terminally differentiated, nonmitotic keratinocytes (Fig. 7-2). Each stem cell and all its progeny have been referred to as the *epidermal proliferative unit.* The histologic correlate of the epidermal proliferative unit can been seen in murine epidermis and occasionally in thin human epidermis, where columns of differentiating cells in the stratum spinosum overlie a cluster of approximately 10 basal cells. These basal cells are arranged with an average ratio of one centrally placed stem cell to nine peripheral transient amplifying cells. [11]

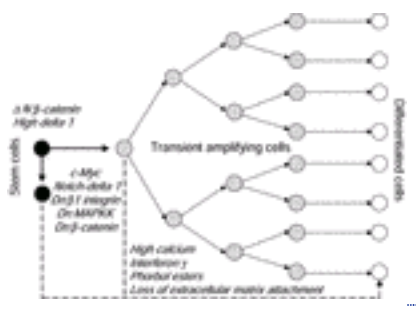

FIGURE 7-2 Stem cells, transient amplifying cells, and differentiated keratinocytes. A single stem cell gives rise to a stem cell and a transient amplifying cell, which goes through several rounds of mitosis prior to becoming a nonmitotic cell committed to terminal differentiation. Stabilized amino-terminally deleted ß-catenin and high levels of delta 1 promote maintenance of a stem cell compartment, whereas c-Myc and stimulation of Notch by delta 1 on adjacent keratinocytes promote the transformation of stem cells into transient amplifying cells. Expression of dominant negative ß $_1$ integrin, mitogen-activated protein kinase kinase, and ß-catenin in keratinocytes also promotes the transformation of stem cells into transient amplifying cells. High concentrations of calcium, interferon-?, and phorbol esters also promote terminal differentiation, as does loss of contact with the extracellular matrix. Dn, dominant negative. (*Adapted from Bickenbach et al.* [9] *and Watt* [23])

The isolation of stem cells has been hampered by difficulties in finding specific and sensitive markers, such as those present in hematopoietic stem cells. Keratin-19 initially was thought to be such a marker [12] but also was found in many non-label-retaining cells. Moreover, since telomerase activity is necessary for indefinite cell proliferation, it was thought that only stem cells would have high telomerase activity. However, both hematologic and epidermal evidence suggests that telomerase activity is greater in rapidly dividing cells (i.e., transient amplifying cells) than in stem cells. [13], [14] Other postulated stem cell markers have included keratin-15, c-Myc, a non-cadherin-associated ß-catenin, p63, the antigens recognized by monoclonal antibodies 10G7 and C8/144B, low expression of E-cadherin, and the high expression of delta 1. [15]

Recently, several lines of evidence have suggested that integrins, the cell adhesion molecules that mediate attachment of basal keratinocytes to collagens, laminins, fibronectin, and vitronectin present in the extracellular matrix, may serve as markers for epidermal stem cells. In the epidermis, integrins are selectively expressed on basal keratinocytes, and the absence of a bound ligand in vitro results in irreversible inhibition of proliferation accompanied by expression of markers of terminal differentiation within a few hours. [16] Of note, ß $_1$ integrin–rich keratinocytes are not distributed at random. Rather, they are concentrated at the tips of dermal papillae in interfollicular skin and at the deep part of the rete ridges in acral skin. [17] These integrin-rich areas have been shown to contain the cells with increased proliferative capacity. [18] Moreover, a number of experiments have shown that keratinocytes with high colony-forming efficiency in vitro can be isolated based on high surface levels of ß $_1$ integrin and rapid adhesion to collagen IV, which is an integrin substrate. [10] The expression of a dominant-negative ß $_1$ integrin mutation in proliferative keratinocytes results in an increased proportion of colonies attributable to transient amplifying cells. [19] However, since many transient amplifying cells and cells of the outer root sheath are also integrin-rich, it is apparent that integrins are not specific markers for epidermal stem cells.

Attempts to isolate epidermal stem cells have significant implications, particularly in the field of gene therapy. Several experiments have shown adequate initial expression of transduced recombinant genes in keratinocytes, with loss of expression after 2 to 6 weeks. This is likely due to terminal differentiation of all transfected cells. Of importance, DNA integration is more efficient in actively dividing cells, requiring selective enrichment and targeting of stem cells in order to gain long-term expression of transduced genes. [20] Enriching stem cells by selecting integrin-rich cells with rapid attachment to collagen IV has enabled persistent expression of retrovirally transfected ß-galactosidase in vitro for at least 12 weeks. [21] More recently, a sorting method, similar to methods used for the isolation of hematopoietic stem cells, was used to isolate epidermal stem cells from transient amplifying cells. [22] The basal keratinocytes were found to be composed of 90 percent transient amplifying cells, 6.5 percent differentiated cells, and 3.5 percent stem cells. Only stem cells formed large, maintainable, undifferentiated colonies in cell culture. Whereas the transient amplifying cells completely differentiated by 2 months, thereby losing expression of retrovirally transduced genes, persistent gene expression lasting over 6 months was seen in the stem cell population. The maintenance of stem cells appears to depend on ß $_1$ integrin signaling through the mitogen-activated protein kinase (MAPK) pathway as well as by the expression of non-cadherin-associated ß-catenin [23], [24] (see Fig. 7-2). Catenins are proteins that generally bind cytoskeletal elements such as keratin and actin to cadherins in desmosomal plaques and adherens junctions.

EPIDERMAL DIFFERENTIATION (See Fig. 7-3)

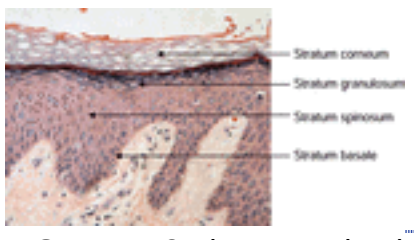

FIGURE 7-3 The normal epidermis. The four major steps in epidermal differentiation are represented by (1) an innermost stratum basale composed of mitotically active proliferative cells, (2) a three- to six-cell-layer-thick stratum spinosum containing cells that are still transcriptionally active but are no longer dividing (these cells can devote most of their translational machinery to expressing keratins), (3) a one- to three-cell-layer-thick stratum granulosum with cells that are transcriptionally active, depositing a cornified cell envelope composed of cross-linked proteins and lipids beneath the plasma membrane, and (4) a five- to twenty-cell-layer-thick stratum corneum, which consists of metabolically inert, anucleate squames that are sloughed from the skin surface. The squames sloughed from the skin surface are merely dead sacs surrounded by the cornified cell envelope and full of keratin macrofibrils. Basal cells express keratins 5 and 14, but as they commit to terminal differentiation, they switch off the expression of keratins 5 and 14 and begin expressing keratins 1 and 10. As epidermal cells move up through the spinous layer, they also express keratin 2e, which, like keratin 1, pairs with keratin 10.

Basal Cell Layer

As discussed earlier, the basal cell layer is composed predominantly of transient amplifying cells that undergo several rounds of mitosis before becoming nonmitotic keratinocytes destined to differentiate into corneocytes. In the basal cell layer, keratinocytes are small and polar, expressing keratins 5 and 14. A major function of the basal layer is to provide a mechanical attachment to the underlying basement membrane zone and dermis through hemidesmosomal attachments.

Keratins 5 and 14 are the predominant intermediate filament proteins of basal keratinocytes. The hemidesmosomal and desmosomal plaques anchor cytoplasmic keratins to the plasma membrane and mediate cell attachment to the basement membrane zone and plasma membranes of adjacent cells, respectively (Fig. 7-4). It appears that laminin-5 in the extracellular matrix triggers recruitment of a $_6$ß $_4$ integrin heterodimers, keratins, and keratin-associated proteins to the cell surface, initiating hemidesmosomal assembly. The intracellular portion of the hemidesmosome is composed of bullous pemphigoid antigen 1 and plectin, two members of the “plakin” group of proteins that serve to bind the intracellular keratin network to the plasma membrane. This binding is more stable than that seen with intermediate filaments of nonstratified epithelia, providing greater stability to the epidermal keratin filament architecture. The transmembrane portion of the hemidesmosome includes bullous pemphigoid antigen 2, which binds to collagen IV in the lamina densa, and integrins, which bind laminins, fibronectin, and collagens in the basement membrane zone. In addition, extracellular laminin-5 induces phosphorylation and dephosphorylation of a $_6$ß $_4$ integrin subunits, thereby allowing the extracellular matrix to modulate cell proliferation, differentiation, apoptosis, migration, and tissue morphogenesis [25] (see Chap. 16).



FIGURE 7-4 Desmosomal and hemidesmosomal structure. Desmoplakins mediate cell adhesion between adjacent keratinocytes, whereas hemidesmosomes attach keratinocytes to the basement membrane. The intracellular portions of these structures are composed of plakin proteins, which bind keratin to the plasma membrane. The plakins include desmoplakins I and II, periplakin, and envoplakin in the desmosomes and bullous pemphigoid antigen 1 and plectin in the hemidesmosomes. Plakoglobin and plakophilin are also components of the intracellular desmosomal plaque. The transmembrane portions are composed of desmogleins and desmocollins in the desmosomes and bullous pemphigoid antigen 1 and integrins in the hemidesmosomes.

Spinous Cell Layer

As keratinocytes leave the basal layer, they become nonmitotic and commence terminal differentiation. The suprabasal cells are more metabolically active and larger than those in the basal layer, with most of their protein synthesis devoted to the production of keratins 1 and 10. Concomitantly, the synthesis of the basal layer keratins (5 and 14) is downregulated.

The spinous layer is so named because of the prominent “spines” visible on light microscopy, which represent cytoplasmic attachments via desmosomes, structures that mechanically couple adjacent keratinocytes (Fig. 7-4). The desmosomal plaque is composed of several intracellular plakin proteins, including desmoplakins I and II, envoplakin, periplakin, and plakophilin. [26] Desmoplakins I and II, alternate splicing products of the identical desmoplakin gene, form the major intracellular portion of the desmosomal plaque. [27] The transmembrane portion of the desmosomal plaque includes desmogleins and desmocollins, which are calcium-dependent adhesion molecules (cadherins). [28] Moreover, desmocalmin, a calmodulin-binding protein, promotes calcium-dependent assembly and function of desmosomes. Hereditary and acquired diseases of the desmosomes and hemidesmosomes generally result in abnormal cell-cell and cell-matrix adhesion, respectively, causing blistering disorders, such as pemphigus, pemphigoid, and hereditary epidermolysis bullosa. However, since desmosomes play a significant role in epidermal differentiation and are part of the cornified cell envelope (see below), mutations in desmosomal components also can cause ichthyosiform and

palmoplantar dermatoses, such as striated palmoplantar keratoderma, Naxos syndrome, and ectodermal dysplasia/skin fragility syndrome. [29], [30] Envoplakin and periplakin, which form homo- and heterodimers in a network radiating from desmosomes and aggregate with keratin intermediate filaments, were identified initially as parts of the cornified cell envelope and are thought to provide the scaffold onto which the cornified cell envelope is later assembled [31] (see below).

As cells progress through the spinous layer, they accumulate increasing amounts of proteins involved in terminal differentiation. Many of these proteins are encoded by a gene cluster on chromosome 1q21 known as the *epidermal differentiation complex.* This gene complex encodes loricrin, involucrin, profilaggrin, a number of small proline-rich peptides, trichohyalin (a hair follicle protein), and S100A calcium-binding proteins. [32]

Most of the processes of terminal keratinocyte differentiation are controlled by the intracellular calcium concentration [33] (Table 7-3). A low-calcium culture medium maintains keratinocytes in a high-proliferation but low-differentiation state, whereas a high-calcium medium promotes the terminal differentiation of keratinocytes. Similarly, protein kinase C, a regulator of intracellular calcium release, promotes the transition from spinous to granular layer cells. The effects of protein kinase C on protein expression are mediated by AP1 transcription factors, including Jun and Fra. [34] Other transcription factors, such as AP2, SP1, and ETS, also enhance the expression of suprabasal keratins, proteins of the epidermal differentiation complex, and transglutaminases (see below). Inhibition of keratinocyte differentiation is mediated by retinoids and transcription factors such as POU domain proteins and CCAAT enhancer binding proteins. [35]

Differentiation Process	Calcium-Dependent Components
Intercellular structure formation	Desmosome assembly and function Gap junction assembly and function
Protein expression	Involucrin Keratins 1, 2e, 9, and 10 Loricrin Profilaggrin Small proline-rich peptides Transglutaminase
Release of keratohyaline granule contents	Release of loricrin and profilaggrin
Enzyme function	Cleavage of profilaggrin to filaggrin Transglutaminase activity

TABLE 7-3 **Terminal Epidermal Differentiation Processes that are Calcium-Dependent**

Electrochemical coupling between cells is mediated by gap junctions, which are formed by the alignment of two connexons on adjacent cell membranes. Each connexon is a hemichannel formed by oligomerization of six homotypic or heterotypic connexin subunits. During epidermal differentiation, there is a progressive change in connexin expression. Connexin 43 in proliferative basal cells is replaced by connexin 26 in nonproliferative spinous keratinocytes. [36], [37] Subsequently, connexin 26 is replaced by connexins 31 and 31.1 during terminal differentiation of keratinocytes into corneocytes. These changes in connexin expression cause alterations in intercellular ionic signaling and affect calcium homeostasis via changes in the intercellular flow of both calcium and second messengers that mediate calcium release. Mutations in connexins have been found to underlie three genodermatoses: classic Vohwinkel syndrome, erythrokeratodermia variabilis, and hidrotic ectodermal dysplasia (Clouston syndrome). [38] Moreover, mutations in calcium ATPases that sequester calcium into organelles result in Darier-White disease and Hailey-Hailey disease. The phenotypes seen in these conditions may result from dysregulation of ionic signaling resulting in abnormal keratinocyte differentiation.

Granular Cell Layer

As cells reach the granular layer, their appearance changes dramatically with the synthesis of intracellular keratohyaline granules that are visible on light microscopy. The keratohyaline granules contain profilaggrin, a large, highly phosphorylated, calcium-binding precursor protein that consists of several filaggrin repeats separated by short hydrophobic linker sequences, as well as amino- and carboxy-terminal domains. Loricrin, another granule component, is released near the plasma membrane, where it initially binds desmosomal plaque proteins [39] (see below).

The amino-terminal domain of profilaggrin contains functional calcium-binding regions that are believed to be important in its processing to filaggrin. [40] As the keratohyaline granule contents are released into the cytoplasm, profilaggrin is dephosphorylated and cleaved proteolytically into individual filaggrin domains in a calcium-dependent process. Filaggrin is a histidine-rich cationic protein that aggregates keratin, forming macrofilaments. [41] Subsequently, filaggrin is degraded into molecules including urocanic acid and pyrrolidone carboxylic acid, which filter ultraviolet radiation and hydrate the stratum corneum. [41], [43]

The lamellar granules of the granular layer, also known as *membrane-coating granules, Odland bodies,* or *keratinosomes,* are dual-function granules that contain both the lipids that provide the permeability barrier of the epidermis and a number of lysosomal enzymes. These granules are first identifiable in the upper spinous layer and become more abundant in the granular layer. The lamellar granule glucosylceramides, the precursors of the stratum corneum ceramides, are formed in the Golgi apparatus by ceramide glucosyltransferase, which is induced during keratinocyte differentiation coincident with the appearance of lamellar granules. [44] Conversely, elevated concentrations of intracellular ceramides inhibit cell proliferation and induce cell differentiation and apoptosis. [45] In the upper granular layer, the lamellar granules orient themselves with the apical surface of the keratinocytes, where they fuse with the plasma membrane and secrete their contents, stacks of membranous lipid-laden disks, into the intercellular space. The lipid-rich lamellae form broad sheets between the keratinocytes and subsequently become part of the cornified cell envelope.

Stratum Corneum and the Cornified Cell Envelope

Drastic remodeling of keratinocytes occurs in the transition to the stratum corneum, where corneocytes devoid of nuclei

and other organelles provide a protective barrier. This barrier includes the cornified cell envelope, an extremely durable protein-lipid polymer with a 10-nm insoluble layer of protein covalently linked to the plasma membrane of the keratinocytes and overlaid by a 5-nm lipid envelope. The insoluble protein component of the cornified envelope comprises approximately 90 percent of its total mass, with the lipid component making up the rest. The cornified cell envelope is first formed interior to the cytoplasmic membrane of differentiating keratinocytes but eventually resides on the exterior of cornified cells. [46]

The formation of the cornified cell envelope is a multistep process. Initially, envoplakin and periplakin are expressed at the desmosomal plaques. Subsequently, involucrin, a highly polymorphous, highly soluble, acidic, glutamine-rich protein found in many types of stratified squamous epithelia, localizes to the cytoplasmic membrane. Transglutaminases are also expressed early in differentiation and cross-link involucrin residues to one another and to envoplakin. Transglutaminases (1 and 3) catalyze the formation of isodipeptide bonds between e-amino groups of lysine and ?-carboxyl groups of glutamine residues. As discussed earlier, after the release of keratohyaline granule contents, loricrin initially accumulates on desmosomes at the cytoplasmic membrane, whereas filaggrin aggregates with keratin intermediate filaments in the cytoplasm. [47] Subsequently, epidermal transglutaminases catalyze the binding of loricrin, keratin macrofilaments, desmosomal peptides, involucrin, small proline-rich peptides, elafin, cystatin A, S100 peptides, cornifins, annexin I, calgizzarin, plasminogen activator inhibitor type 2, and other peptides to the cell membrane in a calcium-dependent fashion, forming the highly insoluble proteinaceous component of the cornified cell envelope at the inner leaflet of the plasma membrane. [1]

It appears that transglutaminase 3, a cytoplasmic enzyme, initially cross-links loricrin and small proline-rich peptides together to form small interchain oligomers, which are then permanently affixed to the developing cornified cell envelope via further cross-linking by transglutaminase 1, a cell membrane–bound and keratinocyte-specific enzyme. [48] Of note, transglutaminase 1 also attaches ?-hydroxyceramide lipids to involucrin glutamine residues, explaining the preferential localization of involucrin to the outer portion of the cornified cell envelope, as opposed to loricrin, which predominates in the inner portions. [49], [50] Other studies indicate that desmosomal envoplakin and periplakin also serve as substrates for the attachment of ceramides. [51] Failure to cross-link epidermal proteins and lipids by transglutaminase 1 may explain the phenotypes of lamellar ichthyosis and nonbullous congenital ichthyosiform erythroderma, which can be caused by mutations in the transglutaminase 1 gene. [52] The exact role of each protein component of the cornified cell envelope is not fully understood, and significant functional overlap exists. Loricrin, as discussed previously, is the major protein component of the cornified cell envelope, comprising over 70 percent of its mass. Loricrin-deficient mice demonstrate congenital erythroderma with a shiny, translucent skin, reduced stratum corneum stability, and easy fragmentation of the cornified cell envelope by mechanical stress. Surprisingly, the skin phenotype disappears 4 to 5 days after birth, concomitant with upregulation of small proline-rich peptides and S100 peptides, which compensate for cornified cell envelope formation. [53] However, transgenic mice expressing a carboxy-terminal truncated form of loricrin demonstrate a phenotype resembling Vohwinkel syndrome. [54] Similarly, involucrin knockout mice appear normal, whereas mice expressing involucrin transgenes demonstrate abnormalities in hair follicle and cornified cell envelope structure. [55], [56] These experiments suggest that whereas functional overlap can overcome deficiencies in structural proteins of the cornified cell envelope, expression of an abnormal protein can interfere with cornified cell envelope assembly through dominant-negative effects.

The small proline-rich peptides are members of the epidermal differentiation complex that cross-link with one another and with loricrin in the cornified cell envelope. [57] These peptides are encoded by two *SPRR1,* eight *SPRR2,* and one *SPRR3* genes that are differentially regulated. The peptides share homology with loricrin and involucrin and can be upregulated in the absence of functional loricrin. Whereas loricrin is the major component of the epidermal cornified cell envelope, the small proline-rich peptides, particularly SPRR1a and b, form 70 percent of the cornified cell envelope in the oral mucosa. [58] The exact functional roles of other cornified cell envelope components such as cystatin A, S100 peptides, and cornifin are less well understood.

Corneocyte Shedding

When the final products of this differentiation process, the squames, finally reach the outermost edge of the epidermis, they are mummified cell remnants composed of a cornified envelope surrounded by stacks of lipids and packed with compact keratin macrofilaments. The squames are then shed, only to be replaced by others derived from keratinocytes that have migrated from the basal layer and followed the differentiation pathway described earlier.

To maintain a constant stratum corneum thickness, the process of corneocyte shedding has to be precisely regulated to match the rate of new corneocyte formation. Corneocytes are held together by corneodesmosomes, modified desmosomal structures that appear as homogeneous electron-dense plugs on electron microscopy. In the upper spinous and granular layers, corneodesmosin, a glycine- and serine-rich glycoprotein, is expressed and stored in the lamellar bodies. After transport and release into the extracellular space, corneodesmosin becomes associated with desmosomal desmogleins and desmocollins. Cleavage of corneodesmosin by the stratum corneum tryptic and chymotryptic enzymes causes separation of adjacent corneocytes with resulting cell shedding. [59] Cathepsin D, a lysosomal aspartate proteinase present in the stratum corneum, which is expressed consequent to the calcium concentration change that accompanies terminal epidermal differentiation, also plays a part in the degradation process. [60] The lamellar bodies are known to store many lysosomal enzymes, and the acidic pH (˜4.5) of the stratum corneum promotes the enzymatic activities of these proteases.

INTERMEDIATE FILAMENT PROTEINS

In all eukaryotic cells, the cytoskeleton is central to cell structure, function, and differentiation. The cytoskeleton is composed of an elaborate network of structural proteins, including actin microfilaments, microtubules, and intermediate filaments. Named after their assembled diameter (10 nm), intermediate between the thin actin microfilaments (6 nm) and the thick microtubules (25 nm), intermediate filaments are the most heterogeneous of the cytoskeleton proteins and have

been divided into six types based on their amino acid sequence and tissue specificity (see Table 7-3).

Keratins

Keratins are the most complex family of intermediate filament proteins, and they provide structural integrity to all epithelial cells. Their relative charges, molecular weights, and antigenic specificity were used by Moll et al. [61] to assign numbered designations to each keratin protein in 1982. Keratin filaments are obligate heterodimers composed of one type I and one type II keratin. Each heterodimer is tissue- and differentiation-specific (Table 7-4). The type I keratins, encoded by a gene cluster on 17q12-q21, are acidic (pK ¡ = 4.5 to 5.5) and relatively smaller in size (˜40 to 56.5 kDa), consisting of keratins 9 to 20 in the epidermis and keratins Ha1 to Ha8 in the hair follicle. The type II keratins, encoded by a gene cluster on 12q11–13, are basic or neutral (pKi = 5.5–7.5) and relatively larger in size (˜52–67 kDa), consisting of keratins 1 to 8 in the epidermis and Hb1 to Hb6 in the hair follicle. More than one allele exists for several of the keratins, including keratins 1, 2, 4, 5, and 6, but the significance of this is unclear.

Type	Protein	Tissue Expression
I	Acidic keratin	Epithelia
II	Basic keratin	Epithelia
III	Vimentin	Mesenchymal cells
	Desmin	Muscle
	Peripherin	Peripheral nervous system
	Glial fibrillary acidic protein	Glial cells and astrocytes
IV	a-Internexin	Neurofilaments
V	Lamins	Nucleus
VI	Nestin	Stem cells of central nervous system and skeletal muscle

TABLE 7-4 **Intermediate Filament Types and Tissue Expression Patterns of Intermediate Filament Proteins**

KERATIN STRUCTURE Keratins share a homologous basic structure with all intermediate filament proteins (Fig. 7-5). The genes for each of the epidermal keratins have been cloned, and their protein structures have been determined. The central a-helical rod domain, composed of 310 to 315 amino acids, is responsible for dimerization and higher-order polymerization and is composed of four highly conserved domains (1A, 1B, 2A, and 2B). The a helix consists of heptad amino acid repeats in which the first and fourth residues are hydrophobic, residing close together on the surface of the helix and enabling two adjacent polypeptides to create a coiled coil. There is a stutter sequence in the helix 2B domain that is associated with reversal of the direction of the a-helix. Mutations that lead to shortening of the rod domain yield keratins that are not only unable to assemble into filaments but also interfere with preexisting keratin filament networks, since keratins are highly dynamic with reversible assembly and disassembly. [62] There is a mutational hotspot in one arginine position of the highly conserved coil 1A region of keratins 9, 10, and 14 that underlies most cases of epidermolytic palmoplantar keratoderma, bullous congenital ichthyosiform erythroderma, and epidermolysis bullosa simplex. This shows that structure and charge are critical elements for keratin assembly and stability.



FIGURE 7-5 Keratin protein structure. E1 and E2 represent the highly-charged end regions, V1 and V2 represent variable regions, and H1 and H2 represent homologous regions of the end domain. The a-helical rod domain is composed of four a-helical domains (1A, 1B, 2A, 2B), which are separated by nonhelical linker domains (L1, L12, L2) and flanked by the helix boundary peptides. There is a stagger domain in the 2B rod domain in which the direction of the a-helix reverses. Type I (acidic) keratins lack an H2 domain.

The four highly conserved a-helical domains are separated by nonhelical linker domains (L1, L12, L2). Since L1 and L12 are rich in both glycine and proline, they disrupt the a helix more effectively than glycine-rich L2. Mutations in keratins 5 and 14 underlying epidermolysis bullosa simplex are clustered in the helix boundary peptides and in the L12 linker domain (see Chap. 65). These linker domain mutations disrupt the ß-sheet structure of the L12 domain and prevent proper filament assembly between keratins 5 and 14. [63] The helix boundary peptides that flank the a-helical rod domain show remarkable evolutionary conservation. Single or few amino acid substitutions and deletions in the most conserved positions of this sequence can result in profound effects on filament assembly in vitro. [64] In addition, there is evidence that the consensus sequence plays an important role in lateral alignment that could affect higher-order interactions in intermediate filaments. [65] All cases of monilethrix and some cases of epidermolysis bullosa simplex are caused by mutations in these helix boundary peptides. Keratin 14 mutants missing the nonhelical carboxy- and amino-terminal domains and small portions of the carboxy end of the rod domain integrate into endogenous keratin filament networks and also form 10-nm filaments with keratin 5. In contrast, small truncations in the amino-terminal end of the rod domain more severely disrupt the filament assembly process and in particular restrict elongation. [66] This demonstrates that the helix boundary peptides are critical for higher-order assembly of keratin filaments. Finally, the amino-terminal head and carboxy-terminal tail regions, which confer antigenic specificity to individual keratins, consist of the two highly homologous (H) subdomains, two variable (V) subdomains, and two highly charged end (E) subdomains. In hair keratins, these domains are cysteine-rich, permitting the formation of disulfide bonds that confer additional stability to the hair shaft. The end regions of keratins are important for a variety of protein interactions. Mutations affecting the tail domain of keratin 1 cause failure of keratin bundling, retraction of the cytoskeleton from the nucleus, and failed translocation of loricrin to the desmosomal plaques. [67] The glycine loops in the V and E subdomains are thought to form hydrophobic bonds with keratin-associated proteins such as loricrin in the cornified cell envelope. Keratin 5 and 14 truncation experiments have shown that the tails of keratins 5 and 14 are required for filament stabilization, that the head of keratin 5 is required for filament elongation and lateral alignment, and that the highly conserved carboxy R/KLLEGE domain is required for lateral alignment. [68] Interestingly, the ability of keratin 19 (a tail-less keratin) to form filaments demonstrates that this domain is not absolutely necessary for filament formation.

KERATIN POLYMERIZATION Whereas other intermediate filaments form homodimers, keratin polypeptides assemble into coiled-coil heterodimers consisting of one type I keratin and one type II keratin. Type I and type II keratins are

coexpressed in epithelial cells and form heterodimers spontaneously without the assistance of other proteins or factors. Nonpaired keratins are rapidly degraded ensuring equimolar amounts of the components of each pair. [69] Keratin heterodimers are arranged in a parallel configuration and are aligned axially (Fig. 7-6). The formation of the heterodimers is initiated by highly conserved trigger motifs that have been characterized in the 1B and 2B rod domains. [70] Although keratin pairs not seen in nature can be created in vitro, the resulting keratin filaments are less stable. For instance, the absence of keratin 10 in knockout mice results in increased expression of keratins 6 and 16, which bind keratin 1 but do not fully compensate for the absence of normal keratin 1/10 dimers. [71]

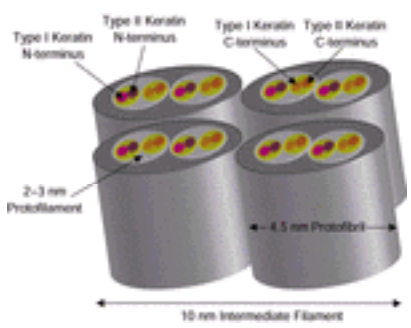

FIGURE 7-6 Keratin intermediate filament structure. Each protofilament is composed of two pairs of staggered, antiparallel keratin dimers. Two protofilaments comprise a protofibril, four of which assemble to make the 10-nm keratin intermediate filament.

Two keratin heterodimers are arranged in an an antiparallel and staggered configuration to form tetramers (double-coiled coils). Antiparallel alignment of keratin pairs is stabilized by specific amino acid residues in the 1A and 2A rod domains and the L2 linker domain. [72] Tetramers then assemble end-to-end into protofilaments (2–3 nm wide), two of which further assemble into protofibrils (4.5 nm wide), and four protofibrils finally assemble into intermediate filaments (10 nm wide). Within this model of filament formation lie two fundamental interactions: lateral interaction between staggered coiled coils and head-to-tail interactions between the same type keratin. This process of keratin filament formation is dynamic, with coiled-coil subunits constantly being added to and deleted from the structures.

CONTROL OF GENE TRANSCRIPTION IN KERATINOCYTES Keratins account for approximately 30 percent of the total protein of basal keratinocytes, and they comprise 85 percent of the cytoplasmic protein of terminally differentiated keratinocytes. The keratin peptides are expressed in a tissue- and differentiation-specific manner. In the skin, the expression of keratins 5 and 14 in the basal layer gives way to keratins 1 and 10 in the spinous layer and subsequently keratins 2e and 10 in the upper spinous and granular layers. In the hair follicle, type II keratin genes are sequentially activated with initial expression of HB5, followed by HB1 and 3, and finally HB6. The tightly regulated changes in keratin expression are controlled by transcription factors, which are DNA-binding proteins that promote or inhibit expression of nearby genes. Most regulatory sites are found in the promoter region upstream of the structural genes, although introns or downstream sequences also may contain regulatory elements. All keratin promoters have a canonical TATA box or a variant thereof, and basal transcription requires the presence of the TATA box and adjacent initiator sequence. Transcription factor TFIID that binds the TATA box is the only transcription factor common to all keratin genes, although binding sites for AP2 transcription factors are also present in most keratin genes. Other transcription factors that affect keratin gene expression include Sp1, NF1 half sites, retinoic acid–responsive elements, steroid hormone–responsive elements, AP1, NF?B, and a number of other factors. [73] Many of these transcription factors are activated by extracellular signals [74] (Fig. 7-7). Binding of interferons and several interleukins (3–6, 12) to cell surface receptors activate specific JAK kinases that in turn phosphorylate tyrosines on signal transducing activators of transcription (STATs). STATs subsequently translocate to the nucleus, bind specific DNA sites, and promote gene transcription. A number of peptides (e.g., epidermal growth factor, transforming growth factor a, amphiregulin, and heregulin) bind the epidermal growth factor receptor and cause receptor dimerization, thereby activating a series of proteins including Ras, a MAPK kinase kinase named Raf1, MEKs, and finally ERKs, which also translocate to the nucleus and activate transcription factors such as SAP1 and Elk1. Tumor necrosis factor a has complex intracellular effects that result in the activation of caspases, resulting in apoptosis, as well as the activation of NFkB, ATF2, and AP1 transcription factors. Although these transcription factor cascades are present in many cell types, there are some keratinocyte-specific transcription factors. These include basonuclin, a zinc finger protein that is found exclusively in the nucleus of the basal and first suprabasal layers, apparently playing a specific role in the control of transcription in the basal layer. [75]

FIGURE 7-7 Transcription factor signaling pathways in keratinocytes. *A.* Transforming growth factor a (TGF-a) and related growth factors bind to the epidermal growth factor receptor (EGF-R) causing dimerization and activation of tyrosine kinase, which lead SHC, Grb2, and SOS to activate RAS that causes downstream activation of several nuclear transcription factors. *B.* There are three principal TNF-a signal-transduction pathways: (1) the apoptosis pathway mediated by caspases, (2) the ceramide pathway, and (3) the TRAF2 pathway. TRAF2 causes downstream degradation of I?B, resulting in activation of nuclear NF?B. Other transcription factors induced by TRAF2 include C/EBPß, ATF2, and AP1. *C.* The interferon-? (IFN-?) and interleukin (IL) pathways. Binding of ligands to receptors causes association with JAK/TYK kinases that phosphorylate STATS, causing dimerization and translocation to the nucleus and subsequent transcriptional activation. (*Adapted from Freedberg et al.* [73])

KERATINS IN DISEASE (See Chap. 51 and Chap. 52) Targeted disruption of keratin genes has allowed further delineation of the function of specific epidermal keratins, and keratin gene mutations have been found to underlie a number of hereditary human diseases (see Table 7-4). The effects of keratin mutations on skin physiology can be partially deduced from the phenotypes seen in keratinopathies. Mutations in keratins 1, 2e, 5, 10, and 14 result in keratinocyte ballooning and degeneration, suggesting that the keratin filament network within keratinocytes provides mechanical strength, cellular structure, and assistance in adhesion molecule attachment.

REFERENCES

1. Jetten AM, Harvat BL: Epidermal differentiation and squamous metaplasia: From stem cell to cell death. *J Dermatol* **24**:711, 1997

2. Wright N: Cell population kinetics in human epidermis. *Int J Dermatol* **16**:449, 1977

3. Lenoir MC et al: Outer root sheath cells of human hair follicle are able to regenerate a fully differentiated epidermis in vitro. *Dev Biol* **130**:610, 1988

4. Ghazizadeh S, Taichman LB: Multiple classes of stem cells in cutaneous epithelium: A lineage analysis of adult mouse skin. *EMBO J* **20**:1215, 2001

5. Rheinwald JG, Green H: Serial cultivation of strains of human epidermal keratinocytes: The formation of keratinizing colonies from single cells. *Cell* **6**:331, 1975

6. Withers HR: Recovery and repopulation in vivo by mouse skin epithelial cells during fractionated irradiation. *Radiat Res* **32**:227, 1967

7. Morris RJ, Potten CS: Highly persistent label-retaining cells in the hair follicles of mice and their fate following induction of anagen. *J Invest Dermatol* **112**:470, 1999

8. Akiyama M et al: Characterization of hair follicle bulge in human fetal skin: The human fetal bulge is a pool of undifferentiated keratinocytes. *J Invest Dermatol* **105**:844, 1995

9. Bickenbach JR, Dunnwalk M: Epidermal stem cells: Characteristics and use in tissue engineering and gene therapy. *Adv Dermatol* **16**:159, 2000

10. Jones PH, Watt FM: Separation of human epidermal stem cells from transit amplifying cells on the basis of differences in integrin function and expression. *Cell* **73**:713, 1993

11. Potten CS: Cell replacement in epidermis (keratopoiesis) via discrete units of proliferation. *Int Rev Cytol* **69**:271, 1981

12. Michel M et al: Keratin 19 as a biochemical marker of skin stem cells in vivo and in vitro: keratin 19 expressing cells are differentially localized in function of anatomic sites, and their number varies with donor age and culture stage. *J Cell Sci* **109**:1017, 1996

13. Bickenbach JR et al: Telomerase is not an epidermal stem cell marker and is downregulated by calcium. *J Invest Dermatol* **111**:1045, 1998

14. Chiu CP et al: Differential expression of telomerase activity in hematopoietic progenitors from adult human bone marrow. *Stem Cells* **14**:239, 1996

15. Watt FM: Epidermal stem cells: Markers, patterning and the control of stem cell fate. *Philos Trans R Soc Lond B Biol Sci* **353**:831, 1998

16. Adams JC, Watt FM: Fibronectin inhibits the terminal differentiation of human keratinocytes. *Nature* **340**:307, 1989

17. Jones PH et al: Stem cell patterning and fate in human epidermis. *Cell* **80**:83, 1995

18. Potten CS, Morris RJ: Epithelial stem cells in vivo. *J Cell Sci Suppl* **10**:45, 1988

19. Zhu AJ et al: Signaling via ß $_1$ integrins and mitogen-activated protein kinase determines human epidermal stem cell fate in vitro. *Proc Natl Acad Sci USA* **96**:6728, 1999

20. Miller DG et al: Gene transfer by retrovirus vectors occurs only in cells that are actively replicating at the time of infection. *Mol Cell Biol* **10**:4239, 1990

21. Bickenbach JR, Roop DR: Transduction of a preselected population of human epidermal stem cells: Consequences for gene therapy. *Proc Assoc Am Physicians* **111**:184, 1999

22. Dunnwald M et al: Isolating a pure population of epidermal stem cells for use in tissue engineering. *Exp Dermatol* **10**:45, 2001

23. Watt FM: Epidermal stem cells as targets for gene transfer. *Hum Gene Ther* **11**:2261, 2000

24. Zhu AJ, Watt FM: Beta-catenin signalling modulates proliferative potential of human epidermal keratinocytes independently of intercellular adhesion. *Development* **126**:2285, 1999

25. Jones JC et al: Structure and assembly of hemidesmosomes. *Bioessays* **20**:488, 1998

26. Robinson NA et al: S100A11, S100A10, annexin I, desmosomal proteins, small proline-rich proteins, plasminogen activator inhibitor-2, and involucrin are components of the cornified envelope of cultured human epidermal keratinocytes. *J Biol Chem* **272**:12035, 1997

27. Green KJ et al: Structure of the human desmoplakins: Implications for function in the desmosomal plaque. *J Biol Chem* 265:2603, 1990

28. Cserhalmi-Friedman PB et al: Structural analysis reflects the evolutionary relationship between the human desmocollin gene family members. *Exp Dermatol* **10**:95, 2001

29. Allen E et al: Mice expressing a mutant desmosomal cadherin exhibit abnormalities in desmosomes, proliferation, and epidermal differentiation. *J Cell Biol* **133**:1367, 1996

30. Haftek M et al: Immunocytochemical evidence for a possible role of cross-linked keratinocyte envelopes in stratum corneum cohesion. *J Histochem Cytochem* **39**:1531, 1991

31. DiColandrea T et al: Subcellular distribution of envoplakin and periplakin: insights into their role as precursors of the epidermal cornified envelope. *J Cell Biol* **151**:573, 2000

32. Mischke D et al: Genes encoding structural proteins of epidermal cornification and S100 calcium-binding proteins form a gene complex (“epidermal differentiation complex”) on human chromosome 1q21. *J Invest Dermatol* **106**:989, 1996

33. Bikle DD, Pillai S: Vitamin D, calcium, and epidermal differentiation. *Endocr Rev* **14**:3, 1993

34. Rutberg SE et al: Differentiation of mouse keratinocytes is accompanied by PKC-dependent changes in AP-1 proteins. *Oncogene* **13**:167, 1996

35. Eckert RL et al: The epidermis: Genes on—genes off. *J Invest Dermatol* **109**:501, 1997

36. Kamibayashi Y et al: Expression of gap junction proteins connexin 26 and 43 is modulated during differentiation of keratinocytes in newborn mouse epidermis. *J Invest Dermatol* **101**:773, 1993

37. Brissette JL et al. Switch in gap junction protein expression is associated with selective changes in junctional permeability during keratinocyte differentiation. *Proc Natl Acad Sci USA* **91**:6453, 1994

38. Willecke K et al: Biological functions of connexin genes revealed by human genetic defects, dominant negative approaches and targeted deletions in the mouse. *Novartis Found Symp* **219**:76, 1999

39. Hohl D et al: Transcription of the human loricrin gene in vitro is induced by calcium and cell density and suppressed by retinoic acid. *J Invest Dermatol* **96**:414, 1991

40. Presland RB et al: Characterization of two distinct calcium-binding sites in the amino-terminus of human profilaggrin. *J Invest Dermatol* **104**:218, 1995

41. Ishida-Yamamoto A et al: Programmed cell death in normal epidermis and loricrin keratoderma: Multiple functions of profilaggrin in keratinization. *J Invest Dermatol Symp Proc* **4**:145, 1999

42. Scott IR, Harding CR: Filaggrin breakdown to water binding compounds during development of the rat stratum corneum is controlled by the water activity of the environment. *Dev Biol* **115**:84, 1986

43. Morrison H: Photochemistry and photobiology of urocanic acid. *Photodermatology* **2**:158, 1985

44. Madison KC et al: Lamellar granule biogenesis: A role for ceramide glucosyltransferase, lysosomal enzyme transport, and the Golgi. *J Investig Dermatol Symp Proc* **3**:80, 1998

45. Geilen CC et al: Ceramide signaling: Regulatory role in cell proliferation, differentiation and apoptosis in human epidermis. *Arch Dermatol Res* **289**:559, 1997

46. Nemes Z, Steinert PM: Bricks and mortar of the epidermal barrier. *Exp Mol Med* **31**:5, 1999

47. Ishida-Yamamoto A et al: Antigen retrieval of loricrin epitopes at desmosomal areas of cornified cell envelopes: An immunoelectron microscopic analysis. *Exp Dermatol* **8**:402, 1999

48. Candi E et al: Transglutaminase cross-linking properties of the small proline-rich 1 family of cornified cell envelope proteins: Integration with loricrin. *J Biol Chem* **274**:7226, 1999

49. Nemes Z et al: A novel function for transglutaminase 1: Attachment of long-chain omega-hydroxyceramides to involucrin by ester bond formation. *Proc Natl Acad Sci USA* **96**:8402, 1999

50. Steinert PM, Marekov LN: The proteins elafin, filaggrin, keratin intermediate filaments, loricrin, and small proline-rich proteins 1 and 2 are isodipeptide cross-linked components of the human epidermal cornified cell envelope. *J Biol Chem* **270**:17702, 1995

51. Marekov LN, Steinert PM: Ceramides are bound to structural proteins of the human foreskin epidermal cornified cell envelope. *J Biol Chem* **273**:17763, 1998

52. Candi E et al: Biochemical, structural, and transglutaminase substrate properties of human loricrin, the major epidermal cornified cell envelope protein. *J Biol Chem* **270**:26382, 1995

53. Koch PJ et al: Lessons from loricrin-deficient mice: Compensatory mechanisms maintaining skin barrier function in the absence of a major cornified envelope protein. *J Cell Biol* **151**:389, 2000

54. Suga Y et al: Transgenic mice expressing a mutant form of loricrin reveal the molecular basis of the skin diseases, Vohwinkel syndrome and progressive symmetric erythrokeratoderma. *J Cell Biol* **151**:401, 2000

55. Djian P et al: Targeted ablation of the murine involucrin gene. *J Cell Biol* **151**:381, 2000

56. Crish JF et al: Tissue-specific and differentiation-appropriate expression of the human involucrin gene in transgenic mice: an abnormal epidermal phenotype. *Differentiation* **53**:191, 1993

57. Steinert PM et al: Small proline-rich proteins are cross-bridging proteins in the cornified cell envelopes of stratified squamous epithelia. *J Struct Biol* **122**:76, 1998

58. Lee CH, et al: Small proline-rich protein 1 is the major component of the cell envelope of normal human oral keratinocytes. *FEBS Lett* **477**:268, 2000

59. Simon M et al: Refined characterization of corneodesmosin proteolysis during terminal differentiation of human epidermis and its relationship to desquamation. *J Biol Chem* **276**:20292, 2001.

60. Horikoshi T et al: Role of endogenous cathepsin D–like and chymotrypsin-like proteolysis in human epidermal desquamation. *Br J Dermatol* **141**:453, 1999

61. Moll R et al: The catalog of human cytokeratins: Patterns of expression in normal epithelia, tumors and cultured cells. *Cell* **31**:11, 1982

62. Albers K, Fuchs E: Expression of mutant keratin cDNAs in epithelial cells reveals possible mechanisms for initiation and assembly of intermediate filaments. *J Cell Biol* **108**:1477, 1989

63. Galligan P et al: A novel mutation in the L12 domain of keratin 5 in the Kobner variant of epidermolysis bullosa simplex. *J Invest Dermatol* **111**:524, 1998

64. Hatzfeld M, Weber K: Modulation of keratin intermediate filament assembly by single amino acid exchanges in the consensus sequence at the C-terminal end of the rod domain. *J Cell Sci* **99**:351, 1991

65. Hatzfeld M, Weber K: A synthetic peptide representing the consensus sequence motif at the carboxy-terminal end of the rod domain inhibits intermediate filament assembly and disassembles preformed filaments. *J Cell Biol* **116**:157, 1992

66. Coulombe PA, et al: Deletions in epidermal keratins leading to alterations in filament organization in vivo and in intermediate filament assembly in vitro. *J Cell Biol* **111**:3049, 1990

67. Sprecher E et al: Evidence for novel functions of the keratin tail emerging from a mutation causing ichthyosis hystrix. *J Invest Dermatol* **116**:511, 2001

68. Wilson AK et al: The roles of K5 and K14 head, tail, and R/K L L E G E domains in keratin filament assembly in vitro. *J Cell Biol* **119**:401, 1992

69. Kulesh DA, et al: Posttranslational regulation of keratins: Degradation of mouse and human keratins 18 and 8. *Mol Cell Biol* **9**:1553, 1989

70. Wu KC et al: Coiled-coil trigger motifs in the 1B and 2B rod domain segments are required for the stability of keratin intermediate filaments. *Mol Biol Cell* **11**:10, 2000

71. Reichelt J et al: Out of balance: consequences of a partial keratin knockout. *J Cell Sci* **110**:2175, 1997

72. Mehrani T et al: Residues in the 1A rod domain segment and the linker L2 are required for stabilizing the A11 molecular alignment mode in keratin intermediate filaments. *J Biol Chem* **276**:2088, 2001

73. Freedberg IM et al: Keratins and the keratinocyte activation cycle. *J Invest Dermatol* **116**:633, 2001

74. Tomic-Canic M et al: Epidermal signal transduction and transcription factor activation in activated keratinocytes. *J Dermatol Sci* **17**:167, 1998

75. Iuchi S, Green H: Basonuclin, a zinc finger protein of keratinocytes and reproductive germ cells, binds to the rRNA gene promoter. *Proc Natl Acad Sci USA* **96**:9628, 1999

T>

Chapter 8

Lowell Goldsmith

Biology of Eccrine and Apocrine Sweat Glands

ANATOMY OF ECCRINE SWEAT GLANDS
CELL BIOLOGY AND FUNCTION OF DIFFERENT CELL TYPES
Nervous Control of Eccrine Sweating
Emotional Sweating
Pharmacology of the Eccrine Sweat Gland and Sweating Rate
Pharmacology and Function of Eccrine Myoepithelium
Energy Metabolism
Composition of Human Eccrine Sweat
Mechanism of Sweat Secretion
Stimulus-Secretion Coupling in Eccrine Sweat Secretion
Mechanism of Ductal Na Reabsorption
APOECCRINE SWEAT GLAND
APOCRINE SWEAT GLAND
Functions
Composition of Secretion
Mode of Secretion
Control of Secretion

REFERENCES

Generalized eccrine sweating is the physiologic response to an increased body temperature during physical exercise or thermal stress and is the most effective means by which humans regulate their body temperature through evaporative heat loss. Failure of this mechanism can lead to heat exhaustion, heat stroke, hyperthermia, and death. Exaggerated local or systemic sweating responses (hyperhidrosis) are a nuisance that may impair social and occupational activities.

Humans have 2 to 4 million eccrine sweat glands distributed over nearly the entire body surface. [1], [2] Although each gland weighs only 30 to 40 µg, the total mass of the eccrine sweat glands roughly equals that of one kidney, i.e., 100 g. A well-acclimatized person can perspire as much as several liters per hour and 10 L/day, a secretory rate far greater than that of other exocrine glands. The secretory activity of the human eccrine sweat gland has two major functions: (1) secretion of an ultrafiltrate of a plasma-like precursor fluid by the secretory coil in response to acetylcholine (ACh), which is released from the sympathetic nerve endings, and (2) reabsorption of sodium in excess of water by the duct, producing hypotonic skin surface sweat. Under extreme conditions, where the amount of perspiration reaches several liters a day, the ductal reabsorptive function assumes a vital role in conserving electrolytes. In addition to the secretion of water and electrolytes, the sweat gland excretes heavy metals, organic compounds, and macromolecules.

ANATOMY OF ECCRINE SWEAT GLANDS

In the adult, sweat glands are most numerous on the sole of the foot (620/cm ^{2}) and least abundant on the back (64/cm ^{2}). [3] Glands first appear in the 31/2-month-old fetus on the volar surfaces of the hands and feet. [4] Early in the fifth fetal month, anlagen of the eccrine sweat glands appear in the axillary skin and, a few weeks later, elsewhere on the body. The anlage of the eccrine sweat gland develops from the epidermal ridge as a cord of epithelial cells growing downward; the apocrine gland derives from the upper portion of the hair follicle as a solid epithelial bud. The anlage of the eccrine sweat gland is double-layered, and the lumen is formed between the middle of the fourth and the eighth fetal months. During the eighth fetal month the lumen broadens, and the secretory cells resemble those of the adult gland. The myoepithelial cells are not recognizable until at least the ninth month and are of uncertain origin. [4]

The eccrine sweat gland consists of two segments, a secretory coil and a duct. The secretory coil is composed of three distinct cell types: clear (secretory), dark (mucoid), and myoepithelial. The clear and dark cells occur in approximately equal numbers (Fig. 8-1). The dark cells border nearly all the apical (luminal) surfaces of the secretory tubules. The clear cells rest either directly on the basement membrane or on the myoepithelial cells. Where two or more clear cells abut, intercellular canaliculi are formed. The canaliculi emerge immediately above the basement membrane or the myoepithelial cells and open directly into the lumen of the gland. The only membrane of the clear cell directly exposed to the lumen is that part of the membrane facing the intercellular canaliculus (Fig. 8-2), which is a pouch extending from the luminal space. Spindle-shaped myoepithelial cells, with masses of myofilaments, lie on the basement membrane and abut the clear cells.

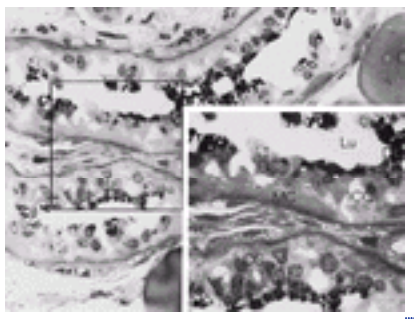

FIGURE 8-1 Light photomicrograph of the secretory coil of an acetylcholine-stimulated monkey-palm eccrine sweat gland. A 1-µm thick section was cut from an Epon-embedded specimen and stained with methylene blue. *Inset:* A higher-power view of the area marked by the square. CC, clear cell; DC, dark cell; ICC, intercellular canaliculi; Lu, lumen; MC, myoepithelial cell.

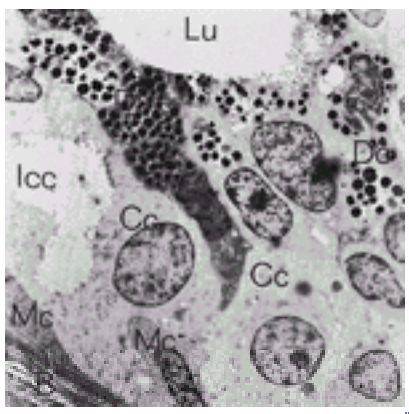

FIGURE 8-2 An electron micrograph of the secretory coil of human eccrine sweat gland. Symbols are the same as in Fig. 8-1. B with *arrow,* basal lamina.

The eccrine sweat duct consists of an outer ring of peripheral or basal cells and an inner ring of luminal or cuticular cells. It seems that the proximal (coiled) duct is functionally more active than the distal straight portion because Na^+, K^+-ATPase activity and the number of mitochondria are higher in the proximal portion. [4], [5] and [6] The luminal cytoplasm of the ductal cells forms a cuticular border consisting of a dense layer of tonofilaments. The basal cells rest on the basement membrane, which is continued from the secretory coil. Their cytoplasmic space contains many mitochondria, suggesting an active role in ductal Na reabsorption. In the epidermis, the duct spirals tightly upon itself.

CELL BIOLOGY AND FUNCTION OF DIFFERENT CELL TYPES

The clear cell contains abundant mitochondria and an autofluorescent body, called a lipofuscin granule, in the cytoplasm. Its cell membrane is rich in villi. In contrast, the dark cell has a relatively smooth cell membrane and contains abundant dark cell granules. The clear cell is most likely responsible for secretion of water and electrolytes. This is suggested by the abundance of membrane villi, membrane infoldings, and mitochondria. Furthermore, when dissociated clear cells are stimulated in vitro by cholinergic agents, they show a dramatic cell shrinkage due to activation of K and Cl channels in the membrane with subsequent net loss of KCl from the cell. [6], [7] and [8]

In addition, cytoplasmic concentrations of Na, K, and Cl decrease during cholinergic stimulation, concomitant with an increase in intracellular Ca concentration. The abundance of the catalytic subunit of Na^+, K^+-ATPase in the basolateral membrane infoldings of the clear cell further supports the above thesis. [9] 15-Lipoxygenase-2 is in secretory cells but its function is unknown. [10]

The function of dark cells is unknown (Fig. 8-3). Because the dark cells represent the only cell type that stains for PAS, it was assumed that the PAS-positive glycoproteins in sweat might be derived from the dark cells.

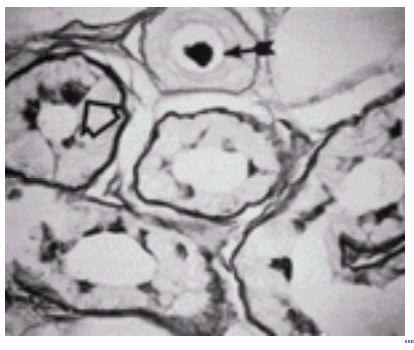

FIGURE 8-3 Presence of PAS-positive, diastase-resistant materials in the dark cells (*open arrow*) as well as in the ductal lumen (*solid arrow*).

The myoepithelial cell is a contractile cell with smooth muscle–like functional characteristics. [9], [11] Its cytoplasm is filled with dense myofilaments that react to anti-actin antibodies. [12] The myofilaments also react to antikeratin monoclonal antibodies, suggesting an epidermal origin. Eccrine myoepithelium responds only to cholinergic stimulation, not to a- or ß-adrenergic agents.

The duct is composed of two layers of cells, the basal and luminal ductal cells. The basal (or peripheral) cells are morphologically and functionally distinct from the luminal cells. The basal ductal cells are replete with mitochondria, and the circumferences of their cell membranes are rich in ATPase (Fig. 8-4), [9] suggesting that the entire cell membrane is involved in Na pumping for ductal Na absorption. In contrast, the luminal ductal cells have fewer mitochondria, much less ATPase activity, and a dense layer of tonofilaments near the luminal membrane, which is often referred to as the *cuticular border*. The cuticular border provides structural resilience to the ductal lumen, which may dilate whenever ductal flow of sweat is blocked. The entire structural organization of the duct is well designed for the most efficient Na absorptive function; the luminal membrane serves as the absorptive surface by accommodating both Na and Cl channels, and the

basal ductal cells serve in Na pumping by providing maximally expanded Na pump sites and efficient energy metabolism. The lumen and the duct contain ß-defensin, an antimicrobial, cysteine-rich, low molecular weight peptide. [13]

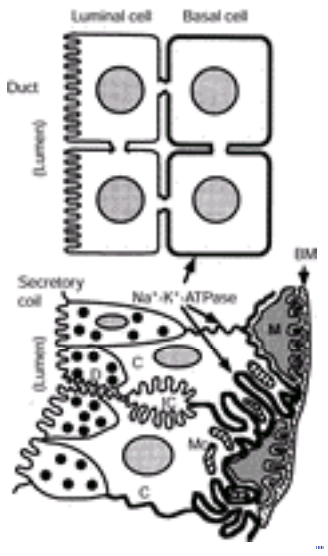

FIGURE 8-4 Illustration of the ultrastructures of the eccrine duct and secretory coil and the localization of Na^+, K^+-ATPase. BM, basement membrane; C, clear cell; D, dark cells; M, myoepithelial cell; Mc, mitochondria. The thick lines indicate the localization of Na^+, K^+-ATPase.

Nervous Control of Eccrine Sweating

Regulation of internal body temperature is among the most fundamental functions of the body. The preoptic hypothalamic area plays an essential role in regulating body temperature: local heating of the preoptic hypothalamic tissue activates generalized sweating, vasodilatation, and rapid breathing, whereas local cooling of the preoptic area causes generalized vasoconstriction and shivering. The elevation of hypothalamic temperature associated with an increase in body temperature provides the strongest stimulus for thermoregulatory sweating responses. Cutaneous temperature influences the rate of sweating. For example, an intense heat stimulus applied to one leg can elicit generalized sweating within 60 s before the tympanic membrane temperature (a measure of hypothalamic temperature) begins to rise, suggesting that neuronal stimuli arising from the heated leg via the cutaneous C fibers activate the hypothalamic sweat center and trigger sweating. Likewise, generalized sweating increases in correlation with an increasing mean skin temperature before core (internal) temperature begins to increase. Nadel et al. [14] quantified various factors involved in determining the rate of local sweating. At a given mean skin and core temperature, an increase in local skin temperature of 10°C triples the local sweating rate until the sweat rate plateaus. On a degree-to-degree basis, an increase in internal temperature is about nine times more efficient than an increase in mean skin temperature in stimulating the sweat center. The local temperature effect is speculated to be due to increased release of periglandular neurotransmitters.

INNERVATION Efferent nerve fibers originating from the hypothalamic preoptic sweat center descend through the ipsilateral brainstem and medulla and synapse in the intermediolateral cell columns of the spinal cord without crossing (although sympathetic vasomotor fibers may partially cross). [15] The myelinated axons rising from the intermediolateral horn of the spinal cord (preganglionic fibers) pass out in the anterior roots to reach (through white ramus communicans) the sympathetic chain and synapse. Unmyelinated postganglionic sympathetic class C fibers arising from sympathetic ganglia join the major peripheral nerves and end around the sweat gland. The supply to the skin of the upper limb is commonly from T2 to T8. The face and the eyelids are supplied by T1 to T4, so that resection of T2 for the treatment of palmar hyperhidrosis is likely to cause Horner's syndrome. The trunk is supplied by T4 to T12 and the lower limbs by T10 to L2. Unlike the sensory innervation, a significant overlap of innervation occurs in the sympathetic dermatome because a single preganglionic fiber can synapse with several postganglionic fibers. The major neurotransmitter released from the periglandular nerve endings is acetylcholine, an exception to the general rule of sympathetic innervation, in which noradrenaline is the peripheral neurotransmitter. In addition to acetylcholine, adenosine triphosphate (ATP), catecholamine, vasoactive intestinal peptide (VIP), atrial natriuretic peptide (ANP), calcitonin gene–related peptide (CGRP), and galanin have been localized in the periglandular nerves. The significance of these peptides or neurotransmitters in relation to sweat gland function is not fully understood. Botulinum toxin interferes with acetylcholine release. Its heavy chain binds the neurotoxin selectively to the cholinergic terminal and the light chain acts within the cells to prevent acetylcholine release. Type A toxin cleaves sensory nerve action potential (SNAP)-25, a 25-kDa synaptosomal-associated protein; the type B light chain cleaves VAMP (vesicle-associated membrane protein, also named synaptobrevin). The use of the Botulinum toxins are discussed in chapters (Chap. 76 and Chap. 276).
DENERVATION Postdenervation hypersensitivity (of postganglionic fibers) of the eccrine sweat gland remains to be explained. In humans, the sweating response to intradermal injection of nicotine or acetylcholine disappears within a few weeks after denervation of the postganglionic fibers. [16] (Note that the sweating response to thermal sweating should stop immediately after resection of the nerves.) For this reason, the human sweat gland was regarded as being the only exception to Cannon's law—the development of supersensitivity after postganglionic denervation. However, in the cat and monkey, the eccrine sweat gland becomes hypersensitive to adrenaline, nicotine, and methacholine for several weeks after postganglionic denervation and/or the effect of these drugs lasts longer than normal. In contrast, after denervation of preganglionic fibers (by spinal cord injuries or neuropathies), pharmacologic responsiveness of the sweat glands is maintained from several months to 2 years, even though their thermally induced sweating is no longer present. [17]

Emotional Sweating

Sweating induced by emotional stress (emotional sweating) can occur over the whole skin surface in some individuals,

but it is usually confined to the palms, soles, axillae, and, in some instances, the forehead. Emotional sweating on the palms and soles ceases during sleep, whereas thermal sweating occurs even during sleep if the body temperature rises. Because both types of sweating can be inhibited by atropine, emotional sweating is cholinergic in nature.

Pharmacology of the Eccrine Sweat Gland and Sweating Rate

Sweat glands respond to cholinergic agents, a- and ß-adrenergic stimulants, and other periglandular neurotransmitters, such as VIP and ATP. Periglandular acetylcholine is the major stimulant of sweat secretion, and its periglandular concentration determines the sweat rate in humans. A striking individual difference exists in the degree of sweating response to a given thermal or physical stress. In general, males perspire more profusely than females. [18], [19] The sweat rate in a given area of the skin is determined by the number of active glands and the average sweat rate per gland. The maximal sweat rate per gland varies from 2 to 20 nL/min per gland. [3], [18] Sweat rate increases during acclimatization, but the morphologic and pharmacologic bases of the individual and regional differences in sweating rate during acclimatization are still poorly understood (Fig. 8-5). In thermally induced sweating, the sweat rate can be mathematically related to the body and skin temperatures in a given subject only at the low sweat rate range. Cholinergic stimulation yields a 5 to 10 times higher sweating rate than does ß-adrenergic stimulation. a-Adrenergic stimulation (by phenylephrine) is no more potent than isoproterenol (ISO) (a ß-adrenergic agonist) in humans in vivo. [18] Whereas cholinergic sweating begins immediately upon intradermal injection, ß-adrenergic sweating requires a latent period of from 1 to 2 min, suggesting that the intracellular mechanism of sweat induction may be different between methacholine (MCh) and ISO. Because the sweat rate by adrenergic agents is rather low, it may be reasonable to surmise that catecholamine in periglandular nerves may be involved in regulation of sweat gland function but not as a stimulant of sweat secretion. One consequence of dual cholinergic and adrenergic innervation is to maximize tissue accumulation of cyclic adenosine monophosphate (cAMP), which may be instrumental in stimulating the synthesis and glandular hypertrophy of the sweat gland. The possibility that periglandular catecholamine is directly involved in emotional sweating or sweating associated with pheochromocytoma [20] may be ruled out because these sweating responses can be blocked by anticholinergic agents.

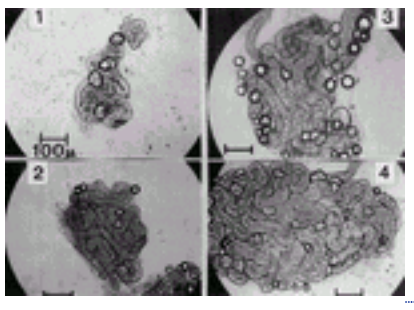

FIGURE 8-5 Individual variation in the size of the sweat gland in four male adults, ages 22 to 28. Sweat glands were isolated from biopsy skin specimens obtained from the upper back behind the axilla. Subject 1 is a sedentary man who does not exercise regularly, whereas subject 4 is a well-acclimatized athletic individual.

Pharmacology and Function of Eccrine Myoepithelium

The periodicity of sweat secretion in vivo is caused by the periodicity of central nerve impulse discharges, which occurs synchronously with vasomotor tonus waves. Sweat secretion induced by intradermal injection of pharmacologic agents is steady and does not show such a periodicity. [21] Myoepithelial contraction occurs with cholinergic stimulation, but neither a- nor ß-adrenergic agents induce tubular contraction. [22] The myoepithelial cell responds only to cholinergic stimulation: (1) myoepithelial contraction is not a prerequisite for inducing or maintaining sweat secretion by the secretory coil and (2) the amount of so-called preformed sweat is so small, due to the narrow lumen, before stimulation that the initial myoepithelial contraction does not expel a significant amount of preformed sweat. The principal function of the myoepithelium may therefore be to provide structural support for the secretory epithelium, especially under conditions where stagnation of sweat flow (due to ductal blockade) results in an increase in luminal hydrostatic pressure. [11]

Energy Metabolism

Sweat secretion is mediated by the energy (i.e., ATP)-dependent active transport of ions, so a continuous supply of metabolic energy is mandatory for sustained sweat secretion. Endogenous glycogen stored in the clear cells can sustain sweat secretion for less than 10 min; thus the sweat gland must depend exclusively on exogenous substrates for its energy metabolism. Mannose, lactate, and pyruvate are nearly as readily utilized as glucose; other hexoses, fatty acids, ketone bodies, intermediates of the tricarboxylic acid (TCA) cycle, and amino acids are either very poorly utilized or not utilized as substrates. The physiologic significance of lactate or pyruvate utilization by the sweat gland is not yet clear. However, because the plasma level of glucose (5.5 m *M*) is much higher than that of lactate (1 to 2 m *M*) or pyruvate (<1 m *M*), glucose may play a major role in sweat secretion. Oxidative metabolism of glucose is favored as the major route of ATP formation for secretory activity. [22]

Composition of Human Eccrine Sweat

INORGANIC IONS Sweat is formed in two steps: (1) secretion of a primary fluid containing nearly isotonic NaCl concentrations by the secretory coil and (2) reabsorption of NaCl from the primary fluid by the duct. Although a number of factors influence ductal NaCl absorption, the sweat rate (and thus the transit time of sweat) is the most important factor influencing final NaCl concentration—namely, sweat concentration is low at the low sweat rate range but increases with the increasing sweat rate to plateau at around 100 m *M* (Fig. 8-6). Potassium (K^+) concentration in sweat is relatively constant. It ranges from 5 to 10 m *M*, which is slightly higher than plasma K^+ concentration. HCO_3^- concentration in the

primary sweat fluid is about 10 m *M*, but that of final sweat is <1 m *M*, indicating that HCO_3^- is reabsorbed by the duct, presumably coupled by ductal acidification. [23] Sweat NaCl concentration is increased in cystic fibrosis (CF) sweat.

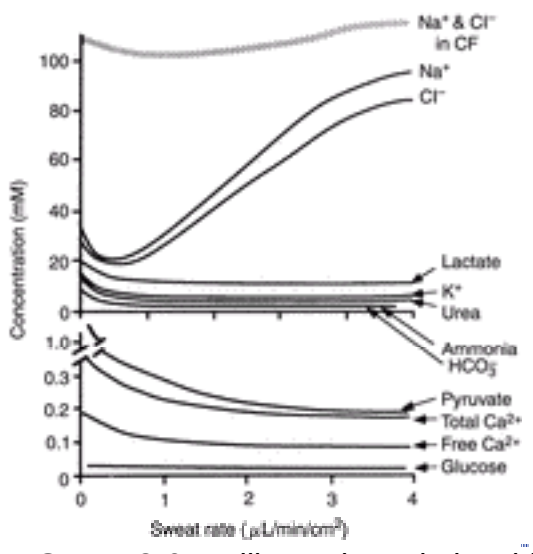

FIGURE 8-6 An illustrative relationship between the concentration of sweat ingredients and the sweat rate in thermally induced human sweat. CF, cystic fibrosis.

LACTATE The concentration of lactate in sweat usually depends on the sweat rate. At low sweat rates, lactate concentration is as high as 30 to 40 m *M*, but it rapidly drops to a plateau at around 10 to 15 m *M* as the sweat rate increases. Acclimatization is known to lower sweat lactate concentrations, whereas arterial occlusion rapidly raises sweat NaCl and lactate concentrations and reduces the sweat rate. [22] Because serum lactate concentration is 1 to 2 m *M* and an isolated sweat gland produces lactate in vitro, [24] sweat lactate is probably produced by glycolysis of glucose by the secretory cells.

UREA Urea in sweat is derived mostly from serum urea. [25] Sweat urea content is usually expressed as a sweat/plasma ratio (S/P urea). S/P urea is high (=2 to 4) at a low sweat rate range but approaches a plateau at 1.2 to 1.5 as the sweat rate increases.

AMMONIA AND AMINO ACIDS Ammonia concentration in sweat is 0.5 to 8 m *M*, [26] which is 20 to 50 times higher than the plasma ammonia level. The concentration of sweat ammonia is inversely related to the sweat rate and sweat pH. Free amino acids are in human sweat. [27] Because of the possibility of contamination by the large amounts of amino acids in epidermis, most published data must be reviewed critically.

PROTEINS AND PROTEASES Proteins are present in human sweat. The concentration of sweat protein in the least contaminated, thermally induced sweat is about 20 mg/dL, with the major portion being low molecular weight proteins (i.e., of weight <10,000). Because sweat samples collected by simple scraping, and even those collected with a plastic bag, can be massively contaminated with plasma or epidermal proteins, previous reports on the presence of a- and ?-globulins, transferrin, ceruloplasmin, orosomucoid, and albumin [28], [29] and IgE must be carefully reexamined. The sweat samples collected over an oil barrier placed on the skin (the least-contaminated sweat) contain no or trace ?-globulin and a very small amount of albumin. Yokozeki et al. [30] reported the presence of cysteine proteinases and their endogenous inhibitors (CPI) in sweat and the sweat gland. Because epidermal growth factor (EGF) receptors are prominent in the human sweat duct, [33] and because EGF is also present in human eccrine sweat, it is tempting to speculate that the predominance of CPI in the sweat duct could be related, at least in part, to its role in the regulation of EGF receptors in the sweat duct. Other organic compounds reported to be present in sweat include histamine, [31] prostaglandin, [32] vitamin K–like substances, [33] and amphetamine-like compounds. [34] Sweat also contains traces of pyruvate and glucose. Sweat glucose increases concurrently with a rise in plasma glucose (Fig. 8-7). Some orally ingested drugs, [22] including griseofulvin [35] and ketoconazole, [36] are secreted in sweat.

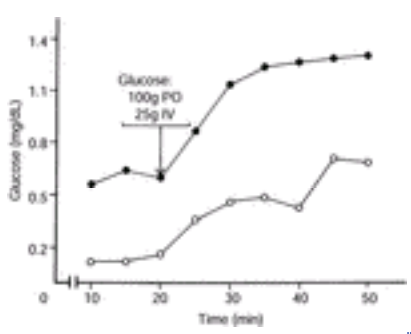

FIGURE 8-7 Sweat glucose concentration before and after glucose bolus in two human subjects. Serum glucose was increased from 85 to 360 mg/dL after glucose bolus, indicated by the *arrow*.

Mechanism of Sweat Secretion

The current model for sweat secretion is derived from the Na-K-2Cl cotransport model. [37], [38] The unique additional features of membrane transport in eccrine clear cells required modification of the original Na-K-2Cl cotransport model—for example, the addition of initial events such as cell shrinkage—and parallel exchangers as shown in Fig. 8-8. [38] The eccrine clear cell is unique in that cholinergic stimulation is followed by dynamic cellular events (as summarized in Table 8-1)—namely, ACh, released from periglandular cholinergic nerve endings in response to nerve impulses, binds to cholinergic receptors, presumably present in the basolateral membrane of the clear cell. The activation of cholinergic receptors somehow stimulates an influx of extracellular Ca into the cytoplasm. The increased cytosolic [Ca] subsequently stimulates Cl channels in the luminal membrane and K channels in the basolateral membrane (see cell 1 in Fig. 8-8), causing a net efflux of KCl from the cell. Consequently, cell volume decreases because water follows the solutes to maintain isoosmolarity. Because the cell cytoplasm also contains osmotically active anions, including amino acids and phosphates (which do not leave the cell so readily), cytoplasmic K and Cl preferentially leave the cell through their

respective ion channels, causing a significant decrease in cytoplasmic [K] and [Cl], despite the fact that the cytosolic water remains isoosmotic to the extracellular fluid during cell shrinkage. The decrease in [K] and [Cl] provides a favorable chemical potential gradient (i.e., the driving force) for Na-K-2Cl cotransporters located in the basolateral membrane. The cotransporters carry Na^+, K^+, and $2Cl^-$ into the cell in an electrically neutral fashion (i.e., two cations and two anions cancel out net charges). Because Na channels are absent in the clear cell membrane, Na-K-2Cl cotransporters are the only means by which Na enters the cells. The increase in cytoplasmic [Na] is well known to stimulate Na pumps, which extrude cytoplasmic Na in exchange for extracellular K, but because the Na-K-2Cl cotransporters are continuously operating, [Na] remains higher than the prestimulation level. One of the interesting features of the Na-K-2Cl cotransport model is that in the steady state (i.e., during the sustained sweat secretion, see cell 2 in Fig. 8-8), K and Na recycle across the basolateral membrane without further loss. The movement of Cl across the apical (luminal) membrane, which is down the electrochemical gradient, depolarizes the apical membrane and generates the negative luminal potential (with respect to the bath). The luminal negative potential then attracts Na into the lumen across the Na-conductive intercellular junction (i.e., paracellular pathway). [38] Thus the Na and Cl that enter the lumen across the cell join in the lumen to form NaCl in the isotonic primary fluid. Although the cotransport model may be the major ionic mechanism for sweat secretion, further modifications of the model have become necessary.

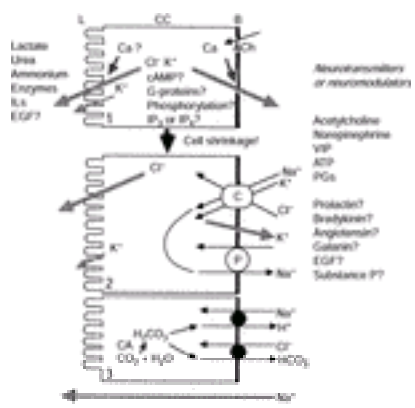

FIGURE 8-8 Modified Na-K-2Cl cotransport model for the ionic mechanism of cholinergic eccrine sweat secretion. Cell 2 is similar to the original cotransport model except that a small K conductance was placed across the luminal (apical) membrane. [51] Periglandular neurotransmitters and possible modulators of cellular function are listed on the basal side of the cell. ACh, acetylcholine; B, basolateral membrane; C, Na-K-2Cl cotransporter; Ca, calcium ion; CA in cell 3, carbonic anhydrase; CC, clear cell; EGF, epidermal growth factor; ILs, interleukins; IP_3 and IP_4, inositol triphosphate and inositol tetrakisphosphate, respectively; L, luminal or apical membrane; P, Na^+, K^+-ATPase-dependent Na pump; and shaded thick arrows, conductive flux of ions through ionic channels. Some of the potentially important ingredients are listed in the luminal side of the cell. Na movement across the cell junction is indicated with a shaded arrow at the bottom of the figure. The initial events are summarized in cell 1.

1. Release of acetylcholine (ACh) from the periglandular nerves.
2. Stimulation of Ca influx by ACh.
3. Increase in cytoplasmic [Ca].
4. Activation of K (basolateral) and Cl (apical) channels by Ca.
5. Influx of Cl into the lumen and efflux of K into the basal interstitium.
6. Loss of cytoplasmic KCl, causing cell shrinkage and a decrease in [K] and [Cl].
7. Activation of Na-K-2Cl cotransporters by an increase in gradients.
8. Na influx, causing an increase in cellular [Na].
9. Activation of Na pump by an increase in [Na].
10. From (5): Cl movement into the lumen, generating luminal negative potential.
11. Luminal negative potential, attracting Na into the lumen across cell junctions to form NaCl for the primary sweat.
12. Recycling of K across the basal membrane.
13. Recycling of Na across the basal membrane.
14. Continuation of (2) through (13) as long as ACh is present.

TABLE 8-1 **Simplified Sequence of Events During Stimulation of Eccrine Clear Cells with Sustained Sweat Secretion (See Text for Detailed Discussion)**

Stimulus-Secretion Coupling in Eccrine Sweat Secretion

Douglas and Rubin [39] originally proposed the concept of *stimulus-secretion coupling* to indicate that a cytoplasmic mediator (such as Ca or cAMP) serves as a link between pharmacologic stimulation and the final secretory processes. In the eccrine cell, Ca may serve as such a link by directly stimulating membrane K and Cl channels, thereby stimulating the cotransport system. The role of cAMP has been established as an intracellular mediator of hormones and ß-adrenergic agonists in a variety of tissues. The data are consistent with the thesis that cAMP may be an intracellular mediator of ß-adrenergic stimulation. Nevertheless, the role of intracellular Ca in cAMP-mediated stimulus secretion coupling is the subject of controversy.

One of the remaining puzzles is whether or not these transporters and channels are completely idle in the resting state.

Mechanism of Ductal Na Reabsorption

The principal function of the sweat duct is absorption of NaCl and HCO_3 from the primary fluid in order to conserve these vital electrolytes for the body. Because Na^+, K^+-ATPase is localized in the entire basal cell membrane [9] and the two cell layers are most likely coupled (and act like a syncytium), the duct functions as though it were made up of a single cell layer, like a nephron (Fig. 8-9). The absorption of NaCl by the duct is due to the active transport of Na ions by the Na pump located in the basal ductal cell membrane. Three homologous sodium epithelial channel subunits have been cloned. [39] Ductal Na reabsorption is ouabian-sensitive [40] and amiloride-sensitive. [41]

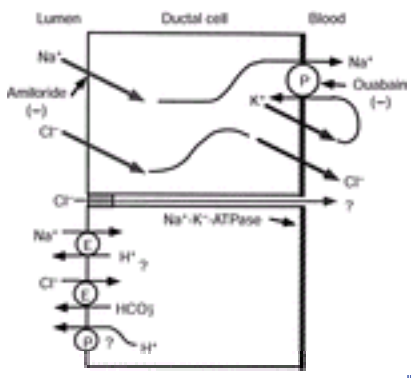

FIGURE 8-9 Illustration of ion transport in the sweat duct. The upper cell is similar to Ussing's classical leak-pump model. The lower cell illustrates parallel exchangers and an H pump, which explain ductal acidification of sweat and partial NaCl absorption in the cystic fibrosis duct where the luminal Cl channels are defective. E, exchanger; P, pump. Shaded arrows indicate conductive permeability down the gradient.

Na must be transported against an electrochemical potential gradient as much as 60 to 70 mV. Chloride is also transported against the chemical gradient of 50 mV (against the gradient of from 20 m *M* in the lumen to 130 m *M* in the dermis), but down a favorable electrical gradient of 10 to 20 mV. Thus, Cl must still overcome the electrochemical potential gradient of 30 to 40 mV. It is widely held that the transport mechanism of the sweat duct largely conforms to Ussing's leak pump model. [42] For example, the presence of Cl channels as well as amiloride-sensitive Na channels has been demonstrated in the luminal membrane. [43] As predicted from the model, Na^+, K^+-ATPase and Cl channels are localized in the basal membrane. [43] The presence of ductal acidification or HCO_3 absorption suggests that additional transport processes such as Na-H exchangers or H pumps may also be involved (see Fig. 8-9). In cystic fibrosis, Cl channels in the luminal membrane are defective and those of the basal membrane are significantly decreased, [44] yet sweat ductal acidification is normal and sweat Na absorption is not totally impaired (i.e., sweat Na concentration never reaches 150 m *M* in cystic fibrosis despite the fact that in the primary fluid Na concentration is 150 m *M*, indicating that limited ductal Na absorption is present). Mutations in the transmembrane conductance regulator (CFTR) are the primary defects in cystic fibrosis. The permeability of chloride but not that of sodium is reduced in cystic fibrosis. A current hypothesis is that CFTR is a downregulator of the epithelial sodium channels and that the cystic fibrosis mutation impairs this regulation and results in increased sodium absorption. This further suggests the partial involvement of Cl-HCO_3 or Cl-OH and Na-H exchangers in the sweat duct. Several drugs are known to modify ductal NaCl reabsorption. When aldosterone is injected systemically or locally, the Na/K ratio in sweat begins to decrease within 6 h, reaching a nadir at 24 h and returning to the preinjection level in 48 to 72 h. [45] The effect of aldosterone on the sweat gland, unlike its effect on kidney tubules, is not accompanied by the so-called escape phenomenon. [46] Na deprivation stimulates both renin and aldosterone secretion, but high thermal stress per se [a single 1-h exposure of humans to a temperature of 40°C (104°F)] is a potent stimulator of renin and aldosterone secretion in either the presence or absence of sodium deprivation. Nevertheless, direct evidence is lacking that enhancement of sweat gland function is mediated solely by aldosterone. It appears that ISO (a ß-adrenergic agonist) may also enhance ductal NaCl reabsorption. [22] In an in vitro sweat gland preparation, neither acetazolamide (a carbonic anhydrase inhibitor) nor antidiuretic hormone changes ductal or secretory function.

APOECCRINE SWEAT GLAND

The apoeccrine sweat gland, an additional member of the family of sweat glands, was discovered during isolation of human axillary sweat from a patient with axillary hyperhidrosis. [40], [47] Although apoeccrine glands (AEG) are readily distinguished from classic eccrine and apocrine glands, the diversity of the gross and fine anatomy of the apoeccrine glands isolated even in the same individual has puzzled investigators (Table 8-2). The AEG develops during puberty from eccrine-like precursor glands and is consistently present in the adult axillae. Its relative frequency varies widely in different adults. However, in patients with axillary hyperhidrosis, as many as 50 percent of all the axillary glands are of the apoeccrine type, whereas in some individuals with no history of axillary hyperhidrosis, the incidence of the apoeccrine glands is much lower. Like the eccrine glands, the AEG has a long duct, which opens directly onto the skin surface (unlike apocrine glands, which open directly into hair follicles). Basically, its secretory tubule consists of a segment of small diameter (as in the eccrine secretory tubule—i.e., less than 80 µm in diameter) and a segment of uniform or irregular dilatation to as much as 500 µm in diameter. These are functionally connected to each other, as was shown by a micropuncture study. The fine morphology of the thick segment is very similar to that of the apocrine gland except that some of the columnar secretory cells contain a large number of mitochondria. The thin segment is indistinguishable from that of the eccrine secretory coil. Like the eccrine gland, the AEG is both cholinergic and adrenergic and its secretory rate is as much as 10 times that of the eccrine gland, mainly because of its large glandular size, [5] suggesting that the AEG may play a role in axillary hyperhidrosis. It is interesting that the AEG responds to epinephrine as avidly as to methacholine. The AEG may be basically an eccrine gland that has undergone “apocrinization” due to local growth factor(s). If so, similar apocrinization could occur elsewhere in the body where similar local growth factors are present.

Appearance	At puberty, develops most likely from an eccrine gland or an eccrine-like precursor.
Size	Variable but larger than eccrine and smaller than apocrine.
Ductal opening	Opens to the nonfollicular skin surface like eccrine.
Duct	Made up of coiled portion and straight portion. Like eccrine duct but tends to have a larger diameter.
Secretory coil	Diameter extremely irregular. Coil is made up of dilated portion and undilated portion. In some coils, the entire secretory coil is irregularly dilated.
Secretory cell type	Very similar to eccrine clear cells in undilated segment, but resembles apocrine cells in dilated portion except that there are some columnar cells. Dilated portion contains rich mitochondria, as in eccrine clear cells.
Intercellular canaliculi	Present in undilated or partially dilated tubules.
Pharmacology	Cholinergic but also responds avidly to epinephrine and isoproterenol and very slightly to phenylephrine.
Sweat secretion	Persistent secretion of clear fluid (as in eccrine) in the presence of acetylcholine.
Sweat rate	Variable but as much as tenfold higher than that of the eccrine glands.

TABLE 8-2 **Some Characteristics of the Apoeccrine Sweat Gland**

APOCRINE SWEAT GLAND

In addition to the eccrine and apoeccrine sweat glands, described above, apocrine sweat glands are found in humans largely confined to the regions of the axillae and perineum. [48] They do not become functional until just before puberty; thus, it is assumed that their development is associated with the hormonal changes at puberty, although the exact hormones have not been identified. Gonadectomy of mature individuals does not affect the function of the apocrine sweat glands, so that if they are to be considered among the secondary sex characteristics, it should be recognized that it is their development and not the maintenance of their functional activity that is dependent on sex hormones.

Functions

A number of functions have been attributed to the apocrine glands, including odoriferous roles as sexual attractants, territorial markers, and warning signals, a role in increasing frictional resistance and tactile sensibility, as well as a role in increasing evaporative heat loss in some species. The production of pheromones by the apocrine glands of many species is well established. [49]

Because the apocrine glands of humans do not begin to function until puberty and are odor-producing, it is attractive to speculate that they have some sexual function, which may now be vestigial. There are high levels of 15-lipoxygenase-2 in the secretory cells of the apocrine gland. Its product 15-HETE, a ligand for the nuclear receptor peroxisome proliferator-activated receptor-?, may function as a signaling molecule and function in secretion or differentiation. [10] For nonhuman primates, apocrine glands may have had an odoriferous function, which furred animals then developed for purposes of thermoregulation.

Composition of Secretion

The apocrine sweat of humans has been described as milky and viscid, without odor when it is first secreted. Subsequent bacterial action is necessary for odor production. Little is known of the chemical composition of apocrine secretion in humans, largely because of the difficulties in collecting secretion that has not been contaminated with that of eccrine glands. Furthermore, the presence of a secretory opening in common with that of the sebaceous glands means that apocrine sweat gland secretion will be mixed with sebum. This could account for the milky appearance of the secretion collected by cannulation of the sudosebaceous duct.

Mode of Secretion

Cannulation of the duct of the human apocrine sweat gland has shown that secretion is pulsatile, and it is assumed that contractions of the myoepithelial cells surrounding the secretory cells are responsible for these pulsations.

Control of Secretion

The apocrine sweat glands of humans respond to emotive stimuli only after puberty. They can be stimulated by either epinephrine or norepinephrine given locally or systemically. Denervation does not abolish the response to emotive stimuli, [50] which suggests that the glands can be stimulated humorally either by circulating epinephrine or norepinephrine. Studies on other species have shown that the apocrine glands are controlled by adrenergic nerves; this is in marked contrast to the eccrine glands, which are under cholinergic control.

Denervation experiments on species other than humans have verified that an intact nerve supply is a functional requirement, but the fact that the glands are usually more sensitive to epinephrine than norepinephrine has led to speculation that elevation of circulating levels of epinephrine may supplement the neural stimulus. It is not known whether apocrine glands of all species have both neural and humoral modes of control, although studies on goats have shown that exercise does not stimulate sympathetically denervated glands.

Although an intact nerve supply is a functional requirement of apocrine sweating, the demonstration of nerve endings or varicosities in close proximity to the glands has been difficult. [48] Local capillary circulation may assist in conveying transmitter substance to the sweat gland cells, a form of neurohumoral transmission.

As would be expected, drugs that affect adrenergic systems also have an effect on apocrine sweat glands. Adrenergic neuron–blocking agents inhibit sweating, as do drugs that deplete the stores of transmitter substance in adrenergic neurons. Specific adrenergic receptor–blocking drugs also inhibit sweating, but the types of receptors differ in various species. The type of receptor that mediates the response of the apocrine glands of humans has not been elucidated.

REFERENCES

1. KunoY: *Human Perspiration*. Springfield, IL, CC Thomas, 1956

2. Szabo G: The number of eccrine sweat glands in human skin, in *Advances in Biology of Skin,* vol 3, edited by W Montagna, R Ellis, A Silver. New York, Pergamon, 1962, p 1

3. Sato K, Dobson RL: Regional and individual variations in the function of the human eccrine sweat gland. *J Invest Dermatol* **54**:443, 1970

4. Ellis R: Eccrine sweat glands: Electron microscopy, cytochemistry and anatomy, in *Handbuch der Haut und Geshlechtskrankheiten, vol 1, Normale and pathologische Anatomie der Haut,* 1st ed, edited by J Jadassohn. Berlin, Springer-Verlag, 1967, p 223

5. Hashimoto K, Gross BG, Lever WF: The ultrastructure of the skin of human embryos. I. The intraepidermal eccrine sweat duct. *J Invest Dermatol* **45**:139, 1965

6. Sato K, Dobson RL, Mali JW: Enzymatic basis for the active transport of sodium in the eccrine sweat gland. Localization and characterization of Na-K-adenosine triphosphatase. *J Invest Dermatol* **57**:10, 1971

7. Takemura T, Sato F, Saga K et al: Intracellular ion concentrations and cell volume during cholinergic stimulation of eccrine secretory coil cells. *J Membr Biol* **119**:211, 1991

8. Suzuki Y, Ohtsuyama M, Samman G et al: Ionic basis of methacholine-induced shrinkage of dissociated eccrine clear cells. *J Membr Biol* **123**:33, 1991

9. Saga K, Sato K: Ultrastructural localization of ouabain-sensitive, K-dependent p-nitrophenyl phosphatase activity in monkey eccrine sweat gland. *J Histochem Cytochem* **36**:1023, 1988

10. Shappell S, Keeney D, Zhang J et al: 15-Lipoxygenase-2 expression in benign and neoplastic sebaceous glands and other cutaneous adnexa. *J Invest Dermatol* **117**:36, 2001

11. Sato K, Nishiyama A, Kobayashi M: Mechanical properties and functions of the myoepithelium in the eccrine sweat gland. *Am J Physiol* **237**:C177, 1979

12. Maiorana A, Nigrisoli E, Papotti M: Immunohistochemical markers of sweat gland tumors. *J Cutan Pathol* **13**:187, 1986

13. Ali R, Falconer A, Ikram M et al: Expression of the peptide antibiotics human beta defensin-1 and human beta defensin-2 in normal human skin. *J Invest Dermatol* **117**:106, 2001

14. Nadel ER, Bullard RW, Stolwijk JA: Importance of skin temperature in the regulation of sweating. *J Appl Physiol* **31**:80, 1971

15. Johnson R Spalding J: *Disorders of the Autonomic Nervous System*. Philadelphia, Davis, 1974

16. Coon J, Rothman S: The sweat response to drugs with nicotine-like action. *J Pharmacol Exp Ther* **23**:1, 1941

17. Faden AI, Chan P, Mendoza E: Progressive isolated segmental anhidrosis. *Arch Neurol* **39**:172, 1982

18. Sato K, Sato F: Defective beta adrenergic response of cystic fibrosis sweat glands in vivo and in vitro. *J Clin Invest* **73**:1763, 1984

19. Buceta JM, Bradshaw CM, Szabadi E: Hyper-responsiveness of eccrine sweat glands to carbachol in anxiety neurosis: Comparison of male and female patients. *Br J Clin Pharmacol* **19**:817, 1985

20. Prout BJ, Wardell WM: Sweating and peripheral blood flow in patients with phaeochromocytoma. *Clin Sci* **36**:109, 1969

21. Foster KG, Haspineall JR, Mollel CL: Effects of propranolol on the response of human eccrine sweat glands to acetylcholine. *Br J Dermatol* **85**:363, 1971

22. Sato K: The physiology, pharmacology, and biochemistry of the eccrine sweat gland. *Rev Physiol Biochem Pharmacol* **79**:51, 1977

23. Sato K, Sato F: Na^{+}, K^{+}, H^{+}, Cl^{-}, and Ca^{2+} concentrations in cystic fibrosis eccrine sweat in vivo and in vitro. *J Lab Clin Med* **115**:504, 1990

24. Sato K, Dobson RL: Glucose metabolism of the isolated eccrine sweat gland. II. The relation between glucose metabolism and sodium transport. *J Clin Invest* **52**:2166, 1973

25. Brusilow SW, Gordes EH: The permeability of the sweat gland to nonelectrolytes. *Am J Dis Child* **112**:328, 1966

26. Brusilow SW, Gordes EH: Ammonia secretion in sweat. *Am J Physiol* **214**:513, 1968

27. Gitlitz PH, Sunderman FWJ, Hohnadel DC: Ion-exchange chromatography of amino acids in sweat collected from healthy subjects during sauna bathing. *Clin Chem* **20**:1305, 1974

28. Page COJ, Remington JS: Immunologic studies in normal human sweat. *J Lab Clin Med* **69**:634, 1967

29. Jirka M, Blanicky P: Micro-isoelectric focusing of proteins in pilocarpine-induced sweat. *Clin Chim Acta* **31**:329, 1971

30. Yokozeki H, Hibino T, Takemura T et al: Cysteine proteinase inhibitor in eccrine sweat is derived from sweat gland. *Am J Physiol* **260**:R314, 1991

31. Garden JW: Plasma and sweat histamine concentrations after heat exposure and physical exercise. *J Appl Physiol* **21**:631, 1966

32. Forstrom L, Goldyne ME, Winkelmann RK: Prostaglandin activity in human eccrine sweat. *Prostaglandins* **7**:459, 1974

33. Seutter E, Sutorius AH: The vitamin K derivatives of some skin-mucins. 3. A route of oxygen transfer. *Int J Vit Nutr Res* **41**:529, 1971

34. Vree TB, Muskens AT, Van R: Excretion of amphetamines in human sweat. *Arch Int Pharmacodyn Ther* **199**:311, 1972

35. Shah VP, Epstein WL, Riegelman S: Role of sweat in accumulation of orally administered griseofulvin in skin. *J Clin Invest* **53**:1673, 1974

36. Harris R, Jones HE, Artis WM: Orally administered ketoconazole: Route of delivery to the human stratum corneum. *Antimicrob Agents Chemother* **24**:876, 1983

37. Sato K, Sato F: Cyclic AMP accumulation in the beta adrenergic mechanism of eccrine sweat secretion. *Pflugers Arch* **390**:49, 1981

38. Sato K: The physiology and pharmacology of the eccrine sweat gland, in *Biochemistry and Physiology of the Skin,* edited by LA Goldsmith. Oxford, Oxford University Press, 1983, p 596

39. Douglas W, Rubin R: The mechanism of catecholamine release from the adrenal medulla and the role of calcium stimulus-secretion coupling. *J Physiol* **167**:288, 1963

40. Sato K, Sato F: Sweat secretion by human axillary apoeccrine sweat gland in vitro. *Am J Physiol* **252**:R181, 1987

41. Garty H, Palmer LG: Epithelial sodium channels: function, structure, and regulation. *Physiol Rev* **77**:359, 1997

42. Ussing HH: Transport of electrolytes and water across epithelia. *Harvey Lect* **59**:1, 1965

43. Sato K et al: Membrane transport and intracellular events in control and cystic fibrosis eccrine sweat glands, in *Cellular and Molecular Basis of Cystic Fibrosis,* edited by G Mastelia, PM Quinton. San Francisco, San Francisco Press, 1988, p 171

44. Sato K, Taylor JR, Dobson RL: The effect of ouabain on eccrine sweat gland function. *J Invest Dermatol* **53**:275, 1969

45. Sato K, Dobson RL: The effect of intracutaneous D-aldosterone and hydrocortisone on human eccrine sweat gland function. *J Invest Dermatol* **54**:450, 1970

46. Conn J et al: The electrolyte content of thermal sweat as an index of adrenal cortical function. *J Clin Invest* **27**:529, 1948

47. Sato K, Leidal R, Sato F: Morphology and development of an apoeccrine sweat gland in human axillae. *Am J Physiol* **252**:R166, 1987

48. Robertshaw D: Apocrine sweat glands, in *Physiology, Biochemistry and Molecular Biology of the Skin,* 2nd ed, edited by LA Goldsmith. Oxford, England, Oxford University Press, 1991, p 763

49. Mykytowycz R: The behavioural role of the mammalian skin glands. *Naturwissenschaften* **59**:133, 1972

50. Shelley W: Apocrine sweat. *J Invest Dermatol* **17**:255, 1951

51. Sato K, Sato F: Nonisotonicity of simian eccrine primary sweat induced in vitro. *Am J Physiol* **252**:R1099, 1987

T>

Chapter 9

Peter Elias Kenneth Feingold Joachim Fluhr

Skin As an Organ of Protection

OVERVIEW OF PROTECTIVE FUNCTIONS OF THE SKIN(See Table 9-1 and Fig. 9-1)
Defense Against Oxidative Stress
Protective, pH-Regulated Functions of the Stratum Corneum
THE TWO-COMPARTMENT MODEL OF THE STRATUM CORNEUM
Evidence for Intercellular Lipid Sequestration
The Role of Lipids in the Permeability Barrier and Clinical Implications
Cellular Basis for Lipid-Protein Sequestration (Fig. 9-5)
EXTRACELLULAR LIPID PROCESSING
EXTRACELLULAR LAMELLAR MEMBRANE GENERATION AND MATURATION
MAINTENANCE OF NORMAL STRATUM CORNEUM FUNCTION
Epidermal Lipid Synthesis under Basal Conditions
Metabolic Responses to Barrier Disruption
SIGNALS OF PERMEABILITY BARRIER HOMEOSTASIS
Ionic Modulations
Cytokine Signaling and Disease Pathogenesis
REQUIREMENTS FOR SPECIFIC LIPIDS VERSUS LIPID MIXTURES FOR BARRIER FUNCTION
The Cutaneous Stress Test

REFERENCES

Life on dry land exists because plants, arthropods, reptiles, birds, and mammals have developed an outer sheath that protects their aqueous interior from water loss into a relatively desiccated environment. The outer sheath of mammalian skin, the stratum corneum, not only protects against excess water loss but also defends against the entry of microorganisms, as well as natural and synthetic toxins. Finally, the stratum corneum and deeper layers of the skin protect from damage by ultraviolet irradiation, mechanical forces, extreme environmental temperatures, and low-voltage electric current.

OVERVIEW OF PROTECTIVE FUNCTIONS OF THE SKIN(See Table 9-1 and Fig. 9-1)

1. Unimportant, desquamation: "basket weave" (up to 1960)
↓
2. Tough, resilient, impermeable: "plastic wrap" (up to 1975)
↓
3. Structural, biochemical heterogeneity: "bricks and mortar" (current)
↓
4. Persistent metabolic activity: "living" (current)
↓
5. Interactive with underlying tissues (current)
a. Metabolic responses to external insults
b. Pathophysiology—signal cascades
c. Biosensor—response to shifts in humidity

TABLE 9-1 **Evolving Concepts of Stratum Corneum**

FIGURE 9-1 The two-compartment “bricks and mortar” model. The “bricks and mortar” model is shown, with lipids restricted to the stratum corneum interstices. In addition, the corneocyte-bound lipid envelope (CLE) is shown as the potential link between the corneocyte and extracellular matrix compartments.

The innermost region of human skin is the *subcutaneous fat layer*. This layer insulates, reduces heat movement into or out of the body, absorbs energy from blunt mechanical trauma, and is active in general energy metabolism. Superficial to the fat layer lies the *dermis,* composed of collagen-glycosaminoglycan complexes, which also protects the body from blunt mechanical trauma. Overlying the dermis is the *epidermis,* which consists of several stratifying layers of nucleated *keratinocytes* and the stratum corneum, which is the major focus of this chapter. *Eccrine sweat glands* and *blood vessels* of the skin aid in the regulation of body temperature. *Sebaceous glands* provide rapid transport of proteins, lipids, and glycerol to the surface of the skin, where the latter is an important determinant of stratum corneum hydration. Afferent and efferent *nerve fibers,* which are chemosensitive, mechanosensitive, and heat sensitive, act as a rapid warning system for potential external trauma.

The *stratum corneum* (SC) is a very resilient tissue, despite its lack of bulk. This resiliency results from these factors: (1) the cornified envelope of individual corneocytes, is highly resistant to both physical and chemical assault; (2) the interdigitation of adjacent corneocytes; (3) the riveting of adjacent corneocytes via specialized desmosomes (corneodesmosomes), which are present and functional in the stratum compactum; and (4) the elasticity (deformability) of the stratum corneum, [1] a property of both its protein and lipid constituents. [2]

An interconnected network of structural proteins disperses the force of external physical insults laterally throughout the tissue. Stratum corneum elasticity is also influenced by (1) the extent of hydration of corneocyte cytosolic proteins, a variable that is regulated by the hygroscopic breakdown products of filaggrin; [3] (2) sebaceous gland-derived glycerol, resulting from high rates of triglyceride turnover; and (3) by changes in external humidity. [4], [5] Stratum corneum proteins,

lipids (especially ceramides), glycerol, and low molecular weight byproducts of keratohyalin (filaggrin) catabolism, known as natural moisturizing factors, bind and retain water in the stratum corneum, thereby maintaining its elasticity. [2]

Because of its loosely organized appearance in skin samples subjected to routine fixation, dehydration, and embedding, the SC was initially not considered functionally important [6] (Table 9-1). Yet, when the SC is frozen-sectioned, and the cornified envelopes of corneocytes are either swollen at alkaline pH or stained with fluorescent, lipophilic dyes, it appears as a compact structure with geometric, polyhedral squames arranged in vertical columns that interdigitate at their lateral margins. Moreover, isolated SC sheets possess both unusually great tensile strength, [1] and very low rates of water permeability. [6] Hence, until the mid-1970s, the SC came to be viewed as a homogeneous film, that is, the “plastic wrap” concept. [6] In the 1970s, the SC was recognized to comprise a structurally-heterogeneous, two-compartment system, [7] with lipid-depleted corneocytes embedded in a lipid-enriched, membranous extracellular matrix (Fig. 9-1). More recently, the SC has come to be appreciated as a tissue with limited types of metabolic activity. [8], [9], [10], [11] and [12] Most importantly, the SC forms an interface that interacts dynamically with underlying epidermal layers. [13] These recent concepts provide new insights into the mechanisms of permeability barrier homeostasis and into the role of external perturbations in initiating cutaneous pathology. [14] In addition to mechanical integrity, hydration, and barrier function, the outer layers of the epidermis also mediate other critical, protective functions, including water repellence, integrity/cohesion/desquamation, resistance to xenobiotics, antimicrobial defense, UV filtration, and antioxidant defense (Table 9-2). Table 9-3 summarizes current concepts about the structural and biochemical bases for most of these functions.



TABLE 9-3 **Protective Functions of the Stratum Corneum**

TABLE 9-2 **Protective Mechanisms of the Epidermis**

Defense Against Oxidative Stress

The stratum corneum, as the interface with the ambient environment, is uniquely exposed to several forms of oxidative stress including ozone, ultraviolet (UV) irradiation, air pollution, pathologic microorganisms, and chemical oxidants, as well as topically applied drugs. [15] To prevent epidermal proteins, lipids, and DNA from damage by oxidative stress, the epidermis contains different enzymatic and nonenzymatic antioxidant systems. [16] The lipid-soluble antioxidant alpha-tocopherol is an important antioxidant in extracutaneous tissues [17] and in stratum corneum. [18] Both ozone and UV irradiation deplete the epidermis of vitamin E and induce lipid peroxidation. [19] Moreover, the water-soluble antioxidants vitamin C, uric acid, and glutathione, which recycle vitamin E, are also depleted by UV radiation and/or ozone. [20]

The role of antioxidant enzymes in epidermis is less clear. Patients with vitiligo display low catalase levels in their involved and uninvolved epidermis in association with high levels of hydrogen peroxide. [21] Repigmentation can be induced in vitiligo by topically applied pseudocatalase. [22] Although, levels of superoxide dismutase decline with age, catalase and glutathione reductase activity increase in photoaged, as well as in naturally aged, epidermis, while alpha-tocopherol and ascorbic acid decrease. [23] Acute UV radiation progressively deletes the catalase activity, while UV irradiation over a lifetime increases the catalase activity in the epidermis and dermis. [24] Finally, topically applied antioxidants appear to prevent UV-induced oxidative damage to antioxidative networks, and to SC lipids and proteins. [25] Thus, the epidermis appears to deploy a rich complement of antioxidant mechanisms against various forms of oxidative stress.

Protective, pH-Regulated Functions of the Stratum Corneum

Several of the functions listed in Table 9-3 are potentially regulated by the pH of the SC. These include not only permeability barrier function and inflammation, as discussed above, but also the related functions of SC integrity, cohesion, and desquamation [11] and anti-inflammatory activity, as well as antimicrobial defense. [26] Normal SC demonstrates a markedly acidic pH (“acid mantle”). [27] While the origins of the acidic pH of the SC are incompletely understood, exogenous influences, such as lactic acid in sweat, [28] microbial metabolites, and free fatty acids from sebum, [29] have long been considered the most-likely sources. But recent studies point, instead, to three unrelated, endogenous pathways that contribute to SC acidification (Fig. 9-2). The first acidifying mechanism results from the deamination of filaggrin-derived histidine to *trans*-urocanic acid (tUCA) by the enzyme, histidine ammonia-lyase (histidase). This key metabolite, in turn, could impact several pH- and non-pH–related functions [30] (Fig. 9-3). With regard to non-pH–dependent, defensive cutaneous functions, tUCA is an effective UV-filter, but as it absorbs incident UVB, it isomerizes to *cis*-UCA, a potent immunosuppressive molecule that is hypothesized to favor development of UVB- and UVA-induced skin cancers. [31] tUCA, with other filaggrin metabolites, is also a potent endogenous humectant (Fig. 9-3);

that is, an important source of SC hydration, [30] which not only regulates skin flexibility (see above), but also regulates downstream effects on epidermal proliferation. [4], [32] The second pathway, phospholipid hydrolysis by lamellar body-derived, secretory phospholipase A_2 ($sPLA_2$), generates a pool of free fatty acids (FFA) that contributes to SC acidification, as well as to SC integrity and cohesion [11] (Fig. 9-2). Third, a sodium-proton membrane antiporter, NHE1, is expressed in the outer nucleated layers of the epidermis, where it acidifies localized membrane domains at the SG-SC interface, with a lesser contribution to the bulk pH of the SC [33] (Fig. 9-2).

FIGURE 9-2 Endogenous pathways for SC acidification. Three endogenous pathways affect SC acidification, thereby regulating one or more of the key SC functions.

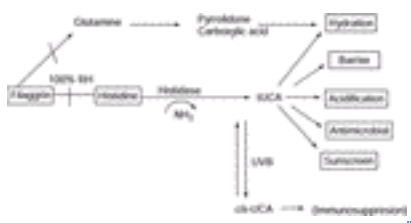

FIGURE 9-3 Filaggrin-histidine-urocanic acid pathway—metabolite functions in the SC.

How does the pH of the SC modulate these many functions? With regard to permeability barrier function, the barrier recovers more slowly after acute insults when exposed to neutral versus acidic buffers. [34] This delay in recovery can be explained by the pH optima of certain key lipid-processing enzymes in the SC interstices (Fig. 9-4). Although $sPLA_2$ displays a neutral pH optimum, two other key lipid-processing enzymes, ß-glucocerebrosidase (ß-GlcCer'ase) and acidic sphingomyelinase (aSMase), are activated at an acidic pH. [35] Hence, phospholipid catabolism yields locally acidifying products [11] (i.e., FFA), which, in turn, appear to activate ß-GlcCer'ase and aSMase, generating ceramides, one of the three key SC barrier lipids, from their polar precursors (Fig. 9-4). Acidification also regulates SC integrity/cohesion, thereby restricting premature desquamation. [11] The basis for this activity relates to corneodesmosome degradation within the SC interstices, a process that requires two serine proteases, the SC chymotryptic and tryptic enzymes, which exhibit neutral-to-alkaline pH optima. [36] Thus, at an acidic pH, low protease activity presumably restricts corneocyte detachment to the low rates that accompany normal desquamation. Furthermore, the release and activation of interleukin (IL)-1a and IL-1ß from their preformed precursor pools in the SC also requires serine protease activity, including the SC chymotryptic enzyme. Thus, the earliest, cutaneous proinflammatory events may be triggered by loss of normal SC acidification. Finally, the defensive antimicrobial function of the skin appears to be dependent upon SC acidification (Fig. 9-2). [37] Whereas normal flora, such as micrococci and corynebacteria, grow better at an acidic pH, pathogenic organisms, such as staphylococci, streptococci, and candida, proliferate more avidly at a neutral pH. [37] Thus, SC pH appears to regulate several of the SC's key defensive functions.

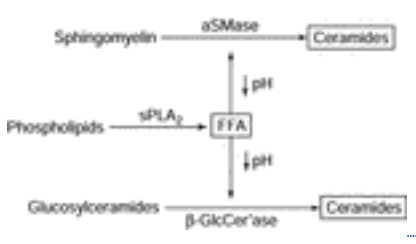

FIGURE 9-4 Generation of free fatty acids (FFA) from phospholipids regulates SC pH and, subsequently, the activities of at least two other key SC enzymes.

THE TWO-COMPARTMENT MODEL OF THE STRATUM CORNEUM

Evidence for Intercellular Lipid Sequestration

Stratum corneum structure is similar in all keratinizing epithelia, comprising protein-enriched corneocytes embedded in a continuous, lipid-enriched, intercellular matrix in the “bricks-and-mortar” model (see Fig. 9-1). [7], [12], [38], [39] and [40] The evidence for such protein-lipid sequestration is based upon freeze-fracture replication; histochemical, biochemical, and cell fractionation; cell separation; and physical–chemical studies. [41] Both freeze-fracture and ruthenium tetroxide postfixation reveal stacks of intercellular bilayers in the intercellular spaces, whereas routine electron microscopy reveals only empty spaces. [42] The two-compartment model also explains both the remarkable capacity of corneocytes to take up water [43] [i.e., the lipid-enriched lamellar bilayers act as semipermeable membranes, while osmotically active molecules (see above) trap water within the cytosol]. However, the two-compartment model must be updated based upon recent evidence both for microheterogeneity (i.e., the presence of extracellular proteins, such as desmosomal components, and abundant hydrolytic enzyme activity within extracellular domains), and for signaling networks that link the stratum corneum to underlying layers(Table 9-1).

The Role of Lipids in the Permeability Barrier and Clinical Implications

The importance of stratum corneum lipids for barrier integrity has been known since it was shown that topical applications of organic solvents produce profound alterations in barrier function. [44] Table 9-4 summarizes the key mechanisms by which SC lipids mediate barrier function. More recently, the importance of bulk SC lipids for the barrier was demonstrated by (1) the inverse relationship between the permeability of the stratum corneum to water and water-soluble molecules at different skin sites (e.g., abdomen versus palms and soles) and the lipid content of that site; [45] (2) the observation that organic solvent-induced perturbations in barrier function occur in direct proportion to the quantities of lipid removed; [44] (3) the finding that SC lipid content is defective in pathologic states that are accompanied by compromised barrier function, such as essential fatty acid deficiency; [46] (4) the observation that replenishment of endogenous SC lipids, following lipid removal by solvents or detergents, parallels the recovery of barrier function; [47] and (5) the finding that topically applied SC lipids normalize or accelerate barrier recovery when applied to solvent-treated, tape-stripped, or surfactant-treated skin. [48], [49]

Intercellular localization
Amount of lipid (lipid wt%)
Tortuous pathway
Lamellar organization
Hydrophobic composition
Correct molar ratio
Unique molecular structures

TABLE 9-4 **How Lipids Mediate Permeability Barrier Function**

These regional differences in SC lipid content have important clinical implications. First, they correlate with susceptibility to the development of contact dermatitis to lipophilic versus hydrophilic antigens at specific skin sites. Whereas allergy to lipophilic antigens, such as poison ivy (urushiol), is more likely to occur on lipid-replete sites, allergy to water-soluble antigens, such as those in metals, foods, flowers, and vegetables, occurs more commonly on lipid-depleted sites such as the palms. Second, persons with atopic dermatitis who display a paucity of SC lipids [10], [50], [51] and [52] are less-readily sensitized to lipid-soluble antigens, [53] but more readily sensitized to hydrophilic antigens, such as nickel. [54] Of course, immunologic abnormalities in atopic individuals could also contribute to differences in sensitization thresholds. [55] Third, percutaneous delivery of topical, lipid-soluble drugs, such as topical steroids and retinoids, occurs more readily on lipid-replete sites, such as the face, axillae, and groin. [56] Hence, the higher propensity to develop cutaneous side effects, such as atrophy from topical glucocorticoids, in these sites. Similarly, lipophilic drugs, such as estradiol, nitroglycerin, scopolamine, clonidine, and fentanyl, are delivered transdermally for systemic therapeutic purposes with relative ease over lipid-replete sites. [57] Finally, the low lipid content of palms and soles explains the increased susceptibility of these sites to the development of soap- or surfactant- and hot water-induced dermatitis; [58] that is, these sites have an intrinsic barrier defect, associated with reduced lipids, and additional lipid removal superimposes a further insult.

Cellular Basis for Lipid-Protein Sequestration (Fig. 9-5)



FIGURE 9-5 Lamellar body products and functional consequences. Lamellar bodies deliver both lipids and enzymes, which impact barrier-related functions and degradation processes, such as desquamation.

Since its earliest descriptions, hypotheses have abounded about the function of the epidermal lamellar body. [59] These ellipsoidal organelles, measuring about 0.3 × 0.5 µm, appear initially in the first suprabasal cell layer, the stratum spinosum, and continue to accumulate in the stratum granulosum, accounting for about 10 percent of the volume of the granular cell cytosol. The lamellar body contents comprise a plastic sheet, which appears like parallel membrane stacks, enclosed by a limiting trilaminar membrane, in cross-section. [60], [61] In the outer granular layer, lamellar bodies move toward the highly invaginated apical surface, where they are poised to undergo rapid exocytosis. [12], [59], [60], [61] and [62] Tracer perfusion studies demonstrate the role of the lamellar body secretory process in barrier formation: The outward egress of water-soluble tracers through the epidermis is blocked at sites where secreted lamellar body contents have been deposited. Membrane specializations, such as tight junctions, are present in these locations, but they are insufficient to account for barrier formation.

The factors that regulate lamellar body secretion were recently elucidated. Low rates of secretion, sufficient to sustain basal barrier function, occur under basal conditions, while both organellogenesis and secretion accelerate under stimulated conditions. For example, acute perturbations of the permeability barrier result in an immediate secretion of most lamellar bodies from outermost granular cells, accompanied by a striking reduction in the numbers of these organelles in the cytosol. [61] Changes in the epidermal calcium gradient regulate these differences in secretion. [63] Depletion of extracellular calcium, which accompanies barrier disruption, stimulates lamellar body secretion. As the gradient is reestablished, lamellar bodies reaccumulate in these cells.

Because lamellar bodies are enriched in sugars and lipids, their contents were thought to be important for epidermal

cohesion and waterproofing. [12], [59], [62] Biochemical studies further support a role for this organelle's contents in barrier formation. [60], [64], [65] and [66] Partially purified lamellar body preparations are enriched in glucosylceramides, free sterols, and phospholipids (Fig. 9-5), precursors of the species that account for almost all of the SC intercellular lipids.

In addition to lipids, the lamellar body is enriched in selected hydrolytic catabolic enzymes (Fig. 9-5), including acid phosphatase, certain proteases, a family of lipases, and a family of glycosidases. [12], [65], [67] As a result of its enzyme contents, the lamellar body has been considered a type of lysosome, but evidence for this concept is lacking. For example, lamellar bodies lack certain acid hydrolases characteristic of lysosomes, such as arylsulfatases A and B, as well as ß-glucuronidase. [65] Instead, the lamellar body appears to be a specialized secretory vesicle, analogous to the lamellar body of alveolar type 2 cells. The same enzymes that are concentrated in lamellar bodies occur in highly specific activity in whole stratum corneum, and they are further localized to intercellular domains. [12] These enzymes appear to fulfill dual roles: some play a role in barrier formation and others in desquamation [11], [12], [36] (Fig. 9-5). The colocalization of the various lipases (phospholipase A_2, sphingomyelinase, steroid sulfatase, acid lipase, and ß- glucocerebrosidase) to the same tissue compartment as “probarrier” lipids results in formation of lamellar membrane structures (Table 9-5). [12] Lamellar body-derived serine proteases appear to regulate corneodesmosomal degradation, leading to desquamation [42], [68] (Fig. 9-5). Indeed, two of these serine proteases, SC chymotryptic and tryptic enzymes, have been extensively characterized and shown to regulate corneodesmosome degradation. [36], [69], [70] Finally, recent information suggests that steroid sulfatase, the microsomal enzyme responsible for desulfation of cholesterol sulfate, also reaches SC membrane domains by the lamellar body secretory pathway. [66], [71] In summary, a variety of barrier-and nonbarrier-related enzymatic activities persist in the SC. These enzymatic activities can be further localized to either the cytosol, the cornified envelope, or the interstices of the SC. Because of these large amounts of persistent metabolic activity, the SC clearly can no longer be viewed as “dead” or “inert”.



TABLE 9-5 **Precursors and Products of Stratum Corneum Lipid Processing Enzymes**

EXTRACELLULAR LIPID PROCESSING

Cosequestration of lipids and selected hydrolytic enzymes within the intercellular spaces of the stratum corneum results from the secretion of the lipid-enriched contents of lamellar bodies from the outermost granular cell. As noted above, barrier formation requires the transformation of the initially secreted lipids (predominantly glucosylceramides, cholesterol, and phospholipids) into a more nonpolar mixture, enriched in ceramides, cholesterol, and free fatty acids, a process that may require acidification of the extracellular domains [9], [11], [49], [60] (see Fig. 9-6). Such an acidic milieu may be required for optimal activation of certain of the key hydrolases, for example, ß-glucocerebrosidase, acid lipase, and acid sphingomyelinase. In contrast, secretory phospholipase A_2 and steroid sulfatase, with their neutral pH optima, may be activated at the higher pHs present in the lower SC. Together, these enzymes generate the requisite nonpolar lipid mixture that forms the hydrophobic, intercellular lamellar membrane system (Table 9-5).

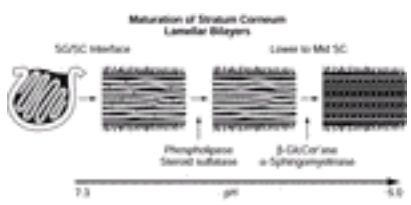

FIGURE 9-6 Maturation of stratum corneum lamellar bilayers. Lamellar body lipids are delivered as pleated sheets at the SC/SG (stratum granulosum) interface and subsequently mature into bilayers along a pH gradient.

Proof of the key role of extracellular ß-glucocerebrosidase in this process came from both inhibitor studies (conduritols) and a transgenic murine model. [35], [72], [73] and [74] In both of these models, lack of enzyme activity leads to a barrier abnormality, which appears to be attributable to both accumulation of glucosylceramides and depletion of ceramides. This biochemical change is accompanied by the persistence throughout the SC interstices of immature membrane structures. Such incompletely processed membrane structures also appear in a subgroup of patients with Gaucher's disease (type II), which is characterized by drastically reduced enzyme levels and ichthyosiform skin lesions. [72] Although inadequate to meet the demands of terrestrial life, these immature, glycosylated membrane structures nevertheless appear to suffice in mucosal epithelia. [75] Pertinently, endogenous ß-glucosidase levels are reduced in oral mucosa. [76] Thus, the persistence of glucosylceramides could indicate either less stringent barrier requirements and/or additional functions of glucosylceramides unique to these tissues.

Extracellular processing of phospholipids is also required for barrier homeostasis. [77] As with ß-glucocerebrosidase, pharmacologic inhibitors of phospholipase A_2 both delay barrier recovery after prior disruption and induce a barrier abnormality in intact murine epidermis. [77] The biochemical abnormality responsible for the barrier defect is product depletion: that is, coapplications of palmitic acid (but not linoleic acid) along with the inhibitors, normalize barrier function. Thus, generation of nonessential FFA by phospholipase-mediated degradation of phospholipids is required for barrier homeostasis. We recently showed the importance of secretory phospholipase A_2-derived FFA for SC acidification, and

defined the role of protons derived from this pathway in mediating SC integrity/cohesion. [11]

Recent studies also demonstrate the importance of regulation of acid sphingomyelinase (aSMase) for homeostasis. [9] aSMase is required for the generation of two of the seven ceramides that form the lamellar bilayers. [78] Finally, steroid sulfatase (SSase), which desulfates cholesterol sulfate, is also required for barrier homeostasis. [79] However, rather than supplying cholesterol for the barrier, the principal importance of SSase is removal of excess cholesterol sulfate, which, when present, in excess, provokes excess scale. In summary, four SC extracellular enzymes are required for permeability barrier homeostasis.

EXTRACELLULAR LAMELLAR MEMBRANE GENERATION AND MATURATION

As noted above, lamellar body exocytosis delivers the precursors of the extracellular lamellar membranes to the stratum granulosum–stratum corneum interface (Fig. 9-5 and Fig. 9-6). [12] Lamellar body-derived membrane sheets then unfurl, fuse, and transform into broad, uninterrupted membrane sheets, which then metamorphose into lamellar membrane unit structures. [12], [42], [61], [80] This sequence normally occurs in its entirety within the lower two to three cell layers of the SC, correlating with changes in lipid composition, that is, from the polar lipid-enriched mixture of glucosylceramides, phospholipids (including sphingomyelin), and free sterols present in lamellar bodies, to the more nonpolar mixture, enriched in ceramides, free sterols, and free fatty acids, present in the SC. As noted above, these structural changes appear to be completely or partially mediated by a family of lipid hydrolases (Table 9-5), [12] delivered to the SC interstices by lamellar body secretion.

The elucidation of lamellar membrane structure in mammalian SC has been impeded by the extensive extraction artifacts produced during processing for light and electron microscopy. [12] Following the application of freeze-fracture replication to the epidermis, the SC interstices were first shown to be replete with a multilamellar system of broad membrane structures. Further detailed information about intercellular lamellar membrane structures resulted from the application of ruthenium tetroxide postfixation to the study of stratum corneum membrane structures. [42], [80], [81] With ruthenium tetroxide postfixation, the electron-lucent lamellae appear as pairs of continuous leaflets, alternating with a single fenestrated lamella. Each electron-lucent lamella is separated by an electron-dense structure of comparable width. The entire multilamellar complex lies external to a hydrophobic envelope, containing covalently-bound ceramides. The lamellar spacing or repeat distance of 12.9 ± 0.2 nm of ruthenium tetroxide-fixed lamellae, analyzed by optical diffraction, correlates extremely well with independent measurements of these domains by x-ray diffraction. [80] Because the repeat distance is more than twice the thickness of typical lipid bilayers, each lamellar repeat unit appears to consist of two apposed bilayers. [80] Multiples of these units (up to three) occur frequently in the SC interstices, [80] and simplifications of the basic unit structure, with deletion of one or more lamellae, occur at the lateral surfaces of corneocytes, that is, at three-cell junctures. [80] Electron-dense dilatations of the electron-dense lamellae correspond to comeodesmosomes in the lower SC, and in higher layers, to sites of comeodesmosome hydrolysis. [42], [80] It has been proposed that these sites correspond to the aqueous “pore pathway” for water, as well as the route for percutaneous drug and xenobiotic movement (Fig. 9-5). [82]

The membrane complex immediately exterior to the cornified envelope, the covalently-bound lipid envelope replaces the true plasma membrane during terminal differentiation. [3] Although a portion of this trilaminar structure survives exhaustive solvent extraction, it is destroyed by saponification. [83] Lipid extracts of saponified fractions yield long chain, ?-hydroxyacid-containing ceramides that are believed to be covalently attached to glutamine residues in the cornified envelope. [76] Because this envelope persists after prior solvent extraction has rendered the SC porous, it does not itself provide a barrier. However, it is required for normal barrier function, [84] perhaps functioning as a scaffold for the deposition and organization of lamellar body-derived, intercellular bilayers. Although, the origin of the covalently bound envelope remains unknown, it does not appear to originate from the pool of lipids deposited during lamellar body secretion, but rather from fusion of the limiting membrane of lamellar bodies with the plasma membrane, immediately prior to cornification. [71]

MAINTENANCE OF NORMAL STRATUM CORNEUM FUNCTION

Epidermal Lipid Synthesis under Basal Conditions

Studies of cutaneous lipid synthesis demonstrate that [85], [86] (1) the skin is a major site of cholesterol synthesis, accounting for 20 to 25 percent of total body synthesis; [87] (2) the skin generates a broad range of lipid species; [88] and (3) most cutaneous sterol and fatty acid synthesis localizes to the dermis—the epidermis is an extremely active site of lipid synthesis, with about 60 to 70 percent of total lipid synthesis occurring in the basal layer. [86], [89] However, considerable epidermal lipid synthesis continues in all of the nucleated layers of the epidermis. [89]

It is now clear that systemic factors influence cutaneous lipid synthesis minimally. Whereas hormonal changes, particularly in thyroid, testosterone, or estrogen status, can alter epidermal lipid synthesis, these hormones appear to have little impact on cutaneous lipid synthesis under day-to-day conditions. [86] In addition, changes in circulating sterols from either diet or drugs do not alter epidermal cholesterol synthesis, presumably because of the paucity of low-density lipoprotein receptors on epidermal cells. [86], [90] The independence of these layers from circulating influences may have evolutionary significance, because it ensures that the differentiating layers are attuned to their own special functional requirements, that is, barrier homeostasis. Yet, despite its relative autonomy, the epidermis incorporates some circulating lipids such as plant sterols, essential fatty acids, polyunsaturated fatty acids, and arachidonic acid (the epidermis lacks the ^{6}?-desaturase). [85] Although these lipids are indicators of the capacity of the epidermis to take up exogenous lipids, the quantitative contribution of extracutaneous lipids to the epidermal pool appears to be small in comparison to de novo

synthesis. [86]

Metabolic Responses to Barrier Disruption

Despite both its relative autonomy and high basal rates of lipid synthesis, the epidermis responds with a further lipid biosynthetic burst when the permeability barrier is disrupted by topical treatment with either organic solvents, tape stripping, or detergents. [13], [86] Regardless of the manner of barrier disruption, an initial, rapid repair response leads to about 50 percent restoration of normal barrier function in about 12 h in humans, with a slower, late phase leading to complete recovery in 72 to 96 h [91] (Fig. 9-7). These acute forms of barrier perturbation can be analogized to administering a “treadmill” examination to the skin. This assay has been used for several purposes, including the linkage of specific metabolic responses to barrier homeostasis. For example, different metabolic events are associated with the rapid versus slow recovery phase (Fig. 9-7). Immediately after barrier disruption, all of the lamellar bodies in the outermost granular cell are secreted, [61] and an increase occurs in both cholesterol and fatty acid synthesis. In contrast, the late phase of barrier recovery is associated with an increase in ceramide synthesis, [92] as well as a stimulation of epidermal ß-glucocerebrosidase [72] and DNA synthesis. [93] That all of these alterations can be attributed to the barrier abnormality is shown by (1) the localization of the increase in synthesis to the underlying epidermis—dermal cholesterol and fatty acid synthetic rates remain unaffected after acute barrier disruption; (2) the extent of the increase in lipid and DNA synthesis is proportional to the degree of the barrier abnormality; [94] (3) the increase in lipid synthesis is prevented when the barrier is artificially restored by application of water vapor-impermeable (but not vapor-permeable) membranes, while the increase in DNA synthesis is partially blocked; [93] and (4) in a sustained model of barrier dysfunction (i.e., rodent essential fatty acid deficiency), lipid synthesis is stimulated, and the increase is normalized when the barrier is restored by either linoleic acid replenishment or occlusion. [94] These results indicate that alterations in barrier function stimulate epidermal lipid synthesis, and suggest further that transcutaneous water loss might be a direct or indirect regulatory factor.

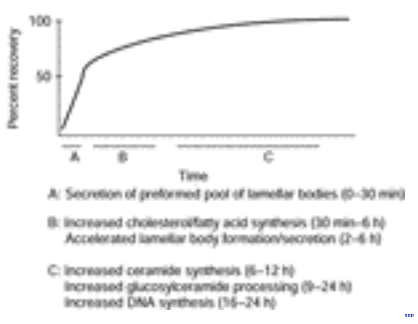

FIGURE 9-7 Three phases of barrier recovery after acute perturbations: Regulated metabolic activities in relation to kinetics of recovery.

The epidermal activities of the rate-limiting enzymes of the three most abundant lipid species, cholesterol, ceramides, and free fatty acids, are high (Fig. 9-8). These include 3-hydroxy-3-methylglutaryl coenzyme A (HMG-CoA) reductase, serine palmitoyltransferase (SPT), acetyl-CoA carboxylase (ACC), and fatty acid synthase (FAS). [92] Moreover, the activities of all these enzymes increase when the barrier is disrupted under both acute and sustained conditions. Yet, the increase in activities of all these enzymes is blocked when the barrier is restored artificially by occlusion with a vapor-impermeable membrane, indicating that the increase is linked to restoration of normal barrier function. [44] Finally, the changes in enzyme activity are preceded by changes in the mRNA for HMG-CoA synthase, HMG-CoA reductase, squalene synthase, ACC, FAS, and SPT, [95], [96] changes that are blocked by occlusion. Transcription of several of these enzymes is, in turn, regulated by one or more transcription factors, sterol regulatory element binding proteins (SREBPs), [97] which modulate cholesterol and fatty acid synthesis in response to changes in the cellular content of these lipids. Thus, acute changes in the barrier initiate a sequence of events, including rapid lamellar body secretion and increased lipid synthesis, which will lead ultimately to barrier restoration. Additional evidence for regulation of lipid synthesis and for an absolute requirement for each of the three key lipids is described below.

FIGURE 9-8 Synthetic pathways and key enzymes for the three key stratum corneum lipids.

SIGNALS OF PERMEABILITY BARRIER HOMEOSTASIS

Ionic Modulations

The ability of occlusion to block the lipid and DNA synthetic response to barrier disruption suggests that transepidermal water loss is a regulatory signal for barrier homeostasis. Yet, a perturbed barrier recovers normally when exposed to isotonic, hypertonic, or hypotonic external solutions, unless calcium, and, to a lesser extent, potassium, are present in the bathing solution. [98] Moreover, calcium and potassium together appear to be synergistic in inhibiting barrier recovery. [98] Because these inhibitory influences are reversed by blockade with inhibitors of both L-type calcium channels and calmodulin, translocation of extracellular calcium into the cytosol appears to be required. [98] The mechanism for the negative ionic signal seems to relate to the presence of a calcium gradient in the epidermis (Fig. 9-9). Barrier disruption,

regardless of method, results in passive outward displacement of the inhibitory ions into the stratum corneum. It is this depletion of calcium that regulates lamellar body exocytosis [99] (Fig. 9-9). These findings may be clinically relevant, because the incidence of dermatitis, particularly hand eczema, is higher where water supplies contain a high mineral content; [100] i.e., elevated ions in tap water could interfere with barrier recovery in individuals with a damaged skin barrier (e.g., patients with atopic dermatitis). Finally, in contrast to the inverse regulation of lamellar body secretion, changes in the calcium gradient directly regulate mRNA levels of corneocyte-specific proteins. Such upregulation of protein synthesis, leading to optimal differentiation, contributes to basal barrier function, which, itself, regulates the integrity of the calcium gradient [63] (Fig. 9-10).

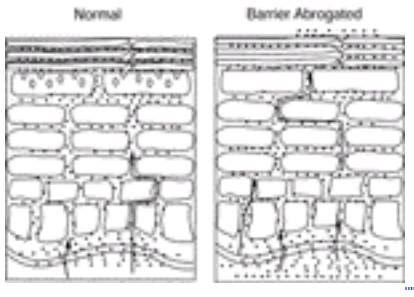

FIGURE 9-9 Changes in calcium gradient after barrier disruption and during repair regulate lamellar body secretion.

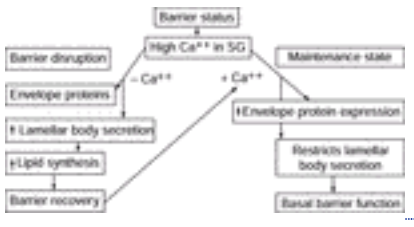

FIGURE 9-10 Barrier-impaired changes in calcium gradient regulates epidermal terminal differentiation—the unifying hypothesis.

Cytokine Signaling and Disease Pathogenesis

Whereas the epidermis generates a large number of biologic response modifiers (BRM), [101] the cytokines IL-1a and IL-1ß appear to be among the few that are present in the SC under basal conditions. [102] In response to all forms of acute barrier disruption, the preformed pool of IL-1a is released, independent of new cytokine formation. [103] In addition, a rapid increase occurs in the mRNA levels and protein content of several downstream cytokines. [99] Likewise, with sustained barrier disruption, as in essential fatty acid deficiency and in a variety of chronic dermatoses, such as psoriasis and atopic dermatitis, both the mRNA and protein content of several cytokines are increased. [104]

Changes in cytokine expression represent part of the physiologic response to barrier disruption. IL-1a, tumor necrosis factor (TNF)-a, and several other epidermis-derived cytokines are potent mitogens, [101] and both IL-1a and TNF-a regulate lipid synthesis in extracutaneous tissues. Moreover, barrier recovery is delayed in IL-1/TNF receptor knockout mice; conversely, exogenous IL-1a and TNF- a enhance barrier recovery. [8] Hence, it appears that these cytokine responses are homeostatic; that is, they signal metabolic responses leading to barrier recovery. Activation of IL-1a and TNF-a (primary cytokinesis) clearly result in a cytokine cascade that can initiate or sustain inflammation. [103] Yet occlusion with a vapor-impermeable membrane does not block the increase in either mRNA or protein expression for most cytokines (except amphiregulin and nerve growth factor), [105] after acute barrier abrogations. [103], [104] Hence, cytokines, via a downstream cascade, operate as physiologic (homeostatic) and pathophysiologic signals. (Fig. 9-11 and Fig. 9-12).

FIGURE 9-11 Parallel signaling mechanisms regulate epidermal homeostasis, but simultaneously may induce disease.

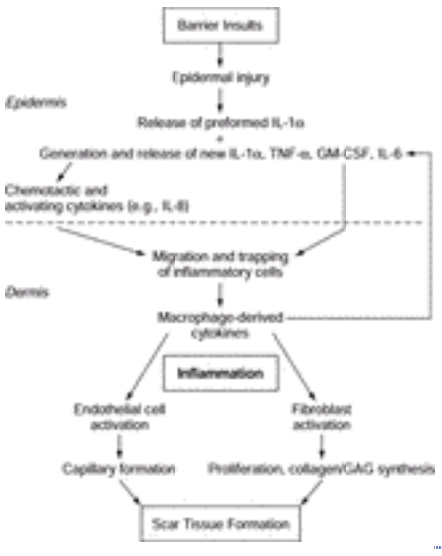

FIGURE 9-12 Physiologic and pathophysiologic consequences of barrier disruption. Related downstream mechanisms mediate homeostatic (repair) and pathologic sequences in the skin. The cytokine cascade, resulting from barrier perturbation, can lead to inflammation, as well as to hypertrophic scar and keloids.

Pertinently, barrier disruption is followed by increased migration of mitotically active Langerhans cells into the epidermis. [106] This view represents an *outside ? inside* concept, as opposed to the dominant *inside ? outside* view, of the pathogenesis of inflammatory skin diseases (Fig. 9-12). [107] In reality, the “outside–inside” paradigm is not new; rather, it provides an explanation for the isomorphic (Koebner) phenomenon. When downstream activation is sustained and excessive, it can explain several important dermatoses, such as chronic plaque-type psoriasis, hypertrophic scars/keloids, and a variety of eczemas (Fig. 9-12). Finally, the cytokine cascade, initiated during wound healing, can even lead to fibrosis and endothelial cell proliferation, resulting in hypertrophic scars and keloids (Fig. 9-14). [107]

FIGURE 9-14 Additional factors that alter barrier homeostasis further amplify cytokine cascade and disease expression.

As noted above, these observations provide an explanation for the pathogenesis of a wide variety of common skin diseases, such as irritant contact dermatitis, psoriasis, and atopic dermatitis, which typically are associated with abnormal barrier function. In Table 9-6, skin diseases are classified as (1) diseases in which a *primary barrier abnormality* exists, that is, under basal conditions or in clinically uninvolved skin; (2) *immunologic abnormalities triggered by* epidermal/ *barrier insults*; (3) *disorders sustained* by an *ongoing barrier abnormality,* where occlusion often reverses the pathology; and (4) processes in which a barrier disorder occurs as a result of a *prior immunologic* or *physical disturbance* (true “inside–outside” disorders), where the epidermis is altered secondarily. Examples of disorders with an inside-to-outside pathogen are the delayed barrier abnormalities that follow UVB exposure [108] and X-irradiation [109] (Fig. 9-13).

TABLE 9-6 **Potential Role of Cutaneous Barrier in Pathophysiology of Skin Disorders**

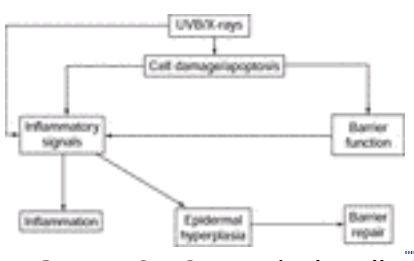

FIGURE 9-13 UVB/X-irradiation lead to cell injury with downstream consequences on inflammatory signaling and barrier function.

All of these disorders, unearthed by the cutaneous treadmill examination, can further aggravate the cytokine cascade, and further increase the risk of disease (Fig. 9-14). Awareness of the potential relationship of all of these disorders to the barrier should lead to more rational deployment of barrier repair therapies (see below) and other preventive strategies. [71]

REQUIREMENTS FOR SPECIFIC LIPIDS VERSUS LIPID MIXTURES FOR BARRIER FUNCTION

Although metabolic studies clearly show that epidermal cholesterol, fatty acid, and ceramide synthesis are modulated by alterations in barrier function, proof that each of these lipids is required for the barrier requires assessment of function after selective deletion of each of these species individually.

By using pharmacologic inhibitors of their rate-limiting enzymes (Fig. 9-8), each of the three key lipids is required for barrier homeostasis, [86] that is, deletion of any leads to abnormal barrier recovery and/or abnormal barrier homeostasis in intact skin.

Having shown that each lipid is required individually, the next issue is whether they function cooperatively; that is, when provided topically, must they be supplied in proportions comparable to those present in SC? Indeed, when cholesterol, free fatty acids, ceramides, or even acylceramides are applied alone, they aggravate rather than improve the barrier. Likewise, any two-component system of the three key stratum corneum lipids is deleterious. In contrast, three-component mixtures of the key lipids, or two-component mixtures of acylceramides and cholesterol, allow normal barrier recovery and can even accelerate barrier recovery at optimized proportions of the three key lipids. [77] The mechanism for the aggravation and amelioration of barrier function by the physiologic lipids is the same: after topical applications they are quickly absorbed into the nucleated cell layers, [48] and incorporated into nascent lamellar bodies (Fig. 9-15). Whereas incomplete mixtures yield abnormal lamellar body contents and disordered intercellular lamellae, complete mixtures result in normal lamellar bodies and compact extracellular membrane unit structures. [110] In contrast, inert lipids such as petrolatum provide an immediate barrier by addition of hydrophobic material, which remains restricted to the SC. [111] Physiologic lipid mixtures alone, at equimolar or optimal molar ratios, or in concert with traditional inert ingredients, provide forms of topical therapy that can be deployed strategically for appropriate indications. [71]

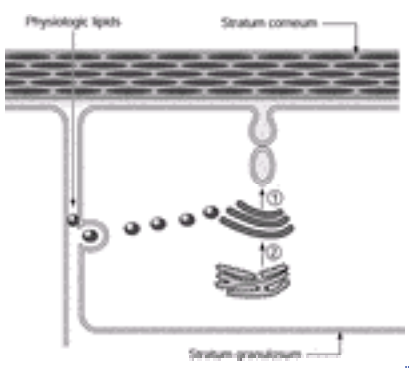

FIGURE 9-15 Topical physiologic lipids traverse the stratum corneum and enter the nucleated cell layers. Within the granular cell, they traffic to sites of the lamellar body formation, bypassing the Golgi apparatus. In the trans-Golgi network they mix with newly synthesized lipids, generated in the endoplasmatic reticulum and delivered to the Golgi apparatus. In contrast, nonphysiologic lipids, such as petrolatum, remain restricted to the stratum corneum.

The Cutaneous Stress Test

Whereas the above studies demonstrate how stress to the barrier can provoke a cytokine-initiated pathogenesis cascade, the cutaneous stress test can be employed to unmask clinically important skin pathology, analogous to stress tests of any organ system. Table 9-6 lists examples of pathology, revealed by assessment of changes in the kinetics of barrier recovery, after the imposition of acute stress to the barrier, which are inapparent under basal conditions.

REFERENCES

1. Leveque JL et al: Are corneocytes elastic? *Dermatologica* **176**:65, 1988

2. Jokura Y et al: Molecular analysis of elastic properties of the stratum corneum by solid-state ^{13}C-nuclear magnetic resonance spectroscopy. *J Invest Dermatol* **104**:806, 1995

3. Engelke M et al: Effects of xerosis and ageing on epidermal proliferation and differentiation. *Br J Dermatol* **137**:219, 1997

4. Denda M et al: Low humidity stimulates epidermal DNA synthesis and amplifies the hyperproliferative response to barrier disruption: Implication for seasonal exacerbations of inflammatory dermatoses. *J Invest Dermatol* **111**:873, 1998

5. Sato J et al: Water content and thickness of the stratum corneum contribute to skin surface morphology. *Arch Dermatol Res* **292**:412, 2000

6. Scheuplein RJ, Blank IH: Permeability of the skin. *Physiol Rev* **51**:702, 1971

7. Elias PM: Epidermal lipids, barrier function, and desquamation. *J Invest Dermatol* **80**(suppl):44s, 1983

8. Jensen JM et al: Roles for tumor necrosis factor receptor p55 and sphingomyelinase in repairing the cutaneous permeability barrier. *J Clin Invest* **104**:1761, 1999

9. Schmuth M et al: Permeability barrier disorder in Niemann-Pick disease: Sphingomyelin-ceramide processing required for normal barrier homeostasis. *J Invest Dermatol* **115**:459, 2000

10. Hara J et al: High-expression of sphingomyelin deacylase is an important determinant of ceramide deficiency leading to barrier disruption in atopic dermatitis. *J Invest Dermatol* **115**:406, 2000

11. Fluhr JW et al: Generation of free fatty acids from phospholipids regulates stratum corneum acidification and integrity. *J Invest Dermatol*

117:44, 2001

12. Elias PM, Menon GK: Structural and lipid biochemical correlates of the epidermal permeability barrier. *Adv Lipid Res* **24**:1, 1991

13. Elias PM, Feingold KR: Lipids and the epidermal water barrier: Metabolism, regulation, and pathophysiology. *Semin Dermatol* **11**:176, 1992

14. Elias PM, Feingold KR: Does the tail wag the dog? Role of the barrier in the pathogenesis of inflammatory dermatoses and therapeutic implications. *Arch Dermatol* **137**:1079, 2001

15. Thiele JJ: Oxidative targets in the stratum corneum. A new basis for antioxidative strategies. *Skin Pharmacol Appl Skin Physiol* **1**(14 suppl):87, 2001

16. Thiele JJ et al: The antioxidant network of the stratum corneum. *Curr Probl Dermatol* **29**:26, 2001

17. Traber MG, Sies H: Vitamin E in humans: Demand and delivery. *Annu Rev Nutr* **16**:321, 1996

18. Thiele JJV: Depletion of human stratum corneum vitamin E: An early and sensitive in vivo marker of UV induced photo-oxidation. *J Invest Dermatol* **110**:756, 1998

19. Thiele JJ et al: In vivo exposure to ozone depletes vitamins C and E and induces lipid peroxidation in epidermal layers of murine skin. *Free Radic Biol Med* **23**:385, 1997

20. Weber SU et al: Vitamin C, uric acid, and glutathione gradients in murine stratum corneum and their susceptibility to ozone exposure. *J Invest Dermatol* **113**:1128, 1999

21. Schallreuter KU: Successful treatment of oxidative stress in vitiligo. *Skin Pharmacol Appl Skin Physiol* **12**:132, 1999

22. Schallreuter KU et al: In vivo and in vitro evidence for hydrogen peroxide (H_2O_2) accumulation in the epidermis of patients with vitiligo and its successful removal by a UVB-activated pseudocatalase. *J Investig Dermatol Symp Proc* **4**:91, 1999

23. Rhie G et al: Aging- and photoaging-dependent changes of enzymic and nonenzymic antioxidants in the epidermis and dermis of human skin in vivo. *J Invest Dermatol* **117**:1212, 2001

24. Fuchs J et al: Impairment of enzymic and nonenzymic antioxidants in skin by UVB irradiation. *J Invest Dermatol* **93**:769, 1989

25. Pelle E et al: Protection against endogenous and UVB-induced oxidative damage in stratum corneum lipids by an antioxidant-containing cosmetic formulation. *Photodermatol Photoimmunol Photomed* **15**:115, 1999

26. Bibel DJ et al: Antimicrobial activity of stratum corneum lipids from normal and essential fatty acid-deficient mice. *J Invest Dermatol* **92**:632, 1989

27. Ohman H, Vahlquist A: In vivo studies concerning a pH gradient in human stratum corneum and upper epidermis. *Acta Derm Venereol* **74**:375, 1994

28. Patterson MJ, Galloway SD, Nimmo MA: Variations in regional sweat composition in normal human males. *Exp Physiol* **85**:869, 2000

29. Kearney JN et al: Correlations between human skin bacteria and skin lipids. *Br J Dermatol* **110**:593, 1984

30. Baden HP, Pathak MA: The metabolism and function of urocanic acid in skin. *J Invest Dermatol* **48**:11, 1967

31. Reeve VE et al: Topical urocanic acid enhances UV-induced tumour yield and malignancy in the hairless mouse. *Photochem Photobiol* **49**:459, 1989

32. Denda M et al: Exposure to a dry environment enhances epidermal permeability barrier function. *J Invest Dermatol* **111**:858, 1998

33. Behne MJ et al: NHE1 regulates the stratum corneum permeability homeostasis. *J Biol Chem* **277**:47399, 2002

34. Mauro T et al: Barrier recovery is impeded at neutral pH, independent of ionic effects: Implications for extracellular lipid processing. *Arch Dermatol Res* **290**:215, 1998

35. Holleran WM et al: Beta-glucocerebrosidase activity in murine epidermis: Characterization and localization in relation to differentiation. *J Lipid Res* **33**:1201, 1992

36. Egelrud T et al: Proteolytic degradation of desmosomes in plantar stratum corneum leads to cell dissociation in vitro. *Acta Derm Venereol* **68**:93, 1988

37. Korting HC et al: Differences in the skin surface pH and bacterial microflora due to the long-term application of synthetic detergent preparations of pH 5.5 and pH 7.0. Results of a crossover trial in healthy volunteers. *Acta Derm Venereol* **70**:429, 1990

38. Elias PM et al: Membrane alterations during cornification of mammalian squamous epithelia: A freeze-fracture, tracer, and thin-section study. *Anat Rec* **189**:577, 1977

39. Pilgram GS et al: Cryo-electron diffraction as a tool to study local variations in the lipid organization of human stratum corneum. *J Microsc* **189**:71, 1998

40. Sheu HM et al: Human skin surface lipid film: An ultrastructural study and interaction with corneocytes and intercellular lipid lamellae of the stratum corneum. *Br J Dermatol* **140**:385, 1999

41. Pilgram GS et al: Electron diffraction provides new information on human stratum corneum lipid organization studied in relation to depth and temperature. *J Invest Dermatol* **113**:403, 1999

42. Fartasch M et al: Structural relationship between epidermal lipid lamellae, lamellar bodies, and desmosomes in human epidermis: An ultrastructural study. *Br J Dermatol* **128**:1, 1993

43. Van Hal DA et al: Structure of fully hydrated human stratum corneum: A freeze-fracture electron microscopy study. *J Invest Dermatol* **106**:89, 1996

44. Grubauer G et al: Lipid content and lipid type as determinants of the epidermal permeability barrier. *J Lipid Res* **30**:89, 1989

45. Lampe MA et al: Human stratum corneum lipids: Characterization and regional variations. *J Lipid Res* **24**:120, 1983

46. Grubauer G et al: Relationship of epidermal lipogenesis to cutaneous barrier function. *J Lipid Res* **28**:746, 1987

47. Ahn SK et al: Functional and structural changes of the epidermal barrier induced by various types of insults in hairless mice. *Arch Dermatol Res* **293**:308, 2001

48. Man MM et al: Optimization of physiological lipid mixtures for barrier repair. *J Invest Dermatol* **106**:1096, 1996

49. Mao-Qiang M et al: Extracellular processing of phospholipids is required for permeability barrier homeostasis. *J Lipid Res* **36**:1925, 1995

50. Murata Y et al: Abnormal expression of sphingomyelin acylase in atopic dermatitis: An etiologic factor for ceramide deficiency? *J Invest Dermatol* **106**:1242, 1996

51. Fartasch M, Diepgen TL: The barrier function in atopic dry skin. Disturbance of membrane-coating granule exocytosis and formation of epidermal lipids? *Acta Derm Venereol Suppl (Stockh)* **176**:26, 1992

52. Di Nardo A et al: Ceramide and cholesterol composition of the skin of patients with atopic dermatitis. *Acta Derm Venereol* **78**:27, 1998

53. Rees J et al: Contact sensitivity to dinitrochlorobenzene is impaired in atopic subjects. Controversy revisited. *Arch Dermatol* **126**:1173, 1990

54. Lammintausta K et al: Patch test reactions in atopic patients. *Contact Dermatitis* **26**:234, 1992

55. Bos JD et al: Immune dysregulation in atopic eczema. *Arch Dermatol* **128**:1509, 1992

56. Feldmann RJ, Maibach HI: Regional variation in percutaneous penetration of ^{14}C cortisol in man. *J Invest Dermatol* **48**:181, 1967

57. Shaw JE et al: Testing of controlled-release transdermal dosage forms. Product development and clinical trials. *Arch Dermatol* **123**:1548, 1987

58. Berardesca E et al: Effects of water temperature on surfactant-induced skin irritation. *Contact Dermatitis* **32**:83, 1995

59. Odland GF, Holbrook K: The lamellar granules of epidermis. *Curr Probl Dermatol* **9**:29, 1981

60. Rassner U et al: Coordinate assembly of lipids and enzyme proteins into epidermal lamellar bodies. *Tissue Cell* **31**:489, 1999

61. Menon GK et al: Lamellar body secretory response to barrier disruption. *J Invest Dermatol* **98**:279, 1992

62. Landmann L: The epidermal permeability barrier. *Anat Embryol (Berl)* **178**:1, 1988

63. Mao-Qiang M et al: Calcium and potassium inhibit barrier recovery after disruption, independent of the type of insult in hairless mice. *Exp Dermatol* **6**:36, 1997

64. Wertz PW et al: Sphingolipids of the stratum corneum and lamellar granules of fetal rat epidermis. *J Invest Dermatol* **83**:193, 1984

65. Grayson S et al: Lamellar body-enriched fractions from neonatal mice: Preparative techniques and partial characterization. *J Invest Dermatol* **85**:289, 1985

66. Elias PM et al: Stratum corneum lipids in disorders of cornification. Steroid sulfatase and cholesterol sulfate in normal desquamation and the pathogenesis of recessive X-linked ichthyosis. *J Clin Invest* **74**:1414, 1984

67. Freinkel RK, Traczyk TN: Acid hydrolases of the epidermis: Subcellular localization and relationship to cornification. *J Invest Dermatol* **80**:441, 1983

68. Watkinson A: Stratum corneum thiol protease (SCTP): A novel cysteine protease of late epidermal differentiation. *Arch Dermatol Res* **291**:260, 1999

69. Ekholm IE et al: Stratum corneum tryptic enzyme in normal epidermis: A missing link in the desquamation process? *J Invest Dermatol* **114**:56, 2000

70. Simon M et al: Refined characterization of corneodesmosin proteolysis during terminal differentiation of human epidermis and its relationship to desquamation. *J Biol Chem* **276**:20292, 2001

71. Elias PM, Feingold KR: Coordinate regulation of epidermal differentiation and barrier homeostasis. *Skin Pharmacol Appl Skin Physiol* **1** (14 suppl):28, 2001

72. Holleran WM et al: Permeability barrier requirements regulate epidermal beta-glucocerebrosidase. *J Lipid Res* **35**:905, 1994

73. Holleran WM et al: Consequences of beta-glucocerebrosidase deficiency in epidermis. Ultrastructure and permeability barrier alterations in Gaucher disease. *J Clin Invest* **93**:1756, 1994

74. Takagi Y et al: Beta-glucocerebrosidase activity in mammalian stratum corneum. *J Lipid Res* **40**:861, 1999

75. Wertz PW et al: Comparison of lipids from epidermal and palatal stratum corneum. *J Invest Dermatol* **98**:375, 1992

76. Chang F et al: Covalently bound lipids in keratinizing epithelia. *Biochim Biophys Acta* **1150**:98, 1993

77. Mao-Qiang M et al: Secretory phospholipase A_2 activity is required for permeability barrier homeostasis. *J Invest Dermatol* **106**:57, 1996

78. Uchida Y et al: Vitamin C stimulates sphingolipid production and markers of barrier formation in submerged human keratinocyte cultures. *J Invest Dermatol* **117**:1307, 2001

79. Zettersten E et al: Recessive X-linked ichthyosis: Role of cholesterol-sulfate accumulation in the barrier abnormality. *J Invest Dermatol*

111:784, 1998

80. Hou SY et al: Membrane structures in normal and essential fatty acid-deficient stratum corneum: Characterization by ruthenium tetroxide staining and x-ray diffraction. *J Invest Dermatol* **96**:215, 1991

81. Madison KC et al: Presence of intact intercellular lipid lamellae in the upper layers of the stratum corneum. *J Invest Dermatol* **88**:714, 1987

82. Menon GK, Elias PM: Morphologic basis for a pore-pathway in mammalian stratum corneum. *Skin Pharmacol* **10**:235, 1997

83. Swartzendruber DC et al: Evidence that the corneocyte has a chemically bound lipid envelope. *J Invest Dermatol* **88**:709, 1987

84. Behne M et al: Omega-hydroxyceramides are required for corneocyte lipid envelope (CLE) formation and normal epidermal permeability barrier function. *J Invest Dermatol* **114**:185, 2000

85. Ziboh VA, Chapkin RS: Metabolism and function of skin lipids. *Prog Lipid Res* **27**:81, 1988

86. Feingold KR: The regulation and role of epidermal lipid synthesis. *Adv Lipid Res* **24**:57, 1991

87. Feingold KR et al: De novo sterologenesis in intact primates. *J Lab Clin Med* **100**:405, 1982

88. Nicolaides N: Skin lipids: Their biochemical uniqueness. *Science* **186**:19, 1974

89. Monger DJ et al: Localization of sites of lipid biosynthesis in mammalian epidermis. *J Lipid Res* **29**:603, 1988

90. Williams ML et al: Free sterol metabolism and low density lipoprotein receptor expression as differentiation markers of cultured human keratinocytes. *J Cell Physiol* **132**:428, 1987

91. Ghadially R et al: The aged epidermal permeability barrier. Structural, functional, and lipid biochemical abnormalities in humans and a senescent murine model. *J Clin Invest* **95**:2281, 1995

92. Holleran WM et al: Regulation of epidermal sphingolipid synthesis by permeability barrier function. *J Lipid Res* **32**:1151, 1991

93. Proksch E et al: Barrier function regulates epidermal DNA synthesis. *J Clin Invest* **87**:1668, 1991

94. Feingold KR et al: Effect of essential fatty acid deficiency on cutaneous sterol synthesis. *J Invest Dermatol* **87**:588, 1986

95. Proksch E et al: Epidermal HMG CoA reductase activity in essential fatty acid deficiency: Barrier requirements rather than eicosanoid generation regulate cholesterol synthesis. *J Invest Dermatol* **99**:216, 1992

96. Harris IR et al: Expression and regulation of mRNA for putative fatty acid transport related proteins and fatty acyl CoA synthase in murine epidermis and cultured human keratinocytes. *J Invest Dermatol* **111**:722, 1998

97. Harris IR et al: Parallel regulation of sterol regulatory element binding protein-2 and the enzymes of cholesterol and fatty acid synthesis but not ceramide synthesis in cultured human keratinocytes and murine epidermis. *J Lipid Res* **39**:412, 1998

98. Lee SH et al: Calcium and potassium are important regulators of barrier homeostasis in murine epidermis. *J Clin Invest* **89**:530, 1992

99. Menon GK et al: Selective obliteration of the epidermal calcium gradient leads to enhanced lamellar body secretion. *J Invest Dermatol* **102**:789, 1994

100. Warren R et al: The influence of hard water (calcium) and surfactants on irritant contact dermatitis. *Contact Dermatitis* **35**:337, 1996

101. Kupper TS: Immune and inflammatory processes in cutaneous tissues. Mechanisms and speculations. *J Clin Invest* **86**:1783, 1990

102. Hauser C et al: Interleukin 1 is present in normal human epidermis. *J Immunol* **136**:3317, 1986

103. Wood LC et al: Barrier disruption stimulates interleukin-1 alpha expression and release from a pre-formed pool in murine epidermis. *J Invest Dermatol* **106**:397, 1996

104. Wood LC et al: Occlusion lowers cytokine mRNA levels in essential fatty acid-deficient and normal mouse epidermis, but not after acute barrier disruption. *J Invest Dermatol* **103**:834, 1994

105. Liou A et al: Amphiregulin and nerve growth factor expression are regulated by barrier status in murine epidermis. *J Invest Dermatol* **108**:73, 1997

106. Proksch E, Brasch J: Influence of epidermal permeability barrier disruption and Langerhans' cell density on allergic contact dermatitis. *Acta Derm Venereol* **77**:102, 1997

107. Elias PM et al: Signaling networks in barrier homeostasis. The mystery widens. *Arch Dermatol* **132**:1505, 1996

108. Haratake A et al: UVB-induced alterations in permeability barrier function: Roles for epidermal hyperproliferation and thymocyte-mediated response. *J Invest Dermatol* **108**:769, 1997

109. Schmuth M et al: Permeability barrier function of skin exposed to ionizing radiation. *Arch Dermatol* **137**:1019, 2001

110. Mao-Qiang M et al: Fatty acids are required for epidermal permeability barrier function. *J Clin Invest* **92**:791, 1993

111. Ghadially R et al: Effects of petrolatum on stratum corneum structure and function. *J Am Acad Dermatol* **26**:387, 1992

T>

Chapter 10

C. Wenger

Thermoregulation

BODY TEMPERATURES AND HEAT TRANSFER IN THE BODY
BALANCE BETWEEN HEAT PRODUCTION AND HEAT LOSS
Metabolic Rate and Sites of Heat Production at Rest
Heat Exchange with the Environment
HEAT DISSIPATION
Sympathetic Control of Skin Circulation
Sweating
THERMOREGULATORY CONTROL
Integration of Thermal Information
Peripheral Modification of Skin Vascular and Sweat Gland Responses
THERMOREGULATORY RESPONSES DURING EXERCISE
RESPONSE TO COLD
FACTORS THAT ALTER TOLERANCE TO HEAT AND COLD

REFERENCES

Lying at The views, opinions, and findings in this chapter are those of the author and should not be construed as an official Department of the Army position, policy, or decision unless so designated by other official documentation. Approved for public release, distribution is unlimited. the boundary between the body and the environment, the skin plays an important role in thermoregulation and serves as both a source of thermal information and an effector organ for controlling heat loss from the body. Living tissue is directly injured if it is heated to temperatures higher than about 45°C (113°F), [1] the level at which heating the skin causes pain, or if it is cooled so that ice crystals form in the cells. Because of its exposed location, the skin is particularly vulnerable to injury by extremes of temperature in the immediate environment, and, in addition to its thermoregulatory responses, local vasodilator responses are elicited when tissue temperature rises toward 40°C (104°F) or falls toward 10°C (50°F); these help to protect the skin against extremes of temperature.

Human beings, like other homeotherms, spend substantial physiologic resources maintaining their internal body temperatures near 37°C (98.6°F) (Fig. 10-1). What biologic advantage is gained by regulating body temperature within such a narrow band? Temperature is a fundamental physicochemical variable that profoundly affects many biologic processes, both through configurational changes affecting the biologic activities of protein molecules—e.g., enzymes, receptors, and membrane channels—and through a general effect on chemical reaction rates. Most reaction rates vary approximately as an exponential function of temperature (*T*) within the physiologic range, and raising *T* by 10°C (18°F) increases the reaction rate by a factor of 2 to 3. A familiar clinical example of the effect of body temperature on metabolic processes is the rule that each 1°C (1.8°F) of fever increases a patient's fluid and calorie needs 13 percent. [2]

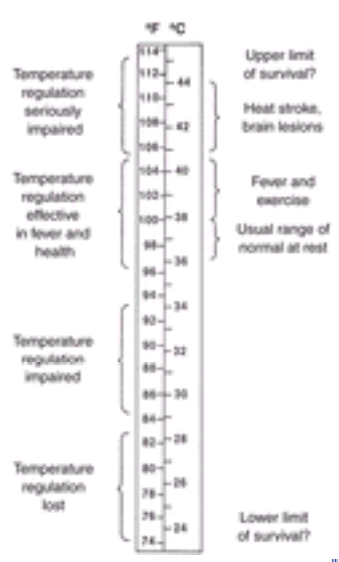

FIGURE 10-1 Ranges of rectal temperature found in healthy persons, patients with fever, and persons with impairment or failure of thermoregulation. (*From Wenger CB, Hardy JD: Temperature regulation and exposure to heat and cold, in Therapeutic Heat and Cold, edited by JF Lehman. Baltimore, Williams & Wilkins, 1990, pp 150–178, with permission. Modified from DuBois.* [2])

BODY TEMPERATURES AND HEAT TRANSFER IN THE BODY

The body is divided into a warm internal *core* and an outer *shell* [3] (Fig. 10-2). It is the temperature of the core, which includes the vital organs in the head and trunk, that is regulated within narrow limits. Although normal body temperature is conventionally taken to be 37°C (98.6°F), individual variation and such factors [4], [5] as time of day, phase of the menstrual cycle, [6], [7] and acclimatization to heat account for differences of up to about 1°C (1.8°F) in core temperatures of healthy subjects at rest. In addition, core temperature may increase several degrees with heavy exercise or fever (Fig. 10-1). Temperature-sensitive neurons and nerve endings at various core sites, including the spinal cord and especially the brain, [8], [9] provide the thermoregulatory system with information about the level of core temperature. Shell

temperature by contrast is not tightly regulated and is strongly influenced by the environment. Nevertheless, thermoregulatory responses greatly affect the temperature of the shell and especially its outermost layer, the skin. The shell's thickness depends on the environment and the need to conserve body heat. In a warm subject, the shell may be less than 1 cm thick; but in a subject conserving heat in a cold environment, it may extend several centimeters below the skin.

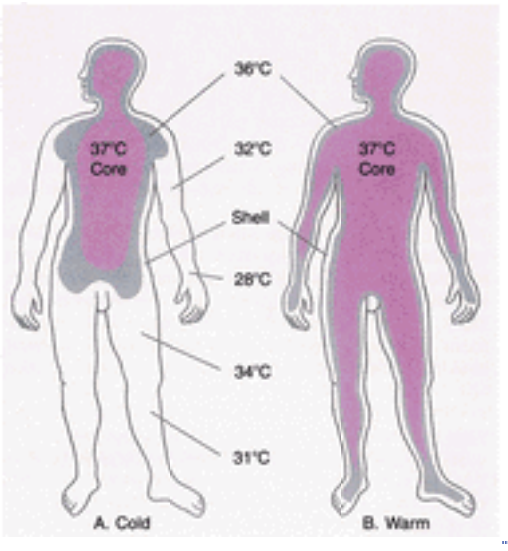

FIGURE 10-2 Distribution of temperatures within the body and division of the body into core and shell during exposure to (*A*) cold and (*B*) warm environments. The temperatures of the surface and the thickness of the shell depend on the environmental temperature, so that the shell is thicker in the cold and thinner in the heat. (*From Wenger CB: The regulation of body temperature, in Medical Physiology, edited by RA Rhoades, GA Tanner. Boston, Little, Brown, 1995, pp 587–613, with permission. Based on Aschoff and Wever*. [3])

The body loses heat only from tissues in contact with the environment, chiefly the skin. Since heat flows from warmer regions to cooler regions, the greatest heat flows within the body are those from major sites of heat production to the rest of the body and from core to skin. Heat is transported within the body by two means: *conduction* through the tissues; and *convection* by the blood, the process by which flowing blood carries heat from warmer tissues to cooler tissues. Heat flow by conduction is proportional to the change of temperature with distance in the direction of heat flow, and the thermal conductivity of the tissues. As Table 10-1 shows, tissues are rather poor heat conductors. Heat flow by convection depends on the rate of blood flow and the temperature difference between the tissue and the blood supplying the tissue.

	Conductivity, kcal/(s·m·°C)	Rate of Heat Flow	
		kcal/h	watts
Copper	0.092	33,120	38,474
Epidermis	0.00005	18	21
Dermis	0.00009	32	38
Fat	0.00004	14	17
Muscle	0.00011	40	46
Water	0.00014	51	59
Oak (across grain)	0.00004	14	17
Dry air	0.000006	2.2	2.5
Glass fiber insulation	0.00001	3.6	4.2

* 1 m² in area and 1 cm thick, with a 1°C (1.8°F) temperature difference between the two faces of the slab.

TABLE 10-1 **Thermal Conductivities and Rates of Heat Flow through Slabs of Different Materials***

Since the shell lies between the core and the environment, all heat leaving the body via the skin must first pass through the shell. Thus, the shell insulates the core from the environment. In a cool subject, skin blood flow is low, so that core-to-skin heat transfer is dominated by conduction; the subcutaneous fat layer adds to the insulation value of the shell, because it increases the thickness of the shell and has a conductivity only about 0.4 times that of dermis or muscle (Table 10-1). In a warm subject, however, the shell is relatively thin and provides little insulation. Furthermore, a warm subject's skin blood flow is high, so that heat flow from the core to the skin is dominated by convection. In these circumstances, the subcutaneous fat layer—which affects conduction but not convection—has little effect on heat flow.

Skin temperature is important both in heat exchange and in thermoregulatory control. Skin temperature is affected by thermoregulatory responses such as skin blood flow and sweat secretion and by heat exchange with underlying tissues and the environment. Skin temperature, in turn, is one of the major factors determining heat exchange with the environment. For these reasons, skin temperature provides the thermoregulatory system with important information about the need to conserve or lose body heat. Many bare nerve endings just under the skin are very sensitive to temperature. Depending on the relation of discharge rate to temperature, they are classified as either warm or cold receptors. [8], [10] In addition to their responses when skin temperature is stable, these receptors have transient responses during temperature changes. With heating of the skin, warm receptors respond with a transient burst of activity, while cold receptors respond with a transient suppression; the reverse happens with cooling. Because skin temperature is not usually uniform over the body surface, a mean skin temperature ($\overline{T}_{sk}$) is frequently calculated from temperature measurements at several sites. $\overline{T}_{sk}$ is used both to summarize the input from skin temperature into the thermoregulatory system and, along with core temperature, to calculate a mean body temperature to represent the body's thermal state.

BALANCE BETWEEN HEAT PRODUCTION AND HEAT LOSS

Although the body exchanges some energy with the environment in the form of mechanical work, most is exchanged as heat, by conduction, convection, and radiation; and as latent heat through evaporation or (rarely) condensation of water (

Fig. 10-3). If the sum of energy production and energy gain from the environment does not equal energy loss, the extra heat is “stored” in or lost from the body. This is summarized in the heat balance equation:

FIGURE 10-3 Exchange of energy with the environment. This hiker gains heat from the sun by radiation; he loses heat by conduction to the ground through the soles of his feet, by convection into the air, by radiation to the ground and sky, and by evaporation of water from his skin and respiratory passages. In addition, some of the energy released by his metabolic processes is converted into mechanical work, rather than heat, because he is walking uphill. (*From Wenger CB: The regulation of body temperature, in Medical Physiology, edited by RA Rhoades, GA Tanner. Boston, Little, Brown, 1995, pp. 587–613, with permission.*)

$$M = E + R + C + K + W + S \qquad (10.1)$$

where *M* is metabolic rate; *E* is rate of heat loss by evaporation; *R* and *C* are rates of heat loss by radiation and convection, respectively; *K* is the rate of heat loss by conduction (only to solid objects in practice, as explained later); *W* is rate of energy loss as mechanical work; and *S* is rate of heat storage in the body, [11], [12] which is positive when mean body temperature is increasing.

Metabolic Rate and Sites of Heat Production at Rest

Heat exchange with the environment can be measured by *direct calorimetry* in an insulated chamber specially constructed so that all heat and water vapor leaving the chamber can be captured and measured. From these measurements one can determine the subject's heat loss, which, at steady state, is equal to metabolic rate. More frequently, metabolic rate is estimated *indirect calorimetry* [13] based on measurements of O_2 consumption, because virtually all energy available to the body depends ultimately on reactions that consume O_2. The heat production associated with consumption of 1 L of O_2 varies somewhat with the fuel—carbohydrate, fat, or protein—that is oxidized. For metabolism of a mixed diet, an average value of 20.2 kJ (4.83 kcal) per liter of O_2 is often used. Since the ratio of CO_2 produced to O_2 consumed in the tissues is 1.0 for oxidation of carbohydrate, 0.71 for fat, and 0.80 for protein, the accuracy of indirect calorimetry can be improved by also measuring CO_2 production and either estimating the amount of protein oxidized or calculating it from urinary nitrogen excretion.

Metabolic rate at rest is approximately proportional to body surface area. In a fasting young man it is about 45 W/m^2 (81 W or 70 kcal/h for 1.8 m^2 body surface area, corresponding to an O_2 consumption of about 240 mL/min). At rest, the trunk viscera and brain account for about 70 percent of energy production, even though they comprise only about 36 percent of the body mass (Table 10-2). Even during very mild exercise, however, the muscles are the chief source of metabolic energy production; during heavy exercise, they may account for up to 90 percent (Table 10-2). A healthy but sedentary young man performing moderate exercise may reach a metabolic rate of 600 W; and a trained athlete performing intense exercise, 1400 W or more. The overall mechanical efficiency of exercise varies enormously, depending on the activity; at best, no more than one-quarter of the metabolic energy is converted into mechanical work outside the body, and the remaining three-quarters or more is converted into heat within the body. [14] Since exercising muscles produce so much heat, they may be nearly 1°C (1.8°F) warmer than the core. They warm the blood that perfuses them; this blood, returning to the core, warms the rest of the body.

	Percent of Body Mass	Percent of Heat Production	
		Rest	Exercise
Brain	2	16	1
Trunk viscera	34	56	8
Muscle and skin	56	18	90
Other	8	10	1

SOURCE: Modified from Wenger CB, Hardy JD: Temperature regulation and exposure to heat and cold, in *Therapeutic Heat and Cold*, edited by JF Lehman. Baltimore, Williams & Wilkins, 1990, pp 150–178.

TABLE 10-2 **Relative Masses and Rates of Metabolic Heat Production of Various Body Compartments During Rest and Severe Exercise**

Heat Exchange with the Environment

Radiation, convection, and evaporation are the dominant means of heat exchange with the environment. In humans,

respiration usually accounts for only a minor fraction of total heat exchange and is not predominantly under thermoregulatory control, although hyperthermic subjects may hyperventilate. Humans therefore exchange most heat with the environment through the skin.

Every surface emits energy as electromagnetic radiation with a power output that depends on its area, its temperature, and its *emissivity* (identical to its *absorptivity*), a number between 0 and 1 that depends on the nature of the surface and the wavelength of the emitted (or absorbed) radiation. Such *thermal radiation* has a characteristic distribution of power as a function of wavelength, which depends on the temperature of the surface. At ordinary tissue and environmental temperatures, virtually all of the emitted energy is in the infrared part of the spectrum, in a region where most surfaces have emissivities near 1, and thus both emit and absorb at nearly the theoretical maximum efficiency. However, bodies like the sun, which are hot enough to glow, emit large amounts of radiation in the near infrared and visible range, in which light surfaces have lower absorptivities than dark ones. Radiative heat exchange (*R*) between the skin and the environment is proportional to the difference between the fourth powers of the surfaces' absolute temperatures, but if the difference between $\bar{T}_{sk}$ and the temperature of the radiant environment (T_r) is much smaller than the absolute temperature of the skin, *R* is nearly proportional to ($\bar{T}_{sk} - T_r$). Some parts of the body surface (e.g., inner surfaces of the thighs and arms) exchange heat by radiation with other parts of the body surface, so that heat exchange between the body and the environment is determined by an *effective radiating surface area* (A_r), which is smaller than the actual surface area. A_r depends on the posture, being closest to the actual surface area in a “spread-eagle” posture and least in someone curled up. The relationship of *R* to emissivity, temperature, and A_r can be represented by Eq. (10-2) in Table 10-3.



$$R = h_r \epsilon_{sk} A_r (\bar{T}_{sk} - \bar{T}_r) \quad (10\text{-}2)$$

where h_r is the radiant heat transfer coefficient, 6.43 W/(m^2·°C) at 28°C; and ϵ_{sk} is the emissivity of the skin.

$$C = h_c \cdot A \cdot (\bar{T}_{sk} - T_a) \quad (10\text{-}3)$$

where A is the body surface area, $\bar{T}_{sk}$ and T_a are mean skin and ambient temperatures, and h_c is the convective heat transfer coefficient. h_c includes the effects of all the factors besides temperature and surface area that affect convective heat exchange. For the whole body, the most important of these factors is air movement, and convective heat exchange (and, thus, h_c) varies approximately as the square root of the air speed except when air movement is very slight.

$$E = h_e A(P_{sk} - P_a) \quad (10\text{-}4)$$

where P_{sk} is the water vapor pressure at the skin surface, P_a is the ambient water vapor pressure, and h_e is the evaporative heat transfer coefficient.

$$C = HF_{sk}/(T_c - \bar{T}_{sk}) \quad (10\text{-}5)$$

where C is shell conductance; HF_{sk} = heat loss through the skin, i.e., total heat loss less heat loss through the respiratory tract; and T_c = core temperature.

TABLE 10-3 **Equations Describing Heat Transfer Between the Skin and the Environment and Between Core and Skin**

Convection is transfer of heat due to movement of a fluid, either liquid or gas. In thermal physiology, the fluid is usually air or water in the environment, or blood inside the body, as discussed earlier. Fluids conduct heat in the same way as solids do, and a perfectly still fluid transfers heat only by conduction. Because air and water are not good conductors of heat (Table 10-1), perfectly still air or water is not very effective in heat transfer. Fluids, however, are rarely perfectly still, and even nearly imperceptible movement produces enough convection to have a large effect on heat transfer. Thus, although conduction plays a role in heat transfer by a fluid, convection so dominates the overall heat transfer that we refer to the entire process as *convection*. The conduction term (*K*) in Eq. (10-1) is therefore, in practice, restricted to heat flow between the body and other solid objects and usually represents only a small part of the total heat exchange with the environment. Convective heat exchange between the skin and the environment is proportional to the skin surface area and the difference between skin and ambient air temperatures, as expressed by Eq. (10-3) in Table 10-3. Convective heat exchange depends on air movement; and h_c, the proportionality constant in Eq. (10-3), depends on air speed and on geometric factors that affect heat exchange with moving air.

A gram of water that is converted into vapor at 30°C (86°F) absorbs 2425 J (0.58 kcal), the *latent heat of evaporation,* in the process. In subjects who are not sweating, evaporative water loss is typically about 13 to 15 g/(m^2•h), corresponding to a heat loss of 16 to 18 W for a surface area of 1.8 m^2. About half of this amount is lost through breathing and half as *insensible perspiration,* [10], [13] i.e., evaporation of water that diffuses through the skin. Insensible perspiration occurs independently of the sweat glands and is not under thermoregulatory control. Water loss through these routes, however, is quite small compared to what can be achieved by evaporation of sweat. Evaporative heat loss from the skin is proportional to skin surface area and the difference between the water vapor pressure at the skin surface and in the ambient air, as summarized in Eq. (10-4) in Table 10-3. Since water vapor, like heat, is carried away by moving air, air movement and other factors affect *E* and h_e in just the same way that they affect *C* and h_c. The water vapor pressure at the skin surface depends on the degree of wetness of the skin surface, and thus on the balance between sweating and evaporation; it is equal to the saturation vapor pressure of water at skin temperature if the skin surface is completely wet. The saturation vapor pressure of water increases substantially over the physiological range of skin temperatures: e.g., from 28.3 torr at 28°C (82.4°F) to 44.6 torr at 36°C (96.8°F). Ambient water vapor pressure, which directly affects evaporation from the skin, is proportional to the actual moisture content in the air. Because the skin is warmed by heat from the body, evaporation from the skin is related only indirectly to relative humidity, which is the ratio between the actual moisture content in the air and the maximum moisture content that is possible at the temperature of the air. This is an important distinction since, for example, sweat can easily evaporate from the skin in cool air even if relative humidity is 100 percent.

HEAT DISSIPATION

Heat produced within the body must be delivered to the skin surface to be eliminated. Heat flows through the shell by two parallel modes: physical conduction through the tissues of the shell and convection by blood perfusing the shell. Since

heat flow by each of these parallel modes depends on the temperature difference between core and skin, the power of the shell to transfer heat is expressed as the *conductance* of the shell, and it is calculated by dividing heat flow through the shell by the difference between core and mean skin temperatures, as shown in Eq. (10-5) in Table 10-3. When skin blood flow is minimal [usually at ambient temperatures below about 28°C (82.4°F) in nude resting subjects], the conductance of the shell is determined chiefly by the thickness of the subcutaneous fat layer and is about 6 W/°C in a lean man. Under these conditions a temperature difference between core and skin of 5°C (9°F) will allow a typical resting metabolic heat production of 80 W to be conducted to the skin surface. In a cool environment, $\bar{T}_{sk}$ may be low enough for this to occur easily. However, in a warm environment or, especially, during exercise, shell conductance must increase substantially to allow all the heat produced to be conducted to the skin without at the same time causing core temperature to rise to dangerous or lethal levels. Fortunately, under such circumstances, increases in skin blood flow occur that can raise shell conductance tenfold or more. Thus a crucial thermoregulatory function of skin blood flow is to control the conductance of the shell and the ease by which heat travels from core to skin. A closely related function is to control $\bar{T}_{sk}$: in a person who is not sweating, an increase in skin blood flow tends to bring $\bar{T}_{sk}$ toward T_c, and a decrease allows $\bar{T}_{sk}$ to approach ambient temperature. Since convective and radiative heat exchange (R+C) depend directly on skin temperature [Eqs. (10-2) and (10-3)], the body can control heat exchange with the environment by adjusting skin blood flow. The *thermoneutral* zone [11] is the range of conditions of metabolic rate and environment within which adjustments in skin blood flow by themselves are sufficient to allow the body to maintain heat balance. If the heat stress is so great that increasing R+C through increasing skin blood flow is not enough to maintain heat balance, the body secretes sweat to increase evaporative heat loss. Once sweating begins, skin blood flow continues to increase as the person becomes warmer, but now the tendency of an increase in skin blood flow to warm the skin is approximately balanced by the tendency of an increase in sweating to cool the skin. Therefore, after sweating has begun, further increases in skin blood flow usually cause little change in skin temperature or dry heat exchange (R+C). The increases in skin blood flow that accompany sweating are important to thermoregulation nevertheless, because they deliver to the skin the heat that is being removed by evaporation of sweat, and facilitate evaporation by keeping the skin warm. Skin blood flow and sweating thus work in tandem to dissipate heat that is produced in the body.

Sympathetic Control of Skin Circulation

Blood vessels in human skin are under dual vasomotor control, involving separate nervous signals for vasoconstriction and for vasodilation. [9], [16], [17] Reflex vasoconstriction, occurring in response to cold and also as part of certain nonthermal reflexes such as baroreflexes, is mediated primarily through adrenergic sympathetic fibers distributed widely over most of the skin. [18] Reducing the flow of impulses in these nerve fibers allows the blood vessels to dilate. In the so-called acral regions—lips, ears, nose, and palmar/plantar surfaces of the hands and feet [17], [18]—and in the superficial veins, [17] vasoconstrictor fibers are the predominant vasomotor innervation, and the vasodilation occurring during heat exposure is largely a result of the withdrawal of vasoconstrictor activity. [19] Blood flow in these skin regions is sensitive to small temperature changes in the thermoneutral range and may be responsible for “fine-tuning” heat loss to maintain heat balance in this range.

In most of the skin, the vasodilation occurring during heat exposure depends on sympathetic nervous signals that cause the blood vessels to dilate, and is prevented or reversed by regional nerve block. [20] Since it depends on the action of nervous signals, such vasodilation is sometimes referred to as *active vasodilation*. It occurs in almost all the skin outside the acral regions [19] and also on the dorsal surfaces of the hands [21] and (presumably) feet. In skin areas where active vasodilation occurs, vasoconstrictor activity is minimal at thermoneutral temperatures; as the body is warmed, active vasodilation does not begin until near the onset of sweating. [17], [22] /SUP>Thus reflex control of skin blood flow in these areas is insensitive to small temperature changes within the thermoneutral range. [19] The neurotransmitter [or other vasoactive substance(s)] responsible for active vasodilation in human skin is not known. [18] However, because sweating and vasodilation operate in tandem in the heat, there has been considerable speculation that the mechanism for active vasodilation is somehow linked to the action of sweat glands. [17], [23] Active vasodilation does not occur in the skin of patients with anhidrotic ectodermal dysplasia, [24] even though their vasoconstrictor responses are intact, implying that active vasodilation either is linked to an action of sweat glands or is mediated through nerves that are absent or nonfunctional in anhidrotic ectodermal dysplasia. An early hypothesis, [25] that bradykinin released by sweat glands accounts for active vasodilation, now seems unlikely. [17] The author evaluated thermoregulatory function of a patient with acquired anhidrosis and heat intolerance of 6 months duration who failed to sweat in response to iontophoresis of pilocarpine or injection of acetylcholine (ACh). During 20 min of cycle exercise, sweating was observed only in the popliteal fossae, but forearm blood flow (a widely used index of skin blood flow) increased normally as his core temperature rose to 39°C (102.2°F), even though sensitive dewpoint hygrometry measurements on the same forearm showed no evidence of sweating. Therefore, if active vasodilation does depend on some action of sweat glands, it must be an action that can occur even without sweat secretion.

The finding of nerve endings that contain both vasoactive intestinal peptide (VIP) and ACh near eccrine sweat glands in human skin [26] suggested that active vasodilation may be mediated by release of a vasoactive *cotransmitter* from the cholinergic endings of sudomotor nerves. [27] This notion is supported by a recent study showing that active vasodilation in human skin is blocked by botulinum toxin, a presynaptic inhibitor of ACh release, even though active vasodilation was shown not to be elicited by either a muscarinic or nonmuscarinic action of ACh. [28] However, VIP is unlikely to be the sole mediator of active vasodilation in human skin, because the skin of patients with cystic fibrosis shows normal active vasodilation, even though their sudomotor nerves are deficient in VIP. [29] It may be that control of active vasodilation inludes several branches operating in parallel. For example, some evidence suggests that release of ACh participates in the development of active vasodilation, even though ACh is not necessary to sustain it (see Ref. [30] for a discussion). In addition, nitric oxide appears to contribute to the development of active vasodilation, even though active vasodilation can be elicited when nitric oxide synthesis is blocked. [30], [31]

Sweating

Humans can dissipate large amounts of heat by secretion and evaporation of sweat; when the environment is warmer than the skin—usually

when the environment is hotter than 36°C (96.8°F), evaporation is the only way to lose heat. Humans possess both *apocrine* sweat glands, which have only a limited regional distribution, [32] and *eccrine* sweat glands, which are widely distributed and are by far the more important type in human thermoregulation. Human sweat glands are controlled through postganglionic sympathetic nerves, which release ACh [33] rather than norepinephrine. Functionally active eccrine glands number about 2 to 3 million. [33] Although this number is fixed before the age of 3, [33] the secretory capacity of the individual glands can change, especially with endurance exercise training and heat acclimatization; a fit man well acclimatized to heat can achieve a peak sweating rate greater than 2.5 L/h. [34], [35] (Such rates cannot be maintained, however, and the maximum daily sweat output is probably about 15 L. [36] Eccrine sweat is essentially a dilute electrolyte solution, though apocrine sweat also contains fatty material. Sweat glands reabsorb Na^+ from the duct by active transport, so that $[Na^+]$ of sweat ranges from less than 5 to 60 meq/L. [37]

THERMOREGULATORY CONTROL

Human thermoregulation includes two distinct subsystems: behavioral thermoregulation and physiologic thermoregulation. Behavioral thermoregulation, through the use of shelter, space heating, and clothing, enables humans to live in the most extreme climates on earth, but it does not provide fine control of body heat balance. Physiologic thermoregulation, on the other hand, is capable of fairly precise adjustments of heat balance but is effective only within a relatively narrow range of environmental temperatures.

Both behavioral and physiologic thermoregulation depend on sensory information about body temperatures. Behavioral thermoregulation is governed by thermal sensation and comfort, and depends largely on conscious actions that reduce discomfort. Warmth and cold on the skin are felt as either comfortable or uncomfortable, depending on whether they decrease or increase the physiologic strain. [38] Thus, a shower temperature that feels pleasant after strenuous exercise may be uncomfortably cold on a chilly morning. Because of the relation between discomfort and physiologic strain, behavioral thermoregulation, by reducing discomfort, also minimizes the physiologic burden imposed by a stressful thermal environment. Thermal sensation and comfort respond to changes in the environment much more quickly than do either core temperature or physiologic thermoregulatory responses. [39], [40] Behavioral responses thus appear to anticipate changes in the body's thermal state, presumably reducing the need for frequent small behavioral adjustments.

Physiologic thermoregulation operates through graded control of heat-production and heat-loss responses. Familiar nonliving control systems, such as heating and air-conditioning systems, usually operate at only two levels, because they act by turning a device on or off. In contrast, most physiologic control systems produce a response that is graded according to the disturbance in the regulated variable. In many physiologic systems, including those that control the heat-dissipating responses, changes in the effector responses are proportional to displacements of the regulated variable from some threshold value, [10] and such control systems are called *proportional control* systems (Fig. 10-4). Each response in Fig. 10-4 has a core-temperature threshold, a temperature at which the response starts to increase, and these thresholds depend on mean skin temperature. Thus at any given skin temperature, the change in each response is proportional to the change in core temperature; increasing the skin temperature lowers the threshold level of core temperature and increases the response at any given core temperature.



FIGURE 10-4 The relations of back (scapular) sweat rate (*left*) and forearm blood flow (*right*) to core temperature and mean skin temperature (T_{sk}). In the experiments shown, core temperature was increased by exercise. (*Left panel drawn from data of Sawka MN et al: Heat exchange during upper- and lower-body exercise. J Appl Physiol 57:1050, 1984. Right panel modified from Wenger CB, et al: Forearm blood flow during body temperature transients produced by leg exercise. J Appl Physiol 38:58, 1975, with permission.*)

Integration of Thermal Information

Temperature receptors in the body core and the skin transmit information about their temperatures through afferent nerves to the brainstem, and especially the hypothalamus, where much of the integration of temperature information occurs. [41] The sensitivity of the thermoregulatory responses to core temperature allows the thermoregulatory system to adjust heat production and heat loss to resist disturbances in core temperature. Their sensitivity to skin temperature allows the system to respond appropriately to mild heat or cold exposure with little change in body core temperature, so that environmentally induced changes in body heat content occur almost entirely in the peripheral tissues. For example, the skin temperature of someone who enters a hot environment rises and may elicit sweating even if there is no change in core temperature. On the other hand, an increase in heat production due to exercise elicits the appropriate heat-dissipating responses through a rise in core temperature. Although temperature receptors in other core sites, including the spinal cord and medulla, participate in the control of thermoregulatory responses, [42] the core temperature receptors involved in thermoregulatory control are concentrated especially in the hypothalamus; [42] temperature changes of only a few tenths of 1°C in the anterior preoptic area of the hypothalamus elicit changes in the thermoregulatory effector responses of experimental mammals.

We may represent the central thermoregulatory integrator (Fig. 10-5) as generating thermal command signals for the control of the effector responses. These signals are based on the information about core and skin temperatures that the integrator receives, and on the thermoregulatory *set point,* [4] a reference point which determines the thresholds of all the thermoregulatory responses. We may think of the set

point as the setting of the body's “thermostat,” and changes in the set point are accompanied by corresponding changes in core temperature at rest. The set point is elevated during fever and lowered slightly by heat acclimatization, as discussed below; it changes in a cyclical fashion with time of day and phase of the menstrual cycle. [4], [6], [7] The set point reaches a minimum in the early morning, several hours before awaking, and a maximum—which is 0.5 to 1°C (0.9 to 1.8°F) higher—in the late afternoon or evening. During the menstrual cycle the set point is at its lowest point just before ovulation; over the next few days it rises 0.5 to 1°C (0.9 to 1.8°F) and remains elevated for most of the luteal phase.

FIGURE 10-5 Control of human thermoregulatory responses. The signs by the inputs to T_{set} indicate that pyrogens raise the set point, and heat acclimation lowers it. Core temperature, T_c, is compared with the set point, T_{set}, to generate an error signal, which is integrated with thermal input from the skin to produce effector signals for the thermoregulatory responses. (*From Wenger CB: The regulation of body temperature, in Medical Physiology, edited by RA Rhoades, GA Tanner. Boston, Little, Brown, 1995, pp 587–613, with permission.*)

Peripheral Modification of Skin Vascular and Sweat Gland Responses

Skin temperature affects heat loss responses not only through the reflex actions described above but also through direct actions on the effectors themselves. Local temperature acts on skin blood vessels in two ways. First, local cooling potentiates the constriction of blood vessels in response to nervous signals and vasoconstrictor substances. [18] Second, in skin regions where active vasodilation occurs, local heating dilates the blood vessels (and local cooling constricts them) through a direct action that is independent of nervous signals. [42], [44] This direct effect is especially strong at skin temperatures above 35°C (95°F); [44] and when the skin is warmer than the blood, increased blood flow helps to cool the skin and protect it from heat injury. The effects of local temperature on sweat glands parallel those on blood vessels, so that local heating magnifies (and local cooling reduces) the sweating response to reflex stimulation or to ACh, [23] and intense local heating provokes sweating directly, even in sympathectomized skin. [45] During prolonged (several hours) heat exposure with high sweat output, sweat rates gradually diminish and the sweat glands' response to locally applied cholinergic drugs is reduced also. The reduction of sweat gland responsiveness is sometimes called sweat gland “fatigue.” Wetting the skin makes the stratum corneum swell, mechanically obstructing the sweat duct and causing a reduction in sweat secretion, an effect called *hidromeiosis*. [46] The glands' responsiveness can be at least partly restored if the skin is allowed to dry (e.g., by increasing air movement [47], but prolonged sweating also causes histologic changes in the sweat glands. [48]

Thermoregulatory responses may be affected by other inputs besides body temperatures and factors that affect the thermoregulatory set point. Nonthermal factors may produce a burst of sweating at the beginning of exercise, [49], [50] and the involvement of sweating and skin blood flow in emotional responses is quite familiar. During exercise and heat stress, skin blood flow is more affected than sweating by nonthermal factors because of its involvement in reflexes that function to maintain cardiac output, blood pressure, and tissue O_2 delivery.

THERMOREGULATORY RESPONSES DURING EXERCISE

At the start of exercise, metabolic heat production increases rapidly, but there is little change in heat loss initially, so heat is stored in the body and core temperature rises. The increase in core temperature, in turn, elicits heat-loss responses, but core temperature continues to rise until heat loss has increased enough to match heat production, so that heat balance is restored and core temperature and the heat-loss responses reach new steady-state levels. The rise in core temperature that elicits heat-dissipating responses sufficient to reestablish thermal balance during exercise is an example of a *load error,* [10] which occurs when any proportional control system resists the effect of some imposed disturbance or “load.” Although the elevated T_c of exercise superficially resembles the elevated T_c of fever, there are some crucial differences. First, although heat production may increase substantially (through shivering) at the beginning of a fever, it does not need to stay high to maintain the fever but, in fact, returns nearly to prefebrile levels once the fever is established; during exercise, however, an increase in heat production not only causes the elevation in core temperature but is necessary to sustain it. Second, while core temperature is rising during fever, rate of heat loss is, if anything, lower than before the fever began; during exercise, however, the heat-dissipating responses and the rate of heat loss start to increase early and continue increasing as core temperature rises.

RESPONSE TO COLD

The body's first response to maintain core temperature in the cold is to minimize heat loss by constricting blood vessels in the shell, especially in the skin. Constriction of arterioles reduces heat transfer to the skin by reducing blood flow, and constriction of superficial limb veins further improves heat conservation by diverting venous blood to the deep limb veins, which lie close to the major arteries of the limbs. (This diversion is made possible by the many penetrating veins that connect the superficial and deep veins.) In the deep veins, cool venous blood returning to the core can take up heat from the warm blood in the adjacent deep limb arteries. Thus, some of the heat contained in the arterial blood as it enters the limbs takes a “short circuit” back to the core, and when the arterial blood reaches the skin, it is already cooler than the core and so loses less heat to the skin than it otherwise would. This mechanism can cool the blood in the radial artery of a cool but comfortable subject to as low as 30°C (86°F) by the time it reaches the wrist. [51] Although furred or hairy animals can increase the thickness of their coats by *piloerection,* this response makes a negligible contribution to heat conservation in humans, although it persists as “gooseflesh.” If the heat-conserving responses

are insufficient to reestablish heat balance, metabolic heat production increases—in adults, almost entirely in skeletal muscles, as a result first of increased tone, and later of frank shivering. Shivering may increase metabolism at rest by more than fourfold acutely, but only about half that amount can be sustained after several hours.

In addition, as the skin is cooled below about 15°C (59°F), its blood flow begins to increase somewhat, a response called *cold-induced vasodilation* (*CIVD*). CIVD is elicited most easily in comfortably warm subjects and is most pronounced in regions rich in arteriovenous anastomoses—i.e., in the hands and feet. The mechanism is uncertain but may involve a direct inhibitory effect of cold on contraction of vascular smooth muscle or on neuromuscular transmission. Although this response increases heat loss from the core somewhat, it keeps the extremities warmer and more functional, and probably protects them from cold injury.

FACTORS THAT ALTER TOLERANCE TO HEAT AND COLD

Prolonged or repeated heat stress, especially when combined with exercise, elicits *acclimatization* to heat, an ensemble of physiologic changes that reduce the physiologic strain that heat stress produces. The classic signs of heat acclimatization are reductions in the levels of core [as much as 1°C (1.8°F)] and skin [1°C (1.8°F) or more] temperatures and heart rate (as much as 30 to 40 beats per minute) reached during exercise in the heat, and increases in sweat production. These changes approach their full development within a week. Heat acclimatization produces other changes [52] as well, including an improved ability to sustain high rates of sweat production; an aldosterone-mediated reduction of sweat sodium concentration (to levels as low as 5 mEq/L), which minimizes salt depletion; an increase in the fraction of sweat secreted on the limbs; and perhaps changes that help protect against heat illness in other ways. The effect of heat acclimatization on performance can be quite dramatic, so that acclimatized subjects can easily complete exercise in the heat that previously was difficult or impossible (see Ref. [53]). The mechanisms that produce these changes are not fully understood but include a modest [˜0.4°C (0.72°F)] lowering of the thermoregulatory set point (reducing the thresholds for sweating and cutaneous vasodilation), increased sensitivity of the sweat glands to cholinergic stimulation, [54] , [55] and a decrease in the sweat glands' susceptibility to hidromeiosis and fatigue. Heat acclimatization disappears in a few weeks if not maintained by repeated heat exposure.

In contrast to heat acclimatization, the changes that occur with cold acclimatization in humans are quite variable and appear to depend on the nature of the acclimatizing cold exposure; they confer only a modest thermoregulatory advantage. For these reasons, it was long questioned whether humans acclimatize to cold. An important adaptive response to cold—although not strictly an example of acclimatization—is enhancement of CIVD. CIVD is rudimentary in hands or feet unaccustomed to cold exposure, but after repeated cold exposure, it begins earlier during cold exposure, produces higher levels of blood flow, and takes on a rhythmical pattern of alternating vasodilation and vasoconstriction, sometimes called the *Lewis hunting response*. This response is often well developed in workers whose hands are exposed to cold, such as fishermen who work with nets in cold water.

Several acute and chronic skin disorders impair thermoregulation through effects on sweating and skin blood flow. Ichthyosis and anhidrotic ectodermal dysplasia are often cited as examples of skin disorders that impair sweating and can profoundly affect thermoregulation in the heat. Since active vasodilation is impaired or absent in anhidrotic ectodermal dysplasia, artificially wetting the skin can only partially correct the thermoregulatory deficit during exercise (when large amounts of body heat need to be carried to the skin) and is likely to be most effective in an environment that is dry enough that evaporation can produce a cool skin. Heat rash (miliaria rubra) also impairs sweating and can reduce exercise tolerance, and its effects may persist after the appearance of the skin has returned to normal. [56] Sunburn also impairs sweating [57] and, in addition, impairs vasoconstriction and heat conservation during cold exposure. [58]

REFERENCES

1. Moritz AR, Henriques FC Jr: Studies of thermal injury: II. The relative importance of time and surface temperature in the causation of cutaneous b*Am J Patho* **23**:695, 1947

2. Du Bois EF: *Fever and the Regulation of Body Temperature* Springfield, IL, CC Thomas, 1948

3. Aschoff J, Wever R: Kern und Schale im Wärmehaushalt des Menschen *Naturwissenschaften* **45**:477, 1958

4. Gisolfi CV, Wenger CB: Temperature regulation during exercise: Old concepts, new ide *Exerc Sport Sci Rev* **12**:339, 1984

5. Mackowiak PA et al: A critical appraisal of 98.6°F, the upper limit of normal body temperature, and other legacies of Carl Reinhold August Wunde *JAMA* **268**:1578, 1992

6. Hessemer V, Brück K: Influence of menstrual cycle on shivering, skin blood flow, and sweating responses measured at ni *J Appl Physiol* **59**:1902, 1985

7. Kolka MA: Temperature regulation in wome *Med Exerc Nutr Health* **1**:201, 1992

8. Hensel H: Neural processes in thermoregulatio *Physiol Rev* **53**:948, 1973

9. Sawka MN, Wenger CB: Physiological responses to acute exercise-heat stress, *Human Performance Physiology and Environmental Medicine at Terrestrial Extreme* edited by KB Pandolf, MN Sawka, RR Gonzalez. Indianapolis, IN, Benchmark Press,1988, pp 97–151

10. Hardy JD: Physiology of temperature regulatio *Physiol Rev* **41**:521, 1961

11. Bligh J, Johnson KG: Glossary of terms for thermal physiolog *J Appl Physiol* **35**:941, 1973

12. Gagge AP, Hardly JD, Rapp GM: Proposed standard system of symbols for thermal physiolo *J Appl Physiol* **27**:439, 1969

13. Ferrannini E: Equations and assumptions of indirect calorimetry: some special problems *Energy Metabolism: Tissue Determinants aand cellular Carollaries* edited by JM Kinney, HN Tucker. New York, Raven, 1992, pp 1–17

14. Åstrand P-O, Rodahl K: *Textbook of Work Physiology*, New York, McGraw-Hill, 1977, pp 523–576

15. Kuno Y: *Human Perspiration* Springfield, IL, CC Thomas, 1956, pp 3–41

16. Fox RH, Edholm OG: Nervous control of the cutaneous circulatio *Br Med Bul* **19**:110, 1963

17. Rowell LB: Cardiovascular adjustments to thermal stress, *Handbook of Physiology. Sec 2: The Cardiovascular System. Vol 3: Peripheral Circulation and Organ Blood Fl* edited by JT Shepherd, FM Abboud. Bethesda, MD, American Physiological Society, 1983, pp 967–1023

18. Johnson JM, Proppe DW: Cardiovascular adjustments to heat stress, *Handbook of Physiology. Sec 4: Environmental Physiolog* edited by MJ Fregly, CM Blatteis. New York, Oxford University Press for the American Physiological Society, 1996, pp 215–243

19. Roddie IC: Circulation to skin and adipose tissue, i *Handbook of Physiology. Sec 2: The Cardiovascular System. Vol 3: Peripheral Circulation and Organ Blood Fl* edited by JT Shepherd, FM Abboud. Bethesda, MD, American Physiological Society, 1983, pp 285–317

20. Rowell LB: Active neurogenic vasodilation in man, *vasodilation*, edited by PM Vanheutte, I Leusen. New York, Raven, 1981, pp 1–17

21. Johnson JM et al: Skin of the dorsal aspect of human hands and fingers possesses an active vasodilator syst *J Appl Physio* **78**:948, 1995

22. Love AHG, Shanks RG: The relationship between the onset of sweating and vasodilation in the forearm during body hea *J Physiol (Lond)* **162**:121, 1962

23. Sawka MN et al: Thermoregulatory responses to acute exercise-heat stress and heat acclimatio *Handbook of Physiology. Sec 4: Environmental Physiolog* edited by MJ Fregly, CM Blatteis. New York, Oxford University Press for the American Physiological Society, 1996, pp 157–185

24. Brengelmann GL et al: Absence of active cutaneous vasodilation associated with congenital absence of sweat glands in hum *Am J Physio* **240**:H571, 1981

25. Fox RH, Hilton SM: Bradykinin formulation in human skin as a factor in heat vasodilati *Physiol (Lond)* **142**:219, 1958

26. Vaalasti A et al: Vasoactive intestinal polypeptide (VIP)-like immunoreactivity in the nerves of human axillary sweat gl *J Invest Dermato* **85**:246, 1985

27. Hökfelt T, Johansson O, Ljungdahl Å et al: Peptidergic neurone *Nature* **284**:515, 1980

28. Kellogg DL Jr et al: Cutaneous active vasodilation in humans is mediated by cholinergic nerve cotransmiss *Circ Res* **77**:1222, 1995

29. Savage MV et al: Cystic fibrosis, vasoactive intestinal polypeptide, and active cutaneous vasodila *J Appl Physiol* **69**:2149, 1990

30. Shastry S, Minson CT, Wilson SA, et al: Effects of atropine and L-NAME on cutaneous blood flow during body heating in hum *J Appl. Physiol* **88**:467, 2000

31. Kellogg DL, Jr., Crandall CG, Liu Y et al: Nitric oxide and cutaneous active vasodilation during heat stress in hum *J Appl. Physiol* **85**:824, 1998

32. Hurley HJ, Shelley WB: The anatomy of the apocrine sweat gland, *The Human Apocrine Sweat Gland in Health and Diseas* edited by HJ Hurley, WB Shelley. Springfield, IL, CC Thomas, 1960, pp 6–26

33. Kuno Y: *Human Perspiration* Springfield, IL, CC Thomas, 1956, pp 42–97

34. Eichna LW et al: The upper limits of environmental heat and humidity tolerated by acclimatized men working in hot environm *J Indust Hyg Toxico* **27**:59, 1945

35. Ladell WSS: Thermal sweating *Br Med Bul* **3**:175, 1945

36. Kuno Y: *Human Perspiration* Springfield, IL, CC Thomas, 1956, pp 251–276

37. Robinson S, Robinson AH: Chemical composition of swe *Physiol Rev* **34**:202, 1954

38. Cabanac M: Physiological role of pleasur *Science* **173**:1103, 1971

39. Hardy JD: Thermal comfort: skin temperature and physiological thermoregulation *Physiological and Behavioral Temperature Regulatio* edited by JD Hardy, AP Gagge, JAJ Stolwijk. Springfield, IL, CC Thomas, 1970, pp 856–873

40. Cunningham DJ et al: Comparative thermoregulatory responses of resting men and wom *J Appl Physio* **45**:908, 1978

41. Boulant JA: Hypothalamic neurons regulating body temperature, *Handbook of Physiology. Sec 4: Environmental Physiolog* edited by MJ Fregly, CM Blatteis. New York, Oxford University Press for the American Physiological Society; 1996, pp 105–126

42. Jessen C: Interaction of body temperatures in control of thermoregulatory effector mechanisms *Handbook of Physiology. Sec 4: Environmental Physiolog* edited by MJ Fregly, CM Blatteis. New York, Oxford University Press for the American Physiological Society, 1996, pp 127–138

43. Crockford GW et al: Thermal vasomotor responses in human skin mediated by local mechanis *J Physiol (Lond)* **161**:10, 1962

44. Wenger CB et al: Effect of nerve block on response of forearm blood flow to local temperat *J Appl Physio* **61**:227, 1986

45. Kuno Y: *Human Perspiration* Springfield, IL, CC Thomas, 1956, pp 277–317

46. Brown WK, Sargent F II: Hidromeiosis *Arch Environ Healt* **11**:442, 1965

47. Nadel ER, Stolwijk JAJ: Effect of skin wettedness on sweat gland respons *J Appl Physio* **35**:689, 1973

48. Dobson RL et al: Some histochemical observations on the human eccrine sweat glands: III. The effect of profuse swea *J Invest Dermato* **31**:147, 1958

49. Stolwijk JAJ, Nadel ER: Thermoregulation during positive and negative work exerci *Fed Proc* **32**:1607, 1973

50. Van Beaumont W, Bullard RW: Sweating: its rapid response to muscular wor *Science* **141**:643, 1963

51. Bazett HC et al: Temperature changes in blood flowing in arteries and veins in m *J Appl Physio* **1**:3, 1948

52. Wenger CB: Human heat acclimatization, i *Human Performance Physiology and Environmental Medicine at Terrestrial Extreme* edited by KB Pandolf, MN Sawka, RR Gonzalez. Indianapolis, IN, Benchmark Press, 1988, pp 153–197

53. Pandolf KB, Young AJ: Environmental extremes and endurance performance, *Endurance in Sport* edited by RJ Shephard, PO Åstrand. Oxford, England, Blackwell, 1992, pp 270–282

54. Collins KJ et al: The local training effect of secretory activity on the response of eccrine sweat glar *J Physiol (Lond)* **184**:203, 1966

55. Kraning KK et al: A non-invasive dose-response assay of sweat gland function and its application in studies of gender comparison, heat acclimation and anticholinergic potency, in *Thermal Physiology 1989* edited by JB Mercer. Amsterdam, Elsevier, 1989, pp 301–307

56. Pandolf KB et al: Persistence of impaired heat tolerance from artificially induced miliaria rut *Am J Physio* **239**:R226, 1980

57. Pandolf KB et al: Human thermoregulatory responses during cold-water immersion after artificially induced sunb *Am J Physio* **262**:R617, 1992

58. Pandolf KB, Gange RW, Latzka WA, et al: Human thermoregulatory responses during cold-water immersion after artificially induced sunt *Am J Physio* **262**:R617, 1992

T>

Chapter 11

Ruth Halaban Daniel Hebert David Fisher

Biology of Melanocytes

PIGMENT CELLS
MELANOCYTES DURING DEVELOPMENT
Wnt/ß-Catenin
Receptor Tyrosine Kinases
Cadherins and Migration to the Skin
LOCALIZATION AND FUNCTION OF MELANOCYTES
Melanocytes in the Skin
Melanocytes in the Hair
Melanocytes in the Ear
Melanocytes in the Eye
MELANIN SYNTHESIS
THE BIOSYNTHESIS, DISTRIBUTION AND TRANSPORT OF MELANOSOMES
Endoplasmic Reticulum Modification and Transport to the Golgi
ER Retention and Production of Antigenic Peptides
Transport from Golgi to Melanosomes
Melanosome Maturation
Melanosome Transport to Dendritic Tips
Melanosome Transfer to Keratinocytes
PIGMENTATION CONTROL BY MELANOCORTINS AND THE MELANOCORTIN RECEPTOR
The Melanocortins and Their Receptors
Regulation and Function of Melanocortin Receptor Activity
TANNING IN RESPONSE TO UV LIGHT
Immediate Pigment Darkening
The Stable Response: Indirect Effects of Ultraviolet on Melanocytes
Direct Effect of Ultraviolet B on Melanocytes
REGULATORS OF MELANOCYTE-SPECIFIC GENE EXPRESSION
Transcriptional Regulation of Mitf Expression
Posttranslational Regulation of Mitf
Mitf and Inherited Human Pigmentation Disorders
MELANOCYTE GROWTH FACTORS AND SIGNAL TRANSDUCTION
Signal Transduction: Immediate Events
Signal Transduction: The RB/E2F Pathway
E2F Transcription Factors
FUTURE PERSPECTIVES

REFERENCES

PIGMENT CELLS

Melanocytes are cells dedicated to the production of melanin (Fig. 11-1). They exert significant biological effects ranging from behavioral consequences of cosmetic importance to the most devastating skin cancer, melanoma. Moreover, additional functions of melanocytes may impact on discrete organ systems, such as hearing and vision, thereby broadening the clinical importance of understanding these cells. Significant progress has been made in unraveling the developmental and mechanistic features of melanocyte biology. Much of this information is derived from molecular studies aimed at probing the basis of inherited conditions and disease syndromes in humans.

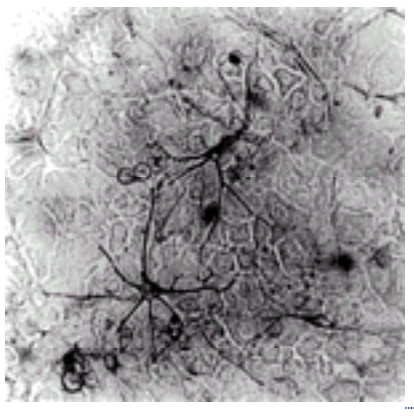

FIGURE 11-1 Melanocytes cultured on keratinocytes. Light micrograph showing dendritic melanocytes from a Black donor loaded with melanin and adjacent pigmented keratinocytes due to transfer of melanosomes. (*From Halaban R et al: bFGF as an autocrine growth factor for human melanomas.* Oncogene Res *3:177–186, 1988, with permission.*)

Melanin determines skin, hair, and eye pigmentation. The process of melanin production and transfer is highly regulated at the cellular, subcellular, biochemical and genetic levels. The natural display of multiple human skin types, and aberrant pigmentation due to genetic disorders or malignant transformation are a testimony to the complexity of pigmentation. Mutations in more than 90 distinct genes that cause pigmentation defects in animals and insects have led to the identification of crucial molecules that have direct or indirect roles in pigment cell function. Consequently,

melanocytes have become a model system for molecular, genetic and developmental processes.

The major events that govern melanocyte distribution and function include:

1. Migration of early melanocyte progenitors, i.e., melanoblasts, from the neural crest, proliferation and localization in the skin and other tissues;
2. Activation of specific cell surface receptors that transmit environmental signals for survival, proliferation and pigmentation;
3. The expression of key enzymes and structural proteins responsible for melanin synthesis;
4. Maintenance of a proper ionic environment within the secretory system conducive to the maturation and activity of key enzymes, as well as to melanosomal organization; and
5. Transport of melanosomes to dendrites and their transfer to epidermal keratinocytes.

Elimination or dysfunction of any of these events by genetic or environmental processes leads to hypo- or hyperpigmentation (see Chap. 90). This chapter summarizes the main aspects of each of these processes. Further information is available from review articles cited for each topic.

MELANOCYTES DURING DEVELOPMENT

Melanocyte progenitors originate from the neural crest, a transient population of cells localized in the dorsal portion of the closing neural tube. The neural crest cells are pluripotent, capable of giving rise to other lineages including glial cells, neurons, and smooth muscle, as well as bony and cartilaginous components of the head. The neural crest cells destined to become melanocytes migrate, proliferate and differentiate along a dorsolateral pathway, and populate the skin, inner ear, choroid, and part of the iris (Fig. 11-2). They reach their destination via a specific route, guided by discrete diffusable signals produced by the immediate neighboring cells that enhance or suppress their proliferation and/or differentiation. The early signals that induce formation of the neural crest include members of the Wnt, fibroblast growth factor (FGF), and bone morphogenetic protein (BMP) families, as well as Noelin-1 (reviewed in Ref. [1]). Some of these signals also help establish the melanocytic lineage by acting as negative or positive activators of melanocyte-specific gene expression. For example, BMP signaling suppresses, [2] whereas Wnt enhances [3] the induction of melanoblasts (early melanocyte progenitors). The positive diffusable factors activate specific cell surface receptors, initiating intracellular signaling cascades that impact on lineage specific gene expression. Deficiencies in these signaling molecules and/or the intracellular cascades that they trigger result in dramatic depigmentation of skin, hair and other sites. The positive signals emanating from the Wnt/ß-catenin, the receptor tyrosine kinases Kit and Met, the G-protein linked multiple-membrane spanning receptor endothelin B, and the cell surface adhesion molecules cadherins are described below.

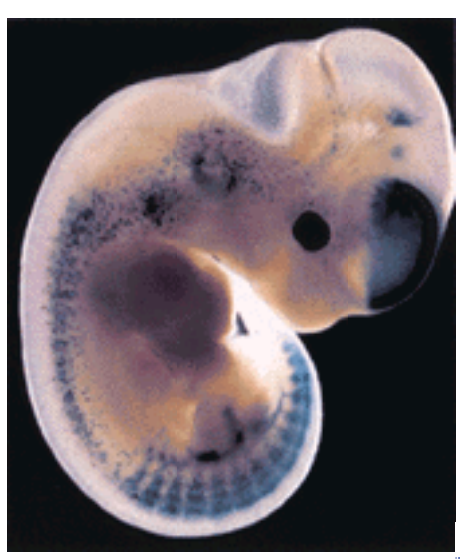

FIGURE 11-2 Migration of melanoblast precursors. Migrating melanoblasts in an E11.5 transgenic mouse embryo expressing the Lac Z reporter gene under the control of the melanocyte-specific Dct (DOPAchrome tautomerase) promoter. The melanoblasts are visualized by staining for ß-galactosidase. (*Courtesy of Ian Jackson and Alison Wilkie, Medical Research Council, Human Genetics Unit, Western General Hospital, Edinburgh, Scotland.*)

Wnt/ß-Catenin

Wnts are secreted glycoproteins that play a critical role in melanocyte determination decisions by activating the Frizzled receptor family. Signaling by Wnt has been genetically implicated in melanocyte development by the severe impact on pigmentation of genetically engineered mice in which Wnt 1 and 3a were eliminated (reviewed in Ref. [1]). Wnt controls ß-catenin via its influence on the Ser/Thr kinase activity of the key enzyme *glycogen synthase kinase 3ß* (GSK3ß). In the absence of Wnt, the active GSK3ß, in protein complex with APC (adenomatous polyposis coli) and axin, phosphorylates ß-catenin on serine residues, facilitating its ubiquitination and proteasome-mediated degradation (Fig. 11-3). Activation of the Frizzled receptor by Wnt, triggers the binding of two inhibitors to GSK3ß, Disheveled (Dvl) and Frat 1, suppressing its kinase activity. As a consequence, the levels of ß-catenin increase, allowing its translocation to the nucleus, which facilitates the activation of genes by Tcf/Lef transcription factors (T-cell transcription factor/lymphoid enhancer factor) (reviewed in Ref. [4]). Lef/ß-catenin complexes then upregulate transcription of specific genes. A key target for Tcf /Lef/ß-catenin in early melanocyte precursors is *MITF*, encoding a critical regulator of melanocyte specific genes. Mitf thus participates in lineage determination for melanocytes, in agreement with the consequences of mutations that cause Mitf disruption in multiple species including man (reviewed in Refs. [5] and [6]) (Mitf is discussed below under " Regulators of

Melanocyte Specific Gene Expression”).

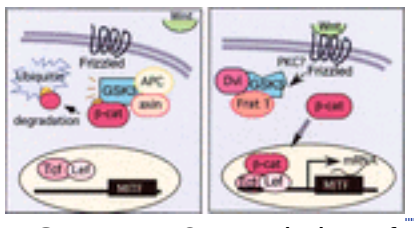

FIGURE 11-3 Regulation of Mitf expression by Wnt signaling. Frizzled (Fzl) is a G-protein–linked seven-membrane–spanning domain receptor. [115] It controls ß-catenin by modulating GSK3ß kinase activity. In the absence of Wnt, GSK3ß is in a tetrameric complex with APC (adenomatous polyposis coli), axin and ß-catenin. This complex destabilizes ß-catenin by enhancing its phosphorylation and proteasome-mediated degradation (*left*). Activation of Frizzled by Wnt (*right*) results in activation of Disheveled (Dvl), which recruits the inhibitory Frat 1 to the protein complex, inhibiting GSK3ß kinase activity and blocking ß-catenin phosphorylation. Consequently, ß-catenin accumulates and translocates to the nucleus where it initiates transcription of Tcf/Lef target genes involved in early development.

Receptor Tyrosine Kinases

STEEL/ *C*-KIT The cytokine Steel factor (also known as mast/stem cell factor, M/SCF), and its receptor, *c*-kit, are essential for the development of early melanocyte precursors. Heterozygous loss-of-function mutations in the cytokine or its receptor result in failure of melanocytes to populate broad cutaneous zones, often involving the abdomen or other surfaces. The ventral surface is frequently affected by mutations that disable neural crest cell migration because it represents the area of greatest distance for the dorsal-to-ventral migration of melanocytic precursors (Fig. 11-2). Homozygous loss of Steel Factor or *c*-kit results in complete absence of melanocytes (as well as defects in hematopoietic and germ-cell lineages). Mutations in these genes cause human piebaldism, a condition manifested as broad unpigmented patches reflecting failure of melanocytes to reach the skin (see Chap. 90 and published review [7]). The *c*-kit receptor is a tyrosine kinase belonging to the PDGF (platelet-derived growth factor) receptor family. Its activation results in stimulation of multiple intracellular signaling cascades, which modulate survival and proliferation (see below, “ Melanocyte Growth Factors and Signal Transduction ”). Although receptor tyrosine kinases in this family are known to signal to the phosphatidylinositol-3-kinase (PI3K) survival pathway, selective disruption of PI3K signaling does not affect pigmentation, suggesting that the survival effects of *c*-kit stimulation are mediated by different intracellular targets (reviewed in Ref. [8]). The presence of Steel factor in keratinocytes contributes to melanocyte localization in the epidermis. First, Steel is expressed by human keratinocytes and activation mutations in *c*-kit further stimulate the melanocytes in the skin and are the cause of hyperpigmentation in mastocytosis. [7], [9] Second, in mouse skin, melanocytes are restricted to the hair follicle, except for the ears and tail, controlled by local production of Steel factor. [10] Transgenic mice engineered to express Steel in epidermal keratinocytes, possess increased number of melanocytes in the epidermis, resulting in “humanized” skin. [11]
HGF/MET Activation of Met by its ligand the hepatocyte growth factor (HGF, also known as Scatter factor, SF) is also required for melanocyte viability and proliferation during development. Targeted ablation of the Met gene in mice (Met -/-) caused a complete loss of melanoblasts, beginning at late stages of neural crest migration (embryonic stage 12). [12] In contrast, overexpression of HGF in various tissues (mtHGF transgenic mice), or specifically in keratinocytes (K14-HGF transgenic mice), enhanced ectopic localization of melanoblasts, and increased the melanocyte population in the dermis and other sites of adult tissues, or only in the dermis, respectively. [12], [13] Although Met inactivation has not yet been identified in any human inherited depigmentation syndromes, this receptor system is a good candidate to explore in certain conditions for which no mutations in established target genes have been discovered.
ENDOTHELINS/ENDOTHELIN RECEPTOR B Another cytokine-receptor pair that is implicated in melanocyte development is the endothelin and endothelin receptor family. Endothelins are growth factors (originally identified in endothelial cells) whose mutation produces significant neural crest defects, including melanocyte deficiency. There are three endothelin proteins (ET1, ET2, and ET3) and two receptors (EdnrA and EdnrB). ET3 binds to EdnrB and mutations in either ET3 or EdnrB produce substantial melanocyte loss in humans and mice. ET3 is unlikely to be the only endothelin involved in melanocyte development because the depigmented phenotype of mice null for ET3 is not as severe as in mice with null EdnrB mutation, and even the latter are not always completely devoid of pigment (reviewed in Ref. [14]). Altogether, it is apparent that melanocyte viability, division, and possibly migration, as well as expression of differentiated functions, are severely affected during embryogenesis by inactivating mutations in several receptors or their cognate ligands. The requirement for multiple receptor activities cannot be explained by marked differences in intracellular signaling cascades activated by each receptor. More likely, each receptor/ligand system is critical at specific developmental stages, determined by the timing of receptor expression at the cell surface and the presence of the respective ligand in the adjacent tissue. For example, in vitro studies demonstrate partial rescue of mouse neural crest-derived melanocyte precursors deficient in *c*-kit when grown in the presence of ET3. [15] Judging by the developmental stage at which melanoblasts express a specific receptor, or disappear when a pathway is ablated, it is likely that the Wnt/ß-catenin signaling pathway is the first to be activated, followed by *kit,* ET3/endothelin B, and then HGF/Met. It is also possible that simultaneous activation of multiple receptors is required as the melanocyte precursors become more and more differentiated in order to achieve the levels and duration of intracellular signal intermediates and activation of transcription factors essential for proliferation and differentiation (see below, in “ Melanocyte Growth Factors and Signal Transduction ”).

Cadherins and Migration to the Skin

The cadherins are calcium-dependent surface receptors that mediate cell adhesion, homing, and invasion into different layers. The expression of cadherins dynamically changes as neural crest cells emerge from the neural tube. Experiments with chicken embryos show that overexpression of the neuroepithelial cadherin (*N*-cadherin) or a crest cadherin (cad7) suppresses migration of melanocyte precursors from the neural crest, causing their accumulation within the neural tube.

[16] Similarly, quantitative studies in mouse embryos reveal that early migrating melanocyte precursors do not express E-cadherin or P-cadherin during their transit into the dermis [17] (Fig. 11-4). However, E-cadherin expression is temporarily upregulated by 200-fold just prior to entering the epidermis, only to be suppressed again as migration continues out of the epidermis into hair follicles. At this transition point, P-cadherin is increased. These patterns of cadherin expression match those of surrounding cells in the same microenvironment. [17], [18]

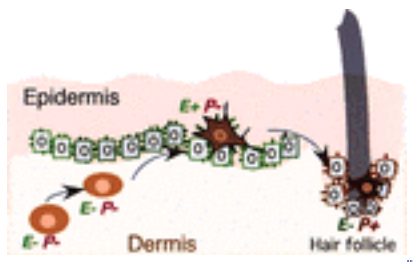

FIGURE 11-4 Expression of cadherins in melanocytes and their early precursor. The migrating cadherin–nonexpressing melanoblasts (round orange cells marked E–, P–), start expressing E-cadherin (green bars on dendritic brown cells) as they enter the epidermis and settle among E-cadherin–positive keratinocytes. E-cadherin is suppressed and P-cadherin is upregulated as the melanocytes enter the hair follicle (brown bars on dark brown dendritic cells) settling among similarly P-cadherin–expressing follicular cells. (*Adapted from Nakagawa S and Takeichi* [16] *and Nishimura et al.* [17])

Interestingly, in the “humanized” transgenic mouse skin model in which Steel factor is overexpressed in epidermal keratinocytes, the retained epidermal melanocytes continue to express high levels of E-cadherin. [17] In the K-14-HGF transgenic mice in which melanocytes were restricted to the dermis, there was also downregulation of E-cadherin expression. [13] This is consistent with a role for these homotypic interactions in epidermal homing and invasion. The cadherins are also potential regulators of invasion or metastatic behavior in melanocytic neoplasms. [19]

LOCALIZATION AND FUNCTION OF MELANOCYTES

Melanocytes exist in various tissues in the body. They are localized in the skin at the dermal-epidermal interface, in the hair matrix, the eye in the retinal pigment epithelium and uveal tract, the ear in the stria vascularis and the vestibular region of the inner ear, the leptomeninges and mucous membranes. Although the most visible role of melanocytes is in the production of melanin in the skin for protection against harmful solar radiation, they have important functions in other tissues that may not relate to pigment production.

Melanocytes in the Skin

Melanocytes are located in the epidermal basal layer and project their dendrites into the epidermis where they transfer melanosomes to keratinocytes (Fig. 11-5A). These dendritic contacts produce interfaces with multiple keratinocytes, thought to number approximately 36 per melanocyte, giving rise to the “epidermal melanin unit.” [20] Melanocytes transfer melanin, packaged within the membrane-bound organelles termed melanosomes, through these dendritic contacts to adjacent keratinocytes, which, in turn, contain the majority of cutaneous pigment (Fig. 11-5B). As keratinocytes mature and differentiate, their most superficial derivatives in the stratum corneum slough off, thus requiring continued synthesis and intercellular transport of melanin for maintaining pigmentation.

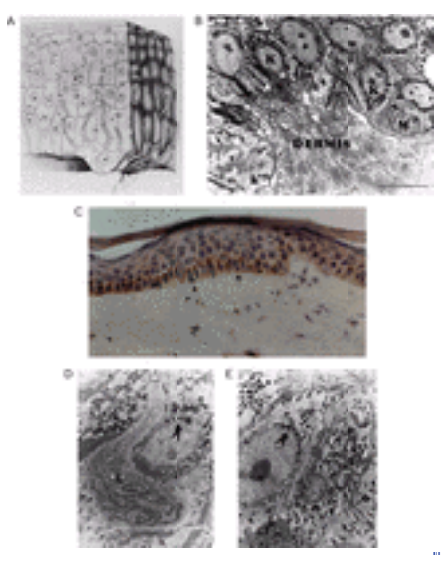

FIGURE 11-5 The epidermal melanin unit. *A.* Representation showing the relationship between basal melanocytes, keratinocytes, and Langerhans cells, shown at the upper layer of the epidermis. *(From Quevedo WC Jr. The control of color in mammals.* Am Zoology *9:531, 1969, with permission.) B.* Electron micrograph of the epidermal-dermal junction of human skin showing a dendritic melanocyte (M) among the basal keratinocytes (K). K' represents a basal keratinocyte undergoing mitosis with condensed chromatin (*arrows*). Bar = 10.0 µm. *(Illustration courtesy of Raymond E. Boissy, Department of Dermatology, University of Cincinnati, Cincinnati, Ohio.) C.* Human epidermis immunostained for FGF2. The figure shows basal keratinocytes with peroxidase reaction indicating the presence of immunoreactive FGF2. *Arrows* point to melanocytes. *(Courtesy of Glynis Scott, M.D., Department of Dermatology, University of Rochester School of Medicine and Dentistry, Rochester, NY.) D* and *E.* Distribution of melanosomes within keratinocytes in lightly pigmented Caucasian and darkly pigmented African American skin. Melanosomes in lightly pigmented Caucasian skin *(D)* are distributed in membrane-bound clusters. In contrast, in darkly pigmented African American skin *(E)* the melanosomes are individually distributed throughout the cytoplasm of epidermal keratinocytes. Melanosomes in both skin types are

frequently concentrated over the apical pole of the nucleus (*arrows*). L, Langerhans ccell. Bar = 3.0 µm. *(From Minwalla L et al.* [21])

The density of epidermal melanocytes varies at different sites in the body. There are about 2000 epidermal melanocytes per square millimeter on the skin of the head and forearm and about 1000 on the rest of the body. This tight regulation of the number of melanocytes in the epidermis is likely to be mediated by keratinocytes that provide growth and survival factors such as fibroblast growth factor 2 (FGF2), also known as basic FGF, to the melanocytes (Fig. 11-5C). The density of melanocytes in the skin is the same regardless of racial backgrounds (see Chap. 88). Normal human skin color is thus determined primarily by the melanogenic activity within the melanocytes, the synthesis of melanin, the production of melanosomes, their size, shape, type, and color, the mode in which they are transferred to the keratinocytes, and their distribution in the keratinocytes. In Caucasians, three to eight melanosomes are clustered into membrane-bound groups within keratinocytes, whereas melanosomes of dark-skinned individuals are larger than those of Caucasians and exist within the keratinocytes, predominantly as individual organelles distributed throughout the cytoplasm [21] (Fig. 11-5D and Fig. 11-5E). Mislocalization of melanocytes in the dermis is usually associated with pigmented lesions such as nevi and melanomas.

There are apparent changes in the coloration of an individual during life. Almost all infants, including blacks, are lighter at birth and become darker during the first week of postnatal life. Freckles, originally apparent only after sun exposure, become more permanent in the first or second decade of life. The dorsal skin of the hand becomes mottled in color in old age related to an age-induced decline in the number of epidermal melanocytes. In areas not exposed to sun, except for genital sites, there is approximately an 8 to 10 percent reduction in the density of melanocytes per decade of life, whereas the changes in the forehead and cheek are less drastic. The persistence of melanocytes in the genital sites suggests an influence of sex hormones that maintains their constant number.

Melanocytes in the Hair

Melanocytes in the hair follicle provide the melanin for hair shaft pigmentation (Fig. 11-6A). The hair bulb melanin unit resides in the proximal anagen bulb, consisting of one melanocyte to five keratinocytes in the hair bulb as a whole, and one melanocyte to one keratinocyte in the basal layer of the hair bulb matrix (Fig. 11-6B). [22] Follicular melanogenesis is not a continuous process as in the epidermis, but is rather tightly coupled to the hair growth cycle (see Chap. 12). This cycle involves melanocyte proliferation during the early period of hair shaft production (anagen), maturation during mid to late anagen, and death via apoptosis during the early regression phase in which the lower two-thirds of the hair follicle is resorbed (catagen) (Fig. 11-6C). The hair follicle contains melanocyte precursors, or possibly melanoblasts, that can even migrate out and populate the interfollicular epidermis upon stimulation [22] (Fig. 11-6D). This is particularly visible in patients with vitiligo undergoing repigmentation by PUVA photochemotherapy (psoralen plus ultraviolet light of A wave length) (see Chap. 266). Vitiligo is an inherited or acquired loss of melanocytes in the skin and other sites due to self-destruction, resulting in patches of white skin. In response to PUVA treatment, pigmented spots frequently develop around hair follicles in the vitiliginous skin, apparently due to the outward migration of residual reservoir of melanocytes in the hair follicle. Graying is caused by the gradual decline in the number of melanocytes in the hair follicles in a fashion determined by age and genetic background.

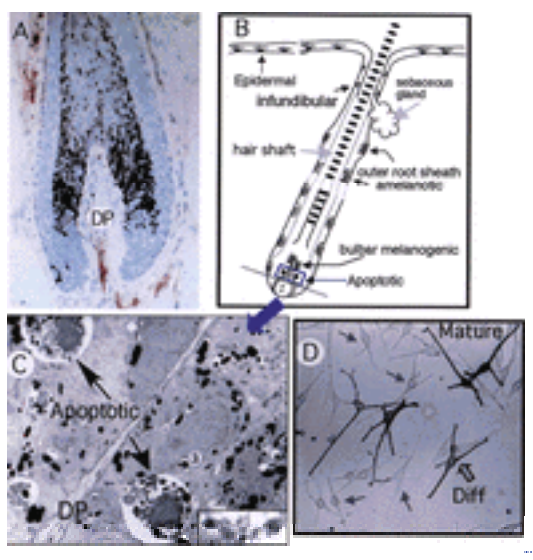

FIGURE 11-6 Melanocytes in the hair. *A.* Pigmented human scalp hair follicle in full anagen with high levels of hair bulb melanogenesis. Mature melanin granules are transferred into cortical keratinocyte. DP, dermal papilla. *B.* Hair scalp bulb. Representation of early catagen hair follicle showing loss of some bulbar melanotic melanocytes via apoptosis. *Arrows* point at melanocytes located in epidermal, infundibular, and outer root sheath regions. *C.* Transmission electron micrograph of section of an early catagen hair bulb showing apoptosis of melanotic melanocytes. Inset, high-power view of premelanosomes. DP, dermal papilla. *D.* Primary culture of human scalp hair follicle melanocytes. Mature, fully differentiated (Diff; large arrow), and less differentiated (*small arrows*) are indicated. (*From Tobin DJ and Paus R,* [22] *with permission.*)

It is not clear whether melanocytes have functions in the hair follicle other than to provide pigment to the hair. They do not serve to protect from UV light, which does not reach the hair follicle. Functions such as restraining keratinocyte proliferation, calcium homeostasis, and protection against reactive oxygen species during rapid cell proliferation and differentiation, have been suggested (reviewed in Ref. [22]). Assigning a function to melanocytes by comparing pigmented to gray hair, however, suffers from drawbacks due to age-related differences that accompany the process of pigment

loss.

Melanocytes in the Ear

Melanocytes in the ear are critical for proper hearing. Individuals who carry mutations in genes that cause suppression of melanocyte development, such as Waardenburg syndrome (see Chap. 90), suffer from hypopigmentation and impaired hearing (reviewed in Ref. [6]). Melanin production, by itself, is not essential, because albinos have normal hearing despite absence of melanin within viable melanocytes (reviewed in Ref. [23]). However, because pigmentation confers protection from trauma, albino individuals may suffer from earlier onset of hearing loss due to noise or exposure to toxic drugs (reviewed in Refs. [23] and [24]).

Melanocytes in the stria vascularis (known as intermediate cells) are crucial for normal cochlear development and maintenance of endolymphatic potential [24] (Fig 11-7). In their absence, the endolymphatic potential is extremely low and can cause deafness. [25] Endolymphatic fluid in the cochlea is one of the few extracellular fluids which is normally high in K^+. Absence of cochlear melanocytes is associated with significantly diminished endolymphatic K^+, suggesting that melanocytes are either directly or indirectly essential for its maintenance. The melanocytes may perform spatial buffering by transporting K^+ from regions of high to low K^+. This function is carried out by plasma membrane ionic channels, collectively known as inwardly rectifying K^+ channels and voltage-dependent outwardly rectifying K^+ channels. The inwardly rectifying K^+ channel, Kir4.1, was identified in the stria intermediate cells (melanocytes) and is considered to play a central role in stria function and normal hearing. [26]

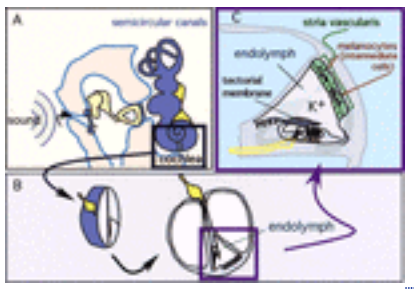

FIGURE 11-7 Melanocytes in the ear. *A.* Anatomy of the ear. Sound moves through the pinna, external canal, tympanic membrane, ossicles, and into the endolymphatic fluid contained within the cochlea (inner ear). Transduced vibrations of the appropriate amplitude bend particular sized cilia on hair cells causing a physical opening of ion channels and movement of potassium ions into the hair cells, triggering neuronal firings. *B.* A cross-section of the cochlea reveals three sections. *C.* The potassium-rich endolymph-filled chamber is conditioned by the stria vascularis, made up of intermediate cells (neural crest–derived melanocytes) sandwiched between marginal and basal cells. One wall of this chamber is lined by the motion-sensing hair cells. (*From Price ER and Fisher DE,* [6] *with permission.*)

Loss of melanocytes even after birth can impair endocochlear potential, as shown by mice carrying the dominant B^{lt} mutation at the brown locus. The mutation affects melanocytes specifically because it alters the yet undetermined function of Tyrp1, a melanocyte-specific protein (discussed below in “Melanin Synthesis” and “The Biosynthesis, Distribution, and Transport of Melanosomes”). The B^{lt} mutation causes a progressive loss of melanocytes with age due to self-destruction by oxidation products derived from the tyrosinase reaction. [27] This is true also for humans. Vitiligo (see Chap. 90), a condition manifested as progressive destruction of melanocytes with age, seems to contribute to susceptibility to hearing loss, particularly in males. Another uncommon autoimmune disease, Vogt-Koyanagi-Harada (VKH), that targets melanocyte-specific proteins, causes vitiligo in the skin and other parts of the body including the inner ear. [28] The autoimmunity is manifested as T cell–mediated inflammation around melanocytes and is associated with a high incidence of hearing impairment (reviewed in Refs. [24] and [28]; see also Chap. 90).

Melanocytes in the Eye

Melanin-containing pigment cells are present in the choroid and retinal pigment epithelium (RPE) layers of the eye (Fig. 11-8). The choroid is populated by neural crest–derived melanocytes, whereas pigment cells in the RPE originate from the neural ectoderm. RPE cells appear to arise through transdifferentiation from the neuroretina in a fashion largely mediated by Mitf. In the absence of Mitf, RPE cells revert to express neuronal markers and proliferate so as to duplicate neuroretinal structures. [29] However, Mitf expression in RPE melanocytes is not stable and is turned off later in development. Therefore, these cells become rapidly nonpigmented when cultured in vitro in the absence of melanocyte mitogens. In contrast, dividing choroidal melanocytes express melanocytic markers persistently in a fashion similar to that of epidermal melanocytes.

FIGURE 11-8 Ocular tissue demonstrating the choroid (C), the retinal pigment epithelium (R), and the photoreceptor cells of the retina (P). The connective tissue of the choroid contains numerous fibroblasts (F) and dendritic melanocytes (M) with cytoplasm filled with mature melanosomes. The retinal pigment epithelium is a single layer of polarized cuboidal melanocytes containing relatively elongated mature melanosomes both within the cell body of the RPE cells and in the numerous slender apical processed (*arrows*) that interdigitate between the rod and cone photoreceptor cells. Bar = 10.0 µm. (*Illustration courtesy of Raymond E. Boissy, Department of Dermatology, University of Cincinnati, Cincinnati, Ohio.*)

Melanocytes are important for normal development and function of the eye and optic nerves, as manifested by abnormalities in individuals with all forms of albinism regardless of the gene affected, including OCA1 and ocular albinism type 1 (OA1) [30], [31] (see Chap. 90). One of the most fascinating functions of melanocytes whose nature still remains unsolved, is in proper routing of the optic nerves at the chiasm during early development of the optic cup. Highly intermixed axons destined to project ipsilaterally and contralaterally to the brain enter the chiasm region and then selectively grow into the correct pathway. Melanin at this crossroad is likely to provide specific guidance cues. In the absence of pigment, the sorting out of intermixed ipsilaterally and contralaterally projecting retinal axons into the appropriate optic tracts is altered, thereby disrupting the gross topographic relationship of fibers in the nerve.

MELANIN SYNTHESIS

Melanin is the major product of melanocytes and is the main determinant of differences in skin color. Melanin is synthesized in two main forms: the dark-colored brown-black, insoluble eumelanin, and the light-colored red-yellow, alkali-soluble, sulfur-containing pheomelanin. The rate-limiting catalytic activity in the production of both types of melanin is the oxidation of tyrosine by tyrosinase, known as the Raper-Mason pathway [32] (Fig. 11-9). Tyrosinase (monophenol, L-dopa: oxygen oxidoreductase, EC 1.14.18.1) is a melanocyte-specific copper-binding enzyme with homology to polyphenol oxidases and some hemocyanins. It catalyzes the oxidation of monohydric and dihydric phenols (catechols) to their corresponding quinones. [33], [34] In vivo, tyrosinase converts tyrosine to DOPAquinone (3,4-dihydroxyphenylalanine quinone), with the intermediate production of DOPA that remains bound to the active site (Fig. 11-9A). DOPA is required for tyrosinase activity (Fig. 11-9B and Fig. 11-9C) because it allows the binding of oxygen to the active site of tyrosinase. This process involves the catalytic oxidation of DOPA to DOPAquinone by the *met*-form of the enzyme (Cu II state without bound dioxygen). This step enables the transition to the oxygen-bound form by reducing the copper atoms in the active site. This oxygen-bound form of tyrosinase is now able to use tyrosine and DOPA as substrates. [34]

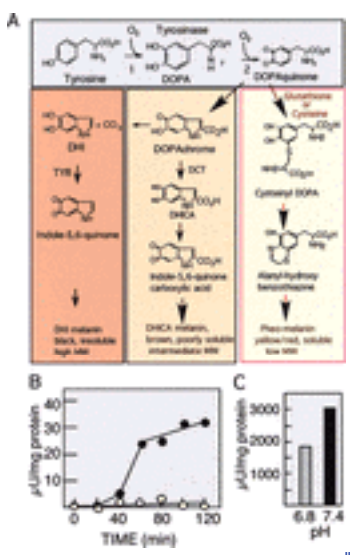

FIGURE 11-9 Pathway for melanin biosynthesis. *A.* The intermediates in the oxidation of tyrosine by tyrosinase as described by the Raper Mason pathway [32] and modified by recent studies (reviewed in Ref. [36]). Tyrosinase catalyzed the two initial steps (1, 2) as well as the conversion of DHI to indole-5,6-quinone. Some of the intermediates are made by spontaneous conversion and others are formed by enzymatic conversion mediated by newly isolated enzymes. DOPAchrome is converted to 5,6-dihydroxyindole-2-carboxylic acid (DHICA) by DCT (DOPAchrome tautomerase). The identity of the enzyme that converts DHICA to indole-5,6-quinone may not be clear because two proteins, Tyrp1 and Silver, have been suggested to perform this function. *B.* Autocatalytic activation of tyrosinase by DOPA and its suppression at acidic pH. Tyrosinase activity was tested in vitro using extracts from normal human melanocytes in the absence of DOPA at pH 6.8 (*open circles*), or pH 7.4 (*solid circles*). Activity is detected only after 40 min of incubation at an alkaline pH but not at an acidic pH. *C.* Tyrosinase activity in the presence of DOPA. Notice that total activity is about 100-fold higher in the presence compared to the absence of DOPA. The fully activated tyrosinase is still more functional at alkaline compared to acidic pH.

DOPA is required continuously for tyrosinase activity and is likely to regenerate from the reduction of DOPAquinone. One possible mechanism is the spontaneous endocyclization of DOPAquinone to cyclodopa, which is then converted to DOPAchrome by redox exchange with DOPAquinone. [34] Another alternative is that DOPAquinone is reduced to DOPA through the oxidation of critical sulfhydryl groups on tyrosinase, forming the final disulfide bond(s) required to stabilize the protein in its native/active form. This regeneration step may explain the lag period in tyrosine oxidation by mammalian tyrosinase in vitro in the absence of added DOPA (Fig. 11-9B), and the suppression of any enzymatic activity at low pH in which DOPA remains protonated (Fig. 11-9B and Fig. 11-9C).

Tyrosinase is the sole supplier of DOPA in melanocytes. Tyrosine hydroxylase, the other DOPA-generating enzyme in dopaminergic neurons, is not expressed in normal melanocytes, and forced expression of a constitutively active form of tyrosine hydroxylase could not substitute for tyrosinase in generating DOPA for the tyrosinase reaction. [35] Interestingly, the structural change induced by DOPA also promotes the maturation of tyrosinase by inducing its transport from the

endoplasmic reticulum (ER) to the Golgi [35] (tyrosinase maturation is discussed below, in “Endoplasmic Reticulum Modification and Transport to the Golgi”).

Additional steps in the pathway participate in the production of melanin in vivo. These include the oxidation of 5,6-dihydroxyindole (DHI) to indole-5,6-quinone by tyrosinase (reviewed in Ref. [36]), the isomerization of DOPAchrome to 5,6-dihydroxyindole-2-carboxylic acid (DHICA) by DOPAchrome tautomerase (DCT) and possibly Tyrp1, and the oxidation of DHICA to carboxylated indole-quinone (Fig. 11-9A). Mouse Tyrp1 was also suggested to perform this latter enzymatic activity, but the inability of human Tyrp1 to catalyze the same function, in spite of high homology between mouse and human proteins (95 percent identity in the putative catalytic domain and 87 percent total identity), casts doubt on the function of Tyrp1 in this reaction.

The oxidation products of DHICA and DHI provide the building blocks for the brown-black, poorly soluble and insoluble eumelanins, respectively (Fig. 11-9A). Pheomelanin is produced from cysteinyldopa and benzothiazine metabolites when DOPAquinone combines with cysteine or glutathione (Fig. 11-9A). Melanin is a mixture of pheomelanic and eumelanic monomers and the ratio between the two determines the final color of the skin and hair. [37] The reduction in eumelanin and the predominant presence of pheomelanin, such as in red hair, is regulated in large part by the melanocortin receptor (see below, in “ Pigmentation Control by Melanocortins and the Melanocortin Receptor (MCR) ”).

The main characteristic of melanin is its ability to absorb and scatter UV radiation (280 to 400 nm) and protect against DNA damage. [38] However, the intermediates in melanin biosynthesis and melanin itself can also be harmful. The quinones produced by the tyrosinase reaction are cytotoxic and mediate cell death when they accumulate at high levels. Furthermore, melanin-related molecules enhance UVA radiation (320 to 400 nm)-induced DNA breakage. [39] Melanin reacts avidly with DNA, is photoreactive, and capable of producing damaging reactive oxygen species in response to UVA. [40] Increased levels of pheomelanin and or melanin intermediates induce higher levels of single-strand breaks in UVA-irradiated cultured human melanocytes derived from light-skin individuals as compared to melanocytes from dark-skin individuals. [41] These results suggest that the higher incidence of light-induced melanomas in red-haired and light-skin individuals is due not only to lack of natural protection, but also to enhanced mutagenesis by pheomelanin and/or melanin intermediates. These side effects of melanin may explain the evolutionary pressure to confine its production and localization to the melanosomes.

THE BIOSYNTHESIS, DISTRIBUTION AND TRANSPORT OF MELANOSOMES

Melanosomes are membrane-bound granules of approximately 200 × 900 nm. They are related to lysosomes because both organelles contain similar marker proteins and are positioned after the Golgi in the secretory pathway (reviewed in Refs. [42] and [43]). The melanosomes are composed of a distinct set of proteins performing a variety of functions that include building and maintaining the granules, melanin synthesis, and trafficking to the dendritic tips (Table 11-1). The targeting of each of these proteins into the melanosomes is highly regulated, initiating at the site of synthesis on ER-bound ribosomes. The maturation process of melanosomal proteins includes their cotranslational glycosylation and proper folding in the ER, transport to the Golgi where complex carbohydrates are acquired, and vesicular transport to the melanosomes (Fig. 11-10A). The specific events governing each step are described in detail for tyrosinase as a model system for other melanocyte-specific proteins.



TABLE 11-1 **Melanocyte Proteins Involved in Organelle Biogenesis, Melanin Synthesis, and Transport of Melanosomes**

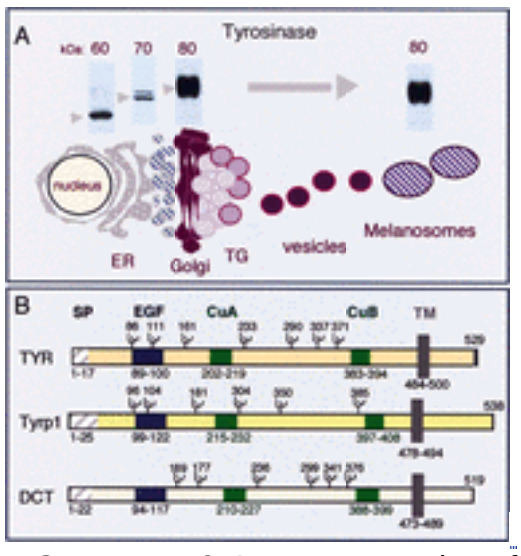

FIGURE 11-10 *A.* Representation of tyrosinase transit through the secretory pathway. Tyrosinase is synthesized on ER-bound ribosomes as the ˜58 kDa polypeptide, and cotranslation transfer of six or seven *N*-linked oligosaccharide chains increases tyrosinase's molecular weight to ˜ 70 kDa. The complex sugar modifications in the Golgi apparatus cause a further increase to ˜80 kDa, the size of the mature wild-type isoform that is then translocated to the melanosomes. The protein bands of the various tyrosinase forms are Western blots of human tyrosinase from normal

melanocytes. *B.* Representation of tyrosinase and two homologous proteins Tyrp1 and Dct. The long horizontal rectangles represent tyrosinase (TYR), Tyrp1, and DCT peptides. The hatched *N*-terminus boxes indicate the signal peptide; the blue areas indicate the EGF-like domain; the green areas indicate the Cu binding sites A and B; and the dark vertical bars indicate the hydrophobic core transmembrane domain (TM). Tyrosinase also possesses an SHL microbodies C-terminal targeting signal represented by the narrow bar at the C-terminus. The range of amino acid for each of these domains is given on the bottom of each bar. The positions of *N*-linked oligosaccharides are represented by the branched structures above the bar, with numbers indicating the position of Asn.

Tyrosinase is a type I membrane glycoprotein of 529 amino acids, with a signal peptide, and catalytic regions composed of two copper-binding domains coordinated by histidine residues (Fig. 11-10B). Tyrosinase also contains 17 cysteine (Cys) residues, one each located in the signal sequence and the cytoplasmic tail, leaving 15 Cys available to form multiple disulfide bonds in the large ectodomain of the protein. While these Cys residues are grouped largely into two Cys-rich domains, their disulfide pairing remains unknown. Tyrosinase has an overall identity of 40 percent with two other cDNAs encoding melanocyte-specific proteins termed tyrosinase-related protein 1 (Tyrp1, also known as TRP1/b-locus/gp75), and DCT (also known as TRP2 or *slaty* locus protein). The homology between these three different proteins is particularly striking in the putative glycosylation sites, the clusters of Cys residues and the two copper-binding sites (Fig. 11-10B). However, among these three, only tyrosinase possesses the catalytic activity of converting tyrosine and DOPA to DOPAquinone, and in its absence (and the presence of normal Tyrp1 and DCT), melanocytes remain devoid of any pigment. This is clearly demonstrated by the albino phenotype of melanocytes expressing null mutant tyrosinase and normal Tyrp1 or DCT, and by the pigmented phenotype of melanocytes with normal tyrosinase but with null mutant Tyrp1 protein. Furthermore, only tyrosinase can induce melanin biosynthesis when expressed in heterologous cellular systems, even in the absence of any other melanocyte specific proteins.

Endoplasmic Reticulum Modification and Transport to the Golgi

The *N*-terminal signal sequence of tyrosinase targets the mRNA-ribosome-tyrosinase complex to the ER, the site of entry to the secretory pathway. Upon emergence of the polypeptide chain into the ER, the 18-amino acid *N*-terminal signal sequence is cleaved and human tyrosinase receives six or seven *N*-linked glycosylations cotranslationally, and disulfide bond formation commences. The *N*-linked glycans are attached as a core 14-unit oligosaccharide (glucose $_3$-mannose $_9$-*N*-acetylglucosamine $_2$) by the oligosaccharyl transferase complex on asparagine (Asn) residues that reside in the sequence Asn-X-Thr/Ser (Fig. 11-11A).

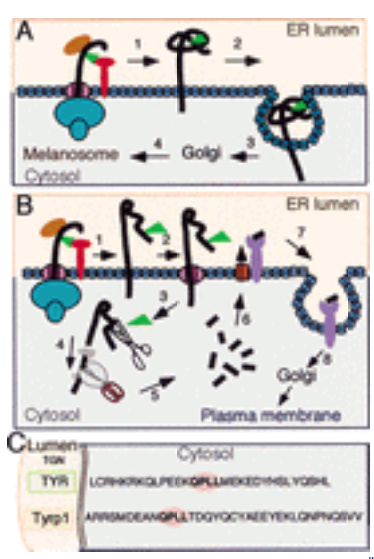

FIGURE 11-11 Maturation and degradation of tyrosinase. *A.* Maturation of correctly folded tyrosinase. Tyrosinase is translated by ER-targeted ribosomes (blue spheres). The protein is cotranslationally translocated through the ER membrane (*blue chain*) and *N*-linked glycosylated (*green triangle*). It interacts with the chaperones, calnexin (*red*) and calreticulin (*orange*), in the ER lumen. The fully folded protein emerges from the chaperone complex (1), and is sorted (2) to transport vesicles that bud from the ER membrane (3) for transit to the Golgi then to the melanosomes (4). *B.* Degradation of misfolded tyrosinase. Tyrosinase misfolds (1) in the ER due to mutations or hostile microenvironment and is targeted for retranslocation to the cytosol (2) where its *N*-linked glycans are removed by a cytosolic *N*-glycanase (3). The soluble and unglycosylated tyrosinase is modified by polyubiquitin (4) that sorts the protein to the 26S proteasome for destruction (5). The polypeptides can then be transported back into the ER lumen through the TAP transporter in the ER membrane (6) for binding to MHC class I heavy chain. The peptide-MHC class I heavy chain complex is transported through the secretory pathway to the cell membrane for antigen presentation. *C.* Amino acid sequences of the cytosolic tails of tyrosinase (TYR) and Tyrp1 indicating the di-leucine domain, the recognition site for binding of AP-3 adapter-protein complex (*purple*) that directs intracellular localization to the melanosome.

The newly synthesized tyrosinase polypeptide is subjected to the quality control system in the ER that monitors protein maturation to ensure that defective proteins are not transported throughout the cell (reviewed in Ref. [44]). The system includes resident proteins such as calnexin, calreticulin, and the glucosyl transferase that recognize incorrectly folded and misassembled proteins, and target them for ER retention. Calnexin and calreticulin are lectin chaperones that bind specifically to glycoproteins containing monoglucosylated glycans (reviewed in Ref. [44]). The monoglucosylated protein is created by the sequential actions of ER glucosidases I and II. The immature, misfolded tyrosinase remains bound to calnexin and calreticulin. [45], [46] and [47] Chaperone binding may enhance the maturation of wild-type tyrosinase, because the expression of tyrosinase in a heterologous nonmelanogenic cell system (COS7 cells) with overexpressed calnexin permitted an approximately twofold enhancement in the appearance of tyrosinase activity. [48]

Inactivating mutations in tyrosinase, or in other melanocyte-specific proteins such as Tyrp1 and OA1 (the latter a

seven-membrane–span G-protein–coupled receptor), can lead to their misfolding and retention in the ER [31], [46], [49], [50] (Fig. 11-11B). In the case of OCA1 (see Chap. 89), the consequent disruption in pigmentation is due to inactivation of tyrosinase and the failure of the protein to reach the site of melanin production, the melanosome. These findings have initiated the hypothesis that only functional tyrosinase passes the quality control test performed by resident ER proteins that permit proteins to be transported out of the ER to the Golgi. [35] This quality control test may involve the production of the tyrosinase cofactor DOPA by the oxidation of the tyrosinase substrate, tyrosine. DOPA can then bind to and stabilize nascent tyrosinase, making it competent for transport.

Other proteins, such as Tyrp1 and DCT, can stabilize tyrosinase in the ER. In cells lacking melanosomes, melanosomal proteins are delivered to the lysosomes and both Tyrp1 and DCT are found to stabilize tyrosinase and to increase its activity. [51] This suggested the presence of a melanogenic complex that might not only be important for enzymatic optimization but also for the trafficking of the proteins out of the ER. A high molecular weight complex containing tyrosinase, Tyrp1, and DCT has been identified, [52], [53] but understanding the significance of this complex requires further studies.

ER Retention and Production of Antigenic Peptides

Similar to albino melanocytes, melanoma cells are frequently rendered amelanotic due to retention of tyrosinase in the early secretory pathway. In these cells, the wild-type protein is inactivated and misfolded due to a hostile environment within the malignant cells. [45] The ER-retained protein is subsequently retranslocated to the cytosol where it is degraded by the 26S proteasome (Fig. 11-11B). These newly generated tyrosinase peptides can become antigenic and elicit an immune response by reentering the ER through TAP (transporter associated with antigen processing) and being presented by the major histocompatibility complex (MHC). [54] Recognition of tyrosinase peptides by tumor-infiltrating lymphocytes in a MHC class I and II restricted manner has been described in patients with melanomas. [55], [56]

The destruction of wild-type tyrosinase in melanoma cells is likely to be due to suppression of the oxidoreductive activity of the enzyme by tumor-induced metabolic changes that cause acidification of the extracellular milieu. Melanoma cells, like other solid tumors grown under hypoxic conditions, acidify their extracellular environment because of increased rates of glycolysis and the accumulation of lactic acid, a process known as the *Warburg effect*. [57]

Transport from Golgi to Melanosomes

After tyrosinase is properly folded, stabilized, and possibly oligomerized, it is no longer recognized and retained by the ER quality control machinery. The protein is then packaged into COPII-coated transport vesicles that bud from the smooth ER. The vesicles traffic through the ER-Golgi-intermediate compartment (ERGIC) to the Golgi where complex sugars are added to the high mannose *N*-linked glycans causing an increase in molecular mass of tyrosinase from ~ 70 kDa to ~ 80 kDa (Fig. 11-10A).

The sorting of tyrosinase and other melanocyte-specific proteins from the Golgi to melanosomes is determined by recognition signals in the cytoplasmic segment (Fig. 11-11C). Mutations that cause deletion of tyrosinase's cytoplasmic tail mistarget the protein to the cell surface and generate an OCA1 phenotype. [58] Intracellular localization to the melanosomes is directed by a di-leucine motif present in the tail of tyrosinase, Tyrp1, silver (also known as Pmel17 and gp100), and P-protein [59], [60] (Fig. 11-11C), by binding to the adapter-like protein complex, AP-3. [61] AP-3, like other adapter complexes, is comprised of four subunits termed ß3-, d-, µ3, and d3-adaptin. This heterotetrameric complex is located in the cytosol until it is recruited to the TGN (*trans*-Golgi network) by an ARF-GTPase. Vesicles containing melanocyte-specific proteins are then transported to the lysosome or lysosome-related organelles.

Mutations in AP-3 produce a variety of classical pigmentation and multi-organellar defects in humans, mice, and Drosophila (reviewed in Refs. [14] and [62]). Hermansky-Pudlak syndrome (HPS) (see Chap. 90) is a human disease that is characterized by altered storage granules and pigmentation. HPS patients experience excessive bleeding, as well as immunologic and pigmentation deficiencies. The mutation that leads to HPS type 2 (HPS2) has been mapped to the ß3A subunit of the AP-3 adapter. This defect results in the enhanced degradation of the ß3A subunit and the reduction in the overall level of the AP-3 complex. Subsequently, proteins possessing di-leucine–based sorting signals, including melanosomal and lysosomal proteins, are mislocalized to the plasma membrane (reviewed in Ref. [42]). That a mutation in AP-3 affects both pigmentation and blood clotting is indicative of the importance of AP-3 in the trafficking of protein to both melanosomes and platelet-dense granules. However, other determinants must also be involved to direct proteins to the individual compartment.

Melanosome Maturation

Melanosomes develop through a series of morphologically defined stages from an unpigmented (stage I) to a striated organelle enriched in melanin (stage IV) (Fig. 11-12A). Stage I melanosomes have an irregular structure and contain internal membranous vesicles that are formed by the invagination of the outer limiting membrane. They likely correspond to the late coated endosomal multivesicular bodies found in nonmelanogenic cells. At stage II, the melanosomes become elongated and form ordered striations. These striations act as templates for melanin polymerization that commences in stage III melanosomes, which possess the functional oxidoreductases and therefore begin to darken. However, stage I melanosomes also possess functional tyrosinase because incubation with DOPA produces melanin within these organelles (Fig. 11-12B). Silver is a type I membrane glycoprotein that appears to play a structural role in the formation of these striations because silver expression in nonmelanogenic cells supports the formation of striations within multivesicular bodies. [43]

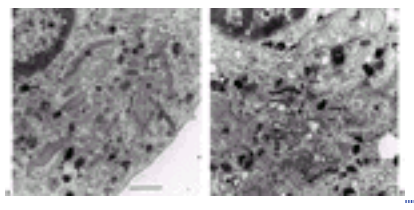

FIGURE 11-12 Perinuclear area of normal human melanocytes from a lightly pigmented Caucasian skin demonstrating melanosomes in various stages of maturation. *A.* Melanosomes in the vicinity of the Golgi apparatus (G) exist as stage I premelanosomes (I) that are more oval in shape containing floccular material and short irregular melanofilaments, stage II melanosomes (II) that are more elongated containing an organized, scaffold-like matrix of melanofilaments, stage III melanosomes (III) with melanin being sequentially deposited on the melanofilament matrix, and stage IV melanosomes (IV) with melanin completely filling the organelle and obscuring the matrix. This melanocyte is from a lightly pigmented Caucasian individual and consists of stages II and III melanosomes predominantly, with relatively few stage IV melanosomes. *B.* DOPA reaction products indicating cellular sites of catalytically functional tyrosinase appear in the trans Golgi network (G) including the *trans*-most cisternae (*arrows*), coated vesicles budding from these cisternae (*arrowheads*), and vesicles migrating from the Golgi apparatus (*arrowheads with asterisk*). Reaction products exist in some stage I premelanosomes (I), indicating incorporation of tyrosinase into these organelles. After DOPA histochemistry, this lightly pigmented, white melanocyte consists of stage IV melanosomes predominantly with relatively few stage II and III melanosomes. M, mitochondria; N, nucleus. Bar = 1.0 µm. (*Illustration courtesy of Raymond E. Boissy, Department of Dermatology, University of Cincinnati, Cincinnati, Ohio.*)

The assembly of melanosomal enzymes and structural proteins into a membrane-limited granule is not sufficient to produce a functional melanosome. Melanin biosynthesis is dependent on proper pH homeostasis, osmotic pressure, transport of substrate into the melanosome lumen, and other yet uncharacterized activities such as that controlled by the OA1 protein. [63] Proper pH and osmotic pressure are likely to require the activity of multiple spanning membrane transport proteins. Two such candidates are the pink-eyed dilution protein (P-protein) and AIM-1/MATP (for antigen in melanoma-1/membrane-associated transporter protein). [64], [65], [66], [67] and [68] These two integral membrane melanosomal proteins each possess 12 putative transmembrane domains. Their homology to transport proteins in lower organisms is supportive of a role in ionic regulation in the melanosomes and possibly even in the ER and the Golgi. The P-protein possesses homology to *E. coli* Na^+/H^+ antiporter and MATP to the sucrose/proton transporters in plants, although sucrose transporters have not been previously identified in mammals. Mutations in the human P and MATP genes are the cause of tyrosinase-positive forms of albinism, OCA2 and OCA4, respectively. In the absence of normal P-protein, there is a disruption in melanosomal structure, and misrouting of tyrosinase and Tyrp1 to other sites, including the cell membrane. [65], [69] The misrouting of melanosomal proteins in p-null melanocytes suggests a role for the P-protein in trafficking or sorting of melanocyte-specific proteins as they leave the Golgi en route to premelanosomes. The effect of the MATP mutation on transport of melanocyte specific proteins is not yet known. Melanosomes in mouse melanocytes with null MATP (underwhite, or uw) are small, irregularly shaped, and less- or nonpigmented when compared with the round or ovoid pigmented melanosomes in wild-type pigment cells. Further experimentation is required to determine the point at which these transporter proteins enter the melanosomes and their role in melanogenesis.

Melanosome Transport to Dendritic Tips

Once melanosomes become enriched with pigment in the cell body (stage IV), they travel to the dendritic tip in a centrifugal manner for transfer to neighboring keratinocytes in the epidermis. The intracellular transport of organelles requires protein motors, cytoskeletal tracks, and adapters/effectors that attach the organelles to the motors. Melanosomes move in a bi-directional manner on microtubules in the dendrites until they are captured at the dendritic tips (Fig. 11-13A).

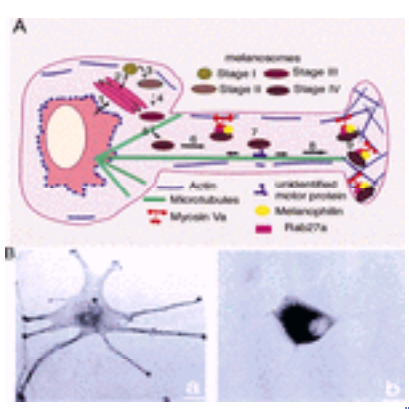

FIGURE 11-13 The trafficking of melanosomes and melanosomal-proteins in melanocytes. *A.* Melanosomal proteins are synthesized by cytosolic ribosomes (*blue balls*) that are targeted to the ER (1) where the proteins fold, and receive *N*-linked glycosylations and disulfide bonds. Correctly matured protein is transported through the Golgi cisternae (2) to melanosomes that mature from stage I to stage IV (3 to 5) in the cell body that surrounds the nuclear region. The melanosomes are centrifugally transported to the dendritic tips on microtubules where they are captured by myosin Va-Rab27a-melanophilin complexes associated with actin filaments. This permits the concentration of melanosomes at the cell tip for transfer to neighboring keratinocytes. *B.* Melanosome in melanocytes from a patient with Griscelli syndrome (b) remain restricted to the perinuclear and fail to distribute to the dendrites as seen in normal melanocytes (a). (*From Bahadoran P et al* [72], *with permission.*)

The motor involved in the centrifugal movement of melanosomes to the microtubules and then to the cell periphery remains to be identified. However, genetic analyses of pigmentation mutants that result in the clustering of melanosomes in the cell body or perinuclear region implicate the interplay among several proteins including myosin Va, rab27a, and

melanophilin (Mlph).

Myosin V family members such as myosin Va operate in concert with actin filaments that line the cell periphery to move granules to dendritic tips. In the absence of functional myosin Va, the bi-directional movement of melanosomes on microtubules is normal, but the melanosomes fail to accumulate at the dendritic tips. Mutations in Rab27a and Mlph produce a similar phenotype suggesting that these two proteins play a role in the cargo selection by myosin Va. Rab proteins are adapter proteins that are involved in the regulation of intracellular vesicular transport partnered with effector molecules. Together, they provide specificity to steps in the trafficking of intracellular vesicles by promoting the binding and fusion of vesicles destined for specific locations within the cell (reviewed in Ref. [43]).

Griscelli syndrome, a rare autosomal recessive disorder, has recently been shown to involve a mutation in *rab27a* and *Myo Va*. While all Griscelli syndrome patients have pigmentation defects, some also possess neurologic or immunologic abnormalities due to defective exocytosis of secretory vesicles from neurons and lytic granules from cytotoxic T lymphocytes, respectively. Griscelli syndrome patients with immune defects have a mutation in rab27a, [70] while patients with neurologic abnormalities have mutations in myosin Va. [71] As expected, defects in these genes cause the accumulation of melanosomes in the cell body [72] (Fig. 11-13B), and are likely to have a similar effect on the dispersion of lytic granules in T lymphocytes and secretory vesicles of neurons. The identification and characterization of the melanocyte proteins involved in the transport of melanosomes has helped to provide a more complete diagnosis for patients with Griscelli syndrome.

Melanosome Transfer to Keratinocytes

Melanosomes enriched in pigment at the dendritic tips are translocated to adjacent keratinocytes where the melanin forms a photoprotective cap over the keratinocyte nuclei. Three methods of transfer have been proposed, although the exact mechanism by which this transfer occurs remains unknown (reviewed in Ref. [73]).

The first mechanism involves the secretion of the melanosomal contents into the intercellular space by the melanocyte that is then endocytosed by the keratinocyte. This model is supported by the similarities between melanosome and lysosome-related organelles such as secretory lysosomes involved in regulated secretion in hemopoietic cells. This model predicts that the melanosomal proteins could be recycled back to the cell body where they can be used again for melanin production.

The second model proposes the direct fusion of melanocyte and keratinocyte plasma membranes supporting the transfer of melanosomes from one cell to the other. This mechanism predicts the presence of cognate SNARE proteins on the plasma membranes of the melanocyte-keratinocyte that initiate the fusion of the two outer membranes. Model three proposes that the dendritic tips of the melanocyte are phagocytosed by the keratinocyte. Keratinocytes have been observed engulfing dendritic tips and latex beads, exhibiting their phagocytic abilities. This theory further predicts the presence of a keratinocyte receptor because phagocytosis is a receptor-mediated process. Recent studies have identified protease-activated receptor-2 (PAR-2) as a protein that controls melanosome ingestion by keratinocytes after UVB irradiation (see below in " Tanning in Response to UV Light").

PIGMENTATION CONTROL BY MELANOCORTINS AND THE MELANOCORTIN RECEPTOR

The Melanocortins and Their Receptors

The melanocortin receptor (MCR) has a central role in constitutive skin color and hair pigmentation and in the ability to tan in response to sunlight. Most red-haired light-skin individuals carry inactive variants of the MCR (see below in " Regulation and Function of MCR Activity"). Our present understanding of the diverse physiologic roles of the MCRs dates back to the first published report by Fuchs, who, in 1912, described an activity in extract from bovine pituitary that caused darkening of frog skin (reviewed in Ref. [74]). This easy assay for the detection of biologic activity of what was termed melanocyte-stimulating hormone, or MSH, was instrumental in identifying the ligand and receptor.

The melanocortins (or MSHs) are a group of peptides derived from a common precursor proopiomelanocortin (POMC) produced in the intermediate lobe of the pituitary, as well as in other tissues, such as the skin. POMC encodes several peptides, ?-MSH, a-MSH, ACTH, ß-MSH ?-lipotropin, and ß-endorphin, with diverse biological functions (reviewed in Refs. [75] and [76]) (Table 11-2 and Fig. 11-14A). The various peptides are produced by endoproteolytic cleavage mediated by two prohormone convertases (PC1 and PC2) that recognize in each region a paired basic amino acid residue (Arg and Lys) (Fig. 11-14A). The hyperpigmentation induced in sun-exposed areas in individuals injected with the superpotent MSH, [77] or the darkening of the skin in patients with Addison's disease that causes hypersecretion of ACTH, indicate that stimulation of the MCR receptor in vivo enhances eumelanin synthesis in human melanocytes. Under normal conditions, the likely source of POMC for melanocytes is skin keratinocytes and not the pituitary, because patients who suffer loss of pituitary function due to tumor growth or other causes have normal pigmentation.

Receptor	Ligand	Function	Chromosomal Localization
MC1-R	α-MSH ACTH	Melanocyte pigmentation	16q2
MC2-R	ACTH	Adrenal function	18p11.2
MC3-R	α-MSH γ-MSH ACTH	Cardiovascular regulation	20q13.2
MC4-R	α-MSH ACTH	Energy homeostasis	18q22
MC5-R	α-MSH ACTH	Exocrine secretion	18p11

Among the POMC peptides, the role of β-MSH has not yet been determined, thus its cognate receptor in vivo is not identified. In vitro, β-MSH can bind the MC1-R and induce melanogenesis.

TABLE 11-2 **Distribution, Function, and Localization of the Melanocortin Receptor (MCR)**

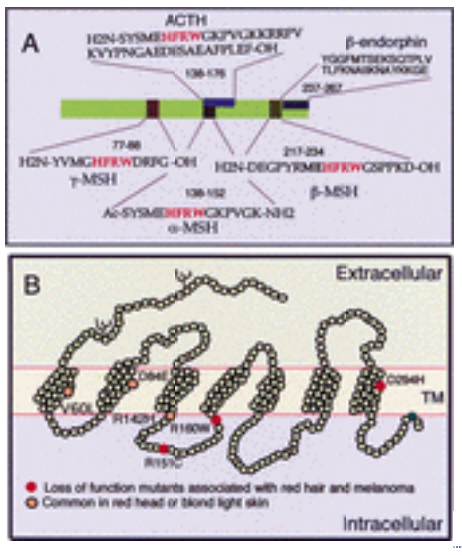

FIGURE 11-14 The MCR and its ligands. *A.* Structure of the proopiomelanocortin precursor. Standard abbreviations for amino acids are used. The synthetic superactive a-MSH analogue NDP-a-MSH is modified by the exchange of methionine (M) with norleucine and L-phenylalanine (F) with D-phenylalanine. Ac, acetylated; NH_2, amidated. In red are critical amino acids required for binding to the MCR. *B.* Schematic representation of the human MC1-R receptor. Each of the 318 amino acid residues in the polypeptide chain of the receptor is represented by an empty circle. Branched structures represent *N*-linked glycosylation sites. Reduced function mutants (*red circles*), variants common in red- or blond-haired and fair skin individuals (*orange circles*), and the conserved *C*-terminal cysteine (*green circle*), the possible site for fatty acid acylation and anchoring to the plasma membrane, are indicated. TM, transmembrane domain.

The melanogenic peptides share a tetrapeptide core indispensable for the recognition and activation of the MCR (Fig. 11-14A). Each of the processed peptides also undergoes posttranslational modifications, such as amidation, acetylation, and glycosylation that stabilize the protein and/or enhance its biological activity. Although a-MSH is the most potent of the peptides for melanogenic activity, a synthetic peptide in which methionine is replaced with norleucine and L-phenylalanine with D-phenylalanine has a further enhanced activity. [77]

The melanocortins bind to and activate their cognate melanocortin receptor (MC1-R) (Fig. 11-14B), a member of a family of receptors for MSH and ACTH peptides, each with a distinct distribution and distinct physiologic roles (Table 11-2). Five genes encoding receptors for melanocortin peptides have been identified, and all belong to the superfamily of G-protein–coupled seven-membrane–spanning receptors. In addition to pigmentation, they participate in other physiologic functions such as obesity, inflammation, thermoregulation, energy homeostasis, and exocrine gland secretion (reviewed in Refs. [74] to [76]).

Regulation and Function of Melanocortin Receptor Activity

MCR activity is mediated through activation or inhibition of adenylyl cyclase that induce changes in intracellular cAMP [cyclic adenosine monophosphate (reviewed in Ref. [74])]. Melanocortins activate, whereas agouti and agouti-related protein (AGRP) block, the stimulation of adenylyl cyclase [78] (Fig. 11-15A). The changes in intracellular levels of cAMP modulate the expression of several melanocyte specific genes, including tyrosinase and Tyrp1 (Fig. 11-15B, Fig. 11-15C), likely by regulating the activity and expression of the transcription factor Mitf (see below about Mitf in " Regulators of Melanocyte-Specific Gene Expression"). Agouti is a competitive antagonist of the MCR, with high affinities for MC1-R in the skin and MC4-R in the brain (reviewed in Refs. [75] and [79]): In mouse skin, agouti is secreted by dermal papillae cells, adjacent to melanocytes. Blockade in melanocortin action at the MC1-R by agouti induces melanocytes to produce the red-yellow color pheomelanin instead of the dark-brown eumelanin (reviewed in Refs. [74] and [79]). However, agouti's role in human pigmentation has not yet been established. No polymorphisms in the coding region of *agouti* were found in individuals with different racial backgrounds expressing different levels and kinds of skin and hair coloration, indicating that the human agouti is unlikely to function in normal human pigmentation. [80]

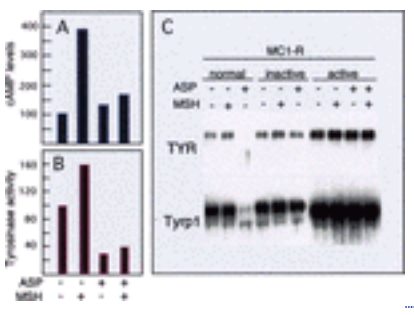

FIGURE 11-15 Physiologic evidence that a-MSH and agouti (ASP) act on MC1-R. Mouse melanocytes were incubated in medium with no addition (-), 1 nM a-MSH, 10 nM ASP, or with both (+). *A.* Intracellular levels of cAMP in wild-type mouse melanocytes at the end of 40-min incubation. *B.* Tyrosinase enzymatic activity in wild-type mouse melanocytes at the end of 6-day incubation. Values are expressed as a percent of control (no addition). *C.* Ligand modulation of tyrosinase and Tyrp1 is contingent on the presence of normal, wild-type MC1-R. Mouse melanocytes expressing normal wild-type (E^+/E^+), inactive mutant (e/e), or constitutively active (E^{so}/E^{so}) MC1-R were treated as indicated above each lane. Cell extracts were collected at the end of 6-day incubation and subjected to Western blot analysis for tyrosinase (TYR) and Tyrp1 as indicated.

Genetic analysis provides the strongest evidence for the MC1-R receptor function on pigment cells in human skin and hair. The common phenotype of individuals with inactive MC1-R is red hair and pale skin resulting from a low eumelanin-to-pheomelanin ratio. These individuals have normal density of melanocytes in the skin and other sites. Sequencing the MC1-R receptor revealed variation in the coding regions that were more common in red-haired light-skin individuals as compared with dark-haired easy-to-tan individuals (reviewed in Ref. [81]). In particular, the red-haired population is homozygous for Arg151Cys, Arg160Trp, or Asp294His, and, in rarer cases, for Arg142His (Fig. 11-14B). The presence of one allele carried a sixfold risk ratio of red hair (i.e., heterozygote individuals) and the presence of two alleles carried a twentyfold risk ratio of red hair (i.e., compound heterozygote). Each of these alleles inactivate the MC1-R receptor, suppressing the production of cAMP by adenylate cyclase. An inactivating mutation in POMC is also associated with red hair in addition to a more complicated endocrine phenotype. [76] Therefore, the presence of inactive MC1-R is a major determinant for sun-sensitivity and increased risk to develop melanomas. [81], [82] It should be noted, however, that there is a rare red-haired population that do not carry the common inactivating MC1-R variants, nor mutations in POMC, and there are dark-haired individuals carrying MC1-R inactivating variants, indicating that other genes may determine the red hair phenotype (reviewed in Ref. [81]).

TANNING IN RESPONSE TO UV LIGHT

Sun-exposed tanning is one of the most visible manifestations of pigment cell activity in the skin and is the natural defense against the deleterious effect of UV radiation. The solar radiation that activates melanocytes is in the nonvisible range of ultraviolet (UV) light (290 to 400 nm). UV light acts as a mutagen and a tumor promoter. It induces cellular damage, including oncogenic mutations and promotes melanocyte proliferation. Excessive exposure to UV light early in life can be manifested later on as malignant transformation of melanocytes, i.e., melanomas due to the proliferation of DNA-damaged neonatal melanocyte progenitors [83], [84] (see also Chap. 38 and Chap. 134).

Immediate Pigment Darkening

Tanning develops in two phases, the early (transitory) and late (stable) response. The immediate transitory darkening in response to long-wave ultraviolet radiation (UVA, 340 to 400 nm) is known as *immediate pigment darkening* (IPD). Its physiologic role is not clear because it provides very little protection against harmful solar radiation. The principal mechanism is photo-oxidation of preexisting melanin, melanin precursors, and/or melanin metabolites. [85], [86] The effect of UVA on melanocytes is direct, as the presence of keratinocytes does not modulate the response. [87] Other proposed changes, such as in cytoskeletal distribution, movement of melanosomes to melanocyte dendrites, increased melanosome transfer, and changes in the pattern of melanosome distribution within keratinocytes, remain controversial [86] (see also Chap. 88).

The Stable Response: Indirect Effects of Ultraviolet on Melanocytes

The long-term effect on pigmentation in response to UV irradiation is due to both direct and indirect effects on melanocytes. UV light activates melanocyte proliferation, the production of melanin and the transfer of melanosomes to keratinocytes. The most convincing evidence for the indirect effect of UV light is the observation that the number of dividing melanocytes increases not only in the exposed skin but also in shielded areas [88] (reviewed in Ref. [89]). The major components that mediate the indirect activation are epidermal keratinocytes and probably fibroblasts in the stroma. UVB activates keratinocytes and fibroblasts to produce factors that stimulate melanocytes. These factors include bFGF, HGF/SF, MGF (Steel factor), ET1, POMC, nitric oxide, and proinflammatory cytokines. Some of these factors, such as bFGF, HGF/SF, and ET1, are potent melanocyte mitogens that act in synergy. [90] ET1, in addition, increases dendricity, and MGF/Steel and POMC are particularly efficient at upregulation of pigmentation. UVB activation of POMC expression in keratinocytes in vivo precedes the activation of melanocyte specific genes involved in pigment synthesis such as tyrosinase, Tyrp1, DCT, and gp100/Pmel17, suggesting a cause and effect [91] (Fig. 11-16). The increase in POMC production in response to UVB may also serve to amplify the signal because MSH increases the levels of cell surface receptors in melanocytes. [92] UV enhances the availability of growth factors by regulating the levels of the respective mRNAs for POMC and for various cytokines, [93] or by activation of the plasminogen activator-plasmin system that induces the release of latent stores in the extracellular matrix. [94], [95]

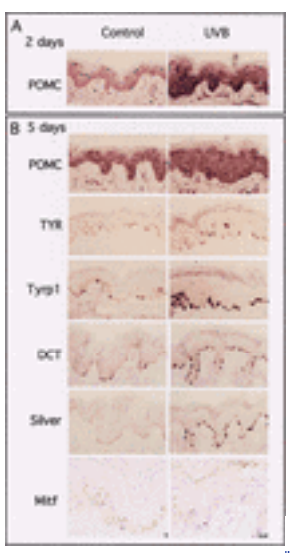

FIGURE 11-16 Upregulation of melanocyte-specific genes in human skin in vivo in response to UVB radiation. The expression of POMC in keratinocytes and a panel of melanocyte specific genes (as indicated) in melanocytes is detected by in situ hybridization with gene-specific probes. *A.* POMC expression after 2 days of UVB treatment (equivalent to 2

MED). Very small changes were detected in mRNA levels of melanocyte-specific genes in melanocytes (not shown). *B.* Expression of mRNA after 5 days of UV treatment. Skin sections from control non-irradiated and UVB-irradiated areas stained with the indicated probes are presented. POMC, precursor proopiomelanocortin; TYR, tyrosinase; DCT, DOPAchrome tautomerase. (*From Suzuki I et al,* [91] *with permission.*)

Tanning in response to UVB irradiation is further amplified by the enhanced keratinocyte uptake of melanosomes. This process is mediated at least in part by PAR-2. [73], [96] PAR-2 is a seven-transmembrane G-protein–coupled receptor that is related to, but distinct from, the thrombin receptors. [73] Cleavage of the extracellular domain of PARs by serine proteases exposes new N-termini, which then act as tethered ligands (Fig. 11-17A). This activation process can be mimicked by the synthetic peptide SLIGKV that corresponds to the newly created N-termini, and is inhibited by trypsin inhibitors. A role for PAR-2 in melanosomal uptake was demonstrated by increased melanosome uptake by keratinocytes in response to SLIGKV. Furthermore, UVB irradiation induces secretion of protease in keratinocytes, which cleaves a peptide comprising the PAR-2 cleavage site in a dose-dependent manner. In an experimental skin model, UVB-induced tanning was inhibited by trypsin inhibitor. Similarly, PAR-2 distribution in the human epidermis that is skin-type-dependent is upregulated following UV irradiation (Fig. 11-17B), and topical treatments with trypsin inhibitors prevent UV-induced tanning, [96] demonstrating its role in melanosome transfer and the tanning response.

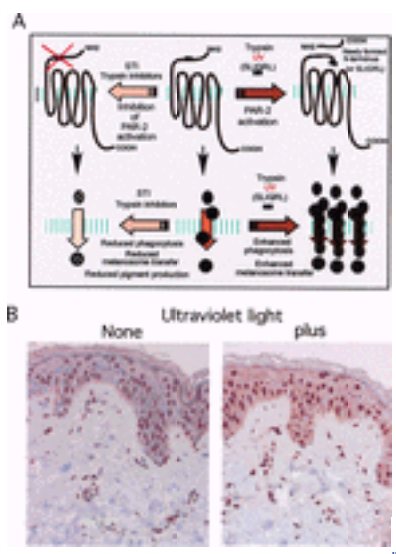

FIGURE 11-17 PAR-2 activation and melanosomal transfer in response to UVB irradiation. *A.* Representation of PAR-2 activation and inhibition and the effects on keratinocyte phagocytosis and melanosome transfer. STI, soybean trypsin inhibitor. *(From Seiberg M,* [73] *with permission.) B.* UVB upregulates PAR-2 expression in type I human skin. Representative samples of control and 24-h UVR-treated skin sections stained for PAR-2. Control shows predominantly basal distribution of PAR-2, whereas immunoreactivity of PAR-2 in postirradiated skin is throughout the epidermis. (*From Scott GA et al,* [96] *with permission.*)

Direct Effect of Ultraviolet B on Melanocytes

UVB induces a transient increase in DNA synthesis and upregulation of melanocyte specific genes in pure cultures of melanocytes, indicating a direct effect not mediated by keratinocytes. This stimulatory activity is likely to be mediated by UV-induced activation of growth factor receptors, as shown for the epidermal growth factor receptor and the insulin receptor. [97], [98] Receptor activation leads to signaling through several intermediates, including Grb-2, phospholipase C-?, and Shc, to the Ras-MAPK cascade (see below, " Melanocyte Growth Factors and Signal Transduction"). This ligand-independent receptor activation is mediated by partial inactivation of receptor-directed tyrosine phosphatases (PTP), such as SHP-1, RPTPa, RPTPs, and DEP-1, that downregulate receptor autophosphorylation. [98] Consequently, receptor activation by UV is likely to involve mostly receptors that are overexpressed at the cell membrane and that undergo spontaneous dimerization and *trans*-phosphorylation/activation. [99] Suppression of PTP by UV could be caused by oxidation of the active center cysteine through an oxidative intermediate because it was prevented and partially reversed by the thiol-protecting agent *N*-acetylcysteine (NAC). [98]

An alternative pathway, which may contribute to tyrosinase upregulation, involves UVB-induced phosphorylation of the transcription factor USF-1 by the stress kinase p38. [100] In this scenario, constitutive expression of tyrosinase is dependent on Mitf, but activation above basal levels is contingent on USF-1 activation. The p38-signaling cascade plays a major role in the cellular response to stress or proinflammatory cytokines. Therefore, activation of p38 may also be induced indirectly by the proinflammatory cytokines produced by UV-irradiated keratinocytes. [93]

REGULATORS OF MELANOCYTE-SPECIFIC GENE EXPRESSION

Melanocyte-specific genes are induced as neural crest cells destined to become melanocytes migrate out and reach their site of residency. The precise timing of each melanocytic marker is not clear. However, Mitf appear first, followed by DCT, Tyrp1, and tyrosinase. The among the proteins that have been studied, it is apparent that Kit and observations that Mitf/Kit/DCT/ Tyrp1-positive amelanotic melanocytes are present in the hair follicle, and possibly also in the skin, are consistent with the notion that tyrosinase expression and/or activity are among the last to be established. Therefore, the definitions of a melanoblast and a melanocyte-precursor will be more precise once the panel of melanocyte-specific genes expressed by these cells is determined.

Numerous transcription factors play critical roles in regulating gene expression within developing melanocytes and their

precursors. Mitf is most notable among the transcription factors whose mutations specifically affect melanocyte development. Mitf is a transcription factor in the basic/helix-loop-helix/leucine-zipper family, which includes the closely related factors TFE3, TFEC, and TFEB, and the less-closely related Myc proto-oncogene and USF families with which it shares nearly identical DNA binding (and possibly target gene) specificity. Mitf first plays a role in promoting the transition of precursor cells to melanoblasts and, subsequently, in melanoblast survival by influencing Kit expression. [101] Mitf expression is maintained during early and late stages of melanocyte development from the neural crest and later on in the normal adult epidermal melanocytes. Although the precise identity of Mitf's target genes remains incomplete, the consensus DNA sequence recognized by Mitf is found (and highly conserved) in many of the major pigmentation genes including tyrosinase, Tyrp1, DCT, and AIM-1/MATP (reviewed in Refs. [68] and [102]). This observation, coupled to Mitf's ability to stimulate artificial promoters derived from these genes, as well as Mitf's regulation by the melanocortin signaling pathway (see below, in " Transcriptional Regulation of Mitf Expression " and " Post-Translational Regulation of Mitf "), suggest that Mitf plays a central role in regulating the pigmentation response in melanocytes.

Other transcription factors that exert major effect on melanocytes are Sox10 and Pax3, members of transcription factor families heavily implicated in developmental regulation for multiple organ systems. Both are expressed early in melanocyte development, and both are likely to remain active at later stages as well. As neural crest cells arrive at the dorsolateral surface, there is some evidence that they retain the capacity to differentiate into either glial cells or melanocytes. This dual lineage choice matches the expression pattern for Sox10, which is seen in both glial tumors and melanomas. In fact, these cancer types share a number of biological features, which, for the most part, connote poor prognosis, and it is plausible that Sox10 expression may underlie some of the shared characteristics. [6], [103], [104]

Transcriptional Regulation of Mitf Expression

The Mitf gene has multiple promoters, each of which contributes alternative initial exons via splicing to a common downstream body of the gene. The major transactivation, DNA binding, and dimerization motifs are all located within the common region of Mitf, so that alternative promoter/first exon usage may be more important for tissue specific expression than for varied protein functions. One of the promoters is thought to be only active in melanocytes and insights into the regulation of this element have provided a remarkable mechanistic linkage for multiple disease genes and factors vital to melanocyte development [5], [102], [105] (Fig. 11-18A, Fig. 11-18B). For example, this melanocyte-restricted Mitf promoter contains a perfect consensus binding sequence for the Tcf/Lef family, which recruits ß-catenin as part of the Wnt signaling pathway critical to early neural crest–melanocyte differentiation (Fig. 11-18C). Another sequence element, located ˜50 base pairs downstream of the TCF/Lef site, is a consensus for the CREB/ATF transcription factor family. CREB becomes activated by phosphorylation after MSH stimulation and is responsible for activating Mitf expression in that context (reviewed in Refs. [5] and [6]). Approximately 50 base pairs upstream of the TCF/Lef, site two additional DNA sequence elements are found, one which is recognized by Sox10 and one by Pax3 (Fig. 11-18C). Each of these Mitf promoter elements is conserved across species between human and mouse and appears to place the transcriptional regulation of Mitf in the center of multiple signaling and transcriptional pathways, which are vital to melanocyte development.

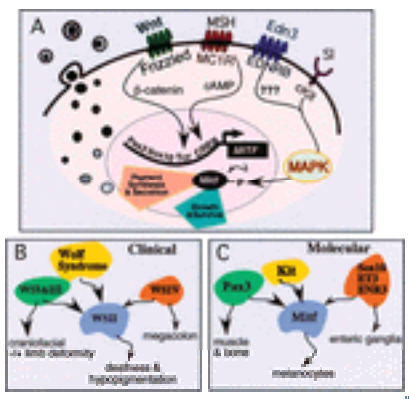

FIGURE 11-18 Regulation of Mitf in response to extracellular signals. *A.* Activation of a cell surface receptor induces *MITF* expression via the ß-catenin and cAMP pathway (induced by Frizzled and the MCR receptors) that impacts on activation of Tcf/Lef and CREB transcription factors, or via phosphorylation induced by MAPK activation (denoted by P). *B* and *C.* Representation of human syndromic deafness conditions associated with hypopigmentation. *B.* Clinical overlaps and divergences. *C.* Molecular relationships of genes implicated in each syndrome. (*From Price ER, Fisher DE* [6], *with permission.*)

Posttranslational Regulation of Mitf

Several growth factors receptor systems impact Mitf activity and expression in melanocytes (Fig. 11-18C). Activation of Kit by Steel results in MAP kinase-mediated phosphorylation of Mitf at a serine residue (S73), which is highly conserved between species. In addition, MAP kinase activates a second kinase, p90 [RSK], to phosphorylate Mitf at another serine residue (S409). These phosphorylations have the dual effect of enhancing binding by coactivators of the p300 family (thus enhancing gene expression), and targeting Mitf for rapid degradation by the ubiquitin-proteasome pathway, a common end-result for activated transcription factors. [106] Rsk activation is also important because one of its known targets is CREB, through which it is likely to upregulate the Mitf promoter in melanocytes. Other ligand/receptor systems also activate MAP kinase, such as HGF/Met, ET3/EdnrB, and a-MSH/melanocortin, suggesting that Mitf is a common target for extracellular signals (reviewed in Ref. [5]).

Mitf and Inherited Human Pigmentation Disorders

Mitf's role as a factor upon which multiple melanocyte developmental pathways converge is highlighted by the phenotypic

and molecular defects seen in a group of related human pigmentation disorders. These disorders most prominently affect melanocyte viability (rather than melanin production per se) and therefore exhibit associated clinical features such as deafness, due to deficiencies of inner ear melanocytes. Waardenburg syndrome (WS) encompasses many of these disorders (see also Chap. 90). It is an autosomal dominant disorder (therefore affecting heterozygotes) characterized by a white forelock and sensorineural deafness. The syndrome is subdivided into four subtypes on the basis of presence or absence of additional discrete clinical features. Type II WS exhibits a “core” melanocyte phenotype, while types I and III exhibit, in addition, craniofacial and skeletal deformities and type IV exhibits megacolon due to defective neural crest–derived enteric ganglia. Additional highly related clinical conditions are Wolf syndrome and Tietz-Smith syndrome, both of which exhibit the core melanocyte defects, though of variable severity.

Molecular lesions have been defined for most of these clinical entities and provide a remarkable linkage to the mechanistic pathways outlined above. WSII patients contain either mutations within Mitf itself or another gene yet to be identified. WSI and III patients harbor mutations within Pax3, and WSIV patients contain mutations in Sox10, ET3, or EdnrB. [6] In addition, Tietz-Smith syndrome patients contain Mitf mutations and Wolf syndrome patients contain inactivating mutations in *c*-kit. Thus a picture emerges wherein the phenotypic consequences of specific molecular lesions reflect the developmental requirements for specific factors in melanocytes and sometimes nonmelanocytes. The melanocyte phenotypes for all these mutants might arise through their common targeting of Mitf, while the nonmelanocyte phenotypes are particular to the other lineages in which the factor(s) are expressed (such as enteric ganglia precursors for Sox10). These molecular-phenotypic connections have enlightened the understanding of the pathways through which environmental cues transmit discrete signals to the nucleus, and the resulting transcriptional programs of importance to the developing melanocyte. Because Mitf is such a key transcriptional regulator in melanocytes, it will be of considerable interest to identify its target genes. This point is particularly pertinent because of the evidence implicating Mitf in both proliferation/survival and pigmentation/differentiation pathways.

MELANOCYTE GROWTH FACTORS AND SIGNAL TRANSDUCTION

For a long time, the study of melanocyte proliferation in vitro was restricted to the use of melanoma cells (especially the murine melanoma B16 and Cloudman S91 cell lines), because attempts to establish normal melanocytes in culture using the standard, serum-supplemented medium, failed. As it turned out, this particular feature of normal melanocytes is the key for understanding their growth controls, as well as phenotypic changes during malignant transformation. Studies by several investigators have shown that, in addition to common mammalian growth factors such as insulin and transferrin, melanocytes require at least two stimulators that act in synergy (reviewed in Ref. [89]) (Fig. 11-19A). The list of synergistic peptide mitogens for human melanocytes in vitro, mirrors that required for melanocyte development during embryogenesis. They include HGF, Steel factor, ET1, and FGF2). So far, FGF2 is the only growth factor without a parallel inherited depigmentation defect. One possible reason is the numerous peptide growth factors in this family with overlapping activity (22 all together).

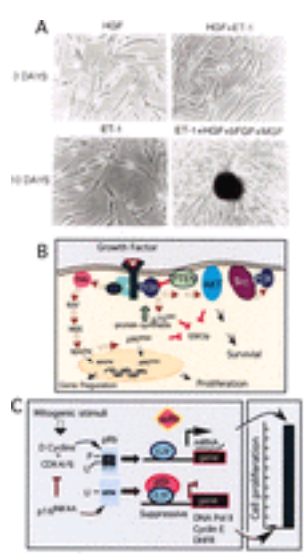

FIGURE 11-19 Proliferation and signal transduction in normal human melanocytes. *A.* Proliferative synergism among selected peptide growth factors. Normal neonatal human melanocytes were incubated in chemically defined medium in the presence of specific peptide growth factors. The photomicrographs show morbid melanocytes cultured for 3 days in the presence of HGF/SF alone (*top left*), proliferating melanocytes in HGF/SF plus ET1 (*top right*), surviving cells with ET1 alone for 10 days (*bottom left*), and highly proliferating cells in presence of four growth factors as indicated (*bottom right*). *(From Böhm M et al* [91], *with permission.) B.* The critical intermediates in growth factor–mediated signal transduction. The phosphorylated tyrosine residues on the activated receptor create docking sites for several preformed complexes of proteins that induce Ras activation by exchanging GDP (guanine diphosphate) with GTP (guanine triphosphate). Ras, in turn, activates a series of tyrosine and serine/threonine kinases known as the MAPK and the PI3K cascades (*orange arrows*). The message emanating from the cell surface is then delivered to the transcriptional machinery in the nucleus by the translocation of phosphorylated forms of several intermediates including MAPK and $p90^{RSK}$ (*arrows*). In addition, the activated Ser/Thr kinases phosphorylate GSK3ß and inactivate its kinase activity (*red bars*). Consequently, factors regulating growth as well as differentiation are induced. Constitutive activation of some members in this pathway, such as aberrant production of growth factors that constantly activate their receptor, overexpression and/or mutational activation of a receptor, and Ras activation (by mutations or by receptor activation), can lead to perpetual mode of proliferation and cellular transformation. *C.* Control of cell-cycle progression by pocket proteins pRb-regulated E2F transcription factors. The model depicts the accepted hypothesis by which mitogenic signals upregulate CDK activity and phosphorylate/inactivate proteins from the retinoblastoma tumor suppressor family (pRb, p107, and p130) (*green arrow*), allowing the production of free E2F transcription factor and the progression from quiescence (G_0/G_1 phase) to DNA synthesis (S phase). Key molecules in CDK regulation are the positive activators cyclins, and the negative regulators, such as $p16^{INK4}$ (*brown arrow*).

Signal Transduction: Immediate Events

Stimulation by growth factors activates the cognate receptors and triggers within seconds, the activation of key regulators of cell growth, such as Ras, which, in turn, activates multiple effector pathways including the Raf/Mek/MAPK cascade (for short, the MAPK pathway, mitogen-activated protein kinase, known also as extracellular-signal regulated kinase or ERK) and PI3K (reviewed in Ref. [107]) (Fig. 11-19B). Each of the melanocyte growth factors described above can activate Ras effectors to various degrees, such as the downstream targets MAPK, p90 ^{RSK}, and p70 S6 kinase. [90], [108] The phosphorylation of some of the intermediates, such as MAPK and p90 ^{RSK}, serves to transport them to the nucleus, where they phosphorylate nuclear factors (such as Mitf and CREB) and change their transcriptional activity via the recruitment of critical elements such as CBP (CREB binding protein). However, proliferation requires high levels and prolonged duration of the phosphorylated/activated state of the signal transduction intermediates, induced only by synergistic growth factors [90] (Fig. 11-19B). The stringent requirement for synergistic growth factors may explain the relatively quiescent nature of melanocytes in the skin. Although keratinocytes produce FGF2 continuously, other growth factors, such as ET1 may be induced only in response to UVB irradiation. Interestingly, as melanocytes become senescent and stop proliferating, they also lose their ability to activate the MAPK cascade (reviewed in Ref. [109]), in agreement with the pivotal role of this pathway in cell division.

Signal Transduction: The RB/E2F Pathway

The growth factor–activated MAPK pathway mediates transit of quiescent cells into DNA synthesis (G_1- to S-phase of the cell cycle). This occurs, in large part, by activating a group of cyclin-dependent kinases (CDK2, CDK4, and CDK6) responsible for the sequential phosphorylation and inactivation of the pRb (retinoblastoma) family of tumor suppressor proteins (pRb, p107, and p130). [110] The pRb proteins are regarded as master regulators of the cell cycle governing the restriction (R) point, i.e., the point of commitment from quiescence (G_0/G_1) to DNA synthesis (S), by regulating the activity of transcription factors from the E2F family (reviewed in Ref. [111]).

The activity of CDKs is coordinated by association with the positive cyclin partners (cyclin D, cyclin A, and cyclin E), and the negative regulators cyclin-dependent kinase inhibitors, termed CKI, belonging to the INK or CIP/KIP families of inhibitors, as well as by site-specific phosphorylations or dephosphorylations carried out by the cyclin activating kinase (CAK) and Cdc25 phosphatase, respectively. Hyperphosphorylation of pRb and family members releases their suppressive association with E2F transcription factors (E2F1 to E2F5). This leads to the accumulation of E2F transcriptional activity and activation of genes responsible for cell-cycle progression (cyclin A, cyclin D1, cyclin E, cdc2, p107, and p21 ^{CIP1}), DNA synthesis (dihydrofolate reductase and DNA polymerase a), and transcription factors c-MYC, c-MYB, B-MYB, as well as E2F1 and E2F2, that participate in induction of early and late response genes (Fig. 11-19C).

Dysregulation of the Rb/E2F pathway is considered a major pathogenic event in cancer cells, including melanomas. Decreased p16 ^{INK4A} CDK-inhibitory activity, which results from gene deletion, transcriptional silencing, or mutation is common in melanomas (reviewed in Ref. [112]). Ablation of p16 ^{IKN4A} in mice leads to the development of several tumors, including melanoma, a process enhanced by treatments with a carcinogen. [113] However, elimination of the negative regulators of CDKs is not sufficient to cause an immediate change in the growth properties of melanocytes. Individuals homozygous for null p16 ^{IKN4A} mutations do not always develop melanomas, and mouse melanocytes with homozygous disruption of p16 ^{INK4A}, p21 ^{CIP1}, or p27 ^{KIP1} are dependent on, and respond normally to, mitogenic stimuli. Furthermore, although p21 ^{CIP1} and p27 ^{KIP1} were originally described as a CDK inhibitors when artificially expressed at high levels, more recent studies demonstrated that these two proteins have a positive role in proliferation by facilitating multicomplex formation between cyclins, CDK, and associated proteins.

E2F Transcription Factors

Exposure to synergistic growth factors, such as FGF2 in combination with HGF/SF, or ET1, or all three factors, is required for maximum stimulation of cyclin levels (cyclin D1 and cyclin A), phosphorylation of the three pRb family of proteins (pRb, p107, and p130), and the accumulation of free E2F-DNA binding activity [114] (Fig. 11-19C). Interestingly, E2F-DNA binding analysis revealed that among the five E2F family members, E2F2 and E2F4 contribute to the major E2F-binding activity in proliferating melanocytes. In growth factor–starved melanocytes, free (and active) E2F-DNA binding activity is drastically reduced, and transcriptional suppressive activity composed of E2F4 in complex with p130, and to a lesser extent pRb, accumulates. [114] In melanoma cells, in contrast, E2F-DNA binding activity is constitutively high, even in the absence of melanocyte growth factors, due mostly to inactivation of pRb by persistent CDK activity and upregulation of the E2F dimerization partner DP1. [114] Inhibition of CDK activity in melanoma cells reconstitutes pRb growth suppressive activity, suggesting a mechanism to control this tumor in patients.

FUTURE PERSPECTIVES

Enormous strides have been made in our understanding of the molecular, cellular, and genetic makeup of pigment cells, since their original description 100 years ago. Indeed, melanocyte biology has emerged as a paradigm for the understanding of tissue-restricted development and homeostasis, based largely upon the rich resource of human and animal genetic mutations whose altered pigmentation minimally affects survival of the host. The future promises increasing opportunities to connect these genetic lesions to the mechanistic pathways they modulate. With the arrival of the postgenomic era, it is increasingly feasible to surmise transcriptional regulatory networks that will connect the effectors of pigmentation to the networks that regulate them. Proteomics promises to provide a new dimension to this analysis, because much of melanocyte biology is regulated at the posttranslational level. Melanocytes represent a novel cell population with the unique mission of protecting and even embellishing the host through pigmentation. Unfortunately,

melanocytes also participate in some of the worst human diseases such as melanoma, which will, hopefully, be more effectively treated as the inner workings of this cell are revealed.

REFERENCES

1. Christiansen JH, Coles EG, Wilkinson DG: Molecular control of neural crest formation, migration and differentiation. *Curr Opin Cell Biol* **12**:719, 2000

2. Jin EJ et al: Wnt and BMP signaling govern lineage segregation of melanocytes in the avian embryo. *Dev Biol* **233**:22, 2001

3. Dunn KJ et al: Neural crest-directed gene transfer demonstrates Wnt1 role in melanocyte expansion and differentiation during mouse development. *Proc Natl Acad Sci U S A* **97**:10050, 2000

4. Grimes CA, Jope RS: The multifaceted roles of glycogen synthase kinase 3beta in cellular signaling. *Prog Neurobiol* **65**:391, 2001

5. Goding CR: MITF from neural crest to melanoma: Signal transduction and transcription in the melanocyte lineage. *Genes Dev* **14**:1712, 2000

6. Price ER, Fisher DE: Sensorineural deafness and pigmentation genes: Melanocytes and the Mitf transcriptional network. *Neuron* **30**:15, 2001

7. Vliagoftis H, Worobec AS, Metcalfe DD: The protooncogene *c-kit* and *c-kit* ligand in human disease. *J Allergy Clin Immunol* **100**:435, 1997

8. Blume-Jensen P, Hunter T: Oncogenic kinase signaling. *Nature* **411**:355, 2001

9. Longley BJ Jr et al: Activating and dominant inactivating *c-kit* catalytic domain mutations in distinct clinical forms of human mastocytosis. *Proc Natl Acad Sci U S A* **96**:1609, 1999

10. Ito M et al: Removal of stem cell factor or addition of monoclonal anti- *c-kit* antibody induces apoptosis in murine melanocyte precursors. *J Invest Dermatol* **112**:796, 1999

11. Kunisada T et al: Murine cutaneous mastocytosis and epidermal melanocytosis induced by keratinocyte expression of transgenic stem cell factor. *J Exp Med* **187**:1565, 1998

12. Kos L et al: Met-HGF signaling is critical for melanocyte development: Implications for Waardenburg syndrome Type II. *Pigment Cell Res* **10**:107, 1997

13. Kunisada T et al: Keratinocyte expression of transgenic hepatocyte growth factor affects melanocyte development, leading to dermal melanocytosis. *Mech Dev* **94**:67, 2000

14. Jackson IJ: Homologous pigmentation mutations in human, mouse and other model organisms. *Hum Mol Genet* **6**:1613, 1997

15. Hou L, Panthier JJ, Arnheiter H: Signaling and transcriptional regulation in the neural crest-derived melanocyte lineage: Interactions between KIT and MITF. *Development* **127**:5379, 2000

16. Nakagawa S, Takeichi M: Neural crest emigration from the neural tube depends on regulated cadherin expression. *Development* **125**:2963, 1998

17. Nishimura EK et al: Regulation of E- and P-cadherin expression correlated with melanocyte migration and diversification. *Dev Biol* **215**:155, 1999

18. Jouneau A et al: Plasticity of cadherin-catenin expression in the melanocyte lineage. *Pigment Cell Res* **13**:260, 2000

19. Herlyn M et al: Lessons from melanocyte development for understanding the biological events in naevus and melanoma formation. *Melanoma Res* **10**:303, 2000

20. Fitzpatrick TB, Breathnach AS: Das epidermale Melanin-Einheitsystem. *Dermatol Wochenschr* **147**:481, 1963

21. Minwalla L et al: Keratinocytes play a role in regulating distribution patterns of recipient melanosomes in vitro. *J Invest Dermatol* **117**:341, 2001

22. Tobin DJ, Paus R: Graying: Gerontobiology of the hair follicle pigmentary unit. *Exp Gerontol* **36**:29, 2001

23. King RA: Albinism, in *The Pigmentary System Physiology and Pathophysiology,* edited by JJ Nordlund, R Boissy, VJ Hearing, RA King, J-P Ortonne. New York, Oxford University Press, 1998, p 553

24. Tachibana M: Sound needs sound melanocytes to be heard. *Pigment Cell Res* **12**:344, 1999

25. Holme RH, Steel KP: Genes involved in deafness. *Curr Opin Genet Dev* **9**:309, 1999

26. Ando M, Takeuchi S: Immunological identification of an inward rectifier K+ channel (Kir4.1) in the intermediate cell (melanocyte) of the cochlear stria vascularis of gerbils and rats. *Cell Tissue Res* **298**:179, 1999

27. Cable J, Jackson IJ, Steel KP: Light (Blt), a mutation that causes melanocyte death, affects stria vascularis function in the mouse inner ear. *Pigment Cell Res* **6**:215, 1993

28. Read RW, Rao NA, Cunningham ET: Vogt-Koyanagi-Harada disease. *Curr Opin Ophthalmol* **11**:437, 2000

29. Nguyen M, Arnheiter H: Signaling and transcriptional regulation in early mammalian eye development: A link between FGF and MITF. *Development* **127**:3581, 2000

30. Incerti B et al: OA1 knock-out: New insights on the pathogenesis of ocular albinism type 1. *Hum Mol Genet* **9**:2781, 2000

31. d'Addio M et al: Defective intracellular transport and processing of OA1 is a major cause of ocular albinism type 1. *Hum Mol Genet* **9**:3011, 2000

32. Raper HS: The aerobic oxidases. *Physiol Rev* **8**:245, 1928

33. Lerner AB et al: Mammalian tyrosinase: Preparation and properties. *J Biol Chem* **178**:185, 1949

34. Riley PA: The great DOPA mystery: The source and significance of DOPA in phase I melanogenesis. *Cell Mol Biol* **45**:951, 1999

35. Halaban R et al: Proper folding and ER to Golgi transport of tyrosinase are induced by its substrates, DOPA and tyrosine. *J Biol Chem* **276**:11933, 2001

36. Pawelek JM, Chakraborty AK: The enzymology of melanogenesis, in *The Pigmentary System Physiology and Pathophysiology,* edited by JJ Nordlund, R Boissy, VJ Hearing, RA King, JP Ortonne. New York, Oxford University Press, 1998, p 391

37. Prota G, D'Ischia M, Napolitano A: The chemistry of melanin and related compounds, in *The Pigmentary System Physiology and Pathophysiology,* edited by JJ Nordlund, R Boissy, VJ Hearing, RA King, JP Ortonne. New York, Oxford University Press, 1998, p 307

38. De Leeuw SM et al: Melanin content of cultured human melanocytes and UV-induced cytotoxicity. *J Photochem Photobiol B* **61**:106, 2001

39. Marrot L et al: The human melanocyte as a particular target for UVA radiation and an endpoint for photoprotection assessment. *Photochem Photobiol* **69**:686, 1999

40. Hill HZ, Hill GJ: UVA, pheomelanin and the carcinogenesis of melanoma. *Pigment Cell Res* **8**:140, 2000

41. Wenczl E et al: (Pheo)melanin photosensitizes UVA-induced DNA damage in cultured human melanocytes. *J Invest Dermatol* **111**:678, 1998

42. Dell' Angelica EC et al: Lysosome-related organelles. *FASEB J* **14**:1265, 2000

43. Marks MS, Seabra MC: The melanosome: Membrane dynamics in black and white. *Nat Rev Mol Cell Biol* **2**:738, 2001

44. Helenius A, Aebi M: Intracellular functions of *N*-linked glycans. *Science* **291**:2364, 2001

45. Halaban R et al: Aberrant retention of tyrosinase in the endoplasmic reticulum mediates accelerated degradation of the enzyme and contributes to the dedifferentiated phenotype of amelanotic melanoma cells. *Proc Natl Acad Sci U S A* **94**:6210, 1997

46. Halaban R et al: Endoplasmic reticulum retention is a common defect associated with tyrosinase-negative albinism. *Proc Natl Acad Sci U S A* **97**:5889, 2000

47. Toyofuku K et al: The molecular basis of oculocutaneous albinism type 1 (OCA1): Sorting failure and degradation of mutant tyrosinases results in a lack of pigmentation. *Biochem J* **355**:259, 2001

48. Toyofuku K et al: Promotion of tyrosinase folding in Cos 7 cells by calnexin. *J Biochem* **125**:82, 1999

49. Berson JF et al: A common temperature-sensitive allelic form of human tyrosinase is retained in the endoplasmic reticulum at the nonpermissive temperature. *J Biol Chem* **275**:12281, 2000

50. Toyofuku K et al: Oculocutaneous albinism types 1 and 3 are ER retention diseases: Mutation of tyrosinase or Tyrp1 can affect the processing of both mutant and wild-type proteins. *FASEB J* **15**:2149, 2001

51. Manga P et al: Mutational analysis of the modulation of tyrosinase by tyrosinase-related proteins 1 and 2 in vitro. *Pigment Cell Res* **13**:364, 2000

52. Orlow SJ et al: High-molecular-weight forms of tyrosinase and the tyrosinase-related proteins: Evidence for a melanogenic complex. *J Invest Dermatol* **103**:196, 1994

53. Jimenez-Cervantes C et al: Molecular interactions within the melanogenic complex: Formation of heterodimers of tyrosinase and TRP1 from B16 mouse melanoma. *Biochem Biophys Res Commun* **253**:761, 1998

54. Mosse CA et al: The class I antigen-processing pathway for the membrane protein tyrosinase involves translation in the endoplasmic reticulum and processing in the cytosol. *J Exp Med* **187**:37, 1998

55. Kang XQ et al: Identification of a tyrosinase epitope recognized by HLA-A24-restricted, tumor-infiltrating lymphocytes. *J Immunol* **155**:1343, 1995

56. Topalian SL et al: Human CD4+ T cells specifically recognize a shared melanoma-associated antigen encoded by the tyrosinase gene. *Proc Natl Acad Sci U S A* **91**:9461, 1994

57. Warburg O: On the origin of cancer cells. *Science* **123**:309, 1956

58. Beermann F et al: Misrouting of tyrosinase with a truncated cytoplasmic tail as a result of the murine platinum (c^{p}) mutation. *Exp Eye Res* **61**:599, 1995

59. Vijayasaradhi S et al: Intracellular sorting and targeting of melanosomal membrane proteins—identification of signals for sorting of the human brown locus protein, gp75. *J Cell Biol* **130**:807, 1995

60. Calvo PA et al: A cytoplasmic sequence in human tyrosinase defines a second class of di-leucine–based sorting signals for late endosomal and lysosomal delivery. *J Biol Chem* **274**:12780, 1999

61. Honing S, Sandoval IV, von Figura K: A di-leucine–based motif in the cytoplasmic tail of LIMP-II and tyrosinase mediates selective binding of AP-3. *EMBO J* **17**:1304, 1998

62. Spritz RA: Multi-organellar disorders of pigmentation: Tied up in traffic. *Clin Genet* **55**:309, 1999

63. Schiaffino MV et al: The ocular albinism type 1 gene product is a membrane glycoprotein localized to melanosomes. *Proc Natl Acad Sci U S A* **93**:9055, 1996

64. Brilliant M, Gardner J: Melanosomal pH, pink locus protein and their roles in melanogenesis. *J Invest Dermatol* **117**:386, 2001

65. Brilliant MH: The mouse p (pink-eyed dilution) and human P genes, oculocutaneous albinism type 2 (OCA2), and melanosomal pH.

Pigment Cell Res **14**:86, 2001

66. Newton JM et al: Mutations in the human orthologue of the mouse underwhite gene (uw) underlie a new form of oculocutaneous albinism, OCA4. *Am J Hum Genet* **69**:981, 2001

67. Fukamachi S, Shimada A, Shima A: Mutations in the gene encoding B, a novel transporter protein, reduce melanin content in medaka. *Nat Genet* **28**:381, 2001

68. Du J, Fisher DE: Identification of Aim-1 as the underwhite mutant and its transcriptional regulation by MITF. *J Biol Chem* **7**:7, 2001

69. Potterf SB et al: Normal tyrosine transport and abnormal tyrosinase routing in pink-eyed dilution melanocytes. *Exp Cell Res* **244**:319, 1998

70. Menasche G et al: Mutations in RAB27A cause Griscelli syndrome associated with haemophagocytic syndrome. *Nat Genet* **25**:173, 2000

71. Pastural E et al: Two genes are responsible for Griscelli syndrome at the same 15q21 locus. *Genomics* **63**:299, 2000

72. Bahadoran P et al: Rab27a: A key to melanosome transport in human melanocytes. *J Cell Biol* **152**:843, 2001

73. Seiberg M: Keratinocyte-melanocyte interactions during melanosome transfer. *Pigment Cell Res* **14**:236, 2001

74. Lu D, Chen W, Cone RD: Regulation of melanogenesis by MSH, in *The Pigmentary System Physiology and Pathophysiology,* edited by JJ Nordlund, R Boissy, VJ Hearing, RA King, JP Ortonne. New York, Oxford University Press, 1998, p 183

75. Wikberg JE et al: New aspects on the melanocortins and their receptors. *Pharmacol Res* **42**:393, 2000

76. Krude H, Gruters A: Implications of proopiomelanocortin (POMC) mutations in humans: The POMC deficiency syndrome. *Trends Endocrinol Metab* **11**:15, 2000

77. Hadley ME et al: Discovery and development of novel melanogenic drugs. Melanotan-I and-II. *Pharm Biotechnol* **11**:575, 1998

78. Barsh GS et al: Molecular pharmacology of Agouti protein in vitro and in vivo. *Ann N Y Acad Sci* **885**:143, 1999

79. Dinulescu DM, Cone RD: Agouti and agouti-related protein: Analogies and contrasts. *J Biol Chem* **275**:6695, 2000

80. Voisey J, Box NF, van Daal A: A polymorphism study of the human Agouti gene and its association with MC1R. *Pigment Cell Res* **14**:264, 2001

81. Rees JL: The melanocortin 1 receptor (MC1R): More than just red hair. *Pigment Cell Res* **13**:135, 2000

82. Palmer JS et al: Melanocortin-1 receptor polymorphisms and risk of melanoma: Is the association explained solely by pigmentation phenotype? *Am J Hum Genet* **66**:176, 2000

83. Whiteman DC, Whiteman CA, Green AC: Childhood sun exposure as a risk factor for melanoma: A systematic review of epidemiologic studies. *Cancer Causes Control* **12**:69, 2001

84. Noonan FP et al: Neonatal sunburn and melanoma in mice. *Nature* **413**:271, 2001

85. Honigsmann H et al: Immediate pigment darkening phenomenon. A reevaluation of its mechanisms. *J Invest Dermatol* **87**:648, 1986

86. Routaboul C, Denis A, Vinche A: Immediate pigment darkening: Description, kinetic and biological function. *Eur J Dermatol* **9**:95, 1999

87. Duval C, Regnier M, Schmidt R: Distinct melanogenic response of human melanocytes in mono-culture, in co-culture with keratinocytes and in reconstructed epidermis, to UV exposure. *Pigment Cell Res* **14**:348, 2001

88. Stierner U et al: UVB irradiation induces melanocyte increase in both exposed and shielded human skin. *J Invest Dermatol* **92**:561, 1989

89. Halaban R: The regulation of normal melanocyte proliferation. *Pigment Cell Res* **13**:4, 2000

90. Böhm M et al: Identification of p90 ^{RSK} as the probable CREB-Ser ^{133} kinase in human melanocytes. *Cell Growth Diff* **6**:291, 1995

91. Suzuki I et al: Increase of POMC mRNA prior to tyrosinase, TYRP1, DCT, Pmel-17, and P-protein mRNAs in human skin after UVB. *J Invest Dermatol* **118**:73, 2002

92. Chakraborty AK et al: UV light and MSH receptors. *Ann N Y Acad Sci* **885**:100, 1999

93. Li D et al: Rays and arrays: The transcriptional program in the response of human epidermal keratinocytes to UVB illumination. *FASEB J* **15**:2533, 2001

94. DeClerck YA: Interactions between tumour cells and stromal cells and proteolytic modification of the extracellular matrix by metalloproteinases in cancer. *Eur J Cancer* **36**:1258, 2000

95. Fujiwara J et al: Identification of the UV-responsive sequence in the human tissue plasminogen activator gene. *Biosci Biotechnol Biochem* **64**:1084, 2000

96. Scott GA et al: Protease-activated receptor-2 (PAR-2), a receptor involved in melanosome transfer, is upregulated in human skin by ultraviolet irradiation. *J Invest Dermatol* **117**:1414, 2001

97. Coffer PJ et al: UV activation of receptor tyrosine kinase activity. *Oncogene* **11**:561, 1995

98. Gross S et al: Inactivation of protein-tyrosine phosphatases as mechanism of UV-induced signal transduction. *J Biol Chem* **274**:26378, 1999

99. Schlessinger J: Cell signaling by receptor tyrosine kinases. *Cell* **103**:211, 2000

100. Galibert MD, Carreira S, Goding CR: The Usf-1 transcription factor is a novel target for the stress-responsive p38 kinase and mediates UV-induced tyrosinase expression. *EMBO J* **20**:5022, 2001

101. Opdecamp K et al: Melanocyte development in vivo and in neural crest cell cultures: Crucial dependence on the MITF

basic-helix-loop-helix-zipper transcription factor. *Development* **124**:2377, 1997

102. Shibahara S et al: Regulation of pigment cell-specific gene expression by MITF. *Pigment Cell Res* **8**:98, 2000

103. Potterf SB et al: Transcription factor hierarchy in Waardenburg syndrome: Regulation of MITF expression by SOX10 and PAX3. *Hum Genet* **107**: 1, 2000

104. Potterf SB et al: Analysis of SOX10 function in neural crest-derived melanocyte development: SOX10-dependent transcriptional control of DOPAchrome tautomerase. *Dev Biol* **237**:245, 2001

105. Fisher DE: Microphthalmia: A signal responsive transcriptional regulator in development. *Pigment Cell Res* **8**:145, 2000

106. Wu M et al: *c-Kit* triggers dual phosphorylations, which couple activation and degradation of the essential melanocyte factor Mi. *Genes Dev* **14**:301, 2000

107. Cobb MH: MAP kinase pathways. *Prog Biophys Mol Biol* **71**:479, 1999

108. Imokawa G, Yada Y, Kimura M: Signaling mechanisms of endothelin-induced mitogenesis and melanogenesis in human melanocytes. *Biochem J* **314**:305, 1996

109. Bandyopadhyay D et al: The human melanocyte: A model system to study the complexity of cellular aging and transformation in non-fibroblastic cells. *Exp Gerontol* **36**:1265, 2001

110. Ewen ME: Where the cell cycle and histones meet. *Genes Dev* **14**:2265, 2000

111. Nevins JR: The Rb/E2F pathway and cancer. *Hum Mol Genet* **10**:699, 2001

112. Ruas M, Peters G: The p16INK4a/CDKN2A tumor suppressor and its relatives. *Biochim Biophys Acta* **1378**:F115, 1998

113. Sharpless NE et al: Loss of p16Ink4a with retention of p19Arf predisposes mice to tumorigenesis. *Nature* **413**:86, 2001

114. Halaban R et al: Deregulated E2F transcriptional activity in autonomously growing melanoma cells. *J Exp Med* **191**:1005, 2000

115. Liu T et al: G protein signaling from activated rat frizzled-1 to the beta-catenin-Lef-Tcf pathway. *Science* **292**:1718, 2001

T>

Chapter 12

Robert Lavker Arthur Bertolino Tung-Tien Sun

Biology of Hair Follicles

EMBRYOLOGY AND ANATOMY
THE HAIR CYCLE
Anagen
Catagen
Telogen
Exogen
DISTRIBUTION OF HAIR
HAIR AS A BIOLOGIC FIBER
Outer Root Sheath and Companion Layer
Cortex
Medulla
Cuticle
HAIR PIGMENTATION
TYPES OF HAIR
REGULATION OF THE HAIR GROWTH CYCLE
Follicular Epithelial Stem Cells
The Hair Follicle as a Guardian of the Epidermis
Involvement of the Hair Follicle in Skin Cancer
Molecular Control of Hair Follicle Development, Differentiation, and Cycling
The Follicular Papilla
Hormones as Regulators of the Hair Cycle

REFERENCES

Hair requires many complex cellular and molecular interactions for its proper formation. Despite its apparent lack of a vital function, for humans the psychological importance of hair is significant. Hair loss can lead to depression, low self-confidence, and humiliation in men and women of all ages. In parallel, growth of facial and body hair in excess of what is deemed culturally acceptable can be just as distressing as hair loss.

From an evolutionary perspective, hairs initially may have served to protect the organism from heat loss and to afford the underlying epidermis a “first line of defense” from abrasion and penetration of noxious chemical agents. The movement of our early ancestors from the shaded tropical rain forests to the exposed savannah may have been accompanied by a gradual loss of dependence on hair as an insulator so that hair on contemporary humans is largely vestigial. While human body hair has little protective value, specialized hairs, such as eyelashes and eyebrows and hairs inside the nostrils and external ears, do afford some protection from the environment. Furthermore, a thick growth of scalp hair provides excellent protection from actinic damage.

Another function of human hair is its role as a “touch organ” involved in sensory reception. [1] All hair follicles have multiple sensory nerve endings that respond to pressure on the hair shaft, thereby providing nearly all the modalities of tactile sensibility. Animals additionally have specialized sinus hairs in the skin of the upper and lower lips, the snout, and above the eyebrows. These tactile hairs (vibrissae), encircled by a blood-filled sinus and with more than 2000 sensory nerve endings, aid nocturnal animals in orientation and function as another set of “eyes.” Hair also acts as a conduit in the delivery of scents secreted by the sebaceous and apocrine glands. Finally, hair is an important component of the body image, conveying a vast array of sexual and social messages through its color and the style in which it is worn.

While the hair fiber itself may not have major functional significance, the cyclic nature of the hair follicle has made this epidermal derivative an excellent model system for studying a number of important biologic problems, including morphogenesis, growth regulation, cell differention, pattern formation, and cyclic control. Since many of these processes are influenced by the mesenchyme, the hair follicle is also an ideal system for investigating mesenchymal-epithelial interactions. In addition, the follicle is believed to play a role in maintaining the epidermis, as well as participating in wound healing and skin tumorigenesis (see below). The recent explosion of data in areas of cellular and molecular biology has helped refine concepts concerning the mechanisms, molecules, and genes that control hair follicle formation, growth, disease, and death.

EMBRYOLOGY AND ANATOMY

In human fetuses, the first primordial hair follicles form at approximately 9 weeks' gestation and are distributed mainly in the areas of the eyebrows, upper lip, and chin. The bulk of the remaining follicles begin to develop at approximately 4 to 5 months' gestation in a cephalad to caudad direction. During fetal life, production of follicles occurs in several interspersed waves. Primary and secondary follicles are formed as the skin expands. The secondary follicle develops on each side of the primary follicle, producing typical groupings of three hairs. It is generally assumed that adult skin cannot develop new follicles under normal circumstances.

Follicular morphogenesis begins with inductive events that involve the exchange of signals between epithelial and mesenchymal cells and proceeds through stages of follicular initiation, elongation, and cellular differentiation. The first signal directing hair follicle formation arises in the mesenchyme, inducing a thickening of the overlying epidermis to form a placode. Epithelial cells within the placode become more elongated than adjacent nonplacode cells. Signals from the placode then induce clustering of the underlying dermal cells to form a dermal condensate, and a “second dermal signal”

from the condensate then induces the proliferation and downward movement of a column of epithelial cells into the dermis, forming the hair germ [2] (Fig. 12-1A). Much progress has been made in identifying the molecules that regulate follicle development. Members of several families of signaling molecules including the Wnt, fibroblast growth factor (FGF), and tumor necrosis factor (TNF) families are potential inducers of epithelial appendages. Wnt signaling appears to be needed for the initial downgrowth of the follicle (placode formation), [3] whereas bone morphogeneic proteins (BMPs) appear to repress placode formation in adjacent skin and thus control the spacing between appendages. [4], [5] Recently, follicular papilla cells have been shown to express members of the sonic hedgehog (SHH) and Wnt signaling cascades. [6] It therefore seems likely that the Wnt and SHH signaling pathways are involved in the crosstalk between the ectoderm and mesenchymal condensates leading to the development of the hair germ.

FIGURE 12-1 Diagrammatic representation of the major stages of follicular neogenesis. *A.* Follicular germ stage, depicting a condensation of mesenchymal cells just beneath the slight downgrowth or “bud” of fetal basal keratinocytes. *B.* Follicular peg stage, depicting the organization of keratinocytes in the follicle and the mesenchyme of the follicular sheath and follicular papilla located at the tip of the follicle. *C.* Bulbous hair peg stage, depicting regions of the differentiated follicle. Two prominent bulge outgrowths are noted; the uppermost will become the sebaceous gland, and the lowermost is the insertion site of the arrector pili muscle as well as the presumptive site of the hair follicle stem cells. (*From Holbrook et al.* [7] *with permission.*)

Even the earliest follicular germ cells acquire features that set them apart from the interfollicular epidermal keratinocytes. For example, the follicular cells express neuronal intercellular adhesion molecules (such as N-CAM and I-CAM), which are not expressed by interfollicular keratinocytes. Similarly, mesenchymal cells of the dermal condensate selectively express tenascin, which has been suggested to promote mesenchymal cell aggregation and epithelial cell growth, and p75, a neurotrophin receptor involved in anagen-to-catagen transformation. [7]

The next stage in follicular neogenesis is known as the *follicular peg,* an elongated follicle germ consisting of a column of keratinocytes extending into the dermis roughly perpendicular to the skin surface (see Fig. 12-1B). Mesenchymal cells surrounding the epidermal cord become specialized, eventually forming the follicular sheath (also known as the *connective tissue* sheath) whereas mesenchymal cells concentrated at the tip form the follicular papilla. The tip of the epithelial cord is flattened and becomes the matrix portion of the bulb. As the follicle continues to elongate, it becomes the bulbous hair peg (see Fig. 12-1C), characterized by the formation of two pouches of outgrowth extending from the outer root sheath cells on the posterior aspect of the follicle. The upper outgrowth gives rise to the sebaceous gland, whereas the lower one gives rise to the bulge, which later becomes the insertion site of the arrector pili muscle. The bulge plays a key role in hair growth because it contains the hair follicular epithelial stem cells (see below). [8]

The deepest portion of the bulbous hair peg forms an invagination encasing the bulk of the follicle-associated and by now highly specialized dermal cells, which develop into the follicular papilla (*dermal papilla*). The matrix keratinocytes of the precortical region ultimately give rise to the hair shaft and inner root sheath. Signaling molecules such as Notch, BMP, and members of the Wnt family are involved in the differentiation of inner root sheath and hair shaft. [5], [9] The melanocytes responsible for pigmentation of the hair fiber reside in the proximal bulb of the anagen follicle, situated among the basal keratinocytes of the matrix. The outer root sheath, comprising the most peripheral epithelial cell layers of the follicle, is contiguous with the epidermis and is most likely derived from the cells of the bulge (see below). [10], [11] As the follicle begins to produce a hair, the central cells of the rudimentary follicle column degenerate, forming a tunnel through which the newly formed hair fiber can emerge.

A useful way to conceptualize the internal organization of the hair follicle is to view it as a series of concentric epithelial rings bounded by an acellular basement membrane, the so-called glassy membrane (Fig. 12-2). Immediately above the bulb, the outer root sheath consists of a single layer, but higher up the follicle it is composed of multilayers of cuboidal cells. At the level of the sebaceous gland and above, the outer root sheath is structurally similar to the epidermis. Adjacent to the outer root sheath is the companion layer, which is in contact with the (outermost) Henle's layer of the inner root sheath. [12] In the prekeratogenous regions of the follicle, the companion layer consists of a single row of flattened cells arranged end to end. In the precortical zone, as Henle's layer becomes keratinized, the companion cells become cuboidal with prominent nuclei. Farther up the follicle, where the inner root sheath is degenerating, the companion cells take on irregular shapes and become keratinized. The companion cells contain a unique keratin (K6hf) and express plasminogen activator inhibitor type 2 (PAI-2), which has been postulated to prevent premature cell destruction. [12] Adjacent to the companion layer is the inner root sheath (IRS), composed of three compartments: the outermost Henle's layer, which is the first to keratinize; the intermediate Huxley's layer, which is the major IRS component; and the innermost cuticle layer of the IRS, which is adjacent to the hair shaft. The inner root sheath is

thought to mold and hold the hair shaft. The hair shaft also has three compartments: an outermost cuticle layer that interlocks with the cuticle of the IRS, a cortex that forms the bulk of the hair shaft, and a variable medulla.

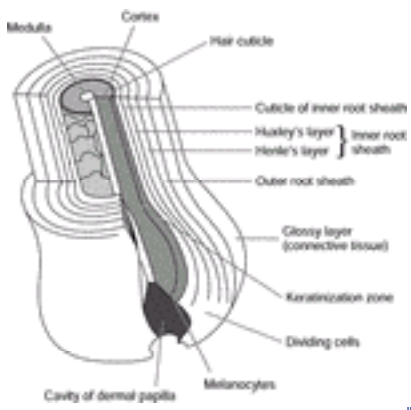

FIGURE 12-2 Diagrammatic representation of a cross section of the hair follicle and hair shaft. Both the follicle and hair shaft are organized as a series of concentric compartments. (*Reproduced from Dawber R: Diseases of the Hair and Scalp, Oxford, Blackwell Scientific Publications, with permission.*)

The longitudinal organization of the follicle can be divided roughly into seven regions with distinct anatomic boundaries (Fig. 12-3): (1) the *hair canal region* extending from the skin surface to the level of the epidermal-dermal junction (its lower part later becomes the intraepidermal "infundibular unit"), (2) the *infundibulum,* which extends down to the opening of the (3) *sebaceous gland,* (4) the *isthmus,* which begins at the sebaceous duct and ends at (5) the *area of the bulge,* the site of insertion of the arrector pili muscle and a region enriched in follicular epithelial stem cells [8], [10] (the transient portion of the follicle, located below the bulge/arrector pili muscle complex, extends to the deepest levels of the follicle), (6) the *lower follicle,* which includes the keratogenous zone and extends from the area of the bulge to the top of the hair bulb, and (7) the *hair bulb,* which is the deepest portion of the follicular structure and envelops the follicular papilla. The *critical line of Auber* is at the widest diameter of the bulb and is of significance in that the bulk of the mitotic activity that gives rise to the hair shaft and inner root sheath occurs below this level.

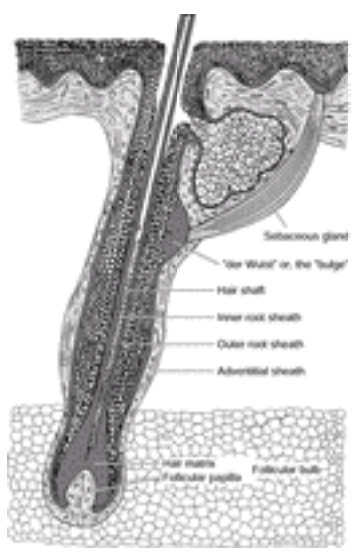

FIGURE 12-3 Diagrammatic representation of the adult human hair follicle. The follicle, an invagination of the surface epidermis, is characterized by an infundibulum that communicates directly with the epidermis and extends to the opening of the sebaceous gland. The portion directly beneath the sebaceous gland and terminating at the bulge is the isthmus. The lowermost portion of the hair follicle is the transient region, which begins just beneath the bulge and terminates at the lowermost part of the follicle. The follicular bulb, the lowermost part of the follicle, consists of matrix keratinocytes and specialized mesenchymal cells known as the follicular papilla. The follicular papilla is contiguous with the adventitial sheath, which lines the entire follicle.(*Courtesy of Michael Joffreda, M.D.*)

Another important anatomic feature of the follicle is that it lies at an angle relative to the skin surface. The side of the follicle that forms an acute angle with the skin surface is its anterior aspect. When the arrector pili muscle contracts, as in response to cold external temperature, it pulls on the posterior side of the follicle. The temporary alteration in local skin architecture gives rise to what has been described in lay terms as "goose bumps." The associated hair becomes more vertically oriented and therefore provides a greater thermal barrier because the relative thickness of the insulating medium is increased.

THE HAIR CYCLE

While it is well known that hair follicles undergo cycles of growth, involution, and rest (Fig. 12-4), it is important to realize that many other changes occur in the skin as a function of the hair cycle. Investigators have demonstrated that in rats and mice the entire skin changes during the hair cycle, with a generalized thickening of the skin during anagen (the growing phase) and a thinning during telogen (the resting phase). [13] The skin vasculature also undergoes hair cycle–related changes. In murine skin, a greater than fourfold increase in perifollicular vessel size occurs during the anagen phase, followed by a rapid reduction in vessel size during catagen and telogen, suggesting that the growing hair follicle can induce its own blood supply to support its metabolic needs. [14] Finally, it has been demonstrated that anagen follicles have the largest numbers of intrafollicular Langerhans cells, lymphocytes, and perifollicular macrophages. [15] It also has been reported that there is an anagen-associated suppression of contact hypersensitivity as well as

photocontact allergy. [15] Such observations have led to the suggestion that anagen phase is associated with an immunosuppressive activity resulting in the formation of a large perifollicular “immune privileged” zone. [15] Taken together, these findings suggest that during the hair cycle the follicle can influence the physiology of many cutaneous structures, such as the sebaceous gland, vasculature, subcutaneous fat, and even immunological activity.

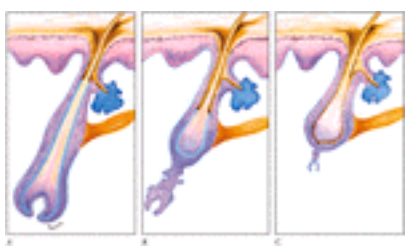

FIGURE 12-4 Diagrammatic representation of the changes that occur to the follicle and hair shaft during the hair growth cycle: *(A)* anagen (growth stage), *(B)* catogen (degenerative stage), *(C)* telogen (resting stage). (*Courtesy of Lynn M. Klein, M.D.*)

Anagen

Anagen can be subdivided into six substages (I to VI), the first five of which are collectively called *proanagen*. The sixth stage, *metanagen,* is defined by the emergence of the hair shaft above the skin surface. At this stage, the anagen follicle penetrates deeply into the subcutaneous fat.

The length of anagen is known to vary markedly depending on body site and species. The anagen of human hair follicles has been estimated to last 2 to 6 years on the scalp (mosaic pattern), 19 to 26 weeks on the leg, 6 to 12 weeks on the arm, and 4 to 14 weeks on the upper lip (mustache). [16] Interestingly, the hair follicles of the merino sheep are thought to be in a permanent state of anagen lasting the animal's entire lifetime.

Catagen

At the end of anagen, the follicle enters into catagen, which shows morphologic and molecular changes that are characteristic of programmed cell death and apoptosis. [17] At the onset of catagen, the scalp hairs show a gradual thinning and decrease of the pigment at the base of the hair shaft. Melanocytes in the matrix portion of the bulb cease producing melanin, resorb their dendrites, and undergo apoptosis. [15] Matrix keratinocytes abruptly cease proliferating and undergo terminal differentiation so that the lower follicle involutes and regresses. The follicular papillary cells round up and remain within the connective tissue sheath, which contracts, pulling the condensed follicular papilla toward the bottom of the epithelial portion of the regressing follicle. The connective tissue sheath also becomes quite thickened during catagen. [16] At the end of catagen, the follicular papilla comes to rest at the bottom of the permanent portion of the hair follicle.

The molecular signals that trigger catagen are presently unknown. In the catagen follicle there is a decline in an antiapoptotic protein, Bcl-2, and an increase in a proapoptotic protein, Bax. [18] At the onset of catagen, various apoptotic-associated receptors (Fas/Apo, p55TNFR, p75NTR) are observed in the lower portion of the follicular epithelium, and in late catagen, all three receptors are noted in the regressing outer root sheath epithelium. [18] Finally, several transcription factors including c-Myc, and c-Myb, and c-Jun, which have been associated with anagen induction, change immediately before or during catagen. [17] For example, c-Myc decreases in late anagen and catagen, whereas c-Myb and c-Jun only decrease in catagen. Another molecule implicated in the control of the anagen-catagen transition is FGF5. [19] Mice deficient in this factor have a prolonged anagen with a long-haired (angora) phenotype. However, it should be noted that in these mice the follicle still enters catagen, indicating that other signaling molecules are involved in the transition from anagen to catagen. Because insulin-like growth factor, keratinocyte growth factor (KGF), and hepatocyte growth factor (HGF) are downregulated at the initiation of catagen, whereas transforming growth factor beta (TGF-ß1) and several neurotrophins are upregulated at the same time, the changes in concentration of these molecules have been suggested to play a role in anagen-catagen transition. [15]

Telogen

The telogen hair has a club-shaped proximal end within the hair follicle, and it is typically shed from the follicle during telogen or the subsequent anagen. The new hair produced from the subsequent anagen does not “push out” the hair from the previous cycle and may on occasion be found adjacent to a so-called retained club hair within a follicle. The inner root sheath, which normally disintegrates in the anagen follicle at the level of the sebaceous duct opening, is absent from the telogen follicle. Eventually, a new growing phase occurs, and the cycle is repeated.

On human scalp, the anagen period is generally quite long; however, catagen lasts only about 2 weeks and telogen 1 to 3 months. [16]

Exogen

Recently, attention has been directed to studying the mechanism of hair shedding, and the term *exogen* has been coined to denote the hair shedding phase. [20] This term describes the relationship between the hair shaft and the base of the telogen follicle rather than the cycling activity of the underlying follicle. [15] Since hairs can be retained for more than one cycle, the shedding phase is most likely independent of anagen and telogen. While little is known about what controls

exogen, proteolytic pathways have been implicated in club hair formation and removal. [15]

Although the cyclic nature of hair growth just described is similar in humans and in animals, the pattern of growth and rest and the rate of growth vary depending on species and body site. For example, hair growth can occur either in a wave, where all follicles are relatively synchronized, or in a mosaic pattern, where the activity of each follicle is independent of its neighbors. [21] Even though it has been stated dogmatically that sometimes hair growth in mice, rats, hamsters, and rabbits occurs in wave patterns, this is true only for the first two hair cycles. Subsequent cycles in these species become less synchronized and eventually assume a mosaic pattern. Guinea pigs, cats, dogs, subhuman primates, and humans exhibit a mosaic pattern of hair cycling. [22] Although humans initially display a wave pattern of hair growth in utero and during the early postnatal period, this synchronization is later lost. At 26 to 28 weeks' gestation, most human scalp hair follicles make the transition to telogen in a wave pattern that spreads from the frontal to parietal regions, marking the last stage of the first hair cycle. [23] Many of these primary hairs are shed in utero, [24] although this may be delayed in some individuals, resulting in abundant hair at birth. [23] It is also typical for a bandlike area of occipital hair follicles to enter the first telogen near birth and for these hairs to shed synchronously 2 to 3 months later. [23], [25] Waves of hair growth occur before the establishement of the mosaic pattern, which is usually present by the end of the first postnatal year.

At any one time, about 85 to 90 percent of human scalp hair follicles are in anagen, about 13 percent are in telogen, and less than 1 percent are in catagen. [16] It is believed that each follicle goes through the hair cycle 10 to 20 times in a lifetime. However, the assumption that all human follicles traverse regularly through the hair growth cycles is unsubstantiated. Investigations of murine hair follicles suggest that follicles remain in telogen for progressively longer periods of time. This makes good biologic sense considering the tremendous amount of energy required to sustain a hair follicle in anagen for several years. The idea that the cycle for human hair follicles also may be discontinuous and/or heterogeneous should be given serious consideration.

DISTRIBUTION OF HAIR

Hair follicles are distributed throughout the integument with the exception of the palms, soles, and portions of the genitalia (so-called glabrous skin). The highest density of follicles is on the scalp, where it has been reported as 1135/cm ^{2} at birth, diminishing to 795 by the end of the first year and 615 by the third decade, commensurate with an increase in scalp skin surface area. [26] Headington [27] used transverse skin sectioning (histologic) techniques to examine scalp skin and found normal adult follicular density to be in the range of 310 to 500/cm ^{2}. Pecoraro et al. [28] reported average scalp hair shaft densities ranging from 170 to 250/cm ^{2} in prepuberal children. By carefully examining the growth of hairs from hair transplant grafts in adults, Unger [29] observed emergent hairs in the range of about 100 to 200/cm ^{2}. It should be noted that the follicular densities obtained by counting emergent hair shafts are significantly less that the number observed in tissue sections due to the fact that very small hairs as well as unpigmented hairs may be missed in clinical counting. The total number of hair follicles in the scalp is approximately 100,000 in people with brown-black hair. It is about 10 percent greater in blondes and 10 percent less in redheads.

HAIR AS A BIOLOGIC FIBER

Mature hair shafts are nonliving biologic fibers. Their integrity and physical properties are due to the accumulation of several groups of highly specialized hair-differentiation products, including the hair (“hard”) keratins, and to the strong intercellular attachments between the various cells of the hair fiber. An important biochemical feature that contributes to the physical properties of the fiber is disulfide bonding between various structural proteins. Such links between the keratins and the high-sulfur proteins produce a sturdy, dense network that largely fills the keratinocytes. These disulfide bonds also help maintain the texture and shape of the fibers; they are chemically broken during the first stage of hair styling with permanents or during straightening and are re-formed after the desired change has been accomplished so that the new form is maintained. Mutations in hair proteins can lead to certain hair diseases. [30]

Outer Root Sheath and Companion Layer

Outer root sheath cells contain several epithelial (“soft”) keratin intermediate filament proteins, including the K5/K14 pair characteristic of basal epidermal cells [31] and the K6/K16 pair characteristic of hyperproliferative keratinocytes. [31] K19 also has been detected in the outer root sheath cells of the adult human hair follicle, with the greatest concentration observed in the bulge region. [32], [33] K17 has been detected in the outer root sheath in a distinct cluster of matrix keratinocytes and in the medulla of murine hair. [34] In human hair extracts, K17 was found in eyebrow and facial hair but not in hairs from other body sites. Based on its polarized location in the matrix and presence in the medulla, K17 has been proposed to play a role in determining hair shape and orientation. [34] Finally, K6hf, a novel human cell type II keratin, has been demonstrated to be exclusively expressed in the companion layer of the hair follicle. [35]

Cortex

The cortex is the major part of the human hair fiber, and it contains the bulk of the hair (“hard”) keratins. The hair keratin filaments are built on the same molecular plan as the epidermal intermediate filaments, in which the 400 to 500 amino acid residues of individual chains are arranged in sequences containing many heptad repeats. Consequently, they can pair together to form coils. Recent work focused on characterizing human hair keratin genes has shown that in the human hair follicle there are nine functional type I (acidic) hair keratin genes located on chromosome 17q12–21 and six functional type II (basic) hair keratin genes located on chromosome 12q13. [36], [37] The type I hair keratins were sorted into three groups on the basis of structure: group A (hHa1, hHa3-I, hHa3-II, and hHa4) and group B (hHa7 and hHa8), each containing highly related hair keratins, and group C (hHa2, hHa5, and hHa6), which contains structurally unrelated hair keratins. The type II hair keratins were sorted into two groups: group A (hHb1, hHb3, and hHb6), containing the highly

related hair keratins, and group C (hHb2, hHb4, and hHb5), containing the less related hair keratins.

Other major proteins found in the cortex, known as keratin-associated proteins, can be divided into two groups: (1) the high-sulfur proteins, rich in cysteine (9–25 kDa), which form a biologic “glue” between the keratin filaments of the cortex, and (2) a less prominent group of high-glycine/tyrosine-containing proteins (6–9 kDa). [38] Sequence analysis of one of these glycine/tyrosine-containing proteins has revealed its capacity to form glycine loops, which could interact with similar glycine loops of the hair keratin filaments. This type of interaction would produce a tightly packed structure for the cortex keratin. [38]

With respect to expression patterns within the anagen hair follicle, hHa5 and hHb5 are detected in the nonproliferating matrix keratinocytes and the precortical cells, sites of early hair follicle differentiation. Somewhat later expression was noted for the type I keratins hHa1, hHa3-I/II, and hHa4 that were expressed sequentially in the cortex. Type II keratins hHb1, hHb3, and hHb6 also were seen in the cortex. The high-sulfur proteins are the last to be produced in the cortex. [38], [39]

Medulla

In the medulla, which is morphologically distinct from the cortex, there are the citrulline-containing e-(?-glutamyl)lysine cross-linked proteins. These medullary proteins, along with trichohyalin, an intermediate filament–associated protein, are also found in the inner root sheath. [40]

Cuticle

The cuticle of the hair shaft is also very important in maintaining the integrity of the fiber. It may be likened to a layer of armor that resembles reptilian scales and protects the cortex. With respect to expression patterns of the hair keratins, the hHa5/hHa2 and hHb5/hHb2 keratins are coexpressed throughout the cuticular cells. As was the case for the cortex, the high-sulfur proteins are the last to be produced in the cuticle. [38] When the cuticle is damaged from physical or chemical exposures, the fiber is more likely to break. When this happens along the shaft (e.g., trichorrhexis nodosa), the fiber is likely to become severed with minor subsequent manipulation; when this happens at the distal end of the shaft, the fiber is likely to fracture longitudinally, producing trichoptilosis (“split ends”).

There are variations in the cross-sectional features of hair fibers. Typical diameters of scalp hairs range from 40 to 120 µm, [41] with hair from whites and blacks generally having narrower diameters than hair from Asians. There are also tendencies for scalp hairs from different races to have specific characteristics: The hair of whites is usually oval in cross section and somewhat curly; the hair of blacks is usually oval and sometimes flattened in cross section and twisted; and the hair of Asians is round in cross section and straight. [42] These relationships do not apply to hairs from other body sites—e.g., eyelashes, beard hairs, and pubic hairs—which tend to share similar features in all races.

HAIR PIGMENTATION

The basic color of the hair is determined by the melanocytes. Hair is actively pigmented only when it grows because the melanogenic activity of follicular melanocytes is coupled to the anagen stage of the hair cycle. In catagen and telogen, melanin formation is switched off. Melanocytes located in the matrix area of the anagen follicle, in the region above the follicular papilla, produce the pigment. Pigment-laden dendritic processes from these melanocytes course among the differentiating hair keratinocytes, which engulf portions of the pigmented dendrites. Although a follicle usually produces only one type of pigment at any given time, two types of pigment can be produced. Eumelanin is the pigment in brown-black hairs, and pheomelanin is the pigment in red-blond hairs. The pigment is predominantly located in the cortex of the hair shaft. Typically, it is not found in the hair shaft during the early stages of new hair formation, and so new hair tips do not usually contain pigment. Similarly, pigment typically is not found in the portion of the hair shaft produced just before the follicle enters the resting phase of the hair cycle, so the proximal portion of normally shed (“club,” or telogen) hair also lacks pigment. One of the more perplexing issues that remains to be solved is what happens to the melanocytes during the catagen/telogen phase of the hair growth cycle. Current belief is that melanocyte loss during catagen is replenished from an undifferentiated melanocyte pool in the “permanent portion” of the hair or from another, as yet unidentified precursor pool. [43]

Variations in the spectrum of hair color shades are relatively simple, yet the factors that produce subtle variations are more complex. The intensity of color is generally proportional to the amount of pigment in the fiber. In the extreme, absence of pigment produces white hair, whereas markedly diminished pigment produces gray hair. Lighter shades of a given color result when less pigment is incorporated in the hair shaft. Subtle variations in hue depend on the refraction and reflection of incident light at the various internal interfaces of the hair shaft as well as the interfaces with the external environment and/or materials that may coat the fiber.

Work in mice has provided insights into the mechanisms of patterning in the hair coat as well as potential genes involved in the control of hair pigmentation. Follicular papillary cells have been found to express the *agouti* gene, which encodes a signaling molecule that causes hair follicle melanocytes to synthesize yellow instead of black pigment. [44] Expression of this gene was shown to be under the control of two different promoters. One is active at the midpoint of anagen, thus controlling the anagen-specific production of pigment. The other remains active throughout the hair cycle but only on the ventral surface, causing mice to have black dorsal hairs and yellow ventral hairs. [45] Another gene, *bcl-2,* that encodes a protooncogene involved in blocking apoptosis, was expressed in the follicular papillae of cycling murine and human hair follicles during the entire cycle. Interestingly, genetic ablation of this gene in mice resulted in the formation of gray hair during the second hair cycle because of a reduced number of follicular melanocytes, suggesting that expression of *bcl-2* might be essential for melanocyte survival. Other molecules implicated in hair pigmentation are stem cell factor (SCF) and its receptor, c-Kit. Evidence for this comes from observations that (1) c-Kit is required for postnatal melanocyte activation, (2) melanocytes in newborn mice are c-Kit–dependent, (3) melanocytes undergo apoptosis when c-Kit

receptors are blocked, and (4) proliferating, differentiating, and melanin-producing melanocytes express c-Kit, whereas the putative melanocyte precursors do not. [46] Furthermore, studies in normal and SCF-overexpressing mice reveal that SCF/c-Kit is required for the formation and trafficking of functional melanocytes during each new hair cycle, whereas the putative melanocyte precursor cells are not dependent on SCF/c-Kit. [47] Since cultured human follicular papillary cells can secrete SCF as well as *agouti* gene product, these cells may play an active role in regulating the pigmentation of hair follicles. [48]

TYPES OF HAIR

Hairs can be classified according to their texture and length; this is species-dependent, since humans and mice have rather different hair types. Thus humans have lanugo hair, vellus hair, intermediate hair, and terminal hair. Lanugo hair is the soft, fine hair that covers much of the fetus and usually is shed before birth. The other terms have most relevance to scalp hair, although the basic principles convey some meaning for other hair sites. The classification is not exact and basically relates to the final length of the hairs: Vellus scalp hairs achieve lengths less than 1 cm, indeterminate scalp hairs are approximately 1 cm in length, and terminal scalp hairs grow longer than 1 cm. The prominence of various hair-shaft features, in general, increases with progression through this series (e.g., amount of pigment, hair-shaft diameter, and extent of medulla formation).

Although the types of hairs are not clearly defined in terms of fiber length for other body sites, the general relationships cited above are conveyed when such terminology is used. Eyebrow or eyelash hairs are typically less than 1 cm in length but are considered terminal hairs. Yet the usual lengths (several millimeters) of beard hairs along with their associated features in normal women would best be described as vellus hair. Using the phrase *terminal beard hair growth* with regard to a woman would indicate that there is a departure from the norm, with the presence of the longer, coarser hairs typical of hirsutism or hypertrichosis.

REGULATION OF THE HAIR GROWTH CYCLE

Much of the recent excitement in the hair field has focused on elucidating the location and biology of the follicular epithelial stem cells, characterizing the follicular papillary cells and their products, identifying the molecular mechanisms involved in the epithelial/mesenchymal regulation of the hair growth cycle, and defining further the hormonal aspects of hair growth regulation.

Follicular Epithelial Stem Cells

A knowledge of follicular epithelial stem cells is essential because these cells play a central role in long-term maintenance of the hair follicle, regulation of the hair growth cycle, and skin tumor initiation. [10], [49] It has been shown that the bulge region of the outer root sheath is a major site of follicular epithelial stem cells because epithelial cells within this region exhibit several important stem cell features. [49] For example, the bulge cells are slow cycling; they can be induced to proliferate in response to various growth stimuli; they are relatively undifferentiated, as evidenced by a primitive-appearing cytoplasm; they have a greater proliferative capacity than epithelial cells from other regions of the hair follicle; and being located at the lowermost part of the permanent portion of the follicle, they are spared from the cellular destruction that occurs during every catagen. The identification of hair follicle stem cells in the bulge region provided a mechanistical model to explain some important features of the hair cycle [8] (the *bulge-activation hypothesis*) (Fig. 12-5). According to this hypothesis, the bulge epithelial stem cells, on receiving mesenchymal signals from the abutting dermal papilla, undergo transient proliferation during early anagen, giving rise to a population of rapidly proliferating, transit amplifying (TA) cells that form an epithelial column growing downward, pushing away the dermal papilla cells. Once the dermal papilla signals are removed, the bulge stem cells resume their slow-cycling state. Since the matrix keratinocytes are TA cells, they have a limited proliferative capacity, and once this growth potential is exhausted, they undergo terminal differentiation/apoptosis—a key event of catagen.

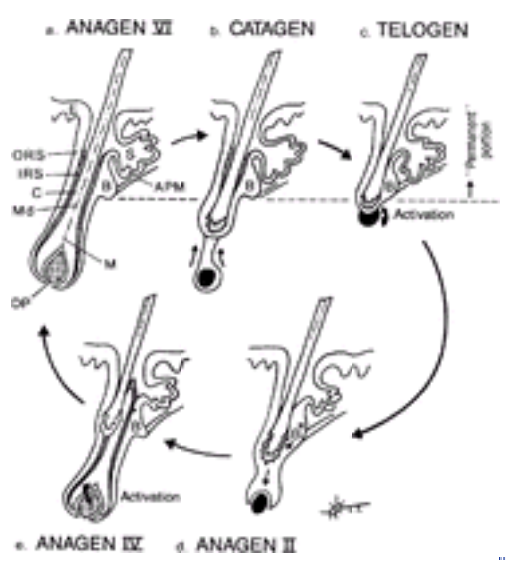

FIGURE 12-5 Hair cycle: the bulge activation hypothesis. Illustrated are the sequential phases of the hair cycle. Abbreviations include epidermis (E), sebaceous glands (S), bulge (B), arrector pili muscle (APM), outer root sheath (ORS), inner root sheath (IRS), hair cortex (C), hair medulla (Md), matrix (M), and follicular (dermal) papilla (DP). Structures above the dashed line constitute the permanent portion of the hair follicle; keratinocytes below this line degenerate during catagen and telogen and therefore are dispensable. Four important tenets of the bulge activation hypothesis include (1) upward movement of the follicular papilla during catagen that will lead to its close proximity to the bulge during telogen, (2) activation of the bulge cells by the adjacent follicular papilla, (3) downward movement of the follicular papilla as anagen begins, followed shortly thereafter by a “turning off” of the now proliferating (B^*) bulge cells,

and (4) activation of the follicular papilla by the new matrix. This hypothesis predicts that a hair cycle will have a duration based on the finite proliferative potential of the matrix TA cells. (*Adapted from Cotsarelis et al.* [8] *with permission.*)

Recent data have provided strong support to the bulge stem cell theory. For example, using a double-labeling technique, Taylor et al. [10] showed that the progeny of the bulge stem cells can migrate downward toward the hair matrix and can give rise to several hair cell types, including the cortex and medulla. Oshima et al. [11] showed by microdissection experiments that the bulge cells of mouse vibrissa can give rise to all cell types of the follicle as well as the sebaceous gland. Taken together, these data strongly support the concept that bulge stem cells can give rise not only to all the cell types of the hair follicle but also to some of the hair-related structures such as the sebaceous gland.

The Hair Follicle as a Guardian of the Epidermis

It has long been appreciated that the follicle may play a role in epidermal wound repair. It is well known, for example, that when the murine epidermis is removed experimentally using a felt wheel, some keratinocytes emigrate out from the follicles, contributing to regeneration of the interfollicular epidermis. [10] A similar follicular origin for repairing keratinocytes was reported in the reepithelialization of human skin following a severe burn. Using a double-labeling method that selectively tagged the progeny (TA) cells of the bulge stem cells, Taylor et al. [10] showed that these bulge-derived TA cells not only can move downward to form the outer root sheath, the matrix, and the hair shaft of the hair follicle but also can move upward to populate the basal layer of the epidermis. Emigration of upper follicular epithelial cells into the epidermis was observed in normal neonatal mouse skin, as well as in adult skin in response to a full-thickness skin wound. Such an upward emigration of follicular epithelial TA cells into even normal epidermis suggests a much closer relationship between the follicle and normal epidermis than was appreciated previously and supports the idea that bulge-derived keratinocytes may be involved in long-term maintenance of the epidermis. [8], [10], [50] The upward migration of the bulge stem cell–derived progeny cells into normal epidermis, combined with the downward migration of the stem cell progeny to form the hair shaft, suggests that the bulge stem cells are at least bipotent [10], [49] (Fig. 12-6). Microdissection studies by Oshima et al. [11] also showed that the ß-galactosidase–tagged bulge cells of mouse vibrissae follicles can give rise not only to the entire follicle but also to the epidermis. Taken together, these studies provide strong evidence that multipotent epithelial stem cells are located within the bulge and that these cells are capable of maintaining the epidermis, the hair follicle, and the sebaceous gland.

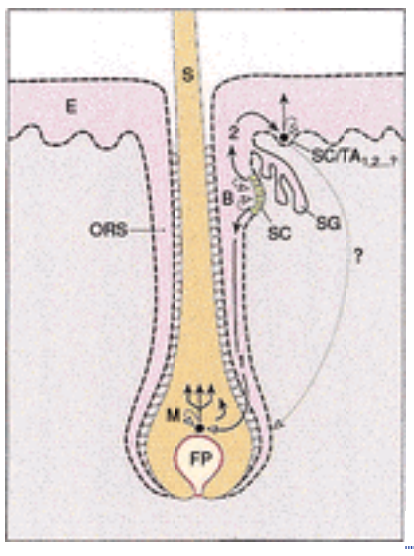

FIGURE 12-6 A schematic diagram of an epidermopilosebaceous unit in hair-bearing skin. The unit consists of the epidermis and the hair follicle with its associated sebaceous gland. The bulge contains a population of putative keratinocyte stem cells that can give rise to (pathway 1) a population of pluripotent and rapidly dividing progenitor (TA) cells in the matrix that yields the hair shaft. Alternatively, the bulge stem cells can give rise to the stem/progenitor cells of the epidermis (pathway 2). It is hypothesized here that the epidermal stem cell represents a form of bulge-derived, young TA cell (SC/TA $_{1,2...}$?). The long, curved arrow denotes the demonstrated capability of adult epidermal cells to form a new hair follicle in response to appropriate mesenchymal stimuli. (B, bulge; E, epidermis; FP, follicular or dermal papilla; M, matrix keratinocytes; ORS, outer root sheath; S, hair shaft; SC, stem cells; SG, sebaceous gland; TA, transit amplifying cells.) (*Reproduced from Lavker and Sun* [49] *with permission.*)

Involvement of the Hair Follicle in Skin Cancer

Since stem cells are known to represent a key target of tumor initiation, [10], [50] it is important to know whether some skin cancers originate from hair follicular stem cells. Several lines of evidence suggest that this is the case. First, many basal cell carcinomas (BCCs) exhibit histologic and biologic features of the hair follicle, including their accumulation of cytoplasmic glycogen similar to that of the outer root sheath and their occasional resemblence to the matrix keratinocytes and to trichoepitheliomas. [50] Second, although ionizing radiation targeting the superficial rat epidermis produces few, if any, skin tumors, deeper radiation causing follicular damage can effectively induce skin tumor formation. Third, skin chemical carcinogenesis studies revealed that topical application of a carcinogen to mice at the onset of anagen (when bulge cells are proliferating) produced greater numbers of tumors than telogen application (when bulge cells are quiescent), suggesting that follicular stem cells can give rise to experimentally induced skin cancers. [51] Fourth, papilloma formation in a *v-Ha-ras* transgenic mouse line showed that the upper follicle is the origin of the tumor. [52] Fifth, studies on papilloma formation using domestic rabbits that have been infected with cottontail rabbit papilloma virus showed that the virus infects primarily the follicle cells that have the highest keratinocyte colony-forming ability (derived from stem cell–enriched regions of the hair follicle). [53] Sixth, a puzzling feature of many of the experimentally induced skin tumors is

that they are associated with the infundibulum of the upper follicle rather than the bulge. [52], [55] This observation may be explained by the fact that the upper hair follicle contains a population of early (young) TA (progenitor) cells that still have a high growth potential. These upper follicle TA cells are highly proliferative, making them particularly susceptible to DNA damage and possibly to tumor initiation. [10] Taken together, these findings support the idea that the hair follicle is the origin of at least some skin tumors and that both the bulge region and the upper follicle may be involved in neoplastic transformation.

Molecular Control of Hair Follicle Development, Differentiation, and Cycling

As mentioned previously, a large number of genes have been implicated in hair follicle development as well as the hair growth cycle. These genes may act on the stem cell population, the matrix keratinocytes, and the follicular papilla. [56], [58] These molecules include members of the Wnt, Notch and SHH signaling pathways, as well as EGF/TGF-a, TGF-ß, BMP, and the FGF families. Ectodysplasin and its receptor (EDA/EDAR) and PGDF-A also have been implicated in follicle development.

Wnt SIGNALING Members of the Wnt signaling pathway have been implicated in regulating hair follicle development and growth. Extracellular Wnt ligands bind to Frizzled receptors, thus inactivating a complex of proteins that normally target ß-catenin for degradation. Thus activation of Wnt signaling causes ß-catenin to accumulate, translocate to the nucleus, bind transcription factors of the TCF/LEF family, and regulate the expression of target genes. [58] ß-Catenin mRNA is upregulated in placodes, and LEF-1 is also expressed in both the ectodermal placodes and the dermal condensates. A reporter gene sensitive to the activity of the LEF–ß-catenin complex is expressed in the placodes and dermal condensates of developing follicles, suggesting that Wnt signaling is important for the crosstalk between epithelium and mesenchyme. [5] Consistent with this hypothesis, mice lacking LEF-1 or ß-catenin have reduced numbers of hair follicles. [3] Conversely, ectopic expression of LEF-1 or stablized forms of ß-catenin in the epidermis mimic an activated Wnt signaling pathway and result in precocious hair follicle formation and, in the presence of ß-catenin, hair follicle tumorigenesis. Stabilizing mutations in the ß-catenin gene are implicated in the etiology of human pilomaticoma, a tumor of hair follicle matrix cells. [58] Members of the Wnt pathway also may play a role in regulating hair shaft formation. The ß-catenin–LEF-1 complex is active in the more differentiated matrix cells (precursors of the hair shaft) of the fully formed hair follicle. [58] Furthermore, Wnt3 and a Wnt effector gene, *Disheveled2,* are expressed in the precortical zone, and the ectopic expression of Wnt3 in the outer root sheath alters hair shaft differentiation, resulting in a shortened hair phenotype. [59] Similar stunted hair growth was observed in mice overexpressing the ß-catenin–related protein plakoglobin. [60] The plakoglobin-induced short hair phenotype was due to a significant decrease in the length of anagen, an early onset of apoptosis, and a reduction in the proliferative rate of the follicular keratinocytes. Thus Wnt family members may provide key signals to the cells that differentiate into various components of the hair shaft. The Wnt pathway also may be involved in activating the normally quiescent hair follicle stem cells during early anagen of the hair cycle. TCF3 protein, a repressor of the Wnt signaling pathway, is expressed in the bulge region of the hair follicle. In mice carrying a reporter gene responsive to the ß-catenin–LEF complexes, the reporter gene was found to undergo transient expression in bulge cells at the start of anagen. [58] Overexpression of TCF3 leads to suppression of epidermal differentiation and promotion of outer root sheath differentiation. In addition, TCF3 was found to function in the maintenance of the stem cell phenotype, suggesting that the repression of Wnt target genes is required to maintain the stem cells in an undifferentiated state. Lifting of this repression and activation of the Wnt signaling pathway thus may be necessary for the conversion of stem cells to TA cells at anagen onset. [58] Further evidence of the potential involvement of Wnt signaling in the determination of hair follicle stem cell fate comes from the observation that in the absence of epithelial ß-catenin, keratinocytes can only adopt an epidermal phenotype, whereas in the presence of ß-catenin, follicular epithelial stem cells can differentiate into follicular or epidermal lineages. [3]

SHH SIGNALING SHH can be produced by one cell to affect the developmental process of its neighboring target cell. [61] SHH interacts with and blocks the function of a cell surface receptor called patched-1 (Ptc1) that normally inhibits a third protein called Smoothened (Smo). Inhibition of Smo activates the expression of genes encoding Ptc1 itself, as well as the transcription factor Gli1. The SHH signaling pathway plays a critical role in regulating hair follicle development. In SHH-deficient mice, hair development is arrested, and the expression of Gli1 and Ptc1, downstream effector molecules in the SHH pathway, is greatly reduced in both epithelial and mesenchymal components, suggesting that SHH signals to both the epithelial and mesenchymal cells of the developing hair follicle. [62] However, mesenchymal condensates do develop in SHH-null mice, suggesting that SHH may act later than Wnt signaling in regulating hair follicle development. Recent results suggest that SHH plays an important role in regulating early anagen. For example, inactivation of SHH protein does not prevent anagen onset but blocks progression of follicles through anagen. [63] Consistent with this, intradermal overexpression of SHH in mouse skin with an adenoviral vector caused telogen follicles to enter anagen. [64] As in morphogenesis, SHH may act downstream of Wnt signaling in early anagen, since anagen onset does not occur in mice lacking epithelial ß-catenin. [3] The hair follicle exhibits several histologic and biologic features of BCCs. [50] In humans, BCCs are known to develop from both follicular and interfollicular epidermis. Given the fact that SHH is required for hair follicle morphogenesis, it is not surprising that SHH signaling also may play a role in BCC formation (see Chaps. 81 and [82]). For example, recent data indicate that BCC in humans results from inappropriate activation of the SHH pathway in the epidermis and is often associated with mutations in *Ptc.* [65], [66] It also has been demonstrated that skin tumors arise in mice following overexpression of SHH and the effectors of the SHH pathway (Gli1, and Gli2) and that many of these tumors resemble BCCs and other hair follicle–derived neoplasias such as trichoepitheliomas and trichoblastomas. [67], [69] Given the fact that the follicular epithelial stem cells are the likely source of many skin tumors, it is possible that the levels of SHH and/or the Gli transcription factors could alter the growth regulation of these stem cells, resulting in BCC development.

NOTCH SIGNALING Notch is a transmembrane receptor that, on ligand binding, undergoes proteolytic release of the Notch intracellular domain (NICD). NICD translocates to the nucleus, where it acts as a part of the transcription complex with CBF1/Su(H)/Lag1 (CSL) proteins. Ligands for Notch include Delta, Jagged-1, and Jagged-2 in vertebrates. [9] Within the hair follicle, the Notch1 receptor colocalizes with its ligand Jagged-1 in the precortical cells. Thus the Notch–Jagged-2 pair may be involved in the transition of matrix cells into the more differentiated components of the hair shaft. [70] Recently it was found that the ectopic expression of Notch1 in the cortex resulted in the abnormal development

of the medulla and cuticle, supporting the idea that Notch expression in one cell type may direct the differentiation of adjacent cell types. [9]

ADDITIONAL INTERCELLULAR SIGNALING MOLECULES The formation of placode seems to be promoted by EDA, a protein related to tumor necrosis factor, and its receptor (*ectodermal dysplasia receptor-EDAR*). The *EDA* gene is mutated in human X-linked anhidrotic ectodermal dysplasia and in the *Tabby* mouse, in both cases causing a reduction in the number of hair follicles. [71] Conversely, members of the BMP family appear to inhibit follicle formation. [71] With respect to hair follicle differentiation, transgenic mice ectopically expressing Noggin (an inhibitor of BMP) in the hair matrix cells and precortical cells were found to have cycling cells present in the precortex and hair shaft. This indicates that BMP signaling suppresses matrix cell proliferation and is required to induce the terminal differentiation of the hair shaft progenitors located in the precortical cells. [4] Another molecule implicated in the conversion of the dermal condensate into the dermal papilla is PDGF-A. Mice lacking PDGF-A have small dermal papilla and correspondingly thin hair when compared with wild-type mice. [72]

The Follicular Papilla

As mentioned earlier, the follicular papilla is a group of specialized mesenchymal cells that plays a central role in follicular development and hair cycle control. For example, the diameter and length of the hair fiber are directly related to the volume of the follicular papilla. [73] A recent study showed that the number of follicular papilla cells and the volume of their associated extracellular matrix were positively correlated with the size of the hair cortex. [73] The hairless phenotype of the *hr/hr* mutant mouse was shown to be due to a failure of the follicular papilla to ascend during the first catagen phase. [74] Perhaps the most striking demonstration of the significance of the follicular papilla in hair growth came from the demonstration that isolated follicular papillae from rat vibrissae, when combined with an interfollicular epidermis, can induce new hair formation. [75] More recently, papillary cells derived from pelage follicles were found to induce pelage-type follicles, whereas cells from the vibrissae induced large vibrissae-type follicles. [76] The hair-inducing ability of follicular papilla cells was further demonstrated when cultured keratinocytes were mixed with either fibroblasts or follicular papilla cells and grafted to a nude mouse. [77] Hair follicles formed if follicular papilla cells were present; however, no hair follicles were formed in the presence of dermal fibroblasts. It is also apparent that the specialized cells located within the connective tissue sheath that surrounds the follicle have the capacity to form a follicular papilla and to induce hair growth. [78] Taken together, these findings clearly demonstrate that follicular papillary cells and dermal sheath cells are distinct from the regular dermal fibroblasts because they can send out signals that can induce hair formation.

Follicular papillary cells produce several growth factors, cytokines, and transcription factors that play a role in regulating the hair cycle. For example, KGF has a stimulatory effect on hair follicle growth in vivo. [79] mRNAs for insulin-like growth factor–binding proteins are localized to the follicular papilla and connective tissue sheath of anagen follicles, suggesting a possible role in modulating insulin-like growth factor during the hair cycle. [80] mRNA for the protease nexin-1, a potent serine protease inhibitor, also has been localized in the follicular papillae of human and rat anagen follicles but not in those of catagen or telogen. [12] Recently, mRNA for osteopontin, a secreted glycosylated phosphoprotein known to play diverse roles in mediating cell-matrix interactions, growth regulation, and various aspects of the inflammation/tissue repair cascade, has been localized to the follicular papillae of catagen follicles but not those in anagen or telogen. [81] This last observation is of particular interest in that it shows that specific genes are turned on during catagen, which is therefore not simply a passive “degenerative” phase. While the functional role of osteopontin in catagen is unclear, it may promote the formation of a tightly aggregated follicular papilla and/or protect the follicular papilla cells from apoptosis induced by cytokines or hypoxia during catagen. [81] In another study, freshly isolated mouse follicular papilla cells were shown to express Ptch and Gli1, molecules in the SHH signaling cascade, as well as Wnt5a, Frizzled 7, Disheveled 2, GSK, ß-catenin, and LEF-1, all components of the Wnt signal transduction cascade. [6] Thus the follicular papillary cells elaborate proteases and their inhibitors, extracellular matrix molecules, growth factors, receptors, and signal-transduction molecules that are involved in the regulation of the hair cycle.

Hormones as Regulators of the Hair Cycle

Systemic factors such as androgens, estrogens, glucocorticoids, thyroid hormones, and growth hormones all can modulate hair growth. [82] Hamilton [83] was the first to recognize the importance of androgens in human hair growth when he noted that men castrated before the age of puberty neither became bald nor grew beards unless they were treated with testosterone. Castration of older men prevented balding. Androgens are known to upregulate the pubic hair, axillary hair, and beard hair but to downregulate genetically predisposed scalp hair follicles in androgenetic alopecia (common baldness). [84] The fact that only select populations of hairs demonstrate such responses exemplifies the diverse responses of hair follicles to similar stimuli. The follicular papilla appears to be the target for androgen effects because these cells have been demonstrated to express androgen receptors and androgen-metabolizing enzymes (such as 5a-reductase, types I and II.) [85] Follicular papillae in the balding scalp have been demonstrated to have higher levels of androgen receptors than those from nonbalding skin. [86]

Some insight into androgen action has been gained from common forms of androgen insensitivity resulting from defects in the androgen receptor or 5a-reductase (the enzyme that converts testosterone to the more potent dihydrotestosterone). [82] Testosterone can have a species-dependent stimulatory or inhibitory effect on cultured dermal papilla cells. For example, in vitro studies employing cultured dermal papillary cells from human beard and scalp follicles have shown that when beard cells are incubated with testosterone, they secrete mitogenic factors that stimulate the growth of other dermal papillary cells and outer root sheath cells. [87] Conversely, in studies using dermal papilla cells from the macaque, testosterone stimulates cells from androgen-sensitive follicles to synthesize inhibitory factors that dampen the growth of follicular epithelial cells in culture. [88] Beard-derived follicular papillary cells express greater amounts of insulin-like growth factor I (IGF-1) in response to testosterone, suggesting that IGF-1 may be a regulatory molecule in hair growth. [89] While a unified mechanism for hormonal control of hair growth is presently lacking, further studies using

the preceding approaches should yield a better understanding of the differential actions of androgens on hair.

REFERENCES

1. Halata Z: Sensory innervation of the hairy skin (light- and electronmicroscopic study). *J Invest Dermatol* **101**:75s, 1993

2. Hardy MH: The secret life of the hair follicle. *Trends Genet* **8**:159, 1992

3. Huelsken J et al:ß-Catenin controls hair follicle morphogenesis and stem cell differentiation in the skin. *Cell* **105**:533, 2001

4. Kulessa H et al: Inhibition of BMP signaling affects growth and differentiation in the anagen hair follicle. *EMBO J* **24**:6664, 2000

5. Reddy S et al: Characterization of *Wnt* gene expression in developing and postnatal hair follicles and identification of *Wnt5a* as a target of sonic hedgehog in hair follicle morphogenesis. *Mech Dev* **107**:69, 2001

6. Kishimoto J et al: Wnt signaling maintains the hair-inducing activity of the dermal papilla. *Gene Dev* **14**:1181, 2000

7. Holbrook KA et al: Expression of morphogens during human follicle development in vivo and a model for studying follicle morphogenesis in vivo. *J Invest Dermatol* **101**:39S, 1993

8. Cotsarelis G et al: Label-retaining cells reside in the bulge of the pilosebaceous unit: Implications for follicular stem cells, hair cycle, and skin carcinogenesis. *Cell* **61**:1329, 1990

9. Lin M-H et al: Activation of the *Notch* pathway in the hair cortex leads to aberrant differentiation of the adjacent hair-shaft layers. *Development* **127**:2421, 2000

10. Taylor G et al: Involvement of follicular stem cells in forming not only the follicle but also the epidermis. *Cell* **102**:451, 2000

11. Oshima H et al: Morphogenesis and renewal of hair follicles from adult multipotent stem cells. *Cell* **104**:233, 2001

12. Jensen PJ et al: Serpins in the human hair follicle. *J Invest Dermatol* **114**:917, 2000

13. Muller-Rover S et al: A comprehensive guide for the accurate classification of murine hair follicles in distinct hair cycle stages. *J Invest Dermatol* **117**:3, 2001

14. Yano K et al: Control of hair growth and follicle size by VEGF-mediated angiogenesis. *J Clin Invest* **107**:409, 2001

15. Stenn KS, Paus R: Controls of hair follicle cycling. *Physiol Rev* **81**:449, 2001

16. Kligman AM: The human hair cycles. *J Invest Dermatol* **33**:307, 1959

17. Seiberg M et al: Changes in expression of apoptosis-associated genes in skin mark early catagen. *J Invest Dermatol* **104**:78, 1995

18. Linder G et al: Analysis of apoptosis during hair follicle regression (catagen). *Am J Pathol* **151**:1601, 1997

19. Hebert JM et al: FGF5 as a regulator of the hair growth cycle: Evidence from targeted and spontaneous mutations. *Cell* **78**:1017, 1994

20. Stenn KS et al: Growth of the hair follicle: A cycling and regenerating biological system, in *Molecular Basis of Epithelial Appendage Morphogenesis,* edited by C-M Chuong. Austin, Landes, 1998

21. Chase HB et al: Critical stages of hair development and growth in the mouse. *Physiol Zool* **24**:1, 1951

22. Takashima I, Kawagishi I: Comparative study of hair growths in mammals, with special reference to hair grouping and hair cycle, and hair growth rate in the juvenile stumptailed macaque, in *Biology and Disease of Hair,* edited by T Kobori, W Montagna. Baltimore, University Park Press, 1976

23. Barman JM et al: The first stage in the natural history of the human scalp hair cycle. *J Invest Dermatol* **48**:138, 1967

24. Kligman AM: Pathologic dynamics of human hair loss. *Arch Dermatol* **83**:175, 1961

25. Saadat M et al: Measurement of hair in normal newborns. *Pediatrics* **57**:960, 1976

26. Giacometti L: The anatomy of the human scalp, in *Advances in Biology of the Skin,* edited by W Montagna. Oxford, Pergamon Press, 1964

27. Headington JT: Transverse microscopic anatomy of the human scalp: A basis for a morphometric approach to disorders of the hair follicle. *Arch Dermatol* **120**:449, 1984

28. Pecoraro V et al: The normal trichogram in the child before puberty. *J Invest Dermatol* **42**:427, 1964

29. Unger WP: *Hair Transplantation*. New York, Decker, 1979

30. Jones LN, Steinert PM: Hair keratinization in health and disease. *Dermatol Clin* **14**:633, 1996

31. Sun T-T et al: Classification, expression and possible mechanisms of evolution of mammalian epithelial 2 keratins: A unifying model, in *Cancer Cells,* edited by A Levine, W Toop, G Vande Woude, J D Watson. Cold Spring Harbor, Cold Spring Harbor Laboratory, 1984, vol I, p169.

32. Stasiak PC et al: Keratin 19: Predicted amino acid sequence and broad tissue distribution suggest it evolved from keratinocyte keratins. *J Invest Dermatol* **92**:707, 1989

33. Michel M et al: Keratin 19 as a biochemical marker of skin stem cells in vivo and in vitro: Keratin 19 expressing cells are differentially localized in function of anatomic sites, and their number varies with donor age and culture stage. *J Cell Sci* **109**:1017, 1996

34. Mcgowin KM, Coulombe PA: Keratin 17 expression in the hard epithelial context of the hair and nail, and its relevance for the pachyonychia congenita phenotype. *J Invest Dermatol* **114**:1101, 2000

35. Winter H et al: A novel human type II cytokeratin, K6hf, specifically expressed in the companion layer of the hair follicle. *J Invest Dermatol*

111:955, 1998

36. Langbein L et al: The catalog of human hair keratins: I. Expression of the nine type I members in the hair follicle. *J Biol Chem* **274**:19874, 1999

37. Langbein L et al: The catalog of human hair keratins: II. Expression of the six type II members in the hair follicle and the combined catalog of human type I and II keratins. *J Biol Chem* **276**:35123, 2001

38. Rogers GE, Powell BC: Hair follicle keratins, in *Handbook of Mouse Mutations with Skin and Hair Abnormalities*, edited by JP Sundberg. Boca Raton, CRC Press, 1994

39. Lynch MH et al: Acidic andbasic hair/nail ("hard") keratins: in Their colocalization in upper cortical and cuticle cells of the human hair follicle and their relationship to "soft" keratins. *J Cell Biol* **103**:2593, 1986

40. Fietz MJ et al: Analysis of the sheep trichohyalin gene: Potential structural and calcium-binding roles of trichohyalin in the hair follicle. *J Cell Biol* **121**:855, 1993

41. Hayashi A et al: Trichogram. *J Invest Dermatol* **60**:70, 1975

42. Lindelof B et al: Human hair form. *Arch Dermatol* **124**:1359, 1988

43. Tobin DJ et al: The fate of hair cycle melanocytes during the hair growth cycle. *J Invest Dermatol* **4**:323, 1999

44. Miller MW et al: Cloning of the mouse *agouti* gene predicts a secreted protein ubiquitously expressed in mice carrying the *Lethal-Yellow* mutation. *Gene Dev* **7**:454, 1993

45. Vrieling H et al: Differences in dorsal and ventral pigmentation result from regional expression of the mouse agouti gene. *Proc Natl Acad Sci USA* **91**:5667, 1994

46. Okura M et al: Effects of monoclonal anti-c-Kit antibody (ACK2) on melanocytes in newborn mice. *J Invest Dermatol* **105**:322, 1995

47. Botchkareva NV et al: SCF/c-Kit signaling is required for cyclic regeneration of the hair pigmentation unit. *FASEB J* **15**:645, 2001

48. Hibberts NA et al: Dermal papilla cells derived from beard hair follicles secrete more stem cell factor (SCF) in culture than scalp cells or dermal fibroblasts. *Biochem Biophys Res Commun* **222**:401, 1996

49. Lavker RM, Sun T-T: Epidermal stem cells: Properties, markers, and location. *Proc Natl Acad Sci USA* **97**:13473, 2000

50. Lavker RM et al: Hair follicle stem cells: Their location, role in hair cycle, and involvement in skin tumor formation. *J Invest Dermatol* **101**:16S, 1993

51. Miller SJ et al: Mouse skin is particularly susceptible to tumor initiation during early anagen of the hair cycle: possible involvement of hair follicle stem cells. *J Invest Dermatol* **101**:591, 1993

52. Hansen LA, Tennant RW: Follicular origin of epidermal papillomas in *v-Ha-ras* transgenic TG.AC mouse skin. *Proc Natl Acad Sci USA* **91**:7822, 1994

53. Schmitt A et al: The primary target cells of the high-risk cottontail rabbit papillomavirus colocalize with hair follicle stem cells. *J Virol* **70**:1912, 1996

54. Binder RL et al: Squamous cell hyperplastic foci: Precursors of cutaneous papillomas induced in SENCAR mice by two-stage carcinogenesis regimen. *Cancer Res* **58**:4314, 1998

55. Morris RJ et al: Evidence that the epidermal targets of carcinogen action are found in the interfollicular epidermis or infundibulum as well as in the hair follicles. *Cancer Res* **60**:226, 2000

56. Millar SE: The role of patterning genes in epidermal differentiation, in *Cytoskeletal-Membrane Interactions and Signal Transduction,* edited by P Cowin, M Klymkowsky. Austin, Landes Bioscience, 1997 p 87

57. Oro AE, Scott MP: Splitting hairs: Dissecting roles of signaling systems in epidermal development. *Cell* **95**:575, 1998

58. Fuchs E et al: At the roots of a never ending cycle. *Dev Cell* **1**:13, 2001

59. Millar SE et al: Wnt signaling in the control of hair growth and structure. *Dev Biol* **207**:133, 1999

60. Charpentier E et al: Plakoglobin suppresses epithelial proliferation and hair growth in vivo. *J Cell Biol* **149**:503, 2000

61. Dlugosz A: The hedgehog and the hair follicle: a growing relationship. *J Clin Invest* **104**:851, 1999

62. Chiang C et al: Essential role for sonic hedgehog during hair follicle morphogenesis. *Dev Biol* **205**:1, 1999

63. Wang LC et al: Conditional disruption of hedgehog signaling pathway defines its critical role in hair development and regeneration. *J Invest Dermatol* **114**:901, 2000

64. Sato N et al: Induction of the hair growth phase in postnatal mice by localized transient expression of sonic hedgehog. *J Clin Invest* **104**:855, 1999

65. Hahn H et al: Mutations of the human homolog of *Drosophila patched* in the nevoid basal cell carcinoma syndrome. *Cell* **85**:841, 1996

66. Johnson RL et al: Human homolog of *patched*, a candidate gene for the basal cell nevus syndrome. *Science* **272**:1668, 1996

67. Oro AE et al: Basal cell carcinomas in mice overexpressing sonic hedgehog. *Science* **276**:817, 1997

68. Nilsson M et al: Induction of basal cell carcinomas and trichoepitheliomas in mice overexpressing Gli-1. *Proc Natl Acad Sci USA* **97**:3438, 2000

69. Grachtchouk M et al: Basal cell carcinomas in mice overexpressing Gli2 in skin. *Nature Genet* **24**:216, 2000

70. Powell BC et al: The *Notch* signaling pathway in hair growth. *Mech Dev* **78**:189, 1998

71. Barsh GS: Of ancient tales and hairless tails. *Nature Genet* **22**:315, 1999

72. Karlsson L et al: Roles for PGDF-A and sonic hedgehog in development of mesenchymal components of the hair follicle. *Development* **126**:2611, 1999

73. Elliott K et al: Differences in hair follicle dermal papilla volume are due to extracellular matrix volume and cell number: Implications for the control of hair follicle size and androgen responses. *J Invest Dermatol* **113**:873, 1999

74. Montagna W et al: Skin of hairless mice: I. Formation of cysts and the distribution of lipids. *J Invest Dermatol* **19**:83, 1952

75. Oliver RF: The experimental induction of whisker growth in the hooded rat by implantation of the dermal papilla. *J Embryol Exp Morphel* **18**:43, 1967

76. Jahoda CA, Reynolds AJ: Dermal-epidermal interactions: Follicle-derived cell populations in the study of hair-growth mechanisms. *J Invest Dermatol* **101**:335, 1993

77. Kamimura J et al: Primary mouse keratinocyte cultures contain hair follicle progenitor cells with multiple differentiation potential. *J Invest Dermatol* **109**:534, 1997

78. Robinson M et al: In vivo induction of hair growth by dermal cells isolated from hair follicles after extended organ culture. *J Invest Dermatol* **117**:596, 2001

79. Danilenko DM et al: Keratinocyte growth factor is an important endogenous mediator of hair follicle growth, development, and differentiation. *Am J Pathol* **147**:145, 1995

80. Batch JA et al: Identification and localization of insulin-like growth factor-binidng protein (IGFBP) messenger RNAs in human hair follicle dermal papilla. *J Invest Dermatol* **106**:471, 1996

81. Yu D-W et al: Osteopontin gene is expressed in the dermal papilla of pelage hair follicles in a hair cycle–dependent manner. *J Invest Dermatol* **117**:1554, 2001

82. Paus R, Cotsarelis G: The biology of hair follicles. *New Engl J Med* **341**:491, 1999

83. Hamilton JB: Male hormone stimulation is a prerequisite and an incidant in common baldness. *Am J Anat* **71**:451, 1942

84. Randall VA: Androgens are the main regulator of human hair growth, in *Hair and Its Disorders: Biology, Pathology, and Management,* edited by F Camacho, VA Randall, V Price. London, Martin Dunitz, 2000, p 69

85. Randall VA et al: Androgen action in cultured dermal papilla cells from human hair follicles. *Skin Pharmacol* **7**:20, 1994

86. Hibberts NA et al: Balding hair follicle dermal papilla cells contain higher levels of androgen receptors than those from non-balding scalp. *J Endocrinol* **156**:59, 1998

87. Randall VA et al: Mechanism of androgen action in cultured dermal papilla cells derived from human hair follicles with varying responses to androgens in vivo. *J Invest Dermatol* **98**:86S, 1992

88. Obana N et al: Inhibition of hair growth by testosterone in the presence of dermal papilla cells from the frontal bald scalp of the postpubertal stumptailed macaque. *Endocrinology* **138**:356, 1997

89. Randall VA: The use of dermal papilla cells in studies of normal and abnormal hair follicle biology, in *Dermatologic Clinics,* edited by DA Whiting. Philadelphia, Saunders, 1996, vol 14

T>

Chapter 13

Antonella Tosti Bianca Piraccini

Biology of Nails

NAIL PLATE
PROXIMAL NAIL FOLD
NAIL MATRIX
Nail Matrix Keratinocytes
Melanocytes
Langerhans Cells
Merkel Cells
NAIL BED
HYPONYCHIUM
BASEMENT MEMBRANE ZONE
THE DERMIS
BLOOD AND NERVE SUPPLY
CHEMICAL PROPERTIES
PHYSICAL PROPERTIES
NAIL GROWTH

REFERENCES

The nail apparatus consists of a horny “dead” product, the nail plate, and four specialized epithelia: the proximal nail fold, the nail matrix, the nail bed, and the hyponychium (Fig. 13-1).

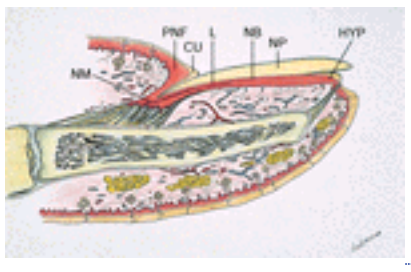

FIGURE 13-1 Drawing of a normal nail. CU, cuticle; HYP, hyponychium; L, lunula region; NB, nail bed; NM, nail matrix; NP, nail plate; PNF, proximal nail fold.

The nail apparatus develops during the ninth embryonic week from the epidermis of the dorsal tip of the digit as a rectangular area, the nail field, which is delineated by a continuous groove. [1] The proximal border of the nail field extends downward and proximally into the dermis to form the nail matrix primordium. By the fifteenth week, the nail matrix is completely developed and starts to produce the nail plate, which will continue to growth until death.

The nail apparatus lies immediately above the periosteum of the distal phalanx. The intimate anatomic relationship between the nail and the bone is responsible for the common occurrence of bone alterations in nail disorders and vice versa. The shape of the distal phalangeal bone also determines the shape and the transverse curvature of the nail.

Fingernails usually present a longitudinal major axis and toenails a transverse major axis. The ratio between length and width is important for the esthetical appearance of the nails. The size of the nails varies in the different digits, the biggest nail being that of the first toe, which covers about 50 percent of the dorsum of the digit.

The nails have numerous functions. Fingernails not only contribute to the esthetic of the hands, but are very important in protecting the distal phalanges, and in enhancing tactile discrimination and the capacity to pick up small objects. They are also widely used for scratching and grooming, and are an efficient natural weapon. Toenails protect the distal toes and contribute to pedal biomechanics.

NAIL PLATE

The nail plate is a fully keratinized structure that is continuously produced throughout life. It results from maturation and keratinization of the nail matrix epithelium and it is firmly attached to the nail bed, which partially contributes to its formation. Proximally and laterally the nail plate is surrounded by the nail folds that cover its proximal and lateral margins. At the tip of the digit, the nail plate separates from the underlying tissues at the hyponychium. The nail plate is rectangular in shape, translucent, and transparent. It is curved in both the longitudinal and transverse axes, especially in the toes. The nail plate surface is smooth, but frequently shows mild longitudinal ridges that increase with aging. The pattern of these ridges can be used for forensic identification. The bottom of the nail plate shows longitudinal ridges that correspond to the rete ridges of the nail bed. The nail plate is homogeneously pink in color, except for its free edge that is white. The pink color of the nail plate is due to the nail bed blood vessels. The proximal part of the fingernails, especially of the thumbs, shows a whitish, opaque, half-moon–shaped area, the lunula, which is the visible portion of the nail matrix. In this area, the nail plate attachment to the underlying epithelium is loose. More than 90 percent of fingernails show a thin distal transverse white band, the onychocorneal band, which marks to the most distal portion of firm attachment of the nail plate to the nail bed. [2] This area represents an important anatomic barrier against environmental hazards and its disruption produces nail plate detachment with onycholysis. The onychocorneal band is

separated from the nail plate white free edge by a 1- to 1.5-mm pink band called the *onychodermal band*.

In transverse sections, the nail plate consists of three portions: dorsal nail plate, intermediate nail plate, and ventral nail plate. [3] The dorsal and the intermediate portions of the nail plate are produced by the nail matrix, whereas its ventral portion is produced by the nail bed. Above the lunula, the nail plate is thinner and consists only of the dorsal and intermediate portions. There is a natural line of cleavage between the dorsal and the intermediate nail plate.

The nail plate progressively thickens from its emergence to its distal margin, the mean toenail thickness at the distal margin being 1.65 ± 0.43 mm in men and 1.38 ± 0.20 mm in women. Fingernails are thinner, their mean thickness being 0.6 mm in men and 0.5 mm in women. There is an increase in nail thickness with age, particularly in the first two decades. Nail thickness depends on the length of the nail matrix and nail bed. [4] Thinning of the nails is usually a sign of nail matrix disorders, whereas nail thickening is most commonly a consequence of nail bed disorders.

PROXIMAL NAIL FOLD

The proximal nail fold is a skin fold that consists of a dorsal and a ventral portion (Fig. 13-2). The dorsal portion is anatomically similar to the skin of the dorsum of the digit but thinner and devoid of pilosebaceous units. The ventral portion, which cannot be seen from the exterior, and which proximally is in continuity with the germinative matrix, covers approximately one-fourth of the nail plate. It closely adheres to the nail plate surface and keratinizes with a granular layer. The limit between the proximal nail fold and the nail matrix can be established histologically at the site of disappearance of the granular layer.

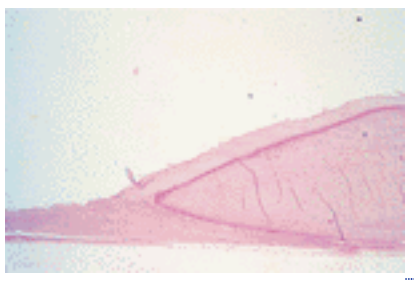

FIGURE 13-2 Histologic section showing the dorsal and the ventral portions of the proximal nail fold. The cuticle provides adhesion between the ventral nail fold and the nail plate.

The horny layer of the proximal nail fold forms the cuticle, which is firmly attached to the superficial nail plate and prevents the separation of the plate from the nail fold. The integrity of the cuticle is essential for maintaining homeostasis of this region. The dermis of the proximal nail fold contains numerous capillaries that run parallel to the surface of the skin. Capillary microscopy permits the observation of both the arterial and the venous limbs of the capillaries, which are arranged in parallel rows and appear as fine regular loops with a small space between the afferent and efferent limbs. The morphology of proximal nail fold capillaries is typically altered in connective tissue diseases.

NAIL MATRIX

The nail matrix is a specialized epithelial structure that lies above the mid-portion of the distal phalanx. After elevation of the proximal nail fold, the matrix appears as a distally convex crescent with its lateral horns extending proximally and laterally.

In longitudinal sections, the matrix has a wedge-shaped appearance and consists of a proximal (dorsal) and a distal (ventral) portion (Fig. 13-3). Nail matrix keratinocytes divide in the basal cell layer and keratinize in the absence of a granular zone. Cornified onychocytes are composed mainly of keratin filaments, high-sulfur matrix proteins, and the marginal band, which consists of precipitated proteins on the cytoplasmic side of the cell membrane. The site of keratinization (keratogenous zone) of nail matrix onychocytes can be clearly distinguished in histologic sections as an eosinophilic area in which cells show fragmentation of their nuclei and condensation of their cytoplasm. [1] In this area, nuclear fragments are destroyed by DNAase and RNAase enzymes. In some conditions, nuclear fragments may persist within the intermediate nail plate, producing leukonychial spots. These, however, frequently disappear before reaching the nail free edge, due to persistence of active DNA and RNA lytic enzymes within the horny nail plate.

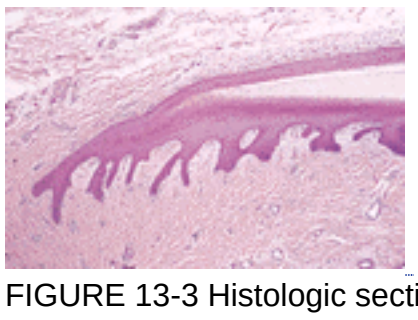

FIGURE 13-3 Histologic section of the proximal nail matrix. (*Courtesy of C. Misciali, M.D.*)

Maturation and differentiation of nail matrix keratinocytes do not follow a vertical axis, as in the epidermis, but occur along a diagonal axis that is distally oriented. For this reason, keratinization of the proximal nail matrix cells produces the dorsal nail plate and keratinization of the distal nail matrix cells produces the intermediate nail plate.

In some fingers, the distal matrix is not completely covered by the proximal nail fold, but is visible through the nail plate as a white half-moon-shaped area, the lunula. The white color of the lunula results from two main anatomic factors: (1) the keratogenous zone of the distal matrix contains nuclear fragments that cause light diffraction; and (2) the nail matrix capillaries are less visible than nail bed capillaries due to the relative thickness of the nail matrix epithelium. [5]

Nail Matrix Keratinocytes

The nail matrix cells are able to synthesize both “soft” or skin-type and “hard” or hair-type keratins. According to Kitahara and Ogawa the dorsal nail matrix keratinocytes in vivo produce soft keratins, while the ventral nail matrix keratinocytes produce hard keratins. Results from in vitro studies, however, indicate that all cells are able to change their course of differentiation and express multiple keratins. [6] When cultured in a chemically defined medium, nail matrix cells are considerably larger than epidermal keratinocytes and show a low nucleus/cytoplasm and a high euchromatin/heterochromatin ratio. The growth rate of cultured nail matrix cells is higher than that of epidermal keratinocytes. [7] When cultured in serum-containing medium, the nail matrix cells show spontaneous migration and stratified growth in a semilunar area, which resembles the architecture of the nail matrix.

Melanocytes

Nail matrix melanocytes are usually quiescent and therefore not detectable in pathologic sections. By using immunohistochemical techniques, two different populations of melanocytes have been recognized in the nail: (1) DOPA-negative, dormant melanocytes localized in the proximal and distal matrix and in the nail bed; and (2) DOPA-positive, activatable melanocytes localized in the distal matrix. [8] DOPA-positive melanocytes possess the key enzymes that are necessary for melanin production and may become activated by a large number of physiologic and pathologic conditions. Nail matrix melanocyte activation produces diffuse or banded nail pigmentation and is more common in blacks and Japanese than in Caucasians.

Nail matrix melanocytes are frequently arranged in small clusters among the suprabasal layers of the nail matrix epithelium. [9] Suprabasal location of nail matrix melanocytes may be a consequence of the distribution of the adhesion molecules in the nail epithelium, where a3ß1 integrin, which possibly regulates melanocyte-keratinocyte adhesion, is expressed in basal and suprabasal locations. [10]

Electron microscopically, nail matrix melanocytes of Caucasians do not contain mature melanosomes, which are normally found in nail matrices of Japanese and blacks. [11]

Langerhans Cells

Langerhans cells are more numerous in the proximal than in the distal nail matrix. As in normal epidermis, Langerhans cells are predominantly found in the suprabasal layers. They may, however, occasionally be seen within the basal layer of the nail matrix epithelium.

Merkel Cells

The presence of Merkel cells has been demonstrated in the nail matrix. By using antibodies against CK8 and CK20 cytokeratins, we detected more than 20 Merkel cells per nail matrix section in adults. [12]

NAIL BED

The nail bed, which contains sparse DOPA-negative melanocytes, [8] extends from the distal margin of the lunula to the onychodermal band and is completely visible through the nail plate. The nail bed epithelium is so adherent to the nail plate that it remains attached to the undersurface of the nail when a nail is avulsed. The nail bed epithelium is thin and consists of two to five cell layers. Its rete ridges, which are longitudinally oriented, interdigitate with the underlying dermal ridges in a tongue-in-groove–like fashion.

Nail bed keratinization produces a thin horny layer that forms the ventral nail plate, and in toto, the nail bed contribution to nail plate formation corresponds to about one-fifth of the terminal nail thickness and mass. [13] In histologic sections, the ventral nail plate is easily distinguishable because of its light eosinophilic appearance. Nail bed keratinization is not associated with the formation of a granular layer. A granular layer may, however, appear when the nail bed becomes exposed after nail avulsion. [1]

HYPONYCHIUM

The hyponychium marks the anatomic area between the nail bed and the distal groove, where the nail plate detaches from the dorsal digit. Its anatomic structure is similar to that of plantar and volar skin, and keratinization occurs through the formation of a granular layer. The horny layer of the hyponychium partially accumulates under the nail plate free margin.

The hyponychium is normally covered by the distal nail plate, but it may become visible in nail biters.

BASEMENT MEMBRANE ZONE

The antigenic structure of the basement membrane zone of the nail is identical to that of the epidermis and there are no

differences in the antigenic composition of the basement membrane zone between the different portions of the nail apparatus. [14] This may explain the involvement of the nails in conditions characterized by mutations of basement membrane-associated genes, as well as in autoimmune skin diseases involving the basement membrane zone antigens. [15]

THE DERMIS

The nail apparatus is devoid of subcutaneous tissue, and its dermis does not contain pilosebaceous units. The arrangement of the rete ridges varies in the different portions of the nail apparatus. The dermis beneath the proximal nail matrix consists of condensed connective tissue that forms a tendon-like structure connecting the matrix to the periosteum of the proximal phalangeal bone (posterior ligament) (Fig. 13-1). A small amount of subdermal fat tissue is present close to the periosteum of the base of the phalanx. [16] The close connection between the lateral horns and the periosteum is possibly responsible for the nail plate's lateral convexity. The rete ridges of the dermis underneath the nail matrix are characteristically long and root-like–shaped, running from lunula to hyponychium. [1] The dermis under the distal matrix consists of a loose network of connective tissue containing numerous blood vessels and rare glomus bodies. The longitudinal orientation of the capillary vessels within the nail bed grooves explains the linear pattern of the nail bed hemorrhages (splinter hemorrhages). The nail bed dermis contains numerous glomus bodies and connective tissue bundles radiating to the phalangeal periosteum.

BLOOD AND NERVE SUPPLY

The nail apparatus has an abundant blood supply provided by the lateral digital arteries. These run along the sides of the digits and produce branches that supply both the matrix and the proximal nail fold and arches that supply the matrix and the nail bed. The matrix therefore has two different sources of blood supply.

The nail bed is richly supplied (10 to 20/cm ^{2}) by encapsulated neurovascular structures containing one to four arteriovenous anastomoses and nerve endings. These glomus bodies are possibly involved in the regulation of the blood supply to the digits in cold weather.

The cutaneous sensory nerves, which originate from the dorsal branches of the paired digital nerves, run parallel to the digital vessels.

CHEMICAL PROPERTIES

The nail plate, like hair, consists mainly of low-sulfur filamentous proteins (keratins) embedded in an amorphous matrix composed of high-sulfur proteins rich in cystine. Other nail constituents include water, lipids, and trace elements. Nail keratins consist of 80 to 90 percent hard “hair-type” keratins and 10 to 20 percent soft “skin-type” keratins. Hard keratins have been identified as the acidic 44K/46K and basic 56K to 60K keratins. Soft keratins have been identified as the 50K/58K and 48K/56K keratin pairs [17] (see Chap. 7).

In normal conditions, the water content of the nail plate is 18 percent, most of it being in the intermediate nail plate. [18] This may, however, significantly vary due to the high porosity of the nail plate, which can be rapidly hydrated and dehydrated. Dehydration is faster when the nails are kept long. When the water content decreases below 18 percent, the nail becomes brittle; when it increases above 30 percent, it becomes opaque and soft.

The nail contains less than 5 percent lipids, mainly cholesterol. Lipid composition of the nail plate varies with age and sex under the influence of sex hormones. [19] The nail also contains traces of several inorganic elements including iron, zinc, and calcium. These, however, do not contribute to nail hardness. Permeability of the nail plate to drugs and water is considerably different from that of the skin (Table 13-1). The nail, in fact, behaves like a hydrophilic gel membrane that is easily penetrated by small hydrophilic molecules. [20]

	Nail Plate	Horny Layer
Thickness	500–1000 μm	10–40 μm
S-S bonds	10.6%	1.2%
Maximal swelling (in water)	25%	200–300%
Lipid content	1–5%	10–20%
Permeability behavior	Hydrophilic membrane	Lipophilic membrane

TABLE 13-1 **Differences Between Nail Plate and Epidermal Horny Layer**

PHYSICAL PROPERTIES

The nail plate is hard, strong, and flexible. Hardness and strength are due to the nail plate's high content of hard keratins and cystine-rich, high-sulfur proteins, while its flexibility depends on its water content and increases with nail plate hydration. [21] The double curvature of the nail plate along its longitudinal and transverse axes enhances nail plate resistance to mechanical stress. [22]

The strength of fingernails is similar to that of wool and human hair, with a maximum elastic stress varying from 420 to 880 kg/cm ^{2}. [23]

The physical properties of the nail also depend on the arrangement and adhesion of onychocytes in the different portions of the nail plate, as well as on the orientation of the keratin filaments within the nail plate onychocytes. [22] The dorsal and

ventral nail plate contain keratin filaments oriented parallel and perpendicular to the nail growth axis, whereas the intermediate nail plate contains keratin filaments oriented perpendicular to the nail growth axis. [24] This explains why the nail plate is more susceptible to transverse than to longitudinal fractures.

At an ultrastructural level, the corneocytes of the dorsal nail plate are flat, with their shorter diameter perpendicular to the nail plate surface. The average sizes of these cells are 34 µm in length, 64 µm in width, and 2.2 µm in height. [25] Cell adhesion is strong and this portion of the nail is responsible for nail plate hardness and sharpness. The onychocytes of the intermediate nail plate show multiple interdigitations of their cell membranes. The average dimensions of these cells are 40 µm in length, 53 µm in width, and 5.5 µm in height. Cell adhesion is provided by desmosomes and complex interdigitations. This part of the nail plate is responsible for nail pliability and elasticity. The ventral nail plate is thin and consists of soft keratins. It provides adhesion to the underlying nail bed.

NAIL GROWTH

The nail plate grows continuously during life. Fingernails grow faster than toenails, mean growth being 3 mm per month for fingernails and 1 mm per month for toenails. Complete replacement of a fingernail requires about 100 to 180 days (6 months). When the nail plate is avulsed, it takes approximately 40 days before the new fingernail will first emerge from the proximal nail fold. After a further 120 days, it will reach the fingertip. The total regeneration time for a toenail is 12 to 18 months. As a consequence of the slow nail growth rate, diseases of the nail matrix become evident with a considerable delay with respect to their onset and require a long time to disappear after treatment.

Nail growth rate varies among different individuals and among the different digits of the same individual. It depends on the turnover rate of the nail matrix cells and is influenced by several physiologic and pathologic conditions. Nail growth rate is slow at birth, slightly increases during childhood, usually reaches its maximum between the second and the third decades of life, and then sharply decreases after the age of 50 years. [26] Conditions that are associated with a slow growth rate include systemic illness, malnutrition, peripheral vascular or neurologic diseases, and treatment with antimitotic drugs. Nails affected by onychomycosis frequently exhibit a slow growth rate. An arrest of nail growth is a typical feature of the yellow-nail syndrome (see Chap. 72). A reduction in the longitudinal nail growth is usually associated with nail thickening. Accelerate nail growth may cause nail thinning and/or longitudinal ridging of the nail plate (nail beading).

Due to their slow growth rate, the nails may provide information on pathologic conditions that have occurred up to several months before the time of observation. Because drugs and toxic substances are stored within the nail, nail clippings can be used to detect previous exposure to drugs or chemicals. The nail of the big toe is the best site for investigation because of its size and slow growth rate.

In some metabolic diseases, nail plate analysis can be used for diagnostic and therapeutic purposes. Nail clippings may also be used for genetic analysis and determination of blood groups. DNA can, in fact, be extracted easily from fingernail clippings and used for enzymatic amplification and genotypic or individual identification.

REFERENCES

1. Zaias N: Fundamentals and techniques, in *The Nail in Health and Disease,* 2d ed, edited by N Zaias. Norwalk, CT, Appleton & Lange, 1990, p. 3

2. Sonnex TS et al: The nature and significance of the transverse white band of human nail . *Semin Dermatol* **10**:12, 1991

3. Dawber RPR: The ultrastructure and growth of human nails. *Arch Dermatol Res* **269**:197, 1980

4. Johnson M et al: Determination of nail thickness and length . *Br J Dermatol* **130**:195, 1994

5. Cohen PR: The lunula. *J Am Acad Dermatol* **34**:943, 1996

6. Kitahara T et al: Cellular features of differentiation in the nail. *Microsc Res Tech* **38**:436, 1997

7. Picardo M et al: Characterization of cultured nail matrix cells. *J Am Acad Dermatol* **30**:434, 1994

8. Perrin CH et al: Anatomic distribution of melanocytes in normal nail unit. *Am J Dermatopathol* **19**:462, 1997

9. Tosti A et al: Characterization of nail matrix melanocytes using anti-PEP1, anti-PEP8, TMH-1 and HMB-45 antibodies. *J Am Acad Dermatol* **31**:193, 1994

10. Cameli N et al: Expression of integrins in human nail matrix. *Br J Dermatol* **130**:583, 1994

11. Hashimoto K: Ultrastructure of the human toenail. *J Invest Dermatol* **56**:235, 1971

12. Cameli N et al: Distribution of Merkel cells in adult human nail matrix. *Br J Dermatol* **139**:541, 1998

13. Johnson M et al: Nail is produced by the normal nail bed: A controversy resolved. *Br J Dermatol* **125**:27, 1991

14. Sinclair RD et al: The basement membrane zone of the nail. *Br J Dermatol* **131**:499, 1994

15. Cameli N et al: Characterization of the nail matrix basement membrane zone: An immunohistochemical study of normal nails and of the nails in Herlitz junctional epidermolysis bullosa. *Br J Dermatol* **134**:178, 1996

16. Drape J-L et al: The lunula: A magnetic resonance imaging approach to the subnail matrix area. *J Invest Dermatol* **106**:1081, 1996

17. Lynch MH et al: Acid and basic hair/nail (“hard”) keratins: Their localization in upper cortical and cuticle cells of the human hair follicle and

their relationship to “soft” keratins. *J Cell Biol* **103**:2593, 1986

18. Jemec GBE et al: Ultrasound structure of the human nail plate. *Arch Dermatol* **125**:643, 1989

19. Helmdach M et al: Age and sex variation in lipid composition of human fingernail plates. *Skin Pharmacol Appl Skin Physiol* **13**:111, 2000

20. Kobayashi et al: Drug permeation through the three layers of the human nail plate . *J Pharm Pharmacol* **51**:271, 1999

21. Finlay AY et al: An assessment of factors influencing flexibility of human fingernails. *Br J Dermatol* **10**:103, 1980

22. Forslind B: Biophysical studies of the normal nail. *Acta Derm Venereol* **50**:161, 1970

23. Young RW et al: Strength of fingernails. *J Invest Dermatol* **44**:35, 1965

24. Garson JC et al: Histological structure of human nail as studied by synchrotron X-ray microdiffraction. *Cell Mol Biol* **46**:1025, 2000

25. Achten G et al: Nails in light and electron microscopy. *Semin Dermatol* **10**:54, 1991

26. Bean WB: Nail growth: 30 years of observation. *Arch Intern Med* **134**:497, 1974

T>

Chapter 14

Jouni Uitto Leena Pulkkinen Mon-Li Chu

Collagen

STRUCTURE
GENETIC HETEROGENEITY
COLLAGEN GENE STRUCTURE
TRANSLATION OF COLLAGEN POLYPEPTIDES
POSTTRANSLATIONAL MODIFICATIONS OF POLYPEPTIDE CHAINS
Synthesis of Hydroxyproline
Synthesis of Hydroxylysine
Glycosylation
CHAIN ASSOCIATION, DISULFIDE BONDING, AND TRIPLE-HELIX FORMATION
SECRETION OF PROCOLLAGEN
CONVERSION OF PROCOLLAGEN TO COLLAGEN
FIBER FORMATION AND CROSS-LINKING
CONTROL OF COLLAGEN PRODUCTION
PHARMACOLOGIC PERSPECTIVE
COLLAGEN DISEASES

REFERENCES

STRUCTURE

The closely related proteins of the collagen family are the main fibrillar components of the connective tissues and the major extracellular proteins of the human body. [1], [2], [3] and [4] The physiologic role of collagen fibers in the skin is to provide the tensile properties that allow the skin to serve as a protective organ against external trauma. In human skin, collagen fibers form the bulk of the extracellular matrix and comprise more than 70 percent of the dry weight of the dermis. The bulk of collagen in dermis is deposited as large bundles of regularly oriented fibers composed of fibrils and microfibrils. The fibrils are aligned in a parallel manner, resulting in a pattern of cross-striations that can be visualized by electron microscopy (Fig. 14-1). The most prominent cross-striations appear as repeating bands spaced approximately 70 nm apart.



FIGURE 14-1 Electron micrograph of collagen fibers from a preparation of human dermis demonstrating the regular banding pattern at approximately 70-nm intervals. × 45,000.

The prototype of the collagens is type I collagen, the most abundant collagen in the dermis and in other connective tissues (Fig. 14-2). The type I collagen molecule has an approximate molecular mass of 290 kDa and is composed of three polypeptide chains, each having a molecular mass of about 94 kDa. These three polypeptides, known as a chains, are coiled around each other much like strands of rope, so that the collagen molecule has a triple-helical structure. This conformation gives the molecule a rigid, rodlike shape with approximate dimensions of 1.5 × 300 nm (Fig. 14-2).

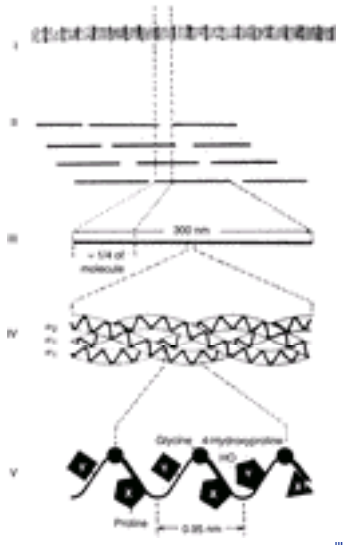

FIGURE 14-2 Representation of the structure of type I collagen. The collagen fibers (I), which on electron microscopy demonstrate a repeating periodicity (see Fig. 14-1), are composed of individual collagen molecules aligned in a quarter-stagger arrangement (II). Each type I collagen molecule is an approximately 300-nm-long rodlike structure (III) consisting of three individual polypeptides, known as a chains, that are twisted around each other in a right-handed triple helix (IV). Each chain is composed of amino acids in a repeating Gly-X-Y sequence (V); as indicated, the X position is frequently occupied by a prolyl residue, and the Y position is frequently occupied by a 4-hydroxyprolyl residue. The individual a chains have a left-handed helical secondary structure with a pitch of 0.95 nm. (*From Uitto J et al: Collagen structure, function, and pathology, In* Progress in Diseases of the Skin, *vol 1, edited by R Fleischmajer. New York, Grune & Stratton, 1981, p 103, with permission.*)

The special structure of the collagen triple helix is largely explainable by the unusual amino acid composition of the a chains. Each a chain of type I collagen has approximately 1000 amino acids, and glycine, the smallest amino acid, accounts for approximately one-third of the total number of amino acids, evenly distributed in the collagenous portion of the polypeptide. Consequently, the polypeptide chains of collagen can be considered to be repeating triplets represented as $(Gly\text{-}X\text{-}Y)_{333}$ (Fig. 14-2). The X and Y positions of the repeating sequence can be occupied by a variety of amino acids, but the X position is often occupied by proline and the Y position is occupied by hydroxyproline. These two amino acids account for about 22 percent of the total amino acid composition of type I collagen. The relatively high contents of these amino acids and the characteristic distribution of glycine in every third position are necessary for the triple-helical conformation of the collagen molecule, and hydroxyproline plays a critical role in stabilizing the triple helix at body temperature (see below). The triple-helical conformation gives collagen many of its unique properties and is essential for normal fibrillogenesis. Mutations that affect the formation of the stable triple helix prevent collagen from forming fibers, resulting in serious defects of connective tissue function. [3], [5]

GENETIC HETEROGENEITY

Collagen comprises a family of closely related yet genetically distinct proteins. In the human genome there are as many as 36 different genes encoding a chains with variable amino acid sequences; these a chains correspond to at least 21 different types of collagen, which have been assigned Roman numerals I to XXI (Table 14-1). Furthermore, several additional collagenous proteins have been identified, largely through recombinant DNA technology or search of the genome database, but the lack of precise information about the structure and the a-chain composition of these collagens precludes assignment of a Roman numeral at this time. In addition to well-characterized collagens, short, triple-helical collagenous segments are present in other proteins, including acetylcholinesterase, the C1q component of the complement system, pulmonary surfactant proteins, macrophage scavenger receptors, and ectodysplasin A, a product of the gene mutated in X-linked anhidrotic ectodermal dysplasia. [6], [7] However, these proteins are not included in the collagen family because the collagenous domains are not a predominant part of the molecules, and the proteins do not function primarily as structural components of the extracellular matrix of connective tissue.



TABLE 14-1 **Genetic Heterogeneity of Collagen**

The genetically distinct collagens can be separated on the basis of their physicochemical properties. Also, peptide mapping with limited enzymatic digestion or chemical reagents, such as cyanogen bromide, which cleaves the polypeptides at each methionyl residue, greatly facilitates the early identification of different genetic forms of collagens.

More recently, molecular cloning approaches and near completion of the human genome database have enabled identification of additional collagen genes with precise knowledge of their chromosomal locations (Table 14-2).

Collagen Type	Constituent Polypeptide	Gene Designation	Chromosomal* Location of the Gene
I	a1(I)	COL1A1	17q21-q22
	a2(I)	COL1A2	7q21-q22
III	a1(III)	COL3A1	2q24-q33
IV	a1(IV)	COL4A1	13q33-q34
	a2(IV)	COL4A2	13q33-q34
	a3(IV)	COL4A3	2q36-q37
	a4(IV)	COL4A4	2q36-q37
	a5(IV)	COL4A5	Xq22
	a6(IV)	COL4A6	Xq22
V	a1(V)	COL5A1	9q34.2-34.3
	a2(V)	COL5A2	2q24-q32
	a3(V)	COL5A3	19p13.2
	a4(V)	COL5A4	ND
VI	a1(VI)	COL6A1	21q22.3
	a2(VI)	COL6A2	21q22.3
	a3(VI)	COL6A3	2q37
VII	a1(VII)	COL7A1	3p21
VIII	a1(VIII)	COL8A1	3q11.1-13.2
	a2(VIII)	COL8A2	1p32.3-34.3
XII	a1(XII)	COL12A1	6q12-13
XIII	a1(XIII)	COL13A1	10q22
XIV	a1(XIV)	COL14A1	8q23
XV	a1(XV)	COL15A1	9q21-22
XVI	a1(XVI)	COL16A1	1p34-35
XVII	a1(XVII)	COL17A1	10q24.3
XVIII	a1(XVIII)	COL18A1	21q22.3
XIX	a1(XIX)	COL19A1	6q12-q13
XXI	a1(XXI)	COL21A1	6p11-12

*ND, not determined

TABLE 14-2 **Molecular Genetics of Collagens Present in Human Skin**

On the basis of the fiber architecture in tissues, the genetically distinct collagens can be divided into different classes (Table 14-1). Collagen types I, II, III, V, and XI align into relatively large fibrils and are therefore designated *fibril-forming collagens*. Type IV is arranged in an interlacing network within the basement membranes, whereas type VI is a distinct microfibril-forming collagen and type VII collagen forms anchoring fibrils. A recently described group, *FACIT* (fibril-associated collagens with interrupted triple helices) collagens, [8] includes types IX, XII, XIV, XIX, XX, and XXI. Many of these collagens are associated with larger collagen fibers and may serve as molecular bridges important for the organization and stability of the extracellular matrices. Type XIII and XVII collagens are transmembrane proteins. An overview of the collagens potentially contributing to skin physiology and pathology is presented below (see Table 14-2). Other collagen types (including II, IX, X, XI, XIX, XX, and XXI) are not discussed in detail because they are apparently not present in the skin in significant quantities.

Type I collagen, the most widely distributed and most extensively characterized form of collagen, is found predominantly in bone and tendon and it accounts for approximately 80 percent of the total collagen of adult human dermis. The type I collagen molecule contains two identical a chains, designated a1(I), and a third chain, called a2(I), clearly different in its amino acid composition. Thus, the chain composition of type I collagen is $[a1(I)]_2a2(I)$. Collagen molecules that consist of three identical a1(I) chains have also been detected, but these so-called a1(I) trimer molecules with chain composition of $[a1(I)]_3$ appear to represent a minor fraction of collagen in connective tissues, such as the skin. [9] Collagen types I and III form the relatively broad extracellular fibers that are primarily responsible for the tensile strength of the human dermis. Mutations in the type I and III collagen genes can result in connective tissue abnormalities in the skin and joints, among other tissues, in different forms of the Ehlers-Danlos syndrome and fragility of bones in osteogenesis imperfecta. [3], [5]

Type III collagen, another genetically distinct form of collagen, predominates in gastrointestinal and vascular connective tissues, but it also represents approximately 10 percent of the total collagen in the adult human dermis. [10] Type III collagen was initially designated *fetal collagen,* as it predominates in human skin during embryonic life. However, the synthesis of type I collagen accelerates during the early postnatal period until the ratio of type I to type III collagen in adult human skin is ˜8:1. [10] Type III collagen is composed of three identical a chains, a1(III), distinguished from the chains of type I collagen by a relatively high content of hydroxyproline and glycine and the presence of a cysteine residue. Mutations in the type III collagen gene cause the vascular type of Ehlers-Danlos syndrome (see below).

Type IV collagen is abundantly present in basement membranes. [11] In the skin, type IV collagen is found in the basement membrane at the dermal–epidermal junction, primarily within the lamina densa, where it forms a lattice rather than the fibers characteristic of dermal collagens. [12] The type IV collagen present in human skin is predominantly a heterotrimer, $[a1(IV)]_2a2(IV)$, although, occasionally, the homopolymers $[a1(IV)]_3$ and $[a2(IV)]_3$ may be assembled. The molecular masses of the a1(IV) and a2(IV) chains are 185 and 175 kDa, respectively. The type IV collagen molecule is characterized by the presence of noncollagenous interruptions within the triple-helical domain, thus conferring flexibility to the molecule. More recently, four additional a chains—a3(IV), a4(IV), a5(IV), and a6(IV)—have been identified. [13] The type IV collagen molecules containing these subunit polypeptides appear to be expressed primarily in glomerular basement membranes and their importance for renal physiology is attested by the fact that mutations in the gene encoding the a5(IV) polypeptide result in Alport's syndrome, [14] an X-linked renal disease. Furthermore, autoantibodies recognizing the a3(IV) chains underlie Goodpasture's syndrome. [15] Finally, the a5 chain of type IV collagen has been shown to be a target of circulating IgG autoantibodies in a novel autoimmune disease with sub-epidermal blisters and renal insufficiency. [16]

Type V collagen consists of a subfamily of similar interrelated collagens that contain four different types of a chains. The predominant form in the skin is $[a1(V)]_2a2(V)$. Type V collagen is present in most connective tissues, and in the skin type V collagen represents less than 5 percent of the total collagen. The importance of type V collagen has been demonstrated by discovery of mutations in the type V collagen genes in patients with classical, autosomal dominant forms (types I and II) of the Ehlers-Danlos syndrome (EDS). [17], [18] It is of interest that a clinically similar, classic type of EDS, can be derived from absence of tenascin-X expression, leading to an autosomal recessive form of the disease. [19] Tenascin-X is developmentally associated with collagen fibrillogenesis and its absence could explain defective collagen fibers similar to those in patients with mutations in the type V collagen genes. The pathoetiologic role of tenascin-X was

confirmed by development of TNX null mice, which exhibit progressive hyperextensibility and reduced tensile strength of their skin. [20]

Type VI collagen was initially thought to be a minor collagen in tissues such as the dermis. However, improved biochemical isolation procedures demonstrate that type VI collagen may be a relatively abundant component in a variety of tissues, including skin. [21] The type VI collagen molecules consist of three distinct a chains—a1(VI), a2(VI), and a3(VI)—which fold into a triple-helical domain of about 100 nm in length, with globular domains at both ends of the molecule. [22] Type VI collagen assembles into relatively thin microfibrils that form a network independent of the previously mentioned broad collagen fibers, which consist primarily of types I and III collagens. [23] The microfibrillar network may perform an anchoring function by stabilizing the assembly of the broad collagen fibers as well as basement membranes. Recent studies demonstrate that mutations in each of the three type VI collagen genes can lead to different forms of congenital muscular dystrophy, with no apparent phenotype in the skin but with limited joint hypermobility. [24], [25]

Type VII collagen, the major component of the anchoring fibrils at the dermal–epidermal basement membrane zone was originally designated as long-chain (LC) collagen because it has an unusually long triple-helical region of about 450 nm. [26] It has only one type of a chain, a1(VII), and the triple-helical domain contains interchain disulfide bonds and a pepsin-sensitive, nonhelical site close to the center of the molecule. [27] The triple-helical collagenous domain is flanked by a large, nonhelical domain (NC-1) at the amino terminus and a shorter carboxyl terminal nonhelical domain (NC-2). Type VII collagen is a major constituent of the anchoring fibrils that extend from the dermal–epidermal junction to the papillary dermis. Type VII collagen molecules become organized into anchoring fibrils through the formation of antiparallel dimers linked through their carboxyl terminal ends. [26] The large amino-terminal, noncollagenous domains of type VII collagen are thought to interact at one end with type IV collagen and/or laminin 5 components of the dermal–epidermal basement membrane and at the other end with basement membrane–like structures, known as anchoring plaques, found in the papillary dermis. [26], [28] These types of structural organizations of the anchoring fibrils could stabilize the attachment of the dermal–epidermal basement membrane to the underlying dermis. Alternatively, it has been suggested that most anchoring fibrils form U-shaped loops that entrap larger fibers consisting of type I and III collagens. [29] Thus, alterations in the expression, structure, or molecular interactions of type VII with other basement membrane components could result in skin fragility. Such a situation is exemplified by *dystrophic epidermolysis bullosa (DEB),* a group of heritable mechanobullous diseases characterized by blistering of the skin as a result of minor trauma [30], [31] and [32] (see Chap. 65). A scarcity of type VII collagen and abnormalities in the anchoring fibrils have been demonstrated in the dominant dystrophic form of epidermolysis bullosa (EB), and anchoring fibrils and type VII collagen are absent in some cases of severe recessive dystrophic EB. Distinct mutations in different forms of DEB have been demonstrated in more than 300 families, and none of the families with DEB studied so far has revealed mutations in genes other than that encoding the a1(VII) polypeptide of type VII collagen. [31], [32] Furthermore, type VII collagen serves as the autoantigen in the acquired form of EB [33] (see Chap. 66).

Type VIII collagen refers to a molecule initially isolated from cultures of endothelial cells and other cell types. [34] It consists of two separate polypeptides, a1(VIII) and a2(VIII), and forms the hexagonal lattices in Descemet's membrane of corneas. These observations explain the finding that mutations in the type VIII collagen gene (COL8A2) result in a form of corneal dystrophy. [35]

Type XII collagen belongs to the group of *FACIT* collagens that contain more than one triple-helical domain separated by noncollagenous segments. They do not undergo proteolytic processing from a larger proform, and therefore are not secreted as procollagens. The FACIT collagens form fibers only in association with fibrillar collagens. For example, type XII collagen, consisting of three identical a1(XII) chains, is localized in dense connective tissues in association with type I collagen. However, skin shows relatively little reactivity with the type XII collagen-specific antibodies, and the precise quantitation and the physiologic role of type XII collagen in the skin remain to be elucidated. However, it has been suggested that type XII collagen mediates interactions between banded collagen fibers and modulates extracellular matrix deformability. [36]

Type XIII collagen, a transmembrane protein, is ubiquitously distributed in small amounts in most tissues, and in particular, the expression of this collagen has been detected in normal human skin and cultured keratinocytes. [37] Immunolabeling studies localized type XIII collagen epitopes in the epidermis to cell-cell contact sites as well as in dermal–epidermal junctions. More refined localization suggested that this collagen may, in fact, be a component of the adherens junctions. [37] An unusual observation is that type XIII collagen mRNAs are present in as many as 17 splice variants, which display differential tissue expression patterns. [38] However, the functional differences of the proteins derived from these splice variants of mRNA are currently unknown.

Type XIV collagen belongs to the FACIT group and has a high structural homology with type XII collagen. By analogy with type IX collagen, a well-characterized component of the cartilaginous matrices, type XIV collagen may be oriented parallel to the surface of large collagen fibers composed of collagen types I and III. Type XIV collagen, like other FACIT collagens, may be involved in determining the interaction of collagen fibrils with each other and with other components of the extracellular matrix.

Type XVII collagen was initially identified as the 180-kDa bullous pemphigoid antigen *(BPAG2)*, which was recognized by circulating autoantibodies in the sera of some patients with bullous pemphigoid or herpes gestationis. [39] This antigen, which is synthesized by basal keratinocytes, was localized by immunoelectron microscopy to the hemidesmosomes at the dermal–epidermal basement membrane zone of human skin. Type XVII collagen is a transmembrane protein in type 2 topography; that is, the amino-terminal end is intracellular while the carboxy-terminal ectodomain is in the extracellular space. [40] The ectodomain consists of 15 collagenous domains with the characteristic repeating Gly-X-Y sequences that form triple helices. [41] These collagenous domains are separated by noncollagenous segments of variable sizes, and consequently, type XVII collagen is a protein characterized by alternating collagenous and non-collagenous segments. [40] The type XVII collagen gene was mapped to the long arm of human chromosome 10. This location is distinct from any

previously mapped collagens and also distinguishes BPAG2 from BPAG1, the 230-kDa bullous pemphigoid antigen, which has been mapped to the short arm of chromosome 6. [42] The importance of the type XVII collagen was also shown by mutations in the corresponding gene *(COL17A1)* that underlie a nonlethal variant of junctional EB, generalized atrophic benign epidermolysis bullosa *(GABEB)*. [40], [43] These patients have protracted, lifelong blistering of the skin, atrophic scarring, alopecia, and nail dystrophy.

Collagens of types XV, XVI, XVIII, XIX, XX, and XXI were recently discovered by cDNA cloning or by examination of the genome database, and their complete primary structures are established. [44], [45], [46], [47], [48], [49], [50] and [51] These all contain multiple triple-helical domains separated by short noncollagenous regions. In addition, they possess a large globular domain at the amino terminus, which shares sequence similarity with the N-termini of minor fibrillar collagens, FACIT collagens, and thrombospondin. These collagens are further divided into two subgroups. Types XV and XVIII collagens contain a large, homologous C-globular domain and both are expressed in basement membranes. Interestingly, C-terminal fragments of type XV and XVIII collagens have been identified as endostatin, an inhibitor of angiogenesis and tumor growth. [52] Types XVI, XIX, XX, and XXI collagens share the characteristic C-terminal features of the FACIT collagens, but it is not known whether they are associated with fibrillar collagen. Type XVI collagen has been localized to the upper papillary dermis at the cutaneous basement membrane zone, in close vicinity to type VII collagen. Furthermore, type XVI collagen colocalizes with fibrillin-1 at the dermal–epidermal junction, but not in deeper layers of the dermis. These observations suggest that type XVI collagen may contribute to the stability of the cutaneous basement membrane zone. [53]

COLLAGEN GENE STRUCTURE

The collagen genes, like most eukaryotic genes, are large, multiexon genes interrupted at several points by noncoding DNA sequences of unknown function called *introns*. [54] Thus, the eukaryotic gene coding for a protein is much larger than would be predicted from the amino acid sequences of the final protein. An example of the complexity of collagen genes is the intron–exon organization of the type VII collagen gene *(COL7A1)* (see Fig. 14-3), which consists of 118 exons, the largest number in any published gene. [55]

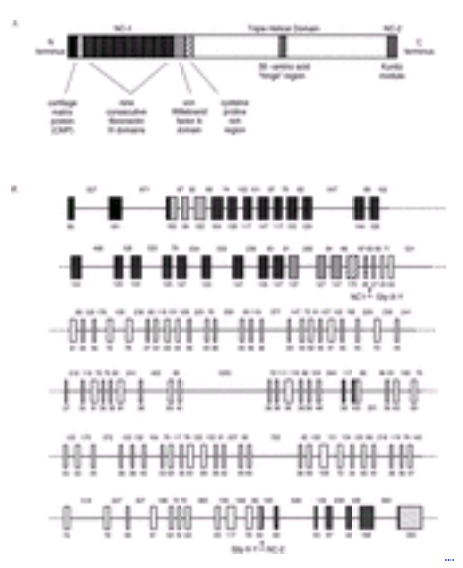

FIGURE 14-3 Structural organization of the type VII collagen polypeptide, the a1(VII) chain, as deduced from molecular cloning, and the intron-exon organization of the corresponding gene, *COL7A1. A.* The a1 (VII) polypeptide consists of a triple-helical domain that contains imperfections or interruptions in the Gly-X-Y repeat sequence, including a 39–amino acid “hinge” region. The central collagenous domain is flanked by noncollagenous segments, the amino-terminal NC-1 domain and the carboxyl-terminal NC-2 domain. The NC-1 domain consists of submodules with homology to known adhesive proteins, as indicated below the molecule. The NC-2 domain has a segment of homology with the Kunitz proteinase inhibitor molecule. *B.* The type VII collagen gene consists of a total of 118 exons *(vertical blocks),* which are separated from each other by intervening noncoding intronic sequences *(horizontal lines).* The sizes (in base pairs) of the introns *(above the lines)* and the exons *(below the blocks)* are indicated. (*Modified from Christiano et al.,* [58] *with permission.*)

During the early stages of gene expression, the entire gene is transcribed into a high-molecular-weight precursor mRNA, which is a complementary copy of the coding strand of the double-helical DNA. The precursor mRNA undergoes posttranscriptional modifications, such as capping and polyadenylation, and the introns are removed by splicing to yield a linear, uninterrupted coding sequence with 5' and 3' untranslated flanking regions. The mature mRNA is then transported into the cytoplasm and translated in cells, such as dermal fibroblasts.

Complementary and genomic DNA clones corresponding to the a chains of various collagen molecules have been described in different laboratories. These clones have been extensively characterized and hybridized with the corresponding mRNA molecules to examine the temporal and topographic expression of these genes by Northern blot and in situ hybridization techniques, respectively. In addition, their nucleotide sequence homology with the corresponding amino acid sequences in the collagen a chains in various animal species has been determined, thus allowing estimates of the evolutionary conservation of certain segments within the collagens. [56] A high degree of conservation implies a region of functional importance within a protein molecule.

Recombinant DNA technology has also facilitated determination of the precise chromosomal location of the different collagen genes within the human genome (Table 14-2). With few exceptions, the collagen genes are widely scattered throughout the human genome. For example, the genes coding for the two constituent polypeptide chains of type I collagen, a1(I) and a2(I), are located on separate chromosomes, 17 and 7, respectively. Knowledge of the precise

chromosomal location of the genes coding for collagens in human skin will allow development of polymorphic markers within the genes and in the flanking DNA for use in genetic linkage studies. In addition, sophisticated mutation detection strategies, based on scanning of the genes, have led to identification of a large number of mutations in different collagen genes with characteristic phenotypic consequences (see, e.g., Refs. [3], [4] and [5], [31], [32], and [57]).

TRANSLATION OF COLLAGEN POLYPEPTIDES

Under physiologic conditions, collagen molecules spontaneously assemble into insoluble fibers. This observation presented a logistic problem because it was difficult to visualize how a collagen molecule could be synthesized inside the cell and then secreted into the extracellular space without premature assembly of the molecules into insoluble fibers. This problem was solved by the demonstration that collagen is initially synthesized as a larger precursor molecule, procollagen, which is soluble under physiologic conditions.

The precursor polypeptides of procollagen, so-called prepro-a chains, are synthesized on the ribosomes of the rough endoplasmic reticulum in fibroblasts and related cells (Fig. 14-4). This initial translation product, the prepro-a chain, contains an amino-terminal signal (or leader) sequence. The signal sequence, a characteristic feature of many secreted proteins, is rich in hydrophobic amino acids and probably serves as a signal for attachment of the ribosomes to the membranes of the rough endoplasmic reticulum and vectorial release of the nascent polypeptides into the cisternae of the rough endoplasmic reticulum. During the transmembrane transport of the polypeptides, the signal sequence is enzymatically removed in a reaction catalyzed by signal peptidase (Table 14-3). The polypeptides released inside the lumen of the rough endoplasmic reticulum are termed *pro-a chains* and are larger than collagen a chains because they contain additional peptide sequences at both ends of the molecule. Various studies show that these noncollagenous extension peptides are different from the collagenous portion of the molecule in that they do not have glycine in every third position, they are relatively poor in proline and hydroxyproline, and they are relatively rich in acidic amino acids. These extension peptides also contain cysteine and tryptophan, which are not present, for example, in type I and II collagens. These noncollagenous domains often contain motifs homologous with sequences found as building blocks in other extracellular matrix proteins, such as the fibronectin III domain, von Willebrand factor A domain, and thrombospondin N-terminal domain sequences. It should be noted that, in spite of their homology, these domains do not have the functional characteristics of the original proteins.

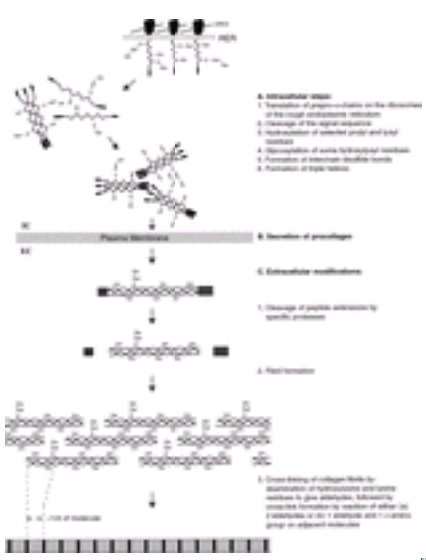

FIGURE 14-4 Biosynthesis of procollagen and the assembly of collagen molecules into the extracellular fibers. Glc-Gal, glucosylgalactose attached to a hydroxylysyl residue; mRNA, messenger RNA; –OH, hydroxyl group of hydroxyproline or hydroxylysine; RER, rough endoplasmic reticulum.



TABLE 14-3 **Characteristics of Enzymes Participating in the Biosynthesis of Collagen**

POSTTRANSLATIONAL MODIFICATIONS OF POLYPEPTIDE CHAINS

After the assembly of amino acids into prepro-a chains on the ribosomes, the polypeptides undergo several modifications before the completed collagen molecules are deposited into extracellular fibers (Fig. 14-4). Most of these modification reactions are catalyzed by specific enzymes, and many of the modifications are characteristic of the biosynthesis of collagen (Table 14-3 and Table 14-4). These events are often termed *posttranslational modifications* to emphasize that these reactions are not directly controlled by the information in the mRNA but occur in the polypeptide chains after the amino acids have been linked together by peptide bonds. The posttranslational modification reactions of collagen include (1) synthesis of hydroxyproline by hydroxylation of selected prolyl residues; (2) synthesis of hydroxylysine by hydroxylation of selected lysyl residues; (3) attachment of carbohydrates, galactose or glucosylgalactose, onto certain hydroxylysyl residues; (4) chain association, disulfide bonding and triple-helix formation; (5) proteolytic conversion of procollagen to collagen; and (6) fiber formation and cross-linking. Current evidence indicates that modification reactions (1) to (4) are intracellular events, whereas proteolytic conversion, fiber formation, and cross-linking probably take place

extracellularly (Fig. 14-4).

TABLE 14-4 **Major Steps in the Biogenesis and Degradation of Collagen and Their Functional Significance**

Synthesis of Hydroxyproline

A characteristic feature of collagen is the presence of relatively large amounts of hydroxyproline (Fig. 14-5). Small amounts of hydroxyproline are also found in elastin (see Chap. 15), as well as in some proteins in which the collagenous domains are a minor portion of the molecule, such as acetylcholinesterase, the C1q component of the complement system, the macrophage scavenger proteins, and ectodysplasin A (see Refs. [6] and [7]). The hydroxyproline in collagen is found in two isomeric forms. *Trans*-4-hydroxy-L-proline accounts for more than 95 percent of the total hydroxyproline in type I and type III collagens. The minor form is *trans*-3-hydroxy-L-proline, which is found in greater amounts in type IV collagen. [58]

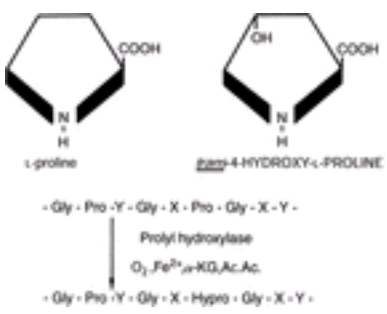

FIGURE 14-5 Structures of proline and hydroxyproline, and schematic representation of the enzymatic hydroxylation of prolyl residues in the Y position of the repeating Gly-X-Y sequence of collagen polypeptides. (*From Uitto J, Prockop DJ: Inhibition of collagen accumulation by proline analogues:* The mechanism of their action, in Collagen Metabolism in the Liver, *edited by H. Popper, K Becker. New York, Stratton intercontinental, 1975, p 139, with permission.*)

The functional role of hydroxyproline in collagen is well established. A critical amount of *trans*-4-hydroxy-L-proline is required for the folding of a chains into the triple helix, the conformation required for the normal secretion of procollagen molecules out of the cells (Fig. 14-6). Thus, in the absence of hydroxyproline, collagen polypeptides would not form the critical triple-helical structure under physiologic conditions, and no functional collagen fibers would appear in the extracellular space.

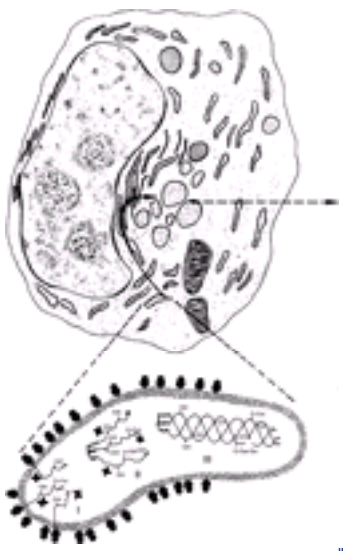

FIGURE 14-6 Representation of the synthesis and secretion of procollagen by a fibroblast. The enlarged area demonstrates events taking place in the rough endoplasmic reticulum of the cells during the synthesis of procollagen. In the first stage (I), the polypeptide chains of procollagen are synthesized on the membrane-bound ribosomes, and the nascent chains are fed into the cisternae of the rough endoplasmic reticulum. Hydroxylation of prolyl and lysyl residues and glycosylation of hydroxylysyl residues are initiated on the growing polypeptide chains. These reactions are completed soon after release of full-size chains from ribosomes (II). Three pro-a chains are linked together by the

formation of interchain disulfide bonds, and the collagenous portions of the polypeptides assume a triple-helical conformation (III). The procollagen molecules are then transferred from the rough endoplasmic reticulum to Golgi vesicles, and are secreted from these vesicles into the extracellular milieu. –OH, hydroxyl groups of hydroxyproline and hydroxylysine; –Gal, galactosyl residue attached to hydroxylysine; –Gal Glc, glucosylgalactosyl residue attached to hydroxylysine; the cloverleaf-like structures signify the hydroxylating and glycosylating enzymes. (*After Prockop DJ et al: Intracellular steps in the biosynthesis of collagen, in* Biochemistry of Collagen, *edited by GN Ramachandran, AH Reddi. New York, Plenum, 1976, p 163, with permission.*)

Although hydroxyproline accounts for about 10 percent of the total amino acids in type I collagen, free hydroxyproline is not incorporated into newly synthesized collagen polypeptides. The hydroxyprolines are synthesized by hydroxylation of certain prolyl residues that are already in peptide linkages (Fig. 14-5). The formation of *trans*-4- and *trans*-3-hydroxyproline is catalyzed by two separate enzymes—prolyl-4-hydroxylase and prolyl-3-hydroxylase—which have been purified and extensively characterized from various vertebrate tissues, including human skin. The prolyl-4-hydroxylase recognizes only prolyl residues in the Y position of the repeating triplet sequence Gly-X-Y of collagen. In contrast, prolyl-3-hydroxylase only hydroxylates prolyl residues in the X position when the Y position is already occupied by a *trans*-4-hydroxyproline. Thus, 3-hydroxyproline is typically found in collagen in a glycine-(3-hydroxyproline)-(4-hydroxyproline)-glycine sequence. The prolyl hydroxylases require molecular oxygen, ferrous iron, a-ketoglutarate, and a reducing agent such as ascorbate as cosubstrates or cofactors for the reactions (Fig. 14-5 and Table 14-3).

The hydroxylation of appropriate prolyl residues begins while the pro-a chains are growing on the ribosomes, and the hydroxylation is completed soon after the release of full-length polypeptide chains from the ribosomes. [58] The enzyme prolyl-4-hydroxylase has been localized to the rough endoplasmic reticulum (Fig. 14-6). Prolyl hydroxylases do not hydroxylate prolyl residues if the collagen substrate is in a triple-helical conformation. Because triple-helix formation takes place in the cisternae of the rough endoplasmic reticulum (see below), hydroxyproline formation must be completed before the procollagen molecules leave this cellular compartment.

As noted above, prolyl hydroxylase requires a reducing agent, such as ascorbate, for its activity. Therefore, ascorbic acid deficiency leads to a decreased formation of collagen fibers, explaining some of the clinical manifestations in scurvy, such as poor wound healing and decreased tensile strength of the connective tissues. [59] An analogous situation may exist in tissues with relative anoxia, because molecular oxygen is a specific requirement for the formation of hydroxyl groups in hydroxyproline. Studies with animal models demonstrate that wound healing is relatively poor under hypobaric conditions, and in such situations the low O_2 levels may limit the synthesis of hydroxyproline. [60] This observation may also explain the decreased healing tendency of wounds and ulcers in peripheral tissues that are anoxic due to relatively poor blood supply.

Synthesis of Hydroxylysine

Hydroxylysine is another amino acid characteristic of collagen (Fig. 14-7). During the intracellular synthesis of procollagen, hydroxylysine serves as an attachment site for the sugar residues and is critical to the formation of cross-links that stabilize the extracellular collagen matrix. Free hydroxylysine is not incorporated into nascent polypeptide chains, but certain lysyl residues in peptide linkages are converted to hydroxylysine. The hydroxylation reaction is catalyzed by an enzyme, lysyl hydroxylase, which, like the prolyl hydroxylases, requires O_2, Fe^{2+}, a-ketoglutarate, and ascorbate as cofactors and cosubstrates. Despite certain similarities, the prolyl and lysyl hydroxylases are different enzyme proteins and products of different genes. Lysyl hydroxylase, like prolyl-4-hydroxylase, hydroxylates only lysyl residues in the Y position of the repeating Gly-X-Y sequence. Even though hydroxylation of lysyl residues in collagen is initiated while the polypeptides are still assembled on the ribosomes, the formation of hydroxylysine continues for some time after the release of peptides from the ribosomes.

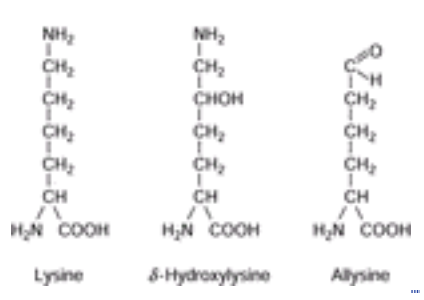

FIGURE 14-7 Structures of lysine, hydroxylysine, and allysine, the aldehyde derivative of lysine. (*From Uitto J, Lichtenstein JR: Defects in the biochemistry of collagen in diseases of connective tissue.* J Invest Dermatol *66:59, 1976, with permission.*)

The extent to which lysyl residues in the Y position of the Gly-X-Y sequence are hydroxylated varies greatly among the collagens from different sources. In particular, type I and type III collagens are frequently hydroxylated to a lesser degree, so that these collagens normally contain approximately four to eight hydroxylysine residues per 1000 amino acids, whereas type II collagen has approximately four to five times as many hydroxylysine residues. In type IV collagen, most of the lysyl residues are converted to hydroxylysine. This variation can be explained in part by differences in the actual number of lysyl residues that are available for maximal hydroxylation in the pro-a chains. The variation in the hydroxylation of lysyl residues can also be explained by the fact that the nature of the amino acids in the X position and in the adjacent triplets influences the rate at which lysyl residues in Gly-X-Lys sequences are hydroxylated. In addition, lysyl hydroxylase does not hydroxylate a collagen substrate that is in the triple-helical conformation. [58] Therefore, folding of the pro-a chains into a triple helix terminates the intracellular formation of hydroxylysyl residues. The rate at which

pro-a chains of different genetic types fold into the triple helix varies, and, in particular, the rate of triple-helix formation is considerably slower during the synthesis of type II procollagen than of type I procollagen. Thus, folding of the procollagen polypeptides into their triple-helical conformation can regulate the amount of hydroxylysyl residues in newly synthesized collagen molecules.

The critical importance of lysyl hydroxylation of collagen is attested to by the deficiency of lysyl hydroxylase in patients with the scoliotic (type VI) form of EDS, characterized by hyperextensible skin, loose-jointedness, severe kyphoscoliosis, and ocular fragility. [61]

Glycosylation

Collagen is a glycoprotein that contains galactosyl and glucosylgalactosyl residues attached to the molecule. The sugar residues are attached to collagen polypeptides during intracellular biosynthesis in a sequential manner, so that a galactosyl residue is first added to the molecule and then a glucose moiety is attached to some of the galactosyl residues [61] (Fig. 14-4 and Fig. 14-5). The link between the carbohydrate unit and the polypeptide is an *O*-glycosidic bond through the hydroxyl group of hydroxylysine. Therefore, the synthesis of hydroxylysine is a prerequisite for the glycosylation of collagen. The two glycosylation reactions are catalyzed by separate, specific enzymes called collagen galactosyl-transferase and collagen glucosyl-transferase (Table 14-3). These enzymes have been extensively purified from a variety of sources; both of them use uridine diphosphate (UDP)-sugars as a source of the carbohydrate and require Mn^{2+} as a cofactor.

The relative number of sugar residues in genetically distinct forms of collagen shows considerable variation. In particular, types II and IV collagens are relatively rich in carbohydrates, whereas collagens of types I and III contain only a few sugar residues. The glycosylation of pro-a chains begins on nascent polypeptides after the synthesis of hydroxylysyl residues. The glycosylation reactions are terminated when the polypeptides fold into a triple-helical conformation, because the transferase enzymes do not glycosylate collagen substrates in a triple-helical form. It appears that the addition of galactose and glucose is accomplished in the cisternae of the rough endoplasmic reticulum and that the rate at which the procollagen polypeptides fold into the triple-helical conformation may partly explain the variability in the number of sugars in various types of collagens. In addition to sugars attached to the hydroxylysyl residues in the triple-helical portion of the molecule, the nonhelical extension peptides contain complex carbohydrates, consisting mainly of mannose. The function of the sugar residues in collagen and also in the extension peptides is not known.

CHAIN ASSOCIATION, DISULFIDE BONDING, AND TRIPLE-HELIX FORMATION

A critical step in the intracellular biosynthesis of procollagen is the association of three pro-a chains and subsequent folding of the collagen portion of the polypeptides into a triple helix (Fig. 14-6). The noncollagenous peptide extensions on the individual pro-a chains assume globular conformations soon after their translation and this conformation contains the specific information that directs the correct association of the three pro-a chains. Such a mechanism might explain the association of pro-a1 and pro-a2 chains in a proper 2:1 ratio during the synthesis of type I procollagen. It would also explain the rapid and efficient association of the pro-a chains and folding of the molecule into the triple helix. The latter point is emphasized by the observation that fully processed collagen a chains isolated from tissues renature into a triple helix very slowly, and 24 h or more are required for about 50 percent of the molecules to become helical. In contrast, newly synthesized pro-a chains of type I procollagen, which contain intact nonhelical amino- and carboxyl terminal extensions, associate and fold into the triple-helical conformation within 5 to 10 min from the time they are synthesized on the ribosomes. The association of the extensions at the carboxyl terminal ends of the polypeptide chains appears to facilitate folding of the molecules into the triple helix, perhaps by providing a nucleation site from which the formation of the triple helix is propagated throughout the collagenous portion of the molecule.

During the process of chain association, the cysteine residues on the extension peptides of the pro-a chains form interchain disulfide bonds linking three pro-a chains together (Fig. 14-6). The interchain disulfide bonds of types I and II procollagens are located in the carboxyl terminal ends of the molecules. Experiments with freshly isolated connective tissue cells have demonstrated that the synthesis of interchain disulfide bonds closely parallels the rate at which the procollagen molecules fold into the triple-helical conformation (Fig. 14-6). On the basis of this observation and other experimental evidence, it appears that the formation of the interchain disulfide bonds may play a role in helix formation during the biosynthesis of procollagen. In addition, it has been shown that the rate at which the pro-a chains fold into the triple helix varies during the intracellular synthesis of genetically different types of procollagens. In particular, studies with isolated matrix-free cells have shown that triple-helix formation by type II procollagen is considerably slower than that by type I procollagen, and the triple-helix formation by type IV procollagen is even slower. As discussed earlier, triple-helix formation limits some of the posttranslational modification reactions, such as hydroxylation of certain lysyl residues and subsequent glycosylation of hydroxylysines. Consequently, the differences in the rate of helix formation may, at least in part, explain the variations in the content of hydroxylysine and glycosylated hydroxylysine, in that type II and type IV collagens, both of which demonstrate relatively slow rates of triple-helix formation, also have the highest hydroxylysine and glycosylated hydroxylysine contents.

SECRETION OF PROCOLLAGEN

Pro-a chains, the precursor polypeptides of procollagen, are assembled on the membrane-bound ribosomes, and the newly synthesized polypeptides are translocated into the cisternae of the rough endoplasmic reticulum. In this cellular compartment, three pro-a chains, which have been hydroxylated and glycosylated, fold into a triple helix, and the triple-helical procollagen molecules are then transported into the extracellular space (Fig. 14-6). Procollagen is secreted in Golgi vacuoles or in vesicles of the cells' smooth endoplasmic reticulum. (Fig. 14-6) The intracellular translocation also involves microtubules, because colchicine and other microtubule-disrupting agents delay the secretion of procollagen, and the procollagen molecules then accumulate in the Golgi vesicles. The rate of procollagen secretion also varies among different types of collagens, as measured in matrix-free cell systems derived from different embryonic tissues. The secretion of type I procollagen by matrix-free tendon cells takes about 15 to 20 min whereas the secretion of

type II procollagen by cartilage cells requires 30 to 35 min. The secretion of type IV procollagen is even slower and the secretion of procollagen synthesized by matrix-free lens cells requires approximately 60 min. The reasons for these differences are not completely understood. However, slower secretion of type II and type IV procollagen may be explained, in part, by delayed triple-helix formation, because triple-helical conformation is required for the secretion of procollagen molecules at an optimal rate.

CONVERSION OF PROCOLLAGEN TO COLLAGEN

After secretion into the extracellular space, procollagen molecules are converted to collagen by limited proteolysis, which removes the extension peptides on the molecule. [62] The conversion of type I procollagen to collagen is catalyzed by two specific enzymes, procollagen N-proteinase and procollagen C-proteinase, that separately remove the amino-terminal and carboxyl terminal extensions, respectively (Table 14-3). Furthermore, the N-proteinase catalyzing the conversion of type III procollagen to collagen is a separate, specific enzyme. [63]

The N-proteinase capable of cleaving type I procollagen belongs to the ADAMTS (a disintegrin and metalloprotease with thrombospondin motifs) family of extracellular proteases, and is specifically ADAMTS-2. [64] The activity of this enzyme is dependent on the native conformation of the amino-terminal propeptides in procollagen, as they do not catalyze the removal of the extension peptides from isolated pro-a chains. Furthermore, the partially purified N-proteinase is inhibited by metal chelators, suggesting a requirement for divalent cations. [63], [65]

C-proteinase is required for removal of the carboxyl-terminal extension from types I, II, III, and V procollagens, allowing the fully processed molecules to form functional fibers. [62] Cloning of the type I procollagen C-proteinase revealed that it is identical with *bone morphogenic protein-1 (BMP-1),* a metalloprotease implicated in pattern formation during development of diverse organisms and also capable of inducing ectopic bone formation. [65], [66] The activity of the C-proteinase/BMP-1 is stimulated by procollagen C-proteinase enhancers, glycoproteins that bind to the C-terminal propeptide of type I procollagen. [67], [68] Thus, the conversion of procollagen to collagen is a complex, carefully controlled process, and lack of removal of either the amino- or the carboxyl terminal extensions results in impaired tensile strength of collagen fibers in the skin. Specifically, deficiency in the removal of the amino-terminal propeptide of type I collagen in vivo causes dermatosparaxis, a disease of fragile skin, originally recognized in various animal species, and more recently recognized in humans. [69], [70] Specifically, the human counterpart is the dermatosparaxis type of EDS (type VIIc), caused by deficiency in N-proteinase activity. [69] It should be noted that a phenotypically similar disease, the arthrochalasia type EDS (types VIIa and b), can be caused by mutations in the type I collagen genes (COL1A1 or COL1A2, respectively) at the cleavage site for the N-proteinase. [71]

FIBER FORMATION AND CROSS-LINKING

After removal of the extension peptides in the extracellular space, the collagen molecules spontaneously align to form fibers. These fibers, however, do not attain the necessary tensile strength until the molecules are linked together by specific covalent bonds known as *cross-links*. [72] The most common forms of cross-links in collagen are derived from lysine or hydroxylysine. The first step in the cross-linking of collagen is the enzymatic synthesis of aldehyde derivatives by removal of the e-amino groups of some of the lysyl and hydroxylysyl residues (Fig. 14-4 and Fig. 14-6). The aldehydes then form cross-links by two kinds of reactions. One reaction involves condensation of an aldehyde with an e-amino group, still present in unmodified lysine or hydroxylysine, to form a Schiff base type of covalent cross-link (Fig. 14-8). The second type of reaction is an aldol condensation between two aldehydes. In addition to these cross-links, collagen contains several more complex cross-links that also involve lysyl or hydroxylysyl residues. The lysine- and hydroxylysine-derived cross-links can be either intramolecular, occurring between two adjacent a chains in the same collagen molecule, or intermolecular, stabilizing the alignment of neighboring collagen molecules along the microfibril.

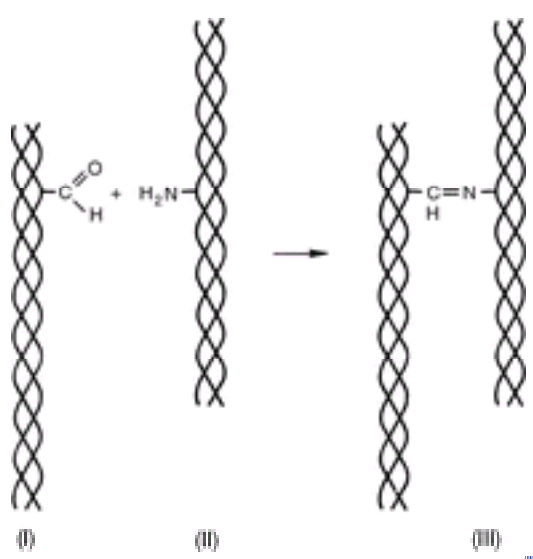

FIGURE 14-8 Representation of the formation of intermolecular cross-links of collagen. The cross-linking is initiated by oxidative deamination of either a lysyl or hydroxylysyl residue to form a corresponding aldehyde derivative (I). The aldehyde then reacts with an e-amino group on an unmodified lysyl or hydroxylysyl residue in an adjacent collagen molecule (II), and they form a Schiff-base-type covalent cross-link. (*From Uitto J, Lichtenstein JR: Defects in the biochemistry of collagen in diseases of connective tissue.* J Invest Dermatol *66:59, 1976, with permission.*)

The first step in collagen cross-linking, the oxidative deamination of certain lysyl and hydroxylysyl residues, is catalyzed by lysyl oxidase. This enzyme requires copper as a cofactor, and its activity is readily inhibited by nitriles, such as

ß-amino-propionitrile, which produce lathyrism in animals. Lysyl oxidase functions in the extracellular space, and it has much greater activity with collagen that has been precipitated as native fibrils as compared with denatured collagen or isolated a chains. It should be noted that several additional lysyl oxidase-like (LOXL) proteins have been identified by molecular cloning. Thus, lysyl oxidase is a family of copper-dependent enzymes although the precise functions of the LOXL proteins is currently unknown. [73] The in vivo formation of aldehydes appears to occur primarily after the onset of fibril formation. Because the cross-links of collagen provide the tensile strength required in certain tissues, a defect in the formation of these covalent bonds could lead to a disturbance in connective tissue function. An example is the occipital horn syndrome (previously known as the Ehlers-Danlos syndrome type IX), which results from reduced lysyl oxidase activity. The primary defect resides in perturbed copper metabolism caused by mutations in a copper transport enzyme protein, an ATPase encoded by the gene MNK-1 that is also involved in Menkes' syndrome. [74], [75] As a result, serum copper levels are reduced, leading to reduced lysyl oxidase activity.

CONTROL OF COLLAGEN PRODUCTION

A major question in collagen biology concerns the mechanisms that control the deposition of collagen in tissues. Such control must exist in vivo, because the consequences of uncontrolled collagen accumulation are demonstrated by diseases such as progressive systemic sclerosis and various other fibrotic conditions. [76]

On the basis of theoretical considerations, the accumulation of collagen in tissues can be controlled at several different levels of biosynthesis and degradation. The possible sites of control include (1) transcriptional and posttranscriptional control of the formation of functional procollagen mRNA molecules; (2) control of the rate of polypeptide assembly through translation of mRNA; (3) posttranslational control of the triple-helix formation, secretion, and conversion of the precursor forms to collagen; and (4) degradation of newly synthesized pro-a chains and removal of extracellular collagen fibers.

Several observations suggest that an important control mechanism acts at the level of mRNA formation through regulation of the transcriptional activity of gene expression. [54], [77] In fact, there is a good correlation between collagen biosynthesis and the level of procollagen mRNAs in several in vitro models by using cultured cells, such as skin fibroblasts. At least in these models, the production of procollagen is primarily regulated at the transcriptional level.

The transcriptional regulation of collagen gene expression involves both *cis*-acting elements and *trans*-acting factors. The *cis*-acting elements are nucleotide sequences in the promoter region of the gene that serve as binding sites for *trans*-acting cellular proteins, which can up or downregulate the transcriptional promoter activity. Some of the *trans*-acting factors are nuclear receptors, such as the retinoic acid receptors (RAR and RXR) [78] that form a complex with the ligand (a retinoid) and then bind to the retinoic acid-responsive elements (RARE) in the target gene. Retinoids, such as all-*trans*-retinoic acid, modulate type I collagen gene expression both in vitro and in vivo. In particular, quiescent nonproliferating cells can be stimulated by retinoic acid to activate collagen gene expression. This may have relevance to the elevated collagen synthesis observed in photodamaged dermis after topical application of all-*trans*-retinoic acid. [79]

One of the most powerful modulators of connective tissue gene expression is transforming growth factor ß (TGF-ß), a member of a family of growth factors that upregulate the expression of several extracellular matrix protein genes, including those encoding collagen types I, III, IV, V, VI, and VII. [80] In the case of these collagens, the elevated mRNA levels result primarily from the enhanced transcription of the collagen promoter, as determined in transient cell transfections with corresponding collagen promoter/reporter gene constructs. [81] Contributing to the elevation of collagen mRNA levels in fibroblast cultures incubated with TGF-ß $_1$ is the increased stability of type I collagen mRNAs. Thus, the elevated collagen mRNA levels observed in cells incubated with TGF-ß could result from a combination of enhanced transcriptional activity and reduced turnover of the mRNA.

PHARMACOLOGIC PERSPECTIVE

In addition to transcriptional modulators of collagen gene expression, such as retinoids, the multiplicity of posttranscriptional reactions can serve as a source of regulation during procollagen production and may provide opportunities for pharmacologic manipulation of collagen production. [82] Of particular interest is the role of prolyl hydroxylation in limiting the formation of triple-helical collagen. As indicated earlier, the presence of *trans*-4-hydroxyproline is necessary for the formation of the triple helix at physiologic temperatures. The triple helix is required, in turn, for normal secretion of procollagen and subsequent collagen fiber formation. Thus, if formation of 4-hydroxyproline is inhibited, the production of collagen decreases. In several experimental systems designed to limit the synthesis of *trans*-4-hydroxyproline, the production of triple-helical procollagens is decreased concomitantly. [82] These observations suggest that the formation of *trans*-4-hydroxyproline could be rate-limiting in procollagen production in vivo. In support of this suggestion, it has been found that the activity of prolyl hydroxylase in tissues correlates with the rate of procollagen synthesis in various clinical and experimental conditions. From these data it is clear that prolyl hydroxylase activity has the capacity to limit collagen production, but it has not been demonstrated thus far that such activity would be rate-limiting under physiologic conditions.

Another control mechanism that determines the amount of extracellular collagen involves degradation of the molecules. Some newly synthesized pro-a chains are degraded intracellularly before secretion, [83] although there are technical difficulties in determining the exact fraction of pro-a chains degraded by this pathway. It has been suggested that this mechanism removes defective pro-a chains that are not able to fold into a triple helix. In addition to the intracellular degradation, continuous removal of extracellular collagen fibers by specific collagenases regulates the amount of tissue collagen (see Chap. 17).

The manner by which hormones regulate collagen gene expression has not been defined in all cases, but a number of endocrinologic disorders dramatically affect the amounts of collagen found in connective tissues. [84] Of special interest is

the effect of various glucocorticoids on collagen in the dermis and other connective tissues. The biosynthesis of collagen is inhibited by hydrocortisone and various fluorinated glucocorticoids used in clinical dermatology. [85] The inhibition is much more pronounced with fluorinated steroids as compared with hydrocortisone. In lower concentrations, the glucocorticoids affect collagen gene expression primarily by inhibiting the rate of transcription, thus resulting in reduced levels of procollagen mRNA. In higher concentrations, glucocorticoids also reduce the activity of prolyl hydroxylase, leading to deficient hydroxylation of collagen polypeptides. As a result, the amount of newly synthesized collagen decreases, possibly explaining connective tissue side effects, such as atrophy of the dermis, often observed after intralesional or prolonged topical application of high potency glucocorticoids. [86]

COLLAGEN DISEASES

The term *collagen disease* implies that a clinical condition involves an abnormality in the structure, synthesis, or degradation of collagen. This term is frequently used to characterize a clinically heterogeneous group of diseases, including lupus erythematosus, scleroderma, and dermatomyositis. In the classic sense, the use of the term in these diseases was based on morphologic changes, known as *fibrinoid degeneration,* that have been interpreted to represent changes in collagen fibers. However, there is currently no conclusive evidence that fibrinoid degeneration of collagen fibers is indicative of a defect in collagen. On the basis of available biochemical evidence, scleroderma is the only clinical condition among the classical collagen diseases that involves any detectable abnormality in the structure or metabolism of collagen (see also Chap. 173).

As discussed above, collagen is an unusual protein in many respects, and its structure and metabolism involve a number of special features that are critical for deposition of normal collagen fibers. Based on our understanding of the biochemistry of normal collagen, it is now possible to identify discrete points at which defects could be introduced into collagen molecules or mature fibers. A defect at any one of these levels could produce a “true” collagen disease. [84] Based on these considerations, the term *collagen disease* should be reserved for conditions in which a defect in collagen can be demonstrated clearly at the molecular level. In a primary collagen disease, such a defect could be an inherited abnormality in the structure of the collagen or procollagen or in the enzymes participating in the biosynthesis and degradation of collagen. In a secondary, acquired type of collagen disease, changes in collagen may be a consequence of initially unrelated metabolic changes. According to these definitions, several clinical disorders that are true collagen diseases are currently known (Table 14-5).



TABLE 14-5 **Heritable Connective Tissue Diseases with Cutaneous Involvement**

Recently, progress in understanding the basic principles of collagen biology in normal tissues has created a foundation for exploration of collagen abnormalities in a variety of diseases affecting the connective tissues. Indeed, there are many diseases in which a basic biochemical defect in collagen has been described, and several heritable connective tissue diseases with cutaneous involvement are now known to result from specific molecular defects in collagen (Table 14-5). Many of these diseases involve insertions, deletions, or single-base substitutions in the collagen genes, which alter the primary structure of the protein. In several acquired diseases, the regulation of collagen gene expression is disturbed, leading to altered deposition of collagen in tissues. The diversity of collagen pathology is exemplified by the Ehlers-Danlos syndrome and fibrotic skin diseases (see Chap. 154 and Chap. 173). The Ehlers-Danlos syndrome comprises a group of phenotypically similar conditions that frequently result from abnormalities in the structure of collagen. [87] In contrast, the fibrotic skin diseases exemplify conditions with altered regulation of collagen gene expression that leads to excessive accumulation of collagen in tissues.

REFERENCES

1. Prockop DJ, Kivirikko KI: Collagens: Molecular biology, diseases, and potentials for therapy. *Annu Rev Biochem* **64**:403, 1995 etc

2. Brown JC, Timpl R: The collagen superfamily. *Int Arch Allergy Immunol* **107**:484, 1995

3. Myllyharju J, Kivirikko KI: Collagens and collagen-related diseases. *Ann Med* **33**:7, 2001

4. Pulkkinen L et al: Progress in heritable skin diseases: Molecular bases and clinical implications. *J Am Acad Dermatol* **47**:91, 2002

5. Kuivaniemi H et al: Mutations in fibrillar collagens (types I, II, III, and XI), fibril-associated collagen (type IX), and network-forming collagen (type X) cause a spectrum of diseases of bone, cartilage, and blood vessels. *Hum Mutat* **9**:300, 1997

6. Elomaa O et al: Cloning of a novel bacteria-binding receptor structurally related to scavenger receptors and xpressed in a subset of macrophages. *Cell* **80**:603, 1995

7. Kere J et al: X-linked anhidrotic (hypohidrotic) ectodermal dysplasia is caused by mutation in a novel transmembrane protein. *Nat Genet* **13**:409, 1996

8. Shaw LM, Olsen BR: FACIT collagens: Diverse molecular bridges in extracellular matrices. *Trends Biochem Sci* **16**:191, 1991

9. Uitto J: Collagen polymorphism: Isolation and partial characterization of a1(I)-trimer molecules in normal human skin. *Arch Biochem Biophys* **192**:371, 1979

10. Epstein EH Jr: [a1(III)] $_3$ Human skin collagen, release by pepsin digestion and preponderance in fetal life. *J Biol Chem* **249**:3225, 1974

11. Heikkilä P, Soininen R: The type IV collagen gene family. *Contrib Nephrol* **117**:105, 1996

12. Timpl R et al: A network model for the organization of type IV collagen molecules in basement membranes. *Eur J Biochem* **120**:203, 1981

13. Lohi J et al: Expression of type IV collagen a1(IV)–a6(IV) polypeptides in normal and developing human kidney and in renal cell carcinomas and oncocytomas. *Int J Cancer* **72**:43, 1997

14. Tryggvason K: Mutations in type IV collagen genes and Alport phenotypes. *Contrib Nephrol* **117**:154, 1996

15. Merkel F et al: Autoreactive T-cells in Goodpasture's syndrome recognize the N-terminal NC1 domain on a3 type IV collagen. *Kidney Int* **49**:1127, 1996

16. Ghohestani RF et al: The a5 chain of type IV collagen is the target of IgG autoantibodies in a novel autoimmune disease with subepidermal blisters and renal insufficiency. *J Biol Chem* **275**:16002, 2000

17. Schwarze U et al: Null alleles of the COL5A1 gene of type V collagen are a cause of the classical forms of Ehlers-Danlos syndrome (types I and II). *Am J Hum Genet* **66**:1757, 2000

18. Michalickova K et al: Mutations of the a2(V) chain of type V collagen impair matrix assembly and produce Ehlers-Danlos syndrome type I. *Hum Mol Genet* **3**:249, 1998

19. Schalkwijk J et al: A recessive form of Ehlers-Danlos syndrome caused by tenascin-X deficiency. *N Engl J Med* **345**:1167, 2001

20. Matsumoto K et al: Tumour invasion and metastasis are promoted in mice deficient in tenascin-X. *Genes Cells* **6**:1101, 2001

21. Olsen DR et al: Collagen gene expression by cultured human skin fibroblasts: Abundant steady-state levels of type VI procollagen mRNAs. *J Clin Invest* **83**:791, 1989

22. Timpl R, Chu M-L: Microfibrillar collagen type VI, in *Extracellular Matrix Assembly and Structure,* PD Yurchenko, DE Birk, RP Mecham, eds. Academic Press, San Diego, 1994, p 207

23. Keene DR et al: Ultrastructure of type VI collagen in human skin and cartilage suggests an anchoring function for this filamentous network. *J Cell Biol* **107**:1995, 1988

24. Scacheri PC et al: Novel mutations in collagen VI genes: Expansion of the Bethlem myopathy phenotype. *Neurology* **58**:593, 2002

25. Camacho-Vanegas O et al: Ullrich scleroatonic muscular dystrophy is caused by recessive mutations in collagen type VI. *Proc Natl Acad Sci U S A* **98**:7516, 2001

26. Burgeson RE: Type VII collagen, anchoring fibrils, and epidermolysis bullosa. *J Invest Dermatol* **101**:252, 1993

27. Christiano AM et al: Cloning of human type VII collagen: Complete primary sequence of the a1(VII) chain and identification of intragenic polymorphisms. *J Biol Chem* **269**:20256, 1994

28. Rousselle P et al: Laminin 5 binds the NC-1 domain of type VII collagen. *J Cell Biol* **138**:719, 1997

29. Shimizu H et al: Most anchoring fibrils in human skin originate and terminate in the lamina densa. *Lab Invest* **76**:753, 1997

30. Fine J-D et al: Revised classification system for inherited epidermolysis bullosa: Report of the Second International Consensus Meeting on diagnosis and classification of epidermolysis bullosa. *J Am Acad Dermatol* **42**:1051, 2000

31. Pulkkinen L, Uitto J: Mutation analysis and molecular genetics of epidermolysis bullosa. *Matrix Biol* **18**:29, 1999

32. Uitto J et al: The molecular basis of the dystrophic forms of epidermolysis bullosa, in *Epidermolysis Bullosa: Clinical, Epidemiologic and Laboratory Advances, and the Findings of the National Epidermolysis Bullosa Registry,* edited by J-D Fine, EA Baner, J McGuire, AN Moshell. Baltimore, The Johns Hopkins University Press, 1999, p 326

33. Lapiere JC et al: Epitope mapping of type VII collagen: Identification of discrete peptide sequences recognized by sera from patients with acquired epidermolysis bullosa. *J Clin Invest* **92**:1831, 1993

34. Levy SG et al: The composition of wide-spaced collagen in normal and diseased Descemet's membrane. *Curr Eye Res* **15**:45, 1996

35. Munier BS et al: Missense mutations in COL8A2, the gene encoding the a2 chain of type VIII collagen, cause two forms of corneal endothelial dystrophy. *Hum Mol Genet* **10**:2415, 2001

36. Nishiyama T et al: Type XII and XIV collagens mediate interactions between banded collagen fibers in vitro and may modulate extracellular matrix deformability. *J Biol Chem* **269**:28193, 1994

37. Peltonen S et al: A novel component of epidermal cell-matrix and cell-cell contacts: Transmembrane protein type XIII collagen. *J Invest Dermatol* **113**:635, 1999

38. Peltonen S et al: Alternative splicing of mouse a1(XIII) collagen RNAs results in at least 17 different transcripts, predicting a1(XIII) collagen chains with length varying between 651 and 710 amino acid residues. *DNA Cell Biol* **16**:227, 1997

39. Li K et al: Cloning of type XVII collagen. Complementary and genomic DNA sequences of mouse 180-kilodalton bullous pemphigoid antigen (BPAG2) predict an interrupted collagenous domain, a transmembrane segment, and unusual features in the 5'-end of the gene and the 3'-untranslated region of the mRNA. *J Biol Chem* **268**:8825, 1993

40. Gatalica B et al: Cloning of the human type XVII collagen gene (COL17A1), and detection of novel mutations in generalized atrophic benign epidermolysis bullosa. *Am J Hum Genet* **60**:352, 1997

41. Areida SK et al: Properties of the collagen type XVII ectodomain. Evidence for N- to C-terminal triple helix folding. *J Biol Chem* **276**:1594, 2001

42. Sawamura D et al: Bullous pemphigoid antigen: cDNA cloning and mapping of the gene to the short arm of human chromosome 6.

Genomics **8**:722, 1990

43. McGrath JA et al: Mutations in the 180-kD bullous pemphigoid antigen (BPAG2), a transmembrane hemidesmosomal collagen (COL17A1), in generalized atrophic benign epidermolysis bullosa. *Nat Genet* **11**:83, 1995

44. Kivirikko S et al: Distribution of type XV collagen transcripts in human tissue and their production by muscle cells and fibroblasts. *Am J Pathol* **147**:1500, 1995

45. Pan TC et al: Cloning and chromosomal location of humana1(XVI) collagen. *Proc Natl Acad Sci U S A* **89**:6565, 1992

46. Oh SP et al: Cloning of cDNA and genomic DNA encoding human type XVIII collagen and localization of the a1(XVIII) collagen to mouse chromosome 10 and human chromosome 21. *Genomics* **19**:494, 1994

47. Sumiyoshi H et al: Ubiquitous expression of the a1(XIX) collagen gene (COL19A1) during mouse embryogenesis becomes restricted to a few tissues in the adult organism. *J Biol Chem* **272**:17104, 1997

48. Koch M et al: a1(XX) Collagen, a new member of the collagen subfamily, fibril-associated collagens with interrupted triple helices. *J Biol Chem* **276**:23120, 2001

49. Fitzgerald J et al: A new FACIT of the collagen family: COL21A1. *FEBS Lett* **505**:275, 2001

50. Chou M-Y, Li H-C: Genomic organization and characterization of the human type XXI collagen (COL21A1) gene. *Genomics* **79**:395, 2002

51. Tuckwell D: Identification and analysis of collagen a1(XXI), a novel member of the FACIT collagen family. *Matrix Biol* **21**:63, 2002

52. O'Reilly MS et al: Endostatin: An endogenous inhibitor of angiogenesis and tumor growth. *Cell* **88**:277, 1997

53. Grassel S et al: Collagen XVI is expressed by human dermal fibroblasts and keratinocytes and is associated with the microfibrillar apparatus in the upper papillary dermis. *Matrix Biol* **18**:309, 1999

54. Chu M-L, Prockop DJ: Collagen: Gene structure, *in Connective Tissue and Its Heritable Disorders:* Molecular, Genetic and Medical Aspects, 2nd ed, edited by PM Royce, B Steinmann. New York, Wiley-Liss, 2002, p 223

55. Christiano AM et al: Structural organization of the human type VII collagen gene (COL7A1), composed of more exons than any previously characterized gene. *Genomics* **21**:169, 1994

56. Blumberg B et al: Basement membrane procollagen IV and its specialized carboxyl domain are conserved in Drosophila, mouse and human. *J Biol Chem* **262**:5947, 1987

57. Christiano AM et al: A strategy for identification of sequence variants in COL7A1 and a novel 2-bp deletion mutation in recessive dystrophic epidermolysis bullosa. *Hum Mutat* **10**:408, 1997

58. Berg RA: Determination of 3- and 4-hydroxyproline. *Methods Enzymol* **82**:372, 1982

59. Davidson JM et al: Ascorbate differentially regulates elastin and collagen biosynthesis in vascular smooth muscle cells and skin fibroblasts by pretranslational mechanisms. *J Biol Chem* **272**:345, 1997

60. Uitto J, Prockop DJ: Synthesis and secretion of underhydroxylated procollagen at various temperatures by cells subject to temporary anoxia. *Biochem Biophys Res Commun* **60**:313, 1974

61. Burrows NP: The Ehlers-Danlos syndrome: On beyond collagens. *J Clin Invest* **24**:99, 1999

62. Prockop DJ et al: Procollagen N-proteinase and procollagen C-proteinase. Two unusual metalloproteinases that are essential for procollagen processing probably have important roles in development and cell signaling. *Matrix Biol* **16**:399, 1998

63. Colige A et al: cDNA cloning and expression of bovine procollagen I N-proteinase: A new member of the superfamily of zinc-metalloproteinases with binding sites for cells and other matrix components. *Proc Natl Acad Sci U S A* **94**:2374, 1997

64. Tang BL: ADAMTS: A novel family of extracellular matrix proteases. *Int J Biochem Cell Biol* **33**:33, 2001

65. Kessler E et al: Bone morphogenetic protein-1: The type I procollagen C-proteinase. *Science* **271**:360, 1996

66. Li SW et al: The C-proteinase that processes procollagens to fibrillar collagens is identical to the protein previously identified as bone morphogenic protein-1. *Proc Natl Acad Sci U S A* **93**:5127, 1996

67. Takahara K et al: Type I procollagen COOH-terminal proteinase enhancer protein: Identification, primary structure, and chromosomal localization of the cognate human gene (PCOLCE). *J Biol Chem* **269**:26280, 1994

68. Scott IC et al: Structural organization and expression patterns of the human and mouse genes for the type I procollagen COOH-terminal proteinase enhancer protein. *Genomics* **55**:229, 1999

69. Nusgens BV et al: Evidence for a relationship between Ehlers-Danlos type VII in humans and bovine dermatosparaxis. *Nat Genet* **1**:214, 1992

70. Colige A et al: Human Ehlers-Danlos syndrome type VII C and bovine determatosparaxis are caused by mutations in the procollagen I N-proteinase gene. *Am J Hum Genet* **65**:308, 1999

71. Byers PH et al: Ehlers-Danlos syndrome type VIIA and VIIB result from splice-junction mutations or genomic deletions that involve exon 6 in the COL1A1 and COL1A2 genes of type I collagen. *Am J Med Genet* **72**:94, 1997

72. Rucker RB, Murray J: Cross-linking amino acids in collagen and elastin. *Am J Clin Nutr* **31**:1221, 1978

73. Mäki JM et al: Cloning and characterization of a fifth human lysyl oxidase isoenzyme: The third member of the lysyl oxidase-related subfamily with four scavenger receptor cysteine-rich domains. *Matrix Biol* **20**:493, 2001

74. Kaler SG et al: Occipital horn syndrome and a mild Menkes phenotype associated with splice site mutations at the MNK locus. *Nat Genet* **8**:195, 1994

75. Das S et al: Diverse mutations in patients with Menkes disease often lead to exon skipping. *Am J Hum Genet* **55**:883, 1994

76. Uitto J, Kouba DJ: Cytokine modulation of extracellular matrix gene expression: Relevance to fibrotic skin diseases. *J Dermatol Sci* **24**:S60, 2000

77. Karsenty G, Park RW: Regulation of type I collagen genes expression. *Int Rev Immunol* **12**:177, 1995

78. de Thé H et al: Identification of a retinoic acid responsive element in the retinoic acid receptor ß gene. *Nature* **343**:177, 1990

79. Griffiths CEM et al: Restoration of collagen formation in photodamaged human skin by tretinoin (retinoic acid). *N Engl J Med* **329**:530, 1993

80. Roberts AB: The ever-increasing complexity of TGF-ß signaling. *Cytokine Growth Factor Rev* **13**:3, 2002

81. Mauviel A, Uitto J: The extracellular matrix in wound healing: Role of the cytokine network. *Wounds* **5**:137, 1993

82. Uitto J et al: Pharmacological inhibition of excessive collagen deposition in fibrotic diseases. *Fed Proc* **43**:2815, 1984

83. Rennard SI et al: Intracellular degradation of newly synthesized collagen. *J Invest Dermatol* **79**(suppl 1):77s, 1982

84. Uitto J, Prockop DJ: Molecular defects in collagen and the definition of “collagen disease,” in *Molecular Pathology,* edited by RA Good, SB Day, JJ Yunis. Springfield, IL, Charles C. Thomas, 1975, p 670

85. Oikarinen AI, Uitto J: Molecular mechanisms of glucocorticosteroid action on connective tissue metabolism, in *Diseases of Connective Tissue: The Molecular Pathology of the Extracellular Matrix,* edited by J Uitto, AJ Perejda, in series: *The Biochemistry of Disease: A Molecular Approach to Cell Pathology,* series editors E Farber, HC Pitot. New York, Marcel Dekker, 1987, p 385

86. Booth BA et al: Steroid-induced dermal atrophy: Effects of glucocorticosteroids on collagen metabolism in human skin fibroblast cultures. *Int J Dermatol* **21**:333, 1982

87. Uitto J et al: Heritable disorders of connective tissue—Ehlers-Danlos syndrome, pseudoxanthoma elasticum and cutis laxa, in *Dermatology,* edited by Bologna JL, Jorizzo JL, Rapini RP. London, Harcourt Publishers (in press)

T>

Chapter 15

Jouni Uitto Mon-Li Chu

Elastic Fibers

STRUCTURE AND DEVELOPMENT OF THE ELASTIC FIBERS
Fetal Development
BIOLOGY OF THE ELASTIC FIBERS
Elastin
The Microfibrillar Proteins
PATHOLOGY OF THE ELASTIC FIBERS IN CUTANEOUS DISEASES

REFERENCES

STRUCTURE AND DEVELOPMENT OF THE ELASTIC FIBERS

Elastic fibers of the connective tissue form a network responsible for the resilient properties of various organs. [1], [2] and [3] The distribution of elastic fibers is variable in different tissues. Their relative concentration is highest in the aorta and arterial blood vessels, but they are also abundant in the lungs (Table 15-1). Elastic fibers are also present in the skin, although they are only a minor component (Fig. 15-1). Specifically, in sun-protected human skin, the elastin content is about 1 to 2 percent of the total dry weight of dermis [4] (Table 15-1). In the papillary dermis, elastic fibers are present either as bundles of microfibrils (oxytalan fibers) or with small amounts of cross-linked elastin (elaunin fibers). In the reticular dermis, the elastic fibers, which consist primarily of elastin, are oriented horizontally in a network with vertical extensions to the papillary dermis in the form of oxytalan fibers.

FIGURE 15-1 Transmission electron microscopy of human skin demonstrating a fibroblast (F) surrounded by elastic structures (E) and collagen fibers (C).

Tissue	Percentage of Dry Weight	
	Elastin	Collagen
Skin	0.6–2.1	71.9
Lung	1–7	10
Aorta	28–32	12–24
Ligamentum nuchae	74.8	17
Achilles tendon	4.4	86.0
Liver	0.16–0.30	3.9

*The values represent determinations from different animal species.

TABLE 15-1 **Relative Concentrations of Elastin and Collagen in Various Tissues** *

Examination of elastic connective tissues by transmission electron microscopy has demonstrated that mature elastic fibers consist of two distinct components (Fig. 15-2). The major component is composed of a well-characterized connective tissue protein, elastin, that shows no distinct periodic banding pattern. This amorphous, electron-lucent elastin component, when visualized by transmission electron microscopy, is surrounded by distinct microfibrillar structures that have a regular diameter of 10 to 12 nm (Fig. 15-2). The microfibrillar component is composed of a variety of recently characterized proteins. [3]



FIGURE 15-2 Transmission electron microscopy of the elastic fibers in normal human skin. Elastin, the electron-lucent core of the fiber, is surrounded by thin, electron-dense microfibrils. Original magnification ×16,000.

Fetal Development

Elastin and the microfibrils exist in close association in various connective tissues. However, the relative proportions of these components vary during embryonic development. The first elements of elastic fibers that form during human fetal development consist of bundles of microfibrils that can be visualized by electron microscopy early in the first trimester of gestation. During the second trimester, the elastic fibers remain relatively immature in structure and composition, but with

increasing fetal age and maturation of the fibers, the amorphous elastin component becomes more prominent. Fully developed elastic fibers consist of a central amorphous core surrounded by an envelope of microfibrils, although some microfibrils are also dispersed within the amorphous component. Electron microscopic estimations of the fully matured elastic fibers suggest that the elastin protein represents well over 90 percent of the total content of such fibers. [5] It should be noted, however, that skin as well as other tissues, contain microfibrils devoid of elastin.

The biochemical characterization of elastin and the microfibrils was hampered for many years by the relative insolubility of these structures, and early information about the structural features of these fibers was gained through electron microscopic observations. However, several recent innovations and improvements in biochemical technology, including the techniques of molecular biology, have greatly facilitated the characterization of these proteins, so that features of their basic structures and several aspects of their biosynthesis are now well understood. Interest in the biochemistry of the elastic connective tissues has increased with the realization that marked changes in the structure of these proteins are observed in various disease processes, many of them affecting the skin.

BIOLOGY OF THE ELASTIC FIBERS

Elastin

PROTEIN STRUCTURE The fibers composed of elastin, when visualized by transmission or scanning electron microscopy, appear as amorphous, branching structures forming continuous sheets in some connective tissues (Fig. 15-2 and Fig. 15-3). The isolation and characterization of the basic polypeptide unit of elastin was hindered for a long time by the extreme insolubility of elastin in mature animal tissues. It was discovered, however, that this insolubility is attributable to the presence of complex covalent cross-links, known as desmosines (see below), whose formation can be prevented by maintaining the animals on a copper-deficient diet or by feeding them lathyrogens, such as ß-aminopropionitrile, which inhibit elastin and collagen cross-linking. Once the formation of the cross-links is prevented, a large fraction of newly synthesized elastin can be extracted from the tissues. By these methods, large quantities of soluble elastin were initially purified from porcine aorta, and short peptide fragments were sequenced. [6] The precise amino acid sequence of human elastin has been deduced from cloned complementary DNAs (cDNAs). [7], [8]

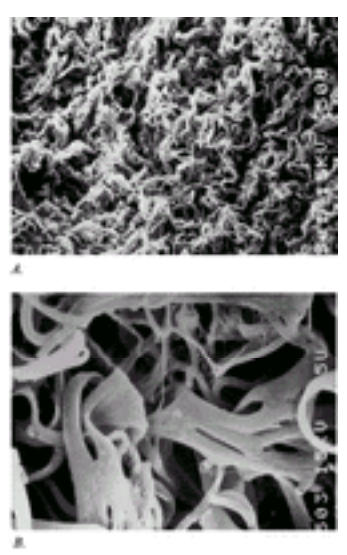

FIGURE 15-3 Scanning electron microscopy of the elastic fibers in human skin. Original magnifications: *A.* ×2000; *B.* ×5000.

The basic molecular unit of elastin is a linear polypeptide, known as tropoelastin, that consists of approximately 800 amino acids with a molecular mass of about 70 kDa. Elastin is relatively rich in hydrophobic residues—such as valine and alanine—and its amino acid composition is similar to that of collagen in that about one-third of the total number of amino acid residues consist of glycine. However, glycine is not evenly distributed in elastin, as it is in a typical collagen sequence. Instead, the glycine residues are grouped in valine and proline-rich regions, which are interspersed with alanine-rich sequences. Elastin also contains some hydroxyproline, but the relative content of this amino acid is considerably lower than that in collagen, and the values for hydroxyproline are variable. Elastin does not contain hydroxylysine or carbohydrate moieties covalently linked to the polypeptide chain. Several models for the molecular structure of elastin have been proposed to account for the special resilient nature of the fibers. The various aspects considered in these models include the prevalence of random-coil conformation, the presence of a helices in the monomeric unit, the frequency and distribution of stabilizing cross-links, and the degree of hydration of the protein. [9], [10] One of the earlier theories described elastin as a rubber-like elastomer with an amorphous network structure. [10] According to this theory, the covalent cross-links, which are randomly distributed, link up to four tropoelastin polypeptides, but there are no specific interactions between the individual chains. According to another theory, elastin is described as an “oiled-coil” that is interrupted by regularly repeating cross-link and a-helical regions. [9] In this model, each desmosine or isodesmosine cross-link connects two individual polypeptides. The oiled-coil regions consist of repeating sequences relatively rich in hydrophobic amino acids. Based on these considerations, one could speculate that during stretching of the fiber network, the hydrophobic groups are exposed to the surrounding aqueous milieu, and the energy for contraction of the fiber is derived from the return of these groups to a nonpolar environment. One characteristic feature of elastic fibers is the presence of cross-links that covalently bind elastin polypeptide chains into a fiber network. The two major cross-link compounds, desmosine and its isomer, isodesmosine, are structures that appear to be unique to elastin [11] (Fig. 15-4). The content of desmosines in various elastin preparations has been shown to be fairly constant, approximately 1.5 residues per 1000 amino acids. Consequently, assay of desmosine and isodesmosine can provide a quantitative measure of the elastin content in tissues. [12]

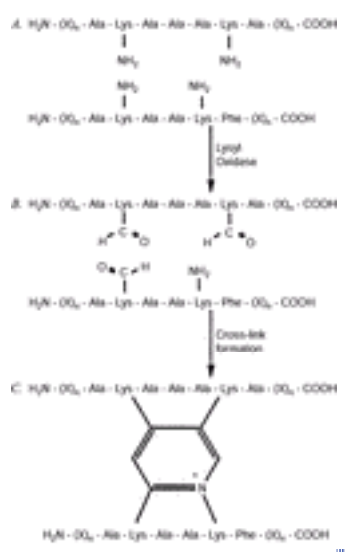

FIGURE 15-4 Formation of intermolecular cross-links, desmosine and isodesmosine, between two tropoelastin polypeptides. *A.* Amino acid sequences of a potential cross-link region within the tropoelastin polypeptides. Note the e-amino group (NH_2) of the four contributing lysyl residues. *B.* Three of the lysyl residues undergo oxidative deamination catalyzed by lysyl oxidase to yield corresponding aldehyde derivatives, allysines. *C.* Three of the allysines and the fourth unmodified lysyl residue, still containing an e-amino group, fuse into a stable desmosine cross-link. (*From Uitto et al.,* [74] *with permission.*)

GENE STRUCTURE Cloning of cDNAs corresponding to the human elastin messenger RNA (mRNA), approximately 3.5 kb in size, has allowed elucidation of the entire primary sequence of tropoelastin [8] (Fig. 15-5). The deduced amino acid sequence depicts alternating segments of cross-link domains, characterized by the presence of lysyl residues separated by two or three alanine residues, and hydrophobic domains. The cross-link domains and the hydrophobic regions are encoded by separate exons [13] (Fig. 15-5). The human elastin gene consists of 34 separate exons spanning a total of 45 kb of genomic DNA [13] (Fig. 15-5). The elastin gene has been mapped to the long arm of chromosome 7 (Fig. 15-6). [14]

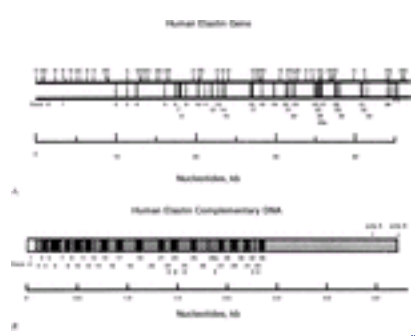

FIGURE 15-5 Representation of the human elastin gene (*A*) and the corresponding cDNA (*B*). *A.* The exons have been numbered starting from the 5' end of the gene and correspond to those shown in the cDNA (see *B*). The presence of restriction endonuclease cleavage sites: *BamHI* (B), *EcoRI* (E), *HindIII* (H); kb = kilobases. *B.* The cDNA, about 3.5 kb in size, is divided into separate exons that are numbered from 1 to 36 and drawn to scale. Note that the human elastin gene contains only 34 exons. However, to maintain a consistent numbering system between the bovine and human elastin genes, the last exon is designated as number 36; thus, the human gene is missing the counterparts of bovine exons 34 and 35. The arrows indicate the exons that have been shown to be subject to alternative splicing. (*From Uitto et al.,* [74] *with permission.*)

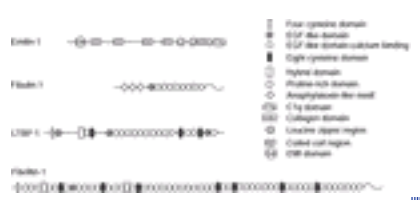

FIGURE 15-6 Modular domain structures of selected elastin associated microfibrillar proteins, including fibrillin (FBN), latent TGF-ß–binding protein (LTBP), fibulin (FBLN), and emilin. The first member of each gene family is represented. The FBN, LTBP, and FBLN families are related because they share common protein motifs. (Adapted from references [3], [59], and [68]).

CONSTITUTIVE AND ALTERNATIVE SPLICING The information stored in the DNA sequence of the elastin gene is transcribed in the nucleus of the cells to a large mRNA precursor, which undergoes several posttranscriptional modifications, including splicing and polyadenylation. The processed molecules are then transported to the cytoplasm, where the functional mRNAs serve as templates for the synthesis of elastin polypeptides during translation. Several lines of evidence suggest that the rate of elastin biosynthesis is largely regulated by the abundance of the functional mRNA. An early observation during the isolation of human elastin cDNAs was that several overlapping clones were identical, with the exception of short sequences that were absent in some clones but present in others. [7], [8], [15] Comparison of these sequences in the cDNAs with the corresponding genomic DNA segments indicated that the differences were due to alternative splicing of certain exons during posttranscriptional processing of the elastin pre-mRNA. In fact, as many as six exons in the human gene are reported to be subject to alternative splicing, and several of the variant mRNAs are translated into protein. This mechanism can provide significant variation in the amino acid composition of individual elastin polypeptides and presumably in the function of the elastic fibers in tissues. However, the developmental significance and tissue specificity of alternative splicing has not been elucidated in detail.

REGULATION OF ELASTIN GENE EXPRESSION Expression of genes at the transcriptional level is regulated by the activity of the promoter region upstream from the 5' end of the coding region. The elastin promoter contains a remarkable constellation of potential binding sites for transcriptional regulatory factors indicative of complex transcriptional regulation. These include multiple Sp1 and AP2 binding sites, putative glucocorticoid-responsive elements, and TPA- and cAMP-responsive elements (CRE). The absence of a TATA box in the promoter region suggests that there may be

multiple sites of transcriptional initiation, and various molecular tests, including S1 protection and primer extension analyses, confirm this fact. [13] Functional analyses of the human elastin promoter segment have been carried out by constructing a panel of promoter-reporter gene [chloramphenicol acetyl transferase (CAT)] constructs. [16] These constructs have been used in transient transfections with a variety of cultured cells, including human skin fibroblasts. These studies indicate that the core promoter necessary for basal expression of the gene is contained within the region -128 to -1 (in reference to translation initiation site -1, +1), and the upstream sequences contain several up- and down-regulatory elements. The positive regulatory and core promoter activities may be explained, at least in part, by the presence of multiple Sp1 and AP2 binding sites within these regions, which may act as general enhancer elements; DNAase footprinting experiments indicate that Sp1 and AP2 sites indeed interact with their respective *trans*-acting factors. This is supported by the observation that deletion of the segment -134 to -87, containing three putative Sp-1 binding sites, reduced the activity to less than 20 percent of the reference construct -475 to -1. Development of transgenic mice expressing the human elastin promoter has revealed that 5.2 kb of DNA flanking the human elastin gene contains the elements necessary for tissue-specific expression. [17] In addition to the 5' upstream sequences, the first introns of both the bovine and human elastin genes contain regions of extremely strong sequence homology. Because it has been demonstrated that the first intron of three different collagen genes contains segments that act as enhancer elements of the promoter activity, [18] the strong conservation within intron 1 of the elastin gene suggests the possible presence of an enhancer in this gene as well. However, functional testing of the homologous segments has thus far not provided conclusive support for this possibility.

CYTOKINE AND HORMONAL REGULATION The presence of multiple *cis*-acting elements in the elastin promoter region suggests that elastin gene expression is subject to modulation at the transcriptional level by *trans*-acting factors. For example, previous studies have indicated that tumor necrosis factor (TNF)-a decreases elastin mRNA abundance primarily by suppressing promoter activity. [19] In other studies, transforming growth factor (TGF)-ß has been shown to upregulate the abundance of human elastin mRNA by up to about 30-fold, [20] but evidence from transient transfection assays suggests that this upregulation is, at least in part, posttranscriptional. [20] In fact, assay of elastin mRNA half-life suggests that TGF-ß stabilizes the elastin mRNA, leading to elevated steady-state levels. At the same time, subcutaneous injection of TGF-ß in transgenic mice expressing the human elastin promoter enhanced the promoter activity in a time-dependent manner up to 10-fold. [21] The latter results suggested that the 5.2-kb upstream segment of the human elastin gene contains *cis*-elements responsive to TGF-ß. Regardless of the mechanism, however, these observations collectively suggest that mediators released from inflammatory cells can modulate elastin gene expression, and such modulation may play a role in diseases characterized by altered accumulation of elastic fibers in tissues. Vitamin D_3 also modulates elastin gene expression. Specifically, incubation of fibroblasts with vitamin D_3 results in an 80 to 90 percent decrease in total accumulation of tropoelastin accompanied by a parallel decrease in steady-state levels of the corresponding mRNA. [22] At the same time, insulin-like growth factor (IGF)-1 enhances elastin gene expression at the transcriptional level. [23] Although there is preliminary evidence for modulation of elastin gene expression by selective growth factors and hormone-like substances, the precise details are largely unknown.

ELASTIN BIOSYNTHESIS Elastin biosynthesis involves several specific steps necessary for the assembly of elastic fibers (Table 15-2). Several studies show that smooth muscle cells in culture synthesize relatively large quantities of elastin, suggesting that they may be the major source of elastin in tissues rich in elastic fibers, such as vascular connective tissue. [24] In addition to smooth muscle cells, human dermal fibroblasts in culture also express the elastin gene, and elastin production by cultured fibroblasts has been demonstrated by immunoblotting using anti-elastin antibodies and by molecular hybridization of mRNA with elastin-specific DNA probes. [15], [25] The amount of elastin synthesized by cultured human skin fibroblasts is relatively small; nonetheless, fibroblasts may be the primary source of elastin in the dermis. Elastin gene expression has also been suggested to occur in cultured epidermal keratinocytes, although the level of expression in keratinocytes is extremely low in comparison to dermal fibroblasts. [26] The biologic significance of elastin gene expression in keratinocytes is unclear.

TABLE 15-2 **Steps at Various Levels of Biosynthesis and Degradation of Elastin and the Functional Significance of These Steps** *

After the completion of translation, newly synthesized polypeptides are translocated into the cisternae of the rough endoplasmic reticulum, in a manner similar to that occurring during the biosynthesis of collagen and other proteins destined for export from the cell. The polypeptides are then transferred from the rough endoplasmic reticulum into the extracellular space by transport mechanisms whose functioning in the case of elastin is not completely understood. It has been demonstrated, however, that incubation of cells synthesizing elastin with colchicine decreases the rate of elastin secretion and that the polypeptides accumulate intracellularly. [27] /SUP>, [28] This observation suggests that the secretion of elastin polypeptides is a process that involves the microtubules of the cells, and that the molecules may be transferred out of the cells packaged in Golgi vacuoles or related vesicles. An interesting feature of elastin is the presence of 4-hydroxyproline. However, the relative hydroxyproline concentration in various elastin preparations is considerably lower than in collagen. Amino acid analyses of elastin isolated from various sources indicate that the hydroxyproline content of the protein can vary from 7 to 25 residues per 1000 amino acids, and that hydroxyproline accounts for about 10 to 20 percent of the total imino acid (proline plus hydroxyproline) content of the molecule. [27], [29] Previous studies clearly demonstrated that hydroxyproline plays an important functional role in the synthesis and secretion of collagen. In contrast, the presence of hydroxyproline is not required for the synthesis and secretion of elastin. This conclusion is based on studies in which cells synthesizing both elastin and procollagen are incubated with a,a'-dipyridyl, an inhibitor of prolyl hydroxylase, which prevents the formation of hydroxyproline. Under such conditions, the cells continue to synthesize and secrete tropoelastin at the normal rate, whereas no intact triple-helical procollagen is recovered in the medium. [27], [29] The hydroxyproline found in elastin, therefore, appears to be a coincidental feature of the molecule in terms of synthesis and secretion of this protein. It has been suggested that, in fact, hydroxyproline may be present in elastin serendipitously, as the elastin polypeptides are synthesized in the same region of the rough endoplasmic reticulum as is procollagen. [27] Thus, prolyl hydroxylase, which is located in this cellular

compartment, hydroxylates some of the prolyl residues occurring in Pro-Gly sequences of the elastin polypeptides. Because the activity of prolyl hydroxylase in the cells can be variable, depending on several factors, including the concentration of cofactors and cosubstrates, this suggestion explains the variability in the hydroxyproline content encountered in elastin isolated from different tissues. As discussed elsewhere (see Chap. 14), during the intracellular biosynthesis of procollagen, in addition to hydroxylation of prolyl residues, several other posttranslational modifications occur; these include hydroxylation of certain lysyl residues, subsequent glycosylation of certain hydroxylysyl residues, and glycosylation of the precursor-specific extension peptides using the lipid-carrier mechanism. In the case of elastin, none of these modifications has been demonstrated. In particular, amino acid analyses have failed to disclose the presence of hydroxylysine, [6] and earlier chemical analyses have not detected any carbohydrates in elastin. [30]

FIBRILLOGENESIS AND CROSS-LINKING The formation of desmosines occurs in the extracellular space, where the first step is the oxidative deamination of lysyl residues to corresponding aldehydes, known as allysines. This conversion is catalyzed by a copper-requiring enzyme, lysyl oxidase. [31] The desmosines are formed by the fusion of three allysines and a fourth unmodified lysyl residue in two adjacent tropoelastin chains. Thus, the desmosines link the individual elastin polypeptides into an insoluble network (see Fig. 15-4). The oxidative deamination of lysyl residues in elastin is catalyzed by lysyl oxidase, an enzyme that requires copper and molecular oxygen as cofactors. It has been shown that in copper-deficient animals the production of functional enzyme is reduced and that the newly synthesized elastic fibers are not stabilized by the formation of desmosines. [32] Consequently, the individual tropoelastin polypeptides remain soluble and the elastin-rich tissues are fragile. Because lysyl oxidase is synthesized and secreted by human skin fibroblasts in culture, [33] these cells are presumably one source of the enzyme in vivo. Lysyl oxidase contains at least three possible copper-binding domains. [31] The human lysyl oxidase (LOX) gene was originally mapped to chromosomal locus 5q23. [34] This enzyme is also identical to a tumor suppressor gene, rrg, whose expression is reduced in transformed cells. [35] Therefore, lysyl oxidase may have a broader spectrum of biologic activity than previously anticipated. More recently, additional genes have been identified encoding proteins with homology to lysyl oxidase. [36] These lysyl oxidase-like (LOXL) genes have been mapped to different chromosomal regions, and the total number of lysyl oxidase genes is currently five (LOX and LOXL1 to 4). Although the enzymatic activity of the LOXL gene products has not been demonstrated, lysyl oxidases seem to form a family of multifunctional amine oxidases. [36]

DEGRADATION AND REMODELING Although the metabolic turnover of elastin is very slow when compared to proteins in general, a portion of the body's elastin is continuously degraded and may partly be replaced by newly synthesized fibers. [37] In addition, degradation of elastin is markedly increased in a variety of pathologic conditions. [38] Thus, the tissues containing elastin must contain proteolytic enzymes that are capable of degrading elastic fibers. Evidence for elastase, a specific elastolytic enzyme, was first obtained from study of the pancreas, and, subsequently, elastolytic enzymes have been detected in several other tissues, as well as in a variety of cell types, including polymorphonuclear leukocytes, monocyte/macrophages, and platelets. [39], [40] The classic elastases are serine proteases that degrade insoluble elastic fibers at neutral or slightly alkaline pH. The activity of these enzymes is inhibited by serum factors, such as a_1-antitrypsin and a_2-macroglobulin. Assay of the amino-terminal amino acids of elastin degradation products demonstrates that these enzymes preferentially cleave the polypeptide at bonds involving glycine, alanine, and valine. However, elastases from different sources (pancreas versus polymorphonuclear leukocytes) have different cleavage specificities, as shown by peptide mapping of degradation products. [41] In addition to the classic elastases, which are serine proteases, others were recently shown to be metalloenzymes requiring calcium for their activity. One such enzyme is secreted by macrophages isolated from human alveolar macrophages exudates. [42] This metalloenzyme is different from leukocyte or pancreatic elastases (see Chap. 17). Elastin-like small molecular weight synthetic substrates, such as succinyl-L-$(alanyl)_3$-paranitroanilide (SAPNA), are often used to detect elastase activity. A convenient feature of these substrates is their degradation even in the presence of inhibitors, such as a_2-macroglobulin, which interfere only with the degradation of large protein substrates by the elastases. By using SAPNA as substrate, an elastase-like enzyme activity has been detected in human serum. [43] This enzyme is clearly inhibited by metal chelators, such as ethylenediaminetetraacetic acid (EDTA), but not by serine protease inhibitors, suggesting that its activity depends on calcium or another divalent cation. Values elevated up to 100-fold over normal have been demonstrated in the serum of a patient with autosomal recessive cutis laxa with histologically demonstrable fragmentation of elastic fibers in the skin. [43] Of particular dermatologic interest is the demonstration of elastase activity in the blister fluid from lesions of dermatitis herpetiformis and bullous pemphigoid. [44], [45] The elastase activity in the lesions of dermatitis herpetiformis is due to a serine protease and probably originates from polymorphonuclear leukocytes abundantly present in the lesions. The activity in the bullous pemphigoid lesions is caused by a metalloenzyme of unknown cellular origin. Regardless of the origin of the elastase activity, these enzymes could play a role in the development of the blisters by degrading the elastic fibers and other structures in the dermal–epidermal junction.

The Microfibrillar Proteins

Microfibrils consist of apparently tubular structures about 10 to 12 nm in diameter. Their staining properties and susceptibilities to enzymatic digestion differ from those of the amorphous elastin. At high resolution, the microfibrils appear in cross-section as an outer electron-dense shell surrounding an inner lucid core and in longitudinal section as a beaded chain, suggesting that they may be composed of more than one protein. Apparently similar microfibrils are present in many tissues, including those containing abundant elastin and those in which there is no visible or immunoreactive elastin, such as the ocular ciliary zonule and the periodontal ligament. In the dermis, the microfibrillary bundles that connect the deep dermal elastic plexus with the dermal–epidermal junction region consist of microfibrils indistinguishable from those associated with elastic fibers. In their superficial distribution, no immunoreactive elastin is associated with them; but as they traverse the dermis, they are associated with an increasing amount of amorphous elastin.

Because of their insolubility and apparent complexity, chemical characterization of the microfibrils progressed slowly until recently. The problem of identifying these structurally important components was compounded by the observation that small amounts of several proteins, including amyloid P and decay-accelerating factor, have been localized to the elastic microfibrils by immunoelectron microscopy. While they may have some functional role, it is unlikely that any one of the latter is a major structural component of the microfibrils. Progress, however, has been made in the identification of a number of proteins as structural components of the elastic microfibrils.

These structural proteins can be divided into several groups based upon their molecular characteristics. Table 15-3 lists these proteins and provides some distinguishing features, including their human chromosomal localizations. These groups include several gene families that share

protein domain motifs and are discussed below.

TABLE 15-3 **Microfibrillar Component Proteins**

FIBRILLINS The largest of the microfibrillar proteins and, quantitatively, perhaps the most important ones, are the fibrillins, 350-kDa glycoproteins that form an integral part of the microfibril structure. [46], [47] Electron microscopic images of human monomeric fibrillin synthesized by fibroblasts in culture show an extended flexible molecule approximately 148 nm long and 2.2 nm wide. Multiple fibrillin molecules align in a parallel head-to-tail fashion to form microfibrils. Molecular cloning studies have so far identified two distinct homologous human genes encoding fibrillins: fibrillin-1 (FBN1) located on chromosome 15q15-21 and fibrillin-2 (FBN2) on chromosome 5q23-q31. [48], [49] Analysis of the fibrillin amino acid sequences, deduced from cloned cDNAs, showed that these proteins contain multiple repeats of a sequence motif previously observed in epidermal growth factor precursor molecule, each motif having six conserved cysteines. [47] Many of these repeats contain consensus sequences that have been associated with calcium binding. A second motif containing eight cysteines, originally found in latent TGF-ß–binding proteins (LTBPs) [50] has also been identified in the fibrillins (see Fig. 15-6 for comparison of structures of the FBNs and LTBPs). Of interest is the report of a protein in jellyfish having extensive homology to mammalian fibrillin, thus identifying fibrillin as a very ancient protein that evolved well before elastin. [51]

LATENT TGF-ß–BINDING PROTEINS Several members of the LTBP family have been cloned and shown to contain repeating domains similar to those found in FBN1 and FBN2 (Fig. 15-6). TGF-ß is always secreted as a latent complex, and in some cases, this complex is bound to a LTBP. [50], [52] To date, four distinct LTBPs (LTBP1 to 4) have been cloned and characterized, ranging in size from 125 to 310 kDa. [53] The function of LTBPs remains to be determined, but it is clear that they are not necessary to maintain TGF-ß in an inactive form and they do not appear to bind mature TGF-ß. Although LTBPs may facilitate the secretion of TGF-ß or binding of the inactive complex to the cell surface where activation takes place, they are also found as free proteins associated with components of the extracellular matrix. Recent development of an LTBP3 knockout mouse has revealed craniofacial malformations, perturbed ossification, and development of osteosclerosis and osteoarthritis. [54] These observations were interpreted to mean that LTBP3 is important for the control of TGF-ß action and, specifically, that LTBPs may modulate TGF-ß bioavailability. Immunohistologic studies have localized both LTBP1 and LTBP2 to microfibrils in elastic fibers, strongly suggesting that one or more of the LTBPs may be a component of these fibrils. [55], [56] Furthermore, levels of LTBP1 are altered in a number of pathologic conditions, including solar elastosis and actinic keratosis. [57]

FIBULINS The fibulins (FBLNs) are a family of extracellular matrix glycoproteins that contain tandem epidermal growth factor (EGF)-like repeats similar to fibrillins and LTBPs. [58], [59] Molecular cloning has identified as many as five distinct fibulin genes [58], [59], [60], [61] and [62] (Table 15-3). The deduced amino acid sequences reveal that the molecules are modular, having the EGF-like repeats and a common carboxyl terminal globular domain (Fig. 15-6). FBLN1 and FBLN2 contain an anaphylatoxin-like domain (Fig. 15-6). FBLN1 is alternatively spliced and four variants have been identified differing from one another at their carboxyl termini. Fibulin proteins are widely distributed in connective tissues, including the skin, and enriched in developing elastin-containing tissues. Fibulins 1, 2, and 5 are located within the elastic fibers but in somewhat different distribution. Specifically, FBLN1 was found to reside within the elastin core in the skin, [63] while FBLN2 is located at the interface between the fibrillin-1 microfibrils and the elastic core. [64] FBLN5 binds both smooth muscle cells and elastin, thus facilitating the cell-matrix interactions. Particularly interesting is the clinical phenotype of FBLN-5 knockout mice, which show progressive laxity of skin associated with vascular abnormalities and emphysematous lung changes; [61], [62] these changes are reminiscent of those noted in patients with congenital cutis laxa. [38] In fact, mutations in the FBLN5 gene have been recently documented in some cases with cutis laxa. [65]

OTHER MICROFIBRILLAR PROTEINS A number of other proteins, unrelated to the FBNs, LTBPs, and FBLNs, are constituents of the microfibrils. When bovine nuchal ligament, a tissue rich in microfibrils, was extracted with saline under reducing conditions, five major bands having apparent molecular weights of 340, 78, 70, 31, and 25 kDa were identified upon gel electrophoresis. [56] Molecular cloning of the 25- and 31-kDa components, designated microfibril-associated glycoproteins (MAGPs), shows that these two proteins share limited regions of homology. [66], [67] The observation that these proteins can be extracted from tissues by solvents containing a strong reducing agent suggests that intermolecular disulfide bonding is an important feature of the association of the polypeptide chains in the fibrils. Other candidate microfibril components include the lysyl oxidases, [31] interface proteins called *emilins*, [68] and several proteins designated microfibril-associated proteins (MFAPs) (see Table 15-3). [69], [70] and [71] Among the latter, MFAP1 is remarkable in that it is extremely acidic, with glutamic acid comprising 23 percent and aspartic acid 6 percent of the residues. The extremely acidic nature of the protein suggests that it may have an important function in the assembly of the very basic tropoelastin molecules. Despite characterization and cloning of several microfibrillar proteins, a number of questions regarding microfibril structure and function remain unresolved. A completely satisfactory molecular model of the microfibrils has yet to be developed, and the precise relationships between the fibrillins and other proposed components of the microfibrils remain obscure. Moreover, while apparently identical microfibrils have been identified ultrastructurally both with and without associated elastin, it has yet to be determined whether structural or compositional differences exist between these two groups or among microfibrils in different tissues.

PATHOLOGY OF THE ELASTIC FIBERS IN CUTANEOUS DISEASES

Several heritable and acquired connective tissue diseases have been shown to affect the elastic fibers, including pseudoxanthoma elasticum (PXE), cutis laxa, and Buschke-Ollendorf syndrome (Table 15-4). In addition, clinically distinct entities with phenotypes closely resembling PXE (e.g., elastoderma) or cutis laxa (e.g., wrinkly skin syndrome) can be recognized. The clinical, genetic and molecular features of these disorders

are detailed in recent reviews. [38], [72], [73] and [74]

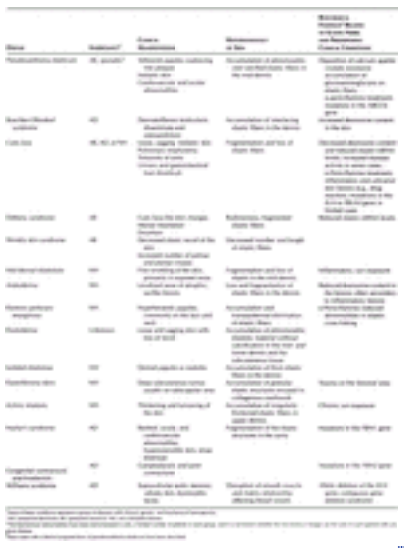

TABLE 15-4 **Clinical Features, Histopathology, Inheritance, Associated Biochemical Findings, and Predisposing Clinical Conditions in Cutaneous Diseases with Elastic Fiber Abnormalities** *

REFERENCES

1. Kielty C et al: Elastic fibers. *J Cell Sc* **115**:2817, 2002

2. Midwood KS, Schwarzbauer JE: Elastic fibers: Building bridges between cells and their mat *Curr Bio* **12**:R279, 2002

3. Rosenbloom J, Abrams WR: Elastin and the microfibrillar apparatus, *Connective Tissue and Its Heritable Disorder*, 2nd ed, edited by RM Royce, B Steinmann. New York, Wiley-Liss, 2002, pp 249–269

4. Uitto J et al: Elastic fibers in human skin: Quantitation of elastic fibers by computerized digital image analyses and determination of elastin by radioimmunoassay of desm *Lab Invest* **49**:499, 1983

5. Ross R et al: The morphogenesis of elastic fibers *Adv Exp Biol Med* **79**:7, 1977

6. Sandberg LB, Davidson JM: Elastin and its gene *Pept Prot Rev* **3**:169, 1984

7. Indik Z et al: Alternative splicing of human elastin mRNA demonstrated by sequence analysis of cloned genomic and complementary I *Proc Natl Acad Sci U S A* **84**:5680, 1987

8. Fazio MJ et al: Cloning of full-length elastin cDNAs from a human skin fibroblast recombinant cDNA library: Further elucidation of alternative splicing utilizing exon-specific oligonucleotides. *J Invest Dermato* **91**:458, 1988

9. Gray WR et al: Molecular model for elastin structure and functio *Nature* **246**:461, 1973

10. Hoeve CAJ: The elasticity in the presence of diluent *Adv Exp Med Bio* **79**:607, 1977

11. Akagawa M, Suyama K: Mechanism of formation of elastin crosslink *Connect Tissue Res* **41**:131, 2000

12. Starcher BC: Determination of the elastin content of tissues by measuring desmosine and isodesmosi *Anal Biochem* **79**:11, 1977

13. Bashir M et al: Characterization of the complete human elastin ger *J Biol Chem* **264**:8887, 1989

14. Fazio MJ et al: Human elastin gene: New evidence for localization to the long arm of chromosom *Am J Hum Gene* **48**:696, 1991

15. Fazio MJ et al: Isolation and characterization of human elastin cDNAs, and age-associated variation in elastin gene expression in cultured skin fibrob *Lab Invest* **58**:270, 1988

16. Kähäri V-M et al: Deletion analyses of 5'-flanking region of the human elastin ge *J Biol Chem* **265**:9485, 1990

17. Hsu-Wong S et al: Tissue-specific and developmentally regulated expression of human elastin promoter activity in transgenic r *J Biol Chem* **269**:18072, 1994

18. Hormuzdi SG et al: A gene-targeting approach identifies a function for the first intron in expression of the a1(I) collagen g *Mol Cell Bio* **18**:3368, 1998

19. Kähäri V-M et al: Tumor necrosis factor-a down-regulates human elastin gene expressi *J Biol Chem* **267**:26134, 1992

20. Kähäri V-M et al: Transforming growth factor-ß upregulates elastin gene expression in human skin fibrobla *Lab Invest* **66**:580, 1992

21. Katchman SD et al: Transforming growth factor-ß up-regulates human elastin promoter activity in transgenic m *Biochem Biophys Res Commu* **203**:485, 1994

22. Pierce RA et al: 1,25-dihydroxyvitamin D_3 repress tropoelastin expression by a posttranscriptional mechanis *J Biol Chem* **267**:11593, 1992

23. Wolfe BL et al: Insulin-like growth factor-1 regulates transcription of the elastin ge *J Biol Chem* **268**:12418, 1993

24. Giro MG et al: Quantitation of elastin production in cultured vascular smooth muscle cells by a sensitive and specific enzyme-linked immunoa *Collagen Rel Res* **4**:21, 1984

25. Sephel GC et al: Heterogeneity of elastin expression in cutis laxa fibroblast strai *J Invest Dermato* **93**:147, 1989

26. Kajiya H et al: Cultured human keratinocytes express tropoelast *J Invest Dermato* **109**:641, 1997

27. Uitto J et al: Synthesis of elastin and procollagen by cells from embryonic aorta: Differences in the role of hydroxyproline and the effects of proline analogs on the secretion of the two proteins. *Arch Biochem Biophys* **173**:187, 1976

28. Rosenbloom J, Cywinski A: Biosynthesis and secretion of tropoelastin by chick aorta ce *Biochem Biophys Res Commu* **69**:613, 1976

29. Rosenbloom J, Cywinski A: Inhibition of proline hydroxylation does not inhibit secretion of tropoelastin by chick aorta c *FEBS Lett* **65**:246, 1976

30. Grant ME et al: Carbohydrate content of insoluble elastins prepared from adult bovine and calf ligamentum nuchae and tropoelastin isolated from copper deficient porcine *Biochem J* **121**:197, 1971

31. Smith-Mungo LI, Kagan HM: Lysyl oxidase: properties, regulation and multiple functions in biolo *Matrix Bio* **16**:387, 1998

32. Rucker RB: Isolation of soluble elastin from copper-deficient chick aort *Methods Enzymo* **82A**:559, 1982

33. Kuivaniemi H et al: Abnormal copper metabolism and deficient lysyl oxidase activity in a heritable connective tissue disc *J Clin Inves* **69**:710, 1983

34. Hämäläinen ER et al: Molecular cloning of human lysyl oxidase and assignment of the gene to chromosome 5q23.3-3 *Genomics* **11**:508, 1991

35. Kenyon K et al: Lysyl oxidase and rrg messenger RN *Science* **253**:802, 1991

36. Csiszar K: Lysyl oxidases: A novel multifunctional amine oxidase fam *Prog Nucleic Acid Res Mol Bio* **70**:1, 2001

37. Goldstein RA, Starcher BC: Urinary excretion of elastin peptides containing desmosine after intratracheal injection of elastase in hams *J Clin Inves* **61**:1286, 1978

38. Uitto J, Pulkkinen L: Heritable diseases affecting the elastic tissues: Cutis laxa, pseudoxanthoma elasticum and related disorde *Emery & Rimoin's Principles and Practice of Medical Genetics*, 4th ed, edited by DL Rimoin, JM Connor, R Pyeritz, BR Korf. New York, Churchill Livingstone, 2002, p 4044

39. Bieth J: Elastases: Structure, function and pathological rol *Front Matrix Bio* **6**:1, 1978

40. Werb Z et al: Proteinases and matrix degradation, *Textbook of Rheumatolog*, 3d ed, edited by WN Kelley, ED Harris Jr, S Ruddy, CB Sledge. Philadelphia, Saunders, 1989, p 300

41. Senior RM et al: Comparison of the elastolytic effects of human leukocyte elastase and porcine pancreatic elast *Adv Exp Med Bio* **79**:249, 1977

42. Shapiro SD et al: Elastase of U-937 monocyte-like cells: Cloning and characterization of a unique elastolytic metalloproteinase produced by human alveolar macrop *J Biol Chem* **268**:23824, 1993

43. Anderson LL et al: Characterization and partial purification of a neutral protease from the serum of a patient with autosomal recessive pulmonary emphysema and cut *J Lab Clin Med* **105**:537, 1985

44. Oikarinen AI et al: Demonstration of collagenase and elastase activities in the blister fluids from bullous skin diseases: Comparison between dermatitis herpetiformis and bullous pemphigoid. *J Invest Dermato* **81**:261, 1983

45. Oikarinen AI et al: Proteolytic enzymes in blister fluids from patients with dermatitis herpetiform *Br J Dermato* **114**:295, 1986

46. Sakai LY et al: Fibrillin, a new 350-kDa glycoprotein, is a component of extracellular microfib *J Cell Bio* **103**:2499, 1986

47. Handford PA et al: Fibrillin: From domain structure to supramolecular assemb *Matrix Bio* **19**:457, 2000

48. Lee B et al: Linkage of Marfan syndrome and a phenotypically related disorder to two different fibrillin ge *Nature* **352**:330, 1991

49. Maslen CL et al. Partial sequence of a candidate gene for the Marfan syndron *Nature* **352**:334, 1991

50. Kanzaki T et al: TGF-ß$_1$ binding protein: A component of the large latent complex of TGF-ß$_1$ with multiple repeat sequences *Cell* **61**:1051, 1990

51. Reber-Muller S et al: An extracellular matrix protein of jellyfish homologous to mammalian fibrillin forms different fibrils depending on the life stage of the a *Dev Bio* **169**:662, 1995

52. Bashir MM et al: Analysis of the human gene encoding latent transforming growth factor-ß–binding protei *Int J Biochem Cell Bio* **28**:531, 1996

53. Oklu R, Hesketh R: The latent transforming growth factor-beta–binding protein (LTBP) fam *Biochem J* **352**:601, 2000

54. Dabovic B et al: Bone abnormalities in latent TGF-[beta]–binding protein (Ltbp)-3-null mice indicate a role for Ltbp-3 in modulating TGF-[beta] bioavail *J Cell Bio* **156**:227, 2002

55. Taipale J et al: Latent transforming growth factor-ß$_1$ associates to fibroblast extracellular matrix via latent TGF-ß–binding prote *J Cell Bio* **124**:171, 1994

56. Gibson MA et al: Bovine latent TGF-ß$_1$–binding protein-1: Molecular cloning, identification of tissue isoforms and immunolocalization to the elastin-associated microfil *Mol Cell Bio* **15**:6932, 1995

57. Karonen T et al: Transforming growth factor beta 1 and its latent form binding protein-1 associate with elastic fibres in human dermis: Accumulation in actinic damage and absence in anetoderma. *Br J Dermato* **137**:51, 1997

58. Argraves WS: Fibulin is an extracellular matrix and plasma glycoprotein with repeated domain struct *J Cell Bio* **111**:3155, 1990

59. Pan T-C et al: Structure and expression of fibulin-2, a novel extracellular matrix protein with multiple EGF-like repeats and consensus motifs for calcium bir *J Cell Bio* **123**:1269, 1993

60. Giltay R et al: Sequence, recombinant expression and tissue localization of two novel extracellular matrix proteins, fibulin-3 and fibu *Matrix Bio* **18**:469, 1999

61. Nakamura T et al: Fibulin-5/DANCE is essential for elastogenesis in vi *Nature* **415**:171, 2002

62. Yanagisawa H et al: Fibulin-5 is an elastin-binding protein essential for elastic fibre development in v *Nature* **415**:168, 2002

63. Roark EF et al: The association of human fibulin-1 with elastic fibers: An immunohistological, ultrastructural, and RNA stu *J Histochem Cytochem* **43**:401, 1995

64. Reinhardt DP et al: Fibrillin-1 and fibulin-2 interact and are colocalized in some tissu *J Biol Chem* **271**:19489, 1996

65. Loeys B et al: Homozygosity for a missense mutation in fibulin (FBLN5) results in a severe form of cutis la *Human Mol Gene* **11**:2113, 2002

66. Gibson MA et al: Further characterization of proteins associated with elastic fiber microfibrils including the molecular cloning of MAGP-2 (MF *J Biol Chem* **271**:1096, 1996

67. Faraco J et al: Characterization of the human gene for microfibril-associated glycoprotein (MFAP2), assignment to chromosome 1p36.1-p35, and linkage to D1 *Genomics* **25**:630, 1995

68. Colombatti A et al: The EMILIN protein family *Matrix Bio* **19**:289, 2000

69. Yeh H et al: Structure of the human gene encoding the associated microfibrillar protein (MFAP1) and localization to chromosome 15q15 *Genomics* **23**:443, 1994

70. Abrams WR et al: Molecular cloning of the microfibrillar protein MFAGP3 and assignment of the gene to human chromosome 5q32-q3 *Genomics* **26**:47, 1995

71. Lausen M, et al: Microfibril-associated protein 4 is present in lung washings and binds to the collagen region of lung surfactant prote *J Biol Chem* **274**:32234, 1999

72. Milewicz DM et al: Genetic disorders of the elastic fiber syster *Matrix Biol J* **19**:471, 2000

73. Uitto J, Bernstein EF: Molecular mechanisms of cutaneous aging: Connective tissue alterations in the derr *J Invest Dermatol Symp Pro* **3**:41, 1998

74. Uitto J et al: Elastic fibers of the connective tissue, i *Biochemistry and Physiology of Ski*, 2d ed, edited by L Goldsmith. New York, Oxford University Press, 1991, p 530

T>

Chapter 16

Leena Bruckner-Tuderman

Basement Membranes

ULTRASTRUCTURE OF THE DERMAL-EPIDERMAL JUNCTION
BIOCHEMICAL CHARACTERIZATION OF THE BASEMENT MEMBRANE
Ubiquitous Components of Basement Membranes
EPITHELIAL-SPECIFIC BASEMENT MEMBRANE COMPONENTS
The Hemidesmosomes
Anchoring Filaments
The Epithelial Lamina Densa
Anchoring Fibrils
THE ORIGIN OF THE BASEMENT MEMBRANES
THE FUNCTION OF BASEMENT MEMBRANES

REFERENCES

Basement membranes underlie epithelial and endothelial cells and separate them from each other or from the adjacent stroma. Another form of basement membrane surrounds smooth muscle or nerve cells. The physiologic functions of basement membranes are diverse. As early as the gastrula stage of development, extracellular macromolecules form scaffolds for cell attachment and migration, and serve as boundaries between cells of different destinies. The resulting compartmentalization is determined and maintained throughout life. As the various organ systems mature, basement membranes continue to serve as substrates and provide support for differentiated cells, maintain tissue architecture during remodeling and repair, and, in some cases, acquire specialized functions, including the ability to serve as selective permeability barriers, e.g., the glomerular basement membrane or the basement membrane of the blood-brain barrier, or acquire strong adhesive properties, like the basement membrane surrounding smooth muscle cells, or that at the dermal-epidermal junction, which provide the tissues resistance against shearing forces.

Ultrastructurally, basement membranes most often appear as trilaminar structures, consisting of a central electron-dense region, known as the *lamina densa,* adjacent on either side to an apparently less-dense area, known as the *lamina lucida* or *lamina rara*. The lamina lucida directly abuts the plasma membranes of the adherent cells. Where basement membranes separate cells from a stromal matrix, the electron-translucent region immediately adjacent to the plasma membrane is defined as the *lamina lucida interna,* whereas the opposite side of the basal lamina is referred to as the *subbasal lamina*. The relative size of each of these regions varies between basement membranes of different tissues, between the basement membranes of the same tissue at different ages, and as a consequence of diseases. For example, the trilaminar glomerular basement membrane in humans varies from 240 to 340 nm in width, whereas the bilaminar basement membrane of the dermal-epidermal junction measures 50 to 90 nm.

Different basement membranes contain both common and unique components. All share a basic network structure to which specific macromolecules have been appended. These molecules are responsible for the specialized structures and functions of different basement membranes. Studies using recombinant proteins and transgenic and knockout mouse technologies have provided a wealth of new information on these aspects (discussed below). Also the recent availability of the complete genomic sequences of humans, *Drosophila melanogaster,* and *Caenorhabditis elegans* makes it possible to compare the genomes and address questions about basement membrane composition and functions with much more confidence than before. [1] Cell adhesion to basement membranes appears ancient and exquisitely conserved. Coelenterates have basement membranes, as do all more complex animals. The basic constituents of these structures are collagen IV, laminin, nidogen/entactin, and proteoglycans of the perlecan type, which all are highly conserved. Comparative analysis demonstrated that the four molecules formed the basis of an early basement membrane that has been preserved in molecular detail. The number of the polypeptide subunits and their individual structures vary between species, but many interesting features, e.g., the organization of collagen IV genes in an antiparallel head-to-head arrangement with a common promoter, can be found in both vertebrates and in Drosophila, suggesting important functional characteristics.

ULTRASTRUCTURE OF THE DERMAL-EPIDERMAL JUNCTION

The dermal-epidermal junction is an example of a highly complex form of basement membrane, [2], [3] which underlies the basal cells and extends into the upper layers of the dermis (Fig. 16-1A). This basement membrane is continuous along the epidermis and skin appendages, including sweat glands, hair shafts, and sebaceous glands. In the upper regions of the dermis, different basement membranes surround capillaries and nerves, but these are excluded from the present discussion. The dermal-epidermal junction can be divided into three distinct zones. The first zone contains the keratin filament-hemidesmosome complex of the basal cells and extends through the lamina lucida to the lamina densa. The plasma membranes of the basal cells in this region contain numerous electron-dense plates known as hemidesmosomes. The intracellular architecture and organization of the basal cells are maintained by keratin intermediate filaments, 7 to 10 nm in diameter, also known as tonofilaments, that course through the basal cells and insert into the desmosomes and hemidesmosomes. External to the plasma membrane is a 25- to 50-nm–wide lamina lucida that contains anchoring filaments, 2 to 8 nm in diameter, originating in the plasma membrane and inserting into the lamina densa. The anchoring filaments can be seen throughout the lamina lucida but they are concentrated in the regions of the hemidesmosomes. Ultrastructurally, the anchoring filaments appear to secure the epithelial cells to the lamina densa.

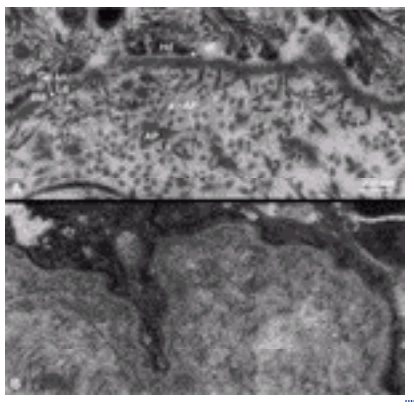

FIGURE 16-1 *A.* Ultrastructure of the human dermal-epidermal junction as visualized by transmission electron microscopy following standard fixation and embedding protocols. af, Anchoring filament; AF, anchoring fibril; AP, anchoring plaque; BM, basement membrane; Hd, hemidesmosome; Ll, lamina lucida; Ls, lamina densa. Bar = 200 nm. *B.* Ultrastructure of the human dermal-epidermal junction by transmission electron microscopy following protocols using high-pressure fixation and embedding techniques. Note the dense character of both the basement membrane and the subjacent papillary dermis. Anchoring filaments, anchoring fibrils, and anchoring plaques are not distinguishable. (*Both photos courtesy of Douglas R. Keene, MD, Shriners Hospital, Portland, Oregon.*)

The existence of the lamina lucida in vivo has been questioned. When the ultrastructure of the basement membrane is evaluated following high-pressure preservation techniques, the lamina densa appears intimately associated with the epithelial cell surface. [2], [4] When the dermal-epidermal junction is similarly prepared, no distinct lamina lucida is seen (Fig. 16-1B). This suggests that the lamina lucida may result from shrinkage of the cell surface away from the lamina densa due to dehydration. The appearance of anchoring filaments spanning the lamina lucida may then result from the firm attachment of constituents of the lamina densa at the hemidesmosome that is subsequently pulled from the lamina densa by shrinkage. Other components that are also tightly fixed to the keratinocyte plasma membrane, either at the hemidesmosomes or at other sites along the membrane between the hemidesmosomes, may similarly become displaced into the shrinkage space. This may account for the localization of laminins to both the lamina lucida and the lamina densa, because laminins are bound to the cells by specific integrins (discussed below). Regardless of its actual occurrence in vivo, the evaluation of the lamina lucida by standard electron microscopy techniques has allowed identification of specific structures that would otherwise have been difficult to detect.

The second zone, the lamina densa, appears as an electron-dense amorphous structure 20 to 50 nm in width. The dermal-epidermal lamina densa is similar in appearance to analogous structures in other organs. At high magnification, it has a granular-fibrous appearance. [2] The major molecular components of the lamina densa are collagen IV, nidogen/entactin, perlecan, and laminins which all can polymerize to networks of variable thickness (Fig. 16-2). [5]



FIGURE 16-2 Images of basement membrane molecules visualized by rotary shadowing. *A.* Collagen IV monomer and a dimer resulting from aggregation of C-terminal NC-1 domains. *B.* Collagen IV tetramer (“spider”) demonstrating the 7-S domain with the four protruding molecules and their large terminal NC-1 domains. *C.* Laminin 1 molecules. *D.* Nidogen molecules. *E.* Procollagen VII. The NC-1 and NC-2 regions are indicated. *F.* Laminin five molecules. (*All micrographs were provided by Douglas R. Keene, MD, Shriners Hospital, Portland, Oregon.*)

The subbasal lamina contains microfibrillar structures. Two of these are readily distinguishable. The first structure, known as *anchoring fibrils,* appears as condensed fibrous aggregates 20 to 75 nm in diameter. [6] At high resolution, they appear to have a nonperiodic cross-striated banding pattern (Fig. 16-1A). The length of the anchoring fibril is difficult to measure because of its random orientation in relation to the plane of the section. In toad skin, these structures have lengths of approximately 800 nm. The anchoring fibrils in human skin appear to be somewhat shorter. The ends of the anchoring fibrils appear to be less-tightly packed, giving a somewhat frayed appearance. The proximal end inserts into the basal lamina, and the distal end is integrated into the fibrous network of the dermis. [7] Many of the anchoring fibrils originating at the lamina densa loop back into the lamina densa in a horse shoe-like manner; [8] others insert their opposite ends into amorphous-appearing structures, termed *anchoring plaques*. [9] These structures are believed to be independent “islands” of electron-dense material, although some controversy exists in the literature. [8] Anchoring fibrils are primarily aggregates of collagen VII. [9]

Tubular fibrillin-containing *microfibrils,* 10 to 12 nm in diameter, are also localized in the sublamina densa region. On the basis of classic histochemical staining procedures, these have been identified as elastic-related fibers. [10] Elastic components of the dermis are formed from microfibrillar and amorphous components. [11] The microfibrillar component in the absence of amorphous component was previously named the oxytalan fibers; the microfibrillar component in the presence of small amounts of amorphous component were designated as the elaunin fibers; and the microfibrillar component in the presence of abundant amorphous component is known as the *elastic fiber*. In the papillary dermis, the microfibrils insert into the basal lamina perpendicular to the basement membrane and extend into the dermis, where they

gradually merge with the elastic fibers to form a plexus parallel to the dermal-epidermal junction. These two elastic components appear to be continuous with the elastic fibers present deep within the reticular dermis. [11] The gradient of an increasing amorphous component from the basal lamina into the reticular dermis may represent a system of increasingly mature elastic fibers.

In summary, the ultrastructure of the dermal-epidermal junction strongly suggests that the lamina densa functions as a structural scaffold for the attachment of the epidermal cells at one surface, secured by anchoring filaments extending from the lamina densa to the hemidesmosomes. The latter also serve as insertion points for intracellular keratin filaments that provide an internal cytoskeleton for the basal cells. On the opposite surface, the extracellular matrix suprastructures of the dermis are firmly attached to the lamina densa. The interaction of different dermal fibers with the basal lamina appears to be mediated by the anchoring fibrils. The elastic system of the dermis inserts directly into the basal lamina via the microfibrils. Thus, the dermal-epidermal junction provides a continuous series of attachments between the reticular dermis and the internal cytoskeleton of the basal cells. These observations suggest three major functions for the epidermal basement membrane: It provides (1) a structural foundation for the secure attachment and polarity of the epidermal basal cells; (2) a barrier function, separating the components of the epidermis and the dermis; and (3) firm attachment of the dermis to the epidermis through a continuous system of structural elements. Biologic and molecular analyses indicate that the basement membranes also modify cellular functions, such as organization of the cytoskeleton and rescue from apoptotic signaling. [12]

BIOCHEMICAL CHARACTERIZATION OF THE BASEMENT MEMBRANE

Basement membranes contain collagenous and noncollagenous glycoproteins, and proteoglycans. The unusual amino acids hydroxyproline and hydroxylysine are found almost exclusively in collagens, and their presence is considered a marker for this family of proteins (for review, see Ref. [13]). The hydroxyproline content suggests that collagen accounts for 40 to 65 percent of the total basement membrane protein. All basement membranes contain collagen IV as the major collagen and the heparan sulfate proteoglycan perlecan, irrespective of tissue source. In addition, many other glycoproteins have been found in basement membranes, including several laminins, nidogen/entactin, fibulins, and fibronectin. [14], [15]

In contrast to the ubiquitous components within all basement membranes, some molecules demonstrate a restricted distribution. Certain collagen IV isoforms, collagens VII and XVII, or several laminins, are not ubiquitous. For example, the a3 chain of collagen IV is localized in the basement membrane of the kidney and lung, but not in those of the skin and blood vessels and, vice versa, collagens VII and XVII are associated with the squamous epithelia of skin but are not found in glomerular and alveolar basement membranes. [14], [15] Differences in macromolecular composition are responsible for morphologic and functional variance of basement membranes. Some of these differences reflect tissue-specific accessory structures, while others result from differences in the constituents of the lamina densa itself (discussed below).

Ubiquitous Components of Basement Membranes

Collagen IV Advances in our knowledge of collagen IV structure have substantially contributed to our understanding of basement membrane architecture. [16] In addition to its unique primary structure, the chain composition and supramolecular organization of collagen IV is different from the classical interstitial collagens (for review, see Refs. [17] and [18]). Collagen IV has a structure closely related to the procollagen form, typical of many collagens (see Chap. 14). A collagen IV a-chain contains three distinct domains (Fig. 16-2A), the N-terminal cysteine-rich (7-S) domain, a central triple-helical domain, and a C-terminal globular domain (NC-l). The chain composition is determined by the NC-l domains, and the a chains are linked to each other by covalent interactions through these domains. [16] The triple helix of collagen IV measures 330 nm, which is longer than that of interstitial collagens. It is not helical throughout its length, but it does contain several sites at which glycine is not present in every third position. [15] These minor discontinuities result in increased flexibility in the collagen IV helix, but also render it susceptible to a variety of proteases. [15] The characteristic fibril structure of the interstitial collagens results from aggregation of molecules in a staggered array, producing a cross-banding pattern in electron microscope after appropriate staining. In contrast, the ultrastructure of the lamina densa indicates no periodic cross-striations, strongly suggesting that the aggregates of collagen IV are different. The suprastructure of collagen IV has been partially elucidated by rotary shadowing electron microscopy that indicated that the major interactions among collagen IV molecules occur at their amino- and carboxyl-terminal domains, and by lateral association of their triple helices (Fig. 16-2A). [15] Covalent interactions among 7-S regions of different molecules are the basis for the specialized network characteristic of basement membranes (Fig. 16-2B). [15] The individual 7-S regions overlap in both the parallel and antiparallel directions, producing a characteristic four-legged “spider” form. The NC-l domains at the end of each leg of the spider interact with the NC-l domain of the adjacent aggregates (Fig. 16-2B). Association is stabilized by covalent bonds. These end-to-end interactions result in an extended two-dimensional network that is the basis of basement membrane organization. The high flexibility of the basement membrane network structure makes the possibility of interactions with other collagens or noncollagenous molecules very attractive. An open meshwork of collagen IV with, for example, laminins or perlecan, can be easily visualized. [17] The implied porosity of this structure would then be limited by the size of the pores in the collagen network and by structural elements associated with it. This model of the basement membrane structure allows considerable mechanical stability while retaining physiologic flexibility. These properties of strength and elasticity would be expected for a dynamic surface, such as that seen in the epidermal-dermal junction and surrounding blood vessels. Collagen IV molecules in different basement membranes contain genetically distinct but structurally homologous a chains. Six different a chains have been identified. The a1 and a2 chains are ubiquitous, but the a3a4, a5, and a6 chains show restricted distribution among tissues. [18] Recent studies have elucidated the chain organization and the discriminatory interactions that govern network assembly in the basement membranes of the glomerulus and smooth muscle. The existence of two networks, namely a1/a2-containing and a3/a4/a5-containing networks, was established in the glomerular basement membrane. The chains are linked to each other by covalent interactions through the NC-l domain, indicating that these domains contain recognition sequences for selection of chains that are sufficient to direct the assembly of the a1/a2-containing or a3/a4/a5-containing networks. [16] Smooth muscle basement membranes have an a1/a2/a5/a6-containing network in

addition to the classical a1/a2-network. [19] The a1/a2/a5/a6-network represents a new arrangement in which a triple-helical molecule containing the a5 and a6 chains is linked to an adjoining molecule composed of the a1 and a2 chains. Together, the six chains of collagen IV are distributed in three major networks, a1/a2, a3/a4/a5, and a1/a2/a5/a6, whose chain composition is determined by the NC-I domains. In the skin, the a1/a2-containing collagen IV network dominates within the dermal-epidermal junction, but a1/a2/a5/a6-containing network is also likely to be present. [20] The a3(IV) chain is the antigen recognized by the circulating autoantibodies in the Goodpasture syndrome, [21] and autoantibodies directed against the NC-I domain of the a5(IV) collagen chain were found in a novel autoimmune disease characterized by subepidermal bullous eruptions and renal insufficiency. [22] Structural aberrations in the genes encoding the a3, a4, a5, and a6 chains cause different forms Alport syndrome, a genetic disease characterized by nephritis and deafness. [18], [23]

LAMININS Laminins are members of a family of very large glycoproteins (600 to 950 kDa) with semirigid and extended structures (for review, see Refs. [24] and [25]). Three types of subunit chains have been designated a (200 to 400 kDa), ß (220 kDa), and ? (155 to 200 kDa) chains. The molecular structure of all laminins is a trimeric aggregate of one of each, a, ß, and ? chains. With rotary shadowing electron microscopy the molecules were shown to have an asymmetric cross-like structure (Fig. 16-2C). The long arm of the cross is approximately 125 nm in length; the short arms are variable, but the largest measure approximately 80 nm. The laminin molecule is divided into globular and rodlike sections. The four extremities of the crosslike structure contain globular domains, and the three short arms of the cross contain globular domains approximately 20 nm from their free ends. The globular and rodlike domains of laminin have been individually implicated in various functions, including cell attachment and spreading, aggregation with itself and with other components of the lamina densa (Fig. 16-3), with neurite outgrowth, and with cellular differentiation.

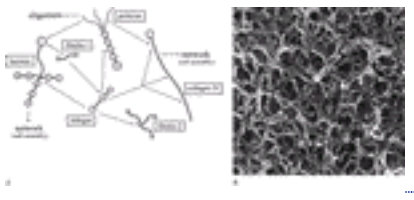

FIGURE 16-3 *A.* Representation of the networks formed by the ubiquitous components of the basement membranes. Monomeric collagen IV self-assembles into dimers and tetramers that further aggregate into a complex lattice. Laminins self-polymerize into networks. Perlecan can oligomerize in vitro, and the glycosaminoglycan side chains interact with the collagen IV framework. Nidogen/entactin is thought to bind components of all three networks and also fibulins. Nidogen therefore plays a central role as a stabilizer of the lamina densa framework. Individual molecules are not drawn to scale. (*Drawing courtesy of Ulrike Mayer, PhD, Wellcome Trust Centre for Cell-Matrix Research, Manchester, UK.*) *B.* Rotary shadowing image of a quick-freeze, deep-etch replica of collagen IV polymers. The replica shows an extensive, branching and anastomosing network with occasional globular structures (*arrowhead*), which can be visualized as a model for the structure of the lamina densa. (*Photo kindly provided by Toshihiko Hayashi, PhD, University of Tokyo, Japan. See also Ref*. [94])

Laminins are present in all basement membranes [24], [25] and ultrastructural studies indicate that they are localized to the lamina lucida/lamina densa. Exceptions may form the ?3 chain-containing laminins 14 and 15 that can be found in tissues without classical basement membranes, such as the central nervous system. [26] By interacting with integrins and other cell surface components laminins can control cellular activities such as adhesion, migration, proliferation, and polarity, or promote neurite outgrowth. [25] The integrins bind to the LG domain of the a chain, at the foot of the long arm of the laminin cross. [27] To date, 15 laminin isoforms have been identified (for review, see Refs. [24], [25], [26] and [27]). The a1 chain containing laminin 1 (a1ß1?1) is the “prototype” laminin. The a2 chain containing laminins 2 and 4 are present primarily within the basement membranes of the muscle fibers, nerves, neuromuscular junction, and glomerulus. Mutations in the laminin a2 chain cause progressive muscular dystrophy and a significant decrease in the amount of basement membrane accumulated surrounding muscle cells. [28] The absence of the muscle basement membrane leads to progressive degeneration of the muscle due to cell death. Therefore, the prediction is that laminins, and basement membranes in general, are required to prevent apoptosis by the cell types they surround. [14] Three additional laminin a chain variants—a3, a4, and a5—are known. The a3 chain is involved in epithelial adhesion [29] (see below), and the a4 and a5 chains are found in a variety of tissues including endothelia, mature epithelia, neuromuscular junction, and glomerulus as components of laminins 8 to 11. [30] Three ß-chain variants are known: ß1, ß2, and ß3. The distribution of the ß2 chain is largely restricted to the neuromuscular junction, but it is also found in nonmuscle tissues such as the glomerular basement membrane of kidney and the capillary basal lamina. [24], [25] Targeted ablation of the ß2 gene leads to muscular dystrophy and renal failure in mice, due to a loss of the neuromuscular folds and the ingrowth of the glial cells within the neuromuscular junction and to fusion of the glomerular podocyte foot processes, respectively. The ß3 chain is involved in epithelial adhesion (see below). At the present time, three ? chain variants—?1, ?2, and ?3—are known. The ?2 chain is found only in laminin 5 (see below), and the ?3 chain is found only in laminins 14 (a4, ß2, and ?3), and 15 (a5, ß2, and ?3), which may play roles in the central nervous system, e.g., in retinal photoreceptor production, stability, and synaptic organization. [31]

NIDOGEN/ENTACTIN Laminin is strongly associated with another lamina densa glycoprotein nidogen/entactin. Rotary shadowing of nidogen indicates a dumbbell shape (Fig. 16-2D). Nidogen binds laminin at a specific site within the ?1 chain in a calcium-dependent manner. [32] Nidogen also binds collagen IV, perlecan, and fibulins. [33] Because isolated laminin will self-assemble in the presence of calcium, these observations support the concept of basement membrane structure where separate networks of collagen IV, perlecan, and laminin are linked by nidogen. Recently, a second nidogen, nidogen 2, was identified. [34] In light of the central role of nidogen as a basement membrane linker, it was surprising that no pathologic phenotype was observed in mice with targeted ablation of the nidogen 1 gene. [35] This led to the prediction that nidogen 2 compensates functionally for the lack of nidogen 1 in the tissues and, therefore, more information on the functions of these ubiquitous basement membrane components can be expected from future double knockout mice lacking both nidogen 1 and 2.

FIBULINS Fibulins are a newly identified family of highly conserved, calcium-binding extracellular matrix proteins, with at least six members. They are located in vessel walls, basement membranes, and microfibrillar structures. [36] Fibulin-2 binds fibrinogen, fibronectin, nidogen, and several other basement membrane molecules, such as the proteoglycans aggrecan and versican. [37] Therefore, fibulins are likely to contribute to the structural networks of different basement

membranes and their ligands.

HEPARAN SULFATE PROTEOGLYCANS Another class of ubiquitous integral basement membrane constituents are the proteoglycans. [38] Three proteoglycans are characteristically present in vascular and epithelial basement membranes: perlecan, agrin, and bamacan. They consist of a core protein of various lengths, and the first two carry primarily heparan sulfate side chains, whereas the latter carries primarily chondroitin sulfate. The name *perlecan* is derived from its rotary shadowing appearance reminiscent of a string of pearls. Perlecan represents a complex multidomain proteoglycan with enormous dimensions and a number of posttranslational modifications. [39] Knockout mice lacking perlecan exhibited abnormalities in many tissues, including basement membranes, and embryonic lethality. [40] The morphology of the basement membranes was not altered but the membranes deteriorated in regions under increased mechanical stress, such as myocardium or skin, resulting in lethal cardiac abnormalities and skin blistering. *Agrin* is a major heparan sulfate proteoglycan of neuromuscular junctions and renal tubular basement membranes. *Bamacan* is likely to be the chondroitin sulphate proteoglycan previously identified in many basement membranes. The proteoglycans are capable of interactions with several other basement membrane components and are believed to contribute to the overall architecture of the basement membrane as well as provide tissue-specific functions (see Fig. 16-3). The high sulfate content of the proteoglycans makes them highly negatively charged and hydrophilic. The charge density of these molecules is responsible for providing the selective permeability of the glomerular basement membrane. *Syndecans* are transmembrane heparan sulfate proteoglycans that are present on most cell types, including basal keratinocytes of the epidermis. They regulate a variety of biologic processes, ranging from growth factor signaling, cell adhesion to ECM and subsequent cytoskeletal organization, to infection of cells with microorganisms. [41]

EPITHELIAL-SPECIFIC BASEMENT MEMBRANE COMPONENTS

The dermal-epidermal junction of skin is an excellent example of specific divergence in basement membrane structure. The structural components of hemidesmosomes, anchoring filaments, and anchoring fibrils in the basement membrane zone have been identified and characterized (for review, see Ref. [2], [3], [12], and [14]). A cartoon depicting the relative locations of the proteins found at the dermal-epidermal junction is shown in Fig. 16-4. These proteins are listed in Table 16-1 and discussed below.

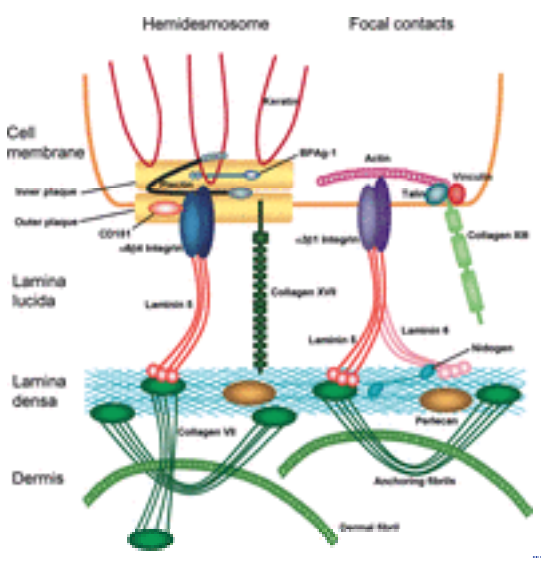

FIGURE 16-4 Model of the hypothetical relationships of molecules within the dermal-epidermal junction basement membrane. The illustration depicts monomeric laminin 5 as the bridge between the transmembrane hemidesmosomal integrin a6ß4 and the collagen VII NC-1 domain. The tight binding of laminin 5 to a6ß4 and to collagen VII provides the primary resistance to frictional forces. The transmembrane collagen XVII also participates in this stabilization, because its extracellular domain also binds laminin 5. Within the epithelial cell, the transmembrane elements bind the proteins of the hemidesmosomal dense plaque, BPAg-1 and plectin, which then associate with the keratins. Experimental evidence suggests that collagen XVII binds BPAg-1, integrin a6ß4, and plectin, and that integrin a6ß4 binds plectin. The laminin 5–6 complex is shown within the basement membrane between hemidesmosomes, bound by integrin a3ß1 where it potentially functions to maintain basement membrane assembly or stability. In vitro, integrin a3ß1 and another transmembrane collagen, type XIII, are localized to the focal contacts. In these structures, they may function, together with vinculin and talin, as the link between the basement membrane and the epithelial cortical actin network. In the lamina densa, collagen IV and perlecan networks are stabilized by nidogen. Anchoring fibrils are secured to the lamina densa by the implanted NC-1 domain of collagen VII. The fibrils project into the dermis and either terminate in anchoring plaques or loop back to the lamina densa. The anchoring fibril network entraps dermal fibrils, thus securing the adhesion of the lamina densa to the papillary dermis. None of the molecules is drawn to scale.



TABLE 16-1 **Molecular Components of the Dermal-Epidermal Junction**

The Hemidesmosomes

Ultrastructurally, the hemidesmosome closely resembles one-half of the desmosome at cell-cell junctions in the epidermis. However, the components of these two structures are distinct. [42] Characterization of the hemidesmosomal proteins was initially aided by the use of autoantibodies in serum of patients with bullous pemphigoid. The antigens recognized by the sera ranged in mass from 120 to 230 kDa, with a considerable variability between individual serum samples. [43], [44], [45] and [46] Monoclonal antibodies and cloning of the cDNAs for the proteins helped identify three distinct proteins: 230 kDa, 180 kDa, and 120 kDa. [45], [46] The 230-kDa protein, *BPAg-1* (bullous pemphigoid antigen-1, or BP230), is a coiled-coil dimeric proteins with homology to plakins, which are able to bind intermediate filaments. [45] BPAg-1 is the major component of the hemidesmosomal inner dense plaque. In a transgenic mouse model, deletions in BPAg-1 caused epidermolysis bullosa simplex (see Chap. 65). The 180-kDa protein, previously called BPAg-2 or BP180, is a transmembrane collagen now known as *collagen XVII,* where the collagenous domain is extracellular. [46], [47] and [48] Mutations in collagen XVII cause junctional epidermolysis bullosa (see Chap. 65), indicating that it directly or indirectly stabilizes interactions of the epithelial cells with the basement membrane. Its intracellular ligands are plectin, BPAg-1 and ß4 integrin. [42] The extracellular ligands are a6 integrin and laminin 5. [49] The 120-kDa protein is the shed ectodomain of collagen XVII. [44], [47], [48]

Plectin, another dimeric plakin homologue, is also a component of the hemidesmosome. However, its tissue distribution is not limited to hemidesmosome-containing basement membranes. Mutations causing the loss of plectin result in epidermolysis bullosa simplex and progressive muscular dystrophy (see Chap. 65), indicating a role for this molecule in the stability of cell-basement membrane adhesion in a variety of tissues.

One key component of the hemidesmosome is the *integrin a6ß4*. Integrins are a large class of transmembrane extracellular matrix binding proteins that provide cell attachment and subsequent signal transduction. Integrin a6ß4 has a high affinity for laminin 5, [42] and therefore is essential to integration of the hemidesmosome with the underlying basement membrane and stroma. Mutations in either the a6 or ß4 chains result in dermal-epidermal instability. In mice, null mutations cause severe junctional epidermolysis bullosa. [50], [51] In humans, different mutations in the a6 or ß4 chains are associated with variably severe skin blistering associated with pyloric atresia. [52], [53]

Recently, a member of the cell surface transmembrane proteins of the tetraspan superfamily, *CD151,* was identified as a component of the hemidesmosome. [54] It colocalizes with a3ß1 and a6ß4 integrins at the basolateral surface of basal keratinocytes and its recruitment into the hemidesmosomes seems to be regulated by a6ß4 integrin. It was suggested that CD151 plays a role in the formation and stability of hemidesmosomes by providing a framework for the spatial organization of the different components. [54]

Anchoring Filaments

Several proteins are candidates for the anchoring filament component(s). *Laminin 5* has been localized to the anchoring filaments. [12], [24], [25], [28], [55] It is a disulfide-bonded complex of a3, ß3, and ?2 chains. Rotary shadowing imaging indicates that laminin 5 has a rodlike structure terminating in the globular regions (see Fig. 16-2F). The component chains are considerably truncated relative to other laminin chains, and this truncation is reflected in the loss of the structures equivalent to the short arms of other laminins. Additionally, the a3 and ?2 chains of laminin 5 are proteolytically processed after secretion from the keratinocyte, further shortening the short arm structures. [56], [57] The shape of the molecule is consistent with its potential to be the anchoring filament protein. Laminin 5 has high affinity for a6ß4 integrin, [42] and it forms covalent complexes with laminin 6 (a3ß1?1), [58] binds to the NC-1 domain of collagen VII, the anchoring fibril protein [59], [60] and to the distal ectodomain of collagen XVII. [49] Genetic evidence suggests that laminin 5 is essential in keratinocyte adhesion, as null mutations in any of its component a3, ß3, or ?2 chains result in severe Herlitz' junctional epidermolysis bullosa (see Chap. 65). Targeted disruption of the LAMA3 gene in mice prevented the synthesis of both laminin 5 and 6 molecules (both contain the laminin a3 chain) and resulted in abnormal hemidesmosomes, lack of survival of mutant epithelial cells, severe junctional blistering, and perinatal lethality. [29] Therefore, the severity of the laminin 5 null phenotype reflects the loss of its ability to bridge the hemidesmosomes and the anchoring fibrils, resulting in a separation within the lamina lucida. The mouse model also demonstrated that defects in the epithelial basement membrane can cause abnormalities of ameloblast differentiation in developing teeth, thus suggesting a role for laminin 5 in enamel formation. [29]

The extracellular domain of *collagen XVII* localizes to the region of the anchoring filament. [61] This protein exists in two forms, as a transmembrane protein, and as a soluble shed ectodomain. [47], [48], [62] It is now known that the 120-kDa and 97-kDa antigens recognized by antisera from patients with linear IgA dermatosis, which have been localized to the lamina lucida/anchoring filament region, represent derivatives of collagen XVII. [63], [64], [65], [66] and [67] The 120-kDa antigen is the intact shed ectodomain, and the 97-kDa antigen is a partially degraded fragment. [44] Proteins implicated as anchoring filament components have also included LAD-1, [64] which several lines of evidence suggest is identical with the shed ectodomain of collagen XVII. [44], [65], [67] Yet another antigen, recognized by monoclonal antibody 19-DEJ-1, localizes to the region of the lamina lucida beneath hemidesmosomes. [68] This antigen appears to be sulfated and may be a proteoglycan. Its identity has so far remained elusive.

The Epithelial Lamina Densa

The basement membrane beneath and between the hemidesmosomes contains the a1/a2-containing collagen IV network, probably some a1/a2/a5/a6-containing *collagen IV* network, as well as nidogen, perlecan, and laminin a3-containing molecules. [14], [20], [55] The laminin a3 chain is also contained in laminin 6, which has the unique property of

forming disulfide-bonded dimers with laminin 5. [58] It is probable that the major a3-containing laminin in the lamina densa between hemidesmosomes is the laminin 5-6 complex. [55], [58] As the laminin a3-chain is a ligand for integrin a3ß1 present between hemidesmosomes, it is expected that binding of laminin 5 to 6 to the intracellular actin cytoskeleton is mediated by integrin a3ß1. This is consistent with studies in mice in which targeted ablation of the integrin a3-chain causes loss of the basement membrane between hemidesmosomes but not beneath them. [69] The laminin 5–6 complex contains a ?1 chain and can therefore bind nidogen and the collagen IV network. [32] There are additional laminins within the dermal-epidermal basement membrane, one of which was assumed to be laminin 1. However, it is now believed that laminin 1 is a relatively minor component, if present at all, and that laminin 10 (a5ß1?1) is more abundant. [24], [25], [70] Laminin 2 may also exist at the dermal-epidermal basement membrane. [71]

Anchoring Fibrils

Collagen VII is the major component of the anchoring fibrils. [7], [8] and [9], [72] The collagen VII molecule is distinguished from other collagens in that it has a triple-helical domain that is 450 nm in length. Globular domains exist at both ends of the triple helix, the N-terminal domain NC-1 is very large and trident-like (see Fig. 16-2E). Collagen VII is synthesized and secreted mainly by keratinocytes as a monomeric procollagen. [72] This is processed by BMP-1, a proteinase that removes the C-terminal propeptide, [73] to yield a mature collagen VII that rapidly dimerizes through disulfide crosslinks at the carboxy terminus. The C-propeptides are believed to facilitate the formation of the centrosymmetric dimers. [74] The dimers then aggregate laterally to form the anchoring fibrils. [7], [8], [72] The fibrils are stabilized by the enzyme tissue transglutaminase which catalyzes the formation of covalent ?-glutamyl-e-lysine cross-links. [75]

The NC-1 domain binds to laminin 5 and collagen IV within the lamina densa (Fig. 16-3). [59], [60] The triple helical domains of an antiparallel collagen VII dimer make the length of the anchoring fibril. It extends perpendicularly from the lamina densa and either loops back into the lamina densa, or inserts into the anchoring plaques. [7], [8] and [9], [72] The anchoring plaques are electron-dense structures that contain collagen IV and laminin 5, and perhaps other basement membrane components, but which are believed to be independent of the lamina densa itself. [7] They are distributed randomly in the papillary dermis below the lamina densa and are interrelated by additional anchoring fibrils. The anchoring fibril network forms a scaffold that entraps large numbers of dermal fibrils, securing the lamina densa to the subjacent dermis. [7], [8] and [9], [72] Correspondingly, null mutations in COL7A1, the gene encoding collagen VII, result in severe, generalized dystrophic epidermolysis bullosa (see Chap. 65). To date, more than 300 COL7A1 mutations have been found in both recessive and dominant forms of dystrophic epidermolysis bullosa, [72], [76] and the spectrum of biologic and clinical phenotypes is much broader than anticipated. [72], [77] Collagen VII–deficient mice recapitulated the clinical and morphologic characteristics of severe recessive dystrophic epidermolysis bullosa in humans. [78]

Recent gene transfer experiments have indicated that an ex vivo gene therapy approach is promising for treatment of dystrophic epidermolysis bullosa. Transfection with a PAC vector carrying the entire COL7A1 gene increased collagen VII production in a keratinocyte line [79] and reverted the collagen VII–deficient phenotype of keratinocytes derived from the skin of a patient with severe dystrophic epidermolysis bullosa. [80] In another approach, a cosmid containing the entire human COL7A1 gene was used to generate transgenic mice. [81] The cosmid was capable of directing stable expression of human collagen VII in the skin of the transgenic mice for at least 19 months. [81]

In the acquired form of epidermolysis bullosa, epidermolysis bullosa acquisita, and in bullous systemic lupus erythematosus, autoantibodies target the NC-1 domain, [82], [83] although epitopes in other domains of collagen VII have also been identified. [74], [84]

THE ORIGIN OF THE BASEMENT MEMBRANES

The basement membrane constituents are products of both epithelial and mesenchymal cells. Models of rodent intestinal development suggested that both laminin and collagen IV were synthesized by mesenchymal cells. [85] In vitro modeling of basement membrane formation clearly shows that, under at least some conditions, the dermal-epidermal junction basement membrane is contributed to by both tissue compartments, and it has been proposed that differentiated fibroblasts exist adjacent to epithelial tissues in vivo, which produce basement membrane components and assist in basement membrane assembly. [86], [87] Of the known basement membrane components, only laminins 5 and 6 are exclusively produced by the epidermis. Epithelial cells also manufacture most of collagen VII, whereas mainly mesenchymal cells synthesize collagen IV, nidogen, perlecan, and the laminin a2 chain. [88] In skin equivalent cultures, [86], [87] and developing mouse organs, [88], [89] fibroblasts are the only source of nidogen at the epithelial-mesenchymal interface. Because the mesenchymal products are translocated to the basolateral epithelial surface where they condense, that surface must provide the localization cues. Integrins a6ß4 and a3ß1, and perhaps collagen XVII, provide this function, suggesting that the laminins initiate basement membrane polymerization. As nidogen is thought to be required for stabilization of the basement membrane, and because it is a mesenchymal product, it is likely that the dermis is essential to development of basement membranes. [20], [24], [25], [86] An interesting regulatory step to basement membrane formation may be added by dermal enzymes, e.g., BMP-1, which process epithelial cell products, such as laminin 5 and procollagen VII, to mature basement membrane molecules. [56], [73]

THE FUNCTION OF BASEMENT MEMBRANES

Basement membranes have five major functions: (1) they serve as a scaffold for tissue organization and as a template for tissue repair; (2) the renal basement membranes serve as selective permeability barriers for the ultrafiltration of serum, and other basement membranes also demonstrate selective filtration; (3) they are physical barriers between different types of cells or between cells and their underlying extracellular matrix; (4) they firmly link an epithelium to its underlying matrix or to another cell layer; and (5) they regulate cellular functions. All of these characteristics of basement

membranes are used during development and differentiation of multicellular organisms.

Their ultrastructure demonstrates that basement membranes serve as substrates for the attachment of differentiated cells and fix their polarity. Their continuity throughout the various organ systems stabilizes the established tissue orientations and provides a template for orderly repair after traumatic injury. [90] In the dermal-epidermal junction, the basement membrane mediates the connections of the basal cells with the connective tissue in the dermis. Tissue healing in adults depends on the presence of both the correct cell types and an intact basement membrane. Major disruptions in the basement membrane result in the formation of scar tissue and the loss of function in that area.

The selective permeability in the kidney is due to the renal basement membranes. Molecules with diameters >7 nm, i.e., larger than serum albumin, infrequently cross the basement membrane. [91] However, size is not the only criterion for membrane permeability; the transmembrane passage of negatively charged molecules is retarded in relation to neutral molecules of equivalent diameter, and the passage of positively charged molecules is facilitated. The components of basement membrane function as molecular sieves and as electrostatic barriers. The strong negative charge of heparan sulfate proteoglycans is believed to be directly responsible for the ion selectivity. The nearly ubiquitous distribution of heparan sulfate proteoglycans in all basement membranes suggests that these serve as selective permeability barriers in multiple locations, including the blood-brain barrier. [92] Ultrafiltration may be especially important during development and morphogenesis of all tissues.

Basement membranes also provide physical separation between different germ layers and between stratified epithelia and their underlying extracellular matrices. This barrier is especially important in the containment of tumors. With the exception of certain cells of the immune system, nonmalignant cells seldom cross a basement membrane. Benign tumor cells, when placed upon isolated amniotic basement membranes, are unable to cross this barrier in vitro. In contrast, malignant cells bind the basement membrane, regionally disrupt its structure at the site of the attachment, and migrate through the rupture. Laminins mediate the tumor-cell binding, and the basement membrane dissolution is catalyzed by metalloproteases produced by the tumor cell (see Chap. 17). The absence of distinguishable basement membranes in tumor biopsies has been an indicator of malignancy, and there appears to be a high correlation between metastasis and basement membrane degradation. [93] These observations underline the importance of the basal lamina as an obstacle to cell migration.

Several mouse models with deficiency of extracellular matrix components have proved the importance of the basement membranes in morphogenesis. The deposition of the basement membrane components between the different germ layers is one of the first manifestations of embryologic compartmentalization of tissues with distinctive developmental roles. These specialized matrices provide a substrate for organized cellular migration leading to morphogenesis. It is likely that basement membranes function in the selective exchange of molecules involved in early tissue-inductive interactions.

By binding biologically active signaling molecules basement membranes can regulate a multitude of biologic events, such as cell adhesion and migration, cytoskeleton and cell form, cell division, differentiation and polarization, and apoptosis. For example, basement membrane proteoglycans can bind growth factors that can be released from the complexes by various matrix-degrading proteinases from fibroblasts or inflammatory cells. The growth factors, including transforming growth factor-ß or fibroblast growth factors, are potent regulators of cell growth, and extracellular matrix formation, in addition to their immunomodulatory and regulatory roles.

REFERENCES

1. Rubin GM et al: Comparative genomics of the eukaryotes. *Science* **287**:2204, 2000

2. Keene DR et al: Immunodissection of the connective tissue matrix in human skin. *Microsc Res Tech* **38**:394, 1997

3. Eady RA et al: Ultrastructural clues to genetic disorders of skin: The dermal-epidermal junction. *J Invest Dermatol* **103**:13S, 1994

4. Goldberg M, Escaig-Haye F: Is the lamina lucida of the basement membrane a fixation artifact? *Eur J Cell Biol* **42**:365, 1986

5. Erickson AC, Couchman JR: Still more complexity in mammalian basement membranes. *J Histochem Cytochem* **48**:1291, 2000

6. Palade GE, Farquhar MG: A special fibril of the dermis. *J Cell Biol* **27**:215, 1966

7. Keene DR et al: Collagen VII forms an extended network of anchoring fibrils . *J Cell Biol* **104**:611, 1987

8. Shimizu H et al: Most anchoring fibrils in human skin originate and terminate in the lamina densa. *Lab Invest* **76**:753, 1997

9. Sakai LY et al: Collagen VII is a major structural component of anchoring fibrils. *J Cell Biol* **103**:1577, 1986

10. Handford PA et al: Fibrillin: From domain structure to supramolecular assembly. *Matrix Biol* **19**:457, 2000

P>11. Ramirez F: Pathophysiology of the microfibril/elastic fiber system. *Matrix Biol* **19**:455, 2000

12. Ryan MC et al: The functions of laminins: Lessons from in vivo studies. *Matrix Biol* **15**:369, 1996

13. Myllyharju J, Kivirikko KI: Collagens and collagen-related diseases. *Ann Med* **33**:7, 2001

14. Burgeson RE, Christiano AM: The dermal-epidermal junction. *Curr Opin Cell Biol* **9**:651, 1997

15. Yurchenco PD, Schittny JC: Molecular architecture of basement membranes. *FASEB J* **4**:1577, 1990

16. Boutaud A et al. Type IV collagen of the glomerular basement membrane. Evidence that the chain specificity of network assembly is encoded by the noncollagenous NC1 domains. *J Biol Chem* **275**:30716, 2000

17. Colognato H, Winkelmann DA, Yurchenco PD: Laminin polymerization induces a receptor-cytoskeleton network. *J Cell Biol* **145**:619, 1999

18. Hudson BG, Reeders ST, Tryggvason K: Type IV collagen: structure, gene organization, and role in human diseases. Molecular basis of Goodpasture and Alport syndromes and diffuse leiomyomatosis. *J Biol Chem* **268**:26033, 1993

19. Borza DB et al. The NC1 domain of collagen IV encodes a novel network composed of the alpha 1, alpha 2, alpha 5, and alpha 6 chains in smooth muscle basement membranes. *J Biol Chem* **276**:28532, 2001

20. Fleischmajer R et al: There is temporal and spatial expression of alpha1 (IV), alpha2 (IV), alpha5 (IV), alpha6 (IV) collagen chains and beta1 integrins during the development of the basal lamina in an in vitro skin model. *J Invest Dermatol* **109**:527, 1997

21. Netzer KO et al. The Goodpasture autoantigen. Mapping the major conformational epitope(s) of alpha3(IV) collagen to residues 17–31 and 127–141 of the NC1 domain. *J Biol Chem* **274**:11267, 1999

22. Ghohestani RF et al: The alpha 5 chain of type IV collagen is the target of IgG autoantibodies in a novel autoimmune disease with subepidermal blisters and renal insufficiency. *J Biol Chem* **275**:16002, 2000

23. Jais JP: X-linked Alport syndrome: natural history in 195 families and genotype-phenotype correlations in males. *J Am Soc Nephrol* **11**:649, 2000

24. Ekblom M et al: Laminin isoforms and epithelial development. *Ann N Y Acad Sci* **857**:194, 1998

25. Aumailley M, Smyth N: The role of laminins in basement membrane function. *J Anat* **193**:1, 1998

26. Koch M et al: Characterization and expression of the laminin gamma3 chain: A novel, non-basement membrane-associated, laminin chain. *J Cell Biol* **145**:605, 1998

27. Timpl R et al: Structure and function of laminin LG modules. *Matrix Biol* **19**:309, 2000

28. Helbling-Leclerc A et al: Mutations in the laminin alpha-2-chain gene (LAMA2) cause merosin-deficient congenital muscular dystrophy. *Nat Genet* **11**:216, 1995

29. Ryan MC et al: Targeted disruption of the LAMA3 gene in mice reveals abnormalities in survival and late stage differentiation of epithelial cells. *J Cell Biol* **145**:1309, 1999

30. Sixt M et al: Endothelial cell laminin isoforms, laminins 8 and 10, play decisive roles in T cell recruitment across the blood-brain barrier in experimental autoimmune encephalomyelitis. *J Cell Biol* **153**:933, 2001

31. Libby RT et al: Laminin expression in adult and developing retinae: Evidence of two novel CNS laminins. *J Neurosci* **20**:6517, 2000

32. Mayer U, Kohfeldt E, Timpl R: Structural and genetic analysis of laminin-nidogen interaction. *Ann N Y Acad Sci* **857**:130, 1998

33. Ries A et al: Recombinant domains of mouse nidogen-1 and their binding to basement membrane proteins and monoclonal antibodies. *Eur J Biochem* **268**:5119, 2001

34. Kohfeldt E et al: Nidogen-2: A new basement membrane protein with diverse binding properties. *J Mol Biol* **282**:99, 1998

35. Murshed M et al: The absence of nidogen 1 does not affect murine basement membrane formation. *Mol Cell Biol* **20**:7007, 2000

36. Zhang H et al: Fibulin-1 and fibulin-2 expression during organogenesis in the developing mouse embryo. *Dev Dyn* **205**:348, 1996

37. Olin AI et al: The proteoglycans aggrecan and versican form networks with fibulin-2 through their lectin domain binding. *J Biol Chem* **276**:1253, 2001

38. Iozzo RV: Heparan sulfate proteoglycans: intricate molecules with intriguing functions. *J Clin Invest* **108**:165, 2001

39. Hopf M et al: Mapping of binding sites for nidogens, fibulin-2, fibronectin and heparin to different IG modules of perlecan. *J Mol Biol* **311**:529, 2001

40. Costell M et al: Perlecan maintains the integrity of cartilage and some basement membranes. *J Cell Biol* **147**:1109, 1999

41. Woods A: Syndecans: Transmembrane modulators of adhesion and matrix assembly. *J Clin Invest* **107**:935, 2001

42. Nievers MG et al: Biology and function of hemidesmosomes. *Matrix Biol* **18**:5, 1999

43. Stanley JR: Autoantibodies against adhesion molecules and structures in blistering skin diseases. *J Exp Med* **181**:1, 1995

44. Schumann H et al: The shed ectodomain of collagen XVII/BP180 is targeted by autoantibodies in different blistering skin diseases. *Am J Pathol* **156**:685, 2000

45. Tamai K et al: The human 230-kD bullous pemphigoid antigen gene (BPAG1). Exon-intron organization and identification of regulatory tissue specific elements in the promoter region. *J Clin Invest* **92**:814, 1993

46. Giudice GJ, Emery DJ, Diaz LA: Cloning and primary structural analysis of the bullous pemphigoid autoantigen BP180. *J Invest Dermatol* **99**:243, 1992

47. Schäke H et al: Two forms of collagen XVII in keratinocytes. A full-length transmembrane protein and a soluble ectodomain. *J Biol Chem* **273**:25937, 1998

48. Hirako Y et al: Cleavage of BP180, a 180-kDa bullous pemphigoid antigen, yields a 120-kDa collagenous extracellular polypeptide. *J Biol Chem* **273**:9711, 1998

49. Tasanen K et al. The ectodomain of collagen XVII organises and stabilises the anchorage of basal keratinocytes to the basement membrane. *Submitted for publication*

50. Georges-Labouesse E et al: Absence of integrin alpha 6 leads to epidermolysis bullosa and neonatal death in mice. *Nat Genet* **13**:370, 1996

51. van der Neut R et al: Epithelial detachment due to absence of hemidesmosomes in integrin beta 4 null mice. *Nat Genet* **13**:366, 1996

52. Ruzzi L et al. A homozygous mutation in the integrin alpha6 gene in junctional epidermolysis bullosa with pyloric atresia. *J Clin Invest* **99**:2826, 1997

53. Vidal F et al: Integrin beta 4 mutations associated with junctional epidermolysis bullosa with pyloric atresia. *Nat Genet* **10**:229, 1995

54. Sterk LM et al. The tetraspan molecule CD151, a novel constituent of hemidesmosomes, associates with the integrin alpha6beta4 and may regulate the spatial organization of hemidesmosomes. *J Cell Biol* **149**:969, 2000

55. Nishiyama T et al: The importance of laminin 5 in the dermal-epidermal basement membrane. *J Dermatol Sci* **1**:(suppl S51), 2000

56. Amano S et al: Bone morphogenetic protein 1 is an extracellular processing enzyme of the laminin 5 gamma 2 chain. *J Biol Chem* **275**:22728, 2000

57. Gagnoux-Palacios L et al: The short arm of the laminin gamma2 chain plays a pivotal role in the incorporation of laminin 5 into the extracellular matrix and in cell adhesion. *J Cell Biol* **153**:835, 2001

58. Champliaud MF et al: Human amnion contains a novel laminin variant, laminin 7, which, like laminin 6, covalently associates with laminin 5 to promote stable epithelial-stromal attachment. *J Cell Biol* **132**:1189, 1996

59. Rousselle P et al: Laminin 5 binds the NC-1 domain of collagen VII. *J Cell Biol* **138**:719, 1997

60. Chen M et al: Development and characterization of a recombinant truncated type VII collagen “minigene”. Implication for gene therapy of dystrophic epidermolysis bullosa. *J Biol Chem* **275**:24429, 2000

61. Nonaka S et al: The extracellular domain of BPAG2 has a loop structure in the carboxy terminal flexible tail in vivo. *J Invest Dermatol* **115**:889, 2000

62. Franzke C-W et al: Transmembrane collagen XVII, an epithelial adhesion protein, is shed from the cell surface by ADAMs. *Submitted for publication*

63. Zone JJ et al. Identification of the cutaneous basement membrane zone antigen and isolation of antibody in linear immunoglobulin A bullous dermatosis. *J Clin Invest* **85**:812, 1990

64. Marinkovich MP et al: LAD-1, the linear IgA bullous dermatosis autoantigen, is a novel 120-kDa anchoring filament protein synthesized by epidermal cells. *J Invest Dermatol* **106**:734, 1996

65. Zone JJ et al: The 97-kDa linear IgA bullous disease antigen is identical to a portion of the extracellular domain of the 180-kDa bullous pemphigoid antigen, BPAg2. *J Invest Dermatol* **110**:207, 1998

66. Egan CA et al: Bullous pemphigoid sera that contain antibodies to BPAg2 also contain antibodies to LABD97 that recognize epitopes distal to the NC16A domain. *J Invest Dermatol* **112**:148, 1999

67. Kromminga A et al: Patients with bullous pemphigoid and linear IgA disease show a dual IgA and IgG autoimmune response to BP180. *J Autoimmun* **15**:293, 2000

68. Fine JD et al: Detection and partial characterization of a midlamina lucida–hemidesmosome associated antigen (19-DEJ-1) present within human skin. *J Invest Dermatol* **92**:825, 1989

69. DiPersio CM et al: Defects in matrix organization and keratinocyte adhesion in the epidermis of mice deficient in alpha3beta1 integrin. *J Cell Biol* **137**:729, 1997

70. Sorokin LM et al: Developmental regulation of the laminin alpha5 chain suggests a role in epithelial and endothelial cell maturation. *Dev Biol* **189**:285, 1997

71. Sewry CA et al: Diagnosis of merosin (laminin-2)-deficient congenital muscular dystrophy by skin biopsy. *Lancet* **347**:582, 1996

72. Bruckner-Tuderman L et al: Biology of anchoring fibrils: Lessons from dystrophic epidermolysis bullosa. *Matrix Biol* **18**:43, 1999

73. Rattenholl A et al: BMP-1 and mTLL-1 process procollagen VII to mature collagen VII. *J Biol Chem*, in press

74. Chen M et al: The carboxyl terminus of type VII collagen mediates antiparallel dimer formation and constitutes a new antigenic epitope for epidermolysis bullosa acquisita autoantibodies. *J Biol Chem* **276**:21649, 2001

75. Raghunath M et al: Cross-linking of the dermo-epidermal junction of skin regenerating from keratinocyte autografts. Anchoring fibrils are a target for tissue transglutaminase. *J Clin Invest* **98**:1174, 1996

76. Whittock NV et al: Comparative mutation detection screening of the type VII collagen gene (COL7A1) using the protein truncation test, fluorescent chemical cleavage of mismatch, and conformation sensitive gel electrophoresis. *J Invest Dermatol* **113**:673, 1999

77. Zimmer P et al: Dysphagia and esophageal stenosis: An extracutaneous form of dystrophic epidermolysis bullosa due to mutations in the collagen VII gene. *Gastroenterology* **122**:220, 2002

78. Heinonen S et al. Targeted inactivation of the type VII collagen gene (Col7a1) in mice results in severe blistering phenotype: A model for recessive dystrophic epidermolysis bullosa. *J Cell Sci* **112**:3641, 1999

79. Compton SH et al: Stable integration of large (>100 kb) PAC constructs in HaCaT keratinocytes using an integrin-targeting peptide delivery system. *Gene Ther* **7**:1600, 2000

80. Mecklenbeck S et al: Microinjection of the COL7A1 gene into collagen VII-deficient epidermolysis bullosa keratinocytes leads to synthesis and secretion of normal procollagen VII. *Human Gene Ther,* in press

81. Sat E et al: Tissue-specific expression and long-term deposition of human collagen VII in the skin of transgenic mice: implications for gene

therapy. *Gene Ther* **7**:1631, 2000

82. Hallel-Halevy D et al: Epidermolysis bullosa acquisita: Update and review. *Clin Dermatol* **19**:712, 2001

83. Shirahama S et al: Bullous systemic lupus erythematosus: Detection of antibodies against noncollagenous domain of type VII collagen. *J Am Acad Dermatol* **38**:844, 1998

84. Tanaka H et al: A novel variant of acquired epidermolysis bullosa with autoantibodies against the central triple-helical domain of type VII collagen. *Lab Invest* **77**:623, 1997

85. Simon-Assmann P, Kedinger M: Tissue recombinants to study extracellular matrix targeting to basement membranes. *Methods Mol Biol* **139**:311, 2000

86. Fleischmajer R et al: Skin fibroblasts are the only source of nidogen during early basal lamina formation in vitro. *J Invest Dermatol* **105**:597, 1995

87. Marinkovich MP et al: Cellular origin of the dermal-epidermal basement membrane. *Dev Dyn* **197**:255, 1993

88. Salmivirta K, Sorokin LM, Ekblom P: Differential expression of laminin alpha chains during murine tooth development. *Dev Dyn* **210**:206, 1997

89. Ekblom P et al: Role of mesenchymal nidogen for epithelial morphogenesis in vitro. *Development* **120**:2003, 1994

90. Nguyen BP et al: Deposition of laminin 5 in epidermal wounds regulates integrin signaling and adhesion. *Curr Opin Cell Biol* **12**:554, 2000

91. Deen WM, Lazzara MJ, Myers BD: Structural determinants of glomerular permeability. *Am J Physiol Renal Physiol* **281**:F579, 2001

92. Pardridge WM: Blood-brain barrier biology and methodology. *J Neurovirol* **5**:556, 1999

93. Liotta LA, Kohn EC: The microenvironment of the tumour-host interface. *Nature* **411**:375, 2001

94. Nakazato K et al: Gelation of the lens capsule type IV collagen solution at a neutral pH. *J Biochem* **120**:889, 1996

T>

Chapter 17

Jo Seltzer Arthur Eisen

The Role of Extracellular Matrix Metalloproteinases in Connective Tissue Remodeling

GENERAL DESCRIPTION OF THE MATRIX METALLOPROTEINASES
GENERAL DESCRIPTIONS OF INDIVIDUAL MMPs
Interstitial Collagenases
Stromelysins
Gelatinases (Type IV Collagenases)
Matrilysin
Membrane-Type Matrix Metalloproteinases
Miscellaneous Matrix Metalloproteinases
Adamalysins
REGULATION OF MMP ACTIVITY
Regulation of Gene Expression
Proenzyme Activation
Regulation of Enzyme Activity by Inhibitors
MMP PHYSIOLOGY
Normal Functions of MMPs
MMPs in Disease
CONCLUSIONS AND FUTURE DIRECTIONS
REFERENCES

Maintenance of the normal tissue architecture of human skin and other tissues requires the deposition, assembly, and turnover of extracellular matrix (ECM) macromolecules, including the collagens, elastin, glucosaminoglycans, and glycoproteins. The ability of resident cells to organize and remodel the surrounding ECM is essential for morphogenesis, angiogenesis, and wound healing. In a great number of pathologic situations, including tumor invasion/metastasis, the arthritides, fibrotic diseases, and inflammatory processes, there is derangement of the dynamic balance between ECM breakdown and synthesis. ECM remodeling in general is a cooperative multistep process involving localized degradation of the existing ECM, cytoskeletal rearrangement, cell translocation, and the deposition of new ECM components. Although each of these steps is controlled by a variety of molecular mechanisms, the initial step may depend on the presence of proteinases capable of initiating the degradation of ECM macromolecules. These enzymes comprise the matrix metalloproteinase (MMP) gene family, [1], [2] and [3] which includes the collagenases, the gelatinases, the stromelysins, the matrilysins, metalloelastase, enamelysin, and the membrane-type MMPs (Fig. 17-1 and Table 17-1). The MMPs have been given historically based numerical designations (see Table 17-1), but the descriptive names will be used in this chapter.

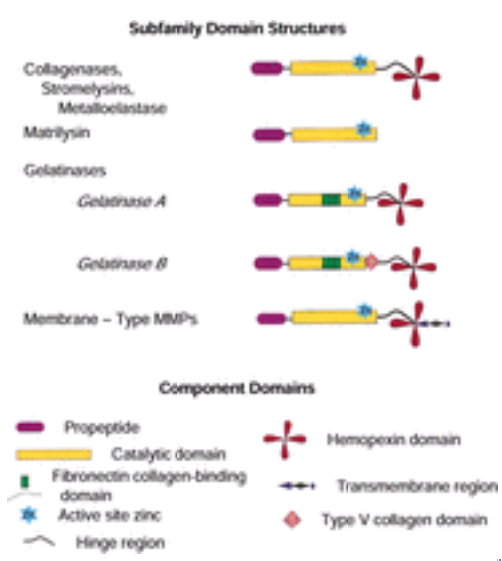

FIGURE 17-1 Domain structure of matrix metalloproteinases.

Enzyme	MMP Number	Activator Peak	Relative Mol. Wt.	Known Matrix Substrate
Interstitial collagenase	MMP-1	Type I collagenase	52,000	Collagens I, II, III, VII, VIII, X, elastin, tenascin, aggrecan, dermatan/ collagens, II, IX, multi-basic protein, ~aminin
Neutrophil collagenase	MMP-8		75,000	Collagens I, II, III, V, VII, VIII, X, gelatin, aggrecan, fibronectin
Collagenase 3	MMP-13		52,000	Collagens I, II, III, IV, IX, X, XIV, aggrecan
Gelatinase A	MMP-2	72-kDa type IV collagenase	72,000	Denatured collagens, collagens IV, V, VII, X, XI, XIV; collagen I; aggrecan-dependent, elastin, fibronectin, laminin, aggrecan, multi-basic protein
Gelatinase B	MMP-9	92-kDa type IV collagenase	92,000	Denatured collagens, collagens IV, V, VII, X, XIV; elastin, entactin, aggrecan, fibronectin, osteonectin, II-IgE, plasminogen, multi-basic protein
Stromelysin 1	MMP-3	Proteoglycanase	57,000	Proteoglycan core protein, laminin, fibronectin, collagens I, IV, V, IX, X, XI; gelatin, elastin, entactin, aggrecan, multi-basic protein, entactin, decorin, osteonectin
Stromelysin 2	MMP-10	Transin 2	53,000	Proteoglycan core protein, collagens III, IV, V, laminin, fibronectin, elastin, aggrecan
Stromelysin 3	MMP-11		47,000	Alpha₁-proteinase inhibitor
Matrilysin	MMP-7	PUMP matrilysin 1	28,000	Collagen IV, denatured collagens, laminin, fibronectin, elastin, aggrecan, entactin, multi-basic protein
Matrilysin 2	MMP-26	Endometase	28,000	Gelatin, alpha₁-proteinase inhibitor
Membrane-type matrix metalloproteinase 1	MMP-14	MT1-MMP	63,000	Progelatinase A, denatured collagen, fibronectin, laminin, osteonectin, entactin, proteoglycan
Membrane-type matrix metalloproteinase 2	MMP-15	MT2-MMP	73,000	Progelatinase A
Membrane-type matrix metalloproteinase 3	MMP-16	MT3-MMP	64,000	Progelatinase A
Membrane-type matrix metalloproteinase 4	MMP-17	MT4-MMP	70,000	Unknown
Membrane-type matrix metalloproteinase 5	MMP-24	MT5-MMP	73,000	Progelatinase A
Membrane-type matrix metalloproteinase 6	MMP-25	MT6-MMP	63,000	Unknown
Metalloelastase	MMP-12		54,000	Elastin, collagen IV, osteonectin, plasminogen, laminin, entactin, fibrinogen, fibrin, fibronectin
Enamelysin	MMP-20		54,000	Amelogenin, aggrecan
MMP-19	MMP-19	RASI-1	57,000	Gelatin, aggrecan, fibronectin
MMP-21	MMP-21		Unknown	Unknown
MMP-22	MMP-22		Unknown	Unknown
MMP-23	MMP-23		44,000	Unknown
Epilysin	MMP-28		56,000	Unknown

TABLE 17-1 **Matrix Metalloproteinases**

GENERAL DESCRIPTION OF THE MATRIX METALLOPROTEINASES

The MMP family is distinguished by several common characteristics. All contain zinc at the active site, complexed to the conserved sequence HEXXHXXGXXHXXXXXXXM. All analyzed thus far by crystallography contain an additional structural zinc. [3] All require octahedral binding of calcium ions to maintain structural integrity. The propeptide portions contain an absolutely conserved PRCVPD sequence immediately upstream of the amino terminus of the active enzyme, important in zymogen activation. Finally, all are inhibited by the tissue inhibitor of metalloproteinases (TIMP) family of proteins.

Analysis of the primary structures of these enzymes allows the identification of structural domains shown in Fig. 17-1. The propeptide domain is immediately amino-terminal to the catalytic domain, containing the zinc binding site. In the collagenases, stromelysins, metalloelastases, and membrane-type MMPs (MT-MMPs), the catalytic domain is attached by a short “hinge” to the carboxyl-terminal pexin-like domain. The pexin-like domain consists of four hemopexin repeats shown by crystallographic analysis to be arranged in a propellar-like structure. A fibronectin-like domain is present only in gelatinases A and B (MMP-1 and -9) and consists of three 58-residue head-to-tail repeats homologous to the type II motif of the collagen-binding domain of fibronectin. This domain is amino-terminal to the catalytic zinc within the catalytic domain. Gelatinase B contains a unique 54-amino-acid-long proline-rich domain, homologous to the a2 chain of type V collagen, also inserted into the catalytic domain, carboxyl-terminal to the zinc. In the MT-MMPs, a short hydrophobic membrane-spanning domain is inserted in the fourth pexin repeat. Crystal structures have been obtained for several complete MMPs, as well as some additional active-site domains. [3]

The structures of a number of the metalloproteinase genes have been determined, and the similarities suggest a common precursor. For example, interstitial collagenase (human and rabbit) and stromelysin (human and rat) consist of 10 exons virtually identical in length. A cluster of MMP genes— *collagenase-1, -2,* and *-3, stromelysin-1* and *-2, matrilysin-1, metalloelastase,* and *enamelysin*—has been mapped to the long arm of human chromosome 11. *Matrilysin-2* [4] is on the short arm of chromosome 11. The *gelatinase A* and *B* genes have three additional exons coding for each of the three fibronectin-like repeats, suggesting that exon shuffling resulted in recruitment of the functional domain from fibronectin to the enzyme protein. The *gelatinase A* and *B* genes have been colocalized on chromosome 16. [5] Chromosomal locations of other MMPs are diverse.

GENERAL DESCRIPTIONS OF INDIVIDUAL MMPs

The MMPs show a great deal of overlapping substrate specificities (see Table 17-1). The identity of the particular enzymes involved in various instances of remodeling and tissue destruction depends to a large degree on tissue specificity and regulation by agents such as cytokines and growth factors. Specific enzymologic differences in members of the same subclass of MMPs, such as collagenases, are subtle but are most likely physiologically meaningful.

Interstitial Collagenases

Interstitial collagenase (MMP-1) was the first enzyme of the MMP family to be discovered. Triple-helical collagen was resistant to all known vertebrate proteinases until Gross and Lapiere [6] demonstrated collagenolytic activity in the medium of cultured tadpole tail skin explants. Human skin collagenase was then isolated in active form from culture medium of skin explants [7] and subsequently as a proenzyme from monolayer fibroblast cultures. [8] Many other cell types, including keratinocytes, synovial cells, and monocytes-macrophages, express an identical enzyme. Interstitial collagenase, like the other MMPs, contains intrinsic zinc in the active site and requires calcium for activity and thermostabilization.

Fibroblasts synthesize collagenase as a preproenzyme and secrete the enzyme as two proenzyme forms with molecular masses of 57 and 52 kDa (see Table 17-1). The minor 57-kDa proenzyme form is the result of posttranslational addition of N-linked complex oligosaccharides to a fraction of the 52-kDa proenzyme. Both potential N-glycosylation sites are contained within the active form of the enzyme. [9] Newly synthesized procollagenase, secreted rapidly after biosynthesis with negligible intracellular storage, is converted extracellularly to the 42- or 47-kDa active enzyme by removal of an 81-amino-acid peptide from the amino-terminal end of the molecule.

Interstitial collagenase degrades collagen types I, II, and III at physiologic pH and temperature by catalyzing a single cleavage three-quarters of the distance from the amino terminus in each of the three polypeptide chains comprising the helical native collagen molecule. Collagenase specifically cleaves the a1(I) chains at a Gly-Ile bond (residues 775 and 776), and the a2(I) chain at a Gly-Leu bond in the homologous region. Ten other Gly-Ile or Gly-Leu bonds within the

triple-helical domain of the interstitial collagens are not cleaved, suggesting that the local conformation of the collagenase cleavage site is a major factor in determining substrate specificity. This region is more hydrophobic than other parts of the collagen molecule and lacks hydroxyproline residues that stabilize the triple helix. Indeed, human fibroblast collagenase catalyzes multiple cleavages in the denatured chains of all collagen types at Gly-Ile and Gly-Leu bonds. Thus it appears that the triple helix of native collagen can drastically after the ability of human fibroblast collagenase to catalyze cleavages that would be permissible from primary sequence cosideration alone. Moreover, even under optimal conditions of cleavage, collagen degradation by human fibroblast collagenase proceeds slowly for an enzymatic process, with a turnover number of approximately 25 molecules of fibrillar collagen degraded per molecule of collagenase per hour. This catalytic rate k_{cat} is the lowest of any mammalian enzyme described to date.

In addition to cleaving interstitial collagen types I, II, and III, fibroblast collagenase also cleaves type VII collagen (anchoring fibrils) [10] and type X collagen but does not degrade collagen types IV and V. Interstitial collagenase produces limited specific cleavages in a variety of noncollagenous substrates such as the plasma antiproteinases: a $_2$-macroglobulin, a $_1$-trypsin inhibitor, and a $_1$-antichymotrypsin. The cleavage sites are often different from those identified in the interstitial collagens. A bulky hydrophobic residue usually occurs on the amino-terminal side of the cleaved bond, similar to the substrate specificity of the bacterial metalloproteinase thermolysin.

Human neutrophil interstitial collagenase (MMP-8) attacks collagens at the same site as does fibroblast collagenase to produce the characteristic three-quarters/one-quarter collagen fragments. The cloned enzyme is highly homologous to fibroblast collagenase but has a molecular mass of 75 kDa due to a high degree of glycosylation. It is not immediately secreted but is stored in granules. Although both collagenases have similar affinities (K_m) for types I and III collagen, fibroblast collagenase degrades soluble type III collagen with a higher turnover rate, [9] whereas neutrophil collagenase degrades soluble type I collagen more rapidly. [8] For both enzymes, the differences in specificity against monomeric collagens are largely abolished when the substrates are reconstituted into the insoluble fibrillar forms found in tissues.

Collagenase-3 (MMP-13), first cloned from breast carcinoma, is homologous to rodent collagenase. The purified recombinant enzyme cleaves helical collagens, giving the characteristic three-quarters/one-quarter fragments. Unlike interstitial and neutrophil collagenases, however, collagenase-3 acts 5 to 10 times more rapidly on soluble type II collagen than on types I and III. Because of its preferential cleavage of type II collagen, and because it is made by both normal and osteoarthritic chondrocytes, collagenase-3 is thought to play an important role in osteoarthritis. Collagenase-3, unlike the other collagenases, can be activated by MT1-MMP.

At physiologic temperature, the products of collagen cleavage become soluble, are thermally unstable, and denature spontaneously, forming gelatins. These denatured gelatins are susceptible to attack by other proteinases. Thus the interstitial collagenases stand at a key point in connective tissue metabolism; they initiate the proteolytic events resulting in the complete degradation of collagen.

Stromelysins

Prostromelysin-1 is constitutively secreted by fibroblasts as a major 57-kDa form and a minor glycosylated 60-kDa form. [12] As with interstitial collagenase, a single mRNA species codes for both secreted proenzyme forms. Stromelysin has a broad substrate specificity, degrading proteoglycans, type IV collagen (principally in its nonhelical region), laminin, and fibronectin. It displays low activity against gelatin and casein (see Table 17-1) Stromelysin does not cleave type I collagen, but it degrades types III and IX collagens and acts as a telopeptidase by cutting intact types II and XI collagens at sites between the cross-linking hydroxylysine residue and the start of the triple helix. [13] It is not known whether stromelysin ever acts in concert with type IV collagenase to degrade basement membrane collagens.

Stromelysin-2 appears to have much the same substrate specificity as stromelysin-1 (see Table 17-1) but differs in tissue distribution. For example, stromelysin-1, but not stromelysin-2, is found in rheumatoid synovia. Both stromelysin-1 and stromelysin-2 are present during bone development, but at different locales; e.g., osteoclasts contain only stromelysin-2. [14] In keratinocytes, stromelysin-2 is induced by cytokines, whereas stromelysin-1 is not. A temporal progression of stromelysin-1 and stromelysin-2 expression is seen in keratinocytes during wound healing (see below). [15]

Stromelysin-3, first cloned from breast carcinoma, [16] differs substantially from the other members of its family. When the full-length enzyme was expressed in a mammalian system, it was found not to cleave the extracellular matrix components normally considered as stromelysin substrates but to cleave a $_1$-trypsin inhibitor in a specific manner. [17] In order to render the enzyme active against normal stromelysin substrates, the carboxyl-terminal domain had to be deleted and a mutation made in Asp-235. [18]

Unlike most other secreted MMPs, stromelysin-3 cannot be activated by organomercurial compounds. The presumably active enzyme is found in the extracellular space with the propeptide already removed. Interestingly, a stretch of 10 amino acids between the propeptide and catalytic domain is suitable for cleavage by the Golgi proteinase furin. Cotransfection of furin and prostromelysin-3 into COS-7 cells resulted in a fully processed proteinase. Furin inhibitors and brefeldin A have been used to confirm that maturation of stromelysin-3 occurs in the trans-Golgi apparatus, followed by secretion.

Because proteolytic activity of stromelysin-3 seems to be limited, its physiologic role is uncertain, although it is found ubiquitiously in stroma surrounding tumors of epithelial origin. It has been suggested [17] that its function is to inactivate serine proteinase inhibitors (serpins) and thus allow enzymes such as plasmin to play a role in the degradation of matrix proteins.

Gelatinases (Type IV Collagenases)

The major component in all basement membranes is type IV collagen, accounting for 40 to 65 percent of the total protein. Interstitial collagenases do not cleave type IV collagen, whereas stromelysins cleave only the globular portions of the molecule. An MMP that could cleave the helical portion of type IV collagen into the prototypical three quarters/one-quarter fragment was first described by Salo et al. [20] from mouse melanoma cell culture. The human enzyme was cloned subsequently as a 72-kDa proenzyme [21] and found to be identical to gelatinase A from fibroblasts and human skin explants. [22] Gelatinase A (MMP-2) has a marked preference for protein substrates with a collagenous primary structure and was hypothesized to be the enzyme responsible for completing the degradation of collagen after cleavage by interstitial collagenase. Gelatinase A digests gelatin more than 100 times faster than does interstitial collagenase and rapidly cleaves collagenous peptides as small as six amino acid residues. [23]

Normal human macrophages, granulocytes, keratinocytes, and other cell types, including many transformed cells, secrete the related MMP gelatinase B (MMP-9). The primary structure of this enzyme contains all the elements of gelatinase A with an additional unique 54-amino-acid proline-rich domain, homologous to the a2 chain of type V collagen, inserted next to the zinc-binding active center domain [24] (see Fig. 17-1). Gelatinase B is a glycoprotein; the role of glycosylation in secreted metalloproteinases is not understood.

As shown in Fig. 17-1, in addition to the three domains also present in interstitial collagenase and stromelysin, both gelatinases A and B contain an insertion of three contiguous copies of fibronectin type II homology units immediately in front of the conserved zinc-binding site. Experiments investigating the functional role of this domain showed it to be responsible for the binding of progelatinases to gelatin, [25] although there is some question whether gelatin binding mediated by this domain is the rate-limiting step in gelatin hydrolysis. Recent studies by Collier et al., [26] applying fractal kinetics to the digestion of gelatin in a three-dimensional matrix, have shown that the carboxyl-terminal hemopexin-like domain plays a role in allowing the gelatinase molecule to move laterally to new binding sites in the solid substrate.

The actual cleavage sites catalyzed by gelatinase A proteolysis were determined in cyanogen bromide peptides of type I gelatin. In addition to the expected cleavages between glycine and hydrophobic residues (Leu, Ile, Ala, Phe), unexpected cleavages were found between glycine and nonhydrophobic residues, specifically Glu, Asn, and Ser. Hexapeptides containing these unexpected cleavages sites were cleaved readily by gelatinase A. Of particular significance with regard to the enzyme's preference for gelatin as a protein substrate was the finding that hydroxyproline brackets the cleavage site at the P5 and P5'positions. A kinetic investigation using synthetic substrates in which hydoxyprolines at these positions were systematically varied showed that the hydroxyprolines increased affinity (lowered K_m) for the substrates. [23] Although gelatinase B digests a similar profile of matrix proteins as gelatinase A (see Table 17-1), careful enzymatic analysis showed major differences in their specificity. Gelatinase A is twice as active against type I gelatin as gelatinase B, whereas gelatinase B digests type IV collagen two to three times faster than gelatinase A. Furthermore, substrates designed to give optimal turnover numbers for gelatinase A were digested at least an order of magnitude slower by gelatinase B. [23]

A unique feature of the gelatinase subclass is that portions of both proenzymes are secreted complexed to a specific MMP protein inhibitor. Some secreted progelatinase B molecules are noncovalently complexed at the carboxyl terminus with the tissue inhibitor of metalloproteinases, TIMP-1. [24] Progelatinase A is complexed in a similar fashion with a related but distinct tissue inhibitor of metalloproteinases, TIMP-2. [27] Nonetheless, both enzymes can be activated by organomercurials; the propeptide domain from the amino terminus is autocatalytically cleaved and removed as with MMPs not complexed to an inhibitor.

Matrilysin

Matrilysin-1 (MMP-7) is the smallest of the MMPs with a proenzyme of only 28 kDa. The only member of this family encoded without a hemopexin-like domain, [28] it contains only the pre, pro, and catalytic domains. Matrilysin displays broad substrate specificity degrading many extracellular matrix proteins including type IV collagen, fibronectin, entactin, elastin, and aggrecan (see Table 17-1). It also cleaves ß4 integrin. Because matrilysin lacks the carboxyl-terminal hemopexin-like domain, it is inhibited by the TIMPs approximately three orders of magnitude less strongly than other secreted MMPs.

The most distinguishing characteristic of matrilysin aside from its size is its tissue distribution. It is found almost exclusively in epithelium of glandular structures and in monocyte-derived marcrophages. [28], [29] It is found in the germinative basal cell layer of fetal epidermis, appendageal buds, and developing hair follicles and sweat glands. In the adult, it is present in the secretory cells of the sweat glands [30] and is produced by other exocrine glands such as mammary and parotid glands, pancreas, liver, prostate, and peribronchial glands of the lung. In many ductal structures it appears to be secreted into the lumen, leading to a suggestion that one of its main functions is to prevent clogging of the ducts.

Matrilysin is found in most carcinomas examined, often in the early stages. In situ hybridization experiments show it to be localized to the tumor islands, in contrast to many other MMPs, which are made by the surrounding stroma. [31]

A new matrix metalloprotienase lacking a carboxy-terminal domain was cloned recently (MMP-26). At first termed *endometase* [32] because it is normally expressed only in endometrium, it also was found in placenta and in tumors of diverse origins and renamed *matrilysin-2.* [4], [33] Like matrilysin, it has a broad substrate specificity, including activation of gelatinase B. In amino acid sequence, matrilysin-2 is most analogous to metalloelastase (MMP-12).

Membrane-Type Matrix Metalloproteinases

Membrane-type matrix metalloproteinases (MT-MMPs) are bound to the cell membrane, in contrast to all other MMPs,

which are secreted extracellularly as proenzymes. [34] With six known MT-MMPs (see Table 17-1), this group is the newest and now largest division of this enzyme family. Widely distributed in both normal and neoplastic tissues, each MT-MMP has a characteristic tissue specificity.

MT-MMPs resemble other MMPs structurally (see Fig. 17-1), with a prodomain, catalytic domain, hinge region, and hemopexin-like domain. In addition, there are three conserved sequence insertions. An extension of the carboxyl terminus is rich in hydrophobic residues, allowing anchoring in the plasma membrane. All except MT4-MMP and M6-MMP have a short cytoplasmic tail. [35] A short (11 amino acid) furin recognition site in the prodomain of all MT-MMPs enables intracellular activation of the zymogen, probably in the trans-Golgi region. Stromelysin-3 also contains this site. MT-MMPs 1, 2, 3, and 5 contain a unique eight-residue insertion in the catalytic domain, possibly related to substrate specificity. [36]

All MT-MMPs, except MT4-MMP, are able to activate progelatinase A (MMP-2) (see below). They are potent proteinases with a broad range of substrates, including collagens, fibronectin, and proteoglycans. [37] The tissue location varies. Synthesis of MT1-MMP as defined by in situ hybridization is mainly confined to fibroblastic cells adjacent to the tumor islands. [38] Immunohistologic staining in some cases has shown the enzyme to be present on the plasma membranes of carcinoma cells. Furthermore, reminiscent of gelatinase A, carcinoma cells in culture can produce MT-MMP. At the cellular level, MT1-MMP is localized to specialized structures descriptively called *invadopodia.* The cytoplasmic tail of the enzyme contains potential phosphorylation sites that might have a role in localizing MT1-MMP at such specific cellular sites. Clustered ß1 integrins form another locus associated with MT1-MMP, which could have a role in cell-matrix interactions. [37]

Miscellaneous Matrix Metalloproteinases

Several members of the growing MMP family do not fit clearly into any of the subfamilies described earlier. Whereas much information is available on metalloelastase, others are simply chromosomal DNA sequences (MMP-21and -22). Since technology increasingly has allowed for the discovery of enzymes by structure rather than by catalytic activitiy, finding even more miscellaneous MMPs can be expected.

Macrophage Metalloelastase Macrophage metalloelastase (MMP-12) was discovered as a cDNA clone from a human alveolar macrophage library. [39] It is relatively potent as an elastase with a turnover rate comparable with that of matrilysin and gelatinase B, i.e., approximately 30 percent the rate of human leukocyte elastase. [39] In the lung, metalloelastase accounts for most of the pathologic destruction of elastin; mice lacking the enzyme do not develop emphysema when made to smoke cigarettes. [40] It is also the most potent MMP in generating angiostatin by cleavage of plasminogen. Angiostatin inhibits endothelial cell proliferation and thus is an inhibitor of angiogenesis. The cDNA of macrophage metalloelastase shows a domain structure similar to that of the interstitial collagenases and stromelysins. However, while medium harvested from alveolar macrophage cultures contains metalloelastase proenzyme, manipulation of the medium during purification produces a mature proteinase of 22 kDa. Activation of the proenzyme in vitro involves removal of the propeptide as well as rapid removal of the carboxyl-terminal domain. It is not known in what form metalloelastase is found in vivo. Metalloelastase is made at the end stage of monocyte differentiation into alveolar macrophages. Peripheral blood monocytes do not make this enzyme, although they do secrete matrilysin, which is an efficient elastase.
OTHER NEWLY FOUND MMPs: MMP-19, -20, -23, AND -28 MMP-19, -20, and -28 all contain the same basic domain structure as collagenase and stromelysin. Enamelysin (MMP-20) is restricted to dental tissues and can degrade amelogenin, the major protein component of the enamel matrix. [41] MMP-19 [42] and -28 [43], [44] have broad tissue distributions and are closely related to each other. Because the catalytic domain of MMP-19 is able to hydrolyze a number of basement membrane proteins, and because of relatively strong expression in normal tissues, it is suggested that these enzymes may play a role in normal tissue turnover. MMP-23, expressed predominantly in ovary, testis, and prostate, shows homologies to other MMPs in the catalytic domain but significant differences in the other domains. It lacks a signal sequence. The putative activating sequence in the prodomain contains an unpaired cyteine but is ALCLLPA instead of the conserved PRCGVPD and is followed by a furin activation sequence. The carboxyl-terminal domain is short and has no similarity to hemopexin. The recombinant enzyme has been shown to cleave peptide substrates. [45]

Adamalysins

Adamalysins are a growing family of cell surface metalloproteinases containing both a metalloproteinase and a disintegrin domain. The best characterized is TACE, the TNF-a converting enzyme. A discussion of these enzymes is beyond the scope of this chapter.

REGULATION OF MMP ACTIVITY

ECM metalloproteinase activity is modulated by gene expression, by the activation of the latent proenzymes, and by interaction with inhibitors.

Regulation of Gene Expression

Cells secrete ECM metalloproteinases in a complex pattern of response to multiple growth factors and oncogenes, indicating a corresponding complexity of gene regulation. Responses to inducers and inhibitors tend to be cell-type specific. For example, transforming growth factor beta (TGF-ß) inhibits production of collagenase (MMP-1) in fibroblasts but stimulates its production in keratinocytes [15]; interferon-1 induces responses similar to TGF-ß.

The genes of all the secreted MMPs, with the exception of gelatinase A, contain in their promoter regions a TATA box for binding transcription initiation factors. Enhancer elements have been identified in the 5'untranslated portions of most MMP genes, including *PEA3, AP1, AP2,* and *SP2*. The best characterized and most universal enhancer is the 8-bp

sequence TGAGTCAC, called the *activator protein-1* (AP-1) site, that binds transcription factors Fos and Jun as a heterodimer. [46] Agents such as interleukin 1 (IL-1), epidermal growth factor (EGF), platelet-derived growth factor (PDGF), tumor necrosis factor alpha (TNF-a), and the chemical tumor promoter TPA upregulate Fos and Jun proteins that in turn bind to the AP-1 sites, resulting in increased expression of MMPs. Ultraviolet light exposure upregulates collagenase in fibroblasts through an autocrine loop, generating IL-1a and basic fibroblast growth factor (bFGF), which in turn upregulates the production of Fos and Jun. Fos and Jun then bind to the AP-1 site. [46]

The AP-1 site is also crucial to glucocorticoid downregulation of MMP synthesis in fibroblasts, as shown by deletion experiments. [46] Glucocorticoids bind to receptors in the cytoplasm. The receptor-ligand complex is then transported to the nucleus, where it can act on glucocorticoid response elements in the genes. In the case of MMP repression, the receptor-ligand complex interacts with Jun, inducing a conformational change. The ability of the Jun-Fos heterodimer to bind to the AP-1 site is greatly reduced, resulting in a suppression of MMP gene transcription. Inhibition of MMP synthesis by retinoids, which have specific receptors in the nucleus, likewise appears to occur via protein interactions that ultimately decrease the binding of the Fos-Jun heterodimer to the AP-1 site.

The structure of the gelatinase A (MMP-2) promoter is completely different from that of the other secreted MMPs. It lacks a conventional TATA box, AP-1 sites, or indeed any sites common to the other MMP 5'untranslated regions. Enhancer and silencer elements have been reported, [46] but reports of actual responses to such agents as cytokines have been inconclusive. Production of gelatinase A by fibroblasts is inhibited by glucocorticoids and retinoids, but due to the lack of an AP-1 site, the mechanism of repression is of necessity different from that of other MMPs.

The immunoglobulin superfamily is involved in MMP regulation through the extracellular matrix metalloproteinase inducer (EMMPRIN). This highly glycosylated transmembrane protein, identical to CD147 or basigin, is enriched on the surface of tumor cells. In cocultures, it stimulates fibroblasts to produce elevated levels of interstititial collagenase, gelatinase A, stromelysin-1, MT1-MMP, and MT2-MMP. [47]

The MMPs also may respond to alterations in the matrix proteins themselves via integrin and other receptors. Production of several MMPs is increased or induced by culturing cells on type I collagen, [48] although enzyme levels are further modulated by cytoskeletal alterations in the fibroblasts [15]; it has been shown that production of interstitial collagenase and stromelysin-1 is increased through the fibronectin integrin receptor. [31]

Proenzyme Activation

MMPs are synthesized as inactive proenzymes. The extent of proenzyme activation thus becomes an important element in the ultimate regulation of connective tissue turnover. In vitro activation of interstitial collagenase has been studied extensively and can be considered the model for most of the secreted MMPs. Either limited proteolysis or treatment with an organomercurial compound such as aminophenyl mercuric acetate sets up a chain of events causing conversion to the fully active form by complete removal of the propeptide.

The serine proteinase trypsin rapidly converts the latent 52-kDa procollagenase to an active 42-kDa enzyme form. The initial cleavage is made between Arg-55 and Asn-56 in the propeptide, generating a 46-kDa conversion intermediate. Further processing of this intermediate is independent of the presence of trypsin and leads to the formation of the stable 42-kDa active collagenase with Val-101 at the amino terminus. [49] The second cleavage is blocked by inhibitors of metalloproteinase activity such as EDTA and 1,10-phenanthroline, as well as the specific tissue inhibitors of metalloproteinases (TIMPs), indicating autoproteolysis. [49] Treatment with organomercurials activates the proenzyme with no initial loss in molecular mass, followed by cleavage to a 44-kDa intermediate, then finally to the 42-kDa active enzyme form, identical to the one obtained with trypsin treatment.

A satisfactory explanation for both pathways of proenzyme activation is the cysteine switch model. [50] The highly conserved propeptide sequence PRCGVPDV immediately upstream from the amino terminus of the active enzyme contains the only unpaired cysteine in the proenzyme molecule. In the latent enzyme this cysteine forms a coordination bond with the zinc atom in the active center, thus effectively chelating the metal necessary for activity. Treatment with an organomercurial compound forms a mercaptide with the cysteine residue, allowing the active center zinc to be exposed with a water molecule substituted in the coordination complex. The release of the cysteine coordination thus creates an active proteinase. Likewise, limited proteolytic cleavage within the propeptide domain allows the cysteine in this conserved PRCGVPDV sequence to be uncoordinated from the active center zinc. Again, the exposed zinc catalyzes autoproteolytic removal of the remainder of the propeptide. The transition from inactive zymogen to the enzymatically active species always involves removal of the amino-terminal propeptide. In addition, interstitial collagenase can be superactivated by proteolytic treatment with stromelysin-1 (MMP-3). [51]

With the exception of gelatinase A, all secreted MMP proenzymes can be similarly activated by serine proteinases or organomercurials. Gelatinase A (MMP-2) cannot be easily activated by serine proteinases, although the propeptide is effectively removed by the cysteine switch mechanism with organomercurials. The cell-associated MT-MMPs are believed to be the physiologic activators of this enzyme, with MT1-MMP (MMP-14) being the best understood. MT1-MMP is anchored in the plasma membrane with a short cytoplasmic tail and the active site domain oriented extracellularly. [34] It acts both as a receptor for gelatinase A (MMP-2) [52] and as a proteolytic activator. As a receptor, MT1-MMP binds the amino terminus of the inhibitor TIMP-2 to its active site. The carboxyl-terminal end of the TIMP-2 can then bind to the carboxyl terminus of progelatinase A. A neighboring MT1-MMP molecule, free of TIMP-2, proteolytically cleaves the bound progelatinase A at Asn-37–Leu-38 in the prodomain. The shortened progelatinase A molecule autocatalytically removes the remainder of the prodomain and can be released to the extracellular space. [37] Because active gelatinase A binds to a $_{v}ß_{3}$ integrin in some cells, clustering of MT1-MMP and integrins in invadopodia may cause the gelatinase A to be immediately tethered to the cell membrane. [37], [53] Also noteworthy is that this activation mechanism is exquisitely sensitive to TIMP-2 concentration. At moderately low TIMP-2 concentrations, there are enough free MT1-MMP molecules

to catalyze gelatinase A activation. As TIMP-2 concentration increases, MT1-MMP active sites become saturated with inhibitor (i.e., are in receptor form), and there are no working molecules to cleave the progelatinase. [52]

The cellular MT-MMPs are also produced as proenzymes. Their mode of activation is not yet fully understood, but these enzymes, as well as stromelysin-3 (MMP-11), contain a sequence susceptible to the Golgi processing enzyme furin in their propeptides. [30] Whether furin or another enzyme in that family is actually responsible for MT-MMP activation is not as yet known.

Regulation of Enzyme Activity by Inhibitors

MACROMOLECULAR INHIBITORS Once proenzymes have been activated, inhibitors can modulate proteolysis. Human serum potently inhibits MMPs; a $_2$-macroglobulin, a nonspecific antiproteinase, accounts for more than 95 percent of this inhibitory activity. However, because of its large size, the role of a $_2$-macroglobulin probably is confined to inactivation of proteinases that have gained access to the bloodstream rather than those found within the interstices of organized connective tissue. The tissue inhibitors of metalloproteinases (TIMPs) are considered to be the major tissue inhibitors. [54] To date, four TIMPs have been described. They are small proteins, and glycosylation accounts for most of the differences in molecular weight; for example, TIMP-1 (˜29 kDa) is a glycoprotein with 184 amino acids, whereas TIMP-2 (˜21 kDa) is unglycosylated with 194 aminino acids All form tight 1:1 stoichiometric complexes with the active site of MMPs, and most MMPs are inhibited by all TIMPs, with some differences in binding constants. An important exception is that TIMP-1 does not inhibit MT-MMPs. The TIMPs share about 40 percent sequence homology and consist of two domains, each stabilized by three disulfide bonds. The amino-terminal domain is the inhibitory domain, as shown by using truncated molecules. The carboxy-terminal domain is involved in the binding of TIMP-1 to progelatinase B (MMP-9) and TIMP-2 and -4 to progelatinase A (MMP-2). [54], [55] TIMPs are secreted proteins, but TIMP-3 is unique in being tightly bound to the extracellular matrix. A mutation in TIMP-3 that apparently deranges the normal disulfide bonding has been correlated with Sorsby's fundus dystrophy, a rare autosomal dominant eye disease in which the structure of Bruch's membrane is compromised. TIMP-3 also differs in that it specifically inhibits TACE, the TNF-a-converting enzyme. [54] The balance between proteolytic enzymes and their inhibitors is tightly regulated during tissue remodeling and physiologic processes. The TIMPs, like the MMPs, are regulated by various agents, although TIMP-1 is generally more responsive to cytokines than TIMP-2. [56] The responses are cell- and tissue-specific. In some cases, the regulation is coordinated with that of MMPs. For example, retinoids induce a two- to threefold increase in the production of TIMP-1 in cultured human fibroblasts, accompanied by decreased quantities of interstititial collagenase mRNA. This inverse regulation suggests tissue stabilization. [54], [58] In pathologic processes, however, the situation is not so clear. While it has been shown that overexpression of TIMPs can inhibit tumor growth, metastasis, and angiogenesis in experimental models, high levels of TIMPs in human tumors often are correlated with an adverse prognosis. [56] The paradoxical findings concerning TIMPs in disease states may reflect the fact that they have functions other than inhibitory. When TIMP-1 was first cloned, it was found identical to an erythroid-potentiating factor. Both TIMP-1 and- 2 subsequently have been shown to act as mitogens on a number of cell lines. TIMP-1 suppresses apoptosis in Burkitt's lymphoma cell lines, [59] /SUP>but overexpression of TIMP-3 induces programmed cell death in some cancer cell lines. [56] These functions are independent of MMP inhibition. Furthermore, the role of TIMP-2 in progelatinase A activation may lead to either tissue destruction or maintenance depending on its level relative to MT-MMP levels (see above). The physiologic function of the progelatinase B–TIMP-1 complex described earlier is not known.

SYNTHETIC MMP INHIBITORS Crystallographic analysis is an important tool for design of specific inhibitors. High-resolution structures have been obtained for the active site domain of several MMPs, including interstitial collagenase, stromelysin-1, and MT1-MMP. All are similar oblate ellipsoids, with the active site cleft notched into the flat ellipsoid surface. All contain a structural zinc and two or three bound calciums. [3] TIMPs also have been mapped, including the TIMP-2 bound to the MT1-MMP active site and TIMP-1 bound to the stromelysin active site. [60] The hemophexin domain of gelatinase A has been crystallized [61] and shows great topologic resemblance to the hemopexin domain of the whole porcine collagenase-1 molecule. This domain consists of four blades arranged in a propeller shape and containing more bound calcium and other ions. The first group of synthetic molecules to be used as MMP-inhibiting drugs contained a zinc-binding group, such as hydroxamate, bound to structures derived from the Leu-Ala-Gly sequence on the carboxyl-terminal side of the interstitial collagenase collagen cleavage site. Because of promising results in animal models, some molecules such as marimastat, AG3340, and BAY 12-9566 have been tested in human clinical trials against arthritis and cancer. The results generally have been disappointing because of debilitating side effects in some cases and ineffectiveness in others. However, because increased synthesis and activation of MMPs are associated with many pathologies (Table 17-2), the search for MMP-inhibiting drugs remains an active area of pharmaceutical research.

Normal Physiology	Pathology
Wound healing	Tumor invasion and metastasis
	Osteoarthritis
Morphogenesis	Rheumatoid arthritis
	Liver fibrosis
Reproductive physiology	Atherosclerosis
	Emphysema
Immune functions	Multiple sclerosis
	Abdominal aneurysms
Angiogenesis	Corneal ulcerations
	Dermatitis herpetiformis
	Sorsby's fundus dystrophy
	Bullous pemphigoid
	Recessive dystrophic epidermolysis bullosa
	Acute lichen planus
	Periodontal disease
	Inflammation
	Restenosis
	Multicentric osteolysis

TABLE 17-2 **Processes Known to Involve MMPs**

MMP PHYSIOLOGY

Evidence for the involvement of the MMPs in both normal and pathologic events has been accumulating at a logarithmic rate (see Table 17-2). In normal physiology, the appearance and disappearance of the individual enzymes and inhibitors are under rigorous temporal control. In pathologic conditions, tissue destruction that accompanies uncontrolled increase in these proteinases may lead to irreversible damage, as in tumor

metastasis and aneurysms. In many cases, the severity of the inflammatory response and resulting tissue destruction may be modulated by anti-inflammatory drugs.

Normal Functions of MMPs

The discovery of interstitial collagenase in the resorbing tissue of the metamorphosing tadpole established a role for MMPs in development. The rise and fall of specific MMPs and their inhibitors has been documented carefully for invasive and remodeling events ranging from implantation to angiogenesis. [62] For example, in the development of human skin, epidermal cells and appendageal buds express matrilysin during mesenchymal invasion. [30] Later in embryogenesis, matrilysin is concentrated only in cells at the distal portion of invading hair follicles and sweat gland appendageal cords. In adult skin, matrilysin is found only in the sweat glands. [29] Gelatinase A can be localized to the stroma directly under developing appendageal cords and is correlated with loss of type VII collagen from the basement membrane zone. [63] Given the precision of these enzymatic appearances, it is quite puzzling that genetic knockout mice lacking specific MMPs develop nearly normally and are fertile. Only mice lacking MT1-MMP (MMP-14) have severe skeletal defects that lead to death in early adulthood. [64] It is hypothesized that because the secreted MMPs have overlapping specificities, one proteinase can substitute for another.

Although expressed at very low levels in normal adult tissues, MMPs become dramatically increased during connective tissue remodeling. The precise enzymes expressed are regulated in a time-dependent and cell-specific manner. The orchestration of the rise and fall of MMPs and their inhibitors is exemplified by recent investigations of wound healing and of the menstrual cycle. In wound healing, keratinocytes migrating over the wound area acquire mRNA for interstitial collagenase (MMP-1) and stromelysin-2 (MMP-10) when they come in contact with the dermal type I collagen. The migrating keratinocytes do not express TIMP. Stromelysin-1 (MMP-3) is expressed by keratinocytes still in contact with basement membrane in the proliferative area just behind the migrating front. With wound closure, keratinocytes ceases production of these enzymes. [15]

MMPs in the cycling endometrium rise and fall with the menstrual cycle. Gelatinase A and TIMP-1 mRNAs are present at all times. Messenger RNAs for matrilysin (MMP-7) in the epithelium and stromelysin-3 (MMP-11) in the stroma are found in all phases except early secretory. All enzymes investigated—interstitial collagenase; gelatinases A and B; stromelysin-1, -2, and -3; and matrilysin—are produced in the menstrual phase, undoubtedly playing a role in tissue sloughing. [65]

It has long been known that interstitial collagenase (MMP-1) rises dramatically in the postpartum uterus, [13], [17] enabling postpartum uterine resorption. In mice, matrilysin (MMP-7), stromelysin-2 (MMP-10), and collagenase-3 (MMP-13) are all elevated in involuting uterus, but matrilysin-deficient mice involute normally. In these mice, other MMPs are elevated during involution, lending substance to the theory that functionally many of these enzymes are interchangeable. [66] Interstitial collagenase, stromelysin-1 (MMP-3), and matrilysin are expressed at high levels in the trophoblast; gelatinase A (MMP-2) and MTI-MMP (MMP-14) appear to be expressed coordinately at the site of implantation.

The immune response involves release of MMPs. Stimulated macrophages release relatively large quantities of interstitial collagenage, stromelysin-1, matrilysin, metalloelastase (MMP-12), and gelatinase B (MMP-9), [67] contributing to connective tissue remodeling. T cells release low levels of the gelatinases, perhaps facilitating their migration through connective tissues. The MMPs released during the inflammatory response are able to cleave TNF-a from its membrane-bound precursor, presumably leading to an augmentation loop of proteolytic activity. MMP inhibitors are able to prevent the release of TNF-a and have a protective effect against septic shock.

MMPs in Disease

TUMOR INVASION AND METASTASIS Both in vitro and in vivo, tumor invasion and metastasis are consistently correlated with increased levels of MMPs. There is great variation in the specific enzymes overexpressed in different tumors, depending on tissue of origin and tumor type. Gelatinases A and B (MMP-2 and -9), matrilysin (MMP-7), stromelysin-3 (MMP-11), and MT1-MMP (MMP-14) have been reported elevated most often, but studies of the more recently discovered MMPs may change this generalization. Within the tumor itself, the MMPs are distributed in a cell-specific manner. For example, in human breast cancer, [68] only matrilysin is produced by epithelial cells, with gelatinase A, stromelysin-3, and MT1-MMP localized to stromal fibroblasts, although having different distribution patterns. Gelatinase B is found only in endothelial and inflammatory cells. Elevated MMP levels are considered prognostic indicators in many instances; expression of interstitial collagenase, for example, is associated with poor prognosis in esophageal and colorectal cancers. In squamous cell carcinomas (SCC), stromelysin-3 is associated with local invasiveness in the head and neck, whereas the level of gelatinase A expression correlates with the prognosis for cervical SCC. Overexpression of collagenase-3 in SCCs of head, neck, and vulva correlates with increased metastasis. The complexity of the physiologic role of MMPs in tumor invasion and metastasis is just beginning to be understood. Given the ability of these enzymes to digest all components of extracelluar matrix, it has long been felt that their main function is to create spaces for growing tumors and pathways for metastasizing cells. From the first observation that the ability to digest type IV collagen was correlated with metastatic capacity in melanoma cells, [69] experimental data have substantiated the importance of proteolytic activity. [37], [70] In melanoma cell lines, active gelatinase A is present only in highly invasive cells lines; the activation is attributed to the expression of MT1-MMP. [71] Conversely, increasing inhibitiory potential by transfection of TIMP-1 into melanoma or *ras*-transformed fibroblasts inhibits invasion and metastasis in vivo. [72] Transfection of a single MMP gene into tumor lines has been shown to affect their invasive and metastatic properties. When a normal mouse mammary epithelial cell line was induced to make stromelysin, the cells became tumorigenic and invasive. [73] Close examination has revealed that MMPs may affect tumor growth itself. Transfection of a normally matrilysin-negative colon carcinoma cell line with the matrilysin gene increased its tumorigenicity in nude mice; transfection of antisense matrilysin into a matrilysin-positive colon carcinoma cell line reduced its tumorigenicity and subequent metastasis to the liver. [74] Likewise, melanoma cells made to overexpress TIMP-1 were shown to extravasate and form lung colonies when injected into nude mice, but the colonies were extremely small. [70] It is quite possible that MMP effects on tumor growth have to do with release of growth factors stored in the extracelluar matrix. For example, digestion of decorin by stromelysin generates TFG-ß, which affects cell proliferation and angiogenesis. MMPs can release insulin-like growth factor (IGF) from inhibitory association with IGF-binding proteins. Angiogenesis, which is necessary for tumor maintenance, seems to require MT-MMP and gelatinase A activity; synthetic MMP inhibitors have been shown to inhibit tumor angiogenesis. MMPs are able to digest proteins other than ECM structural proteins. Different enzymes have been reported to cleave serpins, E-cadherin, and other MMPs. They

can digest integrins and thus disrupt cell-matrix attachments, leading to a promigratory phenotype. Proteolysis of some matrix components is also promigratory. Digestion of laminin-5 by gelatinase A generates a cleavage product that promotes keratinocyte migration. [70] Knockout and transgenic mice have underscored the importance of MMPs in tumor invasion and metastasis. When a strain of mice with a genetic predisposition to intestinal tumors was made matrilysin null, tumors decreased 58 percent. [74] Gelatinase A–deficient mice show reduced angiogenesis, tumor growth, and metastasis in response to injected Lewis lung carcinoma and B16-BL6 melanoma cells. [75] Gelatinase B knockout mice also show reduced tumor growth, probably due to impaired angiogensis. [62] Mice lacking stromelysin-3 have a lowered tumorigenic response to chemical mutagenesis. Transgenic mice in which stromelysin is overexpressed in mammary glands show increased premalignant changes and malignant conversions. [73] Although the discovery of new MMPs still progresses at a rapid rate, understanding of their function remains a challenge. For example, a puzzling recent discovery is the existence of a human knockout syndrome, in which three families with inherited multicentric osteolysis were found to be gelatinase A (MMP-2) null. One mutation in the enzyme showed an early stop codon, whereas another was a single base substitution leading to a nonfunctional protein. [76] The osteolytic phenotype seems counterintuitive to lack of proteolytic capacity; it has been suggested that decreased TGF-ß processing in the absence of gelatinase A may be responsible for the numerous bone problems seen in these patients. [77] MMP inhibitors have been shown to reduce tumor growth and metastasis in a number of animals models. For example, batimastat inhibits local invasive growth and spread of human colorectal carcinoma implanted into mice. However, human clinical trials thus far have proved disappointing. Many patients develop dose-limiting side effects from some of the inhibitors. Other potential drugs are less effective than placebo in treating the late-stage cancers against which they have been used. Evidence seems to be accumulating that the most effective use of these drugs will be as an adjuctive therapy in early stages of the disease.

ARTHRITIS The extensive tissue destruction in osteoarthritis and rheumatoid arthritis is accompanied by high levels of both interstitial collagenase (MMP-1) and stromelysin-1 (MMP-3). In cells such as those in proliferating rheumatoid synovial tissue, the mRNAs for these two proteinases may represent as much as 2 percent of the total mRNAs. The mRNA is accompanied by a high concentration of the secreted proteins. Cartilage extracts from patients with these diseases also show high levels of these enzymes, and the level of enzyme activity correlates with the severity of the disease. In addition, synovial fluid from osteoarthritic patients shows higher than normal levels of these enzymes. [78] Because of its preferential cleavage of type II collagen, it is speculated that collagenase-3 (MMP-13) plays an important role in arthritis. It has been found expressed in the synovial membranes of patients with both osteoarthritis and rheumatoid arthritis. [79] Surprisingly, in cell culture, the enzyme is expressed by chondrocytes but not synoviocytes; it has been detected in articular cartilage from osteoarthritic but not normal patients. [78], [80]

OTHER DISEASES Diseases in which MMPs have been implicated are listed in Table 17-2. It is safe to conclude that MMPs are elevated in any conditions in which connective tissue architecture is deranged, from corneal ulcerations to abdominal aortic aneurisms. Wherever inflammatory infiltrates are present, proteolytic enzymes that can destroy ECM are likely to be released. In addition, any situation in which cytokines such as IL-1 or TNF-a are released likely will result in elevated levels of MMPs.

CONCLUSIONS AND FUTURE DIRECTIONS

Although many questions remain unanswered about MMPs and their inhibitors, their involvement in the maintenance and remodeling of connective tissue seems well established. The discovery that MMPs can cleave TNF-a from its membrane-bound precursor and that an MMP inhibitor was able to protect mice from a lethal dose of endotoxin by inhibiting TNF-a processing and release opens up new classes of physiologic processes in which MMPs may be involved. Indeed, the cellular localization of the newest subfamily, the MT-MMPs, and the discovery of intracellular processing of gelatinase A in normal cells [81] raise the possibility of implicating MMPs in cytoskeletal rearrangements and other intracellular events. Finally, the development of specific inhibitors based on crystallographic structures will be an important tool in evaluating the roles of the different MMPs in both physiologic and pathologic processes. These specific inhibitors could lead to new classes of drugs useful in the treatment of the many diseases in which MMPs are involved.

REFERENCES

1. Murphy G et al: Evaluation of some newer matrix metalloproteinas *Ann NY Acad Sc* **878**:25, 1999

2. Nagase H, Woessner JF Jr: Matrix metalloproteinase *J Biol Chem* **274**:21491, 1999

3. Bode W et al: Structural properties of matrix metalloproteinase *Cell Mol Life Sc* **55**:639, 1999

4. Uria JA, Lopez-Otin C: Matrilysin-2, a new matrix metalloproteinase expressed in human tumors and showing the minimal domain organization required for secretion, latency, and activity. *Cancer Res* **60**:4745, 2000

5. Huhtala P et al: Completion of the primary structure of the human type IV collagenase preproenzyme and assignment of the gene (CLG4) to the q21 region of chromoso *Genomics* **6**:554, 1990

6. Gross J, Lapiere CM: Collagenolytic activity in amphibian tissues: A tissue culture ass *Proc Natl Acad Sci USA* **54**:1197, 1962

7. Eisen AZ et al: Human skin collagenase: Isolation and mechanism of attack on the collagen molec *Biochem Biophys Acta* **151**:637, 1968

8. Bauer EA et al: Collagenase production by human skin fibroblas *Biochem Biophys Res Commu* **64**:232, 1975

9. Wilhelm SM et al: Human fibroblast collagenase: Glycosylation and tissue-specific levels of enzyme synthe *Proc Natl Acad Sci USA* **83**:3756, 1986

10. Seltzer JL et al: Cleavage of type VII collagen by interstitial collagenase and type IV collagenase (gelatinase) derived from human *J Biol Chem* **264**:3822, 1989

11. Freije JM et al: Molecular cloning and expression of collagenase-3, a novel human matrix metalloproteinase produced by breast carcin *J Biol Chem* **269**:16766, 1994

12. Wilhelm SM et al: Human skin fibroblast stromelysin: Structure, glycosylation, substrate specificity, and differential expression in normal and tumorigenic *Proc Natl Acad Sci USA* **84**:6725, 1987

13. Wu JJ et al: Sites of stromelysin cleavage in collagen types II, IX, X, and XI of cartila *J Biol Chem* **266**:5625, 1991

14. Bord S et al: Stromelysin-1 (MMP-3) and stromelysin-2 (MMP-10) expression in developing human bone: Potential roles in skeletal develop *Bone* **23**:7, 1998.

15. Parks WC et al: Matrix metalloproteinases in tissue repair, *Matrix Metalloproteinases* edited by WC Parks, RW Mecham. San Diego, Academic Press, p 263

16. Basset P et al: A novel metalloproteinase gene specifically expressed in stromal cells of breast carcinon *Nature* **348**:699, 1990

17. Pei D et al: Hydrolytic inactivation of a breast carcinoma cell–derived serpin by human stromelysi *J Biol Chem* **269**:25849, 1994

18. Noel A et al: Identification of structural determinants controlling human and mouse stromelysin-3 proteolytic activi *J Biol Chem* **270**:22866, 1995

19. Pei D, Weiss SJ: Furin-dependent intracellular activation of the human stromelysin-3 zymog *Nature* **375**:244, 1995

20. Salo T et al: Purification and characterization of a murine basement membrane collagen-degrading enzyme secreted by metastatic tumor *J Biol Chem* **258**:3058, 1983

21. Collier IE et al: H-*ras* oncogene–transformed human bronchial epithelial cells (TBE-1) secrete a single metalloprotease capable of degrading basement membrane coll *J Biol Chem* **263**:6579, 1988

22. Seltzer JL et al: Purification and properties of a gelatin-specific neutral protease from human s *J Biol Chem* **256**:4662, 1981

23. Xia T et al: Comparison of cleavage site specificity of gelatinases A and B using collagenous peptic *Biochem Biophys Acta* **1293**:259, 1996

24. Wilhelm SM et al: SV40-transformed human lung fibroblasts secrete a 92-kDa type IV collagenase which is identical to that secreted by normal human macroph *J Biol Chem* **264**:17213, 1989

25. Collier IE et al: Alanine scanning mutagenesis and functional analysis of the fibronectin-like collagen-binding domain from human 92-kDa type IV collage *J Biol Chem* **267**:6776, 1992

26. Collier IE et al: Substrate recognition by gelatinase A: The C-terminal domain facilitates surface diffusi *Biophys J* **81**:2370, 2001

27. Stetler-Stevenson WG et al: Tissue inhibitor of metalloproteinase (TIMP-2) A new member of the metalloproteinase inhibitor fa *J Biol Chem* **264**:17374, 1989

28. Wilson CL, Matrisian LM: Matrilysin: An epithelial matrix metalloproteinase with potentially novel functi *Int J Biochem Cell Bic* **28**:123, 1996

29. Parks WC, Sires UI: Matrix metalloproteinases in skin biology and disea *Curr Opin Dermato* **3**:240, 1995

30. Karelina TV et al: Matrilysin (PUMP) correlates with dermal invasion during appendageal development and cutaneous neop *J Invest Dermato* **103**:482, 1994

31. MacDougall JR, Matrisian LM: Contributions of tumor and stromal matrix metalloproteinases to tumor progression, invasion and metas *Cancer Metastas Rev* **14**:351, 1995

32. Park HI et al: Identification and characterization of human endometase (matrix metalloproteinase-26) from endometrial tu *J Biol Chem* **275**:20540, 2000

33. de Coignac AB et al: Cloning of MMP-26: A novel matrilysin-like proteina *Eur J Biochem* **267**:3323, 2000

34. Sato H et al: A matrix metalloproteinase expressed on the surface of invasive tumour c *Nature* **370**:61, 1994

35. Velasco G et al: Human MT6-matrix metalloproteinase: Identification, progelatinase A activation, and expression in brain tur *Cancer Res* **60**:877, 2000

36. Llano E et al: Identification and characterization of human MT5-MMP, a new membrane-bound activator of progelatinase A overexpressed in brain tu *Cancer Res* **59**:2570, 1999

37. Ellerbroek SM, Stack MS: Membrane-associated matrix metalloproteinases in metasta *Bioessays* **21**:940, 1999

38. Okada A et al: Membrane-type matrix metalloproteinase (MT-MMP) gene is expressed in stromal cells of human colon, breast, and head and neck carcin *Proc Natl Acad Sci USA* **92**:2730, 1995

39. Shapiro SD: Elastolytic metalloproteinases produced by human mononuclear phagocytes: Potential roles in destructive lung dis *Am J Respir Crit Care Med* **150**:S160, 1994

40. Shapiro SD: Mighty mice: Transgenic technology “knocks out” questions of matrix metalloproteinase funct *Matrix Bio* **15**:527, 1997

41. Llano E et al: Identification and structural and functional characterization of human enamelysin (MMP-2 *Biochemistry* **36**:15101, 1997

42. Stracke JO et al: Biochemical characterization of the catalytic domain of human matrix metalloproteinase 19: Evidence for a role as a potent basement membrane degrading e *J Biol Chem* **275**:14809, 2000

43. Marchenko GN, Strongin AY: MMP-28, a new human matrix metalloproteinase with an unusual cysteine-switch sequence is widely expressed in tu *Gene* **265**:87, 2001

44. Lohi J et al: Epilysin, a novel human matrix metalloproteinase (MMP-28) expressed in testis and keratinocytes and in response to i *J Biol Chem* **276**:10134, 2001

45. Velasco G et al: Cloning and characterization of human MMP-23, a new matrix metalloproteinase predominantly expressed in reproductive tissues and lacking conserved domains in other family members *J Biol Chem* **274**:4570, 1999

46. Fini ME et al: Regulation of matrix metalloproteinase gene expression *Matrix Metalloproteinases* edited by WC Parks, RW Mecham. San Diego, Academic Press, p 299

47. Sameshima T et al: Glioma cell extracellular matrix metalloproteinase inducer (EMMPRIN) (CD147) stimulates production of membrane-type matrix metalloproteinases and activated gelatinase A in co-cultures with brain-derived fibroblast *Cancer Let* **157**:177, 2000

48. Lee AY et al: Intracellular activation of gelatinase A (72-kDa type IV collagenase) by normal fibrobla *Proc Natl Acad Sci USA* **94**:4424, 1997

49. Grant GA et al: The activation of human fibroblast procollagenase: Sequence identification of the major conversion produ *J Biochem* **262**:5886, 1986

50. Birkedal-Hansen H: Proteolytic remodeling of extracellular matr *Curr Opin Cell Bic* **7**:728, 1995

51. He CS et al: Tissue cooperation in a proteolytic cascade activating human interstitial collagen *Proc Natl Acad Sci USA* **86**:2632, 1989

52. Strongin AY et al: Mechanism of cell surface activation of 72-kDa type IV collagenase: Isolation of the activated form of the membrane metallopro *J Biol Chem* **270**:5331, 1995

53. Murphy G, Gavrilovic J: Proteolysis and cell migration: Creating a pat *Curr Opin Bio* **11**:614, 1999

54. Brew K et al: Tissue inhibitors of metalloproteinases: Evolution, structure and functi *Biochem Biophys Acta* **1477**:267, 2000.

55. Nagase H et al: Engineering of selective TIMPs *Ann NY Acad Sc* **878:**1, 1999

56. Gomez DE et al: Tissue inhibitors of metalloproteinases: Structure, regulation and biological functic *Eur J Cell Bio* **74**:111, 1997

57. Clark SD et al: Regulation of the expression of tissue inhibitor of metalloproteinases and collagenase by retinoids and glucocorticoids in human fibrob *J Clin Inves* **80**:1280, 1987

58. Mauviel A, et al: Cell-specific induction of distinct oncogenes of t *jun* family is responsible for differential regulation of collagenase gene expression by transforming growth factor-beta in fibroblasts and keratinocytes *J Biol Chem* **271**: 10917, 1996

59. Guedez L et al: In vitro suppression of programmed cell death of B cells by tissue inhibitor of metalloproteinase *J Clin Inves* **102**:2002, 1998

60. Bode W, Huber R: Structural basis of the endoproteinase-protein inhibitor interactic *Biochem Biophys Acta* **1477**:241, 2000

61. Libson AM et al: Crystal structure of the haemopexin-like C-terminal domain of gelatinase *Nature Struct Bio* **2**:938, 1995

62. Werb Z et al: Matrix-degrading proteases and angiogenesis during development and tumor format *APMIS* **107**: 11, 1999

63. Karelina TV et al: Basement membrane zone remodeling during appendageal development in human fetal skin: The absence of type VII collagen is associated with gelatinase-A (MMP2) activity. *J Invest Dermato* **114**:371, 2000

64. Holmbeck K et al: MT1-MMP–deficient mice develop dwarfism, osteopenia, arthritis, and connective tissue disease due to inadequate collagen turn *Cell* **99**:81, 1999

65. Rodgers WH et al: Patterns of matrix metalloproteinase expression in cycling endometrium imply differential functions and regulation by steroid horm *J Clin Inves* **94**:946, 1994

66. Fata JE et al: Cellular turnover and extracellular matrix remodeling in female reproductive tissues: Functions of metalloproteinases and their inhi *Cell Mol Life Sc* **57:**77, 2000

67. Goetzl EJ et al: Matrix metalloproteinases in immunit *J Immuno* **156**:1, 1996

68. Heppner KJ et al: Expression of most matrix metalloproteinase family members in breast cancer represents a tumor-induced host respo *Am J Patho* **149**:273, 1996

69. Liotta LA et al: Metastatic potential correlates with enzymatic degradation of basement membrane colla *Nature* **284**:67, 1980

70. McCawley LJ, Matrisian LM: Matrix metalloproteinases: Multifunctional contributors to tumor progress *Mol Med Today* **6**:149, 2000

71. Hofmann UB et al: Matrix metalloproteinases in human melanom *J Invest Dermato* **115**:337, 2000

72. Ray JM, Stetler-Stevenson WG: The role of matrix metalloproteases and their inhibitors in tumour invasion, metastasis and angiogen *Eur Respir J* **7**:2062, 1994

73. Sternlicht MD et al: The stromal proteinase MMP3/stromelysin-1 promotes mammary carcinogene *Cell* **98**:137, 1999

74. Fingleton BM et al: Matrilysin in early stage intestinal tumorigenes *APMIS* **107:**102, 1999

75. Westermarck J, Kahari VM: Regulation of matrix metalloproteinase expression in tumor invasion (revi *FASEB J* **13**:781, 1999

76. Martignetti JA et al: Mutation of the matrix metalloproteinase 2 gene (MMP2) causes a multicentric osteolysis and arthritis syndr *Nature Gene* **28**:261, 2001

77. Vu TH: Don't mess with the matrix *Nature Gene* **28**:202, 2001

78. Smith RL: Degradative enzymes in osteoarthriti *Frontiers Biosc* **4**:D704, 1999

79. Wernicke D et al: Cloning of collagenase 3 from the synovial membrane and its expression in rheumatoid arthritis and osteoartl *J Rheumato* **23**:590, 1996

80. Reboul P et al: The new collagenase, collagenase-3, is expressed and synthesized by human chondrocytes but not by synoviocytes: A role in osteoar *J Clin Inves* **97**:2011, 1996

81. Karelina TV et al: Localization of 92-kDa type IV collagenase in human skin tumors: Comparison with normal human fetal and adult *J Invest Dermato* **100**:159, 1993

T>

Chapter 18

Richard Gallo Janet Trowbridge

Proteoglycans and Glycosaminoglycans of Skin

STRUCTURE AND NOMENCLATURE
THE GAG CHAIN
THE CORE PROTEIN
FUNCTION

REFERENCES

Proteoglycans and their glycosaminoglycan components constitute a considerable portion of the cellular membrane and extracellular milieu of the skin. Their ability to bind and alter protein–protein interactions or enzymatic activity has identified them as important determinants of cellular responsiveness in development, homeostasis, and disease. Because proteoglycans are a structurally unique and highly diverse group of macromolecules, it is important to become familiar with their structure and organization to understand their function. The most distinguishing structural characteristic of proteoglycans is that they comprise both a core protein and covalently linked linear carbohydrate chains known as glycosaminoglycans (GAGs). GAGs are highly polyanionic and bear the highest charge density of any vertebrate macromolecule. It has long been recognized that GAGs are a major component of the skin. More recently, it has been appreciated that the content and composition of GAGs in the skin can change during development and a variety of pathologic processes, and that both core protein and GAGs impart a unique set of functions that are critical to a large number of biologic processes.

STRUCTURE AND NOMENCLATURE

In the past, terms such as *ground substance* or *mucopolysaccharide* were used to describe proteoglycans because of their appearance histologically and their thick and mucinous nature when isolated. Because of these physical properties, proteoglycans were difficult to study and poorly understood. Glycobiology has clearly defined proteoglycans as essential regulatory molecules that control many cellular functions. To attain this understanding, important advances have been made in the identification of specific proteoglycan core proteins and the assembly of their GAG side chains.

Proteoglycans are known by specific gene families based on amino acid sequence information derived from their core proteins and carbohydrate compositional analysis of their GAG side chains. The prototypical proteoglycan consists of a single core protein linked to one or more GAGs (Fig. 18-1). Each core protein has the capacity to accept a variety of GAG chains. Therefore, the nomenclature for proteoglycans is complicated in that individual molecules must be defined based on the core protein and the associated GAGs.

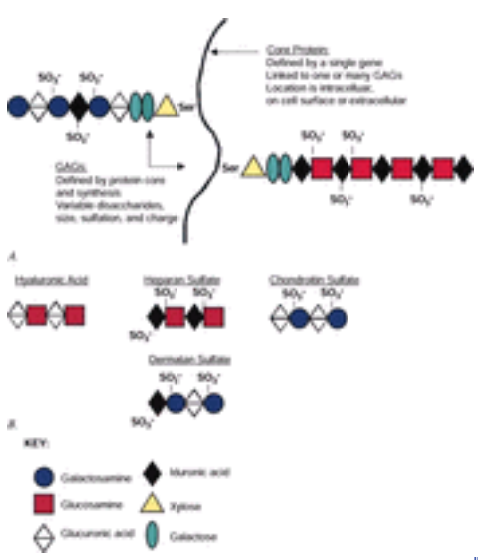

FIGURE 18-1 *A.* Prototype of proteoglycan structure. Core proteins may contain from 1 to 100 glycosaminoglycan (GAG) chains, depending on the core protein sequence. Two different GAG chains are shown: dermatan sulfate (*top left*) and heparan sulfate (*bottom right*). Sites of potential sulfation are indicated. Ser represents a serine amino acid residue in the core protein to which GAGs are attached. *B.* Disaccharide repeating units of glycosaminoglycans shown as tetrasaccharides. Structures of heparan sulfate, dermatan sulfate, chondroitin sulfate A/C, and hyaluronan are shown. Sulfation can vary in heparan sulfate and dermatan sulfate. Chondroitin sulfate A is chondroitin 4-sulfate. Chondroitin sulfate C is chondroitin 6-sulfate.

THE GAG CHAIN

The GAG chain is defined based on the assembly of essential sugar residues. These sugars are organized as disaccharide pairs that usually consist of an acidic sugar that is either an iduronic acid or glucuronic acid alternating with a hexosamine that is either glucosamine or galactosamine. When assembled as disaccharides, the choice of sugars and the linkage between them is used to assign a name to the GAG chain. Thus, several terms are used to define GAGs (Fig. 18-1B), including hyaluronic acid, containing a glucuronic acid alternating with *N*-acetylglucosamine linked ß1–3 and ß1–4; heparan sulfate, containing iduronic or glucuronic acids alternating with *N*-acetylglucosamine linked ß1–4;

chondroitin sulfate, containing glucuronic acid alternating with *N*-acetylgalactosamine linked ß1–3 and ß1–4; and keratan sulfate, containing galactose alternating with *N*-acetylglucosamine linked ß1–4 and ß1–3 (not shown). A fifth general term used to describe GAGs, and of particular importance to cutaneous biology, is *dermatan sulfate*. This form of GAG (also known as chondroitin sulfate B) is similar to other chondroitin sulfates except that it contains a high proportion of iduronic acids in place of glucuronic acid and has more variable sulfation. Dermatan sulfate shares features of both chondroitin sulfate (*N*-acetyl galactosamine) and heparan sulfate (iduronate) (Fig. 18-1B).

The nomenclature described above for GAGs only partly defines the nature of these molecules. The linear chains of linked disaccharide units in a GAG are highly variable in size, ranging from as few as 10 disaccharides to several thousand. Thus, the mass of naturally occurring GAGs typically ranges between 5×10^{3} daltons and 10^{7} daltons for hyaluronic acid. Further variability is introduced into the GAG chain by epimerization reactions and sulfation reactions. The control of these reactions depends both on the nature of the GAG, the core protein to which it may be attached, the cell type, and the cell environment. For example, the simplest GAG, hyaluronic acid, is never sulfated. Other GAGs can be variably sulfated. Heparan sulfate can be sulfated at the N, C-2, and C-6 positions of *N*-acetylglucosamine and at the C-2 position of iduronic acid. Dermatan sulfate can be sulfated at C-2 of iduronate and at C-4 and C-6 of *N*-acetylgalactosamine. These highly sulfated sugars tend to occur in specific regions of the GAG chain and are interspersed with areas of low sulfation. Such discreet domains of low or high sulfation are believed to determine the interactions between proteoglycans and glycosaminoglycans and their many binding partners.

In heparan sulfate from human dermal fibroblasts, the highly sulfated regions resemble the sulfation found in heparin, which are responsible for the anticoagulant activity of heparin. However, heparin lacks the regions of low sulfation found in heparan sulfate. Thus, it is important to distinguish heparin from heparan sulfate for both functional and structural considerations.

The size, disaccharide composition, and sulfation are of utmost importance in understanding GAGs. These parameters influence function and are the mechanism by which instructions are defined within the molecule. Thus, the linear GAG should be considered as a molecule containing information similar to the way information is encoded in a protein. GAG synthesis (with the exception of hyaluronan) occurs in the Golgi apparatus. Sequence information is determined by the activity and location of multiple specific enzymes along this pathway. Today, many of the synthetic enzymes that control heparan sulfate synthesis and those enzymes responsible for postsynthetic modifications have been identified and characterized. [1] The sulfated GAGs are all synthesized on core proteins. The tetrasaccharide xylose, galactose, galactose, glucuronic acid is first assembled on the core protein by beginning with a xylosyltransferase forming a linkage between xylose and a serine residue in the core protein. Subsequent elongation reactions that occur in the Golgi apparatus define the nature of the GAG chain. It is appreciated that part of the information necessary to direct synthesis of the GAG is encoded within the core protein sequence itself. The final product, core protein with attached GAG, defines the proteoglycan (see Fig. 18-1A). Hyaluronan, the only GAG produced without attachment to a core protein, is synthesized by an enzyme complex at the plasma membrane and then extruded into the extracellular space.

THE CORE PROTEIN

Our understanding of proteoglycans has advanced dramatically as a result of increased information about their core proteins and the subsequent use of molecular tools to study the expression and function of both the protein core and GAG components. Many specific proteoglycans can now be defined and studied based on their core protein sequence. For purposes of organization, it is useful to group proteoglycans based on their site of expression by the cell. Specific proteoglycan core proteins have been identified within the cell, attached to the cell surface, bound within the extracellular matrix, and released in soluble form (Table 18-1).

Core Proteins	Locations	Usual GAG Component
Intracellular		
Serglycin	Mast cells, basophils	HS CS
Cell Surface		
Syndecan-1	Keratinocytes, other epithelia	HS CS
Syndecan-2	Fibroblasts, endothelia, liver	HS
Syndecan-3	Neural cells, limbs	HS
Syndecan-4	Ubiquitous, lymphoid	HS CS
NG-2	Neural, melanoma	CS
Glypican (GPC-1)	Brain, vascular endothelia	HS
Gowbaglycan (GPC-2)	Brain only	HS
OCI-5 (GPC-3)	Intestine and mesenchymal	HS
K-glypican (GPC-4)	Kidney, brain	HS
Glypican-5 (GPC-5)	Brain, kidney, bone	HS
Glypican-6 (GPC-6)	Intestine, kidney, lung	HS
Epican	Keratinocytes	HS CS KS
Betaglycan	Fibroblasts, epithelia	HS
Endocan	Endothelia	DS
Thrombomodulin	Endothelia	DS
Extracellular Matrix		
Aggrecan	Cartilage	KS CS
Versican	Fibroblasts	CS DS
Brevican	Brain	CS
Neurocan	Brain	CS
Phosphocan	Brain	CS KS
Decorin	Fibroblasts, others	DS
Biglycan	Bone	DS
Epiphycan	Cartilage	DS
OIF	Cartilage	
Fibromodulin	Fibroblasts	KS
Lumican	Cornea	KS
Agrin	Brain	HS
Perlecan	Basement membranes	HS
Bamacan	Basement membranes	CS

CS, chondroitin sulfate; HS, heparan sulfate; KS, keratan sulfate.

TABLE 18-1 **Core Proteins of Proteoglycans**

Serglycin is the best known intracellular proteoglycan and is found within the secretory granules of hematopoietic cells including mast cells, leukocytes, and eosinophils. This core protein is processed further to contain either heparan sulfate or chondroitin sulfate GAG. The heparan sulfate form is found in serosal mast cells and is a major source from which heparin is pharmacologically derived. The serglycin peptide core is composed primarily of tandem serine-glycine repeats and has an estimated mass of 16 to 18 kDa before GAG addition and 60 to 750 kDa after the addition of multiple heterogenous GAG chains. [2] Thus, serglycin is a unique proteoglycan because of its distinctive core protein sequence and intracellular localization. In the skin, serglycin is found whenever mast cells or eosinophils enter the dermal stroma.

Upon release, serglycin becomes a major source for delivery of highly sulfated heparan sulfate GAG.

Several cell surface proteoglycans have been identified and are the subject of much recent interest because of their ability to function at the interface between the plasma membrane and the extracellular environment. These cell proteoglycans can be found attached to the cell surface either by a phospholipid anchor (e.g., glypican family) or as membrane-spanning core proteins (e.g., syndecan family). The mammalian glypican family is currently known to consist of six distinct proteins: glypican, cerebroglycan, OCI-5, K-glypican, glypican-5, and glypican-6. [3] This family of core proteins shares the glycophosphatidyl inositol (GPI) anchorage mechanism and a unique cysteine motif that is likely to impart a compact tertiary structure to the proteoglycans. Consequently, glypicans can be visualized as a compact protein presenting GAG chains in close proximity to the outer surface of the plasma membrane. Individual members of the glypican family have been identified in a variety of cells and tissues, including lung, kidney, brain, and intestine. [4], [5]

The surface of most cells contains another important family of proteoglycans known as the syndecans. Syndecans, like glypicans, are found in a wide variety of cells and tissues. The structure of these cell surface proteoglycans differs from that of the glypicans. Syndecan core proteins consist of a short C-terminal cytoplasmic region, a transmembrane domain, and an extracellular region containing attachment sites for GAG chains. Unlike glypicans, syndecans span the plasma membrane and extend beyond the surface of the cell. In this way, syndecans are in a unique position to connect extracellular GAG to structures within the cytoplasmic space. The cytoplasmic domain imparts the ability of syndecans to participate in intracellular signal transduction via the protein kinase C pathway. Expression of syndecans is abundant in skin. Syndecan transcripts and proteins are expressed in distinct patterns during development [6] and in mature tissues. [7] Syndecan-1 is particularly abundant on keratinocytes and can vary the nature of attached GAG chains as keratinocytes differentiate. [8] During wound repair, syndecans-1 and -4 are greatly induced in the dermis and granulation tissue. [9] Deletion of syndecan-4 from mice greatly decreases the rate of wound repair. [10] During malignant transformation, syndecan-1 expression decreases in the epidermis [11] and expression can alter malignant behavior in select cell types. [12] Thus, syndecans have received particular attention as proteoglycans that modify cell function. Because syndecans and other proteoglycans can contain more than one GAG species either simultaneously or under different cellular circumstances, GAG expression in addition to protein expression provides an additional mechanism of regulation.

Two other cell surface proteoglycans are worth special mention. Epican and betaglycan are examples of cell surface proteins that are “part-time” proteoglycans. Epican, a splice variant of the cell surface molecule CD44 that can exist as a heparan, chondroitin, or keratin sulfate proteoglycan, mediates cell–cell adhesion, growth, and differentiation. [13] Betaglycan is also known as the transforming growth factor-beta (TGF-ß) type III receptor. Both betaglycan and epican exist as variants without GAG chains and may exert their function at the cell surface with or without GAG addition.

The extracellular matrix contains multiple proteoglycans that have now been identified and studied. As has been discussed for proteoglycans at the cell surface, the extracellular matrix proteoglycans have a variety of distinct structural characteristics. Aggrecan, a large proteoglycan found in cartilage, has been studied extensively. This core protein contains a region with over 100 Ser-Gly dipeptides that serve as attachment sites for chondroitin sulfate GAG. The ˜230 kDa core protein can be modified to contain up to 130 GAG chains and have a final mass of ˜2200 kDa. [14] This densely packed multiple GAG configuration has been described as a “bottle-brush” to illustrate the predicted structure. The aggrecan core protein also contains sites for keratan sulfate attachment and a domain for noncovalent binding to hyaluronic acid. As many as 100 aggrecan molecules can bind to a single hyaluronic acid molecule. Thus, the overall proteoglycan aggregate (from which the name *aggrecan* is derived) can have a mass near 200,000 kDa.

In the skin, fibroblasts produce large aggregating proteoglycans similar to aggrecan. The best known of these large proteoglycans is called *versican*. The core protein of versican contains attachment sites for 12 to 15 GAG chains, which are primarily chondroitin sulfate or dermatan sulfate. Versican, like aggrecan, also binds hyaluronic acid, enabling it to form large aggregates. In skin, versican has been identified in the dermis (fibroblasts) and epidermis (keratinocytes) and demonstrates selective upregulation in response to TGF-ß. [15] Thus, the size, distribution, and abundance of versican in the skin suggest that this is an important molecule in the regulation of the behavior of the skin.

In contrast to the large aggregating extracellular matrix proteoglycans represented by aggrecan and versican, several genes encoding smaller proteoglycans have been identified in the extracellular matrix. One family of the proteoglycans is characterized by a leucine-rich repeat motif. The prototype of this family is decorin, an approximately 36-kDa secreted proteoglycan. Decorin is in abundance in skin and cartilage and is thought to be a ubiquitous component of connective tissue. The relatively small decorin core protein has a single dermatan sulfate chain covalently bound to a serine residue at amino acid position 4 and, like many other proteoglycans, also has *N*-linked oligosaccharides. Thus, after GAG addition and glycosylation, decorin can have a mass of 80 kDa. Decorin received its name from observations that this molecule closely associates with collagen fibrils and can be seen to “decorate” the fibrils in vivo. This interaction is attributed to the ability of the decorin core protein to directly bind to collagen type I. [16] Decorin's single GAG chain binds to tenascin-X, another extracellular matrix protein that colocalizes with collagen fibrils in connective tissues. [17] These binding interactions contribute to collagen fibril formation and influence function. Interestingly, similar phenotypes (see below) showing abnormal collagen morphology are seen in a patient deficient in tenascin-X and in the murine decorin knockout model. [18], [19]

FUNCTION

To understand how proteoglycans function in the skin it is essential to recall the basics of their organization, as previously discussed: (1) Proteoglycans are part protein and part GAG; (2) GAGs are heterogeneous but encode specific information; (3) proteoglycan core proteins are expressed in different cellular compartments; and (4) proteoglycan expression and GAG composition vary according to cellular context. These characteristics are important because the fundamental influence dictating proteoglycan function is the ability to bind to other molecules in its environment. Therefore, the sequences (both amino acid sequence and disaccharide sequence) of the core protein and GAG control

proteoglycan function by influencing binding.

Similar GAGs can be found on multiple core proteins. This ability to interchange GAGs among cores adds complexity in studying proteoglycan function. Therefore, in many cases, proteoglycan function is discussed purely in terms of the function of GAG chains. This implies that a number of genes encoding core proteins containing these GAGs may have a similar function. Figure 18-2 illustrates some of the functions attributed to proteoglycans containing heparan sulfate and dermatan sulfate. The functions proposed for proteoglycans containing these GAGs derive from the ability of these molecules to bind to other components of the extracellular environment and mediate assembly of larger molecular complexes.

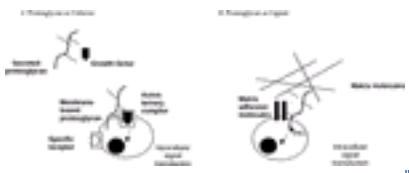

FIGURE 18-2 Theoretical models for proteoglycan function. *A.* Proteoglycans as coreceptors for growth factors. Proteoglycan, growth factor, and specific receptor must all assemble at the cell surface before growth factor can activate the cell. Secreted extracellular proteoglycans may sequester and stabilize growth factors. *B.* Proteoglycans as extracellular matrix receptors. Proteoglycan can assemble with other matrix adhesion receptors (e.g., integrins) to aid in cell adherence. The proteoglycan syndecan-4 also interacts and signals through protein kinase C (PKC) to enable cell activation by matrix adhesion.

The list of molecules to which the major skin proteoglycans heparan sulfate and dermatan sulfate bind is quite extensive (Table 18-2). Therefore, several functions for proteoglycans have been proposed that include the particular biologic system in which the ligand is involved. Some of the most compelling experimental evidence for functions of heparan and dermatan sulfate proteoglycans includes the ability to bind several growth factors, cytokines, and components of the extracellular matrix. [20] Numerous laboratories have shown that heparan sulfate is required for the function of several growth factors including several members of the fibroblast growth factor family, [21], [22] hepatocyte growth factor/scatter factor, [23] and vascular endothelial growth factor. [24] In this model, the heparan sulfate proteoglycan can be found either at the cell surface or in a soluble form. The molecules then assemble to form a ternary complex at the cell surface between the growth factor, its specific high-affinity signaling receptor, and the proteoglycan (Fig. 18-2A). [25] Only after this ternary complex is formed does the cell receive the growth factor's signal to begin to proliferate, differentiate, or migrate. Dermatan sulfate's ability to participate in these interactions was only recently demonstrated. [26], [27] The significance of this assembly to skin biology is illustrated during wound repair. Heparan sulfate-dependent growth factors, such as members of the fibroblast growth factor family, are induced in a healing wound [28] and influence the wound repair process through the stimulation of keratinocyte proliferation, fibroblast growth, and angiogenesis. Heparan sulfate proteoglycans such as syndecan-1 and -4 are also induced at these sites [29] and enable activity of the growth factor. Because dermatan sulfate is the predominant GAG in wound fluid and because it can bind a variety of growth factors, cytokines, and extracellular matrix proteins, the further study of this GAG and the proteoglycans it comprises promises to be a very exciting subject for future investigation.



TABLE 18-2 **Binding Interactions of Heparan Sulfate, Dermatan Sulfate, and Heparin**

The influence of the proteoglycan core protein on cell behavior is thought to relate to the ability of the core protein to influence the amount and localization of GAG expression. In the example of wound repair, heparan and dermatan sulfate expression is influenced by the expression of the syndecan core proteins to which the GAGs are covalently attached. Other molecules, such as the syndecan-inducer PR-39, [29] the syndecan-inhibitor tumor necrosis factor–a, [30] and TGF-ß, can have significant influence on the wound repair process by controlling GAG and proteoglycan expression. [31]

Recently, further study of the expression of proteoglycans has expanded the direct evidence for a function for these molecules. In addition to growth factor binding, heparan sulfate proteoglycans are important molecules involved in adhesion to the extracellular matrix. In this model, cell surface proteoglycan helps the cell adhere to the extracellular matrix in conjunction with other matrix-binding molecules such as the integrins (Fig. 18-2B). Syndecan-4 is selectively enriched in dermal fibroblasts at sites consistent with this function. Furthermore, the formation of these focal adhesions requires heparan sulfate and the subsequent activation of protein kinase C by a domain in the syndecan-4 core protein

cytoplasmic tail. [32] In this example, both the extracellular GAG and intracellular core protein of the proteoglycan have demonstrable function.

Other proteoglycans also interact with matrix molecules. Chondroitin sulfate and dermatan sulfate bind fibronectin and laminin. [33] As mentioned above, decorin, to which dermatan sulfate is typically attached, is known to associate primarily with type I collagen via its core protein. [16] In mice, selective disruption of the decorin gene leads to mice with abnormal collagen morphology and increased skin fragility. [18] Thus, through targeted disruption in the mouse, the function of decorin as a stabilizer of collagen fibrils has been directly confirmed.

The function of the large extracellular matrix proteoglycans in skin is thought to reside primarily in physical properties inherent in their large mass and charge density. Hyaluronan has been studied extensively from this perspective because of its extreme hydrophilicity and viscosity in dilute solution. As discussed earlier, hyaluronic acid is pure GAG and is synthesized extracellularly without a core protein. The genes for human hyaluronan synthase have been cloned and identified. [34] The expression of hyaluronan is developmentally regulated in skin [35] and changes during wound repair. It has been proposed that the physicochemical properties of hyaluronan serve to expand the matrix and thus aid cell movements. Other physical properties attributed to GAG and large proteoglycan complexes, such as those formed with versican or basement membrane proteoglycans, include their ability to act as anionic filters and elastic cushions and their function in salt and water balance. In fetal skin, the high relative content of hyaluronan has been associated with the ability of fetal skin to heal without scar.

Clues to the functions of proteoglycans and GAGs have been gathered from numerous reports of abnormal GAG composition associated with human disease. The well-known mucopolysaccharidoses are lysosomal storage disorders caused by a genetic deficiency of enzymes that degrade GAGs. A disorder in the ability to degrade hyaluronic acid has also been described. [36] These disorders reflect the severe pathology that can be caused by an excess of select GAGs.

The clinical manifestations of a deficiency in a specific proteoglycan are seen in the fetal overgrowth syndrome known as the Simpson-Golabi-Behmel syndrome. This X-linked condition is characterized by pre- and postnatal overgrowth with numerous visceral and skeletal abnormalities. The genetic defect for this syndrome in some families was identified as the cell surface proteoglycan OCI-5, also known as glypican-3. [37]

Multiple cutaneous disorders are associated with abnormal proteoglycan synthesis or deposition. A deficiency of decorin core protein has been described as the etiology of a variant form of Ehlers-Danlos syndrome. Affected individuals have skin that is thin and easily bruised with poor healing or chronic ulcers. [38] Rapid changes in select proteoglycans occur in the skin following injury. [39], [40] This is consistent with their role as growth factor and matrix receptors. Infectious disease is influenced by proteoglycan expression. For example, decorin-deficient mice are somewhat resistant to infection with *Borrelia burgdorferi*. Presumably this resistance is caused by a partial dependence of the organism on decorin for binding in the dermis. [41] During aging, the composition of GAG in the skin undergoes a marked change. [42], [43] It has been proposed that the observed decrease in hyaluronic acid can explain diminished skin turgor in aged skin. Retinoids also effect this response. [44] In keloids, hyaluronic acid synthesis is elevated. [45] Thyroid hormone also has a marked effect on the synthesis of proteoglycans and GAGs. The manifestation of this response is seen in pretibial myxedema, where the mucinous material deposited is predominantly hyaluronic acid and chondroitin sulfate. Other pathologic skin conditions, including pseudoxanthoma elasticum, [46] scleroderma, [47] psoriasis, [48] a variant form of Ehlers-Danlos syndrome, [38] lichen myxedema, [49] and UVB-irradiated skin, [50] have also been reported to have abnormal amounts of proteoglycans. These associations do not imply that abnormal proteoglycan metabolism is responsible for these disorders, yet they suggest that much of the pathophysiology of skin disease can be influenced by the function of cutaneous proteoglycans.

In summary, proteoglycans are best thought of as central regulatory molecules that act to influence a variety of cell behaviors. As more information becomes available regarding the regulation of proteoglycan and GAG synthesis, we have seen that these molecules are essential to cutaneous biology. The time has come to abandon archaic descriptions such as “ground substance” in the dermatology lexicon.

REFERENCES

1. Esko JD, Lindahl U: Molecular diversity of heparan sulfate. *J Clin Invest* **108**:169, 2001

2. Schick BP: Regulation of expression of megakaryocyte and platelet proteoglycans. *Stem Cells* **14**(suppl 1):220, 1996

3. Bernfield M et al: Functions of cell surface heparan sulfate proteoglycans. *Annu Rev Biochem* **68**:729, 1999

4. Litwack E et al: Expression of the heparan sulfate proteoglycan glypican-1 in the developing rodent. *Dev Dyn* **211**:72, 1998

5. Veugelers M et al: Glypican-6, a new member of the glypican family of cell surface heparan sulfate proteoglycans. *J Biol Chem* **274**:26968, 1999

6. Rapraeger AC: Molecular interactions of syndecans during development. *Semin Cell Dev Biol* **12**:107, 2001

7. Kim C et al: Members of the syndecan family of heparan sulfate proteoglycans are expressed in distinct cell-, tissue-, and development-specific patterns. *Mol Biol Cell* **5**:797, 1994

8. Sanderson RD et al: Syndecan, a cell surface proteoglycan, changes in size and abundance when keratinocytes stratify. *J Invest Derm* **99**:1, 1992

9. Gallo RL et al: Syndecans-1 and -4 are induced during wound repair of neonatal but not fetal skin. *J Invest Dermatol* **107**:667, 1996

10. Echtermeyer F et al: Delayed wound repair and impaired angiogenesis in mice lacking syndecan-4. *J Clin Invest* **107**:R9, 2001

11. Inki P, Jalkanen M: The role of syndecan-1 in malignancies. *Ann Med* **28**:63, 1996

12. Hirabayashi K et al: Altered proliferative and metastatic potential associated with increased expression of syndecan-1. *Tumour Biol* **19**:454, 1998

13. Zhou J et al: Growth and differentiation regulate CD44 expression on human keratinocytes. *In Vitro Cell Dev Biol Anim* **35**:228, 1999

14. Watanabe H et al: Roles of aggrecan, a large chondroitin sulfate proteoglycan, in cartilage structure and function. *J Biochem (Tokyo)* **124**:687, 1998

15. Tiedemann K et al: Cytokine regulation of proteoglycan production in fibroblasts: Separate and synergistic effects. *Matrix Biol* **15**:469, 1997

16. Keene DR et al: Decorin binds near the C terminus of type I collagen. *J Biol Chem* **275**:21801, 2000

17. Elefteriou F et al: Binding of tenascin-X to decorin. *FEBS Lett* **495**:44, 2001

18. Danielson KG et al: Targeted disruption of decorin leads to abnormal collagen fibril morphology and skin fragility. *J Cell Biol* **136**:729, 1997

19. Burch GH et al: Tenascin-X deficiency is associated with Ehlers-Danlos syndrome. *Nat Genet* **17**:104, 1997

20. Iozzo R: *Proteoglycans: Structure, Biology and Molecular Interactions*. New York, Marcel Dekker, 2000, p 1–4

21. Ornitz DM, Itoh N: Fibroblast growth factors. *Genome Biol* **2**:Reviews 3005.1–3005.12, 2001

22. Loo BM et al: Binding of heparin/heparan sulfate to fibroblast growth factor receptor 4. *J Biol Chem* **276**:16868, 2001

23. Sergeant N et al: Stimulation of DNA synthesis and cell proliferation of human mammary myoepithelial-like cells by hepatocyte growth factor/scatter factor depends on heparan sulfate proteoglycans and sustained phosphorylation of mitogen-activated protein kinases p42/44. *J Biol Chem* **275**:17094, 2000

24. Tessler S et al: Heparin modulates the interaction of VEGF165 with soluble and cell associated flk-1 receptors. *J Biol Chem* **269**:12456, 1994

25. Schlessinger J et al: Crystal structure of a ternary FGF-FGFR-heparin complex reveals a dual role for heparin in FGFR binding and dimerization. *Mol Cell* **6**:743, 2000

26. Penc SF et al: Dermatan sulfate released after injury is a potent promoter of FGF-2 activity. *J Biol Chem* **273**:28116, 1998

27. Lyon M et al: The mode of action of heparan and dermatan sulfates in the regulation of hepatocyte growth factor/scatter factor. *J Biol Chem* **31**:31, 2001

28. Werner S et al: Large induction of keratinocyte growth factor expression in the dermis during wound healing. *Proc Natl Acad Sci USA* **89**:6896, 1992

29. Gallo RL et al: Syndecans, cell surface heparan sulfate proteoglycans, are induced by a proline-rich antimicrobial peptide from wounds. *Proc Natl Acad Sci U S A* **91**:11035, 1994

30. Kainulainen V et al: Suppression of syndecan-1 expression in endothelial cells by tumor necrosis factor-alpha. *J Biol Chem* **271**:18759, 1996

31. Brown CT et al: Characterization of proteoglycans synthesized by cultured corneal fibroblasts in response to transforming growth factor beta and fetal calf serum. *J Biol Chem* **274**:7111, 1999

32. Oh E et al: Syndecan-4 proteoglycan regulates the distribution and activity of protein kinase C. *J Biol Chem* **272**:8133, 1997

33. Ruoslahti E: Structure and biology of proteoglycans. *Ann Rev Cell Biol* **4**:229, 1988

34. Shyjan AM et al: Functional cloning of the cDNA for a human hyaluronan synthase. *J Biol Chem* **271**:23395, 1996

35. Agren UM et al: Developmentally programmed expression of hyaluronan in human skin and its appendages. *J Invest Dermatol* **109**:219, 1997

36. Natowicz MR et al: Clinical and biochemical manifestations of hyaluronidase deficiency. *N Engl J Med* **335**:1029, 1996

37. Pilia G et al: Mutations in GPC3, a glypican gene, cause the Simpson-Golabi-Behmel overgrowth syndrome. *Nat Genet* **12**:241, 1996

38. Wu J et al: Deficiency of the decorin core protein in the variant form of Ehlers-Danlos syndrome with chronic skin ulcer. *J Dermatol Sci* **27**:95, 2001

39. Brown CT et al: Synthesis of stromal glycosaminoglycans in response to injury. *J Cell Biochem* **59**:57, 1995

40. Oksala O et al: Expression of proteoglycans and hyaluronan during wound healing. *J Histochem Cytochem* **43**:125, 1995

41. Brown EL et al: Resistance to Lyme disease in decorin-deficient mice. *J Clin Invest* **107**:845, 2001

42. Carrino DA et al: Age-related changes in the proteoglycans of human skin. *Arch Biochem Biophys* **373**:91, 2000

43. Ghersetich I et al: Hyaluronic acid in cutaneous intrinsic aging. *Int J Dermatol* **33**:119, 1994

44. Lundin A et al: Topical retinoic acid treatment of photoaged skin: Its effects on hyaluronan distribution in epidermis and on hyaluronan and retinoic acid in suction blister fluid. *Acta Derm Venereol* **72**:423, 1992

45. Alaish SM et al: Hyaluronic acid metabolism in keloid fibroblasts. *J Pediatr Surg* **30**:949, 1995

46. Passi A et al: Proteoglycan alterations in skin fibroblast cultures from patients affected with pseudoxanthoma elasticum. *Cell Biochem Funct*

14:111, 1996

47. Kuroda K, Shinkai H: Decorin and glycosaminoglycan synthesis in skin fibroblasts from patients with systemic sclerosis. *Arch Dermatol Res* **289**:481, 1997

48. Seyger MM et al: Altered distribution of heparan sulfate proteoglycans in psoriasis. *Acta Derm Venereol* **77**:105, 1997

49. Turakainen H et al: Synthesis of glycosaminoglycans and collagen in skin fibroblasts cultured from a patient with lichen myxedematosus. *Arch Dermatol Res* **277**:55, 1985

50. Margelin D et al: Alterations of proteoglycans in ultraviolet-irradiated skin. *Photochem Photobiol* **58**:211, 1993

T>

Chapter 19

Peter Petzelbauer Jeffrey Schechner Jordan Pober

Endothelium

PROPERTIES OF ENDOTHELIAL CELLS
ENDOTHELIAL ORIGIN AND DEVELOPMENT OF THE VASCULAR SYSTEM
MORPHOLOGIC FEATURES AND MOLECULAR MARKERS OF ENDOTHELIUM
General Morphologic Features of Endothelial Cells
Specialized Organelles of Endothelial Cells
Endothelial Junctions
Endothelial Cell-Matrix Interactions
Morphologic Specialization of Endothelial Cells
Molecular Markers of Endothelial Cells
ENDOTHELIUM IN INFLAMMATION
Innate Immunity
ENDOTHELIUM OF THE SKIN
Morphology and Molecular Markers
Skin Microvessels in Inflammation and Repair
REFERENCES

The systemic vascular system is formed by a continuous series of hollow tubes that carry blood from the heart to the tissues and back again. Blood exits the heart through the aorta, a large elastic artery, which gives rise to a series of diverging, progressively narrower muscular arteries and arterioles that deliver the blood to all of the organs of the body. The terminal arterioles arborize into an interconnecting network of microvessels, mostly capillaries, which nourish and cleanse the peripheral tissues. The capillary network empties into a series of converging venules and progressively larger veins that ultimately return the blood to the heart. All segments of this vascular system, as well as the heart itself, are lined by a simple, one-cell–thick layer of epithelial-like cells called *endothelium*. All of these endothelial cells share common features and perform common functions, and hence may be collectively described as one cell type. However, endothelia from one segment of the vascular system may differ in significant ways from the endothelia at other anatomic sites. In the first sections of this chapter, we consider both the commonality and diversity of endothelia, beginning with functional properties of endothelium. We then describe the development of the vascular endothelial system, summarize the shared and morphologic features exhibited by diverse endothelia, describe the shared and variable molecular markers of endothelia as they appear in different segments of the vasculature, discuss the role of endothelial cells in inflammation, and conclude with a consideration of the specialized features of skin endothelium.

PROPERTIES OF ENDOTHELIAL CELLS

As the lining of the vasculature, all endothelial cells must perform three important constitutive functions. First, vascular endothelial cells must maintain homeostasis of the blood that consists of about equal volumes of fluid (plasma) and cellular elements (mostly erythrocytes with a lesser mass of leukocytes and platelets). The plasma contains the proteins of the coagulation system that have the capacity to self-assemble into an insoluble matrix of fibrin, i.e., to form an intravascular thrombus or an extravascular clot when placed in contact with tissue cells or extracellular matrix. In addition, both the leukocytes and the platelets have membrane receptors that trigger cellular activation upon contact with the extravascular environment. The endothelial cell lining acts to prevent intravascular activation both of the coagulation system and of these responsive cellular elements, yet it keeps both systems poised to respond to appropriate stimuli, e.g., wounds or infections. In other words, vascular endothelium forms a blood-compatible container that prevents inappropriate activation of the blood without disabling protective responses.

The second function that must be performed by endothelial cells is to form a barrier that separates circulating blood from the tissues. The barrier formed by endothelial cells permits limited passage of fluid and solutes, allowing the blood to nourish the tissues, while displaying “permselectivity” for macromolecules, and a virtually impenetrable barrier for blood cells (except at specialized sites of high permeability and leukocyte trafficking). In other words, vascular endothelium regulates rather than completely prevents interactions between blood and tissues.

The third constitutive function that must be performed by endothelial cells is to regulate the extent of local blood flow. Blood flow may be shunted, within limits, from one organ to another. Perfusion of particular vascular beds is determined by vessel luminal diameter, which, in turn, is regulated by the tension generated by the smooth-muscle cell layer that invests the endothelial lining of the arteries and arterioles, particularly at the “precapillary sphincter” of the terminal arteriole. Although the tension of these investing smooth muscle cells is tonic, i.e., these cells are never completely relaxed, the level of contraction can be varied. The physiologic signals that affect vascular smooth-muscle tone are largely mediated through the endothelial cell lining, which can produce potent vasodilating or vasoconstricting substances. Remarkably, many direct constrictors of isolated vascular smooth-muscle cells (e.g., acetylcholine or bradykinin) are actually physiologic vasodilators because their actions on smooth-muscle cells are overwhelmed by their ability to concomitantly induce endothelial cells to release potent vasodilators such as nitric oxide (NO) or endothelial-derived hyperpolarizing factor (EDHP). In other words, endothelial cells integrate extrinsic signals and set the level of local vascular smooth-muscle cell tone and tissue perfusion.

These three constitutive functions of endothelium are performed, to some extent, by all vascular endothelial cells. However, endothelium is specialized at various anatomic sites, and the capacity to perform constitutive functions may be influenced by these specializations. For example, the ability of endothelial cells to interact with circulating cells and

macromolecules varies with vessel type. Arterial endothelia are the major producers of von Willebrand factor, a protein that strengthens platelet adhesion so it may resist strong shear forces, which typically are found only in arteries. Leukocytes preferentially interact with venules where endothelia most intensely express adhesion proteins that bind leukocytes. Arterial and arteriolar endothelium are specialized to regulate vasomotor tone and are the primary producers of NO and EDHP. Capillaries are the major site of nutritive exchange with the peripheral tissues, and capillary endothelial cells maintain a high degree of curvature, narrowing the vessel lumen so as to maximize the ratio of lumenal surface to lumenal volume. Moreover, different capillary beds display widely different degrees of permeability and selectivity, from the high resistance tight junction of brain microvessels to the open spaces between the sinusoidal endothelial cells of liver and, in humans, of spleen. Such functional differences among endothelia lining different vascular segments and in different tissues is important in the skin endothelial cell system. Injury to endothelium can lead to impairment or loss of constitutive functions, producing phenomena collectively referred to as *endothelial cell dysfunction*. The consequences of endothelial cell dysfunction also depend on the anatomic site of endothelial cell injury. Such differences have relevance for the role of endothelium in skin diseases.

In addition to their constitutive functions, endothelial cells respond to various proinflammatory stimuli by altering morphology and phenotype. These changes are part of host defense, i.e., they are functional rather than dysfunctional, and are referred to as *endothelial activation* (see below). Endothelial activation can result in an increased local influx of circulating humoral and cellular elements into the vessel wall and surrounding tissues. Again, features of these inducible functions are shared by all endothelium, but activation responses are also modulated by endothelial differences displayed among different vascular segments or in different organs. For example, although venular endothelial cells have become specialized for recruitment and activation of leukocytes in response to inflammatory stimuli, adhesion molecule expression in the lungs also occurs in the capillaries of the alveolar wall, an alternative site of leukocyte trafficking.

ENDOTHELIAL ORIGIN AND DEVELOPMENT OF THE VASCULAR SYSTEM

The first endothelial cells arise from an embryonic progenitor cell type called the *angioblast*. There are few established markers for angioblasts, and until recently, angioblasts were generally identified only after they had differentiated into endothelial cells. The best current marker for angioblasts may be expression of receptors for vascular endothelial growth factor (VEGF, see below) and platelet endothelial cell adhesion molecule (PECAM)-1 (CD31). Early angioblasts may arise from an even more primitive cell type, the hemangioblast, which also gives rise to hematopoietic progenitor cells. [1] In other words, some vascular endothelia may share a common embryonic origin with circulating blood cells rather than with other with vascular (e.g., smooth muscle) or tissue cells. This is reflected in the fact that many markers originally thought to be restricted to hematopoietic cells (e.g., CD34, CD36, and stem cell factor CD117) are also expressed by endothelia, and many markers originally thought to be unique for endothelia (e.g., PECAM-1, CD31; endoglin, CD105; VEGFR-2; Tie-1 and Tie-2) have been found on circulating blood cells. Hemangioblasts arise from mesodermal cells in the yolk sac and, at slightly later stages, from cells of the dorsal mesoderm, and differentiate to form the “blood islands” at these sites. Angioblasts initially arise from within the blood islands. Some angioblasts further differentiate in situ to form the endothelial cell lining of the blood islands while others migrate to elsewhere in the embryo to form the rudimentary vasculature. Later in development, some angioblasts appear to arise directly from cells of the splanchnic mesoderm without passing through a hemangioblast stage. The distinct embryologic origin of angioblasts is not known to result in functional differences among endothelial cells.

Newly formed angioblasts typically migrate as individual cells, differentiating into endothelial cells within tissues of endodermal origin (e.g., lung, heart, and gut). [2] Upon differentiation from individual angioblasts, endothelial cells spontaneously self-associate to form cords and, ultimately, hollow tubes. These tubes of endothelium are the first blood vessels. Endothelial cell tubes subsequently recruit and induce the differentiation of primitive mesenchymal cells into the investing cells of the vessel wall (e.g., smooth-muscle cells and pericytes).

Vessels that supply tissues of ectodermal and mesodermal origin arise primarily from outgrowth of endothelial cells present within preexisting endodermal vessels rather than differentiating from angioblasts. These differentiated endothelial cells typically migrate as cords, rather than as individual cells. The migrating cords of endothelium spontaneously form hollow tubes that, once again, recruit primitive mesenchymal cells to differentiate into investing vessel wall cells.

The formation of endothelial-lined tubes, i.e., primitive blood vessels, from differentiating angioblasts is called *vasculogenesis,* and the development of new blood vessels from preexisting endothelial-lined blood vessels is called *angiogenesis*. The maturation of a simple endothelial-lined tube into a mature blood vessel invested by stromal supporting cells (e.g., pericytes or vascular smooth muscle cells) is a form of *vascular remodeling*. Vascular remodeling also refers to both the growth of some microvessels into larger structures (i.e., arteries and veins) and the concomitant disappearance of other microvessels, largely by apoptosis, as large vessels are formed. Vasculogenesis, angiogenesis, and vascular remodeling are all required for the normal development of the vasculature. The vasculature is the first organ system to be formed in the embryo, but it continues to change throughout fetal and postnatal development. Vasculogenesis is completed during early embryonic development and angiogenesis is completed slightly later during embryonic development (although physiologic angiogenesis resumes in the adult female ovary during the ovulatory cycle). All subsequent development of the vascular system is through vascular remodeling, which normally continues to occur until adulthood.

In the adult, mature endothelial cells retain the capacity to regenerate and, when tissues are injured, new blood vessels can develop as part of the repair process. These vessels are thought to arise primarily by angiogenesis, initiated by endothelial cells in vessels neighboring the wound site. However, recent studies suggest that bone marrow-derived angioblasts present in adult blood are capable of “seeding” the site of injury to supplement angiogenesis. [3] New vessels formed early in wound healing undergo vascular remodeling as young granulation tissue matures. Vascular remodeling may also occur in mature vessels subjected to various stimuli (e.g., hypertension and increased flow).

Vasculogenesis and angiogenesis in the embryo (and angiogenesis in wound healing) require regulation of endothelial

proliferation and migration as well as the coordination between the endothelial and supporting cells. Transgenic and genetic knockout murine models have revealed that the signals that mediate this complex process largely depend on the binding of secreted molecules such as VEGF and angiopoietins, and membrane-bound ephrins that bind to specific receptor tyrosine kinases. [4]

Molecules of the VEGF family are required to initiate the formation of primitive vessels. VEGF was initially identified for its ability to induce vascular permeability and endothelial proliferation, and is now known to also promote migration and inhibit apoptosis. VEGF is a highly specific mitogen for endothelial cells and does not act on vascular smooth muscle, fibroblasts, or epithelial cells. VEGF synthesis by stromal or epithelial cells is increased in settings of hypoxia, and VEGF is largely responsible for angiogenesis that develops in hypoxic tissues. This family of molecules includes five VEGF splice variants (VEGF A–E) and the homologue placental growth factor (PlGF). These molecules variably bind a family of closely related receptor tyrosine kinases named VEGFR-1 (Flt-1), VEGFR-2 (KDR or Flk-1), and VEGFR-3 (Flt-4). VEGFR-2 is the main mediator of VEGF growth and permeability effects on endothelial cells, playing the primary role in driving vascular development and angiogenesis in adults, and binding all VEGF isoforms. The activity of VEGFR-2 can be enhanced by binding of VEGF A to neuropillin-1, which appears to function as a coreceptor. VEGFR-1 binds PlGF and VEGFs A and B, and may have a downregulatory role or act as a decoy receptor. PlGF binding to VEGFR-1 appears to amplify endothelial cell responses to VEGF. Early in embryonic development VEGFR-3 is widely expressed on vascular endothelium, but it later becomes restricted to lymphatic endothelium. VEGFR-3 binds VEGFs C and D, which play a critical role in lymphatic development and post natal lymphangiogenesis.

The importance of tight regulation of VEGF expression during vascular development has been demonstrated in several murine development models. Mice that have undergone the targeted disruption of VEGF or VEGFR-2 genes fail to develop a vasculature. VEGF is so critical for vasculogenesis that even heterozygous knockout animals, which produce 50% as much VEGF as normal animals, show embryonic lethality. Conversely, knockout of the downregulatory VEGFR-1 results in the formation of immature leaky vessels. Similar results are observed when VEGF A is overexpressed. Disruption of VEGFR-3 results in the disorganization of large vessels and lymphatic hypoplasia. A missense mutation in VEGFR-3 occurs in primary human lymphedema. Transgenic overexpression of VEGF C results in lymphatic hyperplasia, indicating the important role of this splice variant in lymphatic development. [4], [5] and [6]

Fibroblast growth factors 1 and 2 (also called acidic and basic FGF, respectively) have been proposed as participants in vasculogenesis and angiogenesis during embryonic development, but this has not been firmly established. The principal signaling receptor for these molecules is FGFR-I. [7] However, knock out of this receptor in mice produces death in the gastrula stage, i.e., before vasculogenesis begins, so specific evaluation of FGF function in vascular development is not possible in these animals. Both FGF-1 and -2 are potent endothelial cell mitogens, although they are not specific for endothelial cells (i.e., they also act on smooth-muscle cells and fibroblasts), and they are active in the same bioassays of angiogenesis as is VEGF. Interestingly, the FGFs can “synergize” with VEGF in stimulating cultured endothelial cell mitogenesis and in bioassays of angiogenesis, giving greater responses than those seen with either agent alone. In the adult, FGF-1 and -2 are stored in the cytoplasm of a variety of cells, consistent with the fact that these proteins lack signal sequences required for efficient secretion. Stored FGFs are released when cells are injured, acting as “wound hormones” to stimulate local angiogenesis and connective tissue growth. [7]

Other polypeptide factors have also been found to act on endothelial cells in vivo and in vitro, including epidermal growth factor (EGF), [8] heparin-binding EGF-like growth factor, [9] and hepatocyte growth factor/ scatter factor. [10] These molecules have some angiogenic potential, but their role in embryonic development is not clear.

Subsequent to the initial vasculogenic actions of VEGFs, another family of receptor tyrosine kinases, Tie-1 and Tie-2 (Tek), are required for vascular remodeling and stabilization. Tie-2 mediates the “dialog” between primitive mesenchymal cells and the endothelium of the immature blood vessel through binding to angiopoietins 1 (Ang-1), 2 (Ang-2), murine angiopoietin 3 (Ang-3), and its human orthologue angiopoietin 4 (Ang-4). Ang-1 binding appears to primarily positively effect vascular stability. Mouse embryos lacking either Ang-1 or Tie-2 develop a normal primary vasculature, but fail to undergo further vascular remodeling. In the heart, there is impaired association between the endocardium and the underlying myocardium. There are defects in the remodeling of vascular beds that appear be due to a similar lack of appropriate association with underlying support cells. Furthermore, venous malformations are found in humans with a Tie-2 mutation, which are typified by enlarged vascular channels with a relative lack of supporting smooth muscle cells. Ang-2 appears to be a competitive inhibitor of Ang-1, and Ang-2 overexpression in transgenic mice results in a phenotype resembling an Ang-1 knockout animal. [11] This suggests that Ang-2 may serve to antagonize Ang-1, perhaps as an early step in angiogenesis and vascular remodeling, i.e., when a preexisting vessel must be destabilized to permit endothelial cell outgrowth and migration. This hypothesis is supported by the impairment of certain forms of postnatal vascular remodeling in Ang-2 knockout mice, and the upregulation of Ang-2 in settings of intense angiogenesis such as in highly angiogenic tumors, and in response to hypoxia and VEGF treatment. Although the ligands for Tie-1 are not known, knockout of this receptor results in similar defects in vascular maturation later in embryonic development. [4], [12]

An important role has recently been identified for the eph family of receptor tyrosine kinases and their corresponding ephrin ligands. Both the eph receptors and the ephrin ligands are membrane bound and it appears that they mediate bidirectional cell to cell signaling. Based on membrane attachment characteristics, the ephrins are divided into two classes, the A class (ephrin-A1 to A5) that generally bind the eight ephA receptors (ephA1 to A8), and the B class (ephrin-B1 to B3) that bind the six ephB receptors (ephB1 to B6). Ephrin-A1 has activity during inflammatory angiogenesis induced by tumor necrosis factor (TNF). Ephrin-B1 promotes endothelial capillary assembly in vitro. Recent knockout mouse studies suggest key roles for ephrin-B2 and its ephB4 receptor during vascular development. Mice lacking ephrin-B2 and its ephB4 receptor have lethal defects in early angiogenic remodeling. [13] During vascular development ephrin-B2 marks the endothelial cells of early arterial vessels and ephB4 marks the endothelium of early veins. This distribution supports the proposal that ephrin-B2 and ephB4 are involved in establishing venous versus arteriolar identity. As development proceeds ephrin-B2 continues to mark the arteriolar endothelium, with additional expression on surrounding arteriolar smooth muscle cells and pericytes, and may be involved in regulating

endothelial–smooth muscle interactions. [14]

Other endothelial cell-derived signals that act on the mesenchymal cells during vascular remodeling have not been identified with certainty, but two leading candidates are platelet-derived growth factor (PDGF) and transforming growth factor-ß (TGF-ß). [21] Both PDGF and TGF-ß are molecules that are secreted by endothelial cells, acting on mesenchymal cells to promote migration, matrix biosynthesis and differentiation. PDGF is a mesenchymal cell mitogen, whereas TGF-ß may promote or inhibit cell growth. Like VEGF and FGF, PDGF acts through receptor protein tyrosine kinase. In contrast, the TGF-ß signaling receptor is a protein serine/threonine kinase rather than a protein tyrosine kinase. TGF-ß also uses a number of nonsignaling receptors that “present” TGF-ß to the signaling receptor. The dimeric nonsignaling endothelial cell TGF-ß binding protein, endoglin (CD105), appears to play an important role in vascular development and angiogenesis. A truncation mutation in the endoglin gene causes a hereditary form of vascular malformations (hereditary hemorrhagic telangiectasia type I) [15] Similar multisystemic vascular dysplasia and hemorrhage are seen in mice heterozygous for CD105. Interestingly, endoglin knockout mice die of defective vascular development. A role for at least some isoforms of PDGF in vascular remodeling in the embryo was recently confirmed in knockout animals. Similar confirmation is lacking for TGF-ß, but it has been difficult to effectively knock out the function of this molecule because complete absence of TGF-ß causes embryonic lethality. In rare, live-born, TGF-ß knockout animals, it is likely that TGF-ß was provided to the developing fetus by the mother. Such animals die young and cannot be easily bred.

Matrix glycoproteins (e.g., fibronectin and laminin) and receptors for matrix glycoproteins (especially ß1 and ß3 integrins) are also believed to play a role in vasculogenesis/angiogenesis. [16] This seems intuitive because neither endothelial cells nor mesenchymal cells can survive unless they interact with matrix proteins via integrin receptors. Knock-out of most of these molecules causes early embryonic lethality, usually prior to development of the vascular system, preventing a direct test of their role in vascular embryology. An exception to this is knock out of B3 integrin, which shows normal development and enhanced tumor ngiogenesis. Finally, two other classes of molecules have been implicated in vessel formation, namely coagulation factors and proinflammatory cytokines. One key coagulation factor, tissue factor, is implicated in vasculogenesis by observations of defective vascular development in tissue factor knockout mice. [17] Coagulation factor V knockout mice may also have some vascular defects, but this phenotype is more variable. It was recently suggested that the effects of deficiencies in the coagulation cascade on vascular development may be the indirect result of defective thrombin production, because knockout of the thrombin receptor PAR-1 produces similar phenotypes. Evidence for a role of proinflammatory cytokines in angiogenesis has come largely from in vivo bioassays. It is not clear if these molecules act directly on endothelial cells, or whether they act by causing release of primary vasculogenic/angiogenic factors (e.g., VEGF or FGF) by other cells (e.g., from mesenchymal cells or from recruited leukocytes). [18] Knockout mice lacking inflammatory cytokines do not show defects in vasculogenesis or angiogenesis. Endothelial cell molecules involved in adhesion of leukocytes [e.g., E-selectin or vascular cell adhesion molecule (VCAM)-1] have also been reported to be signals for angiogenesis, but roles for E-selectin or VCAM-1 in vascular development have also not been confirmed in knockout mice.

The specialization of endothelial cell types at different anatomic sites occurs during vascular remodeling. It has been proposed that specialization is induced by signals that vary with anatomic location. In the adult, vascular remodeling is influenced by mechanical signals such as shear stress or stretch. Cultured endothelial cells respond to mechanical forces, [19] and it is likely that this occurs in the embryo as well. Because mechanical forces differ with anatomic position, they are a candidate for inducing endothelial specialization. In general, mechanical forces are most pronounced in the arterial tree. Mechanical forces can act either through force applied directly to the cell (detected by some unknown signal transducer) or indirectly by “tugging” on the integrin-mediated attachments of endothelial cells to underlying *basement membrane,* a specialized region of the extracellular matrix that forms on the ablumenal surface of the endothelial cells.

The basement membrane itself is an even better candidate to determine endothelial specialization than are mechanical forces. The basement membrane varies in macromolecular composition (both glycoprotein and proteoglycan) and in its structural organization with anatomic site or vessel type. In certain vascular beds (e.g., in splenic sinusoids), the basement membrane is not well formed, i.e., there is a absence of matrix condensation as viewed by electron microscopy. However, all endothelial cells are attached to matrix and will undergo apoptosis if they become detached. Both endothelial cells and nonendothelial cells contribute to basement membrane synthesis and maintenance. The contribution of the surrounding nonendothelial cells to basement membrane composition thus provides a means for the local tissue to influence endothelial cell specialization. This hypothesis is supported by the observation that endothelial cells cultured on specialized basement membranes made by nonendothelial cells may acquire specialized features, e.g., the formation of fenestrae on endothelial cells grown on basement membrane made by epithelial cells. [20] However, cultured endothelial cells may retain some tissue-specific differences, regardless of the matrix used for their culture. Endothelial cell specialization may also be influenced directly by other cells either through cell-cell contact or through diffusable signals. For example, astrocytes cocultured with endothelial cells may stimulate formation of high-resistance junctions, which are characteristic of microvessels in the central nervous system. [21]

When angiogenesis and vascular remodeling occur following injury, the endothelial cells lining the new vessels may not display the same characteristics as the original endothelial cells resident at that anatomic site. For example, capillary endothelia in injured liver may be continuous and lose fenestrae. Similar alterations in the endothelial cell phenotype have been observed in certain skin diseases. We refer to this change in the endothelial cell phenotype as *metaplasia,* analogous to the changes observed in reparative epithelial cells as a response to chronic injury. This term does not imply that individual endothelial cells have changed from one type of specialized endothelium to another, but rather that new endothelial cells arising from angiogenic repair processes may have a distinct phenotype.

MORPHOLOGIC FEATURES AND MOLECULAR MARKERS OF ENDOTHELIUM

General Morphologic Features of Endothelial Cells

Endothelial cells are flattened epithelial-like cells, with a thickness typically less than 10 µm, and a surface area covering

up to 1000 μm ^{2}. In large vessels, endothelial cells assume an elongated shape with their long axis oriented in the direction of blood flow. Endothelial cells located in regions of turbulent flow, i.e., at branch points of the arterial tree, are often polygonal rather than elongated. Cultured endothelial cells are typically more polygonal, but elongate when flowing medium is passed over them for periods of 24 h or more. [22] These observations have led to the conclusion that shear stress, the force imparted by viscous drag of flowing liquid, is responsible for inducing a cytoskeletal rearrangement and the change of shape from polygonal to elongated. The nucleus is centrally located in both polygonal and elongated cells. Interestingly, the microtubular organizing center of endothelial cells, is always found located near the nucleus, oriented toward the heart (i.e., upstream of flow in arteries and downstream of flow in veins) regardless of the direction of blood flow. [23] The basis for this phenomenon is unknown.

In most vessels, the endothelial cells form a continuous monolayer, in which each endothelial cell forms junctional complexes with all of its neighbors. Endothelial cells are in contact with neighboring endothelial cells through gap junctions, and evidence has been presented that they may additionally form functional gaps with both surrounding vessel wall cells and, on occasion, with bound leukocytes. Endothelial cells are normally polarized, concentrating integrin receptors for matrix macromolecules on the basal surface while displaying adhesion molecules for leukocytes almost exclusively on their apical surface, which faces the lumen of the blood vessel. [24]

Specialized Organelles of Endothelial Cells

Endothelial cells have a number of characteristic organelles, the best described of which are Weibel-Palade bodies (WPB), fenestrae, and the caveolar system. WPB are elongated, membrane-bound organelles that display longitudinal striations by electron microscopy. WPB are distributed randomly throughout the cytoplasm in vascular endothelial cells of most vertebrates, and are found in arteries (most prominently), veins, capillaries, and endocardium, but not of lymphatics. They may or may not be expressed in glomerular endothelial cells or in the sinusoidal endothelial cells of liver or spleen. WPB constitutively contain von Willebrand factor (vWF; also called factor VIII-related antigen), P-selectin (CD62P), [25] lysosomal-membrane–associated glycoprotein 3 (LAMP-3 or CD63), [26] 1, 3-fucosyltransferase VI, [27] and interleukin 8. [28] The longitudinal striations within the WPB are formed by highly polymerized forms of vWF, reaching sizes up to 20 Md, and are responsible for cell surface expression of the integral membrane proteins P-selectin and CD63. Upon release, vWF polymers may attach to the basement membrane and stabilize platelet adhesion to the subendothelial matrix, particularly in high-velocity arterial flow. Although vWF is commonly used as an endothelial cell marker (see below), it is also found in megakaryocytes, which appear to lack a physiologic mechanism of release, synthesizing vWF only for storage within the a granules of their platelet progeny. P-selectin is also found in the membranes of platelet a granules. P-selectin mediates leukocyte adhesion to endothelium (see below). CD63 is a 53-kDa lysosomal membrane glycoprotein belonging to the TM4 superfamily that may interfere with neutrophil adhesion to endothelium.

Because vascular endothelium forms a continuous monolayer, most transendothelial transport takes place in the junctions between cells. One important exception is in the fenestrae of capillaries in lymph nodes, capillaries in the intestinal mucosa, renal glomerular endothelial cells, and in hepatic and bone marrow sinusoids. Fenestrae are 175 nm in diameter, are grouped into structures resembling sieve plates, and occupy 6 to 8 percent of the surface capillaries. They are specialized annular patches of attenuated cytoplasm and membrane characterized by an increased concentration of anionic lipids. [29] Fenestrated capillaries are much more permeable to water and small-molecular-size solutes than those of the continuous type. The anionic charge probably precludes the *trans*-fenestral passage of anionic plasma proteins. Fenestrae are unique to endothelial cells. Various factors such as pressure, alcohol, serotonin, nicotine, and infection change the number and diameter of fenestrae. [29] However, even endothelium of the continuous type may become transiently fenestrated.

A second important transport system is vesicular transport. All endothelial cells appear to contain numerous micropinocytotic vesicles beneath the folded surface, both, luminal and abluminal, indicating a high vesicle transport rate in these cells. Although such structures were originally interpreted as vesicles caught in the process of budding off or fusing to the membrane, upon careful examination most of these vesicles turned out to have narrow tubular connections to the plasma membrane. These flask-shaped caveolae, literally “little caves,” are part of the surface membrane, either as single caveola or as more complex racemose invaginations. In fact, free plasmalemmal vesicles are extremely rare in capillary endothelium. Caveolae are maintained by a network of investing protein, called *caveolin*. The lipid composition of the caveolar membranes are enriched for cholesterol and sphingomyelin. It is becoming evident that caveolae serve to harbor signal transducing subcompartments of the plasma membrane, particularly receptor tyrosine kinases associated with growth factor responses (e.g., platelet-derived growth factor receptors), as well as associated proteins such as phosphatidylinositol 3-kinase, Src-like kinases, and phospholipase C. Endothelial nitric oxide synthase is also found associated with caveolin-1. Mice lacking caveolin-1, the main protein component of caveolae, have impaired nitric oxide and calcium signaling in the cardiovascular system, causing aberrations in endothelium-dependent relaxation, contractility, and maintenance of myogenic tone. [30] The caveolar systems are not unique for endothelial cells, but they are particularly well developed in this cell type, especially in brain capillaries.

Endothelial Junctions

Neighboring endothelial cells connect to each other by forming interdigitating protrusions connected by junctions. Junctions possess different degrees of complexity along the vascular tree, reflecting different permeability for proteins and cells. Intercellular tight (occluding) junctions constitute the anatomic basis for the tightly regulated interfaces of the blood-testis and blood-brain barriers. [31] They consist of a continuous belt-like meshwork of six anastomosing junctional strands, which prevent the transport of macromolecules, such as horseradish peroxidase, into the tissue. The transmembrane protein occludin, linked to ZO-1 cytoplasmic proteins, appears to provide the molecular basis of this function. In addition, junctional adhesion molecules, called JAMs, members of the immunoglobulin superfamily, form homophilic adhesion sites in tight junctions and play a role in the generation of cell polarity. [32] Arterial endothelium also possess tight junctions, however they consist of only one to two junctional strands. Tight junctions are virtually absent in

postcapillary venules.

Adherens junctions are found in all vascular endothelium. They are multimeric protein structures consisting of two transmembrane proteins, CD144 (also called cadherin 5 or VE-cadherin) and CD31 (also called PECAM-1) that are linked by proteins of the catenin family to the actin-based cytoskeleton. [33] VE-cadherin is strictly localized to endothelial junctions, whereas PECAM-1 is more broadly distributed over the cell surface. Adherens junction proteins appear to be involved in three different cell functions. First, they participate in capillary tube formation. Indirect evidence for the role of the transmembrane molecules PECAM-1 and VE-cadherin in vessel formation came from investigations of malignant endothelial tumors with primitive or abortive vascular (luminal) differentiation, which had little to no VE-cadherin or PECAM-1 expression. Blocking VE-cadherin and PECAM-1 interactions with monoclonal antibodies inhibited vessel formation in normal endothelial cells. [34] VE-cadherin–negative endothelial cells derived by gene targeting failed to organize in vessel-like structures. [35] Second, PECAM-1 and VE-cadherin participate in the regulation of leukocyte transendothelial migration. Third, PECAM-1 and VE-cadherin may indirectly regulate cell growth by regulating the free cytoplasmic pool of ß-catenin. Endothelial cells also express a neuronal cadherin, N-cadherin. However, this protein is localized outside the junction and appears to be nonfunctional.

The existence of a third type of junction has been demonstrated by transfer of microinjected small-molecular-weight tracers between adjacent endothelial cells indicating the presence of gap junctional interendothelial communications. In endothelium, the gap junctional proteins are connexins-43, -37, and -40.

A fourth kind of adhering junction (“complexus adherens” or “syndesmos”) is particularly abundant in the endothelium-related, stellate cells which form the three-dimensional filter meshwork of the lymph node sinus. They contain cadherin 5, plakoglobin, and desmoplakin, but are negative for vinculin and a-actinin.

Endothelial Cell-Matrix Interactions

In general, continuous as well as fenestrated endothelium rest on a basal lamina. It is thought that fenestrae are partially or completely occluded in all vascular beds by this basal membrane except in hepatic and bone marrow sinusoidal cells. The basal lamina is predominantly formed by both endothelium itself and surrounding cells, and consists of laminin-1, collagens, fibronectin, nidogen (entactin), and heparan sulfate proteoglycans. Surprisingly, immunohistochemical investigations do not reveal qualitative differences between the basal lamina of newly formed capillary sprouts and established vasculature. Interaction with these matrix molecules is essential for maintaining normal endothelial function. For example, the laminin A chain peptide supports endothelial branching and formation of new capillaries. [36] Furthermore, a 20-kDa C-terminal fragment of collagen XVIII specifically inhibits endothelial proliferation and angiogenesis, [37] indicating that collagen XVIII also appears to be a positive regulator of vessel growth. On the other hand, endothelium–collagen V interactions inhibit endothelial attachment and growth. Endothelial cells interact with these components of the basal lamina by numerous transmembrane adhesion molecules. The complexities of these interactions have only been partially characterized. Members of the integrin family are particularly important for this function. For example, $a_6ß_1$, $a_2ß_1$, $a_5ß_1$, and $ß_Vß_3$ receptor complexes are important for endothelial attachment to, and migration on, laminin, collagen, and tenascin therefore serving important roles in angiogenesis. In addition, ligation of integrins by matrix proteins also has a multitude of intracellular effects on the organization of the endothelial actin skeleton and on signaling processes within the cell. [38] Endothelial growth factors have been shown to differentially upregulate the biosynthesis of a_2, a_5, $ß_1$, and $ß_3$ integrins, in order to serve the different needs of endothelium during growth, spreading, and new vessel formation. Moreover, integrins show certain tissue and vessel restricted expression, for example, $a_1ß_1$ is found only in small blood vessels and capillaries, but not in large-vessel endothelium. Matrix proteins such as thrombospondins may also serve as inhibitors of angiogenesis. [39]

Morphologic Specialization of Endothelial Cells

As we noted in the preceding sections, endothelial cells differ along the course of the vasculature with regard to numbers of Weibel-Palade bodies, extent of the development of the caveolar system, the presence or absence of fenestrae, the type of intercellular junction, and the nature of the basement membrane composition and interactions. Additional morphologic specializations also may develop. The best characterized of these occurs in the postcapillary venules of the lymph nodes and mucosal-associated lymphoid tissues. Such endothelial cells loose their characteristic flat morphology of vascular endothelium and acquire a distinct “high” or cuboidal shape. For this reason, these microvessels are called *high endothelial venules* (HEVs). Their endothelial cells display more prominent biosynthetic organelles and synthesize basement membrane highly enriched with sulfated glycosaminoglycans. [40] These features are thought to facilitate transendothelial diapedesis of lymphocytes. Similar morphologic features may be acquired by venular endothelium at sites of chronic inflammation and may represent an adaptation to elevated levels of leukocyte trafficking. [41]

A second specialized type of endothelial cell is the sinusoidal endothelial cell of the spleen. Sinuses in the spleen are not found in all mammals. For example, they are well formed in humans and rats, but are absent in mice. In the spleen, where sinusoids exist, arteries open into splenic parenchyma, and blood is reabsorbed into sinusoids through open spaces at the end, and through interendothelial slits. The spleen sinus traps erythrocytes with denatured hemoglobin (Heinz bodies) by a yet unknown mechanism. The sinusoids drain into the venous system.

Molecular Markers of Endothelial Cells

Endothelial cells display a number of common biochemical/molecular features that have been used to define an antigenic phenotype. The single most widely used marker for vascular endothelium is vWF, which may be detected in WPB or within the biosynthetic organelles (Golgi apparatus or endoplasmic reticulum). vWF is displayed by almost all vascular endothelium, but its level may vary. vWF is essentially undetectable in renal glomerular capillaries. vWF is also found in megakaryocytes and platelets. CD31 (PECAM-1) is shared by endothelium and platelets, but is also found on circulating leukocytes (see below). All endothelium can be recognized by acetylated low-density lipoprotein (acLDL) uptake via the

“scavenger cell pathway” of LDL metabolism. There are at least four different types of scavenger receptors. [42] Some of these receptors are shared with or are unique to macrophages, while some are probably unique to endothelium. However, the uptake of fluorescence-tagged acetylated or oxidized LDL has been used as a marker of endothelium, but does not distinguish among receptors, or between endothelial cells and macrophages. Nearly all endothelial cells secrete and then bind CD143 (angiotensin-converting enzyme) to the cell surface. This characteristic is shared with macrophages. Most endothelial cells express the anticoagulant protein CD141 (thrombomodulin). This feature is shared with trophoblast cells of the placenta, which, like endothelium, form a blood-compatible surface that prevents coagulation.

Some endothelial markers are not proteins. Endothelial cells display proteoglycans rich in heparan sulfate glycosaminoglycans that bind and activate antithrombin III, i.e., have anticoagulant properties. Human vascular endothelial cells express blood group H antigens recognized by the lectin ulex europaeus agglutinin-1 (UEA-1). This expression is also shared with erythrocytes and certain specialized epithelia. Endothelial cells of species other than higher primates (including humans) and Old World monkeys lack a particular fucosyltransferase and cannot synthesize blood group H, but have related carbohydrate moieties that instead bind lectins such as Bandeiraea simplicifolia, peanut, and Dolichos biflorus agglutinin.

Combinations of vWF expression, receptor-mediated acLDL uptake, angiotensin-converting enzyme (ACE) expression, thrombomodulin expression, and blood group H expression are used as molecular identifiers of endothelial cells in vitro and in vivo. As we have noted, none of these markers alone is truly endothelial specific. More recently, VEGF receptors 1 and 2 have been used, but these receptors have recently been found on a growing list of other cell types. Tie-1 and Tie-2 have been suggested to be more specific, but these markers have not been adequately examined as to specificity. Although less widely used, intercellular adhesion molecule (ICAM)-2 may be the single best marker for endothelium. It is not generally found on other cell types and transgenic receptor genes expressed using the ICAM-2 promoter appear to be expressed only on endothelial cells. [43] Other helpful markers are P-selectin and, following cytokine treatment (see below), E-selectin (CD62E). E-selectin expression, when present, appears to be absolutely specific for endothelium, but is not inducible on all endothelial cells.

All endothelial cells share numerous surface proteins with various subpopulations of hematopoietic cells such as CD9, CD13, CD31, CD40, CD54, CD58, CD105 (endoglin), complement receptors for C1q and C5a, and complement regulatory proteins such as CD46, CD55, CD59, and Thy-1. This probably reflects the common embryologic origin of the angioblast and the hematopoietic stem cell. Moreover, endothelial cells express proteins broadly found on many cell types, such as CD26, CD44, CD47, and CD146 (MUC18). Endothelial cells also express class I major histocompatibility complex (MHC) molecules and a characteristic array of integrins. Finally, it should be noted that in normal tissues in vivo, endothelial cells investing blood vessels can be differentiated from endothelial cells investing lymphatics, the latter being Prox-1, Lyve-1 (lymphatic vessel endothelial hyaluronan receptor), podoplanin, and VEGF receptor 3 positive. [44]

True blood capillaries consist of tubes formed by a continuous string of elongated endothelial cells, each curved to form a segment of a hollow cylinder. Capillary endothelial cells express a series of microvessel-specific proteins not found on large vessels such as the PAL-E antigen. [45] Blood capillaries also express CD34, which is also expressed on immature hematopoietic cells. Interestingly, monoclonal antibodies to different CD34 epitopes variably stain hematopoietic cells but uniformly stain endothelial cells. [46] In large mammals, microvascular endothelial cells express class II MHC molecules. CD36 is found on all microvessels with exception of brain endothelial cells and subtypes of skin microvessels, [46], [47] which are CD36 negative. Certain molecules are restricted to distinct microvascular beds such as CD32 and CD206 for liver and skin and CD71 for brain. [48], [49] and [50] Microvascular endothelial cells in certain organs may express unique sialomucins. In the gastrointestinal tract and the breast, they are contained within the 60-kDa core protein MadCAM-1. [51] In the lymph nodes, especially the high endothelial venule, they may be found in the secreted sialomucin GlyCAM-1. Moreover, certain surface proteins of endothelial cells may be decorated with sulfated sialylated and fucosylated carbohydrates, which react with antibody MECA-79, are collectively called peripheral node addressins, and function as L-selectin ligands. [40] They are specifically found in peripheral nodes, but may also be expressed on skin endothelium. [41]

In addition to the constitutively expressed molecules, endothelial cells show a characteristic pattern of inducible markers. At sites of inflammation, endothelial cells may express E-selectin and VCAM-1 (CD106). P-selectin may be increased on the cell surface, as is ICAM-1. Tumor vessels may display ICAM-3.

ENDOTHELIUM IN INFLAMMATION

Innate Immunity

Innate immunity, also called natural or native immunity, comprises the host's defense systems against microbes that are independent of T and B lymphocytes and their receptors for specific antigens. The innate immune system is much older in evolutionary terms than the T- and B-cell–specific immune system, and elements of innate immunity have been found in invertebrates such as sponges and starfish. The principal effector cells of innate immunity in humans are the phagocytic leukocytes, including both neutrophils and mononuclear phagocytes (i.e., blood monocytes and their progeny, tissue macrophages), natural killer (NK) cells, a primordial lymphocyte. Innate immunity has a humoral component, primarily involving the complement system and its alternative pathway of activation. Various acute phase proteins made by the liver cells, macrophages, and vascular endothelium also participate in innate immunity. The cells of the innate immune response, like those of the specific immune response, communicate with each other through release of cytokines. Endothelial cells are both a target and a source of the inflammatory cytokines of innate immunity.

The innate response to microbes is initiated by recognition by the host of the presence of non-self. In general, only a few prototypic foreign structures are recognized and the range of responses of innate immunity are limited. The two key responses are to viruses and bacteria. Cells infected with replicating viruses, but not normal mammalian cells, form double-stranded RNA molecules. Double-stranded RNA signals the presence of non-self by activating certain kinases. The kinases, in turn, trigger the synthesis of interferons a and ß (IFN-a/ß). IFN-a/ß, also called type I IFN, is a cytokine

that induces resistance to viral infections in host cells and renders infected cells more susceptible to lysis by host effector cells. [52] IFN-a/ß also activates NK cells, which are major effector cells of innate immunity.

Antibacterial responses are initiated against bacterial cell-wall constituents not found in mammalian cells, such as lipopolysaccharide (LPS), which comprises the outer wall of gram-negative bacteria. LPS binds to the LPS-binding protein in plasma and is delivered to the cell surface receptor CD14, expressed on the surface of monocytes/macrophages. This complex can activate the transmembrane signaling receptor toll-like receptor 4 and its accessory protein MD2. LPS stimulation activates several intracellular signaling pathways that include the I?B kinase-NF?B and mitogen-activated protein kinase (MAPK) pathways. These signaling pathways in turn activate a variety of transcription factors that include NF?B (p50/p65) and AP-1 (c-fos/c-jun), which coordinate the induction of many genes encoding inflammatory mediators. Endothelial cells lack CD14 but respond to complexes of LPS with soluble CD14. As in macrophages, endothelial activation occurs through toll-like receptor 4. [53] Endothelial cells also express toll-like receptor 2, which serves as a signaling receptor for gram-positive cell wall components. Certain vascular beds express the macrophage mannose receptor (CD206), a receptor for oligosaccharides on the cell wall of bacteria, yeasts, and parasites. Other receptors of the innate immune system include a variety of lectin-type molecules, such as mannose-binding protein or galactins, that recognize bacterial carbohydrates. Mannose-binding protein may activate the alternative pathway of complement activation.

The cellular response to bacterial products such as LPS involves the secretion of several key cytokines, including TNF (sometimes called TNF-a), interleukin-1ß (IL-1ß), IL-6, IL-10, IL-12, and IL-15. TNF and IL-1ß act on endothelial cells to induce proinflammatory changes that are discussed in detail below. TNF also acts on neutrophils to potentiate their oxidative burst response. IL-6 triggers the liver and other cells to make acute phase proteins. IL-12 acts on NK cells to induce secretion of IFN-?; IFN-?, in turn, further activates neutrophils and macrophages, combining with TNF to induce more potent antimicrobial mechanisms such as increased generation of reactive oxygen intermediates and possibly nitric oxide. IL-15 acts as a growth factor for NK cells. Whereas all of the above mentioned cytokines promote inflammation, IL-10 serves to dampen the response, downregulating the synthesis of other cytokines. Knockout mice lacking IL-10 show uncontrolled inflammation, especially in the gut where LPS is abundant.

TNF and IL-1ß appear to be central to many different types of inflammatory reactions. In general, endothelial responses to TNF and IL-1 are similar and are considered together. At least five changes in the phenotype of endothelial cells that promote inflammation, collectively called “endothelial activation”, have been described.

VASODILATORS TNF- or IL-1ß–treated endothelial cells acquire increased capacities to produce vasodilators, such as prostaglandin I_2 (PGI_2) and NO. PGI_2, sometimes called prostacyclin, is synthesized in endothelial cells by a series of three sequential enzyme-catalyzed reactions. First, cytosolic phospholipase A_2 ($cPLA_2$) releases arachidonic acid from the SN-2 position of membrane phosphatidyl choline. Endothelial cells contain an enzyme that can acetylate the now vacant SN-2 hydroxyl group of phosphatidyl choline, generating biologically active platelet-activating factor (PAF); PAF is a potent activator of neutrophils. Second the liberated arachidonic acid is oxidized by O_2 in a two-step reaction catalyzed by prostaglandin H synthase (also called cyclooxygenase) to form prostaglandin H_2 (PGH_2). Third, the PGH_2 is converted to PGI_2 by the enzyme prostacyclin synthase. The total reaction sequence is initiated by the activation of $cPLA_2$. $cPLA_2$ is constitutively expressed in endothelial cells, normally in an inactive form. [54] The enzymatic activity of $cPLA_2$ is increased by phosphorylation, catalyzed either by mitogen-activated protein (MAP) kinases such as ERK-1 or ERK-2, or by stress-activated protein (SAP) kinases such as p38. TNF and IL-1ß efficiently activate p38 in endothelial cells, contributing to $cPLA_2$ activation, whereas autacoids like histamine probably work through ERK-1 or ERK-2. However, in order for activated $cPLA_2$ to efficiently interact with the cellular membrane, where phosphatidyl choline is sequestered, there must also be a rise in cytosolic free calcium. Neither TNF or IL-1ß can cause a rise in cytosolic free calcium in endothelial cells, and this second signal is typically provided by autacoids such as histamine or the complement-derived anaphylatoxin C5a. LPS is an activator of the alternative pathway of complement, which can generate C5a. C5a not only acts on endothelial cells directly, but can also trigger perivascular mast cells to release histamine, which, in turn, acts on endothelial cells. Endothelial cells express one isoform of prostaglandin H synthase, PGHS-1, also called cyclooxygenase (COX)-1, that is constitutively active. Once $cPLA_2$ is activated to release arachidonic acid, PGHS-1 becomes rate limiting. Treatment of endothelial cells with TNF or IL-1ß dramatically increases the level of PGHS activity by inducing de novo expression of a second isoform, PGHS-2, which is also called COX-2. This response markedly increases the capacity of the cell to make PGH_2 from arachidonic acid. It is not known whether prostacyclin synthase activity is limiting or whether it is regulated by cytokines. NO is synthesized by the oxidative conversion of arginine to citrulline and NO. This reaction is catalyzed by an enzyme called nitric oxide synthase (NOS). Normally, endothelial cells express a single isoform of NOS, called NOS-III or endothelial NOS (e-NOS). This enzyme is activated by rises in cytosolic free calcium that are signaled through the calcium-binding protein calmodulin. As noted earlier, TNF or IL-1ß do not directly effect cytosolic calcium levels, but they increase NOS activity by increasing the level of a normally limiting cofactor, tetrahydrobiopterin. (This effect is enhanced by the presence of IFN-?). The net result of these TNF and IL-1ß actions is to increase the synthesis of the vasodilatory molecules PGI_2 and NO by endothelial cells. PGI_2 or NO both relax smooth-muscle cell tension thereby producing local vasodilation and increasing tissue perfusion and hence delivery of leukocytes to the site of cytokine generation. Pharmacologic reduction in the generation of PGI_2 is thought to contribute to the anti-inflammatory actions of aspirin and nonsteroidal anti-inflammatory drugs (NSAIDs) that inhibit PGHS activity.

LEUKOCYTE ADHESION TNF- or IL-1ß–treated endothelial cells exhibit a change in their cell surface that favors the initial tethering, rolling, and, ultimately, firm adhesion of leukocytes. Adhesion is a prelude to extravasation of leukocytes into the tissues. The initial tethering is typically mediated by selectins expressed on the leukocyte or on the endothelial cell. [55] There are three structurally related selectin proteins: L-selectin (CD62L), E-selectin (CD62E), and P-selectin (CD62P). L-selectin is constitutively and exclusively expressed on leukocytes. It binds to certain sialylated and fucosylated carbohydrates that may be attached to several different endothelial plasma membrane proteins, or proteoglycans, including CD34 and MadCAM-1, or on the endothelial cell–secreted proteoglycan, GlyCAM-1. In general, microvessels in peripheral tissues, do not constitutively synthesize L-selectin ligands, even though they express CD34 protein. However, these endothelial cells can change their pattern of glycosaminoglycan synthesis when exposed to TNF

or IL-1ß so that L-selectin ligands are now synthesized and displayed. E-selectin, which binds carbohydrate ligands related to sialylated Lewis X or A moieties on leukocytes, is expressed exclusively by endothelial cells. Endothelial cells do not normally synthesize E-selectin, but its transcription and expression are induced by TNF or IL-1ß. Studies using cultured endothelial cells suggest that synthesis of E-selectin is transient (onset 30 to 60 min, peak 2 to 4 h) and that the level cell surface expression generally conforms to the level of new synthesis, implying rapid internalization and degradation of expressed protein. However, these processes may be partly dissociated, so that E-selectin expression on the cell surface may persist for hours or even days after mRNA synthesis has been downregulated. The relevant glycan moieties expressed on neutrophils that are recognized by E-selectin are principally attached to two different proteins: E-selectin ligand-1 (ESL-1) and L-selectin. The protein that displays E-selectin ligands on lymphocytes appears to be P-selectin ligand-1 (PSGL-1, see below). [56] P-selectin is found in the membrane of secretory storage granules in platelets (i.e. a granules) and endothelial cells (i.e., WPB). P-selectin is rapidly translocated to the endothelial cell surface in response to autacoids. In mice, but not humans, TNF or IL-1ß may increase P-selectin levels by inducing new synthesis in chronic inflammatory settings. The ligands for P-selectin include glycans similar to those for E-selectin and sulfated sialomucins similar to those for L-selectin, but these are displayed on distinct leukocyte surface glycoproteins, principally PSGL-1. [57] The initial interaction of a selectin with its ligand results in leukocyte “tethering” to the endothelial surface, a low-affinity attachment. In the presence of flowing blood, the tethered leukocyte is propelled in the direction of blood flow, rapidly breaking and reforming selectin-mediated attachments. This results in rolling of the leukocyte along the endothelial cell surface. It should be noted that the ligands involved in selectin-mediated adhesion that participate in the initial tethering may not be the same as those involved in rolling, e.g., neutrophils may switch from L-selectin to ESL-1 as the principal E-selectin ligand during these two phases of the interaction. [58] Studies using blocking monoclonal antibodies or adhesion molecule knockout mice have confirmed that selectins are required for neutrophil rolling and subsequent recruitment in vivo, although E- and P-selectin functions may be redundant (i.e., both molecules must be knocked out or inhibited for complete loss of rolling). It is not clear whether this redundancy also applies to humans where E- and P-selectin expression is controlled by different signals. Firm adhesion of leukocytes to endothelium is generally mediated by leukocyte integrins. Leukocytes utilize two different types of integrins to interact with endothelial cells. The first of these are the CD18 or ß $_2$ integrins, including LFA-1 (a $_L$ß $_2$ or CD11a/CD18) and Mac-1 (a $_M$ß $_2$ or CD11b/CD18). Both of these integrins bind to ICAM-1 (also called CD54), a member of the immunoglobulin superfamily of proteins. [59] ICAM-1 is constitutively expressed at low levels by endothelial cells, although typically at higher levels than on tissue cells. However, ICAM-1 synthesis and expression can be dramatically (twentyfold or more) upregulated by TNF or IL-1ß (onset 4 h, plateau at 24 h). IFN-? causes a limited and gradual increase in endothelial cell expression of ICAM-1 (as compared to its rapid and potent effect on keratinocyte or melanocyte ICAM-1 expression), but IFN-? can potentiate the effects of TNF in endothelium. Endothelial cells also constitutively express a structurally related molecule, called ICAM-2 (CD102) that can be recognized by LFA-1 but not Mac-1. Despite the constitutive expression of ICAM-2 at levels comparable to that of induced ICAM-1, there is little evidence that ICAM-2 actually mediates firm adhesion of leukocytes to endothelial cells. Antibody blocking experiments suggest that LFA-1 is more important than Mac-1 for the firm adhesion of neutrophils to endothelium, and that Mac-1 may play a more important role in neutrophil activation (especially in phagocytosis, because Mac-1 is also a receptor for complement protein fragment C3bi). However, this hierarchy may depend on the activating signal (see below). The adhesion mediated by LFA-1 or Mac-1 recognition of ICAM-1 is much stronger than that mediated by selectins so that once these molecules have engaged ICAM-1, leukocytes no longer roll. In the case of neutrophils, integrin engagement results in a gradual slowing of rolling velocity. In contrast, lymphocytes abruptly convert from rolling to firm adhesion. Once adherent, leukocytes spread out and then slowly crawl along the endothelial cell surface until they reach a cell junction where they diapedese through the vessel wall into the tissues. It is likely that LFA-1-mediated attachment, disengagement, and reattachment to ICAM-1 play a role in the spreading, crawling, and diapedesis of leukocytes. Although ICAM-1 is initially (at 4 h) upregulated diffusely on the luminal surface of the endothelial cell, it tends to preferentially localize to the intercellular junctions over the first few days. [24] Studies with blocking antibodies in knockout mice confirm that ß $_2$ integrins and ICAM-1 play a major role in leukocyte adhesion to endothelium and in subsequent recruitment. The second group of integrins on leukocytes that mediate attachment to endothelium are the a $_4$ integrins (CD49d), which may pair with either ß $_1$ (CD29) to form VLA-4 or with ß $_7$ to form LPAM-1. Both a $_4$ß $_7$ and a $_4$ß $_1$ bind to vascular cell adhesion molecule-1 (VCAM-1 or CD106) and to the CS-1 domain of the cell-associated fibronectin isoform. a $_4$ß $_7$ can also bind MadCAM-1, recognizing an immunoglobulin-like domain distinct from the sialomucin moiety recognized by L-selectin. a $_4$ß $_7$ interactions with MadCAM-1 are thought to mediate lymphocyte homing to mucosal lymphoid tissues and will be discussed later in this chapter when we address homing of T cells to skin. In humans, VLA-4 is not found on circulating neutrophils, being restricted in expression to monocytes, T cells, eosinophils and basophils. In rodents, it is expressed on neutrophils as well. The principal endothelial cell ligand for VLA-4 is VCAM-1. This immunoglobulin superfamily member is not expressed on resting endothelial cells under normal circumstances, but is upregulated by TNF or IL-1ß with a time course similar to that observed for ICAM-1. VCAM-1 may be selectively upregulated by interleukin-4, a cytokine associated typically with certain types of specific rather than innate immunity. Although VCAM-1 expression is not responsive to IFN-? itself, IFN intensifies TNF-induced VCAM-1 expression. [60] Interestingly, VCAM-1 may support initial tethering and rolling of leukocytes, as well as firm adhesion, depending on whether the affinity/avidity of the leukocyte VLA-4 is increased by leukocyte activation. Both VLA-4 and VCAM-1 knockout mice are embryonic lethal mutations and shed no light on inflammatory processes; antibody-blocking experiments, however, confirm a role for these molecules in leukocyte recruitment in vivo. [61]

LEUKOCYTE ACTIVATION TNF- or IL-1ß–treated endothelial cells promote the activation of tethered or rolling leukocytes, triggering the transition from selectin-mediated low-affinity attachment to integrin-mediated firm adhesion and the transition from spherical, immotile leukocytes to spread, migrating forms. In some experiments, engagement of selectins appears to be adequate by itself to trigger some of these changes, but most experiments implicate the requirement for a distinct signal. One candidate activator is the lipid mediator PAF, which can be displayed in the endothelial cell plasma membrane. As noted earlier, PAF synthesis is initiated by cPLA $_2$ activation, i.e., the same reaction that provides arachidonic acid for PGI $_2$ synthesis. (In endothelial cells, PAF contains acyl lipids rather than the alkyl lipids favored by leukocytes.) It has been reported that IL-1a (but not IL-1ß) may promote PAF synthesis in endothelial cells, but most studies emphasize the role of autacoids (e.g. histamine), rather than cytokines, as inducers of PAF synthesis. The chemokines constitute an important group of TNF- or IL-1ß induced leukocyte activators, that are defined by the presence and number of amino acids between two N-terminal cysteine residues (i.e. C-C, C-X-C, etc.). Chemokines induce migration and/or activation of various types of leukocytes through interaction with a group of seven *trans*-membrane G-protein-coupled receptors. The C-X-C chemokines (such as IL-8) are particularly important for

neutrophil activation and C-C chemokines (such as MCP-1) are important for monocyte activation. Both IL-8 and MCP-1 are synthesized and secreted by TNF- or IL-1ß–treated endothelial cells. Furthermore, endothelial cells can display their secreted chemokines in a complex with cell surface proteoglycans in a manner that renders them bioavailable to tethered or rolling leukocytes. The bound chemokines displayed by endothelial cells could be made by endothelial cells or could be captured and displayed once made by tissue cells or leukocytes. In addition, there is a transmembrane protein form of a chemokine called fractalkine, with its chemokine domain presented at the top of a mucin-like stalk. Fractalkine can be induced in vascular endothelial cells and functions as an adhesion molecule. Accumulating evidence suggests that fractalkine mediates vascular injury during glomerulonephritis, in allograft rejection and atherosclerotic disease. [62], [63], [64] Chemokines may also play a role in activation and recruitment of specific lymphocyte subsets, as will be discussed later in this chapter.

EXTRAVASATION OF LEUKOCYTES The interaction between TNF- and IL-ß–treated endothelial cells and leukocytes results in degradation of cellular and extracellular matrix barriers that normally separate leukocytes from the tissue space. The endothelial junctions contain proteins, such as PECAM-1 (CD31) that appear to contribute to leukocyte transmigration and, as noted above, chronically activated endothelial cells also concentrate adhesive ligands, such as E-selectin, ICAM-1, and VCAM-1, at these same junctions. The details of interaction between leukocytes and endothelial cells during diapedesis in vivo are unknown, although antibody to PECAM-1 does appear to inhibit this process. A PECAM-1 knockout mouse has a surprisingly mild phenotype with only minor effects on leukocyte transmigration. The two junctional proteins, VE-cadherin and JAM-1, are localized at endothelial adherens and tight junctions, respectively. They control paracellular permeability and leukocyte transmigration by a mechanism not yet fully understood. [65] Recent observations have also implicated CD99 as an endothelial cell junctional protein that participates in trans-endothelial cell migration. TNF- or IL-1ß–treated endothelial cells secrete and activate matrix metalloproteinases (MMPs), which degrade the condensed region of connective tissue matrix, i.e., the basement membrane, that underlies the endothelial monolayer. Endothelial cells may also trigger leukocytes to synthesize or release MMPs, and the signals for this release may be cytokine-inducible molecules such as VCAM-1 or chemokines. [66]

VASCULAR LEAKAGE AND PROVISIONAL MATRIX TNF- or IL-1ß–treated endothelial cells permit the nonspecific extravasation of fluid and plasma proteins commonly called “vascular leak.” The loss of permselectivity and consequent vascular leak is a hallmark of inflammation. The principal purpose of this response is to allow plasma proteins, such as fibronectin and fibrinogen, to deposit in the tissues where they form a provisional matrix that can be used by motile leukocytes. This is important because circulating leukocytes typically lack receptors that allow them to interact with the normal extracellular matrix, composed largely of interstitial collagens. Collectively, these five TNF- or IL-1ß-mediated responses of endothelial cells promote the development of an inflammatory infiltrate initially comprised of neutrophils and, later, of mononuclear phagocytes. The infiltrating leukocytes serve to phagocytose the eliciting microbes (e.g., bacteria) and clean up damaged tissue. Infiltrating phagocytes also can cause tissue damage through the same mediators and enzymes they use to eradicate microbes (e.g., reactive oxygen intermediates, nitric oxide, and matrix degrading enzymes such as elastase and MMPs). These mechanisms can and often do injure local endothelial cells, manifested by endothelial cell retraction and/or denudation and often accompanied by intravascular thrombosis. Intravascular thrombi exacerbate tissue ischemia and injury. Fortunately, TNF-or IL-1ß–treated endothelial cells become more resistant to injury through expression of protective gene products such as detoxifying agents for reactive oxygen intermediates, such as manganese-superoxide dismutase and hemoxygenase, protease inhibitors such as plasminogen activator inhibitor-1 and tissue inhibitors of metalloproteinases (TIMPs), and cytoprotective genes such as the zinc finger protein A20 and Bcl-related antiapoptotic genes such as A1. These protective responses allow endothelial cells to survive many inflammatory reactions without triggering thrombosis and consequent tissue infarction. The acquisition of cytoprotective features has been observed in the endothelial cells of organ grafts that have evaded transplant rejection. [67] However, these protective responses are not always adequate. Moreover, some other TNF- or IL-1ß–mediated endothelial responses, for example, induction of procoagulant proteins such as tissue factor coupled with loss of anticoagulant proteins, such as thrombomodulin, may actually exacerbate tissue and vascular injury. This combination of neutrophil recruitment and activation with alterations in the endothelial coagulation system may underlie the tissue injury that can result from LPS in such experimental models as the local Shwartzman reaction or in gram-negative septicemia. In summary, endothelial cells, through their responses to cytokines, can contribute to host defense reactions mediated by the innate immune system. However, these same effector mechanisms may lead to endothelial injury and exacerbate tissue damage. To date, the only known function of class I and class II MHC molecules is to present peptides to T cells. Vascular endothelial cells constitutively express class I MHC molecules, as well as the proteins involved in generating peptides and involved in loading these peptides into nascent class I molecules. [68] The expression of class I genes (and the gene encoding the associated ß $_2$-microglobulin molecule), as well as for the proteins involved in peptide generation and class I MHC molecule peptide loading, are all upregulated by cytokines, particularly by interferons (IFN-a, ß, and ?), and by TNF. [69] Cultured human endothelial cells do not normally express class II MHC molecules or the proteins responsible for peptide loading of class II molecules; these proteins are all induced by IFN-?, but these actions of IFN-? are inhibited by IFN-a/ß or TNF. In large mammals, including humans, class II molecules are basally expressed on microvascular cells in vivo. [69], [70] It is unclear whether this “constitutive” expression depends upon low levels of circulating IFN-? or is truly constitutive. Class II molecule expression on microvascular endothelial cells of guinea pigs and mice are readily induced upon IFN-? exposure; this seems not to occur in rats, although cultured rat endothelial cells do respond to IFN-? by expressing class II molecules. These species differences could affect the capacities of endothelial cells to present antigens to CD4+ T cells in vivo. The typical diameter of a capillary lumen is less than 10 µm, i.e., narrower than the diameter of a circulating lymphocyte. Consequently, circulating T cells are forced to encounter antigenic peptides complexed to both class I and class II MHC molecules displayed on the microvascular endothelial surface during the course of normal circulation. A key question is what effect does this encounter have on the T cell? Upon recognition of peptide-MHC molecule complexes, T cells may become activated, may remain unchanged, which is a response called immunologic ignorance, or may become inactivated and unable to respond to future encounters (i.e., enter a state of “anergy”). Moreover, activation is a graded response and need not be all or none. Studies of the consequences of T cell recognition of antigen presented by endothelial cells have largely used cell culture systems and have been primarily concerned with allogeneic responses, which are a cross-reaction of T cells specific for foreign peptides complexed with self allelic forms of MHC molecules with peptides (self or foreign) complexed to non-self allelic forms of MHC molecules as may be encountered in transplantation. [71] Such in vitro experiments suggest that naïve T cells ignore antigens presented by endothelial cells (or, in some instances, may become anergized), whereas resting memory T cells or recently activated T blasts respond by new cytokine gene expression and a limited degree of proliferation. However,

endothelial cells are not particularly effective at promoting T cell differentiation as compared to specialized antigen-presenting cells such as dendritic cells. This limitation may correlate with the observation that human endothelial cells are deficient in expressing certain costimulator molecules, e.g., B7.1 (CD80) and B7.2 (CD86) expressed on dendritic cells, and must costimulate T cells largely with LFA-3 (CD58). [71] Interestingly, in certain other species (e.g., pigs) endothelial cells do express B7.2 and well as LFA-3. It is our hypothesis that the primary role of human endothelial cell antigen presentation, which occurs in the capillaries, is to boost the adhesion of circulating memory T cells specific for the antigen by increasing the affinity/avidity of LFA-1 for ICAM-1 (and perhaps ICAM-2). This adhesive response would serve to promote T cell attachment to endothelium, most likely in the venules that drain the capillaries where antigen was presented, thus initiating local T cell diapedesis. This mechanism, if true, would serve to contribute to the efficiency of immune surveillance. This is a potentially important function because T cells specific for any one antigen, even among memory T cells expanded by prior encounter with antigen, are rare (fewer than 1 in 10,000 to 100,000) and presentation of antigen by endothelial cells could markedly increase the likelihood that antigen will be recognized in a timely manner. T cells may differentiate into specialized cytokine-producing subsets. For CD4+ T cells, such responses may become polarized into T_H1 responses, dominated by T cells that produce IFN and lymphotoxin (LT), or into T_H2 responses, dominated by T cells that produce IL-4 and IL-5. The T_H1 subset favors recruitment and activation of mononuclear phagocytes and (in mice, at least) favors production by B cells of antibody isotypes that can efficiently opsonize bacteria for phagocytosis by these cells. The T_H2 subset favors recruitment and activation of eosinophils and favors production of antibody isotypes that target parasites for eosinophil-mediated killing, and trigger mast cells and basophils to release vasoactive mediators and cytokines. It is possible that these same sets of cytokines preferentially alter the adhesion molecule expression pattern of vascular endothelium to favor particular patterns of leukocyte and lymphocyte subset recruitment. For example, IFN-? may combine with LT to cause prolonged expression of E-selectin, an important ligand for T_H1 T cells. T_H1 cells, but not T_H2 cells, are able to bind to P-selectin and E-selectin. Migration of T_H1 cells into inflamed skin can be blocked by antibodies against P- and E- selectin. [72] PSGL-1 appears to functions as P- and E-selectin ligands for T_H1 cells. [72], [73] Although PSGL-1 is expressed on both, T_H1 and T_H2 cells, it only supports binding of T_H1 cells to selectins. The increased expression of the a_3-fucosyltransferases in T_H1 cells correlated with the ability of T_H1, but not T_H2, cells to bind to P-selectin. Thus, the regulation of the binding of effector T_H1 cells to the endothelium, and subsequent trafficking to inflammatory sites, appears to be controlled by the fucosylation state of PSGL-1 mediated by the selective expression of the a_3-fucosyltransferases. In contrast, IL-4 increases VCAM-1 expression while suppressing E-selectin, a cell surface molecule that may favor eosinophil and perhaps T_H2 cell recruitment. In other words, T cell cytokines, produced by specific subsets, may modify the innate endothelial cell responses, e.g., to TNF, in a way that biases leukocyte recruitment toward recruitment of specific effector cells. Finally, differential expression of chemokine receptors may also account for selective recruitment of T cell subsets; e.g., CCR5 and, to a lesser degree, CXCR3 are preferentially found on T_H1 cells, whereas CCR4, CCR8, and, more controversially, CCR3 and CXCR4 are preferentially found on T_H2 cells.

ENDOTHELIUM OF THE SKIN

Morphology and Molecular Markers

ARCHITECTURE OF THE SKIN VASCULATURE The dermal microvasculature consists of two interconnected systems. The superficial vascular plexus (SVP) is comprised of paired arterioles and venules that form an interconnected network of vessels coursing on a plane parallel to and just beneath the epidermal surface. [74] Capillaries arise from the arterioles, extend upward within the papillary dermis at sites between the epidermal rete ridges, and then loop back down to the venules forming arcade-like structures. In normal skin, most of this capillary loop is invested with a basement membrane that resembles that of the arteriole. The capillaries acquire a venular-like investiture only at the level of the deepest rete just proximal to the anastomosis with the venule of the SVP. [75] The arteriolar portion of the papillary loop has a homogeneous-appearing basement membrane, which becomes multilayered at the venular portion. There are no ultrastructural differences between capillary loops at different sites of the skin. Inflammatory leukocytes extravasate through the venule-like portions of the capillary and through the venule proper, but only rarely infiltrate through the arteriole-like portions of the capillary or the arteriole itself. The arterioles and venules of the SVP are connected by short, straight vessels to the arterioles and venules of a deeper planar network of anastomosing vessels called the deep vascular plexus (DVP). The plane of the DVP is parallel to that of the SVP and courses above the boundary between the reticular dermis and the underlying subcutis. The DVP is fed through penetrating vessels from the subcutis. The DVP is drained by valve-containing veins into the subcutaneous fat. Valves are at most places where the small vessels join the larger ones and imply a mechanism involved in forward propulsion of blood. The DVP contains arterioles and venules of larger caliber consisting of three layers—an intima, media, and adventitia—whereas those found within the SVP are smaller, and do not possess an internal or external elastic membrane. The vessel wall in the SVP consists of discontinuous layers of elastic fibers and smooth muscles. Capillary networks connecting the arterioles and venules of the DVP provide nourishment for the adnexal structures within the reticular dermis. The venules of the DVP serve as portals of entry for leukocytes associated with inflammation of the adnexa or for inflammation within the reticular dermis itself, as occurs in cellulitis. Dermal microvessels are surrounded by flat adventitial cells, ultrastructurally most closely resembling a fibroblast, called *veil cells.* [76] Veil cells are external to the wall, demarcating the vessel from the surrounding dermis. These cells are negative for T or B cell markers, are HLA-DR and CD1a negative, and express factor XIIIa, and therefore are also called XIIIa-positive dendrocytes. Interestingly, factor XIIIa-positive dendrocyte rarefaction is found in the classic type of Ehlers-Danlos syndrome, but the significance of this finding is not clear. Unlike veil cells, pericytes are an integral component of the cell wall. They extend long cytoplasmic processes over the surface of the endothelial cells and make interdigitating contacts. The coverage of endothelial cells by pericytes varies considerably between different microvessel types and the location of pericytes on the microvessel is not random but appears to be functionally determined. At points of contact, communicating gap junctions, tight junctions, and adhesion plaques are present. Specifically in the postcapillary venule, there is an intimate interdigitation between pericytes and endothelial cells, one pericyte making contact with two to four endothelial cells. Pericytes are rich in contractile proteins, together with the complex interdigitation with endothelium in postcapillary venules, it can be assumed that they are responsible, at least in part, for gap formation in response to, e.g., histamine or bradykinin (although cultured endothelial cells are capable of contraction in the absence of pericytes). Moreover, interaction between pericytes and endothelium is important for the

maturation, remodeling, and maintenance of the vascular system via the secretion of growth factors or modulation of the extracellular matrix. There is also evidence that pericytes are involved in the transport across the blood-brain barrier and the regulation of vascular permeability.

MOLECULAR MARKERS OF SKIN ENDOTHELIUM In addition to molecules expressed on all endothelium, the skin vasculature shows several site-specific characteristics. Postcapillary venules of the SVP are CD36 negative and thus distinct from capillaries of the DVP and from capillaries of other tissues which are CD36 positive. [77] CD36 antigen is a cellular receptor for thrombospondin, collagen, low-density lipoproteins, long-chain fatty acids, and platelet-agglutinating protein p37. [78] Moreover, CD36 functions as one of the receptors that mediates the adhesion of *Plasmodium falciparum*-infected erythrocytes to microvascular endothelium. The functional consequences of the disparate CD36 expression on SVP versus DVP endothelium are unknown. Microvessels express an epitope recognized by antibody PAL-E, which distinguishes them from lymphatic endothelium. Postcapillary venules of the skin express toll-like receptor family members, CD206 (macrophage mannose receptor, also expressed on lymphatics) and CD32 molecules (Fc?RIIa). [48] CD32 binds complexed IgG and is thought to function in the elicitation of type III hypersensitivity (immune complex-mediated) as well as in immune complex clearing. Moreover, skin microvessels in situ constitutively express HLA class II molecules at their luminal surfaces, which, as discussed previously, implies that endothelial cells may directly participate in the elicitation of antigen-driven immune responses. Indeed, skin microvessels in cell culture appear able to process and present antigen in a class II–restricted manner to T cells. [79]

Skin Microvessels in Inflammation and Repair

SKIN MICROVESSELS IN CUTANEOUS INFLAMMATION It is clear that vascular endothelial cells are important participants in the development of inflammatory responses. Recently, it was elucidated that tissue-specific differences in endothelial cells may partly determine the unique patterns of inflammation observed in different organs. One mechanism by which vascular endothelium may contribute to tissue-specific inflammatory patterns is through distinctive patterns of adhesion molecule expression, resulting in selective recruitment and diapedesis of circulating leukocytes bearing the proper ligands. In the skin, E-selectin, VCAM-1, and ICAM-1 may be particularly important in this process, and they have been extensively evaluated in normal and disease states. In noninflamed skin there is no significant microvascular expression of E-selectin and VCAM-1, and low levels of ICAM-1, as opposed to lesions of active dermatitis and psoriasis, where there is a small amount of VCAM-1, and high levels of E-selectin and ICAM-1. [47], [77], [80] In cutaneous T cell lymphoma (CTCL) there are high levels of VCAM-1. [86] There appear to be differences in the inducibility of these adhesion molecules by leukocyte derived cytokines in different disease states as well. In normal and nonlesional skin explants, E-selectin is inducible by the inflammatory cytokines IL-1 and TNFa, whereas the inducibility of VCAM-1 varies in different disease states. VCAM-1 may only be inducible in skin that has been inflamed (e.g., spongiotic dermatitis), or in perilesional skin as well (e.g., on postcapillary venules of the superficial vascular plexus in psoriasis), [77] or in both lesional and nonlesional skin in CTCL. [86] The changes in dermal endothelial cells that permit VCAM-1 induction in these settings are unknown, but they cannot be reproduced with cytokines. The induction of E-selectin appears to be particularly important in cutaneous inflammatory reactions. In addition to being readily inducible by cytokines, and uniformly associated with leukocytic infiltration, it may play a role in the selective recruitment of lymphocytes to cutaneous sites of inflammation through binding to the cutaneous lymphocyte antigen (CLA). [81], [82] CLA is a carbohydrate moiety on the surface of T cells closely related to sialylated Lewis-X, which has homology to the core structure of P-selectin glycoprotein-1. [56] By using the identifying monoclonal antibody HECA-452, CLA has been found on 80 to 90 percent of skin infiltrating lymphocytes as compared to 5 to 10 percent at other peripheral sites. CLA is also present on circulating precursor Langerhans cells, and presumably plays a role in their eventual localization to the skin. The expression of E-selectin in cultured dermal microvascular endothelial cells is relatively persistent compared to endothelium derived from other sources. This persistent expression of E-selectin in vivo has been proposed to be responsible for the preferential homing of a CLA positive lymphocytes to the skin. Recent work in a chimeric human mouse model of inflammation suggests that CLA-positive lymphocytes specifically migrate through the superficial, as opposed to the deep, vascular plexus. [83] It is unlikely that E-selectin–CLA interactions alone are sufficient for the homing of lymphocytes to the skin. The transmigration of CLA-positive lymphocytes across activated endothelium is dependent on interactions with VCAM-1 and ICAM-1, in addition to E-selectin. The induction of E-selectin on cutaneous microvessels also appears to play a role in immediate hypersensitivity reactions in atopic individuals. These reactions are characterized by an IgE-dependent biphasic response. Within minutes after exposure, the relevant antigen crosslinks IgE bound to the high affinity FcRe receptors on the surface of mast cells, resulting in histamine release. Histamine-dependent stimulation of endothelial cells leads to vasodilatation and increased vascular permeability that produces the classic wheal and flare response, typically resolving within 30 to 90 min. This reaction, known as the early phase response, is not accompanied by endothelial E-selectin upregulation or inflammatory cell recruitment. The late phase reaction begins 3 to 4 h after antigen challenge, and is characterized by the infiltration of eosinophils, neutrophils, and mononuclear cells into the inflamed area. Granulocytes are most prominent at 6 to 8 h, and by 24 to 48 h the cellular infiltrate consists largely of mononuclear cells. The expression of E-selectin, indicating endothelial activation, is detectable at the onset of infiltration. Although this E-selectin induction may simply be due to cytokine release from infiltrating inflammatory cells, there is evidence that the necessary mediators are released from skin resident cells. In skin organ culture, the addition of antigen either prior to or during the culture period results in significant E-selectin expression without inflammatory infiltrate. [84] VCAM-1 may play a role in the specific homing of leukocytes to the skin through binding to the integrin $a_4ß_7$ on the surface of lymphocytes. This integrin is associated with the specific localization of lymphocytes to the gut through binding to the vascular adhesion molecule MadCAM-1 on the endothelium of intestinal microvessels. [86] Another ligand for $a_4ß_7$ includes fibronectin. Recently, $a_4ß_7$ has been found to be expressed on a high percentage of intraepidermal lymphocytes, particularly in CTCL, and, to a lesser degree, in spongiotic dermatitis. [86] Interestingly, in CTCL, the expression of $a_4ß_7$ strongly correlated with the expression of integrin $a_Eß_7$. $a_Eß_7$ is also found on a high percentage of gut (intraepithelial) and intraepidermal lymphocytes. In chronic inflammatory conditions such as psoriasis and CTCL, the cutaneous microvascular endothelium develops a high endothelial venule morphology similar to that seen in peripheral lymph nodes. This is accompanied by the expression of the peripheral lymph node addressin L-selectin ligands identified by the antibody MECA-79. Interestingly, there was MECA-79 reactivity in the perifollicular vessels in noninflamed skin. This has led to the speculation that peripheral node addressins in chronic T cell–mediated skin diseases are responsible for sustained lymphocyte recruitment. The

constitutive expression in normal skin may serve a function in continuous lymphocyte recirculation. [85] Chemokines may also play a role in the selective homing of T cells to the skin. CCR4 is expressed at high levels by CLA-positive memory T cells. The CCR4 receptor TARC is constitutively expressed on endothelial cells in cutaneous postcapillary venules. In vitro TARC triggers CLA-positive T cells that are rolling on E-selectin to firmly adhere ICAM-1. Another skin-associated chemokine, CCL27 (CTACK), is produced by keratinocytes, and also preferentially attracts CLA-positive memory T cells. [87]

ANGIOGENESIS IN THE SKIN The details of the interactions between endothelial cells and angiogenic factors in physiologic and pathologic states were previously outlined. This section focuses on the role of angiogenesis in wound healing, inflammation, and tumorigenesis in the skin. Cutaneous wound healing is a complex process that is, in part, dependent on angiogenesis. The revascularization of wounds is regulated by a combination of adhesion molecules and soluble growth factors derived from endothelial cells, keratinocytes, and inflammatory cells. Two soluble peptides that are particularly important are FGF-2 and VEGF. VEGF is produced by the keratinocytes and infiltrating macrophages in healing wounds. The splice variants of VEGF produced by keratinocytes are potent mitogens for dermal microvascular endothelial cells. [88], [89] VEGFR-2 is also upregulated on endothelial cells at the site of injury. [90] Hypoxia, which often is present in healing wounds and rapidly growing tumors, induces keratinocytes, dermal fibroblasts, and endothelial cells to produce VEGF in vitro. [89] Angiopoietins 1 and 2 are also upregulated during injury, consistent with the role they are thought to play in the destabilizing, followed by stabilization of the vasculature. This allows a window for VEGF-mediated sprouting and elongation, followed by Ang-1–mediated remodeling. [4] FGF-2 is released in cutaneous wounds derived from endothelial cells and by infiltrating macrophages. When blocking antibodies directed against FGF-2 are used, wound angiogenesis is nearly completely inhibited. [91] Adhesion molecules are necessary for physiologic angiogenesis in the skin. The expression of integrin $ß_V ß_3$ on the tips of growing capillaries appears to facilitate endothelial migration, and appears to be required for wound healing. In an in vivo model in which human skin placed on immunodeficient mice is wounded, blocking antibodies directed against $ß_V ß_3$ inhibited both angiogenesis and wound healing. In a similar model, blocking of the binding of CD31 and cadherin 5 with filamentous actin also blocked wound vascularization and healing. [34] Tumor growth is dependent on the growth of nutritive blood vessels. Tumors are known to produce angiogenic factors such as VEGF, FGF-2, EGF, and HGF/SF. [92] Some of theses growth factors play a role in the pathogenesis of both benign and malignant skin tumors. There is a significant vascular component to the growth and metastases of cutaneous melanoma and an increased numbers of vessels in cutaneous melanoma as compared to severely atypical nevi. This vascular proliferative response appears to be in part mediated by FGF-2, which is known to be produced by melanoma cells. Antisense oligonucleotides directed against FGF-2 inhibit the proliferation of both primary and malignant melanoma. [94] HGF/SF and VEGF are also produced by melanoma cells, and may also contribute to their vascularization. Peptide growth factors also appear to play a role in the pathogenesis of benign and malignant vascular tumors. Human endothelial cells acquire a Kaposi's sarcoma cell-like morphology when cultured in the presence of HGF/SF. [94] The spindle cells of Kaposi's sarcoma also produce large amounts of VEGF. The proliferative phase of hemangiomas contain high levels of FGF-2 and VEGF. There is increased FGF-2 in the involuting phase of these benign vascular tumors as well. VEGF-C–mediated tumor lymphangiogenesis is also associated with breast cancer metastasis. [95] The effective use of several angiogenesis inhibitors in murine tumor models have shown that tumor growth and metastases is dependent on an adequate vascular supply. These data have resulted in the ongoing investigational use of angiogenesis inhibitors as anticancer therapy. Vascular remodeling appears to play a role in the pathogenesis of some inflammatory skin diseases, notably psoriasis. Psoriatic vessels become tortuous and elongated, and the normally well defined boundary between capillary endothelium resting on an arteriolar-like homogenous basement membrane and endothelial cells on a venular-like laminated basement membrane becomes unclear. The intrapapillary portions of capillaries acquire a venular phenotype, [96] corresponding to direct metaplasia from a arteriolar to a venular phenotype. It should be noted that this elongation of the capillary loops occurs without the formation of new vessels. Light microscopic investigations on eruptive guttate psoriatic lesions demonstrated that vascular alterations are the first ultrastructurally detectable alterations within the dermal compartment. These alterations consist of gap formation within postcapillary venules, endothelial cell hypertrophy (they acquire a cuboidal shape similar to that seen in high endothelial venules), and compression of the vascular lumen, all of which precedes the invasion of inflammatory cells into the tissue. [96] This morphologic alteration is accompanied by altered endothelial function. For example, there is increased blood flow in perilesional psoriatic skin even in the absence of any microscopically detectable changes. [97] The role angiogenic factors play in vascular remodeling in psoriasis has been partly characterized. It has been suggested that these vascular alterations may, in part, be mediated by increased production of VEGF by keratinocytes in the hyperplastic epidermis. There is also increased expression of the VEGFR1 and VEGFR2 on the papillary dermal microvascular endothelial cells. [98] VEGF appears to directly upregulate expression of ICAM-1, VCAM-1, and E-selectin on endothelial cells. The VEGF-mediated vascular leak and adhesion molecule upregulation can be inhibited by concurrent overexpression of Ang-1. The role of angiogenesis in inflammatory processes has been further exemplified by the anti-inflammatory effects of angiogenesis inhibitors. [99]

REFERENCES

1. Pardanaud L et al: Relationship between vasculogenesis, angiogenesis and haemopoiesis during avian ontogeny. *Development* **105**:473, 1989

2. Risau W, Flamme I: Vasculogenesis. *Annu Rev Cell Dev Biol* **11**:3, 1995

3. Asahara T et al: Isolation of putative progenitor endothelial cells for angiogenesis. *Science* **275**:964, 1997

4. Yancopoulos GD et al: Vascular-specific growth factors and blood vessel formation. *Nature* **407**:242, 2000

5. Makinen T et al: Inhibition of lymphangiogenesis with resulting lymphedema in transgenic mice expressing soluble VEGF receptor-3. *Nat Med* **7**:199, 2000

6. Karkkainen MJ et al: A model for gene therapy of human hereditary lymphedema. *Proc Natl Acad Sci U S A* **98**:12677, 2000

7. Fernig DG, Gallagher JT: Fibroblast growth factors and their receptors: An information network controlling tissue growth, morphogenesis and

repair. *Prog Growth Factor Res* **5**:353, 1994

8. Gospodarowicz D et al: Control of proliferation of human vascular endothelial cells. Characterization of the response of human umbilical vein endothelial cells to fibroblast growth factor, epidermal growth factor, and thrombin. *J Cell Biol* **77**:774, 1978

9. Ushiro S et al: Heparin-binding epidermal growth factor-like growth factor: p91 activation induction of plasminogen activator/inhibitor, and tubular morphogenesis in human microvascular endothelial cells. *Jpn J Cancer Res* **87**:68, 1996

10. Grant DS et al: Scatter factor induces blood vessel formation in vivo. *Proc Natl Acad Sci U S A* **90**:1937, 1993

11. Maisonpierre PC et al: Angiopoietin-2, a natural antagonist for Tie2 that disrupts in vivo angiogenesis. *Science* **277**:55, 1997

12. Jones N et al: Rescue of the early vascular defects in Tek/Tie2 null mice reveals an essential survival function. *EMBO REP* **2**:438, 2001

13. Adams RH et al: Roles of ephrinB ligands and EphB receptors in cardiovascular development: Demarcation of arterial/venous domains, vascular morphogenesis, and sprouting angiogenesis. *Genes Dev* **13**:295, 2000

14. Gale NW et al: Ephrin-B2 selectively marks arterial vessels and neovascularization sites in the adult, with expression in both endothelial and smooth-muscle cells. *Dev Biol* **230**:151, 2000

15. McAllister KA et al: Endoglin, a TGF-beta binding protein of endothelial cells, is the gene for hereditary haemorrhagic telangiectasia type 1. *Nat Genet* **8**:345, 1994

16. Beck L, D'Amore PA: Vascular development: cellular and molecular regulation. *FASEB J* **11**:365, 1997

17. Carmeliet P et al: Role of tissue factor in embryonic blood vessel development. *Nature* **383**:73, 1996

18. Folkman J: Angiogenesis in cancer, vascular, rheumatoid and other disease. *Nat Med* **1**:27, 1995

19. Resnick N, Gimbrone MA: Hemodynamic forces are complex regulators of endothelial gene expression. *FASEB J* **9**:874, 1995

20. Milici AJ et al: The formation of fenestrations and channels by capillary endothelium in vitro. *Proc Natl Acad Sci U S A* **82**:6181, 1985

21. Janzer RC, Raff MC: Astrocytes induce blood-brain barrier properties in endothelial cells. *Nature* **325**:253, 1987

22. Remuzzi A et al: Orientation of endothelial cells in shear fields in vitro. *Biorheology* **21**:617, 1984

23. Rogers KA, Kalnins VI: Comparison of the cytoskeleton in aortic endothelial cells in situ and in vitro. *Lab Invest* **49**:650, 1983

24. Bradley JR, Pober JS: Prolonged cytokine exposure causes a dynamic redistribution of endothelial cell adhesion molecules to intercellular junctions. *Lab Invest* **75**:463, 1996

25. Bonfanti R et al: PADGEM (GMP140) is a component of Weibel-Palade bodies of human endothelial cells. *Blood* **73**:1109, 1989

26. Vischer UM, Wagner DD: CD63 is a component of Weibel-Palade bodies of human endothelial cells. *Blood* **82**:1184, 1993

27. Schnyder CS et al: Localization of a1,3-fucosyltransferase VI in Weibel-Palade bodies of human endothelial cells. *Proc Natl Acad Sci U S A* **97**:8369, 2000

28. Wolff B et al: Endothelial cell “memory” of inflammatory stimulation: Human venular endothelial cells store interleukin 8 in Weibel-Palade bodies. *J Exp Med* **188**:1757, 2000

29. Wisse E et al: Structure and function of sinusoidal lining cells in the liver. *Toxicol Pathol* **24**:100, 1996

30. Drab M et al: Loss of caveolae, vascular dysfunction, and pulmonary defects in caveolin-1 gene-disrupted mice. *Science* **293**:2449, 2000

31. Shivers RR et al: Isolated rat brain capillaries possess intact, structurally complex, interendothelial tight junctions; freeze-fracture verification of tight junction integrity. *Brain Res* **324**:313, 1984

32. Bazzoni G et al: Interaction of junctional adhesion molecule with the tight junction components ZO-1, cingulin, and occludin. *J Biol Chem* **275**:20520, 2000

33. Petzelbauer P et al: Endothelial adherens junctions. *J Invest Dermatol Symp Proc* **5**:10, 2000

34. Matsumura T et al: Endothelial cell tube formation depends on cadherin 5 and CD31 interactions with filamentous actin. *J Immunol* **158**:3408, 1997

35. Vittet D et al: Targeted null-mutation in the vascular endothelial-cadherin gene impairs the organization of vascular-like structures in embryoid bodies. *Proc Natl Acad Sci U S A* **94**:6273, 1997

36. Grant DS et al: Interaction of endothelial cells with a laminin A chain peptide (SIKVAV) in vitro and induction of angiogenic behavior in vivo. *J Cell Physiol* **153**:614, 1992

37. O'Reilly MS et al: Endostatin: An endogenous inhibitor of angiogenesis and tumor growth. *Cell* **88**:277, 1997

38. Miyamoto S et al: Integrin function: Molecular hierarchies of cytoskeletal and signaling molecules. *J Cell Biol* **131**:791, 1995

39. Detmar M: Tumor angiogenesis. *J Invest Dermatol Symp Proc* **5**:20, 2000

40. Yeh JC et al: Novel sulfated lymphocyte homing receptors and their control by a core1 extension ß1,3- *N*-acetylglucosaminyltransferase. *Cell* **105**:957, 2000

41. Lechleitner S et al: Peripheral lymph node addressins are expressed on skin endothelial cells. *J Invest Dermatol* **113**:410, 1999

42. Adachi H et al: Expression cloning of a novel scavenger receptor from human endothelial cells. *J Biol Chem* **272**:31217, 1997

43. Cowan PJ et al: Targeting gene expression to endothelial cells in transgenic mice using the human intercellular adhesion molecule 2

promoter. *Transplantation* **62**:155, 1996

44. Karkkainen MJ et al: Lymphatic endothelium: A new frontier of metastasis research. *Nat Med* **4**:E2, 2002

45. Schlingemann RO et al: Monoclonal antibody PAL-E specific for endothelium. *Lab Invest* **52**:71, 1985

46. Fina L et al: Expression of the CD34 gene in vascular endothelial cells. *Blood* **75**:2417, 1990

47. Petzelbauer P et al: Inducibility and expression of microvascular endothelial adhesion molecules in lesional, perilesional, and uninvolved skin of psoriatic patients. *J Invest Dermatol* **103**:300, 1994

48. Gröger M et al: Dermal microvascular endothelial cells express CD32 receptors in vivo and in vitro. *J Immunol* **156**:1549, 1996

49. Gröger M et al: Dermal microvascular endothelial cells express the 180-kDa macrophage mannose receptor in situ and in vitro. *J Immunol* **165**:5428, 2000

50. Jefferies WA et al: Transferrin receptor on endothelium of brain capillaries. *Nature* **312**:162, 1984

51. Berg EL et al: L-selectin-mediated lymphocyte rolling on MAdCAM-1. *Nature* **366**:695, 1993

52. Gresser I: Wherefore interferon? *J Leukoc Biol* **61**:567, 1997

53. Faure E et al: Bacterial lipopolysaccharide activates NF-6B through toll-like receptor 4 (TLR-4) in cultured human dermal endothelial cells. Differential expression of TLR-4 and TLR-2 in endothelial cells. *J Biol Chem* **275**:11058, 2000

54. Newby AC, Henderson AH: Stimulus-secretion coupling in vascular endothelial cells. *Annu Rev Physiol* **52**:661, 1990

55. Pober JS, Cotran RS: Immunologic interactions of T lymphocytes with vascular endothelium. *Adv Immunol* **50**:261, 1991

56. Fuhlbrigge RC et al: Cutaneous lymphocyte antigen is a specialized form of PSGL-1 expressed on skin-homing T cells. *Nature* **389**:978, 1997

57. Bevilacqua MP: Endothelial-leukocyte adhesion molecules. *Annu Rev Immunol* **11**:767, 1993

58. Lawrence MB et al: Neutrophil tethering to and rolling on E-selectin are separable by requirement for L-selectin. *Immunity* **1**:137, 1994

59. Tonnesen MG et al: Adherence of neutrophils to cultured human microvascular endothelial cells. Stimulation by chemotactic peptides and lipid mediators and dependence upon the Mac-1, LFA-1, p150,95 glycoprotein family. *J Clin Invest* **83**:637, 1989

60. Lechleitner S et al: Interferon enhances tumor necrosis factor-induced vascular cell adhesion molecule 1 (CD106) expression in human endothelial cells by an interferon- related factor 1-dependent pathway. *J Exp Med* **187**:2023, 2000

61. Albelda SM et al: Adhesion molecules and inflammatory injury. *FASEB J* **8**:504, 1994

62. Umehara H et al: Fractalkine and vascular injury. *Trends Immunol* **22**:602, 2000

63. Matsukawa A et al: Chemokines and innate immunity. *Rev Immunogenet* **2**:339, 2000

64. Yoshie O et al: Chemokines in immunity. *Adv Immunol* **78**:57, 2000

65. Dejana E et al: Interendothelial junctions and their role in the control of angiogenesis, vascular permeability and leukocyte transmigration. *Thromb Haemost* **86**:308, 2000

66. Madri JA et al: The roles of adhesion molecules and proteinases in lymphocyte transendothelial migration. *Biochem Cell Biol* **74**:749, 1996

67. Bach FH et al: Accommodation of vascularized xenografts: Expression of “protective genes” by donor endothelial cells in a host Th2 cytokine environment. *Nat Med* **3**:196, 1997

68. Collins T et al: Immune interferon activates multiple class II major histocompatibility complex genes and the associated invariant chain gene in human endothelial cells and dermal fibroblasts. *Proc Natl Acad Sci U S A* **81**:4917, 1984

69. Lapierre LA et al: Three distinct classes of regulatory cytokines control endothelial cell MHC antigen expression. Interactions with immune gamma interferon differentiate the effects of tumor necrosis factor and lymphotoxin from those of leukocyte alpha and fibroblast beta interferons. *J Exp Med* **167**:794, 1988

70. Page C et al: Antigenic heterogeneity of vascular endothelium. *Am J Pathol* **141**:673, 1992

71. Pober JS et al: Can graft endothelial cells initiate a host anti-graft immune response? *Transplantation* **61**:343, 1996

72. Austrup F et al: P- and E-selectin mediate recruitment of T-helper-1 but not T-helper-2 cells into inflamed tissues. *Nature* **385**:81, 1997

73. Hirata T et al: P-selectin glycoprotein ligand 1 (PSGL-1) is a physiological ligand for E-selectin in mediating T helper I lymphocyte migration. *J Exp Med* **192**:1669, 2000

74. Yen A, Braverman IM: Ultrastructure of the human dermal microcirculation: the horizontal plexus of the papillary dermis. *J Invest Dermatol* **66**:131, 1976

75. Braverman IM, Yen A: Ultrastructure of the human dermal microcirculation. II. The capillary loops of the dermal papillae. *J Invest Dermatol* **68**:44, 1977

76. Braverman IM: Ultrastructure and organization of the cutaneous microvasculature in normal and pathologic states. *J Invest Dermatol* **93**:2S, 1989

77. Petzelbauer P et al: Heterogeneity of dermal microvascular endothelial cell antigen expression and cytokine responsiveness in situ and in cell culture. *J Immunol* **151**:5062, 1993

78. Febbraio M et al: CD36: A class B scavenger receptor involved in angiogenesis, atherosclerosis, inflammation, and lipid metabolism. *J Clin*

Invest **108**:785, 2000

79. Vora M et al: Antigen presentation by human dermal microvascular endothelial cells. Immunoregulatory effect of IFN-gamma and IL-10. *J Immunol* **152**:5734, 1994

80. Das PK et al: Differential expression of ICAM-1, E-selectin, and VCAM-1 by endothelial cells in psoriasis and content dermatitis. *Acta Derm Vvenerol Suppl* **186**:21, 1994

81. Berg EL et al: The cutaneous lymphocyte antigen is a skin lymphocyte homing receptor for the vascular lectin endothelial cell-leukocyte adhesion molecule 1. *J Exp Med* **174**:1461, 1991

82. Picker LJ et al: A unique phenotype of skin-associated lymphocytes in humans: preferential expression of the HECA-452 epitope by benign and malignant T cells at cutaneous sites. *Am J Pathol* **136**:1053, 2000

83. Kunstfeld R et al: HECA-452+ T cells migrate through superficial vascular plexus but not through deep vascular plexus endothelium. *J Invest Dermatol* **108**:343, 1997

84. Leung DY et al: Expression of endothelial-leukocyte adhesion molecule-1 in elicited late phase allergic reactions. *J Clin Invest* **87**:1805, 1991

85. Hamann A et al: Role of alpha 4-integrins in lymphocyte homing to mucosal tissues in vivo. *J Immunol* **152**:3282, 1994

86. Schechner JS, Edelson RL, McNiff JM, Heald PW, Pober JS: Expression of integrin a $_4$ß $_7$ on epidermotropic cutaneous T cells in cutaneous T cell lymphoma and spongiotic dermatitis. Lab Invest **79**:601, 1999

87. Pober JS et al: Human endothelial cell presentation of antigen and the homing of memory/effector T cells to skin. *Ann N Y Acad Sci* **941**:12, 2000

88. Brown LF et al: Expression of vascular permeability factor (vascular endothelial growth factor) by epidermal keratinocytes during wound healing. *J Exp Med* **176**:1375, 1992

89. Detmar M et al: Hypoxia regulates the expression of vascular permeability factor/vascular endothelial growth factor (VPF/VEGF) and its receptors in human skin. *J Invest Dermatol* **108**:263, 1997

90. Detmar M et al: Keratinocyte-derived vascular permeability factor (vascular endothelial growth factor) is a potent mitogen for dermal microvascular endothelial cells. *J Invest Dermatol* **105**:44, 1995

91. Broadley KN et al: Monospecific antibodies implicate basic fibroblast growth factor in normal wound repair. *Lab Invest* **61**:571, 1989

92. Leek RD et al: Cytokine networks in solid human tumors: Regulation of angiogenesis. *J Leukoc Biol* **56**:423, 1994

93. Becker D et al: Proliferation of human malignant melanomas is inhibited by antisense oligodeoxynucleotides targeted against basic fibroblast growth factor. *EMBO J* **8**:3685, 1989

94. Naidu YM et al: Role of scatter factor in the pathogenesis of AIDS-related Kaposi sarcoma. *Proc Natl Acad Sci USA* **91**:5281, 1994

95. Skobe M et al: Induction of tumor lymphangiogenesis by VEGF-C promotes breast cancer metastasis. *Nat Med* **7**:192, 2000

96. Braverman IM, Sibley J: Role of the microcirculation in the treatment and pathogenesis of psoriasis. *J Invest Dermatol* **78**:12, 1982

97. Brody I: Dermal and epidermal involvement in the evolution of acute eruptive guttate psoriasis vulgaris. *J Invest Dermatol* **82**:465, 1984

98. Detmar M et al: Overexpression of vascular permeability factor/vascular endothelial growth factor and its receptors in psoriasis. *J Exp Med* **180**:1141, 1994

99. Lange-Asschenfeldt B et al: Increased and prolonged inflammation and angiogenesis in delayed-type hypersensitivity reactions elicited in the skin of thrombospondin-2-deficient mice. *Blood* **99**:538, 2002

T>

Chapter 20

Franz Legat Cheryl Armstrong Thomas Scholzen John Olerud Nigel Bunnett Thomas Luger John Ansel

Neurobiology of the Skin

NEUROGENIC INFLAMMATION
Background
Hallmarks of Neurogenic Inflammation: Vasodilation and Plasma Leakage
Local Effector Function of Sensory Nerve Endings and Axon Reflex Model
THE CUTANEOUS SENSORY NERVOUS SYSTEM
Neuroanatomy
Neuropeptide Receptors
Neuropeptide-Degrading Enzymes
Neurotrophins
NEUROPEPTIDE–TARGET CELL INTERACTIONS IN SKIN INFLAMMATION
THE ROLE OF NEUROGENIC INFLAMMATION IN CUTANEOUS DISEASE AND WOUND HEALING
SUMMARY

REFERENCES

The skin is innervated by a three-dimensional network of nerve fibers that not only participate in the transmission of sensory impulses but also contribute to neurocutaneous inflammation and wound healing. Neuropeptides that are released by cutaneous sensory nerves in response to a variety of noxious stimuli can also mediate a broad range of biologic effects through the interaction with a variety of target cells in the skin. [1], [2], [3] and [4] Likewise, neurohormones such as alpha-melanocyte–stimulating hormone (a-MSH), which are capable of modulating a range of cellular activities, can be detected in peripheral nerves and are produced by different cell types in the skin. [5] The biologic activities of these released cutaneous neuropeptides and neurohormones include the modulation of cell proliferation, cytokine production, and cellular adhesion molecule expression in cutaneous target cells such as keratinocytes, microvascular endothelial cells, Langerhans cells, melanocytes, fibroblasts, dermal leukocytes, and mast cells. [1], [2], [3], [4], [5], [6], [7] and [8] The cutaneous neuroinflammation cascade is regulated by the expression of specific neuropeptide and neurohormone receptors on epidermal and dermal cells, as well as by the activity of proteolytic enzymes in the skin that degrade released neuropeptides, thereby terminating the neuroinflammatory response. [1] Neurocutaneous interactions and responses also depend on the production and activity of neurotrophic factors, such as nerve growth factor (NGF), that can be secreted by skin cells under physiologic and pathophysiologic conditions and can modulate the growth and proliferation of cutaneous nerve fibers. [1], [9] This chapter discusses the role of different components of the sensory nervous system in mediating cutaneous inflammation and wound healing. An overview of our current understanding of the key components of neurogenic inflammation in the skin is presented.

NEUROGENIC INFLAMMATION

Background

The cutaneous sensory nervous system is responsible for relaying sensory information from the skin to the central nervous system (CNS). Early in the twentieth century, Bayliss and Bruce noted that patients with defective cutaneous sensory systems were incapable of mounting normal inflammatory responses in the skin to topically applied proinflammatory agents. [10], [11] Likewise, for many years, clinicians observed that patients with certain cutaneous sensory disorders, such as congenital analgesia syndromes, postherpes analgesia, and diabetic neuropathy, had defective responses to inflammatory stimuli. [12] Such clinical observations had led investigators to examine the role of the cutaneous neurologic system in modulating cutaneous inflammation.

Hallmarks of Neurogenic Inflammation: Vasodilation and Plasma Leakage

The definition of neurogenic inflammation has expanded as our understanding of the complex network of neuropeptides, target cell receptors, and degradatory enzymes involved in this process has grown. Nicholas Jansco coined the term *neurogenic inflammation* to describe the inflammatory response in the skin by direct electrical stimulation of sensory nerves or by stimulation of these nerves by chemical irritants, such as capsaicin, mustard oil, formalin, xylene, or hypertonic solutions. [13], [14] Major consequences of neuroinflammatory responses include vasodilation, increased vascular permeability, and plasma leakage. Jansco first used capsaicin (*trans*-8-methyl- *N*-vanillyl-6-nonenamide), the pungent ingredient in hot chili peppers, as a specific research tool to induce sensory nerve activation and neuroinflammatory responses, when administered in low doses. An increasing number of subsequent studies support the contribution of capsaicin-sensitive nerve fibers and released neuropeptides in mediation of inflammation in the skin. [15] Capsaicin induction of neuropeptide release from sensory nerves triggers a cascade of inflammatory events, such as pain, erythema, and edema in skin and mucosa. The phenomenon of capsaicin-induced *desensitization* that renders nerves in the treated area insensitive to further stimulation by chemical irritants is caused by sensory nerve depletion of neuropeptides, such as substance P and calcitonin gene–related peptide (CGRP), as well as by the destruction of free sensory nerve endings. [15], [16] A specific functional capsaicin-sensitive vanilloid receptor has been identified on sensory nerves. This receptor is believed to respond primarily to localized heat and acidic stimuli. [17]

Local Effector Function of Sensory Nerve Endings and Axon Reflex Model

Neurogenic inflammation in response to the application of capsaicin to the skin is not inhibited by local anesthetics and, thus, the release of neuropeptides from cutaneous sensory nerves appears to be independent of the induction of the neuronal action potential. [15] Released cutaneous neuropeptides are capable of diffusing into surrounding tissues to initiate various inflammatory responses. By this mechanism, nerve endings in the skin mediate local effector inflammatory responses and may act as the first component of the innate immune response after cutaneous injury.

There are also mechanisms by which the activation of sensory nerves can spread to branched nerve endings that are not directly stimulated. The application of cutaneous irritants or the injection of histamine into a localized region of the skin causes reddening (erythema) and edema (wheal), as well as an arteriolar vasodilation (flare) that spreads far beyond the site of initial stimulation. The flare component of this so-called triple response in the skin is dependent on an intact sensory innervation of the skin, because it does not take place in denervated skin. This neurosensory phenomenon may be explained by the so-called axon-reflex model of neurogenic inflammation. This model proposes that after injury of tissue innervated by the sensory nervous system, an immediate orthodromic signal, elicited by the sensory nerves to the dorsal root ganglia and the CNS, allows the host to sense and respond to the injury rapidly by a withdrawal and avoidance response. In addition to this orthodromic response to the CNS, other branched components of these afferent nerves pass nerve impulses antidromically in the reverse direction back to the peripheral innervated tissue. [15], [18] In this antidromic response, neuropeptides are released into the injured tissue where they can interact with potential target cells located in close proximity to the activated sensory nerve fibers. [15], [18]

THE CUTANEOUS SENSORY NERVOUS SYSTEM

Neuroanatomy

The cutaneous sensory nervous system is an important component of the peripheral nervous system. Sensory nerves are derived from dorsal root ganglion neurons and are present in all parts of the skin, representing the initial somatic portion of the afferent sensory pathway. [19] The presence of intraepidermal and dermal nerves has been demonstrated in human skin by using electron microscopy [20] and confocal laser-scanning microscopy [21] and by immunohistochemistry with antibodies directed against neuronal derived proteins (Fig. 20-1). These studies demonstrate that the epidermis is innervated by a three-dimensional network of unmyelinated, fine nerve fibers with free branching endings that converge in the dermis. These afferent sensory neurons in the peripheral nervous system synthesize a heterogeneous group of at least 17 different neuropeptides [18] consisting of 2 to more than 40 amino acids in size. Neuropeptides in the skin are synthesized and released predominantly by a subpopulation of small neurofilament-poor (unmyelinated) afferent neurons (C fibers) designated as *C-polymodal nociceptors,* which represent about 70 percent of all cutaneous C fibers, and, to a far lesser extent, by small myelinated Ad-fibers (Ad mechanothermal receptors). [22] Immunohistochemical studies in the skin demonstrate the presence of multiple neuropeptides and neurohormones such as substance P, neurokinin A, CGRP, vasoactive intestinal peptide, and a-MSH [1], [22] in sensory nerves. Substance P is often considered to be the prototype of the neuropeptides released from sensory C fibers in the skin that are capable of a range of proinflammatory activities. [1], [2], [3] and [4]

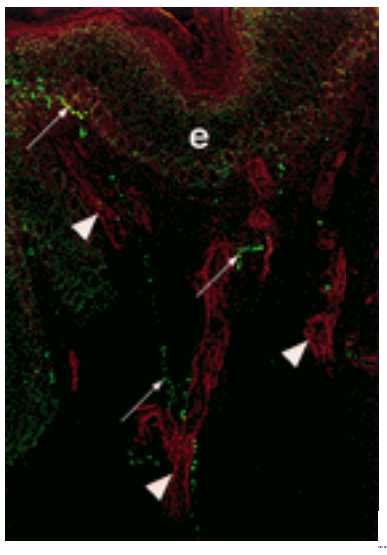

FIGURE 20-1 Nerve fibers in the skin. Confocal microscopy demonstrates CGRP immunoreactivity of nerves in the epidermis and dermis (*small arrows, green staining*). The cutaneous nerves are in close proximity to microvascular structures in the dermis, which are demonstrated by CD34 immunoreactivity (*arrowheads, red staining*).

Although cutaneous nerves are the principal source of neuropeptides in the skin, there is also evidence that neuropeptides or neurohormones may be produced by skin cells such as keratinocytes, microvascular endothelial cells, and fibroblasts. [22] In addition, immune cells that either constitutively reside in the skin or infiltrate the skin under inflammatory conditions both respond to and have been reported to produce certain neuropeptides and neurohormones. [22] Somatostatin, atrial natriuretic peptide, and proopiomelanocortin (POMC) peptides, such as a- and ?-MSH or ß-endorphin, have been detected in human skin or skin cells. [5], [22] POMC peptides, which were originally discovered as pituitary hormones, have also been detected in cutaneous melanocytes, keratinocytes, microvascular endothelial cells, Langerhans cells, mast cells, and fibroblasts, as well as in immune cells such as monocytes and macrophages. [5] A major regulator of POMC transcription is corticotrophin-releasing hormone (CRH), which was also recently detected in the skin. CRH belongs to the stress-responsive mediators and is likely to play a crucial role in modulating immune–neuroendocrine interactions. Stress-induced CRH may affect POMC gene transcription not only in the pituitary, but also in peripheral tissues, including the skin. Thus, POMC peptides can function as mediators of immune and

inflammatory responses and influence the course of certain skin diseases. [5], [23]

Neuropeptide Receptors

Different types of neuropeptide receptors have been identified on neuronal and nonneuronal cells in the skin. Three principal neurokinin (NK) receptors have been described to date—NK-1R, -2R, and -3R—that bind with high affinity to substance P, NK A, and NK B, respectively, although there is considerable cross-reactivity between these different neurokinin peptides and the three NK receptors. [24] NK receptors are seven-transmembrane G protein-coupled peptides. [25] Recent studies indicate that murine keratinocytes predominantly express NK-2R, whereas human keratinocytes and dermal endothelial cells express NK-1R. [26] Thus, these important target cells in the skin that participate in a wide range of cutaneous inflammatory responses express the appropriate receptors for neurokinins released by sensory fibers. Additionally, two subtypes of CGRP receptors have been identified, based on different pharmacologic and biologic responses after activation by various CGRP agonists and antagonists. [28], [29] Dermal microvascular endothelial cells and Langerhans cells have been reported to respond specifically to CGRP. [3], [22] In contrast POMC peptides exert their effects via a group of five G protein-coupled receptors with seven-transmembrane domains, designated as melanocortin (MC) receptors (MC-1R through MC-5R). Epidermal and dermal cells, as well as inflammatory and immunocompetent cells, almost exclusively express MC-1R, which exhibits the highest affinity for aMSH. [5], [23], [30]

Neuropeptide-Degrading Enzymes

In addition to released neuropeptides and appropriate target cell neuropeptide receptors, another key determinant of the neurogenic inflammatory response is the expression of neuropeptidases such as neutral endopeptidase (NEP, CD10). [1], [22] NEP is a cell membrane-associated protease capable of degrading neurokinins such as substance P and is believed to be an important regulator in terminating neurogenic inflammation. This proteolytic enzyme is often colocated on the cell membrane of the target cells that express NK receptors and thus can effectively diminish the inflammatory effect by degrading excess released neuropeptides. [1], [22], [31] Recent work indicates that significant NEP expression and bioactivity can be detected in the epidermis and microvascular endothelial cells of the dermis [32] (Fig. 20-2). The spontaneous vascular leakage and cutaneous edema, which occur in the dermis of mice that lack the NEP gene, also indicate the important function of this enzyme in preventing constitutive neurogenic-mediated inflammation in the skin. [33]

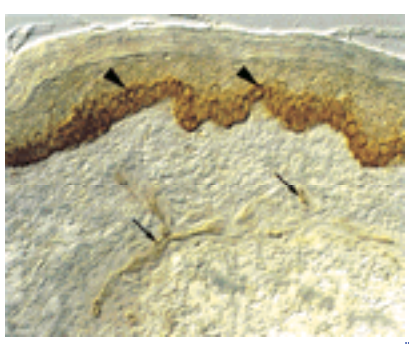

FIGURE 20-2 Neutral endopeptidase in the skin. Immunohistochemistry demonstrates significant neutral endopeptidase in the basal layer of the epidermis (*arrowheads*), as well as in microvascular endothelial cells in the dermis (*small arrows*).

The carboxypeptidase angiotensin-converting enzyme (ACE) also appears to have biologic effects similar to those of NEP. Blockade of ACE by inhibitors of this enzyme (e.g., captopril and enalapril) in wild-type mice caused elevated plasma extravasation, which was mediated by diminished degradation of substance P and bradykinin. [34] This may be of clinical consequence to patients who receive these drugs.

To control the production of POMC peptides, the presence of several peptide processing neuropeptidases, named prohormone convertases, are required. These enzymes have recently been detected in the skin and are upregulated by proinflammatory stimuli such as UV light. [5]

These data indicate that the complex process known as neurogenic inflammation depends on a number of biologic factors, including the types and quantities of neuropeptides released, the types of receptors located on target cells, the presence and localization of NEP and other proteases, the activation state of target cells, as well as the presence of other mediators of inflammation such as prostaglandins and cytokines.

Neurotrophins

Neurotrophic growth factors are essential for the growth, proliferation, and maintenance of cutaneous nerves. Neurotrophic factors that may play a role in the skin include nerve growth factor (NGF), brain-derived NGF, neurotrophin-3, and human neurotrophin-4/5. [1], [9] NGF is the best characterized member of the neurotrophin family. It was isolated more than 40 years ago as an agent that stimulates neurite growth and development in embryonic sensory cells. [35] In the adult animal, NGF plays a continuous dynamic role in regulating peptide neurotransmitter levels and synthesis in mature neurons. [36] NGF is synthesized in increased quantities in inflamed tissue, and after uptake and retrograde transport by sensory nerves, contributes to increased neurite neuropeptide synthesis. [37] During cutaneous inflammation the nerves innervating the inflamed skin demonstrate increased NGF content and eventually increased neuronal substance P and CGRP levels. [38] This increase of neuropeptide content in sensory nerves was prevented by anti-NGF antibodies indicating that NGF plays an important role in the stimulation of neuropeptide synthesis during

cutaneous inflammation. [38]

Murine and human keratinocytes also express, synthesize, and release NGF. [9] NGF synthesis and release from keratinocytes is increased by cutaneous neuropeptides such as substance P and neurokinin A, [39] after UV-irradiation, [9] and in cutaneous wounds. [40] Greater amounts of NGF are secreted by proliferating preconfluent keratinocytes than by more differentiated stratified cells. [9] In addition, NGF stimulates the proliferation of human dermal microvascular endothelial cells (HDMEC). [41] After skin injury, increased amounts of NGF may contribute to wound healing by direct stimulatory effects on keratinocytes, as well as on dermal microvascular endothelial cells, [9], [41], [42] and by the regeneration of damaged nerves and reinnervation of the damaged skin area. [16]

Recent studies similarly demonstrate neurotrophic activity for the angiogenic factors such as vascular endothelial growth factor (VEGF). VEGF stimulates axonal outgrowth from dorsal root ganglia by the activation of the VEGF receptor flk-1, [43] suggesting cross-talk between the nervous and vascular system.

NEUROPEPTIDE–TARGET CELL INTERACTIONS IN SKIN INFLAMMATION

A key experimental finding that has expanded our understanding of neurogenic inflammation was the observation that various nonneural cells express specific neuropeptide receptors and thus are capable of responding to released neuropeptides. [1] Lymphoid cells, such as T cells, B cells, and monocytic cells, express specific receptors for neurotransmitters [1] so that they can respond to these neuropeptides with the induction of modified cytotoxic activities, antibody secretion, cytokine production, and adhesion molecule expression. [22], [44] Thus, in a direct way the neurologic system may be able to modulate immune responses.

It has been established by a number of investigators that neuropeptides are capable of activating mast cells to release mediators of immediate hypersensitivity such as histamine. [45] Mast cells are also capable of secreting mediators of late-phase inflammatory responses such as tumor necrosis factor (TNF)-a. Substance P specifically induces mast cell TNF-a mRNA expression and increases secreted TNF-a activity. [1], [4] Additionally, substance P treatment of skin explants causes mast cell degranulation and subsequent TNF-a–mediated induction of E-selectin on postcapillary venular endothelial cells. [1], [4] In addition, UVB-induced CGRP release from sensory afferent nerve fibers and the subsequent CGRP-induced release of TNF-a from skin mast cells play an important role in the UVB-induced suppression of the cutaneous hypersensitivity (CHS) reaction to dinitrofluorobenzene (DNFB). [46] Thus, these studies support the role of the neurologic system in directly activating mast cells and modulating immediate and delayed inflammatory responses in the skin.

Recently, a new mechanism of sensory nerve–mast cell interaction was reported in which mast cell-derived tryptase was found to be able to directly stimulate the release of neuropeptides such as substance P and CGRP, by the activation of protease-activated receptor-2 (PAR-2) on sensory afferent nerves. [47] The protease-induced local release of neuropeptides eventually induces localized neurogenic inflammation. [47] In addition, small amounts of PAR-2 agonists, including mast cell tryptase, are able to sensitize sensory afferent neurons and induce thermal and mechanical hyperalgesia. [48] Thus, this new mechanism of protease-induced neurogenic inflammation may contribute to the proinflammatory effects of mast cells in human disease. In normal human skin, PAR-2 receptors are also found on epidermal and dermal cells, with increased expression of PAR-2 receptors noted in keratinocytes and endothelial cells in inflamed atopic and psoriatic skin. In these skin diseases, the number of mast cells was also found to be increased. [49] PAR-2 activation of mast cells may contribute to the pathophysiology of these chronic inflammatory diseases.

It has been noted that cutaneous sensory fibers extend into the epidermis where they come in direct contact with both keratinocytes and Langerhans cells [3], [50] (see Fig. 20-1). Neuropeptides released by epidermal nerve fibers may modulate cutaneous inflammation, in part by the induction of keratinocyte cytokine production. Substance P is capable of directly activating both murine and normal human keratinocytes to secrete cytokines such as interleukin-1 (IL-1) in a dose-dependent manner in vitro and in vivo. This effect was inhibited by specific NK receptor antagonists. [1], [22] A number of recent studies also have focused on the relationship between Langerhans cells and CGRP, released from cutaneous sensory nerve fibers. [3] It has been proposed that CGRP is capable of suppressing delayed-type hypersensitivity (DTH) reactions and CHS reactions by the reduction of Langerhans cell density and the inhibition of Langerhans cell antigen presentation to T cells. [3], [51], [52] CGRP was also found to inhibit both proliferation and antigen presentation of peripheral blood mononuclear cells. [53] It has been proposed that CGRP may also impair antigen presentation required for cutaneous CHS and DTH reactions by the induction of anti-inflammatory cytokines, such as IL-10, that may, in turn, suppress T cell functions. [53]

Dermal microvascular endothelial cells are also potentially important targets and modulators of cutaneous neurogenic inflammation. Cutaneous sensory nerve fibers are found in close contact with dermal microvascular endothelial cells [27] (see Fig. 20-1). Cutaneous neuropeptides affect two important inflammatory activities of endothelial cells: cytokine production and cellular adhesion molecule expression. Neuropeptides such as CGRP released by cutaneous sensory nerves induce IL-8 production in normal HDMEC. [1] IL-8 is a principal chemotactic factor for neutrophils and facilitates their vascular transmigration. HDMEC also can be activated directly by substance P to express increased cellular adhesion molecules in a dose-dependent fashion in vitro and in vivo. [1], [27] Thus, released cutaneous neuropeptides can directly modulate HDMEC inflammatory activities.

Among the multiple POMC peptides, a-MSH and ß-endorphin are regarded as neurohormones with extensive immunomodulatory capacities. ß-Endorphin is synthesized in peripheral blood mononuclear cells and has been demonstrated to favor a Th2-type immunoresponse. [54] a-MSH regulates proliferation and differentiation of keratinocytes and melanocytes and modulates fibroblast and endothelial cell cytokine production in vitro. [5], [55], [56] Locally, as well as

systemically, a-MSH impairs immunologic functions and induces anti-inflammatory cytokines such as IL-10. [5], [23] Additionally, a-MSH antagonizes the proinflammatory effects of cytokines such as IL-1, IL-6, and TNF-a, and downregulates the production of interferon-? by T cells, as well as the expression of accessory molecules such as CD86 and CD40, which are required for T cell activation. These observations suggest that this neurohormone may play a crucial role in the downregulation of inflammatory reactions within the skin. [5], [23], [57]

THE ROLE OF NEUROGENIC INFLAMMATION IN CUTANEOUS DISEASE AND WOUND HEALING

There are a number of human clinical diseases that appear to have a significant neurogenic component, including ophthalmic herpesvirus infections, inflammatory bowel disease, asthma, and inflammatory arthritis. [1] In the skin, there is evidence of a neurogenic component in the pathogenesis of urticaria, psoriasis, atopic dermatitis, and hypersensitivity reactions, and in the physiologic process of wound healing. [1]

As previously indicated, there is a close anatomic association of cutaneous nerves and mast cells in the skin, thus providing a direct physical link for these two systems to interact. [58] The ability of neuropeptides to activate mast cells and induce urticaria has been appreciated for a number of years. [45] Investigators have demonstrated that NKs such as substance P are capable of binding to and directly activating mast cells and triggering the release of immediate hypersensitivity mediators. [45] Neuropeptides may also be responsible for the release of mast cell cytokines, which can mediate late-phase inflammatory responses. [1] In addition, recent reports also revealed the induction of neurogenic inflammation by mast cell tryptase via the activation of PAR-2 on sensory afferent nerves. [47]

A neurogenic component for the pathophysiology of psoriasis is suggested by both clinical and experimental findings. [59], [60] and [61] Clinically, lesions often have a symmetric distribution and occur in regions that are traumatized. The so-called Koebner phenomenon in psoriasis may be partly initiated by the release of proinflammatory neuropeptides in the traumatized skin. [60] Investigators also report increased levels of neuropeptides and sensory nerves in psoriatic skin lesions, and capsaicin, a chemical that is capable of depleting neuropeptides from nerve endings, is reported to have some therapeutic value in clearing psoriatic lesions. [59], [61] In addition, NGF, which plays an important role in synthesis and release of neuropeptides in sensory nerves, is significantly increased in inflamed lesional skin from psoriatic patients when compared to normal healthy skin. [62] Likewise, in atopic dermatitis, increased lesional staining of cutaneous nerves and abnormal cutaneous responses to injected neuropeptides have been reported. [63], [64]

The role of POMC peptides in the pathogenesis of atopic dermatitis is supported by the in vitro observation that a-MSH modulates IgE production and the finding of increased levels of POMC peptides in the skin of patients with atopic dermatitis. [65], [66] Recently, the POMC-derived neurohormone a-MSH also was shown to induce the release of the potent pruritogen histamine from human skin mast cells and from skin bunch biopsies in a dose-dependent manner. [67]

Neuropeptides appear to play a role in both immediate and DTH reactions in the skin. CGRP and substance P have been demonstrated to participate in or modulate immediate-type skin hypersensitivity reactions. DTH and CHS are delayed T cell–mediated immune reactions occurring in the skin after a first injection (as in DTH) or contact sensitization (as in CHS) with an antigen, followed by a second contact with the hapten (elicitation). Topical application of substance P on mouse ears significantly increases the ear-swelling response to a contact allergen, [68] whereas inhibitors of substance P diminish CHS and DTH responses in mice and humans. [69], [70] These experiments suggest a proinflammatory effect of substance P in CHS and DTH. Other neuropeptides appear to have a suppressive effect on hypersensitivity reactions in the skin. CGRP, which is released by sensory neurons during the elicitation phase of CHS, [71] appears to suppress DTH and CHS reactions through interactions with Langerhans cells, as described above. [3], [52] Systemic pretreatment of adult mice with capsaicin, which causes the depletion of neuropeptides from sensory nerves, results in an increased CHS to contact allergens as well as increased DTH to alloantigens, suggesting both proinflammatory and immunosuppressive effects of neuropeptides released from cutaneous sensory nerves in CHS and DTH. [71], [72]

a-MSH is one of the most powerful neurohormones in terms of its ability to modify CHS reactions. a-MSH inhibits both the sensitization and elicitation phase of CHS and induces hapten-specific tolerance in mice. [73] This is mediated, at least in part, by the inhibition of accessory signals on antigen-presenting cells and the induction of the immunosuppressive cytokine IL-10, which has been shown to inhibit the elicitation phase of CHS and induce tolerance. On the other hand, the effect of a-MSH on the elicitation phase could be explained by its capacity to downregulate the endothelial cell adhesion molecule expression required for adhesion and transmigration of inflammatory cells. [5], [23]

Interestingly, many skin diseases in which neuropeptides are proposed to play a role are affected by UV light. Phototherapy of psoriasis, atopic dermatitis, as well as prurigo nodularis is well established, and phototherapy is able to suppress chronic urticaria as well as skin CHS reaction. [74] The release of neuropeptides such as substance P and CGRP from cutaneous sensory nerves by erythemogenic doses of UV-light and the reduction of UV-induced inflammation by receptor antagonists to substance P and CGRP, as well as the increase of UV-induced inflammation in genetically engineered mice deficient for NEP, clearly indicate that neuropeptides are important mediators of UV-induced cutaneous inflammation. [75], [76] and [77] Furthermore, experimental phototherapy with repeated suberythemogenic doses of UVB significantly increased the content of substance P and CGRP in sensory nerves and augmented the mustard oil-induced cutaneous inflammation. [78]

The involvement of neuropeptides in UV-induced immunosuppression is also well established. CGRP is an important mediator in UVB-induced local and systemic immunosuppression, in part by the interaction with skin mast cells. [46], [79], [80] and [81] The role of CGRP in UV-induced immunosuppression has been confirmed by the ability of the CGRP-antagonist CGRP8-37, applied at cutaneous UV-irradiated sites before sensitization to a contact allergen, to restore the UV-induced suppression of the CHS reaction induced by DNFB. [46], [81] The inhibitory effects of CGRP on antigen presentation by

Langerhans cells and macrophages was previously discussed. [3] In addition, CGRP applied to rat skin reduced the number of Langerhans cells in the epidermis to that of UV-exposed rat skin. [81] UV light also induces the release of a-MSH from keratinocytes, and upregulates the expression of POMC mRNA. a-MSH, then, is able to exert a variety of antiinflammatory and immunomodulating effects. [82] Taken together these studies suggest that effects of phototherapy on diseases such as psoriasis or atopic dermatitis may, at least in part, be explained by its modulation of the cutaneous sensory nervous system and neurohormones.

There is also increasing evidence that the neurologic system may also play an important role in mediating normal wound healing responses. Released neuropeptides may modulate a number of important aspects of normal wound healing such as cell proliferation, cytokine and growth factor production, and neovascularization. [22] NEP expression appears to be both increased and redistributed in the wound environment during the healing processes. [32] Abnormal wound healing responses in the lower limbs of insulin dependent diabetics is also accompanied by overexpression of cutaneous NEP. [83] Surgical resection of cutaneous nerves results in delayed wound healing in animal models. [84] In addition, patients with cutaneous sensory defects due to lepromatous leprosy, spinal cord injury, or diabetic neuropathy develop ulcers that fail to heal in spite of aggressive wound care and wound protection. [1] Experimental evidence indicates that the neurologic system also appears to have an important trophic effect for tissue integrity and function. [1]

SUMMARY

The neurobiologic system of the skin plays a much wider role than simply the transmission of sensory impulses to the CNS. It is now appreciated that in the skin there are complex interactions between sensory nerve fibers, released neuropeptides, cutaneous target cells bearing neuropeptide receptors, proteases that degrade cutaneous neuropeptides, and neurotrophins that influence innervation. Indeed, the cutaneous neurosensory system may represent an important early component of the innate immune system in the skin. New therapies for inflammatory skin diseases or impaired wound healing, which are mediated by the modulators of neurocutaneous interactions, are likely to result from continued scientific investigations in this field.

REFERENCES

1. Ansel JC et al: Interactions of the skin and nervous system. *J Invest Dermatol Symp Proc* **2**:23, 1997

2. Brain SD: Sensory neuropeptides in the skin, in *Neurogenic Inflammation,* edited by P Geppetti, P Holzer. Boca Raton, FL, CRC Press, 1996, p 229

3. Hosoi J et al: Regulation of Langerhans cell function by nerves containing calcitonin gene-related peptide. *Nature* **363**:159, 1993

4. Lotti T et al: Neuropeptides in skin. *J Am Acad Dermatol* **33**:482, 1995

5. Luger TA et al: Cutaneous immunomodulation and coordination of skin stress responses by a-melanocyte–stimulating hormone. *Ann N Y Acad Sci* **840**:381, 1998

6. Slominski A et al: Corticotropin-releasing hormone and proopiomelanocortin involvement in the cutaneous response to stress. *Physiol Rev* **80**:979, 2000.

7. Toyoda M et al: Calcitonin gene–related peptide upregulates melanogenesis and enhances melanocyte dendricity via induction of keratinocyte-derived melanotrophic factors. *J Invest Dermatol Symp Proc* **4**:116, 1999

8. Slominski A, Wortsman J: Neuroendocrinology of the skin. *Endocr Rev* **21**:457, 2000.

9. Pincelli C, Yaar M: Nerve growth factor: Its significance in cutaneous biology. *J Invest Dermatol Symp Proc* **2**:31, 1997

10. Bayliss W: On the origin from the spinal cord of vasodilator fibers of the hind limb, and on the nature of these fibers. *J Physiol* **26**:173, 1901

11. Bruce AN: Vasodilator axon reflexes. *Q J Exp Physiol* **6**:339, 1913

12. Lewis T, Marvin H: Observations relating to vasodilatation arising from antidromic impulses, to herpes zoster and trophic effects. *Heart* **14**:27, 1927

13. Jancso N: Role of the nerve terminals in the mechanism of inflammatory reactions. *Bull Millard Fillmore Hosp (Buffalo, NY)* **7**:53, 1960

14. Jancso N et al: Direct evidence for neurogenic inflammation and its prevention by denervation and by pretreatment with capsaicin. *Br J Pharmacol Chemother* **31**:138, 1967

15. Holzer P: Capsaicin: Cellular targets, mechanism of action, and selectivity for thin sensory neurons. *Pharmacol Rev* **43**:144, 1991

16. Schicho R, Skofitsch G, Donnerer J: Regenerative effect of human recombinant NGF on capsaicin-lesioned sensory neurons in the adult rat. *Brain Res* **815**:60, 1999

17. Caterina MJ, Julius D: The vanilloid receptor: A molecular gateway to the pain pathway. *Annu Rev Neurosci* **24**:487, 2001

18. Holzer P: Local effector functions of capsaicin-sensitive sensory nerve endings: Involvement of tachykinins, calcitonin gene-related peptide and other neuropeptides. *Neuroscience* **24**:739, 1988

19. Sternini C: Organization of the peripheral nervous system: Autonomic and sensory ganglia. *J Invest Dermatol Symp Proc* **2**:1, 1997

20. Hilliges M et al: Ultrastructural evidence for nerve fibres within all vital layers of the human epidermis. *J Invest Dermatol* **104**:134, 1995

21. Reilly DM et al: The human epidermal nerve fibre network: Characterization of nerve fibres in human skin by confocal microscopy and assessment of racial variations. *Br J Dermatol* **137**:163, 1997

22. Scholzen T et al: Neuropeptides in the skin: Interactions between the neuroendocrine and the skin immune systems. *Exp Dermatol* **7**:81,

1998

23. Luger TA et al: The role of alpha-MSH as a modulator of cutaneous inflammation. *Ann N Y Acad Sci* **917**:232, 2000

24. Hershey A et al: Organization, structure, and expression of a gene encoding the rat substance P receptor. *J Biol Chem* **266**:4366, 1991

25. Krause J et al: Structure, functions, and mechanisms of substance P receptor action. *J Invest Dermatol* **98**:2SA, 1992

26. Song I-S et al: Substance P induction of murine keratinocyte PAM 212 interleukin 1 production is mediated by the neurokinin 2 receptor (NK-2R). *Exp Dermatol* **9**:42, 2000

27. Quinlan KL et al: Neuropeptide regulation of human dermal microvascular endothelial cell ICAM-1 expression and function. *Am J Physiol* **275**:C1580, 1998

28. Aiyar N et al: A cDNA encoding the calcitonin gene-related peptide type 1 receptor. *J Biol Chem* **271**:11325, 1996

29. Dumont Y et al: A potent and selective CGRP2 agonist, [Cys(Et)2,7] hCGRP alpha: Comparison in prototypical CGRP1 and CGRP2 in vitro bioassays. *Can J Physiol Pharmacol* **75**:671, 1997

30. Cone RD et al: The melanocortin receptors: Agonists, antagonists, and the hormonal control of pigmentation. *Recent Prog Horm Res* **51**:287, 1996

31. Okamoto A et al: Interactions between neutral endopeptidase (EC 3.4.24.11) and the substance P (NK1) receptor expressed in mammalian cells. *Biochem J* **299**:683, 1994

32. Olerud JE et al: Neutral endopeptidase (NEP) expression by human keratinocytes: Distribution in skin and wounds. *J Invest Dermatol* **112**:873, 1999

33. Lu B et al: The control of microvascular permeability and blood pressure by neutral endopeptidase. *Nat Med* **3**:904, 1997

34. Grady E et al: Mechanisms attenuating cellular responses to neuropeptides: Extracellular degradation of ligands and desensitization of receptors. *J Invest Dermatol Symp Proc* **2**:69, 1997

35. Levi-Montalcini R: The nerve growth factor: Thirty-five years later. *EMBO J* **6**:1145, 1987

36. Lindsay RM et al: Neuropeptide expression in cultures of adult sensory neurons: Modulation of substance P and calcitonin gene-related peptide levels by nerve growth factor. *Neuroscience* **33**:53, 1989

37. Raivich G et al: NGF receptor mediated reduction in axonal NGF uptake and retrograde transport following sciatic nerve injury and during regeneration. *Neuron* **7**:151, 1991

38. Donnerer J et al: Increased content and transport of substance P and calcitonin gene-related peptide in sensory nerves innervating inflamed tissue: Evidence for a regulatory function of nerve growth factor in vivo. *Neuroscience* **49**:693, 1992

39. Burbach GJ et al: The neurosensory tachykinins substance P and neurokinin A directly induce keratinocyte nerve growth factor. *J Invest Dermatol* **117**:1075, 2001

40. Matsuda H et al: Role of nerve growth factor in cutaneous wound healing: Accelerating effects in normal and healing-impaired diabetic mice. *J Exp Med* **187**:297, 1998

41. Raychaudhuri SK et al: Effect of nerve growth factor on endothelial cell biology: Proliferation and adherence molecule expression on human dermal microvascular endothelial cells. *Arch Dermatol Res* **293**:291, 2001

42. Tuveri M et al: NGF, a useful tool in the treatment of chronic vasculitic ulcers in rheumatoid arthritis. *Lancet* **356**:1739, 2000

43. Sondell et al: Vascular endothelial growth factor is a neurotrophic factor which stimulates axonal outgrowth through the flk-1 receptor. *Eur J Neurosci* **12**:4243, 2000

44. Bhardwaj R et al: Evidence for the differential expression of the functional alpha-melanocyte-stimulating hormone receptor MC-1 on human monocytes. *J Immunol* **158**:3378, 1997

45. Church MK et al: Mast cells, neuropeptides and inflammation. *Agents Actions* **27**:8, 1989

46. Niizeki H et al: Calcitonin gene-related peptide is necessary for ultraviolet B-impaired induction of contact hypersensitivity. *J Immunol* **159**:5183, 1997

47. Steinhoff M et al: Agonists of protease-activated receptor-2 induce inflammation by a neurogenic mechanism. *Nat Med* **6**:151, 2000

48. Vergnolle N et al: Proteinase-activated receptor-2 and hyperalgesia: A novel pain pathway. *Nat Med* **7**:821, 2001

49. Steinhoff M et al: Proteinase-activated receptor-2 in human skin: Tissue distribution and activation of keratinocytes by mast cell tryptase. *Exp Dermatol* **8**:282, 1999

50. Dalsgaard C-J et al: Cutaneous innervation in man visualized with protein gene product 9.5 (PGP 9.5) antibodies. *Histochemistry* **92**:385, 1989

51. Torii H et al: Calcitonin gene-related peptide and Langerhans cell function. *J Invest Dermatol Symp Proc* **2**:82, 1997

52. Asahina A et al: Inhibition of the induction of delayed-type and contact hypersensitivity by calcitonin gene-related peptide. *J Immunol* **154**:3056, 1995

53. Fox FE et al: Calcitonin gene-related peptide inhibits proliferation and antigen presentation by human peripheral blood mononuclear cells: Effects on B7, interleukin 10, and interleukin 12. *J Invest Dermatol* **108**:43, 1997

54. Panerai AE, Sacerdote P: Beta-endorphin in the immune system: A role at last? *Immunol Today* **18**:317, 1997

55. Hartmeyer M et al: Human dermal microvascular endothelial cells express the melanocortin receptor type 1 and produce increased levels of

IL-8 upon stimulation with alpha-melanocyte-stimulating hormone. *J Immunol* **159**:1930, 1997

56. Schulte U et al: Evidence for a functional melanocortin receptor on human fibroblasts. *J Invest Dermatol* **110**:479, 1998

57. Taylor AW et al: Alpha-melanocyte stimulating hormone suppresses antigen-stimulated T cell production of gamma-interferon. *Neuroimmunomodulation* **1**:188, 1994

58. Naukkarinen A et al: Immunohistochemical analysis of sensory nerves and neuropeptides, and their contacts with mast cells in developing and mature psoriatic lesions. *Arch Dermatol Res* **285**:341, 1993

59. Bernstein JE et al: Effect of topically applied capsaicin on moderate and severe psoriasis vulgaris. *J Am Acad Dermatol* **15**:504, 1986

60. Farber EM et al: Stress, symmetry and psoriasis: Possible role of neuropeptides. *J Am Acad Dermatol* **14**:305, 1986

61. Naukkarinen A et al: Quantification of cutaneous sensory nerves and their substance P content in psoriasis. *J Invest Dermatol* **92**:126, 1989

62. Fantini F et al: Nerve growth factor is increased in psoriatic skin. *J Invest Dermatol* **105**:854, 1995

63. Giannetti A, Girolomoni G: Skin reactivity to neuropeptides in atopic dermatitis. *Br J Dermatol* **121**:681, 1989

64. Pincelli C et al: Neuropeptides in skin from patients with atopic dermatitis: An immunohistochemical study. *Br J Dermatol* **112**:745, 1990

65. Glinski W et al: Increased concentration of beta-endorphin in the sera of patients with severe atopic dermatitis. *Acta Derm Venereol* **75**:9, 1995

66. Aebischer I et al: Neuropeptides are potent modulators of human in vitro immunoglobulin E synthesis. *Eur J Immunol* **24**:1908, 1994

67. Grutzkau A et al: Alpha-melanocyte stimulating hormone acts as a selective inducer of secretory functions in human mast cells. *Biochem Biophys Res Commun* **278**:14, 2000

68. Gutwald J et al: Neuropeptides enhance irritant and allergic contact dermatitis. *J Invest Dermatol* **96**:695, 1991

69. Wallengren J: Substance P antagonist inhibits immediate and delayed-type cutaneous hypersensitivity reactions. *Br J Dermatol* **124**:324, 1991

70. Scholzen TE et al: Neutral endopeptidase terminates substance P-induced inflammation in allergic contact dermatitis. *J Immunol* **166**:1285, 2001

71. Ek L, Theodorsson E: Tachykinins and calcitonin gene-related peptide in oxazolone-induced allergic contact dermatitis in mice. *J Invest Dermatol* **94**:761, 1990

72. Girolomoni G, Tigelaar RE: Capsaicin-sensitive primary sensory neurons are potent modulators of murine delayed-type hypersensitivity reactions. *J Immunol* **145**:1105, 1990

73. Grabbe S et al: Alpha-melanocyte-stimulating hormone induces hapten-specific tolerance in mice. *J Immunol* **156**:473, 1996

74. Horio T: Indications and action mechanisms of phototherapy. *J Dermatol Sci* **23**:(suppl 1)S17, 2000

75. Benrath J et al: Calcitonin gene-related peptide, substance P and nitric oxide are involved in cutaneous inflammation following ultraviolet irradiation. *Eur J Pharmacol* **293**:87, 1995

76. Scholzen TE et al: Effect of ultraviolet light on the release of neuropeptides and neuroendocrine hormones in the skin: Mediators of photodermatitis and cutaneous inflammation. *J Invest Dermatol Symp Proc* **4**:55, 1999

77. Benrath J et al: Differential time course of skin blood flow and hyperalgesia in the human sunburn reaction following UV irradiation of the skin. *Eur J Pain* **5**:155, 2001

78. Legat FJ et al: UVB irradiation with non-erythematogenic doses increases neuropeptides in the skin of rat ears. *Photochem Photobiol* **69**:55, 1999

79. Garssen J et al: A role for neuropeptides in UVB-induced systemic immunosuppression. *Photochem Photobiol* **68**:205, 1998

80. Hart PH et al: Mast cells in UVB-induced immunosuppression. *J Photochem Photobiol B* **55**:81, 2000

81. Gillardon F et al: Calcitonin gene-related peptide and nitric oxide are involved in ultraviolet radiation-induced immunosuppression. *Eur J Pharmacol* **293**:395, 1995

82. Luger TA et al: Role of epidermal cell-derived alpha-melanocyte stimulating hormone in ultraviolet light mediated local immunosuppression. *Ann N Y Acad Sci* **885**:209, 1999

83. Spenny M et al: Neutral endopeptidase inhibition improves wound repair in diabetic mice. *J Invest Dermatol* **117**:441, 2001

84. Lusthaus S et al: Effect of denervation on incision wound scars in rabbits. *J Ger Dermatol* **1**:11, 1993

T>

Chapter 21

Vincent Falanga

Mechanisms of Cutaneous Wound Repair

INFLAMMATORY PHASE (PHASE 1)
Platelet Release and Aggregation
The Process of Coagulation and Inflammation
Recruitment of Leukocytes
PROLIFERATION AND TISSUE FORMATION (PHASE 2)
Hypoxia
Fibroplasia
Angiogenesis
Keratinocyte Migration
TISSUE REMODELING (PHASE 3)
Fibronectin and Associated Components
Hyaluronic Acid and Proteoglycans
Collagen
Myofibroblasts and Contraction
THE WORLD OF CHRONIC WOUNDS
CONCLUSION
REFERENCES

Wound healing and *wound repair* are terms often used interchangeably, but they actually stand for two quite different sets of events and outcomes. *Wound healing* is a term that technically should be used only in the context of regeneration, when the original architecture and structure of an organ or anatomic part is completely restored to the way it was before injury. More primitive animals, such as small amphibians and reptiles, are still capable of this type of regeneration. However, as animals became larger and more complex, regeneration was no longer possible. In adult humans, with the possible exception of the liver, true regeneration does not occur. Rather, humans and other higher vertebrates heal by a process of repair, whereby the eventual outcome is not anatomic restoration but a functional compromise. Teleologically and from an evolutionary standpoint, the process of repair for higher animals needed to be rapid and to allow for immediate survival of the organism. As noted below, this type of repair is characterized by a substantial amount of scarring and fibrosis. Another consideration is that most of the mechanisms of wound repair that have evolved are aimed at addressing acute tissue injury. From an evolutionary standpoint, humans were not supposed to develop degenerative diseases or live long enough to develop arterial, venous, and pressure ulcers or neuropathic ulcers from diabetes. Therefore, humans are quite unprepared for these types of chronic wounds, and there are no specific mechanisms that have evolved to deal with them in an effective way.

There are three recognized phases that characterize the cutaneous repair process: the inflammatory phase, the proliferative or migratory phase (tissue formation), and the remodeling phase (Fig. 21-1). Each phase will be discussed individually and the main components and events that characterize each will be identified. However, it should be noted that breaking down the overall process of wound repair into these three phases is somewhat artificial because they overlap considerably. [1]

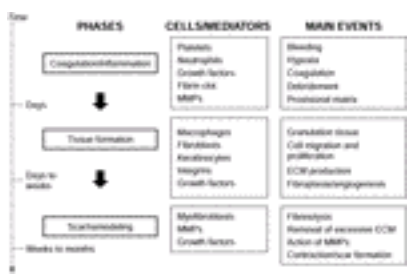

FIGURE 21-1 Schematic representation of the different phases of wound repair and the cells and events involved at different time points. ECM, extracellular matrix, MMP, matrix metalloproteinase.

INFLAMMATORY PHASE (PHASE 1)

The first phase, that of inflammation, begins immediately after an acute injury. Disruption of blood vessels leads to local release of blood cells and blood-borne elements resulting in clot formation. While the blood clot within the vessel lumen provides hemostasis, the clot within the injury site acts as a provisional matrix for cell migration. [2] The inflammatory phase is dominated by the platelet, which directs clotting of the fresh wound by the intrinsic and extrinsic coagulation pathways. Platelets also release a number of chemotactic factors that attract other platelets, leukocytes, and fibroblasts to the site of injury. The inflammatory phase continues as leukocytes, specifically neutrophils and macrophages, enter the scene. Their initial role is to debride the wound by phagocytosing and killing bacteria and scavenging cellular debris.

However, it should be recognized that neutrophils and macrophages also release growth factors and other important mediators during this period of time.

This first phase of wound repair can be best understood by breaking it down into the following components: (1) platelet

release and aggregation, (2) the processes of coagulation and inflammation, and (3) recruitment of leukocytes.

Each of these processes will be discussed in turn, again emphasizing that such events are high interrelated.

Platelet Release and Aggregation

Platelets are essential components of the repair process and are critical to successful hemostasis. Tissue injury leads to blood vessel damage, platelet release, and activation of blood coagulation. [3] Platelets first adhere to interstitial connective tissue and then aggregate. Platelets at the wound site are exposed to thrombin and fibrillar collagen, which trigger their activation, adhesion, and aggregation. During aggregation, platelets release many mediators, including adenosine diphosphate, (ADP), and also express several clotting factors on their membrane surface. The process of coagulation is greatly facilitated by these platelet products that, in turn, lead to further platelet activation.

Besides ADP, the mediators released by the alpha granules of activated platelets include several adhesive proteins, such as fibrinogen, fibronectin, thrombospondin, and von Willibrand factor VIII. Fibrinogen, fibronectin, and thrombospondin serve as ligands for platelet aggregation, whereas von Willibrand factor VIII facilitates platelet adhesion to fibrillar collagens. [4] These activities result in the formation of a platelet plug. Thrombin polymerization of fibrinogen leads to fibrin, which amplifies the clot and will form part of the provisional extracellular matrix required for the migration of cells into the wound. It should be emphasized that no cell acts alone at any stages of the wound healing process. For example, in this platelet-dominated phase, endothelial cells produce several factors that limit platelet aggregation and clot formation to the area of injury. Among these activities are inhibition of platelet aggregation(by prostacyclin), inhibition of thrombin activity (by antithrombin III), degradation of coagulation factors V and VIII (by protein C), and initiation of clot lysis by converting plasminogen to plasmin with plasminogen activator. [5]

In addition to these critical roles in clot formation and the inflammatory phase of wound repair, platelets also release a number of growth factors and cytokines. These factors participate in the initial inflammatory phase but, equally important, also serve as signals for the migration of certain critical cells to the site of injury. Among these growth factors are platelet-derived growth factor (PDGF), transforming growth factor ß1 (TGF-ß1), platelet factor 4, connective tissue activating peptide (CTAP-III), beta-thromboglobulin, and neutrophil-activating peptide 2 (NAP-2). It should be noted that platelets are the most important storage site for TGF-ß1, one of three TGF-ß isoforms, that plays a critical role in wound repair. [6]

The Process of Coagulation and Inflammation

During the process of coagulation, plasma and other blood elements leak from injured blood vessels and contribute to the formation of a thrombus through the intrinsic and extrinsic pathways. The intrinsic pathway is initiated when blood is exposed to subendothelial tissue, an event that leads to activation of factor X. Conversely, the extrinsic pathway begins when thromboplastin activates factor VII. The intrinsic and extrinsic pathways both lead to the formation of thrombin, which cleaves fibrinopeptides A and B as well as other fragments from fibrinogen and ultimately leads to polymerization of fribrinogen to fibrin. [7], [8] However, the stability of fibrin and, indeed, its biologic activity are very much dependent on its cross-linking, which occurs as a result of the action of factor XIII. [9] Blood coagulation ends when the different stimuli for the activation of the coagulation cascade resolve. However, there are also active processes in place to downregulate the coagulation cascade. Among these are the inhibition of platelet aggregation by prostacyclin, inhibition of thrombin activity when this molecule binds to antithrombin III, and the action of protein C, an “anticoagulant” factor that degrades factors V and VIII.

Migration to the site of injury of a number of key cells, such as keratinocytes, fibroblasts, endothelial cells, and monocytes, is aided by their receptors for various components of the thrombus. However, a host of other mediators is produced and plays an important role in the amplification of the inflammatory/coagulation phase. For example, the formation of bradykinin, as well as C3a and C5a, is stimulated by activated Hageman factor. [5], [9] The end result of the action of these and other mediators is increased vascular permeability, neutrophil and monocyte recruitment, and release of factors from mast cells. Cleavage of fibronogen, as mentioned, leads to a number of active fragments, such as the fibrinopeptides, that are important in stimulating migration to the wound site of certain cells, including fibroblasts.

Recruitment of Leukocytes

There is a constant cascade of inflammatory molecules and recruitment of inflammatory cells during the early phases of wound healing. [10] Neutrophils and monocytes arrive at the site of injury at about the same time. Initially, neutrophils are present in greater numbers because they constitute a larger fraction of peripheral white cells. Both neutrophils and monocytes are attracted to the wound by such chemotactic factors as kallikrein, fibrinopeptides released from fibrinogen, and fibrin degradation products. However, the list of reactants and chemotactic agents is long. In addition to the growth factors released by the platelets and the fragments resulting from the polymerization and cross-linking of fibrinogen, there are other by-products of proteolysis and other matrix components, as well as formyl methionyl peptides cleaved from bacterial proteins. [11] These and other chemotactic factors also stimulate the expression of CD11/CD18 complex on the surface of neutrophils, thereby enhancing the adherence of neutrophils to blood vessel endothelium and facilitating their diapedesis between adjacent endothelial cells. [12], [13] It is important to understand that in order to enter the wound, leukocytes must exit the circulation, a process that is highly regulated by molecular changes on the surface of endothelial cells in blood vessels within and adjacent to the wound. This endothelial-leukocyte interaction provides the means to select the types of leukocytes entering the site of tissue injury. As a response to injury, endothelial cells express selectins, which by their adhesion properties cause the circulating leukocytes to slow down, roll, and be pulled from the blood. Both E and P selectins probably are required for the full recruitment of neutrophils and macrophages. [14] Once these weaker adhesions slow down the leukocytes, tighter interactive adhesions provided by $ß_2$ integrins cause the

leukocytes to negotiate the space between endothelial cells and reach the wound. [15]

Neutrophils are important in tissue debridement and in bacterial killing, events that produce further products of complement activation with inflammatory and chemotactic properties. New evidence suggests that neutrophils are also a rich source of cytokines, such as PDGF-like molecules. Connective tissue growth factor (CTGF) is one such peptide. [16], [17] The action of neutrophils is enhanced by integrins, cell surface receptors that facilitate cell-matrix interactions. [18], [19] and [20] However, neutrophils do not appear to be absolutely critical for wound repair, since neutropenia by itself does not interfere with the healing process. [21] Similarly, guinea pigs depleted of neutrophils are able to heal normally. [21]

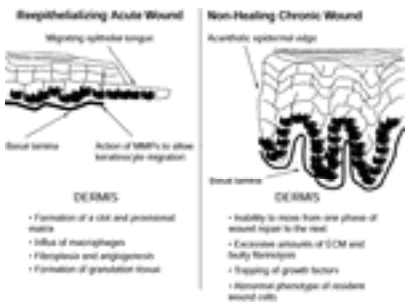

FIGURE 21-2 Diagrammatic representation of the epidermal edge of a normally healing wounds (*left*) and of a nonhealing wound (*right*). The healing wound shows separation from the underlying basal lamina and a thick epithelial tongue. The chronic wound edge shows the typical acanthotic epidermis. The bottom portion of the figure shows events presents in the dermis during repair.

As the inflammatory process continues, within 24 to 48 h after injury, monocytes replace neutrophils and become the predominant leukocyte. Monocytes are attracted to the injury site by some of the same chemoattractants responsible for recruitment of neutrophils, such as kallikren, fibrinopeptides, and fibrin degradation products. [13] Other, more specific chemoattractants then take over in recruiting monocytes, and they include fragments of collagen, fibronectin, elastin, and TGF-ß1. Monocytes undergo a phenotypic change to tissue macrophages and, unlike neutrophils, they are critical for the progression of wound healing. Macrophages phagocytose and kill bacteria and scavenge tissue debris. [22] They also release several growth factors, including PDGF, fibroblast growth factor (FGF), TGF-ß, and TGF-a, thereby stimulating migration and proliferation of fibroblasts, as well as production and modulation of extracellular matrix. It has long been stated that the macrophage is the central and critical cell for wound repair. The basis for this assertion is experiments in which animals depleted of macrophages by the use of antimacrophage serum and steroids failed to heal properly. [23] However, it is important to consider that what may delay or impair healing is not so much the presence or absence of inflammation and certain cells but rather an inappropriate inflammatory response. For example, there is evidence that healing may occur in the absence of an inflammatory infiltrate. [24] Conversely, experiments in mice constitutively expressing the chemotactic cytokine IP-10 show that an intense inflammatory infiltrate can impair neovascularization and the formation of appropriate granulation tissue. [25] Therefore, the true role of inflammation in tissue repair remains somewhat controversial from an experimental point of view. From a clinical standpoint, one can make the observation that in certain cutaneous wounds, such as pemphigus or pyoderma gangrenosum, downregulation of inflammation with the use of glucocorticoids is generally helpful. Possibly, modulation and “correction” of the inflammatory response by glucocorticoids may be helpful in these selected clinical entities.

A few days after tissue injury, the remaining neutrophils are phagocytosed by tissue macrophages, and the first phase of wound healing comes to an end, whereas the second phase of proliferation and tissue formation is under way.

PROLIFERATION AND TISSUE FORMATION (PHASE 2)

The first phase of wound repair lays the groundwork for the more formative second phase of proliferation and tissue formation (see Fig. 21-1). The term *tissue formation,* rather than *proliferation,* is clearly more appropriate. In this phase of wound repair, one is dealing with both cellular proliferation and migration, processes that are aided by a number of events, such as hypoxia, as well as specific adhesion proteins and extracellular matrix components. Platelet aggregation and release, the early inflammatory process, and entry into the wound of neutrophils and subsequently monocytes-macrophages have served a number of functions that will now allow and facilitate the proliferation of key resident cells, such as fibroblasts, the migration of endothelial cells and the process of neovascularization, and keratinocyte migration. Keratinocytes undergo a remarkable change in morphology and function. They migrate to the wound bed, release a number of proteins and enzymes that help facilitate their migration and other cellular functions, and ultimately reconstitute the damaged epidermis and basement membrane. [26], [27] The later stages of the second phase of wound repair feature formation of granulation tissue and reconstitution of the dermal matrix (fibroplasia) and development of new blood vessels (angiogenesis)(Fig. 21-1 and Fig. 21-2). Fibroblasts and endothelial cells undergo activation, phenotypic alteration, and migration much like keratinocytes do. Another critical background component of this phase is hypoxia, which begins immediately after injury and severance of blood vessels but whose effects have a profound impact on the migration and proliferation of fibroblasts and endothelial cells as well as, possibly, keratinocyte migration. In the context of this second phase of wound repair, the following components and events will be discussed: (1) hypoxia, (2) fibroplasia, (3) angiogenesis, (4) keratinocyte migration, (5) extracellular matrix production, and (6) the role of integrins.

Hypoxia

Immediately following acute injury, the wound becomes temporarily hypoxic due to severence of blood vessels. There are some common misconceptions about hypoxia and its role in wound repair, possibly for two reasons. The major reason is that one incorrectly equates hypoxia with ischemia. The latter implies that both blood flow and oxygen delivery are impaired. However, hypoxia by itself, without a significant decrease in blood flow, may have different biologic

consequences. The second reason for misconceptions about hypoxia is that chronic wounds are often treated with hyperbaric oxygen. Whether this type of treatment is helpful or not is beyond the scope of this discussion. However, the very fact that high oxygen delivery is sought by some clinicians caring for difficult to heal wounds implies that low oxygen tension is always highly undersirable.

However, from a physiologic standpoint, there is evidence that low oxygen tension actually plays an important stimulatory role in the early tissue repair process. Evidence points to low oxygen tension as an important early stimulus for fibroblast (and endothelial cell) activation. Fibroblast replication and longevity are enhanced in hypoxia, [28] and low oxygen tension stimulates clonal expansion of dermal fibroblasts seeded as single cells. [29] Moreover, the synthesis of a number of growth factors is enhanced in hypoxic cells. Macrophages secrete an angiogenic substance only when they are exposed to low oxygen tension. This reversible effect was observed at an oxygen tension of 15 to 20 mmHg. [30] TGF-ß1 transcription and peptide synthesis are enhanced in cultures of human dermal fibroblasts exposed to a similar level of hypoxia. [31] In addition, hypoxia upregulates the synthesis of endothelin-1, [32] PDGF B chain, [33] and VEGF in endothelial cells. [34] It appears that, at least in some cases, the effect of hypoxic conditions is mediated by hypoxic inducible factor 1 (HIF-1), a DNA-binding complex shown to contain at least two basic helix-loop-helix PAS-domain proteins. [35], [36]

In a totally anaerobic (anoxic) environment, the synthesized procollagen is underhydroxylated and accumulates intracellularly. Thus, in studies where fibroblasts were exposed to temporary (90 min) but absolute anoxia followed by reexposure to atmospheric oxygen at 37°C, the secreted procollagen was found to be about 15 percent underhydroxylated. [37] While hypoxia enhances collagen mRNA levels, [38] reoxygenation may be necessary to the excretion of a final functional product. There is, of course, a high likelihood that periods of reoxygenation are common in wounds. How oxygen radicals formed during reoxygenation affect collagen synthesis is not known. [39], [40] These highly reactive oxygen species include the superoxide anion, hydrogen peroxide, and hydroxyl radical. However, it has been shown that interleukin 1a (IL-1a) and IL-6 are increased in endothelial cells exposed to a cycle of hypoxia/reoxygenation. Interestingly, dismutase and glutathione peroxidase prevented these increases in IL-1 and IL-6, suggesting a role for oxygen-derived free radicals in cytokine synthesis. [41]

Fibroplasia

During the process of reepithelialization, the wound is also undergoing fibroplasia and angiogenesis (discussed below).

Fibroplasia refers to formation of granulation tissue and reconstitution of the dermal matrix. The key cell in this aspect of wound repair is the fibroblast. It is generally accepted that fibroblasts migrate into the wound; produce large amounts of collagens, proteoglycans, elastin, and other matrix proteins; and participate in wound contraction. Fibroblasts, like keratinocytes, undergo phenotypic changes that modify their interactions with the extracellular matrix, allowing them to perform a number of functions. [42] There is evidence for the existence of subpopulations of fibroblasts, with each subpopulation responsible for a different aspect of healing. [43], [44] For example, the response of clonal populations of fibroblasts to certain signals, including growth factors, is quite heterogeneous. [43], [44] Because fibroblasts and other mesenchymal or epithelial cells do not have easily definable markers, like lymphocytes do, this heterogeneity in fibroblast subpopulations is not understood. However, the next several years are likely to see improvements in the techniques available to identify mesenchymal and epithelial cells of the same lineage.

Soon after injury, the formation of a clot provides an appropriate early matrix for cell migration. Fibrin and fibronectin, components of that clot, act as the provisional matrix for fibroblast migration. The behavior of fibroblasts is highly linked to PDGF, a peptide to which they are exposed immediately after wounding. [45] It should be recognized that fibroblasts in unwounded skin are surrounded by a collagen-rich matrix, are biosynthetically inactive, and express high levels of the collagen integrin receptor a_2. This changes dramatically when the fibroblasts arrive at the provisional matrix and are exposed to a number of highly active peptides, including PDGF. Fibroblasts in the fibrin-fibronectin environment of the provisional matrix that are exposed to PDGF upregulate the integrin subunits a_3 and a_5. [45] Gelsolin, a protein involved in capping and the severing of actin may be critical to subsequent movement related to the actinomyosin cytoskeleton during fibroblast migration. [46] These integrins facilitate fibroblast migration into the wound bed, where fibroblasts may be influenced by other growth factors and cytokines to proliferate or undergo further phenotypic changes. Ultimately, as the wound heals, the new collagen-rich extracellular matrix will cause downregulation of fibroblast integrins a_3 and a_5 while increasing levels of a_2. [45] Other factors are at work in regulating fibroblast migration into the wound. [45], [47], [48], [49], [50] and [51] Gelsolin is a downstream effector of Rac, a GTPase molecule that is activated by PDGF. Just as it attracts monocytes and neutrophils to the wound area, TGF-ß1 also has been implicated as an important chemoattractant for fibroblasts. [52] As stated earlier, TGF-ß1 upregulates the expression of provisional matrix integrins $a_5ß_1$ and $a_vß_3$. [53], [54] However, there are other mechanisms by which TGF-ß1 might affect locomotion. [55] It has been shown that production of hyaluronan (HA) and RHAMM, a cell surface receptor for HA, is increased by TGF-ß1 and is necessary for locomotion of tumor cells. [56]

Another HA receptor, CD44, has slightly different functions from the RHAMM receptor, but it ultimately mediates movement of fibroblasts on HA substrates. [57], [58] and [59] Fibroblasts in hypertrophic scar tissue express greater amounts of CD44 and have decreased internalization of CD44 in the presence of HA. [60]

Fibroblasts begin to migrate into the wound 48 h after injury. They move along the fibrin-fibronectin matrix deposited in the initial clot, and they themselves produce fibronectin, which can facilitate their movement. Other extracellular matrix components, such as tenascin, are additional signals for fibroblast adhesion and movement. The Arg-Gly-Asp-Ser (RGDS) tetrapeptide, which is common to these and other extracellular matrix proteins, is important in the binding of these molecules to cell surface integrin receptors. [61], [62]

Fibroblasts produce other extracellular matrix components, including type I and III collagen, elastin, glycosaminoglycans,

and proteoglycans. Type III collagen, which is present in large quantities in fetal dermis but not in adult dermis, is the predominant collagen type during early wound repair. Synthesis of type III collagen becomes maximal 5 to 7 days after injury. [61], [63] TGF-ß has been shown to stimulate fibroblast production of types I and III collagen both in vitro and in vivo. [43] There is evidence that fibroblast clones with a greater collagen synthetic phenotype are selected during the early stages of wound repair. [44]

As the new connective tissue is formed, some fibroblasts undergo a further phenotypic change to actin-rich myofibroblasts. These cells display features characteristic of fibroblasts and smooth muscle cells. They contain an extensive network of rough endoplasmic reticulum, presumably needed to produce large amounts of matrix proteins. [64] Myofibroblasts are largely responsible for wound contraction and are prominently present in granulation tissue. [64], [65] Unlike other cells involved in the wound healing process, myofibroblasts undergo organized arrangements along the lines of contraction. [66] Exposure to a number of mediators, including angiotensin, prostaglandins, bradykinis, and endothelins, leads to muscle-like contractions of the myofibroblasts. PDGF isoforms AB and BB also play an important role in how myfibroblasts contract the collagen matrix. [1] Understanding myofibroblasts and their function has other implications besides tissue repair. Hypertrophic scars and Dupuytren's contracture are conditions in which myofibroblasts play important roles. [67] The ultimate amount of wound contraction depends to a large extent on the depth of the wound. Skin wounds can be classified as either full or partial thickness. In full-thickness wounds, the injury extends deeper than the adnexa. These wounds heal at least in part by contraction, which results in an approximate 40 percent decrease in wound size. [68] In full-thickness wounds, epithelialization occurs from the wound edge alone. Partial-thickness wounds, in contrast, are not as deep, and parts of the adnexa remain in the wound bed. Partial-thickness wounds display less contraction, and epithelialization occurs from both the wound edge and from the adnexal structures with the wound bed. [69]

Angiogenesis

Antiogenesis describes the process by which new vessel growth, called *neovascularization,* takes place. Angiogenesis occurs at the same time as fibroplasia, and in fact, the two are interdependent. As with other processes of wound repair, new vessel formation occurs in the context of the changing extracellular matrix. The chief cell of angiogenesis is the endothelial cell, which, like the keratinocyte and fibroblast, must undergo specific changes in order to migrate to the wound bed, proliferate, and direct new vessel formation. Migration of endothelial cells into the wound depends on chemotactic signals supplied by the extracellular matrix and neighboring cells. FGF-2, or basic fibroblast growth factor, appears to be critical to these procecces. For example, blocking of this peptide will greatly interfere with angiogenesis (Table 21-1). Some of the effects of FGF-2 may be mediated through vascular endothelial growth factor (VEGF), although this peptide also may be stimulated in the wound by keratinocyte growth factor (KGF) and transforming growth factor a (TGF-a). Receptors for these peptides are upregulated by endothelial cells at the site of injury. Among these are flt-1, a VEGF receptor. VEGF receptor 2 and its coreceptor neuropilin 1 are also upregulated. There is evidence that like reepithelialization, cell migration is a more important component of angiogenesis than proliferation. However, many signals that are involved in endothelial cell migration, such as fibronectin and heparin, also may stimulate proliferation. [1], [2], [42]



TABLE 21-1 **Partial List of Growth Factors and Cytokines in the Context of Wound Repair and Their Roles in Some Cellular Functions and Matrix Production**

Aside from their role in angiogenesis, endothelial cells play an active role in the inflammatory stage of wound healing. They produce several factors that control propagation of the initial clot, thereby limiting platelet aggregation and clot formation to the area of injury. These mediators include prostacyclin, which inhibits platelet aggregation; antithrombin III, which inhibits thrombin activity; protein C, which degrades coagulation factors V and VIII; and most important, plasminogen activator, which initiates clot lysis by converting plasminogen to plasmin. [5]

Experiments with the avascular cornea have shown that phenotypic alteration of endothelial cells during wound healing includes the development of pseudopodia that project through fragmented basement membranes. The stimulus for this phenotypic change is not as well known as those outlined for keratinocytes and fibroblasts. By the second day following acute injury, endothelial cells at the wound edge begin to migrate into the perivascular space, and those remaining in the blood vessel begin to proliferate. [42]

A number of factors have been implicated in stimulating angiogenesis. As described before, low oxygen tension in the early wound environment appears to potentiate angiogenesis and fibroplasias. [70] Low oxygen tension also may stimulate macrophages to produce and secrete angiogenic factors. [30] Growth factors shown to be angiogenic include TGF-ß1 and FGF. Of interest is that TGF-ß1 is a potent inhibitor of endothelial cell proliferation, yet it induces a dramatic angiogenic response when injected into the dermis. This is probably so because TGF-ß leads to the recruitment of macrophages, which in turn secrete substances that stimulate endothelial cell ingrowth. This example underscores the complexities involved in this phase of wound repair and the difficulty in assigning definite effects to any particular factor or cell. However, it does appear that the FGF family is by far the most important in stimulating angiogenesis. These peptides are released by macrophages and interact with heparin, which enhances their biologic activity. As discussed earlier, macrophages are essential to the wound healing process.

As it does with other phases of wound healing, the extracellular matrix plays a critical role in angiogenesis. One

component of the provisional matrix is secreted protein acidic and rich in cysteine (SPARC). Released from fibroblasts and macrophages, SPARC, or its proteolytic fragments, stimulate angiogenesis during formation of granulation tissue. [71] SPARC, tenascin, and thrombospondin are all components of the early provisional matrix and also can be found in tissues where cells are dividing or migrating. [72] They are considered antiadhesive proteins and have been shown to promote cell rounding and partial detachment. [71] In addition to these effects, SPARC also can stimulate the production of collagenase, stromalysin, and gelatinase. Heparin and fibronectin, two other components of the provisional matrix, stimulate endothelial cells to project pseudopodia through basement membrane defects at the site of injury. [42] FGF further stimulates cells to release procollagenase and plasminogen activator (PA). [42] PA converts plasminogen to plasmin and activates collagenase. These enzymes help to break down the basement membrane and facilitate endothelial cell migration into the perivascular space.

Just as with other stages of wound healing, cell-to-cell and cell-to-matrix interactions play a key role in determining endothelial cell invasion, migration, and proliferation. During wound repair, a number of adhesive proteins are expressed in the basement membrane zone of blood vessels, including vWF, fibronectin, and fibrinogen. Studies have shown that several integrin receptors, especially a $_{v}$ß $_{3}$, are upregulated on the surface of smooth muscle cells and endothelial cells during angiogenesis. [73] ß $_{v}$ß $_{3}$ is the endothelial cell receptor for vWF, fibrinogen/fibrin, and fibronectin. In one study, a $_{v}$ß $_{3}$ was found to be expressed in newly formed blood vessels in granulation tissue but not in normal unwounded skin. [73]

Keratinocyte Migration

The process of reepithelialization begins several hours after tissue injury. Keratinocyte migration, rather than proliferation, is actually responsible for most of the resurfacing of the epidermal defect. The process by which reepithelialization occurs in acute wounds is quite different from what one observes in wounds that fail to heal. Figure 21-2 shows a diagrammatic representation of the migrating epithelial tongue in acute wounds, contrasting it with the acanthotic epidermis generally seen in wounds that do not heal. This point will be discussed in more detail below because it is pertinent to understanding the overall mechanisms of wound repair. The events regulating keratinocyte migration are highly heterogenous and yet interrelated. These events have to do with changes in the shape of keratinocytes, in restructuring of their cytoskeleton and keratin expression, and in expression of proteases. Phenotypic alteration of keratinocytes enables them to migrate both from the wound edge and from any adnexal structures remaining in the wound bed. One to two days after the initial injury, epidermal cells at the wound edge and within the wound begin to divide and proliferate, thereby contributing to the population of migrating cells. For small wounds, the proliferative event is minor and probably not as important. However, for large wounds, there is a very dramatic burst of proliferative activity without which proper and timely resurfacting of the wound would not occur. This discrepancy between small and large wounds has created some confusion, and frequently one hears the erroneous statement that proliferation is not important for keratinocyte migration.

Nevertheless, several studies have shown that, in a pure sense, keratinocyte migration and proliferation can be regarded as two independent processes. One way to investigate this is to block keratinocyte proliferation with TGF-ß, which is a prominent and potent inhibitor of epithelial cell growth. In one such study, [74] investigators exposed keratinocytes to a matrix of collagen that stimulated marked motility and later to TGF-ß, which resulted in marked inhibition of proliferation. Despite this effect, the keratinocytes continued to migrate. In fact, migration was enhanced by TGF-ß. [74]

As discussed previously, keratinocytes undergo profound changes in morphology as they migrate or, perhaps stated more properly, as they are empowered to migrate. Basal keratinocytes undergo a morphologic change from their normal cuboidal shape to a flattened cell with extended lamellipodia that project into the wound bed. [75] Hemidesmisomes are retracted from the plasma membrane, and the number of gap junctions increases. Integrin receptor expression changes to facilitate keratinocyte movement on collagens, and keratinocytes begin to synthesize and release types I and IV collagenases.

The expression of new integrins clearly aids keratinocyte migration. For example, the ability of keratinocytes to get hold of and migrate over the provisional matrix is intimately linked to their expression of a $_{5}$ß $_{1}$ and a $_{v}$ß $_{6}$ fibronectin/tenascin receptors. [76] Vitronectin and its integrin receptor (a $_{v}$ß $_{5}$) are also critical components of this migration. Indeed, in a model of bioengineered skin, vitronectin and its integrin counterpart have been found to be essential for the migration of keratinocytes over the surface of the construct (epiboly). Keratinocyte migration begins and is associated with several morphologic and biochemical changes. [77] The keratinocytes at the edges of the wound upregulate proteases to allow their migration in the context of a fibrin clot. Experimental observations indicate that the process of occlusion greatly aids this migration and that in such circumstances the keratinocyte actually may migrate indiscriminately over a number of surfaces placed within the wound. Thus occlusion may speed up reepithelialization by stimulating keratinocytes to migrate in less specific ways. For keratinoyctes to migrate, they need to detach themselves from the basal lamina to which they are attached through the hemidesmosomes, anchoring contacts linking laminin via a $_{6}$ß $_{6}$ to the keratinocyte's keratin filament network. [78] The migration of keratinocytes over extracellular matrix as well as the provisional wound matrix is aided by the expression of new integrins, mainly the a $_{5}$ß $_{1}$ and a $_{v}$ß $_{6}$ fibronectin/tenascin receptors and the a $_{v}$ß $_{5}$ vitronectin receptors. Movement over collagen requires the a $_{2}$ß $_{1}$ integrin. [79], [80], [81] and [82] Crawling over these surfaces by the keratinocytes is achieved through morphologic changes and lamellopodial movement. The cytoskeleton is critical to these changes and to cell migration. Thus contraction of the actinomyosin filaments inserting into adhesion complexes results in and facilitates cell crawling. It is now thought that crawling and movement are not confined to the basal keratinocytes at the wound edge. Rather, suprabasal keratinocytes seem to “leapfrog” over the basal cells. Strength for keratinocyte locomotion is provided by keratins, which are important in both lamellopodial crawling and in the pursestring-type of closure observed in embryonic wounds. Keratins 6, 16, and 17 are induced in keratinocytes at the wound's edge. [83]

Various cytokines and matrix proteins stimulate keratinocyte migration on the wound bed. Connective tissue promoters of

migration include fibronectin and type IV collagen, both of which can be synthesized by keratinocytes, [84] and native denatured type I collagen. [75] Growth factors, such as TGF-ß and epidermal growth factor (EGF), stimulate keratinocytes to migrate. TGF-ß also increases keratinocyte production of fibronectin. Signal-transduction pathways critical to keratinocyte migration are being elucidated. The p38-MAPK/SAPK pathway is required for the migration of keratinocytes on a collagen substrate. [85]

As in other physiologic processes, stops or brakes are in place to allow an end to the events facilitating keratinocyte migration. One such signal is the reconstitution of laminin, which is a major component of the lamina lucida zone of the basement membrane. In intact unwounded skin this large glycoprotein acts by preventing direct contact between keratinocytes and collagens contained within the basement membrane (types IV and VII) and dermis (types I, III, and VI). [26], [75], [86] With injury to the skin, the laminin component is disrupted, and this event allows contact of keratinocytes with the underlying collagens, thereby stimulating migration. It has been shown that laminin reappears in the dermal-epidermal junction after keratinocytes have migrated and resurfaced the wound and thus serves as a signal for keratinocytes to stop migrating. [2]

The process of reepithelialization could not occur unimpeded without the appropriate expression and action of enzymes needed to dissolve substrates and matrix materials for keratinocytes to migrate. [87], [88] and [89] Ultimately, these enzymes also play a fundamental role in tissue remodeling. Migrating keratinocytes upregulate tissue-type plaminogen activator (tPA) and the urokinase-type plaminogen activator (uPA) and its receptor. These enzymes are critical for the movement of keratinocytes through the fibrin clot. [90], [91] and [92] Other proteases are also important. The matrix metalloproteinases (MMPs) enzyme family comprises more than 20 different members, some of which, during the process of cutaneous repair, are very tightly expressed and regulated. MMPs are zinc-dependent endopeptidases that are activated by other proteinases such as plasmin. Their activity is blocked or downregulated by tissue inhibitors of metalloproteinases. Collagenase-1 (MMP-1), stromelysin-2 (MMP-10), and the 92-kDa gelatinase (MMP-9) are expressed by keratinocytes at the edges of the wound. MMP-1 is needed for keratinocyte migration on type I collagen and is upregulated in keratinocytes at the very edge of the wound, after the cells have freed themselves from the basal lamina, a process that is aided by MMP-9. MMP-10 degrades a number of extracellular matrix proteins other than collagen. Other MMPs are spatially upregulated just proximal to the wound's edge. In this category are stromelysin-2 (MMP-10) and the newly described epilysin (MMP-28), which is associated with keratinocyte proliferation rather than migration during wound repair. [93] There is evidence that keratinocyte migration is blocked by inhibitors of MMPs. [94]

Integrin expression is also regulated by growth factors, including TGF-ß, PDGF, and VEGF. The expression of a $_5$ß $_1$ and a $_v$ß $_3$ in cultured fibroblasts and the ß $_4$ subunit in cultured keratinocytes is increased by TGFß-1. [95], [96] and [97] This cytokine also upregulates a $_5$ß $_1$ and a $_v$ß $_5$ in keratinocytes. [86] The effect of cytokines and growth factors on the regulation of integrin expression must be viewed in context of the matrix surrounding the target cell. It has been shown that PDGF-BB, a prominent component of the early wound environment, upregulates a $_5$ß $_1$ and a $_3$ß $_1$ expression in fibroblasts grown in fibronectin-rich tissue culture of fibrin. [45] However, fibroblasts grown on collagen gels, thereby approximating the normal dermis or late wound environment, do not show upregulation of these integrins, even in the presence of PDGFF-BB. The vast array of cytokines affecting integrin expression are initially released by aggregating platelets in the early wound. [98] Later they are produced by fibroblasts, keratinocytes, monocytes, and macrophages. [86]

TISSUE REMODELING (PHASE 3)

In the third and final phase of wound repair, the formed tissue is degraded and remodeled, and cells undergo apoptosis and other drastic changes. Typically, this phase can last several months. Although the functional outcome is not ideal, in that tissue regeneration has not occurred, the remodeling process allows the host to develop a stable scar that has approximately 70 percent of the original strength. Closure of the wound is of paramount importance from a survival and evolutionary standpoint, and the outcome of repair reflects this priority and is a compromise between functional and structural needs. In many ways, this phase of wound repair resembles many other unrelated physiologic processes in which the initial outcome is exaggerated. Thus, during the process of wound repair, there is probably an overabundance of cellular migration and proliferation and even excessive deposition of many types of extracellular matrix components. This “exaggeration” of the repair response is important in ensuring a proper inflammatory reaction and clearing of bacteria, wound debridement, and removal of necrotic tissue. Fibroplasia and angiogenesis are critical to the development of the appropriate wound bed required for keratinocyte migration and reepithelialization. However, as stated, the abundance of cells and extracellular matrix material must now be dealt with, and a remodeling process is required for downregulating the response and returning to an approximation of the prewounded state. Apoptotic mechanisms and the enzymatic activity of MMPs and other proteinases will be at work to achieve a balance within the newly reepithelialized wound.

Events of remodeling are closely linked to those which have allowed the deposition of certain extracellular matrix components and migration of cells to the wound site in the first place. The reason for this is that no remodeling can take place unless the primary stimulatory signals are turned off. Therefore, the discussion about what is critical to the formation of tissue is appropriate when viewed in the context of how this formed tissue is now modified. To be sure, this third phase of wound repair is not as well studied as the processes of inflammation and proliferation, and therefore, many more questions remain. It also should be recognized that the remodeling phase does not occur homogeneously within the wound, either in location or in time. In the context of the remodeling phase of wound repair, the following events and key extracellular matrix components will be discussed in turn: (1) fibronectin and associated components, (2) hyaluronic acid and proteoglycans, (3) collagen, and (4) contraction and the emergence of myofibroblasts.

Fibronectin and Associated Components

Fibroblasts produce fibronectin as they enter the wound site, and at least initially, the concentrations of fibronectin are very high. By 4 to 5 days after injury, the fibronectin network is well established. [54] It is important to note that the process

by which fibroblasts leave their collagen-rich environment to enter the wound site requires them to modify their behavior and characteristics. Fibroblasts need to become activated and modify their integrin repertoire, which will dictate what they bind to and where they will go. To a certain extent, this is regulated by cytokines. For example, exposure of fibroblasts to PDGF can upregulate the integrin subunits a_3 and a_5, which are considered more adapt at binding to provisional wound matrix components. Conversely, the a_2 integrin subunit is upregulated in fibroblasts in a collagen-rich environment.

The production of fibronectin is stimulated by a number of growth factors, but certainly TGF-ß, which also upregulates integrin receptors' binding to fibronectin. [45], [99] This cytokine is critical in the deposition of extracellular matrix and is often implicated in the pathogenesis of excessive scarring and fibrosis. TGF-ß is a chemoattractant for fibroblasts [100] and stimulates their proliferation, [101] as well as causing an overall increase in extracellular matrix formation. [99] There is directionality to the deposition of fibronectin, which is important in the way other extracellular matrix proteins are laid down. For example, collagen deposition will align itself after the fibronectin pattern, which in turn mirrors the axis of alignment of fibroblasts. [54] Ultimately, during remodeling and contraction, myofibroblasts will make use of the fibronectin network to cause wound contraction.

A number of hypotheses have been proposed for the mechanims in addition to fibronectin underlying the adhesion of fibroblasts to extracellular matrix. One hypothesis is proteinase-based, whereby the assembly of the actin cytoskeleton is dictated by the action of proteinases on specific cellular sites. [72] The deposition of ECM-associated molecules, such as tenascin, SPRC, thrombospondin, and dermatan sulfate, is another way of influencing and modifying the overall ECM makeup. [72] For example, SPARC upregulates fibroblast expression of metalloproteinases, especially collagenase, whereas thrombospondin and tenascin have both adhesive and antiadhesive properties. [102] To a large extent, regulation of how SPARC induces collagenase expression is related to which ECM components fibroblasts are exposed to. Thus SPARC leads to collagenase production in fibroblasts grown on collagen types I, II, III, and V and on vitronectin, but not on collagen type IV. Eventually, the fibronectin-rich environment of the initial wound is modified and remodeled by cell and plasma proteases. Over time, fibronectin is replaced by type III collagen and ultimately by type I collagen.

Hyaluronic Acid and Proteoglycans

The glycosaminoglycan (GAG) hyaluronic acid (hyaluronan) is also an abundant component of the provisional matrix and one whose deposition needs to be modified during the remodeling process. High levels of hyaluronic acid are present in the early embryo, where it is thought to offer less resistance to cell migration. Indeed, embryonic wound repair is characterized by a hyaluronic acid–rich environment, thought to be at least in part responsible for the “scarless” healing of embryonic wounds. Fibroblasts from early granulation tissue produce large amounts of hyaluronic acid, and proliferating cells express CD44, which is the receptor for this GAG molecule. [99], [103] Besides the issue of offering less resistance to cell movement, hyaluronic acid may stimulate cell motility by altering cell-matrix adhesion. One example of this is that hyaluronic acid weakens the adhesion of heparan sulfate and fibronectin. [104] Perhaps more important from a physical/spatial standpoint is that hyaluronic acid creates a highly hydrated structure leading to tissue swelling and interstitial spaces and thus an environment more conducive to cell movement. [99] The effects of hyaluronic acid are also regulated by growth factors and cytokines. Upregulation of hyaluronic acid expression and its receptors (e.g., RHAAMM) by TGF-ß1 stimulates fibroblast motility. [105], [106]

Eventually, as remodeling occurs, hyaluronic acid is degraded by hyaluronidase and replaced by sulfated proteoglycans, which contribute a stronger structural role in late granulation tissue formation and in scars while being less able to stimulate cellular movement. Two major proteoglycans, chondroitin-4-sulfate and dermatan sulfate, are produced by mature scar fibroblasts.

Collagen

Three main classes of collagens are present normally in connective tissue: fibrillar collagens (types I, III, and V), basement membrane collagen (type IV), and other interstitial collagens (types VI, VII, and VIII). These are merely examples of the many different types of collagen present in skin. Importantly, however, the fibrillar collagens serve as the major structural collagens in all connective tissues. [42], [99]

During the initial phases of wound repair, it appears that the wound tends to recapitulate the processes involved in embryogenesis. Thus granulation tissue is initially comprised of large amounts of type III collagen, which is a minor component of adult dermis and indeed is present in larger amounts in fetal wound repair. During the phase of remodeling, over a period of a year or more, type III collagen is gradually replaced by type I collagen. Type I collagen replacement is associated with increased tensile strength of the scar. However, the final tensile strength of a scar is only about 70 percent of that of preinjured skin. [106] The process of converting the collagen content of the dermis from type III to type I collagen is controlled by interactions involving synthesis of new collagen with lysis of old collagen. [43] Key to this process of conversion are metalloproteinases and specifically the collagenases.

Matrix-degrading metalloproteinases (MMP) are proenzymes that need to be activated and are considered to be the physiologic mediators of matrix degradation. The prototypic MMP is interstitial collagenase, but over 20 such enzymes have been described. There are three broad classes of these zinc-dependent enzymes: collagenases, gelatinases, and stromelysins. The collagenases include interstitial collagenase (fibroblast collagenase, MMP-1), which acts on collagens I, II, III, VII, and X. Collagen type II is a particularly good substrate for MMP-1. Another important member of the collagenase class is neutrophil collagenase (MMP-1), which also degrades type II and III collagens but is particularly active against type I collagen. Gelatinases break down denatured collagen (gelatin). Among the most important gelatinases are gelatinase A (MMP-2), which breaks down gelatins, collagen IV, and elastin. Another key gelatinase is gelatinase B (MMP-9), which is produced by many cell types, including macrophases, neutrophils, and keratinocytes. Stromelysins have a relatively broad substrate specificity. Both stromelysin 1 (MMP-3) and 2 (MMP-10) act on proteoglycans, fibronectin, laminin, gelatins, and collagens III, IV, and IX. Another member of the stromelysin family,

matrilysin (MMP-7), degrades mainly fibronectin, gelatins, and elastin. One of the newest member of the MMP family is epilysin (MMP-28), which appears to be produced by proliferating keratinocytes distal to the wound edge. [93] It may be needed to restructure the basement membrane.

Stimulation of the production of MMPs and their activation are not only by growth factors and cytokines, such as IL-1, but also by extracellular matrix components and other chemicals. For example, trypsin, organomercurials, plasmin, and SDS can activate MMPs, whereas calcium stabilizes them. As stated, MMPs are dependent on zinc, which is located at the center of the molecule at a conserved sequence known as HEXGH. A number of chelators, including tissue inhibitor of metalloproteinase (TIMP), inhibit several members of the MMP family, whereas a $_2$-macroglobulin entraps them. [1], [87], [89]

The remodeling phase is more than a breakdown of excess macromolecules formed during the proliferative phase of wound healing. Cells within the wound are returned to a stable phenotype, extracellular matrix material is altered (i.e., collagen type III to type I), and the granulation tissue that was so exuberant during the early phases of wound healing disappears.

Myofibroblasts and Contraction

During the earlier stages of wound repair, beginning around 4 days after injury, granulation tissue forms. [1] Granulation tissue is so named based on its granule-like appearance, which is rich in vascular structures. In the more mature wound and during remodeling, this granulation tissue has to be modified. One of the primary events is wound contraction. There are different degrees of contraction depending on the host, the location of the wound, and its depth. For example, rodents heal in large part by contraction, which must be kept in mind when extrapolating to humans the results of experimentally induced wounds in mice and rats. The location of the wound is important too; much more contraction appears to occur over rounded surfaces, such as shoulders and the nose. The reasons for these differences due to location are not known. Certainly, more tension may be present in certain locations, and this could modify the type of extracellular matrix laid down, as well as having an effect on fibroblast phenotype and selection. However, of the utmost importance to the development and extent of contraction is wound depth. Partial-thickness wounds, down only to papillary dermis, heal with less scarring and contraction. Full-thickness wounds, which encompass the fat and subcutaneous tissue, tend to heal with much more scarring and rely on contraction for faster repair. Anyhow, the mass of tissue that has formed in the earlier phases of wound repair must now be made smaller, and contraction is an effective and dependable way of doing so. The myofibroblast plays a critical role in the contraction process. One often reads that myofibroblasts are “transformed” wound fibroblasts that express a-smooth muscle actin and are smooth muscle–like cells. The term *transformed* is incorrect, since transformation is used properly only in the context of the path to neoplasia. The mechanisms leading to the myofibroblast phenotype are largely unknown, but certain growth factors, such as TGF-ß1, can regulate this process. It is also known that myofibroblasts can play a fundamental pathogenic role in certain fibrotic conditions, such as Dupuytren's contracture, and have critical consequences for the clinical expression of certain other conditions. For example, hypertrophic scars are myofibroblast-rich and thus both contract and eventually resolve over time. In contrast, keloids generally lack a significant component of myofibroblasts and therefore neither contract nor resolve easily. [42], [64], [65] and [66]

THE WORLD OF CHRONIC WOUNDS

The preceding discussion has been centered on cutaneous wound repair after acute injury. It must be recognized, however, that the applicability of those events and processes is limited when it comes to chronic wounds, such as in diabetes, in venous and arterial insufficiency, and in a variety of situations complicated by inflammatory processes and faulty response from the host. Acute wounds, such as those created by surgery or trauma, have a predictable time frame for healing and generally heal quite readily. However, chronic wounds display what has been called a “failure to heal.” A number of observations have been made with regard to chronic wounds, and hypotheses have been proposed for their failure to heal. The scientific rigor of these hypotheses and possible mechanisms is less than what has been described in the preceding discussion for the general principles of wound repair, for it has been far more difficult to study chronic wounds in humans, and experimental models of chronic injury are few and not ideal. Yet it is useful to briefly describe some of the abnormalities that have been found and thus provide a contrast with the highly regulated principles of the different phases of wound repair.

Perhaps the best example where some progress has been made in understanding a chronic wound and its failure to heal is in ulcers due to venous insufficiency. The underlying abnormality in the development of venous ulcers is venous hypertension, which refers to the inability of venous pressure in the foot to decrease in response to exercise. In this sense, the term *hypertension* is a misnomer, for the pressure is not increased in an absolute sense. Venous “hypertension” is most commonly the result of faulty valves in the lower extremities, with or without blockage of blood flow in the deep veins. However, it should be recognized that the calf muscle pump, responsible for propelling blood back toward the heart, acts as a unit made up of veins and muscles. Thus a decrease in muscle function also could result in venous “hypertension”. The first true hypothesis to address the pathophysiology of venous ulceration in a rational way suggested that the loss of tissue integrity and the development of ulceration were the result of venous “hypertension” and the leakage of fibrinogen from the intravascular compartment. [107], [108], [109] and [110] The fibrinogen quickly polymerized to fibrin around blood vessels (“fibrin cuffs”). It was hypothesized that the fibrin cuffs would prevent the diffusion of oxygen and other nutrients from the blood to the dermis. This “functional ischemia” was proposed to lead to loss of tissue integrity and, ultimately, ulceration. Since the fibrin cuff hypothesis was first proposed, there has been continued reassessment of its validity. While fibrin cuffs have been found in more than 90 percent of biopsies from venous ulcers and surrounding skin, at the same time a strong dynamic relationship between the presence or absence of these cuffs and ulceration has not been detected. Also, it has been realized that polymerized fibrin has gaps within its structure that are large enough for oxygen and large molecules to get through. Still, further reevaluation has determined that given a sluggish blood flow, pericapillary fibrin cuffs could contribute to the pathogenesis by altering or decreasing the exchange of certain substances between blood and dermis. Moreover, there is substantial evidence that patients with venous disease and ulceration have decreased fibrinolytic capacity, which contributes to the development and persistence of

fibrin cuffs. [108]

Hypotheses for the development of chronic wounds are not necessarily mutually exclusive. The complexity of chronic wounds is such that a number of pathogenic steps are involved. It has been reported that as a consequence of venous “hypertension”, damage to the endothelium occurs and neutrophils adhering to the damaged blood vessels release a number of inflammatory mediators that compound the damage. Another hypothesis has to do with the unavailability of growth factors in chronic wounds. [110] There is evidence that growth factors in chronic wounds are bound to and trapped by macromolecules such as albumin, fibrinogen, a $_2$-macroglobulin leaking into the dermis. The a $_2$-macroglobulin molecule is a scavenger for growth factors, including PDGF. [111], [112]

The critical importance of MMPs in cutaneous wound repair, particularly in the context of keratinocyte migration has been discussed previously. However, in chronic wounds, MMPs may have a darker side. For example, in venous ulcers and other types of chronic wounds, the wound fluid contains excessive amounts of metalloproteinases, which break down the extracellular matrix and, most likely, cytokines and growth factors. [113], [114], [115] and [116]

It also should be recognized that tissues around chronic wounds are not normal and that indeed they are altered by the primary pathogenic mechanisms that had to the inability to heal readily. Clinically, the best example of this is the intense fibrosis surrounding venous ulcers, which is termed *lipodermatosclerosis.* Once lipodermatosclerosis becomes established, it can lead to ulcers and becomes the site of ulcer recurrence. Indeed, venous ulcers surrounded by lipodermatosclerosis are much more difficult to heal. The reason for these observations may lie in an increasing body of evidence suggesting that the cellular makeup of wounds that do not heal is altered. Because of the ease with which they are grown and studied in culture, the best evidence comes from wound fibroblasts. We now know that ulcer fibroblasts are senescent [117], [118] and are unresponsive to certain selected cytokines and growth factors. For example, it has been shown that venous ulcer fibroblasts are unresponsive to the action of transforming growth factor (TGF-ß1) [119] and platelet-derived growth factor (PDGF). [120] The synthetic program of cells in diabetic ulcers also may be altered so that such chronic wounds are said to be “stuck” in a certain phase of the repair process. There is evidence for this in diabetic ulcers. [121] A close relationship has been reported between some of these abnormalities and the inability to heal. For example, a correlation has been found between fibroblast senescence and wounds that do not heal. [117]

CONCLUSION

Characterizing the number of events and the interrelationships that occur after tissue injury represents a rather daunting task. Yet, over the last several decades, the orderly progression from injury to inflammation and coagulation, to the development of a provisional matrix, to the formation of granulation tissue, and to tissue remodeling has been elucidated. Although somewhat artificial, the different phases of wound repair described here are the platform on which more knowledge can be built. Much still needs to be learned, but the framework is there for understanding tissue repair and for developing ways to accelerate it. Indeed, due to breakthroughs in science and technology, progress has been exponential in the last few years. In the long run, one would like to discuss how skin can be regenerated and not simply repaired. For that to occur, we will need an even greater understanding of the science involved. What may look detailed today will turn out to be sketchy tomorrow. It is also possible that lessons learned from failure to heal, as in chronic wounds, will provide valuable lessons for the general principles of wound healing.

REFERENCES

1. Clark RA: Wound repair: overview and general considerations, in *The Molecular and Cellular Biology of Wound Repair,* 2d ed, edited by RAF Clark. New York, Plenum, 1996, p 3

2. Clark RA et al: Fibronectin and fibrin provide a provisional matrix for epidermal cell migration during wound reepithelialization. *J Invest Dermatol* **79**:264, 1982

3. Santoro SA: identification of a 160,000 dalton platelet membrane protein that mediates the initial divalent cation-dependent adhesion of platelets to collagen. *Cell* **46**:913, 1986

4. Moncada S et al; An enzyme isolated from arteries transforms prostaglandin endoperoxides to an unstable substance that inhibits platelet aggregation. *Nature* **263**:663, 1976

5. Loskutoff DJ, Edgington TE: Synthesis of a fibrinolytic activator and inhibitor by endothelial cells. *Proc Natl Acad Sci USA* **74**:3903, 1977

6. Roberts AB: Transforming growth factor-beta, in *The Molecular and Cellular Biology of Wound Repair,* 2d ed, edited by RAF Clark, New York, Plenum, 1996, p 275

7. Furie B: The molecular basis of blood coagulation. *Cell* **53**:505, 1988

8. Weisel JW et al: The sequence of cleavage of fibrinopeptides from fibrinogen is important for protofibril formation and enhancement of lateral aggregation in fibrin clots. *J Mol Biol* **232**:285, 1993

9. Weiss E et al: Un-cross-linked fibrin substrates inhibit keratinocyte spreading and replication: Correction with fibronectin and factor XIII cross-linking. *J Cell Physiol* **174**:58, 1998

10. Dipietro LA et al: Modulation of macrophage recruitment into wounds by monocyte chemoattractant protein-1. *Wound Repair Regen* **9**:28, 2001

11. Riches X: Macrophage involvement in wound repair, remodelling and fibrosis, in *The Molecular and Cellular Biology of Wound Repair,* 2d ed, edited by RAF Clark. New York, Plenum, 1996, P 95

12. Tonnesen MG: Neutrophil-endothelial cell interactions: Mechanisms of neutrophil adherence to vascular endothelium. *J Invest Dermatol* **93**:535, 1989

13. Doherty DE et al: Human monocyte adherence: A primary effect of chemotactic factors on the monocyte to stimulate adherence to human

endothelium. *J Immunol* **138**:1762, 1987

14. Subramaniam M et al: Role of endothelial selectins in wound repair. *Am J Pathol* **150**:1701, 1997

15. Springer X: Traffic signals for lymphocyte recirculation and leukocyte emigration: The multistep paradigm. *Cell* **76**:301, 1994

16. Grotendorst GR: Connective tissue growth factor: A mediator of TGF-beta action on fibroblasts. *Cytokine Growth Factor Rev* **8**:171, 1997

17. Hubner G et al: Differential regulation of pro-inflammatory cytokines during wound healing in normal and glucocorticoid-treated mice. *Cytokine* **8**:548, 1996

18. Gresham HD et al: A novel member of the integrin receptor family mediates Arg-Gly-Asp–stimulated neutrophil phagocytosis. *J Cell Bio* **108**:1935, 1989

19. Grinnell F: Wound repair, keratinocyte activation and integrin modulation. *J Cell Sci* **101**:1, 1992

20. Cass DL et al: Epidermal integrin expression is upregulated rapidly in human fetal wound repair. *J Pediatr Surg* **33**:312, 1998

21. Simpson DM, Ross R: The neutrophilic leukocyte in wound repair a study with antineutrophil serum. *J Clin Invest* **51**:2009, 1972

22. Newman SL et al: Phagocytosis of senescent neutrophils by human monocyte-derived macrophages and rabbit inflammatory macrophages. *J Exp Med* **156**:430, 1982

23. Leibovich SJ, Ross R: The role of the macrophage in wound repair: A study with hydrocortisone and antimacrophage serum. *Am J Pathol* **78**:71, 1975

24. Hopkinson-Woolley J et al: Macrophage recruitment during limb development and wound healing in the embryonic and foetal mouse. *J Cell Sci* **107**:1159, 1994

25. Luster AD et al: Delayed wound healing and disorganized neovascularization in transgenic mice expressing the IP-10 chemokine. *Proc Assoc Am Physicians* **110**:183, 1998

26. Kubo M et al: Fibrinogen and fibrin are anti-adhesive for keratinocytes: A mechanism for fibrin eschar slough during wound repair. *J Invest Dermatol* **117**:1369, 2001

27. Hauck CR et al: The focal adhesion kinase: A regulator of cell migration and invasion *IUBMB Life* **53**:115, 2002.

28. Packer L, Fuehr K: Low oxygen concentration extends the lifespan of cultured human diploid cells. *Nature* **267**:423, 1977

29. Falanga V, Kirsner RS: Low oxygen stimulates proliferation of fibroblasts seeded as single cells. *J Cell Physiol* **154**:506, 1993

30. Knighton DR et al: Oxygen tension regulates the expression of angiogenesis factor by macrophages. *Science* **221**:1283, 1983

31. Falanga V et al: Hypoxia upregulates the synthesis of TGF-beta 1 by human dermal fibroblasts. *J Invest Dermatol* **97**:634, 1991

32. Kourembanas S et al: Hypoxia induces endothelin gene expression and secretion in cultured human endothelium. *J Clin Invest* **88**:1054, 1991

33. Kourembanas S et al: Oxygen tension regulates the expression of the platelet-derived growth factor-B chain gene in human endothelial cells. *J Clin Invest* **86**:670, 1990

34. Shweiki D et al: Vascular endothelial growth factor induced by hypoxia may mediate hypoxia-initiated angiogenesis. *Nature* **359**:843, 1992

35. Semenza GL et al: Hypoxia-inducible factor 1: From molecular biology to cardiopulmonary physiology. *Chest* **114**:405, 1998

36. Wang GL et al: Hypoxia-inducible factor 1 is a basic-helix-loop-helix-PAS heterodimer regulated by cellular O_2 tension. *Proc Natl Acad Sci USA* **92**:5510, 1995

37. Uitto J, Prockop DJ: Hydroxylation of peptide-bound proline and lysine before and after chain completion of the polypeptide chains of procollagen. *Arch Biochem Biophys* **164**:210, 1974

38. Falanga V et al: Low oxygen tension increases mRNA levels of alpha 1 (I) procollagen in human dermal fibroblasts. *J Cell Physiol* **157**:408, 1993

39. Faller DV: Endothelial cell responses to hypoxic stress. *Clin Exp Pharmacol Physiol* **26**:74, 1999

40. Stadman X: Protein oxidation and aging. *Science* **267**:1220, 1992

41. Ala Y et al: Hypoxia/reoxygenation stimulates endothelial cells to promote interleukin-1 and interleukin-6 production: Effects of free radical scavengers. *Agents Actions* **37**:134, 1992

42. Singer AJ, Clark RA: Cutaneous wound healing. *New Engl J Med* **341**:738, 1999

43. Yamaguchi Y et al: Lack of co-ordinate expression of the alpha 1 (I) and alpha 1 (III) procollagen genes in fibroblast clonal cultures. *Br J Dermatol* **143**:1149, 2000

44. Falanga V et al: Human dermal fibroblast clones derived from single cells are heterogeneous in the production of mRNAs for alpha 1(I) procollagen and transforming growth factor-beta 1. *J Invest Dermatol* **105**:27, 1995

45. Xu I, Clark RA: Extracellular matrix alters PDGF regulation of fibroblast integrins. *J Cell Biol* **132**:239, 1996

46. Witke W et al: Hemostatic, inflammatory, and fibroblast responses are blunted in mice lacking gelsolin. *Cell* **81**:41, 1995

47. McClain SA et al: Mesenchymal cell activation is the rate-limiting step of granulation tissue induction. *Am J Pathol* **149**:1257, 1996

48. Greiling D, Clark RA: Fibronectin provides a conduit for fibroblast transmigration from collagenous stroma into fibrin clot provisional matrix.

J Cell Sci **110**:861, 1997

49. Georges-Labouesse EN et al: Mesodermal development in mouse embryos mutant for fibronectin. *Dev Dyn* **207**:145, 1996

50. Ffrench-Constant C et al: Reappearance of an embryonic pattern of fibronectin splicing during wound healing in the adult rat. *J Cell Biol* **109**:903, 1989

51. Brown GL et al: Enhancement of epidermal regeneration by biosynthetic epidermal growth factor. *J Exp Med* **163**:1319, 1986

52. Hartwig JH et al: Thrombin receptor ligation and activated Rac uncap actin filament barbed ends through phosphoinositide synthesis in permeabilized human platelets. *Cell* **82**:643, 1995

53. Eckes B et al: Interactions of fibroblasts with the extracellular matrix: Implications for the understanding of fibrosis. *Springer Semin Immunopathol* **21**:415, 1999

54. Welch MP et al: Temporal relationships of F-actin bundle formation, collagen and fibronectin matrix assembly, and fibronectin receptor expression to wound contraction. *J Cell Biol* **110**:133, 1990.

55. Samuel SK et al: TGF-beta 1 stimulation of cell locomotion utilizes the hyaluronan receptor RHAMM and hyaluronan. *J Cell Biol* **123**:749,1993

56. Hardwick C et al: Molecular cloning of a novel hyaluronan receptor that mediates tumor cell motility. *J Cell Biol* **117**:1343, 1992

57. Estes JM et al: Hyaluronate metabolism undergoes an ontogenic transition during fetal development: Implications for scar-free wound healing. *J Pediatr Surg* **28**:1227, 1993

58. Thomas L et al: CD44H regulates tumor cell migration on hyaluronate-coated substrate. *J Cell Biol* **118**:971, 1992

59. Underhill C: CD44: The hyaluronan receptor. *J Cell Sci* **103**:293, 1992

60. Messadi DV, Bertolami CN: CD44 and hyaluronan expression in human cutaneous scar fibroblasts. *Am J Pathol* **142**:1041, 1993

61. Mosher X: Assembly of extracellular matrix. *Curr Opin Cell Biol* **4**:810, 1992

62. Wu C et al: The alpha 5 beta 1 integrin fibronectin receptor, but not the alpha 5 cytoplasmic domain, functions in an early and essential step in fibronectin matrix assembly. *J Biol Chem* **268**:21883, 1993

63. Kurkinen M et al: Sequential appearance of fibronectin and collagen in experimental granulation tissue. *Lab Invest* **43**:47, 1980

64. Majno G et al: Contraction of granulation tissue in vitro: similarity to smooth muscle. *Science* **173**:548, 1971

65. Gabbiani G et al: Granulation tissue as a contractile organ: A study of structure and function. *J Exp Med* **135**:719, 1972

66. Grinnell F: Fibroblasts, myofibroblasts, and wound contraction. *J Cell Biol* **124**:401, 1994

67. Chiu HF, McFarlane RM: Pathogenesis of Dupuytren's contracture: A correlative clinical-pathological study. *J Hand Surg* **3**:1, 1978

68. Bailey AJ et al: Characterization of the collagen of human hypertrophic and normal scars. *Biochim Biophys Acta* **405**:412, 1975

69. Levenson X: The healing of rat skin wounds. *Ann Surg* **161**:293, 1965

70. Falanga X: Growth factors and wound healing. *Dermatol Clin* **11**:667, 1993

71. Gailit J, Clark RA: Wound repair in the context of extracellular matrix. *Curr Opin Cell Biol* **6**:717, 1994

72. Tremble PM et al: SPARC, a secreted protein associated with morphogenesis and tissue remodeling, induces expression of metalloproteinases in fibroblasts through a novel extracellular matrix-dependent pathway. *J Cell Biol* **121**:1433, 1993

73. Brooks PC et al: Requirement of vascular integrin alpha v beta 3 for angiogenesis. *Science* **264**:569, 1994

74. Sarret Y et al: Human keratinocyte locomotion: The effect of selected cytokines. *J Invest Dermatol* **98**:12, 1992

75. Woodley DT et al: Re-epithelialization: Human keratinocyte locomotion. *Dermatol Clin* **11**:641, 1993

76. Regezi JA et al: Tenascin and beta 6 integrin are overexpressed in floor of mouth in situ carcinomas and invasive squamous cell carcinomas. *Oral Oncol* **38**:332, 2002

77. Gabbiani G et al: Cytoplasmic filaments and gap junctions in epithelial cells and myofibroblasts during wound healing. *J Cell Biol* **76**:561, 1978

78. Krawczyk WS, Wilgram GF: Hemidesmosome and desmosome morphogenesis during epidermal wound healing. *J Ultrastruct Res* **45**:93, 1973

79. Haapasalmi K et al: Keratinocytes in human wounds express alpha v beta 6 integrin. *J Invest Dermatol* **106**:42, 1996

80. Breuss JM et al: Expression of the beta 6 integrin subunit in development, neoplasia and tissue repair suggests a role in epithelial remodeling. *J Cell Sci* **108**:2241, 1995

81. Cavani A et al: Distinctive integrin expression in the newly forming epidermis during wound healing in humans. *J Invest Dermatol* **101**:600, 1993

82. Yamada X: Provisional matrix, *The Molecular and Cellular Biology of Wound Repair,* 2d ed, edited by RAF Clark. New York, Plenum, 1996, p 51

83. Paladini RD et al: Onset of re-epithelialization after skin injury correlates with a reorganization of keratin filaments in wound edge keratinocytes: defining a potential role for keratin 16. *J Cell Biol* **132**:381, 1996

84. O'Keefe EJ et al: Spreading and enhanced motility of human keratinocytes on fibronectin. *J Invest Dermatol* **85**:125, 1985

85. Li W et al: The p38–MAPK/SAPK pathway is required for human keratinocyte migration on dermal collagen. *J Invest Dermatol* **117**:1601, 2001

86. Gailit J et al: TGF-beta 1 stimulates expression of keratinocyte integrins during re-epithelialization of cutaneous wounds. *J Invest Dermatol* **103**:221, 1994

87. Circolo A et al: Differential regulation of the expression of proteinases/antiproteinases in fibroblasts: Effects of interleukin-1 and platelet-derived growth factor. *J Biol Chem* **266**:12283, 1991

88. Laiho M et al: Transforming growth factor-beta induction of type-1 plasminogen activator inhibitor: Pericellular deposition and sensitivity to exogenous urokinase. *J Biol Chem* **262**:17467, 1987

89. Overall CM et al: Independent regulation of collagenase, 72-kDa progelatinase, and metalloendoproteinase inhibitor expression in human fibroblasts by transforming growth factor-beta. *J Biol Chem* **264**:1860, 1989

90. Grondahl-Hansen J et al: Urokinase-and tissue-type plasminogen activators in keratinocytes during wound reepithelialization in vivo. *J Invest Dermatol* **90**:790, 1988

91. Romer J et al: Differential expression of urokinase-type plasminogen activator and its type-1 inhibitor during healing of mouse skin wounds. *J Invest Dermatol* **97**:803, 1991

92. Romer J et al: The receptor for urokinase-type plasminogen activator is expressed by keratinocytes at the leading edge during re-epithelialization of mouse skin wounds. *J Invest Dermatol* **102**:519, 1994

93. Saarialho-Kere U et al: Epilysin (MMP-28) expression is associated with cell proliferation during epithelial repair. *J Invest Dermatol* **119**:14, 2002

94. Nagase H, Brew K: Engineering of tissue inhibitor of metalloproteinases mutants as potential therapeutics. *Arthritis Res* **4**:551, 2002

95. Roberts CJ et al: Transforming growth factor beta stimulates the expression of fibronectin and of both subunits of the human fibronectin receptor by cultured human lung fibroblasts. *J Biol Chem* **263**:4586, 1988

96. Heino J et al: Regulation of cell adhesion receptors by transforming growth factor-beta: Concomitant regulation of integrins that share a common beta 1 subunit. *J Biol Chem* **264**:380, 1989

97. Ignotz RA et al: Regulation of cell adhesion receptors by transforming growth factor-beta: Regulation of vitronectin receptor and LFA-1. *J Biol Chem* **264**:389, 1989

98. Assoian RK et al: Transforming growth factor-beta in human platelets: Identification of a major storage site, purification, and characterization. *J Biol Chem* **258**:7155, 1983

99. Lawrence X: Physiology of the acute wound. *Clin Plast Surg* **25**:321, 1998

100. Postlethwaite AE et al: Stimulation of the chemotactic migration of human fibroblasts by transforming growth factor beta. *J Exp Med* **165**:251, 1987

101. Loef X: Induction of c-six RNA and activity similar to platelet-derived growth factor by transforming growth factor-beta: A proposed model for indirect mitogenesis involving autocrine activity. *Proc Nat1 Acad Sci USA* **83**:2453, 1986

102. Lawler X: Cell attachment to thrombospondin: The role or ARG-GLY-ASP, calcium and integrin receptors. *J Cell Biol* **107**:2351, 1988

103. Laurent TC, Fraser JR: Hyaluronan. *Faseb J* **6**:2397, 1992

104. Lark MW et al: Close and focal contact adhesions of fibroblasts to a fibronectin-containing matrix. *Fed Proc* **44**:394, 1985

105. Yang B et al: Identification of two hyaluronan-binding domains in the hyaluronan receptor RHAMM. *J Biol Chem* **268**:8617, 1993

106. Abercrombie X: Wound contraction in relation to collagen formation in scorbutic guinea pigs. *J Embryol Exp Morphol* **4**:167, 1956

107. Browse NL, Burnand KG: The cause of venous ulceration. *Lancet* **2**:243, 1982

108. Falanga V et al: Dermal pericapillary fibrin in venous disease and venous ulceration. *Arch Dermatol* **123**:620, 1987

109. Falanga V et al: Heterogeneity in oxygen diffusion around venous ulcers. *J Dermatol Surg Oncol* **17**:336, 1991

110. Coleridge Smith PD: The microcirculation in venous hypertension. *Vasc Med* **2**:203, 1997

111. Higley HR et al: Extravasation of macromolecules and possible trapping of transforming growth factor-beta in venous ulceration. *Br J Dermatol* **132**:79, 1995

112. Falanga V, Eaglstein WH: The “trap” hypothesis of venous ulceration. *Lancet* **341**:1006, 1993

113. Grinnell F et al: Degradation of fibronection and vitronectin in chronic wound fluid: analysis by cell blotting, immunoblotting, and cell adhesion assays. *J Invest Dermatol* **98**:410, 1992

114. Ladwig GP et al: Ratios of activated matrix metalloproteinase-9 to tissue inhibitor of matrix metalloproteinase-1 in wound fluids are inversely correlated with healing of pressure ulcers. *Wound Repair Regen* **10**:26, 2002

115. Wysocki AB, Grinnell F: Fibronectin profiles in normal and chronic wound fluid. *Lab Invest* **63**:825, 1990

116. Wysocki AB et al: Wound fluid from chronic leg ulcers contains elevated levels of metalloproteinases MMP-2 and MMP-9. *J Invest Dermatol* **101**:64, 1993

117. Stanley A, Osler T: Senescence and the healing rates of venous ulcers. *J Vasc Surg* **33**:1206, 2001

118. Stanley AC et al: Reduced growth of dermal fibroblasts from chronic venous ulcers can be stimulated with growth factors *J Vasc Surg* **26**:994, 1997

119. Hasan A et al: Dermal fibroblasts from venous ulcers are unresponsive to the action of transforming growth factor-beta 1. *J Dermatol Sci* **16**:59,1997

120. Agren MS et al: Proliferation and mitogenic response to PDGF-BB of fibroblasts isolated from chronic venous leg ulcers is ulcer-age dependent. *J Invest Dermatol* **112**:463, 1999

121. Loots MA et al: Differences in cellular infiltrate and extracellular matrix of chronic diabetic and venous ulcers versus acute wounds. *J Invest Dermatol* **111**:850, 1998

T>

Chapter 22

Jenny Kim Robert Modlin

Innate Immunity and the Skin

INNATE IMMUNITY
Physical Barrier
COMPLEMENT COMPONENTS
KERATINOCYTES
PHAGOCYTES
Pattern Recognition Receptors
Toll
Effector Functions of Phagocytes
CD40

REFERENCES

Throughout evolution, the immune system has developed complex and intricate mechanisms to defend the host against infection and cancer. The ability of the immune system to distinguish self from non-self is critical in determining when a response will be elicited. The immune system of higher vertebrates uses both rapid (innate) and sustained (adaptive) immune responses, which differ in the way they recognize foreign antigens, and the speed in which they respond (Fig. 22-1). The innate immune system uses germ-line–encoded pattern recognition receptors to respond to biochemical structures commonly shared by a number of different pathogens and elicits a rapid response against encountered pathogens, although no lasting immunity is generated. In contrast, cells of the adaptive immune system recognize molecules specific to particular pathogens, and clonally expand cells bearing antigen-specific receptors. A few of these cells become memory cells when the infection subsides, and thus have the capability of providing long-lasting protective immunity. Together, the innate and adaptive immune systems defend the host against infections and disease, making survival possible. This chapter describes the distinct role of the innate immune responses in generating host defense mechanisms in skin.

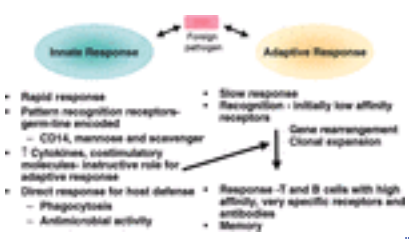

FIGURE 22-1 The immune system of higher vertebrates uses both innate and adaptive immune responses. These immune responses differ in the way they recognize foreign antigens, and the speed in which they respond; yet, they complement each other in eradicating foreign pathogens.

INNATE IMMUNITY

While adaptive immunity occurs only in vertebrates, the innate immune system exists in all multicellular organisms.

Defense mechanisms that are used by the host immediately after encountering a foreign ligand are referred to as innate immunity. These include physical barriers such as the skin and mucosal epithelium, soluble factors such as complement, antimicrobial peptides, chemokines, and cytokines, and cells of the innate immune system including monocytes/macrophages, dendritic cells, and polymorphonuclear leukocytes (PMNs) (Fig. 22-2).

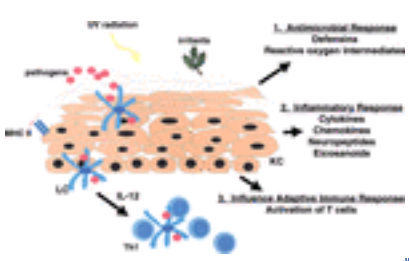

FIGURE 22-2 The innate immune response in skin. In response to exogenous factors such as foreign pathogens, UV radiation, and chemical irritants, innate immune cells mount multiple immune responses including (1) release of antimicrobial agents; (2) induction of inflammatory mediators, including cytokines, chemokines, neuropeptides, and eicosanoids; and (3) influencing the type of adaptive immune response. KC, keratinocytes; LC, Langerhans cells; MHC, major histocompatibility complex; SC, stratum corneum.

Physical Barrier

Physical structures prevent most pathogens and environmental toxins from harming the host. The skin and the epithelial lining of the respiratory, gastrointestinal, and the genitourinary tract provide physical barriers between the host and the

external world. Skin, once thought to be an inert structure, plays a vital role in protecting the individual from the external environment. The epidermis impedes penetration of microbial organisms, chemical irritation, and toxins, absorbs and blocks solar and ionized radiation, and inhibits water loss.

The stratum corneum, the outermost layer of the epidermis that results from the terminal differentiation of the keratinocytes, forms the primary layer of protection from the external environment. This layer of anucleated keratinocytes is composed of highly cross-linked proteinaceous cellular envelopes with extracellular lipid lamellae consisting of ceramides, free fatty acids, and cholesterol [1] (see Chap. 7 and Chap 9). The free fatty acids create an acidic environment that inhibits colonization by certain bacteria such as *Staphylococcus aureus,* [2] providing further protection.

The oral mucosa, gastrointestinal, and respiratory linings have special features to protect the body from microbes and other foreign materials. In the mouth and in the upper gastrointestinal tract, chemical substances such as digestive enzymes and acidic secretions inhibit microbial growth. Furthermore, nonpathogenic microbes colonize the epithelium of the gut and prevent invasion by pathogenic microbes. The protective role of the normal flora becomes clear when the use of antibiotics destroys these nonpathogenic bacteria, opening up a window of opportunity for invasion by pathogenic bacteria. Finally, the upper respiratory tract is lined by ciliated columnar epithelium, and the movement of cilia protects inhaled foreign particles from entering the alveolar space. Given these vital functions, it is not surprising that a break in this physical barrier, as often occurs in patients with severe burn or large wounds, results in high morbidity and mortality.

COMPLEMENT COMPONENTS (See Chap. 33)

One of the first innate defense mechanisms awaiting pathogens that overcome the epithelial barrier is the alternative pathway of complement. Unlike the classical complement pathway that requires antibody triggering, the alternative pathway of complement activation can be activated by microbial surfaces in the absence of specific antibody. In this way, the host defense mechanism comes into play immediately after encountering the pathogen without the 5 to 7 days required for antibody production.

Initially, the complement component C3 undergoes spontaneous hydrolysis to give C3(H_2O), which binds to factor B, allowing it to be cleaved by factor D into Ba and Bb. The C3(H_2O)Bb complex, which is a C3 convertase, forms cleaving C3 to C3a and C3b. C3b can attach covalently through its reactive thioester group to the surfaces of host cells or to pathogens. The bound C3b is able to bind factor B, which is then cleaved by factor D to yield Ba and the active protease Bb. If C3bBb forms on the surface of the host cells, it is rapidly inactivated by complement regulatory proteins expressed on the host cell such as CR1 (complement receptor 1), DAF (decay-accelerating factor), factor H, and MCP (membrane cofactor of proteolysis). However, bacterial surfaces do not express complement regulatory proteins, and properidin (factor P) binds and stabilizes the C3bBb complex. C3bBb complex also is a C3 convertase and initiates the cleavage of further molecules of C3 leading to opsonization by C3b and the generation of $C3b_2Bb$, the alternative pathway C5 convertase, leading to activation of the terminal complement components.

Not all microbial surfaces allow for activation of the alternative complement pathway. Although the content of sialic acid (high levels are present on the surfaces of vertebrate cells) has been implicated as one of the factors that determine the ability to trigger the alternative complement pathway, it is not clear exactly what distinguishes surfaces that allow the complement cascade to proceed.

KERATINOCYTES

Once thought to be inert, keratinocytes, the predominant cells in the epidermis, can mount an immune response through secretion of antimicrobial peptides. Human epithelial cells produce ß-defensins, cysteine-rich cationic low molecular weight antimicrobial peptides. Antimicrobial peptides are an important evolutionarily conserved innate host-defense mechanism in many organisms. The first human ß-defensin, HBD-1, was isolated from human hemofiltrate obtained from a patient with end-stage renal disease. [3] HBD-1 is constitutively expressed in the epidermis, is not transcriptionally regulated by inflammatory agents, [4] and has antimicrobial activity against gram-negative bacteria. [5] In addition, recent findings suggest that HBD-1 plays a role in keratinocyte differentiation. [6] A second human ß-defensin, HBD-2, was discovered in extracts of lesions from psoriasis patients. [7] Unlike HBD-1, HBD-2 expression is inducible by microbes including *Pseudomonas aeruginosa, S. aureus,* and *Candida albicans.* [7], [8] and [9] In addition to stimulation by microbes, proinflammatory cytokines such as tumor necrosis factor (TNF)-a and interleukin (IL)-1 can also induce HBD-2 transcription in keratinocytes. [7], [8] and [9] When tested for antimicrobial activity, HBD-2 also showed effective activity against gram-negative bacteria such as *Escherichia coli* and *P. aeruginosa,* but not against gram-positive bacteria such as *S. aureus.* [7] Recently, a third ß-defensin, HBD-3, was isolated and characterized. [10] Contact with TNF-a and with bacteria were found to induce HBD-3 mRNA expression. In addition, HBD-3 demonstrated potent antimicrobial activity against *S. aureus* and vancomycin-resistant *Enterococcus faecium.* Therefore, HBD-3 is among the first human ß-defensins in skin to demonstrate effective antimicrobial activity against a gram-positive bacteria. The localization of human ß-defensins to the outer layer of the skin and the fact the ß-defensins have antimicrobial activity against a variety of microbes suggest that human ß-defensins are essential parts of cutaneous innate immunity. Furthermore, evidence indicating that human ß-defensins attract dendritic cells and memory T cells via the chemokine receptor CCR6, [11] provide a link between the innate and the adaptive immunity is skin.

Other innate antimicrobial peptides, called *cathelicidins,* have also been identified in skin. [12] Animal studies show that these cathelicidins are an important component of innate host defense in mice and protect against necrotic skin infections produced by group A streptococci. These peptides are produced in increasing amounts following skin wounding due to their release by neutrophils and increased synthesis by keratinocytes. [12], [13]

Keratinocytes can also mount an immune response through the secretion of inflammatory cytokines. Keratinocytes constitutively release very low levels of cytokines; however, upon injury or stimulation with exogenous factors such as

lipopolysaccharides (LPS), silica, poison ivy catechols, *Staphylococcus* toxins, and UV radiation, keratinocytes secrete high levels of IL-1, IL-6, IL-8, IL-10, and TNF-a (see Chap. 26). These cytokines can induce differentiation and growth of keratinocytes and other resident or migrating cells in the epidermis, dermis, and vessels. Furthermore, they are important mediators of both local and systemic inflammatory and immune responses.

In addition to cytokines, keratinocytes secrete other factors such as neuropeptides, eicosanoids, and reactive oxygen species. These mediators have potent inflammatory and immunomodulatory properties and play an important role in the pathogenesis of cutaneous inflammatory and infectious diseases as well as in aging.

PHAGOCYTES

Effective host defense against invading microorganisms requires detection of the foreign pathogens and the rapid deployment of an effective antimicrobial response. This function is imparted to the innate immune system that recognizes the molecular structures of microbial invaders. The microbes are rich with molecular arrays or patterns that are shared among groups of pathogens. Examples include LPS of gram-negative bacteria, lipoteichoic acids of gram-positive bacteria, lipoproteins of bacteria and parasites, glycolipids of mycobacteria, mannans of yeast, bacterial DNA sequences, and double-stranded RNA of viruses. Phagocytes, such as macrophages and PMNs, are the major cellular component of the innate immune system and have the capacity to detect these microbial patterns using complement receptors on their surface.

In the epidermis, there are skin-specific cells known as Langerhans cells. After encountering a pathogen in the epidermis, Langerhans cells take up the pathogen by an endocytotic process and migrate to the draining lymph nodes where they develop into mature dendritic cells. These migrating cells lose the ability to take up and process antigen but they upregulate MHC molecules and costimulatory molecules to activate naïve T cells.

Neutrophils are normally not present in skin; however, during inflammatory processes, these cells migrate to sites of infection and inflammation where they are the earliest phagocytic cells to be recruited. PMNs can phagocytose microbes coated with antibody and with the complement component C3b. In addition, PMNs have specific receptors that recognize pathogens directly.

Phagocytes express pattern recognition receptors that function to recognize pathogen-associated molecular patterns. Examples of pattern recognition receptors include the mannose receptor that recognizes mannan and CD14 that recognizes the lipid A portion of LPS. Pattern recognition receptors are nonclonal receptors that are present on all cells of a class, e.g., macrophages, and do not depend on immunologic memory because they are germ-line encoded. Recently, a new mammalian pattern recognition receptor, the Toll-like receptor, has been identified and important studies are emerging to provide new insights into the mechanisms by which the innate response recognizes and combats microbial invaders.

Pattern Recognition Receptors

How do phagocytes recognize foreign pathogens? One way that pathogens can be recognized and destroyed by the innate immune system is via receptors on phagocytic cells. Unlike adaptive immunity, the innate immune response relies on a relatively small set of germ-line–encoded receptors that recognize conserved molecular patterns found only on microorganisms. The phagocytic cells recognize pathogen-associated molecular patterns that are shared by a large group of pathogens. These pathogen-associated molecular patterns are usually conserved molecular structures required for survival of the microbes and therefore are not subject to selective pressure. In addition, pathogen-associated molecular patterns are specific to microbes and are not expressed in the host system. Consequently, the innate immune system has mastered a clever way of distinguishing between self and non-self and of relaying this message to the adaptive immune system.

Molecules that recognize pathogen-associated molecular patterns are known as pattern-recognition receptors. Pattern-recognition receptors can be divided into several families of proteins by their structure. For example, Toll and CD14 are pattern-recognition receptors that contain leucine-rich repeats, collectins have calcium-dependent lectin domains, and macrophage scavenger receptors contain scavenger-receptor protein domains. These pattern-recognition receptors can also be divided into three different classes by their function: secreted, endocytic, and signaling. Secreted pattern-recognition receptors function as opsonins by binding to microbial cell walls and flagging them for recognition by the classical complement system and phagocytes. The best-characterized receptor of this class is the mannan-binding lectin. The macrophage mannose receptor is an endocytic pattern recognition receptor that functions by recognizing carbohydrates with a large number of mannose residues that are characteristic of microorganisms, and mediating their phagocytosis by macrophages. Signaling receptors recognize pathogen-associated molecular patterns and activate signal transduction pathways that lead to the expression of a number of immune response genes, including cytokine genes. The recently identified family of Toll-like receptors is a pattern-recognition receptor family.

Toll

There is now substantial evidence to support a role for mammalian Toll-like receptors in innate immunity (Fig. 22-3). First, Toll-like receptors are pattern-recognition receptors that recognize pathogen-associated molecular patterns present on a variety of bacteria and fungi. Second, Toll-like receptors are expressed at the interface with the environment where the host must defend against microbial threats. Third, the activation of Toll-like receptors induces expression of costimulatory molecules and the release of cytokines that instruct the adaptive immune response. Fourth, Toll-like receptors directly activate host defense mechanisms that then combat the foreign invader.

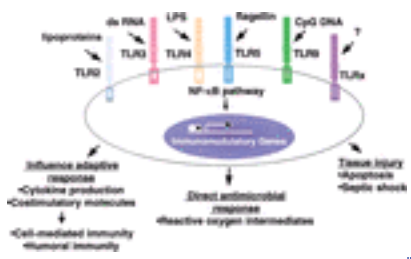

FIGURE 22-3 Toll-like receptors mediate innate immune response in host defense. Activation of Toll-like receptors by specific ligands induces (1) cytokine release and costimulatory molecules that instruct the type of adaptive immune response; (2) direct antimicrobial response; and (3) tissue injury.

Toll was first identified in dorsoventral patterning in the *Drosophila melanogaster* embryo and in antifungal defense in adult flies. [14], [15] Since then, at least 10 mammalian Toll homologues, Toll-like receptors, have been identified. The extracellular domain has leucine-rich repeats and recognizes a spectrum of microbial products. Studies suggest that mammalian Toll homologues, Toll-like receptors, mediate responsiveness to specific molecular structures from both gram-positive and gram-negative organisms. For example, LPS activates Toll-like receptor 4; microbial lipoproteins, peptidoglycans, and *S. aureus* lipoteichoic acid activate Toll-like receptor 2 [16], [17], [18], [19], [20] and [21]; a specific bacterial DNA, an unmethylated cytidine-phosphate-guanosine (CpG) activates Toll-like receptor 9 [22]; bacterial flagellin activates Toll-like receptor 5 [23]; and double-stranded RNA activates Toll-like receptor 3. [24]

The intracellular domain of Toll-like receptors has homology to the IL-1 receptor and shares common signaling molecules of the Rel/NF-?B pathway. [16], [17] Considerable progress has been made toward understanding the cell-signaling events that occur after Toll-like receptor activation with emphasis on the activation of NF-?B, a transcription factor involved in the expression of many proinflammatory cytokines. The Toll-like receptor signaling pathway has been analyzed and found to share features in common with Toll signaling in *Drosophila*. [25], [26] LPS activation via Toll-like receptors has been shown to induce an intracellular signaling cascade involving MyD88, IL-1 receptor accessory protein kinase (IRAK), TNF-receptor associated factor (TRAF-6), and NF-?B–inducing kinase (NIK) leading to activation of NF-?B and subsequent immunoregulatory gene transcription. [25], [26] and [27] Further study of mammalian Toll-like receptor signaling pathways could identify different downstream events according to the nature of the microbial ligand and Toll-like receptor family member that has been activated.

Toll-like receptors were initially found to be expressed in all lymphoid tissue but were most highly expressed in peripheral blood leukocytes. [28] Expression of Toll-like receptor mRNA has been found in monocytes, B cells, T cells, granulocytes, and dendritic cells. [29], [30] Protein expression of toll family members has been verified by using monoclonal antibodies for B cells, monocytes, and dendritic cells. Underhill et al. suggest that following phagocytosis, Toll-like receptors are recruited to the pathogen-containing phagosomes and discriminate between gram-positive and gram-negative bacteria, [31] thus surveying the intracellular compartments of the cells for microbial invaders. The expression of Toll-like receptors on cells of the monocyte/macrophage lineage is consistent with the role of Toll-like receptors in modulating inflammatory responses via cytokine release. Because these cells migrate into sites that interface with the environment, lung, skin, and gut, the location of Toll-like receptor expressing cells would be situated to defend against invading microbes. Toll-like receptor expression by adipocytes, intestinal epithelial cells, and dermal endothelial cells supports the notion that Toll-like receptors serve a sentinel role for invading microorganisms. The regulation of Toll-like receptor expression is critical to their role in host defense, yet few factors have been identified that modulate their expression. IL-4 acts to downregulate Toll-like receptor expression, [32] suggesting that T_H2 cell adaptive immune responses might inhibit Toll-like receptor activation.

LPS and lipoproteins have historically been known to be potent inducers of cytokine production. However, not until the identification of Toll-like receptors was a receptor linked to this response. Medzhitov et al. first demonstrated that constitutive activation of Toll-like receptor 4, using a dominant active construct transfected in a human monocytoid line, induced cytokine production and upregulation of costimulatory molecules. [33] Since then, critical proinflammatory and immunomodulatory cytokines, such as IL-1, IL-6, IL-8, IL-10, IL-12, and TNF-a, have been shown to be induced following activation of Toll-like receptors by microbial ligands. [18], [28], [33], [34] Evidence suggests that monocyte-derived dendritic cells produce the proinflammatory IL-12, and not the anti-inflammatory IL-10, upon activation with lipoproteins. Activation of Toll-like receptors on dendritic cells triggers their maturation, in terms of expression of CD83, MHC class II, as well as the costimulatory molecules CD80 and CD86. In this manner, the activation of dendritic cells via Toll-like receptors enhances their ability to present antigen to T cells and generate T_H1 cytokine responses critical for cell-mediated immunity (CMI). Consequently, activation of Toll-like receptors, as part of the innate response, can lead to instruct the nature of the adaptive T cell response.

In *Drosophila, Toll* is critical for host defense. Flies with a mutation in *Toll* are highly susceptible to fungal infection. It is now evident that mammalian Toll-like receptors play a prominent role in directly activating host defense mechanisms. Activation of Toll-like receptor 2 by microbial lipoproteins induces activation of the inducible nitric oxide (iNOS) promoter, which leads to the production of nitric oxide (NO), a known antimicrobial agent. There is strong evidence that Toll-like receptor 2 activation leads to killing of intracellular *Mycobacterium tuberculosis* in both mouse and human macrophages. [35] In mouse macrophages, bacterial lipoprotein activation of Toll-like receptor 2 leads to a nitric oxide–dependent killing of intracellular tubercle bacilli. In human monocytes and alveolar macrophages, bacterial lipoproteins similarly activated Toll-like receptor 2 to kill intracellular *M. tuberculosis;* however, this occurred by an antimicrobial pathway that is nitric oxide independent. These data provide evidence that mammalian Toll-like receptors have retained not only the structural features of *Drosophila* Toll that allow them to respond to microbial ligands, but also the ability directly to activate antimicrobial effector pathways at the site of infection. In *Drosophila,* activation of Toll leads to the NF-?B–dependent induction of a variety of antimicrobial peptides, including metchnikowan, defensins, cecropins, and drosomycin. [14], [36], [37] The clues from *Drosophila* suggest that exploring the mechanisms of induction of antimicrobial peptides in mammalian cells is warranted. In this regard, it was recently shown that LPS induces ß-defensin-2 in tracheobronchial epithelium, [38]

suggesting the conservation of the *Drosophila* Toll pathway of antimicrobial peptide induction.

The activation of Toll-like receptors can also be detrimental, leading to tissue injury. The administration of lipopolysaccharides to mice can result in manifestations of septic shock, which is dependent on Toll-like receptor 4. [39] Evidence suggests that Toll-like receptor 2 activation by *Propionibacterium acnes* induces inflammatory responses in acne vulgaris leading to tissue injury (J. Kim and R.L. Modlin, unpublished). Aliprantis et al. demonstrated that microbial lipoproteins induced features of apoptosis via Toll-like receptor 2. [19] Thus, microbial lipoproteins have the ability to induce both Toll-like receptor–dependent activation of host defense and tissue pathology. This dual signaling pathway is similar to TNFR and CD40 signaling, which can induce both NF-?B activation and apoptosis. [40] In this manner, it is possible for the immune system to activate host defense mechanisms, and then, by apoptosis, to downregulate the response to prevent it from causing tissue injury. Activation of Toll-like receptors can lead to the inhibition of MHC class II antigen presentation pathway, which can downregulate immune responses leading to tissue injury but could also contribute to immunosuppression. [41]

The susceptibility of mice with spontaneous mutations in Toll-like receptors to bacterial infection implicates Toll-like receptors as critical receptors in mammalian host defense. [42], [43] and [44] Toll-like receptor 4 mutations are associated with lipopolysaccharide hyporesponsiveness in humans. [45] By inference, we anticipate that humans with genetic alterations in other Toll-like receptors may have increased susceptibility to certain microbial infections. Furthermore, it should be possible to exploit the pathway of Toll-like receptor activation as a means to adjuvant immune responses in vaccines and treatments for infectious diseases, as well as to abrogate responses detrimental to the host.

Effector Functions of Phagocytes

Activation of phagocytes by pathogens induces several important effector mechanisms. One such mechanism is the triggering of cytokine production. A number of important cytokines are secreted by macrophages in response to microbes, including IL-1, IL-6, TNF-a, IL-8, IL-12, and IL-10. IL-1, IL-6, and TNF-a play critical roles in inducing the acute-phase response in the liver and in inducing fever for effective host defense. TNF-a induces a potent inflammatory response to contain infection; IL-8 is important as a mediator of PMN chemotaxis to the site of infection.

One of the most important cytokines produced by monocytes is IL-12 (see Chap. 26). Both in murine models of infection and in human infectious disease, susceptibility or resistance to infection is often determined by the T_H1 and T_H2 T cell cytokine patterns. It has become increasingly evident that IL-12 is a pivotal regulator of T_H1 responses and hence is essential for promoting CMI against intracellular microbial pathogens. In this manner, the ability of the innate immune system to release IL-12 influences the nature of the adaptive immune response.

Phagocytes also secrete an inhibitory cytokine, IL-10, that has many anti-inflammatory activities. The importance of IL-10 is underscored in both human disease and murine infection models. IL-4 and IL-10 production is associated with the progressive forms of leishmanial, schistosomal, and trypanosomal infections. In leprosy, IL-10 expression in lesions correlates with susceptibility to infection. [46] Thus, IL-10 appears to inhibit aspects of CMI required for the effective elimination of intracellular pathogens.

There is strong evidence that dysregulation of IL-10 is associated with human allergic diseases. In addition, a number of studies have reported the production of IL-10 in association with malignant cell types including carcinomas of skin, breast, colon, kidney, bladder, ovary, and lung. The production of IL-10 by tumors has been implicated as one of the mechanisms that neoplastic cells use to evade the local immune response. [47]

Another important defense mechanism triggered in phagocytes in response to pathogens is the induction of a direct antimicrobial responses. Phagocytic cells such as PMNs and macrophages recognize pathogens, engulf them, and induce antimicrobial effector mechanisms to kill the pathogens. PMNs generate oxygen-dependent or oxygen-independent killing. The release of toxic oxygen radicals, lysosomal enzymes, and antimicrobial peptides such as the human neutrophil defensins, leads to direct killing of the microbial organisms. [48], [49] Similarly, activation of Toll-like receptors on macrophages by microbial ligands upregulates iNOS, which results in rapid generation of NO and powerful microbicidal activity. Macrophages use this mechanism to contain some infectious organisms not susceptible to PMN attack, such as mycobacteria, certain fungi, and parasites. In addition, stimulation of monocytes by activated T cells also leads to the generation of NO.

Finally, Langerhans cells, monocytes, and macrophages present antigens to T and B lymphocytes, the adaptive immune cells. Upon pathogen recognition, monocytes are able to discriminate self from non-self molecules and foreign antigens are presented to lymphocytes for initiation of adaptive immune response. This important function of antigen presenting cells is discussed in detail in Chap. 23.

CD40

Phagocytic cells of the innate immune system can also be activated by cells of the adaptive immune system. CD40 is a 50-kDa glycoprotein present on the surface of B cells, monocytes, dendritic cells, and endothelial cells, and its ligand is CD40L. CD40–CD40L interactions play a crucial role in the development of effector functions. CD40–CD40L interactions between T cells and macrophages play a role in maintenance of T_H1 type cellular responses and mediation of inflammatory responses. Other studies have established a role for CD40–CD40L interactions in B cell activation, differentiation, and in Ig class switching. [51] In addition, CD40–CD40L interaction leads to upregulation of B7.1 and B7.2 on B cells. This costimulatory activity induced on B cells then acts to amplify the response of the T cells. [52] These mechanisms underscore the importance of the interplay between the innate and the adaptive immune system in generating an effective host response.

Thus, the innate immune response is a critical first line of defense. It is rapid, allowing for early detection of microbial pathogens and control of infection. Using germ-line–encoded receptors, the innate immune system distinguishes pathogens from self-antigens and activates appropriate effector mechanisms. Furthermore, the innate immune response controls the initiation of the adaptive immune response by regulating costimulatory molecules and releasing effector cytokines. In contrast, the adaptive immune response is delayed in onset, is characterized by highly specific receptors that are distributed clonally on subsets of particular cells, and involves immunologic memory. Not only do the innate and adaptive immune response complement each other, they are interactive in that the innate immune response influences the type of adaptive response and the adaptive immune response influences the function of innate cells.

REFERENCES

1. Elias PM et al: Lipid-related barriers and gradients in the epidermis. *Ann N Y Acad Sci* **548**:4, 1988

2. Fluhr JW et al: Generation of free fatty acids from phospholipids regulates stratum corneum acidification and integrity. *J Invest Dermatol* **117**:44, 2001

3. Bensch KW et al: hBD-1: A novel beta-defensin from human plasma. *FEBS Lett* **368**:331, 1995

4. Valore EV et al: Human beta-defensin-1: An antimicrobial peptide of urogenital tissues. *J Clin Invest* **101**:1633, 1998

5. Goldman MJ et al: Human beta-defensin-1 is a salt-sensitive antibiotic in lung that is inactivated in cystic fibrosis. *Cell* **88**:553, 1997

6. Frye M et al: Expression of human beta-defensin-1 promotes differentiation of keratinocytes. *J Mol Med* **79**:275, 2001

7. Harder J et al: A peptide antibiotic from human skin. *Nature* **387**:861, 1997

8. Singh PK et al: Production of beta-defensins by human airway epithelia. *Proc Natl Acad Sci U S A* **95**:14961, 1998

9. Harder J et al: Mucoid *Pseudomonas aeruginosa,* TNF-alpha, and IL-1beta, but not IL-6, induce human beta-defensin-2 in respiratory epithelia. *Am J Respir Cell Mol Biol* **22**:714, 2000

10. Harder J et al: Isolation and characterization of human beta-defensin-3, a novel human inducible peptide antibiotic. *J Biol Chem* **276**:5707, 2001

11. Yang D et al: Beta-defensins: Linking innate and adaptive immunity through dendritic and T cell CCR6. *Science* **286**:525, 1999

12. Nizet B et al: Innate antimicrobial peptide protects the skin from invasive bacterial infection. *Nature* **22**:414, 2001

13. Dorschner RA et al: Cutaneous injury induces the release of cathelicidin antimicrobial peptides active against group A Streptococcus. *J Invest Dermatol* **117**:91, 2001

14. Lemaitre B et al: The dorsoventral regulatory gene cassette spatzle/ Toll/cactus controls the potent antifungal response in Drosophila adults. *Cell* **86**:973, 1996

15. Hashimoto C et al: The Toll gene of Drosophila, required for dorsal-ventral embryonic polarity, appears to encode a transmembrane protein. *Cell* **52**:269, 1988

16. Gay NJ et al: Drosophila Toll and IL-1 receptor. *Nature* **351**:355, 1991

17. Belvin MP et al: A conserved signaling pathway: The Drosophila toll-dorsal pathway. *Annu Rev Cell Dev Biol* **12**:393, 1996

18. Takeuchi O et al: Differential roles of TLR2 and TLR4 in recognition of gram-negative and gram-positive bacterial cell wall components. *Immunity* **11**:443, 1999

19. Aliprantis AO et al: Cell activation and apoptosis by bacterial lipoproteins through Toll-like receptor-2. *Science* **285**:736, 1999

20. Means TK et al: Human Toll-Like receptors mediate cellular activation by *Mycobacterium tuberculosis*. *J Immunol* **163**:3920, 1999

21. Yoshimura A et al: Recognition of gram-positive bacterial cell wall components by the innate immune system occurs via Toll-like receptor 2. *J Immunol* **163**:1, 1999

22. Hemmi H et al: A Toll-like receptor that recognizes bacterial DNA. *Nature* **408**:740, 2000

23. Hayashi F et al: The innate immune response to bacterial flagellin is mediated by Toll-like receptor 5. *Nature* **410**:1099, 2001

24. Alexopoulou L et al: Recognition of double-stranded RNA and activation of NF-kappaB by Toll-like receptor 3. *Nature* **413**:732, 2001

25. Muzio M et al: The human toll signaling pathway: Divergence of nuclear factor and JNK/SAPK activation upstream of tumor necrosis factor receptor-associated factor 6 (TRAF6). *J Exp Med* **187**:2097, 1998

26. Yang RB et al: Signaling events induced by lipopolysaccharide-activated toll-like receptor 2. *J Immunol* **163**:639, 1999

27. Kawai T et al: Unresponsiveness of MyD88-deficient mice to endotoxin. *Immunity* **11**:115, 1999

28. Yang RB et al: Toll-like receptor-2 mediates lipopolysaccharide-induced cellular signalling. *Nature* **395**:284, 1998

29. Akashi S et al: Cutting edge: Cell surface expression and lipopolysaccharide signaling via the toll-like receptor 4-MD-2 complex on mouse peritoneal macrophages. *J Immunol* **164**:3471, 2000

30. Muzio M et al: Differential expression and regulation of toll-like receptors (TLR) in human leukocytes: selective expression of TLR3 in dendritic cells. *J Immunol* **164**:5998, 2000

31. Underhill DM et al: The Toll-like receptor 2 is recruited to macrophage phagosomes and discriminates between pathogens. *Nature* **401**:811,

1999

32. Staege H et al: Human toll-like receptors 2 and 4 are targets for deactivation of mononuclear phagocytes by interleukin-4. *Immunol Lett* **71**:1, 2000

33. Medzhitov R et al: A human homologue of the Drosophila Toll protein signals activation of adaptive immunity. *Nature* **388**:394, 1997

34. Toura I et al: Cutting edge: Inhibition of experimental tumor metastasis by dendritic cells pulsed with alpha-galactosylceramide. *J Immunol* **163**:2387, 1999

35. Thoma-Uszynski S et al: Induction of direct antimicrobial activity through mammalian toll-like receptors. *Science* **291**:1544, 2001

36. Lemaitre B et al: Drosophila host defense: Differential induction of antimicrobial peptide genes after infection by various classes of microorganisms. *Proc Natl Acad Sci U S A* **94**:14614, 1997

37. Hoffmann JA et al: Phylogenetic perspectives in innate immunity. *Science* **284**:1313, 1999

38. Becker MN et al: CD14-dependent LPS-induced beta-defensin-2 expression in human tracheobronchial epithelium. *J Biol Chem* **275**:29731, 2000

39. Poltorak A et al: Defective LPS signaling in C3H/HeJ and C57BL/10ScCr mice: Mutations in Tlr4 gene. *Science* **282**:2085, 1998

40. Aliprantis AO et al: The apoptotic signaling pathway activated by Toll-like receptor-2. *EMBO J* **19**:3325, 2000

41. Noss EH et al: Toll-like receptor 2-dependent inhibition of macrophage class II MHC expression and antigen processing by 19-kDa lipoprotein of *Mycobacterium tuberculosis*. *J Immunol* **167**:910, 2001

42. O'Brien AD et al: Genetic control of susceptibility to *Salmonella typhimurium* in mice: Role of the LPS gene. *J Immunol* **124**:20, 1980

43. Cross A et al: The importance of a lipopolysaccharide-initiated, cytokine-mediated host defense mechanism in mice against extraintestinally invasive *Escherichia coli*. *J Clin Invest* **96**:676, 1995

44. Medina E et al: Resistance ranking of some common inbred mouse strains to *Mycobacterium tuberculosis* and relationship to major histocompatibility complex haplotype and Nramp1 genotype. *Immunology* **93**:270, 1998

45. Arbour NC et al: TLR4 mutations are associated with endotoxin hyporesponsiveness in humans. *Nat Genet* **25**:187, 2000

46. Yamamura M et al: Defining protective responses to pathogens: Cytokine profiles in leprosy lesions. *Science* **254**:277, 1991

47. Kim J et al: IL-10 production in cutaneous basal and squamous cell carcinomas. A mechanism for evading the local T cell immune response. *J Immunol* **155**:2240, 1995

48. Leffell MS et al: Intracellular and extracellular degranulation of human polymorphonuclear azurophil and specific granules induced by immune complexes. *Infect Immun* **10**:1241, 1974

49. Ganz T et al: Defensins. Natural peptide antibiotics of human neutrophils. *J Clin Invest* **76**:1427, 1985

50. Tian L et al: Activated T cells enhance nitric oxide production by murine splenic macrophages through gp39 and LFA-1. *Eur J Immunol* **25**:306, 1995

51. Hollenbaugh D et al: The role of CD40 and its ligand in the regulation of the immune response. *Immunol Rev* **138**:23, 1994

52. Grewal IS et al: Requirement for CD40 ligand in costimulation induction, T cell activation, and experimental allergic encephalomyelitis. *Science* **273**:1864, 1996

T>

Chapter 23

Georg Stingl Dieter Maurer Conrad Hauser Klaus Wolff

The Skin: An Immunologic Barrier

ANTIGEN-PRESENTING CELLS: LANGERHANS CELLS AND DERMAL DENDRITIC CELLS
Definition
Morphology
Tissue Distribution
Life Cycle (Fig. 23-4)
Functional Properties
Phenotypic and Functional Alterations in Disease
Effects of Physicochemical Agents and Drugs
KERATINOCYTES
Secretory Functions
The Keratinocyte as an Immunologic Target Cell
LYMPHOCYTES
SYNOPSIS (Fig. 23-8)

REFERENCES

Microbial attack poses a major, potentially lethal threat to all higher organisms. Anatomically, the first barrier to microbiologic invasion is the skin, particularly the epidermis. Today we know that the capacity of the skin to protect the integrity of the host not only is based on its physical and structural properties, but also includes an immunologic component of both the innate (e.g., rapid production and release of proinflammatory cytokines and antimicrobial peptides by epidermal cells exposed to microbial pathogens) and the adaptive type. A robust innate reaction is also the major trigger of an adaptive response initiated by dendritic antigen-presenting cells in the epidermis [Langerhans cells (LCs)] and dermis [dermal dendritic cells (DDCs)]. When appropriately stimulated and loaded with antigenic peptides, these cells can leave the skin and migrate to regional lymphoid tissues where they induce lymphocyte activation and expansion at a clonal level.

In the recent past, we began to understand that the immunosurveillance function of the skin is finely tuned and tailored to the needs of the host. Inasmuch as it guarantees the rapid recognition of and response to microbial danger signals, it also prevents the occurrence of such a reaction toward harmless and innocuous substances.

This chapter describes the contributions of the cell populations of skin to the immunologic barrier function of this organ and points to some of the factors that injure and/or restore its function.

ANTIGEN-PRESENTING CELLS: LANGERHANS CELLS AND DERMAL DENDRITIC CELLS

Definition

In 1868, the medical student Paul Langerhans, driven by his interest in the anatomy of skin nerves, identified a population of dendritically shaped cells in the suprabasal regions of the epidermis after impregnating human skin with gold salts. [1] These cells, which later were found in virtually all stratified squamous epithelia of mammals, are now eponymously referred to as *Langerhans cells*. There also exist substantial numbers of dendritic leukocytes in the dermis. Although some of them represent LCs on their way into or out of the epidermis, most of these cells are phenotypically slightly different from LCs and are generally referred to as *dermal dendritic cells*. [2] LCs and DDCs are lineage-negative (Lin–), bone marrow-derived leukocytes endowed with exquisite antigen-presenting properties. Thus, they phenotypically and functionally resemble other dendritic cells (DCs) present in most, if not all, lymphoid and nonlymphoid tissues. [3] As the gatekeepers of the immune system, they control the response to events perturbing tissue homeostasis.

Morphology

LCs/DDCs cannot be readily recognized in routinely fixed and stained paraffin-embedded sections of mammalian skin. Apart from identifying LCs on the basis of their unique ultrastructural markers, that is, the Birbeck granules (see below), LCs/DDCs can be selectively visualized at the light microscopic level with certain histochemical and, more importantly, immunolabeling procedures.

HISTOCHEMICAL METHODS The demonstration of a membrane-bound, formalin-resistant, sulfhydryl-dependent adenosine triphosphatase (ATPase) is an excellent method for the identification of LCs in humans and rodents. [4] Intraepidermal ATPase+ cells are found mainly at a suprabasal position (Fig. 23-1). Their pronounced dendritic shape, as well as their distribution and density, can be even better appreciated by an *en face* view of whole epidermal mounts that have been subjected to this staining procedure (Fig. 23-2).

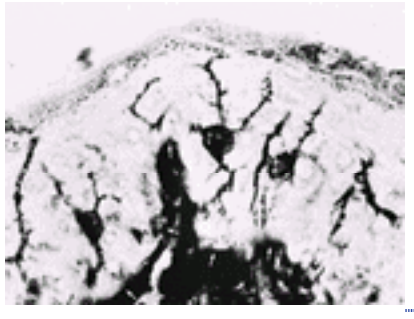

FIGURE 23-1 Suprabasal dendritic Langerhans cells in human epidermis as revealed by the ATPase technique. Arrows denote the dermal–epidermal junction. (*From Wolff K: Die Langerhans-Zelle. Ergebnisse neuerer experimenteller Untersuchungen. Arch Klin Exp Dermatol 229:54, 1967, with permission.*)

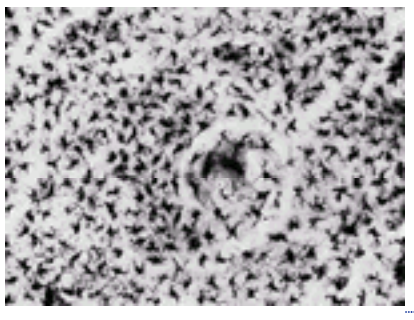

FIGURE 23-2 Histochemical (ATPase technique) demonstration of the Langerhans cell population in a sheet preparation of guinea pig epidermis. (*From Wolff K et al: Proceedings of the 13th International Congress of Dermatology, Munich, 1967, vol 2. Berlin, Springer, 1968, p 1502, with permission.*)

IMMUNOLABELING PROCEDURES Extensive antibody screening of LCs has led to the identification and characterization of many surface and/or cytoplasmic antigenic determinants on these cells (Table 23-1). Although all these moieties may be important for the functional repertoire of LCs, the only ones that can be used for the identification of intraepidermal LCs are those that are displayed by essentially all LCs, but which are not expressed by other cells in the epidermis.



TABLE 23-1 **Phenotype of Resident vs. Cytokine-Activated Human Epidermal Langerhans Cells**

In human epidermis, markers fulfilling these criteria include (1) CD1a antigens, that is, major histocompatibility antigen (MHC) class I-related restriction elements also found on cortical thymocytes; (2) MHC class II-encoded human leukocyte antigen (HLA)-DR/DQ/DP antigens; (3) a Birbeck granule-associated antigen defined by the monoclonal antibodies (MAb) Lag and DCGM4; and (4) CD39, recently identified as LC ATPase. [5] Among these markers, the authors consider anti-CD1a immunolabeling the most reliable approach for identifying intraepidermal human LCs. Because of its high expression density on both the surface and in the cytoplasm, even one-step immunolabeling procedures usually suffice for reliable LC labeling. Equally important is that, in the epidermis, CD1a is selectively present on LCs not only in normal skin, but, with few exceptions, also in perturbed/inflamed skin. The situation is quite different for HLA-DR antigens, which, while confined to LCs in normal epidermis, are also expressed by keratinocytes in many inflammatory skin diseases. This makes it often difficult, if not impossible, to recognize HLA-DR–bearing LCs in perturbed skin. Bone marrow-derived DDCs are somewhat heterogeneous, and the various subtypes cannot always be easily distinguished and differentiated from each other. In addition to LCs migrating in or out of the epidermis, there exists the distinctive population of DDCs that reportedly express MHC class I and II molecules, CD45, CD1c and to a lesser extent CD1a, CD11c, CD40, CD54, CD80, the myeloid markers CD33 and CD36, and subunit A of the clotting proenzyme factor XIII (factor XIIIa). As opposed to classical macrophages, they express only low to negligible amounts of CD14.

ELECTRON MICROSCOPY (Fig. 23-3)

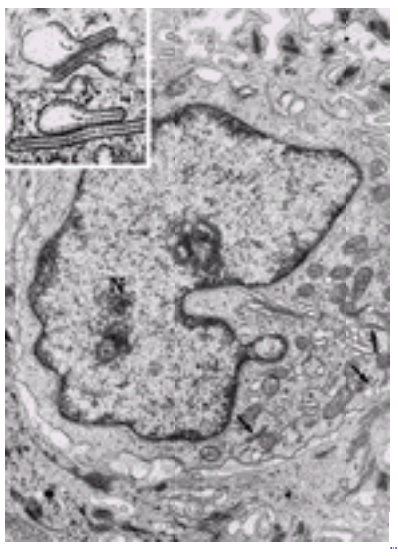

FIGURE 23-3 Electron micrograph of a Langerhans cell in human epidermis. Arrows denote Birbeck granules. N,

nucleus. (*From Stingl G: New aspects of Langerhans cell functions. Int J Dermatol 19:189, 1980, with permission* .) Inset: High-power electron micrograph of Birbeck granules. The curved arrows indicate the zipper-like fusion of the fuzzy coats (*F*) of the vesicular portion of the granule. The delimiting membrane (*M*) envelops two sheets of particles (*B*) attached to it and a central lamella composed of two linear arrays of particles (*A*). (*From Wolff K: The fine structure of the Langerhans cell granule. J Cell Biol 35:466, 1967, with permission.*)

In 1961, Birbeck et al. [6] established the criteria that allow the recognition and identification of LCs at any location. These criteria include a clear cytoplasm devoid of tonofilaments, desmosomes, or melanosomes; a lobulated, frequently convoluted nucleus; and the presence of a distinctive, pentilaminar cytoplasmic organelle, termed a *Langerhans cell granule* or *Birbeck granule*. This granule usually appears as a rod-shaped organelle of variable length and position; but, occasionally, the limiting membrane may expand on one of the rod's ends, thus giving the granule a tennis racket-shaped appearance. From the variable images obtained in different planes of section, it can be assumed that the Birbeck granule is usually a flat, platelike, occasionally twisted or cup-shaped structure with a vesicular bleb protruding from one of its ends (reviewed in Ref. [4]). The derivation and function of Birbeck granules have long been a matter of debate. Most investigators now favor the “endocytosis theory,” which claims that these organelles originate from the cell membrane and subserve intracellular transport functions. Support for this hypothesis came from studies with the LC-specific MAb DCGM4, which stains both the cell surface and the cytoplasm. By immunoprecipitation, DCGM4 identifies a 40-kDa molecule, termed *Langerin*. It is a type II Ca^{2+}-dependent lectin displaying mannose-binding specificity. While sparing MHC class II+ cytoplasmic compartments, Langerin colocalizes with Birbeck granules. When incubated with freshly isolated LCs, the anti-Langerin MAb is internalized into Birbeck granules. Together with the demonstration of Birbeck granule formation after transfection of Langerin cDNA into fibroblasts, this finding indicates that Langerin is an antigen-capturing molecule that channels the antigen into Birbeck granules and, perhaps, provides access to a nonclassical, non-MHC class II-dependent antigen-processing pathway. [7] Ultrastructurally, DDCs exhibit a folded nucleus and a highly ruffled, irregular surface. Their cytoplasm is relatively dark and contains the organelles needed for an active cellular metabolism, but it is devoid of Birbeck granules. [2]

Tissue Distribution

Apart from their occasional occurrence at extraepithelial sites (dermis, dermal lymphatics, aortic wall, lymph nodes, thymus), LCs, as defined by the presence of Birbeck granules, are essentially confined to stratified squamous epithelia of mammals. [4] Certain intraepidermal ATPase+ DCs contain very few, or even no Birbeck granules, but are otherwise indistinguishable from classic LCs. Some of these “indeterminate” cells probably represent “activated” LCs (see below), prepared to begin their journey from the epidermis to the regional lymph node.

In the epidermis, the density of the LC population varies regionally. In the mouse, LC densities differ considerably according to strain, sex, age, and body region. LCs are sparse in the tail epidermis because of the structural patterning of this particular region. They are virtually absent from parakeratotic scale regions but are present in orthokeratotic interscale zones. Such observations have prompted speculations about the involvement of LCs in the control of epidermal cell proliferation. The paucity or, even, absence of LCs in the mouse tail, as well as in other areas such as the central cornea, and hamster cheek pouch may contribute to the impaired ability of a contactant to induce sensitization when applied to these sites (see below).

There also exist regional differences in the number of LCs per unit area of human skin. On head, face, neck, trunk, and limb skin, the LC density ranges between 600 and 1000/mm^2. Comparatively low densities (~200/mm^2) are encountered in palms, soles, anogenital and sacrococcygeal skin, as well as the buccal mucosa. The density of human LCs decreases with age, and LC counts in skin with chronic actinic damage are significantly lower than those in skin not exposed to ultraviolet (UV) light.

DDCs are located primarily in the vicinity of the superficial vascular plexus.

Life Cycle (Fig. 23-4)

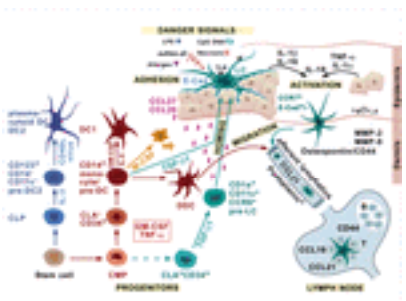

FIGURE 23-4 Schematic of ontogeny, migration, and maturation pathways of cutaneous dendritic leukocytes. a $_6$/ß $_{1,4}$ integrins; B, B cells; CCL, CC chemokines; CCR, CC chemokine receptor; CD, cluster of differentiation-nomenclature of leukocyte antigens; CLA, cutaneous lymphocyte-associated antigen; CLP, common lymphoid progenitor cell; CMP, common myeloid progenitor cell; CpG DNA, immunostimulatory cytosine- and guanine-rich sequences of deoxyribonucleic acid; DC, dendritic cell; DDC, dermal dendritic cell; dsRNA, double-stranded ribonucleic acid; E-Cad, E-cadherin; GM-CSF, granulocyte/macrophage colony-stimulating factor; IL, interleukin; LC, Langerhans cell; LPS, lipopolysaccharide; Mf, macrophage; M-CSF, macrophage colony-stimulating factor; MMP, matrix metalloproteinase; T, T cells; TGF-ß1, transforming growth factor beta 1; TLR, toll-like receptor; TNF-a, tumor necrosis factor alpha.

Although it has been known for a long time that LCs originate from precursors in the bone marrow, [8] individual steps of LC

ontogeny were elucidated only recently.

A major breakthrough in the understanding of LC development came from the observation that the exposure of CD34+ hematopoietic progenitor cells (HPCs) to granulocyte-macrophage colony-stimulating factor (GM-CSF) and tumor necrosis factor-a (TNF-a) gives rise to a progeny of CD1a+, E-cadherin+, Birbeck granule-containing cells with immunostimulatory properties strikingly resembling those of LCs isolated from human skin. [9] Subsequent studies have delineated the phenotype of LC progenitors at their various states of maturation/differentiation. It is now clear that, already at the CD34+ precursor stage, cells exist that are committed to the LC lineage. A useful marker for the identification of these cells is the cutaneous lymphocyte-associated antigen (CLA), which is detectable on both skin-homing T cells and on LCs in situ. CLA is abundantly expressed by LC precursors rather than by cells giving rise to non-LC DCs. It remains to be determined whether this E- and P-selectin ligand can mediate skin homing of LCs/LC progenitors.

A great deal about the developmental steps of LCs and DDCs was learned from studies by Caux et al. [10] demonstrating the emergence of two distinctive subsets of LC/DC precursor cells in GM-CSF– and TNF-a–supplemented liquid cultures of CD34+ HPCs. Precursor cells in the CD1a+/CD14– subset, when isolated and further cultured in GM-CSF– and TNF-a–supplemented medium for 12 to 14 days, develop into cells displaying all the features of LCs including the expression of E-cadherin and Birbeck granules. [10] Evidence exists that a cell type with phenotypic features indistinguishable from those of in vitro generated CD1a+/CD14– LC precursors exists in the peripheral blood. It starts to express E-cadherin and Langerin and to display Birbeck granules within 1 day of culture in the presence of GM-CSF, interleukin (IL)-4, and transforming growth factor (TGF)-ß1.

The second DC precursor subset appearing in GM-CSF– and TNF-a–stimulated HPC cultures displays the CD1a–/CD14+ phenotype. [10] The lineage commitment of these cells is much less restricted than that of the CD1a+ precursors. While they give rise to a monocyte/macrophage progeny when exposed to macrophage colony-stimulating factor (M-CSF), they develop into cells with a DDC phenotype in the presence of GM-CSF and TNF-a as evidenced by their expression of CD1a, CD11b, CD11c, CD36, CD68, and factor XIIIa and by their lack of E-cadherin and Birbeck granules.

With regard to the factors promoting the development of DCs and LCs/DDCs in particular, stem cell factor (SCF) and Flt3 ligand (FL) do apparently amplify the DC differentiation pathway initiated by GM-CSF and TNF-a, but without any selectivity for LCs/DDCs.

The factor most critically needed for the development of LCs/DDCs is TGF-ß1. This is evidenced by the lack of LCs in TGF-ß $_1$–/– mice, and by the absolute requirement of TGF-ß1 for the generation of LCs in GM-CSF– and TNF-a–supplemented serum-free stem cell cultures. [11] In vitro data show that paracrine stimulation with TGF-ß1 of CD14+/CD11c+/CD11b– and CD14+/CD11c+/CD11b+ cells developing in GM-CSF– and TNF-a–stimulated HPC cultures results in bona fide LCs and DDCs, respectively. [12] Cells with an identical phenotype exist within normal human dermis, and the generation of true LCs from CD14+/CD11c+ dermal cells was recently demonstrated. [13] There also exist reports on the transformation of peripheral blood monocytes into LCs or DCs with LC features by TGF-ß1 and IL-15, respectively. It remains to be seen under which conditions such events would occur in vivo.

The mechanisms responsible for the rather selective homing of LCs/DDCs or their precursors to the skin and of LCs/LC precursors to the epidermis are still not completely understood. Recent evidence points to an important role of macrophage inflammatory protein 3a (MIP-3a)/CCL20 in the recruitment of LCs to the epidermis: (1) on day 6 of GM-CSF– and TNF-a–supplemented HPC cultures, CD1a+ LC precursors express only one CC chemokine receptor, CCR6, in a prominent fashion and migrate to its ligand MIP-3a/CCL20 in a selective manner [14]; and (2) CD14+ LC precursors as well as LCs in situ express CCR6. [13], [14] IL-10, and probably also TGF-ß1, are mainly responsible for CCR6 induction and upregulation on LCs/LC precursors, whereas IL-4 and interferon (IFN)-? suppress this event.

However, CCR6 is also expressed on certain non-LC DCs in Peyer's patches, and its ligand MIP-3a/CCL20 is expressed in epithelia other than the epidermis. Thus, the actual significance of this chemokine/chemokine receptor combination in LC recruitment to the epidermis has yet to be resolved. Another chemokine possibly involved in this process is the cutaneous T cell-attracting chemokine (CTACK). [15] It is constitutively produced by keratinocytes, and its ligand, CCR10, is expressed by endothelial cells, fibroblasts, melanocytes, T cells, and LCs, but not by other DCs. [16] The role, if any, of CCR10 and other cytokines in the regulation of LC influx in the epidermis (e.g., TNF-a, IL-6, IL-12) is still unclear.

Within the epidermis, LCs are anchored to surrounding keratinocytes by E-cadherin–mediated homotypic adhesion. [17] This event and the display of TGF-ß1 also prevent terminal differentiation and migration (see below), thus securing intraepidermal residence for the cells under homeostatic conditions.

HLA-DR+/ATPase+ DCs can be identified in the human epidermis by 6 to 7 weeks of estimated gestational age. These cells must originate from hemopoietic stem cells in the yolk sac or fetal liver, the primary sites of hemopoiesis during the embryonic period. Until the twelfth week of pregnancy, these cells are CD1a– and lack Birbeck granules. Thereafter, there occurs a dramatic increase in LC CD1a expression, an event that coincides with the initiation of bone marrow function.

The fact that epidermal LCs originate from bone marrow precursors does not mean that every LC that either leaves or is removed from the epidermis is replenished by a precursor cell newly immigrating into the skin. Cell division probably also contributes to the maintenance of epidermal LC numbers as evidenced by the demonstration of cycling/mitotic events in these cells, [4] as well as by the finding that the LC population of human skin grafted onto a nude mouse remains rather constant for the life of the graft, despite epidermal proliferation and the absence of circulating cells. The partial depletion of LCs from these grafts by UV radiation, topical glucocorticoids, or tape stripping is followed by their restoration, within a

few weeks, to pretreatment levels, and by a substantial increase in dividing LCs.

Finally, there remains the question about the ultimate fate of the epidermal LC population. Major perturbation of the cutaneous microenvironment (danger signal [18]) leads to their activation, resulting either in their elimination via the stratum corneum [4] or, more importantly, in their migration to lymphoid tissues where they initiate type 1 (T_H1/T_c1)-dominated T cell responses (see below). By contrast, what happens in normal skin is unclear. Does LC shedding occur under physiologic (nondanger) conditions? Is there a natural flux of LCs/DDCs to the regional lymph nodes? If so, what are the functional consequences of such an occurrence? Evidence exists that melanin granules captured in the skin accumulate in the regional lymph nodes but not in other tissues. The further observation of only very few melanin granule-containing cells in TGF-ß1 –/– mice suggests that, under steady-state conditions, epidermal and/or dermal antigens are carried to the regional lymph nodes by TGF-ß1–dependent cells (most likely LCs/DDCs) only. Evidence now exists that T lymphocytes encountering such antigen-presenting cells (APCs) in vivo are rendered unresponsive in an antigen-specific manner. [19] It may therefore be assumed that absence of pathogenic T cell autoimmunity and/or lack of reactivity against innocuous environmental compounds (e.g., aeroallergens) in the periphery is primarily the consequence of an active immune response rather than the result of its nonoccurrence.

Upon receipt of danger signals (e.g., chemical haptens, hypoxia), the situation is quite different. After a few hours, LCs begin to enlarge, to display increased amounts of surface-bound MHC class II molecules, and to migrate downward in the dermis where they enter afferent lymphatics and, finally, reach the T cell zones of draining lymph nodes. During this process, LCs undergo phenotypic changes similar to those that occur in single epidermal cell cultures [20]; that is, downregulation of molecules/structures responsible for antigen uptake and processing as well as for LC attachment to keratinocytes (e.g., Fc receptors, Birbeck granules, E-cadherin) and upregulation of moieties required for active migration and stimulation of robust responses of naive T cells (e.g., CD40, CD80, CD83, CD86) (Table 23-1; Fig. 23-5).

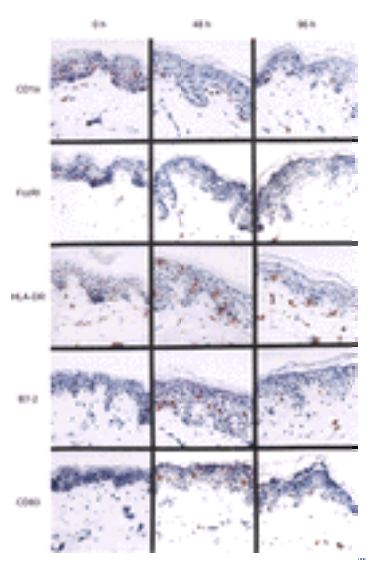

FIGURE 23-5 Phenotypic changes and emigration of epidermal Langerhans cells (LCs) after perturbation of the cutaneous microenvironment. Cryostat sections of freshly excised or ex vivo cultured (48 h, 96 h) human split-thickness skin were reacted with antibodies against CD1a, FceRI, HLA-DR, B7-2, or CD83 and then processed for peroxidase immunolabeling. Before culture, LCs are CD1a+, FceRI+, CD83- and reside mainly at a suprabasal position within the epidermis. In skin organ culture, LCs progressively lose surface-bound CD1a and FceRI; upregulate HLA-DR, B7-2, and CD83; and move downward.

The mechanisms governing LC migration are becoming increasingly clear. TNF-a and IL-1ß (in a caspase 1-dependent fashion) are critical promoters of this process, whereas IL-10 inhibits its occurrence. Increased cutaneous production and/or release of the proinflammatory cytokines is probably one of the mechanisms by which certain immunostimulatory compounds applied on or injected in the skin [e.g., imiquimod, unmethylated cytosine-guanosine (CpG) oligonucleotides] accelerate LC/DDC migration. IL-16 induces LC mobilization. This event could perhaps be operative in atopic dermatitis. In this disease, DCs of lesional skin exhibit surface IgE bound to high affinity Fc receptors (FceRI), and allergen-mediated receptor cross-linking results in enhanced IL-16 production.

An important hurdle for emigrating LCs is the basement membrane. During their downward journey, LCs probably attach to it via a $_6$-containing integrin receptors and produce proteolytic enzymes such as type IV collagenase (matrix metalloproteinase 9) to penetrate it and to pave their way through the dense dermal network into the lymphatic system. Evidence is accumulating that LC/DDC migration occurs in an active, directed fashion. Osteopontin is a chemotactic protein that is essential in this regard. It initiates LC emigration from the epidermis and attracts LCs/DDCs to draining nodes by interacting with an N-terminal epitope of the CD44 molecule. [21] The entry into and active transport of cutaneous DCs within lymphatic vessels appears to be mediated by macrophage chemotactic proteins (MCPs) binding to CCR2 and by the secondary lymphoid-organ chemokine (SLC)/CCL21 produced by lymphatic endothelial cells of the dermis and binding to CCR7 on maturing LCs. [22]

Besides its presence on mature DCs, CCR7 is expressed by naive T cells and by a small subset of circulating, lymph node-seeking “central memory” T lymphocytes. These expression patterns suggest that the interaction between CCR7 and its ligands SLC/CCL21 and Epstein-Barr virus (EBV)-induced molecule 1 ligand chemokine (ELC)/CCL19 are of central importance in bringing together mature DCs and naive T cells in the T cell zones of the lymph nodes.

The question of where and how the life cycle of an LC ends has not yet been completely resolved, but some evidence exists that DCs, upon cognate interaction with T cells, physically disappear from the lymph nodes. [23] This is largely due to an apoptotic process triggered by ligation of CD40 on mature LCs and is effected by the interaction of CD95/Fas-bearing

mature LCs and CD95L/FasL-expressing activated T cells. The biologic significance of this finding is underscored by studies in humans and experimental animals deficient in this or other death receptor/death receptor ligand pairs. [24] Their capacity for clearing antigen-bearing LCs in lymph nodes is significantly delayed. As a consequence, ongoing T cell responses are not sufficiently downregulated or terminated, and signs of autoimmunity may develop.

Functional Properties

Compelling evidence exists that LCs and other skin DCs, as members of the family of “professional” APCs, play a pivotal role in the induction of adaptive immune responses against pathogens and cancer cell-associated neoantigens introduced into and/or generated in the skin (immunosurveillance). The immunogenic potential of DCs is regulated by surface receptors triggered by ligands secreted or presented by other somatic cells or, alternatively, by microbial products (danger or competence signals). Many of the receptor structures that sense such signals are “rented” from the innate immune system where they are used to recognize molecular patterns demarcating infectious nonself, as well as normal and abnormal self (pattern recognition receptors). Thus, and according to Janeway and Medzhitov's theory, innate immunity controls the development and nature of adaptive immunity. [25] Some evidence also exists that DCs that have not received such competence signals are not stimulatory, but actively downregulate or prevent potentially harmful immune responses by tolerizing T cells or by inducing T cells with suppressive properties (regulatory T cells). For a better understanding of the functional properties of skin DCs, the basic principles of antigen uptake, processing, and presentation are briefly reviewed.

GENERAL PRINCIPLES OF ANTIGEN PRESENTATION (Fig. 23-6)

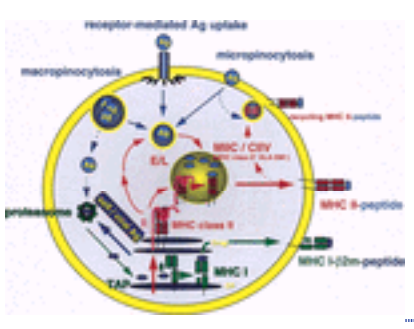

FIGURE 23-6 Schematic of MHC class I- and MHC class II-dependent antigen-presentation pathways. *MHC class II presentation (red):* Exogenous antigens (Ag) taken up via fluid phase micro- or macropinocytosis or via receptor-mediated endocytosis enter the endo-/lysosomal (E/L) pathway of protein degradation. Resulting peptides reach subcellular organelles rich in MHC class II and HLA-DM/H2M antigens [MHC class II compartments (MIIC); class II-containing vesicles (CIIV)]. Newly synthesized MHC class II antigens arrive in these compartments because of their physical association with the invariant chain (Ii), which then undergoes proteolysis by the action of cellular enzymes leaving only a small fragment of Ii [class II-associated invariant peptide (CLIP)] in the place of the MHC class II peptide binding groove. Upon removal of CLIP by HLA-DM/H2M, the newly synthesized MHC class II moieties can bind the exogenous Ag-derived peptides generated in the endo-/lysosomal system. As also outlined in this figure, cell surface-bound MHC class II can be internalized into recycling endosomes (*RE*) and, within these compartments, acquire certain peptides derived from exogenous Ag. *MHC class I presentation pathway (green):* In the classic form, the proteasome degrades cytosolic Ag synthesized by the cell itself (e.g., self and viral Ag). The resulting peptides are then imported into the endoplasmic reticulum (*ER*) in a TAP-dependent manner, loaded onto MHC class I molecules and, finally, transported to the cell surface in the form of a peptide-MHC class I ß2 microglobulin (ß2m) complex en route of the Golgi complex. At least in certain APCs, not only endogenous but also exogenous Ag-derived peptides can get access to the MHC class I presentation pathway (see text). This MHC class I peptide loading can occur either in a TAP-dependent (e.g., following a macropinosome to cytosol transfer of exogenous Ag) or in a TAP-independent fashion (e.g., targeting of MHC class I molecules into MIIC/CIIV followed by their loading with peptides generated in endolysosomes).

Unlike B cells, T cells cannot recognize soluble protein antigen per se; their antigen receptor T cell receptor (TCR) is designed to see antigen-derived peptides bound to MHC locus-encoded molecules expressed by APCs. [26] For the antigen-specific activation of T helper (T_H) cells, exogenous antigen-derived peptides are usually presented in the context of MHC class II molecules. [27] In this situation, peptides are generated in the endocytic, endo-/lysosomal pathway and are bound to MHC class II; the resulting MHC–peptide complex is expressed at the APC surface for encounter by the TCR of CD4+ T_H cells. In contrast, most CD8+ T cells, destined to become cytotoxic T cells, recognize the endogenous antigen in association with MHC class I molecules. [27] Because most nucleated cells transcribe and express MHC class I genes/gene products, it is evident that many cell types can serve as APCs for MHC class I-restricted antigen presentation and/or as targets for MHC class I-dependent attack by T cells. In the MHC class II-dependent antigen-presentation pathway, DCs, including LCs and DDCs (see below), B cells, and monocytes/macrophages are the major APC populations.

MHC CLASS I-RESTRICTED ANTIGEN PRESENTATION [28]

The classic MHC class I presentation pathway Immediately after their biosynthesis, MHC class I heavy and light ($ß_2$-microglobulin) chains are inserted into the membranes of the endoplasmic reticulum. The third subunit of the functional MHC class I complex is the peptide itself. The major sources of peptides for MHC class I loading are cytosolic proteins, which can be targeted for their rapid destruction through the catalytic attachment of ubiquitin. Cytosolic proteinaceous material undergoes enzymatic digestion by the proteasome to yield short peptide chains of 8 to 12 amino acids, an appropriate length for MHC class I binding. In its basic conformation, the proteasome is a constitutively active “factory” for self-peptides. IFN-?, by replacing or adding certain proteasomal subunits, induces “immunoproteasomes,” presumably to fine-tune the degradation activity and specificity to the demands of the immune response. The processed peptides are translocated to the endoplasmic reticulum by the transporter associated with antigen processing (TAP), an MHC-encoded dimeric peptide transporter. With the aid of chaperons (calnexin, calreticulin, tapasin), MHC class I molecules are loaded with peptides, released from the endoplasmic reticulum, and transported to the cell surface. Several infectious antigens with relevance to skin biology have adopted strategies to subvert MHC class I presentation and, thus, the surveillance of cell integrity by interfering with defined molecular targets. Important examples for such an interference are the inhibition

of proteasomal function by the Epstein-Barr virus-encoded EBNA-1 protein, the competition for peptide-TAP interactions by a herpes simplex virus protein, and the retention/destruction of MHC class I molecules by adenovirus- and human cytomegalovirus-encoded products.

Alternative MHC class I presentation pathways (cross-presentation) Under certain conditions, exogenous antigen can reach the MHC class I presentation pathway. Significant evidence for this cross-presentation first came from in vivo experiments in mice demonstrating that viral, tumor, and MHC antigens can be transferred from MHC-mismatched donor cells to host bone marrow-derived APCs to elicit antigen-specific cytotoxic T cell responses that are restricted to self MHC molecules. [29] In vitro studies have now defined that exosomes (i.e., small secretory vesicles of about 100 nm in diameter secreted by various cell types including tumor cells), heat shock proteins (hsp), immune complexes, and apoptotic cells (taken up via CD36 and avß3 or avß5 integrins) can all serve as vehicles for the delivery of antigen to DCs in a manner that permits the cross-presentation of antigen. In all in vitro systems in which a direct comparison has been made, DCs, but not monocytes/macrophages, were capable of cross-presentation. Three distinct pathways are currently exploited by which antigen can access MHC class I molecules of DCs: (1) a recycling pathway for MHC class I in which antigen is loaded in the endosome; (2) a pathway by which retrograde transport of the antigen from the endosome to the endoplasmic reticulum facilitates entry into the classic MHC class I antigen presentation pathway; and (3) an endosome to the cytosol transport pathway, again allowing antigen processing via the classic MHC class I antigen presentation pathway.

MHC class II-restricted antigen presentation [30] MHC class II molecules predominantly bind peptides within endo-/lysosomal compartments. Sampling peptides in these subcellular organelles allows class II molecules to associate with a broad array of peptides derived from proteins targeted for degradation after internalization by fluid phase or receptor-mediated endocytosis, macropinocytosis, or phagocytosis. One of the striking structural differences between MHC class I and class II molecules is the conformation of their peptide-binding grooves. Whereas MHC class I molecules have binding pockets to accommodate the charged termini of peptides and, thus, selectively associate with short peptides, the binding sites of MHC class II molecules are open at both ends. Thus, MHC class II molecules bind peptides with preferred lengths of 15 to 22 amino acids but can also associate with longer moieties. Newly synthesized MHC class IIa and ß subunits assemble in a stoichiometric complex with trimers of the type II transmembrane glycoprotein invariant chain (Ii). The association with Ii contributes in at least three different ways to the function of class II molecules: (1) Ii assembly promotes the proper folding of class II molecules in the endoplasmic reticulum; (2) the abluminal portion of Ii contains signal sequences that facilitate the export of MHC class II–Ii complexes through the Golgi system to endo-/lysosomes; and (3) Ii prevents class II molecules from premature loading by peptides intended for binding to MHC class I molecules in the endoplasmic reticulum. The segment of Ii functioning as a competitor for peptide binding to class II is termed class II-associated Ii peptide (CLIP; residues 81 to 104 of Ii). Once the nascent MHC class IIa/ß–Ii trimers arrive in the endo-/lysosomal system, Ii is subject to proteolysis by acid hydrolases. The last proteolytic step, the generation of LIP, is catalyzed by cathepsin S in DCs, by cathepsin L in thymic epithelial cells, and by cathepsin F in macrophages. Upon HLA-DM–chaperoned exchange of CLIP for exogenous antigen-derived peptide, fully assembled class II molecules are exported to the cell surface and acquire a stable conformation. Depending on the cell type and the activation status of a cell, the half-life of class II-peptide complexes varies from a few hours to days. It is particularly long (more than 100 h) on DCs that have matured into potent immunostimulatory cells of lymphoid organs upon encounter with an inflammatory stimulus in nonlymphoid tissues. The very long retention of peptide-class II complexes on mature DCs ensures that only those peptides generated at sites of inflammation will be displayed in lymphoid organs for T cell priming.

CD1-dependent antigen presentation [31] Recently, it became clear that, besides peptides, self glycosphingolipids and bacterial lipoglycans may act as T cell stimulatory ligands. Molecules that bind and present these moieties belong to the family of nonpolymorphic, MHC class I- and II-related CD1 proteins. In the skin, members of the CD1 family are expressed mainly by LCs and DDCs (see above). The CD1 isoforms, CD1a, b, c, and d, sample both recycling endosomes of the early endocytic system and late endosomes and lysosomes to which lipid antigens are delivered. In contrast to the MHC class II pathway, antigen loading in the CD1 pathway occurs in a vacuolar acidification-independent fashion. T cells expressing a Va24-containing canonic TCR, natural killer (NK) T cells, and CD4–/CD8– T cells, include the most prominent subsets of CD1-restricted T cells. CD1-restricted T cells play important roles in host defense against microbial infections. Accordingly, human subjects infected with *M. tuberculosis* showed elevated responses to CD1c-mediated presentation of a microbial lipid antigen, when compared to control subjects, and activation of CD1d-restricted NK T cells with a synthetic glycolipid antigen resulted in improved immune responses to several infectious pathogens. Thus, the CD1 pathway of antigen presentation and glycolipid-specific T cells may provide protection during bacterial and parasite infection, probably by the secretion of proinflammatory cytokines, the direct killing of infected target cells, and B cell help for immunoglobulin production.

DENDRITIC CELLS IN THE CONTEXT OF SKIN IMMUNITY

Induction of protective immunity via the skin Both in vitro and in vivo studies imply that the major function of LCs and of other skin DCs is to provide the sensitizing signal for the occurrence of skin-induced immune responses against a wide variety of antigens, including alloantigens, tumor antigens, microorganisms, and contact allergens. This is best illustrated by the early observations (1) that the epidermal LC density positively correlates with the outcome of the immune response to the contact sensitizers dinitrofluorobenzene (DNFB), trinitrochlorobenzene (TNCB), and oxazolone, [32] and (2) that LC-containing, but not LC-depleted, epidermal cell suspensions pulse-exposed to either soluble protein antigens or haptens elicit a genetically restricted, antigen-specific, proliferative in vitro response in T cells. [33] Murine skin that is either naturally deficient in LCs (tail skin) or experimentally depleted of LCs (by UV light or glucocorticoids) failed to induce contact hypersensitivity (CHS), [32] and skin grafts depleted of LCs by vigorous tape stripping enjoy a prolonged survival on class II-disparate recipients. Similarly, the attempt to sensitize Syrian hamsters via the cheek pouch epithelium, a unique tissue because of its low LC density and virtual absence of lymphatic drainage, is not followed by a productive immune response. This failure to sensitize is frequently not an immunologic “null event” but can also result in a state of specific immunologic unresponsiveness that is associated with and probably caused by the generation of suppressor/regulatory T lymphocytes (see below). Although these observations clearly show that the LC/DC system is indispensable for the occurrence of antigen-specific skin immunity, it is equally clear that LCs/DCs as they occur in their tissue residence are poorly, if at all, stimulatory for naive T cells. In 1986, Inaba et al. [34] found that freshly isolated murine LCs (“immature” LCs) can present soluble antigen to primed MHC class II-restricted T cells but are only weak stimulators of naive, allogeneic T cells and primary antibody responses. In contrast, LCs purified from epidermal cell suspensions after a culture period of 72 h or LCs purified from freshly isolated murine epidermal cells and cultured for 72 h in the presence of GM-CSF and IL-1 (“mature” LCs) are extremely potent stimulators of primary T cell-proliferative responses to

alloantigens, [34] soluble protein antigens, [35] and haptens, [35] and of primary T cell-dependent B cell responses. The strong immunostimulatory potential of mature LCs for resting T cells does not mean that they are superior to freshly isolated, immature LCs in every functional aspect. In fact, immature LCs far excel cytokine-activated LCs in their capacity to take up and process native protein antigens. [36] Accordingly, immature rather than mature LCs/DDCs express antigen uptake receptors/pattern recognition receptors including the mannose-binding receptors Langerin (expressed by LCs only) [7] and macrophage mannose receptor (expressed by DDCs), the C-type lectin receptor DEC-205, the low-affinity IgG receptor CD32/Fc?RII, the high-affinity IgE receptor FceRI, and the thrombospondin receptor CD36 (Table 23-1). Immature LCs present the resulting peptide fragments as effectively as they can present peptides loaded onto the cells from the exterior. Mature LCs, while fully capable of presenting these peptides, have lost their capacity to process and present the native protein. [36] This cytokine-/culture-induced switch from the processing/peptide loading to the presentation mode is a highly regulated LC function attributable to fundamental molecular changes in protein synthesis and vesicle trafficking. LCs in their immature state display MHC class II antigens in lysosomal, HLA-DM–containing, peptide-loading compartments (MIIC) and, to a much lesser extent, on the cell surface. When LCs mature in situ, the degree of class II and HLA-DM colocalization decreases, and MHC class II molecules are transferred to the plasma membrane. Likewise, MHC class I surface expression is upregulated during the process of DC maturation. While MHC class II and invariant chain synthesis is high in the immature state, it is diminished or entirely shut off during the process of LC maturation. The display of MHC-peptide complexes on the DC surface delivers the “first signal” to T cells; that is, the triggering of the TCR by the APC-bound peptide-MHC complex. However, this signal alone is insufficient for the induction of productive and protective T cell immunity. In fact, certain cell types that express MHC class II molecules in an inducible fashion (keratinocytes, endothelial cells, fibroblasts) or xenogeneic cells that are genetically engineered to express the antigen/MHC complex, when encountered by antigen-specific T cells, induce a state of anergy in these cells. [37] “Second signals” delivered by professional APCs critically determine the occurrence, the magnitude, and the quality of T cell responses. In skin DCs, as well as in DCs from other locations, molecules that deliver second signals are upregulated in a strictly maturation-dependent fashion (Table 23-1). Second signals include membrane-bound costimulators and secreted cytokines. The best-defined costimulators for T cells are the two members of the B7 family, B7.1/CD80 and B7–2/CD86. [38] LCs/DCs in situ do not express or express only minute amounts of these costimulatory molecules, but greatly upregulate these moieties during maturation. The necessity for these costimulatory molecules is best illustrated in experiments showing that when T cells are exposed to an antigen-pulsed APC in the presence of B7 antagonists, or if CD28-deficient T cells encounter an antigen, the cells do not expand but are anergized or undergo apoptosis. [39] Other costimulatory molecules include the intercellular adhesion molecule (ICAM)-1 that binds to lymphocyte function-associated antigen (LFA)-1, and LFA-3, the ligand of T cell-expressed CD2. Further important ligand-receptor pairs mediating APC-T cell interactions include heat-stable antigen (CD24)/CD24 ligand (L), CD40/CD40L, CD27L/CD70, OX40L/OX40 (CD134), and RANKL/RANK. Although inducible by rather simple manipulations, that is, by culture of explanted skin (Fig. 23-5), LC/DC maturation is a highly regulated process that is initiated by the triggering of surface receptors. Evidence exists that cytokines released as a consequence of physicochemical or infection-associated tissue perturbation (e.g., keratinocyte-derived GM-CSF, TNF-a, IL-1) and/or ligation of CD40 molecules on LCs can provide the critical signals for the induction of LC maturation. Epicutaneously applied contact sensitizers, but not irritants or tolerogens, activate certain protein tyrosine kinases, modify the cellular content and structure of intracytoplasmic organelles (increase in coated pits and vesicles, endo- and lysosomes, and Birbeck granules) and, thus, induce LC maturation directly or indirectly via the release of cytokines from keratinocytes. Of particular importance is that microbes, microbial products, and the consequences of microbial tissue damage can deliver signals that regulate DC maturation and, thus, decisively control whether protective immunity or immunologic paralysis ensues. [40] Maturation signals are delivered to DCs by the uptake of necrotic, but not of apoptotic, cells, [41] virus-derived double-stranded RNA, intact microorganisms (e.g., leishmania major amastigotes, dengue virus), and compounds that trigger members of the family of Toll-like receptors (TLRs). Toll receptors are evolutionary conserved between insects and humans and are regarded as prototype innate defense receptors because of their affinity for pathogens/pathogenic products. Ten members of the TLR family have been classified so far. [42] LC express at least TLR1 to TLR4. Ligands of TLR2 include lipoproteins from *Mycobacterium tuberculosis, Borrelia burgdorferi, Treponema pallidum,* mycobacterial lipoarabinomannan, lipopolysaccharide (LPS), peptidoglycan, zymosan, and glycophosphatidyl inositol anchors from *Treponema pallidum* and *Trypanosoma cruzi* lipoproteins. TLR4 binds hsp60 and is the most important receptor for LPS from gram-negative bacteria. TLR7 recognizes the synthetic substance imiquimod, and CpG-rich DNA triggers TLR9. [42], [43] Signals initiated by TLR and by certain other DC receptors result in the maturation-related downregulation of antigen/pathogen uptake receptors. Thus, maturation signals force skin DCs to focus on the presentation of skin-related dangerous antigens and prevent them from taking up irrelevant moieties during the final journey of the cells from the epidermis–dermis to the regional lymph node. The importance of LC/DC maturation and migration to regional lymph nodes for the induction of adaptive immunity is best evidenced by the findings that (1) LCs disappear from the epidermis and migrate via dermal lymphatics to the regional lymph nodes in response to contact sensitizers [44]; (2) mature, but not immature, DCs, after intracutaneous injection, migrate efficiently to regional nodes; (3) the inhibition of LC migration toward regional nodes by genetic ablation or antibody-mediated inhibition of migration-inducing factors (e.g., IL-1ß, osteopontin, CD44, SLC) can prevent the occurrence of sensitization to topically applied contact allergens [21], [45], [46]; and (4) DCs, isolated from skin-draining nodes after hapten application to the skin, can induce CHS when administered into naive mice, and can stimulate the proliferation of nonsensitized T cells. These and other experiments strongly indicate that hapten-bearing DCs appearing in the regional lymph nodes after epicutaneous application of the contact-sensitizing hapten are derived from the skin. They most likely represent LCs (and DDCs) that had left the skin after epicutaneous sensitization, migrated to the regional lymph node, and, on arrival, initiated allergen-specific T cell activation. The finding that the injection of particulate antigen into the skin converts dermal monocytic cells into fully stimulatory DCs that migrate to the regional nodes, highlights the enormous plasticity of the skin immune system. The restriction elements presenting hapten/haptenated peptide epitopes include MHC class I and MHC class II. The LC-expressed ATPase CD39/ectonucleotidase triphosphate diphosphohydrolase can also function as a hapten-presenting molecule when high hapten concentrations are applied. [47] In line with a critical role of CD39 in LC function is also the observation that CD39 knockout mice show severely attenuated CHS responses to oxazolon. [5] Surprisingly, these mice have exacerbated skin inflammation to topically applied irritant chemicals as a result of a deficiency in catalyzing keratinocyte-derived extracellular ATP/ADP (adenosine diphosphate). As LCs are the only epidermal cells with ATPase activity, the results point to an unexpected function of LCs in the maintenance of epidermal homeostasis; that is, the scavenging of inflammation-inducing nucleotides. Once LCs arrive in the lymph nodes, they exert their superior immunostimulatory

activity not only by their cell surface molecules but also by their secretory activity. Difficulties in isolating sufficient numbers of LCs and other skin DCs prevented detailed analyses of their secretory repertoire for a considerable time period, but the development of sensitive molecular techniques and in vitro culture systems to expand LCs and DDC-like cells from hematopoietic precursors allowed important accomplishments. Pioneering work in this field demonstrated that, after exposure to contact allergens, LC rapidly upregulates IL-1ß mRNA expression [48]; this finding suggests an important role for IL-1ß in the initiation of primary immune responses. Subsequently, the expression of TNF-a, IL-6, MIP-1a, MIP-1?, and IL-12 by isolated LCs has been reported. In vitro-generated LCs and DDCs both produce a broad array of immunologically relevant cytokines. [49] Both LCs and DDCs spontaneously produce mRNA encoding IL-1a, IL-1ß, IL-6, IL-7, IL-12 (p35 and p40), IL-15, IL-18, TNF-a, TGF-ß, M-CSF, and GM-CSF, but lack expression of IL-2, IL-3, IL-4, IL-5, IL-9, and IFN-?. IL-12 secretion was maximal after triggering of CD40. LCs, even after activation, fail to express the immunoregulatory cytokine IL-10, whereas the DDC-like cells could secrete this cytokine, even in the absence of stimulatory agents. A massive body of evidence suggests that the mode of DC activation/maturation determines the quality of T cell responses. On the basis of the type of lymphokines they produce, CD4+ helper T cells can be divided into three major subsets: T_H1, T_H2, and T_H0. [50] T_H1 cells produce IFN-? and predominantly promote delayed-type hypersensitivity, whereas T_H2 cells, which produce IL-4, IL-5, and IL-13, provide help for certain B cell responses. T cells exhibiting a not (yet) polarized secretion pattern with the production of cytokines typical of both T_H1 and T_H2 exist in both humans and rodents and were designated T_H0 cells. Differentiation toward the T_H1 or T_H2 phenotype is directed by cytokines present at the time of the first APC–T cell encounter. The key factors are IL-4 and the heterodimeric cytokine IL-12. IL-4 promotes T_H2 cell development, whereas IL-12 is a potent inducer of T_H1 cells. Consistent with this concept are the findings that IL-12p40 –/– as well as STAT-4 –/– (signal transducer and activator of transcription, involved in IL-12 receptor signaling) mice are defective in IFN-? production and almost completely lack the ability to generate a T_H1 response. Conversely, knocking out the IL-4 or STAT-6 (involved in IL-4 receptor signaling) genes resulted in deficient T_H2 responses. Although DCs, including LCs, do not produce IL-4, they can elaborate significant amounts of IL-12 when appropriately stimulated. IL-12-inducing stimuli are signals that are delivered during the T cell–APC interaction (cross-linking of CD40 or HLA-DR on the APC surface, IFN-?) [49] as well as microorganisms. [40] In fact, ingestion of yeast cells from *Candida albicans* activates DCs for IL-12 production and priming of protective T_H1 cells, whereas ingestion of *Candida albicans* hyphae inhibits IL-12, induces T_H2 cells, and does not lead to protective antifungal immunity. [51] Similarly, IL-10, glucocorticoids, and prostaglandin E_2 render DCs deficient in IL-12 production and promote the development of T_H2 cells. [52] The recently identified new members of the B7 family, B7H/B7RP-1 and B7-H1, ligands of the T cell-expressed activation-induced costimulator ICOS and a yet to be characterized T cell receptor, respectively, induce high-level production of the immunosuppressive cytokine IL-10 and thus a T_H2-like or T regulatory (see below) profile in T cells. [53] In view of their inability to secrete IL-12, B cells may be involved in the elicitation of T_H2 responses only, whereas DCs, depending on their activation state and the milieu surrounding them, may promote either T_H1 or T_H2 differentiation. LCs are also implicated in the generation of cytotoxic T cell responses. Indeed, it is the current view that LC-dependent activation of CD8+ T cells is the major pathogenic mechanism of allergic contact dermatitis [54] and may be of relevance in several other immune-mediated inflammatory skin diseases (see below). Evidence exists that LCs/DCs induce the generation of MHC class I-restricted allo-, hapten-, and virus-specific cytotoxicity in resting T lymphocytes. Such DC-induced proliferative and cytotoxic responses are MHC class I-restricted and can occur even in the absence of CD4+ T helper cells when DCs have been stimulated via their CD40 surface receptor. [55]

Therapeutic use of the immunostimulatory capacity of DCs to induce protective immunity Driven by the discovery of the superior stimulatory capacity of mature LCs for CD4+ and CD8+ T cells, a solid body of evidence has been compiled suggesting that skin DCs are capable of inducing protective immunity against cancer. Grabbe et al. [56] demonstrated that the repeated subcutaneous injection of GM-CSF–activated LCs that had been loaded with tumor fragments derived from a spindle cell tumor line resulted in host resistance to a subsequent challenge with viable tumor cells. In keeping with this observation is the finding that murine epidermal DCs, pulsed with synthetic ovalbumin (OVA) peptides (e.g., SIINFEKL, amino acids 257 to 264 of OVA) and injected subcutaneously, elicit OVA-specific CD8+ T cells that lyse OVA-expressing target cells in vitro and prevent the growth of OVA-transfected, but not of nontransfected, melanoma cells in vivo. This potent immunostimulatory function is apparently mediated by mature LCs. As long as this advanced maturational stage has not been reached, the exposure of LCs to suppressive factors, for example, IL-10, can abrogate their capacity to induce antitumor immunity, whereas the fully matured cells become resistant to this inhibitory effect. These data support the hypothesis that immune surveillance exists in the epidermis and that LCs are the critical cellular elements of this host defense mechanism. According to this concept, the development of protein/peptide- and DNA-based immunization strategies to optimize antigen presentation by skin DCs is a rational approach to anticancer vaccine design. Cutaneous genetic immunization with naked DNA results in the transfection and/or uptake of DNA-encoded proteins by skin DCs, which migrate to draining lymph nodes and efficiently elicit antigen-specific, cytotoxic, and helper T cell responses. [57] Other strategies currently being pursued aim at introducing tumor antigen-encoding cDNA under the control of DC-specific promoters, cancer cell-derived RNA, tumor antigen-derived peptides, tumor antigen–hsp complexes, tumor cell-derived exosomes, or even apoptotic or necrotic tumor cells selectively into skin DCs or into ex vivo purified or in vitro-generated DCs for the induction of cytotoxic T cell responses. What has been learned from the human trials reported so far is that administration of DCs is safe and under certain conditions leads to substantial immune responses and to limited clinical responses. [58]

Downregulation of immune responses via the skin Early observations indicated that the application of hapten to LC-deficient skin/mucosa caused hapten-specific T cell tolerance (see above). More recent evidence suggests that both the site onto which the allergen is applied as well as its dose may be critical for whether T cell immunity or tolerance occurs. Steinbrink et al. [59] demonstrated that the painting of minute quantities of hapten onto ears of naive mice results in a state of long-lasting, hapten-specific tolerance, whereas the application of standard immunizing doses to ears of control animals was followed by the regular delayed-type ear swelling response that appears after hapten challenge. Although it is tempting to speculate that DCs with tolerizing potential are present in the skin, it must be remembered that haptens diffuse rapidly from the application site, spread through the circulation, and, thus, may be presented by immature DCs in many organs, or even by nonprofessional or non-APCs. “Low zone” tolerance is associated with a lymphokine secretion pattern suggestive of a T_H2-biased immune reaction. The recently identified “regulatory” T cells, cells with the capacity to antigen specifically or nonspecifically downregulate T cell-mediated immune reactions in vitro and in vivo, display a T

$_H$2-like cytokine secretion profile. [60] Regulatory T cells display the IL-2 receptor a-chain/CD25, the B7 ligand CTLA-4, and secrete IL-10, TGF-ß, and, depending on their derivation, IFN-?. Immature, but not mature, DCs stimulate the induction or, at least, the expansion of regulatory T cells. [61] UV radiation can induce a distinct T regulatory type 1-like T suppressor cell population that may block the activation of T $_H$1 cell-mediated immune responses. [62] Hapten-reactive CD4+ T regulatory cells that produce high levels of IL-10, low levels of IFN-?, and no IL-4 have been isolated from the blood and skin of allergic individuals, and these cells express an adhesion molecule and chemokine receptor pattern that supports their skin-homing properties; these findings suggest that, during every immune response induced via the skin, the effector arm (i.e., cytotoxic T cells, CD4+ effector cells) and a downregulatory component are activated. [63] Thus, the balance between the two components in sensitized individuals critically determines whether a given antigen or pathogen that appears in the skin is subject to immune attack or is recognized but ignored by the immune system. LCs may also directly downregulate ongoing immune reactions. Experimental evidence suggests that they may impose suppressive effects during the elicitation phase of contact hypersensitivity and, when stimulated by CD40 ligation, but not by LPS or IFN-?, can kill T cells in a FasL-dependent fashion.

Phenotypic and Functional Alterations in Disease

ALLERGIC DISORDERS
Contact hypersensitivity Studies in the late 1970s and early 1980s first claimed a role for LCs in the development of CHS. [32] Today we know that certain haptens but not irritants, when applied to the skin, can induce changes in its cellular constituents, resulting in conditions that promote activation of LCs/DDCs and their migration to the draining lymph nodes where they stimulate the proliferation of nonsensitized T cells in a hapten-specific manner. The likelihood of sensitization depends on the chemical structure of the hapten and on the genetic susceptibility of the individual exposed to it. In vitro studies are in progress to predict the allergenicity of a given chemical on the basis of its capacity to induce maturational events in DCs and to endow them with immunostimulatory properties. As opposed to the earlier view that CHS responses are mediated by CD4+ type 1 T cells, it now appears that CD8+ type 1 T cells are the main effector cells and that the concomitantly generated, hapten-specific CD4+ T cells are downregulating this response. [54] Notwithstanding the critical role of LCs/DDCs in CHS induction, epidermal LCs are apparently not needed for the challenge reaction to occur. The cell(s) actually responsible for it has (have) yet to be identified.
Atopic dermatitis Lesional skin of patients with atopic dermatitis (AD) contains increased numbers of DCs in both the epidermis and the dermis. In the epidermis, they represent either classical LCs or so-called inflammatory dendritic epidermal cells (IDECs). IDECs can be distinguished from LCs by a limited set of markers including FceRI ^{high}, Fc?RII/CD32 ^{high}, CD1b, and CD36. [64] In patients with AD and hyperimmunoglobulinemia E, IDECs and, to a lesser extent, LCs often express FceRI-bound surface IgE. Allergen-induced cross-linking of these IgE moieties in vitro facilitates their processing and presentation to T cells [65] and induces transcription and expression of proinflammatory molecules including IL-1, TNF-a, and IL-16. [66] Should these processes also be operative in vivo, they may well be responsible not only for the often severe and rapid outbreaks of eczematous skin lesions after allergen exposure, but also for the maintenance and, thus, chronicity of allergic tissue inflammation.
INFECTIOUS DISEASES Cutaneous DCs play a pivotal role in the host defense against pathogenic microorganisms penetrating or introduced into the skin (see above). As might be expected, microorganisms have found ways and strategies to circumvent immunosurveillance by these cells. Examples of this microbial escape include the downregulation of MHC class II molecules on epidermal LCs in *Lyme borreliosis,* the inhibition of LC migration by *Schistosoma mansoni*-derived prostaglandin D $_2$, and the prevention of LC/DC maturation and differentiation on infection with measles virus. LCs/DDCs are also an important target of HIV infection [67] and, at mucosal sites, could be an important point of virus entry during sexual intercourse. Once infected, LCs can sustain viral replication [68] and supposedly transmit the infection to the lymphoid tissue. Very active HIV-1 replication has been observed in DC–T cell conjugates emigrating from skin explants. [69] The in vivo role, if any, of DC-SIGN in the uptake and presentation of the virus [70] has yet to be determined. Patients with AIDS have reduced LC numbers because of viral cytopathicity and/or immunologic elimination.
SKIN CANCER The outcome of immune responses triggered by LCs/DDCs is critically dependent on the state of cell maturation. While terminally differentiated IL-12–producing LCs/DDCs favor the development of type 1 T cell-dominated responses and, thus, of protective microbial and cancer immunity, cells with a more immature phenotype promote the generation of type 2 T cells, or even regulatory T cells (see above). In the case of cancer, the latter scenario is highly undesirable and may have disastrous consequences for the affected individual. Thus, it is not surprising that the presence of fully matured LCs/DCs within or around the neoplasm is usually associated with tumor regression, whereas progressive cancers are mostly infiltrated with and surrounded by immature DCs. This is best demonstrated in melanoma and Langerhans cell histiocytosis itself. Prevention of DC maturation is caused by the production and release of immunoinhibitory cytokines and, perhaps, certain angiogenetic factors by cancer cells, as well as the direct negative effects of certain carcinogens. [71] Decreased LC densities have been encountered in lesions of squamous cell and basal cell carcinoma, in Bowen's disease, in actinic keratoses, and in human papillomavirus (HPV)-induced acanthomas. Several factors may be responsible for this phenomenon, including UV-and/or drug-induced immunosuppression of the host, as well as putative adverse effects of HPV on the LC population.

Effects of Physicochemical Agents and Drugs

UVB UVB has many adverse biologic effects, the most severe being the initiation and promotion of skin cancers. Originally, it was thought that UVB promotes the development of cutaneous neoplasia solely by its direct transforming effect on the genome of the host cells. Later, it was recognized that UVB induces a state of immunodeficiency, which is best exemplified by the inability of UVB-irradiated mice to mount a protective immune response against highly immunogenic UVB-induced tumors. These and other observations led to the concept that there exists a link between UVB-induced immune dysfunction and carcinogenesis. [72] Many investigators set out to probe this concept by using CHS as a read-out system. In one series of experiments, mice were irradiated with very high, nonphysiologic (>10 [5] J/m ^{2}) doses of UVB and were then exposed to the hapten either at the irradiated site or at a distant, nonirradiated site. In both instances, mice developed a hapten-specific unresponsiveness that could be transferred to naive recipients. Although

UVB does not penetrate further than the upper dermis, these high-dose UVB-irradiated animals develop a systemic defect of APC function. In contrast to this high-dose model of UVB-induced immunosuppression, Toews et al. [32] irradiated mice with 100 J/m ^{2} of UVB on 4 consecutive days and then applied the hapten to either the irradiated or the nonirradiated site. While they succeeded in inducing CHS via the nonirradiated site, application of the hapten to the irradiated site did not result in sensitization. This hapten-specific unresponsiveness could not be reversed by resensitization with the same hapten at a distant skin site, but it could be adoptively transferred by spleen and lymph node cells into immunologically naive syngeneic mice. Although not inducible in all mouse strains, this low-dose model of UVB-induced immunosuppression is certainly biologically more relevant than the high-dose model because it uses fluences of UVB (100 to 300 J/m ^{2} per single exposure) that are equivalent to one minimal erythema dose in humans. Although evidence exists that hapten sensitization is less likely to occur via UVB-irradiated skin than via non UVB-exposed skin in humans, human epidermal cells appear to be less susceptible to UVB than their murine counterparts. It is important to account for these differences in susceptibility when data on the effects of UVB radiation on the immune system in rodents are extrapolated to humans. LCs are probably the major targets in the induction of UVB-induced immunosuppression: (1) UVB irradiation of skin leads to their dose-dependent reduction and injury [32]; (2) the injection of purified UVB-irradiated LCs into naive mice not only fails to sensitize, but even tolerizes these animals [73]; and (3) UVB irradiation of single epidermal cells leads to a dose-dependent inhibition of their immunostimulatory properties. [33] This finding is true for type 1 (T_H1, T_c1) T cells but not for type 2 or regulatory T cells. With respect to the mechanism(s) of UVB-induced immunosuppression, the generation of cyclobutane pyrimidine dimers and, as a consequence, apoptosis appear to be the key events. [74] Indeed, the excision of these dimers by a liposome-incorporated repair enzyme restores the antigen-presenting activity of cutaneous DCs. [75] In this context, it should be mentioned that accelerated excision repair can also be accomplished by IL-12, [76] a cytokine critical for the induction and expansion of type 1 T cells. In addition to its direct DNA-damaging effect, UVB also triggers the production/release by epidermal cells of substances that downregulate or prevent the occurrence of immune responses dominated by type 1 T cells. A cytokine that probably plays an essential role in this process is IL-10. This mediator is secreted by UV-irradiated keratinocytes and can be found in skin biopsies and suction blister fluid from UV-exposed human volunteers as well as in the serum of UV-irradiated animals. In addition to its inhibitory action on IFN-? production by activated type 1 T cell clones, IL-10 profoundly alters the function of APCs by blocking their synthesis and/or upregulation of costimulatory molecules such as IL-1ß, CD54, and CD80. Studies from several laboratories convincingly demonstrate that (1) IL-10-treated LCs can tolerize T_H1 cells; (2) in vivo administration of recombinant IL-10 induces tolerance to contact-sensitizing haptens [77]; and (3) IL-10 knockout mice are resistant to the UVB-induced suppression of certain delayed type hypersensitivity reactions. Another molecule implicated in UVB-induced immunosuppression is urocanic acid. It is synthesized normally in skin in the *trans*-isomerized form via deamination of histidine within keratinocytes. After absorption of UVB radiation, *trans*-urocanic acid is converted to the *cis* isomer. Both in vivo and in vitro studies indicate that *cis*-urocanic acid can suppress T cell-mediated responses by interfering with the antigen-presenting function of LCs/DCs. [78] On the basis of the observation that mice treated with indomethacin become resistant to UVB-induced suppression of CHS, it was suggested that prostaglandins, predominantly PGE_2, are somehow involved in generating immunosuppression. It now appears that PGE_2 exerts its effects by increasing IL-10 secretion and, conversely, by downregulating IL-12 and TNF-a production/secretion. Although the above data are perfectly consistent with the concept of LCs playing a critical role in UVB-induced immunosuppression, the derivation and nature of the cells(s) delivering tolerizing signals in the lymphoid tissues have not yet been elucidated. Because conflicting data exist about the effect of UVB irradiation on LC migration and LC maturation, several, non-mutually exclusive scenarios are conceivable. First, UVB, while arresting LCs in an immature state, allows them to migrate to T cell zones in the regional lymph nodes. In the absence of costimulatory molecules, LCs would transmit tolerizing signals. Second, LCs of UVB-irradiated skin undergo apoptosis and are replaced by a population of IL-10-producing, tolerance-inducing APCs. [79] Third, UVB pushes LCs into apoptosis and thus prevents their migration to the lymph nodes. Antigenic material would reach the afferent lymphatics and be transported to the lymph node in unbound form. Uptake of this material by immature DCs residing there would again result in tolerization.

UVA, PUVA UVA can also adversely affect the number, phenotype, and function of LCs, [80] resulting in a state of immunosuppression. Recent data indicate that UVA II acts primarily on epidermal LCs, whereas UVA I leaves LCs apparently unaltered, but induces emigration of DDCs from the skin. The actual epidermal damage seen after UVA (and also UVB) irradiation has been ascribed, in part, to the generation of reactive oxygen intermediates. Reports exist that antioxidants (e.g., vitamin C, vitamin E, flavonoids) can prevent, at least partially, the deleterious effects of UV irradiation on cutaneous immunity. In both humans and experimental animals, PUVA treatment causes a transitory reduction and a functional impairment of ATPase+/MHC class II+ epidermal cells in a dose-dependent fashion. It remains to be seen whether these effects contribute to PUVA carcinogenicity.

IONIZING RADIATION Both x-radiation and Grenz rays produce significant reductions in the number and/or function of LCs.

HYPERTHERMIA Prolonged exposure of mice to mild whole-body hyperthermia enhances LC migration in the absence of foreign antigen. This finding indicates that increases in local or systemic body temperature, as they occur during infection and inflammation, have per se a regulatory effect on immune function.

IMMUNOSTIMULATORY COMPOUNDS When applied to or injected into the skin, imidazoquinolones such as imiquimod and resiquimod as well as CpG-containing oligonucleotides induce activation and functional maturation of LCs/DDCs. This opens new and exciting avenues for the induction of protective, type 1 T cell-dominated antimicrobial and antitumor immune responses.

IMMUNOSUPPRESSIVE DRUGS Many of the immunoinhibitory and/or anti-inflammatory substances used in dermatology (glucocorticoids, cyclosporine, tacrolimus, methotrexate, azathioprine, and vitamin D_3 analogues) may adversely influence LCs/DDCs at the phenotypic and/or functional level. It is not always clear whether the effects of the respective drugs are a result of their direct or indirect (via their symbionts) actions on cutaneous DCs.

RETINOIDS Controversy exists as to whether or not retinoids can protect LCs from depletion by UVB or tumor-promoting phorbol esters.

KERATINOCYTES

The contention that the regulatory effects of cytokines on the phenotype and function of dendritic APCs in vitro are of

great in vivo relevance gains support from immunomorphologic studies documenting a close proximity between dendritic APCs and resident skin cells that produce soluble mediators of the inflammatory and immune response.

DDCs are members of the “dermal microvascular unit” and can conceivably receive signals from the other cellular components of this unit; that is, endothelial cells, pericytes, mast cells, and T cells. In the epidermis, the LC enjoys an even closer association with its symbionts. Evidence exists that nerves containing calcitonin gene–related peptide (CGRP) frequently impinge on LCs of the human epidermis. [81] This physical interaction is probably of great functional importance because CGRP and the neuropeptide substance P can inhibit the immunostimulatory capacity of LCs.

Although LCs may also have occasional encounters with melanocytes and Merkel cells, their most important epidermal partner is, unquestionably, the keratinocyte.

Keratinocytes not only have structural functions but also participate actively in inflammatory and immunologic processes. This action became evident when it was discovered that these cells produce a wide variety of biologically active molecules, some of which act as mediators of the inflammatory reaction and the immune response, for example, cytokines, neuropeptides, antimicrobial peptides, and eicosanoids.

In addition to their role as immunomodulating cells, keratinocytes can also participate directly in immune reactions as both inducers and targets. As such, they play a pivotal role in the pathogenesis and expression of many skin diseases, including eczema, psoriasis, pemphigus, erythema multiforme, and graft-versus-host-disease (GVHD).

Secretory Functions

CYTOKINES Keratinocytes are capable of producing/secreting a large number of cytokines that may affect neighboring cells (paracrine pattern), modulate their own functional status (autocrine pattern), and, in situations of massive release, reach the circulation and affect the function of cells at distant sites (endocrine pattern). Some of these factors [e.g., IL-1, IL-1 receptor antagonist, IL-6, IL-7, IL-8 and other chemokines, IL-10, IL-12, IL-15, IL-18 (IFN-?–inducing factor, IGIF), TNF-a, GM-CSF, M-CSF, SCF] are important mediators of the inflammatory and/or immune response, whereas others (e.g., TGF-a and -ß, platelet-derived growth factor, basic fibroblast growth factor, keratinocyte growth factor, nerve growth factor, vascular endothelial cell growth factor) regulate the growth of different epithelial and/or mesenchymal cells (Table 23-2). The latter factors are dealt with elsewhere in this volume (see Chap. 26).

Interleukins
IL-1a (IL-1F1), IL-1ß (IL-1F2) and homologues (IL-1F5, IL-1F7, IL-1F9, IL-1F10), IL-1RA (IL-1F3), IL-18 (IGIF, IL-1F4)
IL-6, IL-7, IL-10, IL-12, IL-15
TNF-a, lymphotoxin-a, LIF, MIF, IFN-a, IFN-ß, IFN-e
Chemokines
CXC chemokines: Gro-a (CXCL1), IL-8 (CXCL8), Mig (CXCL9), IP-10 (CXCL10), I-TAC/IP-9 (CXCL11)
CC chemokines: MCP-1 (CCL2), RANTES (CCL5), TARC (CCL17), MIP-3a/LARC (CCL20), MDC (CCL22), CTACK (CCL27)
Colony-stimulating factors
GM-CSF, M-CSF, SCF (c-kit), flt-3 ligand
Other growth factors
TGF-a, TGF-ß, KGF, PDGF, NGF, bFGF, VEGF
Cytokine receptors
IL-1R type I (active) and II (decoy receptor)
TNF-aR type I (p55)
IL-4Ra, IL-4R, IL-10R1, IL-13Ra1, IL-18R, IL-20R1/IL-20R2, IL-22R1/IL-20R2
IFN-g receptor, IL-17R (by inference)
Chemokine receptors
CXCR1, CXCR2, CCR1, CCR6

TABLE 23-2 **Keratinocyte-Derived Cytokines and Cytokine Receptors**

Keratinocytes of unperturbed skin produce only a few of these mediators, such as IL-1, IL-7, and TGF-ß, constitutively. Resident keratinocytes contain large quantities of preformed and biologically active IL-1a, as well as immature IL-1ß in their cytoplasm. [82] The likely in vivo role of this stored intracellular IL-1 is that of an immediate initiator of inflammatory and repair processes after epidermal injury; that is, after its release into the extracellular space. IL-7 is an important lymphocyte growth factor that, in the mouse, promotes the proliferation of dendritic epidermal T cells (DETCs) and keeps them alive. The role of this cytokine in the survival and proliferation of the T lymphocytes of human skin is unclarified. Some evidence exists for the IL-7–driven propagation of Sézary lymphoma cells. TGF-ß, in addition to its growth-regulating effects on keratinocytes and fibroblasts, modulates the inflammatory as well as the immune response, [83] and is important for LC development (see above). [11] Upon delivery of certain noxious, or at least potentially hazardous stimuli (e.g., hypoxia, trauma, nonionizing radiation, haptens and other rapidly reactive chemicals, microbial toxins), the production and/or release of many cytokines is often dramatically enhanced. The biologic consequences of this event are manifold and include the initiation of inflammation (IL-1, TNF-a, IL-6, members of the chemokine family), the modulation of LC phenotype and function (IL-1, GM-CSF, TNF-a, IL-10, IL-15), T cell activation (IL-15, IL-18), T cell inhibition (IL-10, TGF-ß), and skewing of the lymphocytic response in the type 1 direction (IL-12). [82], [84], [85], [86] and [87] In some cases, keratinocytes may also play a role in amplifying inflammatory signals in the epidermis originating from numerically minor epidermal cell subsets. One prominent example is the induction of proinflammatory cytokines such as TNF-a in keratinocytes by LC-derived IL-1ß in the initiation phase of allergic contact dermatitis. [48] In the case of a robust stimulus, keratinocyte-derived cytokines may be released into the circulation in quantities that cause systemic effects. During a severe sunburn reaction, for example, serum levels of IL-1, IL-6, and TNF-a are clearly elevated and probably responsible for the systemic manifestations of this reaction, such as fever, leukocytosis, and the production of acute phase proteins. [88] There is also evidence that the UV-inducible cytokines IL-6 and IL-10 can induce the production of autoantibodies and, thus, be involved in the exacerbation of autoimmune diseases such as lupus erythematosus. The fact that secreted products of keratinocytes can reach the circulation could conceivably also be used for therapeutic purposes. The demonstration by Fenjves et al. [89] that grafting of apolipoprotein E (apo-E) gene-transfected human keratinocytes onto mice results in the detection of apo-E in the circulation of the mouse supports the feasibility of such an approach. Another important function of keratinocytes is the production/secretion of factors governing the influx and efflux of leukocytes into and out of the skin. Two good examples are the chemokines TARC (CCL17) and CTACK (CCL27) that have corresponding receptors selectively expressed on skin-homing T lymphocytes. Blocking of both chemokines drastically inhibited the migration of T cells to the skin in a murine model of CHS. [90] Another more distinct function of a keratinocyte-derived chemokine in the recruitment of leukocyte subpopulations to the epidermis is

suggested by the selective expression of the MIP-3a receptor, CCR6, on LCs and LC precursors [14] (see above). Because certain cytokines function as inducers of others, it could often not be decided whether a given cytokine triggered a particular tissue reaction by acting directly or indirectly, that is, via the induction of other mediators, on the relevant target cell(s). Studies with genetically modified animals, that is, animals overexpressing or lacking a particular gene, proved to be valuable tools in this regard. Examples include (1) the appearance of an inflammatory and hyperproliferative skin disease in mice overexpressing IL-1a or IL-1 receptor type I in basal keratinocytes; (2) the inhibition of some aspects of skin inflammation in mice overexpressing the IL-1 receptor type II (decoy receptor); (3) the impaired development of CHS to TNCB in some, but not all, IL-1ß–deficient mice; (4) the occurrence of cachexia and GVHD-type skin changes in keratin-14 (K14) promoter-driven TNF-a transgenic mice; (5) the presence of subtle epidermal changes but absence of leukocytic infiltration in K14/IL-6 transgenic mice; (6) the recruitment to skin of LCs and other DCs in mice overexpressing monocyte chemoattractant protein 1 in basal keratinocytes; (7) the occurrence of exaggerated cutaneous inflammatory responses in IL-10–deficient mice; (8) the development of a lymphoproliferative skin disease in K14/IL-7 transgenic mice; and (9) the inhibition of skin development by overexpression of TGF-ß1 in the epidermis of transgenic mice.

NEUROPEPTIDES The skin is a rich source of neuropeptides including neurotransmitters (e.g., CGRP, substance P, somatostatin) and neurohormones. The inhibitory effects of CGRP and substance P on LC antigen presentation function already were briefly discussed. The neurohormone proopiomelanocortin (POMC) is produced by the pituitary gland as well as by a number of cell types, including keratinocytes. [91] POMC is synthesized as a large prohormone and is cleaved posttranslationally in active peptide hormones such as a-, ß-, and ?- melanocyte-stimulating hormone (MSH), adrenocorticotropin (ACTH), corticotropin-like intermediate lobe peptide, and others. Resident and freshly isolated keratinocytes produce very low amounts of POMC peptides. When stimulated with IL-1, UVB, or tumor promoters, these cells abundantly express POMC transcripts and release bioactive a-MSH. POMC peptides exert their bioactivities by binding to one of the melanocortin receptors, which differ with regard to their cellular expression as well as their binding specificity and avidity. For example, the melanocortin receptor 1, which exclusively binds a-MSH, is expressed on melanocytes, mononuclear phagocytes, and probably also on keratinocytes. a-MSH profoundly affects the inflammatory and the immune responses. It antagonizes the effects of proinflammatory cytokines. and modulates IgE synthesis in vitro. It appears that the anti-inflammatory properties of this neuropeptide are because of its IL-10–inducing effect, its ability to induce CD25+CD4+ regulatory T cells, or its capacity to interfere with important effector pathways, for example, inhibition of the inducible macrophage isoform of nitric oxide synthase (NOS-II) in macrophages. In the skin, a-MSH can downregulate the differentiation-driven hsp70 expression by keratinocytes and thus appears to regulate the cells' cytoprotective protein equipment. a-MSH reportedly suppresses both the sensitization and elicitation limbs of hapten-induced contact allergy. This hyporesponsiveness probably reflects a state of hapten-specific tolerance mediated by the a-MSH–triggered production of IL-10. [92]

ANTIMICROBIAL PEPTIDES Antimicrobial peptides are increasingly recognized as important players in the innate immune system. [93] Also, keratinocytes produce such peptides including cathelicidins (LL-37) [94] and ß-defensins (BD-1, BD-2, BD-3). [95] Their antimicrobial mechanism of action may relate to membrane insertion and pore formation. Adrenomedullin, members of the calcitonin-related peptide superfamily, a-MSH, and secretory leukocyte protease inhibitor (SLPI, ALP, HUSI-I) are among previously identified peptides with antimicrobial activities discovered later. BD-1 is constitutively produced by keratinocytes. Its production and that of others (LL-37, BD-2, and SLPI) is enhanced/induced by bacteria, proinflammatory cytokines, [95] or trauma. [96] Although these natural antibiotics generally have broad and overlapping antimicrobial spectra, it has recently been shown that selective deficiency of LL-37 in mice can aggravate skin infections with group A streptococci. [97] Additional functions of these peptides include the chemotactic attraction of leukocytes, induction of cell proliferation, and alteration of cell metabolism. An example of the close interplay between constituents of innate and adaptive immunity is the capacity of human BD-2 to attract T lymphocytes and DCs through binding to CCR6. [98] Cathelicidins may play a role in skin host defense by attracting neutrophilic granulocytes, and BD-2 and LL-37 by induction of mediator release from mast cells via a G protein-dependent IgE-independent mechanism.

OTHER MEDIATORS Other secreted protein mediators that can be synthesized and released from keratinocytes and that may play a role in host defense are the complement components C3 and factor B. Keratinocytes are among the cells that synthesize eicosanoids, an ensemble of lipid mediators regulating inflammatory and immunologic reactions. They can produce and release the cyclooxygenase product PGE_2 that has both proinflammatory and immunosuppressive properties and, when acting on DCs, promotes the development of type 2 T cells responses. [52] Other keratinocyte-derived eicosanoids include the neutrophil chemoattractant leukotriene $(LT)B_4$, the proinflammatory 12-lipoxygenase product 12(s)-hydroxyeicosatetraenoic acid (12(S)HETE), and 15-HETE, an anti-inflammatory and immunosuppressive metabolite of the 15-lipoxygenase pathway. Another group of biologic response modifiers originating in keratinocytes and other epidermal cells are free radical molecules, now generally referred to as reactive oxygen species. These include the superoxide radical (O_2), hydrogen peroxide (H_2O_2), the hydroxyl radical (HO), nitric oxide (NO), and others. These radicals are generally viewed as dangerously reactive entities threatening the integrity of many tissues. The skin is particularly at risk because it is exposed to O_2 from both inside and outside, and because of the activation of oxygen by light. Free radicals probably contribute to solar damage and photoaging of the skin. However, certain reactive oxygen species have potent inflammation-inducing (e.g., oxygen free radicals) as well as immunomodulatory (e.g., NO) properties, and thus provide an important host defense mechanism against microbial invasion. For discussion of these molecules, the reader is referred to appropriate reviews. [99], [100]

The Keratinocyte as an Immunologic Target Cell

The demonstration of cytokine receptors on and cytokine responsiveness by keratinocytes (Table 23-2) established that the functional properties of these cells can be subject to regulation by cells of the immune system. As a consequence, keratinocytes express or are induced to express immunologically relevant surface moieties that can be targeted by leukocytes for stimulatory or inhibitory signal transduction.

Keratinocytes can synthesize complement and related receptors, including the C3b receptor (CR1, CD35), the Epstein-Barr virus receptor CR2 (C3d receptor, CD21), the C5a receptor (CD88), the membrane cofactor protein (CD46), the decay-accelerating factor (CD55), and complement protectin (CD59). CD59 may protect keratinocytes from attack by

complement. Its engagement by CD2 stimulates the secretion of proinflammatory cytokines from keratinocytes. Membrane cofactor (CD46) is reported to be a receptor for M protein of group A streptococci. Its ligation induces proinflammatory cytokines in keratinocytes such as IL-a, IL-6, and GM-CSF.

Cross-linking of CD23 (FceRII), induced by IFN-? or IL-4 on cultured keratinocytes, results in the secretion of TNF-a, IL-6, IL-10, and nitric oxygen via inducible NOS. CD40 is very weakly expressed by keratinocytes under steady-state conditions. It is upregulated by IFN-?, an event probably operative in psoriasis. Engagement of CD40 induces enhanced keratinocyte ICAM-1 and Bcl-x expression, the release of IL-8, and the arrest of the cell cycle followed by keratinocyte differentiation.

In addition to their role in maintaining and securing the structural properties of the epidermis (see Chap. 6), keratinocyte-bound adhesion molecules may also subserve immune functions. A particular role was suspected for the LFA-1 (integrin) ligand ICAM-1 because it is expressed in keratinocytes in a large variety of inflammatory skin conditions. When this adhesion molecule was overexpressed under the control of a K14 promoter, however, no phenotype was found, even under inflammatory conditions. Gluing together keratinocytes is also not the sole function of E-cadherin. Homotypic interactions with LCs anchor these cells in the epidermis, [17] and heterotypic binding to a $_E$ ß $_7$ helps to immobilize murine DETCs as well as CD8+ T lymphocytes in this tissue.

Cytokine action on keratinocytes not only leads to a modulation of the inflammatory and/or immune response but can also result in a change of their proliferation and differentiation program. For example, IFN-? and IL-1 induce the de novo expression of keratin 17 and keratin 6/16, respectively. [101] MIP-1a reportedly inhibits the proliferation of undifferentiated keratinocytes.

ROLE OF MHC CLASS I ON KERATINOCYTES Attempts to quantitate surface molecules on nonstimulated keratinocytes revealed that MHC class I products are expressed on these cells in even higher density than on nonstimulated LCs. As outlined above, peptides derived from self or foreign (e.g., viral) antigens synthesized in the cytosol associate with MHC class I and are displayed at the cell surface as ligands for antigen receptors of T cells. Because the CD8 molecule binds to nonpolymorphic framework determinants of the MHC class I heavy chain, keratinocytes represent targets for CD8+ cytotoxic T lymphocytes. Cytotoxic T cells may induce cytolysis either by secretory products (perforin, granzymes; TNF-a, lymphotoxin-a and -ß) or through cell-bound ligands (CD95L, TRAIL) of death-domain–carrying receptors on the target cell (e.g., CD95/Fas/Apo-1, TRAMP/DR3/Apo-3, TRAIL receptors 1, 2, 3). [102], [103] Although through different receptor/signaling pathways, both mechanisms can result in apoptosis of the target cell (a form of cell death that involves protein synthesis and DNA fragmentation). MHC class I-restricted T cell-mediated keratinocyte lysis is apparently an important event in CHS, [104] and may be involved in herpes simplex virus infection, lichen planus, acute cutaneous GVHD, and other skin disorders exhibiting a lichenoid T cell infiltrate and keratinocyte damage. Keratinocyte apoptosis was recently shown to be involved in spongiosis, a histologic feature of various forms of eczema. Massive keratinocyte apoptosis occurs in toxic epidermal necrolysis in an MHC-independent fashion. Evidence exists that this event can be halted by the administration of pooled intravenous immunoglobulins through blocking of keratinocyte CD95 interaction with its ligands. [105] In addition to being susceptible to the cytotoxic effects of perforin and granzyme, keratinocytes can produce these very same molecules and, thus, contribute to skin inflammation and host defense. Fas-induced apoptosis is also a consequence of UV irradiation (sunburn cell formation on a histologic level) and involves pathways that are either dependent on or independent of its ligand.

INDUCTION AND FUNCTION OF MHC CLASS II ON KERATINOCYTES Keratinocytes of normal skin fail to display MHC class II molecules, but their expression can be triggered by several factors, particularly IFN-?. IFN-? exerts this effect via the induction of transcription factors for MHC class II a- and ß-chain genes, among them the class II transactivator, CIITA, and RFX5, a DNA-binding protein of the RFX family. As a consequence, IFN-?-stimulated keratinocytes start to express not only MHC class II a- and ß-chains, but also acquire two other central elements of the MHC class II presentation pathway—the invariant chain of MHC class II and HLA-DM. In many skin disorders, MHC class II expression by keratinocytes has been found in connection with a prominent lymphocytic infiltration and, thus, has been attributed to IFN-? production by the infiltrating T cells. [106] MHC class II-bearing keratinocytes are capable of inducing proliferation in allogeneic CD4+ T cell lines but not in resting T cells. [107] Although containing many essential elements of the MHC class II presentation pathway, keratinocytes do not efficiently display peptides from exogenously added protein antigens in their surface-bound MHC class II. It remains to be seen whether this relates to inefficient liberation of immunogenic peptides or to a poor accessibility of MHC class II-containing vesicles for exogenous material in these cells. Nevertheless, keratinocytes present processing-independent, synthetic peptides to T cell hybridomas, indicating that these cells can display functional peptide/class II complexes. In vivo, this presentation pathway may become operative when sufficient regurgitation of peptides from antigen processing-competent cells (i.e., LCs) occurs. Alternatively, it is conceivable that many of the IFN-?–inducible MHC class II moieties are occupied by peptides derived from cellular proteins. Studies of the functional consequences of MHC class II presentation to T cells have demonstrated that, at least in T $_H$1 clones, class II+ keratinocytes can induce antigen-specific nonresponsiveness (tolerance) to subsequent restimulation. [107], [108] While primed T cells enter a state of functional anergy on encountering keratinocyte-bound antigen, naive T cells may undergo apoptosis on receipt of the same antigenic stimulus displayed on the epithelial cell surface. [109] Nondelivery of costimulatory signals or production of inhibitory factors (e.g., TGF-ß, PGE $_2$) may be responsible for T cell downregulation. In vivo, the injection of hapten-modified, MHC class II+ keratinocytes into naive mice leads to a specific, yet transient, hyporesponsiveness to subsequent sensitization by hapten. Class II+ keratinocytes can also be killed by MHC class II-restricted T cells. [107] DCs and class II+ T cell blasts are apparently well suited for the elicitation of CD4+ T cells with cytotoxic potential. Perforin/granzyme B and Fas ligand are the proapoptotic effector molecules used by CD4+ T cells. The antigenic moieties recognized by these cells include minor transplantation and viral antigens. Thus, it is likely that CD4+ cytotoxic T cells critically contribute to the keratinocyte damage in a variety of autoimmune-mediated, allergic, infectious, and other (still idiopathic) skin disorders.

LYMPHOCYTES

Normal skin is the prototype of a nonlymphoid organ, that is, an organ in which primary lymphocyte responses are not

initiated. However, normal skin is not entirely devoid of lymphocytes.

In murine epidermis, for instance, there exists a distinctive population of T lymphocytes * that are uniformly dendritic in shape (hence their name dendritic epidermal T cells) and exhibit a very restricted TCR repertoire. [112] In fact, almost all DETCs carry virtually identical TCRs encoded by V?3/J?1/C? and V1d/Dd2/Jd1/Cd genes rearranged in the canonical sequence. The same TCR configuration is found on early fetal thymocytes which, in all likelihood, are the natural DETC predecessors. [113]

The (patho)physiologic function(s) of DETCs remain(s) elusive. Several, partly contradictory concepts have received experimental support. One suggests that DETCs represent a broadly acting, first-line defense system that, upon perturbation of the skin (e.g., by stress, carcinogens, microbial assault, and haptens), undergoes activation and expansion to ultimately eliminate the pathogen or restore the integrity of the skin/epidermis. An entirely different concept suggests that DETCs act as regulatory cells suppressing or eliminating T effector cells, thus protecting the epidermis from excessive immunologic injury.

Although T cells represent the vast majority of lymphocytes in human skin and outnumber, by far, NK cells and B cells, a human analogue of the rodent DETC population has not been identified. On the contrary, most T cells of human skin are round to polygonal in shape, reside in the dermis rather than in the epidermis, and predominantly express TCR aß rather than TCR ?d. [114], [115] Although the ratio of TCR aß+ and ?d+ T cell subsets in human skin is similar to that in blood, [115] the TCR repertoire of skin-associated T cells is apparently not determined by random sampling of peripheral blood T cells, as evidenced by a restricted usage of Va, Vß, and Vd/Jd specificities in normal human skin as compared to the blood.

Dermal T cells, which comprise more than 90 percent of the T cell population of the skin, are preferentially clustered around postcapillary venules of the superficial plexus high in the papillary dermis (Fig. 23-7). They are often situated just beneath the dermal–epidermal junction and within, or in close proximity to, adnexal appendages, such as hair follicles and eccrine sweat ducts. Dermal T cells express the classic markers CD2 and CD5 and are primarily single positive for CD4 or CD8 coreceptors, showing either an equal distribution or preference for the CD4+ subset. Most belong to the CD45RO+ memory population and are CD7 negative.

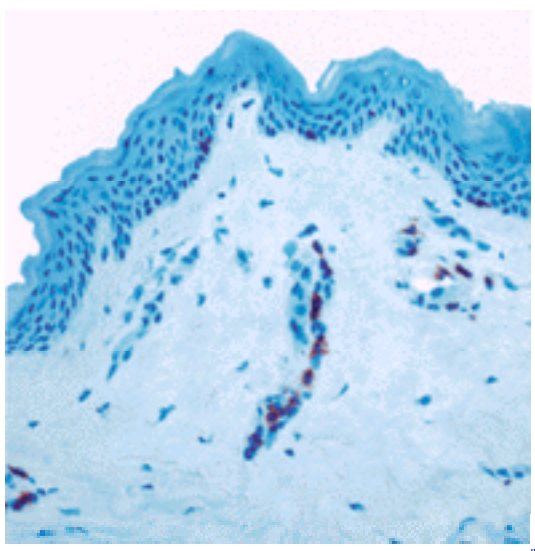

FIGURE 23-7 Visualization of T lymphocytes in a cryostat section of normal human skin using a monoclonal anti-CD3 antibody in an indirect immunoperoxidase technique. Stained cells are predominantly located around the superficial vascular plexus in the dermis and, to a much lesser extent, in the basal layer of the epidermis. (*Courtesy of Christine Bangert, MD.*)

Approximately half of these CD3+ cells express the skin-homing receptor CLA with no obvious difference between the CD4+ and CD8+ subsets. [116]

At perivascular sites, most T cells express HLA-DR and/or CD25, indicating that some of them represent effector cells and others belong to the recently defined subset of regulatory T cells. [117]

Epidermal T cells account for approximately 2 to 3 percent of all CD3+ cells in normal human skin. They reside primarily in the basal and suprabasal layers (Fig. 23-7), often in close apposition to LCs. Most of them bear TCRaß dimers and exhibit the single positive (CD4–/CD8+>>CD4+/CD8–) and, occasionally, the double negative [118] (CD4–/CD8–) phenotype. CD4–/CD8+ TCRaß-bearing epidermal cells express the CD8aa homodimer at frequencies considerably higher than those in paired samples of peripheral blood.

Human epidermal T cells are typically CD2+ and CD5+, often lack the CD7 antigen, and mostly have the memory cell phenotype (CD45RO+/CD45RA–). Various portions express CD25 (IL-2Ra), CD57, and Fas (CD95). Many T cells of the human epidermis react with the MAb HECA-452 and HML-1, which define CLA and the $a_E ß_7$ integrin (CD103), respectively. A minor population of human epidermal T cells display TCR?d heterodimers, and most of these are CD4–/CD8–. In sharp contrast to epidermal T cells of rodents, human epidermal T cells exhibit an irregular distribution, being particularly abundant in volar skin and in the acrosyringeal epithelium of eccrine sweat ducts.

The derivation of intraepidermal memory cells can be explained in two, mutually nonexclusive ways. First, they might be generated by chronic antigenic stimulation of naive T cells residing indigenously in the epidermis. Alternatively, they could enter the skin/epidermis in an already sensitized state. Although the existence of an indigenous T cell population in the human epidermis is still a matter of speculation, one should not forget that some of the T cell subsets in the human

epidermis, that is, TCRaß+CD8+ and CD4–/CD8– T cells, respond to nonpeptide lipid and glycolipid antigens in a CD1-restricted fashion. [31] Because expression of CD1 proteins is a prominent feature of LCs and DDCs, it could be hypothesized that cutaneous immunosurveillance also includes the sensitization of resident epidermal T cells to skin-specific pathogens via skin-associated APCs. Another line of thought postulates that TCRaß+CD8+ epidermal T cells represent potentially autoreactive cells. [119] In unperturbed skin, they would be kept in a state of anergy towards self-antigens by immature DCs (LCs) and nonprofessional APCs (keratinocytes). After the delivery of danger signals, keratinocytes and LCs would express costimulatory molecules and could conceivably activate these epidermal T cells. Although attractive, this concept still awaits experimental proof.

The theory that the pool of intraepidermal memory cells would derive from and be continuously replenished by primed T cells recruited from the peripheral blood to the skin is mainly based on studies with the MAb HECA-452. This antibody reacts with 10 to 20 percent of peripheral blood T cells exhibiting the memory cell phenotype, with the vast majority of skin-infiltrating T cells in cutaneous sites of chronic inflammation, with more than half of epidermal T cells of normal human skin (see above), but with relatively few T cells in extracutaneous inflammatory sites. [116], [120] Cell attachment experiments have shown that memory T cells, but not naive T cells, adhere to E-selectin+ endothelial cells and that the HECA-452+ T cell subset is the predominant E-selectin–binding population among circulating lymphocytes. The further observations that E-selectin is preferentially expressed on endothelial cells of venules in inflammatory skin lesions and that these venules are associated with a predominantly HECA-452+ T cell infiltrate suggest that, in inflamed skin, the interaction between CLA and E-selectin is of critical importance for the adhesion and, finally, transmigration of memory T cells to/through the dermal microvasculature. The question still remains as to which mechanism is operative in T cell homing to clinically normal skin. The possibility exists that, even at sites of only subclinical inflammation, E-selectin expression is induced on dermal microvascular endothelial cells in quantities sufficient for trapping CLA-bearing memory T cells.

Leukocytes and nonleukocytes residing in the skin can produce chemokines with T cell chemotactic properties such as IL-8, GR0 a, IP-10, monokine-induced by interferon-? (Mig), MCP-1, 2, 3, RANTES (regulated on activation, normal T cell expressed and secreted), MIP-1a, MIP-1ß, and lymphotactin. Of particular importance for the homing of CLA+ T cells to the skin, at least under inflamed conditions, appears to be the CC chemokine CCL27/CTACK. [15] It is produced by basal keratinocytes and is also displayed on the surface of dermal endothelial cells. Its expression is upregulated by IL-1ß and TNF-a and downregulated by glucocorticoids. The receptor for CCL27, CCR10, is expressed on CLA+ T cells, and in vivo experiments have demonstrated a pivotal role for CCL27–CCR10 interactions in T cell-mediated skin inflammation. [121]

The recruitment of CLA-expressing type 2 (T_H2) T cells into the skin, as apparently happens in atopic dermatitis, can also be mediated by thymus and activation-regulated chemokine (TARC). This CC chemokine is expressed in basal keratinocytes of atopic dermatitis lesions and attracts CLA+ T cells by binding and signaling to CCR4 expressed on those cells. [122]

Adhesion molecule interactions that help to anchor T cells in the epidermis include the attachment of LFA-1 (CD11a)-bearing T cells to ICAM-1 (CD54)+ keratinocytes in inflamed skin and, more physiologically, the $a_E ß_7$–E-cadherin–mediated binding of T cells to nonactivated keratinocytes.

With regard to the factors responsible for the survival and/or expansion of human epidermal cells, it appears that analogous to the mouse system, IL-7 and IL-15 play important roles in these processes. Both T cell growth factors can be produced by human epidermal cells, and both are overexpressed in the T cell-rich skin lesions of patients with tuberculoid leprosy.

Despite the large preponderance of memory cells, small numbers of CD45 RA+/RO– T cells also exist in normal human skin. Little is known about their functional repertoire and about the mechanisms governing their influx into the skin. The homing of CCR7-expressing naive T cells to secondary lymphoid organs is known to occur via so-called high endothelial venules (HEVs). The attachment of naive T cells to HEV is mediated by the interaction of lymphocyte L-selectin and so-called peripheral node addressins defined by the MAb MECA-79. The actual transmigration and attraction of the cells into the nodes is accomplished by the CCR7 ligands CCL21/SLC and CCL19/MIP-3ß/ELC.

MECA-79–reactive endothelial cells have been detected in the perifollicular areas of chronically inflamed skin and, to a much lesser extent, in normal human skin. [123] It is possible, therefore, to speculate that the presence of HEV-like vessels allows for a minor influx of naive T cells into the skin under steady-state conditions and that this process can be amplified when conventional migratory pathways of lymph node-primed T memory cells do not sufficiently eliminate the pathogen.

SYNOPSIS (Fig. 23-8)

Evidence presented in this chapter demonstrates that the skin is both a physical barrier between the host and the environment as well as an immunologic gatekeeper destined to optimally serve the needs of the host.

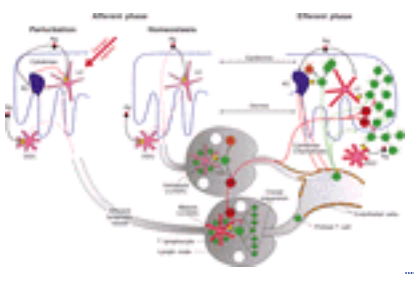

FIGURE 23-8 The mechanisms operative in the initiation, expression, and downregulation of cutaneous immune responses. *Induction of productive T cell immunity via the skin:* The epi-and/or intracutaneous de novo appearance of

antigens (i.e., pathogens such as microorganisms and haptens) results in the elicitation of productive antigen-specific immunity when “danger signals” (i.e., DNA rich in CpG repeats in microbacteria, Toll-like receptor ligands, etc.) are present at the time of antigenic exposure. The receipt of danger signals leads to tissue perturbation as evidenced by the increased secretion of GM-CSF, TNF-a, and IL-1 by KCs and other skin cells. Antigen-presenting cells (LCs, DDCs) that pick up the antigen, process it, and reexpress it as a peptide/MHC complex on the surface are also profoundly affected by danger signals or danger signal-induced cytokines. The alterations of LCs/DDCs include the increased expression of MHC antigens, costimulatory molecules, and cytokines (IL-1ß, IL-6, IL-12), as well as the enhanced emigration of these cells from the skin to the paracortical areas of the draining lymph nodes. At this site, the skin-derived dendritic cells provide activation stimuli to naive resting T cells surrounding them. This occurs in an antigen-specific fashion and, thus, results in the expansion of the respective clone(s). These primed T cells begin to express skin homing receptors (e.g., cutaneous lymphocyte-associated antigen) as well as receptors for various chemoattractants that promote their attachment to dermal microvascular endothelial cells of inflamed skin and, ultimately, their entry into this tissue. *Elicitation of T cell-mediated tissue inflammation and pathogen defense:* On receipt of a renewed antigenic stimulus by cutaneous antigen-presenting cells (LCs, DDCs), the skin-homing primed T cells expand locally and display the effector functions needed for the elimination or, at least, the attack of the pathogen. Alternatively, primed T cells may encounter the antigen on the surface of nonprofessional antigen-presenting cells (e.g., MHC class II-bearing KCs), a situation that conceivably results in a state of clonal T cell anergy. *Downregulation and prevention of cutaneous T cell immunity:* In the absence of danger signals (tissue homeostasis), antigen-loaded LCs/DDCs also leave the cutaneous compartment and migrate towards the draining lymph node. These cells or, alternatively, resident lymph node dendritic cells that had picked up antigenic moieties from afferent lymphatics present this antigen in a nonproductive fashion; that is, induce antigen-specific T cell unresponsiveness or allow the responding T cell(s) to differentiate into immunosuppressive T regulatory cells. The latter may limit antigen-driven clonal T cell expansion during primary immune reactions in lymph nodes and during secondary immune reactions at the level of the peripheral tissue. Such events can result in the downregulation of both desired (antitumor, antimicrobial) and undesired (hapten-specific, autoreactive) immune responses. Ag, antigen; DDC, dermal dendritic cell; KC, keratinocyte; LC, Langerhans cell; T, T cell (naive); T', primed T cell; T*, anergic T cell; TCR, T cell receptor; Treg, T regulatory cell.

On recognition of “danger” signals (e.g., microbial invasion) by receptors of the innate immune system, a cascade of cellular and molecular events is initiated that allows dendritic APCs (LCs, DDCs) to pick up and process the antigens, to emigrate from the skin, and to terminally (i.e., irreversibly) mature into extremely potent immunostimulatory cells. On arrival in the secondary lymphoid organs, they trigger pathogen-specific protective immune responses in naive, resting lymphocytes. T cell blasts generated in skin-draining peripheral lymph nodes, but not those originating from other lymphoid tissues, begin to express skin-specific homing receptors such as CLA. The interaction with corresponding addressins on cytokine-activated endothelial cells of the dermal microvasculature allows these cells to find their way back to the site harboring the pathogen, which, under optimal circumstances, would then be neutralized or eliminated.

In other situations (steady-state conditions, UV irradiation, application of immunosuppressive compounds), LC/DDC activation fails to occur. Such immunologically immature DCs and perhaps also other, nonprofessional APCs (e.g., keratinocytes, fibroblasts) will deliver signals directly or indirectly to silence T cells.

It thus appears that the components of skin-associated lymphoid tissues [124] (i.e., dendritic APCs, cytokine-producing keratinocytes, and skin-homing T cells originating in skin-draining peripheral lymph nodes) can subserve a dual function. On the one hand, they provide the skin with unique immune surveillance mechanisms for the successful prevention of or combat against cancer and infectious diseases. On the other hand, they secure the homeostasis of the integument by preventing the development of exaggerated, tissue-destructive immune responses against per se innocuous moieties such as autoantigens and allergens.

---

*For our purpose, T cells are defined by the surface expression of CD3-associated TCRs. TCR species identified so far include aß and ?d heterodimers. [110] TCRs aß are expressed on most peripheral T cells and usually recognize the antigenic fragment in conjunction with MHC, [26] occasionally also together with CD1 antigens. [31] TCRs ?d are present on early fetal thymocytes, on a minor fraction of adult thymocytes and peripheral T cells, and, at least in the mouse system, on various proportions of lymphocytes populating epithelial tissues. These TCR ?d-bearing cells recognize a heterogeneous array of ligands including classic and nonclassic MHC antigens, bacterial heat shock proteins, and multiple self proteins. [111]

REFERENCES

1. Langerhans P: Über die Nerven der menschlichen Haut. *Virchows Arch* **44**:325, 1868

2. Cerio R et al: Characterization of factor XIIIa positive dermal dendritic cells in normal and inflamed skin. *Br J Dermatol* **121**:421, 1989

3. Banchereau J, Steinman RM: Dendritic cells and the control of immunity. *Nature* **392**:245, 1998

4. Wolff K: The Langerhans cell, in *Current Problems in Dermatology,* vol IV. Basel, Karger, 1972, p 79. Editor: J.W.H. Mali, Nijmegen, the Netherlands

5. Mizumoto N et al: CD39 is the dominant Langerhans cell-associated ecto-NTPDase: Modulatory roles in inflammation and immune responsiveness. *Nat Med* **8**:358, 2002

6. Birbeck M et al: An electron microscope study of basal melanocytes and high-level clear cells (Langerhans cells) in vitiligo. *J Invest Dermatol* **37**:51, 1961

7. Valladeau J et al: Langerin, a novel C-type lectin specific to Langerhans cells, is an endocytic receptor that induces the formation of Birbeck granules. *Immunity* **12**:71, 2000

8. Katz SI et al: Epidermal Langerhans cells are derived from cells originating in bone marrow. *Nature* **282**:324, 1979

9. Caux C et al: GM-CSF and TNF-a cooperate in the generation of dendritic Langerhans cells. *Nature* **360**:258, 1992

10. Caux C et al: CD34+ hematopoietic progenitors from human cord blood differentiate along two independent dendritic cell pathways in response to GM-CSF + TNF-a. *J Exp Med* **184**:695, 1996

11. Strobl H et al: TGF-ß1 promotes in vitro development of dendritic cells from CD34+ hemopoietic progenitors. *J Immunol* **157**:1499, 1996

12. Jaksits S et al: CD34+ cell-derived CD14+ precursor cells develop into Langerhans cells in a transforming growth factor ß1-dependent manner. *J Immunol* **163**:4869, 1999

13. Larregina AT et al: Dermal-resident CD14+ cells differentiate into Langerhans cells. *Nat Immunol* **2**:1151, 2001

14. Charbonnier A-S et al: Macrophage inflammatory protein 3a is involved in the constitutive trafficking of epidermal Langerhans cells. *J Exp Med* **190**:1755, 1999

15. Morales J et al: CTACK, a skin-associated chemokine that preferentially attracts skin-homing memory T cells. *Proc Natl Acad Sci U S A* **96**:14470, 1999

16. Homey B et al: Cutting edge: the orphan chemokine receptor G protein-coupled receptor-2 (GPR-2, CCR10) binds the skin-associated chemokine CCL27 (CTACK/ALP/ILC). *J Immunol* **164**:3465, 2000

17. Tang A et al: Adhesion of epidermal Langerhans cells to keratinocytes mediated by E-cadherin. *Nature* **361**:82, 1993

18. Matzinger P: Tolerance, danger, and the extended family. *Annu Rev Immunol* **12**:991, 1994

19. Hawiger D et al: Dendritic cells induce peripheral T cell unresponsiveness under steady state conditions in vivo. *J Exp Med* **194**:769, 2001

20. Schuler G, Steinman RM: Murine epidermal Langerhans cells mature into potent immunostimulatory dendritic cells in vitro. *J Exp Med* **161**:526, 1985

21. Weiss JM et al: Osteopontin is involved in the initiation of cutaneous contact hypersensitivity by inducing Langerhans and dendritic cell migration to lymph nodes. *J Exp Med* **194**:1219, 2001

22. Kriehuber E et al: Isolation and characterization of dermal lymphatic and blood endothelial cells reveal stable and functionally specialized cell lineages. *J Exp Med* **194**:797, 2001

23. Ingulli E et al: In vivo detection of dendritic cell antigen presentation to CD4+ T cells. *J Exp Med* **185**:2133, 1997

24. Wang J et al: Inherited human caspase 10 mutations underlie defective lymphocyte and dendritic cell apoptosis in autoimmune lymphoproliferative syndrome type II. *Cell* **98**:47, 1999

25. Medzhitov R, Janeway CA Jr: Innate immunity: Impact on the adaptive immune response. *Curr Opin Immunol* **9**:4, 1997

26. Davis MM et al: Ligand recognition by aß T cell receptors. *Annu Rev Immunol* **16**:523, 1998

27. Germain RN, Margulies DH: The biochemistry and cell biology of antigen processing and presentation. *Annu Rev Immunol* **11**:403, 1993

28. Pamer E, Cresswell P: Mechanisms of MHC class I-restricted antigen processing. *Annu Rev Immunol* **16**:323, 1998

29. Huang AYC et al: Role of bone marrow-derived cells in presenting MHC class I-restricted tumor antigens. *Science* **264**:961, 1994

30. Watts C: Capture and processing of exogenous antigens for presentation on MHC molecules. *Annu Rev Immunol* **15**:821, 1997

31. Porcelli SA, Modlin RL: The CD1 system: Antigen-presenting molecules for T cell recognition of lipids and glycolipids. *Annu Rev Immunol* **17**:297, 1999

32. Toews GB et al: Epidermal Langerhans cell density determines whether contact hypersensitivity or unresponsiveness follows skin painting with DNFB. *J Immunol* **124**:445, 1980

33. Stingl G et al: Antigen presentation by murine epidermal Langerhans cells and its alteration by ultraviolet B light. *J Immunol* **127**:1707, 1981

34. Inaba K et al: Immunologic properties of purified epidermal Langerhans cells. Distinct requirements for stimulation of unprimed and sensitized T lymphocytes. *J Exp Med* **164**:605, 1986

35. Hauser C, Katz SI: Activation and expansion of hapten- and protein-specific T helper cells from nonsensitized mice. *Proc Natl Acad Sci U S A* **85**:5625, 1988

36. Romani N et al: Presentation of exogenous protein antigens by dendritic cells to T cell clones. Intact protein is presented best by immature, epidermal Langerhans cells. *J Exp Med* **169**:1169, 1989

37. Mueller DL et al: Clonal expansion versus functional clonal inactivation: A costimulatory signaling pathway determines the outcome of T cell antigen receptor occupancy. *Annu Rev Immunol* **7**:445, 1989

38. Greenfield EA et al: CD28/B7 costimulation: A review. *Crit Rev Immunol* **18**:389, 1998

39. van Parijs L, Abbas AK: Homeostasis and self-tolerance in the immune system: Turning lymphocytes off. *Science* **280**:243, 1998

40. Rescigno M et al: Coordinated events during bacteria-induced DC maturation. *Immunol Today* **20**:200, 1999

41. Sauter B et al: Consequences of cell death: exposure to necrotic tumor cells, but not primary tissue cells or apoptotic cells, induces the maturation of immunostimulatory dendritic cells. *J Exp Med* **191**:423, 2000

42. Akira S et al: Toll-like receptors: critical proteins linking innate and acquired immunity. *Nat Immunol* **2**:675, 2001

43. Hemmi H et al: Small anti-viral compounds activate immune cells via the TLR7 MyD88-dependent signaling pathway. *Nat Immunol* **3**:196, 2002

44. Silberberg-Sinakin I et al: Antigen-bearing Langerhans cells in skin, dermal lymphatics and in lymph nodes. *Cell Immunol* **25**:137, 1976

45. Weiss JM et al: An essential role for CD44 variant isoforms in epidermal Langerhans cell and blood dendritic cell function. *J Cell Biol* **137**:1137, 1997

46. Engeman TM et al: Inhibition of functional T cell priming and contact hypersensitivity responses by treatment with anti-secondary lymphoid chemokine antibody during hapten sensitization. *J Immunol* **164**:5207, 2000

47. Stoeckl J et al: Monomorphic molecules function as additional recognition structures on haptenated target cells for HLA-A1-restricted, hapten-specific CTL. *J Immunol* **167**:2724, 2001

48. Enk AH, Katz SI: Early molecular events in the induction phase of contact sensitivity. *Proc Natl Acad Sci U S A* **89**:1398, 1992

49. de Saint-Vis B et al: The cytokine profile expressed by human dendritic cells is dependent on cell subtype and mode of activation. *J Immunol* **160**:1666, 1998

50. Abbas AK et al: Functional diversity of helper T lymphocytes. *Nature* **383**:787, 1996

51. Fé d'Ostiani C et al: Dendritic cells discriminate between yeasts and hyphae of the fungus *Candida albicans*. Implications for initiation of T helper cell immunity in vitro and in vivo. *J Exp Med* **191**:1661, 2000

52. Kalinski P et al: Final maturation of dendritic cells is associated with impaired responsiveness to IFN-? and to bacterial IL-12 inducers: Decreased ability of mature dendritic cells to produce IL-12 during the interaction with Th cells. *J Immunol* **162**:3231, 1999

53. Dong H et al: B7-H1, a third member of the B7 family, costimulates T-cell proliferation and interleukin-10 secretion. *Nat Med* **5**:1365, 1999

54. Xu H et al: T cell populations primed by hapten sensitization in contact sensitivity are distinguished by polarized patterns of cytokine production: interferon ?-producing (Tc1) effector CD8+ T cells and interleukin (IL) 4/IL-10-producing (Th2) negative regulatory CD4+ T cells. *J Exp Med* **183**:1001, 1996

55. Ridge JP et al: A conditioned dendritic cell can be a temporal bridge between a CD4+ T-helper and a T-killer cell. *Nature* **393**:474, 1998

56. Grabbe S et al: Tumor antigen presentation by murine epidermal cells. *J Immunol* **146**:3656, 1991

57. Condon C et al: DNA-based immunization by in vivo transfection of dendritic cells. *Nat Med* **2**:1122, 1996

58. Steinman RM, Dhodapkar M: Active immunization against cancer with dendritic cells: The near future. *Int J Cancer* **94**:459, 2001

59. Steinbrink K et al: Low zone tolerance to contact allergens in mice: A functional role for CD8+ T helper type 2 cells. *J Exp Med* **183**:759, 1996

60. Shevach EM et al: Control of T-cell activation by CD4+ CD25+ suppressor T cells. *Immunol Rev* **182**:58, 2001

61. Jonuleit H et al: Induction of interleukin 10-producing, nonproliferating CD4+ T cells with regulatory properties by repetitive stimulation with allogeneic immature human dendritic cells. *J Exp Med* **192**:1213, 2000

62. Shreedhar VK et al: Origin and characteristics of ultraviolet-B radiation-induced suppressor T lymphocytes. *J Immunol* **161**:1327, 1998

63. Cavani A et al: Effector and regulatory T cells in allergic contact dermatitis. *Trends Immunol* **22**:118, 2001

64. Wollenberg A et al: Langerhans cell phenotyping: a new tool for differential diagnosis of inflammatory skin diseases. *Lancet* **346**:1626, 1995

65. Stingl G, Maurer D: IgE-mediated allergen presentation via FceRI on antigen-presenting cells. *Int Arch Allergy Immunol* **113**:24, 1997

66. Kraft S, Bieber T: FceRI-mediated activation of transcription factors in antigen-presenting cells. *Int Arch Allergy Immunol* **125**:9, 2001

67. Tschachler E et al: Epidermal Langerhans cells—A target for HTLV-III/LAV infection. *J Invest Dermatol* **88**:233, 1987

68. Kawamura T et al: Low levels of productive HIV infection in Langerhans cell-like dendritic cells differentiated in the presence of TGF-ß1 and increased viral replication with CD40 ligand-induced maturation. *Eur J Immunol* **31**:360, 2001

69. Pope M et al: Conjugates of dendritic cells and memory T lymphocytes from skin facilitate productive infection with HIV-1. *Cell* **78**:389, 1994

70. Geijtenbeek TBH et al: DC-SIGN, a dendritic cell-specific HIV-1-binding protein that enhances *trans*-infection of T cells. *Cell* **100**:587, 2000

71. Woods GM et al: Carcinogen-modified dendritic cells induce immunosuppression by incomplete T-cell activation resulting from impaired antigen uptake and reduced CD86 expression. *Immunology* **99**:16, 2000

72. Kripke ML: Photoimmunology. *Photochem Photobiol* **52**:919, 1990

73. Cruz PD Jr et al: Disparate effects of in vitro low-dose UVB irradiation on intravenous immunization with purified epidermal cell subpopulations for the induction of contact hypersensitivity. *J Invest Dermatol* **92**:160, 1989

74. Kripke ML et al: Pyrimidine dimers in DNA initiate systemic immunosuppression in UV-irradiated mice. *Proc Natl Acad Sci U S A* **89**:7516, 1992

75. Vink AA et al: The inhibition of antigen-presenting activity of dendritic cells resulting from UV irradiation of murine skin is restored by in vitro photorepair of cyclobutane pyrimidine dimers. *Proc Natl Acad Sci U S A* **94**:5255, 1997

76. Schwarz A et al: Interleukin-12 suppresses ultraviolet radiation-induced apoptosis by inducing DNA repair. *Nat Cell Biol* **4**:26, 2002

77. Enk AH et al: Induction of hapten-specific tolerance by interleukin 10 in vivo. *J Exp Med* **179**:1397, 1994

78. Beissert S et al: Regulation of tumor antigen presentation by urocanic acid. *J Immunol* **159**:92, 1997

79. Hammerberg C et al: Active induction of unresponsiveness (tolerance) to DNFB by in vivo ultraviolet-exposed epidermal cells is dependent upon infiltrating class II MHC+ CD11b bright monocytic/macrophagic cells. *J Immunol* **153**:4915, 1994

80. Aberer W et al: Ultraviolet light depletes surface markers of Langerhans cells. *J Invest Dermatol* **76**:202, 1981

81. Hosoi J et al: Regulation of Langerhans cell function by nerves containing calcitonin gene–related peptide. *Nature* **363**:159, 1993

82. Kupper TS, Groves RW: The interleukin-1 axis and cutaneous inflammation. *J Invest Dermatol* **105**:62S, 1995

83. Cerwenka A, Swain SL: TGF-ß1: Immunosuppressant and viability factor for T lymphocytes. *Microbes Infect* **1**:1291, 1999

84. Schroeder J-M: Cytokine networks in the skin. *J Invest Dermatol* **105**:20S, 1995

85. Enk AH, Katz SI: Identification and induction of keratinocyte-derived IL-10. *J Immunol* **149**:92, 1992

86. Blauvelt A et al: Interleukin-15 mRNA is expressed by human keratinocytes, Langerhans cells, and blood-derived dendritic cells and is downregulated by ultraviolet B radiation. *J Invest Dermatol* **106**:1047, 1996

87. Stoll S et al: Production of IL-18 (IFN-?–inducing factor) messenger RNA and functional protein by murine keratinocytes. *J Immunol* **159**:298, 1997

88. Koeck A et al: Human keratinocytes are a source for tumor necrosis factor a: Evidence for synthesis and release upon stimulation with endotoxin or ultraviolet light. *J Exp Med* **172**:1609, 1990

89. Fenjves ES et al: Systemic distribution of apolipoprotein E secreted by grafts of epidermal keratinocytes: implications for epidermal function and gene therapy. *Proc Natl Acad Sci U S A* **86**:8803, 1989

90. Reiss Y et al: CC chemokine receptor (CCR)4 and the CCR10 ligand cutaneous T cell- attracting chemokine (CTACK) in lymphocyte trafficking to inflamed skin. *J Exp Med* **194**:1541, 2001

91. Schauer E et al: Proopiomelanocortin-derived peptides are synthesized and released by human keratinocytes. *J Clin Invest* **93**:2258, 1994

92. Grabbe S et al: a-Melanocyte–stimulating hormone induces hapten-specific tolerance in mice. *J Immunol* **156**:473, 1996

93. Risso A: Leukocyte antimicrobial peptides: Multifunctional effector molecules of innate immunity. *J Leukoc Biol* **68**:785, 2000

94. Frohm M et al: The expression of the gene coding for the antibacterial peptide LL-37 is induced in human keratinocytes during inflammatory disorders. *J Biol Chem* **272**:15258, 1997

95. Harder J et al: Isolation and characterization of human ß–defensin-3, a novel human inducible peptide antibiotic. *J Biol Chem* **276**:5707, 2001

96. Dorschner RA et al: Cutaneous injury induces the release of cathelicidin anti-microbial peptides active against group A *Streptococcus. J Invest Dermatol* **117**:91, 2001

97. Nizet V et al: Innate antimicrobial peptide protects the skin from invasive bacterial infection. *Nature* **414**:454, 2001

98. Yang D et al: ß-Defensins: linking innate and adaptive immunity through dendritic and T cell CCR6. *Science* **286**:525, 1999

99. Darr D, Fridovich I: Free radicals in cutaneous biology. *J Invest Dermatol* **102**:671, 1994

100. Bruch-Gerharz D et al: Nitric oxide in human skin: Current status and future prospects. *J Invest Dermatol* **110**:1, 1998

101. Freedberg IM et al: Keratins and the keratinocyte activation cycle. *J Invest Dermatol* **116**:633, 2001

102. Kaegi D et al: Molecular mechanisms of lymphocyte-mediated cytotoxicity and their role in immunological protection and pathogenesis in vivo. *Annu Rev Immunol* **14**:207, 1996

103. Chan FK-M et al: Signaling by the TNF receptor superfamily and T cell homeostasis. *Immunity* **13**:419, 2000

104. Kehren J et al: Cytotoxicity is mandatory for CD8+ T cell-mediated contact hypersensitivity. *J Exp Med* **189**:779, 1999

105. Viard I et al: Inhibition of toxic epidermal necrolysis by blockade of CD95 with human intravenous immunoglobulin. *Science* **282**:490, 1998

106. Volc-Platzer B et al: Evidence of HLA-DR antigen biosynthesis by human keratinocytes in disease. *J Exp Med* **159**:1784, 1984

107. Gaspari AA, Katz SI: Induction and functional characterization of class II MHC (Ia) antigens on murine keratinocytes. *J Immunol* **140**:2956, 1988

108. Bal V et al: Antigen presentation by keratinocytes induces tolerance in human T cells. *Eur J Immunol* **20**:1893, 1990

109. Marelli-Berg FM et al: Antigen presentation by epithelial cells induces anergic immunoregulatory CD45RO+ T cells and deletion of CD45RA+ T cells. *J Immunol* **159**:5853, 1997

110. Clevers H et al: The T cell receptor/CD3 complex: A dynamic protein ensemble. *Annu Rev Immunol* **6**:629, 1988

111. Hayday AC: ?d Cells: A right time and a right place for a conserved third way of protection. *Annu Rev Immunol* **18**:975, 2000

112. Stingl G et al: Thy-1+ dendritic epidermal cells express T3 antigen and the T-cell receptor chain. *Proc Natl Acad Sci U S A* **84**:4586, 1987

113. Havran WL, Allison JP: Origin of Thy-1+ dendritic epidermal cells of adult mice from fetal thymic precursors. *Nature* **344**:68, 1990

114. Foster CA et al: Human epidermal T cells predominately belong to the lineage expressing a/ß T cell receptor. *J Exp Med* **171**:997, 1990

115. Bos JD et al: T-cell receptor ?d bearing cells in normal human skin. *J Invest Dermatol* **94**:37, 1990

116. Bos JD et al: Skin-homing T lymphocytes: Detection of cutaneous lymphocyte-associated antigen (CLA) by HECA-452 in normal human skin. *Arch Dermatol Res* **285**:179, 1993

117. Levings MK et al: Human CD25+ CD4+ T regulatory cells suppress naive and memory T cell proliferation and can be expanded in vitro without loss of function. *J Exp Med* **193**:1295, 2001

118. Groh V et al: Double-negative (CD4– CD8–) lymphocytes bearing T-cell receptor a and ß chains in normal human skin. *Proc Natl Acad Sci U S A* **86**:5059, 1989

119. Shiohara T, Moriya N: Epidermal T cells: Their functional role and disease relevance for dermatologists. *J Invest Dermatol* **109**:271, 1997

120. Picker LJ et al: A unique phenotype of skin-associated lymphocytes in humans. Preferential expression of the HECA-452 epitope by benign and malignant T cells at cutaneous sites. *Am J Pathol* **136**:1053, 1990

121. Homey B et al: CCL27-CCR10 interactions regulate T cell-mediated skin inflammation. *Nat Med* **8**:157, 2002

122. Vestergaard C et al: A Th2 chemokine, TARC, produced by keratinocytes may recruit CLA+CCR4+ lymphocytes into lesional atopic dermatitis skin. *J Invest Dermatol* **115**:640, 2000

123. Lechleitner S et al: Peripheral lymph node addressins are expressed on skin endothelial cells. *J Invest Dermatol* **113**:410, 1999

124. Streilein JW: Skin-associated lymphoid tissues (SALT): Origins and functions. *J Invest Dermatol* **80**:12S, 1983

T>

Chapter 24

Madeleine Duvic

Influence of the HLA System on Disease Susceptibility

ORIGINS AND STRUCTURE OF HLA
The Trimolecular Complex
HLA AND DISEASE ASSOCIATIONS
Psoriasis
Vasculitis
Behçet's Syndrome
Sarcoidosis
Bullous or Blistering Diseases
Skin Cancer
SIGNIFICANCE

REFERENCES

ORIGINS AND STRUCTURE OF HLA

In 1948, Gorer and coworkers found that rejection of tissue transplants between two incompatible members of the same species is caused by an immunologic reaction against “histocompatibility” antigens expressed on the surface of cells. [1] In humans, the major histocompatibility complex (MHC) or human leukocyte antigen (HLA) system is highly polymorphic; that is, each gene can have many variations or alleles. Human MHC is found on chromosome 6p21, where it extends over about 4000 kilobases of DNA [2] (Fig. 24-1). Antigens A, B, and C were defined by antibody reactivity from sera of multiparous women, and D was initially defined by lymphocyte cross reactivity. The C locus is located between A and B, and D lies on the other side of B. The genes for the fourth component of complement were localized between those for HLA-B and HLA-D. Class I, II, and III genes are usually inherited as a genetic unit, the haplotype. A haplotype consists of the complete set of A, B, C, and D (-DR, -DQ, and -DP) antigens present on one chromosome, but in approximately 1 percent of the population genetic recombination (crossover) occurs. [2] Each person expresses two antigens (alleles) for each locus (A, B, C, D), and each parent has two haplotypes. The child inherits (according to Mendelian laws) one haplotype from each parent.



FIGURE 24-1 A simplified map of the major histocompatibility complex on the short arm (p) of chromosome 6. Only genes encoding a known protein product are shown, and class I and II genes are given special attention.

Class I HLA antigens (A, B, C) are 43- to 45-kDa cell surface glycoproteins with three external domains that complex with a smaller ß $_2$-microglobulin encoded by a gene on chromosome 19. Class I antigens are expressed on all nucleated cells but not on red blood cells.

Several other nonclassical MHC class I–like, or class Ib, genes encode nonpolymorphic molecules: CD1, the neonatal Fc receptor for IgG, HLA-G, HLA-E, the MHC class I chain–related gene A, and Hfe. [3]

Class II genes (D) encode surface B cell alloantigens or Ia antigens expressed only on immunocompetent cells: B lymphocytes, macrophages, dendritic cells, and Langerhans cells. Three major subregions of class II are HLA-DR, -DQ, and -DP. Class II molecules present antigens to the T cell receptors on helper (CD4+) T cells. [4] Both immune response and immune suppression genes are thought to exist in the D region.

The class III region contains complement genes and genes for the tumor necrosis factors. Class III genes encode the C2 and C4 components of the classical complement pathway and factor B (Bf) of the alternate complement pathway. [5] Tumor necrosis factor (alpha and beta) and the steroid hormone 21-hydroxylase are in this region.

The Trimolecular Complex

The trimolecular complex or immunologic synapse is composed of the antigen-presenting cell expressing the HLA molecules, antigen, and the T cell receptor (TCR). [6] Antigen-presenting cells contain proteolytic enzymes that process proteins and transporter-associated proteins (TAPs) to load peptides onto the appropriate class I or class II MHC chain within the endoplasmic reticulum (see Fig. 24-2 and Fig. 28-3). Small polypeptides of 8 or 9 amino acids or 12 to 15 amino acids bind to MHC class I or class II molecules and are presented to CD8+ or CD4+ T cells, respectively. TCR is a heterodimer consisting of an a and ß chain, each containing a variable and constant region. The presence or absence of costimulatory molecules (B7, CD28) on T cells and antigen-presenting cells is also critical in determining whether a T cell becomes activated or remains quiet (tolerance). [6], [7] TCRs occur solely on T cell surfaces and recognize antigen fragments only when they are bound to MHC molecules from an identical source. [7] Thus, T cells are largely responsible

for the control of self versus non-self differentiation.

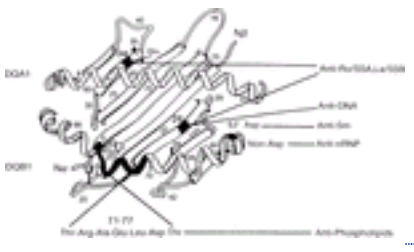

FIGURE 24-2 Representation of class II MHC structure for HLA-DQ molecules. Numbers indicate outermost domain amino acid positions encoded by HLA-DQA1 and -DQB1 alleles. Specific amino acid positions showing the strongest associations with selected lupus autoantibodies are highlighted. (*From Arnett and Reveille,* [90] *with permission.*)

HLA AND DISEASE ASSOCIATIONS

Autoreactive helper T cells are involved in the onset and maintenance of autoimmune disease. Environmental injury (toxin, viral disease, or bacterial pathogen) may trigger autoimmunity by providing antigen that mimics a host protein (molecular mimicry). [8] HLA antigens control which peptides are ultimately seen by T cells and thereby may be a major disease determinant for immunologically mediated diseases. HLA and other genetic factors are termed *susceptibility genes* as they modify the risk of getting a disease but are neither necessary nor sufficient for it to develop. For most autoimmune skin diseases, HLA-DQ genes are the primary susceptibility genes in this region, although other genes may contribute.

In addition to traditional antigen presentation, specific sequences on HLA chains can link superantigens to the TCR, resulting in T cell proliferation. [9] With respect to skin diseases, ?-interferon can induce keratinocytes to express HLA class II molecules, in turn, activating T cells in the presence of superantigens. [10] Several skin diseases, including Kawasaki's disease, atopic dermatitis/eczema, psoriasis, and cutaneous T cell lymphoma (CTCL), are thought to be initiated or exacerbated by streptococcal or staphylococcal bacterial superantigens. Superantigens bypass the need for antigen processing but depend on specific amino acids for binding to HLA class II molecules.

Certain HLA alleles are more common among different ethnic groups, and they are inherited together as a common haplotype. Thus, connections between disease incidence and frequency of HLA alleles often differ by race or ethnicity. In some cases, however, the same epitopes that cause susceptibility may be carried on other haplotypes. In studying HLA frequency in a disease, the control group must be composed of healthy, unrelated persons and must coincide with the disease group for ethnic lineage and geographic area of residence. A quantitative measure of the strength of an association between a given disease and an HLA antigen is called the *relative risk* (RR). The RR represents a measure of the risk of contracting a disease for an individual who possesses the antigen in question, as compared to the risk for an individual lacking that antigen (see footnote to Table 24-1 for calculation of RR).



TABLE 24-1 **HLA Alleles and Dermatologic Disease Associations**

The first HLA disease associations in humans related to cancer—nasopharyngeal carcinoma and the antigen HLA-Bw46 (formerly Singapore 2). This antigen is found only in those areas of Asia where nasopharyngeal carcinoma is comparatively common. (In antigen designations that include a w, such as Bw46, the w indicates a working status; the antigen has not been completely or officially acknowledged internationally.) In the Japanese and black Africans, in whom B27 is rare, ankylosing spondylitis is also rare, whereas in North American Indians, in whom B27 is common, ankylosing spondylitis is also common. [11]

A positive association of a gene with a disease can arise in one of two ways: (1) the associated polymorphism truly does have a pathogenic role in the disease, or (2) it is in linkage disequilibrium with a pathogenic mutation on another gene nearby. An individual's MHC ancestral haplotype is the clearest single determinant of susceptibility to MHC-associated immunopathologic diseases, and it defines the alleles carried at all loci in the MHC. There are 150 to 200 genes in the MHC, but their direct effect in causing disease is difficult to determine because recombination occurs only at defined hot spots. [12]

Because HLA chain variable sequences are critical for peptide binding, there was an expectation that associated peptides could be isolated from the HLA groove and unlock the secret of autoimmune diseases. This has proven to be more difficult than expected. Furthermore, in the case of psoriasis, as noted below, HLA associations appear to result only from linkage disequilibrium with an unknown disease-causing gene. In this case, the polymorphic alleles of the HLA region served as the first genetic markers for finding disease-related genes through association and linkage studies. Table 24-1 outlines some published associations between HLA antigens with selected dermatologic diseases discussed below.

Psoriasis (See Chap. 42)

Psoriasis is a T cell–mediated immune reaction causing increased keratinocyte proliferation. Like type I diabetes, psoriasis is a complex genetic trait with major susceptibility conferred by the HLA locus and an environmental trigger. [13] Psoriasis was first associated with HLA class I alleles and subsequently with the extended HLA haplotype: HLA-DR4, -DR7, -DQw7, -DQw9, -DP15, and -DP18. [14] The RR for Cw6 in all forms of psoriasis is only 7.0, whereas for HLA-DR*406 it is 21.6. [15] The sequences of DR4 subtypes show a unique serine substitution for tyrosine at position 37 in DR406 that may influence the configuration of the HLA groove and peptide binding. [16]

Type I or early onset psoriasis is associated with the HLA-Cw6, allele Cw*0602, found in up to 67 percent of patients with psoriasis. Psoriasis develops in only about 10 percent of HLA-Cw6-positive individuals. [13], [14] Guttate psoriasis can be triggered by group A ß-hemolytic streptococcus superantigen. [17] All patients with guttate psoriasis have the HLA-Cw*602 allele, in contrast to 20 percent of controls having the allele, suggesting an important and highly significant relationship (odds ratio = infinity; 95 percent confidence limits 25.00-infinity; P corrected < 0.0000002). [18]

Recent studies suggest that Cw6 is not the disease-conferring gene; rather, it is found on a common inherited ancestral haplotype in linkage disequilibrium with a more closely linked putative disease-causing gene PSORS1. [13] The psoriasis gene resides within a 111-kb interval telomeric to HLA-C and centromeric to the corneodesmosin gene. [19] Several genes, including corneodesmosin (S-gene) and HCR, have been excluded, and the OTF3 polymorphism may confer susceptibility independent of HLA-Cw*602. [13], [19], [20], [21] and [22] Psoriasis susceptibility loci have also been mapped to other chromosomes. [14], [23], [24]

Approximately 5 to 7 percent of patients with psoriasis also have psoriatic arthritis, and genetic heterogeneity is suggested. HLA-B38 and -B39 are increased in those whose peripheral joints are affected, but these antigens are not in linkage with HLA-Cw6. Although the strong association between ankylosing spondylitis and B27 is widely known, HLA-B27 also is found among 50 percent of patients with psoriasis who have arthritis of the spine (sacroiliitis or spondylitis). Antigens B27, B39, and DQw3 have also been shown to be risk factors for (and important predictors of) progression of psoriatic arthritis. Pustular forms of psoriasis also have a strong association with HLA-B27 (56 to 75 percent of patients versus 8 percent of normal control subjects) but not with Cw6, B13, B17, or B37. An increased frequency of HLA-DRB1*0402 is found in psoriasis patients with rheumatoid arthritis (RA)-like arthritis. [25] Thus, these patients differ, clinically and genetically, from those having psoriasis vulgaris limited to the skin. [26]

Vasculitis (See Chap. 174 and Chap. 175)

Vasculitis, a heterogeneous group of disorders, is characterized by vessel type and size and composition of circulating immune complexes. Various genes, including the MHC, gender, and environmental factors may account for differences in clinical presentation. [27] In giant cell arteritis, HLA-DRB1*04 alleles are associated with risk of ominous visual complications. Takayasu's arteritis, involving the aorta and coronary arteries, occurs in Japan in association with the haplotype HLA-Bw52, Dw12, DRB2, and DQw1. [27] In Kawasaki's disease, a polymorphism of the MHC class I chain-related gene (MICA), located near HLA-B, is associated with susceptibility to coronary aneurysm formation. [28]

There are no clear-cut HLA associations to distinguish primary systemic vasculitides involving medium to small vessels: polyarteritis nodosa (PAN), microscopic polyangiitis, Wegener's granulomatosis (WG), and Churg-Strauss syndrome (CSS). WG is associated with HLA-DR1, DR2, and HLA-DQw7. [28] An HLA class I deficiency has been reported in a few patients with destructive granuloma in the respiratory mucosa resembling WG who were found to have defective expression of the TAP-2, an HLA locus gene. [29]

Small vessel vasculitis includes Henoch-Schönlein purpura (HSP), hypersensitivity vasculitis, cutaneous leukocytoclastic angiitis (CLA), and vasculitis secondary to essential mixed cryoglobulinemia. Patients with HSP may have deficiencies in the second and fourth components of complement, including C4 gene deletion. Associations with HLA-B35, HLA-DRB1*01, and DRB1*11 have been described. [30] HLA-DRB1*11 is associated with hepatitis C–associated cryoglobulinemia with vasculitis. [31]

Behçet's Syndrome (See Chap. 192)

Behçet's syndrome is characterized by severe uveitis, aphthae-like lesions of the mouth and genitalia, arthritis, and diffuse vasculitis. The etiology is unknown, but there is a strong association with HLA-B51, which suggests a genetic basis. The disorder is prevalent in males in the Near and Far East. Arber et al. found that HLA-B51 and -B52 were present in 24 of 38 (63 percent) Jews and 8 of 38 (21 percent) Arabs in Israel, as compared with 13 of 151 (9 percent) control subjects (RR = 18.2 and 2.8, respectively). [32] B51 antigen has 21 alleles, B*5101–B*5121. [33] Although HLA-B*5101 and HLA-B*5108 are increased in Italian and Arab patients, HLA-B*5101 is most highly significant in Japanese patients (RR = 9.3). [33], [34] In Chinese patients, DQ alleles associated with mucocutaneous disease

distinguished Behçet's syndrome from recurrent aphthous stomatitis. [35]

What is the significance of the B51 association? Excessive function of peripheral blood neutrophils in Behçet's syndrome has been related to B51. Behçet's syndrome is found only in B51 suballeles sharing amino acid residues at positions 63 and 67 and positions 77 to 83 for specific peptide binding and natural killer (NK) cell interactions. [34] Finally, a non-HLA gene carried on the HLA-B*5101 haplotype may be responsible for susceptibility to Behçet's syndrome. [36]

Sarcoidosis (See Chap. 183)

Sarcoidosis, a systemic noncaseating granulomatous disorder of unknown etiology, affects skin as well as other organs. Sarcoid is associated with HLA-A1, -B8, and -DR3 in European patients. HLA alleles are associated with specific clinical features: HLA-B27 with lung disease, HLA-B13 and -B35 with early onset, and HLA-DR3 with good outcome. HLA may interact with immunoglobulin to influence severity of the disease. One cluster, HLA-DR4, C4BQ0, Gm (1, 3, 17 23 5*, 21, 28), and BfF, is associated with stage II sarcoidosis, and another, HLA-DR3, C4AQ0, ? $_m$ (1) and Gm (3 23 5*), is associated with stage I disease. [37]

In multiplex families, multipoint nonparametric linkage (NPL) analysis showed linkage (NPL score > 2.5; $P < 0.006$) for the entire MHC region with a maximum NPL score of 3.2 ($P = 0.0008$) at marker locus D6S1666 in the class III gene cluster. [38] Lung-restricted expansions of T cells with a specific T cell receptor are associated with HLA-DRB1*0301 (DR17) and -DRB3*0101 alleles, suggesting the presence of a specific antigen triggering sarcoidosis. [39]

Bullous or Blistering Diseases

The bullous diseases have a humoral response to distinct adhesion molecules in epidermis or dermoepidermal basement membrane zone. Autoreactive T cells play a role in antibody production and are HLA restricted.

PEMPHIGUS VULGARIS AND FOLIACEUS (See Chap. 59) Pemphigus vulgaris (PV) is a potentially fatal autoimmune blistering disease, more common in Jewish persons in the fourth or fifth decades. Susceptibility to PV is associated with HLA-DR4 serologic specificity among Ashkenazi Jews, and with DR4 (DRB1*0402) as well as DR6 (DR14) in linkage disequilibrium with DQB1*0503 in other ethnic groups. [40] Serum from patients with PV has autoantibodies against desmoglein 3 (Dsg3), whereas pemphigus foliaceus (PF) is characterized by more superficial ulcerations and by autoantibodies to desmoglein 1. Nine Japanese patients with PV and five of seven patients with PF carried one or two alleles of HLA-DRB1*04 (*0403, *0406) and HLA-DRB1*14 (*1401, *1405, *1406) subtypes. Sequence analysis of DRB1*04 and DRB1*14 alleles showed conservation of phenylalanine at position 26 and valine at position 86 with the DRB1*0402 allele that reportedly also confers a strong susceptibility to PV in Ashkenazi Jews. [41] In a study of 87 Italian patients with PV and PF, DRB1*04 and DRB1*14 were increased, while DRB1*07 was decreased in both groups of patients relative to control subjects. [42] A significant association was found between DRB1*1401 and PV ($P < 0.0001$) as well as PF ($P < 0.0001$) in addition to a significant increase of the linked DQB1*0503 (PV $P < 0.0001$; PF $P < 0.0001$). The association between DRB1*0402 and PV ($P < 0.0001$) has been confirmed; and furthermore, PV and PF share DRB1*1401 and DQB1*0503, as susceptible HLA alleles, whereas DRB1*0402 is found to be associated only with PV. Three groups of Brazilian patients with fogo selvagem (FS) carried DRB1*0404, *1402, or *1406 ($P < 0.005$, RR = 14). These share the same amino acid sequence at positions 67 to 74 on the third hypervariable region of the DRB1 gene, LLEQRRAA, suggesting that inheritance of this epitope is involved in the susceptibility to FS ($P < 0.00001$, RR = 6.4). Because both PV and PF carry the same susceptible HLA alleles, the explanation for differences in the diseases are not yet known and are hypothesized to reside in other genes or in environmental exposure. The HLA alleles associated with drug-triggered pemphigus are identical to those predisposing to idiopathic pemphigus, suggesting that HLA alleles may be true disease susceptibility genes in pemphigus. Of interest, healthy unaffected relatives with the same HLA types as affected patients with pemphigus may also have pemphigus autoantibodies. [43] Pemphigoid gestationis (see Chap. 64) is a rare autoimmune vesiculobullous disease associated with pregnancy that is closely related to the pemphigoid group of blistering disorders. It is characterized by linear deposition of C3 along the basement membrane zone (BMZ) of perilesional skin. The disease may be triggered by inappropriate expression of HLA on the placenta, presenting antigen that cross-reacts with skin. DR3 and DR4 class II are associated with pemphigoid gestationis. [44]

BULLOUS PEMPHIGOID (See Chap. 61) In mucous membrane pemphigoid (MMP) circulating IgA or IgG antibodies detect BMZ antigens (BP230 and BP180). The HLA-DQB1*0301 allele confers a predisposition to all subgroups of MMP. DQB1*0301 is increased in patients with detectable circulating anti-BMZ IgG compared with those negative for IgG ($P < 0.0096$, P corrected < 0.019) but not for the subgroups with or without BP180 or BP230 target antigens. Haplotype frequencies show an increase in DRB1*04, DQB1*0301 (P corrected < 0.000066) and DRB1*11, DQB1*0301 (P corrected < 0.000002) among patients when compared with controls. [45]

ERYTHEMA MULTIFORME (See Chap. 58) Erythema multiforme (EM) includes EM minor, EM major (Stevens-Johnson syndrome), and toxic epidermal necrolysis (TEN). Autoantibodies against the desmosomal proteins desmoplakin I and II are detected in patients with EM defining clinical subsets. There is an increased frequency of certain HLA antigens reported in association with EM, including HLA-B15(B62), HLA-B35, HLA-A33, HLA-DR53, and, more recently, HLA-DQB1*0301. [46] Recurrent EM in young adults follows recurrent herpes simplex where it is highly associated with the DQB1*0301 allele (RR = 6.5; $P < 0.001$). [47] Certain HLA-DQB1 alleles may also be related to severity of mucous membrane or ocular involvement. Of 21 patients with herpes-associated EM, 13 had only minor or no involvement of mucous membranes and carried the HLA allele DQB1*0302 (phenotype frequency 61.9 percent versus 18.8 percent in controls, P corrected = 0.0008). All three patients with major involvement of mucous membranes had the rare HLA allele DQB1*0402 (phenotype frequency in controls 6.4 percent, P corrected = 0.017). [47] In another study, HLA-DQB1*0601, but not DQB1*0302, was found in a significantly disproportionate number of white patients with Stevens-Johnson syndrome and ocular complications. [48]

DERMATITIS HERPETIFORMIS (See Chap. 67) Dermatitis herpetiformis (DH), an autoimmune blistering disease in which granular IgA is deposited at the dermal–epidermal junction, is associated with gluten-sensitive enteropathy or celiac disease. HLA-DR3 is expressed in 95 percent and HLA-DQw2 in 100 percent of patients with DH. [49] Both DH and

celiac disease are strictly associated with class II HLA alleles A1*0501 and B1*02 encoding the HLA-DQ2 heterodimer. [50] Both are most highly associated with HLA DRB1*0301 (91 percent versus 22 percent of controls), HLA DQB1*02 (100 percent versus 32 percent of controls), and DPB1*0101 (39 percent and 14 percent). All patients with DH are positive for the DQA1*0501/DQB1*02 dimer in *cis* or *trans,* and this is probably responsible for presenting gliadin peptide implicated in the disease process. [50] HLA-DQw2 sequences in patients with DH do not differ from those in normal HLA-DQw2 subjects. Patients with celiac disease are homozygous for DR2 in contrast to patients with DH (65 percent versus 39 percent). Differences in dosage of HLA class II genotypes between DH and celiac disease may explain the milder gastrointestinal symptoms characteristic of DH. [51] There may be interactions between a specific DQ molecule and one of several different DPB1 alleles that contribute to susceptibility to the intestinal lesion that is common to DH and celiac disease. Sex differences have been found with regard to HLA DQ2 susceptibility in females. [51] The ancestral haplotype 8.1 (HLA-A1, C7, B8, C4AQ0, C4B1, DR3, DQ2) is carried by most whites with HLA-B8 and contains the tumor necrosis factor allele polymorphism TNF2. [52] This haplotype is also associated with accelerated HIV disease and susceptibility to insulin-dependent diabetes mellitus (IDDM), systemic lupus erythematosus (SLE), common variable immunodeficiency, IgA deficiency, myasthenia gravis, and several other conditions. [17]

EPIDERMOLYSIS BULLOSA (See Chap. 65) Epidermolysis bullosa (EB) has many variations caused by mutations in the components of the anchoring fibrils and BMZ proteins. In a small study, patients with recessive dystrophic EB had higher gene frequencies of haplotypes HLA-Bw62, HLA-DR4, DQw3, and HLA-Bw60, DR4, DQ3 than expected. [53]

EPIDERMOLYSIS BULLOSA ACQUISITA (See Chap. 66) Epidermolysis bullosa acquisita (EBA) and bullous SLE both have circulating IgG autoantibodies that react with type VII collagen molecules in anchoring fibrils. [54] HLA-DR2 is significantly increased in both black and white patients with EBA, and in patients with bullous SLE. [54]

SYSTEMIC LUPUS ERYTHEMATOSUS (See Chap. 171) Susceptibility to SLE is governed by a number of genes in the HLA region. [55] In whites, the association between the haplotype carrying HLA-B8, HLA-DR3, C4A gene deletion and tumor necrosis factor a (TNFa)–308A, the polymorphic variant of TNF-a, is well described. [55], [56] In Native Americans, DQ4 and DR8 are associated with SLE; and B7, DR2, and DQ6 are associated with SLE in Asians. In a large study of minority populations with lupus, HLA-DRB1*0301 (DR3), DRB1*1503 (DR2), and DRB1*08 (DR8) alleles were more frequently found in whites, African Americans, and Hispanics, respectively. Hispanics were more likely to have cardiac and renal disease; African Americans were more likely to have neurologic and renal disease. Patients with HLA-DRB1*01 had less renal disease. Disease severity was associated with poor socioeconomic status, suggesting that both genetic and environmental factors govern the presentation of SLE. [56] As many as 100 other genes may participate in SLE pathogenesis, and the contribution of the MHC is weak with a RR of 2 to 3. [57] Complete deficiency of one of the early complement components is the strongest known genetic risk factor for SLE. When the homozygous C4A null phenotype and HLA-DR2 are both present, the RR for SLE is 24.9. Davies et al. [56] found that the strongest association with SLE was for the combination of DQA*0501 and C4A*QO. Both DQA*0501 ($P = 0.02$) and C4A*QO ($P = 0.03$) seemed to have significant individual effects on SLE susceptibility, with a significant statistical interaction between the two loci ($P = 0.01$). Distinguishing between the effects of null genes for C4 and HLA-DR3 has been difficult due to marked linkage disequilibrium between DR3 and a null allele of C4A (C4A QO) in white populations. In patients who were negative for the anti-La antibody, only C4A*QO had a significant individual effect, although a significant statistical interaction between DQA*0501 and C4A*QO was again detected. These results suggest that susceptibility to SLE is related to several genes with different roles; HLA-DQA*0501 may affect autoantibodies, while C4A*QO may be implicated in immune complex clearance. [56] Autoantibodies to nucleic acids as well as proteins have been reported in the sera of patients with SLE (Table 24-2). The presence of particular autoantibodies or clinical manifestations are more highly correlated with specific HLA alleles in both SLE and systemic sclerosis than is the development of the disease per se. [57]

Disease	Autoantibody	HLA Allele
Systemic lupus erythematosus	Anti-Ro (SS-A)	HLA-DQA1,-DQB1
	Anti-La (SS-B)	HLA-DQA1,-DQB1
	Anti-phospholipids	HLA-DQB1
	Anti-Sm	HLA-DQA1*0102, -DQB1*0602
	Anti-nRNP	HLA-DQA1*0101, -DQB1*0501,
	Anti-dsDNA	HLA-DQB1*0201, *0602,0302
	Anti-EBA	HLA-DR2
Systemic sclerosis	Anticentromere	HLA-DQB1*0301, *0501,0402
	Anti-Topo I	HLA-DQB1*0301, *0302,*0602
	Anti-PM-Scl	HLA-DQB1*0201, (linked DR3)
	Anti-U1-RNP	HLA-DR4
	Anti-U3-RNP (fibrillarin)	HLA-DQB1*0602, *0604

*See Fig. 24-2.
Source: SLE: from Arnett and Reveille,[55] with permission; Rio: from Arnett,[56] with permission.

TABLE 24-2 **HLA-Determined Autoantibody Associations**

SYSTEMIC SCLEROSIS (See Chap. 173) Scleroderma [systemic sclerosis (SSc)] is an autoimmune disease with fibrosis of the skin and internal organs. A large study of 202 patients with SSc and with well-defined clinical phenotypes and serologic typing for the presence of disease-specific autoantibodies showed strong associations between the clinical phenotype and the presence of specific autoantibodies. [58] Antitopoisomerase autoantibody (ATA) was associated with pulmonary fibrosis ($P = 0.00002$), the anti-RNA polymerase autoantibody (ARA) with renal involvement ($P = 0.0000006$) and diffuse skin disease ($P = 0.00001$), and the anticentromere autoantibody (ACA) with limited skin involvement ($P = 0.00002$) and protection against pulmonary fibrosis ($P = 0.0000003$). HLA-DPB1*1301 was significantly associated with the ATA (P corrected = 0.0001). In addition, ATA was associated with HLA-DRB1*11 and the ACA with HLA-DRB1*04, HLA-DRB1*08 ($P = 0.001$) and HLA-DQB1 alleles with a glycine residue at position 26. HLA-DQB1*0301 is significantly associated with SSc per se in all ethnic groups. Whites were likely to have more ACA and African Americans more anti-U1-ribonucleoprotein (RNP) and anti-U3-RNP (fibrillarin) autoantibodies. HLA-DRB1*11 correlated with the antitopoisomerase I antibody response, and HLA-DRB1*01, DRB1*04, and DQB1*0501 with ACA. [59] The frequency of antibodies to fibrillin differs among ethnic groups but is not associated with HLA alleles. Class II antigens may influence the ability of the immune system to generate a response to intracellular autoantigens such as ATA to which it is not tolerized. [59] Previous studies have shown associations of DRB1 alleles with SSc but have rarely determined DQA1 allele frequencies. The DQA1*0501 allele is significantly increased among men with SSc as compared to healthy men [odds ratio (OR) 2.3, $P = 0.006$, P corrected = 0.04]. DQA1*0501 is associated with diffuse SSc in men (OR 3.0, $P = 0.004$, P corrected = 0.03) but not with limited SSc in men. DRB1 associations may be due to linkage disequilibrium with DQA1. The contribution of HLA genes to the risk of SSc appears to be greater in men than in parous women. [60] Lichen sclerosis

et atrophicus and morphea are both considered as localized variants of scleroderma with distinct presentations and occasional *Borrelia burgdorferi* infection. In a small case series, five of seven patients with lichen sclerosis and morphea had HLA-DQ7. [61], [62]

LICHEN PLANUS (See Chap. 49) Lichen planus (LP) is a T cell–mediated immune response similar to graft-versus-host disease. HLA alleles may vary depending on the cutaneous manifestations and with the presence of hepatitis C virus. Across ethnic groups, there appear to be no uniform HLA associations with LP. In Israeli Jewish patients with oral erosive LP, there was a significant association with HLA-DR2 (RR = 4.7) and a decrease in DR4 (RR = 0.3). [63] Arab patients with cutaneous LP had significant increases in the frequencies of HLA-DR1 (RR = 3.68) and DR10 (RR = 8.27). [64] Among 42 Japanese patients with oral LP, the frequency of DRw9 was significantly increased (RR = 3.3), and when DRw9 was carried on a Bw61/DRw9 haplotype, the RR was increased to 6.0. [65] In white British patients, HLA-Bw57 appeared to predispose a person to oral LP, whereas HLA-DQ1 seemed to be associated with resistance to it. [66] Patients with exclusive oral LP and hepatitis C virus infection possess the HLA-DR6 allele more frequently than patients with exclusive oral LP without hepatitis C virus infection (52 percent versus 18 percent, respectively; *P* corrected = 0.028, RR = 4.93). [67]

ALOPECIA AREATA (See Chap. 71) Alopecia areata (AA) is an organ-specific autoimmune reaction with T cells targeted to the hair follicle and phenotypic heterogeneity with progression to complete hair loss (alopecia totalis and universalis). In a study of identical twins, there was 55 percent concordancy, similar to psoriasis, which suggests that both genetic and environmental factors play a role. [68] Class I HLA associations for AA include HLA-B12 (RR = 5.4) for patchy AA, and HLA-B18, -B13, and -B27. [69] In 88 white Americans with AA, HLA-DR4 and -DR5 were increased relative to controls, and DRB3-w52a was significantly reduced (*P* = 0.00001). [70] The DR5 (DRw11) subtype DRB*1104 is significantly associated with persistent AA and juvenile onset. [71] DR5 associations reflect linkage disequilibrium with DQ alleles. Class II HLA-DQB1*03 alleles (*0301, *0302, or *0303) are found in 80 percent of all white patients with AA (n = 85) and in 92 percent of the subset with alopecia totalis or alopecia universalis (*P* corrected = 0.00003) (RR = 12). [71] DQB1*03 alleles are thought to participate directly in the pathogenesis of AA by binding peptides that initiate the immune response. These alleles all have a proline at position 55 that may interact in forming salt bridges between HLA-DQ a and ß heterodimers and stabilizing the HLA heterodimers. [71] In a cohort of Turkish patients with AA, the frequencies of HLA-A1, HLA-B62 (B15), HLA-DQ1, and HLA-DQ3 were significantly higher than those in control subjects, while HLA-DR16 was less frequent. Juvenile and severe involvement were related to HLA-Cw6 and HLA-DR1, respectively. [72] To confirm association studies in unrelated patients with AA, transmission dissociation testing and linkage were performed in AA multiplex families. [73] There is a significant association between AA and alleles of HLA-DQB (*P* = 0.009) and HLA-DR (*P* = 0.008). In particular, DQB1*302 (*P* = 0.0002), DQB1*601 (*P* = 0.041), DQB*603 (*P* = 0.027), HLA-DR4 (*P* = 0.005), and HLA-DR6 (*P* = 0.005) are associated with AA in families. Linkage between AA and class II loci is supported with a maximal logarithm of odds (LOD) score of 2.42 to HLA-DQ at 5 percent recombination and 2.34 to HLA-DR at 0 percent recombination.

VITILIGO (See Chap. 90) Vitiligo is seen in association with other autoimmune diseases and after treatment of melanoma; it is mediated by skin-homing CD8+ lymphocytes. In Italians, HLA-BfS, -C4A3, -C4B1, -DR5, and -DQW3 characterize the early onset form of vitiligo, while HLA-BfS, -C4A3, -C4B1, -DR7, and -DQw2 distinguish the adult form. [74] Vitiligo may have an autosomal dominant pattern of inheritance with linkage to HLA alleles affecting the age of onset. In a family-based case-control association study, linkage and association of the DRB4*0101 allele were found with vitiligo (*P* corrected = 0.0016, RR = 2.21). Evidence for linkage and association of the DQB1*0303 allele was found (? ^{2} = 7.36, *P* = 0.006). The DRB4*0101/0101 genotype carries a 3.58 percent risk of developing vitiligo. Both DRB4*0101 and DQB1*0303 alleles provide significant susceptibility for vitiligo. [75]

Skin Cancer

MALIGNANT MELANOMA (See Chap. 93) Antitumor immune responses to melanoma-associated antigens involves HLA antigen presentation, which is vital for developing vaccines and other immunotherapies. HLA associations in malignant melanoma have been correlated with response to immunotherapy and with disease progression. HLA-A2 class I associations were first reported and correlated with melanoma antigens (MARTs) and with peptides derived from tyrosinase. [76] Melanoma predominantly affects whites, a population in whom expression of HLA-A2 is prevalent. Among HLA-A2 subtypes, HLA-A*0201 is widely expressed; and HLA-A*0201-restricted, tumor-reactive cytotoxic T lymphocyte responses have been studied extensively. [77] Non-HLA-A*0201 subtypes (*0202, *0204, and *0205) may also be found in patients with melanoma who show responses to different peptide antigens. Specific peptides of tyrosinase, Ty 56-70 and Ty 448-462, which are HLA-DRB1*0401 restricted, are recognized by CD4+ T cells. Other tyrosinase antigens are also HLA-A2 restricted and may elicit a CD8+ T cell tumor necrosis factor response. For all patients, Lee et al. showed that HLA-DQB1*0301 is associated with an increased risk for cutaneous melanoma. [78] HLA-DQ1 was recently associated with clinical response and with prolonged survival in patients treated with interleukin 2 immunotherapy. [79] In Japanese individuals, HLA-B13 is increased in patients with melanoma compared with control subjects and is particularly common in nodular melanoma, whereas HLA-B61 is decreased in patients with melanoma. Almost 50 percent of patients with acral lentiginous melanomas express HLA-B51, which is not found in any patients with nodular melanomas. [80] The importance of lower expression of HLA-A and HLA-B antigens on melanomas and its mechanisms are controversial. [81] About 15 percent of melanomas studied have deletions in or loss of chromosome 6p and consequently do not express HLA antigens, which could increase their selective survival. [82] Defective TAP could also lead to lower HLA expression on melanomas. [83]

NONMELANOMA SKIN CANCER (See Chap. 80 and Chap. 81) Data for HLA associations with nonmelanoma skin cancers (basal cell and squamous cell carcinomas) are from immunosuppressed and renal transplant patients at increased risk for squamous cell cancer. HLA-DR1 is increased in nonimmunosuppressed patients who are younger than 60 years old and have multiple squamous cancers. [84] Bouwes Bavinck et al. found a significant negative association between HLA-11 and skin cancer (RR = 0.05) in one study and an increased risk (RR = 1.7) in a second study. [85] HLA-B27 is associated with the development of basal cell carcinomas. [86]

CUTANEOUS T CELL LYMPHOMA (See Chap. 157) Mycosis fungoides (MF) and its leukemic variant, Sézary syndrome, are the most common variants of CTCL. HLA-DR5 was initially reported to be associated with MF.

HLA-DQB1*03 alleles linked to DR5 are more significantly associated with MF. [87] The strongest association for MF is between DQB1*0502 and Sézary syndrome (odds ratio = 7.75). [87]

SIGNIFICANCE

Histocompatibility antigens play a critical role in determining the type of response a host can raise to a particular peptide antigen, whether self-antigen, viral antigen, or superantigen. HLA chains bind antigen for presentation to T cells, with HLA class I being important for CD8+ activation and HLA class II being important for CD4+ helper T cells. The details of these interactions and epitopes or sequences of the HLA chains and the peptides have yet to be clarified in most skin diseases. T cells are also important in evoking humoral or antibody responses. HLA alleles are significantly associated with specific autoantibody responses rather than with the disease. [88]

The allelic polymorphisms of the HLA antigens are useful markers for other disease susceptibility genes, even when they are not themselves disease enabling. HLA alleles confer susceptibility underlying immune or autoimmune skin reactions, and may influence time of onset, severity, or sex predilection. In the future, knowledge of an individual's HLA type could be invaluable to prevent autoimmune skin diseases, especially when recognized trigger factors or viral infections call for immediate therapeutic intervention. Understanding the immune response at the molecular level offers the possibility of blocking the reaction by anti-idiotypic antibodies, DNA vaccines, or peptides that bind to specific areas of the receptors. [89]

REFERENCES

1. Benacerraf B, Rock KL: The significance of MHC restriction, in *Major Histocompatibility System: The Gorer Symposium,* edited by P Medawar, T Lehner. London, Blackwell Scientific, 1985, p 16

2. Dupont B: The HLA system: An introduction, in *The HLA System: A New Approach,* edited by J Lee. New York, Springer-Verlag, 1990, p 1

3. Blumberg RS et al: The multiple roles of major histocompatibility complex class I-like molecules in mucosal immune function. *Acta Odontol Scand* **59**:139, 2001

4. Kumar V, Sercarz E: An integrative model of regulation centered on recognition of TCR peptide/MHC complexes. *Immunol Rev* **182**:113, 2001

5. Moulds JM: Ethnic diversity of class III genes in autoimmune disease. *Front Biosci* **6**:D986, 2001

6. Bromley SK et al: The immunological synapse and CD28–CD80 interactions. *Nat Immunol* **2**:1159, 2001

7. Rudolph MG et al: Crystal structure of an isolated V(alpha) domain of the 2C T-cell receptor. *J Mol Biol* **314**:1, 2001

8. Mackay IR, Rosen FS: Autoimmune diseases. *N Engl J Med* **345**:345, 2001

9. Janeway CA: Are there cellular superantigens? *Immun Rev* **131**:189, 1993

10. Strange P et al: Interferon gamma treated keratinocytes activate T cells in the presence of superantigens: Involvement of major histocompatibility complex class II molecules. *J Invest Dermatol* **102**:150, 1994

11. Reveille JD et al: HLA-B27 and genetic predisposing factors in spondyloarthropathies. *Curr Opin Rheumatol* **13**:265, 2001

12. Price P et al: The genetic basis for the association of the 8.1 ancestral haplotype (A1, B8, DR3) with multiple immunopathological diseases. *Immunol Rev* **167**:257, 1999

13. Elder JT et al: The genetics of psoriasis 2001: The odyssey continues. *Arch Dermatol* **137**:1447, 2001

14. Barker JN: Genetic aspects of psoriasis. *Clin Exp Dermatol* **26**:321, 2001

15. Harrison P et al: Association of HLA-antigens with psoriasis. *J Invest Dermatol* **98**:557A, 1992

16. Hall JR, Arnett FC: The HLA system and cutaneous diseases, in *Immunologic Diseases of the Skin,* edited by RE Jordon. Norwalk, CT, Appleton & Lange, 1991, p 101

17. Leung DY et al: Evidence for a streptococcal superantigen-driven process in acute guttate psoriasis . *J Clin Invest* **96**:2106, 1995

18. Mallon E et al: HLA-C and guttate psoriasis. *Br J Dermatol* **143**:1177, 2000

19. Oka A et al: Association analysis using refined microsatellite markers localizes a susceptibility locus for psoriasis vulgaris within a 111-kb segment telomeric to the HLA-C gene. *Hum Mol Genet* **8**:2165, 1999

20. O'Brien KP et al: The HCR gene on 6p21 is unlikely to be a psoriasis susceptibility gene. *J Invest Dermatol* **116**:750, 2001

21. Gonzalez S et al: The OTF3 gene polymorphism confers susceptibility to psoriasis independent of the association of HLA-Cw*0602. *J Invest Dermatol* **115**:824, 2000

22. Enerback C et al: Stronger association with HLA-Cw6 than with corneodesmosin (S-gene) polymorphisms in Swedish psoriasis patients. *Arch Dermatol Res* **292**:525, 2000

23. Bowcock AM et al: Insights into psoriasis and other inflammatory diseases from large-scale gene expression studies. *Hum Mol Genet* **10**:1793, 2001

24. Lee YA et al: Genomewide scan in German families reveals evidence for a novel psoriasis-susceptibility locus on chromosome 19p13. *Am J Hum Genet* **67**:1020, 2000

25. Gladman DD et al: HLA-DRB1*04 alleles in psoriatic arthritis: Comparison with rheumatoid arthritis and healthy controls. *Hum Immunol*

62:1239, 2001

26. Barton AC et al: Genetic studies of psoriatic arthritis: Dissecting joints and skin. *J Rheumatol* **28**:3, 2001

27. Gonzalez-Gay MA, Garcia-Porrua C: Epidemiology of the vasculitides. *Rheum Dis Clin North Am* **27**:1, 2001

28. Huang Y et al: Polymorphism of transmembrane region of MICA gene and Kawasaki disease. *Exp Clin Immunogenet* **17**:130, 2000

29. Hauser C: Granulomatous disease associated with HLA class I deficiency. *Br J Dermatol* **144**:901, 2001

30. Amoli MM et al: HLA-DRB*01 association with Henoch-Schönlein purpura in patients from northwest Spain. *J Rheumatol* **28**:1266, 2001

31. Cacoub P et al: HLA-DR phenotypes influence the risk of hepatitis C virus-associated mixed cryoglobulinemia. *Arthritis Rheum* **43**(suppl):S1911, 2000

32. Arber N et al: Close association of HLA-B51 and B52 in Israeli patients with Behçet's syndrome. *Ann Rheum Dis* **50**:351, 1991

33. Mizuki N et al: HLA-B*51 allele analysis by the PCR-SBT method and a strong association of HLA-B*5101 with Japanese patients with Behçet's disease. *Tissue Antigens* **58**:181, 2001

34. Kotter I et al: Comparative analysis of the association of HLA-B*51 suballeles with Behçet's disease in patients of German and Turkish origin. *Tissue Antigens* **58**:166, 2001

35. Sun A et al: Some specific human leukocyte antigen (HLA)-DR/DQ haplotypes are more important than individual HLA-DR and -DQ phenotypes for the development of mucocutaneous type of Behçet's disease and for disease shift from recurrent aphthous stomatitis to mucocutaneous type of Behçet's disease. *J Oral Pathol Med* **30**:402, 2001

36. Gul A et al: Linkage mapping of a novel susceptibility locus for Behçet's disease to chromosome 6p22-23. *Arthritis Rheum* **44**:2693, 2001

37. Martinetti M et al: HLA-Gm/?m interaction in sarcoidosis. Suggestions for a complex genetic structure. *Eur Respir J* **16**:74, 2000

38. Schurmann M et al: Familial sarcoidosis is linked to the major histocompatibility complex region. *Am J Respir Crit Care Med* **162**:861, 2000

39. Grunewald J et al: Lung T-helper cells expressing T-cell receptor AV2S3 associate with clinical features of pulmonary sarcoidosis. *Am J Respir Crit Care Med* **161**:814, 2000

40. Scharf SJ et al: Specific HLA-DQB and HLA-DRB1 alleles confer susceptibility to pemphigus vulgaris. *Proc Natl Acad Sci U S A* **86**:6215, 1989

41. Miyagawa S et al: HLA-DRB1*04 and DRB1*14 alleles are associated with susceptibility to pemphigus among Japanese. *J Invest Dermatol* **109**:615, 1997

42. Lombardi ML et al: Common human leukocyte antigen alleles in pemphigus vulgaris and pemphigus foliaceus Italian patients. *J Invest Dermatol* **113**:107, 1999

43. Ahmed AR et al: Linkage of pemphigus vulgaris antibody to the major histocompatibility complex in healthy relatives of patients. *J Exp Med* **177**:419, 1993

44. Engineer L et al: Pemphigoid gestationis: A review. *Am J Obstet Gynecol* **183**:483, 2000

45. Setterfield J et al: Mucous membrane pemphigoid: HLA-DQB1*0301 is associated with all clinical sites of involvement and may be linked to antibasement membrane IgG production. *Br J Dermatol* **145**:406, 2001

46. Schofield JK et al: Recurrent erythema multiforme: Tissue typing in a large series of patients. *Br J Dermatol* **131**:532, 1994

47. Malo A et al: Recurrent herpes simplex virus-induced erythema multiforme: Different HLA-DQB1 alleles associate with severe mucous membrane versus skin attacks. *Scand J Immunol* **47**:408, 1998

48. Power WJ et al: HLA typing in patients with ocular manifestations of Stevens-Johnson syndrome. *Ophthalmology* **103**:1406, 1996

49. Hall RP et al: Alterations in HLA-DP and HLA-DQ antigen frequency in patients with dermatitis herpetiformis. *J Invest Dermatol* **93**:501, 1989

50. Spurkland A et al: Dermatitis herpetiformis and celiac disease are both primarily associated with the HLA-DQ (alpha 1*0501, beta 1*02) or the HLA-DQ (alpha 1*03, beta 1*0302) heterodimers. *Tissue Antigens* **49**:29, 1997

51. Holopainen P et al: Candidate gene regions and genetic heterogeneity in gluten sensitivity. *Gut* **48**:696, 2001

52. McManus R et al: TNF2, a polymorphism of the tumor necrosis-alpha gene promoter, is a component of the celiac disease major histocompatibility complex haplotype. *Eur J Immunol* **26**:2113, 1996

53. Vaidya S et al: HLA and epidermolysis bullosa. Association between the HLA complex and recessive dystrophic epidermolysis bullosa. *Arch Dermatol* **127**:1524, 1991

54. Gammon WR et al: Increased frequency of HLA-DR2 in patients with autoantibodies to epidermolysis bullosa acquisita antigen: Evidence that the expression of autoimmunity to type VII collagen is HLA class II allele associated. *J Invest Dermatol* **91**:228, 1988

55. Sullivan KE: Genetics of systemic lupus erythematosus. *Rheum Dis Clin North Am* **26**:229, 2000

56. Davies EJ et al: Relative contributions of HLA-DQA and complement C4A loci in determining susceptibility to systemic lupus erythematosus. *Br J Rheumatol* **34**:221, 1995

57. Tan FK, Arnett FC: The genetics of SLE. *Curr Opin Rheumatol* **10**:399, 1998

58. Gilchrist FC et al: Class II HLA associations with autoantibodies in scleroderma: A highly significant role for HLA-DP. *Genes Immun* **2**:76, 2001

59. Reveille JD et al: Systemic sclerosis in 3 US ethnic groups: A comparison of clinical, sociodemographic, serologic, and immunogenetic

determinants. *Semin Arthritis Rheum* **30**:332, 2001

60. Lambert NC et al: HLA-DQA1*0501 is associated with diffuse systemic sclerosis in Caucasian men. *Arthritis Rheum* **43**:2005, 2000

61. Farrell AM et al: Genital lichen sclerosis associated with morphea or systemic sclerosis: Clinical and HLA characteristics. *Br J Dermatol* **143**:598, 2000

62. Azurdia RM et al: Lichen sclerosus in adult men: A study of HLA associations and susceptibility to autoimmune disease. *Br J Dermatol* **140**:79, 1999

63. Roitberg-Tambur et al: Serologic and molecular analysis of the HLA system in Israeli Jewish patients with oral erosive lichen planus. *Tissue Antigens* **43**:219, 1994

64. White AG, Rostom AI: HLA antigens in Arabs with lichen planus. *Clin Exp Dermatol* **19**:236, 1994

65. Watanabe T et al: Analysis of HLA antigens in Japanese with oral lichen planus. *J Oral Pathol Med* **15**:529, 1986

66. Porter K et al: Class I and II HLA antigens in British patients with oral lichen planus. *Oral Surg Oral Med Oral Pathol Oral Radiol Endod* **75**:176, 1993

67. Carrozzo M et al: Increased frequency of HLA-DR6 allele in Italian patients with hepatitis C virus-associated oral lichen planus. *Br J Dermatol* **144**:803, 2001

68. Jackow C et al: Alopecia areata and cytomegalovirus infection in twins: Genes versus environment. *J Am Acad Dermatol* **38**:418, 1998

69. Zhang L et al: HLA associations with alopecia areata. *Tissue Antigens* **38**:89, 1991

70. Duvic M et al: HLA-D locus associations in alopecia areata: DRw52 may confer disease resistance. *Arch Dermatol* **127**:64, 1991

71. Colombe BW et al: HLA class II antigen associations help to define two types of alopecia areata. *J Am Acad Dermatol* **33**:757, 1995

72. Kavak A et al: HLA in alopecia areata. *Int J Dermatol* **39**:589, 2000

73. de Andrade M et al: Alopecia areata in families: Association with the HLA locus. *J Invest Dermatol Symp Proc* **4**:220, 1999

74. Finco O et al: Age of onset in vitiligo: Relationship with HLA supratypes. *Clin Genet* **39**:48, 1991

75. Zamani M et al: Linkage and association of HLA class II genes with vitiligo in a Dutch population. *Br J Dermatol* **145**:90, 2001

76. Rivoltini L et al: Binding and presentation of peptides derived from melanoma antigens MART-1 and glycoprotein-100 by HLA-A2 subtypes: Implications for peptide-based immunotherapy. *J Immunol* **156**:3882, 1996

77. Anichini A et al: Cytotoxic T cells directed to tumor antigens not expressed on normal melanocytes dominate HLA-A2.1–restricted immune repertoire to melanoma. *J Immunol* **156**:208, 1996

78. Lee JE et al: HLA-DQB1*0301 association with increased cutaneous melanoma risk. *Int J Cancer* **59**:510, 1994

79. Brady MS et al: CD4(+) T cells kill HLA-class-II-antigen-positive melanoma cells presenting peptide in vitro. *Cancer Immunol Immunother* **48**:621, 2000

80. Ichimiya M et al: Putative linkage between HLA class I polymorphism and the susceptibility to malignant melanoma. *Australas J Dermatol* **37**(suppl 1):S39, 1996

81. Gasparollo A et al: Unbalanced Expression of HLA-A and -B antigens: A specific feature of cutaneous melanoma and other non-hemopoietic malignancies reverted by gamma interferon. *Int J Cancer* **91**:500, 2001

82. Sette A et al: HLA expression in cancer: Implications for T cell-based immunotherapy. *Immunogenetics* **53**:255, 2001

83. Kamarashev J et al: TAP1 down-regulation in primary melanoma lesions: An independent marker of poor prognosis. *Int J Cancer* **95**:23, 2001

84. Glover MT et al: HLA antigen frequencies in renal transplant recipients and non-immunosuppressed patients with non-melanoma skin cancer. *Eur J Cancer* **29A**:520, 1993

85. Bouwes Bavinck JN et al: The risk of skin cancer in renal transplant recipients in Queensland, Australia: A follow-up study. *Transplantation* **61**:715, 1996

86. Czarnecki D et al: Skin cancers and HLA frequencies in renal transplant recipients. *Dermatology* **185**:9, 1992

87. Jackow CM et al: HLA-DR5 and DQB1*03 class II alleles are associated with cutaneous T-cell lymphoma. *J Invest Dermatol* **107**:373, 1996

88. Arnett FC: HLA and autoimmunity in scleroderma (systemic sclerosis). *Int Rev Immunol* **12**:107, 1995

89. Wang E et al: T-cell-directed cancer vaccines: The melanoma model. *Expert Opin Biol Ther* **1**:277, 2001

90. Arnett FC, Reveille JD: Genetics of systemic lupus erythematosus. *Rheum Clin North Am* **18**:865, 1992

T>

Chapter 25

Lela Lee

Immunoglobulin Structure and Function

ANTIBODY STRUCTURE
ANTIBODY CLASSES (see Table 25-1)
IgM
IgD
IgA
IgG
IgE
MECHANISMS FOR THE GENERATION OF ANTIBODY DIVERSITY
B CELL MATURATION
ANTIGENS BOUND BY B CELLS
B CELL AND ANTIBODY FUNCTION
B CELLS AND ANTIBODIES IN DISEASE

REFERENCES

During evolution, jawed vertebrates developed the capacity to respond with exquisite specificity to foreign organisms. [1] Specific immunity is characterized by an enormous diversity of possible responses and by refinement in the immune response with successive exposures to the organism. [2] The cells that can discriminate with fine specificity through their vast repertoire of receptors are lymphocytes. Specific immunity, also called *adaptive immunity* because it develops as an adaptation to infection, can be segregated into humoral immunity, mediated by antibodies produced by B lymphocytes, and cellular immunity, mediated by T lymphocytes. These two forms of specific immunity developed to serve different functions. Humoral immunity is directed primarily toward extracellular antigens, such as circulating bacteria and toxins. Cellular immunity is directed primarily toward antigens that infect or inhabit cells. To combat extracellular pathogens, the defending agent needs to be abundant and widely distributed in the body, particularly at its interfaces with the environment. Antibodies fulfill these characteristics by being capable of being secreted in great quantity from the cells that produce them and by being distributed in blood, mucosa, and interstitial fluid. In addition, antibodies can attach through Fc receptors to the surface of certain other cells of the immune system, such as mast cells, conferring antigen specificity to cells that do not have their own endogenously produced antigen-specific receptors.

ANTIBODY STRUCTURE

Antibodies, or immunoglobulins (Ig), are a family of glycoproteins that share a common structure. [2], [3] and [4] The antibody molecule has a symmetric Y shape consisting of two identical light chains, each about 24 kDa, that are covalently linked to two identical heavy chains, each about 55 or 70 kDa, that are covalently linked to one another (Fig. 25-1). Within the light and heavy chains are variable and constant regions. The major function of the variable region is to recognize antigens, whereas the constant region mediates effector functions. The light and heavy chains contain a series of repeating, homologous units of about 110 amino acids that assume a lobular structure and are called *Ig domains.* The Ig domain motif is found not only in antibody molecules but also in a variety of other molecules of the Ig “superfamily,” including the T cell receptor, the major histocompatibility complex (MHC), CD4, CD8, and intercellular adhesion molecule 1 (ICAM-1), among other molecules. The light chains have two major domains, a variable (V_L) and a constant (C_L) domain. The heavy chains have four or five domains, a variable (V_H) and three (in IgA, IgD, and IgG) or four (in IgM and IgE) constant (C_H1–4) domains. In IgA, IgD, and IgG, there is a hinge region between C_H1 and C_H2 that confers additional flexibility to the molecule. The variable domains are at the N terminus. At the C terminus are the constant domains and, in the heavy chains of membrane-bound antibodies, the transmembrane and cytoplasmic domains.

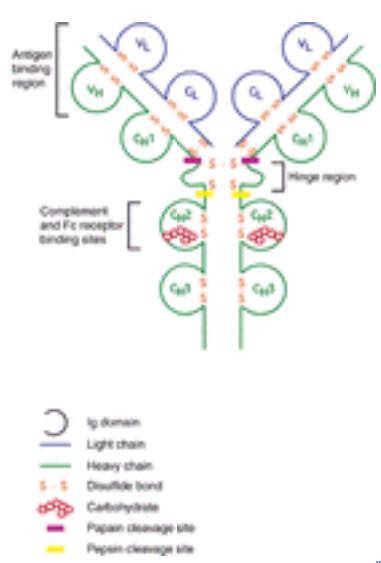

FIGURE 25-1 Schematic representation of an IgG molecule.

Within the variable regions of the light and heavy chains are three areas of intense variability called *hypervariable regions.* These three regions, which are in proximity to one another in the three-dimensional (3D) structure of the antibody, are the areas most responsible for binding antigen. Because the hypervariable regions form a shape

complementary with that of the antigen, the hypervariable regions are also called the *complementarity-determining regions* (CDRs). The unique areas formed by the hypervariable regions are present in too low an amount in the individual to generate self-tolerance. Thus the immune system may not distinguish the unique portion of the antibody as self and may produce antibodies to that region of the antibody. The area of the antibody capable of generating an immune response is called an *idiotope,* and antibody responses to idiotopes result in a network of idiotypic–anti-idiotypic interactions that may help regulate the humoral immune response. [5]

There are two types of light chains, ? and ?, each encoded on different chromosomes. Each antibody molecule has either two ? or two ? chains, never one of each. The functional differences, if any, between ? and ? are not known. There are five types of heavy chains, a, d, e, ?, and µ, corresponding to the antibody classes IgA, IgD, IgE, IgG, and IgM, respectively. The different heavy chain classes have significantly different functions, as will be discussed below. The IgA and IgG classes contain closely related subclasses, consisting of IgA1 and IgA2 and IgG1, IgG2, IgG3, and IgG4 (Table 25-1).

TABLE 25-1 **Immunoglobulin Classes and Their Functions**

Enzymatic digestion of IgG molecules by papain results in three cleavage products, two identical Fab fragments consisting of a light chain bound to the V-C_H1 region of the heavy chain and an Fc portion consisting of two C_H2-C_H3 heavy chains bound to each other. Fab was so named for its property of antigen binding, and Fc was so named for its property of crystallizing. When IgG is digested by pepsin, the C-terminal region is digested into small fragments. The remaining product consists of the Fab region along with the hinge region. Fab fragments containing the hinge region are termed Fab'. When the two Fab'fragments in an antibody molecule remain associated, the fragment is called $F(ab')_2$.

ANTIBODY CLASSES (see Table 25-1)

IgM

IgM is the first Ig molecule to be expressed during B cell development. Its secretory form is a pentamer consisting of five IgM molecules joined at their C termini by tail pieces and stabilized by a molecule called a *joining (J) chain.* The engagement of membrane-bound IgM by antigen results in the activation of naive B cells. Secreted IgM recognizes antigen, usually through low-affinity interactions, and it can activate complement. IgM is the major effector of the primary antibody response. Although IgM interactions typically are low-affinity, IgM can be very effective in responding to a polyvalent antigen (such as a polysaccharide with repeating epitopes) because its pentameric structure allows for multiple low-affinity interactions, resulting in a high-avidity interaction. (*Avidity* refers to the overall strength of attachment, whereas *affinity* refers to the strength of attachment at a single antigen-binding site.)

IgD

The IgD molecule exists primarily in a membrane-bound form and is the second antibody class to be expressed during B cell development. Its function is not completely understood, but in its membrane-bound form it can serve as an antigen receptor for naive B cells. [6]

IgA

IgA is the most abundant Ig in the body, being present in large quantity at mucosal sites. It is responsible for mucosal immunity and is secreted in breast milk, thus contributing to neonatal immunity. In its secreted form, it exists as a monomer, dimer, or trimer, with the multimers being formed by interactions between tail pieces and stabilized by the J chain. For transport across epithelial surfaces, IgA dimers attach to a type of Fc receptor called the *polymeric Ig receptor.* [7] Once the transport process is complete, the IgA dimers remain attached to the extracellular portion of the receptor, called the *secretory component,* that protects the IgA from proteolysis. Cells of the immune system that have receptors for IgA include neutrophils, eosinophils, and monocytes.

IgG

IgG is the most abundant Ig in the circulation. Its secreted form is a monomer. IgG plays an important role in secondary antibody responses, and its interactions with antigen tend to be high-affinity, particularly as the immune response matures. A number of cells have Fc receptors for IgG, including monocytes, neutrophils, eosinophils, natural killer (NK) cells, and B cells. IgG opsonizes (coats) antigen, allowing phagocytosis of the antigen, and activates complement. An exception is IgG4, which does not activate complement. IgG is the only Ig class to cross the placenta, and therefore, it plays an important role in neonatal immunity. The interaction of IgG with the MHC class I–related receptor FcRn is involved in the delivery of IgG across the placenta as well as in prolonging its level in the circulation. [8] The serum half-life of IgG is 23 days, considerably longer than that of the other Ig classes.

IgE

IgE is found in very small amounts in the circulation. High-affinity receptors for the Fc portion of IgE are present on mast cells, basophils, and eosinophils, and low-affinity receptors are present on B cells and Langerhans cells. In mast cells,

basophils, and eosinophils, IgE engagement with antigen activates the cells. IgE mediates immediate hypersensitivity, but its principal protective role may be to combat parasites.

MECHANISMS FOR THE GENERATION OF ANTIBODY DIVERSITY

The information encoded by an individual's DNA is limited by the need for the DNA to fit into a package the size of a cell. This space is far too small for sufficient DNA to encode billions of different lymphocyte receptors if the genes were encoded separately. Lymphocytes have adapted to this limitation by special mechanisms that increase by orders of magnitude the number of different possible antigen receptors. [9] Each clone of B cells produces identical antigen receptors (i.e., antibodies) with unique specificities. It is estimated that an individual has about 10 [9] different B cell clones, resulting in 10 [9] distinct antibodies. A major mechanism for generating this enormous diversity is gene rearrangement, whereby segments of DNA within a lymphocyte undergo somatic recombinations. [10] Light chain genes contain three regions, V (variable), J (joining), and C (constant), and heavy chain genes contain four regions, V, D (diversity), J, and C. Within each region are many gene segments from which to select for the final antibody product, which is comprised of one gene segment from each region. The initial event in antibody formation is the joining of one D and one J segment from a heavy chain gene, with subsequent deletion of the DNA between the two segments. Next, a V segment is selected to join to the DJ segment, and any remaining D segments are deleted. The VDJ complex has attached 3'to it any remaining J segments plus the C region. The unused J segments are removed during RNA processing. A similar process occurs in light chain loci; because there are no D segments in light chain loci, a VJ rather than a VDJ complex is formed.

The ability to select one segment each from the many segments available in the V, D, and J regions leads to a vast increase in the repertoire of possible antibodies. Additional diversity is generated by the juxtaposition of a rearranged light chain to a rearranged heavy chain and by the addition, deletion, or transposition of nucleotides at the junctions between V and D, D and J, and V and J segments, a phenomenon called *junctional diversity.*

B CELL MATURATION

Bone marrow and fetal liver stem cells that give rise to B cells are initially pluripotent. [2] The stem cells may proceed to develop in the lymphocytic pathway, where they can give rise to B, T, or NK cells. The earliest cell committed to the B cell lineage is called a *pro-B cell.* At the pro-B cell stage, the cell expresses recombinase-activating gene (RAG) and terminal deoxyribonucleotidyl transferase (TdT), which will be needed subsequently for somatic recombination and nucleoside transfers involved in junctional diversity, respectively. At the pro-B cell stage, somatic recombination has not taken place, and therefore, Ig is not yet expressed.

The next stage of B cell maturation is represented by the pre-B cell and is marked by the synthesis of a cytoplasmic µ heavy chain. Since light chains are not yet expressed at this stage, surface Ig is not present. Some of the µ heavy chains associate with invariant molecules called *surrogate light chains* to form complexes called *pre-B cell receptors.* These receptors are then expressed on the pre-B cell surface and provide important signals for the proliferation and maturation of the developing B cell. [11]

The formation of light chains marks the next stage in B cell maturation, the immature B cell. When light chains join with the µ heavy chains, an IgM molecule results and can be expressed on the cell surface. The cytoplasmic tails of IgM molecules are too short to transduce signals. Signal transduction is rather a function of two other molecules, called Iga and Igß, associated with IgM in a B cell receptor complex on the cell surface. Although the presence of a B cell receptor complex confers the ability to recognize specific antigens, at this stage such recognition does not result in proliferation or differentiation. Rather, the cells may undergo negative selection when antigen is encountered. Immature B cells recognizing self-antigen may be deleted through apoptosis [12] or may undergo receptor editing, a process by which a new, non-self specificity is acquired. [13]

Acquisition of the ability to express IgD as well as IgM is the hallmark of the next stage, the mature B cell. The cell is naive because it has not been activated by antigen, but it is competent to respond to antigen. Mature B cells exit the bone marrow and migrate to blood and lymphoid tissues, where they constitute the majority of B cells in those locations.

The encounter of antigen by mature naive B cells leads to B cell activation, proliferation, and differentiation. A subset of B cells become memory B cells, which are then activated if the antigen is encountered subsequently. [14] Another subset of B cells differentiates into cells that make progressively less membrane-bound Ig and more secreted Ig. These cells can undergo class switching from IgM and IgD to IgA, IgE, or IgG. [15] The terminally differentiated B cells committed to the production of secreted Ig are plasma cells and have abundant rough endoplasmic reticulum, consistent with the function of the cells as antibody factories.

ANTIGENS BOUND BY B CELLS

B cells recognize a variety of macromolecules, including proteins, lipids, and nucleic acids. The portion of the macromolecule recognized by the antibody is called an *epitope* or *determinant.* B cells recognize both linear epitopes (epitopes formed by several adjacent amino acids) and, quite commonly, conformational epitopes (epitopes present as a result of folding of the macromolecule). [16] In contrast to B cells, T cell responses are almost entirely restricted to linear epitopes of peptides.

Macromolecules, particularly large proteins, may contain several different epitopes, and a humoral response to a macromolecule typically is comprised of multiple different antibodies. Although each different antibody is specific for a given epitopic configuration, similarities in epitopes may exist such that an antibody to a given epitope on a given macromolecule also may be able to bind a different epitope on a different macromolecule. This phenomenon is called

cross-reactivity and may be important in the genesis of autoimmune antibody responses.

Macromolecules that have multiple identical epitopes are classified as being polyvalent or multivalent. Antibodies to these macromolecules or aggregates of macromolecules may form complexes called *immune complexes* with the antigen. At a particular concentration of antibody and antigen, called the *zone of equivalence,* a large network of linked antigens and antibodies forms. At lower or higher concentrations of antibody or antigen, the complexes are much smaller. Immune complexes, formed in the circulation or in tissue, may be responsible for disease through the initiation of an inflammatory response.

B CELL AND ANTIBODY FUNCTION

On engagement of the mature B cell receptor by antigen, clustering of receptors initiates signaling transduced by Iga and Igß. The resulting signaling cascade eventuates in the expression of genes involved in B cell activation. B cell activation is facilitated by second signals, one of which may be provided by the complement protein C3d. [17]

The subsequent response to an antigen often involves a complex interaction between B cells and T cells, leading to a fine-tuning of the immune response. B cells are capable of functioning as antigen-presenting cells. In response to a protein antigen, B cells take up the antigen, process it, and present peptide–class II MHC complexes to T cells. T cells recognizing the peptide–class II MHC complexes receive a primary signal from the complex and a secondary signal from costimulatory interactions, notably binding of B7-1 and B7-2 on B cells to CD28 on T cells. [18] These T cells are activated, and their activation in turn provides signals to the B cells through the actions of cell surface molecules (in particular, CD40 on B cells and CD40 ligand on T cells) and cytokines [e.g., interleukin 2 (IL-2), IL-4, IL-5, and IL-6]. [2] The overall effects on B cells are activation, proliferation, and differentiation. T cell interaction with B cells also results in class switching from IgM to IgA, IgE, or IgG and affinity maturation, whereby the affinity of antibodies for the antigen progressively increases. During affinity maturation, somatic hypermutations in antibody genes result in antibodies with both greater and lesser affinity for the antigen. [19], [20] Those antibodies with greater affinity confer a survival advantage on the B cells that produce them. Progressively, the population of B cells evolves in favor of those producing higher-affinity antibodies for the antigen.

As noted earlier, T cell responses are limited almost entirely to peptides. Thus B cell responses to non-protein antigens may not result in T cell help through the mechanisms described earlier. [21] One type of T cell–independent B cell response produces so-called natural antibodies, IgM antibodies that are largely anticarbohydrate antibodies produced without apparent antigen exposure. [22] These natural antibodies are characterized by a limited repertoire and are thought to be produced by B1 peritoneal cells stimulated by bacteria that colonize the gut.

Antigen occupation of antibody-binding sites leads to functional results, called *effector functions.* Many effector functions are mediated through the binding of Ig to Fc receptors (FcRs) [23] FcRs generally are divided into those that trigger cell activation and those that do not. Those that can trigger activation contain one or more motifs called *immunoreceptor tyrosine-based activation motifs* (ITAMs). Of those that do not trigger activation, some can inhibit cell activation and contain a motif called the *immunoreceptor tyrosine-based inhibition motif* (ITIM). FcRs that neither activate nor inhibit cell activation are involved in the transport of Ig through epithelia and the prolongation of the half-life of IgG.

The effector functions of antibodies serve to eliminate the antigen that initiated the immune response and also to downregulate the immune response when activation is not required. Effector functions of antibodies include neutralization of antigen, complement activation, cell activation (of monocytes, neutrophils, eosinophils, and B cells), phagocytosis (by monocytes and neutrophils), and antibody-dependent cell-mediated cytotoxicity (mediated by NK cells). In addition, engagement of IgG by antigen provides a negative signal to B cells, mediated through the binding of the antigen-antibody complex to an Fc? receptor, Fc?IIB, on the B cell. [24]

B CELLS AND ANTIBODIES IN DISEASE

Disorders of B cells or antibodies cause or contribute to many diseases of dermatologic relevance. [25], [26], [27], [28], [29] and [30] Immunodeficiency diseases may result from abnormalities of B cell development or activation or from abnormalities in effector function pathways. B cell lymphomas may result from failure to regulate proliferation, differentiation, or programmed cell death. Antibodies may initiate an inflammatory response that results in injury, as in IgE-mediated allergic reactions or immune-complex diseases. In some cases, the antigen may not be obviously harmful, but the response to the antigen is. In other cases, the antigen may be pathogenic, but the character or magnitude of the immune response is inappropriate or inadequately controlled. The regulatory systems that protect an organism from attack by its own immune system occasionally fail. In some cases, autoimmunity may be initiated as a result of an immune response to a pathogen. The pathogen may act as a nonspecific activator of the immune system or may activate the immune response specifically, e.g., by containing an epitope or epitopes that are cross-reactive with an autoepitope. These responses may be particularly difficult to control because the major stimulus for the immune response, the antigen, is a normal component of “self” and cannot be eliminated. Thus, through many mechanisms, the normal protective B cell response, which developed as an elegant means to discriminate very finely among various potential pathogens, can be subverted to result in harm to the organism.

REFERENCES

1. Litman GW et al: Evolution of antigen binding receptors. *Annu Rev Immunol* **17**:109, 1999

2. Abbas AK et al: *Cellular and Molecular Immunology,* 4th ed. Philadelphia, Saunders, 2000

3. Alzari PM et al: Three-dimensional structure of antibodies. *Annu Rev Immunol* **6**:555, 1988

4. Davies DR, Metzger H: Structural basis of antibody function. *Annu Rev Immunol* **1**:87, 1983

5. Pan Y et al: Anti-idiotypic antibodies: Biological function and structural studies. *FASEB J* **9**:43, 1995

6. Preud'homme JL et al: Structural and functional properties of membrane and secreted IgD. *Mol Immunol* **37**:871, 2000

7. Mostov KE: Transepithelial transport of immunoglobulins. *Annu Rev Immunol* **12**:63, 1994

8. Ghetie V, Ward ES: Multiple roles for the major histocompatibility complex class I–related receptor FcRn. *Annu Rev Immunol* **18**:739, 2000

9. Honjo T: Immunoglobulin genes. *Annu Rev Immunol* **1**:499, 1983

10. Gellert M: Recent advances in understanding V(D)J recombination. *Adv Immunol* **64**:39, 1997

11. Ghia P et al: B-cell development: A comparison between mouse and man. *Immunol Today* **19**:480, 1998

12. Norvell A et al: Engagement of the antigen-receptor on immature murine B lymphocytes results in death by apoptosis. *J Immunol* **154**:4404, 1995

13. Casellas R et al: Contribution of receptor editing to the antibody repertoire. *Science* **291**:1541, 2001

14. Fearon DT et al: Arrested differentiation, the self-renewing memory lymphocyte, and vaccination. *Science* **293**:248, 2001

15. Stavnezer J: Antibody class switching. *Adv Immunol* **61**:79, 1996

16. Benjamin DC et al: The antigenic structure of proteins: A reappraisal. *Annu Rev Immunol* **2**:67, 1984

17. Mongini PK et al: The affinity threshold for human B cell activation via the antigen receptor complex is reduced upon co-ligation of the antigen receptor with CD21 (CR2). *J Immunol* **159**:3782, 1997

18. Lenschow DJ et al: CD28/B7 system of T cell costimulation. *Annu Rev Immunol* **14**:233, 1996

19. Martin A, Scharff MD: Immunology: Antibody alterations. *Nature* **412**:870, 2001

20. Wagner SD, Neuberger MS: Somatic hypermutation of immunoglobulin genes. *Annu Rev Immunol* **14**:441, 1996

21. Mond JJ et al: T cell-independent antigens type 2. *Annu Rev Immunol* **13**:655, 1995

22. Boes M: Role of natural and immune IgM antibodies in immune responses. *Mol Immunol* **37**:1141, 2000

23. Daeron M: Fc receptor biology. *Annu Rev Immunol* **15**:203, 1997

24. Cambier JC et al: The unexpected complexity of Fc gamma RIIB signal transduction. *Curr Top Microbiol Immunol* **244**:43, 1999

25. Paller AS: Update on selected inherited immunodeficiency syndromes. *Semin Dermatol* **14**:60, 1995

26. Cerroni L, Kerl H: New concepts in cutaneous B-cell lymphomas. *Curr Top Pathol* **94**:79, 2001

27. Kay AB: Allergy and allergic diseases, part 2. *N Engl J Med* **344**:109, 2001

28. Lotti T et al: Cutaneous small-vessel vasculitis. *J Am Acad Dermatol* **39**:667, 1998; quiz 688

29. Lin MS et al: The desmosome and hemidesmosome in cutaneous autoimmunity. *Clin Exp Immunol* **107**(suppl 1):9, 1997

30. Lee LA: Lupus erythematosus, in *Dermatology,* edited by JL Bolognia, JL Jorizzo, RP Rapini. London, Mosby, 2002

T>

Chapter 26

Ifor Williams Benjamin Rich Thomas Kupper

Cytokines

HISTORIC PERSPECTIVES
CYTOKINE SIGNAL TRANSDUCTION PATHWAYS
NF-?B, I?B, and Primary Cytokines
Jak-STAT Signal Transduction Pathway
IL-1 FAMILY OF CYTOKINES (IL-1a, IL-1ß, IL-18)
TNF: THE OTHER PRIMARY CYTOKINE
CLASS I (HEMATOPOIETIN RECEPTOR) FAMILY OF CYTOKINE RECEPTORS AND THEIR LIGANDS
Cytokines with Receptors That Include the ?c Chain: IL-2, IL-4, IL-7, IL-9, IL-15, and IL-21
Cytokines with Receptors That Use the IL-3Rß Chain: IL-3, IL-5, and GM-CSF
IL-6 and Other Cytokines with Receptors That Use GP130
IL-12: The Pivotal Cytokine for TH1 Responses
THE CLASS II FAMILY OF CYTOKINE RECEPTORS AND THEIR LIGANDS
Interferons: Prototypes of Cytokines Signaling through a Jak-STAT Pathway
IL-10: An “Anti-inflammatory” Cytokine
Novel IL-10–Related Cytokines: IL-19, IL-20, IL-22, and IL-24
THE TGF-ß FAMILY AND ITS RECEPTORS
CHEMOKINES: SECONDARY CYTOKINES CENTRAL TO LEUKOCYTE MOBILIZATION
THE CYTOKINE NETWORK—THERAPEUTIC IMPLICATIONS AND APPLICATIONS

REFERENCES

When cells and tissues in complex organisms communicate over distances greater than one cell diameter, soluble factors are required. A subset of these factors is produced or released transiently under infectious or injurious challenge to orchestrate complex and carefully choreographed responses in the microenvironment of the tissues. Such responses mobilize certain circulating white blood cells to the relevant injured area (but not elsewhere), and guide other leukocytes, particularly T and B cells, involved in host defense to specialized lymphatic tissue remote from the infectious lesion but sufficiently close to contain antigens from the relevant pathogen. After a limited period of time in this setting (i.e., lymph node), antibodies produced by B cells and effector memory T cells can be released into the circulation and localize at the site of infection. Soluble factors produced by resident tissue cells at the site of injury, by leukocytes and platelets that are recruited to the site of injury, and by memory T cells ultimately recruited to the area, all conspire to generate an evolving and effective response to a challenge to host defense. The degree of this response must be appropriate to the challenge, and the duration of response must be transient—that is, long enough to decisively eliminate the pathogen but short enough to minimize damage to healthy host tissues. The cell-to-cell communication involved in the coordination of this response is accomplished by cytokines.

Cytokines (which include the large family of chemokines, discussed in Chap. 27) are soluble polypeptide mediators that play pivotal roles in communication between cells of the hematopoietic system and other cells in the body. [1] Cytokines influence many aspects of leukocyte function including differentiation, growth, activation, and migration. Although many cytokines are substantially upregulated in response to injury to allow a rapid and potent host response, cytokines also play important roles in the development of the immune system and in homeostatic control of the immune system under basal conditions. The growth and differentiation effects of cytokines are not limited to leukocytes, but soluble factors that principally mediate the growth and differentiation of cells other than leukocytes are not discussed in this chapter.

General features of cytokines are their pleiotropism and redundancy. Before the advent of a systematic nomenclature for cytokines, most newly isolated cytokines were named according to the biologic assay being used to isolate and characterize the active molecule (e.g., T cell growth factor for the molecule that was later renamed interleukin-2). Often, independent groups studying quite disparate bioactivities isolated the same molecule, thus revealing the pleiotropic effects of these cytokines. For example, before being termed interleukin-1 (IL-1), this cytokine had been variously known as endogenous pyrogen, lymphocyte-activating factor, and leukocytic endogenous mediator. [2] Many cytokines have a wide range of activities, causing multiple effects in responsive cells and a different set of effects in each type of cell capable of responding. The redundancy of cytokines typically means that in any single bioassay (such as induction of T cell proliferation), multiple cytokines will display activity. In addition, the absence of a single cytokine (such as in mice with targeted mutations in cytokine genes) can often be largely or even completely compensated for by other cytokines with overlapping biologic effects.

HISTORIC PERSPECTIVES

The first cytokines described had distinct and easily recognizable biologic activities, exemplified by IL-1, IL-2, and the interferons (IFNs). The term *cytokine* was first coined in 1975 to describe several such activities released into the supernatant of an epithelial cell line. [3] Before this time, such activities had been thought to be the exclusive domain of lymphocytes (lymphokines) and monocytes (monokines), and were considered a function of the immune system. Keratinocyte cytokines were first discovered in 1981, [4] and the list of cytokines produced by this epithelial cell rivals that of nearly any other cell type in the body. [5] The number of molecules that can be legitimately termed cytokines has exploded in recent years and has brought under the cytokine rubric molecules with a broad range of distinct biologic activities. The progress in genomic approaches has led to identification of novel cytokine genes based on homologies to known cytokine genes. Making sense of this plethora of mediators is a greater challenge than ever, and strategies to simplify the analysis of the cytokine universe are sorely needed.

The concept of “primary” and “secondary” cytokines continues to be extremely useful for discussion of cytokine function. [6] Primary cytokines are those cytokines that can, by themselves, initiate all the events required to bring about leukocyte infiltration in tissues. IL-1 (both a and ß forms) and tumor necrosis factor (TNF; includes both TNF-a and TNF-ß) function as primary cytokines, as do certain other cytokines that signal through receptors that trigger the nuclear factor ?B (NF-?B) pathway (e.g., IL-18). IL-1 and TNF induce cell adhesion molecule expression on endothelial cells [both selectins and immunoglobulin superfamily members such as intercellular adhesion molecule-1 (ICAM-1) and vascular cell adhesion molecule-1 (VCAM-1)], induce a variety of cells to produce a host of additional cytokines, and induce expression of chemokines that provide a chemotactic gradient, allowing the directed migration of specific leukocyte subsets into a site of inflammation (see below). Primary cytokines can be viewed as part of the “innate” immune system, and in fact, share signaling pathways with the so-called Toll-like receptors (TLRs), a recently described family of receptors that recognize molecular patterns characteristically associated with microbial products. [7], [8] In spite of sometimes potent inflammatory activity, other cytokines do not duplicate this full repertoire of activities. Many qualify as secondary cytokines, whose production is induced after cell stimulation by IL-1 and/or TNF family molecules. The term “secondary” does not imply that they are less important or less active than primary cytokines; rather, it indicates that their spectrum of activity is more restricted.

Another concept that has withstood the test of time is the assignment of many T cell-derived cytokines into one of two groups on the basis of which of the two helper T cell subsets (T_H1 and T_H2) produce them (see Chap. 28). [9] Commitment to one of these two patterns of cytokine secretion also occurs with CD8 cytotoxic T cells and ? d T cells, leading to the suggestion that the type 1 and type 2 terminology should not be restricted to CD4+ aß T cells, but should be applied instead to all classes of T cells. [10] Dominance of type 1 or type 2 cytokines in a T cell immune response has profound consequences for the outcome of immune responses to certain pathogens and extrinsic proteins capable of serving as allergens. [9], [10] A third pattern of T cell cytokine production by CD4 T cells, in which transforming growth factor-ß (TGF-ß) is the dominant cytokine produced, has also been recognized. These T_H3 cells typically function as regulatory T cells. [11]

Not all useful classifications of cytokines are based solely on analysis of function. Structural biologists, fueled by improved methods of generating homogeneous preparations of proteins and establishment of new analytic methods (e.g., solution magnetic resonance spectroscopy) that complement the classic x-ray crystallography technique, have solved the three-dimensional structure of many cytokines. These efforts led to the identification of groups of cytokines that fold to generate similar three-dimensional structures and bind to groups of cytokine receptors that also share similar structural features. For example, most of the cytokine ligands that bind to receptors of the hematopoietin cytokine receptor family are members of the four-helix bundle group of cytokines. [12] These proteins have a shared tertiary architecture consisting of four antiparallel a-helical stretches separated by short connecting loops. The normal existence of some cytokines as oligomers rather than monomers was discovered in part as the result of structural investigations. For example, IFN-? is a four-helix bundle cytokine that naturally exists as a noncovalent dimer. The bivalency of the dimer enables this ligand to bind and oligomerize two IFN-? receptor complexes, thereby facilitating signal transduction. [13] TNF-a and TNF-ß are both trimers that are composed almost exclusively of ß sheets folded into a “jelly roll” structural motif. Ligand-induced trimerization of receptors in the TNF receptor family is believed to be critical for initiation of signaling by these receptors. [14]

CYTOKINE SIGNAL TRANSDUCTION PATHWAYS

To mediate their effects, cytokines must first bind with specificity and high affinity to receptors on the cell surface of responding cells. Many aspects of the pleiotropism and redundancy manifested by cytokines can be understood through an appreciation of the shared mechanisms of signal transduction mediated by cell surface receptors for cytokines. In the early years of the cytokine biology era, the emphasis of most investigative work was on the purification and eventual cloning of new cytokines and a description of their functional capabilities in vitro and in vivo. In recent years, many of the cytokine receptors have been cloned, and several of the signaling cascades initiated by cytokines have been described in detail. Most cytokine receptors can be classified into a relatively small number of families and superfamilies (Table 26-1), the members of which function in an approximately similar fashion. A major theme of this chapter is that most cytokines send signals to cells through pathways that are very similar to those of other cytokines using the same class of receptors. The fact that individual cytokines often use several downstream pathways of signal transduction accounts in part for the pleiotropic effects of these molecules. Nevertheless, we propose that a few major signaling pathways account for most effects attributable to cytokines. Of particularly central importance are the NF-?B pathway and the Jak-STAT pathway.



TABLE 26-1 **Major Families of Cytokine Receptors**

NF-?B, I?B, and Primary Cytokines

A major mechanism contributing to the extensive overlap between the biologic activities of the primary cytokines IL-1 and TNF is the shared use of the NF-?B signal transduction pathway. IL-1 and TNF use completely distinct cell surface receptor and proximal signaling pathways, but these pathways converge at the activation of the NF-?B transcription

factor. NF-?B is of central importance in immune and inflammatory processes because a large number of genes that elicit or propagate inflammation have NF-?B recognition sites in their promoters. NF-?B regulated genes include cytokines, chemokines, adhesion molecules, nitric oxide (NO) synthase, cyclooxygenases, and phospholipase A_2. [15]

In nonstimulated cells, NF-?B heterodimers formed from p65 and p50 subunits are inactive because they are sequestered in the cytoplasm as a result of tight binding to inhibitor proteins in the I?B family (Fig. 26-1). Signal transduction pathways that activate the NF-?B system do so through the activation of an I?B kinase complex consisting of two kinase subunits (IKKa and IKKß) and a regulatory subunit (IKK?). The IKK complex phosphorylates I?Ba and I?Bß on specific serine residues, yielding a target for recognition by an E3 ubiquitin ligase complex. The resulting polyubiquitination marks this I?B for rapid degradation by the 26S proteasome complex in the cytoplasm. Once I?B has been degraded, the free NF-?B (which contains a nuclear localization signal) is able to pass into the nucleus and induce expression of NF-?B–sensitive genes. [16] Among the genes regulated by NF-?B are IL-1ß and TNF-a; this endows IL-1ß and TNF-a with the capacity to establish a positive regulatory loop that favors persistent inflammation. [15] Most cytokines (other than IL-1 and TNF) do not activate the NF-?B pathway as part of their signal transduction mechanisms, although the presence of ?B recognition sites in the promoters of these same cytokines is very common.

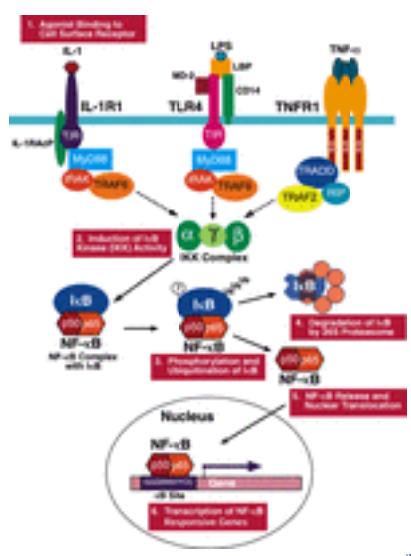

FIGURE 26-1 Activation of NF-?B regulated genes after signaling by receptors for primary cytokines or by TLRs engaged by microbial products. Under resting conditions, NF-?B (a heterodimer of p50 and p65 subunits) is tightly bound to an inhibitor called I?B, which sequesters NF-?B in the cytoplasm. Engagement of one of the TLRs or the signal transducing receptors for IL-1 or TNF family members leads to induction of I?B kinase activity that phosphorylates I?B on critical serine residues. Phosphorylated I?B becomes a substrate for ubiquitination, which triggers degradation of I?B by the 26S proteasome. Loss of I?B results in release of NF-?B, permitting it to move to the nucleus and activate transcription of genes whose promoters contain ?B recognition sites. DD, death domain; TRADD, TNFR1-associated DD protein; RIP, receptor-interacting protein.

Proinflammatory cytokines are not the only stimuli that can activate the NF-?B pathway. Bacterial products (e.g., lipopolysaccharide), oxidants, activators of protein kinase C (e.g., phorbol esters), viruses, and ultraviolet radiation are other stimuli that can stimulate NF-?B activity. [15] Recently, a cell surface receptor for the complex of lipopolysaccharide (LPS), LPS-binding protein, and CD14 was identified as TLR4. [17] The cytoplasmic domain of TLR4 is similar to that of the IL-1R1 and other IL-1R family members, [18] and is known as the TIR domain (for Toll/IL-1 receptor). When ligand is bound to this TIR domain, an adapter protein called MyD88 is recruited. In turn, MyD88 recruits one or more of the IL-1R–associated kinases (which include IRAK-1, -2, and -M), [19] which then signal through TRAF6, a member of the TNF receptor-associated factors (TRAF) family, to activate the IKK complex. Because most incident solar UV radiation is absorbed by resident cells in the epidermis and dermis, UV radiation effects on the NF-?B pathway are particularly relevant to the biology of skin. The cell surface receptors for IL-1, TNF, and epidermal growth factor (EGF) are rapidly clustered and internalized after exposure to UV radiation, leading to ligand-independent activation of both NF-?B and the c-Jun *N*-terminal kinases (JNKs). [20]

Hench's discovery of the anti-inflammatory effects of glucocorticoids was acknowledged with a Nobel Prize in 1950. Glucocorticoids inhibit as broad a range of proinflammatory effects as primary cytokines induce, and while their pharmacologic use is rife with potential complications, their anti-inflammatory activity is undisputed. A link between glucocorticoids and primary cytokines was made through the discovery that these pharmacologic agents increase the gene expression of I?Ba, thus serving to replace I?Ba degraded by proteasomes after phosphorylation and ubiquitination, and ultimately to sequester NF-?B dimers in the cytoplasm. [21] Effectively, then, glucocorticoids tip the balance between sequestered and active NF-?B by inducing I?Ba synthesis, while primary cytokines promote inflammation by liberating NF-?B from its association with I?B. Thus, glucocorticoids attack the central pathway by which primary cytokines work, and the plethora of effects that they have on inflammation is mirrored by those of genes inducible by NF-?B.

Jak-STAT Signal Transduction Pathway

A major breakthrough in the analysis of cytokine-mediated signal transduction was the identification of a common cell surface to nucleus pathway used by most cytokines. This “Jak-STAT” pathway was first elucidated through careful analysis of signaling initiated by interferon receptors (Fig. 26-2), [22] but was subsequently shown to play a role in signaling by all cytokines that bind to members of the hematopoietin receptor family. [23] The Jak-STAT pathway operates through the sequential action of a family of four nonreceptor tyrosine kinases (the Jaks or *Ja*nus family *k*inases) and a series of latent cytosolic transcription factors known as STATs (*s*ignal *t*ransducers and *a*ctivators of *t*ranscription). The

cytoplasmic portions of many cytokine receptor chains (Table 26-2) are noncovalently associated with one of the four Jaks (Jak1, Jak2, Jak3, and Tyk2).

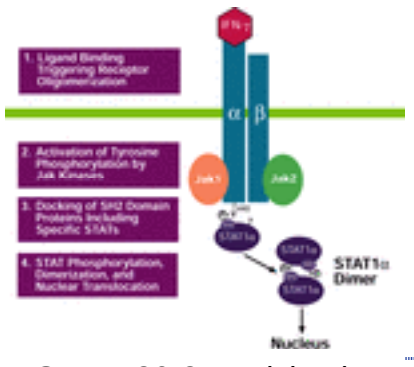

FIGURE 26-2 Participation of Jak and STAT proteins in IFN-? signaling. Binding of human IFN-? (a dimer) to its receptor brings about oligomerization of receptor complexes composed of a and ß chains. The nonreceptor protein tyrosine kinases Jak1 and Jak2 are activated and phosphorylate critical tyrosine residues in the receptor, such as the tyrosine at position 440 of the a chain (Y^{440}). STAT1a molecules are recruited to the IFN-? receptor based on the affinity of their SH2 domains for the phosphopeptide sequence around Y^{440}. Receptor-associated STAT1a molecules then dimerize through reciprocal SH2-phosphotyrosine interactions. The resulting STAT1a dimers translocate to the nucleus and stimulate transcription of IFN-? regulated genes.

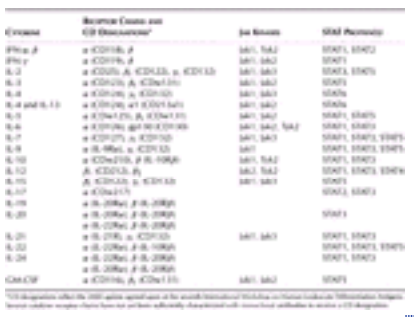

TABLE 26-2 **Use of Janus Kinases and STAT Proteins in Signal Transduction by Selected Cytokine Receptors**

Jak activity is upregulated after stimulation of the cytokine receptor. Ligand binding to the cytokine receptors leads to the association of two or more distinct cytokine receptor subunits and brings the associated Jaks into close proximity with each other. This promotes cross-phosphorylation or autophosphorylation reactions that in turn fully activate the kinases. Tyrosines in the cytoplasmic tail of the cytokine receptor, as well as tyrosines on other associated and newly recruited proteins, are also phosphorylated. A subset of the newly phosphorylated tyrosines can then serve as docking points for attachment of additional signaling proteins bearing src homology 2 (SH2) domains. Cytoplasmic STATs possess SH2 domains and are recruited to the phosphorylated cytokine receptors via this interaction. Homodimeric or heterodimeric STAT proteins are phosphorylated by the Jak kinases and subsequently translocate to the nucleus. In the nucleus, they bind recognition sequences in DNA and stimulate transcription of specific genes, often in cooperation with other transcription factors. [24] As shown in Table 26-2, the same STAT molecules can be involved in signaling by multiple different cytokines. The specificity of the response in these instances may depend on the formation of complexes involving STATs and other transcription factors that then selectively act on a specific set of genes.

Further investigation into the regulation of the Jak-STAT signaling has identified at least three general regulatory pathways that dampen the effects of Jak-STAT–mediated cytokine signaling. [25] The actions of tyrosine phosphatases such as SHP-1 attenuate the effects of tyrosine phosphorylation occurring after cytokine receptor activation. Members of the suppressor of cytokine synthesis (SOCS) family are negative regulatory proteins that are induced by cytokines and inhibit cytokine signaling as part of a negative feedback loop. Finally, protein inhibitor of activated STAT (PIAS) family members mediate their inhibition of cytokine signaling by inhibiting the DNA-binding activity of STATs.

IL-1 FAMILY OF CYTOKINES (IL-1a, IL-1ß, IL-18)

IL-1 is the prototype of a cytokine that has been discovered many times in many different biologic assays. [2] Distinct genes encode the a and ß forms of human IL-1, with only 26 percent homology at the amino acid level. Both IL-1s are translated as 31-kDa molecules that lack a signal peptide, and both reside in the cytoplasm. This form of IL-1a is biologically active, but the 31-kDa IL-1ß molecule must be cleaved by caspase-1 (initially termed IL-1ß–converting enzyme or ICE) to generate an active molecule [26]; this process occurs concurrently with release from the cell through a recently defined pathway of microvesicle shedding. [27] IL-1a can be cleaved by calpain to a 17-kDa form to facilitate its release from cells. [28]

IL-1ß appears to be the dominant form of IL-1 produced by monocytes, macrophages, Langerhans cells, and dendritic cells. IL-1a predominates in epithelial cells including keratinocytes, probably because epithelial IL-1a is stored in the cytoplasm of cells that comprise an interface with the external environment. Such cells, when injured, can release biologically active 31-kDa IL-1a and therefore can initiate inflammation. [6] However, if uninjured, these cells will differentiate and effectively release their IL-1 contents into the environment. Leukocytes, including dendritic and Langerhans cells, carry their cargo of IL-1 inside the body, where its unregulated release could cause significant tissue damage. Thus, the release of biologically active IL-1ß from cells is controlled at several levels: IL-1ß gene transcription, caspase-1 gene transcription, and transcription of the protease that activates caspase-1 to generate mature IL-1ß, all of which must occur efficiently for such cells to release IL-1ß. The role of IL-1ß in the migration of Langerhans cells from the

epidermis during the initiation of contact hypersensitivity was explored in several recent studies, leading some to suggest that this event is pivotal in the egress of Langerhans cells from the epidermis and the generation of successful sensitization. [29] Recent studies of mice deficient in IL-1a and IL-1ß genes suggest that both molecules are important in contact hypersensitivity, but that IL-1a is more critical. [30]

Active forms of IL-1 bind to the IL-1R1, or type I IL-1 receptor. [18] IL-1R1 is the sole signal transducing receptor for IL-1, and its cytoplasmic domain bears little homology to other cytokine receptors, showing greatest homology with the *Toll* gene product identified in *Drosophila*. A second cell surface protein, the IL-1R associated protein (IL-1RAcP), must associate with the IL-1R1 for signaling to occur. Both IL-1R1 and the IL-1RAcP are essential for IL-1 signaling, as mice deficient in either of these molecules exhibit absent IL-1 signaling. [31] When IL-1 associates with the IL-1R1/IL-1RAcP complex, the MyD88 adapter is recruited, followed by association of one or more of the IRAKs. In turn, these kinases associate with TRAF6. [32] Stepwise activation and recruitment of additional signaling molecules culminates in the induction of IKK activity. The net result is the NF-?B–mediated activation of a series of genes, including adhesion molecules, chemokines, secondary cytokines, nitric oxide synthase, and cyclooxygenases.

A molecule known as the IL-1 receptor antagonist, or IL-1ra, can bind to the IL-1R1, but does not induce signaling through the receptor. [33] This IL-1ra exists in three alternatively spliced forms, and an isoform produced in monocytes is the only ligand for the IL-1R1 that both contains a signal peptide and is secreted from cells. Two other isoforms of the IL-1ra, both lacking signal peptides, are contained in epithelial cells. [34] The function of the IL-1ra seems to be as a pure antagonist of IL-1 ligand binding to the IL-1R1, and binding of IL-1ra to the IL-1R1 does not induce the mobilization of the IL-1RAcP. Consequently, while both IL-1a/ß and the IL-1ra bind with equivalent affinities to the IL-1R1, the association of the IL-1R1 with IL-1RAcP increases the affinity for IL-1a/ß manyfold, without affecting the affinity for the IL-1ra. This finding is consistent with the observation that a vast molar excess of IL-1ra is required to fully antagonize the effects of IL-1. The biologic role of IL-1ra is likely to be in the quenching of IL-1–mediated inflammatory responses, and mice deficient in the IL-1ra have exaggerated and persistent inflammatory responses. [35]

A second means of antagonizing IL-1 activity occurs via expression of a second receptor for IL-1, the IL-1R2. This receptor has a short cytoplasmic domain and binds IL-1a/ß and IL-1ra. IL-1R2 is a 68-kDa receptor that can be cleaved from the cell surface by an unknown protease and released as a stable soluble 45-kDa molecule that retains avid IL-1a/ß binding function, but loses affinity for IL-1ra. [36] By binding the functional ligands for the IL-1R1, the IL-1R2 serves to inhibit IL-1–mediated responses. It is likely that the IL-1R2 inhibits IL-1 activity in another way—by associating with the IL-1RAcP at the cell surface and removing and sequestering it from the pool available to associate with the IL-1R1. Thus, soluble IL-1R2 binds to free IL-1, while cell surface IL-1R2 sequesters IL-1RAcP. Expression of the IL-1R2 can be upregulated by a number of stimuli, including glucocorticoids and IL-4. [37] However, IL-1R2 can also be induced by inflammatory cytokines, including IFN-? and IL-1, probably as a compensatory signal designed to limit the scale and duration of the inflammatory response. [38] Production of the IL-1R2 serves to make the producing cell and surrounding cells resistant to IL-1–mediated activation. Some of the most efficient IL-1-producing cells are also the best producers of the IL-1R2.

IL-18 was first identified by its capacity to induce IFN-?. [39] One name initially proposed for this cytokine was IL-1?, because of its homology to IL-1a and ß. Like IL-1ß, it is translated as an inactive precursor molecule of 23 kDa, and is cleaved to an active 18-kDa species by caspase-1. It is produced by multiple cell types in skin, including keratinocytes, Langerhans cells, and monocytes. [40] IL-18 induces proliferation, cytotoxicity, and cytokine production by T_H1 and NK cells, mostly synergistically with IL-12. [41] The IL-18 receptor bears striking similarity to the IL-1R1. [18] The binding chain (IL-18R) is an IL-1R1 homologue, originally cloned as IL-1Rrp1. IL-18R alone is a low-affinity receptor that must recruit IL-18RAcP (a homologue of IL-1RAcP). As for IL-1, both chains of the IL-18 receptor are required for signal transduction. Although there is no IL-18 homologue of the IL-1ra, a molecule known as IL-18 binding protein (IL-18BP) binds to soluble mature IL-18 and prevents it from binding to the IL-18R complex.

It is clear that there is a large family of receptors homologous to the IL-1R1 and IL-18R molecules, [18] having in common a TIR motif (see Fig. 26-1). Some of them may be receptors for recently cloned molecules homologous to IL-1a and IL-1ra. All of them share analogous signaling pathways initiated by the MyD88 adapter molecule. Thus, the IL-1R1, the IL-18R, the TLRs, and their ligands, are all best viewed as elements of the innate immune system that signal the presence of danger/injury to the host.

When IL-1 produced by epidermis was originally identified, it was noted that both intact epidermis and stratum corneum contained significant IL-1 activity. This observation led to the concept that epidermis was a shield of sequestered IL-1 surrounding the host, waiting to be released upon injury. More recently, it was observed that high levels of the IL-1ra coexist in keratinocytes [42]; however, repeated experiments show that in virtually all cases, the amount of IL-1 present is sufficient to overcome any potential for inhibition mediated by the IL-1ra. Mechanical stress to keratinocytes promotes the release of large amounts of IL-1 in the absence of cell death. [43] Release of IL-1 induces expression of endothelial adhesion molecules, including E-selectin, ICAM-1, and VCAM-1, as well as chemotactic and activating chemokines. This attracts not only monocytes and granulocytes, but also a specific subpopulation of memory T cells that bear cutaneous lymphocyte antigen (CLA) on their cell surface. CLA+ memory T cells are abundant in inflamed skin, comprising the majority of T cells present. Therefore, any injury to the skin, no matter how trivial, releases IL-1 and attracts this population of memory T cells. If the cells encounter their antigen in this microenvironment, their activation and subsequent cytokine production will amplify the inflammatory response. This process of injury and subsequent cytokine release has been proposed as the basis of the clinical observation known as the Koebner reaction. [43]

TNF: THE OTHER PRIMARY CYTOKINE

TNF-a is the prototype for a family of related signaling molecules that mediate their biologic effects through a family of related receptor molecules. TNF-a was initially cloned on the basis of its ability to mediate two biologic effects: (1)

hemorrhagic necrosis of malignant tumors and (2) inflammation-associated cachexia. Although TNF-a exerts many of its biologically important effects as a soluble mediator, newly synthesized TNF-a exists as a transmembrane protein on the cell surface. A specific metalloprotease known as TNF-a–converting enzyme (TACE) is responsible for most TNF-a release by T cells and myeloid cells. [44] Closely related to TNF-a is TNF-ß, also known as lymphotoxin a (LT-a). Other related molecules in the TNF family include lymphotoxin ß (LT-ß), Fas ligand (FasL), TNF-related apoptosis-inducing ligand (TRAIL), TNF-related activation-induced cytokine (TRANCE), and CD40 ligand (CD154). [14] Although some of these other TNF family members have not been traditionally regarded as cytokines, their structure (all are type II membrane proteins with an intracellular N terminus and an extracellular C terminus) and signaling mechanisms are closely related to those of TNF. The soluble forms of TNF-a, LT-a, and FasL are homotrimers; and the predominant form of lymphotoxin-ß is a membrane-bound heterotrimer of one LT-a chain and two LT-ß chains. Trimerization of TNF receptor family members by their trimeric ligands appears to be required for initiation of signaling and expression of biologic activity.

The initial characterization of TNF receptors led to the discovery of two receptor proteins capable of binding TNF-a with high affinity. The p55 receptor for TNF (TNFR1) is responsible for most biologic activities of TNF, but the p75 TNF receptor (TNFR2) is also capable of transducing signals (unlike the IL-1R2, which acts solely as a biologic sink for IL-1). TNFR1 and TNFR2 have substantial stretches of close homology and are both present on most types of cells. Nevertheless, there are some notable differences between the two TNFRs (see below).

Unlike cytokine receptors from several of the other large families, TNF signaling does not involve the Jak-STAT pathway. TNF-a evokes two types of responses in cells: proinflammatory effects and induction of apoptotic cell death. The proinflammatory effects of TNF-a, which include upregulation of adhesion molecule expression and induction of secondary cytokines and chemokines, stem in large part from activation of NF-?B and can be transduced through both TNFR1 and TNFR2. Induction of apoptosis by signaling through TNFR1 depends on a region known as a “death domain,” which is absent in TNFR2, and the association of additional proteins with death domains with the TNFR1 signaling complex. Signaling initiated by ligand binding to TNFR1, Fas, or other death domain-containing receptors in the TNF family eventually leads to activation of caspase-8 or -10 and the nuclear changes and DNA fragmentation characteristic of apoptosis. [14]

At least two TNF receptor family members (TNFR1 and the LT-ß receptor) also contribute to the normal anatomic development of the lymphoid system. [45] Mice deficient in TNF-a lack germinal centers and follicular dendritic cells. TNFR1 mutant mice have the same abnormalities plus an absence of Peyer's patches. Mice with null mutations in LT-a or LT-ß have further abnormalities in lymphoid organogenesis and fail to develop peripheral lymph nodes.

TNF-a is an important mediator of cutaneous inflammation, and its expression is induced in the course of almost all inflammatory responses in skin. Normal human keratinocytes and keratinocyte cell lines produce substantial amounts of TNF-a after stimulation with LPS or UV light. [46] Cutaneous inflammation stimulated by irritants and contact sensitizers is associated with strong induction of TNF-a production by keratinocytes, a response that is blunted by administration of anti-TNF and in TNF-a–deficient mice. [47], [48] Intradermal injection of TNF-a is associated with the migration of Langerhans cells to draining lymph nodes, allowing for sensitization of naive T cells. [49] One molecular mechanism that may contribute to TNF-a–induced migration of Langerhans cells toward lymph nodes is reduced expression of the E-cadherin adhesion molecule after exposure to TNF-a. [50] The predominant TNF receptor expressed by keratinocytes is TNFR1 [51]; autocrine signaling loops involving keratinocyte-derived TNF-a and TNFR1 lead to keratinocyte production of a variety of TNF-inducible secondary cytokines.

The central role of TNF-a in inflammatory diseases, including rheumatoid arthritis and psoriasis, has become evident from clinical studies. Two new clinical drugs target the TNF pathway: a humanized anti–TNF-a antibody infliximab (Remicade) and the soluble TNF receptor etanercept (Enbrel). Although larger studies are needed, these drugs appear to have a more profound effect on psoriasis than any other biologic response modifiers. [52], [53] Paradoxically, they do not work in all autoimmune diseases—multiple sclerosis appears to worsen slightly after treatment with these reagents.

CLASS I (HEMATOPOIETIN RECEPTOR) FAMILY OF CYTOKINE RECEPTORS AND THEIR LIGANDS

The hematopoietin receptor family (also known as class I cytokine receptor family) is the largest of the cytokine receptor families and comprises a number of structurally related type I membrane-bound glycoproteins. The cytoplasmic domains of these receptors associate with non-receptor tyrosine kinase molecules including Jak and src family kinases. After ligand binding and receptor oligomerization, these associated non-receptor tyrosine kinases phosphorylate intracellular substrates leading to signal transduction. Most of the multiple chain receptors in the hematopoietin receptor family consist of a cytokine-specific a chain subunit paired with one or more shared receptor subunits. Four shared receptor subunits have been described: the common ? chain (? $_c$); the common ß chain shared between the IL-2 and IL-15 receptors; a distinct common ß chain shared between the granulocyte-macrophage colony-stimulating factor (GM-CSF), IL-3, and IL-5 receptors; and, finally, the gp130 molecule, which participates in signaling by IL-6 and related cytokines.

Cytokines with Receptors That Include the ? $_c$ Chain: IL-2, IL-4, IL-7, IL-9, IL-15, and IL-21

The receptor complexes that use the ? $_c$ chain are the IL-2, IL-4, IL-7, IL-9, IL-15, and IL-21 receptors. [54] Two of these receptors, the IL-2R and the IL-15R, also use the IL-2Rß $_c$ chain. The ? $_c$ chain is physically associated with Jak3 kinase, and activation of Jak3 kinase is critical to most signaling initiated through this subset of cytokine receptors. [55]

IL-2 AND IL-15 IL-2 and IL-15 can each activate natural killer (NK) cells and stimulate proliferation of activated T cells. IL-2 is a product of activated T cells, and IL-2R is largely restricted to lymphoid cells. The IL-15 gene is expressed by nonlymphoid tissues, and its transcription is induced by UVB light in keratinocytes and fibroblasts and by LPS in

monocytes and dendritic cells. Multiple isoforms of IL-15Ra are found in various hematopoietic and non-hematopoietic cells. The IL-2R and IL-15R complexes of lymphocytes incorporate up to three receptor chains, whereas most other cytokine receptor complexes have two. The affinities of IL-2R and IL-15R for their respective ligands can be regulated, and, to some extent, IL-2 and IL-15 compete with each other. The highest affinity receptor complexes for each ligand (~ 10^{-11} M) consist of the IL-2Rß $_c$ and ? $_c$ chains, as well as their respective a chains (IL-2Ra, also known as CD25, and IL-15Ra). ? $_c$ and IL-2Rß $_c$ without the a chains form a functional lower affinity receptor for either ligand (10^{-8} to 10^{-10} M). While both ligands transmit signals through the ? $_c$ chain, those signals elicit overlapping but distinct responses in various cells. Activation of naive CD4 T cells by T cell receptor (TCR) and costimulatory molecules induces expression of IL-2, IL-2Ra, and IL-2Rß $_c$, leading to vigorous cell proliferation. Prolonged stimulation of the TCR and IL-2R leads to expression of Fas ligand and activation-induced cell death (AICD). While IL-2 signaling facilitates the death of CD4 T cells in response to sustained exposure to antigen, IL-15 inhibits IL-2 mediated AICD as it stimulates growth. Similarly, IL-15 promotes proliferation of memory CD8 T cells while IL-2 inhibits such proliferation. These contrasting biologic roles are illustrated by mice deficient in IL-2 or IL-2Ra that develop autoimmune disorders and mice deficient in IL-15 or IL-15Ra that have lymphopenia and immune deficiencies. Thus, IL-15 appears to have an important role in promoting effector functions of antigen-specific T cells, whereas IL-2 is involved in controlling autoreactive T cells. [56]

IL-4 AND IL-13 IL-4 and IL-13 are products of activated T $_H$2 cells that share limited structural homology (~30 percent) and overlapping but distinct biologic activities. A specific receptor for IL-4, which does not bind IL-13, is found on T cells and NK cells. It consists of IL-4Ra (CD124) and ? $_c$ and transmits signals via Jak1 and Jak3. A second receptor complex that can bind either IL-4 or IL-13 is found on keratinocytes, endothelial cells, and other nonhematopoietic cells. [57] It consists of IL-13Ra1 (CD213a1) and IL-4Ra and transmits signals via Jak1 and Jak2. These receptors are expressed at low levels in resting cells and their expression is increased by various activating signals. Both signal transduction pathways appear to converge with the activation of STAT6, which is both necessary and sufficient to drive T $_H$2 differentiation, as well as the insulin receptor substrates 1 and 2 (IRS-1 and IRS-2) and Shc. Another cell surface molecule homologous to IL-13Ra1, termed IL-13Ra2 (CD213a2), binds with high affinity to IL-13 but is not known to transmit any signals and may function as a decoy receptor. [58] The biologic effects of engagement of the IL-4 receptor vary depending on the specific cell type, but most pertain to its principal role as a growth and differentiation factor for T $_H$2 cells. [59] Exposure of naive T cells to IL-4 stimulates them to proliferate and differentiate into T $_H$2 cells, which produce more IL-4; this cycle leads to autocrine stimulation that prolongs T $_H$2 responses. Thus, the expression of IL-4 early in the immune response can initiate a cascade of T $_H$2 cell development leading to a predominately T $_H$2 response. The genes encoding IL-4 and IL-13 are located in a cluster with IL-5 that undergoes structural changes during T $_H$2 differentiation that are associated with increased expression. While naive T cells can make low levels of IL-4 when activated, it is also produced by activated NKT cells. Mast cells and basophils also release preformed IL-4 from secretory granules in response to FceRI-mediated signals. [60] A prominent activity of IL-4 is the stimulation of class switching of the immunoglobulin genes of B cells. As critical factors in T $_H$2 differentiation and effector function, IL-4 and IL-13 are mediators of atopic immunity. In addition to controlling the behavior of effector cells, they also act directly on resident tissue cells such as in inflammatory airway reactions.

IL-7 Mutations abrogating the function of IL-7, IL-7Ra (CD127), ? $_c$, or Jak3 in mice or humans cause profound immunodeficiency as a result of T and NK cell depletion. [55] This is principally due to the indispensable role of IL-7 in promoting the expansion of lymphocytes and regulating the rearrangement of their antigen receptor genes. IL-7 is a potent mitogen and survival factor for immature lymphocytes in the bone marrow and thymus. The second function of IL-7 is as a modifier of effector cell functions in the reactive phase of certain immune responses. IL-7 transmits activating signals to mature T cells and certain activated B cells. Like IL-2, IL-7 stimulates proliferation of cytolytic T cells (CTL) and lymphokine-activated killer (LAK) cells in vitro, and enhances their activities in vivo. Monocytes exposed to IL-7 release IL-6, IL-1a, IL-1ß, and TNF-a, and exhibit enhanced tumoricidal activity in vitro. IL-7 is a particularly significant cytokine for lymphocytes in the skin and other epithelial tissues. It is expressed by keratinocytes in a regulated fashion, and this expression is thought to be part of a reciprocal signaling dialogue between dendritic epidermal T cells and keratinocytes in murine skin. Keratinocytes release IL-7 in response to IFN-? and dendritic epidermal T cells secrete IFN-? in response to IL-7. [61]

IL-9 AND IL-21 IL-9 is a product of activated T $_H$2 cells that acts as an autocrine growth factor as well as a mediator of inflammation. [62] It is also produced by mast cells in response to IL-10 or stem cell factor. It stimulates proliferation of T and B cells and promotes expression of IgE by B cells. It also exerts proinflammatory effects on mast cells and eosinophils. Mice deficient in IL-9 have deficits in mast cell and goblet cell differentiation. Thus, IL-9 appears to be a potent effector of allergic inflammatory processes. IL-21 is a recently discovered cytokine that triggers signals through a receptor composed of a specific a chain (IL-21R) and ? $_c$. [63] IL-21 elicits varied responses from different lymphocytes; most notably it promotes proliferation and maturation of NK cells.

Cytokines with Receptors That Use the IL-3Rß Chain: IL-3, IL-5, and GM-CSF

The receptors for IL-3, IL-5, and GM-CSF consist of unique cytokine-specific a chains paired with a common ß chain known as IL-3Rß, or ß $_c$ (CDw131). Each of these factors acts on subsets of early hematopoietic cells. [64] IL-3, previously known as multilineage colony-stimulating factor, is principally a product of CD4+ T cells and causes proliferation, differentiation, and colony formation of various myeloid cells from bone marrow. IL-5 is a product of T $_H$2 CD4+ cells, as well as of activated mast cells, that conveys signals to B cells and eosinophils. IL-5 has costimulatory activity on B cells in that it enhances their proliferation and immunoglobulin expression in conjunction with antigen. In conjunction with an eosinophil-attracting chemokine known as eotaxin, IL-5 plays a central role in the accumulation of eosinophils that accompanies parasite infections and some cutaneous inflammatory processes. IL-5 appears to be required to generate a pool of eosinophil precursors in bone marrow that can be rapidly mobilized to the blood, while eotaxin recruits these eosinophils from blood into specific tissue sites. [65] GM-CSF is a growth factor for myeloid progenitors in the bone marrow. It is produced by activated T cells, phagocytes, keratinocytes, fibroblasts, and vascular endothelial cells. In addition to its role in early hematopoiesis, GM-CSF has potent effects on macrophages and dendritic cells. Fresh Langerhans cells cultured in vitro in the presence of GM-CSF are transformed into mature dendritic cells with maximal immunostimulatory potential for naive T cells. The effects of GM-CSF on dendritic cells probably account for the dramatic ability of GM-CSF

to evoke therapeutic antitumor immunity when tumor cells are engineered to express it. [66]

IL-6 and Other Cytokines with Receptors That Use GP130

Receptors for a group of cytokines including IL-6, IL-11, leukemia inhibitory factor (LIF), oncostatin M (OSM), ciliary neurotrophic factor (CNTF), and cardiotrophin-1 (CT-1) interact with a hematopoietin receptor family member, gp130 (*g*lyco *p*rotein, *130* kDa), that does not appear to interact with any ligand by itself. gp130 is recruited into signaling complexes with other receptor chains when they engage their cognate ligands; these complexes may result in the formation of gp130 homodimers (as in the case of IL-6 and IL-11 signaling) or heterodimers between gp130 and the cytokine-specific a chain (as occurs with LIF, OSM, CNTF, and CT-1). [67]

IL-6 is the most thoroughly characterized of the cytokines that use gp130 for signaling, and it serves as a paradigm for discussion of the biologic effects of this family of cytokines. IL-6 is yet another example of a highly pleiotropic cytokine with multiple effects. Different names (including interferon-ß2, B cell stimulatory factor 2, plasmacytoma growth factor, cytotoxic T cell differentiation factor, and hepatocyte-stimulating factor) were used for IL-6 before it was recognized that a single molecular species could account for all of these activities. IL-6 acts on a wide variety of cells of hematopoietic origin. IL-6 stimulates immunoglobulin secretion by B cells and has mitogenic activity on B lineage cells and plasmacytomas. IL-6 also promotes maturation of megakaryocytes and differentiation of myeloid cells. In addition to its participation in hematopoietic development and reactive immune responses, IL-6 is a central mediator of the systemic acute phase response. Increases in circulating IL-6 levels stimulate hepatocytes to synthesize and release acute phase proteins.

Two distinct signal transduction pathways are triggered by IL-6. [67] The first is mediated through the gp130 molecule, which dimerizes on engagement by the complex of IL-6 and IL-6Ra. Homodimerization of gp130 and its associated Jak kinases (Jak1, Jak2, Tyk2) leads to activation of STAT3. A second pathway of gp130 signal transduction involves Ras and the MAP kinase cascade and results in phosphorylation and activation of a transcription factor originally designated nuclear factor of IL-6 (NF-IL6).

IL-6 is an important cytokine for skin and is subject to dysregulation in several human diseases including some with skin manifestations. [68] IL-6 is produced in a regulated fashion by keratinocytes, fibroblasts, and vascular endothelial cells, as well as by leukocytes infiltrating the skin. IL-6 can stimulate the proliferation of human keratinocytes under some conditions. [69] Psoriasis is one of several inflammatory skin diseases in which the expression of IL-6 is elevated. [69] Human herpesvirus-8 (HHV-8) produces a viral homologue of IL-6 that may be involved in the pathogenesis of HHV-8–associated diseases, including Kaposi's sarcoma and body cavity-based lymphomas. [70]

The other cytokines that use gp130 as a signal transducer have diverse bioactivities. IL-11 inhibits production of inflammatory cytokines and has shown some therapeutic activity in patients with psoriasis. [71] Exogenous IL-11 also stimulates platelet production and has been used to treat thrombocytopenia occurring after chemotherapy. [72] As their names imply, OSM and LIF can suppress growth and metastasis of certain malignant cells; while in other systems, they either promote or inhibit differentiation, tissue repair, and other cellular processes.

IL-12: The Pivotal Cytokine for T_H1 Responses

IL-12 is distinct from most other cytokines in that in its active form it is a heterodimer of two proteins, p35 and p40. IL-12 is principally a product of antigen-presenting cells such as dendritic cells, monocytes, and macrophages, as well as certain B cells in response to bacterial components, GM-CSF, and IFN-?. Activated keratinocytes are an additional source of IL-12 in skin. Human keratinocytes constitutively make the p35 subunit, and expression of the p40 subunit can be induced by stimuli such as contact allergens, phorbol esters, and UV radiation. [73]

IL-12 is a critical immunoregulatory cytokine that is central to the initiation and maintenance of T_H1 responses. [74] T_H1 responses that depend on IL-12 provide protective immunity to intracellular bacterial pathogens, while IL-12–mediated T_H1 responses are central to several autoimmune diseases. IL-12 also has stimulatory effects on NK cells, promoting their proliferation, cytotoxic function, and the production of cytokines including IFN-?. IL-12 stimulates protective antitumor immunity in a number of animal models. [66]

Two chains that are part of the cell surface receptor for IL-12 have been cloned. Both are homologous to other ß chains in the hematopoietin receptor family and are currently designated $ß_1$ and $ß_2$. The $ß_1$ chain is associated with Tyk2, and the $ß_2$ chain interacts directly with Jak2. The signaling component of the IL-12R is the $ß_2$ chain. The $ß_2$ chain is expressed in T_H1 but not T_H2 cells and appears to be critical for the commitment of T cells to production of type 1 cytokines. IL-12 signaling induces the phosphorylation of STAT1, STAT3, and STAT4, but it is STAT4 that is essential for induction of a T_H1 response. [74]

Recently, a novel cytokine that uses the p40 chain of IL-12 was discovered. IL-23, which is comprised of the IL-12 p40 chain and a distinct p19 chain, has activities that overlap with those of IL-12, but also appears to induce proliferation of memory T cells. [75]

THE CLASS II FAMILY OF CYTOKINE RECEPTORS AND THEIR LIGANDS

A second major class of cytokine receptors with common features includes two types of receptors for interferons, the IL-10R, and the recently discovered receptors for additional IL-10–related cytokines, including IL-19, IL-20, IL-22, and IL-24.

Interferons: Prototypes of Cytokines Signaling through a Jak-STAT Pathway

IFNs were one of the first families of cytokines to be characterized in detail. The IFNs were initially subdivided into three classes: IFN-a (the leukocyte IFNs), IFN-ß (fibroblast IFN), and IFN-? (immune IFN). The a and ß IFNs are collectively called type I IFNs, and all of these molecules signal through the same two-chain receptor (the IFN-aß receptor). [76] The second IFN receptor is a distinct two-chain receptor specific for IFN-?. [13] Both receptors are present on many cell types in skin, as well as in other tissues. Each of the chains comprising the two IFN receptors is associated with one of the Jak kinases (Tyk2 and Jak1 for the IFN-aßR and Jak1 and Jak2 for the IFN-?R). Only in the presence of both chains and two functional Jak kinases does effective signal transduction occur after IFN binding.

Viruses, double-stranded RNA, and bacterial products are among the stimuli that elicit release of the type I IFNs from cells. Many of the effects of the type I IFNs directly or indirectly increase host resistance to the spread of viral infection. Additional effects mediated through the IFN-aßR are increased expression of major histocompatibility complex (MHC) class I molecules and stimulation of NK cell activity. [76] In addition to its well-known antiviral effects, IFN-a also can modulate T cell responses by favoring the development of a T_H1 type of T cell response. [77] Finally, the type I IFNs also inhibit the proliferation of a variety of cell types, providing a rationale for their use in the treatment of some types of cancer. [77] Forms of IFN-a are used clinically to treat hairy cell leukemia, various lymphoid and nonlymphoid cutaneous malignancies, and papillomavirus infections.

Production of IFN-? is restricted to NK cells, CD8 T cells, and the subset of CD4 T cells producing type 1 cytokines (T_H1 cells). T_H1 cells produce IFN-? after engagement of the T cell receptor, and IL-12 can provide a strong costimulatory signal for T cell IFN-? production. [74] NK cells produce IFN-? in response to cytokines released by macrophages including TNF-a, IL-12, and IL-18. IFN-? has antiviral effects but is a less potent mediator than the type I IFNs for induction of these effects. The major physiologic role of IFN-? is its capacity to modulate immune responses. IFN-? induces synthesis of multiple proteins that play essential roles in antigen presentation to T cells, including MHC class I and class II glycoproteins, invariant chain, the Lmp2 and Lmp7 components of the proteasome, and the TAP1 and TAP2 intracellular peptide transporters. These changes increase the efficiency of antigen presentation to CD4 and CD8 T cells. IFN-? is also required for activation of macrophages to their full antimicrobial potential, permitting them to eliminate microorganisms capable of intracellular growth. Like type I interferons, IFN-? also has strong antiproliferative effects against some cell types. Finally, IFN-? is an inducer of selected chemokines (e.g., IP-10 and Mig) and an inducer of endothelial cell adhesion molecules (e.g., ICAM-1 and VCAM-1). Because of the breadth of its activities, IFN-? comes the closest of the T cell cytokines to behaving as a primary cytokine.

IL-10: An “Anti-inflammatory” Cytokine

IL-10 is one of several cytokines that primarily exert regulatory rather than stimulatory effects on immune responses. [78] IL-10 was first identified as a cytokine produced by T_H2 T cells that inhibited cytokine production after activation of T cells by antigen and antigen-presenting cells. IL-10 acts through a cell surface receptor on macrophages, dendritic cells, neutrophils, B cells, T cells, and NK cells. The ligand binding chain of the receptor is homologous to the receptors for IFN-a/ß and IFN-?, and signaling events mediated through the IL-10 receptor use a Jak-STAT pathway. IL-10 binding to its receptor activates the Jak1 and Tyk2 kinases and leads to the activation of STAT1 and STAT3. Inhibitory effects of IL-10 on antigen-presenting cells such as monocytes, macrophages, and dendritic cells include inhibition of expression of class II MHC and costimulatory molecules (e.g., B7-1, B7-2) and decreased production of T cell-stimulating cytokines (e.g., IL-1, IL-6, and IL-12). At least four viral genomes harbor viral homologues of IL-10 that are biologically active after binding to the IL-10R. There are several cell types for which IL-10 has stimulatory rather than inhibitory effects; IL-10 stimulates B cell synthesis of class II MHC molecules and costimulates the growth of mast cells.

Epidermal keratinocytes are a major source of IL-10 in skin. IL-10 production by keratinocytes is upregulated after cell activation; one of the best characterized activating stimuli for keratinocytes is UV irradiation. [79] UV-induced keratinocyte IL-10 production leads to local and systemic effects on immunity. Some of the well-documented immunosuppressive effects that occur after exposure to UV light exposure are the result of the liberation of keratinocyte-derived IL-10 into the systemic circulation. [80] IL-10 also plays a dampening role in other types of cutaneous immune and inflammatory responses, because the absence of IL-10 predisposes mice to exaggerated irritant and contact sensitivity responses. [81]

Novel IL-10–Related Cytokines: IL-19, IL-20, IL-22, and IL-24

Cytokines related to IL-10 have been identified and shown to engage a number of receptor complexes with shared chains. IL-19, IL-20, and IL-24 transmit signals via a complex consisting of IL-20Ra and IL-20Rß. Transgenic mice overexpressing IL-20 develop severe cutaneous inflammation and altered epidermal proliferation and differentiation. Expression of the IL-20R chains is strongly induced when they are triggered and they are only detected on keratinocytes, endothelial cells, and certain monocytes in association with inflammatory conditions such as psoriasis. [82] IL-22 activates a receptor consisting of IL-22R and IL-10Rß, while IL-20 and IL-24 also engage a complex incorporating IL-20Rß and IL-22R. [83], [84] The profound effects of IL-20 expression in transgenic mice and the association of IL-20R expression with psoriasis point toward a central role for these cytokines in the epidermal changes associated with cutaneous inflammation.

THE TGF-ß FAMILY AND ITS RECEPTORS

TGF-ß1 was first isolated as a secreted product of virally transformed tumor cells capable of inducing normal cells in vitro to show phenotypic characteristics associated with transformation. More than 30 additional members of the TGF-ß family have been identified and are grouped into several families: the prototypic TGF-ßs (TGF-$ß_1$ to TGF-$ß_3$), the bone

morphogenetic proteins (BMPs), the growth/differentiation factors (GDFs), and the activins. [85] The TGF name for this family of molecules is somewhat of a misnomer, because TGF-ß has antiproliferative rather than proliferative effects on most cell types. Many of the TGF-ß family members play an important role in development, influencing the differentiation of uncommitted cells into specific lineages. TGF-ß family members are made as precursor proteins that are biologically inactive until a large pro-domain is cleaved. Monomers of the mature domain of TGF-ß family members are disulfide-linked to form dimers that strongly resist denaturation. [86]

Participation of at least two cell surface receptors (type I and type II) with serine/threonine kinase activity is required for biologic effects of TGF-ß. Ligand binding by the type II receptor (the true ligand-binding receptor) is associated with the formation of complexes of type I and type II receptors. This allows the type II receptor to phosphorylate and activate the type I receptor, a “transducer” molecule responsible for downstream signal transduction. Downstream signal transmission from the membrane-bound receptors in the TGF-ß receptor family to the nucleus is primarily mediated by a family of cytoplasmic Smad proteins that translocate to the nucleus and regulate transcription of target genes. [87]

TGF-ß has a profound influence on several types of immune and inflammatory processes. A combination of effects of TGF-ß on fibroblast function make it one of the most fibrogenic of all cytokines studied. [88] Fibroblasts treated with TGF-ß display enhanced production of collagen and other extracellular matrix molecules. In addition, TGF-ß inhibits the production of metalloproteinases by fibroblasts and stimulates the production of tissue inhibitors of the same metalloproteinases (TIMPs). TGF-ß effects on fibroblasts may be important in promoting wound healing. An immunoregulatory role for TGF-ß $_1$ was identified in part through analysis of TGF-ß $_1$ knockout mice. These mice develop a wasting disease at 20 days of age that is associated with a mixed inflammatory cell infiltrate involving many internal organs. Development of cells in the dendritic cell lineage is also perturbed in mice deficient in TGF-ß $_1$, as evidenced by an absence of epidermal Langerhans cells and specific subpopulations of lymph node dendritic cells. [89]

CHEMOKINES: SECONDARY CYTOKINES CENTRAL TO LEUKOCYTE MOBILIZATION

Chemokines are a large superfamily of small cytokines that have two major functions. First, they guide leukocytes via chemotactic gradients in tissue. Typically, the purpose is to bring an effector cell to where its activities are required. Second, a subset of chemokines has the capacity to increase the binding of leukocytes via their integrins to ligands at the endothelial cell surface, thus facilitating firm adhesion and extravasation of leukocytes in tissue. The complex activities of this important class of cytokines are discussed in Chap. 27.

THE CYTOKINE NETWORK—THERAPEUTIC IMPLICATIONS AND APPLICATIONS

Although many things may change in the world of cytokines, certain key concepts have stood the test of time. Principal among them is the idea that cytokines are emergency molecules, designed to be released locally and transiently in tissue microenvironments. When cytokines are released persistently, the result typically is chronic disease. One potential way to treat such diseases is with cytokine antagonists or other drugs that target cytokines or cytokine-mediated pathways.

For the clinician, certain key questions have arisen around the therapeutic use of cytokines. Several cytokines have already entered clinical trials, and some, such as type I interferons, have been used for years to treat melanoma and cutaneous lymphomas. With certain notable exceptions, systemic cytokine therapy has been disappointing and is often accompanied by substantial morbidity. In contrast, the local administration of cytokines, including transduction of autologous melanoma cells with factors such as GM-CSF or IL-12, may yield more promising results. [66] This is consistent with the idea that if used locally and transiently, cytokines are powerful biologic response modifiers. The use of GM-CSF and IL-12 as vaccine adjuvants is being extensively tested. Conversely, agents that specifically block cytokine activity are also being developed. The natural antagonist of IL-1 (IL-1ra), antibodies to TNF-a, and a recombinant soluble TNFR1 have already been approved for clinical use. These antagonists of TNF-a activity appear highly effective at inducing durable remissions in patients with psoriasis. [52], [53] Specific antagonists of other cytokines are also being developed. Cytokines that have predominantly anti-inflammatory effects, such as IL-10 and IL-11, are being used to treat inflammatory skin diseases such as psoriasis. [71], [90] Finally, fusion toxins linked to cytokines, such as DAB $_{389}$IL-2 (Ontak), exploit the cellular specificity of certain cytokine receptor interactions to kill target cells. [91] Each of these approaches is still new and open to considerable future development. An understanding of cytokines by clinicians of the future is likely to be central to effective patient care.

REFERENCES

1. Oppenheim JJ: Cytokines: Past, present, and future. *Int J Hematol* **74**:3, 2001

2. Dinarello CA: Interleukin-1. *Cytokine Growth Factor Rev* **8**:253, 1997

3. Bigazzi PE et al: Production of lymphokine-like factors (cytokines) by simian virus 40-infected and simian virus 40-transformed cells. *Am J Pathol* **80**:69, 1975

4. Luger TA et al: Epidermal cell (keratinocyte)-derived thymocyte-activating factor (ETAF). *J Immunol* **127**:1493, 1981

5. Kupper TS: The activated keratinocyte: A model for inducible cytokine production by non-bone marrow-derived cells in cutaneous inflammatory and immune responses. *J Invest Dermatol* **94**:146S, 1990

6. Kupper TS: Immune and inflammatory processes in cutaneous tissues. Mechanisms and speculations. *J Clin Invest* **86**:1783, 1990

7. Rock FL et al: A family of human receptors structurally related to *Drosophila* Toll. *Proc Natl Acad Sci U S A* **95**:588, 1998

8. Sieling PA, Modlin RL: Toll-like receptors: mammalian “taste receptors” for a smorgasbord of microbial invaders. *Curr Opin Microbiol* **5**:70, 2002

9. Mosmann TR, Coffman RL: T_H1 and T_H2 cells: Different patterns of lymphokine secretion lead to different functional properties. *Annu Rev Immunol* **7**:145, 1989

10. Mosmann TR, Sad S: The expanding universe of T-cell subsets: T_H1, T_H2 and more. *Immunol Today* **17**:138, 1996

11. Weiner HL: Induction and mechanism of action of transforming growth factor-ß–secreting T_H3 regulatory cells. *Immunol Rev* **182**:207, 2001

12. Nicola NA, Hilton DJ: General classes and functions of four-helix bundle cytokines. *Adv Protein Chem* **52**:1, 1998

13. Bach EA et al: The IFN? receptor: a paradigm for cytokine receptor signaling. *Annu Rev Immunol* **15**:563, 1997

14. Chan KF et al: Signaling by the TNF receptor superfamily and T cell homeostasis. *Immunity* **13**:419, 2000

15. Barnes PJ, Karin M: Nuclear factor-? B: A pivotal transcription factor in chronic inflammatory diseases. *N Engl J Med* **336**:1066, 1997

16. Karin M, Delhase M: The I ?B kinase (IKK) and NF-?B: Key elements of proinflammatory signaling. *Semin Immunol* **12**:85, 2000

17. Poltorak A et al: Defective LPS signaling in C3H/HeJ and C57BL/10ScCr mice: Mutations in Tlr4 gene. *Science* **282**:2085, 1998

18. Sims JE: IL-1 and IL-18 receptors, and their extended family. *Curr Opin Immunol* **14**:117, 2002

19. Jensen LE, Whitehead AS: IRAK1b, a novel alternative splice variant of interleukin-1 receptor-associated kinase (IRAK), mediates interleukin-1 signaling and has prolonged stability. *J Biol Chem* **276**:29037, 2001

20. Rosette C, Karin M: Ultraviolet light and osmotic stress: Activation of the JNK cascade through multiple growth factor and cytokine receptors. *Science* **274**:1194, 1996

21. Scheinman RI et al: Role of transcriptional activation of I ?Ba in mediation of immunosuppression by glucocorticoids. *Science* **270**:283, 1995

22. Darnell JE Jr et al: Jak-STAT pathways and transcriptional activation in response to IFNs and other extracellular signaling proteins. *Science* **264**:1415, 1994

23. Leonard WJ: Role of Jak kinases and STATs in cytokine signal transduction. *Int J Hematol* **73**:271, 2001

24. Takeda K, Akira S: STAT family of transcription factors in cytokine-mediated biological responses. *Cytokine Growth Factor Rev* **11**:199, 2000

25. Greenhalgh CJ, Hilton DJ: Negative regulation of cytokine signaling. *J Leukoc Biol* **70**:348, 2001

26. Thornberry NA et al: A novel heterodimeric cysteine protease is required for interleukin-1ß processing in monocytes. *Nature* **356**:768, 1992

27. MacKenzie A et al: Rapid secretion of interleukin-1ß by microvesicle shedding. *Immunity* **15**:825, 2001

28. Kobayashi Y et al: Identification of calcium-activated neutral protease as a processing enzyme of human interleukin 1a. *Proc Natl Acad Sci U S A* **87**:5548, 1990

29. Enk AH et al: An essential role for Langerhans cell-derived IL-1ß in the initiation of primary immune responses in skin. *J Immunol* **150**:3698, 1993

30. Nakae S et al: IL-1a, but not IL-1ß, is required for contact-allergen-specific T cell activation during the sensitization phase in contact hypersensitivity. *Int Immunol* **13**:1471, 2001

31. Cullinan EB et al: IL-1 receptor accessory protein is an essential component of the IL-1 receptor. *J Immunol* **161**:5614, 1998

32. Cao Z et al: TRAF6 is a signal transducer for interleukin-1. *Nature* **383**:443, 1996

33. Hannum CH et al: Interleukin-1 receptor antagonist activity of a human interleukin-1 inhibitor. *Nature* **343**:336, 1990

34. Muzio M et al: Cloning and characterization of a new isoform of the interleukin 1 receptor antagonist. *J Exp Med* **182**:623, 1995

35. Hirsch E et al: Functions of interleukin 1 receptor antagonist in gene knockout and overproducing mice. *Proc Natl Acad Sci U S A* **93**:11008, 1996

36. Symons JA et al: Soluble type II interleukin 1 (IL-1) receptor binds and blocks processing of IL-1ß precursor and loses affinity for IL-1 receptor antagonist. *Proc Natl Acad Sci U S A* **92**:1714, 1995

37. Colotta F et al: Interleukin-1 type II receptor: A decoy target for IL-1 that is regulated by IL-4. *Science* **261**:472, 1993

38. Groves RW et al: Inducible expression of type 2 IL-1 receptors by cultured human keratinocytes. Implications for IL-1-mediated processes in epidermis. *J Immunol* **154**:4065, 1995

39. Dinarello CA et al: Overview of interleukin-18: More than an interferon-? inducing factor. *J Leukoc Biol* **63**:658, 1998

40. McInnes IB et al: Interleukin 18: A pleiotropic participant in chronic inflammation. *Immunol Today* **21**:312, 2000

41. Nakanishi K et al: Interleukin-18 regulates both T_H1 and T_H2 responses. *Annu Rev Immunol* **19**:423, 2001

42. Hammerberg C et al: Interleukin-1 receptor antagonist in normal and psoriatic epidermis. *J Clin Invest* **90**:571, 1992

43. Lee RT et al: Mechanical deformation promotes secretion of IL-1a and IL-1 receptor antagonist. *J Immunol* **159**:5084, 1997

44. Killar L et al: Adamalysins. A family of metzincins including TNF-a converting enzyme (TACE). *Ann N Y Acad Sci* **878**:442, 1999

45. von Boehmer H: Lymphotoxins: from cytotoxicity to lymphoid organogenesis. *Proc Natl Acad Sci U S A* **94**:8926, 1997

46. Kock A et al: Human keratinocytes are a source for tumor necrosis factor a: Evidence for synthesis and release upon stimulation with endotoxin or ultraviolet light. *J Exp Med* **172**:1609, 1990

47. Piguet PF et al: Tumor necrosis factor is a critical mediator in hapten induced irritant and contact hypersensitivity reactions. *J Exp Med* **173**:673, 1991

48. Pasparakis M et al: Immune and inflammatory responses in TNF-a-deficient mice: A critical requirement for TNF-a in the formation of primary B cell follicles, follicular dendritic cell networks and germinal centers, and in the maturation of the humoral immune response. *J Exp Med* **184**:1397, 1996

49. Cumberbatch M et al: Langerhans cell migration. *Clin Exp Dermatol* **25**:413, 2000

50. Schwarzenberger K, Udey MC: Contact allergens and epidermal proinflammatory cytokines modulate Langerhans cell E-cadherin expression in situ. *J Invest Dermatol* **106**:553, 1996

51. Trefzer U et al: The 55-kD tumor necrosis factor receptor on human keratinocytes is regulated by tumor necrosis factor-a and by ultraviolet B radiation. *J Clin Invest* **92**:462, 1993

52. Mease PJ et al: Etanercept in the treatment of psoriatic arthritis and psoriasis: A randomised trial. *Lancet* **356**:385, 2000

53. Chaudhari U et al: Efficacy and safety of infliximab monotherapy for plaque-type psoriasis: A randomised trial. *Lancet* **357**:1842, 2001

54. Taniguchi T: Cytokine signaling through nonreceptor protein tyrosine kinases. *Science* **268**:251, 1995

55. Notarangelo LD et al: Of genes and phenotypes: the immunological and molecular spectrum of combined immune deficiency. Defects of the ? $_c$-JAK3 signaling pathway as a model. *Immunol Rev* **178**:39, 2000

56. Waldmann TA et al: Contrasting roles of IL-2 and IL-15 in the life and death of lymphocytes: Implications for immunotherapy. *Immunity* **14**:105, 2001

57. Kawakami K et al: The interleukin-13 receptor a2 chain: An essential component for binding and internalization but not for interleukin-13-induced signal transduction through the STAT6 pathway. *Blood* **97**:2673, 2001

58. Bernard J et al: Expression of interleukin 13 receptor in glioma and renal cell carcinoma: IL13Ra2 as a decoy receptor for IL13. *Lab Invest* **81**:1223, 2001

59. Seder RA et al: The presence of interleukin 4 during in vitro priming determines the lymphokine-producing potential of CD4+ T cells from T cell receptor transgenic mice. *J Exp Med* **176**:1091, 1992

60. Plaut M et al: Mast cell lines produce lymphokines in response to cross-linkage of FceRI or to calcium ionophores. *Nature* **339**:64, 1989

61. Takashima A et al: Interleukin-7-dependent interaction of dendritic epidermal T cells with keratinocytes. *J Invest Dermatol* **105**:50S, 1995

62. Soussi-Gounni A et al: Role of IL-9 in the pathophysiology of allergic diseases. *J Allergy Clin Immunol* **107**:575, 2001

63. Vosshenrich CA, Di Santo JP: Cytokines: IL-21 joins the ? $_c$-dependent network? *Curr Biol* **11**:R175, 2001

64. Geijsen N et al: Specificity in cytokine signal transduction: lessons learned from the IL-3/IL-5/GM-CSF receptor family. *Cytokine Growth Factor Rev* **12**:19, 2001

65. Collins PD et al: Cooperation between interleukin-5 and the chemokine eotaxin to induce eosinophil accumulation in vivo. *J Exp Med* **182**:1169, 1995

66. Mach N, Dranoff G: Cytokine-secreting tumor cell vaccines. *Curr Opin Immunol* **12**:571, 2000

67. Taga T, Kishimoto T: Gp130 and the interleukin-6 family of cytokines. *Annu Rev Immunol* **15**:797, 1997

68. Paquet P, Pierard GE: Interleukin-6 and the skin. *Int Arch Allergy Immunol* **109**:308, 1996

69. Grossman RM et al: Interleukin 6 is expressed in high levels in psoriatic skin and stimulates proliferation of cultured human keratinocytes. *Proc Natl Acad Sci USA* **86**:6367, 1989

70. Neipel F et al: Human herpesvirus 8 encodes a homolog of interleukin-6. *J Virol* **71**:839, 1997

71. Trepicchio WL et al: Interleukin-11 therapy selectively downregulates type I cytokine proinflammatory pathways in psoriasis lesions. *J Clin Invest* **104**:1527, 1999

72. Schwertschlag US et al: Hematopoietic, immunomodulatory and epithelial effects of interleukin-11. *Leukemia* **13**:1307, 1999

73. Enk CD et al: UVB induces IL-12 transcription in human keratinocytes in vivo and in vitro. *Photochem Photobiol* **63**:854, 1996

74. Sinigaglia F et al: Regulation of the IL-12/IL-12R axis: A critical step in T-helper cell differentiation and effector function. *Immunol Rev* **170**:65, 1999

75. Oppmann B et al: Novel p19 protein engages IL-12p40 to form a cytokine, IL-23, with biological activities similar as well as distinct from IL-12. *Immunity* **13**:715, 2000

76. Bogdan C: The function of type I interferons in antimicrobial immunity. *Curr Opin Immunol* **12**:419, 2000

77. Belardelli F, Gresser I: The neglected role of type I interferon in the T-cell response: Implications for its clinical use. *Immunol Today* **17**:369, 1996

78. Moore KW et al: Interleukin-10 and the interleukin-10 receptor. *Annu Rev Immunol* **19**:683, 2001

79. Enk CD et al: Induction of IL-10 gene expression in human keratinocytes by UVB exposure in vivo and in vitro. *J Immunol* **154**:4851, 1995

80. Shreedhar V et al: A cytokine cascade including prostaglandin E2, IL-4, and IL-10 is responsible for UV-induced systemic immune suppression. *J Immunol* **160**:3783, 1998

81. Berg DJ et al: Interleukin 10 but not interleukin 4 is a natural suppressant of cutaneous inflammatory responses. *J Exp Med* **182**:99, 1995

82. Blumberg H et al: Interleukin 20: Discovery, receptor identification, and role in epidermal function. *Cell* **104**:9, 2001

83. Dumoutier L et al: Cutting edge: STAT activation by IL-19, IL-20 and mda-7 through IL-20 receptor complexes of two types. *J Immunol* **167**:3545, 2001

84. Wang M et al: Interleukin 24 (MDA-7/MOB-5) Signals through two heterodimeric receptors, IL-22R1/IL-20R2 and IL-20R1/IL-20R2. *J Biol Chem* **277**:7341, 2002

85. Kingsley DM: The TGF-ß superfamily: New members, new receptors, and new genetic tests of function in different organisms. *Genes Dev* **8**:133, 1994

86. Bonewald LF: Regulation and regulatory activities of transforming growth factor-ß. *Crit Rev Eukaryot Gene Expr* **9**:33, 1999

87. Miyazono K et al: TGF-ß signaling by Smad proteins. *Adv Immunol* **75**:115, 2000

88. Denton CP, Abraham DJ: Transforming growth factor-ß and connective tissue growth factor: Key cytokines in scleroderma pathogenesis. *Curr Opin Rheumatol* **13**:505, 2001

89. Strobl H, Knapp W: TGF-ß1 regulation of dendritic cells. *Microbes Infect* **1**:1283, 1999

90. McInnes IB et al: IL-10 improves skin disease and modulates endothelial activation and leukocyte effector function in patients with psoriatic arthritis. *J Immunol* **167**:4075, 2001

91. Gottlieb SL et al: Response of psoriasis to a lymphocyte-selective toxin (DAB389IL-2) suggests a primary immune, but not keratinocyte, pathogenic basis. *Nat Med* **1**:442, 1995

T>

Chapter 27

Sam Hwang

Chemokines

STRUCTURE
CHEMOKINE RECEPTORS AND SIGNAL TRANSDUCTION
CHEMOKINES AND CUTANEOUS LEUKOCYTE TRAFFICKING
Multistep Model of Leukocyte Recruitment
Chemokine-Mediated Migration of T Cells
Chemokines in the Trafficking of Dendritic Cells from Skin to Regional Lymph Nodes
CHEMOKINES IN DISEASE
Atopic Dermatitis
Psoriasis
Cancer
Infectious Diseases

REFERENCES

The skin is an organ in which the migration, influx, and egress of leukocytes occurs in both homeostatic and inflammatory processes. Chemokines and their receptors are accepted as vital mediators of cellular trafficking. Since the discovery of the first *chemo*attractant cyto *kine* or chemokine in 1977, 50 new chemokines and 17 chemokine receptors have been discovered. Most chemokines are small proteins with molecular weights in the 8 to 10 kDa range; they are synthesized constitutively in some cells and can be induced in many cell types by cytokines. Initially associated only with recruitment of leukocyte subsets to different inflammatory sites, it has become quite clear that chemokines play roles in angiogenesis, neural development, cancer metastasis, hematopoiesis, and infectious diseases. [1]

This chapter focuses primarily on the function of chemokines in inflammatory conditions, but it also touches on the role of these molecules in other settings. An overview of the structure of chemokines and chemokine receptors as well as details of the molecular signaling pathways initiated by the binding of a chemokine to its cognate receptor is provided. Expression patterns of chemokine receptors are noted, particularly in light of the many types of immune cells that potentially can be recruited to skin under inflammatory conditions. Individual chemokine receptors are highlighted in regard to observed biologic function, including facilitation of migration of effector T cells into the skin and the egress of antigen-presenting cells out of the skin. Finally, the roles of chemokines and their receptors in disease—atopic dermatitis, psoriasis, cancer, and infectious disease—are described to emphasize the diversity of chemokine functions in skin.

STRUCTURE

Chemokines can be grouped into four subfamilies based on the spacing of amino acids between the first two cysteines. The CXC chemokines (also called a-chemokines) show a C-X-C motif with one non conserved amino acid between the two cysteines. The other major subfamily is termed the CC subfamily (or ß-chemokines) because of the lack of the additional amino acid. The two remaining subfamilies contain only one member each: the C subfamily is represented by lymphotactin, and fractalkine is the only member of the CXXXC (or CX3C) subfamily. Chemokines can also be assigned to one of two broad, and perhaps overlapping, functional groups. One type mediates the attraction and recruitment of immune cells to sites of active inflammation [e.g., regulated on activation, normal T cell expressed and secreted (RANTES); macrophage inflammatory protein (MIP)-1a/ß; and liver and activation-regulated chemokine (LARC)], while other chemokines [e.g., secondary lymphoid-tissue chemokine (SLC) and stromal-derived factor-1 (SDF-1)] appear to play roles in constitutive or homeostatic migration pathways. [1]

The complexity and redundancy in the nomenclature of chemokines has led to the proposal by Zlotnik and Yoshie [1] for a systematic nomenclature for chemokines based on the type of chemokine (C, CXC, CX3C, or CC) and a number based on the order of discovery. For example, SDF-1, a CXC chemokine, has the systematic name CXCL12. Because this nomenclature is not yet universally used and because the original names (abbreviated in most cases) are commonly found in the literature, an original name with an abbreviation is used throughout this chapter. Table 27-1 provides a list of chemokine receptors that are discussed in this chapter, as well as the major chemokine ligands that bind to them. The systematic names of the chemokines are also shown.

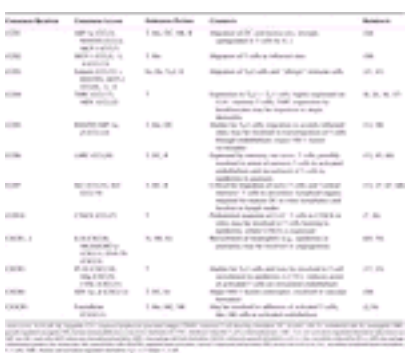

TABLE 27-1 **Chemokine Receptors in Skin Biology**

Chemokines are highly conserved and have similar secondary and tertiary structures. On the basis of crystallography studies, a disordered amino terminus followed by three conserved antiparallel ß-pleated sheets is a common structural feature of chemokines. Fractalkine is unique in that the chemokine domain sits atop a mucin-like stalk tethered to the plasma membrane via a transmembrane domain and short cytoplasmic tail. [2] Although CXC and CC chemokines form multimeric structures under conditions required for structural studies, these associations may be relevant only when chemokines associate with cell-surface components such as glycosaminoglycans (GAGs) or proteoglycans. Because most chemokines have a net positive charge, these proteins tend to bind to negatively charged carbohydrates present on GAGs. Indeed, the ability of positively charged chemokines to bind to GAGs is thought to enable chemokines to preferentially associate with the lumenal surface of blood vessels despite the presence of shear forces from the blood that would otherwise wash the chemokines away.

CHEMOKINE RECEPTORS AND SIGNAL TRANSDUCTION

Chemokine receptors are seven transmembrane-spanning domain membrane proteins that couple to intracellular heterotrimeric G proteins containing a, ß, and ? subunits. [1] They represent a part of a large family of G-protein coupled receptors (GPCR), including rhodopsin, that have critical biologic functions. Leukocytes express three Ga protein subtypes (s, i, and q), while the ß and ? subunits have 5 and 11 known subtypes, respectively. This complexity in the formation of the heterotrimeric G-protein may account for specificity in the action of certain chemokine receptors. Normally, G-proteins are inactive when guanosine diphosphate (GDP) is bound, but they are activated when the GDP is exchanged for guanosine triphosphate (GTP) (Fig. 27-1). After binding to ligand, chemokine receptors rapidly associate with G-proteins, which, in turn, increases the exchange of GTP for GDP. Pertussis toxin is a commonly used inhibitor of GPCR that irreversibly adenosine diphosphate (ADP)-ribosylates Ga subunits of the a $_{¡}$ class and subsequently prevents most chemokine receptor-mediated signaling. Activation of G-proteins leads to the dissociation of the G $_{a}$ and G $_{ß?}$ subunits (Fig. 27-1). The G $_{a}$ subunit activates protein tyrosine kinases and mitogen-activated protein kinase, leading to cytoskeletal changes and gene transcription. The G $_{a}$ subunit retains GTP, which is slowly hydrolyzed by the GTPase activity of this subunit. This GTPase activity is both positively and negatively regulated by GTPase-activating proteins [also known as regulator of G-protein signaling (RGS) proteins]. The G $_{ß?}$ dimer initiates critical signaling events in regard to chemotaxis and cell adhesion. It activates phospholipase C (PLC), [3] leading to formation of diacylglycerol (DAG) and inositol triphosphate [Ins(1,4,5)P $_{3}$]. Ins(1,4,5)P $_{3}$ stimulates Ca $^{2+}$ entry into the cytosol, which, along with DAG, activates protein kinase C isoforms. Although the G $_{ß?}$ subunits are critical for chemotaxis, the G $_{ai}$ subunit has no known role in chemotactic migration. There is also evidence that binding of chemokine receptors results in the activation of other intracellular effectors including Ras, Rho, and phosphatidylinositol-3-kinase (PI3K). [4] RhoA and protein kinase C appear to play a role in integrin affinity changes, whereas PI3K may be critical for changes in the avidity state of leukocyte factor antigen-1 (LFA-1). Other proteins have been found that regulate the synthesis, expression, or degradation of G-protein coupled receptors. For example, receptor–activity-modifying proteins (RAMPS) act as chaperones of seven transmembrane-spanning receptors and regulate surface expression as well as the ligand specificity of chemokine receptors (see Fig. 27-1). After chemokine receptors are exposed to appropriate ligands, they are frequently internalized, leading to an inability of the chemokine receptor to mediate further signaling. This downregulation of chemokine function, which is termed *desensitization,* occurs because of phosphorylation of Ser/Thr residues in the C-terminal tail by proteins termed *GPCR kinases* (GRK) and subsequent internalization of the receptor (see Fig. 27-1). Desensitization may be an important mechanism for regulating the function of chemokine receptors by inhibiting cell migration as leukocytes arrive at the primary site of inflammation.

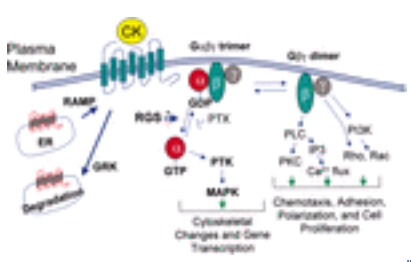

FIGURE 27-1 Chemokine receptor-mediated signaling pathways. CK, chemokine; DG, 1,2-diacylglycerol; ER, endoplasmic reticulum; GRK, G-protein coupled receptor kinase; IP3, inositol-1,4,5-triphosphate; MAPK, mitogen-activated protein kinase; PIP2, phosphatidylinositol-4,5-bisphosphate; PKC, protein kinase C; PLC, phospholipase C; PTK, protein tyrosine kinase(s); PTX, pertussis toxin; RAMP, receptor–activity-modifying protein; RGS, regulator of G-protein signaling.

CHEMOKINES AND CUTANEOUS LEUKOCYTE TRAFFICKING

Generally speaking, chemokines are thought to play at least three different roles in the recruitment of host defense cells, predominantly leukocytes, to sites of inflammation. First, they provide the signal or signals required to cause leukocytes to come to a complete stop (i.e., arrest) in blood vessels at inflamed sites such as skin. Second, chemokines have a role in the transmigration of leukocytes from the lumenal side of the blood vessel to the ablumenal side. Third, after transmigration, chemokines likely drive the migration of leukocytes to sites of inflammation either in the dermis or even the epidermis. Keratinocytes are a rich source of chemokines when stimulated by appropriate cytokines. In addition, chemokines and their receptors play critical roles in the emigration of resident skin dendritic cells (DC) (i.e., Langerhans cells and dermal DC) from the skin to draining lymph nodes via afferent lymphatic vessels, a process that is essential for the development of acquired immune responses.

This section is divided into three subsections. The first introduces basic concepts of how all leukocytes arrest in inflamed blood vessels before transmigration by introducing the multistep model of leukocyte recruitment; the second details

mechanisms of T cell migration; and the final subsection focuses on the mechanisms by which chemokines mediate the physiologic migration of DC from the skin to regional lymph nodes.

Multistep Model of Leukocyte Recruitment

For leukocytes to adhere and migrate to peripheral tissues, they must overcome the pushing force of the vascular blood stream as they bind to activated endothelial cells at local sites of inflammation. According to the multistep or cascade model of leukocyte recruitment (Fig. 27-2), one set of homologous adhesion molecules termed *selectins* mediates the transient attachment of leukocytes to endothelial cells, while another set of adhesion molecules termed *integrins* and their receptors (*immunoglobulin superfamily members*) mediates stronger binding (i.e., arrest) and transmigration. [5] The selectins (E, L, and P) show great homology and are part of a larger family of carbohydrate-binding proteins termed lectins. E- and P-selectin are expressed by endothelial cells and platelets (P-selectin only), whereas L-selectin is expressed by all classes of leukocytes. The selectins bind their respective carbohydrate ligands with low affinity and rapid on/off kinetics, enabling the behavior noted in the transient binding or “rolling” of leukocytes on endothelial cells.

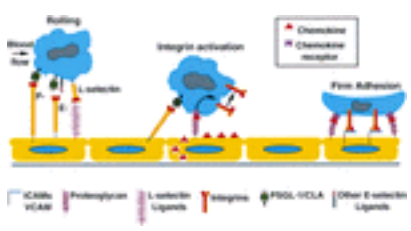

FIGURE 27-2 Multistep model of leukocyte recruitment. Leukocytes, pushed by the bloodstream, first transiently bind or “roll” on the surface of activated endothelial cells via rapid interactions with P-, E-, or L-selectin. Chemokines are secreted by endothelial cells and bind to proteoglycans that present the chemokine molecules to chemokine receptors on the surface of the leukocyte. After chemokine receptor ligation, intracellular signaling events lead to a change in the conformation of integrins and changes in their distribution on the plasma membrane resulting in “integrin activation.” These changes result in high-affinity/avidity binding of integrins to endothelial cell intercellular adhesion molecules (ICAMs) and vascular cell adhesion molecule (VCAM)-1 in a step termed *firm adhesion,* which is then followed by transmigration of the leukocytes between endothelial cells and into tissue. PSGL-1/CLA, P-selectin glycoprotein ligand-1/cutaneous lymphocyte-associated antigen.

The major skin-associated vascular selectin is E-selectin. It is upregulated on endothelial cells by inflammatory cytokines such as tumor necrosis factor (TNF)-a and binds to sialyl Lewis x-based carbohydrates. E-selectin ligands are detected on a subset of human memory T cells by a monoclonal antibody (HECA452). [6] Because most T cells at inflamed skin sites express these carbohydrate epitopes, this antigen has been termed the *cutaneous lymphocyte-associated antigen* (CLA). CLA is expressed by 10 to 40 percent of memory T cells and has been suggested as a marker for skin-homing T cells. [6] At least two chemokine receptors (CCR10 and CCR4) show preferential expression in CLA^{+} memory T cells. [7], [8] While E-selectin is likely to be an important component of skin-selective homing, there is evidence to suggest that L-selectin may also be involved in T cell migration to skin. [9], [10]

In the second phase of this model, leukocyte integrins such as those of the $ß_2$ family must be “turned on” or activated from their resting state in order to bind to their counterreceptors such as intercellular adhesion molecule-1 (ICAM-1) that are expressed by endothelial cells. A vast array of data suggests that the binding of chemokines to leukocyte chemokine receptors plays a critical role in activating both $ß_1$ and $ß_2$ integrins. [4], [11] Activation of chemokine receptors leads to a complex signaling cascade (see Fig. 27-1) that causes a conformational change in individual integrins, which leads to increases in the affinity of individual leukocyte integrins for their ligands. Moreover, chemokine receptor signaling causes clustering of integrins in certain areas on the plasma membrane, prompting an increase in the avidity of these integrins for their ligands (see Fig. 27-2). Furthermore, later steps of migration (i.e., transmigration or diapedesis) are also dependent on chemokines in selective cases. [12] The ability of neutrophils to roll on inflamed blood vessels likely depends on their expression of L-selectin and E-selectin ligands, whereas their arrest on activated endothelia likely depends on their expression of CXCR1 and CXCR2 as described below for wound healing. Integrin activation via chemokine-mediated signals appears to be more complex in T cells, which appear to use multiple chemokine receptors, as described in more detail below.

Chemokine-Mediated Migration of T Cells

Antigen-inexperienced T cells are termed *naive* and can be identified by expression of three cell surface proteins: CD45RA (an isoform of the pan-leukocyte marker), L-selectin, and the chemokine receptor CCR7. These T cells migrate efficiently to secondary lymphoid organs (e.g., lymph nodes), where they may make contact with antigen-bearing DC from the periphery. Once activated by DC presenting antigen, T cells then express CD45RO, are termed *memory* T cells, and appear to express a variety of adhesion molecules and chemokine receptors that facilitate their extravasation from blood vessels to inflamed peripheral tissue. A specific subset of CCR7-negative, L-selectin-negative memory T cells has been proposed to represent an effector memory T cell subset that is ready for rapid deployment at peripheral sites in terms of cytotoxic activity and ability to mobilize cytokines. [13]

Although chemokines are both secreted and soluble, the net positive charge on most chemokines enables them to bind to negatively charged proteoglycans such as heparan sulfate that are present on the lumenal surface of endothelial cells. Thus, chemokines, in effect, are presented to T cells as they roll along the lumenal surface (see Fig. 27-2). After ligand binding, chemokine receptors send intracellular signals that lead to increases in the affinity and avidity of T cell integrins such as LFA-1 and very-late antigen-4 (VLA-4) for their endothelial receptors ICAM-1 and vascular cell adhesion molecule-1 (VCAM-1), respectively. Only a few chemokine receptors (CXCR4, CCR7, CCR4, and CCR6) are expressed

at sufficient levels on resting peripheral blood T cells to mediate this transition. With activation and interleukin (IL)-2 stimulation, increased numbers of chemokine receptors (e.g., CXCR3) are expressed on activated T cells, making them more likely to respond to other chemokines. In several different systems, inhibition of specific chemokines produced by endothelial cells dramatically influences T cell arrest in vivo [14] and in vitro. [15]

The possible roles of several chemokines including thymus and activation-regulated chemokine (TARC), eotaxin, LARC, the interferon-inducible protein-10 (IP-10), and fractalkine have been described in relationship to T cell homing and arrest in cutaneous sites. Several of these are discussed separately in the section dealing with chemokines and specific skin diseases. However, all can be expressed by inflamed endothelial cells and induce arrest of T cells in vitro. Potentially, these chemokines could regulate the entry of different T cell subsets to the skin under specific inflammatory conditions.

Fractalkine, the sole member of the CX3C chemokine family, can present itself because its chemokine domain sits atop a relatively rigid mucin-like, protein stalk that is tethered to the membrane surface of endothelial cells. Like LARC, fractalkine is highly upregulated by endothelial cells that are stimulated with TNF-a. Fractalkine may be of particular importance in recruiting natural killer (NK) cells and monocytes, both of which highly express the fractalkine receptor CX3CR1. [16] It may also be involved in recruiting activated T cells, which begin to express CX3CR1 after exposure to IL-2. [16]

CXCR3 serves as a receptor for chemokine ligands monokine-induced by interferon-? (Mig), IP-10, and interferon-inducible T cell a chemoattractant (I-TAC). These three chemokines are distinguished from other chemokines by being highly upregulated by interferon-? (IFN-?). Resting T cells do not express functional levels of CXCR3 but upregulate this receptor with activation and cytokines such as IL-2. Once expressed on T cells, CXCR3 is capable of mediating arrest of memory T cells on activated endothelial cells. [17] The expression of its chemokine ligands is strongly influenced by IFN-?, which synergistically works with proinflammatory cytokines such as TNF-a to increase expression of these ligands by activated endothelial cells [17] and epithelial cells.

In general, activation of T cells by cytokines such as IL-2 is associated with the enhanced expression of chemokine receptors including CCR1, CCR2, CCR5, and CXCR3. Just as T_H1 and T_H2 (T helper cells 1 and 2) subsets have different functional roles, it might have been predicted that these two subsets of T cells would express different chemokine receptors. Indeed, the chemokine receptors CCR4 [18], [19] and [20] and CCR3 [21] are associated with T_H2 cells in vitro, whereas T_H1 cells are associated with other receptors such as CCR5 and CXCR3. [22]

In some instances, chemokine receptors may be regarded as functional markers that identify T_H1- versus T_H2-type lymphocytes, while also promoting their recruitment to inflammatory sites characterized by “allergic” or “cell-mediated” immunity, respectively. In T_H1-predominant disease, many infiltrating T cells express CCR5 and CXCR3. [23] When T cells are activated in vitro in the presence of T_H1-promoting cytokines, the same chemokine receptors—CCR5 and CXCR3—appear to be highly expressed, whereas in the presence of T_H2-promoting cytokines, the receptors CCR4, CCR8, and CCR3 predominate. There is likely to be some overlap as demonstrated under some conditions in which both T_H1- and T_H2-type T cells express CCR4. [19]

After T cells have extravasated from the bloodstream and enter dermal tissue, they likely home to the epidermis via chemokines as well. The epidermis is a particularly rich source of chemokines, including RANTES, MCP-1, IP-10, IL-8, LARC, and TARC. Keratinocytes from patients with distinctive skin diseases appear to express somewhat different chemokine expression profiles. For instance, keratinocytes derived from patients with atopic dermatitis synthesized mRNA for RANTES at considerably earlier time points in response to IL-4 and TNF-a than did keratinocytes derived from normal individuals and patients with psoriasis. [24] Keratinocytes derived from patients with psoriasis synthesized higher levels of IP-10 with cytokine stimulation as well as higher constitutive levels of IL-8, [24] a chemokine that recruits neutrophils. This finding has also been observed in the lesional skin of patients with psoriasis (a T_H1-predominant skin disease) and may explain the large numbers of neutrophils that localize to the suprabasal and cornified layers of the epidermis in this disease. IP-10 may recruit activated T cells of the T_H1 phenotype to the epidermis and has been postulated to have a role in the recruitment of malignant T cells to the skin in cutaneous T cell lymphomas. [25]

A new chemokine, termed *cutaneous T cell attractant chemokine* (CTACK), was recently described and is selectively expressed in the epidermis. [26] Expression is constitutive, although it is upregulated under inflammatory conditions. CTACK has been reported to preferentially attract CLA^+ memory T cells in vitro and may play a role in recruiting, and perhaps even in retaining, skin-homing T cells in the epidermis. [26]

Chemokines in the Trafficking of Dendritic Cells from Skin to Regional Lymph Nodes

Antigen-presenting cells, including DC of the skin, are critical initiators of immune responses, and their trafficking patterns are thought to influence immunologic outcomes. Their mission includes taking up antigen at sites of infection or injury and bringing these antigens to regional lymph nodes where they both present antigen and regulate the responses of T and B cells. When activated by inflammatory cytokines, lipopolysaccharide, or injury, DC leave peripheral sites such as the skin, enter afferent lymphatic vessels, and migrate to draining regional lymph nodes, where they encounter both naïve and memory T cells.

Chemokines guide the DC on the journey from the skin to a regional draining lymph node via afferent lymphatic vessels. After a skin DC such as a Langerhans cell is activated by a variety of stimulating molecules including lipopolysaccharide, TNF-a, and IL-1ß, it migrates out of the epidermis and enters the dermis. During this process, E-cadherin expression is downregulated (presumably so that Langerhans cells can detach from keratinocytes). At the same time, activated (migrating) DC strongly upregulate synthesis of CCR7, the major receptor for SLC, which is expressed constitutively by

lymphatic endothelial cells. [27], [28] Presumably, sensing a gradient of SLC, DC then enter dermal lymphatic vessels and flow with the lymph to regional draining lymph nodes (Fig. 27-3).

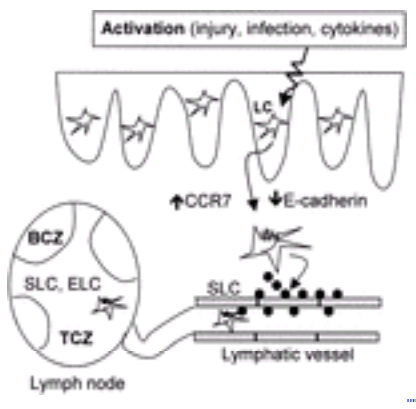

FIGURE 27-3 Trafficking of epidermal Langerhans cells to regional lymph nodes. Langerhans cells (LC) are activated by a variety of stimuli including injury, infectious agents, and cytokines such as IL-1ß and TNF-a. Having sampled antigens, the activated LC downregulate E-cadherin and strongly upregulate CCR7. Sensing the CCR7-ligand and SLC, that is produced by lymphatic endothelial cells, the LC migrate into lymphatic vessels, passively flow to the lymph nodes, and stop in the T cells zones (TCZ) that are rich in two CCR7 ligands—SLC and Epstein-Barr virus–induced molecule 1 ligand chemokine (ELC). BCZ, B cell zones.

Secondary lymphoid organs such as lymph nodes strongly express SLC in the paracortical T cell zones and express other chemokines in B cell zones. Presumably, SLC acts as signal to retain maturing DC in T cell–rich areas. DC may also have direct effects on B cells, which localize to B cell areas of secondary lymphoid organs via expression of CXCR5. [29] CXCR5 is expressed by a subset of skin DC and may be involved in targeting some DC to B cell areas that express the CXCR5 ligand, B lymphocyte chemoattractant (BLC). [30] Naïve T cells also strongly express CCR7 and use this receptor to arrest on high endothelial venules. [14] The importance of the CCR7 pathway is demonstrated by Langerhans cells from CCR7 knockout mice that demonstrate poor migration from the skin to regional lymph nodes [31] and by the observation that antibodies to SLC block migration of DC from the periphery to lymph nodes, [27] inhibiting contact hypersensitivity responses. [32] Thus, CCR7 and its ligands facilitate the recruitment of at least two different kinds of cells—naïve T cells and DC—to the lymph nodes through two different routes. The expression of CCR7, however, by naïve T cells appears to be constitutive, whereas the expression of CCR7 is highly regulated by DC and triggered only by activation and maturation.

After DC reach the lymph nodes, they must physically interact with naive and memory T cells. The resulting contact zone between the DC and T cell is termed the *immunologic synapse* and is critical for T cell activation. Activated DC secrete many different chemokines, including RANTES, macrophage-derived chemokine (MDC), and TARC, [33] which would presumably attract T cells to the vicinity of DC. Moreover, skin-derived DC release sufficient MDC into the culture medium to stimulate the chemotaxis of antigen-primed, but not naïve, T cells. [34] Recent data show that chemokine expression by DC leads to the rapid attachment of antigen-primed T cells to DC in a pertussis toxin–sensitive manner. [35] Therefore, chemokines orchestrate a complex series of migration patterns by bringing both DC and T cells to the confines of the lymph nodes, where the expression of chemokines by DC themselves appears to be a direct signal for binding of the T cells.

CHEMOKINES IN DISEASE

Atopic Dermatitis (See Chap. 122)

Atopic dermatitis is a T_H2-mediated allergic skin disease. It is manifested by xerotic, red, scaly, and sometimes lichenified patches of skin in characteristic locations, and other systemic “allergic” symptoms. The inflammatory infiltrate in atopic dermatitis usually contains variable numbers of eosinophils, lymphocytes, mast cells, and monocytes/macrophages. The serum IgE level is usually elevated due to enhanced IL-4 production. The pathogenesis of atopic dermatitis is unclear, although its course is often self-limited. Acute or seasonal flare-ups, however, may occur over the lifetime of the patient. Therapy often consists of skin hydration and topical anti-inflammatory medications, including glucocorticoids and tacrolimus.

The mechanism of lymphocyte homing to skin in the setting of atopic dermatitis has been clarified by experimental data showing that the T_H2-associated chemokine receptor, CCR4, in conjunction with its ligand, TARC, may play a role in recruiting T cells to atopic skin. A mouse model of atopic dermatitis (the NC/Nga mouse) has been described, in which skin at 8 weeks of age spontaneously begins to exhibit erosions, dryness, and erythema. Histologically, an infiltrate similar to that of human atopic dermatitis begins at the same time, and IL-4 is abundantly produced in the skin. As in humans, the serum IgE level is strikingly increased. An exogenous pathogen (allergen) is suspected to play a role in the development of the atopic dermatitis-like lesions because lesions do not appear when the animals are raised in an environment that is cleaner than those of conventional mice. Agents (glucocorticoids and tacrolimus) that are effective in the treatment of human atopic dermatitis are also effective in the skin lesions of these mice.

TARC was strongly expressed in the basal cell layer of lesional, but not unaffected, skin of NC/Nga mice. [36] In contrast, TARC expression in the skin was negligible when animals were raised under clean conditions. In humans with atopic dermatitis, CLA^+CCR4^+ lymphocytes were increased in number in the peripheral blood compared to control subjects. [20] Moreover, serum levels of TARC in patients with atopic dermatitis were tenfold higher than concentrations found in unaffected individuals and correlated with disease severity, [37] while patients with psoriasis showed only a minimal

elevation of TARC in the serum. Thus, there are strong correlative data in humans to support a role for TARC and CCR4 in the pathogenesis of atopic dermatitis.

Other chemokine receptors may also play a role in atopic dermatitis. The recruitment of eosinophils to skin is a frequent finding in allergic skin diseases, including atopic dermatitis and cutaneous drug reactions. Eotaxin, initially isolated from the bronchoalveolar fluid of guinea pigs after experimental allergic inflammation, binds primarily to CCR3, a receptor expressed by eosinophils, [38] basophils, and T_H2-type T cells. [21] Injection of eotaxin into the skin promotes the recruitment of eosinophils, whereas antieotaxin antibodies delay the dermal recruitment of eosinophils in the late-phase allergic reaction in mouse skin. [39]

CCR3 was recently shown to be expressed by keratinocytes, but it is generally expressed at lower levels than those found in eosinophils. [40], [41] Immunoreactivity and mRNA expression of eotaxin and CCR3 were both increased in lesional skin of patients with atopic dermatitis, but not in nonatopic control subjects. [42] Eotaxin increases proliferation of CCR3-expressing keratinocytes in vitro. [40] Serum levels of eotaxin, RANTES, MCP-1, and MIP-1ß are elevated in patients with atopic dermatitis. [43] Finally, expression of eotaxin (and RANTES) by dermal endothelial cells correlates with the appearance of eosinophils in the dermis in patients with onchocerciasis who experience allergic reactions after treatment with ivermectin. [44] Thus, the production of eotaxin in the skin may contribute to the recruitment of eosinophils and T_H2 lymphocytes via direct binding to CCR3. In addition, CCR3 expression by keratinocytes may actually play a role in driving keratinocyte proliferation.

Psoriasis (See Chap. 42)

Psoriasis, an inflammatory skin disorder characterized by thickened, pruritic plaques, does not have a clear etiology, although it is considered a T cell–mediated, autoimmune disease. Histologically, there are abundant neutrophils in the epidermis, T cells in the epidermis and dermis, and other immune cells, such as mast cells, which may be present in greater than normal numbers.

Multiple potential trafficking pathways may be mediated by chemokines in psoriasis. Chemokines expressed by vascular endothelial cells likely induce the arrest of effector memory T cells. LARC mediates the arrest of a subset of T cells expressing CCR6 to activated endothelial cells under conditions in vitro that simulate blood flow. [15] Besides endothelial cells, keratinocytes produce LARC, which may be a factor in recruiting T cells and immature DC to the epidermis. [45], [46] Indeed, LARC and CCR6 are upregulated in the skin of patients with psoriasis. [45]

TARC is produced by dermal endothelial cells from psoriatic skin lesions. [8] Although its receptor, CCR4, has been associated with T_H2-type T cells, [18] there is evidence suggesting that T_H1-type T cells can also express this receptor. [19] Although TARC is expressed in lesional skin in atopic dermatitis, it is unknown whether or not keratinocytes in psoriatic skin lesions express this chemokine.

Neutrophils in the epidermis of psoriatic skin are likely to be attracted there by high levels of IL-8, which would act via CXCR1 and CXCR2. In addition to attracting neutrophils, IL-8 is an ELR^+ CXC chemokine that is angiogenic and able to attract endothelial cells (see "Cancer" below). This proangiogenic effect may lead to the formation of the long, tortuous capillary blood vessels in the papillary dermis that are characteristic of psoriasis. Moreover, keratinocytes also express CXCR2 and thus may be autoregulated by the expression of CXCR2 ligands in the skin.

Multiple chemokines, including TARC, LARC, RANTES, Mig, and CTACK, [26] are expressed in psoriatic epidermis, but they are also found in a variety of skin diseases, including cutaneous T cell lymphomas (CTCL) and atopic dermatitis. [24] Activated T cells would generally express all the chemokine receptors required to signal through the five chemokines noted above. The necessity of any one of them to the recruitment of T cells to the epidermis is difficult to discern without a specific way of individually blocking their activity. The very redundancy of chemokine expression in psoriasis suggests that blocking any single chemokine pathway may not prove to be effective in the clinical management of this disease. Keratinocytes derived from patients with psoriasis do seem to express more IL-8 and IP-10, whereas claims have been made for greater expression of TARC from keratinocytes of patients with atopic dermatitis. [20] Both RANTES and MCP-1 were produced by stimulated cultured keratinocytes from patients with psoriasis and atopic dermatitis. [24] Whether these patterns of expression may be applied to larger populations of patients with psoriasis and atopic dermatitis is unknown.

Cancer

Chemokines may play a role in tumor formation and immunity in several distinct ways including the control of angiogenesis and the induction of tumor immune responses. [47] CXC chemokines that express a three amino acid motif consisting of Glu-Leu-Arg (ELR) immediately preceding the CXC signature are angiogenic, whereas most non-ELR CXC chemokines, except SDF-1, are angiostatic. It is not clear that ELR^- chemokines actually bind to chemokine receptors to reduce angiogenesis. It has been proposed that they act by displacing growth factors from proteoglycans. In any event, the balance between ELR^+ and ELR^- chemokines is thought to contribute to the complex regulation of angiogenesis at tumor sites. IL-8, a prototypical ELR^+ chemokine, can be secreted by melanoma cells and has been detected in conjunction with metastatic dissemination of this cancer. [48] IL-8 may also act as an autocrine growth factor for melanoma, [49] as well as for several other types of cancer. Although CXCR1 and CXCR2 bind IL-8 in common, several other ELR^+ CXC chemokines, including growth-regulated oncogene a (GRO a) and epithelial-neutrophil–activating peptide-78 (ENA-78), bind primarily to CXCR2. CXCR2 appears, in most instances, to be associated with both the angiogenic and growth regulatory properties of tumors. [50]

Tumors, including melanoma, have long been known to secrete chemokines and are capable of attracting a variety of

immune cells. The question arises as to why this behavior is not deleterious to the tumor itself. Breast cancers, for instance, secrete macrophage chemotactic protein-1 (MCP-1), which attracts macrophages through CCR2. Higher tissue levels of MCP-1 correlate with increasing numbers of macrophages in the tissue. An initial hypothesis might be that the attraction of immune cells would contribute to the immunologic clearance of the tumor. Recent data, however, suggest that inflammatory cells such as macrophages may actually play a critical role in tumor invasion and metastasis. First, MCP-1 may increase expression of macrophage IL-4 through an autocrine feedback loop and possibly skew the immune response from a cell-mediated (antitumor) response to one that is humoral. Secondly, there is evidence that certain immune cells, such as macrophages, actually promote tumor invasion and metastasis. Mice that are deficient in colony-stimulating factor-1 (CSF-1), a factor required for the survival and development of macrophages, have a decreased risk for developing invasive/metastatic tumors. [51] Although the precise mechanism by which macrophages delay tumor progression is unknown, growth factors, angiogenic factors, and matrix metalloproteases produced by macrophages could all possibly influence tumor growth and metastasis. Thus, the production of chemokines by tumors and the corresponding recruitment of certain cells, such as macrophages, may be advantageous in terms of increasing vascularity and promoting metastasis.

The antitumor effects of particular chemokines may occur by a variety of mechanisms. ELR ¯ CXCR3 ligands such as IP-10 are potently antiangiogenic and may act as downstream effectors of IL-12–induced, NK cell–dependent angiostasis. [52] Of note, some tumors, such as breast cancer, can synthesize LARC, and these tumors attract immature DC that express CCR6. [53] Experimentally, LARC has been transduced into murine tumors, where it attracts DC in mice and suppresses tumor growth in experimental systems. [54] It is not clear, however, that in humans the ability of tumors to express LARC correlates with a better clinical prognosis.

The production of cytokines and chemokines at tumor sites or by tumors may at first seem to be disadvantageous to the tumor. However, many tumors initially arise from chronically inflamed sites (i.e., chronic wounds in the case of squamous cell carcinoma) or as a result of infection [i.e., Kaposi's sarcoma and human herpesvirus (HHV)-8]. The initial setting of many tumors may indeed be one in which the recruitment of inflammatory cells is advantageous to the organism as a whole. Tumors that arise and survive in such a milieu may be resistant to the usual antitumor effects of immune cells.

Tumor metastasis is the most common source of mortality and morbidity in cancer. With skin cancers such as melanoma, there is a propensity for specific sites such as brain, lung, and liver, as well as distant skin sites. Cancers may also metastasize via afferent lymphatics and eventually reach regional draining lymph nodes. The discovery of nodal metastasis often portends a poor prognosis. In fact, the presence of nodal metastases is the most powerful predictor of poor survival in melanoma.

Chemokines may play an important role in the site-specific metastases of cancers of the breast and of melanoma. Human breast cancer as well as melanoma cell lines express the chemokine receptors CXCR4 and CCR7, whereas normal breast epithelial cells and melanocytes do not appear to express these receptors. [55] Extracts from tissues that are the common sites of breast cancer metastasis (e.g., lung) induce the chemotaxis of breast cancer cell lines in a CXCR4-dependent manner. [55] Furthermore, in a nude mouse system, anti-CXCR4 antibodies blocked metastasis of human breast cancer cell lines. [55] Given the clear demonstration that CCR7 is involved in the migration of DC into afferent lymphatics and draining lymph nodes after activation (see earlier section “ Chemokine-Mediated Migration of T Cells”), the acquisition of CCR7 by cancer cells may allow these cells to home to afferent lymphatics and the draining lymph nodes as well. In support of this hypothesis, CCR7- transfected B16 murine melanoma cells were found to metastasize at significantly higher efficiency to regional lymph nodes than parental mock-transfected B16 cells after inoculation into the footpads of mice. [56] Neutralizing anti-SLC antibodies coinjected with the CCR7-expressing melanoma cells prevented the metastasis to the regional lymph nodes, [56] suggesting that therapy directed toward CCR7 ligands (or CCR7 itself) may be of value in reducing nodal metastasis.

Infectious Diseases

Although chemokines and chemokine receptors may have evolved as a host response to infectious agents, recent data suggest that infectious organisms may have co-opted chemokine- or chemokine receptor-like molecules to their own advantage in selected instances. Various microorganisms, including cytomegalovirus and Kaposi's sarcoma herpesvirus (human herpesvirus-8), express chemokine receptor–like proteins once they are integrated within the host cell.

In the case of Kaposi's sarcoma herpesvirus GPCR, this receptor is able to promiscuously bind several chemokines. More importantly, it is constitutively active and may work as a growth promoter in Kaposi's sarcoma. [57]

The human immunodeficiency virus (HIV)-1 is an enveloped retrovirus that enters cells via receptor-dependent membrane fusion. [58] CD4 is the primary fusion receptor for all strains of HIV-1 and binds to HIV-1 proteins gp120 and gp41. However, different strains of HIV-1 have emerged that preferentially use CXCR4 (T-tropic), or CCR5 (M-tropic), or either chemokine receptor as a receptor for entry. While other chemokine receptors can potentially serve as coreceptors, most clinical HIV-1 strains are primarily dual-tropic for either CCR5 or CXCR4. [58]

The discovery of a 32-base pair deletion (?32) in CCR5 in some individuals that leads to low levels of CCR5 expression in T cells and DC, and that correlates with a dramatic resistance to HIV-1 infection, demonstrated a clear role for CCR5 in the pathogenesis of HIV-1 infection. [59] The frequency of ?32 mutations in humans is surprisingly high, and the complete absence of CCR5 in homozygotes has been associated only with a more clinically severe form of sarcoidosis. Otherwise, these individuals are healthy. In fact, there is an association of less severe autoimmune disease with this mutation. [60]

Langerhans cells reside in large numbers in the genital mucosa and may be one of the first initial targets of HIV-1 infection. [61] Because infected (activated) Langerhans cells likely enter dermal lymphatic vessels (see the earlier section “

Chemokines in the Trafficking of Dendritic Cells from Skin to Regional Lymph Nodes ") and then localize to regional lymph nodes, the physiologic migratory pathway of Langerhans cells may also coincidentally lead to the transmission of HIV-1 to T cells within secondary lymphoid organs. CCR5 is expressed by immature or resting Langerhans cells in the epidermis, and analogues of RANTES block HIV infection in Langerhans cells. [62] By preventing CCR5 expression on Langerhans cells, the ?32 mutation may reduce HIV-1 infection of Langerhans cells as well as of T cells. Thus, CCR5 antagonists may be of therapeutic use in the treatment or prevention of HIV-1 disease.

CXCR4 may also play a role in the transmission of HIV-1 through skin DC. As DC mature, they strongly express CXCR4 along with CCR7. In this setting, they may be able to be infected with dual-tropic viruses or with T-tropic viruses and migrate to draining lymph nodes. The role of CXCR4 clinically is unclear because human polymorphisms in CXCR4 have not been unequivocally associated with either a protective or a deleterious effect in HIV-1 disease. There is a single-nucleotide polymorphism in the 3' untranslated region of SDF-1; however, that may be related to delayed progression of HIV-1 disease. [63] Deletion mutants in humans for CXCR4 are unlikely to exist because CXCR4 appears to be essential for the formation of vascular systems in the gut and heart, as demonstrated by neonatal lethality after targeted deletion of CXCR4 in mice. [64]

Inasmuch as chemokines constitute a mechanism to protect higher organisms from microbes, microbes have evolved mechanisms for usurping chemokines and their receptors for their own advantage. Of note, microbes themselves (e.g., molluscum contagiosum virus and HHV-8) produce broad-spectrum chemokine antagonists that may be responsible for the lack of inflammation at the site of infection. Recent work with chemokine antagonists of CCR5 suggests the real possibility that chemokine-based agents will be used to treat or prevent HIV-1 disease and that refinement of chemokine antagonists may lead to the development of effective anti-inflammatory agents. [65]

Signaling pathways are just beginning to be understood, and further work needs to be done to understand the regulation of these receptors, the specificity of their intracellular activities, and the mechanisms by which they work in the face of multiple chemokines present in inflammatory sites.

REFERENCES

1. Zlotnik A, Yoshie O: Chemokines: A new classification system and their role in immunity. *Immunity* **12**:121, 2000

2. Bazan JF et al: A new class of membrane-bound chemokine with a CX3C motif. *Nature* **385**:640, 1997

3. Jiang H et al: Pertussis toxin-sensitive activation of phospholipase C by the C5a and fMet-Leu-Phe receptors. *J Biol Chem* **271**:13430, 1996

4. Constantin G et al: Chemokines trigger immediate ß2 integrin affinity and mobility changes: Differential regulation and roles in lymphocyte arrest under flow. *Immunity* **13**:759, 2000

5. Springer TA: Traffic signals for lymphocyte recirculation and leukocyte emigration: The multistep paradigm. *Cell* **76**:301, 1994

6. Berg EL et al: The cutaneous lymphocyte antigen is a skin lymphocyte homing receptor for the vascular lectin endothelial cell-leukocyte adhesion molecule 1 (ELAM-1). *J Exp Med* **174**:1461, 1991

7. Homey B et al: The orphan chemokine receptor G protein-coupled receptor-2 (GPR-2, CCR10) binds the skin-associated chemokine CCL27 (CTACK/ALP/ILC). *J Immunol* **164**:3465, 2000

8. Campbell JJ et al: The chemokine receptor CCR4 in vascular recognition by cutaneous but not intestinal memory T cells. *Nature* **400**:776, 1999

9. Lechleitner S et al: Peripheral lymph node addressins are expressed on skin endothelial cells. *J Invest Dermatol* **113**:410, 1999

10. Hwang ST, Fitzhugh DJ: Aberrant expression of adhesion molecules by Sézary cells: Functional consequences under physiologic shear stress conditions. *J Invest Dermatol* **116**:466, 2001

11. Campbell JJ et al: Chemokines and the arrest of lymphocytes rolling under flow conditions. *Science* **279**:381, 1998

12. Kawai T et al: Selective diapedesis of Th1 cells induced by endothelial cell RANTES. *J Immunol* **163**:3269, 1999

13. Sallusto F et al: Two subsets of memory T lymphocytes with distinct homing potentials and effector functions. *Nature* **401**:708, 1999

14. Stein JV et al: The CC chemokine thymus-derived chemotactic agent 4 (TCA-4, secondary lymphoid tissue chemokine, 6Ckine, Exodus-2) triggers lymphocyte function-associated antigen 1-mediated arrest of rolling T lymphocytes in peripheral lymph node high endothelial venules. *J Exp Med* **191**:61, 2000

15. Fitzhugh DJ et al: Cutting edge: CC chemokine receptor-6 (CCR6) is essential for arrest of a subset of memory T cells on activated dermal microvascular endothelial cells under physiologic flow conditions in vitro. *J Immunol* **165**:6677, 2000

16. Imai T et al: Identification and molecular characterization of fractalkine receptor CX3CR1, which mediates both leukocyte migration and adhesion. *Cell* **91**:521, 1997

17. Piali L et al: The chemokine receptor CXCR3 mediates rapid and shear-resistant adhesion-induction of effector T lymphocytes by the chemokines IP10 and Mig. *Eur J Immunol* **28**:961, 1998

18. Imai T et al: Selective recruitment of CCR4-bearing Th2 cells toward antigen-presenting cells by the CC chemokines thymus and activation-regulated chemokine and macrophage-derived chemokine. *Int Immunol* **11**:81, 1999

19. Andrew DP et al: C-C chemokine receptor 4 expression defines a major subset of circulating nonintestinal memory T cells of both Th1 and Th2 potential. *J Immunol* **166**:103, 2001

20. Vestergaard C et al: A T_H2 chemokine, TARC, produced by keratinocytes may recruit CLA+CCR4+ lymphocytes into lesional atopic dermatitis skin. *J Invest Dermatol* **115**:640, 2000

21. Sallusto F et al: Selective expression of the eotaxin receptor CCR3 by human T helper 2 cells. *Science* **277**:2005, 1997

22. Bonecchi R et al: Differential expression of chemokine receptors and chemotactic responsiveness of type 1 T helper cells (Th1s) and Th2s. *J Exp Med* **187**:129, 1997

23. Qin S et al: The chemokine receptors CXCR3 and CCR5 mark subsets of T cells associated with certain inflammatory reactions. *J Clin Invest* **101**:746, 1998

24. Giustizieri ML et al: Keratinocytes from patients with atopic dermatitis and psoriasis show a distinct chemokine production profile in response to T cell-derived cytokines. *J Allergy Clin Immunol* **107**:871, 2001

25. Sarris AH et al: Interferon-inducible protein 10 as a possible factor in the pathogenesis of cutaneous T-cell lymphomas. *Clin Cancer Res* **3**:169, 1997

26. Morales J et al: CTACK, a skin-associated chemokine that preferentially attracts skin-homing memory T cells. *Proc Natl Acad Sci U S A* **96**:14470, 1999

27. Saeki H et al: Cutting edge: Secondary lymphoid-tissue chemokine (SLC) and CC chemokine receptor 7 (CCR7) participate in the emigration pathway of mature dendritic cells from the skin to regional lymph nodes. *J Immunol* **162**:2472, 1999

28. Gunn MD et al: A chemokine expressed in lymphoid high endothelial venules promotes the adhesion and chemotaxis of naïve T lymphocytes. *Proc Natl Acad Sci U S A* **95**:258, 1998

29. Förster R et al: A putative chemokine receptor, BLR1, directs B cell migration to defined lymphoid organs and specific anatomic compartments of the spleen. *Cell* **87**:1037, 1996

30. Saeki H et al: A migratory population of skin-derived dendritic cells expresses CXCR5, responds to B lymphocyte chemoattractant in vitro, and colocalizes to B cell zones in lymph nodes in vivo. *Eur J Immunol* **30**:2808, 2000

31. Förster R et al: CCR7 coordinates the primary immune response by establishing functional microenvironments in secondary lymphoid organs. *Cell* **99**:23, 1999

32. Engeman TM et al: Inhibition of functional T cell priming and contact hypersensitivity responses by treatment with anti-secondary lymphoid chemokine antibody during hapten sensitization. *J Immunol* **164**:5207, 2000

33. Sallusto F et al: Distinct patterns and kinetics of chemokine production regulate dendritic cell function. *Eur J Immunol* **29**:1617, 1999

34. Tang HL, Cyster JG: Chemokine upregulation and activated T cell attraction by maturing dendritic cells. *Science* **284**:819, 1999

35. Wu M et al: Cutting edge: CC chemokine receptor-4 (CCR4) mediates antigen-primed T cell binding to activated dendritic cells. *J Immunol* **167**:4791, 2001

36. Vestergaard C et al: Overproduction of TH2-specific chemokines in NC/Nga mice exhibiting atopic dermatitis-like lesions. *J Clin Invest* **104**:1097, 1999

37. Kakinuma T et al: Thymus and activation-regulated chemokine in atopic dermatitis: Serum thymus and activation-regulated chemokine level is closely related with disease activity. *J Allergy Clin Immunol* **107**:535, 2001

38. Combadiere C et al: Cloning and functional expression of a human eosinophil CC chemokine receptor. *J Biol Chem* **271**:11034, 1996

39. Teixeira MM et al: Chemokine-induced eosinophil recruitment. Evidence of a role for endogenous eotaxin in an in vivo allergy model in mouse skin. *J Clin Invest* **100**:1657, 1997

40. Petering H et al: Characterization of the CC chemokine receptor 3 on human keratinocytes. *J Invest Dermatol* **116**:549, 2001

41. Wakugawa M et al: Expression of CC chemokine receptor 3 on human keratinocytes in vivo and in vitro—upregulation by RANTES. *J Dermatol Sci* **25**:229, 2001

42. Yawalkar N et al: Enhanced expression of eotaxin and CCR3 in atopic dermatitis. *J Invest Dermatol* **113**:43, 1999

43. Kaburagi Y et al: Enhanced production of CC-chemokines (RANTES, MCP-1, MIP-1alpha, MIP-1beta, and eotaxin) in patients with atopic dermatitis. *Arch Dermatol Res* **293**:350, 2001

44. Cooper PJ et al: Eotaxin and RANTES expression by the dermal endothelium is associated with eosinophil infiltration after ivermectin treatment of onchocerciasis. *Clin Immunol* **95**:51, 2000

45. Homey B et al: Upregulation of macrophage inflammatory protein-3a/CCL20 and CC chemokine receptor 6 in psoriasis. *J Immunol* **164**:6621, 2000

46. Dieu MC et al: Selective recruitment of immature and mature dendritic cells by distinct chemokines expressed in different anatomic sites. *J Exp Med* **188**:373, 1998

47. Schneider GP et al: The diverse role of chemokines in tumor progression: Prospects for intervention (review). *Int J Mol Med* **8**:235, 2001

48. Singh RK et al: Expression of interleukin 8 correlates with the metastatic potential of human melanoma cells in nude mice. *Cancer Res* **54**:3242, 1994

49. Schadendorf D et al: IL-8 produced by human malignant melanoma cells in vitro is an essential autocrine growth factor. *J Immunol* **151**:2667, 1993

50. Addison CL et al: The CXC chemokine receptor 2, CXCR2, is the putative receptor for ELR+ CXC chemokine-induced angiogenic activity. *J Immunol* **165**:5269, 2000

51. Lin EY et al: Colony-stimulating factor 1 promotes progression of mammary tumors to malignancy. *J Exp Med* **193**:727, 2001

52. Yao L et al: Contribution of natural killer cells to inhibition of angiogenesis by interleukin-12. *Blood* **93**:1612, 1999

53. Bell D et al: In breast carcinoma tissue, immature dendritic cells reside within the tumor, whereas mature dendritic cells are located in peritumoral areas. *J Exp Med* **190**:1417, 1999

54. Fushimi T et al: Macrophage inflammatory protein 3alpha transgene attracts dendritic cells to established murine tumors and suppresses tumor growth. *J Clin Invest* **105**:1383, 2000

55. Müller A et al: Involvement of chemokine receptors in breast cancer metastasis. *Nature* **410**:50, 2001

56. Wiley H et al: Expression of CC chemokine receptor-7 (CCR7) and regional lymph node metastasis of B16 murine melanoma. *J Natl Cancer Inst* **93**:1638, 2001

57. Arvanitakis L et al: Human herpesvirus KSHV encodes a constitutively active G-protein–coupled receptor linked to cell proliferation. *Nature* **385**:347, 1997

58. Locati M, Murphy PM: Chemokines and chemokine receptors: Biology and clinical relevance in inflammation and AIDS. *Annu Rev Med* **50**:425, 1999

59. Liu R et al: Homozygous defect in HIV-1 coreceptor accounts for resistance of some multiply-exposed individuals to HIV-1 infection. *Cell* **86**:367, 1996

60. Gerard C, Rollins BJ: Chemokines and disease. *Nat Immunol* **2**:108, 2001

61. Blauvelt A: The role of skin dendritic cells in the initiation of human immunodeficiency virus infection. *Am J Med* **102**:16, 1997

62. Kawamura T et al: Candidate microbicides block HIV-1 infection of human immature Langerhans cells within epithelial tissue explants. *J Exp Med* **192**:1491, 2000

63. Winkler C et al: Genetic restriction of AIDS pathogenesis by an SDF-1 chemokine gene variant. ALIVE Study, Hemophilia Growth and Development Study (HGDS), Multicenter AIDS Cohort Study (MACS), Multicenter Hemophilia Cohort Study (MHCS), San Francisco City Cohort (SFCC). *Science* **279**:389, 1998

64. Tachibana K et al: The chemokine receptor CXCR4 is essential for vascularization of the gastrointestinal tract. *Nature* **393**:591, 1998

65. Schön MP, Ruzicka T: Psoriasis: The plot thickens. *Nat Immunol* **2**:91, 2001

66. Liao F et al: CC-chemokine receptor 6 is expressed on diverse memory subsets of T cells and determines responsiveness to macrophage inflammatory protein 3a. *J Immunol* **162**:186, 1999

67. Gunn MD et al: Mice lacking expression of secondary lymphoid organ chemokine have defects in lymphocyte homing and dendritic cell localization (see comments). *J Exp Med* **189**:451, 1999

68. Förster R et al: CCR7 coordinates the primary immune response by establishing functional microenvironments in secondary lymphoid organs. *Cell* **99**:23, 1999

69. Kulke R et al: Colocalized overexpression of GRO-alpha and IL-8 mRNA is restricted to the suprapapillary layers of psoriatic lesions. *J Invest Dermatol* **106**:526, 1996

70. Rossi D, Zlotnik A: The biology of chemokines and their receptors. *Annu Rev Immunol* **18**:217, 2000

T>

Chapter 28

Robert Modlin

Lymphocytes

TYPES OF LYMPHOCYTES
TRAFFICKING OF LYMPHOCYTES INTO SKIN
T CELL POPULATIONS IN SKIN
ANTIGEN PRESENTATION IN SKIN
COSTIMULATORY MOLECULES
CYTOTOXIC T cellS
THE TH1/TH2 PARADIGM

REFERENCES

The unique role of lymphocytes in the immune system is the ability to recognize, with great specificity, the diversity of foreign antigens. All lymphocytes derive from a common bone marrow stem cell. This finding has been exploited in various clinical settings; it is possible to restore the entire lymphocyte pool by bone marrow or stem cell transplantation. There are three kinds of lymphocytes: B cells, natural killer (NK) cells, and T cells.

TYPES OF LYMPHOCYTES

B cells mature in the fetal liver and adult bone marrow. B cells produce antibodies: protein complexes that bind specifically to particular molecules known as antigens. Each B cell produces a different antibody molecule. Some of this antibody is present on the surface of the B cell, conferring the unique ability of that B cell to recognize a specific antigen. Much of the antibody is secreted; the secreted antibody mediates humoral immune responses. In skin, humoral immunity contributes to the immune defense against extracellular pathogens. Antibodies bind to microbial agents and neutralize them or facilitate uptake of the pathogen by phagocytes that destroy them. Antibodies are also responsible for mediating certain pathologic conditions in skin. In particular, antibodies against self-antigens lead to autoimmune disease, typified in the pathogenesis of pemphigus and bullous pemphigoid. Furthermore, IgE antibodies to foreign substances contribute to allergic disease, including atopic dermatitis.

NK are large granular-appearing lymphocytes that survey the body, looking for altered host cells. All nucleated cells express the major histocompatibility complex (MHC) class I molecules. NK cells have receptors, called killer inhibitory receptors, which recognize the self MHC class I molecules. [1], [2] Recognition of self MHC class I delivers a negative signal to the NK cell that paralyzes it. However, if a nucleated cell loses expression of its MHC class I molecules, the NK cell, upon encountering it, will become activated and kill it. Because many virus infected cells and tumor cells have reduced expression of MHC class I molecules, NK cells are able to recognize and kill them. In addition, NK cells have activating receptors that bind MHC-like ligands on target cells.

T cells mature in the thymus where they are selected to live or die. Those T cells that will have the capacity to recognize foreign antigens are positively selected and can enter the circulation. Those T cells that react to self are negatively selected and destroyed. If the immune system is envisioned as a bureaucracy, the T cell is the ideal bureaucrat. T cells have the unique ability to direct other cells of the immune system. They do this by releasing cytokines. For example, T cells contribute to cell-mediated immunity, required to eliminate intracellular pathogens, by releasing cytokines that activate macrophages and other T cells. T cells release cytokines that activate NK cells, and also release cytokines that permit the growth, differentiation and activation of B cells.

TRAFFICKING OF LYMPHOCYTES INTO SKIN

Lymphocytes are not prominent in normal human skin; in fact, only a small number can be detected around blood vessels. This contrasts to normal mouse skin, in which a resident population of dendritic T cells have been observed in the epidermis. [3], [4] The few T cells present in normal skin are likely on a mission: to survey the skin and detect foreign antigens which pose a threat to the host. No one knows for sure. However, in inflammatory skin conditions, there is a dramatic increase in the number of lymphocytes found in skin. Depending on the condition, lymphocytes may be evident in the epidermis, dermis, and/or the subcutaneous fat. Part of the increase in cell number may be due to the local proliferation of resident lymphocytes. Most of the increase in cell number is due to the rapid influx of lymphocytes. How do lymphocytes get into skin?

The mechanism by which T lymphocytes traffic into skin depends on a chain of molecular interactions between cells (Fig. 28-1). For many inflammatory conditions, the foreign antigen, be it a contact allergen, bacterial molecule, or tumor-associated protein, is initially encountered in the epidermis. The antigen is first taken up by Langerhans cells, dendritic-appearing cells that form a network lattice in the epidermis for detecting and capturing foreign substances. It has been documented clearly that the Langerhans cell with this foreign antigen exits the skin via the lymphatics and travels to draining lymph nodes.

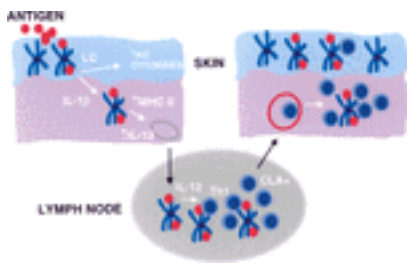

FIGURE 28-1 How T cells get into skin. Langerhans cells (LC) pick up antigen in skin and traffic via lymphatics to draining lymph nodes. There, antigen presentation induces expression of cutaneous lymphocyte antigen (CLA), the skin homing receptor, on T cells. These activated T cells traffic via blood vessels to skin, where they can participate in an immune response. Keratinocyte release of interleukin (IL)-10 can downregulate the local T cell response.

Langerhans cells are part of the family of “dendritic cells”; professional antigen-presenting cells with dendritic morphology and extraordinary antigen-presenting function. The encounter of the Langerhans cell with antigen upregulates its immunostimulating capacity by inducing expression of antigen presenting elements such as major histocompatability molecules; costimulatory molecules, such as B7-1 required for optimal presentation; and cytokines, such as interleukin (IL)-12 required for the generation of cell-mediated immunity (CMI). In the lymph node, these activated Langerhans cells present the antigen to T cells. Next, the T cells become activated and expand. They enter blood vessels and journey towards the skin. The interaction of T cells with antigen and Langerhans cells results in the induction of a cell surface molecule known as cutaneous lymphocyte antigen (CLA). [5] CLA is a glycoprotein that defines a subset of memory T cells that home to skin. CLA is a glycosylated form of P-selectin glycoprotein ligand-1 (PSGL-1), that is expressed constitutively on all human peripheral-blood T cells. The level of CLA on cells is regulated by an enzyme, a(1,3)-fucosyl transferase VII, that modifies PSGL-1. In this manner, CLA-positive cells bind to both E-selectin and P-selectin, strengthening the interaction between circulating T cells and cutaneous endothelium, whereas CLA-negative cells bind P-selectin but do not bind E-selectin. [6], [7]

In patients with contact dermatitis, the CLA+ subset, but not the CLA– subset, contains the T cells with the capacity to respond to the allergen. [8] Furthermore, greater than 90 percent of T cells in inflammatory skin disease are CLA+. CLA facilitates the entry of T lymphocytes into skin by mediating tethering and rolling of T cells on vascular endothelial cells, through binding to E-selectin. Chemokines released by the endothelial cells activate T cells to express adhesion molecules, leukocyte factor antigen (LFA)-1 and very-late antigen (VLA)-4. T cells firmly adhere to endothelium by the interaction of LFA-1 with intercellular adhesion molecule (ICAM) and VLA-4 with vascular cell adhesion molecule (VCAM). The interaction with the endothelial cells is sufficiently strong to permit transmigration of the T cell into the skin and allow their participation in the inflammatory process.

T CELL POPULATIONS IN SKIN

The accumulation of T cells in skin is not stochastic. It is abundantly clear that specific populations of T cells, identified by cell surface determinants and their cytokine profile, localize to the skin. Various cell surface determinants on T cells enable us to detect their presence. Initially, functional T cell populations could be delineated in skin according to their expression of the CD4 and CD8 molecules. In the majority of inflammatory conditions studied, including lichen planus, psoriasis, atopic dermatitis and basal cell carcinoma, CD4+ T cells outnumbered CD8+ T cells, in a manner similar to or somewhat greater than that present in the peripheral blood. However, in the study of human leprosy skin lesions, CD4+ T cells were found to be predominant in the tuberculoid form of the disease and CD8+ T cells were found to be predominant in the lepromatous form of the disease. [9] Because all leprosy patients had an excess of CD4+ T cells in their blood, the abundance of CD8+ T cells in lepromatous skin lesions provides clear evidence for the specific accumulation of T cell populations in skin.

A perhaps more relevant marker of T cell populations is the diversity of their T cell receptor (TCR). The TCR is the part of the T cell that recognizes antigen. The TCR is found to be associated with a set of cell surface proteins known collectively as CD3 that are specific for T cells. One characteristic of CD3 is the presence of a long cytoplasmic tail. When the TCR is triggered by antigen, a signal is delivered through the cytoplasmic tail of CD3 that results in T cell activation.

The majority of T cells have a TCR heterodimer composed of a and ß protein chains. A smaller population of peripheral T cells has been identified in which the T cells have a TCR composed of ? and d protein chains. Most T cells in skin have aß TCRs; however, in some conditions, such as human leprosy and leishmaniasis, ? d T cell accumulations can represent as many as 35 percent of infiltrating cells. [10] The function of these ? d T cells may be to recognize small nonpeptide pyrophosphate molecules, which are ubiquitous to microbial pathogens and thus form an initial line of defense against infection. [11] ? d T cells may provide immune surveillance against malignancy, using additional cell surface receptors to kill cancer cells. [12]

The diversity of T cells infiltrating skin can be more precisely assessed by examining the repertoire of TCRs in the infiltrate (Fig. 28-2). The TCR complex is composed of a variable (V), diversity (D), joining (J), and constant region gene segments that define the antigen specificity of the T cell. The accumulation of specific populations of T cells in skin can be inferred by finding a dominant V gene usage in the infiltrate. This is accomplished by using the polymerase chain reaction to amplify small numbers of skin biopsy-derived mRNAs that encode for the TCR proteins. The clearest example is the clonality of the T cell population in cutaneous T cell lymphoma (CTCL), in which a single V gene usage is found to predominate in different skin lesions from the same individual. [13] The dominant expression of several TCR V genes in an infiltrate is thought to indicate that a small number of antigens drive the local inflammatory response. A limited TCR V gene usage has been reported to be present in the skin lesions of leprosy, [14] psoriasis, [15] basal cell carcinoma, and countless other reactions in which T cells are present. However, in no instance has the limited set of antigens been

defined and correlated with the TCR usage.

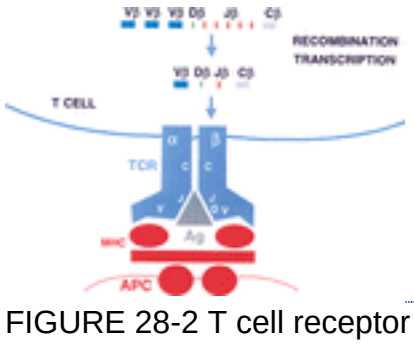

FIGURE 28-2 T cell receptor gene rearrangements. This diagram shows how diversity in TCRs is generated by gene rearrangement. In this instance, rearrangement of the ß chain is shown. The encoded TCR can then recognize antigen in the context of an appropriate antigen-presenting molecule.

The most direct indication of relevant T cell populations in skin is to determine the number of T cells which recognize the antigen. It has been documented that 1/1000 to 1/10,000 T cells in the peripheral blood recognize a given antigen. However in the skin, approximately 1/50 to 1/100 T cells recognize the antigen causing the disease. [16], [17] Thus, there is as much as a 100-fold enrichment of antigen-reactive T cells at the site of cutaneous inflammation.

ANTIGEN PRESENTATION IN SKIN

To carry out its specific mission, the recruited T cell must recognize its antigen in skin so that it can be activated to perform its effector function. In 1972, Doherty and Zinkernagel discovered that T cells recognize antigen in the context of antigen-presenting molecules, a discovery for which they won the Nobel prize in 1996. It has been the paradigm, since the early 1980s, that T cells recognize peptide antigens in association with the MHC encoded structures, which vary from individual to individual (Fig. 28-3) (see Chap. 23). These molecules present small peptides to T cells. [18] Specifically, CD4+ T cells recognize 15-amino-acid peptides bound to MHC class II molecules, such as HLA-DR. CD8+ T cells recognize 8- to 9-amino-acid peptides in the context of MHC class I molecules, such as HLA-A or HLA-B. Many of the HLA associations seen in human skin disease are likely to reflect the ability of that particular MHC molecule to present a disease-relevant peptide to T cells.

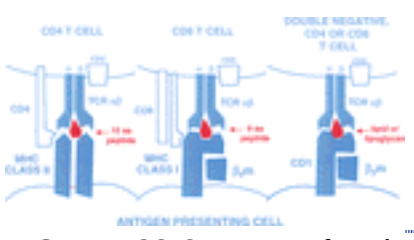

FIGURE 28-3 Types of antigen presentation. The molecules that mediate antigen presentation and the types of antigens presented are shown.

Peptide presentation by MHC class I and II molecules is now widely accepted as the basic mechanism underlying specific T cell recognition of viruses, bacteria, multicellular parasites and many types of tumors. These antigen-presenting molecules have different mechanisms by which they encounter antigen [19], [20] (Fig. 28-4). Most of the peptides presented by class I molecules are derived from the degradation of proteins in the cytoplasm. This degradation is thought to occur in a multisubunit unit complex of low molecular weight proteins called the *proteasome*. Peptides are transported from the cytoplasm to the ER by TAP, a transporter located in the ER and *cis*-Golgi membranes. Within the ER and *cis*-Golgi, peptides can be loaded into class I molecules by displacing invariant chain peptides and the new peptide–class I complex is exported to the cell membrane. In contrast, most of the peptides presented by the class II pathway are extracellular in origin. Proteins that enter the cells by endocytosis traffic to endosomes, where they are processed into small peptides. Upon acidification of the endosome to pH 5, these peptides can be loaded into MHC class II molecules with the assistance of the loading facilitator, HLA-DM. The stable peptide–MHC class II complex can be exported to the cell surface.

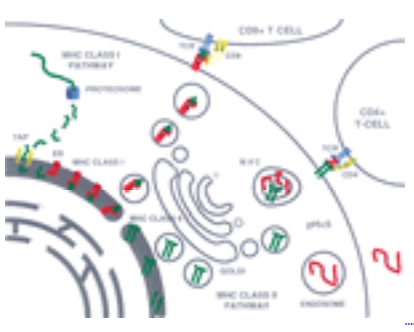

FIGURE 28-4 Antigen-processing pathways. The intracellular antigen processing pathways for MHC class I and MHC class II presentation are shown. The MHC class I pathway involves the processing of cytoplasmic proteins; whereas, the MHC class II pathway involves the processing of exogenous proteins.

A third pathway of antigen presentation has been identified and this pathway has been demonstrated to contribute to

immunologic responses in skin. The human CD1 family is encoded by five genes with an intron/exon structure similar to MHC class I genes. The genes encode polypeptides with a modest but significant level of homology to both MHC class I and II proteins. However, unlike the MHC molecules that are polymorphic, in that they differ from individual to individual, CD1 molecules are nonpolymorphic, in that they are identical in all individuals. At least four human CD1 proteins (the CD1a, -b, -c, and -d isoforms) are expressed on the surface of cells in association with ß $_2$-microglobulin. Human CD1a, -b, and -c proteins are also expressed on a variety of specialized antigen-presenting cells, including dendritic cells in skin. These CD1 molecules can be induced on virtually all circulating human monocytes by exposure to granulocyte-macrophage colony-stimulating factor (GM-CSF) and IL-4, suggesting that they might be upregulated on tissue macrophages in many inflammatory lesions.

The unique feature of the CD1 system is its ability to participate in the presentation of nonpeptide antigens to T cells (see Fig. 28-3). So far, the CD1 antigen presentation pathway has been shown to be involved in the presentation of lipid and glycolipid antigens. [21], [22] CD1-restricted T cell responses have been shown to contribute to CMI in the skin lesions of patients with leprosy, by releasing interferon (IFN)-? and lysing macrophages containing bacteria. Given the expression of the CD1 molecule on Langerhans cells and dermal dendritic cells, it is anticipated that CD1-mediated presentation is involved in other infectious and inflammatory conditions in skin.

COSTIMULATORY MOLECULES

Antigen presentation by MHC molecules or MHC-like molecules provides one of two signals required for proper T cell activation. The second signal is delivered by the interaction of cell surface proteins present on the T cell with determinants on the antigen-presenting cell, collectively termed *costimulatory molecules*. One crucial interaction appears to involve CD28 present on the T cell with B7-1 or B7-2 located on the antigen-presenting cell. [23] The engagement of the T cell receptor by the antigen/MHC complex in the absence of costimulation can induce T cell unresponsiveness, a condition known as *anergy*. Of special interest to cutaneous immunity, B7-1 is not normally expressed on Langerhans cells, but upon activation by antigen or other exogenous stimuli, Langerhans cells express B7 molecules. In this manner, it is possible to regulate immunologic reactions in skin through the induction of B7 expression.

CYTOTOXIC T cellS

In responding to an intracellular pathogen, either a virus, bacteria, or parasite, the T cell must lyse the infected cell. This reduces the reservoir of infected cells, dispersing the pathogen so that activated macrophages can take up and destroy the released microorganisms. The process of targeted T cell lysis is called cytotoxicity. Two distinct subsets for cytotoxic T cells have been identified and can be differentiated by the mechanism by which they kill targets. [24] The end result is the induction of a programmed cell death known as *apoptosis*. [25], [26] The first mechanism of cytotoxicity involves the interaction of two cell surface proteins, Fas ligand on the T cells with Fas on the target. Ligation of these molecules delivers a signal through Fas that induces the apoptosis cascade in the target. The second mechanism involves the release of cytoplasmic granules present in such T cells. These granules contain perforin that induces a pore in the target, and granzymes, serine esterases that, when injected into cells, trigger the apoptotic pathway. Such granules also contain *granulysin*, a protein with a broad spectrum of antimicrobial activity against bacteria, fungi, and parasites. [24], [27] In this manner, cytotoxic T cells can directly kill microbial invaders. Besides contributing to host defense against infection and tumors, cytotoxic T cells can also contribute to tissue injury. For example, cytotoxic T cells recognize self-antigens of melanocytes and may contribute to the pathogenesis of vitiligo. [28]

THE T $_H$1/T $_H$2 PARADIGM

T cells regulate cytotoxic T cell induction, B cell function and macrophage function. They do this by the release of cytokines. How are they able to achieve specificity in the kind of immune response they trigger?

A major paradigm shift in how we think about immunoregulation resulted from the analysis of cytokine patterns produced by murine CD4+ T cell clones [29] (Fig. 28-5). T cells that produce IL-2 and IFN-?, termed T $_H$ *1 cells*, contribute to cell-mediated immune reactions, whereas T cells that produce IL-4, IL-5, and IL-10, termed T $_H$ *2 cells*, augment humoral responses. In murine models of intracellular infection, resistant versus susceptible immune responses appear to be regulated by these two T cell subpopulations. [30], [31] and [32] T $_H$1 cells, primarily by the release of IFN-?, activate macrophages to kill or inhibit the growth of the pathogen and trigger cytotoxic T cell responses, resulting in mild or self-healing disease. In contrast, T $_H$2 cells facilitate humoral responses and inhibit some cell-mediated immune responses, resulting in progressive infection. These cytokine patterns are cross-regulatory. The T $_H$1 cytokine IFN-?, downregulates T $_H$2 responses. The T $_H$2 cytokines, IL-4 and IL-10, downregulate both T $_H$1 responses and macrophage function. The result is that the host responds in an efficient manner to a given pathogen by making either a T $_H$1 or T $_H$2 response. Sometimes the host chooses an inappropriate cytokine pattern, resulting in clinical disease.

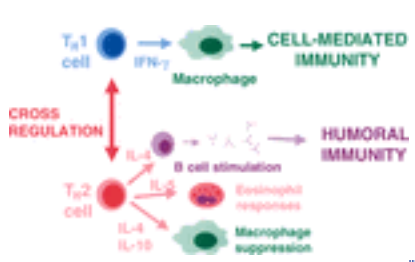

FIGURE 28-5 The T $_H$1/T $_H$2 paradigm. Two major subsets of T cells can be differentiated according to their cytokine patterns. These two subsets have different functional roles in immunologic responses.

The discovery that T_H1/T_H2 responses could contribute to the outcome of human disease caused by a single antigen, was first delineated by the study of leprosy. Because leprosy presents as a spectrum of clinical manifestations that correlate with the immune response to the pathogen, it provides an extraordinary window onto immune regulation in humans: At one end of the spectrum, patients with tuberculoid leprosy typify the resistant response that restricts the growth of the pathogen. The number of lesions is few, although tissue and nerve damage is frequent. At the opposite end of this spectrum, patients with lepromatous leprosy represent extreme susceptibility to *Mycobacterium leprae* infection. In lepromatous leprosy, the skin lesions are numerous and growth of the pathogen is unabated, resulting in many viable bacteria throughout the skin lesions. These clinical presentations correlate with the level of CMI against *M. leprae*. The standard measure of CMI to the pathogen is the Mitsuda reaction. Patients are challenged by intradermal injection of *M. leprae* and induration is measured 3 weeks later. The test is positive in tuberculoid patients and negative in lepromatous patients. It is widely agreed that T cells involved in CMI are pivotal in determining the outcome of infection with *M. leprae*, because skin test and lymphocyte reactivity are positive in tuberculoid patients, but negative in lepromatous patients. Yet, there is an interesting paradox in that CMI and humoral responses exhibit an inverse relationship. Anti- *M. leprae* antibodies are most elevated in patients with the lepromatous form of the disease, and therefore, are not thought to play a role in protection.

This paradox can best be explained according to the patterns of cytokines in the lesions. [33], [34] The T_H1 cytokines, principally IL-2 and IFN-?, are more strongly expressed in tuberculoid lesions; while the T_H2 cytokines, notably IL-4, IL-5, and IL-10, are characteristic of lepromatous lesions. These cytokine patterns can be assigned to the major T cell subset observed in the lesions: CD4+ T cells predominate in tuberculoid lesions and CD8+ T cells predominate in lepromatous lesions. All of the *M. leprae*-specific CD4+ T cells derived from tuberculoid patients produce IL-2 and IFN-? and are designated CD4+ “type 1” cells. The CD8+ T cells derived from lepromatous lesions produce high levels of IL-4 and low levels of IFN-? and are designated CD8+ “type 2” cells.

In terms of the immunopathogenesis of leprosy, the abundance of IL-2 and IFN-? in tuberculoid lesions is likely to contribute to the resistant state of immunity in these patients. IL-2 may contribute to host defense by inducing the clonal expansion of immune-activated cytokine-producing T cells and augmenting the production of IFN-?. IFN-? is well known to enhance production of reactive oxygen and nitrogen intermediates by macrophages and stimulate them to kill or restrict the growth of intracellular pathogens. The cytokines found to be increased in lepromatous lesions might be expected to contribute to the immune unresponsiveness and failure of macrophage activation in these individuals. IL-4 may contribute to the elevated anti- *M. leprae* antibodies in lepromatous patients via its role in differentiation and immunoglobulin class switching of B cells but it also has a negative immunoregulatory effect on CMI, downregulating T cell and macrophage function.

Of particular interest to immunologists is the delineation of factors that influence the T cell cytokine pattern. The innate immune response is one important factor involved in determining the type of T cell cytokine response (Fig. 28-6). Innate immunity pertains to those cells that have been preprogrammed to respond to foreign molecules using pattern recognition receptors that respond to biochemical patterns of foreign ligands (see Chap. 22). Cells of the innate immune response include macrophages, NK cells, and mast cells. Innate immunity can be contrasted to acquired immunity, which involves the selection and expansion of immune cells with the development of memory. The acquired immune response involves T and B cells, with highly specific receptors that are selected by gene rearrangement. Cells of the innate immune response release cytokines that, in turn, bias the cytokine profile of the acquired T cell response.



FIGURE 28-6 The role of innate immunity in determining the type of cytokine response.

The ability of the innate immune response to induce the development of a T_H1 response is mediated by release of IL-12, a 70-kDa heterodimeric protein. [35], [36] and [37] For example, in response to an intracellular pathogen, macrophages release IL-12, which acts on NK cells to release IFN-?. The presence of IL-12, IL-2, and IFN-?, with the relative lack of IL-4, facilitates T_H1 responses. In contrast, in response to allergens or extracellular pathogen, mast cells or basophils release IL-4, which, in the absence of IFN-?, leads to differentiation of T cells along the T_H2 pathway. It is intriguing to speculate that keratinocytes may also influence the nature of the T cell cytokine response. Keratinocytes can produce IL-10, particularly after exposure to UVB. [38] The released IL-10 can specifically downregulate T_H1 responses, thus facilitating the development of T_H2 responses.

The T_H1/T_H2 paradigm provides insight into the pathogenesis of many skin diseases in which T cells have an immunologic role. There is ample evidence that the T_H1–T_H2 paradigm is not rigid; there are situations in which a mixture of cytokines is found and examples of T cell clones, known as T_H *0 cells*, that secrete a combination of T_H1 and T_H2 cytokines. However, it has been possible to find a number of dermatologic conditions in which either a T_H1 or T_H2 cytokine pattern predominates. In the realm of cutaneous infection, leishmaniasis is an outstanding example of a disease with a clinical spectrum in which T_H1 and T_H2 cytokines appear to have a pathogenic role. Leishmaniasis, like leprosy, is not a single disease entity, but a set of clinical entities, each with a differing immunopathogenesis. Similar to leprosy, the type 1 cytokine pattern is characteristic of leishmaniasis lesions in which CMI to the parasite is strong and the lesions self-cure; the type 2 pattern typifies lesions in which immunity to the parasite is weak and the cutaneous lesions are

progressive. [39], [40] Studies in animal models suggest that it may be possible to induce effective CMI by vaccination using a combination of parasite antigens and recombinant IL-12. [41] This immunotherapeutic strategy engenders a T_H1 cytokine response. T_H1 responses are involved in immunologic resistance to *Borrelia burgdorferi*, the causative agent of Lyme disease. [42]

Pathogenic concepts of atopic dermatitis include a central role for allergen-specific T cells that produce T_H2 or "type 2" cytokines, including IL-4 and IL-5. Allergen-specific T cells that produce this cytokine profile have been demonstrated in the peripheral blood and skin lesions of subjects with active disease. [43], [44] and [45] In addition, the lesions of atopic dermatitis contain abundant IL-10, although the source of this cytokine is likely to be tissue macrophages and keratinocytes. [46] Together the T_H2 pattern of cytokines is thought to induce increased immunoglobulin production, particularly IgE mast cell growth and the infiltration of eosinophils. These cytokines may also downregulate T_H1 responses, accounting for the increased susceptibly to cutaneous bacterial infection. To alter the T_H2 response in atopic dermatitis, clinical trials involving the administration of IFN-? have shown that treatment with IFN-? induces significant, but modest, improvement in some patients. [47] Interestingly, moderate clinical improvement occurred in the absence of reduction in the levels of IgE. It is thought, however, that T cells producing T_H2 cytokines help B cells produce autoantibodies in pemphigus vulgaris. [48]

In allergic contact dermatitis, sensitization involves the development of a T_H1 response. T_H1 cytokines predominate in murine T cells sensitized in vitro to haptenated antigen-presenting cells. [49] Likewise, in humans with contact dermatitis, nickel-specific T cells produce a T_H1 cytokine pattern. [50] Induction of contact hypersensitivity involves the production of IL-12; in fact, neutralization of IL-12 leads to tolerance or nonresponsiveness to the allergen. [51] In the examination of the lesions during the elicitation phase of allergic contact dermatitis, a T_H2 response is found, both in animal models and in human reactions. [52], [53] The mechanism underlying the switch from a T_H1 to a T_H2 response is unknown. For a long time now, allergic contact dermatitis has been regarded as a delayed-type hypersensitivity response (type IV immune reaction). Yet, in 1938, Sulzberger and Baer suggested that "the contact-type of reaction of the human skin is a form of allergy with special and peculiar characteristics which are not necessarily identical with the cutaneous hypersensitivity…." [54] The presence of a T_H2 cytokine pattern in the elicitation phase of allergic contact dermatitis, as compared to the T_H1 pattern in tuberculin hypersensitivity, [46] points to the existence of distinct immunologic mechanisms underlying these cutaneous reactions. Alternatively, the T_H2 cytokines IL-4 and IL-10 may act to downregulate and shut off the allergic response.

T_H1/T_H2 responses may be involved in antitumor immunity. For example, IL-4 and IL-10 predominate in the lesions of basal cell and squamous cell carcinoma, as compared to the T_H1 response present in benign neoplasms. [55] The source of the IL-10 in these cutaneous carcinomas is the tumor itself, a mechanism by which the cancer can downregulate antitumor T cell responses. Similarly, CTCL represents a T_H1 cytokine response, whereas patients with the more progressive Sézary syndrome exhibit a T_H2 cytokine response. [56] Finally, T_H1 cytokine responses predominate in skin lesions of psoriasis, including uninvolved skin from psoriatic patients. [57], [58] These T_H1 cells may be autoimmune, responding to self-antigens in the epidermis.

Whatever the role for the observed cytokine patterns in human skin disease, the T_H1–T_H2 paradigm exposes new targets for therapy. Trials are underway to exploit this knowledge through the use of cytokine agonists and antagonists to shift the balance between the T_H1 and T_H2 patterns for the benefit of the patient. In general, understanding the functional role of lymphocytes in skin, both in terms of normal function and in disease, will enhance our ability to help our patients.

REFERENCES

1. Moretta A et al: Existence of both inhibitory (p58) and activatory (p50) receptors for HLA-C molecules in human natural killer cells. *J Exp Med* **182**:875, 1995

2. Pende D et al: The natural killer cell receptor specific for HLA-A allotypes: A novel member of the p58/p70 family of inhibitory receptors that is characterized by three immunoglobulin-like domains and is expressed as a 140-kD disulfide-linked dimer. *J Exp Med* **184**:505, 1996

3. Caughman SW et al: Culture and characterization of murine dendritic Thy-1+ epidermal cells. *J Invest Dermatol* **86**:615, 1986

4. Tigelaar RE et al: TCR gamma/delta+ dendritic epidermal T cells as constituents of skin-associated lymphoid tissue. *J Invest Dermatol* **94**:58S, 1990

5. Butcher EC, Picker LJ: Lymphocyte homing and homeostasis. *Science* **272**:60, 1996

6. Fuhlbrigge RC et al: Cutaneous lymphocyte antigen is a specialized form of PSGL-1 expressed on skin-homing T cells. *Nature* **389**:978, 1997

7. Robert C et al: Interaction of dendritic cells with skin endothelium: A new perspective on immunosurveillance. *J Exp Med* **189**:627, 1999

8. Santamaria Babi LF et al: Circulating allergen-reactive T cells from patients with atopic dermatitis and allergic contact dermatitis express the skin- selective homing receptor, the cutaneous lymphocyte-associated antigen. *J Exp Med* **181**:1935, 1995

9. Modlin RL et al: T lymphocyte subsets in the skin lesions of patients with leprosy. *J Am Acad Dermatol* **8**:182, 1983

10. Modlin RL et al: Lymphocytes bearing antigen-specific gamma/delta T-cell receptors in human infectious disease lesions. *Nature* **339**:544, 1989

11. Tanaka Y et al: Nonpeptide ligands for human gamma delta T cells. *Proc Natl Acad Sci U S A* **91**:8175, 1994

12. Girardi M et al: Regulation of cutaneous malignancy by gamma delta T cells. *Science* **294**:605, 2001

13. Wood GS et al: Detection of clonal T-cell receptor gamma gene rearrangements in early mycosis fungoides/Sézary syndrome by polymerase chain reaction and denaturing gradient gel electrophoresis (PCR/DGGE). *J Invest Dermatol* **103**:34, 1994

14. Wang X-H et al: Selection of T lymphocytes bearing limited T-cell receptor beta chains in the response to a human pathogen. *Proc Natl Acad Sci U S A* **90**:188, 1993

15. Chang JC et al: CD8+ T cells in psoriatic lesions preferentially use T-cell receptor V beta 3 and/or V beta 13.1 genes. *Proc Natl Acad Sci U S A* **91**:9282, 1994

16. McCluskey RT et al: Studies on the specificity of the cellular infiltrate in delayed hypersensitivity reactions. *J Immunol* **90**:466, 1963

17. Modlin RL et al: Learning from lesions: Patterns of tissue inflammation in leprosy. *Proc Natl Acad Sci U S A* **85**:1213, 1988

18. Engelhard VH: Structure of peptides associated with class I and class II MHC molecules. *Annu Rev Immunol* **12**:181, 1994

19. Germain RN, Margulies DH; The biochemistry and cell biology of antigen processing and presentation. *Annu Rev Immunol* **11**:403, 1993

20. Cresswell P: Assembly, transport, and function of MHC class II molecules. *Annu Rev Immunol* **12**:259, 1994

21. Beckman EM et al: Recognition of a lipid antigen by CD1-restricted aß+ T cells. *Nature* **372**:691, 1994

22. Sieling PA et al: CD1-restricted T cell recognition of microbial lipoglycans. *Science* **269**:227, 1995

23. Linsley PS, Ledbetter JA: The role of the CD28 receptor during T cell responses to antigen. *Annu Rev Immunol* **11**:191, 1993

24. Stenger S et al: Differential effects of cytolytic T cell subsets on intracellular infection. *Science* **276**:1684, 1997

25. Berke G: The binding and lysis of targeT cells by cytotoxic lymphocytes: Molecular and cellular aspects. *Annu Rev Immunol* **12**:735, 1994

26. Kagi D et al: Cytotoxicity mediated by T cells and natural killer cells is greatly impaired in perforin-deficient mice [see comments]. *Nature* **369**:31, 1994

27. Stenger S et al: An antimicrobial activity of cytolytic T cells mediated by granulysin. *Science* **282**:121, 1998

28. Palermo B et al: Specific cytotoxic T lymphocyte responses against Melan-A/MART1, tyrosinase and gp100 in vitiligo by the use of major histocompatibility complex/peptide tetramers: The role of cellular immunity in the etiopathogenesis of vitiligo. *J Invest Dermatol* **117**:326, 2001

29. Mosmann TR et al: Two types of murine helper T cell clones I. Definition according to profiles of lymphokine activities and secreted proteins. *J Immunol* **136**:2348, 1986

30. Heinzel FP et al: Reciprocal expression of interferon gamma or interleukin 4 during the resolution or progression of murine leishmaniasis. Evidence for expansion of distinct helper T cell subsets. *J Exp Med* **169**:59, 1989

31. Pearce EJ et al: Downregulation of T_H1 cytokine production accompanies induction of T_H2 responses by a parasitic helminth, *Schistosoma mansoni*. *J Exp Med* **173**:159, 1991

32. Pond L et al: Evidence for differential induction of helper T cell subsets during *Trichinella spiralis* infection. *J Immunol* **143**:4232, 1989

33. Yamamura M et al: Defining protective responses to pathogens: Cytokine profiles in leprosy lesions. *Science* **254**:277, 1991

34. Salgame P et al: Differing lymphokine profiles of functional subsets of human CD4 and CD8 T cell clones. *Science* **254**:279, 1991

35. Gately MK et al: Regulation of human lymphocyte proliferation by a heterodimeric cytokine, IL-12 (cytotoxic lymphocyte maturation factor). *J Immunol* **147**:874, 1991

36. Manetti R et al: Natural killer cell stimulatory factor [interleukin 12 (IL-12)] induces T helper type 1 (T_H1)-specific immune responses and inhibits the development of IL-4-producing T_H cells. *J Exp Med* **177**:1199, 1993

37. Trinchieri G: Interleukin-12: A proinflammatory cytokine with immunoregulatory functions that bridge innate resistance and antigen-specific adaptive immunity. *Annu Rev Immunol* **13**:251, 1995

38. Enk AH, Katz SI: Identification and induction of keratinocyte-derived IL-10. *J Immunol* **149**:92, 1992

39. Pirmez C et al: Cytokine patterns in the pathogenesis of human leishmaniasis. *J Clin Invest* **91**:1390, 1993

40. Caceres-Dittmar G et al: Determination of the cytokine profile in American cutaneous leishmaniasis using the polymerase chain reaction. *Clin Exp Immunol* **91**:500, 1993

41. Afonso LC et al: The adjuvant effect of interleukin-12 in a vaccine against Leishmania major. *Science* **263**:235, 1994

42. Yssel H et al: *Borrelia burgdorferi* activates a T helper type 1-like T cell subset in Lyme arthritis. *J Exp Med* **174**:593, 1991

43. Van Reijsen FC et al: Skin-derived aeroallergen-specific T-cell clones of T_H2 phenotype in patients with atopic dermatitis. *J Allergy Clin Immunol* **90**:184, 1992

44. van der Heijden FL et al: High frequency of IL-4-producing CD4+ allergen-specific T lymphocytes in atopic dermatitis lesional skin. *J Invest Dermatol* **97**:389, 1991

45. Hamid Q et al: Differential in situ cytokine gene expression in acute versus chronic atopic dermatitis. *J Clin Invest* **94**:870, 1994

46. Ohmen JD et al: Overexpression of IL-10 in atopic dermatitis: Contrasting cytokine patterns with delayed-type hypersensitivity reactions. *J*

Immunol **154**:1956, 1995

47. Hanifin JM et al: Recombinant interferon gamma therapy for atopic dermatitis. *J Am Acad Dermatol* **28**:189, 1993

48. Lin MS et al: Development and characterization of desmoglein-3 specific T cells from patients with pemphigus vulgaris. *J Clin Invest* **99**:31, 1997

49. Hauser C: Cultured epidermal Langerhans cells activate effector T cells for contact sensitivity. *J Invest Dermatol* **95**:436, 1990

50. Kapsenberg ML et al: TH1 lymphokine production profiles of nickel-specific CD4+T- lymphocyte clones from nickel contact allergic and nonallergic individuals. *J Invest Dermatol* **98**:59, 1992

51. Riemann H et al: Neutralization of IL-12 in vivo prevents induction of contact hypersensitivity and induces hapten-specific tolerance. *J Immunol* **156**:1799, 1996

52. Brown MS, Goldstein JL: A receptor-mediated pathway for cholesterol homeostasis. *Science* **232**:34, 1986

53. Gautam SC et al: Anti-inflammatory action of IL-4. Negative regulation of contact sensitivity to trinitrochlorobenzene. *J Immunol* **148**:1411, 1992

54. Sulzberger MB, Baer RL: Sensitization to simple chemicals: III. Relationship between chemical structure and properties, and sensitizing capacities in the production of eczematous sensitivity in man. *J Invest Dermatol* **1**:45, 1938

55. Kim J et al: IL-10 production in cutaneous basal and squamous cell carcinomas. A mechanism for evading the local T cell immune response. *J Immunol* **155**:2240, 1995

56. Saed G et al: Mycosis fungoides exhibits a T_H1-type cell-mediated cytokine profile whereas Sézary syndrome expresses a T_H2-type profile. *J Invest Dermatol* **103**:29, 1994

57. Uyemura K et al: The cytokine network in lesional and lesion-free psoriatic skin is characterized by a T-helper type 1 cell-mediated response. *J Invest Dermatol* **101**:701, 1993

58. Schlaak JF et al: T cells involved in psoriasis vulgaris belong to the T_H1 subset. *J Invest Dermatol* **102**:145, 1994

T>

Chapter 29

Shireen Guide Steven Holland

Regulation of the Production and Activation of Neutrophils

NEUTROPHIL ONTOGENY AND DEVELOPMENT
GRANULE CONTENT AND FUNCTION
CHEMOATTRACTANTS AND CHEMOTAXIS
ADHESION
PHAGOCYTOSIS
MECHANISMS OF KILLING
Oxygen-Independent Pathways
Oxygen-Dependent Pathways
PHARMACOLOGIC MODULATION

REFERENCES

Human bone marrow commits enormous resources to the creation of neutrophils, producing about 10^{11} daily with a circulating half-life of about 7.5 hours and tissue survival of 1 to 2 days. In contrast, erythropoiesis yields cells that last 120 days, and the products of lymphopoiesis may last a lifetime. Neutrophils are absolutely required for the prevention of infection and are not yet amenable to significant external replacement therapy. The neutrophil not only plays a central role in host defense but also can be responsible for significant tissue damage. Understanding the pathophysiology of the neutrophil indicates pathways that can be exploited to enhance protection from infection. Selective abrogation of those pathways that are injurious in certain settings is also possible. Future clinical studies will focus on enhancement of neutrophil recruitment, adherence, and activation; prevention of these same activities in the setting of myocardial, cerebral, or bowel infarction may reduce injury. Regulation of neutrophil responses in the skin is a major concern. This chapter will present an overview of neutrophil biology and function and use a few well-characterized defects of myeloid function as illustrations.

NEUTROPHIL ONTOGENY AND DEVELOPMENT

Like the other components of the hematopoietic system, the neutrophil is ultimately derived from a pluripotent stem cell. The commitment of a myeloid cell down a developmental pathway is largely determined by ambient cytokines and reflected in its surface markers, morphology, and functional characteristics. The myeloblast is fully committed to the neutrophil lineage and is the first morphologically distinct cell in neutrophil development. All subsequent stages of neutrophil development occur in the setting of granulocyte colony-stimulating factor (G-CSF) and granulocyte-macrophage colony-stimulating factor (GM-CSF). Four to six days are required for maturation through the mitotic phase to the myelocyte and 5 to 7 days more for the myelocyte to develop into a mature neutrophil. Following the myelocyte stage, the maturing neutrophil passes through the metamyelocyte and band stages before acquiring the fully developed neutrophil phenotype. Development of neutrophils through the myelocyte stage occurs exclusively in the bone marrow, which is composed of about 60 percent developing neutrophils. The mature neutrophil measures 10 to 12 µm and has a highly condensed, segmented, multilobulated nucleus, usually with three to five lobes. As noted above, approximately 10^{11} neutrophils are generated daily, but this number can rise tenfold in the setting of infection. The calculated circulating granulocyte pool is 0.3×10^{9} cells per kilogram of blood, and the marginated pool is 0.4×10^{9} cells per kilogram of blood, comprising only 3 and 4 percent of the total granulocyte pool, respectively. [1] The bone marrow releases 1.5×10^{9} cells per kilogram of blood per day to this pool but keeps 8.8×10^{9} cells per kilogram of blood in the marrow in reserve. An additional reserve of immature and less competent neutrophils, 2.8×10^{9} cells per kilogram of blood, is also available.

Granulocyte colony-stimulating factor (G-CSF) is a glycoprotein that is critically important for neutrophil production. Mice lacking the G-CSF gene show only 20 to 30 percent of normal neutrophil numbers and are unable to upregulate neutrophil numbers in response to infection. [2] Mice heterozygous for the G-CSF deletion show lower levels of neutrophils than wild-type mice, suggesting a gene dosage effect. Exogenously administered human G-CSF was able to significantly elevate circulating neutrophil counts in these animals, similar to the effect seen in human neutropenia. [2] Dong et al. [3] have recognized dominant mutations in the G-CSF receptor that are associated with severe neutropenia and eventual development of leukemia. However, the mutations leading to severe congenital neutropenia and cyclic neutropenia are not in the G-CSF or G-CSF receptor genes but rather in those for neutrophil elastase. [4]

GRANULE CONTENT AND FUNCTION

Neutrophils are characterized by cytoplasmic granules and partially condensed nuclei. Granules are first found at the promyelocyte stage. Primary (azurophilic) granules are the first to arise, measure about 0.8 µm in diameter, and contain numerous antimicrobial products, including lysozyme, myeloperoxidase, and defensins (Table 29-1). All the primary granules that will be available to the mature neutrophil are synthesized at the promyelocyte stage, which leads into the myelocyte, the last cell of the neutrophil lineage with proliferative potential. Therefore, cytokines or agents that increase total neutrophil production must act at or before the myelocyte stage. During the myelocyte stage, the smaller secondary (specific) granules appear. These granules measure about 0.5 µm in diameter and contain lactoferrin, collagenase, gelatinase, vitamin B_{12}–binding protein, and complement receptor 3 (CR3; CD11b/CD18). $gp91^{phox}$ and $p22^{phox}$ comprise the specific granule component cytochrome b_{558}, defects in which cause chronic granulomatous disease (CGD), characterized by infections with particular catalase-producing bacteria. Gelatinase has been shown recently to cleave and potentiate the activity of interleukin 8 (IL-8). [5] Primary granules are synthesized only during the promyelocyte

stage and distributed to daughter cells during division, so they are eventually outnumbered by about 3:1 by the specific granules that are produced throughout the myelocyte stage.

Azurophil (Primary) Granule	Specific (Secondary) Granule	Other Granule[a]
Microbicidal enzymes		
Bactericidal permeability-increasing protein (BPI)		
Defensins	p15	
Lysozyme	Lysozyme	
Myeloperoxidase		
Elastase		
Cathepsin G		
Proteinase 3	Proteinase 3	
Azurocidin		
Phospholipase A_2 (PLA_2)		
Acid hydrolases		
Cathepsin B	Cathepsin B	Cathepsin B
Cathepsin D	Cathepsin D	Cathepsin D
β-Glycerophosphatase		β-Glycerophosphatase
β-Glucuronidase		β-Glucuronidase[b]
N-acetyl-β-glucosaminidase		N-Acetyl-β-glucosaminidase
α-Mannosidase		α-Mannosidase[b]
Receptors		
	N-Formyl-methionyl-leucyl-phenylalanine (fMLF)	
	CR3 (Mac-1, CD11b/CD18) (binds to C3bi)	
	Laminin	
	Vitronectin	
Other		
Collagenase	Procollagenase	Metalloproteinases
	Progelatinase	
	Gelatinase	Gelatinase
	Lactoferrin	
	Vitamin B_{12}-binding proteins	
	Cytochrome b_{558}	
	Histaminase	

[a]Heterogeneous population of organelles including the C azurophilic, and secretory vesicles.
[b]Location not entirely certain.
Source: Adapted from Refs. 7 and 54.

TABLE 29-1 **Human Neutrophil Granule Components**

Granules fuse in a sequential fashion with incoming phagocytic vacuoles, such as ingested bacteria. Secondary granules fuse to the phagosome within the first 30 s after ingestion and release their enzymes, many of which function best at neutral or alkaline pH. [6] By 3 min after ingestion, the primary granules have fused to the phagolysosome, leading to rapid and marked lowering of the intravacuolar pH. In the presence of foreign objects too large to be ingested or certain stimuli, degranulation to the cell surface occurs, and granule contents are released into the surrounding environment. This can be inferred by detection of lactoferrin levels in blood.

Neutrophil granules and their content are critical to effective neutrophil function. [7] There are two genetic examples of disordered granule biogenesis. Chediak-Higashi syndrome (CHS) is a rare autosomal recessive disorder with a generalized abnormality of primary granule and lysosome formation. Cells of almost all lineages fail to form lysosomes and other intracytoplasmic granules appropriately. Giant azurophilic granules in neutrophils are seen on light microscopy. Abnormal skin and hair pigmentation is due to defective melanin distribution, leading to partial oculocutaneous albinism and silvery hair. Associated findings are photophobia, nystagmus, peripheral neuropathy, and mental retardation. Neutrophil bactericidal activity is reduced, as is natural killer (NK) cell function. Many patients die in childhood from infection, and about half the patients who survive into adolescence develop an aggressive “lymphoproliferative” phase with diffuse organ infiltration and death. In adulthood, an aggressive, severe, debilitating peripheral neuropathy is common. Many mammalian mutants have the autosomal recessive traits of giant lysosomes and pigmentary dilution characteristic of CHS. The *beige* mouse has been used extensively as a model for the neutrophil dysfunction of CHS. The gene responsible for CHS has been cloned and identified as *lyst* (lysosomal transporter). Understanding the function of this gene promises to better inform our knowledge of pigmentation, neuropathy, and immune response.

Neutrophil-specific granule deficiency is a rare autosomal recessive condition clinically characterized by a profound susceptibility to bacterial infections. There is a paucity or absence of neutrophil-specific granules, specific granule proteins (e.g., lactoferrin), and their respective mRNAs and very low levels of the primary granule products defensins and their mRNAs. Specific granule deficiency is due to loss of the transcriptional factor CCAAT/enhancer binding protein e (C/EBP-e), which is essential in normal myeloid development. [8] Acquired abnormalities of neutrophil granules are seen in some myeloid leukemias in which primary granule contents may be aberrantly accumulated (e.g., Auer rods in acute myelogenous leukemia). In acute thermal injury, secondary granules degranulate shortly after injury. The discharge of secondary granules may contribute to the neutrophil hypofunction sometimes seen in severe burns. [9]

CHEMOATTRACTANTS AND CHEMOTAXIS

The ability of neutrophils to move toward very slight gradients of chemical signals was noted by Metchnikoff over a century ago. The classic chemoattractants *N*-formyl-methionyl-leucyl-phenylalanine (fMLF), complement factor 5a (C5a), leukotriene B_4 (LTB_4), and platelet-activating factor (PAF) were known to be potent agents for the migration of neutrophils. [10] More recently, chemokines (chemoattractant cytokines), a class of small (<10 kDa), extremely active chemoattractant proteins, have been identified. The chemokines fall into several broad families: CXC chemokines tend to be chemoattractant to neutrophils and T lymphocytes and have a cysteine-X-cysteine motif in the amino-terminal portion of the molecule; CC chemokines tend to be chemoattractant for monocytes and T lymphocytes and have a cysteine-cysteine motif in the amino-terminal portion of the molecule; other classes of chemokines have a C or a CX_3C motif. Among the CXC chemokines, the peptide sequence glutamic acid–leucine–arginine (ELR) immediately proximal to the CXC motif confers potent neutrophil chemoattraction. The CXC chemokine genes are all 25 to 90 percent identical to each other and are physically located on chromosome 4q12-q21. The CC chemokine genes are all 25 to 70 percent identical to each other and located on chromosome 17, suggesting common evolutionary origins for these gene families.

IL-1 activates the release of IL-8 from neutrophils. IL-8 is a potent chemoattractant and neutrophil activator. Blockade of IL-8 by neutralizing anti–IL-8 antibody in rabbit models of pulmonary inflammation was successful in preventing neutrophil accumulation and reperfusion injury, confirming the central role for this chemokine in neutrophil recruitment to sites of inflammation. [11], [12] Many different cellular sources for IL-8 have been identified, including neutrophils, monocytes, T cells, B cells, NK cells, basophils, eosinophils, fibroblasts, endothelial cells, keratinocytes, and smooth muscle. Exudative neutrophils are particularly effective at synthesizing IL-8, probably through a calcium-regulated

mechanism. [13]

Exuberant neutrophil function is implicated in Sweet's syndrome (acute febrile neutrophilic dermatosis), as shown by the frequent association of the syndrome with hematologic malignancies, dysmyelopoiesis, and sometimes the use of G-CSF. [14] The classic chemoattractants and chemokines use receptors that have in common seven predicted transmembrane regions and an extracellular amino-terminal domain and transduce their signals through pertussis toxin–sensitive heterotrimeric G-proteins. These are the same type of receptor through which is mediated signal transduction for light, neuropeptides, and neurotransmitters. Chemoattractant receptor binding by a cognate ligand leads to exchange of bound GDP for GTP by the a subunit of the heterotrimeric G protein, which, in turn, leads to the dissociation of the ß-? subunit of the complex, stimulation of phospholipase C, and generation of inositol triphosphate and diacylglycerol from phosphatidylinositol bisphosphate. Inositol triphosphate stimulates the release of calcium from intracellular “calciosomes,” whereas diacylglycerol activates protein kinase C. Extracellular calcium also enters the cell, preparing it for subsequent movement, generation of oxidants, and secretion of vesicles (Fig. 29-1).

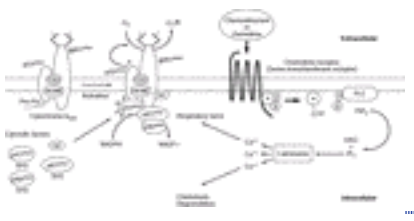

FIGURE 29-1 The neutrophil can be activated by interaction of a chemoattractant with its receptor on the cell surface, leading to release of secondary mediators and resulting in an increase in intracellular calcium concentration. Ligation of the seven-transmembrane receptor results in dissociation of the heterotrimeric G protein, leading to activation of phospholipase C (PLC) and generation of phosphatidylinositol bisphosphate (PIP_2), diacylglycerol (DAG), and inositol triphosphate (IP_3). Assembly of the NADPH oxidase following cellular activation is depicted. The cytosolic factors $p47^{phox}$, $p67^{phox}$, and $p40^{phox}$ are shown with *src*-homology 3 (SH3) domains. The proline-rich tail of $p22^{phox}$ is schematized (ProPro). Following activation, $p47^{phox}$ is multiply phosphorylated (P) and binds to $p67^{phox}$. This complex then binds via the $p47^{phox}$ SH3 domain to the $p22^{phox}$ proline tail. An electron is taken from NADPH and transferred to molecular oxygen in the extracellular space or inside a phagolysosome. $p40^{phox}$ appears to serve a regulatory role. Defects in any of the four structural proteins of the NADPH oxidase lead to inability to produce superoxide and cause CGD. FAD, flavin adenine dinucleotide. a,ß, and ? are subunits of the heterotrimeric GTP-coupled receptors.

Ras-related GTPases of the Rho superfamily are other key signaling intermediates involved in actin cytoskeletal regulation and adhesion. [15] Phosphatidylinositol-3-kinase (PI3K) is activated by Rho and Ras and is a pivotal signaling molecule shown recently to be necessary for the neutrophil respiratory burst, adhesion, endothelial transmigration, and chemotaxis. [16] Mitogen-activated protein kinases (MAPKs) are serine-threonine kinases that include p38, Erk1, Erk2, and Jnk and are involved in neutrophil signaling and adhesion. Inhibition of p38 impairs chemotaxis and tumor necrosis factor a (TNF)a mediated superoxide production and adhesion along with impaired release of secondary granules. [17] Erk activation is required for neutrophil homotypic aggregation. Interestingly, salicylate inhibition of neutrophil adhesion has been shown to act through Erk inhibition. [18]

The medical interest in chemokines and their receptors has been vastly augmented by numerous reports that several chemokine receptors function as HIV coreceptors. HIV is unable to penetrate CD4+-expressing T lymphocytes or monocytes in the absence of specific chemokine receptors. The demonstration of a defect in the chemokine receptor CCR5 that is protective against HIV infection has spawned a whole new field of investigation into uses of chemokine receptor blockade to prevent the acquisition or spread of HIV infection. [19]

ADHESION

Neutrophils exist in at least two states in the circulation: free flowing (that which is sampled on blood drawing) and marginated (those cells which are attached to the endothelium or are traversing the lung). Neutrophils rolling along the endothelium recognize sites of activation (e.g., chemokine expression), adhere to those sites, and traverse the endothelium to enter the tissue and fight infection. Leukocyte physical interaction with endothelium and other leukocytes is mediated by three main sets of molecules: integrins, selectins, and members of the immunoglobulin supergene family (intercellular adhesion molecules, ICAMs) (Fig. 29-2).

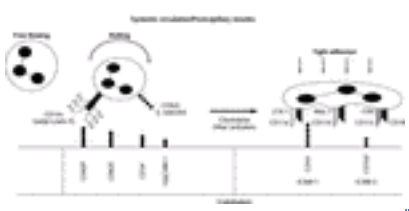

FIGURE 29-2 The interaction of selectins and integrins with endothelia is depicted. One population of neutrophils flows freely in the circulation. A substantial number of neutrophils roll gently along the endothelial wall using endothelial and leukocyte selectins and glycoproteins. CD15s interacts with CD62P and CD62E, whereas CD62L interacts with CD34 and GlyCAM-1. Abnormalities in fucosylation of CD15s cause leukocyte adhesion deficiency 2 (congenital defect of glycosylation llc). Activation of the neutrophils leads to display of higher-affinity leukocyte integrins with common CD18 chains that bind to CD54 and CD102 on the endothelial surface. Defects in CD18 (black) lead to inability to exit the circulation at sites of infection, causing leukocyte adhesion deficiency 1.

Elaboration of chemoattractants or display of activation markers on endothelium triggers leukocyte high-affinity binding by ß $_2$ integrins, heterodimeric surface molecules stored in the secondary granules of neutrophils that are displayed on the cell surface on leukocyte activation. There are three ß $_2$ integrin heterodimers comprised of different a chains, CD11a, -b, and -c, and a common ß chain, CD18. Each CD11-CD18 complex has separate and overlapping activities. CD11a-CD18 (leukocyte function–associated molecule 1, LFA-1) binds to other leukocytes and mediates tight adhesion to the endothelium through ICAM-1 and ICAM-2. CD11b-CD18 (Mac-1, Mo-1, or complement receptor 3, CR3) binds to the inactivated form of the third component of complement (C3bi) and thereby facilitates complement-mediated phagocytosis. CD11b-CD18 also binds to bacteria directly, to fibrinogen, and to endothelium through ICAM-1. Divalent cations Ca^{2+} and Mg^{2+}/Mn^{2+} also mediate adhesion through ß $_2$ integrin A domains containing a metal ion–dependent adhesion site (MIDAS). CD11b-CD18 is thought to mediate transendothelial migration and may induce the expression of the ß $_1$ integrin VLA-6 (CD49f-CD29), derived from neutrophil granules, to aid in tissue infiltration. The integrin-associated protein (IAP or CD47), expressed on both neutrophils and endothelial cells, is also involved in the transendothelial migration of neutrophils. [20] Metalloproteinases may be involved in cleavage of L-selectin, allowing neutrophil migration through the basement membrane. [21]

Absence of CD18 causes leukocyte adhesion deficiency type 1 (LAD1) and is characterized by a clinical picture that is largely predicted from the molecular defect. Neutrophils lacking CD18 roll normally along the endothelium but are unable to stick to the vessel wall or exit the circulation after chemotactic stimulation. [22] Absence of LFA-1 (CD11a-CD18) makes neutrophils unable to bind tightly to and traverse activated endothelium to infected areas. Affected patients have chronic neutrophil leukocytosis, presumably from inability of neutrophils to bind tightly to endothelium and exit the circulation, thus leading to a reduction in the marginated pool and an increase in the circulating pool. Patients have poor neutrophil penetration to sites of bacterial invasion, leading to necrotic ulcers that are characteristically lacking neutrophils on biopsy. Absence of Mac-1 (CD18-CD11b or CR3) leads to inability to perform complement-mediated phagocytosis, although antibody-mediated phagocytosis remains intact.

LAD1 is a rare autosomal recessive disorder that falls into two broad categories depending on the degree of CD18-CD11 deficiency. [23] Severe LAD1 (<1.0 percent of normal protein expression) is manifested by delayed umbilical stump separation, umbilical stump infection, persistent leukocytosis in the absence of active infection (>15,000/µL), and severe, destructive periodontitis with associated loss of teeth and alveolar bone. Recurrent infections of the skin, upper and lower airways, bowel, and perirectal area and septicemia are common and usually due to *Staphylococcus aureus* or gram-negative rods. Severe LAD1 patients should receive bone marrow transplantation as early as possible. Patients with moderate LAD1 (2.5 to 30 percent of normal protein expression) tend to be diagnosed later in life and less commonly have life-threatening infections. Leukocytosis is still the rule, as are delayed wound healing and periodontal disease. Patients with the moderate form of the disease are less ill and tend to live past childhood. Fluorescent-activated cell sorting (FACS) showing reduction or absence of CD18 and the coexpressed molecules CD11a, CD11b, and CD11c confirms the diagnosis.

The ability of neutrophils to roll along the endothelium is mediated by selectins, surface glycoproteins on the endothelium, and sialyl-Lewis ^{x} (CD15s), a highly fucosylated surface glycoprotein on neutrophils. [24] Endothelial cells express E-selectin (CD62E) and P-selectin (CD62P), whereas leukocytes express L-selectin (CD62L). Although endothelial E-selectin and P-selectin bind to the sialyl-Lewis ^{x} (CD15s) antigen on neutrophils, the neutrophil molecule L-selectin probably binds to distinct antigens on endothelium, including CD34, and is highly sensitive to glycosylation. [24] L-selectin is shed by neutrophils on activation, allowing neutrophil migration into sites of inflammation. Cross-linking of L-selectin on neutrophils results in superoxide generation and may result in upregulation of TNF-a, IL-8, and tyrosine phosphorylation and activation of MAP kinase. [25] Leukocyte adhesion deficiency type 2 (LAD2) occurs in the absence of properly fucosylated CD15s, leading to neutrophilia, recurrent pulmonary, periodontal, and cutaneous infections, and abnormal chemotaxis. The underlying defect is in the inability to fucosylate CD15 as well as other molecules. Three cases of LAD2 have been reported, confirming the critical role of selectins in neutrophil function. Since the enzyme responsible for this defect is a GDP-fucose transporter, this disease is now classified as a congenital disorder of glycosylation (CDG) and known as CDG-IIc. [26] Interestingly, although infections are common early in life, LAD2 (CDG-IIc) patients appear to improve with age. [27] Administration of fucose to patients with LAD2 has been reported to be therapeutic. [28] The patients reported also had mental retardation, short stature, distinctive facies, and the Bombay (*hh*) blood phenotype, indicating the multiple systems in which fucosylation is critical.

Doerschuk and coworkers have recognized that while the CD18-containing integrin pathway is critically important for inflammation in the skin, it is not necessary for accumulation of neutrophils in the lung or peritoneum in mice. [29], [30] CD18-deficient mice have normal or above-normal recruitment of neutrophils into pulmonary alveoli and alveolar septa in response to *Streptococcus pneumoniae* or *Escherchia coli* and normal or above-normal recruitment of neutrophils into peritoneum in response to *S. pneumoniae* or the sterile irritant thioglycollate. In contrast, CD18-deficient mice do not recruit neutrophils into skin irritated with croton oil. These findings remain remarkable, since administration of blocking antibody to CD18 in normal mice blocks neutrophil accumulation at most sites of infection. [31] In addition, CD11a-deficient mice show a defect in thioglycollate peritonitis. Overall, these data indicate that while CD18-dependent pathways are critical for cutaneous inflammation, CD18-independent pathways exist for pulmonary inflammation. Further, in the setting of congenital absence of CD18, compensatory pathways exist in the mouse to respond to peritoneal inflammation.

PHAGOCYTOSIS

Recognition, binding, signaling, adherence, cytoskeletal remodeling, engulfment, and membrane fusion are required for the complex process of phagocytosis. Two mechanisms are well characterized, one mediated by immunoglobulin and one mediated by complement.

Receptors for the Fc portions of IgG (Fc?R) are present on many components of the cellular immune response, including

neutrophils, monocytes, macrophages, eosinophils, and basophils. Fc?RI (CD64) is a receptor for IgG_1 and IgG_3 on monocytes, macrophages, and eosinophils and is upregulated on neutrophils after interferon-? stimulation. Fc?RII (CD32) binds IgG with rather low affinity, with the binding of IgG_1 and IgG_3 greater than that of IgG_2 and IgG_4. Fc?RIII (CD16) binds IgG_1 and IgG_3 with intermediate affinity. [32] The form of Fc?RIII expressed on neutrophils, Fc?RIIIB, is bound to the membrane through a glycan phosphatidyl inositol (GPI) linkage, which is largely cleavable by phosphatidyl inositol–specific phospholipase C. Since Fc?RIIIB has no cytoplasmic domain, its role in signal transduction requires further clarification. It may function through association with Fc?RII. [33] Cross-linking of these receptors by antibody leads to rapid engulfment of targets with release of granule contents and oxygen metabolites into the phagolysosome. In the event that the target is too large for ingestion, degranulation occurs against the antibody-coated surface. [34]

The complement receptors CR1 and CR3 are expressed on the surfaces of neutrophils, eosinophils, and basophils. Complement receptor 1 (CR1) is designated CD35 and is found on many cell types. It binds C3b and enhances its degradation to C3dg by factor I, thereby removing that molecule from further activation of the alternative pathway. [35] Complement receptor 3 (CR3, CD11b-CD18) binds iC3b and fibrinogen, as well as certain bacteria, parasites, and fungi. CR1 and CR3 are not able *per se* to stimulate phagocytosis, but in the presence of a second signal, such as one given through Fc?R or by cytokines, phagocytosis proceeds.

MECHANISMS OF KILLING

Neutrophil granules contain enzymes and proteins for killing ingested bacteria and fungi. Some of these bactericidal mechanisms are dependent on the generation of oxygen metabolites for microbicidal activity, but others are not. In addition to mobilizing its own resources, neutrophils produce a multitude of cytokines that stimulate and attract other phagocytes as well as lymphocytes. [36]

Oxygen-Independent Pathways

Bactericidal/permeability-increasing protein (BPI) is a highly potent antibacterial granule protein synthesized at the time of development of the primary granules in which it is stored. [37] BPI is a highly basic (pH > 9.6) protein of 452 amino acids and about 58 kDa. [38] Sequence homology to lipopolysaccharide-binding protein (LBP), a critical endotoxin-binding acute-phase reactant, [39] suggests that it acts by directly binding to LPS. BPI is cytotoxic to gram-negative bacteria at concentrations as low as 10^{-9} *M*, but it is much less effective against gram-positive organisms. Binding to lipopolysaccharide (LPS) leads to insertion of BPI into the outer membrane of the organism and eventual insertion into the inner membrane. Arrest of bacterial growth occurs by mechanisms not yet characterized but is solely dependent on the N-terminal half of the molecule. The C-terminal fragment serves as an anchor to the membrane. [38] BPI appears to exert its effect within the phagolysosome. Not all gram-negative rods are sensitive to BPI, especially *Burkholderia (Pseudomonas) cepacia* and *Serratia marcescens,* pathogens in patients who lack oxidative killing.

Defensins are small (<4 kDa) cationic proteins found in the primary granules of neutrophils involved in killing ingested gram-positive and gram-negative bacteria. [40] Defensins are synthesized during the promyelocyte-myelocyte stage as prepropeptides, stored predominantly in a dense subset of the primary neutrophil granules as propeptides, and released during neutrophil degranulation. [41] Defensins generally require an actively metabolizing target and are capable of killing transformed mammalian cells as well as prokaryotes and yeasts. Defensins and BPI act synergistically against gram-negative bacteria. As primary granule contents, defensins are present in reduced amounts in the Chediak-Higashi syndrome [42] but are absent in specific granule deficiency, indicating that defensin transcription is controlled by C/EBPe. [43]

Proteinase 3 (PR-3), the antigen against which the cANCA is directed in Wegener's granulomatosis, is found predominantly in primary granules but also in secondary and secretory granules. Synthesis and surface display are upregulated by cytokines such as TNF-a. [44] Elastase is another myeloid serine protease found in primary granules that has remarkable roles in host defense. On the one hand, mice with elastase defects have decreased resistance to gram-negative bacteria. [45] On the other hand, human neutrophil elastase deficiency is the cause of severe congenital neutropenia and cyclic neutropenia. [4] There are many forms of phospholipase A_2 (PLA_2) that are also found in neutrophil granules, where they act both directly and synergistically with BPI to kill intracellular bacteria. [46]

Lactoferrin is an iron-binding protein present in specific granules of neutrophils and in mucosal secretions. When released into the phagolysosome, lactoferrin binds iron and inhibits the growth of phagocytosed bacteria and some fungi. The mechanisms through which lactoferrin exerts its antimicrobial action probably include the depletion of iron from an organism's environment, but iron-binding–independent antimicrobial activities and direct immunomodulatory effects are also reported. [47] Lactoferrin is readily released into the circulation following burns and experimental endotoxemia, presumably from neutrophil degranulation. [48]

Oxygen-Dependent Pathways

An extremely potent microbicidal property of neutrophils is the ability to produce toxic oxygen metabolites through the assembly of the reduced nicotinamide dehydrogenase phosphate (NADPH)–oxidase complex. This enzyme complex catalyses the addition of an electron to molecular oxygen, leading to the formation of superoxide anion, which is converted to hydrogen peroxide by superoxide dismutase (see Fig. 29-1). In the presence of the primary granule component myeloperoxidase, hydrogen peroxide is combined with halogen (chloride in neutrophils) to form hypohalous acid (bleach). The NADPH oxidase is a multiprotein complex that in the basal state exists in separate membrane-bound and cytosolic compartments. On cell activation, the cytosolic components translocate to the membrane, resulting in an active NADPH oxidase (see Fig. 29-1) that yields the respiratory burst.

The genes required for mounting the respiratory burst have been cloned and sequenced and are named as members of the phagocyte oxidase complex (*phox*). Secondary granules contain cytochrome b_{558}, a heme- and flavin-binding protein heterodimer composed of a 91-kDa glycosylated beta chain ($gp91^{phox}$) and a 22-kDa alpha chain ($p22^{phox}$). The cytosolic compartment contains three factors, $p47^{phox}$, $p67^{phox}$, and the small guanine nucleotide (GTP)–binding protein Rac. Assembly of the NADPH complex is caused by diverse stimuli. $p47^{phox}$ and $p67^{phox}$ contain *src*-homology type 3 domains (SH3 boxes) that bind to proline-rich targets in themselves and other members of the NADPH complex. Stimulation leads to structural changes in $p47^{phox}$ that promote its interaction with $p22^{phox}$ through $p47^{phox}$ SH3 domains and $p22^{phox}$ C-terminal proline-rich sequences (see Fig. 29-1).

Pathologic mutations in the four required components destroy the generation of phagocyte superoxide and cause chronic granulomatous disease (CGD), a disease characterized by recurrent life-threatening infections with bacteria and fungi and exuberant granuloma formation. [49] The reported frequency is 1 in 200,000 persons, but the real frequency is likely higher. About 70 percent of cases are X-linked ($gp91^{phox}$), and the remainder are autosomal recessive mutations in the other three structural proteins. CGD is quite variable, ranging in time of presentation from infancy to late adulthood, with the majority of patients diagnosed as toddlers and young children. [50] Frequent sites of infection are skin, lung, lymph nodes, liver, bone, perianal region, and gingiva. The most common infectious agents in CGD are S. *aureus, B. cepacia, S. marcescens, Nocardia* sp., and *Aspergillus* sp. [49], [50] Granulomata in CGD originate from an improperly regulated inflammatory response to persistent infection or irritation (e.g., sutures, residual bacterial or fungal antigens). The fact that these inflammatory responses are abnormally exuberant in the absence of superoxide production indicates the critical role that superoxide and its metabolites play in resolution of inflammation through degradation of leukotrienes, complement, and other chemotactic factors. [51]

Interferon-? (IFN-?) is a potent T lymphocyte cytokine that acts on myeloid cells and enhances host defense activity in patients with CGD through mechanisms as yet unknown but independent of superoxide formation. [52] Homologous recombinant knockout animals have been made for the $gp91^{phox}$ and $p47^{phox}$ genes (reviewed in Ref. [49]). These animals display no superoxide production and are highly susceptible to agents similar to those found in human CGD patients. The $p47^{phox}$ knockout has a phenotype like human CGD, with spontaneous infections, granulomatous inflammation, abnormally exuberant inflammatory reactions, and reduction in infections seen with prophylactic IFN-?. [53]

PHARMACOLOGIC MODULATION

As neutrophils are overrecruited to tissues in neutrophilic dermatoses, they produce reactive oxygen intermediates, activate proteinases, and release chemotactic cytokines, all of which contribute to further tissue injury and inflammation. Therefore, the development of treatments to inhibit neutrophil adhesion and chemotaxis, suppress generation of or damage by reactive oxygen intermediates, and suppress the release of lysosomal enzymes and chemotactic factors is a high priority.

Dapsone is often used for chronic neutrophilic dermatoses such as subcorneal pustular dermatosis or erythema elevatum diutinum. Dapsone is thought to suppress neutrophil adherence and subsequent migration, scavenge reactive oxygen intermediates, and interfere with the myeloperoxidase-halide system. Thalidomide augments CD8+ lymphocyte activity and interferes with the stability of TNF-a mRNA. Colchicine inhibits neutrophil chemotaxis, presumably through the inhibition of microfilament formation that may have effects on the release of lysosomal enzymes, and the production of oxygen intermediates. Antibiotics such as tetracyclines, macrolides, and metronidazole also have putative antioxidant properties and may interfere with neutrophil chemotaxis. Sulfasalazine induces neutrophil apoptosis and enhances adenosine release at sites of inflammation.

REFERENCES

1. Athens JW et al: Leukokinetic studies: IV. The total blood, circulating and the granulocyte turnover rate in normal subjects. *J Clin Invest* **40**:989, 1961

2. Lieschke GJ et al: Mice lacking granulocyte colony-stimulating factor have chronic neutropenia, granulocyte and macrophage progenitor cell deficiency, and impaired neutrophil mobilization. *Blood* **84**:1737, 1994

3. Dong F et al: Mutations in the gene for the granulocyte colony-stimulating factor receptor in patients with acute myeloid leukemia preceded by severe congenital neutropenia. *N Engl J Med* **333**:487, 1995

4. Aprikyan AA, Dale DC: Mutations in the neutrophil elastase gene in cyclic and congenital neutropenia. *Curr Opin Immunol* **13**:535, 2001

5. Van den Steen PE et al: Neutrophil gelatinase B potentiates interleukin-8 tenfold by aminoterminal processing, whereas it degrades CTAP-III, PF-4, and GRO-alpha and leaves RANTES and MCP-2 intact. *Blood* **96**:2673, 2000

6. Bainton DF: Sequential degranulation of the two types of polymorphonuclear leukocyte granules during phagocytosis of microorganisms. *J Cell Biol* **58**:249, 1973

7. Borregaard N, Cowland JB: Granules of the human neutrophilic polymorphonuclear leukocyte. *Blood* **89**:3503, 1997

8. Lekstrom-Himes JA et al: Neutrophil-specific granule deficiency results from a novel mutation with loss of function of the transcription factor CCAAT/enhancer binding protein epsilon. *J. Exp Med* **189**:1847, 1999

9. Davis JM et al: Neutrophil degranulation and abnormal chemotaxis after thermal injury. *J Immunol* **124**:1467, 1980

10. Zigmond SH: Ability of polymorphonuclear leukocytes to orient in gradients of chemotactic factors. *J Cell Biol* **75**:606, 1977

11. Broaddus VC et al: Neutralization of IL-8 inhibits neutrophil influx in a rabbit model of endotoxin-induced pleurisy. *J Immunol* **152**:2960,

1994

12. Sekido N et al: Prevention of lung reperfusion injury in rabbits by a monoclonal antibody against interleukin-8. *Nature* **365**:654, 1993

13. Kuhns DB, Gallin JI: Increased cell-associated IL-8 in human exudative and A23187-treated peripheral blood neutrophils. *J Immunol* **154**:6556, 1995

14. Hensley CD, Caughman SW: Neutrophilic dermatoses associated with hematologic disorders. *Clin Dermatol* **18**:355, 2000

15. Hall A: Rho GTPases and the actin cytoskeleton. *Science* **279**:509, 1998

16. Hirsch E et al: Central role for G protein-coupled phosphoinositide 3-kinase gamma in inflammation. *Science* **287**:1049, 2000

17. Ward RA et al: Priming of the neutrophil respiratory burst involves p38 mitogen-activated protein kinase-dependent exocytosis of flavocytochrome b_{558}–containing granules. *J Biol Chem* **275**:36713, 2000

18. Capodici C et al: Phosphatidylinositol 3-kinase mediates chemoattractant-stimulated, CD11b/CD18-dependent cell-cell adhesion of human neutrophils: Evidence for an ERK-independent pathway. *J Immunol* **160**:1901, 1998

19. Baggiolini M, Moser B: Blocking chemokine receptors. *J Exp Med* **186**: 1189, 1997

20. Cooper D et al: Transendothelial migration of neutrophils involves integrin-associated protein (CD47). *Proc Natl Acad Sci U S A* **92**:3978, 1995

21. Walcheck B et al: Neutrophil rolling altered by inhibition of L-selectin shedding in vitro. *Nature* **380**:720, 1996

22. von Andrian UH et al: In vivo behavior of neutrophils from two patients with distinct inherited leukocyte adhesion deficiency syndromes. *J Clin Invest* **91**:2893, 1993

23. Anderson DC, Springer TA: Leukocyte adhesion deficiency: An inherited defect in the Mac-1, LFA-1, and p150,95 glycoproteins. *Annu Rev Med* **38**:175, 1987

24. McEver RP: Selectins. *Curr Opin Immunol* **6**:75, 1994

25. Frohlich D et al: The Fc? receptor–mediated respiratory burst of rolling neutrophils to cytokine-activated, immune complex–bearing endothelial cells depends on L-selectin but not on E-selectin. *Blood* **91**:2558, 1998

26. Lubke T et al: Complementation cloning identifies CDG-IIc, a new type of congenital disorders of glycosylation, as a GDP-fucose transporter deficiency. *Nature Genet* **28**:73, 2001

27. Etzioni A, Tonetti M: Leukocyte adhesion deficiency II-from A to almost Z. *Immunol Rev* **178**:138, 2000

28. Etzioni A, Tonetti M: Fucose supplementation in leukocyte adhesion deficiency type II. *Blood* **95**:3641, 2000

29. Hogg JC, Doerschuk CM: Leukocyte traffic in the lung. *Annu Rev Physiol* **57**:97, 1995

30. Mizgerd JP et al: Neutrophil emigration in the skin, lungs, and peritoneum: Different requirements for CD11/CD18 revealed by CD 18-deficient mice. *J Exp Med* **186**:1357, 1997

31. Conlan JW, North RJ: *Listeria monocytogenes,* but not *Salmonella typhimurium,* elicits a CD18-independent mechanism of neutrophil extravasation into the murine peritoneal cavity. *Infect Immun* **62**:2702, 1994

32. Kurlander RJ, Batker J: The binding of human immunoglobulin G_1 monomer and small, covalently cross-linked polymers of immunoglobulin G_1 to human peripheral blood monocytes and polymorphonuclear leukocytes. *J Clin Invest* **69**:1, 1982

33. Boros P et al: IgM anti-Fc?R autoantibodies trigger neutrophil degranulation. *J Exp Med* **173**:1473, 1991

34. Johnston RB Jr et al: Generation of superoxide anion and chemiluminescence by human monocytes during phagocytosis and on contact with surface-bound immunoglobulin G. *J Exp Med* **143**:1551, 1976

35. Medof ME et al: Unique role of the complement receptor CR1 in the degradation of C3b associated with immune complexes. *J Exp Med* **156**:1739, 1982

36. Cassatella MA: The production of cytokines by polymorphonuclear neutrophils. *Immunol Today* **16**:21, 1995

37. Elsbach P et al: Integration of antimicrobial host defenses: Role of the bactericidal/permeability-increasing protein. *Trends Microbiol* **2**:324, 1994

38. Ooi CE et al: A 25-kDa NH_2-terminal fragment carries all the antibacterial activities of the human neutrophil 60-kDa bactericidal/permeability-increasing protein. *J Biol Chem* **262**:14891, 1987

39. Schumann RR et al: Structure and function of lipopolysaccharide-binding protein. *Science* **249**:1429, 1990

40. Lehrer RI et al: Defensins: Endogenous antibiotic peptides of animal cells. *Cell* **64**:229, 1991

41. Rice WG et al: Defensin-rich dense granules of human neutrophils. *Blood* **70**:757, 1987

42. Ganz T et al: Microbicidal/cytotoxic proteins of neutrophils are deficient in two disorders: Chediak-Higashi syndrome and “specific” granule deficiency. *J Clin Invest* **82**:552, 1988

43. Gallin JI et al: Human neutrophil-specific granule deficiency: A model to assess the role of neutrophil-specific granules in the evolution of the inflammatory response. *Blood* **59**:1317, 1982

44. Witko-Sarsat V et al: Presence of proteinase 3 in secretory vesicles: Evidence of a novel, highly mobilizable intracellular pool distinct from azurophil granules. *Blood* **94**:2487, 1999

45. Belaaouaj A et al: Mice lacking neutrophil elastase reveal impaired host defense against gram-negative bacterial sepsis. *Nature Med* **4**:615,

1998

46. Degousee N et al: Groups IV, V and X phospholipases A_2 in human neutrophils: Role in eicosanoid production and gram-negative bacterial phospholipid hydrolysis. *J Biol Chem* **6**:6, 2001

47. Brock J: Lactoferrin: A multifunctional immunoregulatory protein? *Immunol Today* **16**:417, 1995

48. Kuhns DB et al: Increased circulating cytokines, cytokine antagonists, and E-selectin after intravenous administration of endotoxin in humans. *J Infect Dis* **171**:145, 1995

49. Segal BH et al: Genetic, biochemical, and clinical features of chronic granulomatous disease. *Medicine* **79**:170, 2000

50. Winkelstein JA et al: Chronic granulomatous disease: Report on a national registry of 368 patients. *Medicine* **79**:155, 2000

51. Segal B et al: Leukotrienes, the NADPH oxidase, and complement are critical regulators of thioglycollate peritonitis in mice. *J Leukocyte Biol* **71**:410, 2002

52. A controlled trial of interferon gamma to prevent infection in chronic granulomatous disease. The international Chronic Granulomatous Disease Cooperative Study Group. *N Engl J Med* **324**:509, 1991

53. Jackson SH et al: IFN-? is effective in reducing infections in the mouse model of chronic granulomatous disease (CGD). *J Interferon Cytokine Res* **21**:567, 2001

54. Bainton D: Developmental biology of neutrophils and eosinophils. In *Inflammation: Basic Principles and Clinical Correlates,* edited by Gallin JI, Snyderman R, Philadelphia, Lippincott-Raven, 1998.

T>

Chapter 30

Adrienne Rencic Lisa Beck

Regulation of the Production and Activation of Eosinophils

BONE MARROW PRODUCTION AND TISSUE DISTRIBUTION
Eosinophil Ultrastructure and Surface Receptors
Surface Receptors
ACTIVATION
INFLAMMATORY MEDIATORS AND POTENTIAL PHYSIOLOGIC EFFECTS
TRAFFICKING OF EOSINOPHILS INTO TISSUES
Eosinophil-Activating Cytokines
Endothelial-Activating Cytokines and Chemokines
THERAPEUTIC STRATEGIES

REFERENCES

Eosinophils are bone marrow-derived cells that normally account for 1 to 3 percent of peripheral blood leukocytes or less than 350 cells per cubic millimeter of blood. As proinflammatory cells, their presence within tissue sites is usually associated with diseased states. In general, the diseased states can be divided into parasitic infections, atopic diseases, reactive eosinophilias, and idiopathic eosinophilic syndromes. This chapter reviews the biologic actions of eosinophils with particular focus on what controls eosinophil production, activation, and tissue trafficking. It ends with a review of the mechanisms of several antieosinophilic treatment strategies with particular attention paid to their theoretical mode of action.

BONE MARROW PRODUCTION AND TISSUE DISTRIBUTION

Eosinophils are derived from a common myeloid progenitor known as the colony-forming unit-granulocyte/erythroid/macrophage/megakaryocyte (CFU-GEMM), which is a pluripotent stem cell that also gives rise to red blood cells, platelets, monocytes, neutrophils, and basophils. It is hypothesized that cytokines generated at sites of inflammation act in a paracrine fashion on stromal cells in the bone marrow microenvironment to differentiate CFU-GEMMs into more cell-specific progenitors. In the case of eosinophil production, this is thought to be the eosinophil/basophil-CFU (Eo/B-CFU). This hybrid cell, which has been found in the circulation of patients with atopic dermatitis, is characterized by granule contents that have features of both cell types as well as by the expression of the interleukin (IL)-5 receptor and the chemokine receptor CCR3. [1] Eo/B-CFUs have been found in inflamed tissues of patients with allergic diseases. Because these tissues also produce many of the hematopoietic cytokines, it has been proposed that some hematopoiesis may occur within sites of inflammation in addition to the bone marrow. [2]

The cytokines important in the development of eosinophilia from these bone marrow progenitors have been extensively studied in mouse models. These studies demonstrate the primary importance of the hematopoietic cytokine, IL-5, and the CCR3 ligand, eotaxin. For example, IL-5 transgenic mice develop peripheral blood and tissue eosinophilia, whereas experiments with neutralizing anti-IL-5 antibodies in wild-type mice lead to a significant reduction in baseline levels of circulating eosinophils and diminished eosinophilia in response to infection with various parasites or challenge with allergen. [3], [4] Despite the massive eosinophilia in IL-5 transgenic mice, these mice do not develop the tissue damage observed in eosinophilic diseases, probably because eosinophils must also be activated to degranulate and/or release their inflammatory mediators. The chemokine eotaxin has been thought to act as both a granulocyte-macrophage colony-stimulating factor by increasing myeloid progenitors in general and, more specifically, as a facilitator of emigration of Eo/B-CFU progenitors and mature eosinophils from the bone marrow compartment into the systemic circulation. [5] Mice deficient in both eotaxin and IL-5 have the greatest reduction in tissue eosinophils in experimental models of asthma. [6]

With the development of antibodies specific for eosinophil granule major basic protein (MBP), it has become possible to screen both diseased and normal human tissues for the presence of degranulated eosinophils as well as intact eosinophils. These studies demonstrate that eosinophils are a significant component of the inflammatory infiltrate in several cutaneous diseases such as urticaria and atopic dermatitis (AD), which contains few intact eosinophils but extensive MBP-staining of the dermal collagen fibers. Furthermore, in samples of normal tissue, eosinophils are resident cells in lymph nodes, thymus, and spleen where they are largely intact. [7] This finding supports the notion that eosinophils predominantly reside in the tissues, much like mast cells and basophils. Similarly, eosinophils are present in the lamina propria of the stomach and intestines in healthy individuals, but appreciable degranulation is observed at these sites. It is surmised from this constitutive tissue localization that eosinophils probably play a role in innate immunity. [8]

Eosinophil Ultrastructure and Surface Receptors

ULTRASTRUCTURE The eosinophil is easily identifiable by light microscopy by virtue of its basic granules, which have a high affinity for acidic dyes such as eosin, Giemsa, and fluorescein derivatives such as FITC (fluorescein isothiocyanate), and typically stain with a distinctive tinctorial property (Fig. 30-1A). [9] The availability of fluorescent-labeled eosinophil granule-specific antibodies has made it possible to demonstrate degranulated eosinophils as well (Fig. 30-1B). Eosinophils typically contain a bilobed nucleus; however, their distinguishing feature is the distinctive cytoplasmic granules. By electron microscopy these so-called specific or secondary granules consist of two compartments, the outer matrix and the inner electron-dense crystalline core (Fig. 30-1C). Four highly basic proteins are found within these granules: MBP, eosinophil cationic protein (ECP), eosinophil-derived neurotoxin (EDN), and eosinophil peroxidase (EPO).

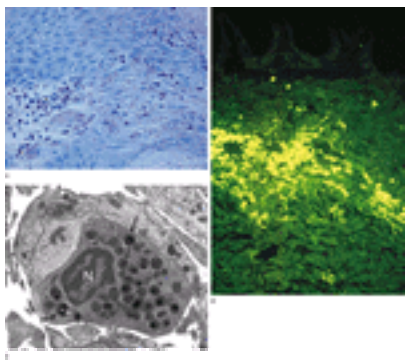

FIGURE 30-1 Eosinophil morphology. *A.* Giemsa-stained section of skin from a patient with idiopathic hypereosinophilic syndrome. Eosinophils stain a bright red color. In the reproduction, the color is pink/purple. There are both intact eosinophils and free cytoplasmic granules within the dermis (×400 magnification). *B.* FITC-conjugated anti-MBP staining of a human skin biopsy specimen from a regulated on activation, normal T cell expressed and secreted (RANTES)-challenged site. Both intact and degranulated eosinophils are present. This technique is probably the most sensitive one for identification of tissue eosinophil (×160 magnification). *C.* Representative electron micrograph of a tissue eosinophil illustrating the secondary or specific granules that contain the eosinophil basic proteins: MBP, ECP, EDN, and ECP (*arrows*). In one of the granules, the electron-dense core (c) and lucent matrix (m) are labeled. N, nucleus.

MBP is the most abundant of the granule proteins (786 mg/10 [6] eosinophils). [10] It is the only one of the four basic proteins located in the core of the secondary granule. ECP is present in the matrix of the granules and is 10 times less abundant than MBP. EDN is also located in the matrix and is much less abundant than either MBP or ECP. EPO is the least abundant of these four proteins and is also located in the matrix. EPO is the granule protein most specific for eosinophils because MBP is found in basophils, neutrophils, and placental X cells; ECP is found in basophils, neutrophils, and monocytes; and EDN is found in neutrophils and basophils. Other proteins found in the secondary granules include enzymes, cytokines, growth factors, and chemokines. Other cytoplasmic granules are relatively nonspecific and consist of unicompartmental primary granules, lipid bodies, small granules, vesicles, and elongated tubules. The Charcot-Leyden crystal protein (CLC-P), also known as galectin-10, is found in primary granules. It was first described in the postmortem blood and spleen of a leukemia patient, in 1853, by Charcot and Robin, and later, in 1872, by Leyden in the sputum of patients with asthma. Although its role in eosinophil function is unclear, its distinctive hexagonal bipyramidal crystals tend to be found at sites of eosinophil infiltration and degranulation. It was once thought to possess lysophospholipase activity but has more recently been found to bind to lysophospholipases. [11] Although once considered to be an exclusive marker of eosinophilia, CLC-P has been identified in basophils as well. Lipid bodies and small granules increase in number in response to eosinophil activation. Recent work suggests that lipid bodies may be the site of eicosanoid production and cytokine storage. Small granules are probably analogous to lysosomes in other cell types. Rough endoplasmic reticulum and Golgi structures are present but are not prominent in mature eosinophils. [12]

Surface Receptors

Multiple receptors are present on the surface of eosinophils, but no single surface protein is uniquely expressed. These receptors have been identified either by flow cytometry or by functional assays, and can be grouped as follows: chemotactic factor receptors (chemokine, complement, and others); immunoglobulin and other immunoglobulin supergene family (IgSF) members; cytokine receptors; adhesion molecule receptors; and receptors involved in apoptosis [13] (Table 30-1).



TABLE 30-1 **Receptors on Eosinophils**

CHEMOTACTIC FACTOR RECEPTORS Chemotactic factors are thought to be important in orchestrating cellular trafficking to sites of inflammation as well as physiologic homing (e.g., gastrointestinal tract). Many chemotactic agents [leukotrienes (LTB_4), platelet-activating factor (PAF), bacterial products (fMLP), and complement components (C5a)] have potent effects on eosinophils but are nonselective. In as much as many eosinophilic diseases are characterized by tissue eosinophilia with little to no neutrophilia, the identification of more selective chemotaxins such as LTD_4, LTE_4, C3a, and C-C chemokines was an important breakthrough. Specific members of the chemokines or chemotactic cytokines family are thought to be essential for the cellular trafficking of eosinophils. Chemokines are a family of 8- to 15-kDa proteins that can be subdivided into four structural subfamilies based on the number and location of conserved cysteine residues in their primary sequence: CC, CXC, C, and CX3C (see Chap. 27). [14] The biologic effects of chemokines are mediated through specific, high-affinity chemokine receptors, which are typically selective for unique but

overlapping subsets of chemokines. The binding of chemokines to their respective receptors on the eosinophil mediates many biologic effects in addition to cell shape change and migration, such as cell activation, receptor internalization, induction of the respiratory burst, and transient activation of integrin adhesiveness (see " Trafficking of Eosinophils into Tissues," below). The chemokine receptor CCR3 and its major ligands [eotaxin 1–3, monocyte chemoattractant protein (MCP)-4, and regulated on activation, normal T cell expressed and secreted (RANTES)] play a critical role in both the homeostatic and inflammation-induced recruitment of eosinophils to tissue sites. [11] The most highly expressed CCR present on human eosinophils is CCR3, with occasional individuals expressing modest levels of CCR1. Although there appears to be some variability in the expression of the major chemokine receptors CCR3 and CCR1 on eosinophils from different donors, our work and that of others suggest that this finding cannot be explained by in vitro priming, and expression levels of allergic and nonallergic donors do not differ. Under the influence of various stimuli in vitro, eosinophils express other chemokine receptors, such as CXCR2 through 4, and it is implied that they express CCR6 because they migrate in response to its ligand, macrophage inflammatory protein (MIP)-3a. [15], [16]

IMMUNOGLOBULIN RECEPTORS AND MEMBERS OF THE IMMUNOGLOBULIN SUPERGENE FAMILY In the immunoglobulin family the receptor most highly expressed on eosinophils is Fc?R11 (CD32), which binds aggregated IgG, particularly of the subclasses IgG_3 and IgG_1. The binding of IgG to this receptor can alter eosinophil survival. There is conflicting evidence concerning the presence of the high affinity IgE receptor FceR1 on the surface of eosinophils. [17] The intracellular a chain may account for the immunohistochemical findings suggesting that eosinophils express FceR1. FcaRI (CD89), the IgA receptor, is present on the surface of eosinophils. [18] The binding of IgA-opsonized particles to this receptor triggers a variety of immune effector functions. This finding and the fact that there are many eosinophils in the lamina propria of the stomach and intestines suggest that eosinophils play an important role in mucosal immunity. Members of the IgSF are type I transmembrane molecules that share common structural characteristics of the globular domains in immunoglobulins. Intracellular adhesion molecule (ICAM)-1 (CD54) and ICAM-3 (CD50) are expressed on eosinophils and are thought to be important in leukocyte–leukocyte and leukocyte–tissue cell adhesion using leukocyte function-associated antigen (LFA)-1($aLß_2$; CD11a) as its counterligand. CD4 is present at low levels on the surface of eosinophils and binds HIV. [19] Lastly, like all leukocytes, eosinophils express HLA-class I and on activation express HLA-DR (class II).

CYTOKINE RECEPTORS Cytokine receptors are present at low levels on the surface of eosinophils. Receptors for IL-3 (CD123), IL-5 (CD125), and granulocyte-macrophage colony-stimulating factor (GM-CSF) (CD116) are most readily detectable, and all share a common ß chain (CD132). Eosinophil activation by a variety of other cytokines has been identified despite the fact that their receptors are not readily detected by flow cytometry. These include stem cell factor (*c-kit* receptor; CD117), interferon (IFN)-? (CD119), tumor necrosis factor (TNF)-a (CD120), IL-4 (CD124), IL-9 (CD129 and CD132), IL-13ß receptor (gp65), IL-2 (CD25), and transforming growth factor (TGF)-ß receptors.

ADHESION MOLECULE RECEPTORS Adhesion molecule receptors are expressed on the eosinophil cell surface to mediate trafficking to tissues and within tissues, and for general cell–cell interactions. These receptors fall into three groups: IgSF, selectins and their glycoprotein counterligands, and integrins. L-selectin (CD62L) and P-selectin glycoprotein ligand-1 (PSGL-1, CD162) are expressed at high levels, whereas E-selectin ligands [e.g., sialyl-Lewis X (CD15s)] are expressed at very low levels. P selectin and PSGL-1 are the most important selectin pair in eosinophil migration into tissues. [20] Eosinophils express a variety of integrins on their surface, which facilitate their adhesion to the extracellular matrix proteins vascular cell adhesion molecule (VCAM)-1 (CD106) on activated endothelium or ICAM-1 on resting or activated epithelium and activated endothelium. Eosinophils express $ß_1$, $ß_2$, and $ß_7$ integrins. Integrins are composed of two subunits that exist as noncovalently associated heterodimers, with an a and a ß subunit. The $ß_1$ integrins expressed on eosinophils include $a_4ß_1$ (VLA-4), which binds to both VCAM-1 on activated endothelium and an alternatively spliced form of fibronectin. Eosinophil adhesion to fibronectin induces the autocrine production of eosinophil survival cytokines (IL-3, IL-5, and GM-CSF). The other $ß_1$ integrin expressed on eosinophils is $a_6ß_1$, which binds laminin. [21] Four $ß_2$ integrins are found on eosinophils: $aLß_2$ (LFA-1), $aMß_2$ (Mac-1), $aXß_2$, and $aDß_2$. These integrins bind to ICAM-1, -2, and -3; VCAM-1; fibrinogen; and the complement fragment C3bi. Lastly, eosinophils also express $a_4ß_7$, the ligand for the gut mucosal addressin cell adhesion molecule-1 (MAdCAM-1), which is thought to be important in homing of eosinophils to intestinal mucosa. [11] $a_4ß_7$ also mediates adhesion to fibronectin and VCAM-1.

RECEPTORS INVOLVED IN APOPTOSIS Apoptosis plays an important role in many biologic processes. Diseases characterized by eosinophilia are thought to result in part from a delayed or defective apoptotic pathway in eosinophils. Eosinophils have at least two cell surface receptors, CD95 (fas) and CD69, that induce apoptosis on activation. [22] In contrast, CD9, and receptors for IL-3, IL-5, GM-CSF, and IFN-? are involved in eosinophil survival.

ACTIVATION

Various inflammatory mediators, including cytokines (TNF-a, GM-CSF, IL-3, and -5, and IFN-?), complement components (C3a and C5a), lipid mediators (LTC_4 and PAF), engagement of IgA and IgG Fc receptors, and chemokines, activate eosinophils. Several members of the CC chemokine subfamily (eotaxin, eotaxin-2, RANTES, and MCP-2 to -4) are potent activators of eosinophils as demonstrated by actin polymerization/chemotaxis, respiratory burst, and production of reactive oxygen species. [14] Eosinophils activated in vitro or in vivo develop phenotypic changes that include a reduction in the number of granules, vacuolization, and an expansion of their cytoplasm, leading to a decrease in cell density. They are referred to as hypodense, in contrast to normal-density eosinophils (normodense). The number of hypodense cells has been correlated with allergic disease severity, and it is believed that this finding primarily reflects in vivo exposure to eosinophil survival cytokines (see above). A cell surface arker that can distinguish hypodense from normodense eosinophils has not been identified. There are, however, several surface markers with enhanced expression on in vitro or in vivo activated or hypodense cells: aM integrin (CD11b), aX integrin (CD11c), Fc?R111 (CD16), hyaluronic acid receptor (CD44), ICAM-1 (CD54), CD69, and HLA-DR. [23]

INFLAMMATORY MEDIATORS AND POTENTIAL PHYSIOLOGIC EFFECTS

Eosinophils contain many substances that mediate inflammation, [10] including the four cationic granule proteins, arachidonic acid–derived lipids, hydrolytic enzymes, neuropeptides, reactive oxygen species, and cytokines/chemokines. MBP serves a variety of toxic functions. It is an antihelminthic toxin, bactericidal, and cytotoxic. It causes histamine

release from basophils and rat mast cells and activates neutrophils to release IL-8. [24] It is thought to have procoagulant activity because it neutralizes heparin, likely through its inactivation of thrombomodulin, and it is a strong platelet agonist. [25] ECP has activities similar to those of MBP. Some of its other functions include potent neurotoxicity, weak RNase activity, and the ability to alter fibrinolysis. EDN is also a potent neurotoxin, with RNase activity and antihelminthic activity. EPO in the presence of hydrogen peroxide and halide kills microorganisms and tumor cells. It causes histamine release and degranulation from rat mast cells. The activities of these granule proteins are likely responsible for some of the signs and symptoms of eosinophilic skin diseases (see Chap. 96).

All four of the cationic granule proteins likely contribute to the edema in many eosinophilic diseases in that they induce the release of histamine from mast cells and basophils. MBP injected into the skin of humans causes a dose-dependent wheal-and-flare response. NERDS (nodules, eosinophilia, rheumatism, dermatitis, and swelling), bullous pemphigoid, herpes gestationis, episodic angioedema with eosinophilia, urticaria, Well's syndrome (eosinophilic cellulitis), and even insect bite reactions have various degrees of edema. [26]

Membrane damage and muscle contraction can be a direct result of toxic granules. The application of MBP, ECP, or EPO to airway epithelium in primates produces ciliostasis, desquamation, and hyperreactivity of respiratory smooth muscle. MBP and ECP damage parasite membranes. In idiopathic hypereosinophilic syndrome (IHES), the damage to the endothelium is thought to be the initiating factor in the cardiomyopathy in these patients. Pulmonary disease in IHES and Churg-Strauss syndrome is initially characterized by airway hyperreactivity.

Thrombosis has been noted in IHES, and several cases of hepatic vein obstruction (Budd-Chiari syndrome) have been reported. The etiology of this thrombosis is not completely clear. It could be the result of direct endothelial damage or of the procoagulant activity of MBP and ECP. MBP and ECP neutralize heparin, and MBP is a strong platelet agonist. PAF is an additional eosinophil-derived inflammatory mediator that could potentiate this effect by inducing platelet aggregation.

The lipid mediators released by eosinophils are primarily arachidonic acid metabolites. LTC_4 is the only leukotriene produced intracellularly by eosinophils. LTC_4 and its metabolites, LTD_4 and LTE_4, are called cysteinyl leukotrienes and were previously referred to as the slow-reacting substances of anaphylaxis (SRS-A). These molecules cause bronchoconstriction, increased airway reactivity, increased mucus secretion, hypotension, and increased vascular permeability. The cysteinyl leukotrienes and PAF are likely major mediators of asthma. The predominant lipid mediator produced in eosinophils via the cyclooxygenase pathway is thromboxane B_2, but this and the other mediators produced through this pathway are minor when compared to those produced by the lipoxygenase pathway.

Many hydrolytic enzymes have been identified in human eosinophils, but their role in disease remains largely speculative. Arylsulfatase B, ß-glucuronidase, acid phosphatase, catalase, 5-lipoxygenase, phospholipase A_2 (PLA_2), and histaminase are present in eosinophil small granules. Eosinophils stimulated with IL-5 or PAF release matrix metalloproteinase-9, which is thought to be important in migration through the basement membrane. [27] Collagenase, which degrades type I and type III collagen, may play a role in tissue remodeling during wound healing.

The reactive oxygen species that are important in tissue injury and are induced by eosinophils include superoxide and hydrogen peroxide. They are produced by NADPH oxidase during the respiratory burst initiated on eosinophil activation. Hydrogen peroxide can generate cytotoxic hypohalous acids through the action of EPO. Reactive oxygen species can also propagate the inflammatory response by inducing gene expression and T cell proliferation. [28]

Eosinophils from both healthy and diseased individuals produce several neuro-active mediators, including vasoactive intestinal peptide (VIP) and substance P. This fact, and the fact that eosinophils (both intact and degranulated) are often observed in close approximation to nerve endings, suggest some crosstalk. Eosinophil-induced nerve dysfunction is thought to be responsible for the gastric dysmotility that occurs in patients with food allergies or the dysfunction of vagal muscarinic M2 receptors in patients with asthma. [29]

A variety of cytokines and chemokines are produced by eosinophils: TGF-a, TGF-ß, nerve growth factor (NGF), platelet-derived growth factor (PDGF)-ß, TNF-a, IL-1a, IL-2 thru -6, IL-10, IL-12, IL-16, GM-CSF, IL-8, MIP-1a, lymphocyte chemoattractant factor (LCF), eotaxin, and RANTES. [30]

The release of TGF-a and TGF-ß from eosinophils and the ability of eosinophil mediators to induce platelet release of TGF-ß lead to fibroblast proliferation and extracellular matrix production. Other eosinophilic mediators may contribute to altered fibrinolysis including ECP, MMP-9, and collagenase. The clinical correlate to this is the fibrosis in the lungs and the heart of patients with IHES. Additionally, this may contribute to the fibrosis in Schulman's syndrome (eosinophilic fasciitis), eosinophilia myalgia syndrome, and toxic oil syndrome.

Eosinophils have other physiologic functions related to their ability to secrete chemokines and cytokines. Chemoattractants, colony-stimulating factors, and endothelial-activating cytokines released by eosinophils lead to augmentation of cellular infiltrates. Moreover, eosinophils may be able to act as antigen-presenting cells. [31] They express CD4, the IL-2 receptor (CD25), and HLA-DR (MHC class II) on their cell surface.

Eosinophils have been found in a variety of cancers, particularly in lymphomas, leukemias, and colon cancer. They are thought to confer a poor prognosis in several tumors such as nodular sclerosing Hodgkin's disease, Sézary syndrome, and gastric carcinoma. [32] One possible explanation is that the tumor cells produce IL-5, thereby inducing eosinophil production, and such production reflects the tumor burden. Clinical studies have also suggested that tumors associated with tissue and/or peripheral eosinophilia may have a more favorable prognosis. [33] The specific nature of eosinophil-dependent antitumor activity has not been sufficiently explored, but it might include direct cytotoxic effects on tumor cells by eosinophil cationic proteins, antigen presentation, vascular compromise via microthrombi formation

(secondary to release of heparinases and PAF), or enhancement/synergism with the antitumor response of other leukocytes (e.g., superoxide and nitric oxide generation). [34], [35]

We and others have observed similar eosinophil accumulation and activation in biopsies from postvaccination tumor delayed hypersensitivity responses in humans after autologous GM-CSF gene-transduced renal cell carcinoma and melanoma cell trials. [36], [37] One patient undergoing treatment for renal cell carcinoma developed objective evidence of tumor regression as noted by chest CT. At approximately the same time, this patient developed an unusually large area (80 × 80 mm) of erythema and induration at a tumor skin test site, which was characterized by an intense infiltration of eosinophils with prominent degranulation as measured by extracellular MBP staining. [37]

TRAFFICKING OF EOSINOPHILS INTO TISSUES

The selective recruitment of eosinophils into sites of inflammation is largely a function of eosinophil-activating cytokines, endothelial-activating cytokines, and chemokines.

Eosinophil-Activating Cytokines

The eosinophil-activating cytokines (IL-3, IL-5, and GM-CSF) enhance eosinophil survival, maturation, chemotactic responses, and leukotriene production. IL-5 is most specific for eosinophils, whereas the others have similar effects on other leukocytes. For example, eosinophils from patients with atopic dermatitis have increased migratory responses in vitro to several common chemotaxins (N-fMLP, IL-4, and PAF) in comparison to eosinophils from normal individuals, suggesting that they were exposed to one of these activating cytokines in vivo. [38] In fact, IL-5 treatment of eosinophils from normal donors induced the migratory responses seen with eosinophils from patients with atopic dermatitis. Similarly, we have observed that the kinetics of eosinophil recruitment in response to intradermal challenge with RANTES are profoundly faster in allergic individuals. [39] Eosinophils from patients with atopic dermatitis demonstrate prolonged survival ex vivo when compared to eosinophils from normal controls, providing further evidence that they have been primed in vivo by activating cytokines like IL-5. [40] Although eosinophil-activating cytokines can be produced by many cell types (keratinocytes, endothelial cells, monocytes, and T cells), eosinophils themselves may be a major source, and thus there may be an autocrine feedback loop. [40] The local reactions observed in response to GM-CSF administered subcutaneously as an adjunct to chemotherapy demonstrate both intact and degranulated eosinophils, suggesting that eosinophil activation by GM-CSF coupled with cutaneous trauma may be sufficient to induce tissue recruitment. [41]

Endothelial-Activating Cytokines and Chemokines

The regulation of endothelial adhesion molecules important in cell migration is discussed in Chap. 27. The initial step of eosinophil recruitment involves rolling on endothelial selectins (and perhaps the L-selectin counterligand or VCAM-1). This step is followed by a firm adhesion, or “tethering” of the eosinophil. Recent in vitro studies show that tethering or firm adhesion of eosinophils to VCAM-1 or ICAM-1 is a process that is substantially increased by eotaxin, MCP-3, and RANTES. [42] This is thought to be mediated by transient effects of chemokines on ß $_1$ and ß $_2$ integrin avidity. Thus, the transition of an eosinophil from a rolling cell to a firmly adherent one is likely to be facilitated, if not primarily mediated, by chemokines on the endothelial surface. Chemokines produced by structural cells such as fibroblasts, smooth muscle cells, and epithelium are probably important in directing migration and activation of eosinophils in tissues.

THERAPEUTIC STRATEGIES

Although many available therapies (glucocorticoids, myelosuppressive drugs, IFN-a, IFN-?, leukotriene antagonists, and possibly even antihistamines) inhibit eosinophilic inflammation, none is specific for eosinophils. Glucocorticoids are the most effective. They are thought to affect tissue eosinophil infiltration by three mechanisms: induction of eosinophil apoptosis, reduction of eosinophil production by bone marrow, and inhibition of the cytokines and chemokines important in eosinophil trafficking. [43] Steroids suppress the production of several cytokines important for the induction of adhesion molecules on endothelial cells (IL-1, TNF-a, IL-4, and IL-13) and the release of eosinophil-active chemokines (eotaxin, MCP-3, MCP-4, RANTES). The immediate reduction (<3 h) in circulating eosinophils observed after systemic administration of steroids is thought to occur as a consequence of sequestration into extramedullary organs (liver, spleen, and lymph nodes), as shown in rodents. The mechanism for this action may be that steroids induce the expression of CXCR4 on eosinophils, thereby enabling them to respond to the CXCR4 ligand stromal cell–derived factor-1 (SDF-1) that is produced by stromal cells in extramedullary organs. [15]

Several myelosuppressive drugs (hydroxyurea, interferons, and cyclophilins) are beneficial in eosinophilic disorders alone or as steroid-sparing agents. Interferons are thought to act by inhibiting eosinophil degranulation and inflammatory mediator release. [44] Cyclophilins (cyclosporine, FK506, and ascomycin) are thought to act by inhibiting T cell cytokine release, including cytokines that induce eosinophilic inflammation (IL-4, IL-5, and GM-CSF). Leukotriene antagonists, including 5-lipoxygenase inhibitors (zileuton) and cysLT1 receptor antagonists (zafirlukast and montelukast) decrease tissue eosinophils in allergic individuals and may diminish the biologic actions of eosinophil-derived leukotrienes. [45] Lastly, there have been conflicting reports about the ability of the newer generation antihistamines (cetirizine and fexofenadine) to inhibit eosinophil recruitment in cutaneous and airway allergen challenge models. [46]

With advances in our understanding of eosinophil biology, new, more specific therapeutic strategies have emerged. The approaches that are in preclinical or early clinical development include: anti-IL-5 humanized monoclonal antibodies, small molecular weight antagonists for CCR3 and VLA-4, antisense molecules to VCAM-1 and ICAM-1, and glycomimetics to PSGL-1, the p-selectin ligand on eosinophils. [45]

REFERENCES

1. Sehmi R, Denburg JA: Differentiation of human eosinophils, in *Human Eosinophils: Biological and Clinical Aspects,* edited by G Marone. Basel, Karger, 2000, p 29

2. Kim Y-K et al: Immunolocalization of CD34 in nasal polyposis: Effect of topical corticosteroids. *Am J Respir Cell Mol Biol* **20**:388, 1999

3. Tominaga A et al: Transgenic mice expressing a B-cell growth and differentiation factor gene (interleukin-5) develop eosinophilia and autoantibody production. *J Exp Med* **173**:429, 1991

4. Foster PS et al: Interleukin 5 deficiency abolishes eosinophilia, airways hyperreactivity, and lung damage in a mouse asthma model. *J Exp Med* **183**:195, 1996

5. Peled A et al: The chemotactic cytokine eotaxin acts as a granulocyte-macrophage colony-stimulating factor during lung inflammation. *Blood* **91**:1909, 1998

6. Mould AW et al: The effect of IL-5 and eotaxin expression in the lung on eosinophil trafficking and degranulation and the induction of bronchial hyperreactivity. *J Immunol* **164**:2142, 2000

7. Kato M et al: Eosinophil infiltration and degranulation in normal human tissue. *Anat Rec* **252**:418, 1998

8. Rothenberg ME et al: Gastrointestinal eosinophils. *Immunol Rev* **179**:139, 2001

9. Spry CJF: *Eosinophils: A Comprehensive Review, and Guide to the Scientific and Medical Literature*. Oxford, Oxford University Press, 1988

10. Gleich GJ et al: Eosinophils, in *Inflammation: Basic Principles and Clinical Correlates,* 2nd ed, edited by JI Gallin, IM Goldstein, R Snyderman. New York, Raven, 1992, p 663

11. Ackerman SJ et al: Charcot-Leyden crystal protein (galectin-10) is not a dual-function galactin with lysophospholipase activity, but binds a lysophospholipase inhibitor in a novel structural fashion. *J Biol Chem* **277**:14859, 2002

12. Dvorak AM, Weller PF: Ultrastructural analysis of human eosinophils, in *Human Eosinophils: Biological and Clinical Aspects,* edited by G Marone. Basel, Karger, 2000, p 1

13. Tachimoto H, Bochner BS: The surface phenotype of human eosinophils, in *Human Eosinophils: Biological and Clinical Aspects,* edited by G. Marone. Karger, Basel, 2000, p 45

14. Nickel R et al: Chemokines and allergic disease. *J Allergy Clin Immunol* **104**:723, 1999

15. Nagase H et al: Glucocorticoids preferentially upregulate functional CXCR4 expression in eosinophils. *J Allergy Clin Immunol* **106**:1132, 2000

16. Nagase H et al: Regulation of chemokine receptor expression in eosinophils. *Int Arch Allergy Immunol* **125**:29, 2001

17. Seminario M et al: Intracellular expression and release of Fc epsilon RI alpha by human eosinophils. *J Immunol* **162**:6893, 1999

18. Abu-Ghazaleh RI et al: IgA-induced eosinophil degranulation. *J Immunol* **142**:2393, 1989

19. Weller PF et al: Infection, apoptosis, and killing of mature human eosinophils by human immunodeficiency virus-1. *Am J Respir Cell Mol Biol* **13**:610, 1995

20. Symon FA et al: Functional and structural characterization of the eosinophil P-selectin ligand. *J Immunol* **157**:1711, 1996

21. Georas SN et al: Expression of a functional laminin receptor ($a_6ß_1$, VLA-6) on human eosinophils. *Blood* **82**:2872, 1993

22. Walsh GM et al: Ligation of CD69 induces apoptosis and cell death in human eosinophils cultured with granulocyte-macrophage colony-stimulating factor. *Blood* **87**:2815, 1996

23. Matsumoto KJ et al: CD44 and CD69 represent different types of cell-surface activation markers for human eosinophils. *Am J Respir Cell Mol Biol* **18**:860, 1998

24. Page S et al: Stimulation of neutrophil IL-8 production by eosinophil granule major basic protein. *Am Respir Cell Mol Biol* **21**:230, 1999

25. Mukai H et al: MBP binding to thrombomodulin potentially contributes to the thrombosis in patients with eosinophilia. *Br J Hematol* **90**:892, 1995

26. Butterfield J et al: Nodules, eosinophilia, rheumatism, dermatitis and swelling (NERDS): A novel eosinophilic disorder. *Clin Exp Allergy* **23**:571, 1993

27. Okada S et al: Migration of eosinophils through basement membrane components in vitro: Role of matrix metalloproteinase-9. *Am J Respir Cell Mol Biol* **17**:519, 1997

28. Pahl H, Baeuerle P: Activation of NF-kappa B by ER stress requires both Ca^{2+} and reactive oxygen intermediates as messengers. *FEBS Lett* **392**:129, 1996

29. Jacoby DB et al: Human eosinophil major basic protein is an endogenous allosteric antagonist at the inhibitory muscarinic M2-receptor. *J Clin Invest* **91**:1314, 1993

30. Lacy P, Moqbel R: Eosinophil cytokines, in *Human Eosinophils: Biological and Clinical Aspects,* edited by G Marone. Basel, Karger, 2000, p 134

31. Shi H et al: Lymph node trafficking and antigen presentation by endobronchial eosinophils. *J Clin Invest* **105**:945, 2000

32. Suchin K et al: Increased interleukin 5 production in eosinophilic Sézary syndrome: Regulation by interferon alfa and interleukin 12. *J Am Acad Dermatol* **44**:28, 2001

33. Goldsmith MM et al: The importance of the eosinophil in head and neck cancer. *Otolaryngol Head Neck Surg* **106**:27, 1992

34. Kubo H et al: Cytotoxin properties of eosinophil granule major basic protein for tumor cells. *Int Arch Allergy Immunol* **118**:426, 1999

35. Hung K et al: The central role of CD4+ T cells in the antitumor immune response. *J Exp Med* **188**:2357, 1998

36. Soiffer R et al: Vaccination with irradiated autologous melanoma cells engineered to secrete human granulocyte-macrophage colony-stimulating factor generates potent antitumor immunity in patients with metastatic melanoma. *Proc Natl Acad Sci U S A* **1998**:13141, 1998

37. Simons JW et al: Bioactivity of autologous irradiated renal cell carcinoma vaccines generated by ex vivo granulocyte-macrophage colony-stimulating factor gene transfer. *Cancer Res* **57**:1537, 1997

38. Dubois GR et al: IL-4 induces chemotaxis of blood eosinophils from atopic dermatitis patients, but not from normal individuals. *J Invest Dermatol* **102**:843, 1994

39. Beck LA et al: Cutaneous injection of RANTES causes eosinophil recruitment: Comparison of nonallergic and allergic subjects. *J Immunol* **159**:2962, 1997

40. Wedi B et al: Delayed eosinophil programmed cell death in vitro: A common feature of inhalant allergy and extrinsic and intrinsic atopic dermatitis. *J Allergy Clin Immunol* **100**:536, 1997

41. Mehregan DR et al: Cutaneous reactions to granulocyte-monocyte colony-stimulating factor. *Arch Dermatol* **128**:1055, 1992

42. Cooper PJ et al: Sequential expression of RANTES and eotaxin by the dermal vascular endothelium is associated with the appearance of eosinophils in the skin after the treatment of onchocerciasis with ivermectin. *Clin Immunol* **95**:51, 2000

43. Schleimer RP et al: Inhibition of inflammatory cell recruitment by glucocorticoids: cytokines as primary targets, in *Topical Glucocorticoids in Asthma: Mechanisms and Clinical Actions,* edited by RP Schleimer, WW Busse, P O'Byrne. New York, Marcel Dekker, 1997, p 203

44. Stevens SR et al: Long-term effectiveness and safety of recombinant human interferon gamma therapy for atopic dermatitis despite unchanged serum IgE levels. *Arch Dermatol* **134**:799, 1998

45. Hansel TT, Barnes PJ: *New Drugs for Asthma, Allergy and COPD*. Basel, Karger, 2001

46. Charlesworth EN et al: Effect of cetirizine on mast cell-mediator release and cellular traffic during the cutaneous late-phase response. *J Allergy Clin Immunol* **83**:905, 1989

T>

Chapter 31

John Schroeder

Regulation of the Production and Activation of Basophils

HISTORICAL ASPECTS
ONTOGENY AND DEVELOPMENT
PHENOTYPIC MARKERS
IgE-DEPENDENT ACTIVATION
Release and Function of Preformed Mediators
Newly Generated Mediators and Function
Activation of Basophils Independent of IgE Cross-Linking
BASOPHILS IN DISEASE
REFERENCES

The basophil has long been recognized as an effecter cell in allergic inflammation. It secretes histamine and leukotriene (LT) C_4, two of the most potent inflammatory mediators contributing to the acute symptoms associated with diseases such as allergic rhinitis, asthma, and urticaria. Furthermore, there is now firm evidence that basophils are a major source of interleukin (IL)-4 and IL-13, arguably the two most critical proinflammatory cytokines contributing to the pathogenesis of allergic disease. This information, along with new evidence that basophils selectively infiltrate allergic lesions, particularly in the skin, emphasizes the growing belief that these cells play an essential and unique role in the intricate cellular interactions of allergic disease.

HISTORICAL ASPECTS

Although they are easily distinguished from other leukocytes when properly stained (Fig. 31-1), the fact that basophils are rare, representing less than 1 percent of the white blood cells, initially made it difficult for investigators to study their function. It was not until the early 1950s that basophils were identified as the sole source of histamine released in a reaction dependent on IgE among blood leukocytes challenged with specific antigen. [1] The belief that they might be a substitute for studying the hard-to-recover tissue mast cell was supported by evidence that the releasability of a patient's basophils in response to ragweed antigen, in vitro, could predict the clinical responsiveness of the patient to this allergen during ragweed season. [2] The “surrogate” concept, however, was abandoned during the 1980s, with advances in the methods for isolating both cell types. Subsequent studies showed that many functional differences exist between basophils and mast cells. Basophils, in fact, were found to be far more “excitable” than mast cells, releasing histamine after exposure to a diverse assortment of substances and independent of IgE/receptor cross-linking.

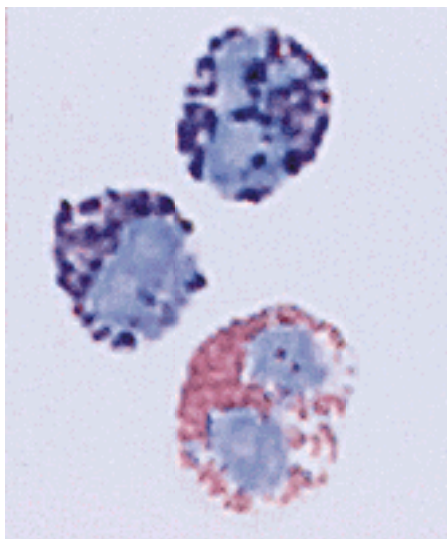

FIGURE 31-1 Wright's stain showing two basophils with one eosinophil. Original magnification × 400.

The recent movement toward studies of IgE-mediated cytokine generation arose from work published in 1989, showing that IL-3–dependent murine mast cells generated, de novo, IL-4, IL-5, IL-6, and other cytokines that were previously thought to be made only by a subset of activated CD4+ T cells, T helper 2 (T_H2) cells. [3] The basophil, by secreting T_H2 cytokines in addition to histamine and LTC_4, possesses both effector and modulatory functions in allergic lesions. Table 31-1 summarizes the more common characteristics of basophils.

Properties	Features
Morphology	5–8 μm in size
	Large and few cytoplasmic granules
	Lobed nucleus
Natural history	Originates and matures in bone marrow
	Important growth factor: IL-3
	Life span: days (without IL-3)
Major surface receptors	FcεRI (30,000–1,000,000)
	High IL-3 receptor expression
	Low c-kit expression
	CD40L
Major inflammatory mediators released	Histamine (1 μg/10^6 cells)
	Leukotriene C_4 (60 ng/10^6 cells)
Specific cytokines secreted	IL-4 (10–1000 pg/10^6 cells)
	IL-13 (0–1000 pg/10^6 cells)
	MIP-1α (0–1500 pg/10^6 cells)

TABLE 31-1 **Selected Properties of Human Basophils**

ONTOGENY AND DEVELOPMENT

As with other hematopoietic cells, basophils are ultimately derived from a pluripotent stem cell. However, unlike mast cells, which mature at specific tissue sites in the lung, gut, and skin after the release of a committed progenitor from the bone marrow, basophils are thought to mature in the marrow and to be released as cells with essentially no capacity for further development. [4] Evidence shows that basophils are more developmentally related to eosinophils than to mast cells. The number of eosinophil/basophil progenitors is higher in the bone marrow and blood of patients with asthma than in normal subjects, [5], [6] and allergen provocation increases the frequency of these cells. [7] Much of the knowledge about the factors involved in the maturation of human basophils has come from studies in which these cells are cultivated in vitro from CD34+ precursor cells found in bone marrow, cord blood, and whole blood. It is currently accepted that IL-3 possesses substantial activity for the development of basophils and is likely the key factor involved. [8] Other cytokines, however, particularly granulocyte-macrophage colony-stimulating factor (GM-CSF), IL-5, and, to a lesser extent, nerve growth factor (NGF), have all been reported to influence basophil development. [9], [10] Furthermore, in vivo studies with nonhuman primates show increased numbers of basophils, eosinophils, and their progenitors in the blood of animals infused with either IL-3 or GM-CSF. [11]

PHENOTYPIC MARKERS

Basophils share with other leukocytes, the expression of various adhesion molecules, including members of the selectin, immunoglobulin, and integrin superfamilies, that enable these cells to migrate from the blood across the endothelial barrier and into tissue (reviewed in Refs. [12] and [13]). Of particular importance is their expression of a $_4$ß $_2$ integrins, which are also found on eosinophils and subclasses of T lymphocytes. These adhesion molecules specifically bind vascular cell adhesion molecule-1 (VCAM-1), and it is this interaction that is most responsible for the selective migration of these cell types into sites of allergic inflammation. [14], [15] and [16]

Basophils also express receptors that bind various chemokines and cytokines that play a key role in the trafficking and activation of these cells. The eotaxins (I and II) and RANTES (regulated on activation, normal T cell expressed and secreted) are potent chemoattractants for basophils that interact through the highly expressed CCR3 receptor on these cells (see Chap. 27). The CCR1 and CCR2 receptors provide overlapping specificity for the monocyte chemotactic proteins (MCP)-1, -3, and -4, all of which activate basophils. Basophils also express the CXCR4 receptor—a coreceptor important for HIV entry into lymphocytes. The most prominent cytokine receptor expressed on basophils is that for IL-3 (i.e., CD123), which binds this cytokine with high affinity, initiating signals important for both the survival and activation of these cells. Other cytokine receptors on basophils include those for IL-5, GM-CSF, NGF, IL-2, IL-4, and IL-8. Indirect evidence for the expression of receptors for stem cell factor (SCF), interferon-? (IFN-?), and tumor necrosis factor a (TNF-a) on basophils comes from studies reporting that these cytokines modulate mediator release.

Basophils and mast cells differ from other immune cells in that they express the high affinity receptor for IgE (FceRI). The cloned receptor consists of an a, a ß, and two ? subunits associated with one another to form an aß ? $_2$ tetramer. Although monocytes, certain dendritic cells, Langerhans cells, and eosinophils all are reported to express FceRI, none of these cells appear to have the full tetrameric structure on their cell surface. Like basophils and mast cells, each of these cells also expresses the a-subunit, which confers the high affinity (Ka <10 [10] /M) for IgE. However, these cells lack the ß subunit, which is thought to play a critical role in amplifying the intracellular signals initiated upon cross-linking of IgE/receptor complexes. [17]

The expression of FceRI on basophils differs significantly among donors, ranging from 30,000 to 1,000,000 per cell. Studies conducted more than 25 years ago suggested a positive correlation between FceRI expression on basophils and the levels of total IgE in serum. [18] Credence for this belief has come with the recent development of anti-IgE therapy. For instance, MacGlashan et al. showed that serum IgE levels in patients allergic to dust mites were reduced by more than 90 percent with the infusion of a humanized anti-IgE antibody (E25 or Omalizumab). [19] Subsequently, there was a decrease in the expression of FceRIa on the basophils of these individuals and a significant loss of reactivity to the antigen. Upon completion of the therapy, both the IgE serum levels and FceRIa expression returned, as did the responsiveness to dust mite antigen. [20] Basophils also bind IgG through the expression of Fc?RII (CD32). Cross-linking antigen-specific IgG bound to this receptor with antigen-specific IgE on FceRI induces intracellular signals that prevent degranulation and mediator release. [21]

Other activation-linked markers are found on basophils, including the ligand for CD40, CD40L. This molecule, which was previously found on the cell surface of only a few cell types, such as activated T cells, dendritic cells, and endothelial cells, plays a critical role in costimulating B lymphocytes for IgE synthesis. As a result, basophils provide both the soluble factors (IL-4/IL-13) and the cellular interactions (via CD40L) required to induce IgE production by B cells in vitro. [22]

IgE-DEPENDENT ACTIVATION

Release and Function of Preformed Mediators

Cross-linking of IgE/FceRI complexes on the surface of basophils and mast cells, either by the natural interaction with antigen or by artificial stimulation with anti-IgE, initiates a cascade of intracellular events that leads to the rapid release of preformed and newly generated products. Histamine is a preformed mediator of most interest in the basophil, and its release is essentially complete 20 min after cell stimulation. On average, basophils store approximately 1 pg/cell of histamine in their cytoplasmic granules, as compared to the 3 to 8 pg/cell found in mast cells. As noted above, essentially all of the histamine present in normal human blood is derived from basophils, a fact that has long allowed the use of washed leukocytes in studies of the parameters of IgE-mediated secretion of histamine. The physiologic importance of histamine lies in its ability to contract smooth muscle and to induce vascular leakage by binding to receptor sites in lung tissue, skin, and mucosa. Although tryptase and major basic protein are thought to be mast cell- and eosinophil-specific products, respectively, low amounts of a-tryptase [23] and major basic protein have been identified in human basophils.

Monoclonal antibodies have been developed that identify other granule-specific proteins found only in basophils. The monoclonal antibody 2D7 identifies a 72-kDa protein that is released on cell degranulation. [24] The monoclonal antibody BB1 is specific for a high-molecular-weight complex of ~5×10 [6] Da referred to as basogranulin. [25] As discussed below, these antibodies have greatly facilitated the detection of basophils in tissue.

Newly Generated Mediators and Function

LEUKOTRIENES Through enzymatic activity mediated largely by cytosolic phospholipase A_2 (PLA_2), activated basophils cleave phospholipids (such as phosphatidylinositol and phosphatidylcholine) to release arachidonic acid. The arachidonic acid provides the substrate for LTC_4 synthesis. Unlike mast cells, basophils do not synthesize prostaglandins. The amount of LTC_4 generated by basophils (10 to 100 fg/cell) varies among donors and is much less than the amount of histamine released from these cells. It is, however, far more potent than histamine at inducing smooth-muscle constriction. These cysteinyl leukotrienes are the major mediators involved in the late-phase response (see below). The clinical efficacy of the cysteinyl leukotriene receptor antagonists and 5-lipoxygenase inhibitors supports this belief. [26], [27]

CYTOKINES As noted above, the cytokines made by basophils, which include IL-4 and IL-13, are commonly found in allergic lesions and could be critical for IgE synthesis by B cells. In fact, more mRNA and protein for these cytokines are produced by basophils than by any other leukocyte circulating in blood (reviewed in Ref. [28]), as evidenced in studies with stimuli that specifically activate basophils and in studies with antigen stimulation, which is capable of also activating T lymphocytes. [29] The explanation for this finding is relatively straightforward: all basophils (i.e., approximately 1 in 200 leukocytes) potentially express antigen-specific IgE, whereas the number of antigen-specific T lymphocytes in blood is estimated at 1 in several thousand. The biologic activities of both IL-4 and IL-13 suggest that basophils, by producing these cytokines, could play a critical role in orchestrating allergic inflammation (Fig. 31-2). The synthesis of IgE by B cells depends on the ability of these cytokines to induce isotype-switching from IgM to IgE. Both also enhance the expression of major histocompatibility complex (MHC) class II antigens on antigen-presenting cells (APCs) and VCAM-1 on endothelial cells. Individually, IL-4 is currently the only cytokine capable of fostering the development of T_H2 cells from T_H0 lymphocytes, whereas IL-13 has been implicated in mucus production and collagen synthesis.

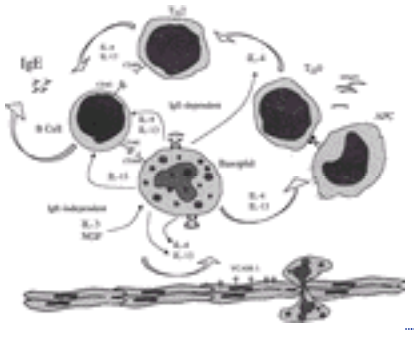

FIGURE 31-2 Potential biologic functions for IL-4 and IL-13 secreted by human basophils. Basophils secrete IL-4 and IL-13 in response to IgE-dependent stimuli (i.e., antigen). Substances such as IL-3 and NGF, which act independently of IgE, can also stimulate basophils for IL-13 secretion. These cytokines, along with the costimulatory effects of CD40L (on basophils) interacting with CD40, can induce IgE synthesis in B lymphocytes. Both IL-4 and IL-13 also upregulate VCAM-1 expression on endothelium, thus promoting the migration of eosinophils, basophils, and lymphocytes into lesion sites. By upregulating the expression of major histocompatibility complex class II molecules, these cytokines also facilitate antigen presentation to T cells. Finally, the IL-4 required for the development of T_H2 cells also may be derived from activated basophils.

The parameters important for the production of IL-4 and IL-13 by basophils, resulting from IgE-mediated activation, strongly indicate that signals are initiated for the de novo synthesis of these cytokines. Cycloheximide, an inhibitor of protein synthesis, completely inhibits the secretion of IL-4 and IL-13 by basophils, which suggests that little, if any, protein for these cytokines is stored in the cytoplasmic granules. Unlike histamine and LTC_4, both of which are released minutes after activation, the accumulation of IL-4 mRNA in basophils is first evident at a time (~30 min) when mediator release is essentially over. The secretion of protein for IL-4 peaks 4 to 6 h after activation. The generation of IL-13 appears to be more variable, with much of the current evidence suggesting that its production, while slower to develop, is more protracted than that of IL-4. Protein for IL-13 is first measurable 1 to 2 h after cell stimulation, and its levels peak 18 to 20 h after stimulation (Fig. 31-3). The secretion of both IL-4 and IL-13 is exquisitely dependent on the prolonged changes in cytosolic calcium initiated with concentrations of antigen (or anti-IgE) that are nearly tenfold less than those optimal for mediator release. This finding, combined with pharmacologic evidence that the immunosuppressants FK506 and cyclosporin A (CsA) are potent inhibitors of this response, has implicated a role for the nuclear factor of activated T cells (NFAT) family of transcription factors in the generation of these cytokines.

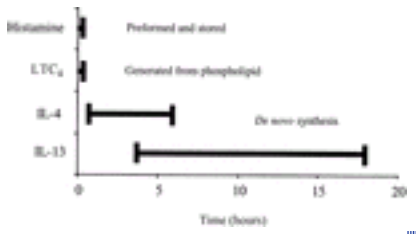

FIGURE 31-3 Relative duration of mediator release (histamine and LTC_4) and cytokine secretion (IL-4 and IL-13) resulting from the IgE-dependent activation of basophils in vitro.

Of those agents previously shown to inhibit mediator release, including B_2 agonists, H_1 agonists, glucocorticoids, and cyclosporine/ FK506, essentially all are relatively more potent against cytokine production. [30], [31], [32] and [33] However, it remains to be seen whether this ability to inhibit mediator release and cytokine secretion from basophils can be attributed to the clinical efficacy of these drugs.

Activation of Basophils Independent of IgE Cross-Linking

Many substances that activate basophils for mediator release, independently of IgE/FceRI cross-linking, have essentially no effect on mast cells. Some of the earliest substances described were complement factors (i.e., C5a) and bacterial-derived peptides (i.e., f-met-leu-phe, fMLP). Although they induce mediator release, neither stimulus induces IL-4 or IL-13 secretion sufficiently in the absence of a costimulus, indicating a dissociation between mediator release and cytokine secretion. This characteristic is also seen among the various chemokines that activate basophils. The MCPs (MCP-1, -3, and -4), RANTES, the eotaxins (I and II), and stromal-derived factor-1 (SDF-1) all induce histamine release, albeit primarily from basophils isolated from allergic donors. There are no reports of these chemokines directly inducing either IL-4 or IL-13. Overall, it seems apparent that the chemokines are less effective at inducing cytokine production and mediator release from basophils than they are at promoting cell migration.

In addition to the chemokines listed above, several other cytokines (predominately growth factors) modulate basophil function. In particular, IL-3 modulates several aspects of the basophil response. It plays a critical role in the development and maturation of basophils from precursor cells; exerts antiapoptotic-like activity on mature basophils, facilitating their survival in culture for weeks [34]; and affects both early and late activation responses in basophils. Early effects, which occur within 15 min of exposure, include the ability to “prime” or enhance the secretion of histamine, LTC_4, and cytokines in response to IgE-dependent and -independent activation. In fact, at high concentrations (e.g., 300 n *M*), IL-3 directly induces histamine release from cells of some allergic patients. When used alone, IL-3 also induces relatively late, yet protracted, production of IL-13 from basophils, with secreted protein first detected after 4 hours incubation and continuing for more than 48 hours. [35] Remarkably, this production of IL-13 is not sensitive to FK506, unlike the case with FceRI-mediated cell activation. [31] Both IL-5 and GM-CSF, which bind to receptors that share a common ß-chain with the IL-3 receptor, are also reported to prime basophils for increased histamine release, but these cytokines do not appear to mediate the same late effects, such as IL-13 production, that are seen with IL-3 exposure. [36] However, NGF, which also primes basophils for increased mediator release by binding to the so-called TrkA receptor, was recently shown to activate basophils for IL-13 production, with parameters similar to those seen with IL-3 activation. [37]

Both mediator release and cytokine secretion are enhanced in basophils exposed to recombinant histamine-releasing factor (HRF). Originally referred to as IgE-dependent HRF, this protein is now thought to be a cytokine that binds a specific receptor on basophils, eosinophils, and lymphocytes, rather than IgE. [38], [39] HRF directly induces histamine release and IL-4 secretion from the basophils of certain allergic individuals, [40] whereas it primes for IgE-mediated release of histamine, IL-4, and IL-13 from cells of nonallergic individuals. [41] Collectively, HRF and the cytokines noted above, all of which have been identified in allergic lesions, are thought to amplify ongoing allergic responses, in part by enhancing and/or prolonging the responses of basophils and other immune cells.

BASOPHILS IN DISEASE

Under specific pathologic conditions, basophils selectively migrate into tissue sites, accumulating in numbers manyfold those circulating in normal blood. Nowhere has this recruitment been more evident than in the allergic inflammation associated with the so-called late-phase response (LPR) resulting from experimental allergen challenge. These reactions unfold 6 to 12 h after a reduction in symptoms resulting from the early response. LPR lesional sites have long been characterized by a striking influx of eosinophils and mononuclear cells. Nonetheless, basophils have been identified in all models of the LPR, including those of the upper and lower airways and in the skin. [42], [43] and [44] As a result, some portion of the symptoms associated with the LPR could be basophil-mediated.

A resurgence in studies investigating the role basophils play in allergic lesions has arisen from two developments: the use of monoclonal antibodies allowing their identification in tissues with immunohistochemistry, and the discovery that basophils produce large quantities of IL-4 and IL-13 in vitro. In two independent studies, each using different monoclonal antibodies, basophils were identified in late reactions of the skin 6 to 24 h after experimental allergen challenge. [45], [46] The results from both studies were remarkably similar, showing that the percentage of basophils infiltrating these skin lesions approached nearly 50 percent of the infiltrating eosinophils, and thus suggest a far greater presence of these cells than that previously reported. These antibodies have also identified basophils in the lung and nose 6 to 24 h after allergen challenge, albeit at percentages somewhat less than those described in the skin. [46], [47] and [48]

Recent evidence shows that the basophils infiltrating LPR lesions also secrete IL-4. In one study, the ex vivo production of IL-4 by cells recovered in bronchoalveolar lavage (BAL) samples was seen only in fractions containing basophils. [9] In another study, dual-staining immunohistochemical techniques showed the presence of IL-4 mRNA and protein in cells colabeled with the basophil-specific antibody 2D7. [50] In this study, basophils accounted for nearly 80 percent of the cells expressing IL-4. These findings challenge the long-held belief that T lymphocytes are the major source of IL-4 in allergic

reactions. It remains to be seen whether the IL-13 expressed in the LPR [51] is also derived from basophils.

Other studies show the involvement of basophils in natural disease. With the 2D7 monoclonal antibody, large numbers of basophils were found in the lungs of individuals dying from asthma. [52] In the same study, basophils were not found in the lungs of individuals dying from nonasthma–related causes, including those with a history of asthma. Basophils have been identified in skin lesions of patients with atopic dermatitis and urticaria. [53], [54] and [55] Increasing evidence shows that basophils from patients presenting with these diseases, in particular atopic dermatitis, are reactive to enterotoxins derived from *Staphylococcus aureus* organisms. [56] It seems certain that future studies will address the role of basophils in such lesions now that their detection in tissue can be facilitated with the monoclonal antibodies described.

Finally, it has long been demonstrated that basophils selectively migrate into the so-called cutaneous basophilic hypersensitivity (CBH) reaction, which closely resembles the Jones-Mote reactions originally described in guinea pigs. Unlike LPRs, these reactions are reported to evolve independently of IgE and instead are thought to have a cell-mediated component responsible for modulating the influx of basophils. During the 1970s, the Dvoraks demonstrated CBH in humans after inducing allergic contact dermatitis reactions with rhus toxoid (the active agent in poison ivy) or dinitrochlorobenzene in patch tests. [57], [58] They also noted the appearance of basophils in several other conditions involving a cellular component, including tumor and skin allograft rejection, [59], [60] bullous pemphigoid, [61] Crohn's disease, [62] and viral hypersensitivity. [63] The active degranulation process (so-called piecemeal degranulation) occurring in the basophils in all of these conditions has suggested a commonality for their activation in these lesions.

REFERENCES

1. Ishizaka T et al: Identification of basophil granulocytes as a site of allergic histamine release. *J Immunol* **108**:1000, 1972

2. Lichtenstein L et al: Clinical and in vitro studies on the role of immunotherapy in ragweed hay fever. *Am J Med* **44**:514, 1968

3. Plaut M et al: Mast cell lines produce lymphokines in response to cross-linkage of Fc epsilon RI or to calcium ionophores. *Nature* **339**:64, 1989

4. Murakami I et al: Studies on the kinetics of human leukocytes in vivo with ^{3}H-thymidine autoradiography. II. Eosinophils and basophils. *Acta Haematol* **32**:384, 1969

5. Denburg J: The origins of basophils and eosinophils in allergic inflammation. *J Allergy Clin Immunol* **102**:S74, 1998

6. Denburg JA et al: Increased numbers of circulating basophil progenitors in atopic patients. *J Allergy Clin Immunol* **76**:466, 1985

7. Wood L et al: Changes in bone marrow inflammatory cell progenitors after inhaled allergen in asthmatic subjects. *Am J Respir Crit Care Med* **157**:99, 1998

8. Kirshenbaum AS et al: IL-3-dependent growth of basophil-like cells and mastlike cells from human bone marrow. *J Immunol* **142**:2424, 1989

9. Tsuda T et al: Synergistic effects of nerve growth factor and granulocyte-macrophage colony-stimulating factor on human basophilic cell differentiation. *Blood* **77**:971, 1991

10. Dvorak AM et al: Ultrastructure of eosinophils and basophils stimulated to develop in cord blood mononuclear cell cultures containing recombinant human interleukin-5 or interleukin-3. *Lab Invest* **61**:116, 1989

P>11. Dvorak A et al: Ultrastructure of monkey peripheral blood basophils stimulated to develop in vivo by recombinant human interleukin-3. *Lab Invest* **61**:677, 1989

12. Agis H et al: Comparative immunophenotypic analysis of human mast cells, blood basophils, and monocytes. *Immunology* **87**:535, 1996

13. Bochner B: Systemic activation of basophils and eosinophils: Markers and consequences. *J Allergy Clin Immunol* **106**:S292, 2000

14. Schleimer RP et al: IL-4 induces adherence of human eosinophils and basophils but not neutrophils to endothelium. *J Immunol* **148**:1086, 1992

15. Moser R, Fehr J: IL-4 controls the selective endothelium-driven transmigration of eosinophils from allergic individuals. *J Immunol* **149**:1432, 1992

16. Thornhill MA et al: IL-4 increases human endothelial cell adhesiveness for T cells but not for neutrophils. *J Immunol* **144**:3060, 1990

17. Donnadieu E et al: A second amplifier function for the allergy-associated Fc(epsilon)RI- beta subunit. *Immunity* **12**:515, 2000

18. Malveaux FJ et al: IgE receptors on human basophils. Relationship to serum IgE concentration. *J Clin Invest* **62**:176, 1978

19. MacGlashan D Jr et al: Down-regulation of FceRI expression on human basophils during in vivo treatment of atopic patients with anti-IgE antibody. *J Immunol* **158**:1438, 1997

20. Saini S et al: Down-regulation of human basophil IgE and Fc epsilon RI alpha surface densities and mediator release by anti-IgE-infusions is reversible in vitro and in vivo. *J Immunol* **162**:5624, 1999

21. Kepley C et al: Negative regulation of FcepsilonRI signaling by FcgammaRII costimulation in human blood basophils. *J Allergy Clin Immunol* **106**:337, 2000

22. Gauchat J-F et al: Induction of human IgE synthesis in B cells by mast cells and basophils. *Nature* **365**:340, 1993

23. Xia HZ et al: Quantitation of tryptase, chymase, FceRIa, and FceRI? messenger RNAs in human mast cells and basophils by competitive reverse transcription-polymerase chain reaction. *J Immunol* **154**:5472, 1995

24. Kepley C et al: Identification and partial characterization of a unique marker for human basophils. *J Immunol* **154**:6548, 1995

25. McEuen A et al: Development and characterization of a monoclonal antibody specific for human basophils and the identification of a unique

secretory product of basophil activation. *Lab Invest* **79**:27, 1999

26. Calhoun W et al: The effect of Accolate (zafirlukast) on cellular mediators of inflammation: BAL findings after segmental allergen challenge. *Am J Respir Crit Care Med* **157**:1381, 1998

27. Kane GC et al: A controlled trial of the 5-lipoxygenase inhibitor, zileuton, on lung inflammation produced by segmental antigen challenge in human beings. *J Allergy Clin Immunol* **97**:646, 1996

28. Schroeder J, MacGlashan D Jr, Lichtenstein L: Human basophils: Mediator release and cytokine production. *Adv Immunol* **77**:93, 2001

29. Devouassoux G et al: Frequency and characterization of antigen-specific IL-4– and IL-13–producing basophils and T cells in peripheral blood of healthy and asthmatic subjects. *J Allergy Clin Immunol* **104**:811, 1999

30. Gibbs B et al: Inhibition of interleukin-4 and interleukin-13 release from immunologically activated basophils due to the actions of anti-allergic drugs. *Naunyn Schmiedebergs Arch Pharmacol* **357**:573, 1998

31. Redrup A et al: Differential regulation of IL-4 and IL-13 secretion by human basophils: Their relationship to histamine release in mixed leukocyte cultures. *J Immunol* **160**:1957, 1998

32. Schroeder J et al: Inhibition of cytokine generation and mediator release by human basophils treated with desloratadine. *Clin Exp Allergy* **31**:1, 2001

33. Schroeder J et al: Regulation of IgE-dependent IL-4 generation by human basophils treated with glucocorticoids. *J Immunol* **158**:5448, 1997

34. MacGlashan D Jr et al: In vitro regulation of FceRIa expression on human basophils by IgE antibody. *Blood* **91**:1633, 1998

35. Ochensberger B et al: Human blood basophils produce interleukin-13 in response to IgE-receptor–dependent and –independent activation. *Blood* **88**:3028, 1996

36. Miura K et al: Differences in functional consequences and signal transduction induced by IL-3, IL-5, and nerve growth factor in human basophils. *J Immunol* **167**:2282, 2001

37. Sin A et al: Nerve growth factor or IL-3 induces more IL-13 production from basophils of allergic subjects than from basophils of nonallergic subjects. *J Allergy Clin Immunol* **108**:387, 2001

38. MacDonald S: Human recombinant histamine-releasing factor. *Int Arch Allergy Appl Immunol* **113**:187, 1997

39. Wantke F et al: The human recombinant histamine releasing factor: Functional evidence that it does not bind to the IgE molecule. *J Allergy Clin Immunol* **103**:642, 1999

40. Schroeder J, Lichtenstein L, MacDonald S: An IgE-dependent recombinant histamine-releasing factor induces IL-4 secretion from human basophils. *J Exp Med* **183**:1265, 1996

41. Schroeder J, Lichtenstein L, MacDonald S: Recombinant histamine releasing factor enhances immunoglobulin E-dependent interleukin-4 and -13 secretion by human basophils. *J Immunol* **159**:447, 1997

42. Bascom R et al: The influx of inflammatory cells into nasal washings during the late response to antigen challenge. *Am Rev Respir Dis* **138**:406, 1988

43. Guo C-B et al: Identification of IgE-bearing cells in the late phase response to antigen in the lung as basophils. *Am J Resp Cell Mol Biol* **10**:384, 1993

44. Charlesworth EN et al: Cutaneous late-phase response to allergen. Mediator release and inflammatory cell infiltration. *J Clin Invest* **83**:1519, 1989

45. Irani A-M et al: Immunohistochemical detection of human basophils in late-phase skin reactions *J Allergy Clin Immunol* **101**:354, 1998

46. Macfarlane AJ et al: Basophils, eosinophils, and mast cells in atopic and nonatopic asthma and in late-phase allergic reactions in the lung and skin. *J Allergy Clin Immunol* **105**:99, 1999

47. Gauvreau G et al: Increased numbers of both airway basophils and mast cells in sputum after allergen inhalation challenge of atopic asthmatics. *Am J Respir Crit Care Med* **161**:1473, 2000

48. KleinJan A et al: Basophil and eosinophil accumulation and mast cell degranulation in the nasal mucosa of patients with hay fever after local allergen challenge. *J Allergy Clin Immunol* **106**:677, 2000

49. Schroeder J et al: IL-4 production by human basophils found in the lung following segmental allergen challenge. *J Allergy Clin Immunol* **107**:265, 2001

50. Nouri-Aria K et al: Basophil recruitment and IL-4 production during human allergen-induced late asthma. *J Allergy Clin Immunol* **108**:205, 2001

51. Huang S-K et al: IL-13 expression at the site of allergen challenge in patients with asthma. *J Immunol* **155**:2688, 1995

52. Kepley C et al: Immunohistochemical detection of human basophils in postmortem cases of fatal asthma. *J Allergy Clin Immunol* **107**:A160, 2001

53. Henocq E, Gaillard J: Cutaneous basophil hypersensitivity in atopic dermatitis. *Clin Allergy* **11**:13, 1981

54. Mitchell E et al: Basophils in allergen-induced patch test sites in atopic dermatitis. *Lancet* **1**:127, 1982

55. Mitchell E et al: Cutaneous basophil hypersensitivity to inhalant allergens in atopic dermatitis patients: Elicitation of delayed responses containing basophils following local transfer of immune serum but not IgE antibody. *J Invest Dermatol* **83**:290, 1984

56. Leung D et al: Presence of IgE antibodies to staphylococcal exotoxins on the skin of patients with atopic dermatitis. Evidence for a new group of allergen. *J Clin Invest* **92**:1374, 1993

57. Dvorak HF et al: Cutaneous basophil hypersensitivity. II. A light and electron microscopic description. *J Exp Med* **132**:558, 1970

58. Dvorak HF, Mihm MC Jr: Basophilic leukocytes in allergic contact dermatitis. *J Exp Med* **135**:235, 1972

59. Dvorak HF: Role of basophil leukocytes in allograft reactions. *J Immunol* **106**:279, 1971

60. Dvorak H et al: Rejection of first-set skin allografts in man. The microvasculature is the critical target of the immune response. *J Exp Med* **150**:322, 1979

61. Dvorak AM et al: Bullous pemphigoid, an ultrastructural study of the inflammatory response: Eosinophil, basophil and mast cell granule changes in multiple biopsies from one patient. *J Invest Dermatol* **78**:91, 1982

62. Dvorak AM, Monahan RA: Crohn's disease. Ultrastructural studies showing basophil leukocyte granule changes and lymphocyte parallel tubular arrays in peripheral blood. *Arch Pathol Lab Med* **106**:145, 1982

63. Dvorak HF, Hirsh MS: Role of basophil leukocytes in cellular immunity to vaccinia virus infections. *J Immunol* **107**:1576, 1971

T>

Chapter 32

Fred Hsieh Clifton Bingham K. Austen

The Molecular and Cellular Biology of the Mast Cell

DISTRIBUTION AND IDENTIFICATION
DEVELOPMENTAL BIOLOGY
MAST CELL RECEPTORS, LIGANDS, AND CHEMOTAXIS
MAST CELL–DERIVED MEDIATORS
Preformed Secretory Granule Mediators
Lipid-Derived Mediators of Inflammation
Cytokines and Chemokines: Constitutive and Induced

REFERENCES

The mast cell (MC) has long been recognized as a primary effector cell in immediate-type hypersensitivity reactions. Recent studies have focused on its lineage development and tissue heterogeneity and its response to innate and adaptive immunologic stimuli. These insights provide evidence that the MC participates in a broad spectrum of biologic processes ranging from allergic inflammation to innate immune responses against gram-negative bacteria and helminths. Mast cells also may play a physiologic role in wound healing, tissue remodeling, and angiogenesis. The focus of this chapter is on the biology of the human MC with references to rodent systems as necessary for completeness.

DISTRIBUTION AND IDENTIFICATION

Mast cells are dispersed widely throughout the body, although their numbers are highest at mucosal surfaces, where they are exposed to foreign stimuli. [1] The number of MCs increases at inflammatory sites in various disorders, including atopic dermatitis, inflammatory bowel disease, multiple sclerosis, and asthma. [2], [3], [4] and [5] Dermal MCs often are located in close proximity to blood vessels, nerves, and lymphatics, with an estimated density of 7000 to 20,000 MCs per cubic millimeter of skin. [1]

Mast cells can be identified by numerous granules that undergo red-purple metachromatic staining with the basic dye toluidine blue. These cells exhibit a variable morphology ranging from round to spindle-shaped with sizes up to 25 µm. A unilobed nucleus may be round to oval in shape and typically is positioned eccentrically. Monoclonal antibodies directed against the membrane receptor c- *kit* and the granule proteases tryptase, chymase, and carboxypeptidase A identify MCs in situ. Chloroacetate esterase, which reacts with the granule proteases of MCs, identifies MCs in tissues but also reacts with cathepsin-G in neutrophil granules.

The cytoplasmic granules of human MCs contain macromolecular complexes of proteoglycans and proteases with distinct morphology that are detected by immunocytochemistry and electron microscopy. [1] This characteristic led to an early descriptive classification based on anatomic localization and staining characteristics (Fig. 32-1). Mast cells containing only tryptase (MC_T or reactive MC phenotype) demonstrate scroll-like granules by electron microscopy. They tend to predominate in the intestinal mucosa and lung parenchyma. Mast cells containing tryptase, chymase, and carboxypeptidase A (MC_{TC} or constitutive tissue phenotype) tend to predominate in the skin and submucosa of many tissues. Their granules are scroll-poor with a grating or lattice-like structure with periodicity. [6] Mast cells with granules containing chymase without tryptase (referred to as MC_C) have been identified in the skin, lymph nodes, and intestinal submucosa. Thus there exists every combination of phenotypic heterogeneity for these three proteases.

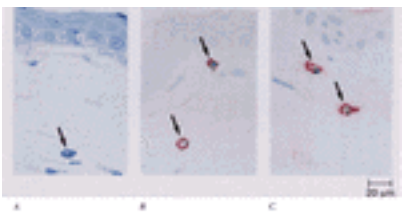

FIGURE 32-1 Human skin MCs (*arrows*) identified by three different staining methods: (*A*) the basic dye toluidine blue; (*B*) immunochemical reaction with chloroacetate esterase; (*C*) immunoalkaline phosphatase staining with monoclonal antibody against tryptase. (*Courtesy of Daniel S. Friend, M.D., Brigham and Women's Hospital.*)

DEVELOPMENTAL BIOLOGY

Mast cells originate from hematopoietic committed progenitors (PrMC) in the bone marrow that mature and differentiate in the target tissue. The development of tissue MCs in both rodents and humans requires the interaction between the receptor tyrosine kinase c- *kit* (CD117) and its fibroblast- or stromal cell–derived ligand stem cell factor (SCF). It is further modulated by additional factors in the tissues that account for MC functional and immunohistochemical heterogeneity. In particular, a constitutive baseline MC subpopulation resides in perivascular connective tissues and varies in number depending on the anatomic site, whereas an immunohistochemically and functionally distinctive reactive MC subpopulation develops and expands in mucosal surfaces in response to T cell–derived growth factors. [7], [8]

The earliest evidence that the interaction between SCF and c- *kit* profoundly influences MC development came from

analyses of mice with naturally occurring MC deficiencies. The W/W $_?$ mouse strain lacks MCs due to a mutation of the gene that encodes c- *kit,* whereas the *Sl/ Sl* $_d$ mouse strain also lacks MCs and has a mutation of the gene that encodes for SCF (also known as the *kit* ligand or Steel factor). [7] The MC deficiency of W/W $_?$ mice was corrected by transplantation of bone marrow cells from normal congenic mice, thereby confirming the hematopoietic origin of MCs and indicating that correction of the defect in c- *kit* permitted normal MC development. In several cytokine-independent human and rodent MC lines, a single-amino-acid substitution in the tyrosine kinase domain of the cytoplasmic portion of c- *kit* results in a constitutively phosphorylated and activated receptor. [9], [10] Functional mutations of the same type have been found in association with several types of systemic mastocytosis in humans—indolent mastocytosis, systemic mastocytosis with an associated clonal hematologic non-mast cell lineage disease, and mast cell leukemia. [11] Thus decreased signaling through c- *kit* results in MC deficiency, whereas excessive activation of this receptor leads to aberrant MC proliferation.

Human PrMCs were recognized initially as CD34+, c- *kit*+, CD14– mononuclear progenitor cells found in bone marrow [12] and peripheral blood with SCF-dependent culture systems. [13] These observations supported the bone marrow origin of human MCs and suggested that human PrMCs also reach target tissues by the peripheral circulation and differentiate in an SCF-dependent manner. Human MCs can be derived in culture from various sources, including cord blood, using SCF in combination with accessory cytokines such as interleukin 6 (IL-6) and IL-10. [14], [15] and [16] Whereas SCF and intact c- *kit* are essential and sufficient to support normal numbers of constitutive-tissue MCs, additional factors are necessary for the expansion of MC subpopulations. The importance of IL-3 in reactive intestinal mucosal MC hyperplasia is demonstrated by targeted disruption of the IL-3 gene. [17] Mice lacking the IL-3 gene have a markedly attenuated jejunal intraepithelial MC hyperplasia in response to helminth infection even though they have normal numbers of constitutive submucosal MCs. Humans with T cell immunodeficiencies lack MCs in the intestinal mucosa but not in the adjacent submucosa, thereby providing evidence for the existence of a constitutive T cell–independent population of MCs as well as a reactive population dependent on T cells for expansion. [18] Other T cell–derived cytokines, including IL-4, IL-5, IL-6, and IL-9, function synergistically with SCF to amplify the numbers of MCs in human cord blood–derived cultures [16] and at inflamed mucosal sites in mice. [19] Thus important developmental parallels are seen in the mouse and human MC, since both require SCF and its intact receptor c- *kit* to maintain in situ development of constitutive and T cell–modulated populations.

MAST CELL RECEPTORS, LIGANDS, AND CHEMOTAXIS

Mast cell activation occurs through perturbation of the high-affinity IgE receptor FceRI that is expressed on the surface of not only MCs but also basophils and Langerhans cells. [20] In MCs and basophils, FceRI is a tetrameric structure consisting of one alpha chain that binds the Fc portion of IgE, one transmembrane ß chain, and two disulfide-linked ? chains participating in signal transduction. The two ? chains are disulfide-linked and display significant structural homology to the zeta chain of the T cell receptor with two tandem cytoplasmic immunoregulatory tyrosine activation motifs (ITAMs). [21] Activation through FceRI occurs when adjacent IgE-bearing receptors are cross-linked by a multivalent antigen or by an immune complex composed of IgE.

Inhibitory receptors that attenuate FceRI activation have been identified on both human and mouse MCs. Both the low-affinity IgG receptor Fc?RIIb1 and gp49B1, a transmembrane receptor member of the immunoglobulin supergene family, contain immunoregulatory tyrosine-based inhibition motifs (ITIMs) in their cytoplasmic domains. Coligation of FceRI with either Fc?RIIb1 or gp49B1 leads to decreased MC degranulation and cysteinyl leukotriene generation. [22], [23] Phosphorylation of the ITIM motif of Fc?RIIb1 activates polyphosphoinositol 5-phosphatase (SHIP), and phosphorylation of the ITIM motif on gp49B1 activates Src homology protein tyrosine phosphatase 1 (SHP-1). [24], [25] Whereas FceRIIb1 is recruited by the Fc portion of an immune complex during an adaptive immune response, the ligands for gp49B1 are believed to be innate and may include an integrin. [26] The targeted disruption of either FceRIIb1 or gp49B1 increases the susceptibility of mice to anaphylactic reactions. [27], [28]

Chemotactic proteins such as chemokines play an essential role in the selective recruitment and activation of MCs at sites of inflammation (see Chap. 27). Eotaxin and RANTES (regulated on activation, normal T cell expressed and secreted) are members of the beta or CC chemokine family and are chemotactic for cord blood–derived MCs. [29] RANTES binds to the CCR1, CCR3, and CCR5 chemokine receptors, and progenitor cord blood–derived MCs express CCR5; progenitor and mature MCs express CCR3. [16] In situ MCs in the skin and intestinal submucosa express CCR3. Stromal cell–derived factor 1a (SDF-1a), a member of the a or CXC chemokine family, can induce calcium flux and concentration-dependent transendothelial migration in cord blood–derived MCs by binding to CXCR4. [30] IL-8, which binds to the CXCR1 and CXCR2 chemokine receptors, stimulates chemotaxis in cord blood–derived MCs and the immature human MC line HMC-1. [31] SCF also can act as a chemotactic factor for HMC-1, an effect dependent on fibronectin and blocked by antibodies to SCF. [32] Other factors such as the anaphylatoxins C3a and C5a are able to stimulate the laminin-dependent migration of cord blood– or skin-derived MCs. [33]

MAST CELL–DERIVED MEDIATORS

Mast cell–derived mediators can be preformed and stored in secretory granules, newly generated from phospholipid membrane components, or induced by de novo gene expression. This sequence with redundant functions likely allows the MCs to participate in sustained inflammatory responses.

Preformed Secretory Granule Mediators

Histamine is a biogenic amine produced by MCs, basophils, and platelets and is stored in secretory granules. [34] Histamine is exocytosed rapidly in response to immunologic and nonimmunologic stimuli. Histamine acts through the H $_1$

receptor to mediate increased vascular permeability, bronchial and intestinal smooth muscle contraction, and increased nasal mucus production; it acts through the H_2 receptor to increase vascular permeability, gastric acid secretion, and airway mucus production. [35] H_3 and H_4 receptors have been cloned recently to describe an entire family of G protein–coupled receptors; the precise function of these new receptors is still being addressed. [36]

The metachromatic staining of MC granules is due to sulfated anionic *proteoglycans* composed of a novel peptide core, serglycin, common to all hematopoietic cell secretory granule proteoglycans, and of adducts such as heparin and chondroitin sulfate. [37] Human lung MCs contain both heparin and chondroitin sulfate proteoglycans. [38] Mast cells developed from transgenic mice strains defective in heparin synthesis have altered granule morphology with defects in histamine and MC proteases, suggesting posttranslational control of granule constituents. [39], [40] The tryptase gene family encodes the predominant *proteases* of the human MCs. This serine endopeptidase exhibits trypsin-like substrate specificity and cleaves basic amino acid residues from proteins. Several members of the family have been described, including a, ß, ?, and mouse MC protease 7 (mMCP-7)–like tryptases. The tryptase locus resides on chromosome 16p13.3, and sequencing of the locus led to identification of a novel tryptase gene related to mMCP-7. Along with mMCP-6, mMCP-7 has been shown to play a distinct role in inflammation. [41] The ?-tryptases, also on this chromosome, contain a C-terminal hydrophobic domain that may serve as a membrane anchor. [42], [43]

The tryptases are stored as a cationic tetramer with heparin. [44] ß-Tryptase is stored in the secretory granule and released during exocytosis. Serum levels of ß-tryptase rise within 15 min of anaphylactic events and peak at 1 to 2 hours. [45] a-Tryptase is constitutively released from MCs, and levels of both a- and ß-tryptase are elevated in patients with mastocytosis due to an increased burden of MCs. [45], [46] Tryptase levels are elevated in the bronchoalveolar lavage (BAL) fluid of patients with asthma and in nasal secretions of those with allergic rhinitis. [47], [48]

Tryptase inactivates certain neuropeptides, including the bronchodilatory vasoactive intestinal peptide, and also targets matrix metalloproteinases, procoagulant proteins, and proteinase-activated receptor 2. [49], [50] In vitro, tryptase stimulates fibroblast proliferation and mRNA synthesis for procollagen and upregulates the expression of IL-8 and intercellular adhesion molecule 1 (ICAM-1) in bronchial epithelial cells. [51], [52] Recombinant human $ß_1$-tryptase instilled into the mouse trachea increases the number of neutrophils in the BAL fluid and improves bacterial clearance in the lungs of $W/W_?$ mice; this finding suggests a role for $ß_1$-tryptase in innate immune responses in the lung. a-Tryptase was ineffective in this regard, and thus it appears that relevant functional distinctions exist in vivo. [53]

The MC_{TC} subpopulation of human MCs contains the chymotryptic-like serine endopeptidase *chymase* and/or a second member of this gene family, cathepsin-G. [54] A single human MC chymase gene composed of five exons has been identified on chromosome 14. [55] Chymase also binds to heparin in a macromolecular complex. [34] In vitro, chymase has a 100-fold greater potency than angiotensin-converting enzyme in the conversion of angiotensin I to angiotensin II. It inactivates bradykinin and the neuropeptides vasoactive intestinal peptide and substance P; cleaves laminin, type IV collagen, and fibronectin with attendant basement membrane degradation; and can convert the precursor of IL-1ß to an active form, stimulating secretion from airway serous cells. [56]

Mouse MCs contain five separate chymases (mMCP-1, -2, -4, -5, and -9). These chymases have been cloned and immunochemically defined to allow further study of the phenotypic diversity and plasticity of MCs influenced by various cytokines in vitro and in vivo. [57] The mouse chymase genes are located on chromosome 14 and exhibit a similar genomic organization to the human genes, with mMCP-5 being the closest in evolution. [58] Cytokine regulation of the profile of chymase family expression in vitro is based on induction of transcript stability. [59] The diversity of chymase expression during the initiation and resolution of intestinal mastocytosis during helminth infection in the mouse likely reflects such transcript regulation in situ by T cell–secreted cytokines.

Lipid-Derived Mediators of Inflammation

Lipid mediators are newly formed from membrane phospholipids after cell activation. Membrane phospholipids serve as the source of the 20-carbon arachidonic acid substrate used to form the prostaglandins (PGs) and leukotrienes (LTs). Phospholipase (PL) A_2 enzymes release arachidonic acid from the *sn*-2 position of phospholipids to provide substrate for eicosanoid products and platelet-activating factor (PAF). The integral perinuclear membrane PG endoperoxide synthases (PGHS-1 and -2, or cyclooxygenase 1 and 2) metabolize the released arachidonic acid directly to the intermediates PGG_2 and PGH_2 for processing by terminal PG synthases. Mast cells contain hematopoietic cell–type PGD_2 synthase, which converts PGH_2 to PGD_2. [60]

In activated mouse bone marrow–derived mast cells (BMMCs), the two isoforms of PGHS serve different functions. A constitutive phase of PGD_2 generation occurring within minutes after activation of MCs via FceRI or the c- *kit* receptor is linked to the constitutively expressed PGHS-1. This immediate PGD_2 production is accompanied by the rapid phosphorylation and translocation of cytosolic PLA_2 ($cPLA_2$) to a membrane compartment, an event dependent on the MAP kinase pathway. [61] A delayed phase of PGD_2 generation occurring over several hours in response to SCF and IL-10 plus FceRI cross-linking requires the de novo induction of PGHS-2 and is linked to heparin-sensitive cell membrane–associated low-molecular-weight PLA_2 and $cPLA_2$. [62]

PGD_2 appears in bronchial and nasal secretions after allergen challenge, and its metabolite, 9a,11ß-PGF_2, appears in the urine of patients with systemic mastocytosis and in those with aspirin-induced asthma. [63], [64] The intradermal injection of PGD_2 leads to a wheal and flare response due to vasodilation and increased vascular permeability, and the inhalation of PGD_2 causes the bronchoconstriction of airway smooth muscle. [65] Two seven-transmembrane G protein–coupled receptors for PGD_2 have been described: the DP receptor, which is expressed on endothelial and airway smooth muscle

cells, and CRTH2, which is selectively expressed on T_H2 cells, eosinophils, and basophils. [66], [67] The binding of PGD_2 to CRTH2 may provide a positive-feedback pathway between MCs and T_H2 lymphocytes in allergic inflammation. T_H2 cells would support cytokine-mediated, SCF-dependent coproliferation of mucosal MCs with augmented capacity to generate cysteinyl leukotrienes, whereas PGD_2 would continue to recruit T_H2 cells to the inflammatory focus.

The first enzyme in the leukotriene pathway, 5-lipoxygenase (5-LO), undergoes calcium-dependent translocation to the perinuclear membrane after cell activation. There, arachidonic acid released by $cPLA_2$, in the presence of the integral membrane protein 5-lipoxygenase–activating protein (FLAP), is presented to 5-LO for conversion to the epoxide leukotriene A_4 (LTA_4). LTA_4 is subsequently converted into the cysteinyl leukotriene LTC_4 by LTC_4 synthase, an integral perinuclear membrane protein that conjugates glutathione to LTA_4. [68] The targeted disruption of LTC_4 synthase has demonstrated that this enzyme, and not microsomal or cytosolic glutathione- *S*-transferases, is the major LTC_4-producing enzyme in vivo. Cysteinyl leukotrienes are the predominant mediators of the permeability changes that accompany IgE-dependent MC activation. [69]

Activated human MCs produce LTC_4, which undergoes carrier-mediated export for conversion to the active metabolites LTD_4 and LTE_4. The three cysteinyl leukotrienes each increase microvascular permeability, are potent inducers of long-lasting wheal and flare responses, and when inhaled, elicit bronchoconstriction, with LTC_4 and LTD_4 providing more than 1000-fold greater potency than histamine. [70] Levels of cysteinyl leukotrienes are elevated in the nasal secretions of patients with allergic rhinitis and in BAL fluid from patients with asthma. The gene for human LTC_4 synthase is localized distal to the gene cluster for the T_H2-type cytokines IL-3, IL-4, IL-5, and IL-13 and granulocyte-macrophage colony-stimulating factor (GM-CSF) on chromosome 5. [71] Two cysteinyl leukotriene receptors have been described, CysLT1 and CysLT2, with CysLT1 having a greater binding affinity for LTD_4 than LTC_4 or LTE_4, and CysLT2 having equal affinities for LTC_4 and LTD_4 and poor affinity for LTE_4. [72], [73] IL-4 priming of cord blood–derived human MCs uncovers a response to LTC_4 and to pyrimidinergic ligands that is blocked by CysLT1 receptor inhibitors and is subject to cross-desensitization between these ligands. [74]

Human MCs from different tissues have different capacities to generate eicosanoids. Both total PGD_2 generation and the PGD_2–cysteinyl leukotriene ratio are marked by quantitative and relative tissue-related differences. [8] In mouse BMMCs, upregulation of the intermediate enzymes for prostaglandin or leukotriene generation depends on different cytokines, e.g., SCF for the PGD_2 pathway and IL-3 for the cysteinyl leukotriene pathway. [75] In human MCs derived in vitro from cord blood, IL-4, IL-3, and IL-5 prime for increased cysteinyl leukotriene production, with each cytokine targeting distinct steps in the cysteinyl leukotriene biosynthetic pathway. IL-4 induces the expression of FceRI and LTC_4 synthase, whereas IL-3 and IL-5 translocate 5-lipoxygenase to the nucleus. [76]

Cytokines and Chemokines: Constitutive and Induced

The MC is increasingly recognized as a source of multifunctional cytokines that may participate in the recruitment and activation of other cells in the inflammatory microenvironment. Mast cells with different secretory granule protease phenotypes exhibit differences in their cytokine profiles, thus indicating further heterogeneity based on tissue localization. [77]

Human tissue MCs demonstrate transcripts and immunoreactive protein for IL-4 in situ, and dispersed human lung MCs release IL-4 and IL-5 after activation with IgE and antigen. [77], [78] When mouse BMMCs are stimulated with SCF plus IL-10, the mRNA transcripts for IL-6 are upregulated, but little protein is released. However, when IL-1ß is added to the culture, steady-state transcripts persist with attendant IL-6 protein release due to the induction of a stabilizing factor that prolongs the half-life of IL-6 mRNA and permits its translation. [79] Cord blood–derived human MCs can release IL-5, IL-13, GM-CSF, and tumor necrosis factor a (TNF-a), as well as the chemokine macrophage inhibitory protein 1a (MIP-1a), after activation through FceRI. [80]

Although TNF-a (cachexin) can be constitutively stored in the granule, most is induced with immunologic activation of mouse MCs. [81] TNF-a also can be released in response to bacterial infection through the interaction of lipopolysaccharide with toll-like receptor 4 or bacterial FimH with CD48. [82], [83] Recent studies with MC-deficient $W/W_?$ mice have demonstrated the importance of MC-derived TNF-a in neutrophil recruitment in bacterial peritonitis [83], [84] and in protection from endotoxic shock, a response mediated by Janus kinase 3. [85] Mast cell–derived TNF-a also upregulates endothelial leukocyte adhesion molecule 1 (ELAM-1) and ICAM-1 expression on endothelial cells, facilitating adhesion and ingress of eosinophils and T cells to the inflammatory locus. [86]

Transcripts for transforming growth factor ß (TGF-ß), a potent fibroblast activator and proliferation factor, are localized in human MCs from fibrotic lung and rheumatoid synovium. [87] Cultured mouse BMMCs activated through FceR1 release bioactive TGF-ß, which upregulates a_1 (I) collagen mRNA transcripts in fibroblasts. [88] Rat peritoneal MCs synthesize nerve growth factor (NGF), as determined by both transcript and protein. [89] Mouse MCs contain the chemokines RANTES and members of the MIP family. [90]

The biology of the MC traditionally has been studied in the context of the cell's central pathobiologic role in allergy and allergic inflammation. Recent studies have focused on MC development in the hematopoietic lineage and integrin-selective tissue localization of committed circulating progenitors. Detailed histologic and molecular analysis of the determinants of MC heterogeneity in tissues has led to the concept of constitutive and reactive MC populations developed from a single lineage of committed progenitors. Compelling evidence has been evolving to identify MCs involved in innate host defense against bacteria as those of the constitutive phenotype, whereas MCs involved in the

host defense against helminths arise from prelocalized resident progenitors that amplify, mature, and differentiate under the control of T cell signals.

REFERENCES

1. Weidner N, Austen KF: Evidence for morphologic diversity of human mast cells: An ultrastructural study of mast cells from multiple body sites. *Lab Invest* **63**:63, 1990

2. Damsgaard TE et al: Mast cells and atopic dermatitis: Stereological quantification of mast cells in atopic dermatitis and normal human skin. *Arch Dermatol Res* **289**:256, 1997

3. Bischoff SC et al: Quantitative assessment of intestinal eosinophils and mast cells in inflammatory bowel disease. *Histopathology* **28**:1, 1996

4. Ibrahim MZ et al: The mast cells of the multiple sclerosis brain. *J Neuroimmunol* **70**:136, 1996

5. Crimi E et al: Increased numbers of mast cells in bronchial mucosa after the late-phase asthmatic response to allergen. *Am Rev Respir Dis* **144**:1282, 1991

6. Irani AA et al: Two types of human mast cells that have distinct neutral protease compositions. *Proc Natl Acad Sci USA* **83**:4464, 1986

7. Galli SJ et al: The kit ligand, stem cell factor. *Adv Immunol* **55**:1, 1994

8. Austen KF, Boyce JA: Mast cell lineage development and phenotypic regulation . *Leuk Res* **25**:511, 2001

9. Furitsu T et al: Identification of mutations in the coding region of the proto-oncogene c- *kit* in a human mast cell leukemia cell line causing ligand independent activation of c- *kit* product. *J Clin Invest* **92**:1736, 1993

10. Tsujimura T et al: Ligand independent activation of c- *kit* receptor tyrosine kinase in a murine mastocytoma cell line P-815 generated by a point mutation. *Blood* **83**:2619, 1994

11. Valent P et al: Diagnostic criteria and classification of mastocytosis: A consensus proposal. *Leuk Res* **25**:603, 2001

12. Kirshenbaum AS et al: Demonstration of the origin of human mast cells from CD34+ bone marrow progenitor cells. *J Immunol* **146**:1410, 1991

13. Rottem M et al: Mast cells cultured from the peripheral blood of normal donors and patients with mastocytosis originate from a CD34+/FceR1- population. *Blood* **84**:2489, 1994

14. Furitsu T et al: Development of human mast cells in vitro. *Proc Natl Acad Sci USA* **86**:10039, 1989

15. Mitsui H et al: Development of human mast cells from umbilical cord blood cells by recombinant human and murine c- *kit* ligand. *Proc Natl Acad Sci USA* **90**:735, 1993

16. Ochi H et al: T helper type-2 cytokine-mediated comitogenic responses and CCR3 expression during differentiation of human mast cells in vitro . *J Exp Med* **190**:267, 1999

17. Lantz CS et al: Role for interleukin-3 in mast cell and basophil development and in immunity to parasites. *Nature* **392**:90, 1998

18. Irani AM et al: Deficiency of the tryptase-positive, chymase-negative mast cell type in gastrointestinal mucosa of patients with defective T lymphocyte function. *J Immunol* **138**:4381, 1987

19. Finkelman FD, Urban JF Jr: The other side of the coin: The protective role of TH2 cytokines. *J Allergy Clin Immunol* **107**:772, 2001

20. Bieber T et al: Human epidermal Langerhans cells express the high affinity receptor for immunoglobulin E (FceRI). *J Exp Med* **175**:1285, 1992

21. Scharenberg AM, Kinet JP: FceRI and the FcRß amplifier. *Int Arch Allergy Immunol* **117**:113, 1997

22. Katz HR et al: Mouse mast cell gp49B1 contains two immunoreceptor tyrosine-based inhibition motifs and suppresses mast cell activation when coligated with the high affinity Fc receptor for IgE. *Proc Natl Acad Sci USA* **93**:10809, 1996

23. Daeron M et al: Regulation of high-affinity IgE receptor-mediated mast cell activation by murine low affinity IgG receptors. *J Clin Invest* **95**:577, 1995

24. Ono M et al: Role of the inositol phosphatase SHIP in negative regulation of the immune system by the receptor Fc?RIIB. *Nature* **383**:263, 1996

25. Lu-Kuo JM et al: gp49B1 inhibits IgE-mediated mast cell activation through both immunoreceptor tyrosine-based inhibitory motifs, recruitment of the src homology 2 domain-containing phosphatase-1, and suppression of early and late calcium mobilization. *J Biol Chem* **274**:5791, 1999

26. Castells MC et al: gp49B1-alpha v beta 3 interaction inhibits antigen-induced mast cell activation. *Nature Immunol* **2**:436, 2001

27. Ujike A et al: Modulation of immunoglobulin (Ig)E-mediated systemic anaphylaxis by low-affinity Fc receptors for IgG. *J Exp Med* **189**:1573, 1999

28. Daheshia M et al: Increased severity of local and systemic anaphylactic reactions in gp49B1-deficient mice. *J Exp Med* **194**:227, 2001

29. Romagnani P et al: Tryptase-chymase double-positive human mast cells express the eotaxin receptor CCR3 and are attracted by CCR3-binding chemokines. *Am J Pathol* **155**:1195, 1999

30. Lin TJ et al: Human mast cells transmigrate through human umbilical vein endothelial monolayers and selectively produce IL-8 in response to stromal cell–derived factor-1a. *J Immunol* **165**:211, 2000

31. Nilsson G et al: Mast cell migratory response to interleukin-1 is mediated through interaction with chemokine receptor CXCR2/interleukin-8RB. *Blood* **93**:2791, 1999

32. Nilsson G et al: Stem cell factor is a chemotactic factor for human mast cells. *J Immunol* **153**:3717, 1994

33. Hartmann K et al: C3a and C5a stimulate chemotaxis of human mast cells. *Blood* **89**:2863, 1997

34. Schwartz LB et al: Quantitation of histamine, tryptase, and chymase in dispersed human T and TC mast cells. *J Immunol* **138**:2611,1987

35. Falus A, Meretey K: Histamine: An early messenger in inflammatory and immune reactions. *Immunol Today* **13**:154, 1992

36. Hough LB: Genomics meets histamine receptors: New subtypes, new receptors. *Mol Pharmacol* **59**:415, 2001

37. Avraham S et al: Cloning and characterization of the mouse gene that encodes the peptide core of secretory granule proteoglycans and expression of this gene in transfected rat fibroblasts. *J Biol Chem* **264**:16719, 1989

38. Stevens RL et al: Identification of chondroitin sulfate E and heparin proteoglycans in the secretory granules of human lung mast cells. *Proc Natl Acad Sci USA* **85**:2284, 1988

39. Forsberg E et al: Abnormal mast cells in mice deficient in a heparin-synthesizing enzyme. *Nature* **400**:773, 1999

40. Humphries DE et al: Heparin is essential for the storage of specific granule proteases in mast cells. *Nature* **400**:769, 1999

41. Huang C et al: Regulation and function of mast cell proteases in inflammation. *J Clin Immunol* **18**:169, 1998

42. Caughey GH et al: Characterization of human gamma-tryptases, novel members of the chromosome 16p mast cell tryptase and prostasin gene families. *J Immunol* **164**:6566, 2000

43. Wong GW et al: Cloning of the human homolog of mouse transmembrane tryptase. *Int Arch Allergy Immunol* **118**:419, 1999

44. Schwartz LB: Structure and function of human mast cell tryptase, in *Biological and Molecular Aspects of Mast Cell and Basophil Differentiation and Function,* edited by Y Kitamura New York, Raven, 1995

45. Schwartz LB et al: Time course of appearance and disappearance of human mast cell tryptase in the circulation after anaphylaxis. *J Clin Invest* **83**:1551, 1989

46. Schwartz LB et al: The a form of human tryptase is the predominant type present in blood at baseline in normal subjects and is elevated in those with systemic mastocytosis. *J Clin Invest* **96**:2702, 1995

47. Wenzel SE et al: Activation of pulmonary mast cells by broncheoalveolar allergen challenge: In vitro release of histamine and tryptase in atopic subjects with and without asthma. *Am Rev Respir Dis* **137**:1002, 1988

48. Rasp G, Hochstrasser K: Tryptase in nasal fluid is a useful marker of allergic rhinitis. *Allergy* **48**:72, 1993

49. Tam EK, Caughey GH: Degradation of airway neuropeptides by human lung tryptase. *Am J Respir Cell Mol Biol* **3**:27, 1990

50. Corvera CU et al: Mast cell tryptase regulates colonic myocytes through proteinase-activated receptor-2. *J Clin Invest* **100**:1383, 1997

51. Gruber BL et al: Synovial procollagenase activation by human mast cell tryptase: Dependence upon matrix metalloproteinase 3 activation. *J Clin Invest* **84**:1657, 1989

52. Cairns JA, Walls AF: Mast cell tryptase is a mitogen for epithelial cells: Stimulation of IL-8 production and intracellular adhesion molecule-1 expression. *J Immunol* **156**:275, 1996

53. Huang C et al: Evaluation of the substrate specificity of human mast cell tryptase ß $_1$ and demonstration of its importance in bacterial infection of the lung. *J Biol Chem* **276**:26276, 2001

54. Schechter NM et al: Identification of a cathepsin G-like proteinase in the MCTC type of human mast cell. *J Immunol* **145**:2652, 1990

55. Caughey GH et al: Structure, chromosomal assignment, and deduced amino acid sequence of a human gene for mast cell chymase. *J Biol Chem* **266**:12956, 1991

56. Fukami H et al: Chymase: Its pathophysiological roles and inhibitors. *Curr Pharm Des* **4**:439, 1998

57. Gurish MF et al: Tissue-regulated differentiation and maturation of a v- *abl*-immortalized mast cell-committed precursor. *Immunity* **3**:175, 1995

58. Gurish MF et al: A closely linked complex of mouse mast cell specific chymase genes on chromosome 14. *J Biol Chem* **268**:11372, 1993

59. Xia Z et al: Post-transcriptional regulation of chymase expression in mast cells: A cytokine-dependent mechanism for controlling the expression of granule neutral proteases of hematopoietic cells. *J Biol Chem* **271**:8747, 1996

60. Kanaoka Y et al: Cloning and crystal structure of hematopoietic prostaglandin D synthase. *Cell* **96**:449, 1997

61. Murakami M et al: The immediate phase of c *-kit* ligand stimulation of mouse bone marrow-derived mast cells elicits rapid leukotriene C $_4$ generation through posttranslational activation of cytosolic PLA $_2$ and 5-lipoxygenase. *J Exp Med* **182**:197, 1995

62. Bingham CO III et al: A heparin-sensitive phospholipase A $_2$ and prostaglandin endoperoxide synthase are functionally linked in the delayed phase generation of prostaglandin D $_2$ generation in mouse bone marrow-derived mast cells. *J Biol Chem* **271**:25936, 1996

63. O'Sullivan S et al: Increased urinary excretion of the prostaglandin D $_2$ metabolite 9a,11ß-prostaglandin F $_2$ after aspirin challenge supports mast cell activation in aspirin-induced airway obstruction. *J Allergy Clin Immunol* **98**:421, 1996

64. Roberts LJ II et al: Increased production of prostaglandin D $_2$ in patients with systemic mastocytosis. *N Engl J Med* **180**:1400, 1980

65. Hardy CC et al: The bronchoconstrictor effect of inhaled prostaglandin D $_2$ in normal and asthmatic men. *N Engl J Med* **311**:209, 1984

66. Narumiya S et al: Prostanoid receptors: structures, properties, and functions. *Physiol Rev* **79**:1193, 1999

67. Hirai H et al: Prostaglandin D_2 selectively induces chemotaxis in T helper type 2 cells, eosinophils, and basophils via seven-transmembrane receptor CRTH2. *J Exp Med* **193**:255, 2001

68. Lam BK et al: Leukotriene C_4 synthase. *J Lipid Mediat Cell Signal* **12**:333,1995

69. Kanaoka Y et al: Attenuated zymosan-induced peritoneal vascular permeability and IgE-dependent passive cutaneous anaphylaxis in mice lacking leukotriene C_4 synthase. *J Biol Chem* **276**:22608, 2001

70. Arm JP, Lee TH: Sulphidopeptide leukotrienes in asthma. *Clin Sci (Colc)* **84**:501, 1993

71. Penrose JF et al: Molecular cloning of the gene for human leukotriene C_4 synthase, organization, nucleotide sequence, and chromosomal localization to 5q35. *J Biol Chem* **271**:11356, 1996

72. Lynch KR et al: Characterization of the human cysteinyl leukotriene cysLT1 receptor. *Nature* **399**:789, 1999

73. Heise CE et al: Characterization of the human cysteinyl leukotriene 2 (CysLT2) receptor. *J Biol Chem* **275**:30531, 2000

74. Mellor EA et al: Cysteinyl leukotriene receptor 1 is also a pyrimidinergic receptor and is expressed by human mast cells. *Proc Natl Acad Sci USA* **98**:1964, 2001

75. Murakami M et al: Interleukin 3 regulates development of the 5-lipoxygenase/leukotriene C_4 synthase pathway in mouse mast cells. *J Biol Chem* **270**:22653, 1995

76. Hsieh FH et al: T helper cell type 2 cytokines coordinately regulate IgE-dependent cysteinyl leukotriene production by human cord blood–derived mast cells: Profound induction of leukotriene C_4 synthase expression by IL-4. *J Exp Med* **193**:123, 2001

77. Bradding P et al: Heterogeneity of human mast cells based on cytokine content. *J Immunol* **155**:297, 1995

78. Jaffe JS et al: Human lung mast cell IL-5 gene and protein expression: Temporal analysis of upregulation following IgE mediated activation. *Am J Resp Cell Mol Biol* **13**:665,1995

79. Lu-Kuo JM et al: Post-transcriptional stabilization by interleukin-1ß of interleukin-6 mRNA induced by c- *kit* ligand and interleukin 10 in mouse bone marrow-derived mast cells. *J Biol Chem* **271**:22169, 1996

80. Ochi H et al: IL-4 and -5 prime human mast cells for different profiles of IgE-dependent cytokine production. *Proc Natl Acad Sci USA* **97**:10509, 2000

81. Gordon JR, Galli SJ: Release of both preformed and newly synthesized tumor necrosis factor alpha (TNF-a)/cachectin by mouse mast cells stimulated via the FceRI: A mechanism for the sustained action of mast cell-derived TNF-a during IgE-dependent biological responses. *J Exp Med* **174**:103, 1991

82. Malaviya R et al: The mast cell tumor necrosis factor alpha response to FimH-expressing *Escherichia coli* is mediated by the glycosyl-phosphatidylinositol-anchored molecule CD48 . *Proc Natl Acad Sci USA* **96**:8110, 1999

83. Supajatura V et al: Protective roles of mast cells against enterobacterial infection are mediated by toll-like receptor 4 . *J Immunol* **167**:2250, 2001

84. Echtenacher B et al: Critical protective role of mast cells in a model of acute septic peritonitis. *Nature* **381**:75,1996

85. Malaviya R et al: Role of Janus kinase 3 in mast cell-mediated innate immunity against gram-negative bacteria. *Immunity* **18**:313, 2001

86. Klein LM et al: Degranulation of human mast cells induces an endothelial antigen central to leukocyte adhesion. *Proc Natl Acad Sci USA* **86**:8972, 1989

87. Qu Z et al: Mast cells are a major source of basic fibroblast growth factor in chronic inflammation and cutaneous hemangioma. *Am J Pathol* **1147**:564, 1995

88. Gordon JR, Galli SJ: Promotion of mouse fibroblast collagen gene expression by mast cells stimulated via the FceRI: Role for mast cell-derived transforming growth factor ß and tumor necrosis factor a. *J Exp Med* **180**:2027, 1994

89. Leon A et al: Mast cells synthesize, store, and release nerve growth factor. *Proc Natl Acad Sci USA* **91**:3739, 1994

90. Burd PR et al: Interleukin 3-dependent and -independent mast cells stimulated with IgE and antigen express multiple cytokines. *J Exp Med* **170**:245, 1989

T>

Chapter 33

Irma Gigli

Human Complement System

BIOCHEMISTRY OF THE PROTEINS OF THE COMPLEMENT SYSTEM AND ACTIVATION MECHANISMS
Activation of the Classical Pathway (Table 33-1, Fig. 33-1)
Activation of the Mannan-Binding Lectin Pathway (Table 33-1, Fig. 33-1)
Activation of the Alternative Pathway (Table 33-2, Fig. 33-1)
Assembly of the Membrane Attack Complex (Table 33-3, Fig. 33-1)
REGULATION MECHANISMS OF COMPLEMENT ACTIVATION AND FUNCTION
Regulation of the Classical and the MBL Pathways (Fig. 33-2)
Regulation of the Alternative Pathway (Fig. 33-2)
Regulation of the Membrane Attack Complex (Table 33-3)
BIOLOGIC ACTIVITY OF THE PRODUCTS OF COMPLEMENT ACTIVATION
Biologic Effects of Complement Activation on Target Particles
Biologic Effects Mediated by the Interaction of Products of Complement Activation with Cell Membrane Receptors
Anaphylatoxins (Table 33-6)

REFERENCES

The complement system consists of a group of plasma and cell membrane proteins that mediate a number of biologic reactions. Investigations in humans and the development of experimental disease models have demonstrated the participation of complement in inflammation, tissue injury, hemostasis, and antigen-specific immune responsiveness. These diversified tasks are achieved either by complement components alone or by their interaction with other plasma proteins or specific cell membrane receptors (complement receptors).

The components of the classical pathway and the membrane attack sequence are named by the letter C followed by a number: C1, C4, C2, C3, C5, C6, C7, C8, and C9. Some of the earlier components were named before their position in the sequence was known, thus leading to the apparent inconsistency in their order in the nomenclature. C1 consists of three distinct subcomponents, designated C1q, C1r, and C1s. The activation components of the mannan-binding lectin (MBL) pathway are designated by capital letters representing the initials of the proteins involved: MBL and mannan-associated serine proteases (MASPs). The proteins of the alternative pathway are designated by capital letters: B, D, P, H, and I. C3 is an essential protein of all pathways. Because it was originally recognized as a component of the classical pathway, the original nomenclature is retained. Activation fragments and fragments resulting from regulatory cleavage of a component are denoted by lowercase letters, as in C3a, C3b, C3c, C3dg, and C3d; the letter i signifies an inactive product of a component, as in iC3b. [1] Receptors for fragments of complement proteins (CR) are named after their ligand or indicated by an arabic number: CR for C3b/C4b = CR1; CR for C3dg = CR2; and CR for iC3b = CR3.

The activation of the complement system is organized in three pathways (classical, mannan-binding lectin, and alternative) and in a final common event, the assembly of the membrane attack complex (MAC). Activation is controlled by a number of plasma and cell membrane proteins. Complement activation results in the development of active enzymes from their precursors in a series of limited proteolytic processes, in which the product of one reaction is the catalyst for the next. The terminal components in the sequence form a nonenzymatic, self-associating multimolecular complex that binds firmly to target membranes by means of hydrophobic interactions with the membrane lipid bilayer. Extensive structural information that is now available through the cloning and sequencing of DNA coding for complement proteins and receptors reveals homologies among a number of proteins in the system. [2] This information, together with studies on the chromosomal localization of the genes, provides evidence of genetic linkage among complement and noncomplement genes. Polymorphic variants for most complement proteins have been described, a number of which are of clinical relevance. [2]

BIOCHEMISTRY OF THE PROTEINS OF THE COMPLEMENT SYSTEM AND ACTIVATION MECHANISMS

Central to the functions of the complement system is the activation of the third component, C3. This protein is activated by two enzymes termed *C3 convertases,* which are generated during complement activation (Fig. 33-1). Complement activation can be triggered by antigen–antibody complexes (classical pathway) and by bacterial, viral, and surface carbohydrates (MBL pathway), but C3 also has the capability for direct recognition of foreign materials (alternative pathway). The latter two forms of complement activation represent a primitive antibody-independent immune system (native immunity).

FIGURE 33-1 Activation of the classical, mannan-binding lectin (MBL), and alternative pathways, and formation of the

membrane attack complex.

Activation of the Classical Pathway (Table 33-1, Fig. 33-1)

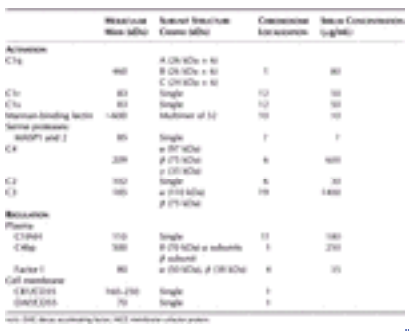

TABLE 33-1 **Proteins of the Classical and the Mannan-Binding Lectin Pathways**

The activation of the classical pathway is initiated primarily by antibody complexed with an antigen, which may be a cell surface constituent or a soluble protein. [1] Activation can also be initiated in the absence of antibody by certain oligosaccharides, porins from gram-negative bacteria, ligand-bound C-reactive protein, and a variety of charged substances. Photoactive substances, double-stranded DNA, some oncoviruses, and products of tissue damage, such as mitochondrial cardiolipin, mitochondrial proteins, and nucleic acid, may also activate the classical pathway. These mechanisms of activation most likely differ from that afforded by antigen–antibody complexes and may involve the MBL pathway. [3]

Aggregation of IgG or IgM molecules, either specifically by interaction with an antigen or nonspecifically by heat or by chemical cross-linking, is necessary for the binding and activation of the recognition unit of the classical pathway, C1. [4] At least two IgG molecules are required for C1 activation, whereas only one IgM molecule bound to two or more antigenic sites is sufficient. C1 is a Ca^{2+}-dependent molecular complex composed of three distinct proteins, C1q, C1r, and C1s. [5] C1 reacts with antigen–antibody complexes, and probably with other activators, through the C1q subunit. C1q has an unusual amino acid composition; it contains glycine, hydroxyproline, and hydroxylysine residues, with glycosylgalactosyl residues coupled to them. [6] This composition indicates the presence of a collagen-like structure. C1q is visualized by electron microscopy as a molecule consisting of six peripheral globular units joined by connective strands to a common central fibril-like portion. The globular segments are, in fact, the binding sites for the Fc portion of IgG [7] or for the constant domain of IgM. [8] IgG3 binds C1q most efficiently, followed by IgG1 and IgG2, whereas in most cases, IgG4 does not bind C1q. On binding to the antigen–antibody complexes, C1q is thought to produce an allosteric change in the proenzyme C1r that triggers its autocatalytic activation. [9] Activated C1r hydrolyzes a single peptide bond in precursor C1s and generates a serine esterase active site, activated C1s. C1r and C1s are very similar in size, and the amino acid sequence of the active site has considerable homology with other serine esterases, yet their substrate specificity is quite distinct. [9] The only natural substrate of C1r is precursor C1s, whereas C1s will hydrolyze bonds only in the next two components in the sequence, C4 and C2. [1]

C4 is a highly polymorphic protein composed of three disulfide-linked polypeptide chains: a, ß, and ?. C4 is synthesized as a single-chain precursor and is posttranslationally cleaved into its three chains. [10] The amino acid sequence of the a chain shows homology with the sequence of C3 and C5, suggesting that these three proteins may have originated by gene duplication. [11]

During complement activation, C1s cleaves the a chain of C4 at the N terminus, releasing C4a, a 9-kDa peptide. [11] C4a is one of three complement-derived peptides with anaphylatoxin activity. The larger fragment, C4b, has a transiently active binding site, provided by an internal thioester. [12] It can react with hydroxyl or amino groups in immune complexes or membranes, resulting in the stable binding of C4b to them. Although most activated C4 molecules remain free in the fluid phase and quickly become inactive (iC4b), the high serum concentration of C4 enables a single C1s molecule to deposit a large number of C4b molecules at the site of an antigen–antibody complex. The cleavage of C4 exposes an acceptor site in the resulting C4b molecule that permits, in the presence of Mg^{2+}, the reversible binding of C2. [13] C2 is a single-chain molecule that is cleaved by C1s to generate the fragments C2a and C2b. C2a (73 kDa) remains attached to C4b in a thermolabile protein-protein enzymatic complex, C4b2a, the classical pathway C3 convertase. [1] C2a contains the catalytic site and activates C3 and C5. The smaller fragment, C2b (34 kDa), is released into the fluid phase, and it has been reported to develop kinin-like activity if cleaved by plasmin. [14]

C3 is a glycoprotein; it is also synthesized as a single-chain precursor and is posttranslationally cleaved into two covalently bonded chains, a and ß. [15] C3 is the complement protein present in the highest concentration in plasma and is essential for the classical, MBL, and alternative pathways. The catalytic site within the C4b2a complex hydrolyzes a single peptide bond from the N terminus of the a chain of C3 to generate two fragments, C3a and C3b. [1] The C3a peptide (9 kDa), containing the 77 N-terminal amino acids, is a potent anaphylatoxin. [16] The major fragment, C3b, like C4b, is transiently capable of forming a stable linkage with immune complexes and cell surfaces through an internal thiol ester within the a chain. [12] If an appropriate binding site is not available, the C3b is inactivated in the fluid phase (iC3b).

Activation of the Mannan-Binding Lectin Pathway (Table 33-1, Fig. 33-1)

An antibody- and C1-independent pathway leading to the assembly of the classical C3 convertase, C4b2a, was recently discovered. [3] This pathway uses MBL and calcium to recognize bacterial, viral, and fungal pathogens expressing terminal

mannose or *N*-acetylglucosamine on their surfaces. MBL is structurally similar to C1q, consisting of four to six C-lectin domains connected to a central region by triple-helical collagen stems. [17] MBL circulates in blood in a complex with zymogen forms of serine proteases called MASPs, which have modular structures identical to C1r and C1s. Thus, the MBL–MASPs complex is structurally similar to the C1 complex (C1q, C1r, C1s). Binding of MBL to carbohydrate structures on pathogens results in activation of the single-chain zymogen MASP to an active two-chain serine protease, which, in turn, sequentially cleaves C4 and C2, resulting in the formation of pathogen-bound C3 convertase C4bC2a. In addition, human MBL is able to substitute for C1q and interact directly with C1r, and C1s to activate the classical pathway. A potential link between the specific immune response and native immunity has been suggested following the observation that agalactosyl immunoglobulins (Ig-GO) complex with MBL and bind C1r and C1s so that complement activation proceeds. Thus, MBL may be viewed as a molecule of the innate immune system with pluripotent activities. [17]

Activation of the Alternative Pathway (Table 33-2, Fig. 33-1)

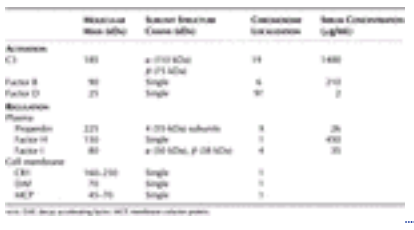

TABLE 33-2 **Proteins of the Alternative Pathway**

The alternative pathway of complement activation endows the host with a natural humoral defense mechanism against infections. [18] Although antigen–antibody complexes are capable of initiating the alternative pathway, [19] more often activation occurs independent of immunoglobulins. The lack of a requirement for antibodies or the early components of the classical pathway is readily demonstrable with sera from individuals congenitally deficient in gamma globulins or in C4 and C2. The alternative pathway may be activated by bacteria, virus-infected cells, certain viruses, some lymphoblastoid cell lines, and abnormal erythrocytes. The plasma proteins involved in the alternative pathway are C3, factor B, factor D, and the regulatory protein properdin (P). Proteolytic generation of C3b from native C3 is necessary for the alternative pathway to function, and the central enzyme of the pathway that cleaves C3 contains C3b as an essential component. [20] This initial step includes C3(H_2O), a nonenzymatic event that results from the spontaneous hydrolysis of an internal thioester in the C3 molecule upon interaction with H_2O. [21] This C3, modified only at the thioester site, binds factor B in a Mg^{2+}-dependent reaction [C3(H_2O)B] and allows its cleavage by the serine protease factor D. [22] Factor D is present in plasma in active form but cleaves factor B only when it is bound to C3(H_2O) or C3b. In this process, a 33-kDa fragment, Ba, is released, while the major fragment, Bb, remains associated with C3(H_2O) to form C3(H_2O)Bb. [21] This is the initial C3 convertase; the catalytic site is located in the Bb subunit, and it hydrolyzes additional C3 molecules at the same site as does C4b2a. Once formed, C3b either is inactivated by regulatory proteins or initiates amplified C3b deposition by forming the alternative pathway C3 convertase (C3bBb). This enzyme amplifies the cleavage of C3 and the deposition of newly generated C3b. [21], [22] and [23] The C3b-dependent positive feedback is a unique feature of the alternative pathway.

Assembly of the Membrane Attack Complex (Table 33-3, Fig. 33-1)

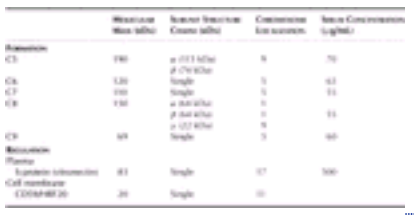

TABLE 33-3 **Proteins of the Membrane Attack Complex**

The classical and MBL pathway C3 convertase C4b2a, as well as the alternative pathway convertase C3bBb, can function in the cleavage of the next component, C5, provided that additional C3b molecules are available in close proximity. [24] The role of C3b is to transiently bind C5 [25] and modify its conformation so that a peptide bond may be cleaved from the N terminus of the a chain to generate C5a and C5b. C5a is released into the fluid phase and functions as the most potent complement-derived anaphylatoxin. [26] The larger fragment, C5b, becomes, without further enzymatic cleavage, the focal point for the assembly of MAC. C5b is composed of the rest of the a chain and the ß chain that expresses labile binding sites. One site allows the transient association of C5b with membranes, and a second interacts with C6. C5b6 reacts with the next component, C7, to form a trimolecular complex, C5b67. The binding site in the nascent C5b67 differs from the binding site on C3b in that C5b, despite structural homologies with C3 and C4, lacks the internal thiolester. [12] The complex does not bind to membranes covalently; rather, it attaches firmly to the lipid moiety through hydrophobic groups exposed on the surface of C7. [27] C5b67 interacts with C8, which penetrates the lipid portion of the cell membrane and induces the polymerization of multiple C9 molecules. [28] Polymerized C9 leads to the insertion of MAC into membranes and the formation of transmembrane channels that allow water, ions, and small molecules to enter the cell, thereby causing cell swelling and lysis. Nucleated cells are more resistant to lysis because ion pumps counteract the influx of ions and water through the channel and limit cell swelling. In addition, an active recovery process takes place by removal of MAC from the cell membrane by either endocytosis or exocytosis. [28] Nucleated cells can recover from limited complement damage, but their function may be altered (Table 33-4).

Cell	Biologic Effects
Neutrophil	Reactive oxygen metabolites and LTB_4 production Vesiculation
Platelet	Prothrombinase activation Vesiculation TXB_2 production
Monocyte-macrophage	Reactive oxygen metabolites, PGE_2, and TXB_2 production
Synovial cells	Reactive oxygen metabolites and PGE_2 production

Note: LT, leukotriene; PG, prostaglandin; TX, thromboxane

TABLE 33-4 **Nonlytic Effects of C5b-9 on Human Cells**

REGULATION MECHANISMS OF COMPLEMENT ACTIVATION AND FUNCTION

The activation process and functions of the complement system are strictly regulated by plasma proteins that prevent spontaneous or abnormal activation in the fluid phase, by plasma proteins that downregulate or upregulate normal activation against target substances, and by membrane proteins that protect host cells from the lytic action of complement.

Regulation of the Classical and the MBL Pathways (Fig. 33-2)

FIGURE 33-2 Regulation of the classical, mannan-binding lectin (MBL), and alternative pathways by plasma and cell membrane proteins. CR1, C3b receptor; DAF, decay accelerating factor; MCP, membrane cofactor protein.

The classical pathway convertase is readily activated in serum by immune complexes, but little activation takes place in their absence. Although C1 may autoactivate by an intramolecular mechanism, autoactivation is controlled by the inhibitor of the first component of complement (C1INH). [29] C1INH prevents the proteolysis of C1r and C1s by interacting with a form of C1 that is in a transitional state, conformationally distinct from native C1 but not yet activated. C1INH also inhibits the enzymatic activities of C1r and C1s by covalently binding to the catalytic site of these proteins, dissociating them from C1q and preventing the cleavage of C4 and C2. Immune complexes activate C1 in serum because the activation rate of the enzyme is faster than its inactivation by C1INH. The interaction of C1INH with C1 has physiologic relevance that is not limited to the regulation of the classical pathway. At the cellular level, the binding site on C1q for the C1q receptor on peripheral blood leukocytes and monocytes becomes available only after C1 interacts with C1INH. [4] Similar to its action on C1r and C1s, the C1INH inhibits activated MASP. [17] Thus, the C1INH may regulate the activation of the MBL pathway in a manner similar to the classical pathway. In addition to its action on C1, C1INH is a point of convergence of the complement system with the clotting and kinin-forming systems, two other effector systems of the inflammatory process [30], [31] (see Chap. 117).

The assembly and function of the C3 convertase generated by the classical and MBL pathways are regulated by the inherent instability of the C4b2a enzyme at 37°C (98.6°F) and by two plasma proteins: C4b-binding protein (C4bp), and the enzyme C4b/C3b inactivator (factor I), for which C4bp is a cofactor. [32] C4bp is a multivalent protein that can bind to a number of C4b molecules. This interaction mediates three functional changes: (1) it accelerates the dissociation of C2a from the C4b2a enzyme; (2) it prevents the uptake of C2 by C4b; and (3) it facilitates the proteolytic cleavage of C4b by factor I. [33] Factor I cleaves two peptide bonds from the a' chain of C4b, thereby generating three fragments. One fragment, C4d, remains attached to the activating particle; the other two fragments, a_3 and a_4, remain covalently bonded to the ß chain, forming C4c, and no longer participate in the activation of the system. Complement activation on cell membranes is controlled by three membrane proteins that act in a similar way to C4bp. The decay accelerating factor (DAF) [34] prevents the binding of C2 to C4b and dissociates the C4b2a complex once it is formed. The C3b receptor (CR1) and the membrane cofactor protein (MCP) also have cofactor activity for factor I. [35]

The fluid phase and membrane cofactor proteins (C4bp, factor H, CR1, DAF, and MCP) share structural features. Each is constructed from a limited number of structural domains with highly conserved cysteine residues (short consensus repeats) present in multiple copies in the molecules. [36]

Regulation of the Alternative Pathway (Fig. 33-2)

The effectiveness of regulatory proteins to either limit or amplify the deposition of C3b-9 molecules on activating substances discriminates between nonactivators and activators of the alternative pathway. [23], [37] The presence or absence of sialic acid on the activating surface seems to determine the accessibility of the deposited C3b to plasma regulatory proteins. [38] Substances poor in sialic acid favor activation, whereas those rich in sialic acid do not. Some of the proteins that regulate C4b2a also regulate the alternative pathway. The C3b/C4b inactivator (factor I), CR1, MCP, and DAF are common to both the classical and the alternative pathways, whereas factors H and P function exclusively in the regulation of the alternative pathway (Table 33-1 and Table 33-2). Factor H accelerates the temperature-dependent dissociation of Bb from the C3bBb complex, [39] prevents the uptake of factor B by C3b, and impairs the formation of the

amplification convertase. It also promotes the cleavage of the a' chain of C3b by factor I. This process results in the generation of an inactive form of the protein (iC3b) that consists of 43- and 68-kDa fragments linked to the intact ß chain (Fig. 33-2). The cell membrane proteins CR1, MCP, and DAF have a function similar to that of factor H. They prevent amplification of C3b deposition by accelerating the decay of Bb from the C3bBb complex; however, only CR1 and MCP serve as cofactors for factor I. CR1 is the only cofactor molecule that catalyzes further cleavage of the 68-kDa fragment to generate C3dg and C3c. [40] In contrast to these proteins that downregulate the formation of C3bBb, P upregulates its function. P is recruited from plasma; it binds to C3bBb (C3bBbP), retarding both the temperature- and factor H-dependent dissociation of Bb. [21], [37]

Regulation of the Membrane Attack Complex (Table 33-3)

The final step in the activation of the complement system, the assembly of the C5b-9 complex (MAC), is also strictly regulated, resulting in the protection of cells from lysis. The formation and function of MAC may be prevented by several plasma inhibitors, the most important being the adhesive molecule vitronectin (S-protein). This acidic glycoprotein binds to C5b67 at a site that prevents the formation of a stable, membrane-bound C5b67 complex and polymerization of C9. [41] Binding of nascent C5b67 to membranes is also inhibited nonspecifically by plasma lipoproteins.

A glycolipid-anchored membrane protein has been described that is presumably responsible for protecting the cells of the host from lysis when complement activation takes place (Table 33-3). This ˜20-kDa [42], [43] protein has been assigned different names—membrane inhibitory protein (MIP), MACIF, HRF 20, and CD59. It acts by binding to C8 and C9 on the cell membrane, successfully preventing C9 polymerization and channel formation.

BIOLOGIC ACTIVITY OF THE PRODUCTS OF COMPLEMENT ACTIVATION

The biologic significance of the complement system is not limited to the completion of the reaction sequence and the role it plays in the death of affected cells. Perhaps of greater importance are the various other biologic effects that are mediated by three kinds of products of complement activation, namely, antigen-bound components, inactive fluid-phase intermediates, and enzyme-cleaved peptides that may serve as ligands to specific receptors on a variety of cells.

Biologic Effects of Complement Activation on Target Particles

EARLY COMPLEMENT COMPONENTS IN VIRUS NEUTRALIZATION [44] The biologic activities that result from the binding and subsequent activation of C1, C4, and C2 are relatively unknown. In vitro C1 and C4 enhance the capacity of specific IgM antibodies to neutralize herpes simplex virus. [45] The neutralization of vesicular stomatitis virus by normal human serum involves the components of the classical pathway through C3 and a nonimmunoglobulin serum factor. The reaction is initiated by the direct attachment of C1 to the external glycoprotein of the virus, which leads to the deposition of complement components on the viral envelope. Complement-mediated neutralization of influenza [46] and Epstein-Barr viruses (EBV) [47] by low levels of specific or cross-reacting antibodies together with C1, C4, C2, and C3, but not with late-acting components, has also been observed. The viruses that cause Newcastle disease and vaccinia are similarly neutralized. These studies indicate that virus neutralization generally requires activation of the classical pathway only through the C3 step. Enveloped viruses are also susceptible to complement-dependent lysis that leads to irreversible loss of viral activity. [48]

COMPLEMENT RECEPTORS AND VIRAL INFECTIONS Some complement receptors serve as fusion proteins for certain viruses. The surface glycoprotein gp 57/67, known to participate in the binding of measles virus to host cells, has been identified as the complement regulatory protein MCP/CD46. [49], [50] A second complement receptor involved in the infection of B lymphocytes by EBV is the CR2 receptor. The binding of CR2 to EBV allows the virus to penetrate and infect B lymphocytes. [51], [52] Complement also appears to participate in all stages of the HIV life cycle. The mechanism of entry of the virus into the cell, the activation of proviral DNA through signaling via complement receptors, viral budding, and extracellular survival of the virus all involve complement products. [53]

C3B-MEDIATED SOLUBILIZATION OF IMMUNE COMPLEXES In vitro the interaction of antibodies and antigen at high concentrations results in the formation of large aggregates that precipitate. In vivo this precipitation is inhibited by complement proteins, thereby preventing the deposition of insoluble complexes in tissue. [54], [55] The binding of C3b to the immune complexes interferes with lattice formation, limits aggregation, and renders the immune complexes more soluble. Although activation of the classical pathway alone may suffice, optimal solubilization of immune aggregates requires participation of both the classical and the alternative pathways. The significance of these processes in disease pathogenesis is demonstrated by the high incidence of immune complex-mediated diseases in patients deficient in C3, C1, C4, or C2. [56]

MEMBRANE ATTACK COMPLEX IN CELL ACTIVATION The terminal complex C5b-9 has been regarded as the lytic event in complement activation. However, the assembly of MAC on the membranes of nucleated cells that are resistant to lysis by homologous complement may result in cell stimulation and the release of proinflammatory molecules. [28] In vitro MAC induces the production and release of reactive oxygen metabolites, eicosanoids, enzymes, and other proinflammatory mediators (see Table 33-4).

Biologic Effects Mediated by the Interaction of Products of Complement Activation with Cell Membrane Receptors

Some of the most important biologic activities of complement known today stem from products of activation and degradation of C3 and C5. The interaction of complement fragments with cells bearing receptors for them may set off a variety of cellular reactions that depend on the cell types carrying the receptors (Table 33-5). At least three distinct reactions may be triggered by receptor–ligand interactions: phagocytosis of immune complexes bearing complement fragments, immune regulation and differentiation of cells, and changes in cellular metabolism.

TABLE 33-5 **Function and Localization of C3 Receptors**

PHAGOCYTOSIS AND CLEARANCE OF IMMUNE COMPLEXES The rate and amount of phagocytosis of antigen–antibody complexes containing IgG by neutrophils and macrophages are greatly augmented by the presence of C3b and iC3b. [56] This reaction is mediated by the presence of specialized receptors for C3b (CR1) and iC3b (CR3) on the membrane of phagocytic cells [57] (Table 33-5). CR1 has the widest distribution of all complement receptors, but more than 90 percent of CR1 in blood is expressed on erythrocytes. Immune complexes bearing C3b become bound to erythrocytes and are transported to the liver, where they are cleared by fixed macrophages. [58] The binding of immune complexes to erythrocytes is an active process; the C3b on the immune complexes attached to CR1 is cleaved by factor I, and the complex is released. The immune complex is gradually reduced in size and becomes more soluble. Thus, under physiologic conditions, complement and erythrocytes have a synergistic role to facilitate removal and prevent precipitation of immune complexes. CR3 is present, among other cells, on neutrophils, macrophages, dendritic cells, and lymphocytes involved in antibody-dependent cell cytotoxicity. The primary ligand for CR3 is iC3b. [59] CR3 is composed of two chains, a (CD11b) and ß (CD18); the ß chain is identical to the ß chain of the leukocyte surface protein, leukocyte function-associated–1 antigen (CD11a/CD18). [60] The presence of CR3 on phagocytes is essential for normal clearance of foreign particles; individuals deficient in CR3 experience impaired phagocytosis and repeated bacterial infections. [60] A molecule similar in function to CR3 but distinct in the size of its chain has been named CR4.

COMPLEMENT RECEPTORS AND IMMUNE REGULATION Cells bearing receptors for complement may carry immune complexes to specific sites where such cells accumulate. The concentration of complexes at such sites may explain the phenomenon of localization of particular antigens in B cell areas of lymphoid organs. [61] The finding that the complexes are released from C3b receptors as a result of the action of factor I, thus acquiring the ability to bind to C3d receptors (CR2), [62] supports the hypothesis that complexes containing C3d are transportable by cells having receptors for them. [63] B lymphocytes, follicular dendritic cells, and natural killer cells express CR2. [64], [65] CR2 binds C3dg and C3d as well as the Epstein-Barr virus (EBV), but the EBV-binding site is distinct from the C3 fragment-binding site. [51], [52] Several lines of evidence support the view that the interaction of complement fragments and complement receptors plays a role in the control of antigen-specific immune responsiveness. Animals depleted of complement may be immunocompromised. It has been suggested that the binding of C3b and C3d triggers the proliferation of B lymphocytes. [66] The production of C3b and C3d in serum may account, in the absence of T lymphocytes, for the activation of B lymphocytes with thymus-dependent antigens. [67], [68] Complement may also play a role in maintaining immunologic memory. Thymectomized, C3-depleted animals do not produce memory B cells, whereas thymectomized animals with an intact complement system do. Moreover, animals that are depleted of C3 or are genetically deficient in C3 or CR2 do not exhibit a secondary immune response. [63], [68], [69] and [70] The evidence obtained from animal models has not yet been related to humans.

Anaphylatoxins (Table 33-6)



TABLE 33-6 **Function of Anaphylatoxins in Human Tissue**

Among the peptides generated by enzyme cleavage during the activation of the complement system are the three anaphylatoxins, C4a, C3a, and C5a (Table 33-6). [26], [71] They cause release of histamine from mast cells, degranulation of basophils, contraction of guinea pig ileum in vitro with tachyphylaxis, and a local increase in vascular permeability when injected intracutaneously in humans and guinea pigs. C3a also induces 5-hydroxytryptamine release from platelets and thromboxane release from macrophages, and it mediates the directed chemotaxis of eosinophils but not neutrophils. The injection of C3a and C5a into human skin results in erythema, edema, and pruritus; pretreatment with antihistamines abolishes the reaction to C3a. [72] The significance of C4a in vivo is not clear. The action of the anaphylatoxins C3a and C5a is attributed to their ability to bind to specific G protein-coupled seven transmembrane receptors on a variety of cells. [26], [73], [74] Most of the chemotactic activity in serum induced by immune complexes, endotoxins, and bacterial products may be ascribed to C5a and C5a des-arg. Moreover, the injection of highly purified C5a into the skin of laboratory animals results in massive accumulation of polymorphonuclear leukocytes followed by the accumulation of macrophages. In vitro C5a is chemotactic for monocytes, macrophages, and eosinophils, as well as for polymorphonuclear leukocytes, and produces neutrophil adhesiveness. It also stimulates neutrophil oxidative metabolism and the production of toxic oxygen species. It induces the release of lysosomal enzymes from a variety of phagocytic cells, the secretion of IL-1, IL-6, IL-8 from macrophages, and the secretion of platelet-activating factor from numerous cell types. The biologic functions of the three anaphylatoxins are modulated by the carboxypeptidase N in serum. [75] This protein cleaves the C-terminal arginine residue (des-arg) of all three anaphylatoxins. C3a and C4a become inactive. C5a des-arg loses its spasmogenic activity, but it retains chemotactic and other neutrophil-stimulating effects at a reduced potency. Evidence for the biologic significance of anaphylatoxins in inflammatory processes has centered on neutrophil adhesiveness and degranulation. In disease processes, anaphylatoxins have been identified as possible mediators in complications of hemodialysis and cardiopulmonary bypass procedures, pulmonary leukostasis, and other inflammatory processes

involving blood vessels.

REFERENCES

1. Müller-Eberhard HJ: Molecular organization and function of the complement system. *Annu Rev Biochem* **57**:321, 1988

2. Crawford K, Alper CA. Genetics of the complement system. *Rev Immunogenet* **2**:323, 2000

3. Petersen SV et al: The mannan-binding lectin pathway of complement activation: biology and disease association. *Mol Immunol* **38**:133, 2001

4. Hughes-Jones N: The classical pathway, in *Immunobiology of the Complement System,* edited by GD Ross. New York, Academic Press, 1986, p 21

5. Gigli I et al: Preparation of the unactivated form of the first component of human complement, C1, and investigation of the mechanism of action. *Biochem J* **157**:541, 1976

6. Reid KBM: A collagen-like amino acid sequence in a polypeptide chain of human C1q (subcomponent of the first component of complement). *Biochem J* **141**:189, 1974

7. Burton DR et al: C1q receptor site on immunoglobulin G. *Nature* **288**:338, 1980

8. Wright JF et al: C1 binding by murine IgM. The effect of a Pro-to-Ser exchange at residue 436 of the µ chain. *J Biol Chem* **263**:11221, 1988

9. Arlaud GJ et al: Purified proenzyme C1r. Some characteristics of its activation and subsequent proteolytic cleavage. *Biochim Biophys Acta* **616**:116, 1980

10. Gigli I et al: The isolation and structure of C4, the fourth component of human complement. *Biochem J* **165**:439, 1977

11. Gorski JP et al: C4a: The third anaphylatoxin of the human complement system. *Proc Natl Acad Sci U S A* **76**:5299, 1979

12. Tack BF: The ß-Cys-?-Glu thiol ester bond in human C3, C4, and a $_2$-macroglobulin. *Springer Semin Immunopathol* **6**:259, 1983

13. Nagasawa S, Stroud RM: Cleavage of C2 by C1s into the antigenically distinct fragments C2a and C2. *Proc Natl Acad Sci U S A* **74**:2998, 1977

14. Strang CJ et al: Angioedema induced by a peptide derived from complement component C2. *J Exp Med* **168**:1685, 1988

15. Brade V et al: Biosynthesis of pro C3, a precursor of the third component of complement. *J Exp Med* **146**:759, 1977

16. Hugli TE: Structure and function of C3a anaphylatoxin. *Curr Topics Microbiol Immunol* **153**:181, 1990

17. Kawasaki T: Structure and biology of mannan-binding protein, MBP, an important component of innate immunity. *Biochim Biophys Acta* **1473**:186, 1999

18. Fearon DT, Austen KF: Current concepts in immunity. The alternative pathway—a system for host resistance to microbial infections. *N Engl J Med* **303**:259, 1980

19. Müller-Eberhard HJ, Schreiber RD: Molecular biology and chemistry of the alternative pathway of complement. *Adv Immunol* **29**:1, 1980

20. Müller-Eberhard HJ, Goetz O: C3 proactivator convertase and its mode of action. *J Exp Med* **135**:1003, 1972

21. Pangburn MK, Müller-Eberhard HJ: The alternative pathway of complement, in *Complement,* edited by HJ Müller-Eberhard, PA Miescher. Berlin, Springer, 1984, p 185

22. Fearon DT et al: Formation of a hemolytically active cellular intermediate by the interaction between properdin factors B and D and the activated third component of complement. *J Exp Med* **138**:1305, 1973

23. Schreiber RD et al: Initiation of the alternative pathway of complement: Recognition of activators by bound C3b and assembly of the entire pathway from six isolated proteins. *Proc Natl Acad Sci U S A* **75**:3948, 1978

24. Müller-Eberhard HJ: The membrane attack complex, in *Complement,* edited by HJ Müller-Eberhard, PA Miescher. Berlin, Springer, 1984, p 22

25. Isenman DE et al: The interaction of C5 with C3b in free solution: A sufficient condition for cleavage by fluid phase C3/C5 convertase. *J Immunol* **124**:326, 1980

26. Ember JA, Hugli TE. Complement factors and their receptors. *Immunopharmacology* **38**:3, 1997

27. Tschopp J et al: The membrane attack complex of complement: C5b-8 complex as C9 receptor and catalyst of C9 polymerization. *J Immunol* **134**:495, 1985

28. Morgan BP: Complement membrane attack on nucleated cells: Resistance, recovery and non-lethal effects. *Biochem J* **264**:1, 1989

29. Ziccardi RJ: The first component of human complement (C1): Activation and control, in *Complement,* edited by Müller-Eberhard, PA Miescher. Berlin, Springer-Verlag, 1985, p 167

30. Schreiber AD et al: Inhibition by C1INH of Hageman factor fragment activation of coagulation, fibrinolysis, and kinin generation. *J Clin Invest* **52**:1402, 1973

31. Gigli I et al: Interaction of plasma kallikrein with the C1 inhibitor. *J Immunol* **104**:574, 1970

32. Gigli I et al: Modulation of the classical pathway C3 convertase by the plasma proteins C4-binding protein and C3b inactivator. *Proc Natl Acad Sci U S A* **76**:6596, 1979

33. Fujita T et al: Human C4-binding protein. II. Role in proteolysis of C4b by C3b-inactivator. *J Exp Med* **148**:1044, 1979

34. Nicholson-Weller A et al: Isolation of a human erythrocyte membrane glycoprotein with decay-accelerating activity for C3 convertases of the complement system. *J Immunol* **129**:184, 1982

35. Liszewski MK et al: Control of the complement system. *Adv Immunol* **61**:201, 1996

36. Hourcade D et al: The regulators of complement activation (RCA) gene cluster. *Adv Immunol* **45**:381, 1989

37. Fearon DT, Austen KF: Activation of the alternative complement pathway due to resistance of zymosan-bound amplification convertase to endogenous regulatory mechanisms. *Proc Natl Acad Sci U S A* **74**:1683, 1977

38. Fearon DT: Relation by membrane sialic acid of ß1H-dependent decay-dissociation of amplification C3 convertase of the alternative complement pathway. *Proc Natl Acad Sci U S A* **75**:1971, 1978

39. Pangburn MK et al: Complement C3 convertase: Cell surface restriction of ß1H control and generation of restriction on neuraminidase-treated cells. *Proc Natl Acad Sci U S A* **75**:2416, 1978

40. Davis AE et al: Physiologic inactivation of fluid phase C3b: Isolation and structural analysis of C3c, C3dg (a2D) and C3g. *J Immunol* **132**:1960, 1984

41. Podack ER et al: Inhibition of C9 polymerization within SC5b-9 complex of complement by S protein. *Acta Pathol Microbiol Immunol Scand* **92**:89, 1984

42. Sugita Y et al: Molecular cloning and characterization of MACIF, an inhibitor of membrane channel formation of complement. *J Biochem* **106**:555, 1989

43. Okada N et al: A novel membrane glycoprotein capable of inhibiting membrane attack by homologous complement. *Int Immunol* **1**:205, 1989

44. Cooper NR, Nemerow GR: Complement, viruses and virus infected cells, in *Complement,* edited by HJ Müller-Eberhard, PA Miescher. Berlin, Springer, 1984, p 345

45. Daniels CA et al: Neutralization of sensitized virus by purified components of complement. *Proc Natl Acad Sci U S A* **65**:528, 1970

46. Beebe DP et al: Neutralization of influenza virus by normal human sera: Mechanisms involving antibody and complement. *J Immunol* **130**:1317, 1983

47. Nemerow GR et al: Neutralization of Epstein-Barr virus by nonimmune human serum: Role of cross-reacting antibody to herpes simplex virus and complement. *J Clin Invest* **70**:1081, 1982

48. Leddy JP et al: Effect of selective complement deficiency on the rate of neutralization of enveloped viruses by human sera. *J Immunol* **118**:28, 1977

49. Naniche D et al: Human membrane cofactor protein (CD46) acts as a cellular receptor for measles virus. *J Virol* **67**:6025, 1993

50. Manchester M et al: Multiple isoforms of CD46 (membrane cofactor protein) serve as receptors for measles virus. *Proc Natl Acad Sci U S A* **91**:2161, 1994

51. Nemerow GR et al: Identification and characterization of the Epstein-Barr virus receptor on human B lymphocytes and its relationship to the C3d complement receptor (CR2). *J Virol* **55**:347, 1985

52. Fingerroth JD: Epstein-Barr virus receptor of human B lymphocytes is C3d receptor CR2. *Proc Natl Acad Sci U S A* **81**:4510, 1984

53. Stoiber H et al: Role of complement in HIV infection. *Annu Rev Immunol* **15**:649, 1997

54. Schifferle JA, Paccaud JP: Complement and its receptor: A physiological transport system for circulating immune complexes, in *Contributions to Nephrology,* edited by G D'Amico et al. Basel, Karger, 1989, p 1

55. Miller GW, Nussenzweig V: A new complement function: Solubilization of antigen-antibody aggregates. *Proc Natl Acad Sci U S A* **72**:418, 1975

56. Ehlenberger AG, Nussenzweig V: The role of membrane receptors for C3b and C3d in phagocytosis. *J Exp Med* **145**:357, 1977

57. Ahearn JM, Fearon DT: Structure and function of the complement receptors, CR1 (CD35) and CR2 (CD21). *Adv Immunol* **46**:183, 1989

58. Shifferli JA et al: The role of complement and its receptor in the elimination of immune complexes. *N Engl J Med* **315**:488, 1986

59. Ross GD, Rabellino EM: Identification of a neutrophil and monocyte complement receptor (CR3) that is distinct from lymphocyte CR1 and CR2 and specific for a site contained with C3bi (abstr). *Fed Proc* **38**:1467, 1979

60. Arnaout MA et al: Deficiency of a granulocyte-membrane glycoprotein (gp150) in a boy with recurrent bacterial infections. *N Engl J Med* **306**:693, 1982

61. Bianco C et al: Follicular localization of antigen: Possible role of lymphocytes bearing a receptor for antigen-antibody complement complexes, in *Morphological and Functional Aspects of Immunity,* edited by K Lindahl-Kiessling et al. New York, Plenum, 1971, p 251

62. Ross GD et al: Two different complement receptors on human lymphocytes. One specific for C3b and one specific for C3b inactivator-cleaved C3b. *J Exp Med* **138**:798, 1973

63. Croix DA et al: Antibody response to a T-dependent antigen requires B cell expression of complement receptors. *J Exp Med* **183**:1857, 1996

64. Miller GW, Nussenzweig V: Complement as regulator of interactions between immune-complexes and cell membranes. *J Immunol* **113**:464, 1974

65. Wahlin B et al: C3 receptor on human lymphocyte subsets and recruitment of ADCC effector cells by C3 fragments. *J Immunol* **130**:2831,

1983

66. Meuth JL et al: Suppression of T lymphocyte functions by human C3 fragments. I. Inhibition of human T cell proliferative responses by kallikrein cleavage fragment of human iC3b. *J Immunol* **130**:2605, 1983

67. Fearon DT, Carroll MC. Regulation of B lymphocyte responses to foreign and self-antigens by CD19/CD21 complex. *Ann Rev Immunol* **18**:393, 2000

68. Hebell T et al: Suppression of the immune response by soluble complement receptor of B lymphocytes. *Science* **254**:102, 1991

69. Carroll MC: The role of complement in B cell activation and tolerance. *Adv Immunol* **74**:61, 2000

70. Fischer MB et al: Regulation of the B cell response to T-dependent antigens by classical pathway complement. *J Immunol* **157**:549, 1996

71. Bitter-Suermann D: The anaphylatoxins, in *The Complement System,* edited by K Rother, GO Till. Berlin, Springer, 1988, p 367

72. Wuepper KD et al: Cutaneous response to human C3a anaphylatoxin in man. *Clin Exp Immunol* **11**:13, 1972

73. Gerard C, Gerard NP: C5a anaphylatoxin and its seven transmembrane-segment receptor. *Annu Rev Immunol* 12:775, 1994

74. Drouin SM et al: Expression of the complement anaphylatoxin C3a and C5a receptors on bronchial epithelial and smooth muscle cells in models of sepsis and asthma. *J Immunol* **166**:2025, 2001

75. Bokisch VA, Müller-Eberhard HJ: Anaphylatoxin inactivator of human plasma: Its isolation and characterization as a carboxypeptidase. *J Clin Invest* **49**:2427, 1970

T>

Chapter 34

Alice Pentland

Eicosanoids

BIOCHEMISTRY
Phospholipases
Prostaglandins and Thromboxanes
Lipoxygenases
PROSTAGLANDIN ACTIONS IN NORMAL ORGAN FUNCTION
EICOSANOID FORMATION AND ACTION IN INFLAMMATION, INJURY, AND DISEASE
INHIBITORS OF EICOSANOID FORMATION AND ACTION

REFERENCES

Arachidonic acid and its metabolites, termed *eicosanoids,* are ubiquitous bioactive mediators formed from the unsaturated fatty acids present in cell membranes. Eicosanoids function as local hormones, regulating many important physiologic and pathologic processes such as pain, fever, clotting, and parturition. [1], [2] Medications that alter their formation are readily available. Biochemically, they are formed by the addition of oxygen to polyunsaturated fatty acids such as arachidonic acid and linoleic acid, which leads to the formation of a large array of biologically active mediators. The fatty acid metabolism of arachidonic acid has been most thoroughly studied, because it is the most common substrate for cyclooxygenase, lipoxygenase, and monooxygenase enzymes. Studies of this class of compounds began in the 1930s with the discovery of prostaglandins. [3], [4]

BIOCHEMISTRY

Eicosanoids have potent biologic effects in picomolar amounts. The extreme biologic potency of this class of compounds necessitates careful regulation of their synthesis and degradation. Arachidonic acid is stored in the phospholipids of cell membranes and is released by phospholipases after the specific stimulation of cell surface receptors. [1] In addition to carefully regulated release by receptor stimulation, arachidonic acid is released during membrane dissolution induced by cellular necrosis or apoptosis. [2], [5] Once cleaved from the membrane, arachidonic acid is immediately oxygenated to form products that are released from the cell or are reesterified into membrane phospholipids. Because arachidonic acid metabolites are not stored, the synthesis of products of arachidonic acid is synonymous with their release. [1], [2]

Eicosanoid synthesis has specific structural requirements. Eicosanoids are derived from the essential omega-6 fatty acids [eicosatetraenoic acid (20:4n-6) and eicosatrienoic acid (20:3n-9)] and their omega-3 derivatives, eicosapentaenoic acid (EPA, 20:5n-3) and docosahexaenoic acid (DHA, 22:6n-3). Among these fatty acids, arachidonic acid, also known as 5,8,11,14-eicosatetraenoic acid (20:4n-6), is the usual substrate for eicosanoid formation and is usually stored in the sn-2 position of phospholipid (Fig. 34-1). The essential role of eicosanoids in physiologic processes is believed to be the reason for the dietary requirement for omega-6 fatty acids. The terminology of the eicosanoids formed from omega-6 and omega-3 fatty acids is dictated by the number of double bonds present in the substrate fatty acid. For example, prostaglandin (PG) E_2 is derived from arachidonic acid and has two double bonds remaining in its side chain, whereas PGE_1 is derived from linoleic acid and has only one double bond remaining.

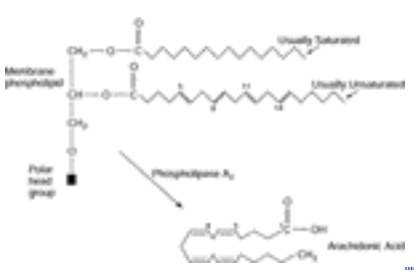

FIGURE 34-1 Synthesis of eicosanoids. Unsaturated fatty acids are required as a substrate. These are usually stored in the sn-2 position of membrane phospholipids.

A specific location of double bonds in the *cis* configuration is required for synthesis of eicosanoid products from fatty acid precursors. The usual location of double bonds in arachidonic acid is shown in Fig. 34-1. Folding of the arachidonic acid molecule to form a prostaglandin requires these specific areas of desaturation to allow the final molecular conformation.

Arachidonic acid and its metabolites act locally to regulate autocrine and paracrine functions. Their metabolism does not affect the function of cells at distant sites. [1], [6] These local actions are regulated in several ways. The array of products that can be synthesized from free arachidonic acid are not produced in each cell type; each cell has a unique set of enzymes and receptors that permit rapid, selective, local regulation (Table 34-1). [2], [7] Each cell has a characteristic set of enzymes for eicosanoid synthesis, which determines its product profile. The nature of the stimulus also influences the products that are formed by each type of cell (i.e., particulate versus soluble). [7]

TABLE 34-1 **Effects of Arachidonic Acid Metabolites and Their Tissue Source in Skin**

In addition to regulating the synthesis of these compounds, cells also tune their responses by regulating the expression of their receptors for detecting prostaglandins and leukotrienes. [8], [9] A cell in its resting state may express only a few products, but after cytokine stimulation it may synthesize new enzymes and receptors or may downregulate receptors selectively. The complexity of this regulatory system explains the diverse effects that a single metabolite of arachidonic acid may have between tissues as well as in different species. [7], [10]

Phospholipases

Because arachidonic acid is a membrane constituent, its release from membrane phospholipids by phospholipase is a key regulatory event in initiating eicosanoid synthesis. [1], [11] Phospholipases have unique substrate interaction characteristics that influence how they can act to release substrate. Because the substrate is present in membranes, the phospholipase enzyme must first bind to the membrane (an equilibrium reaction), after which it “scoots” on the membrane surface to liberate its substrate. [11]

Multiple phospholipases exist that can selectively hydrolyze fatty acid from the phospholipid present in cell membranes. They are named for the location of the bond they attack during substrate hydrolysis. The enzymes attacking these four sites of hydrolysis are named phospholipase A_1 (PLA_1), phospholipase A_2 (PLA_2), phospholipase C (PLC), and phospholipase D (PLD). [12] In addition to the nomenclature based on substrate specificity, mammalian PLA_2s are divided into two major types: secretory and cytosolic.

SECRETORY PHOSPHOLIPASES Secretory phospholipases require calcium for catalysis, are generally of low molecular weight (approximately 14 kDa), and fall into two major groups: pancreatic (type I, digestive) and nonpancreatic (type II, inflammatory). For example, secretory phospholipases play a role in mast cell-mediated inflammation, where mast cell-derived secretory phospholipase releases arachidonic acid for metabolism by adjacent cells (termed *transcellular metabolism*). They show no selectivity in their hydrolysis of fatty acid from the sn-2 position of membrane phospholipid, leaving lysophospholipid and free fatty acid. Secretory phospholipases are thought to be key in the release of arachidonic acid in inflammatory disease states, such as arthritis. [12], [13], [14] and [15]
CYTOSOLIC PLA_2 In contrast to the secretory phospholipases, cytosolic phospholipases are higher in molecular weight (39 to 100 kDa) and are generally selective in their preference for arachidonic acid over other fatty acid constituents of membrane phospholipid. Some of these enzymes are calcium dependent, while others are not. High-molecular-weight, calcium-dependent, cytosolic phospholipase A_2 ($cPLA_2$) is thought to be responsible for the majority of eicosanoid product formation. Cytosolic phospholipase is a major source of arachidonic acid in skin. [12], [13], [16], [17]
PHOSPHOLIPASE C In some tissues (such as platelets) arachidonic acid is released indirectly by PLC. This enzyme cleaves inositol-containing phospholipids, releasing diacylglycerol. Diacylglycerol is subsequently cleaved by diacylglycerol lipase to generate free arachidonic acid. [18] PLC-mediated release of diacylglycerol is also important because diacylglycerol is a cofactor for protein kinase C activation. [19] Activation of this pathway also results in the simultaneous release of inositol phosphates, which mobilize intracellular calcium. [20] Therefore, after PLC activation, three different mediators are produced: arachidonic acid, inositol phosphates, and diacylglycerol. Once free arachidonic acid is in the cell cytosol, there are three main pathways of metabolism: cyclooxygenase, lipoxygenase, and monooxygenase. Cyclooxygenase metabolism leads to the synthesis of prostaglandins and thromboxanes, which interact with specific receptors to initiate tissue responses (Fig. 34-2). Lipoxygenase enzymes catalyze the formation of 5-, 12-, or 15-hydroperoxyeicosatetraenoic acid (HPETE) intermediates, which are subsequently reduced, leading to the formation of hydroxyeicosatetraenoic acid (HETE) as shown in Fig. 34-3. [21], [22] and [23] The 5-lipoxygenase pathway is particularly important among these lipoxygenase reactions because it forms the highly active leukotriene derivatives of arachidonic acid, [24] which interact with specific receptors, and also contributes to lipoxin formation. [25] Lastly, monooxygenases (members of the cytochrome P_{450} family) are also responsible for the formation of arachidonic acid oxygenation products. In addition, these pathways play an important role in both eicosanoid degradation and in the formation of products with biologic activity. [26]



FIGURE 34-2 Prostaglandin and thromboxane formation. Prostaglandins are formed by the serial action of phospholipases and cyclooxygenases. Their effects are mediated through specific receptor activation. COX, cyclooxygenase; PGHS, prostaglandin endoperoxide synthase; DP, IP, EP, FP, and TP are receptors for PGD_2, PGI_2, PGE_2, PGF_{2a}, and thromboxane, respectively.

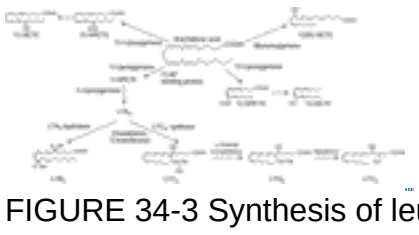

FIGURE 34-3 Synthesis of leukotrienes and HETEs.

Prostaglandins and Thromboxanes

Arachidonic acid is converted to prostaglandins by the prostaglandin endoperoxide synthase, also known as cyclooxygenase. There are two isoforms of cyclooxygenase known as COX-1 and COX-2. COX-1 is present constitutively in most prostaglandin-producing cells. COX-2 expression is inducible by exposure of cells to agents such as growth factors and cytokines, such as interleukin-1, and in inflammatory states. COX-2 is an endoplasmic reticulum-associated homodimer composed of 72-kDa subunits requiring heme binding and glycosylation for activity. [6], [27], [28] The PGH_2 produced by prostaglandin endoperoxide synthase serves as a substrate for the formation of PGE_2, PGF_2, PGD_2, thromboxane (TX) A_2, and prostacyclin (PGI_2) through the action of specific isomerases. [29]

In the small vessels of the skin, TXA_2, PGE_2, and PGI_2 are key mediators in regulating peripheral vascular tone and clotting. When appropriately stimulated (as by a breach in the endothelium or the presence of bacteria), blood elements such as platelets, monocytes, and macrophages synthesize TXA_2 through the action of the microsomal cytochrome P_{450} enzyme, thromboxane synthase. [30] TXA_2 is a potent inducer of vasoconstriction and platelet aggregation. TXA_2 has a very short half-life (30 s); it spontaneously hydrolyzes to TXB_2, an inactive degradation product. This short half-life allows modulation of vasoconstriction over very short time periods.

PGD_2 is the primary prostaglandin synthesized in mast cells, and therefore is an important mediator in allergic responses. [31] It also appears to be the predominant prostaglandin formed by Langerhans cells. [32] It is found abundantly in the central nervous system and male genitalia. Two types of enzyme synthesize PGD_2: the lipocalin, or brain type, and the hematopoietic type, which is the predominant form in skin. PGD_2 is a peripheral vasodilator, allergic and inflammatory mediator, mediator of nociceptive responses, and an inhibitor of platelet aggregation. Its effects outside skin include sleep induction and centrally induced hypothermia. [33], [34] and [35]

To balance the formation of the potent vasoconstrictor TXA_2 by blood elements, vascular endothelium and smooth muscle actively synthesize PGI_2 and PGE_2, which are potent vasodilators, via their respective microsomal cytochrome P_{450} synthases. [36], [37] and [38] In addition to its vasodilatory properties, PGI_2 is an antiaggregatory agent, making it capable of stopping proliferation of a platelet thrombus. Like TXA_2, it has a very short 10-min half-life, after which it hydrolyzes spontaneously to 6-keto-PGF_{1a}. PGE_2 is synthesized in endothelium and causes capillary vascular smooth muscle dilatation and plasma exudation, potentiates histamine- and bradykinin-induced effects on vascular permeability, and enhances the sensation of pain from these mediators. [6], [40], [41] and [42] Its actions are more long-lasting than those of PGI_2. Thus, the balance between the synthesis of vasodilators by vascular cells and vasoconstrictors released from blood cells can determine vascular tone and modulate clot propagation and inflammatory pain.

PGF_{2a} is synthesized by keratinocytes in skin, as well as in a number of other organs, by the action of PGF synthase. It can act as a vasopressor, can stimulate fibroblast proliferation, [2] and is important in labor and delivery. [43] Three separate pathways lead to the formation of PGF_{2a}: 9,11-endoperoxide reduction of PGH_2, 11-ketoreduction of PGD_2, and 9-ketoreduction of PGE_2. Conversion of PGH_2 to PGF_{2a} appears to be the predominant pathway. Two different active sites on PGF synthase are responsible for the reduction of both PGD_2 and PGH_2. [44], [45] and [46] PGD_2 can also be metabolized to a diastereoisomer of PGF_{2a} by an NADPH-dependent mechanism. This compound has the same biologic activities as the PGF_{2a} produced by 9,11-endoperoxide reduction of PGH_2. [47]

Prostaglandins produce their effects through interaction with specific G-protein–linked receptors (see Fig. 34-2). Prostaglandin receptors have a structural motif common to G-protein–coupled rhodopsin-type receptors, with seven putative transmembrane domains, an extracellular amino-terminal domain, and an intracellular carboxyl-terminal domain that specifies G-protein interactions. [8] This carboxyl-terminal domain determines linkage to different intracellular signaling pathways. Specific receptors have been identified for each of the major prostaglandin types: the thromboxane receptor,

termed TP; four PGE_2 receptors, designated as EP_1, EP_2, EP_3, and EP_4 [48], [49]; the PGF_{2a} receptor, FP; the PGI_2 receptor, IP; and two distinct PGD_2 receptors, DP and DP_2. [50], [51] Structural analysis of the receptors shows that their overall homology is not high. The TP, EP_2, and EP_3 receptors are on chromosomes 10, 15, and 3, respectively. Their structural homology is restricted to the consensus sequence of the seventh transmembrane domain and the second extracellular loop. [8]

Three major types of signaling pathways may be triggered by prostaglandin binding. Depending upon the structure of the receptor and the G protein associated with it, stimulation of the prostaglandin receptors may trigger a rise in calcium, mediate a rise in intracellular levels of cyclic adenosine monophosphate (cAMP), or inhibit cAMP formation. On the basis of these signaling responses, prostaglandin receptors can be grouped into three general categories. The relaxant receptors (IP, DP_1, EP_2, and EP_4) increase levels of cAMP and induce smooth muscle relaxation. The contractile receptors (TP, FP, DP_2, and EP_1) mediate Ca^{++} mobilization and induce smooth muscle contraction. Lastly, the EP_3 and DP_2 receptors are able to decrease levels of cAMP. The EP_3 receptor inhibits smooth muscle contraction in this way, while DP_2 receptors are present on eosinophils and counteract eosinophil responses mediated through the DP_1 receptor. The balance between the DP receptors may have a role in eosinophil recruitment in asthma. Great potential for the development of useful new therapeutic agents exists as specific agonists and antagonists of prostaglandin receptors are developed. [8], [48], [49], [52]

Lipoxygenases

Lipoxygenases are a family of enzymes in mammalian cells that catalyze the insertion of oxygen into unsaturated fatty acids to produce a hydroperoxy derivative. [2] Three classes of lipoxygenase enzymes insert oxygen into the 5-, 12-, or 15-carbon of arachidonic acid and are designated by their substrate site preference as 5-, 12-, or 15-lipoxygenases (see Fig. 34-3).

The 5-lipoxygenase pathway is particularly important in the regulation of biologic systems, because it is necessary for the formation of leukotrienes. [22], [24] Leukotrienes are so named because of their predominant synthesis by leukocytes and their conjugated triene structure. 5-Lipoxygenase translocates to the nuclear membrane in the presence of Ca^{2+}, where it interacts with the 5-lipoxygenase-activating protein (FLAP) to form the leukotriene intermediate, leukotriene (LT) A_4. [53], [54] and [55] 5-Lipoxygenase is present in neutrophils, macrophages, mast cells, and lung epithelium. [22] LTA_4 hydrolase can act on LTA_4 to form LTB_4. LTA_4 hydrolase is cytosolic and is found in a wide variety of tissues, including leukocytes, lung, heart, and intestine. [54] Some tissues that contain LTA_4 hydrolase do not contain 5-lipoxygenase and therefore depend upon LTA_4 being provided transcellularly for their synthesis of leukotrienes. LTB_4 is one of the most potent chemotactic and chemokinetic substances known, with maximal activities in the 10^{-9} M range. LTB_4 can induce degranulation of polymorphonuclear leukocytes and their adherence to vascular endothelium. LTB_4 is the predominant eicosanoid metabolite of neutrophils and is also produced by macrophages. [54], [55] 5-Lipoxygenase activity has been reported in keratinocytes by some investigators, [56] but its presence has since been refuted. [57]

The actions of LTB_4 are mediated by interaction with its receptors. [58] In the neutrophil, LTB_4 receptors are associated with a guanosine triphosphate (GTP)-binding protein that regulates receptor affinity for LTB_4 and transduces the signal. Two receptor populations have been described. The high-affinity binding site dissociation constant is 4 to 5×10^{-10} M, in the range of the minimal effective concentration for chemotaxis. The low-affinity binding site has a molar dissociation constant of 0.6 to 5.0×10^{-7} M, in the concentration range required for secretion of neutrophil granules. [55], [58] Thus, chemotaxis of neutrophils is initiated toward a site of inflammation through activation of their high-affinity receptor. Degranulation then occurs when the concentration of LTB_4 surpasses that necessary for activation of the low-affinity receptor, nearer the site of inflammation.

The 5-lipoxygenase pathway also leads to the generation of the cysteinyl leukotrienes, also known as slow-reacting substance of anaphylaxis. [24], [55], [58] LTC_4 is formed by the action of LTC_4 synthase, which adds glutathione at the 6-carbon position of LTA_4. The removal of glutamic acid from LTC_4 by ?-glutamyl transpeptidase produces LTD_4. Dipeptidase can further metabolize LTD_4 by removal of a glycine residue. Once the leukotrienes have been formed, their release from the cell is mediated by an export carrier system. LTB_4 and LTC_4 have individual carrier systems. The LTC_4 transporter is a 190-kDa glycoprotein, which also can transport related substances out of the cell. Transport is adenosine triphosphate (ATP)-dependent for both LTC_4 and LTB_4. [55], [58], [59] To eliminate these potent mediators, oxidative inactivation occurs via the combination of hydrogen peroxide produced through the respiratory burst of activated cells and extracellular chloride ion to produce hypochlorous acid, which attacks the sulfur of the cysteinyl adduct. This inactivation is important in the local environment of a site of inflammation. However, in primates LTE_4 is primarily eliminated through urinary excretion. [60], [61]

As is the case for the prostaglandin receptors, the leukotriene receptors are highly heterogeneous. Receptors for LTB_4, LTC_4, and LTD_4 have been cloned. Biochemical evidence indicates the LTB_4 receptors are linked via a G-protein to PLC. Cysteinyl leukotrienes also appear to be coupled via a Gq protein to IP3 turnover and increases in intracellular Ca^{2+}. [55], [58] /SUP>, [60] Two classes of LTC_4 receptors are present, termed cysteinyl leukotriene (CysLT) $_1$ and $CysLT_2$. [62] Leukotriene receptors are expressed in the airway as well as in smooth muscle, microvasculature, blood elements, and skin. Splice variants of the $CysLT_1$ have been identified in the mouse, suggesting the opportunity for specific pharmacology. [62]

Arachidonate 12-lipoxygenase activity is found in platelets, leuko-cytes, mast cells, and epithelial cells, where it is present in abundance. [63], [64]

and [65] 12-S-hydroxyeicosatetraenoic acid has been reported to enhance tumor cell growth, endothelial cell invasion, and aIIbß3 integrin expression. [66] The leukocyte isoform is capable of metabolizing linoleic acid to [9Z,11E,(13S)]-13-hydroperoxyoctadecadienoic acid (13-HpODE), which is subsequently reduced to 13-hydroxyoctadecadienoic acid (13-HODE). These compounds are capable of forming DNA adducts, increasing epidermal growth factor-dependent signaling, and stimulating progression of breast carcinoma in a mouse model. [67], [68] and [69]

The third major lipoxygenase enzyme present in mammalian cells is 15-lipoxygenase. The 15-lipoxygenase metabolic pathway is prominent in eosinophils and human airway epithelial cells. 15-HETE has been reported to induce hyperalgesia. It can also influence the synthesis of lipoxygenase and leukotriene products in mast cells, platelets, neutrophils, and eosinophils and has been implicated in atherogenesis. The 15-lipoxygenase is also capable of forming 13-HODE from linoleic acid. [70], [71]

The lipoxins are a family of compounds that can be derived from arachidonic acid by the serial action of 5-, 12-, or 15-lipoxygenase, followed by further lipoxygenase metabolism. Lipoxins A_4 and B_4 contain a conjugated tetraene structure and appear to be generated by transcellular events during cell-cell interactions. [25] Studies in vitro have shown that lipoxin A_4 causes arteriolar dilation, antagonizes LTB_4-induced inflammation, and inhibits polymorphonuclear (PMN) leukocyte adhesion to endothelial cells. Lipoxin B_4 can stimulate monocyte colony formation, and both products are bronchoconstrictors. [2], [25], [72] The lipoxin receptor has recently been cloned. It is a classic seven transmembrane domain-type receptor, and its mRNA is found in lung, myeloid cell types, and tissues with a high degree of phagocytic infiltrates. [72] Lipoxin A_4 binding on PMNs is G-protein coupled. Lipoxins also act on a pharmacologically defined subclass of LTC_4-LTD_4 receptor; thus their actions may be like those of leukotrienes at these receptor sites. [73]

Cytochrome P_{450} enzymes can also metabolize eicosanoids. In contrast to cyclooxygenases and lipoxygenases, which introduce molecular oxygen (O_2) into their substrates, cytochrome P_{450} monooxygenation reactions introduce one atom of an oxygen molecule while cooxygenating a nearby molecule. [26] The epoxy acids have several significant physiologic functions. They are able to mobilize microsomal calcium and to alter K^+ and Na^+ ion flux. This capacity to regulate ion transfer may make monooxygenase products important in regulating cell water balance. ?-Hydroxylation by cytochrome P_{450} enzymes is also a predominant metabolic pathway for LTB_4. [26], [58]

PROSTAGLANDIN ACTIONS IN NORMAL ORGAN FUNCTION

Information about normal function due to specific eicosanoids interacting with their receptors comes from studies of knockout animals and receptor localization studies (Table 34-2). The E series prostaglandins are important modulators of normal cell proliferation and play an important role in wound repair. [6], [8] Cyclooxygenase inhibitors decrease epithelial proliferation and migration across a wound bed by 50 percent. Production of collagen fibrils in the dermal matrix is also decreased in the absence of PGE_2. In addition, collagenase activity from stimulated monocytes and macrophages depends upon the concomitant synthesis of PGE_2. In the epidermis and intestine, normal apoptotic sloughing of intestinal epithelium is regulated by COX-2–dependent PGE_2 synthesis. However, in the stomach, mucus secretion is modulated by COX-1–dependent PGE_2 synthesis. [74], [75], [76] and [77]

Disrupted Gene	Major Phenotypes of Knockout Mice
DP	Reduced responses in allergic asthma
EP_1	Reduction in carcinogen-induced colorectal neoplasia
EP_2	Impaired ovulation and fertilization Salt-sensitive hypertension
EP_3	Impaired febrile response to pyrogens Impaired duodenal bicarbonate secretion
EP_4	Patent ductus arteriosus Decreased inflammatory bone resorption
FP	Parturition failure
IP	Thrombotic tendency, decreased inflammatory swelling
TP	Bleeding tendency

"Extensive studies have used knockout mouse strategies to demonstrate the functional role played by prostanoid receptors."

TABLE 34-2 **Major Phenotypes of Mice Deficient in Prostanoid Receptors**

Prostaglandins mediate many key functions beyond the skin. PGE_2-mediated regulation of water balance in the kidney occurs due to the selective presence of receptors and the presence of inducible COX-2. EP_3 receptors are expressed in the tubular epithelium of the outer medulla, EP_1 receptor is in the papillary collecting ducts, and EP_4 receptor is in the glomerulus. This distribution pattern matches with known PGE_2-mediated functions in the kidney regulating ion transport, water reabsorption, and glomerular filtration. The contribution of COX-2 to regulation of renal function is demonstrated by selective knockout studies in transgenic mice. [74] The elimination of COX-2 disturbs normal renal tubular water balance because antidiuretic hormone responses in the proximal tubule are mediated by COX-dependent PGE_2 synthesis. [8], [78], [79]

PGE_2 also modulates fertility, where its absence decreases conception. Luteinizing hormone and follicle-stimulating hormone induce high levels of COX-2 and EP_2 receptor signaling, which act together to enhance cumulus expansion and rupture of the oocyte in the ovary. An important contribution to the oocyte's ability to be fertilized is also made via this signaling pathway; in mice lacking the EP_2 receptor, fertilization is decreased more than tenfold. Implantation is also supported by COX-2–mediated synthesis of PGI_2. [80] At the end of pregnancy, onset of labor is stimulated by the production of PGF_{2a}, which is COX-1 dependent. This delayed onset of labor causes decreased pup survival. These effects on fertility are observed primarily in knockout animals and are subtle if inhibitors are used.

EP_4 receptor activation is needed for closure of the ductus arteriosus immediately after birth. Knockout animals have a high mortality rate from failure of the ductus to close at birth. The EP_4 receptor is also important in bone remodeling; bone resorption is greatly decreased in EP_4 receptor knockout mice. [8]

EICOSANOID FORMATION AND ACTION IN INFLAMMATION, INJURY, AND DISEASE

Many of the early events in inflammation are extensively influenced by metabolites of arachidonic acid. After the skin is exposed to inflammatory stimuli, mast cells located perivascularly release PGD_2 and LTC_4 (converted to LTD_4 and LTE_4), which promote vasodilation and plasma exudation. [34], [55], [58], [81], [82] Mast cell histamine stimulates PGI_2 synthesis by vascular endothelium and PGE_2 synthesis by nearby fibroblasts; these mediators, in turn, potentiate the effects of histamine in the vessels of the dermis. Secretory phospholipase release also allows release of arachidonic acid from nearby cells. This mediator release appears clinically as a wheal-and-flare response.

In mastocytosis, there is a well-documented role for PGD_2 in the vasodilation and syncope that accompany the syndrome. In addition to the release of histamine by mast cells, PGD_2 is important in mediating the symptoms of the disease. Effective treatment of symptoms is often achieved by the simultaneous use of aspirin and antihistamines. [83]

In acute injury, the release of thromboxane by platelets contributes to platelet aggregation and clot formation. Neutrophils release LTB_4 at the injury site, recruiting more neutrophils in the initial phases of inflammation. [55], [58] Macrophages arrive somewhat later at the injury site and release more TXA_2, PGF_{2a}, PGE_2, LTB_4, and LTC_4, further contributing to the inflammation. Phospholipase activation enhances the inflammation. The synthesis of these inflammatory mediators contributes significantly to the pattern of inflammation observed early in the injury response. [7]

Another common form of injury in which prostaglandin synthesis plays a role is ultraviolet light (UVB) injury. After exposure to three times the minimal erythema dose of UVB, there occurs a prolonged increase in the release of PGE_2, PGF_{2a}, and 6-keto-PGF_{1a}. [84], [85] and [86] In the first 24 h after UV exposure, this prostaglandin release contributes substantially to the pain and erythema induced. Early treatment with indomethacin inhibits erythema, demonstrating the role of prostaglandins in the process. [87], [88] Increased synthesis of $cPLA_2$ is partially responsible for increased prostaglandin formation in the first 24 h. At later time points, an increase in COX-2 occurs. [17], [85], [88]

Substantial evidence demonstrates the deranged metabolism of eicosanoids in psoriasis. Increased levels of 12-HETE and free arachidonic acid are reported in lesional skin. [89], [90] In addition, increased amounts of the potent chemotactic agent LTB_4 are found, which is likely a result of the presence of neutrophils in psoriatic skin samples. [91] However, evidence for the importance of these metabolites in the pathophysiology of the disease remains circumstantial. Drugs that decrease the synthesis of lipoxygenase products (steroids, anthralin) improve psoriasis, [2], [92] whereas inhibitors of prostaglandin synthesis may exacerbate the disease. [93] The exact role of these changes in the pathogenesis of psoriasis remains obscure.

Eicosanoids are very important to pain and fever responses. The first evidence supporting the role of prostaglandins in pain and fever was the discovery that aspirin is an inhibitor of cyclooxygenase. [6], [8] Further work with knockout animals has shown that fever is mediated by the EP_3 receptor, [8] while pain perception is modulated by the EP_1 receptor. [94] The role of specific prostaglandins in mediating pain is supported by the location of receptors in neurons of the dorsal root ganglion.

Recent evidence also implicates cyclooxygenase in the pathogenesis of cancer of the colon. [95], [96] and [97] Studies in individuals with familial polyposis demonstrate that long-term treatment with nonsteroidal anti-inflammatory drugs (NSAIDs, COX inhibitors) decreases the incidence of colon carcinoma by 50 percent. This result appears to be due to the regulation of PGE_2-dependent growth in the intestine, which stops progression of initiated tumor cells. Similar profound inhibition of tumor formation has been demonstrated with UV-induced tumors in mice. [98], [99] and [100]

Reductions in the risk of myocardial infarction have been demonstrated in patients taking the COX-inhibitor aspirin. Individuals with unstable angina who take low-dose aspirin have a 33 percent decrease in their risk of a cardiovascular event. Similar reductions in the risk of stroke occur, and the risk of death is decreased by one-sixth. [101] Prostaglandins are also important in toxemia of pregnancy, as demonstrated by the decrease of toxemia symptoms in patients treated with low-dose aspirin beginning in the second trimester. [102]

Epidemiologic and clinical studies suggest than NSAIDs can inhibit the progression of Alzheimer's disease. Histochemical stains show that there is an increased level of COX-1 in ß-amyloid plaques in the brains of patients with Alzheimer's disease, suggesting that COX-1 activity may be important in patients with this disorder. [103]

In asthma, it is well documented that there is airway hyperresponsiveness, increased airway smooth-muscle contraction, mucus hypersecretion, and increased vascular permeability. When asthma is triggered by a specific antigen, the initial event is antigen-mediated mast cell activation. [58] Similar mechanisms are involved in allergic responses of the skin. [81] In cases of exercise induced asthma, local dehydration is thought to result in hyperosmolarity, resulting in mast cell activation. Mast cells permeate the airways in individuals with asthma. When stimulated, these cells release stored histamine from granules and synthesize PGD_2 and leukotrienes. LTC_4, LTD_4, and LTE_4 control at least three signs of asthma: smooth muscle contraction, mucus secretion, and edema formation. LTE_4 is generally less potent than LTC_4 or LTD_4. In the asthmatic airway, the leukotrienes potentiate the effect of histamine 1000-fold. Leukotrienes are 2000 times more potent as bronchoconstrictors than histamine. [58]

INHIBITORS OF EICOSANOID FORMATION AND ACTION

Despite the extensive knowledge about the physiology of arachidonic acid metabolites and their receptors, most of the drugs presently available to the physician in practice to manipulate eicosanoid formation are not specific. Aspirin and most NSAIDs act through the inhibition of cyclooxygenase activity. [6] Whereas these drugs are relatively specific in their inhibition of the cyclooxygenases, the synthesis of all prostaglandins and thromboxanes occurs via these enzymes. Efforts to produce selective inhibitors of COX-2 have resulted in two new selective agents: rofecoxib (Vioxx) and celecoxib (Celebrex). [104] Drugs of this class permit COX-1–mediated activities, such as clotting and stomach mucus secretion, to occur, while COX-2–mediated prostaglandin synthesis contributing to inflammation is blocked. These drugs are highly efficacious in arthritis and have demonstrated some efficacy as cancer chemopreventive agents. [95], [96], [97] and [98] Studies are ongoing of their activity as skin cancer chemopreventive agents. This is likely to add to the already observed benefit of NSAIDs in colon carcinoma.

Some prostaglandin analogues are currently available that are used for their specific therapeutic benefit. For example, the PGE_1 analogue misoprostol is used for the prevention of NSAID-induced gastric ulcers, [105] the PGE_2 analogue dinoprostone is used for cervical ripening and reduction of time in labor, and the PGF_{2a} analogue latanoprost is used for glaucoma. [106]

Leukotriene receptor antagonists are now available for treatment of asthma. Because they are receptor blockers, they must bind to the CysLT receptor to prevent agonist-stimulated synthesis of leukotrienes. Several such drugs are now on the market, such as Montelukast (Singulair) and zafirlukast (Accolate). Both these drugs bind to the $CysLT_1$ receptor, leaving an opportunity for better drug development if antagonists to the $CysLT_2$ receptor can also be developed. A second drug interfering with leukotriene synthesis is zileuton (Zyflo), a competitive inhibitor of 5-lipoxygenase. [107], [108] Like the leukotriene receptor antagonists, it must be present before the induction of leukotriene synthesis to be effective. These drugs are often combined with prednisone to produce maximum benefit in patients with asthma. Prednisone influences the synthesis of eicosanoids by two methods. First, it decreases the synthesis of $cPLA_2$, thereby decreasing the release of arachidonic acid. [102], [109] Second, it blocks the synthesis of COX-2, thereby decreasing the synthesis of prostaglandins. [110] Prednisone also has an important effect on eicosanoid synthesis in mast cells by stabilizing the cell membranes, thereby decreasing cell degranulation in response to antigen or other stimuli. [108]

In summary, the metabolism of eicosanoids by mammalian cells is a ubiquitous process that locally regulates many fundamental cellular functions. Eicosanoids play important roles in the normal inflammatory response and are also involved directly or indirectly in the pathophysiology of many diseases. Clearly, there is a great opportunity for the development of therapeutic agents that modulate eicosanoid action. Effective drugs are available to regulate the synthesis of prostaglandins as a group; and selective agents for inhibiting the release of arachidonic acid, its metabolism into lipoxygenase or monooxygenase products, or interaction of its metabolites with specific receptors are being developed. Steroids suppress the formation of some of these metabolites.

REFERENCES

1. Fitzpatrick FA, Soberman R: Regulated formation of eicosanoid. *J Clin Invest* **107**:1347, 2001
2. Fogh K, Kragballe K: Eicosanoids in inflammatory skin disease. *Prostaglandins Other Lipid Mediat* **63**:43, 2000
3. Goldblatt MW: Properties of human seminal plasma. *J Physiol* **84**:208, 1935
4. Van Euler US: A depressor substance in the vesicular gland. *J Physiol* **84**:21P, 1935
5. Marnett LJ: Aspirin and the potential role of prostaglandins in colon cancer. *Cancer Res* **52**:5575, 1992
6. Marnett LJ et al: Arachidonic acid oxygenation by COX-1 and COX-2. *J Biol Chem* **274**:22903, 1999
7. Tripp CS et al: Calcium ionophore enables soluble agonists to stimulate macrophage 5-lipoxygenase. *J Biol Chem* **260**:5895, 1985
8. Narumiya S et al: Prostanoid receptors: Structures, peptides and function. *Phys Rev* **79**:1193, 1999
9. Dahlen SE: Pharmacological characterization of leukotriene receptors. *Am J Respir Crit Care Med* **161**:S41, 2000
10. Marks F, Furstenberger G: Cancer chemoprevention through interruption of multistage carcinogenesis. The lessons learnt by comparing mouse skin carcinogenesis and human large bowel cancer. *Eur J Cancer* **36**:314, 2000
11. Gelb MH et al: Do membrane-bound enzymes access their substrates from the membrane or aqueous phase: Interfacial versus non-interfacial enzymes. *Biochim Biophys Acta* **1488**:20, 2000
12. Hurley JH et al: Floundering about at cell membranes: A structural view of phospholipid signaling. *Curr Opin Struct Biol* **10**:737, 2000
13. Dennis EA: Diversity of group types, regulation, and function of phospholipase A2. *J Biol Chem* **269**:13057, 1994
14. Cho W: Structure, function, and regulation of group V phospholipase A_2. *Biochim Biophys Acta* **1488**:48, 2000
15. Mao-Qiang M et al: Secretory phospholipase A2 activity is required for permeability barrier homeostasis. *J Invest Derm* **106**:57, 1996
16. Pickard RT et al: Identification of essential residues for the catalytic function of 85-kDa cytosolic phospholipase A_2. Probing the role of histidine, aspartic acid, cysteine, and arginine. *J Biol Chem* **271**:19225, 1996
17. Gresham A et al: Increased synthesis of high-molecular-weight $cPLA_2$ mediates UV-induced PGE_2 in human skin. *Am J Physiol* **39**:C1037, 1996

18. Hokin LE: Receptors and phosphoinositide-generated second messenge *Ann Rev Biochem* **54**:205, 1985

19. Nakamura S et al: Lipid mediators and protein kinase C activation for the intracellular signaling netw *J Biochem* **115**:1029, 1994

20. Exton JH: Regulation of phosphoinositide phospholipases by hormones, neurotransmitters, and other agonists linked to G prot *Ann Rev Pharm Toxico* **36**:481, 1996

21. Yedgar S et al: Inhibition of phospholipase A(2) as a therapeutic targ *Biochim Biophys Acta* **1488**:182, 2000

22. Radmark O: Arachidonate 5-lipoxygenase *J Lipid Mediat Cell Si* **12**:171, 1995

23. Kuhn et al: Arachidonate 15-lipoxygenase *J Lipid Mediat Cell Si* **12**:157, 1995

24. Henderson WR: The role of leukotrienes in inflammatio *Basic Sci Rev* **121**:684, 1994

25. Serhan CN, Romano M: Lipoxin biosynthesis and actions: role of the human platelet LX-synthe *J Lipid Mediat Cell Si* **12**:293, 1995

26. Carroll MA, McGiff JC: A new class of lipid mediators: cytochrome P_{450} arachidonate metabolites *Thorax* **55**:S13, 2000

27. Morita I et al: Different intracellular locations for prostaglandin endoperoxide H synthase-1 and *J Biol Chem* **270**:10902, 1995

28. Picot D et al: The x-ray crystal structure of the membrane protein prostaglandin $_2$ synthase-1. *Nature* **367**:243, 1994

29. Jakobsson PJ et al: Identification of human prostaglandin E synthase; a microsomal, glutathione-dependent, inducible enzyme, constituting a potential novel drug *Proc Nat Acad Sci U S A* **96**:7220, 1999

30. Hsu PY et al: Expression, purification and spectroscopic characterization of human thromboxane synth *J Biol Chem* **274**:762, 1999

31. Roberts LJ et al: Prostaglandin, thromboxane and 12-hydroxy-5,8,10, 14-eicosatetraenoic acid production by ionophore-stimulated rat serosal mast *Biochim Biophys Acta* **575**:185, 1979

32. Rosenbach I et al: Comparison of eicosanoid generation by highly purified human Langerhans cells and keratinoc *J Invest Dermato* **95**:104, 1990

33. Urade Y, Hayaishi O: Biochemical, structural, genetic, physiological and pathophysical features of lipocalin-type prostaglandin D synt *Biochim Biophys Acta* **1482**:259, 2000

34. Matsuoka T et al: Prostaglandin D_2 as a mediator of allergic asthma *Science* **287**:2013, 2000

35. Satoh S et al: Promotion of sleep induced by prostaglandin D_2 in rats. *Proc Natl Acad Sci U S A* **93**:5980, 1996

36. Tanioka T et al: Molecular identification of cytosolic prostaglandin E_2 synthase that is functionally coupled with cyclooxygenase-1 in immediate prostaglandin $_2$ biosynthesis. *J Biol Chem* **275**:32775, 2000

37. Jakobsson PJ et al: Identification of human prostaglandin E synthase: A microsomal, glutathione-dependent, inducible enzyme, constituting a potential novel drug *Proc Nat Acad Sci U S A* **96**:7220, 1999

38. Nowak J, Fitzgerald GA: Redirection of prostaglandin endoperoxide metabolism at the platelet-vascular interface in r *J Clin Inves* **83**:380, 1989

39. Hara S et al: Isolation and molecular cloning of prostacyclin synthase from bovine endothelial c *J Biol Chem* **269**:19897, 1994

40. Pentland AP, Needleman PN: Modulation of keratinocyte proliferation in vitro by endogenous prostaglandin synth *J Clin Inves* **77**:246, 1986

41. Rheins LA et al: Suppression of the cutaneous immune response following topical application of the prostaglandin P_2. *Cell Immunc* **106**:33, 1987

42. Santoli D et al: Suppression of interleukin-2–dependent human T cell growth in vitro by prostaglandin E (PGE) and their precursor fatty a *J Clin Inves* **85**:424, 1990

43. O'Brien WF: The role of prostaglandins in labor and deliver *Clin Perinato* **22**:973, 1995

44. Watanabe K et al: Enzymatic formation of prostaglandin F_{2a} from prostaglandin H and D *J Biol Chem* **260**:7035, 1985

45. Hong Y et al: The role of selenium-dependent and selenium-independent glutathione peroxidases in the formation of prostaglandi $_{2a}$. *J Biol Chem* **264**:13793, 1989

46. Watanabe K et al: Stereospecific conversion of prostaglandin D_2 to (5Z,13E)-(15S)-9 alpha-11 beta, 15-trihydroxyprosta-5,13-dien-1-oic acid (9 alpha, 11 beta-prostaglandin $_2$) and of prostaglandin H_2 to prostaglandin F_2 alpha by bovine lung prostaglandin F synthase *Proc Natl Acad Sci U S A* **83**:1583, 1986

47. Liston TE, Roberts LJ: Transformation of prostaglandin D_2 to 9 alpha, 11-beta-(15S)-trihydroxyprosta-(5Z, 13E)-dien-1-oic acid (9 alpha, 11 beta-prostaglandin $_2$): A unique biologically active prostaglandin produced enzymatically in vivo in huma *Proc Natl Acad Sci U S A* **82**:6030, 1985

48. Negishi M et al: Prostaglandin E receptors *J Lipid Mediat Cell Si* **12**:379, 1995

49. Kotani M et al: Molecular cloning and expression of multiple isoforms of human prostaglandin E receptor $_3$ subtype generated by alternative messenger RNA splicing: Multiple second messenger systems and tissue-specific distributions *Mol Pharmaco* **48**:869, 1995

50. Monneret G et al: Prostaglandin D_2 is a potent chemoattractant for human eosinophils that acts via a novel DP recep *Blooc* **98**:1942, 2001

51. Hirai H, et al: Prostaglandin D_2 selectively induces chemotaxis in T helper type 2 cells, eosinophils, and basophils via seven-transmembrane receptor CR *J Exp Med* **193**:255, 2001

52. Coleman RA et al: International Union of Pharmacology classification of prostanoid receptors: Properties, distribution and structure of the receptors and their sub *Pharmacol Rev*

46:205, 1994

53. Rouzer CA, Samuelsson B: Reversible, calcium-dependent membrane association of human leukocyte 5-lipoxygen *Proc Natl Acad Sci U S A* **84**:7393, 1987

54. Haeggstrom JZ: Structure, function, and regulation of leukotriene A4 hydrolas *Am J Respir Crit Care Me* **161**:S25, 2000

55. Samuelsson B: The discovery of the leukotriene *Am J Respir Crit Care Me* **161**:S2, 2000

56. Grabbe J et al: Production of LTB-like chemotactic arachidonate metabolites from human keratinocy *J Invest Dermato* **85**:527, 1985

57. Breton J et al: Human keratinocytes lack the components to produce leukotriene *J Invest Dermato* **106**:162, 1996.

58. Devillier P et al: Leukotrienes, leukotriene receptor antagonists and leukotriene synthesis inhibitors in asthma: An update. Part 1: Synthesis, receptors and role of leukotrienes in asthma. *Pharmacol Res* **40**:3, 1999

59. Jakobsson PJ et al: Identification and characterization of a novel human microsomal glutathione S-transferase with leukotriene C4 synthase activity and significant sequence identity to 5-lipoxygenase-activating protein and leukotriene C4 synthas *J Biol Chem* **271**:22203, 1996

60. Metters KM: Leukotriene receptors *J Lipid Mediat Cell Si* **12**:413, 1995

61. Orning L et al: In vivo metabolism of leukotriene C4 in man: Urinary excretion of leukotriene *Biochem Biophys Res Commu* **130**:214, 1985

62. Maekawa A et al: Identification in mice of two isoforms of the cysteinyl leukotriene-1 receptor that result from alternative spli *Proc Natl Acad Sci U S A* **98**:2256, 2001

63. Funk CD et al: Molecular cloning, primary structure and expression of the human platelet/erythroleukemia cell 12-lipoxyger *Proc Natl Acad Sci U S A* **87**:5638, 1990

64. Yoshimoto T et al: Cloning and sequence analysis of the cDNA for arachidonate 12-lipoxygenase of porcine leukoc *Proc Natl Acad Sci U S A* **87**:2142, 1990

65. Holtzman MJ et al: A regiospecific monooxygenase with novel stereo preference is the major pathway for arachidonic acid oxygenation in isolated epiderma *J Clin Inves* **84**:1446, 1989

66. Honn KV et al: 12-lipoxygenases and 12(S)-HETE: Role in cancer metastas *Cancer Metastasis Rev* **13**:365, 1994

67. Liehr J et al: Lipid hydroperoxide-induced endogenous DNA adducts in hamsters: Possible mechanism of lipid-hydroperoxide-mediated carcinoge *Arch Biochem Biophys* **316**:38, 1995

68. Wang M, Liehr J: Identification of fatty acid hydroperoxide cofactors in the cytochrome P450-mediated oxidation of estrogens to quinone metab *J Biol Chem* **269**:284, 1994

69. Rose DP et al: Effects of linoleic acid on the growth and metastasis of two human breast cancer cell lines in nude mice and the invasive capacity of these cell lines i *Cancer Res* **54**:6557, 1994

70. Zhao H et al: Lipoxygenase mRNA in cultured human epidermal and oral keratinocy *J Lipid Res* **36**:2444, 1995

71. Yla-Herttuala S et al: Transfer of 15-lipoxygenase gene into rabbit iliac arteries results in the appearance of oxidation-specific lipid-protein adducts characteristic of oxidized low-density lipoprotein. *J Clin Inves* **95**:2692, 1995

72. Serhan CN, Oliw E: Unorthodox routes to prostanoid formation: New twists in cyclooxygenase-initiated pathw *J Clin Inves* **107**:1481, 2001

73. Papayianni A et al: Lipoxin A4 and B4 inhibit leukotriene-stimulated interactions of human neutrophils and endothelial *J Immuno* **156**:2264, 1996

74. Morham SG et al: Prostaglandin synthase 2 gene disruption causes severe renal pathology in the mo *Cell* **83**:473, 1995

75. Langenbach R: Prostaglandin synthase 1 gene disruption in mice reduces arachidonic acid-induced inflammation and indomethacin-induced gastric ulcer *Cell* **83**:483, 1995

76. Blumenkrantz N, Sondergaard I: Effects of prostaglandin F_1 and F_{1a} on biosynthesis of collagen *Nature* **239**:246, 1972

77. Leong L et al: Cyclooxygenases in human and mouse skin and cultured human keratinocytes: Association of COX-2 expression with human keratinocyte differen *Exp Cell Res* **224**:79, 1996

78. Lin L et al: Role of prostanoids in renin-dependent and renin-independent hypertensi *Hypertension* **17**:517, 1991

79. Breyer MD, Breyer RM: Prostaglandin E receptors and the kidne *Am J Physiol Renal Physio* **279**:F12, 2000

80. Hizaki H et al: Abortive expansion of the cumulus and impaired fertility in mice lacking the prostaglandin E receptor subtype E *Proc Nat Acad Sci U S A* **96**:10501, 1999

81. Soter NA et al: Local effects of synthetic leukotrienes (LTC_4, LTD_4, LTE_4, and LTB_4) in human skin. *J Invest Dermato* **80**:115, 1983

82. Maurice PDL et al: The effect of prostaglandin D_2 on the response of human skin to histamine *J Invest Dermato* **89**:245, 1987

83. Roberts LJ et al: Increased production of prostaglandin D_2 in patients with systemic mastocytosis *N Engl J Mec* **303**:1400, 1980

84. Pentland AP et al: Enhanced prostaglandin synthesis after ultraviolet injury is mediated by endogenous histamine stimula *J Clin Inves* **86**:566, 1990

85. Black AK et al: Time course changes in levels of arachidonic acid and prostaglandins $_2$, E_2, F_{2a} in human skin following ultraviolet B irradiatio *Br J Clin Pharmacc* **10**:453, 1980

86. Hruza LL, Pentland AP: Mechanisms of UV-induced inflammatio *J Invest Dermato* **100**:35S, 1993

87. Snyder DS, Eaglstein WH: Topical indomethacin and sunburr *Brit J Dermato* **90**:91, 1974

88. Grewe M et al: Analysis of the mechanism of ultraviolet (UV) B radiation-induced prostaglandin $_2$ synthesis by human epidermoid carcinoma cells *J Invest Derm* **101**:528, 1993

89. Hammarstrom S et al: Arachidonic acid transformations in normal and psoriatic sk*J Invest Dermato* **73**:180, 1979

90. Duell EA et al: Determination of 5-, 12-, and 15-lipoxygenase products in keratomed biopsies of normal and psoriatic *J Invest Dermato* **91**:446, 1988

91. Bain SD: Psoriasis and leukotriene B_4. *Lancet* **2**:762, 1982

92. Bedford CJ et al: Anthralin inhibition of mouse epidermal arachidonic acid lipoxygenase in v*J Invest Dermato* **81**:566, 1983

93. Katayama H, Kawada A: Exacerbation of psoriasis induced by indomethac*J Dermato* **8**:323, 1981

94. Stock JL et al: The prostaglandin E_2 EP_1 receptor mediates pain perception and regulates blood pressur*J Clin Inves* **107**:325, 2001

95. Rao CV et al: Modulation of experimental colon tumorigenesis by types and amounts of dietary fatty ac*Cancer Res* **61**:1927, 2001

96. Rao C et al: Chemoprevention of colon carcinogenesis by sulindac, and nonsteroidal anti-inflammatory ag*Cancer Res* **55**:1464, 1995

97. Prescott SM, Fitzpatrick FA: Cyclooxygenase-2 and carcinogenes*Biochim Biophys Acta* **1470**:M69, 2000

98. Pentland AP et al: Reduction o UV-induced skin tumors in hairless mice by selective COX-2 inhibiti*Carcinogenesis* **20**:1939, 1999

99. Fisher SM et al: Chemopreventive activity of celecoxib, a specific cyclooxygenase-2 inhibitor, and indomethacin against ultraviolet light-induced skin carcinoge*Mol Carcinog* **25**:231, 1999

100. Giovannucci E et al: Aspirin use and the risk for colorectal cancer and adenoma in male health professior*Ann Intern Mec* **121**:241, 1994

101. Day L, Barnfield M: Who should be taking aspirin*Practitioner* **239**:426, 1995

102. Dekker GA, Sundler R: Dexamethasone down-regulates the 85-kDa phospholipase$_2$ in mouse macrophages and suppresses its activatior*Biochem J* **307**:499, 1995

103. Yermakova A, O'Banion MK: Cyclooxygenases in the central nervous system: implications for treatment of neurological disor*Current Pharm Des* **6**:1755, 2000

104. Crofford LJ et al: Basic biology and clinical application of specific cyclooxygenase-2 inhibitc*Arthritis Rheum* **43**:4, 2000

105. Moses MF et al: Prevention of acute graft rejection by the PGE_1 analog misoprostol in renal transplant recipients treated with cyclosporine and prednisoN *Engl J Med* **322**:1183, 1990

106. Rulo AH et al: Reduction of intraocular pressure with treatment of latanoprost once daily in patients with normal-pressure glauc*Ophthalmology* **103**:1276, 1996

107. Barnes NC: Effects of antileukotrienes in the treatment of asthm*Am J Respir Crit Care Med* **161**:S73, 2000

108. Devillier P et al: Leukotrienes, leukotriene receptor antagonists and leukotriene synthesis inhibitors in asthma: An update. Part II. Clinical studies with leukotriene receptor antagonists and leukotriene synthesis inhibitors in asthma*Pharmacol Res* **40**:15, 1999

109. Dolan-O'Keefe M et al: Transcriptional regulation and structural organization of the human cytosolic phospholipase A(2) g*Am J Physiol Cell Physic* **278**:L649, 2000

110. Irahara M et al: Glucocorticoid receptor-mediated post-ceramide inhibition of the interleukin-1 beta-dependent induction of ovarian prostaglandin endoperoxide synthase-2*Biol Rpts. Reprod* **60**:946, 1999

T>

Chapter 35

Kenneth Kraemer

Cellular Hypersensitivity and DNA Repair

USE OF CULTURED CELLS FOR ASSESSMENT OF HYPERSENSITIVITY
ASSESSMENT OF CELLULAR HYPERSENSITIVITY
Tests of Intact Cell Function
Tests of Chromosome Integrity
DNA REPAIR
DNA Repair Pathways
Complementation Groups
HUMAN DNA REPAIR GENES
XP Complementation Group A
XP Complementation Group B
XP Complementation Group C
XP Complementation Group D
XP Complementation Group E
XP Complementation Group F
XP Complementation Group G
CS Complementation Group A
CS Complementation Group B
XP Variant
ROLE OF DNA REPAIR GENES IN EXCISION REPAIR
REFERENCES

A group of heritable diseases with differing clinical features share the common characteristics of in vitro or in vivo cellular hypersensitivity to damage by several physical or chemical agents. [1], [2] and [3] These diseases include those with ultraviolet hypersensitivity (xeroderma pigmentosum, Cockayne syndrome, trichothiodystrophy, and familial melanoma with dysplastic nevi), those with x-ray hypersensitivity (ataxia-telangiectasia and basal cell nevus syndrome), and those with chromosome instability (Bloom syndrome, Fanconi anemia, and ataxia-telangiectasia). This cellular hypersensitivity may be of diagnostic utility and may suggest measures for therapeutic or prophylactic intervention. Knowledge of the molecular basis of the cellular hypersensitivity is rapidly emerging. In this chapter, the major tests used to assess cellular hypersensitivity and DNA repair are outlined. The clinical features and cellular abnormalities in these disorders are included in Chap. 82, Chap. 93, and Chap. 155.

USE OF CULTURED CELLS FOR ASSESSMENT OF HYPERSENSITIVITY

Cells obtained directly from patients and grown in culture medium are termed *primary* cultures. Dermal fibroblasts generally grow easily in culture and can be subcultured. Recent advances in cell-culture techniques have permitted prolonged growth and subculture of keratinocytes and melanocytes. Lymphocytes may be stimulated to divide by means of ‘mitogens’ such as phytohemagglutinin (PHA), a plant lectin, or interleukin (IL)-2.

Primary cultures of skin dermal fibroblasts can generally be established from a 2- to 4-mm sterile skin punch biopsy. The inner surface of the upper arm has proven to be a suitable site because this area heals easily, the resulting scar is not readily visible, the site is shielded from ultraviolet radiation, and a large proportion of the attempts to establish cultures have been successful. The tissue is placed in sterile culture medium (or sterile saline) with antibiotics and transported to a cell-culture laboratory at room temperature.

Primary cultures have a limited life span. Their growth rate slows dramatically and they cannot be successfully subcultured. To avoid this cellular senescence, techniques have been developed to immortalize cultured cells. Transformation of lymphocytes with Epstein-Barr (EB) virus or fibroblasts with SV40 virus results in cultures of cells that grow indefinitely without senescence. Transformed lymphocytes, termed lymphoblastoid cell lines, resemble immature lymphoid cells. Lymphoblastoid cell lines can generally be established by EB virus treatment of 10 to 20 mL of sterile whole blood [collected in sterile tubes containing acid citrate dextrose (ACD) or heparin].

Established cell cultures may be frozen at liquid nitrogen temperatures and stored indefinitely in a state of suspended animation. When thawed, the cells resume growth in fresh culture medium. Human cell cultures (skin fibroblasts or blood cells) are established, frozen, and made available for research by the Human Genetic Mutant Cell Repository (401 Haddon Ave, Camden, NJ 08103, telephone 800-752-3805; http://locus.umdnj.edu/ccr/).

ASSESSMENT OF CELLULAR HYPERSENSITIVITY

Tests to assess cellular hypersensitivity to physical or chemical agents may be divided into tests of intact cellular function or chromosome integrity (Table 35-1) and tests that measure the mechanism of impairment of cell function such as DNA repair.

Intact cell function
Growth rate
Colony-forming ability
Cell mutagenesis
Host-cell reactivation
Chromosome integrity
Chromosome breakage
Sister chromatid exchanges

TABLE 35-1 **Tests of Cellular Sensitivity to Physical or Chemical Agents**

Tests of Intact Cell Function

Tests of cellular function measure the capacity of the intact cell to recover from the damage induced. These tests do not provide information as to the specific type of damage resulting in cellular injury or the mechanism of cellular recovery, but they do form the basis for identifying cells as hypersensitive.

GROWTH RATE One of simplest tests of cellular function is the assessment of the growth rate of cells in mass culture following exposure to UV or x-ray. Cells from patients with xeroderma pigmentosum or Cockayne syndrome are hypersensitive to UV and cells from patients with ataxia-telangiectasia are hypersensitive to killing by x-ray.
COLONY-FORMING ABILITY Colony-forming ability assesses the capacity of a single cell to proliferate enough to form a visible colony. Xeroderma pigmentosum fibroblasts from two affected siblings (XP12TA and XP25TA), their father (XPH27TA), unaffected brother (35TA), and normal fibroblasts (96TA and HSTA) were treated with 254-nm ultraviolet radiation (UVC) and colony-forming ability determined (Fig. 35-1). The XPC fibroblast strains from the affected siblings were much more sensitive than the normal strains and showed similar post-UV hypersensitivity. Cells from the unaffected brother and the clinically normal father, a heterozygous carrier of the XPC defect, had normal post-UV survival. [4]

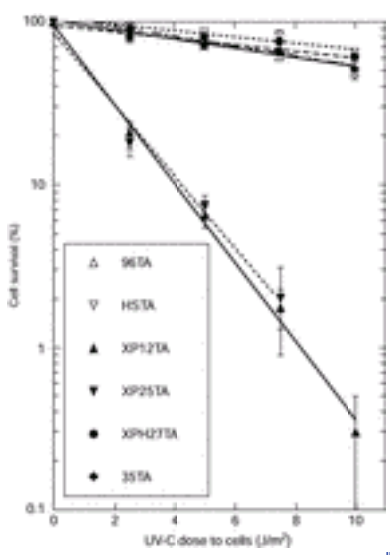

FIGURE 35-1 Colony-forming ability assay of cell sensitivity. Ultraviolet sensitivity of XP complementation group C fibroblasts. Colony forming ability of fibroblasts from two affected siblings (XP12TA and XP25TA) following exposure to various doses of UVC was reduced compared to that of the normal controls (96TA and HSTA). Fibroblasts from the clinically normal father (XPH27TA) who is an obligate XPC heterozygote and the unaffected brother (35TA) had normal post-UV colony-forming ability. [4]

MUTAGENESIS Assays of induced mutations measure the frequency of induction of mutated cells following treatment with damaging agents. A limited number of mutated characteristics, such as thioguanine resistance [resulting from loss of activity of the enzyme hypoxanthine guanine phosphoribosyltransferase (HGPRT)] and ouabain resistance [caused by an alteration in membrane adenosine triphosphatase (ATPase)] have been examined in culture. The growing cells can have mutations (alterations in DNA sequence) induced in their DNA by treatment with UV. Such somatic mutations are thought to be related to induction of cancer in vivo. Cells from XP patients are hypermutable after UV exposure.
HOST-CELL REACTIVATION These assays rely on the fact that DNA viruses or plasmids do not have the ability to repair damage to their DNA but depend on cellular repair systems. Thus, damaged viruses or plasmids would be expected to grow better on cells with normal repair capacity than on cells with reduced repair capacity. Host-cell reactivation assays (Fig. 35-2) have been developed that utilize plasmids, which are small, double-stranded DNA that can replicate independently in bacteria and often carry genes for antibiotic resistance. Molecular biologic techniques have been used to modify plasmids to permit expression of bacterial genes in mammalian cells.

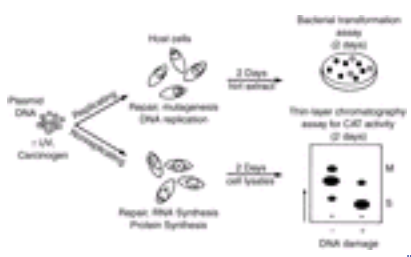

FIGURE 35-2 Plasmid host-cell reactivation assays of cell sensitivity. Plasmid DNA is treated in vitro with UV radiation or another carcinogen and then introduced into the human host cells by transfection. A nonreplicating plasmid is used to measure the DNA repairability of the host cell (lower path). A replicating plasmid measures DNA replication and mutagenesis in addition to DNA repair (upper path). See text for further details.

A plasmid DNA repair assay uses a nonreplicating plasmid, pRSVCAT, which contains a gene for the bacterial enzyme chloramphenicol acetyl transferase (CAT), or for luciferase, which is constructed to permit expression in human cells. The plasmid is damaged by UV radiation and introduced into cultured human cells by a transfection technique. The cells' DNA repair enzymes repair the damage in a similar manner to the repair of cellular DNA. Repaired DNA will then function to transcribe mRNA, which then results in synthesis of the CAT enzyme in the human cell. The amount of CAT activity reflects the efficiency of the cellular DNA repair system. This assay can also be used to determine the complementation group by cotransfecting UV-treated plasmid plus plasmids expressing wild-type XP cDNA. Figure 35-3 shows the results of plasmid host-cell reactivation experiments and complementation group assignment with DNA excision repair-deficient

XP65BE cells. UV treated plasmid showed low expression in the XP65BE cells that was increased only by cotransfection with a plasmid expressing the wild-type *XPG* cDNA. This result indicates that XP65BE cells are in XP complementation group G.

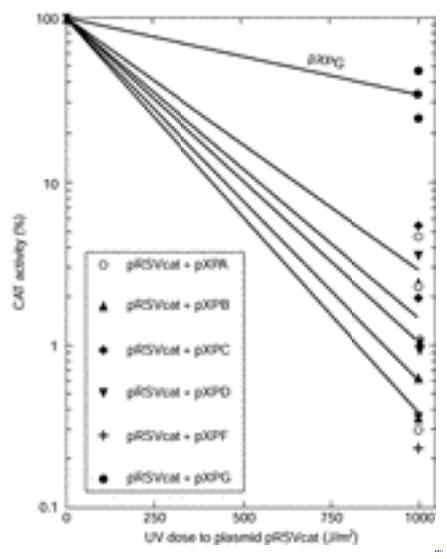

FIGURE 35-3 Plasmid host cell reactivation and assignment to XP complementation group G. A 1000 J/m ^{2} UVC-treated reporter gene plasmid (pRSVcat) was cotransfected with a wild-type XP cDNA containing plasmid [pXPA (*open circle*), pXPB (*triangle*), pXPC (*diamond*), pXPD (*inverted triangle*), pXPF (*cross*), pPXG (*closed circle*)] into triplicate cultures of primary patient fibroblasts (XP65BE). Each symbol represents the relative reporter gene activity in an independent transfection experiment 48 h after transfection compared with the corresponding unirradiated control reporter gene plasmid. The low level of host-cell reactivation typical of XP cells was increased only by adding the plasmid expressing wild-type XPG cDNA, indicating that the XP65BE cell is in XP complementation group G. [15]

Replicating plasmids can be used to measure mutagenesis in human cells. Xeroderma pigmentosum and Cockayne syndrome cells show post-UV plasmid hypermutability. [5]

Tests of Chromosome Integrity

CHROMOSOME BREAKAGE Chromosome breakage is usually assessed in primary cultures of mitogen-stimulated peripheral blood leukocytes or in long-term cultures of fibroblasts or lymphoblastoid cell lines. Cell-cycle progression is stopped at metaphase by treatment of the cells with a mitotic inhibitor such as colchicine. With this procedure, the 23 pairs of metaphase chromosomes from a single cell are spread over a discrete area of the slide and stained (usually with Giemsa). Chromosome preparations may be analyzed for the number of chromosomes per metaphase, the morphology of the individual chromosomes, and the attachments or rearrangements of chromosomes with each other. Increased spontaneous chromosome breakage is seen in three cancer-prone diseases; Bloom syndrome, ataxia-telangiectasia, and Fanconi anemia. Chromosome breakage may also be assessed after treatment of cells with DNA-damaging agents. Xeroderma pigmentosum cells are hypersensitive to chromosome breakage following ultraviolet radiation. Ataxia-telangiectasia cells are hypersensitive to chromosome breakage following treatment with x-rays or bleomycin. In another assay, *G2 chromosome breakage,* fibroblasts or lymphocytes are exposed to low-dose x-rays and metaphases are collected beginning 1.3 h later. (Cells in metaphase at that time were in the G2 phase at the time of x-ray exposure.) The frequency of chromatid breaks and gaps is scored at several time intervals. With normal cells, there is a rapid decline in frequency of chromatid breaks and gaps. Cells from XP patients show a normal initial level of breaks and gaps but these persist longer than normal. [6] With obligate XP heterozygotes (parents of XP patients), the initial level of damage was similar, but there was an intermediate level of persistent breaks and gaps. [7] This assay has also been found to be abnormal with other genetic disorders such as ataxia- telangiectasia, familial melanoma with dysplastic nevi, basal cell nevus syndrome, Bloom syndrome, Fanconi anemia, and retinoblastoma.
SISTER CHROMATID EXCHANGE During cell growth, chromatids occasionally exchange positions along the arms of a chromosome. This “sister chromatid exchange” (SCE) may be detected by permitting the cells to grow through two cycles of replication in medium containing the nucleic acid analogue bromodeoxyuridine (BrUdR) (Fig. 35-4). After the first cycle of replication, the DNA of the newly synthesized strand is labeled with BrUdR while the older strand is unlabeled. Such chromosomes appear uniformly dark with Giemsa stain. After a second cycle of replication in BrUdR-containing medium, one arm of a chromosome will contain two labeled chromatids, while the other will contain one labeled and one unlabeled chromatid. The doubly substituted arm will stain lightly, while the singly substituted arm will stain darkly. If an SCE occurred during replication, a portion of each chromosome arm would be doubly substituted and the remainder singly substituted with BrUdR. SCEs are thought to be related to DNA damage and repair, although their precise significance is not understood. Figure 35-5 shows the appearance of mitogen-stimulated peripheral blood lymphocytes from a patient with Bloom syndrome that have been treated to reveal the elevated frequency of spontaneous SCEs. Lymphocytes from normal individuals generally have 8 to 10 SCEs per metaphase. The Bloom syndrome metaphase shown has 152 SCEs [8]. Xeroderma pigmentosum cells have an abnormally great increase in SCEs after UV radiation.

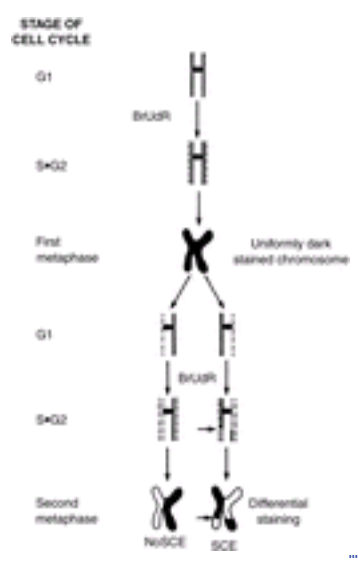

FIGURE 35-4 Schematic of sister chromatid exchange (SCE) assay of cell sensitivity. Cultured cells are permitted to go through two cycles of replication in medium containing bromodeoxyuridine. Staining with Giemsa or Hoechst dye number 33258 differentiates singly substituted from doubly substituted chromosomes, thus permitting recognition of SCEs.

FIGURE 35-5 Sister chromatid exchange (SCE) assay of cell sensitivity. *A*. Undamaged normal cultured peripheral blood lymphocytes have about 10 SCEs per metaphase. *B*. Cultured peripheral blood lymphocytes from a patient with Bloom syndrome have a manyfold increase in SCEs. (*From Chaganti et al.*, [14] *with permission.*)

DNA REPAIR

Many environmental physical and chemical agents kill cells by damaging the cellular DNA. Table 35-2 lists some of the agents commonly used in laboratory studies on human cells and the type of damage induced. Normal cells contain enzyme systems that repair DNA damage. In bacteria, yeast, and rodent cells, many mutants that are hypersensitive to killing by physical agents (UV, X-ray) or chemicals have defective DNA repair. Some of these same hypersensitivity characteristics have been found in cells from patients who may also have defective DNA repair.

Agent	Damage
Ultraviolet radiation	DNA dipyrimidine (cyclobutane dimers (CT, TC, CC, or TT)), pyrimidine-pyrimidine (6-4) photoproducts (mostly TC), Pyrimine glycols, DNA-protein cross-links
X radiation	DNA strand breaks, altered bases (thymine glycols)
Psoralens plus UVA	DNA psoralen monoadducts, DNA interstrand cross-links (bends to T at TA sequences, psoralen-protein binding high dose)
Mitomycin C	DNA interstrand cross-links
Benzo[a]pyrene	Bends to guanine in DNA making bulky adducts
Oxidation	Base damage (8-oxo-deoxyguanine)

TABLE 35-2 **Cellular Damage Induced by Physical and Chemical Agents**

DNA Repair Pathways

The nucleotide excision repair (NER) pathway is known to act on DNA damaged with UV radiation (forming cyclobutane pyrimidine dimers and other photoproducts) or damaged with certain carcinogens (such as benzo-[a]-pyrene) (Table 35-2). In this pathway, the damaged nucleotide is removed and replaced with undamaged DNA. This pathway is defective in most XP patients and is discussed in more detail later in this chapter. Other pathways involve base excision repair, mismatch repair, photoreactivation, and bypass repair. More extensive descriptions of these pathways may be found in references. [1], [2] and [3]

One of the most commonly used tests of NER is unscheduled DNA synthesis (UDS). This test has been used to measure DNA repair in intact human skin, in cultured epidermal or dermal cells, in blood cells, and for prenatal diagnosis using amniotic fluid cells. UDS measures the combined action of endonuclease, exonuclease, and polymerase in the nucleotide excision repair system. Cells are treated with UV radiation or another DNA-damaging agent and then incubated in medium containing radioactive thymidine. During the process of NER, the damage is removed and the radioactive thymidine is incorporated into the repaired region. The cells are treated with fixative, coated with autoradiographic (photographic) emulsion, kept in the dark for an appropriate interval, and then the emulsion is developed. During the exposure interval, the decay of tritium from the thymidine incorporated into the DNA exposes a small portion of the overlying emulsion. The tritium is revealed as a microscopic, dark grain in the developed emulsion above the cellular location of the incorporated thymidine. UV radiation of normal fibroblasts results in a large increase in the number of grains over all the nuclei. In marked contrast, radiation of the (DNA repair-defective) XP fibroblasts results in very few grains over their nuclei (Fig. 35-6 and Fig. 35-7).

FIGURE 35-6 Schematic of cell fusion technique. Cocultured fibroblasts from two donors (A + B) are treated with inactivated Sendai virus or polyethylene glycol to induce cell fusion.

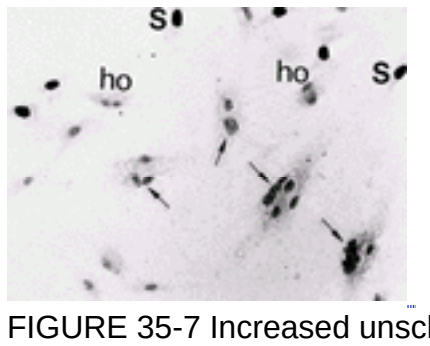

FIGURE 35-7 Increased unscheduled DNA synthesis in complementing xeroderma pigmentosum heterokaryons. A mixed culture of fused xeroderma pigmentosum fibroblasts was exposed to UV radiation and unscheduled DNA synthesis was determined. The nuclei of S-phase cells (*S*) are heavily labeled with radioactive thymidine. The unfused mononuclear cells have the same low level of unscheduled DNA synthesis as the fused homokaryons (*ho*). The heterokaryons (*arrows*), containing nuclei from both xeroderma pigmentosum fibroblast strains, have increased unscheduled DNA synthesis, indicating mutual correction of their DNA repair defects.

Complementation Groups

Cell fusion studies have been used to determine whether cells have different types of DNA repair defects. Fusion of fibroblasts from two XP patients with different DNA repair defects is followed by UV exposure and autoradiographic determination of unscheduled DNA synthesis (Fig. 35-6 and Fig. 35-7). The heterokaryons (from different donors) have a markedly increased amount of unscheduled DNA synthesis in comparison with the homokaryons (from a single donor) or the unfused mononuclear XP cells. This implies that the two fused XP strains had complementary DNA repair defects. Each strain supplied what the other was lacking. Such XP fibroblasts are said to be in different DNA repair complementation groups. Heterokaryons resulting from XP patients with the same DNA repair defect do not show an increase in post-UV unscheduled DNA synthesis. Such cells are said to be in the same complementation group. Seven complementation groups (genes) have been identified with fibroblasts from patients with XP, two from patients with Cockayne syndrome (CS) and three from trichothiodystrophy (TTD) patients (Table 35-3). This implies that each of these clinical disorders can be associated with more than one molecular defect.



TABLE 35-3 **Cloned DNA Repair Genes Associated with Human Diseases**

HUMAN DNA REPAIR GENES

In recent years, more than 100 DNA repair genes have been identified (www.cgal.icnet.uk/DNA_Repair_Genes.html#NER). [9] Figure 35-8 shows a schematic of the repair of DNA by several of the XP proteins acting in concert.

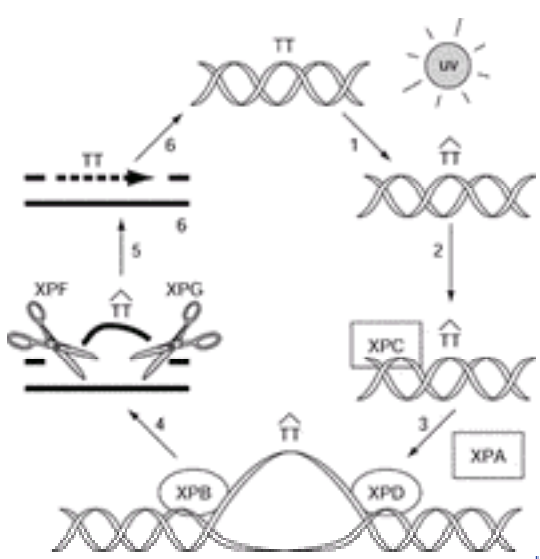

FIGURE 35-8 DNA excision repair scheme. Undamaged DNA contains adjacent pyrimidines in one strand (*top*). (1) Exposure to ultraviolet radiation in sunlight results in formation of photoproducts at the adjacent pyrimidines. (2) The XPC protein (in conjunction with other proteins such as XPE) detects the presence of the photoproduct and binds to the DNA,

thereby marking the site for further processing. (3) The XPB and XPD proteins (in a complex containing the components of basal transcription factor TFIIH) unwind the DNA helix in the region of the photoproduct. (4) The XPF and XPG proteins (in complex with other proteins) make single-strand cuts 5' and 3' to the photoproduct, resulting in a gap of about 30 nucleotides. (5) The gap is filled in by DNA polymerase, which synthesizes new DNA using the other (undamaged) strand as a template. (6) DNA ligase joins the newly synthesized DNA to the older portion of the DNA strand, restoring the original undamaged DNA sequence. Further details are in the text.

XP Complementation Group A

The *XPA* gene is located on human chromosome 9 and codes for a messenger RNA of about 1000 bases, corresponding to a protein of 273 amino acids that binds to damaged DNA. Most XP-A patients have XP with neurologic abnormalities. More than 90 percent of Japanese XP-A patients have the same single base substitution mutation in this gene. [10] A diagnostic test for this mutation based on the polymerase chain reaction (PCR) and differences in enzymatic digestion of normal and mutated products and has been developed for rapid diagnosis of XP-A homozygotes and heterozygotes, as well as for prenatal diagnosis. [11]

XP Complementation Group B

The *XPB* gene on human chromosome 2 codes for a 2900-base messenger RNA, which corresponds to a protein of 782 amino acids that functions as a 3'to 5'DNA helicase in unwinding DNA (Fig. 35-8). Remarkably, this *XPB* gene was also found to be part of the TFIIH complex that is involved in regulation of the basal rate of transcription (RNA synthesis) of active genes. Analysis of the DNA of XP-B cells showed a single-base substitution mutation within the *XPB* (ERCC3) gene. [10] The XP-B phenotype was seen in three patients with the XP/CS complex and one with TTD.

XP Complementation Group C

The *XPC* gene on chromosome 3 codes for a 3500-base messenger RNA that corresponds to a protein of 940 amino acids. The XPC protein is involved with recognition of DNA damage (Fig. 35-8). Single-base substitution and splice mutations have been found in XP-C patients [12]; most XP-C patients have XP without neurologic abnormalities.

XP Complementation Group D

The *XPD* gene on chromosome 19 codes for a 760-amino acid protein that, like the XPB protein, is also a DNA helicase (but unwinds DNA in the 5'to 3'direction) and part of basal transcription factor TFIIH (Fig. 35-8). Different base substitution mutations within the *XPD* gene result in the different clinical phenotypes seen: XP, XP with neurologic abnormalities, the XP/CS complex, TTD, and XP/TTD. [13], [14]

XP Complementation Group E

The *XPE* gene on chromosome 11 codes for a DNA damage-binding protein of 1140 amino acids. While two XP-E patients had mutations in the *XPE* gene, other XP-E patients did not have mutations. [10] These patients generally have mild skin symptoms without neurologic abnormalities.

XP Complementation Group F

The *XPF* gene on chromosome 16 codes for a 905-amino acid protein that serves as a DNA endonuclease 5'to the lesion (Fig. 35-8). XP-F patients generally have XP without neurologic abnormalities. Most were described in Japan. [10]

XP Complementation Group G

The *XPG* gene on chromosome 13 codes for a protein of 1186 amino acids that functions as a DNA endonuclease 3'to the lesion (Fig. 35-8). Mutations resulting in markedly truncated proteins are found in XP-G patients with the XP/CS complex, whereas XP-G patients without neurologic disease have missense mutations that retain some activity. [15]

CS Complementation Group A

The *CSA* gene on chromosome 5 codes for a 396 amino acid protein that is involved with transcription-coupled DNA repair. Mutations have been reported in a few patients. [10]

CS Complementation Group B

The *CSB* gene on human chromosome 10 codes for a protein of 1493 amino acids, which is a DNA helicase involved in transcription-coupled DNA repair. Mutations have been described in 24 patients. [16], [17]

XP Variant

The XPV gene (polymerase eta) codes for an error-prone polymerase on chromosome 6 (Table 35-3). [18], [19] XP variant patients are clinically identical to other XP patients with cutaneous symptoms without neurologic abnormalities.

ROLE OF DNA REPAIR GENES IN EXCISION REPAIR

The cloning of the human DNA repair genes has permitted study of the role of their encoded proteins in DNA excision repair. Several laboratories have developed cell-free assay systems that partially reconstitute portions of the nucleotide excision repair system using defined proteins. [20], [21] A more detailed picture of nucleotide excision repair is emerging. Figure 35-8 shows a schematic version of the functions of XP genes in nucleotide excision repair. Double-stranded DNA contains adjacent pyrimidines. (1) Exposure to UV radiation from sunlight forms cyclobutane dimers or other photoproducts at adjacent pyrimidines, thereby distorting the DNA. (2) The *XPC* or *XPA* gene products bind to the damaged DNA, marking it for further processing. The *XPC* gene product may function in conjunction with the *XPE* gene product in lesion recognition. The *XPA* gene product probably functions in conjunction with replication protein A (RPA), TFIIH, and ERCC1. (3) The *XPB* and *XPD* gene products partially unwind the DNA in the region of the damage, thereby exposing the lesion for further processing. These proteins are part of the TFIIH basal transcription factor and appear to prefer to repair damage to actively transcribing genes before inactive genes. (4) The *XPF* gene product, in a complex with ERCC1, makes a single-strand nick at the 5'side of the lesion, while the *XPG* gene product makes a similar nick on the 3'side, resulting in the release of a region of about 30 nucleotides containing the damage. (5) The resulting gap is filled by DNA polymerase using the other (undamaged) strand as a template in a process involving proliferating cell nuclear antigen (PCNA). (6) DNA ligase I seals the region restoring the original undamaged sequence.

Recently, mouse models of DNA repair-deficient disorders have been generated by using recombinant DNA technology to alter embryonal mouse stem cells. [22] This gene targeting may be used to either completely inactivate a DNA repair gene, resulting in a knockout mutant, or to partially inactivate a gene by introducing the same mutations that are found in humans with disease. Like XP patients, these mice are hypersensitive to UV exposure and have an increased post-UV skin cancer susceptibility. Mouse models for CS and TTD have also been produced. These mice have some skin symptoms similar to those of humans but differ with respect to neurologic disease. This area of research is just beginning. Future studies may provide insights into multiple effects of DNA repair genes including immune abnormalities and possible interactions among these genes.

REFERENCES

1. Van Steeg H, Kraemer KH: Xeroderma pigmentosum and the role of UV-induced DNA damage in skin cancer. *Mol Med Today* **5**:86, 1999

2. Bootsma D et al: Nucleotide excision repair syndromes: Xeroderma pigmentosum, Cockayne syndrome, and trichothiodystrophy, in *The Genetic Basis of Human Cancer,* edited by B Vogelstein, KW Kinzler. New York, McGraw-Hill, 1998, p 245

3. Hoeijmakers JH: Genome maintenance mechanisms for preventing cancer. *Nature* **411**:366, 2001

4. Slor H et al: Clinical, cellular, and molecular features of an Israeli xeroderma pigmentosum family with a frameshift mutation in the XPC Gene: Sun protection prolongs life. *J Invest Dermatol* **115**:974, 2000

5. Gözükara EM et al. The human DNA repair gene, ERCC2 (XPD), corrects ultraviolet hypersensitivity and ultraviolet hypermutability of a shuttle vector replicated in xeroderma pigmentosum group D cells. *Cancer Res* **54**:3837, 1994

6. Parshad R et al: Cytogenetic evidence for differences in DNA incision activity in xeroderma pigmentosum group A, C, and D cells after X-irradiation during G2 phase. *Mutat Res* **294**:149, 1993

7. Parshad R et al: Carrier detection in xeroderma pigmentosum. *J Clin Invest* **85**:135, 1990

8. Chaganti RS et al: A manyfold increase in sister chromatid exchanges in Bloom's syndrome lymphocytes. *Proc Natl Acad Sci U S A* **71**:4508, 1974

9. Wood RD et al: Human DNA repair genes. *Science* **291**:1284, 2001

10. Cleaver JE et al: A summary of mutations in the UV-sensitive disorders: Xeroderma pigmentosum, Cockayne syndrome, and trichothiodystrophy. *Hum Mutat* **14**:9, 1999

11. Kore-eda S et al: A case of xeroderma pigmentosum group A diagnosed with a polymerase chain reaction (PCR) technique. Usefulness of PCR in the detection of point mutation in a patient with a hereditary disease. *Arch Dermatol* **128**:971, 1992

12. Chavanne F et al: Mutations in the XPC gene in families with xeroderma pigmentosum and consequences at the cell, protein, and transcript levels. *Cancer Res* **60**:1974, 2000

13. Lehmann AR: The xeroderma pigmentosum group D (XPD) gene: One gene, two functions, three diseases. *Genes Dev* **15**:15, 2001

14. Broughton BC et al: Two individuals with features of both xeroderma pigmentosum and trichothiodystrophy highlight the complexity of the clinical outcomes of mutations in the XPD gene. *Hum Mol Genet* **10**:2539, 2001

15. Emmert S et al: Relationship of neurologic degeneration to genotype in three xeroderma pigmentosum group G patients. *J Invest Dermatol* **118**:972, 2002

16. Mallery DL et al: Molecular analysis of mutations in the CSB (ERCC6) gene in patients with Cockayne syndrome. *Am J Hum Genet* **62**:77, 1998.

17. Colella S et al: Alterations in the CSB gene in three Italian patients with the severe form of Cockayne syndrome (CS) but without clinical photosensitivity. *Hum Mol Genet* **8**:935, 1999

18. Johnson RE et al: hRAD30 mutations in the variant form of xeroderma pigmentosum. *Science* **285**:263, 1999

19. Masutani C et al: The XPV (xeroderma pigmentosum variant) gene encodes human DNA polymerase eta. *Nature* **399**:700, 1999

20. Araujo SJ et al: Nucleotide excision repair of DNA with recombinant human proteins: Definition of the minimal set of factors, active forms of TFIIH, and modulation by CAK. *Genes Dev* **14**:349, 2000

21. Petit C, Sancar A: Nucleotide excision repair: From *E. coli* to man. *Biochimie* **81**:15, 1999

22. Friedberg EC, Meira LB: Database of mouse strains carrying targeted mutations in genes affecting cellular responses to DNA damage. Version 4. *Mutat Res* **459**:243, 2000

T>

Chapter 36

Andrzej Dlugosz Stuart Yuspa

Carcinogenesis: Chemical

CUTANEOUS CANCER AND PUBLIC HEALTH
CHEMICALS ASSOCIATED WITH SKIN CANCER INDUCTION IN HUMANS
THE NATURE OF CHEMICAL CARCINOGENS: CHEMISTRY AND METABOLISM
HEREDITARY CANCER SYNDROMES
ANIMAL MODELS VERIFY THE GENETIC BASIS FOR CUTANEOUS NEOPLASMS
TUMOR BIOLOGY AND BIOCHEMISTRY
General Principles
The Pathogenesis of Basal Cell Carcinomas (see Chap. 81 and Chap. 82)
The Pathogenesis of Squamous Cell Carcinomas (see Chap. 79 and Chap. 80)
Constitutional Modifiers of Carcinogenesis
Exogenous Modifiers of Carcinogenesis
NOVEL MOLECULAR TARGETS BASED ON NEW MECHANISTIC DATA

REFERENCES

CUTANEOUS CANCER AND PUBLIC HEALTH

Cutaneous cancers account for more than half of all malignancies in North America, totaling more than 1 million nonmelanoma skin cancers [mainly basal cell carcinomas (BCCs) and squamous cell carcinomas (SCCs)] and 50,000 melanomas in 2001. Death rates from nonmelanoma skin cancers equal those of Hodgkin's disease and uterine cancer, while deaths from melanoma are increasing at an alarming rate. Cutaneous cancers also significantly impact health care costs, and treatment is associated with considerable morbidity and cosmetic defects. For these reasons, understanding the etiology and pathogenesis of cutaneous cancers is a significant public health goal, and development of rational nondeforming therapies to reduce morbidity and mortality is urgently needed. The high prevalence of skin cancer, the external location of the tumors, and well-defined preneoplastic lesions provide an excellent opportunity for studying the factors regulating cutaneous cancer induction in humans. Those qualities that facilitate the study of cutaneous neoplasms in human populations have also been useful in establishing relevant animal models. Advances in molecular genetics, keratinocyte cell culture, and construction of genetically altered mice have greatly facilitated the analysis of basic mechanisms of cutaneous carcinogenesis. This chapter focuses on nonmelanoma skin cancer: the reader is referred to Chap. 93 for further discussion of melanoma.

CHEMICALS ASSOCIATED WITH SKIN CANCER INDUCTION IN HUMANS

The ultraviolet radiation (UVR) in sunlight is the primary etiologic agent for all skin cancers, and thus UVR is the major carcinogen in the human environment. The powerful carcinogenic activity of UVR is attributable to its ability to damage DNA and cause mutations, its capacity to clonally expand incipient neoplastic cells whose altered signaling pathways provide a survival advantage in the face of ultraviolet-induced cytotoxicity, and its activity as an immune suppressant (see Chap. 38 and Chap. 39). The association of UVR with skin cancer is so strongly supported by clinical, epidemiologic, and experimental data that it represents the most clear-cut etiologic factor in human malignancy. Also implicated in the development of human skin cancer are various chemicals, as a result of environmental, occupational, or medicinal exposures (Table 36-1). In 1775, Sir Percivall Pott [1] attributed the increased incidence of scrotal cancer in chimney sweeps to repeated exposure to soot. This report provided the first link between occupational exposure and the development of cancer, as well as the first example of chemical carcinogenesis. In the last 30 years, the mechanisms by which chemicals cause cancer have been unraveled and they reveal striking similarities to the properties responsible for UVR carcinogenicity, namely DNA damage, selective cytotoxicity, and immune suppression.



TABLE 36-1 **Environmental Agents Associated with the Development of Human Skin Cancer**

The carcinogenic potential of coal and petroleum derivatives is now firmly established as a result of experimental animal studies and epidemiologic reports. Petroleum products and grease, as well as insecticides, herbicides, and fungicides, are particularly pathogenic for SCC, whereas fiberglass and dry-cleaning agents increase the incidence of BCC. Recent evidence suggests that cigarette and pipe smokers have an overall twofold increased risk for cutaneous SCC, and the risk increases with the intensity of the tobacco use. [2]

Arsenic exposure is associated with the development of premalignant keratoses, Bowen's disease, SCC, and BCC, as well as a number of internal malignancies. [3] While Fowler's solution (1% potassium arsenite) is no longer used in medical practice, certain herbal medicines are still a source of arsenic exposure. Occupational exposures to arsenic as a component of agricultural pesticides, sheep and cattle dip, mining and smelting, glass manufacturing, and other industries are well-documented. A more insidious source of environmental arsenic exposure is contaminated drinking

water or shell fish, and analysis of affected populations shows a dose-dependent increase in skin cancer. Mouse models provide evidence for an interaction of ingested arsenic acting as a cocarcinogen with solar radiation to increase the frequency and size of cutaneous carcinomas and reduce the latency period. [4]

A variety of medications have been associated with the development of skin cancer. Systemic treatment with immunosuppressive agents results in an increased incidence of both benign and malignant skin lesions. [5] Topical nitrogen mustard also increases the risk of developing skin cancer. Despite the clear-cut association between occupational exposure to tars and skin cancer, the use of crude coal tar in the treatment of psoriasis appears to pose a relatively low risk for the development of skin tumors. In contrast, the use of ionizing radiation to treat a variety of skin diseases increases the risk of BCC in all treated patients and SCC in individuals with sun-sensitive skin. [6]

Systemic administration of 8-methoxypsoralen combined with ultraviolet A treatments (PUVA) is associated with a dose-dependent increase in the risk of developing cutaneous SCC that persists following discontinuation of therapy. [7] Patients receiving high-level exposures (= 337 PUVA treatments) had more than a 100-fold increase in SCC incidence while those receiving <100 treatments had a fivefold higher than expected incidence. Of individuals with PUVA-associated SCC, 3.8 percent developed metastases, and SCCs developed on the male genitalia much more frequently than in the general population. The incidence of BCC and melanoma is also increased in PUVA patients. PUVA is thus a potent stimulus for the induction of epithelial skin cancer in humans and also induces SCC in mice. While this implies that PUVA is a complete carcinogen by virtue of its DNA-damaging properties, the frequent detection of human papilloma virus DNA in PUVA-induced cancers suggests that immunosuppression may also contribute to carcinogenesis in this setting. [8]

THE NATURE OF CHEMICAL CARCINOGENS: CHEMISTRY AND METABOLISM

How can such a diverse group of chemical and physical agents contribute to cutaneous cancer when the great majority of environmental agents to which humans are exposed are not carcinogenic? We now know that carcinogens can be genotoxic, nongenotoxic, or both. Genotoxic carcinogens have high chemical reactivity (such as alkylating agents like nitrogen mustard) or they can be metabolized to reactive intermediates by the host (such as petroleum products). They form covalent adducts with macromolecules and target DNA in the nucleus and mitochondria. [12] Because there is a good correlation between the ability to form covalent DNA adducts and the potency to induce tumors in laboratory animals, DNA is considered the ultimate target for most genotoxic carcinogens. The interaction with DNA is not random, and each class of agents reacts selectively with purine and pyrimidine targets. [9] Furthermore, targeting of carcinogens to particular sites in DNA is determined by nucleotide sequence, by host cell, and by selective DNA repair processes, making some genetic material at risk over others. As expected from this chemistry, genotoxic carcinogens are potent mutagens, particularly adept at causing base mispairing or small deletions, leading to missense or nonsense mutations. Others may cause macrogenetic damage such as chromosome breaks and large deletions. In all cases, mutations detected in tumors represent a combination of the effect of the mutagenic change on the function of the protein product and the effect of the functional alteration on the behavior of the specific host cell type.

A number of chemicals that cause cancers in laboratory rodents and contribute to human skin cancer incidence are not demonstrably genotoxic. Synthetic pesticides and herbicides, dry-cleaning reagents, and arsenic may fall within this group. The mechanism of action by nongenotoxic carcinogens is controversial and may be related in some cases to toxic cell death and regenerative hyperplasia. Induction of endogenous mutagenic mechanisms such as DNA oxyradical damage, depurination of DNA, and deamination of 5-methylcytosine may contribute to carcinogenicity of these agents. Nongenotoxic carcinogens may interfere with host protective mechanisms, as has been suggested for the action of arsenic in suppressing DNA repair or inhibiting the activity of tumor-suppressor genes. [4] Thus, nongenotoxic carcinogens may serve as modifiers in concert with genotoxic agents such as UVR.

A number of metabolic pathways activate or detoxify carcinogens and procarcinogens (chemicals that can be transformed into active carcinogens). These pathways are complex and interactive, [10] and genetic polymorphisms, both in animal models and in humans, contribute to cancer susceptibility. In general, metabolic activation of carcinogens involves oxidation at carbon–carbon double bonds or saturated carbon atoms, or oxidation or reduction at nitrogen moieties yielding reactive intermediates that bind to DNA. Conjugates are also frequent intermediates of metabolism of many carcinogens and can be both activating and detoxifying pathways. [10] Metabolic activation of carcinogens and the polymorphic nature of metabolic activity among individuals provide an approach to estimate individual risk profiles for particular exposures. Furthermore, a number of metabolic pathways are inducible and modified by diet, hormones, and additional exposures, adding further complexity to the process of carcinogenesis.

HEREDITARY CANCER SYNDROMES

If DNA is the target for carcinogens and mutagenesis is the underlying mechanism of cancer pathogenesis, how do we determine the genetic targets that contribute to the phenotype of cutaneous neoplasms? Considerable insight into the genetic basis of sporadic skin cancers has come from the elucidation of specific genes or genetic loci that define hereditary skin tumor syndromes (Table 36-2). [11], [12] In particular, the importance of DNA as a target for carcinogenesis was strongly supported by the discovery of defects in DNA repair genes that comprise the complementation groups of skin cancer prone xeroderma pigmentosum (XP) families (see Chap. 35). At least six independent genes, on distinct chromosomal loci, define proteins involved in nucleotide excision repair, a process critical for the protection of DNA against both UVR and chemical carcinogen-induced damage. Among these are proteins that recognize and bind to sites of DNA damage (XPA, XPC), helicases (XPB, XPD), and endonuclease components (XPG, XPF), defects in any of which give a skin cancer–prone phenotype. Potential polymorphisms with functional consequences in these and other DNA repair genes may also contribute to susceptibility states in the general population. [13], [14] Examination of SCCs and BCCs from XP patients has also revealed potential target genes for cancer induction because signature mutations in *PTCH1, Ras, p53,* and *INK4a-ARF* ($p16^{INK4a}$ and *ARF*) have been found with high frequency. [15], [16] Chromosomal mapping studies in the nevoid basal cell carcinoma syndrome (Chap. 82), coupled with genetic and functional studies in

Drosophila, implicated mutations in the *PTCH1* gene and other defects in the Sonic hedgehog (Shh) signaling pathway in the development of hereditary and many sporadic BCCs. [17] The *INK4a* locus, and specifically mutations in the *p16* INK4a gene, was identified in the etiology of hereditary melanoma [18] through mapping of the inheritance pattern of familial melanoma. Detection of specific mutations in Cowden's syndrome (*PTEN*), Muir-Torre syndrome (*MSH2, MLH1*), pilomatricoma [*CTNNB (ß-catenin)*], and trichoepithelioma (*PTCH1, p16* INK4a) has illuminated defects associated with the development of adnexal tumors. The delineation of the specific genes mutated in other syndromes where locus mapping is confirmed (see Table 36-2) should provide even more insight into the broader spectrum of skin neoplasms.



TABLE 36-2 **Gene Targets for Mutations in Hereditary and Sporadic Cutaneous Cancers**

ANIMAL MODELS VERIFY THE GENETIC BASIS FOR CUTANEOUS NEOPLASMS

Using human hereditary cancer syndromes as a guide, genetically based animal models have been developed that validate the contribution of individual genes to human cancer susceptibility by prospective experimental analysis. [19] These models have also contributed to the understanding of gene-environment interactions by testing the influence of chemical and physical carcinogens on tumor development in the setting of an altered genetic makeup. The discovery of inactivating *PTCH1* and *SMO* mutations in BCCs (Fig. 36-1) led to the development of several mouse models exploring the role of deregulated Shh signaling in BCC tumorigenesis. Keratinocyte-targeted overexpression of Shh or an activated form of the downstream signaling molecule SMO (M2SMO) resulted in the development of basal cell–like proliferations in newborn mouse skin. Overexpression of SHH in human keratinocytes grafted onto severe combined immunodeficiency disease (SCID) mice also resulted in BCC-like lesions. Mice with heterozygous disruption of the *Ptch1* gene have features in common with nevoid basal cell carcinoma syndrome patients, including microscopic hair follicle–derived tumors and various macroscopic skin tumors, including BCCs, after treatment with UVR or ionizing radiation. [20] When Gli1 or Gli2 transcription factors, which are nuclear effectors of Shh signaling, are targeted to mouse keratinocytes, multiple BCCs develop. Interestingly, Gli1 mice displayed a variety of follicle-derived tumors with relatively few BCCs, [21] while Gli2 mice developed BCCs exclusively. [22] Collectively, these findings provide strong evidence that constitutive Shh signaling plays a key role in, and may be sufficient for, BCC development.

FIGURE 36-1 Current model depicting proposed molecular basis of basal cell carcinoma. In contrast to the stepwise evolution of SCC, which affects multiple signaling pathways, clinical and experimental studies suggest that deregulation of the SHH pathway plays a central role in BCC development, and may be sufficient for tumorigenesis. In the absence of SHH in normal cells (resting state), signaling is repressed due to inhibition of the transmembrane protein SMO by PTCH1. During physiologic activation of this pathway, secreted SHH binds and inhibits PTCH1, resulting in SMO-mediated signaling and induction of the SHH target genes *PTCH1*, *GLI1*, and others, which are likely to influence cellular growth control. GLI1 and GLI2 are candidate nuclear effectors regulating expression of target genes. In contrast to reversible, SHH-dependent signaling under normal conditions, this pathway is constitutively activated in basal cell carcinomas and certain other tumors: *PTCH1* mutations result in functional loss of the inhibitory PTCH1 protein, while *SMO* mutations result in an altered SMO protein that is largely resistant to inhibition by PTCH1. (*Modified from Dlugosz A et al*, [19] *with permission of Blackwell Publishing, Oxford, UK.*)

The multistage induction of cutaneous SCC (Fig. 36-2) and the absence of a hereditary syndrome that specifically imparts uniquely high susceptibility to this lesion have made the delineation of specific genetic loci involved in SCC induction more complex. Nevertheless, the analysis of genetic defects in human SCCs has focused attention on specific targets such as DNA repair genes, *Ras, p53, p16* INK4a, and the epidermal growth factor receptor (EGFR) pathway (Table 36-3). Mouse models for XPA, XPC, and XPD deficiency have been constructed, and all show sensitivity to UVR and enhanced development of SCC after either UVR or chemical carcinogen exposure. [23] A number of other DNA repair-deficient mutant mice are also being tested for cancer susceptibility and may reveal the mechanistic basis for new clinical syndromes by reverse genetics. [23] Mouse mutants targeting the *ras* gene have revealed important information concerning the contribution of the Ras pathway to particular stages of SCC development. Heterozygous activating *ras* gene mutations are sufficient to induce a benign squamous papilloma, the precursor to SCC, and the yield of chemically induced tumors in mice genetically deleted in the *H-ras* allele is markedly reduced. [24] Homozygosity of a mutant *ras* gene is associated with progression to SCC, suggesting that high penetrance of the Ras pathway can recruit additional changes required for progression. Transgenic targeting of oncogenic *ras* to suprabasal epidermis produces terminally benign tumors while targeting to basal cells or hair follicle outer root sheath cells encourages progression to SCC, indicating that the target cell for early mutations may also determine the tumor phenotype. [25] While heterozygous *p53* inactivation is detected early in human SCC, *p53* deletion in mice enhances malignant progression but does not increase benign tumor formation. This may be analogous to the common loss of heterozygosity (LOH) seen at the *p53* locus later in human SCC development. [26] Of particular interest for human tumor development is the frequent observation that

double heterozygotes for *p53* deletion and other cancer-prone phenotypes (such as DNA repair deficiency) further sensitize mouse skin to tumor induction by UVR or chemical carcinogens. [23] Mice with genetically defined defects in the *p16* ^{INK4a} locus or its downstream effector CDK4 are sensitive to both squamous tumor and melanoma induction after treatment with carcinogenic chemicals, consistent with defects in this pathway detected in both melanoma and nonmelanoma human skin cancers. [27], [28]

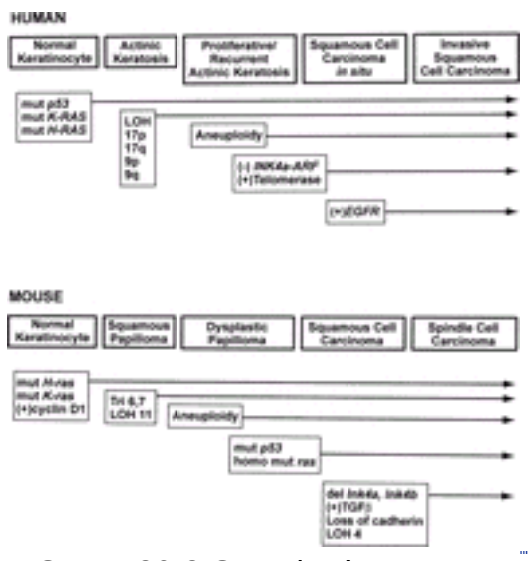

FIGURE 36-2 Genetic changes associated with development of cutaneous squamous cell arcinomas. The multistage evolution of invasive squamous cell cancer in humans is depicted schematically with frequently associated genetic changes. Single base mutations in early lesions frequently are characteristic of ultraviolet light-induced damage, while later changes are associated with genomic instability. Increased activity of telomerase (deletion of inhibitor) or epidermal growth factor receptor (EGFR) tyrosine kinase (gene amplification) may also result from epigenetic changes. In chemically induced mouse cutaneous squamous cell carcinoma, the multistage evolution to anaplastic or spindle cell tumors in this model is highly ordered, both temporally and genetically. *Ras* mutations are characteristic of chemical mutagens used to initiate tumor formation. Early upregulation of cyclin D1 and later upregulation of transforming growth factor (TGF)-ß $_1$ occur through epigenetic mechanisms and appear to be important components of carcinogenesis. (*Modified from Dlugosz A et al*, [19] *with permission of Blackwell Publishing, Oxford, UK. Assistance for the construction of this figure was provided by Luowei Li, M.D.*)

Initiating Agents	Promoting Agents
Polycyclic aromatic hydrocarbons	Phorbol esters
Benzo[a]pyrene*	12-O-Tetradecanoylphorbol-13-acetate
7,12-Dimethylbenz[a] anthracene	Croton oil*
3-Methylcholanthrene	Aromatics
Tobacco tar*	Phenol*
Dibenz[a,h]anthracene*	Anthralin*
Aromatic amines	7-Bromomethylbenz[a]anthracene
2-Acetylaminofluorene	Other
Alkylating agents	Dihydroteleocidin (fungal product)*
β-Propiolactone*	Wounding*
4-Nitroquinoline-N-oxide	Abrasion*
Bis(chloromethyl)ether*	Cigarette smoke condensate*
Nitrogen mustard*	Benzoyl peroxide*
Cisplatin*	2,3,7,8-Tetrachlorodibenzo-p-dioxin*
Nitrosamines and nitrosamides	Diacylglycerols
N,N'-Dimethylnitrosourea*	Ultraviolet radiation*
N-Methyl-N'-nitro-N-nitrosoguanidine*	Dodecane
Other	Retinoic acid*
Urethane*	
Dinitropyrene*	
Ionizing radiation*	
Ultraviolet radiation*	

*Known human contact.

TABLE 36-3 **Examples of Agents Capable of Inducing Skin Cancer in Rodents**

TUMOR BIOLOGY AND BIOCHEMISTRY

General Principles

Malignant tumors exhibit fundamental alterations in behavior that distinguish them from the normal tissues in which they arise. These differences include a reduced requirement for growth stimuli, impaired response to growth inhibitory/differentiation signals, alterations in apoptosis, delayed or blocked senescence, prolonged angiogenesis, and the capacity for invasion and metastasis. Although one or more of these abnormalities can be detected at different stages of tumor progression and may thus be seen in premalignant lesions, all are present in advanced cancers. The driving force behind these changes is genomic instability, which facilitates the accumulation of mutations in both oncogenes and tumor-suppressor genes that contribute to the observed aberrations in cell function. [29] While some of these changes are cell autonomous and can be studied in purified populations of tumor cells, others depend on various additional cell types recruited to participate in the development and progression of cancer in intact organisms. Both the intrinsic alterations in neoplastic keratinocytes and the influence of collaborating cell types in skin tumor biology are being elucidated through the use of experimental models.

From analyses of both human SCC pathogenesis and experimental skin tumor induction by chemical carcinogens, specific premalignant and malignant stages have been identified that have typical phenotypic, genetic and biochemical characteristics (Fig. 36-2). Note that in contrast to SCCs and most other cancers, BCCs do not appear to have precursor lesions or give rise to more aggressive cancers. This is likely related to the observation that the genomic instability that fuels neoplastic progression in other tumor types is largely missing in BCCs, even though a substantial proportion of

these tumors harbor *p53* mutations that would be expected to facilitate the accumulation of additional genetic defects. SCC starts as a single or small number of specific mutations in a cell that has the capacity to cycle, a change understood as the “initiation” of carcinogenesis. Upon clonal expansion, initiated cells form a premalignant lesion, such as a squamous papilloma in the mouse or an actinic keratosis in the human. Agents that enhance clonal expansion of initiated cells are called tumor promoters. Tumor promotion may occur as a consequence of exogenous exposures such as UVR, topical chemicals or medications, infections, or wound healing. Promotion may be an endogenous process influenced by diet, smoking, or immune suppression. The acquisition of additional mutations that provide a growth advantage to the incipient cancer cell may also serve as an autonomous promoting stimulus. Premalignant lesions undergo further phenotypic changes, often in a predictable sequence and commonly multifocal within a single lesion. [30] Some foci or lesions progress at a faster rate than others, and these are at highest risk for malignant conversion. [31] Premalignant progression encompasses the majority of the tumor latency period prior to malignant conversion, when the lesion shows invasive properties.

Initiation is usually a low-frequency genetic event and is directly dependent on carcinogen dose. A large variety of carcinogen classes can initiate skin tumors in rodents (Table 36-3). The phenotype of initiated epidermal cells as defined from in vitro analysis includes a defect in maturation, escape from senescence, and an enhanced growth potential, but initiated cells are still responsive to negative regulation, for example by TGF-ß. At the molecular level, initiation involves an alteration in signal transduction pathways that regulate cellular responses to extracellular signals, and these are internally regulated by protooncogenes and tumor-suppressor genes. [32] Tumor promotion is generally a nongenotoxic stimulus that results in a disturbance of tissue homeostasis. [30] Multiple classes of agents have promoting properties in experimental skin carcinogenesis (Table 36-3). The mechanisms of tumor promotion include activation of cell surface receptors, activation or inhibition of cytosolic enzymes and nuclear transcription factors, stimulation of proliferation, inhibition of apoptotic cell death, and direct cytotoxicity. Genotoxic carcinogens also can have promoting properties, and repeated exposures to low concentrations of genotoxic carcinogens can induce tumors more effectively than fewer exposures to the same total dose in experimental carcinogenesis. Exogenous tumor promoters can determine the target site for tumor formation, and the promoting action of UVR may, in part, contribute to skin targeting for tumors when germ-line mutations produce an initiated state in multiple cell types. In general, initiated cells respond differently to promoters than normal cells, allowing for clonal selection of an initiated population. [33] Premalignant progression in an initiated cell clone occurs spontaneously but is accelerated by additional exposures to genotoxic agents including some cancer chemotherapeutic drugs. [34] Premalignant progression in chemically induced mouse skin carcinogenesis is associated with nonrandom, sequential chromosomal aberrations including amplifications, duplications, deletions, and loss of heterozygosity, suggesting repeated episodes of cell selection, producing specific chromosomal aberrations that become modally dominant within the progressing focus. Thus, at least one function of the relevant genetic events in premalignant progression must result in a growth advantage for the affected cell. Epigenetic changes are also associated with malignant conversion, and upregulation of AP-1 transcriptional activity, alterations in cell-cycle regulatory genes and secreted proteases, and changes in gene splicing and expression of modified cell surface molecules have all been reported. Together these changes could facilitate migration and invasion that characterize the malignant phenotypes. Alterations in methylation of DNA in tumor cells could also contribute to this stage of carcinogenesis. [35]

The Pathogenesis of Basal Cell Carcinomas (see Chap. 81 and Chap. 82)

Animal models for induction of skin tumors by chemical and physical agents have been extremely valuable for exploring mechanisms of carcinogenesis in an experimental setting (Table 36-4). Rats exposed to chemical carcinogens [3-methylcholanthrene (MCA), 7,12-dimethyl-benzanthracene (DMBA)] or ionizing radiation preferentially develop BCCs that are phenotypically similar to human BCCs. In contrast, mice are resistant to BCC induction in the absence of genetic modification, and even *Ptch1* ± mutant mice (modeling patients with nevoid basal cell carcinoma syndrome) develop SCC in addition to BCC when treated with UVR. [20] Interestingly, mice develop BCC when exposed either subcutaneously or topically to dehydroretronecine, [36] an observation that has never been explored mechanistically.

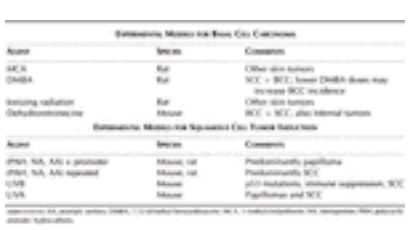

TABLE 36-4 **Animal Models for Cutaneous Cancer Induction by Exogenous Agents**

As noted earlier, BCCs represent an intriguing exception to the rule of multistage cancer development. These tumors consist of homogeneous, slowly growing cells that very rarely metastasize, although they can cause extensive local damage. Even those rare BCCs exhibiting cellular atypia generally have a benign course, suggesting that the full complement of factors driving malignant progression in SCCs and other neoplasms is not operating in these tumors. BCC cells exhibit abnormalities in growth control and terminal differentiation, induce clinically apparent angiogenesis, and invade their immediate surroundings. However, transplantation studies using human BCCs or transgenic mouse skin with BCC-like lesions suggest that the tumor cells are critically dependent on adjacent stroma for survival. This property may help explain both the lack of BCC metastases and the difficulty in establishing BCC cell lines.

Studies performed using human and rodent BCCs have identified candidate molecules that may be important in the biology of these tumors. Upregulation of various matrix metalloproteases (MMPs), both in tumor cells and stroma, is likely to be important in the local invasion of BCC, and may impact on growth control and other cellular functions given the emerging role of MMPs in regulating signaling at multiple levels. [37] Expression of several adhesion molecules is downregulated in BCCs, which may account for the characteristic appearance of clefts between tumor cells and stroma in histologic sections, but the functional significance of this finding in BCC biology has not been established. The

antiapoptotic molecule Bcl-2 is consistently upregulated in BCCs, but does not appear sufficient to block apoptosis in these tumors as it does in other settings. Indeed, the remarkably slow growth rate of BCCs has been attributed to apoptotic cell loss. Expression studies in human BCCs and experimental models suggest the involvement of growth factor signaling pathways such as platelet-derived growth factor (PDGF). [38] Several lines of evidence point to components of the cell-cycle machinery as potentially critical targets in mitogenic responses to Shh signaling. Keratinocytes overexpressing Shh have enhanced proliferative potential and fail to undergo growth arrest in response to the cell cycle inhibitor p21; [39] in the absence of Shh, Ptch1 interacts with and may sequester Cyclin B1, a component of M-phase promoting factor that is required for mitosis and cell-cycle progression; [40] and Shh can drive proliferation of immature cerebellar cells by causing prolonged induction of Cyclins D1, D2, and E. [41] As additional Shh target molecules are uncovered, their potential involvement in keratinocyte tumor biology can be examined using the recently-developed mouse models of BCC.

The Pathogenesis of Squamous Cell Carcinomas (see Chap. 79 and Chap. 80)

Both mice and rats are sensitive to SCC induction by a variety of chemical and physical agents (see Table 36-4), and the induction of SCC in mice by UVR closely mimics the pathogenesis of SCC in human skin. In addition, multistage chemical carcinogenesis in mouse skin is a powerful tool for delineating many of the fundamental concepts underlying epithelial carcinogenesis in other organs. Building on the association of deregulated EGFR signaling in human cancer, mouse models suggest that constitutive EGFR activation is an important component of skin tumor formation because transgenic targeting of TGF-a to the epidermis can produce a benign tumor phenotype in the absence of activating *ras* mutations. [42] However, activation of the EGFR by ligand overexpression is not sufficient for autonomous tumor formation because many of these tumors regressed. Nevertheless, small benign skin tumors form upon oncogenic *ras* transformation of *EGFR* null keratinocytes, suggesting that a *ras*-induced compensatory pathway for tumor growth exists in the premalignant tumor. [43] Additional evidence implicating enhanced growth factor signaling in SCC is provided by transgenic studies that use a dominant form of SOS, an adapter molecule involved in transducing growth-stimulatory signals from receptor tyrosine kinases such as EGFR, which result in spontaneous development of papillomas in mouse skin. [44] Overexpression of ErbB2, a receptor tyrosine kinase related to and capable of interacting with EGFR, results in spontaneous skin tumor development in transgenic mice. [45] Insulin-like growth factor-1 (IGF-1), when overexpressed in mouse skin, also triggerled development of squamous papillomas, some of which progressed to carcinomas. [46] While most of these studies invoke an autocrine mechanism for growth stimulation of tumor cells, factors produced by cells in the tumor stroma may also supply mitogenic or angiogenic signals to keratinocytes. [47] Additional studies performed in mice suggest that specific components of the cell-cycle machinery, including E2F1, cyclin D1, and Cdk4, can contribute to SCC development and/or progression.

In addition to deregulated growth control, there is a progressive loss in the capacity for terminal differentiation during SCC progression (see Fig. 36-2), culminating in a tumor with a spindle cell morphology that is indistinguishable from malignancies originating in mesenchymal tissues. Although the mechanisms responsible for defective differentiation at different stages of human skin cancer are not known, there is evidence that deregulation of the protein kinase C (PKC) family of enzymes plays a role in aberrant differentiation of mouse skin keratinocytes expressing the *ras* oncogene. [30] PKCd, which has been implicated in terminal differentiation of normal epidermal keratinocytes, is rendered inactive as a result of tyrosine-phosphorylation in ras-transformed keratinocytes. Restoring PKCd to its native, nontyrosine phosphorylated state reversed the block to terminal differentiation in ras-transformed keratinocytes. In addition, overexpression of PKCd in the skin of transgenic mice inhibits the development of squamous papillomas and carcinomas. [48] In contrast, skin-targeted overexpression of PKCe resulted in less differentiated SCCs that rapidly metastasized to regional lymph nodes. [49] Additional work is needed to better understand the mechanism by which SCC tumor cells evade signals that trigger differentiation of normal keratinocytes.

Prostaglandin metabolism (see Chap. 34) is activated by UV radiation and is constitutively induced in human SCCs, probably due to overexpression of the enzyme cyclooxygenase-2 (COX-2). Although the mechanism by which changes in prostaglandins influence skin cancer is not clear, prostaglandins appear to operate at the tumor promotion stage. Telomerase activity is detected in a substantial proportion of human skin cancers, suggesting that these tumor cells are capable of evading cellular senescence, and telomerase-deficient mice are resistant to chemical carcinogenesis. [50] Additional contributors that are likely to be involved in SCC development and progression include mediators of angiogenesis, MMPs, and integrins, as well as other molecules involved in cellular adhesion and migration.

Spontaneous or carcinogen-induced tumor formation on genetically modified mice has revealed genes and pathways that appear to be important in skin cancer induction but would not have been apparent from hereditary cancer syndromes or analysis of human skin cancers. Suprabasal targeting of c-Myc in transgenic mice permits suprabasal cells to cycle and produces the papilloma phenotype while basal cell targeting of c-Myc is not oncogenic. [51] Deletion of the cyclin/CDK inhibitor p21 ^{waf1}, a downstream effector of p53, increases the number of benign tumors but not the rate of premalignant progression. [52], [53] TGF-ß suppresses premalignant progression but is required for progression from SCC to a spindle-cell phenotype. [54] Two AP-1 transcription factors influence distinct stages of skin tumor development, where c-Jun is essential for papilloma and c-Fos is essential for SCC development. [55] Additional molecules now implicated in experimentally induced mouse SCCs are ornithine decarboxylase, p16 ^{Ink4a}, p15 ^{Ink4b}, and E-cadherin. [56], [57] and [58] These pathways are frequently altered in human SCC, but their contribution to pathogenesis remains to be proven by studies that directly transform human keratinocytes and study them in an in vivo setting.

Constitutional Modifiers of Carcinogenesis

Inbred mouse strains differ in susceptibility to particular carcinogenic exposures by several orders of magnitude, and transplantation studies indicate sensitivity resides in the target tissue rather than systemically. Genomic scans of backcrossed mice among sensitive and resistant mouse strains indicate that constitutional determinants are multigenic and distinct for benign tumor formation or progression. [59] Similar studies indicate genetic loci determine the survival

potential for tumor-bearing animals. [60] While identifying genes involved in susceptibility and resistance in animal models is likely to reveal determinants important for human skin cancer risk, the classic genetic approaches are difficult and complex because multiple interacting loci are likely to be involved. [61] Genetically modified mouse models have revealed pathways associated with skin tumor susceptibility. Alterations in p53, drug metabolizing enzymes, T cell function, and DNA repair modify risk for experimental skin cancer induction. Remarkably, polymorphisms in drug metabolizing enzymes and DNA repair pathways, [62], [63] and variable responses in the p53 tumor-suppressor pathway or in T cell immunity after exposure to skin carcinogens, [64] modify the human risk for skin cancer.

Exogenous Modifiers of Carcinogenesis

In experimental models, antioxidants and agents that alter microsomal metabolism of carcinogens can reduce or prevent tumor initiation by inhibiting the formation of ultimate carcinogens or accelerating their detoxification (Table 36-5). Similar mechanisms may influence ultraviolet light or ionizing radiation mutagenesis through inhibition of mutagenic oxyradicals produced endogenously following exposure. Scavengers prevent reactive mutagens from reaching critical targets. Cell-cycle inhibitors prevent fixation of mutations, allowing for DNA repair while cytotoxic agents kill initiated cells prior to their expansion into a tumor mass.

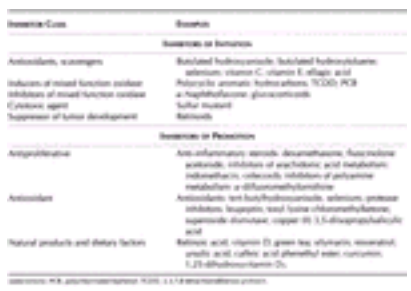

TABLE 36-5 **Modifiers of Carcinogenesis**

A number of agents are effective in the postinitiation phase of experimental tumor development, and some are being clinically evaluated. Inhibitors of COX-2 (celecoxib, indomethacin) and ornithine decarboxylase (difluoromethylornithine) prevent both UVR and chemically induced tumors. [65], [66] While the mechanism of action of retinoids as modifiers of tumor development is not clear, retinoids are effective inhibitors of benign tumor formation in mouse skin carcinogenesis studies, and show promise as inhibitors of actinic keratoses and cutaneous tumors in human studies (see Chap. 257). Predictable and parallel alterations in retinoid receptors in mouse and human cutaneous SCC indicate that the retinoid pathway must be central to cancer development in epidermis. [67] Considerable interest has developed in dietary factors that modify skin carcinogenesis. Restricted fat/energy diets reduce papilloma incidence in mouse models [68] and decrease the frequency of actinic keratoses in human populations. [69] Diverse dietary or natural factors such as green tea, caffeic acid phenethyl ester from honey bee hives, resveratrol from grapes, silymarin from milk thistle, ginger extract, crocetin, and ursolic acid from the rosemary plant are among natural products shown to be effective inhibitors of skin tumor formation by topical application or systemic exposure. [70] Several of these agents are believed to be antioxidants, but the precise mechanism of inhibition and their effectiveness as chemopreventive agents for human skin cancer remain to be established. Finally, immune response modifiers such as imiquimod may be effective for treating some types of skin cancer by modulating cytokine expression. [71]

NOVEL MOLECULAR TARGETS BASED ON NEW MECHANISTIC DATA

The substantial progress in our understanding of factors involved in skin tumor pathogenesis holds the promise of new approaches to treatment and prevention. In addition to the identification of new therapeutic targets, improved strategies are being developed for altering gene and protein function in skin with great selectivity. The abundance and unrivaled accessibility of skin cancers and precancers makes them prime targets for rigorous translational studies and clinical trials. Based on the basic research studies outlined above, potential therapeutic targets include p53; COX-2; telomerase; EGFR or other receptor tyrosine kinases, and intracellular signaling elements such as SOS; Ras; ornithine decarboxylase; the DNA repair machinery; MMPs; PKC; molecules involved in cell-cycle progression, such as cyclins D1 and D2, CDK4, p16 ^{INK4a}, and E2F1; retinoid receptors; and c-Fos. In all cases, the potential efficacy of the proposed treatments would need to be carefully evaluated in animal models or human tissues grown in immune-deficient mice. Because the great majority of cutaneous SCCs are effectively treated using surgery or radiation therapy, perhaps the greatest utility of these studies for dermatology patients would be in the identification of agents capable of preventing the appearance of premalignant lesions or blocking neoplastic progression to SCC in predisposed individuals. Along these lines, a recent double-blind study reported a significant reduction in the development of actinic keratoses and BCCs in xeroderma pigmentosum patients treated topically with the DNA repair enzyme T4 endonuclease V, administered over a 1-year period. [72]

In contrast to the multiple genetic and biochemical changes associated with SCC development, the majority of BCCs have mutations in *PTCH1* or *SMO,* and essentially all of these tumors exhibit uncontrolled activation of the Shh pathway. Because several experimental models suggest that deregulated Shh signaling may be sufficient for BCC formation, this pathway is a prime target for mechanism-based drug development.

Cyclopamine and related molecules block Shh signaling by inhibiting SMO function and may therefore be useful clinically. However, Shh is a key embryonic signaling molecule whose inhibition causes profound developmental defects, so attempts to treat or prevent human BCCs by modulating this pathway will need to be approached with care. Given the recent advances in our understanding of nonmelanoma skin cancer, it seems likely that new, rationally designed medical

approaches for intervention will soon be available for these common neoplasms.

REFERENCES

1. Pott P: Cancer scrotic, in *Chirurgical Observations Relative to the Cataract, the Polypus of the Nose, the Cancer of the Scrotum, the Different Kinds of Ruptures, and the Mortification of the Toes and Feet.* London, Hawes, Clarke, and Collins, 1775, p 63

2. De Hertog S et al: Relation between smoking and skin cancer. *J Clin Oncol* **19**:231, 2001

3. Schwartz RA: Arsenic and the skin. *Int J Dermatol* **36**:241, 1997

4. Rossman TG et al: Arsenite is a cocarcinogen with solar ultraviolet radiation for mouse skin: An animal model for arsenic carcinogenesis. *Toxicol Appl Pharmacol* **176**:64, 2001

5. Penn I: Post-transplant malignancy: The role of immunosuppression. *Drug Saf* **23**:101, 2000

6. Lichter MD et al: Therapeutic ionizing radiation and the incidence of basal cell carcinoma and squamous cell carcinoma. The New Hampshire Skin Cancer Study Group. *Arch Dermatol* **136**:1007, 2000

7. Stern RS et al: Oral psoralen and ultraviolet-A light (PUVA) treatment of psoriasis and persistent risk of nonmelanoma skin cancer. PUVA Follow-up Study. *J Natl Cancer Inst* **90**:1278, 1998

8. Harwood CA et al: Detection of human papillomavirus DNA in PUVA-associated non-melanoma skin cancers. *J Invest Dermatol* **111**:123, 1998

9. Dipple A: DNA adducts of chemical carcinogens. *Carcinogenesis* **16**:437, 1995

10. Yuspa SH, Shields PG: Etiology of Cancer: Chemical Factors, in *Cancer Principles of Oncology,* 5th ed, edited by VT DeVita, S Hellman, SA Rosenberg. Philadelphia, Lippincott-Raven, 1997, p 185

11. Halpern AC, Altman JF: Genetic predisposition to skin cancer. *Curr Opin Oncol* **11**:132, 1999

12. Tsao H: Genetics of nonmelanoma skin cancer. *Arch Dermatol* **137**:1486, 2001

13. Wood RD et al: Human DNA repair genes. *Science* **291**:1284, 2001

14. Winsey SL et al: A variant within the DNA repair gene XRCC3 is associated with the development of melanoma skin cancer. *Cancer Res* **60**:5612, 2000

15. Soufir N et al: Association between INK4a-ARF and p53 mutations in skin carcinomas of xeroderma pigmentosum patients. *J Natl Cancer Inst* **92**:1841, 2000

16. Bodak N et al: High levels of patched gene mutations in basal-cell carcinomas from patients with xeroderma pigmentosum. *Proc Natl Acad Sci U S A* **96**:5117, 1999

17. Bale AE, Yu KP: The hedgehog pathway and basal cell carcinomas. *Hum Mol Genet* **10**:757, 2001

18. Hussussian CJ et al: Germline p16 mutations in familial melanoma. *Nat Genet* **8**:15, 1994

19. Dlugosz A et al: Progress in cutaneous cancer research. *J Invest Dermatol* 2003 (in press)

20. Aszterbaum M et al: Ultraviolet and ionizing radiation enhance the growth of BCCs and trichoblastomas in patched heterozygous knockout mice. *Nat Med* **5**:1285, 1999

21. Nilsson M et al: Induction of basal cell carcinomas and trichoepitheliomas in mice overexpressing GLI-1. *Proc Natl Acad Sci U S A* **97**:3438, 2000

22. Grachtchouk M et al: Basal cell carcinomas in mice overexpressing Gli2 in skin. *Nat Genet* **24**:216, 2000

23. Friedberg EC, Meira LB: Database of mouse strains carrying targeted mutations in genes affecting cellular responses to DNA damage. Version 4. *Mutat Res* **459**:243, 2000

24. Ise K et al: Targeted deletion of the H-ras gene decreases tumor formation in mouse skin carcinogenesis. *Oncogene* **19**:2951, 2000

25. Brown K et al: The malignant capacity of skin tumours induced by expression of a mutant H-ras transgene depends on the cell type targeted. *Curr Biol* **8**:516, 1998

26. Ahmadian A et al: Genetic instability in the 9q22.3 region is a late event in the development of squamous cell carcinoma. *Oncogene* **17**:1837, 1998

27. Krimpenfort P et al: Loss of p16Ink4a confers susceptibility to metastatic melanoma in mice. *Nature* **413**:83, 2001

28. Sotillo R et al: Invasive melanoma in Cdk4-targeted mice. *Proc Natl Acad Sci U S A* **98**:13312, 2001

29. Lengauer C et al: Genetic instabilities in human cancers. *Nature* **396**:643, 1998

30. Yuspa SH: The pathogenesis of squamous cell cancer: Lessons learned from studies of skin carcinogenesis—Thirty-third G.H.A. Clowes Memorial Award Lecture. *Cancer Res* **54**:1178, 1994

31. Hennings H et al: Induction of papillomas with a high probability of conversion to malignancy. *Carcinogenesis* **6**:1607, 1985

32. Blume-Jensen P, Hunter T: Oncogenic kinase signaling. *Nature* **411**:355, 2001

33. Hennings H et al: Development of an in vitro analogue of initiated mouse epidermis to study tumor promoters and antipromoters. *Cancer Res* **50**:4794, 1990

34. Hennings H et al: Enhanced malignant conversion of benign mouse skin tumors by cisplatin. *J Natl Cancer Inst* **82**:836, 1990

35. Robertson KD, Jones PA: DNA methylation: past, present and future directions. *Carcinogenesis* **21**:461, 2000

36. Johnson WD et al: Dehydroretronecine-induced skin tumors in mice. *J Natl Cancer Inst* **61**:85, 1978

37. Sternlicht MD, Werb Z: How matrix metalloproteinases regulate cell behavior. *Annu Rev Cell Dev Biol* **17**:463, 2001

38. Xie J et al: A role of PDGFRalpha in basal cell carcinoma proliferation. *Proc Natl Acad Sci U S A* **98**:9255, 2001

39. Fan H, Khavari PA: Sonic hedgehog opposes epithelial cell cycle arrest. *J Cell Biol* **147**:71, 1999

40. Barnes EA et al: Patched1 interacts with cyclin B1 to regulate cell cycle progression. *EMBO J* **20**:2214, 2001

41. Kenney AM, Rowitch DH: Sonic hedgehog promotes G(1) cyclin expression and sustained cell cycle progression in mammalian neuronal precursors. *Mol Cell Biol* **20**:9055, 2000

42. Dominey AM et al: Targeted overexpression of transforming growth factor a in the epidermis of transgenic mice elicits hyperplasia, hyperkeratosis, and spontaneous squamous papillomas. *Cell Growth Differ* **4**:1071, 1993

43. Hansen LA et al: The epidermal growth factor receptor is required to maintain the proliferative population in the basal compartment of epidermal tumors. *Cancer Res* **60**:3328, 2000

44. Sibilia M et al: The EGF receptor provides an essential survival signal for SOS-dependent skin tumor development. *Cell* **102**:211, 2000

45. Kiguchi K et al: Constitutive expression of erbB2 in epidermis of transgenic mice results in epidermal hyperproliferation and spontaneous skin tumor development. *Oncogene* **19**:4243, 2000

46. DiGiovanni J et al: Constitutive expression of insulin-like growth factor-1 in epidermal basal cells of transgenic mice leads to spontaneous tumor promotion. *Cancer Res* **60**:1561, 2000

47. Skobe M, Fusenig NE: Tumorigenic conversion of immortal human keratinocytes through stromal cell activation. *Proc Natl Acad Sci U S A* **95**:1050, 1998

48. Reddig PJ et al: Transgenic mice overexpressing protein kinase C delta in the epidermis are resistant to skin tumor promotion by 12-*O*-tetradecanoylphorbol-13- acetate. *Cancer Res* **59**:5710, 1999

49. Jansen AP et al: Protein kinase C-epsilon transgenic mice: A unique model for metastatic squamous cell carcinoma. *Cancer Res* **61**:808, 2001

50. Gonzalez-Suarez E et al: Telomerase-deficient mice with short telomeres are resistant to skin tumorigenesis. *Nat Genet* **26**:114, 2000

51. Waikel RL et al: Deregulated expression of c-Myc depletes epidermal stem cells. *Nat Genet* **28**:165, 2001

52. Missero C et al: The absence of p21 $^{Cip1/WAF1}$ alters keratinocyte growth and differentiation and promotes *ras*-tumor progression. *Genes Dev* **10**:3065, 1996

53. Weinberg WC et al: Genetic deletion of p21 ^{waf1} enhances papilloma formation but not malignant conversion in experimental mouse skin carcinogenesis. *Cancer Res* **59**:2050, 1999

54. Portella G et al: Transforming growth factor ß is essential for spindle cell conversion of mouse skin carcinoma in vivo: Implications for tumor invasion. *Cell Growth Differ* **9**:393, 1998

55. Young MR et al: Transgenic mice demonstrate AP-1 (activator protein-1) transactivation is required for tumor promotion. *Proc Natl Acad Sci U S A* **96**:9827, 1999

56. Clifford A et al: Role of ornithine decarboxylase in epidermal tumorigenesis. *Cancer Res* **55**:1680, 1995

57. Linardopoulos S et al: Deletion and altered regulation of *p16* ^{INK4a} and *p15* ^{INK4b} in undifferentiated mouse skin tumors. *Cancer Res* **55**:5168, 1995

58. Navarro P et al: A role for the E-cadherin cell–cell adhesion molecule during tumor progression of mouse epidermal carcinogenesis. *J Cell Biol* **115**:517, 1991

59. Mock BA et al: Multigenic control of skin tumor susceptibility in SENCAR/Pt mice. *Carcinogenesis* **19**:1109, 1998

60. Nagase H et al: A subset of skin tumor modifier loci determines survival time of tumor-bearing mice. *Proc Natl Acad Sci U S A* **96**:15032, 1999

61. Balmain A: Cancer as a complex genetic trait. Tumor susceptibility in humans and mouse models. *Cell* **108**:145, 2002

62. Nelson HH et al: The XRCC1 Arg399Gln polymorphism, sunburn, and non-melanoma skin cancer: Evidence of gene-environment interaction. *Cancer Res* **62**:152, 2002

63. Lear JT et al: Detoxifying enzyme genotypes and susceptibility to cutaneous malignancy. *Br J Dermatol* **142**:8, 2000

64. Ramachandran S et al: Susceptibility and modifier genes in cutaneous basal cell carcinomas and their associations with clinical phenotype. *J Photochem Photobiol B* **63**:1, 2001

65. Fischer SM et al: Chemopreventive activity of celecoxib, a specific cyclooxygenase-2 inhibitor, and indomethacin against ultraviolet light-induced skin carcinogenesis. *Mol Carcinog* **25**:231, 1999

66. Takigawa M et al: Inhibition of mouse skin tumor promotion and of promoter-stimulated epidermal polyamine biosynthesis by difluoromethylornithine. *Cancer Res* **43**:3732, 1983

67. Xu XC et al: Progressive decreases in nuclear retinoid receptors during skin squamous carcinogenesis. *Cancer Res* **61**:4306, 2001

68. Birt DF et al: High-fat diet blocks the inhibition of skin carcinogenesis and reductions in protein kinase C by moderate energy restriction. *Mol Carcinog* **16**:115, 1996

69. Black HS et al: Effect of a low-fat diet on the incidence of actinic keratosis. *N Engl J Med* **330**:1272, 1994

70. Gupta S, Mukhtar H: Chemoprevention of skin cancer through natural agents. *Skin Pharmacol Appl Skin Physiol* **14**:373, 2001

71. Marks R et al: Imiquimod 5% cream in the treatment of superficial basal cell carcinoma: Results of a multicenter 6-week dose-response trial. *J Am Acad Dermatol* **44**:807, 2001

72. Yarosh D et al: Effect of topically applied T4 endonuclease V in liposomes on skin cancer in xeroderma pigmentosum: A randomised study. Xeroderma Pigmentosum Study Group. *Lancet* **357**:926, 2001

T>

Chapter 37

Douglas Lowy

Oncogenes and Viral Carcinogenesis

EXPERIMENTAL VIRAL CARCINOGENESIS
MECHANISMS OF TUMORIGENESIS
TUMOR-PROMOTING GENES AND TUMOR-SUPPRESSOR GENES
VIRUSES IN HUMAN TUMORS

REFERENCES

The study of carcinogenesis induced by viruses has been influenced by several complementary goals. The cornerstone has been to detect transmissible etiologic agents of naturally occurring human tumors. The principal clinical importance of this goal is that once such viral agents are identified, it may be possible to use this information to intervene prophylactically or therapeutically by focusing attention on the virus. Prophylactic approaches to intervention include interrupting viral transmission through the development of effective prophylactic vaccines and the establishment of appropriate public health measures. Therapeutic approaches include viral-specific therapies via vaccines and drugs that interfere with an important viral function.

In recent years, compelling evidence has been presented for the role of viruses in the pathogenesis of several types of human tumors (Table 37-1). [1], [2], [3], [4] and [5] Identification of hepatitis B virus as a cause of hepatocellular carcinoma and the development of an effective prophylactic vaccination against this virus demonstrated that the vaccine can reduce the incidence of liver carcinomas in an endemic area. [6]



TABLE 37-1 **Viruses That Are Tumorigenic in Animals**

Another important goal of viral carcinogenesis is to use tumor viruses to develop models for the experimental study of carcinogenesis (Table 37-2). [3], [7], [8] The ability of certain animal viruses to induce tumors experimentally in animal hosts was first shown in the early part of the twentieth century. [9] Since then, many animal viruses have been found to cause tumors either in their natural host species or in heterologous species. In addition to providing enormous insight into the mechanisms by which animal and human tumor viruses induce tumors, results derived from the analysis of viral carcinogenesis have also had direct implications for the pathogenesis of nonvirally induced tumors. These experimental studies uncovered a group of cellular genes (called *oncogenes* or *transforming genes*) that play an important pathogenetic role in many naturally occurring human tumors, as well as in those induced experimentally by viruses, carcinogens, and ionizing radiation. [7], [8], [10] Tumor virology has also provided important insights into the function of *tumor-suppressor genes*. This class of cellular genes, which normally inhibit unrestrained cell growth, also plays key roles in the development of many human tumors not associated with viruses. [11], [12] Tumor virus systems emphasize the theme that tumors are induced by specific proteins, which can be encoded either by viral or cellular genes, as well as the important contribution of host and environmental factors in determining whether infection will result in a benign or malignant outcome. [11], [13], [14]



Virus Group	Virus	Tumor
Papillomavirus	Several HPV types (especially 5, 8, 16, 18, 31, 33)	Cutaneous carcinomas in epidermodysplasia verruciformis, urogenital carcinomas
Hepadnavirus	Hepatitis B	Hepatocellular carcinoma
Flavivirus	Hepatitis C	Hepatocellular carcinoma
Herpesvirus	HHV-8/KSHV	Kaposi's sarcoma
Retrovirus	HTLV, HIV	Some T cell lymphomas, AIDS-related malignancies

TABLE 37-2 **Viruses Associated with Human Tumors**

EXPERIMENTAL VIRAL CARCINOGENESIS

Tumor viruses are usually identified by their capacity to induce tumors in animal hosts. [15] Members of several different families of DNA viruses may have oncogenic potential. [1], [2] and [3] Among the RNA viruses, some retroviruses are clearly tumorigenic. [16] Retroviruses may be considered a form of DNA virus in that their entire genetic information is converted to DNA after infection of the host cell, although their viral genetic information is RNA when these viruses are particles outside the cell. Some hepatocellular carcinomas are attributable to infection with hepatitis C virus, an RNA virus that does not have a DNA form. [17], [18] The finding that one member of a given virus family may be oncogenic does not mean

that all viruses from the family will share this capacity.

Each tumor virus induces a reproducible spectrum of tumors in a given host. In addition to the virus, tumor formation may depend on host factors as well as on the virus. Consequently, it is not uncommon for a virus to be oncogenic in one host but not in another. In some instances, such as some adenoviruses and polyomaviruses, the virus may induce tumors in heterologous species but not in its natural host species. Only a few animal herpesviruses cause tumors in their natural hosts. Oncogenic retroviruses typically induce malignant disease in their natural hosts, while papillomaviruses and poxviruses usually induce benign tumors. However, a small proportion of the benign tumors induced by certain human papillomaviruses and animal papillomaviruses can progress to frank malignancy. Such viruses clearly have malignant potential, despite the fact that the frequency of benign tumor formation (warts) induced by these viruses far exceeds that of malignant growths. [19], [20]

In general, a virus will induce a tumor only after the virus has actually infected the target cell (the cell that will ultimately give rise to the tumor). In most instances, however, infection of a potential target cell by itself may not be sufficient for tumor formation. Tumor formation thus represents the outcome of the interaction between the virus and the infected target cell. Even those viruses that are highly oncogenic will infect many more cells than will ultimately give rise to tumors. For a given virus, the cells that become malignant therefore represent only a small subset of the infected cells. The risk of malignancy is often increased by immunologic impairment of the host, especially in the case of tumors attributable to viral infection. [21] Hormonal factors may also play a role. Exposure to certain environmental agents, such as carcinogens that are active in the target cell, may shorten the latency period to malignancy and increase the frequency with which malignant tumors develop.

Virus-induced tumors usually do not produce infectious virus particles even when tumor growth continues to require the expression of some viral genes. This fact should be considered when searching for evidence of participation of a virus in the production of a tumor of unknown etiology. Once the virus particle (virion) gets inside the target cell, the viral genetic information required for tumor formation often does *not* include those viral genes actually encoding the proteins that form new virions; it often does include virus-encoded nonvirion protein(s). The production of virion proteins is presumably selected against in the tumor cell because their presence might be directly toxic to the cell and/or render the cell susceptible to destruction by the immune defenses of the host. In some instances of malignancy attributable to viral infection, nonmalignant cells may continue to produce virus particles. In Marek's disease, a lymphomatosis of chickens induced by a herpesvirus, the lymphoid tumor cells express some viral genes but do not produce virus particles; infectious virus is, however, produced in the otherwise normal skin appendages of the same bird.

Viral-mediated immunosuppression can also lead indirectly to tumor formation. For example, immunosuppression secondary to infection with the human immunodeficiency virus (HIV) is associated with Kaposi's sarcoma and a number of other tumors, but the tumor cells do not appear to contain HIV. [22], [23] and [24] Instead, the evidence suggests that the immunologic impairment induced by HIV permits other infectious agents to induce the tumors, such as HHV-8/KSHV in Kaposi's sarcoma. [25], [26]

MECHANISMS OF TUMORIGENESIS

As described in other chapters, tumors may also be induced experimentally by noninfectious agents, such as chemicals or ultraviolet radiation (see Chap. 36 and Chap. 38). One of the most important conclusions derived from the study of chemically induced tumors (where viruses are not involved) is that the transition of a cell from normal to malignant is typically a multistep (rather than a single-step) process. Most investigators believe that the most important changes in the tumor cell represent alterations in cellular genes. [11]

The cellular mechanisms by which virus infection may give rise to tumors may be usefully considered in the context of the multistage theory of carcinogenesis. If a virus is thought of as a group of foreign genes that have been introduced into the potential target cell by means of the virus particle, tumor induction by viruses may be viewed as occurring by one of three general mechanisms:

1. The genes of a virus may directly specify all the functional changes (one or more viral-encoded proteins) required to convert a normal cell to a malignant one. Such a virus would induce tumors in a single step; the growths would therefore develop after a very short latency period. Because the virus was supplying all the abnormal functions for the cell, the continued presence of the virus would be required for the malignant properties of the cell to be maintained. Under some circumstances, the high-level expression of a single retroviral oncogene may induce malignant tumors, although combinations of two oncogenes, which are found in some transforming animal retroviruses, are usually required for the direct induction of malignant tumors. Most DNA tumor viruses contain more than one viral oncogene, and each contributes to the oncogenic properties of the virus. In vitro studies show that some oncogenes, whether from retroviruses or from DNA viruses, serve principally to prolong the life span of the cell, while others directly stimulate cell growth and division. Both functions are necessary for tumor formation. [7], [27] In the absence of a cooperating immortalizing gene, expression of an oncogene that stimulates abnormal cell growth usually also induces the cell to undergo senescence or apoptosis (programmed cell death), a potent mechanism to protect the organism from cancer. [5], [28] Immortalizing genes blunt the apoptotic mechanism, thus accounting for the strong oncogenic activity when an immortalizing and a directly transforming gene are expressed together.
2. A virus may directly specify some, but not all, of the functional changes required for tumor development. In these instances, the virus would help the infected cell on its way to become a tumor cell, but certain additional cellular changes (such as alterations in cellular genes) would be required for the cell to give rise to a tumor. This appears to be by far the most common mechanism by which viruses induce tumors in people. The cellular changes in tumors fall into one of two functional classes. Most frequently, the changes are alterations that complement the viral functions, in which case the presence of viral genetic information would continue to be required. Alternatively, in some experimental tumors the changes have supplanted the viral functions, so that persistence of the virus is no

longer necessary (as in some Abelson murine leukemia virus-induced tumors). [29] Tumors that require cellular changes in addition to viral infection typically take considerably longer, months to years, to develop as compared to tumors in which the virus supplies all the abnormal functions required for tumor formation. In well-studied forms of experimental viral carcinogenesis, most tumors require the continued presence of at least a portion of the viral genetic information. The same seems to be true of most virally associated human tumors.

3. Viruses can induce tumors by an even more indirect process. Instead of directly supplying some of the specific abnormal functions associated with tumorigenesis, infection by the virus may simply increase the likelihood that the cellular changes required for tumor formation will occur. Activation of the expression of a cellular proto-oncogene by chromosomal integration of the viral regulatory elements near the proto-oncogene, [30] is a occurs with some retroviruses and the woodchuck hepatitis virus, [31] clear example of this process. Tumor viruses that function by this mechanism typically induce tumors only after a very long latency period.

TUMOR-PROMOTING GENES AND TUMOR-SUPPRESSOR GENES

An important biologic feature of many tumor viruses is that they (or their isolated viral genetic sequences) can induce morphologic transformation of at least some cells in culture. [15] Here, transformation means that the cells are converted toward the tumorigenic phenotype. The capacity of these viruses to transform cells in vitro usually correlates with their ability to induce tumors in animals. These in vitro systems make it possible to define the mechanisms by which these viruses transform cells. Such in vitro studies have shown that the capacity of tumor viruses to directly transform cells is due to the expression of one or more genes encoded by the virus. These genes are called viral oncogenes or transforming genes.

Although most viral genes are not closely related to cellular genes, the oncogenes of retroviruses are actually derived from a class of cellular genes that are highly conserved in evolution. [7], [30] These cellular genes are normally present in all species from yeasts to humans (more than 100 such genes have now been found in humans). This group of cellular genes was first identified by their close homology to retroviral oncogenes, so its members have been called proto-oncogenes. Most of them serve important roles in normal growth and development. While the expression and activity of proto-oncogenes are carefully controlled, these genes become constitutively active when they are present in retroviruses. A variation on this activation within the virus occurs during tumorigenesis by retroviruses that lack their own viral oncogene. In many instances, members of this class of retrovirus integrate their viral DNA near a proto-oncogene, leading to the deregulated expression of the proto-oncogene.

Deregulation of one or more proto-oncogenes occurs in a wide variety of human and animal tumors, regardless of etiology. [11], [32] As with retroviral oncogenes, such deregulation renders the proto-oncogene constitutively active, which probably serves an important pathogenic role in the tumors. Most of these deregulated proto-oncogenes can induce morphologic transformation of tissue culture cells; the normal forms will be negative, or less active, in the same assay. Viral genes that promote tumorigenesis may also do so by the inhibition of cellular senescence, apoptosis, DNA repair, genetic stability, or immune defense mechanisms. Analogous changes are also found in cancers that lack an infectious etiology. [10], [12]

The oncogenes of DNA tumor viruses are not derived directly from cell-encoded proteins. Most of the oncogenic activities of their encoded proteins fall into one of three categories. Some, such as the epidermal growth factor homologues of poxviruses, mimic activities of proteins encoded by cellular proto-oncogenes. [33] Others, such as the middle T antigen of polyoma virus, activate proteins encoded by proto-oncogenes. [34] Still others, such as the E6 and E7 proteins of some papillomaviruses, the large T antigen of SV40 virus, or the E1A and E1B proteins of adenoviruses, bind to and functionally inactivate cellular proteins encoded by tumor-suppressor genes. [15], [35], [36] and [37] Most genes of this class inhibit the growth of the target cell, so that the loss of this inhibitory activity contributes to transformation by these viral oncoproteins. Functional inactivation of tumor-suppressor genes, usually by genetic alteration, has been identified in many nonviral tumors in animals and humans. [11], [12]

VIRUSES IN HUMAN TUMORS

In humans, members of several different virus families are associated with the development of malignancy (see Table 37-1). The evidence for believing viruses are involved in these tumors includes the regular association of a specific virus with certain tumors, epidemiologic data that infection with the virus is a risk factor for tumor development, finding viral genetic information in the tumor tissue, increased incidence of the tumor in immunosuppressed individuals, and the observation that similar animal viruses may be oncogenic when inoculated into experimental animals. In addition, Epstein-Barr and hepatitis B viruses are oncogenic for experimental animals, and specific genes of Epstein-Barr virus, HHV-8, and certain papillomaviruses can induce cellular transformation in vitro. These viruses are associated with a long latency period, which implies that cellular changes, in addition to viral infection, are required for malignancy.

The Epstein-Barr virus (EBV), [38], [39] which is the etiologic agent of infectious mononucleosis, is implicated in African Burkitt's lymphoma (but not in most American cases), in nasopharyngeal carcinomas in the Far East, in immunoblastic B cell lymphomas in immunosuppressed patients, and in Hodgkin's disease. [40], [41] EBV is well known for its capacity to immortalize normal lymphoid cells. African Burkitt's lymphoma seems to exemplify the situation in which virus infection may be necessary, but not sufficient for malignancy. In virtually all cases of EBV-associated Burkitt's lymphoma, there is deregulated expression of the *myc* proto-oncogene, in addition to EBV infection. Because overexpression of *myc* can induce B cell neoplasms in mice, it is reasonable to conclude that the constitutive *myc* expression contributes, in concert with EBV, to the malignant phenotype in these lymphomas.

Certain human papillomaviruses (HPVs) are associated with the development of malignancy. [19], [20], [42] Only a limited number of the HPV types are associated with malignant potential, and typical cutaneous warts should not be considered premalignant lesions. In epidermodysplasia verruciformis, there is a close relationship between the virus-induced benign

papillomas and subsequent cutaneous squamous cell carcinomas. Although the malignant lesions do not contain viral particles, the HPV genetic information is retained in primary tumors and metastatic lesions. Papillomaviruses are also found regularly in bowenoid papulosis and in many noncutaneous urogenital carcinomas. Virtually all cases of cervical carcinomas contain HPV DNA. [43] As with adenovirus and SV40, the oncoproteins of the genital papillomaviruses functionally inactivate proteins of tumor-suppressor genes. [35], [36] and [37]

A retrovirus that does not contain a cell-derived oncogene [human T cell lymphoma/leukemia virus (HTLV)] is implicated in the pathogenesis of some adult T cell lymphomas/leukemias. [44] This tumor was originally described in certain regions of Japan, but has a worldwide distribution. Tumor cells from many patients have been shown to harbor this virus or portions of its genetic information. HTLV shares many features with feline and bovine leukemia viruses, retroviruses that are causative agents of lymphomas/leukemias in cats and cattle, respectively.

The consistent finding of HHV-8/KHSV in Kaposi's sarcoma, whether associated with AIDS or with the African or classic forms, argues that this virus contributes to the development of the condition. [25], [26], [45] As with other human tumor viruses, only a subset of infected individuals appear to develop the tumors.

The identification of specific viruses as etiologic agents of human tumors suggests it may be possible to prevent tumors by vaccination. As noted earlier, this has been accomplished with the vaccine against hepatitis B leading to a reduction in liver cancer associated with this virus. [6] Vaccination with the major structural viral protein of papillomavirus has produced excellent protection against experimental animal papillomavirus infection. [46], [47] and [48] The development of effective therapies against HIV has reduced the incidence of some AIDS-associated malignancies, especially Kaposi's sarcoma. [49]

REFERENCES

1. Minson A, Neil J, McCrae M, editors: *Viruses and Cancer,* vol 51. Cambridge, Cambridge University Press, 1994, p 309

2. Morris JDH et al: Viral infection and cancer. *Lancet* **346**:754, 1995

3. Knipe DM, Howley PM et al, editors: *Fields Virology*. New York, Lippincott Williams & Wilkins, 2001

4. Zur Hausen H: Viruses in human cancers. *Eur J Cancer* **35**:1878, 1999

5. Young LS et al: Viruses and apoptosis. *Br Med Bull* **53**:509, 1997

6. Chang MH: Universal hepatitis B vaccination in Taiwan and the incidence of hepatocellular carcinoma in children. *N Engl J Med* **26**:1855, 1997

7. Cooper GM: *Oncogenes*. Boston, Jones and Barlett, 1995

8. Lowy DR: The causes of cancer, in *Molecular Oncology,* edited by JM Bishop, RA Weinberg. New York, Scientific American, 1996, p 41

9. Rous P: Transmission of a malignant new growth by means of a cell-free filtrate. *JAMA* **56**:198, 1911

10. Kinzler K, Vogelstein B, editors: *The Genetic Basis of Human Cancer*. New York, McGraw-Hill, 1998

11. Weinberg RA, Hanahan D: Molecular pathogenesis of cancer, in *Molecular Oncology,* edited by JM Bishop, RA Weinberg. New York, Scientific American, 1996, p 41

12. Hanahan D, Weinberg R: The hallmarks of cancer. *Cell* **100**:57, 2000

13. Khanna R et al: Immune regulation in Epstein-Barr virus-associated diseases. *Microbiol Rev* **59**:387, 1995

14. Doria G et al: Genetic control of immune responsiveness, aging and tumor incidence. *Mech Ageing Dev* **96**:1, 1997

15. Nevins JR: Cell transformation by viruses, in *Fields Virology*, edited by D Knipe, P Howley, et al. New York, Lippincott Williams & Wilkins, 2001, p 245

16. Coffin JM: *Retroviruses*. Plainview, NY, Cold Spring Harbor Laboratory Press, 1997

17. Monto A, Wright T: The epidemiology and prevention of hepatocellular carcinoma. *Semin Oncol* **28**:441, 2001

18. Bonkovsky H, Mehta S: Hepatitis C: A review and update. *J Am Acad Dermatol* **44**:159, 2001

19. IARC: *Human Papillomaviruses. IARC Monographs on the Evaluation of Carcinogenic Risks to Humans,* vol 64. Geneva, WHO, 1995

20. Lowy D, Howley P: Papillomaviruses, in *Fields Virology,* edited by DM Knipe, PM Howley et al. New York, Lippincott Williams & Wilkins, 2001, p 2231

21. Frisch M et al: Association of cancer with AIDS-related immunosuppression in adults. *JAMA* **285**:1736, 2001

22. Knowles DM: Etiology and pathogenesis of AIDS-related non-Hodgkin's lymphoma. *Hematol Oncol Clin North Am* **10**:1081, 1996

23. Aboulafia DM, Mitsuyasu RT: Lymphomas and other cancers associated with acquired immunodeficiency syndrome, in *AIDS: Biology, Diagnosis, Treatment and Prevention,* edited by VT DeVita, S Hellman, SA Rosenberg. Philadelphia, Lippincott-Raven, 1997, p 319

24. Haller JO: AIDS-related malignancies in pediatrics. *Pediatr Oncol Imaging* **35**:1517, 1997

25. Boshoff C, Chang Y: Kaposi's sarcoma-associated herpesvirus: A new DNA tumor virus. *Annu Rev Med* **52**:453, 2001

26. Herndier B, Ganem D: The biology of Kaposi's sarcoma. *Cancer Treat Res* **104**:89, 2001

27. Hunter T: Cooperation between oncogenes. *Cell* **64**:249, 1991

28. Pan HCY, Van Dyke T: Apoptosis and cancer mechanisms. *Cancer Surv* **29**:305, 1997

29. Gunwald DJ et al: Loss of viral gene expression and retention of tumorigenicity by Abelson lymphoma cells. *J Virol* **43**:92, 1982

30. Varmus H: An historical view of oncogenes, in *Oncogenes and the Molecular Origins of Cancer,* edited by RA Weinberg RA. Cold Spring Harbor, NY, Cold Spring Harbor Laboratory, 1989

31. Buendia MA: Hepatitis B viruses and liver cancer: The woodchuck model, in *Viruses and Cancer,* vol 51, edited by A Minson, J Neil, M McCrae. Cambridge, Cambridge University Press, 1994, p 173

32. Bishop JM: Molecular themes in oncogenesis. *Cell* **64**:235, 1991

33. Buller RML et al: Cell proliferative response to vaccinia virus is mediated by VGF. *Virology* **164**:182, 1988

34. Courtneidge SA. Further characterization of the complex containing middle T antigen and pp60. *Curr Top Microbiol Immunol* **144**:121, 1989

35. Howley P, Lowy D: Papillomavirus replication, in *Fields Virology,* vol 2, edited by D Knipe, P Howley et al. New York, Lippincott Williams & Wilkins, 2001, p 2197

36. Huibregtse JM, Beaudenon SL: Mechanism of HPV E6 proteins in cellular transformation. *Semin Cancer Biol* **7**:317, 1996

37. Jones DL, Munger K: Interactions of the human papillomavirus E7 protein with cell cycle regulators. *Semin Cancer Biol* **7**:327, 1996

38. Rickinson AB, Kieff E: Epstein-Barr virus, *Fields Virology*. New York, Lippincott Williams & Wilkins, 2001, p 2511

39. Farrell PJ et al: Epstein-Barr virus genes and cancer cells. *Biomed Pharmacother* **51**:258, 1997

40. Niedobitek G et al: Epstein-Barr virus infection and human malignancies . *Int J Exp Pathol* **82**:149, 2001

41. Oudejans JJ et al: Epstein-Barr virus in Hodgkin's disease: More than just an innocent bystander. *J Pathol* **181**:353, 1997

42. Zur Hausen H: Papillomavirus infections—A major cause of human cancers. *Biochim Biophys Acta Rev Cancer* **1288**:F55, 1996

43. Walboomers JM et al: Human papillomavirus is a necessary cause of invasive cervical cancer worldwide. *J Pathol* **189**:12, 1999

44. Yoshida M: Multiple viral strategies of HTLV-1 for dysregulation of cell growth control. *Annu Rev Immunol* **19**:475, 2001

45. Gillison ML, Ambinder RF: Human herpesvirus-8. *Curr Opin Oncol* **9**:440, 1997

46. Breitburd F et al: Immunization with virus-like particles from cottontail rabbit papillomavirus (CRPV) can protect against experimental CRPV infection. *J Virol* **69**:3959, 1995

47. Suzich JA et al: Systemic immunization with papillomavirus L1 protein completely prevents the development of viral mucosal papillomas. *Proc Natl Acad Sci U S A* **92**:11553, 1995

48. Harro CD et al: Safety and immunogenicity trial in adult volunteers of a human papillomavirus 16 L1 virus-like particle vaccine. *J Natl Cancer Inst* **93**:284, 2001

49. Rabkin CS. AIDS and cancer in the era of highly active antiretroviral therapy (HAART). *Eur J Cancer* **37**:1316, 2001

T>

Chapter 38

Margaret Kripke Honnavara Ananthaswamy

Carcinogenesis: Ultraviolet Radiation

ULTRAVIOLET CARCINOGENESIS IN HUMANS
Epidemiologic Findings
Factors Affecting Carcinogenesis
EXPERIMENTAL UV CARCINOGENESIS
Tumor Induction by UV Radiation
Wavelength
Dose Response
Interactions with Other Agents
Immunology
GENETICS
MOLECULAR MECHANISMS
UV RADIATION AND MELANOMA
PREVENTION

REFERENCES

Cancer of the skin is the most common type of neoplasm in countries with predominantly Caucasian populations and high levels of ambient solar radiation. The incidence of new cases of skin cancer exceeds 1 million per year in the United States alone. [1] Precise information on the incidence of and mortality from skin cancer is difficult to obtain; with the exception of cutaneous melanoma, skin cancers generally are not reported to cancer registries, and skin cancer as a cause of death probably is underreported. However, the incidence of nonmelanoma skin cancer is thought to have been increasing since the early part of the twentieth century, and special surveys have indicated that it is continuing to climb. [1], [2] Most of these nonmelanoma skin cancers are thought to result from chronic exposure of the skin to solar ultraviolet (UV) radiation. This idea originated around the turn of the twentieth century from the astute observations of physicians who noted that skin cancers occurred in the sun-damaged skin of persons who pursued outdoor occupations. Thus sunlight was one of the first agents recognized to be carcinogenic for humans.

The increasing incidence of skin cancers, including melanoma, has been attributed to increasing exposure of the population to sunlight. During the past century, changes in clothing styles, recreational activities, longevity, and other aspects of lifestyle have resulted in increases in exposure to sunlight. Other factors, such as chemicals or viruses, also may be playing a role in the increasing incidence of skin cancer, but at present there is no evidence to support this idea. The wavelengths of solar radiation involved in tumor induction appear to be within the UV region of the spectrum (wavelengths between 200 and 400 nm), especially in the UVB (290–320 nm) range. A relatively small amount of UVB radiation is present in sunlight because wavelengths in this region are strongly absorbed by the layer of ozone present in the upper atmosphere. UV wavelengths below 290 nm (UVC radiation) are completely absorbed by ozone and thus are not present in natural sunlight (see Chap. 133). Experimental evidence suggests that stratospheric ozone may have been decreasing since around 1980 because of the release of chlorofluorocarbon compounds (from human uses) into the atmosphere. This downward trend is expected to continue into the early years of the twenty-first century and then gradually to return to the pre-1980 equilibrium over the next 50 years, assuming that the worldwide phaseout of these chemicals proceeds as expected. [3] Decreases in the concentration of stratospheric ozone are expected to cause a corresponding increase in the amount of UV radiation in sunlight, particularly in the UVB region. The increasing incidence of nonmelanoma skin cancer experienced to date is unlikely to be related to ozone depletion, however. This is so because the estimated decreases in ozone concentration over populated parts of the globe are small and have occurred too recently to have had an impact on skin cancer incidence. [3] On the other hand, the likelihood that the ozone concentration will remain lower than normal for another half-century implies that the incidence of skin cancer has not peaked and will continue to rise in the future.

ULTRAVIOLET CARCINOGENESIS IN HUMANS

Although it is not possible to prove directly that sunlight, particularly the UVB radiation in sunlight, causes skin cancer in humans, the circumstantial evidence for its role is quite convincing. Taken together, epidemiologic studies and experimental studies in laboratory animals indicate that repeated exposure to solar UV radiation is the primary cause of most nonmelanoma skin cancers in light-skinned populations.

Epidemiologic Findings

Evidence supporting the idea that sunlight causes nonmelanoma skin cancers in humans comes from a variety of observations on human subjects. [4] Most compelling is the finding that these skin cancers, especially squamous cell carcinomas, appear on parts of the body that receive maximum exposure to sunlight in sites that exhibit chronic UV damage. The face, head, neck, backs of the hands, and arms are the predominant sites for development of nonmelanoma skin cancers. The incidence of these skin cancers increases with increasing age as well, implying that cumulative lifetime exposure to sunlight is responsible for skin cancer induction. [5]

Persons who spend the most time out of doors, such as those with outdoor occupations, generally have a higher incidence of squamous cell carcinoma than those who work indoors, suggesting that there is a dose-response relationship between sunlight exposure and skin cancer incidence. An interesting illustration of this point comes from a study of Maryland watermen, a relatively stable and homogeneous group of Caucasians who make their living fishing on

the Chesapeake Bay. Among this group, the incidence of squamous cell carcinoma, but not basal cell carcinoma, correlated directly with the individual's personal exposure to sunlight. The higher the dose of UVB radiation received, the higher was the probability of developing squamous cell carcinoma. [6]

Geographically, there is a direct association between the amount of environmental solar radiation and the incidence of skin cancer in light-skinned individuals in the population. [4] Thus the incidence of skin cancer in Caucasians increases as one approaches the equator. The latitude gradient is steeper for squamous cell than for basal cell carcinomas. [5] This finding suggests that the incidence of squamous cell carcinoma is more dependent on sunlight exposure than that of basal cell carcinoma and that other factors in addition to sunlight may be involved in the induction of basal cell carcinoma. In fact, epidemiologic studies suggest that the incidence of basal cell carcinoma correlates poorly with cumulative lifetime exposure to sunlight [6], [7] and may be more related to intermittent (recreational) exposure and exposure during the childhood years. [7], [8]

Pigmentation, which is protective against sunburning, is also protective against skin cancer. The most striking example of this is seen in the high incidence and early occurrence of squamous cell carcinomas in African albinos compared with the extremely low incidence in their pigmented counterparts. [8] In addition to albinism, there are other genetic diseases associated with increased incidence of skin cancers on sun-exposed body sites. Xeroderma pigmentosum is characterized by extreme sun sensitivity, development of multiple skin cancers on sun-exposed parts of the body, and a decreased ability of somatic cells to repair UV-induced lesions in DNA (see Chap. 35). The association between defective DNA repair and skin cancer development constitutes direct evidence in humans that the UV radiation in sunlight is responsible for its carcinogenic effects. Another genetic disease, basal cell nevus or Gorlin's syndrome, is associated with a high incidence of multiple basal cell carcinomas, which occur preferentially on sun-exposed areas or in skin exposed to x-rays (see Chap. 82). These genetic diseases are discussed in further detail below.

Taken together, these findings present compelling evidence that exposure to sunlight is the cause of most nonmelanoma skin cancers. Furthermore, the studies of patients with xeroderma pigmentosum and the Maryland watermen strongly suggest that the carcinogenic wavelengths in sunlight fall mainly within the UVB region of the solar spectrum. This suggestion has been substantiated by many types of experiments in laboratory animals and by recent molecular studies of human and murine skin cancers.

Factors Affecting Carcinogenesis

Clearly, susceptibility to nonmelanoma skin cancer is dictated by a combination of factors, including sun exposure habits, occupation, and the degree of skin pigmentation. In addition to these major factors, other less obvious ones also may contribute to an individual's susceptibility to solar carcinogenesis. For example, persons with erythrodysplasia verruciformis sometimes develop squamous cell carcinomas. When this occurs, the tumors generally appear on sun-exposed body sites. [9] This observation suggests that there may be an interaction between papillomaviruses and sunlight exposure that promotes the development of skin cancer.

Once a person has developed a nonmelanoma skin cancer, the risk of developing a second primary tumor is greatly increased over the risk of persons of comparable skin type developing skin cancer. In one prospective study, one-third of the patients with basal cell carcinoma developed a second cancer within 5 years. [10] Thus, having had skin cancer constitutes a risk factor for the development of subsequent tumors.

One factor that has been clearly associated with an increased risk of nonmelanoma skin cancers is chronic immunosuppression. This observation came from studies of malignancies arising in renal transplant patients, which demonstrated that the risk of developing skin cancer was increased four to sevenfold in areas of low sun exposure and more than twentyfold in areas of high sun exposure. [11] These tumors appear predominantly on sun-exposed body sites and generally occur within a few years of transplantation. Careful examination of the skin of such patients revealed a high incidence of warts as well as carcinoma in situ and squamous cell carcinoma. [12] Human papillomavirus has been associated with the skin cancers as well as with benign warts, suggesting that immune suppression, papillomaviruses, and UV radiation all may interact to produce skin cancer in these individuals. These observations imply that a person's immune status is an important component in the risk of developing skin cancer.

It is also possible that exposure to certain chemicals may enhance the induction of skin cancers by UV radiation. Studies in animal models have demonstrated that there are many possible types of interactions between chemicals and UV radiation that can increase or even decrease tumor formation. For example, repeated application of a chemical tumor-promoting agent such as croton oil to murine skin initiated with UV radiation results in a high incidence of skin cancers, even though treatment with either agent alone produces few or no tumors. [13] In humans, however, such interactions have been documented only in the case of psoralens, which are photosensitizing compounds. The long-term use of 8-methoxypsoralen plus UVA radiation (PUVA) for therapy of psoriasis has been associated with an increased incidence of squamous cell carcinoma in some studies. [14] However, these skin cancers do not occur preferentially on parts of the body that receive the highest solar UV radiation, suggesting that they are related to the therapy alone rather than to an interaction between solar UV radiation and PUVA therapy. Recent molecular studies support the view that PUVA is carcinogenic for humans by itself.

Based on studies of xeroderma pigmentosum, it seems likely that the intrinsic ability of one's cells to repair UV-induced lesions in DNA also influences the risk of developing skin cancer. Because many genes are involved in the repair of DNA damage, one might expect individuals to differ in the ability of their cells to repair DNA damaged by chemicals and radiation and, consequently, to differ in their susceptibility to UV carcinogenesis. Such a correlation was, in fact, oted in a comparison of the ability of skin fibroblasts from patients with basal cell carcinoma and normal control subjects to repair cyclobutylpyrimidine dimers induced in vivo by solar-simulated UV radiation. The occurrence of basal cell carcinoma was associated with decreased excision repair of such lesions in DNA. [15] Molecular epidemiologic studies showed that lymphocytes from basal cell carcinoma patients also exhibited reduced DNA repair capacity and that persons with more

than four basal cell cancers had the lowest DNA repair capability. [16] Therefore, DNA repair capacity also may contribute to an individual's risk of developing skin cancer.

EXPERIMENTAL UV CARCINOGENESIS

Much of our information on UV carcinogenesis has come from investigations of the process in animal models, particularly in the mouse. This system is especially convenient for quantitative studies of carcinogenesis because the carcinogen can be delivered in an accurately measured dose. In addition, the carcinogen is present only during the time of application and does not persist in the tissues, and it does not require metabolic activation. Furthermore, the tumors can be identified at an early stage, and their development, progression, or regression can be followed by visual observation without the need for invasive procedures.

Tumor Induction by UV Radiation

Skin cancers have been induced experimentally with UV radiation in a variety of laboratory animals, including mice, rats, guinea pigs, and opossums. The tumor types vary somewhat depending on the species, but in mice they are mainly squamous cell carcinomas, fibrosarcomas, and undifferentiated or spindle cell tumors. Many factors influence the induction of tumors by UV radiation, even within a single species. [17] For example, hairless mice develop primarily squamous cell carcinomas after UV radiation, whereas haired mice tend to develop tumors of spindle cell morphology. Within a single mouse strain, tumor types can be influenced by UV dose. Different strains of mice can differ in their rate of tumor development, the proportions of different histologic types of tumors, and the anatomic sites of tumor development. Other variables influencing carcinogenesis include the amount of pigmentation in the skin, skin thickness, thickness of the keratin layer, and the age of the skin at the time of the first radiation.

Wavelength

The first studies of experimental UV carcinogenesis were carried out by Findlay, [18] who demonstrated that chronic exposure of albino mice to UV radiation from a quartz-mercury vapor lamp produced skin tumors on the ears and depilated dorsal skin. Shortly thereafter, Roffo [19] performed experiments with albino rats using sunlight filtered through window glass to produce skin cancers. These studies demonstrated that UV radiation could be used to produce skin cancers in laboratory rodents and determined that the primary carcinogenic waveband of sunlight fell within the wavelength range between 290 and 320 nm. Since that time, a number of different approaches have been used in an attempt to define more precisely an action spectrum for UV carcinogenesis, which is a plot of relative carcinogenic effectiveness as a function of wavelength. Knowledge of the action spectrum for UV carcinogenesis would be useful for several reasons. First, it could give information about the mechanisms of cancer induction by UV radiation. Second, knowing the important wavelengths for UV carcinogenesis would be helpful for designing sunscreens to prevent cancer induction. Third, knowledge of the action spectrum is essential for estimating the increased risk of skin cancer development resulting from ozone depletion.

Using combinations of light sources and filters, several groups have provided evidence that the action spectrum for carcinogenesis in the albino hairless mouse closely approximates the action spectra for UV-induced erythema in human skin [20] and UV-induced edema in murine skin. [21] Thus the most effective wavelengths for cancer induction in the hairless mouse are between 295 and 305 nm, and the activity decreases sharply with increasing wavelengths above this range (Fig. 38-1). Because of the similarity of this action spectrum to that of the erythema-inducing activity of UV radiation on human skin, and because of similarities in the dose-response relationships between UV carcinogenesis in humans and in mice, this action spectrum is often used as an approximation of the carcinogenic effectiveness of UV radiation for human skin.

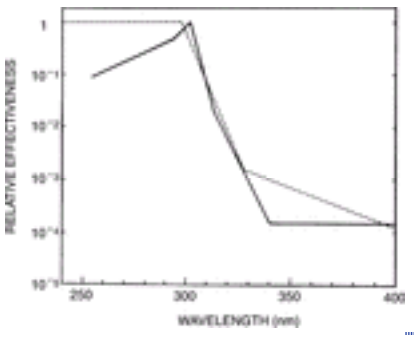

FIGURE 38-1 Action spectrum for photocarcinogenesis in the hairless albino mouse (—) and a standardized action spectrum for UV-induced erythema in humans (—). (*Adapted from van der Leun JC et al: Human health, in UN Environment Programme: Environmental Effects Panel Report. New York, United Nations, November 1989, p18, with permission of the authors.*)

Studies on the wavelength dependence of UV carcinogenesis in mice indicate that UVB radiation is around 1000 times more efficient than UVA radiation in producing murine skin cancers. This does not mean, however, that UVA radiation is noncarcinogenic. On the contrary, when given in sufficient doses, UVA radiation also produces skin cancers in mice. [22] Whether UVA radiation contributes to solar carcinogenesis in human skin is not clear, however. Although its carcinogenic effectiveness is much less than that of UVB radiation, it is present in much greater amounts in sunlight. Some experimental studies have suggested that UVA radiation actually potentiates cancer induction by UVB radiation, but whether it does so under natural environmental conditions is uncertain. Molecular analysis of human skin cancers does not support a role for UVA radiation as a mutagenic initiator of carcinogenesis; however, UVA radiation could serve as an

important tumor promoter.

Dose Response

Beginning around 1940, Blum [23] and colleagues initiated a monumental series of quantitative studies of tumor formation on the ears of haired albino mice exposed to UV radiation from various sources. These studies, which used large numbers of animals and carefully monitored light sources, addressed the energy requirements and time and dose relationships for tumor induction.

An important finding from this work was that cessation of irradiation before tumors appeared did not inhibit tumor formation. It did, however, reduce the rate of tumor formation dramatically compared with that in animals in which the irradiations were continued until tumors appeared. This finding suggests that limiting sun exposure in persons already exhibiting solar damage may at least retard tumor development. Another interesting feature of this system is that reciprocity of time and dose is observed only within a narrow range of conditions and that, in general, UV radiation given as many small doses is more carcinogenic than the same total dose of UV radiation given in a few very large doses. The basis for this lack of reciprocity is not known; it may be due to greater repair of DNA damage during the longer intervals between treatments with the high doses of UV radiation. Alternatively, the high doses may be killing many cells, thereby removing them from the pool of potential cancer cells. Regardless of the mechanisms involved, these studies indicate that UV carcinogenesis is achieved most efficiently with multiple low doses of UV radiation.

Interactions with Other Agents

One of the conclusions Blum drew from his studies was that UV carcinogenesis was a continuous process in which the effects of the UV radiation accumulated to lead, eventually, to the formation of skin cancers. This interpretation was reevaluated following the proposal by Berenblum [24] that chemical carcinogenesis in mouse skin was a two-stage process involving an irreversible initiation step and a reversible promotion phase. Subsequent studies demonstrated that a single, noncarcinogenic dose of UV radiation followed by repeated applications of a tumor-promoting agent (croton oil) produced tumors in murine skin. [13] This finding demonstrated that UV radiation was an initiator of carcinogenesis, like many of the chemical carcinogens. UV radiation also can serve as a tumor promoter after an initiating dose of a chemical carcinogen. Thus UV radiation may play a variety of roles during cutaneous carcinogenesis.

In addition to its interactions with other initiators and tumor promoters, tumor induction by UV radiation can be influenced by a variety of chemical and physical agents. One of these is retinoic acid, which has been shown both to augment and to reduce UV carcinogenesis under different experimental conditions. Antioxidants, such as butylated hydroxytoluene (BHT) and vitamin C, have been shown to inhibit UV carcinogenesis, suggesting that oxygen-dependent mechanisms are involved in tumor induction by UV radiation, most likely in the promotion phase. Studies in both mice and humans have demonstrated that a low-fat diet can reduce skin cancer induction. [25] The mechanisms involved are not known.

Obviously, any agent that reduces the amount of UV radiation reaching the target cells in the skin by either blocking or absorbing the radiation has the potential to inhibit carcinogenesis. Absorbers of UV radiation commonly used in commercial sunscreen preparations include *para*-aminobenzoic acid, cinnamates, benzophenones, and 2-ethylhexyl-*para*-dimethylaminobenzoate; blocking agents are zinc oxide and titanium dioxide (see Chap. 247).

Physical factors also have been shown to influence UV carcinogenesis. There are suggestions that x-irradiation may act synergistically with UV radiation in the production of skin cancers and that high temperature, wind, and high relative humidity can all increase susceptibility to UV carcinogenesis.

Immunology

Studies of UV carcinogenesis in the mouse demonstrated that there is an important immunologic component to tumor induction in this system. Investigation of the antigenic properties of skin cancers induced in haired, inbred mice demonstrated that these tumors are highly antigenic. When transplanted into normal, genetically identical mice, most of these tumors are rejected by the immune system of the recipient animal, although they will grow progressively in immunosuppressed mice. This finding raised the question of how such highly antigenic tumors were able to persist and grow in the primary host. Transplantation experiments demonstrated that early in the course of chronic UV radiation, before primary tumors were evident, the mice lost their ability to reject UV-induced tumors. Thus UV radiation had a systemic effect on the mice that interfered with tumor rejection. [26] The importance of the systemic effect for tumor induction was shown by experiments in which mice were exposed to UV radiation for a limited period to induce the systemic effect and then exposed to carcinogenic doses of UV radiation at a separate site. Mice that had been preirradiated at a distant site showed an increase in the rate of tumor induction. [27] Similar studies using UV radiation as the initiator and croton oil as the promoter suggested that the systemic effect of UV radiation was exerted during the promotion phase of two-stage carcinogenesis. [28]

The inability of UV-irradiated mice to reject UV-induced tumors could be passively transferred with lymphoid cells, demonstrating that the systemic alternation was immunologic in nature. Subsequent studies demonstrated that T lymphocytes were responsible for this effect and that these T suppressor cells inhibited the rejection of primary UV-induced skin cancers. [26] Recent evidence indicates that the T suppressor cells belong to a specialized subset of cells with features of both natural killer cells and T lymphocytes termed NK-T cells that regulate immune responses to lipid-containing molecules. [29] These studies indicated that exposure of the skin to UV radiation caused profound systemic changes in immune function and, moreover, that the immunosuppressive effects of UV radiation were of critical importance in the process of UV carcinogenesis. Mechanisms of UV-induced immunosuppression are discussed in Chap. 39.

The demonstration of an increased incidence of skin cancers in immunosuppressed human subjects supports the notion

that immunologic factors are also important in UV carcinogenesis in humans. Moreover, recent studies have demonstrated that patients with sunlight-associated skin cancers are more sensitive to UV-induced immunosuppression than are normal subjects. [30] This finding implies, in addition, that susceptibility to the immunologic effects of UV radiation may be an important determinant of skin cancer development in humans. UV-induced immune suppression also has been suggested as a possible explanation for the latitude gradient of non-Hodgkin's lymphoma and the increased incidence of this malignancy in persons with nonmelanoma skin cancer. In support of this notion, recent experimental studies showed that UV radiation accelerates that development of lymphoid malignancies in genetically susceptible mice. [31]

GENETICS

Cancers of many types involve mutations in genes that control cellular growth. Some genes facilitate cell growth (cellular oncogenes); others inhibit this process (tumor suppressor genes). A mutation that results in activation or overexpression of an oncogene or production of an altered oncogene product ultimately can lead to cancer formation. Similarly, mutations that inactivate genes or the products of genes involved in negative regulation of cell growth can contribute to cancer induction. In addition, alterations in genes involved in the repair of UV-induced DNA damage can lead to the development of UV-associated cancers. The occurrence of rare hereditary diseases associated with a high incidence of specific types of cancer has led to the identification of several genes involved in skin cancer development. Xeroderma pigmentosum is an autosomal recessive disease caused by the mutation of genes involved in DNA repair. Nine such genes have been identified so far. The disease is characterized by a high incidence of both melanoma and nonmelanoma skin cancers with an early age of onset. The association of skin cancer with defective DNA repair indicates the importance of DNA repair genes as determinants of susceptibility to UV carcinogenesis. As mentioned earlier, DNA repair capacity seems to be a determinant of skin cancer susceptibility in the general population as well as in xeroderma pigmentosum patients.

Patients with Li-Fraumeni syndrome, another hereditary disease, have a high incidence of multiple internal malignancies. These individuals inherit one defective copy of *p53,* a gene involved in regulation of the cell cycle. This tumor suppressor gene is lost or mutated in a variety of cancers, especially in skin and lung carcinomas. In both mice and humans, UV-induced skin cancers exhibit a high frequency (60–100 percent) of mutations in *p53,* and these can be detected in irradiated skin long before skin cancers are apparent. [32] It has been found that *p53* knockout mice with only one copy of the *p53* gene are highly susceptible to UV carcinogenesis. [33] Mice lacking both copies of the *XPA* or *XPC* DNA repair genes also exhibit increased susceptibility to skin cancer induction by UV radiation, and mice lacking both copies of *XPC* and one copy of *p53* are even more susceptible. [34], [35]

Studies of patients with Gorlin's syndrome, also known as *nevoid basal cell carcinoma syndrome,* have led to the identification of genes associated with basal cell carcinoma. This syndrome is a rare autosomal dominant disorder characterized by multiple basal cell carcinomas that appear at a young age on sun-exposed areas of the skin. Patients with Gorlin's syndrome were found to have germ-line mutations in the human homologue of the *patched* gene *(ptc)* that is involved in the regulation of development in *Drosophila.* [36] This gene is mutated in tumors from many patients with sporadic basal cell carcinoma as well, suggesting that genetic alterations in the *ptc* gene also may play a role in the development of sporadic basal cell carcinoma. *Ptc* normally functions to inhibit the sonic hedgehog (Shh) signal transduction pathway, and binding of Shh to *ptc* relieves the inhibition, allowing for transduction to continue through a series of additional steps. Mutations in *ptc* result in loss of its function and subsequent overexpression of downstream proteins, leading to uncontrolled cell division. Mutations resulting in overexpression of Shh also can lead to basal cell carcinoma formation [37] (see Chap. 81 and Chap. 82).

The *ras* family of oncogenes is also mutated in a small percentage of murine and human skin cancers (10–40 percent). [38] These genes are also involved in the transduction of signals from the cell membrane to the nucleus. Mutations that activate *ras* genes lead to persistent signal transduction, resulting in a loss of normal cellular growth control. *Ras* mutations are present in other types of solid tumors as well. One other gene that has been implicated in susceptibility to skin cancer in humans is the gene for glutathione *S*-transferase 1 *(GSTM1)*. Alleles of this gene code for enzymes involved in detoxification of electrophilic molecules and reactive oxygen species. Persons homozygous for the null allele, which makes no enzyme, have a slightly elevated risk of developing multiple basal and squamous cell carcinomas. [39] The mechanism by which these isoenzymes protect against skin carcinogenesis is not clear, but they could counteract certain steps in tumor promotion by either UV radiation or chemicals.

MOLECULAR MECHANISMS

From the experimental studies of UV carcinogenesis, it is clear that UV radiation can play a variety of roles in the development of skin cancers. It can serve as a complete carcinogen and induce tumors in animals and in cells in vitro in the absence of any other stimulus. It also can serve as an initiating agent in multistage carcinogenesis, in which tumor promoters are required for tumor development. UV radiation also shares many properties with chemical tumor promoters, such as induction of proliferation, stimulation of the production of enzymes involved in tumor promotion, and induction of inflammation, all of which probably contribute to the carcinogenic process. The immunosuppressive effect of UV radiation also contributes to its carcinogenic activity. In addition, UV radiation may have other effects on the local environment in which the tumors develop—such as increased vascularity and production of growth factors—that could contribute to tumor growth and progression. Finally, any one of these effects of UV radiation may contribute to the induction of skin cancers by other agents such as x-rays, viruses, or chemical carcinogens. Thus UV radiation may serve as a cofactor in other types of cutaneous carcinogenesis in addition to inducing skin cancers directly.

The molecular mechanisms by which UV radiation exerts its varied effects are not completely understood. The carcinogenic process probably involves multiple sequential steps, some, but not all of which involve alterations in DNA structure (mutations). Evidence that UV-induced lesions in DNA are involved in the formation of skin cancer comes from a variety of systems. In humans, the association between defective DNA repair and sunlight-induced skin cancers in xeroderma pigmentosum patients provides strong evidence for the involvement of UV-induced lesions in DNA.

Experimental studies using species whose cells contain a light-activated DNA repair enzyme suggest further that cyclobutyl pyrimidine dimers induced by UV radiation between adjacent pyrimidine bases on the same strand of DNA are a critical component of the carcinogenic process. Studies with the Amazon molly (*Poecilia formosa*) demonstrated that the formation of UV-induced cancers of the thyroid tissue could be prevented by exposing the tissue to visible light after UV radiation. [40] The visible light activated an enzyme that specifically repairs pyrimidine dimers in DNA. Studies with the South American opossum (*Monodelphis domestica*) demonstrated similarly that skin cancer induction by chronic UV radiation could be inhibited by exposure of the skin to UVA radiation plus visible light after each UV radiation exposure. [41]

Theoretically, any alteration capable of causing a mutation in specific target genes could contribute to UV carcinogenesis because there is a close correlation between mutation and transformation by UV radiation. Other lesions in DNA produced after UVB radiation include [6–4] photoproducts, purine photoproducts, cytosine photohydrates, single-strand breaks, and sister chromatid exchanges. Furthermore, DNA damage can result from reactive oxgyen species, such as singlet oxygen, superoxide anion, and hydrogen peroxide, that are generated during exposure of mammalian cells to UV radiation. Based on detailed molecular analysis of the mutations in the *p53* gene in both human and murine skin tumors, cyclobutyl pyrimidine dimers and [6–4] photoproducts seem to be the predominant mutagenic lesions contributing to skin cancer induction. Most *p53* mutations are C?T transitions and CC?TT double-tandem mutations at dipyrimidine sites, which result from cyclobutyl pyrimidine dimers and [6–4] photoproducts. These mutations are characteristic of UVB and UVC radiation but not of UVA radiation or chemical carcinogens, implying that UVB radiation is the most important mutagenic agent for the induction of skin cancer by sunlight. [42] Therefore, other molecular alterations must contribute to carcinogenesis by causing mutations in genes other than *p53* or by contributing to nonmutational steps in the carcinogenic process.

Molecular analysis of *p53* mutations in murine skin cancers induced by PUVA revealed that PUVA also induced unique mutations in this gene, different from those induced by UVB radiation. This information prompted a study of *p53* mutations in skin cancers obtained from patients undergoing PUVA therapy to ascertain the etiology of these cancers. Although some were UVB signature mutations, the majority of the *p53* mutations observed in skin cancers from these patients occurred at or adjacent to 5'-TA/5'-TAT sites, which are characteristic of PUVA-induced mutations. [43] Thus this study suggests that PUVA is carcinogenic in humans and that the majority of the skin cancers that occur in patients undergoing PUVA therapy are related to the treatment rather than to sunlight exposure.

UV RADIATION AND MELANOMA

In contrast to the clear relationship between UV exposure and basal cell and squamous cell carcinomas, the role played by UV radiation in the induction and pathogenesis of cutaneous melanoma remains unclear. Only lentigo maligna melanoma exhibits a relationship to sunlight exposure similar to that of the nonmelanoma skin cancers. The other types of melanoma do not occur preferentially on the most heavily exposed body sites, nor does their incidence continue to rise with increasing age. Furthermore, their occurrence does not correlate with occupational or cumulative lifetime exposure to sunlight. [5] On the other hand, there is a latitude gradient for melanoma, although the relationship is not as strong as that for either basal cell or squamous cell carcinoma.

More attention has been focused on this issue in recent years because of concerns about the consequences of ozone depletion and the rapid rise in the incidence of melanoma. Although the evidence remains largely circumstantial, it supports the conclusion that UV radiation is a contributing factor in the development of at least some cutaneous melanomas in addition to being the primary cause of lentigo maligna melanoma. This evidence can be summarized as follows:

1. Case-control studies indicate that a higher risk of melanoma development is associated with intense sun exposure early in life. [44]
2. The increasing incidence of melanoma parallels that of nonmelanoma skin cancer. [2]
3. Pigmentation is inversely correlated with the incidence of cutaneous melanoma. [45]
4. The risk of melanoma development in patients with xeroderma pigmentosum is 2000 times higher than that in the general population. Furthermore, there is evidence that at least some of these melanomas have UV-induced mutations in oncogenes (see Chap. 93).
5. Immigrant studies demonstrate an increased incidence of melanoma among persons who are native to sunny regions or who immigrate to such areas before the age of puberty as compared with persons who immigrate later in life. [46]

In addition, there is evidence from animal models that supports a relationship between exposure to UV radiation and melanoma induction. In addition to other types of skin and ocular tumors, cutaneous melanomas occur in the marsupial *M. domestica* after long-term chronic exposure of adults [47] or after acute exposure of neonates [48] to UV radiation. Furthermore, precancerous melanotic lesions were prevented by treatment with visible light after UV irradiation, suggesting that they may result from UV-induced lesions in DNA. [47] Certain hybrid species of tropical fish are prone to melanoma development following exposure to UV radiation. In this model also photoactivation of an enzyme that repairs thymine dimers reduces the incidence of melanoma. [49] However, an action spectrum for the induction of melanoma in the fish model demonstrated that UVA radiation also induced melanoma. [50] This finding has raised questions about the accuracy of predictions concerning the increased risk of melanoma that would result from ozone depletion (which affects only UVB) and and has generated concern about the effectiveness of UVB sunscreens for preventing skin cancer.

In mice, melanomas can be induced by combinations of UV radiation and tumor promoters and chemical carcinogens and UV radiation. [51] In addition, exposing murine skin to UV radiation has been reported to accelerate the development of both primary [51] and transplantable [52] melanomas within the site of UV radiation. Studies on the mechanism of this effect of UV radiation suggest that both the production of melanoma-specific growth factors from UV-irradiated epidermis and

decreased immunologic reactivity of the skin may be involved.

The weight of evidence, though admittedly circumstantial, favors the conclusion that UV radiation contributes in some way to the induction and pathogenesis of cutaneous melanoma. The relationship between exposure to UV radiation and the development of melanoma clearly differs from that of solar UV radiation and the nonmelanoma skin cancers in terms of dose response, age dependence, and perhaps the participation of other carcinogenic factors. Molecular evidence for the involvement of UV radiation as an initiator of melanoma induction is quite limited. In contrast to the high frequency of UV-induced mutations in *p53* in skin carcinomas, *p53* is rarely mutated in melanomas and therefore is unlikely to play a major role in melanoma development. However, genetic abnormalities in $p16^{INK4a}$ and $p14^{ARF}$ genes have been shown to play a role in human melanoma. [53] The *INK4a-ARF* locus on human chromosome 9p21 encodes two proteins, $p16^{INK4a}$ and $p14^{ARF}$ ($p19^{ARF}$ in mice), known to function as tumor suppressors via the retinoblastoma or the p53 pathway. [54] Deletions and mutations in $p16^{INK4a}$ and $p14^{ARF}$ have been reported in familal and sporadic melanoma, [53], [55], [56] and studies using $p16^{INK4a}$ and $p19^{ARF}$ knockout mice have shown that these mice develop both spontaneous and chemical carcinogen-induced malignant melanoma. [57], [58] These studies support the notion that $p16^{INK4a}$ and $p19^{ARF}$ genes play a critical role in the pathogenesis of malignant melanoma. An additional melanoma-associated gene is that coding for hepatocyte growth factor (or scatter factor). A single erythemal UV radiation exposure of neonatal, but not adult, transgenic mice that overexpress hepatocyte growth factor/scatter factor results in the development of cutaneous melanoma. [59] This mouse model may be useful for determining the reasons for the association between childhood sunburn and the subsequent development of melanoma in humans. Aside from its possible function as an initiator, UV radiation probably can play a number of different roles in the induction of melanoma. Also, UV radiation may be only one of several carcinogens involved in the pathogenesis of this tumor. To date, however, other such carcinogens have not been identified.

PREVENTION

For the nonmelanoma skin cancers, the most logical approach to prevention is to limit exposure of the skin to natural and artificial sources of UV radiation. This can be achieved in numerous ways, including the use of sunscreens, the avoidance of outdoor activities during the noon hours when the amount of UV radiation in sunlight is maximal, and the use of protective clothing. Reducing the lifetime dose of UV radiation reduces the risk of skin cancer development in mice and presumably in humans as well. Because the effects of UV radiation in causing nonmelanoma skin cancers are cumulative, we would expect that reducing sunlight exposure at any age would retard the rate of tumor development.

For melanoma and perhaps even for some basal cell carcinomas, it is not clear whether this strategy would be effective because there is not a simple, direct relationship between dose of UV radiation and melanoma induction. For example, if melanoma results from childhood exposure to UV radiation, as has been suggested, reducing sunlight exposure during adult life may not be beneficial in attempting to decrease the incidence of melanoma. Obviously, more information on the dose response, wavelength dependence, and mechanism of action of UV radiation in the induction of melanomas is needed to devise effective strategies for preventing even the melanomas that are sunlight-related.

REFERENCES

1. Rowe DE et al: Prognostic factors for recurrence, metastasis, and survival rates in squamous cell carcinoma of the skin, ear, and lip. *J Am Acad Dermatol* **26**:976, 1992

2. Glass AG, Hoover RN: The emerging epidemic of melanoma and squamous cell skin cancer. *JAMA* **262**:2097, 1989

3. Madronich S et al: Changes in ultraviolet radiation reaching the earth's surface. *Ambio* **24**:143, 1995

4. Urbach F: Geographic pathology of skin cancer, in *The Biologic Effects of Ultraviolet Radiation*, edited by F Urbach. Oxford, England, Pergamon, 1969, p 635

5. Fears TR et al: Mathematical models of age and ultraviolet effects on the incidence of skin cancer among whites in the United States. *Am J Epidemiol* **105**:420, 1977

6. Vitasa BC et al: Association of nonmelanoma skin cancer and actinic keratosis with cumulative solar ultraviolet exposure in Maryland watermen. *Cancer* **65:**2811, 1990

7. Kricker A et al: Does intermittent sun exposure cause basal cell carcinoma? A case-control study in western Australia. *Int J Cancer* **60**:489, 1995

8. Kricker A et al: Sun exposure and non-melanocytic skin cancer. *Cancer Causes Control* **5**:367, 1994

9. Jablonska S et al: Epidermodysplasia verruciformis as a model in studies on the role of papovavirus in oncogenesis. *Cancer Res* **32**:583, 1972

10. Robinson JK: Risk of developing another basal cell carcinoma: A 5-year prospective study. *Cancer* **60**:118, 1987

11. Penn I: Tumors of the immunocompromised patient. *Annu Rev Med* **39**:63, 1988

12. Bouwes-Bavinck JN: Epidemiological aspects of immunosuppression: Role of exposure to sunlight and HPV on the development of skin cancer. *Hum Exp Toxicol* **14**:98, 1994

13. Epstein JH, Roth HL: Experimental ultraviolet light carcinogenesis: A study of croton oil promoting effects. *J Invest Dermatol* **50**:387, 1968

14. Stern RS, Lander EJ: Risk of squamous cell carcinoma in patients treated with oral methoxsalen (psoralen) and UV-A radiation: A meta-analysis. *Arch dermatol* **134:**1582, 1998

15. Alcalay J et al: Excision repair of pyrimidine dimers induced by simulated solar radiation in the skin of patients with basal cell carcinoma. *J*

Invest Dermatol **95**:506, 1990

16. Wei Q et al: DNA repair and aging in basal cell carcinoma: A molecular epidemiologic study. *Proc Natl Acad Sci USA* **90**:1614, 1993

17. Ananthaswamy HN, Kripke MK: Experimental skin carcinogenesis by ultraviolet radiation, in *Pathophysiology of Dermatologic Disease,* edited by NA Soter, HP Baden. New York, McGraw-Hill, 1990 p 483.

18. Findlay GM: Ultraviolet light and skin cancer: *Lancet* **215**:1070, 1928

19. Roffo AH: Cancer et soleil: Carcinomes et sarcomes provoques par l'action du soleil in toto. *Bull Assoc France Etude Cancer* **23**:590, 1934

20. Sterenborg HJCM, van der Leun JC: Action spectra for tumorigenesis by ultraviolet radiation, in *Human Exposure to Ultraviolet Radiation: Risks and Regulations*, edited by WF Passichier, BFM Bosnjakovic. Amsterdam, Elsevier, 1987, p 173

21. Cole CA et al: An action spectrum for photocarcinogenesis. *Photochem Photobiol* **4**:275, 1986

22. Sterenborg HJCM, van der Leun JC: Tumorigenesis by a long wavelength UV-A source. *Photochem Photobiol* **51**:325, 1990

23. Blum HF: *Carcinogenesis by Ultraviolet Light*. Princeton, NJ, Princeton University Press, 1959

24. Berenblum I: A speculative review: The probable nature of promoting action and its significance in the understanding of the mechanism of carcinogenesis. *Cancer Res* **14:**471, 1954

25. Black HS et al: Evidence that a low-fat diet reduces the occurrence of non-melanoma skin cancer. *Int J Cancer* **62**:165, 1995

26. Kripke ML: Immunology and photocarcinogenesis: New light on an old problem. *J Am Acad Dermatol* **14**:149, 1986

27. deGruiji F, van der Leun JC: Systemic influence of pre-irradiation of a limited skin area on UV-tumorigenesis. *Photochem Photobiol* **35**:379, 1982

28. Strickland PT et al: Enhancement of two-stage skin carcinogenesis by exposure of distant skin to UV radiation. *J Natl Cancer Inst* **74**:1129, 1985

29. Moodycliff AM et al: Immune suppression and skin cancer development regulation by NKT cells. *Nature Immunol* **1**:521, 2000

30. Yoshikawa T et al: Susceptibility to effects of UVB radiation on induction of contact hypersensitivity as a risk factor for skin cancer in human. *J Invest Dermatol* **95**:530, 1990

31. Jiang W et al: UV irradiation augments lymphoid malignancies in mice with one functional copy of wild-type *p53*. *Proc Natl Acad Sci USA* **98**:9790, 2001

32. Ananthaswamy HN et al: Sunlight and skin cancer: Inhibition of *p53* mutations in UV-irradiated mouse skin by sunscreens. *Nature Med* **3**: 310, 1997

33. Jiang W et al: *p53* protects against skin cancer induction by UV-B radiation. *Oncogene* **18**:4247, 1999

34. Nakane H et al: High incidence of ultraviolet-B–or chemical-carcinogen–induced skin tumours in mice lacking the xeroderma pigmentosum group A gene. *Nature* **377**:165, 1995

35. Cheo DL et al: Synergistic interactions between *XPC* and *p53* mutations in double-mutant mice: Neural tube abnormalities and accelerated UV radiation-induced skin cancer. *Curr Biol* **6**:1691, 1996

36. Johnson RL et al: Human homolog of *patched,* a candidate gene for the basal cell nevus syndrome. *Science*. **272**:1668, 1996

37. Ingham PW: Transducing hedgehog: The story so far. *EMBO J* **17**:3505, 1998.

38. Ananthaswamy HN, Pierceall WE: Molecular mechanisms of ultraviolet radiation carcinogenesis. *Photochem Photobiol* **52**:1119, 1990

39. Heagerty AHM et al: Glutathione *S*-transferase *GSTM1* phenotypes and protection against cutaneous tumours. *Lancet* **343**:366, 1994

40. Hart RW et al: Evidence that pyrimidine dimers in DNA can give rise to tumors. *Proc Natl Acad Sci USA* **74**:5574, 1977

41. Ley RD et al: UVA/visible light suppression of ultraviolet radiation–induced skin and eye tumors of the marsupial *Monodelphis domestica*. *Photochem Photobiol* **47**:45S, 1998

42. Nataraj AJ et al: *p53* gene mutations and photocarcinogenesis. *Photochem Photobiol* **62**:218, 1995

43. Nataraj AJ et al: *p53* mutation in squamous cell carcinomas from psoriasis patients treated with psoralen plus UVA (PUVA). *J Invest Dermatol* **109**:238, 1997

44. Lew RA et al: Sun exposure habits in patients with cutaneous melanoma: A case control study. *J Dermatol Surg Oncol* **9**:981, 1983

45. Crombie IK: Racial differences in melanoma incidence. *Br J Cancer* **40**:185, 1979

46. Holman CDJ, Armstrong BK: Cutaneous malignant melanoma and indicators of total accumlated exposure to the sun: An analysis separating histogenetic types. *J Natl Cancer Inst* **73**:75, 1984

47. Ley RD et al: Ultraviolet radiation-induced malignant melanoma in *Mondelphis domestica. Photochem Photobiol* **50**:1, 1989

48. Robinson ES et al: Malignant melanoma in ultraviolet irradiated laboratory opossums: Initiation in suckling young, metastasis in adults, and xenograft behavior in nude mice. *Cancer Res* **54:**5986, 1994

49. Setlow RB et al: Animal model for ultraviolet radiation–induced melanoma: Platyfish-swordtail hybrid. *Proc Natl Acad Sci USA* **86**:8922, 1989

50. Setlow RB et al: Wavelengths effective in induction of malignant melanoma. *Proc Natl Acad Sci USA* **90**:6666, 1993

51. Romerdahl CA et al: The role of ultraviolet radiation in the induction of melanocytic skin tumors in inbred mice. *Cancer Commun* **4**:209, 1989

52. Romerdahl CA et al: Effect of UV-B radiation on the in vivo growth of murine melanoma cells. *Cancer Res* **48**:4007, 1988

53. Fitzgerald MG et al: Prevalence of germ-line mutations in *p16*, *p19* ^{ARF}, and *CDK4* in familial melanoma: Analysis of a clinically-based population. *Proc Natl Acad Sci USA* **93**:8541, 1996

54. Quelle DE et al: Alternative reading frames of the *INK4a* tumor suppressor gene encodes two unrelated proteins capable of inducing cell cycle arrest. *Cell* **83**:993, 1995

55. Pollock PM et al: Evidence for UV induction of *CDKN2* mutations in melanoma cell lines. *Oncogene* **11**:663, 1995

56. Flores JF et al: Loss of *p16* ^{INK4a} and *p15* ^{INK4b} genes, as well as neighboring 9p21 markers, in sporadic melanoma. *Cancer Res* **56**:5023, 1996

57. Chin L et al: Cooperative effects of *INK4a* and *ras* in melanoma susceptibility in vivo. *Genes Dev* **11**:2822, 1997

58. Krimpenfort P et al: Loss of *p16* ^{INK4a} confers susceptibility to metastatic melanoma in mice. *Nature* **413**:83, 2001

59. Noonan FP et al: Neonatal sunburn and melanoma in mice. *Nature* **413**:271, 2001

T>

Chapter 39

Richard Granstein

Photoimmunology

SKIN-ASSOCIATED LYMPHOID TISSUES
IMMUNOLOGIC ASPECTS OF ULTRAVIOLET CARCINOGENESIS
DNA Effects
Antigenicity of UVR-Induced Tumors
Regulatory T Cells
Antigen-Presenting Cell Function in UVR-Treated Mice
Human Studies
EFFECTS OF UVR ON CONTACT AND DELAYED-TYPE HYPERSENSITIVITY
Hypothetical Pathway for UVR-Induced Skin Cancer Formation
Human Studies
LANGERHANS CELLS
KERATINOCYTE-DERIVED CYTOKINES
EFFECTS OF WHOLE-BODY EXPOSURE TO UVR ON LYMPHOCYTES IN HUMANS

REFERENCES

Photoimmunology is the science that concerns itself with the effects of nonionizing radiation on the immune system. Although some data are available from human studies, most of the information currently available concerns the effects of ultraviolet radiation (UVR) in murine systems. Nonetheless, this work may have great relevance for understanding analogous or similar effects in humans.

SKIN-ASSOCIATED LYMPHOID TISSUES

The protective role of the skin includes collective properties that allow it to be considered as an immune organ. The skin contains antigen-presenting cells [Langerhans cells, (LC)] capable of communicating with T, and probably non-T, lymphocytes. In addition, keratinocytes can produce a number of cytokines that may also participate in immune recognition in the skin (see below). Streilein and his colleagues labeled these cells and the regional draining lymph nodes as *skin-associated lymphoid tissues* (SALT). [1]

Skin can clearly serve as an environment for antigen presentation in both the elicitation phase of an immune response (such as contact dermatitis) and in the induction phase of the immune response. Overwhelming evidence shows that LC are capable of presentation of various antigens to T cells (see below) and much data support the concept that certain T cells preferentially circulate between the skin and its regional lymph nodes. [1] Recently, a specific antigen, known as the *cutaneous lymphocyte antigen* (CLA), has been found to be expressed on memory T cells that traffic to the skin. [2] CLA appears to interact with E-selectin on endothelial cells. [2]

It has long been known that normal epidermis contains lymphocytes. In the mouse, most of these are highly dendritic and bear gamma/delta T cell receptors. [3] In the human, the majority are not dendritic and bear conventional alpha/beta T cell receptors. [4]

As the main barrier between the organism and the environment, the skin encounters viruses, fungi, bacteria, and chemical and physical carcinogens from which the organism must be protected. Presumably, SALT has evolved to meet the antigenic challenges of protecting the organism from infection and, perhaps, from cutaneous carcinogenesis. Immunosuppressed patients have increased rates of skin cancer, suggesting that immunosurveillance against skin cancer exists. [5]

IMMUNOLOGIC ASPECTS OF ULTRAVIOLET CARCINOGENESIS

This topic is covered in detail in Chap. 38; it is dealt with briefly here. Unna is generally credited with first describing the relationship between skin cancer and exposure to sunlight. [6] Early studies, in the 1920s, demonstrated that UVR can cause skin cancer in mice. [7] Midrange UVR (UVB, 280 to 320 nm) is more efficient than short-wave UVR (UVC, 200 to 280 nm) in producing tumors in mice. [8], [9] Also, no UVC radiation reaches the earth's surface; it is totally absorbed by the atmospheric ozone layer. Long-wave UVR (UVA, 320 to 400 nm), when added to UVB radiation, may accelerate carcinogenesis. [10] UVA radiation alone, however, appears to be at least 1600 times less carcinogenic than UVB radiation. [10]

DNA Effects

The transformation of cells by UVR is thought to occur, at least in part, as a consequence of changes induced in DNA. The energy required to damage DNA increases greatly for longer wavelengths, with at least four times more energy required at 310 nm than at 254 to 300 nm. [11] Pyrimidine dimer production by UVR (290 to 360 nm) occurs in vivo in human skin. [12] The role of DNA damage in the production of some human carcinomas by UVR is supported by the finding that cells from patients with xeroderma pigmentosum, a condition marked by numerous sunlight-related cutaneous malignancies, are defective in their ability to repair UV-damaged DNA. [13], [14]

Evidence that UV-induced pyrimidine dimers in DNA can give rise to tumors comes from studies of a small fish that can be grown in clones, the Amazon molly *Poecilia formosa*. [15] Thyroid tissue irradiated with 254-nm radiation and transplanted into the abdominal cavity of another fish grows into a tumor. However, if the 254-nm radiation is followed by photoreactivating illumination (to activate photoreactivating enzyme, which removes pyrimidine dimers), the percentage of fish yielding tumors is markedly reduced. Additionally, the marsupial *Monodelphis domestica* expresses photoreactivating enzyme. This animal develops both nonmelanoma and melanoma skin tumors after appropriate exposure to UVB radiation. [16] Photoreactivating illumination reduces both nonmelanoma and melanoma tumors. [16] Other evidence suggests that certain other DNA photoproducts are mutagenic and thus may also be involved in carcinogenesis. [17], [18]

DNA photochemistry is believed to exert its effects by producing activation of oncogenes and mutations in tumor suppressor genes. Involvement of pyrimidine dimers in activation of the *N-ras* oncogene in vitro has been shown. [19] There are conflicting reports on the rate of mutations within ras oncogenes in human nonmelanoma and melanoma skin cancers. [20] However, there is much evidence for mutations in the tumor suppressor gene *p53* in human nonmelanoma skin cancer. [21] Mutations in the genes of the hedgehog signaling pathway (especially in *patched*-1 and *smoothened*) appear central to the development of basal cell carcinoma. [22] This area is covered in detail within chapters dealing specifically with each type of skin cancer (see Chap. 79, Chap. 80, Chap. 81 and Chap. 82 and Chap. 93).

Antigenicity of UVR-Induced Tumors

As early as 1939, it was reported that UVR-induced skin cancers were difficult to transplant, even to isogenic mice. At the time, this was attributed to bacterial contamination. [23] Later, it was found that most UVR (280 to 320 nm)-induced fibrosarcomas and squamous cell carcinomas were highly antigenic, at least in some strains of mice. These tumors regressed when transplanted to syngeneic normal mice but grew in immunosuppressed mice. [24] Furthermore, UV-irradiated nontumor–bearing mice were susceptible to challenge with syngeneic UVR-induced tumors, even when subcarcinogenic doses of UVR were given. [25] Second-set rejection of syngeneic UVR-induced tumors in animals that had been specifically immunized before UVR exposure was normal, [25] implying that a specific step in acquiring immunity is most likely affected by UVR.

Regulatory T Cells

Normal mice can be rendered susceptible to syngeneic UVR-induced tumors by the adoptive transfer of lymphoid cells from either tumor-bearing or non-tumor-bearing UV-irradiated donors (Fig. 39-1). These cells, which have been shown to be T cells, [26] recognize UVR-induced specificities found on most UVR-induced tumors as their adoptive transfer renders the recipients susceptible to most UV-induced tumors. Lethally x-irradiated mice reconstituted with lymphoid cells from normal donors are resistant to UVR-induced tumor challenge, whereas those receiving lymphoid cells from UV-irradiated donors do not reject tumor. Mice given equal numbers of cells from both categories of donor also do not reject tumor. [27] These findings imply that the T cells involved in inducing susceptibility to tumors are suppressor cells. Experiments demonstrate that CD4+ T cells account for this phenomenon. [28] Because these cells appear to arise in UV-irradiated mice prior to animals developing tumors, UVR tumor-associated antigenic determinants are presumably induced in the skin by UVR even before the overt appearance of a tumor.

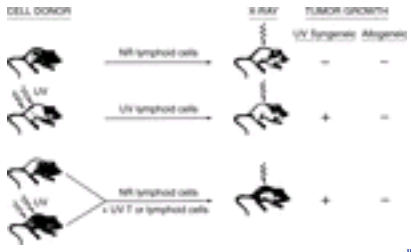

FIGURE 39-1 Experimental protocol used to demonstrate the immunologic basis of the UV in radiation-induced systemic alteration. Lymphoid cells from normal or UV-irradiated mice were used to reconstitute the immune system of lethally x-irradiated animals. Susceptibility to the growth of UVR-induced skin cancers was transferred with lymphoid cells taken from UVR-irradiated mice and was specific for UVR-induced syngeneic tumors. Mixing studies demonstrated that the effect was due to T lymphocytes in the lymphoid cell preparation. NR, nonirradiated age-matched controls. (*Reprinted from Kripke ML: Immunology and photocarcinogenesis. New light on an old problem. J Am Acad Dermatol* ***14*** *:149, 1986, with permission from Mosby-Year Book, Inc.*)

There is additional evidence that suppressor T cells (TS) cells are necessary for the development of primary skin cancers. [29] Groups of lethally x-irradiated mice had their lymphoid systems reconstituted with spleen and lymph node cells from syngeneic normal mice, with cells from chronically UV-irradiated mice, or with a mixture of both types of cells. Four weeks later, all three groups of mice received skin grafts from the irradiated areas of mice that had received chronic exposure to UVR. Significantly more tumors arose in the skin grafted to mice reconstituted with lymphoid cells from UVR-treated mice or a mixture of lymphoid cells from UVR-treated and normal mice than in the skin of those that had received only normal cells. In additional experiments, groups of mice were given intravenous injections of T cells from either normal or chronically UVR-irradiated syngeneic mice. These mice, as well as mice that had not received injections, were then exposed to UVR until tumors developed. Recipients of T cells from UVR-treated mice developed more tumors than did uninjected mice or mice that had received normal T cells; they also developed them earlier. [29] These two experiments demonstrate that the TS cells induced in mice by UVR not only inhibit the rejection of tumor transplants but also play an important role in carcinogenesis. This study illustrates the importance of immunologic regulatory

mechanisms in the control of cancer growth in the primary host.

Antigen-Presenting Cell Function in UVR-Treated Mice

Studies show that splenic antigen-presenting cells (APC) from UV-irradiated mice do not present antigen effectively for priming UV-irradiated mice for a delayed-type hypersensitivity (DTH) response. This defective antigen presentation not only prevents the induction of a normal DTH response, it also stimulates the production of TS cells that are specific for the “improperly” presented antigen. [30]

Defective antigen presentation may explain the appearance of suppressor cells in UVR-irradiated animals that prevent the rejection of UVR-induced tumors. After UVR exposure, new antigens, related in specificity to tumor antigens, presumably appear in the skin. At the same time, the defect in antigen presentation occurs with inappropriate presentation of certain of these antigens to the lymphoid system, resulting in the formation of TS cells with specificity for certain tumor antigens present in UVR-induced skin cancers. In this regard, LC pulsed in vitro with tumor-associated antigens (TAA) can present TAA for in vivo antitumor immunity [31] when administered subcutaneously to naive mice. Furthermore, a number of cytokines, including granulocyte-macrophage colony-stimulating factor (GM-CSF), interleukin (IL) 10, and tumor necrosis factor (TNF)-a, modulate the ability of LC to present TAA for induction of antitumor immunity. [31] Exposure to GM-CSF is necessary for LC to induce substantial immunity against an experimental tumor. Exposure of LC to IL-10 before, but not after, activation with GM-CSF inhibits the ability of LC to prime naive mice for immunity to a tumor. Conversely, TNF-a exposure inhibits the ability of LC to present TAA when exposure occurs after, but not before, activation with GM-CSF. In addition, in vitro exposure of LC to UVB radiation inhibits LC presentation of TAA. These results highlight the complexity of the interaction of regulatory signals in vivo. The recent finding that the epidermis can serve as a source of both cellular and humoral elements that are capable of downregulation of immunity may be important in this regard. These studies have been performed primarily in contact hypersensitivity and in vitro systems and are discussed in detail below.

Human Studies

Involvement of the immune system in human cutaneous carcinogenesis is suggested by the increased risk of malignancy in patients undergoing immunosuppressive therapies. The frequency of skin cancers including basal cell carcinomas, squamous cell carcinomas and possibly melanoma is increased in immunosuppressed patients. [32], [33] The overall increased risk of skin cancer in renal transplant patients is approximately sevenfold, mostly due to squamous cell carcinomas that are increased over 36-fold. [34]

B and T lymphocytes have been isolated from both human basal cell carcinomas and squamous cell carcinomas in numbers comparable to those found in biopsies of DTH reactions. [35] Some patients demonstrate immunologic reactivity against tumor cells by their own serum or peripheral blood lymphocytes. [36] However, patients in another study with large (>3 cm) squamous cell carcinomas were found to have defective cell-mediated immunity as measured by intradermal antigen reactivity and dinitrochlorobenzene (DNCB) sensitization. [37]

These studies suggest that some human skin tumors are antigenic and demonstrate that immunosuppression leads to an increased risk of some skin malignancies. The possibility that factors other than immunosuppression alone may play a role in skin cancer susceptibility in transplant patients comes from the findings that recipients of renal transplants lacking HLA-A11 are resistant to the development of skin cancer [38] and that recipients mismatched for HLA-B antigens (but not HLA-A or HLA-DR) demonstrate an increased risk of cutaneous squamous cell carcinoma but not basal cell carcinoma. [39] This latter study also indicated that there may be a slightly higher risk of squamous cell carcinoma in recipients homozygous for HLA-DR. The reasons for an increased rate of squamous cell carcinoma in HLA-B-mismatched recipients remain unclear, and these patients did not have higher cumulative doses of immunosuppressive drugs.

Thus, in the murine system, immunologic changes induced in the host by UVR are of great significance in the development and growth of UVR-induced skin tumors. UVR appears to have at least two effects in mice: it both induces transformation of epidermal cells and produces specific immunologic changes that result in the appearance of TS cells with activity for UVR-induced tumors. The development of these cells accompanies or even precedes the development of clinically overt UVR-induced tumors. These cells are demonstrated by adoptive transfer and appear to be responsible for the failure of immune mechanisms to destroy the tumor. [28], [29]

The relevance of these findings to human skin cancer is difficult to evaluate directly. The types of experiments described here cannot be performed with human tumors because of ethical considerations and the lack of a syngeneic testing system. Nonetheless, this murine system provides important evidence that immunologic regulatory pathways control the immune response to some types of cancer, even in the primary host. Findings that UVR-treated mice have an increased incidence of leukemia and lymphoma suggest that UV-induced immunologic changes may have significance for cancers in organs other than the skin. [40], [41]

EFFECTS OF UVR ON CONTACT AND DELAYED-TYPE HYPERSENSITIVITY

Studies examining UVR effects on contact hypersensitivity (CHS) and DTH in animal models provide clues as to possible mechanisms by which UVR induces the immunologic changes that, at least in part, permit UVR regressor tumors to develop and grow. Two murine models have been extensively studied: one, termed high-dose, employs relatively large doses of short-term UVB radiation that suppresses the ability to induce CHS even at irradiated and nonirradiated sites; the other, termed low-dose, employs doses of UVB radiation that do not induce marked changes in murine skin and lead to the suppression of CHS only after induction at the irradiated sites.

In the high-dose model, mice are given doses of UVR that induce gross changes in their skin within a few days. [42] Mice

are immunized by contact sensitization with a hapten at a nonirradiated site. Upon challenge several days later for a CHS response, a reduced response is observed compared to control animals (Fig. 39-2). This suppressed response is associated with the appearance of a population of TS lymphocytes in the spleens of these mice. Evidence suggests that these cells are T helper (T_H1) cells. [43] Similar irradiation schedules will also suppress the induction of DTH to subcutaneously injected antigens. [44] A causal relationship between the apparent defect in antigen presentation and the suppressed induction of CHS has been hypothesized. The mechanisms by which UVR exposure induces these changes is not well understood. Several hypotheses have been formulated. Cutaneous exposure to UVR may induce release of mediators that circulate and alter immunologic events throughout the animal. In support of this possibility, sera from mice exposed to short-term high-dose UVR downregulate the induction of CHS along with the appearance of transferable TS cells. [45] Furthermore, UVR exposure of keratinocytes in vitro causes the release of factors that suppress the induction of CHS. [46], [47] At least one of these factors is IL-10. A large body of work supports the idea that release of IL-10 subsequent to UVR exposure of the skin is responsible for the inhibition of the ability of mice to be sensitized to subcutaneously injected proteins (DTH), while release of TNF-a plays a role in inhibition of sensitization to contact sensitizers [47] (see below). Indeed, IL-10–deficient, gene-targeted mice are not suppressed by UVB radiation for induction for a DTH response but are normally suppressed for induction of CHS. [48]

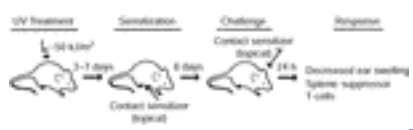

FIGURE 39-2 Mice are irradiated on the dorsum, then 3 to 7 days later sensitized on the ventral surface. Upon elicitation of contact hypersensitivity 6 days later, a decreased response is observed compared to nonirradiated controls in association with the development of splenic antigen-specific suppressor T cells. (*Reprinted from Kripke ML: Photoimmunology Photochem Photobiol* ***52*** *:919, 1990, with permission from Pergamon Press.*)

It has also been suggested that urocanic acid, present in the stratum corneum and epidermis, may play a role. *trans*-Urocanic acid undergoes an isomerization after exposure to UVB radiation to the *cis* form. *cis*-Urocanic acid is immunosuppressive in a number of models. [49] Prostaglandins may also have a role in these effects because indomethacin treatment of irradiated mice prevents immunosuppression. [50] There is substantial evidence that *cis*-urocanic acid suppresses DTH reactions but not CHS, in a manner similar to IL-10. [51] In this regard, *cis*-urocanic acid appears to modulate the rate of IL-10 formation in the epidermis after UVR exposure. [51] There is also a report that *cis*-urocanic acid may produce its effects by inducing mast cell degranulation with release of mediators including IL-10. [52] The exact role of *cis*-urocanic acid remains unclear as other data suggest that there is not a good relationship between *cis*-urocanic acid formation and suppression of the induction of DTH by UVB radiation. [53] In addition to *cis*-urocanic acid, there is also evidence in the literature suggesting that the neuropeptide calcitonin gene–related peptide (CGRP) is a mediator of UVB-induced suppression of contact hypersensitivity in this model. [54] CGRP has also been studied in the low-dose model (see below).

Other hypotheses to explain the effects of high-dose UVB radiation on APC function in this model include the possibility that UVR may reach and alter APC as they circulate through the dermal microvasculature; the suggestion that LC are altered by UVR exposure and then migrate to other anatomic sites where they function as abnormal APC; and the possibility that inflammation produced by UVR exposure alters trafficking of immunocompetent cells with consequences that manifest in an inability to induce CHS in animals at nonirradiated sites. Available evidence does not support these mechanisms as having major responsibility for the effects observed.

In the low-dose model of UVR-induced suppression of the induction of CHS, gross changes are not induced in the skin [55] and immunization with a hapten must be performed at the irradiated site. A suppressed response is observed, accompanied by induction of specific tolerance (inability to be subsequently immunized to the same antigen seen through the UVR-exposed site) and the appearance of splenic hapten-specific TS cells (Fig. 39-3). Recent data suggest that these cells are also T_H1 cells. [56] Susceptibility to this local effect of UVR appears to be genetically determined. [57] As mentioned above, however, data suggest that induction of the release of TNF-a locally by UVR exposure may mediate the suppression of CHS. [57] Thus, the difference between UVR-susceptible and UVR-resistant strains may relate to their ability to produce or respond to TNF-a after exposure to UVR. In this model, application of the sensitizer at a nonirradiated site produces a normal response. The mechanisms by which UVR produces these effects are not entirely clear. Immunosuppressive factors released by keratinocytes, similar to those discussed above, or release of TNF-a may mediate the suppression observed. Also, a direct effect of UVR on LC function in situ may be involved. Certain aspects of LC function, including the ability to present certain antigens, are disturbed by UVR exposure in vitro. [58], [59] Other studies have demonstrated that exposure of LC to UVB radiation in vitro prevents normal presentation of antigen by LC to T_H1 cells but spares their ability to present antigens to T_H2 cells. [59] There is also evidence that CGRP plays a role in immune suppression in this model. [60], [61] CGRP changes the number and morphology of epidermal LC and the presence of a CGRP inhibitor can block the UVB-induced suppression. In the same report, evidence supporting a role for nitric oxide in UVB-induced immunosuppression was also presented. [60] Some evidence exists that this effect of CGRP may be mediated by induction of mast cell degranulation with release of mediators including TNF-a and IL-10. [61] This hypothesis would, perhaps, unify the data implicating TNF-a with the data supporting a role for CGRP in the low-dose immunosuppression model. Indeed, there is some evidence that while TNF-a plays a role in failure of induction of immunity, IL-10 is important for induction of tolerance in the low-dose model. [62] Alterations in LC antigen processing and presentation by these various mechanisms may then lead to inappropriate presentation of antigen, resulting in predominant induction of downregulation of immunity. In this regard, it is also of interest that cellular elements within the epidermis can induce tolerance and/or suppression when exposed to antigen and injected intravenously without UVR exposure. [63], [64] Finally, LC, after exposure to UVR in vitro, will also induce downregulation of immunity in this manner. [63]

These observations might suggest that UVR exposure alters LC so that they do not efficiently present antigen for CD4-dependent immunity while preserving or enhancing the ability of epidermal elements to generate signals for immunologic downregulation. With regard to the mechanism(s) by which the induced suppressor cells mediate downregulation of immunity, there is evidence that they function, at least in part, by inducing Fas/Fas ligand-mediated apoptosis in hapten-coupled APC. [65]



FIGURE 39-3 Mice are irradiated on the dorsum. Then, 1 to 3 days later they are sensitized at the irradiated site. Upon elicitation of a contact hypersensitivity response 6 days later, a decreased response is observed in association with the development of antigen-specific splenic suppressor T cells. (*Reprinted from Kripke ML: Photoimmunology. Photochem Photobiol* ***52*** *:919, 1990, with permission from Pergamon Press.*)

Data also suggest a role for pyrimidine dimers (the major DNA photoproduct after UVR exposure) in both the local and systemic models of UVR suppression of CHS. [66] By using the marsupial *Monodelphus domestica* (which expresses photoreactivating enzymes), it was demonstrated that after UVR exposure in both the high- and low-dose models, subsequent exposure to 320- to 500-nm light ("photoreactivating light") prevented suppression of the induction of CHS. Photoreactivating light removed about 85 percent of the dimers. Further support for involvement of DNA comes from experiments utilizing the bacterial enzyme T4 endonuclease V, which accelerates the repair of cyclobutylpyrimidine dimers in mice. Application of this enzyme to murine skin after UVR exposure inhibits suppression of the induction of CHS at a nonirradiated site. [67] This observation supports the involvement of DNA photoproducts in the systemic suppression of CHS by UVR. Use of this enzyme to minimize pyrimidine dimers after UVR exposure, however, only partially inhibited suppression of CHS in the low-dose local model, [68] suggesting involvement of other mechanisms in local suppression.

Given the clear effects of UVR on these immunologic parameters, the question of whether UVR can alter immune responses to infectious organisms has been explored. In mice, exposure of the site of inoculation to UVR 24 h before and every 48 to 72 h after inoculation with *Leishmania major* promastigotes results in inhibition of skin lesion development. [69] Furthermore, this irradiation regimen suppresses the induction of DTH to leishmanial antigens. The number of parasites recovered from injection sites was the same in control and irradiated animals. Thus, the locus of UVR appears to be host reactivity rather than the parasites themselves. Other studies also using a murine model have shown that a single large dose of UVR inhibits DTH to *Candida albicans*. This inhibition is associated with the generation of transferable splenic-suppressor cells if irradiation occurs prior to immunization. [70] However, if irradiation occurs after immunization, DTH is still inhibited, but without the appearance of splenic-suppressor cells. [70] In addition, UVR inhibits the ability of rats to clear *Listeria monocytogenes.* [71] UVR exposure results in more severe primary infection to herpes simplex virus type 1 in mice, [72] and inhibits murine T_H1 immune responses to *Borrelia burgdorferi,* while leaving T_H2 responses intact. [73] Also, it has been shown that local UVR exposure reduces the granulomatous reaction to lepromin in sensitized individuals. [74] However, no effect of UV radiation was observed in a murine model of infection with *Schistosoma mansoni*. [75]

Hypothetical Pathway for UVR-Induced Skin Cancer Formation

Correlation of data from studies examining UVR effects on CHS and the photocarcinogenesis experiments discussed above might suggest the following hypothesis as to the mechanism by which UVR-induced immunologic changes participate in the generation of UVR-induced skin cancers (Fig. 39-4). UVR may produce two effects. Presumably, it induces a transformation of keratinocyte targets to a malignant phenotype with the expression of TAA. Additionally, UVR would produce changes in epidermal antigen-presenting function with alteration of the balance between the induction of immunity and the induction of tolerance/suppression toward downregulation. This may occur through UVR-induced changes in LC, mediated in part by UVR-induced cytokine signals, preventing efficient presentation of antigen for effector immune mechanisms with preservation or enhancement of downregulatory signals. Certain TAA are then presented for the induction of TS cells that prevent immunologic destruction of the incipient tumor. Although not shown directly, this hypothesis is consistent with the available data.

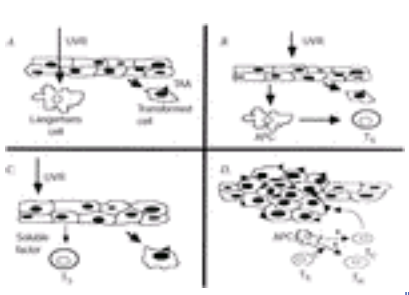

FIGURE 39-4 Model of UVR-induced tumorigenesis. Experimental evidence exists to suggest several mechanisms for UVR-induced downregulation of the immune response to UVR-induced tumor-associated antigens (TAA). A. Direct functional derangement or elimination of antigen-presenting cells (APC, presumably Langerhans cells) from the epidermis that are capable of presenting antigen from transformed cells for CD4-dependent responses. B. Selection or preservation of UVR-resistant APC (I-A+; or Thy 1+) that may present TAA for activation of T suppressor (TS) cells. C. UVR-induced release of an epidermal factor(s) resulting in preferential activation of TS cells and immunologic downregulation. D. Clonal proliferation of transforming cell clone expressing TAA. Immune rejection is inhibited by lack of functional APC to induce T helper activity directed against TAA (A), or presence of APC primed for suppression (B),

and/or epidermal immunosuppressive factor release (C). (*Reprinted with permission from Gallo RL et al: Physiology and pathology of skin photoimmunology, in* Skin Immune System, *edited by JD Bos. Boca Raton, CRC Press, 1989, p 381. Copyright CRC Press, Inc., Boca Raton, FL.*)

Human Studies

The importance of these observations for humans is difficult to evaluate. Nonetheless, some observations might suggest that similar mechanisms may apply. Relatively modest exposures of UVR have immunologic effects on normal persons. [76], [77] Exposure to 1 h of summer sunlight on 12 occasions resulted in significant increases in suppressor/cytotoxic (CD8) lymphocytes and a decrease in helper phenotype (CD4) cells in peripheral blood. [76] These subjects also demonstrated increased nonspecific suppressor cell activity in their peripheral blood mononuclear cell (PBMC) populations. In a similar study, individuals given 30-min exposures in a commercial solarium with an irradiation source emitting 0.04% UVB radiation and 10.6% UVA radiation demonstrated reduced cutaneous responses to DNCB, increased nonspecific suppressor cell activity, decreased natural killer cell activity, and a decrease in the CD4 to CD8 cell ratio compared to controls. [77] A report suggests that humans may vary in their susceptibility to the ability of local UVB radiation to inhibit the induction of CHS. [78] In this study, a dose of UVB radiation that depletes LC from skin was followed by application of DNCB. Sixty percent of individuals became sensitive to DNCB from this protocol (UVB-sensitive), whereas others did not. Skin cancer patients had a higher rate of nonresponse (92 percent), and 45 percent of them became tolerant to DNCB, while no normal subjects became tolerant. The analogy to the situation with inbred strains of mice (discussed above) might suggest a genetic basis for UVB susceptibility in this manner and that the ability to suppress CHS with UVB radiation might be a risk factor for skin cancer susceptibility. [78]

Human epidermal cells obtained after exposure to UVB radiation are capable of activating suppressor-inducer lymphocytes. This activity appears to reside in non-Langerhans CD1-DR+ macrophage-like APC that appear in the epidermis 1 to 3 days after exposure to UVB radiation. [79] Macrophages recruited into skin by UVR exposure are also capable of inducing immunologic downregulation to a hapten. [80] There are data suggesting that the suppressive activity of these cells relates to release of IL-10 and TNF-a after binding of iC3b to these cells. [81] There are also data from mice indicating that similar mechanisms also play a role in UV-induced immunosuppression in mice. [82] These findings suggest mechanisms by which UVR exposure of human skin might enhance suppressor pathways.

In addition to the studies suggesting that exposure to UVR can alter immunologic parameters in humans, there is evidence that human skin cancer development is at least partially under immunologic control. As mentioned above, immunosuppressed persons, suppressed either due to underlying illness or because of immunosuppressive treatment for cancer or for the maintenance of transplanted organs, have greatly increased rates of skin cancer. Squamous cell carcinomas are increased 30- to 40-fold, and smaller increases in the incidence of basal cell carcinomas have been documented. [32], [34] The rate of melanoma occurrence in these patients may also be increased. [34] The majority of the nonmelanoma skin cancers in these individuals occur in sun-exposed areas.

LANGERHANS CELLS

Exposure of LC to UVR in vitro alters their ability to present antigen in some situations. [58], [59] LC are bone marrow-derived, dendritic, Ia-bearing cells capable of presenting various antigens to T lymphocytes. [31], [83], [84] When isolated in vitro, these cells mature, at least partly under the influence of GM-CSF, to become much more potent antigen-presenting cells for primary immune responses. They are very similar to dendritic cells found in lymphoid organs. [84], [85]

For 40 years LC have been known to be sensitive to UVR. [86] After UVR exposure in vivo, LC density decreases, as determined by Ia antigen expression and ATPase staining; [87] some LC appear to be present in the epidermis when examined by electron microscopy, although with altered morphology. The ability to induce CHS in mice appears to have a relationship to the density of ATPase-positive cells in the epidermis. [88] Furthermore, if LC are UVR-exposed in vitro, coupled to hapten, and transferred to primed mice by subcutaneous administration, immunity fails to develop; [89] instead, a state of specific tolerance occurs associated with the appearance of transferable splenic TS cells. Thus, exposure to UVR alters antigen presentation by a mixed population of epidermal cells. This does not, however, prove that such effects are due to changes in LC.

KERATINOCYTE-DERIVED CYTOKINES

Keratinocytes are able to produce a number of cytokines with immunologic or inflammatory activities, depending on their state of activation. These include IL-1a, IL-1ß, IL-3, IL-6, IL-7, IL-8, IL-12, IL-15, granulocyte colony-stimulating factor, macrophage-stimulating factor, GM-CSF, TNF-a, transforming growth factor-a, and transforming growth factor-ß, among others [90], [91], [92], [93] and [94] (see also Chap. 26). IL-1, IL-6, IL-8, IL-10, TNF-a, and GM-CSF expression are reportedly increased in keratinocytes after UVB exposure. [84], [90], [95], [96] IL-7 expression is downregulated by UVB radiation, [91] and controversy exists regarding the effects of UVB radiation on IL-15 expression in keratinocytes. [94], [97] Additionally, serum or plasma levels of IL-1 activity increase after total-body exposure to UVR in mice, [98] rabbits, [99] and also humans. [98], [100] Similarly, it has been found that exposure of humans to UVR results in increased circulating IL-6 and TNF-a activity. [101], [102] Hypothetically, alterations in cytokine production secondary to exposure to UVR may play a role in the immunologic changes observed after exposure of animals to UVR in vivo. As discussed above, there is evidence that release of IL-10 and TNF-a, subsequent to in vivo UVR exposure, plays a role in UVR-induced immunosuppression. Although not proven, it is thought that production of these cytokines occurs in the skin. Changes in cytokine release by epidermal cells after UVR exposure might also play a role in the exacerbation of certain autoimmune diseases by sunlight exposure.

UVR may also affect the biology of adhesion molecules. Exposure of keratinocytes to UVR inhibits the ability of cytokines to induce intercellular adhesion molecule (ICAM)-1, an important cell surface molecule involved in the adhesion function of certain cells including keratinocytes and endothelial cells. [103], [104] This effect might also be involved in the modulation of cutaneous inflammatory activity by UVR. The effect of UVB radiation on expression of the costimulatory molecules B7-1 (CD80) and B7-2 (CD86) has also been examined. Irradiation of LC in vitro inhibited the upregulation of B7-1 and B7-2 that occurs when LC are cultured. [105] However, exposure of human skin in-situ with erythemogenic doses of solar simulating UV radiation resulted in strong up-regulation of B7-1 and B7-2 between 12 and 24 h after exposure. [106] The importance of an understanding of the effect of UVR on expression of these molecules relates to their importance in activation of T cells. Indeed, interactions of CD86 with its receptors appears to be important for UVR-induced immune suppression. [107] Transgenic mice with a functional disruption in B7-mediated stimulation of T cells have reduced UVR-induced skin cancer formation. [108]

EFFECTS OF WHOLE-BODY EXPOSURE TO UVR ON LYMPHOCYTES IN HUMANS

As early as 1928, investigators were interested in the medical effects of nonionizing radiation [109] because of the perception that both sunlight and artificial sources of radiation might be of clinical benefit in some disease states. It was found that acute or chronic exposure to radiation increased the number of PBMC. These studies are difficult to interpret because various radiation sources were used, and both healthy subjects and patients with disease were examined.

This question was later reexamined. [110] Normal subjects were given a single, whole-body exposure to UVB radiation to produce a mild or a marked erythema. Circulating leukocytes in these subjects were monitored over the following 72 h. Shortly after exposure to UVR, the subjects who developed erythema had a decreased proportion of circulating T lymphocytes. This effect was most pronounced at 8 to 12 h after exposure, followed by a return to normal levels by 72 h. The proportion of B cells did not change. This effect was accompanied by a fall in the response of the circulating cells to the T cell mitogen phytohemagglutinin. Subjects who developed only a slight erythema did not show this decrease in reactivity to phytohemagglutinin, suggesting that this effect may be dose-related. Both groups showed an increase in the number of circulating polymorphonuclear leukocytes. Also, as discussed above, Hersey et al. demonstrated that individuals exposed to 1 h of summer sunlight for 12 exposures or to 30-min exposures in a commercial solarium demonstrated a decrease in the ratio of CD4+ to CD8+ lymphocytes in their peripheral blood. [92]

Taken together, it is clear that ultraviolet radiation alters a number of parameters of immunologic function after exposure both in vitro and in vivo. Table 39-1 summarizes the observations that have been made in this regard. These findings, of course, do not speak to the pathways by which UVR alters the immunologic status of an intact organism. A major challenge for the future is to understand the interactions of these various phenomena within a whole animal. These questions are of importance to medicine. For example, it is of clinical relevance to understand the mechanisms by which nonionizing radiation interacts with the skin to induce exacerbations of autoimmune disease. Also, a further understanding of the role of UVR exposure in infectious and neoplastic conditions may be important in designing new therapeutic modalities.

In vitro
Alters ability of antigen-presenting cells (including Langerhans cells) to present antigen
Alters ability of lymphocytes to respond to mitogens or antigens
Alters cytokine production
Induces the release of immunosuppressive factors
In vivo
Induces skin cancer formation
Alters Langerhans cell morphology and function
Suppresses the induction of contact hypersensitivity
Suppresses the induction of delayed-type hypersensitivity
Alters cell trafficking
Increases circulating levels of certain cytokines
Alters proportions of lymphocyte subtypes in peripheral blood

TABLE 39-1 **Ultraviolet Radiation Effects**

Perhaps the area in which photoimmunology has received the most attention is photocarcinogenesis (see Chap. 38). Skin cancer induced in animal models by UVR clearly represents a system in which the skin, the immune system, and light interact to produce pathology. Circumstantial evidence indicates that similar mechanisms may be involved in human cutaneous photocarcinogenesis. As discussed above, there is epidemiologic evidence demonstrating increased rates of skin cancer in immunosuppressed individuals, highlighting the role of the immune system in the regulation of these tumors. Also, as discussed above, modest doses of UVR clearly induce changes in immunologic parameters in humans that are at least measurable. The direct relevance of these changes for future disease is, of course, unknown. It would seem clear that avoidance of exposure to prolonged and excessive sunlight is prudent, given the current state of knowledge of the role of sunlight in the development of cutaneous malignancies; it would also prevent sunlight-induced aging of the skin. The possible role of exposure to sunlight in the development of other pathologies, such as infectious disease, remains to be more fully investigated.

Portions of this chapter were modified from Granstein RD: Ultraviolet radiation effects on immunologic function. *Reg Immunol* 3:112, 1990, © Wiley, Inc, 1990.

REFERENCES

1. Streilein JW, Tigelaar RE: SALT: Skin-associated lymphoid tissues, in *Photoimmunology,* edited by JA Parrish ML Kripke, WL Morison. New York, Plenum, 1983, p 95

2. Santamaria LF et al: Allergen specificity and endothelial transmigration of T cells in allergic contact dermatitis and atopic dermatitis are associated with the cutaneous lymphocyte antigen. *Int Arch Allergy Immunol* **107**:359, 1995

3. Steiner G et al: Characterization of T cell receptors on resident murine dendritic epidermal cells. *Eur J Immunol* **18**:1323, 1988

4. Groh V et al: Human lymphocytes bearing T cell receptor gamma/delta are phenotypically diverse and evenly distributed throughout the lymphoid system. *J Exp Med* **169**:1277, 1989

5. Kinlen LJ et al: Collaborative United Kingdom–Australia study of cancer in patients treated with immunosuppressive drugs. *Br Med J* **2**:1461, 1979

6. Unna PG: *The Histopathology of the Disease of the Skin.* Edinburgh, WF Clay, 1894

7. Findlay GM: Ultra-violet light and skin cancer. *Lancet* **2**:1070, 1928

8. Freeman RG et al: Ultraviolet wavelength factors in solar radiation and skin cancer. *Int J Dermatol* **9**:232, 1970

9. Urbach F et al: Ultraviolet carcinogenesis: Experimental, global, and genetic aspects, in *Sunlight and Man: Normal and Abnormal Photobiologic Responses,* edited by MA Pathak LL Harber, M Seiji, A Kukita; TB Fitzpatrick, consulting editor. Tokyo, University of Tokyo Press, 1974, p 259

10. Appendix F, in *Protection Against Depletion of Stratospheric Ozone by Chlorofluorocarbons*. Washington, DC, National Academy of Sciences, 1979, p 325

11. Tan EM et al: Action spectrum of ultraviolet light-induced damage to nuclear DNA in vitro. *J Invest Dermatol* **55**:439, 1970

12. Sutherland BM et al: Pyrimidine dimer formation and repair in human skin. *Cancer Res* **40**:3181, 1980

13. Cleaver JE: Defective repair replication of DNA in xeroderma pigmentosum. *Nature* **218**:652, 1968

14. Epstein JH et al: Defect in DNA synthesis in skin of patients with xeroderma pigmentosum demonstrated in vivo. *Science* **168**:1477, 1970

15. Hart RW et al: Evidence that pyrimidine dimers in DNA can give rise to tumors. *Proc Natl Acad Sci U S A* **74**:5574, 1977

16. Ley RD, Reeve VE, Kusewitt DF: Photobiology of *Monodelphus domestica. Dev Comp Immunol* **24**:503, 2000.

17. Brash DE, Haseltine WA: UV-induced mutation hotspots occur at DNA damage hotspots. *Nature* **298**:189, 1982

18. Brash DE: UV mutagenic photoproducts in *Escherichia coli* and human cells: A molecular genetics perspective on human skin cancer. *Photochem Photobiol* **48**:59, 1988

19. van der Lubbe JLM et al: Activation of *N-ras* induced by ultraviolet light in vitro. *Oncogene Res* **3**:9, 1988

20. Campbell C et al: Codon 12 Harvey- *ras* mutations are rare events in non-melanoma human skin cancer. *Br J Dermatol* **128**:111, 1993

21. Ren ZP et al: Human epidermal cancer and accompanying precursors have identical *p53* mutations different from *p53* mutations in adjacent areas of clonally expanded non-neoplastic keratinocytes. *Oncogene* **12**:765, 1996

22. Bonifas J et al: Activation of expression of hedgehog target genes in basal cell carcinoma. *J Invest Dermatol* **116**:739, 2001

23. Rusch HP, Baumann CA: Tumor production in mice with ultraviolet irradiation. *Am J Cancer* **35**:55, 1939

24. Kripke ML: Antigenicity of murine skin tumors induced by ultraviolet light. *J Natl Cancer Inst* **53**:1333, 1974

25. Kripke ML, Fisher MS: Immunologic parameters of ultraviolet carcinogenesis. *J Natl Cancer Inst* **57**:211, 1976

26. Spellman CW, Daynes RA: Modification of immunological potential by ultraviolet radiation. II. Generation of suppressor cells in short-term UV-irradiated mice. *Transplantation* **24**:120, 1977

27. Fisher MS, Kripke ML: Systemic alteration induced in mice by ultraviolet light irradiation carcinogenesis. *Proc Natl Acad Sci U S A* **74**:1688, 1977

28. Ullrich SE, Kripke ML: Mechanisms in the suppression of tumor rejection produced in mice by repeated UV irradiation. *J Immunol* **133**:2786, 1984

29. Fisher MS, Kripke ML: Suppressor T lymphocytes control the development of primary skin cancers in ultraviolet-irradiated mice. *Science* **216**:1133, 1982

30. Greene MI et al: Impairment of antigen-presenting cell function by ultraviolet radiation. *Proc Natl Acad Sci U S A* **76**:6591, 1979

31. Grabbe S, Granstein RD: Modulation of antigen-presenting cell function as a potential regulatory mechanism in tumor-host reactions. *In Vivo* **7**:265, 1993

32. Hill BHR: Immunosuppressive drug therapy potentiator of skin tumors in five patients with lymphoma. *Aust J Dermatol* **17**:46, 1976

33. Jensen P et al: Skin cancer in kidney and heart transplant recipients and different long-term immunosuppressive therapy regimens. *J Am Acad Dermatol* **40**:177, 1999

34. Hoxtell EO et al: Incidence of skin carcinoma after renal transplantation. *Arch Dermatol* **113**:436, 1977

35. Viac J et al: Characterization of mononuclear cells in the inflammatory infiltrates of cutaneous tumors. *Br J Dermatol* **97**:1, 1977

36. Nairn RC et al: Specific immune response in human skin carcinoma. *Br Med J* **4**:701, 1971

37. Weimar VM et al: Cell-mediated immunity in patients with basal and squamous cell skin cancer. *J Am Acad Dermatol* **2**:143, 1980

38. Bouwes Bavinck JN et al: HLA-A11-associated resistance to skin cancer in renal transplant recipients. *N Engl J Med* **323**:1350, 1990

39. Bouwes Bavinck JN et al: Relation between skin cancer and HLA antigens in renal-transplant recipients. *N Engl J Med* **325**:843, 1991

40. Eaton GJ et al: Effects of ultraviolet light on nude mice: Cutaneous carcinogenesis and possible leukemogenesis. *Cancer* **42**:182, 1978

41. Ebbesen P: Enhanced lymphoma incidence in BALB/c mice after ultraviolet light treatment. *J Natl Cancer Inst* **67**:1077, 1981

42. Noonan FP et al: Suppression of contact hypersensitivity in mice by ultraviolet irradiation is associated with defective antigen presentation. *Immunology* **43**:527, 1981

43. Shreedhar VK et al: Origin and characteristics of ultraviolet-B radiation-induced suppressor T lymphocytes. *J Immunol* **161**:1327, 1998

44. Molendijk A et al: Suppression of delayed-type hypersensitivity to histocompatability antigens by ultraviolet radiation. *Immunology* **62**:299, 1987

45. Schwartz T et al: Inhibition of the induction of contact hypersensitivity by a UV-mediated epidermal cytokine. *J Invest Dermatol* **87**:289, 1986

46. Kim TY et al: Immunosuppression by factors released from UV-irradiated epidermal cells: Selective effects on the generation of contact and delayed hypersensitivity after exposure to UVA or UVB radiation. *J Invest Dermatol* **94**:26, 1990

47. Rivas JM, Ullrich SE: The role of IL-4, IL-10 and TNF-alpha in the immune suppression induced by ultraviolet radiation. *J Leuk Biol* **56**:769, 1994

48. Beissert S et al: Impaired immunosuppressive response to ultraviolet radiation in interleukin-10–deficient mice. *J Invest Dermatol* **107**:553, 1996

49. DeFabo EC, Noonan FP: Mechanism of immune suppression by ultraviolet radiation in vivo. I. Evidence for the existence of a unique photoreceptor in skin and its role in photoimmunology. *J Exp Med* **158**:84, 1983

50. Chung H-T et al: Involvement of prostaglandins in the immune alterations caused by the exposure of mice to ultraviolet radiation. *J Immunol* **137**:2478, 1986

51. Moodycliffe AM et al: Differential effects of a monoclonal antibody to cis-urocanic acid on the suppression of delayed and contact hypersensitivity following ultraviolet irradiation. *J Immunol* **157**:2891, 1996

52. Reeve VE et al: Differential photoimmunoprotection by sunscreen ingredients is unrelated to epidermal cis urocanic acid formation in hairless mice. *J Invest Dermatol* **103**:801, 1994

53. Hart PH et al: A critical role for dermal mast cells in cis-urocanic acid-induced systemic suppression of contact hypersensitivity responses in mice. *Photochem Photobiol* **70**:807, 1999

54. Garssen J, Buckley TL, Van Loveren H: A role for neuropeptides in UVB-induced systemic immunosuppression. *Photochem Photobiol* **68**:205, 1988

55. Elmets CA et al: In vivo low dose UVB irradiation induces suppressor cells to contact sensitizing agents, in *The Effect of Ultraviolet Light on the Immune System,* edited by JA Parrish. Skillman, NJ, Johnson & Johnson Press, 1983, p 317

56. Schwarz A et al: Evidence for functional relevance of CTLA-4 in ultraviolet-radiation-induced tolerance. *J Immunol* **165**:1824, 2000

57. Streilein JW et al: Functional dichotomy between Langerhans cells that present antigen to naive and to memory/effector T lymphocytes. *Immunol Rev* **117**:159, 1990

58. Stingl G et al: Antigen presentation by murine epidermal cells and its alteration by ultraviolet B light. *J Immunol* **127**:1707, 1981

59. Simon JC et al: Low dose ultraviolet B-irradiated Langerhans cells preferentially activate CD4+ cells of the T helper 2 subset. *J Immunol* **145**:2087, 1990

60. Gillardon F et al: Calcitonin gene-related peptide and nitric oxide are involved in ultraviolet radiation-induced immunosuppression. *Eur J Pharmacol* **293**:395, 1995

61. Kitazawa T et al: Hapten-specific tolerance promoted by calcitonin gene–related peptide. *J Invest Dermatol* **115**:942, 2000

62. Niizeki H et al: Hapten-specific tolerance induced by acute, low-dose ultraviolet B radiation of skin is mediated via interleukin-10. *J Invest Dermatol* **109**:25, 1997

63. Tan K-C et al: Epidermal cell presentation of tumor-associated antigens for induction of tolerance. *J Immunol* **153**:760, 1994

64. Sullivan S et al: Induction and regulation of contact hypersensitivity by resident, bone marrow derived, dendritic epidermal cells: Langerhans and Thy-1+ epidermal cells. *J Immunol* **137**:2460, 1986

65. Schwarz T et al: Ultraviolet light-induced immune tolerance is mediated via the Fas/Fas ligand system. *J Immunol* **160**:4262, 1998

66. Applegate LA et al: Identification of the molecular target for the suppression of contact hypersensitivity by ultraviolet radiation. *J Exp Med* **170**:1117, 1989

67. Kripke ML et al: Pyrimidine dimers in DNA initiate systemic immunosuppression in UV-irradiated mice. *Proc Natl Acad Sci U S A* **89**:7516, 1992

68. Wolf P et al: Sunscreens and T4N5 liposomes differ in their ability to protect against ultraviolet-induced sunburn cell formation, alterations of dendritic epidermal cells, and local suppression of contact hypersensitivity. *J Invest Dermatol* **104**:287, 1995

69. Giannini MS: Suppression of pathogenesis in cutaneous leishmaniasis by UV radiation. *Infect Immun* **51**:838, 1986

70. Denkins Y et al: Exposure of mice to UV-B radiation suppresses delayed hypersensitivity to *Candida albicans*. *Photochem Photobiol* **49**:615, 1989

71. Goettsch W et al: Effects of ultraviolet-B exposure on the resistance to *Listeria monocytogenes* in the rat. *Photochem Photobiol* **63**:672,

1996

72. El-Ghorr AA, Norval M: The effect of UV-B irradiation on secondary epidermal infection of mice with herpes simplex virus type 1. *J Gen Virol* **77**:485, 1996

73. Brown EL et al: Modulation of immunity to *Borrelia burgdorferi* by ultraviolet irradiation: Differential effect on Th1 and Th2 immune responses. *Eur J Immunol* **25**:3017, 1995

74. Cestari TF et al: Ultraviolet radiation decreases the granulomatous response to lepromin in humans. *J Invest Dermatol* **105**:8, 1995

75. Noonan FP, Lewis FA: UVB-induced immune suppression and infection with *Schistosoma mansoni*. *Photochem Photobiol* **61**:99, 1995

76. Hersey P et al: Alteration of T cell subsets and induction of suppressor T cell activity in normal subjects after exposure to sunlight. *J Immunol* **131**:171, 1983

77. Hersey P et al: Immunological effects of solarium exposure. *Lancet* **1**:545, 1983

78. Yoshikawa T et al: Susceptibility to effects of UVB radiation on induction of contact hypersensitivity as a risk factor for skin cancer in humans. *J Invest Dermatol* **95**:530, 1990

79. Cooper KD: Cell-mediated immunosuppressive mechanisms induced by UV radiation. *Photochem Photobiol* **63**:400, 1996

80. Hammerberg C et al: Active induction of unresponsiveness (tolerance) to DNFB by in vivo ultraviolet-exposed epidermal cells is dependent upon infiltrating class II MHC+; CD1b bright monocytic/macrophage cells. *J Immunol* **153**:4915, 1994

81. Yoshida Y et al: Monocyte induction of IL-10 and down-regulation of IL-12 by iC3b deposited in ultraviolet-exposed human skin. *J Immunol* **161**:5873, 1998

82. Hammerberg C: Activated complement component 3 (C3) is required for ultraviolet induction of immunosuppression and antigenic tolerance. *J Exp Med* **187**:1133, 1998

83. Katz SI et al: Epidermal Langerhans cells are derived from cells originating in bone marrow. *Nature* **282**:324, 1979

84. Grabbe S et al: Mechanisms of ultraviolet radiation carcinogenogenesis. *Chem Immunol* **58**:291, 1994

85. Schuler G, Steinman RM: Murine epidermal Langerhans cells mature into potent immunostimulatory dendritic cells in vitro. *J Exp Med* **161**:526, 1985

86. Fan J et al: A study of the epidermal clear cells with special reference to their relationship to the cells of Langerhans. *J Invest Dermatol* **32**:445, 1959

87. Aberer W et al: Ultraviolet light depletes surface markers of Langerhans cells. *J Invest Dermatol* **76**:202, 1981

88. Toews GB et al: Epidermal Langerhans cell density determines whether contact hypersensitivity or unresponsiveness follows skin painting with DNFB. *J Immunol* **124**:445, 1980

89. Sauder DN et al: Induction of tolerance to topically applied TNCB using TNP-conjugated ultraviolet light-irradiated epidermal cells. *J Immunol* **127**:261, 1981

90. Luger TA, Schwarz T: Epidermal cell-derived cytokines, in *Skin Immune System,* edited by JD Bos. Boca Raton, FL, CRC Press, 1990, p 257

91. Takashima A et al: Interleukin-7-dependent interaction of dendritic epidermal T cells with keratinocytes. *J Invest Dermatol* **105**:50S, 1995

92. Venner TJ et al: Interleukin-8 and melanoma growth-stimulating activity (GRO) are induced by ultraviolet-B radiation in human keratinocyte cells lines. *Exp Dermatol* **4**:138, 1995

93. Yawalkar N et al: Constitutive expression of both subunits of interleukin-12 in human keratinocytes. *J Invest Dermatol* **106**:80, 1996

94. Blauvelt A et al: Interleukin-15 mRNA is expressed by human keratinocytes, Langerhans cells, and blood-derived dendritic cells and is down-regulated by ultraviolet B radiation. *J Invest Dermatol* **106**:1047, 1996

95. Gahring L et al: Effect of ultraviolet radiation on production of epidermal cell thymocyte-activating factor/interleukin 1 in vivo and in vitro. *Proc Natl Acad Sci U S A* **81**:1198, 1984

96. Ansel JC et al: The effect of in vitro and in vivo UV irradiation on the production of ETAF activity by human and murine keratinocytes. *J Invest Dermatol* **81**:519, 1983

97. Mohamadzadeh M et al: Ultraviolet B radiation up-regulates the expression of IL-15 in human skin. *J Immunol* **155**:4492, 1995

98. Granstein RD, Sauder DN: Whole-body exposure to ultraviolet radiation results in increased serum interleukin-1 activity in humans. *Lymphokine Res* **6**:187, 1987

99. Ansel JC et al: Fever and increased serum IL-1 activity as a systemic manifestation of acute phototoxicity in New Zealand White rabbits. *J Invest Dermatol* **89**:32, 1987

100. Konnikov N et al: Elevated plasma interleukin-1 levels in humans following ultraviolet light therapy for psoriasis. *J Invest Dermatol* **92**:235, 1989

101. Urbanski A et al: Ultraviolet light induces increased circulating interleukin-6 in humans. *J Invest Dermatol* **94**:808, 1990

102. Kock A et al: Human keratinocytes are a source for tumor necrosis factor alpha: Evidence for synthesis and release upon stimulation with endotoxin or ultraviolet light. *J Exp Med* **172**:1609, 1990

103. Norris DA et al: Ultraviolet radiation can either suppress or induce expression of intercellular adhesion molecule 1 (ICAM-1) on the surface of cultured human keratinocytes. *J Invest Dermatol* **95**:132, 1990

104. Krutmann J et al: Tumor necrosis factor beta and ultraviolet radiation are potent regulators of human keratinocyte ICAM-1 expression. *J*

Invest Dermatol **95**:127, 1990

105. Denfeld RW et al: Further characterization of UVB radiation effects on Langerhans cells: altered expression of the costimulatory molecules B7-1 and B7-2. *Photochem Photobiol* **67**:554, 1998

106. Laihia JK et al: Up-regulation of human epidermal Langerhans' cell B7-1 and B7-2 co-stimulatory molecules in vivo by solar-simulating irradiation. *Eur J Immunol* **27**:984, 1997

107. Ullrich SE et al: Antibodies to the costimulatory molecule CD86 interfere with ultraviolet radiation-induced immune suppression. *Immunology* **94**:417, 1998

108. Beissert S et al: Reduced ultraviolet-induced carcinogenesis in mice with a functional disruption is B7-mediated costimulation. *J Immunol* **163**:6725, 1999

109. Laurens H: The physiological effects of radiation. *Physiol Rev* **8**:1091, 1928

110. Morison WL et al: In vivo effects of UVB on lymphocyte function. *Br J Dermatol* **101**:513, 1979

T>

Chapter 40

Thomas Koenig Sylvia Garnis-Jones Adrienne Rencic Francisco Tausk

Psychological Aspects of Skin Diseases

ROLE OF THE DERMATOLOGIST IN TREATING PSYCHOCUTANEOUS PATIENTS
CLASSIFICATION OF PSYCHOCUTANEOUS DISEASES
Primary Psychiatric Disorders
Self-Inflicted Dermatoses (Factitious Disorders)
PSYCHOTROPIC MEDICATIONS USED IN DERMATOLOGY
Antipsychotics
Antidepressants
Anxiolytics
NONPHARMACOLOGIC TREATMENTS FOR PSYCHOCUTANEOUS DISORDERS
Primary Dermatologic Diseases

REFERENCES

Scientific advances are shedding new light on the understanding and treatment of long-recognized conditions located at the interface of dermatology and psychiatry. Both arising from ectoderm, the skin and the nervous system are connected by more than just their common origins. The skin is one of the major avenues by which we perceive the world, and, in turn, are perceived by it. When these perceptions go awry, great distress may result to the patient, as is the case in delusional parasitosis. When the skin itself is markedly affected by a primary dermatologic condition, psychological sequelae often follow, greatly impacting the patient's self-esteem, confidence, and overall quality of life.

The central nervous system can influence the health (both actual and perceived) of other organ systems including the skin. Psychophysiologic mechanisms for this interaction range from the stress responses mediated by neuroadrenal connections and associated changes in immunologic function, to the systemic and local action of various neuropeptides and neurohormones. [1], [2]

ROLE OF THE DERMATOLOGIST IN TREATING PSYCHOCUTANEOUS PATIENTS

Between 20 and 40 percent of patients seeking treatment for skin complaints have some type of psychiatric or psychological problem causing or complicating the presenting symptoms. A large number of these patients lack insight into the possible psychogenic origin of their symptoms and are often reluctant to accept any kind of psychiatric referral. Therefore, in the absence of a psychiatry liaison clinic in the dermatologic setting, the dermatologist must be familiar with the most common of these diagnoses, their clinical manifestations (both psychological and dermatologic), and the basic principles of treatment.

CLASSIFICATION OF PSYCHOCUTANEOUS DISEASES

Following the original description of C. Koblenzer, [3] psychocutaneous diseases can be classified based on their primary etiology as:

- Primary psychiatric disorders, which can present with a variety of symptoms and behaviors, that can lead to perceived or actual dermatologic conditions, or
- Primary dermatologic disorders that can be exacerbated through psychophysiologic mechanisms such as stress or that may cause demoralization, anxiety, and distress through their impact on the patient's physical appearance and well being.

Primary Psychiatric Disorders

MONOSYMPTOMATIC HYPOCHONDRIACAL PSYCHOSIS—DELUSIONAL PARASITOSIS Dermatologic patients will occasionally show evidence of psychosis, characterized by the presence of delusions, hallucinations, or formal thought disorder. Delusions are fixed false beliefs that patients hold with unshakeable conviction not endorsed by the larger cultural, ethnic, or religious community. Hallucinations are sensory perceptions that occur without any external stimulus, and can occur in any of the five sensory modalities. Misinterpretations of existing stimuli (e.g., an inanimate piece of fiber seen as a worm or other parasite) are better understood as illusions or delusional misrepresentations. Formal thought disorder describes the disorganization of thought processes as reflected in the speech of the patient. The most frequent form of this condition seen by dermatologists is *delusional parasitosis* (DP). Because this “monosymptomatic hypochondriasis” is frequently the only overt manifestation of the subject's psychosis, these patients most often present to dermatologists and entomologists rather than to psychiatrists.

Epidemiology This disease predominates in middle aged to elderly females with premorbid social isolation. “Folie a deux” occurs when delusional symptoms have been “induced” in another individual (usually a family member) by a patient.

Clinical characteristics Patients with delusional parasitosis frequently present to the clinician in an anxious, ruminative, overwhelmed state, with a history of visits to multiple prior physicians without satisfaction. In addition to proffering a long and detailed history that includes visual or tactile hallucinations of the organisms, the patient also frequently provides “evidence” of the parasitic infection in the form of lint, fibers, and the like, which are delusionally misinterpreted as entire organisms, body parts, larvae, or ova. Skin manifestations can be quite variable, if present. Oftentimes they reflect unsuccessful attempts at treating the infestation resulting in lesions ranging between mild excoriations to large ulcers, [4]

including the damage from “topical” treatments undertaken by the patient in an attempt to free themselves of the perceived infestation.

Differential diagnosis Actual infestation must be ruled out. Subsequently, the differential diagnosis of psychosis must be parsed through, distinguishing between the primary psychiatric conditions that manifest with delusions of infestation. True monosymptomatic hypochondriasis represents a form of delusional disorder characterized by a rather discrete, circumscribed delusional belief with possible associated hallucinations without clear syndromic changes in affect or personality. [5] On the contrary, patients with uni- or bipolar depressive psychosis will describe classic changes in mood, motivations, sleep, and appetite, along with altered self-attitude. Schizophrenic patients often show a deterioration in global functioning, impaired social relatedness, thought disorder, and more bizarre delusions and hallucinations.

Treatment The critical tenet of treatment is to keep the patient engaged. Because these patients will frequently reject psychiatric referrals, [6] various authors have suggested means by which patients can be retained in treatment paving the road leading to the psychiatric referral. [6], [7] Targeted therapy is undertaken with antipsychotic medications. [4] Pimozide has been used historically as the drug of choice, although it is now replaced by atypical antipsychotics such as olanzapine and risperidone, which are associated with fewer side effects.

Course and prognosis Although often regarded as chronic, unremitting and difficult to treat, these patients have a good recovery rate following appropriate pharmacologic therapy.

BODY DYSMORPHIC DISORDER *Body dysmorphic disorder* (BDD) is a condition characterized by an excessive preoccupation or concern with a presumed defect in physical appearance despite normal or only minimally objective anomalous findings. Also known as *dysmorphophobia,* this is a psychological experience that also results in functional impairment in various arenas of the patient's life. [5] The nosological classification of BDD revolves around the intensity with which patients hold on to their abnormal beliefs. Those with unshakeable convictions are currently diagnosed as having a delusional disorder. [5] However, there appears to be a continuum of intensity and insight from preoccupations, through overvalued ideas to clear delusions. [8] There are no differences in the demographics, family history, course of illness, or, perhaps most importantly, response to specific treatments in patients with the psychotic and nonpsychotic forms of this illness. The evidence linking BDD to the obsessive-compulsive spectrum of disorders [9] has significant potential treatment implications.

Epidemiology The prevalence of BDD, is estimated to be from 1 percent in the general population to 12 percent in dermatology clinic patients. Classic presentation is in the mid to late teens without a significant gender prevalence, often in association with mood disorders. A lifetime history of psychotic and obsessive-compulsive disorders is also seen with increased frequency. [10]

Clinical manifestations Patients present with intensely articulated distress about various body parts. Most patients also develop ideas of reference in which they think or are convinced that others notice and comment upon the presumed defect. [10] Frequent, almost compulsive behaviors often accompany the worrisome thoughts, consuming hours each day, including repeated examination in mirrors, covering up the defect and asking others for reassurance. Consultations with other physicians are common and a history of past operations on the perceived defect is seen in a significant proportion of patients. Marked restriction in social and occupational functioning is seen in up to 98 percent of individuals, and 30 percent of patients were described as housebound. [10] Thoughts and attempts of suicide, some occasionally successful, are frequent. Current or past suicidal ideation should thus be routinely assessed by the practitioner.

Treatment As noted before, many patients with body dysmorphic disorder will seek dermatologic, surgical, or other nonpsychiatric treatment over the course of their illness. Evidence suggests that if patients receive such treatment they do not improve, are usually disappointed with the results, and may even experience an exacerbation of their symptoms. Thus, it is strongly recommended that these lines of treatment be avoided. Pharmacologic trials show a good response to selective serotonin reuptake inhibitors (SSRIs) including fluoxetine, paroxetine, fluvoxamine, sertraline and the tricyclic antidepressant clomipramine. Adequate titration and persistence are important, because these patients require higher doses and longer treatment times than those used in the typical treatment of major depression. Although starting doses are lower, average effective doses are in the range of 40 to 60 mg/day of fluoxetine, 175 mg/day of clomipramine, and 240 mg/day of fluvoxamine with average time to response between 7 and 14 weeks. A significant proportion of patients who fail one adequate SSRI trial respond favorably to a trial with another SSRI, suggesting that serial trials of similarly acting agents should be administered in initially refractory cases. Interestingly, patients with delusional and nondelusional forms of body dysmorphic disorder respond at least equally well to treatment with SSRIs. [10], [11] Responses to other treatments are not as promising. Lack of clear success has been noted with other agents such as antipsychotics (including pimozide), tricyclic antidepressants (other than clomipramine), benzodiazepines, and anticonvulsants. [10], [11]

Course and prognosis Body dysmorphic disorder is a chronic illness without clear evidence for spontaneous remission without treatment. As seen above, pharmacotherapy with appropriate medications may lead to improvement in a majority of patients. However, the data also suggest that recurrence rates are extremely high with discontinuation of treatment [10] and thus patients may require long-term treatment, which may also include insight oriented psychotherapy.

Self-Inflicted Dermatoses (Factitious Disorders)

TRICHOTILLOMANIA This is a condition currently classified as an impulse control disorder, [5] which is characterized by repetitive pulling of hair resulting in alopecia. Strict criteria also include a build up of tension before hair pulling or when resisting an urge to do so, pleasure or relief after pulling out the hair, and significant functional impairment and distress in the patient.

Epidemiology Prevalence rates are estimated to be between 0.5 and 3.5 percent with a mean age of onset between 10 and 13 years. Despite its current classification, there are marked similarities with obsessive-compulsive disorder, which may have important treatment implications. Comorbid psychiatric disorders are depression, anxiety, and obsessive-compulsive disorder.

Clinical characteristics (Fig. 40-1)

FIGURE 40-1 Trichotillomania. Hairs broken at different lengths. (*Courtesy of Ciro Martins, MD.*)

Trichotillomania presents clinically with nonscarring alopecia, most commonly with hairs broken at different lengths; occasionally, repeated trauma may ultimately result in some scarring. Body areas involved typically include the scalp, eyelashes, eyebrows, and pubic hair, with a majority of patients pulling hair from more than one site. Rarely, this is followed by the ingestion of the hair, leading to the potentially dangerous complication of trichobezoar. Awareness of the behavior is partial to complete in a vast majority of patients, and frequently occurs while patients are engaged in isolated, sedentary activities. Attempts to resist the behavior and to disguise its cosmetic sequelae are common. Typical histopathologic findings that may be helpful in confirming the diagnosis in questionable cases include catagen hairs, pigment casts, and traumatized hair bulbs without significant inflammation or scarring.

TREATMENT Because of trichotillomania's similarities to obsessive-compulsive disorder, the use of SSRIs and clomipramine has received much attention. Successful monotherapy with paroxetine, sertraline, venlafaxine, olanzapine, and clomipramine have been reported, as well as the augmentation of serotonin reuptake inhibitors with the addition of olanzapine, risperidone, or pimozide. Low-dose atypical antipsychotic agents in combination with SSRIs appear to have promising results. Nonpharmacologic treatment of trichotillomania relies heavily upon behavioral therapies, especially habit reversal, which entails engaging the patient in a behavior incompatible with hair pulling when the urge appears, such as performing a manual task that occupies both hands. Cognitive-behavioral treatment also has an important role and is even more effective than treatment with clomipramine; [12] hypnotherapy may also be very useful, particularly in the treatment of the pediatric population. [13] Insight-oriented psychotherapy also has good results.

Course and prognosis Trichotillomania is a chronic disorder and data on long-term success of pharmacologic and psychotherapeutic interventions are inconclusive. Although short-term success occurs, sustained improvement has yet to be shown convincingly.

DERMATITIS ARTEFACTA This is a form of factitious disorder in which patients will intentionally feign symptoms and produce signs of disease in an attempt to assume the patient role. Unlike patients with malingering who engage in similar behavior for external or “secondary gain” (such as monetary reward or relief from occupational or other social responsibilities), the factitious patient seeks the “primary gain” of the emotional and psychological benefits that accrue to those who are “ill.” Patients with borderline personality disorder may also exhibit self-mutilatory behavior. Occasionally, a psychologically disturbed adult will induce skin lesions in their children, a form of Munchausen syndrome by proxy.

Epidemiology Predominating in females, the age of onset varies significantly with patients in adolescence through the seventh and eighth decades of life. Patients with factitious disorder have often been exposed to (through upbringing) or engaged in some aspect of the health professions. Comorbid depressive and personality disorders may also be seen.

Clinical characteristics (Fig. 40-2 and Fig. 40-3)

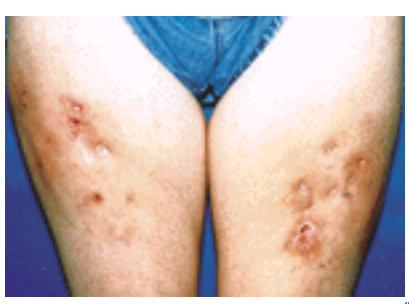

FIGURE 40-2 Dermatitis artefacta, secondary to subcutaneous injections of Demerol, and persistent excoriations.

FIGURE 40-3 Dermatitis artefacta. Linear sharply bordered ulcer.

Although it has long been observed that patients with dermatitis artefacta may present with lesions in virtually all areas of the body that can mimic most dermatoses, some common elements may hint at this diagnosis. Lesions are often in areas readily accessible to the patient, and may have geometric patterns or angulated borders surrounded by completely healthy skin. Morphology is often bizarre and does not conform to typical presentations of known dermatoses (Fig. 40-4 and Fig. 40-5). Patients are often unable to provide a clear history of the initial appearance or evolution of the process, and typically deny any role in the production of the lesions. Characteristically, the histopathology is unrevealing.

FIGURE 40-4 Dermatitis artefacta. Telltale linear streaks from application of caustic solution. (*Courtesy of Hahnemann University Hospital.*)

FIGURE 40-5 Dermatitis artefacta. *A.* Solitary ulcer on the dorsum of the hand; tendons are visible at the base. *B.* Deeply and sharply punched-out ulcerations with necrotic eschars. (*Courtesy of the Hospital of the University of Pennsylvania.*)

Differential diagnosis As in all cases of factitious disease, the clinician must rule out possible disease entities that are consistent with the history and clinical findings. Unusual presentations of common illnesses and rare conditions must be entertained. However, exhaustive searches for primary skin pathology without supporting clinical evidence may compound the problem and actually perpetuate the patient's factitious behavior. Occlusive dressings (e.g., an Unna boot) or other means of preventing manipulation by the patient lead to healing of the lesions and are often helpful strategies in clarifying the diagnosis.

Treatment A supportive, nonconfrontational, empathic approach to the patient is indicated initially. Immediate confrontation regarding the suspicion that the patient's lesions are self-induced can be counterproductive in that the patient will often flee from treatment at that point. Frequent visits and symptomatic topical treatments are useful in the beginning. However, the clinician must be careful not to collude in the patient's abnormal illness behavior and, ultimately, the recognition of the patient's role in the production of the lesions must be broached. The goal is to establish a trusting and supportive enough relationship with the patient that he or she will accept a psychiatric referral to explore the complex personality and behavioral derangements that often underlie this condition. Antidepressants and low-dose atypical antipsychotics have also been reported to be useful adjunctive therapies. [14], [15] In the case of Munchausen syndrome by proxy, in which the lesions are induced in children by parents or caregivers, child protective services or equivalent agencies must be alerted immediately to safeguard the welfare of the child.

Course and prognosis These are fundamentally determined by the underlying psychopathology. In those patients with severely disturbed personalities, the recurrent self-defeating and destructive behaviors are likely to continue.

NEUROTIC EXCORIATIONS This is also a condition in which patients induce skin lesions through repetitive, compulsive excoriation of their skin. However, unlike patients with dermatitis artefacta, these patients admit their role in the production of the lesions. This condition seems to be associated with underlying obsessive-compulsive personality traits and depressive disorders.

Epidemiology Neurotic excoriations have been reported in up to 2 percent of dermatology clinic patients with a predominance in middle-aged females, and is frequently associated with obsessive-compulsive personality and mood disorders.

Clinical characteristics Patients with neurotic excoriation often describe significant itch leading to persistent scratching, which is frequently antedated by considerable psychological stressors. The development of this disorder has also been noted to be associated with the marked limitation in activity seen in illness or senescence. [16] The repeated excoriation can lead to the development of an “itch–scratch cycle,” perpetuating the behavior. Patients present with multiple excoriations in various stages of evolution and healing, with postinflammatory hyperpigmentation and frequent scarring (Fig. 40-6). The distribution of the lesions reflects their self-inflicted nature with most being on the extensor surfaces of the extremities, upper back, and face, sparing unreachable areas. Frequently, patients develop neurotic excoriations overlying preexisting dermatosis, such as folliculitis and acne. Prurigo nodularis can be considered an extreme variant of this entity, characterized by severely pruritic nodules that may vary from a few millimeters to 1 to 2 cm in diameter, preferentially located on the lower extremities.

FIGURE 40-6 Neurotic excoriations. Lesions present in all stages of evolution.

Differential diagnosis The clinician must evaluate the patient for causes of pruritus (see Chap. 41) and rule out possible

internal diseases including neoplasms. The differential for the underlying psychiatric disorder, if present, must include depressive and anxiety disorders and, more rarely, excoriations secondary to delusions of parasitosis.
Treatment Treatment should be directed at underlying psychopathology when identifiable. Antidepressants, helpful in the treatment of both depressive and anxiety disorders including obsessive-compulsive disorder, may have some utility. Supportive psychotherapeutic approaches are usually helpful and well-tolerated, and behavioral interventions similar to that used to treat self-injurious behaviors in Tourette's syndrome may be useful.
Course and prognosis This can be a chronic condition whose prognosis depends on the underlying psychiatric illness. With appropriate therapy, patients with affective and anxiety disorders may have excellent outcomes, with a symptom-free, normally functioning state.
ATYPICAL CHRONIC PAIN SYNDROME Occasionally, patients will present to dermatologists with complaints of burning, pain, or dysesthesias in the skin or mucus membranes for which no identifiable pathology can be found. This can be a frustrating situation for patient and clinician alike. A psychiatric approach to these patients may offer a means of understanding the complex factors underlying this syndrome, such as comorbid affective disorders, personality vulnerabilities, behavioral problems, and life circumstances that may perpetuate the pain cycle and maintain the patient in an illness role. There is a significantly increased rate of depression in patients with chronic pain syndromes and a clear relationship between lifetime depression and the development of medically unexplained symptoms, including pain. Depression not only worsens the experience of pain by psychologically magnifying negative perceptions, but may also interfere with the function of descending monoaminergic neurons that dampen nociceptive transmission. This could explain the role for tricyclic antidepressants in analgesia. Other complicating factors include anxiety, which is also commonly seen in patients with chronic pain. Personality disorders influence all aspects of patients' lives and may make the burden of a chronic condition more challenging to bear. At times, family or social environments may unwittingly play a role in undermining the chronic pain patient's rehabilitation by rewarding illness behaviors with well-meaning, yet oversolicitous, attention. Pain states can further be complicated if the patient develops an inappropriate pattern of using prescribed analgesics. For all of these reasons, the best course of action for patients presenting with poorly explained chronic pain is to refer them to a multidisciplinary pain center where thorough evaluation and treatment can be undertaken.
PSYCHOGENIC PRURITUS Psychogenic pruritus and itch in general are discussed in Chap. 41.

PSYCHOTROPIC MEDICATIONS USED IN DERMATOLOGY

A number of different classes of psychotropic medications are routinely used by those dermatologists who elect to treat psychocutaneous disorders. Knowledge of the drugs and their actions, indications, side effects, therapeutic doses, and potential drug interactions is, therefore, critical.

These drugs are classified according to their clinical utility (e.g., antidepressants or antipsychotics) and further identified by their chemical structure and/or mechanism of action. All of the drugs discussed in this section exert their clinical effects through modulation of neurotransmitter function in the central nervous system by altering presynaptic reuptake of the transmitters, blocking their pre- and/or postsynaptic receptor binding, stimulating those receptors or some combination of the above. The most appropriately used in each of the following three major classes are discussed: antipsychotics, antidepressants, and anxiolytics.

Antipsychotics

These medications have a wide variety of uses in psychiatry, but their primary indication in psychocutaneous medicine is in the symptomatic treatment of disorders characterized by delusions and/or hallucinations. The most common indications in dermatology are delusional parasitosis and, less frequently, for the treatment of self-induced dermatosis. [14], [17] The drugs are believed to exert their beneficial effects by the blockade of postsynaptic dopamine receptors in the central nervous system (CNS). Dopaminergic tracts in the mesolimbic and mesocortical systems are felt to be the most important with regard to the production of symptoms of psychotic illness. However, dopamine is found widely throughout the brain and its blockade in the nigrostriatal and tuberoinfundibular pathways can lead to significant side effects.

Antipsychotics are now classified as typical (or conventional) and atypical. The older, typical antipsychotics include pimozide, haloperidol, fluphenazine, and chlorpromazine. These drugs are potent, nonspecific blockers of postsynaptic D_2 dopamine receptors and have varying degrees of inherent anticholinergic activity. The newer atypical antipsychotics have different affinities for dopamine receptors subtypes and serotonergic blocking properties at the $5\text{-}HT_2$ receptor. This combination allows a continued potent antipsychotic effect but with a much more preferable neurologic side-effect profile because of decreased interference with dopamine transmission in the basal ganglia. Agents in this subclass include olanzapine, risperidone, quetiapine, and ziprasidone.

DOSING Of the typical antipsychotics, pimozide was the most widely used in dermatology, although evidence for its utility from convincing double-blind, placebo-controlled trials is sparse at best. Following appropriate cardiac evaluation and monitoring, a starting dose of 1 mg daily can be gradually increased in 1 mg increments on a weekly to biweekly basis, depending on clinical response and side effects; doses above 6 mg/day have little clinical utility. Because of the important cardiovascular and neurologic side effects associated with this drug, we now tend to use alternatives in the form of atypical antipsychotics (see above). We discuss olanzapine as a prototype of this subclass. A typical starting dose of 1.25 mg (one-half tablet) to 2.5 mg at bedtime may be increased slowly by 2.5 mg increments. Dermatologic patients reportedly respond extremely well to very low doses of this drug, (ranging between 1.25 and 5 mg/day). [14], [17] However, because no clear evidence exists yet for established dosage ranges for the treatment of delusional parasitosis, close follow-up with gradual titration is necessary. Doses beyond 20 mg daily are unlikely to yield increasing clinical response although higher doses are used in the treatment of schizophrenia. As with the typical antipsychotics, clinical response may take weeks for full effect, although some results can be seen early. In addition to its antipsychotic action this drug has antihistamine activity (H_1) and anxiolytic properties at low doses (2.5 to 5 mg), making it a valuable addition to the dermatologic armamentarium.
SIDE EFFECTS The most dramatic side effects of the typical antipsychotics, including pimozide, are neurologic. They are divided into acute and delayed. The acute neurologic side effects are a result of dopaminergic blockade in the

striatum causing (1) dystonias (acute increases in tone and abnormal posturing, typically involving muscles of the face, neck, tongue, and pharynx), (2) parkinsonism (with tremor, gait disturbance, stiffness, cog wheeling rigidity, marked facies, and general bradykinesia), and (3) akathisia (an experience of marked restlessness in the muscles which should be distinguished from psychic anxiety or agitation). These acute neurologic side effects are best managed by coadministration of an anticholinergic medication such as benztropine 0.5 to 2.0 mg twice daily or diphenhydramine 75 to 100 mg po IM for severe acute dystonia. The most worrisome delayed side effect of antipsychotic treatment is tardive dyskinesia (TD), characterized by repetitive movements that usually involve the lips, tongue, face, and upper extremities. It is rare in patients with fewer than 6 months of treatment. Risk factors for the development of TD may include older age, female gender, and the presence of affective disorder. Treatment of TD includes decrease or discontinuation of the antipsychotic if the underlying psychiatric illness allows, and stopping anticholinergic medications. A majority of patients will have significant, if not total, improvement of the dyskinetic movements. Nonneurologic side effects include sedation, galactorrhea and the effects on the QT interval. Because of pimozide's effect on the repolarization phase of cardiac conduction, prolongation of the QT interval is possible, which is a potential risk factor for the development of fatal ventricular tachyarrhythmias. Baseline electrocardiograms (ECGs) should be obtained on all patients and after dose changes. In those patients with existing QTc prolongation, or in those patients who develop it during treatment, pimozide should be discontinued. Finally, neuroleptic malignant syndrome (NMS), characterized by fever, autonomic instability, diffuse increase in muscle tone, mental status changes, rhabdomyolysis and renal failure, is, fortunately, a rare but potentially fatal complication of antipsychotic treatment. This can occur at any time during treatment, but is more common during the first few weeks or months, or during rapid dose increases. Patients presenting with such features should be referred for emergent evaluation and subsequent treatment if indicated. The atypical antipsychotics have a much more favorable neurologic side effect profile secondary to less interference in striatal dopamine transmission. This includes the acute neurologic symptoms as well as a lower risk for developing TD. Serious NMS may also be seen, albeit much less frequently. The most common side effects of treatment with olanzapine are sedation and weight gain (which can be very significant). Patients may develop glucose intolerance, and signs and symptoms of hyperglycemia should be monitored during the treatment. In general, olanzapine and other atypical antipsychotics are fairly well-tolerated by patients, which make them the treatment of choice over the older typical antipsychotics.

Antidepressants

A wide array of antidepressant options currently exist. This section discusses the classes of antidepressants most commonly used by dermatologists: tricyclic antidepressants and SSRIs. In dermatology, these drugs are used to treat affective disorders such as major depression, anxiety disorders, and obsessive-compulsive spectrum disorders such as trichotillomania and body dysmorphic disorder.

TRICYCLIC ANTIDEPRESSANTS The tricyclic antidepressants are agents that block the presynaptic reuptake of monoamines from the synapse in the central nervous system. Thus, norepinephrinergic and serotonergic transmission is potentiated. Most agents in this class block this reuptake rather nonspecifically, although the drug clomipramine acts most prominently on serotonin reuptake, which underlies its special utility in the treatment of some obsessive-compulsive disorders. The tricyclic doxepin has found frequent use in dermatology (perhaps even more than psychiatry currently) because of its potent antihistaminergic properties in addition to its antidepressant effects. In those patients with anxious depressions in whom pruritus is a significant comorbid dermatologic symptom, this may be the antidepressant of choice.
Dosing Typical dose ranges for the most commonly prescribed tricyclic antidepressants are listed in Table 40-1. In general, low initial dosing with gradual titration to therapeutic levels is advised. As most are sedating, bedtime dosing is recommended. An advantage of this class of antidepressants is that serum levels are readily obtainable and can aid in the choice of appropriate daily doses. Because individual metabolism of these compounds varies radically, objective evidence of actual blood levels is quite helpful. These levels can inform the clinician about patient compliance and subtherapeutic dosing, two major factors that must be considered when the treatment regimen is unsuccessful.

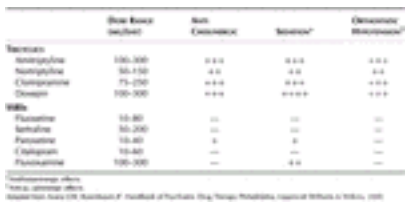

TABLE 40-1 **Dose Ranges and Receptor-Mediated Side Effects of Commonly Used Antidepressants**

Side effects The tricyclic antidepressants not only affect monoaminergic transmission in the CNS, but also have varying degrees of anticholinergic, antihistaminergic, and peripheral anti–a_1-adrenergic properties that can lead to significant side effects. These side effects include constipation, dry mouth, urinary retention, marked sedation, and orthostatic hypotension. Orthostatic pulse and blood pressure measurements should be documented in the record for all patients receiving tricyclic antidepressants. These drugs can also lead to significant alteration in the repolarization phase of cardiac conduction, increasing the risk for ventricular tachyarrhythmias. A baseline ECG should be obtained in all patients. Tricyclics should not be used in those patients with significant prolongation of the QTc interval, left bundle-branch block, or bifascicular block. They also cause tachycardia as a result of a reflex increase secondary to orthostatic hypotension and a general decrease in vagal tone to the heart. They may also induce seizures. Like all antidepressants, the tricyclics have the potential to precipitate an episode of mania or hypomania if used in patients with bipolar affective disorder. These patients should be screened for such a history before initiating therapy and referred to a psychiatrist who can follow the patient closely for signs of an emerging manic episode. Tricyclics are also potentially fatal in overdose; therefore patients who express suicidal ideations are best treated by a psychiatrist.
SELECTIVE SEROTONIN REUPTAKE INHIBITORS As their name implies, SSRIs selectively block the reuptake of serotonin into the presynpatic nerve terminal. Effective antidepressants, they are also very valuable agents in the treatment of anxiety and obsessive-compulsive disorders.
Dosing Table 40-1 lists the usual dose ranges for SSRIs. For obsessive-compulsive spectrum disorders, sometimes higher doses of these agents are required for clinical effect.
Side effects These are generally well-tolerated medications, even in the geriatric population. Unlike tricyclics, most of these drugs are somewhat stimulating and morning dosing is the rule. Decreased appetite, insomnia, akathisia, nausea, and diarrhea (due to serotonin's action on gut motility) are fairly common. These are typically seen upon initiation of

therapy or after dose changes, and often disappear with continued treatment. Approximately 30 percent of patients will experience sexual dysfunction, with decreased libido and orgasmic delay or anorgasmia being seen in both sexes. Like the tricyclics, SSRIs can lead to manic episodes in bipolar patients. They may actually be more likely to cause rapid cycling in which the patient experiences several depressive and manic swings in a relatively short period of time. The SSRIs are relatively safe in overdose. Because of their lack of effect on the myocardium and minimal, if any, impact on seizure threshold, they do not have the same risks as tricyclics. However, because they can be somewhat activating, patients with suicidal ideation treated with SSRIs should be followed extremely closely as energy may return before the dysphoria and suicidal wishes disappear. These drugs also inhibit subtypes of the cytochrome P_{450} system; therefore, other drugs metabolized by this system are subject to significant alterations in serum levels. Dose adjustment and careful monitoring are important when coadministering such medications.

Anxiolytics

Although antidepressants can be used to treat anxiety disorders, the symptomatic treatment of anxiety occasionally involves the use of other anxiolytics. Benzodiazepines are currently the most widely used class of anxiolytics, supplanting previous use of barbiturates. Buspirone, a nonbenzodiazepine anxiolytic, has also found some limited utility in certain patients.

Benzodiazepines are CNS depressants, exerting their influence through action at the GABA receptor. GABA is the major inhibitory neurotransmitter in the CNS. Thus, in addition to treating anxiety, other effects include sedation, loss of muscle coordination and possible amnesia or blackouts. Buspirone is a partial $5\text{-}HT_{1A}$ receptor agonist without the same liability for dependence and subsequent withdrawal phenomena common to all GABA active agents. Because of the potential for physical and psychological dependence, benzodiazepines should be used with great caution. Potent, short-acting benzodiazepines such as alprazolam and lorazepam may have more of a possibility of inducing dependency. In general, the short-term symptomatic treatment of anxiety symptoms while other more definitive pharmacologic and psychotherapeutic measures are being undertaken remains the main indication for the use of these medications by the nonpsychiatrist.

Buspirone is an anxiolytic medication approved for the treatment of generalized anxiety disorder. It is thought to mediate its effects through serotonergic mechanisms. Unlike benzodiazepines, buspirone must be taken chronically for anxiolytic effects to be seen. It is generally prescribed at 5 mg three times daily with increase to a total daily dose of 30 mg.

NONPHARMACOLOGIC TREATMENTS FOR PSYCHOCUTANEOUS DISORDERS

The dermatologist should request a consultation with a psychiatrist or a liaison clinic during the treatment of patients with psychocutaneous disorders as soon as it is amenable to the patient. Although dermatologists are becoming more comfortable with the use of certain psychotropic medications, they generally do not have the time or the training to use effectively other treatment modalities such as psychotherapy and hypnosis. It is therefore sufficient that the practicing dermatologist be aware that a variety of psychotherapeutic approaches are available, including insight-oriented, cognitive-behavioral, supportive, and, to a lesser extent in current practice, psychodynamic therapy. Certain types of therapies may be more effective for a given condition which underscores a fundamental point: diagnosis should drive choice of therapy and patients should not be formulated based upon rigid therapeutic/theoretical biases.

Primary Dermatologic Diseases

THE ROLE OF STRESS IN SKIN DISEASES The presence of a force that threatens to disrupt the organism's homeostatic balance is perceived as a stressor, and the ensuing reaction reflects the normal response aimed at the preservation of life. Mammalian organisms respond to external (i.e., physical, environmental) or internal provocations (infections, anxiety, or anticipatory stress) by triggering a cascade of events that ultimately activate the hypothalamus-pituitary-adrenal (HPA) axis, [18] allowing the organism to cope with noxious stimuli and mount a successful “fight-flight” reaction. This adaptation to challenges (“stress response” [19] is critical for survival following an acute provocation; however, its persistence chronically can lead to exhaustion, distress, and, eventually, disease. Whereas short-lived (acute) stressors are known to enhance immunity, chronic stress has an adverse effect on health and life expectancy, alters immunity, and favors the progression of infections as well as an increase in the development of experimentally induced neoplasms. [2] A number of studies provide clear evidence that psychosocial factors, including stress and other emotional states (such as depression), have a deleterious effect on the outcome of numerous human diseases including those of the skin. [2], [20] Although suspected for many years, retrospective and prospective studies have provided the clinical basis to support the notion that stressful events can correlate with the onset or exacerbation of skin diseases. Additional evidence was gleaned from the results of therapeutic trials utilizing psychotherapeutic approaches and stress reducing interventions [21] in the treatment of dermatologic ailments such as atopic eczema, psoriasis, urticaria, herpes simplex infection, alopecia areata, warts, and malignant melanoma, among others.
Atopic eczema More than most other skin diseases, atopic eczema exemplifies the delicate balance between inherited factors, environmental influences and psychosocial issues in the maintenance of health. Up to 70 percent of atopic subjects reported preceding emotional stressors prior to the first episode of dermatitis, [22] while numerous patients with eczema suffer exacerbations of their skin symptoms following episodes of psychological stress. These subjects have increased anxiety, altered coping mechanisms, and a close connection between severity of symptoms and stressful life events. Psychodynamic approaches have emphasized the role played by an abnormal family structure and altered mother-child relationships in this disease, an issue that is highlighted by the improvement in the symptoms of children with atopic eczema when their mothers receive psychological treatment. Other psychosocial interventions found to be effective as sole or adjuvant therapies for pediatric and adult patients [21] include behavioral therapies and biofeedback, stress reduction regimens, psychoanalysis, hypnosis, and relaxation techniques.
Psoriasis Psychosocial issues appear to be closely linked to the well-being of patients with psoriasis. Stressors often precede the initial onset of the disease or subsequent flares. Individual or group psychotherapy, behavioral approaches, and biofeedback, among other techniques, have resulted in improvement of the psoriatic plaques, as well as

enhancement of overall well being. [23], [24] Recent randomized controlled trials showed that highly suggestible patients treated with hypnosis significantly improved when compared to the control group, [25] and patients who used meditation tapes at the time of phototherapy cleared in half the time when compared to those who did not use them. [26]

Herpes simplex There is strong evidence to support the role of stress in the evolution of herpes simplex virus (HSV) infections. Experimental restraint stress correlates with the reactivation of latent HSV infection in the dorsal root ganglion neuron of rats. Human studies show that persistent, but not single, stressful events are associated with the frequency of recurrences, [27] which is in accordance with findings that chronic but not acute stress correlates with the development of experimental viral infections in normal volunteers. [28] Furthermore, psychosocial interventions decrease the frequency of recurrences of herpes simplex infections.

Urticaria The relationship between stress and some forms of urticaria is supported by numerous anecdotal observations. Patients suffering from adrenergic urticaria report that their symptoms invariably follow acute stressful events. Others, with hereditary angioedema are known to have symptoms frequently triggered by emotional stress. The finding that stress mediates the degranulation of mast cells via corticotropin-releasing factor (CRF) [29] and neuropeptides, [30] supports its putative role in the pathogenesis of urticaria. Almost all inflammatory skin diseases have been anecdotally reported at one time or another to be associated to stressors. Up to 50 percent of females with acne suffer flares following stress, and patients with seborrheic dermatitis, lichen planus, pemphigus vulgaris, and alopecia areata have been reported to have symptoms triggered or exacerbated by emotional stress.

MECHANISMS OF STRESS IN THE SKIN The underlying mechanisms that could explain how stressful events can modify skin diseases relate to (1) the effect of steroid hormones and catecholamines on immune cells, (2) abnormalities in the HPA axis, and (3) local (tissue) factors such as the secretion of neuropeptides and neurohormones and alterations in the barrier function of the skin.

Effect of stress hormones on immunity The bi-directional communication between immune and endocrine-neural systems is highlighted by the effects that follow a stressful event: CRF from the paraventricular nucleus of the hypothalamus is secreted into the pituitary, stimulating the release of adrenocorticotropic hormone (ACTH) from the pituitary leading to cortisol secretion from the adrenal glands. Simultaneously, cortical and limbic input also act on the locus ceruleus, activating the sympathetic system, mediating the resulting surge in norepinephrine and the release of peripheral neuropeptides. [18] However, the stress response is not only triggered by psychological or physical provocations. For example, infections induce monocyte/macrophage-derived inflammatory cytokines such as interleukin (IL)-1, IL-6, and tumor necrosis factor (TNF)-a, which cross the blood-brain barrier, resulting in CRF release from the hypothalamus. The secretion of cortisol and norepinephrine causes profound effects on the immune system by regulating the differentiation of T cells and macrophages, and by modifying inflammation and immunity. [31] Two distinct populations of T helper (T_H) lymphocytes, which generally oppose each other, regulate immune function through the secretion of stimulatory or suppressive soluble cytokines (see Chap. 26). T_H1 cells mediate cellular immunity through the production of interferon (IFN)-? and IL-2, and T_H2 induce humoral immunity through IL-4, IL-5, IL-10, and IL-13. The cytokines from one cell type curb the differentiation and proliferation of the other type. Physiologic doses of glucocorticosteroids inhibit the transcription of cytokines and chemokines and act on macrophages leading to a shift towards a T_H2 response, [32] while pharmacologic doses lead to the suppression of both T cell subsets (hence their use in the treatment of T_H1-, as well as T_H2-, driven diseases). Similarly, catecholamines also stimulate differentiation of the T_H2 phenotype through binding to lymphocyte $ß_2$ adrenergic receptors, and the suppression of IFN-?. These neurotransmitters inhibit macrophage IL-12, which is critical in the induction of T_H1 cells, and induce secretion of macrophage derived IL-10, a potent suppressor of antigen presentation, as well as an inducer of the T_H2 response. Some of these effects that lead to the inhibition of cellular immunity and stimulation of immunoglobulin production are not prevented by hypophysectomy or adrenalectomy, which could be explained by the other pathways such as the direct innervation of immune organs and cells. This combined effect on the T_H1/T_H2 balance may explain why the activity of some diseases appears to fluctuate during periods of stress or concurrent infections. Autoimmune diseases including pemphigus or systemic lupus erythematosus (SLE), or conditions with T_H2 predominance, such as acute stages [33] of atopic eczema may deteriorate if the immunity is shifted toward the humoral T_H2 response with concomitant increased production of immunoglobulins, particularly IgE. Additionally, atopic patients that are exposed to experimental stress demonstrate alterations in lymphocyte trafficking, cytokine profiles, and distribution of eosinophils and T cells. [34] Similarly, when patients with SLE are confronted with a stressor such as an infection, the T_H1-mediated symptoms could improve, while T_H2-mediated involvement (i.e., immune complex-mediated pathology) may deteriorate. Also, steroidal (among other) hormonal changes during pregnancy may shift the T_H1/T_H2 balance in patients with diseases in which there is T_H1 predominance, such as psoriasis or acne, inducing the transient improvement of symptoms seen in these women. The nature, timing, and duration of the stressor is critical in determining its effect on the immune system. Short-lived (acute) stress is usually associated with enhancement, whereas chronic stress is linked to suppression of the immune functions. [35]

Abnormalities of the HPA axis Genetic factors can condition the stress response and its influence on inflammation. Indeed, some rat strains have an inherited hypothalamic deficiency that makes them hypo-responsive to stress, succumbing to T_H1-type inflammatory diseases secondary to the inadequate production of corticosterone following exposure to stressors. Interestingly, a similar mechanism has been reported in patients with rheumatoid arthritis, [36] and in children and adult patients with atopic eczema, who were found to have an impaired cortisol response to laboratory stressors or to infused CRF, when compared to healthy controls. [37] These findings may explain why some patients with chronic eczema, who have a T_H1/T_H2 combined profile with T_H1 predominance (thus differing from the acute phase), suffer clinical exacerbations during concomitant stressful events due to the inability to maintain appropriate cortisol levels during these adverse events. Environmental factors have also been found to modify the stress response at the level of the central nervous system. Traits acquired during early life condition responses to stressors in adulthood. For example, women who suffered physical, or sexual abuse during childhood have significant alterations in the HPA axis response to stressors as adults. [38]

Local effect of neuropeptides and neurohormones Cutaneous nerves have a direct effect on inflammation of the skin, either through direct innervation or through the release of neuropeptides and neurohormones (see Chap. 20). During acute stress, leukocytes are mobilized and redistributed to accumulate in peripheral organs, such as the skin, to prepare the organism to confront foreign challenges (e.g., an infection). [39] This type of stress not only enhances overall cellular

immunity, but also increases delayed-type hypersensitivity (DTH) in the skin, [39] and induces the degranulation of mast cells, a process involving neurokinins, peripheral nerves and cutaneous production of urocortin and CRH, which promote local inflammation. [29], [40], [41] In contrast, chronic stress has opposite effects; it suppresses DTH [39] and significantly impairs wound healing in animals and humans. Some of these effects could be mediated by a–melanocyte-stimulating hormone (MSH), a peptide with local immunosuppressive effects [41] that also suppresses skin DTH when administered to the brain either exogenously, or endogenously, as it occurs under stress. The effects of emotional stress on the skin are not only restricted to changes in the local immunity, but also induce alterations in skin barrier functions, which can be reversed by glucocorticosteroid receptor antagonists or by the administration of anxiolytics. [2], [42] This phenomenon may explain the effect of stress on the evolution of some skin diseases with altered *trans*-epidermal water loss, such as atopic dermatitis and psoriasis. [43]

THE ROLE OF SKIN DISEASES ON PSYCHOSOCIAL WELL-BEING The physical or perceived disfigurement of the integument itself can become a source of significant stress, with a considerable impact on an individual's psychological, social, and physical well being. This is often overlooked or underestimated by the general public, many health insurers, and the medical community, including dermatologists. Although dermatologic conditions are responsible for a significant source of social stigmatization in many human societies and cultures, it is only recently that we have begun to quantitate the effect of skin disease on an individual's quality of life (QOL). Psoriasis, for example, impairs the social life of 40 percent of patients and 64 percent feel that their disease significantly impacts their socioeconomic functioning. The impairment of QOL correlates with disease severity in patients with atopic dermatitis, which is also associated with high levels of anxiety, sleep, and mood disturbances. Urticaria patients suffer QOL impairments similar to that of patients with coronary artery disease waiting for bypass surgery. Children with alopecia areata suffer significant psychiatric impact from their disease, with higher levels of anxiety, depression, decreased concentration, and increased aggression or withdrawal. Acne patients, with fewer symptoms than those with conditions such as psoriasis or eczema, have similar levels of deleterious emotional states. The Dermatology Life Quality Index (DLQI) [44] and the Skindex-16 [45] are simple and practical validated instruments that can be used both in the office setting and for research purposes to quickly evaluate QOL. Specific instruments, are also available for patients with psoriasis, eczema, acne, and urticaria among others. These tests are helpful tools that can assess improvement in both the physical and the psychosocial aspects of a patient's disease. The sum of observations, studies, and therapeutic interventions suggests that stress plays a significant role in the biology and clinical expression of skin diseases, and supports the notion that therapies that address this issue may have a positive impact on the well being of patients with dermatologic diseases. Adjuvant psychosocial interventions could also mediate an increased adherence to medical treatments, provide social support, decrease stress or alter the response to stress, ameliorate anxiety, aid patients to develop better coping mechanisms, improve depression, and help with self image or distorted body perception.

REFERENCES

1. Panconesi E, Hautmann G: Psychophysiology of stress in dermatology. The psychobiologic pattern of psychosomatics. *Dermatol Clin* **14**:399, 1996

2. Tausk FA, Nousari H: Stress and the skin. *Arch Dermatol* **137**:78, 2001

3. Koblenzer CS: *Psychocutaneous Disease*. Orlando, FL, Grune and Stratton, 1987

4. Driscoll MS et al: Delusional parasitosis: A dermatologic, psychiatric, and pharmacologic approach. *J Am Acad Dermatol* **29**:1023, 1993

5. American Psychiatric Association: *DSM-IV. Diagnostic and Statistic Manual of Mental Disorders,* 4th ed. Washington, DC, Author, 1994

6. Gould WM, Gragg TM: Delusions of parasitosis. An approach to the problem. *Arch Dermatol* **112**:1745, 1976

7. Koblenzer C: Psychologic aspects of skin diseases, in *Fitzpatrick's Dermatology in General Medicine,* 5th ed, edited by Freedberg IM, Eisen AZ, Wolff K, Austen KF, Goldsmith LA, Katz SI, Fitzpatrick TB, New York, McGraw-Hill, 1999, p 475

8. Hollander E, Phillips K: *Body Image and Experience Disorders*. Washington, DC, American Psychiatric Press, 1993

9. Phillips KA et al: Body dysmorphic disorder: An obsessive-compulsive spectrum disorder, a form of affective spectrum disorder, or both? *J Clin Psychiatry* **56**(suppl 4):41, 1995

10. Phillips KA et al: Body dysmorphic disorder: 30 cases of imagined ugliness. *Am J Psychiatry* **150**:302, 1993

11. McElroy SL et al: Body dysmorphic disorder: Does it have a psychotic subtype? *J Clin Psychiatry* **54**:389, 1993

12. Ninan PT et al: A placebo-controlled trial of cognitive-behavioral therapy and clomipramine in trichotillomania. *J Clin Psychiatry* **61**:47, 2000

13. Cohen HA et al: Hypnotherapy: An effective treatment modality for trichotillomania. *Acta Paediatr* **88**:407, 1999

14. Koblenzer CS: Dermatitis artefacta. Clinical features and approaches to treatment. *Am J Clin Dermatol* **1**:47, 2000

15. Garnis-Jones S et al: Treatment of self-mutilation with olanzapine. *J Cutan Med Surg* **4**:161, 2000

16. Gupta MA et al: Neurotic excoriations: A review and some new perspectives. *Compr Psychiatry* **27**:381, 1986

17. Gupta MA, Gupta AK: Olanzapine is effective in the management of some self-induced dermatoses: Three case reports. *Cutis* **66**:143, 2000

18. Chrousos GP: The hypothalamic-pituitary-adrenal axis and immune-mediated inflammation. *N Engl J Med* **332**:1351, 1995

19. Selye H: The general adaptation syndrome and the disease of adaptation. *J Clin Endocrinol* **6**:117, 1946

20. Kimyai-Asadi A, Usman A: The role of psychological stress in skin disease. *J Cutan Med Surg* **5**:140, 2001

21. Gupta MA, Gupta AK: Psychodermatology: An update. *J Am Acad Dermatol* **34**:1030, 1996

22. Faulstich ME, Williamson DA: An overview of atopic dermatitis: Toward a bio-behavioural integration. *J Psychosom Res* **29**:647, 1985

23. Ginsburg IH: Coping with psoriasis: A guide for counseling patients. *Cutis* **57**:323, 1996

24. Ginsburg IH: Psychological and psychophysiological aspects of psoriasis. *Dermatol Clin* **13**:793, 1995

25. Tausk F, Whitmore SE: A pilot study of hypnosis in the treatment of patients with psoriasis. *Psychother Psychosom* **68**:221, 1999

26. Kabat-Zinn J et al: Influence of a mindfulness meditation-based stress reduction intervention on rates of skin clearing in patients with moderate to severe psoriasis undergoing phototherapy (UVB) and photochemotherapy (PUVA). *Psychosom Med* **60**:625, 1998

27. Cohen F et al: Persistent stress as a predictor of genital herpes recurrence. *Arch Intern Med* **159**:2430, 1999

28. Cohen S et al: Psychological stress and susceptibility to the common cold. *N Engl J Med* **325**:606, 1991

29. Theoharides TC et al: Corticotropin-releasing hormone induces skin mast cell degranulation and increased vascular permeability, a possible explanation for its proinflammatory effects. *Endocrinology* **139**:403, 1998

30. Singh LK et al: Acute immobilization stress triggers skin mast cell degranulation via corticotropin releasing hormone, neurotensin, and substance P: A link to neurogenic skin disorders. *Brain Behav Immun* **13**:225, 1999

31. Chrousos GP: The hypothalamic-pituitary-adrenal axis and immune-mediated inflammation. *N Engl J Med* **332**:1351, 1995

32. Elenkov IJ, Chrousos GP: Stress hormones, Th1/Th2 patterns, pro/anti-inflammatory cytokines and susceptibility to disease. Trends Endocrinol Metabol **10**:359, 2000

33. Grewe M et al: A role for Th1 and Th2 cells in the immunopathogenesis of atopic dermatitis. *Immunol Today* **19**:359, 1998

34. Schmid-Ott G et al: Different expression of cytokine and membrane molecules by circulating lymphocytes on acute mental stress in patients with atopic dermatitis in comparison with healthy controls. *J Allergy Clin Immunol* **108**:455, 2001

35. Kiecolt-Glaser JK et al: Psychoneuroimmunology and psychosomatic medicine: Back to the future. *Psychosom Med* **64**:15, 2002

36. Gudbjornsson B et al: Intact adrenocorticotropic hormone secretion but impaired cortisol response in patients with active rheumatoid arthritis. Effect of glucocorticoids. *J Rheumatol* **23**:596, 1996

37. Buske-Kirschbaum A et al: Psychobiological aspects of atopic dermatitis: An overview. *Psychother Psychosom* **70**:6, 2001

38. Heim C et al: Pituitary-adrenal and autonomic responses to stress in women after sexual and physical abuse in childhood. *JAMA* **284**:592, 2000

39. Dhabhar FS, McEwen BS: Enhancing versus suppressive effects of stress hormones on skin immune function. *Proc Natl Acad Sci USA* **96**:1059, 1999

40. Singh LK et al: Potent mast cell degranulation and vascular permeability triggered by urocortin through activation of corticotropin-releasing hormone receptors. *J Pharmacol Exp Ther* **288**:1349, 1999

41. Slominski A et al: Corticotropin releasing hormone and proopiomelanocortin involvement in the cutaneous response to stress. *Physiol Rev* **80**:979, 2000

42. Garg A et al: Psychological stress perturbs epidermal permeability barrier homeostasis. *Arch Dermatol* **137**:53, 2001

43. Taieb A: Hypothesis: From epidermal barrier dysfunction to atopic disorders. *Contact Dermatitis* **41**:177, 1999

44. Finlay AY, Khan GK: Dermatology Life Quality Index (DLQI)—A simple practical measure for routine clinical use. *Clin Exp Dermatol* **19**:210, 1994

45. Chren MM et al: Measurement properties of Skindex-16: A brief quality-of-life measure for patients with skin diseases. *J Cutan Med Surg* **5**:105, 2001

T>

Chapter 41

Malcolm Greaves

Pathophysiology and Clinical Aspects of Pruritus

CLASSIFICATION AND TYPES OF ITCH
ITCHY SKIN: ALLOKNESIS
ITCH ORIGINATING FROM NERVES IN THE SKIN
The Search for Specific Itch Neurons in Human Skin
Itch-Producing Mediators in Skin
CENTRAL MECHANISMS OF ITCH
Gate Control
ITCHING IN PATHOLOGIC STATES
Pruritus of Chronic Renal Disease
Pruritus of Cholestasis
Pruritus of Endocrine Disease
Iron Deficiency
Pruritus in Hematologic Disease
Pruritus as a Manifestation of Solid Malignant Tumors
Pruritus of HIV-1 Infection
Itching in Senescence
Itching as a Manifestation of Psychiatric Disease
MISCELLANEOUS ITCHES
Aquagenic Pruritus
Hydroxyethyl Starch-Induced Pruritus
Notalgia Paraesthetica
Brachioradial Pruritus
Pruritus of Anorexia Nervosa
Pruritus of Creutzfeldt-Jakob Disease ("Prion Pruritus")
Itching in Atopic Eczema
Prurigo Nodularis
INVESTIGATION OF GENERALIZED PRURITUS WITH NO RASH
TREATMENT OF PRURITUS
General Measures
Chronic Renal Disease
Cholestasis
Aquagenic Pruritus and Water-Induced Itching of Polycythemia Vera
Pruritus of HIV

REFERENCES

Pruritus (itching) is the predominant symptom of skin disease and can best be defined indirectly as a sensation that leads to a desire to scratch. Pain and itch are separate and distinct sensations, although both modalities follow the same gross neural pathways. Because of the subjective nature of itching, with difficulty in arriving at a precise definition and reproducible methods of measurement, as well as a lack of convincing animal models, progress in this field has been slow. However significant progress has been made in the past few years, mainly as a result of application of new technology, especially the use of microneurography that enables recordings to be made from individual afferent neurons following stimulation in man in vivo. The concept of "central" itch—itch generated in the central nervous system, rather than peripherally, has gained more support and this has led to a new neuropathophysiology-based classification of itch (discussed below). These advances have yet to be translated into new safe and effective antipruritic treatments, but these are round the corner.

CLASSIFICATION AND TYPES OF ITCH

Recently, Twycross et al. [1] proposed classifying itches into pruritoceptive (originates in diseased skin); neurogenic (due to molecular or neurophysiologic dysfunction in the nervous system, e.g., cholestasis, opioid-induced pruritus); neuropathic (due to nervous system pathology, e.g., multiple sclerosis, Creutzfeldt-Jakob disease); and psychiatric (e.g., parasitophobia). This classification system recognizes the important role the central nervous system plays as a source of itch as well as a regulator of itch traffic.

ITCHY SKIN: ALLOKNESIS

That pruritoceptive itch, which is itself heterogeneous, was recognized by Bickford, [2] who described two responses to an itchy stimulus applied to the skin: an itch that is well localized to the site of the stimulus, persisting only briefly after the itch is removed, and a subsequent, diffuse, poorly localized area that does not itch spontaneously but that itches intensely when subjected to light touch or other minor stimulus. Bickford called the former "spontaneous itch" and the latter "itchy skin." We use the term *alloknesis* to describe "itchy skin." Alloknesis is analogous to the better known allodynia (injury to skin results in well-localized, short-lived, intense pricking pain and a surrounding diffuse area of hyperalgesia). Whether spontaneous itch involves different sensory fibers than does alloknesis is unclear. It was originally suggested [3] that these two qualities are served by rapidly conducting (A delta) and slowly conducting (C) fibers, respectively. An alternative, more attractive explanation from Graham et al. [4] states that the more diffuse state of alloknesis is due to activation within sensory relays of the cord of interneuronal facilitating circuits following low-intensity stimulation of pain fibers. Possibly the facilitation may be peripheral, due to local release of pharmacologic activity in the

skin as proposed for allodynia by Lewis [5] and more recently by Lynn. [6]

The phenomenon of alloknesis is familiar to the dermatologist. The development of an urticarial wheal is associated with well-defined localized spontaneous itching, as well as with a surrounding area of skin that responds with itching to any mild mechanical stimulus, persisting for hours or even days after the wheal has subsided. The same phenomenon may account, to a greater or lesser degree, for the itchy discomfort of patients with atopic eczema, who frequently experience bouts of intense pruritus due to sweating.

ITCH ORIGINATING FROM NERVES IN THE SKIN

A characteristic of itch is that the only peripheral tissues from which it can be evoked are skin, mucous membranes, and cornea. Itch sensitivity is not evenly distributed; there are itch points in a spotty distribution. [7], [8] and [9] Shelley and Arthur [9] inserted itch-producing spicules from the plant *Mucuna pruriens* to varying levels below the skin surface and showed maximum itch sensitivity at the basal layer. When itch-producing substances are injected deeply into skin, they produce pain, and when the epidermis is removed, itch can no longer be generated. [9], [10] Itch cannot be produced from completely denervated skin as in herpes zoster or leprosy. [10] The C neuron toxin capsaicin, although initially producing intense irritation, abolishes the ability to produce itch after repeated application. [11] Itch persists even when all the large A neurons are blocked by an inflated sphygmomanometer cuff. [1], [9] It is evident that C and perhaps A delta neurons are unique in their ability to provoke itch. Although it is widely accepted that there are no specialized structures behaving as “itch receptors” in skin, free nerve endings specifically serving the sensation of itch have not yet been identified. Light and ultrastructural studies have demonstrated the presence of intraepidermal free nerve endings that stain positively for neuropeptides, but it could not be confirmed that these served the sensation of itch. [12]

The Search for Specific Itch Neurons in Human Skin

Classic theory proposes that itch and all other primary sensations are associated with activation of specialized neurons, one for each sensation. Search for a so-called itch fiber has been enabled by the development of human microneurography in which an ultrafine glass microelectrode is inserted percutaneously into peripheral nerves to record active single neurons in conscious individuals. By this method recordings were made from unmyelinated neurons that responded to *Mucuna pruriens* spicules or histamine. [13] By using electrical field stimulation coupled with microneurography in ulnar and peroneal nerves, a subset of ultraslow-conducting C neurons innervating a wide territory of skin was identified by Handwerker and colleagues. [14] These neurons, which represent 10 to 15 percent of the total number of C fibers in the nerve were coresponsive to heat. This finding could explain the well-known observation that the itch threshold is lowered in warmed skin. [15] The same technique can be used to produce microstimulation within a neuron. Occasionally, this stimulation produces a sensation of itch.

The existence of a subset of dedicated itch-transmitting C neurons receives further support from recent studies of spinal cord pathways. Itch-transmitting primary afferent C neurons synapse with secondary transmission neurons that cross over to the contralateral spinothalamic tract and ascend to the thalamus. In the cat, microneurography identified lamina 1 neurons in the lateral spinothalamic tract that selectively responded to histamine, suggesting a central dedicated nerve pathway for itch. [16]

Itch-Producing Mediators in Skin

HISTAMINE Histamine applied in low concentrations at the level of the dermoepidermal junction causes intense itching, but deeper intracutaneous injections cause pain. Histamine is synthesized in the mast cells of the skin and stored in mast cell granules. It is released by these cells in response to a variety of injurious stimuli. Histamine acts to produce itch by way of the H_1 receptor and not via H_2 receptors. [17] Histamine also causes rapid tachyphylaxis with respect to vasodilation and increased vascular permeability. [17] Therefore, it is unlikely to behave as a mediator of sustained inflammation, although it is an important mediator in short-lived wheal-and-flare reactions of the urticarial type. Some itch-producing substances owe their action to release of histamine from mast cells. Prior depletion of histamine from these cells abolishes itch caused by these substances that act by way of mast cells. Therefore, pharmacologic studies to characterize new itch-producing substances should include investigation for their ability to degranulate mast cells.
SEROTONIN (5-HYDROXYTRYPTAMINE) This amine, present in platelets but not in human mast cells, can cause itching in skin through histamine release from dermal mast cells, [18] but probably also has a more important regulatory action on itch via 5-HT_3 receptors within the central nervous system (discussed below).
ENDOPEPTIDASES Endopeptidases such as trypsin or papain (present in the spicules of *Mucuna pruriens*) cause itch. Trypsin is an important component of dermal mast cells, and is secreted upon mast cell activation. Recent studies [19] suggest that mast cell-derived tryptase, by its action on proteinase-activated receptor-2 (PAR-2) contained in adjacent C neuron terminals, evokes release of pruritogenic neuropeptides by the same terminals. This forms an additional pathway for itch, and represents an example of interaction between the immune and nervous systems. Kallikrein is a kinin-forming enzyme, the best known product of which, bradykinin, causes predominantly pain rather than itch, by a peripheral action.
NEUROPEPTIDES Substance P, localized in C neuron terminals, is released from this site by the action of mast cell tryptase on PAR-2 (discussed above) and causes itching both by a direct action, and by release of dermal mast cell histamine via NK-1 receptors. [20] Opioid peptides have both a central and a peripheral itch-producing action. Low doses of intradermal morphine produce itch, and the effect is independent of prostaglandins or mast cell degranulation. One site of action of opioid receptor agonists is on the dorsal root ganglia or spinal cord, because low doses of epidural morphine cause segmental itching. Patients with cholestatic itching obtain relief from the selective μ receptor opioid antagonist naloxone, but it is unknown whether this is a central or peripheral action. [21] However, opioid agonists acting on opioid ? receptors are antipruritic, raising the possibility that some types of itch could be relieved by a combination of opioid μ receptor antagonists and ? receptor agonists. [22]
EICOSANOIDS Arachidonic acid transformation products (prostaglandins, leukotrienes, and other hydroxy fatty acids) possess powerful proinflammatory properties but are not directly pruritic. Prostaglandin E (PGE), although not itself a

cause of itching, does enhance itching due to other mediators. Pretreatment of human skin by low concentrations of PGE_1 lowered the threshold of the treated skin to itch produced by subsequent intradermal injection of histamine at the same site. [23] However, aspirin, a cyclooxygenase inhibitor, does not relieve pruritus. [24]

CENTRAL MECHANISMS OF ITCH

Two issues remain to be addressed: Why is itch specific to skin and why does it not affect deep tissues? Why does itch respond (temporarily) to scratching? By comparison with deep tissue, skin is characterized by the ability to localize itch stimuli precisely. This is achieved by the presence in the sensory pathways of effective surround inhibition. This is illustrated by applying a very gentle point stimulus to a sensitive area such as the lip. This causes poorly localized itching. Enlarging the area of application, for example, by applying a weak blunt stimulus, abolishes the itch as a consequence of activating surround inhibition. The punctate stimulus activated a small group of C neurons to cause itching, whereas the blunt stimulus caused inhibition to activation of inhibitory neuronal circuits in the dorsal horn. Scratching and rubbing activate low threshold touch-and-pressure–conducting myelinated A neurons, setting up surround inhibition involving suppression of both pre- and postsynaptic pathways. The practical consequence of this observation was the setting up of *trans*-epidermal nerve stimulation as a treatment for itch. [25] The arrival of volleys in large A fibers inhibits the response of spinal cord cells to C neuron input.

Gate Control

The dorsal horn of the cord receives afferent impulses but is also subject to powerful descending controls from the brain. Histamine-induced discharge of dorsal horn cells is strongly suppressed by stimulation of the midbrain periaqueductal grey. This is one example of many descending inhibitory controls, but there are equally important excitatory controls. All these pathways form the descending limbs of the gate control, [26] which enables higher centers to exert influence on the severity of itch—possibly one reason for the common observation that itching is generally more severe at night.

ITCHING IN PATHOLOGIC STATES

Pruritus associated with underlying internal disease is often multifactorial, involving both systemic and external factors, including ambient temperature and humidity. Itching associated with skin disease may also include central (neurogenic) and pruritogenic components.

Pruritus of Chronic Renal Disease (See also Chap. 165)

Pruritus is one of the most distressing symptoms of chronic renal failure. It affects 20 to 50 percent of patients, especially those on dialysis, although it is recently becoming less prevalent, probably due to more efficient dialysis techniques. [27] Scratching is common and the patient may be heavily excoriated. However, the skin may show nummular eczematous, prurigo nodularis-like, or lichenified appearances. The back is invariably affected, and the arm bearing the arteriovenous fistula is also a common site in dialysis patients. Patients being dialyzed with membranes that are less permeable and biocompatible (cuprophan) are more likely to suffer pruritus than those patients who are using more permeable polysulphone membranes. Patients with uremic pruritus often have a dry skin, but correction of this by emollients usually provides only mild relief. The expanding number of alleged pathogenetic factors bears testimony to the elusiveness of the causes. These include secondary hyperparathyroidism, increased numbers of dermal mast cells, elevated plasma histamine levels, abnormal levels of divalent cations, proliferation of sensory nerve endings in skin, release of pruritogenic cytokines during hemodialysis, and elevated levels of vitamin A. [28], [29], [30], [31] and [32] Secondary hyperparathyroidism, though common in patients with renal failure, is a rare cause of renal pruritus. The proliferation of nerve endings in skin is most likely a response to incessant scratching and rubbing, rather than a primary cause of pruritus in these patients. Elevation of histamine levels, with or without increased population density of dermal mast cells, is also unlikely to be important because antihistamines are rarely effective. Recent evidence based upon response of patients to naltrexone, a selective opioid antagonist, raises the possibility that opioid peptides may be involved, although this finding has been challenged. [33], [34]

Pruritus of Cholestasis (See also Chap. 164)

The highly distressing and persistent pruritus of biliary obstruction often begins with an acral distribution, but later becomes more generalized. Both peripheral and central mechanisms are important. Cholestatic pruritus is associated with high plasma levels of bile salts, but there is little or no evidence of a correlation between concentrations of bile salts and itching, whether the bile salts are measured in the blood or skin itself. [35] However it is evident that bile salts are highly pruritic when applied to blister bases or to scarified skin. Furthermore, administration of an exchange resin, cholestyramine, which lowers bile salt levels, does provide some relief. This finding also probably explains the benefit of plasma perfusion through charcoal beads.

That patients with cholestatic itching also have elevated plasma opioid levels was first demonstrated by Thornton and Losowsky in 1988. [36] They found elevated concentrations of methionine enkephalin and leucine enkephalin, and showed that the pruritus improved after treatment by the opioid antagonist nalmefene. These observations were later developed and extended by Bergasa and Jones. [37] Briefly, their evidence may be stated as follows. Animal models of cholestasis are associated with elevated levels of opioid peptides and scratching, relieved by naloxone [38] and with increased proenkephalin mRNA expression in the adult rat liver. [39] Also, plasma from patients with pruritus of cholestasis, which was relieved by naloxone, [40] causes scratching in monkeys when injected into the dorsal horn. Human-controlled trials of naloxone infusions showed a significant benefit in patients with pruritus of cholestasis. [21], [41] In the light of these findings, combination of both bile salt-lowering and opioid antagonist strategies appear reasonable in the management of pruritus of cholestasis.

Pruritus of Endocrine Disease

Generalized intractable itching is a recognized feature of thyrotoxicosis and may be a presenting symptom [42] (see Chap. 169). This is usually due to increased blood flow, which raises the skin temperature, which, in turn, reduces the threshold to itching. [15] The skin is warm, moist, and flushed. However, itching in thyrotoxicosis may be localized to the anogenital area, in which case, it is usually due to mucocutaneous candidosis. Hypothyroidism may also present with widespread pruritus, in this case, due to excessive skin dryness. The skin is cool, dry, slightly scaly, and may be thickened and sallow (myxedema).

Generalized itching is not a feature of diabetes mellitus. Although there was a suggestion in the early literature that widespread pruritus could be a presenting feature, this is not substantiated by more recent studies. [43] However, anogenital itching is common, is often a presenting feature, and is due to mucocutaneous candidosis. Localized itching of the scalp can also be a manifestation of diabetic neuropathy, [44] which may respond to topical capsaicin treatment. [45] Postmenopausal pruritus may be generalized or localized, and, in the latter case, it is usually anogenital and due to candidosis. Generalized pruritus is less common, often episodic, and associated with postmenopausal hot flushes. The presence of elevated plasma levels of pituitary luteinizing hormone and follicular stimulating hormone should support the diagnosis.

Iron Deficiency

The role of iron deficiency in the causation of pruritus is controversial. Several reports have implicated iron deficiency as a cause of pruritus in otherwise normal-looking skin. [46] Pruritus and iron deficiency are sometimes associated in patients with polycythemia vera, the cause of the deficiency usually being venesection. In these patients, correction of iron deficiency is associated with clinical improvement. [47] However, a study of a large series of patients with severe iron deficiency revealed no evidence of pruritus in any of these over a period of 6 months. [48] Although patients with iron deficiency may complain of pruritus, it is unlikely that iron deficiency is responsible and other causes should be sought.

Pruritus in Hematologic Disease (See also Chap. 157, Chap. 158 and Chap. 163)

Itch is common in hematologic disorders. In Sézary syndrome (T cell leukemia) it is invariable, intense, and generalized. In polycythemia vera, it occurs in about 50 percent of patients, is often precipitated by contact with water (“bath itch”) and is associated with raised blood histamine levels. [49], [50] and [51] In Hodgkin's disease, it may be a presenting symptom, [52] and may persist after remission. In cutaneous mastocytosis, itching occurs locally following rubbing the skin, although it can be widespread in severely affected patients, when it is usually associated with systemic symptoms. Itching may occur in patients with myeloid and lymphatic leukemia and myelodysplasia.

Pruritus as a Manifestation of Solid Malignant Tumors

Traditionally the onset of pruritus in a middle-aged or elderly patient with an otherwise normal-looking skin prompts a thorough investigation for underlying systemic causes including internal neoplasia, although the latter is an uncommon cause. Although pruritus may occasionally be present years before the tumor becomes clinically detectable, even if resources are available, full investigation for a causative solid tumour is probably not worthwhile. [53], [54]

Pruritus of HIV-1 Infection (See also Chap. 225)

Itch is an early symptom of HIV disease and may be associated with skin disease (scabies, pediculosis, seborrheic eczema, xerosis) or a result of systemic causes (hepatic disease, renal disease, lymphoma, adverse drug reaction, systemic and skin infection including *Staphylococcus aureus* and Pityrosporum). However, it may occur as a primary symptom of HIV. Eosinophilic folliculitis is an intensely pruritic eruption characteristically occurring in HIV-positive individuals with a CD4 count less than 300/µL. Clinically, it presents with follicular and nonfollicular urticarial papules and plaques, which may or may not be pustular on the upper trunk, extremities, and face. [55] It may be associated with elevated serum IgE and may flare up on administration of antiretroviral treatment. [56]

Itching in Senescence (See also Chap. 144)

At least 50 percent of persons aged 70 years or older will suffer from prolonged bouts of troublesome pruritus. Pruritic skin diseases such as scabies, lichen planus prebullous pemphigoid, pemphigoid nodularis, or low-grade eczema should be considered, as well as underlying systemic disease, especially cholestasis and renal failure. However, in many instances, no cause is found. In many of these cases, the cause is desiccation of the skin due to a combination of decline in natural moisturizing factors in aging skin and low atmospheric humidity, as in a heated institutional environment. Occasionally, the pruritus may be provoked by water contact, mimicking aquagenic pruritus (discussed below). However, unlike true aquagenic pruritus, water-evoked itching in senescent skin responds well to emollient treatment.

Itching as a Manifestation of Psychiatric Disease (See also Chap. 40)

Localized pruritus, especially anogenital pruritus, is a common manifestation of chronic anxiety, although candidosis with or without accompanying diabetes mellitus, pinworms, and dermatitis medicamentosa must always be excluded. In cases in which these have been excluded, sympathetic explanation of the cause of the itch, advice regarding local hygiene, change in lifestyle, and prescription of a mild anxiolytic drug such as a beta blocker may be all that is required. If the localized area is persistently rubbed, lichenification may develop (lichen simplex, neurodermatitis). Parasitophobia is a much more serious problem, the patient persisting in claiming skin infestation, although careful inspection reveals no evidence of parasites. The patient will often bring “evidence” in the form of collected fragments, although on examination

the material proves to be nonspecific debris. One patient of the author's habitually brought to the outpatient clinic not only debris, but also her own small portable microscope to make sure her “evidence” was fully examined! Such patients have a delusional psychosis and a psychiatric referral is wise.

MISCELLANEOUS ITCHES

Aquagenic Pruritus

Originally described by Shelley [57] and subsequently characterized by Greaves et al., [58] aquagenic pruritus is a rare but well-recognized and intractable pruritus mainly of the middle-aged and elderly. Characteristically, local itching is provoked by contact with water at any temperature, provoking a bout of itching lasting for 30 to 60 min, with no visible signs in the skin. During attacks patients are usually considerably distressed, but there are no other systemic manifestations. Laboratory investigations are negative, but occasionally patients with aquagenic pruritus and normal blood indices can progress to polycythemia vera. [59] The condition is persistent and most patients present with a history going back several years. Because of the lack of a visible rash, these patients are frequently labeled as “neurotic.” However elevated levels of histamine are found in blood and skin. [58] The condition must be distinguished from water-induced itching of the elderly (unlike true aquagenic pruritus, this condition is relieved by emollients) and from the “bath itch” of polycythemia vera. The cause of aquagenic pruritus is unknown, but both acetylcholine and histamine are involved, although antihistamines are usually ineffective in reducing the itching. Increased acetylcholinesterase activity is present in cutaneous nerve fibers in affected skin, and the itch can be relieved by local application of atropine-like drugs. [58] Increased tissue fibrinolytic activity has also been demonstrated in the skin of patients with this condition. [60] Table 41-1 lists case reports of disease associations with aquagenic pruritus. Aquagenic pruritus has been comprehensively reviewed. [61]

Underlying Abnormality	Reference
Hypereosinophilic syndrome	Newton JA et al.[62]
Myelodysplastic syndrome	Mc Crath JA, Greaves MW[63]
Juvenile xanthogranuloma	Handfield-Jones SE et al.[64]
Squamous carcinoma of the cervix	Ferguson JA et al.[65]
Antimalarial drug therapy (for lupus)	Jimenez-Alonso J et al.[66]

TABLE 41-1 **Case Reports of Disease/Drug Associations with Aquagenic Pruritus**

Hydroxyethyl Starch-Induced Pruritus

There have been several reports, mainly in European journals, of intense itching, lasting for as long as 1 year, following hydroxyethyl starch intravenous infusion for vascular insufficiency. The pruritus is associated with ultrastructural evidence of deposition of hydroxyethyl starch in the Schwann cells of peripheral nerve fibers, endothelial cells, and macrophages, and is probably an example of a neurogenic itch. [67]

Notalgia Paraesthetica

This is a common chronic localized itch, affecting mainly the interscapular area especially the T2–T6 dermatomes, but occasionally with a more widespread distribution, involving the shoulders, back, and upper chest. The sensation perceived by the patient is part itch, part paraesthesia. There are no specific cutaneous signs, apart from those attributed to scratching and rubbing. Amyloid deposition may be found in skin biopsies, but this is a secondary event. The current view on etiology is that it is a neuropathic itch due to entrapment of spinal nerves as they emerge through the epaxial muscles of the back. [68] It may respond to topical capsaicin treatment.

Brachioradial Pruritus

This localized pruritus is becoming increasingly common. Patients, usually fair skinned, affluent, and middle aged, habitually indulge in golf, tennis, sailing, or other leisure outdoor activities in sunny climates. [69] They develop persistent pruritus of the outer surface of the upper arm elbow and forearm, associated with clinical evidence of chronic sun damage and xerosis in the pruritic skin. The itch may gradually become more widespread. Results of phototesting are negative and the problem seems consequent upon straightforward chronic ultraviolet overexposure. It may respond to capsaicin cream.

Pruritus of Anorexia Nervosa

Pruritus has long been a recognized feature of the symptomatology of anorexia nervosa [70] and usually subsides following weight restoration. Possible causes include compulsive washing, impaired renal or hepatic function, and thyroid disease. However, in many patients, no cause is apparent. A recent study of 19 patients suggests that abnormalities of regional blood flow, serotonergic, and opioid tone may underlie this symptom. [71] It is suggested that anorexia nervosa should be considered as a cause in any low-body-weight patient with otherwise unexplained pruritus.

Pruritus of Creutzfeldt-Jakob Disease (“Prion Pruritus”)

Three patients have been reported as presenting with intense itching during the prodromal period of the disease. Creutzfeldt-Jakob disease is a spongiform encephalopathy related to scrapie, also a prion disease of animals, regularly associated with itching and scratching. [72] All three of these patients had evidence of brainstem dysfunction and it is proposed that “prion pruritus” is a central (neuropathic) pruritus in patients with no evidence of other systemic or

cutaneous causes.

Itching in Atopic Eczema (See also Chap. 122)

This remains a controversial area and the molecular basis of pruritus in atopic eczema remains largely unexplained. Whether the itch precedes the eczema, or the other way round is also an unresolved issue. What is certain is that an itch-scratch vicious cycle exists in atopic patients, in which scratch damage enhances itch. Itching is particularly acute in response to punctate stimuli such as wool fibers; rubbing or scratching elicits surround inhibition (discussed earlier). Alloknesis (discussed earlier) is a prominent feature of the itch of atopic eczema and explains the bouts of intense itching associated with sweating, sudden changes in temperature, dressing, and undressing. That there is a central (neurogenic) component to the itch of atopic eczema is suggested by the poor response to low sedation H_1 antihistamines. [73] This also suggests that histamine is not a major mediator of atopic eczema; [74] alternative candidates include cytokines. Opioid peptides may serve as central mediators because opioid antagonists are effective in some patients. Nocturnal scratching is a major problem in atopic eczema, occurs during sleep stages 1 and 2 (superficial sleep), and occupies 10 to 20 percent of the total sleeping time, leading to tiredness and irritability. Treatment should be directed first at managing dryness and infection—two important and remediable causes of itch. Sedative antihistamines may be useful. Topical steroids allay itching where this is a result of inflamed skin, using the lowest effective concentration. Phototherapy (UVB, photochemotherapy) may be effective in some patients. For selected, severely handicapped, treatment-resistant patients, recourse may be made to oral azathioprine or to cyclosporin. Most recently, tacrolimus, a topically applied macrolide immunosuppressive with an action resembling that of oral cyclosporin, was shown to be effective in relieving the pruritus of atopic eczema. [75]

Prurigo Nodularis

Prurigo nodularis is a chronic papulonodular intensely itchy eruption of unknown cause. It occurs symmetrically, predominantly on the extensor surfaces of the limbs, lower back, and abdomen. The palms, soles, head, and neck are rarely involved. The surrounding skin looks healthy. Histologically, apart from the obvious hyperkeratosis and massive acanthosis, there is also “colossal hyperplasia” of neural fibers (Pautrier's neuroma) although this is the result of chronic scratching or rubbing, and is not diagnostic. [76] Recently, immunoelectron microscope studies demonstrated overexpression of p75 nerve growth factor receptor in Schwann cells and perineurium cells, which may be the immediate cause of the hyperplasia. [77] Topical treatment, including emollients, corticosteroids, and possibly capsaicin, may be beneficial. Systemically, sedative antihistamines may help patients sleep at night. Some authors advocate cyclosporin, but probably the most effective treatment is thalidomide, [78] but it must not be administered to fertile women, and polyneuropathy is a troublesome side effect.

INVESTIGATION OF GENERALIZED PRURITUS WITH NO RASH

Careful history, including a full drug history, and physical examination are the starting points, and the latter should include rectal, and in women, pelvic, examination. The history should take into account the multidimensional nature of itching and should include details of quality, distribution, and timing. Any patient referred with generalized pruritus should be assumed to have scabies until proved otherwise—skin signs may be clinically inapparent, perhaps confined to a few small nodules on the genitalia. Investigations should include full blood count, including a differential count for eosinophilia, urinalysis, stool examination for evidence of parasites, and occult blood. Chest x-ray, thyroid, liver function, and renal function tests should be carried out, together with a search for evidence of infection by hepatitis B or C, HIV, plasma protein electrophoresis, immunoelectrophoresis, and an analysis of serum iron. A CT scan of the abdomen is usually justifiable to help rule out lymphoma. A skin biopsy is useful to exclude clinically inapparent cutaneous mastocytosis.

TREATMENT OF PRURITUS

Treatment of pruritus depends upon identifying and removing the cause whether systemic or cutaneous. False hopes of highly effective treatment for those patients in whom no cause can be found should not be raised; there are no effective selective systemic or topical antipruritic agents with acceptable tolerability. One reason for this is the lack of convincing animal models for itch and the paucity of quantitative statistically analyzable methods for measuring itch; most methods are indirect, involving quantification of scratch or subjective in which a visual analogue scale is used. It is important to elicit from a detailed history—taking the precise quality, timing, and distribution of the itch, so that more focused therapy can be instituted. The “Eppendorf itch questionnaire” is an example of this approach. [79]

General Measures

The sensation of itching is heightened if the skin is warm, [15] therefore measures should be taken to cool the skin down, including tepid showering, light clothes, and air conditioning where appropriate. Cooling lotions, such as calamine or oil-in-water vanishing creams, may help. Aqueous menthol lotion 1% is effective in the treatment of histamine-induced itching. [80] Menthol can also be formulated in an aqueous cream base. Topical steroids are not antipruritic, and are not indicated unless there is evidence of cutaneous inflammation as a cause for the itching. For localized itches, topical capsaicin (8-methyl- *N*-vanillyl-6-nonenamide), the active ingredient of chili pepper, may be effective. Unfortunately, compliance is poor because initial application causes intense irritation because of the release of neuropeptides via an action on C neuron terminals via VR1 receptors. [81] Doxepin is a tricyclic antidepressant with potent anti-H_1-and anti-H_2 histamine-receptor properties. Topical application of a doxepin 5% cream is effective in eczema-associated pruritus, but its usefulness is limited by sedation because of percutaneous absorption. Other strategies for intractable localized pruritus include electrical stimulation treatment by TENS (transepidermal electrical nerve stimulation) and CFS (cutaneous field stimulation). [82], [83] These probably work by creating surround inhibition (discussed earlier). [25] Other measures possibly worth trying include paroxetine, a selective serotonin reuptake inhibitor (SSRI; claimed to be effective

in relieving the itch of terminal cancer sufferers), [84] 5-HT $_3$–receptor antagonists such as odansetron, [85] and opiate receptor antagonists administered orally or parenterally. [86]

Chronic Renal Disease

Excessive dryness of the skin should be treated with emollients. Where secondary hyperthyroidism is responsible, this should be dealt with. [28] UVB phototherapy, including narrow band UVB, is effective, and probably the treatment of choice for most patients. [87] Remissions may last for as long as 18 months. This treatment decreases the population density of mast cells by inducing apoptosis, causes nerve dysfunction, and reduces divalent cations in the skin. Naltrexone was shown to be effective in a double-blind randomized crossover trial, [33] although this finding has been challenged, [34] and odansetron may also be of value. [88]

Cholestasis

Cholestyramine is effective in the treatment of cholestatic itch, especially in primary biliary cirrhosis, but it is ineffective in the presence of total biliary obstruction. It chelates intestinal bile acids, therefore reducing the enterohepatic circulation of bile salts. Usually 4 g is administered before and after breakfast, and repeated at midday and evening meals (maintenance, 12 g/day). Unfortunately patient compliance is poor because of nausea; the treatment is unpalatable. Rifampicin is also useful and acts as a hepatic enzyme inducer, in addition to inhibiting hepatocyte uptake of bile salts. The controlled trial evidence of the value of the opioid antagonist naloxone has already been referred to (see above) [21] and oral opioid μ-receptor antagonists (naltrexone, nalmefene) are also available. [89] Development of opioid withdrawal symptoms has been noted in some treated cholestasis patients. [21], [36] This can be avoided by giving a slow infusion of naloxone [0.002 μg/kg per min (160 to 200 μg/24h)], doubling the rate of infusion every 3 h if no adverse events occur. Other treatments worth trying include codeine, [90] hydroxyethyl rutosides, [91] ultraviolet phototherapy, [92] ursodeoxycholic acid, [93] charcoal superfusion, [94] and odansetron. [95]

Aquagenic Pruritus and Water-Induced Itching of Polycythemia Vera

Antihistamines are rarely of value, despite the association of elevated histamine levels with this disorder. Although UVB phototherapy is effective in some patients, PUVA is the preferred treatment. [96] At least 50 percent of patients experience sustained improvement, although the treatment may have to be repeated on a 6 month or annual basis. [96] In the case of aquagenic pruritus associated with polycythemia vera, repeated venesection often relieves the pruritus. Aspirin has been advocated by some authors. Other treatments which have been advocated include attenuated androgens and interferon-a2b. [97], [98]

Pruritus of HIV

As indicated above, pruritus is an extremely common complaint in HIV sufferers and the causes are legion. Very thorough examination needs to be carried out, both in the skin and systemically, bearing in mind that there may be concurrently more than one cause. Pruritic papular eruptions including eosinophilic folliculitis are often treatment resistant. Phototherapy (UVB) [99] is well worth trying. Other measures include PUVA and pentoxifylline. [100]

REFERENCES

1. Twycross R et al: Itch: More than scratching the surface. *QJM* **96**:7, 2003

2. Bickford RGL: Experiments relating to itch sensation, its peripheral mechanism and central pathways. *Clin Sci* **3**:377, 1938

3. Rothman S: Physiology of itching. *Physiol Rev* **21**:357, 1941

4. Graham DT et al: Neural mechanisms involved in itch, “itchy skin” and tickle sensations. *J Clin Invest* **30**:37, 1951

5. Lewis T: Experiments relating to cutaneous hyperalgesia and its spread through somatic nerves. *Clin Sci* **2**:373, 1936

6. Lynn B: Cutaneous hyperalgesia. *Br Med Bull* **33**:103, 1977

7. Frey M von: Zur physiologie der juckempfinding. *Arch Neerl Physiol* **7**:142 1922

8. Bishop GH: Responses to electrical stimulation of single sensory units of skin . *J Neurophysiol* **6**:361, 1943

9. Shelley WE, Arthur RP: The neurohistology and neurophysiology of the itch sensation in man. *Arch Dermatol* **76**:296, 1957

10. Torok L: Uber das Wesen der Juckempfinding. *Ztschr Psychol* **46**:23, 1907

11. Toth Kasa I et al: Capsaicin prevents histamine-induced itching. *Int J Clin Pharmacol Res* **6**:163, 1986

12. Hillige M, Wang L et al: Ultrastructural evidence for nerve fibers within all vital layers of the human epidermis. *J Invest Dermatol* **104**:134, 1995

13. Torebjork HE: Afferent C units responding to mechanical, thermal and chemical stimuli in human non-glabrous skin. *Acta Physiol Scand* **92**:374, 1974

14. Schmelz M et al: Specific C receptors for itch in human skin. *J Neurosci* **17**:8003, 1997

15. Fruhstorfer H et al: The effect of thermal stimulation on clinical and experimental itch. *Pain* **24**:259, 1986

16. Andrew D, Craig AD: Spinothalamic lamina 1 neurons selectively sensitive to histamine: A central neural pathway for itch. *Nat Neurosci*

4:72, 2001

17. Davies MG, Greaves MW: Sensory responses of human skin to synthetic histamine analogues and to histamine. *Br J Pharmacol* **9**:255 1967

18. Greaves MW, Shuster S: Responses of skin blood vessels to bradykinin, histamine and 5-hydroxytryptamine. *J Physiol* **193**:255, 1967

19. Steinhoff M et al: Agonists of proteinase-activated receptor 2 induce inflammation by a neurogenic mechanism. *Nature Medicine* **6**:151, 2000

20. Jorrizo JL et al: Vascular responses of human skin to substance P and mechanism of action. *Eur J Pharmacol* **87**:67, 1983

21. Bergasa NV et al: Effects of naloxone infusions in patients with the pruritus of cholestasis. A double blind randomized controlled trial. *Ann Int Med* **123**:161, 1995

22. Kumagai H, Sasamua H, Hayashi M et al: Prospects for a novel opioid ? receptor agonist TRK-820 in uremic pruritus. *Proc Int Workshop on Itch, Singapore,* p 59, 2001

23. Greaves MW, Mc Donald Gibson W: Itch, the role of prostaglandins. *BMJ* **3**:601, 1967

24. Daly, BM, Shuster, S, Effect of aspirin in pruritus. *BMJ* **293**:907, 1986

25. Wall PD, Sweet WH: Temporary abolition of pain in man. *Science* **155**:108, 1967

26. Melzack R, Wall PD: Pain mechanisms: A new theory. *Science* **150**:971, 1965

27. Szepietowski JC, Schwartz RA: Uremic pruritus. *Int J Dermatol* **37**:247, 1998

28. Hampers CL et al: Disappearance of “uremic” itching after subtotal parathyroidectomy. *N Engl J Med* **279**:695, 1968

29. Cawley EP: Presidential address: A surfeit of mast cells in the skin of patients with uremia. *Arch Dermatol* **111**:1663, 1663

30. Carmichael AJ et al: Serological markers of renal itch in patients receiving long-term haemodialysis. *BMJ* **296**:1575, 1988

31. Pereira, BJG Dinarello, CA, Production of cytokines and cytokine inhibitory proteins in patients on dialysis. *Nephrol Dial Transplant* **9**(suppl 2):60, 1994

32. Berne B et al: UV treatment of uraemic pruritus reduces the vitamin A content of the skin. *Eur J Clin Invest* **14**:203, 1968

33. Peer G et al: Randomised crossover trial of naltrexone in renal pruritus. *Lancet* **348**:1552, 1996

34. Pauli-Magnus C, Mikus G, Alscher DM et al: Naltrexone does not relieve uremic pruritus: Results of a randomised, placebo-controlled crossover study. *J Am Soc Nephrol* **11**:514, 2000

35. Ghent CN et al: Elevations in skin tissue levels of bile acids in human cholestasis: Relation to serum levels and to pruritus. *Gastroenterology* **73**:1125, 1977

36. Thornton JR, Losowsky MS: Opioid peptides and primary biliary cirrhosis. *BMJ* **297**:1501, 1988

37. Bergasa NV, Jones EA: The pruritus of cholestasis: Potential pathogenic and therapeutic implications of opioids. *Gastroenterology* **108**:1582, 1995

38. Bergasa NV et al: Cholestasis in the male rat is associated with naloxone-reversible antinociception. *J Hepatol* **20**:85, 1994

39. Bergasa NV et al: Cholestasis is associated with proenkephalin mRNA expression in the adult rat liver. *Am J Physiol* **268**:G346, 1995

40. Bergasa NV et al: Plasma from patients with pruritus of cholestasis induces opioid receptor-mediated scratching in monkeys. *Life Sci* **53**:1253, 1993

41. Bergasa NV et al: A controlled trial of naloxone infusions for the pruritus of chronic cholestasis. *Gastroenterology* **102**:544, 1992

42. Caravati CM Jr et al: Cutaneous manifestations of hyperthyroidism. *South Med J* **62**:1127, 1969

43. Neilly JB et al: Pruritus in diabetes mellitus: Investigation of prevalence and correlation with diabetes control. *Diabetes Care* **9**:273, 1986

44. Scribner M: Diabetes and pruritus of the scalp. *JAMA* **237**:1559, 1977

45. Ross DR, Varipapa RJ: Treatment of painful diabetic neuropathy with topical capsaicin. *N Engl J Med* **321**:474, 1989

46. Lewiecki EM, Rahman F: Pruritus: A manifestation of iron deficiency. *JAMA* **236**:2319, 1976

47. Salem HH et al: Pruritus and severe iron deficiency in polycythaemia vera. *BMJ* **285**:91, 1982

48. Tucker WFG et al: Absence of pruritus in iron deficiency following venesection. *Clin Exp Dermatol* **9**:186, 1984

49. Berlin, NI: Diagnosis and classification of polycythaemias. *Semin Hematol* **12**:339, 1975

50. Gilbert HS et al: A study of histamine in myeloproliferative disease. *Blood* **78**:795, 1966

51. Archer CB et al: Polycythaemia vera can present with aquagenic pruritus. *Lancet* **1**:1451, 1988

52. Botero F: Pruritus as a manifestation of systemic disorders. *Cutis* **21**:873, 1978

53. Kantor GR, Lookingbill DP: Generalised pruritus and systemic disease. *J Am Acad Dermatol* **9**:375, 1983

54. Paul R et al: Itch and malignancy prognosis in generalized pruritus: A 6-year follow up of 125 patients. *J Am Acad Dermatol* **16**:1179, 1987

55. Rosenthal D et al: Human immunodeficiency virus-associated eosinophilic folliculitis: A unique dermatosis associated with advanced human immunodeficiency virus infection. *Arch Dermatol* **127**:206, 1991

56. Rodwell GEL, Berger TG: Pruritus and cutaneous inflammatory conditions in HIV disease. *Clin Dermatol* **18**:479, 2000

57. Shelley WB: Questions and answers: Post-wetness (aquagenic) pruritus. *JAMA* **212**:1385, 1970

58. Greaves MW et al: Aquagenic pruritus. *BMJ* **282**:2008, 1981

59. Archer, CB et al: Polycythaemia vera can present with aquagenic pruritus. *Lancet* **1**:1451, 1988

60. Steinman HK et al: Polycythaemia rubra vera and water induced pruritus: Blood histamine levels and cutaneous fibrinolytic activity before and after water challenge. *Br J Dermatol* **116**:329, 1987

61. Menage HduP, Greaves MW: Aquagenic pruritus. *Semin Dermatol* **14**:313, 1995

62. Newton JA et al: Aquagenic pruritus associated with the idiopathic hypereosinophilic syndrome. *Br J Dermatol* **122**:103, 1990

63. Mc Grath JA, Greaves MW: Aquagenic pruritus and the myelodysplastic syndrome. *Br J Dermatol* **123**:414, 1990

64. Handfield-Jones SE et al: Aquagenic pruritus associated with juvenile xanthogranuloma. *Clin Exp Dermatol* **18**:253, 1993

65. Ferguson JA et al: Aquagenic pruritus associated with metastatic squamous cell carcinoma of the cervix. *Clin Exp Dermatol* **19**:257, 1994

66. Jimenez-Alonso J et al: Antimalarial drug-induced aquagenic-type pruritus in patients with lupus. *Arthritis Rheum* **41**:744, 1998

67. Metze D et al: Persistent pruritus after hydroxyethyl starch infusion therapy: A result of long-term storage in cutaneous nerves. *Br J Dermatol* **136**:553, 1997

68. Eisenberg E et al: Notalgia paraesthetica associated with nerve root impingement. *J Am Acad Dermatol* **37**:998, 1997

69. Walcyk PJ, Elpern DJ: Brachioradial pruritus: A tropical dermopathy. *Br J Dermatol* **115**:177, 1986

70. Taniguchi S et al: Generalised pruritus in anorexia nervosa. *Br J Dermatol* **134**:510, 1996

71. Morgan JF, Lacey JH: Scratching and fasting: A study of pruritus and anorexia nervosa. *Br J Dermatol* **140**:453, 1999

72. Shabtai H et al: L Pruritus in Creutzfeldt-Jakob disease. *Neurology* **46**:940, 1996

73. Krause L, Shuster S: Mechanism of action of antipruritic drugs. *BMJ* **287**:1199, 1983

74. Rukweid R et al: Mast cell mediators other than histamine induce pruritus in atopic dermatitis patients: A dermal microdialysis study. *Br J Dermatol* **142**:1 2000

75. Ruzicka T et al: A short term trial of tacrolimus ointment for atopic dermatitis. *N Engl J Med* **337**: 816, 1997

76. Lindley RP, Payne CMER: Neural hyperplasia is not a diagnostic requirement in nodular prurigo. *J Cutan Pathol* **16**:14, 1989

77. Liang Y et al: Light and electron microscopic immunohistochemical observations of p75 nerve growth factor receptor—Immunoreactive dermal nerves in prurigo nodularis. *Arch Derm Res* **291**:14, 1999

78. Winkelmann RK et al: Thalidomide treatment of prurigo nodularis. *Acta Derm Venereol* **64**:412, 1984

79. Darsow U et al: New aspects of itch pathophysiology: Component analysis of atopic itch using the “Eppendorf itch questionnaire.” *Int Arch Allergy Immunol* **124**:326, 2001

80. Bromm B et al: Effects of menthol and cold on histamine-induced itch and skin reactions in man. *Neurosci Lett* **187**:157, 1995

81. Caterina MJ et al: The capsaicin receptor: A heat-activated ion channel in the pain pathway. *Nature* **389**:816, 1997

82. Tang WYM et al: Evaluation on the antipruritic role of transepidermal electrical nerve stimulation in the treatment of pruritic dermatoses. *Dermatology* **199**:237, 1999

83. Wallengren J: Cutaneous field stimulation in the treatment of severe itch. *Arch Dermatol* **137**:1323, 2001

84. Zylicz Z et al: Paroxetine for pruritus in advanced cancer. *J Pain Symptom Manage* **16**:121, 1998.

85. Sanger GJ, Twycross R: Making sense of emesis pruritus 5-HT and 5-HT-3 receptor antagonists. *Progr Pall Care* **4**:7, 1996

86. Metze, D et al: Efficacy and safety of naltrexone, an oral opiate receptor antagonist in the treatment of pruritus in internal and dermatological diseases. *J Am Acad Dermatol* **41**:533, 1999

87. Gilchrest BA et al: Ultraviolet B phototherapy for uremic pruritus. Long-term results and possible mechanism of action. *Ann Intern Med* **91**:17, 1979

88. Balaskas EV et al: Histamine and serotonin in uremic pruritus: Effect of odansetron in CAPD-pruritic patients. *Nephron* **78**:395 1998

89. Bergasa NV et al: Open label trial of oral nalmefene therapy for the pruritus of cholestasis. *Hepatology* **27**:679, 1998

90. Zylicz Z, Krajnik M: Codeine for pruritus in primary biliary cirrhosis. *Lancet* **353**:813, 1999

91. Hishon S et al: The relief of pruritus in primary biliary cirrhosis by hydroxyethyl rutosides. *Br J Dermatol* **105**:457, 1981

92. Maggiore G et al: Phototherapy for pruritus in chronic cholestasis of childhood. *Eur J Pediatr* **139**:90, 1982

93. Matzusaki Y et al: Improvement of biliary enzyme and itching as a result of long-term administration of ursodeoxycholic acid in primary

biliary cirrhosis. *Am J Gastroenterol* **85**:15, 1990

94. Duncan JS et al: Treatment of pruritus due to chronic obstructive liver disease. *BMJ* **289**:22, 1984

95. Schworer H, Ramamadori G: Improvement of cholestatic pruritus by odansetron. *Lancet* **341**:1277, 1995

96. Menage H du P et al: The efficacy of psoralen photochemotherapy in aquagenic pruritus. *Br J Dermatol* **127**:163, 1993

97. Kolodny L et al: Danazol relieves refractory pruritus associated with myeloproliferative disorders and other diseases. *Am J Hematol* **51**:112, 1996

98. Muller EW et al: Long-term treatment with interferon-a2b for severe pruritus in patients with polycythemia vera. *Br J Haematol* **89**:313, 1995

99. Lim HW et al: UVB phototherapy is an effective treatment for pruritus in patients infected with HIV. *J Am Acad Dermatol* **37**:414, 1997

100. Berman B et al: Efficacy of pentoxifylline in the treatment of pruritic papular eruption of HIV-infected persons. *J Am Acad Dermatol* **38**:955, 1998

T>

Chapter 42

Enno Christophers Ulrich Mrowietz

Psoriasis

HISTORIC ASPECTS
EPIDEMIOLOGY
Incidence
Age of Onset
Mode of Inheritance
CLINICAL FEATURES
General Considerations
Clinical Patterns of the Skin Presentation (Table 42-2)
Quality of Life
Natural History
Trigger Factors
Systemic Associations
Immunopathology
Concomitant Diseases
LABORATORY ABNORMALITIES
Bacteriology of Psoriatic Plaques
PATHOLOGY
Chronic (Plaque-Type) Psoriasis
Eruptive (Guttate) Psoriasis
The Initial Lesion
DIAGNOSIS AND DIFFERENTIAL DIAGNOSIS
PATHOGENESIS
Background
Immunopathology
TREATMENT
Topical Treatment
Treatment with Ultraviolet Light
Systemic Treatment
Other New Methods to Treat Psoriasis

REFERENCES

Psoriasis is a chronic relapsing disease of the skin characterized by variable clinical features. The cutaneous lesions are usually so distinct that a clinical diagnosis is easy to make. The lesions are classified as erythrosquamous, which indicates that both the vasculature (erythema) and the epidermis (increased scale formation) are involved.

The morphology of the skin lesions varies considerably. Table 42-1 lists the terms commonly used to describe the different morphologic types of the disease (also see Fig. 42-1, Fig. 42-2, Fig. 42-3, Fig. 42-4, Fig. 42-5 and Fig. 42-6). Psoriasis vulgaris is the most common type of psoriasis. Circular plaques are predominant on the elbows, knees, lower back, and umbilical area, whereas eruptive (guttate) lesions often are confined to the trunk and proximal extremities.

Annular psoriasis	Gyrate psoriasis
Circinate psoriasis	Inverse psoriasis
Follicular psoriasis	Nummular psoriasis
Generalized psoriasis	Pustular psoriasis
Geographic psoriasis	Sebopsoriasis
Guttate psoriasis	

TABLE 42-1 **Terms Describing Morphologic Features of Psoriasis**

FIGURE 42-1 Chronic stationary psoriasis located at typical sites.

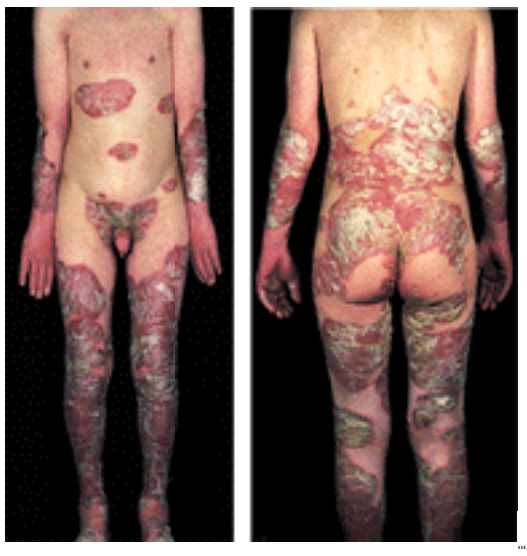

FIGURE 42-2 Chronic stationary psoriasis covering large areas of the body.

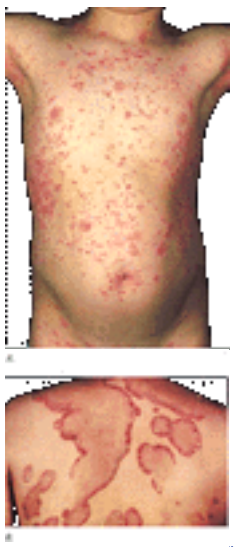

FIGURE 42-3 *A.* Recent onset of eruptive guttate psoriasis showing highly erythematous macules and papules. *B.* Chronic stationary psoriasis presenting as annular lesions.

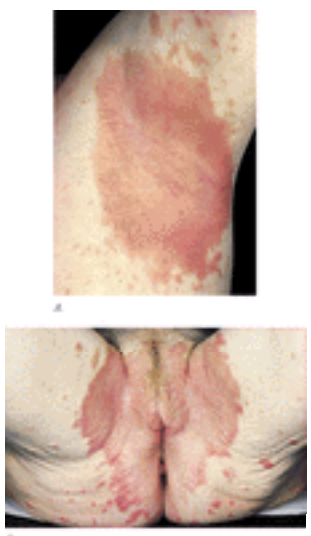

FIGURE 42-4 Inverse psoriasis (*A, B*). The skin in the intertriginous areas is highly erythematous, and typical scaling is lacking.

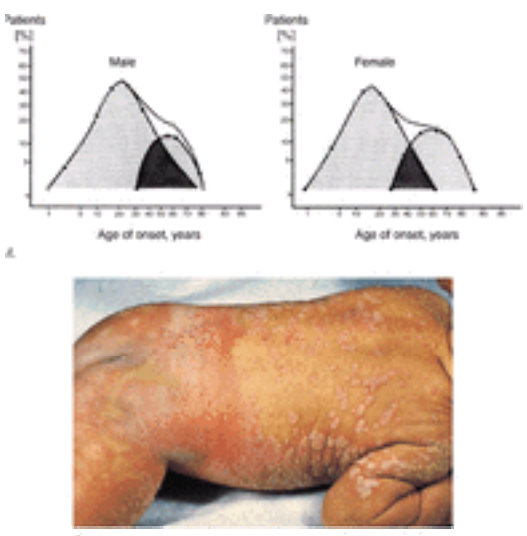

FIGURE 42-5 *A.* Age of patients at the first onset of psoriasis. A total of 2147 patients suffering from various types of psoriasis were examined and the age of onset was recorded. Most patients of both sexes had an early onset [age 16 (F) and 22 (M)], while nearly one-quarter had a late onset (age 56). See original publication for details. (*From Henseler and Christophers,* [4] *with permission.*) *B.* Psoriasis presenting in early infancy.

FIGURE 42-6 Psoriasis vulgaris of the scalp extending onto the neck (*A*). Psoriatic lesions on palm (*B*) and heel (*C*) skin.

Psoriatic erythroderma involves the entire body, presenting with generalized erythema and varying degrees of scale.

Psoriasis also may present in a pustular form. There is a generalized form, usually referred to as *pustular psoriasis* (von Zumbusch), and a localized variant, confined to the palms and soles, known as *pustulosis palmaris et plantaris* (PPP; see Chap. 70). In rare instances in psoriasis of the plaque type or guttate psoriasis, pustules may develop after acute relapses (psoriasis with pustules).

The clinical presentation varies depending on a number of factors, which may cause an individual to present with a few localized psoriatic plaques or with generalized skin involvement and the development of pustules. The disease activity is reflected predominantly as scaling in stationary plaques and as inflammation in the eruptive guttate lesions.

Psoriasis can be disabling not only because of skin involvement but also because of concomitant joint disease. Psoriatic arthritis is the only recognized noncutaneous manifestation of the disease and is discussed in detail in Chap. 43.

HISTORIC ASPECTS

The earliest descriptions of what appears to represent psoriasis are given at the beginning of medicine in the *Corpus Hippocraticum.* This work was edited in Alexandria 100 years after the death of Hippocrates (460–377 B.C.), who presumably was the author. Hippocrates used the terms *psora* and *lepra* for conditions that can be recognized as psoriasis. Later, Celsus (*ca.* 25 B.C.), who translated the writings of Tiberius Claudius Menekrates (the personal physician of Emperor Tiberius) into Greek, described, among 40 different dermatoses, a form of impetigo that was interpreted by R. Willan (1757–1812) as being psoriasis. Willan separated two diseases as psoriasiform entities, a discoid lepra Graecorum and a polycyclic confluent psora leprosa, which later was called *psoriasis.* In 1841, the Viennese dermatologist Ferdinand von Hebra (1816–1880) unequivocally showed that Willan's lepra Graecorum and psora leprosa were one disease that had caused much confusion because of differences in the size, distribution, growth, and involution of lesions.

EPIDEMIOLOGY

Incidence

Psoriasis is universal in occurrence. In the United States, psoriasis affects about 2 percent of the population, with approximately 150,000 newly diagnosed cases per year. The worldwide incidence varies considerably. Reasons for such variations range from racial to geographic and environmental. [1] For instance, in the Faeroe Islands, 2.8 percent of the population are affected. While inbreeding may contribute to this incidence, the normal positive effect of sunlight on psoriasis also may play a role because the Faeroe Islands are 61° north latitude. [2] Other data demonstrate that the incidence of psoriasis ranges from 0.97 percent in South America to 1.3 percent in Germany, 1.6 percent in Great Britain, 1.7 percent in Denmark, and 2.3 percent in Sweden. Psoriasis is rare in West African and North American blacks. The incidence of the disease is also low in Japanese and Eskimos. Psoriasis is nearly absent in North American Indians, and in an examination of 26,000 South American Indians, not a single case was seen. Psoriasis is equally common in males and females. [1]

Age of Onset

The onset of psoriasis constitutes a lifelong threat. It has been reported to be present at birth and was described recently as having its onset at age 108. [3] As demonstrated by several studies, most patients develop the initial lesions of psoriasis in the third decade of life. First signs appear in males at a mean age of 29 and in females at age 27. [1] A study of the onset of psoriasis in 2400 patients showed a peak incidence at 22.5 years of age; a second peak of onset around age 55 was found in 11.8 percent of the patients [4] (see Fig. 42-5A). In a study of psoriasis in 245 children, the mean age of onset was 8.1 years, [5] and in a census study from the Faeroe Islands, the mean age of onset was 12.5 years. [2] An early onset (before age 15) predicts more severe disease relative to the percentage of body surface involved with psoriasis and the response to therapy. Also, the earlier the onset, the greater is the probability of a positive family history of psoriasis. [6]

Mode of Inheritance

The major support for concluding that there is a genetic predisposition to psoriasis comes from studies showing (1) an increased incidence in psoriasis among relatives of affected probands, (2) a proportionally increased incidence of psoriasis in offspring of matings in which one or both parents are afflicted, (3) high rates of concordance for psoriasis

among monozygotic twins when one is afflicted, and (4) susceptibility loci located on various chromosomes, including disequilibrium of certain major histocompatibility antigens. [7], [8] and [9]

Approximately one-third of patients with psoriasis report some relative with the disease. [10] In a recent study it was found that when one parent had psoriasis, psoriasis also developed in 8.1 percent of the offspring. This value increased to 41 percent when both parents had psoriasis. These data are in accordance with a trait of inheritance involving more than one gene.

The incidence of psoriasis has been recorded in 117 monozygotic twins. Of these, 65 percent were concordant for the disease. This percentage contrasts with a 30 percent concordance for psoriasis in 112 dizygotic twins, of whom at least one twin in each pair has psoriasis. Reconsideration of those population-based studies as well as the twin studies confirmed that psoriasis is a heritable disease with a multilocus model of inheritance. Environmental factors are likely to play a role in triggering the disease.

As noted, there is disequilibrium (greater than expected frequency) between certain class I antigens (human leukocyte antigens, or HLAs) of the histocompatibility locus on human cells and psoriasis. The HLA types most frequently reported to be associated with psoriasis are HLA-B13, HLA-Bw57, HLA-Cw6, and HLA-DR7. [8], [11]

Mapping of HLA phenotypes in families with psoriasis supports the genetic linkage for psoriasis as well as a link between psoriasis and arthritis.

In a study of 2100 patients with nonpustular psoriasis, evaluation of the age of onset revealed two peaks, one occurring at the age of 16 years in females and 22 years in males and a second near the age of 60 years in both females and males [4] (see Fig. 42-5A). Nearly 50 percent of the first-degree family members of patients with early onset were found to be affected, and 85 percent of the patients were HLA-Cw6+. By contrast, only 15 percent of patients with late onset were HLA-Cw6+. Psoriasis in patients with early onset was noted to follow an unstable course, generally with a more severe disease expression. [4]

Generalized pustular psoriasis appears to be in disequilibrium with HLA-B27. [12] This finding contrasts with observations of pustular psoriasis of the palms and soles, in which there is no disequilibrium between the disease and HLA antigens. Patients with psoriasis who also have peripheral arthritis have an association with HLA-B27. This disequilibrium is most marked if spondylitis is present, and this finding may link classic ankylosing spondylitis, Reiter's disease, and psoriasis.

CLINICAL FEATURES

General Considerations

SKIN Various morphologic forms of psoriasis have been distinguished and given special names (see Table 42-1). Lesions of psoriasis show four prominent features: (1) they are sharply demarcated with clear-cut borders, (2) the surface consists of noncoherent silvery scales, (3) under the scale the skin has a glossy, homogeneous erythema, and (4) there is an Auspitz sign. The size of a single lesion varies from a pinpoint to plaques that cover large areas of the body. The clinical presentation of psoriasis is better understood when it is realized that disease activity can range from a chronic stationary phase, to a resolving process, to flares of disease that may be associated with numerous sterile pustules. The Auspitz sign is a specific feature of the erythrosquamous lesion of psoriasis. It is noted when the hyperkeratotic scales are mechanically removed from a psoriatic plaque by scraping. Within a few seconds after mechanical removal of the scale, small blood droplets appear on the shiny erythematous surface (Fig. 42-7A, Fig. 42-7B, Fig. 42-7C and Fig. 42-7D). The Auspitz sign has diagnostic value; it is not present in inverse or pustular psoriasis and may help to differentiate psoriasis from other skin conditions with a similar morphology.

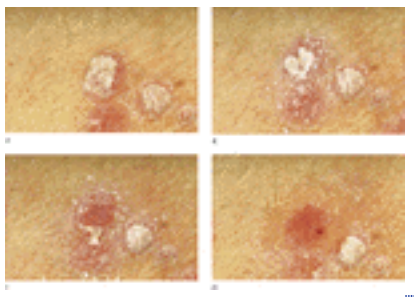

FIGURE 42-7 The Auspitz phenomenon in its three phases: *A.* Native psoriatic lesion. *B.* Scratching generates silvery-opaque scale. *C.* Further scratching leads to removal of the scale, and a glossy area is visible. *D.* Further scratching produces blood droplets.

In addition to the Auspitz sign, the Koebner phenomenon can be elicited in approximately 20 percent of patients. After nonspecific irritation, psoriatic lesions develop in areas where they were not present previously.

NAILS Nail changes are frequent in psoriasis. Based on a questionnaire to 5600 patients, Farber and Nall [1] reported that fingernails are involved in 50 percent of subjects and toenails in 35 percent. The variety of nail changes ranges from minor defects in the nail plate (pits) to severe alterations of the nail organ (onychodystrophy) and loss of the nail plate when the pustular forms of psoriasis involve the nail. These morphologic alterations reflect the extent to which the psoriatic process affects the various portions of the nail organ—i.e., the proximal nail fold, nail matrix, nail bed, and hyponychium. The degree of nail involvement depends on the localization of the psoriatic tissue changes at these sites as well as on how long these processes last. Three main morphologic alterations in the structure of the nail are appreciated:

1. Pits are evident within the nail plate. This morphologic pattern apparently is due to defective keratinization of the dorsal side of the proximal nail fold (Fig. 42-8A).

FIGURE 42-8 Nail psoriasis shows various features depending on the location of the psoriatic process: *A.* Nail pits. *B.* Characteristic yellowish or brown color known as an *oil spot. C.* Involvement of nearly the entire nail bed with onychodystrophy. *D.* Involvement of nearly the entire nail bed followed by loss of nails.

2. Yellowish macules beneath the nail plate often extend distally toward the hyponychium. This morphologic pattern appears to be caused by psoriatic processes located in the nail bed (see Fig. 42-8B).
3. Severe onychodystrophy results in yellowish keratinous material. This morphologic pattern is believed to be secondary to psoriasis involving the nail matrix (see Fig. 42-8C).

In pustular psoriasis, the nail changes consist of subungual pustules of the nail bed or the nail matrix. If major portions of either are affected with this process, loss of the nail plate, or even dystrophy of the matrix (anonychia) can occur (see Fig. 42-8D). In pustular psoriasis of the palms and soles, nail changes are rare. Nail changes are more frequent in patients with arthritis.

Clinical Patterns of the Skin Presentation (Table 42-2)

Nonpustular	Pustular
	Pustular psoriasis of von Zumbusch
Psoriasis vulgaris, early and late onset	
Psoriatic erythroderma	Pustulosis palmaris et plantaris
	Pustular psoriasis, annular type
	Acrodermatitis continua
	Impetigo herpetiformis

TABLE 42-2 **Clinical Classification of Psoriasis**

PSORIASIS VULGARIS, CHRONIC STATIONARY PSORIASIS, PLAQUE-TYPE PSORIASIS This clinical pattern is the most frequent. Red scaly lesions, as described earlier, persist for months to years (see Fig. 42-1, Fig. 42-3B, and Fig. 42-9). There is constant production of large amounts of scale with little alteration in shape or distribution of individual plaques. Areas of predilection are the elbows (see Fig. 42-1A), the knees (see Fig. 42-1B), the scalp (see Fig. 42-1C) and, in particular, the retroauricular region, the lumbar area (Fig. 42-1D), and the umbilicus. Single small lesions may become confluent, forming plaques in which the borders resemble a land map (psoriasis geographica) (see Fig. 42-3B). Lesions may extend laterally and become circinate because of the confluence of several plaques (psoriasis gyrata). Occasionally there is partial central clearing, resulting in ringlike lesions (annular psoriasis) (see Fig. 42-3B).

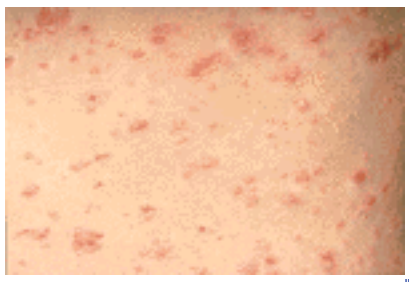

FIGURE 42-9 Guttate (eruptive) psoriasis with highly erythematous lesions. These can become confluent within weeks after their first appearance.

Psoriasis lesions may be localized in the major skin folds, such as the axillae, the genitocrural region, and the neck (psoriasis inversa) (see Fig. 42-4A, Fig. 42-4B). Here, scaling is absent, and the lesions show a glossy, sharply demarcated erythema.

Eruptive (guttate) psoriasis Typically, this pattern (see Fig. 42-3A) presents as small (0.5–1.5 cm in diameter) lesions over the upper trunk and proximal extremities. This form is characteristic of psoriasis of an early age of onset and as such is found frequently in young adults. As noted below (see " Trigger Factors" below), streptococcal throat infection frequently precedes the onset or flare of guttate psoriasis. Occasionally, a disseminated macular drug eruption may precede this pattern of psoriasis. Very active lesions of psoriasis of many types can have pustules that are 1 to 2 mm in diameter and are surrounded by an intensive wall of erythema. This process usually signals an acute exacerbation of disease. Predisposing factors for such an event are bacterial infection, aggressive local therapy, or withdrawal of systemic glucocorticoids (see " Trigger Factors" below).

Psoriatic erythroderma Psoriatic erythroderma (Fig. 42-10) represents the generalized form of the disease that affects all body sites, including the face, hands, feet, nails, trunk, and extremities. Although all the symptoms of psoriasis are present, erythema is the most prominent feature, and scaling usually is less severe compared with chronic stationary psoriasis. Psoriatic erythroderma may have different degrees of disease activity, presenting suddenly as a generalized erythema or evolving gradually from chronic plaque psoriasis into a generalized exfoliative phase. In the latter phase there are usually some areas of uninvolved skin.

FIGURE 42-10 Psoriatic erythroderma. There is generalized erythema and various degrees of scaling in the severe form of psoriasis (*A, B*). The lips (*C*) and the glans penis (*D*) are involved.

Psoriatic erythroderma may be the response to nontolerated topical treatment (e.g., anthralin, ultraviolet B, or UVB), representing a generalized Koebner reaction. Generalized pustular psoriasis may revert to only erythroderma, pustule formation being diminished or absent. This form shows all the features of pustular psoriasis, including fever, malaise, frequent relapses, and relatively high mortality after prolonged courses. There may be complete loss of nail growth due to destruction of the nail matrix. Further descriptions of the effects of exfoliative erythroderma on the body are covered in Chap. 44 and under " Systemic Effects" below.

Generalized pustular psoriasis (von Zumbusch) Pustular psoriasis of the von Zumbusch type (Fig. 42-11) appears as a distinctive acute variant of psoriasis. It is unusual to see other forms of psoriasis on the skin at the same time. Attacks of pustular psoriasis are characterized by fever that lasts several days. A sudden generalized eruption of sterile pustules 2 to 3 mm in diameter parallels the onset of fever. The pustules are disseminated over the trunk and extremities, including the nail beds, palms, and soles. The pustules usually arise on highly erythematous skin, first as patches and then becoming confluent as the disease becomes more severe. In addition to the pustule formation of the nail matrix and loss of the entire nail, the fingertips may become atrophic in patients with prolonged disease. As with other forms of psoriasis, the face usually remains free of lesions. The erythema that surrounds the pustules often spreads and becomes confluent, leading to erythroderma. Characteristically, the disease occurs in waves of fever and pustules. This syndrome is further described below (see " Systemic Effects").

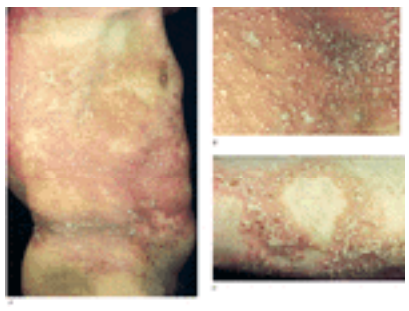

FIGURE 42-11 Pustular psoriasis. There are tiny pustules, 1 to 2 mm in diameter, on a highly erythematous slightly indurated skin surface (*A, B*). These pustules may acquire annular shapes (*C*).

Annular pustular psoriasis A rare variant of pustular psoriasis is an annular, or circinate, form of the disease (see Fig. 42-11C) occurring during episodes of pustular eruptions. Lesions may appear at the onset of pustular psoriasis, with a tendency to spread and form enlarged rings, or they may develop during the course of generalized pustular psoriasis. The main features are pustules on a ringlike erythema that sometimes resembles erythema annulare centrifugum. Histologically, there is mild acanthosis and a neutrophil accumulation with formation of microabscesses. Identical lesions are found in patients with impetigo herpetiformis, a pustular form of psoriasis associated with pregnancy (see Chap. 142).

Localized pustular psoriasis Localized pustular psoriasis presents as two distinct conditions that must be considered separate from the generalized disease. Systemic symptoms are absent. The two distinct varieties are pustulosis palmaris et plantaris and acrodermatitis continua. They are discussed in Chap. 70.

Quality of Life

Psoriasis represents a lifelong burden for affected patients. A comparative study reported reduction in physical functioning and mental functioning comparable with that seen in cancer, arthritis, hypertension, heart disease, diabetes, and depression. [13] According to a recent survey of the National Psoriasis Foundation, 79 percent of patients with severe psoriasis reported a negative impact on their lives. In terms of treatment, 40 percent felt frustrated with the ineffectiveness of their current therapies. [14] Among the chief complaints of patients with psoriasis are the lowered self-esteem and feelings of being socially outcast. The presence of pruritus and pain can aggravate these symptoms. The increased incidence of arthritis in patients with psoriasis makes arthralgia a frequent complaint (see Chap. 43).

Natural History

Most studies indicate that once psoriasis appears as an early localized disease, it persists throughout life, manifesting at unpredictable intervals. [1] Spontaneous remissions do occur with varying frequencies. In two separate studies involving about 200 patients per study, remission ranged from 17 to 55 percent. In another study of 2800 patients, 29 percent reported a remission. The duration of these remissions ranges from 1 to 54 years. Data relative to permanent remissions, either spontaneous or induced, appear to be unavailable.

Trigger Factors

External factors may provoke manifestations of psoriatic skin lesions; they may be called *trigger factors.*

Natural incidence studies suggest that environment plays a predisposing role. Hot weather and sunlight are reported to be beneficial, whereas cold weather appears to have an opposite effect. The increased prevalence of psoriasis in the Nordic population of the Faeroe Islands supports this notion.

PHYSICAL TRAUMA: THE KOEBNER PHENOMENON In 1872, Koebner described a patient who, 5 years after developing psoriasis, noted that various traumatic insults to his skin resulted in lesions of psoriasis. Specifically, psoriasis occurred in the precise spots where his horse had bitten him. Shortly thereafter his psoriasis generalized. Koebner hypothesized that there were intervals in the course of psoriasis when skin injury results in disease (Fig. 42-12).

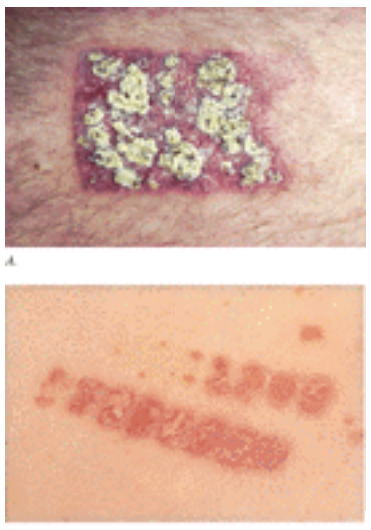

FIGURE 42-12 Koebner's phenomenon. As shown (*A*) by the appearance of typical erythematosquamous lesions within a scar or (*B*) after various doses of UVB.

The original description by Koebner suggests that the incidence of the Koebner phenomenon in psoriatic subjects is increased when the disease is active. Patients with the Koebner reaction appear more likely to have developed psoriasis at an early age and to require multiple therapies to control their disease.

INFECTIONS Infections have long been recognized as a trigger for the onset or exacerbation of psoriasis. The frequency with which infections trigger psoriasis varies from a low of 15 percent in a retrospective analysis of clinic charts of 255 patients to a high of 76 percent in mailed questionnaires to over 500 patients. Up to 54 percent of children are reported to exacerbate existing psoriasis during the 2- to 3-week interval after an upper respiratory infection. [5] Acute guttate psoriasis frequently follows an acute streptococcal infection by 1 to 2 weeks. Among patients with acute guttate psoriasis, 56 to 85 percent have immediately preceding evidence of streptococcal disease. Strep infections may play a role in exacerbating other forms of psoriasis. *Streptococcus pyogenes* (beta-hemolytic streptococci, group A) was isolated in 26 percent of patients with acute guttate psoriasis, 14 percent of patients with guttate flare of plaque psoriasis, and 16 percent of patients with chronic psoriasis. [15] *S. pyogenes* was isolated in 7 percent of the control population. The serotypes did not differ significantly from those of the community. Thus, while streptococcal pharyngitis appears to be a trigger factor, it is not type-specific. [15] Infection with the human immunodeficiency virus type 1 (HIV-1) may represent another important trigger factor, although the incidence varies considerably. [16] Patients may present with two distinct clinical patterns. One is localized, showing either guttate or large plaques. The other is a more diffuse psoriasiform dermatitis, often associated with palmoplantar keratoderma. The psoriasiform dermatitis may be the first clinical manifestation of HIV infection. Rapid onset of acute eruptive psoriasis, as well as exacerbations in patients with previous chronic stable plaque psoriasis, suggests the possibility of underlying HIV disease.

STRESS Clinical studies support patients' perceptions that psoriasis is made worse by stress in approximately 30 to 40 percent of cases. No personality disorders or traits unique to patients with psoriasis have been found. It is commonly believed that alcohol has an adverse effect on psoriasis, but this impression has not been confirmed. This belief appears to be based on observations of alcoholics who have psoriasis, begin to drink excessive amounts of alcohol, and subsequently have a flare of disease.

ANATOMIC SITES Certain anatomic sites are prone to develop disease and as such can be considered within the realm of trigger factors. In chronic stationary psoriasis, the scalp is involved most frequently, followed by the knees and elbows. Reasons for this pattern are unknown.

DRUGS Beta-adrenergic blockers can exacerbate psoriasis or trigger the development of first lesions. The reported exacerbations of psoriasis associated with antimalarials may have been overemphasized in the past. Lithium is a strong inducer of psoriasis lesions. Certain angiotensin-converting enzyme inhibitors also have been reported as exacerbating drugs in psoriasis. [17]

Systemic Associations

ARTHRITIS AND INFLAMMATORY BOWEL DISEASE The association of arthritis and psoriasis is discussed in Chap. 43. Therapy of psoriasis with ultraviolet light leads to improvement in the arthritis. Linkage beyond this (i.e., both diseases being mediated by similar inflammatory processes) remains speculative. The strong linkage of HLA-B27 to ankylosing spondylitis and ulcerative colitis and the increased frequency of this haplotype in patients with psoriasis and arthritis (about six times normal) suggest that ulcerative colitis should be seen more frequently in patients with psoriasis. Recent studies tend to confirm this impression. The frequency of psoriasis among patients with ulcerative colitis and Crohn's disease is, respectively, 3.8 and 1.6 times normal. [18]

Immunopathology

GENETIC STUDIES Studies conducted in various countries revealed psoriasis as a multifactorial disorder where multiple genes are involved. These are likely to interact with each other as well as with environmental trigger factors. Susceptibility loci located on various chromosomes (see Table 42-3) have been found. [19]

Locus	Position	Candidate Genes
PSORS1	6p21.3	Corneodesmosin, HCR
PSORS2	17q25	
PSORS3	4q	
PSORS4	1q21	Epidermal differentiation Complex gene cluster
PSORS5	3q	SLC12A8
PSORS6	19p	
PSORS7	1p	

TABLE 42-3 **Genetic Susceptibility Loci in Psoriasis**

Linkage disequilibrium studies have shown strong association with a gene or genes within the major histocompatibility complex (MHC) within a 12-cM region on chromosome 6p21.3. [20] In fact, there is a strong association of early-onset psoriasis with class I and II HLA markers—including B13, Bw57, Cw6, and DR7—in contrast to psoriasis of late onset, in which A2 as well as B27 were moderately increased. [4], [21] The strongest association was seen in type I psoriasis, with Cw6 being present in over 80 percent of cases. Extended haplotypes for type I psoriasis were observed by oligonucleotide typing. In addition to Cw6, these consist of DRB1*0701/2, DQA1*0201, and DQB1*0303. [22] Comparison of all HLA loci revealed Cw6 being in linkage disequilibrium with DQB1*0303 as the most powerful disease marker. The association with HLA-Cw6 is noted worldwide, but only 10 percent of HLA-Cw6+ individuals develop psoriasis. This is likely to be due to the presence of more than one gene necessary to produce disease in addition to the effect of environmental factors. Whereas HLA-C can be excluded as an psoriasis-causing allele, a gene likely to be responsible for 30 to 50 percent of psoriatic disease expression [20], [23] appears to reside within a 300-kb interval centered around the centromeric end of class I MHC beyond HLA-C and toward HLA-A. [19], [20] Candidate genes in this region are *corneodesmosin* and *HCR* as well as novel yet unidentified genes in this region. Patients with early-onset psoriasis (type I) are more likely to carry the *PSORS I* gene. Poststreptococcal guttate psoriasis generally is HLA-Cw6+, indicating that the *PSORS I* gene plays a major role in psoriasis developing at young age. In addition, HLA-Cw6 is often seen in patients with psoriatic arthritis, and this is more often present as compared with HLA-B27, indicating that HLA-B27 is not the major determinant for psoriatic arthritis. Evidence for linkage of patients with psoriatic joint disease with a chromosome 17q locus has been presented. This locus is also seen in familial rheumatoid arthritis. Genetic studies on Crohn's disease have found linkage to a candidate locus on chromosome 16. Since the risk for psoriasis is 7 times higher in patients with Crohn's disease, this disease association could indicate a genetic background. Taking these genetic findings together shows that aside from *PSORS I* in HLA, various non-MHC genes are likely to play a role in modulating disease expression.

Concomitant Diseases

Epidemiologic data reveal a distinct number of diseases associated with psoriasis more often than expected from surveys in nonpsoriatic control individuals. These include (1) arthritis (10–15 times more common), (2) Crohn's disease (4 times more common), and (3) cardiovascular disease, hyperpertension, and diabetes (1.5 times more common). On the other hand, atopy, atopic dermatitis, and urticaria are noted infrequently in psoriasis patients. In addition, the relative paucity of cutaneous infections adds to the distinct pattern of associated disorders in psoriasis. [24]

The frequency of concurrent diseases in patients with psoriasis was reexamined recently in a controlled inpatient study. [24] As a result, a distinct group of systemic disorders—including hypertension, heart failure, obesity, and diabetes, in addition to chronic oropharyngeal infections—was found to be significantly more frequent in psoriasis patients as compared with age-matched control patients suffering from nonpsoriatic skin disorders. In contrast, bacterial and several viral skin infections were reduced significantly.

SYSTEMIC EFFECTS OF PSORIASIS Beyond the foregoing systemic effects are those associated with pustular psoriasis and exfoliative erythroderma. The physical and laboratory findings associated with exfoliative erythroderma are considerable and are described in greater detail in Chap. 44. Generalized pustular psoriasis, as described by von Zumbusch, is the form associated with systemic findings. This form of psoriasis appears as waves of sterile pustules on an erythematous skin. Characteristically, short episodes of fever (39–40°C) are followed by another wave of new pustules. In addition to the fever, there are systemic signs of disease, such as weight loss, muscle weakness, leukocytosis, hypocalcemia, and an increased sedimentation rate. These systemic complications may be fatal, usually as a result of the protean manifestations of severe systemic disease, congestive heart failure, and intercurrent infections. The skin symptoms may resolve spontaneously, leading to full recovery. The cause of this dramatic illness is obscure; however, a number of provoking agents or events are well recognized. They range from local irritating substances, as in von Zumbusch's original case, to pregnancy, oral contraceptives, lithium, infections, hypocalcemia secondary to hypoalbuminemia, and withdrawal from glucocorticoids. In patients with pustular psoriasis, arthropathy is common, as is the HLA-B27 haplotype. The disease is uncommon but well documented in children.

ASSOCIATION WITH MALIGNANCY Studies of approximately 500 patients suggest that patients with psoriasis have a normal risk of systemic cancer and possibly an increased risk of cutaneous cancer. [25] These analyses do not include the risk of developing skin carcinomas in patients undergoing treatments with psoralen plus ultraviolet A (PUVA) [26] (see "Photochemotherapy," below).

PSORIASIS AND OTHER SKIN DISEASES A number of skin diseases are reported to occur concomitantly in patients with psoriasis, and psoriasis may develop in association with preexisting skin diseases. In a study involving more than 2000 patients with atopic dermatitis and 800 with psoriasis, the observed incidence of patients having both diseases was much lower than calculated by their incidence rates. [27] It is suggested that both diseases are mutually exclusive, representing two contrasting types of cutaneous immunopathology.

LABORATORY ABNORMALITIES

Laboratory abnormalities in psoriasis are usually not specific and may not be found in all patients with the exception of those with generalized pustular psoriasis and psoriatic erythroderma (Table 42-4).

Elevated uric acid
Mild anemia
Negative nitrogen balance
Increased α_2-macroglobulin
Immunoglobulin aberrations, increased IgA levels, and increased quantities of immune complexes

TABLE 42-4 **Common Laboratory Abnormalities in Psoriasis**

Serum uric acid is elevated in up to 50 percent of patients and is mainly correlated with the extent of lesions and the activity of disease. There is an increased risk of developing gouty arthritis. Elevated serum uric acid levels usually cease after therapy.

In severe psoriasis vulgaris, generalized pustular psoriasis, and erythroderma, a negative nitrogen balance can be detected, mainly consisting in a decrease of serum albumin.

C-reactive protein, a $_2$-macroglobulin, as well as sedimentation rate, can be increased in psoriasis related to disease activity and body involvement. Increased serum IgA levels and IgA immune complexes have been observed in psoriasis, the role of this phenomenon still being unclear.

Bacteriology of Psoriatic Plaques

There are no qualitative differences in the cutaneous bacterial flora when plaques are compared with adjacent normal skin. However, the number of bacteria per unit area is increased by more than two times. [28] This increase can be a problem if the patient with psoriasis is colonized with *Staphylococcus aureus.*

PATHOLOGY

Microscopic changes are present in both the epidermis and the upper dermis of lesions of psoriasis. It is difficult to judge which is more severe and more relevant to the disease. In pustular and guttate psoriasis, the inflammatory features are more prominent than in plaque-type psoriasis.

Chronic (Plaque-Type) Psoriasis

The essential histopathologic features of plaque-type psoriasis (Fig. 42-13) include

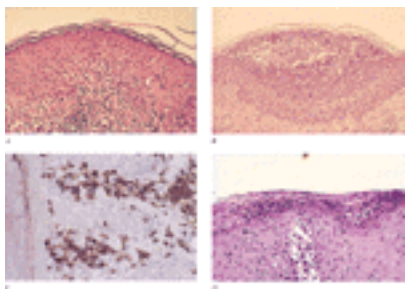

FIGURE 42-13 Histopathology of psoriasis. *A.* The earliest changes in psoriasis consist of papillary edema with a marked infiltrate of mononuclear cells, which tend to invade the spongiotic epidermis. Later, neutrophils follow. *B.* Pustular psoriasis with large spongiform abscesses in the subcorneal zone without marked epidermal hyperplasia. *C.* Neutrophils migrating into the stratum corneum form so-called Munro's microabscesses. *D.* In plaque-type psoriasis, large numbers of CD3+ T cells are present and tend to migrate into the affected epidermal portions.

1. An epidermis in which epidermal mass is increased three to five times. Whereas the granular layer is constantly absent over the tips of the dermal papillae and parakeratosis is an accompanying feature, a thick granular layer may be seen between the rete ridges, and above these areas keratinization may be normal. Relative to normal, there are many more mitoses in the psoriatic epidermis, with mitotic figures frequently seen above the basal layer (see " Pathogenesis," below).
2. A dermis in which thin, elongated papillae are prominent. These papillae contain dilated, tortuous capillaries embedded in an edematous papillary stroma.
3. A moderate inflammatory infiltrate around the blood vessels consisting of lymphocytes, macrophages, neutrophils, and increased numbers of mast cells. This infiltrate is confined to the papillary dermis.
4. Collections of polymorphonuclear leukocytes, which sometimes extend from the tip of the dermal papillae into the epidermis, where they are associated with focal spongiosis and occasionally cell necrosis. These skin changes result in Munro microabscesses, which are formed from invading leukocytes. In chronic plaque-type psoriasis, the number of neutrophils is sparse compared with that in guttate psoriasis, in which they are more numerous. [28]

Eruptive (Guttate) Psoriasis

Eruptive (guttate) psoriasis, especially when only a few days old, may differ from plaque-type psoriasis in the following features:

1. Epidermal hyperplasia is less marked, and the rete ridges are usually only slightly longer than normal. There may be areas of spongiosis located above the tips of the dermal papillae. There is focal absence of the granular layer.
2. Serum is discharged from the tips of the papillae into the epidermis, and neutrophils accumulate. These cells migrate through the basement membrane individually and sometimes aggregate subcorneally in the suprapapillary areas, forming subcorneal pustules (Fig. 42-14). There may be extravasated erythrocytes in the suprapapillary areas.

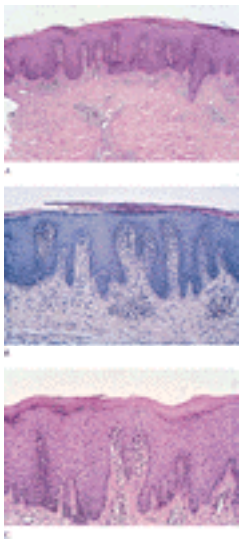

FIGURE 42-14 The histology of psoriasis varies depending on the activity of the disease. There is acanthosis and parakeratosis and a lymphohistiocytic infiltrate in the papillary dermis (*A*), which becomes more pronounced (*B*) as the disease activity increases. *C.* Single dermal papillae repeatedly become edematous and infiltrated with neutrophils

The Initial Lesion

Few attempts have been made to examine the earliest skin changes histologically. When pinhead-sized (macular) lesions were examined as the earliest clinical sign of psoriasis, marked edema and round cell infiltrate in the upper dermis were found. These findings are usually confined to the area of one or two papillae. The overlying epidermis soon becomes spongiotic and shows focal loss of the granular layer (see Fig. 42-14). The venules in the upper dermis dilate, and these structures are surrounded by a mononuclear cell infiltrate.

Ultrastructural attempts to analyze the initial tissue changes sequentially revealed mast cell degranulation as well as endothelial activation, followed by macrophage immigration before epidermal changes.

DIAGNOSIS AND DIFFERENTIAL DIAGNOSIS

In patients with typical psoriatic lesions, the features are usually characteristic enough to establish the diagnosis. Difficulties arise when psoriasis is changing its disease activity—i.e., when eruptive, pustular, or erythematous phases are evolving—or when psoriasis is complicated by other diseases. Diagnoses to be considered in the differential diagnosis of psoriasis include eczema, pityriasis rubra pilaris, seborrheic dermatitis, pityriasis lichenoides et varioliformis, candidiasis, tinea, syphilis, cutaneous T cell lymphoma (mycosis fungoides), in situ squamous cell carcinoma (Bowen's disease), and Paget's disease. Thus the morphologic appearance and distribution of a given patient's psoriasis are significant factors in the differential diagnosis, which is further delineated in Table 42-5. In any case, the Auspitz phenomenon provides a diagnostic lead in making the proper diagnosis (see Fig. 42-7).

Type of Psoriasis	Differential Diagnosis
Chronic plaque type	Nummular eczema
	Mycosis fungoides, plaque stage
	Tinea corporis
Guttate	Pityriasis rosea
	Pityriasis lichenoides et varioliformis
	Syphilis, psoriasiform type
	Tinea corporis
Erythroderma	Atopic dermatitis
	Sézary syndrome
	Drug eruption
	Generalized contact dermatitis
Intertriginous psoriasis	Candidiasis
	Contact dermatitis
	Darier's disease
Nail psoriasis	Tinea unguium
	Dyskeratosis secondary to injury (trauma, dermatitis, etc.)
Scalp and face	Seborrheic dermatitis
Genitalia	In situ squamous cell carcinoma

TABLE 42-5 **Differential Diagnosis of Psoriasis**

PATHOGENESIS

Background

Psoriasis is unique because it represents excessive but controlled cellular proliferation and inflammation, both occurring

within 0.2 mm of the skin's surface. There is no experimental model, and the pathogenesis is not fully understood.

The role of immune mechanisms is documented by a significant number of activated T cells within the altered epidermis and dermis, by macrophages, and by the proven effects of immunosuppressive or immunomodulating therapy. Second, the predominant changes consist of highly increased, persistent keratinocyte proliferation in conjunction with a characteristic inflammatory pattern.

Further, the genetic character represents a hallmark of psoriasis; the inheritance is polygenic with a genetic risk ratio of nearly 10 for first-degree relatives of patients with early-onset psoriasis. [19] It appears that several factors are involved in the pathogenesis of the disease (Fig. 42-15).

FIGURE 42-15 Potential pathogenetic sequence in psoriasis. Noncutaneous eliciting factors may serve as antigens/superantigens or may generate psoriatic “autoantigens.” In response to these factors, (1) susceptibility genes are activated, some of which are HLA-associated; (2) the nature of the eliciting factor creates T_H1-T_H2 imbalance within a yet to be defined set of cytokines; (3) possibly by genetic determination, there is a lack of downregulation; with the influx of neutrophils and monocytes/macrophages, lipid mediators are generated with amplifying effects on the inflammatory response; (4) further mediator systems (e.g., proteases) become activated and lead to phenotypical disease expression; and (5) this hypothetical model may become modulated at each phase (1 to 5), whereby the heterogeneity of clinical disease ensues.

KERATINOCYTE PROLIFERATIVE ACTIVITY A characteristic feature of involved skin of psoriatic subjects is hyperproliferation, first defined by Van Scott and Ekel. [29] Currently, there is evidence of more than an eightfold shortening of the epidermal cell cycle (36 h versus 311 h for normal) in involved skin of patients with psoriasis. Further, there is a twofold increase in the proliferative cell population, and 100 percent of the germinative cells of the epidermis appear to enter the growth fraction compared with 60 to 70 percent for normal subjects. These alterations result in a hyperplastic epidermis generating 35,000 cells/mm^2 per day from a proliferative compartment containing approximately 52,000 cells/mm^2 of skin surface. Normal skin produces only 1218 cells/mm^2 per day from a proliferative compartment of 26,000 cells/mm^2. [29] Although there are still no similarly sophisticated studies of uninvolved skin, various investigators have noted significantly altered epidermal proliferation (nearly twice normal) in normal-appearing skin. Additionally, the regeneration response following tape stripping has been noted to be increased in the normal skin of patients with psoriasis. Transplantation studies of human skin to congenitally athymic (nude) mice provide additional insights. These studies demonstrate that epidermal proliferation (as measured by labeling indices) of both uninvolved and involved skin from patients with psoriasis approaches a common mean and that both remain elevated above that of normal skin. In these experiments in which epidermal proliferation of involved and uninvolved skin is elevated, there is no evidence of clinical lesions, i.e., erythema, scale, or induration. Thus excessive epidermal proliferation does not in itself give rise to a lesion of psoriasis.

Immunopathology

IMMUNE SYSTEM As outlined earlier, there are several hints of participation of the immune system in the etiology and pathogenesis of psoriasis. Among the most important are (1) the presence of numerous activated T cells within psoriatic lesions, (2) the antipsoriatic effects of treatment modalities that can reduce cutaneous T cell activation and infiltration, (3) immune-dependent expressions of adhesion molecules on psoriatic keratinocytes, (4) the relative absence of T_H2-related skin disorders, including atopic dermatitis and urticaria, [24] and (5) lymphokine profiles suggesting a T_H1-driven disorder. [30], [31]

T Cells Cells prevailing within the psoriatic lesion consist of activated T cells, macrophages, and polymorphonuclear cells. In an early lesion, macrophages are noted within the epidermis, followed by lymphocytes and neutrophils. CD4+ T cells migrate into skin with aggravation of disease as new lesions develop. The majority of CD4+ T cells localize within the affected dermis, whereas those migrating into the epidermis are noted to predominantly consist of the CD8 “killer” phenotype. These T cells appear to be activated, expressing high levels of MHC class II molecules as well as CD25 interleukin 2 (IL-2) receptor. [32] Analysis of the T cell receptor repertoire revealed oligoclonal expansion of T cells derived from lesional psoriatic skin. CD4+ T cells showed significant overrepresentation of Vß2, Vß5.1, and Vß6 T cell receptors as compared with T cells of peripheral blood or normal skin. [33], [34] In a longitudinal study it could be demonstrated that the T cell receptor repertoire in lesional skin remains constant during several exacerbations of psoriasis in the same patients. [34] Constant oligoclonal expression of Vß3 and Vß13.1 T cell receptors also was found for lesional CD8+ T cells. [35] From these studies, the presence of an antigen responsible for constant oligoclonal T cell expansion may be hypothesized. However, results from other studies reveal that superantigens may not be pathogenetically relevant in chronic plaque-type psoriasis. [36] T cell migration into psoriatic skin is mediated by receptors on dermal endothelial cells or papillary endothelial cells. In addition, CD4+ CD45 RO+ (memory) T cells selectively bind to papillary endothelial cells, whereas CD8+ T cells localize on high endothelial venules. T cell migration into the skin is stimulated by lipid mediators such as 12[*R*]-hydroxyeicosatetraenoic acid, peptide chemoattractants such as IL-8, MIP-1a and -1ß, MCP-1, MCP-2, MCP-3 as well as IP10, and as yet uncharacterized peptides. Extravasation of T cells, monocytes, and neutrophils follows their adhesion to endothelial cells mediated by adhesion molecules. Within the psoriatic lesion, endothelial cells show increased expression of the intercellular adhesion molecule 1 (ICAM-1) and E-selectin. A subset of T cells expressing cutaneous lymphocyte antigen (CLA) consists of memory T cells preferentially homing to skin. These cells bind to E-selectin, and their number is greatly increased in psoriasis. [37]

Therapies suppressing the immune system are effective in psoriasis Support for the assumption that T cells are fundamentally important in psoriasis comes from therapies known to affect the immune system, experimentally shown by improvement of severe disease following intravenous application of anti-CD3, anti-CD4, and anti-TNF-a monoclonal

antibodies. Complete clearing of skin lesions is also obtained by cyclosporine, used as low-dose treatment in severe psoriasis, and by tacrolimus as well as a T cell–selective immunotoxin, DAB $_{389}$IL-2 or fusion proteins such as alefacept. These drugs are able to selectively suppress T cell–mediated immune responses. In addition, PUVA and UVB are able to deplete affected skin of immune-competent cells, notably T cells, when applied in appropriate doses. [38], [39] Furthermore, cure of disease was reported in a patient receiving allogeneic bone marrow transplantation, [40] whereas development of psoriasis was observed in a bone marrow recipient from a psoriatic donor. [41] These observations indicate that depletion of activated T cells from diseased skin correlates with clinical improvement.

GRANULOCYTES Formation of spongiform microabscesses (Munro microabscesses) filled with granulocytes is a hallmark of psoriasis. The presence of these cells in psoriatic lesions is variable and becomes more pronounced with disease activity, e.g., in acute guttate or pustular psoriasis. Ultramicroscopically, degranulation is absent in these cells; instead, they appear to remain intact while migrating in response to chemotactic stimuli. A number of studies recently conducted with isolated peripheral neutrophils revealed signs of activation mostly correlating with disease activity. Expression of ICAM-1 and E-selectin is found on endothelial cells, and both are important for the adhesion of neutrophils, T cell subsets, and monocytes. They are upregulated by IL-1, TNF-a, or lipopolysaccharides. Interestingly, E-selectin is known to be preferentially expressed at sites of chronic inflammation of the skin. It binds skin-homing memory T cells bearing a cutaneous lymphocyte antigen (CLA) as a unique antigen on T cell subsets, which are greatly augmented in psoriasis. [42] Several cytokines were identified in tissue extracts of patients with psoriasis (Table 42-6). Cytokines isolated and characterized from lesional psoriatic skin include IL-1a and IL-1ß, IL-6, and IL-8. [43] An additional set of cytokines is expressed by keratinocytes in culture; their significance is still not well understood.

Cytokine[a]	Present in Normal Skin	Changes in Lesional Psoriatic Skin
IL-1a	+	↑↑↑
IL-1ß	+	
IL-6	+	↑↑
NAP-1/IL-8	+	↑↑
MGSA/gro	+	↑↑
TNF-a	−	↑
TGF-a	+	↑
IFN-a	−	↑
GM-CSF	+	↑
G-CSF	+	↑
M-CSF	+	↑
MCP-1	+	↑

[a]IL, interleukin; NAP, neutrophil-activating peptide; TNF, tumor necrosis factor; TGF, transforming growth factor; IFN, interferon; GM-CSF, granulocyte-macrophage colony-stimulating factor; G-CSF, granulocyte-colony-stimulating factor; M-CSF, monocyte/macrophage-colony-stimulating factor; MCP, monocyte-chemotactic and activating factor.

TABLE 42-6 **Cytokines Detected in Normal Skin and Lesional Psoriatic Skin**

PROTEASES Another potential mediator system under consideration is the protease-antiprotease system. The demonstration of increased protease activity in lesions of psoriasis has implicated this system as a potential mediator of many of the abnormal findings in psoriasis. Proteases are recognized in other cell systems as important regulators of cell proliferation, and they have the ability to generate inflammatory mediators via the complement cascade. [44] Further, cell surface proteases can be activated or inactivated at a local level, a phenomenon that fits with clinical observations. Without local activation and inactivation, it seems likely that all skin would express disease. The observation that plasminogen activator activity increases in uninvolved skin after transplantation to the nude mouse supports the contention that this is a mediator system. [45] Another protease, human leukocyte elastase, is greatly increased in psoriatic lesional skin. This enzyme—which shows proteolytic activity toward a variety of substrates, including collagen types III and IV, proteoglycans, and elastin—is normally regulated by antiproteases, one of which was discovered recently in human epidermis. [46] In psoriasis, the presence of excess elastase in an unblocked form suggests increased proteolytic activity within the affected epidermis.

TREATMENT

Various forms of treatment have been developed in the past several decades. They have mostly been developed empirically, and as with all other diseases of unknown cause, new regimens are being tried constantly. Recently, biotechnology has allowed the development of monoclonal antibodies and fusion proteins targeting single epitopes or compounds with relevance in the psoriatic tissue reaction. Furthermore, the experimental administration of recombinant cytokines such as IL-10 showed beneficial effects at least in a subgroup of psoriasis patients. These new-generation therapies will gain importance in the routine treatment of psoriasis in the near future.

There is debate as to whether the aim of any psoriasis therapy should be total clearing of the lesions. Under many circumstances, patients may regard the successful clearing of scaling a sufficient therapeutic response; however, when lesions are present in visible areas such as the hands, complete resolution is necessary. [47] Complete clearing normally needs a much higher therapeutic effort, in particular when patients present with severe, frequently relapsing psoriasis. In these pateints, discussion about the therapeutic goal between dermatologist and patient should define the individual treatment strategy.

Topical Treatment (See also Chap. 244 and Chap. 251)

ANTHRALIN Anthralin (1,8-dihydroxyanthrone; cignolin, dithranol) was introduced by Galewsky and Unna in 1916. This compound is still a widely used remedy for psoriasis in different vehicles and application modes. A major advantage of anthralin is the lack of any long-term side effects, which allows unlimited reintroduction of the drug as long as therapy is required.

Mode of action Anthralin possesses antiproliferative activity on human keratinocytes. In recent years it has become clear that this compound also exerts strong anti-inflammatory effects mainly on cells of the inflammatory infiltrate. Inhibition of neutrophil and monocyte functions and production and ?-oxidation of leukotriene B $_4$ from neutrophils have been observed. It was found recently that anthralin induces nuclear transcription factor NF-? B in murine keratinocytes. [48] Since NF-?B is involved in the transcription of proinflammatory cytokines such as IL-6, IL-8, and TNF-a, these findings may be helpful in explaining the irritant properties of anthralin.

Clinical use Chronic plaque-type psoriasis responds best to anthralin treatment. Guttate psoriasis also can be treated effectively. Classic anthralin therapy starts with low concentrations (0.05–0.1%) incorporated in petrolatum or zinc paste and given once daily. To prevent autooxidation, salicylic acid (1–2%) should be added. The concentration is increased

weekly in individually adjusted increments up to about 5% until the lesions resolve. Short-contact treatment is an alternative mode of application. Higher concentrations of anthralin (1–5%) in water-soluble vehicles are applied to the lesions for a short period of time (usually 10–20 min) and thereafter washed off. Application time is increased weekly until the lesions have cleared. A new galenical formulation (Micanol) reduces local irritation and staining of skin and equipment. A leukoderma-like zone ("pseudoleukoderma") may become visible at the site of treated lesions.

Adverse events Anthralin can cause irritant reactions ("anthralin dermatitis") in susceptible patients or after increasing the concentration too fast. Since anthralin can stain the hair a purple to greenish color, scalp psoriasis should be treated only with great caution. At higher concentrations, anthralin causes brownish discoloration of the surrounding skin ("anthralin-brown") and of clothing that comes into contact with the compound. Since these oxidation products remain at the upper levels of the stratum corneum, discoloration disappears within days after stopping anthralin application. Removal of stains from clothing, however, is difficult or impossible.

VITAMIN D $_3$ AND ANALOGUES Since the first report about the beneficial effects of vitamin D $_3$ in psoriasis by Morimoto et al., [49] new analogues have been developed to decrease hormonal effects on calcium/phosphate homeostasis and to maintain effects on keratinocyte proliferation and differentiation. Soon after the introduction of the first vitamin D $_3$ analogue, calcipotriol (also called calcipotriene in some countries), to topical therapy, it became a widely used remedy for plaque-type psoriasis. [50] Another vitamin D $_3$ analogue, tacalcitol, is available in some countries. [51] Recently, active hormone 1,25-dihydroxyvitamin D $_3$ (calcitriol) was registered for topical psoriasis treatment in a number of countries. [52]

Mode of action Vitamin D $_3$ and its analogues inhibit keratinocyte proliferation and induce terminal differentiation. [53] Anti-inflammatory properties of these compounds include inhibition of nuclear factor NF-?B protein in lymphocytes, leading to a reduced transcription of IL-2. [54] Calcitriol and calcipotriol can inhibit production of IL-6 from cytokine-stimulated human dermal microvascular endothelial cells and reduce the antigen-presenting function of Langerhans cells. Calcitriol is a potent inhibitor of dendritic cell differentiation. [55]

Clinical use Calcitriol, calcipotriol, and tacalcitol are used for plaque-type psoriasis twice or once daily, respectively. Treatment is limited by the area of application and time due to possible effects on calcium/phosphate homeostasis. Calcipotriol is inactivated by salicylic acid; therefore, lesions should not be pretreated with this compound. When calcipotriol is used in combination with ultraviolet (UV) light, application should follow light exposure because of the UV-absorbing properties of calcipotriol.

Adverse effects Local irritation may occur at the beginning of treatment. Some patients develop facial rashes after application of calcipotriol elsewhere on the body. Changes in calcium and/or phosphate metabolism are rare when application follows the respective guidelines.Calcipotriol has been found to be a safe treatment for children with psoriasis. [56]

TAZAROTENE Tazarotene is a retinoid for topical use that reduces mainly scaling and plaque thickness, with limited effectiveness on erythema. In comparison with other topical drugs for psoriasis, tazarotene has a lower efficacy. However, efficacy can be enhanced by combination with UVB therapy. [57]

TAR The use of tar either as coal tar or wood tar (birch, pine, beech) has a long history in antipsoriatic therapy. These tars contain a great variety of compounds, most of which are not well defined. Very little is known about how tars act in skin. Preparations of 2% to 5% tar in various bases have been shown to be preferentially effective in chronic plaque-type psoriasis. These preparations are nonirritant, and serious side effects are not seen even after long periods of treatment.

TOPICAL GLUCOCORTICOIDS Topical glucocorticoids can be used effectively in psoriasis. They are discussed in detail in Chap. 243.

BLAND EMOLLIENTS Between treatment periods, skin care with bland emollients should be performed in order to avoid dryness, leading to early recurrence, and to prolong therapy-free intervals. The addition of urea (up to 10%) is helpful to improve hydration of the skin and remove scaling of early lesions.

Treatment with Ultraviolet Light

PHOTOCHEMOTHERAPY (PUVA) (See Chap. 266) The use of systemic psoralens plus ultraviolet A (PUVA) to treat psoriasis was introduced in 1974 by Parrish and coworkers. [58] The effectiveness of PUVA in clearing psoriasis has now been widely documented and confirmed by cooperative clinical studies in the United States and in Europe. [59] Treatment consists of oral ingestion of a potent photosensitizer such as 8-methoxypsoralen (8-MOP) or trimethoxypsoralen at a constant dose (0.6–0.8 mg/kg) and variable doses of UVA, depending on the sensitivity of the patient. Approximately 2 h after ingestion of the psoralen, UVA is started, usually at a dose of 1 J/cm ^{2}, adjusting upward for skin type. The UVA dose is increased by suberythematous amounts, generally ranging from 0.5 to 1.5 J/cm ^{2}. The dose of UVA for a given treatment should not lead to brisk erythema. Treatments are performed two or three times a week or, under a more intensive protocol, four times a week. In most patients, clearing occurs after 19 to 25 treatments, and the amount of UVA needed ranges from 100 to 245 J/cm ^{2}. PUVA results in rapid pigmentation of the skin, making it necessary to increase the dosages of light. Overdosage results in a sunburn type of reaction, which characteristically is more delayed than that seen with UVB; i.e., it occurs 24 to 48 h after treatment. Administration of lower doses of psoralen or UVA, as well as prolonged treatment courses, may demonstrate psoriasis that is nonresponsive and may even result in relapses in patients under treatment. Psoralens such as 8-MOP intercalate with DNA. With the energy of UVA, psoralens covalently cross-link nucleic acids between opposing strands of duplex regions of DNA. The formation of these cross-linking bifunctional photoadducts leads to irreversible photoinhibition of DNA synthesis and mitosis. [60] This reaction is thought to be important in the hyperproliferative psoriatic epidermis. Because demonstration of interstrand cross-links in treated human epidermis has yet to be shown, mechanisms other than DNA binding need to be considered. Since PUVA was shown to be therapeutically effective in a variety of dermatoses, some of which are not related to hyperproliferation, more than one mode of action appears to be likely. Side effects and the consequences of overdosage include nausea, dizziness, and headache. Approximately 95 percent of the drug is excreted via the kidneys within 8 h. During this time, cutaneous sensitivity to UV light is increased considerably. Measures for sun protection must be taken during the 8 to 12 h after ingestion of the psoralen. To protect the eyes, UVA-blocking plastic wraparound glasses should be worn outdoors for the 24 h after ingesting psoralen. Indoors, especially in a bright fluorescent light, the same type of protective eyewear is recommended. The psoralen molecule reaches highest concentrations in skin within 2 to 3 h after oral ingestion; the concentration slowly decreases during the following 8 h. During the entire day of treatment, exposure to sunlight should be avoided by wearing protective clothing and taking other appropriate precautions. Since psoralens are found in the

lens, ophthalmologic examinations should be performed at yearly intervals. Long-term side effects are of considerable importance and make it necessary to restrict PUVA to patients with widespread and severe psoriasis. A major early side effect is pruritus, which usually can be managed by the topical use of emollients or low-potency glucocorticoids. Late sequelae include the spectrum of long-term actinic skin damage, e.g., solar elastosis, dry and wrinkled skin, and hyper- and hypopigmentation. PUVA freckles, which may persist for years, represent the potential for the development of skin cancers. Stern et al. [26] analyzed 13,800 patients who had been receiving PUVA therapy and had been followed up for 5.7 years; in this group there was a dose-related increased frequency of squamous cell carcinomas. [26] Patients who have received relatively high dosages of PUVA had a 12.8 times higher incidence of genital squamous cell carcinomas than patients exposed to lower dosages of PUVA. This finding was independent of skin pigmentation, prior tar therapy, or prior x-irradiation. [26] Malignant melanoma risk increases especially in those with more than 250 treatments. [61]

BATH PUVA Another way to deliver the photosensitizer (8-MOP or 5-MOP) to the skin is by addition of these compounds to bath water, first described by Fischer and Alsins in 1976. [62] Major advantages of bath PUVA are the lack of systemic effects, such as gastrointestinal complaints (nausea is present in about 13 percent of patients taking 8-MOP orally), and the overall reduction of UV dose down to one-quarter of that required to obtain therapeutic results similar to those of conventional PUVA, thus reducing the risk of nonmelanoma skin cancer. [63] Furthermore, erythema is less frequent in bath PUVA patients, and eye protection by sunglasses is not required. Experimental studies have shown that bath PUVA reduces keratinocyte proliferation and suppresses activation of lesional T cells. To reduce the cost of the larger amounts of liquid 8-MOP required when using bath PUVA in a tub (volume of 150–200 L), the employment of a polyethylene sheet bath has been proposed and has been shown to achieve therapeutic results similar to those conventional bathing in a large volume. [64]

BALNEOPHOTOTHERAPY Empirically, it has been known that the combination of salt-water bathing and sunlight exposure is an effective treatment for psoriasis. From studies at the Dead Sea, it became clear that highly concentrated salt water (>20%) together with UVB light is most effective. [65] This therapeutic strategy also was termed *balneophototherapy;* it has become increasingly popular in Europe, where concentrated salt-water baths together with artificial UVB sources are used in psoriasis treatment centers. A possible mechanism of concentrated salt-water bathing is the elution of biologically active peptide mediators and enzymes such as human leukocyte elastase from the inflamed skin.

SELECTIVE UVB THERAPY Treatment with UVB without UVA, also known as *selective UVB phototherapy* (SUP), can be performed as monotherapy or preferably in combination with topical treatments such as glucocorticoids, vitamin D_3 and analogues, tazarotene, or anthralin. SUP is very effective in guttate psoriasis and also improves lesions of the plaque type. Today, narrow-band UVB treatment (311 nm, Philips TL01 bulbs) has become a standard therapy for plaque-type and guttate psoriasis. Several new aspects of UVB action on the skin have been elucidated. These include depletion of Langerhans cells, decreased leukocyte adhesion to the microvasculature, depletion of intraepidermal T cells, and induction of IL-10 production from macrophages, which acts as an anti-inflammatory mediator.

Systemic Treatment

Systemic treatment of psoriasis is required in cases of severe disease when lesions are widespread or pustular or when psoriasis is in an active phase, with rapid flare-ups after topical courses including UV light. Systemic treatment should be monitored carefully.

METHOTREXATE (See Chap. 256) Methotrexate (MTX) was introduced as an antipsoriatic agent in 1958. It is a widely used systemic regimen for severe forms of psoriasis and most beneficial in pustular forms of the disease. MTX is the drug of choice for severe psoriatic arthritis.

Mechanism of action MTX inhibits DNA synthesis (S phase of the cell cycle) by competing as a substrate for dihydrofolate reductase; originally, it was thought to act primarily on the rapidly dividing basal keratinocytes of the psoriatic lesion. The group of Weinstein [66] demonstrated that proliferating lymphoid cells in psoriatic lesions are over 1000 times more sensitive to the cytotoxic effects of MTX than primary human keratinocytes. It also has been shown that MTX exerts anti-inflammatory effects mediated through intracellular accumulation of 5-aminoimidazole-4-carboxyamide ribonucleotide (AICAR), thereby increasing the release of adenosine. Adenosine exerts anti-inflammatory effects mainly on neutrophils, where an inhibition of adhesion and reactive oxygen intermediate production has been demonstrated. New data suggest that MTX induces apoptosis in activated T cells and keratinocytes. [67], [68]

Clinical use Pustular psoriasis and psoriatic arthritis are treated most effectively with MTX. In psoriasis vulgaris of the chronic plaque type, MTX monotherapy is less efficacious and should be combined with topical compounds to achieve clearing of the lesions.

Dosage The usual dosage of MTX is between 10 and 25 mg once a week. The preferred mode of delivery is intravenous or intramuscular in order to obtain best efficacy and to control treatment. MTX can also be given orally using a dosing schedule in which 5 mg is given every 12 h over a 36-h period. This regimen may be as effective as treatment with a once-weekly parenteral dose.

Adverse effects Most commonly nausea, anorexia, fatigue, headaches, and alopecia are encountered as adverse effects. Development of leukopenia and thrombocytopenia indicates serious dysfunction of the bone marrow and may be a sign of MTX overdose. In this case, a folinic acid rescue (25 mg of leucovorin intramuscularly) should be performed, preferably within the first 4 h. In case of renal dysfunction, leucovorin is given repeatedly until renal function improves. Since MTX is excreted mainly via the kidneys, patients with a history of kidney dysfunction should not be treated with MTX so as to avoid increased kidney toxicity. A rare but life-threatening side effect of MTX therapy is acute interstitial pneumonitis, which is believed to be a result of a hypersensitivity reaction. Interestingly, in contrast to rheumatoid arthritis therapy, there are only very few reports of pneumonitis in psoriasis patients treated with MTX. Lethality is about 15 percent in rheumatoid arthritis patients treated with the same doses of MTX as are used for psoriasis. Hepatotoxicity is a major concern with MTX treatment. Patients with a history of liver disease or alcohol abuse must be excluded. The risk of developing liver fibrosis or cirrhosis increases with the overall cumulative MTX dose. Above a cumulative MTX dose of 1.5 g, monitoring of structural liver changes is mandatory.

Control of MTX therapy Routine measurement of hematologic parameters, as well as liver and kidney function, should be performed in MTX-treated patients. A recent study indicates that serial measurement of type III procollagen aminopeptide (PIIINP) is of value in detecting liver damage and may reduce the need for liver biopsy in MTX-treated patients. [69] On the other hand, comparisons of susceptibility to the development of structural liver changes in patients

with rheumatoid arthritis and psoriasis reveal a higher risk in psoriasis patients for reasons yet unknown. [70] The dermatologic guidelines for the use of MTX therefore still recommend liver biopsy after a cumulative dose of 1.5 g and thereafter at 1- to 1.5-g intervals. [71]

CYCLOSPORINE (See Chap. 262) Cyclosporine is a cyclic polypeptide that is used widely for the prevention of graft rejection. It is accepted for the treatment of severe psoriasis in many countries.

Mode of action After penetration into the cell by a putative receptor, cyclosporine binds to cyclophilin, a member of the immunophilin group. The cyclosporine-cyclophilin complex binds to the phosphatase calcineurin, thereby blocking its ability to dephosphorylate the cytosolic component of transcription factor NF-AT (nuclear factor of activated T cells). This results in an impaired translocation of the NF-AT component to the nucleus. The nuclear component of NF-AT is required for functional activity to enhance transcription of the IL-2 gene. [72] Other pharmacologic effects of cyclosporine with possible relevance for psoriasis are an inhibition of the antigen-presenting capacity of Langerhans cells and mast cell functions such as degranulation and cytokine production.

Clinical use Multicenter studies have shown that cyclosporine is effective in about 70 percent of patients with severe chronic plaque-type psoriasis when a low-dose regimen (<5 mg/kg per day) is used. Clearing requires several weeks of therapy, which can be maintained continuously. [73] Improvement of nail changes as well as of associated psoriatic arthritis can be seen during long-term therapy. Cyclosporine therapy can be recommended as a short-term intermittent regimen in which the drug is tapered off as soon as major improvement is seen or as long-term continuous treatment in recalcitrant cases. Cyclosporine is also effective in erythrodermic as well as generalized pustular psoriasis. Despite several attempts to develop ointment formulations, cyclosporine is without effect when used topically.

Dosage The recommended dosage of cyclosporine—arrived at as a result of multicenter studies and consensus meetings—is to start with 2.5 to 3 mg/kg per day divided into two daily doses. This can be increased up to a maximum of 5 mg/kg per day. After clinical response is achieved, the cyclosporine dose can be lowered to the best level for the individual patient.

Adverse effects Among the side effects of cyclosporine, which are dose-related, is impairment of kidney function, which is largely reversible after drug withdrawal; also, hypertension may develop. A rise in serum cholesterol and triglycerides also has been observed. Clinically, hypertrichosis, gingival hyperplasia, tremor, and fatigue may occur. Recent investigations showed that long-term cyclosporine treatment increase the risk for development of skin cancer. This risk is particularly high in patients with a history of PUVA therapy using high doses of UVA. [74]

Control of cyclosporine treatment Control of cyclosporine therapy includes blood pressure measurement and determination of serum creatinine as the most useful parameters for detecting decreased kidney function in clinical practice. If serum creatinine levels rise above 30 percent of individual baseline, the dose of cyclosporine must be reduced. In case of persistently enhanced creatinine values, the drug must be withdrawn. Dermatologic examination is necessary in order to early detect skin malignancies.

RETINOIDS (See Chap. 257) Acitretin, a derivative of vitamin A, is used mainly for the treatment of psoriasis. Best clinical results have been obtained in pustular forms of psoriasis. Acitretin has replaced formerly used etretinate. The half-life of etretinate is about 100 days and that of acitretin 2 to 3 days. When acitretin was introduced, this short half-life was thought to overcome long-lasting accumulation in the tissues, which meant severe restrictions in the use of etretinate in women due to the risk of teratogenic effects. However, it turned out that a portion of acitretin is reesterified in vivo into *iso*-acitretin and etretinate. [75] Therefore, restrictions on the use of acitretin in women of childbearing age remain the same as for etretinate.

Mechanism of action Retinoids regulate growth and terminal differentiation of keratinocytes, thereby normalizing the hyperproliferative state in psoriasis. After passing the cell membrane, retinoids form complexes with cytosolic binding proteins, which, after translocation into the nucleus, regulate gene transcription through nuclear response elements. Retinoids also exert some anti-inflammatory effects, such as inhibition of neutrophil functions.

Clinical use Etretinate and acitretin are clinically effective in pustular forms of psoriasis, including generalized pustular psoriasis and PPP. For plaque-type psoriasis, retinoids show lower response rates than other systemic modalities. In combination with PUVA (Re-PUVA), retinoids can improve the clinical effectiveness of acitretin in some cases. After prolonged therapy, retinoids may lead to an improvement in psoriatic arthritis.

Dosage In severe psoriasis vulgaris and psoriatic erythroderma, acitretin is given in a dose of 0.3 to 0.5 mg/kg per day initially, which is increased at 3- to 4-week intervals to 0.75 mg/kg per day. To achieve improvement, treatment over 3 to 4 months is necessary. Pustular psoriasis requires an initial dose of 1 mg/kg per day of acitretin, which is given until clinical improvement is seen. Thereafter, the dose is lowered gradually to a maintenance dose of about 0.5 mg/kg per day, which is given for 3 to 4 months.

Adverse effects The side effects of etretinate/acitretin therapy are dose-related. The most prominent symptoms are cheilitis, sicca symptoms of the eyes and mouth, generalized pruritus, dryness of the skin, and loss of the stratum corneum of palms and soles, leading to soreness in these areas. There may be considerable hair loss during treatment with acitretin. Muscle and joint pain as well as gastrointestinal complaints also may be present. An elevation of serum lipids is seen frequently during systemic retinoid treatment, especially in patients with a history of lipid abnormality, obesity, diabetes, smoking, and/or alcohol abuse. Elevations in liver enzymes (SGOT, SGPT, LDH) may occur. A major concern with the use of systemic retinoids is their high teratogenic potential. Since acitretin is remetabolized into long-lived compounds, use of this drug should be restricted to men and to women with no childbearing potential. If acitretin is given to women of childbearing age, strict contraception is required for the time of therapy and for an additional 2 years after drug withdrawal.

Control of retinoid treatment Liver and kidney function, blood glucose, and serum lipids should be monitored initially at 3-week intervals and later every 2 months. Symptomatic treatment for dry skin, mouth, and eyes should be given.

FUMARIC ACID ESTERS A mixture of fumaric acid monoethyl and dimethyl esters is approved in Germany for systemic treatment of severe psoriasis. Clinical experience exists since 1959 when fuamrates were introduced.

Mode of action Inhibition of TNF-a–induced keratinocyte ICAM-1 expression by dimethylfumarate has been demonstrated. Monomethylfumarate, the main metabolite of dimethylfumarate, was shown to stimulate release of T_H2 cytokines IL-4 and IL-5 from human peripheral blood T cells without changing production of T_H1 cytokines IL-2 and interferon-?. [76] Dimethylfumarate potently inhibits dendritic cell differentiation. [77] Recently, dimethylfumarate was shown to induce apoptosis is a number of cells, including dendritic cells. [77] Furthermore, this compound inhibits cytokine production by blocking NF?B signaling. [78], [79]

Clinical use Fumaric acid esters are used for the treatment of severe psoriasis vulgaris. [80] Multicenter studies have shown that about 70 percent of psoriasis patients respond to therapy. [81] There are reports of long-term use of fumarates,

which seems to be possible in patients with recalcitrant psoriasis. Experience with fumarates for the treatment of erythrodermic and pustular psoriasis as well as psoriatic arthritis is very limited.

Adverse effects The most frequently observed adverse effects with fumaric acid ester therapy for psoriasis are gastrointestinal complaints and flush. Symptoms of the first can vary from nausea to severe diarrhea; they are dose-dependent and sometimes limit the use of the drug. Flush is seen in many different forms from rashes and classical flush to headache-like symptoms that occur irregularly for short periods. Leukocytopenia and lymphopenia frequently are associated with fumarate therapy. There also may be an increase of eosinophils. In rare cases, impairment of renal function has been observed.

Dosage Fumaric acid ester therapy follows a dosing schedule that begins with a low-strength formulation and is increased weekly for 3 weeks. Then therapy continues with a normal-strength formulation that is increased weekly up to a maximum of 1.29 g/day. Dosage is usually adjusted to an individual level, which can be low in susceptible patients.

Control of fumarate therapy Monitoring of hematologic parameters with particular emphasis on leukocyte and differential counts and of renal function, including urinary protein excretion, is most important. Liver enzymes as well as electrolytes also should be monitored.

SYSTEMIC GLUCOCORTICOIDS Systemic use of glucocorticoids should be restricted to a few selected patients with refractory psoriasis. Although transient improvement can be achieved, this is almost always accompanied by a severe rebound to an even worse situation than before therapy. Transition from psoriasis vulgaris into generalized pustular forms after withdrawal of systemic glucocorticoids can be seen.

EXPERIMENTAL APPROACHES Based on the evidence that psoriasis is a T cell–mediated inflammatory disease, a number of new therapeutic approaches have been developed. [82]

Strategies targeting cellular epitopes on T cells or antigen-presenting cells Targeting activated T cells, which are thought to be of primary importance for the pathogenesis of psoriasis, is a principle adressed in a number of new therapeutic approaches. A fusion protein of IL-2 and diphtheria toxin (DAB $_{389}$IL-2) was given intravenously to patients with severe psoriasis and led to improvement of only a subgroup of patients. [83] IL-2 signaling pathways also can be abrogated by blockade of IL-2 receptors (CD25, a-chain). Treatment with the specific monoclonal antibody basiliximab was found to be effective in a patient with active psoriasis. [84] However, in an open study in plaque-type psoriasis, the anti-CD25 antibody daclizumab showed only a 30 percent reduction of severity score after 8 weeks of therapy. [85] Treatment with the fusion protein blocking LFA3-CD2 interaction (alefacept, Amevive) led to improvement of up to 53 percent in the PASI score in a recent study. [86] There is evidence that alefacept treatment preferentially reduces the number of memory T cells (CD45RO+).

Strategies targeting cytokines By using a monoclonal antibody against TNF-a (infliximab, Remicade) or a fusion protein mimicking the TNF-a receptor (etanercept, Enbrel), improvement of lesions can be achieved in plaque-type psoriasis. [87], [88]

Strategies using recombinant cytokines Systemic application of human recombinant IL-10 proved to be efficacious at least in a subgroup of patients. [89] This therapy lead to to a variety of changes in T cell function and cytokine secretion in vivo, as demonstrated recently. [90]

OTHER NEW DRUG DEVELOPMENTS

Macrolactams Macrolactams show improvement of lesions by topical use under occlusion, not, however, when applied without oclusion. [91], [92] A recent report show a high efficacy in psoriasis within a short time when the macrolactam pimecrolimus (SDZ ASM 981; Elidel) was given orally.

Other New Methods to Treat Psoriasis

Among a variety of newly described methods for treatment of psoriasis, use of the excimer laser may be of future importance. This laser generates light at 308 nm in the UVB range. In a first study it was shown that about four treatments lead to improvement of lesions with a sustained treatment response. [93]

COMBINATION THERAPY A combination of different therapeutic principles may help to speed resolution of the lesions, reduce adverse events, and reduce overall doses when systemic compounds are used. Several combination regimes have already been established for clinical use, such as topical glucocorticoids with UVB or PUVA, retinoids with PUVA (Re-PUVA), and vitamin D $_3$ and analogues or tazarotene with UVB. The combination of coal tar baths, UVB, and anthralin is known as the *Ingram method.* Goeckerman in 1925 introduced the widely used combination of coal tar application followed by suberythemic doses of UV light. Classic anthralin treatment followed by UVB or bath PUVA is also a very effective combination regimen. More recent studies indicate that combining cyclosporine with calcipotriol or anthralin augments efficacy and reduces cyclosporine dose. Calcipotriol also improves the response to PUVA.

ROTATION TREATMENT To minimize risk to the patient with severe psoriasis requiring systemic treatment, rotation therapy should be performed. Changing between different compounds—with respect to individual risk factors, cumulative dose (for MTX), response, and duration of therapy—should be performed at intervals. Recently published guidelines for rotation therapy may be helpful in scheduling long-term systemic treatment.

REFERENCES

1. Farber EM, Nall ML: The natural history of psoriasis in 5600 patients. *Dermatologica* **148**:118, 1974

2. Lomholt G: *Psoriasis: Prevalence, Spontaneous Course and Genetics: A Census Study on the Prevalence of Skin Diseases on the Faroe Islands.* Copenhagen, GEC Gad, 1963, p 163

3. Buntin DM et al: Onset of psoriasis at age 108. *J Am Acad Dermatol* **9**:276, 1983

4. Henseler T, Christophers E: Psoriasis of early and late onset: Characterization of two types of psoriasis vulgaris. *J Am Acad Dermatol* **13**:450, 1985

5. Nyfors A, Lemholt K: Psoriasis in children: A short review and a survey of 245 cases. *Br J Dermatol* **92**:437, 1975

6. Melski JW, Stern RS: The separation of susceptibility to psoriasis from age of onset. *J Invest Dermatol* **77**:474, 1981

7. Russell TJ et al: Histocompatibility (HL-A) antigens associated with psoriasis. *N Engl J Med* **287**:738, 1972

8. Watson W et al:The genetics of psoriasis. *Arch Dermatol* **105**:197, 1972

9. White SH et al: Disturbance of HL-A antigen frequency in psoriasis. *N Engl J Med* **287**:740, 1972

10. Andresen C, Henseler T: Erblichkeit der Psoriasis. *Hautarzı* **33**:214, 1982

11. Tiilikainen A et al: Psoriasis and HLA-Cw6. *Br J Dermatol* **102**:179, 1980

12. Zachariae H et al: HLA antigens in pustular psoriasis. *Dermatologica* **134**:73, 1977

13. Rapp SR et al: Psoriasis causes as much disability as other major medical diseases. *J Am Acad Dermatol* **41**:401, 1999

14. Krueger G et al: The impact of psoriasis on quality of life: Results of a 1998 National Psoriasis Foundation patient-membership survey. *Arch Dermatol* **137**:280, 2001

15. Chalmers RJG et al: Streptococcal serotypes in patients with guttate psoriasis. *Arch Dermatol* **118**:141, 1982

16. Sadick NS et al: Papulosquamous dermatoses of AIDS. *J AM Acad Dermatol* **22**:1270, 1990

17. Tsankov N et al: Drug-induced psoriasis. Recognition and management. *Am J Clin Dermatol* **1**:159, 2000

18. Yates VM et al: Further evidence for an association between psoriasis, Crohn's disease and ulcerative colitis. *Br J Dermatol* **106**:323, 1982

19. Elder JT et al: The genetics of psoriasis 2001: The odyssey continues. *Arch Dermatol* **137**:1447, 2001

20. Barker JN: Genetic aspects of psoriasis. *Clin Exp Dermatol* **26**:321, 2001

21. Christophers E, Henseler T: Psoriasis type I and type II as subtypes of nonpustular psoriasis, in *Psoriasis,* 2d ed, edited by HH Roenigk, H Maibach. New York, Marcel Dekker, 1990, pp 15–21

22. Schmidt-Egenolf M et al: Oligonucleotide typing reveals association of type I psoriasis with the HLA-DRB1*0701/2, -DQA1*0201, -DQB1*0303 extended haplotype. *J Invest Dermatol* **100**:749, 1993

23. Trembath RC et al: Identification of a major susceptibility locus on chromosome 6p and evidence for further disease loci revealed by a two stage genome-wide search in psoriasis. *Hum Mol Genet* **6**:813,1997

24. Henseler T, Christophers E: Disease concomitance in psoriasis. *J Am Acad Dermatol* **32**:982, 1995

25. Stern R et al: Psoriasis and the risk of cancer. *J Invest Dermatol* **78**:147, 1982

26. Stern RS et al: Cutaneous squamous cell carcinomas in patients treated with PUVA. *N Engl J Med* **310**:1156, 1984

27. Christophers E, Henseler T: Contrasting disease patterns in psoriasis and atopic dermatitis. *Arch Dermatol Res* **279**:S48, 1987

28. Aly R et al: Bacterial flora in psoriasis. *Br J Dermatol* **95**:603, 1976

29. Van Scott EJ, Ekel TM: Kinetics of hyperplasia in psoriasis. *Arch Dermatol* **88**:373, 1963

30. Uyemura K et al: The cytokine network in lesional and lesion-free psoriatic skin is characterized by a T-helper type 1 cell-mediated response. *J Invest Dermatol* **101**:701, 1993

31. Schlaak JF et al: T cells involved in psoriasis vulgaris belong to the Th1 subset. *J Invest Dermatol* **102**:145, 1994

32. Kägi MK et al: Differential cytokine profiles in peripheral blood lymphocyte supernatants and skin biopsies from patients with different forms of atopic dermatitis, psoriasis and normal individuals. *Int Arch Allergy Immunol* **103**:332, 1994

33. Lewis HM et al: Restricted T-cell receptor V_b gene usage in the skin of patients with guttate and chronic plaque psoriasis. *Br J Dermatol* **129**:514, 1993

34. Menssen A et al: Evidence for an antigen-specific cellular immune response in skin lesions of patients with psoriasis vulgaris. *J Immunol* **155**:4078, 1995

35. Chang JCC et al: CD8+ T cells in psoriatic lesions preferentially use T cell receptor $V_b 3$ and/or $V_b 13.1$ genes. *Proc Natl Acad Sci USA* **91**: 9282, 1994

36. Boehncke W-H et al: T-cell-receptor repertoire in chronic plaque-stage psoriasis is restricted and lacks enrichment of superantigen-associated V_b regions. *J Invest Dermatol* **104**:725, 1995

37. Babi LFS et al: Migration of skin-homing T cells across cytokine-activated human endothelial cell layers involves interaction of the cutaneous lymphocyte-associated antigen (CLA), the very late antigen-4 (VLA-4), and the lymphocyte function-associated antigen-1 (LFA-1). *J Immunol* **154**:1543, 1995

38. Vallat VP et al: PUVA bath therapy strongly suppresses immunological and epidermal activation in psoriasis: A possible cellular basis for remittive therapy. *J Exp Med* **180**:283, 1994

39. Krueger JG et al: Successful ultraviolet B treatment of psoriasis is accompanied by a reversal of keratinocyte pathology and by selective depletion of intraepidermal *T* cells. *J Exp Med* **182**:2057, 1996

40. Eedy DJ et al: Clearance of severe psoriasis after allogeneic bone marrow transplantation. *BMJ* **300**:908, 1990

41. Gardembas-Pain M et al: Psoriasis after allogeneic bone marrow transplantation. *Arch Dermatol* **126**:1523, 1991

42. Picker LJ et al: Differential expression of homing-associated adhesion molecules by T cell subsets in man. *J Immunol* **145**:3247, 1990

43. Gearing AJH et al: Cytokines in skin lesions of psoriasis. *Cytokine* **2**:68, 1990

44. Fraki JE et al: Correlation of epidermal plasminogen activator activity with disease activity in psoriasis. *Br J Dermatol* **108**:39, 1983

45. Fraki JE et al: Uninvolved skin from psoriatic patients develops signs of involved psoriatic skin after being grafted onto nude mice. *Science* **215**:685, 1982

46. Wiedow O et al: An elastase-specific inhibitor of human skin. *J Biol Chem* **265**:1491, 1990

47. Al Suwaidan SN, Feldman SR: Clearance is not a realistic expectation of psoriasis treatment. *J Am Acad Dermatol* **42**:796, 2000

48. Schmidt KN et al: Anti-psoriatic drug anthralin activates transcription factor NF-? B in murine keratinocytes. *J Immunol* **156**:4514, 1996

49. Morimoto S et al: An open study of vitamin D_3 treatment in psoriasis vulgaris. *Br J Dermatol* **115**:421, 1986

50. Kragballe K et al: Long-term efficacy and tolerability of topical calcipotriol in psoriasis. *Acta Derm Venereol (Stockh)* **71**:475, 1991

51. Gerritsen MJP et al: The effect of tacalcitol [1,24(OH)$_2$D$_3$] on cutaneous inflammation, epidermal proliferation and keratinization in psoriasis: A placebo-controlled, double-blind study. *Br J Dermatol* **131**:57, 1994

52. Gerritsen MJ et al: Long-term safety of topical calcitriol 3 µg/g ointment *Br J Dermatol* **144**(suppl 58):17, 2001

53. Van de Kerkhof PCM: Biological activity of vitamin D analogues in the skin, with special reference to antipsoriatic mechanisms. *Br J Dermatol* **132**:675, 1995

54. Yu X-P et al: Down-regulation of NF-kappa B protein levels in activated human lymphocytes by 1,25-dihydroxyvitamin D_3. *Proc Natl Acad Sci USA* **92**:10990, 1995

55. Penna G, Adorini L: 1a, 25-dihydroxyvitamin D_3 inhibits differentiation, maturation, activation, and survival of dendritic cells leading to impaired alloreactive T cell activation. *J Immunol* **164**:2405, 2000

56. Oranje AP et al: Topical calcipotriol in childhood psoriasis. *J Am Acad Dermatol* **36**:203, 1997

57. Koo JY: Tazarotene in combination with phototherapy. *J Am Acad Dermatol* **39**:S144, 1998

58. Parrish JA et al: Photochemotherapy of psoriasis with oral methoxsalen and long-wave ultraviolet light. *N Engl J Med* **291**:1207, 1974

59. Henseler T et al: Oral 8-methoxypsoralen photochemotherapy of psoriasis. European PUVA Study: A cooperative study among 18 European centres. *Lancet* **1**:853, 1981

60. Pathak MA et al: Photobiology and photochemistry of furocoumarins (psoralens), in *Sunlight and Man: Normal and Abnormal Photobiologic Responses,* edited by MA Pathak, TB Fitzpatrick. Tokyo, Tokyo University Press, 1974, p 25

61. Stern RS et al: Malignant melanoma in patients treated for psoriasis with methoxsalen (psoralen) and ultraviolet A radiation (PUVA). *N Engl J Med* **336**:1041, 1997

62. Fischer T, Alsins, J: Treatment of psoriasis with trioxsalen baths and dysprosium lamps. *Acta Derm Venereol (Stockh)* **56**:383, 1976

63. Stern RS, Lange R: Non-melanoma skin cancer occurring in patients treated with PUVA five to ten years after first treatment. *J Invest Dermatol* **91**:120, 1988

64. Streit V et al: Treatment of psoriasis with polyethylene sheet bath PUVA. *J Am Acad Dermatol* **35**:208, 1996

65. Abels DJ, Kattan-Byron J: Psoriasis treatment at the Dead Sea: A natural selective ultraviolet phototherapy. *J Am Acad Dermatol* **12**:639, 1985

66. Jeffes EWB III et al: Methotrexate therapy of psoriasis: Differential sensitivity of proliferating lymphoid and epithelial cells to the cytotoxic and growth-inhibitory effects of methotrexate. *J Invest Dermatol* **104**:83, 1995

67. Genestier L et al: Immunosuppressive properties of methotrexate: Apoptosis and clonal deletion of activated peripheral T cells. *J Clin Invest* **102**:322, 1998

68. Heenen M et al: Methotrexate induces apoptotic cell death in human keratinocytes. *Arch Dermatol Res* **290**:240, 1998

69. Zachariae H et al: The value of amino-terminal propeptide of type III procollagen in routine screening for methotrexate-induced liver fibrosis: A 10-year follow-up. *Br J Dermatol* **144**:100, 2001

70. Hassan W: Methotrexate and liver toxicity: Role of surveillance liver biopsy. *Ann Rheum Dis* **55**:273, 1996

71. Roenigk HH et al: Methotrexate in psoriasis: Consensus conference. *J Am Acad Dermatol* **38**:478, 1998

72. Schreiber SL, Crabtree GR: The mechanism of action of cyclosporin A and FK506. *Immunol Today* **13**:136, 1992

73. Mrowietz U et al: Long-term maintenance therapy with cyclosporine and post-treatment survey in severe psoriasis, results of a multicenter study. *J Am Acad Dermatol* **33**:470, 1995

74. Marcil I, Stern RS. Squamous-cell cancer of the skin in patients given PUVA and ciclosporin: Nested cohort crossover study. *Lancet* **358**:1042, 2001

75. Almond-Roesler B, Orfanos CE: *trans*-Acitretin is metabolized back to etretinate: Importance for oral retinoid therapy. *Hautarzt* **47**:173, 1996

76. De Jong P et al: Selective stimulation of T helper 2 cytokine responses by the anti-psoriasis agent monomethylfumarate. *Eur J Immunol* **26**:2067, 1996

77. Zhu K, Mrowietz U: Inhibition of dendritic cell differentiation by fumaric acid esters. *J Invest Dermatol* **116**:203, 2001

78. Vandermeeren M et al: Dimethylfumarate is an inhibitor of cytokine-induced nuclear translocation of NF-kappa B1, but not RelA in normal human dermal fibroblast cells. *J Invest Dermatol* **116**:124, 2001

79. Stoof TJ et al: The antipsoriatic drug dimethylfumarate strongly suppresses chemokine production in human keratinocytes and peripheral blood mononuclear cells. *Br J Dermatol* **144**:1114, 2001

80. Mrowietz U et al: Treatment of severe psoriasis with fumaric acid esters: Scientific background and guidelines for therapeutic use. *Br J Dermatol* **141**:424, 1999

81. Altmeyer P et al: Antipsoriatic effect of fumaric acid derivatives: Results of a multicenter double-blind study in 100 patients. *J Am Acad Dermatol* **30**:977, 1994

82. Krueger IG: The immunologic basis for the treatment of psoriasis with new biologic agents. *J Am Acad Dermatol* **46**:1, 2002

83. Bagel J et al: Administration of DAV $_{389}$ IL-2 to patients with recalcitrant psoriasis: A double-blind, phase II multicenter trial. *J Am Acad Dermatol* **38**:938, 1998

84. Mrowietz U et al: Treatment of severe psoriasis with anti-CD25 monoclonal antibodies. *Arch Dermatol* **136**:675, 2000

85. Krueger JG et al: Successful in vivo blockade of CD25 (high-affinity interleukin 2 receptor) on T cells by administration of humanized anti-Tac antibody to patients with psoriasis. *J Am Acad Dermatol* **43**:448, 2000

86. Ellis CN, Krueger GG: Treatment of chronic plaque psoriasis by selective targeting of memory effector T lymphocytes. *N Engl J Med* **345**:248, 2001

87. Chaudhari U et al: Efficacy and safety of infliximab monotherapy for plaque-type psoriasis: A randomised trial. *Lancet* **357**:1842, 2001

88. Mease PJ et al: Etanercept in the treatment of psoriatic arthritis and psoriasis: A randomised trial. *Lancet* **356**:385, 2000

89. Asadullah K et al: IL-10 is a key cytokine in psoriasis. Proof of principle by IL-10 therapy: A new therapeutic approach. *J Clin Invest* **101**:783, 1998

90. Reich K et al: Response of psoriasis to interleukin-10 is associated with suppression of cutaneous type 1 inflammation, downregulation of the epidermal interleukin-8/CXCR2 pathway and normalization of keratinocyte maturation. *J Invest Dermatol* **116**:319, 2001

91. Mrowietz U et al: The novel ascomycin derivative SDZ ASM 981 is an effective anti-psoriatic compound when used topically under occlusion. *Br J Dermatol* **139**:992, 1998

92. Zonneveld IM et al: Topical tacrolimus is not effective in chronic plaque psoriasis: A pilot study. *Arch Dermatol* **134**:1101, 1998

93. Asawanonda P et al: 308-nm excimer laser for the treatment of psoriasis: A dose-response study. *Arch Dermatol* **136**:619, 2000

T>

Chapter 43

Robert Winchester

Psoriatic Arthritis

DEFINITION AND CLASSIFICATION
HISTORIC ASPECTS
EPIDEMIOLOGY
A MODEL OF THE STAGES OF DISEASE PATHOGENESIS
Stage One: Genetic Factors Defining Predisposition
Stage Two: Triggering of Self-Tolerant T Cells
Stage Three: Clonal Expansion and the Development of Psoriasis
Stage Four: Transition of the Autoimmune Response to the Joint
Stage Five: Development of Joint Inflammation and Injury
NATURE OF THE INFLAMMATORY INFILTRATE IN FULLY DEVELOPED PSORIATIC ARTHRITIS
CLINICAL MANIFESTATIONS
Onset and Occurrence
Skin Disease
Joint Disease Patterns and Radiology
Tenosynovitis and Enthesitis
Nail Disease
Pediatric Psoriatic Arthritis
Psoriatic Arthritis and HIV Infection
COURSE AND PROGNOSIS
TREATMENT
Mild to Moderate Joint Involvement
Severe Destructive Arthritis
HIV Infection
Surgery and Related Techniques

REFERENCES

DEFINITION AND CLASSIFICATION

Psoriatic arthritis is a CD8 T cell–driven autoimmune inflammation that affects the ligaments, tendons, fascia, and spinal or peripheral joints in persons with psoriasis. The pathologic processes in psoriatic arthritis exhibit many parallels to processes found in the skin lesions. Psoriatic arthritis is recognized in about 10 percent of individuals with well-established psoriasis. However in 10 to 15 percent of those with psoriatic arthritis, either the arthritis appears synchronously with the first evidence of skin disease, or no cutaneous involvement is ever detected. In parallel with the skin disease, psoriatic arthritis is exacerbated by physical stress, nonspecific inflammation, or certain infections. Unlike most autoimmune diseases, psoriatic arthritis increases in prevalence and severity in those with advancing AIDS, and special concerns exist about its therapy in this setting.

Psoriatic arthritis is a prototypic major histocompatibility gene complex MHC) class I-associated autoimmune form of arthritis, in which genetic susceptibility is provided by the MHC class I allele HLA-B27, and additional class I alleles, including those implicated in psoriasis susceptibility. Psoriatic arthritis is classified as one of the seronegative spondyloarthritis group of disorders that includes ankylosing spondylitis, undifferentiated spondylitis, Reiter's syndrome, reactive arthritis, and enteropathic arthritis. These disorders share involvement of the spine (spondylo) and sacroiliac joints and some degree of genetic susceptibility associated with HLA-B27. In particular, many features of the pathogenesis of psoriatic arthritis, including the importance of CD8 T cells, are similar to those of Reiter's syndrome/reactive arthritis and are highly distinct from features of rheumatoid arthritis. The older term “spondyloarthropathy” is falling from use as evidence of the importance of inflammation increases. In addition to synovitis, the spondyloarthritis group of disorders has the singularly distinctive feature of inflammation involving the periarticular structures, particularly tendons and ligaments at their respective points of insertion, which is termed *enthesitis.* This condition results in tendinitis, dactylitis (sometimes graphically termed “sausage digits”), and fasciitis.

Psoriatic arthritis is distinguished from the other spondyloarthritides, such as ankylosing spondylitis, by the limited extent and frequency of spinal involvement, the predominance of peripheral joint involvement, and the relationship to psoriasis. The peripheral joints are involved in a variety of patterns at presentation (Table 43-1), and these patterns are often useful diagnostically as emphasized by Moll and Wright in their classic paper. [1] Indeed, distal interphalangeal joint involvement in an individual with psoriasis is a pattern of joint disease that immediately suggests the diagnosis of psoriatic arthritis. However, these patterns are not stable. Over time the disease follows one of two principal patterns of joint involvement: (1) predominant axial disease, the less common form consisting of sacroiliitis with or without peripheral arthritis, and (2) the more common form of peripheral disease without sacroiliitis. [2]

Asymmetric or symmetric peripheral joint involvement
Distal interphalangeal joint involvement
Small joints of hands and feet
Large joints, primarily of legs
Combination of above (erosive arthritis without osteopenia)
Axial disease
Spine and sacroiliac joints, with or without peripheral joint involvement
Associated Features
Tenosynovitis
Enthesitis
Onychodystrophy, especially with distal interphalangeal joint involvement
New bone formation (vertebral squaring, entheses)
Joint fibrosis and ankylosis
Osteolysis and mutilating arthritis

TABLE 43-1 **Patterns of Psoriatic Arthritis**

HISTORIC ASPECTS

The identification of psoriatic arthritis in skeletal remains of individuals who sought refuge in ancient Middle Eastern Byzantine monasteries suggests that psoriasis with psoriatic arthritis was one of the forms of biblical “leprosy,” attesting to the severe and ancient nature of this condition. [3] The association of arthritis with psoriasis was first formally described in 1818 by Alibert, and was designated psoriasis arthritique by Bazin in 1860. The notion of a distinctive arthritis associated with psoriasis became widely accepted, [4], [5] but after World War II psoriatic arthritis was grouped with rheumatoid arthritis as a “rheumatoid variant” or “rheumatoid spondylitis.” Subsequently, the distinct nature of psoriatic arthritis was again emphasized, using as criteria the absence of rheumatoid factor and the presence of HLA-B27, enthesitis, and spondylitis. [6], [7] and [8] Furthermore, whereas rheumatoid arthritis commonly regresses with advancing HIV infection, psoriatic arthritis becomes more prevalent and intense. [9], [10] and [11]

EPIDEMIOLOGY

Psoriatic arthritis is found in just under 10 percent of individuals with psoriasis, [12], [13] but some series report a much higher prevalence that could reflect in part the absence of sensitive and fully developed criteria for diagnosing joint involvement. [14] If the frequency of psoriasis is between 1 and 3 percent, the prevalence of psoriatic arthritis in the general Caucasian population, according to current criteria, would be from 0.05 to 0.24 percent, a value approaching half that of the prevalence of seropositive rheumatoid arthritis and in agreement with recent prevalence studies. [13] A critical review of the syndromic criteria used to diagnose psoriatic arthritis emphasized that all currently used classification/diagnosis criteria have a high specificity but low sensitivity, including those of Moll and Wright, the European Spondyloarthropathy Study Group, and the Amor classification criteria. [15] Importantly, criteria with low sensitivity fail to provide sufficient guidance to the physician for patient diagnosis.

A MODEL OF THE STAGES OF DISEASE PATHOGENESIS

In common with other autoimmune diseases, psoriasis and, subsequently, psoriatic arthritis can be considered to develop in stages, beginning with genetically defined predisposition and ending with overt joint disease (Fig. 43-1). The following sections describe in some detail the stages in the pathogenesis of psoriatic arthritis.



FIGURE 43-1 Hypothetical stages in the development of psoriasis or psoriatic arthritis. The first stage is one of genetically defined susceptibility. MHC class I molecules, self-peptides, and other, still unknown genes interact to select a T cell repertoire that has the property of recognizing a self-peptide critical to the pathogenesis of psoriasis or psoriatic arthritis. The second compartment depicts several possible initiation events where the T cell clones selected in stage one are triggered to recognize a self-peptide. This physiologic adaptive immune response is initiated by a specific microorganism or by nonantigen-specific inflammation or trauma. In the third stage, the unlimited amount of self-peptide autoantigen drives the immune response to clonal expansion and an effector phenotype that results in psoriasis. In the fourth stage, these T cell clones acquire the ability to respond to a self-antigen of the joint. In the final stage, these clones acquire the potential to injure the joint by the release of chemokines that recruit and activate monocytes and nonantigen-specific T cells. Multiple inflammatory mechanisms characterize this stage.

Stage One: Genetic Factors Defining Predisposition

Typically, the predisposition phase lasts two or more decades. Germ-line genes contribute in an important way to the definition of the predisposition to develop psoriasis and psoriatic arthritis, as is shown by the strong familial aggregation of psoriatic arthritis and high twin concordance rates. [16] Psoriatic arthritis or psoriasis was found in 40 percent of first-degree relatives of those with the same disease, [17] a likelihood forty-fold greater than that of their unaffected spouses. [6], [18], [19] The ratio of familial psoriatic arthritis prevalence to its population prevalence (? $_S$) is 20 to 30, being much greater than that for rheumatoid arthritis. Some relatives of a psoriatic arthritis proband may exhibit only typical

psoriasis; others may have only an atypical undifferentiated spondyloarthritis; and still others may exhibit classic psoriatic arthritis and psoriasis. [18]

The inheritance of psoriatic arthritis has a mixed pattern found in many autoimmune diseases that either simulates a partially dominant mode of inheritance that is incompletely penetrant [1] or fits a recessive mode. [20] The concordance rate for psoriatic arthritis in both members of an identical twinship is 30 to 40 percent, [16] suggesting that only a third of those with a genetic predisposition actually develop psoriatic arthritis. This finding suggests that the development of psoriatic arthritis depends on nongerm-line–encoded events that could be environmental, involving infection or trauma, [21] or stochastic factors such as T cell repertoire development.

HLA CLASS I GENES INVOLVED IN DETERMINING SUSCEPTIBILITY The first report of a specific allele marking susceptibility to psoriatic arthritis was by Brewerton et al., [8] who identified a HLA-B27 allele in approximately 20 percent of patients with the peripheral joint involvement of psoriatic arthritis. In addition, the influence of immunogenetic factors on the pattern of joint involvement in psoriatic arthritis was shown by an increase of the frequency of HLA-B27 to approximately 70 percent in patients with spine involvement. These studies have been widely confirmed. [2], [19], [22] In some populations, additional rare class I alleles, such as HLA-B38 and HLA-B39, are associated with psoriatic arthritis, [23] but not with psoriasis. These alleles appear to be functional alternatives to HLA-B27 in terms of analogous peptide-binding properties, but they do not share ancestral haplotypes with HLA-B27 alleles. Other class I MHC alleles also have been implicated, including HLA-B13 and HLA-B57. These alleles sharply distinguish psoriatic arthritis from the other spondyloarthritides that do not exhibit any associations of susceptibility with them. The allele group characterized by HLA-Cw6 is found in strong linkage disequilibrium with both HLA-B57 and HLA-B13, but not with HLA-B27, HLA-B38, or HLA-B39; this observation provides the first molecular evidence of potential genetic heterogeneity in psoriatic arthritis (see Chap. 24 and Chap. 42). HLA-Cw6 is present in well over half of all persons with psoriatic arthritis in some studies. [23], [24] Alleles encoding HLA-B13 and HLA-B57 are also in strong linkage disequilibrium with the HLA-DR7 and the DQA1*0201 alleles, emphasizing the large genomic distances over which ancestral haplotypes extend. HLA-DR7 and the DQA1*0201 alleles have also been reported at increased frequency in psoriatic arthritis and psoriasis. [25], [26] A recent study suggests that the major region determining susceptibility to psoriatic arthritis is centromeric of the HLA-B locus. [27] At this time, the most probable interpretation of the association of HLA-B27 and the second group of HLA class I alleles, including HLA-B13, HLA-B57, and HLA-Cw6, with the susceptibility to develop psoriasis or psoriatic arthritis, is that these HLA molecules act to select a particular repertoire of CD8 T cells by binding and presenting certain self-peptides during the phase of positive thymic selection of the T cell repertoire. The presence of a T cell repertoire containing clones that can react with a particular self-peptide is a necessary but insufficient condition for psoriatic arthritis.

Stage Two: Triggering of Self-Tolerant T Cells

The second stage of the disease is activation of one or a few clones of CD8 T cells directed to a self-antigen in what is the first part of an adaptive immune response. If tolerization to self in the negative selection phase of repertoire formation were efficient, it would remove all the clones produced in the positive selection phase, because these were all selected on self-peptides. The individuals with psoriatic susceptibility alleles are left with potentially self-reactive CD8 T cells in their repertoire. In some instances, the clone may be in a state termed *clonal ignorance* rather than tolerance, because the provision of appropriate costimulatory signals to the T cells by accessory molecules will result in the response of the T cell clone. The events that trigger the CD8 T cells to become autoreactive are unknown.

Stage Three: Clonal Expansion and the Development of Psoriasis

The third phase of the immunopathogenesis of the immune response leading up to clinical skin disease consists of further substantive CD8 T cell clonal expansion and differentiation to an effector phenotype driven by psoriatic self antigens, as depicted in the third compartment in Fig. 43-1. Typically, the phase of psoriasis without joint involvement lasts nearly another decade until the phase of overt arthritis is precipitated. Detailed aspects of this adaptive immune response are covered in Chap. 42. Ultimately, the number of effector T cell clones with the requisite specificities accumulates to a level capable of initiating a disease-inducing autoimmune response to dermal keratinocytes.

Stage Four: Transition of the Autoimmune Response to the Joint

In a subset of individuals with psoriasis, the autoimmune response advances to involve the joint in what appears to be a similar disease process. There are two alternative possibilities. The autoimmune response affecting the joint is identical to that affecting the skin in terms of peptide recognition, or there is an additional joint-specific immune response that recognizes a peptide distinct from that recognized in keratinocytes. In either case, the development of joint inflammation appears to require a large pool of expanded antigen-reactive CD8 T cell clones with an effector cell phenotype.

Stage Five: Development of Joint Inflammation and Injury

A model for sustained immune stimulation responsible for stage five (Fig. 43-2) envisions a CD8 T cell that cognitively recognizes the specific self-peptide responsible for psoriasis and psoriatic arthritis and responds with activation and proliferation, which drive the inflammatory response responsible for joint inflammation and destruction. A cascade of secondary immune responses occurs in the joint tissue as a result of this drive. Chemokines and cytokines released by this activation (see Chap. 26 and Chap. 27), act on vascular endothelium and monocyte macrophages to affect their pattern of gene expression, and also instigate the nonantigen-specific recruitment of other CD8 T cells and CD4 T cells into the site of inflammation, as well as additional monocytes. These recruited bystander cells, in turn, release additional cytokines that act on synovial lining cells and other cells in the fibroblast lineage to alter their pattern of gene expression, proliferate, and induce new bone formation, in a manner similar to that postulated for their effect on keratinocytes in psoriatic plaques. [28] The combination of cytokines, chemokines, and other proinflammatory factors from these cell types results in joint and tendon inflammation, destruction, and fibrosis.

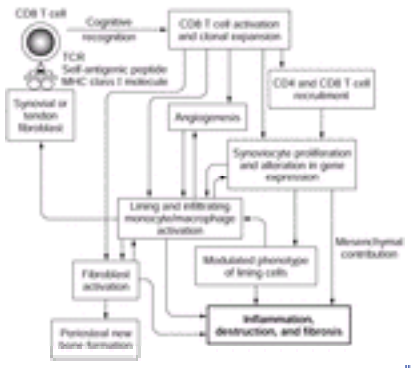

FIGURE 43-2 Scheme for pathogenesis of inflammation and tissue destruction in psoriatic arthritis. The process is driven by cognitive recognition of a self-peptide presented to a CD8 T cell by a MHC class I molecule on a joint cell. The ensuing T cell activation and clonal expansion initiates nonantigen-specific recruitment of CD4 and CD8 T cells, angiogenesis, and monocyte recruitment and activation by the release of cytokines and chemokines. The activated cells, in turn, alter patterns of gene expression in cells comprising the joint and related structures. These alterations result in inflammation, fibrosis, new bone formation, erosions, and osteolysis.

NATURE OF THE INFLAMMATORY INFILTRATE IN FULLY DEVELOPED PSORIATIC ARTHRITIS

The striking feature in the synovium and joint fluid of patients with psoriatic arthritis is the presence of a small number of very large CD8 T cell clonal expansions with structural features that strongly imply they result from an autoantigen drive. [29], [30] These form groups of structurally related clones with the same CDR3 length and the same or homologous CDR3 amino acid sequences. The CD8 T cell clones are derived from an effector precursor pool that is highly expanded in blood (> 20 cell divisions) and could be the population involved in mediating the skin disease. These cells appear to be the CD8 T cells originally selected in the predisposition phase, and they now drive the psoriatic inflammatory process in an autoantigen-driven adaptive immune response (Fig. 43-2). The activation of these cells and their release of chemokines and cytokines are considered to be the basis of the arthritis and enthesitis.

The synovium in active arthritis also contains a preponderant infiltrate of polyclonal, nonantigen-specific CD4 T cells (Fig. 43-3), as shown by analysis of the T cell receptor (TCR) ß chain ($V_{ß}$) repertoire at a molecular level. [29], [30] These nonantigen-specific T cells arise via recruitment mediated by chemokines, such as monocyte chemotactic protein 1 (MCP-1), which is locally produced in the synovium. [31] Cytokines implicated in the pathogenic process of psoriatic arthritis include interleukin (IL)-6, IL-1ß, IL-2, and sIL-2R. [32] T cells in infiltrates elaborate regulated on activation, normal T cell expressed and secreted (RANTES), while macrophages in the lining are gro-a positive, and those in infiltrates are Mig positive. [33] IL-8, a chemokine that could be responsible for the attraction of neutrophils to the joint fluid in psoriatic arthritis is expressed at a high level in the synovial lining cells, and to a lesser extent, in cells located in the perivascular areas. Compared with rheumatoid arthritis synovium, there is markedly less interferon-? and IL-1 in the psoriatic arthritis synovium. This finding is consistent with the lack of a T_H1 pattern of cytokine production and the dominant role of CD8 T cells. [34] Vascular abnormalities are early histopathologic changes that occur in the psoriatic plaque and are also prominent in the psoriatic synovium; these changes are likely to reflect specific cytokine profiles augmented in the patient with psoriasis. The destruction of cartilage differs from that in rheumatoid arthritis by the presence of minimally elevated levels of aggrecan and greatly increased concentrations of cartilage oligomeric matrix protein. [35]

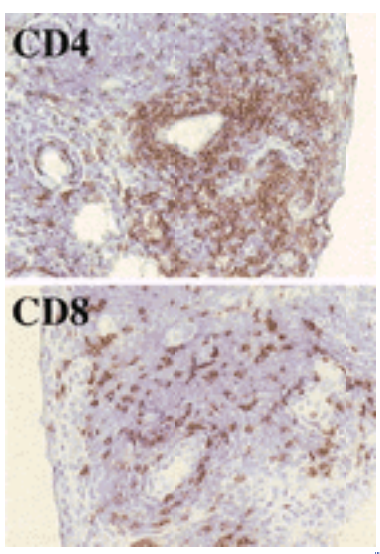

FIGURE 43-3 Inflammatory infiltrate of active synovitis in psoriatic arthritis, showing the predominant infiltration of CD4 T cells and somewhat fewer CD8 T cells. (*Courtesy of D. Kane.*)

Other types of bystander-type clonal expansions found in joint fluid are directed to diverse viral and other antigens unrelated to the presumed autoantigens driving the joint disease. These are presumably attracted to the inflammatory milieu and may secondarily contribute to the intensification of arthritis.

The mode of action of methotrexate on the inflammatory T cell infiltrate was recently elucidated by characterization of the T cell repertoire in synovial biopsies of methotrexate-treated patients with full drug-induced remissions. [30] The polyclonal infiltration of predominantly CD4 T cells that dominates the synovium in acute arthritis largely disappears, but the CD8 antigen-driven oligoclonal expansions identified by their sequence remained largely undiminished over 12 to 18 months

of therapy. The inability of methotrexate therapy to eliminate the expanded CD8 clones suggests that the methotrexate is suppressive rather than curative. It appears that tumor necrosis factor (TNF) blockade therapy also eliminates major components of the effector pathways of joint inflammation, without significantly altering the lymphocyte populations underlying the autoimmune drive of psoriatic arthritis. [36] Reductions were noted in lining layer thickness, vascularity, and infiltration with neutrophils and macrophages that paralleled the beneficial effect of anti–TNF-a therapy. It is likely that anti-TNF agents exert their beneficial effect largely, if not solely, on the later parts of the inflammatory cascade shown in Fig. 43-2.

CLINICAL MANIFESTATIONS

Onset and Occurrence

Psoriatic arthritis characteristically develops between ages 35 and 45, an average of 10 years after the appearance of psoriasis, but can occur at nearly any age. Onset earlier in adulthood or in childhood is associated with a heightened likelihood of developing destructive arthritis. Typically, early onset psoriatic arthritis occurs in a setting of a strong family history of the disease. [17] The sex ratio parallels that of psoriasis, with a preponderance of females in early childhood, but an essentially equivalent incidence in both sexes in adults.

The onset of arthritis is usually insidious, but occasionally is abrupt, sometimes following a joint injury. In these latter cases, the intensity of the disease may suggest Reiter's syndrome or gout. The subsequent course of posttraumatic psoriatic arthritis is indistinguishable from that of spontaneous onset arthritis. [37] Pitting edema of the hands or feet, sometimes asymmetric, secondary to enthesitis and tenosynovitis has been reported as a first, isolated manifestation of psoriatic arthritis. [38] The development of insidious inflammatory back pain is an important clue to the recognition of axial disease, and this symptom may be the initial manifestation of psoriatic arthritis (Table 43-2). Constitutional features, including fever and malaise, are uncommon and usually are evident only in a fulminant onset with widespread joint disease. However, the erythrocyte sedimentation rate and the serum complement level are commonly elevated, reflecting activation of acute phase reactants by cytokines. [19]

- Onset before age 40
- Insidious dull, deep buttock or low back pain
- Poorly localized; does not follow nerve root
- Persists > 3 months
- Stiffness/pain on arising in the morning or during sleep
- Improvement with exercise
- Differential diagnosis from mechanical or degenerative spine disease

TABLE 43-2 **Inflammatory Back Pain from Spondylitis, Sacroiliitis, or Axial Enthesitis as Initial Manifestation of Psoriatic Arthritis**

Skin Disease

Susceptibility to the development and severity of arthritis generally increases with the severity of cutaneous involvement. However, remissions and exacerbations of the joint disease correlate poorly with similar changes in the skin disease. [12]

Joint Disease Patterns and Radiology

The pattern of peripheral joint involvement [2] and the associated findings of nail disease, tenosynovitis, enthesitis, ankylosis, periosteal new bone formation, erosions, osteolysis, and axial involvement provide hallmarks for the recognition of psoriatic arthritis at the bedside and through radiology (Table 43-1; Fig. 43-4). Approximately three-fourths of persons diagnosed with psoriatic arthritis manifest peripheral, usually asymmetric, oligoarthritis that involves the small joints of the hands and feet, the large joints of the legs, or a combination of both small and large joints. When only a few joints are involved, the distribution appears asymmetric. The hand involvement can include stiffness and dactylitis that are attributable to enthesitis as well as synovitis. Dactylitis is strongly suggestive of psoriatic arthritis when it occurs in an individual with psoriasis. [39] Deformity secondary to fibrosis and contractures may occur. The classic pencil-in-cup joint is sometimes seen, consisting of symmetric and conical osteolysis of the proximal head, with enlargement of the base of the distal head by new bone formation. Acral osteolysis and erosions at the tip of the tuft of the digit are characteristic, especially when they involve the hallux. Ankylosis of one or more isolated joints is another distinctive feature due to fibrosis and new bone formation. Sometimes the initial or only manifestation of psoriatic arthritis is hallux rigidus, implying the subtle nature of joint inflammation and the need for its earlier recognition.

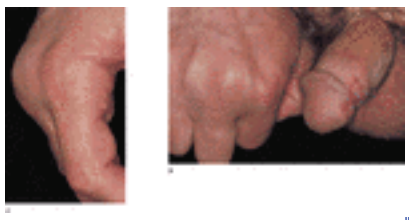

FIGURE 43-4 Psoriatic arthritis, acute, monarticular. Arthritis and psoriasis presented coincidentally in a 42-year-old male. *A.* Acute arthritis of the metacarpophalangeal joint. *B.* The patient was unaware of any psoriatic lesions; however, psoriatic lesions were noted on the penis and intergluteal cleft, associated with the development of pits in the fingernails.

Inflammation of one or many of the distal interphalangeal joints is virtually pathognomonic for psoriatic arthritis or Reiter's syndrome; it need only be distinguished from Heberden's nodes, which occur in a form of osteoarthritis infection, or

crystalline arthritides such as gout. In addition to the points of distinction summarized in Table 43-3, the distal interphalangeal joint is rarely, if ever, affected by rheumatoid arthritis. Typically, nail involvement is marked in the digit affected with arthritis, and there may be additional evidence of acral keratodystrophy.

	Psoriatic Arthritis	Rheumatoid Arthritis
Elevated ESR*	Yes	Yes
Susceptibility alleles	MHC class I	MHC class II
Amelioration with progressive HIV infection	No	Yes
Implied class of lymphocytes driving inflammation	CD8	CD4
Autoantibodies	No	Yes
Immune complexes	No	Yes
Vasculitis	No	Yes
Fibroblastic response	Yes	No
Sacroiliitis	Yes	No
Enthesitis, dactylitis	Yes	No

*ESR, erythrocyte sedimentation rate.

TABLE 43-3 **Contrasts between Psoriatic Arthritis and Rheumatoid Arthritis**

The large joints that are affected in psoriatic arthritis include the hips, knees, and ankles. Often only a single hip or knee joint is involved; the dominant diagnostic considerations in adults include degenerative osteoarthritis or posttraumatic arthritis rather than psoriatic arthritis. Posttraumatic forms of psoriatic arthritis in athletes are particularly challenging to distinguish from purely mechanical injuries. In approximately 5 percent of persons with psoriatic arthritis, the character of the joint injury becomes profoundly destructive with marked osteolysis, resulting in what is sometimes referred to as *arthritis mutilans*. In rare instances this process is generalized, but much more commonly one or a few joints are characterized by destruction out of proportion to the remainder of the illness. Pustular psoriasis or erythroderma is more common among this group. [40]

In occasional patients the sternomanubrial and temporomandibular joints may become involved, in association with extensive typical psoriatic arthritis. Certain syndromes simulate psoriatic arthritis but increasingly appear to be distinct entities; these include the anterior chest wall syndrome of sternomanubrial or costoclavicular involvement, where sternomanubrial disease occurs in isolation; the so-called SAPHO syndrome; and recurrent multifocal osteomyelitis. See reference [41] for a brief review of these entities.

Axial involvement is often most evident in the lower spine and sacroiliac joints. The predisposition to axial involvement is strongly influenced by the presence of HLA-B27. Scattered submarginal syndesmophytes and apophyseal or odontoid erosions without vertebral squaring or ligamentous calcification are found. Sometimes the nonmarginal syndesmophytes become bulky, broad paravertebral excrescences that contrast with the vertically oriented outgrowths of bone in the outer margins of the annulus fibrosus in ankylosing spondylitis. [42], [43] Vertebral squaring from new bone formation, apophyseal joint involvement, and ligamentous calcification in the lumbar spine are similar to those found in ankylosing spondylitis. Asymmetric or symmetric sacroiliitis is frequent and is readily identified by computed tomography (CT) or magnetic resonance (MR) imaging. Symphysitis is also present. CT and MR imaging are far more sensitive and specific than conventional x-rays for demonstrating sacroiliitis. [44] By directly imaging changes in the synovium, articular cartilage, and subchondral bone, MR imaging is the most sensitive and specific technique for detecting sacroiliitis and other changes in the axial skeleton. [44]

Whether ascertainment of joint involvement by clinical and classic x-ray procedures in those with psoriasis is adequate has been the subject of several studies with newer imaging modalities such as radionuclide scanning, ultrasonography, and nuclear MR imaging. In a study using MR imaging to examine the frequency of hand involvement in patients with nummular and/or plaque psoriasis who did not have arthritic symptoms, Offidani et al. [45] found that 68 percent of patients with psoriasis had at least one arthritic sign, such as soft-tissue swelling, periarticular effusion, joint effusion–synovial pannus, tendon sheath effusion, bone erosion, subluxation, bone cysts, and subchondral signal intensity abnormalities; by contrast, standard x-rays revealed joint abnormalities in only 32 percent. The ability of magnetic resonance to image ligaments and cartilage is a particular strength, as is its ability to identify tissue edema or small effusions by various types of signal weighting. In a report by Barozzi et al., [46] ultrasonography was shown to delineate the swelling of the entheses and the peritendinous soft tissues, as well as the distention of adjacent bursae by fluid collections. MR imaging showed the inflammation of the bone adjacent to the insertion as well as the soft tissue changes.

Tenosynovitis and Enthesitis

Tenosynovitis, dactylitis, and enthesitis are hallmarks of psoriatic arthritis and the other spondyloarthritides. They are not found in rheumatoid arthritis. Enthesitis may be quite subtle and is sometimes relatively easy to overlook. It may present only as nonspecific foot pain, “tennis elbow” in the nondominant hand, or isolated posterior tibial tendinitis, which are not considered by the patient to be part of the illness. Enthesitis is commonly widespread and often symmetric, a point that differentiates it from posttraumatic tendon injury. Bone scintigraphy is often useful in identifying the precise location of the sometimes asymptomatic enthesitis.

Nail Disease

Onychodystrophy, nail pitting, subungual keratosis, Beau's lines (ridging), leukonychia, crumbling nail plate, and discoloration are more strongly associated with arthritis than with psoriasis alone, being found in 85 percent of those with arthritis versus 31 percent of those with the isolated cutaneous form of the disease. [47] The most prevalent findings are pitting and onycholysis. Onychodystrophy is closely related to involvement of the distal interphalangeal joint of the same digit, suggesting a broader acral dystrophic state. The appearance of onychodystrophy is closely related in time to the appearance of the arthritis.

Pediatric Psoriatic Arthritis

Psoriatic arthritis in children usually resembles the disease in adults; however, monarticular disease, often presenting in the knee, is much more prevalent, especially during the early stages of disease. Juvenile psoriatic arthritis has a peak incidence with female preponderance between 2 and 4 years of age and a second peak in both sexes beginning at age 11 to 12 years that extends into adulthood. Psoriatic arthritis appears earlier than the other forms of juvenile spondyloarthritides. [48] In contrast to the usual sequence in adults, almost half of juvenile patients presented with arthritis before skin disease, with the interval between the onset of arthritis and psoriasis as long as 8 years. [49] Psoriasis, or a positive family history of psoriasis, usually provides the diagnosis, but if it is absent, diagnosis is often delayed due to the similarities of the disorder with pauciarticular juvenile rheumatoid arthritis. Axial arthritis is common in juvenile spondyloarthritis and is often associated with HLA-B27. Axial involvement is less frequent in juvenile psoriatic arthritis, but when it occurs, it is associated with an increased incidence of HLA-B27. Potentially ominous chronic anterior uveitis, indistinguishable from that seen in young (ages 2 to 4 years) girls with juvenile rheumatoid arthritis, is found in about 15 percent of patients with juvenile psoriatic arthritis and frequently occurs with antinuclear antibodies (ANA). [50] This finding places this subset of juvenile psoriatic arthritis apart from the other juvenile spondyloarthritides, with which it is commonly grouped. [51] The uveitis that occurs in the other spondyloarthritides is typically acute and self-limited, and ANA are not a feature.

The long-term course of juvenile psoriatic arthritis is typically polyarticular with asymmetric involvement of both upper and lower extremities and prominent digital involvement. Criteria have been developed for the classification of childhood psoriatic arthritis where, in addition to the presence of arthritis and psoriasis or a positive family history for these disorders, emphasis is placed on dactylitis, nail pitting, symmetry of arthritis, disease course (oligoarthritis or polyarthritis), ANA, and uveitis. [52] Of five HLA-B27 children reported with what was termed juvenile reactive arthritis after *Salmonella enteritidis* infection, three developed typical psoriasis in the months after the arthritis [53]; this finding emphasizes the interplay between various precipitating events and the development of what is classified as psoriatic arthritis.

Psoriatic Arthritis and HIV Infection

In North America and most of Europe, the considerable earlier problem of psoriasis, psoriatic arthritis, and Reiter's syndrome has abated to some degree in parallel with better antiretroviral therapy and management of other infections; but in some regions of the world these complications of HIV remain a major problem (see ref. [41]). The onset of psoriatic arthritis in HIV-infected individuals may appear explosive, with many features indistinguishable from those of Reiter's syndrome, including an antecedent infection with an arthritogenic gram-negative organism, or they may appear in a more insidious manner. [9], [10] and [11], [54] However, the psoriasiform skin disease is usually more severe. [55] The progression of the arthritis takes two general forms: an accumulative pattern evolving to full intensity over several weeks to months, or the more common, milder, intermittent pattern of recrudescences and remissions. The accumulative form is often associated with widespread polyarticular but asymmetric arthritis and is characterized by synovial thickening, erosions, and juxtaarticular osteoporosis. Hand and upper extremity involvement predominates in the accumulative pattern. The intermittent form usually has oligoarticular knee or ankle joint involvement. Severe enthesopathy of the Achilles tendon, plantar fascia, and anterior or posterior tibial tendons may cause some patients to exhibit a characteristic broad-based “AIDS” gait, walking with the feet in inversion and extension in an attempt to diminish pain by distributing weight on the lateral margins. Multidigit dactylitis frequently occurs and, in combination with plantar fasciitis and extensor tenosynovitis, may simulate cellulitis or pedal edema. Whereas synovitis of the knee is prominent, hip disease and shoulder girdle involvement are uncommon. Axial involvement appears to be uncommon, with sacroiliitis only occasionally present.

The cutaneous manifestations overlap those of HIV-associated Reiter's syndrome (see Chap. 182). The rash often resembles widespread pustular psoriasis with a greater tendency for involvement of the groin and intertriginous regions (inverse or sebopsoriasis). A progressive intensification of changes in the distal digits is often very prominent. Acrokeratosis is common, often associated with erythema and periungual pseudoparonychia formation. Severe alterations in the nails of the hands and feet often accompany distal interphalangeal joint (DIP) involvement and are manifested clinically as onychodystrophy with or without subungual hyperkeratoses.

COURSE AND PROGNOSIS

For most patients with psoriatic arthritis, the musculoskeletal manifestations are much milder than those of rheumatoid arthritis. After 8 years of disease, two-thirds of patients with psoriatic arthritis were effectively employed, [56], [57] and only 8 percent progressed to an advanced stage of musculoskeletal impairment. [58] However, despite a much greater degree of vitality among those with psoriatic arthritis, evaluation showed quality of life to be diminished as much as in patients with rheumatoid arthritis. [59]

Several patterns of disease progression are evident. For most, the arthritis waxes and wanes in severity, but remains persistently active. About one-fifth of prospectively followed patients experience sustained remissions that last an average of 2.6 years. [60] Among the remainder with persistently active disease, mild but sometimes troublesome localized disease, such as foot pain or recurrent tendinitis or enthesitis, forms a dominant pattern of involvement. For these individuals the overall prognosis is very good. Other patients with psoriatic arthritis progress to fibrous or bony ankylosis of one or a few joints, which may be unnoticed if there are no occupational demands. In yet another pattern, largely asymptomatic axial joint involvement, not ameliorated by any of the specific therapeutic measures, progresses independently of the state of the skin or peripheral joint disease. [61] A few patients with psoriatic arthritis have severe and sustained joint involvement or enthesitis, especially in the HIV-associated form. Persons with hip or knee involvement may eventually require joint replacement.

TREATMENT

Drugs available for treatment of psoriatic arthritis fall into two categories: agents such as nonsteroidal anti-inflammatory drugs (NSAIDs) and sulfasalazine, which have no, or minimal beneficial effect on skin disease; and others, such as etretinate, methotrexate, cyclosporin A, or TNF blockers, which usually benefit both skin and joint disease. The choice among the various agents is dictated by the relative intensity of the cutaneous and articular involvement.

Mild to Moderate Joint Involvement

For most patients with mild to moderate joint involvement or enthesitis, the goals of therapy are the control of inflammation with NSAIDs or analgesics, the maintenance of joint range of motion and function by physical therapy, and the avoidance of potentially injurious extreme joint stress through counseling against repetitive injury. NSAIDs do not appreciably alter the natural history of arthritis, but they do lessen stiffness and pain and thus increase range of motion.

Several biochemical families of NSAIDs or analgesics are available for therapy. Although these agents have some differences in anti-inflammatory efficacy and toxicity, choosing which NSAID to start is mainly dictated by physician experience and the individual response of a patient. Naproxen and indomethacin are traditionally considered representative of NSAIDs with the greatest efficacy in treating spondyloarthritides. Adverse effects shared by all NSAIDs include gastric and renal toxicity; hypersensitivity reactions; central nervous system effects, in particular tinnitus and headache; and coagulation abnormalities. In some patients with psoriasis, NSAIDs induce an idiosyncratic flare of the psoriatic skin lesions, possibly the result of the enhanced production of leukotrienes that occurs with cyclooxygenase inhibition. Most patients have had experience with self-prescribed drugs of this class; and before NSAID therapy is initiated, patients should be asked whether aspirin has caused a flare of psoriasis.

Lack of adequate response to NSAIDs or the presence of progressive or moderate to severe arthritis usually requires additional drug therapy. Intraarticular glucocorticoid injections may relieve an isolated episode of severe synovitis. Injections into the tendon sheaths, usually under ultrasound imaging, may be particularly effective in reducing enthesitis. Systemic glucocorticoid therapy should usually be avoided because of low efficacy coupled with the risks of inciting a transition to pustular psoriasis and a rebound of the skin disease on withdrawal. Sulfasalazine is helpful in reducing clinical parameters of joint disease activity in approximately 30 to 40 percent of patients in extensively documented double blind trials, [62] especially in those with spondylitis. [63] Untoward reactions have been few, mainly a hypersensitivity dermatitis or gastrointestinal intolerance. Parenteral or oral gold salts are rarely used because of their limited efficacy. [62]

Severe Destructive Arthritis

For the treatment of severe destructive arthritis, NSAIDs are supplemented with a more potent anti-inflammatory agent with immunomodulatory properties, such as methotrexate, cyclosporin A, or TNF blockers. The efficacy of both parenteral and, to a lesser degree, oral methotrexate has been extensively documented, and this drug is the current mainstay of therapy for severe arthritis. [64], [65] The better-documented efficacy of parenteral methotrexate suggests that this route of administration may be optimal for initial or maintenance therapy in instances of more severe disease. [62] The side effects of methotrexate are discussed in Chap. 42 and Chap. 256. Minimal immune impairment is sometimes encountered, and the uncommon possibility of developing opportunistic infections such as *Pneumocystis carinii* should be kept in mind in the differential diagnosis of pneumonitis developing during methotrexate therapy.

In view of the important role of TNF-a as an effector of inflammation in psoriatic arthritis, the anti–TNF agents etanercept and infliximab are taking a place in the therapy of severe destructive psoriatic arthritis, especially in individuals who do not respond to methotrexate. [66], [67] and [68] Parallel improvement in skin lesions usually occurs. In one 12-week trial, 73 percent of patients treated with etanercept given subcutaneously twice weekly exhibited an improvement in ACR20 as compared to 13 percent in the placebo group. This is a relatively modest response criteria set, but other less well-controlled studies indicate a greater joint response. Infliximab, administered intravenously at weeks 0, 2, and 6 resulted in marked improvement of arthritis and clearing of some histologic features of inflammation. [36] Considering the central role of TNF-a in the effector arm of the adaptive and innate immune response, blockade of this pathway will subtly impair immunity, as is reflected by instances of activation of latent *Mycobacterium tuberculosis* infection with therapy. [69] The evolving guidelines for use of these blockers should be consulted before therapy is considered. Attention to the development of anti-DNA antibodies and other evidence of autoimmunity with therapy is also warranted.

Cyclosporin A improves both the skin and the joint disease in about 50 percent of patients treated with it. Improvement in skin disease occurs after 2 to 6 weeks of treatment, whereas joint disease took longer to improve. [63], [70] Within 4 weeks of discontinuing the drug, exacerbations of both skin and joint disease appeared. Untoward effects of cyclosporin A include usually reversible renal toxicity, with hypertension and azotemia, and the uncommon potential for the development of Epstein-Barr virus-related B cell lymphomas.

The place of DNA antimetabolites in the therapy of psoriatic arthritis has not received extensive analysis. Azathioprine was comparable in efficacy to methotrexate in a randomized trial. [62] Mycophenolate mofetil was used in six patients with psoriatic arthritis with good results. [71] A single report of the notable efficacy of 6-thioguanine in the treatment of psoriasis, associated with the depletion and induction of apoptosis in activated T lymphocytes, suggests that this compound may be beneficial in severe psoriatic arthritis as a complement to the mode of action of methotrexate and TNF blockade. [72]

HIV Infection

In psoriatic arthritis associated with HIV infection, NSAIDs such as naproxen are the first line of therapy. However, in many patients, this drug does not adequately control inflammation, especially the very disabling enthesitis. Etretinate

may be particularly useful in the treatment of this form of psoriatic arthritis because it lacks immunosuppressive effects. [73] Methotrexate, although effective in this setting, has been associated with the abrupt development of opportunistic infection and death in individuals with advanced HIV infection. [10] Therefore, methotrexate and similar potentially immunosuppressive agents must be used with caution. Attention should be directed toward monitoring viral levels and overall immunologic competency during such therapy. The use of etanercept to treat psoriatic arthritis associated with HIV infection achieved an excellent clinical response of the skin and joint manifestations, but the drug had to be discontinued because of the development of multiple infections. [74] These observations emphasize the need for considering the presence of HIV infection when instituting immunosuppressive therapy in an individual with recent onset severe psoriatic arthritis.

Surgery and Related Techniques

Arthroscopic synovectomy or intraarticular injection of short-lived radioactive isotopes of elements such as ytterbium are experimental approaches that have been effective in treating instances of severe chronic monarticular synovitis. Because of the enhanced tendency to fibrosis associated with these therapies, anti-inflammatory and physical therapy measures aimed at improving range of motion are important adjuncts to these interventions. Joint replacement and forms of reconstructive therapy are appropriate in situations of advanced joint destruction. Anecdotal reports of the recurrence of psoriatic arthritis in the setting of a fully reconstituted donor marrow suggest that this approach, while promising for rheumatoid arthritis, is not likely to succeed in psoriatic arthritis. [75]

REFERENCES

1. Moll JM, Wright V: Psoriatic arthritis. *Semin Arthritis Rheum* **3**:55, 1973

2. Marsal S et al: Clinical, radiographic and HLA associations as markers for different patterns of psoriatic arthritis. *Rheumatology (Oxford)* **38**:332, 1999

3. Zias, J, Mitchell P: Psoriatic arthritis in a fifth-century Judean Desert monastery. *Am J Phys Anthropol* **101**:491, 1996

4. Hench PS: Arthropathia psoriatica: Presentation of a case. *Proc Staff Meet Mayo Clin* **2**:89, 1927

5. Bauer W et al: The pathology of joint lesions in patients with psoriasis and arthritis. *Trans Assoc Am Physicians* **56**:349, 1941

6. Wright V: Psoriasis and arthritis. *Ann Rheum Dis* **15**:348, 1956

7. Ball J: Enthesopathy of rheumatoid and ankylosing spondylitis. *Ann Rheum Dis* **30**:213, 1971

8. Brewerton DA et al: HL-A 27 and arthropathies associated with ulcerative colitis and psoriasis. *Lancet* **1**:956, 1974

9. Johnson TM et al: AIDS exacerbates psoriasis. *N Engl J Med* **313**:1415, 1985

10. Winchester R et al: The co-occurrence of Reiter's syndrome and acquired immunodeficiency. *Ann Intern Med* **106**:19, 1987

11. Winchester R et al: Implications from the occurrence of Reiter's syndrome and related disorders in association with advanced HIV infection. *Scand J Rheumatol* **74**:89, 1988

12. Hellgren L: Association between rheumatoid arthritis and psoriasis in total populations. *Acta Rheumatol Scand* **15**:316, 1969

13. Shbeeb M et al: The epidemiology of psoriatic arthritis in Olmsted County, Minnesota, USA, 1982. *J Rheumatol* **27**:1247, 2000

14. Gladman DD, Brockbank J: Psoriatic arthritis. *Expert Opin Investig Drugs* **9**:1511, 2000

15. Salvarani C et al: Psoriatic arthritis. *Curr Opin Rheumatol* **10**:299, 1998

16. Gottlieb M et al: Discordance for psoriatic arthropathy in monozygotic twins. *Arthritis Rheum* **22**:805, 1979

17. Rahman P et al: Comparison of clinical and immunogenetic features in familial versus sporadic psoriatic arthritis. *Clin Exp Rheumatol* **18**:7, 2000

18. Moll JMH et al: Associations between ankylosing spondylitis, psoriatic arthritis, Reiter's disease, the intestinal arthropathies and Behçet's syndrome. *Medicine (Baltimore)* **53**:343, 1974

19. Kammer GM et al: Psoriatic arthritis: A clinical, immunologic, and HLA study of 100 patients. *Semin Arthritis Rheum* **9**:75, 1979

20. Swanbeck G et al: A population genetic study of psoriasis. *Br J Dermatol* **131**:32, 1994

21. Moll JMH, Wright V: Familial occurrence of psoriatic arthritis. *Ann Rheum Dis* **22**:181, 1973

22. Gerber LH et al: Human lymphocyte antigens characterizing psoriatic arthritis and its subtypes. *J Rheumatol* **9**:703, 1982

23. Arnett FC, Bias WB: HLA-Bw38 and Bw39 in psoriatic arthritis: Relationships and implications for peripheral and axial involvement. *Arthritis Rheum* **23**:649, 1980

24. Tiilikainen A et al: Psoriasis and HLA-Cw6. *Br J Dermatol* **102**:179, 1980

25. Ikaheimo I et al: Immunogenetic profile of psoriasis vulgaris: Association with haplotypes A2, B13, Cw6, DR7, DQA1*0201 and A1, B17, Cw6, DR7, DQA1*0201. *Arch Dermatol Res* **288**:63, 1996

26. Schmitt-Egenolf M et al: Familial juvenile onset psoriasis is associated with the human leukocyte antigen (HLA) class I side of the extended haplotype Cw6-B57-DRB1*0701-DQA1*0201-DQB1*0303: A population- and family-based study. *J Invest Dermatol* **106**:711, 1996

27. Gonzalez S et al: Polymorphism in MICA rather than HLA-B/C genes is associated with psoriatic arthritis in the Jewish population. *Hum*

Immunol **62**:632, 2001

28. Grossman RM et al: Interleukin 6 is expressed in high levels in psoriatic skin and stimulated proliferation of cultured human keratinocytes. *Proc Nat Acad Sci USA* **86**:6367, 1989

29. Costello PJ et al: Psoriatic arthritis joint fluids are characterized by CD8 and CD4 T cell clonal expansions appear antigen driven. *J Immunol* **166**:2878, 2001

30. Curran SA et al: Psoriatic arthritis synovium is characterised by non-antigen-specific T cells that are selectively suppressed by methotrexate therapy. *Arthritis Rheumatol* **44**:S235, 2001

31. Ross EL et al: Localized monocyte chemotactic protein-1 production correlates with T cell infiltration of synovium in patients with psoriatic arthritis. *J Rheumatol* **27**:2432, 2000

32. Wong WM et al: Interleukin-2 is found in the synovium of psoriatic arthritis and spondyloarthritis, not in rheumatoid arthritis. *Scand J Rheumatol* **25**:239, 1996

33. Konig A et al: Mig, GRO alpha and RANTES messenger RNA expression in lining layer, infiltrates and different leucocyte populations of synovial tissue from patients with rheumatoid arthritis, psoriatic arthritis and osteoarthritis. *Virchows Arch* **436**:449, 2000

34. Canete JD et al: Differential Th1/Th2 cytokine patterns in chronic arthritis: Interferon gamma is highly expressed in synovium of rheumatoid arthritis compared with seronegative spondyloarthropathies. *Ann Rheum Dis* **59**:263, 2000

35. Mansson B et al: Release of cartilage and bone macromolecules into synovial fluid: Differences between psoriatic arthritis and rheumatoid arthritis. *Ann Rheum Dis* **60**:27, 2001

36. Baeten D et al: Immunomodulatory effects of anti-tumor necrosis factor alpha therapy on synovium in spondyloarthropathy: Histologic findings in eight patients from an open-label pilot study. *Arthritis Rheum* **44**:186, 2001

37. Punzi L et al: Clinical, laboratory and immunogenetic aspects of post-traumatic psoriatic arthritis: A study of 25 patients. *Clin Exp Rheumatol* **16**:277, 1998

38. Cantini F et al: Distal extremity swelling with pitting edema in psoriatic arthritis: A case-control study. *Clin Exp Rheumatol* **19**:291, 2001

39. Rothschild BM et al: Dactylitis: Implications for clinical practice. *Semin Arthritis Rheum* **28**:41, 1998

40. Koo T et al: Subsets in psoriatic arthritis formed by cluster analysis. *Clin Rheumatol* **20**:36, 2001

41. Winchester R: Psoriatic arthritis and the spectrum of syndromes related to the SAPHO syndrome. *Curr Opin Rheumatol* **11**:251, 1999

42. McEwen C et al: Ankylosing spondylitis and spondylitis accompanying ulcerative colitis, regional enteritis, psoriasis, and Reiter's disease. *Arthritis Rheum* **14**:291, 1971

43. Jones MD et al: Bony overgrowths and abnormal calcifications about the spine. *Radiol Clin North Am* **26**:1213, 1988

44. Luong AA, Salonen DC: Imaging of the seronegative spondyloarthropathies. *Curr Rheumatol Rep* **2**:288, 2000

45. Offidani A et al: Subclinical joint involvement in psoriasis: Magnetic resonance imaging and x-ray findings. *Acta Derm Venereol* **78**:463, 1998

46. Barozzi L et al: Seronegative spondyloarthropathies: Imaging of spondylitis, enthesitis and dactylitis. *Eur J Radiol* **27**(suppl 1):S12, 1998

47. Taggart A, Wright V: Psoriatic arthritis, *in Epidermis: Disorders of Cell Kinetics and Differentiation*. 1990

48. Prieur AM, Chedeville G: Prognostic factors in juvenile idiopathic arthritis. *Curr Rheumatol Rep* **3**:371, 2001

49. Shore A, Ansell BM: Juvenile psoriatic arthritis—An analysis of 60 cases. *J Pediatr* **100**:529, 1982

50. Cabral DA et al: Visual prognosis in children with chronic anterior uveitis and arthritis. *J Rheumatol* **21**:2370, 1994

51. Petty RE: Juvenile psoriatic arthritis, or juvenile arthritis with psoriasis? *Clin Exp Rheumatol* **12**(suppl 10):S55, 1994

52. Roberton DM et al: Juvenile psoriatic arthritis: Followup and evaluation of diagnostic criteria. *J Rheumatol* **23**:166, 1996

53. Kanakoudi-Tsakalidou F et al: Persistent or severe course of reactive arthritis following Salmonella enteritidis infection. A prospective study of 9 cases. *Scand J Rheumatol* **27**:431, 1998

54. Reveille JD et al: Specific amino acid residues in the second hypervariable region of HLA-DQA1 and DQB1 chain genes promote the Ro (SS-A)/La (SS-B) autoantibody responses. *J Immunol* **146**:3871, 1991

55. Duvic M et al: Acquired immunodeficiency syndrome associated psoriasis and Reiter's syndrome. *Arch Dermatol* **123**:1622, 1987

56. Kaarela K et al: Work capacity of patients with inflammatory joint diseases. An eight-year follow-up study. *Scand J Rheumatol* **16**:403, 1987

57. Gladman DD et al: Psoriatic arthritis (PSA)—An analysis of 220 patients. *QJM* **62**:127, 1987

58. Coulton BL et al: Outcome in patients hospitalised for psoriatic arthritis. *Clin Rheum* **8**:261, 1989

59. Husted JA et al: Health-related quality of life of patients with psoriatic arthritis: A comparison with patients with rheumatoid arthritis. *Arthritis Rheum* **45**:151, 2001

60. Gladman DD et al: Remission in psoriatic arthritis. *J Rheumatol* **28**:1045, 2001

61. Hanly JG et al: Psoriatic spondyloarthropathy: A long-term prospective study. *Ann Rheum Dis* **47**:386, 1988

62. Jones G et al: Interventions for psoriatic arthritis. *Cochrane Database Syst Rev* 3, 2000

63. Salvarani C et al: A comparison of cyclosporine, sulfasalazine, and symptomatic therapy in the treatment of psoriatic arthritis. *J Rheumatol* **28**:2274, 2001

64. Zachariae H, Zachariae E: Methotrexate treatment of psoriatic arthritis. *Acta Derm Venereol Suppl (Stockh)* **67**:270, 1987

65. Steinsson K et al: Cyclosporin A in psoriatic arthritis: An open study. *Ann Rheum Dis* **49**:603, 1990

66. Mease PJ et al: Etanercept in the treatment of psoriatic arthritis and psoriasis: A randomised trial. *Lancet* **356**:385, 2000

67. Braun J et al: New treatment options in spondyloarthropathies: Increasing evidence for significant efficacy of anti-tumor necrosis factor therapy. *Curr Opin Rheumatol* **13**:245, 2001

68. Ogilvie AL et al: Treatment of psoriatic arthritis with antitumour necrosis factor-alpha antibody clears skin lesions of psoriasis resistant to treatment with methotrexate. *Br J Dermatol* **144**:587, 2001

69. Keane J et al: Tuberculosis associated with infliximab, a tumor necrosis factor alpha-neutralizing agent. *N Engl J Med* **345**:1098, 2001

70. Mahrle G et al: Anti-inflammatory efficacy of low-dose cyclosporin A in psoriatic arthritis. A prospective multicentre study. *Br J Dermatol* **135**:752, 1996

71. Grundmann-Kollmann M et al: Treatment of chronic plaque-stage psoriasis and psoriatic arthritis with mycophenolate mofetil. *J Am Acad Dermatol* **42**:835, 2000

72. Murphy FP et al: Clinical clearing of psoriasis by 6-thioguanine correlates with cutaneous T-cell depletion via apoptosis: evidence for selective effects on activated T lymphocytes. *Arch Dermatol* **135**:1495, 1999

73. Louthrenoo W: Successful treatment of severe Reiter's syndrome associated with human immunodeficiency virus infection with etretinate. Report of 2 cases. *J Rheumatol* **20**:1243, 1993

74. Aboulafia DM et al: Etanercept for the treatment of human immunodeficiency virus-associated psoriatic arthritis. *Mayo Clin Proc* **75**:1093, 2000

75. Snowden JA et al: Long-term outcome of autoimmune disease following allogeneic bone marrow transplantation. *Arthritis Rheum* **41**:453, 1998

T>

Chapter 44

Ming Jih Arash Kimyai-Asadi Irwin Freedberg

Exfoliative Dermatitis

HISTORICAL ASPECTS
EPIDEMIOLOGY
ETIOLOGY AND PATHOGENESIS
CLINICAL MANIFESTATIONS
Dermatologic Manifestations
Systemic Associations
LABORATORY FINDINGS
PATHOLOGY
TREATMENT AND PROGNOSIS

REFERENCES

Also referred to as erythroderma, exfoliative dermatitis is an inflammatory skin disease with erythema and scaling that affects nearly the entire cutaneous surface. It may be either primary (idiopathic) or secondary to a variety of drugs or underlying disorders. Primary exfoliative dermatitis has also been referred to as the “red man” or “ *l'homme rouge*” syndrome. (See Chap. 138 for a discussion of exfoliative dermatitis associated with drugs; Chap. 157 for a discussion of exfoliative dermatitis associated with cutaneous T cell lymphoma.)

HISTORICAL ASPECTS

The classification of exfoliative dermatitis into Wilson-Brocq (chronic relapsing), Hebra or pityriasis rubra (progressive), and Savill (self-limited) types may have had historical value, but it currently lacks pathophysiologic or clinical utility.

EPIDEMIOLOGY

Exfoliative dermatitis is a rare, yet easily recognized, potentially serious skin condition. Its reported incidence varies widely: from 1 to 71 per 100,000 dermatologic outpatients. [1], [2], [3] The higher incidences occurred in parts of Asia where the use of traditional medicaments by patients is common. A recent study in the Netherlands found an incidence of 0.9 patients per 100,000 inhabitants. [4] In most case series, men outnumber women in a proportion of two to four men for every one woman, and the mean age is between 40 and 60 years.

ETIOLOGY AND PATHOGENESIS

Although a significant percentage of patients with exfoliative dermatitis have idiopathic disease (approximately 25 percent), the majority of cases result from pre-existing skin diseases, in particular psoriasis (23 percent) and spongiotic disorders (16 percent), cutaneous T cell lymphoma (16 percent), and drug reactions (15 percent). [1], [2], [3], [4], [5], [6], [7], [8], [9] and [10] A survey of all dermatologists in the Netherlands indicated that, because practitioners refer only a minority of patients to academic centers, the number of idiopathic and malignancy-associated cases may be overestimated in many case series. [4]

The list of drugs that cause exfoliative dermatitis is large and continuously growing (Table 44-1). The association of most of these drugs with exfoliative dermatitis has come from isolated case reports with no clear dose-dependence, although it appears that antiepileptics, cimetidine, lithium, gold, allopurinol, quinidine, and calcium channel blockers may be particularly noteworthy as offending agents. However, it is important to consider all drug exposures, as intradermal and topical ocular preparations have been reported to induce exfoliative dermatitis.

TABLE 44-1 **Drugs That Cause Exfoliative Dermatitis**

A large number of systemic diseases, malignancies (hematologic or solid tumors), and infections may also play a role (

Table 44-2). Exfoliative dermatitis may be the initial manifestation of HIV infection, although drug eruptions are the most common cause of exfoliative dermatitis in HIV-positive patients. [11] In infants with exfoliative dermatitis, seborrheic dermatitis, atopic dermatitis, psoriasis, and staphylococcal scalded skin syndrome are the most common causes. When the condition is congenital, however, the clinician should consider a variety of genetic disorders, in particular Netherton's syndrome and hereditary immunodeficiency syndromes. [12]



TABLE 44-2 **Processes Reported in Association with Exfoliative Dermatitis**

In most patients with pre-existing skin diseases, the exfoliative phase follows previous localized disease. For example, psoriatic exfoliative dermatitis can occur in association with the withdrawal of systemic or topical glucocorticoids, the use of systemic medications such as lithium and antimalarials, phototherapy burns, infection, pregnancy, and systemic illnesses in patients with previously limited psoriasis.

Regarding the pathogenesis of exfoliative dermatitis, it is not clear whether dermal inflammation or epidermal dysfunction is primary. Drug- and malignancy-induced exfoliative dermatitis suggests an inflammatory etiology, whereas exfoliative dermatitis in ichthyoses associated with transglutaminase mutations suggests a primary epidermal etiology. It is likely that exfoliative dermatitis represents an end-stage inflammatory state that affects the entire integument, in which there is an uncontrolled feedback loop between the epidermis and the dermis.

The epidermis produces significantly elevated amounts of circulating vascular permeability factor/vascular endothelial growth factor in erythrodermic skin, resulting in dermal vascular proliferation and increased vascular permeability. [13] The increases in adhesion molecule expression (VCAM-1, ICAM-1, E-selectin, and P-selectin) seen in exfoliative dermatitis promote chronic dermal inflammation, which may, in turn, promote both epidermal proliferation and epidermal production of inflammatory mediators. [14] The dermal infiltrates may demonstrate either a T_H1 cytokine profile, as in benign reactive exfoliative dermatitis, or a T_H2 cytokine profile, as in Sézary syndrome. [15] This finding is consistent with the fact that a wide range of distinct immunologic processes (e.g., atopic dermatitis and contact dermatitis) may produce exfoliative dermatitis. Alterations in levels of various pro-inflammatory molecules (interleukins 2, 3, and 8; interferon-?; and ICAM-1) also have occurred with exfoliative dermatitis. However, these changes may be a secondary factor in the exfoliative dermatitis rather than an immunopathogenic cause.

The basic pathophysiology of exfoliative dermatitis involves an increased rate of epidermal turnover. The number of germinative cells and their absolute mitotic rate increase, whereas the transit time of keratinocytes through the epidermis decreases. Consequently, more cellular material is lost from the surface. Because of the rapid cell turnover in exfoliative dermatitis, the stratum corneum retains a number of components that are normally resorbed or metabolized. The desquamated cells show increased amounts of nucleic acids and their degradation products, as well as increased amounts of soluble protein. Although the large amount of protein lost each day has a potentially adverse effect on systemic metabolism (see below), the losses of nucleic acids and other minor constituents are too small to be of metabolic significance.

CLINICAL MANIFESTATIONS

Dermatologic Manifestations

Despite the wide range of underlying dermatologic disorders that may lead to exfoliative dermatitis, the clinical manifestations in all cases are similar. The disease generally starts as erythematous patches resulting from capillary dilation. Over days to weeks, these patches spread until bright red erythema affects the entire skin surface. The epidermis appears thin, giving the skin a shiny appearance.

Desquamation begins a few days after the onset of the erythema and often appears first in flexures. The scales are generally white or yellow and fine, although large platelike sheets of scale may develop, particularly in acute stages and on the palms and soles. As the desquamation progresses, the skin appears dry with a dull scarlet color and a gray hue. It is covered with small laminated scales that exfoliate profusely (Fig. 44-1). In some cases, particularly in the presence of bacterial colonization, there may be profuse moist, adherent crusts, leading to a characteristic musty odor. [11] A purple hue is often evident in dependent areas, and there may be straw-colored exudates.

FIGURE 44-1 Exfoliative dermatitis.

With time, induration and thickening of the skin from a combination of edema and lichenification may impart a sensation of severe skin tightness to the patient. In mild or early exfoliative dermatitis, the disease may be apparent only by blanching of the skin to demonstrate the mild macular erythema. In darkly pigmented patients, this early sign may be easily overlooked.

Chronic exfoliative dermatitis results in diffuse shedding of hair. The nails become thickened, ridged, dull, and brittle. Subungual hyperkeratosis, distal onycholysis, and splinter hemorrhages are common, and occasionally, the nails may be shed. Paronychia, onycholysis, subungual hyperkeratosis, and Beau lines of the nails may develop. [1] Once these changes develop, they generally overshadow any nail findings of the underlying disease process. “Shoreline” nails, reported to be a specific manifestation of drug-induced exfoliative dermatitis, are characterized by alternating bands of nail plate discontinuity and leukonychia representing periods in which the offending drug was used. [16] Chronic periorbital involvement, resulting in induration and decreased laxity of the eyelids, may lead to ectropion and epiphora. Palmoplantar keratoderma with thick, fissured scales has been reported in up to 80 percent of patients with chronic exfoliative dermatitis, and crusted, seborrheic scaling of the scalp is common. [17] Exfoliative dermatitis does not generally involve mucosal surfaces.

Occasionally, clinical features may be suggestive of the underlying etiology. Isolated typical psoriatic plaques may remain distinguishable from the surrounding skin changes, and clinical or radiographic evidence of psoriatic arthritis may be present. The violaceous papules and buccal mucosal lesions of lichen planus may be visible. In early cases, nail changes typical of the underlying disease process may be discernible. In exfoliative dermatitis associated with pityriasis rubra pilaris, islands of normal skin, peripheral horny plugs, orange-colored palmoplantar keratoderma, and follicular papules on juxtaarticular extensor surfaces may be evident. The presence of heavily crusted palms and soles with subungual hyperkeratosis should alert the clinician to the possibility of Norwegian scabies. In cases associated with pemphigus foliaceus, crusted patches and erosions may appear on the face and upper trunk. A heliotrope rash, Gottron's papules, periungual telangiectases, and muscle weakness may be seen in erythrodermic dermatomyositis. [18] Papuloerythroderma of Ofuji presents in elderly men as flat-topped red papules that coalesce into generalized erythrodermic plaques, characteristically sparing the abdominal skin folds (“deck chair” sign). Alopecia in infantile exfoliative dermatitis may be a sign of Netherton or Omenn syndromes. [12] In some cases, what initially appears as exfoliative dermatitis rapidly progresses to epidermal necrosis, foretelling toxic epidermal necrolysis, a pathophysiologically different process (see Chap. 58).

Long-term exfoliative dermatitis may resolve with residual dyspigmentation, particularly in darkly pigmented patients. Generalized vitiligo, disseminated pyogenic granulomas, anhidrosis, and xanthomas have been reported to occur after the resolution of exfoliative dermatitis.

Systemic Associations

Axillary and inguinal lymphadenopathy occur in up to 62 percent of patients. [7], [9] In general, the lymph nodes are moderately enlarged with a rubbery consistency. The histologic findings are frequently those of dermatopathic lymphadenopathy, with enlarged paracortical areas indicating the proliferation of T lymphocytes, but lacking effacement of the lymph node structure by malignant cells. Hepatomegaly is reported in up to 37 percent of cases; splenomegaly, in up to 23 percent. [7], [9] The presence of lymphadenopathy and hepatosplenomegaly, particularly in association with liver dysfunction and fever, may suggest a drug hypersensitivity syndrome or malignancy.

Patients with exfoliative dermatitis develop poikilothermia, with their core temperatures fluctuating according to the ambient temperature, because the uncontrolled dilation of cutaneous blood vessels results in an increased blood flow to the skin and an inability to compensate for ambient temperature changes. Moreover, the increased transepidermal water loss from the defective cutaneous barrier promotes the evaporation of skin surface fluids, resulting in further heat loss. [10] The dilated dermal vessels provide a low-resistance path for systemic blood flow, occasionally resulting in high-output cardiac failure. This may cause severe cardiac compromise in patients with pre-existing cardiac disease, or it may unmask previous subclinical cardiac insufficiency or coronary artery disease. More common than poikilothermia and high-output cardiac failure, however, are tachycardia and fever, which may develop in up to 80 percent of patients. [9] There is also compensatory hypermetabolism and an elevation of the basal metabolic rate, without an associated abnormality in thyroid function.

Increased fluid losses from both the greater transepidermal water loss and the higher basal metabolic rate may result in dehydration, an elevated blood urea nitrogen level, and renal insufficiency. Normally, approximately 400 mL of water are

lost from the skin each day; two-thirds of this amount is diffused directly through the stratum corneum, and the remainder is lost by the evaporation of sweat. Fluid losses are highest when scaling is at its peak, and careful monitoring of intake and output reproducibly demonstrates that extrarenal water losses decrease 5 to 6 days prior to a decrease in scaling. This can provide an objective method of monitoring patients. [19]

The diffuse shedding of scale can result in a protein loss of as much as 20 to 30 g/m ^{2} per day. This should be contrasted with the 500 to 1000 mg of exfoliated material normally shed from the surface of the glabrous skin each day. [20] On average, psoriatic exfoliative dermatitis results in significantly more protein loss than exfoliative dermatitis from drug reactions and eczema (12.8, 4.2, and 5.6 g/d, respectively). [21] This loss may result in negative nitrogen, potassium, and folate balances. The signs of a negative nitrogen balance include hypoalbuminemia, edema, and loss of muscle mass. Hypoalbuminemia results from decreased synthesis, elevated catabolism to compensate for protein loss, and hypervolemia. Peripheral edema is due to fluid shifts, hypoalbuminemia, and increased capillary permeability. Pulmonary capillary leak syndrome and acute respiratory distress syndrome are rare fatal complications of exfoliative dermatitis. Gynecomastia has been reported in some patients, possibly reflecting a hyperestrogenic state, although the significance of this finding is unclear. [9]

LABORATORY FINDINGS

Laboratory evaluation often reveals anemia (70 percent), lymphocytosis (41 percent), eosinophilia (35 percent), an elevated erythrocyte sedimentation rate (36 percent), and depressed serum protein levels (34 percent). [1], [7] Eosinophilia is generally a nonspecific finding, although a highly elevated eosinophil count raises the possibility of underlying Hodgkin's lymphoma. Dehydration may result in abnormal serum electrolyte concentrations and abnormal renal function. Polyclonal gammaglobulinemia appears in approximately 40 percent of patients, and an elevated serum IgE level occurs in up to 80 percent, even in cases not associated with atopic dermatitis. [7], [8], [17] Decreased counts of lymphocytes, including CD4 cells, may result from lymphocyte sequestration in the skin. [22]

Circulating Sézary cells may be present, but whereas less than 10 percent is considered nonspecific in the setting of exfoliative dermatitis, the presence of 20 percent or more Sézary cells is highly specific for Sézary syndrome. [6], [9] In exfoliative dermatitis associated with actinic reticuloid, there is an increased proportion of CD8+ lymphocytes in the skin, whereas in Sézary syndrome there are often clonal, circulating T cell populations and predominantly CD4+ cutaneous infiltrates. [23] Bone marrow biopsies of patients with idiopathic exfoliative dermatitis may demonstrate eosinophilia (32 percent) or benign hyperplasia (20 percent). [17]

PATHOLOGY

Biopsy specimens from patients with exfoliative dermatitis tend to have many nonspecific features, such as hyperkeratosis, parakeratosis, acanthosis, and chronic inflammatory infiltrates. These findings often mask the histologic features of the underlying disease process. Although in some series histologic evaluation was considered to be of no diagnostic benefit, [24] other series have demonstrated that a histologic diagnosis can be made in most cases. The submission of multiple biopsy specimens obtained simultaneously from patients with exfoliative dermatitis enhances the accuracy of histopathologic diagnosis.

In one study, blinded histologic diagnoses were compared with final diagnoses in 56 skin biopsy specimens from 40 patients with exfoliative dermatitis. The histologic and final clinicopathologic diagnoses were consistent in two-thirds of cases, even though the microscopic features were more subtle than those in the underlying diseases. [25] In another study comparing histologic diagnosis with final diagnosis, the mean diagnostic accuracy was 53 percent among a group of dermatopathologists who independently evaluated 56 specimens. [26]

Whereas erythrodermic psoriasis produces diagnostic histologic features in up to 90 percent of patients, [27] the histologic features of erythrodermic cutaneous T cell lymphoma are even more subtle than those of the patch and plaque stages of mycosis fungoides. Even in the presence of a peripheral blood population of clonal T-cells, nonspecific histologic features of chronic dermatitis can occur in one-third of patients with Sézary syndrome. [28] Of note, the presence of a lichenoid infiltrate suggests a lichenoid drug eruption as the etiology. [29]

Direct immunofluorescence studies may be helpful in the diagnosis of exfoliative dermatitis secondary to pemphigus foliaceus, bullous pemphigoid, graft-versus-host disease, and connective tissue disorders. Electron microscopy can be helpful in the evaluation of infantile exfoliative dermatitis, including congenital nonbullous ichthyosiform erythroderma and epidermolytic hyperkeratosis. Premature lamellar body secretion and foci of electron-dense material in the intercellular spaces of the stratum corneum are sensitive and specific markers of Netherton syndrome, permitting early diagnosis before the appearance of hair shaft abnormalities. [30]

TREATMENT AND PROGNOSIS

No matter what the cause of exfoliative dermatitis, the initial treatment is generally similar. It is essential not only to discontinue any suspected offending drug, but also to keep in mind that drugs such as antimalarials and lithium may cause or exacerbate diseases such as psoriasis, and drugs such as phenytoin may cause a clinical picture indistinguishable from that of Sézary syndrome. The patients are more comfortable if they are in a warm, humid environment. Although most patients can be managed as outpatients, some should be admitted to the hospital for monitoring of fluid intake and output, as well as renal function. Careful observation for signs of cardiac failure should be routine. Patients should receive a protein-fortified diet providing approximately 130 percent of the normal balanced diet protein as well as folate supplementation. [21], [31]

Supportive skin care with frequent application of bland emollients, soaks, and compresses, as well as mild-to-moderate strength topical glucocorticoid ointments, will usually result in an improvement over 1 to 2 weeks. Patients should avoid irritating topical agents such as tar preparations and anthralin. Because of altered barrier function, there is a possibility of significant systemic absorption with all topical agents. The systemic absorption of up to 20 percent of topically applied hydrocortisone is not uncommon in this condition, and thus, systemic effects may occur even with the topical use of low-potency glucocorticoids. [32] Moreover, erythrodermic patients may develop salicylism from the topical application of preparations that contain salicylic acid. Antihistamines may help control pruritus, and behavioral therapy may help to attenuate scratching.

The systemic administration of appropriate antibiotics may be necessary to control bacterial superinfection. Clinicians should consider antibiotics in all cases, as staphylococcal colonization of the skin may exacerbate exfoliative dermatitis and patients are then at risk for fatal staphylococcal septicemia. As patients with exfoliative dermatitis may contribute to the nosocomial spread of methicillin-resistant *Staphylococcus aureus,* appropriate contact precautions must be employed. [33]

When a patient's medical condition is severe or refractory or when it requires more rapid control of the cutaneous disease, a variety of systemic therapies are available. Cyclosporine, methotrexate, acitretin, and mycophenolate mofetil may be used for psoriatic exfoliative dermatitis; cyclosporine, for spongiotic disease; retinoids, glucocorticoids and extracorporeal photochemotherapy, for pityriasis rubra pilaris; glucocorticoids, for drug hypersensitivity syndrome; and extracorporeal photochemotherapy, for graft-versus-host disease. Cutaneous T cell lymphoma has been treated with glucocorticoids, psoralen plus ultraviolet A, total body electron beam irradiation, interferon-a, systemic chemotherapy, and extracorporeal photochemotherapy. Although acitretin is highly effective in the treatment of ichthyosiform exfoliative dermatitis, the clinician must weigh the benefits against the risks of long-term oral retinoid use, particularly in children. In cases of increased systemic capillary permeability, the administration of parenteral glucocorticoids and intravenous infusions of plasma may be imperative.

When the cause of exfoliative dermatitis is not known, the systemic use of glucocorticoids warrants great caution in order to prevent generalized pustular psoriasis or rebound flares of spongiotic disease. The systemic administration of steroids may also increase fluid retention. Similarly, phototherapy requires great caution, as erythrodermic patients may be exquisitely photosensitive, and a phototoxic reaction may exacerbate their disease.

Some measures may reduce the risk of exfoliative dermatitis. For example, the administration of irradiated blood products can prevent transfusion-related postsurgery exfoliative dermatitis, which is likely a variant of graft-versus-host disease and may be associated with a 90 percent mortality rate. Patients should strictly avoid medications that previously may have caused exfoliative dermatitis, as even topical contact may lead to a recurrence of exfoliative dermatitis. Similarly, erythrodermic systemic contact dermatitis has been reported in patients who have contact allergy to neomycin and who received gentamycin intravenously, and in rhus-allergic patients who took herbal medications, including rhus lacquer. [34], [35]

The prognosis of exfoliative dermatitis depends on its cause. Drug-induced cases have the best prognosis, as rapid improvement follows drug discontinuation. [2], [7], [24] However, toxic epidermal necrolysis and severe drug hypersensitivity reactions associated with hepatotoxicity are associated with a more grave prognosis. [7] Exfoliative dermatitis secondary to underlying skin diseases tends to improve over a few weeks, and as many as two-thirds of patients enter remission. [8] Psoriatic exfoliative dermatitis may recur in up to 20 percent of patients. [36]

Exfoliative dermatitis secondary to cutaneous T cell lymphoma and internal malignancies tends to be more persistent. In these patients, favorable prognostic factors include age less than 65 years, duration of symptoms before diagnosis greater than 10 years, absence of malignant lymph node infiltrates, and the absence of circulating Sézary cells. Depending on the presence or absence of these risk factors, median survival may range from 1.5 to 10.2 years. [37] In a study of 38 patients with exfoliative dermatitis of unknown etiology (“red man” syndrome), 4 patients progressed to mycosis fungoides, and an additional 9 were suspected of having mycosis fungoides. In this group, only one-third of the patients went into complete remission, whereas half of the patients died during the observation period (1 to 23 years). [17]

In the published reports of the past 50 years, the mortality rates associated with exfoliative dermatitis have consistently remained high, ranging from 20 to 60 percent. [5], [10], [38] Most deaths were in patients with malignancy, severe drug reactions, pemphigus foliaceus, or idiopathic disease; they occurred secondary to pneumonia, underlying malignancy, septicemia, and cardiovascular compromise. [5], [10] More recent studies have demonstrated significantly lower mortality rates. In one series of 82 patients, no patient with underlying benign skin disease died, whereas the mortality rate was 25 percent in patients with cutaneous T cell lymphoma, usually from progression of disease, complications of therapy, or bacterial sepsis. [7] In infantile cases, the mortality rate has been reported to be 16 percent. [12]

REFERENCES

1. Sehgal VN, Srivastava G: Exfoliative dermatitis: A prospective study of 80 patients. *Dermatologica* **173**:278, 1986
2. Hasan T, Jansen CT: Erythroderma: A follow-up of fifty cases. *J Am Acad Dermatol* **8**:836, 1983
3. Wong KS et al: Generalised exfoliative dermatitis: A clinical study of 108 patients. *Ann Acad Med Singapore* **17**:520, 1988
4. Sigurdsson V et al: The incidence of erythroderma: A survey among all dermatologists in the Netherlands. *J Am Acad Dermatol* **45**:675, 2001
5. Abrahams I et al: One hundred and one cases of exfoliative dermatitis. *Arch Dermatol* **87**:96, 1963

6. Sigurdsson V et al: Idiopathic erythroderma: A follow-up study of 28 patients. *Dermatology* **194**:98, 1997

7. King LE Jr et al: Erythroderma: Review of 82 cases. *South Med J* **79**:1210, 1986

8. Botella-Estrada R et al: Erythroderma: A clinicopathological study of 56 cases. *Arch Dermatol* **130**:1503, 1994

9. Sigurdsson V et al: Erythroderma: A clinical and follow-up study of 102 patients, with special emphasis on survival. *J Am Acad Dermatol* **35**:53, 1996

10. Nicolis GD, Helwig EB: Exfoliative dermatitis: A clinicopathologic study of 135 cases. *Arch Dermatol* **108**:788, 1973

11. Morar N et al: Erythroderma: A comparison between HIV positive and negative patients. *Int J Dermatol* **38**:895, 1999

12. Pruszkowski A et al: Neonatal and infantile erythrodermas: A retrospective study of 51 patients. *Arch Dermatol* **136**:875, 2000

13. Creamer D et al: Circulating vascular permeability factor/vascular endothelial growth factor in erythroderma. *Lancet* **348**:1101, 1996

14. Sigurdsson V et al: Expression of VCAM-1, ICAM-1, E-selectin, and P-selectin on endothelium in situ in patients with erythroderma, mycosis fungoides, and atopic dermatitis. *J Cutan Pathol* **27**:436, 2000

15. Sigurdsson V et al: Interleukin 4 and interferon-gamma expression of the dermal infiltrate in patients with erythroderma and mycosis fungoides: An immuno-histochemical study. *J Cutan Pathol* **27**:429, 2000

16. Shelley WB, Shelley ED: Shoreline nails: Sign of drug-induced erythroderma. *Cutis* **35**:220, 1985

17. Thestrup-Pedersen K et al: The red man syndrome: Exfoliative dermatitis of unknown etiology. A description and follow-up of 38 patients. *J Am Acad Dermatol* **18**:1307, 1988

18. Nousari HC et al: Paraneoplastic dermatomyositis presenting as erythroderma. *J Am Acad Dermatol* **39**:653, 1998

19. Freedberg IM, Baden HP: The metabolic response to exfoliation. *J Invest Dermatol* **38**:277, 1962

20. Goldschmidt H, Kligman AM: Quantitative estimation of keratin production by the epidermis. *Arch Dermatol* **88**:709, 1963

21. Kanthraj GR et al: Quantitative estimation and recommendations for supplementation of protein lost through scaling in exfoliative dermatitis. *Int J Dermatol* **38**:91, 1999

22. Griffiths TW et al: Acute erythroderma as an exclusion criterion for idiopathic CD4+ T lymphocytopenia. *Arch Dermatol* **130**:1530, 1994

23. Bakels V et al: Differentiation between actinic reticuloid and cutaneous T cell lymphoma by T cell receptor gamma gene rearrangement analysis and immunophenotyping. *J Clin Pathol* **51**:154, 1998

24. Leenutaphong V et al: Erythroderma in Thai patients. *J Med Assoc Thai* **82**:743, 1999

25. Zip C et al: The specificity of histopathology in erythroderma. *J Cutan Pathol* **20**:393, 1993

26. Walsh NM et al: Histopathology in erythroderma: Review of a series of cases by multiple observers. *J Cutan Pathol* **21**:419, 1994

27. Tomasini C et al: Psoriatic erythroderma: A histopathologic study of forty-five patients. *Dermatology* **194**:102, 1997

28. Trotter MJ et al: Cutaneous histopathology of Sézary syndrome: A study of 41 cases with a proven circulating T-cell clone. *J Cutan Pathol* **24**:286, 1997

29. Patterson JW et al: Lichenoid histopathologic changes in patients with clinical diagnoses of exfoliative dermatitis. *Am J Dermatopathol* **13**:358, 1991

30. Fartasch M et al: Altered lamellar body secretion and stratum corneum membrane structure in Netherton syndrome: Differentiation from other infantile erythrodermas and pathogenic implications. *Arch Dermatol* **135**:823, 1999

31. Hild DH: Folate losses from the skin in exfoliative dermatitis. *Arch Intern Med* **123**:51, 1969

32. Aalto-Korte K, Turpeinen M: Quantifying systemic absorption of topical hydrocortisone in erythroderma. *Br J Dermatol* **133**:403, 1995

33. Love JB et al: Exfoliative dermatitis as a risk factor for epidemic spread of methicillin resistant *Staphylococcus aureus*. *Intensive Care Med* **18**:189, 1992

34. Guin JD, Phillips D: Erythroderma from systemic contact dermatitis: A complication of systemic gentamicin in a patient with contact allergy to neomycin. *Cutis* **43**:564, 1989

35. Park SD et al: Clinical features of 31 patients with systemic contact dermatitis due to the ingestion of *Rhus* (lacquer). *Br J Dermatol* **142**:937, 2000

36. Boyd AS, Menter A: Erythrodermic psoriasis: Precipitating factors, course, and prognosis in 50 patients. *J Am Acad Dermatol* **21**:985, 1989

37. Kim YH et al: Prognostic factors in erythrodermic mycosis fungoides and the Sézary syndrome. *Arch Dermatol* **131**:1003, 1995

38. Wilson HTH: Exfoliative dermatitis: Its etiology and prognosis. *Arch Dermatol* **69**:577, 1954

T>

Chapter 45

Lowell Goldsmith Howard Baden

Pityriasis Rubra Pilaris

INCIDENCE
ETIOLOGY
CLINICAL MANIFESTATIONS
PATHOLOGY
DIFFERENTIAL DIAGNOSIS
TREATMENT
COURSE AND PROGNOSIS

REFERENCES

Pityriasis rubra pilaris (PRP) refers to a group of chronic disorders characterized by reddish orange, scaling plaques and keratotic follicular papules. Both familial and acquired forms of the disorder have been described. There is a recent extensively referenced review including historical aspects of the disease. [1]

INCIDENCE

The disease is rare, with estimates that it is the presenting problem in from 1 in 5000 to 1 in 50,000 dermatology patients. [2] Both sexes are affected equally. The age incidence curve is at least bimodal with a familial type that starts early in childhood. The acquired type occurs in the fifth and sixth decades. [2]

ETIOLOGY

The familial type has an autosomal dominant mode of inheritance. [3] Vitamin A deficiency and abnormal vitamin A metabolism have been incriminated as an etiologic entity in this disease. This is based primarily on the finding of cutaneous changes suggestive of pityriasis in a group of patients studied by Frazier and Hu in 1931 and thought to be lacking vitamin A. These patients in all likelihood had multiple vitamin deficiencies; attempts to produce keratotic lesions by vitamin A deprivation have been unsuccessful, and there are no data consistent with an abnormality of vitamin A metabolism.

CLINICAL MANIFESTATIONS

Cohen and Prystowsky [4] have reviewed the disease extensively, and a classification of acquired pityriasis rubra pilaris has been proposed by Griffiths. [2], [5] Types I and III, the classic types of adult and juvenile onset, are the most common; they seem to be the same disease and have good prognoses. Two cases of a circumscribed childhood form have been described associated with Down's syndrome. The onset is gradual in the familial type and can be more rapid in the acquired type. Redness and scaling of the face and scalp are often seen first, followed by redness and thickening of the stratum corneum of the palms (Fig. 45-1) and soles. The follicular papules so characteristic of the disease soon appear as keratotic follicular plugs surrounded by erythema (Fig. 45-2B). The follicular papules are not always present but are very prominent in black South Africans. [6] They are seen most commonly on the dorsal aspects of the proximal phalanges (Fig. 45-2A), the elbows, and the wrists. They can occur on other areas of the extremities and even the trunk (Fig. 45-2B, Fig. 45-2C) but appear rarely on the face. A more widespread eruption consisting of scaling orange-red plaques is observed on the trunk and extremities (Fig. 45-2C and Fig. 45-3) and occasionally on the face. The lesions have sharp borders, and islands of normal skin within them are characteristic (see Fig. 45-3). The lesions may expand and coalesce (Fig. 45-2C) and eventually cover the entire body (Fig. 45-2C and Fig. 45-3). The scales vary from fine to thick, the latter being particularly common on the palms and soles, which also may fissure and have an intense yellow-orange hue, and may cover the scalp in thick sheets. The disease has been associated with HIV infection; these patients commonly have nodulocystic and pustular acneiform lesions. [7], [8]

FIGURE 45-1 Hyperkeratotic palmar lesions seen in pityriasis rubra pilaris. Characteristically, the palms are smooth and glistening with prominent creases and occasional fissures.

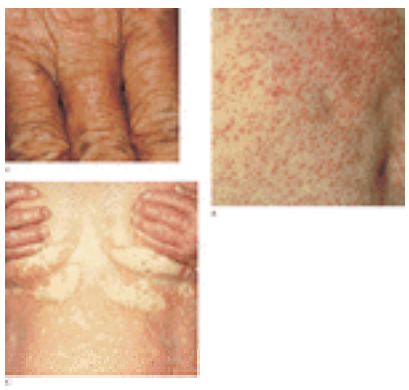

FIGURE 45-2 *A*. Acuminate follicular papules of pityriasis rubra pilaris. (*From Bergeron JR, Stone OJ:* Dermatologica *136:362, 1968, with permission.*) *B*. Close-up of discrete follicular papules on the trunk. *C*. Confluent follicular papules of pityriasis rubra pilaris that have formed large orange-red plaques. The lesions have sharp margins and islands of normal skin within them are characteristic.

FIGURE 45-3 Generalized pityriasis rubra pilaris (large orange plaque). Note areas of sparing, leaving islands of normal skin; this is characteristic but not pathognomonic.

Dermatomyositis, often associated with internal malignancy, with a PRP eruption, clinically and histologically, has been described and named the *Wong form* of dermatomyositis by some. [9] An association with inflammatory polyarthritis has been reported. [10] A juvenile case with hypogammaglobulinemia and furunculosis also has been reported. [11] The association with neoplasia is probably fortuitous. [12]

Hair and teeth are normal. Nail changes are said to be characteristic, with distal yellow-brown discoloration, subungual hyperkeratosis, nail plate thickening, and splinter hemorrhages, [13] but these findings also can be observed in psoriasis. The changes in mucous membranes include a diffuse whitish appearance of the buccal mucosa [14] as well as lacy white plaques and erosions. [15]

The familial type often persists throughout life, but the acquired form may have periods of remission. Systemic symptoms are uncommon except when total-body involvement occurs, and then they are similar to those occurring in exfoliative dermatitis, especially with frequent peripheral edema in older patients (see Chap. 44). Pruritus is uncommon.

PATHOLOGY

Hyperkeratosis is the most obvious feature on histologic examination. Parakeratosis is seen around the follicular openings, creating a shoulder effect. Alternating vertical and horizontal parakeratosis in the interfollicular stratum corneum is said to be characteristic. Irregular acanthosis and acantholytic dyskeratosis may accompany a mild chronic inflammatory infiltrate in the upper dermis.

DIFFERENTIAL DIAGNOSIS

When the typical features of follicular hyperkeratosis on the back of the fingers—an orange-colored eruption with spared areas and palmoplantar keratoderma—are observed, the diagnosis can be made with reasonable certainty. This is especially true in patients with a negative family history of psoriasis. Most patients present with fewer diagnostic features, and many of these end up having a clinical course most consistent with psoriasis. Difficulty with diagnosis is especially a problem in the pediatric age group. Even in patients who have a presentation and course consistent with PRP, there may be times when their lesions are more typical of psoriasis. Confusion with psoriasis presents the major diagnostic problem, particularly in early phases of the disease.

TREATMENT

The use of a keratolytic solution containing propylene glycol and lactic acid under an occlusive plastic dressing for 2 to 4 h followed by a glucocorticoid ointment for 4 to 8 h under an occlusive dressing has proved a valuable mode of therapy in PRP. Isotretinoin also has been reported to be of value, [16] although a recent review suggests that acitretin may be more effective in clearing patients, and today most patients are treated first with acitretin. [17] In the past, megadoses of vitamin A were used. [18] Calcipotriol has been effective. [19] Methotrexate therapy, [20] using the guidelines established for psoriasis, can induce a remission in a significant number of patients; a combination of methotrexate and a retinoid gives even better results. [17] Ultraviolet B (UVB) radiation treatment, as used for psoriasis, has not been helpful, but a retinoid plus psoralen and ultraviolet A (Re-PUVA) can be effective. Narrow-wave-band UVB also worked in connection with acitretin. [21] Unlike psoriasis, PRP does not respond to cyclosporine.

COURSE AND PROGNOSIS

The inherited form of the disorder is persistent throughout life. The acquired disease usually shows remissions and exacerbations, but some patients continue to have trouble for years. [4], [22] Some patients with universal involvement are desperate enough to attempt suicide.

REFERENCES

1. Albert MR, Mackool BT: Pityriasis rubra pilaris. *Int J Dermatol* **38**:1, 1999

2. Griffiths WA: Pityriasis rubra pilaris. *Clin Exp Dermatol* **5**:105, 1980

3. Vanderhooft SL et al: Familial pityriasis rubra pilaris. *Arch Dermatol* **131**:448, 1995

4. Cohen PR, Prystowsky JH: Pityriasis rubra pilaris: A review of diagnosis and treatment. *J Am Acad Dermatol* **20**:801, 1989

5. Griffiths WA: Pityriasis rubra pilaris: The problem of its classification. *J Am Acad Dermatol* **26**:140, 1992

6. Jacyk WK: Pityriasis rubra pilaris in black South Africans. *Clin Exp Dermatol* **24**:160, 1999

7. Martin AG et al: Pityriasis rubra pilaris in the setting of HIV infection: Clinical behaviour and association with explosive cystic acne. *Br J Dermatol* **126**:617, 1992

8. Miralles ES et al: Pityriasis rubra pilaris and human immunodeficiency virus infection. *Br J Dermatol* **133**:990, 1995

9. Lupton JR et al: An unusual presentation of dermatomyositis: The type Wong variant revisited. *J Am Acad Dermatol* **43**:908, 2000

10. Conaghan PG et al: The relationship between pityriasis rubra pilaris and inflammatory arthritis: Case report and response of the arthritis to anti-tumor necrosis factor immunotherapy. *Arthritis Rheum* **42**:1998, 1999

11. Castanet J et al: Juvenile pityriasis rubra pilaris associated with hypogammaglobulinaemia and furunculosis. *Br J Dermatol* **131**:717, 1994

12. Sanchez-Regana M et al: Pityriasis rubra pilaris as the initial manifestation of internal neoplasia. *Clin Exp Dermatol* **20**:436, 1995

13. Sonnex TS et al: The nails in adult type 1 pityriasis rubra pilaris: A comparison with Sezary syndrome and psoriasis. *J Am Acad Dermatol* **15**:956, 1986

14. Marshall J: Care of pityriasis rubra pilaris with lesions of buccal mucosa. *Arch Derm Syph* **66**:626, 1952

15. Baden HP, Roth SI: Oral lesions in pityriasis rubra pilaris. *Oral Surg Oral Med Oral Pathol* **25**:691, 1968

16. Goldsmith LA et al: Pityriasis rubra pilaris response to 13- *cis*-retinoic acid (isotretinoin). *J Am Acad Dermatol* **6**:710, 1982

17. Clayton BD et al: Adult pityriasis rubra pilaris: A 10-year case series. *J Am Acad Dermatol* **36**:959, 1997

18. Randel H: Toxic doses of vitamin A for pityriasis rubra pilaris. *Arch Dermatol* **116**:888, 1980

19. Van de Kerkhof PC, Steijlen PM: Topical treatment of pityriasis rubra pilaris with calcipotriol. *Br J Dermatol* **130**:675, 1994

20. Brown J, Perry HO: Pityriasis rubra pilaris: Treatment with folic acid antagonists. *Arch Dermatol* **94**:636, 1966

21. Kirby B, Watson R: Pityriasis rubra pilaris treated with acitretin and narrow-band ultraviolet B (Re-TL-01). *Br J Dermatol* **142**:376, 2000

22. Davidson CL et al: Pityriasis rubra pilaris: A follow-up study of 57 patients. *Arch Dermatol* **100**:175, 1969

T>

Chapter 46

Alf Björnberg Eva Tegner

Pityriasis Rosea

HISTORICAL ASPECTS
EPIDEMIOLOGY
Prevalence and Incidence
Sex Distribution
Age Distribution
Seasonal Variations
ETIOLOGY AND PATHOGENESIS
Infection
Drugs
Other Factors
CLINICAL MANIFESTATIONS
Classic Pityriasis Rosea
Atypical Pityriasis Rosea
Pigmentary Disturbances
LABORATORY FINDINGS
PATHOLOGY
DIAGNOSIS AND DIFFERENTIAL DIAGNOSIS
"Christmas Tree" Eruptions
Annular Eruptions
Papular Eruptions
TREATMENT

REFERENCES

Pityriasis rosea (PR) is an acute, self-limiting skin eruption with a distinctive and constant course. The initial lesion is a primary plaque that is followed after 1 or 2 weeks by a generalized secondary rash with a typical distribution and lasting for about 6 weeks.

HISTORICAL ASPECTS

The literature of the past two centuries records descriptions of disorders apparently identical to the condition now known as pityriasis rosea. [1] The disease has been given many names, such as erythema annulatum (Rayer), herpes tonsurans maculosus et squamosus (Hebra), lichen annulatus serpiginosus (Wilson), pityriasis circiné (Horand), pityriasis disseminé (Hardy), pityriasis marginée et circinée (Vidal), pityriasis rubra aigu disseminé (Bazin), pseudoexanthème erythématodesquamatif (Besnier), roseola annulata (Willan), roseola furfuracea herpetiformis (Behrend), and roseola squamosa (Nicolas and Chapard).

EPIDEMIOLOGY

Prevalence and Incidence

Pityriasis rosea is reported in all races. The prevalence in total populations has been calculated as 0.13 percent in men and 0.14 percent in women, most patients being in the age group of 10 to 43 years. The incidence at different dermatologic centers has varied between 0.3 and 3 percent. In Minnesota, a steady decline has been noted [2]; in Uganda, an increase has been reported [3]; and in Sweden [4] and in eastern Anatolia, [5] no change has been observed.

Sex Distribution

The disease has been reported to be equally common in the two sexes or slightly more common in women. [4]

Age Distribution

Pityriasis rosea is rare in both the very young and the very old. However, it has been described in infants as young as 3 months of age. A feature common to several studies is a steeply rising incidence during childhood to a plateau-like maximum between 10 and 35 years of age, followed by a slow decline.

Seasonal Variations

Pityriasis rosea seems to be prevalent all over the world, irrespective of climate. In temperate zones, it is usually considered to be most common during spring and autumn or during the cool part of the year, [2] but it also has been reported to be common during summer. In a Swedish study, an increase was demonstrated in spring and particularly in autumn, when the "epidemic" accumulation was the result of a successive rise in incidence. The seasonal variation was surprisingly constant from year to year. [4] In Uganda, no peaks of greatly increased incidence have been reported at any time [3]; in Singapore, no monthly variation was observed [6]; whereas in Australia, India, and Malaysia, PR has been found to be most common in the hot, dry season.

ETIOLOGY AND PATHOGENESIS

Infection

The monomorphous clinical picture of PR with its characteristic primary plaque, secondary eruption, and limited course resembles in some respects that of the communicable exanthemas. Like PR, most viral and bacterial infections show increased incidence in autumn and winter, with a decrease in summer. A relationship with recent upper respiratory infection has been recorded. [7]

CLUSTERING Pityriasis rosea has been reported to occur in the same intimate environment, [4] usually in two but also in three or even four people. Physicians' families are included in these reports. When specifically asked, 4 of 108 patients with PR mentioned cases of the disease in their immediate environment. [4] The incidence was higher in people working at or attending educational establishments, and this was considered to support the hypothesis that PR is caused by an infectious agent. A three- to fourfold increase has been demonstrated among dermatologists as compared with ear, nose, and throat surgeons.

TRANSMISSION EXPERIMENTS Most attempts at transmitting PR have failed, but there are interesting accounts of successful transfer of PR with an extract of scales or blister fluid. A typical primary plaque appeared at the site of inoculation after 10 to 15 days and was followed by a classic secondary rash. The primary plaque sometimes develops at the site of a recent lesion, such as a minor cutaneous infection, flea bite, wasp sting, or smallpox or bacille Calmette-Guérin (BCG) vaccination. A PR-like eruption has been reported after hepatitis B vaccination. [8] This again has raised the question of possible inoculation with an infective agent.

ATTEMPTS TO ISOLATE AN INFECTIVE AGENT Owing to its clinical resemblance to dermatophytosis, PR originally was thought to be a fungal infection. *Staphylococcus albus,* hemolytic streptococci, and spirochetes have all been incriminated. T lymphocytes specific for group A streptococcal antigens occasionally have been demonstrated in PR (as in guttate psoriasis). [9] After inoculation of a suspension of PR scales and biopsy material into the kidney of an African green monkey, a dermatotrophic virus of the picorna series was isolated. The findings in blood, sputum, urine, and feces were normal. Picornavirus-like particles have been seen on electron microscopy. [10] Structures resembling mycoplasma have been detected in ultrastructural studies of the primary plaque. [11]

RECURRENCE Recurrences are regarded as unusual, suggesting lasting immunity after an attack of PR. True recurrence may be seen after several months or years. When specifically looked for, however, recurrence seems to be quite common and may be encountered in 3 percent or more of patients. Multiple recurrences also have been reported. [2] In fact, there seem to be patients with a predisposition to PR who will have 10 or more attacks. During a recurrence, the primary plaque may develop at the same location as before or at another site.

ANTIBODY STUDIES Antistreptolysin titers are normal. *Legionella* antibodies were found in 33 percent of PR patients. [12] No significant rise in titer has been seen in any of the complement-fixation tests for adenovirus; influenza A or B; parainfluenza I, II, or III; or *Mycoplasma.* [13] Antibody studies have yielded no clues with respect to respiratory syncytial virus, ornithosis-psittacosis, herpes-varicella, cytomegalovirus, and Q fever. Antibodies for Epstein-Barr virus early antigen have been demonstrated in a large number of PR patients. Anticytoplasmic IgM antibodies to keratinocytes have been found in the sera of patients with PR, and it was suggested that these induced the development of the secondary eruption. [14] Most other studies on anticutaneous antibodies in PR have yielded negative results. Circulating immune complexes seem unimportant for the development of the secondary rash in PR because no such complexes have been found in the blood or skin. A significant, transient increase in IgD/IgM-bearing cells has been reported during the acute phase of PR in conjunction with a slight increase in the T cell population. A cell-mediated immune mechanism with Langerhans cells involvement may be important. [15], [16] and [17]

HHV-6 and HHV-7 Extensive research has been carried out in patients with PR with respect to the newly identified human herpes viruses HHV-6 and HHV-7. The results from different studies, however, are contradictory. [18], [19] The virus also has been identified in normal controls. It is thus possible but not yet proved that HHV-6 and HHV-7 play a part in some patients with PR but that other causative agents also may exist. CD-4 serves as the cellular membrane receptor for the lymphotropic HHV-7, as well as for HIV. [20] Interestingly, PR and PR-like eruptions occur in AIDS patients. [21]

Drugs

Many drugs have been reported to cause PR or PR-like rashes. These include arsenic, barbiturates, bismuth, captopril, clonidine, gold, interferon-a, isotretinoin, ketotifen, organic mercurials, methoxypromazine, metronidazole, omeprazole, D-penicillamine, salvarsan, terbinafine, and tripelene amine hydrochloride. Drug-induced PR may be of the classic type, but it often shows atypical features, a protracted course, large lesions, striking resistance to therapy, subsequent marked hyperpigmentation, and transformation to lichenoid dermatitis.

Other Factors

Atopy has been shown to be more common in PR patients than in controls. [2], [4] Pityriasis rosea is relatively common in patients with seborrheic dermatitis and acne vulgaris, and dandruff is more common in PR patients than in controls. [4] The quantitative occurrence of *Pityrosporon ovale* is similar in PR patients and controls. [4] Because the distribution of the skin lesions in PR sometimes coincides with the locations of various garments on the body, it has been thought that these precipitate or affect the course of the disease. The proportion of pregnant women with PR has been reported to be high (possibly due to new clothing), but others have been unable to confirm this. Pityriasis rosea–like eruptions have been observed repeatedly after bone marrow transplantation. [22] There is no evidence that PR is a psychosomatic disease. [4]

CLINICAL MANIFESTATIONS

Classic Pityriasis Rosea

The prodromal symptoms of PR have been reported repeatedly as general malaise, nausea, loss of appetite, fever, joint pain, and swelling of lymph nodes (in the acute vesicular form). In a controlled study, headache and gastrointestinal symptoms occurred more frequently in PR patients than in controls.

The primary plaque (plaque primitive, herald patch, primary medallion, mother patch; Fig. 46-1) is seen in 50 to 90 percent of cases. It will, in a few days, reach a diameter of a few centimeters. It is oval or round with a central, wrinkled, salmon-colored area and a darker red peripheral zone, separated by a collarette of fine scaling (Fig. 46-2 and Fig. 46-3). When the plaque is irritated, it will have an “eczematous,” papulovesicular appearance. The primary plaque is usually situated on the trunk in areas covered by clothes, but sometimes it is on the neck or extremities. Localization to the face or penis is rare. The site of the primary lesion does not differ between men and women.

FIGURE 46-1 Pityriasis rosea. Double herald patch.

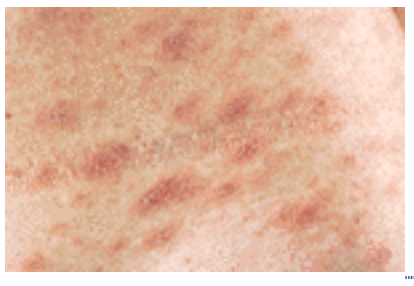

FIGURE 46-2 Pityriasis rosea. Generalized eruption. The long axis of the lesions follow the lines of cleavage. Typical marginal collarettes of scale.

FIGURE 46-3 Detail of Fig. 46-2.

The interval between the primary and secondary eruption is 2 days to 2 months. Cases have been reported in which the primary and secondary lesions appeared at the same time. The secondary eruption appears in crops at intervals of a few days and reaches its maximum in about 10 days. Occasionally new lesions continue to develop for several weeks. The symmetric eruption is localized mainly to the trunk and adjacent regions of the neck and extremities. The most pronounced lesions extend over the abdomen and anterior surface of the thorax as well as over the back. Lesions distal to the elbows and knees are not uncommon. Two main types of lesion are seen at the classic secondary rash: (1) small plaques resembling primary plaques in miniature, with the two red zones separated by the scaling ring, distributed with their long axes following the lines of cleavage of the skin, forming a “Christmas tree” pattern (Fig. 46-4), and (2) small, red, usually nonscaling papules that with increasing degrees of inflammation will increase in number and spread peripherally. Both forms may exist concomitantly.

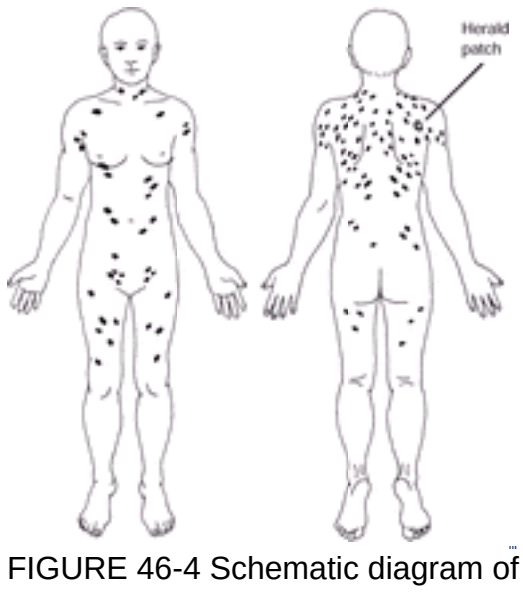

FIGURE 46-4 Schematic diagram of the herald patch and typical truncal distribution along the lines of cleavage.

The duration of the secondary eruption varies between 2 and 10 weeks. In severely eczematous or drug-induced rashes, the course may be very protracted (PR perstans).

Itching is severe in 25 percent of patients with uncomplicated PR, slight to moderate in 50 percent, and absent in 25 percent. When PR is irritated, itching is usually prominent.

Atypical Pityriasis Rosea

In about 20 percent of patients, the picture diverges from the classic one. The primary plaque may be missing or present as double or multiple lesions (see Fig. 46-1), often close together. The primary plaque may be the sole manifestation of the disease. The distribution of the secondary rash may be exclusively peripheral (PR inversa). Facial involvement has been reported mainly in children. The vulva may be involved. Localized forms comprise cervicocephalic PR, including the scalp, and the girdle type, affecting the axillae and groins. Unilateral distribution occurs, as well as localization to a small area. The lesions of PR gigantea are fewer than in the small-lesion forms, often develop around the primary plaque, and are not uncommonly confined to a limited region of the trunk; they may be circinate and sometimes confluent, persisting for months (pityriasis circinata et marginata of Vidal).

Enanthema of the mouth may occur exceptionally with or without hemorrhagic patches and even bullae on the tongue and cheeks. The lesions may resemble aphthous ulcers. Nail dystrophy after PR has been reported.

The morphology of the solitary elements of the secondary eruption may be atypical. Macules may lack scaling, papules may be follicular, and plaques may be absent or resemble psoriasis. The vesicular type (Fig. 46-5) is uncommon and usually affects children and young adults. It is said to be common in Africa. A purely vesicular form exists, but plaques may occur concomitantly or may develop later within the area of intense vesicular exanthema. The palms and soles sometimes are involved, and the clinical picture may simulate a widespread eczematous eruption. The lesions may be weeping and crusted. A pustular form of PR also exists. PR urticata may, during the first few days, mimic acute urticaria. The whealing is then localized mainly to the borders of the plaques, which tend to become confluent. Purpuric PR is not uncommon, and again, children seem to be predisposed to this form. The hemorrhagic lesions may or may not show scaling, and the skin may be spattered with tiny purpuric spots. A type resembling erythema multiforme also has been described. [23] PR may at the same time show various atypical features, as combined vesicular and purpuric lesions with peripheral localization.

FIGURE 46-5 Pityriasis rosea, vesicular type. Even the herald patch is vesicular.

Pigmentary Disturbances

Both hypo- and hyperpigmentation may follow the inflammatory stage. In the black skin of Africans, hyperpigmentation predominates, [3] and intense hyperpigmentation is seen in drug-induced PR. Previous sun tanning may influence the distribution of the secondary rash; the lesions may be confined to the tanned areas, but in some cases, tanning apparently protects the skin from PR lesions.

LABORATORY FINDINGS

The blood picture is usually normal, but leukocytosis, neutrophilia, basophilia, and lymphocytosis have been reported. Slight increases in erythrocyte sedimentation rate, total protein, alpha $_1$ and alpha $_2$ globulins, and albumin also have

been observed. Tests for rheumatoid factor, cold agglutinins, and cryoglobulins have been normal.

PATHOLOGY

The histologic findings are similar in the primary plaque and the secondary rash (Fig. 46-6 and Fig. 46-7). They are not pathognomonic. Patchy parakeratosis is characteristic, however, and in rare cases may be diffuse. The granular cell layer is reduced or absent. Slight acanthosis occurs. Focal spongiosis rarely may progress to vesiculation. A most impressive sign of PR is the presence of microscopic vesicles, sometimes subcorneal, in a clinically dry lesion. In the papillary dermis there is edema with homogenization of the collagen. A superficial perivascular infiltration consists of lymphocytes, histiocytes, and occasionally eosinophils. The histologic picture may be indistinguishable from that of superficial gyrate erythema. [24] Extravasated erythrocytes may be seen not only in the papillae but also in the epidermis. [25] Other histologic features that have been reported include focal necrosis of epidermal cells; dyskeratotic cells within the upper and middle epidermis with an eosinophilic, homogeneous appearance, suggesting primary damage to the basal cells; multinucleated epidermal giant cells such as are seen in other inflammatory states; focal acantholytic dyskeratosis; and a unique cytolytic degeneration of keratinocytes adjacent to Langerhans cells in the primary plaque.

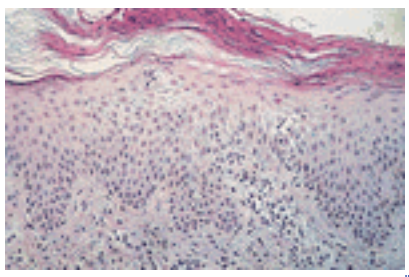

FIGURE 46-6 Pityriasis rosea. Patchy parakeratosis, absence of granular layer, slight acanthosis, spongiosis, superficial dermal infiltrate.

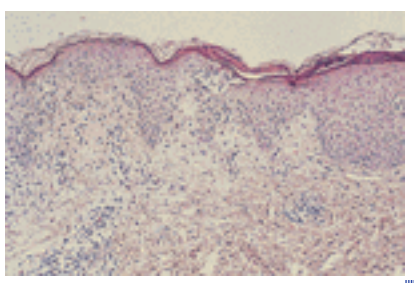

FIGURE 46-7 Pityriasis rosea. Absence of granular layer, acanthosis, spongiosis, and discrete inflammatory changes in upper dermis.

In older lesions, the perivascular infiltration is often both superficial and deep, with less spongiosis and more pronounced epidermal hyperplasia. [24] These late lesions may be difficult to distinguish from psoriasis and lichen planus.

DIAGNOSIS AND DIFFERENTIAL DIAGNOSIS

Both the solitary plaque and localized PR gigantea may closely resemble superficial tinea, and widespread eruptions of *Microsporum canis* may simulate generalized PR. Mycologic investigations will be necessary to settle the diagnosis.

“Christmas Tree” Eruptions

Any condition with a “Christmas tree” distribution can be confused with PR. Such conditions include erythema dyschromicum perstans (ashy dermatosis) in its small-lesion form. In ashy dermatosis, slight erythema precedes the characteristic bluish brown patches following the clefts of the skin. The color also differs from the tawny postlesional pigmentation that follows PR and that also fades faster. The histology of erythema dyschromicum perstans, with its hydropic degeneration of the basal cells of the epidermis, is different from that of PR. Classic PR with a primary plaque progressing to typical erythema dyschromicum perstans has been reported. Lichen planus and lichenoid reactions (lichen pigmentosus) with PR distribution often are caused by drugs. Cases have been reported in which lesions characteristic of both PR and lichen planus, both on naked-eye examination and on microscopy, have been present concomitantly. Pityriasis lichenoides may present with a “Christmas tree” pattern on the trunk, but as a rule, typical lesions will be found on the extremities. Histologically, PR can mimic this state. Kaposi's sarcoma may, in the aggressive form associated with HIV infection, show a PR pattern with oval, violaceous papules and nodules chiefly on the arms, neck, and trunk [26] associated with ecchymotic lesions. [27] A variety of papulosquamous dermatoses including PR of the persistent type also may be connected with HIV infection. [21] Histologic examination is necessary.

Annular Eruptions

Pityriasis alba occurs on the face, arms, and thorax in children and young adults. When the skin is irritated, an annular erythema may develop. Pityriasis rosea of the giant annular type may have the same localization, but the course is briefer in PR. Nummular eczema localized to the trunk also can pose difficulties in diagnosis. The lesions are usually round, not oval, and the papulovesicular elements are more prominent than in PR. Again, the course of PR is shorter. Seborrheic dermatitis can present precipitously with annular or figurate lesions on the trunk and arms; it sometimes may simulate localized PR. As a rule, the scalp and face show the typical picture of seborrheic dermatitis, and the course is protracted. Superficial tinea, when acute and with multiple lesions, may resemble PR; mycologic investigation is

necessary.

Papular Eruptions

Papular eruptions may be excluded when there is no primary plaque. Various drug eruptions and erythema multiforme of the small-lesion type may have to be considered. The Gianotti-Crosti syndrome can be very difficult to distinguish from inverse papular PR in children. Guttate psoriasis may cause difficulties in differential diagnosis when only a few superficial lesions are present. Histologic examination is not always helpful. Psoriasis runs a chronic course. Secondary syphilis may present with slightly scaling lesions and can mimic papular PR with no primary plaque. Mucosal lesions and enlargement of lymph nodes may occur in both PR and syphilis, but as with involvement of the palms and soles, these are much more common in the latter. Serologic tests for syphilis will differentiate the two.

TREATMENT

Since PR is self-limited, there is no need for active treatment in uncomplicated cases. Water, soap, wool, and sweating may cause irritation and should be avoided in the acute stages. When there is itching, zinc oxide or calamine lotion usually will suffice. In the widespread, severe forms, including vesicular PR, topical glucocorticoids are indicated and, exceptionally, a brief course of an oral glucocorticoid preparation. However, exacerbations with glucocorticoid treatment have been reported. [28] Dapsone has been used in severe vesicular PR. Erythromycin has been shown recently to clear PR in 2 weeks. Complete response was observed in 73 percent of a treatment group and none of a placebo-treated group. [29]

Some therapeutic effect of ultraviolet radiation has been confirmed in controlled studies. [30] A dose large enough to produce erythema and desquamation is necessary. Postinflammatory pigmentation at the site of the PR lesion may follow ultraviolet radiation therapy and has prompted a warning against this form of treatment.

REFERENCES

1. Gibert CM: *Traité Pratique des Maladies de la Peau et de la Syphilis,* 3d ed. Paris, Plon, 1860, p 402

2. Chuang T-Y et al: Pityriasis rosea in Rochester, Minnesota, 1969 to 1978: A 10-year epidemiologic study. *J Am Acad Dermatol* **7**:80, 1982

3. Vollum DI: Pityriasis rosea in the African. *Trans St Johns Hosp Dermatol Soc* **59**:269, 1973

4. Björnberg A, Hellgren L: Pityriasis rosea: A statistical, clinical, and laboratory investigation of 826 patients and matched healthy controls. *Acta Derm Venereol (Stockh)* **42**(suppl 50):1, 1962

5. Harman M et al: An epidemiological study of pityriasis rosea in the eastern Anatolia. *Eur J Epidemiol* **14**:495, 1998

6. Tay YK, Goh CL: One-year review of pityriasis rosea at the National Skin Centre, Singapore. *Ann Acad Med Singapore* **28**:829, 1999

7. Chuang T-Y et al: Recent upper respiratory tract infection and pityriasis rosea: A case-control study of 249 matched pairs. *Br J Dermatol* **108**:587, 1983

8. De Keyser F et al: Immune-mediated pathology following hepatitis B vaccination: Two cases of polyarteritis nodosa and one case of pityriasis rosea-like drug eruption. *Clin Exp Rheumatol* **18**:81, 2000

9. Baker BS et al: Group A streptococcal antigen-specific T lymphocytes in guttate psoriatic lesions. *Br J Dermatol* **128**:493, 1993

10. Metz J: An electronmiscroscopic investigation of the pityriasis rosea. *Am J Dermatopathol* **4**:228, 1977

11. Aoshima T et al: Ultrastructural observations of a herald patch in vesicular pityriasis rosea. *Am J Dermatopathol* **5**:273, 1978

12. Gjenero-Margan I et al: Pityriasis rosea (Gibert): Detection of *Legionella micdadei* antibodies in patients. *Eur J Epidemiol* **11**:459, 1995

13. Hudson LD et al: Pityriasis rosea: Viral complement fixation studies. *J Am Acad Dermatol* **4**:544, 1981

14. Takaki Y et al: Immunological studies of pityriasis rosea (Gibert). *J Dermatol (Tokyo)* **4**:37, 1977

15. Parsons JM: Pityriasis rosea update: 1986. *J Am Acad Dermatol* **15**:159, 1986

16. Bos JD et al: Pityriasis rosea (Gibert): Abnormal distribution pattern of antigen presenting cells in situ. *Acta Derm Venereol (Stockh)* **65**:132, 1985

17. Aiba S, Tagami H: Immunohistologic studies in pityriasis rosea: Evidence for cellular immune reaction in lesional epidermis. *Arch Dermatol* **121**:761, 1985

18. Drago F et al: Human herpesvirus 7 in pityriasis rosea. *Lancet* **349**: 1367, 1997

19. Kempf W et al: Pityriasis rosea is not associated with human herpesvirus 7. *Arch Dermatol* **135**:1070, 1999

20. Black JB, Pellett PE: Human herpesvirus 7. *Rev Med Virol* **9**:245, 1999

21. Sadick NS et al: Papulosquamous dermatoses of AIDS. *J Am Acad Dermatol* **22**:1270, 1990

22. Spelman LJ et al: Pityrisis rosea-like eruption after bone marrow transplantation. *J Am Acad Dermatol* **31**:348, 1994

23. Friedman SJ: Pityriasis rosea with erythema multiforme-like lesions. *J Am Acad Dermatol* **17**:135, 1987

24. Ackerman AB: *Histologic Diagnosis of Inflammatory Skin Diseases.* Philadelphia, Lea & Febiger, 1978

25. Panizzon R, Bloch PH: Histopathology of pityriasis rosea (Gibert): Qualitative and quantitative light-microscopic study of 62 biopsies of 40 patients. *Dermatologica* **165**:551, 1982

26. Myskowski PL et al: Kaposi's sarcoma in young homosexual men. *Cutis* **29**:31, 1982

27. Schwartz RA et al: Ecchymotic Kaposi's sarcoma. *Cutis* **56**:104, 1995

28. Leonforte JF: Pityriasis rosea: Exacerbation with corticosteroid treatment. *Dermatologica* **163**:480, 1981

29. Sharma PK et al: Erythromycin in pityriasis rosea: A double-blind, placebo-controlled clinical trial. *J Am Acad Dermatol* **42**:241, 2000

30. Leenutaphong V, Jiamton S: UVB phototherapy for pityriasis rosea: A bilateral comparison study. *J Am Acad Dermatol* **33**:996, 1995

T>

Chapter 47

Gary Wood Chung-Hong Hu

Parapsoriasis

HISTORICAL ASPECTS
EPIDEMIOLOGY
Large Plaque Parapsoriasis (LPP)
Small Plaque Parapsoriasis (SPP)—Including Digitate Dermatosis
ETIOLOGY AND PATHOGENESIS
DIFFERENTIAL DIAGNOSIS
TREATMENT
COURSE AND PROGNOSIS

REFERENCES

Parapsoriasis is a group of disorders characterized by a persistent, scaling, inflammatory eruption. Two clinicopathologic features set the parapsoriasis group apart from other purely inflammatory dermatoses: the relation to malignant lymphoproliferative lesions and the coexistence and/or overlapping of entities in this group. The current, generally accepted classification includes three entities [1]: large-plaque parapsoriasis (LPP), small-plaque parapsoriasis (SPP), and pityriasis lichenoides (Table 47-1). Each of these entities has distinct skin lesions and several morphologic variants. Some authors regard lymphomatoid papulosis as a variant of pityriasis lichenoides, whereas others consider it to be a separate disease. This issue is discussed further in Chap. 48 and Chap. 159.

1. Large-plaque parapsoriasis—Variants: poikilodermatous, retiform
2. Small-plaque parapsoriasis—Variant: digitate dermatosis
3. Pityriasis lichenoides
   a. Pityriasis lichenoides et varioliformis acuta (Mucha-Habermann)
   b. Pityriasis lichenoides chronica (Juliusberg)
   c. Lymphomatoid papulosis

TABLE 47-1 **Classification of Parapsoriasis**

HISTORICAL ASPECTS

The parapsoriasis group, described and debated for nearly a century, has spawned a confusing nomenclature. In addition to the proliferation of terminologies over the years, many conceptual schemes concern the group's clinical and biologic evolution.

In 1902, Brocq proposed the term *parapsoriasis* to serve as a central link of his grand design encompassing all inflammatory dermatoses. [1] Notably, he subdivided the parapsoriasis group into three forms: guttate, plaque, and lichenoid. In pre-Brocq years, there had been reports describing a number of dermatoses as parapsoriasis, and various morphologic entities were described during the subsequent 50 years. These have been reviewed in detail. [1] Between about 1950 and 1970, the parapsoriasis group was divided into two categories [2]: pityriasis lichenoides and parapsoriasis en plaques. The emphasis was on the potential of parapsoriasis en plaques to evolve into mycosis fungoides. In the 1970s, two observations concerning parapsoriasis en plaques were of importance. First, the distinction between SPP and LPP gained general acceptance, [3] as advanced previously by Degos [4] and Montgomery. [5] The second was the concept that the different types of LPP are all variants of the patch stage of mycosis fungoides. [6]

It has become a generally accepted practice to include the entities listed in Table 47-1 in the parapsoriasis group. There are authors, however, who still prefer to limit the term to LPP and SPP. [7], [8] This chapter focuses on these two disorders. Pityriasis lichenoides and lymphomatoid papulosis are discussed in Chap. 48 and Chap. 159, respectively.

EPIDEMIOLOGY

Large-plaque parapsoriasis (LPP) and SPP are, in general, diseases of middle-aged and older people, with a peak incidence in the fifth decade. Occasionally, lesions arise in childhood and may be associated with pityriasis lichenoides. Small plaque parapsoriasis shows a definite male predominance of approximately 3:1. Large plaque parapsoriasis is probably more common in males, but the difference is not as striking as in SPP. Both occur in all racial groups and geographic regions.

Large Plaque Parapsoriasis (LPP)

CLINICAL MANIFESTATIONS Large-plaque parapsoriasis lesions are either oval or irregularly shaped patches or very thin plaques that are asymptomatic or mildly pruritic. They may be well marginated or may blend imperceptibly into the surrounding skin. The size is variable, but typically most lesions are greater than 5 cm in size, often measuring more than 10 cm in diameter. Lesions are stable in size and may increase in number gradually. They are found mainly on the “bathing trunk” and flexural areas (Fig. 47-1). Extremities and the upper trunk, especially the breasts in women, also may be involved. Light red-brown or salmon-pink in color, their surface is covered with small and scanty scales. Lesions may appear finely wrinkled—“cigarette paper” wrinkling. Such lesions exhibit varying degrees of epidermal atrophy. Telangiectasia and mottled pigmentation also are observed when the atrophy becomes prominent (Fig. 47-2). This triad of atrophy, mottled pigmentation, and telangiectasia defines the term *poikiloderma* or *poikiloderma atrophicans vasculare,*

which also may be seen in certain genodermatoses (Rothmund-Thomson syndrome, Bloom's syndrome, and dyskeratosis congenita) and collagen vascular diseases (dermatomyositis and lupus erythematosus). *Retiform parapsoriasis* refers to a rare variant of LPP that presents as an extensive eruption of scaly macules and papules in a netlike or zebra-stripe pattern that eventually becomes poikilodermatous (Fig. 47-3).

FIGURE 47-1 Large-plaque parapsoriasis. Irregularly shaped patches of variable size on the arm of a 16-year-old girl.

FIGURE 47-2 Large-plaque parapsoriasis. Poikilodermatous variant.

FIGURE 47-3 Large-plaque parapsoriasis. Retiform variant.

HISTOPATHOLOGIC FEATURES In early LPP lesions, the epidermis is mildly acanthotic and slightly hyperkeratotic with spotty parakeratosis. The dermal lymphocytic infiltrate tends to be perivascular and scattered (Fig. 47-4). In the more advanced lesions one observes an interface infiltrate with definite epidermotropism. These invading lymphocytes may be scattered singly or in groups, sometimes associated with mild spongiosis. In addition, the poikilodermatous lesions show atrophic epidermis, dilated blood vessels, and melanophages (Fig. 47-5). Immunohistologic studies have shown similar features in LPP and early mycosis fungoides, including a predominance of CD4+ T cell subsets, frequent CD7 antigen deficiency, and widespread epidermal expression of human leukocyte antigen (HLA-DR). [9], [10], [11], [12], [13] and [14]

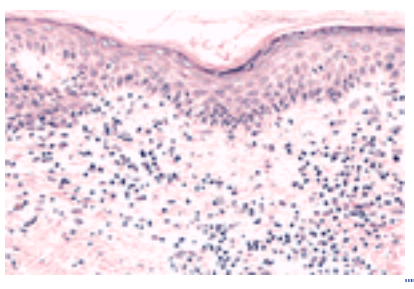

FIGURE 47-4 Large-plaque parapsoriasis. Mildly hyperkeratotic and focally parakeratotic epidermis with moderately dense superficial perivascular infiltrate. Lymphoid cells are mostly small, cytologically normal lymphocytes, and there is focal single-cell epidermotropism. (*Courtesy of Helmut Kerl, M.D.*)

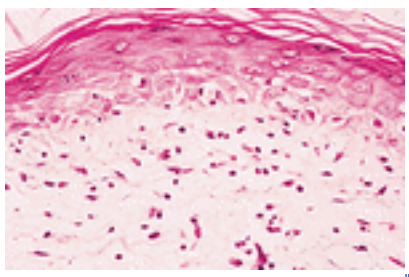

FIGURE 47-5 Large-plaque parapsoriasis. Atrophic variant. Sparse superficial lymphoid infiltrate with mild epidermotropism and epidermal atrophy.

Small Plaque Parapsoriasis (SPP)—Including Digitate Dermatosis

CLINICAL MANIFESTATIONS Small-plaque parapsoriasis characteristically occurs as round, oval, discrete patches or very thin plaques, mainly on the trunk (Fig. 47-6). The lesions measure less than 5 cm in diameter; they are asymptomatic and covered with fine, moderately adherent scales. The general health of the patient is unaffected. A distinctive variant with lesions of the finger shape, known as *digitate dermatosis,* [3] is yellowish or fawn in color (Fig. 47-7). It follows lines of cleavage of the skin and gives the appearance of a hug that left fingerprints on the trunk. The long axis of these lesions often measures greater than 5 cm. *Chronic superficial dermatitis* is a synonym for SPP. [15] Digitate lesions with a yellow hue were referred to in the past as *xanthoerythrodermia perstans.* [1]

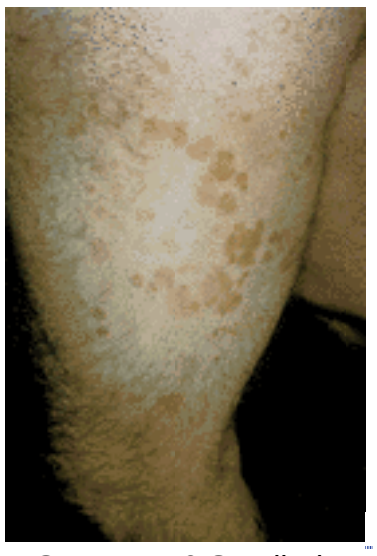

FIGURE 47-6 Small-plaque parapsoriasis. Small, discrete patches less than 5 cm in diameter.

FIGURE 47-7 Small-plaque parapsoriasis. Digitate dermatosis variant. Typical “fingerprint” patches on the flank. Note that their length often exceeds 5 cm.

HISTOPATHOLOGY Small-plaque parapsoriasis exhibits mild spongiotic dermatitis with focal areas of hyperkeratosis, parakeratosis, scale crust, and exocytosis. In the dermis, there is a mild superficial perivascular lymphohistiocytic infiltrate and dermal edema (Fig. 47-8). There is no progression of the histologic features with time. Immunohistologic studies reveal a predominantly CD4+ T cell infiltrate with nonspecific features resembling those seen in various types of dermatitides. [10]

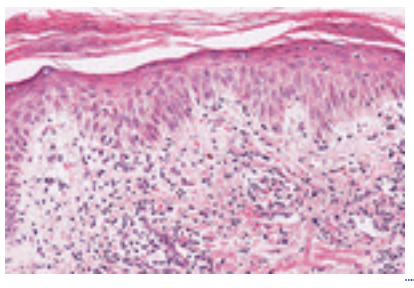

FIGURE 47-8 Small-plaque parapsoriasis. Superficial perivascular lymphoid infiltrate, mild spongiosis, parakeratosis, and focal scale crust.

ETIOLOGY AND PATHOGENESIS

It is likely that a complete understanding of the pathogenesis of parapsoriasis will require a similar comprehension of the pathogenesis of both chronic dermatitis and mycosis fungoides because in many ways parapsoriasis appears to bridge these other disorders (see Chap. 157). The T cells that mediate most inflammatory skin diseases belong to the skin-associated lymphoid tissue (SALT). [17] These T cells express the cutaneous lymphocyte-associated antigen (CLA) and traffic between the skin and the T cell domains of peripheral lymph nodes via the lymphatics and bloodstream. Mycosis fungoides has been shown to be a neoplasm of SALT T cells. Sensitive polymerase chain reaction (PCR)–based tumor clonality assays have underscored the SALT nature of mycosis fungoides tumor clones by showing that they can continue to traffic after neoplastic transformation [18] and can even participate in delayed-type hypersensitivity reactions to contact allergens. [19] This implies that rather than being a skin lymphoma per se, mycosis fungoides is actually a SALT lymphoma, i.e., a malignancy of a T cell circuit rather than one particular tissue. Trafficking of mycosis fungoides tumor cells has been detected even in patients with very early stage disease whose lesions were consistent clinicopathologically with LPP. [18] Therefore, it can be said that at least in some cases LPP is a monoclonal proliferation of SALT T cells that have the capacity to traffic between the skin and extracutaneous sites.

This view is also supported by the presence of structural and numerical chromosomal abnormalities in the peripheral blood mononuclear cells of patients with LPP. [20] In this context, LPP can be regarded as the clinically benign end of the mycosis fungoides disease spectrum, which eventuates in transformed large cell lymphoma at its malignant extreme. To say that these diseases belong to the same disease spectrum is not to say that they are biologically equivalent disorders. To lump them all together simply as “mycosis fungoides” would be to ignore their distinctive clinicopathologic features that are likely due to genetic and/or epigenetic differences, such as the *p53* gene somatic mutations observed in some cases of large cell transformation of mycosis fungoides. [21], [22] and [23] It is likely that several such differences separate these clinicopathologically defined disorders in a stepwise fashion analogous to the sequential acquisition of somatic mutations that occurs in the colon cancer disease spectrum as colonic epithelial cells progress through normal, hyperplastic, in situ carcinoma, invasive carcinoma, and metastatic carcinoma stages. [24]

A unifying feature of the parapsoriasis group of diseases is that all of them appear to be cutaneous T cell lymphoproliferative disorders; i.e., LPP, [11], [12], [14], [18], [25], [26], [27], [28] and [29] SPP, [12], [16] pityriasis lichenoides, [30], [31] and [32] and lymphomatoid papulosis [12], [33], [34] and [35]; all have been shown to be monoclonal disorders in many cases. In some instances, this has been demonstrated by genomic Southern blot analysis of T cell receptor gene rearrangements, but in others it has required more sensitive PCR-based techniques that are better suited to small skin biopsy specimens containing sparse lymphoid infiltrates. Studies of LPP/early mycosis fungoides, in which PCR-based assays detected monoclonality much more often than genomic Southern blotting, [11], [12], [14], [18], [25], [26], [27], [28] and [29] have suggested a dominant clonal density of roughly 1 to 10 percent. This is less than is seen in more advanced mycosis fungoides, where a dominant clone is consistently demonstrable by genomic Southern blotting and can have a density as high as 50 percent or more. These relationships suggest that progression from LPP through the various stages of the mycosis fungoides disease spectrum is accompanied by an increasing gradient of dominant T cell clonal density resulting from mutations that confer increasing growth autonomy to the neoplastic T cell clone. [36] Interestingly, analysis of peripheral blood has demonstrated that clonal T cells are often detectable in patients with LPP/early mycosis fungoides [28] or SPP, [37] again supporting the systemic SALT nature of these “primary” skin disorders.

It is important to realize that dominant clonality as seen in the parapsoriasis disease group, follicular mucinosis, pagetoid reticulosis (see Chap. 157), and certain other disorders does not equate to clinical malignancy. In fact, most patients with these diseases follow a benign clinical course, in some cases with complete resolution of their disease. In addition, there are other types of chronic cutaneous T cell infiltrates that sometimes exhibit dominant clonality, including primary (idiopathic) erythroderma and nonspecific chronic spongiotic dermatitis. This has given rise to the concept of clonal dermatitis, [25] originally described in the context of clonal nonspecific chronic spongiotic dermatitis but later expanded to include other nonlymphomatous cutaneous T cell infiltrates that harbor occult monoclonal T cell populations. During the past few years, several cases of clonal dermatitis, some of which have progressed to mycosis fungoides, have been identified. [25], [29] We suspect that within each disease with a potential for progression to mycosis fungoides, the principal risk may reside within its clonal dermatitis subset because this is the subset within which dysregulation has begun to occur.

The postulated relationships among mycosis fungoides, clonal dermatitis, and selected types of chronic dermatitis are depicted in Fig. 47-9. Each of the entities shown is postulated to be at risk for mycosis fungoides through a clonal dermatitis intermediate. In this model, mycosis fungoides becomes the final common pathway for the clonal evolution of neoplastic T cells emerging from the polyclonal SALT T cell populations present in each of the various precursor diseases.

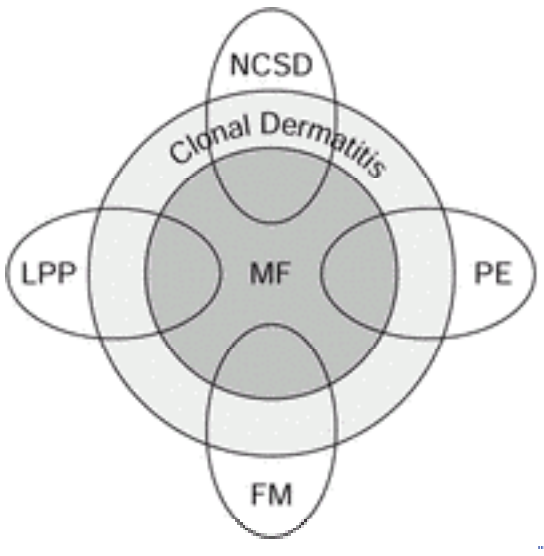

FIGURE 47-9 The relationship of clonal dermatitis to mycosis fungoides and various types of chronic dermatitis. The proportions of each entity that represent clonal dermatitis and mycosis fungoides vary with each disease and are not drawn to scale. Abbreviations: MF, mycosis fungoides; NCSD, nonspecific chronic spongiotic dermatitis; PE, primary erythroderma; FM, follicular mucinosis; LPP, large-plaque parapsoriasis.

DIFFERENTIAL DIAGNOSIS

Large-plaque parapsoriasis is distinguished from SPP by the larger size, asymmetric distribution, and irregular shape of its lesions that are less discrete and often poikilodermatous. Large-plaque parapsoriasis may be clinically and histopathologically indistinguishable from the patch stage of mycosis fungoides. Both LPP and SPP are readily distinguished from more advanced infiltrated plaques of mycosis fungoides because parapsoriasis lesions are, by definition, not thicker than patches or at most very thin plaques. This is so because the English equivalent of the French term *plaques* is *patches,* i.e., lesions that are essentially flat and devoid of induration or palpable infiltration. [38] Failure to appreciate this important distinction has led to considerable confusion and misuse of the terms *large-plaque* and *small-plaque parapsoriasis* by some individuals. These designations more appropriately might be thought of as large-patch and small-patch parapsoriasis.

The degree to which LPP is differentiated from early mycosis fungoides depends primarily on the histopathologic criteria used to diagnose the latter disorder (see Chap. 157). Unfortunately, there are no universally accepted minimal criteria for the diagnosis of mycosis fungoides; however, one set developed at Stanford University that has proved useful over the years is listed in Table 47-2. [39] Assuming that histopathologic examination does not disclose features diagnostic of some other dermatosis, these criteria allow lesions to be classified into one of four categories: diagnostic of mycosis fungoides, consistent with mycosis fungoides, suggestive of mycosis fungoides, or nonspecific chronic dermatitis. For the practical purposes of clinical management, patients presenting clinically with patch lesions that fall into the first two categories are considered to have unequivocal mycosis fungoides, whereas those in the latter two categories are not. Obviously, the more liberal the histopathologic criteria, the more cases will be considered to be mycosis fungoides. However, there will always be some cases that fail to meet any specific set of criteria, and the designation LPP is a useful term to apply to them because it guides treatment and follow-up and conveys an understanding that the risk of dying from lymphoma is small.

1. Multiple Pautrier microaggregates
2. Diffuse infiltration of many individual atypical lymphocytes* into the epidermis†
3. A few small intraepidermal clusters of a few atypical lymphocytes
4. A few individual intraepidermal atypical lymphocytes
5. Dense upper dermal bandlike interface infiltrate that includes atypical lymphocytes
6. Mild to moderate polymorphous upper dermal infiltrate that includes atypical lymphocytes and has a focal interface pattern
7. Extension of the infiltrate into the deep dermis

Categories diagnostic of MF: 1; 2; 3 + 4 + 5; 3 + 4 + 6 + 7
Categories consistent with MF: 3 + 5; 3 + 6; 4 + 5; 4 + 6 + 7
Categories suggestive of MF: 3; 4; 5; 6

*Lymphocytes with scant cytoplasm and hyperchromatic, convoluted cerebriform nuclei. Cell size may vary.
†Epidermal involvement is characteristically not associated with prominent intercellular edema spongiosis.
SOURCE: Adapted with minor modifications from the criteria of Alvin I. Cox, M.D., Professor Emeritus of Dermatology and Pathology, Stanford University, with permission.

TABLE 47-2 **Histopathologic Criteria for Mycosis Fungoides**

The clinical and/or histopathologic differential diagnosis of LPP also includes those genodermatoses and collagen vascular diseases exhibiting poikilodermatous features, lichenoid drug eruptions, secondary syphilis, and chronic radiodermatitis. These generally can be distinguished by their associated clinical findings. The histopathologic differentiation among these diseases is included in the discussion of pseudo-mycosis fungoides in Chap. 159.

Small-plaque parapsoriasis, when it presents with its distinctive digitate lesions parallel to skin lines in a truncal distribution, stands out from other types of parapsoriasis. Individual SPP lesions may show some superficial resemblance to pityriasis lichenoides chronica. Small-plaque parapsoriasis is distinguished from psoriasis by the absence of the Auspitz sign, micaceous scale, nail pits, and typical psoriatic lesions involving scalp, elbows, and knees. Histologically, its mild spongiotic dermatitis distinguishes it from both pityriasis lichenoides chronica and psoriasis.

Sometimes patients with mycosis fungoides may exhibit small patches of disease at presentation; however, these lesions typically have histopathologic features at least consistent with mycosis fungoides (as defined in Table 47-2) and generally are associated with larger, more classic lesions of mycosis fungoides elsewhere on the skin. They also may show poikilodermatous features not seen in SPP. Furthermore, the presence of well-developed, moderate to thick small plaques, as seen in some mycosis fungoides patients, is incompatible with the diagnosis of SPP because the latter disorder includes only lesions that are no more than patches or very thin plaques. It is also important to recognize that

partially treated or early relapsing lesions of mycosis fungoides may show only nonspecific features that should not be taken as evidence of a pathogenetic link to SPP or any other dermatosis.

TREATMENT

Patients with SPP should be reassured and may be left untreated. The disease may be treated with emollients, topical tar preparations, topical corticosteroids, and/or ultraviolet B (UVB) phototherapy. Response to therapy is variable. Patients should be examined initially every 3 to 6 months and subsequently every year to ensure that the character of the process is stable.

Large-plaque parapsoriasis requires more aggressive therapy: high-potency topical corticosteroids with phototherapy such as UVB, narrowband UVB, or psoralen and ultraviolet A (PUVA). The goal of treatment is to suppress the disorder to prevent possible progression to overt mycosis fungoides. Other methods of treatment, such as topical nitrogen mustard, have been used, particularly for the poikilodermatous type. The patient should be examined carefully every 3 months initially and every 6 months to 1 year subsequently for evidence of progression. Repeated multiple biopsies of suspicious lesions should be performed. Cases that satisfy the clinicopathologic criteria for early mycosis fungoides usually are treated with UVB, narrowband UVB, PUVA, topical nitrogen mustard, or topical carmustine (BCNU). Electron-beam radiation therapy generally is reserved for more advanced, infiltrated lesions of mycosis fungoides.

COURSE AND PROGNOSIS

Both LPP and SPP may persist for years to decades with little change in appearance clinically or histopathologically. Approximately 10 to 30 percent of cases of LPP progress to overt mycosis fungoides. [1], [40] In this context, LPP represents the clinically benign end of the mycosis fungoides disease spectrum, with transformation to large cell lymphoma at the opposite extreme. The rare retiform variant is said to progress to overt mycosis fungoides in virtually all cases. [1]

In contrast to the malignant potential of LPP, SPP is a clinically benign disorder. Patients with this disease as defined in this chapter rarely, if ever, develop overt mycosis fungoides as defined in Table 47-2. [15] Despite this fact and what most observers consider to be its nonspecific histopathologic features, some authors favor lumping SPP within the mycosis fungoides disease spectrum as a very early, nonprogressive variant. [41] This issue has been debated at length. [31], [42], [43]

REFERENCES

1. Lambert WC, Everett MA: The nosology of parapsoriasis. *J Am Acad Dermatol* **5**:373, 1981

2. Ingram JT: Pityriasis lichenoides and parapsoriasis. *Br J Dermatol* **65**:293, 1953

3. Hu C-H, Winkelmann RK: Digitate dermatosis: A new look at symmetrical, small plaque parapsoriasis. *Arch Dermatol* **107**:65, 1973

4. Degos R: *Dermatologie.* Paris, Flammarion, 1953, p 188

5. Montgomery H: *Parapsoriasis in Dermatopathology,* edited by H Montgomery. New York, Harper & Row, 1967, p 337

6. Sánchez JL, Ackerman AB: The patch stage of mycosis fungoides. *Am J Dermatopathol* **1**:5, 1979

7. Lever WF, Schaumburg-Lever G: Parapsoriasis, in *Histopathology of the Skin,* edited by WF Lever, G Schaumburg-Lever. Philadelphia, Lippincott, 1990, p 165

8. Ross S, Sánchez JL: Parapsoriasis: A century later. *Int J Dermatol* **29**:329, 1990

9. Lindae ML et al: Poikilodermatous mycosis fungoides and atrophic large-plaque parapsoriasis exhibit similar abnormalities of T-cell antigen expression. *Arch Dermatol* **124**:366, 1988

10. Ralfkiaer E et al: Phenotypic characterization of lymphocyte subsets in mycosis fungoides: Comparison with large plaque parapsoriasis and benign chronic dermatoses. *Am J Clin Pathol* **84**:610, 1985

11. Kikuchi A et al: Parapsoriasis en plaques: Its potential for progression to malignant lymphoma. *J Am Acad Dermatol* **29**:419, 1993

12. Zelickson BD et al: T-cell receptor gene rearrangement analysis: Cutaneous T cell lymphoma, peripheral T cell lymphoma, and premalignant and benign cutaneous lymphoproliferative disorders. *J Am Acad Dermatol* **25**:787, 1991

13. Buchner SA: Parapsoriasis en plaques: Characterization of the cellular infiltrate using monoclonal antibodies. *Z Hautkr* **63**:423, 1988

14. Menni S et al: Parapsoriasis in two children: A clinical, immunophenotypic, and immunogenotypic study. *Pediatr Dermatol* **11**:151, 1994

15. Samman PD: The natural history of parapsoriasis en plaque (chronic superficial dermatitis) and pre-reticulotic poikiloderma. *Br J Dermatol* **87**:405, 1972

16. Haeffner AC et al: The differentiation and clonality of lesional lymphocytes in small plaque parapsoriasis. *Arch Dermatol* **131**:321, 1995

17. Bos JD (ed): *Skin Immune System.* Boca Raton, FL, CRC Press, 1990

18. Veelken H et al: Molecular staging of cutaneous T cell lymphoma: Evidence for systemic involvement in early disease. *J Invest Dermatol* **104**:889, 1995

19. Veelken H et al: Detection of low-level tumor cell trafficking to allergic contact dermatitis induced by mechlorethamine in patients with mycosis fungoides. *J Invest Dermatol* **106**:685, 1996

20. Karenko L et al: Chromosomal abnormalities in cutaneous T-cell lymphoma and in its premalignant conditions as detected by G-banding and interphase cytogenetic methods. *J Invest Dermatol* **108**:22, 1997

21. Chooback L et al: Overexpression of p53 protein in cutaneous T-cell lymphoma (CTCL): Relationship to large cell transformation (LCT) and disease progression. *J Invest Dermatol* **104**:674, 1995

22. McGregor JM et al: p53 gene mutations in cutaneous T-cell lymphoma. *J Invest Dermatol* **106**:855, 1996

23. Kim BK et al: p53 protein status in cutaneous T-cell lymphoma. *J Cutan Pathol* **24**:107, 1997

24. Fearon ER, Vogelstein B: A genetic model for colorectal tumorigenesis. *Cell* **61**:759, 1990

25. Wood GS et al: Detection of clonal T-cell receptor ? gene rearrangements in early mycosis fungoides/Sézary syndrome by polymerase chain reaction and denaturing gradient gel electrophoresis (PCR/DGGE). *J Invest Dermatol* **103**:34, 1994

26. Bergman R: How useful are T-cell receptor gene rearrangement studies as an adjunct to the histopathologic diagnosis of mycosis fungoides? *Am J Dermatopathol* **21**:498, 1999

27. Simon M et al: Large plaque parapsoriasis: Clinical and genotypic correlations. *J Cutan Pathol* **27**:57, 2000

28. Muche JM et al: Demonstration of frequent occurrence of clonal T cells in the peripheral blood of patients with primary cutaneous T-cell lymphoma. *Blood* **90**:1636, 1997

29. Siddiqui J: Clonal dermatitis: A potential precursor of CTCL with varied clinical manifestations. *J Invest Dermatol* **108**:584, 1997

30. Weiss LM et al: Clonal T-cell populations in pityriasis lichenoides et varioliformis acuta (Mucha-Habermann disease). *Am J Pathol* **126**:417, 1988

31. Shieh S et al: Differentiation and clonality of lesional lymphocytes in pityriasis lichenoides chronica. *Arch Dermatol* **137**:305, 2001

32. Dereure O et al: T-cell clonality in pityriasis lichenoides et varioliformis acuta: A heteroduplex analysis of 20 cases. *Arch Dermatol* **136**:1483, 2000

33. Weiss LM et al: Clonal T-cell populations in lymphomatoid papulosis: Evidence of a lymphoproliferative origin for a clinically benign disease. *N Engl J Med* **315**:475, 1986

34. Kadin ME et al: Clonal composition of T-cells in lymphomatoid papulosis. *Am J Pathol* **126**:13, 1987

35. Chott A et al: The same dominant T cell clone is present in multiple regressing skin lesions and associated T cell lymphomas of patients with lymphomatoid papulosis. *J Invest Dermatol* **106**:696, 1996

36. Wood GS: Lymphocyte activation in cutaneous T-cell lymphoma. *J Invest Dermatol* **105**:105S, 1995

37. Muche JM et al: Demonstration of frequent occurrence of clonal T cells in the peripheral blood but not the skin of patients with small plaque parapsoriasis. *Blood* **94**:1409, 1999

38. Burg G et al: Cutaneous lymphomas consist of a spectrum of nosologically different entities including mycosis fungoides and small plaque parapsoriasis. *Arch Dermatol* **132**:567, 1996

39. Wood GS: The benign and malignant cutaneous lymphoproliferative disorders including mycosis fungoides, in *Neoplastic Hematopathology,* 2d ed, edited by DM Knowles. Baltimore: Williams & Wilkins, 2001, p 1183

40. Lazar AP et al: Parapsoriasis and mycosis fungoides: The Northwestern University experience, 1970 to 1985. *J Am Acad Dermatol* **21**:919, 1989

41. King-Ismael D, Ackerman AB: Guttate parapsoriasis/digitate dermatosis (small plaque parapsoriasis) is mycosis fungoides. *Am J Dermatopathol* **14**:518, 1992

42. Burg G, Dummer R: Small plaque (digitate) parapsoriasis is an abortive cutaneous T-cell lymphoma and is not mycosis fungoides. *Arch Dermatol* **131**:336, 1995

43. Ackerman AB: If small plaque (digitate) parapsoriasis is a cutaneous T-cell lymphoma, even an “abortive” one, it must be mycosis fungoides! *Arch Dermatol* **132**:562, 1996

T>

Chapter 48

Mazen Daoud Mark Pittelkow

Pityriasis Lichenoides

HISTORIC ASPECTS
ETIOLOGY AND PATHOGENESIS
CLINICAL MANIFESTATIONS
HISTOPATHOLOGY
DIFFERENTIAL DIAGNOSIS
TREATMENT
COURSE AND PROGNOSIS

REFERENCES

HISTORIC ASPECTS

Pityriasis lichenoides [Greek, *pityron* (“bran”) + *iasis* (condition); Greek *leichen* (lichen-like eruption), *eidos* (“form”)] is an uncommon, idiopathic, acquired dermatosis first described by Neisser [1] and Jadassohn [2] in 1894. Based on differences in morphology and temporal evolution and course of the disorder, acute (*acuta*) and chronic (*chronica*) variants have been identified. Pityriasis lichenoides is characterized by evolving groups of erythematous, scaly papules that may either persist for weeks to months (chronica) or erupt and recur in acute exacerbations, often accompanied by vesiculopustular lesions, ulceration, hemorrhage, and crusting (acuta). The original reports by Neisser and Jadassohn included, but did not distinguish between, the acute and chronic forms of the disease. Juliusberg later delineated the chronic form of pityriasis lichenoides and named it pityriasis lichenoides chronica. [3]

The clinical parameters and temporal course of pityriasis lichenoides led Brocq [4] to include it with a group of skin disorders that he had previously described as small-plaque and large-plaque parapsoriasis; he united these under the term *erythrodermies pityriasques en plaques disseminées*. Brocq thought that these heterogeneous dermatoses shared many features, including an unknown etiology, chronic course, lack of symptoms, and poor response to therapy. The prefix *para* (Greek for “alongside of” “near”) was used to denote the similarities of these features with those of psoriasis; the terminology was not based on any clinical morphologic resemblance. *Parapsoriasis en gouttes* (Latin guttae, “in drops”) was the term Brocq applied to pityriasis lichenoides.

The variable, ill-defined, and confusing terminology and the lack of clear clinical descriptions to guide early clinicians in the diagnosis of pityriasis lichenoides undoubtedly led Mucha, [5] in 1916, to redescribe acute pityriasis lichenoides as distinct from pityriasis lichenoides chronica, and, in 1925, Habermann designated the condition, *pityriasis lichenoides et varioliformis acuta* (PLEVA). [6] To the present, Mucha-Habermann disease is synonymous with PLEVA. When referring to pityriasis lichenoides chronica, the acronym PLC is often used to distinguish it from PLEVA.

Unfortunately, the classification scheme and terminology that were developed by Brocq at the turn of the century have led to long-standing confusion, and a plethora of alternative terms and abbreviations have subsequently been applied to the acute and chronic forms of pityriasis lichenoides (Table 48-1). Pityriasis lichenoides can be distinguished on clinical and histologic grounds from small- or large-plaque parapsoriasis, and it is widely accepted that pityriasis lichenoides is a distinct and separate entity from plaque-type parapsoriasis. The historic and nosologic perspectives on pityriasis lichenoides and parapsoriasis are intriguing and represent a prime example of the value of accurately defining and carefully assigning dermatologic nomenclature. The reader is referred to several excellent reviews on this subject. [7], [8]

Pityriasis Lichenoides et Varioliformis Acuta	Pityriasis Lichenoides Chronica
PLEVA	PLC
PLVA	
Mucha-Habermann disease	Pityriasis lichenoides, Juliusberg
Parapsoriasis lichenoides et varioliformis acuta	Parapsoriasis lichenoides chronica
Parapsoriasis acuta	Parapsoriasis chronica
Acute parapsoriasis	Chronic parapsoriasis
Acute guttate parapsoriasis	Chronic guttate parapsoriasis
Acute pityriasis lichenoides	Chronic pityriasis lichenoides
Parapsoriasis varioliformis	Dermatitis psoriasiformis nodularis

SOURCE: Adapted from Lambert and Everett.[7]

TABLE 48-1 **Pityriasis Lichenoides: Alternative Terminology and Abbreviations**

The separation of pityriasis lichenoides into two entities, acuta and chronica, remains controversial. [7] There is a rationale for separating these forms when identifying the distinguishing features and, possibly, the different etiologies of the acute and chronic variants of pityriasis lichenoides. However, to recognize that a melding of clinical features can occur and to facilitate establishing a diagnosis, it is prudent to consider pityriasis lichenoides as a single entity with a spectrum of clinical and histologic variations, ranging from PLEVA to pityriasis lichenoides chronica, and including intermediate or overlapping forms of the disease. Expansion of this classification scheme to the more recently defined and dramatic variants includes the acute form of pityriasis lichenoides with ulceronecrosis and hyperthermia (PLUH) first reported by Degos et al. [9] The spectrum extends to the distinctive, and possibly separate, entity lymphomatoid papulosis, which was initially reported by Dupont [10] in 1965, and further characterized and named by McCaulay [11] in 1968 (see Chap. 159).

The relationship between lymphomatoid papulosis and pityriasis lichenoides is still being debated. [7], [12], [13] and [14] Because of the clinical similarities and the histologic presence of atypical lymphocytes in selected cases of pityriasis

lichenoides, lymphomatoid papulosis was considered by some investigators as a variant of pityriasis lichenoides with atypical cells. [14] However, other dermatologists believe that the distinctive clinical, histopathologic, and prognostic differences (see below) are sufficient to separate lymphomatoid papulosis from other variants of pityriasis lichenoides. With the tools for molecular genotyping now available, there is evidence that these diseases, or subsets thereof, represent a clonal T cell lymphoproliferative disorder, which may justify reunifying these seemingly disparate conditions. [15], [16], [17] and [18]

ETIOLOGY AND PATHOGENESIS

Pityriasis lichenoides chronica and PLEVA have no apparent racial or geographic predilection. These dermatoses often affect both children and adults in the early decades of life. Nonetheless, pityriasis lichenoides has been observed at birth through the ninth decade of life for both men and women. A gender difference in incidence has been observed, with variable male predominance in both the pediatric and adult age groups (1.5:1 to 3:1). [19], [20] and [21] The crude incidence in Brazil of pityriasis lichenoides chronica has been reported as 1:2000; PLEVA is approximately one-third to one-sixth as common. [20]

The etiology of pityriasis lichenoides is unknown. Sporadic outbreaks suggest the possibility of an infectious association. Cases with a history of preceding upper respiratory infection or streptococcal pharyngitis have been reported. The most widely accepted hypothesis invokes an immunologic or “hypersensitivity” reaction to an infectious agent as the underlying mechanism for the development of pityriasis lichenoides. The pathogenic immune reaction includes both immune complex disease and a cell-mediated hypersensitivity response. Elevated circulating immune complexes are found in a high proportion of patients with pityriasis lichenoides. [22] Deposits of IgM and C3 have been identified around blood vessels and at the epidermal basement membrane zone in active cutaneous lesions of PLEVA. Whether the deposition of immunoreactants is the primary event, similar to allergic or leukocytoclastic vasculitis, or represents an epiphenomenon resulting from the inflammatory reaction is unknown. The presence of suppressor rather than helper T lymphocytes in the perivascular spaces in conjunction with Langerhans cells suggests that cell-mediated immune mechanisms may also be important. [23] Furthermore, a reduction of the ratio in circulating T helper (CD4)/T suppressor (CD8) cells also supports this contention.

Southern blot or polymerase chain reaction analysis of T cell receptor gene rearrangements of lesional skin or blood in cases of PLEVA demonstrates the presence of clonal population(s) of T lymphocytes in selected cases, thus identifying PLEVA as a lymphoproliferative rather than an inflammatory process. [16], [17] Recently, monoclonal T cell receptor-? gene rearrangements were detected in skin biopsies from three of six patients with pityriasis lichenoides chronica. [18] Similar findings of clonal T cell population have been observed in a significant percentage of cases of lymphomatoid papulosis. [15] Lymphomatoid papulosis eventuates in lymphoma with some frequency; [15] pityriasis lichenoides, on the other hand, is most often a clinically benign entity and shows no significantly documented association with malignant lymphoma, [17], [18], [20] except for a few cases. [24] These disparities between PLEVA and lymphomatoid papulosis suggest different causation or an altered biologic ability to control the T cell lymphoproliferative response and accompanying inflammatory reaction that develop in the skin of patients with these dermatoses.

On the other hand, clonality of some cases of pityriasis lichenoides [17], [18] gives further support to the theory that PLEVA and pityriasis lichenoides chronica, at least in some cases, should be classified as cutaneous T cell lymphoproliferative disorders. Further evidence exists to support this view. Pityriasis lichenoides chronica is associated with the development of parakeratosis variegata, a type of retiform parapsoriasis, that is a variant of large-plaque parapsoriasis. [7], [25]

Moreover, typical cases of pityriasis lichenoides chronica represent a paraneoplastic phenomenon to an underlying non-Hodgkin's lymphoma or to herald malignant lymphoma of the skin. [26] Papular lesions that resemble pityriasis lichenoides clinically were found to represent mycosis fungoides histologically in three children. [27] These findings reinforce the concept that pityriasis lichenoides should be classified with the lymphoproliferative disorders.

There are likely immunogenetic factors that govern the development of the lymphoproliferative process as well as the inflammatory reaction. No specific genetic components have yet been identified; however, the development of pityriasis lichenoides in multiple family members may be informative in eventually uncovering genetic determinants and/or infectious agents involved in the genesis of this dermatosis.

CLINICAL MANIFESTATIONS

The morphologic findings in typical cases of pityriasis lichenoides chronica or acuta are characteristic but can be more protean, depending on whether the acute or chronic forms of the disease manifest independently or simultaneously. Not infrequently, both types of lesions develop concurrently or sequentially, and thus exhibit intermediate features of both variants. Pityriasis lichenoides chronica, the more common form, is characterized by successive crops of asymptomatic, red-brown, oval to round, lichenoid papules that are firm and measure 3 to 10 mm in diameter (Fig. 48-1). The lesions display a centrally adherent, mica-like scale that can be detached by gentle scraping or curettage, revealing a shiny brown, pigmented surface. The scale becomes more evident and less adherent peripherally, sometimes displaying a “collarette” appearance. The papules usually appear on the trunk and proximal extremities and spare the palms, soles, and face; however, lesions may involve these areas, as well as, on occasion, the scalp and mucous membranes. Individual papules may coalesce in a retiform pattern. Rarely, a segmental distribution is observed. [28] As the eruption evolves, the papules flatten and the scale separates spontaneously over the course of 4 to 6 weeks, typically leaving hyperpigmented macules. A transient or more protracted leukoderma may result (Fig. 48-2). New crops of lesions appear while others fade, giving pityriasis lichenoides chronica the characteristic polymorphous appearance with lesions of different age (Fig. 48-3). Scarring is very unusual in pityriasis lichenoides chronica.

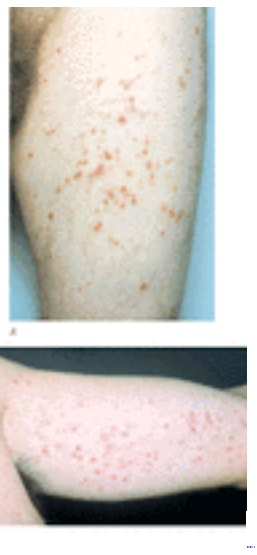

FIGURE 48-1 Pityriasis lichenoides chronica. *A.* Clustered red-brown papules, some with fine adherent scale. *B.* Erythematous lesions in various stages of development and involution.

FIGURE 48-2 Pityriasis lichenoides chronica. Chronic phase with pink to tan, flat papules (covered by fine, branny scale). Coalescence of papules and secondary hypopigmentation within resolving lesions.

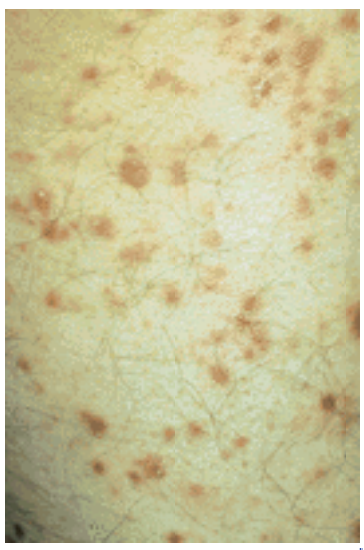

FIGURE 48-3 Pityriasis lichenoides chronica. Polymorphous appearance ranging from early erythematous papules to scaling brown-red lesions and tan-brown involuting, flat papules and macules.

In PLEVA, the acute form of pityriasis lichenoides, the cutaneous eruption is usually the first manifestation of the disease; however, low-grade fever, headache, malaise, and arthralgias may occasionally precede or accompany the skin findings. Multiple, disseminated, erythematous, and edematous papules appear and eventually form central vesiculation and, occasionally, pustular or even hemorrhagic necrosis (Fig. 48-4). The vesicles subsequently rupture, leaving crusted erosions or, in the case of severe necrosis, punched-out ulcers that heal with varioliform scars (Fig. 48-5). Hyper- or hypopigmentation may also result. Lesions may be symptomatic and cause pruritus or, occasionally, a burning sensation. They are distributed mainly on the trunk and flexural aspects of the limbs, and usually spare the palms, soles, face, scalp, and mucous membranes, except in rare instances. As in pityriasis lichenoides chronica, a polymorphous appearance of PLEVA results from the presence of many lesions in different stages of development (Fig. 48-6).

FIGURE 48-4 Pityriasis lichenoides et varioliformis acuta. *A.* Adolescent with multiple erythematous papules and crusted lesions in various stages of evolution. *B.* Larger papulovesicular and hemorrhagic, crusted lesions in an adult. Note: Varioliform scars adjacent to active lesions on posterior thigh and leg. *C.* Pustules, crusts, and necrotic-centered papules with erythematous, indurated base.

FIGURE 48-5 Pityriasis lichenoides et varioliformis acuta. Characteristic varioliform ulcer with raised erythematous collar and central purulent exudate.

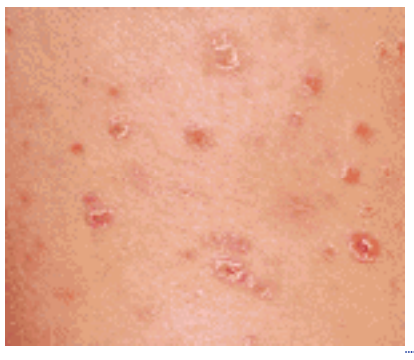

FIGURE 48-6 Pityriasis lichenoides et varioliformis acuta. Polymorphous lesions with overlapping features of pityriasis lichenoides chronica. Brown-red scaling lesions, resolving papules with collarette scale, and more prominent erythematous lesions with hemorrhagic crusts.

Gelmetti et al. found that the duration of the disease in children with lesions confined mainly to distal extremities (peripheral) was longer than those with truncal (central) distribution. [21] The disease in both groups lasted longer than in patients with diffuse lesions. Therefore, these authors recommended classification of pityriasis lichenoides into diffuse, central, or peripheral forms because distribution correlated better with duration of disease than the development of chronic or acute lesions that often coexisted. However, this classification scheme could not be confirmed in a more recent study of pediatric cases. [19]

PLUH, the rare hyperacute, ulceronecrotic variant of PLEVA is characterized by the sudden onset of diffuse purpuric papules with necrotic centers measuring from a few millimeters to centimeters. This variant is more destructive, with the development of large necrotic ulcers associated with high fever (40°C/104°F), malaise, myalgias, arthralgias, and gastrointestinal and central nervous system symptoms. PLUH may develop de novo or evolve from either pityriasis lichenoides chronica or PLEVA. Association with Epstein-Barr virus or cytomegalovirus infections has been reported. The distribution of lesions is similar to that of PLEVA, with occasional involvement of oral mucosa. Ulcerations are usually larger on the trunk and intertriginous areas, and often become secondarily infected. [29] Ulcers evolve from necrotic lesions that are surmounted by black oyster shell-like crusts (Fig. 48-7). Pruritus and pain are often prominent features. The ulceronecrotic lesions typically resolve with atrophic and dyschromic scars.

FIGURE 48-7 Pityriasis lichenoides, ulceronecrotic, hyperacute variant. Large necrotic eschar with halo erythema developing in febrile patient with antecedent PLEVA.

In most cases, laboratory findings are not helpful. Occasionally, viral or other infectious agent serologies or direct viral detection by in situ hybridization or polymerase chain reaction methods may be positive. Leukocytosis has been reported in more severe cases of PLEVA and PLUH; erythrocyte sedimentation rate, C-reactive protein, and serum lactic dehydrogenase are elevated. Hyperalbuminemia or increased a $_2$-globulins may be observed.

HISTOPATHOLOGY

The histopathologic findings in PLEVA and pityriasis lichenoides chronica share many features. Microscopic changes correlate with the acute, hyperacute, or chronic variants as well as the stage of the lesions. Dense perivascular lymphocytic inflammation with epidermal exocytosis of lymphocytes, parakeratosis, and focal spongiosis are the most common features in both conditions (Fig. 48-8). Dermal papillary hemorrhage and prominent endothelial swelling are also seen. Features that favor the diagnosis of PLEVA are the dense perivascular lymphocytic infiltrate with fibrinoid necrosis, which has been referred to as “lymphocytic vasculitis,” and the presence of basilar epidermal cytoid bodies and epidermal necrosis (Fig. 48-9). Some authors feel that the finding of deeper inflammatory infiltrates favors the diagnosis of PLEVA; however, these differences are a matter of degree. A bandlike lymphocytic infiltrate is more suggestive of pityriasis lichenoides chronica.

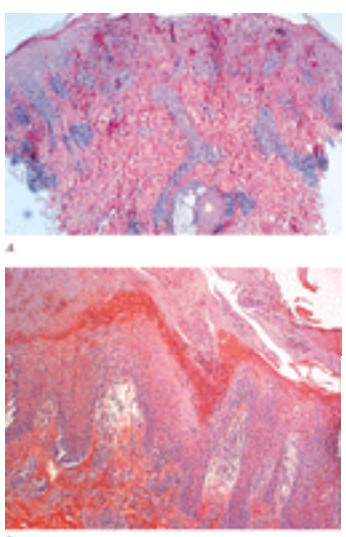

FIGURE 48-8 Pityriasis lichenoides et varioliformis acuta. *A.* Ulcerated papule with epidermal necrosis, hemorrhage and superficial and deep perivascular lymphocytic infiltrate. Hematoxylin and eosin (H&E) stain. *B.* Parakeratosis and crust with marked spongiosis and epidermal necrosis. Lymphocyte exocytosis and basal hydropic changes. H& E stain.

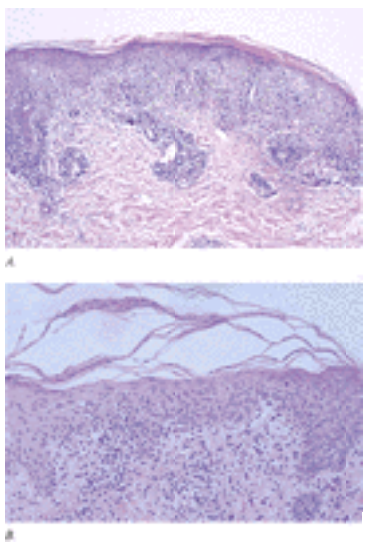

FIGURE 48-9 Pityriasis lichenoides chronica. *A.* Compact parakeratosis, lymphocytic exocytosis, occasional eosinophilic necrotic keratinocytes, edema, and diffuse lymphocytic infiltrate localizing to epidermal-dermal interface and perivascular sites within dermis. Hematoxylin and eosin (H&E) stain. *B.* Parakeratosis, spongiosis, and a predominant mononuclear cell infiltrate in the epidermis and dermis with papillary edema. H&E stain.

The edema and diffuse lymphocytic infiltrate in both the acute and chronic forms of the disease are present in the

papillary dermis and mainly around blood vessels. CD8 lymphocytes predominate in the dermis and are also found in the epidermis of patients with PLEVA, [17] whereas CD4 lymphocyte predominance is more common in pityriasis lichenoides chronica. [18] The pathologic findings are typically characteristic for well-developed papules, but older lesions create more difficulty in histologic diagnosis.

In the febrile, ulceronecrotic variant PLUH, pathologic findings are similar to those seen in PLEVA but with prominent fibrinoid necrosis of vessel wall and nuclear dust resembling leukocytoclastic vasculitis. [29] Intravascular thrombus formation and necrosis have been reported. Lymphocytes and other inflammatory cells within walls of blood vessels are also seen.

Immunopathologic findings have been reported in several studies and demonstrate reduced Langerhans cell (CD1) density as well as generalized induction of major histocompatibility complex class II HLA-DR on keratinocytes within the epidermis. [30] Endothelial cells are also HLA-DR+. The T cells in PLEVA show CD3+/CD8+ lymphocyte predominance, [31] whereas CD3+/CD4+ cells are more frequent in pityriasis lichenoides chronica. IgM, C3, and fibrin deposits localize to the perivascular and vascular spaces in the early, acute lesions. [23] Both cellular and humoral immune components show evidence of activation in pityriasis lichenoides.

In summary, differences between PLEVA and pityriasis lichenoides chronica are mainly differences in the depth and density of the inflammatory infiltrates and epidermal changes. The lack of atypical lymphocytes in the infiltrate and the interface (dermal–epidermal) changes distinguish pityriasis lichenoides from lymphomatoid papulosis.

DIFFERENTIAL DIAGNOSIS

Pityriasis lichenoides chronica is occasionally difficult to distinguish from small-plaque parapsoriasis. The latter tends to occur in older patients, with male predominance. The characteristic association of papular lesions at different stages of evolution and hypopigmentation differentiates pityriasis lichenoides chronica from small-plaque parapsoriasis, which is characterized by well-defined, slightly scaly, erythematous, yellow or brown macules or thin plaques. Histologically, the presence of superficial perivascular lymphohistiocytic infiltrates without interface or epidermal changes is characteristic of parapsoriasis en plaque.

The chronic form of pityriasis lichenoides may resemble guttate psoriasis, pityriasis rosea, or secondary papulosquamous syphilis. Predilection for involvement of different body sites usually distinguishes secondary syphilis from pityriasis lichenoides chronica. The palms and soles, mucous membranes, scalp, and face often show the monomorphous eruption of syphilis, and serologic tests for syphilis are positive. Psoriasis also exhibits a more uniform morphology, with a micaceous scale that is adherent, diffuse, and less cohesive than the scale of pityriasis lichenoides. At the onset, pityriasis lichenoides and pityriasis rosea may mimic one another, but the distinguishing features of the latter include the herald patch, larger lesions, differences in scaling and distribution, and the shorter, self-limited course of the eruption.

PLEVA is usually distinctive and rarely confused with other dermatoses. Cutaneous necrotizing vasculitis or varicelliform secondary syphilis may show papulopustular, vesicular, or hemorrhagic lesions that resemble PLEVA. Syphilides are usually more widespread and monomorphous. Vasculitis shows more prominent leukocytoclastic and necrotizing changes by histologic examination. In children, Gianotti-Crosti syndrome and varicella need to be differentiated from PLEVA.

The presence of grouped papular or self-healing nodular or, occasionally, tumorous lesions that show the characteristic histopathologic changes distinguishes lymphomatoid papulosis from pityriasis lichenoides. Histologically, two types of lymphomatoid papulosis have been described: the nonepidermotropic type A lesion shows a dermal infiltrate composed of CD30+, large, atypical lymphocytes that resemble Reed-Sternberg cells admixed with neutrophils and eosinophils; it is rarely a problem to distinguish it from pityriasis lichenoides. Type B lymphomatoid papulosis differs from pityriasis lichenoides by the predominance of large and hyperchromatic cerebriform mononuclear cells; the presence of a small number of neutrophils, especially in vascular lumina; mitotic figures; and, principally, epidermotropism of lymphocytes. In contrast to pityriasis lichenoides, lymphomatoid papulosis type B usually lacks basal cell vacuolization and epidermal keratinocyte necrosis.

TREATMENT

Various factors prevent comprehensive evaluation of specific therapeutic interventions and the clinical responses and outcomes in pityriasis lichenoides. The unknown etiology of the disease limits current therapies to empiric regimens. The relatively low frequency of the disease and the unpredictability of its course are also limiting factors in evaluating the effectiveness of treatment. However, the unsightly appearance, widespread distribution, symptoms of pruritus, sequelae such as pigment alterations and scarring, and reports of a clonal T cell population in some patients with PLEVA favor treatment of the condition.

Topical steroids and antihistamines are prescribed routinely and may decrease the inflammatory component of the dermatosis but do not significantly influence the course of the disease. Systemic glucocorticoids such as prednisone, 40 to 60 mg/day, are helpful in controlling the cutaneous and systemic symptoms in acute flares of PLEVA and the ulceronecrotic variant PLUH. A variety of antibiotics have been tried, primarily for PLEVA, with variable results. Tetracycline at higher doses (2 g/day for 4 weeks in adults) [32] or erythromycin (2 g/day in adults or 30 to 50 mg/kg per day in children) [33] may yield favorable results. Tapering the antibiotics slowly at the end of the course of treatment may minimize recurrences.

Phototherapy provides the best therapeutic response. Ultraviolet B phototherapy is a useful treatment option. [34], [35] Three to five treatment sessions per week over 1.5 to 2 months provides a good response, probably through alteration of local

immunity in skin mediated by UVB. PUVA photochemotherapy has also shown therapeutic benefit. [36], [37] Relapses following discontinuation of phototherapy are not uncommon. Maintenance PUVA or UVB phototherapy should be considered, ranging from one session per week to one session every 3 weeks. UVAI phototherapy has recently shown efficacy in the treatment of PLEVA and PLC. [38] Sun exposure to induce tanning or simple UVA treatments may be convenient and helpful for the patient in hastening resolution of pityriasis lichenoides.

For more acute and problematic cases of PLEVA, methotrexate in the dose range of 15 to 20 mg per week can be initiated. [39], [40] Maintenance therapy with lower doses prevents recurrence. Use of methotrexate is rarely justified in children, however.

For the ulceronecrotic form of pityriasis lichenoides, systemic glucocorticoids, a combination of PUVA and oral methotrexate, [41] intravenous methotrexate, and gamma-globulin [42] reportedly exerts favorable results.

In 1989, a comprehensive review of the existing literature on treatment of pityriasis lichenoides and lymphomatoid papulosis by Lynch revealed that many therapies have shown variable response rates when evaluated independently. [43] This is not surprising given our lack of knowledge on the pathogenesis of pityriasis lichenoides. However, UVB phototherapy, PUVA photochemotherapy, and, for more severe disease, methotrexate offer the most consistent therapeutic responses. This coincides with the known immunomodulating effects of these agents in other inflammatory, papulosquamous skin diseases such as psoriasis. Therefore, in refractory or debilitating cases, oral pharmacologic agents such as cyclosporine [44], [45] or retinoids [46] should also be considered as alternative therapeutic interventions.

COURSE AND PROGNOSIS

Pityriasis lichenoides is a chronic immunoreactive or lymphoproliferative dermatosis with the continuous appearance of new lesions that fade over a few weeks. The disease may regress in a few months or, more rarely, persist for years. PLEVA usually has a shorter duration than pityriasis lichenoides chronica. The febrile, ulceronecrotic, and hemorrhagic form, PLUH, usually resolves in a few months; however, a fatal outcome may rarely ensue in elderly, compromised patients.

Pityriasis lichenoides has long been regarded as a benign reactive condition with no malignant potential. The presence of a clonal T cell population and occasional instances of atypical CD30+ cells in a small proportion of cases raises the question of whether these lesions are pityriasis lichenoides or a distinctive form bridging pityriasis lichenoides and lymphomatoid papulosis. Furthermore, there is no strong evidence that clonality in these cases is necessarily a harbinger of lymphoma. The absence of significant systemic involvement and complications portends a generally good prognosis for the various forms of pityriasis lichenoides.

REFERENCES

1. Neisser A: Zur Frage der lichenoiden eruptionen. *Verh Dtsch Dermatol Ges* **4**:4495, 1894

2. Jadassohn J: Über ein eigenartiges psoriasiformes und lichenoides Exanthem. *Verh Dtsch Dermatol Ges* **4**:524, 1894

3. Juliusberg F: Über die pityriasis lichenoides chronica (Psoriasiform lichenoides Exanthem). *Arch Dermatol Syphilol (Wien)* **50**:359, 1899

4. Brocq L: Les parapsoriasis. *Ann Dermatol Syphiligr (Paris)* **3**:433, 1902

5. Mucha V: Über einen der Parakeratosis variegata (Unna) bzw. Pityriasis lichenoides chronica (Neisser-Juliusberg) nahestehenden eigentumlichen Fall. *Arch Dermatol Syphilol* **123**:586, 1916

6. Habermann R: Über die akut verlaufende, nekrotisierende Unterart der Pityriasis lichenoides (Pityriasis lichenoides et varioliformis acuta). *Dermatol Ztschr (Berlin)* **45**:42, 1925

7. Lambert WC, Everett MA: The nosology of parapsoriasis. *J Am Acad Dermatol* **5**:373, 1981

8. Everett MA: Historical aspects of pityriasis lichenoides, in Proceedings of the First International Parapsoriasis Symposium. Rochester, MN, Mayo Foundation, 1989, p 1

9. Degos R et al: Le parapsoriasis ulceronecrotique hyperthermique. *Ann Dermatol Syphiligr* **93**:481, 1966

10. Dupont A: Langsam verlaufende und klinische gutartige Reticulopathie mit höchst maligner histologischer Struktur. *Hautzart* **16**:2824, 1965

11. McCaulay WL: Lymphomatoid papulosis: A continuing self-healing eruption—Clinically benign, histologically malignant. *Arch Dermatol* **97**:23, 1968

12. Rogers M: Pityriasis lichenoides and lymphomatoid papulosis. *Semin Dermatol* **11**:73, 1992

13. Cerroni L: Lymphomatoid papulosis, pityriasis lichenoides et varioliformis acuta, and anaplastic large-cell (Ki-1+) lymphoma. *J Am Acad Dermatol* **37**:287, 1997

14. Black MM: Lymphomatoid papulosis and pityriasis lichenoides: Are they related? *Br J Dermatol* **106**:717, 1982

15. el-Azhary RA et al: Lymphomatoid papulosis: A clinical and histopathologic review of 53 cases with leukocyte immunophenotyping, DNA flow cytometry, and T-cell receptor gene rearrangement studies. *J Am Acad Dermatol* **30**:210, 1994

16. Panhans A et al: Pityriasis lichenoides of childhood with atypical CD30-positive cells and clonal T-cell receptor gene rearrangements. *J Am Acad Dermatol* **35**:489, 1996

17. Dereure O et al: T-cell clonality in pityriasis lichenoides et varioliformis acuta: A heteroduplex analysis of 20 cases. *Arch Dermatol* **136**:1483, 2000

18. Shieh S et al: Differentiation and clonality of lesional lymphocytes in pityriasis lichenoides chronica. *Arch Dermatol* **137**:305, 2001

19. Romani J et al: Pityriasis lichenoides in children: Clinicopathologic review of 22 patients. *Pediatr Dermatol* **15**:1, 1998

20. Rivitti EA: Pityriasis lichenoides: Review of cases seen in two major dermatology centers in Sao Paolo, Brazil, 1977 to 1989, in Proceedings of the First International Parapsoriasis Symposium. Rochester, MN, Mayo Foundation, 1989, p 14

21. Gelmetti C et al: Pityriasis lichenoides in children: A long-term follow-up of 89 cases. *J Am Acad Dermatol* **23**:473, 1990

22. Clayton R et al: Pityriasis lichenoides—An immune complex disease. *Br J Dermatol* **97**:629, 1977

23. Muhlbauer JE et al: Immunopathology of pityriasis lichenoides acuta. *J Am Acad Dermatol* **10**:783, 1984

24. Fortson JS et al: Cutaneous T-cell lymphoma (parapsoriasis en plaque): An association with pityriasis lichenoides et varioliformis acuta in young children. *Arch Dermatol* **126**:1449, 1990

25. Niemczyk UM et al: The transformation of pityriasis lichenoides chronica into parakeratosis variegata in an 11-year-old girl. *Br J Dermatol* **137**:983, 1997

26. Panizzon RG et al: Atypical manifestations of pityriasis lichenoides chronica: Development into paraneoplasia and non-Hodgkin lymphomas of the skin. *Dermatology* **184**:65, 1992

27. Ko JW et al: Pityriasis lichenoides-like mycosis fungoides in children. *Br J Dermatol* **142**:347, 2000

28. Cliff S et al: Segmental pityriasis lichenoides chronica. *Clin Exp Dermatol* **21**:461, 1996

29. Fink-Puches R et al: Febrile ulceronecrotic pityriasis lichenoides et varioliformis acuta. *J Am Acad Dermatol* **30**:261, 1994

30. Wood GS et al: Immunohistology of pityriasis lichenoides et varioliformis acuta and pityriasis lichenoides chronica. *J Am Acad Dermatol* **16**:559, 1987

31. Jang KA et al: Expression of cutaneous lymphocyte-associated antigen and lymphocytes in pityriasis lichenoides et varioliformis acuta an papulosis: Immunohistochemical study. *J Cutan Pathol* **28**:453, 2001

32. Piamphongsant T: Tetracycline for the treatment of pityriasis lichenoides. *Br J Dermatol* **91**:319, 1974

33. Truhan AP et al: Pityriasis lichenoides in children: Therapeutic response to erythromycin. *J Am Acad Dermatol* **15**:66, 1986

34. LeVine MJ: Phototherapy of pityriasis lichenoides. *Arch Dermatol* **119**:378, 1983

35. Tham SN: UV-B phototherapy for pityriasis lichenoides. *Australas J Dermatol* **26**:9, 1985

36. Brenner W et al: Erprobung von PUVA bei verschiedenen Dermatosen. *Hautzarl* **29**:541, 1978

37. Powell FC, Muller SA: Psoralens and ultraviolet A therapy of pityriasis lichenoides. *J Am Acad Dermatol* **10**:59, 1984

38. Pinton PC et al: Medium-dose ultraviolet A1 therapy for pityriasis lichenoides et varioliformis acuta and pityriasis lichenoides chronica. *J Am Acad Dermatol* **47**:410, 2002

39. Lynch PJ, Saied NK: Methotrexate treatment of pityriasis lichenoides and lymphomatoid papulosis. *Cutis* **23**:634, 1979

40. Cornelison RL Jr et al: Methotrexate for the treatment of Mucha-Habermann disease. *Arch Dermatol* **16**:507, 1972

41. Lopez-Estebaranz JL et al: Febrile ulceronecrotic Mucha-Habermann disease. *J Am Acad Dermatol* **29**:903, 1993

42. Korppi M et al: Mucha-Habermann disease: A diagnostic possibility for prolonged fever associated with systemic and skin symptoms. *Acta Pediatr* **82**:627, 1993

43. Lynch PJ: Treatment of pityriasis lichenoides and lymphomatoid papulosis, in Proceedings of the First International Parapsoriasis Symposium. Rochester, MN, Mayo Foundation, 1989, p 113

44. Gupta AK et al: Oral cyclosporine in the treatment of inflammatory and noninflammatory dermatoses. *Arch Dermatol* **126**:339, 1990

45. Lim KK et al: Cyclosporine in the treatment of dermatologic disease: An update. *Mayo Clin Proc* **71**:1182, 1996

46. Orfanos CE et al: Current use and future potential role of retinoids in dermatology. *Drugs* **53**:358, 1997

T>

Chapter 49

Mazen Daoud Mark Pittelkow

Lichen Planus

HISTORICAL ASPECTS
EPIDEMIOLOGY AND GENETICS
ETIOLOGY AND PATHOGENESIS
Lichen Planus-Specific Antigen Recognition
Cytotoxic Lymphocyte Activation
Keratinocyte Apoptosis
CLINICAL MANIFESTATIONS
CLINICAL VARIANTS
Configuration of Lesions
Morphology of Lesions
Site of Involvement
SPECIAL FORMS OF LICHEN PLANUS/LICHENOID ERUPTION
Drug-Induced Lichen Planus
Lichen Planus–Lupus Erythematosus Overlap Syndrome
Lichen Planus Pemphigoides
Keratosis Lichenoides Chronica (Nekam's Disease)
Lichen Planus and Malignant Transformation
Lichenoid Reaction of Graft-Versus-Host Disease
Lichenoid Keratosis
Lichenoid Dermatitis
ASSOCIATED CONDITIONS
LABORATORY FINDINGS
PATHOLOGY
DIAGNOSIS AND DIFFERENTIAL DIAGNOSIS
TREATMENT
Oral Lichen Planus
Cutaneous Lichen Planus
COURSE AND PROGNOSIS

REFERENCES

Lichen planus (Greek *leichen,* “tree moss”; Latin *planus,* “flat”) is a unique, common inflammatory disorder that affects the skin, mucous membranes, nails, and hair. The appearance of lichen planus and lichen planus-like or lichenoid dermatoses has been likened to the scurfy, finely furrowed, dry excrescences of the symbiotic vegetation known as lichen. Although this morphologic comparison may be antiquated, lichen planus is a distinctive entity with prototypic “lichenoid” papules that show distinctive color and morphology, develop in typical locations, and manifest characteristic patterns of evolution. Microscopic features, similar to the gross morphology, are distinctive although the microscopic pattern of inflammation and skin response is shared by several dermatoses. The term *lichenoid reaction* is the histologic description used to capsulize the pathologic characteristics of skin diseases resembling lichen planus.

The term *lichen ruber planus* (Latin *ruber,* “red” or “ruddy”) has been used to denote the distinctive color of the lesion, but this terminology has largely been abandoned. The *four Ps*—purple, polygonal, pruritic, papule—is the abbreviation often used to recall the constellation of symptoms and skin findings that characterize lichen planus.

HISTORICAL ASPECTS

In 1869, Erasmus Wilson delineated and named the condition leichen (lichen) planus, but the dermatosis was probably described earlier by Hebra as leichen ruber. Kaposi first described a distinctive clinical variant of the disease with blisters, lichen ruber pemphigoides, in 1892. Wickham, in 1895, described the characteristic appearance of whitish striae and punctations that develop atop the flat-surfaced papules. The histologic findings were elaborated by Darier in 1909. Scalp and follicular involvement were reported initially by Graham-Little in 1919.

Lichen planus is classified as a papulosquamous disease, although scaling is not prominent as in psoriasis and other skin diseases included in this category. Lichen planus represents the model for lichenoid reactions. Pinkus [1] formally defined the lichenoid tissue reaction, in 1973, “… as one exhibiting epidermal basal cell damage and the chain of histobiologic events resulting from such damage. It is not essential whether damage to the basal cells is primary or is itself due to preceding events in the dermis. This tissue reaction may be called ‘lichenoid’ because lichen planus is the prototype.”

EPIDEMIOLOGY AND GENETICS

The exact incidence and prevalence of lichen planus are unknown, but the overall prevalence is believed to be somewhat less than 1 percent of the general population. Estimates between 0.14 and 0.8 percent have been reported worldwide and approximately 0.44 percent in the United States. No racial predilection has been observed. [2]

At least two-thirds of cases occur between the ages of 30 and 60 years. No sexual predilection is evident. Females are usually affected in their fifties and sixties, whereas males develop lichen planus at a somewhat earlier age. The disease is less common in the very young and the elderly. The development of lichen planus may be affected by seasonal or environmental factors. An increased incidence in the months of December and January or from January to July has been

reported. [2]

Fewer than 100 cases of familial lichen planus have been reported. The familial form tends to be more protracted and severe and presents in erosive, linear, or ulcerative patterns or with atypical features affecting young adults and children. [3] Some believe that the familial form represents a separate, unique dermatosis. Different human leukocyte antigen (HLA) haplotypes were reported in familial lichen planus, including HLA-B7, -Aw19, -B18, and -Cw8. In nonfamilial lichen planus HLA-A3, -A5, -A28, -B8, -B16, and -Bw35 are more common. [4] HLA-B8 is more common in patients with oral lichen planus as a sole manifestation, and HLA-Bw35 is more strongly associated with cutaneous lichen planus. In a British population, HLA-B27, -B51, and -Bw57 have been found to be associated with oral lichen planus. Of class II antigens, HLA-DR1, -DR9, and -DQ1 are found more frequently. It must be noted, however, that the ethnicity of the populations composing these studies and the selection of specific anatomic and clinicopathologic types of lichen planus may significantly bias the HLA analyses that have been reported.

ETIOLOGY AND PATHOGENESIS

It is evident that immunologic mechanisms almost certainly mediate the development of lichen planus. No consistent alterations in immunoglobulins have been shown in lichen planus, and humoral immunity most likely is a secondary response in the immunopathogenesis.

Cell-mediated immunity, on the other hand, plays the major role in triggering the clinical expression of the disease. Both CD4+ and CD8+ T cells are found in lesional skin of lichen planus. Progression of disease may lead to preferential accumulation of CD8+ cells. The majority of the lymphocytes in the infiltrate of lichen planus are CD8+ and CD45RO (memory) positive cells and express the aß T cell receptor, and in a minority, the ?d receptor. This later cell subtype is not normally found in healthy skin. These cells are considered responsible for the development of the most characteristic change observed in the lichenoid reaction, namely, apoptosis. The inflammatory process that leads to apoptosis is complex and not fully understood. The epithelial–lymphocyte interaction can be divided into three major stages: antigen recognition, lymphocyte activation, and keratinocyte apoptosis.

Lichen Planus-Specific Antigen Recognition

It is evident that the majority of T cells in the infiltrate of lichen planus, both within the epithelium and adjacent to damaged basal keratinocytes, are activated CD8+ cytotoxic lymphocytes. Evidence from oral lichen planus suggests that CD8+ lesional T cells recognize a lichen planus-specific antigen associated with MHC class I on lesional keratinocytes. The nature of this antigen is unknown. Theoretically, the antigen may be an autoreactive peptide, thus classifying lichen planus as an autoimmune disease. Alternatively, it may represent an exogenous antigen such as an altered protein, drug, contact allergen, viral or infectious agent, or an unidentified immunogenic target. [5]

The role of T helper (CD4) cells in the pathogenesis of lichen planus is not fully defined. T cells may become activated via antigen-presenting cells such as Langerhans cells or accessory cells such as epidermal keratinocytes in association with members of the major histocompatibility complex II and specific cytokines. T helper lymphocytes may also propagate CD8+ cytotoxic lymphocytes through cellular cooperation and release of cytokines.

The nature of antigenic stimulation is not known. Contact sensitizers such as metals could act as haptens and elicit an immunologic response. Enhanced lymphocyte reactivity to inorganic mercury, a component of dental amalgam, has been found in patients with oral lichenoid reactions. Low-grade chronic exposure to mercury, and possibly to other metals such as gold, may stimulate a lymphocytic reaction that manifests as lichen planus. A list of contact chemicals and drugs that can elicit lichenoid reactions is discussed below. The role of infection in the development of lichen planus has been repeatedly raised over the years. Though provocative, no conclusive evidence has molecularly linked lichen planus to any of the following infections or microorganisms: syphilis, herpes simplex virus 2, HIV, amebiasis, chronic bladder infections, hepatitis C virus, *Helicobacter pylori,* and human papillomavirus.

Cytotoxic Lymphocyte Activation

Following antigen recognition, CD8+ T cells are activated. Activated cytotoxic lymphocytes undergo lesional tissue clonal expansion, leading to oligoclonal and occasionally to monoclonal proliferation as detected by analysis of the T cell receptor (TCR)-? chain gene products. [6]

Activated lymphocytes, both by helper subsets (T_H1 and T_H2) and cytotoxic-suppressor cells, release soluble mediators (cytokines and chemokines), such as interleukin (IL)-2, IL-4, IL-10, interferon (IFN)-?, tumor necrosis factor (TNF)-a, and transforming growth factor-ß1, that attract lymphocytes and regulate their biologic activities within and adjacent to the epithelium. Both pro- and anti-inflammatory cytokines, that is, mixed T_H1 and T_H2 cytokine products, are generated simultaneously. The balance between lymphocytic activation and downregulation determines the clinical behavior of the disease. [7] IFN-?, produced by T helper cells during the antigen recognition stage, induces keratinocytes to produce lymphotoxin-a and TNF-a, and to upregulate MHC class II, thus increasing interactions with helper T cells. Furthermore, IFN-? upregulates the expression of intercellular adhesion molecule ICAM)-1 and vascular cell adhesion molecule (VCAM)-1 by basal keratinocytes, Langerhans cells, and other macrophage–dendritic cells. [8] ICAM-1 is a ligand for the $ß_2$-integrin, leukocyte function-associated antigen (LFA)-1, on the surface of lymphocytes, which further enhances the interaction of these lymphocytes with the antigen-presenting cells. [9] Laminin-5 and collagen types IV and VII, are increased in lesional lichen planus and serve as ligands for $ß_1$-integrin on the surface of lymphocytes, thus allowing for enhanced association of lymphocytes with the basement membrane. Integrin a_3 is present on activated, skin-homing T cells and may localize these effector cells to the epidermal–dermal interface and basement membrane, which contain epiligrin/laminin-5, a ligand for this integrin. [10] This close interaction between lymphocytes and basement membrane targets metalloproteinases produced by lymphocytes to alter extracellular matrix proteins and integrins, and the process

eventuates in apoptosis, basement membrane disruption, reduplication, and subepidermal cleft formation (see below). TNF-a upregulates the expression of matrix metalloproteinase (MMP)-9 mRNA in lesional T lymphocytes, thus further enhancing basement membrane disruption (see below). [11]

Keratinocytes also participate in the response by producing IL-1ß, IL-4, IL-6, granulocyte-macrophage colony-stimulating factor, and TNF-a. These cytokines further activate tissue macrophages and peripheral blood mononuclear cells [12] and upregulate expression of cell surface adhesion molecules and migration activity. Keratinocyte-produced cytokines also upregulate expression of specific keratin genes. Keratin (K)17, usually restricted to adnexal structures, is variably expressed in the basal and suprabasal layers of the interfollicular epithelium of affected epidermis. K6 and K16 also become detectable in the basal and suprabasal layers. K4 and K13 are reduced in the suprabasal compartment in areas with orthokeratosis, associated with increased production of K1 and K10. [13]

Keratinocyte Apoptosis

The exact mechanisms used by activated cytotoxic T cells to trigger apoptosis of keratinocytes is not completely known. Possible mechanisms include: (1) T cell secreted TNF-a binding to the TNF-a R1 receptor on the keratinocyte surface; (2) T cell surface CD95L (Fas ligand) binding CD95 (Fas) on the keratinocyte; and (3) T cell secreted granzyme B entering the keratinocyte via perforin-induced membrane pores. All these mechanisms may activate the keratinocyte caspase cascade resulting in keratinocyte apoptosis. [5]

Recruited lymphocytes may further contribute to apoptosis via a different mechanism, the loss of a basement membrane-derived cell survival signal that normally prevents the onset of apoptosis. Hence, basement membrane disruption may trigger apoptosis. Principle mediators are the MMPs, a family of zinc-containing endoproteinases that primarily function to degrade connective tissue matrix proteins. The action of these enzymes is also regulated by inhibitors such as tissue inhibitors of metalloproteinases (TIMPs) (see Chap. 17). It has been shown that lesional T cells in lichen planus have higher MMP-9 levels than peripheral blood T cells. Lesional T cell MMP-9 activity increases following stimulation with TNF-a, but not TIMP-1, an inhibitor for MMP-9. [5] These observations suggest that T cell secreted MMP-9 disrupts epithelial basement membranes, blocking cell survival signals to keratinocytes and inducing apoptosis.

Various other environmental, behavioral, or infectious factors have been observed on occasion to be associated with the development or exacerbation of lichen planus. However, no well-established association has been documented between emotional stress, tobacco use, oral or gastrointestinal candidiasis, and development of lichen planus.

CLINICAL MANIFESTATIONS

The classic cutaneous lesion of lichen planus is a faintly erythematous to violaceous, flat-topped, polygonal papule, sometimes showing a small central umbilication (Fig. 49-1). A thin, transparent, and adherent scale may be discerned atop the lesion. Fine, whitish puncta or reticulated networks referred to as *Wickham striae,* named after the dermatologist who described the finding, are present over the surface of many well-developed papules. These are considered to be highly characteristic and are more easily observed after applying oil, xylene, or water and visualizing the lesions with a magnifying lens or a handheld dermatoscope. The surface alteration may result from localized thickening of the keratohyalin-containing cell layers of the stratum granulosum, although a focal increase in the activity of lichen planus may account for the morphologic alteration of Wickham striae.

FIGURE 49-1 Lichen planus. Variable sized flat-topped, violaceous papules and plaques with Wickham striae involving the extremity.

Lichen planus begins as faintly erythematous macules that form purplish papules over several weeks. Sometimes multiple lesions develop rapidly over a short time, with dissemination following the initial appearance of only a few papules. Further spread of lesions after the initial limited expression occurs in approximately a third of cases. In generalized disease, the eruption often spreads within 1 to 4 months from onset. The initial lesions almost always appear on the extremities, with the lower extremities being somewhat more common.

The lesions are usually distributed symmetrically and bilaterally over the extremities. Lichen planus tends to involve the flexural areas of the wrists, arms, and legs (Fig. 49-2). The thighs, lower back, trunk, and neck may also be affected. Oral mucous membranes and the genitalia are additional sites of involvement (Fig. 49-3). The face is usually spared in

typical cases, and palmoplantar involvement is unusual. Inverse lichen planus usually affects the axillae, groin, and inframammary areas.

FIGURE 49-2 Lichen planus. Dusky violaceous coalescing papules on the flexural aspect of the wrist and forearm.

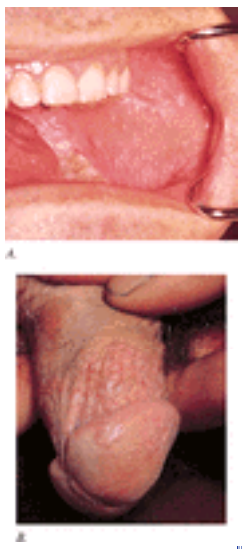

FIGURE 49-3 Mucosal lichen planus. *A.* A typical whitish, punctate to reticulated pattern of oral lesions is seen on the buccal mucosa. *B.* Agminate pattern of lesions involving the meatus, glans, and sulcus areas of the penis.

Lichen planus tends to be quite pruritic, although some patients are completely asymptomatic. The degree of pruritus is generally related to the extent of involvement, with more intense pruritus in generalized cases. An exception is hypertrophic lichen planus, which is more localized but extremely pruritic. Oral involvement is generally asymptomatic unless erosions or ulcers developed. Erosive oral lichen planus is usually extremely painful. In the acute, evolving stages of the disease, scratching, injury, or trauma may induce an isomorphic (Koebner's) response (Fig. 49-4). Lichen planus usually heals with hyperpigmentation, which is more prominent among patients with darker skin color. Hypopigmentation uncommonly develops following resolution of lesions.

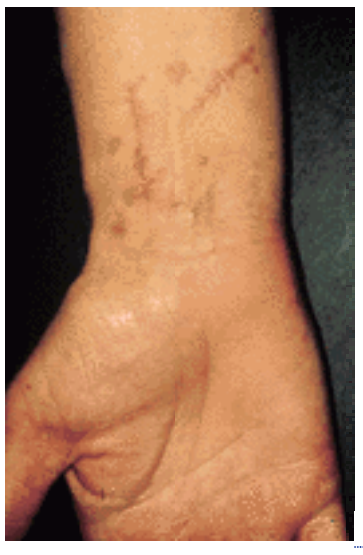

FIGURE 49-4 Lichen planus. Linear pattern with Koebner's response adjacent to clustered papules on the flexural wrist.

Although the clinical and pathologic features of childhood lichen planus are similar to those in adults, scalp, nail, and hair involvement is not common. Mucous membrane involvement, thought to be rare, may occur in up to one-third of patients. The hypertrophic variant occurs in one fourth of children with lichen planus.

CLINICAL VARIANTS

Many variations in the clinical presentation have been described and are generally categorized according to (1) the configuration of lesions, (2) the morphologic appearance, or (3) the site of involvement. These variations are patterned by subtle or unknown properties of the disease. The prototypic papule can be altered or modified in configuration, morphology, or anatomic distribution. Table 49-1 reviews and classifies these distinctive variants and other special types of lichen planus that overlap with other dermatoses.

Configuration
Annular
Linear
Morphology of lesion
Hypertrophic
Atrophic
Vesiculobullous
Erosive and ulcerative
Follicular
Actinic
Lichen planus pigmentosus
Other rare forms: perforating, guttate, etc.
Site of involvement
Palm and soles
Mucous membranes
Nails
Scalp
Special forms
Drug-induced (lichenoid drug eruption)
Lichen planus–lupus erythematosus overlap
Lichen planus pemphigoides
Keratosis lichenoides chronica
Lichen planus and malignant transformation
Lichenoid reaction of graft-versus-host disease
Lichenoid keratosis
Lichenoid dermatitis

TABLE 49-1 **Classification of Lichen Planus Variants**

Configuration of Lesions

ANNULAR LICHEN PLANUS Annular lesions occur in approximately 10 percent of cases and commonly develop as arcuate groupings of individual papules that develop rings or peripheral extension of clustered papules with central clearing. They tend to occur in blacks and are more common on the penis and scrotum (Fig. 49-5). [2] Another form of annular lichen planus occurs when larger lesions reach 2 to 3 cm in diameter and become hyperpigmented, with a raised outer rim. This form may occur on the trunk or extremities. Actinic lichen planus, seen in subtropical zones on sun-exposed, dark-skinned young adults and children, is frequently annular in shape.

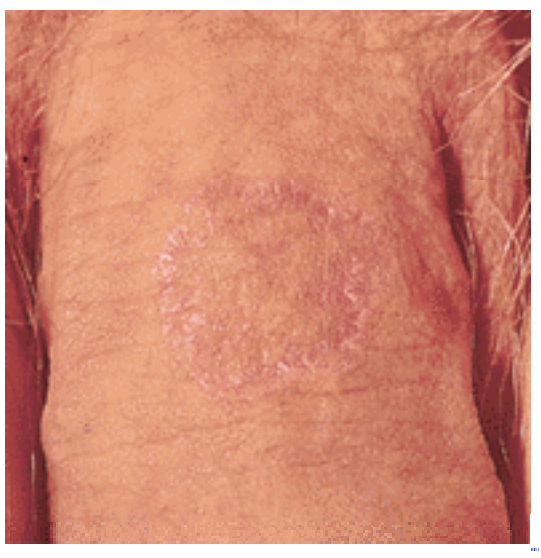

FIGURE 49-5 Lichen planus. Annular lesion on the shaft of the penis.

LINEAR LICHEN PLANUS Papules of lichen planus may develop a linear pattern secondary to trauma (koebnerization) or, uncommonly, as a spontaneous, isolated eruption, usually on the extremities, and rarely on the face. This linear pattern should be differentiated from nevus unius lateralis and lichen striatus. A zosteriform pattern has also been described, [14] and lichen planus can develop in the site of healed herpes zoster.

Morphology of Lesions

HYPERTROPHIC LICHEN PLANUS Hypertrophic lichen planus (lichen planus verrucosus) usually occurs on the extremities, especially the shins and interphalangeal joints, and tends to be the most pruritic variant. Lesions are thickened and elevated, purplish or reddish-brown in color, and hyperkeratotic. Occasionally, verrucous plaques develop. Lesions may show accentuated and elevated follicular induration and chalklike scale. This variant usually heals with scar formation and hyper- or hypopigmentation. Chronic venous insufficiency is frequently present.

ATROPHIC LICHEN PLANUS The atrophic variant is rare and is characterized by the presence of a few well-demarcated, white-bluish papules or plaques with central superficial atrophy. [2] Sometimes the lesions show more erythema. The lesions are a few millimeters wide but may coalesce to form larger plaques. They are most common on the lower extremities or trunk. The lesions often resemble lichen sclerosus et atrophicus. However, the histologic features are diagnostic.

VESICULOBULLOUS LICHEN PLANUS Bullous lichen planus is a rare variant of the disease characterized by the development of vesicles and bullae within the lesions (Fig. 49-6). The bullae, which appear most commonly on the extremities, arise from papules of lichen planus and rarely from normal-appearing skin. They may appear suddenly during an acute flare of disease and are usually associated with mild constitutional symptoms. These lesions usually resolve in a few months. Bulla arising in oral lichen planus can lead to painful erosions. Histologically, the typical changes of lichen planus are seen in conjunction with subepidermal separation. The duration of this variant is no different

from that of classic lichen planus. Bullae arising from normal skin are more characteristic of lichen planus pemphigoides and should be differentiated from bullous lichen planus by direct and indirect immunofluorescence (see below).

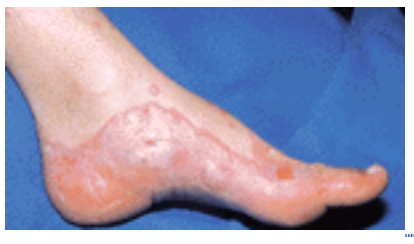

FIGURE 49-6 Lichen planus. Vesicles and bullae within violaceous-erythematous papules or plaques of the foot.

EROSIVE AND ULCERATIVE LICHEN PLANUS Ulcerative lichen planus is a rare variant presenting with chronic, painful bullae and ulcerations of the feet. Often, cicatricial sequelae are evident (Fig. 49-7). This variant is usually associated with more typical lesions of the nails, mucosal surfaces, and skin, which often aids in establishing the diagnosis. Permanent loss of toenails and cicatricial alopecia of the scalp are common. Because squamous cell carcinoma (SCC) may develop in lesions of ulcerative lichen planus, persistent ulceration should raise suspicions of malignancy, and this potential complication should be ruled out by biopsy. Excision and skin grafting should be considered if conservative therapy is ineffective. [15]

FIGURE 49-7 Lichen planus. Ulcerative variant showing erosions, granulation tissue, and scarring of toes and interdigital web space.

Erosive to ulcerative lesions of lichen planus are also seen with greater frequency in more severe cases of oral lichen planus. Lesions may involve the buccal mucosa, alveolar epithelium, and sulci, and may extend to the posterior pharynx and laryngeal area. Though rare, erosive esophageal disease may result in dysphagia and stenosis.
FOLLICULAR LICHEN PLANUS This form may occur alone or in association with other forms of cutaneous or mucosal lichen planus. [16] The term *lichen planopilaris* has been used to describe this distinctive variant, but other terms include *lichen planus follicularis, peripilaris,* and *acuminatus*. Individual keratotic follicular papules and studded plaques are seen. Sites of predilection include the trunk and medial aspects of the proximal extremities. Follicular lichen planus may affect the scalp with the development of cicatricial alopecia (see " Lichen Planus of the Scalp," below) (Fig. 49-8). The triad of follicular lichen planus of skin (lichen planus spinulosus) and/or scalp, multifocal cicatricial alopecia of the scalp, and nonscarring alopecia of the axillary and pubic areas, has been described as Graham-Little-Piccardi-Lassueur (or Graham-Little-Feldman) syndrome. Sometimes more typical lesions of the skin and nails are seen. Other variants of follicular lichen planus include the pseudopeladic form of Brocq, the lichen planus follicularis tumidus form with oval pseudotumoral plaques of the mastoid area, postmenopausal frontal fibrosing alopecia, and lichen planoporitis, with the lichenoid reaction centered over the acrosyringium and eccrine ducts entering the epidermis. [17]

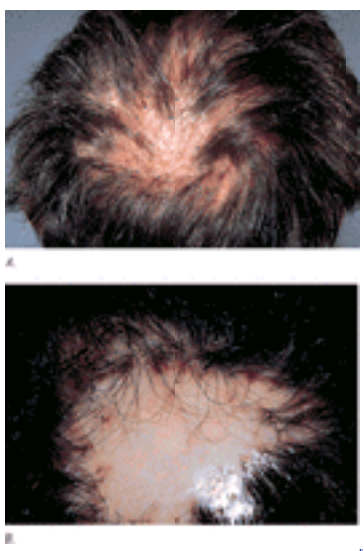

FIGURE 49-8 Lichen planus. *A.* Irregular patches of alopecia with violaceous papules and a coalescing plaque of lichen planus within scalp. *B.* Lichen planopilaris resulting in atrophic, scarred, porcelain-colored area centrally, with bordering follicular involvement consisting of dusky erythema, perifollicular hyperkeratosis and scale, and follicular convergence resulting in doll's hair formation.

LICHEN PLANUS PIGMENTOSUS This uncommon variant is characterized by hyperpigmented, dark-brown macules in sun-exposed areas and flexural folds. This entity tends to occur in Latin Americans and other patients with darker-pigmented skin. Histologically, an atrophic epidermis, a vacuolar alteration of the basal cell layer with a scarce lymphohistiocytic lichenoid infiltrate, and pigment incontinence are seen. This variant of lichen planus bears significant similarity to ashy dermatosis or erythema dyschromicum perstans (dermatoses cinecienta) and may represent overlap in the phenotypic spectrum of lichenoid inflammation in darkly pigmented skin, with ethnic/genetic factors influencing the expression of disease. [18] There are similar histopathologic findings among these diseases. However, distinct clinical, histologic, and immunopathologic differences among these three conditions have been emphasized by some investigators. Erythema dyschromicum perstans may be strongly influenced by environmental agents as well. The sequela of healing (late waning, resolving) is often slightly atrophic, hyperpigmented skin. In cases where the

inflammatory phase was minimal, such as lichen planus “invisible de Gougerot,” the pigmentation may be long-lasting and one of the few signs of previously active disease.

ACTINIC LICHEN PLANUS This variant is also known as lichen planus subtropicus, lichen planus tropicus, summertime actinic lichenoid eruption, lichen planus actinicus, lichen planus atrophicus annularis, and lichenoid melanodermatosis. Actinic lichen planus is more common in Middle Eastern countries in spring and summer, where sunlight appears to have a precipitating effect. Exposed areas of the face, dorsal hands and arms, and the nape of the neck are usually affected. Papules are hyperpigmented with violaceous-brown color and a thready, rolled edge showing well-defined borders. Typical lichen planus lesions may be present over the extremities. Pruritus and scaling are minimal.

OTHERS A perforating variant has been described. Transepidermal elimination of lichen planus-like inflammatory tissue is observed. Guttate lichen planus is another variant that resembles guttate psoriasis but with the characteristic lichenoid histology. Exfoliative and exanthematous forms are very rare and may represent manifestations of lichenoid drug reactions (Fig. 49-9). The rare entity of invisible lichen planus describes lesions that are not perceptible with visible light illumination but become apparent with Wood's lamp examination. Pruritus is present and biopsy evaluation shows lichenoid histology. This entity may be a minimal variant of lichen planus “invisible de Gougerot.”

FIGURE 49-9 Lichen planus-like eruption. Generalized violaceous papules with superficial scale coalescing to form erythematous variant. History of associated drug exposure leading to lichenoid reaction.

Site of Involvement

LICHEN PLANUS OF THE SCALP Lichen planopilaris or follicular lichen planus may affect the scalp in a distinctive clinical and histologic pattern. Individual keratotic follicular papules that coalesce and merge over the scalp to form patches are typically seen. Cutaneous, nail, or mucous membrane involvement with lichen planus may also be present. This condition affects women more than men. Patients present with uni- or multifocal hair loss that may be extensive and involve the entire scalp (Fig. 49-10). Perifollicular erythema and acuminate keratotic plugs are characteristic features. Follicular-centered lesions are usually observed under close inspection of the scalp and orifices, particularly at the margins of the alopecic area or within patches still bearing hair.

FIGURE 49-10 Lichen planus. Extensive hair loss leading to pseudopelade of Brocq appearance. Several remaining tufts of hair showing violaceous erythema and disease activity.

End-stage disease is characterized by a nondescript scarring alopecia that has led to the use of several clinical terms describing the entity; lichen planopilaris, folliculitis decalvans et atrophicus, lichen spinulosus at folliculitis decalvans, and Graham-Little syndrome are different terms that likely describe the same entity. [16] Pseudopelade of Brocq is a rare clinical syndrome of scarring alopecia and fibrosis, in which distinct pathologic features are absent. It is generally accepted that pseudopelade of Brocq is the end stage of follicular fibrosis caused by a primary inflammatory dermatosis such as lichen planus, lupus erythematosus, pustular-scarring forms of folliculitis, or fungal infections, including favus, scleroderma, and sarcoidosis. [16]

MUCOSAL LICHEN PLANUS Lichen planus can affect the mucosal surfaces of mouth, vagina, esophagus, conjunctiva, urethra, anus, nose, and larynx. Its prevalence is estimated at approximately 1 percent of the adult population. Oral involvement occurs in approximately 60 to 70 percent of patients with lichen planus. It may be the only manifestation in 20 to 30 percent of patients. Oral involvement appears to be the sole manifestation in 15 to 25 percent of patients with lichen planus attending general dermatology clinics, but is far more common in stomatology/mucosal disease specialty referral practices. Different types of oral lichen planus have been described, including reticular, plaque-like, atrophic, papular, erosive-ulcerative, and bullous forms of the disease. [19] The reticular pattern is considered the most common, but in oral medicine clinics, erosive forms predominate as a consequence of the symptomatology and chronicity. Erosive lichen planus is more common in the elderly and tends to cause a painful, burning sensation. The buccal, gingival, and glossal mucosae are the most commonly affected areas. The palate, floor of the mouth, retromolar pads, and lips may also be affected. Gingival involvement may take the form of gingival stomatitis or desquamative gingivitis, and as a sole presentation, represents 8 to 10 percent of oral lichen planus. Oral lichenoid reaction may be seen on the buccal mucosa adjacent to amalgam dental fillings. [20] Patch tests frequently show positive reactions to mercury, gold, and other metals. [20], [21] Because of the prolonged course and associated pain and discomfort, patients with oral lichen planus tend to be depressed, and psychological help should be offered to them. Bilateral reticular keratotic or atrophic changes of the buccal mucosa and lichenoid atrophic patches over the dorsal tongue have been described in patients with HIV infection. The eruptions usually follow zidovudine or ketoconazole intake. Histologically, liquefaction degradation of basal keratinocytes and epithelial atrophy with lichenoid lymphocytic infiltrate are seen. Male genitalia are involved in 25 percent of cases, and the glans penis is most commonly affected, with annular lesions frequently present. Female genital involvement consists of patches of leukoplakia or erythroplakia, sometimes with erosions, and, occasionally, as a more

generalized desquamative vaginitis. Vaginal adhesions and labial agglutination may result. Anal lesions of mucosal lichen planus present with leukokeratosis, hyperkeratosis, fissuring, and erosions (Fig. 49-11).

FIGURE 49-11 Lichen planus. Perianal leuko- and hyperkeratosis with hypertrophic, folded violaceous epithelium, fissures, and healing biopsy site.

A special form of mucosal lichen planus characterized by involvement of vulvar and gingival tissues has been described. [22] The characteristic features include erythema and erosions of the gingivae and tongue and, occasionally, white reticulated plaques, in association with pain and discomfort. Desquamation and erosions of vulva and vagina in association with burning pain, dyspareunia, and vaginal discharge mirror the oral findings. Conjunctival lichen planus may manifest as cicatricial conjunctivitis. Histologically, irregular thickening with reduplication of the basement membrane is seen. Direct immunofluorescence distinguishes ophthalmic lichen planus from cicatricial pemphigoid.

LICHEN PLANUS OF THE NAILS Nail involvement occurs in 10 to 15 percent of patients. [23] Lichen planus limited to the nails is uncommon, and the initial involvement is followed, in many cases, by the development of typical lesions elsewhere. Lichen planus of nails is infrequent in children. Thinning, longitudinal ridging, and distal splitting of the nail plate (onychoschizia) are the most common findings. Onycholysis, longitudinal striation (onychorrhexis), subungual hyperkeratosis, or even absence (anonychia) of the nail plate can also be seen. Twenty-nail dystrophy (trachyonychia) may represent an isolated nail finding of lichen planus. Psoriasis and alopecia areata can also lead to these distinctive nail changes. Nail loss may result from ulcerative lichen planus involving the nail unit. Pterygium or forward growth of the eponychium with adherence to the proximal nail plate is a classic finding of lichen planus of the nail (Fig. 49-12). An atrophic cicatrizing form of lichen planus with random and progressive nail loss in Asians and blacks has also been reported. The “tenting” or “pup-tent” sign is observed as a result of nail bed involvement that elevates the nail plate and may cause longitudinal splitting. [2]

FIGURE 49-12 Lichen planus. Classic pterygium formation and tenting of several fingers with loss of nail plates.

INVERSE LICHEN PLANUS The inverse pattern occurs only rarely and is characterized by red-brownish, discrete papules and nodules. The eruption occurs mainly in the flexural areas such as axillae, inframammary, groin, and, less likely, the popliteal and antecubital areas. Koebnerized lesions are occasionally present.

PALMOPLANTAR LICHEN PLANUS This acral, localized variant of lichen planus is rare and may create difficulty in diagnosis if it is present as an isolated finding. Very pruriginous, erythematous, scaly plaques with or without hyperkeratosis are characteristic. Lesions are often seen on the internal plantar arch. [24] Yellowish, compact keratotic papules or papulonodules are seen on the lateral margins of the fingers and hand surfaces; however, they are less likely to affect the fingertips. They appear like callosities with an inflammatory, erythematous halo. The lesions resemble psoriasis vulgaris, warts, calluses, porokeratosis, hyperkeratotic eczema, tinea, or secondary syphilis. [24] Histologically, findings are identical of those of classic lichen planus.

SPECIAL FORMS OF LICHEN PLANUS/LICHENOID ERUPTION

Drug-Induced Lichen Planus

Lichen planus-like or lichenoid eruptions describe a group of cutaneous reactions identical or similar to lichen planus. [25] Lichenoid drug eruptions have been reported after ingestion, contact, or inhalation of certain chemicals (Table 49-2 and Table 49-3). A lichenoid drug eruption may be typical or atypical for classic lichen planus, with localized or generalized eczematous papules and plaques and variable desquamation. Lichenoid drug eruptions typically manifest postinflammatory hyperpigmentation and alopecia, and fail to exhibit classic Wickham striae. The eruptions usually appear symmetrically on the trunk and extremities, unlike the flexural distribution of classic lichen planus. A photodistributed pattern is often found, and several drugs frequently induce this reaction (Table 49-4). Mucous membrane involvement is less common and is often associated with specific drugs and chemicals (Table 49-5).

	Less-Common Inducers	
Common Inducers	Commonly Prescribed Drugs	Uncommonly Prescribed Drugs
Gold salts	ACE inhibitors	Methyldopa
Beta blockers	Calcium channel blockers	Anti-tuberculosis
Antimalarials	Sulfonylurea hypoglycemic agents	Sulfasalazine
Thiazide diuretics	Nonsteroidal anti-inflammatory drugs	Heavy metals (arsenic, mercury)
Furosemide	Ketoconazole	Lithium
Spironolactone	Tetracycline	Iodides and radiocontrast media
Penicillamine	Phenothiazine derivates	Antimony
		Carbamazepine

TABLE 49-2 **Agents Inducing Lichen Planus and Lichenoid Reactions**

Color film developers
PPDA (p-phenylenediamine)
IPPD (p-isopropylaminodiphenylamine)
CD_2
CD_3
TTS (4-amino-N-diethyl-aniline sulfate)
Antimony trioxide
Dental restorative materials
Musk ambrette
Nickel
Aminoglycoside antibiotics
Gold

SOURCE: With permission from Halevy S, Shai A. Lichenoid drug eruptions. *J Am Acad Dermatol* 28:249, 1993.

TABLE 49-3 **Inducers of Lichenoid Drug Eruption—Contact Chemicals**

5-Fluorouracil
Carbamazepine
Chlorpromazine
Diazoxide
Ethambutol
Pyritinol
Quinine, quinidine
Tetracyclines
Thiazide diuretics and furosemide

SOURCE: With permission from Halevy S, Shai A. Lichenoid drug eruptions. *J Am Acad Dermatol* 28:249, 1993.

TABLE 49-4 **Drugs That Induce Lichenoid Drug Eruption—Photodistributed**

Allopurinol
Angiotensin-converting enzyme inhibitors
Cyanamide
Dental restorative materials
Gold salts
Ketoconazole
Methyldopa
Nonsteroidal anti-inflammatory drugs
Penicillamine
Sulfonylurea hypoglycemia agents

SOURCE: With permission from Halevy S, Shai A. Lichenoid drug eruptions. *J Am Acad Dermatol* 28:249, 1993.

TABLE 49-5 **Drugs That Induce Lichen Drug Eruption—Oral Predilection**

The latency period for development of a lichenoid drug eruption by these agents varies from months to a year or more based on the dosage, host response, previous exposure, and concomitant drug administration. Resolution of the eruptions is quite variable, but most disappear in 3 to 4 months. Resolution of a gold-induced lichenoid eruption may require up to 2 years after discontinuation of the drug. For many inciting drugs, the severity and extent of the eruption influences the rate of clearance. Occasionally, the lichenoid drug eruption disappears or may recur intermittently despite continuation of treatment.

Lichenoid contact dermatitis may result from contact with compounds such as color film developers, dental restoration materials, metals (e.g., mercury, silver, and gold), and aminoglycoside antibiotics. [25] Oral lichenoid drug eruptions related to amalgam seem to be caused by mercury, although gold may be the more common metal sensitizer in oral lichenoid eruptions. Table 49-6 compares the findings in lichen planus and lichenoid during eruptions.

	Idiopathic Lichen Planus	Lichenoid Drug Eruption
Lesions	Smaller	Larger and scaly
Wickham striae	Usually present	Usually absent
Residual hyperpigmentation	Possible	Common
Alopecia	Uncommon	Common
Predilection	Flexural/extremities	Sun-exposed areas
Mucous membrane involvement	Very common	Less common
Cytoids in granular layer	Very uncommon	Common
Parakeratosis	Not seen	Common

TABLE 49-6 **Clinical and Histologic Differences between Idiopathic Lichen Planus and Lichenoid Drug Reaction**

Lichen Planus–Lupus Erythematosus Overlap Syndrome

This rare variant is characterized by lesions that share features of lichen planus and lupus erythematosus. Atrophic plaques and patches with hypopigmentation and a livid red to blue-violet color with telangiectasia and minimal scaling are characteristic. Transient bullae may develop. Classic lesions of lichen planus are not usually seen. Photosensitivity, pruritus, and follicular plugging are also not common. Lesions may develop anywhere, but are most common on the extremities (Fig. 49-13). Some patients with this overlap syndrome may progress to systemic lupus erythematosus. In other instances, laboratory evaluation may reveal only a weak-positive antinuclear antibody. This disease variant is characterized by a prolonged course and lack of response to treatment. Histologically, a lichenoid reaction typical for lichen planus and histologic features of lupus erythematosus are usually present in the same biopsy. [26] By direct immunofluorescence, the most common finding is the presence of cytoids staining with IgG, IgM, and C3 intraepidermally or at the dermal–epidermal junction, as seen in classic lichen planus. Linear to granular deposition of IgM and C3 (as seen in lupus erythematosus, but not in lichen planus) has been observed occasionally. Shaggy deposition of fibrinogen at the basement membrane zone, typical of lichen planus, is sometimes found. [26]

FIGURE 49-13 Lichen planus–lupus erythematosus overlap syndrome. Lichenoid lesions involving dorsal hand and forearm with direct immunofluorescence evidence of lupus erythematosus.

Lichen Planus Pemphigoides

Lichen planus pemphigoides is characterized by the development of tense blisters atop lesions of lichen planus or the development of vesicles de novo on uninvolved skin (Fig. 49-14). It is important to differentiate this entity from bullous lichen planus, in which blisters develop in lesions of long-standing lichen planus as a result of intense lichenoid inflammation and extensive liquefaction degeneration of basal keratinocytes. The etiology of this variant is not clear. It was proposed that basal cell keratinocyte damage by lymphocytes in lichen planus may unmask hidden antigenic determinants and lead to autoantibody formation and induction of bullous lesions. Histologic findings resemble those of lichen planus. Direct immunofluorescence shows linear deposition of IgG and C3 at the dermal–epidermal junction. Sera from these patients react with the epidermal side of NaCl-split human skin. Circulating IgG autoantibodies react to the major noncollagenous extracellular domain (NC16A) of the 180-kDa bullous pemphigoid antigen within the basement membrane zone. Further mapping showed that lichen planus pemphigoides serum reacts with amino acids 46 to 59 of domain NC16A, a protein segment that was previously shown to be unreactive with bullous pemphigoid sera. This newly described epitope is designated MCW-4. [27]

FIGURE 49-14 Lichen planus pemphigoides. Lichenoid maculopapular erythema, erosions, and bullae with direct immunofluorescence showing features of bullous pemphigoid. Indirect immunofluorescence also was positive.

Keratosis Lichenoides Chronica (Nekam's Disease)

Keratosis lichenoides chronica was originally described by Kaposi (as lichen ruber verrucosus et reticularis), but was named after Nekam reported a typical case in 1938. The current descriptive term was introduced in 1972, and the disease is generally felt to represent a special form of lichen planus. Keratosis lichenoides chronica is a rare dermatosis characterized by violaceous papular and nodular lesions, often arranged in a linear and reticulate pattern on the dorsal hands and feet, extremities, and buttocks (Fig. 49-15). The mucous membranes, genitalia, nails, palms, and soles may also be affected. Seborrheic dermatitis-like scaling and telangiectasias of the scalp, face, and neck may develop. Histologically, hyperkeratosis, parakeratosis, and hypergranulosis are seen. The epidermis is usually acanthotic, with mild liquefactive degeneration of basal keratinocytes. A bandlike lymphocytic infiltrate with perivascular and periappendegeal involvement is present. Few plasma cells are seen in the infiltrates. The disease is very refractory to treatment. Photochemotherapy may be helpful, and calcipotriene has shown therapeutic benefit. [28]

FIGURE 49-15 Keratosis lichenoides chronica. Linear to reticulated, hyperpigmented, and hyperkeratotic lesions on the lower leg.

Lichen Planus and Malignant Transformation

There has been considerable controversy as to whether oral lichen planus inherently harbors malignant potential. It is currently believed that the risk of malignant transformation is fairly low. Risk factors that increase the ikelihood of developing oral cancer are long-standing disease, erosive or atrophic types, and tobacco use. It is generally accepted that 0.5 to 5 percent of patients with oral lichen planus develop SCC. The majority of these cases are in situ carcinoma or with microinvasive pattern. [29] The most common site for malignant transformation is the tongue (Fig. 49-16), followed by buccal mucosa, gingiva, and, rarely, the lip. Clinically, the lesions appear as indurated, nonhealing ulcers or exophytic lesions with a keratotic surface in majority of cases. Red atrophic plaques could also be seen and often correlate with SCC in situ. Advanced cases could result in nodal metastases and occasionally death. [29]

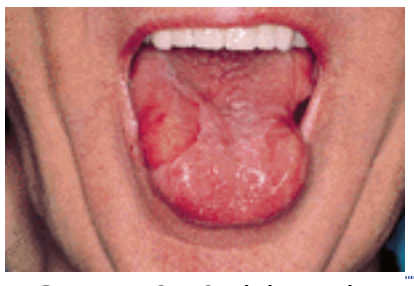

FIGURE 49-16 Lichen planus and squamous cell carcinoma. Long-standing oral lichen planus with scarring changes of tongue. Circumscribed erythroplakia and erosion of the right lateral tongue was biopsied and confirmed squamous cell carcinoma.

The risk of skin malignancy in cutaneous lichen planus is extremely low. Most patients developing SCC in cutaneous lichen planus had a history of either arsenic or x-ray exposure.

Lichenoid Reaction of Graft-Versus-Host Disease (See also Chap. 118)

Chronic graft-versus-host disease (GVHD) (occurring 100 days after transplant) may present as a lichenoid eruption indistinguishable clinically and histologically from lichen planus. Lichenoid GVHD favors the trunk, buttocks, hips, thighs, palms, and soles. In oral mucosa, xerostomia and oral ulcerations are occasionally seen. Histologically, the findings in lichen planus and oral GVHD are similar, although infiltrating CD3+ T lymphocytes are present in larger numbers in oral lichen planus than in lichenoid lesions of oral GVHD. [30] In a comparative study between those two entities, the number of natural killer cells, Leu-8–positive T cells (homing receptor: CD62L, LECAM), CD25–positive lymphocytes, and the CD4:CD8 ratio were not different. Langerhans cells are often increased in both conditions.

Lichenoid Keratosis

Lichenoid keratoses are brown to red, scaling maculopapules found on sun-exposed skin of extremities. Histologic features of lichen planus are present, with the additional finding of focal parakeratosis. They frequently occur with solar lentigo, seborrheic keratosis, and actinic keratosis, and likely represent an “involuting lichenoid plaque.” [31]

Lichenoid Dermatitis

The wide range of disorders and presentations reviewed in this chapter constitute many of the more representative types of lichenoid dermatitis. Additional members of the lichenoid dermatitis group of skin disease include lupus erythematosus, other connective tissue diseases, secondary syphilis, and lymphoproliferative diseases such as lymphomatoid papulosis, mycosis fungoides, and Sézary syndrome. [32] The lymphoproliferative group should be considered carefully in the differential diagnosis of enigmatic lichenoid dermatitis. Special studies, such as direct immunofluorescence, and immunophenotypic and T cell receptor genotypic analyses, are often required to define the underlying pathology manifesting as lichenoid dermatitis more precisely.

ASSOCIATED CONDITIONS

Lichen planus is seen with increased frequency in association with liver diseases such as autoimmune chronic active hepatitis, primary biliary cirrhosis, and postviral chronic active hepatitis. [33] The association with primary biliary cirrhosis is observed regardless of treatment with D-penicillamine, a drug that may cause an exacerbation of lichen planus.

The role of infection in development of lichen planus has been repeatedly raised over the years. Association of lichen planus with syphilis, herpes simplex virus 2, HIV, amebiasis, and chronic bladder infections has been reported. [2] Recently, a more widespread and chronic viral disease, hepatitis C virus (HCV), has been implicated in triggering lichen planus. The prevalence of HCV infection varied between 16 and 29 percent in 517 mainly southern European patients with lichen planus in four different studies. [34], [35] On the other hand, many studies from Northern Europe and the United States did not substantiate any link. [36], [37] Genetic factors controlling disease susceptibility and prevalence of certain HCV genotypes in certain geographic areas may have significantly influenced these results. A large series of oral lichen planus in the United States found no association with HCV.

Recently, several reports described lichen planus-like eruptions following hepatitis B vaccination. [38]

There is no evidence to link lichen planus to diabetes mellitus, autoimmune diseases, nor internal malignancies. Cases of severe erosive gingivitis and stomatitis with histologic appearance of lichen planus in association with internal malignancies may represent cases of paraneoplastic pemphigus. The pathologic spectrum of findings and target organ involvement in this condition is broad, ranging from lichenoid dermatitis to frank acantholysis, such that a preferred term is *paraneoplastic autoimmune multiorgan syndrome* (PAMS). [39]

LABORATORY FINDINGS

No specific abnormalities of laboratory analyses are seen in lichen planus. The total white blood cell count and lymphocytes may be decreased. This could be related to cytokine activation and local trafficking of cells to skin or other tissue compartments.

Patch tests in patients with oral or cutaneous lichen planus usually reveal positive results in a majority of patients. [20], [21] Sensitivity to mercury and gold is often positive in half the cases. Chromate, flavoring agents, acrylate, and thimerosal are common sensitizers. [20], [21]

PATHOLOGY

The two major pathologic findings in lichen planus are basal epidermal keratinocyte damage and lichenoid-interface lymphocytic reaction. [1] The epidermal changes include hyperkeratosis, wedge-shaped areas of hypergranulosis, and elongation of rete ridges that resemble a sawtooth pattern (Fig. 49-17). Multiple apoptotic cells or colloid-hyaline (Civatte) bodies are seen at the dermal–epidermal junction. Eosinophilic colloid bodies are present in the papillary dermis. They are PAS-positive and measure about 20 µm in diameter. A bandlike lymphocytic infiltrate is seen in the papillary dermis that abuts the epidermis. Many histiocytes and few plasma cells are seen. Plasma cells are more prominent in mucous membrane specimens. Few eosinophils are seen in drug-induced lichen planus or lichenoid drug eruptions. Melanin pigmentation is invariably present and is more pronounced in older, waning lesions and in dark-skinned individuals. Separation of the epidermis in small clefts (Max Joseph cleft formation) is occasionally seen (Fig. 49-18).

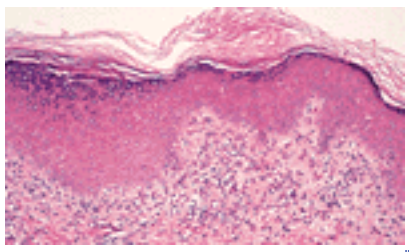

FIGURE 49-17 Lichen planus. Typical hyperkeratosis, hypergranulosis, early sawtooth changes and lichenoid interface reaction of classic lichen planus.

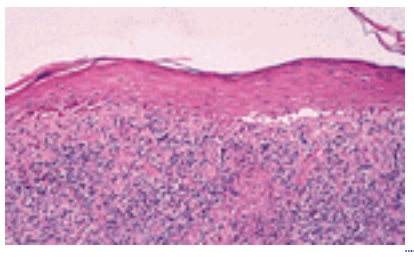

FIGURE 49-18 Lichen planus. More extensive epidermal alterations with hydropic changes, thinned epidermis, focal wedge-shaped hypergranulosis, compact orthokeratosis, and pronounced lichenoid inflammation with focal hemorrhage.

Direct immunofluorescence shows numerous apoptotic cells at the dermal–epidermal junction staining with IgM and, occasionally, with IgG and IgA. Shaggy deposition of fibrinogen at the dermal–epidermal junction is characteristic of lichen planus (Fig. 49-19). Immunocytochemical studies show that the majority of the cells in the infiltrate are T lymphocytes, with scattered B lymphocytes. An increased density of Langerhans cells, dermal dendritic cells, and

histiocytes have also been seen, especially in early active lesions.

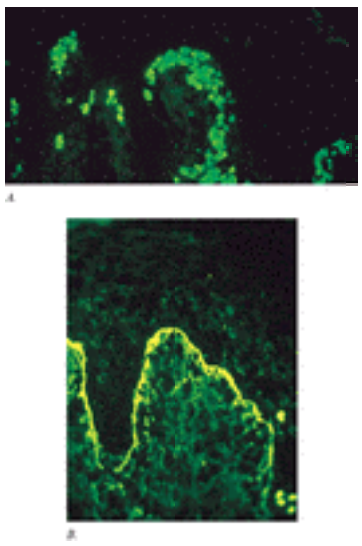

FIGURE 49-19 Lichen planus. Direct immunofluorescence examination of involved skin. *A.* Numerous IgM-positive cytoids at the dermal–epidermal junction. *B.* Fibrinogen/fibrin, shaggy pattern at the dermal–epidermal junction.

Different forms of lichen planus share the main pathologic findings and differ by few features. Atrophic lichen planus is characterized by thinning of the epidermis and loss of rete ridges, in contrast to hypertrophic lichen planus, where hyperkeratosis and epidermal hyperplasia are prominent. In the latter, vertical streaking of collagen bundles is found, similar to lichen simplex chronicus. Lichen planus pigmentosus is characterized by the prominent pigment incontinence that extends deeper into the reticular dermis. The inflammatory infiltrate is also less prominent. Psoriasiform acanthosis, vacuolar degeneration, and apoptosis are prominent in keratosis lichenoides chronica. Lichen planus pemphigoides is characterized by the subepidermal separation and the linear deposition of IgG and C3 along the dermal–epidermal junction. In lichen planopilaris, perifollicular lymphocytic inflammation enveloping the upper third of hair follicle epithelium is usually associated with follicular plugging and hydropic changes of the basal cell layer of the external root sheath. Perifollicular and mid-dermal fibrosis with loss of elastic tissue around follicular epithelium is also found. Classic changes of interface dermatitis as seen in lichen planus are not common in the interfollicular epithelium. Direct immunofluorescence is usually positive in two-thirds of the patients, and should be performed to establish the diagnosis of lichen planopilaris and to rule out other disorders causing cicatricial alopecia, such as lupus erythematosus. [16]

Features that may be seen in lichenoid drug eruptions, but not in lichen planus, include the presence of abundant plasma cells and eosinophils in the infiltrate, focal parakeratosis and hypogranulosis, and the presence of cytoid bodies high in the stratum corneum. Furthermore, lymphocytic infiltration is less dense and not as bandlike as that seen in classic lichen planus.

Lichen planus-like keratosis resembles lichen planus histologically. Lichenoid lymphocytic infiltrates with hyperkeratosis, hypergranulosis, focal acanthosis, and parakeratosis in the absence of keratinocyte atypia are the features of lichen planus-like keratosis. [31] Atypia is present, however, in lichenoid actinic keratosis.

Electron microscopic examination demonstrates basal epidermal alterations with basal lamina interruption and reduplication. Vacuolar changes may be prominent and correlate with tonofilament disruption and loss of desmosome connections. Apoptotic keratinocytes showing typical features of colloid bodies are seen, as well as increased numbers of Langerhans cells, similar to light microscopic changes.

DIAGNOSIS AND DIFFERENTIAL DIAGNOSIS

The appearance of the typical papule of lichen planus is usually sufficient to make the correct diagnosis. Different forms of the disease with various configurations, morphology, or anatomic location are usually associated with more classic lichen planus elsewhere on the body. Careful and thorough skin examination is therefore required. Histopathologic and immunofluorescent evaluation will confirm the diagnosis in cases presenting with atypical lesions.

Other papulosquamous diseases must be differentiated from lichen planus. Psoriasis affecting the penis or the nail may resemble lichen planus; however, classic cutaneous or mucosal lichenoid lesions assist in differentiation. Nail involvement may resemble psoriasis, onychomycosis, or alopecia areata. Genital lesions may resemble psoriasis or seborrheic dermatitis. Lesions of palms and soles should be differentiated from secondary syphilis.

Annular lichen planus may resemble granuloma annulare, but the latter lacks any scale or Wickham striae. Linear lichen planus should be differentiated from nevus unius lateris, lichen striatus, and linear epidermal nevus. Hypertrophic lichen planus may resemble lichen simplex chronicus, prurigo nodularis, lichenoid cutaneous amyloidosis or, on occasion, Kaposi's sarcoma. Atrophic lichen planus may mimic lichen sclerosus et atrophicus. Follicular lichen planus may resemble lichen nitidus and lichen spinulosus. Lichen planopilaris should be differentiated from other causes of cicatricial alopecia such as lupus erythematosus, inflammatory folliculitis, alopecia areata, and cicatricial pemphigoid of Brunsting-Perry. Graham-Little syndrome needs to be distinguished from keratosis follicularis spinulosa decalvans, a genetic disorder with progressive scarring alopecia. Routine histology and direct immunofluorescence findings will separate these disorders.

Severe erosive PAMS-paraneoplastic pemphigus may resemble erosive oral lichen planus and may primarily involve the oral mucosa. Direct and indirect immunofluorescence are usually required to establish the appropriate diagnosis. Oral

patches of lichen planus should be differentiated from leukokeratosis, candida infection, lupus erythematosus, mucous patches of secondary syphilis, or traumatic bite line.

Childhood lichen planus should be distinguished from lichen nitidus, lichen striatus, papular acrodermatitis of childhood, and pityriasis lichenoides.

TREATMENT

Management of lichen planus can be challenging and discouraging for both the patient and physician. Lichen planus may be associated with only minor symptoms or may cause considerable discomfort and disability. Hence, treatment options should be assessed for attendant risks and benefits and tailored to the extent and severity of disease. Avoidance of exacerbating drugs, unless necessary, and minimizing trauma to skin and mucosal tissues are routinely recommended.

Various drugs have been proposed for the treatment of cutaneous and oral lichen planus and the majority of these consist of small series of patients or anecdotes. Many of the advocated treatments lack conclusive evidence for efficacy. Many excellent reviews have dealt with this issue. [40], [41]

Oral Lichen Planus

GENERAL MEASURES For oral lichen planus, good oral hygiene and regular personal and professional dental care need to be encouraged. Several treatment approaches are useful for oral or mucous membrane lichen planus. Replacement of amalgam or gold dental restorations with composite material is frequently of considerable benefit in patients with oral lichenoid reactions, even in the apparent absence of relevant patch test results. Chronic lesions on the buccal mucosa in contact with metal or other contact sensitizers frequently heal promptly after replacement, [20], [21] and, occasionally, lesions at sites distant to oral lesions may also clear following removal of metal restorations. Gingival lesions may respond less favorably. The decision to undergo removal and restoration is often difficult and usually depends on the chronicity, severity, and clinical and patch test evidence for involvement by the metal/prosthesis as well as the level of frustration of the patient.

TOPICAL STEROIDS Topical steroids are the first-line therapy in mucosal lichen planus. [42] A variety of topical glucocorticoids have been shown to be effective. Use of occlusive materials suitable for mucous membranes, such as Orabase, may provide protection and sustained tissue contact with the glucocorticoid, as well as alleviate the discomfort associated with erosive lesions. Fluocinonide in an adhesive gel or base, 0.1% fluocinolone acetonide, and 0.05% clobetasol propionate in Orabase showed good results. Application four to six times a day is recommended. Treatment may be complicated by frequent infections with oral candidiasis. The use of chlorhexidine gluconate mouthwashes and topical anticandidal medications is recommended during therapy. In some situations where secondary irritation and inflammation of oral tissues appears to be related to colonization of the mouth by candida, an antifungal treatment course (troche or oral) may be indicated. Topical anesthetics also provide symptomatic benefit for patients who have difficulty with eating and chewing, and is often compounded with topical corticosteroids. Glucocorticoids containing vaginal and rectal suppositories are usually helpful for mucosal involvement in these areas. Glucocorticoids can be administered by intralesional injections or application under occlusion by a flexible vaginal prosthetic device or cloth strips.

SYSTEMIC GLUCOCORTICOIDS Systemic glucocorticoids provide effectiveness in erosive oral and vulvovaginal lichen planus. Systemic dosing can be used alone, or, more commonly, in conjunction with topical glucocorticoids. A dose range from 30 to 80 mg/day, tapered over 3 to 6 weeks shows benefit. Relapses are common after dose reduction or discontinuation. Higher doses are often needed for esophageal lichen planus. Oral candidiasis is a common complication.

RETINOIDS Topical retinoic acid (tretinoin gel) has been shown to be effective in erosive as well as plaquelike oral lesions. Irritation often makes this localized approach to therapy less attractive. Isotretinoin gel is also effective, especially in nonerosive oral lesions. Improvement is usually noted after 2 months; however, recurrence is common after discontinuation of therapy. Topical retinoids are often used in conjunction with topical glucocorticoids. Although not proven in clinical trials, this may improve the efficacy and lessen the side effects. Etretinate orally has been used at 75 mg/day (0.6 to 1.0 mg/kg per day) in erosive oral lichen planus with significant improvement in the majority of patients. Relapses are common following discontinuation of medication. [43] In a double-blind, placebo-controlled study, two-thirds of patients showed marked improvement or complete remission within 8 weeks of instituting acitretin, 30 mg/day. [44] Only the aromatic retinoid acitretin is currently available by prescription following the removal of etretinate from the US market. There is no conclusive data on the efficacy of oral tretinoin or isotretinoin.

CYCLOSPORINE, TACROLIMUS, AND PIMECROLIMUS Topical application of cyclosporine, 100 mg/mL, 5 mL three times daily has shown benefit for oral lichen planus. Application modalities include mouthwashes and manual administration with local massage. Topical cyclosporine washes seem to be effective in oral lichen planus, especially the severe erosive forms, [45] but they do not appear to be better than local glucocorticoid therapy. Lack of effectiveness in a few cases, [46] the high cost of this medication, as well as the lack of a commercial formulation for topical application limits its use. Availability of alternate topical immunosuppressive agents, tacrolimus and pimecrolimus, currently provide useful substitutes to topical cyclosporine. Tacrolimus, a member of the immunosuppressive macrolide family which suppresses T cell activation is effective in erosive mucosal disease, providing rapid relief from pain and burning with minimal side effects. [47] Oral cyclosporine at dose regimens of 3 to 10 mg/kg per day has been used for severe ulcerative disease.

MISCELLANEOUS The polyene antifungal, griseofulvin, has been used empirically for treatment of oral and cutaneous lichen planus; however, it lacks clear effectiveness. Newer antifungal agents (e.g., fluconazole, itraconazole) may be useful in oral lichen planus with evidence of candida overgrowth, especially concomitantly with systemic glucocorticoids. In one study, hydroxychloroquine at 200 to 400 mg/day for at least 6 months resulted in complete healing of oral erosions of lichen planus. [48] Caution should be used with hydroxychloroquine because antimalarials are implicated as possible inducers of lichen planus. Thalidomide should be reserved for cases recalcitrant to other remedies. The dose could be started at 50 mg/day and increased gradually to 200 mg/day. [49] Extracorporeal photochemotherapy (ECP) twice a week for 3 weeks and then tapered has had favorable results. In one study, all seven patients experienced complete remission. [50] Azathioprine, cyclophosphamide, and mycophenolate mofetil have shown benefit in oral lichen planus, but randomized clinical trials are lacking. [41]

Cutaneous Lichen Planus

TOPICAL GLUCOCORTICOIDS A large variety of topical and systemic therapies are available for the treatment of cutaneous lichen planus, and this range of options may be attributed to the chronicity, symptomatology, and variable responsiveness of the dermatosis. Topical glucocorticoids are typically used for limited cutaneous disease. [42] Potent topical glucocorticoids, with or without occlusion, are occasionally beneficial in cutaneous lichen planus. Intralesional triamcinolone acetonide (5 to 10 mg/mL) is effective in treating oral and cutaneous lichen planus. This may also be used in lichen planus of the nails with injection of the proximal nail fold every 4 weeks. Regression of lesions occurs within 3 to 4 months. For hypertrophic lichen planus, higher concentrations of intralesional glucocorticoid (10 to 20 mg/mL) may be required. Regular and close observation should be performed to monitor for any signs of atrophy or localized hypopigmentation that may develop; treatment should be discontinued promptly with development of these complications. Systemic glucocorticoids are often useful and effective in doses greater than 20 mg/day (e.g., 30 to 80 mg prednisone) for 4 to 6 weeks with subsequent taper over 4 to 6 weeks. Other regimens include prednisone 5 to 10 mg/day for 3 to 5 weeks. Symptoms are often alleviated, and patients in the early stages of evolution or experiencing a flare have marked benefit and attenuation or aborted progression of disease. However, the rate of relapse following termination of therapy is unknown. In lichen planopilaris, potent topical glucocorticoids in conjunction with oral glucocorticoids, 30 to 40 mg/day, for at least 3 months, seems to be successful; however, relapse typically occurs following discontinuation. Long-term, chronic continuation of oral or injected glucocorticoids is contraindicated in most cases because of the high risk of complications.

RETINOIDS The systemic retinoids demonstrate anti-inflammatory activity and have been used in the treatment of lichen planus. Remission and marked improvement was achieved with 30 mg/day of acitretin for 8 weeks. [44] Oral tretinoin (10 to 30 mg/day) provided complete remission or marked improvement in greater than 90 percent of patients over a period of 1 to 19 months of treatment. Side effects were mild. [51] Low-dose etretinate (10 to 20 mg/day) use has been associated with complete remission of cutaneous, oral, and nail lichen planus after 4 to 6 months of treatment. Prompt beneficial response was noted with the use of 75 mg/day of etretinate, [52] but side effects of retinoids are dose-related and may limit use of higher dose therapeutic regimens. The combination of retinoids and PUVA therapy has not been evaluated.

PHOTOCHEMOTHERAPY PUVA photochemotherapy is usually successful in generalized cutaneous lichen planus. It has been used in conjunction with oral glucocorticoids to hasten the response. In an open study of 75 patients who underwent bath-PUVA therapy with trioxsalen, 65 percent were cured and an additional 15 percent improved; 50 mg of trioxsalen was added to 150 L of water, and the patients were exposed to UVA after 10 min of bathing. [53] During 2- to 5-year follow up, 25 percent of these patients had a relapse. In another study, recurrence rate was higher in patients treated with PUVA than those with placebo. This study indicates that although oral and bath methoxsalen PUVA have a favorable immediate clearing effect, they may prolong the course of the disease. [54] UVA1 phototherapy may also benefit more protracted lichen planus.

IMMUNOSUPPRESSIVE AGENTS Systemic cyclosporine has been used successfully in recalcitrant lichen planus. [55] The administered dose can range from 3 to 10 mg/kg per day. Pruritus usually disappears after 1 to 2 weeks. Clearance of the rash is seen in 4 to 6 weeks. Low doses (1 to 2.5 mg/kg per day) are probably sufficient to achieve remission. Adverse effects on renal function, development of hypertension, and other significant side-effects, as well as relapse after discontinuation of the drug, limit its use to severe cases. [56] Azathioprine may be useful in recalcitrant, generalized cutaneous lichen planus and in lichen planus pemphigoides. [57] Similar results are seen with mycophenolate mofetil at a dose of 1500 mg twice daily. [58]

MISCELLANEOUS Complete healing was seen in two-thirds of patients with cutaneous and oral lichen planus within 4 months of treatment with dapsone orally at 200 mg/day. [59] Partial improvement was seen in an additional 19 percent of patients. Antimalarials (200 to 400 mg/day) have been reported to be particularly useful in actinic lichen planus. IFN-a2b has been administered for treatment of generalized lichen planus with improvement, but this biologic response modifier also has been implicated in development or exacerbation of lichen planus. [60] Thalidomide led to healing in a case of severe acral erosive lichen planus unresponsive to other therapies. [61] Oral metronidazole 500 mg twice daily for 1 to 2 months also reportedly clears the majority of cases of generalized lichen planus. [62] Based on the benefit in bullous pemphigoid, combination therapy with tetracycline or doxycycline and nicotinamide has been reported as useful in the treatment of lichen planus pemphigoides. [63] Low molecular weight heparin in low doses has lymphoid antiproliferative and immunomodulatory properties. At a dose of 3 mg weekly, heparin injections have been reported to significantly improve the symptoms of pruritus and activity of the disease. Four to six injections of heparin induced complete regression of lesions within 4 to 10 weeks. Cutaneous involvement and reticulated oral lesions had the best response. [64] Oral lichen planus showed minimal improvement with this regimen. Skin grafting has been beneficial in the management of ulcerative lichen planus of the feet that is recalcitrant to other treatments. Cyclophosphamide, methotrexate, and phenytoin reportedly are useful but should be reserved for cases refractory to less-toxic drugs.

COURSE AND PROGNOSIS

Lichen planus is an unpredictable disease that typically persists for 1 to 2 years, but which may follow a chronic, relapsing course over many years. The duration varies according to the extent and site of involvement and morphology of lesions. Tompkins reported an average duration of 1 year for patients with cutaneous disease only, 17 months for skin and mucous membrane disease, about 5 years for patients with oral involvement only, and over 8 years for hypertrophic lichen planus. [65] Interestingly, generalized eruptions tend to have a rapid course and heal spontaneously faster than limited cutaneous disease. Lichen planopilaris is one of the most chronic and often progressive disease variants with little potential for hair regrowth following follicular inflammation and destruction. [16] Hypertrophic lichen planus typically follows a protracted, unremitting course. [2] Spontaneous regression is also an uncommon feature of oral lichen planus. The mean duration for oral lichen planus is 5 years. The reticular variant has a better prognosis than erosive disease that does not heal spontaneously. Generally, the duration of disease conforms to the following order: generalized < cutaneous < cutaneous + mucous membrane < mucous membrane < hypertrophic = lichen planopilaris.

Relapse of disease occurs in 15 to 20 percent of cases and tends to occur in the same area as the initial episode.

Recurrences are more common in generalized lichen planus and are usually of shorter duration.

Malignant transformation may occur, and SCC usually develops in fewer than 1 percent of persistent oral–mucous lesions on long-term follow-up. [66]

REFERENCES

1. Pinkus H: Lichenoid tissue reactions. *Arch Dermatol* **107**:840, 1973

2. Boyd AS, Nelder KH: Lichen planus. *J Am Acad Dermatol* **25**:593, 1991

3. Mahood JM: Familial lichen planus. *Arch Dermatol* **119**:292, 1983

4. LaNasa G et al: HLA antigen distribution in different clinical subgroups demonstrates genetic heterogeneity in lichen planus. *Br J Dermatol* **132**:897, 1995

5. Sugerman PB et al: Oral lichen planus. *Clin Dermatol* **18**:533, 2000

6. Schiller PI et al: Detection of clonal T cells in lichen planus. *Arch Dermatol Res* **292**:568, 2000

7. Simark-Mattsson C et al: Distribution of interleukin-2, -4, -10, tumor necrosis factor-alpha and transforming growth factor-beta mRNA in oral lichen planus. *Arch Oral Biol* **44**:499, 1999

8. Walton LJ et al: VCAM-1 and ICAM-1 are expressed by Langerhans cells, macrophages and endothelial cells in oral lichen planus. *J Oral Pathol Med* **23**:262, 1994

9. Eversole LR et al: Leukocyte adhesion molecules in oral lichen planus: A T cell-mediated immunopathologic process. *Oral Microbiol Immunol* **9**:376, 1994

10. Wayner EA et al: Epiligrin, a component of epithelial basement membranes, is an adhesive ligand for alpha 3, beta 1 positive T lymphocytes. *J Cell Biol* **121**:1141, 1993

11. Zhou XJ et al: Matrix metalloproteinases and their inhibitors in oral lichen planus. *J Cutan Pathol* **28**:72, 2001

12. Yamamoto T et al: The mechanism of mononuclear cell infiltration in oral lichen planus: The role of cytokines released from keratinocytes. *J Clin Immunol* **20**:294, 2000

13. Bloor BK et al: Gene expression of differentiation-specific keratins (K4, K13, K1, and K10) in oral nondysplastic keratoses and lichen planus. *J Oral Pathol Med* **29**:376, 2000

14. Lutz ME et al: Zosteriform lichen planus without evidence of herpes simplex virus or varicella-zoster virus by polymerase chain reaction. Report of two cases. *Acta Derm Venereol* **77**:491, 1997

15. Stinco G et al: Surgery and cyclosporine in the treatment of erosive lichen planus of the feet. *Eur J Dermatol* **8**:243, 1998

16. Mehregan DA et al: Lichen planopilaris: Clinical and pathologic study of forty-five patients. *J Am Acad Dermatol* **27**:935, 1992

17. Kossard S: Postmenopausal frontal fibrosing alopecia: A frontal variant of lichen planopilaris. *J Am Acad Dermatol* **36**:59, 1997

18. Vega ME et al: Ashy dermatosis versus lichen planus pigmentosus: A controversial matter. *Int J Dermatol* **31**:87, 1992

19. Silverman S, Bahl S: Oral lichen planus update: Clinical characteristics, treatment responses, and malignant transformation. *Am J Dent* **10**:259, 1997

20. Yiannias JA et al: Relative contact sensitivities in oral lichen planus. *J Am Acad Dermatol* **42**:177, 2000

21. Scalf LA et al: Dental metal allergy in patients with oral, cutaneous, and genital lichenoid reactions. *Am J Contact Dermatol* **12**:146, 2001

22. Eisen D: The vulvovaginal-gingival syndrome of lichen planus. The clinical characteristics of 22 patients. *Arch Dermatol* **130**:1379, 1994

23. Tosti A et al: Nail lichen planus: Clinical and pathologic study of twenty-four patients. *J Am Acad Dermatol* **28**:724, 1993

24. Sanchez-Perez J et al: Lichen planus with lesions on the palms and/or soles: Prevalence and clinicopathological study of 36 patients. *Br J Dermatol* **142**:310, 2000

25. Ellgehausen P et al: Drug-induced lichen planus. *Clin Dermatol* **16**:325, 1998

26. Romero RW et al: Unusual variant of lupus erythematosus or lichen planus. Clinical, histopathologic, and immunofluorescence studies. *Arch Dermatol* **113**:741, 1977

27. Zillikens D et al: Autoantibodies in lichen planus pemphigoides reacts with a novel epitope within the C-terminal NC16A domain of BP180. *J Invest Dermatol* **113**:117, 1999

28. Grunwald MH et al: Keratosis lichenoides chronica: Response to topical calcipotriol. *J Am Acad Dermatol* **37**:263, 1997

29. Mignogna MD et al: Clinical guidelines in early detection of oral squamous cell carcinoma arising in oral lichen planus: A 5-year experience. *Oral Oncol* **37**:262, 2001

30. Mattsson T et al: A comparative immunological analysis of the oral mucosa in chronic graft-versus-host disease and oral lichen planus. *Arch Oral Biol* **37**:539, 1992

31. Glaun RS et al: A proposed new classification system for lichenified keratosis. *J Am Acad Dermatol* **35**:772, 1996

32. Oliver GF et al: Lichenoid dermatitis: A clinicopathologic and immunopathologic review of sixty-two cases. *J Am Acad Dermatol* **21**:284, 1989

33. Rebora A: Lichen planus and the liver. *Int J Dermatol* **31**:392, 1992

34. Mignogna MD et al: Oral lichen planus and HCV infection: A clinical evaluation of 263 cases. *Int J Dermatol* **37**:575, 1998

35. Imhof M et al: Prevalence of hepatitis C virus antibodies and evaluation of hepatitis C virus genotypes in patients with lichen planus. *Dermatology* **195**:1, 1997

36. Van Der Meij EH, Van Der Waal I: Hepatitis C virus infection and oral lichen planus: A report from the Netherlands. *J Oral Pathol Med* **29**:255, 2000

37. Ingafou M et al: No evidence of HCV infection or liver disease in British patients with oral lichen planus. *Int J Oral Maxillofac Surg* **27**:65, 1998

38. Usman A et al: Lichenoid eruption following hepatitis B vaccination: First North American case report. *Pediatr Dermatol* **18**:123, 2001

39. Nguyen VT et al: Classification, clinical manifestations and immunopathological mechanisms of the epithelial variant of paraneoplastic autoimmune multiorgan syndrome: A reappraisal of paraneoplastic pemphigus. *Arch Dermatol* **137**:193, 2001

40. McCreary CE, McCartan BE: Clinical management of oral lichen planus. *Br J Oral Maxillofac Surg* **37**:338, 2001

41. Popovsky JL, Camisa C: New and emerging therapies for diseases of the oral cavity. *Dermatol Clin* **18**:113, 2000

42. Lozada-Nur F, Miranda C: Oral lichen planus: Topical and systemic therapy. *Semin Cutan Med Surg* **16**:295, 1997

43. Gorsky M, Ravin M: Efficacy of etretinate (Tegison) in symptomatic oral lichen planus. *Oral Surg Oral Med Oral Pathol* **73**:52, 1992

44. Laurberg G et al: Treatment of lichen planus with acitretin. A double-blind, placebo-controlled study in 65 patients. *J Am Acad Dermatol* **24**:434, 1991

45. Eisen D et al: Effect of topical cyclosporine rinse on oral lichen planus. A double-blind analysis. *N Engl J Med* **323**:290, 1990

46. Jungell P, Malmstrom M: Cyclosporin A mouthwash in the treatment of oral lichen planus. *Int J Oral Maxiofacial Surg* **25**:60, 1996

47. Rozycki TW et al: Topical tacrolimus in the treatment of symptomatic oral lichen planus: A series of 13 patients. *J Am Acad Dermatol* **46**:27, 2002

48. Eisen D: Hydroxychloroquine sulfate (Plaquenil) improves oral lichen planus: An open trial. *J Am Acad Dermatol* **28**:609, 1993

49. Camisa C, Popovsky JL: Effective treatment of oral lichen planus with thalidomide. *Arch Dermatol* **136**:1442, 2000

50. Becherel PA et al: Extracorporeal photochemotherapy for chronic erosive lichen planus. *Lancet* **351**:805, 1998

51. Ott F et al: Efficacy of oral low-dose tretinoin (all- *trans*-retinoic acid) in lichen planus. *Dermatology* **192**:334, 1996

52. Hersle K et al: Severe oral lichen planus: Treatment with an aromatic retinoid (etretinate). *Br J Dermatol* **106**:77, 1982

53. Karvonen J, Hannuksela M: Long term results of topical trioxsalen PUVA in lichen planus and nodular prurigo. *Acta Derm Venereol Suppl (Stockh)* **120**:53, 1985

54. Helander I et al: Long-term efficacy of PUVA treatment in lichen planus: Comparison of oral and external methoxsalen regimens. *Photodermatol* **4**:265, 1987

55. Pigatto PD et al: Cyclosporin A for the treatment of severe lichen planus. *Br J Dermatol* **122**:121, 1990

56. Lim KK et al: Cyclosporine in the treatment of dermatologic disease: An update. *Mayo Clin Proc* **71**:1182, 1996

57. Verma KK et al: Generalized severe lichen planus treated with azathioprine. *Acta Derm Venereol* **79**:493, 1999

58. Nousari HC et al: Successful treatment of resistant hypertrophic and bullous lichen planus with mycophenolate mofetil. *Arch Dermatol* **135**:1420, 1999

59. Kumar B et al: Dapsone in lichen planus [letter]. *Acta Derm Venereol* **74**:334, 1994

60. Hildebrand A et al: Successful treatment of generalized lichen planus with recombinant interferon alfa-2b. *J Am Acad Dermatol* **33**:880, 1995

61. Dereure O et al: Erosive lichen planus: Dramatic response to thalidomide. *Arch Dermatol* **132**:1392, 1996

62. Buyuk AY, Kavala M: Oral metronidazole treatment of lichen planus. *J Am Acad Dermatol* **43**:260, 2000

63. Fivenson DP, Kimbrough TL: Lichen planus pemphigoides: Combination therapy with tetracycline and nicotinamide. *J Am Acad Dermatol* **36**:638, 1997

64. Stefanidou MP et al: Low molecular weight heparin: A novel alternative therapeutic approach for lichen planus. *Br J Dermatol* **141**:1002, 1999

65. Tompkins JK: Lichen planus: Statistical study of 41 cases. *Arch Dermatol* **71**:515, 1955

66. Eisen D: The clinical features, malignant potential, and systemic associations of oral lichen planus: A study of 723 patients. *J Am Acad Dermatol* **46**:207, 2002

T>

Chapter 50

Mazen Daoud Mark Pittelkow

Lichen Nitidus

EPIDEMIOLOGY
ETIOLOGY AND PATHOGENESIS
CLINICAL MANIFESTATIONS
PATHOLOGY
DIAGNOSIS AND DIFFERENTIAL DIAGNOSIS
TREATMENT AND COURSE

REFERENCES

Lichen nitidus (Latin nitidus, “shiny” or “glistening”) is an uncommon, usually asymptomatic cutaneous eruption first described by Felix Pinkus in 1901 and further characterized by him in 1907. [1], [2] The dermatosis consists of small, glistening, flesh-colored to pink or reddish-brown papules that may be limited to the penis, genitalia, abdomen, and extremities or less frequently may occur as a generalized condition. The histopathologic findings are characteristic. Although the condition is often chronic, the prognosis is good, and no clearly associated systemic illnesses have been documented.

EPIDEMIOLOGY

Because the disease is uncommon, accurate epidemiologic characteristics of lichen nitidus have yet to be defined. In general, lichen nitidus is an infrequently occurring dermatosis that has been reported to affect blacks more than Caucasians, although no strong predisposition for any race is clearly evident. Perhaps the relative prominence of pale lesions on dark skin accounts for the reported increased incidence in blacks. A predilection for children, young adults, and males has also been reported in the literature, but, again, these data are not well established. The incidence is estimated to be approximately 3.4 cases per 10,000 population, based on a 25-year survey of skin diseases in blacks. [3] Compared to the more common dermatosis lichen planus, the crude ratio of lichen nitidus to lichen planus is 1.7:100, based on pathologic diagnosis of cases evaluated over several decades at Mayo Clinic.

ETIOLOGY AND PATHOGENESIS

Once considered a tuberculoid reaction, lichen nitidus is currently regarded as a disorder of unknown etiology. The relationship between lichen nitidus and lichen planus has been debated for many years. [4] The coexistence of both diseases in some patients and the observation that the discrete, tiny papules of lichen planus are indistinguishable from those of lichen nitidus were used to support the view that lichen nitidus is a variant of lichen planus. However, most experienced clinicians, as well as research studies, favor the separation of these two diseases as distinct entities based on both clinical and immunodermatopathologic differences and the characteristic and distinctive histologic changes (see below). Table 50-1 summarizes some of these differences and similarities. Another etiologic theory of lichen nitidus proposes that an allergen may cause epidermal and dermal antigen-presenting cells (e.g., Langerhans cells) to activate a cell-mediated response, initiate lymphocyte accumulation, and form discrete inflammatory papules. The presence of large numbers of Langerhans cells in the infiltrate supports this theory. [5] Specific cytokines produced by the inflammatory cells influence the immune response and may shift the T lymphocyte response toward the T helper 2 subset (T_H2) that has the potential to produce the superficial dermal granulomas seen in lichen nitidus. [6] Functional impairment in cellular immunity has been reported in generalized lichen nitidus, [7] and lichenoid photoeruptions similar to lichen nitidus were seen in a patient with HIV infection. [8] Rare cases of lichen nitidus associated with atopic dermatitis, Crohn's disease, and juvenile chronic arthritis have been reported. Induction of allergic contact dermatitis by topical application of dinitrochlorobenzene (DNCB) in a patient with lichen nitidus cleared the eruption, presumably by altering the cellular immunity, cellular infiltration, and cytokine expression. [6]

TABLE 50-1 **Comparison of Features between Lichen Nitidus and Lichen Planus**

A rare familial presentation of lichen nitidus has been reported, although no genetic factors of the disease have been identified. [9]

CLINICAL MANIFESTATIONS

Lichen nitidus is composed of multiple, discrete, smooth, flat, round papules. Individual papules are 1 to 2 mm in size,

flesh-colored to slightly pink or, in blacks, hypopigmented, with a glistening appearance (Fig. 50-1). Sometimes, minimal scale is present or can be elicited by rubbing the surface of the papules. Occasionally, the papules are grouped and the isomorphic or Koebner's phenomenon is observed. Lesions may occur anywhere over the skin surface; however, the most frequent sites of predilection are the flexural surfaces of the arms and the wrists, lower abdomen, breasts, the glans and shaft of the penis, and other areas of the genital region. Rare sites of involvement include mucous membranes, nails, palms, and soles. Rare clinical variants include vesicular, hemorrhagic, spinous follicular, linear, generalized, and actinic types. [10], [11], [12], [13], [14], [15] and [16]

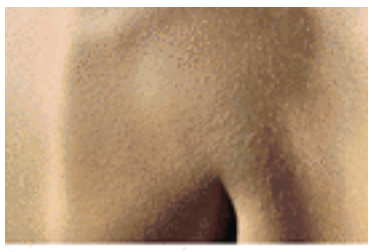

FIGURE 50-1 Lichen nitidus. *A*. Pinpoint to pinhead, discrete, dome-shaped papules over upper back, shoulder, and arm. Side-lighting, as performed here, enhances visualization of multiple small lesions. *B*. Individual papules, flesh- to pink-colored over chest and arm, becoming more grouped over anterior axilla.

Palmoplantar involvement may manifest several morphologic forms. Bilateral hyperkeratosis of palms and soles with erythema, fissuring, and a texture resembling fine sandpaper has been observed. [13], [14] Occasionally, minute keratotic spicules on the palmar surfaces or multiple pinpoint papules that extend to the dorsa of the extremities are observed (Fig. 50-2). Nail abnormalities usually manifest as longitudinal, beaded ridging, and terminal splitting with or without irregular pitting. Lesions of lichen planus may infrequently be present simultaneously. [17] Lichen nitidus is usually asymptomatic; however, pruritus is occasionally present and sometimes intense. There are no constitutional symptoms or systemic abnormalities associated with the disease.

FIGURE 50-2 Lichen nitidus. Wrist and palmar involvement with development of hyperkeratotic lesions.

PATHOLOGY

A dense mass of infiltrating lymphohistiocytic cells is situated immediately below the epidermis and results in widening of the papillary dermis with elongation and the appearance of embracement by neighboring rete ridges (Fig. 50-3). Occasionally, two or three papillary spaces merge together as part of the inflammatory infiltrate. The overlying epidermis is thinned and occasionally demonstrates central parakeratosis without hypergranulosis. This is a characteristic diagnostic finding, when observed. Minimal hydropic degeneration with few dyskeratotic cells is usually observed within the basal epidermal layer adjacent to the papillary dermal infiltrate. With the development of hydropic degeneration, basal cell disruption, and epidermal thinning, the epidermis may partially detach from the dermis. Colloid bodies are rarely seen in lichen nitidus, in contrast to their frequent occurrence in lichen planus. The dermal infiltrate is well circumscribed and composed of closely associated histiocytes, lymphocytes, and occasional foreign body or Touton-type giant cells. Usually, no plasma cells or eosinophils are seen. In some cases, the majority of the cells in the infiltrate are histiocytic. Palmar lesions may show a deep parakeratotic plug. Transepithelial elimination of the inflammatory infiltrate has been described. [5] Purpuric or hemorrhagic lesions are associated with capillary wall degeneration and red blood cell extravasation. [11]

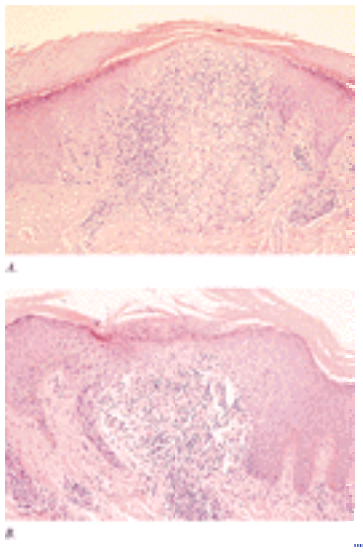

FIGURE 50-3 Lichen nitidus. *A*. Distinctive, circumscribed infiltrate of papillary dermis situated directly beneath thinned epidermis. Many histiocytes mingle with lymphocytes that are enveloped by bordering rete ridges. [Hematoxylin and eosin (H & E)] *B*. Central parakeratosis, epidermal thinning, and loss of granular layer with focus of granuloma-appearing, inflammatory cells and reactive, finger-like extensions of epidermis. (H & E).

The majority of the cells in the infiltrate are T lymphocytes intermixed with few to many histiocyte–macrophages that stain with CD68, as well as epidermal Langerhans cells and indeterminate cells that express S-100 protein. CD4+ cells predominate over CD8+ T lymphocytes. Many cells in the infiltrate express human leukocyte antigen (HLA)-DR antigen, which implicates them as antigen-presenting cells. [5]

Direct immunofluorescence examination of lichen nitidus is usually negative for deposition of immunoglobulins at the dermal–epidermal junction, in contrast to the vast majority (95 percent) of cases of lichen planus. [18] Cytoids are also not usually observed in lichen nitidus. The results of ultrastructural studies coincide with light microscopic findings and also show activated lymphocyte morphology with convoluted nuclei, resembling Sézary cells. [19]

DIAGNOSIS AND DIFFERENTIAL DIAGNOSIS

The diagnosis of lichen nitidus is easily established based on the characteristic morphology, distribution, and usual lack of symptoms. The pathognomonic microscopic changes seen on skin biopsy will confirm the diagnosis in atypical cases.

The relationship between lichen nitidus and lichen planus has been debated for decades. Immunohistochemical studies show that the majority of cells in the infiltrate of lichen nitidus are T helper (CD4) lymphocytes. However, in contrast to lichen planus, histiocyte–macrophages predominate and form the characteristic granulomatous appearance in lichen nitidus. Fewer cells expressing the skin homing receptor HECA-452 (leukocyte common antigen, LCA) are seen. [4]

Confluent lesions may form plaques that resemble psoriasis, especially if located on the elbows or knees. The plaques, however, are usually brownish and lack the silvery scales seen in psoriasis. Verruca planus can be mistaken for lichen nitidus. However, flat warts are more variable in size, have a more verrucous surface on close examination with a magnifying lens, usually present with fewer lesions than are seen in lichen nitidus, and are less likely to involve multiple anatomic areas. Keratosis pilaris, lichen spinulosus, and papular eczema usually exhibit more keratotic or scaling lesions, unlike the smoother surfaced papules of lichen nitidus. Lichen scrofulosorum usually occurs in young patients with tuberculosis. The lesions are characterized by perifollicular, occasionally keratotic papules and are readily distinguishable from lichen nitidus. Lichenoid syphilitic lesions, bowenoid papulosis, sarcoidosis, and lichen amyloidosis should also be considered in the differential diagnosis.

Palmoplantar involvement of lichen nitidus may be difficult to differentiate from chronic hand eczema; however, the presence of classic lesions of lichen nitidus at other body sites helps to establish the diagnosis.

TREATMENT AND COURSE

Because the disease is asymptomatic and self-limiting, no intervention is required in most cases. Treatment of lichen nitidus is warranted when it is associated with protracted pruritus or when the appearance interferes with the patient's daily activities and outlook. Topical glucocorticoids may yield favorable results. A short course of oral glucocorticoids may also be helpful and hasten resolution of more extensive, generalized, or symptomatic disease. PUVA, [20] UVA/UVB phototherapy and oral glucocorticoids, [21] astemizole, [22] acitretin or etretinate, [14], [17] low-dose cyclosporine, [23] and oral itraconazole [24] have also been used successfully when indicated for more problematic disease. One patient with amenorrhea and lichen nitidus responded favorably to estrogen-progesterone combination therapy. [25]

Lichen nitidus is typically a focal, asymptomatic, chronic inflammatory reaction that eventually resolves spontaneously after months to a year in two-thirds of patients or, less frequently, over a few years. Rarely, the eruption may persist indefinitely. New lesions may continue to develop as older lesions resolve. Lesions heal without scar formation or pigmentary abnormalities.

REFERENCES

1. Pinkus F: Verhand. *Berlin Dermat Gessel* **12**:3, 1901

2. Pinkus F: Uber eine neue knotchenformige Hauteruption: Lichen nitidus. *Arch Dermatol Syph* **85**:11, 1907

3. Hazen HH: Syphilis and skin diseases in the American Negro: Personal observations. *Arch Dermatol Syphilol* **31**:316, 1935

4. Smoller BR, Flynn TC: Immunohistochemical examination of lichen nitidus suggests that it is not a localized papular variant of lichen planus. *J Am Acad Dermatol* **27**:232, 1992

5. Wright AL et al: An immunophenotypic study of lichen nitidus. *Clin Exp Dermatol* **15**:273, 1990

6. Kano Y et al: Improvement of lichen nitidus after topical dinitrochlorobenzene application. *J Am Acad Dermatol* **39**:305, 1998

7. Maeda M: A case of generalized lichen nitidus with Koebner's phenomenon. *J Dermatol* **21**:273, 1994

8. Berger TG, Dhar A: Lichenoid photoeruptions in human immunodeficiency virus infection. *Arch Dermatol* **130**:609, 1994

9. Kato N: Familial lichen nitidus. *Clin Exp Dermatol* **20**:336, 1995

10. Jetton RL et al: Vesicular and hemorrhagic lichen nitidus. *Arch Dermatol* **105**:430, 1972

11. Endo M et al: Purpuric lichen nitidus. *Eur J Dermatol* **8**:54, 1998

12. Itami A et al: Perforating lichen nitidus. *Int J Dermatol* **33**:382, 1994

13. Munro CS et al: Lichen nitidus presenting as palmoplanter hyperkeratosis and nail dystrophy. *Clin Exp Dermatol* **18**:381, 1993

14. Lucker GP et al: Treatment of palmoplantar lichen nitidus with acitretin. *Br J Dermatol* **130**:791, 1994

15. Soroush V et al: Generalized lichen nitidus: Case report and literature review. *Cutis* **64**:135, 1999

16. Kanwar AJ, Kaur S: Lichen nitidus actinicus. *Arch Dermatol* **135**:714, 1999

17. Aram H: Association of lichen planus and lichen nitidus. Treatment with etretinate. *Int J Dermatol* **27**:117, 1988

18. Waisman M et al: Immunofluorescent studies in lichen nitidus. *Arch Dermatol* **107**:200, 1973

19. Clauson J et al: Lichen nitidus: Electron microscopic and immunofluorescence studies. *Acta Derm Venereol (Stockh)* **62**:15, 1982

20. Randle HW, Sander HM: Treatment of generalized lichen nitidus with PUVA. *Int J Dermatol* **25**:330, 1986

21. Chen W et al: Generalized lichen nitidus. *J Am Acad Dermatol* **36**:630, 1997

22. Ocampo J, Torne R: Generalized lichen nitidus: Report of two cases treated with astemizole. *Int J Dermatol* **28**:49, 1989

23. Lestringant GG et al: Coexistence of atopic dermatitis and lichen nitidus in three patients. *Dermatology* **192**:171, 1996

24. Libow LF, Coots NV: Treatment of lichen planus and lichen nitidus with itraconazole: Report of six cases. *Cutis* **62**:247, 1998

25. Taniguchi S et al: Recurrent generalized lichen nitidus associated with amenorrhea. *Acta Derm Venereol (Stockh)* **74**:224, 1994

T>

Chapter 51

John DiGiovanna

Ichthyosiform Dermatoses

CLINICAL PRESENTATION
ETIOLOGY AND PATHOGENESIS
ICHTHYOSIS VULGARIS
X-LINKED ICHTHYOSIS
AUTOSOMAL RECESSIVE ICHTHYOSIS
LAMELLAR ICHTHYOSIS
CONGENITAL ICHTHYOSIFORM ERYTHRODERMA
EPIDERMOLYTIC HYPERKERATOSIS
DISORDERS RESEMBLING EPIDERMOLYTIC HYPERKERATOSIS
ICHTHYOSIS IN THE NEWBORN
ACQUIRED ICHTHYOSIS
LESS-COMMON ICHTHYOSES
TREATMENT
PRENATAL DIAGNOSIS

REFERENCES

The disorders of cornification form a heterogeneous group of diseases characterized by abnormal differentiation (cornification) of the epidermis. The ichthyoses, a member of this group, are distinguished clinically by generalized scaling. The name *ichthyosis* is derived from the Greek *ichthys* meaning “fish,” and refers to the similarity in appearance of the skin to fish scale. The ichthyoses themselves are a heterogeneous group of disorders, with both inherited and acquired forms. Early reports of ichthyosis in the Indian and Chinese literature date back to several hundred years B.C., and the condition was discussed by Willan in 1808. [1]

Ichthyosis can present at birth or develop later in life. It can occur as a disease limited to the skin or in association with abnormalities of other organ systems. There are a number of well-defined types of ichthyosis that have characteristic features and can be reliably diagnosed. However, because of the great clinical heterogeneity and the profound effect of the environment on scaling, in certain patients and families, a specific diagnosis can be challenging.

Van Scott, Frost, and Weinstein proposed a classification of the ichthyoses based on differences in rates of epidermal turnover, characterizing them as either disorders of epidermal hyperproliferation or disorders of prolonged retention of the stratum corneum. [2], [3] Subsequently, Williams and Elias proposed a classification that lists the disorders of cornification in which clinical, genetic, or biochemical data suggest a distinct disease. [4] Recently, genetic approaches to understanding the inherited disorders of cornification have successfully deciphered the defects underlying several of these genodermatoses. [5], [6] and [7] A new classification is evolving based on a series of discoveries of the underlying genetic and molecular bases of these disorders. Knowing which gene is mutated directs us to the underlying pathophysiologic process. A listing of the more common and the better understood hereditary ichthyoses according to pattern of inheritance and clinical features is shown in Table 51-1. Grouping these ichthyosiform disorders according to class of disorder (underlying abnormality) facilitates understanding of the clinical phenotypes in terms of underlying mechanism. However, further work is necessary to clearly understand how the gene mutations and resultant protein disruptions result in clinical disease, and, furthermore, how therapeutic interventions can be creatively developed.

Download image
in PDF format

TABLE 51-1 **Features of Selected Ichthyosiform Dermatoses**

CLINICAL PRESENTATION

A specific diagnosis in an individual or family with ichthyosis can help to predict prognosis and is important for genetic counseling. Several features are useful in distinguishing different forms of ichthyosis. These include the age of onset, quality of scale, presence/absence of erythroderma, abnormalities in other parts of the skin (e.g., ectropion, eclabium) and adnexal structures (e.g., alopecia, hair follicle or shaft abnormality), and involvement of other organ systems. A family pedigree may clarify the pattern of inheritance. However, many autosomal dominant diseases [e.g., *epidermolytic hyperkeratosis (EHK)*] have a high frequency of spontaneous mutation, and the lack of a positive family history does not rule out autosomal dominant inheritance. Alternatively, the presence of parental consanguinity may suggest autosomal recessive inheritance. Light-microscopic features are usually diagnostic in EHK and can be helpful in selected ichthyoses (e.g., Refsum's disease, neutral lipid storage disease, acquired ichthyosis of sarcoidosis), but histopathologic examination may not be useful to distinguish other ichthyoses. The development of ichthyosis in adulthood may be a marker of systemic disease. Acquired ichthyosis is usually mild, resembling ichthyosis vulgaris, and has been associated with malignancy, some medications, AIDS, and sarcoidosis.

ETIOLOGY AND PATHOGENESIS

The fully differentiated end product of the epidermis is the stratum corneum, which is composed of corneocytes (“bricks”) surrounded by an intercellular matrix (“mortar”). The corneocyte bricks are protein-enriched, and the intercellular mortar is composed of hydrophobic, lipid-enriched membrane bilayers. [4] The keratin-laden corneocytes are thought to be responsible for the resilience and water retention properties of the stratum corneum, while the matrix is the barrier to water loss. The normal stratum corneum undergoes desquamation in an organized and invisible manner, with individual corneocytes separating from each other and shedding as single cells. Ichthyotic skin has an abnormal quality and quantity of scale, the barrier function of the stratum corneum is compromised, and there may be alterations in the kinetics of epidermal cell proliferation. The stratum corneum can be viewed as a compartment, with thickening of the stratum corneum being the result of cells entering the compartment at an increased rate or leaving (corneocyte disadhesion) too slowly or both.

The process of cornification is complex and not completely understood. Defects in many different aspects and steps of this process can lead to a similar end result: abnormal stratum corneum, scale, and hyperkeratosis. In some of these disorders, the underlying abnormality has been identified. For example, mutations in the genes that encode the epidermal differentiation keratins, keratins 1 and 10, cause EHK. [5] Mutations in the gene encoding transglutaminase-1, an enzyme that catalyzes the cross-linking of proteins and attachment of ceramides during the formation of corneocytes, cause lamellar ichthyosis. [8], [9], [10] and [11] The observation that key components of this process cause disorders of cornification highlights the importance and complexity of orderly cornification in normal keratinocyte differentiation.

Steroid sulfatase controls the hydrolysis of cholesterol sulfate in corneocytes and is thought to be important in the regulation of corneocyte desquamation. Deficiency of steroid sulfatase causes X-linked ichthyosis. [12], [13] The observation that several drugs that lower serum cholesterol (e.g., nicotinic acid, triparanol) can induce ichthyotic skin changes indicates the importance of lipid homeostasis in normal cornification. [14] Further evidence is the identification of mutations in the genes encoding cholesterol biosynthetic enzymes as a cause of X-linked dominant chondrodysplasia punctata and CHILD (congenital hemidysplasia with ichthyosiform erythroderma and limb defects) syndrome. The recent identification of mutations in SPINK5 (*s*erine *p*rotease *in*hibitor, *K*azal type 5), encoding a serine protease inhibitor, confirms a role for protease inhibitors in normal differentiation. The discoveries of connexin abnormalities as causes for erythrokeratodermia variabilis, KID (keratitis, ichthyosis, and deafness) syndrome, and other disorders involving ectodermal tissues highlight the role of intercellular communication for properly functioning skin. [7] These examples demonstrate the complexity of the process of forming a normally functioning stratum corneum and demonstrate that diverse abnormalities can result in similar clinical phenotypes of hyperkeratosis and scaling. Furthermore, our evolving understanding of these mechanisms continues to clarify the multisystem, clinical phenotypes observed in several ichthyosiform disorders.

ICHTHYOSIS VULGARIS

Ichthyosis vulgaris, the most common ichthyosis, is relatively mild. The disease is inherited in an autosomal dominant pattern, and its incidence may be as common as 1 in 250. [15] While infants usually have normal skin, the disease often manifests within the first year.

The scale of ichthyosis vulgaris is usually most prominent on the extensor surfaces of the extremities with flexural sparing (Fig. 51-1). The diaper area tends to be spared. There may be fine, white scale over large areas. Particularly on the lower extremities, which are often the most severely involved area, the scale may be centrally attached, with “cracking” (superficial fissuring through the stratum corneum) at the edges. This turning up at the edges can lead to the skin feeling rough.

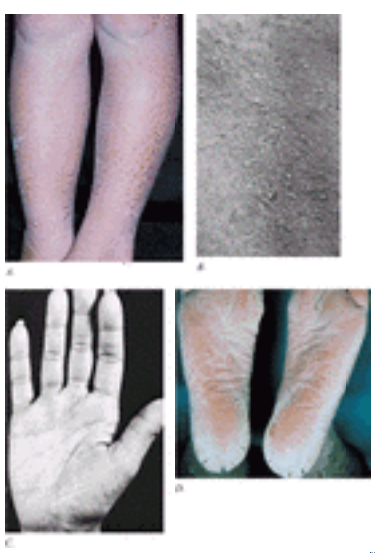

FIGURE 51-1 Ichthyosis vulgaris. *A.* Mosaic-like scales are present on the legs. *B.* Back of woman showing fine scales with “pasted-on” appearance. *C.* Palm of 19-year-old girl showing accentuation of palmar markings. *D.* Soles showing marked thickening with splitting of heels.

A number of other findings are commonly observed in association with ichthyosis vulgaris. [16] Hyperlinear palms are usually present, and some patients may have thickening approaching a keratoderma. Keratosis pilaris is common, even in individuals with mild ichthyosis vulgaris, and usually involves the posterior arms, thighs, and buttocks. Atopy is also frequently observed and can manifest as hay fever, eczema, or asthma. These findings can confound an accurate diagnosis, because hyperlinear palms and keratosis pilaris may be seen in atopic individuals who do not have ichthyosis

vulgaris. Rarely, individuals with ichthyosis vulgaris may have hypohidrosis with heat intolerance. There is great variation in the severity of clinical manifestations between affected individuals in the same family (expressivity). The condition usually worsens in climates that are dry and cold and improves in warm, humid environments, where the disease may clear dramatically. By clinical examination, it can sometimes be difficult to distinguish individuals with mild ichthyosis vulgaris from those with simple dry skin (xerosis), because the spectrum of both conditions appears to overlap. In addition, on the basis of skin findings alone, males with severe ichthyosis vulgaris may be difficult to differentiate from those affected with X-linked ichthyosis. [16], [17] The histopathologic findings (Fig. 51-2A) may be distinctive in specimens taken from areas with the most prominent scaling, showing mild hyperkeratosis and diminished or absent granular layer. Even when the granular layer is present on light microscopy, examination by electron microscopy can show keratohyalin granules that are small, abnormally shaped, and crumbly in appearance. [18] Filaggrin is an epidermal protein, localized to keratohyalin granules, that is thought to be important in the aggregation of keratin intermediate filaments. These filaments form a network, or cell matrix, that gives structural integrity to the epidermal keratinocytes. Biochemical studies of epidermis from patients with ichthyosis vulgaris have shown absence of or decrease in filaggrin and its precursor, profilaggrin. The defective profilaggrin expression may be due to impaired posttranscriptional control. [19]

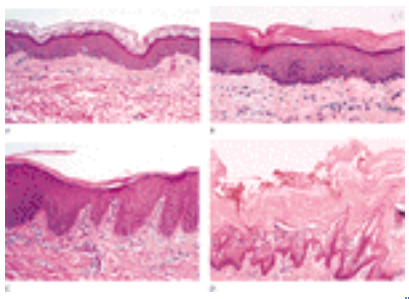

FIGURE 51-2 Histopathology. *A.* Ichthyosis vulgaris. Note diminished granular layer. *B.* Lamellar ichthyosis. Thickened stratum corneum composed of compact hyperkeratosis. *C.* Congenital ichthyosiform erythroderma. Hyperkeratosis and acanthosis. *D.* Epidermolytic hyperkeratosis. The stratum corneum is thickened (hyperkeratosis) and there is prominent vacuolar degeneration of suprabasalar epidermis most marked at the granular layer.

X-LINKED ICHTHYOSIS

In the 1960s, recessive X-linked ichthyosis was distinguished clinically from other ichthyoses. [15] Shortly thereafter, the syndrome of placental steroid sulfatase deficiency was described in pregnancies with failure to initiate labor as a condition with low maternal urinary estrogens. Because the majority of maternal urinary estrogens are derived from the fetal adrenal and are metabolized by the placenta, low levels can reflect fetal abnormalities or death. However, in this condition, low levels do not indicate severe fetal morbidity. The association between failure to initiate or progress labor and ichthyosis in the male offspring was not appreciated until later. [12], [13] Steroid sulfatase hydrolyzes sulfate esters, which include cholesterol sulfate and sulfated steroid hormones. [20] Sulfated fetal adrenal hormones undergo desulfation to estrogens, which are excreted in maternal urine. The absence of steroid sulfatase enzyme in the fetal placenta leads to low maternal urinary estrogens and in some pregnancies, to a failure of labor to initiate or to progress normally. In males with recessive X-linked ichthyosis, steroid sulfatase enzyme activity is decreased or absent in many tissues, including epidermis, stratum corneum, and leukocytes, and in cultured fibroblasts. [21] In addition, cholesterol sulfate, an enzyme substrate, accumulates in the scale. Carrier females have been found to have leukocyte steroid sulfatase levels intermediate between those observed in normal individuals and those in affected males.

Recessive X-linked ichthyosis occurs in approximately 1 in 2000 to 6000 males. [15], [22] Scaling may begin in the newborn period and is usually most prominent on the extensor surfaces, although there is significant involvement of the flexural areas. While the extent and degree of scaling are variable, X-linked ichthyosis can usually be distinguished from ichthyosis vulgaris on clinical criteria. [15] The latter tends to be associated with hyperlinear palms and soles, keratosis pilaris, and a family history of atopy. X-linked ichthyosis tends to have more severe involvement with larger scale, and comma-shaped, corneal opacities may be present in half of adult patients [23], [24] (Fig. 51-3). Corneal opacities do not affect vision and may be present in female carriers. [24] Affected males have an increased risk of cryptorchidism, and independently, they are at increased risk for the development of testicular cancer. [25] Cholesterol sulfate levels are elevated in the serum, epidermis, and scale, [26] and there is increased mobility of ß-lipoproteins (low-density lipoproteins) on electrophoresis, a feature that can indicate the diagnosis. Confirmation of the diagnosis is usually made by finding an elevation in serum cholesterol sulfate levels (normal is 80 to 200 µg/dL; X-linked ichthyosis is 2000 to 9000 µg/dL). Steroid sulfatase is one of a group of arylsulfatases located on chromosome Xp22. More than 80 percent of the mutations in X-linked ichthyosis are deletions, explaining the failure to find immunologically detectable enzyme protein in some patients. Deletions that include adjacent sulfatases explain the overlap syndromes involving chondrodysplasia punctata and X-linked ichthyosis. [27]

FIGURE 51-3 X-linked ichthyosis. *A.* The scales are large and dark and most evident on the flexural areas in this patient. *B.* The blue arc is a cross-section of the cornea as seen by slit-lamp examination. The opacities appear white.

In the epidermis, steroid sulfatase catalyzes the hydrolysis of cholesterol sulfate. The identification of steroid sulfatase deficiency in X-linked ichthyosis supports the importance of cholesterol sulfate hydrolysis in normal desquamation. Topical application of cholesterol sulfate in mice can induce a scaling disorder, further supporting the role of cholesterol sulfate hydrolysis in corneocyte disadhesion.

A family was described with an ichthyosis inherited in an X-linked pattern but with normal steroid sulfatase activity and the absence of corneal opacities. [28] This demonstrates heterogeneity within X-linked ichthyosis. Because of its frequent occurrence, steroid sulfatase deficiency accounts for most cases of X-linked ichthyosis, but a normal steroid sulfatase level in a male with ichthyosis does not rule out an X-linked pattern of inheritance.

AUTOSOMAL RECESSIVE ICHTHYOSIS

Congenital ichthyosis can occur alone or as part of a syndrome where it is one component of multiple system abnormalities. When it occurs alone, the term *congenital autosomal recessive ichthyosis* is useful to describe the heterogeneous group of disorders that present at birth with generalized involvement of the skin and lack of manifestations in other organ systems. Autosomal recessive ichthyosis is rare and has been estimated to occur in about 1 in 300,000 persons. [15]

In older literature, nonbullous congenital ichthyosiform erythroderma [*lamellar ichthyosis (LI),* with autosomal recessive inheritance] was distinguished from bullous congenital ichthyosiform erythroderma (EHK, with autosomal dominant inheritance) based on clinical appearance (bullae) and pattern of inheritance. [2], [29] That the term *lamellar ichthyosis* was used interchangeably with *nonbullous congenital ichthyosiform erythroderma* and included a spectrum of phenotypes has led to some confusion. Williams and Elias distinguished LI from nonbullous congenital ichthyosiform erythroderma [usually called *congenital ichthyosiform erythroderma (CIE)*], a milder erythrodermic form. [30] Some patients with LI can be clearly distinguished from those with CIE on the basis of clinical features. LI has large, dark, platelike scale, and while infants may be red at birth, adults have little to no erythroderma (Fig. 51-4). In the more severe, classic presentation of LI, tautness of the facial skin leads to traction on the eyelids and lips, leading to ectropion and eclabium. Scarring alopecia, most prominent at the periphery of the scalp, may be partly due to traction at the hair line. In contrast, CIE has generalized redness and fine, white scale (Fig. 51-5). Patients with classic CIE have little to no ectropion, eclabium, or alopecia. However, many patients do not fit neatly into these two clinical descriptions, [31] in that they have features of both LI and CIE and a clinical phenotype intermediate between both disorders. Therefore, it can be useful to consider these two distinctive presentations as ends of a spectrum, between which lie a gradation of clinical phenotypes with variable degrees of erythema and coarseness of scale. Individual features such as collodion membrane (discussed below), ectropion, and alopecia can occur across the spectrum. The collodion presentation may, over time, evolve into a disease that falls anywhere within the clinical spectrum of severity and can develop into LI, CIE, or have minimal involvement (self-healing collodion baby). [32] So far, attempts to refine the categorization of these disorders by using biochemical and ultrastructural observations have failed to yield a consistent and replicable classification scheme. [33] Identification of the spectrum of specific molecular defects underlying these conditions will undoubtedly help in developing an accurate classification of the disorders.

FIGURE 51-4 Classic lamellar ichthyosis phenotype. (*Top left*) Ectropion. (*Bottom left, right*) Large, brown, platelike scale. (*From Russell et al.* [8], *with permission.*)

FIGURE 51-5 Congenital ichthyosiform erythroderma. Bright, red erythroderma with fine, white scale.

Most patients with LI or CIE inherit the disease in an autosomal recessive pattern. Rarely, families have been described with similar phenotypes, where the disease is inherited as an autosomal dominant trait. [33] This is an important consideration for genetic counseling.

LAMELLAR ICHTHYOSIS

LI is apparent at birth, and the newborn usually presents encased in a collodion membrane, a translucent covering that desquamates over the subsequent 10 to 14 days (Fig. 51-6). At this time the skin may be red. Over time, the skin develops with large, platelike scales, which appear to be arranged in a mosaic pattern (see Fig. 51-4). In some areas, the scales are centrally attached with raised borders. The scales tend to be largest over the lower extremities where the large, platelike scale separated by superficial cracking can lead to an appearance similar to that of a dry riverbed. During childhood and into adulthood, the degree of erythema may vary, but the severe presentation of classic LI usually has minimal to no erythroderma. Involvement of the palms and soles in LI is variable and ranges from minimal hyperlinearity to severe keratoderma.

FIGURE 51-6 Collodion baby. The infant is 36 h old and is covered with a membrane that shows fissures; note ectropion and eclabium. The condition may develop over time into various clinical phenotypes including lamellar ichthyosis, congenital ichthyosiform erythroderma, and self-healing collodion baby.

The lips and mucous membranes tend to be spared in LI, but the adnexal structures may be compromised by the adherent, firm scale. Thick stratum corneum on the scalp tends to encase hairs and, in conjunction with the tautness of the skin, usually leads to a scarring alopecia, which is most marked at the periphery. The hyperkeratosis can interfere with normal sweat gland function, resulting in hypohidrosis, but the degree of impairment varies between patients. Some patients have severe heat intolerance and must be vigilant to avoid overheating. Treatment with oral retinoids can improve or prevent some sequelae of LI. Patients frequently notice an increase in sweating with improved heat tolerance. While retinoid therapy can cause blepharitis or even conjunctivitis, it is usually well tolerated by patients with LI. Moreover, the ability of systemic retinoid therapy to decrease thick periocular scale can decrease the tendency to develop ectropion. Nevertheless, patients with severe, classic LI usually require careful eye maintenance. Because of the ectropion (see Fig. 51-4), the lids may fail to close fully, particularly during sleep; hydration with liquid tears during the day and ophthalmic lubricants at night can prevent exposure keratitis.

Histopathologic examination typically shows orthokeratotic hyperkeratosis with mild to moderate acanthosis (see Fig. 51-2C). Rates of epidermal proliferation are normal or only slightly elevated in patients with LI, in contrast to those with CIE, which has significantly greater labeling indices.

In 1994, genetic linkage studies were performed on a group of families affected with the severe phenotype of classic LI (large, platelike scale; ectropion; and minimal to no erythema). The group included families from the United States and from an inbred Egyptian population. This study found classic LI to be linked to markers on chromosome 14 in the region of the transglutaminase 1 gene locus. [8] The transglutaminases catalyze calcium-dependent cross-linking of proteins through the formation of e-(?-glutamyl)lysine isodipeptide bonds. During the formation of the stratum corneum, transglutaminase catalyzes the cross-linking of cellular proteins, mostly involucrin, loricrin, and small proline-rich proteins. The resulting protein complex is deposited on the inner side of the plasma membrane to form the cornified envelope. Transglutaminase also attaches ceramides to cornified envelope proteins, notably involucrin, and thereby is important in the formation of both the protein and lipid components of the stratum corneum. [11]

Subsequently, mutations in *TGM1,* the gene encoding transglutaminase 1, were found in several families with LI, solidifying the role for transglutaminase 1 in the formation of a normal stratum corneum and its role as a cause of LI. [9], [10] In a human skin/immunodeficient mouse xenograph model, transfer of a transglutaminase-1 gene into transglutaminase-1–deficient keratinocytes from LI patients resulted in normalization of transglutaminase expression and epidermal architecture in addition to restoration of cutaneous barrier function. [34] Additional disease-causing loci have been found; however, the responsible genes have not been identified. [35] Further genetic heterogeneity within congenital autosomal recessive ichthyosis was demonstrated with exclusion of *TGM1* as the disease-causing gene in two families with a phenotype of mild redness and fine scale and whose condition was clinically distinguishable from both classic LI and CIE. [36] An erythrodermic form of autosomal recessive ichthyosis has been linked to chromosome 3. [35]

CONGENITAL ICHTHYOSIFORM ERYTHRODERMA

As with LI, CIE is apparent at birth, and the newborn usually presents with a taut, shiny, collodion membrane (see Fig. 51-6). After shedding of the membrane, the skin of infants with CIE remains red, usually with a fine, white, generalized scale (see Fig. 51-5). On the lower legs, the scale may be larger and darker. The classic presentation of CIE has little to no ectropion, eclabium, or alopecia in contrast to LI. As in LI, there is a wide variation in the ability to sweat, and patients with CIE may have minimal sweating with severe heat intolerance. Mucous membranes are usually spared. Palm/sole involvement is variable. Nails may have ridging, but they are often spared. Dermatophyte infection of the skin and nails is common.

Histopathologic examination shows hyperkeratosis, acanthosis, and often parakeratosis. Studies of epidermal proliferation have shown markedly increased epidermal cell turnover, in contrast to LI. A small subset of patients with CIE have been found to have mutations in *TGM1,* and two siblings with a collodion presentation, CIE, and palmoplantar keratoderma had a mutation in the cornified envelope protein loricrin. [37] In addition, two other genetic loci (3p21 and 17p13.2-13.1) have been found to be associated with CIE.

EPIDERMOLYTIC HYPERKERATOSIS

In 1902, Brocq described bullous ichthyotic erythroderma and distinguished the blistering type from the nonblistering type of congenital ichthyotic erythroderma. [38] The original description included three unrelated patients whose clinical manifestations varied. However, this was probably the first description of EHK. Today, the disease is named for the distinctive histopathologic features of vacuolar degeneration of the epidermis (i.e., epidermal lysis) and associated hyperkeratosis. EHK is also known as *bullous congenital ichthyosiform erythroderma,* an earlier descriptive name signifying the blistering, neonatal presentation, scaling, and redness.

EHK is transmitted as an autosomal dominant trait with a prevalence of approximately 1 in 200,000 to 300,000 persons. However, there is a high frequency of spontaneous mutation, and as many as one-half the cases have no family history and represent new mutational events. [29] The disease usually presents at birth with blistering, redness, and peeling (Fig. 51-7). With time, generalized hyperkeratosis may develop, which may or may not be associated with erythroderma. EHK skin usually has a characteristic pungent odor.

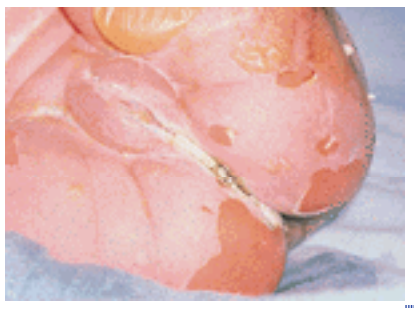

FIGURE 51-7 Epidermolytic hyperkeratosis. Newborn showing blistering and erosions.

In contrast to most other ichthyoses, the histopathologic picture of EHK is distinctive. There are a tremendously thickened stratum corneum and vacuolar degeneration of the upper epidermis, leading to the histologic term *epidermolytic hyperkeratosis* (see Fig. 52-2D). The vacuolar degeneration usually involves the upper epidermis and occasionally all of the suprabasilar keratinocytes. Granular cells exhibit dense, enlarged, irregularly shaped masses that appear to be keratohyalin granules. [2] On electron-microscopic examination, clumping of filaments is observed to begin in the first suprabasal layer. These aggregated filaments are clumps of keratin intermediate filaments that contain the terminal differentiation-specific keratins 1 and 10.

There is striking clinical heterogeneity between EHK families. In a study of 52 patients with histologically confirmed EHK from 21 families, the specific clinical features and heterogeneity of this disorder were characterized. [38] Within this group, six clinical phenotypes (Table 51-2) were distinguished (Fig. 51-8). A useful differentiating characteristic was presence versus absence of severe palmar/plantar hyperkeratosis. Three subgroups had *palm/sole (PS types)* hyperkeratosis, while the other three subgroups had *no palm/sole (NPS types)* hyperkeratosis. The subtypes were further distinguished by the presence or absence of erythroderma, quality of scale, extent of involvement, presence of digital contractures, and gait abnormality.

TABLE 51-2 **Clinical Subtypes of Epidermolytic Hyperkeratosis**

FIGURE 51-8 Clinical phenotypes of epidermolytic hyperkeratosis. *A.* NPS-1 (no severe palm/sole hyperkeratosis, type 1). *Top left:* Generalized involvement with thick, brown verrucous hyperkeratosis. *Top right, bottom left:* Hyperkeratosis is arrayed in a characteristic cobblestone or hystrix (porcupine-like) pattern. *Bottom right:* Shows spared palms. *B.* NPS-2 (no severe palm/sole hyperkeratosis, type 2). *Top left, bottom left, bottom right:* Seven-year-old patient with brown hyperkeratosis. Palms are spared. Compared to the verrucous hyperkeratosis in NPS-1, involvement is much milder. *Top right:* Three-year-old patient with blistering and hyperkeratosis, demonstrating hypertrichosis and relative sparing of the skin between the joints. *C.* NPS-3 (no severe palm/sole hyperkeratosis, type 3). *Right:* Generalized erythroderma with white scale and hyperkeratosis. *Left:* Minimal thickening and scale of the palms. *D.* PS-1 (severe palm/sole hyperkeratosis, type 1). *Three left plates:* Palmar and plantar hyperkeratosis with sharp border delineated by a red halo. Blisters are present at the border.Note the relatively smooth surface. *Right plate:* Characteristic involvement at the joints. *E.* PS-2 (severe palm/sole hyperkeratosis, type 2). *Top left, top right:* Hands of a 15-year-old patient with severe palmar hyperkeratosis and contractures. *Right center:* Flank of same patient exhibiting generalized erythroderma and scaling. *Bottom left* (two plates): Hands of a 36-year-old patient with severe palmar hyperkeratosis, contractures, and ainhum-like constricting digital bands. The palmar hyperkeratosis limits spreading of the fingers. *Bottom right:* Eight-year-old boy with generalized redness and peeling. *F.* PS-3 (severe palm/sole hyperkeratosis, type 3). *Top right*: Four-year-old patient with hyperkeratosis in a distinctive cerebriform pattern on the palms and soles (not shown). *Bottom right:* Hyperkeratosis in a cobblestone pattern on the knees. *Left:* Generalized pebbly hyperkeratosis. Note the loss of superficial epidermis on shoulder. (*From DiGiovanna and Bale,* [38] *adapted with permission.*)

Sporadic EHK due to a postzygotic, spontaneous mutation during embryogenesis can present in a mosaic pattern of skin involvement. Areas of hyperkeratosis alternating with normal skin are often distributed in streaks along Blaschko's lines (Fig. 51-9A). These may be limited to a few streaks, or there may be many, with widespread, patchy involvement. Unilateral localization can also occur. This clinical mosaic pattern correlates with underlying genetic mosaicism in that keratin mutations characteristic of EHK, which were found in lesional skin, were absent in normal skin. [39], [40] If the germ line is involved, individuals with mosaic EHK can transmit the mutation, which leads to generalized EHK in affected offspring (Fig. 51-9B). [40]

FIGURE 51-9 Mosaic epidermolytic hyperkeratosis. *A.* Streaks of hyperkeratosis distributed along Blaschko's lines in a sporadic case due to postzygotic occurrence of new mutation. *B.* Grandchild of patient shown in Panel *A.* Generalized involvement (in this case the NPS-2 clinical phenotype) is transmitted to subsequent generations in an autosomal dominant inheritance pattern.

Genetic linkage studies performed on a large family with a mild type of EHK (PS-1) identified linkage to the cluster of type II (basic) keratin genes located on chromosome 12, implicating keratin 1 in that family as the disease-causing gene. [41] Sequencing the keratin 1 gene in that family identified a mutation that was present in all affected and no unaffected family members. [42] Within keratinocytes, keratin intermediate filaments form an elaborate network that confers structural stability to the cells. In the suprabasilar differentiating keratinocytes, this network is formed by keratins 1 and 10. In EHK, failure of this network leads to keratinocyte fragility (particularly of the upper epidermis), easy blistering, abnormal epidermal kinetics (hyperproliferation), and thickened stratum corneum (hyperkeratosis). Keratin 10 is the coexpressed partner of keratin 1, both of which are required to form keratin intermediate filaments in the cells of the suprabasal layers of the epidermis. It is not surprising, then, that abnormalities in keratin 10 could also cause EHK. To date, a number of EHK families have been studied and found to have mutations in either keratin 1 or 10. [5] Mutations in keratin 9 (a keratin

that occurs only in palmar and plantar skin) have been found in families with the type of EHK limited exclusively to the palms and soles (Vörner). [43]

DISORDERS RESEMBLING EPIDERMOLYTIC HYPERKERATOSIS

Ichthyosis bullosa of Siemens is a rare autosomal dominant genodermatosis that is similar in clinical appearance to EHK. Patients are born with redness and blistering. The redness subsides over the subsequent weeks to months, while the skin develops hyperkeratosis, particularly over flexural areas. In some areas there may be a lichenified appearance to the skin. As with EHK, the epidermis is fragile; however, the fragility is more superficial. This can result in loss of the uppermost epidermis (predominantly stratum corneum), yielding a characteristic, collarette-like lesion that has been described as “molting.” Histologically, the epidermis shows hyperkeratosis and vacuolization, similar to EHK but confined to the granular layer. In four families with ichthyosis bullosa of Siemens and two originally diagnosed with EHK but who lacked mutations in keratins K1 and K10, mutations were found in the gene encoding keratin 2e, [44] a differentiation keratin of the suprabasilar epidermis that is expressed in the more superficial epidermal layers.

Ichthyosis hystrix of Curth and Macklin is a rare, autosomal dominant disorder that clinically resembles EHK. Clinical expression varies, even within families, from palmoplantar keratoderma to a severe generalized involvement. There can be widespread patchy, thick, gray-brown hyperkeratosis, most marked at the extensor arms and legs. Patients with extensive involvement resemble those with the NPS-1 type of EHK, with verrucous or porcupine-like (hystrix) hyperkeratosis. However, in contrast to EHK, blistering does not occur. Histologic examination of the epidermis shows acanthosis, papillomatosis, and severe orthokeratotic hyperkeratosis, with frequent binucleate cells. Keratinocytes within the granular and upper spinous layers may have perinuclear vacuolization, and some have prominent perinuclear shells. On electron microscopy, there are concentric, unbroken shells of tonofilaments surrounding the nucleus. Study of a three-generation family with ichthyosis hystrix of Curth and Macklin identified a mutation in the variable tail domain (V2) of the keratin 1 gene. Structural analyses of the resulting keratin 1 abnormality showed a failure of keratin intermediate filament bundling, retraction of the cytoskeleton from the nucleus, and failure of translocation of loricrin to desmosomal plaques. [45]

ICHTHYOSIS IN THE NEWBORN

A *collodion baby* is the usual presentation of congenital recessive ichthyosis (see Fig. 51-6). The child is born encased in a translucent, parchment-like membrane, which is taut and may impair respiration and sucking. In addition, the birth is often premature, which adds to morbidity. During the first 2 weeks of life, the membrane breaks up and peels off, often leaving fissures, with impairment of the barrier to infection and water loss. This can lead to difficulties in thermal regulation, an increased risk of infection, and hypernatremic dehydration. [46] Newborn care should include careful monitoring of temperature, hydration, and electrolytes and measures to keep the peeling membrane soft and lubricated to facilitate desquamation. The newborn should be in a humidified incubator where the air is saturated with water; wet compresses followed by bland lubricants can be used to further hydrate the membrane and achieve maximum pliability. If, during peeling, residual areas of the membrane are allowed to dry and harden in areas such as the extremities, the taut membrane can constrict and lead to distal swelling. Collodion presentation can develop into a wide spectrum of ichthyotic phenotypes as the child grows. This includes the spectrum of congenital autosomal recessive ichthyosis (severe classic LI, CIE, and intermediate phenotypes) and Netherton's syndrome. In addition, an autosomal recessive, self-healing collodion baby has been described, where the skin clears within the first few weeks and transitions into normal skin thereafter. [32]

A dramatic, severe, and usually fatal presentation of ichthyosis is that of *harlequin ichthyosis* (Fig. 51-10). The child is often premature and born with massive, shiny plates of stratum corneum separated by deep, red fissures that tend to form geometric patterns. There are poorly developed or absent ears and marked ectropion and eclabium. The first report is from the diary of Rev. Oliver Hart, of Charleston, South Carolina, who described these features in 1750. [47] These children are at great risk during the neonatal period and often die shortly after birth. Abnormal water loss through the skin and poor temperature regulation lead to risk of fluid and electrolyte imbalance. The infants are also at risk for infection beginning in the skin, but at the same time, because of poor temperature regulation, do not show the usual signs of infection. Normal respiration may be restricted by the taut skin. Treatment with isotretinoin or etretinate during the newborn period can facilitate desquamation of the membrane. [48], [49] Advances in neonatal intensive care together with facilitating desquamation with judicious use of systemic retinoid therapy have led to improvements in survival and to the use of the name “harlequin baby” rather than “harlequin fetus.” Some babies have had gastrointestinal disturbances such as poor absorption, leading to failure to thrive and requiring tube feeding. The skin of those who survive the newborn period usually resembles the skin of those with a severe phenotype of CIE. [48], [49]

FIGURE 51-10 Harlequin ichthyosis. Note rudimentary ears and the distorted appearance as a result of the thick “plates” of stratum corneum. This baby died in a few days.

Occurrence of harlequin ichthyosis in consanguineous families suggests autosomal recessive inheritance. [50] However, most cases are sporadic with no evidence of consanguinity, which is also consistent with a new dominant mutation. Therefore, there may be genetic heterogeneity. Studies of epidermal proteins suggest that there may be three types of harlequin ichthyosis. Keratohyalin granules look fairly normal in type 1, are too small to be seen by light microscopy in

type 2, and are absent in type 3. In all types, there are no lamellar granules; instead, there are small vesicles that lack internal structure. There is also no evidence of the lipid lamellae that form between granular and cornified cells as a result of discharge of lamellar granule contents into the intercellular space. [51]

The newborn affected with one of the more severe, generalized types of *EHK* usually has erythema, blistering, widespread erosions, and denuded skin.

Because there is a high frequency of new mutations, the disease may be unexpected and the diagnosis may be unknown. Epidermolysis bullosa or staphylococcal scalded-skin syndrome may be suspected, and the infant treated with antibiotics. The newborn may require intensive care with fluid and electrolyte monitoring. Specialized skin care can minimize blistering and enhance healing of erosions and should include lubrication to decrease friction and mechanical trauma, protective padding, and specialized wound dressings. The newborn with extensive erosions is prone to bacterial infection and sepsis, and carefully chosen topical and systemic antibiotics can minimize the extent of infection.

ACQUIRED ICHTHYOSIS

The development of ichthyosis in adulthood can be a manifestation of systemic disease, and it has been described in association with malignancies, drugs, endocrine and metabolic disease, HIV infection, and autoimmune conditions. While Hodgkin's disease is the most common malignancy reported with acquired ichthyosis, non-Hodgkin's lymphomas and a variety of other malignancies have also been observed. [52] The skin involvement may follow the course of malignancy and clear with effective cancer treatment. Acquired ichthyosis is commonly seen in association with AIDS, and ichthyotic or xerotic skin has been observed in up to 30 percent of AIDS patients. [53] A study of HIV-1–positive intravenous drug users found acquired ichthyosis occurred only after profound helper T cell depletion, more frequently with coinfection with *human T cell leukemia/lymphoma virus type II (HTLV-II),* and suggested that it may be a marker for concomitant infection with HIV-1 and HTLV-II. [54]

In acquired ichthyosis occurring in association with sarcoidosis, skin biopsy can be diagnostic, showing noncaseating granulomas in the dermis. [55] Acquired ichthyosis may be a marker of autoimmune disease, occurring with systemic lupus erythematosus, dermatomyositis, mixed connective tissue disease, and eosinophilic fasciitis. [56], [57] It has been described in bone marrow transplant recipients, where it may be related to graft-versus-host disease. [58]

While occurrence in association with cholesterol-lowering agents (nicotinic acid, triparanol) highlights the relationship between cholesterol metabolism and normal desquamation, acquired ichthyosis has been observed with a variety of drugs, including butyrophenone (antipsychotic), dixyrazine (major tranquilizer), and nafoxidine (estrogen antagonist). [14]

Confluent and reticulated papillomatosis of Gougerot and Carteaud is an uncommon but distinctive acquired ichthyosiform dermatosis characterized by persistent dark, scaly papules and plaques. Lesions tend to be localized predominantly on the central trunk (intermammary and interscapular regions) where they tend to be confluent and become reticulated towards the periphery (Fig. 51-11). The lesions bear a clinical resemblance to tinea versicolor, a skin infection with Pityrosporum species. A variety of treatment approaches have been reported, including topical (keratolytics, derivatives of vitamin A and D, antimicrobials) and systemic (antibiotics, retinoids) agents. A series of six cases reported responsiveness to various antibiotics including oral minocycline, fusidic acid, clarithromycin, erythromycin, and azithromycin. [59] Minocycline has been suggested as a first-line treatment, and successful retreatment of recurrences supports the concept that this condition is an abnormal response to an infection. [60]

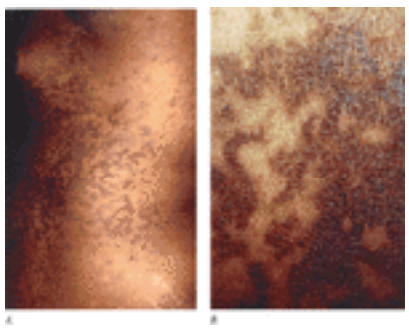

FIGURE 51-11 Confuent and reticulated papillomatosis of Gougerot and Carteaud. *A.* Dark, scaly papules and plaques on the trunk which become reticulated towards the periphery. *B.* Close-up view of the distinctive, scaly, reticulated papules and plaques. (*Courtesy of Andrew Montemarano, Do, and Stephen Krivda, MD.*)

LESS-COMMON ICHTHYOSES

Netherton's syndrome is a rare, autosomal recessive disorder that is characterized by the concurrence of ichthyosis, a structural hair shaft abnormality, and atopy. [61], [62] The usual cutaneous manifestation is *ichthyosis linearis circumflexa,* a distinctive condition of generalized hyperkeratosis and polycyclic and serpiginous erythematous plaques with a characteristic, migratory, double-edged scale at the margins (Fig. 51-12A). At birth this may present as generalized erythroderma or a collodion phenotype. Infants and children may have feeding problems, with poor absorption and failure to thrive. [63] With atopic dermatitis, there may be pruritus, and scratching can lead to lichenification at the flexures. In some patients, the ichthyosis resembles LI or CIE. [33], [61] Histopathologic examination is not specific and may show features of hyperkeratosis, psoriasis, and atopic dermatitis. Most patients have a specific hair shaft abnormality called *trichorrhexis invaginata,* in which the distal hair segment is telescoped into the proximal one, forming a ball-and-socket–like deformity on microscopic examination (Fig. 51-12B). This is also known as “bamboo hair” and is due to abnormal cornification of the internal root sheath. Hair from multiple areas should be examined, because only 20

to 50 percent of hair may be affected, and the characteristic abnormality may be more commonly observed on eyebrow hair. [64] Trichorrhexis nodosa and pili torti may also occur. Atopy in these patients may manifest as atopic dermatitis or asthma, and marked elevations of serum IgE may occur. In some patients, a generalized aminoaciduria, mild developmental delay, and impaired cellular immunity may also be present. Netherton's syndrome has been found to be due to mutations in *SPINK5,* a gene encoding LEKTI (*l*ympho- *e*pithelial *K*azal- *t*ype related *i*nhibitor). [65] LEKTI is a serine protease inhibitor that is predominantly expressed in epithelial and lymphoid tissues, and may be important in the downregulation of inflammatory pathways. This discovery highlights the importance of the regulation of proteolysis in the overlap between epithelial barrier function and the hypersensitivity of atopy. Subsequently, LEKTI was associated with common atopy and atopic dermatitis. [66] Prenatal testing for Netherton's syndrome using molecular data has been successfully accomplished. [67] Tacrolimus ointment, a topical immunosuppressant, is effective in common atopic dermatitis with minimal systemic absorption. However, Netherton's syndrome is complicated by an abnormal skin barrier, allowing increased percutaneous absorption and associated risk for systemic toxic effects. This should be considered when using topical agents such as tacrolimus where monitoring of serum levels may be necessary. [68]

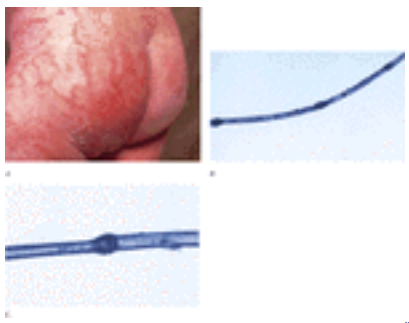

FIGURE 51-12 Netherton's syndrome. *A.* Ichthyosis linearis circumflexa showing typical annular lesions. (*Courtesy of James Stroud, MD.*) Bamboo hair shaft (*B*), under higher power (*C*) shows features of trichorrhexis invaginata.

In 1957, Sjögren and Larsson reported on 13 families from north Sweden with a syndrome of congenital ichthyosis, spastic paralysis, and mental retardation. *Sjögren-Larsson syndrome (SLS)* is a rare, autosomal recessive disorder that presents at birth with an ichthyosis that may range from fine scaling to generalized hyperkeratosis. Erythema may be present at birth but tends to gradually clear by 1 year of age. Collodion-like membranes are rarely seen. The ichthyosis manifests as fine scale, large scale, or a thickening of the stratum corneum without scale and may be pruritic. Thickened areas may be yellow to brown in color and have a lichenified appearance with accentuated skin markings. The most involved areas are the sides and back of the neck, lower abdomen, and flexures. Hair, nails, and the ability to sweat are generally normal. [69] During the first 2 to 3 years, neurologic manifestations of spastic diplegia or tetraplegia and mental retardation develop and can be accompanied by speech defects and seizures. A characteristic ophthalmologic finding is the presence of glistening white dots in the macula of the retina; these occur after 1 year of age and may not be present in all patients. Histologic findings of hyperkeratosis, papillomatosis, acanthosis, and a mildly thickened granular layer are nonspecific. Electron-microscopic examination of the skin shows lamellar membranous inclusions in the granular and cornified cells.

Rizzo et al. found deficient *fatty alcohol:NAD oxidoreductase (FAO)* activity in cultured fibroblasts from patients with SLS. FAO is a complex enzyme with two separate proteins that sequentially catalyze the oxidation of fatty alcohol to fatty aldehyde and subsequently to fatty acid. Further work identified the fatty aldehyde dehydrogenase component as the affected component of FAO in SLS. Fatty aldehyde dehydrogenase is a microsomal enzyme that catalyzes the oxidation of medium- and long-chain aliphatic aldehydes derived from metabolism of fatty alcohol, phytanic acid, ether, glycerolipids and leukotriene B4. [70] Mutations found in the fatty aldehyde dehydrogenase gene (FALDH, ALDH10) of three unrelated SLS patients confirmed the role for this enzyme in the etiology of this disorder and the importance of this pathway for normal desquamation. [71]

The identification of decreased fibroblast FAO activity in a family with atypical cutaneous findings (lack of ichthyosis or discrete plaques rather than generalized ichthyosis) has expanded the spectrum of clinical phenotypes associated with abnormal FAO activity. [72]

The *erythrokeratodermias* are a clinically heterogeneous group of disorders characterized by hyperkeratosis and localized erythema. Within a broad spectrum of phenotypes, at least two disorders can be delineated: erythrokeratodermia variabilis and progressive symmetric erythrokeratodermia. There are overlapping clinical features and phenotypic variability within these two designations.

Erythrokeratodermia variabilis, described by Mendes da Costa in 1925, is a rare autosomal dominant disorder that usually presents at birth or during the first year of life. At least two distinct clinical presentations can be distinguished. One type (Fig. 51-13A) is characterized by generalized, persistent, brown hyperkeratosis with accentuated skin markings. A second, localized type (Fig. 51-13B) has involvement that is limited in extent and characterized by sharply demarcated, hyperkeratotic plaques; these are symmetrically arrayed and remain relatively fixed for months to years. In the localized type, there may be considerable variability between affected family members, and the disorder may not be apparent until later in life. Both types are characterized by striking, sharply demarcated, migratory red patches, which vary in size from a few to many centimeters. These geographic, figurate red patches appear or regress over minutes to hours; some individuals complain of burning at these sites, while in others they are asymptomatic. The red patches develop independently of the hyperkeratosis. Both types of skin lesions may be triggered by trauma to the skin or change in temperature. Palmoplantar hyperkeratosis may be present in either type, but hair, nails, and mucous membranes are unaffected. Histopathologic features are nonspecific and include hyperkeratosis, acanthosis, papillomatosis, and capillary dilatation. Epidermis involved with severe papillomatosis and suprapapillary thinning may result in a “church

spire" appearance histologically.

FIGURE 51-13 Erythrokeratodermia variabilis. *A.* Generalized type with widespread hyperkeratosis and migratory, figurate, red patches. *B.* Localized type. Sharply demarcated, symmetric, hyperkeratotic plaques and migratory, figurate, red patches.

Erythrokeratodermia with ataxia (Giroux-Barbeau type) is an autosomal dominant disorder that presents during infancy with well-defined, symmetric hyperkeratotic plaques and underlying erythema distributed over the extensor surface of the extremities. [73] Skin lesions regress during adulthood while a progressive spinocerebellar ataxia develops. Both the localized type of erythrokeratodermia variabilis and erythrokeratodermia with ataxia have been mapped to a common region (chromosome 1p34-35). [74] Subsequently, Richard et al. found mutations in *GJB3,* the gene encoding connexin 31, in four families with erythrokeratodermia variabilis. [75] Connexins are a family of proteins that form gap junctions, which are important channels for intercellular communication. This intercellular signaling system is crucial for maintaining tissue homeostasis, growth control, development, and synchronized response of cells to stimuli. The identification of connexin mutations as the cause of erythrokeratodermia variabilis implicates this pathway in epidermal differentiation and in the mechanism of skin response to external factors. Different mutations in the same connexin 31 gene (*GJB3*) have been found in other patients with deafness and also in some with peripheral neuropathy. Mutations in the related connexin 30.3 have been found in other families with erythrokeratodermia variabilis. [76]

Progressive symmetric erythrokeratodermia, first described by Darier in 1911, is characterized by well-demarcated, erythematous, hyperkeratotic plaques that are symmetrically distributed over the extremities and buttocks, and often the face. [77] The trunk tends to be spared, but palms and soles may be involved. The plaques appear shortly after birth, progress slowly during the first few years, and then stabilize in early childhood. The plaques usually remain stable in location and appearance but may undergo partial regression at puberty. The variable, migratory erythema that defines erythrokeratodermia variabilis is absent. The disorder is inherited in an autosomal dominant pattern but with incomplete penetrance and variable expressivity. A mutation in the cornified envelope protein loricrin was found in one family. [78]

KID syndrome is a rare disorder characterized by *k*eratitis (with progressive corneal opacification), *i*chthyosis, and *d*eafness (neurosensory). Involvement of multiple ectodermal tissues qualifies KID syndrome as an ectodermal dysplasia. Most cases are compatible with autosomal dominant inheritance. However, occurrence in an inbred sibship suggests the existence of an autosomal recessive form. The disease is characterized by discrete erythematous plaques, and there may be a mild, generalized hyperkeratosis. The distinctive plaques may have a discrete border and a verrucous appearance with crusting and may be conspicuously figurate and symmetric on the face (Fig. 51-14). There may be prominent follicular hyperkeratosis, which can result in a scarring alopecia of the scalp. Several authors have suggested that because the plaques do not scale, this disorder is more accurately designated an erythrokeratodermia rather than an ichthyosis. [79] The nails may be dystrophic and teeth may be small. Auditory evoked potential studies allow detection of the hearing deficit in infancy. Affected individuals can have an increased susceptibility to bacterial, fungal, or viral infections. Squamous cell carcinoma of the skin and tongue have also been reported. In contrast to many other ichthyotic conditions, treatment of these patients with oral retinoids has been reported to be of little benefit and possibly to exacerbate the corneal neovascularization.

FIGURE 51-14 KID syndrome. Discrete, symmetric areas of hyperkeratosis are present on the face. There is a scarring alopecia.

Richard et al. discovered dominant mutations in *GJB2,* the gene encoding connexin 26 in eight sporadic cases and one family with KID syndrome. Functional studies of cells expressing mutated connexin 26 demonstrated failure of a fluorescent tracer to pass through gap junction channels to neighboring cells, consistent with disruption of intercellular communication. [80] Different mutations in the same gene (*GJB2*) encoding connexin 26 have also been found in a family with a mutilating palmoplantar keratoderma (Vohwinkle's disease) and deafness (without ichthyosis). [81] Connexin proteins aggregate to form gap junction channels, which span the cell membrane between adjacent cells. These channels are flexible structures that are constantly remodeled, and enable a direct cytoplasmic connection that allows the passage of a variety of small particles between cells. The identification of mutations in the genes encoding a variety of connexin proteins has highlighted the role of connexin mediated intercellular communication through gap junctions in the development and maintenance of ectodermal tissues. Connexins 26, 30, and 31 are expressed in the stratified epithelia of the cochlea and epidermis, and abnormalities in these proteins can cause sensorineural hearing impairment and/or skin disorders. [7]

Refsum's disease (heredopathia atactica polyneuritiformis) is a rare, progressive, degenerative disorder of lipid metabolism resulting from the failure to break down dietary phytanic acid and its subsequent accumulation in tissues. This autosomal recessive condition affects mostly the Scandinavians and populations originating from northern Europe. Clinical manifestations include retinitis pigmentosa, peripheral neuropathy, cerebellar ataxia, cranial nerve dysfunction (neural deafness, anosmia), miosis, electrocardiographic abnormalities, cardiomyopathy, renal tubular dysfunction, and skeletal abnormalities (epiphyseal dysplasia). Ichthyosis, which is variable, generally develops in adulthood after the neurologic and ophthalmologic manifestations. Often there are small white scales over the trunk and extremities resembling ichthyosis vulgaris. Routine [hematoxylin and eosin (H&E)] histologic examination shows variably sized vacuoles in the epidermal basal and suprabasal cells, which correspond to lipid accumulation seen with lipid stains of frozen sections. [82]

Phytanic acid (a 20-carbon, branched-chain fatty acid) is derived from a variety of dietary sources including dairy products, ruminant fats, and chlorophyll-containing foods. The disease is caused by a deficiency of phytanoyl-CoA hydroxylase (PhyH), a peroxisomal protein that catalyzes the a-oxidation of phytanic acid. This is the first step in the breakdown of phytanic acid, and PhyH deficiency leads to the accumulation of phytanic acid in the serum and tissues, where it substitutes for the fatty acids normally present. While mutations in *PAHX,* the gene encoding PhyH are responsible for some cases of Refsum's disease, [83] there is genetic heterogeneity. [84] Some affected patients have mutations in the *PEX7* gene, which is the same gene mutated in rhizomelic chondrodysplasia punctata (see below).

Because of the therapeutic effects of systemic retinoid drugs on ichthyosis, it is interesting to note the relationship between phytanoids and retinoids. Phytanic acid and other chlorophyll metabolites bind the *retinoid X receptor (RXR),* as does its natural ligand, 9- *cis*-retinoic acid, and they may be physiologically active in coordinating cellular metabolism through RXR-dependent signaling pathways. [85] Phytanic acid also appears to be a natural ligand for RXRa in that it promotes the formation of an RXRa/RXR response element complex and induces a conformational change similar to that induced by 9- *cis*-retinoic acid. The role of RXR in the pathogenesis of Refsum's disease is unclear.

The diagnosis can be made by detection of elevated levels of plasma phytanic acid. In children who do not have elevated plasma levels of phytanic acid, the diagnosis may be made by measuring PhyH activity in cultured fibroblasts. [86] Treatment includes dietary restriction of foods containing phytanic acid and its precursors and can include plasmapheresis or lipapheresis. In the clinical setting of a delayed onset of ichthyosis in association with neurologic impairment, this disease should be considered since therapy can arrest progression.

Chondrodysplasia punctata is a clinically and genetically diverse group of rare diseases, first described by Conradi, that share the features of stippled epiphyses and skeletal changes. They are characterized by abnormal deposition of calcium in the areas of enchondral bone formation during fetal development and early infancy. Several forms also include ichthyosiform changes. Clinical severity ranges from severe dwarfism and death during infancy to a self-limited radiographic abnormality in others. An autosomal recessive (rhizomelic) type and both X-linked dominant [87] and recessive forms [88] have been described. The validity of the originally described autosomal dominant Conradi-Hünermann type has been questioned, because some reported cases were later shown to belong to the X-linked dominant type, and occurrences previously considered sporadic have subsequently been recognized as resulting from warfarin (Coumadin) anticoagulant embryopathy. [87], [89]

Rhizomelic chondrodysplasia punctata (RCDP) (autosomal recessive) is also known as peroxisomal biogenesis disorder complementation group 11 (CG11). It is a rare, multisystem developmental disorder characterized by dwarfism due to symmetric shortening of the proximal long bones (i.e., rhizomelia), specific radiologic abnormalities (i.e., the presence of stippled calcifications of cartilage, vertebral body clefting), joint contractures, congenital cataracts, ichthyosis, and severe mental retardation. Skin changes are present in approximately 25 percent of patients. Patients have low levels of red cell plasmalogens and accumulation of phytanic acid, starting with normal levels at birth and increasing to more than 10 times normal by age 1 year. RCDP is a disorder of peroxisomes, membrane bound multifunctional organelles found in all nucleated cells. Their functions vary with cell type and include a variety of pathways (e.g., hydrogen peroxide based respiration, fatty acid ß-oxidation, and lipid and cholesterol synthesis) involving the synthesis and degradation of various compounds. Hereditary human peroxisomal disorders are subdivided into disorders of peroxisome biogenesis, in which the organelle is not formed normally, and those involving a single peroxisomal enzyme. RCDP is one of the group of peroxisome biogenesis disorders, which are characterized by loss of multiple peroxisomal metabolic functions and have been sorted into at least 12 different complementation groups. Many have been found to be due to defects in peroxins, factors required for the import of proteins into the organelle. RCDP is caused by mutations in *PEX7,* a gene that encodes peroxin 7, a receptor required for targeting a subset of enzymes to peroxisomes. [90] Refsum's disease, another

peroxisome disorder, exhibits genetic heterogeneity. In Refsum's disease due to mutations in *PAHX,* the gene for PhyH, there is deficiency of the single peroxisomal enzyme PhyH. Refsum's disease can also result from mutations in *PEX7,* and fibroblast cell cultures from those patients show deficiency of several peroxisomal enzymes similar to fibroblasts from patients with RCDP. It is remarkable that different mutations in the same gene can result in such a wide spectrum of clinical disease.

X-linked recessive chondrodysplasia punctata (CDPX) can involve skin (linear or whorled atrophic or ichthyosiform hyperkeratosis, follicular atrophoderma; may begin as erythroderma) (Fig. 51-15), hair (coarse, lusterless, cicatricial alopecia), short stature and skeletal abnormalities, cataracts, and deafness. Curry et al. studied a family who had atypical ichthyosis and elevated cholesterol sulfate in two affected males and identified an X chromosomal deletion (Xp22) that included the gene for steroid sulfatase. [88] There is a cluster of arylsulfatase genes at this location. Mutations in *ARSE,* the gene encoding the enzyme arylsulfatase E, were found in five patients; however, it is possible that the disorder may also be caused by mutations in adjacent arylsulfatase genes. [91] The similarity to warfarin embryopathy suggests that warfarin embryopathy may be due to drug-induced inhibition of the same enzyme.

FIGURE 51-15 Chondrodysplasia punctata. Newborn child. Generalized erythroderma with scales forming a whorled pattern.

Happle and coworkers identified X-linked dominant chondrodysplasia punctata (CDPX2) (Conradi-Hünermann-Happle syndrome) as a distinct variant characterized by a mosaic pattern of skin involvement and occurrence almost exclusively in females, with loss of the gene function hypothesized to be lethal to males. [87], [92] Affected females have a normal life expectancy and there may be increased disease expression in successive generations (anticipation). Occurrence in a male has been observed in association with a 47,XYY karyotype. CDPX2 presents at birth as a congenital ichthyosiform erythroderma that clears over months and is replaced by linear hyperkeratosis, follicular atrophoderma, and pigmentary abnormalities. Happle hypothesized that the linear involvement is due to mosaic X-chromosome inactivation (Lyonization). Hair shaft abnormalities and cicatricial alopecia can also occur. Stippled calcifications are seen in radiographs of areas of endochondral bone formation during childhood but may no longer be visible after puberty. Stature may be short, with asymmetric shortening of the legs. Cataracts occur, usually asymmetrically, in about two-thirds of patients. Histochemical staining for calcium may show calcifications within the epidermis, especially within hair follicles, in young children, which may not be present in older children. [93] Mutations in the gene encoding the emopamil-binding protein (EBP) cause the Conradi-Hünermann-Happle Syndrome. EBP was first identified as a binding target for the drug emopamil, a calcium-channel blocker. It was later found to be 3ß-hydroxysteroid-?8-?7-isomerase that catalyses an intermediate step in the conversion of lanosterol to cholesterol. [94] How this defect causes clinical manifestations is unclear.

The *CHILD syndrome* is a rare disorder consisting of *c*ongenital *h*emidysplasia, *i*chthyosiform erythroderma, and *l*imb *d*efects, which is found almost exclusively in females. [95] The disorder is related to CDPX2, also has skin and skeletal abnormalities, but is distinguished by a sharp midline demarcation of the ichthyosis, with minimal linear or segmental contralateral involvement. Involvement of the right side occurs more frequently than the left. There may be bands of normal skin on the affected side. A case with bilateral involvement has been described. Limb defects occur ipsilateral to the ichthyosis and range from digital hypoplasia to agenesis of the extremity. There may be punctate calcification of cartilage. Unilateral hypoplasia can involve the central nervous system and cardiovascular, pulmonary, renal, endocrine, and genitourinary systems. Studies of kindreds have suggested both an autosomal dominant and recessive inheritance as well as an X-linked dominant form that is lethal in males. Peroxisomal deficiency has been described in a study that showed fibroblasts from involved skin had fewer peroxisomes and accumulated cytoplasmic lipid; ultrastructurally, they accumulated lamellated membrane and vacuolar structures. Subsequently, mutations in either of two peroxisomal genes were found to cause CHILD syndrome. One patient was found to have a mutation in the gene encoding EBP (3ß-hydroxysteroid-?8-?7-isomerase) (the gene underlying CDPX2) [96] and six patients (including one boy) were found to have mutations in NSDHL (*N*AD(P)H *s*teroid *d*e *h*ydrogenase- *l*ike protein) encoding a 3ß-hydroxysteroid dehydrogenase. [97] Each enzyme functions in the cholesterol biosynthetic pathway catalyzing intermediate steps in the conversion of lanosterol to cholesterol.

In 1971, Tay described an autosomal recessive disorder characterized by a congenital ichthyosiform erythroderma, growth and mental retardation, progeria-like facies, and brittle hair. This association of *ichthyosis, brittle hair, intellectual impairment, decreased fertility, and short stature* has been given the acronym *IBIDS syndrome* (*Tay's syndrome, trichothiodystrophy*). [98] Newborns may have a collodion presentation, followed by decreasing erythema over weeks and evolution into a generalized ichthyosis, usually without erythema, which varies from fine, translucent scaling to large, dark yellow-brown hyperkeratosis. [98], [99] There may be flexural sparing, palmoplantar keratoderma, and dystrophic nails (ridging, splitting). Ectropion usually does not occur. There can be low birth weight, lack of subcutaneous fat (progeria-like facies), short stature, and delayed psychomotor development. Hypogonadism manifests as cryptorchidism in males and impaired sexual maturation in females. An increased susceptibility to infection has been described. Hair is sparse and under microscopic examination shows trichoschisis (transverse fracturing), pili torti, trichorrhexis nodosa (transverse, frayed fractures), and undulating contour of the shaft; under polarization, it has a pattern of alternating bright- and dark-banding (tiger-tail) (Fig. 51-16). [98], [100] Banded hairs have abnormally low sulfur content due to a

decrease in sulfur-containing amino acids, which led to the term *trichothiodystrophy,* which was coined by Price.



FIGURE 51-16 Trichothiodystrophy hair shows tiger-tail banding (*A*) under polarization, which is not observed with normal hair (*B*).

A spectrum of trichothiodystrophy-related syndromes has been recognized. [101] Similar hair and systemic abnormalities but without the ichthyosiform changes have been described as the *BIDS syndrome* (*b*rittle hair, *i*ntellectual impairment, *d*ecreased fertility, and *s*hort stature). A similar constellation of findings, with the addition of photosensitivity, is distinguished as *PIBI(D)S syndrome*. [102] In contrast to IBIDS syndrome, the ichthyosis is mild and not congenital, and hypogonadism is usually absent. There is a relationship with xeroderma pigmentosum in that virtually all PIBI(D)S patients have a deficiency in the nucleotide excision repair (NER) of UV-induced DNA damage that is indistinguishable from that of xeroderma pigmentosum group D, and mutations have been found in the XP group D helicase gene (*ERCC2/XPD*). In a few patients, mutations have been found in the XP complementation group B helicase gene (*ERCC3/XPB*). Although many trichothiodystrophy patients have photosensitivity, in contrast to xeroderma pigmentosum, these photosensitive patients have not been observed to be at high risk for the development of skin cancer. NER is one normal cellular mechanism by which structural DNA damage (e.g., UV induced cyclobutane pyrimidine dimers) is removed and repaired (see Chap. 35 and Chap. 155). TFIIH is involved in the initiation of transcription and in NER, and consists of a complex of proteins including the XPD and XPB proteins. In the vicinity of the damage, these two helicase subunits of TFIIH unwind the DNA in opposite directions.

Chanarin-Dorfman syndrome (neutral lipid storage disease) is an autosomal recessive disorder characterized by accumulation of triglycerides in the cytoplasm of leukocytes, muscle, liver, fibroblasts, and other tissues. Blood lipid levels, however, are normal. To date, approximately 30 patients have been reported, mainly from the Mediterranean basin. The ichthyosis is a generalized fine scaling with variable erythema, resembling congenital ichthyosiform erythroderma. Presentation is often that of a collodion baby with ectropion and eclabion. Extracutaneous involvement, which is variable and may be mild, includes cataracts, decreased hearing, psychomotor delay, myopathy with elevations in serum muscle enzymes, and neurologic abnormalities.

Histopathology of an oil red O or Sudan III stain of frozen sections of the skin shows lipid droplets in dermal cells, in the basal layer (and, to a lesser extent, suprabasally), as well as in the acrosyringia of the eccrine ducts. On electron-microscopic examination there are lipid droplets within the cytoplasm and within lamellar bodies, which disrupt the normal lamellations. These distortions persist after extrusion into the intercellular space. [103] Examination of peripheral blood smears show lipid vacuoles within granulocytes, eosinophils, and monocytes, a feature that may also be present in carriers. [104] Lefèvre et al. identified mutations in the *CGI-58* gene in nine families. [105] CGI-58 belongs to a large family of proteins, most of which are enzymes; however, its exact function has not yet been elucidated.

Multiple sulfatase deficiency is a rare autosomal recessive disorder that is characterized by a deficiency of several sulfatases, which results in the accumulation of sulfatides, glycosaminoglycans, sphingolipids, and steroid sulfates in tissues and body fluids. [106] The activity of both lysosomal (arylsulfatases A and B) and microsomal (arylsulfatase C/steroid sulfatase of X-linked ichthyosis) arylsulfatases is impaired. The disorder is a composite of the clinical features of both metachromatic leukodystrophy and of a mucopolysaccharidosis. Clinical features include neurologic deterioration, skeletal abnormalities, facial dysmorphism, and an ichthyosis resembling that seen in X-linked steroid sulfatase deficiency. This disorder has been proposed to be due to a defect, common to all sulfatases, in posttranslational protein modification that is required for generating a catalytically active enzyme. [107]

The *peeling skin syndrome* is an autosomal recessive disorder characterized by lifelong peeling of the stratum corneum. It may be associated with pruritus, short stature, and easily removed anagen hairs. Low plasma tryptophan levels and aminoaciduria have also been reported. [108] Traupe suggested that there are two types of peeling skin syndrome. [33] Type A, which is noninflammatory and asymptomatic, is characterized by generalized peeling in thin superficial flakes of differing size and shape. On electron microscopy, the intracellular separation occurs in the stratum corneum, that is, within the corneocytes and not between adjacent cells. Intercellular electron-dense globular deposits representing abnormal lipids have been observed localized to the stratum corneum. [109] In contrast, type B presents with congenital ichthyotic erythroderma and evolves into erythematous, scaling, migratory patches. This type is pruritic and may be associated with elevated levels of IgE, aminoaciduria, and short stature. The stratum corneum is easily separated mechanically from the lower epidermis, and histologically the split, which occurs intercellularly, is seen between the stratum corneum and the granular layer. On electron microscopy, electron-dense, irregularly vacuolated bodies have been observed in the granular layer, but observations have been variable. [110] A variant, clinically similar to the

inflammatory type B but with associated hair shaft abnormalities has been described. [110]

Rud's syndrome is a poorly characterized disorder, probably of recessive inheritance, that includes epilepsy, mental retardation, infantilism, congenital ichthyosis, and retinitis pigmentosa. Steroid sulfatase deficiency has been reported in some patients. Traupe critically reviewed the literature and suggested that the clinical constellation usually labeled Rud's syndrome is associated steroid sulfatase deficiency (X-linked recessive ichthyosis); because both the neurologic involvement and the ichthyosis are ill defined, the term *Rud's syndrome* should be abandoned. [33]

TREATMENT

Current therapies for the inherited ichthyoses are symptomatic and focus on hydration, lubrication, and keratolysis. Ichthyotic skin, even if thickened, has a decreased barrier function and increased transepidermal water loss. Because pliability of the stratum corneum is a function of its water content, hydration can soften the surface of the skin. In moist, humid climates, most ichthyoses improve, and mild ichthyoses (e.g., ichthyosis vulgaris) may undergo extensive clearing. Moistening the skin with, for example, long baths, can hydrate it. Well-hydrated areas of hyperkeratosis can more easily be thinned with mild abrasives (sponges, buff puffs, pumice stones, etc.). Addition of bath oils or application of lubricants before drying can prolong the hydration and softening. Depending on the ichthyosis and environmental conditions, individual patients may prefer specific lubricating agents, which can take the form of lotions, creams, ointments, oils, or petrolatum. In dry climates and winter months, humidifiers can be used to create a hospitable environment.

Keratolytic agents are used to enhance corneocyte disadhesion and thereby remove scale and thin hyperkeratotic stratum corneum. There are many commercially available keratolytic creams and lotions containing urea, salicylic acid, or a-hydroxy acids (e.g., lactic acid, glycolic acid). Urea may function by its capacity to bind water. Propylene glycol (60% in water), with or without occlusion, can also be effective in scale removal. Occlusion can effectively increase skin hydration and facilitate desquamation; it can also enhance the effect of keratolytic agents. Special care should be taken when using extensive areas of occlusion with keratolytic agents and in individuals who may be heat intolerant. Topical retinoid or vitamin D preparations may also be effective but can be irritating in some patients. The markedly impaired barrier function in ichthyosis should be considered when using topical preparations over large areas of body surface. For example, widespread use of topical salicylic acid preparations can lead to significant absorption, intoxication (e.g., nausea, tinnitus, dyspnea, hallucinations), and even death. [111] Children are at greater risk because they have a greater body surface area per unit weight than adults, a situation that effectively heightens the possibility of developing systemic toxicity from topicals. [33] The abnormal skin barrier should be considered when treating concomitant dermatoses in ichthyosis patients. Topical 0.1% tacrolimus ointment is effective in atopic dermatitis with minimal systemic absorption. However, the atopic dermatitis of Netherton's syndrome is complicated by a defective ichthyotic skin barrier. The defective barrier is associated with increased percutaneous absorption and risk for systemic toxic effects. This should be considered when using topical agents such as tacrolimus, where increased systemic absorption has been observed and monitoring of serum levels may be necessary. [68]

Another risk to children is that in several types of ichthyosis, because of the large turnover of scale, nutritional requirements may be high, and inadequate nutrition can lead to failure to thrive. Some patients with ichthyosis (particularly LI and CIE) have decreased sweating with heat intolerance. It is important for the parents of a newborn with ichthyosis to be aware of the possibility of decreased sweating and to be attentive for signs of heat intolerance, such as flushing and lethargy, particularly during hot weather and, as the child grows, during exercise. Avoiding hot environments and carrying spray bottles with water to moisten the skin and cool it through evaporation can minimize heat stress.

Systemic retinoid therapy with isotretinoin or acitretin can induce dramatic improvement in many ichthyoses and is particularly useful in LI, CIE, and erythrokeratodermia variabilis. The decision to initiate systemic retinoid therapy should be weighed carefully, because once the drug is started, continued benefit usually requires chronic therapy. Treatment of the harlequin newborn with systemic retinoid therapy during the newborn period can be lifesaving due to enhanced desquamation of a constricting membrane.

Fungal infections are common, both of skin and nails, and are often undiagnosed because of the generalized scaling. A high index of suspicion can help diagnose tinea corporis, capitis, or versicolor where the only symptom may be localized pruritus and the only sign a difference in the character of scale or a localized area of alopecia.

The management of epidermolytic hyperkeratosis has acute and chronic aspects and varies with the clinical type. Areas of thick, hard hyperkeratosis, which are not pliable and have a hard rough surface, are prone to mechanical trauma. In patients with the hystrix type of porcupine-like hyperkeratosis, the rough surface causes high traction with objects moving across the skin surface, which tend to catch on the hyperkeratotic horn and peel it off. Topical agents such as lubricants and keratolytics can reduce the thickened, rough areas and help to minimize blistering and erosion. Bacterial infection of the skin is common, often leads to enhanced blistering, and may require frequent therapy with topical and oral antibiotics. In patients with extensive involvement, systemic retinoid therapy can be dramatically effective in decreasing the hyperkeratosis and the frequency of infections. Because these drugs can enhance blistering in epidermolytic hyperkeratosis patients, they should be administered carefully and started at low doses.

PRENATAL DIAGNOSIS

Molecular diagnosis is preferred when possible. Alternative methods, including fetoscopy and fetal skin biopsy, have the disadvantage of not being able to be performed early in pregnancy. Both harbor a risk of fetal mortality. Fetal skin biopsy at approximately 20 to 22 weeks' gestation has been accomplished in LI, CIE, epidermolytic hyperkeratosis, and Sjögren-Larsson syndrome. In harlequin ichthyosis, prenatal diagnosis has been successfully performed by fetal skin biopsy [112] and ultrasonography. [113] When it is possible to do prenatal diagnosis by molecular analysis of a fetal sample, it is optimally performed early in pregnancy. This can be done with chorionic villous sampling or by amniocentesis in disorders where the underlying genetic defect is known and the specific mutation in the family has been identified. If a

specific mutation has not been identified, in some circumstances where there is an appropriate family structure, prenatal diagnosis can be done using linkage analysis. Prenatal diagnosis by mutational analysis has been accomplished in epidermolytic hyperkeratosis; [114] lamellar ichthyosis (*TGM1*); Sjögren-Larsson syndrome (*FALDH*); ichthyosis bullosa of Siemens (*K2e*); PIBI(D)S (*ERCC2/XPD, ERCC3/XPB*); autosomal recessive rhizomelic chondrodysplasia punctata (*PEX7*); X-linked chondrodysplasia punctata (arylsulfatase gene cluster at Xp22); and Netherton's syndrome (*SPINK5*). [67] In Sjögren-Larsson syndrome, the diagnosis can be made by assay of enzyme activity in cultured amniocytes, even if the mutation in FALDH is undefined. For autosomal recessive disorders where the mutation is known (e.g., LI and Sjögren-Larsson syndrome), carrier detection may be performed for at-risk relatives.

The National Registry for Ichthyosis and Related Disorders is funded by the National Institutes of Health to identify and enroll individuals affected with the ichthyoses in an effort to improve diagnosis and treatment of these disorders and is located at the University of Washington, Dermatology/Box 356524, Rm.BB1353, 1959 NE Pacific St., Seattle, WA 98195-6524 (Tel: 1-800-595-1265; http://www.skinregistry.org/; e-mail: http://info@skinregistry.org/).

The Foundation for Ichthyosis and Related Skin Types is an organization providing support and information for affected individuals, family members, and friends. It can be reached at F.I.R.S.T., Suite 17, 650 N. Cannon Avenue, Lansdale, PA 19446 (Tel: 215-631-1411; http://www.scalyskin.org/; e-mail: http://info@scalyskin.org/).

REFERENCES

1. Willan R: *On Cutaneous Diseases.* Vol 1., London, Barnard, 1808

2. Frost P, Van Scott EJ: Ichthyosiform dermatoses. Classification based on anatomic and biometric observations. *Arch Dermatol* **94**:113, 1966

3. Frost P: Ichthyosiform dermatoses. *J Invest Dermatol* **60**:541, 1973

4. Williams ML, Elias PM: Genetically transmitted, generalized disorders of cornification. The ichthyoses. *Dermatol Clin* **5**:155, 1987

5. DiGiovanna JJ, Bale SJ: Epidermolytic hyperkeratosis: Applied molecular genetics. *J Invest Dermatol* **102**:390, 1994

6. Bale SJ, DiGiovanna JJ: Genetic approaches to understanding the keratinopathies. *Adv Dermatol* **12**:99, 114, 1997

7. Richard G: Connexins: A connection with the skin. *Exp Dermatol* **9**:77, 2000

8. Russell LJ et al: Linkage of autosomal recessive lamellar ichthyosis to chromosome 14q. *Am J Hum Genet* **55**:1146, 1994

9. Russell LJ et al: Mutations in the gene for transglutaminase 1 in autosomal recessive lamellar ichthyosis. *Nat Genet* **9**:279, 1995

10. Huber M et al: Mutations of keratinocyte transglutaminase in lamellar ichthyosis. *Science* **267**:525, 1995

11. Nemes Z et al: A novel function for transglutaminase 1: attachment of long-chain omega-hydroxyceramides to involucrin by ester bond formation. *Proc Natl Acad Sci USA* **96**:8402, 1999

12. Webster D et al: X-linked ichthyosis due to steroid-sulphatase deficiency. *Lancet* **1**:70, 1978

13. Koppe G et al: X-linked ichthyosis. A sulphatase deficiency. *Arch Dis Child* **53**:803, 1978

14. Williams ML et al: Ichthyosis induced by cholesterol-lowering drugs. Implications for epidermal cholesterol homeostasis. *Arch Dermatol* **123**:1535, 1987

15. Wells RS, Kerr CB: Clinical features of autosomal dominant and sex-linked ichthyosis in an English population. *Br Med J* **1**:947, 1966

16. Mevorah B et al: Autosomal dominant ichthyosis and X-linked ichthyosis. Comparison of their clinical and histological phenotypes. *Acta Derm Venereol* **71**:431, 1991

17. Cuevas-Covarrubias SA et al: Accuracy of the clinical diagnosis of recessive X-linked ichthyosis vs ichthyosis vulgaris. *J Dermatol* **23**:594, 1996

18. Anton-Lamprecht I, Hofbauer M: Ultrastructural distinction of autosomal dominant ichthyosis vulgaris and X-linked recessive ichthyosis. *Humangenetik* **15**:261, 1972

19. Nirunsuksiri W et al: Decreased profilaggrin expression in ichthyosis vulgaris is a result of selectively impaired posttranscriptional control. *J Biol Chem* **270**:871, 1995

20. Rose FA: Review: The mammalian sulphatases and placental sulphatase deficiency in man. *J Inherit Metab Dis* **5**:145, 1982

21. Epstein EH Jr, Leventhal ME: Steroid sulfatase of human leukocytes and epidermis and the diagnosis of recessive X-linked ichthyosis. *J Clin Invest* **67**:1257, 1981

22. Lykkesfeldt G et al: Placental steroid sulfatase deficiency: Biochemical diagnosis and clinical review. *Obstet Gynecol* **64**:49, 1984

23. Jay B et al: Ocular manifestations of ichthyosis. *Br J Ophthalmol* **52**:217, 1968

24. Sever RJ et al: Eye changes in ichthyosis. *JAMA* **206**:2283, 1968

25. Lykkesfeldt G et al: Testis cancer. Ichthyosis constitutes a significant risk factor. *Cancer* **67**:730, 1991

26. Epstein EH Jr, Bonifas JM: Recessive X-linked ichthyosis: Lack of immunologically detectable steroid sulfatase enzyme protein. *Hum Genet* **71**:201, 1985

27. Ballabio A et al: Deletion of the distal short arm of the X chromosome (Xp) in a patient with short stature, chondrodysplasia punctata, and X-linked ichthyosis due to steroid sulfatase deficiency. *Am J Med Genet* **41**:184, 1991

28. Robledo R et al: X-linked ichthyosis without STS deficiency: Clinical, genetical, and molecular studies. *Am J Med Genet* **59**:143, 1995

29. Simpson JR: Congenital ichthyosiform erythroderma. *Trans St John's Hosp Derm Soc* **50**:93, 1964

30. Williams ML, Elias PM: Heterogeneity in autosomal recessive ichthyosis. Clinical and biochemical differentiation of lamellar ichthyosis and nonbullous congenital ichthyosiform erythroderma. *Arch Dermatol* **121**:477, 1985

31. Bernhardt M, Baden HP: Report of a family with an unusual expression of recessive ichthyosis. Review of 42 cases. *Arch Dermatol* **122**:428, 1986

32. Frenk E, de Techtermann F: Self-healing collodion baby: Evidence for autosomal recessive inheritance. *Pediatr Dermatol* **9**:95, 1992

33. Traupe H: *The Ichthyoses*: *A Guide To Clinical Diagnosis, Genetic Counseling, and Therapy*. New York, Springer-Verlag, 1989, page 116

34. Choate KA et al: Corrective gene transfer in the human skin disorder lamellar ichthyosis. *Nat Med* **2**:1263, 1996

35. Fischer J et al: Two new loci for autosomal recessive ichthyosis on chromosomes 3p21 and 19p12-q12 and evidence for further genetic heterogeneity. *Am J Hum Genet* **66**:904, 2000

36. Bale SJ et al: Congenital recessive ichthyosis unlinked to loci for epidermal transglutaminases. *J Invest Dermatol* **107**:808, 1996

37. Matsumoto K et al: Loricrin keratoderma: A cause of congenital ichthyosiform erythroderma and collodion baby. *Br J Dermatol* **145**:657, 2001

38. DiGiovanna JJ, Bale SJ: Clinical heterogeneity in epidermolytic hyperkeratosis. *Arch Dermatol* **130**:1026, 1994

39. Paller AS et al: Genetic and clinical mosaicism in a type of epidermal nevus. *N Engl J Med* **331**:1408, 1994

40. Nazzaro V et al: Epidermolytic hyperkeratosis: Generalized form in children from parents with systematized linear form. *Br J Dermatol* **122**:417, 1990

41. Compton JG et al: Linkage of epidermolytic hyperkeratosis to the type II keratin gene cluster on chromosome 12q. *Nat Genet* **1**:301, 1992

42. Chipev CC et al: A leucine-proline mutation in the H1 subdomain of keratin 1 causes epidermolytic hyperkeratosis. *Cell* **70**:821, 1992

43. Reis A et al: Keratin 9 gene mutations in epidermolytic palmoplantar keratoderma (EPPK). *Nat Genet* **6**:174, 1994

44. Rothnagel JA et al: Mutations in the rod domain of keratin 2e in patients with ichthyosis bullosa of Siemens. *Nat Genet* **7**:485, 1994

45. Sprecher E et al: Evidence for novel functions of the keratin tail emerging from a mutation causing ichthyosis hystrix. *J Invest Dermatol* **116**:511, 2001

46. Giroux JD et al: Severe hypernatremic dehydration disclosing Netherton syndrome in the neonatal period. *Arch Fr Pediatr* **50**:585, 1993

47. Waring JI: Early mention of a harlequin fetus in America. *Am J Dis Child* **43**:442, 1932

48. Roberts LJ: Long-term survival of a harlequin fetus. *J Am Acad Dermatol* **21**:335, 1989

49. Haftek M et al: A longitudinal study of a harlequin infant presenting clinically as non-bullous congenital ichthyosiform erythroderma. *Br J Dermatol* **135**:448, 1996

50. Unamuno P et al: Harlequin foetus in four siblings. *Br J Dermatol* **116**:569, 1987

51. Milner ME et al: Abnormal lamellar granules in harlequin ichthyosis. *J Invest Dermatol* **99**:824, 1992

52. Schwartz RA, Williams ML: Acquired ichthyosis: A marker for internal disease. *Am Fam Physician* **29**:181, 1984

53. Goodman DS et al: Prevalence of cutaneous disease in patients with acquired immunodeficiency syndrome (AIDS) or AIDS-related complex. *J Am Acad Dermatol* **17**:210, 1987

54. Kaplan MH et al: Acquired ichthyosis in concomitant HIV-1 and HTLV-II infection: A new association with intravenous drug abuse. *J Am Acad Dermatol* **29**:701, 1993

55. Feind-Koopmans AG et al: Acquired ichthyosiform erythroderma and sarcoidosis. *J Am Acad Dermatol* **35**:826, 1996

56. Humbert P, Agache P: Acquired ichthyosis: A new cutaneous marker of autoimmunity. *Arch Dermatol* **127**:263, 1991

57. de la Cruz-Alvarez J et al: Acquired ichthyosis associated with eosinophilic fasciitis. *J Am Acad Dermatol* **34**:1079, 1996

58. Spelman LJ et al: Acquired ichthyosis in bone marrow transplant recipients. *J Am Acad Dermatol* **35**:17, 1996

59. Jang HS et al: Six cases of confluent and reticulated papillomatosis alleviated by various antibiotics. *J Am Acad Dermatol* **44**:652, 2001

60. Montemarano AD et al: Confluent and reticulated papillomatosis: Response to minocycline. *J Am Acad Dermatol* **34**:253, 1996

61. Altman J, Stroud J: Netherton's syndrome and ichthyosis linearis circumflexa. *Arch Dermatol* **100**:550, 1969

62. Hurwitz S et al: Reevaluation of ichthyosis and hair shaft abnormalities. *Arch Dermatol* **103**:266, 1971

63. Stoll C et al: Severe hypernatremic dehydration in an infant with Netherton syndrome. *Genet Couns* **12**:237, 2001

64. Powell J: Increasing the likelihood of early diagnosis of Netherton syndrome by simple examination of eyebrow hairs. *Arch Dermatol* **136**:423, 2000

65. Chavanas S et al: Mutations in SPINK5, encoding a serine protease inhibitor, cause Netherton syndrome. *Nat Genet* **25**:141, 2000

66. Walley AJ et al: Gene polymorphism in Netherton and common atopic disease. *Nat Genet* **29**:175, 2001

67. Sprecher E et al: The spectrum of pathogenic mutations in SPINK5 in 19 families with Netherton syndrome: Implications for mutation detection and first case of prenatal diagnosis. *J Invest Dermatol* **117**:179, 2001

68. Allen A et al: Significant absorption of topical tacrolimus in 3 patients with Netherton syndrome. *Arch Dermatol* **137**:747, 2001

69. Jagell S, Liden S: Ichthyosis in the Sjögren-Larsson syndrome. *Clin Genet* **21**:243, 1982

70. Rizzo WB et al: Fatty aldehyde dehydrogenase: Genomic structure, expression and mutation analysis in Sjögren-Larsson syndrome. *Chem Biol Interact* **130–132**:297, 2001

71. De Laurenzi V et al: Sjögren-Larsson syndrome is caused by mutations in the fatty aldehyde dehydrogenase gene. *Nat Genet* **12**:52, 1996

72. Nigro JF et al: Redefining the Sjögren-Larsson syndrome: Atypical findings in three siblings and implications regarding diagnosis. *J Am Acad Dermatol* **35**:678, 1996

73. Giroux JM, Barbeau A: Erythrokeratodermia with ataxia. *Arch Dermatol* **106**:183, 1972

74. Richard G et al: Linkage studies in erythrokeratodermias: Fine mapping, genetic heterogeneity, and analysis of candidate genes. *J Invest Dermatol* **109**:666, 1997

75. Richard G et al: Mutations in the human connexin gene GJB3 cause erythrokeratodermia variabilis. *Nat Genet* **20**:366, 1998

76. Macari F et al: Mutation in the gene for connexin 30.3 in a family with erythrokeratodermia variabilis. *Am J Hum Genet* **67**:1296, 2000

77. Ruiz-Maldonado R et al: Erythrokeratodermia progressiva symmetrica: Report of 10 cases. *Dermatologica* **164**:133, 1982

78. Ishida-Yamamoto A et al: The molecular pathology of progressive symmetric erythrokeratoderma: A frameshift mutation in the loricrin gene and perturbations in the cornified cell envelope. *Am J Hum Genet* **61**:581, 1997

79. Caceres-Rios H et al: Keratitis, ichthyosis, and deafness (KID syndrome): Review of the literature and proposal of a new terminology. *Pediatr Dermatol* **13**:105, 1996

80. Richard G et al: Missense mutations in *GJB2* encoding connexin-26 cause the ectodermal dysplasia Keratitis-Ichthyosis-Deafness Syndrome. *Am J Hum Genet* **70**:1341, 2002

81. Maestrini E et al: A molecular defect in loricrin, the major component of the cornified cell envelope, underlies Vohwinkel's syndrome. *Nat Genet* **13**:70, 1996

82. Davies MG et al: Epidermal abnormalities in Refsum's disease. *Br J Dermatol* **97**:401, 1977

83. Jansen GA et al: Refsum disease is caused by mutations in the phytanoyl-CoA hydroxylase gene. *Nat Genet* **17**:190, 1997

84. Wanders RJ et al: Refsum disease, peroxisomes and phytanic acid oxidation: A review. *J Neuropathol Exp Neurol* **60**:1021, 2001

85. Kitareewan S et al: Phytol metabolites are circulating dietary factors that activate the nuclear receptor RXR. *Mol Biol Cell* **7**:1153, 1996

86. Poulos A et al: Patterns of Refsum's disease. Phytanic acid oxidase deficiency. *Arch Dis Child* **59**:222, 1984

87. Happle R: X-linked dominant chondrodysplasia punctata. Review of literature and report of a case. *Hum Genet* **53**:65, 1979

88. Curry CJ et al: Inherited chondrodysplasia punctata due to a deletion of the terminal short arm of an X chromosome. *N Engl J Med* **311**:1010, 1984

89. Hosenfeld D, Wiedemann HR: Chondrodysplasia punctata in an adult recognized as vitamin K antagonist embryopathy. *Clin Genet* **35**:376, 1989

90. Motley AM et al: Mutational spectrum in the PEX7 gene and functional analysis of mutant alleles in 78 patients with rhizomelic chondrodysplasia punctata type 1. *Am J Hum Genet* **70**:612, 2002

91. Franco B et al: A cluster of sulfatase genes on Xp22.3: Mutations in chondrodysplasia punctata (CDPX) and implications for warfarin embryopathy. *Cell* **81**:15, 1995

92. Happle R: X-linked dominant ichthyosis. *Clin Genet* **15**:239, 1979

93. Kolde G, Happle R: Histologic and ultrastructural features of the ichthyotic skin in X-linked dominant chondrodysplasia punctata. *Acta Derm Venereol* **64**:389, 1984

94. Becker K et al: Identification of a novel mutation in 3beta-hydroxysteroid-Delta8- Delta7-isomerase in a case of Conradi-Hünermann-Happle syndrome. *Exp Dermatol* **10**:286, 2001

95. Herman GE: X-Linked dominant disorders of cholesterol biosynthesis in man and mouse. *Biochim Biophys Acta* **1529**:357, 2000

96. Grange DK et al: CHILD syndrome caused by deficiency of 3beta-hydroxysteroid-delta8, delta7-isomerase. *Am J Med Genet* **90**:328, 2000

97. Konig A et al: Mutations in the NSDHL gene, encoding a 3beta-hydroxysteroid dehydrogenase, cause CHILD syndrome. *Am J Med Genet* **90**:339, 2000

98. Jorizzo JL et al: Ichthyosis, brittle hair, impaired intelligence, decreased fertility and short stature (IBIDS syndrome). *Br J Dermatol* **106**:705, 1982

99. Happle R et al: The Tay syndrome (congenital ichthyosis with trichothiodystrophy). *Eur J Pediatr* **141**:147, 1984

100. Broughton BC et al: Two individuals with features of both xeroderma pigmentosum and trichothiodystrophy highlight the complexity of the

clinical outcomes of mutations in the XPD gene. *Hum Mol Genet* **10**:2539, 2001

101. Itin PH et al: Trichothiodystrophy: update on the sulfur-deficient brittle hair syndromes. *J Am Acad Dermatol* **44**:891, 2001

102. Rebora A, Crovato F: PIBI(D)S syndrome—Trichothiodystrophy with xeroderma pigmentosum (group D) mutation. *J Am Acad Dermatol* **16**:940, 1987

103. Elias PM, Williams ML: Neutral lipid storage disease with ichthyosis. Defective lamellar body contents and intracellular dispersion. *Arch Dermatol* **121**:1000, 1985

104. Srebrnik A et al: Dorfman-Chanarin syndrome. A case report and a review. *J Am Acad Dermatol* **17**:801, 1987

105. Lefevre C et al: Mutations in CGI-58, the gene encoding a new protein of the esterase/lipase/thioesterase subfamily, in Chanarin-Dorfman syndrome. *Am J Hum Genet* **69**:1002, 2001

106. Soong BW et al: Multiple sulfatase deficiency. *Neurology* **38**:1273, 1988

107. Schmidt B et al: A novel amino acid modification in sulfatases that is defective in multiple sulfatase deficiency. *Cell* **82**:271, 1995

108. Aras N et al: Peeling skin syndrome *J Am Acad Dermatol* **30**:135, 1994

109. Silverman AK et al: Continual skin peeling syndrome. An electron microscopic study. *Arch Dermatol* **122**:71, 1986

110. Mevorah B et al: Peeling skin syndrome with hair changes. *Dermatology* **197**:373, 1998

111. Germann R et al: Life-threatening salicylate poisoning caused by percutaneous absorption in severe ichthyosis vulgaris [in German]. *Hautarzt* **47**:624, 1996

112. Suzumori K, Kanzaki T: Prenatal diagnosis of harlequin ichthyosis by fetal skin biopsy; report of two cases. *Prenat Diagn* **11**:451, 1991

113. Watson WJ, Mabee LM Jr: Prenatal diagnosis of severe congenital ichthyosis (harlequin fetus) by ultrasonography. *J Ultrasound Med* **14**:241, 1995

114. Rothnagel JA et al: Prenatal diagnosis of epidermolytic hyperkeratosis by direct gene sequencing. *J Invest Dermatol* **102**:13, 1994

T>

Chapter 52

Howard Stevens David Kelsell Irene Leigh

The Inherited Keratodermas of Palms and Soles

DEFINITIONS AND CLASSIFICATIONS
SIMPLE KERATODERMAS
Diffuse PPK
Simple Focal PPK
Simple Punctate PPK
COMPLEX KERATODERMAS
Complex Diffuse PPK
Complex Focal PPK
Ectodermal Dysplasias
Syndromic Keratodermas

REFERENCES

DEFINITIONS AND CLASSIFICATIONS

The palmoplantar keratodermas (PPKs) are a heterogeneous group of disorders characterized by abnormal thickening of the palms and soles. Autosomal recessive, X-linked, and dominant modes of inheritance as well as acquired forms have all been described. The acquired forms are listed in Table 52-1, and most are discussed in detail elsewhere in this text. Other genodermatoses associated with PPK are listed in Table 52-2. Clinically, three distinct clinical patterns of PPK may be identified [1]:

Keratoderma	Chapter Reference
AIDS-associated	225
Anemical keratoses	79
Calluses	130
Climacteric keratoderma	144
Corns (clavi)	130
Eczema	125
Human papillomavirus	223
Keratoderma blenorrhagicum	182
Lichen planus	49
Norwegian scabies	238
Paraneoplastic keratoderma	184
Psoriasis	42
Reiter's syndrome	182
Secondary syphilis	228
Tinea pedis	205
Sézary syndrome	157
Tuberculosis verrucosa cutis	200

TABLE 52-1 **The Acquired Keratodermas**

Genodermatosis	Chapter Reference
Basal cell nevus syndrome	82
Congenital bullous ichthyosiform erythroderma	51
Darier-White disease (keratosis follicularis)	54
Epidermodysplasia verruciformis (Lewandowsky-Lutz)	223
Epidermolysis bullosa simplex (Dowling-Meara)	65
Ichthyosis vulgaris (autosomal dominant type)	51
Lamellar ichthyosis (autosomal dominant and recessive type)	51
Pityriasis rubra pilaris (familial type)	45

TABLE 52-2 **Other Genodermatoses Associated with Palmoplantar Keratoderma**

1. *Diffuse PPK,* which is characterized by an even, thick, symmetric hyperkeratosis over the whole of the palm and sole. This pattern is usually evident at birth or in the first few months of life.
2. *Focal PPK,* in which large, compact masses of keratin develop at sites of recurrent friction, principally on the feet, although also on the palms and other sites. The pattern of calluses in this focal group may be either discoid (nummular) or linear.
3. *Punctate PPK,* in which multiple tiny “raindrop” keratoses involve the palmoplantar surface. They may involve the whole of the palmoplantar surface or may be more restricted in their distribution (i.e., palmar creases). Considerable intra- and interfamily variation is often seen.

Historically, emphasis in clinical diagnosis has been placed on the extent of spread (*transgrediens*) of the keratoderma onto the wrists, dorsa of the hands, knuckles, elbows, and knees. *Transgrediens* is a highly variable feature, even within the same family, and probably represents little more than the normal variation in the extent of ridged skin in that particular patient. Similarly, the progression with age (*progrediens*) is unhelpful because many of the keratodermas are induced by physical trauma; thus the severity of the keratoderma may reflect the physical activity of that patient.

The keratodermas additionally are classified into three further subgroups [2] as summarized in Table 52-3:



TABLE 52-3 **The Complex PPKs**

1. *Simple keratodermas* with only PPK
2. *Complex keratodermas* with PPK associated with lesions of nonvolar skin, hair, teeth, nails, and/or sweat glands, including the ectodermal dysplasias
3. *Syndromic keratodermas* with PPK associated with abnormalities of other organs, including deafness and cancer

The differentiation of the simple PPKs, in which only the skin is involved, from those in which multiple ectodermal structures are involved (derived from the embryonic ectoderm) is important in the classification of the keratodermas. To understand how PPK may be associated with more generalized anomalies, it is useful to consider their embryonic origins in relation to other organ systems that may be involved in these diseases. The ectoderm of the flat trilaminar embryo contributes to the whole of the surface ectoderm, including the epidermis, hair, nails, cutaneous and mammary glands, anterior pituitary gland, enamel of the teeth, inner ear, and lens. In addition, the neuroectoderm-derived structures include the neural crest (cranial and sensory nerves, medulla of adrenal gland, and pigment cells) and the central nervous system (including the retina, pineal body, and posterior pituitary gland).

Although many of the structural proteins found in the specialized palmoplantar epidermis are not palmoplantar-specific, others such as keratin K9 are unique to this site. Keratins K6 and K16 are found in the palmoplantar epidermis, nail plate, hair follicle, oral mucosa, sweat gland, and larynx but not in normal skin. Thus abnormalities of these keratins are likely to be distributed clinically in these sites. Keratin K17 has a limited basal expression in the palmoplantar epidermis but is expressed extensively in the outer hair root sheath and the nails; abnormalities of this keratin are likely in these sites. The codistribution of certain structural proteins with other tissues (e.g., muscle, nerve, and brain) may explain some genetic diseases associated with multiple organ involvement, such as epidermolysis bullosa simplex with muscular dystrophy in which plectin mutations [3] have been identified and connexin mutations associated with PPK and deafness. [4] With our greater understanding of the molecular biologic basis of many of these diseases, a modified clinical classification of the PPKs is evolving. [1], [2]

SIMPLE KERATODERMAS

Diffuse PPK

DIFFUSE EPIDERMOLYTIC PPK (PPK cum degeneratione granulosa Vörner, Vörner's epidermolytic PPK)
Clinical features Diffuse epidermolytic PPK is one of the most common patterns of PPK. It is an autosomal dominant condition that presents within the first few months of life. The keratoderma presents as a well-demarcated, symmetric thickening of palms and soles and often has a “dirty” snakeskin appearance due to the underlying epidermolysis (Fig. 52-1). Knuckle pads have been reported rarely, and there may be minimal involvement of the elbows and knees.

FIGURE 52-1 Epidermolytic palmoplantar keratoderma. A “dirty” keratoderma involving the entire palmar surface is demonstrated. (*Courtesy of Royal Hospitals Trust, United Kingdom.*)

Histology There is marked hyperkeratosis, acanthosis, and papillomatosis. Keratinocytes throughout the spinous and granular cell layers show epidermolysis with keratin aggregates and cytolysis. Since epidermolysis is easily missed if the biopsy is performed from the edge of the palm or sole, it is important to biopsy a weight-bearing area or the thenar or hypothenar eminence. A family has been described in whom epidermolysis was associated with a tonotubular cytoskeleton. [5]
Associated malignancy There is no association with malignancy. There was a reported link with breast and ovarian cancer in a French family, but this was a result of two distinct mutations cosegregating in a family, a keratin 9 mutation underlying the PPK and a BRCA1 mutation associated with the cancer susceptibility.
Genetics Keratin 9 mutations have been reported in an increasing number of families. [6] In other families with a milder form of epidermolytic PPK, a keratin 1 mutation has been demonstrated. [7]
Treatment Oral retinoid therapy may be helpful but may lead to desquamation of the whole palmoplantar surfaces, resulting in painful erosions.
DIFFUSE NONEPIDERMOLYTIC PPK (Unna-Thost disease, diffuse orthohyperkeratotic keratoderma, tylosis, keratosis palmoplantaris diffusa circumscripta, keratosis extremitatum progrediens)

Clinical features The keratoderma is inherited as an autosomal dominant condition and is present from infancy. Clinically, there is a well-demarcated, symmetric, often “waxy” keratoderma involving the whole of the palms and soles (Fig. 52-2) with a sharp cutoff at the wrist. Spread of the hyperkeratosis to the dorsa of the hands and wrists is a variable feature within most pedigrees. The dorsa of the fingers are often involved, with a scleroderma-like thickening of the skin distal to the proximal interphalangeal joint. “Parrot beaking” of the fingernails and widening of the onychocorneal band are characteristic. A “cobblestone” hyperkeratosis of the knuckles may be seen, but the elbows and knees are rarely involved.

FIGURE 52-2 Diffuse nonepidermolytic palmoplantar keratoderma. Note the waxy keratoderma involving the entire plantar surface with involvement of the non-weight-bearing digits. (*Courtesy of Royal Hospitals Trust, United Kingdom.*)

Spread of the keratoderma to the dorsum of the hand and to the wrist has led to the attribution of *PPK of Sybert* in some of these families. Secondary dermatophyte infection, leading to maceration and peeling of the palms and soles, is a common complication of this pattern of keratoderma.

Histology The histology of this pattern of keratoderma is nonspecific and is distinguished from epidermolytic PPK by the absence of epidermolysis. The existence of this pattern of PPK has been questioned as a result of reexamination of the histology of the index family of Unna-Thost disease, which has led subsequent authors to suggest that this disease does not exist as a distinct clinical entity. [2]

Genetics Disease in a number of families has now been linked to chromosome region 12q11-q13, which harbors the type II keratin gene cluster. In these families, keratin mutations have been excluded by fine mapping and sequence analysis. [8] However, in one family in which the keratoderma is not restricted to the palmoplantar epidermis, a mutation in the V1 region of keratin 1 has been reported. [9] This region of keratin 1 has been suggested to have a role in keratin-loricrin interactions.

Treatment The disease responds well to oral retinoids. Before starting therapy, it is important to biopsy the thenar or hypothenar eminence to exclude epidermolytic PPK. Long-term treatment with a systemic antifungal agent, itraconazole 100 mg daily, is beneficial in these patients when dermatophyte infection coexists. Topical Whitfield's ointment is a useful keratolytic.

MAL DE MELEDA (Mutilating PPK of the Gamborg-Nielsen type, acral keratoderma, PED [palmoplantar ectodermal dysplasia] type VIII)

Clinical features This autosomal recessive keratoderma presents at birth or in early infancy. The keratoderma is diffuse, symmetrically involving the palms and soles with spread to the dorsa of the hands in a glove-and-stocking distribution. Knuckle pads with elbow and knee hyperkeratosis have been described. Constricting bands (pseudoainhum) around the digits may develop, resulting in loss of function and autoamputation of digits. Koilonychia, subungual hyperkeratosis, longitudinal grooving, onychogryphosis, and leukokeratosis also have been described. Other associations include angular cheilitis, hyperhidrosis, and poor physical development with electroencephalographic anomalies and brachydactyly. A case associated with perioral erythema reported by Brambilla and colleagues may represent a case of Olmsted's syndrome. [10]

Associated malignancy There is no clear association, although there have been four reports of malignant melanomas developing in affected palmoplantar epidermis and a single report of squamous cell carcinoma of affected skin. [1]

Histology The palmoplantar epidermis shows compact orthokeratosis, acanthosis, and hypergranulosis without epidermolysis.

Genetics The disease maps to chromosome 8q24.3, and mutations in the gene encoding SLURP1 have been identified. [11] The protein is thought to be secreted and involved in cell signaling and adhesion.

Treatment Clinical improvement is seen with retinoids, and the pseudoainhum may be treated with either retinoids or Z-plasty to relieve the constriction.

Simple Focal PPK

STRIATE PPK (Brünauer-Fuhs-Siemens type, keratosis palmoplantaris varians, Wachters PPK, acral keratoderma)

Clinical features This is an autosomal dominant keratoderma principally involving the soles with onset in infancy or the first few years of life. The hands may show minimal callous formation; however, with manual labor, a striate pattern of PPK is seen over the palmar aspects of the digits (Fig. 52-3). Elbow and knee involvement is seen variably. Patients also report increased skin fragility, with the skin splitting following trauma, but blistering does not occur. Nails and hair may be variably involved, with ridging of the nails and cuticular hyperkeratosis; woolly hair has been reported in a few individuals.

FIGURE 52-3 Striate keratoderma. Linear calluses extend up the fingers; this phenotype is highly variable even within the same family. (*Courtesy of Royal Hospitals Trust, United Kingdom.*)

Histology /I>*The histology of the palmar plantar epidermis shows nonspecific changes, with marked hyperkeratosis, acanthosis, and papillomatosis but without any epidermolysis.*
Genetics *Mutations in two desmosomal proteins have been shown to cause the simple form of striate PPK. These are in the gene for desmoglein 1 on chromosome 18q11-12 or the desmoplakin gene on chromosome 6p21.* [12], [13] *A mutation in the V2 domain of keratin 1 is also associated with striate PPK.* [14]

Simple Punctate PPK

KERATOSIS PUNCTATA PALMARIS ET PLANTARIS *(Buschke-Fischer-Brauer disease, keratosis papulosa, papulotranslucent acrokeratoderma, keratoderma punctatum, maculosa disseminata, Davis Colley disease)*
Clinical features *This autosomal dominant PPK with variable penetrance develops at 12 to 30 years of age. Clinically, there are multiple, tiny, punctate keratoses over the entire palmoplantar surfaces, but they begin over the lateral edge of the digits. Lesions are induced by physical trauma and made worse by paring and/or chiropody. The punctate keratoses coalesce into a more diffuse pattern over the pressure points of the sole. Variable nail changes have been described but are an inconsistent part of the phenotype. An association with diverse malignancies in a few families is likely to have occurred by chance.*
SPINY KERATODERMA *(Punctate keratoderma, punctate porokeratosis of the palms and soles, porokeratosis punctata palmaris et plantaris)*
Clinical features *This is an autosomal dominant keratoderma of late onset that develops in patients aged 12 to 50 years. Multiple tiny keratotic plugs, mimicking the spines on a music box, involve the entire palmoplantar surfaces.* [15] *It may be associated with facial sebaceous hyperplasia. Histology shows columnar parakeratosis, which resembles the cornoid lamella of porokeratosis, with a poorly developed granular cell layer.* [15]
FOCAL ACRAL HYPERKERATOSIS *(Acrokeratoelastoidosis lichenoides, degenerative collagenous plaques of the hands)*
Clinical features *A late-onset keratoderma, inherited as an autosomal dominant condition, presents with oval or polygonal crateriform papules developing along the border of the hands, feet, and wrists.* [16] *A more confluent pattern is seen over the palms or soles to give a diffuse pattern. The disease is principally found in black races. Elastorrhexis has been reported.* [16]

COMPLEX KERATODERMAS

Complex Diffuse PPK

ERYTHROKERATODERMA VARIABILIS *(Progressive symmetric erythrokeratoderma, keratosis palmoplantaris transgrediens et progrediens, keratosis extremitatum progrediens)*
Clinical features *This keratoderma is inherited in an autosomal dominant fashion. The PPK is evident in infancy and increases in severity throughout childhood. Sharply outlined geographic areas of erythrokeratoderma are distributed symmetrically over the body. Erythematous desquamation of the palms and soles with hyperhidrosis is characteristic, but the disease is not palmoplantar-specific. Spread of the keratoderma to the dorsa of the hands and feet is seen commonly. Associated defects are rare in erythrokeratoderma variabilis (EKV); however, neurologic anomalies (deafness, peripheral neuropathy, decreased tendon reflexes, nystagmus, dysarthria, and cerebellar ataxia) and onychodystrophy have been described.*
Histology *Histology is not diagnostic and shows only orthohyperkeratosis and acanthosis with a well-preserved granular cell layer. Electron microscopy is normal apart from the stratum granulosum, where a prominent tonofilament-keratohyalin complex envelops a clear cytoplasmic halo around an often-crenellated nucleus.* [17]
Genetics *EKV has been mapped to the chromosomal region 1p35-p34, and mutations in the genes encoding either connexin 31 (Cx31) or connexin 30.3 (Cx30.3) have been identified in some cases.* [18], [19] *However, a family with a disease with clinical similarities to EKV, progressive symmetric erythrokeratoderma (PSEK), has been described associated with a mutation in loricrin.* [20]
Treatment *Good results are obtained with oral retinoid therapy.*
PPK OF SYBERT *(Greither palmoplantar keratoderma, keratosis palmoplantaris transgrediens et progrediens, keratosis extremitatum hereditaria progrediens)*
Clinical features *PPK of Sybert is an extremely rare autosomal dominant keratoderma with symmetric severe involvement of the whole palmoplantar surface in a glove-and-stocking distribution. Spread of the keratoderma involves elbows and knees.* [21] *Pseudoainhum formation with amputation of the digits has been described.*
Histology *The histology of involved skin demonstrates accumulation of lipid-laden cells in the stratum corneum, giving the cells a clear, punctate profile. Amyloid deposition has been noted in the superficial zone of the papillary dermis after treatment with retinoids.*
Treatment *Good clinical responses have been obtained with systemic retinoids.*
OLMSTED SYNDROME *(Mutilating palmoplantar keratoderma with periorificial keratotic plaques, polykeratosis of Touraine)*
Clinical features *With the exception of one family in which a mother and son were affected, suggesting autosomal dominant transmission, all cases are sporadic. Diffuse multilating keratoderma of the palms and soles with flexion deformity of the digits begins in infancy.* [22] *Constricting bands around the digits lead to autoamputation of the digits. There*

are progressive perioral, perianal, and perineal hyperkeratotic plaques that may extend to the inner thigh and groin. [22] Alopecia, deafness, nail dystrophy, and dental loss have all been reported. Corneal epithelial dysplasia, leading to corneal scarring and visual impairment, has been reported in one patient, and leukokeratosis has been reported in two patients. Acrodermatitis enteropathica needs to be excluded by measurement of serum zinc levels.

Histology Plantar biopsy demonstrates marked hyperkeratosis without parakeratosis and mild acanthosis with an intact granular layer.

Treatment Skin grafting of the palmar surface has resulted in considerable clinical improvement. [22]

CONGENITAL POIKILODERMA WITH TRAUMATIC BULLA FORMATION, ANHIDROSIS, AND KERATODERMA (Naegeli-Franceschetti-Jadassohn syndrome)

Clinical features This autosomal dominant condition, with onset within the first few years of life, presents with reticulate pigmentation, which may be extensive and not preceded by any inflammation. The pigmentation particularly involves the neck and axilla. A diffuse keratoderma with punctiform and linear accentuations is usually seen, and adermatoglyphia occurs. The hair is normal, but variable nail changes have been described, from almond nails to onychodystrophy. The teeth have enamel defects, are abnormally shaped, and are lost early. Hypohidrosis or anhidrosis is the principal problem, leading to heat intolerance. [23] Since this disorder was considered initially to be a noninflammatory variant of incontinentia pigmenti, transitional cases between the two syndromes have been described.

Histology Skin biopsy typically shows patchy hyperpigmentation of the epidermis and marked secondary pigmentary incontinence, with numerous melanophages, containing melanin granules, in the upper dermis. Eccrine glands appear normal in size and number. [24]

Genetics The disease has been mapped to chromosomal region 17q21-q25.

Complex Focal PPK

PACHYONYCHIA CONGENITA TYPE I (Jadassohn-Lewandow-sky syndrome)

Clinical features This autosomal dominant keratoderma principally involves the plantar surfaces. Onset of plantar calluses may be delayed up to 7 years of age. Nail changes may be evident at birth but more commonly develop within the first few months of life (Fig. 52-4). They are characterized by an upward angulation of the distal end of the nail as a result of subungual hyperkeratosis, giving the characteristic “door wedge” distal hyperkeratosis. Calluses develop over the plantar pressure points; palmar calluses are not seen except in manual workers. Blistering may occur on walking. Hair abnormalities and oral, laryngeal, and follicular hyperkeratosis have all been described.

FIGURE 52-4 Pachyonychia congenita type I. This figure demonstrates a focal PPK involving most of the plantar surface but with sparing of the non-weight-bearing digits. (Courtesy of Royal Hospitals Trust, United Kingdom.)

Histology Epidermolysis mirrors the distribution of keratin K6 and K16 within the epidermis. Keratinocyte tonofilament condensation has been described in the palmoplantar epidermis.

Genetics K16 and K6a mutations have been identified in a number of families. [26], [27]

FOCAL PALMOPLANTAR KERATODERMA WITH ORAL MUCOSAL HYPERKERATOSIS (Keratosis palmoplantaris nummularis, hereditary painful callosity syndrome, keratosis follicularis)

Clinical features This disease represents a clinical overlap syndrome with pachyonychia congenita type I but without the classic nail involvement. It is an autosomal dominant keratoderma in which calluses develop over plantar pressure points. Sparing of palms occurs except in manual workers. Oral hyperkeratosis is seen, particularly involving the labial attached gingiva. The follicular hyperkeratosis evident over the arms and legs becomes less prominent with age. Nail changes range from widening of the onychocorneal band with splinter hemorrhages to the door-wedge subungual hyperkeratosis characteristic of pachyonychia type I. Blistering may occur on walking, thus limiting physical activity. Epidermolysis is a variable feature. [28]

Histology Epidermolysis may or may not be present in the plantar epidermis.

Genetics Mutations in the helix initiation region of keratin K16 have been described. [28]

Treatment Symptomatic chiropody is often beneficial to pare off excess calluses. Oral retinoids may result in rapid improvement but can lead to desquamation of the calluses and markedly increased pain. If used, they should be started at low dosage. Secondary fungal infection of the calluses results in splitting and increased pain. Symptomatic improvement may be obtained from systemic antifungal agents in patients with superimposed fungal infections.

PACHYONYCHIA CONGENITA TYPE II (Jackson-Sertoli syndrome, Jackson-Lawler pachyonychia congenita)

Clinical features This is an autosomal dominant keratoderma presenting with a limited focal plantar keratoderma that may be very minor. Nail changes may be evident at birth but more commonly develop within the first few months of life. The nail changes are characterized by an upward angulation of the distal end of the nail as a result of subungual hyperkeratosis to give the characteristic door-wedge distal hyperkeratosis. Multiple epidermal cysts and steatocystoma are seen. All individuals have woolly scalp hair, and the eyebrows grow straight out, giving a bushy appearance. Natal teeth are seen variably. [26]

Histology Keratin filament aggregation is restricted to sites of keratin K17 and K6b expression, particularly the deep outer hair root sheath and ducts of the sebaceous glands. The exact histology of the cysts seen in both pachyonychia

congenita type II and steatocystoma multiplex depends on the part of the pilosebaceous unit involved. Most consist of vellous hair cysts, but epidermal cysts, keratin-filled cysts, and steatocysts also may be seen.
Genetics *Mutations in K17 and K6b have been described in a number of families.* [26], [29]
PAPILLON-LEFÈVRE SYNDROME
Clinical features *This autosomal recessive disease develops within the first few months of life. The pattern is focal and involves most of the palmoplantar surface with punctiform accentuation in some areas, particularly along the palmoplantar creases* [30] *(Fig. 52-5). Spread of the keratoderma to the dorsa of the hands and to the Achilles' tendons, elbows, and knees is found in some cases. Severe periodontitis occurs following eruption of deciduous dentition and recurs with permanent dentition. A subtle, generalized, whitish opalescence of the oral mucosa has been described. Transverse ridging of nails, onychogryphosis, and sheeted follicular hyperkeratosis have all been described. A proneness to infections also has been reported.*

FIGURE 52-5 Papillon-Lefèvre syndrome. A complex pattern of keratoderma with focal and punctate lesions involving the sole is demonstrated. (Courtesy of Royal Hospitals Trust, United Kingdom.)

Histology *The skin lesions show hyperkeratosis with occasional parakeratotic patches, acanthosis, and slight perivascular infiltrates. The periodontal lesions are characterized by pocket formation, with secondary ulceration of the pocket epithelium and a mixed inflammatory cell infiltrate.* [30]
Genetics *The disease maps to chromosome 11q14-q21, and mutations have been identified in the gene encoding the lysosomal protease cathepsin C.* [31]
Treatment *Clinical improvement in the severity of the PPK may be observed with the use of systemic retinoids. The loss of the teeth cannot be stopped, but elective extraction of involved teeth may prevent excess bone resorption. Recurrent infections may be serious and require appropriate antibiotic therapy.*

Ectodermal Dysplasias

HIDROTIC ECTODERMAL DYSPLASIA *(Fischer-Jacobsen-Clouston syndrome, alopecia congenita with keratosis palmoplantaris, keratosis palmaris with drumstick fingers, PPK and clubbing) This entity is discussed in Chap. 53.*
ACROKERATOTIC POIKILODERMA *(Hyperkeratosis-hyperpigmentation syndrome* [32] *)*
Clinical features *This is an autosomal dominant keratoderma; patients present with hyperpigmentation at approximately 12 years of age, with the PPK delayed until 15 years of age. The keratoderma has a cobblestoned appearance, with spread to the dorsa of the hands and feet. Poikiloderma is seen, particularly in the sun-exposed areas, and is associated with acral bullae formation and acral lichenoid keratoses. Two families have been described with poikiloderma developing in early childhood associated with a gradual palmoplantar sclerosis and leading to the development of linear or reticulate sclerotic or hyperkeratotic bands with a flexural acral distribution.* [33]
DERMATOPATHIC PIGMENTOSA RETICULARIS *(Dermatopathia pigmentosa reticularis hypohidotica et atrophica, dermatopathia pigmentosa reticularis hyperkeratotica et mutilans)*
Clinical features *This is a rare inherited disorder of presumed autosomal dominant inheritance that presents with reticulate hyperpigmentation with truncal accentuation.* [34] *A number of other associated features have been described, including onychodystrophy, alopecia, adermatoglyphia, pigmentation of the oral mucosa, and ocular abnormalities (lachrymal keratosis, corneal punctae, and pigmentation of Bowman's membrane).* [35] *Palmoplantar hyperkeratosis with punctiform accentuation is seen, and generalized dry ichthyosis, hypohidrosis, and widespread scattered keratotic lesions have been described.* [34] *Ainhum formation, traumatic bullae formation, and severe periodontal disease also have been described.*
Histology *Striking localized pigmentary incontinence with clumps of melanin-filled macrophages and liquefaction degeneration of the basal cell layer are reported. A diffuse hyalinized change of the dermal collagen is a consistent feature.*

Syndromic Keratodermas

PALMOPLANTAR KERATODERMA ASSOCIATED WITH ESOPHAGEAL CANCER *(Palmoplantar ectodermal dysplasia type III, tylosis)*
Clinical features *This autosomal dominant keratoderma occurs with late onset. The keratoderma principally is of the focal type involving the plantar pressure points (Fig. 52-6). More diffuse patterns may be seen in some patients, but the non-weight-bearing digits are always spared. The age of onset is usually between 7 and 8 years of age. The palms are usually not involved, but there may be callus formation in manual workers. Oral leukokeratosis often predates the onset of the PPK and involves the buccal mucosa more than the labial attached gingival mucosa.* [1] *Widespread follicular hyperkeratosis is evident, particularly in children. The nails are normal, and this is an important differentiating feature from focal PPK with oral hyperkeratosis.*

FIGURE 52-6 Palmoplantar keratoderma associated with esophageal malignancy. Note the focal PPK involving most of the plantar surface but with sparing of the non-weight-bearing digits. (Courtesy of Royal Hospitals Trust, United Kingdom.)

Associated malignancy *The risk of developing esophageal squamous cell carcinoma in these families has been reported as between 40 and 90 percent of those affected by age 65.* [1], [36] *Oral squamous cell carcinomas also have been reported, and there may be an increased incidence of other tumors.*
Histology *Acanthosis of the sole and palm skin with a prominent granular cell layer and marked hyperkeratosis without parakeratosis are seen. The sweat ducts of the dermis are thickened, and the epithelium is hyperplastic, appearing to occlude the lumen in places.*
Genetics *In three families, the disease has been mapped to chromosomal region 17q25.* [36]
OCULOCUTANEOUS TYROSINEMIA *(Tyrosinemia type II, Richer-Hanhart syndrome; see also Chap. 147)*
Clinical features *This is an autosomal recessive condition with onset between ages 2 and 4 years, when painful circumscribed callosities develop on the pressure points of the palm and sole. Occasionally, calluses also may develop on the elbows and knees. Photophobia and corneal erosions develop within the first few months of life. The corneal erosions may progress to corneal ulceration and glaucoma. Mental retardation develops if patients are not treated.* [37]
Histology *Histology of the palmoplantar lesions may be helpful diagnostically in demonstrating eosinophilic cytoplasmic inclusions.*
Genetics *Tyrosine aminotransferase deficiency is the underlying metabolic defect; it results in raised serum tyrosine and phenolic acid metabolites.* [38]
Treatment *When patients are placed on a low-tyrosine, low-phenylalanine diet, the cutaneous and ocular manifestations disappear.*
VOHWINKEL SYNDROME *(Keratoma hereditaria multilans* [39]*)*
Clinical features *This diffuse autosomal dominant keratoderma with onset in early infancy presents with a honeycombed keratoderma involving the palmoplantar surfaces. Flexion contractures and constricting bands of digits, particularly of the fifth digit, result in autoamputation (Fig. 52-7). Spread of the keratoderma occurs with linear and/or starfish keratoses on the extensor surfaces of the elbows, knees, and knuckles. Mild to moderate sensorineural hearing loss is often associated. A diffuse, generalized ichthyosiform dermatosis may be seen in some affected individuals and is specific to the form associated with normal hearing, which is due to loricrin mutations. Nail dystrophy, alopecia, onychogryphosis, and a variety of neurologic abnormalities other than sensorineural hearing loss, such as spastic paraplegia, and myopathy have been described.*

FIGURE 52-7 Vohwinkel syndrome. Note the diffuse pattern of keratoderma with pseudoainhum formation. (Courtesy of Department of Dermatology, University of Heidelberg, Germany.)

Histology *Histopathology demonstrates the characteristic feature of hyperkeratosis and “round” retained nuclei with hypergranulosis.*
Genetics *Mutations in the gene encoding the gap junction protein, connexin 26, underlies the classical form of Vohwinkel's syndrome.* [40] *A mutation in loricrin (a major component of the cornified cell envelope) has been associated with Camisa disease, the variant form of Vohwinkel's with ichthyosis and normal hearing.* [41] *Other forms of PPK with sensorineural hearing loss have been shown to be due to mitochondrial mutations.* [42]
Treatment *The keratoderma and pseudoainhum respond well to systemic retinoids.*
HURIEZ SYNDROME *(PPK with sclerodactyly, scleroatrophic and keratotic dermatosis of limbs, sclerotylosis)*
Clinical features *This autosomal dominant keratoderma with sclerodactyly presents from birth with a diffuse symmetric keratoderma of the palms and soles. The fingers have a pseudosclerodermatous appearance. Atrophic fibrosis of limb skin also may be seen. Variable nail features have been described, with longitudinal ridging hypoplasia and clubbing.*

Associated malignancy *Squamous cell carcinoma develops in the atrophic skin in the third to fourth decades,* [35] *and bowel cancer also has been described in association with this phenotype. An Indian pedigree with "tylosis" and cancer is probably of this type.* [43]

Genetics *The disease gene has been mapped to chromosomal region 4q23.* [44]

DIFFUSE PPK, WOOLLY HAIR AND ARRYTHMOGENIC RIGHT VENTRICULAR CARDIOMYOPATHY *(Naxos disease)*

Clinical features *Both recessive and dominant conditions have been described. The recessive disorder (Naxos disease) has a clear association with cardiomyopathy. The disorder is characterized by the development, during infancy, of a diffuse keratoderma over the plantar pressure points. Other cutaneous anomalies include acanthosis nigricans of the axilla and groin, diffuse xerosis, follicular hyperkeratosis over the zygoma, and palmoplantar hyperhidrosis. Woolly hair over the scalp and short, scanty eyebrows, eyelashes, beard, and axillary and pubic hair are seen. Nails, teeth, and sweat gland function are all normal. Endomyocardial fibrodysplasia with ventricular tachycardia and right ventricular dilatation with right ventricular bands have been reported.* [45]

Histology *Skin biopsy demonstrates compact hyperkeratosis, hypergranulosis, and acanthosis.*

Genetics *The recessive disorder maps to chromosomal region 17q21 and is due to mutations in the desmosomal and adherens junction protein plakoglobin.* [46]

STRIATE PPK, WOOLLY HAIR AND LEFT VENTRICULAR DILATED CARDIOMYOPATHY

Clinical features *Both dominant and recessive forms have been described but only the recessive forms have a clear association with cardiomyopathy. The skin disease presents as a striate PPK with some nonvolar involvement, particularly at sites of pressure or abrasion.* [47], [48] *Cardiologic investigation of a number of affected family members has been reported with the diagnosis of a left ventricular dilated cardiomyopathy often resulting in heart failure during adolescence.*

Histology *Histology of the skin of patients with the recessive form of the condition reveals large intercellular spaces between suprabasal keratinocytes. Basal cells, however, appeared normal. Electron microscopy of affected palmar skin shows clumping of desmosomes at the sites of cell-cell adhesion.*

Genetics *The recessive form of the condition maps to chromosomal region 6p24, and mutations in the desmosomal protein desmoplakin have been demonstrated.* [48]

KERATITIS-ICHTHYOSIS-DEAFNESS (KID) SYNDROME *(Ichthyosiform erythroderma, corneal involvement, and deafness; Desmons' syndrome* [49], [50] *)*

Clinical features *This autosomal recessive disorder with sensorineural deafness presents from birth. Ichthyosiform erythroderma develops with a well-marginated serpiginous outline. Follicular hyperkeratosis, changes perioral furrowed plaques, and oral leukokeratosis have been described. Other changes include a diffuse keratoderma with a reticulate surface, recurrent infections, sensorineural deafness, keratoconjunctivitis and photophobia, hepatitis, mental retardation, and skeletal abnormalities with short stature and pes cavus. Hypotrichosis and nail dystrophy may occur.*

Histology *Epidermal glycogen deposition has been reported in one patient.*

Associated malignancy *Multiple cutaneous squamous cell carcinomas are seen.*

CORNEODERMATOSSEOUS SYNDROME *(CDO syndrome* [51] *)*

Clinical features *The characteristic features of this autosomal dominant condition with onset in infancy include corneal dystrophy, photophobia, diffuse PPK, distal onycholysis, skeletal abnormalities with brachydactyly, short stature, and medullary narrowing of digits. The teeth are soft and subject to early decay.*

PALMOPLANTAR KERATODERMA AND SPASTIC PARAPLEGIA *(Charcot-Marie-Tooth disease with PPK and nail dystrophy* [52] *)*

Clinical features *This autosomal dominant or X-linked dominant keratoderma begins in early childhood with a thick focal keratoderma over the soles and to a lesser extent the palms. Punctate keratoderma has been described in one family.* [53] *Pes cavus, frontal balding, spastic paraplegia (motor and sensory neuropathy), and mental retardation are reported. Muscular atrophy that develops at approximately 40 years of age starts in the lower legs, with weakness, progressive gait difficulties, and stumbling. Nail dystrophy is an inconsistent feature.* [52]

Histology *Palmar biopsy shows pronounced orthokeratosis, acanthosis, and regular papillomatosis.*

Genetics *A mutation in the neurofilament-light gene is associated with Charcot-Marie-Tooth type II and PPK in a single family.* [54]

EYELID CYSTS, PALMOPLANTAR KERATOSIS, HYPODONTIA, AND HYPOTRICHOSIS *(Schöpf-Schulz-Passarge syndrome* [55] *)*

Clinical features *This is an autosomal recessive condition with diffuse symmetric PPK. PPK and fragility of the nails begin around age 12. Hair becomes sparse by age 25, and cysts of the eyelid margins occur at age 60. Other changes include facial telangiectasia, early loss of teeth, generalized hypotrichosis, and longitudinal and oblique furrows in nails.*

Associated malignancy *Multiple squamous cell carcinomas in the area of the palmoplantar keratoderma are reported, as well as eccrine poromas, hypernephroma, and basal cell carcinoma.* [55]

Histology *Apocrine hidrocystoma of the eyelid margins is one manifestation.*

CARDIOFACIOCUTANEOUS SYNDROME [56]

Clinical features *This is reported as an autosomal recessive condition, but autosomal dominant transmission cannot be excluded. Typical features include a characteristic "high boxy" craniofacial appearance, psychomotor and growth retardation, and congenital cardiac defects. Various hair defects have been reported with focal PPK. Alopecia, reduced eyebrows and body hair, and curly, woolly, and brittle hair are all described. The skin manifestations include ichthyosis, follicular hyperkeratosis, keratosis pilaris atrophicans faciei, unpleasant body odor, cavernous hemangiomas, café-au-lait spots, and hyperpigmented macules or stripes. The nails are dystrophic, and there is dysplasia of the teeth.*

Histology *Nonspecific features of ichthyosis with hyperkeratosis of the epidermis and thinning of the granular layer are seen. In one patient, scalp biopsy showed adnexal hyperkeratosis with hyperplasia and dystrophy of sweat ducts. The hair follicles were immature or disrupted by inspissated keratin.*

REFERENCES

1. *Stevens HP et al: Linkage of an American pedigree with palmoplantar keratoderma and malignancy (palmoplantar ectodermal dysplasia type III) to 17q24: Literature survey and propsed updated classification of the palmoplantar keratodermas. Arch Dermatol* ***132****:640, 1996*

2. *Hatsell S, Kelsell D: The diffuse palmoplantar keratodermas. Acta Dermatoven APA* ***9****:47, 2000*

3. Smith FJD et al: Plectin deficiency results in muscular dystrophy with epidermolysis bullosa. Nature Genet **13**:450, 1996

4. Kelsell DP et al: Connexin mutations in skin disease and hearing loss. Am J Hum Genet **68**:559, 2001

5. Wevers A et al: Palmoplantar keratoderma with tonotubular keratin. J Am Acad Dermatol **24**:638, 1991

6. Reis A et al: Keratin 9 gene mutations in epidermolytic palmoplantar keratoderma (EPPK). Nature Genet **6**:174, 1994

7. Hatsell SJ et al: Novel splice site mutation in keratin 1 underlies mild epidermolytic palmoplantar keratoderma in three kindreds. J Invest Dermatol **116**:606, 2001

8. Kelsell DP et al: Fine genetic mapping of diffuse non-epidermolytic palmoplantar keratoderma to chromosome 12q11-q13: Exclusion of the mapped type II keratins. Exp Dermatol **8**:388, 1999

9. Kimonis V et al: A mutation in the V1 end domain of keratin 1 causes non-epidermolytic palmar-plantar keratoderma. J Invest Dermatol **103**:764, 1994

10. Brambilla L et al: Unusual case of Meleda keratoderma treated with aromatic retinoid etretinate. Dermatologica **168**:283, 1994

11. Fischer J et al: Mutations in the gene encoding SLURP-1 in mal de meleda. Hum Mol Genet **10**:875, 2001

12. Rickman L et al: N-terminal deletion in a desmosomal cadherin causes the autosomal dominant skin disease striate palmoplantar keratoderma. Hum Mol Genet **8**:971, 1999

13. Armstrong D et al. Haploinsufficiency of desmoplakin causes a striate subtype of palmoplantar keratoderma. Hum Mol Genet **8**:143, 1999

14. Whittock NV et al: Frameshift mutation in the V2 domain of keratin 1 causes the striate form of palmoplantar keratoderma. J Invest Dermatol **118**:838, 2002

15. Osman Y et al: Spiny keratoderma of the palms and soles. J Am Acad Dermatol **26**:879, 1992

16. Dowd PM et al: Focal acral hyperkeratosis. Br J Dermatol **109**:97, 1983

17. MacFarlane AW et al: Is erythrokeratoderma one disorder? A clinical and ultrastructural study of two siblings. Br J Dermatol **124**:487, 1991

18. Richard G et al: Mutations in the human connexin gene GJB3 cause erythrokeratodermia variabilis. Nature Genet **20**:366, 1998

19. Macari F et al: Mutation in the gene for connexin 30.3 in a family with erythrokeratodermia variabilis. Am J Hum Genet **67**:1296, 2000

20. Ishida-Yamamoto A et al: The molecular pathology of progressive symmetric erythrokeratoderma: A frameshift mutation in the loricrin gene and pertubations in the cornified cell envelope. Am J Hum Genet **61**:581, 1997

21. Sybert VP et al: Palmar-plantar keratoderma: A clinical, ultrastructural, and biochemical study. J Am Acad Dermatol **18**:75, 1988

22. Atherton DJ et al: Mutilating palmoplantar keratoderma with periorificial keratotic plaques (Olmsted syndrome). Br J Dermatol **122**:245, 1990

23. Itin PH et al: Natural history of the Naegeli-Franceschetti-Jadassohn syndrome and further delineation of its clinical manifestations. J Am Acad Dermatol **28**:942, 1993

24. Sparrow GP et al: Hyperpigmentation and hypohidrosis (the Naegeli-Franceschetti-Jadassohn syndrome): Report of a family and review of the literature. Clin Exp Dermatol **1**:127, 1976

25. Whittock NV et al: The gene for Naegeli-Franceschetti-Jadassohn syndrome maps to 17q21. J Invest Dermatol **115**:694, 2000

26. McLean WHI et al: Keratin 16 and keratin 17 mutations cause pachyonychia congenita. Nature Genet **9**:273, 1995

27. Bowden PE et al: Mutation of a type II keratin gene (K6a) in pachyonychia congenita. Nature Genet **10**:363, 1995

28. Shamsher M et al: Novel mutations in keratin 16 gene underlie focal non-epidermolytic palmoplantar keratoderma (NEPPK) in two families. Hum Mol Genet **4**:1875, 1995

29. Smith FJD et al: A mutation in human keratin K6b produces a phenocopy of the K17 disorder pachyonychia congenita type 2. Hum Mol Genet **7**:1143, 1998

30. Haneke E: The Papillon-Lefèvre syndrome: Keratosis palmoplantaris with periodontopathy. Report of a case and review of the cases in the literature. Hum Genet **51**:1, 1975

31. Toomes C et al: Loss-of-function mutations in the cathepsin C gene result in periodontal disease and palmoplantar keratosis. Nature Genet **23**:421, 1999

32. Cantú JM et al: A “new” autosomal dominant genodermatosis characterised by hyperpigmented spots and palmoplantar hyperkeratosis. Clin Genet **14**:165, 1978

33. Weary PE et al: Hereditary sclerosing poikiloderma: Report of two families with an unusual and distinctive geneodermatosis. Arch Dermatol **100**:413, 1969

34. Maso MJ et al: Dermatopathia pigmentosa reticularis. Arch Dermatol **126**:935, 1990

35. Gahlen W: Dermatopathia pigmentosa reticularis hypohidotica et atrophica. Dermatol Wochenschr **150**:193, 1964

36. Kelsell DP et al: Close mapping of focal non-epidemolytic palmoplantar keratoderma (PPK) locus associated with oesophageal cancer (TOC). Hum Mol Genet **5**:857, 1996

37. Goldsmith LA: Tyrosine-induced skin disease. Br J Dermatol **98**:119, 1978

38. Natt E et al: Point mutations in the tyrosine aminotransferase gene in tyrosinemia type II. Proc Natl Acad Sci USA **89**:9297, 1992

39. Vohwinkel KH: Keratoma hereditarium mutilans. Arch Derm Syph **158**:354, 1929

40. Maestrini E et al: A missense mutation in connexin26, D66H, causes mutilating keratoderma with sensorineural deafness (Vohwinkel's syndrome) in three unrelated families. Hum Mol Genet **8**:1237, 1999

41. Maestrini E et al: A molecular defect in loricrin, the major component of the cornified cell envelope, underlies Vohwinkel's syndrome. Nature Genet **13**:70, 1996

42. Sevior KB et al. Mitochondrial A7445G mutation in two pedigrees with palmoplantar keratoderma and deafness. Am J Med Genet **75**:179, 1998

43. Yesudian P et al: Genetic tylosis with malignancy: A study of a South Indian pedigree. Br J Dermatol **102**:597, 1980

44. Lee YA et al: A gene for an autosomal dominant scleroatrophic syndrome predisposing to skin cancer (Huriez syndrome) maps to chromosome 4q23. Am J Hum Genet **66**:326, 2000

45. Protonotarios N et al: Cardiac abnormalities in familial palmoplantar keratosis. Br Heart J **56**:321, 1986

46. McKoy G et al: Identification of a deletion in plakoglobin in arrhythmogenic right ventricular cardiomyopathy with palmoplantar keratoderma and woolly hair (Naxos disease). Lancet **355**:2119, 2000

47. Carvajal-Huerta L: Epidermolytic palmoplantar keratoderma with woolly hair and dilated cardiomyopathy. J Am Acad Dermatol **39**:418, 1998

48. Norgett EE et al: Recessive mutation in desmoplakin disrupts desmoplakin-intermediate filament interactions and causes dilated cardiomyopathy, woolly hair and keratoderma. Hum Mol Genet **9**:2761, 2000

49. Wilson GN et al: Keratitis, hepatitis, ichthyosis, and deafness: Report and review of KID syndrome. Am J Med Genet **40**:255, 1991

50. Nazzaro V et al: Familial occurrence of KID (keratitis, ichthyosis, deafness) syndrome: Case reports of a mother and daughter. J Am Acad Dermatol **23**:385, 1990

51. Stern JK et al Corneal changes, hyperkeratosis, short stature, brachydactyly, and premature birth: A new autosomal dominant syndrome. Am J Med Genet **18**:67, 1984 /P>

52. Fitzsimmons JS et al: Four brothers with mental retardation, spastic paraplegia and palmoplantar hyperkeratosis: A new syndrome? Clin Genet **23**:329, 1983

53. Powell FC et al: Keratoderma and spastic paralysis. Br J Dermatol **109**:589, 1983

54. Mersiyanova IV et al: A new variant of Charcot-Marie-Tooth disease type 2 is probably the result of a mutation in the neurofilament-light gene. Am J Hum Genet **67**:37, 2000

55. Monk BE et al: Schöpf-Schulz-Passarge syndrome. Br J Dermatol **127**:33, 1992

56. Borradori L, Blanchet-Bardon C: Skin manifestations of cardio-cutaneous syndrome. J Am Acad Dermatol **28**:815, 1993

T>

Chapter 53

Virginia Sybert

Ectodermal Dysplasias

HYPOHIDROTIC ECTODERMAL DYSPLASIA (ANHIDROTIC ECTODERMAL DYSPLASIA; CHRIST-SIEMENS-TOURAINE SYNDROME; MIM 305100)
Historical Aspects
Epidemiology
Etiology/Pathogenesis
Genetics
Clinical Manifestations
Pathology
Diagnosis/Differential Diagnosis
Treatment
HIDROTIC ECTODERMAL DYSPLASIA (CLOUSTON SYNDROME; MIM 129500)
Historical Aspects/Epidemiology
Etiology/Pathogenesis
Genetics
Clinical Manifestations
Pathology
Diagnosis/Differential Diagnosis
Treatment
AEC SYNDROME (ANKYLOBLEPHARON FILIFORME ADENATUM-ECTODERMAL DYSPLASIA-CLEFT PALATE; HAY-WELLS' SYNDROME; MIM 106260)
History/Epidemiology
Etiology/Pathogenesis
Genetics
Clinical Features
Pathology
Diagnosis/Differential Diagnosis
Treatment/Prognosis
ECTRODACTYLY–ECTODERMAL DYSPLASIA–CLEFT LIP/PALATE (EEC) SYNDROME; SPLIT HAND–SPLIT FOOT–ECTODERMAL DYSPLASIA–CLEFT LIP/PALATE SYNDROME (MIM 129900)
Historical Aspects/Epidemiology
Etiology/Pathogenesis
Genetics
Clinical Manifestations
Diagnosis/Differential Diagnosis
Treatment
RAPP-HODGKIN SYNDROME (MIM 129400)
TOOTH AND NAIL SYNDROME (WITKOP SYNDROME; HYPODONTIA WITH NAIL DYSGENESIS; MIM 189500)
Historical Aspects/Epidemiology
Etiology/Pathogenesis/Genetics
Clinical Manifestations
Diagnosis/Differential Diagnosis
Treatment/Prognosis

REFERENCES

The ectodermal dysplasias (EDs) are a group of inherited disorders that share in common developmental defects involving at least two of the major structures classically held to derive from the embryonic ectoderm—hair, teeth, nails, sweat glands. Freire-Maia and Pinheiro [1] published an exhaustive review and classification system for these disorders using a numeric system of 1 (hair), 2 (teeth), 3 (nail), and 4 (sweat glands) for characterization. This system has little utility in practice, although it did allow for a rational approach to a previously chaotic field. Freire-Maia and Pinheiro laid claim to more than 150 ectodermal disorders in their most recent compilation. [2] This chapter will cover only the most common of these conditions and those whose ectodermal defects are likely to bring them to a dermatologist for diagnosis and medical attention.

The first major step in the algorithm for making a specific diagnosis of an ectodermal dysplasia is the presence of (hidrotic) or absence of (hypohidrotic/anhidrotic) sweating. The involvement of other ectodermal structures and of non-ectodermally derived tissues provide further branching points in a diagnostic hierarchy. Mode of inheritance may differ within a seemingly uniform diagnostic group, and care must be taken in evaluating family members before providing recurrence risks.

Within the last few years, causal genes have been identified in many of the EDs, and this is likely to continue, making any textbook chapter passé before it is printed. The reader is directed to the following resources: http://www3.ncbi.nlm.nih.gov/Omim (Victor McKusick's online catalog of Mendelian inheritance in humans) and http://www.genetests.org/ (Roberta Pagon's up-to-date listing of laboratories offering molecular testing). The MIM (Mendelian Inheritance in Man) numbers with each section heading refer to the numbering system in OMIM (Online Mendelian Inheritance in Man). The National Foundation for Ectodermal Dysplasias (http://www.nfed.org/) is a lay support group that has numerous informative pamphlets for families and physicians, as well as a strong advocacy program for dental care, insurance coverage, and research.

HYPOHIDROTIC ECTODERMAL DYSPLASIA (ANHIDROTIC ECTODERMAL DYSPLASIA;

CHRIST-SIEMENS-TOURAINE SYNDROME; MIM 305100)

Historical Aspects

X-linked hypohidrotic ectodermal dysplasia (X-LHED) was described over 200 years ago and enjoys status as a condition referred to by Charles Darwin in his writings on the variation of species. In 1913, Christ characterized it as a congenital ectodermal defect, and Siemens reaffirmed the X-linked nature of inheritance in 1921. In 1936, Touraine published on the wide range of features. In 1944, Felsher suggested the use of the term *hypohidrotic* rather than *anhidrotic* because sweating, while functionally absent, was not absolutely so.

Epidemiology

The disorder occurs in all racial groups and is thought to have an incidence at birth of approximately 1 in 100,000 males. [3]

Etiology/Pathogenesis

The condition results from alterations in the gene *ectodysplasin* (*EDA, EDA1*) located at Xq12-13. [4] The gene codes for a transmembrane protein, ectodysplasin, of 391 amino acids. The gene has alternative splicing forms, the significance of which is not known. More than 50 different mutations in this gene causing X-LHED have been identified. There does not appear to be a correlation between the nature of the mutation and the clinical features [5]; i.e., to date there have been no phenotype:genotype correlations. Inter- and intrafamilial variations occur to a mild degree. Ectodysplasin belongs to the tumor necrosis factor (TNF) family and plays a role in regulation of the formation of ectodermal structures. It forms trimers; is expressed in keratinocytes, the outer root sheath of hair follicles, and sweat glands; and localizes to the lateral and apical surfaces of cells.

Genetics

As is typical of X-linked recessive disorders, expression is full blown in affected males, and carrier females may express no, some, or all the features of the disorder, often in a patchy distribution. The disorder can be inherited from a carrier mother or occur in an affected individual as the result of a de novo mutation. Approximately 70 percent of affected males will have inherited the mutation from a carrier mother. Between 60 and 80 percent of carrier females will express some clinical signs of the disorder; the most frequent are patchy hypotrichosis and hypodontia.

Mutations in an autosomal gene mapped to 2q11q13, *dl* or *downless,* have been implicated in an autosomal dominant form of HED (MIM 129490) and in an autosomal recessive form (MIM 224900) [6] that is clinically similar to X-LHED. Both these entities are much more rare. Mutations in yet another gene, *crinkled,* have been identified recently in autosomal recessive HED. [7] Individuals with autosomal dominant HED appear to have a milder defect in the ability to sweat.

Very recently, certain mutations in the X-linked *NEMO* gene, which causes incontinentia pigmenti in females, have been shown to result in males with HED and immune defects. [8]

Clinical Manifestations

There have been several reviews of a large number of affected individuals over the years, providing the basis for the stated prevalence of clinical features; the most recent appeared in 1987. [9]

DERMATOLOGIC Affected males may present at birth with a collodion membrane or with marked scaling of the skin, [10] similar to congenital ichthyosis. Scalp hair is usually sparse, fine, and blonde. It may thicken and darken at puberty, and secondary sexual hair, especially the beard, may be normal. Other body hair is usually sparse or absent. The ability to sweat is significantly compromised, and most affected males will have marked heat intolerance. Sweat pores are usually undetectable on physical examination, and fingerprint ridges are effaced. The inability to sweat adequately in response to environmental heat results in an elevation of core temperature and bouts of unexplained high fevers, usually leading to an extensive workup for infectious disease, malignancy, or autoimmune disease before the correct diagnosis is recognized. In older series of patients, mental retardation was reported as a feature of X-LHED. Currently, this is believed to have been due to damage from prolonged high fevers and convulsions and not to be an intrinsic feature of the disorder. The nails are usually normal; reports of thin, fragile nails are not convincing, and nail dystrophy plays little role in the burden of the disorder. [11] Periorbital wrinkling and hyperpigmentation are typical and often present, albeit unappreciated, at birth (Fig. 53-1A, Fig. 53-1B and Fig. 53-1C). Eczema plagues more than two-thirds of affected males and is often difficult to manage. Hyperplasia of sebaceous glands, particularly on the face, can develop over time and appear as small, pearly, flesh-colored to white papules that may resemble milia.

FIGURE 53-1 Hypohidrotic ectodermal dysplasia. *A.* Newborn with periorbital wrinkling, beaked nose. Diagnosis would not be suspected unless there was a positive family history. *B.* Peg-shaped teeth; fine periorbital wrinkling can be appreciated. (*From Sybert VP:* Genetic Skin Disorders. *New York, Oxford University Press, 1997.*) *C.* Two unrelated males with X-LHED; adult is wearing dentures; periorbital wrinkling and hyperpigmentation are evident. (*Courtesy of the National Foundation for Ectodermal Dysplasias.*)

SYSTEMIC ASSOCIATIONS Hypodontia and oligodontia or anodontia are invariable features of X-LHED in affected males. Appreciation of hypoplastic gum ridges can be an early clue to the diagnosis of the disorder. Teeth that do erupt are usually peg-shaped and small (see Fig. 53-1B). The facies of the disorder are characterized by frontal bossing and a depressed midface with a saddle nose and full, everted lips. Otolaryngologic manifestations include thick nasal secretions and impaction, ozana, sinusitis, recurrent upper respiratory tract infections and pneumonias, decreased saliva production, hoarse voice, and an increased frequency of asthma. Gastroesophageal reflux and feeding difficulties may be a problem in infancy. Preliminary studies suggest that there may be failure to thrive in infancy and early childhood in as many as 20 to 40 percent of affected boys, with catch-up growth seen later. Although several reviews have suggested that infant mortality may be increased, unbiased confirmatory data are lacking. Female carriers for X-LHED may be affected as severely as males or show few, if any, signs of the disorder (Fig. 53-2A, Fig. 53-2B). Heat intolerance, if present, is usually mild; adult carrier women will comment that they do not sweat much or that they do not like very warm weather, but it is unusual for a female to experience fever due to inability to sweat. Typically, a few teeth may be peg-shaped or missing; scalp hair may be patchy or thin. Careful examination of the skin of carrier females often will reveal a diminution in or patchy distribution of sweat pores. This sometimes can be appreciated readily just by magnification of fingertip pads or may require more sophisticated sweat testing.

FIGURE 53-2 Hypohidrotic ectodermal dysplasia. *A.* Female carrier of X-LHED with two affected sons. (*Courtesy of the National Foundation for Ectodermal Dysplasias.*) *B.* Two sisters with X-LHED manifesting to different degrees. Note periorbital hyperpigmentation, full everted lips, and sculpted noses. (*From Sybert VP: Genetic Skin Disorders. New York, Oxford University Press, 1997.*)

VARIANTS As noted earlier, the autosomal dominant and autosomal recessive forms of HED are similar, although the autosomal dominant form may be milder. The X-linked form is by far the most common and always should be the diagnosis of default in a sporadic case.

Pathology

The epidermis is thinned and flattened. There is a reduction in the number of sebaceous glands and hair follicles. Eccrine glands are absent or incompletely developed.

Diagnosis/Differential Diagnosis

The scaling skin at birth may result in a misdiagnosis of congenital ichthyosis. Repeated bouts of fever may be thought to have an infectious source. The diagnosis of HED is recognized readily when expected, such as when an at-risk male is born into a family in which the disorder is known to segregate. Examination for sweat pores and a panorex view of the jaw will lead quickly to the correct diagnosis. In an isolated, fully expressing female, the autosomal dominant and recessive forms of HED need to be considered. Family history, examination of parents, and molecular testing may be helpful. Mothers, especially, always should be examined fully to detect mild manifestations of the X-linked form. Molecular testing is not indicated for clinical diagnosis in most instances.

Treatment

Maintenance of cool ambient temperatures is vital to prevent hyperpyrexia. Most children do well with simple measures such as wet T-shirts, air conditioning in home and school, wet headbands, etc. Occasionally, cooling vests can play a role in allowing a broader range of participation in sports and vigorous physical activity in warm climates.

Dental restoration is of primary importance, and early implementation of dentures and ultimate use of dental implants are mainstays of treatment.

Management of otolaryngologic complications, asthma, and recurrent infections needs to be individualized. The eczema may be quite refractory to care.

The National Foundation for Ectodermal Dysplasias (http://www.nfed.org/) has several pamphlets for individuals and professionals dealing with diagnosis and treatment. These are readily available at cost from the organization and are highly recommended.

Although infancy and childhood are complicated by many problems, most individuals with HED lead adult lives that allow them to function successfully in society. Heat intolerance seems to decrease due to the development of some ability to sweat in adolescence or to the development of common sense and adaptation of lifestyle or both.

HIDROTIC ECTODERMAL DYSPLASIA (CLOUSTON SYNDROME; MIM 129500)

Historical Aspects/Epidemiology

Clouston [12] first described this disorder in a French-Canadian kindred. It has been reported in other ethnic groups, but the majority of affected individuals can trace their ancestry back to an original French-Canadian settler.

Etiology/Pathogenesis

The disorder is caused by mutations in a connexin gene, *GJB6* or *connexin-30.* [13] Different mutations in the same gene are responsible for a form of nonsyndromic autosomal dominant deafness. Other connexin genes show similar variability in mutation: disease correlations (e.g., mutations in *connexin-31, GJB3*, can cause either erythrokeratodermia variabilis or late-onset autosomal deafness). The pathway by which allelic mutations result in such different diseases is not yet known.

Genetics

HED is autosomal dominant with variable expression (the degree of severity can vary within and between families). Males and females are affected in equal numbers and to equal degree. The gene maps to the centromeric region of the long arm of chromosome 13.

Clinical Manifestations

The scalp hair is wiry, brittle, and pale, and there is often patchy alopecia (Fig. 53-3A). This progresses in adult life and may lead to total alopecia. Body and facial hair are affected. The nails may be milky white in infancy and early childhood, gradually thickening and becoming dystrophic. The nail plates in adults are thick, short, slow growing, and separate distally from the nail bed (see Fig. 53-3C). Anonychia has been reported. Not all the nails are necessarily affected to the same degree. Progressive palmar/plantar hyperkeratosis is common (see Fig. 53-3B). In contrast to hypohidrotic ectodermal dysplasia, sweating is normal, as are the teeth. Oral leukoplakia has been reported. Conjunctivitis and blepharitis, possibly due to poor function of sparse eyelashes, are common.

FIGURE 53-3 Hidrotic ectodermal dysplasia (Clouston syndrome) *A.* Patchy alopecia in adult. Coarseness of hair can be appreciated. *B.* Palmar hyperkeratosis. *C.* Nail dystrophy.

Pathology

The thickened palms and soles show orthohyperkeratosis with a normal granular layer. On electron microscopy, an increase in the number of desmosomes in the cells of the stratum corneum is found. The hair shows nonspecific changes.

Diagnosis/Differential Diagnosis

The diagnosis is straightforward. The involvement of nails and hair and palmar/plantar thickening, in the absence of other

signs of ectodermal dysplasia, are reasonably specific. Other palmar/plantar hyperkeratoses do not have similar hair changes. Orofacial clefting differentiates other forms of autosomal dominant HED, such as ankyloblepharon filiforme adenatum–ectodermal dysplasia–cleft palate (AEC) syndrome or Rapp-Hodgkin syndrome. While the nail changes are similar to those of pachyonychia congenita, the hair changes are distinctive.

Treatment

Occasionally, ablation of the nail matrix is necessary for relief of pain. Wigs may provide cosmetic benefit.

AEC SYNDROME (ANKYLOBLEPHARON FILIFORME ADENATUM-ECTODERMAL DYSPLASIA-CLEFT PALATE; HAY-WELLS' SYNDROME; MIM 106260)

History/Epidemiology

Described first in 1976, [14] Hay-Wells syndrome has been found in ethnically and geographically disparate families.

Etiology/Pathogenesis

The disorder is caused, in at least some families, by mutations in the tumor-suppressor gene *p*63 (also known as *p*51 or *KET*), a gene that has been implicated in the pathogenesis of ectrodactyly–ectodermal dysplasia–cleft lip/palate (EEC) syndrome, limb-mammary syndrome, acro-dermato-ungual-lacrimal-tooth (ADULT) syndrome, and other autosomal dominant forms of ectodermal dysplasia. Mutations that cause EEC and AEC cluster in different regions of the gene. [15]

Genetics

AEC syndrome is an autosomal dominant disorder with complete penetrance (if you have the gene, you show clinical evidence of it) and variable expression.

Clinical Features

DERMATOLOGIC Ninety percent of affected infants present at birth with red, cracking, peeling skin and superficial erosions, similar to the appearance of a collodion membrane [11] (Fig. 53-4A). This sheds within a few weeks, and the skin underneath is dry and thin. The scalp is almost invariably involved, and many affected individuals are plagued by a chronic erosive dermatitis with abnormal granulation tissue on the scalp (see Fig. 53-4B, Fig. 53-4C). Recurrent bacterial infection of the scalp is common. Patchy alopecia is the rule, and the scalp hair that is present is often wiry, coarse, and light in color. Sparseness to absence of body hair is typical. Ankyloblepharon filiforme adnatum—strands of skin between the eyelids—are seen in approximately 70 percent of affected infants (see Fig. 53-4D). These may tear spontaneously or require surgical lysis. Lacrimal duct atresia or obstruction is common. The nails may be normal, hyperconvex and thickened, absent, or partially dystrophic, and all changes can be found in a single individual. Sweating is usually normal, although some affected individuals describe subjective heat intolerance. Supernumerary nipples and ectopic breast tissue are seen occasionally, as is mild cutaneous syndactyly of toes two and three.

FIGURE 53-4 AEC (Hay-Wells) syndrome. *A.* Newborn with peeling collodion membrane. *B.* Superficial erosion and thin skin of scalp in same patient, age 5 days *C.* Abnormal granulation tissue on scalp in older affected female. *D.* Fine strands of tissue (ankyloblepharon filiforme adenatum) between eyelids.

SYSTEMIC ASSOCIATIONS Cleft palate, with or without cleft lip, occurs in 80 percent of reported cases. There may be hypodontia with missing or misshapen teeth. Malformed auricles have been described in some. Recurrent otitis media and secondary conductive hearing loss are common and may be consequences of the cleft palate rather than primary. Hypospadias has been described in several affected males.

Pathology

Some patients show a decrease in the number of sweat glands. Electron microscopy of hairs shows a defective cuticular structure. There is a decrease in the keratins of the basal and suprabasal layers of the epidermis and disorganized keratin filaments in the stratum corneum.

Diagnosis/Differential Diagnosis

Among the autosomal dominant ectodermal dysplasias associated with clefting, Rapp-Hodgkin syndrome lacks the ankyloblepharon and has a much lower occurrence of scalp involvement. Some argue that it is the same disorder. The EEC syndrome is characterized by bony hand and foot abnormalities not seen in AEC and also lacks the ankyloblepharon. The peeling, eroded skin of the newborn can lead to misdiagnosis of epidermolysis bullosa or congenital ichthyosis. Ankyloblepharon filiforme adnatum can occur in the absence of syndromic associations, and the strands have been seen in several forms of arthrogryposis, in association with chromosomal aneuploidy, and in CHANDS (curly hair, ankyloblepharon, and nail dysplasia syndrome), an autosomal recessive form of ectodermal dysplasia.

Treatment/Prognosis

Light emollients should be used until the collodion membrane sheds. Ankyloblepharon may require surgical lysis. Ongoing ocular hygiene is important. Vigorous and meticulous but gentle scalp care with prompt treatment of infection is extremely important. Grafting of skin to the scalp is not often successful. Clefting will require a team approach for repair and follow-up for secondary issues, such as feeding difficulties, speech defects, orthodontia, and ear infections.

ECTRODACTYLY–ECTODERMAL DYSPLASIA–CLEFT LIP/PALATE (EEC) SYNDROME; SPLIT HAND–SPLIT FOOT–ECTODERMAL DYSPLASIA–CLEFT LIP/PALATE SYNDROME (MIM 129900)

Historical Aspects/Epidemiology

EEC syndrome is an ectodermal dysplasia classified as a multiple congenital anomaly syndrome because it has major involvement of structures other than those derived ectodermally. It was described by Cockayne in 1936 and given its acronym in 1970 by Rudiger and colleagues. EEC syndrome has occurred in all racial groups worldwide.

Etiology/Pathogenesis

Mutations in *p*63, a tumor-suppressor gene mapped to 3q27, have been found in most individuals with EEC syndrome. [16] The gene is expressed widely, including in the basal cells of proliferating epithelial tissues. Mutations in the same gene appear to cause some cases of isolated split hand–split foot disease, limb-mammary syndrome, and Hay-Wells syndrome. There appear to be genotype-phenotype correlations. [17] All alterations identified thus far in Hay-Wells syndrome have been missense mutations in the sterile alpha motif (SAM) domain; in EEC syndrome, the majority of mutations result in single-amino-acid substitutions in the DNA-binding domain. [15] Frameshift mutations in *p*63 cause limb-mammary syndrome, in which ectodermal structures other than the mammary gland often, but not always, appear normal.

Genetics

EEC syndrome is an autosomal dominant disorder with variable expression and reduced penetrance. Intra- and interfamilial differences in severity are common.

Clinical Manifestations

DERMATOLOGIC The ectodermal dysplasia may be quite mild. The hair is usually blond, coarse, and dry (Fig. 53-5A). It may be sparse and slow growing. Axillary and pubic hair also may be affected. The nails are dystrophic in about four-fifths of individuals with transverse ridging, pitting, and slow growth (see Fig 53-5D). Dry skin and thickening of the palms and soles can occur. Sweating is usually normal.

FIGURE 53-5 EEC (ectrodactyly–ectodermal dysplasia–clefting) syndrome. *A.* Mild thinness of hair. (*Courtesy of the National Foundation for Ectodermal Dysplasias.*) *B.* Hands and feet of affected infant. *C, D*. Feet and hands of parent of infant in *B* demonstrating variability of expression both among limbs and between family members. Note also the nail dystrophy especially evident on the thumbs.

SYSTEMIC ASSOCIATIONS Hypodontia and premature loss of secondary teeth and the dental abnormalities associated with clefting are found in most affected individuals. Lacrimal gland abnormalities are common. The major distinguishing feature of EEC syndrome is ectrodactyly—abnormal development of the median rays of the hands and feet. The feet are involved more frequently than the hands, and there may be asymmetry of involvement (see Fig. 53-5B, Fig. 53-5C and Fig. 53-5D). Cleft palate, with or without cleft lip, occurs in 70 to 100 percent depending on the series. [18], [19] Secondary conductive hearing loss is frequent. Genitourinary abnormalities that include hydronephrosis, and structural renal or genital malformations affect a third or more of persons with EEC syndrome. Although mental retardation has been reported, it is not believed to be an inherent feature of the disorder.

Diagnosis/Differential Diagnosis

Among disorders with limb defects that need to be considered in the differential diagnosis of EEC syndrome are the

odontotrichomelic syndrome (MIM 273400), in which there are severe absence deformities of the limbs, and aplasia cutis congenita with limb defects (Adams-Oliver syndrome, MIM 100300), which does not have clefting or ectodermal defects other than absence of skin. Other ectodermal dysplasias with clefting include Hay-Wells syndrome, Rapp-Hodgkin syndrome, and limb-mammary syndrome, all of which, in at least some families, appear to be allelic to EEC syndrome. Ectrodactyly with cleft palate without ectodermal dysplasia (ECP syndrome, MIM 129830) also may be a distinct entity. Prenatal diagnosis by ultrasound for detection of limb abnormalities is unreliable; molecular testing may prove useful in some families.

Treatment

As for other ectodermal dysplasias with orofacial clefting and ophthalmologic involvement, management requires a team approach. Similarly, treatment for the limb defects must be individualized. Renal ultrasound and a high index of suspicion for urinary tract problems may be appropriate.

RAPP-HODGKIN SYNDROME (MIM 129400)

Described in 1968, Rapp-Hodgkin syndrome is an autosomal dominant disorder that shares in common with Hay-Wells syndrome cleft palate with or without cleft lip, hypohidrosis usually without episodes of frank hyperpyrexia, abnormal hair with pili torti or pili trianguli et canaliculi and progressive balding, and nail dystrophy. [20], [21] The face in Rapp-Hodgkin syndrome is striking, with a short nasal columella and maxillary hypoplasia, thin upper lip, and full lower lip (Fig. 53-6A, Fig. 53-6B). The nails are thick and short, worsening with age (see Fig. 53-6C). The teeth may be conical and prone to caries (see Fig. 53-6D). The lacrimal puncta are aplastic in almost one-third of affected individuals. Hypospadias has been reported in two-fifths of affected males; labial hypoplasia and absence of the opening of the vagina have been reported in a single female. These features are also reminiscent of the EEC syndrome. Rapp-Hodgkin syndrome may prove to be allelic due to mutations in *p*63. Treatment is the same as described for these similar disorders.

FIGURE 53-6 Rapp-Hodgkin syndrome. *A.* Affected infant at 5 months. *B.* Fine, blond, sparse hair; beginnings of nail changes on middle finger of right hand. (*Courtesy of the National Foundation for Ectodermal Dysplasias*.) *C.* Abnormal nails in same patient as *A,* at age 41/2 years with thickened and friable nail plates. (*From Sybert VP:* Genetic Skin Disorders. *New York, Oxford University Press, 1997*.) *D.* Abnormal dentition, missing teeth, and peg teeth.

TOOTH AND NAIL SYNDROME (WITKOP SYNDROME; HYPODONTIA WITH NAIL DYSGENESIS; MIM 189500)

Historical Aspects/Epidemiology

This is a rare disorder, first described in 1965 and expanded on in 1975. [22]

Etiology/Pathogenesis/Genetics

A nonsense mutation in *MSX1*, a gene expressed in the developing teeth and nail beds in mice, has been found in one family with Witkop syndrome. [23] Other mutations in *MSX1* have been associated with isolated tooth agenesis or tooth agenesis with cleft palate. Tooth and nail syndrome is autosomal dominant, with variable expression and intrafamilial variability.

Clinical Manifestations

DERMATOLOGIC The nails are thin, small, and friable and may show koilonychia at birth. Toenails are usually more severely involved than fingernails (Fig. 53-7B). Nail changes improve with age and may be unappreciated in affected adults. A few individuals have reported thin, fine hair.

FIGURE 53-7 Tooth-nail syndrome. *A.* Primary teeth still in place; failure of adult teeth to erupt. *B.* Dystrophic toenails with flattening of nail plates.

SYSTEMIC ASSOCIATIONS The primary teeth usually are unaffected, although they may be small. The secondary teeth may fail to erupt, and there can be partial or total absence (see Fig. 53-7A) The mandibular incisors, second molars, and maxillary canines are missing most often. No other ectodermal structures are affected.

Diagnosis/Differential Diagnosis

This is an easy condition to miss. The nail changes may be subtle. The tooth abnormalities may be mild enough to escape detection by a physician. The lack of associated features, either dermatologic or systemic, readily distinguish Witkop syndrome from other ectodermal dysplasias. There is a presumed autosomal recessive disorder characterized by taurodontia (cone-shaped teeth), absent teeth, sparse hair, and hypoplastic nails that appears similar.

Treatment/Prognosis

The nails usually require no treatment. Restorative dentistry is important.

REFERENCES

1. Freire-Maia N, Pinheiro M: *Ectodermal Dysplasias: A Clinical and Genetic Study*. New York, Liss, 1984

2. Freire-Maia N, Pinheiro M: Ectodermal dysplasias: A clinical classification and a causal review. *Am J Med Genet* **53**:153, 1994

3. Stevenson AC, Kerr CB: On the distribution of frequencies of mutations to genes determining harmful traits in man. *Mutat Res* **4**:339, 1967

4. Kere J et al: X-linked anhidrotic (hypohidrotic) ectodermal dysplasia is caused by a mutation in a novel transmembrane protein. *Nature Genet* **13**:409, 1996

5. Vincent MC et al: Mutational spectrum of the *ED1* gene in X-linked hypohidrotic ectodermal dysplasia. *Eur J Hum Genet* **9**:355, 2001

6. Monreal AW et al: Mutations in the human homologue of mouse *dl* cause autosomal recessive and autosomal dominant hypohidrotic ectodermal dysplasia. *Nature Genet* **22**:366, 1999

7. Headon DJ et al: Gene defect in ectodermal dysplasia implicates a death domain adaptor in development. *Nature* **414**:913, 2001

8. Aradhya S et al: Atypical forms of incontinentia pigmenti result from mutations of a cytosine tract in exon 10 of *NEMO*(*IKK-?*). *Am J Hum Genet* **68**:765, 2001

9. Clarke A et al: Clinical aspects of X-linked hypohidrotic ectodermal dysplasia. *Arch Dis Child* **62**:989, 1987

10. The Executive and Scientific Advisory Boards of the National Foundation for Ectodermal Dysplasias: Scaling skin in the neonate: A clue to the early diagnosis of X-linked hypohidrotic ectodermal dysplasia (Christ-Siemens-Touraine syndrome). *J Pediatr* **114**:600, 1989

11. Sybert V: *Genetic Skin Disorders*. New York, Oxford University Press, 1997

12. Clouston HR: A hereditary ectodermal dysplasia. *Can Med Assoc J* **21**:18, 1929

13. Lamartine J et al: Mutations in *GJB6* cause hidrotic ectodermal dysplasia. *Nature Genet* **26**:142, 2000

14. Hay RJ, Wells RS: The syndrome of ankyloblepharon, ectodermal defects and cleft lip and palate: An autosomal dominant condition. *Br J Dermatol* **94**:277, 1976

15. McGrath JA et al: Hay-Wells syndrome is caused by heterozygous missense mutations in the SAM domain of *p*63. *Hum Mol Gene* **10**:221, 2001

16. Celli J et al: Heterzozygous germline mutations in the *p*53 homolog *p*63 are the cause of EEC syndrome. *Cell* **99**:143, 1999

17. Van Bokhaven H et al: *p*63 gene mutations in EEC syndrome, limb-mammary syndrome and isolated split hand–split foot malformation suggest a genotype-phenotype correlation. *Am J Hum Genet* **69**:481, 2001

18. Buss PW et al: Twenty-four cases of the EEC syndrome: Clinical presentation and management. *J Med Genet* **32**:716, 1995

19. Roelfsema NM, Cobben JM: The EEC syndrome: A literature study. *Clin Dysmorphol* **5**:115, 1996

20. Schroeder HW Jr, Sybert VP: Rapp-Hodgkin ectodermal dysplasia. *J Pediatr* **110**:72, 1987

21. Walpole IR, Goldblatt J: Rapp-Hodgkin hypohidrotic ectodermal dysplasia syndrome. *Clin Genet* **39**:114, 1991

22. Hudson CD, Witkop CJ Jr: Autosomal dominant hypodontia with nail dysgenesis: Report of 29 cases in six families. *Oral Pathol* **39**:409, 1975

23. Jumlongras D et al: A nonsense mutation in *MSX1* causes Witkop syndrome. *Am J Hum Genet* **69**:67, 2001

T>

Chapter 54

Lowell Goldsmith Howard Baden

Darier-White Disease (Keratosis Follicularis) and Acrokeratosis Verruciformis

DARIER-WHITE DISEASE (KERATOSIS FOLLICULARIS)
Etiology and Pathogenesis
Genetics
Clinical Manifestations17
Pathology
Differential Diagnosis
Treatment
ACROKERATOSIS VERRUCIFORMIS48
Clinical Manifestations
Pathology
Differential Diagnosis
Treatment
Course
REFERENCES

DARIER-WHITE DISEASE (KERATOSIS FOLLICULARIS)

Darier-White disease (DWD) is an autosomal dominant disorder with altered keratinization of the epidermis, nails, and mucous membranes. Mutations in a sarcoplasmic endoreticulum Ca^{2+}-ATPase isoform 2 (SERCA2) cause all cases of DWD. [1] Darier and White separately reported the disease in 1889. Although it was suggested initially that the dyskeratotic cell represented an organism, this idea was soon dispelled. White recognized the genetic nature of the disease by discovering that a mother and daughter were affected.

Etiology and Pathogenesis

DWD is not present at birth and usually begins in the first or second decade. [2], [3] Males and females are equally affected. Characteristic sites of predilection are the face, forehead, scalp, chest, and the back. Although these sites have many sebaceous glands, lesions also occur commonly in sites without sebaceous glands—the palms and soles—as well as in keratinizing and nonkeratinizing epithelia, such as mucous membranes, cornea, and submandibular glands. [4], [5]

DWD is frequently worse in the summer, with heat and humidity as the major factors, and can be exacerbated by ultraviolet B (UVB) light [6] and mechanical trauma, e.g., under the collar of sweaters. The first American patient, described by White in 1889, was well until he entered the Northern army in 1862 at the age of 22, and his eruption appeared under his knapsack after a long march. Lesions have been precipitated by oral lithium and by phenol or ethyl chloride spray. [7] Common complications and causes of exacerbation are bacterial infection and infection with herpes simplex virus, but there are no consistent immunologic abnormalities. [8] The disease does not seem to predispose to cutaneous malignancies, although basal cell carcinomas and one rare sweat gland tumor have been reported. [9] Associated disorders include retinitis pigmentosa [10] and occasional asymptomatic bone cysts. [11] Affective disorders and decreased intelligence have been associated with DWD in recent studies. [12]

Genetics

DWD is inherited as an autosomal dominant trait. New mutations are common, and penetrance is very high, over 95 percent. The largest known pedigree is in upstate New York and southern Pennsylvania. [13] The incidence of DWD is at least 1 in 100,000 in Denmark and has been estimated to be 1 in 36,000 in northeast England. [14] No unique phenotype for genetic homozygotes has been described, and there is no evidence for X-linked or autosomal recessive forms of the disorder. There is no history of anticipation. A diverse set of mutations in Ca^{2+}-ATPase isoform 2 (SERCA2) (see Chap. 5) has been identified, including missense mutations, alternative splicing, deletions, insertions, in-frame exon skipping, frameshift mutations, and premature codon mutations. [15] The locations of these mutations are summarized in Fig. 54-1.

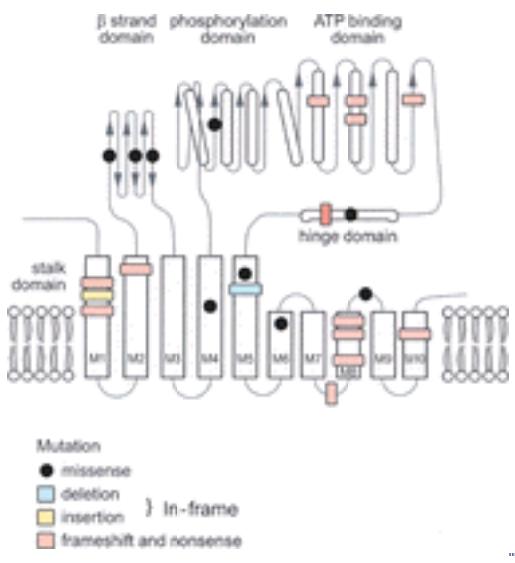

FIGURE 54-1 Schematic diagram of the ATP2A2 molecule. Different regions of the molecule have different functional characteristics or functions as indicated. Mutations have been found in most domains. The cell membrane is designated by circles and irregular lines. Ten intramembrane domains are depicted (M1 to M10), and in DWD these domains have missense, deletion, insertion, frameshift, and nonsense mutations as indicated.

Knockout mice (on a mixed 129/Svj and Black Swiss background) heterozygous for a SERCA2 null mutation developed spontaneous squamous cell carcinoma in the upper digestive tract, oral mucosa, and skin (5 of 14 animals) and hyperkeratosis of a toenail. As discussed below, malignancy is not a common feature of DWD, and this difference between mice and humans deserves further study. [16]

Clinical Manifestations [17]

Multiple discrete, scaling, rough, crusted, pruritic papules that are frequently malodorous and disfiguring characterize DWD. The distribution of lesions in DWD corresponds to the “seborrheic areas” of the body. The chest (Fig. 54-2), back, ears, nasolabial folds, forehead, scalp, and groin are involved commonly. The lesions may first appear as skin-colored papules that are soon covered with a yellowish tan, rough-textured, scaly crust (Fig. 54-3). When this is removed, a pore- or slitlike opening may be seen. The lesions may coalesce into large plaques. At times, these become quite thick, forming hypertrophic warty masses [18] (Fig. 54-4 and Fig. 54-5A) that are foul smelling, particularly in intertriginous areas, as a result of secondary infection. The hair is normal, although the scalp is frequently covered with thick greasy scales and crusts. Permanent alopecia has been observed as a result of extensive scalp involvement (Fig. 54-6), but this is the exception. Flat wartlike papules may be seen on the dorsa of the feet and hands (Fig. 54-7B), and punctate keratoses, either raised or with a central pit, on the palms and soles (see Fig. 54-7A). Hypopigmented macules, probably postinflammatory, may be present. [19]

FIGURE 54-2 Anterior trunk demonstrating typical distribution of lesions in DWD.

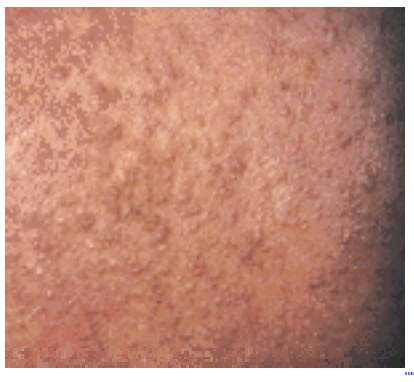

FIGURE 54-3 Close-up of keratotic papules in DWD. Some of the papules are associated with hair follicles; others are not.

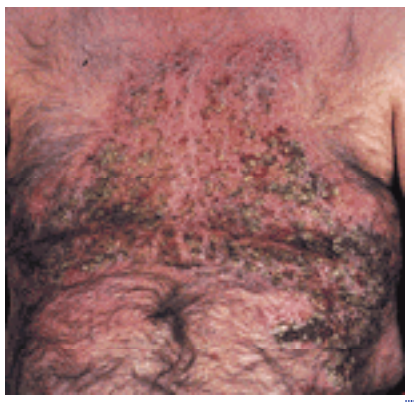

FIGURE 54-4 Hypertrophic, eroded, and infected lesion in DWD.

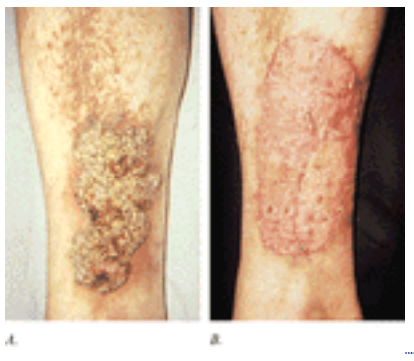

FIGURE 54-5 Hypertrophic lesion of anterior leg (*A*), which has been excised and grafted with permanent remission in grafted site (*B*).

FIGURE 54-6 There is extensive involvement of the scalp with heavy crust-scale formation that has led to scarring alopecia.

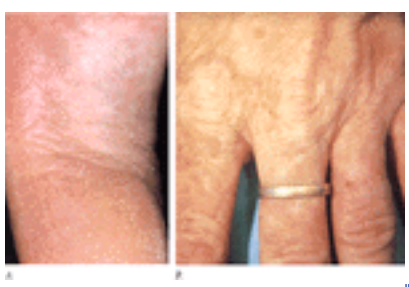

FIGURE 54-7 DWD with tiny keratoses of sole (*A*) and dorsum of the hand (*B*). The hand lesions are clinically identical to those of acrokeratosis verruciformis.

The nails [20] are thin and tend to break distally and show characteristic V-shaped scalloping and subungual thickening (Fig. 54-8). There are longitudinal ridges as well as red and white lines parallel to their long axis. Mucous membrane lesions (Fig. 54-9) appear as white, centrally depressed papules on the mucosae of the cheeks, hard and soft palate, and gums [21] and often present as “cobblestone” lesions. Salivary gland obstruction with histologic changes of DWD in the ductal epithelium has been reported with resulting kerostomia. [22] Rectal mucosal involvement also occurs, [23] and disease localized to the vulva has been reported. [24] Lesions also may be confined to one area of the body in a zosteriform distribution and resemble an epidermal nevus. [25], [26] Two cases have been shown to be somatic mosaics with SERCA mutations in affected skin and not in uninvolved skin or peripheral leukocytes. [27] Such mosaic cases have not been reported with familial disease. One case of a Darier-like epidermal nevus has been seen in association with Gardner's syndrome that is a mutation of the *APC* (*adenomatous polyposis coli*) gene. [28] Hemorrhagic DWD, often acral, has been reported, characterized by hemorrhagic macules and vesicles [29] (Fig. 54-10); a vesiculobullous form also has been reported. [30] Cutaneous malignancies are reported only rarely with DWD and include two patients with human papilloma virus 16 (HPV-16)–related lesions subungually and on the scrotum. [31], [32]

FIGURE 54-8 Nails in DWD. Note the subungual keratoses with V-shaped nicks. There are longitudinal ridges as well as red and white lines.

FIGURE 54-9 Hard palate demonstrating small “cobblestone-like” papules in DWD.

FIGURE 54-10 Acral hemorrhagic lesions in a patient with classic DWD.

Pathology

Premature and abnormal keratinization and loss of epidermal adhesion with acantholysis characterize the disorder, [33] as do eosinophilic dyskeratotic cells in the spinous layer (corps ronds) and in the stratum corneum (grains). Suprabasal clefts (lacunae) are seen frequently, as are acantholytic cells, and are interpreted as altered adhesion within the epidermis. Papillary overgrowth of the epidermis and hyperkeratosis are common (Fig. 54-11 and Fig. 54-12).

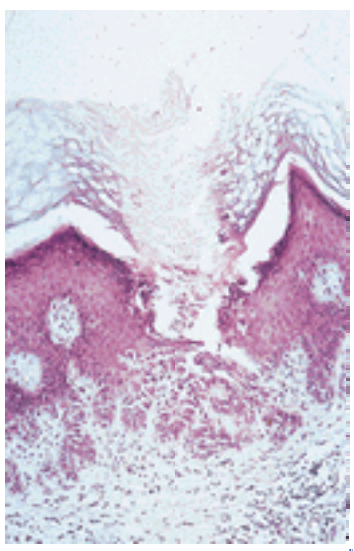

FIGURE 54-11 Darier-White disease. The disease is characterized by the downgrowth of narrow cords of epidermal cells from the basal regions and the conjoint exaggeration of the pattern of dermal papillae. There is also faulty cohesion of cells in the epidermal downgrowths, resulting in suprabasal clefts. Above the clefts there is evidence for faulty epidermal differentiation manifested by parakeratotic material and dyskeratotic cells.

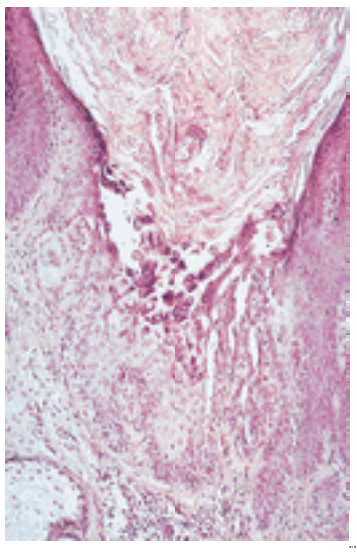

FIGURE 54-12 Darier-White disease: intraepidermal clefts and dyskeratotic cells. There are rounded cells with bright eosinophilic cytoplasm and an irregular dark basophilic nucleus; these dyskeratotic cells are commonly observed in DWD.

Electron microscopic studies show basal cell vacuolization, decreased numbers of desmosomes on the lateral borders of basal cells, separation of tonofilaments from their insertions on the cell membrane, and tonofilaments in large, circular aggregates around the nucleus. [33] The corps ronds contain multiple lamellar bodies, organelles usually associated with the late stages of cornification and epidermal barrier formation (see Chap. 9). The corps ronds have many of the characteristics of apoptotic cells. The lesional morphology led to extensive studies of keratins and cell adhesion proteins, all of which failed to elucidate a primary defect. [34] Cultured DWD keratinocytes show increased locomotion, disorganized growth, and slim intercellular bridges with normal or slightly “immaturely constructed” desmosomes that appear “frail,” very widened intercellular spaces, and increased cell dissociation. [35] Burge et al. [36] found increased plasminogen staining in suprabasal cells, in acantholytic cells, and in the keratotic plug.

The identical tissue histopathology seen in the genetic forms of DWD has been described rarely in epidermal nevi, [25] warty dyskeratoma, actinic keratoses, Grover's disease (transient acantholytic disease), after interleukin 4 (IL-4) therapy, [34] and other skin lesions. [38]

Hyperkeratotic papules on the dorsal surface of the hands of DWD patients have a specific histopathology, with a disordered acanthotic epidermis and angular, raised church spire-like epidermal changes. [39] The pathology is consistent with acrokeratosis of Hopf (see below). These lesions are almost always associated with DWD, although there are rare families reported with only acrokeratosis of Hopf. [40]

Hailey-Hailey disease (see Chap. 68) is a disorder of the epidermis in which the lesions are acantholytic but usually lack the extensive dyskeratotic changes seen in DWD. It has been mapped to a different chromosomal location on 3q21-q24 [41] and codes for a different sarco/endoplasmic reticulum ATPase, ATP2C1. Transient acantholytic disease (Grover's disease; see Chap. 55) occurs in middle-aged or elderly adults (usually men), has no familial incidence, and often begins after sun exposures. Four patients who were studied did not have SERCA2 mutations. [42] SERCA is a complex enzyme with 10 transmembrane domains, an intracellular ATP-binding domain, a phosphorylation domain, and a hinge region (see Fig. 54-1). All regions of the molecule have been mutated in families with DWD. Attempts at genotype-phenotype correlation have been unsuccessful except possibly for the nonspecific association of the acral hemorrhagic form of the disease with transmembrane mutations in a small number of families.

DWD is one of several skin diseases, including Hailey-Hailey disease, desmoplakin-related striate palmoplantar hyperkeratosis, Rubinstein-Tabyi syndrome, and some of the transcription factors associated with DNA repair, in which there is deficiency of one copy of gene and a genetic disease. This is called *haploinsufficiency.* [27] This is distinct from the usual situation with enzyme defects, in which the heterozygote with one abnomal gene usuallly has a normal phenotype. This suggests that in the complex membrane structures in which these ATPases function, they are not present in great excess so that half the normal gene product, when coupled with another factor such as UVB or mechanical trauma, causes the clinical phenotype.

Differential Diagnosis

The history of familial involvement, clinical appearance, and histologic features make the diagnosis certain. Clinical diagnosis of small lesions in adolescence may be difficult and may require biopsy. The condition may be confused with seborrheic dermatitis because of the distribution and waxy appearance of the lesions. Benign familial pemphigus (Chap. 68) and particularly pemphigus foliaceous (Chap. 59) must be considered in the diagnosis but usually can be distinguished on clinical and histologic grounds. The localized and linear form must be differentiated from epidermal nevi with pathologic features. Eruptive forms occurring late in life have been described recently, but these are likely to be examples of transient acantholytic dermatosis.

Treatment

Sunscreens (at least SPF 30) are essential for the management of this disorder, and in those with precipitation by mechanical factors, avoidance of, for example, high sweaters around the neck that may trigger lesions is mandatory.

As with several other genetic disorders affecting the epidermis, the disease is improved by therapy with topical or

systemic retinoids, including topical tazarotene and adapalene. [43], [44] Systemic isotretinoin remains a reasonable first choice of a systemic therapy. If the disease is not responsive, a trial of acitretin is appropriate. Systemic therapy doses can be modified based on the seasonal variation of the disease. All the safety recommendations concerning systemic retinoids apply to DWD treatment, with the added proviso that therapy will be a long-term, albeit intermittent, process. Tazarotene gel has been effective in children as well as adults. [45] Surgical treatment has been used in the hypertrophic froms of the disease [46] /SUP>, [47] (see Fig. 54-5B). Many exacerbations are precipitated by bacterial infection, and appropriate antibiotic therapy can provide dramatic improvement.

ACROKERATOSIS VERRUCIFORMIS [48]

This disease is associated with DWD. Acrokeratosis verruciformis was first described by Hopf in 1931, and the familial nature was reported by Niedelman and McKusick. [40] It is a rare autosomal dominant disorder appearing at birth or in early childhood, although it has been reported to present as late as adulthood. Individual cases are reported with Hailey-Hailey disease, steatocystoma multiplex, and basal cell nevus syndrome, but these may be chance associations.

Clinical Manifestations

The lesions [49] are small, verrucous, flat papules resembling flat warts; they are present predominantly on the dorsa of the hands and feet but may appear on the forearms, knees, and elbows (see Fig. 54-7B). They are flesh-colored or reddish brown. Punctate keratoses are present on the palm, and the nail plates may show a variety of changes.

Pathology

Slight papillomatosis is evident, with thickening of the stratum corneum, granular layer, and stratum spinosum.

Differential Diagnosis

Patients with DWD show identical changes (see Fig. 54-7B), and on the basis of gross or histologic appearance of the lesions, it may be impossible to separate the conditions, [50] although dyskeratotic cells are not present in acrokeratosis verruciformis. [48] Similar lesions can be seen in epidermodysplasia verruciformis (see Chap. 223), but the histologic appearance distinguishes the two conditions. Verruca plana also has a distinctive histologic picture. The hard nevus of Unna can be differentiated by its late onset, the presence of seborrheic keratoses on the trunk, and the histologic appearance.

Treatment

The only effective therapy is superficial destruction.

Course

The lesions persist but, because of darkening, are more noticeable after prolonged sun exposure.

REFERENCES

1. Sakuntabhai A et al: Mutations in ATP2A2, encoding a C_{2+} pump, cause Darier disease *Nature Genet* **21**:271, 1999

2. Getyler N, Flint A: Keratosis follicularis: A study of one famil *Arch Dermato* **93**:545, 1966

3. Svendsen I, Albrechtsen B: The prevalence of dyskeratosis follicularis (Darier's disease) in Denmark: An investigation of the heredity in 22 fam *Acta Derm Venereol (Stockh)* **39**:256, 1959

4. Tegner E, Jonsson N: Darier's disease with involvement of both submandibular glan *Acta Derm Venereol (Stockh)* **70**:451, 1990

5. Blackman HJ et al: Corneal epithelial lesions in keratosis follicularis (Darier's diseas *Ophthalmology* **87**:931, 1980

6. Baba T, Yaoita H: UV radiation and keratosis folliculari *Arch Dermato* **120**:1484, 1984

7. Penrod J: Observations on keratosis follicularis *Arch Dermato* **82**:367, 1960

8. Halevy S et al: Immunologic studies in Darier's diseas *Int J Dermato* **27**:101, 1988

9. Latour DL et al: Darier's disease associated with cutaneous malignanci *J Dermatol Surg Onco* **7**:408, 1981

10. Itin P et al: Darier's disease and retinitis pigmentosa: Is there a pathogenetic relationsh *Br J Dermato* **119**:397, 1988

11. Crisp AJ et al: The prevalence of bone cysts in Darier's disease: A survey of 31 cas *Clin Exp Dermato* **9**:78, 1984

12. Craddock N et al: Familial cosegregation of major affective disorder and Darier's disease (keratosis follicula *Br J Psychiatry* **164**:355, 1994

13. Beck ALJ et al: Darier's disease: A kindred with a large number of cas *Br J Dermato* **97**:335, 1977

14. Munro CS: The phenotype of Darier's disease: Penetrance and expressivity in adults and child *Br J Dermato* **127**:126, 1992

15. Sakuntabhai A et al: Spectrum of novel ATP2A2 mutations in patients with Darier's disea *Hum Mol Genet* **8**:1611, 1999

16. Liu LH et al: Squamous cell tumors in mice heterozygous for a null allele of Atp2a2, encoding the sarco(endo)plasmic reticulum Ca^{2+}-ATPase isoform 2 Ca^{2+} pump. *J Biol Chem* **276**:26737, 2001.

17. Burge S: Management of Darier's disease. *Clin Exp Dermatol* **24**:53, 1999

18. Elsbach E, Nater J: The hypertrophic form of Darier's disease. *Dermatologica* **120**:93, 1960

19. Rowley MJ et al: Hypopigmented macules in acantholytic disorders. *Int J Dermatol* **34**:390, 1995

20. Zaias N, Ackerman AB: The nail in Darier-White disease. *Arch Dermatol* **107**:193, 1973

21. Gorlin R, Chaundhry A: The oral manifestation of keratosis follicularis. *Oral Surg* **12**:1468, 1959

22. Graham-Brown RA et al: Darier's disease with salivary gland obstruction. *J R Soc Med* **76**:609, 1983

23. Klein A et al: Rectal mucosa involvement in keratosis follicularis. *Arch Dermatol* **109**:560, 1974

24. Barrett JF et al: Darier's disease localized to the vulva: Case report. *Br J Obstet Gynaecol* **96**:997, 1989

25. Demetree JW et al: Unilateral, linear, zosteriform epidermal nevus with acantholytic dyskeratosis. *Arch Dermatol* **115**:875, 1979

26. O'Malley MP et al: Localized Darier disease: Implications for genetic studies. *Arch Dermatol* **133**:1134, 1997

27. Sakuntabhai A et al: Mosaicism for ATP2A2 mutations causes segmental Darier's disease. *J Invest Dermatol* **115**:1144, 2000

28. Romiti R al: Epidermal naevus with Darier's disease-like changes in a patient with Gardner's syndrome. *J Am Acad Dermatol* **43**:380, 2000

29. Foresman PL et al: Hemorrhagic Darier's disease. *Arch Dermatol* **129**:511, 1993

30. Telfer N: Vesiculo-bullous Darier's disease. *Br J Dermatol* **122**:831, 1990

31. Downs AM et al: Subungual squamous cell carcinoma in Darier's disease. *Clin Exp Dermatol* **22**:277, 1997

32. Orihuela E et al: Developoment of human papillomavirus type 16–associated squamous cell carcinoma of the scrotum in a patient with Darier's disease treated with systemic isotretinoin. *J Urol* **153**:1940, 1995

33. Caulfield J, Wilgram G: An electron microscope study of dyskeratosis and acantholysis in Darier's disease. *J Invest Dermatol* **41**:57, 1963

34. Burge SM, Schomberg KH: Adhesion molecules and related proteins in Darier's disease and Hailey-Hailey disease. *Br J Dermatol* **127**:335, 1992

35. Ishibashi Y et al: Tissue culture of epidermal cells in some acantholytic dermatoses. *Curr Probl Dermatol* **10**:91, 1980

36. Burge SM: Darier's disease: An immunohistochemical study using monoclonal antibodies to proteases. *Br J Dermatol* **121**:613, 1989

37. Mahler SJ et al: Transient acantholytic dermatosis induced by recombinant human interleukin. *J Am Acad Dermatol* **29**:206, 1993

38. Ackerman AB: Focal acantholytic dyskeratosis. *Arch Dermatol* **106**:702, 1972

39. Herndon JJ, Wilson J: Acrokeratosis verruciformis (Hopf) and Darier's disease. *Arch Dermatol* **93**:305, 1966

40. Niedelman M, McKusick V: Acrokeratosis verruciformis (Hopf). *Arch Dermatol* **86**:779, 1962

41. Ikeda S et al: Localization of the gene whose mutations underlie Hailey-Hailey disease to chromosome. *Hum Mol Genet* **3**:1147, 1994

42. Powell J et al: Grover's disease, despite histological similarity to Darier's disease, does not share an abnormality in the ATP2A2 gene. *Br J Dermatol* **143**:658, 2000

43. Burge S: Management of Darier's disease. *Clin Exp Dermatol* **24**:53, 1999

44. English JC et al: Effective treatment of localized Darier's disease with adapalene 0.1% gel. *Cutis* **63**:227, 1999

45. Micali G, Nasca MR: Tazarotene gel in childhood Darier disease. *Pediatr Dermatol* **16**:243, 1999

46. Wheeland RG, Gilmore, WA: The surgical treatment of hypertrophic Darier's disease. *J Dermatol Surg Oncol* **11**:420, 1985

47. Toombs EL, Peck GL: Electrosurgical treatment of etretinate-resistant Darier's disease. *J Dermatol Surg Oncol* **15**:1277, 1989

48. Panja RK: Acrokeratosis verruciformis (Hopf): A clinical entity. *Br J Dermatol* **96**:643, 1977

49. Rook A, Stevanovic D: Acrokeratosis verruciformis. *Arch Dermatol* **69**:450, 1957

50. Waisman M: Verruciform manifestations of keratosis follicularis. *Arch Dermatol* **81**:1, 1960

T>

Chapter 55

Peter Heenan Christopher Quirk

Transient Acantholytic Dermatosis (Grover Disease)

HISTORIC ASPECTS
ETIOLOGY AND PATHOGENESIS
CLINICAL MANIFESTATIONS
PATHOLOGY
DIFFERENTIAL DIAGNOSIS
TREATMENT

REFERENCES

Grover disease (transient acantholytic dermatosis) is a polymorphic, pruritic, papulovesicular dermatosis characterized histologically by acantholysis. Although the disease is predominantly self-limited, the duration ranges from weeks to many months, so the term *transient* is often inappropriate; Grover disease appears to be the best name at present for the condition.

HISTORIC ASPECTS

In 1970, [1] Grover described six patients with an apparently unique pruritic, self-limited, primary acantholytic skin disease that he termed *transient acantholytic dermatosis* (TAD). Chalet et al. [2] reviewed 54 patients and described the clinical and histologic features in more detail, including the four characteristic patterns of acantholysis; a further 24 patients were reported by Heenan and Quirk in 1980. [3] Other sporadic reports of adult-onset papular acantholytic disorders may represent variants of Grover disease. [4], [5] and [6]

ETIOLOGY AND PATHOGENESIS

Grover disease is a common disorder that has been reported in many countries. The cause is unknown. The majority of cases have occurred in white males over the age of 40 years.

In several reports, the disease has been linked to excessive sun exposure, [3] heat, sweating, [2], [3] and [4], [7], [8] and [9] and occlusion of sweat ducts, analogous to miliaria. Other sporadic associations include febrile illness in immunocompromised patients, [8] leukemia, [10], [11] lymphoma, solid tumors, and hospitalization, [11] perhaps also related to heat, persistent fever, and sweating. The ultrastructural and light microscopic appearances suggest that disordered keratinization plays an important role in the pathogenesis, with the different patterns of acantholysis perhaps reflecting different stages in development of the lesions.

CLINICAL MANIFESTATIONS

Although some lesions are not pruritic, [12] most patients complain of pruritus of sudden onset, often disproportionate to the extent of the eruption. This eruption may consist of sparse or numerous smooth or warty papules, papulovesicles, eczematous plaques, or shiny, translucent, sometimes excoriated nodules (Fig. 55-1 and Fig. 55-2). Bullous lesions have been seen. Commonly affected sites are the trunk, neck, and proximal limbs. The submammary area is a characteristic site. Many cases are transient, but others are persistent. [6] The mean duration in one series was 47 weeks, [3] in another 94 weeks, [11] and in a third series 360 weeks. [13] Reports of a chronic relapsing course are not uncommon. [11] In a retrospective study of 375 cases, Grover showed associations with eczema of various types. [14]

FIGURE 55-1 Grover disease. Upper trunk of a 72-year-old man. Multiple discrete polymorphic lesions, including papules and excoriated nodules.

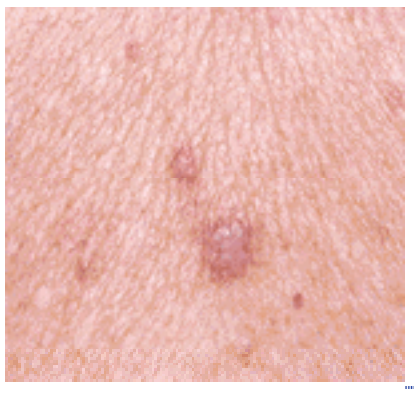

FIGURE 55-2 Grover disease: erythematous papules.

PATHOLOGY

The characteristic acantholysis occurs in four main patterns, described by Chalet et al. [2] as resembling Darier-White disease (keratosis follicularis), pemphigus, Hailey-Hailey disease (familial benign chronic pemphigus), and a spongiotic form with acantholysis (Fig. 55-3). These different patterns may occur singly but are more often seen in combination, the Darier-White type being most common overall. [3] The histologic changes typically occupy tiny, circumscribed foci, so several biopsies and multiple sections are often necessary to obtain the representative histologic changes.

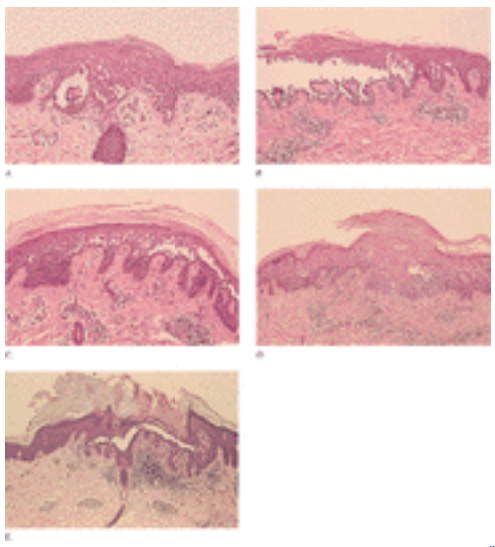

FIGURE 55-3 Grover disease: histology. *A.* Darier-White-type lesion with small suprabasal clefts, dyskeratotic cells, and dermal lymphocytic inflammation. *B.* Pemphigus-like lesion with acantholytic cells in a suprabasal cleft. *C.* Hailey-Hailey-like lesion with acantholysis involving most of the stratum malpighii. *D.* Spongiotic lesion with acantholytic cells in the vesicle and a separate focus of dyskeratosis (*left*). *E.* Focus of acantholytic dyskeratosis and suprabasal clefting overlying an eccrine duct.

The acantholysis usually occurs in a suprabasal location in lesions of the Darier-White and pemphigus types and throughout most layers of the stratum malpighii in those resembling Hailey-Hailey disease, resulting in the formation of small intraepidermal clefts or, infrequently, bullae. [15] Additional epidermal changes include hyperkeratosis, acanthosis, and parakeratosis. These changes tend to be most severe in lesions of the Darier-White type, which sometimes have vertical columns of parakeratosis overlying dyskeratotic, acantholytic foci, whereas other changes are less severe or absent in lesions of the pemphigus type. [3] Lesions are sometimes seen in association with an acrosyringium (see Fig. 55-3E), but this association has not been consistently demonstrated. [16] The dermis in most cases contains a superficial perivascular infiltrate of lymphocytes and histiocytes, sometimes with scattered eosinophils.

Immunofluorescence [3], [11], [17], [18] and immunohistochemical [11], [19] studies have not demonstrated consistent patterns of positivity. Electron microscopic studies have shown ultrastructural changes resembling those of true Darier-White disease [20] and pemphigus, whereas some differences in detail from Hailey-Hailey disease have been reported. [21]

DIFFERENTIAL DIAGNOSIS

The clinical appearance of many types of papular eruptions may simulate Grover disease. When the papules are scattered, the process may mimic prurigo simplex, miliaria rubra, papular urticaria, folliculitis, scabies, papular eczema, papular infiltrates, or dermatitis herpetiformis. When the papular lesions are so numerous as to be almost confluent, the suspicion of Grover disease is heightened, although some drug eruptions can present a similar appearance. Because of its frequent association with other skin diseases, specifically eczema, dual pathology always should be suspected. [14]

The histologic features of each pattern of acantholysis when seen alone are not specific for Grover disease. Lesions of the Darier-White type are often indistinguishable from those of true Darier-White disease, but tiny foci of dyskeratotic acantholysis with small suprabasal clefts, without an overlying column of parakeratosis, are more typical of Grover disease. [22] The presence of acantholysis within spongiotic vesicles is thought to be a helpful clue to the diagnosis of Grover disease [2] or even unique to this disease. [22] The bland appearance of the pemphigus-like lesions with very few, if any, eosinophils in the dermis helps to distinguish these changes from pemphigus vulgaris, and the distinction is confirmed by negative immunofluorescence. The Hailey-Hailey pattern also occurs only in tiny foci, usually in

combination with one or more of the other acantholytic patterns.

The best histologic evidence for the diagnosis of Grover disease is the presence of several different patterns of acantholysis in the same biopsy, occupying very small, circumscribed foci. However, several patterns of acantholysis may occur in association with other acantholytic processes, such as pemphigus vulgaris, [2] so the final diagnosis depends on the correlation of clinical and histologic findings.

TREATMENT

Assessment of efficacy of therapy is difficult because some cases remit spontaneously and others demonstrate a fluctuant course. Avoidance of heat and sweat-inducing activities is important in achieving clinical improvement; rapid temperature changes often aggravate the condition. Topical glucocorticoids and antipruritics are helpful in controlling the pruritus in mild cases. Systemic glucocorticoids generally are effective in the more severe cases, but relapse is frequent on withdrawal of the drug.

Reports of the successful treatment of other disorders of keratinization, including Darier-White disease, with vitamin A [23] led to its use in Grover disease, with good results in some cases. [24] The synthetic retinoids etretinate, acitretin, [13] and isotretinoin [13], [25] have been used in some cases with good effects, but double-blind trials have not been performed with either these drugs or vitamin A. PUVA therapy also has met with some success. [26]

REFERENCES

1. Grover RW: Transient acantholytic dermatosis. *Arch Dermatol* **101**:426, 1970

2. Chalet M et al: Transient acantholytic dermatosis: A reevaluation. *Arch Dermatol* **113**:431, 1977

3. Heenan PJ, Quirk CJ: Transient acantholytic dermatosis. *Br J Dermatol* **102**:515, 1980

4. Heaphy MR et al: Benign papular acantholytic dermatosis. *Arch Dermatol* **112**:814, 1976

5. Gisslen H, Mobacken H: Acute adult-onset Darier-like dermatosis. *Br J Dermatol* **98**:217, 1978

6. Simon RS et al: Persistent acantholytic dermatosis. A variant of transient acantholytic dermatosis (Grover's disease). *Arch Dermatol* **112**:1429, 1976

7. Hu CH et al: Transient acantholytic dermatosis (Grover's disease): A skin disorder related to heat and sweating. *Arch Dermatol* **121**:1439, 1985

8. Horn TD, Groleau GE: Transient acantholytic dermatosis in immunocompromised febrile patients with cancer. *Arch Dermatol* **123**:238, 1987

9. Quarterman MJ, Davis LS: Transient acantholytic dermatosis in a postoperative febrile patient. *Int J Dermatol* **34**:113, 1995

10. Yaffee HS: Possible dysglobulinemia and Grover's disease. *Arch Dermatol* **117**:3, 1981

11. Davis MD et al: Grover's disease: Clinicopathological review of 72 cases. *Mayo Clin Proc* **74**:229, 1999

12. Guana A, Cohen P: Transient acantholytic dermatosis in oncology patients. *J Clin Oncol* **12**:1703, 1994

13. Streit M et al: Transitory acantholytic dermatosis (Grover disease). An analysis of the clinical spectrum based on 21 histologically assessed cases. *Hautarzt* **51**:244, 2000

14. Grover RW, Rosenbaum R: The association of transient acantholytic dermatosis with other skin diseases. *J Am Acad Dermatol* **11**:253, 1984

15. Waisman M et al: Bullous transient acantholytic dermatosis. *Arch Dermatol* **112**:1440, 1976

16. Antley CM et al: Grover's disease: Relationship of acantholysis to acrosyringia. *J Cutan Pathol* **25**:545, 1998

17. Bystryn J-C: Immunofluorescence studies in transient acantholytic dermatosis (Grover's disease). *Am J Dermatopathol* **1**:325, 1979

18. Millns JL et al: Positive cutaneous immunofluorescence in Grover's disease. *Arch Dermatol* **116**:515, 1980

19. Gretzula JC, Penneys NS: Transient acantholytic dermatosis: An immunohistochemical study. *Arch Dermatol* **122**:972, 1986

20. Grover RW, Duffy JL: Transient acantholytic dermatosis: Electron microscopic study of the Darier type . *J Cutan Pathol* **2**:111, 1975

21. Grover RW: Transient acantholytic dermatosis: Electron microscopic study. *Arch Dermatol* **104**:26, 1971

22. Ackerman AB: *Histological Diagnosis of Inflammatory Skin Diseases*. Philadelphia, Lea & Febiger, 1978

23. Porter AD et al: Vitamin A in Darier's disease. *Arch Dermatol* **56**:306, 1947

24. Rohr J, Quirk CJ: Treatment of transient acantholytic dermatosis. *Arch Dermatol* **115**:1033, 1979

25. Helfman RJ: Grover's disease treated with isotretinoin. *J Am Acad Dermatol* **12**:981, 1985

26. Paul BS, Arndt KA: Response of transient acantholytic dermatosis to photochemotherapy. *Arch Dermatol* **120**:121, 1984

T>

Chapter 56

Elisabeth Wolff-Schreiner

Porokeratosis

HISTORICAL ASPECTS
ETIOLOGY AND PATHOGENESIS
Hereditary Factors
Additional Factors
CLINICAL MANIFESTATIONS
Porokeratosis Mibelli
Disseminated Superficial Porokeratosis and Disseminated Superficial Actinic Porokeratosis
Porokeratosis Palmaris et Plantaris Disseminata
Linear Porokeratosis
Punctate Porokeratosis
HISTOPATHOLOGY
DIAGNOSIS AND DIFFERENTIAL DIAGNOSIS
TREATMENT
COURSE AND PROGNOSIS

REFERENCES

Porokeratosis is a specific disorder of keratinization that is characterized histologically by the presence of a cornoid lamella—a thin column of closely stacked, parakeratotic cells extending through the stratum corneum. Clinically, the basic lesion is sharply demarcated and hyperkeratotic, and it may be annular with central atrophy, either linear or punctate.

Five clinical variants are recognized (Table 56-1): (1) classic porokeratosis Mibelli; (2) disseminated superficial porokeratosis (DSP) and disseminated superficial actinic porokeratosis (DSAP); (3) porokeratosis palmaris et plantaris disseminata (PPPD); and (4) linear porokeratosis. A fifth form, not listed in the table, is punctate porokeratosis, which is usually associated with the linear or Mibelli variants.



TABLE 56-1 **Distinguishing Features of Four Types of Porokeratosis**

HISTORICAL ASPECTS

Mibelli described the lesions of classic porokeratosis in 1893 as one or more localized, chronically progressive, hyperkeratotic, irregular plaques with central atrophy and a prominent peripheral keratotic ridge. At about the same time, Respighi and, later, Andrews independently described a more superficial, disseminated form. [1] The linear variants were delineated early in the twentieth century. In 1966, Chernosky described DSAP, [2] and in 1971 Guss and associates added disseminated porokeratosis with palmar and plantar involvement (PPPD) to the spectrum. [3] In 1977, punctate porokeratosis was delineated as a minor form, usually associated with the linear or Mibelli variants. [4]

ETIOLOGY AND PATHOGENESIS

The etiology of the different variants of porokeratosis is unknown, but is certainly multifactorial.

Hereditary Factors

The coexistence of various forms of porokeratosis in one patient or in several members of an affected family suggests that the forms are different phenotypic expressions of a common genetic defect. An autosomal dominant mode of inheritance with reduced penetrance has been reasonably well established for porokeratosis Mibelli, PPPD, DSP, and DSAP. A gene locus involved in the phenotypic expression of DSAP has been identified on the long arm of chromosome 12. [5] Linear porokeratosis has been observed in monozygotic twins, is often associated with the disseminated forms of porokeratosis, and has been interpreted as a type 2 segmental manifestation of DSP [6] or DSAP. [7] Sporadic cases may be due to somatic mutations.

All porokeratoses share the cornoid lamella, a thin, parakeratotic column at the periphery of typical lesions. It has been suggested that, at the base of this parakeratotic column, an inherited mutant clone of keratinocytes expands peripherally, leading to the formation of a cornoid lamella between the clonal cells and normal keratinocytes. [8]

Additional Factors

In genetically disposed skin, additional factors are assumed to trigger the clinical manifestations. Irradiation with ultraviolet (UV) light from natural or artificial sources, for example, has induced lesions of DSAP and exacerbations. Additionally, there are increasing numbers of reports of DSP and DSAP in connection with or after organ transplantation, [9], [10] bone marrow transplantation, [11] transplant induction therapy, [12] chronic renal [13] and hepatic failure, [14] hepatitis C virus infection with or without hepatocellular carcinoma, [15] HIV infection, [16], [17] and various other causes of impaired immunocompetence. It has been suggested that local immunosuppression may explain the promoting effect of UV light. [18] Malignancies rarely arise in porokeratosis lesions in immunosuppressed individuals, [19], [20] although profound immunosuppression may facilitate the emergence of abnormal keratinocyte clones and eventually malignant transformation. [16], [20], [21]

A high rate of abnormal DNA-ploidy [22] and certain phenotypic features indicative of malignant transformation or altered differentiation (i.e., overexpression of p53, decreased mdm2, normal 21Waf1/Cip1 expression; [23], [24] abnormal expression of psi-3, cytokeratins, filaggrin, and involucrin) suggest an increased proliferative potential in affected keratinocytes. Cultured fibroblasts from lesional and nonlesional skin may exhibit chromosomal instability [22] and hypersensitivity to x-irradiation. [25] An alternative hypothesis for the hyperproliferative state of keratinocytes in porokeratosis comes from the finding that underneath the epidermis bearing a cornoid lamella there resides an inflammatory mononuclear infiltrate composed of helper T cells, suppressor T cells, and Langerhans cells. [26] Soluble factors released by activated T cells may provide a mitotic stimulus for overlying keratinocytes. The role of the dermis in the pathologic process is further enhanced by the fact that lesions recur after destruction of the epidermis, but not the dermis, and that lesions may develop in predisposed skin after dermal injury.

A hypothetical infectious/transmissible agent has been postulated as an explanation for the high incidence of porokeratoses in transplant recipients, in immunosuppressed patients, and in connection with hepatitis C virus and HIV infection. [27], [28]

CLINICAL MANIFESTATIONS

Porokeratosis Mibelli

Lesions of porokeratosis Mibelli start as small, brownish papules that slowly enlarge to form irregular, annular, hyperkeratotic or verrucous plaques. The lesions have a well demarcated, raised hyperkeratotic border that is usually more than 1 mm in height and contains a diagnostic, threadlike groove so that the border resembles a dike split by a longitudinal furrow (Fig. 56-1). The center is usually atrophic, hairless, anhydrotic, and hyper- or hypopigmented. Porokeratosis Mibelli can occur practically anywhere on the body, but preferentially it is localized to the limbs where lesions may involve palms and soles; lesions can occur on the face, sometimes extending to the lips and the oral mucosa, and in the genital and perigenital region. Porokeratosis Mibelli usually presents as one or a few, generally asymptomatic, lesions from millimeters to several centimeters in diameter, but giant lesions do occur. Malignant degeneration can occur in large lesions of long duration.

FIGURE 56-1 Typical large prominent lesion of porokeratosis Mibelli.

Onset is during childhood, and lesions enlarge slowly over the years. Family studies suggest an autosomal dominant mode of inheritance (see Table 56-1).

Disseminated Superficial Porokeratosis and Disseminated Superficial Actinic Porokeratosis

A more generalized process than porokeratosis Mibelli, DSP involves mainly the extremities in a bilateral, symmetric fashion (Fig. 56-2A). In about 50 percent of the cases, lesions develop only in sun-exposed areas (DSAP), and patients often offer a history of exacerbations during the summer months with pruritus, burning, or stinging sensations.

FIGURE 56-2 *A*. Multiple disseminated lesions of superficial actinic porokeratosis on the forearm. *B*. Very discrete, superficial lesions on the forearm in another patient with characteristic furrows in the periphery of lesions (*arrows*).

Early lesions are small papules, often with a central dell, measuring 1 to 3 mm in diameter. They enlarge over months or years to form superficial, ringlike lesions with a slightly atrophic center, surrounded by a delicate keratotic ridge that is topped by a barely visible furrow (Fig. 56-2B). Irregular centrifugal growth and coalescence of lesions may give rise to circinate configurations. Lesions are erythematous, pigmented, or the color of normal skin, and they are typically dry and anhydrotic. Literally hundreds of lesions can be disseminated preferentially over the extensor surfaces of the extremities (see Fig. 56-2A); they spare the axillary vaults, inguinal folds, perigenital region, palms, soles and mucous membranes. Involvement of the face is rare in DSP or DSAP.

The course is slowly progressive over years. Disseminated superficial actinic porokeratosis occurs more often in geographic areas with high sun exposure. Irradiation with natural and artificial UV light, photochemotherapy, and phototherapy for psoriasis can lead to exacerbation or persistence of DSAP lesions.

Attempts to induce new lesions by trauma (the Koebner phenomenon) have failed. Autotransplantation of normal skin into a lesion has resulted in re-formation of the lesional ridge within the graft, whereas it disappeared from lesional skin grafted into a normal bed.

The disseminated forms of porokeratosis are relatively common. The apparent slight preponderance of female patients is probably not due to genetic factors, but to the fact that women are more likely to seek medical advice than men. Disseminated superficial actinic porokeratosis seems to be extremely rare in blacks. Onset is usually in the third and fourth decades; in no instance has the condition been described in childhood. [5] The mode of inheritance is autosomal dominant with reduced penetrance at a young age (see Table 56-1).

Porokeratosis Palmaris et Plantaris Disseminata

Lesions of PPPD are superficial, small, relatively uniform, and demarcated by a distinct peripheral ridge of no more than 1 mm in height (Fig. 56-3). In palmar and plantar lesions, which are generally more hyperkeratotic, the characteristic longitudinal furrow along this ridge may be quite pronounced (Fig. 56-4). Lesions first arise on palms and soles and spread in large numbers over the extremities, the trunk, and other parts of the body, including areas not exposed to sunlight. They can cause pruritus and stinging sensations. Lesions involving the mucous membranes are small, annular or serpiginous, opalescent, asymptomatic, and they can be quite numerous.

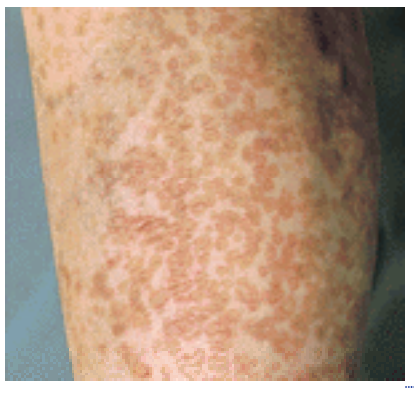

FIGURE 56-3 Porokeratosis palmaris et plantaris disseminata. Multiple superficial lesions on the calf. Note similarity to disseminated superficial actinic porokeratosis shown in Fig. 56-2A.

FIGURE 56-4 Plantar lesions in porokeratosis palmaris et plantaris disseminata. Note ridge and furrow surrounding the lesions.

Onset is usually during adolescence or early adulthood. Transmitted in an autosomal dominant mode, PPPD affects males twice as often as it affects females (see Table 56-1).

Linear Porokeratosis

In some cases, linear porokeratosis occurs in a unilateral, linear systematized form resembling a linear verrucous epidermal nevus. Clinically, the basic lesions are identical to those of the Mibelli type, including lichenoid papules, annular lesions, hyperkeratotic plaques with central atrophy, and the characteristic peripheral ridge (Fig. 56-5). The condition is strictly unilateral. It may involve only one extremity, but may also be present on the other extremity, the trunk, and the face on the same side. On the extremities, lesions are grouped and linearly arranged, affecting the distal portion more than the proximal areas; on the trunk, the distribution may be zosteriform. Association with other variants of porokeratosis in one patient or within an affected family is possible. Malignant degeneration has been described.

FIGURE 56-5 Linear porokeratosis. The similarity to an epidermal nevus is evident.

Onset is usually in infancy and childhood. No definite inheritance pattern has been established (see Table 56-1). In one instance, linear porokeratosis was observed in monozygotic twins.

Punctate Porokeratosis

Usually, punctate porokeratosis is associated with either the Mibelli or linear types. Multiple, minute, and discrete punctate, hyperkeratotic, seedlike lesions surrounded by a thin, raised margin are present on palms and soles. Lesions may occur in a linear arrangement, or they may aggregate to form plaques. Punctate porokeratosis must be differentiated clinically and histopathologically from punctate keratoderma, also referred to as punctate porokeratotic keratoderma or as porokeratosis punctata palmaris et plantaris.

HISTOPATHOLOGY

The histopathologic hallmark common to all clinical variants of porokeratosis is the cornoid lamella, [8] which represents the pathologic substrate for the longitudinal furrow in the keratotic ridgelike border (Fig. 56-6). The cornoid lamella arises in the interfollicular epidermis and may involve the ostia of hair follicles or sweat ducts, which has led to the misnomer porokeratosis. [1] It consists of a tightly packed, thin column of parakeratotic cells extending through the entire thickness of the surrounding orthokeratotic stratum corneum. Below the cornoid lamella the granular layer is missing, and single or clustered dyskeratotic cells and vacuolated keratinocytes lie at its base (Fig. 56-7). The adjacent epidermis is hyperkeratotic and acanthotic to a variable degree.

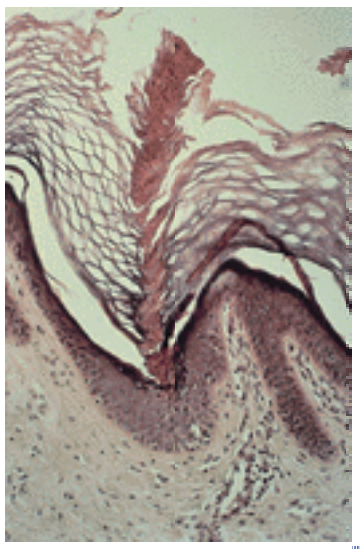

FIGURE 56-6 Porokeratosis, margin of lesion. Cornoid lamella arises from a small indentation of the epidermis and extends like a thin column through the entire stratum corneum.

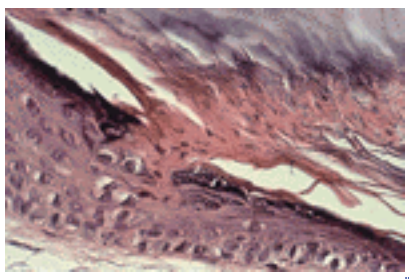

FIGURE 56-7 Base of cornoid lamella showing absence of stratum granulosum and vacuolated cells.

The cornoid lamella occupies an indentation of the epidermis that is generally tilted away from the center of the lesion. [29] The underlying papillary dermis contains a moderately dense inflammatory infiltrate and dilated capillaries. In the center of the lesion, the epidermis is usually atrophic, with areas of liquefaction degeneration in the basal layer, colloid bodies, and flattening of rete ridges. The dermis can be edematous or fibrotic with telangiectasia. Below long-standing lesions of DSP, there may be deposits of amyloid derived from keratinocytes. [30]

In essence, histopathologic changes are similar in all forms of porokeratoses; however, in DSP, DSAP, and PPPD, the cornoid lamella is less pronounced or so minimal as to be difficult to recognize. The ultrastructural findings—vacuolization of keratinocytes, clumping of keratin filaments, and dyskeratosis—are the same in porokeratosis Mibelli, DSP, and DSAP. Large, long-standing, eroded lesions require special attention to malignant transformation.

DIAGNOSIS AND DIFFERENTIAL DIAGNOSIS

Porokeratosis is usually diagnosed with ease, both histopathologically and clinically. The cornoid lamella is the diagnostic criterion for porokeratosis, but the phenomenon of cornoid lamellation can also occur in a number of unrelated diseases, including inflammatory, hyperplastic, and neoplastic conditions. Clinically, the continuous keratotic ridge cleaved by a longitudinal furrow, which surrounds the lesions both in the Mibelli type and in the other variants, is quite diagnostic, as is the localization and distribution of lesions.

Elastosis perforans can appear quite similar to porokeratosis Mibelli, but it consists of erythematous, keratotic papules and lacks the continuous ridge with its furrow. The superficial, disseminated types of porokeratosis may resemble actinic keratoses, stucco keratoses, flat seborrheic keratoses, or flat warts. Small, discrete lesions may be mistaken for lichen sclerosus et atrophicus, lichen planus, acrokeratosis verruciformis, and pityriasis rubra pilaris, but each of these lack the fine, slightly raised, threadlike border. Neoplasic disorders, such as cutaneous T cell lymphoma (CTCL), can mimic lesions of DSAP or porokeratosis Mibelli clinically. Histologically, the lesions lack a cornoid lamella and reveal infiltrates typical of CTCL.

Porokeratosis plantaris discreta is a not uncommon, acquired condition of the soles that is unrelated to the porokeratoses discussed in this chapter. [31] Clinically, it appears as sharply circumscribed, firm nodules up to 0.5 cm in diameter with a yellowish, depressed center surrounded by erythema. There is a central conical plug from which a yellowish, waxy material can be curetted. Lesions occur singly and in groups. They are painful and most often misdiagnosed as calluses or plantar warts. Although a cornoid lamella–like parakeratotic column can be found in these lesions histologically, the condition is unrelated to the porokeratoses. It is thought to be induced by pressure resulting in keratotic plugging of the distal eccrine duct, which produces secondary cystic dilation of the underlying sweat glands. [31]

Punctate keratoderma consists clinically of small, spinelike protruding keratotic excrescences that are limited to the palms, soles, and volar and plantar surfaces of the digits. Histopathologically, these lesions consist of sharply circumscribed spines of densely packed parakeratotic material overlying a shallow pit with a reduced or absent granular layer. In some cases of punctate keratoderma, hereditary transmission as an autosomal dominant trait has been recorded.

TREATMENT

Therapy is disappointing in all forms of porokeratosis, and recurrences can occur with any therapeutic modality. The optimal procedure depends on the size and location of the lesion, the functional and aesthetic requirements, and the age

and condition of the patient. Circumscribed lesions of porokeratosis Mibelli or linear porokeratosis may be excised and grafted, destroyed by cryotherapy, electrodesiccation, dermabrasion, CO_2 laser, [32] 585-nm pulsed dye laser, [33] and Nd:YAG laser. [34] Lubrication for superficial lesions and keratolytic treatment of hyperkeratotic variants usually ease symptoms.

Successful treatment has been reported with topical 5-fluorouracil in porokeratosis Mibelli, linear porokeratosis, as well as in DSP and DSAP. In the author's experience, a brisk inflammatory response seems to be a prerequisite for clearing, which can occur as a delayed reaction. Treatment with calcipotriol and topical tacalcitol has been successful in DSAP. [35], [36] Oral retinoids have yielded conflicting results: although the results obtained in some patients with DSAP, widespread porokeratosis Mibelli, PPPD, and linear porokeratosis have been excellent, the side effects of oral retinoids and the probability of relapses weeks or months after discontinuation of retinoid therapy require consideration. It has been reported, however, that retinoid therapy causes cytologic atypia to disappear and may have an inhibitory effect on cutaneous carcinogenesis in porokeratotic lesions. [37], [38] Therapeutic measures that might increase the malignant potential, such as irradiation, immunosuppression, and excessive UV exposure, should be avoided.

COURSE AND PROGNOSIS

Porokeratotic lesions usually increase in size and number with time. Although this may be an extremely slow process in porokeratosis Mibelli, progression can be quite pronounced in DSP. Eruptions similar to those induced by drugs occur in patients with DSAP after UV exposure. [39] In cases of impaired immunocompetence, fluctuations in severity and remissions may parallel the state of immunocompetence. Thus, sudden aggravation of DSP or DSAP should prompt a search for underlying immunosuppression. [40] Malignant degeneration (squamous cell carcinoma, Bowen's disease, basal cell epithelioma) has occurred; it is more common in large, isolated, long-standing lesions of the Mibelli type of porokeratosis [41] and linear porokeratosis, [42], [43] but it also occurs in DSP, DSAP, and PPPD. [38] Statistically, Japanese patients develop earlier, and more often multiple, malignant tumors in lesions of porokeratosis. [41] Widespread metastasis and fatal outcome, as well as soft tissue destruction and mutilation in cases of giant lesions of porokeratosis Mibelli in an acral location, have been reported. [44], [45]

REFERENCES

1. Andrews GC: Porokeratosis (Mibelli) disseminated and superficial type. *Arch Dermatol Syphilol* **36**:1111, 1937

2. Chernosky ME: Porokeratosis: Report of twelve patients with multiple superficial lesions. *South Med J* **59**:289, 1966

3. Guss SB et al: Porokeratosis plantaris, palmaris, et disseminata: A third type of porokeratosis. *Arch Dermatol* **104:**366, 1971

4. Rahbari HR et al: Punctate porokeratosis: A clinical variant of porokeratosis of Mibelli. *J Cutan Pathol* **4**:338, 1977

5. Xia JH et al: Identification of a locus for disseminated superficial actinic porokeratosis at chromosome 12q23.2-24.1. *J Invest Dermatol* **114**:1071, 2000

6. Murata Y et al: Type 2 segmental manifestation of disseminated superficial porokeratosis showing a systematized pattern of involvement and pronounced cancer proneness. *Eur J Dermatol* **11**:191, 2001

7. Freyschmidt PP et al: Linear porokeratosis superimposed on disseminated superficial actinic porokeratosis: Report of two cases exemplifying the concept of type 2 segmental manifestation of autosomal dominant skin disorders. *J Am Acad Dermatol* **41**:644, 1999

8. Reed RJ, Leone P: Porokeratosis—A mutant clonal keratosis of the epidermis. *Arch Dermatol* **101**:340, 1970

9. Knoell KA et al: Sudden onset of disseminated porokeratosis of Mibelli in a renal transplant patient . *J Am Acad Dermatol* **41**:830, 1999

10. Kanitakis J et al: Porokeratosis in organ transplant recipients. *J Am Acad Dermatol* **44**:144, 2001

11. Rio B et al: Disseminated superficial porokeratosis after autologous bone marrow transplantation. *Bone Marrow Transplant* **19**:11, 1997

12. Fields LL et al: Rapid development of disseminated superficial porokeratosis after transplant induction therapy. *Bone Marrow Transplant* **15**:993, 1995

13. Hernandez MH et al: Disseminated porokeratosis associated with chronic renal failure: A new type of disseminated porokeratosis? *Arch Dermatol* **136**:1568, 2000

14. Hunt SJ et al: Linear and punctate porokeratosis associated with end-stage liver disease. *J Am Acad Dermatol* **25**:937, 1991

15. Kono T et al: Synchronous development of disseminated superficial porokeratosis and hepatitis C virus–related hepatocellular carcinoma. *J Am Acad Dermatol* **43**:966, 2000

16. Kanitakis J et al: Disseminated superficial porokeratosis in a patient with AIDS. *Br J Dermatol* **131**:284, 1994

17. Rodriguez EA et al: Porokeratosis of Mibelli and HIV infection. *Int J Dermatol* **35**:402, 1996

18. Allen AL, Glaser DA: Disseminated superficial actinic porokeratosis associated with topical PUVA. *J Am Acad Dermatol* **43**:720, 2000

19. Kanitakis J et al: Porokeratosis and immunosuppression. *Eur J Dermatol* **8**:459, 1998

20. Anzai S et al: Squamous cell carcinoma in a renal transplant recipient with linear porokeratosis. *J Dermatol* **26**:244, 1999

21. Bencini PL et al: Porokeratosis and immunosuppression. *Br J Dermatol* **132**:74, 1995

22. Otsuka F M et al: Porokeratosis with large skin lesions: Histologic, cytologic and cytogenetic study of three cases. *Acta Derm Venereol*

71:437, 1991

23. Nelson C et al: p53, mdm-2, and 21 waf-1 in the porokeratoses. *Am J Dermatopathol* **21**:420, 1999

24. Kawakami T et al: Overexpression of p21Waf1/Cip1 immunohistochemical staining in Bowen's disease, but not in disseminated superficial porokeratosis. *Br J Dermatol* **141**:647, 1999

25. Watanabe R, Otsuka F: Cultured skin fibroblasts derived from three patients with disseminated superficial actinic porokeratosis (DSAP) are hypersensitive to the lethal effects of x-radiation but not to those of ultraviolet (UV) light. *Exp Dermatol* **2**:175, 1993

26. Shumack S et al: Disseminated actinic porokeratosis: A histological review of 61 cases with particular reference to lymphocyte inflammation. *Am J Dermatopathol* **13**:26, 1993

27. Webster GF: Are porokeratoses an infection? *Arch Dermatol* **137**:665, 2001

28. Mizukawa Y, Shiohara T: Onset of porokeratosis of Mibelli in organ transplant recipients: Lack of a search for transmissible agents in these patients. *J Am Acad Dermatol* **44**:143, 2001

29. Crefeld W: Zur Histogenese der Porokeratosis Mibelli. *Z Haut Geschlechtskr* **44**:453, 1969

30. Kim JH et al: Secondary cutaneous amyloidosis in disseminated superficial porokeratosis: A case report. *J Korean Med Sci* **15**:478, 2000

31. Taub J, Steinberg M: Porokeratosis plantaris discreta: A previously unrecognized dermatologic entity. *Int J Dermatol* **9**:83, 1970

32. Rabbin PE, Baldwin HE: Treatment of porokeratosis of Mibelli with CO_2 laser vaporization versus surgical excision with split-thickness skin graft: A comparison. *J Dermatol Surg Oncol* **19**:199, 1993

33. Alster TS, Nanni CA: Successful treatment of porokeratosis with 585 nm pulsed dye laser irradiation. *Cutis* **63**:265,1999

34. Liu HT: Treatment of lichen amyloidosis (LA) and disseminated superficial porokeratosis (DSP) with frequency-doubled Q-switched Nd:YAG laser. *Dermatol Surg* **26**:958, 2000

35. Harrison P, Stollery N: Disseminated superficial actinic porokeratosis responding to calcipotriol. *Clin Exp Dermatol* **19**:95, 1994

36. Bohm M et al: Disseminated superficial actinic porokeratosis: Treatment with topical tacalcitol. *J Am Acad Dermatol* **40**:479, 1999

37. Goldman GD, Milstone LM: Generalized linear porokeratosis treated with etretinate. *Arch Dermatol* **131**:496, 1995

38. Seishima M et al: Squamous cell carcinoma arising from lesions of porokeratosis palmaris et plantaris disseminata. *Eur J Dermatol* **10**:478, 2000

39. Kroiss MM et al: Disseminated superficial porokeratosis induced by furosemide. *Acta Derm Venereol (Stockh)* **80**:52, 2000

40. Levin RM, Heymann WR: Superficial disseminated porokeratosis in a patient with myelodysplastic syndrome. *Int J Dermatol* **38**:138, 1999

41. Otsuka F et al: Porokeratosis large skin lesions are susceptible to skin cancer development: Histological and cytological explanation for the susceptibility. *J Cancer Res Clin Oncol* **119**:395, 1993

42. Sasson M, Krain AD: Porokeratosis and cutaneous malignancy: A review. *Dermatol Surg* **22**:339, 1996

43. Happle R: Cancer proneness of linear porokeratosis may be explained by allelic loss. *Dermatology* **195**:20, 1997

44. Handa S et al: Mutilating lesions in porokeratosis of Mibelli. *Dermatology* **191**:162, 1995

45. Rahbari H et al: Destructive facial porokeratosis. *J Am Acad Dermatol* **33**:1049, 1995

T>

Chapter 57

Elisabeth Wolff-Schreiner

Kyrle Disease and Other Perforating Disorders

KYRLE DISEASE
Definition and Historical Aspects
Etiology and Pathogenesis
Clinical Findings
Associated Diseases
Histopathology
Differential Diagnosis
Therapy
PERFORATING FOLLICULITIS
Definition and Historical Aspects
Etiology and Pathogenesis
Clinical Findings
Histopathology
Differential Diagnosis
Therapy
ACQUIRED PERFORATING DERMATOSIS
Definition and Historical Aspects
Etiology and Pathogenesis
Clinical Findings
Histopathology
Differential Diagnosis
Therapy

REFERENCES

KYRLE DISEASE

Definition and Historical Aspects

Kyrle in 1916 described a major dermatosis characterized by numerous up to cherry-sized hyperkeratotic, verrucous, clefted papules and nodules involving almost the entire skin. [1] The histopathologic picture of Kyrle disease was that of a "hyperkeratosis follicularis et parafollicularis in cutem penetrans." Since the original description, the distinctiveness of this rare syndrome has been blurred or questioned altogether. [2] Kyrle disease can be defined as a distinct entity, however; similarly, the syndrome of acquired perforating dermatosis, which is most often misdiagnosed as Kyrle disease, can be delineated. [3]

Etiology and Pathogenesis

The etiology of Kyrle disease is not known. Disease occurrence in siblings suggests a genetic background, possibly an autosomal recessive mode of inheritance. [4] The basic pathogenic event seems to be an uncoupling of epithelial proliferation and differentiation that results in a gradual and progressive lowering of the level of keratinization toward the dermal-epidermal junction. [5] The eventual discontinuity of the basement membrane and direct contact between the partly parakeratotic plug and the dermis lead to granuloma formation and scarring. In Kyrle disease, transepidermal elimination is of no pathogenic significance.

Clinical Findings

Kyrle disease is a chronic, generalized dermatosis that starts most frequently during the third to fifth decades, although the onset may occur in infancy and childhood. [4] It seems to affect females twice as often as males. Kyrle disease preferentially involves the extensor surfaces of the extremities, the scapular region, and the buttocks, but may also involve the axillary vaults, [1] face, hands, and feet. [4] The mucous membranes are invariably spared, although lesions may occur on the vulva and perianal region. [4]

Individual lesions start as pinhead-sized, skin-colored hyperkeratotic papules. As they increase in size, they become more elevated and yellowish brown, with a tightly adherent scale or squamous crust (Fig. 57-1A). Older, up to cherry-sized lesions consist of a grayish, verrucous, clefted, cone-shaped horny mass surrounded by a narrow brownish-reddish rim (Fig. 57-1B and Fig. 57-2). Dense clustering and slow peripheral expansion of grouped lesions result in coalescence and the formation of polycyclic, verrucous growths (Fig. 57-2 and Fig. 57-3A). The clefted horny mass can be removed easily, leaving an oozing or bleeding crater or a clefted, cup-shaped excavation (see Fig. 57-2). Lesions heal with atrophic scars with spotty hyper- and hypopigmentation. Lesions crop up in an asynchronous fashion so that different stages of development occur side by side (Fig. 57-1A and Fig. 57-3B); recurrences, within or at the periphery of scars, are frequent [1], [5] (see Fig. 57-1A, Fig. 57-3A, and Fig. 57-3B). The eruption is asymptomatic or slightly pruritic. Larger lesions can be mechanically disturbing and tender, particularly after they have been traumatized.

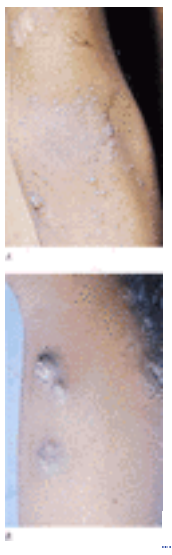

FIGURE 57-1 Kyrle disease. *A*. Early lesions: multiple cone-shaped hyperkeratotic papules in a 12-year-old girl. Note atrophic scars with spotty pigmentation. A larger hyperkeratotic nodule is present at the edge of a scar. *B*. Larger lesions with massive, partly clefted hyperkeratoses on the forearm of a 6-year-old boy (brother of the girl in Fig. 57-1A and Fig. 57-3A and Fig. 57-3B).

FIGURE 57-2 Kyrle disease. Note the protruding, warty, clefted hyperkeratoses, grouping of lesions, and the oozing, hemorrhagic, cup-shaped depression on the right thigh after removal of a hyperkeratotic nodule. Scarring is only minor in this case of short duration.

FIGURE 57-3 Kyrle disease. *A*. Multiple warty lesions over the knees of the 12-year-old patient shown in Fig. 57-1A. Clefted, verrucous lesions of variable size are grouped or localized in the periphery of atrophic scars with spotty pigmentation. *B*. Anogenital region of the same patient with severe atrophic scarring and a number of large, verrucous lesions, which also involve the labia majora. The vaginal introitus is free of lesions. Note small, early hyperkeratotic papules on the left buttock.

The course of Kyrle disease is extremely chronic over decades. There have been no reports of spontaneous remissions.

Associated Diseases

The small number of authentic cases of Kyrle disease and the notorious problem of distinguishing it from acquired perforating dermatosis (see below) make an evaluation of its association with diabetes difficult. Kyrle original patient was nondiabetic at the time of the first description, [1] but 8 years later had developed diabetes. Several other cases with diabetes are described in the literature; however, the association is statistically not significant. [4] No association exists between Kyrle disease and renal disease.

Histopathology

Serial sectioning of the lesions, essentially parallel to the longitudinal axis of the follicles, makes it possible to appreciate the histopathologic development of Kyrle disease. Lesions occur both in the follicular and interfollicular epidermis and in the acrosyringium. [1] Early lesions reveal a focal thickening of the horny layer with some parakeratotic cells. The epidermis is acanthotic, and the cells of the germinative layer are increased in number, stain more intensely, and are arranged in a somewhat disorderly fashion. In this stage, the papillary dermis is widened, but without inflammatory

changes.

In lesions with verrucous hyperkeratosis, the follicular infundibulum or acrosyringium is widely dilated by a funnel-shaped, brightly eosinophilic horny plug (Fig. 57-4A). The central portion consists of a parakeratotic column that, at its tip, is in continuity with and seems to emerge from individual or clustered dyskeratotic cells in the underlying epidermis (see Fig. 57-4A). These cells have a brightly eosinophilic cytoplasm and darkly staining nuclei, and they retain their normal contacts with the surrounding keratinocytes. Gradually, they merge into the parakeratotic column, and with new dyskeratotic cells developing at its tip, the column approaches the dermal-epidermal junction (Fig. 57-4B).

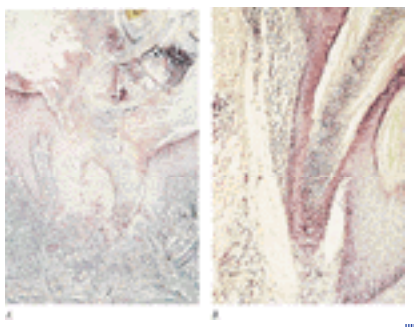

FIGURE 57-4 Lesions of Kyrle disease before perforation. *A.* Massive hyperkeratosis with central parakeratotic column. At the base of the parakeratotic column, individual cell keratinization can be followed down almost to the basal layer. The surrounding epidermis is acanthotic. (*From Tappeiner et al.,* [4] *with permission of* Hautarzt.) *B*. Higher magnification of the parakeratotic column in the center of a lesion of Kyrle disease.

Ultimately establishing contact with the dermis through a focal defect in the basement membrane, the horny plug can reach fairly deep into the dermis. [1], [4] The perforation often lies near the opening of the sebaceous gland duct or in eccrine glands in the pit of the acrosyringium. [1] The surrounding epidermis either thins because of the pressure or becomes acanthotic. Before penetration, mononuclear cells invade the dermis below the dyskeratotic cells and the adjacent epidermis (see Fig. 57-4A). After penetration, lymphocytes, polymorphonuclear leukocytes, epithelioid cells, and foreign-body giant cells containing eosinophilic fragments of engulfed keratin infiltrate the papillary dermis. In healing lesions, atrophic scar tissue replaces the granuloma.

In the interfollicular epidermis, the histopathologic changes are less dramatic. Lesions are less hyperkeratotic, and perforation, with its severe consequences, occurs less frequently. Clinically, this histopathologic variant corresponds to smaller lesions that grow slowly and regress more readily with no or only mild scarring. [1] Perforation is not obligatory for diagnosis and occurs far less frequently in Kyrle disease than in other perforating disorders (see below). Of importance is the central parakeratotic column that arises from individual cell keratinization and finally establishes direct contact between the keratotic plug and the dermis (Fig. 57-4B). Basophilic debris within the follicular compartment is not typical for Kyrle disease. [1]

Differential Diagnosis

Clinically, the early lesions of Kyrle disease can be similar to the early lesions of dyskeratosis follicularis, punctate psoriasis, or keratosis pilaris. The mature exophytic, clefted, verrucous papules or nodules; the distribution pattern, including face, hands, feet, and, eventually, the axillary vaults and perianal-perigenital region; the insignificance of pruritus; and the general lack of an underlying chronic disease allow the clinical differentiation from other perforating disorders. In contrast, acquired perforating dermatosis runs a different clinical course and has an association with certain chronic diseases (see below).

Histopathologically, the differential diagnosis includes all the other perforating diseases. The characteristic keratotic plug, individual cell keratinization in the germinative layer, and the resulting parakeratotic column typical of Kyrle disease do not occur in any of the other perforating dermatoses.

Therapy

No specific therapy for Kyrle disease is known. The small number of authentic cases of the disease makes a comparison of various therapeutic modalities practically impossible.

Kyrle treated his own patient by curetting the hyperkeratoses prior to ultraviolet (UV) irradiation. After a short remission, lesions recurred. [1] The use of high-dose vitamin A, oral retinoids, and a combination of oral retinoids and psoralen plus UVA (Re-PUVA) may have a beneficial effect. Discontinuation of the medication results in prompt recurrence. Topical therapy is unsatisfactory: keratolytics and retinoic acid preparations help to improve the cosmetic appearance; electrocautery, cryotherapy, and CO_2 laser surgery are only temporarily effective.

PERFORATING FOLLICULITIS

Definition and Historical Aspects

In 1968, Mehregan and Coskey described 25 patients with a discrete follicular keratotic eruption involving mainly the hairy parts of the extremities; they termed the condition perforating folliculitis. [6] Clinically, somewhat similar eruptions have occurred in patients with chronic renal failure with or without hemodialysis and/or diabetes [3] (see " Acquired

Perforating Dermatosis," below).

Etiology and Pathogenesis

The etiology of perforating folliculitis is unknown. A perforation of the follicular wall has been considered the initial pathogenic event. [6] Chemical components in textiles (e.g., formaldehyde), as well as curled-up hairs or fragments thereof have been incriminated as the cause of such perforations. Transepidermal elimination, by which dermal components are eliminated through newly formed channels, seems to be coincidental in perforating folliculitis. The fact that the number of new cases has declined since the original description favors an exogenous pathogen.

Clinical Findings

Perforating folliculitis is a chronic, either asymptomatic or mildly pruritic, dermatosis affecting healthy young adults of both sexes. Lesions develop preferentially on the hairy parts of the arms, forearms, thighs, and buttocks as discrete, erythematous, follicular papules 2 to 8 mm in diameter with a central, tightly adherent, whitish keratinous plug that may be pierced by a hair. Removal of the plug leaves a small, bleeding crater. Lesions develop slowly over weeks or months and heal with a hypopigmented spot or a shallow scar. Periods of remission and exacerbation can alternate over months or years.

Histopathology

Early lesions appear as suppurative folliculitis. [7] The infundibular portion of the follicular epithelium is disrupted frequently and early in the course of perforating folliculitis so that the follicular contents spill into the dermis. In fully developed lesions, keratotic material mixed with necrotic debris, inflammatory cells, elastic fibers, and, occasionally, hair-shaft fragments within the follicle or in the adjacent dermis plug a widely dilated hair follicle. A chronic inflammatory infiltrate and foreign-body granuloma with brightly eosinophilic elastic fibers surround perforated follicles. In healing lesions, the follicular epithelium grows in from the periphery of the defect, and the contents of the follicle are sequestrated into the follicular compartment.

Differential Diagnosis

Clinical differential diagnosis of early lesions includes bacterial folliculitis and acne vulgaris. The age of the patient, the distribution pattern, and the presence or absence of other acne lesions are helpful diagnostic hints. Keratosis pilaris is purely keratotic, noninflammatory, and associated with xerosis. The other perforating dermatoses, Kyrle disease, elastosis perforans serpiginosa, reactive perforating collagenosis, and acquired perforating dermatosis vary in their distribution, clinical course, genetic findings, associated chronic diseases, and histopathologic characteristics.

Therapy

No specific treatment for perforating folliculitis is known. Topical keratolytics and tretinoin, systemic isotretinoin, acitretin, and PUVA therapy can prove useful.

ACQUIRED PERFORATING DERMATOSIS

Definition and Historical Aspects

In 1982, White and Hurwitz, together with their colleagues, described several patients whose eruptions were clinically and histopathologically similar to those of perforating folliculitis and who shared a background of chronic renal failure, with or without hemodialysis or peritoneal dialysis, and/or diabetes mellitus. [8], [9] Rapini and colleagues delineated this disorder in the setting of chronic renal failure and/or diabetes mellitus under the catch-all term *acquired perforating dermatosis* and postulated a common cause for all these eruptions. [3] Over the last two decades, a number of authorities have supported the concept of acquired perforating dermatosis. However, the condition is not identical to Kyrle disease, [1], [5] and the synonymic use of Kyrle disease for acquired perforating dermatosis is incorrect and confusing. [2]

Etiology and Pathogenesis

A causal relationship of acquired perforating dermatosis with pruritus, chronic renal failure, and/or diabetes mellitus is well documented. In the majority of cases, the chronic renal failure is secondary to diabetic nephropathy. [2], [10] Acquired perforating dermatosis can precede, accompany, or follow hemodialysis or peritoneal dialysis, and it affects about 10 percent of dialysis patients after a variable duration of chronic renal failure and/or treatment. [9], [11] Dialysis does not cause acquired perforating dermatosis, [12] however, as it occurs also after kidney transplantation. In addition, there have been reported associations with chronic active hepatits, [13] sclerosing cholangitis, [14] liver failure, internal malignancy, [15] hypothyroidism, [13] herpes zoster, [16] and a number of other sporadic diseases.

The term *perforation* is to be understood not as an active process, but as a transepithelial elimination through discontinuities of the basement membrane and the epidermis. Several factors have been incriminated—although none of them proven responsible beyond doubt—in the pathogenesis of acquired perforating dermatosis:

- Mild to severe pruritus in some conditions (e.g., chronic renal failure, chronic liver disease, lymphoma, internal malignancies) leads to superficial traumatization through scratching or rubbing. In combination with poor blood supply because of microangiopathy in long-standing—particularly insulin-dependent—diabetes, this minor trauma may trigger dermal necrosis with elimination of the necrotic material through the epidermis. [17]

- Exocytosis and disintegration of polymorphonuclear cells leading to the release of DNA and proteolytic enzymes may alter collagen or elastic fibers, open up the transepidermal route by alterations and discontinuities of the basement membrane, and precede the sequestration and elimination of cellular debris and degenerated fibers through transepidermal channels. [18], [19] There is, however, no consistent evidence for morphologic defects in collagen or elastic fibers below early lesions. [18], [20]
- Transepithelial elimination may be a form of foreign-body reaction to altered constituents of the dermis.
- Dermal microdeposits of crystalline substances (i.e., uric acid, hydroxyapatite [12] may cause an inflammatory reaction, connective tissue degradation, and release of mediators, resulting in epidermal hyperplasia, activation and penetration of mononuclear cells, focal dissolution of the basement membrane, widening of intercellular spaces, and transepidermal elimination of harmful deposits from the dermis. [12]
- In patients with uremia, dysregulation of epithelial differentiation and proliferation caused by defects in the metabolism of vitamins A and D may result in epithelial perforation. [9]
- In patients with diabetes mellitus and uremic nephropathy, the serum level and dermal matrix deposition of fibronectin, an adhesive glycoprotein, are consistently elevated, which may induce physiologically aberrant epithelial turnover or locomotion. [21] Furthermore, macrophages can produce fibronectin and are mobilized as well by it, which may point to a pathogenic role of Langerhans cells. [21]
- The fact that dialysis does not alleviate pruritus and acquired perforating dermatosis may be due to the accumulation of an unidentified, poorly dialysable “uremic” substance. [22]
- Transepidermal elimination of altered dermal components may not be the result of the pathologic process but rather may be secondary to the perforation. [3]

Clinical Findings

The basic lesion of acquired perforating dermatosis is a dome-shaped, umbilicated keratotic papule, 1 to 10 mm in diameter, with a central keratinous plug that can be removed with some force. Lesions are preferentially localized over the extensor surfaces of the extremities, but can also occur on the trunk, neck, face, and, occasionally, the scalp. Lesions can aggregate to form prurigo-like, [3] hyperkeratotic plaques (Fig. 57-5), particularly in patients with severe pruritus who chronically rub the itchy lesions. Lesions may develop in scratch marks (Koebner phenomenon; see Fig. 57-5). The course of acquired perforating dermatosis is chronic, with new lesions developing while old ones eventually regress after months without major scarring.

FIGURE 57-5 Acquired perforating dermatosis in a 42-year-old patient with diabetes. Note multiple pinhead- to pea-sized umbilicated papules in various stages of development with central keratotic plugs, as well as grouping of lesions and linear arrangement (Koebner phenomenon).

Histopathology

Most commonly, multiple perforations occur within invaginations of the epidermis. It is occasionally possible to identify hair follicles or fragments of hair shafts in association with lesions. [18] Microdeposits of uric acid and hydroxyapatite have appeared in acquired perforating dermatosis–like lesions. [12]

In early lesions, a vigorous suppurative inflammatory reaction takes place at the site of perforation. [7] In older lesions, a more chronic inflammation and foreign-body granuloma are followed by sequestration of necrotic debris and, occasionally simultaneous, elimination of collagen and/or elastic fibers into the necrotic hyperkeratotic plug. [3] In excoriated lesions, collagen bundles in the reticular dermis are continuous with collagen bundles in the necrotic mass through epidermal tunnels. In the healing process, the regeneration of the epidermis, together with the elimination of the necrotic mass, pulls the collagen bundles through the epidermal channels out of the crater. [23] In long-lasting lesions with severe pruritus, a thickened papillary dermis, dome-shaped hyperkeratosis, and irregular epidermal hyperplasia are suggestive of prurigo nodularis.

Differential Diagnosis

Clinically, as well as histopathologically, the other perforating diseases must be excluded before acquired perforating dermatosis can be diagnosed. Diagnostic clues are chronic renal failure, possibly combined with hemodialysis or peritoneal dialysis; diabetes mellitus or another underlying disease; and as a common symptom, pruritus. Histopathologically, multiple perforations, an acutely suppurative early stage, elimination of necrotic material together

with elastic and collagen fibers, and a keratotic, intensely basophilic plug are diagnostic.

Therapy

The many therapeutic approaches to acquired perforating dermatosis include lubrication and topical use of keratolytics; topical and/or intralesional use of steroids; topical use of capsaicin or tretinoin; [11] systemic use of isotretinoin; [22] systemic rifampicin; [14] UVB irradiation; [12] PUVA therapy; and, for individual lesions, cryotherapy. It has been suggested that remissions in patients treated with allopurinol result from, besides the uricostatic effect, an immunomodulating and differentiation-promoting effect of allopurinol or the antioxidative effect of allopurinol on glycation and crosslinking of collagen. [24], [25] and [26] Spontaneous remissions, [27] remissions after cancer surgery, [15] and remissions after cessation of hemodialysis and kidney transplantation have been described. [7], [8] and [9]

REFERENCES

1. Kyrle J: Über einen ungewöhnlichen Fall von universeller follikulärer und parafollikulärer Hyperkeratose (Hyperkeratosis follicularis et parafollicularis in cutem penetrans). *Arch Dermatol Syphilol (Berlin)* **123**:466, 1916

2. Rapini RP: Perforating disorders, in *Cutaneous Medicine and Surgery: An Integrated Program in Dermatology,* vol 1, edited by KA Arndt, PE Leboit, JK Robinson, BU Winthroub. Philadelphia, WB Saunders, 1996, p 407

3. Rapini RP et al: Acquired perforating dermatosis: Evidence for combined transepidermal elimination of both collagen and elastic fibers. *Arch Dermatol* **125**:1074, 1989

4. Tappeiner J et al: Morbus Kyrle. *Hautarzt* **20**:296, 1969

5. Constantine VS, Carter VH: Kyrle's disease: II. Histopathologic findings in five cases and review of the literature. *Arch Dermatol* **97**:633, 1968

6. Mehregan AH, Coskey RJ: Perforating folliculitis. *Arch Dermatol* **97**:394, 1968

7. White CR Jr: The dermatopathology of perforating disorders. *Semin Dermatol* **5**:359, 1986

8. White CR et al: Perforating folliculitis of hemodialysis. *Am J Dermatopathol* **4**:109, 1982

9. Hurwitz RM et al: Perforating folliculitis in association with hemodialysis. *Am J Dermatopathol* **4**:101, 1982

10. Kawakami T, Saito R: Acquired perforating collagenosis associated with diabetes mellitus: Eight cases that meet Faver's criteria. *Br J Dermatol* **140**:521, 1999

11. Morton CA et al: Acquired perforating dermatosis in a British dialysis population. *Br J Dermatol* **135**:671, 1996

12. Haftek M et al: Acquired perforating dermatosis of diabetes mellitus and renal failure: Further ultrastructural clues to its pathogenesis. *J Cutan Pathol* **20**:350, 1993

13. Faver IR et al: Acquired perforating collagenosis: Report of six cases and review of the literature. *J Am Acad Dermatol* **30**:575, 1994

14. Skiba G et al: Successful treatment of acquired perforating dermatosis with rifampicin in an Asian patient with sclerosing cholangitis. *Liver* **19**:160, 1999

15. Bong JL et al: Reactive perforating collagenosis associated with underlying malignancy. *Br J Dermatol* **142**:390, 2000

16. Lee HN et al: Two cases of reactive perforating collagenosis arising at the site of healed herpes zoster. *Int J Dermatol* **40**:191, 2001

17. Farell AM: Acquired perforating dermatosis in renal and diabetic patients. *Lancet* **349**:895, 1997

18. Patterson JW, Brown PC: Ultrastructural changes in acquired perforating dermatosis. *Int J Dermatol* **31**:201, 1992

19. Zelger B et al: Acquired perforating dermatosis: Transepidermal elimination of DNA material and possible role of leukocytes in pathogenesis. *Arch Dermatol* **127**:695, 1991

20. Beck HI et al: Adult acquired reactive perforating collagenosis: Report of a case including ultrastructural findings. *J Cutan Pathol* **15**:124, 1988

21. Morgan MB et al: Fibronectin and the extracellular matrix in the perforating disorders of the skin. *Am J Dermatopathol* **20**:147, 1998

22. Maurice PD: Acquired perforating dermatosis in renal patients. *Nephrol Dial Transplant* **12**:2774, 1997

23. Yanagihara M et al: The pathogenesis of the transepithelial elimination of the collagen bundles in acquired reactive perforating collagenosis: A light and electron microscopical study. *J Cutan Pathol* **23**:398, 1996

24. Krüger K et al: Erworbene reaktiv perforierende Dermatose. Erfolgreiche Behandlung mit Allopurinol in 2 Fällen. *Hautarzt* **50**:115, 1999

25. Munch M et al: Treatment of perforating collagenosis of diabetes and renal failure with allopurinol. *Clin Exp Dermatol* **25**:615, 2000

26. Querings K et al: Treatment of reactive perforating collagenosis with allopurinol. *Br J Dermatol* **145**:174, 2001

27. Chang P, Fernandez V: Acquired perforating disease: Report of nine cases. *Int J Dermatol* **32**:874, 1993

T>

Chapter 58

Peter Fritsch Ramon Ruiz-Maldonado

Erythema Multiforme, Stevens-Johnson Syndrome, and Toxic Epidermal Necrolysis

CLASSIFICATION AND HISTORY
ERYTHEMA MULTIFORME
Definition
Incidence and Epidemiology
Etiology
Pathogenesis
Clinical Manifestations
Course and Prognosis
Pathology
Laboratory Investigations
Differential Diagnosis
Treatment
STEVENS-JOHNSON SYNDROME AND TOXIC EPIDERMAL NECROLYSIS
Definition
Incidence and Epidemiology
Etiology
Pathogenesis
Clinical Manifestations
Course
Pathology
Laboratory Investigations
Differential Diagnosis
Treatment
Prognosis

REFERENCES

The erythema multiforme group of diseases encompasses a number of acute self-limited exanthematic intolerance reactions that share at least two characteristic features: target lesions (stable circular erythemas or urticarial plaques with areas of blistering, necrosis, and/or resolution in a concentric array) and, histologically, satellite-cell (or more widespread) necrosis of the epidermis. These features are the expression of an archetypic polyetiologic reaction pattern of the skin (i.e., a cytotoxic immunologic attack on keratinocytes expressing non-self antigens). Antigens involved are predominantly microbes (viruses) or drugs.

At present, two main subsets are recognized: (1) erythema multiforme—a fairly common, usually mild and relapsing eruption that is most often triggered by recurrent herpes simplex virus (HSV) infection; and (2) the Stevens-Johnson syndrome–toxic epidermal necrolysis complex (SJS–TEN)—an infrequent severe mucocutaneous intolerance reaction that is most often elicited by drugs. Entities that may be grouped very close to the erythema multiforme spectrum are the acute graft-versus-host disease, fixed drug eruption, and erythema multiforme–like disseminated allergic contact dermatitis. The exact relationship among these entities is still a matter of controversy, as are aspects of therapy and management. The pathogenesis is only incompletely understood.

CLASSIFICATION AND HISTORY

No generally accepted classification of the erythema multiforme spectrum exists. Morphology remains the predominant basis for disease definitions, which have been the arena of terminologic disputes for more than a century. Lumping and splitting of entities, introduction of new terms, continued use of discarded ones, and too liberal usage of the term *erythema multiforme* for ill-defined cutaneous eruptions have led to terminologic and conceptual confusion that leaves most of the traditional terms without an unequivocal meaning and jeopardizes the accessibility of the erythema multiforme literature. The confusion can be disentangled only through a review of the historical development.

Descriptions of erythema multiforme date back to antiquity (Celsus). Bateman first described the target lesion in 1814, and Bazin first recognized mucosal involvement and constitutional symptoms in 1862. It was von Hebra who noted the multiform character of erythema multiforme and grouped several then-recognized disorders into a single entity, which he christened erythema exudativum multiforme. Von Hebra's description exactly fits the appearance of what is now known as HSV-associated erythema multiforme, except that he made no reference to oral mucosal involvement. Stevens and Johnson described a severe mucosal disease with “purplish cutaneous macules and necrotic centers” in 1922. In 1950, Thomas proposed that erythema multiforme and the Stevens-Johnson syndrome (SJS) were variants of the same pathologic process, differing only in severity, and that they should be termed erythema multiforme minor and erythema multiforme major, respectively. Although this suggestion was broadly accepted, the term *Stevens-Johnson syndrome* continued to be used as a synonym for erythema multiforme major.

In 1956, Lyell described TEN, again as a separate clinical entity (Lyell's syndrome), as a life-threatening, rapidly evolving mucocutaneous reaction characterized by erythemas, necrosis, and bullous detachment of the epidermis resembling scalding. [1] Lyell's series included not only patients suffering from what would still be called TEN today, but also others

with staphylococcal scalded-skin syndrome and generalized fixed drug eruption; [2] thus, the series fueled terminologic disputes for many years. In the following decades, the notion gained ground that, in most or even in all instances, TEN was equivalent to SJS of maximal severity. Lyell himself suggested that the term *toxic epidermal necrolysis* be abandoned, [3] but its use has been retained.

Clearly, the erythema multiforme spectrum has for decades been considered to include the mild “minor” and the less common, but more severe, “major” types of the disorder—the distinctive mark being the presence of mucous membrane involvement—surmounted by the rare devastating TEN. All these categories were interpreted as polyetiologic, with an almost unlimited number of potential causative factors held responsible. It was thought that the milder forms were caused more often by infections; the more severe ones, by drugs. These prototypes were theoretically well defined, but their distinction often proved difficult in practice because of their overlapping features.

Important recent advances have, paradoxically, added to the confusion. It has become clear that mild erythema multiforme is strongly linked to HSV infection. [4] However, HSV-related erythema multiforme cannot simply be equated with “erythema multiforme minor,” because it frequently involves mucosal sites (most often oral) that have previously been attributed to “erythema multiforme major.” Labeling such cases erythema multiforme major is again confusing, [5], [6] because “erythema multiforme major” is firmly engrained as a synonym for SJS.

Clinical and histopathologic observations, mostly by a team of French investigators, have suggested that there are two main morphologic patterns within the erythema multiforme spectrum. The investigators proposed that these patterns be considered different disorders with distinct causes [5], [6] and [7] (Table 58-1): HSV-related erythema multiforme, characterized by target lesions and a predominantly inflammatory histopathologic pattern, and the primarily drug-related SJS-TEN complex, characterized by atypical or no target lesions at all and a predominantly necrotic histopathologic pattern. Stevens-Johnson syndrome and TEN were taken to differ only in the body surface area (BSA) involved and the severity.

TABLE 58-1 **Comparison of Clinical Features of Erythema Multiforme (EM) and Stevens-Johnson Syndrome–Toxic Epidermal Necrolysis (SJS-TEN)**

Consensus papers have provided clinical criteria for the entities of the erythema multiforme spectrum that have been widely used in subsequent publications. The basis of the proposed definitions for SJS-TEN is quantitative: [5], [7] SJS represents cases of less than 10 percent BSA involvement; TEN indicates more than 30 percent; and those in between are labeled SJS-TEN “overlap.” Although somewhat artificial and not particularly simple, this classification is definitely useful for epidemiologic purposes (BSA is a prognostic factor in SJS–TEN) and permits the determination of medication risks. Also, it corresponds to a classification proposed earlier by one of us (R.R.M.). [8]

Several problems remain to be clarified: (1) the issue of overlapping features has not been resolved; [7] (2) the question of whether all instances of erythema multiforme that are not SJS-TEN by clinical criteria are HSV-related has not been properly addressed; (3) it has not been proven that all instances of extensive TEN, in fact, represent variants of SJS (e.g., what has been called “TEN without spots” [5]); and (4) the conditions characterized by mucosal lesions only (formerly “ectodermosis pluriorificialis”) find no place in this classification.

We deem it unwise to coin new terms before more is known about the molecular pathophysiology of the conditions concerned. Therefore, we will use the term *erythema multiforme* for all instances of the erythema multiforme spectrum that are not SJS-TEN, and the term *SJS-TEN complex* for both SJS and TEN.

ERYTHEMA MULTIFORME

Definition

Erythema multiforme is a self-limited, usually mild and relapsing exanthematic reaction of the skin that is etiologically most often related to recurrent HSV infection. It is clinically characterized by target-shaped, urticarial plaques, and it frequently presents with mucous membrane lesions.

Incidence and Epidemiology

Erythema multiforme is relatively common; it may account for up to 1 percent of dermatologic outpatient visits. The exact incidence is difficult to assess because practically all published series contain cases of SJS and/or erythema multiforme–like cases. Based on our own records, we estimate that erythema multiforme is at least 10 times as frequent as the SJS-TEN complex, for which an incidence of 1.9 cases/million population/year has been reported in Germany. [9] Erythema multiforme may occur in patients of all ages, but it occurs predominantly in adolescents and young adults; it is rare both under the age of 3 years and over the age of 50 years; 75 percent of patients are younger than 40 years. A

slight preponderance has been reported both for females and males. [10], [11] There is no predominance for ethnic groups or geographic locations. Seasonal clustering in spring is common ("typus annuus"), presumably caused by ultraviolet light provocation of recurrent HSV infection. Erythema multiforme is often recurrent, probably in the majority of the cases. [11] It is impossible at present to determine how often erythema multiforme occurs as a truly single event. Recurrences may occur at short intervals and reappear for many years.

Etiology

Although suspected since the early nineteenth century, it has been recognized only in recent years that HSV infection is the dominant causative factor of erythema multiforme, both in adults and in children. [4], [10], [12] Both HSV-1 and HSV-2 may trigger erythema multiforme, whereas the closely related varicella-zoster virus shows no such association.

Evidence linking HSV to erythema multiforme is best for recurrent erythema multiforme, as clinical lesions of recurrent HSV infection precede an outbreak of erythema multiforme in about 80 percent of patients. [12] In situ hybridization and the polymerase chain reaction have demonstrated HSV-DNA in the epidermal cells (not in the dermis) of erythema multiforme lesions in up to 90 percent of patients, [13], [14] even in individuals without obvious preceding HSV infection. [15] In addition, immunofluorescence and immune histochemistry have demonstrated HSV-specific antigens in lesional skin. Most patients with recurrent erythema multiforme are seropositive for HSV, and it is occasionally possible to recover HSV from circulating immune complexes. [16] Peripheral blood mononuclear cells from patients with HSV infection and those with HSV-related erythema multiforme exhibit a similarly skewed T cell receptor response on stimulation with HSV antigen, indicating a specific immune response against HSV in both conditions. [17] Proof for the pathogenetic relevance of HSV infection derives from the fact that the prophylactic administration of acyclovir can effectively prevent recurrent HSV-associated erythema multiforme; [18] this is also true for many patients with no clinical evidence of HSV infection. There are no data at present, however, to prove that nonrecurring erythema multiforme is as strongly related to HSV as recurring erythema multiforme.

It is a matter of terminology (and therefore controversy) whether cases should be classified as erythema multiforme if they fulfill the clinical criteria, but do not show evidence of preceding HSV infection. There is little doubt that such eruptions exist, but it is unclear how frequent they are; they may occur more often in nonrecurrent erythema multiforme. The evidence for causative factors other than HSV infection is only circumstantial. Published reports implicate hepatitis B and C virus, as well as other viral infections. [19], [20] Progesterone may elicit chronic recurrent erythema multiforme that responds to tamoxifen treatment [21] and oophorectomy. Drugs are a rare cause of erythema multiforme with mucous membrane lesions. [7] It may, of course, be argued whether these eruptions were truly erythema multiforme or mere imitators; moreover, subclinical HSV infection generally cannot be ruled out. Other problems are idiopathic cases, in which neither HSV infection nor any other cause can be uncovered. Such cases are fairly common under routine circumstances, but are even found in studies that specifically looked for HSV infection. [21] Many such cases respond to prophylactic acyclovir treatment and are thus likely to have been triggered by subclinical HSV infection; some, however, are resistent. [21]

Erythema multiforme–like dermatitic eruptions result from contact sensitization to sulfonamides, antihistamines, dinitrochlorobenzene (DNCB), diphencyprone (DPCP), rosewood, *Rhus,* primula, tea tree oil, cutting oils, cinnamon, and other substances; these rashes should be viewed as only imitators of erythema multiforme, despite clinical and histopathologic similarities. [22]

Pathogenesis

The current belief is that erythema multiforme is a cell-mediated immune reaction leading to the destruction of keratinocytes expressing HSV antigens. However, many aspects of the underlying pathomechanisms are not known.

Although erythema multiforme lesions can exhibit viral antigens and DNA, attempts at viral cultures almost invariably fail, and electron microscopy cannot detect intact virions. Therefore, erythema multiforme lesions are not sites of regular HSV replication, as can be suspected from their histopathologic appearance. This paradox has been partially resolved: [14] no viable HSV particles are present in epidermal keratinocytes; there are only DNA fragments, most often encoding viral DNA polymerase. Fragments of DNA persisted for 1 to 3 months in the epidermis after healing (as in acute HSV lesions); viral polymerase RNA, however, was identified only in fresh, not in healed erythema multiforme lesions. These data suggest that transcription and translation are limited, and that the development of erythema multiforme lesions may be associated with the expression of viral polymerase (and/or additional antigens), stimulating a specific immune response.

Obviously, HSV-DNA reaches distant cutaneous locations from a site of active replication via the bloodstream. Immune complexes may mediate hematogenous transport; [16] more importantly, however, peripheral blood mononuclear cells, which contained HSV-DNA in more than 60 percent of patients during acute erythema multiforme episodes, may be the transport vehicle. [13] The use of this vehicle may explain viral DNA fragmentation: monocytes are nonpermissive for HSV replication, which may lead to DNA damage. [14] Upregulation of adhesion molecules greatly increases binding of HSV-containing mononuclear cells to endothelial cells; HLA-class I and adhesion molecule upregulation in endothelial cells may account for the dermal inflammatory response. [23] The reason that viral DNA fragments home to the specific predilection sites of erythema multiforme—or elicit the formation of lesions there (HSV-DNA has been recovered from apparently healthy control skin [13])—is a matter of speculation. Precipitating factors such as ultraviolet light may play a role: sun exposure is known to trigger erythema multiforme ("light-sensitive" erythema multiforme), and the lesions are often confined to sun-exposed areas. At times, erythema multiforme may even assume the clinical appearance of polymorphous light eruption and juvenile spring eruption. [24]

Cytotoxic effector cells (CD8+ T lymphocytes), which predominate in the rather scarce inflammatory infiltrate within the

epidermis, carry out the immunologic attack on HSV-expressing epidermal keratinocytes. These induce apoptosis of individual scattered keratinocytes, leading to satellite-cell necrosis in early lesions or to more widespread necrosis in older ones. [25] Exocytosis of these cells into the epidermis is facilitated by strong expression of intercellular adhesion molecule 1 (ICAM 1) in the basal layer and pockets of the spinous layer, which may be caused by interferon-? released from dermal CD4+ T lymphocytes. [26] Neighboring epidermal cells are HLA-DR-positive. [4]

In comparison to SJS-TEN, erythema multiforme displays much less striking epidermal necrosis, but more intense dermal inflammation, which is mediated chiefly by CD4+ T lymphocytes and monocytes, [27] and is responsible for the wheal-like clinical appearance of the typical target lesions. Inflammation is associated with microvascular damage that is likely to be caused by HSV-containing mononuclear cells binding to the endothelium. [23] The explanation for these obvious differences in pathology may lie in the observation that skin lesions of HSV-related erythema multiforme express interferon-?, but not tumor necrosis factor–a (TNF-a), whereas the reverse is true for drug-induced SJS-TEN. [28] The two subsets thus appear to be “mechanistically” different, and erythema multiforme may have a delayed type hypersensitivity component that is absent from SJS-TEN.

As recurrent HSV infection is common and erythema multiforme episodes are much less so, it is obvious that HSV-related erythema multiforme must be linked to a specific predisposition. Clinically, HSV lesions associated with erythema multiforme are not different from those without such an association. [11] One report indicated not differences between the specific immune responses of patients suffering from recurrent HSV infection with associated erythema multiforme and those of patients without such an association. [29] Increased frequencies of certain HLA antigens were described in association with HSV-related erythema multiforme, particularly HLA-Bw62 (B15), -B35, and -DR53. [30] Kämpgen and colleagues demonstrated significant associations with the DR4 and DQw3 alleles; the relative risk for DQw3 was 44.2. [31] There was no such correlation in patients with recurrent HSV infection without associated erythema multiforme.

Clinical Manifestations

As noted in Table 58-1, prodromal symptoms are absent in most cases of erythema multiforme. If present, they are mild, variable, and nonspecific, merely suggesting an upper respiratory infection (e.g., cough, rhinitis, low-grade fever).

The skin rash arises abruptly. In most patients, all lesions appear within 3 days; but in some, several crops follow each other during one episode of erythema multiforme. Up to hundreds of lesions may form, most in a symmetric, acral distribution on the extensor surfaces of the extremities (dorsa of hands and feet, elbows, and knees) and the face; they appear less often on palms and soles, thighs, buttocks, and trunk (Fig. 58-1). Lesions often first appear acrally and then spread in a centripetal manner. Mechanical (Koebner phenomenon) and actinic (predilection of sun-exposed sites) factors appear to influence the distribution of lesions. Zosteriform hemicorporeal and linear distribution along Blaschko's lines of erythema multiforme lesions may occur. [32] Although patients occasionally report burning and itching, the eruption is usually symptomless.

FIGURE 58-1 Erythema multiforme. *A*. Papular, urticarial, and vesicular target lesions in acral distribution. *B*. Herpes iris of Bateman. *C*. Vesicular and target lesions of erythema multiforme.

As the name implies, the clinical picture of erythema multiforme is variable, but the rash is usually monomorphous in a given patient. Variability results from the variable morphologic expression along a scale of severity of a single prototypic lesion. Typically, this lesion is a highly regular, circular, wheal-like erythematous papule or plaque that is stable (i.e., of fixed position and persistent for 1 week or more); it measures from a few millimeters to about 2 cm and may expand slightly over 24 to 48 hours. While the periphery remains erythematous and edematous, the center becomes violaceous and dark; inflammatory activity may regress or relapse in the center, thus giving rise to concentric rings of color change (Fig. 58-1A). Often, the center turns purpuric and/or necrotic or transforms into a tense vesicle or bulla. The result is the classic target or iris lesion (Fig. 58-1A).

According to the proposed classification, typical target lesions consist of at least three concentric components: (1) a dusky central disk, or blister; (2) more peripherally, a ring of pale edema; and (3) an erythematous halo. [5], [7] Not all lesions of erythema multiforme are typical: some display two rings only (“raised atypical targets”), but none are flat, which is the typical lesion of SJS-TEN. In some patients with erythema multiforme, most lesions are livid vesicles overlying a just slightly darker central portion, encircled by an erythematous margin (Fig. 58-1C). Larger lesions may have a central

bulla and a marginal ring of vesicles (herpes iris of Bateman; Fig. 58-1B).

Mucosal lesions are present in up to 70 percent of patients, [11] almost exclusively limited to the oral cavity and most often only a few. Predilection sites are the lips, palate, and gingivae. On the lips, identifiable target lesions may form; otherwise, vesicles, erosions, and crusting are evident. Extensive, painful oral involvement with only few skin lesions occasionally occurs. Cervical lymphadenopathy is usually present in these patients. “Ectodermosis pluriorificialis” is a rare occurrence characterized by severe involvement of two or three mucosal sites in the absence of skin lesions. Its place within the erythema multiforme spectrum is not quite clear, but its often relapsing nature suggests that it is HSV-related.

In most cases, erythema multiforme affects well under 10 percent of the BSA. Rare instances of extensive skin lesions and prominent involvement of the oral mucosa (at times called “bullous erythema multiforme” or “erythema multiforme major”—see “ Classification and History,” above) may be difficult to distinguish from SJS-TEN.

Patients with erythema multiforme are afebrile, physical examination is normal, and there are no reports of joint or muscular complaints or lymphadenopathy, except in patients with mucosal erosions.

Course and Prognosis

Erythema multiforme runs a mild course in most cases, and each individual attack subsides within 1 to 4 weeks. Recovery is complete, and there are no sequelae (not even in mucosal lesions), except for transient hypo- or hyperpigmentation in some cases. The condition does not progress to SJS-TEN. Recurrences are common and may occur in the majority of cases. In one report on a large series of patients with recurrent erythema multiforme, the mean number of attacks was 6 per year (range, 2 to 36), and the mean total duration of disease was 9.5 years; in 33 percent, the condition persisted for more than 10 years. [10] Up to 50 recurrences have been described in a single patient. [21] The severity of episodes in patients with recurrent erythema multiforme is highly variable and unpredictable. The frequency of episodes and cumulative duration of disease are not correlated with the severity of attacks. The frequency and severity of recurrent erythema multiforme tend to improve spontaneously over time (after 2 years or more), parallel to the improvement of recurring HSV infection.

RELATIONSHIP TO RECURRENT HSV INFECTION In more than 70 percent of patients with recurrent erythema multiforme, an episode of recurrent HSV infection precedes the rash; the association with herpes labialis predominates (9:1) over that with genital herpes, or that with herpes in other locations. The average interval is 8 days (range, 2 to 17); [10] the duration of the lag period appears to be specific for individual patients. In a small number of patients, HSV recrudescence and erythema multiforme may occur simultaneously. Not all episodes of erythema multiforme are preceded by clinically evident HSV infection, and not all HSV episodes are followed by erythema multiforme. Episodes of recurrent HSV infection may precede the development of HSV-related erythema multiforme for many years.
CONTINUOUS AND PERSISTENT ERYTHEMA MULTIFORME A small fraction of patients experience a prolonged series of overlapping attacks of erythema multiforme; this constellation has been labeled “continuous erythema multiforme” [21] and has been connected to the systemic administration of glucocorticoids. Similar rare cases with widespread and therapy-resistant lesions have been described as “persistent erythema multiforme.” [33] It is doubtful that all these cases truly represent erythema multiforme.

Pathology

Early lesions of erythema multiforme exhibit lymphocyte accumulations at the dermal-epidermal interface, with exocytosis into the epidermis, scattered keratinocyte necrosis with lymphocytes attached to the necrotic keratinocyte (satellite-cell necrosis), spongiosis, vacuolar degeneration of the basal layer, and focal junctional and subepidermal cleft formation (Fig. 58-2). Epidermal necrosis is more extensive in central portions and older lesions. The papillary dermis is often highly edematous with a dense mononuclear cell infiltrate, which is more abundant in older lesions than in fresh lesions. The vessels are ectatic with swollen endothelial cells; there may be extravasated erythrocytes and eosinophils. Advanced lesions show subepidermal blisters and frank epidermal necrosis (Fig. 58-3). Immunofluorescence findings are nonspecific. In late lesions, melanophages may be prominent.

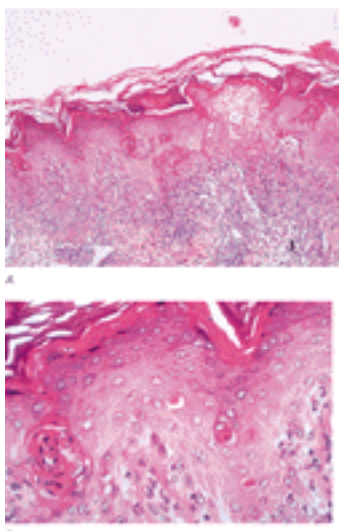

FIGURE 58-2 Histopathology of erythema multiforme (early lesion). *A*. An intense lymphohistiocytic infiltrate fills the mid-dermis and obliterates many blood vessels. The dermal papillae are edematous and contain material with the staining properties of fibrin. There is subepidermal cleft formation and circumscribed necrosis of the epidermis. *B*. High-power magnification of scattered keratinocyte necrosis.

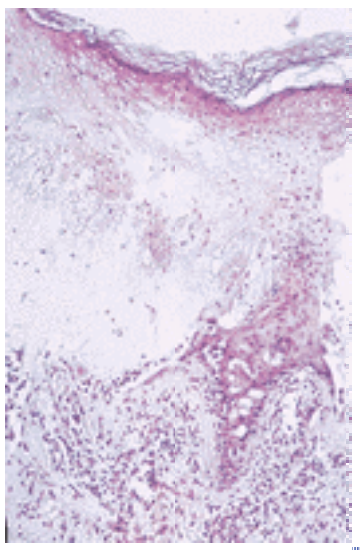

FIGURE 58-3 Erythema multiforme: advanced lesions with subepidermal blister and epidermal necrosis.

The histopathologic appearance of erythema multiforme is different from that of SJS-TEN, in which dermal inflammation is moderate to absent and epidermal necrosis is much more pronounced. [27], [34], [35] Formerly interpreted as expressions of the variability of the erythema multiforme spectrum [36] or as consecutive stages in the dynamic evolution of target lesions, [37] these differences have been demonstrated in very early lesions of the respective entities and thus appear to be inherent features. Still, the histopathologic appearances are somewhat overlapping and do not allow the distinction of erythema multiforme from SJS-TEN in all instances. [38]

Laboratory Investigations

Laboratory findings are usually normal in patients with erythema multiforme. In more severe cases, an elevated erythrocyte sedimentation rate, moderate leukocytosis, acute phase proteins, and mildly elevated liver transaminase levels may occur.

Differential Diagnosis

In typical cases, erythema multiforme is easily identifiable because of its characteristic appearance, stability, and symmetric acral distribution of the target lesions. At times, however, atypical cases display features of a variety of other skin conditions (Table 58-2). A disorder frequently mistaken for erythema multiforme is acute annular urticaria, which is often drug-induced; this disorder is characterized by annular polycyclic, concentric, or arcuate urticarial lesions that extend peripherally, leaving central ecchymotic violaceous areas, thus mimicking target lesions. Histologically, only slight edema and minimal perivascular infiltrates are found. “Target purpura” (acute hemorrhagic edema of infancy) is a manifestation of leukocytoclastic vasculitis in infants and small children; it is characterized by symmetric erythematous and purpuric concentric rings in acral locations, similar to target lesions, that spontaneously resolve in about a week. Erythema multiforme–like lesions are sometimes found in lupus erythematosus (“Rowell's syndrome”). [39] It may sometimes be difficult to distinguish mucosal lesions from pemphigus vulgaris and herpetic gingivostomatitis. Disseminated contact dermatitis may exhibit lesions that mimic target lesions closely, both clinically and histologically. [22]

Urticaria
Urticarial vasculitis
Figurate erythemas
Acute febrile neutrophilic dermatosis (Sweet's syndrome)
Disseminated lesions of contact dermatitis
Bullous pemphigoid, linear IgA dermatosis, herpes gestationis
Lupus erythematosus

TABLE 58-2 **Differential Diagnosis of Erythema Multiforme**

Treatment

In most cases, erythema multiforme causes little discomfort and regresses spontaneously within about 2 weeks. Symptomatic treatment with shake lotions, topical steroids, analgesics, and antihistamines has little impact on the course, but may reduce subjective symptoms. Liquid antacids, topical glucocorticoids, and local anesthetics relieve symptoms of painful mouth erosions. The systemic administration of glucocorticoids is unnecessary and may even have worsened some cases.

In recurrent erythema multiforme, early treatment of HSV infection with oral acyclovir (200 mg five times per day for 5 days) or its derivatives with better bioavailability (e.g., valacyclovir or pencyclovir) may prevent erythema multiforme, but often it comes too late. In such cases, continuous administration of low-dose acyclovir (400 to 800 mg per day) or valacyclovir (500 mg per day) for a 6-month period is indicated. This regimen is highly effective in preventing episodes of both HSV infection and erythema multiforme as long as it is continued, even in patients in whom HSV is not the obvious precipitating factor. [10] Attacks recur after withdrawal, but generally tend to be less frequent and less severe. As alternatives for patients who do not respond to this treatment, dapsone, antimalarials, and even azathioprine and thalidomide have been advocated.

STEVENS-JOHNSON SYNDROME AND TOXIC EPIDERMAL NECROLYSIS

Definition

Stevens-Johnson syndrome and toxic epidermal necrolysis are severe, episodic, acute mucocutaneous reactions that are most often elicited by drugs and occasionally elicited by infections. They are closely related or identical, differing only in the extent of BSA involved (see above). [5], [7] Both are characterized by rapidly expanding, often irregular macules ("atypical target lesions") and involvement of more than one mucosal site (oral, conjunctival, and anogenital). In TEN, the rash coalesces to widespread dusky erythema, necrosis, and detachment of the epidermis resembling scalding. Constitutional symptoms and internal organ involvement occur often and may be severe. In principle, SJS and TEN are self-limited; the mortality rate in TEN is significant, however, and sequelae may develop because of mucosal scarring. It is currently impossible to draw an absolutely sharp line of distinction between SJS-TEN and the more severe forms of erythema multiforme.

Incidence and Epidemiology

The incidence of SJS-TEN is estimated at 2 to 3 cases per million population per year in Europe and the United States. [9], [40], [41] In Germany, it was found to be 1.9 cases per million population per year; the relative proportions of SJS, "SJS-TEN overlap," and TEN were 3:2:1. [9] Stevens-Johnson syndrome–toxic epidermal necrolysis occurs worldwide and affects females about twice as frequently as males. [41] The disorder appears most often in adults, but also occurs in children. [8] It typically occurs sporadically, but epidemics have followed the mass use of drugs. [42] In most cases, SJS-TEN is a single event; after reexposure to the culprit drug, it takes a more severe course. [43] The incidence is increased up to three orders of magnitude in the HIV-infected population. [44] An association of SJS-TEN with the HLA-A29 and -B12 (relative risk, 13.4), and with the HLA-B12 and DR7 haplotypes, has been found. [45] Population-based and case-control studies on SJS-TEN have been initiated in the United States and Europe to clarify pending issues of epidemiology and drug etiology. [46], [47]

Etiology

Although SJS-TEN has a polyetiologic reaction pattern, drugs are clearly the leading causative factor (80 to 95 percent of patients with TEN, more than 50 percent of those with SJS; see Table 58-3), and only a minority of cases appear to be linked to infection, vaccination, or graft-versus-host disease. In a small percentage of patients with SJS-TEN (less than 5 percent for TEN), neither drugs nor other potential causes become apparent (idiopathic SJS-TEN). The lack of appropriate diagnostic in vitro and skin tests hampers the identification of the responsible trigger factors. Circumstantial evidence, therefore, usually serves as the only criterion.

Drugs Most Frequently Associated*	Drugs Also Associated
Sulfadoxine	Cephalosporins
Sulfadiazine	Fluoroquinolones
Sulfasalazine	Vancomycin
Co-trimoxazole	Rifampin
Hydantoins	Ethambutol
Carbamazepine	Fenbufen
Barbiturates	Tenoxicam
Benoxaprofen/	Tiaprofenic acid
Phenylbutazone	Diclofenac
Isoxicam†	Sulindac
Piroxicam	Ibuprofen
Chlormezanone	Ketoprofen
Allopurinol	Naproxen
Amithiozone	Thiabendazole
Aminopenicillins	

* Together these drugs account for approximately two-thirds of the cases attributed to drugs in large series in France, Germany, and the United States.
† This drug is no longer marketed.
SOURCE: Roujeau et al.[49]

TABLE 58-3 **Drugs Associated with Stevens-Johnson Syndrome and Toxic Epidermal Necrolysis**

Uncertainty still exists about the relative risk of SJS-TEN associated with individual drugs and the role of accompanying factors. Obviously, the many case reports or retrospective studies in which more than 100 drugs have been found to elicit SJS-TEN do not provide this information. [40], [41] Similarly, population-based studies that correlate the incidence of SJS-TEN with the number of drug users or the daily drug dose consumed in a certain population, do not supply reliable data because of the rarity of SJS-TEN. [46] To solve this problem, investigators have begun prospective case-control studies to compare the drugs taken by index patients to those taken by controls. The relative risks and the influence of cofactors such as age, gender, region, multiple drug intake, or underlying diseases can thus be calculated by multivariate analysis. Initial results have been published, [47], [48] but more are to follow.

Although the list of causative drugs may vary from country to country and over time because of differences in drug use, three groups are cited as the most common triggers in all surveys and reviews: antibacterial sulfonamides, anticonvulsants, and nonsteroidal anti-inflammatory drugs (NSAIDs). Antimalarials, allopurinol, and a few others follow a close second.

Sulfa drugs, particularly long-acting sulfonamides and co-trimoxazole, appear to elicit SJS-TEN most often, with an estimated incidence of 1 to 10 per 100,000 users; [48] the relative risk is 172. Particularly aggressive cases have occurred in HIV-infected patients in the context of *Pneumocystis carinii* infection and malaria prophylaxis. Anticonvulsive drugs such as phenytoin, carbamazepine, and phenobarbital may carry relative risks from 11 to 15. [48] Carbamazepine may elicit SJS-TEN most frequently (14 per 100,000 users). [49] Hydantoins are considered the main cause of TEN in children. [5] Valproic acid, often used as an alternative for hydantoins, has an equally high relative risk. [49] Severe SJS-TEN has developed in patients who received phenytoin simultaneously with cranial irradiation. [50] There have been several cases

of SJS-TEN due to the new anticonvulsant lamotrigine. [51] Nonsteroidal anti-inflammatory drugs such as butazone and oxicam derivatives have often been reported as inciting drugs; isoxicam, for instance, was withdrawn in France following 13 cases of TEN. [40] The case-control study confirmed the association for oxicam derivatives (relative risk, 18) and, to a lesser degree, for propionic acid derivatives (relative risk, 4.5). Pyrazolones and salicylates, formerly often thought to cause SJS-TEN, had only low relative risks. [48]

Allopurinol and chlormezanone (a tranquilizer unrelated to benzodiazepines) are important causes of SJS-TEN in developed countries, [48], [52] whereas antituberculosis drugs play an important role in Third World countries. [53] Antibiotics have been more often suspected than actually shown to be causative; however, relevant risks may exist for cephalosporins, tetracyclines, aminopenicillins, quinolones, and imidazole antifungals. [49] In recent years, antiretroviral drugs, such as nevirapine and protease inhibitors, emerged as important causes of SJS-TEN. [54] A variety of other agents, such as hormones, chinine-containing beverages, airborne and contact allergens, and toxins, have been reported to cause SJS-TEN. In 3 of 20 cases of TEN observed in Singapore, Chinese herbs were found to be responsible. [55]

It is a problem in determining the etiology of SJS-TEN that drugs taken during the prodromal phase to alleviate symptoms cannot be distinguished from those that actually caused the disease. The often listed antibiotics, pyrazolones, and salicylates may be such drugs. The same possibly holds true for systemic glucocorticoids, which were found to be associated with a surprisingly high relative risk of 12. [48]

The significance of individual predisposing factors that may promote SJS-TEN has not been fully elucidated. Familial occurrence is rarely a feature of SJS-TEN, but there may be a genetic susceptibility, as documented by the association with certain HLA haplotypes. Synergistic effects (e.g., viral infection and drug intake [56]) and drug interactions are likely to play roles in many cases; in one study, patients had taken a mean of 4.4 drugs prior to the onset of TEN. [57] Physical factors such as ultraviolet light and x-rays may precipitate drug-induced SJS-TEN, with the skin lesions being of maximal intensity at the sites of exposure. [50], [57] Also, SJS-TEN appears to occur preferentially in patients with multiple accompanying diseases, particularly those that activate the immune system, such as collagen vascular diseases, neoplasia and lymphoma, and acute graft-versus-host disease; it may even follow vaccination. [58]

Infectious agents play a much less prominent role in the etiology of SJS-TEN. The most thoroughly documented cases were caused by *Mycoplasma pneumoniae,* [59] which has been isolated from the lesions of SJS-TEN. Less well documented cases have been linked to histoplasmosis, adenovirus infections, hepatitis A, infectious mononucleosis, coxsackievirus B5, varicella-zoster virus, gram-negative septicemia, milker's nodules, and yersiniosis. The link to other infectious agents is more tenuous.

Acute graft-versus-host disease is an obviously rare cause of SJS-TEN, but its incidence in allogeneic bone marrow recipients is high (9 of 152, according to one survey [60]). The relationship between acute graft-versus-host disease and TEN is difficult to assess because the skin lesions that appear in patients with these conditions are nearly indistinguishable, both clinically and histologically; differences pertain more to type and severity of internal organ involvement (e.g., gastrointestinal tract, liver) than to skin symptoms. Also, bone marrow allograft recipients are subject to factors that in their own right (or synergistically) may precipitate TEN (e.g., x-rays, cytotoxic drugs, cytomegalovirus infection). It is clear, however, that TEN may result from acute graft-versus-host disease independently from drug intake: it was observed in a patient with thymus hypoplasia who took no drugs, [61] and it can be reproduced in an animal model for acute graft-versus-host disease. [62] Among patients with acute graft-versus-host disease, TEN has been shown to have a 100 percent mortality rate.

Identification of the provocative agent rests mainly on history; skin testing and in vitro tests are usually not helpful, [63] and exposure tests are ethically unacceptable. Exceptional reports describe positive intracutaneous and patch tests with positive lymphocyte transformation tests, [52] or increased lymphocyte susceptibility to cytotoxic killing by liver microsome–induced drug intermediates [64] in patients with drug-induced TEN.

Pathogenesis

The pathomechanisms of SJS-TEN are only partially understood. There are similarities to the pathomechanisms of HSV-related erythema multiforme, but important differences have become apparent. Like erythema multiforme, SJS-TEN is viewed as a cytotoxic immune reaction aimed at the destruction of keratinocytes expressing foreign (drug-related) antigens. The characteristic lag between exposure and disease onset (1 to 45 days; mean, 14), which tends to be much briefer at repeated exposure, also suggests an immune pathogenesis. Drug-specific activation of T cells (including both CD4+ and CD8+) has been shown in vitro on peripheral blood mononuclear cells of patients with bullous drug eruptions; [65] a high production rate of interleukin (IL)-5, in addition to that of other cytokines, was noted. As in HSV-related erythema multiforme, epidermal injury is based on the induction of apoptosis. [25] Furthermore, in both conditions, memory CD4+ lymphocytes appear to dominate dermal mononuclear cells, whereas CD8+ cytotoxic cells (and large granular lymphocytes) were prevalent in the epidermis. [66] In both conditions, epidermal keratinocytes express ICAM-1 and class II major histocompatibility complex (MHC) antigens; Langerhans cells are notably reduced or absent. [67]

It has always puzzled investigators how the relatively few cytotoxic cells present in the epidermis of patients with SJS-TEN may induce an epidermal injury far in excess of that of erythema multiforme, which features many more such effector cells. Paquet and colleagues demonstrated that in contrast to erythema multiforme, inflammatory cells in SJS-TEN contain large numbers of activated macrophages and factor XIII+ dendrocytes. [27], [68] Furthermore, there is a drastic overexpression of TNF-a (less so of IL-6) in the epidermis with SJS-TEN, [69] while only minute amounts of this cytokine occur in erythema multiforme. As TEN blister fluid contains viable CD8+ lymphocytes and high amounts of TNF-a, [70], [71] it appears likely that TNF-a plays an important role in epidermal destruction by inducing apoptosis directly, by attracting cytotoxic effector cells, or both. [28] The source of TNF-a may be both macrophages and keratinocytes; mutual

stimulation is likely. Interestingly, physical factors that precipitate or accentuate drug-induced SJS-TEN are known to stimulate TNF-a expression in keratinocytes (ultraviolet light and x-rays).

The nature of the antigens that drive the cytotoxic cellular immune reaction is not well understood. It has been proposed that drugs or their metabolites act as haptens and render keratinocytes antigenic by binding to their surfaces. [72], [73] Obviously, the drug-modified peptide may be presented on both MHC I and MHC II molecules. [64] Shear and colleagues linked cutaneous drug eruptions to a defect of the detoxification systems (in both liver and skin): [73] aromatic drug metabolism by cytochrome P_{450} leads to the formation of reactive hydroxylamines from sulfonamides or arene oxides from aromatic anticonvulsants that bind to cell constituents if not rapidly detoxified by epoxide hydrolases. Genetically determined defective detoxification may thus result in direct toxicity or alteration of the antigenic properties of keratinocytes. This attractive hypothesis gains support from the association of SJS-TEN with the carbamazepine or hydantoin hypersensitivity syndromes, [74] the association of sulfonamide-triggered SJS-TEN with the slow acetylator phenotype, [75] preliminary results of in vitro cytotoxicity assays, [76] and the overproportional occurrence in HIV-infected patients who are deficient in glutathione, an important scavenger of toxic compounds. [77] It has been hypothesized that the cytotoxic assault may be directed at viral antigens that persist in the skin. [78] High amounts of mRNA for inducible nitric oxide synthase have been detected in the inflammatory infiltrate of SJS-TEN; [78] nitric oxide, which is known to induce apoptosis and necrosis, may thus have a role in the pathogenesis of SJS-TEN. Although drug-induced SJS-TEN occasionally occurs in animals, no animal model is available at present.

Autoantibodies against desmoplakin I and II have been detected in a subset of SJS. [79] In these cases, suprabasal acantholysis was present, while the clinical disease was no different from that manifested in other patients with SJS who lacked these antibodies.

Clinical Manifestations

In at least half of the patients, SJS-TEN begins with a nonspecific prodrome of 1 to 14 days (see Table 58-1): fever, malaise, headache, rhinitis, cough, sore throat, chest pain, vomiting, diarrhea, myalgias, and arthralgias. Patients often feel ill and receive antimicrobial and anti-inflammatory treatment that later may cause difficulties in determining the offending factor. The onset of disease is sudden; cases vary within wide limits in terms of length of the lag period between exposure and onset of the eruption, rapidity of evolvement, BSA involved and degree of confluence, prominence of mucous membrane involvement, accompanying constitutional symptoms, and internal organ involvement.

A macular, often morbilliform rash appears first on the face, neck, chin, and central trunk areas; it may then spread to the extremities and the rest of the body. The individual lesions may have dusky centers reminiscent of target lesions, or they may be mere roundish, irregularly shaped and moderately well defined pale livid macules (Fig. 58-4). They are often larger than target lesions, flat, and tender, and exhibit a positive Nikolsky sign (Fig. 58-4B, Fig. 58-5A, and Fig. 58-5C); some form flaccid and occasionally hemorrhagic blisters. Despite these obvious differences from erythema multiforme, occasional raised atypical, or even typical, target lesions may appear. The lesions rapidly increase in number and size, usually reaching maximal disease expression within 4 to 5 days; however, new crops may emerge considerably later if a long-acting drug is the inciting agent.

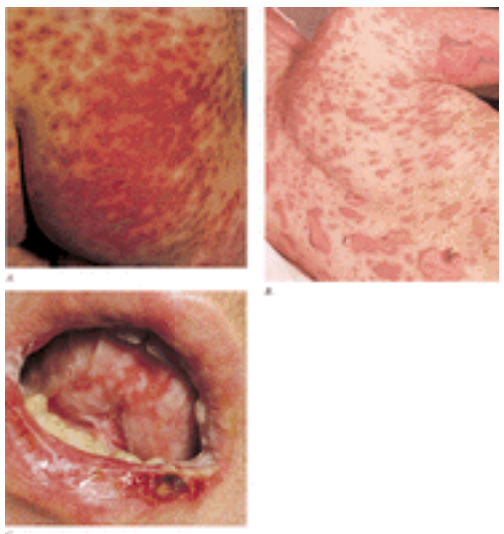

FIGURE 58-4 Stevens-Johnson syndrome. *A*. Initial stage: partially confluent erythematous lesions with dusky centers, presenting as flat atypical target lesions. Note the positive Nikolsky sign. *B*. Advanced stage: generalized macular eruption with detachment of necrotic epidermis. *C*. Extensive necrosis and erosions of the lips and oral mucosa.

FIGURE 58-5 Toxic epidermal necrolysis. *A*. Confluent morbilliform eruption; note the positive Nikolsky sign. *B*. Diffuse erythema of the face with shedding of the cilia and epidermis of the eyelids, severe erosions, and hemorrhagic crusting of the lips. *C*. Diffuse generalized shedding of the epidermis of the entire back reminiscent of scalding.

There is a striking tendency for coalescence; confluence is only partial, limited to the predilection sites (face, neck, chest) in SJS, but widespread to total in TEN (see Fig. 58-5). Areas of confluence represent extensive, diffuse erythemas; individual macular lesions remain discernible in the periphery. Within such lesions, the epidermis becomes loose and easily detached following minimal frictional trauma. Large flaccid blisters form; the blister roofs turn necrotic and rupture easily. Sheets of necrotic epidermis slide off the face and at pressure points such as the back and shoulders, leaving intensely red, oozing erosions (see Fig. 58-5C). Denudation may involve 10 to 90 percent of the BSA. In severe cases of TEN, prominent involvement of the skin appendages may lead to shedding of the finger- and toenails, as well as loss of the eyebrows and cilia (see Fig. 58-5B).

Mucous membrane lesions parallel or even precede the rash. The oral cavity (buccal mucosa, palate) and the vermilion border of the lips (see Fig. 58-4C and Fig. 58-5B) are almost invariably affected; less often, the bulbar conjunctiva and anogenital mucosae. All three sites are involved in approximately 40 percent of cases. [11] Signs that herald lesions are sore and burning sensations of the conjunctivae, lips, and buccal mucosa; edema; and erythema; following these signs are blisters that rupture and become extensive, hemorrhagic dull red erosions coated by grayish-white pseudomembranes (necrotic epithelium and fibrin; see Fig. 58-4C) or shallow aphthous-like ulcers. Massive hemorrhagic crusts cover the lips. Oral lesions are severely painful and cause eating and breathing difficulties and hypersalivation. The process may extend to the gingiva, tongue, pharynx, nasal cavity, and even to the larynx, esophagus, and respiratory tree. Otitis media may develop. Conjunctival involvement features inflammation and chemosis, vesiculation and painful erosions, and bilateral lacrimation. Less common are purulent conjunctivitis with photophobia and/or pseudomembranes, corneal ulceration, anterior uveitis, and panophthalmitis. Genital involvement most often includes painful hemorrhagic bullous-erosive or purulent lesions of the fossa navicularis and glans penis, or of the vulva and vagina, and may lead to urinary retention and phimosis. Anal erosions are less frequent.

TEN WITHOUT SPOTS In a small minority of cases, TEN does not arise from confluent lesions of SJS, but presents with primary, ill-demarcated, diffuse erythemas that are rapidly progressive and may become erythrodermic. Mucous membranes may sometimes remain unaffected. A trickle of such cases have been recorded through the decades, but TEN without spots is still an ill-defined entity. It affects predominantly elderly females. The same drugs that trigger SJS-TEN may trigger TEN without spots, but “idiopathic” cases occur more often. The majority of cases of TEN caused by the graft-versus-host reaction represent this type of TEN, and the prognosis may be worse than that of SJS-TEN. Differentiation from generalized fixed drug eruption is difficult; it rests mainly on the presence of prominent systemic signs in TEN.

EXTRACUTANEOUS SYMPTOMS Constitutional signs of SJS-TEN include fever, arthralgias, weakness, and prostration. Internal organ involvement is rare in SJS, but may be severe in TEN, most often affecting the respiratory and gastrointestinal tracts. Tracheal and bronchial symptoms include breathing difficulties, sloughing of the respiratory tract mucosa leading to persistent cough, bronchial obstruction and expectoration of bronchial casts, adult respiratory distress syndrome, tracheitis, patchy pulmonary disease, bronchopneumonia, and pneumothorax. [80] Less commonly, ileal involvement, diarrhea, abdominal pain, esophageal and gastrointestinal bleeding, excretion of necrotic intestinal epithelium, colonic perforation, melena, and hepatitis have been reported. [81] Toxicity, dehydration, and water and electrolyte imbalance may proceed to hemodynamic shock, pulmonary edema, mental obtusion, confusion, coma, and seizures. Myocarditis and myocardial infarction are common in fatal cases, although they are generally uncommon. Except for microalbuminuria, renal complications are rare; if present, they are more often linked to septicemia or septic shock than to TEN. Acute tubular necrosis, membranous glomerulonephritis, and renal failure have been described. [82]

LATE COMPLICATIONS Skin lesions heal with transitory hyper- and/or hypopigmentation. Scarring does not usually appear except in extensive cases with secondary infection, where contractures, alopecia, and anonychia may develop. Scarring is a characteristic and frequent (up to 30 percent in TEN) late complication of mucosal lesions; it is most serious in the eyes, as symblepharon, synechiae, entropion and ectropion, trichiasis, corneal opacities or scarring, and pannus formation potentially result in blindness. Lesions of the lips and oral mucosa usually resolve without sequelae, but esophageal, bronchial, vaginal, urethral, and anal strictures develop at times. A Sjögren-like syndrome may develop as the result of damage to the salivary and lacrimal glands.

Course

Following the outbreak, SJS-TEN enters a phase of progression that usually lasts 4 to 5 days, but can be more protracted. Progression may halt at any point of BSA involvement (from 10 to close to 100 percent), and the patient enters a plateau phase that again may take from a few days up to 2 weeks, depending on the severity of SJS-TEN and the physical constitution of the patient. It is during this phase that the hazard of systemic complications is highest. A

lightening of the erythema, lessening of oozing and skin tenderness, and transformation of the detached epidermis into dry blackish parchment-like squames heralds the phase of regression. Reepithelialization may take several weeks.

Pathology

In contrast to the only scanty signs of inflammation in both epidermis and dermis, epidermal necrosis is prominent in SJS-TEN. Epidermal injury may appear as satellite-cell necrosis in early stages and progresses to more extensive eosinophilic necrosis of the basal and suprabasal layers; subepidermal separation may be evident (Fig. 58-6). In TEN, there is total thickness necrosis and sloughing of the epidermis. There is a moderately dense to sparse mononuclear cell infiltrate in the papillary dermis, with exocytosis into the epidermis. Spongiosis and dermal edema are most often absent. Neutrophils and nuclear dust are occasionally evident.

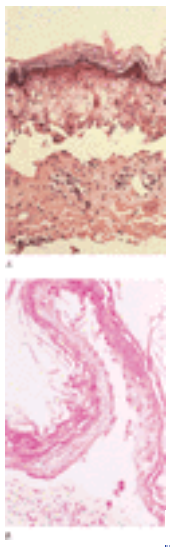

FIGURE 58-6 Histologic appearance of TEN. *A*. Eosinophilic necrosis of the epidermis in the peak stage, with little inflammatory response in the dermis. Note cleavage in the junction zone. *B*. The completely necrotic epidermis has detached from the dermis and folded like a sheet.

In severe SJS-TEN, extensive fibrinoid necrosis may occur in several internal organs, including the stomach, spleen, trachea, and bronchi. Despite the frequency of pulmonary radiologic abnormalities, the pathology in uncomplicated cases is limited to sparse mononuclear cell infiltrates.

Laboratory Investigations

An elevated erythrocyte sedimentation rate accompanies SJS-TEN; in addition, patients may develop moderate leukocytosis, fluid-electrolyte imbalance, microalbuminuria, hypoproteinemia, elevation of liver transaminase levels, and anemia. In the acute phase, patients with TEN may have a transient decrease of peripheral CD4+ T lymphocyte counts, accompanied by reduced allogeneic and natural-killer–cell cytotoxicity, which return to normal after 7 to 10 days. These laboratory abnormalities resemble, to some degree, those found in second-degree burn injuries; however, they are usually less severe. Neutropenia, which occurs in a minority of cases, is regarded as an unfavorable prognostic sign. [11] Eosinophilia may be found in some cases. Circulating immune complexes have been demonstrated in several reports, but are not, in general, accompanied by complement consumption. Renal abnormalities such as proteinuria and elevated blood urea nitrogen levels occur in about 5 percent of cases. [11] A host of other laboratory findings may become abnormal as involvement of internal organs or secondary infection occurs.

Differential Diagnosis

Most often, SJS-TEN is a straightforward diagnosis. Difficulties may arise in two situations: (1) in viral or drug-induced macular exanthems, in which it is difficult to predict whether they will proceed to SJS-TEN, or (2) in other eruptions characterized by widespread erythema and detachment of the skin.

Table 58-4 lists other entities to be considered in the differential diagnosis. Macular morbilliform eruptions, for example, may be morphologically indistinguishable from the initial SJS-TEN lesions that are not yet confluent or necrotic. The lesions are not tender, do not exhibit a positive Nikolsky's sign, and lack prominent involvement of mucous membranes, however. (For a comparison of the clinical features of SJS-TEN with those of erythema multiforme, see Table 58-1.)

SJS	TEN
Erythema multiforme	Staphylococcal scalded-skin syndrome
Viral exanthems	Generalized fixed drug eruption
Ampicillin rash	Burns, cauterization, etc.
Morbilliform drug eruptions	Toxic erythroderma
Fixed drug eruption	
Acute graft-versus-host disease	

TABLE 58-4 **Differential Diagnosis of Stevens–Johnson Syndrome (SJS) and Toxic Epidermal Necrolysis (TEN)**

MULTILOCULAR OR GENERALIZED BULLOUS FIXED DRUG ERUPTION A classic differential diagnosis of SJS-TEN, multilocular or generalized bullous fixed drug eruption appears in many series of patients with SJS-TEN, particularly those with recurrences. The main points of distinction are its primary lesions, which are large erythemas (faintly discernible even after confluence), most often irregularly distributed and of a characteristic purplish-livid color, at times with flaccid blisters; the rarity of mucous membrane involvement; and the paucity of constitutional symptoms. Histopathology is similar to that of SJS-TEN, except for the more pronounced inflammation and a marked edema of the

papillary dermis. Often, history reveals milder prior episodes following intake of the culprit drugs. Generalized bullous fixed drug eruption takes a much milder course than SJS-TEN. Recovery is rapid and complete, without sequelae. Drug-induced linear IgA dermatosis mimicking SJS-TEN has been observed. [83]

STAPHYLOCOCCAL SCALDED-SKIN SYNDROME A disorder unrelated to SJS-TEN, staphylococcal scalded-skin syndrome is caused by staphylococcal epidermolysin toxinemia and characterized by subcorneal acantholysis. It occurs almost exclusively in children and may be confused with SJS-TEN because of a resemblance to scalding that is common to both. A wide range of clinical criteria (e.g., absence of mucosal lesions and of internal organ involvement) facilitate the differential diagnosis. In ambiguous cases, the diagnosis can be rapidly made by exfoliative cytology or frozen sections of biopsy material (see Chap. 195).

PHYSICAL AND CHEMICAL INJURY The diagnosis of physical and chemical injury, such as scalding and burns, solar erythema, and chemical burns (e.g., kerosene or paraffin burns) is clear if a history is available, but may be difficult in unconscious patients. Injury by exogenous agents displays an artificial distribution pattern, mucous membranes are only rarely involved, and there is no antecedent macular rash. If necrosis arises, it tends to involve deeper layers, including the skin appendages, whereas it is purely epidermal in SJS-TEN.

Treatment

The fate of patients depends on rapid referral to a specialized center experienced in the management of SJS-TEN and in general skin care (i.e., to a dermatology center with inpatient facilities), if available. Under no circumstances may a patient with SJS-TEN be treated on an ambulatory basis because supportive care and constant supervision are no less important than are active therapeutic measures. This is true, even though in the initial stages of SJS-TEN, patients may feel fairly well or even euphoric and may be unwilling to be admitted to the hospital. Although widely claimed, referral to an intensive care unit or to a burn center is not mandatory except when disease is extensive or complications are severe. If properly treated, SJS-TEN is linked to many fewer systemic symptoms than second-degree burns of the same BSA. Furthermore, the literature does not support the conclusion that mortality rates are higher in dermatologic wards than in intensive care units.

The management of SJS-TEN rests on three cornerstones: (1) identification and elimination of the provocative agent (i.e., withdrawal of the offending drug or treatment of the underlying infection, if available), (2) active therapy, and (3) supportive measures. There are no generally accepted regimens or treatment guidelines for SJS-TEN, and no controlled therapeutic trials have ever been published. This is because SJS-TEN is an infrequent and life-threatening disease of high clinical variability that requires complex treatment and individually adapted care.

WITHDRAWAL OF THE SUSPECTED OFFENDING DRUGS Obviously, the causative drug should rapidly be identified and withdrawn. Prompt withdrawal of all non–life-sustaining drugs in patients with incipient SJS-TEN may reduce the death risk by about 30 percent per day. [83] This measure, however, does not immediately halt disease progression. At present, the detection of the most likely culprit is a matter of empirical calculation based on a careful history of drug intake with special focus on recent drug use, its relation to the development of symptoms, and prior episodes of SJS-TEN. The most likely offending drug is one that has been newly administered in the past 4 weeks and is known as a risk drug for SJS-TEN. The intake of multiple drugs, drugs newly administered for the treatment of prodromal symptoms (i.e., antimicrobials, analgesics, or NSAIDs), drug interactions, and infections may obscure matters.

ACTIVE SUPPRESSION OF DISEASE PROGRESSION A number of anti-inflammatory and/or immunosuppressive treatment modalities have been proposed to have beneficial effects on SJS-TEN. The lack of controlled trials and the lack of a clear-cut distinction between progression and peak phases in many of the single case reports and small (usually heterogeneous) patient series described in the literature mars the evidence, however. Thus, there is currently no consensus regarding which, if any, therapeutic measure will shorten the natural course of the disease. Furthermore, many of the treatment modalities bear potential harmful side effects that clinicians must weigh against the benefits. As a consequence, many clinicians rely only on supportive measures. This view, which is unique in the context of an acute immune system–mediated life-threatening disease, must be attributed to a much too far-reaching and unjustified equation of SJS-TEN with burn injuries. Burns result from a single thermal trauma, whereas TEN is an immunological-cytotoxic attack that may progress for more than a week (not just 3 to 4 days, as often claimed), depending on detoxification and excretion of the offending agent. It should be the treatment strategy of this early phase to halt disease progression and thus limit the extent of skin and mucosal necrosis and reduce the severity of sequelae.

Glucocorticoids The systemic administration of glucocorticoids has been the mainstay of the treatment of SJS-TEN for a long time, but has come into disrepute in the past years. The scientific community is divided over their use; fervent supporters fiercely oppose those who condemn glucocorticoids and even consider them “detrimental.” [56], [73], [84] The discussion arose because glucocorticoids, if given for longer than the phase of progression, clearly increase the risk of infection and thus may contribute to mortality. Surgical intensive care specialists who were striving to shape the treatment of SJS-TEN according to the principles of the management of burns, where the systemic administration of glucocorticoids is obviously not indicated, adopted this position. The argument was expanded by the assumption that glucocorticoids, in principle, have no effect on disease progression. Additional observations supported this idea: mortality rates do not differ significantly between countries where physicians commonly use glucocorticoids (e.g., Germany: 80 percent use glucocorticoids) and those where physicians are reluctant to use them (e.g., France: 20 percent use glucocorticoids), and SJS-TEN may arise in patients who are on long-term, albeit low-dose, glucocorticoid treatment for other reasons. [86] Mortality rates are highly different in published series, however, ranging from zero to more than 50 percent, both with and without the use of steroids. Long-term sequelae were apparent in 7 of 11 children with TEN who were not treated by the systemic administration of glucocorticoids. [87] If steroids do curb disease progression in the initial phase, which may be expected in an immune system–mediated disease, they do not shorten the peak and regression phases. Obviously, they must be used with utmost caution. If given, relatively high initial doses are required (1 to 2 mg/kg methyl prednisolone per day given orally), and rapid tapering is indicated as soon as disease progression halts. They should be given only as part of a total program (see below) if the physical condition of the patient permits. It is absolutely unacceptable to consider steroids as the only measure.

Immunoglobulins Recently, the intravenous administration of pooled human immunoglobulins (IVIG) has emerged as a promising strategy for blocking the progression of SJS-TEN, based on the immunoglobulins' content of antibodies against Fas ligand that are capable of preventing apoptotic cell death in vitro. [88] In the original study, 10 patients were treated,

with IVIG dosages ranging from 0.2 to 0.75 g/kg body weight per day for 4 consecutive days. In all patients, rapid decrease of disease progression and evidence of recovery were observed. Similar favorable results have been reported since in a number of cases. [89], [90] Pending adequately sized controlled studies, however, this very expensive treatment should be reserved for clinical trials. Although IVIG has a good safety profile, nephropathy is a rare but dangerous side effect that may result in renal failure.

Plasmapheresis and Hemodialysis Scattered and partially contradictory reports suggest that the removal of the causative drug, its metabolites, or other toxic molecules from the circulation may stop progression of SJS-TEN. [91], [92] In the absence of formal proof and in view of the stress on the patient associated with the treatments, these strategies are not recommended at the present time.

Cyclophosphamide Cyclophosphamide is an inhibitor of cell-mediated cytotoxicity. Although it has been used successfully in a small number of patients with TEN, it is a potent immunosuppressive agent and has itself been the cause of several cases of SJS-TEN.

Cyclosporine Again, several case reports suggest the efficacy of cyclosporine in SJS-TEN. [93] It has been suggested that cyclosporine interacts with TNF-a metabolism. [64]

N-Acetylcysteine Along with *S*-adenosyl-L-methionine, *N*-acetylcysteine may act through replenishing cells with antioxidant capacity and by inhibiting cytokine (TNF-a)–mediated immune reactions. [94] The evidence as to its use in SJS-TEN is sporadic.

Thalidomide The rationale for the experimental use of thalidomide, a known inhibitor of TNF-a, was the hypothesized pivotal role of this cytokine in the genesis of SJS-TEN. [69] Yet, in a randomized placebo controlled study, the thalidomide group exhibited a significantly higher mortality rate than the control group, and the study had to be discontinued. [95] (See also Chap. 264.) It remains unclear whether this outcome was due to paradoxical enhancement of TNF-a production or effects, or to IL-2–mediated T cell stimulation.

MAINTENANCE OF HEMODYNAMIC EQUILIBRIUM, PROTEIN AND ELECTROLYTE HOMEOSTASIS The rationale for treating patients with TEN in burn units would be to apply the therapeutic principles of burn injuries (i.e., rigorous adjustment of fluid, protein, and electrolyte balance; control of infection; and early surgical debridement of skin lesions). This rationale is questionable because, despite the clinical similarities, the pathomechanisms of SJS-TEN are totally different from those of burn injuries. The main difference is the virtual absence of vascular damage in SJS-TEN; consequently, edema and loss of fluid into the interstitial tissues are not a prominent feature. There is also much less loss of fluid to the outside, as tense and large blisters form only rarely. Water loss in SJS-TEN mainly occurs through evaporation from erosions and is thus highest in the peak phase. Metabolic acidosis is not a regular feature. All of these factors cooperate to render the fluid and electrolyte imbalances associated with SJS-TEN much less drastic and of later onset than those associated with burns. Hemodynamic shock is a possibility, but it is rare and occurs primarily in unsatisfactory clinical settings and in patients with cardiovascular or metabolic compromise. Also, second-degree burn injuries are more painful than SJS-TEN. Blood pressure, hematocrit, and levels of blood gases, electrolytes and serum proteins must be monitored and adjusted appropriately. Fluid replacement regimens are recommended only when required. Central venous lines (as well as urinary catheters) should not routinely be inserted.

ANTIBIOTIC/ANTIMICROBIAL TREATMENT It is universally agreed that infections pose the most important threat for patients with SJS-TEN. Bacterial and fungal cultures should therefore be taken two to three times per week from skin and mucosal erosions, blood, and sputum; oral and genital mucosae should be repeatedly inspected for infection with HSV or *Candida*. In many series, patients received antibiotics only when clinical symptoms of infection were already present and the causative organism identified. This is probably due to the reluctance of many clinicians to use antibiotics prophylactically or to their fear of introducing a further drug into a patient with drug intolerance. Clinicians should take into account, however, the fact that antibiotics are only rarely the offending drug in SJS-TEN and that those with a known risk of severe cutaneous reactions are easily avoidable. It has been the strategy of our group (P.O.F.) to start prophylactic antibiotic treatment (sodium penicillin, 2 × 10 million units per day) from the beginning, and to adjust the antibiotic according to the cultured organism; pursuing this strategy, the mortality rate of patients with TEN has been kept to less than 10 percent in our institution throughout the past two decades.

SUPPORTIVE TREATMENT

Skin Loose sheets of detached epidermis may be cautiously removed, but early aggressive debridement as performed in burn patients is not indicated because the necrosis is only superficial and represents no obstacle for reepithelialization. As a rule, spontaneous reepithelialization is rapid. Erosions should be covered with gauze or hydrocolloid dressings. Sulfonamide-containing topicals should be avoided. When topical antibiotics or antiseptics are used, the possibility of systemic absorption has to be considered. Fresh-frozen or cryopreserved cadaver allograft and porcine xenograft skin, as well as biosynthetic dressings, have been advocated, but their value is questionable because—unlike burn injuries—SJS-TEN leaves the dermis largely uninvolved and reepithelialization is not a problem.

Eyes In the acute phase of conjunctival involvement, lubricants, steroid and antibiotic drops should be applied several times a day. Lid-globe adhesions should be cautiously removed twice daily with a glass rod to avoid occlusion of the fornices; care must be taken not to strip pseudomembranes, which may lead to bleeding and increased conjunctival scarring. [96]

Respiratory Tract Supportive pulmonary care includes postural drainage and, if necessary, cautious suctioning.

Alimentation Patients with SJS-TEN are often unable to eat and drink because of their oral and/or esophageal mucosal involvement, or their poor general condition. Local anesthetics, as a mouthwash before the meals, may be helpful. A high-calorie and high-protein diet or intravenous administration is recommended, although the risk of septicemia associated with intravenous lines must be taken into account.

Prognosis

The prognosis for patients with SJS-TEN depends on the severity of disease and the quality of medical care. The mortality rate is low (less than 1 percent) for SJS, [7] and it ranges from 5 to 50 percent for TEN. Old age, extensive skin lesions, neutropenia, impaired renal function, and intake of multiple drugs appear to be unfavorable prognostic signs. A recently proposed severity-of-illness score for TEN identified seven independent risk factors: [97]

1. Age over 40 years
2. Malignancy
3. Tachycardia more than 120 beats per minute

4. Initial epidermal detachment of more than 10 percent
5. Serum urea level greater than 10 mmol/L
6. Serum glucose level greater than 14 mmol/L
7. Bicarbonate level less than 20 mmol/L

Excellent agreement was found between expected and actual mortality.

Fatal outcome is most often the result of septicemia (e.g., *Staphylococcus aureus, Pseudomonas, Candida*), pneumonia, gastrointestinal hemorrhage, myocardial infarction, and cardiac insufficiency. Much more rarely, it results from renal insufficiency and hemodynamic shock. [98] Recovery is slow; it may require 3 to 6 weeks or more, depending on the presence of complications. Healing occurs with a tendency for scar and stricture formation at mucosal sites.

REFERENCES

1. Lyell A: Toxic epidermal necrolysis: An eruption resembling scalding of the skin. *Br J Dermatol* **68**:355, 1956

2. Lyell A: Toxic epidermal necrolysis (the scalded skin syndrome): A reappraisal. *Br J Dermatol* **100**:69, 1979

3. Lyell A: Requiem for toxic epidermal necrolysis. *Br J Dermatol* **122**:837, 1990

4. Huff JC: Erythema multiforme and latent herpes simplex infection. *Semin Dermatol* **11**:207, 1992

5. Bastuji-Garin S et al: Clinical classification of cases of toxic epidermal necrolysis, Stevens-Johnson syndrome and erythema multiforme. *Arch Dermatol* **129**:92, 1993

6. Roujeau JC: The spectrum of Stevens-Johnson syndrome and toxic epidermal necrolysis. *J Invest Dermatol* **102**:28S, 1994

7. Assier H et al: Erythema multiforme with mucous membrane involvement and Stevens-Johnson syndrome are different disorders with distinct causes. *Arch Dermatol* **131**:539, 1995

8. Ruiz-Maldonado R: Acute disseminated epidermal necrolysis types 1, 2, and 3: Study of sixty cases. *J Am Acad Dermatol* **13**:623, 1985

9. Rzany B et al: Epidemiology of erythema exsudativum multiforme majus, Stevens-Johnson syndrome, and toxic epidermal necrolysis in Germany (1990–1992): Structure and results of a population-based registry. *J Clin Epidemiol* **49**:769, 1996

10. Schofield JK et al: Recurrent erythema multiforme: Clinical features and treatment in a large series of patients. *Br J Dermatol* **128**:542, 1993

11. Brice SL et al: Erythema multiforme, in *Current Problems in Dermatology,* edited by WL Weston. Chicago, Year Book, 1990

12. Howland WW et al: Erythema multiforme: Clinical histopathologic and immunologic study. *J Am Acad Dermatol* **10**:438, 1984

13. Brice SL et al: Examination of non-involved skin, previously involved skin and peripheral blood for herpes simplex virus DNA in patients with recurrent herpes-associated erythema multiforme. *J Cutan Pathol* **21**:408, 1994

14. Imafuku S et al: Expression of herpes simplex virus DNA fragments located in epidermal keratinocytes and germinative cells is associated with the development of erythema multiforme. *J Invest Dermatol* **109**:550, 1997

15. Weston WL et al: Herpes simplex virus in childhood erythema multiforme. *Pediatrics* **89**:32, 1992

16. Kazmierowski JA et al: Herpes simplex antigen in immune complexes of patients with erythema multiforme. *JAMA* **247**:2547, 1982

17. Imafuku S et al: T cell repertoire usage in herpes simplex infections and erythema multiforme. *J Invest Dermatol* **104**:565, 1995

18. Tatnall FM et al: A double blind placebo controlled trial of continuous acyclovir therapy in recurrent erythema multiforme. *Br J Dermatol* **132**:267, 1995

19. Dumas V et al: Recurrent erythema multiforme and chronic hepatitis C: Efficacy of interferon alpha. *Br J Dermatol* **142**:1248, 2000

20. Loche F et al: Erythema multiforme associated with hepatitis B immunization. *Clin Exp Dermatol* **25**:167, 2000

21. Leigh IM et al: Recurrent and continuous erythema multiforme—Clinical and immunological study. *Clin Exp Dermatol* **10**:58, 1985

22. Puig L et al: Erythema multiforme–like eruption due to topical contactants: Expression of adhesion molecules and their ligands and characterization of the infiltrate. *Contact Dermatitis* **33**:329, 1995

23. Larcher C et al: Interaction of HSV-1 infected peripheral blood mononuclear cells with cultured dermal microvascular endothelial cells: A potential model for the pathogenesis of HSV-1 induced erythema multiforme. *J Invest Dermatol* **116**:150, 2001

24. Wolf P et al: Recurrent post-herpetic erythema multiforme mimicking polymorphic light and juvenile spring eruption: Report of two cases in young boys. *Br J Dermatol* **131**:364, 1994

25. Inachi S et al: Epidermal apoptotic cell death in erythema multiforme and Stevens-Johnson syndrome: Contribution of perforin-positive cell infiltration. *Arch Dermatol* **133**:845, 1997

26. Bennion SD et al: In three types of interface dermatitis, different patterns of expression of intercellular adhesion molecule-1 (ICAM-1) indicate different triggers of disease. *J Invest Dermatol* **105**:71S, 1995

27. Paquet P et al: Erythema multiforme and toxic epidermal necrolysis: A comparative study. *Am J Dermatopathol* **19**:127, 1997

28. Kokuba H: Herpes simplex virus–associated erythema multiforme: Interferon-gamma is expressed in HAEM lesions and tumor necrosis factor-alpha in drug-induced erythema multiforme lesions. *J Invest Dermatol* **113**:808, 1999

29. Brice SL et al: The herpes-specific immune response of individuals with herpes-associated erythema multiforme compared with that of

individuals with recurrent herpes labialis. *Arch Dermatol Res* **285**:193, 1993

30. Schofield JK et al: Recurrent erythema multiforme: Tissue typing in a large series of patients. *Br J Dermatol* **131**:532, 1994

31. Kämpgen E et al: Association of herpes simplex virus induced erythema multiforme with the human leukocyte antigen Dqw3. *Arch Dermatol* **124**:1372, 1988

32. Micalizzi C, Farris A: Erythema multiforme along Blaschko's lines. *J Eur Acad Dermatol Venereol* **14**:203, 2000

33. Drago F et al: Persistent erythema multiforme: Report of two new cases and review of the literature. *J Am Acad Dermatol* **33**:366, 1995

34. Cote B et al: Clinicopathological correlation in erythema multiforme and Stevens-Johnson syndrome. *Arch Dermatol* **131**:1268, 1995

35. Rzany B et al: Histopathological and epidemiological characteristics of patients with erythema exsudativum multiforme majus, Stevens-Johnson syndrome and toxic epidermal necrolysis. *Br J Dermatol* **135**:6, 1996

36. Orfanos CE et al: Dermal and epidermal types of erythema multiforme. *Arch Dermatol* **109**:682, 1974

37. Ackerman AB et al: Erythema multiforme exudativum: Distinctive pathological process. *Br J Dermatol* **84**:554, 1971

38. Hering O et al: The dermal type of erythema multiforme: A rare variant of Stevens-Johnson syndrome or cases of clinical misclassification? *Acta Derm Venereol* **77**:217, 1997

39. Rowell NR et al: Lupus erythematosus and erythema multiforme–like lesions. *Arch Dermatol* **88**:176, 1963

40. Roujeau JC et al: Toxic epidermal necrolysis (Lyell syndrome): Incidence and drug etiology in France, 1981–1985. *Arch Dermatol* **126**:37, 1990

41. Schopf E et al: Toxic epidermal necrolysis and Stevens-Johnson syndrome: An epidemiologic study from West Germany. *Arch Dermatol* **127**:839, 1991

42. Hernborg A: Stevens-Johnson syndrome after mass prophylaxis with sulfadoxine for cholera in Mozambique. *Lancet* **1**:1072, 1985

43. Correia O et al: Evolving pattern of drug-induced toxic epidermal necrolysis. *Dermatology* **186**:32, 1993

44. Rzany B et al: Incidence of Stevens-Johnson syndrome and toxic epidermal necrolysis in patients with the acquired immunodeficiency syndrome in Germany. *Arch Dermatol* **129**:1059, 1993

45. Roujeau JC et al: Genetic susceptibility to toxic epidermal necrolysis. *Arch Dermatol* **123**:1171, 1987

46. Kaufman DW: Epidemiologic approaches to the study of toxic epidermal necrolysis. *J Invest Dermatol* **102**:31S, 1994

47. Kelly JP et al: An international collaborative case-control study of severe cutaneous adverse reactions (SCAR): Design and methods. *J Clin Epidemiol* **48**:1099, 1995

48. Roujeau JC et al: Medication use and the risk of Stevens-Johnson syndrome or toxic epidermal necrolysis. *N Engl J Med* **333**:1600, 1995

49. Roujeau JC et al: Severe adverse reactions to drugs. *N Engl J Med* **331**:1272, 1994

50. Duncan KO et al: Stevens-Johnson syndrome limited to multiple sites of radiation therapy in a patient receiving phenobarbitural. *J Am Acad Dermatol* **40**:493, 1999

51. Bushan M et al: Prolonged toxic epidermal necrolysis due to lamotrigine. *Clin Exp Dermatol* **39**:621, 2000

52. Auböck J et al: Asymptomatic hyperuricaemia and allopurinol induced toxic epidermal necrolysis. *BMJ* **290**:1969, 1985

53. Nanda A et al: Drug-induced toxic epidermal necrolysis in developing countries. *Arch Dermatol* **126**:125, 1990

54. Fagot JP et al: Nevirapine and the risk of Stevens-Johnson syndrome or toxic epidermal necrolysis. *AIDS* **15**:1843, 2001

55. Chan HL: Toxic epidermal necrolysis in Singapore, 1989 through 1993: Incidence and antecedent drug exposure. *Arch Dermatol* **131**:1212, 1995

56. Chosidow O et al: Drug rashes: What are the targets of cell mediated cytotoxicity? *Arch Dermatol* **130**:627, 1994

57. Fritsch PO, Sidoroff A: Drug-induced Stevens-Johnson syndrome/toxic epidermal necrolysis. *Am J Clin Dermatol* **1**:349, 2000

58. Ball R et al: Stevens-Johnson syndrome and toxic epidermal necrolysis after vaccination: Reports to the vaccine adverse event reporting system. *Pediatr Infect Dis J* **20**:219, 2001

59. Tay YK et al: *Mycoplasma pneumoniae* infection is associated with Stevens-Johnson syndrome, not erythema multiforme (von Hebra). *J Am Acad Dermatol* **35**:757, 1996

60. Villada G et al: Toxic epidermal necrolysis after bone marrow transplantation: Study of nine cases. *J Am Acad Dermatol* **23**:870, 1990

61. McCarty JR et al: Toxic epidermal necrolysis from graft-vs-host disease: Occurrence in a patient with thymic hypoplasia. *Am J Dis Child* **132**:282, 1978

62. Streilein JW et al: An analysis of graft-vs-host disease in Syrian hamsters. I. The epidermolytic syndrome: Description and studies on its procurement. *J Exp Med* **132**:163, 1970

63. Wolkenstein P et al: Patch testing in severe cutaneous adverse drug reactions, including Stevens-Johnson syndrome and toxic epidermal necrolysis. *Contact Dermatitis* **35**:234, 1996

64. Friedmann PS et al: Investigation of mechanism in toxic epidermal necrolysis induced by carbamazepine. *Arch Dermatol* **130**:598, 1994

65. Mauri-Hellweg D et al: Activation of drug-specific CD4+ and CD8+ T cells in individuals allergic to sulfonamides, phenytoin and

carbamazepine. *J Immunol* **155**:462, 1995

66. Redondo P et al: Drug-induced hypersensitivity syndrome and toxic epidermal necrolysis: Treatment with *N*-acetylcysteine. *Br J Dermatol* **136**:645, 1997

67. Correia O et al: Cutaneous T-cell recruitment in toxic epidermal necrolysis: Further evidence of CD8+ lymphocyte involvement. *Arch Dermatol* **129**:466, 1993

68. Villada G et al: Immunopathology of toxic epidermal necrolysis: Keratinocytes, HLA-DR expression, Langerhans cells, and mononuclear cells. An immunopathologic study of five cases. *Arch Dermatol* **128**:50, 1992

69. Paquet P et al: Macrophages and tumor necrosis factor alpha in toxic epidermal necrolysis. *Arch Dermatol* **130**:505, 1994

70. Paquet P, Pierard GE: Soluble fractions of tumor necrosis factor-alpha, interleukin-6 and of their receptors in toxic epidermal necrolysis: A comparison with second-degree burns. *Int J Mol Med* **1**:459,1998

71. Le Cleach L et al: Blister fluid T lymphocytes during toxic epidermal necrolysis are functional cytotoxic cells which express human natural killer (NK) inhibitory receptors. *Clin Exp Immunol* **119**:225, 2000

72. Paquet P et al: Immunoregulatory effector cells in drug-induced toxic epidermal necrolysis. *Am J Dermatopathol* **22**:413, 2000

73. Shear NH et al: Differences in metabolism of sulfonamides predisposing to idiosyncratic toxicity. *Ann Intern Med* **105**:179, 1986

74. Roujeau JC: Drug-induced toxic epidermal necrolysis: II. Current aspects. *Clin Dermatol* **11**:493, 1993

75. Conger LA et al: Dilantin hypersensitivity reaction. *Cutis* **57**:223, 1996

76. Wolkenstein P et al: A slow acetylator genotype is a risk factor for sulphonamide-induced toxic epidermal necrolysis and Stevens-Johnson syndrome. *Pharmacogenetics* **5**:255, 1995

77. Wolkenstein P et al: Metabolic predisposition to cutaneous adverse drug reactions: Role in toxic epidermal necrolysis caused by sulfonamides and anticonvulsants. *Arch Dermatol* **131**:544, 1995

78. Lerner LH et al: Nitric oxide synthase in toxic epidermal necrolysis and Stevens-Johnson syndrome. *J Invest Dermatol* **114**:196, 2000

79. Födinger D et al: Autoantibodies to desmoplakin I and II in patients with erythema multiforme. *J Exp Med* **181**:169, 1995

80. McIvor RA et al: Acute and chronic respiratory complications of toxic epidermal necrolysis. *J Burn Care Rehabil* **17**:237, 1996

81. Michel P et al: Ileal involvement in toxic epidermal necrolysis (Lyell syndrome). *Dig Dis Sci* **38**:1938, 1993

82. Blum L et al: Renal involvement in toxic epidermal necrolysis. *J Am Acad Dermatol* **34**:1088, 1996

83. Hughes AP, Callen JP: Drug-induced linear IgA bullous dermatosis mimicking toxic epidermal necrolysis. *Dermatology* **202**:138, 2001

84. Garcia-Doval I et al: Toxic epidermal necrolysis and Stevens-Johnson syndrome: Does early withdrawal of causative drugs decrease the risk of death? *Arch Dermatol* **136**:323, 2000

85. Tripathi A et al: Corticosteroid therapy in an additional 13 cases of Stevens-Johnson syndrome: A total of 67 cases. *Allergy Asthma Proc* **21**:101, 2000

86. Guibal F et al: Characteristics of toxic epidermal necrolysis in patients undergoing long-term glucocorticoid therapy. *Arch Dermatol* **131**:669, 1995

87. Sheridan RL et al: Long-term consequences of toxic epidermal necrolysis in children. *Pediatrics* **109**:74,2002

88. Viard I et al: Inhibition of toxic epidermal necrolysis by blockade of CD95 with human intravenous immunoglobulin. *Science* **282**:490, 1998

89. Morici MV et al: Intravenous immunoglobulin therapy for children with Stevens-Johnson syndrome. *J Rheumatol* **27**:2494, 2000

90. Stella M et al: Toxic epidermal necrolysis treated with intravenous high-dose immunoglobulins: Our experience. *Dermatology* **203**:45,2001

91. Egan CA et al: Plasmapheresis as an adjunct treatment in toxic epidermal necrolysis. *J Am Acad Dermatol* **40**:458, 1999

92. Furubake A et al: Lack of significant treatment effect of plasma exchange in the treatment of drug-induced toxic epidermal necrolysis. *Intensive Care Med* **25**:1307,1999

93. Arevalo JM et al: Treatment of toxic epidermal necrolysis with cyclosporin A. *J Trauma* **48**:473,2000

94. Redondo P et al: *N*-acetylcysteine inhibits production of tumor necrosis factor-alpha and interleukin-1 beta;. *Arch Intern Med* **156**:1238, 1996

95. Wolkenstein P et al: Randomized comparison of thalidomide versus placabo in toxic epidermal necrolysis. *Lancet* **352**:1586, 1998

96. Lehmann SS: Long-term ocular complication of Stevens-Johnson syndrome. *Clin Pediatr* **38**:425, 1999

97. Bastuj-Garin S et al: Scorten: A severity-of-illness score for toxic epidermal necrolysis. *J Invest Dermatol* **115**:149, 2000

98. Avakian R et al: Toxic epidermal necrolysis: A review. *J Am Acad Dermatol* **25**:69, 1991

T>

Chapter 59

John Stanley

Pemphigus

DEFINITION AND CLASSIFICATION
HISTORICAL ASPECTS
EPIDEMIOLOGY
Incidence and Prevalence
Fogo Selvagem
ETIOLOGY AND PATHOGENESIS
Electron Microscopy
Immunopathology
Pathophysiology of Acantholysis
Abnormal Immune Response and Immune Response Genes
CLINICAL MANIFESTATIONS
Pemphigus Vulgaris
Pemphigus Foliaceus
Neonatal Pemphigus
Drug-Induced Pemphigus
Associated Diseases
PATHOLOGY
Pemphigus Vulgaris
Pemphigus Foliaceus
TREATMENT AND PROGNOSIS

REFERENCES

DEFINITION AND CLASSIFICATION

The term *pemphigus* refers to a group of autoimmune blistering diseases of skin and mucous membranes that are characterized histologically by intraepidermal blisters due to acantholysis (i.e., separation of epidermal cells from each other) and immunopathologically by in vivo bound and circulating IgG directed against the cell surface of keratinocytes. The nosology of this group of diseases is outlined in Table 59-1. Essentially, pemphigus can be divided into four major types: vulgaris, foliaceus, paraneoplastic (see Chap. 60), and IgA pemphigus (see Chap. 69). In pemphigus vulgaris, the blister occurs in the deeper part of the epidermis, just above the basal layer, and in pemphigus foliaceus, also called superficial pemphigus, the blister is in the granular layer. [1]

Type	Form
Pemphigus vulgaris	Pemphigus vegetans: localized Drug-induced
Pemphigus foliaceus	Pemphigus erythematosus: localized Fogo selvagem: endemic Drug-induced
Paraneoplastic pemphigus	
IgA Pemphigus	Subcorneal pustular dermatosis Intraepidermal neutrophilic IgA dermatosis

TABLE 59-1 **Classification of Pemphigus**

HISTORICAL ASPECTS

The history of the discovery of pemphigus, and its various forms, is covered in Lever's classic monograph *Pemphigus and Pemphigoid*. [1] Both pemphigus vulgaris and pemphigus foliaceus display a spectrum of disease. Various points along these spectra have been given unique names, but because the presentation of these diseases is fluid, patients' disease usually crosses these artificial designations over time. Thus, patients with pemphigus vulgaris may present with more localized disease, one form of which is called pemphigus vegetans of Hallopeau. This may become slightly more extensive and may merge into pemphigus vegetans of Neumann. Finally, with more severe disease, full-blown pemphigus vulgaris may appear. Similarly, patients with pemphigus foliaceus may present with more localized disease, represented by pemphigus erythematosus. However, these patients will often go on to more widespread pemphigus foliaceus.

The discovery by Beutner and Jordon in 1964 of circulating antibodies against the cell surface of keratinocytes in the sera of patients with pemphigus vulgaris pioneered our understanding that pemphigus vulgaris is a tissue-specific autoimmune disease of skin and mucosa. Ultimately, their work led the way to the discoveries of autoantibodies in other autoimmune bullous diseases of the skin. [2]

EPIDEMIOLOGY

Several retrospective surveys of patients with pemphigus vulgaris and/or pemphigus foliaceus allow certain general conclusions regarding the epidemiology of pemphigus [1], [3], [4], [5], [6], and [7]. The prevalence of pemphigus of both types in men and women is about equal. The mean age of onset of disease is about 50 to 60 years; however, the range is broad, and disease may start in the elderly and in children.

Incidence and Prevalence

The exact incidence of disease and the prevalence of pemphigus vulgaris compared with that of pemphigus foliaceus depend very much on the population studied. Pemphigus vulgaris is more common in Jews and probably in people of Mediterranean descent. This same ethnic predominance does not exist for pemphigus foliaceus. Therefore, in areas where the Jewish population predominates, the incidence of pemphigus, as well as the ratio of pemphigus vulgaris to pemphigus foliaceus cases, tends to be higher. For example, in Jerusalem, the incidence of pemphigus vulgaris has been estimated to be 1.6 per 100,000 population, whereas in Finland, where there are very few Jews and people of Mediterranean origin, the incidence is much lower, 0.76 per million population. In addition, in New York and Los Angeles, the ratio of pemphigus vulgaris to pemphigus foliaceus cases is about 5 to 1, whereas in Finland, it is about 0.5 to 1. In France, the incidence of pemphigus vulgaris is 1.3 cases per million population per year and that of pemphigus foliaceus is 0.5 cases per million per year.

Fogo Selvagem

Also called endemic pemphigus foliaceus, fogo selvagem is a disease that is clinically, histologically, and immunopathologically the same as sporadic pemphigus foliaceus in any individual patient, but its epidemiology is unique.[8] Fogo selvagem is endemic in the rural areas of Brazil, especially along inland riverbeds. The geographic distribution of disease clustering is similar to that of a black fly, *Simulium nigrimanum,* thought by natives to be a vector of this disease. A study of potential environmental risk factors has also implicated the bite of this black fly, showing it to be significantly more frequent among those with the disease compared to an age-, sex-, and occupation-matched control population with unrelated dermatoses.[9] The prevalence in some rural areas of Brazil is as high as 3.4 percent.[10]

Fogo selvagem occurs often in children and young adults, unlike sporadic pemphigus foliaceus, which is a disease of mostly middle-aged and older patients. Also unlike pemphigus foliaceus, fogo selvagem occurs not infrequently in genetically related family members, although it is not contagious. This fact probably implies a common exposure, as well as susceptibility. There is no known racial or ethnic predominance, and anyone moving into an endemic area may be susceptible to disease. Finally, the development of the rural endemic areas of Brazil decreased the incidence of disease. Certainly, this fascinating disease holds clues to the triggering mechanism for the autoimmune response.

ETIOLOGY AND PATHOGENESIS

Electron Microscopy

Ultrastructural studies of the blisters in pemphigus have focused on the appearance of desmosomes, because these are the most prominent cell-to-cell adhesion junctions in stratified squamous epithelia. Early studies of pemphigus vulgaris lesions seemed to demonstrate early dissolution of cell-to-cell membrane contacts between intact desmosome junctions, with later separation and disappearance of the desmosomes.[11] However, other studies have suggested that dissolution of desmosomes or failure to form them might result in the blisters.[12] For example, biopsies of uninvolved skin from patients with pemphigus vulgaris show disruption of desmosomes and decreased numbers of desmosomes. Further, the addition of pemphigus vulgaris serum to cultured keratinocytes affects desmosome structure by causing the retraction of the tonofilaments that normally attach to desmosomal plaques.[13]

Similarly, in lesions of pemphigus foliaceus, electron microscopy was reported to show abnormalities in desmosome structure in early acantholysis.[14] The earliest of these changes seemed to be retraction of tonofilaments from the desmosome-dense plaque. Later, there was a decrease or absence of desmosomes. These electron microscopic studies are difficult to interpret regarding the time course of events, but they all indicate that, at least in some stage of acantholysis, desmosomes are destroyed.

Immunopathology

IMMUNOFLUORESCENCE The hallmark of pemphigus is the finding of IgG autoantibodies against the cell surface of keratinocytes. These autoantibodies were first discovered in patients' sera by indirect immunofluorescence and soon thereafter were discovered by direct immunofluorescence of patients' skin.[15] Essentially all patients with active pemphigus vulgaris or pemphigus foliaceus have a positive finding on a direct immunofluorescence test for IgG on the cell surface of keratinocytes in perilesional skin (Fig. 59-1A).[16] The diagnosis of pemphigus should be seriously questioned if the test result of direct immunofluorescence is negative. Depending on the substrate used for indirect immunofluorescence, more than 80 percent of patients with pemphigus have circulating antiepithelial cell surface IgG (Fig. 59-1B).[17] Patients with early localized disease and those in remission are most likely to have negative findings on an indirect immunofluorescence test.

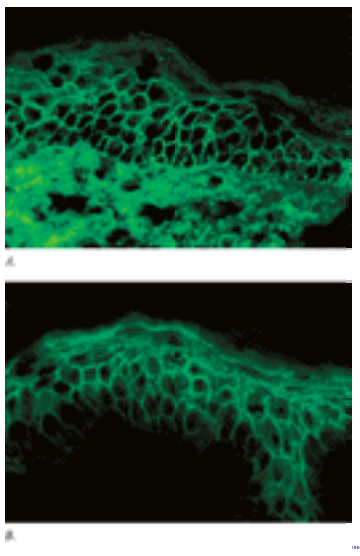

FIGURE 59-1 Immunofluorescence in pemphigus. *A*. Direct immunofluorescence for IgG of perilesional skin from a patient with pemphigus vulgaris. Note cell surface staining throughout the epidermis. *B*. Indirect immunofluorescence with the serum from a patient with pemphigus foliaceus on normal human skin. Note IgG on the cell surface throughout the epidermis.

Patients with pemphigus vulgaris and those with pemphigus foliaceus display similar direct and indirect immunofluorescence findings with IgG on the cell surface of epidermal cells throughout the epidermis. Therefore, it is not possible to differentiate the two diseases by the pattern of immunofluorescence. The substrate used to detect pemphigus antibody binding in indirect immunofluorescence greatly influences the sensitivity of the test, however. In general, monkey esophagus is more sensitive for detecting pemphigus vulgaris antibodies, and guinea pig esophagus is a superior substrate for detecting pemphigus foliaceus antibodies. [17] There is a positive, but imperfect, correlation between the titer of circulating anti–cell surface antibody and the disease activity in pemphigus vulgaris and in pemphigus foliaceus. [18] Although this correlation may hold in general, and although patients in remission often show serologic remission with negative direct and indirect immunofluorescence findings, [19], [20] disease activity in individual patients does not necessarily correlate with antibody titer. Therefore, in the day-to-day management of these patients, following disease activity is much more important than following antibody titer. Recently, antigen-specific enzyme-linked immunosorbent assays have been shown to be more sensitive and specific (e.g., they can differentiate pemphigus vulgaris from pemphigus foliaceus) than immunofluorescence, and their titer correlates much better than that of indirect immunofluorescence with disease activity. [21], [22] Pemphigus erythematosus is a localized form of pemphigus foliaceus with a characteristic direct immunofluorescence finding of immunoreactants, usually IgG and C3, at the basement membrane zone of erythematous facial skin. These immunoreactants are in addition to the epidermal cell surface IgG. [23]
PEMPHIGUS ANTIGENS Immunologic evidence and molecular cloning have demonstrated that pemphigus antigens are desmogleins, transmembrane glycoproteins of desmosomes (organelles important in cell-to-cell adhesion). Immunoelectron microscopy has localized both pemphigus vulgaris and pemphigus foliaceus antigens to the cell surface of keratinocytes in desmosomal junctions. [24], [25] and [26] Characterization of pemphigus antigens at a molecular level has confirmed that they are molecules in desmosomes. Immunoprecipitation and immunoblotting studies with extracts from cultured keratinocytes or epidermis have demonstrated that pemphigus foliaceus antigen (as well as the fogo selvagem antigen) is desmoglein 1, a 160-kDa transmembrane glycoprotein of desmosomes. [27], [28] and [29] Molecular cloning of the cDNA encoding pemphigus vulgaris antigen identified it as desmoglein 3, another desmoglein isoform encoded by a separate gene. [30] All patients with pemphigus vulgaris have anti–desmoglein 3 antibodies, and some of these patients also have anti–desmoglein 1 antibodies. [21], [31] Patients with pemphigus vulgaris that affects predominantly mucous membranes tend to have only anti–desmoglein 3 antibodies, while those with mucocutaneous disease usually have both anti–desmoglein 3 and anti–desmoglein 1 antibodies. [32], [33] and [34] The dual antibody status of some patients with pemphigus vulgaris is in contrast to the single antibody status of pemphigus foliaceus patients, who have antibodies against only desmoglein 1. Desmogleins 1 and 3 are closely related members of the cadherin supergene family. The original members of this family (e.g., E-cadherin) have been shown to be transmembrane, calcium-dependent, homophilic cell adhesion molecules. Presumably, the desmogleins fulfill similar functions in desmosomes. Pemphigus foliaceus and pemphigus vulgaris sera bind calcium-sensitive, conformational epitopes on desmogleins 1 and 3, respectively, suggesting that they might interfere with a calcium-sensitive adhesion function. [35], [36] Although other cell surface molecules, such as acetylcholine receptors, may modulate adhesion, their direct involvement in the pathophysiology of pemphigus is controversial. [37], [38] and [39]

Pathophysiology of Acantholysis

Pemphigus autoantibodies both from patients with pemphigus vulgaris and from those with pemphigus foliaceus are pathogenic. The occurrence of neonatal pemphigus vulgaris demonstrates that maternal IgG can cross the placenta and cause disease. [40] However, neonatal pemphigus foliaceus is very rare. [41]

Essentially, neonatal pemphigus vulgaris results from the passive transfer of IgG to the fetus. Similar experimental passive transfer studies show that pemphigus vulgaris and pemphigus foliaceus IgG cause acantholysis at the suprabasilar and granular layers of the epidermis, respectively, when added to skin in organ culture. [42], [43] Antibody-induced acantholysis in this system occurs without the participation of complement or inflammatory cells.

Further compelling evidence of autoantibody-mediated pathology in pemphigus comes from studies of the passive transfer of pemphigus vulgaris and pemphigus foliaceus IgG to neonatal mice. These mice develop blisters and erosions that clinically and histologically mimic the corresponding type of pemphigus. [44], [45] Complement fixation is not necessary to produce disease, and, consistent with this observation, even monovalent Fab' immunoglobulin fragments are pathogenic in these mice. [45], [46]

Additional studies have shown that the pathology-causing autoantibodies in pemphigus are those directed against desmogleins 1 and 3. IgG that is affinity-purified from pemphigus vulgaris sera on the extracellular domain of desmoglein 3 can cause suprabasilar acantholysis, the typical histologic finding of pemphigus vulgaris lesions, when injected into neonatal mice. [47], [48] Furthermore, the extracellular domain of desmoglein 3 can adsorb out of pemphigus vulgaris sera antibodies pathogenic in neonatal mice. [49] Similarly, the extracellular domain of desmoglein 1 can adsorb out all pathogenic antibodies from pemphigus foliaceus sera, and antibodies affinity-purified on desmoglein 1 are pathogenic. [50] Finally, an active animal model of pemphigus vulgaris has been established by immunizing mice that are not tolerant of desmoglein 3 (i.e., mice whose desmoglein 3 gene has been deleted) in order to generate an immune response against desmoglein 3. [51] After the passive transfer of lymphocytes from these immunized mice to normal mice, the latter develop clinically and histologically typical lesions of pemphigus vulgaris and have anti–desmoglein 3 antibodies in their skin and sera.

These data strongly suggest that pemphigus vulgaris and pemphigus foliaceus autoantibodies against desmogleins 3 and 1, respectively, cause the blister formation in these diseases. Recent data indicate that they do so by interfering with a cell-to-cell adhesion function of these desmogleins or with their role in desmosome assembly. If indeed the pathophysiology of pemphigus arises from such antibodies directly inhibiting the function of desmoglein, interfering with the function of the desmoglein in some other way should result in a process that mimics pemphigus. This hypothesis was recently tested by genetically engineering a mouse with a targeted deletion of the desmoglein 3 gene. [52] The phenotype of this mouse closely resembled that of patients with pemphigus vulgaris, with suprabasilar blisters developing in the oral mucosa and skin. These data, then, are consistent with the idea that autoantibodies directly cause a loss of adhesion of keratinocytes.

Another line of evidence that inactivation of desmogleins causes the blistering of pemphigus comes from studies of bullous impetigo and staphylococcal scalded-skin syndrome, which are caused by exfoliative toxin released by *Staphylococcus aureus*. Desmoglein 1 is the specific receptor for exfoliative toxin. The enzyme proteolytically cleaves desmoglein 1, resulting in blisters identical to those seen in pemphigus foliaceus. [53] Thus, inactivation of desmoglein 1 can cause blisters identical to those seen in pemphigus foliaceus, which suggests that the anti–desmoglein 1 antibodies in pemphigus foliaceus patients also inactivate desmoglein 1.

Although the anti-desmoglein antibodies in pemphigus may directly inactivate desmogleins in desmosomes, it is also possible that they interfere with the incorporation of the desmoglein into desmosomes. In this way, they may ultimately deplete the desmosome of their particular desmoglein target. [54]

If depletion or inactivation of desmoglein isoforms results in blistering, then why do blisters in pemphigus vulgaris and pemphigus foliaceus have specific tissue localizations that do not necessarily correlate with the sites at which the antibodies bind by immunofluorescence? In pemphigus foliaceus, for example, the anti–desmoglein 1 antibodies bind throughout the epidermis and mucous membranes, [55] yet blisters occur only in the superficial epidermis. This apparent paradox has been explained by desmoglein compensation, as outlined in Figure 59-2. The concept of desmoglein compensation originates in the assumptions that autoantibodies against one desmoglein isoform inactivate only that isoform and that another isoform co-expressed in the same area can compensate in adhesion. [56], [57] Desmoglein compensation also explains why neonatal pemphigus foliaceus is so unusual, even though the anti–desmoglein 1 antibodies cross the placenta; in neonatal skin, as opposed to adult skin, desmoglein 3 is co-expressed with desmoglein 1 in the superficial epidermis. [58] The validity of desmoglein compensation has been proven by the demonstration that transgenic mice with forced expression of desmoglein 3 in the superficial epidermis are protected against blistering by passive transfer of pemphigus foliaceus IgG. [58]

FIGURE 59-2 Desmoglein compensation. Triangles represent the distribution of desmoglein (Dsg) 1 and 3 in skin and mucous membranes. Anti-Dsg1 antibodies in pemphigus foliaceus cause acantholysis only in the superficial epidermis of skin. In the deep epidermis and in mucous membranes, Dsg3 compensates for antibody-induced loss of function of Dsg1. In early pemphigus vulgaris, antibodies are present only against Dsg3, which cause blisters only in the deep mucous membrane where Dsg3 is present without compensatory Dsg1. However, in mucocutaneous pemphigus, antibodies against both Dsg1 and Dsg3 are present, and blisters form in both mucous membrane and skin. The blister is deep probably because antibodies diffuse from the dermis and interfere first with the function of desmosomes at the base of the epidermis.

Abnormal Immune Response and Immune Response Genes

Compared to a matched population, patients with pemphigus vulgaris have a markedly increased frequency of certain class II major histocompatibility complex (MHC) antigens. Among Ashkenazi Jews with pemphigus vulgaris, the serologically defined HLA-DR4 haplotype is predominant, whereas in other ethnic groups with pemphigus vulgaris, the DQ1 allele is more common. [59] However, the association with disease susceptibility becomes even more striking in an

analysis of these MHC alleles at a genetic level to determine the amino acid sequence of the cell surface molecules that they encode. Patients with the DR4 serotype almost all have an unusual allele called DRB1*0402, and patients with the DQ1 serotype almost all have a rare allele called DQB1*0503. The protein chains encoded by these alleles vary from those encoded by the alleles found in HLA-DR4 and DQ1 controls without disease in only a few amino acids.

These MHC alleles encode cell surface molecules that are necessary for antigen presentation to the immune system; therefore, it is hypothesized that the disease-associated MHC class II molecules allow presentation of desmoglein 3 peptides to T cells. Consistent with this hypothesis is the finding that certain peptides from desmoglein 3, predicted to fit into the DRB1*0402 peptide-binding pocket, were able to stimulate T cells from patients. [60] Furthermore, in this binding pocket, if one of the negatively charged amino acids specific for the DRB1*0402 subtype of DR4 was changed to a positively charged amino acid (characteristically present in other subtypes of DR4) by site-directed mutagenesis, then the desmoglein 3 peptide could no longer be effectively presented to the T cells. Other studies have confirmed that the immune response in pemphigus is restricted to certain desmoglein peptides and immune response genes coding for antigen presentation molecules. [61], [62] and [63] These studies suggest that certain populations are susceptible to pemphigus vulgaris because of the genetics of their immune response genes.

CLINICAL MANIFESTATIONS

Pemphigus Vulgaris

SKIN The skin lesions in pemphigus vulgaris are rarely pruritic, but are often painful. [1] The primary lesion of pemphigus vulgaris is a flaccid blister, which may occur anywhere on the skin surface (Fig. 59-3A). Usually, the blister arises on normal-appearing skin, but it may develop on erythematous skin. Even new blisters are usually flaccid or become so within a short time. Because these blisters are fragile, intact blisters may be sparse. The most common skin lesions that occur in these patients are erosions, often painful, subsequent to broken blisters. These erosions are often quite large, as they have a tendency to spread at their periphery (Fig. 59-4A). The clinician can elicit this characteristic finding in pemphigus patients with active blistering by applying lateral pressure to normal-appearing skin at the periphery of active lesions. The result is a shearing away of the epidermis, a phenomenon known as the Nikolsky sign (Fig. 59-4B). This sign is not specific for pemphigus vulgaris or pemphigus foliaceus, but is evident in other active blistering diseases, such as bullous pemphigoid and erythema multiforme.

FIGURE 59-3 Pemphigus vulgaris. *A*. Flaccid blisters. (*Courtesy of Lawrence Lieblich, MD.*) *B*. Oral erosions.

FIGURE 59-4 Pemphigus vulgaris. *A*. Extensive erosions due to blistering. Almost the entire back is denuded. Note intact, flaccid blisters at the lower border of eroded lesions. *B*. The bulla has been extended following pressure with the finger (Nikolsky's sign).

In certain patients, erosions have a tendency to develop excessive granulation tissue and crusting (Fig. 59-5); that is, these patients display more vegetating lesions. This type of lesion tends to occur more frequently in intertriginous areas, in the scalp, or on the face (Fig. 59-5A). In pemphigus vegetans of Hallopeau, vegetating lesions are present from the outset of disease (Fig. 59-5B). Before the advent of effective therapy for pemphigus, the prognosis for these patients was not as grave as that for patients with the more usual type of pemphigus vulgaris. In other patients (e.g., those with pemphigus vegetans of Neumann), ordinary pemphigus vulgaris erosions may tend to develop vegetations. The vegetating type of response may also appear in certain lesions that tend to be resistant to therapy and remain for long periods of time in one place. Thus, vegetating lesions seem to be one reactive pattern of the skin to the autoimmune

insult of pemphigus vulgaris, with certain areas of the skin showing more of a tendency to form vegetations.

FIGURE 59-5 *A*. Crusted, vegetating lesions in pemphigus vulgaris. *B*. Extensive, vegetating granulomatous lesions in pemphigus vegetans.

MUCOUS MEMBRANES In the majority of patients, painful mucous membrane erosions are the presenting sign of pemphigus vulgaris and may be the only sign for an average of 5 months before skin lesions develop. [3] The mucous membranes most often affected are those of the oral cavity, which is involved in almost all patients with pemphigus vulgaris and is often the only area involved (Fig. 59-3B). Intact blisters are rare, probably because they are fragile and break easily. Scattered and often extensive erosions may appear on any part of the oral cavity, although they perhaps occur most frequently on the buccal mucosa. These erosions may spread to involve the pharynx and larynx with subsequent hoarseness. Often, these erosions are so uncomfortable that the patient is unable to eat or drink adequately. Mucous membranes in other areas may also be involved with painful erosions; these include conjunctiva, anus, penis, vagina, and labia. [64] Even the esophagus has been reported to be involved in unusual cases. [65]

Pemphigus Foliaceus

SKIN The characteristic clinical lesions of pemphigus foliaceus are scaly, crusted erosions, often on an erythematous base. [1], [66] In more localized and early disease, these lesions are usually well demarcated and scattered in a seborrheic distribution, including the face, scalp, and upper trunk (Fig. 59-6A). The primary lesions of small flaccid blisters are often inconspicuous and difficult to find. Disease may stay localized for years, or it may rapidly progress to sometimes generalized involvement, resulting in an exfoliative erythroderma (Fig. 59-6B). Exposure to sun and/or heat may exacerbate disease activity. Patients with pemphigus foliaceus often complain of pain and burning in the skin lesions. In contrast to patients with pemphigus vulgaris, those with pemphigus foliaceus only very rarely, if ever, have mucous membrane involvement, even with widespread disease.

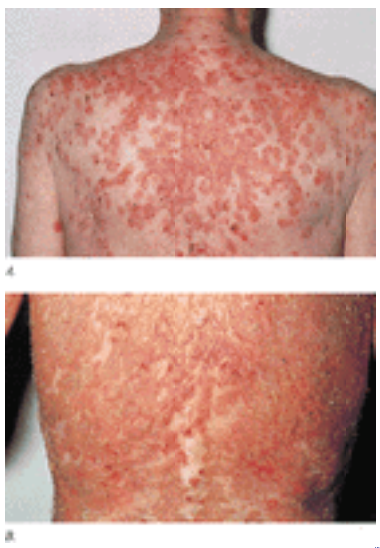

FIGURE 59-6 Pemphigus foliaceus. *A*. Scaly, crusted lesions on upper back. *B*. Exfoliative erythroderma due to confluent lesions.

The colloquial term for Brazilian endemic pemphigus, *fogo selvagem* (Portuguese for “wild fire”), takes into account many of the clinical aspects of this disease: the burning feeling of the skin, the exacerbation of disease by the sun, and the crusted lesions that make the patients appear as if they had been burned.

PEMPHIGUS ERYTHEMATOSUS Also known as Senear-Usher syndrome, pemphigus erythematosus is simply the localized form of pemphigus foliaceus. Typical scaly and crusted lesions of pemphigus foliaceus occur across the malar area of the face and in other seborrheic areas. Pemphigus erythematosus may remain localized for years, or it may evolve into more generalized pemphigus foliaceus. If there is a unique aspect of pemphigus erythematosus, it is the immunopathology noted earlier. In addition, many patients with pemphigus erythematosus show serologic findings suggestive of systemic lupus erythematosus, especially the presence of antinuclear antibodies, although few patients have been reported to actually have the two diseases concurrently. [67]

Neonatal Pemphigus

Infants born to mothers with pemphigus vulgaris may display clinical, histologic, and immunopathologic signs of pemphigus. [40] The degree of involvement varies from none to severe enough to result in a stillbirth. If the infant survives, disease tends to remit as maternal antibody is catabolized. Mothers with pemphigus foliaceus may also transmit their autoantibodies to the fetus, but, as discussed earlier, neonatal pemphigus foliaceus occurs only rarely. [68], [69] Neonatal

pemphigus should be distinguished from pemphigus vulgaris and pemphigus foliaceus that occur in childhood, which are similar to the autoimmune diseases seen in adults. [70]

Drug-Induced Pemphigus

Although there are sporadic case reports of pemphigus associated with the use of several different drugs, the association with penicillamine, and perhaps captopril, is the most significant. [71] The prevalence of pemphigus in penicillamine users is estimated to be about 7 percent. Pemphigus foliaceus (including pemphigus erythematosus) is more common than pemphigus vulgaris in these penicillamine-treated patients, although either may occur. The findings of direct and indirect immunofluorescence are positive in most of these patients. Three patients with drug-induced pemphigus foliaceus and one with drug-induced pemphigus vulgaris have been shown to have autoantibodies to the same molecules involved in sporadic pemphigus, namely, desmoglein 1 and desmoglein 3, respectively. [72] Therefore, by immunofluorescence and immunochemical determinations, these patients with drug-induced pemphigus resemble those with sporadic disease.

Both penicillamine and captopril contain sulfhydryl groups that may interact with the sulfhydryl groups in desmoglein 1 and/or 3, thereby causing pemphigus either by directly interfering with these adhesion molecules or, more likely, by modifying them so that they become more antigenic. The use of these drugs may also lead to a more generalized dysregulation of the immune response, allowing production of other autoantibodies such as those resulting in myasthenia gravis. Most, but not all, patients with drug-induced pemphigus go into remission after they stop taking the offending drug.

Associated Diseases

Myasthenia gravis and/or thymoma have been associated with pemphigus vulgaris and pemphigus foliaceus. [73] Approximately one-half of associated pemphigus cases are vulgaris; one-half, foliaceus or erythematosus. Most of these data, however, were reported before the recognition of paraneoplastic pemphigus as a distinct entity. Therefore, although thymoma may clearly be associated with pemphigus vulgaris and pemphigus foliaceus, it may also be associated with paraneoplastic pemphigus (see Chapter 60). The course of myasthenia gravis and the course of pemphigus seem independent of each other. Likewise, the thymic abnormality may either precede or follow the onset of pemphigus. Thymic abnormalities include benign or malignant thymoma and thymic hyperplasia. Irradiation of the thymus or thymectomy, while clearly beneficial for myasthenia gravis, may not improve the pemphigus disease activity. Although this association is reported in at least 30 cases, the finding of thymoma or myasthenia gravis in a patient with pemphigus vulgaris or pemphigus foliaceus is still unusual.

Although very uncommon, pemphigus vulgaris or pemphigus foliaceus has been associated with bullous pemphigoid in the same patient. [74] Finally, pemphigus vulgaris has rarely evolved into pemphigus foliaceus, and vice versa, as determined by clinical, histologic and immunochemical criteria. [75]

PATHOLOGY

Pemphigus Vulgaris

The characteristic histopathologic finding in pemphigus vulgaris is a suprabasilar blister with acantholysis (Fig. 59-7). Just above the basal cell layer, epidermal cells lose their normal cell-to-cell contacts and form a blister. Often, a few rounded up (acantholytic) keratinocytes are in the blister cavity. The basal cells stay attached to the basement membrane, but may lose the contact with their neighbors; as a result, they may appear to be a “row of tombstones.” Usually, the upper epidermis (from one or two cell layers above the basal cells) remains intact, as these cells maintain their cell adhesion. Pemphigus vegetans shows not only suprabasilar acantholysis, but also papillomatosis of the dermal papillae and downward growth of epidermal stands into the dermis, with hyperkeratosis and scale-crust formation. In addition, pemphigus vegetans lesions may show intraepidermal abscesses composed of eosinophils. [1] Early pemphigus vulgaris lesions may show eosinophilic spongiosis. [76]

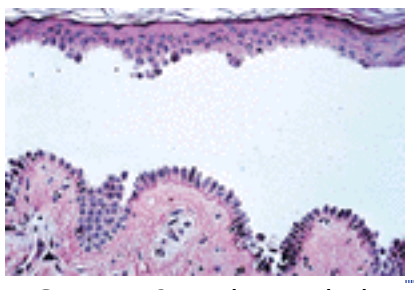

FIGURE 59-7 Histopathology of pemphigus vulgaris. Suprabasilar acantholysis. The row of tombstones. × 250.

Pemphigus Foliaceus

The histopathology of early blisters in pemphigus foliaceus patients demonstrates acantholysis (loss of cell-to-cell contact) just below the stratum corneum and in the granular layer (Fig. 59-8A). The stratum corneum is often lost from the surface of these lesions. The deeper epidermis, below the granular layer, remains intact. Another frequent finding is subcorneal pustules, with neutrophils and acantholytic epidermal cells in the blister cavity (Fig. 59-8B). These histologic findings are indistinguishable from those seen in bullous impetigo. Pemphigus erythematosus has histologic findings identical to those of pemphigus foliaceus. As in pemphigus vulgaris lesions, very early pemphigus foliaceus lesions may

show eosinophilic spongiosis. [76]

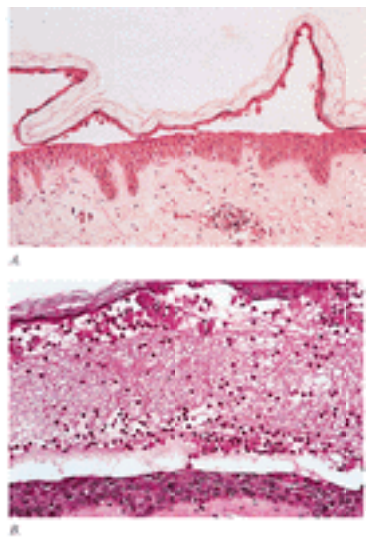

FIGURE 59-8 Histopathology of pemphigus foliaceus. *A*. Acantholysis in the granular layer. × 250. *B*. Subcorneal pustule with acantholysis. × 250.

TREATMENT AND PROGNOSIS

Before the advent of glucocorticoid therapy, pemphigus vulgaris was almost invariably fatal, and pemphigus foliaceus was fatal in about 60 percent of patients. Pemphigus foliaceus was almost always fatal in elderly patients with concurrent medical problems. [77]

The systemic administration of glucocorticoids and the use of immunosuppressive therapy have dramatically improved the prognosis for patients with pemphigus; however, pemphigus is still a disease associated with a significant morbidity and mortality. [78], [79] Infection is often the cause of death, and by causing the immunosuppression necessary in the treatment of active disease, therapy is frequently a contributing factor. [80] With glucocorticoid and immunosuppressive therapy, the mortality (from disease or therapy) of pemphigus vulgaris patients followed from 4 to 10 years is about 10 percent or less whereas that of pemphigus foliaceus is probably even less.

It is generally agreed that pemphigus vulgaris, even if initially limited in extent, should be treated at its onset, because it will ultimately generalize, and the prognosis without therapy is very poor. In addition, it is probably easier to control early disease than widespread disease, and mortality may be higher if therapy is delayed. [81]

Because pemphigus foliaceus may be localized for many years, and the prognosis without systemic therapy may be good, patients with this type of pemphigus do not necessarily require treatment with systemic therapy; the use of topical glucocorticoids may suffice. When the disease is active and widespread, however, the therapy for pemphigus foliaceus is, in general, similar to that for pemphigus vulgaris.

The systemic administration of glucocorticoids, usually prednisone, is the mainstay of therapy for pemphigus. At one time, primarily before adjuvant immunosuppressive therapy was available, very high initial doses of prednisone were recommended for therapy. Now, however, few authorities recommend such high doses, and many feel that intermediate or low doses, especially if used in combination with immunosuppressive therapy and, if necessary, with tolerance of some residual disease activity, result in fewer complications and decreased mortality. [6], [80], [82], [83] Once disease activity is controlled, tapering prednisone to an alternate-day dosage will decrease the incidence of glucocorticoid side effects.

Although there are no controlled studies, most authors feel that immunosuppressive agents, such as mycophenolate mofetil, azathioprine, and cyclophosphamide, have a steroid-sparing effect, decrease the incidence of side effects of therapy, and may increase the numbers of remissions. [20], [77], [78], [83], [84] Treatment regimens often begin with both an immunosuppressive agent and prednisone in moderate to intermediate doses, depending on disease activity, although some authors suggest first determining if the disease responds to a course of glucocorticoids alone. [20], [79], [83] In any case, if there are contraindications to glucocorticoid use, if the glucocorticoids do not control the disease, or if the dosage low enough to minimize the risk of steroid complications is not effective, the patient should receive adjuvant therapy, usually consisting of immunosuppressive agents.

Results obtained by using prednisone and immunosuppressive agents to treat patients with pemphigus vulgaris, although not controlled, have been impressive. For example, in a series of 29 patients treated with prednisone and azathioprine, about 50 percent went into clinical and serologic remission and continued off therapy for a mean follow-up of 4 years. [20] Many of these patients were considered cured. Only 1 patient in this study died because of complications of therapy. The disease activity of most of the other patients was well controlled.

Mycophenolate mofetil, in particular, has been shown to have a rapid effect in lowering pemphigus antibody titers and to decrease disease activity, even in patients whose disease is unresponsive to azathioprine. [84] As it probably has fewer adverse reactions than azathioprine, it may ultimately replace azathioprine as a first-line agent in treating these patients.

Early localized pemphigus vulgaris may be treated with relatively low-dose prednisone (e.g., 40 mg) either given initially on alternate days or rapidly tapered to alternate-day dosage, often with an immunosuppressive agent. [85] The decision to use immunosuppressive agents in young patients must take into account the potential increased incidence of

malignancies that might be associated with the use of these drugs, as well as the risks of infertility (especially associated with cyclophosphamide) and teratogenicity. In some patients, especially those who are elderly with limited disease or those in whom glucocorticoids are contraindicated, immunosuppressive agents alone may be used. [86] Because patients may die from complications of therapy, it is important to monitor all patients closely for potential side effects, such as infection; diabetes; leukopenia; thrombocytopenia; anemia; gastrointestinal ulcer disease; and bleeding, liver and renal function abnormalities, high blood pressure, electrolyte disturbances, and osteoporosis.

There are additional, innovative therapies that are usually used when more standard treatment is not effective. For example, the intravenous, pulse administration of methylprednisolone, 250 to 1000 mg given over about 3 h every 24 h for 4 to 5 consecutive days, can result in long-term remissions and decrease the total dose of glucocorticoids necessary to control disease. [87] Although the purpose of this therapy is to decrease the incidence of complications of long-term steroid use, it can result in all the usual glucocorticoid complications, as well as cardiac arrhythmias and anaphylaxis, and its use is controversial. [88] Intravenous pulse therapy with cyclophosphamide, with or without pulse therapy with glucocorticoids, has also been reported to result in remissions of pemphigus vulgaris. [89] Pulses of cyclophosphamide, given intravenously, are thought to allow a decrease in the daily oral dosage and thereby cut down on the side effects.

Plasmapheresis is another therapy for severe pemphigus, especially if the disease is unresponsive to a combination of prednisone and immunosuppressive agents. Although one controlled study found it to be ineffective, [90] other studies have found that it both reduces serum levels of pemphigus autoantibodies and controls disease activity. [91] For maximum effectiveness, it is probably necessary to perform plasmapheresis on patients taking immunosuppressive agents to prevent the antibody-rebound phenomenon that can follow the removal of IgG. Another creative approach to therapy has been to synchronize plasmapheresis and pulse therapy with cyclophosphamide to cause maximum cytotoxicity when pathogenic B cell clones might be proliferating as a result of the loss of the negative feedback of IgG on antibody production. [92] However, whether this approach is any better than simply using plasmapheresis in patients on continual immunosuppressive therapy is not known.

Another method of suppressing autoantibody production is the intravenous use of gamma globulin. It is probably ineffective in pemphigus when used alone, but may be useful as adjuvant therapy in those whose condition is failing to respond to more conventional therapy. [93]

Other potential therapies for pemphigus, used less frequently than those that have been discussed, include immunoablative therapy without stem cell rescue; the administration of cyclosporine, gold, antimalarials, or dapsone; and extracorporeal photochemotherapy. [78], [94]

All in all, there has been a tremendous advance in the armamentarium of therapies for pemphigus since the time before the development of glucocorticoids when pemphigus vulgaris was a fatal disease. Thanks to these advances, the “row of tombstones” seen in the pathology of pemphigus vulgaris no longer alludes to its prognosis.

REFERENCES

1. Lever WF: *Pemphigus and Pemphigoid.* Springfield, IL, Charles C Thomas, 1965

2. Beutner EH, Jordon RE: Demonstration of skin antibodies in sera of pemphigus vulgaris patients by indirect immunofluorescent staining. *Proc Soc Exp Biol Med* **117**, 505, 1964

3. Krain LS: Pemphigus: Epidemiologic and survival characteristics of 59 patients, 1955–1973. *Arch Dermatol* **110**:862, 1974

4. Pisanti S et al: Pemphigus vulgaris: Incidence in Jews of different ethnic groups, according to age, sex, and initial lesion. *Oral Surg Oral Med Oral Pathol* **38**:382, 1974

5. Rosenberg FR et al: Pemphigus: A 20-year review of 107 patients treated with corticosteroids. *Arch Dermatol* **112**:962, 1976

6. Hietanen J, Salo OP: Pemphigus: An epidemiological study of patients treated in Finnish hospitals between 1969 and 1978. *Acta Derm Venereol (Stockh)* **62**:491, 1982

7. Bastuji-Garin S et al: Comparative epidemiology of pemphigus in Tunisia and France: Unusual incidence of pemphigus foliaceus in young Tunisian women. *J Invest Dermatol* **104**:302, 1995

8. Diaz LA et al: Endemic pemphigus foliaceus (fogo selvagem): II. Current and historical epidemiological aspects. *J Invest Dermatol* **92**:4, 1989

9. Lombardi C et al: Environmental risk factors in endemic pemphigus foliaceus (fogo selvagem). The Cooperative Group on Fogo Selvagem Research. *J Invest Dermatol* **98**:847, 1992

10. Warren SJ et al: The prevalence of antibodies against desmoglein 1 in endemic pemphigus foliaceus in Brazil. The Cooperative Group on Fogo Selvagem Research. [Comments]. *N Engl J Med* **343**:23, 2000

11. Hashimoto K, Lever WF: An electron microscopic study on pemphigus vulgaris of the mouth and the skin with special reference to the intercellular cement. *J Invest Dermatol* **48**:540, 1967

12. Grando SA et al: Ultrastructural study of clinically uninvolved skin of patients with pemphigus vulgaris. *Clin Exp Dermatol* **16**:359, 1991

13. Caldelari R et al: A central role for the armadillo protein plakoglobin in the autoimmune disease pemphigus vulgaris. *J Cell Biol* **153**:823, 2001

14. Wilgram GF et al: An electron microscopic study of acantholysis and dyskeratosis in pemphigus foliaceus. *J Invest Dermatol* **43**:287, 1964

15. Beutner EH et al: Autoantibodies in pemphigus vulgaris. *JAMA* **192**:682, 1965

16. Judd KP, Lever WF: Correlation of antibodies in skin and serum with disease severity in pemphigus. *Arch Dermatol* **115**:428, 1979

17. Harman KE et al: The use of two substrates to improve the sensitivity of indirect immunofluorescence in the diagnosis of pemphigus. *Br J Dermatol* **142**:1135, 2000

18. Krasny SA et al: Specificity and sensitivity of indirect and direct immunofluorescent findings in the diagnosis of pemphigus, in *Immunopathology of the Skin,* 3rd ed, edited by EH Beutner et al. New York, Wiley, 1987, p 207

19. O'Loughlin S et al: Fate of pemphigus antibody following successful therapy: Preliminary evaluation of pemphigus antibody determinations to regulate therapy. *Arch Dermatol* **114**:1769, 1978

20. Aberer W et al: Azathioprine in the treatment of pemphigus vulgaris: A long-term follow-up. *J Am Acad Dermatol* **16**:527, 1987

21. Ishii K et al: Characterization of autoantibodies in pemphigus using antigen-specific enzyme-linked immunosorbent assays with baculovirus-expressed recombinant desmogleins. *J Immunol* **159**:2010, 1997

22. Amagai M et al: Usefulness of enzyme-linked immunosorbent assay using recombinant desmogleins 1 and 3 for serodiagnosis of pemphigus. *Br J Dermatol* **140**:351, 1999

23. Chorzelski T et al: Immunopathological investigations in the Senear-Usher syndrome (coexistence of pemphigus and lupus erythematosus). *Br J Dermatol* **80**:211, 1968

24. Rappersberger K et al: Immunomorphological and biochemical identification of the pemphigus foliaceus autoantigen within desmosomes. *J Invest Dermatol* **99**:323, 1992

25. Karpati S et al: Pemphigus vulgaris antigen, a desmoglein type of cadherin, is localized within keratinocyte desmosomes. *J Cell Biol* **122**:409, 1993

26. Shimizu H et al: Pemphigus vulgaris and pemphigus foliaceus sera show an inversely graded binding pattern to extracellular regions of desmosomes in different layers of human epidermis. *J Invest Dermatol* **105**:153, 1995

27. Koulu L et al: Human autoantibodies against a desmosomal core protein in pemphigus foliaceus. *J Exp Med* **160**:1509, 1984

28. Stanley JR et al: A monoclonal antibody to the desmosomal glycoprotein desmoglein 1 binds the same polypeptide as human autoantibodies in pemphigus foliaceus. *J Immunol* **136**:1227, 1986

29. Stanley JR et al: Antigenic specificity of fogo selvagem autoantibodies is similar to North American pemphigus foliaceus and distinct from pemphigus vulgaris autoantibodies. *J Invest Dermatol* **87**:197, 1986

30. Amagai M et al: Autoantibodies against a novel epithelial cadherin in pemphigus vulgaris, a disease of cell adhesion. *Cell* **67**:869, 1991

31. Eyre RW, Stanley JR: Identification of pemphigus vulgaris antigen extracted from normal human epidermis and comparison with pemphigus foliaceus antigen. *J Clin Invest* **81**:807, 1988

32. Ding X et al: Mucosal and mucocutaneous (generalized) pemphigus vulgaris show distinct autoantibody profiles. *J Invest Dermatol* **109**:592, 1997

33. Amagai M et al: The clinical phenotype of pemphigus is defined by the anti-desmoglein autoantibody profile. *J Am Acad Dermatol* **40**:170, 1999

34. Miyagawa S et al: Late development of antidesmoglein 1 antibodies in pemphigus vulgaris: correlation with disease progression. *Br J Dermatol* **141**:1084, 1999

35. Eyre RW, Stanley JR: Human autoantibodies against a desmosomal protein complex with a calcium-sensitive epitope are characteristic of pemphigus foliaceus patients. *J Exp Med* **165**:1719, 1987

36. Amagai M et al: Conformational epitopes of pemphigus antigens (Dsg1 and Dsg3) are calcium dependent and glycosylation independent. *J Invest Dermatol* **105**:243, 1995

37. Stanley JR et al: Pemphigus: Is there another half of the story? *J Invest Dermatol* **116**:489, 2001

38. Grando SA et al: Pemphigus: An unfolding story. *J Invest Dermatol* **117**:990, 2001

39. Stanley JR et al: Pemphigus: An unfolding story. [Reply]. *J Invest Dermatol* **117**:994

40. Chowdhury MMU, Natarajan S: Neonatal pemphigus vulgaris associated with mild oral pemphigus vulgaris in the mother during pregnancy. *Br J Dermatol* **139:**500, 1998

41. Rocha-Alvarez R et al: Pregnant women with endemic pemphigus foliaceus (fogo selvagem) give birth to disease-free babies. *J Invest Dermatol* **99**:78, 1992

42. Schiltz JR, Michel B: Production of epidermal acantholysis in normal human skin in vitro by the IgG fraction from pemphigus serum. *J Invest Dermatol* **67**:254, 1976

43. Hashimoto K et al: Anti-cell surface pemphigus autoantibody stimulates plasminogen activator activity of human epidermal cells. *J Exp Med* **157**:259, 1983

44. Anhalt GJ et al: Induction of pemphigus in neonatal mice by passive transfer of IgG from patients with the disease. *N Engl J Med* **306**:1189, 1982

45. Rock B et al: Monovalent Fab' immunoglobulin fragments from endemic pemphigus foliaceus autoantibodies reproduce the human disease in neonatal Balb/c mice. *J Clin Invest* **85**:296, 1990

46. Anhalt GJ et al: Defining the role of complement in experimental pemphigus vulgaris in mice. *J Immunol* **137**:2835, 1986

47. Amagai M et al: Autoantibodies against the amino-terminal cadherin-like binding domain of pemphigus vulgaris antigen are pathogenic. *J*

Clin Invest **90**:919, 1992

48. Ding X et al: The anti-desmoglein 1 autoantibodies in pemphigus vulgaris sera are pathogenic. *J Invest Dermatol* **112**:739, 1999

49. Amagai M et al: Absorption of pathogenic autoantibodies by the extracellular domain of pemphigus vulgaris antigen (Dsg3) produced by baculovirus. *J Clin Invest* **94**:59, 1994

50. Amagai M et al: Antigen-specific immunoabsorption of pathogenic autoantibodies in pemphigus foliaceus. *J Invest Dermatol* **104**:895, 1995

51. Amagai M et al: Use of autoantigen-knockout mice in developing an active autoimmune disease model for pemphigus. *J Clin Invest* **105**:625, 2000

52. Koch PJ et al: Targeted disruption of the pemphigus vulgaris antigen (desmoglein 3) gene in mice causes loss of keratinocyte cell adhesion with a phenotype similar to pemphigus vulgaris. *J Cell Biol* **137**:1091, 1997

53. Amagai M et al: Toxin in bullous impetigo and staphylococcal scalded-skin syndrome targets desmoglein 1. *Nature Med* **6**:1275, 2000

54. Aoyama Y, Kitajima Y: Pemphigus vulgaris-IgG causes a rapid depletion of desmoglein 3 (Dsg3) from the triton X-100 soluble pools, leading to the formation of Dsg3-depleted desmosomes in a human squamous carcinoma cell line, DJM-1 cells. *J Invest Dermatol* **112**:67, 1999

55. Rivitti EA et al: Pemphigus foliaceus autoantibodies bind both epidermis and squamous mucosal epithelium, but tissue injury is detected only in the epidermis. The Cooperative Group on Fogo Selvagem Research. *J Am Acad Dermatol* **31**:954, 1994

56. Shirakata Y Lack of mucosal involvement in pemphigus foliaceus may be due to low expression of desmoglein 1. *J Invest Dermatol* **110**:76, 1998

57. Mahoney MG et al: Explanation for the clinical and microscopic localization of lesions in pemphigus foliaceus and vulgaris. *J Clin Invest* **103**:461, 1999

58. Wu H et al: Protection of neonates against pemphigus foliaceus by desmoglein 3. *N Engl J Med* **343**:31, 2000

59. Wucherpfennig KW, Strominger JL: Selective binding of self peptides to disease-associated major histocompatibility complex (MHC) molecules: A mechanism for MHC-linked susceptibility to human autoimmune diseases. [Comment]. *J Exp Med* **181**:1597, 1995

60. Wucherpfennig KW et al: Structural basis for major histocompatibility complex (MHC)-linked susceptibility to autoimmunity: Charged residues of a single MHC binding pocket confer selective presentation of self-peptides in pemphigus vulgaris. *Proc Natl Acad Sci USA* **92**:11935, 1995

61. Lin MS et al: Development and characterization of desmoglein-3 specific T cells from patients with pemphigus vulgaris. *J Clin Invest* **99**:31, 1997

62. Hertl M et al: Heterogeneous MHC II restriction pattern of autoreactive desmoglein 3 specific T cell responses in pemphigus vulgaris patients and normals. *J Invest Dermatol* **110**:388, 1998

63. Hertl M et al: Recognition of desmoglein 3 by autoreactive T cells in pemphigus vulgaris patients and normals. *J Invest Dermatol* **110**:62, 1998

64. Hodak E et al: Conjunctival involvement in pemphigus vulgaris: A clinical, histopathological and immunofluorescence study. *Br J Dermatol* **123**:615, 1990

65. Trattner A et al: Esophageal involvement in pemphigus vulgaris: A clinical, histologic, and immunopathologic study. *J Am Acad Dermatol* **24**:223, 1991

66. Perry HO, Brunsting LA: Pemphigus foliaceus. *Arch Dermatol* **91**:10, 1965

67. Amerian ML, Ahmed AR: Pemphigus erythematosus: Senear-Usher syndrome. *Int J Dermatol* **24**:16, 1985

68. Eyre RW, Stanley JR: Maternal pemphigus foliaceus with cell surface antibody bound in neonatal epidermis. *Arch Dermatol* **124**:25, 1988

69. Avalos-Diaz E et al: Transplacental passage of maternal pemphigus foliaceus autoantibodies induces neonatal pemphigus. *J Am Acad Dermatol* **43**:1130, 2000

70. Kanwar AJ et al: Further experience with pemphigus in children. *Pediatr Dermatol* **11**:107, 1996

71. Mutasim DF et al: Drug-induced pemphigus. [Review]. *Dermatol Clin* **11**:463, 1993

72. Korman NJ et al: Drug-induced pemphigus: Autoantibodies directed against the pemphigus antigen complexes are present in penicillamine and captopril-induced pemphigus. *J Invest Dermatol* **96**:273, 1991

73. Patten SF, Dijkstra JW: Associations of pemphigus and autoimmune disease with malignancy or thymoma. [Review]. *Int J Dermatol* **33**:836, 1994

74. Korman NJ et al: Coexistence of pemphigus foliaceus and bullous pemphigoid: Demonstration of autoantibodies that bind to both the pemphigus foliaceus antigen complex and the bullous pemphigoid antigen. *Arch Dermatol* **127**:387, 1991

75. Ishii K et al: Development of pemphigus vulgaris in a patient with pemphigus foliaceus: antidesmoglein antibody profile shift confirmed by enzyme-linked immunosorbent assay. *J Am Acad Dermatol* **42**:859, 2000

76. Emmerson RW, Wilson-Jones E: Eosinophilic spongiosis in pemphigus. *Arch Dermatol* **97**:252, 1968

77. Carson PJ et al: Influence of treatment on the clinical course of pemphigus vulgaris. *J Am Acad Dermatol* **34**:645, 1996

78. Stanley JR: Therapy of pemphigus vulgaris. *Arch Dermatol* **135**:76, 1999

79. Bystryn JC, Steinman NM: The adjuvant therapy of pemphigus: An update. [Review]. *Arch Dermatol* **132**:203, 1996

80. Ahmed AR, Moy R: Death in pemphigus. *J Am Acad Dermatol* **7**:221, 1982

81. Seidenbaum M et al: The course and prognosis of pemphigus: A review of 115 patients. *Int J Dermatol* **27**:580, 1988

82. Ratnam KV et al: Pemphigus therapy with oral prednisolone regimens: A 5-year study. *Int J Dermatol* **29**:363, 1990

83. Fine JD: Management of acquired bullous skin diseases. [Comments]. [Review]. *N Engl J Med* **333**:1475, 1995

84. Enk AH, Knop J: Mycophenolate mofetil is effective in the treatment of pemphigus vulgaris. *Arch Dermatol* **135**:54, 1998

85. Lever WF: Pemphigus and pemphigoid. *J Am Acad Dermatol* **1**:2, 1979

86. Lever WF, Schaumburg Lever G: Immunosuppressants and prednisone in pemphigus vulgaris: therapeutic results obtained in 63 patients between 1961 and 1975. *Arch Dermatol* **113**:1236, 1977

87. Werth VP: Treatment of pemphigus vulgaris with brief, high-dose intravenous glucocorticoids. *Arch Dermatol* **132**:1435, 1996

88. Roujeau JC: Pulse glucocorticoid therapy: The 'big shot' revisited. *Arch Dermatol* **132**:1499, 1996

89. Pasricha JS et al: Dexamethasone-cyclophosphamide pulse therapy for pemphigus. *Int J Dermatol* **34**:875, 1995

90. Guillaume JC et al: Controlled study of plasma exchange in pemphigus. *Arch Dermatol* **124**:1659, 1988

91. Turner MS et al: The use of plasmapheresis and immunosuppression in the treatment of pemphigus vulgaris. *J Am Acad Dermatol* **43**:1058, 2000

92. Euler HH et al: Synchronization of plasmapheresis and pulse cyclophosphamide therapy in pemphigus vulgaris. *Arch Dermatol* **123**:1205, 1987

93. Engineer L et al: Analysis of current data on the use of intravenous immunoglobulins in management of pemphigus vulgaris. *J Am Acad Dermatol* **43**:1049, 2000

94. Hayag MV et al: Immunoablative high-dose cyclophosphamide without stem cell rescue in a patient with pemphigus vulgaris. *J Am Acad Dermatol* **43**:1065, 2000

T>

Chapter 60

Grant Anhalt H. Nousari

Paraneoplastic Pemphigus

HISTORICAL ASPECTS
EPIDEMIOLOGY
ETIOLOGY AND PATHOGENESIS
CLINICAL FEATURES
Dermatologic
SYSTEMIC ASSOCIATIONS
LABORATORY FINDINGS
PATHOLOGY
IMMUNOPATHOLOGY
DIAGNOSIS AND DIFFERENTIAL DIAGNOSIS
Differential Diagnosis
TREATMENT AND PROGNOSIS
Systemic Treatment
REFERENCES

Paraneoplastic pemphigus is an autoimmune disorder that is almost invariably linked to an underlying lymphoproliferative disorder. These features define it: (1) Painful stomatitis and a polymorphous cutaneous eruption with lesions that may be blistering, lichenoid or resemble erythema multiforme. (2) Histologic findings that reflect the variability of the cutaneous lesions, showing acantholysis, lichenoid or interface change. (3) Direct immunofluorescence demonstrating deposition of IgG and complement in the epidermal intercellular spaces, and often granular/linear complement deposition along the epidermal basement membrane zone. (4) Serum autoantibodies that bind the cell surface of skin and mucosae in a pattern typical for pemphigus, but in addition, bind to simple, columnar, and transitional epithelia. (5) These serum autoantibodies identify desmogleins 1 and 3, but additionally identify members of the plakin family of epithelial proteins, such as desmoplakins, envoplakin, and periplakin. The disease is associated in the majority of cases with non-Hodgkin's lymphoma, chronic lymphocytic leukemia and Castleman's disease. Treatment of the autoimmune disease is difficult and most patients die from complications of the disease, including pulmonary involvement with respiratory failure.

HISTORICAL ASPECTS

In December 1990, Anhalt et al. published observations based on five cases that defined a previously unrecognized autoimmune mucocutaneous disease linked to underlying lymphoproliferative neoplasms, and proposed the term *paraneoplastic pemphigus* to describe this syndrome. [1] Since then, numerous cases have been reported that verified the essential features of the disease as first described, with some important additions and clarifications. It is clear that this syndrome of paraneoplastic pemphigus (PNP) was not a “new” disease. Based on a retrospective literature review, it is apparent that cases of paraneoplastic pemphigus were identified over the years. These cases, however, were often characterized as atypical cases of pemphigus vulgaris, [2] as unusual cases of erythema multiforme with pemphigus-like antibodies, [3] or as an unusual paraneoplastic bullous disease without further clarification. [4]

EPIDEMIOLOGY

The incidence of the disease is unknown, but it is less common than pemphigus vulgaris or foliaceus. In a recent analysis of adverse event reporting in 100,000 patients with known non-Hodgkin's lymphoma and chronic lymphocytic leukemia, there were 12 cases of paraneoplastic pemphigus (Nagy S and Anhalt GJ, manuscript in preparation). Of note, only three of these cases were identified by the reporting physician as such, and the remainder were identified by retrospective data analysis. That implies that the majority of cases are still not properly diagnosed. The commonest misdiagnoses applied in this series were erythema multiforme, Stevens-Johnson syndrome, toxic epidermal necrolysis, and drug reaction.

ETIOLOGY AND PATHOGENESIS

In almost all cases, this syndrome is associated with a limited number of lymphoproliferative neoplasms. The approximate frequency of specific neoplasms has been estimated, based upon 140 cases of PNP diagnosed by our laboratory and confirmed by immunoprecipitation demonstration of the characteristic autoantibody profile, to be 44 percent non-Hodgkin's lymphoma (NHL), 19 percent chronic lymphocytic leukemia (CLL), 16 percent Castleman's disease (giant follicular hyperplasia), 8 percent thymoma (malignant and benign), 7 percent sarcomas that are retroperitoneal and often poorly differentiated, 4 percent Waldenström's macroglobulinemia, and in 2 percent no identified neoplasm. The majority of cases are associated with NHL and CLL, but the disproportionate representation of Castleman's disease is notable because of the rarity of this disorder. The association with Castleman's is even more striking in pediatric cases, where it is the underlying neoplasm in almost all cases. [5] Prior to the description of paraneoplastic pemphigus there were many cases of Castleman's disease associated with atypical forms of pemphigus, and we suspect most were cases of PNP. [6] Archived clinical material was available from one such case, which subsequently confirmed that the patient had autoantibodies specific for PNP. [7]

Almost without exception, more common cancers, such as adenocarcinomas of breast, bowel, and lung, or basal cell and squamous cell carcinoma of skin have not been associated with PNP. There are a few reports of PNP occurring with tumors such as squamous cell carcinoma, but most of these diagnoses have not been confirmed by immunochemical testing, so the association remains unproven.

The mechanisms by which these tumors induce autoimmunity against epithelial proteins remains speculative. One hypothesis states that the tumors constitutively or anomalously express epithelial proteins. These proteins are targeted by the antitumor immune response that cross-reacts with normal constitutive epithelial proteins of the host. This mechanism occurs in several neurologic paraneoplastic syndromes. [8] This antitumor immune response may be initiated by reactivity against plakin proteins, and the antitumor immune response may cross react with normal constitutive proteins of epithelia.

Alternate mechanisms are also possible, for it has been observed that treatment with cytokines may induce PNP, [9] raising the possibility of more complex interactions between the tumor cells and the immune system. There is some evidence that dysregulated cytokine production by tumor cells drives the development of autoimmunity. Patients with PNP have evidence of markedly elevated levels of interleukin 6 (IL-6). [10] It has been observed that in a subset of cases of non-Hodgkin's lymphomas, [11] CLL, and Castleman's tumors, the tumor cells will secrete massive amounts of IL-6 in vitro. IL-6 is known to promote B cell differentiation and to drive immunoglobulin production, and dysregulated IL-6 production has been implicated in certain autoimmune diseases. Castleman tumors are known to be associated with other autoimmune phenomena such as myasthenia gravis and autoimmune cytopenias, and these patients also have high serum levels of IL-6. Symptoms attributable to Castleman tumors are routinely reversed by complete excision of the affected node(s), and, coincidentally, serum IL-6 levels revert to normal. Administration of anti-IL-6 monoclonal antibodies will also effectively reverse systemic manifestations of Castleman's disease. [12]

Almost all patients have autoantibodies against desmogleins, demonstrable by enzyme-linked immunosorbent assay (ELISA), and when the desmoglein autoantibodies from these patients are injected into neonatal mice, acantholytic skin lesions are induced. [13] However, none of features of the disease that suggest cell-mediated autoimmunity [14] are recreated by immunoglobulin injections. No other internal organs are involved, and there is no lymphocyte-mediated cell damage. This is also an indication that humoral immunity alone will reproduce features of acantholysis, but passive transfer of autoimmune cells from these patients may be necessary to reproduce the complete spectrum of the disease in animals.

CLINICAL FEATURES

Dermatologic

The most constant clinical feature of the disease is the presence of intractable stomatitis (Fig. 60-1). This is the earliest presenting sign, and after treatment it is the one feature that persists throughout the course of the disease and is extremely resistant to therapy. This stomatitis consists of erosions and ulcerations that can affect all surfaces of the oropharynx. The lesions differ from those seen in pemphigus vulgaris in that they show more necrosis and lichenoid change. They also preferentially localize to the lateral borders of the tongue, and characteristically extend onto and involve the vermilion of the lips. Occasionally, oral lesions are the only manifestation of the disease. [15]

FIGURE 60-1 *A.* Extensive erosions involving the vermillion of the lips in a patient presenting with paraneoplastic pemphigus and an occult lymphoma. The characteristic severe stomatitis, accompanied by polymorphous cutaneous lesions are the most consistent features of the disease. *B.* Painful ulcerations tend to localize to the lateral border of the tongue. *C.* Lesions of the trunk from the same patient pictured in *A.* Erythematous macules and papules coalesce, and become erosive on the upper chest as the cutaneous lesions evolve. *D.* Lesions from the forearm of the same patient. These lesions clinically resemble erythema multiforme, but biopsy will show a mix of individual cell necrosis, interface change and acantholysis.

The cutaneous lesions of paraneoplastic pemphigus are quite variable, and different morphologies may occur in an individual patient according to the stage of the disease. The initial patients reported with the syndrome had episodes of waves of blistering affecting the upper trunk, head and neck, and proximal extremities. These lesions consisted of blisters that ruptured easily leaving erosions. The blisters on the extremities were sometimes quite tense, resembling those seen in bullous pemphigoid, or they had surrounding erythema, clinically resembling erythema multiforme. On the upper chest and back, confluent erosive lesions can develop, producing a picture resembling toxic epidermal necrolysis (TEN). The similarity of the mucocutaneous features to erythema multiforme/TEN explains why this is the most common differential diagnosis for PNP. However, it is important to note that erythema multiforme/TEN are self-limited events that evolve and resolve over several weeks, whereas PNP is a relentlessly progressive disease that continuously evolves over months.

Cutaneous lichenoid eruptions are very common and they may be the only cutaneous signs of the disease, [16] or may develop in lesions that had previously been blistered. When cutaneous lichenoid lesions are present, severe stomatitis is also invariably present. In the chronic form of the disease and after treatment, this lichenoid eruption may predominate over blistering on the cutaneous surface. Both blisters and lichenoid lesions affecting the palms and the soles as well as the paronychial tissues are common, and help to distinguish this from pemphigus vulgaris in which acral and paronychial lesions are uncommon.

VARIANTS There are a small number of patients that appear to have PNP, but who do not have demonstrable circulating autoantibodies. These patients tend to have predominantly lichenoid skin and mucosal lesions, but behave in every other way like antibody-positive patients, and have the same underlying neoplasms. Because the definition of the disease relies so heavily on demonstration of the specific autoantibody markers, further study is required to know how to classify these patients. The disease has also been identified in a horse [17] and a dog. [18] In animal species, the disease has the same associated neoplasms and clinical outcomes.

SYSTEMIC ASSOCIATIONS

PNP is the only form of pemphigus that has involvement of nonstratified squamous epithelium. Approximately 30 to 40 percent of cases will develop pulmonary injury, often with a fatal outcome. [19] The earliest symptoms are progressive dyspnea associated initially with an absence of findings on chest radiography. Pulmonary functions studies show airflow obstruction, involving large and small airways. Inflammation of the large airways evolves, and is evidenced by endoscopic biopsy showing acantholysis of bronchial respiratory epithelium. Pulmonary function deteriorates in most cases despite immunosuppressive therapy, and radiologic, histologic and functional changes characteristic of bronchiolitis obliterans develop. [20]

LABORATORY FINDINGS

The key finding is the serologic identification of polyclonal IgG autoantibodies against plakin proteins and, in most cases, desmogleins 1 and 3. [21] The plakins are a group of sequence-related proteins that form the intracellular plaque of desmosomes and hemidesmosomes, and mediate attachment of cytoskeletal intermediate filaments to transmembrane adhesion molecules such as the desmogleins. Autoantibodies against these proteins are the most characteristic surrogate markers for the disease. The pattern of antigens recognized by individual patients shows considerable variability, but the most characteristic and consistently recognized plakin antigens are envoplakin [22] and periplakin [23] (210 and 190 kDa, respectively). Next most frequently detected are antibodies against desmoplakin I and desmoplakin II (250 and 210 kDa, respectively). Less commonly, patients recognize bullous pemphigoid Ag 1 (230 kDa), plectin and plakoglobin. The identity and frequency of an antigen band at 170 kDa is not well defined. PNP patients may also have clinical and serologic evidence of other autoimmune phenomena such as myasthenia gravis and autoimmune cytopenias (Fig. 60-2 and Fig. 60-3).

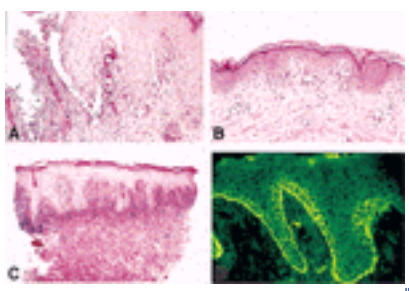

FIGURE 60-2 *A.* Histopathology of a blistering cutaneous lesion in PNP. This demonstrates the characteristic presence of vacuolar interface change and suprabasilar acantholysis. [hematoxylin and eosin (H&E), 200×] *B.* Macular and papular lesions may show just vacuolar interface change. (H&E, 100×) *C.* Lichenoid lesions demonstrate lichenoid infiltrates on histologic exam. (H&E, 40×) The presence of these varied histologic findings help differentiate PNP from pemphigus vulgaris. *D.* Direct immunofluorescence can be negative in a significant number of cases, but when positive, the most characteristic changes are those of deposition of IgG and complement components on both the surface of basilar and suprabasilar keratinocytes and along the epidermal basement membrane zone. (Immunofluorescence with fluoresceinated anti-IgG, 200×)

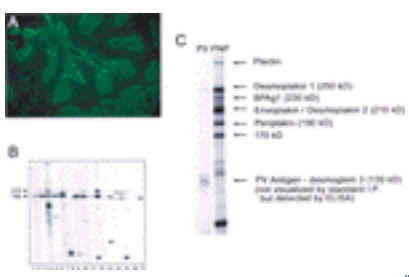

FIGURE 60-3 Diagnosis of PNP depends upon the demonstration of anti-plakin antibodies. **series (A)** This can be accomplished by indirect immunofluorescence of patient serum on rodent urinary bladder demonstrating binding of IgG to the cell surface of transitional epithelial cells. A positive result implies the presence of anti-plakin antibodies. This technique, although easily performed, has the lowest sensitivity and specificty. **series (B)** Immunoblotting against epidermal cell extracts is much more sensitive and specific. This shows detection of envoplakin (210 kD) and/or periplakin (190 kD) in 15 patients with PNP. Lane 16 is a normal control and lane 17 shows a monoclonal antibody against periplakin. This technique employs denatured antigen extracts, so it does not reliably detect some of the PNP antigens, but antibodies against the most characteristic plakin antigens, envoplakin and periplakin are easily detected. **series (C)** Immunoprecipitation using radiolabeled, non-denatured epidermal extracts and serum from a patient with PNP and pemphigus vulgaris. In this case, the PNP patient's serum identifies all of the plakin antigens. Envoplakin and desmoplakin II migrate as a doublet at 210 kD. This technique is the most sensitive and specific test for demonstration of anti-plakin antibodies in PNP, but has limited availability. Although this technique readily detects the anti-plakin antibodies, desmoglein 3 is not always efficiently identified, and this is best shown by using ELISA.

To screen for PNP autoantibodies, one can test for IgG autoantibodies by indirect IF reactive with rodent urinary bladder

epithelium. A positive result implies the presence of plakin autoantibodies; however, the sensitivity and specificity of this serologic test are only about 75 percent and 83 percent, respectively. [24] More specific and sensitive tests include immunoblotting against epidermal cell extracts that can effectively detect antibodies against envoplakin, periplakin, and desmoplakin, and immunoprecipitation, using radiolabeled keratinocyte extracts, which can detect antibodies against any of the plakin proteins.

The PNP autoantibody profile is more complex than that observed in pemphigus vulgaris or foliaceus, where there are autoantibodies produced only against the desmogleins. The humoral immunity in PNP may represent an example of epitope spreading in which patients develop autoantibodies against structurally related plakin proteins and structurally unrelated transmembrane cell surface protein (the desmogleins) that are physically linked to the plakin proteins in the desmosome and hemidesmosome. [25]

PATHOLOGY

The histopathology of PNP is distinctive from pemphigus vulgaris and foliaceus for two reasons. First, because the lesions can be clinically very polymorphous, there is substantial variability in the histologic findings. [26], [27] Second, findings due to cell-mediated cytotoxicity are frequently observed.

Biopsy of oral lesions is difficult to interpret because the mucositis is extremely severe and many biopsies will yield nonspecific changes of inflammation and ulceration. If one can biopsy perilesional epithelium, a lichenoid mucositis with variable degrees of individual cell necrosis and suprabasilar acantholysis can be observed.

When evaluating biopsies from skin lesions, one must recognize that lesions with different clinical morphologies will yield differing histologic findings. In noninflammatory cutaneous blisters, suprabasilar acantholysis is expected to be more prominent than the interface/lichenoid change (see Fig. 60-2A). When erythematous macules and papules are sampled, interface and lichenoid dermatitis will be predominant (see Fig. 60-2B and Fig. 60-2C). Lesions with a mixed clinical pattern will also show mixed histologic features of concomitant suprabasilar acantholysis and interface/lichenoid dermatitis.

There is also variability of the interface and lichenoid dermatitis observed. The spectrum of changes can include: (1) individual keratinocyte necrosis with lymphocytic infiltration into the epidermis, reminiscent of that seen in erythema multiforme or graft versus host disease; (2) vacuolar interface change with sparse lymphocytic infiltrate of the basilar epithelium, resembling cutaneous lupus erythematosus or dermatomyositis; and (3) a thick lichenoid band along the dermal–epidermal junction similar to that seen in lichen planus. Although most of the specimens show a complex overlap of histologic patterns, there is a relatively good correlation between the clinical and the predominant histologic pattern.

The histopathologic variability of this disease may be related to the fact that it is a presumed antitumor immune response. If this speculation is correct, one would expect to observe a combination of both humoral and cell-mediated immunity that is aberrantly directed against normal epithelium. In such a setting, one would expect to see changes of the sort described above. This degree of cell-mediated immunity is not seen in pemphigus vulgaris or foliaceous; hence the unique histopathologic features, and, presumably, the unique clinical features, as well.

IMMUNOPATHOLOGY

Patients should have evidence of IgG autoantibodies bound to the cell surface of affected epithelium by direct immunofluorescence. However, false negatives are more common in PNP than in pemphigus vulgaris and repeated biopsies may be necessary to demonstrate this finding. In a minority of cases, one might also see a combination of both cell surface and basement membrane zone deposition of IgG and complement components, but the absence of this combined cell surface/basement membrane zone staining does not negate the diagnosis.

DIAGNOSIS AND DIFFERENTIAL DIAGNOSIS

Not all patients demonstrate all of the five criteria that were originally proposed to define the disease. The following represent the minimal criteria for diagnosis of PNP with a high degree of confidence:

1. Painful, progressive stomatitis, with preferential involvement of the tongue. This finding is so consistent that the diagnosis should not be considered if stomatitis is absent.
2. Histologic features of acantholysis, lichenoid, or interface dermatitis. Although acantholysis is most readily detected in oral lesions, the necrosis and secondary inflammation makes this difficult to detect without repeated biopsies. Some patients never develop skin lesions. Some show only lesions that clinically and histologically are lichenoid or resemble erythema multiforme. Direct immunofluorescence (IF) is very frequently negative, and the serologic markers for the disease are so specific that demonstration of tissue bound autoantibodies is not an essential criteria.
3. Demonstration of anti-plakin autoantibodies. These are the key serologic markers for the entity. Positive indirect IF on rodent bladder is readily available, but not highly reliable. Immunochemical techniques are much more precise and should demonstrate, at a minimum, autoantibodies against periplakin and/or envoplakin. [28] Patients with PNP should have a positive indirect IF test on monkey esophagus, and have antibodies against desmoglein 3 by ELISA, but this will not discriminate PNP from pemphigus vulgaris.
4. Demonstration of an underlying lymphoproliferative neoplasm. Approximately two-thirds of cases arise in the context of known malignant disease, most often NHL or CLL. In approximately one-third of cases, there is no known neoplastic lesion at the time the mucocutaneous disease develops. These cases tend to be associated with Castleman's disease, abdominal lymphoma, thymoma, or retroperitoneal sarcomas. In most cases, the occult neoplastic lesion can be detected by the investigations shown in Table 60-1. The most effective radiologic investigation is computed tomography of chest, abdomen, and pelvis, which will detect most of these neoplasms.

- Biopsy skin or mucosa for H&E, direct immunofluorescence, serum for indirect immunofluorescence on monkey esophagus and rodent bladder epithelium
- Serum for immunoblotting or immunoprecipitation against epidermal extracts
- Complete blood count, chemistry panel, serum protein electrophoresis
- Examine liver, spleen, lymph nodes, and abdomen for organomegaly or masses
- Computed tomography of chest, abdomen and pelvis

TABLE 60-1 **Recommended Investigations for Suspect Paraneoplastic Pemphigus**

Differential Diagnosis

The major differential diagnosis for patients with only oral involvement should include pemphigus vulgaris, oral lichen planus, and major aphthous stomatitis. Those with more lichenoid skin lesions and mucositis can closely resemble extensive lichen planus. Patients with skin and oral involvement most closely resemble erythema multiforme, TEN, or pemphigus vulgaris. There are a small number of patients with recurrent erythema multiforme major that have antibodies against desmoplakins, and will therefore have a positive indirect IF on bladder epithelium. These cases are distinguished from PNP because they do not have an underlying malignancy, and they do not have antibodies against the plakin proteins envoplakin and periplakin, which are more specific for PNP. [29]

TREATMENT AND PROGNOSIS

Systemic Treatment

Individuals with benign or encapsulated tumors such as Castleman's tumors or thymoma should have them surgically excised, for if the entire lesion can be excised, the disease generally improves substantially or goes into complete remission. [30] The remission of the autoimmune disease may take 1 to 2 years after surgery, so continued immunosuppression during this period is required. The usual treatment involves combined use of prednisone, 0.5 mg/kg, cyclosporine 5 mg/kg, and oral cyclophosphamide 2 mg/kg, tapering as symptoms improve. In pediatric cases with respiratory disease, the persistent autoimmunity immediately postsurgery can cause ongoing pulmonary injury, and lung transplantation might be required for long-term survival. [31]

In patients with malignant neoplasms, there is no consensus regarding a therapeutic regimen that is consistently effective. Although there are a couple of individual reports of long-term survivors, [32] almost all patients with NHL or CLL will succumb in a period of 1 month to 2 years after diagnosis. Oral corticosteroids in a dose of 0.5 to 1 mg/kg will produce partial improvement, but not complete resolution of lesions. Although cutaneous lesions respond more quickly to therapy, the stomatitis is generally quite refractory to any form of therapy. In addition to corticosteroids, many other agents have been tried in individual cases, but none have proven to be particularly effective. Methods that have been tried and that have generally failed include immunosuppression with cyclophosphamide or azathioprine, gold, dapsone, plasmapheresis, and photopheresis. A subset of patients, usually with CLL as an underlying neoplasm, have responded to a combination of prednisone, 0.5 to 1 mg/kg per day and cyclosporine, 5 mg/kg per day. [33] Additional treatment with intermittent pulse cyclophosphamide to control the underlying CLL was also used in many of these cases, and this also may have contributed to the good outcome. Some patients have shown improvement after treatment with rituximab in combination with prednisone and cyclophosphamide. [34] It is not known why PNP is so refractory to the type of immunosuppressive treatments that usually work well in pemphigus vulgaris and other autoimmune diseases.

In those patients who do succumb, death has been attributed in individual cases to multiple factors including sepsis, gastrointestinal bleeding, “multiorgan failure,” and respiratory failure. Patients with autoimmune disease associated with B cell neoplasms are known to have a high frequency of autoimmune cytopenias, and some fatal episodes of sepsis are suspect to have occurred because of sudden and unexplained neutropenia, possibly due to this mechanism. Respiratory failure is a common terminal event. The development of shortness of breath with obstructive disease progressing to bronchiolitis obliterans is a terminal pathway in most cases. Because these patients have autoantibodies that react with desmoplakins, and because desmoplakins are present in respiratory epithelium, respiratory failure may be due to autoantibody-mediated injury to bronchial epithelium, with plugging of terminal bronchioles, resulting in airflow obstruction and ventilation/perfusion abnormalities. Additionally, direct damage to alveolar epithelium could cause a diffusion barrier and subsequent intractable hypoxia. These mechanisms are speculative at present. The pulmonary injury does not respond to medical treatment, and the development of shortness of breath and hypoxia in a patient with this syndrome is an ominous prognostic sign.

In patients with malignant neoplasms there is no definite correlation between tumor burden and the activity of the autoimmune syndrome. Treatment of the primary malignancy does not affect the activity of the autoimmune disease. It seems that once the process in initiated by the malignancy, the autoimmunity progresses independently. An example of the disconnect between tumor burden and autoimmunity is found in the case reported by Fullerton et al. [19] in which paraneoplastic pemphigus occurred after successful autologous bone marrow transplantation for non-Hodgkin's lymphoma. This patient was free of detectable tumor burden at the time of his death, but died from pulmonary injury secondary to paraneoplastic pemphigus. It is notable that the patient underwent autologous bone marrow transplantation, and therefore received his own memory T cells, or possibly individual malignant lymphoid cells that were not detectable by routine autopsy methods.

REFERENCES

1. Anhalt GJ et al: Paraneoplastic pemphigus: An autoimmune mucocutaneous disease associated with neoplasia. *N Engl J Med* **323**:1729, 1990

2. Redon J et al: Pemphigus associated with giant lymph node hyperplasia. *Br Med J* **287**:176, 1983

3. Matsuoka LY et al: Epidermal autoantibodies in erythema multiforme. *J Am Acad Dermatol* **21**:677, 1989

4. Panielieyva GA: Paraneoplastic bullous dermatoses. *Vestn Dermatol Venerol* **2**:50, 1990

5. Mimouni D et al: Paraneoplastic pemphigus in children and adolescents. *Br J Dermatol* **147**:725, 2002

6. Tagami H et al: Severe erosive stomatitis and giant lymph node hyperplasia of retroperitoneum (Castleman's tumor). *Dermatologica* **157**:138, 1978

7. Plewig G et al: Castleman tumor, lichen ruber und pemphigus vulgaris: Paraneoplastiche assoziation immunologischer erkrankungen? *Hautarzt* **41**:662, 1990

8. Kornguth SE: Neuronal proteins and paraneoplastic syndromes. *N Engl J Med* **321**:1607, 1989

9. Kirsner RS et al: Treatment with alpha interferon associated with the development of paraneoplastic pemphigus. *Br J Dermatol* **132**:474, 1995

10. Nousari HC et al: Elevated levels of interleukin-6 in paraneoplastic pemphigus. *J Invest Dermatol* **112**:396, 1999

11. Yee C et al: A possible autocrine role for interleukin-6 in two lymphoma cell lines. *Blood* **74**:798, 1989

12. Beck JT et al: Alleviation of systemic manifestations of Castleman's disease by monoclonal anti–interleukin-6 antibody. *N Engl J Med* **330**:602, 1994

13. Amagai M et al: Antibodies against desmoglein 3 (pemphigus vulgaris antigen) are present in sera from patients with paraneoplastic pemphigus and cause acantholysis in vivo in neonatal mice. *J Clin Invest* **102**:775, 1998

14. Reich K et al: Graft-versus-host disease-like immunophenotype and apoptotic keratinocyte death in paraneoplastic pemphigus. *Br J Dermatol* **141**:739, 1999

15. Bialy-Golan A et al: Paraneoplastic pemphigus: Oral involvement as the sole manifestation. *Acta Derm Venerol* **76**:253, 1996

16. Stevens SR et al: Paraneoplastic pemphigus presenting as a lichen planus pemphigoides-like eruption. *Arch Dermatol* **129**:866, 1993

17. Williams MA et al: Paraneoplastic bullous stomatitis in a horse. *J Am Vet Med Assoc* **207**:331, 1995

18. de Bruin A et al: Periplakin and envoplakin are target antigens in canine and human paraneoplastic pemphigus. *J Am Acad Dermatol* **40**:682, 1999

19. Fullerton SH et al: Paraneoplastic pemphigus with immune deposits in bronchial epithelium. *JAMA* **267**:1550, 1992

20. Nousari HC et al: The mechanism of respiratory failure in paraneoplastic pemphigus. *N Engl J Med* **340**:1406, 1999

21. Ohyama M et al: Clinical phenotype and anti-desmoglein autoantibody profile in paraneoplastic pemphigus. *J Am Acad Dermatol* **44**:593, 2001

22. Kim SC et al: cDNA cloning of the 210-kDa paraneoplastic pemphigus antigen reveals that envoplakin is a component of the antigen complex. *J Invest Dermatol* **109**:365, 1997

23. Mahoney MG et al: The members of the plakin family of proteins recognized by paraneoplastic pemphigus antibodies include periplakin. *J Invest Dermatol* **111**:308, 1998

24. Helou J et al: Accuracy of indirect immunofluorescent testing in the diagnosis of paraneoplastic pemphigus. *J Am Acad Dermatol* **32**:44, 1995

25. Craft J, Fatenetad S. Self antigens and epitope spreading in systemic autoimmunity *Arthritis Rheum* **40**:1374, 1997

26. Horn TD, Anhalt GJ: Histologic features of paraneoplastic pemphigus. *Arch Dermatol* **128**:1091, 1991

27. Mehregan DR et al: Paraneoplastic pemphigus: A subset of patients with pemphigus and neoplasia. *J Cutan Pathol* **20**:203, 1993

28. Kiyokawa C et al: Envoplakin and periplakin are components of the paraneoplastic pemphigus antigen complex. *J Invest Dermatol* **111**:1236, 1998

29. Foedinger D et al: Autoantibodies to desmoplakin I and II in patients with erythema multiforme. *J Exp Med* **181**:169, 1995

30. Jansen T, Plewig G: Castleman tumor, lichen ruber and pemphigus vulgaris: Paraneoplastic association of immunologic disease (letter)? *Hautarzt* **42**:727, 1991

31. Chin AC et al: Paraneoplastic pemphigus and bronchiolitis obliterans associated with a mediastinal mass: A rare case of Castleman's disease with respiratory failure requiring lung transplantation. *J Pediatr Surg* **36**:E22, 2001

32. Camisa C et al: Paraneoplastic pemphigus: A report of three cases including one long-term survivor. *J Am Acad Dermatol* **27**:547, 1992

33. Ståhle-Backdähl M et al: Paraneoplastic pemphigus: A report of two patients responding to cyclosporine. *Eur J Dermatol* **5**:671, 1995

34. Borradori L et al: Anti-CD20 monoclonal antibody (rituximab) for refractory erosive stomatitis secondary to CD20(+) follicular lymphoma-associated paraneoplastic pemphigus. *Arch Dermatol* **137**:269, 2001

T>

Chapter 61

John Stanley

Bullous Pemphigoid

EPIDEMIOLOGY
ETIOLOGY AND PATHOGENESIS
Electron Microscopy
Immunopathology
Pemphigoid Antigens
Pathophysiology of Lesion Production
CLINICAL MANIFESTATIONS
Skin and Mucous Membrane Involvement
Precipitating Factors
Laboratory Abnormalities
Associated Diseases
PATHOLOGY
DIFFERENTIAL DIAGNOSIS
TREATMENT AND PROGNOSIS

REFERENCES

Bullous pemphigoid is a subepidermal blistering skin disease, usually occurring in the elderly, that is characterized by large, tense blisters and the immunopathologic findings of C3 (the third component of complement) and IgG at the epidermal basement membrane zone. Mucous membranes are spared in most cases, with the exception of nonscarring bullae or erosions of the oral mucous membranes in a minority of patients.

Walter Lever was a pioneer in classifying bullous pemphigoid as a disease different from pemphigus with its own distinctive clinical and histologic features. [1] This was important because at the time pemphigus vulgaris usually was fatal, whereas bullous pemphigoid had a comparatively good prognosis. This classification of bullous pemphigoid and pemphigus was confirmed and fully justified by the distinctive immunopathologic features of these diseases discovered about 12 years later. [2], [3]

EPIDEMIOLOGY

The majority of patients with bullous pemphigoid are over 60 years old at the age of onset. [4] Although bullous pemphigoid does occur rarely in children, [5] reports earlier than about 1970 (when the use of immunofluorescence for diagnosis became more widespread) were inaccurate because these most likely included children with chronic bullous disease of childhood, which is now differentiated from bullous pemphigoid by the presence of IgA, rather than IgG, at the basement membrane zone. There is no known ethnic, racial, or sexual predilection for developing bullous pemphigoid. The incidence of bullous pemphigoid is estimated to be 7 per million per year in both France and Germany. [6], [7]

ETIOLOGY AND PATHOGENESIS

Electron Microscopy

Ultrastructural studies demonstrate that early blister formation in bullous pemphigoid occurs in the lamina lucida, between the basal cell membrane and the lamina densa. [8] With blister formation, there is loss of anchoring filaments and hemidesmosomes. With degranulation of infiltrating leukocytes, there is fragmentation and ultimate loss of the lamina densa. [9] In addition, degranulation of mast cells near the epidermal basement membrane has been observed both by light and electron microscopy. [10]

Immunopathology

Direct immunofluorescence of perilesional skin from pemphigoid patients reveals immunoreactants deposited in a linear pattern at the epidermal basement membrane. [2], [3] C3 is detected in almost all patients, sometimes as the sole immunoreactant; however, IgG is also detected in most patients. [11], [12] and [13] (Fig. 61-1A).

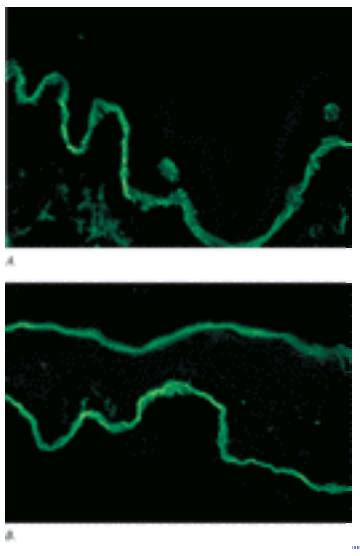

FIGURE 61-1 Immunofluorescence in bullous pemphigoid. *A.* Direct immunofluorescence of perilesional skin shows a linear band of C3 (×340). *B*. Indirect immunofluorescence shows a linear pattern of IgG binding to the epidermal basement membrane of normal skin (×340).

Indirect immunofluorescence indicates that about 70 to 80 percent of patients with bullous pemphigoid have circulating IgG that binds to the basement membrane of normal stratified squamous epithelia, such as human epidermis or monkey esophagus [11], [12], [13] and [14] (Fig. 61-1B). Most patients with circulating anti–basement membrane IgG also have anti–basement membrane IgE in their sera. [15], [16] If the immunofluorescence substrate is incubated first in 1 *M* NaCl to separate the epidermis from the dermis at the lamina lucida, then an even higher percentage of patients will have detectable circulating antibody. [17], [18] Besides being more sensitive, the other advantage of this 1 *M* NaCl-split substrate is that bullous pemphigoid antibodies bind to the roof of the artificially induced blister (i.e., the bottom of the basal cells) and thus can be differentiated from the antibodies of patients with epidermolysis bullosa acquisita; their antibodies bind the base (i.e., dermal side) (Fig. 61-2). In contrast to pemphigus, in bullous pemphigoid the indirect immunofluorescence antibody titer does not usually correlate with disease extent or activity [19].

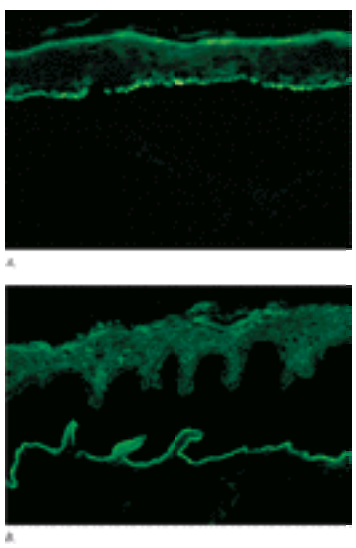

FIGURE 61-2 Indirect immunofluorescence on normal skin previously incubated in 1 *M* NaCl. *A.* IgG from bullous pemphigoid serum binds to the roof of the artificial blister (×330). *B.* IgG in epidermolysis bullosa acquisita serum binds to the base (×215).

In addition to C3, other components of both the classical and alternative complement pathways and the complement regulatory protein ß1H are deposited at the epidermal basement membrane zone in bullous pemphigoid patients. [20], [21] and [22] Furthermore, activated complement components are found in the blister fluid of these patients, and in vitro complement fixation immunofluorescence assays indicate the ability of bullous pemphigoid sera to fix complement components of the classical and alternative pathways to the epidermal basement membrane. These studies suggest that bullous pemphigoid IgG causes complement activation by the classical pathway, with activation of the alternative pathway by the C3 amplification mechanism.

Pemphigoid Antigens

Immunoelectron microscopic studies have localized bullous pemphigoid antigen in the hemidesmosome, an organelle important in anchoring the basal cell to the basement membrane. [23], [24] Autoantibodies bind both inside the cell to the plaque of the hemidesmosome and outside the cell to the extracellular face of the hemidesmosome.

Molecular characterization of bullous pemphigoid antigen by immunochemical methods revealed the unexpected finding that autoantibodies from these patients bind two distinct molecules. [25] Essentially all bullous pemphigoid patients have antibodies against a 230-kDa molecule. [26] Cloning of the cDNA encoding this molecule (now called *BPAG1* or *BPAG1e*) indicated that it belongs to a gene family that includes desmoplakin I, a desmosome plaque protein that is important in anchoring keratin intermediate filaments to the desmosome. [27], [28] BPAG1e has been localized ultrastructurally to the plaque of the hemidesmosome, exactly where keratin intermediate filaments insert. [29] Further proof that the function of BPAGle is to anchor keratin intermediate filaments to the hemidesmosome was obtained by analysis of a mouse that was genetically engineered with a targeted deletion of this molecule. [30] This mouse showed fragility of basal cells due to

collapse of the keratin filament network but no epidermal-dermal adhesion defect, suggesting that bullous pemphigoid antibodies do not act by inhibiting the function of BPAG1e. In fact, since BPAG1e is inside the cell, it is unclear if patient autoantibodies normally have access to it. Interestingly, an alternatively spliced form of BPAG1e is expressed in neural tissue. Now termed BPAG1n, this form stabilizes the cytoskeleton of sensory nerves, [31], [32] just as BPAG1e stabilizes the cytoskeleton of epidermal cells.

Immunochemical studies have revealed that almost all patients with bullous pemphigoid, as well as patients with herpes gestationis, also have autoantibodies against a 180-kDa molecule now called BPAG2 or *type XVII collagen*. [33], [34] and [35] The cDNA encoding the BPAG2 molecule has been cloned, and the expressed protein is a transmembrane molecule with a collagenous extracellular domain. [36] Antibodies against BPAG2 localize it as a transmembrane molecule at the hemidesmosome, and cell biologic studies indicate that its cytoplasmic domain targets it to that location. [37], [38] The extracellular domain of BPAG2 has been localized to anchoring filaments. [39] The autoantibodies from most patients with bullous pemphigoid (as well as those from patients with herpes gestationis) recognize a particular epitope in a small noncollagenous region of BPAG2 that is just outside the membrane. [40], [41] As discussed below, antibodies against this epitope are capable of mediating subepidermal blister formation in neonatal mice. In addition, antibody titers against this epitope, as determined by enzyme-linked immunoassay, correlate with disease activity. [16] Further evidence that BPAG2 mediates epidermal-dermal adhesion comes from analysis of the gene defect in patients with the genetic subepidermal blistering disease *generalized atrophic benign epidermolysis bullosa*. These patients have recessively inherited mutations in the *BPAG2* gene that result in a missing or dysfunctional protein. [42]

Not only patients with bullous pemphigoid and herpes gestationis but also patients with linear IgA disease, cicatricial pemphigoid, and lichen planus pemphigoides have antibodies against BPAG2 or its metabolic products. [43]

Pathophysiology of Lesion Production

Autoantibodies, particularly those against BPAG2, detected in patients with bullous pemphigoid are probably pathogenic. Bullous pemphigoid IgG injected into rabbit cornea fixes to the basement membrane and causes subepithelial blister formation. [44] Furthermore, it has been demonstrated that antibodies against BPAG2 can induce disease by passive transfer to neonatal mice. [45] In these studies, antibodies were raised in rabbits against the epitope on mouse BPAG2 that corresponds to the epitope that most human bullous pemphigoid and herpes gestationis sera recognize. Passive transfer of these rabbit antibodies to neonatal mice induces blisters with histology very similar to that of bullous pemphigoid lesions. In this model, complement, neutrophils, and neutrophil elastase are necessary for anti-BPAG2 induction of blister formation. [46] In vitro studies with normal human skin sections indicate that the bullous pemphigoid IgG is capable of activating complement by the classical pathway, thereby causing leukocyte adherence to the basement membrane, with degranulation and resulting dermal-epidermal separation. [47]

The preceding immunopathologic observations are consistent with proposed pathophysiologic explanations for blister formation in bullous pemphigoid. [48] The initial step in blister formation is postulated to be antibody binding to the bullous pemphigoid antigen. Fixation of IgG to the basement membrane activates the classical complement cascade and probably also the C3 amplification mechanism. Activated complement components cause chemotaxis of leukocytes as well as degranulation of mast cells. Mast cell products cause chemotaxis of eosinophils through mediators such as eosinophil chemotactic factor of anaphylaxis. Finally, leukocyte and mast cell proteases result in dermal-epidermal separation. For example, eosinophils, the predominant inflammatory cell at the basement membrane in bullous pemphigoid lesions, produce a gelatinase that cleaves the collagenous extracellular domain of BPAG2, probably contributing to blister formation. [49]

In light of identification of the bullous pemphigoid antigens as components of the hemidesmosome, it also must be considered that antibodies may interfere directly with the function of this organelle, thought to be important in anchoring the basal cells to the basement membrane. In this regard, a mechanism of blister formation in which antibodies against BPAG2 interfere with hemidesmosome formation has been proposed. [50]

As in most autoimmune diseases, the cause of the induction of autoantibody production in bullous pemphigoid remains obscure, although the overexpression of the class II major histocompatability complex (MHC) allele *DQß1*0301* in bullous pemphigoid patients suggests that presentation of BPAG2 peptides to the immune system in a way that causes disease is restricted to individuals with certain immune response genes. [51]

CLINICAL MANIFESTATIONS

Skin and Mucous Membrane Involvement

The skin lesion characteristic of bullous pemphigoid is a large, tense blister arising on normal skin or on an erythematous base [4] (Fig. 61-3A). These lesions are most common on the lower abdomen, inner or anterior thighs, and flexor forearms, although they may occur anywhere. The bullae usually are filled with clear fluid but may be hemorrhagic. Eroded skin from ruptured blisters usually shows a good tendency to reepithelialize, and unlike pemphigus vulgaris, these erosions do not tend to expand at the periphery. However, new, discrete vesicles may form at the edge of old, resolving lesions. The lesions of bullous pemphigoid do not scar. There is usually, but not always, marked pruritus.

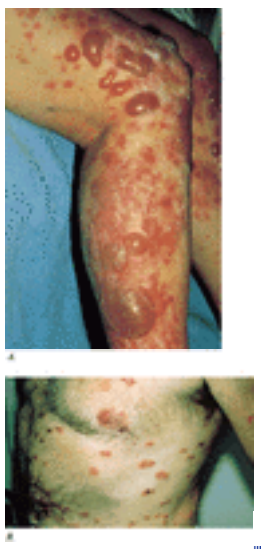

FIGURE 61-3 Bullous pemphigoid. *A*. Large, tense bullae and erythematous macules on the thighs and lower legs. (*Courtesy of James Fitzpatrick, MD.*) *B.* Urticarial lesions of bullous pemphigoid.

Sometimes the erythematous component predominates, and patients may present with urticarial lesions, especially early in the course of disease (see Fig. 61-3B). The erythematous component also can appear serpiginous, with peripheral blisters, and may be quite extensive (Fig. 61-4). Resolution usually occurs from the center and may be accompanied by hyperpigmentation.

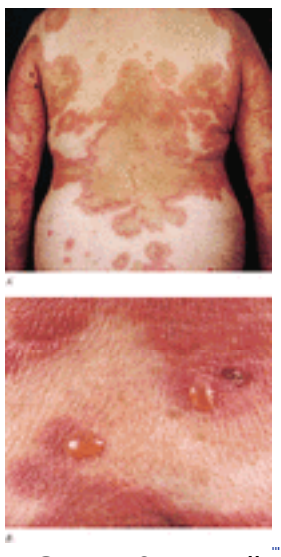

FIGURE 61-4 Bullous pemphigoid. *A.* Extensive urticarial, inflammatory plaques with central regression and hyperpigmentation. *B.* Large, tense bullae and erythematous urticarial-type lesions.

Mucous membrane lesions occur in about 10 to 35 percent of patients and are almost always limited to the oral mucous membranes, especially the buccal mucosa. [4], [11] Intact blisters or, more usually, erosions are seen. These do not scar and usually are not extensive. Unlike erythema multiforme, the vermillion border of the lips is involved rarely.

In addition to the characteristic clinical findings described earlier, there have been descriptions of bullous pemphigoid with unusual presentations. [52] In all these cases, the diagnosis has been confirmed by immunofluorescence findings. For example, lesions in bullous pemphigoid sometimes are localized, most commonly to the lower legs. [53] These patients with localized disease have antibodies against the same pemphigoid antigens described earlier [54], [55] and they may go on to generalized bullous pemphigoid or remain localized for years. There is a specific type of localized pemphigoid described in childhood in which blisters and erosions are limited to the vulvar and perivulvar area. [56] As in other forms of localized pemphigoid and childhood pemphigoid, antibodies from this disease bind the pemphigoid antigens. [5], [56] Not infrequently, especially early in disease, patients may have only urticarial and eczematous lesions without bullae. Other less usual presentations include erythroderma, prurigo nodularis-like or vegetating lesions, and dyshidrotic dermatitis-like lesions. Again, the antibodies from these patients show typical immunofluorescence localization and bind the pemphigoid antigens. [57], [58], [59] and [60]

Precipitating Factors

Most cases of bullous pemphigoid occur sporadically without any obvious precipitating factors. However, there are several reports of precipitation of bullous pemphigoid by ultraviolet (UV) light, either UVB or psoralens with UVA, and radiation therapy. [61], [62], [63] and [64]

Laboratory Abnormalities

In addition to the immunopathologic features described earlier, almost one-half of patients will have elevated total serum IgE, levels of which are positively correlated with IgG anti–basement membrane zone immunofluorescence titers. [13], [65], [66] Furthermore, elevated levels of IgE correlate with the presence of pruritus. [13] Finally, about one-half of patients have peripheral blood eosinophilia, sometimes marked, but not correlated with serum IgE levels. [13], [67]

Associated Diseases

There have been many case reports of bullous pemphigoid associated with malignancy. However, bullous pemphigoid occurs in elderly patients, as does malignancy, and case-control studies suggest that there is no increase, or a very small increase, in the incidence of malignancy in patients compared with age-matched controls. [68], [69] and [70] However, there may be an increased incidence of malignancy in bullous pemphigoid patients with negative indirect immunofluorescence as compared with those with positive indirect immunofluorescence. [11], [71] Whether this increase means that in indirect immunofluorescence–negative patients with bullous pemphigoid there is an overall increased incidence of malignancy compared with age-matched controls is not known. Most authors agree that, other than a general physical examination and good review of systems, an extensive screening workup for an asymptomatic malignancy is not indicated for a bullous pemphigoid patient.

The coexistence of bullous pemphigoid and lichen planus, referred to as *lichen planus pemphigoides,* has been well documented. [72] These cases show typical clinical, histologic, and immunopathologic features of both diseases. It is postulated that anti–basement membrane zone antibodies develop as a consequence of the damage induced by the T cell lymphocytic infiltrate at the basement membrane in lichen planus. Some authors have reported an association of bullous pemphigoid with various other autoimmune diseases, including pemphigus. [73], [74], [75] and [76] These associations occur only rarely. Finally, there may be a slight increased incidence of psoriasis in bullous pemphigoid patients as compared with age-matched controls. [77], [78]

PATHOLOGY

Biopsy of an early small blister is most diagnostic. Histology of such a biopsy will show a subepidermal blister without epidermal necrosis and a superficial dermal infiltrate consisting characteristically of lymphocytes, histiocytes, and eosinophils [4] (Fig. 61-5A). The degree of the infiltrate ranges from intense to sparse, but it characteristically contains some eosinophils. Biopsies from blisters arising on erythematous bases tend to have more extensive infiltrates. Eosinophils are also seen often in the blister cavity. Neutrophils may be seen in the infiltrate, but in contrast to histologic findings in dermatitis herpetiformis, they seldom form microabscesses in the papillary tips. Urticarial lesions may show only a superficial dermal infiltrate of lymphocytes, histiocytes, and eosinophils with papillary dermal edema. Histology of these urticarial lesions also may display degranulating eosinophils at the dermal-epidermal junction, with early separation of individual basal cells from the basement membrane and/or eosinophilic spongiosis [79] (See Fig. 61-5B).

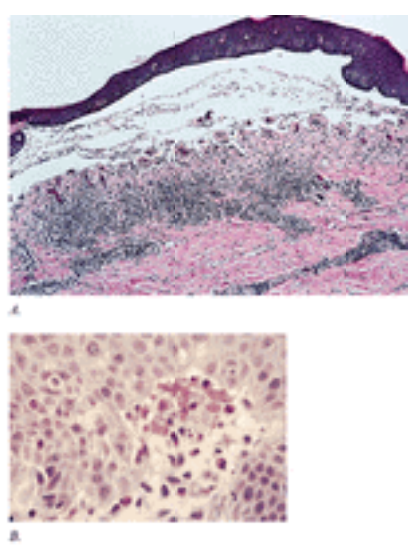

FIGURE 61-5 Histopathology of bullous pemphigoid. *A.* Subepidermal blister with an inflammatory cell infiltrate, containing eosinophils, in the superficial dermis. *B.* Degranulating eosinophils at the epidermal basement membrane and eosinophilic spongiosis.

DIFFERENTIAL DIAGNOSIS

Bullous pemphigoid can be differentiated easily from most other blistering diseases, such as linear IgA disease, chronic bullous disease of childhood, dermatitis herpetiformis, erythema multiforme, and pemphigus, by histology and immunofluorescence. The most difficult diseases to differentiate from bullous pemphigoid are epidermolysis bullosa acquisita (EBA) and cicatricial pemphigoid. [80], [81] EBA usually can be distinguished by clinical criteria if it presents as a noninflammatory mechanobullous disease (see Chap. 67). However, occasionally it may present as an inflammatory disease that may be similar clinically and histologically to bullous pemphigoid. [80] By routine direct and indirect immunofluorescence, these diseases also may show indistinguishable findings. However, EBA may be distinguished from bullous pemphigoid by indirect or direct immunofluorescence on skin incubated in 1 *M* sodium chloride to cause a split in the lamina lucida, as discussed earlier [82] (see Fig. 61-2). Immunoelectron microscopy also distinguishes these diseases because the IgG in EBA is below the lamina densa on the anchoring fibrils, [83] whereas the IgG in bullous pemphigoid is closely associated with the basal cell hemidesmosomes. Finally, autoantibodies from EBA patients bind type VII collagen. [84]

As opposed to bullous pemphigoid, cicatricial pemphigoid usually manifests clinical activity predominantly, if not exclusively, on mucous membranes (see Chap. 62). Cicatricial pemphigoid is characterized by desquamative gingivitis as well as inflammation and scarring of conjunctiva. If there is blistering of the skin, it may be transient or may result in scarring. Large, tense blisters, which are characteristic of bullous pemphigoid, are usually not seen in cicatricial

pemphigoid.

TREATMENT AND PROGNOSIS

Bullous pemphigoid, even without therapy, is often a self-limited disease, but it may last from several months to many years. Lever [4] reported that 8 of 30 adults with bullous pemphigoid, before the advent of glucocorticoid therapy, went into remission after about 15 months (range 3–38 months) of active disease. Eight of these patients, all above 65 years of age, died with bullous pemphigoid as a contributing cause of death, whereas none of 16 adult patients less than 65 years of age died. A more recent study of bullous pemphigoid patients, mean age 79, showed a 17 and 31 percent mortality at 3 and 6 months, respectively, mainly from sepsis and cardiovascular disease. [85] Old age (>86 years old), poor general health, and generalized disease were associated with poor prognosis, as might be expected. Other authors feel that these mortality rates are higher than their experience and that of previous reports of approximately 20 percent at 1 year and 30 percent at 3 years. [86] Thus bullous pemphigoid is a potentially fatal disease mostly in the elderly, whose health already may be fragile.

About one-half of treated patients will go into remission within about 2.5 to 6 years; however, in individual patients, disease may continue for 10 years or more. [11], [13] Clinical remission with reversion of direct and indirect immunofluorescence to negative has been noted in patients, even those with severe generalized disease, treated with oral glucocorticoids alone or with azathioprine. [12], [13]

Localized bullous pemphigoid often can be treated successfully with topical glucocorticoids alone. [12], [13], [87] More extensive disease, which is often more difficult to control than less extensive disease, [12] is usually treated with oral prednisone. [87] However, a study from France has shown that potent topical steroids are effective in both moderate and severe bullous pemphigoid. [88] In elderly patients, the complications of systemic glucocorticoid therapy (such as osteoporosis, diabetes, and immunosuppression) may be especially severe. [89] Therefore, it is important (1) to try to minimize the total dose and duration of therapy with prednisone and (2) to attempt to either treat initially with or taper rapidly to alternate-day therapy. In addition, immunosuppressive agents such as azathioprine (and less often methotrexate or cyclophosphamide) often are used for their potential steroid-sparing effects. [87], [90], [91] and [92] However, one study found that if systemic glucocorticoids are given at rather high dosage for 4 weeks without taper, the addition of azathioprine does not add appreciable benefit. [93] Therefore, the beneficial effects of azathioprine probably reside in its steroid-sparing effects. [90] In elderly patients, these immunosuppressives may be used during initial therapy and even may be used without accompanying prednisone in limited disease. However, to bring widespread disease under rapid control, systemic glucocorticoids often are necessary because their effect is usually rapid (within days), whereas immunosuppressives take at least 4 to 6 weeks to show any effect. High-dose “pulse” therapy with intravenous methylprednisolone also has been reported to be effective in rapidly controlling active blister formation in bullous pemphigoid. [94]

Sulfones may be effective in a minority of patients. Dapsone and sulfapyridine have been reported to control disease activity in 15 to 44 percent of bullous pemphigoid patients. [95], [96] and [97]

An increasing number of reports have described successful treatment of some bullous pemphigoid patients with tetracycline and nicotinamide or variations on this theme, such as erythromycin and nicotinamide or tetracycline alone. [98], [99] and [100] In small numbers of patients, other therapies reported to be effective include mycophenolate mofetil [101], [102] (which may provide a less toxic alternative for azathioprine), leflunomide, [103] chlorambucil, [104] plasmapheresis, [105] and intravenous gammaglobulin. [106]

REFERENCES

1. Lever WF: Pemphigus. *Medicine* **32**:1, 1953

2. Jordon RE et al: Basement zone antibodies in bullous pemphigoid. *JAMA* **200**:751, 1967

3. Beutner EH et al: Autoantibodies in pemphigus vulgaris. *JAMA* **192**:682, 1965

4. Lever WF: *Pemphigus and Pemphigoid.* Springfield, Ill.: Charles C. Thomas, 1965

5. Trüeb RM et al: Childhood bullous pemphigoid: Report of a case with characterization of the targeted antigens. *J Am Acad Dermatol* **40**:338, 1999

6. Bernard P et al: Incidence and distribution of subepidermal autoimmune bullous skin diseases in three French regions. Bullous Diseases French Study Group. *Arch Dermatol* **131**:48, 1995

7. Zillikens D et al: Incidence of autoimmune subepidermal blistering dermatoses in a region of central Germany. *Arch Dermatol* **131**:957, 1995

8. Lever WF: Pemphigus and pemphigoid. *J Am Acad Dermatol* **1**:2, 1979

9. Schaumburg-Lever G et al: Electron microscopic study of bullous pemphigoid. *Arch Dermatol* **106**:662, 1972

10. Wintroub BU et al: Morphologic and functional evidence for release of mast-cell products in bullous pemphigoid. *New Engl J Med* **298**:417, 1978

11. Person JR, Rogers RS 3d: Bullous and cicatricial pemphigoid: Clinical, histopathologic, and immunopathologic correlations. *Mayo Clin Proc* **52**:54, 1977

12. Ahmed AR et al: Bullous pemphigoid. *Arch Dermatol* **113**:1043, 1977

13. Hadi SM et al: Clinical, histological and immunological studies in 50 patients with bullous pemphigoid. *Dermatologica* **176**:6, 1988

14. Beutner EH et al: The immunopathology of pemphigus and bullous pemphigoid. *J Invest Dermatol* **51**:63, 1968

15. Parodi A, Rebora A: Serum IgE antibodies bind to the epidermal side of the basement membrane zone splits in bullous pemphigoid (letter). *Br J Dermatol* **126**:526, 1992

16. Dopp R et al: IgG4 and IgE are the major immunoglobulins targeting the NC16A domain of BP180 in bullous pemphigoid: Serum levels of these immunoglobulins reflect disease activity. *J Am Acad Dermatol* **42**:577, 2000

17. Gammon WR et al: Differentiating anti-lamina lucida and anti-sublamina densa anti-BMZ antibodies by indirect immunofluorescence on 1.0 *M* sodium chloride separated skin. *J Invest Dermatol* **82**:139, 1984

18. Kelly SE, Wojnarowska F: The use of chemically split tissue in the detection of circulating anti-basement membrane zone antibodies in bullous pemphigoid and cicatricial pemphigoid. *Br J Dermatol* **118**:31, 1988

19. Sams WM Jr, Jordon RE: Correlation of pemphigoid and pemphigus antibody titres with activity of disease. *Br J Dermatol* **84**:7, 1971

20. Jordon RE, Bushkell LL: The complement system in pemphigus, bullous pemphigoid and herpes gestationis. *Int J Dermatol* **18**:271, 1979

21. Carlo JR et al: Demonstration of the complement regulating protein, B1H, in skin biopsies from patients with bullous pemphigoid. *J Invest Dermatol* **73**:551, 1979

22. Dahl MV et al: Deposition of the membrane attack complex of complement in bullous pemphigoid. *J Invest Dermatol* **82**:132, 1984

23. Mutasim DF et al: Definition of bullous pemphigoid antibody binding to intracellular and extracellular antigen associated with hemidesmosomes. *J Invest Dermatol* **92**:225, 1989

24. Shimizu H et al: Demonstration of intra- and extracellular localization of bullous pemphigoid antigen using cryofixation and freeze substitution for postembedding immunoelectron microscopy. *Arch Dermatol Res* **281**:443, 1989

25. Stanley JR: Cell adhesion molecules as targets of autoantibodies in pemphigus and pemphigoid, bullous diseases due to defective epidermal cell adhesion. *Adv Immunol* **53**:291, 1993

26. Stanley JR et al: Characterization of bullous pemphigoid antigen: A unique basement membrane protein of stratified squamous epithelia. *Cell* **24**:897, 1981

27. Stanley JR et al: Isolation of cDNA for bullous pemphigoid antigen by use of patients' autoantibodies. *J Clin Invest* **82**:1864, 1988

28. Green KJ et al: Comparative structural analysis of desmoplakin, bullous pemphigoid antigen and plectin: Members of a new gene family involved in organization of intermediate filments. *Int J Biol Macrobiol* **14**:145, 1992

29. Tanaka T et al: Production of rabbit antibodies against carboxy-terminal epitopes encoded by bullous pemphigoid cDNA. *J Invest Dermatol* **94**:617, 1990

30. Guo L et al: Gene targeting of BPAG1: Abnormalities in mechanical strength and cell migration in stratified epithelia and neurologic degeneration. *Cell* **81**:233, 1995

31. Brown A et al: The mouse dystonia musculorum gene is a neural isoform of bullous pemphigoid antigen 1. *Nature Genet* **10**:301, 1995

32. Yang Y et al: An essential cytoskeletal linker protein connecting actin microfilaments to intermediate filaments. *Cell* **86**:655, 1996

33. Labib RS et al: Molecular heterogeneity of the bullous pemphigoid antigens as detected by immunoblotting. *J Immunol* **136**:1231, 1986

34. Haase C et al: Detection of IgG autoantibodies in the sera of patients with bullous and gestational pemphigoid: ELISA studies utilizing a baculovirus-encoded form of bullous pemphigoid antigen 2. *J Invest Dermatol* **110**:282, 1998

35. Zillikens D et al: A highly sensitive enzyme-linked immunosorbent assay for the detection of circulating anti-BP180 autoantibodies in patients with bullous pemphigoid. *J Invest Dermatol* **109**:679, 1997

36. Giudice GJ et al: Cloning and primary structural analysis of the bullous pemphigoid autoantigen BP180. *J Invest Dermatol* **99**:243, 1992

37. Ishiko A et al: Human autoantibodies against the 230-kD bullous pemphigoid antigen (BPAG1) bind only to the intracellular domain of the hemidesmosome, whereas those against the 180-kD bullous pemphigoid antigen (BPAG2) bind along the plasma membrane of the hemidesmosome in normal human and swine skin. *J Clin Invest* **91**:1608, 1993

38. Borradori L et al: The localization of bullous pemphigoid antigen 180 (BP180) in hemidesmosomes is mediated by its cytoplasmic domain and seems to be regulated by the beta4 integrin subunit. *J Cell Biol* **136**:1333, 1997

39. Masunaga T et al: The extracellular domain of BPAG2 localizes to anchoring filaments and its carboxyl terminus extends to the lamina densa of normal human epidermal basement membrane (see comments). *J Invest Dermatol* **109**:200, 1997

40. Giudice GJ et al: Bullous pemphigoid and herpes gestationis autoantibodies recognize a common non-collagenous site on the BP180 ectodomain. *J Immunol* **151**:5742, 1993

41. Zillikens D et al: Tight clustering of extracellular BP180 epitopes recognized by bullous pemphigoid autoantibodies. *J Invest Dermatol* **109**:573, 1997

42. McGrath JA et al: A homozygous deletion mutation in the gene encoding the 180-kDa bullous pemphigoid antigen (BPAG2) in a family with generalized atrophic benign epidermolysis bullosa. *J Invest Dermatol* **106**:771, 1996

43. Zillikens D et al: Autoantibodies in lichen planus pemphigoides react with a novel epitope within the C-terminal NC16A domain of BP180. *J Invest Dermatol* **113**:117, 1999

44. Anhalt GJ et al: Pathogenic effects of bullous pemphigoid autoantibodies on rabbit corneal epithelium. *J Clin Invest* **68**:1097, 1981

45. Liu Z et al: A passive transfer model of the organ-specific autoimmune disease, bullous pemphigoid, using antibodies generated against the

hemidesmosomal antigen, BP180. *J Clin Invest* **92**:2480, 1993

46. Liu Z et al: A critical role for neutrophil elastase in experimental bullous pemphigoid. *J Clin Invest* **105**:113, 2000

47. Gammon WR et al: An in vitro model of immune complex-mediated basement membrane zone separation caused by pemphigoid antibodies, leukocytes, and complement. *J Invest Dermatol* **78**:285, 1982

48. Sams WM Jr, Gammon WR: Mechanism of lesion production in pemphigus and pemphigoid. *J Am Acad Dermatol* **6**:431, 1982

49. Stahle-Backdahl M et al: 92-kD gelatinase is produced by eosinophils at the site of blister formation in bullous pemphigoid and cleaves the extracellular domain of recombinant 180-kD bullous pemphigoid autoantigen. *J Clin Invest* **93**:2022, 1994

50. Kitajima Y et al: Internalization of the 180 kDa bullous pemphigoid antigen as immune complexes in basal keratinocytes: An important early event in blister formation in bullous pemphigoid. *Br J Dermatol* **138**:71, 1998

51. Yancey KB, Egan CA: Pemphigoid: Clinical, histologic, immunopathologic, and therapeutic considerations. *JAMA* **284**:350, 2000

52. Provost TT et al: Unusual subepidermal bullous diseases with immunologic features of bullous pemphigoid. *Arch Dermatol* **115**:156, 1979

53. Person JR et al: Localized pemphigoid. *Br J Dermatol* **95**:531, 1976

54. Domloge-Hultsch N et al: Autoantibodies from patients with localized and generalized bullous pemphigoid immunoprecipitate the same 230-kD keratinocyte antigen. *Arch Dermatol* **126**:1337, 1990

55. Schumann H et al: A child with localized vulval pemphigoid and IgG autoantibodies targeting the C-terminus of collagen XVII/BP180. *Br J Dermatol* **140**:1133, 1999

56. Farrell AM et al: Childhood vulval pemphigoid: a clinical and immunopathological study of five patients. *Br J Dermatol* **140**:308, 1999

57. Strohal R et al: Nonbullous pemphigoid: Prodrome of bullous pemphigoid or a distinct pemphigoid variant? *J Am Acad Dermatol* **29**:293, 1993

58. Borradori L et al: Localized pretibial pemphigoid and pemphigoid nodularis. *J Am Acad Dermatol* **27**:863, 1992

59. Chan LS et al: Pemphigoid vegetans represents a bullous pemphigoid variant: Patient's IgG autoantibodies identify the major bullous pemphigoid antigen. *J Am Acad Dermatol* **28**:331, 1993

60. Korman NJ, Woods SG: Erythrodermic bullous pemphigoid is a clinical variant of bullous pemphigoid. *Br J Dermatol* **133**:967, 1995

61. Cram DL, Fukuyama K: Immunohistochemistry of ultraviolet-induced pemphigus and pemphigoid lesions. *Arch Dermatol* **106**:819, 1972

62. Thomsen K, Schmidt H: PUVA-induced bullous pemphigoid. *Br J Dermatol* **95**:568, 1976

63. Koerber WA Jr et al: coexistent psoriasis and bullous pemphigoid. *Arch Dermatol* **114**:1643, 1978

64. Knoell KA et al: Localized bullous pemphigoid following radiotherapy for breast carcinoma. *Arch Dermatol* **134**:514, 1998

65. Baba T et al: An eosinophil chemotactic factor present in blister fluids of bullous pemphigoid patients. *J Immunol* **116**:112, 1976

66. Arbesman CE et al: IgE levels in sera of patients with pemphigus or bullous pemphigoid. *Arch Dermatol* **110**:378, 1974

67. Bushkell LL, Jordon RE: Bullous pemphigoid: A cause of peripheral blood eosinophilia. *J Am Acad Dermatol* **8**:648, 1983

68. Stone SP, Schroeter AL: Bullous pemphigoid and associated malignant neoplasms. *Arch Dermatol* **111**:991, 1975

69. Lindelof B et al: Pemphigoid and cancer. *Arch Dermatol* **126**:66, 1990

70. Venning VA, Wojnarowska F: The association of bullous pemphigoid and malignant disease: A case control study. *Br J Dermatol* **123**:439, 1990

71. Hodge L et al: Bullous pemphigoid: The frequency of mucosal involvement and concurrent malignancy related to indirect immunofluorescence findings. *Br J Dermatol* **105**:65, 1981

72. Stingl G, Holubar K: Coexistence of lichen planus and bullous pemphigoid. *Br J Dermatol* **93**:313, 1975

73. Callen JP: Internal disorders associated with bullous disease of the skin. *J Am Acad Dermatol* **3**:107, 1980

74. Chorzelski TP et al: Coexistence of pemphigus and bullous pemphigoid. *Arch Dermatol* **109**:849, 1974

75. Leibovici V et al: Coexistence of pemphigus and bullous pemphigoid. *Int J Dermatol* **28**:259, 1989

76. Ishiko A et al: Combined features of pemphigus foliaceus and bullous pemphigoid: Immunoblot and immunoelectron microscopic studies (letter). *Arch Dermatol* **131**:732, 1995

77. Grattan CEH: Evidence of an association between bullous pemphigoid and psoriasis. *Br J Dermatol* **113**:281, 1985

78. Kirtschig G et al: Acquired subepidermal bullous diseases associated with psoriasis: A clinical immunopathological and immunogenetic study. *Br J Dermatol* **135**:738, 1996

79. Crotty C et al: Eosinophilic spongiosis: A clinicopathologic review of seventy-one cases. *J Am Acad Dermatol* **8**:337, 1983

80. Gammon WR et al: Epidermolysis bullosa acquisita: A pemphigoid-like disease. *J Am Acad Dermatol* **11**:820, 1984

81. Venning VA et al: Mucosal involvement in bullous and cicatricial pemphigoid: A clinical and immunopathological study. *Br J Dermatol* **118**:7, 1988

82. Gammon WR et al: Direct immunofluorescence studies of sodium chloride–separated skin in the differential diagnosis of bullous

pemphigoid and epidermolysis bullosa acquisita. *J Am Acad Dermatol* **22**:664, 1990

83. Karpati S et al: In Situ localization of IgG in epidermolysis bullosa acquisita by immunogold technique. *J Am Acad Dermatol* **26**:726, 1992

84. Woodley DT et al: Epidermolysis bullosa acquisita antigen is the globular carboxyl terminus of type VII procollagen. *J Clin Invest* **81**:683, 1988

85. Roujeau JC et al: High risk of death in elderly patients with extensive bullous pemphigoid. *Arch Dermatol* **134**:465, 1998

86. Korman NJ: Bullous pemphigoid: The latest in diagnosis, prognosis, and therapy (letter, comment). *Arch Dermatol* **134**:1137, 1998

87. Fine JD: Management of acquired bullous skin diseases (see comments). *New Engl J Med* **333**:1475, 1995

88. Joly P et al: A comparison of oral and topical cortieosteroids in patients with bullous pemphigoid. *N Engl J Med* **346**:321, 2002

89. Savin JA: The events leading to the death of patients with pemphigus and pemphigoid. *Br J Dermatol* **101**:521, 1979

90. Burton JL et al: Azathioprine plus prednisone in treatment of pemphigoid. *BMJ* **2**:1190, 1978

91. Paul MA et al: Low-dose methotrexate treatment in elderly patients with bullous pemphigoid. *J Am Acad Dermatol* **31**:620, 1994

92. Heilborn JD et al: Low-dose oral pulse methotrexate as monotherapy in elderly patients with bullous pemphigoid. *J Am Acad Dermatol* **40**:741, 1999

93. Guillaume JC et al: Controlled trial of azathioprine and plasma exchange in addition to prednisolone in the treatment of bullous pemphigoid. *Arch Dermatol* **129**:49, 1993

94. Siegel J, Eaglstein WH: High-dose methylprednisolone in the treatment of bullous pemphigoid. *Arch Dermatol* **120**:1157, 1984

95. Person JR, Rogers RS III: Bullous pemphigoid responding to sulfapyridine and the sulfones. *Arch Dermatol* **113**:610, 1977

96. Venning VA et al: Dapsone as first line therapy for bullous pemphigoid. *Br J Dermatol* **120**:83, 1989

97. Bouscarat F et al: Treatment of bullous pemphigoid with dapsone: Retrospective study of thirty-six cases. *J Am Acad Dermatol* **34**:683, 1996

98. Berk MA, Lorincz AL: The treatment of bullous pemphigoid with tetracycline and niacinamide: A preliminary report. *Arch Dermatol* **122**:670, 1986

99. Fivenson DP et al: Nicotinamide and tetracycline therapy of bullous pemphigoid. *Arch Dermatol* **130**:753, 1994

100. Kolbach DN et al: Bullous pemphigoid successfully controlled by tetracycline and nicotinamide. *Br J Dermatol* **133**:88, 1995

101. Bohm M et al: Bullous pemphigoid treated with mycophenolate mofetil. *Lancet* **349**:541, 1997

102. Nousari HC et al: Successful therapy for bullous pemphigoid with mycophenolate mofetil. *J Am Acad Dermatol* **39**:497, 1998

103. Nousari HC, Anhalt GJ: Bullous pemphigoid treated with leflunomide: A novel immunomodulatory agent. *Arch Dermatol* **136**:1204, 2000

104. Milligan A, Hutchinson PE: The use of chlorambucil in the treatment of bullous pemphigoid. *J Am Acad Dermatol* **22**:796, 1990

105. Roujeau JC et al: Plasma exchange in bullous pemphigoid. *Lancet* **2**:486, 1984

106. Engineer L, Ahmed AR: Role of intravenous immunoglobulin in the treatment of bullous pemphigoid: Analysis of current data. *J Am Acad Dermatol* **44**:83, 2001

T>

Chapter 62

Kim Yancey

Cicatricial Pemphigoid

HISTORICAL ASPECTS
Epidemiology
Etiology and Pathogenesis
Electron Microscopy
Immunofluorescence Microscopy
Autoantigens
Disease Pathophysiology
Clinical Manifestations
Mucous Membranes
Skin
Systemic Associations
VARIANTS
Brunsting-Perry Pemphigoid
Ocular Cicatricial Pemphigoid
Pathology
Differential Diagnosis
Treatment and Prognosis

REFERENCES

Cicatricial pemphigoid is a rare chronic autoimmune subepithelial blistering disease characterized by erosive lesions of mucous membranes and skin that result in scarring of at least some sites of involvement. [1], [2] and [3] Lesions commonly involve the oral mucosa and the conjunctivae. Other sites that may be affected include the nasopharyngeal, laryngeal, esophageal, genital, and rectal mucosae. Skin lesions are present in about one-third of patients; tend to predominate on the scalp, face, and upper trunk; and usually consist of a few scattered erosions or tense blisters on an erythematous or urticarial base. Cicatricial pemphigoid is typically chronic and progressive; it may result in serious complications. Immunopathologic studies of perilesional mucosa and skin demonstrate in situ deposits of immunoreactants in epithelial basement membranes. Circulating anti–basement membrane autoantibodies can be detected in the sera of some but not all patients. Studies have shown that a variety of different autoantigens are recognized by autoantibodies in patients with cicatricial pemphigoid. These and other findings have led to the idea that cicatricial pemphigoid is not a single nosologic entity but rather a disease phenotype that develops as a consequence of mucosal injury arising from different mechanisms.

HISTORICAL ASPECTS

Cicatricial pemphigoid has been referred to by a variety of designations based largely on its site of involvement. Examples of such terminology include *desquamative gingivitis, ocular pemphigus,* and *benign mucous membrane pemphigoid.* Currently, such designations are thought to be confusing or somewhat misleading (e.g., pemphigus in this context is a misnomer, and this disorder is hardly benign given the extent of morbidity it can cause). Moreover, some designations (e.g., *desquamative gingivitis*) are limited when the potential spectrum of this chronic disease is considered.

Epidemiology

Cicatricial pemphigoid is rare, occurring in perhaps 1 person per million annually. Females are affected 1.5 to 2 times as often as males. Cicatricial pemphigoid is a disease with a mean age of onset in the early to middle 60s. Although there is no known racial or geographic predilection, some forms have been associated with certain immunogenetic haplotypes. [5], [6], [7] and [8] Specifically, the *HLA-DQB1*0301* allele has been shown to be significantly increased in frequency in patients with oral, ocular, and generalized bullous pemphigoid [5], [8]; amino acid residues at positions 57 and 71–77 of the DQB1 protein may represent a specific disease susceptibility marker for these patients. [6], [7]

Etiology and Pathogenesis

Electron Microscopy

Ultrastructural studies found that blisters of skin and mucous membranes in patients with cicatricial pemphigoid develop within the lamina lucida. [9] The basal lamina may appear partially or completely destroyed in older lesions. A generally held impression is that blisters form below those of bullous pemphigoid, since scarring is more common in patients with this disease. Reports of patients with blisters in the sublamina densa region may represent mucosal-predominant forms of epidermolysis bullosa acquisita (see below).

Immunofluorescence Microscopy

Direct immunofluorescence microscopy of normal-appearing perilesional tissue from patients with cicatricial pemphigoid shows continuous deposits of immunoreactants in epithelial basement membranes. [2], [10] The most commonly detected immunoreactants are IgG and C3 (Fig. 62-1); the predominant subclass of these autoantibodies is IgG_4. [11] IgA, IgM, and/or fibrin are found in some patients. [12] One study of skin and mucosal samples from 10 patients found

immunoreactants more commonly in perilesional mucosal biopsies, suggesting that mucous membranes are the preferred biopsy site for direct immunofluorescence microscopy studies. [10] Splitting tissue samples with 1 *M* NaCl increases the sensitivity of direct immunofluorescence microscopy and facilitates identification of immunoreactants as well as their relative distribution within epithelial basement membranes. [13]

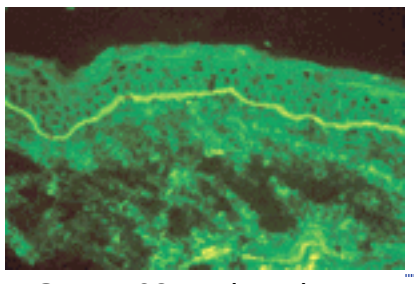

FIGURE 62-1 Direct immunofluorescence microscopy of normal-appearing perilesional skin from a patient with cicatricial pemphigoid shows continuous linear deposits of C3 in the epidermal basement membrane.

Indirect immunofluorescence microscopy studies using intact skin or mucosa often find low-titer IgG (and/or IgA) anti–basement membrane autoantibodies in patients with cicatricial pemphigoid. [2], [14] Studies employing 1 *M* NaCl split skin as a test substrate substantially increase the detection of such autoantibodies. [15], [16] and [17] In such studies, IgG (and/or IgA) binding is usually directed against the epidermal side of 1 *M* NaCl split skin, although combined epidermal and dermal or exclusively dermal binding can occur. In fact, this heterogeneity in autoantibody binding patterns was one of the first clues that cicatricial pemphigoid is associated with different autoantibody systems. While some studies have suggested that the use of human mucosal tissue substrates increases the likelihood of detecting autoantibodies in patients with cicatricial pemphigoid, other studies have not obtained similar results. [1], [10] Recent studies found that patients with both IgG and IgA anti–basement membrane autoantibodies had a worse prognosis as defined by requirements for medications to control disease as well as overall clinical severity score. [18], [19]

Autoantigens

Recent studies have shown that autoantibodies from patients with cicatricial pemphigoid may recognize a variety of different antigens present in epithelial basement membranes (Table 62-1). Some of these autoantigens are relatively well characterized, whereas others are identified only on the basis of their molecular weight and reactivity with autoantibodies present in the sera of patients with this phenotype. Several well-characterized patient subsets are reviewed briefly below.



TABLE 62-1 **Autoantigens in Patients with Cicatricial Pemphigoid**

Many cicatricial pemphigoid patients who have circulating IgG that binds the epidermal side of 1 *M* NaCl split skin have autoantibodies reactive with bullous pemphigoid antigen 2 (BPAG2), a 180-kDa type II transmembrane protein associated with hemidesmosomes in basal keratinocytes. [20], [21] and [22] Autoantibodies in such patients typically bind the distal extracellular domain of BPAG2 alone or in association with reactivity to an epitope situated near the plasma membrane of basal keratinocytes. [21] The latter, the NC16A domain of BPAG2, is also targeted by IgG autoantibodies from patients with bullous pemphigoid and pemphigoid gestationis. [23] Interestingly, immunoelectron microscopy studies have shown that anti-BPAG2 IgG from patients with cicatricial pemphigoid localizes within the lower lamina lucida near its junction with the lamina densa, [22] a site that corresponds to the localization of the distal extracellular domain of BPAG2 in epidermal basement membrane. [24], [25] This observation may explain the greater likelihood of scar formation in patients with this disease rather than those with bullous or gestational pemphigoid.

In contrast to the patients just described, some cicatricial pemphigoid patients have IgG autoantibodies directed exclusively against the dermal side of 1 *M* NaCl split skin. Some of these patients have IgG autoantibodies that bind the superior surface of the lamina densa at its interface with the lamina lucida and immunoprecipitate a set of disulfide-linked polypeptides produced by human keratinocytes. [26], [27] Because the protein that was identified initially as this autoantigen was at the time termed *epiligrin,* this form of disease was called *antiepiligrin cicatricial pemphigoid.* [16] Subsequent studies showed that epiligrin is identical to laminin-5 ($a_3ß_3?_2$) and that these patients' autoantibodies usually bind the alpha subunit of this protein. [28] Because this subunit is immunologically cross-reactive with the alpha subunit of laminin-6 ($a_3ß_1?_1$), these patients' autoantibodies recognize this protein as well. [29], [30]

Examples of other cicatricial pemphigoid autoantigens that appear to be restricted to certain sites of disease or represent rare variants are briefly summarized below. Sera from some patients with ocular cicatricial pemphigoid have been shown to bind a 205-kDa protein in extracts of epithelial cell lines and also isolate a cDNA clone corresponding to the cytoplasmic domain of integrin subunit $ß_4$ (a component of hemidesmosomes in basal keratinocytes). [31], [32] Recent in vitro studies have shown that such autoantibodies may be pathogenic (see below). [33] Although less well characterized, a 168-kDa polypeptide in extracts of mucosal tissue was found to be specifically reactive with autoantibodies from

cicatricial pemphigoid patients with oral involvement. [34] This antigen is not apparently related to bullous pemphigoid antigen 1, BPAG2, or laminin-5. Patients with a mucosal-predominant form of epidermolysis bullosa acquisita are often indistinguishable from patients with cicatricial pemphigoid. [35] Like other patients with epidermolysis bullosa acquisita, these individuals have circulating and/or in situ deposits of IgG against type VII collagen in anchoring fibrils. [3], [36] Other patients with the cicatricial pemphigoid phenotype have IgA anti–basement membrane autoantibodies. While IgA from some of these patients has been shown to bind BPAG2, autoantigens identified in other patients have not been characterized (or shown to be relevant to disease pathophysiology). [14], [37], [38]

Disease Pathophysiology

The immunopathologic findings in patients with cicatricial pemphigoid have suggested that autoantibodies in these patients (like those in patients with pemphigus or bullous pemphigoid) are pathogenic. However, for most autoantibody systems associated with cicatricial pemphigoid, additional study is required to confirm this hypothesis. As noted earlier, BPAG2 is the major autoantigen in cicatricial pemphigoid patients with IgG autoantibodies that bind the epidermal side of 1 *M* NaCl split skin. Such sera typically bind the distal extracellular domain of this protein alone or in association with its more proximal NC16A epitope. [21] Passive-transfer studies have shown that experimental antibodies directed against the murine homologue of the NC16A portion of human BPAG2 elicit subepidermal blisters in neonatal mice with clinical, histologic, and immunopathologic features like those seen in patients with bullous pemphigoid. [39] However, it remains to be determined if antibodies against the distal extracellular portion of BPAG2 elicit mucosal-predominant scarring lesions in experimental animals that mimic those seen in patients with cicatricial pemphigoid.

Recent studies showed that passive transfer of anti–laminin-5 IgG to neonatal mice induced subepidermal blisters of skin and mucous membranes with the same clinical, histologic, and immunopathologic features as those seen in patients with antiepiligrin cicatricial pemphigoid. [40] Anti–laminin-5 IgG induced the same lesions in complement- or mast cell–deficient mice, suggesting that such antibodies may elicit epidermal detachment in vivo in a noninflammatory and perhaps direct manner. [40] Moreover, recent studies showed that injection of IgG from patients with this form of cicatricial pemphigoid into human skin grafts on immunodeficient mice elicited noninflammatory subepidermal blisters, confirming that these patients' autoantibodies are pathogenic in vivo. [41]

Using a human conjunctival organ culture system, investigators showed that antibodies against integrin subunit ß $_4$ elicited subepithelial blister formation in vitro—a finding suggesting that such antibodies are pathogenic in humans in vivo. [33] As is true for disease that predominates on skin, epidermolysis bullosa acquisita affecting mucous membranes is thought to be mediated by anti-type VII collagen autoantibodies. This hypothesis awaits experimental confirmation.

Clinical Manifestations

Mucous Membranes

The mouth is the most frequent site of involvement in patients with cicatricial pemphigoid; it is often the first site affected. Lesions in the mouth often involve the gingiva, buccal mucosa, and palate (Fig. 62-2 and Fig. 62-3); other sites such as the alveolar ridge, tongue, and lips are also susceptible. [4], [42] The most frequent oral manifestation is desquamative gingivitis. Other lesions may present as tense blisters that rupture easily or as mucosal erosions that form as a consequence of epithelial fragility. Lesions in the mouth may result in a delicate white pattern of reticulated scarring. In severe disease, adhesions may develop between the buccal mucosa and the alveolar process, around the uvula and tonsillar fossae, and between the tongue and the floor of the mouth. Gingival involvement can result in tissue loss and dental complications (e.g., caries, periodontal ligament damage, and loss of bone mass and teeth). Disease may be limited to the mouth.

FIGURE 62-2 Cicatricial pemphigoid. Erosive lesions on the hard palate.

FIGURE 62-3 Cicatricial pemphigoid. Denuded sites on the oral mucosa.

Ocular involvement in patients with cicatricial pemphigoid is common and may become sight-threatening. [43] Ocular lesions typically manifest as conjunctivitis that progresses insidiously to scarring. Early ocular disease can be quite subtle and nonspecific. Although disease is usually bilateral, it often begins unilaterally and progresses to both eyes within several years. Patients may complain of burning, dryness, or a foreign-body sensation in one or both eyes; frank blisters on conjunctival surfaces are rarely seen. Early disease is best appreciated by slit-lamp examination. Because disease may be localized to the upper tarsal conjunctiva, it may escape detection without eversion of the eyelids. Chronic ocular involvement can result in scarring characterized by shortened fornices, symblephara (i.e., fibrous tracts between bulbar and palpebral conjunctival surfaces), and in severe disease, ankyloblephara (i.e., fibrous tracts fusing the superior and inferior palpebral conjunctivae with obliteration of the conjunctival sac). Conjunctival scarring also can cause entropion and trichiasis (i.e., in-turning of the eyelashes) that results in corneal irritation, superficial punctate keratinopathy, corneal neovascularization, corneal ulceration, and blindness. Additional ocular complications include scarring of lacrimal ducts, decreased tear secretion, and loss of mucosal goblet cells leading to decreased tear mucus content and unstable tear films. It is very important for patients with suspected ocular involvement to be examined by an ophthalmologist because early disease may be subtle, is only identified by slit-lamp examination, and can result in severe complications. Cicatricial pemphigoid may be limited to the eyes.

Other mucous membranes that may be involved by cicatricial pemphigoid include the nasopharyngeal, laryngeal, esophageal, genital, and rectal mucosae. Nasopharyngeal lesions can result in discharge, epistaxis, excessive crust formation, impaired airflow, chronic sinusitis, scarring, and tissue loss. Laryngeal involvement may present as hoarseness, sore throat, or loss of phonation. Chronic laryngeal erosions, edema, and scarring may result in supraglottic stenosis and airway compromise that eventually necessitates tracheostomy. [44] Esophageal involvement may result in stricture formation, dysphagia, odynophagia, weight loss, and/or aspiration. Moreover, it has been suggested that esophageal dysfunction and gastroesophageal reflux may elicit or exacerbate laryngeal disease and/or bronchospasm in such patients. Although involvement of the genital and/or rectal mucosae in patients with cicatricial pemphigoid is rare, it can be a source of substantial pain and morbidity. Rare cases of urethral stricture, vaginal stenosis, and anal narrowing have developed as a consequence of this disease.

Skin

The skin is involved in 25 to 35 percent of patients with cicatricial pemphigoid. The most frequently affected areas are the scalp, head, neck, and upper trunk. Lesions typically consist of small vesicles or bullae situated on erythematous and/or urticarial bases. Lesions rupture easily and are often seen as small, crusted papules or plaques. In general, the extent and number of cutaneous lesions are small. Skin lesions sometimes recur in the same areas.

Systemic Associations

A cohort of 35 patients with antiepiligrin cicatricial pemphigoid was reported to have an increased relative risk for solid cancer. [45] Ten patients in this cohort had solitary solid cancers (three lung, three gastric, two colon, two endometrial); eight patients developed cancer after the onset of cicatricial pemphigoid (six within a year, seven within 14 months). The time between blister onset and cancer diagnosis was approximately 14 months in 9 of the 10 patients. Eight patients in this cohort died as a consequence of their cancer; all deaths occurred within 21 months. This form of cicatricial pemphigoid appears to have a relative risk for malignancy that approximates that for adults with dermatomyositis; as is true for the latter, the risk for cancer appears to be particularly high in the first year of disease.

VARIANTS

Brunsting-Perry Pemphigoid

In 1957, Brunsting and Perry described seven patients with locally recurrent and scarring subepidermal blistering lesions of the head or neck that for many years was thought to be a form of cicatricial pemphigoid. [46] Although these patients were elderly, had subepithelial bullous lesions that scarred, and demonstrated deposits of immunoreactants in their epidermal basement membranes like other patients with cicatricial pemphigoid, Brunsting-Perry pemphigoid predominated in men and lacked mucous membrane involvement. Recently, patients with the same clinical, histologic, and immunopathologic features have been reported to have autoantibodies directed against bullous pemphigoid antigens or type VII collagen. [3], [47] Identification of similar patients with blister planes beneath the lamina densa further suggests that some individuals with this phenotype represent localized forms of epidermolysis bullosa acquisita. Additional study will clarify this variant further.

Ocular Cicatricial Pemphigoid

Some patients have disease that is limited to conjunctival mucous membranes, and several series have segregated patients on the basis of this finding. [5], [6], [8], [48] Additional studies hopefully will determine if there is further heterogeneity among these patients in respect to their autoantibody systems, pathophysiology, and/or response to treatment.

Pathology

Although light microscopy studies of lesional skin or mucosa from patients with cicatricial pemphigoid often are nonspecific, they characteristically show a subepidermal blister and a dermal leukocytic infiltrate composed of lymphocytes and histiocytes as well as variable numbers of neutrophils and eosinophils. Plasma cells often are seen in mucosal lesions, whereas eosinophils and neutrophils are seen most commonly in skin lesions. Biopsies of older lesions may be relatively “cell poor” and correlate with the noninflammatory character of such sites clinically. Light microscopy studies of older lesions often show fibroblast proliferation and lamellar fibrosis (i.e., fibrosis characterized by collagen bundles ordered parallel to the surface epithelium).

Differential Diagnosis

The diagnosis of cicatricial pemphigoid is suggested when patients present with bullous or erosive lesions of mucous membranes and demonstrate continuous deposits of immunoreactants in epithelial basement membranes of perilesional tissue. The distinction of cicatricial pemphigoid from other autoimmune bullous diseases such as pemphigus vulgaris, bullous pemphigoid, epidermolysis bullosa acquisita, and linear IgA dermatosis can be difficult and may require specialized immunopathologic studies and/or immunoelectron microscopy. In contrast to cicatricial pemphigoid, lesions in patients with pemphigus vulgaris form as a consequence of acantholysis and show deposits of immunoreactants on the surfaces of keratinocytes. Lesions in patients with bullous pemphigoid dominate on the skin, consist of large, tense blisters or vesicles situated on urticarial and/or erythematous bases, and (except in rare cases, e.g., excoriation) do not scar. Circulating IgG autoantibodies in patients with bullous pemphigoid bind BPAG1 and BPAG2 and by immunoelectron microscopy localize to hemidesmosomal plaques and the portion of the lamina lucida adjacent to plasma membranes of basal keratinocytes. In epidermolysis bullosa acquisita, lesions can resemble those seen in patients with bullous pemphigoid or present as dermolytic erosions on areas exposed to pressure or trauma. IgG autoantibodies in patients with epidermolysis bullosa acquisita are directed against type VII collagen in anchoring fibrils. [36] As noted previously, mucosal-predominant forms of this disease do exist, are important to recognize, and often represent management challenges. Some forms of linear IgA dermatosis clinically resemble bullous pemphigoid or dermatitis herpetiformis, whereas others dominate on mucous membranes. These patients are distinguished by continuous deposits of IgA in their epidermal basement membranes and (in many cases) circulating IgA anti–basement membrane autoantibodies. Because immunofluorescence microscopy, immunoblotting, and immunoelectron microscopy studies have demonstrated that a number of different proteins in the lamina lucida or sublamina densa region are targeted by autoantibodies in these patients, mucosal forms of linear IgA dermatosis are considered heterogeneous and incompletely characterized at present.

Other disorders that must be differentiated from cicatricial pemphigoid include lichen planus, erythema multiforme, lupus erythematosus, paraneoplastic pemphigus, lichen sclerosus, and—in the case of ocular disease—cicatrizing conjunctivitis that results from chronic use of certain ophthalmologic preparations (e.g., pilocarpine, guanethidine, or ephedrine used in the treatment of glaucoma or idoxuridine used as an antiviral). It also has been reported that some cases of ocular cicatricial pemphigoid develop after an acute episode of severe ocular inflammatory injury secondary to Stevens-Johnson syndrome. [49] Interestingly, the time between Stevens-Johnson syndrome and the onset of ocular cicatricial pemphigoid in these patients can range from a few months to more than 30 years.

Treatment and Prognosis

Cicatricial pemphigoid is typically a chronic and progressive disorder, although involvement may be limited to a given anatomic site (e.g., the mouth, the conjunctivae) for many years. Cicatricial pemphigoid rarely goes into spontaneous remission; its treatment is largely tempered by its severity and sites of involvement. Scarring can only be prevented in these patients; it never is completely reversed. The following overview is representative of most treatment regimens. Mild lesions of the oral mucosa and skin sometimes can be reated effectively with topical glucocorticoids. Mouthwash (dexamethasone 100 µg/mL, 5 mL per rinse) used in a “swish and spit” regimen for 5 min two to three times each day is one approach. Topical glucocorticoids in a gel or occlusive base (e.g., Orobase) applied two to four times each day is another. These agents are particularly effective before bed because oral secretions diminish during sleep. Because it is difficult to maintain contact of topical agents with mucous membranes (and because lesions often are localized to the gingiva), customized delivery trays to occlude topical glucocorticoids over lesional sites in the mouth are also useful. [50] This approach also facilitates interactions with professionals who can manage other complications in these patients (e.g., dental complications). For oral disease resistant to topical glucocorticoids, these agents can (in some instances) be administered intralesionally.

A number of reports have suggested that dapsone (50–150 mg by mouth daily) may be effective. [43], [51] Others have found that cicatricial pemphigoid does not respond to this agent. In severe cases, systemic glucocorticoids can be administered alone (e.g., 20–60 mg of prednisone by mouth each morning) or in combination with dapsone. Because of potentially severe complications, ocular, laryngeal, and/or esophageal involvement requires aggressive management by teams of physicians familiar with specialized care of these organ systems. For mild or moderate ocular involvement, systemic glucocorticoids (e.g., 20–40 mg of prednisone by mouth each morning) alone or in conjunction with daily dapsone may be effective. Patients whose ocular disease is complicated by trichiasis may benefit from permanent epilation, although this decision is best made by an ophthalmologist. For severe disease affecting the ocular, pharyngeal, or urogenital epithelia, a combination of systemic glucocorticoids and an immunosuppressive drug is indicated. In such cases, cyclophosphamide (1–2 mg/kg per day) is often used in conjunction with daily prednisone (1 mg/kg per day). In this regimen, daily prednisone is tapered gradually over approximately 6 months, and the patient is maintained on cyclophosphamide alone for an additional 6 to 12 months. Such combined regimens have had success in halting the progression of severe ocular disease, limiting scarring, and producing long-term remissions. In an effort to avoid adverse effects and complications produced by prolonged treatment with immunosuppressive agents, attempts have been made to treat patients with intravenous immunoglobulin (i.e., IVIG, 2–3 g/kg of body weight administered over 2–3 days every 2–6 weeks for 4–6 months). [52] Additional experience with this agent is required to confirm preliminary results suggesting

potential utility.

Involvement of the nasopharynx or esophagus potentially has severe complications and requires aggressive and specialized care. Nasal lesions often benefit from twice-daily irrigation of nasal passages with saline or tap water as well as the use of topical emollients. Esophageal involvement requires medical management to avert dysphagia, pain, tissue loss, and secondary complications such as gastroesophageal dysfunction, stricture formation, aspiration, laryngeal irritation, or bronchospastic pulmonary disease. All patients with cicatricial pemphigoid require long-term follow-up because of the possibility for this chronic disease to relapse.

REFERENCES

1. Lever WF: *Pemphigus and Pemphigoid.* Springfield, IL, Charles C Thomas, 1965

2. Bean SF et al: Cicatricial pemphigoid: Immunofluorescence studies. *Arch Dermatol* **106**:195, 1972

3. Fleming TE, Korman NJ: Cicatricial pemphigoid. *J Am Acad Dermatol* **43**:571, 2000

4. Laskaris G et al: Bullous pemphigoid, cicatricial pemphigoid, and pemphigus vulgaris: A comparative clinical survey of 278 cases. *Oral Surg Oral Med Oral Pathol* **54**:656, 1982

5. Ahmed RA et al: Association of DQw7 (*DQB1*0301*) with ocular cicatricial pemphigoid. *Proc Natl Acad Sci USA* **88**:11579, 1991

6. Yunis JJ et al: Common major histocompatibility complex class II markers in clinical variants of cicatricial pemphigoid. *Proc Natl Acad Sci USA* **91**:7747, 1994

7. Delgado JC et al: A common major histocompatibility complex class II allele *HLA-DQB1*0301* is present in clinical variants of pemphigoid. *Proc Natl Acad Sci USA* **93**:8569, 1996

8. Chan LS et al: Significantly increased occurrence of *HLA-DQB1*0301* allele in patients with ocular cicatricial pemphigoid. *J Invest Dermatol* **108**:129, 1997

9. Bernard P et al: Studies of cicatricial pemphigoid autoantibodies using direct immunoelectron microscopy and immunoblot analysis. J Invest Dermatol 94:630, 1990

10. Fine JD et al: Immunofluorescence and immunoelectron microscopic studies in cicatricial pemphigoid. *J Invest Dermatol* **82**:39, 1984

11. Hsu R et al: Noncomplement fixing, IgG_4 autoantibodies predominate in patients with antiepiligrin cicatricial pemphigoid. *J Invest Dermatol* **109**:557, 1997

12. Leonard JN et al: The relationship between linear IgA disease and benign mucous membrane pemphigoid. *Br J Dermatol* **110**:307, 1984

13. Gammon WR et al: Immunofluorescence studies of sodium chloride-separated skin in the differential diagnosis of bullous pemphigoid and epidermolysis bullosa acquisita. *J Am Acad Dermatol* **22**:664, 1990

14. Sarret Y et al: Salt-split human skin substrate for the immunofluorescent screening of serum from patients with cicatricial pemphigoid and a new method of immunoprecipitation with IgA antibodies. *J Am Acad Dermatol* **24**:952, 1991

15. Kelly S, Wojnarowska F: The use of chemically split tissue in the detection of circulating anti–basement membrane zone antibodies in bullous pemphigoid and cicatricial pemphigoid. *Br J Dermatol* **118**:31, 1988

16. Domloge-Hultsch N et al: Anti-epiligrin cicatricial pemphigoid: A subepithelial bullous disorder. *Arch Dermatol* **130**:1521, 1994

17. Lazarova Z, Yancey KB: Reactivity of autoantibodies from patients with defined subepidermal bullous diseases against 1 mol/L NaCl-split skin. *J Am Acad Dermatol* **35**:398, 1996

18. Setterfield J et al: Mucous membrane pemphigoid: A dual circulating antibody response with IgG and IgA signifies a more severe and persistent disease. *Br J Dermatol* **138**:602, 1998

19. Setterfield J et al: Cicatricial pemphigoid: Serial titres of circulating IgG and IgA anti–basement membrane antibodies correlate with disease activity. *Br J Dermatol* **140**:645, 1999

20. Bernard P et al: The major cicatricial pemphigoid antigen is a 180-kDa protein that shows immunologic cross-reactivities with the bullous pemphigoid antigen. *J Invest Dermatol* **99**:174, 1992

21. Balding SD et al: Cicatricial pemphigoid autoantibodies react with multiple sites on the BP180 extracellular domain. *J Invest Dermatol* **106**:141, 1996

22. Bedane C et al: Bullous pemphigoid and cicatricial pemphigoid autoantibodies react with ultrastructurally separable epitopes on the BP180 ectodomain: Evidence that BP180 spans the lamina lucida. *J Invest Dermatol* **108**:901, 1997

23. Giudice GJ et al: Bullous pemphigoid and herpes gestationis autoantibodies recognize a common non-collagenous site on the BP180 ectodomain. *J Immunol* **151**:5742, 1993

24. Hirako Y et al: Demonstration of the molecular shape of BP180, a 180-kDa bullous pemphigoid antigen and its potential for trimer formation. *J Biol Chem* **271**:13739, 1996

25. Masunaga T et al: The extracellular domain of BPAG2 localizes to anchoring filaments and its carboxyl terminus extends to the lamina densa of normal human epidermal basement membrane. *J Invest Dermatol* **109**:200, 1997

26. Domloge-Hultsch N et al: Epiligrin, the major human keratinocyte integrin ligand, is a target in both an acquired autoimmune and an inherited subepidermal blistering skin disease. *J Clin Invest* **90**:1628, 1992

27. Shimizu H et al: Autoantibodies from patients with cicatricial pemphigoid target different sites in epidermal basement membrane. *J Invest Dermatol* **104**:370, 1995

28. Kirtschig G et al: Anti–basement membrane autoantibodies in patients with antiepiligrin cicatricial pemphigoid bind the a subunit of laminin

5. *J Invest Dermatol* **105**:543, 1995

29. Chan LS et al: Laminin 6 and laminin 5 are recognized by autoantibodies in a subset of cicatricial pemphigoid. *J Invest Dermatol* **108**:848, 1997

30. Lazarova Z et al: Antiepiligrin cicatricial pemphigoid represents an autoimmune response to subunits present in laminin 5 (a $_3$ß $_3$? $_2$). *Br J Dermatol* **139**:791, 1998

31. Mohimen A et al: Detection and partial characterization of ocular cicatricial pemphigoid antigens on COLO and SCaBER tumor cell lines. *Curr Eye Res* **12**:741, 1993

32. Tyagi S et al: Ocular cicatricial pemphigoid antigen: Partial sequence and biochemical characterization. *Proc Natl Acad Sci USA* **93**:14714, 1996

33. Chan RY et al: The role of antibody to human beta $_4$ integrin in conjunctival basement membrane separation: Possible in vitro model for ocular cicatricial pemphigoid. *Invest Ophthalmol Vis Sci* **40**:2283, 1999

34. Ghohestani RF et al: Identification of a 168-kDa mucosal antigen in a subset of patients with cicatricial pemphigoid. *J Invest Dermatol* **107**:136, 1996

35. Luke ML et al: Mucosal morbidity in patients with epidermolysis bullosa acquisita. *Arch Dermatol* **135**:954, 1999

36. Woodley DT et al: The epidermolysis bullosa acquisita antigen is the globular carboxyl terminus of type VII collagen. *J Clin Invest* **81**:683, 1988

37. Egan CA et al: Characterization of the antibody response in oesophageal cicatricial pemphigoid. *Br J Dermatol* **140**:859, 1999

38. Egan CA et al: The immunoglobulin A antibody response in clinical subsets of mucous membrane pemphigoid. *Dermatology* **198**:330, 1999

39. Liu Z et al: A passive transfer model of the organ-specific autoimmune disease, bullous pemphigoid, using antibodies generated against the hemidesmosomal antigen, BP180. *J Clin Invest* **92**:2480, 1993

40. Lazarova Z et al: Passive transfer of anti-laminin 5 antibodies induces subepidermal blisters in neonatal mice. *J Clin Invest* **98**:1509, 1996

41. Lazarova Z et al: Human anti-laminin 5 autoantibodies induce subepidermal blisters in an experimental human skin graft model. *J Invest Dermatol* **114**:178, 2000

42. Rogers RS et al: Desquamative gingivitis: Clinical, histopathologic, immunopathologic, and therapeutic observations. *J Am Acad Dermatol* **7**:729, 1982

43. Foster CS: Cicatricial pemphigoid. *Trans Am Ophthalmol Soc* **84**:527, 1986

44. Lazor JB et al: Management of airway obstruction in cicatricial pemphigoid. *Laryngoscope* **106**:1014, 1996

45. Egan CA et al: Antiepiligrin cicatricial pemphigoid and relative risk for cancer. *Lancet* **357**:1850, 2001

46. Brunsting LA, Perry HO: Benign pemphigoid? A report of seven cases with chronic, scarring, herpetiform plaques about the head and neck. *Arch Dermatol* **75**:489, 1957

47. Joly P et al: Brunsting-Perry cicatricial pemphigoid: A clinical variant of localized acquired epidermolysis bullosa? *J Am Acad Dermatol* **28**:89, 1993

48. Chan LS et al: Immune-mediated subepithelial blistering diseases of mucous membranes. *Arch Dermatol* **129**:448, 1993

49. Chan LS et al: Ocular cicatricial pemphigoid occurring as a sequelae of Stevens-Johnson syndrome. *JAMA* **266**:1543, 1991

50. Aufdemorte TB et al: Modified topical steroid therapy for the treatment of oral mucous membrane pemphigoid. *Oral Surg Oral Med Oral Pathol* **59**:256, 1985

51. Tauber J et al: Systemic chemotherapy for ocular cicatricial pemphigoid. *Cornea* **10**:185, 1991

52. Foster CS, Ahmed AR: Intravenous immunoglobulin therapy for ocular cicatricial pemphigoid: A preliminary study. *Ophthalmology* **106**:2136, 1999

T>

Chapter 63

Caroline Rao Russell Hall

Linear IgA Dermatosis and Chronic Bullous Disease of Childhood

EPIDEMIOLOGY
ETIOLOGY AND PATHOGENESIS
Immunopathology
CLINICAL MANIFESTATIONS
Cutaneous Manifestations
Mucosal Involvement
Disease Associations
PATHOLOGY
DIFFERENTIAL DIAGNOSIS
TREATMENT AND PROGNOSIS

REFERENCES

Linear IgA dermatosis is a rare immune-mediated blistering skin disease that is defined by the presence of homogeneous linear deposits of IgA at the cutaneous basement membrane (Fig. 63-1). Although in the original description of patients with linear IgA dermatosis it was considered to be a manifestation of dermatitis herpetiformis (DH), it has now been clearly separated from DH on the basis of its immunopathology, immunogenetics, and lack of consistent association with a gluten-sensitive enteropathy. [1], [2] and [3] Patients with linear IgA dermatosis can present with phenotypic characteristics suggestive of epidermolysis bullosa acquisita (EBA), DH, bullous pemphigoid, lichen planus, or cicatricial pemphigoid. [1], [2], [3] and [4]

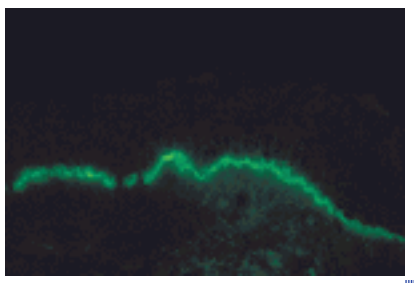

FIGURE 63-1 Direct immunofluorescence of normal-appearing perilesional skin from a patient with linear IgA dermatosis. A homogeneous band of IgA is present at the dermal-epidermal junction.

These different clinical presentations appear to result from the IgA binding to different epidermal antigens. Chronic bullous disease of childhood (CBDC) is a rare blistering disease that occurs predominantly in children younger than 5 years of age and has an identical pattern of homogeneous linear IgA deposits at the epidermal basement membrane. [5], [6] Recent studies have demonstrated that in some patients CBDC and linear IgA dermatosis represent different presentations of the same disease process. [7], [8]

EPIDEMIOLOGY

Linear IgA dermatosis occurs most often after puberty, with most patients presenting after the fourth decade of life. [2], [9], [10] A slight predominance of females has been noted in several studies. [2], [9] In contrast, CBDC presents most often before the age of 5 years. [9] As in patients with linear IgA dermatosis, there is a slight female predominance in patients with CBDC. [6], [9]

Evaluation of the HLA association in patients with linear IgA dermatosis and CBDC has yielded conflicting results. Some investigators have found an increased frequency of the human histocompatibility antigen HLA-B8 in patients with linear IgA dermatosis, whereas others have found no increased frequency. [11], [12], [13] and [14] In CBDC, an increased frequency of HLA-B8 has been noted, with up to 76 percent of patients expressing HLA-B8. [9] Recently, Collier et al. [13] demonstrated an increased frequency of B8, DR3, and DQ2 in CBDC that was not seen in adults with linear IgA dermatosis. These authors suggested that these haplotypes may have a role in earlier disease presentation. In addition, the *TNF2* allele was found with increased frequency in both adults and children with linear IgA disease when compared with normal subjects. There was, however, no increase seen in either adults or children when compared with HLA-DR3+ controls.

ETIOLOGY AND PATHOGENESIS

Immunopathology

Linear IgA dermatosis and CBDC are defined by the presence of a homogeneous linear band of IgA at the dermal-epidermal basement membrane. A minority of patients in both groups have additional deposits of other immunoreactants, most often IgG and occasionally the third component of complement (C3). [9] Since IgA is the predominant immunoglobulin of the secretory immune system, numerous investigators have attempted to determine if the IgA present in the skin of these patients is of mucosal origin. Characterization of the IgA subclass in the skin has

revealed almost exclusively IgA1 and not the subclass most often associated with mucosa, IgA2. [14], [15] and [16] In addition, neither secretory piece nor J chain, both of which are present in secretory IgA, have been found in the IgA present in the skin of patients with linear IgA deposits. [17] Although these data have led to suggestions that the IgA is not of mucosal origin, the true origin of the IgA deposits in the skin of these patients is not known. Initially it was thought that patients with linear IgA dermatosis and CBDC rarely had circulating IgA antibodies against the epidermal basement membrane. Indirect immunofluorescence, using 1 *M* NaCl-split normal human skin as a substrate, demonstrates that the majority of patients with CBDC have low-titer circulating antibodies against the epidermal side of the split skin. [9], [18] Circulating low-titer IgA antibodies directed against the epidermal basement membrane also have been found in adults with linear IgA dermatosis. [9], [18] Others have reported binding of these antibodies to the dermal side of normal human split skin, suggesting that more than one antigen may be the target for the IgA anti–basement membrane antibodies. [18]

Immunoelectron microscopic studies have been performed to determine the exact location of the IgA in the skin of patients with both linear IgA dermatosis and CBDC. Immunoelectron microscopy of the skin of patients with linear IgA deposits has revealed three distinct patterns of immunoreactants. In some patients with linear IgA dermatosis, the IgA deposits are found in the lamina lucida region of the basement membrane zone, similar to the location of immunoreactants present in the skin of patients with bullous pemphigoid. [19], [20] A second pattern of IgA deposition has been detected in which the IgA deposits are present at and below the lamina densa in a pattern similar to that seen in EBA. [19], [20] and [21] Prost et al. [20] have described a third pattern of immunoreactants in some patients with linear IgA dermatosis in which the IgA deposits are found both above and below the lamina densa. In a similar manner, immunoelectron microscopic studies of patients with CBDC have shown the IgA immunoreactants to be in either the lamina lucida or a sublamina densa location. [21], [22] These findings further support the possibility that multiple antigens may be involved as the targets in both adults and children with linear IgA deposits in the skin.

Although the relatively low titer of IgA antibodies against the basement membrane present in the sera of patients with both linear IgA dermatosis and CBDC has complicated the search for specific antigenic targets for the IgA, several investigators have made significant observations regarding the antigenic targets in these diseases. Zone et al. [23] studied sera from patients who had circulating IgA antibodies that bound to the epidermal side of 1 *M* NaCl-split normal human skin, as shown by indirect immunofluorescence. Using immunoblotting, they found that serum IgA from these patients bound to a 97-kDa protein present in both dermal and epidermal extracts of normal human skin. Specificity was demonstrated by eluting IgA from the 97-kDa protein and demonstrating that it bound in the same location in skin as the serum IgA. In a similar manner, these authors eluted IgA that had bound to normal human skin and demonstrated that it also bound to the 97-kDa protein. Zone et al. [7] also have demonstrated similar findings in patients with CBDC who have IgA antibodies that bind to the epidermal side of split skin, as shown by indirect immunofluorescence. Immunoelectron microscopy revealed that the 97-kDa antigen is present in the lamina lucida, below the hemidesmosome of normal human skin, in a location similar to where the IgA is localized in patients with CBDC and linear IgA dermatosis. [24]

Subsequently, Zone et al. [25] determined that the 97-kDa linear IgA bullous disease antigen is identical to a portion of the extracellular domain of the 180-kDa bullous pemphigoid antigen (BPAG2 or collagen XVII), which is essential in anchoring basal keratinocytes to the epidermal basement membrane. The antigen consists of a 180-kDa transmembrane protein and 120-kDa portion that corresponds to the collagenous ectodomain. Roh et al. [26] and Schumann et al. [27] have reported that autoantibodies in patients with linear IgA dermatosis recognize the soluble 120-kDa ectodomain of type XVII collagen. The 120-kDa antigen target is not unique to linear IgA dermatosis because it is also the antigen targeted by autoantibodies in some patients with cicatricial pemphigoid and bullous pemphigoid. This may explain in part the overlap in clinical and histologic features of these conditions. [26], [27]

Wojnarowska et al. [28] also have identified a possible target antigen in patients with linear IgA dermatosis and CBDC. They studied the sera of patients in whom the IgA bound to the epidermal side of 1 *M* NaCl-split skin on routine indirect immunofluorescence. Using immunoblot techniques, they found that IgA in the sera of some patients with these diseases bound to a 285-kDa protein and that the protein was not the 230-kDa bullous pemphigoid antigen or type VII collagen, the EBA antigen. [28] These investigators have not shown, however, that the IgA that binds the 285-kDa protein in vitro is able to bind to skin in a pattern similar to that seen in tissue from patients. The reasons for the differences between these two suggested antigenic targets of the IgA from these patients is not known, and further studies are needed to resolve these findings.

In addition to the two target antigens noted earlier, additional proteins have been detected that bind IgA from some patients with linear IgA dermatosis or CBDC. Smith et al. [29] have identified a 45-kDa protein that binds IgA from patients with a clinical phenotype most suggestive of cicatricial pemphigoid but who have linear IgA deposits at the epidermal basement membrane. In patients with linear IgA dermatosis and IgA antibodies that bind to the dermal side of 1 *M* NaCl-split normal human skin, the IgA has been shown to bind to the EBA antigen, type VII collagen. [30] The antibody from at least one of these patients bound to a different region of the EBA antigen than the region recognized by the sera of most patients with EBA. This suggests that the difference in the binding site in patients with linear IgA diseases, compared with those with EBA, may account for the clinical differences seen in these two groups of patients. [28]

In summary, a number of different antigenic targets have been identified in patients with linear IgA diseases. The specific antigen detected appears to be related to the clinical phenotype, the cutaneous localization of the immunoreactants, and at the current time the laboratory performing the study. Further analysis that takes into account the clinical phenotype, molecular characterization of the antigens, and the continued exchange of sera and other reagents should allow for the more precise characterization of the antigens involved in patients with linear IgA dermatosis and CBDC.

CLINICAL MANIFESTATIONS

Cutaneous Manifestations

The clinical manifestations of linear IgA dermatosis are heterogeneous and often indistinguishable from those seen in patients with DH. [2], [9], [10], [31] Patients may present with combinations of annular or grouped papules, vesicles, and bullae (Fig. 63-2 and Fig. 63-3). Typically, these lesions are distributed symmetrically on extensor surfaces, including elbows, knees, and buttocks. Lesions most often are very pruritic, resulting in numerous crusted papules (Fig. 63-4). The clinical presentation can be difficult to distinguish from that seen in patients with DH. However, the degree of pruritus seen in patients with linear IgA dermatosis is variable and, in general, less severe than that seen in patients with DH. Some patients with linear IgA dermatosis present with larger bullae, in a pattern more consistent with that seen in patients with bullous pemphigoid, or occasionally with cutaneous findings similar to those seen in patients with EBA.

FIGURE 63-2 Patient with linear IgA dermatosis with crusted erosions, papules, and vesicles on the back and neck.

FIGURE 63-3 Patient with linear IgA dermatosis with annular erythematous plaques on the thighs.

FIGURE 63-4 Patient with linear IgA dermatosis with grouped urticarial papules on the back with scattered crusted erosions.

The clinical presentation of CBDC is characterized most often by the development of tense bullae, often on an inflammatory base. [4] These lesions occur most frequently in the perineum and perioral region and often may occur in clusters, giving a “cluster of jewels” appearance (Fig. 63-5, Fig. 63-6, and Fig. 63-7). New lesions sometimes appear around the periphery of previous lesions, with a resulting “collarette” of blisters. Patients often report significant pruritus and/or a burning of the skin with the development of skin lesions. Patients with CBDC often present with the acute development of large numbers of tense blisters, which may rupture and become secondarily infected.

FIGURE 63-5 Patient with chronic bullous disease of childhood. Tense bullae and crusted papules are present on the abdomen, with a clustering of bullae noted in the perineal region.

FIGURE 63-6 Chronic bullous disease of childhood. Tense blisters on erythematous bases in the pubic and inguinal areas.

FIGURE 63-7 Extensive chronic bullous disease of childhood. Note tense and flaccid blisters without notable inflammation.

Rarely, patients with linear IgA dermatosis may present with an acute febrile illness with arthritis, arthralgias, and generalized malaise. [33] The presence of multiple papules and vesicles in a patient with systemic signs and symptoms has led to the evaluation of these patients for systemic infections, including viral infections. Routine direct immunofluorescence, however, has revealed linear deposits of IgA, and these patients have responded to conventional therapy.

Mucosal Involvement

Mucosal involvement is an important clinical manifestation seen in patients with linear IgA dermatosis and CBDC. This involvement can range from largely asymptomatic oral ulcerations and erosions to severe oral disease alone as well as to severe conjunctival and oral disease typical of that seen in cicatricial pemphigoid. [9], [35], [36] Oral lesions may occur in up to 70 percent of patients with linear IgA disease. [9] Although most patients with linear IgA dermatosis and mucosal involvement have significant cutaneous disease, cases have been reported in the literature in which the presenting and predominant clinical manifestations are lesions of the mucous membranes. [35], [37] These patients may present with desquamative gingivitis and oral lesions consistent with those seen in patients with cicatricial pemphigoid. Patients also may present with conjunctival disease and scar formation typical of that seen in patients with cicatricial pemphigoid. It appears likely that the different clinical manifestations seen in patients with linear IgA deposits will relate to the difference in antigenic targets.

Disease Associations

The similar clinical presentation of many patients with linear IgA disease to that seen in patients with DH led to the investigation of patients with linear IgA disease for an associated gluten-sensitive enteropathy. Although some investigators have found evidence of minimal inflammatory changes in the small bowel of patients with linear IgA disease, numerous investigators have failed to show that the majority of patients with linear IgA disease have significant evidence of the villous atrophy characteristically seen in patients with DH. [1], [38] In addition, the clinical manifestations of linear IgA disease have not been controlled by the use of a gluten-free diet. [39] Circulating autoantibodies against tissue transglutaminase, which occur in high frequency in patients with untreated gluten-sensitive enteropathy and DH, have not been found in most patients with linear IgA diseases. [40] Recently, Egan et al. [41] reported a patient with linear IgA dermatosis and well-documented gluten-sensitive enteropathy. This patient responded to a gluten-free diet with normalization of small bowel mucosal and control of the skin disease. In addition, this patient's skin disease flared with reinstitution of gluten in the diet. This case and documentation in the literature that a minority of patients with linear IgA disease have minimal changes of small bowel mucosal consistent with that seen in gluten-sensitive enteropathy suggest that there may be a subset of linear IgA patients who have an associated gluten-sensitive enteropathy and that their skin

disease may respond to a gluten-free diet. [39], [41]

Other conditions have been reported in association with CBDC. Baldari et al. [42] reported a case of CBCD occurring after acute mononucleosis. These authors suggest that this virus may have a role in initiation of the disease through immune stimulation. CBDC also has been reported in association with chronic granulomatous disease in the setting of *Paecilomyces* lung infection. [43] The relationship between these conditions and CBDC has yet to be established.

Linear IgA disease has been associated with the administration of a variety of drugs. Case reports have described patients with the relatively acute onset of clinical, histologic, and immunopathologic findings consistent with linear IgA disease who have been taking a variety of drugs, including vancomycin, lithium, furosemide, atorvastatin, captopril, and diclofenac. The mechanism of this interaction is not known. However, it is clear that some drugs can induce linear IgA deposits in the skin and the associated skin disease.

Linear IgA disease also has been associated rarely with a variety of malignancies. Patients with linear IgA disease have been reported with both lymphoid and nonlymphoid malignancies. [44], [45] Godfrey et al. [44] reported three cases of lymphoid malignancies in 70 patients with linear IgA disease followed for a mean of 8.5 years. This represented an increase over the predicted number of 0.2 cases in an age- and sex-matched population. No increase in the rate of nonlymphoid malignancies was seen. These findings suggest a small risk of lymphoid malignancy in these patients. However, larger population-based studies need to be done to confirm these findings.

PATHOLOGY

Routine histopathology of an early lesion in patients with linear IgA dermatosis and CBDC reveals a subepidermal bulla with collections of neutrophils along the basement membrane, often accumulating at the papillary tips (Fig. 63-8). A mild lymphocytic infiltrate may be present around the superficial dermal blood vessels without any evidence of neutrophilic vasculitis. Occasionally, the inflammatory infiltrate is composed of eosinophils, but most frequently neutrophils are the major component of the subepidermal inflammation. [9], [46], [47] Electron microscopic examination of the blisters found in patients with both linear IgA dermatosis and CBDC has revealed that the blister forms either within the lamina lucida or in a sublamina densa location. [19], [22]

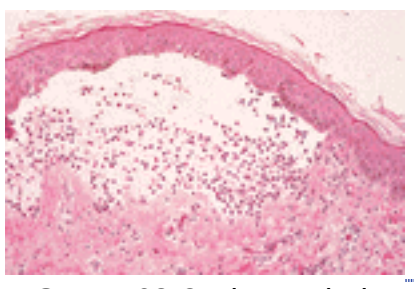

FIGURE 63-8 Histopathology of lesional skin from a patient with linear IgA dermatosis showing a subepidermal blister filled with neutrophils. (*Courtesy of Kim B. Yancey, MD.*)

Most often the histopathology seen in linear IgA disease is difficult to distinguish from that seen in patients with DH. Smith et al. [46] reported that patients with linear IgA disease tended to have fewer papillary microabscesses and a more diffuse infiltrate of neutrophils at the basement membrane zone. However, Blenkinsopp et al. [47] found no significant difference between the histopathology found in patients with linear IgA disease and those with DH. In general, the histopathology of blisters in linear IgA disease, CBDC, and DH is virtually indistinguishable.

DIFFERENTIAL DIAGNOSIS

Linear IgA dermatosis often closely mimics the clinical pattern seen in patients with DH. Some patients may have findings that resemble those seen in patients with bullous pemphigoid, cicatricial pemphigoid, or EBA. In a similar manner, patients with CBDC must be differentiated from those with DH of childhood and childhood bullous pemphigoid. The findings of linear IgA deposits at the basement membrane by direct immunofluorescence, most often in the absence of IgG and the third component of complement (C3), can distinguish this disease from bullous pemphigoid, cicatricial pemphigoid, and EBA, whereas granular IgA deposits are found at the basement membrane in patients with DH.

TREATMENT AND PROGNOSIS

Adults with linear IgA dermatosis have an unpredictable course. [2], [9] Many patients have disease that continues for years, with few, if any, episodes of remission. Occasionally, patients may have a spontaneous remission with loss of clinical features of the disease and disappearance of the linear IgA deposits in the skin. Patients with severe mucosal disease, especially of the eyes, may have persistent problems with symblepharon formation and resulting structural problems with the eyelids and cornea, even after active blistering has remitted.

Patients with linear IgA disease most often respond dramatically to dapsone or sulfapyridine. This response usually occurs within 24 to 48 h, in a manner similar to that seen with DH; as such, it is not a helpful diagnostic sign for linear IgA disease. [2], [9], [10] While most patients are well controlled with dapsone or sulfapyridine alone, some patients require low-dose prednisone therapy to suppress blister formation. [9], [10] The majority of patients with linear IgA disease cannot control their skin disease with a gluten-free diet. [39]

CBDC is most often a self-limited disease, with most children going into remission within 2 years of the onset of the disease. [5], [6], [9] Occasionally, the disease persists well into puberty but often is less severe than the initial eruption. Patients with CBDC respond in a similar dramatic fashion to dapsone or sulfapyridine. [4] Many children, however, require the addition of relatively small doses of prednisone to bring the disease under control. [5], [6] Isolated case reports suggests that some patients with CBDC may respond to antibiotics, including sulphonamides, dicloxacillin, and erythromycin. [48], [49] However, spontaneous remission in these patients cannot be ruled out.

REFERENCES

1. Lawley TJ et al: Small intestinal biopsies and HLA types in dermatitis herpetiformis patients with granular and linear IgA skin deposits. *J Invest Dermatol* **74**:9, 1980

2. Leonard JN et al: Linear IgA disease in adults. *Br J Dermatol* **107**:301, 1982

3. Chorzelski TP et al: Immunofluorescence studies in the diagnosis of dermatitis herpetiformis and its differentiation from bullous pemphigoid. *J Invest Dermatol* **56**:373, 1971

4. Cohen DM et al: Linear IgA disease histopathologically and clinically masquerading as lichen planus. *Oral Surg Oral Med Oral Pathol Oral Radiol Endod* **88**:196, 1999

5. Chorzelski TP, Jablonska S: IgA linear dermatosis of childhood (chronic bullous disease of childhood). *Br J Dermatol* **101**:535, 1979

6. Jablonska S et al: Linear IgA bullous dermatosis of childhood (chronic bullous dermatosis of childhood). *Clin Dermatol* **9**:393, 1992

7. Zone JJ et al: Antigenic specificity of antibodies from patients with linear basement membrane deposition of IgA. *Dermatology* **189**(suppl):64, 1994

8. Dmochowski M et al: Immunoblotting studies of linear IgA disease. *J Dermatol Sci* **6**:194, 1993

9. Wojnarowska F et al: Chronic bullous disease of childhood, childhood cicatricial pemphigoid and linear IgA disease of adults: A comparative study demonstrating clinical and immunopathologic overlap. *J Am Acad Dermatol* **19**:792, 1988

10. Chorzelski TP et al: Linear IgA bullous dermatosis of adults. *Clin Dermatol* **9**:383, 1992

11. Venning VA et al: HLA type in bullous pemphigoid, cicatricial pemphigoid and linear IgA disease. *Clin Exp Dermatol* **14**:283, 1989

12. Sachs JA et al: A comparative serological and molecular study of linear IgA disease and dermatitis herpetiformis. *Br J Dermatol* **118**:759, 1988

13. Collier PM et al: Adult linear IgA disease and chronic bullous disease of childhood: The association with human lymphocyte antigens Cw7, B8, DR3 and tumour necrosis factor influences disease expression. *Br J Dermatol* **141**:867, 1999

14. Wojnarowska F et al: Chronic bullous disease of childhood and linear IgA disease of adults are IgA1-mediated diseases. *Br J Dermatol* **131**:201, 1994

15. Flotte TJ et al: Immunopathologic studies of adult linear IgA bullous dermatosis. *Arch Pathol Lab Med* **109**:457, 1985

16. Hall RP, Lawley TJ: Characterization of circulating and cutaneous IgA immune complexes in patients with dermatitis herpetiformis. *J Immunol* **135**:1760, 1985

17. Leonard JN et al: Evidence that the IgA in patients with linear IgA disease is qualitatively different from that of patients with dermatitis herpetiformis. *Br J Dermatol* **110**:315, 1983

18. Wojnarowska F et al: The localization of the target antigens and antibodies in linear IgA disease is heterogeneous and dependent on the methods used. *Br J Dermatol* **132**:750, 1995

19. Karpati S et al: Ultrastructural immunogold studies in two cases of linear IgA dermatosis: Are there two distinct types of this disease? *Br J Dermatol* **127**:112, 1992

20. Prost C et al: Diagnosis of adult linear IgA dermatosis by immunoelectron microscopy in 16 patients with linear IgA deposits. *J Invest Dermatol* **92**:39, 1989

21. Bhogal B et al: Linear IgA bullous dermatosis of adults and children: An immunoelectron microscopic study. *Br J Dermatol* **117**:289, 1987

22. Dabrowski J et al: The ultrastructural localization of IgA deposits in chronic bullous disease of childhood (CBDC). *J Invest Dermatol* **72**:291, 1979

23. Zone JJ et al: Identification of the cutaneous basement membrane zone antigen and isolation of antibody in linear immunoglobulin A bullous dermatosis. *J Clin Invest* **85**:812, 1990

24. Ishiko A et al: 97-kDa linear IgA bullous dermatosis (LAD) antigen localizes to the lamina lucida of the epidermal basement membrane. *J Invest Dermatol* **106**:739, 1996

25. Zone JJ et al: IgA Antibodies in chronic bullous diseases of childhood react with a 97-kDa basement membrane zone protein. *J Invest Dermatol* **106**:1277, 1996

26. Roh JY et al: The 120-kDa soluble ectodomain of type XVII collagen is recognized by autoantibodies in patients with pemphigoid and linear IgA dermatosis. *Br J Dermatol* **143**:104, 2000

27. Schumann H et al: The shed ectodomain of collagen XVII/BP180 is targeted by autoantibodies in different blistering skin diseases. *Am J Pathol* **156**:685, 2000

28. Wojnarowska F et al: Identification of the target antigen in chronic bullous disease of childhood and linear IgA disease of adults. *Br J*

Dermatol **124**:157, 1991

29. Smith EP et al: Identification of a basement membrane zone antigen reactive with circulating IgA antibody in ocular cicatricial pemphigoid. *J Invest Dermatol* **101**:619, 1993

30. Hashimoto T et al: A case of linear IgA bullous dermatosis with IgA anti-type VII collagen autoantibodies. *Br J Dermatol* **134**:336, 1996

31. Peters MS, Rogers RS: Clinical correlations of linear IgA deposition at the cutaneous basement membrane zone. *J Am Acad Dermatol* **20**:761, 1989

32. Marsden RA et al: A study of benign chronic bullous dermatosis of childhood and comparison with dermatitis herpetiformis and bullous pemphigoid occurring in childhood. *Clin Exp Dermatol* **5**:159, 1980

33. Leigh G et al: Linear IgA dermatosis with severe arthralgia. *Br J Dermatol* **119**:789, 1988

34. Blockmans D et al: Linear IgA dermatosis: A new cause of fever of unknown origin. *Neth J Med* **47**:214, 1995

35. Leonard JN et al: The relationship between linear IgA disease and benign mucous membrane pemphigoid. *Br J Dermatol* **110**:307, 1984

36. Kelly SE et al: A clinicopathological study of mucosal involvement in linear IgA disease. *Br J Dermatol* **119**:161, 1988

37. Porter SR et al: Linear IgA disease manifesting as recalcitrant desquamative gingivitis. *Oral Surg Oral Med Oral Pathol* **74**:179, 1992

38. deFranchis R et al: Small-bowel involvement in dermatitis herpetiformis and in linear IgA bullous dermatosis. *J Clin Gastroenterol* **5**:429, 1983

39. Leonard JN et al: Experience with a gluten-free diet in the treatment of linear IgA disease. *Acta Derm Venereol (Stockh)* **67**:145, 1987

40. Rose C et al: Circulating autoantibodies to tissue transglutaminase differentiate patiens with dermatitis herpetiformis from those with linear IgA disease. *J Am Acad Dermatol* **41**:957, 1999

41. Egan CA et al: Linear IgA bullous dermatosis responsive to gluten-free diet. *Am J Gastroenterol* **96**:1927, 2001

42. Baldari U et al: Chronic bullous disease of childhood following Epstein-Barr virus seroconversion: A case report. *Clin Exp Dermatol* **21**:123, 1996

43. Smitt JH et al: Chronic bullous disease of childhood and a *Paecilomyces* lung infection in chronic granulomatous disease. *Arch Dis Child* **77**:150, 1997

44. Godfrey K et al: Linear IgA disease of adults: Association with lymphoproliferative malignancy and possible role of other triggering factors. *Br J Dermatol* **123**:447, 1990

45. McEvoy MT, Connolly SM: Linear IgA dermatosis: Association with malignancy. *J Am Acad Dermatol* **22**:59, 1990

46. Smith SB et al: Linear IgA bullous dermatosis v dermatitis herpetiformis: Quantitative measurements of dermoepidermal alterations. *Arch Dermatol* **120**:324, 1984

47. Blenkinsopp WK et al: Histology of linear IgA disease, dermatitis herpetiformis and bullous pemphigoid. *Am J Dermatopathol* **5**:547, 1983

48. Powell J et al: Mixed immunobullous disease of childhood: a good response to antimicrobials. *Br J Dermatol* **144**:769, 2001.

49. Siegfried EC et al: Chronic bullous disease of childhood: Successful treatment with dicloxacillin. *J Am Acad Dermatol* **39**:797, 1998

T>

Chapter 64

Stephen Katz

Pemphigoid Gestationis (Herpes Gestationis)

ETIOLOGY AND PATHOGENESIS
CLINICAL MANIFESTATIONS
HISTOPATHOLOGY
IMMUNOLOGIC FEATURES
Direct Immunofluorescence Studies
Indirect Immunofluorescence Studies
IMMUNOGENETIC STUDIES
DIFFERENTIAL DIAGNOSIS
TREATMENT

REFERENCES

Pemphigoid gestationis (PG) is a rare, pruritic, polymorphic, inflammatory, subepidermal, bullous dermatosis of pregnancy and the postpartum period. Since it is unrelated to any known viral infection and has characteristics of bullous pemphigoid, the former name, *herpes gestationis* (HG), has been abandoned in favor of PG. Its incidence has been roughly estimated to be 1 in 1700 [1] to 1 in 10,000 deliveries. [2] Definitive diagnosis can be made with specific immunopathologic studies.

ETIOLOGY AND PATHOGENESIS

The etiology of PG is unknown. It is not related to herpes group viruses. The consistent finding of C3 deposition at the basement membrane zone of lesional and normal-appearing skin, in addition to the usual findings of an avidly complement-fixing IgG antibody (HG factor) in the serum, points to a role for immunologic mechanisms. One can postulate that the IgG antibodies are initiated in response to an antigenic stimulus peculiar to pregnancy, perhaps in the amnion. [3] These antibodies, as well as T cells, have specificity for a 14-amino-acid stretch of the ectodomain of the 180-kDa antigen (BPAG2, BP180, or type XVII collagen) that is a hemidesmosomal protein. [4], [5] and [6] The antibodies bind to an extracellular site located near the membrane-spanning domain of this protein. [5], [6] and [7] Once deposited at the basement membrane zone, these antibodies activate the complement cascade, which in turn generates an inflammatory response and the cutaneous features of inflammation that are morphologically recognized as PG. IgG_1 and IgG_3 are the major subclasses of immunoglobulin that target the antigen. [8] These IgG antibodies can, in most cases, cross the placenta—hence the occasional genesis of the transient blistering or papular disease in the infant. The infant's catabolism of the maternal IgG rapidly terminates the immunologic assault on the infant's skin. An animal model using passive transfer of antibodies to the extracellular domain of BP180 has demonstrated that mice injected with these antibodies develop subepidermal blisters that mimic those in bullous pemphigoid and PG. [9]

Ultrastructurally, the C3 and the IgG are deposited along the lamina lucida and on the dermal side of the basal cell plasma membranes. [10] Necrosis of basal cells occurs in both early lesional skin and in many areas of normal-appearing skin. [10]

Hormonal factors undoubtedly play an important role in the pathogenesis of PG. The onset in pregnancy or very shortly thereafter, the postpartum flares, the associated exacerbations with hormone-producing tumors, [11] and the oral contraceptive exacerbation of the disease in patients whose diagnoses have been verified immunologically are all well documented. To date, however, an immunologically verified PG-like dermatosis has not been reported from the use of oral contraceptive agents in patients without a prior history of PG.

CLINICAL MANIFESTATIONS

Pemphigoid gestationis usually presents as an extremely pruritic papulovesicular eruption on the abdomen but may involve other areas, including the palms, soles, chest, back, and face. [10], [12] Mucosal surfaces usually are spared. Lesions vary from erythematous, edematous papules to large, tense bullae (Fig. 64-1), with many intermediate forms including small vesicles, confluent papules and vesicles, and urticaria-like plaques (Fig. 64-2) with and without grouped vesicles, bullae, erosions, and crusts. Although the more severe cases show a combination of many of these lesions (Fig. 64-3), milder cases may present only with moderate pruritus and a few erythematous papules or isolated edematous plaques 1 to 2 cm in diameter [12], [13] (see Fig. 64-2).

FIGURE 64-1 Herpes gestationis. Polymorphic lesions on dorsa of feet.

FIGURE 64-2 Herpes gestationis. Urticarial papules and plaques on the trunk.

FIGURE 64-3 Herpes gestationis. Erythematous urticarial and bullous lesions on the chest and shoulders.

Pemphigoid gestationis usually begins from the fourth to the seventh month of pregnancy, but the onset has been reported during the first trimester and in the immediate postpartum period. [12], [14], [15] Postpartum exacerbations as well as flares with the first few menstrual periods are common. Although the disease is self-limited for a particular episode, it may or may not recur in subsequent pregnancies; if it does, it is likely to begin earlier. PG may be exacerbated by the use of estrogen- or progesterone-containing medications. [12]

Fetal prognosis has been sought in several studies. One review of fetal and maternal risk factors in 41 immunologically verified cases revealed significant fetal death and premature deliveries, [14] and another series of 11 evaluable cases showed one intrauterine death. [16] Some studies have suggested that there is no increase in fetal mortality, [15], [17], [18] whereas others have indicated an increase in prematurity and small-for-gestational-age infants. [19] Less than 5 percent of babies are born with urticarial, vesicular, or bullous lesions. [12], [14] These lesions almost always resolve spontaneously during the first several weeks.

HISTOPATHOLOGY

The histopathologic features are variable. Both superficial and deep dermal vascular plexuses usually are surrounded by an infiltrate (of varying intensity) composed of lymphocytes, histiocytes, eosinophils, and occasionally a few neutrophils. Eosinophil infiltration is thought by some to be the most constant histopathologic feature. [20], [21] There is edema of the dermal papillae and epidermis together with characteristic foci of basal cell necrosis over the tips of the dermal papillae. [22] Some authors have suggested that liquefaction degeneration or a variable degree of spongiosis represents the most constant epidermal finding and that dermal infiltration by eosinophils is the single most consistent finding in PG. [15] Vesicular lesions show subepidermal blister formation in a bulbous teardrop shape, although sections cut through the lateral extensions of the blisters at times may appear to show intraepidermal vesicles (Fig. 64-4). Although the findings may be characteristic, they are not diagnostic of PG.

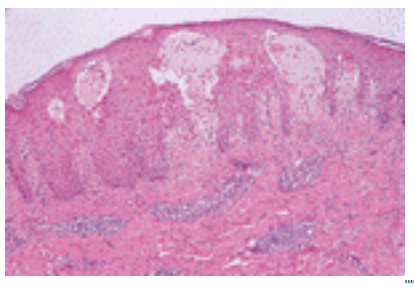

FIGURE 64-4 Herpes gestationis. Subepidermal vesicle formation; dermal edema; infiltrate consisting of lymphocytes, histiocytes, eosinophils, and a few neutrophils; and focal basal cell necrosis. Note bulbous, teardrop-like vesicles.

IMMUNOLOGIC FEATURES

Direct Immunofluorescence Studies

The examination of peribullous and urticarial lesions or of normal-appearing skin in PG consistently has demonstrated heavy, homogeneous linear deposition of C3 along the basement membrane zone (Fig. 64-5) with concomitant IgG deposition in approximately 30 to 40 percent of patients. When monoclonal antibodies are used, IgG $_1$ may be detected in the skin basement membrane zone of all patients. [23] IgA and IgM deposition have been noted infrequently. Properdin and, less frequently, properdin factor B, components of the alternative complement pathway, also may be detected along the basement membrane zone. C1q and C4, components of the classical complement pathway, have been detected less frequently, and C5 deposition also has been reported. The heavy deposition of C3 at the basement membrane zone of skin, however, is the diagnostic hallmark in patients with PG. [24], [25] and [26] The immunofluorescence findings may persist in these patients' skin for several months and for as long as a year after lesions have resolved.

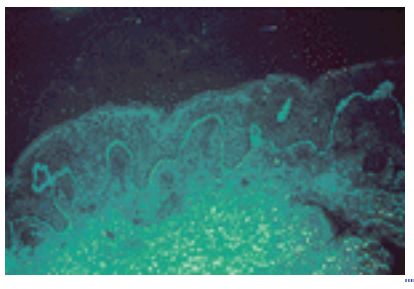

FIGURE 64-5 Herpes gestationis. Linear deposition of C3 along the basement membrane zone.

Similar direct immunofluorescence findings have been noted in infants born of affected mothers. The C3 deposition has been noted in clinically normal as well as affected infants' skin.

Indirect Immunofluorescence Studies

Using routine indirect immunofluorescence techniques, IgG serum anti–basement membrane antibodies are detected in only about 20 percent of patients with PG, [14] whereas ELISA and immunoblotting assays will detect autoantibodies in greater than 71 percent of sera. [27], [28] However, when monoclonal antibodies are used, almost all sera have been shown to contain an IgG $_1$ anti–basement membrane zone antibody. [23] Several reports have indicated the presence of a serum complement-fixing factor in many, but not all, patients with PG. [14], [24], [25] and [26] This factor, termed the *HG factor,* is an avid complement-fixing IgG antibody (presumably IgG $_1$) frequently present in the sera of patients in such low concentrations as to escape detection by routine indirect immunofluorescence techniques. The HG factor binds to amniotic epithelial basement membrane [3] and also has been detected in cord sera of some infants born of affected mothers.

IMMUNOGENETIC STUDIES

A genetic predisposition has been proposed for PG in that there is a marked increase in the HLA-B8, -DR3, and -DR4 genotypes in affected patients, [29] particularly with DRB1*0301 and DRB1*0401/ 040X. [30] Complement polymorphism studies also have demonstrated a 90 percent frequency of the C4 null allele in patients with a history of HG. [31]

DIFFERENTIAL DIAGNOSIS

The disease most often confused with PG is pruritic urticarial papules and plaques of pregnancy (PUPPP), an eruption that begins on the abdomen (usually in striae), manifests as papules and plaques (often with blanched halos), usually occurs late in pregnancy, and is severely pruritic [32] (see Chap. 142). In PUPPP, there are no immunoreactants seen at the dermal-epidermal junction. Differentiation of PG from other dermatoses of pregnancy is discussed elsewhere (see Chap. 142).

The tendency for the vesicles and bullae to group and the intense pruritus in PG have erroneously promoted the idea that PG is related to, or identical with, dermatitis herpetiformis (see Chap. 67). Another source of confusion is erythema multiforme (see Chap. 58). However, these two diseases, erythema multiforme and dermatitis herpetiformis, should be easily distinguished from PG by routine direct immunofluorescence techniques. In dermatitis herpetiformis, IgA deposition occurs along the basement membrane zone of perilesional and normal-appearing skin; in erythema multiforme,

immunoglobulin and complement may be seen only in the superficial blood vessels.

The possible relation between PG and bullous pemphigoid is unresolved. The features suggesting a close relationship between PG and bullous pemphigoid are (1) the morphologic similarity of the cutaneous lesions in the two diseases, (2) the similar direct immunofluorescence findings, (3) the persistence of PG in rare patients, and most important, (4) the very close relationship, if not the identity, of the PG antigen with the 180-kDa bullous pemphigoid antigen. [4], [5] and [6] There are several dissimilar features, however, that necessitate caution in proposing a common etiology between HG and bullous pemphigoid. These are (1) the patient population at risk, (2) the provocative factors (i.e., estrogens or progesterones), (3) the almost universal tendency toward remission following and between pregnancies, (4) the complement-fixing ability of the anti–basement membrane antibody in PG, which frequently exceeds the anti–basement membrane antibody titer (by comparison, the anti–basement membrane antibody titer of bullous pemphigoid sera frequently exceeds the complement-fixing titer), and (5) ultrastructural studies suggesting that blister formation in bullous pemphigoid occurs between the lamina densa and the basal cell membrane, whereas in PG the separation may occur at the level of the degenerated basal cells. [10]

TREATMENT

The treatment of PG is designed to suppress blister formation and to relieve the intense pruritus. These goals usually can be achieved by giving 20 to 40 mg of prednisone per day in the morning; however, the itching may be so severe that divided doses may be required. Exacerbations of the pruritus and blistering commonly occur at parturition and may then require an increase in prednisone. The prednisone is tapered gradually during the postpartum period, but exacerbations at the time of menses may demand a temporary increase in dosage. This is true for most patients; however, a few patients do not require systemic prednisone and can be managed with antihistamines and topical steroids or emollients. [12] At the other extreme, some individuals, after parturition, require azathioprine in addition to the prednisone for control of their disease.

Infants born of affected mothers who have received high doses of prednisone should be examined carefully by a neonatologist for evidence of adrenal insufficiency. This complication is rare but is theoretically possible if continuous large doses of glucocorticoids are employed for several months prior to birth to control the mother's disease. The cutaneous lesions noted in such infants are of a transient nature requiring no therapy.

REFERENCES

1. Roger D et al: Specific pruritic diseases of pregnancy: A prospective study of 3192 pregnant women. *Arch Dermatol* **130**:734, 1994

2. Kolodny RG: Herpes gestationis: A new assessment of incidence, diagnosis and fetal prognosis. *Am J Obstet Gynecol* **104**:39, 1969

3. Ortonne JP et al: Herpes gestationis factor reacts with the amniotic epithelial basement membrane. *Br J Dermatol* **117**:147, 1987

4. Morrison LH et al: Herpes gestationis autoantibodies recognize a 180-kDa human epidermal antigen. *J Clin Invest* **81**:2023, 1988

5. Giudice GJ et al: Bullous pemphigoid and herpes gestationis autoantibodies recognize a common non-collagenous site on the BP180 ectodomain. *J Immunol* **151**:5742, 1993

6. Lin MS et al: Identification and characterization of epitopes recognized by T lymphocytes and autoantibodies from patients with herpes gestationis. *J Immunol* **162**:4991, 1999

7. Bedane C et al: Bullous pemphigoid and cicatricial pemphigoid autoantibodies react with ultrastructurally separable epitopes on the BP180 ectodomain: Evidence that BP180 spans the lamina lucida. *J Invest Dermatol* **108**:901, 1977

8. Chimanovitch I et al: IgG_1 and IgG_3 are the major immunoglobulin subclasses targeting epitopes within the NC16A domain of BP180 in pemphigoid gestationis. *J Invest Dermatol* **109**:140, 1999

9. Liu Z et al: A passive transfer model of the organ-specific autoimmune disease, bullous pemphigoid, using antibodies generated against the hemidesmosomal antigen, BP180. *J Clin Invest* **92**:2480, 1993

10. Yaoita H et al: Herpes gestationis: Ultrastructure and ultrastructural localization of in vivo–bound complement. Modified tissue preparation and processing for horseradish peroxidase staining of skin. *J Invest Dermatol* **66**:383, 1976

11. Halkier-Sorensen L et al: Herpes gestationis in association with neoplasma malignum generatisatum: A case report. *Acta Derm Venereol (Stockh)* **120**:96, 1985

12. Jenkins RE et al: Clinical features and management of 87 patients with pemphigoid gestationis. *Clin Exp Dermatol* **24**:255, 1994

13. Ogilvie P et al. Pemphigoid gestationis without blisters. *Hautartz* **51**:25, 2000

14. Lawley T et al: Fetal and maternal risk factors in herpes gestationis. *Arch Dermatol* **114**:552, 1978

15. Shornick JK et al: Herpes gestationis: Clinical and histologic features of twenty-eight cases. *J Am Acad Dermatol* **8**:214, 1983

16. Merchaoui J et al: Obstetrical prognosis of gestational pemphigoid: Study of a series of 13 cases and review of the literature. *J Gynecol Obstet Biol Reprod (Paris)* **21**:963, 1992

17. Holmes RC et al: A comparative study of toxic erythema of pregnancy and herpes gestationis. *Br J Dermatol* **106**:499, 1982

18. Harrington CI, Bleehan SS: Herpes gestationis: Immunopathological and ultrastructural studies. *Br J Dermatol* **100**:389, 1979

19. Shornick JK, Black MM: Fetal risks in herpes gestationis. *J Am Acad Dermatol* **26**:63, 1992

20. Shornick JK: Herpes gestationis. *J Am Acad Dermatol* **17**:539, 1987

21. Borrego L et al: Polymorphic eruption of pregnancy and herpes gestationis: Comparison of granulated cell proteins in tissue and serum. *Clin Exp Dermatol* **24**:213, 1999

22. Hertz KC et al: Herpes gestationis: A clinicopathologic study. *Arch Dermatol* **112**:1543, 1976

23. Kelly SE et al: The distribution of IgG subclasses in pemphigoid gestationis: PG factor is an IgG1 autoantibody. *J Invest Dermatol* **92**:695, 1989

24. Provost TT, Tomasi TB Jr: Evidence for complement activation via the alternate pathway in skin diseases: I. Herpes gestationis, systemic lupus erythematosus and bullous pemphigoid. *J Clin Invest* **52**:1779, 1973

25. Katz SI et al: Herpes gestationis: Immunopathology and characterization of the HG factor. *J Clin Invest* **57**:1434, 1976

26. Jordon RE et al: The immunopathology of herpes gestationis: Immunofluorescent studies and characterization of HG factor. *J Clin Invest* **57**:1426, 1976

27. Giudice GJ et al: Development of an ELISA to detect anti-BP180 autoantibodies in bullous pemphigoid and herpes gestationis. *J Invest Dermatol* **102**:878, 1994

28. Murakami H et al: Analysis of antigens recognized by autoantibodies in herpes gestationis: Usefulness of immunoblotting using a fusion protein representing and extracellular domain of the 180-kDa bullous pemphigoid antigen. *J Dermatol Sci* **13**:112, 1996

29. Shornick JK et al: High frequency of histocompatibility antigens HLA-DR3 and -DR4 in herpes gestationis. *J Clin Invest* **68**:553, 1981

30. Shornick JK et al: Class II MHC typing in pemphigoid gestationis. *Clin Exp Dermatol* **20**:123, 1995

31. Shornick JK et al: Complement polymorphism in herpes gestationis: Association with C4 null allele. *J Am Acad Dermatol* **29**:545, 1993

32. Lawley T et al: Pruritic urticarial papules and plaques of pregnancy. *JAMA* **241**:1696, 1979

T>

Chapter 65

M. Marinkovich Paul Khavari G. Herron Eugene Bauer

Inherited Epidermolysis Bullosa

EPIDERMOLYSIS BULLOSA AS A DISEASE ENTITY
THE DERMAL EPIDERMAL BASEMENT MEMBRANE
Overview
Keratin Filaments
Hemidesmosomes
Anchoring Filaments
Anchoring Fibrils
DISEASE DESCRIPTIONS
EB Simplex
Molecular Pathology of EBS
Junctional EB
Molecular Pathology of JEB
Dystrophic EB
DOMINANT DEB
RECESSIVE DEB
Molecular Pathology of DEB
APPROACH TO THE PATIENT
Diagnosis
Genetic Counseling
THERAPY
Supportive Skin Care
Care for Extracutaneous Involvement
Systemic Therapies
Future Potential Therapies
DISEASE MODELS

REFERENCES

EPIDERMOLYSIS BULLOSA AS A DISEASE ENTITY

Epidermolysis bullosa (EB) refers to a group of inherited disorders that involve the formation of blisters following trivial trauma. The most obvious signs are vesicles and bullae within the skin and mucous membranes; however, internal organs may also be involved and clinical heterogeneity is a manifestation of a variety of heritable molecular defects. Marked skin and mucosal fragility causing painful vesicles and bullae define this disease. Abnormal wound repair responses that eventuate into chronic erosions, scarring, and invasive carcinoma are common. Although the milder phenotypes share several of these features, the most severe recessively inherited forms are mutilating, multiorgan disorders that threaten both the quality and length of life.

A number of early studies identified the major subtypes of EB. Epidermolysis bullosa was known to be distinct from pemphigus since the time of von Hebra and the term *epidermolysis bullosa hereditaria* was first coined by Koebner. Hallopeau was the first to distinguish between simplex (nonscarring) and dystrophic (scarring) forms of the disease, while Weber and Cockayne, Dowling and Meara, and Koebner each described unique forms of epidermolysis bullosa simplex. Hoffman, Cockayne, Touraine, Pasini, and Bart provided much of the information about subtypes of dystrophic epidermolysis bullosa. Herlitz described epidermolysis bullosa letalis which was later found to be a part of the third major category of epidermolysis bullosa, the junctional form. The application of electron microscopy toward diagnosis of epidermolysis bullosa led to the studies of Pearson [1] and collaborators who classified the patients not only on the basis of clinical findings but also on the existence of ultrastructural changes. Recent major advances have led to the identification of specific protein and genetic abnormalities in most types of epidermolysis bullosa patients. These studies permitted an improved understanding of the biologic basis of epidermolysis bullosa and, finally, a classification of epidermolysis bullosa based on molecular etiology that will provide a rational approach to future specific therapy.

THE DERMAL EPIDERMAL BASEMENT MEMBRANE

Overview (See also Chap. 16)

Epidermolysis bullosa arises from defects associated with basal keratinocytes and the dermal–epidermal basement membrane zone (BMZ). Many tissues, such as the skin and cornea, which are subjected to external disruptive forces, contain a complex BMZ composed of a group of specialized components that combine together to form anchoring complexes (Fig. 65-1). At the most superior aspect of the BMZ, keratin-containing intermediate filaments of the basal cell cytoskeleton insert upon electron-dense condensations of the basal cell plasma membrane termed *hemidesmosomes*. Anchoring filaments span the lamina lucida connecting hemidesmosomes with the lamina densa and anchoring filaments. At the most inferior aspect of the BMZ, type VII, collagen-containing anchoring fibrils extend from the lamina densa into the papillary dermis and combine with the lamina densa and anchoring plaques, trapping interstitial collagen fibrils. Thus the cutaneous BMZ connects the extensive basal cell cytoskeletal network with the abundant network of interstitial collagen fibrils in the dermis. [2], [3]

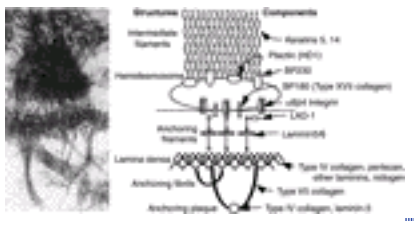

FIGURE 65-1 The ultrastructural elements of the dermal–epidermal basement membrane, as shown in the electron micrograph on the *left*, are correlated with the known molecular composition of this structure, as shown in the schematic on the *right*.

Keratin Filaments (See also Chap. 7)

Keratins are obligate heteropolymers composed of pairs of acidic and basic monomers. The keratin pair 5 and 14 assemble together to form the extensive intermediate filament network of the basal cell cytoskeleton. [4] Keratins contain a central a-helical rod with several nonhelical interruptions, as well as nonhelical carboxyl- and amino-terminal regions. The regions of highest conservation among the keratins are located on the ends of the keratin rod in the helix boundary motifs. Extensive mutagenesis studies suggest that helical regions near the ends of the central rod are important in keratin filament elongation, whereas the nonhelical domains may be important in forming lateral associations. As noted, keratin intermediate filaments insert into the hemidesmosomes.

Hemidesmosomes (See also Chap. 16)

Hemidesmosomes contain intracellular proteins including plectin and BP230. *Plectin* (also termed *HD1* and *IFAP 300*) is a 500-kDa protein that is believed to act as an intermediate filament binding protein. It is possible that plectin also interacts with microfilaments, as plectin contains a domain with similarity to the actin-binding domain of spectrin. [5] BP230, also known as BPAG1, is a 230-kDa protein that has homology both to desmoplakin [6] and to plectin. Several splicing variants of BPAG1 are of vital importance in the nervous system. [7] BP230 localizes to a region referred to as the inner plate on the cytoplasmic surface of the hemidesmosome and, like HD1, is suspected to function in the connection between hemidesmosomes and intermediate filaments. BP230 negative transgenic mice lack a hemidesmosomal inner plate and the connection between hemidesmosomes and intermediate filaments is severed, creating a cytoplasmic zone of mechanical fragility just above the hemidesmosomes. [8] In these mice, neither hemidesmosome stability nor cell substratum adhesion appear to be weakened. Consequently, neither BP230 nor HD1/plectin appears to be essential for hemidesmosome assembly.

Anchoring Filaments (See also Chap. 16)

Hemidesmosomes also contain the transmembrane proteins *type XVII collagen* (also termed *BPAG2*) [9] and a6ß4 integrin. [10] The cytoplasmic portions of these molecules make up part of the hemidesmosome dense plaque, whereas the extracellular portions of these molecules make up portions of the anchoring filament and probably contribute to the structure known as the subbasal dense plate that underlies hemidesmosomes in the lamina lucida region. ß $_4$ integrin is known to combine with only the a $_6$ subunit, whereas the a $_6$ subunit can combine either with the ß $_4$ integrin or with the ß $_1$ integrin. Both the a $_6$ß $_1$ or a $_6$ß $_4$ integrin combinations act as receptors for laminins and a $_6$ß $_4$ integrin appears specifically to act as a receptor for laminin 5. [11] a $_6$ß $_4$ integrin plays a central role in hemidesmosome formation in that transgenic mice lacking the ß $_4$ integrin show skin devoid of hemidesmosomes with severe deficits in cell adhesion. [12] The ß $_4$ integrin contains an especially large cytoplasmic domain that is suspected to function in the interaction with other proteins of the hemidesmosomal plaque.

Type XVII collagen (BPAG2, type XVII collagen) is a collagenous protein with a type II transmembrane orientation. Based on electron microscopy and cross-linking studies, type XVII collagen assembles into a triple-helical homotrimer and contains three main regions: an intracellular amino-terminal globular head, a central rod, and an extracellular flexible tail. [13] Type XVII collagen associates with laminin 5 and a $_6$ß $_4$ integrin in adhesion structures termed *stable-anchoring contacts* formed by keratinocytes in vivo. These structures are thought to represent pre-hemidesmosomes. [14] Type XVII collagen undergoes processing in keratinocyte cultures. [15] LAD-1, the autoantigen in linear IgA bullous dermatosis [15], [16] (see Chap. 63) is a 120-kDa protein that was recently shown, by peptide sequencing, to contain the exodomain of type XVII collagen. [17] Thus LAD-1 appears to be the processed product of the type XVII collagen exodomain. [19]

In addition to a $_6$ß $_4$ integrin and type XVII collagen, anchoring filaments contain the molecules laminin 5 and laminin 6. Like all members of the family of laminin proteins, [20] laminin 5 is a large heterotrimeric molecule, containing a $_3$, ß $_3$, and ? $_2$ chains. [21], [22] The first laminins to be described contained three short arms and one long arm, forming a cross shape as shown by rotary shadowing analysis. In contrast, laminin 5 contains truncations of each short arm. [23], [24] and [25] Because of these short arm truncations, laminin 5 cannot self-polymerize with other laminins or bind to nidogen. Instead, laminin 5 forms a disulfide bonded attachment to laminin 6, [26] the other known anchoring filament laminin [27] that contains a $_3$, ß $_1$ and ? $_1$ chains, laminin 5. Laminin 5 also undergoes processing of its ? $_2$ and a $_3$ chains, [22] which may be mediated by bone morphogenic protein 1, [28] plasmin, [29] matrix metalloproteinase 2, [30] or membrane-type matrix metalloproteinase 1. [31] The ? $_2$ chain short arm appears important in the assembly of laminin 5 into basement membrane. [32] The antigen recognized by monoclonal antibody (MAb) 19-DEJ-1 [33] also localizes to anchoring filaments; however, this protein remains incompletely characterized.

Anchoring Fibrils (See also Chap. 16)

Type VII collagen is the major constituent of anchoring fibrils. Analysis of the deduced amino acid sequence of type VII collagen [34] reveals the presence of a long central collagenous region characterized by repeating Gly-X-Y sequences that contains a number of noncollagenous interruptions, including a 39–amino-acid noncollagenous segment in the center of the helix that corresponds to the “hinge region” predicted by biochemical studies. [35], [36] These interruptions account for the flexibility of the type VII collagen molecule, and explain its ability to loop around and entrap dermal matrix molecules, in order to provide its function of stabilizing the basement membrane to the underlying papillary dermis. [37] A 50-kDa component of anchoring fibrils has also been identified that appears to localize to the insertion sites of anchoring fibrils to the lamina densa. [38]

Primary sequence analysis has determined that the 145-kDa N-terminal end of type VII collagen contains the largest noncollagenous domain. This domain inserts onto the lamina densa and anchoring plaques. Type IV collagen, the most abundant component of these structures, binds to type VII collagen NC-1 domain. A direct interaction between anchoring filaments and anchoring fibrils has been demonstrated by studies that demonstrate a specific interaction between the anchoring filament component laminin 5 and type VII collagen NC-1 domain. [39], [40] Type VII collagen appears to interact with the ß $_3$ chain on laminin 5. [41] /SUP>Like all collagens, type VII collagen assembles into a triple helix. Because only one chain of type VII collagen, the a $_1$ chain, has been identified, one gene codes for an entire molecule. Type VII collagen triple helices are joined together at their processed NC-2 globular domains to form antiparallel dimers. [37], [42] Anchoring fibrils may derive from lateral associations of the antiparallel dimers.

DISEASE DESCRIPTIONS

Table 65-1 presents a simplified classification of EB based on the ultrastructural level within which the cleavage plane of the blister occurs. Thus, for the practitioner, the current diagnostic “gold standard” for grouping EB remains electron microscopy, although immunomapping of basement membrane antigens adjacent to the tissue split provides complementary data. The three disease groups are (1) epidermolytic or EB simplex (EBS), (2) junctional EB (JEB), and (3) dermolytic or dystrophic EB (DEB). Within each of these groups there are several distinct types of EB based on clinical, genetic, histologic, and biochemical evaluation. [43] Table 65-2 shows these different subclassifications of EB.

Blister Location	Disease Group	Inheritance
Intraepidermal	EB simplex	Autosomal dominant*
		Autosomal recessive
Basement membrane zone	Junctional EB	Autosomal recessive
Sublamina densa	Dystrophic EB	Autosomal recessive
		Autosomal dominant

*The vast majority of EB simplex patients are from autosomal dominant kindreds.

TABLE 65-1 **Classification of Epidermolysis Bullosa (EB)**

[illegible]	[illegible]	[illegible]
Generalized EBS (Koebner)	EB-gravis (Herlitz)	Generalized KDEB (Hallopeau/Siemens)
Localized EBS (Weber/Cockayne)	EB-mitis	Localized KDEB
EB herpetiformis (Dowling/Meara)	EB-pulmo atresia	Dominant DEB (Cockayne/Touraine)
EBS-Ogna	CARDB	Dominant DEB (Bauquet/Pasini)
Muscular dystrophy-EBS	Localized JEB	

[illegible]

TABLE 65-2 **Clinical Heterogeneity of Epidermolysis Bullosa (EB)**

EB Simplex

Epidermolytic EB is defined by the occurrence of intraepidermal blistering; the vast majority of cases are due to keratin gene mutations. However, there is considerable phenotypic variation among different subgroups (Table 65-3). [44] At least 11 distinct forms of EBS exist, 7 of which are dominantly inherited. The four most common EBS types are dominantly inherited and include generalized EBS (Koebner), localized EBS (Weber-Cockayne), EBS of the Ogna variety found in Norwegian kindreds, and the herpetiform EBS of Dowling-Meara. All these varieties share the common features of heat-sensitive formation of serous or serosanguineous, nonscarring vesicles and bullae.

Disease*	Gene†	Protein	Reference
EBS-DM	KRT5, 14	Keratins 5, 14	4, 45
EBS-WC	KRT5, 14	Keratins 5, 14	4, 45
EBS-K	KRT5, 14	Keratins 5, 14	4, 45
Recessive EBS-MD	PLEC1	Plectin	47, 56
Recessive EBS-K	KRT14	Keratin 14	49, 50
JEB-lethal	LAMA3, B3, C2	Laminin 5 (α3, β3, γ2)	63, 64, 65
JEB-PA	ITGA6, B4	Integrin α6β4	70
CARDB	COL17A1, LAMB3	BP180, Laminin	62, 66, 69, 70
DDEB	COL7A1	Type VII collagen	27, 77
RDEB	COL7A1	Type VII collagen	27, 77

*Disease categories reflect clinical phenotypes of individual EB patients drawn from a selected cohort.
†Genes indicated represent candidate genes identified by DNA sequence analysis or combining with disease phenotype. Examples of genetic defects include KRT5 or 14 heterozygous missense or in-frame deletions in epidermal forms of EBS, KRT5 or 14 heterozygous missense or nonsense mutations causing EBS-DM, EBS-WC, or EBS-K, PLEC1 heterozygous or homozygous PTC or in-frame deletion or heterozygous PTC or EBS-PA, COL17A1 heterozygous PTC/heterozygous or homozygous PTC, or LAMB3 (LN-5β3) heterozygous or homozygous PTC or gly substitution or DDEB-HR, COL7A1 heterozygous PTC or gly substitution or heterozygous PTC/gly substitution or RDEB-HR, COL7A1 heterozygous PTC or gly substitution or heterozygous PTC/gly substitution or RDEB-HR.
DDEB, dominant dystrophic EB; DM, DM variant; EBS, EB simplex; Dowling-Meara type, EBS-K; HR, severe; Kobner type, EBS-K; CARDB, generalized atrophic benigna EB; JEB-lethal, junctional EB lethal; MD, Mitsuhashi/Dreyfus type; PA, pyloric atresia; RDEB, recessive dystrophic EB.

TABLE 65-3 **Clinical Phenotype–Molecular Defect Correlations in Epidermolysis Bullosa**

GENERALIZED EBS In the Koebner variant of generalized EBS onset is at birth to early infancy with a predilection for hands, feet, and extremities. Palmar-plantar hyperkeratosis and erosions may be present (Fig. 65-2). Nails, teeth and oral mucosa are usually spared but if they are affected, the changes are minimal compared to recessive junctional or dystrophic EB.

FIGURE 65-2 Generalized EBS: clinical appearance. Note the typical blisters of the feet with hyperkeratosis and callus formation.

LOCALIZED EBS The Weber-Cockayne subtype of EBS is characterized by onset in childhood or later in life, and this variant is the most common form of EBS. The disease may not present itself until adulthood, when thick-walled blisters on the feet or hands occur after excessively strenuous exercise, such as during athletic competition or in the military. Hyperhidrosis of the palms and soles is common. Secondary infection of blistered lesions on the feet is the most common complication of this disorder.

EB HERPETIFORMIS The onset of Dowling-Meara EBS is at birth with a generalized distribution. Oral mucosa is often involved with variable lesions in infancy. A pronounced inflammatory phase with transient milium formation may occur in infancy; however, blisters are nonscarring by early childhood (Fig. 65-3A). Spontaneous grouped or “herpetiform”' blisters occur on the trunk and proximal extremities and heal without scarring (Fig. 65-3B). Nails may shed and regrow with dystrophy. A distinctive feature is that heat does not appear to exacerbate the blistering in EB herpetiformis as it does in the Koebner and Weber-Cockayne forms. After the age of 6 or 7 years, hyperkeratosis of the palms and soles may develop. Laryngeal involvement [45] and pyloric atresia [46] have also been reported in patients with severe forms of EB herpetiformis.

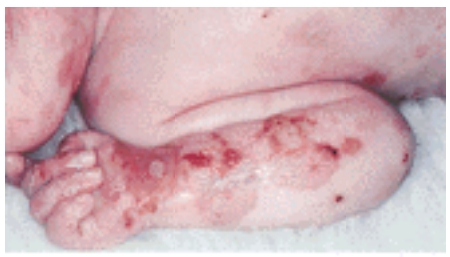

A.

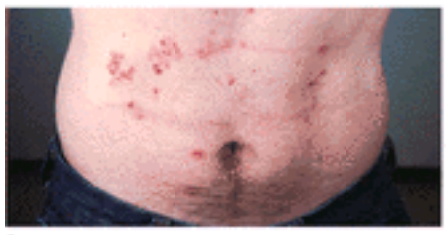

B.

FIGURE 65-3 Epidermolysis bullosa herpetiformis. *A.* Clinical appearance in newborn. Note the extensive erosions and milia. *B.* Clinical appearance in an adult male. Note the grouped vesicles.

EBS OF OGNA Onset in infancy is common with seasonal blistering (summer) on the acral areas. Small hemorrhagic and serous blisters occur primarily on the extremities. Healing occurs without scarring. All patients described thus far have come from Norway and a genetic linkage to erythrocyte glutamic-pyruvic transaminase (GPT) may help to explain the tendency toward easy bruising and hemorrhagic blisters which characterize Ogna EBS.

EBS WITH MUSCULAR DYSTROPHY This rare clinical entity is the first and only epidermolytic EB described that is not caused by a keratin gene mutation. [47] It presents as generalized intraepidermal blistering similar to EBS of Koebner; however, an adult onset muscular dystrophy is associated with the disease.

Molecular Pathology of EBS

Most of the patients with EB simplex analyzed at the genetic level have been found to be associated with mutations of the genes coding for keratins 5 and 14. [48] The level of separation of the skin in these patients is at the mid-basal cell, shown in Fig. 65-4, associated with variable intermediate filament clumping. Hemidesmosomes and other BMZ structures are normal by electron microscopy. The majority of keratin gene mutations associated with epidermolysis bullosa simplex are dominantly inherited due to abnormalities in the multimeric assembly of keratin filaments. There is a smaller subset of patients with recessively inherited disease of varying severity. [49], [50]

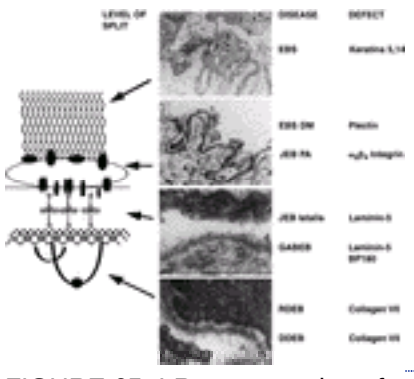

FIGURE 65-4 Representation of cutaneous basement membrane zone with examples of ultrastructural abnormalities observed in EB skin. The figure depicts four subtypes of EB based upon their respective levels of cleavage within the BMZ and examples of the candidate gene defect correlated with each blistering disorder (see text for details).

Mutations coding for the most conserved regions of keratins 5 and 14, the helix boundary domains, [51] correlate with the most severe forms of epidermolysis bullosa simplex, such as the Dowling-Meara subtype, which exhibits intermediate filament clumping. On the other hand, milder types of disease, such as the Weber-Cockayne subtype, are associated with mutations coding for regions of keratins 5 and 14 that are less conserved. Mutations that code for a specific region of the amino terminus of keratin 5 are associated with mottled pigmentation in certain epidermolysis bullosa simplex patients, [52] although significance of this mutation and its association with pigmentary abnormalities remains unclear. [53], [54] This condition is distinct from the large melanocytic nevi that can be seen in all three EB types. [55]

A small group of patients with recessive EB simplex have been shown to have associated muscular dystrophy and they have been shown to harbor mutations in the gene coding for HD1/plectin. [47], [56], [57] In these patients, the level of blistering is just above the hemidesmosome and complete disruption of the connection between the cytoskeleton and hemidesmosome is observed ultrastructurally. The mutations associated with this disease thus far are homozygous and produce premature termination codons which result in lack of expression of plectin. Plectin is normally expressed in a wide range of tissues, including muscle. While the mechanism of muscular ystrophy in plectin-deficient patients is unknown, it has been observed that disorganization of muscle sarcomeres occurs in the absence of plectin. It is possible that absence of plectin's spectrin-like domain, which may normally interact with actin filaments in muscle, may be a key factor in the muscle pathology. [58]

Junctional EB

Of all EB types, JEB shows the most genetic variation with at least seven different basement membrane components serving as candidate genes in this disorder (Table 65-3). All patients with JEB share the common histopathologic feature of blister formation within the lamina lucida of the BMZ either as part of stable anchoring complexes (i.e., hemidesmosomes) or anchoring filaments. This trait is inherited in an autosomal recessive manner and represents a spectrum of clinical phenotypes, depending on the type of genetic lesion present and a variety of environmental factors.

There are at least six clinical subtypes of JEB; however, three principal forms are most common. Herlitz disease, JEB gravis or lethal JEB are synonymous terms used to describe patients presenting with the most severe phenotypic disease. A more indolent form of JEB is termed *mitis JEB* and a third, relatively mild form is called *generalized atrophic benign EB* (GABEB) (Table 65-2).

JEB GRAVIS Patients with Herlitz EB often do not survive infancy and death rates are estimated at 40 percent the first year of life. The majority of patients succumb by 5 years of age. This makes Herlitz disease the most lethal of all EB ubtypes. Generalized blistering is observed at birth (Fig. 65-5) with severe and clinically distinctive periorificial granulation tissue, which can also occur in nonlethal subtypes (Fig. 65-6). Nails are usually lost early and are dystrophic when present. Teeth are dysplastic due to enamel defects and most mucosal surfaces are involved with chronic erosions. Scalp lesions consisting of chronic nonhealing erosions with hyperplastic granulation tissue are common.

FIGURE 65-5 Junctional epidermolysis bullosa (Herlitz variant): clinical appearance in a newborn. Note the extensive erosion.

FIGURE 65-6 Junctional epidermolysis bullosa (Herlitz variant): clinical appearance in a child with typical periorificial involvement and exuberant granulation tissue. Severe laryngeal involvement necessitated tracheostomy.

Associated systemic findings in severe cases include the entire spectrum of epithelial blistering with respiratory, gastrointestinal, and genitourinary organ systems involved. Tracheolaryngeal blistering, stenosis, or obstruction are commonly associated with Herlitz disease, and hoarseness in early infancy is an ominous sign. Marked growth retardation and a refractory, mixed anemia complicate management. Patients usually die of sepsis, multiorgan system dysfunction, and inanition. A rare and distinct clinical variant of lethal JEB is that type presenting at birth with severe junctional blistering associated with pyloric and/or duodenal atresia. These patients exhibit extreme mucosal and cutaneous fragility due to integrin mutations in either the *ITGA6* or *ITGB4* genes. [59] Patients diagnosed as junctional EB with pyloric atresia (JEB-PA) may also have various urologic abnormalities, including hydronephrosis and nephritis. JEB with pyloric stenosis has also been reported in association with hydronephrosis.

JEB MITIS Some patients present at birth with moderate junctional disease or present with severe JEB but survive infancy and clinically improve with age. Hoarseness is usually mild or absent. Scalp and nail lesions are prominent and periorificial nonhealing erosions commonly characterize this disease in children between the ages of 4 and 10 years. Although the disease process is debilitating, patients who present in this way may be designated as having *nonlethal JEB* or *JEB mitis*. Several of these patients have heterozygous laminin 5 mutations with one allele of a single laminin 5 subunit representing a premature termination codon and the other a missense mutation or an in-frame splicing mutation. There are other rare variants of nonlethal JEB that present with localized junctional blistering of the extremities or intertriginous areas.

GENERALIZED ATROPHIC BENIGN EB A separate form of nonlethal JEB also presents at birth with generalized cutaneous involvement. [60], [61] Variable-sized bullae occur, predominantly on the extremities; however, the trunk, scalp, and face are also involved. Survival to adulthood is the rule with persistent serous or serosanguineous bullae and chronic erosions of the extremities, trunk, and scalp. Blistering activity is particularly pronounced with increased ambient temperature. Nail dystrophy can be severe and a nonscarring alopecia (Fig. 65-7) with atrophic scarring of healed blisters are distinctive features of this EB subtype. Mucous membrane involvement of the oral cavity is mild and enamel defects contribute to dystrophic dentition. Blistering improves with age but the dental abnormalities and atrophic scalp lesions persist into adulthood. Overall growth is normal and anemia is rarely seen. In contrast to Herlitz disease, GABEB patients have a normal life span.

FIGURE 65-7 Junctional epidermolysis bullosa (generalized atrophic benign variant): clinical appearance. Note the typical alopecia.

Molecular Pathology of JEB

Molecular diagnostic analysis has shown that different patients with JEB can carry mutations in any of the three laminin 5 subunits (i.e., a $_{3'}$ ß $_{3'}$? $_{2}$). [62], [63] and [64] However, about 80 percent of laminin 5 mutations can be traced to one of two recurrent nonsense mutations in the *LAMB3* gene making prenatal testing for laminin 5 lesions easier than other EB candidate genes. [65] In the letalis patients, all of the mutations so far detected have been those producing a premature termination codon, resulting in absence of expression of laminin-5. The combination of severe skin involvement and mucosal fragility since birth, hoarseness, absence of laminin 5 expression, and premature termination codons in both alleles of a laminin 5 subunit are the best indicators of Herlitz EB.

In the JEB variant GABEB, blistering occurs in the lamina lucida region and abnormalities of hemidesmosomes/anchoring filaments are usually present (see Fig. 65-4). Some patients with GABEB display a reduced but still positive expression of laminin 5. [62], [66], [67] Mutation-induced disruption of the connection of laminin 5 to other BMZ ligands such as type VII collagen or laminin 6 may provide an explanation for the patient's

phenotype. Thus, partial loss of laminin 5 function leads to a more benign phenotype, whereas total loss of laminin 5 function leads to a lethal phenotype.

While laminin 5 mutations underlie a subset of GABEB patients, the majority of these patients have abnormalities of the hemidesmosomal protein type XVII collagen. A number of mutations of the gene coding for type XVII collagen [68], [69] have been described in GABEB patients, including premature termination codon mutations, missense mutations, and a glycine substitution mutation. Of interest, one mosaic GABEB patient was identified who demonstrated well-defined areas of blistering associated with absence of type XVII collagen expression as well as areas of nonblistering skin associated with normal type XVII collagen expression. Careful analysis of the patient's keratinocytes revealed reversion of one of the two alleles of the mutation, most likely due to a mitotic gene conversion involving nonreciprocal exchange of parental allele DNA. [70]

Mutations of the genes coding for the $ß_4$ and a_6 integrin are also associated with JEB; [71] in this group of diseases, pyloric atresia is present, and separation of the skin occurs at the level of the hemidesmosome region. Often fragments of the basal cell cytoplasm are found associated with the base of the split. In these patients, hemidesmosomes are almost absent or rudimentary at best, and the level of separation is such that fragments of the basal cell plasma membrane remain adherent to the base of the blister. The skin ultrastructure in patients with $a_6ß_4$ defects is remarkably similar to the $ß_4$ integrin knockout mice described above. Nonlethal cases have been characterized which appear to result from a partial loss of function of $ß_4$ integrin. [72] Interestingly, nonlethal JEB can sometimes ameliorate itself through alterations in mRNA splicing. [73], [74]

Dystrophic EB

Dystrophic EB (DEB) is a “dermolytic” disease and healing after blister formation is usually accompanied by scarring and milium formation. There are four principal subtypes of heritable DEB and all share the common pathogenetic features of subepidermal blistering due to anchoring fibril type VII collagen mutations (Table 65-2 and Table 65-3); however, several rarer forms also exist. The main types, which are separated on clinical grounds, include dominant DEB of Cockayne-Touraine; dominant DEB of the albopapuloid or Pasini variant; localized recessive DEB; and generalized recessive DEB (Table 65-2).

DOMINANT DEB

In Cockayne-Touraine disease blistering is usually acral with nail dystrophy and onset in infancy or early childhood. Healing occurs with milia and scar formation, which may be hypertrophic or hyperplastic. Oral lesions are uncommon and teeth are usually normal.

The Pasini variant of DEB is usually seen at birth and blistering is more extensive with atrophic scarring and milium formation. Flesh-colored, scarlike papular lesions appear spontaneously on the trunk in the absence of obvious trauma and are called *albopapuloid lesions*. As these same lesions have been observed in other subtypes of EB, the specificity of this sign is debatable. Later in life, blisters are located primarily on the extremities but occasionally may be generalized. Dystrophic or absent nails are common; however, mucosal surfaces and teeth are often minimally affected.

RECESSIVE DEB

The clinical phenotypes of recessive DEB (RDEB) include a wide spectrum of disease severity. A localized, less severe form, often called *RDEB-mitis,* occurs at birth and usually involves the acral areas with atrophic scarring of the joint surfaces and nail dystrophy but little mucosal involvement. The mild subtype of localized recessive DEB makes it clinically indistinguishable from some forms of localized dominant DEB.

Severe recessive DEB is a mutilating disease, known also as the Hallopeau-Siemens (HS) variant. Generalized blistering is present at birth and progression during infancy and childhood (Fig. 65-8) results in remarkable scarring, shown in Fig. 65-9A. Acquired syndactyly leading to “mitten-like” deformities of the hands and feet are the rule and the scarring process may extend proximally to involve the entire extremity in flexion contracture (Fig. 65-9B). Milia formation may be considerable (Fig. 65-10). Nails, teeth, and scalp are affected. Most mucosal surfaces are invariably involved with recurrent blisters and erosions leading to esophageal strictures and webbing, urethral and anal stenosis, phimosis and ocular surface scarring. Malnutrition, growth retardation, and chronic mixed anemia are common.

FIGURE 65-8 Recessive dystrophic epidermolysis bullosa. Note the flaccid blisters and erosions over elbows and sacral region.

FIGURE 65-9 *A*. Recessive dystrophic epidermolysis bullosa (Hallopeau-Siemens variant): clinical appearance. Note the extensive full thickness erosions, ulcers, and thick scarring. *B.* Note “mitten” deformity of fingers and nail loss.

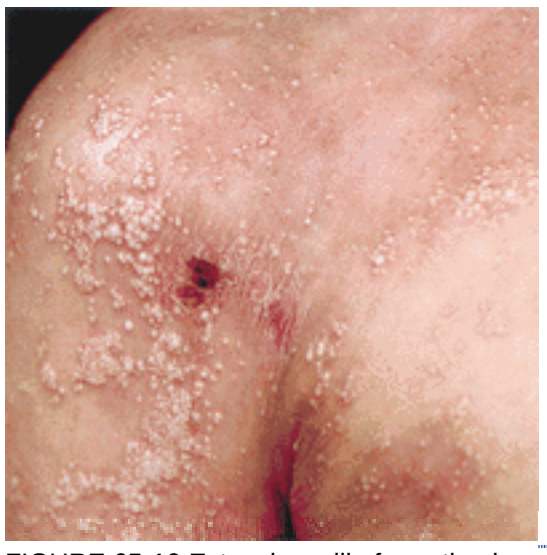

FIGURE 65-10 Extensive milia formation in previously blistered areas in recessive dystrophic epidermolysis bullosa.

Perhaps the most devastating complication of HS-RDEB is the high risk of developing aggressive squamous cell carcinomas in areas of chronic erosions. In more than 50 percent of HS-RDEB, patients develop these “scar” carcinomas by 30 years of age and many of these die of metastatic disease.

Molecular Pathology of DEB

Abnormalities of anchoring fibrils are present in DEB patients ranging from subtle changes in some patients with dominant disease, to absence of anchoring fibrils in patients with the severe recessive form of this disease. A sublamina densa plane of blister cleavage is present (Fig. 65-4). These observations correlate with indirect immunofluorescent microscopic analysis of DEB patients that demonstrates varying degrees of linear basement membrane staining in patients with dominant disease and totally absent staining in severe patients with recessive disease. In some patients, there is a cytoplasmic retention of type VII collagen that can be demonstrated in patient biopsy sections and analysis of patient keratinocytes. [75]

In all cases thus far, dystrophic EB is associated with mutations of the gene coding for type VII collagen (COL7A1) (Table 65-3). In the recessive forms, mutations usually cause premature termination codons that result in lack of type VII collagen in tissue. It is known that mRNAs bearing premature stop codons show accelerated turnover. [76] In addition, truncated proteins that are secreted would not assemble into anchoring filaments and may also show accelerated turnover. Either or both of these mechanisms can explain the lack of detectable type VII collagen in the tissue of individuals with severe RDEB associated with mutations that produce premature termination codons. [37], [77], [78]

Generally, *COL7A1* mutations that do not cause premature termination codons produce less-severe disease. For example, mutations that produce glycine substitutions of the triple-helical region interfere with triple-helical assembly of the type VII collagen molecule. These types of mutations are present in many patients with milder dominant forms of this disease. [79], [80], [81], [82], [83], [84], [85] and [86] In these patients, type VII collagen molecules may not be able to assume the proper conformation needed to polymerize into anchoring fibrils. Other *COL7A1* mutations are associated with impaired secretion of type VII collagen, resulting in intracellular accumulation of this molecule. [87], [88], [89] and [90] In one study, DEB patient mutations that involve the area of the gene coding for the type VII collagen NC2 domain were shown to interfere with NC2 processing and the assembly of anchoring fibrils. [91]

APPROACH TO THE PATIENT

Diagnosis

Technological advances in our approach to EB patient diagnosis have provided new insights into clinical phenotype-genotype correlations. [3] This approach integrates multiple analytic steps and unifies EB disease classification, course, genetic counseling and management options (Fig.

65-11). Each step in this approach utilizes our previous clinical experience with EB patients, detailed understanding of the molecular components of the cutaneous basement membrane and rapid advances in DNA mutation detection and gene transfer technology.

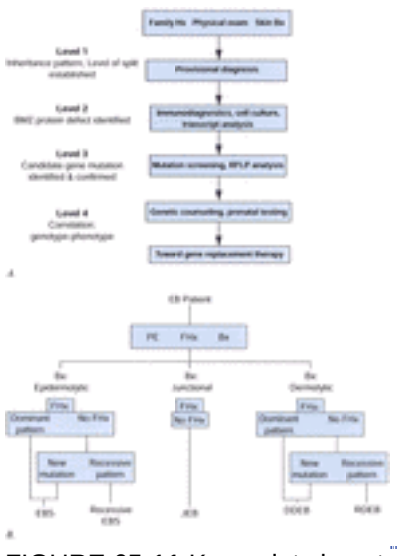

FIGURE 65-11 Key points in establishing a provisional diagnosis for an EB patient involve clinical clues in combination with the level of blister formation within the cutaneous basement membrane. Inheritance patterns guide the clinician to an accurate provisional diagnosis. While spontaneous mutations in EB candidate genes are rarely found, they should not be overlooked when the family history shows no evidence of EB. Diagrammatic overview of the approach toward molecular diagnosis EB patients. Clinical encounter with unknown patient manifesting mechanobullous disease characteristics requires detailed family history, physical exam and skin biopsy to assess first level, provisional diagnosis. Second level of diagnostic work-up requires analysis of EB candidate gene defect by immunofluorescence microscopy of skin biopsy, and/or immunoblotting and candidate gene transcript analysis from EB patient's cultured keratinocytes. When a provisional diagnosis is correlated with an EB candidate gene product defect, the next level of analysis is performed by screening proband DNA for mutations in the specific candidate gene identified. In most circumstances, confirmation of a homozygous or heterozygous mutation is performed on nuclear family DNA via restriction fragment length polymorphism (RFLP; if the genetic defect involves a restriction enzyme site) or allele-specific oligonucleotide hybridization. Complete knowledge of the genetic defect will allow correlation of clinical phenotype and highest level EB patient care via genetic counseling, prenatal testing services and ultimately gene replacement.

Ideally, the clinician will provide EB patient tissue samples that can be divided into several pieces: one for hematoxylin-and-eosin (H&E) light microscopy, one for immunofluorescence microscopy, one for electron microscopy and another for cell culture. Blood samples or buccal swabs are usually obtained from the nuclear family members for genetic analysis. In the majority of cases, not all diagnostic steps are necessary to arrive at a final diagnosis; however, the information provided by these studies is helpful for eventual development of targeted gene transfer and ultimately gene therapy of the EB patient.

Provisional diagnosis is made by a combination of patient history/physical exam and histopathology at the light microscope level on perilesional skin biopsy (Fig. 65-12). For example, EB simplex can often be classified at this stage and in the vast majority of cases a dominant family history is obtained. However, when no family history is given (or available), a recessive pattern should be considered, especially if the epidermolytic disease is severe or associated with extracutaneous disorders (e.g., muscular dystrophy). When a junctional cleavage pattern is recognized, recessive disease is the rule.

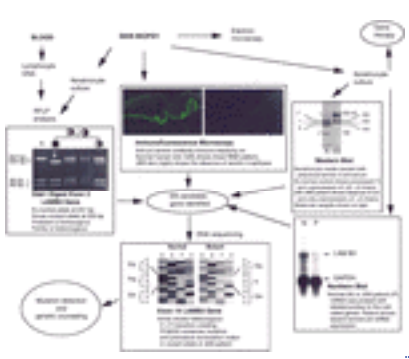

FIGURE 65-12 Examples of methodology used in the molecular diagnosis of EB: analysis of a Herlitz variant junctional EB patient at the protein, mRNA, and DNA levels. Lack of expression of EB candidate gene product (i.e., laminin 5 $ß_3$ chain) is demonstrated by both immunofluorescence microscopy on skin biopsy and by Western blotting of patient-derived keratinocyte culture media. Transcript analysis by Northern blot hybridization shows decreased LAMB3 mRNA levels from the same keratinocytes. All three analyses point to identification of LAMB3 as the candidate gene responsible for skin fragility in this Herlitz patient and suggest that the mutation(s) in the LAMB3 gene results in functionally null alleles inherited from both parents. Sequence analysis of patient DNA demonstrates that one allele harbors a C ? T transition in exon 14 of the LAMB3 gene, converting an arginine at position 1825 to a premature termination codon (AGT), confirming a compound heterozygous state. Further mutation detection analysis can identify the other LAMB3 mutant allele and provide data for genetic counseling in the family. Detection of common DNA mutations found in the LAMB3 gene can be performed directly on DNA derived from either lymphocytes or cultured skin cells using restriction fragment length polymorphism (RFLP) techniques. In a different junctional EB case the restriction enzyme, Dde1, is used to digest LAMB3 exon 3 from the proband and family DNA. The normal state shows three digestion products (bands at 257, 90, and 69 base pairs), whereas the proband (*solid square*) shows a new band at 225 bp with no 257 bp band. The unaffected sister and both parents show heterozygosity of this Dde1 RFLP. Such information can be used to identify the EB candidate gene for subsequent DNA mutation analysis.

Information derived from molecular diagnostic analyses can be used directly to design therapeutic gene delivery strategies for individual EB patients.

Because light microscopy cannot distinguish junctional from dermolytic EB, ultrastructural analysis is required to provide definitive information about both blister location and alterations of basal keratinocyte anchoring complexes. However, the use of new immunodiagnostic reagents is often comparable to ultrastructural studies and in many cases these reagents provide more precise information about specific EB candidate gene product dysfunction. For example, immunofluorescence microscopy may show absence or diminished expression of a specific basement membrane component and this information helps to guide the search for genetic defects in EB candidate genes.

After a provisional diagnosis is made, several additional steps may be required, especially in cases where the mode of inheritance and/or previous diagnostic clues are unclear. For instance, often the clinical severity in patients with localized forms of RDEB makes them indistinguishable from those having mild dominant dystrophic forms or even localized, mild junctional EB. Furthermore, ultrastructural analysis may show only subtle alterations in anchoring complexes and immunofluorescence of skin may show normal expression of all EB candidate gene products at the BMZ, making the diagnosis even more difficult. In these cases, the combination of clinical signs, modern immunodiagnostic analysis and mutational studies are required to classify the EB type. A distinction between mild dominant dystrophic EB and recessive dystrophic EB can be made by mutation analysis. The presence of a single mutant *COL7A1* allele in both the proband and one parent or affected sibling confirms the former diagnosis, whereas, the latter diagnosis would be applicable if two mutant alleles were found (i.e., compound heterozygous or homozygous). In the absence of any *COL7A1* mutations, one of the many JEB candidate genes may harbor missense mutations or a combination of missense and nonsense mutations (Fig. 65-12).

Establishing cell cultures from biopsy specimens serves multiple purposes (Fig. 65-12). Easily cultured proband fibroblasts can be grown to provide DNA for mutation analysis. If keratinocytes can be grown, they can be immortalized to provide large amounts of biochemical and genetic material for subsequent analyses. Both immunofluorescence microscopy and immunoblotting (Western) can be performed on keratinocyte culture media to confirm the results of tissue analysis. Northern blot hybridization confirms diminished or absent mRNA levels. This information is essential to implement gene therapy efforts utilizing ex vivo protocols (see below).

Genetic Counseling

Genetic information provided by mutation analyses on EB candidate genes provides an immediate benefit to families of EB patients. Siblings of a proband with recessive EB at reproductive age who contemplate having a child often want to know whether or not they carry a mutant allele. Most importantly, prenatal diagnosis of EB in affected families is now a genetic-based protocol provided the original proband has had mutational analysis or identification of the defective gene. Fetal skin biopsies and fetoscopy with their increased risk of pregnancy loss can now be avoided by analysis of either chorionic villus sampling as early as 8 to 10 weeks or amniocentesis in the second trimester. [92] The development of highly informative intragenic and flanking polymorphic DNA markers in EB candidate genes together with rapid screening of genetic “hotspots” makes genetic screening of at risk pregnancies a viable option. [93], [94] Coupling of the technique of in vitro fertilization with EB prenatal diagnosis, preimplantation diagnosis has now been successfully performed for EB cases. [95]

THERAPY

Therapy for EB is tailored to the severity and extent of skin involvement and consists of supportive skin care, supportive care for other organ systems in indicated subtypes, and use of systemic therapies in an attempt to alter disease progression. Because of the involvement of multiple organ systems in severe EB subtypes, a multidisciplinary approach to patient care is often required. In most cases, the triad of wound management, nutritional support, and infection control are key to management of all EB patients.

Supportive Skin Care

Comprehensive topical therapy is a mainstay of treatment in EB, with avoidance of trauma a central goal. In EBS, maintenance of a cool environment and the use of soft, well-ventilated leather shoes is advisable. Blistered skin can be treated with modified Dakin's or simple saline compresses followed by topical antibiotics; in inflamed lesions the limited use of topical steroids may produce some degree of relief as well. Topical treatment for patients severely affected with junctional or dystrophic EB with the use of nonadhering dressings, such as Exu-Dry or Omniderm, over Vaseline or Aquaphor is extremely helpful in providing symptomatic relief. Gentle bathing and cleansing in modified Dakin's solution is best followed by application of a protective emollient and nonadherent dressing. In addressing the chronic hypertrophic granulation tissue seen in the periorificial regions of the face in JEB (Fig. 65-6), the use of keratinocyte autografts may be worthy of consideration. Such autografts, however, have demonstrated no significant benefit in the treatment of nonhypertrophic granulation tissue wounds in RDEB. In dystrophic epidermolysis bullosa, use of finger splinting and appropriate hand protection against trauma is indicated. Management of cutaneous infections is an important part of EB patient care. Systemic antibiotic therapy is frequently indicated for cutaneous wound infection and chronic wound colonization is managed best by regular cleansing with modified Dakin's solution and topical antibiotics as needed.

Surgical treatment is often required in the management of patients with dystrophic EB [96] and surgical intervention benefits from specialized anesthesia care. [97] Surgical release of fused digits followed by splinting is a therapeutic option for severely affected patients; however, therapy may require repetition at periodic intervals. [96], [98], [99] Surgery to correct limb, perioral, and perineal contractures may also be required; however, recurrence is common in dystrophic EB. [100], [101] Patients with RDEB frequently develop squamous cell carcinoma [102], [103] and prompt treatment of these tumors is indicated because they may develop metastases. Surgical excision is an important first-line modality, with radiation therapy limited by poor tumor response and impaired site healing. [104]

Care for Extracutaneous Involvement

Severe cases of JEB and DEB can involve multiple organ systems and require a multidisciplinary patient care approach. An additional source of support for patients and families include several important organizations that assist with patient education and support including Dystrophic Epidermolysis Bullosa Research Association (DEBRA) and Epidermolysis Bullosa Medical Research Foundation. A pediatric dentist is often of great help in managing the dental conditions with the use of a very soft brush and water pulsation devices preferable to hard brushing. Nutritional supplementation somewhat similar to that required for burn victims is important and a blenderized diet should be used for all patients with esophageal symptoms. Treatment of hematologic problems, primarily iron deficiency anemia, is important as is the overall nutritional support of these patients. Gastrointestinal involvement in DEB and JEB can include dysphagia with stricture formation requiring surgical release most common in RDEB and DDEB. Additional gastrointestinal procedures such as dilatation and gastrostomy may be indicated in those who suffer from severe involvement of the upper gastrointestinal system. [105] For the treatment of constipation seen in EB patients, increased fluid and fiber intake and stool softeners may be of value. In patients with airway involvement, there is danger of pulmonary aspiration. Ocular involvement in epidermolysis bullosa may include corneal abrasions and stromal scarring in junctional and dystrophic EB. Significant eye involvement should be managed with the assistance of an ophthalmologist to prevent clouding of the corneal stroma and serious visual compromise.

Systemic Therapies

Systemic therapies have not been effective in ameliorating the fundamental bullous tendency in EB patients. Historically, tetracycline and phenytoin have been used in the past for this disorder but are not current mainstays of treatment. Antimalarials and retinoids have also been used; however, the utility of these agents has not been definitively established. Systemic corticosteroids have not proven useful in these disorders.

Future Potential Therapies

Future potential therapies include protein and gene therapy as well as the use of tissue engineered skin equivalents. In the former case, the missing or defective protein is produced by recombinant methods and applied directly to blistered skin. This may be of most utility in proteins such as laminin 5 chains that do not require complex processing or transmembrane cellular anchorage. In the case of gene therapy, delivery of genes targeted to restore normal protein expression is the goal. Recent genomic expression profiling model studies have suggested that gene transfer may effect normalization of gene expression more broadly than protein transfer. [106] Successful corrective gene delivery was recently achieved in human EB tissue in the immune-deficient model system described below for both laminin 5 and Type XVII collagen. [107], [108] Thus, genetic therapies may be of significant utility in the future. In the case of tissue-engineered skin, application of skin equivalents recently demonstrated some promise in wound healing and in improvement of quality of life, [109] and thus represents an area of future investigation.

DISEASE MODELS

A number of new models have recently been developed to facilitate the study and development of therapy for epidermolysis bullosa. Some of these models use mouse genetic approaches to produce entirely murine tissue models. [110] These include transgenic mouse models with skin targeted expression of *trans*-dominant molecules [111]—including inducible-disease phenotype models. [112] These include dominant-negative basal keratins in models of epidermolysis bullosa simplex. Murine knockout models have also been used, including knockout of basal keratin genes in a model of the same disorder and of the a_6 and $ß_4$ integrins, laminin 5, and type VII collagen. [12], [113], [114], [115] and [116] These targeted gene disruptions in mice have accurately recapitulated the blistering phenotype of the corresponding human disorders. These murine genetic models have been of great utility in clarifying our understanding of the pathogenesis of this group of disorders and in providing disease models for development of potential future therapies.

In addition to such purely murine tissue models, human skin/mouse chimeras have been generated in an attempt to produce true human tissue models of epidermolysis bullosa. These chimeras have either used full thickness grafting of EB patient skin or epidermis regenerated on skin composites and sheets from EB keratinocytes grown in culture. [117] Immune-deficient SCID (severe combined immunodeficiency disease) and nude mice readily accept such xenografts and the grafted EB skin retains the clinical and molecular characteristics of the patient donor. This approach has been reported for recessive dystrophic EB due to mutations in type VII collagen, and for benign junctional EB due to mutations in type XVII collagen. Because human epidermis differs dramatically from mouse epidermis in tissue architecture, these in vivo models of human tissue in EB may be of special utility in development of models for gene therapy of these disorders. In addition to gene therapy applications, these models are attractive for attempts at protein therapy, as in the case of topical laminin 5, in some subtypes of JEB.

REFERENCES

1. Pearson RW: Studies on the pathogenesis of epidermolysis bullos *J Invest Dermato* **39**:551, 1962
2. Burgeson RE, Christiano AM: The dermal–epidermal junctio *Curr Opin Cell Bio* **9**:651, 1997
3. Marinkovich MP: Update on inherited bullous dermatose *Dermatol Clir* **17**:473, 1999
4. Fuchs E, Cleveland DW: A structural scaffolding of intermediate filaments in health and disea *Science* **279**:514, 1998
5. Wiche G: Domain structure and transcript diversity of plectir *Biol Bul* **194**:381, 1998
6. Stanley JR: Pemphigus and pemphigoid as paradigms of organ-specific, autoantibody-mediated disea *J Clin Inves* **83**:1443, 1991
7. Leung CL et al: The BPAG1 locus: Alternative splicing produces multiple isoforms with distinct cytoskeletal linker domains, including predominant isoforms in neurons and mu *J* les.

Cell Bio. **154**:691, 2001

8. Guo LL, Degenstein L et al: Gene targeting of BPAG1: Abnormalities in mechanical strength and cell migration in stratified squamous epithelia and severe neurological degene *Cell* on. **81**:233, 1995

9. Giudice GJ et al: Cloning and primary structural analysis of the bullous pemphigoid autoantigen BP1 *J Invest Dermato* **99**:243, 1992

10. Sonnenberg A et al: Integrin $a_6ß_4$ complex is located in hemidesmosomes, suggesting a major role in epidermal cell-basement membrane adhe *J Cell Bio* **113**:907, 1991

11. Niessen CM et al: The $a_6ß_4$ integrin is a receptor for both laminin and kalini *Exp Cell Res* **211**:360, 1995

12. Dowling J et al: Beta4 integrin is required for hemidesmosome formation, cell adhesion and cell surv *J Cell Bio* **134**:559, 1996

13. Hirako Y et al: Demonstration of the molecular shape of BP180, a 180-kDa bullous pemphigoid antigen and its potential for trimer form *J Biol Chem* **271**:13739, 1996

14. Carter WG et al: Distinct functions for integrins $a_3ß_1$ in focal adhesions and $a_6ß_4$/bullous pemphigoid antigen in a new stable-anchoring contact (SAC) of keratinocytes: Relation to hemidesmosomes. *J Cell Bio* **111**:3141, 1990

15. Schäcke H et al: Two forms of collagen XVII in keratinocytes. A full-length transmembrane protein and a soluble ectodo *J Biol Chem* **273**:25937, 1998

16. Zone JJ et al: Identification of the cutaneous basement membrane antigen in linear IgA bullous dermat *J Clin Inves* **85**:812, 1990

17. Marinkovich MP et al: LAD-1, the linear IgA bullous dermatosis autoantigen, is a novel 120-kDa anchoring filament protein synthesized by epidermal cells [published erratum appears in *J Invest Dermato* 106:1343, 1996]. *J Invest Dermato* **106**:734, 1996

18. Zone JJ et al: The 97-kDa linear IgA bullous disease antigen is identical to a portion of the extracellular domain of the 180-kDa bullous pemphigoid antigen, B *J Invest Dermato* **110**:207, 1998

19. Schumann H et al: The shed ectodomain of collagen XVII/BP180 is targeted by autoantibodies in different blistering skin disea *Am J Patho* **156**:685, 2000

20. McGowan KA, Marinkovich MP: Laminins and human diseas *Microsc Res Tech* **51**:262, 2000

21. Rousselle P et al: Kalinin: An epithelium-specific basement membrane adhesion molecule that is a component of anchoring filam *J Cell Bio* **114**:567, 1991

22. Marinkovich MP et al: The anchoring filament protein kalinin is synthesized and secreted as a high molecular weight precu *J Biol Chem* **267**:17900, 1992

23. Gerecke DR et al: Hemidesmosomes, anchoring fibrils, i *Extracellular Matrix Assembly and Structure* edited by RP Mecham, DE Birk, PD Yurchenko. San Diego, Academic Press, 1994, p 417

24. Ryan MC et al: Cloning of the gene encoding the $ß_3$ chain of the adhesive ligand epiligrin. Expression in wound repa *J Biol Chem* **269**:22779, 1994

25. Kallunki P et al: A truncated laminin chain homologous to the $ß_2$ chain: Structure, spatial expression, and chromosomal assignme *J Cell Bio* **119**:679, 1992

26. Champliaud MF et al: Human amnion contains a novel laminin variant, laminin 7, which, like laminin 6, covalently associates with laminin 5 to promote stable epithelial-stromal attachment. *J Cell Bio* **132:1**189, 1996

27. Marinkovich MP et al: The dermal–epidermal junction of human skin contains a novel laminin vari *J Cell Bio* **119**:695, 1992

28. Amano S et al: Bone morphogenetic protein 1 is an extracellular processing enzyme of the laminin 5 gamma 2 c *J Biol Chem* **275**:22728, 2000

29. Goldfinger LE et al: The a_3 laminin subunit, $a_6ß_4$ and $a_3ß_1$ integrin coordinately regulate wound healing in cultured epithelial cells and in the s *J Cell Sc* **112:2**615, 1999

30. Giannelli G et al: Induction of cell migration by matrix metalloprotease-2 cleavage of lamini *Science* **277**:225, 1997

31. Koshikawa N et al: Role of cell surface metalloprotease MT1-MMP in epithelial cell migration over lamini *J Cell Bio* **148**:615, 2000

32. Gagnoux-Palacios L et al: The short arm of the laminin gamma 2 chain plays a pivotal role in the incorporation of laminin 5 into the extracellular matrix and in cell ad *J Cell Bio* **153**:835, 2001

33. Fine JD et al: 19-DEJ-1, a hemidesmosome-anchoring filament complex associated monoclonal antibody. Definition of a new skin basement membrane antigenic defect in junctional and dystrophic epidermolysis bullosa *Arch Dermato* **125**:520, 1989

34. Parente MG et al: Human type VII collagen: cDNA cloning and chromosomal mapping of the gene (COL7A1) on chromosome 3 to dominant dystrophic epidermolysis b *Am J Hum Genet* **24**:119, 1991

35. Burgeson RE et al: The structure and function of type VII collage *Ann N Y Acad Sc* **580**:32, 1990

36. Bachinger HP et al: The relationship of the biophysical and biochemical characteristics of type VII collagen to the function of anchoring fi *J Biol Chem* **265**:10095, 1990

37. Bruckner-Tuderman L et al: Biology of anchoring fibrils: Lessons from dystrophic epidermolysis bullo *Matrix Bio* **18**:43, 1999

38. Gayraud B et al: Characterization of a 50-kDa component of epithelial basement membranes using GDA-J/F3 monoclonal antib *J Biol Chem* **272**:9531, 1997

39. Chen M et al: Interactions of the amino-terminal noncollagenous (NC1) domain of type VII collagen with extracellular matrix compo *J Biol Chem* **272**:14516, 1997

40. Rousselle P et al: Laminin 5 binds the NC-1 domain of type VII collage *J Cell Bio* **138**:719, 1997

41. Chen M et al: NC1 domain of type VII collagen binds to the beta3 chain of laminin 5 via a unique subdomain within the fibronectin-like re *J Invest Dermato* **112**:177, 1999

42. Chen M et al: The carboxyl terminus of type VII collagen mediates antiparallel-dimer formation and constitutes a new antigenic epitope for EBA autoantib *J Biol Chem* **27**:27, 2001

43. Fine JD et al: Revised classification system for inherited epidermolysis bullosa: Report of the Second International Consensus Meeting on diagnosis and classification of epidermolysis bullosa. *J Am Acad Dermato* **42**:1051, 2000

44. Horn HM, Tidman MJ: The clinical spectrum of epidermolysis bullosa simple *Br J Dermato* **142**:468, 2000

45. Shemanko CS et al: Laryngeal involvement in the Dowling-Meara variant of epidermolysis bullosa simplex with keratin mutations of severely disruptive pc *Br J Dermato* **142**:315, 2000

46. Morrell DS et al: Congenital pyloric atresia in a newborn with extensive aplasia cutis congenita and epidermolysis bullosa sin *Br J Dermato* **143**:1342, 2000

47. McLean WH et al: Loss of plectin causes epidermolysis bullosa with muscular dystrophy: cDNA cloning and genomic organiza *Genes Dev* **10**:1724, 1996

48. Epstein E: Finding the mutations causing hereditary diseases of the ski *Prog Dermato* **26**:1, 1992

49. Rugg EL et al: A functional "knockout" of human keratin 1 *Genes and Developmen* **8**:2563, 1994

50. Jonkman MF et al: Effects of keratin 14 ablation on the clinical and cellular phenotype in a kindred with recessive epidermolysis bullosa sin *J Invest Dermato* **107**:764, 1996

51. Coulombe PA: The cellular and molecular biology of keratins: Beginning a new e *Curr Opin Cell Bic* **5**:17, 1993

52. Uttam J et al: The genetic basis of pidermolysis bullosa simplex with mottled pigmentati *Proc Natl Acad Sci USA* **93**:9079, 1996

53. Irvine AD et al: Molecular confirmation of the unique phenotype of epidermolysis bullosa simplex with mottled pigment *Br J Dermato* **144**:40, 2001

54. Moog U et al: Epidermolysis bullosa simplex with mottled pigmentation: Clinical aspects and confirmation of the P24L mutation in the KRT5 gene in further pa *Am J Med Gene* **86**:376, 1999

55. Bauer JW et al: Large melanocytic nevi in hereditary epidermolysis bullo *J Am Acad Dermato* **44**:577, 2001

56. Gache Y et al: Defective expression of plectin/HD1 in epidermolysis bullosa simplex with muscular dystro *J Clin Inves* **97**:2289, 1996

57. Dang M et al: Novel compound heterozygous mutations in the plectin gene in epidermolysis bullosa with muscular dystrophy and the use of protein truncation test for detection of premature termination codon mutations *Lab Inves* **78**:195, 1998

58. Uitto J et al: Plectin and human genetic disorders of skin and muscle. The paradigm of epidermolysis bullosa with muscular dystro *Exp Dermato* **5**:237, 1996

59. Gil SG et al: Junctional epidermolysis bullosis: Defects in expression of epiligrin/nicein/kalinin and integrin beta 4 that inhibit hemidesmosome form *J Invest Dermato* **103**:31S, 1994

60. Hashimoto I et al: Epidermolysis bullosa hereditaria with junctional blistering in an ad *Dermatologica* **152**:72, 1976

61. Hintner H, Wolff K: Generalized atrophic benign epidermolysis bullos *Arch Dermato* **118**:375, 1982

62. McGrath JA et al: Altered laminin 5 expression due to mutations in the gene encoding the $_3$ chain in generalized atrophic benign epidermolysis bullos *J Invest Dermato* **104**:467, 1995

63. McGrath JA et al: A recurrent homozygous nonsense mutation within the LAMA3 gene as a cause of Herlitz junctional epidermolysis bullosa in patients of Pakistani ancestry: Evidence for a founder effect. *J Invest Dermato* **106**:781, 1996

64. Aberdam D et al: Herlitz's junctional epidermolysis bullosa is linked to mutations in the gene (LAMC2) for the ?2 subunit of nicein/kalinin (LAMINI *Nat Genet* **6**:299, 1994

65. Kivirikko S et al: Mutational hotspots in the LAMB3 gene in the lethal (Herlitz) type of junctional epidermolysis bull *Hum Mol Gene* **5**:231, 1996

66. Cserhalmi-Friedman PB et al: Molecular basis of non-lethal junctional epidermolysis bullosa: Identification of a 38-base pair insertion and a splice site mutation in exon 14 of the LAMB3 gene. *Exp Dermato* **7**:105, 1998

67. Pulkkinen L et al: LAMB3 mutations in generalized atrophic benign epidermolysis bullosa: Consequences at the mRNA and protein le *Lab Inves* **78**:859, 1998

68. McGrath JA et al: Mutations in the 180-kD bullous pemphigoid antigen (BPAG2), a hemidesmosomal transmembrane collagen (COL17A1), in generalized atrophic benign epidermolysis bullosa. *Nat Genetics* **11**:83, 1995

69. Jonkman MF: Hereditary skin diseases of hemidesmosome *J Dermatol Sc* **20**:103, 1999

70. Jonkman MF et al: Revertant mosaicism in epidermolysis bullosa caused by mitotic gene convers *Cell* **88:5**43, 1997

71. Vidal F et al: Integrin beta 4 mutations associated with junctional epidermolysis bullosa with pyloric atre *Nat Genet* **10**:229, 1995

72. Inoue M et al: A homozygous missense mutation in the cytoplasmic tail of beta4 integrin, G931D, that disrupts hemidesmosome assembly and underlies non-Herlitz junctional epidermolysis bullosa without pyloric atresia *J Invest Dermato* **114**:1061, 2000

73. Chavanas S et al: Splicing modulation of integrin beta4 pre-mRNA carrying a branch point mutation underlies epidermolysis bullosa with pyloric atresia undergoing spontaneous amelioration with aging *Hum Mol Gene* **8**:2097, 1999

74. Gache Y et al: Genetic bases of severe junctional epidermolysis bullosa presenting spontaneous amelioration with a *Hum Mol Gene* **10**:2453, 2001

75. Smith LT, Sybert VP: Intra-epidermal retention of type VII collagen in a patient with recessive dystrophic epidermolysis bul *J Invest Dermato* **94**:261, 1990

76. Cui Y et al: Identification and characterization of genes that are required for the accelerated degradation of mRNAs containing a premature translational termination *Genes Dev* **9**:423, 1995

77. Uitto J et al: Molecular basis of the dystrophic and junctional form of epidermolysis bullosa: Mutations in the type VII collagen and kalinin (laminin-5) g *J Invest Dermato* **103**:39S,

1994

78. Christiano AM et al: Premature termination codons in the type VII collagen gene (COL7A1) underlie severe, mutilating recessive dystrophic epidermolysis bu *Genomics* **21**:160, 1994

79. Christiano AM et al: Dominant dystrophic epidermolysis bullosa: Identification of a Gly ? Ser substitution in the triple-helical domain of type VII coll *Proc Natl Acad Sci USA* **91**:3549, 1994

80. Nordal EJ et al: Generalized dystrophic epidermolysis bullosa: Identification of a novel, homozygous glycine substitution, G2031S, in exon 73 of COL7A1 in monozygous tı *Br J* s. *Dermato* **144**:151, 2001

81. Jonkman MF et al: Dominant dystrophic epidermolysis bullosa (Pasini) caused by a novel glycine substitution mutation in the type VII collagen gene (COL *J Invest Dermato* **112**:815, 1999

82. Lee JY, Li C, Chao SC, et al., A de novo glycine substitution mutation in the collagenous domain of COL7A1 in dominant dystrophic epidermolysis bu *Arch Dermatol Res* **292**:159, 2000.

83. Masunaga T et al: Combination of novel premature termination codon and glycine substitution mutations in COL7A1 leads to moderately severe recessive dystrophic epidermolysis bullosa. *J Invest Dermato* **114**:204, 2000

84. Rouan F et al: Novel and de novo glycine substitution mutations in the type VII collagen gene (COL7A1) in dystrophic epidermolysis bullosa: Implications for genetic coun *J Invest Dermato* **111**:1210, 1998

85. Tasanen K et al: Collagen XVII is destabilized by a glycine substitution mutation in the cell adhesion domain C *J Biol Chem* **275**:3093, 2000

86. Terracina M et al: Compound heterozygosity for a recessive glycine substitution and a splice site mutation in the COL7A1 gene causes an unusually mild form of localized recessive dystrophic epidermolysis bullosa *J Invest Dermato* **111**:744, 1998

87. Sakuntabhai A et al: Deletions within COL7A1 exons distant from consensus splice sites alter splicing and produce shortened polypeptides in dominant dystrophic epidermolysis bullosa. *Am J Hum Gene* **63**:737, 1998

88. Hammami-Hauasli N et al: Some, but not all, glycine substitution mutations in COL7A1 result in intracellular accumulation of collagen VII, loss of anchoring fibrils, and skin blis *J* ring. *Biol Chem* **273**:19228, 1998

89. Chen M et al: The recombinant expression of full-length type VII collagen and characterization of molecular mechanisms underlying dystrophic epidermolysis bu *J Biol Chem* **277**:2118, 2002

90. Hatta N et al: Spontaneous disappearance of intraepidermal type VII collagen in a patient with dystrophic epidermolysis bul *Br J Dermato* **133**:619, 1995

91. Bruckner-Tuderman L et al: Immunohistochemical and mutation analyses demonstrate that procollagen VII is processed to collagen VII through removal of the NC-2 d *J Cell Bio* **131**:551, 1995

92. Marinkovich MP et al: Prenatal diagnosis of Herlitz junctional epidermolysis bullosa by amniocente *Prenat Diagr* **15**:1027, 1995

93. Uitto J, Pulkkinen L: Molecular complexity of the cutaneous basement membrane zo *Mol Biol Rep* **23**:35, 1996

94. McGrath JA et al: First trimester DNA-based exclusion of recessive dystrophic epidermolysis bullosa from chorionic villus samp *Br J Dermato* **134**:734, 1996

95. Cserhalmi-Friedman PB et al: Preimplantation genetic diagnosis in two families at risk for recurrence of Herlitz junctional epidermolysis bul *Exp Dermato* **9**:290, 2000

96. Terrill PJ et al: Experience in the surgical management of the hand in dystrophic epidermolysis bullo *Br J Plast Surg* **45**:435, 1992

97. Iohom G, Lyons B: Anaesthesia for children with epidermolysis bullosa: A review of 20 years' experie *Eur J Anaesthesio* **18**:745, 2001

98. Ladd AL et al: Surgical treatment and postoperative splinting of recessive dystrophic epidermolysis bull *J Hand Surg [Br]* **21**:888, 1996

99. Glicenstein J et al: The hand in recessive dystrophic epidermolysis bullo *Hand Clin* **16**:637, 2000

100. Terrill PJ et al: The surgical management of dystrophic epidermolysis bullosa (excluding the har *Br J Plast Surg* **45**:426, 1992

101. Vozdvizhensky SI, Albanova VI: Surgical treatment of contracture and syndactyly of children with epidermolysis bull *Br J Plas Surg* **46**:314, 1993

102. McGrath JA et al: Epidermolysis bullosa complicated by squamous cell carcinoma: report of 10 cas *J Cutan Patho* **19**:116, 1992

103. Newman C et al: Squamous cell carcinoma secondary to recessive dystrophic epidermolysis bullosa. A report of 4 patients with 17 primary cutaneous maligna *J Dermatol Surg Onco* **18**:4, 1992

104. Bastin KT et al: Radiation therapy for squamous cell carcinoma in dystrophic epidermolysis: Case reports and literature re *Am J Clin Onco* **20**:55, 1997

105. Ergun GA et al: Gastrointestinal manifestations of epidermolysis bullosa. A study of 101 patier *Medicine (Baltimore)* **71**:121, 1992

106. Robbins PB et al: Impact of laminin 5 beta3 gene versus protein replacement on gene expression patterns in junctional epidermolysis bu *Hum Gene Ther* **12**:1443, 2001

107. Seitz CS et al: BP180 gene delivery in junctional epidermolysis bullo *Gene Ther* **6**:42, 1999

108. Robbins PB et al: In vivo restoration of laminin 5 beta 3 expression and function in junctional epidermolysis bull *Proc Natl Acad Sci USA* **98**:5193, 2001

109. Falabella AF et al: Tissue-engineered skin (Apligraf) in the healing of patients with epidermolysis bullosa wou *Arch Dermato* **136**:1225, 2000

110. Rothnagel JA et al: Transgenic models of skin disease *Arch Dermato* **129**:1430, 1993

111. Vassar R et al: Mutant keratin expression in transgenic mice causes marked abnormalities resembling a human genetic skin dise *Cell* **64**:365, 1991

112. Cao T et al: An inducible mouse model for epidermolysis bullosa simplex: Implications for gene there *J Cell Bio* **152**:651, 2001

113. Peters B et al: Complete cytolysis and neonatal lethality in keratin 5 knockout mice reveal its fundamental role in skin integrity and in epidermolysis bullosa si *Mol Biol Cel* **12**:1775, 2001

114. Heinonen S et al: Targeted inactivation of the type VII collagen gene (Col7a1) in mice results in severe blistering phenotype: A model for recessive dystrophic epidermolysis bullosa. *J Cell Sc* **112**:3641, 1999

115. Georges-Labouesse E et al: Absence of integrin alpha 6 leads to epidermolysis bullosa and neonatal death in m *Nat Genetics* **13**(3) **:3**70, 1996

116. Ryan MC et al: Targeted disruption of the LAMA3 gene in mice reveals abnormalities in survival and late stage differentiation of epithelial *J Cell Bio* **145**:1309, 1999

117. Kim YH et al: Recessive dystrophic epidermolysis bullosa phenotype is preserved in xenografts using SCID mice: Development of an experimental in vivo *J Invest Dermato* **98**:191, 1992

T>

Chapter 66

David Woodley Mei Chen W. Gammon Robert Briggaman

Epidermolysis Bullosa Acquisita

HISTORICAL ASPECTS
ETIOLOGY AND PATHOGENESIS
CLINICAL MANIFESTATIONS
Classical Presentation
Bullous Pemphigoid–like Presentation
Cicatricial Pemphigoid–like Presentation
Brusting-Perry Pemphigoid–like Presentation
IgA Bullous Dermatosis–like Presentation
PATHOLOGY
IMMUNOLOGIC PARAMETERS
Routine Immunofluorescence
Immunoelectron Microscopy
Indirect Salt-Split Skin Immunofluorescence
Direct Salt-Split Skin Immunofluorescence
Western Immunoblotting
Enzyme-Linked Immunosorbent Assay
DIAGNOSIS
TREATMENT

REFERENCES

Epidermolysis bullosa acquisita (EBA) is a chronic subepidermal blistering disease associated with autoimmunity to the collagen (type VII collagen) within anchoring fibril structures that are located at the dermal-epidermal junction. Although it is an acquired disease that usually begins in adulthood, it was placed in the category epidermolysis bullosa (EB) approximately 100 years ago because physicians were struck by how similar the lesions were to those seen in children with hereditary dystrophic forms of EB.

HISTORICAL ASPECTS

Two cases of a blistering disease with adult onset and features highly reminiscent of hereditary dystrophic EB were reported by Elliott in 1895. These clinical features included skin fragility, erosions, blisters, and a healing response characterized by scarring and the formation of milia cysts. In the early decades of the twentieth century, other similar case reports appeared. It is not certain if all these early reports were of EBA patients as defined today, but the existence of an acquired form of EB was recognized.

In the early 1970s, Roenigk et al. [1] summarized the EBA world literature, reported three new cases, and suggested the first diagnostic criteria: (1) a negative family and personal history for a previous blistering disorder, (2) an adult onset of the eruption, (3) spontaneous or trauma-induced blisters that resemble those of hereditary dystrophic EB, and (4) the exclusion of all other bullous diseases.

It was thought that immunofluorescence studies would separate EBA from other primary subepidermal bullous diseases such as bullous pemphigoid (BP), cicatricial pemphigoid (CP), and herpes gestationis. In 1973, however, Kushniruk [2] showed that patients with EBA had IgG deposits at the dermal-epidermal junction just like patients with BP. This observation was confirmed by Gibbs and Minus [3] and by Nieboer et al. [4] Some EBA patients also had an anti–basement membrane autoantibody circulating in their plasma. Therefore, it became obvious that both indirect and direct immunofluorescence studies could be identical in EBA and BP patients.

In the early 1980s, Nieboer et al. [4] and Yaoita et al. [5] showed that while EBA and BP have identical immunofluorescence findings, they could be separated by immunoelectron microscopy. The IgG deposits in EBA are located within and below the lamina densa area of the basement membrane zone, whereas BP immune deposits are within hemidesmosomes and high in the lamina lucida (see Chap. 61). The ability to separate EBA from the BP group has become more relevant with the observations of Gammon et al., [6] Dahl, [7] and others [8], [9], [10] and [11] that EBA does not always have the “classical” presentation of a mechanobullous EB-like disease and may present with a clinical syndrome highly reminiscent of BP, Brunsting-Perry pemphigoid, or CP.

ETIOLOGY AND PATHOGENESIS

The etiology of EBA is unknown, but most of the evidence suggests an autoimmune etiology. Direct immunofluorescence of perilesional skin biopsies from EBA patients reveals IgG deposits at the dermal-epidermal junction. [2], [3], [4] and [5] EBA antibodies bind to type VII collagen within anchoring fibrils. [12], [13] Anchoring fibrils are wheat stack–like structures that emanate from the lamina densa in a perpendicular fashion and stretch about 200 to 300 nm into the papillary dermis, where they associate with globular structures called *anchoring plaques* that contain type IV collagen, a component shared with the lamina densa zone of the basement membrane zone between the epidermis and dermis (see Chap. 16).

Anchoring fibrils anchor the epidermis and its underlying basement membrane zone to the papillary dermis. Patients with hereditary forms of dystrophic EB (see Chap. 65) and EBA have decreased numbers of anchoring fibrils in their

dermal-epidermal junction. [14] This paucity of anchoring fibrils is associated with two similar clinical phenotypes, EBA and dystrophic forms of heretitary EB, because both diseases are characterized by skin fragility, subepidermal blisters, milia formation, and scarring. While both EBA and hereditary forms of dystrophic EB are etiologically unrelated in terms of their underlying pathogenesis, they share the common feature of decreased anchoring fibrils. In the case of dystrophic forms of hereditary EB, the cause of decreased or absent anchoring fibrils is a genetic defect in the gene that encodes for type VII collagen alpha chains that ultimately results in small, nonfunctional or decreased anchoring fibrils. [15] The gene coding for type VII collagen is located on the short arm of chromosome 3, approximately 21 cM from zero. [16] The gene defects involved in hereditary forms of dystrophic EB have been identified at variable locations, but the severity of the disease appears to correlate with the degree of type VII collagen and anchoring fibril perturbations. [17] In EBA, the IgG autoantibodies binding to the type VII collagen alpha chains result in decreased anchoring fibrils, but the pathway leading to this reduction is unknown. It may be that type VII collagen alpha chains that are newly synthesized but decorated with EBA autoantibodies cannot form triple-helical structures and stable anchoring fibrils. Healed burn wounds that have been covered with cultured keratinocyte sheets also have decreased numbers of anchoring fibrils within the first year after transplantation, and this is associated with spontaneous blister formation, shortened suction blistering times, and skin fragility. [18] These observations provide indirect evidence that anchoring fibrils play a role in maintaining adherence between the epidermis and dermis.

The type VII collagen alpha chain has a molecular mass between 250 and 320 kDa, and the collagen consists of a homotrimer of three identical alpha chains (see Chap. 16). Each alpha chain consists of a large globular noncollagenous amino terminus called the *noncollagenous 1* (NC-1) *domain* that is approximately half the entire mass of the alpha chain. Next, there is a helical domain with typical glycine-X-Y repeats. At the carboxyl terminus is a second globular noncollagenous domain, NC-2, that is much smaller than NC-1. Most EBA autoantibodies recognize four predominant antigenic epitopes within the NC-1 domain and do not recognize the helical or NC-2 domains. [19], [20] There may be something intrinsically “antigenic” about the NC-1 domain because the available monoclonal antibodies that have been generated against type VII collagen (anti–C-VII antibodies) specifically recognize only NC-1 subdomains.

Type VII collagen has affinity for fibronectin, a large glycoprotein in the papillary dermis. [21] The interaction between fibronectin and type VII collagen may play a role in adhering the basement membrane beneath the epidermis onto the dermis. Lapiere et al. [22] and Chen et al. [23] have identified two fibronectin-binding sites within the type VII collagen alpha chain. One of these is within the NC-1 domain where EBA autoantibodies are targeted. [23] Therefore, it is conceivable that when EBA autoantibodies bind to type VII collagen, the interaction between type VII collagen and fibronectin is abrogated and results in poor epidermal-dermal adherence.

Further evidence for the pathogenic role of EBA antibodies also comes from the observation that when patients with systemic lupus erythematosus (SLE) develop autoantibodies to the EBA antigen, they develop widespread skin blisters and fall into a subset of SLE called *bullous SLE.* [24] This “experiment of nature” also suggests that EBA autoantibodies are pathogenic and capable of inducing disadherence between the epidermis and dermis. Nevertheless, consistent induction of blisters in an animal by the passive transfer of EBA IgG autoantibodies into the animal has not been achieved despite numerous attempts. [25]

Although EBA is not a genetic disease with a Mendelian inheritance pattern, some EBA patients may have a genetic predisposition to autoimmunity. [26] African American patients in the southeastern part of the United States who have either EBA or bullous SLE have a high incidence of the HLA-DR2 phenotype. The calculated relative risk for EBA in HLA-DR2+ individuals is 13.1 in these patients. These results also suggest that EBA and bullous SLE are immunogenetically related and that either the HLA-DR2 gene is involved with autoimmunity to anchoring fibril collagen or is some sort of a marker for some other gene that exists in linkage disequilibrium with it. [26]

CLINICAL MANIFESTATIONS

The common denominator for patients with EBA is autoimmunity to type VII (anchoring fibril) collagen. [10], [13] Although the clinical spectrum of EBA is still being defined, there are at least five clinical presentations: (1) a classical presentation, (2) a BP-like presentation, (3) a CP-like presentation, (4) a presentation reminiscent of Brunsting-Perry pemphigoid with scarring lesions and a predominant head and neck distribution, and (5) a presentation reminiscent of linear IgA bullous dermatosis or chronic bullous disease of childhood (see Chap. 63).

Classical Presentation

The classical presentation (Fig. 66-1 and Fig. 66-2A) is of a noninflammatory bullous disease with an acral distribution that heals with scarring and milia formation. This presentation is reminiscent of porphyria cutanea tarda (PCT) (see Chap. 149) when it is mild and of the hereditary form of recessive dystrophic EB when it is severe (see Chap. 65). The classical form of EBA is thus a mechanobullous disease marked by skin fragility. These patients have erosions, tense blisters within noninflamed skin, and scars over trauma-prone surfaces such as the backs of the hands, knuckles, elbows, knees, sacral area, and toes (Fig. 66-3 and Fig. 66-2A). Some blisters may be hemorrhagic or develop scales, crusts, or erosions. The lesions heal with scarring and frequently with the formation of pearl-like milia cysts within the scarred areas. Although this presentation may be reminiscent of PCT, these patients do not have other hallmarks of PCT, such as hirsutism, a photodistribution of the eruption, or scleroderma-like changes, and their urinary porphyrins are within normal limits. A scarring alopecia and some degree of nail dystrophy may be seen.

FIGURE 66-1 A patient with EBA who has severe blistering, erosions, scarring, and milia formation on trauma-prone areas of her skin.

FIGURE 66-2 *A.* Classical presentation of EBA with scarring and milia over trauma-prone areas of skin. *B.* Bullous pemphigoid–like presentation of EBA with a widespread inflammatory vessiculobullous dermatosis. *C.* Cicatricial pemphigoid–like presentation of EBA with a mucosal-centered bullous scarring eruption. *D.* Brunsting-Perry pemphigoid–like presentation of EBA with bullous and scarring lesions predominantly on the head and neck.

FIGURE 66-3 An EBA patient with involvement of the leg. Note bullae, crusts, and scarring at site of trauma.

Although the disease is usually not as severe as that of patients with hereditary forms of recessive dystrophic EB, EBA patients with the classical form of the disease may have many of the same sequelae, such as scarring, loss of scalp hair, loss of nails, fibrosis of the hands and fingers, and esophageal stenosis. [27]

Bullous Pemphigoid–like Presentation

A second clinical presentation of EBA is of a widespread, inflammatory vesiculobullous eruption involving the trunk, central body, and skin folds in addition to the extremities. [6] The bullous lesions are tense and surrounded by inflamed or even urticarial skin. Large areas of inflamed skin may be seen without any blisters and only erythema or urticarial plaques. These patients often complain of pruritus and do not demonstrate prominent skin fragility, scarring, or milia formation. This clinical constellation is more reminiscent of BP (Fig. 66-2B and Fig. 66-4) than a mechanobullous disorder. Like BP, the distribution of the lesions may show an accentuation within flexural areas and skin folds.

FIGURE 66-4 An EBA patient demonstrating two presentations of the disease: the classical mechanobullous presentation with erosions, scarring, and milia over the elbows and the more inflammatory BP-like lesions on her trunk.

Cicatricial Pemphigoid–like Presentation

Both the classical and BP-like forms of EBA may have involvement of mucosal surfaces. However, EBA also may present

with such predominant mucosal involvement that the clinical appearance is reminiscent of CP [7] (Fig. 66-2C). These patients usually have erosions and scars on the mucosal surfaces of the mouth, upper esophagus, conjunctiva, anus, or vagina with or without similar lesions on the glabrous skin.

Brusting-Perry Pemphigoid–like Presentation

Brunsting-Perry cicatricial bullous pemphigoid is a chronic recurrent vesiculobullous eruption localized to the head and neck and characterized by residual scars, subepidermal bullae, IgG deposits at the dermal-epidermal junction, and minimal or no mucosal involvement (see Chap. 62). The antigenic target for the IgG autoantibodies, however, has not been defined. Nevertheless, a patient reported with this constellation of findings had IgG autoantibodies directed to anchoring fibrils below the lamina densa. [11] We have seen three additional patients with the features of Brunsting-Perry pemphigoid and autoantibodies directed to type VII collagen (unpublished observations). Therefore, it appears that EBA patients may present with a clinical phenotype of Brusting-Perry pemphigoid (Fig. 66-2D).

IgA Bullous Dermatosis–like Presentation

This form of EBA is manifested by a subepidermal bullous eruption, a neutrophilic infiltrate, and linear IgA deposits at the basement membrane zone when viewed by direct immunofluorescence (DIF). It may resemble linear IgA bullous dermatosis (LABD), dermatitis herpetiformis, or chronic bullous disease of childhood (CBDC) and may feature tense vesicles arranged in an annular fashion and involvement of mucous membranes [28], [29], [30], [31], [32] and [33] (see Chap. 63). The autoantibodies are usually IgA, IgG, or both.

The diagnosis of these subepidermal blistering cases with IgA anti-C-VII antibodies showing linear IgA deposition at the basement membrane zone is disputable. Some clinicians regard the patients as having purely LABD, [30] whereas others regard them as having a subset of EBA. [31] In a recent study, [32] 20 EBA patients' sera were evaluated for serum IgA anti-C-VII antibodies by immunoblotting. This study showed that low titers of IgA anti-C-VII antibodies were detected in 80 percent of patients in addition to IgG antibodies.

Childhood EBA is a rare disease. It has a variable presentation with 5 of 14 patients reviewed presenting with an LABD-like disease, 5 with BP-like disease, and 4 with the classical type. [33] Eleven of 14 had mucosal involvement, and all had deposits of IgG, as well as other immunoreactants, at the basement membrane zone by DIF. Indirect immunofluorescence (IIF) was positive in 10 of 14 patients' sera, and the predominant serum antibody was of the IgG class. Although mucosal involvement is frequent and severe in childhood EBA, the overall prognosis and treatment are more favorable than in EBA. [29], [33]

According to the authors' experience, about 25 percent of patients with EBA may present with a BP-like clinical appearance. The disease of some of these patients eventually will smolder into a more noninflammatory mechanobullous form. However, both the classical and BP-like forms of the disease may coexist in the same patient [27] (Fig. 66-4). The clinical phenotype of EBA that is reminiscent of pure CP occurs in fewer than 10 percent of all EBA cases.

A number of published reports suggest that EBA may be associated with various systemic diseases [1], [34] such as inflammatory bowel disease, SLE, amyloidosis, thyroiditis, multiple endocrinopathy syndrome, rheumatoid arthritis, pulmonary fibrosis, chronic lymphocytic leukemia, thymoma, diabetes, and other diseases in which an autoimmune pathogenesis has been implicated. At the University of North Carolina, Stanford, and Northwestern, with a combined experience of following over 60 EBA patients, it appears that inflammatory bowel disease is the systemic disease most frequently associated with EBA. [35]

PATHOLOGY

Routine histologic examination of lesional skin obtained from EBA patients shows a subepidermal blister and a clean separation between the epidermis and dermis. The degree of inflammatory infiltrate within the dermis usually reflects the degree of inflammation of the lesion observed by the clinician. Lesions that are reminiscent of recessive dystrophic EB or PCT usually have a notable scarcity of inflammatory cells within the dermis. Lesions that are clinically reminiscent of BP usually have significantly more inflammatory cells within the dermis, and these cells may be a mixture of lymphocytes, monocytes, neutrophils, and eosinophils. The histology of EBA skin specimens obtained from BP-like lesions may be difficult to distinguish from BP itself.

Ultrastructural studies of EBA skin have demonstrated a paucity of anchoring fibrils and an amorphous, electron-dense band just beneath the lamina densa. [8] Despite the sub–lamina densa deposits, EBA blisters frequently separate above the immune deposits within the lamina lucida. [36] The lamina lucida is the Achilles' Heel of the cutaneous basement membrane zone and is more susceptible to disadherence than the sub–lamina densa zone. Briggaman et al. [37] have shown that the entire cutaneous basement membrane zone is susceptible to degradation by a number of proteolytic enzymes that exist within inflammatory cells. Therefore, the cleavage plane of the blister is not a good way to discriminate EBA from other subepidermal bullous diseases.

IMMUNOLOGIC PARAMETERS

Routine Immunofluorescence

Patients with EBA have IgG deposits within the dermal-epidermal junction of their skin. [2], [5] This is best detected by DIF of a biopsy specimen obtained from a perilesional site (Fig. 66-5). IgG is the predominant immunoglobulin class, but deposits of complement, IgA, IgM, factor B, and properdin also may be detected. The DIF staining demonstrates an

intense linear fluorescent band at the dermal-epidermal junction. Yaoita et al. [5] have suggested that a positive DIF and IgG deposits within the sub–lamina densa zone are necessary criteria for the diagnosis of EBA.

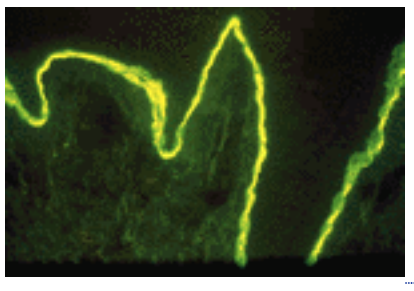

FIGURE 66-5 Direct immunofluorescence staining for IgG deposits in perilesional skin of an EBA patient. Note the dense deposits within the dermal-epidermal junction (the epidermis is on top in this section).

Patients with PCT, which may mimic EBA clinically, frequently have IgG and complement deposits at the dermal-epidermal junction similar to those of EBA patients (see Chap. 149). However, the DIF feature that distinguishes PCT from EBA is that PCT skin also demonstrates immune deposits around the dermal blood vessels.

Patients with EBA may have autoantibodies in their blood directed against the dermal-epidermal junction. [12] These antibodies can be detected by IIF of the patient's serum on a substrate of monkey or rabbit esophagus or human skin and will stain the dermal-epidermal junction in a linear fashion that may be indistinguishable from bullous pemphigoid sera.

Immunoelectron Microscopy

The localization of the immune deposits within the dermal-epidermal junction of the skin of EBA patients by immunoelectron microscopy is the “gold standard” for the diagnosis. As demonstrated by Nieboer et al. [4] and Yaoita et al., [5] patients with EBA have immune deposits within the sub–lamina densa zone of the cutaneous basement membrane zone. This localization is clearly distinct from the deposits in BP, which are higher up in the hemidesmosome area or lamina lucida area of the basement membrane. It is also distinct from CP, which has antigenic targets confined to the lamina lucida (see Chap. 61 and Chap. 62).

Indirect Salt-Split Skin Immunofluorescence

When human skin is incubated in 1 *M* NaCl, the dermal-epidermal junction fractures cleanly through the lamina lucida zone. [38] This fracture places the BP antigen on the epidermal side of the split and all other basement membrane structures on the dermal side of the separation. Salt-split skin substrate can be used to distinguish EBA and BP sera. [39] If the serum antibody is IgG and labels the epidermal roof, the patient does not have EBA, and BP should be considered. If, on the other hand, the antibody labels the dermal side of the separation, the patient usually has either EBA or bullous SLE. The latter can be ruled out by other serology and by clinical criteria.

It was thought that only EBA and bullous SLE gave dermal labeling when salt-split skin immunofluorescence technology was used. It was also thought that the dermal fluorescent pattern on salt-split skin was indicative of immune deposits localized within the lamina densa or sub–lamina densa space, whereas epidermal-roof labeling was seen when deposits were localized within hemidesmosomes or the lamina lucida space. These conclusions are not correct and need modification with the advent of new knowledge about several new blistering disorders. The first new disease is found in a subset of CP patients who have autoantibodies against laminin-5, a noncollagenous component of anchoring filaments within the lamina lucida compartment. [40] The second is a BP-like disease in which the patients have autoantibodies to a 105-kDa lamina lucida glycoprotein that is unrelated to laminin-5. [41] In both diseases, the immune deposits are within the lower lamina lucida, and salt-split skin immunofluorescence gives a dermal-floor pattern of staining identical to EBA. As shown by Ceilley et al., [42] this is so because laminin-5 and the 105-kDa protein go down with the dermis when the skin basement membrane zone is fractured by salt. The third newly discovered disease that gives dermal staining by salt-split skin immunofluorescence is a subepidermal blistering disease associated with renal insufficiency reported by Ghohestani and colleagues. [43] In this disease, the IgG autoantibodies are directed against the a5 chain of type IV collagen, a component of the lamina densa zone of the basement membrane zone. In Table 66-1, these subepidermal bullous diseases that can give dermal fluorescence by salt-split skin immunofluorescence are summarized.

1. Epidermolysis bullosa acquisita
2. Bullous SLE
3. Anti–laminin-5 cicatricial pemphigoid
4. p105 pemphigoid (Chan's disease)
5. Anti–type IV collagen bullous disease (Ghohestani's disease)

TABLE 66-1 **Subepidermal Autoimmune Bullous Diseases That Show Dermal Fluorescence on Immunofluorescent Analysis of Salt-Split Skin**

Direct Salt-Split Skin Immunofluorescence

Perilesional skin incubated in cold 1 *M* NaCl is fractured through the dermal-epidermal junction, which effectively places the BP antigen (and any associated immune deposits) on the epidermal roof and the EBA antigen (and any associated immune deposits) on the dermal floor of the separation. [44] If the patient has EBA, immune deposits are detected on the

dermal side of the separation by a routine DIF method employing fluorescein-conjugated anti–human IgG.

Western Immunoblotting

Antibodies in EBA sera will bind to a 290-kDa band in Western blots of human skin basement membrane proteins containing type VII collagen, whereas sera from all other primary blistering diseases will not. [12] This band is the alpha chain of type VII collagen. Often a second band of 145 kDa will be labeled with EBA antibodies. This band is the amino-terminal globular NC1 domain of the type VII collagen alpha chain, which is rich in carbohydrate and contains the antigenic epitopes of EBA autoantibodies, bullous SLE autoantibodies, and monoclonal antibodies against type VII collagen. [12], [45]

Enzyme-Linked Immunosorbent Assay

Chen et al. [23] have produced milligram quantities of recombinant, purified, posttranslationally modified NC1 in stably transfected human cells and have used this NC1 to develop an enzyme-linked immunosorbent assay (ELISA) for autoantibody detection in EBA patients and in patients with bullous SLE. [46] This new ELISA is more sensitive than immunofluorescence and Western blotting, and yet it is very specific for antibodies to type VII collagen.

DIAGNOSIS

The diagnostic criteria developed by Yaoita et al. [5] for the diagnosis of EBA still stand. These criteria, with slightly updated modifications, are as follows:

- A bullous disorder within the clinical spectrum outlined earlier
- No family history of a bullous disorder
- Histology showing a subepidermal blister
- Deposition of IgG deposits within the dermal-epidermal junction, i.e., a positive DIF of perilesional skin
- IgG deposits localized to the lower lamina densa and/or sub–lamina densa zone of the dermal-epidermal junction when perilesional skin is examined by direct immunoelectron microscopy

Alternatives for the last item are indirect or direct salt-split skin immunofluorescence, Western blotting, and ELISA (see above).

TREATMENT

EBA is a very difficult disease to treat. EBA patients are refractory to high doses of systemic glucocorticoids, azathioprine, methotrexate, and cyclophosphamide, especially when they have the classical mechanobullous form of the disease. These agents are somewhat helpful in controlling EBA when it appears as an inflammatory BP-like disease. Some EBA patients improve on dapsone, especially when neutrophils are present in their dermal infiltrate.

Cyclosporine, an immunosuppressive agent that is used chiefly in organ transplantation, has been shown to be beneficial in EBA. [47], [48] However, the long-term toxicity of this drug limits its use.

There are now three independent reports of EBA patients responding to high doses of colchicine. [49] This is often used as a first-line drug because its side effects are relatively benign compared with other therapeutic choices. Diarrhea is a common side effect of colchicine, however, which makes it difficult for many patients to achieve a high enough dose to control the disease. Moreover, because of this side effect, we are hesitant to try colchicine in EBA patients who also have inflammatory bowel disease. In addition, there are patients who do not respond to colchicine. [49] Colchicine is a well-known microtubule inhibitor, but it also appears to have properties that have the potential to inhibit antigen presentation to T cells, which could downregulate autoimmunity. [50]

Photophoresis has been used in Sézary syndrome, mycosis fungoides, and a variety of autoimmune bullous diseases (see Chap. 266). Photophoresis had a dramatic effect on one EBA patient in a life-threatening situation, [51] and in three other EBA patients it improved some clinical parameters and remarkably lengthened the suction blistering times of the patients, suggesting an improvement in their dermal-epidermal adherence. [52]

Intravenous immunoglobulin has been used in dermatomyositis, an entity in which autoimmunity may play a role. Intravenous immunoglobulin has been reported to be effective in some patients with EBA. [53] The mechanism by which gamma globulin may invoke a positive response in EBA is unknown.

Supportive therapy is warranted in all patients with EBA. This includes instruction in open wound care and strategies for avoiding trauma. Patients should be warned not to overwash or overuse hot water or harsh soaps and to avoid prolonged or vigorous rubbing of their skin with a washcloth or towel. In some patients it appears that prolonged sun exposure may aggravate or promote new lesions on the dorsal hands and knuckles. Avoidance of prolonged sun exposure and the use of sunscreens may be helpful. The patient should be educated to recognize localized skin infections and to seek medical care and antibiotic therapy promptly when they occur.

REFERENCES

1. Roenigk HH et al: Epidermolysis bullosa acquisita: Report of three cases and review of all published cases. *Arch Dermatol* **103**:10, 1971

2. Kushniruk W: The immunopathology of epidermolysis bullosa acquisita. *Can Med Assoc J* **108**:1143, 1973

3. Gibbs RB, Minus HR: Epidermolysis bullosa acquisita with electron microscopical studies. *Arch Dermatol* **111**:215, 1975

4. Nieboer C et al: Epidermolysis bullosa acquisita: Immunofluorescence, electron microscopic and immunoelectron microscopic studies in four patients. *Br J Dermatol* **102**:383, 1980

5. Yaoita H et al: Epidermolysis bullosa acquisita: Ultrastructural and immunological studies. *J Invest Dermatol* **76**:288, 1981

6. Gammon WR et al: Epidermolysis bullosa acquisita: A pemphigoid-like disease. *J Am Acad Dermatol* **11**:820, 1984

7. Dahl MGC: Epidermolysis bullosa acquisita: A sign of cicatricial pemphigoid? *Br J Dermatol* **101**:475, 1979

8. Richter BJ, McNutt NS: The spectrum of epidermolysis bullosa acquisita. *Arch Dermatol* **115**:1325, 1979

9. Provost TT et al: Unusual sub-epidermal bullous diseases presenting as an inflammatory bullous disease. *Arch Dermatol* **115**:156, 1979

10. Woodley DT: Epidermolysis bullosa acquisita. *Prog Dermatol* **22**:1, 1988

11. Kurzhals G et al: Acquired epidermolysis bullosa with the clinical features of Brunsting-Perry cicatricial bullous pemphigoid. *Arch Dermatol* **127**:391, 1991

12. Woodley DT et al: Identification of the skin basement membrane autoantigen in epidermolysis bullosa acquisita. *N Engl J Med* **310**:1007, 1984

13. Woodley DT et al: The epidermolysis bullosa acquisita antigen is the globular carboxyl terminus of type VII procollagen. *J Clin Invest* **81**:683, 1988

14. Ray TL et al: Epidermolysis bullosa acquisita and inflammatory bowel disease. *J Am Acad Dermatol* **6**:242, 1982

15. Christiano AM et al: A common insertion mutation in COLA1 in two Italian families with recessive dystrophic epidermolysis bullosa. *J Invest Dermatol* **106**:679, 1996

16. Parente MG et al: Human type VII collagen: cDNA cloning and chromosomal mapping of the gene. *Proc Natl Acad Sci USA* **88**:6931, 1991

17. Shimizu H: Molecular basis of recessive dystrophic epidermolysis bullosa: Genotype/phenotype correlation in a case of moderate clinical severity. *J Invest Dermatol* **106**:119, 1996

18. Woodley DT et al: Burn wounds resurfaced by cultured epidermal autografts show abnormal reconstitution of anchoring fibrils. *JAMA* **259**:2566, 1988

19. Lapiere J-C et al: Epitope mapping of type VII collagen: Identification of discrete peptide sequences recognized by sera from patients with acquired epidermolysis bullosa. *J Clin Invest* **92**:1831, 1993

20. Jones DA et al: Immunodominant autoepitopes of type VII collagen are short, paired peptide sequences within the fibronectin type III homology region of the non-collagenous (NC1) domain. *J Invest Dermatol* **104**:231, 1995

21. Woodley DT et al: Specific affinity between fibronectin and the epidermolysis bullosa acquisita antigen. *J Clin Invest* **179**:1826, 1987

22. Lapiere J-C et al: Type VII collagen specifically binds fibronectin via a unique subdomain within the collagenous triple helix. *J Invest Dermatol* **103**:637, 1994

23. Chen M et al: Interactions of the amino-terminal noncollagenous (NC1) domain of type VII collagen with extracellular matrix components. *J Biol Chem* **272**:14516, 1997

24. Gammon WR et al: Evidence that antibasement membrane zone antibodies in bullous eruption of systemic lupus erythematosus recognize epidermolysis bullosa acquisita autoantigens. *J Invest Dermatol* **84**:472, 1985

25. Barradori L et al: Passive transfer of autoantibodies from a patient with mutilating epidermolysis bullosa acquisita induces specific alterations in the skin of neonatal mice. *Arch Dermatol* **131**:590, 1995

26. Gammon WR et al: Increased frequency of HLA DR2 in patients with autoantibodies to EBA antigen: Evidence that the expression of autoimmunity to type VII collagen is HLA class II allele associated. *J Invest Dermatol* **91**:228, 1988

27. Stewart MI, Woodley DT: Acquired epidermolysis bullosa and associated symptomatic esophageal webs. *Arch Dermatol* **127**:373, 1991

28. Park SB et al: Epidermolysis bullosa aquisita in childhood: A case mimicking chronic bullous dermatosis of childhood. *Clin Exp Dermatol* **22**:220, 1997

29. Callot-Mellot C et al: Epidermolysis bullosa aquisita in childhood. *Arch Dermatol* **133**:1122, 1997

30. Hashimoto T et al: A case of linear IgA bullous dermatosis with IgA anti-type VII collagen autoantibodies. *Br J Dermatol* **134**:336, 1996

31. Bauer JW et al: Ocular involvement in IgA-epidermolysis bullosa acquisita. *Br J Dermatol* **141**:887, 1999

32. Lee CW: Serum IgA autoantibodies in patients with epidermolysis bullosa acquisita: A high frequency of detection. *Dermatology* **200**:83, 2000

33. Edwards S et al: Bullous pemphigoid and epidermolysis bullosa acquisita: Presentation, prognosis and immunopathology in 11 children. *Pediatr Dermatol* **15**:184, 1998

34. Burke WA et al: Epidermolysis bullosa acquisita in a patient with multiple endocrinopathies syndrome. *Arch Dermatol* **122**:187, 1986

35. Chan L, Woodley DT: Pemphigoid: Bullous and cicatricial, in *Current Therapy in Allergy, Immunology and Rheumatology*, 5th ed, edited by LM Lichtenstein, AS Fauci. St. Louis, Mosby, 1996, p 93

36. Fine JD et al: The presence of intra-lamina lucida blister formation in epidermolysis bullosa acquisita: Possible role of leukocytes. *J Invest*

Dermatol **92**:27, 1989

37. Briggaman RA et al: Degradation of the epidermal-dermal junction by proteolytic enzymes from human skin and human polymorphonuclear leukocytes. *J Exp Med* **160**:1027, 1984

38. Woodley DT et al: Localization of basement membrane components after dermal-epidermal junction separation. *J Invest Dermatol* **81**:149, 1983

39. Gammon WR et al: Differentiating anti-lamina lucida and antisublamina dense anti-BMZ antibodies by direct immunofluorescence on 1.0 *M* sodium chloride separated skin. *J Invest Dermatol* **84**:215, 1984

40. Domloge-Hultsch N et al: Antiepiligrin cicatricial pemphigoid: A subepithelial bullous disorder. *Arch Dermatol* **130**:1521, 1994

41. Chan LS et al: A newly identified 105-kDa lower lamina lucida autoantigen is an acidic protein distinct from the 105-kDa gamma 2 chain of laminin 5. *J Invest Dermatol* **105**:75, 1995

42. Ceilley E et al: Labeling of fractured human skin with antibodies to BM 600/nicein, epiligrin, kalinin and other matrix components. *J Dermatol Sci* **5**:97, 1993

43. Ghohestani RF et al: The a5 chain of type IV collagen is the target of IgG autoantibodies in a novel autoimmune disease with subepidermal blisters and renal insufficiency. *J Biol Chem* **275**:16002, 2000

44. Gammon WR et al: Direct immunofluorescence studies of sodium chloride–separated skin in the differential diagnosis of bullous pemphigoid and epidermolysis bullosa acquisita. *J Am Acad Dermatol* **22**:664, 1990

45. Woodley DT et al: Epidermolysis bullosa acquisita antigen, a new major component of cutaneous basement membrane, is a glycoprotein with collagenous domains. *J Invest Dermatol* **86**:668, 1986

46. Chen M et al: Development of an ELISA for rapid detection of anti–type VII collagen autoantibodies in epidermolysis bullosa acquisita. *J Invest Dermatol* **108**:68, 1997

47. Connolly SM, Sander HM: Treatment of epidermolysis bullosa acquisita with cyclosporin. *J Am Acad Dermatol* **16**:890, 1987

48. Crow LL et al: Clearing of epidermolysis bullosa acquisita on cyclosporin A. *J Am Acad Dermatol* **19**:937, 1988

49. Cunningham BB et al: Colchicine for epidermolysis bullosa (EBA). *J Am Acad Dermatol* **34**:781, 1996

50. Mekori YA et al: Inhibition of delayed hypersensitivity reaction by colchicine: Colchicine inhibits interferon-gamma-induced expression of HLA-DR on an epithelial cell line. *Clin Exp Immunol* **78**:230, 1989

51. Miller JL et al: Remission of severe epidermolysis bullosa acquisita induced by extracorporeal photochemotherapy. *Br J Dermatol* **133**:467, 1995

52. Gordon K et al: Treatment of refractory epidermolysis bullosa acquisita with extracorporeal photochemotherapy. *Br J Dermatol* **136**:415, 1997

53. Meier F et al: Epidermolysis bullosa acquisita: Efficacy of high dose intravenous immunoglobulins. *J Am Acad Dermatol* **29**:334, 1993

T>

Chapter 67

Stephen Katz

Dermatitis Herpetiformis

HISTORICAL ASPECTS
ETIOLOGY AND PATHOGENESIS
CLINICAL MANIFESTATIONS
LABORATORY FINDINGS
In Vivo Bound IgA and Complement
Serum Studies
IMMUNOGENETIC FINDINGS
PATHOLOGY
ASSOCIATED PROBLEMS
Gastrointestinal Manifestations
Malignancy
Other Diseases
DIAGNOSIS
TREATMENT
Sulfones
Gluten-Free Diet
Elemental Diet

REFERENCES

Dermatitis herpetiformis (DH) is characterized by an intensely itchy, chronic papulovesicular eruption that usually is distributed symmetrically on extensor surfaces. The disease can be clearly distinguished from the other subepidermal blistering eruptions by histologic, immunologic, and gastrointestinal criteria. The prevalence of DH in various Caucasian populations varies between 10 and 39 per 100,000 persons. [1], [2] and [3] It may start at any age, including childhood; however, the second, third, and fourth decades are the most common. After presentation, DH persists indefinitely, although with varying severity. Most patients have an associated gluten-sensitive enteropathy (GSE) that is usually asymptomatic.

HISTORICAL ASPECTS

In 1884, Louis Duhring first described the clinical features and natural history of a polymorphous pruritic disorder that he called *dermatitis herpetiformis.* [4] Not all of his patients would now be considered to have DH, since Duhring probably included patients with bullous pemphigoid. In 1888, Brocq described patients with a very similar disorder and called it *dermatite polymorphe prurigineuse.* [5] In addition, he analyzed Duhring's report and excluded several types of patients from the diagnosis. Since that time, several important discoveries have been made. In 1940, Costello [6] demonstrated the efficacy of sulfapyridine in the treatment of DH. In the early 1960s, Pierard and Whimster [7] and MacVicar et al. [8] found that early lesions of DH are characterized by neutrophilic microabscesses in the dermal papillae. In 1967, Cormane [9] found that the skin of DH patients contained granular immunoglobulin deposits in dermal papillary tips, and in 1969, van der Meer [10] extended these studies and found that the most regularly detected immunoglobulin deposited in DH is IgA. The association between DH and intestinal abnormalities was first observed by Marks et al. [11] in 1966. Fry et al. [12] and Shuster et al. [13] identified the intestinal findings as a GSE. In 1973, Fry et al. [14] demonstrated that strict adherence to a gluten-free diet would improve the skin disease as well as reverse the intestinal abnormality, as occurs in celiac disease. Katz et al. [15] identified a strong association between DH and certain histocompatibility antigens in 1972. In 1979, Chorzelski et al. [16] distinguished those patients with linear IgA deposits from those with granular IgA deposits and defined a distinct entity. In 1999, Dieterich et al. [17] identified antibodies to tissue transglutaminases in the sera from DH patients. Distinguishing between various types of transglutaminases enabled Sardy et al. [18] in 2002 to demonstrate that epidermal transglutaminase is the dominant autoantigen in DH.

ETIOLOGY AND PATHOGENESIS

Gluten, a protein found in wheat, barley, and rye, plays a critical role in the pathogenesis of DH. Oats, long thought to contain gluten and play a role in inducing DH lesions, has been shown to be devoid of toxicity in patients with DH. [19], [20] In 1966, Marks et al. [11] first noted a gastrointestinal abnormality in patients with DH. Shortly thereafter it was shown that the lesion was reversible by avoidance of the dietary protein gluten. [12], [13] Initially, the intestinal abnormality was thought to be present in 60 to 75 percent of DH patients. However, this view has been modified in two ways. First, the diagnostic criteria for DH have now been delineated more precisely, and second, it can be shown that certain patients without apparent gastrointestinal pathology can be “induced” to develop gastrointestinal lesions by subjecting them to a large gluten intake; such patients have been said to have *latent celiac sprue.* [21] Thus most patients with DH have a gastrointestinal abnormality similar (if not identical) to celiac disease, however minimal that may be when the patient is ingesting a normal gluten load. As in celiac disease, there is an increased density of intraepithelial (gut) T cells with a gamma/delta T cell receptor in the jejunum of patients with DH. [22] The finding that T cell lines from patients with DH produce significantly more interleukin 4 (IL-4) than those from patients with GSE suggests that different cytokine patterns may play a role in the varied clinical manifestations of these two diseases. [23] Increased serum IL-2 receptor levels may reflect an ongoing immune response in the gastrointestinal tract. [24]

The GSE seen in DH patients probably relates to the IgA deposits that are found in the skin of these patients, although a

direct relationship has not been demonstrated. It has long been thought that IgA deposits may represent complexes of immunoglobulin and gastrointestinally derived antigens, and recent studies have strongly suggested that this may be the case. It is known that patients with both GSE and DH have antibodies to transglutaminases (TGs) that are thought to be the major autoantigens in these diseases. [17] There appears to be a predilection for the autoantibodies to bind to epidermal TG in DH, whereas the predilection is for autoantibodies to bind tissue TG in GSE. [18] The epidermal TG autoantibody probably binds to the TG in the gut and circulates as an immune complex and deposits in skin. [18]

Whether the IgA skin deposits play a role in the pathophysiology of blister formation is not known. The finding of IgA and complement in almost all skin sites, not only in lesional skin, makes one postulate that if IgA (either alone or as a part of an immune complex) does play a role, additional factors are still needed to explain the initiation of lesions. With these additional factors, IgA activates complement, probably via the alternative pathway, with the subsequent chemotaxis of neutrophils that release their enzymes and produce the tissue injury known as DH. Alternatively, it may be that after neutrophils arrive at the site of immune complex formation, they release factors such as cytokines or proteases that induce basal keratinocytes to produce collagenases or stromelysin-1 that contributes to the formation of blisters. [25], [26] Other studies have suggested that T cells may play a role in the pathogenesis of the skin lesions [27]; however, no specific T cell responses to gluten have been detected. [28]

It has been known for some time that iodides, administered orally, can exacerbate or elicit eruptions of DH, and this has, in former times, been used for diagnostic purposes. The availability of immunopathologic techniques for the detection of IgA deposits in skin has made such provocation tests obsolete.

CLINICAL MANIFESTATIONS

The primary lesion of DH is either an erythematous papule, an urticaria-like plaque, or most commonly, a vesicle (Fig. 67-1, Fig. 67-2, and Fig. 67-3). Large bullae occur infrequently. Vesicles, especially if they occur on the palms, may be hemorrhagic. The continual appearance and disappearance of lesions may result in hyperpigmentation and hypopigmentation. Patients may present with only crusted lesions, and a thorough search may not reveal a primary lesion. The herpetiform (herpes-like) grouping of lesions is often present in some areas (see Fig. 67-1 and Fig. 67-3), but patients also may have many individual nongrouped lesions.

FIGURE 67-1 Dermatitis herpetiformis. Extensive eruption with grouped papules, vesicles, and crusts on the back.

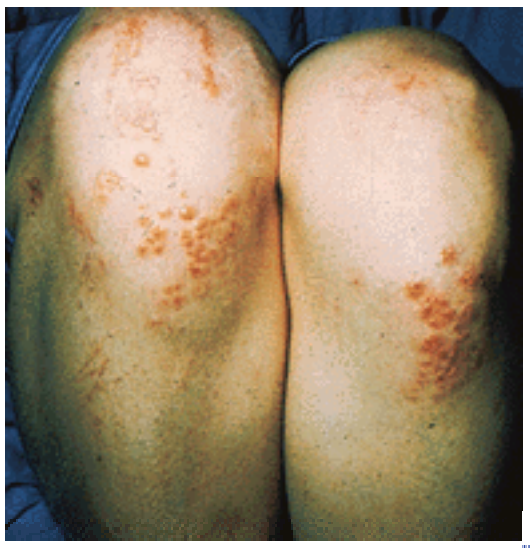

FIGURE 67-2 Dermatitis herpetiformis. Papules, vesicles, and crusts on knees.

FIGURE 67-3 Dermatitis herpetiformis. This patient has many firm-topped vesicles and bullae, some erosions, and residual hyperpigmentation. Some of the vesicles are arranged in an annular pattern.

Symptoms vary considerably from the usually severe burning and itching in most patients to the almost complete lack of symptoms in a rare patient. Most patients usually can predict the eruption of a lesion as much as 8 to 12 h before its appearance because of localized stinging, burning, or itching.

The usual symmetric distribution of lesions on elbows, knees, buttocks, shoulders, and sacral areas is seen in most patients at one time or another (see Fig. 67-1 through Fig. 67-4). Although these regions are affected most commonly, most patients will have scalp lesions and/or lesions in the posterior nuchal area. Another commonly affected area is the face and facial hairline. Mucous membrane lesions are uncommon, as are lesions on the palms and soles.

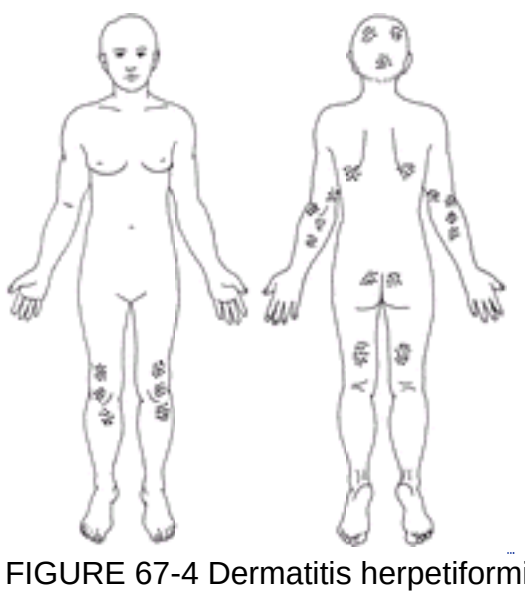

FIGURE 67-4 Dermatitis herpetiformis. Pattern of distribution.

LABORATORY FINDINGS

In Vivo Bound IgA and Complement

After Cormane [9] demonstrated that both perilesional and uninvolved skin of patients with DH contained granular (or fibrillar) immunoglobulin deposits located in dermal papillary tips, van der Meer [10] found that the most regularly detected immunoglobulin class in DH skin was IgA (Fig. 67-5). Seah and Fry [29] were able to detect IgA deposits in the skin of each of 50 patients studied, with only 2 patients requiring a second biopsy for IgA detection. Others have failed to find IgA in a very small minority of patients who, on other grounds, are considered to have DH. [30]

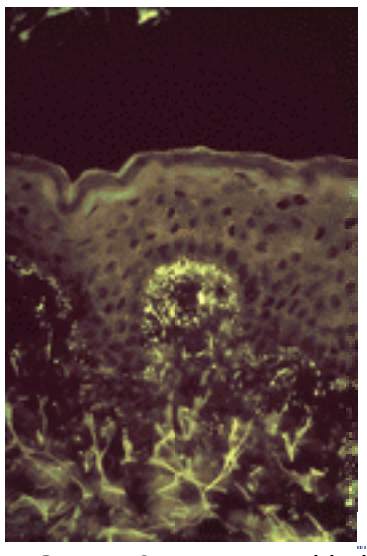

FIGURE 67-5 Dermatitis herpetiformis. Direct immunofluorescence showing granular dermal papillary deposits of IgA.

Granular IgA deposits in normal-appearing skin are the most reliable criteria for the diagnosis of DH. [29], [30] and [31] These IgA deposits are unaffected by treatment with drugs but may decrease in intensity or disappear after long-term adherence to a gluten-free diet. [32], [33] The IgA deposits are not uniformly intense throughout the skin and may be detected more easily in normal-appearing skin near active lesions. [34] In DH, other immunoglobulins sometimes are bound to the skin in

the same areas as the IgA. [29] IgA deposits also may be seen in the skin of patients with bullous pemphigoid, scarring pemphigoid, Henoch-Schönlein purpura, and alcoholic liver disease, although in different patterns of distribution than those seen in DH.

Because of the IgA skin deposits and the association between DH and GSE (celiac disease), several groups have studied the IgA subclasses in DH. IgA_1 is the predominant (or exclusive) subclass that has been identified in the skin of DH patients. [35], [36] Most IgA_1 is produced in the bone marrow, whereas most IgA_2 is produced at mucosal sites. This does not negate the possibility that the IgA_1 in skin may still be of mucosal origin.

The third component of complement (C3) is frequently found in the same location as IgA. The presence of C3 in both perilesional and normal-appearing skin is not affected by treatment with dapsone (diaminodiphenyl sulfone), [37] but C3 may not be detectable after treatment with a gluten-free diet. [33], [38] C5 and components of the alternative complement pathway also may be seen in areas corresponding to the IgA deposits. The C5-C9 membrane attack complex, which is formed as the terminal event in complement activation, is also seen in normal-appearing and perilesional skin of patients. [39]

The exact site of the IgA deposits in DH skin has been studied by immunoelectron microscopy. Early studies indicated that IgA is preferentially associated with bundles of microfibrils and with anchoring fibrils of the papillary dermis immediately below the basal lamina. [40], [41] More recent studies, however, have indicated that some or almost all of the IgA deposits are related to nonfibrillar components of skin and other connective tissues. [42], [43] There is also no agreement as to whether the IgA deposits in DH colocalize to fibrillin, a major component of the elastic microfibrillar bundles.

Serum Studies

Antireticulin antibodies of the IgA and IgG classes have been detected in the sera of 17 to 93 percent of patients with DH and in higher percentages of patients with other diseases, especially celiac disease. [45] Thyroid microsomal antibodies [46] and antinuclear antibodies also have been detected in increased incidence in the sera of patients with DH. Putative immune complexes have been detected in the sera of 25 to 40 percent of patients. [47], [48]

Chorzelski et al. [49] have described an IgA antibody that binds to an intermyofibril substance (endomysium) of smooth muscle. The nature of this antigen has been identified recently by the studies of Sardy et al., [18] who showed that these IgA autoantibodies have specificity for transglutaminases, particularly epidermal-specific transglutaminases.

IMMUNOGENETIC FINDINGS

There is a marked increase in the incidence of certain major histocompatibility complex antigens in patients with DH. Worldwide studies have found that 77 to 87 percent of DH patients have HLA-B8 [31], [50] (compared with 20–30 percent of normal individuals). In addition, the class II major histocompatibility complex antigens HLA-DR and -DQ are associated with DH even more frequently than is HLA-B8. [51], [52] Park et al. [53] reported that more than 90 percent of patients expressed Te24, which was later shown to be similar to HLA-DQw2, and this finding has been confirmed by others. Molecular studies indicate that susceptibility to DH is not associated with a unique HLA-DQw2 molecule. [54] Virtually all patients with DH have genes that encode the HLA-DQ (a1*0501, ß1*02) or the HLA-DQ (a1*03, ß1*0302) heterodimers, a pattern identical to that seen in celiac disease. [54], [55] and [56] This strong association between susceptibility genes and DH and GSE is important clinically and pathophysiologically in that there is a strong concordance of these two diseases in monozygotic twins. [57] Furthermore, first-degree relatives of both DH and GSE patients are often (4–5 percent) affected with one or the other of these diseases. [58]

PATHOLOGY

The histology of an early skin lesion (clinically nonvesicular) is characterized by dermal papillary collections of neutrophils (microabscesses), neutrophilic fragments, varying numbers of eosinophils, fibrin, and at times, separation of the papillary tips from the overlying epidermis (Fig. 67-6). In addition, in such early lesions, the upper and middle dermal blood vessels are surrounded by a lymphohistiocytic infiltrate as well as some neutrophils and an occasional eosinophil. [7], [8] At times, early lesions may be difficult or impossible to differentiate from those of linear IgA disease (see Chap. 63), the bullous eruption of lupus erythematosus (see Chap. 171), bullous pemphigoid (see Chap. 61), or the neutrophil-rich form of epidermolysis bullosa acquisita (see Chap. 66). The histology of older lesions shows subepidermal vesicles that may be impossible to differentiate from other subepidermal bullous eruptions, such as bullous pemphigoid, erythema multiforme (see Chap. 58), bullous drug eruption, and pemphigoid gestationis (see Chap. 64). Immunofluorescent localization and ultrastructural studies of the site of blister formation in DH have demonstrated that the blister forms above the lamina densa—within the lamina lucida. [59], [60] This is thought to occur because the lamina lucida is the most vulnerable component of the dermal-epidermal junction.

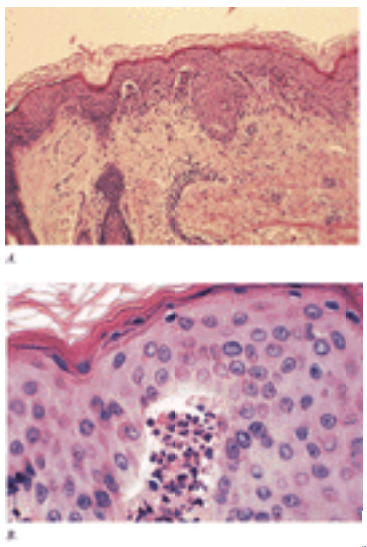

FIGURE 67-6 Dermatitis herpetiformis. Biopsy of an early lesion showing dermal papillary collections of neutrophils and eosinophils and subepidermal vesiculation at low (*A*) and high (*B*) magnification.

ASSOCIATED PROBLEMS

Gastrointestinal Manifestations

It is now well accepted that most, if not all, DH patients have an associated gastrointestinal abnormality that is caused by gluten sensitivity. [30], [31], [61] The pathology of the GSE associated with DH and that in celiac disease (GSE unassociated with DH) is essentially the same, although the lesion in the latter is usually much more severe; this applies to the epithelial cell derangement as well as to the character of the lymphoplasmacytic infiltrate. In addition, the distribution of the gastrointestinal lesion in the small intestine is, as a general rule, more widespread in celiac disease. The functional changes in the bowel and clinical sequelae encountered in the GSE associated with DH and those encountered in celiac disease are similar but again differ in degree, those in the latter being more severe. Thus in DH one observes steatorrhea (20–30 percent of patients), abnormal D-xylose absorption (10–33 percent of patients), and occasional anemia secondary to iron or folate deficiency. In patients not taking dapsone or related drugs, the latter is usually due to malabsorption. Studies using elemental diets (see below) in the treatment of DH have questioned the critical role attributed to gluten in the pathogenesis of this disease. In addition to the small intestinal lesion, patients with DH have an increased incidence of achlorhydria and atrophic gastritis. [62], [63] Reports of pernicious anemia and antibodies to gastric parietal cells are thus likely to be due to more than chance.

Malignancy

Leonard et al. [64] have reported an increased frequency of malignancies, especially gastrointestinal lymphomas, and Collin et al. [65] have reported a significant increase in non-Hodgkin's lymphomas in patients with DH. A combined retrospective study from both these groups suggests a protective role for a gluten-free diet against gastrointestinal lymphomas. [66]

Other Diseases

In addition to celiac disease, atrophic gastritis, and pernicious anemia (see above), DH patients have a higher incidence of other autoimmune diseases such as thyroid disease, insulin-dependent diabetes, lupus erythematosus, Sjögren's syndrome, and vitiligo. [46], [67], [68] This predilection for associated autoimmune diseases may be due to the high frequency of the 8.1 ancestral haplotype in these DH patients. [69]

DIAGNOSIS

DH may be confused with numerous other conditions because of its pleomorphic manifestations and the occasional lack of diagnostic lesions. Erythema multiforme, neurotic excoriations, scabies, eczema, papular urticaria, transient acantholytic dermatosis, pemphigoid, herpes gestationis, and various other dermatoses can be differentiated easily on the basis of histologic and immunologic criteria. Linear IgA disease may be more difficult to differentiate clinically and histologically, but it is distinctive immunologically. A high index of suspicion is very helpful in that even in the absence of primary lesions, DH can be diagnosed based on the typical in vivo–bound granular IgA deposits in normal-appearing skin.

TREATMENT

Sulfones

Diaminodiphenyl sulfone (dapsone), sulfoxone (diasone—not available in the United States), and sulfapyridine provide prompt improvement in symptoms and signs of the disease. Symptoms may abate in as few as 3 h or as long as a few days after the first pill is taken, and new lesions no longer erupt after 1 to 2 days of treatment. Exacerbations occur from hours to days after cessation of treatment. This response to therapy was, for a long time, the most important element in making a diagnosis. The preferred treatment for an adult is dapsone at an initial dosage of 100 to 150 mg per day (this usually can be taken at one time of day). An occasional patient may require 300 to 400 mg of dapsone for initial improvement. Patients should be instructed to take the minimal dose required to suppress signs and symptoms. Not all patients require daily treatment; in rare cases, 25 mg weekly is sufficient. Sulfapyridine, in a dosage of 1 to 1.5 g daily, is particularly useful in patients intolerant of dapsone, in elderly patients, and in those with cardiopulmonary problems. The

pharmacology, mechanism(s) of action, adverse effects, and monitoring of dapsone are discussed in Chap. 254. It is important to know that nonsteroidal anti-inflammatory drugs often exacerbate DH, even in patients taking dapsone. [70]

Gluten-Free Diet

EFFECT ON THE SMALL INTESTINE There is no doubt that the intestinal lesion in DH responds to dietary gluten withdrawal. The time course of the response in adults with DH is the same as that in adults with celiac disease.
EFFECT ON THE SKIN DISEASE Strict adherence to a gluten-free diet will, after variable periods of time (from 5 months to 1 year), reduce or completely eliminate the requirement for medication in most, but not all, patients. The most extensive early study by Fry et al. [14] has been confirmed by several groups. However, it is only the very highly motivated patient who can adhere to the diet, which requires counseling by an individual who is very familiar with its use.

Elemental Diet

Studies in small numbers of DH patients have indicated that elemental diets (composed of free amino acids, short-chain polysaccharides, and small amounts of triglycerides) can be very beneficial in alleviating the skin disease within a few weeks. [71], [72] The beneficial effect on the skin disease may be achieved even if the patient ingests large amounts of gluten. [72] Unfortunately, elemental diets are difficult to tolerate for long periods.

REFERENCES

1. Reunala T, Lokki J: Dermatitis herpetiformis in Finland. *Acta Derm Venereol (Stockh)* **58**:505, 1978

2. Moi H: Incidence and prevalence of dermatitis herpetiformis in a county in central Sweden, with comments on the course of the disease and IgA deposits as diagnostic criterion. *Acta Derm Venereol (Stockh)* **64**:144, 1984

3. Smith JB et al: The incidence and prevalence of dermatitis herpetiformis in Utah. *Arch Dermatol* **128**:1608, 1992

4. Duhring L: Dermatitis herpetiformis. *JAMA* **3**:225, 1884

5. Brocq L: De la dermatite herpétiforme de Duhring. *Ann Dermatol Syphiligr* (second series):9, 1888

6. Costello M: Dermatitis herpetiformis treated with sulfapyridine. *Arch Dermatol Syphilol* **41**:134, 1940

7. Pierard J, Whimster I: The histological diagnosis of dermatitis herpetiformis, bullous pemphigoid and erythema multiforme. *Br J Dermatol* **73**:253, 1961

8. MacVicar DN et al: Dermatitis herpetiformis, erythema multiforme and bullous pemphigoid: A comparative histopathological and histochemical study. *J Invest Dermatol* **41**:289, 1963

9. Cormane RH: Immunofluorescent studies of the skin in lupus erythematosus and other diseases. *Pathol Eur* **2**:170, 1967

10. van der Meer JB: Granular deposits of immunoglobulins in the skin of patients with dermatitis herpetiformis: An immunofluorescent study. *Br J Dermatol* **81**:493, 1969

11. Marks J et al: Small bowel changes in dermatitis herpetiformis. *Lancet* **2**:1280, 1966

12. Fry L et al: Small-intestinal structure and function and haematological changes in dermatitis herpetiformis. *Lancet* **2**:729, 1967

13. Shuster S et al: Coeliac syndrome in dermatitis herpetiformis. *Lancet* **1**:1101, 1968

14. Fry L et al: Clearance of skin lesions in dermatitis herpetiformis after gluten withdrawal. *Lancet* **1**:288, 1973

15. Katz SI et al: HL-A8: A genetic link between dermatitis herpetiformis and gluten-sensitive enteropathy. *J Clin Invest* **51**:2977, 1972

16. Chorzelski TP et al: Linear IgA bullous dermatosis, in *Immunopathology of the Skin,* 2d ed, edited by EH Beutner, TP Chorzelski, and S Jablonska. New York, Wiley, 1979, p 315

17. Dieterich W et al: Antibodies to tissue transglutaminase as serologic markers in patients with dermatitis herpetiformis. *J Invest Dermatol* **113**:133, 1999

18. Sardy M et al: Epidermal transglutaminase (Tgase 3) is the autoantigen of dermatitis herpetiformis. *J Exp Med* **195**:1, 2002

19. Hardman CM et al: Absence of toxicity of oats in patients with dermatitis herpetiformis. *New Engl J Med* **337**:1884, 1997

20. Reunala T et al: Tolerance to oats in dermatitis herpetiformis. *Gut* **43**:490, 1998

21. Weinstein WM: Latent celiac sprue. *Gastroenterology* **66**:489, 1974

22. Savilahti E et al: Density of gamma/delta T cells in the jejunal epithelium of patients with coeliac disease and dermatitis herpetiformis is increased with age. *Clin Exp Immunol* **109**:464, 1997

23. Hall RP et al.TCR Vb expression in the small bowel of patients with dermatitis herpetiformis and gluten-sensitive enteropathy. *Exp Dermatol* **9**:275, 2000

24. Ward MM et al: Soluble interleukin-2 receptor levels in patients with dermatitis herpetiformis. *J Invest Dermatol* **97**:568, 1991

25. Airola K et al: Urokinase plasminogen activator is expressed in basal keratinocytes before interstitial collagenase, stromelysin-1, and laminin-5 in experimentally induced dermatitis herpetiformis lesions. *J Invest Dermatol* **108**:7, 1997

26. Salmela MT et al: Parallel expression of macrophage metalloelastase (MMP-12) in duodenal and skin lesions of patients with dermatitis herpetiformis. *Gut* **48**:496, 2001

27. Garioch JJ et al: T cell receptor V beta expression is restricted in dermatitis herpetiformis skin. *Acta Derm Venereol (Stockh)* **77**:184, 1997

28. Baker BS et al: Absence of gluten-specific T lymphocytes in the skin of patients with dermatitis herpetiformis. *J Autoimmun* **8**:75, 1995

29. Seah PP, Fry L: Immunoglobulins in the skin in dermatitis herpetiformis and their relevance in diagnosis. *Br J Dermatol* **92**:157, 1975

30. Marks JM: Dogma and dermatitis herpetiformis. *Clin Exp Dermatol* **2**:189, 1978

31. Katz SI et al: Dermatitis herpetiformis: The skin and the gut. *Ann Intern Med* **93**:857, 1980

32. Leonard J et al: Gluten challenge in dermatitis herpetiformis. *New Engl J Med* **308**:816, 1983

33. Reunala T: Gluten-free diet in dermatitis herpetiformis: II. Morphological and immunological findings in the skin and small intestine of 12 patients and matched controls. *Br J Dermatol* **98**:69, 1978

34. Zone JJ et al: Deposition of granular IgA relative to clinical lesions in dermatitis herpetiformis. *Arch Dermatol* **132**:912, 1996

35. Hall RP, Lawley TJ: Characterization of circulating and cutaneous IgA immune complexes in patients with dermatitis herpetiformis. *J Immunol* **135**:1760, 1985

36. Barguthy FS et al: Identification of IgA subclasses in skin of patients with dermatitis herpetiformis. *Int Arch Allergy Appl Immunol* **85**:268, 1988

37. Katz SI et al: Effect of sulfones on complement deposition in dermatitis herpetiformis and on complement-mediated guinea pig reactions. *J Invest Dermatol* **67**:688, 1976

38. Ljunghall K, Tjernlund U: Dermatitis herpetiformis: Effects of gluten-restricted and gluten-free diet on dapsone requirement and on IgA and C3 deposits in uninvolved skin. *Acta Derm Venereol (Stockh)* **63**:129, 1983

39. Dahlbäck K et al: Vitronectin colocalizes with Ig deposits and C9 neoantigen in discoid lupus erythematosus and dermatitis herpetiformis, but not in bullous pemphigoid. *Br J Dermatol* **120**:725, 1989

40. Yaoita H: Identification of IgA binding structures in skin of patients with dermatitis herpetiformis. *J Invest Dermatol* **71**:213, 1978

41. Stingl G et al: Ultrastructural localization of immunoglobulins in dermatitis herpetiformis. *J Invest Dermatol* **67**:507, 1976

42. Karpati S et al: Dermatitis herpetiformis bodies. *Arch Dermatol* **126**:1469, 1990

43. Karpati S et al: Ultrastructural binding sites of endomysial antibodies from sera of patients with dermatitis herpetiformis and coeliac disease. *Gut* **33**:191, 1992

44. Dahlbäck K, Sakai L: IgA immunoreactive deposits colocal with fibrillin immunoreactive fibers in dermatitis herpetiformis. *Acta Derm Venereol (Stockh)* **70**:194, 1990

45. Hällström O: Comparison of IgA-class reticulin and endomysium antibodies in caeliac disease and dermatitis herpetiformis. *Gut* **30**:1225, 1989

46. Zettinig G et al: Dermatitis herpetiformis is associated with atrophic but not with goitrous variant of Hashimoto's thyroiditis. *Eur J Clin Invest* **30**:53, 2000

47. Zone JJ et al: Circulating immune complexes of IgA type in dermatitis herpetiformis. *J Invest Dermatol* **75**:152, 1980

48. Hall RP et al: IgA containing circulating immune complexes in dermatitis herpetiformis, Henoch-Schönlein purpura, systemic lupus erythematosus and other diseases. *Clin Exp Immunol* **40**:431, 1980

49. Chorzelski TP et al: IgA class endomysium antibodies in dermatitis herpetiformis and coeliac disease. *Ann NY Acad Sci* **420**:325, 1983

50. Reunala T et al: Histocompatibility antigens and dermatitis herpetiformis with special reference to jejunal abnormalities and acetylator phenotype. *Br J Dermatol* **94**:139, 1976

51. Keuning JJ et al: HLA-DW3 associated with coeliac disease. *Lancet* **1**:506, 1976

52. Thomsen M et al: Association of Ld-8a and Ld-12a with dermatitis herpetiformis. *Tissue Antigens* **7**:60, 1976

53. Park MS et al: The 90% incidence of HLA antigen (Te24) in dermatitis herpetiformis. *Tissue Antigens* **22**:263, 1983

54. Otley CC et al: DNA sequence analysis and restriction fragment length polymorphism (RFLP) typing of the HLA-DQw2 alleles associated with dermatitis herpetiformis. *J Invest Dermatol* **97**:318, 1991

55. Spurkland A et al: Dermatitis herpetiformis and celiac disease are both primarily associated with the HLA-DQ (a1*0501, ß1*02) or the HLA-DQ (a1*03, ß1*0302) heterodimers. *Tissue Antigens* **49**:29, 1997

56. Balas A et al: Absolute linkage of celiac disease and dermatitis herpetiformis to HLA-DQ. *Tissue Antigens* **50**:52, 1997

57. Hervonen K et al: Concordance of dermatitis herpetiformis and celiac disease in monozygotous twins. *J Invest Dermatol* **115**:990, 2000

58. Hervonen K et al: First-degree relatives are frequently affected in coeliac disease and dermatitis herpetiformis. *Scand J Gastroenterol* **37**:51, 2002

59. Klein GF et al: Junctional blisters in acquired bullous disorders of the dermal-epidermal junction zone: Role of the lamina lucida as the mechanical locus minoris resistentiae. *Br J Dermatol* **109**:499, 1983

60. Smith JB et al: The site of blister formation in dermatitis herpetiformis is within the lamina lucida. *J Am Acad Dermatol* **27**:209, 1992

61. Fry L et al: The small intestine in dermatitis herpetiformis. *J Clin Pathol* **27**:817, 1974

62. O'Donoghue DP et al: Gastric lesion in dermatitis herpetiformis. *Gut* **17**:185, 1976

63. Stockbrugger H et al: Autoimmune atrophic gastritis in patients with dermatitis herpetiformis. *Acta Derm Venereol (Stockh)* **56**:111, 1976

64. Leonard JN et al: Increased incidence of malignancies in dermatitis herpetiformis. *BMJ* **286**:16, 1983

65. Collin P et al: Malignancy and survival in dermatitis herpetiformis: A comparison with coeliac disease. *Gut* **38**:528, 1996

66. Lewis HM et al: Protective effect of gluten-free diet against development of lymphoma in dermatitis herpetiformis. *Br J Dermatol* **135**:363, 1996

67. Fry L: Dermatitis herpetiformis. *Baillieres Clin Gastroenterol* **9**:371, 1995

68. Reunala T, Collin P: Diseases associated with dermatitis herpetiformis. *Br J Dermatol* **136**:315, 1997

69. Price P et al: The genetic basis for the association of the 8.1 ancestral haplotype (A1, B8, DR3) with multiple immunopathological diseases. *Immunol Rev* **167**:257, 1999

70. Griffiths CEM et al: Dermatitis herpetiformis exacerbated by indomethacin. *Br J Dermatol* **112**:443, 1985

71. Zeedijk N et al: Dermatitis herpetiformis: Consequences of elemental diet. *Acta Derm Venereol (Stockh)* **66**:316, 1986

72. Kadunce DP et al: The effect of an elemental diet with and without gluten on disease activity in dermatitis herpetiformis. *J Invest Dermatol* **97**:175, 1991

T>

Chapter 68

Robin Graham-Brown

Familial Benign Pemphigus (Hailey-Hailey Disease)

ETIOLOGY
CLINICAL MANIFESTATIONS
PATHOLOGY
DIFFERENTIAL DIAGNOSIS
TREATMENT
COURSE

REFERENCES

Familial benign pemphigus (FBP), or "Hailey-Hailey disease," is a rare blistering disorder, first described by the Hailey brothers in 1939 [1] and characterized by recurrent vesicles and erosions, particularly involving flexural areas.

ETIOLOGY

The sexes are equally affected by FBP, which is inherited in an autosomal dominant manner, but because only 70 percent of patients have a clear family history, there must be some variability in gene penetrance.

Lesions are frequently precipitated by friction and infection with various bacteria. Yeasts and viruses also appear to play a role in some patients.

The major underlying pathologic process in FBP is acantholysis and the changes appear in isolated keratinocyte cultures, [2] indicating a fundamental defect in the keratinocytes themselves. Cell adhesion is abnormal, [3], [4], [5], [6] and [7] the fragility occurring in the adhesion complex. [8], [9], [10] and [11] The gene responsible for upregulation of P-cadherin has been reported [12] to be located on chromosome 3, the location being 3q21-q24. [13], [14] and [15] It has been established that the genetic abnormality for FBP lies in *ATP2C1,* which encodes an adenosine triphosphate (ATP)-powered calcium pump. [16], [17]

CLINICAL MANIFESTATIONS

Signs first appear from the age of 11 or older, with most patients first experiencing lesions in the third or fourth decade. Most individuals have disease of relatively limited extent, [18] although widespread and severe involvement can occur. [19] The most commonly affected sites are the axillae (Fig. 68-1), groins (Fig. 68-2), intertriginous areas such as the inframammary folds, and the neck; nearly half the patients in the largest series reported to date recalled that their first lesions appeared on the sides of the neck. [18] Lesions may also occur on the trunk and in the antecubital and popliteal fossae. Seborrheic dermatitis-like involvement of the scalp has also been described. [20]

FIGURE 68-1 Familial benign pemphigus. Sites of predilection are the intertriginous areas, especially the axillae.

FIGURE 68-2 A site commonly involved is the groin as illustrated here. Erosions on an erythematous base give rise to the highly characteristic, tiny, fissured lesions on scrotum.

Mucosal surfaces are only rarely involved, but lesions have been reported in the mouth, [21] esophagus, [22] larynx, [23] and the perianal and vulvovaginal areas. [24], [25] and [26] Genital lesions may resemble warts. [27]

Longitudinal white streaks may appear in the nails. [18], [28]

Individual lesions consist primarily of flaccid vesicles and blisters on an erythematous background, but because of friction and secondary infection, it is more common to find eroded plaques in the sites of predilection, with a highly characteristic fissured appearance (Fig. 68-3). Crusting, scaling, and hypertrophic, vegetative changes may also occur. The involved areas tend to extend peripherally before stabilizing, often producing annular or serpiginous shapes. Recurrence is very common.

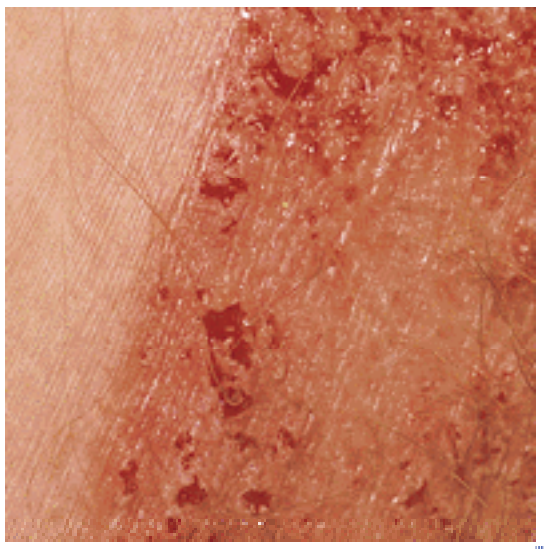

FIGURE 68-3 Familial benign pemphigus. Erosions are present on an erythematous base in the axilla of this patient.

Most patients remain healthy, but they complain of significant discomfort and some find that the condition severely restricts their work and leisure activities. [18] Many patients are also aware of an unpleasant odor arising from the diseased areas, and notice that external friction by clothing, adhesive bandages, and even electrocardiographic electrodes may induce lesions. Sunlight has been reported either to improve or exacerbate FBP, while deterioration has been noted either with stress or premenstrually. [18] Occasionally a severe exacerbation with a generalized systemic disturbance and varicelliform vesicular pustules may be associated with widespread infection with herpes simplex virus. [29]

PATHOLOGY

Light microscopy reveals suprabasal cleavage, acantholysis, and intercellular edema (Fig. 68-4). The appearance has been likened to that of a “dilapidated brick wall”; [30] it is often indistinguishable from pemphigus vulgaris. Occasionally, however, a few dyskeratotic cells, similar to the corps ronds of Darier's disease, are seen in the granular layer. Both direct and indirect immunofluorescence for intercellular antibodies is negative. The electron microscopic changes are consistent with a defect of desmosomal adhesion: there is separation of tonofilaments from desmosomes and a reduction of visible desmosomes on the cell surfaces; electron-dense material is seen around the nucleus. [3], [4]

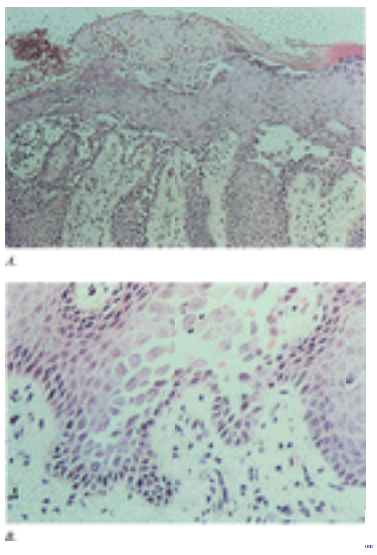

FIGURE 68-4 Familial benign pemphigus. Suprabasal bulla formation with acantholysis is seen. *A.* The resulting partial adherence of the epidermal keratinocytes has been likened to a “dilapidated brick wall.” *B.* Few dyskeratotic cells are seen in the lower power view.

DIFFERENTIAL DIAGNOSIS

The diagnosis of FBP is often delayed with genital and perianal lesions particularly leading to diagnostic confusion with other disorders. FBP must be distinguished clinically from chronic bacterial or fungal infections and intertrigo. Because anti-infective agents may improve FBP, the diagnosis can be made only on biopsy. Pemphigus vulgaris or vegetans can

be confused with FBP both clinically and histologically, but these disorders generally affect wider areas, including the mouth. Immunofluorescence will provide further differentiation. Histologically, Darier's disease and the transient acantholytic dermatosis of Grover can produce similar appearances. Lesions of Darier's disease, however, generally show less-marked acantholysis, while evidence of dyskeratosis, in the form of grains and corps ronds, is much more striking. Clinical distinction is generally straightforward, with Darier's disease typically producing warty papules in the “seborrheic” areas. Darier's disease and FBP have, however, been described in the same individual. [31] As a consequence, it was suggested that there may be genetic overlap between the two disorders, but this is not the case, [32] although both diseases are associated with mutations in calcium pump protein. Grover's disease also shows more limited cleavage and acantholysis but greater dyskeratosis than FBP.

TREATMENT

Simple anti-infective agents, administered either topically or systemically, reduce the severity of exacerbations and remain the mainstay of treatment. Topically, tetracyclines, fusidic acid, and imidazoles are all useful, while systemically, tetracyclines seem to work better than most. It may be best to combine anti-infective therapy with topical glucocorticoids, as 86 percent of patients in Burge's series found them helpful, especially if started immediately at the onset of discomfort. [18] Generally, moderate to potent agents are required, although some patients find weaker glucocorticoids useful. A few patients seem to benefit from short courses of systemic glucocorticoids to control major exacerbations, but this may result in a rebound of the disease when the drugs are withdrawn. [19]

Responses have also been described with a number of other therapeutic modalities. Superficial (Grenz) rays have been reported to induce remission in several patients, [20] but very few centers now have the equipment needed. Dapsone and topical and systemic cyclosporine have been reported to be successful in a few patients. [33], [34], [35] and [36] Methotrexate [37] and retinoids [18] have also been used to treat resistant disease. Gonadotrophin-releasing hormone analogue therapy followed by oophorectomy virtually abolished FBP in a patient with marked premenstrual flares. [38] If secondary infection with herpes simplex is suspected, appropriate antiviral therapy should be instituted.

Finally, there may be a place for surgical approaches to disease of limited extent. Surgical excision and grafting have been advocated, [39] although there may be recurrences, especially around the edges of the treated areas or upon further friction or trauma. Patients have also been treated with dermabrasion [40] and carbon dioxide laser vaporization. [41]

COURSE

The usual pattern of disease activity is of frequent exacerbations with temporary periods of quiescence. In some patients, lesions appear almost continuously. Some, however, report prolonged remissions; in general, the condition becomes less troublesome with age.

REFERENCES

1. Hailey H, Hailey H: Familial benign chronic pemphigus. *Arch Dermatol Syphilol* **39**:679, 1939

2. Regnier LM et al: Histological defects of chronic benign familial pemphigus expressed in tissue culture. *Arch Dermatol Res* **281**:538, 1990

3. Wilgram GF et al: An electron microscopic study of acantholysis and dyskeratosis in Hailey and Hailey's disease. *J Invest Dermatol* **39**:373, 1962

4. Gottlieb SK, Lutzner MA: Hailey-Hailey disease: An electron microscopic study. *J Invest Dermatol* **54**:368, 1970

5. Ishibashi Y et al: The nature and pathogenesis of dyskeratosis in Hailey-Hailey's disease and Darier's disease. *J Dermatol* **11**:335, 1984

6. Setoyama M et al: Desmoplakin I and II in acantholytic dermatoses: Preservation in pemphigus vulgaris and pemphigus erythematosus and dissolution in Hailey-Hailey's disease and Darier's disease. *J Dermatol Sci* **2**:9, 1991

7. Burge SM, Garrod DR: An immunohistochemical study of desmosomes in Darier's disease and Hailey-Hailey disease. *Br J Dermatol* **124**:242, 1991

8. Hashimoto K et al: Junctional proteins of keratinocytes in Grover's disease, Hailey-Hailey's disease and Darier's disease. *J Dermatol* **22**:159, 1995

9. Metze D et al: Involvement of the adherens junction-actin filament system in acantholytic dyskeratosis of Hailey-Hailey disease. A histological, ultrastructural, and histochemical study of lesional and non-lesional skin. *J Cutan Pathol* **23**:211, 1996

10. Cooley JF et al: Hailey-Hailey disease keratinocytes: Normal assembly of cell-cell junctions in vitro. *J Invest Dermatol* **107**:877, 1996

11. Burge SM, Schomberg KH: Adhesion molecules and related proteins in Darier's disease and Hailey-Hailey disease. *Br J Dermatol* **127**:335, 1992

12. Hakuno M et al: Upregulation of P-cadherin expression in the lesional skin of pemphigus, Hailey-Hailey disease and Darier's disease. *J Cutan Pathol* **28**:277, 2001

13. Ikeda S et al: Localization of the gene whose mutations underlie Hailey-Hailey disease to chromosome 3q. *Hum Mol Genet* **3**:1147, 1994

14. Peluso AM et al: Narrowing of the Hailey-Hailey disease gene region on chromosome 3q and identification of one kindred with a deletion in this region. *Genomics* **30**:77, 1995

15. Richard G et al: Hailey-Hailey disease maps to a 5 cM interval on chromosome 3q21-q24. *J Invest Dermatol* **105**:357, 1995

16. Hu Z et al: Mutations in ATP2C1, encoding a calcium pump, cause Hailey-Hailey disease. *Nat Genet* **24**:61, 2000

17. Subra KR et al: Hailey-Hailey disease is caused by mutations in ATP2C1 encoding a novel Ca(2+) pump. *Hum Mol Genet* **9**:1131, 2001

18. Burge SM: Hailey-Hailey disease: The clinical features, response to treatment and prognosis. *Br J Dermatol* **126**:275, 1992

19. Marsch WC, Stütgen G: Generalized Hailey-Hailey disease. *Br J Dermatol* **99**:553, 1978

20. Marren P, Burge SM: Seborrhoeic dermatitis of the scalp: A manifestation of Hailey-Hailey disease in a predisposed individual? *Br J Dermatol* **126**:294, 1992

21. Botvinick I: Familial benign chronic pemphigus with oral mucous membrane lesions. *Cutis* **12**:371, 1973

22. Kahn D, Hutchnison E: Esophageal involvement in familial benign chronic pemphigus. *Arch Dermatol* **109**:718, 1974

23. Schneider W et al: Zur Frage der schleimhautbeteiligung beim pemphigus benignus familiaris chronicus. *Arch Klin Exp Dermatol* **225**:74, 1966

24. Wilkin JK: Chronic benign familial pemphigus: Minimal involvement mimicking chronic perianal candidiasis. *Arch Dermatol* **114**:136, 1978

25. Vaclavinkova Y, Neumann E: Vaginal involvement in familial chronic benign pemphigus (morbus Hailey-Hailey). *Acta Derm Venereol Suppl (Stockh)* **62**:80, 1982

26. Evron S et al: Familial benign chronic pemphigus appearing as leukoplakia of the vulva. *Int J Dermatol* **23**:556, 1984

27. Langenberg A et al: Genital benign chronic pemphigus (Hailey-Hailey disease) presenting as condylomas. *J Am Acad Dermatol* **26**:951, 1992

28. Kirtshig G et al: Leukonychia longitudinalis als ein Leitsymptom des Morbus Hailey-Hailey. *Hautarzt* **43**:451, 1992

29. Flint ID et al: Eczema herpeticum in association with familial benign chronic pemphigus. *J Am Acad Dermatol* **28**:257, 1993

30. Haber H, Russell B: Sisters with familial benign chronic pemphigus (Gougerot, Hailey and Hailey). *Br J Dermatol Syph* **62**:458, 1950

31. Ganor S, Sagher F: Keratosis follicularis (Darier) and familial benign chronic pemphigus (Hailey-Hailey) in the same patient. *Br J Dermatol* **77**:24, 1965

32. Welsh EA et al: Hailey-Hailey disease is not allelic to Darier's disease. *J Invest Dermatol* **102**:992, 1994

33. Sire DJ, Johnson BL: Benign familial chronic pemphigus treated with dapsone. *Arch Dermatol* **103**:262, 1971

34. Jitsukawa K et al: Topical cyclosporine in chronic benign familial pemphigus (Hailey-Hailey disease). *J Am Acad Dermatol* **27**:625, 1992

35. Ormerod AD et al: Benign familial pemphigus responsive to cyclosporin: A possible role for cellular immunity in pathogenesis. *Br J Dermatol* **124**:299, 1991

36. Berth-Jones J et al: Benign familial chronic pemphigus (Hailey-Hailey disease) responds to cyclosporin. *Clin Exp Dermatol* **20**:70, 1995

37. Fairris GM et al: Methotrexate for intractable benign familial chronic pemphigus. *Br J Dermatol* **115**:640, 1986

38. James MP, Williams RM: Benign familial pemphigus-premenstrual exacerbation suppressed by goserelin and oophorectomy. *Clin Exp Dermatol* **20**:54, 1995

39. Shelley WB, Randall P: Surgical eradication of familial benign chronic pemphigus from the axillae. *Arch Dermatol* **100**:275, 1969

40. Zachariae H: Dermabrasion of Hailey-Hailey disease. *J Am Acad Dermatol* **27**:136, 1992

41. Don PC et al: Carbon dioxide laser abrasion: A new approach to management of familial benign chronic pemphigus (Hailey-Hailey disease). *J Dermatol Surg Oncol* **13**:1187, 1987

T>

Chapter 69

Herbert Hönigsmann Franz Trautinger Klaus Wolff

Subcorneal Pustular Dermatosis (Sneddon-Wilkinson Disease)

INCIDENCE
ETIOLOGY
CLINICAL FEATURES
HISTOPATHOLOGY
DIAGNOSIS AND DIFFERENTIAL DIAGNOSIS
TREATMENT
COURSE AND PROGNOSIS

REFERENCES

Subcorneal pustular dermatosis (SPD) is a rare, chronic, recurrent, pustular eruption characterized histopathologically by subcorneal pustules that contain abundant neutrophils. The condition was originally described in 1956 by Sneddon and Wilkinson, [1] who separated SPD from other previously unclassified pustular eruptions. Up to 1966, when the first comprehensive review appeared, more than 130 cases had been reported, but not all fulfilled the clinical and histopathologic criteria required for this diagnosis. [2] A considerable number of additional cases have since appeared in the literature, and a subtype clinically resembling SPD with intraepidermal IgA deposits has been recognized [3] (SPD-type IgA pemphigus).

INCIDENCE

There is no racial predilection. Most of the reported cases have been in whites, but the disease has also been observed in Africans, Japanese, and Chinese. The condition is more common in women and in persons older than 40 years of age, but SPD may occur at any age. [2] A pustular eruption that is clinically and histologically similar to the human disease, which also responds to dapsone treatment, has been observed in dogs. [4]

ETIOLOGY

The cause of SPD is unknown. Cultures of the pustules consistently fail to reveal bacterial growth. The role of trigger mechanisms such as preceding or concomitant infections, though repeatedly discussed, has remained speculative. Immunologic mechanisms have been implicated in the pathogenesis, and in a subset of patients, whose disease clinically resembled SPD, intraepidermal IgA deposits have been detected. Some of these patients also had circulating IgA antibodies against the same sites within the epidermis. Desmocollin I has been described to be the target of these antibodies. [3], [5] Although the pathogenetic role of IgA in intraepidermal pustule formation remains elusive, these findings led to the concept of a separate disease clinically and histopathologically similar to SPD with intraepidermal IgA deposits. This condition has been designated subcorneal pustular dermatosis type IgA pemphigus and is clinically indistinguishable from classical SPD. [6]

The occasional association of SPD with certain other diseases may represent more than a mere coincidence. Increased serum IgA has been detected in a number of patients, and the disease has been reported to occur in cases of IgA-paraproteinemia and IgA multiple myeloma. [7], [8], [9] and [10] In addition, SPD is associated with pyoderma gangrenosum, [11], [12] ulcerative colitis, [13] and Crohn's disease. [14] On the other hand, pyoderma gangrenosum is not uncommon in patients with inflammatory bowel disease, paraproteinemia, and myeloma. Whether or not the coexistence of these conditions reflects common pathogenetic mechanisms remains to be clarified, but an additional common denominator linking these disorders is their response to sulfone and sulfonamide therapy.

Further associations reported to date include IgG paraproteinemia, [15], [16] CD30+ anaplastic large-cell lymphoma, [17] non–small-cell lung cancer, [18] apudoma, [19] rheumatoid arthritis, [20], [21] hyperthyroidism, [22] and mycoplasma pneumoniae infection. [23]

CLINICAL FEATURES

The primary lesions are small, discrete, flaccid pustules or vesicles that rapidly turn pustular and usually arise in crops within a few hours on clinically normal or slightly erythematous skin. In dependent regions, pus characteristically accumulates in the lower half of the pustule; as the pustules usually have the tendency to coalesce, they often, but not always, form annular, circinate, or bizarre serpiginous patterns. After a few days the pustules rupture and dry up to form thin, superficial scales and crusts, closely resembling impetigo. Peripheral spreading and central healing leave polycyclic, erythematous areas in which new pustules arise as others disappear (Fig. 69-1). There is no atrophy or scarring, but an occasional brownish hyperpigmentation may mark previously affected sites. Variable intervals of quiescence, lasting from a few days to several weeks, may be followed by the sudden development of new lesions. The eruptions tend to occur symmetrically, affecting mainly the axillae, groins, abdomen, submammary areas, and the flexor aspects of the limbs. In rare cases, the face, [24] palms, and soles [2], [25] may be involved. Scalp and mucous membranes invariably remain free of lesions. Episodic itching and burning represent subjective symptoms in a small number of patients, but there are no systemic symptoms or abnormalities in routine laboratory parameters.

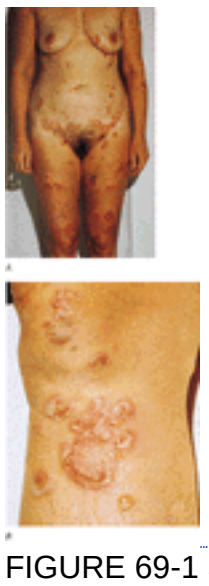

FIGURE 69-1 Subcorneal pustular dermatosis. *A.* Typical distribution. Note accentuated involvement of groins and abdomen. Hyperpigmented macules mark previously affected areas. *B.* Close-up showing coalescence of pustules, which form annular and circinate patterns. Lesions of different developmental stages are seen side by side. At the lower right, newly formed pustule with characteristic hypopyon formation.

HISTOPATHOLOGY

The hallmark of the disease is a strictly subcorneal pustule filled with polymorphonuclear leukocytes, [1] with only an occasional eosinophil. [2] Acantholysis is not involved in pustule formation, but a few acantholytic cells may be found in older lesions (secondary acantholysis). Surprisingly, the epidermal layers underlying the pustule exhibit little pathology, and, apart from a variable number of migrating leukocytes, there is little evidence of spongiosis or cytolytic damage to the epidermal cells. The dermis contains a perivascular infiltrate composed of neutrophils and rarely mononuclear cells and eosinophils (Fig. 69-2).

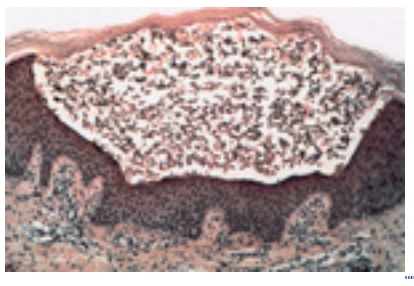

FIGURE 69-2 Subcorneal pustular dermatosis. Strictly subcorneal pustule filled with polymorphonuclear leukocytes, the underlying epidermal layers exhibiting only slight edema and some migrating leukocytes. There is a mild inflammatory infiltrate around dermal blood vessels (33×).

In a subset of patients, direct immunofluorescence reveals intraepidermal IgA deposits. [15] In these cases, IgA is usually present in a pemphigus-like intercellular pattern, either in the entire epidermis or confined to its upper layers. By indirect immunofluorescence, circulating IgA antibodies directed against the intercellular substance of the epidermis were detected in single cases.

Ultrastructural examination of paralesional skin has shown cytolysis of keratinocytes confined to the granular layer; [26] the formation of pustules has been regarded as a secondary event caused by invasion and subcorneal accumulation of leukocytes.

DIAGNOSIS AND DIFFERENTIAL DIAGNOSIS

SPD must be differentiated from impetigo contagiosa, dermatitis herpetiformis, pemphigus foliaceus, glucagonoma syndrome, and acute generalized pustulosis. An early localized eruption of SPD may be clinically and histologically indistinguishable from impetigo, but the distribution pattern of the lesions, the absence of bacteria in the pustules, the ineffectiveness of topical and systemic antibiotic therapy, and the course of the disease lead to the correct diagnosis. Dermatitis herpetiformis is a papulovesicular eruption with subepidermal vesicle formation; it is highly pruritic, affecting primarily the extensor surfaces. In a high percentage of the patients, there are changes in the jejunal mucosa, a phenomenon not as yet observed in SPD. The typical pattern of IgA deposits in the dermal papillae as revealed by direct immunofluorescence, which is diagnostic for dermatitis herpetiformis, is not found in SPD.

Occasionally, lesions of pemphigus foliaceus may be misdiagnosed on clinical examination and, if acantholysis is not very prominent, can be mistaken for SPD histologically. However, SPD either fails to exhibit the immunofluorescence pattern typical for pemphigus or presents with intraepidermal IgA deposits (SPD type IgA pemphigus, see above). Generalized pustular psoriasis (von Zumbusch type) may sometimes present differential diagnostic difficulties. Systemic symptoms (fever, malaise, leukocytosis), the presence of spongiform pustules within the epidermis, and the failure of pustular psoriasis to respond to sulfones represent reliable criteria to distinguish it from SPD. The necrolytic migratory eruption of glucagonoma syndrome can be differentiated by its distribution, lack of actual pustule formation, erosions of the lips and oral mucosa, and, histologically, necrobiosis of the upper epidermis. Biochemically, excess levels of glucagon are diagnostic. Acute generalized pustulosis is a widespread pustular eruption, with predilection of the distal

parts of the extremities, that histologically exhibits leukocytoclastic vasculitis. Juvenile bullous pemphigoid and erythema multiforme should not give rise to confusion.

TREATMENT

The drugs of choice are the sulfones, such as dapsone in a dose of 50 to 150 mg daily. The response is slower and less dramatic than in dermatitis herpetiformis, but complete remission is most often obtained. In some patients, the treatment may be withdrawn after several months, although in others it may have to be continued for years; the minimal effective dose to suppress disease should be determined in these patients. Sulfapyridine (1.0 to 3.0 g daily) is also beneficial; systemic corticosteroids are less effective, although they can suppress generalized flares when given in large doses. Obviously, the long-term use of potentially dangerous drugs in the treatment of a benign disease should be carefully considered. Retinoids, PUVA, and UVB have been reported to induce remissions, but this awaits confirmation. [27], [28], [29] and [30] Responses to colchicine, cyclosporine, and topical tacalcitol (1a-24 *R*-dihydroxyvitamin D_3) have been anecdotally reported, and a combination of antitumor necrosis factor a antibody followed by retinoids reportedly results in remission. [31]

COURSE AND PROGNOSIS

SPD is a benign condition. Without treatment, attacks recur over many years and remissions are variable, lasting from a few days to several weeks. Despite the protracted course and the occasional involvement of large areas of the skin, the general health of the patient is not impaired. However, one of our own cases who had SPD, pyoderma gangrenosum, and IgA paraproteinemia of more than 20 years' duration died of septicemia with staphylococcal abscesses in the lungs, liver, and spleen.

REFERENCES

1. Sneddon IB, Wilkinson DS: Subcorneal pustular dermatosis. *Br J Dermatol* **68**:385, 1956

2. Wolff K: A contribution to the nosology of subcorneal pustular dermatosis (Sneddon-Wilkinson) [in German]. *Arch Klin Exp Dermatol* **224**:248, 1966

3. Robinson ND et al: The new pemphigus variants. *J Am Acad Dermatol* **40**:649, 1999

4. Kalaher KM, Scott DW: Subcorneal pustular dermatosis in dogs and in human beings: Comparative aspects. *J Am Acad Dermatol* **22**:1023, 1990

5. Hashimoto T et al: Human desmocollin 1 (Dsc1) is an autoantigen for the subcorneal pustular dermatosis type of IgA pemphigus. *J Invest Dermatol* **109**:127, 1997

6. Reed J, Wilkinson J: Subcorneal pustular dermatosis. *Clin Dermatol* **18**:301, 2000

7. Lautenschlager S et al: Subcorneal pustular dermatosis at the injection site of recombinant human granulocyte-macrophage colony-stimulating factor in a patient with IgA myeloma. *J Am Acad Dermatol* **30**:787, 1994

8. Takata M et al: Subcorneal pustular dermatosis associated with IgA myeloma and intraepidermal IgA deposits. *Dermatology* **189**:111, 1994

9. Vaccaro M et al: Subcorneal pustular dermatosis and IgA lambda myeloma: An uncommon association but probably not coincidental. *Eur J Dermatol* **9**:644, 1999

10. Stone MS, Lyckholm LJ: Pyoderma gangrenosum and subcorneal pustular dermatosis: Clues to underlying immunoglobulin A myeloma. *Am J Med* **100**:663, 1996

11. Scerri L et al: Pyoderma gangrenosum and subcorneal pustular dermatosis, without monoclonal gammopathy. *Br J Dermatol* **130**:398, 1994

12. Kohl PK et al: Pyoderma gangrenosum followed by subcorneal pustular dermatosis in a patient with IgA paraproteinemia. *J Am Acad Dermatol* **24**:325, 1991

13. Miyakawa K et al: Vesiculopustular dermatosis with ulcerative colitis. Concomitant occurence of circulating IgA anti-intercellular and anti-basement membrane zone antibodies. *Eur J Dermatol* **5**:122, 1995

14. Delaporte E et al: Subcorneal pustular dermatosis in a patient with Crohn's disease. *Acta Derm Venereol* **72**:301, 1992

15. Lutz ME et al: Subcorneal pustular dermatosis: A clinical study of ten patients. *Cutis* **61**:203, 1998

16. Yamamoto T et al: A variant of subcorneal pustular dermatosis with monoclonal IgG gammopathy of undetermined significance. *Eur J Dermatol* **5**:640, 1995

17. Guggisberg D, Hohl D: Intraepidermal IgA pustulosis preceding a CD30+ anaplastic large T-cell lymphoma. *Dermatology* **191**:352, 1995

18. Buchet S et al: Pustulose sous-cornee associee a un carcinome epidermoide du poumon. *Ann Dermatol Venereol* **118**:125, 1991

19. Villey MC et al: Apudoma and subcorneal pustular dermatosis (Sneddon-Wilkinson disease). *Dermatology* **185**:269, 1992

20. Roger H et al: Subcorneal pustular dermatosis associated with rheumatoid arthritis and raised IgA: Simultaneous remission of skin and joint involvements with dapsone treatment. *Ann Rheum Dis* **49**:190, 1990

21. Butt A, Burge SM: Sneddon-Wilkinson disease in association with rheumatoid arthritis. *Br J Dermatol* **132**:313, 1995

22. Taniguchi S et al: Subcorneal pustular dermatosis in a patient with hyperthyroidism. *Dermatology* **190**:64, 1995

23. Winnock T et al: Vesiculopustular eruption associated with Mycoplasma pneumoniae pneumopathy. *Dermatology* **192**:73, 1996

24. Lotery HE et al: Subcorneal pustular dermatosis involving the face. *J Eur Acad Dermatol Venereol* **12**:230, 1999

25. Haber H, Wells GC: Subcorneal pustular dermatosis of the soles. *Br J Dermatol* **71**:253, 1959

26. Metz J, Schröpl F: Ultrastructural investigations of subcorneal pustular dermatosis [in German]. *Arch Klin Exp Dermatol* **236**:190, 1970

27. Bauwens M et al: Subcorneal pustular dermatosis treated with PUVA therapy. A case report and review of the literature. *Dermatology* **198**:203, 1999

28. Marliere V et al: Successful treatment of subcorneal pustular dermatosis (Sneddon-Wilkinson disease) by acitretin: Report of a case. *Dermatology* **199**:153, 1999

29. Cameron H, Dawe RS: Subcorneal pustular dermatosis (Sneddon-Wilkinson disease) treated with narrowband (TL-01) UVB phototherapy. *Br J Dermatol* **137**:150, 1997

30. Orton DI, George SA: Subcorneal pustular dermatosis responsive to narrowband (TL-01) UVB phototherapy. *Br J Dermatol* **137**:149, 1997

31. Voigtländer C et al: Infliximab (antitumor herpes factor a antibody). A novel, highly effective treatment of recalcitrant subcorneal pustular dermatosis (Sneddon-Wilkinson disease). *Arch Dermatol* **137**:1521, 2001

T>

Chapter 70

Enno Christophers Ulrich Mrowietz

Pustular Eruptions of Palms and Soles

PUSTULOSIS PALMARIS ET PLANTARIS
Epidemiology
Etiology
Clinical Features
Histopathology
Laboratory Findings
Diagnosis and Differential Diagnosis
Treatment
Combination and Sequential Treatment
Prognosis
ACRODERMATITIS CONTINUA
Clinical Features
Histopathology
Laboratory Findings
Diagnosis and Differential Diagnosis
Treatment
Course and Prognosis
INFANTILE ACROPUSTULOSIS

REFERENCES

Pustular eruptions of the palms and soles include pustulosis palmaris et plantaris (PPP; synonym: pustular psoriasis of the Barber type), acrodermatitis continua (Hallopeau's disease), and infantile acropustulosis (Table 70-1). The entities present with chronic and persistent eruptions of sterile, purulent vesicles. The sites of predilection are the thickened skin of the palms and soles, and the unifying histologic feature in all of these conditions is the presence of sterile pustules within the epidermis.

TABLE 70-1 **Pustular Eruptions of Palms and Soles**

PUSTULOSIS PALMARIS ET PLANTARIS

PPP is a chronic recurrent pustular dermatosis localized on the palms and soles only. Histologically, it is characterized by intraepidermal vesicles filled with neutrophils.

For historical reasons this condition has been given different designations. The terms pustulosis palmaris et plantaris, persistent palmoplantar pustulosis, and pustular psoriasis of the extremities have been used synonymously. Controversy has arisen as to whether the so-called pustular bacterid of Andrews should be considered as a distinct entity. [1] In 1935, Andrews and Machacek described 15 patients with recurrent purulent vesicles on the hands and feet that clinically and histologically resembled the condition previously described as pustular psoriasis of hands and feet by Barber. [2] The presence of foci of bacterial infection, mainly of the teeth and tonsils, together with the absence of signs of overt psoriasis, prompted the authors to question the psoriatic nature of these changes. The term pustular bacterid was chosen for the condition because a close association with bacterial infections was assumed. Because clinically and histologically these conditions cannot be distinguished with certainty and evidence for the pathogenic role of bacteria is scarce, we use the term pustulosis palmaris et plantaris for this condition.

Epidemiology

The disease has a worldwide distribution. It is a rare condition, but the exact incidence is not known. At the Department of Dermatology in Stockholm, 272 patients were seen during a 10-year period. [3]

Females show a higher incidence than males, with a ratio of approximately 3:1. Onset of the disease occurs mostly between the ages of 20 and 60; rarely, the condition occurs after the sixth decade of life, and in 10 percent of the patients the onset is before the age of 20 years. [2] In a group of 272 patients with PPP, a positive family history of psoriasis was recorded in 25 percent of the patients. [3] Other studies have shown psoriasis to be associated with palmoplantar pustules in less than 10 percent of patients. [4] HLA typing of patients with PPP reveals no increased frequency of any of the known psoriasis-linked alloantigens. [4] In a Japanese survey, PPP was found in 4.7 percent of patients with spondyloarthropathies. [5]

Etiology

The cause of PPP is not known. In some patients, the association with psoriasis elsewhere on the body is striking, but others may show palmoplantar pustules in the absence of other cutaneous changes. The association of PPP with Sweet's syndrome [6] suggests that PPP is a response pattern in genetically predisposed patients to neutrophil activation. [7]

An imbalance of the protease/antiprotease system in the skin consisting of decreased antileukoprotease (elafin/SKALP) activity in pustular psoriasis has been discussed as a possible mechanism of pustule formation. [8] Exacerbation of PPP has been observed after patch testing with metals and was accompanied by elevated leukotriene by levels in plasma and pustules. [9]

In a long-term survey from Japan, the incidence of PPP was found to be positively correlated to heavy smoking (>20 cigarettes per day), tonsillitis, and seasonal factors such as high humidity and high temperature. [10] A normal proliferative response of peripheral blood mononuclear cells to a streptococcal preparation in PPP patients has been described as a distinct feature from the reduced responses observed in patients with psoriasis vulgaris. [11]

Clinical Features

The primary lesions are pustules of nearly equal size measuring 2 to 4 mm in diameter. Crops of pustules usually arise within a few hours on the normal-appearing palmar and plantar skin (Fig. 70-1). Single lesions then become surrounded by an erythematous ring. Rarely, the pustules extend to the dorsa of the fingers, the feet, or over the volar wrists (Fig. 70-1C). Episodes of new pustular eruptions occur at varying intervals and remain strictly confined to the sites of predilection.

FIGURE 70-1 Pustulosis palmaris et plantaris. *A* and *B.* Groups of pustules measuring 1 to 3 mm in diameter occur on erythematous skin on palms and soles. Both feet and both hands are normally affected symmetrically. *C* and *D*. Lesions may occasionally spread beyond the predilection sites and pustules may appear on the wrists. Within several days after pustule formation, lesions dry, flatten, and acquire a brownish color. This may be followed by eczematous changes with scaling and fissuring.

As pustules become older, their yellow color changes to dark brown, so that in untreated PPP, the lesions show various shades of color (Fig. 70-1C and Fig. 70-1D). Dried pustules are shed within approximately 8 to 10 days.

There are no symptoms other than some itching or a burning sensation, which may precede new crops of lesions. While the eruptions occasionally occur unilaterally, most patients show symmetric involvement, and hands and soles are usually equally affected. [2]

As remission begins, fewer pustules are produced, but the skin may remain erythematous and hyperkeratotic, resembling eczema. Remissions last for weeks or months until pustulation again occurs.

PPP is frequently noted in patients with chronic recurrent multifocal osteomyelitis as well as with noninfectious inflammatory bone lesions. An association of PPP and osteoarthritis of the anterior chest wall was first described in Japan. [12] As reported by Swedish authors, involvement of the manubriosternal joint is present in 6 percent and of the sternoclavicular joints in 10 percent of patients. [13] Scintigraphic investigations showed sternocostoclavicular joint involvement to be present in 16 of 73 patients. [14] For this condition, the term *SAPHO syndrome* (synovitis, acne, pustulosis, hyperostosis, osteitis) has been established. [15] Clinical manifestations of SAPHO syndrome are similar whether they occur in relation to severe acne (mostly acne conglobata) or PPP (see also Chap. 98). The primary lesion consists of a sterile abscess containing neutrophils. The site of predilection is the anterior chest wall. SAPHO syndrome can be associated with pseudoinfectious arthritis. Involvement of the sacroiliac joints may be present. [16]

Histopathology

Histologically there is an intraepidermal cavity filled with polymorphonuclear leukocytes associated with spongiform changes within the surrounding epidermis (Fig. 70-2). Compacted collections of neutrophils may be seen within the stratum corneum, and a variably dense mononuclear infiltrate with some neutrophils is found around the dilated vessels of the upper dermis.

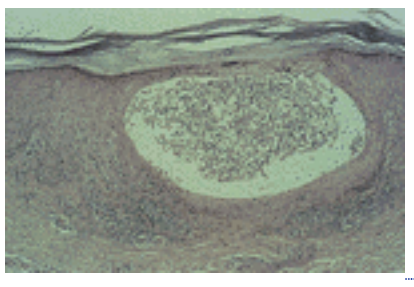

FIGURE 70-2 Histologically, there are spongiform pustules and a moderate lymphohistiocytic infiltrate.

Sequential histologic studies of the various stages of pustule formation reveal that spongiosis of the epidermis due to the invasion of mononuclear cells is the first step in pustule formation.

Laboratory Findings

The lesions of PPP are sterile; a moderately increased white blood cell count may occasionally be observed, but all other laboratory tests are normal.

Diagnosis and Differential Diagnosis

PPP is a distinct entity. The course of the disease, together with the characteristic morphology and the occasional association with psoriasis elsewhere on the body, permit the proper diagnosis. The disease must be differentiated from “dyshidrotic” eczematous dermatitis (pompholyx), especially when pustules due to secondary infection are present (see Chap. 125). In this condition, the onset is also acute, but clear vesicles of various sizes are scattered on the palms, soles, and volar and interdigital aspects of the fingers. These may coalesce and secondarily become pustular because of secondary bacterial infection; in such cases, the signs of inflammation will become more prominent. Tinea of the palms and soles only rarely shows the presence of pustules of equal size and symmetry. Similarly, pustules developing in infected scabies lack the features mentioned previously. Bacterial cultures or demonstration of hyphae or mites will clearly separate these entities from PPP. Biopsies will further demonstrate spongiform pustule formation as a distinctive sign.

Treatment

Pustular palmoplantar psoriasis is difficult to treat and attempts to clear the affected sites rapidly by conventional measures are usually not very rewarding.

When erythema and hyperkeratosis are prominent, potent or superpotent topical steroids under occlusion will provide relief. Treatment with either topical or systemic psoralen plus ultraviolet irradiation (PUVA) usually leads to clearing and may produce long-lasting remissions. Antipsoriatic remedies such as dithranol or ultraviolet radiation have been used with variable success.

Methotrexate (15 to 25 mg per week) may be given for severe forms; this procedure will reduce pustulation as long as methotrexate is given and for a short time thereafter.

Therapeutic success has been obtained with etretinate. [17] At a daily dose of 25 to 50 mg orally, this drug effectively prevents the formation of new pustules and rapidly clears the skin. Relapses will occur when patients are taken off the drug. Acitretin, which has now replaced etretinate in most countries, is equally effective. The recommended dose is 1 mg/kg per day initially. After improvement is seen, the dose is tapered down to 0.5 mg/kg per day, which is given for several weeks to months. Because of their teratogenic potential, systemic retinoids should be given to women of childbearing age only with great caution, if at all.

Systemic steroids are of questionable value. Withdrawal is usually followed by a rebound. Therefore, the use of systemic steroids in PPP is not recommended.

Low-dose cyclosporine is an effective regimen to treat recalcitrant PPP. Treatment may be short-term (<3 months), followed by topical therapy after major improvement is achieved, or long-term, with continuous treatment in severe cases. [18], [19]

Colchicine, known as a potent inhibitor of leukocyte motility, has also been reported to be effective clinically in suppressing pustulation. [20]

Combination and Sequential Treatment

In difficult-to-treat dermatoses, such as PPP, the combination of different regimens is superior to monotherapy. Established combinations for PPP include potent or superpotent steroids together with bath or cream PUVA.

In some patients, topical vitamin D_3 or analogues such as calcipotriol/calcipotriene are effective in maintaining improvement achieved with topical steroids before. Tazarotene may also be tried after steroid pretreatment.

Systemic therapy should always be combined with topicals to speed-up time of improvement and to reduce dosage of the

systemic treatment.

Prognosis

The disease tends to pursue a chronic course with remissions lasting up to a few months. In one series, most cases showed remissions lasting for 5 to 10 years.

ACRODERMATITIS CONTINUA

Acrodermatitis continua is a rare, sterile, pustular eruption of the fingers or toes that slowly extends proximally. Continuous pustulation may cause nail destruction and atrophy of the distal phalanx. Synonyms are pustular acrodermatitis, acrodermatitis continua suppurativa Hallopeau, dermatitis perstans, and dermatitis repens Crocker.

In 1888, Crocker [21] described a relapsing bullous and pustular eruption on hands and feet; this was further delineated by Hallopeau. [22] Dermatitis continua is now classified as a form of acropustular psoriasis.

Clinical Features

The disease most often begins at the tips of one or two fingers (Fig. 70-3), less often on the toes. The nail folds are affected very early, and trauma is thought to play an initiating role. The first signs consist of small pustules, which, on bursting, leave an erythematous, shiny area in which new pustules develop. These then tend to coalesce, forming polycyclic lakes of pus. As the disease extends proximally the affected area shows either glossy erythema or a crusted, keratotic, and fissured surface with newly formed pustules underneath (see Fig. 70-3). Pustulation of the nail bed and the nail matrix almost always occurs and quite often leads to loss of the nail plate or severe onychodystrophy (see Fig. 70-3). Acrodermatitis continua of long duration may show complete destruction of the nail organ and thus lead to anonychia. The skin becomes shiny and severely atrophic, and there is atrophic thinning of the distal part of the phalanx.

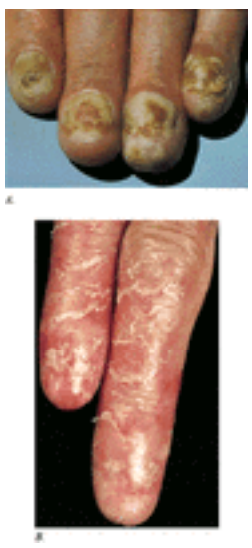

FIGURE 70-3 *A.* Acrodermatitis continua demonstrating acral pustule formation and subungual lakes of pus with destruction of the nail plate. *B.* Repeated eruptions lead to nail loss and severe atrophy. Note pustulation within the atrophic epidermis of the distal phalanges.

The disease may remain confined to the original site, sometimes up to several years, but more often it spreads proximally to cover the hand, dorsum of forearm, or foot. In such instances more than one extremity is involved.

As in pustular psoriasis, lesions may occur elsewhere on the body. Especially during long courses of acrodermatitis continua, pustulation may extend to involve the entire body skin, being indistinguishable from the von Zumbusch type of pustular psoriasis. In such cases, systemic reactions with fever, leukocytosis, a high sedimentation rate, and malaise occur (see also Chap. 42).

Histopathology

The main histopathologic feature of acrodermatitis continua is a subcorneal cavity filled with polymorphonuclear neutrophils. Epidermal cell necrosis and spongiosis do not occur, but the roof and shoulder zones adjacent to the pustule show aggregated leukocytes between the epidermal cells, forming spongiform pustules of Kogoj. There is a moderate lymphohistiocytic infiltrate in the upper dermis, together with focal edema.

Lesions of long duration show severe atrophy of the papillary dermis and thinning of the epidermis.

Laboratory Findings

Systemic abnormalities are absent, and laboratory tests are usually noncontributory. The pustules are sterile. In advanced cases, x-ray films may reveal atrophy of the distal phalanx and arthropathy of the interphalangeal joints.

Diagnosis and Differential Diagnosis

Acrodermatitis continua at an early stage must be differentiated from acute paronychia caused by bacteria or fungi.

Cultures and smears will help rule out infectious causes. The distal localization and the tendency of the pustules to become confluent, forming denuded, erythematous, or crusted lesions, distinguishes acrodermatitis continua from PPP or pustular dyshidrotic eczema. Atrophy and loss of nails do not occur in these conditions. Contact dermatitis with secondary infection and pustulation has less clearly defined margins, runs a different clinical course, and lacks the persistence typical for acrodermatitis continua.

Treatment

As in pustular psoriasis, no specific drug brings about lasting remissions. Potent or superpotent topical steroids, preferentially under occlusion, are useful in blocking pustulation. Caution is advised in cases already showing atrophy. PUVA suppresses the eruption of new pustules and can be employed for long periods as maintenance treatment (see Chap. 266).

Treatment with a combination of systemic acitretin and local calcipotriol/calcipotriene was successful in one patient in a left/right comparison. [23] In recalcitrant patients, dapsone may be tried. [24]

In principle, regimens used for treatment of PPP may also be used for therapy of acrodermatitis continua. The therapeutic result lasts as long as the drugs are given, and relapses occur after withdrawal.

Course and Prognosis

Acrodermatitis continua shows a chronic course with a tendency of the lesions to spread proximally. Spontaneous improvement is rare, and episodes of acute pustulation occur without apparent cause. The development of pustules at other sites, or even the eruption of generalized pustular psoriasis, supports the idea that acrodermatitis continua is a variant of psoriasis.

INFANTILE ACROPUSTULOSIS

This entity is discussed in Chap. 143.

REFERENCES

1. Andrews GC, Machacek GF: Pustular bacterids of the hands and feet. *Arch Dermatol Syphilol* **32**:837, 1935

2. Barber HW: Acrodermatitis continua vel perstans (dermatitis repens) and psoriasis pustulosa. *Br J Dermatol* **42**:500, 1930

3. Hellgren L, Mobaken H: Pustulosis palmaris et plantaris. *Acta Derm Venereol Suppl (Stockh)* **51**:284, 1971

4. Ward JM, Barnes RMR: HLA antigens in persistent palmoplantar pustulosis and its relationship to psoriasis. *Br J Dermatol* **99**:477, 1978

5. Hukuda S et al: Spondyloarthropathies in Japan: Nationwide questionnaire survey performed by the Japan Ankylosing Spondylitis Society. *J Rheumatol* **28**:554, 2001

6. Gambichler T et al: Sweet's syndrome with eruptions of pustulosis palmaris. *J Eur Acad Dermatol Venereol* **14**:327, 2000

7. Van de Kerkhof PCM: Pustulosis palmaris et plantaris. *J Eur Acad Dermatol Venereol* **14**:248, 2000

8. Kuijpers ALA et al: Skin-derived antileukoprotease (SKALP) is decreased in pustular forms of psoriasis: A clue to the pathogenesis of pustule formation? *Arch Dermatol Res* **288**:641, 1996

9. Nakamura K et al: Exacerbation of pustulosis palmaris et plantaris after topical application of metals accompanied by elevated levels of leukotriene B_4 in pustules. *J Am Acad Dermatol* **42**:1021, 2000

10. Akiyama T et al: The relationships of onset and exacerbation of pustulosis palmaris et plantaris to smoking and focal infections. *J Dermatol* **22**:930, 1995

11. Takahashhi K et al: Normal proliferative responses of peripheral blood mononuclear cells to streptococcal preparation OK-432 in patients with pustulosis palmaris et plantaris constitute a distinct feature from the reduced responses observed in those with psoriasis vulgaris, pustular psoriasis and acrodermatitis continua of Hallopeau. *J Dermatol* Sci **25**:87, 2001

12. Sasaki T: A case with osteomyelitis of the bilateral clavicles associated with pustulosis palmaris et plantaris. *Rinsho Sei Keigara* **2**:333, 1967

13. Bergdahl K et al: Pustulosis palmoplantaris and its relation to chronic recurrent multifocal osteomyelitis. *Dermatologica* **159**:37, 1979

14. Hradil E et al: Skeletal involvement in pustulosis palmo-plantaris with special reference to the sternocostoclavicular joints. *Acta Derm Venereol Suppl (Stockh)* **68**:65, 1988

15. Benhamou CL et al: Synovitis-acne-pustulosis-hyperostosis-osteomyelitis syndrome (SAPHO): A new syndrome among the spondyloarthropathies? *Clin Exp Rheumatol* **6**:109, 1988

16. Kahn MF, Chamot AM: SAPHO syndrome. *Rheum Dis Clin North Am* **18**:225, 1992

17. Reymann F: Two years' experience with Tegison treatment of pustulosis palmo-plantaris and eczema keratoticum manuum. *Dermatologica* **164**:209, 1982

18. Meinardi MMHM et al: Oral cyclosporin A is effective in clearing persistent pustulosis palmaris et plantaris. *Acta Derm Venereol Suppl (Stockh)* **70**:77, 1990

19. Erkko P et al: Double-blind placebo-controlled study of long-term low-dose cyclosporin in the treatment of palmoplantar pustulosis. *Br J*

Dermatol **139**:997, 1998

20. Takigawa M et al: Treatment of pustulosis palmaris et plantaris with oral doses of colchicine. *Arch Dermatol* **118**:458, 1982

21. Crocker HR: *Diseases of the Skin*. London: HK Lewis; 1888

22. Hallopeau H: Sur une asphyxie locale des extrémités avec polydactylite suppurative chronique et pussées éphéméres des dermatite pustuleuse disséminées et symmétriques. *Ann Dermatol Syphiligr (Paris)* **1**:420, 1890

23. Kuijpers AL et al: Acrodermatitis continua of Hallopeau: Response to combined treatment with acitretin and calcipotriol ointment. *Dermatology* **192**:357, 1996

24. Nikkels AF et al: Breaking the relentless course of Hallopeau's acrodermatitis by dapsone. *Eur J Dermatol* **9**:126, 1999

T>

Chapter 71

Elise Olsen

Hair

HAIR CYCLE
DIAGNOSTIC TECHNIQUES
Techniques to Assess Cycling Abnormalities
Biopsy
Hair Shaft Evaluation
ALOPECIA
Diffuse (Global) Hair Loss
Focal Hair Loss
EXCESS HAIR
Hirsutism
Hypertrichosis
Treatment of Hypertrichosis
CONCLUSION

REFERENCES

As with abnormalities of other organ systems, hair disorders can represent either a primary or secondary dysfunction and can be related to exogenous or endogenous causes. Hair is unique when compared to other organ systems, however, in that it undergoes repetitive planned obsolescence and rebirth, laying open the possibility of clinical disorders based on cycling abnormalities. Further difficulties arise when the type and/or amount of hair in a given body area deviates from the expected norm. The end result of any of these abnormalities, either hair loss or overgrowth, often leads to major psychological problems for patients.

This section on hair abnormalities reviews the primary causes of hair loss and hair overgrowth and defines the significant pathophysiologic and clinical features and therapeutic options of each.

HAIR CYCLE (See also Chap. 12)

Knowledge of the hair cycle is vital to understanding hair problems. The duration and rate of growth of the anagen (growth) phase normally vary at different body sites, in different individuals, and at various ages, and determine the ultimate length of hair in that area. [1] Catagen is the transitional portion of the cycle between anagen and telogen and is short-lived (2 to 4 weeks) in duration. Telogen duration also varies greatly in different body sites, but interindividual variability appears more limited. In a normal scalp, telogen is assumed to last 3 to 4 months and anagen to last 3-plus years. With age, there is both a diminution in anagen duration and an increase in the time interval between two anagen cycles. [2] At any given time, ˜90 percent of the scalp hair is in anagen and 10 percent in telogen; this is subject to some seasonal variability. [3]

At the end of anagen, each hair bulb moves from its location in the subcutaneous tissue or dermis (depth of location is determined by whether the follicle is terminal or vellus) to a more superficial location by means of shrinkage and remolding of that portion of the follicle below the “bulge” where the arrector pili muscle inserts. The concentric layers of the inner root sheath, which anchor the hair shaft in the follicle, are only present to the bottom of the isthmus of the follicle, the region to which the hair bulb ascends in telogen (Fig. 71-1). Consequently, the hair shaft in telogen is no longer anchored securely in the tissue, as it was in anagen, and it may be dislodged with the gentle traction of shampooing, combing, brushing, etc. The recapitulation of the anagen follicle and initiation of growth of a new anagen hair leads to the shedding of any remaining telogen hair in the follicular canal (see Fig. 12-5).

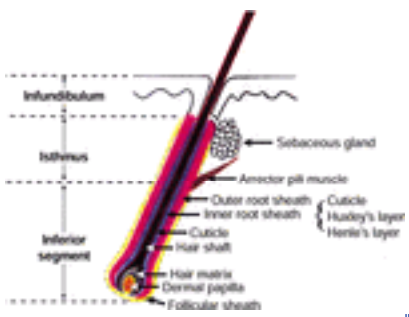

FIGURE 71-1 Diagram of a normal anagen hair follicle.

DIAGNOSTIC TECHNIQUES

Techniques to Assess Cycling Abnormalities

There are several tools for determining aberrations of scalp hair cycling. The first is the *hair pull,* which should be done on every patient with a complaint of hair loss. This simple technique involves manually grasping a group of 50 to 100 scalp hairs and applying gentle traction from the base to the terminal ends and repeating this in various areas of the

scalp. [4] Normally, in the author's experience, only three to five hairs *total* are dislodged on six to eight such hair pulls *if* the hair has been shampooed regularly: shedding of more than three to five hairs *per* hair pull is pathologic. This is a subjective test and results normally will vary slightly in any given patient depending upon the physician performing the test, each of whom may exert different degrees of traction on different sizes of hair clumps. In the case of increased shedding, the proximal ends of the hairs so obtained should be evaluated microscopically to determine whether there is an intact hair shaft and bulb, indicating either an effluvium (Latin, “a flowing out”) or hair breakage. The hair bulbs should be further evaluated to determine whether they are normal telogen (indicating a physiologic aberration) versus dystrophic telogen or anagen hairs (indicating a pathologic process).

There is little reason to do a *hair pluck* today. This momentarily painful technique involves applying a clamp or needle holder to the base of 50 to 100 hairs and quickly pulling the hairs out en masse. Although this technique, which is used in a *trichogram,* allows one to determine an anagen/telogen ratio by inspection of the proximal hair bulbs, it fails to give critical information about the type of hair being shed.

A third means of determining specifics regarding the hair cycle is the *phototrichogram*. [5] In this technique, hairs are clipped very short or shaved in a given target area and comparative photographs are taken of the target area at baseline and again 2 to 3 days later. As only the anagen hairs will have increased their length on subsequent follow-up (normal hair growth is ˜ 1 cm/month), this technique can be used to determine (1) the percentage of hairs in anagen based on the number of longer hairs compared to total hairs and (2) with sophisticated cameras and computer software, the hair growth rate. To be reliable, a phototrichogram requires locating the same precise target site at each time point, standardized photography, and standardized hair counting by image analysis. A related procedure, called a *hair window,* involves clipping or shaving the hairs in a given area and having the patient return anywhere from 3 to 30 days later to evaluate regrowth. Without photography, this is a gross technique for assessing the potential for regrowth in a given area, and does not yield reliable information regarding the specifics of cycling in the target area.

Biopsy

A biopsy of the scalp may or may not help with the diagnosis of a particular hair disorder. The information it delivers about cycling aberrations is merely confirmatory to that obtained by other simpler, less expensive means, and the diagnosis of hair shaft abnormalities cannot be made by a scalp biopsy. The real value of a scalp biopsy is the insight it can offer into mechanisms of alopecia. A 4-mm punch biopsy is preferred to a 3-mm one because of the ease of laboratory preparation and accumulated quantifying data on normal scalp in the larger specimen. The biopsy should be taken in the direction of the follicle growth and to a sufficient depth to contain the follicular bulbs in anagen (generally into the subcutaneous tissue). Vertical sectioning of the biopsy specimen gives an immediate overview of the anatomy of the tissue from the epidermis down to the fat, but unless multiple step sections are taken, the view is limited to a snapshot of a few follicles. Horizontal (or transverse) sectioning of the specimen gives a simultaneous overview of many follicles. [6] This latter technique requires sectioning at several different levels of the skin because the terminal portion of the hair follicles will be at different depths depending on the type (terminal versus vellus) of hair and part of the cycle (anagen versus telogen) they are in, and because the pathology may lie anywhere along the length of the follicle. Once appropriate sectioning is done, however, all the follicles in a given horizontally sectioned biopsy can be viewed simultaneously, giving a much greater amount of information than is available from a similar number of vertical sections.

Hair Shaft Evaluation

The preferred hairs to examine in patients with a complaint of shedding are those gently pulled from the scalp. This avoids the two major problems of a hair pluck: physical distortion of the hair shaft by a clamp and the distortion of all anagen hair bulbs so obtained. The proximal portions of the collected hairs should be lined up on a slide in a drop of cyanoacrylic glue, a coverslip applied, and the hairs viewed under light microscopy. Telogen hairs have a cornified rounded-up bulb without an attached root sheath (Fig. 71-2A). Anagen hairs are recognized clinically by their pigmented, somewhat distorted, malleable bulb. Anagen hairs should not normally be found in a hair *pull* except in very young children—in this case, anagen hairs with an attached ruffled cuticle, so-called *loose anagen hairs* (Fig. 71-2B), may be found in small numbers, probably secondary to poor hair shaft anchoring to the root sheath. [7] Comparison with a normal anagen hair obtained by hair *pluck* is shown in Fig. 71-2C.



FIGURE 71-2 *A.* Normal telogen hair obtained by hair pull. *B.* Loose anagen hair obtained by hair pull; note the ruffled cuticle. *C.* Proximal end of normal anagen hair obtained by hair pluck. *D.* Distal ends of newly regrowing anagen hairs; note the tapered tips and comparative diameter with established anagen hairs.

In those in whom the hair appears to be breaking off, “not growing,” or unruly, the distal portion of the hair shaft should be evaluated. If a fungal infection is suspected, potassium hydroxide (KOH) instead of glue should be placed on the slide and the proximal hair examined for spores and hyphae. The proximal hairs may need to be plucked from the scalp in this case. In other situations, where a hair shaft disorder is suspected, a gentle hair pull should be used to obtain hairs, but if no hairs are forthcoming, then hairs should be cut, not plucked, for evaluation. A newly growing anagen hair will have a tapered distal tip (Fig. 71-2D) rather than the blunt distal end of hairs that have been cut or trimmed or in which the ends are intrinsically broken. Most hair shaft abnormalities can be diagnosed by light microscopic examination, although some types will require further examination by scanning electron microscopy to confirm findings only suggested by light microscopy (e.g., longitudinal grooving). Polariscopic examination should be performed if trichoschisis (a particular pattern of hair breakage) is seen under light microscopy in order to evaluate potential trichothiodystrophy (sulfur-deficient hair).

The etiology of brittle hair can be further pursued by direct amino acid analysis of whole-hair hydrolysates and electrophoretic characterization of the main classes of proteins in hair (generally defined by their cysteine content and designated ultrahigh-, high-, and low-cysteine or ultrahigh, high-, and low-sulfur proteins).

ALOPECIA

To begin a discussion of hair loss or aberrant hair growth, it is useful to have a means of organizing, rather than merely cataloguing the myriad causes of alopecia. Deciding whether the hair loss is diffuse (global) or focal (patchy or localized) can facilitate differentiation of the types of alopecia. The following pathophysiologic categories can aid in further defining the diffuse hair loss: (1) failure to produce or continue to produce a normal hair *follicle;* (2) aberrations in the production of a normal hair *shaft;* (3) aberration of the normal hair cycle; and (4) destruction of the hair follicle. Determining whether the hair loss is a destructive or a nondestructive process (clinically suggested by observing whether follicular openings are preserved in areas of hair loss) can further narrow the differential diagnosis. An approach that uses the aforementioned diagnostic tools to aid in assignment of the hair loss process to one of these categories is given in Table 71-1.

Diffuse (global) hair loss
Nonscarring
Failure of follicle production
Congenital universal atrichia
Atrichia with papular lesions
Hereditary vitamin D-resistant rickets
Hair shaft abnormality
Hair breakage
Unruly hair
Abnormality of cycling (shedding)
Telogen effluvium
Anagen effluvium
Loose anagen syndrome
Alopecia areata
Focal hair loss
Nonscarring
Production decline
Triangular alopecia
Pattern hair loss
Hair breakage
Trichotillomania
Traction alopecia
Tinea capitis
Primary or acquired hair shaft abnormality
Unruly hair
Hair shaft abnormality
Abnormality of cycling
Alopecia areata
Syphilis
Scarring hair loss

TABLE 71-1 **Differential Diagnosis of Hair Loss**

Diffuse (Global) Hair Loss

FAILURE OF FOLLICLE PRODUCTION There has been a recent explosion of knowledge, largely fueled by null mutant rodent models, regarding the genetic causes of diffuse alopecia presenting in infancy and childhood. The most notable finding is the abnormality of the human homologue of the mouse hairless (*hr*) gene, which causes *congenital universal atrichia* and *atrichia with papular lesions*. [8], [9] and [10] The atrichia may be present from birth or develop over the first year of life: this is concordant with an abnormality in recapitulation of the anagen follicle after the first pelage as seen in hairless knockout mice. The patients with atrichia with papular lesions develop follicular cysts, generally 3 to 18 years after the alopecia (Fig. 71-3). The hairless gene product is a putative multifunctional transcription factor and the gene locus is on chromosome 8p12. A similar clinical phenotype with universal hair loss during the first year of life and cutaneous cysts years later but accompanied by rachitic bones is seen in *hereditary vitamin D-resistant rickets*. [11] This condition is secondary to mutations in the vitamin D receptor, probably in the zinc finger domain, which, like the *hr* gene, acts as a transcription factor. Patients previously diagnosed with alopecia universalis (alopecia areata) at birth or few months of age may, in fact, have one of the conditions noted above, particularly if the universal hair loss is persistent and/or familial.

FIGURE 71-3 Atrichia with papular lesions. (Photograph courtesy of Abraham Zlotogorski, MD.)

HAIR SHAFT ABNORMALITIES Diffuse hair loss in infancy is more commonly one of hypotrichosis than total atrichia and may be secondary to abnormal production of a subset of hair follicles and/or hair shafts. Most of the hereditary alopecias do not occur alone but in the company of a constellation of other anomalies, most frequently bone, central nervous system, or eye. Freire-Maia has suggested a classification system for those hereditary disorders of ectodermally derived tissue that demonstrate a primary abnormality of two of the following: hair, teeth, nails, or eccrine glands: these are termed *type A ectodermal dysplasias*. [12] An abnormality of one of these four major anomalies plus one other "ectodermal" sign is termed *type B ectodermal dysplasia*. Those ectodermal dysplasias that involve hair have been further catalogued in the available detail by Olsen using the classification system of type A ectodermal dysplasias. [13] Most reported syndromes that involve hair are also discussed and regularly updated, including genetic information, in McKusick's *Mendelian Inheritance in Man*. [14] These three sources facilitate the diagnosis of hereditary childhood alopecias. Hair shaft abnormalities can be primary and hereditary or secondary to external factors. Some hair shaft abnormalities represent common endpoints to various forms of trauma or inherent shaft weaknesses, and some are specific to a particular constellation of findings or inherent make-up of the hair shaft. Hair shaft abnormalities can be divided into those associated with hair breakage and those associated with unruly hair.

Hair shaft abnormalities associated with hair breakage

TRICHORRHEXIS NODOSA The most common defect of the hair shaft leading to hair breakage is *trichorrhexis nodosa.* [15] Mechanical or chemical damage triggers this response, which can occur in normal hair, but occurs much more readily in inherently weak hair. Microscopically, the affected hair develops a breach in the cuticle, with eventual separation and fraying of the exposed cortical fibers leading to a nodal swelling. [16] The fibers then fracture and the shaft breaks with the resultant appearance of a splayed paintbrush or fanlike array (Fig. 71-4). Trichorrhexis nodosa may be congenital or acquired.

FIGURE 71-4 Trichorrhexis nodosa.

Congenital trichorrhexis nodosa may be present at birth or may appear within the first few months of life. Although it might occur as an isolated defect or, rarely, with follicular hyperkeratosis or teeth/nail defects, [15] the occurrence of congenital trichorrhexis nodosa should lead to a search for an underlying metabolic disorder. Patients with *argininosuccinic aciduria,* primarily those with the late-onset form (occurring at >2 years of age), [15] have associated hair defects. In this condition, in which absence of the enzyme argininosuccinase leads to an accumulation of the nitrogenous waste precursor argininosuccinic acid, brittle lusterless hair develops along with psychomotor retardation and ataxia. The diagnosis is established by finding acidosis, hyperammonemia, and low serum arginine. [17] Citrulline (the normal precursor of argininosuccinic acid in the urea cycle) accumulates in the condition *citrullinemia,* which is caused by a defect in the enzyme argininosuccinic acid synthetase. In this condition, the hair is brittle and both trichorrhexis nodosa and pili torti (another common hair shaft defect) may be present. [15], [18] Affected infants have an associated dermatitis that may be widespread but more pronounced in the perioral and diaper area. Patients with *Menkes syndrome,* caused by a defect in copper efflux, [19] and *trichothiodystrophy,* caused by a defect in the synthesis of the ultrahigh- and high-sulfur proteins integral to hair, [20] both have trichorrhexis nodosa apparent on microscopic examination of the associated brittle hair. *Acquired trichorrhexis nodosa* may be either distal or proximal. Proximal breakage appears most commonly in African-American women, usually after repetitive chemical or hot-comb straightening. [15] Distal trichorrhexis nodosa is more commonly secondary to excessive brushing, back-combing, or sporadic use of permanent waves. Treatment of trichorrhexis nodosa, congenital or acquired, is by avoidance of chemical or physical trauma to the hair.

TRICHOSCHISIS The break in *trichoschisis* is a clean transverse fracture through the entire hair shaft at a location where there is a focal absence of cuticle (Fig. 71-5A). Trichoschisis is usually, but not specifically, a marker for the sulfur-deficient hair of *trichothiodystrophy,* in which the hairs of the scalp, eyelashes, and brows are short and brittle. [15] The hair abnormality of trichothiodystrophy identifies a group of autosomal recessive disorders in which acronyms or eponyms identify particular constellations of extratrichologic neuroectodermal abnormalities (Table 71-2). In affected individuals, the hair cystine content is less than half normal, primarily from a major reduction and altered composition of the ultrahigh-sulfur matrix proteins. [20] Polariscopic examination of affected hairs characteristically shows alternating light and dark bands, presumably secondary to variations in sulfur content [15] (Fig. 71-5B). Sulfur and/or amino acid analysis of the hair is diagnostic.

TABLE 71-2 **Trichothiodystrophy**



FIGURE 71-5 Trichothiodystrophy. *A.* Hair shaft with trichoschisis without polarization (light micrograph ×100). *B.* Hair shaft with polarization (light micrograph ×100). (*From Whiting,* [15] *with permission.*)

Patients with trichothiodystrophy, particularly the 50 percent with associated photosensitivity, may have a defect in excision repair of ultraviolet damage but without an increased risk of skin cancer. [21] Recent data support correlation of mutations in the DNA repair and transcription gene *ERCC2* locus with the nucleotide excision repair characteristics of both trichothiodystrophy and xeroderma pigmentosa. [22] No treatment is currently available, but photosensitive patients should be tested for their cellular response to ultraviolet radiation and encouraged to practice sun protection.

PILI TORTI The short and brittle hairs in patients with *pili torti,* when viewed through a microscope, appear flattened and twisted through 90° to 360°. [15] The twisting must be differentiated from the normal twisting seen in Negroid hair and in the pubic/axillary hairs of other races; the hairs are distinguished by the multiple irregular intervals of twisting along an otherwise straight hair shaft (Fig. 71-6A).

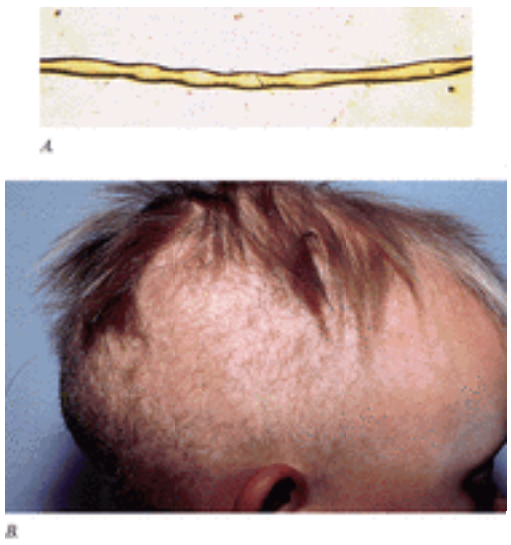

FIGURE 71-6 Pili torti. *A.* Irregularly spaced 180° twists in hair shaft. (*From Whiting,* [15] *with permission.*) *B.* Brittle broken hair typical of congenital pili torti.

As with trichorrhexis nodosa, pili torti does not signify a particular abnormality but can be seen in many different syndromes and in the presence of other hair shaft abnormalities. Hereditary pili torti as an isolated finding, usually autosomal dominant, but potentially autosomal recessive or sporadic, is present at birth or develops over the first 2 years of life (Fig. 71-6B). Clinically, the patient may have patchy alopecia with coarse stubble or longer broken hairs. The hair abnormality may improve after puberty. Pili torti, or a facsimile best characterized as “twisting hair dystrophy,” [23] may occur with other abnormalities (Table 71-3). Particularly notable is the association of pili torti with *Menkes' syndrome* or *trichopoliodystrophy*. Infants with Menkes' syndrome develop sparse, depigmented brittle hairs that show pili torti or trichorrhexis nodosa on microscopic examination. [15] The affected child characteristically has pale, lax skin, and mental and neurologic impairment secondary to degeneration of cerebral, cerebellar, and connective tissue. [24] In this X-linked recessive disorder, the defective gene, *MKN* or *ATP7A,* which maps to Xq13.3, encodes a copper-translocating membrane protein ATPase that prevents effective copper transport and leads to the accumulation of intracellular copper in some tissues. [19] The excessive intracellular copper inappropriately triggers the synthesis of metallothionein, whose normal function is to chelate copper to prevent cellular toxicity. This further deprives the copper-requiring enzymes of the copper needed for normal function. [25] A low serum level of ceruloplasmin is diagnostic. Copper replacement is ineffective in preventing the inevitable progressive and lethal neurologic decline, but copper-histidine given immediately postpartum may prevent or ameliorate the severe neurodegeneration. [26]

Endocrine
Hypo- or hyperthyroidism
Postpartum
Peri- or postmenopausal state
Nutritional
Biotin deficiency
Caloric deprivation
Essential fatty acid deficiency
Iron deficiency
Protein deprivation
Zinc deficiency
Drugs (only those with incidence >1% noted here)
Angiotension-converting enzyme inhibitors
Anticoagulants
Antimitotic agents (dose dependent)
Benzimidazoles
Beta blockers
Interferon
Lithium
Oral contraceptives
Retinoids
Valproic acid
Vitamin A excess
Physical stress
Anemia
Surgery
Systemic illness
Psychological stress

TABLE 71-3 **Causes of Telogen Effluvium**

TRICHORRHEXIS INVAGINATA *Trichorrhexis invaginata* (“bamboo hair”) is a distinctive hair shaft abnormality that may occur sporadically, either in normal hair or with other hair shaft abnormalities, or regularly as a marker for Netherton's syndrome. The primary defect appears to be abnormal keratinization of the hair shaft in the keratogenous zone, allowing

intussusception of the fully keratinized and hard distal shaft into the incompletely keratinized and soft proximal portion of the shaft. [27] This leads to the typical “ball-and-socket” deformity (Fig. 71-7) or, if fracture of the shaft occurs, a golf tee-shaped distal end of the shaft.

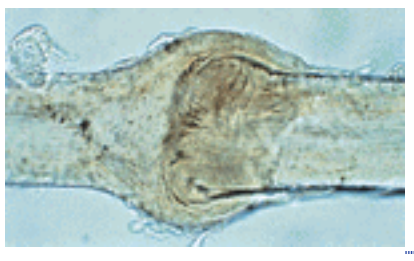

FIGURE 71-7 Trichorrhexis invaginata (light micrograph ×400). *(From Whiting,* [15] *with permission.)*

Netherton's syndrome (see Chap. 51) is an autosomal recessive inherited disorder consisting of a triad of ichthyosis, atopic diathesis, and trichorrhexis invaginata. [15] Affected hairs are generally short and brittle and may be irregularly distributed over the scalp; this may lead to potential sampling errors on hair shaft evaluation. The ichthyosis is usually polycyclic ichthyosis linearis circumflexa but may be lamellar ichthyosis or even ichthyosis vulgaris or X-linked ichthyosis. The atopic diathesis may include erythroderma. Recurrent infections, short stature, and mental retardation are rarely reported with Netherton's syndrome. The Netherton's syndrome gene product is LEKTI, a serine protease inhibitor; the gene (*SPINK5*) locus is chromosome 5q32. [28] Retinoids and phototherapy may be of value, although the condition may improve spontaneously over time.

MONILETHRIX The hair abnormality of *monilethrix* is distinctive, with extremely short, brittle hairs emerging from keratotic follicular papules [29] (Fig. 71-8A). The onset may be delayed until patients are in their teens, and the loss may be localized or diffuse. Microscopically, hairs show elliptical nodes with a regular periodicity of 0.7 to 1 mm. [15] Between the nodes, the hair shaft is constricted, and it is in these areas that the hair usually fractures (Fig 71-8B). The disorder is caused by mutations in the genes for type II hair keratins hHb1 or hHb6 in the type II keratin gene cluster on chromosome 12q13. [30], [31] Both hHb1 and hHb6 are expressed in the hair cortex cells with the abnormality in the helix termination or initiation motifs. [30]

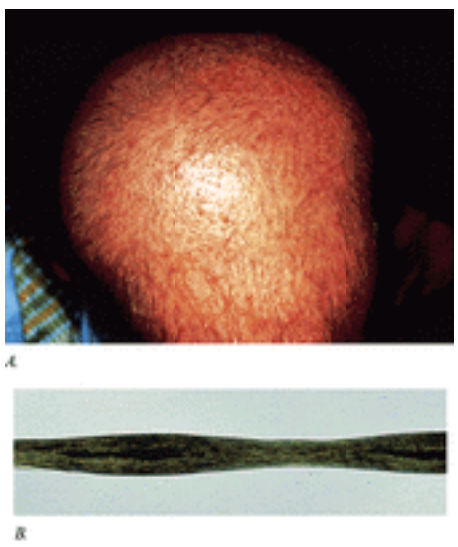

FIGURE 71-8 Monilethrix. *A.* Keratotic papules in areas of alopecia. *B.* Typical beaded appearance of hair as seen under light microscopy (×40). (*From Whiting,* [15] *with permission.*)

Most cases of monilethrix are of autosomal dominant inheritance, with variable expressivity—the hair defect can be mild and localized to the occiput. [15], [31] The hair defect may occur alone or in association with keratosis pilaris, physical retardation, syndactyly, cataracts, and nail/teeth abnormalities. Retinoids and topical minoxidil may be useful treatments, although this condition may also improve spontaneously with age.

Hair shaft abnormalities associated with unruly hair

UNCOMBABLE HAIR SYNDROME The distinctive hair of patients with *uncombable hair syndrome* may present any time from infancy to puberty. The slow-growing, silvery blonde, “spun-glass” hair is generally unmanageable and disorderly but not unduly fragile [15], [32] (Fig. 71-9A). The condition may be autosomal dominant or sporadic. Under light microscopy, the hair appears normal or may have some suggestion of a longitudinal groove or ribbon-like flattening (Fig. 71-9B). Scanning electron microscopy confirms a longitudinal groove, and the hair may, if viewed on cross-section, show a kidney bean or triangular shape, which accounts for the alternate term of *pili trianguli et canaliculi*. The longitudinal groove in the hair shaft is not specific to this syndrome but can be seen in normal hair, in other etiologies of unruly hair, and in several types of ectodermal dysplasia. [15] The defect may be secondary to an abnormal configuration of the inner root sheath, which keratinizes before the hair shaft and thus determines its shape. [32] Biotin supplementation has been advocated in one case report, [33] but generally there is no effective treatment for the syndrome.

FIGURE 71-9 Uncombable hair syndrome. *A.* Typical clinical picture. *(Photograph courtesy of Vera H. Price, MD.) B.* Longitudinal groove seen in uncombable hair syndrome (light micrograph ×400). (*From Whiting,* [15] *with permission.*)

WOOLY HAIR *Wooly hair* is the presence of Negroid hair on the scalp of persons of non-Negroid background. Microscopically, the hairs are tightly coiled. The unruly hair presents at birth or in infancy, usually as a solitary problem inherited in an autosomal dominant fashion. [34] However, two families with either autosomal dominant or autosomal recessive inheritance and associated palmoplantar keratoderma and cardiac abnormalities have been reported. [35] A sporadic variant has been reported with fine white-blond hair (Fig. 71-10). *Diffuse partial wooly hair,* a recently described autosomal dominant condition, presents in young adulthood with two distinct populations of scalp hair, one straight and the other very curly. [36] The curly hairs are thinner than normal hairs, which may contribute to the clinical appearance of a reduction in hair density.

FIGURE 71-10 Sporadic recessive wooly hair.

MARIA-UNNA TYPE OF HEREDITARY HYPOTRICHOSIS This autosomal dominant condition is unusual in that the hair abnormality varies with age. The scalp hair in *Maria-Unna type of hereditary hypotrichosis* is sparse or absent at birth, with variable coarse, wiry hair regrowth in childhood, and potential loss again at puberty. [37] Body hair is sparse to absent. Light microscopic examination of the hairs shows irregular twisting, and scanning electron microscopic examination shows longitudinal ridging and cuticle peeling. Diffuse follicular hyperkeratosis and facial milia-like lesions may be present. A distinct gene in chromosomal region 8p21 close to the hairless (*hr*) locus has been noted. [38]

Hair shaft abnormalities unassociated with breakage or unruly hair There are a few specific abnormalities of the shaft that should be noted here because of their frequency. The hair in *pili annulati,* an autosomal dominant (occasionally sporadic) condition, shows alternating light and dark bands both clinically and under light microscopy secondary to air-filled spaces in the cortex. [39] Cuticle folding and holes in the cortex are seen with electron microscopy. [15] Clinically, the hair in *pseudo pili annulati* shows a similar light microscopic picture, but the condition is nonhereditary and is not associated with any hair shaft cortex abnormality. [40] The cause of the latter appears to be periodic flattening of the hair shaft that causes light to be reflected as bright bands. Both conditions appear primarily in blond hair and are not associated with hair breakage. With transverse illumination, the banding in pili annulati is seen in whatever way light strikes the hair, whereas pseudo pili annulati is seen only when the hair is rotated into certain positions. [39]

ABNORMALITIES OF HAIR CYCLING

Telogen effluvium This common type of hair loss may occur at any age and represents a precipitous shift of a percentage of anagen hairs to telogen. Telogen effluvium is a reaction pattern to a variety of physical or mental stressors; the most common causative factors are given in Table 71-3. Any drug can potentially cause telogen effluvium, although some classes of drugs routinely cause this. The clinical increase in scalp hair shedding (over a normal of 50 to 100 hairs per day) usually begins as the first group of anagen hairs to be thrown prematurely into telogen finally completes telogen and moves once again into anagen, 3 to 4 months after the inciting event. If the inciting cause is removed the shedding will resolve over the next several months as the percentage of hairs in telogen return to normal; however, the hair density may take 6 to 12 months to return to baseline. In a significant number of patients, no obvious cause is found for telogen effluvium, and the increased shedding, and concomitantly the decreased density, of the scalp hair may become chronic. [41] Telogen effluvium is always potentially reversible and does not lead to total scalp hair loss, as the percentage of hairs in telogen rarely goes beyond 50 percent (Fig. 71-11).

FIGURE 71-11 Telogen effluvium.

Anagen effluvium The daily loss of some telogen hairs is entirely normal, but it is always abnormal to shed anagen hairs. The term *anagen effluvium,* as currently used to describe the pathologic loss of anagen hairs, is somewhat misleading because the abnormal anagen hairs in this condition are usually broken off rather than shed. The anagen

hairs in *loose anagen syndrome,* however, are shed in toto. The classic and easily recognizable causes of anagen effluvium of the scalp are radiation therapy to the head and systemic chemotherapy, especially with alkylating agents. These agents can impair or totally disrupt the anagen cycle. The net result is either anagen hairs that break off within the follicle or at the level of the scalp secondary to a weak point in the hair shaft and are then shed without roots, or dystrophic anagen hairs that are easily dislodged from the usual follicular moorings. Replacement with a normal pelage usually occurs rapidly after discontinuation of chemotherapy although high-dose busulfan as part of the preparatory treatment for bone marrow transplantation may lead to permanent alopecia. [42] Regrowth after radiation therapy depends on type, depth, and dose-fractionation. [43] In the absence of these obvious causes of anagen disruption, one must consider exposure to toxic agents. *Mercury intoxication,* through either chronic industrial exposure, consumption of polluted water or seafood, or inadvertent exposure to mercury-containing antiseptics or fungicides, can lead to hair loss with or without other symptoms, especially neurologic ones. [44] Diagnosis is by documenting elevated mercury levels in hair, blood, or urine. *Boric acid intoxication* may be through exposure to household pesticides or ingestion of some common household products in which boric acid is a preservative. Patients may develop hair loss along with gastrointestinal, central nervous system, and renal symptoms, a hemorrhagic diathesis, and exfoliation or bullae. [43], [45] Blood boric acid levels are elevated in affected patients. *Thallium poisoning* has the most dramatic associated hair loss, with complete epilation occurring 2 to 3 weeks after intoxication. [46] Acutely, patients experience primarily neurologic symptoms including irritability, dysesthesia, ataxia, convulsions and coma. Blood and urine levels are positive at the time of acute poisoning. Toxic exposure to colchicine and ingestion of certain plants can lead to anagen loss. [43] Severe *protein malnutrition* may also lead to anagen effluvium. Arsenic exposure does not cause hair loss; instead, arsenic is concentrated in the hair, which facilitates a diagnosis long after intoxication may have occurred.

Loose anagen syndrome This recently described syndrome has been primarily described in fair-haired children who have easily dislodgable hair (Fig. 71-12A). [47], [48] However, *loose anagen syndrome* can occur in adults and may be familial. This condition can be, and probably previously was, misdiagnosed as telogen effluvium if the shed hair roots are not examined microscopically. The hair loss may be inapparent except when traumatic pulling or extraction easily dislodges clumps of hair; this is particularly so in the parents of affected children, who themselves may have a mild, but previously unrecognized, variant of the condition that clinically may appear indistinguishable from a mild persistent telogen effluvium. The hair may also present with unruliness, occasionally causing confusion with uncombable hair syndrome or wooly hair (Fig. 71-12B). Microscopically, the proximal shed hair shows a normal anagen bulb, with a ruffled cuticle but without the usual attached root sheath [7] (see Fig. 71-2B). A scalp biopsy, which is unnecessary for diagnosis, may show premature and abnormal keratinization of the inner root sheath, with clefts between the inner and outer sheath and the hair shaft. The hair loss may improve with age, and gentle handling decreases shedding.

FIGURE 71-12 Loose anagen syndrome. *A.* Diffuse hair loss. *B.* Unruly hair. (From Olsen, [7] with permission.)

Alopecia areata At any given time, approximately 0.2 percent of the population has alopecia areata and approximately 1.7 percent of the population will experience an episode of alopecia areata during their lifetime. [49], [50] Clinically, patients with alopecia areata may have patchy or confluent hair loss on the scalp and/or body (Fig. 71-13A). *Alopecia totalis* refers to the total absence of terminal scalp hair, and *alopecia universalis* refers to the total loss of terminal body and scalp hair. [51] *Ophiasis* refers to a bandlike pattern of hair loss over the periphery of the scalp (Fig 71-13B). Hair loss may also be diffuse, mimicking anagen effluvium (Fig. 71-13C).

FIGURE 71-13 *A.* Extensive patchy alopecia areata. *B.* Ophiasis pattern of alopecia areata. *C.* Diffuse pattern of loss in alopecia areata. (*Reprinted with permission from Hardinsky MK: Alopecia areata, in* Disorders of Hair Growth: Diagnosis and Treatment, *edited by EA Olsen. New York, McGraw-Hill, 1994.*)

The scalp appears normal in alopecia areata. In affected areas, anagen is abruptly terminated prematurely and affected

hairs move prematurely into telogen, with resultant often precipitous hair shedding. The near pathognomonic "exclamation point" hairs may be present, particularly at the periphery of areas of hair loss (Fig. 71-14). These short broken hairs, whose distal ends are broader than the proximal ends, illustrate their inherent sequence of events: follicular damage in anagen and then a rapid transformation to telogen. White or graying hairs are frequently spared and probably account, in cases of fulminant alopecia areata, for the mysterious phenomenon of "going gray overnight." There is an increased incidence of autoimmune diseases in patients with alopecia areata, particularly thyroid-related disease, [52] and there is a higher prevalence of pigmentary defects in patients with alopecia areata. [53] Nails in patients with alopecia areata may show fine pitting or, less commonly, mottled lunula, trachyonychia, or onychomadesis. [54]

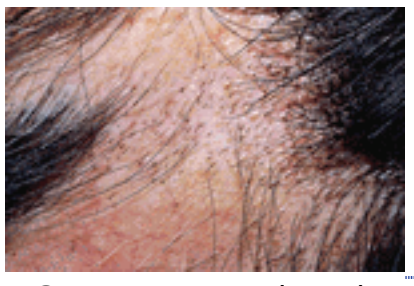

FIGURE 71-14 Exclamation mark hairs of alopecia areata. (*From Olsen EA: Clinical tools for assessing hair loss, in Disorders of Hair Growth: Diagnosis and Treatment, edited by EA Olsen, New York, McGraw-Hill, 1994, with permission.*)

A scalp biopsy is generally unnecessary to establish the diagnosis of alopecia areata, except in the uncommon presentation of diffuse shedding in which telogen or anagen effluvium is also a consideration. Typically, a biopsy of involved scalp shows a peribulbar, perivascular, and outer root sheath mononuclear cell infiltrate of T cells and macrophages. [55] Follicular dystrophy, including abnormal pigmentation and matrix degeneration, may also be present. [56] The pathogenesis of alopecia areata is still obscure, although most authors tend to classify alopecia areata as an autoimmune disease. As opposed to normal hairs, strong major histocompatibility complex (MHC) class I and class II immunoreactivity are found in lesional alopecia areata follicles, which also display aberrant expression of adhesion molecules known to direct hematopoietic cell migration. [54] One potential explanation for the failure of repression of MHC expression necessary for autoimmunity to develop in alopecia areata is the release of cytokines by certain stimuli, including trauma, neurogenic inflammation, or infectious agents. The elusive follicular autoantigens so exposed may be of keratinocyte or melanocyte origin, but the almost exclusive attack on melanogenically active anagen follicles makes this a particularly attractive hypothesis. That there is a genetic association with both susceptibility to and severity of alopecia areata is clearly shown by recent human leukocyte antigen (HLA) studies. [57] Spontaneous remission is common in patchy alopecia areata, but is less so with alopecia totalis or universalis. [52] Spontaneous or treatment-related regrowth is also adversely affected by the location of hair loss (ophiasis pattern is particularly recalcitrant), the age of onset (children younger than 5 years old with alopecia totalis or universalis have the worse prognosis), association of atopy, and duration of hair loss in a given area. [52], [58] Current treatment is not, at this point, directed at the etiology of alopecia areata but rather at the resulting inflammatory infiltrate and (presumably) the growth inhibitory factors produced by this response. Relapse is common, both acutely and over a lifetime. Treatment of alopecia areata is with either immunosuppressives (local or systemic) or with irritants/immunogens, and is generally tailored to the severity of the disease. [54] For localized patchy alopecia areata, intralesional steroids given at 4- to 6-week intervals are usually effective, with the main side effect being local dermal/subcutaneous atrophy related to the depth and concentration of injected steroid. Topical glucocorticoids classes I to V are also effective but take several months for initiation of hair growth, rather than the weeks for intralesional steroids. Side effects of topical steroids are generally limited to acne/hypertrichosis on the face from inadvertent transfer from the scalp and local epidermal atrophy with the more potent steroids. Systemic steroids, particularly short courses (less than 8 weeks) of tapering doses, are often used either alone or in conjunction with topical agents. In this setting, acne and weight gain are commonly seen side effects. [59] PUVA is another immunosuppressant treatment that may be effective in alopecia areata, particularly in patients with extensive scalp and body hair loss. Between 30 and 80 treatments may be necessary before hair induction occurs, and there is an increased risk of photodamage/photoaging and skin cancer with PUVA use. [60] The immunostimulation of topical irritants, especially anthralin, or topical immunogens (diphencyprone, squaric acid dibutylester) can be very effective in alopecia areata, but their use runs the risk of intolerable irritation if the dose titration is inappropriate. The particular mechanism of action of contact dermatitis that makes it a treatment for alopecia areata is purely speculative at this time, but it may include enhanced clearance of the putative follicular antigens through recruitment of new T cells and antigenic competition and interference with the initial or continued production of proinflammatory cytokines by the follicular keratinocytes. [61] Five percent topical minoxidil, as a nonspecific hair growth promoter, may be a useful drug as a single agent or as an adjuvant with topical anthralin. [62] There is a low incidence of local dryness/irritation and facial hypertrichosis with topical minoxidil. Although rare, the potential for systemic effects of topical minoxidil, particularly in young children, must be considered and the total amount applied kept to the recommended = 2 mL/day. Patients with alopecia areata need psychological support and physical means of camouflaging their hair loss. The latter often requires the use of a wig, which should be considered an integral part of treatment in patients with extensive scalp hair loss. The National Alopecia Areata Foundation is an excellent source of information for patients (http://www.naaf.org/).

Focal Hair Loss

NONSCARRING HAIR LOSS

Production decline

TRIANGULAR (TEMPORAL) ALOPECIA *Triangular alopecia* may be congenital but usually appears in childhood as a focal patch of hair loss. The hair loss either may be complete or fine vellus hairs may remain. [13], [63] The underlying scalp is normal. The temporal region is a common location, and the hair loss is frequently bilateral (Fig. 71-15). Histologically, the affected area shows a transition from terminal to vellus hair. The alopecia is usually persistent.

FIGURE 71-15 Triangular alopecia.

PATTERN HAIR LOSS The term androgenetic alopecia was previously applied to both men and women with a very common, potentially reversible scalp hair loss that generally spares the “Hippocratic wreath” portion of the scalp. The hair loss condition in men and women has in common miniaturization and shortening of anagen duration of affected hairs and, consequently, an increased percentage of affected hairs in telogen. [64], [65] Men with this type of alopecia tend to have somewhat synchronous behavior of hairs in the four different regions of the top of the scalp (vertex, mid, frontal, and bitemporal) along with potentially profound degrees of miniaturization leading to recognizable patterns of hair loss (Fig. 71-16). [65] In men, this male pattern baldness is hereditary (probably autosomal dominant) and androgen dependent, specifically dihydrotestosterone-related. [64], [66]

FIGURE 71-16 Hamilton-Norwood classification of pattern hair loss in men. (*From Olsen,* [65] *with permission.*)

Women, on the other hand, have lesser degrees of miniaturization of terminal hairs in affected areas and, hence, rarely any “balding” when compared to men. Patterning is less obvious then in men, although three patterns of hair loss do exist in women (Fig. 71-17A, Fig. 71-17B). [65] Not all women with pattern hair loss have proven androgen-dependence. Women with profound hyperandrogenemia, which is usually tumor related, may develop a Hamilton pattern of hair loss or severe diffuse central scalp hair loss, and women with other stigmata of hyperandrogenemia/hypersensitivity, such as those with polycystic ovarian syndrome, may present with pattern hair loss in the second to third decades. [65] The majority of women with pattern hair loss, however, have no increase in serum androgens, no other signs/symptoms of androgen hypersensitivity, and do not respond to androgen inhibition with reversal of hair loss. [64], [65] Therefore, the preferred more encompassing “umbrella” term for this hair loss in women is *female pattern hair loss*. Subcategories of “early onset female pattern hair loss with or without androgen excess” and “late postmenopausal onset female pattern hair loss with or without androgen excess” [65] will allow sorting out of the genetic (e.g., polycystic ovarian syndrome and early male pattern baldness appear genetically linked) [67] and cellular mechanisms of these various subtypes.

FIGURE 71-17 Pattern hair loss in women. *A.* Different phenotypic expressions. *B.* Characteristic frontal accentuation.

Androgen-mediated hair growth (or loss) requires formation of an androgen-androgen receptor complex, which then binds to the androgen-response element DNA-binding site leading, in turn, to transcription of certain protein(s). [64] Androgens are 19-carbon steroid structures (Fig. 71-18), that are normally produced by both adrenal glands and gonads. The most potent androgens (testosterone, dihydrotestosterone, and androstenediol) are those with a 17-hydroxy group, as this moiety is necessary for high-affinity androgen receptor binding. The weaker 17-ketosteroids, such as dehydroepiandrosterone and androstenedione, assume importance by their interconversion by 17-OH steroid dehydrogenase to more potent androgens at the end-organ site, including the hair follicle. The enzyme 5a-reductase converts testosterone to dihydrotestosterone, which has greater affinity and avidity for the androgen receptor. [68] Two isozymes of 5a-reductase, called 5aR1 and 5aR2, have been cloned and their corresponding genes are located on chromosomes 5 and 2 respectively. [66] Although type I 5a-reductase appears to be more ubiquitously distributed in skin, particularly in the sebaceous gland, 5a-reductase type 2 is found in the outer root sheath [69] and dermal papillae of hair follicles, but is differentially expressed in various tissues. [64] That 5a-reductase type 2 is involved in male pattern baldness

is suggested by the absence of balding in men with 5a-reductase type 2 deficiency; [66] the increased expression of 5a-reductase in balding versus nonbalding scalp; [70] the results in animal models of androgenetic alopecia showing reversal of hair loss with type 2 but not type 1 5a-reductase inhibitors; [64] and the response of men with male pattern baldness to finasteride, an inhibitor of 5a-reductase type 2. [71]

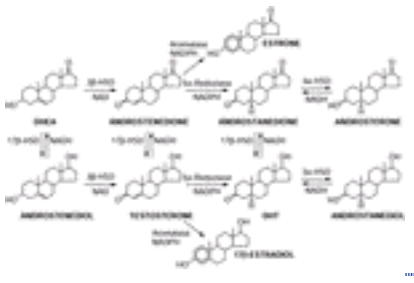

FIGURE 71-18 Androgen pathway. (*From Kaufman,* [66] *with permission.*)

Effective treatment of pattern hair loss in both men and women can include both medical and surgical approaches. Topical minoxidil (2% and 5%) is a nonspecific hair-growth promoter affecting anagen induction, duration, and size of hair shaft. Although the mechanism of action in hair growth promotion is unclear, its calcium channel opener activity appears to be important. [64] The medication should be applied to the scalp twice a day, with the earliest clinical response seen at 4 to 6 months and generally a maximum response at 1 year. [64] About 20 to 25 percent of persons so treated will have notable clinical regrowth, although most patients will experience at least a stabilization of loss. [72] There is slight risk of facial hypertrichosis and of irritation/allergic contact dermatitis, secondary to either the minoxidil or propylene glycol. Both side effects are more frequent with the 5% versus the 2% preparation. [64] Whether the facial hypertrichosis is from inadvertent transfer from the scalp or secondary to a local reaction to low levels of serum minoxidil is not clear. Surgical treatment of pattern hair loss has undergone dramatic improvement in recent years [73] (see Chap. 277). It is based on the premise of “donor dominance” whereby hairs from a nonandrogen-dependent site (occiput) can be successfully transplanted to a bald androgen-dependent site. Cosmetic coverage is currently limited by the amount and density of available occipital donor hair and the expertise of the surgeon. Ideally, male candidates for this procedure should be those in whom final resculpturing of the frontal hair line has naturally occurred. A combination of minigrafts (1.5- to 2.5-mm grafts) and micrografts (one to two hairs each graft) of donor hair are used more frequently now than the once standard 4-mm plugs to fill in areas of baldness. The micrografts are particularly useful because they do not require removal of a plug of tissue into which to insert the graft; rather, a small hole or incision can be made to accommodate a single or a few donor hairs. Micrografting is the surgical treatment of choice in women with pattern hair loss, who, unlike men, never develop baldness and for whom the use of standard hair transplants means sacrificing terminal hair when a recipient plug of tissue is removed. For women with pattern hair loss, at least those who have documented androgen excess or androgen hypersensitivity, the use of medications that block either the production of or the cellular utilization of androgens may be helpful. Although the systemic antiandrogens spironolactone (in doses = 100 mg daily), [74] flutamide (in doses of 250 to 500 mg bid to tid), [75] and cyproterone acetate [76] have shown some effectiveness in women with pattern hair loss, none of these have been studied in large placebo-controlled trials or with stratification of women by presence or absence of hyperandrogenism. This is especially important today because there is a lower threshold, given our knowledge of coincident insulin resistance, to identify polycystic ovarian syndrome, a potential cause of hyperandrogenism and concomitant pattern hair loss. Spironolactone is a potassium-sparing diuretic whose main side effects are hyperkalemia, irregular menses, and breast tenderness/bloating. Flutamide users must be monitored for potential hepatotoxicity. Because both drugs can cause feminization of a male fetus, they should be used only in women of non-childbearing potential or in those women of childbearing potential who are using effective contraception, preferably combination oral contraceptive pills. Cyproterone acetate (CPA) is marketed outside the United States in conjunction with ethinyl estradiol, either in a reversed sequential regimen of 100 mg CPA on days 5 to 15 and 50 µg ethinyl estradiol on days 5 to 25, or in a low-dose combined formulation of 2 mg CPA and 50 µg ethinyl estradiol on days 5 to 25. Side effects are similar to those of oral contraceptive pills. [64] Topical antiandrogens, which theoretically could also be used in men, are not commercially available at this time. Men with androgenetic alopecia may use a systemic 5a-reductase inhibitor without the biologic concerns of emasculinization seen with systemic antiandrogens since there is neither a decrease in testosterone levels nor any effect on androgen-receptor binding. In men with androgenetic alopecia, placebo- controlled studies of the type 2 5a-reductase inhibitor finasteride have shown increased hair growth in ˜50 percent of men at 1 year and 66 percent by 2 years. [71] The placebo-treated group, by comparison, had hair growth in 7 percent at 1 year and a progressive decline at 2 years that continued over a 5-year follow-up. [77] Sexual adverse events (1.8 percent of those on 1 mg finasteride versus 1.3 percent of those on placebo) were the only significant side effects and generally cleared, either on or off treatment. [71]

Hair breakage

TRICHOTILLOMANIA *Trichotillomania* (Greek, “hair pulling madness”) is a common, but difficult to manage, cause of focal scalp hair loss. It is classified as an impulse control disorder in which patients pull, pluck, or cut their hair. [78], [79] The clinical presentation is usually quite distinctive, with a confluence of very short sparse hairs within an otherwise normal area of the scalp (Fig. 71-19A, Fig. 71-19B). Microscopic examination of the ends of cut or plucked hairs generally reveals either the tapered tips of newly regrowing anagen hairs or bluntly cut hairs. (A hair pull here is usually negative because the telogen hairs have generally all been dislodged) The differential diagnosis includes alopecia areata and tinea capitis, and because patients generally deny any role in the hair loss, these usually need to be definitively ruled out. A scalp biopsy can be diagnostic, showing the characteristic increase in the number of catagen hairs (rarely seen in biopsies of normal scalp), trichomalacia, and melanin within the follicular canal secondary to traumatic hair removal and the absence or sparsity of a perifollicular inflammatory infiltrate. [80], [81]

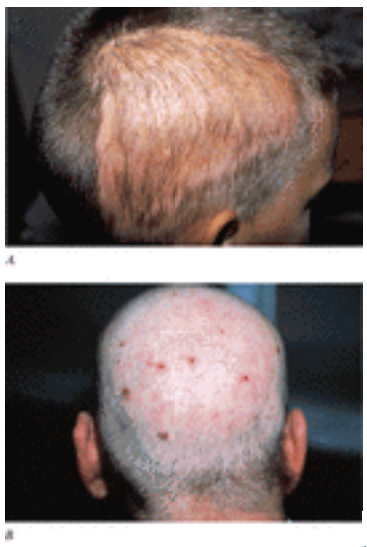

FIGURE 71-19 Trichotillomania. *A.* Bizarre pattern of localized hair loss in a boy. *B.* Extensive hair loss in a woman.

Treatment of these patients is challenging. Children with trichotillomania may have a form of habit tic, which can be broken by mere acknowledgment of the problem or behavior modification. Adolescents and adults with this condition, who tend to be primarily females, are usually particularly reluctant to accept the diagnosis and often require psychological intervention and/or medication to help modify their behavior. [78], [79] Clomipramine may be particularly effective.

TRACTION ALOPECIA *Traction alopecia* is caused by inadvertent prolonged traction on the scalp by the physical pressure of tight braids, certain hair styles (e.g., pony tail), foam rollers, etc (Fig. 71-20). While potentially reversible, the hair loss may be persistent if the traction is unrelenting over months to years.

FIGURE 71-20 Traction alopecia.

TINEA CAPITIS (See also Chap. 205) *Tinea capitis* is a very common cause of hair breakage or loss, particularly in children. Typically, there is either a seborrheic dermatitis presentation, with or without erythema of the scalp (Fig. 71-21A), or a noninflammatory "black dot ring-worm" presentation, with broken hairs filling, but not projecting from, follicular orifices (Fig. 71-21B). Less commonly, tinea capitis can present as a pyoderma-like kerion.

FIGURE 71-21 Tinea capitis. *A.* Endothrix infection caused by *Trichophyton tonsurans* presenting as seborrheic dermatitis. *B.* Endothrix infection caused by *T. tonsurans*. Note "black dots" of broken, infected hairs within the follicular canals. (*Reprinted with permission from DeVillez RL: Infections, physical, and inflammatory causes of hair and scaly abnormalities, in* Disorders of Hair Growth: Diagnosis and Treatment, *edited by EA Olsen. New York, McGraw-Hill, 1994, pp 71–90.*)

The etiologic agent(s) of tinea capitis varies in different parts of the world. Currently in the United States, in which the condition is far more prevalent in African Americans and Hispanics than in Caucasians, the usual fungal isolate is *Trichophyton tonsurans.* [82] This is an endothrix infection and KOH examination of affected hairs shows arthrospores and hyphae interspersed among the keratin fibers of the hair shaft. To establish a diagnosis, hairs should be cultured as well as examined after KOH preparation, since a positive yield by KOH alone is dependent on the amount of inflammation and may vary from 29 to 66 percent. [83] Only ectothrix fungal infections fluoresce under Wood's light. Treatment of tinea capitis must be by the systemic route, and contacts must be sought and treated to prevent reinfection. Asymptomatic carriers are common. Treatment is with griseofulvin, terbinafine, or one of the newer azoles. [82], [84], [85] Griseofulvin, 20 to 25 mg/kg per day of the microsized product (or 10 to 15 mg/kg of the ultramicrosized product), is given with a fat-containing meal until the culture is negative (generally 6 to 10 weeks). [82] Griseofulvin is fungistatic. Terbinafine, an allylamine, is not significantly affected by food and is fungicidal: doses of 62.5 to 250 mg qd for 4 weeks (62.5 mg/day for those weighing <20 kg, 125 mg/day for those weighing 20 to 40 kg, 250 mg/day for those weighing > 40 kg) are effective. The azoles, itraconazole at 100 mg qd, or fluconazole 6 to 8 mg/kg for 4 to 6 weeks are effective alternative treatments. Both latter drugs inhibit the cytochrome P_{450} system so drug–drug interactions should be considered. Fluconazole bioavailability is not affected by food. Topical sporicidal agents, such as selenium sulfide or ketoconazole, help to limit the spread of

infectious spores.

Primary or acquired localized hair shaft abnormalities

ACQUIRED LOCALIZED TRICHORRHEXIS NODOSA *Acquired localized trichorrhexis nodosa* may be seen in hair that is subject to repetitive rubbing, such as with lichen simplex chronicus or trichotillomania. It may also present in focal areas secondary to trauma from chemical or heat processing of hair. *Acquired pili torti* may present as a focal patch of fragile hair. This is usually secondary to trauma or some underlying, potentially scarring, scalp abnormality. [15] Hypervitaminosis in patients with anorexia nervosa or retinoids have also been associated with acquired pili torti. *Bubble hair* is a recently recognized and very distinctive abnormality of the hair shaft and is characterized by rows of bubbles seen microscopically within localized areas of brittle hair. [86] Exposure to prolonged high temperatures from curling irons or hair dryers are the usual causative factors, and the defect is completely reversible.

Unruly hair

WOOLY HAIR NEVUS *Wooly hair nevus* is a nonhereditary focal condition which usually appears within the first 2 years of life but can occur as late as adolescence. [87] Fifty percent of cases have an associated epidermal, verrucous, or pigmented nevus, although not necessarily immediately under the affected hair. [15] There may be associated ocular abnormalities, such as persistent papillary membrane or retinal abnormality. Spontaneous improvement in the hair may occur with age.

ACQUIRED PROGRESSIVE KINKING This condition has been primarily reported in postpubescent males with androgenetic alopecia. [88] It presents with gradual curling and darkening of the frontal, temporal, auricular, and vertex hairs. Microscopically, affected hairs show kinks and twists, with or without longitudinal grooving.

Abnormality of cycling

ALOPECIA AREATA As noted previously, alopecia areata can (and usually does) present as focal hair loss.

SYPHILIS Hair loss may be one or the sole cutaneous manifestation of *secondary syphilis.* This may present as a patchy "moth-eaten" alopecia or as generalized thinning (Fig. 71-22). A scalp biopsy may show either a superficial and deep perivascular mixed lymphocytic/macrophage/plasma cell infiltrate, a peribulbar perifollicular lymphocytic infiltrate mimicking alopecia areata, or a noninflammatory telogen effluvium picture. [89], [90] Serologic testing should be positive, and treatment with appropriate antibiotics will reverse the hair loss.

FIGURE 71-22 Alopecia of secondary syphilis.

Scalp conditions associated with focal hair loss Most eczematous conditions of the scalp do not cause hair loss, the exception being pityriasis amiantacea, severe scalp psoriasis and malignancies such as cutaneous T cell lymphoma or histiocytosis X. In *pityriasis amiantacea,* thick tenaciously adherent scale infiltrates and surrounds the base of a group of scalp hairs [91] (Fig. 71-23). The condition may mimic psoriasis clinically, but, in contradistinction to psoriasis, the hair in involved areas is dislodged on attempts to physically remove the scale. Removal of the scale in this manner can lead to scarring alopecia. The condition usually presents in children, is best treated with keratolytics, and usually improves with age.

FIGURE 71-23 Pityriasis amiantacea. Note area of patchy alopecia after manual removal of adherent scale.

CICATRICIAL ALOPECIA (DESTRUCTION OF THE FOLLICLE) The term *cicatricial or scarring alopecia* implies the potential of permanent destruction of the hair follicle. Clinically, there is effacement of follicular orifices, always in a patchy or focal distribution. A biopsy is confirmative, showing replacement of follicles with fibrotic stellae and either fibrosis or hyalization of surrounding collagen. [92], [93] and [94] Although some cases of cicatricial alopecia are due to physical or developmental causes (e.g., pressure or aplasia cutis congenita), or to the hair follicle being secondarily involved in a destructive process (e.g., "kerion" fungal infection or metastatic/primary neoplasm), most patients seeking medical attention have a primary cicatricial alopecia. Although these conditions have a common endpoint, they have varied clinical and histologic features and virtually no therapies able to turn the process completely off. There is direct evidence in the mouse, and indirect evidence in the human, that compromising the integrity of the sebaceous gland and/or bulge is important in the development of the scarring process in the primary cicatricial alopecias. [95] Selective destruction of the stem cell region in mice and graft versus host disease, [96] in which an inflammatory infiltrate involves the stem cells, can lead to follicular destruction. Moreover, alopecia areata, in which the inflammation spares the stem cell area, does not lead to permanent hair loss. In the asebia mouse, which lacks one gene responsible for normal sebum production, the hair follicle is destroyed when the shaft is unable to exit the follicle properly. [95] Other animals with sebaceous gland pathology also develop cicatricial alopecia. A new classification system based on the type of inflammatory infiltrate on biopsy (Table 71-4) along with recommended standardization of biopsy site, processing and pathology parameters, and cataloguing of clinical findings, [97] will help us to identify and evaluate significant differences between these entities. The primary cicatricial alopecias are presented in keeping with this classification system.

Lymphocytic
Chronic cutaneous lupus erythematosus
Lichen planopilaris (LPP)
Classic LPP
Frontal fibrosing alopecia
Graham Little Syndrome
Classic pseudopelade (Brocq)*
Central centrifugal cicatricial alopecia**
Alopecia mucinosa
Keratosis follicularis spinulosa decalvans
Neutrophilic
Folliculitis decalvans
Dissecting cellulitis/folliculitis (*perifolliculitis abscedens et suffodiens*)
Mixed
Folliculitis (acne) keloidalis
Folliculitis (acne) necrotica
Erosive pustular dermatosis
Nonspecific†

*Clinically discrete, smooth, flesh-tone or white areas of alopecia without follicular hyperkeratosis or perifollicular inflammation

**Cicatricial alopecia starting in the central scalp and progressing centrifugally. This entity has previously been referred to by other terms (i.e., follicular degeneration syndrome, pseudopelade in African-Americans, central elliptical pseudopelade in caucasians) but we are suggesting this more descriptive term which embraces all previous entities.

†Nonspecific cicatricial alopecia is defined as an idiopathic scarring alopecia with inconclusive clinical and histopathological findings. This category may include the end stage of a variety of inflammatory cicatricial alopecias such as lichen planopilaris and folliculitis decalvans.

TABLE 71-4 **Proposed Working Classification of Primary Cicatricial Alopecia**

Primary cicatricial alopecia

LUPUS ERYTHEMATOSUS (See also Chap. 171) *Chronic cutaneous lupus erythematosus* may present in the scalp, usually with erythema, atrophy and variable hypopigmentation and/or follicular plugging (Fig. 71-24). Patients may have no other clinical lesions nor serologic evidence of lupus erythematosus. Scalp biopsy is generally confirmative, showing vacuolar degeneration of the basal cell layer, a perivascular and periadnexal lymphoid infiltrate, increased dermal mucin and sebaceous gland loss. [92] Direct immunofluorescence studies most commonly demonstrate granular deposits of IgG and C3 at the dermal–epidermal junction and at the junction of the dermis and follicular epithelium. Potentially effective treatments include topical, intralesional, and systemic steroids, antimalarials, systemic retinoids, and thalidomide. [93], [98]



FIGURE 71-24 Lupus erythematosus.

LICHEN PLANOPILARIS Areas of active alopecia in *lichen planopilaris* are clinically distinguished by perifollicular erythema and/or a violaceous discoloration of the scalp (Fig. 71-25). Keratotic follicular papules may be evident. Evidence of lichen planus may be present elsewhere, and this should be sought to help confirm the diagnosis. Histologically, there is a perifollicular lymphoid, often bandlike, infiltrate primarily in the infundibular and isthmus portions of the follicle, with or without the presence of adjacent colloid bodies. The typical overlying histologic changes of lichen planus may or may not be present; these include sawtooth rete ridges, interface dermatitis, hypergranulosis, and Civatte bodies. [99] Immunofluorescence findings consist of globular deposits of IgM adjacent to follicular epithelium and patchy or linear fibrogen deposits along the basement membrane zone. Glucocorticoids are the mainstay of treatment.

FIGURE 71-25 Lichen planopilaris.

Lichen planopilaris histologically can be seen in two other disparate conditions. *Graham-Little syndrome* is characterized by lichen planus-like lesions and a follicular “spines”/keratosis pilaris-like picture that develop in areas of alopecia on the scalp, eyebrows, axillary, and pubic areas. [92] *Frontal fibrosing alopecia* is a term given to the frontotemporal hairline recession and eyebrow loss in postmenopausal women that is associated with perifollicular erythema, especially along the hairline. [100] Scalp biopsy is indistinguishable from lichen planopilaris. Topical and intralesional steroids, topical and systemic retinoids, and hormone replacement therapy do not prevent the hair loss progression; oral steroids and chloroquine have been demonstrated to slow the progression in a few patients. A lichenoid inflammatory infiltrate has also been seen in a progressive inflammatory (perifollicular erythema and follicular keratosis) scarring alopecia limited to the area of pattern hair loss. [101] There appears to have some overlap with frontal fibrosing alopecia.

PSEUDOPELADE OF BROCQ In clinical terms, *pseudopelade of Brocq* implies flesh- to pink-colored, irregularly shaped alopecia that may begin in a moth-eaten pattern with eventual coalescence into larger patches of alopecia [102] (Fig. 71-26). There has been considerable debate as to the specificity of this diagnosis versus an assignation of the term to describe all noninflammatory scarring alopecias, including the end-stage of a variety of initially inflammatory conditions. Histologically, the lesions are characterized by a perifollicular and perivascular lymphocytic infiltrate primarily at the level of the follicular infundibulum, loss of sebaceous epithelium, and fibrotic streams into the subcutis without interface or follicular plugging changes. [103] Elastin stains may distinguish pseudopelade (persistent elastic fibers around the midshaft of the follicle) from lichen planopilaris and lupus erythematosus (loss of elastic fibers in this location). [104] Direct immunofluorescence is negative in the majority of cases. It is unclear what treatment specifically helps.

FIGURE 71-26 Pseudopelade of Brocq.

CENTRAL CENTRIFUGAL CICATRICIAL ALOPECIA Recently, a subset of cicatricial alopecia has been identified in African Americans and given the name of *central centrifugal cicatricial alopecia* (CCCA). [97] This condition has also been called hot comb alopecia, follicular degeneration syndrome, and central centrifugal scarring alopecia, the latter meant to be an umbrella term for follicular degeneration syndrome as well as other causes of central scalp hair loss. [105] Affected patients with CCCA show follicular loss primarily over the crown, with little in the way of either bogginess or tautness to the scalp (Fig. 71-27). Inflammation has been reported more commonly in affected men than in affected women. [106] Histologically, the earliest and most distinctive change is premature desquamation of the inner root sheath with later changes including migration of the hair shaft through the outer root sheath, a mononuclear infiltrate primarily at the isthmus, and, finally, loss of the follicular epithelium and replacement with fibrous tissue. [106] Although tight braiding, hot combs, and hair straightening agents are often invoked as causative or at least contributory factors and their use discouraged in CCCA, this has not been definitely proven. The distribution of CCCA overlaps that of pattern hair loss but the sex distribution is tremendously skewed toward women.

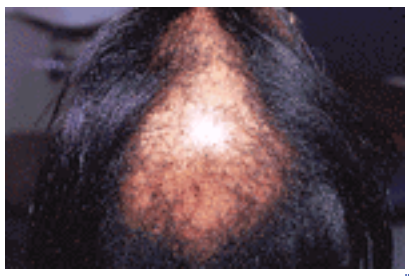

FIGURE 71-27 Central centrifugal cicatricial alopecia.

ALOPECIA MUCINOSA *Alopecia mucinosa* generally presents, but not exclusively, as erythematous plaques or flat patches without hair primarily on the scalp and face. [94] Biopsy reveals prominent follicular, epithelial and sebaceous gland mucin, and perifollicular lymphohistiocytic infiltrate without concentric lamellar fibrosis. [92], [94]

KERATOSIS FOLLICULARIS SPINULOSA DECALVANS Keratosis follicularis spinulosa decalvans (KFSD) is an X-linked disorder with the gene located at Xp22.13–p22.2. [107] Female carriers are frequently affected. The disorder is characterized by follicular hyperkeratosis, scarring alopecia of the scalp, absence of eyebrows and sometimes eyelashes, severe photophobia, and resulting corneal dystrophy. Onset is in early childhood and the symptoms decrease with age. Histopathologically, there is plugging of the pilosebaceous orifices with keratinaceous debris, and superficial and deep perivascular and periappendageal infiltrate of lymphocytes and plasma cells. Retinoids may be useful in treatment.

FOLLICULITIS DECALVANS *Folliculitis decalvans* is an inflammatory alopecia that leads to bogginess or induration of involved parts of the scalp along with pustules, erosions, crusts, and scale [108] (Fig. 71-28). Predictably, *Staphylococcus aureus* is usually cultured from these pustules, but whether this is a primary or secondary process is unclear. Histologically, early lesions show an acute suppurative folliculitis with neutrophils and eosinophils, later mixed with lymphocytes and histocytes. [92], [93] Loss of sebaceous epithelium and perifollicular fibrosis is common. [92] Systemic antibiotics with or without rifampin, systemic and/or topical steroids, and systemic retinoids may also be helpful. [108]

FIGURE 71-28 Folliculitis decalvans.

DISSECTING FOLLICULITIS *Dissecting folliculitis* or *perifolliculitis capitis abscedens et suffodiens of Hoffman* is another inflammatory condition of the scalp that can lead to scarring alopecia. African Americans are primarily affected. This condition begins with deep inflammatory nodules, primarily over the occiput, that progress to coalescing regions of boggy scalp (Fig. 71-29). Sinus tracts may form and dislodge purulent material. As in folliculitis decalvans, *S. aureus* is the most common bacterial isolate. Biopsy of early lesions shows follicular plugging and suppurative follicular or perifollicular abscesses with a mixed inflammatory infiltrate of neutrophils, lymphocytes, plasma cells, or eosinophils. [92], [93] and [94] Later, foreign-body giant cells, granulation tissue, and, finally, scarring with sinus tracts occur. Control is difficult to attain, but systemic steroids, systemic antibiotics, dapsone, or retinoids [109] are useful therapies. Surgical incision and drainage, excision with grafting, and/or x-ray epilation are occasionally used for refractory cases.

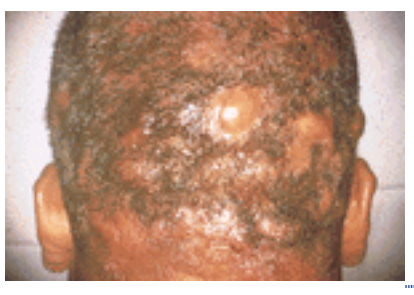

FIGURE 71-29 Dissecting folliculitis.

ACNE KELOIDALIS *Acne keloidalis (nuchae)* is a destructive scarring folliculitis that occurs almost exclusively on the occipital scalp of African Americans, primarily men (Fig. 71-30). The clinically distinctive lesions begin as follicular pustules and papules and progress to persistent firm papules or coalesce into hairless keloid-like plaques. [110] On histopathologic examination of an early lesion, there is follicular dilatation and a mixed peri-infundibular infiltrate that goes into follicular rupture and foreign body granulomas, loss of sebaceous glands, and lamellar fibroplasia. Treatment with systemic antibiotics, topical and/or intralesional steroids, and cryosurgery is usually helpful.

FIGURE 71-30 Acne keloidalis.

ACNE NECROTICA The primary lesion in acne necrotica is a pruritic or painful erythematous follicular-based papule that develops central necrosis and crusting and heals with a varioliform scar. [111] The lesions are concentrated on the nose, forehead and anterior scalp but may spread, primarily to the trunk. The course is chronic. Pathology is characterized by follicular dilatation, an early mixed lymphocytic/neutrophilic infiltrate in the peri-infundibulum, and later a lymphocytic/plasmacytic perivascular and perifollicular infiltrate. Lymphocytic exocytosis and individual cell necrosis of keratinocytes within the outer root sheath and surrounding epidermis go on to confluent necrosis of the central follicle. Treatment with tetracycline is generally helpful and *cis*-retinoic acid may be of value. [111]

EROSIVE PUSTULAR DERMATOSIS Erosive pustular dermatosis of the scalp presents with pustules, erosions, and crusts on the scalp of primarily older Caucasean females (Fig. 71-31). [112] On biopsy, there is a lymphoplasmacytic infiltrate ± foreign body giant cells and pilosebaceous atrophy. These lesions have a slow but progressive course. Multiple organisms, both bacterial and fungal, have been cultured but these probably represent secondary colonization; patients do not generally respond to antibacterial or antifungal drugs. Potent topical steroids, zinc sulfate, or isotretinoin may be helpful.

FIGURE 71-31 Pustular dermatosis of the scalp.

Secondary Cicatricial Alopecia Cicatricial alopecia may present as a hereditary or development problem, alone or as part of a syndrome. Examples of the latter are Conradi-Hünermann chondrodysplasia punctata; incontinentia pigmenti; ankyloblepharon, ectodermal defect, cleft lip or palate (AEC) syndrome; Hallermann-Streiff syndrome; and generalized atrophic benign epidermolysis bullosa. [13] The most common congenital cicatricial alopecia is *aplasia cutis congenita,* which is the congenital focal absence of epidermis with or without absence of other layers of the skin. [13] Hair follicles in the involved areas are variably affected. The condition may present at birth as an ulceration, crust, scar, or parchment-like membrane (Fig. 71-32). Eighty-five percent of aplasia cutis congenita presents on the scalp, and 70 percent of affected patients have only a single lesion. The lesions are usually small and round but can be large and extend to the dura or meninges. Aplasia cutis congenita may occur alone or in conjunction with various other abnormalities. Unless the lesions of aplasia cutis congenita are very large, no specific treatment is needed.

FIGURE 71-32 Aplasia cutis congenita. (*Photograph courtesy of Neil Prose, MD.*)

EXCESS HAIR

Hirsutism refers to hair growth in women in areas of the body where hair growth is under androgen control and in which normally only postpubescent males have terminal hair growth. These areas include the moustache, beard, chest, escutcheon, and inner thigh.

Hypertrichosis specifically refers to hair density or length beyond the accepted limits of normal for a particular age, race, or sex. The excess hair may be generalized or localized and may consist of lanugo, vellus, or terminal hair.

Hirsutism

Table 71-5 lists the causes of hirsutism. Most cases of hirsutism secondary to hyperandrogenism are associated with

irregular menses or amenorrhea. There may be evidence of other cutaneous androgen-sensitive disorders such as acne and female pattern hair loss, or cutaneous clues to a related systemic problem such as acanthosis nigricans seen with insulin-resistant diabetes. Virilization is uncommon and should lead one to consider an underlying androgen-producing tumor.

Androgen secreting tumors
Adrenal
Adenoma
Adenocarcinoma (rare)
Ectopic ACTH-secreting tumor (rare)
Ovarian
Gonadal stromal tumor
Thecoma
Lipoid tumor
Functional androgen excess
Adrenal enzyme deficiencies (congenital adrenal hyperplasia)
Early onset 21-hydroxylase deficiency
Late-onset 21-hydroxylase deficiency
11β-hydroxylase deficiency
3β-ol dehydrogenase deficiency
Cushing's syndrome
Polycystic ovarian disease
With or without adrenal contribution
Hyperthecosis
"Idiopathic" hirsutism
Medication/drug use

Source: Hughes EL: Hirsutism, in Disorders of Hair Growth: Diagnosis and Treatment, Edited by E.A.Olsen, New York, McGraw-Hill, 1994, p.444.

TABLE 71-5 **Hirsutism**

For endogenous causes of hirsutism, a simple screening test of serum free or total testosterone will often determine whether further testing is necessary. Elevation of testosterone levels well above the upper limits of normal indicates the necessity of screening for an ovarian or adrenal tumor. Far more common is the mild elevation of androgens in an otherwise healthy woman, which is most commonly secondary to either polycystic ovarian syndrome (PCOS) or late-onset congenital adrenal hyperplasia (CAH). PCOS is multifactorial, with a pituitary and gonadal component, as well as hyperinsulinemia that may lead to increased production of androgen, decreased production of estrogen, and anovulation. [113], [114] The most common cause of late-onset CAH is 21-hydroxylase deficiency with overproduction of 17-hydroxyprogesterone. [64] 3ß-Hydroxylase and 11ß-hydroxylase deficiency may also present with late-onset hirsutism; overproduction of 17-hydroxypregnenolone and 11-deoxycortisol, respectively, occur with these enzyme deficiencies. The diagnosis of late-onset CAH, while suggested by an elevated level of dehydroepiandrosterone and testosterone, can only be established by a cosyntropin-stimulation test showing the expected rise in the specific steroid hormone that builds up immediately behind the enzyme blockade or deficiency. [64] Women with hyperprolactinemia may have an increase in functional androgens through adrenal overproduction and through a decrease in sex hormone-binding globulin (SHBG) caused by a diminution of ovarian estrogen production; a prolactin level is diagnostic. [115]

The effective treatment of hirsutism depends on the cause, but the mainstays of treatment are oral contraceptive pills, both for their direct effect on lowering androgen production and indirect effect on lowering androgen bioavailability by increasing SHBG, and for their contraceptive effect when used with antiandrogens or 5a-reductase inhibitors. Antiandrogens, such as spironolactone, flutamide, or cyproterone acetate (see discussion of antiandrogens in " Pattern Hair Loss," above), are particularly useful in hirsutism as is finasteride. [116] There are marginal differences in efficacy between these agents but all generally take 6 to 12 months for sufficient miniaturization of terminal hairs to occur to be clinically significant. Treatment of congenital adrenal hyperplasia may also be accomplished through the use of low-dose dexamethasone. Hyperprolactinemia may be treated directly with either medical (bromocriptine) or surgical treatment of the hyperprolactinoma, and/or an antiandrogen may be utilized.

Hypertrichosis

GENERALIZED HYPERTRICHOSIS: INHERITED *Congenital hypertrichosis lanuginosa* presents as a confluent, generalized overgrowth of silvery blonde to gray lanugo hair at birth or in early infancy. It is rare (1 in 1 billion) and thought to occur as an autosomal dominant trait with variable expressivity. In most cases, other than possibly anomalous dental eruptions, children are otherwise healthy. The hair may persist, increase, or decrease with age. [117] There are several other congenital disorders associated with generalized hypertrichosis, but none that are so evenly distributed as congenital hypertrichosis lanuginosa. These are noted in Table 71-6. [118] Patients with the autosomal dominant *Ambras syndrome* or *hypertrichosis universalis congenita* present with much longer, thicker hair, with accentuation over the entire face, ears, and shoulders. [119] Associated facial dysmorphism and dental anomalies are common. Members of the five-generation family described with *congenital generalized hypertrichosis* also have excess terminal hair on the face and upper body, more severe in men than women in keeping with the X-linked dominant inheritance. [120] Patients with the autosomal dominant (rarely autosomal recessive) *gingival fibromatosis* frequently have hypertrichosis, mostly on the face, eyebrows, limbs, and upper back, along with seizures and oligophrenia. [118] Hypertrichosis may be delayed until puberty although gingival fibromatosus in this situation usually appears with the emergence of the primary, versus secondary, teeth.

Congenital/hereditary:
Congenital hypertrichosis lanuginosa
Ambras syndrome
Congenital generalized hypertrichosis
With gingival fibromatosis
Hereditary gingival fibromatosis with generalized hypertrichosis
Ainhum-like cultural syndrome
Barton syndrome
Beachman de Lange syndrome
Biedermann's syndrome
Cantu's generalized hypertrichosis with osteochondrodysplasia
Fischer's syndrome
Reticular ichthyosiform erythroderma
Donohue syndrome (leprechaunism)
Bonthron syndrome
Kabuki syndrome
Porfiria syndrome
Rothmund syndrome
Cohen-Hirsi syndrome
Cantrell syndrome
Hypertrichotic cirrhosis disorder
Schmeid-Cinthre syndrome
Lawrence-Sinclair syndrome
Generalized smooth muscle hamartoma
Michelin-Tito syndrome
Acquired
Acquired hypertrichosis lanuginosa (malignancy)
Drugs
Minoxidil
Diazoxide
Phenytoin sodium
Cyclosporine
PUVA
Topical steroids
Streptomycin
Acetazolamide
Cephalosporinoline
Anagrelid
Porphyria
Porphyria cutanea tarda
Hepatoerythropoietic porphyria
Variegate porphyria
Erythropoietic porphyria
POEMS syndrome
Juvenile dermatomyositis
Hypothyroidism
Anorexia
Malabsorption syndrome
CNS-related problems or trauma
Mild encephalitis
Multiple sclerosis
Schizophrenia
Head injury
Hypoxemia/anemia
Anomalous pathways

TABLE 71-6 **Causes of Generalized Hypertrichosis**

ACQUIRED GENERALIZED HYPERTRICHOSIS There are few more ominous signs in dermatology than the onset of generalized hypertrichosis without an obvious drug-related explanation. *Acquired hypertrichosis lanuginosa* almost always signals an underlying malignancy or is a harbinger of one to develop in the near future (Fig. 71-33). [121]

FIGURE 71-33 Acquired hypertrichosis lanuginosa. (*From Olsen,* [118] *with permission.*)

There are several drugs that routinely cause generalized hypertrichosis (see Table 71-6). [118] Oral minoxidil, a piperidinopyramidine derivative that is a potassium channel opener and antihypertensive agent when used systemically, causes hypertrichosis in 80 percent of patients, most prominently over the face, shoulders, and extremities. Diazoxide, a benzothiadiazine used primarily in malignant hypertension or idiopathic hypoglycemia of infancy, leads to lanugo-like hypertrichosis of the face, trunk, and extremities in 1 to 20 percent of adults but in almost 100 percent of children. Dilantin use leads to terminal hair hypertrichosis in 5 to 12 percent of patients, again first over the extremities, trunk, and face. Cyclosporine, a cyclic undecapeptide of fungal origin and an immunosuppressive agent, causes terminal hair hypertrichosis in 40 to 95 percent of patients, with a more diffuse distribution of excess hair, but primarily over the upper body (Fig. 71-34). [122], [123] Both diazoxide and cyclosporine are also associated with gingival hyperplasia.

FIGURE 71-34 Cyclosporine-related hypertrichosis.

Certain medical illnesses are associated with widespread, although not confluent, hypertrichosis. They are listed in Table 71-6.

Localized Hypertrichosis Table 71-7 lists the conditions associated with localized hypertrichosis. These are generally either inherited, developmental, or secondary to irritation or trauma.

Congenital/hereditary:
Midline hypertrichosis with underlying neuroectodermal abnormality
Spina bifida occulta
Tethered cord (e.g., meningocele manqué)
Diastematomyelia
Facial cervical hypertrichosis
Hairy elbows
Anterior cervical hypertrichosis
Hairy pinna
Trichomegaly alone
Congenital smooth muscle hamartoma
Winchester syndrome
Nevoid hypertrichosis
Stiff skin syndrome
Congenital pigmented nevus
Hemimacrohelical dysplasia
Acquired
Becker's nevus
Melorheostatic scleroderma
Poikiloderma
Reflex sympathetic dystrophy
Osteoarthritis monitoring
Scrotal hair in male infants
Drugs
Interferon
Sodium tetradecyl sulfate
Topical latanoprost
Topical minoxidil
Urokinase
Intralesional
Repeated trauma
Friction (e.g., neck beards, cinctures)
Lichen simplex chronicus
Biting
Insect bites
Toxic/lymphedema
Congenital A-V fistula
Denervated areas
Chronic osteomyelitis
Site of immunizations
Smallpox
Diphtheria-tetanus
Chickenpox
HIV
Peripheral burned area
Kala-azar (visceral leishmaniasis)

TABLE 71-7 **Causes of Localized Hypertrichosis**

Treatment of Hypertrichosis

Removal of the inciting cause should be the prime approach to treatment and usually leads to regression of the hypertrichosis. However, in situations where that is not possible, one must either help the patient deal psychologically with the physical anomaly and/or use means of either temporarily or permanently removing the hair. Depilatories, plucking, waxing, and shaving are all means of temporarily removing hair but, with the exception of shaving, may be associated with irritation and/or pseudofolliculitis barbae. Potentially, electrolysis can permanently remove unwanted hair, but this technique varies widely in effectiveness depending on the training of the electrologist, the type of machine, the pulse frequency, the intensity and duration applied, and the probe used. [1] Two main types of electrolysis are in general use, thermolysis (AC current) with destruction of the hair by local heat production and "the blend," a combination of thermolysis and galvanic (DC current) which produces destruction of the hair by local production of caustic lye and H_2 gas. Potential, but ultimately controllable, side effects of electrolysis are pain, scarring, infection, and folliculitis.

Recently, several different kinds of laser have been approved for removal of hair. [1] The lasers selectively target the hair follicle, either by targeting a chromophore that is a natural component of the follicle, such as melanin, or one that is introduced into the follicle. The ruby (694 nm), alexandrite (755 nm), and semiconductor diode (800 nm) lasers, as well as a flash-lamp device with filters able to deliver light of >590 nm, each target melanin in the hair shaft and cause selective thermal injury. [1] The limiting factor in selecting melanin as the target is the concomitant absorption by epidermal melanin with both potential epidermal injury and a diminution in energy dispersal down the hair follicle. The Q-switched neodymium:yttrium-aluminum-garnet (Nd:Yag) laser with a wavelength of 1064 nm does not target melanin; instead, it targets a topically applied carbon-based material that leads to both thermal and mechanical damage to the follicle. All of the aforementioned lasers induce temporary hair removal. None of these techniques has been proven to lead to complete and permanent hair removal, although those that target melanin clearly can lead to a long-term reduction in terminal hair density, much apparently due to miniaturization, versus destruction, of the follicles. [124] A more experimental treatment is photodynamic therapy based on a topical photosensitizer (aminolevulinic acid), and subsequent exposure to red light, which causes selective follicular damage by the synthesis of the potent photosensitizer, protoporphyrin. [1]

CONCLUSION

The range of abnormalities in hair disorders mirrors the complexities of hair production. The astute clinician is able to diagnose hair disorders by a combination of clinical clues, microscopic evaluation of hairs, a biopsy of the affected area, and confirmatory laboratory tests. Treatment efficacy mirrors diagnostic accuracy although we are currenly woefully short of treatment to help those patients with herediary disorders of hair follicle or shaft production. As we come to better understand the genetic and molecular controls on hair growth, earlier diagnosis and implementation of effective directed treatments for the primary disorders of hair loss or overgrowth will become possible.

REFERENCES

1. Olsen EA: Methods of hair removal. *J Am Acad Dermatol* **40**:143, 1999

2. Courtois M et al: Ageing and hair cycles. *Br J Dermatol* **132**:86, 1995

3. Randall VA, Ebling FJG: Seasonal changes in human hair growth. *Br J Dermatol* **124**:146, 1991

4. Olsen EA: Clinical tools for assessing hair loss, in *Disorders of Hair Growth: Diagnosis and Treatment,* edited by EA Olsen. New York, McGraw-Hill, 2003

5. Olsen EA: Current and novel methods for assessing efficacy of hair growth promoters in pattern hair loss. Accepted for publication. *J Am Acad Dermatol* **48**:253, 2003

6. Solomon AR: The transversely sectioned scalp biopsy specimen: The technique and the algorithm for its use in the diagnosis of alopecia. *Adv Dermatol* **9**:127, 1994

7. Olsen EA et al: The presence of loose anagen hairs obtained by hair pull in the normal population. *J Invest Dermatol* **4**:258, 1999

8. Pantelleyev AA et al: The role of the hairless (*hr*) gene in the regulation of hair follicle catagen transformation. *Am J Pathol* **155**:159, 1999

9. Ahmad W et al: Genomic organization of the human hairless gene (*hr*) and identification of a mutation underlying congenital atrichia in an Arab Palestinian family. *Genomics* **56**:144, 1999

10. Zlotogorski A et al: Clinical and molecular diagnostic criteria of congenital atrichia with papular lesions. *J Invest Dermatol* **117**:1662, 2001

11. Miller J et al: Atrichia caused by mutations in the vitamin D receptor gene is a phenocopy of generalized atrichia caused by mutations in the hairless gene. *J Invest Dermatol* **117**:612, 2001

12. Freire-Maia N: Ectodermal dysplasias. *Hum Hered* **21**:309, 1971

13. Olsen EA: Hair loss in childhood, in *Disorders of Hair Growth: Diagnosis and Treatment,* edited by EA Olsen. New York, McGraw-Hill, 2003

14. McKusick VA ed: *Mendelian Inheritance in Man.* Maryland, Johns Hopkins University, 1998

15. Whiting DA: Hair shaft defects, in *Disorders of Hair Growth: Diagnosis and Treatment,* edited by EA Olsen. New York, McGraw-Hill, 2003

16. Dawber RPR, Comaish S: Scanning electron microscopy of normal and abnormal hair shafts. *Arch Dermatol* **101**:316, 1970

17. Batshaw ML et al: New approaches to the diagnosis and treatment of inborn errors of urea synthesis. *Pediatrics* **68**:290, 1981

18. Goldblum OM et al: Neonatal citrullinemia associated with cutaneous manifestations and arginine deficiency. *J Am Acad Dermatol* **14**:321, 1986

19. Davies K: Cloning the Menkes disease gene. *Nature* **361**:98, 1993

20. Gillespie JM, Marshall RC: Effect of mutations on the proteins of wool and hair, in *The Biology of Wool and Hair,* edited by GE Rogers, PJ Reis, KA Ward, RC Marshall. London, Chapman & Hall, 1989, p 257

21. Price VH et al: Trichothiodystrophy: Sulfur-deficient brittle hair as a marker for a neuroectodermal symptom complex. *Arch Dermatol* **116**:1375, 1990

22. Takayama K et al: Defects of the DNA repair and transcription gene ERCC2(XPD) in trichothiodystrophy. *Am J Hum Genet* **58**:263, 1996

23. Sinclair RD et al: *Handbook of Diseases of the Hair and Scalp*. Oxford, Blackwell Science, 1999, p 161

24. Kaler SG: Menkes disease. *Adv Pediatr* **41**:263, 1994

25. Leone A et al: Menke's disease: Abnormal metallothionein gene regulation in response to copper. *Cell* **40**:301, 1985

26. Tümer Z et al: Early copper-histidine treatment for Menkes disease. *Nat Genet* **12**:11, 1996

27. Ito M et al: Pathogenesis in trichorrhexis invaginata (bamboo hair). *J Invest Dermatol* **83**:1, 1984

28. Chavanas S et al: Mutations in SPINK5, encoding a serine protease inhibitor, cause Netherton syndrome. *Nat Genet* **25**:141, 2000

29. Gilchrist TC: A case of monilethrix with an unusual distribution. *J Cutan Genito-Urinary Dis* **16**:157, 1898

30. Korge BP et al: Identification of novel mutations in basic hair keratins hHb1 and hHb6 in monilethrix: Implications for protein structure and clinical phenotype. *J Invest Dermatol* **113**:607, 1999

31. Birch-Machin MA et al: Mapping of monilethrix to the type II keratin gene cluster at chromosome 12q13 in three new families, including one with variable expressivity. *Br J Dermatol* **137**:339, 1997

32. Mallon ME et al: Cheveux incoiffables—Diagnostic, clinical and hair microscopic findings, and pathogenic studies. *Br J Dermatol* **131**:608, 1994

33. Shelley WB, Shelley ED: Uncombable hair syndrome: Observation on response to biotin and occurrence in siblings with ectodermal dysplasia. *J Am Acad Dermatol* **13**:97, 1985

34. Hutchinson PE et al: Woolly hair: Clinical and genetic aspects. *Trans St John's Hosp Dermatol Soc* **60**:160, 1974

35. Tosti A et at: Wooly hair, palmoplantar keratoderma and cardiac abnormalities: Report of a family. *Arch Dermatol* **130**:522, 1994

36. Guidetti MS et al: Diffuse partial woolly hair. *Acta Derm Venereol (Stockh)* **75**:141, 1995

37. Solomon LM et al: Hereditary trichodysplasia: Marie Unna's hypotrichosis. *J Invest Dermatol* **57**:389, 1971

38. Cichon S et al: A distinct gene close to the hairless locus on chromosome 8p underlies Marie Unna type hypotrichosis in a German family. *Br J Dermatol* **143**:811, 2000

39. Price VH: Structural anomalies of the hair shaft, in *Hair and Hair Diseases,* edited by CE Orfanos, R Happle. Berlin, Springer-Verlag, 1990, p 363

40. Price VH et al: Pseudopili annulati: An unusual variant of normal hair. *Arch Dermatol* **102**:354, 1970

41. Whiting DA: Chronic telogen effluvium. *Dermatol Clin* **14**:723, 1996

42. Ljungman P et al: Busulfan concentration in relation to permanent alopecia in recipients of bone marrow transplants. *Bone Marrow Transplant* **15**:869, 1995

43. Sinclair R et al: Anagen hair loss, in *Disorders of Hair Growth: Diagnosis and Treatment,* edited by EA Olsen. New York, McGraw-Hill, 2003

44. Elhassani SB: The many faces of methylmercury poisoning. *J Toxicol* **19**:875, 1982

45. Stein KM et al: Toxic alopecia from ingestion of boric acid. *Arch Dermatol* **108**:95, 1973

46. Bank WJ et al: Thallium poisoning. *Arch Neurol* **26**:456, 1972

47. Price VH, Gummer CL: Loose anagen syndrome. *J Am Acad Dermatol* **20**:249, 1989

48. Baden HP et al: Loose anagen hair as a cause of hereditary hair loss in children. *Arch Dermatol* **128**:1349, 1992

49. Safavi K: Prevalence of alopecia areata in the First National Health and Nutrition Examination Survey. *Arch Dermatol* **128**:702, 1992

50. Price VH: Alopecia areata: Clinical aspects. *J Invest Dermatol* **96**:68S, 1991

51. Olsen EA et al: Alopecia areata investigational assessment guidelines. *J Am Acad Dermatol* **40**:242, 1999

52. Muller SA, Winkelman RK: Alopecia areata. An evaluation of 736 patients. *Arch Dermatol* **88**:290, 1963

53. Paus R et al: Is alopecia areata an autoimmune response against melanogenesis-related proteins exposed by abnormal MHC Class I expression in the anagen hair bulb? *Yale J Biol Med* **66**:541, 1994

54. Hordinsky MK: Alopecia areata, in *Disorders of Hair Growth: Diagnosis and Treatment,* edited by EA Olsen. New York, McGraw-Hill, 2003

55. Headington JT: The histopathology of alopecia areata. *J Invest Dermatol* **96**:69S, 1991

56. Tobin DJ et al: Ultrastructural observations on the hair bulb melanocytes and melanosomes in acute alopecia areata. *J Invest Dermatol* **94**:803, 1990

57. Colombe BW et al: HLA class II alleles in long standing alopecia totalis/universalis and long standing patchy alopecia areata differentiate these two clinical groups. *J Invest Dermatol* **104**:4S, 1995

58. Ikeda T: A new classification of alopecia areata. *Dermatologica* **131**:421, 1965

59. Olsen EA et al: Systemic steroids with or without 2% topical minoxidil in the treatment of alopecia areata. *Arch Dermatol* **128**:1457, 1992

60. Claudy AL, Gagnaire D: PUVA treatment of alopecia areata. *Arch Dermatol* **119**:975, 1983

61. Shapiro J: Topical immunotherapy in the treatment of chronic severe alopecia areata. *Dermatol Clin* **11**:611, 1993

62. Fiedler VC et al: Treatment-resistant alopecia areata: Response to combination therapy with minoxidil plus anthralin. *Arch Dermatol* **126**:756, 1990

63. Trakimas C et al: Clinical and histologic findings in temporal triangular alopecia. *J Am Acad Dermatol* **31**:205, 1994

64. Olsen EA: Pattern hair loss, in *Disorders of Hair Growth: Diagnosis and Treatment,* edited by EA Olsen. New York, McGraw-Hill, 2003

65. Olsen EA: Female pattern hair loss. *J Am Acad Dermatol* **45**:S70, 2001

66. Kaufman KD: Androgen metabolism as it affects hair growth in androgenetic alopecia. *Dermatol Clin* **14**:697, 1996

67. Carey AH et al: Polycystic ovaries and premature male pattern baldness are associated with one allele of the steroid metabolism gene CYP17. *Hum Mol Genet* **3**:1873, 1994

68. Zhou Z-X et al: Specificity of ligand-dependent androgen receptor stabilization: Receptor domain interactions influence ligand dissociation and receptor stability. *Mol Endocrinol* **9**:208, 1995

69. Bayne EK et al: Immunohistochemical localization of types 1 and 2 5a-reductase in human scalp. *Br J Dermatol* **141**:481, 1999

70. Sawaya ME, Price VH: Different levels of 5a-reductase type I and II, aromatase and androgen receptor in hair follicles of women and men with androgenetic alopecia. *J Invest Dermatol* **109**:296, 1997

71. Kaufman KD et al: Finasteride in the treatment of men with androgenetic alopecia. *J Am Acad Dermatol* **39**:578, 1998

72. Price VH, Menefee E: Quantitative estimation of hair growth: Comparative changes in weight and hair count with 5% and 2% minoxidil, placebo and no treatment, in *Hair Research for the Next Millenium,* edited by D van Neste, VA Randall. Amsterdam, Elsevier Science BV, 1996, p 67

73. Unger WS: Surgical approach to hair loss, in *Disorders of Hair Growth: Diagnosis and Treatment,* edited by EA Olsen. New York, McGraw-Hill, 2003

74. Rushton DH et al: Quantitative assessment of spironolactone treatment in women with diffuse androgen-dependent alopecia. *J Soc Cosmet Chem* **42**:317, 1991

75. Cusan L et al: Treatment of hirsutism with the pure antiandrogen flutamide. *J Am Acad Dermatol* **23**:462, 1990

76. Dawber RPR et al: Oral antiandrogen treatment of common baldness in women. *Br J Dermatol* **107**(suppl 22):20, 1982

77. The Finasteride Male Pattern Hair Loss Study Group: Long-term (5-year) multinational experience with finasteride 1 mg in the treatment of men with androgenetic alopecia. *Eur J Dermatol* **12**:38, 2002

78. Rothbaum BO, Ninan PT: The assessment of trichotillomania. *Behav Res Ther* **32**:651, 1994

79. Stein DJ et al: Trichotillomania and obsessive-compulsive disorder. *J Clin Psychiatry* **56**:28, 1995

80. Muller SA: Trichotillomania: A histopathologic study in sixty-six patients. *J Am Acad Dermatol* **23**:56, 1990

81. Mehregan AH: Trichotillomania: A clinicopathologic study. *Arch Dermatol* **102**:129, 1970

82. Elewski BE: Tinea capitis: A current perspective. *J Am Acad Dermatol* **42**:21, 2000

83. Gan VN et al: Epidemiology and treatment of tinea capitis: Ketoconazole vs. griseofulvin. *Pediatr Infect Dis J* **6**:46, 1987

84. Roberts J, Devillez R: Infectious, physical, and inflammatory causes of hair and scalp abnormalities, in *Disorders of Hair Growth: Diagnosis and Treatment,* edited by EA Olsen. New York, McGraw-Hill, 2003

85. Jones TC: Overview of the use of terbinafine (Lamisil) in children. *Br J Dermatol* **132**:683, 1995

86. Detwiler SP et al: Bubble hair: A case caused by an overheating hair dryer and reproducibility in normal hair with heat. *J Am Acad Dermatol* **30**:54, 1994

87. Reda AM et al: Wooly hair nevus. *J Am Acad Dermatol* **22**:377, 1990

88. Esterly NB et al: Acquired progressive kinking of the hair. *Arch Dermatol* **125**:813, 1989

89. Cuozzo DW et al: Essential syphilitic alopecia revisited. *J Am Acad Dermatol* **32**:840, 1995

90. Jordaan HF, Louw M: The moth-eaten alopecia of secondary syphilis. *Am J Dermatopathol* **17**:158, 1995

91. Bettencourt MLS, Olsen EA: Pityriasis amiantacea: A report of two cases in adults. *Cutis* **64**:187, 1999

92. Whiting DA: Cicatricial alopecia: A review of clinico-pathological findings and treatment and a clinico-pathological examination of 358 cases using horizontal and vertical sections of scalp biopsies. *Clin Dermatol* **19**:211, 2001

93. Bergfeld WF, Elston DM. Primary cicatricial alopecia (and other causes of permanent alopecia), in *Disorders of Hair Growth: Diagnosis and Treatment,* edited by EA Olsen. New York, McGraw-Hill, 2003

94. Templeton SF, Solomon AR: Scarring alopecia: A classification based on microscopic criteria. *J Cutan Pathol* **21**:97, 1994

95. Stenn K et al: Hair follicle biology, the sebaceous gland and scarring alopecias. *Arch Dermatol* **135**:973, 1999

96. Sale GE: Does graft versus host disease attack epithelial stem cells? *Mol Med Today* **2**:114, 1996

97. Olsen EA et al: Summary of NAHRS sponsored workshop on cicatricial alopecia, Duke University Medical Center, Feb 10–11, 2001. *J Am Acad Dermatol* Accepted for publication

98. George SJ: Lichen planopilaris treated with thalidomide. *J Am Acad Dermatol* **45**:965, 2001

99. Mehregan DA et al: Lichen planopilaris: Clinical and pathologic study of forty-five patients. *J Am Acad Dermatol* **22**:935, 1992

100. Kossard S et al: Postmenopausal frontal fibrosing alopecia: A frontal variant of lichen planopilaris. *J Am Acad Dermatol* **36**:59, 1997

101. Zinkernagel MS, Trüeb RM: Fibrosing alopecia in a pattern distribution. *Arch Dermatol* **136**:205, 2000

102. Brocq L et al: Recherches sur l'alopecie atrophiante, variete pseudopelade. *Ann Dermatol Syphil* **6**:97, 1905

103. Braun-Falco O et al: Pseudopelade of Brocq. *Dermatologica* **172**:18, 1986

104. Pinkus H: Differential patterns of elastic fibres in scarring and non-scarring alopecia. *J Cutan Pathol* **5**:93, 1978

105. Sperling LC et al: A new look at scarring alopecia. *Arch Dermatol* **136**:235, 2000

106. Sperling LC et al: Follicular degeneration syndrome in men. *Arch Dermatol* **130**:763, 1994

107. Oosterwijk JC et al: Refinement of the localization of the X linked keratosis follicularis spinulosa decalvans (KFSD) gene in Xp22.13-p22.2. *J Med Genet* **32**:736, 1995

108. Bronzena SJ et al: Folliculitis decalvans—Response to rifampin. *Cutis* **42**:512, 1988

109. Bjellerup M, Wallengran J: Familial perifolliculitis capitis abscedens et suffodiens in two brothers successfully treated with isotretinoin. *J Am Acad Dermatol* **23**:752, 1990

110. Sperling LC et al: Acne keloidalis is a form of primary scarring alopecia. *Arch Dermatol* **136**:479, 2000

111. Kossard S et al: Necrotizing lymphocytic folliculitis: The early lesion of acne necrotica (varioliformis). *J Am Acad Dermatol* **16**:1007, 1987

112. Caputo R, Veraldi S: Erosive pustular dermatosis of the scalp. *J Am Acad Dermatol* **28**:96, 1993

113. Hatch R et al: Hirsutism: Implications, etiology, and management. *Am J Obstet Gynecol* **140**:815, 1981

114. Barbieri RL et al: The role of hyperinsulinemia in the pathogenesis of ovarian hyperandrogenism. *Fertil Steril* **50**:197, 1988

115. Glickman SP et al: Multiple androgenic abnormalities, including elevated free testosterone, in hyperprolactinemic women. *J Clin Endocrinol Metab* **55**:251, 1982

116. Wong IL et al: A prospective randomized trial comparing finasteride to spironolactone in the treatment of hirsute women. *J Clin Endocrinol Metab* **80**:233, 1995

117. Partridge JW: Congenital hypertrichosis lanuginosa: Neonatal shaving. *Arch Dis Child* **62**:623, 1987

118. Olsen EA: Hypertrichosis, in *Disorders of Hair Growth: Diagnosis and Treatment,* edited by EA Olsen. New York, McGraw-Hill, 2003

119. Baumeister FAM et al: Ambras syndrome: Delineation of a unique hypertrichosis universalis congenita and association with a balanced pericentric inversion (8) (p11.2;q22). *Clin Genet* **44**:121, 1993

120. Figuera LE et al: Mapping of the congenital generalized hypertrichosis locus to chromosome x q24-q27.1. *Nat Genet* **10**:202, 1995

121. Hovenden A: Acquired hypertrichosis lanuginosa associated with malignancy. *Arch Intern Med* **147**:2013, 1987

122. European Multicentre Trial Group: Cyclosporin in cadaveric renal transplantation: One year follow-up of a multicentre trial. *Lancet* **2**(2):986, 1983

123. Beneci PL et al: Cutaneous lesions in 67 cyclosporine treated renal transplant recipients. *Dermatologica* **172**:24, 1986

124. Dierickx CC et al: Permanent hair removal by normal mode ruby laser. *Arch Dermatol* **134**:837, 1998

T>

Chapter 72

Robert Baran Antonella Tosti

Nails

PATTERNS OF DISRUPTION OF THE COMPONENTS OF THE NAIL UNIT1
Variations in General Contour
Variations in Nail Surface
Variations in Nail Color
Variations in Direction of Nail Growth
Pathologic Reactions in Periungual Tissue
Variation in Consistency
NAIL ABNORMALITIES IN DERMATOLOGIC DISORDERS
PSORIASIS
PUSTULAR PSORIASIS/HALLOPEAU'S ACRODERMATITIS CONTINUA
PARAKERATOSIS PUSTULOSA
LICHEN PLANUS
ALOPECIA AREATA
DARIER'S DISEASE
CONTACT DERMATITIS
NAIL ABNORMALITIES ASSOCIATED WITH GENERAL MEDICAL CONDITIONS7
Collagen disorders
HEREDITARY AND CONGENITAL NAIL DISORDERS9
TUMORS INVOLVING THE NAIL AREA10
Epithelial Tumors
Fibrous Tumors
Vascular Tumors
Osteocartilaginous Tumors
Degenerative Lesions
Melanocytic Lesions15

REFERENCES

PATTERNS OF DISRUPTION OF THE COMPONENTS OF THE NAIL UNIT[1]

The diagnosis of disorders of the nail unit is based mainly on the sites of primary and secondary pathology. This chapter is based upon such an approach. The biology of the nail unit is presented in Chap. 13 and surgery of the nail is described in Chap. 280.

Variations in General Contour

Clubbing is defined as increased transverse and longitudinal nail curvature. It is made up of hypertrophy of the soft tissue components of the digit's pulp; hyperplasia of the fibrovascular tissue at the base of the nail, allowing the plate to be “rocked”; and local cyanosis. In normal individuals, the opposition of the dorsum of two fingers from opposite hands delineates a diamond-shaped “window” formed at the base of the nail beds (Fig. 72-1). Early clubbing obliterates this window and creates a prominent distal angle between the ends of the nails (Fig. 72-2). Almost 80 percent of cases are caused by intrathoracic disorders (Table 72-1).

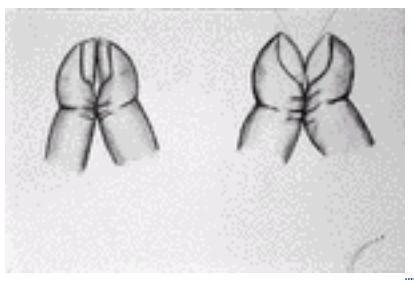

FIGURE 72-1 Opposition of the dorsum of two fingers from opposite hands in normal individuals.

FIGURE 72-2 Early clubbing.

Cardiovascular disorders	Aortic aneurysm[1]
	Congenital cardiopathy[2]
Bronchopulmonary conditions[3]	Intrathoracic neoplasms
	Chronic intrathoracic suppurative disease
Gastrointestinal disorders	Inflammatory bowel disease
	Gastrointestinal neoplasms
	Liver disorders
	Multiple polyposis
	Bacillary and amoebic dysentery
Chronic methemoglobinemia	

[1] Unilateral
[2] With cyanosis
[3] Associated with hypertrophic osteopathy

TABLE 72-1 **Causes of Clubbing**

In addition to clubbing, *hypertrophic pulmonary osteoarthropathy* is associated with acromegalic limb changes, pseudoinflammatory symmetric large joint arthropathy, bilateral proliferative periostitis, peripheral cyanosis and paresthesia, local pain, and swelling. The distal digit disorders may be relieved by treating the underlying disease. When only the lower limbs are affected, the condition results from aortofemoral bypass grafts, reversed patent ductus, or aortointestinal fistula, all of which may be complicated by infection. Pachydermoperiostosis is a rare type of idiopathic hypertrophic osteoarthropathy.

In *koilonychia* (spoon nails) (Fig. 72-3), the nail is concave with raised edges. Involvement of the first three fingernails suggests an occupational origin of the deformity. Koilonychia is physiologic in early infancy. Iron-deficiency anemia associated with Plummer-Vinson's syndrome is rarely observed in association with spoon nails.

FIGURE 72-3 Koilonychia.

In *transverse overcurvature,* the nail may be tile-shaped or, more often, it displays an increase in curvature along the nail bed (pincer or trumpet nail). Overcurvature may extend to the point of encompassing a cone of nail bed soft tissue, which can be extremely painful.

In *racquet nail* (Fig. 72-4), the width of the nail bed and nail plate is greater than their length. The racquet thumb is usually inherited as an autosomal dominant trait due to premature obliteration of the epiphyseal line.

FIGURE 72-4 Racquet nail.

Anonychia implies the absence of all or part of one or several nails, which may be congenital (with underlying bone abnormalities) or acquired (e.g., through lichen planus).

Variations in Nail Surface

There are various causes of grooves, ridges, and pits, including local trauma to the nail matrix and acute febrile systemic disease. Poor nutrition to the matrix leads to a defective band of nail formation resulting in a *transverse groove* of thin nail plate (Beau's line) (Fig. 72-5). Recurrent disease will produce recurrent transverse grooves separated by normal nail. The depression may extend all the way to the nail plate, leading to temporary loss of nail. By measuring the position of the transverse grooves, it is possible to date previous illness. Transverse grooves are sometimes found in psoriasis. These should be differentiated from “wash-board” nails in which there is also a longitudinal depression usually affecting one or both thumb nails; this commonly results from habitually pushing back the cuticle.

FIGURE 72-5 Beau's lines.

Longitudinal ridges are small rectilinear projections extending from the proximal nail fold to the free edge of the nail. They may be interrupted at regular intervals, giving rise to a beaded appearance. A *longitudinal groove* may run all or part of the length of the nail. *Median canaliform dystrophy of Heller* (Fig. 72-6) is the most distinctive nail surface anomaly. It may be split in the midline with a fir-tree-like appearance of backwards-angled ridges. Thumbs, which are most commonly involved, show usually an enlarged lunula resulting probably from pressure on the base of the nail repeatedly exerted.

FIGURE 72-6 Median canaliform dystrophy of Heller.

A single, wide groove, or *canal,* develops from pressure, permanent or intermittent, on the matrix; it is caused by a tumor-like myxoid cyst (Fig. 72-7). *Ridging* is pronounced in old age, lichen planus, rheumatoid arthritis, peripheral vascular disease, and Darier's disease.

FIGURE 72-7 Canal developed from permanent pressure on the matrix due to myxoid cyst.

Pits are punctate depressions in the nail, arranged in haphazard or regular patterns. They are characteristic of psoriasis (Fig. 72-8) but may also be found in alopecia areata or in eczema.

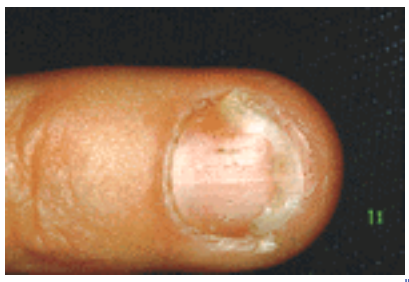
FIGURE 72-8 Pits associated with onycholysis.

Trachyonychia (rough nail) is observed in dermatologic diseases as a 20-nail dystrophy or in single finger nails, resulting from external chemical treatment.

Variations in Nail Color

The term *chromonychia* indicates an abnormality in color of the substance and/or the surface of the nail plate and/or subungual tissues. Examination of abnormal nails should be done with the fingers completely relaxed and not pressed against a surface. To differentiate between discoloration of the nail plate itself and the vascular nail bed, the finger tip should be blanched to determine whether the color changes. If the pigment originates from the blood vessels (e.g., in methemoglobinemia), it will usually disappear. If the pigmentation is not altered in the blanching test, it may be obliterated by a penlight pressed against the pulp, meaning that the pigment is deposited in the nail bed; the exact position of the discoloration can then more easily be identified. All digits are usually involved when pigmentation is a result of systemic absorption of a chemical through the skin. When the cause is endogenous, the discoloration often

corresponds to the shape of the lunula (Fig. 72-9). By contrast, when the discoloration follows the shape of the *proximal nail fold (PNF),* it is caused by an external contactant (Fig. 72-10). In that case, finger pressure producing blanching does not alter the pigmentation, nor does a penlight placed against the finger pulp. The discoloration can sometimes be removed by scraping or cleaning the nail plate with a solvent such as acetone. To determine if the color is within the nail, a piece of nail should be excised and examined while it is immersed in water. In deeper or subungual impregnation of the nail keratin, microscopic studies (KOH; PAS stain) may be indicated.

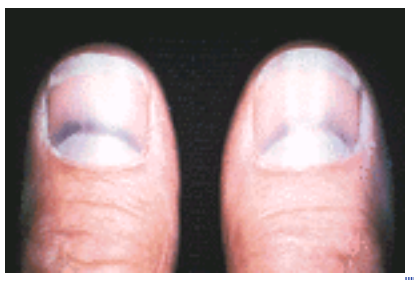

FIGURE 72-9 Argyria. The discoloration distal to the lunula corresponds to its shape.

FIGURE 72-10 External contactant. The discoloration follows the shape of the proximal nail fold.

LEUKONYCHIA

True leukonychia This white discoloration of the nail is attributable to matrix dysfunction and presents five patterns: (1) total leukonychia (usually inherited); (2) subtotal leukonychia, when the distal portion of the nail appears normally pink; (3) transverse leukonychia, in which there is a 1- to 2-mm wide transverse arcuate band (Fig. 72-11) reflecting a systemic disorder when several nails are involved; (4) punctate leukonychia, in which white spots result, usually from minor trauma (manicure); and (5) longitudinal leukonychia, which may be associated with Darier's disease.

FIGURE 72-11 Transverse true leukonychia.

Pseudoleukonychia This term is used when the nail plate alteration has an external origin, such as in onychomycosis or in keratin granulations observed after nail enamel applications.

Apparent leukonychia The white appearance of the nail is due to changes in the underlying tissue and may present as the following:

1. *Terry's nail* (Fig. 72-12), in which the white discoloration stops suddenly 1 to 2 mm from the distal edge, leaving a pink-brown area 0.5 to 3.0 mm wide. This condition, which involves all nails uniformly, is associated with cirrhosis of the liver, chronic congestive heart failure, or adult-onset diabetes mellitus.

   FIGURE 72-12 Apparent leukonychia: Terry's nail.

2. *Half-and-half nail* with the two parts showing a sharp demarcation. The proximal area is dull white, and the distal area (20 to 60 percent of the total length) is brownish. It has been reported in uremic patients.
3. *Muehrcke's paired, narrow white bands* (Fig. 72-13) parallel the lunula in the nail bed and are commonly associated with hypoalbuminemia or following chemotherapy.

FIGURE 72-13 Apparent leukonychia: Muehrcke's paired, narrow white bands.

SPLINTER HEMORRHAGES These longitudinal hemorrhages in the distal nail bed conform to the pattern of subungual vessels. Emphasis has recently been given to their association with the antiphospholipid syndrome. Proximal splinter hemorrhages have been reported in bacterial endocarditis, trichinosis, and onychomatricoma. They may be seen following external trauma.

Variations in Direction of Nail Growth

ONYCHOGRYPHOSIS (Fig. 72-14)

FIGURE 72-14 Onychogryphosis.

In this disorder, the nail is severely distorted, thickened, opaque, brownish, spiraled, and without attachment to the nail bed. The nail of the great toe is particularly vulnerable; it is often shaped like a ram's horn or an oyster. Nail keratin is produced by the nail matrix at uneven rates, with the faster-growing side determining the direction of the deformity. Onychogryphosis is usually caused by pressure from footwear in the elderly. In rare cases, it may be produced by acute trauma, and rarely it is inherited as an autosomal dominant trait. Hemionychogryphosis with lateral deviation of the nail plate often results from congenital malalignment of the big toenail.

MALALIGNMENT OF THE NAIL PLATE Congenital malalignment of the nail of the great toe (Fig. 72-15) [2] is often misdiagnosed even though it is a common condition. It consists of a lateral deviation of the long axis of nail growth relative to the distal phalanx. This would be of minor importance if it were not for local complications that may arise both in infancy and adulthood. Some cases of this inherited condition have, however, a tendency to improve spontaneously. Photographic surveys should be made at regular intervals to monitor the need for possible surgery which rotates the nail plate. Acquired traumatic malposition may follow acute trauma. Broad lateral longitudinal surgical excision of the nail apparatus may also cause malalignment of the remaining nail. Acquired traumatic malposition may follow acute trauma.

FIGURE 72-15 Malalignment of the great toe nails.

HOOK NAIL This reflects bowing of the nail bed due to a lack of support from the short bony phalanx.

Pathologic Reactions in Periungual Tissue

ABNORMALITIES IN PARONYCHIAL TISSUE The proximal nail fold (PNF) adheres tightly to the dorsum of the nail plate, and its free border, producing the cuticle, seals the proximal nail groove. The PNF can become acutely or chronically inflamed. *Acute paronychia* may follow any break in the skin. The infection starts in the paronychium at the side of the nail, with local redness, swelling, and pain. If it does not show clear signs of response to penicillinase-resistant antibiotics within 2 days, partial avulsion of the base of the nail plate should be performed. *Chronic paronychia* is a separate disorder prevalent in individuals whose hands are subjected to moist local environments and is often due to contact dermatitis. It manifests as a red, semicircular indurated cushion around the base of the nail, which is detached from the distal portion of the PNF that has lost its cuticle. This is followed by secondary retraction of the paronychial tissue. From time to time, the persistent low-grade inflammation may flare into subacute painful exacerbations. This causes disturbances of the nail plate that may produce discolored, cross-ridged lateral edges, reflecting *Candida* invasion. *Dorsal pterygium* (Fig. 72-16) consists of a gradual shortening of the proximal nail groove, leading to progressive thinning of the nail plate and secondary fissuring caused by the fusion of the PNF to the matrix and subsequently to the nail bed. The portions of the divided nail plate progressively decrease in size as the pterygium

widens. After several years, the pathologic process results in total loss of the nail, with permanent atrophy and sometimes scarring in the nail area. Pterygium is characteristic of lichen planus. It may also follow severe bullous dermatoses, radiotherapy, trauma, or digital ischemia. Rarely, it is congenital.

FIGURE 72-16 Dorsal pterygium.

Ventral pterygium (Fig. 72-17) is a distal extension of the hyponychial tissue that is anchored to the undersurface of the nail, thereby obliterating the distal groove. Several conditions can cause ventral pterygium including: scleroderma associated with Raynaud's phenomenon, causalgia of the median nerve, trauma, and a reaction to a formaldehyde-containing nail cosmetic. Congenital forms exist.

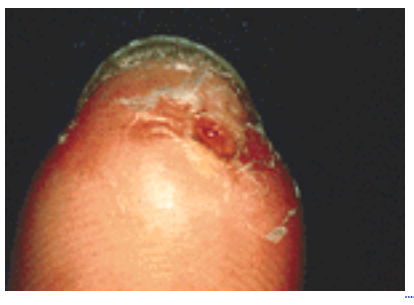

FIGURE 72-17 Ventral pterygium.

FAULTY ATTACHMENT OF NAIL PLATE AND SOFT TISSUE *Nail shedding,* which is the spontaneous separation of the nail from the matrix, is called *onychomadesis* and is usually latent (Fig. 72-18). The nail plate shows a transverse split but continues growing for some time because there is no disruption in its attachment to the nail bed. Growth ceases when the nail is cast off after losing this connection. The process termed *onychoptosis defluvium,* or alopecia unguium, is sometimes a component of alopecia areata, even though it is confined to the nails. *Onycholysis* (Fig. 72-19) refers to the detachment of the nail from its bed starting at its distal and/or lateral attachment. The nail plate–nail bed separation extends proximally along a convex line, creating a subungual space that gathers dirt and keratin debris. The grayish-white color is due to the presence of air beneath the nail, but the color may vary according the etiology.

FIGURE 72-18 Latent onychomadesis.

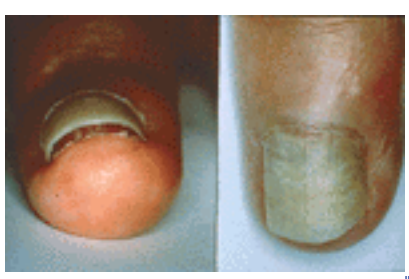

FIGURE 72-19 Onycholysis.

Variation in Consistency

Hard nails are a major characteristic of the pachyonychia congenita syndrome. *Soft nail* disease may be congenital (unusual) or acquired, occupational contact with water and chemicals being the most common cause. *Brittle nails* may be

divided into three types, in isolation or combination:

1. Splitting, more often single than multiple, sometimes associated with shallow parallel furrows, called *onychorrhexis,* and running along the dorsum of the nail.
2. Lamellar, splitting involving either the free edge, following frequent water immersion, or the proximal surface of the nail associated with lichen planus, or oral retinoids therapy.
3. Transverse splitting and breaking of the lateral edge close to the free margin.

The dorsum of the nail may be friable in superficial onychomycosis as well as following nail enamel use. Friability may extend throughout the entire nail in advanced psoriasis and onychomycosis.

NAIL ABNORMALITIES IN DERMATOLOGIC DISORDERS

PSORIASIS

Nail abnormalities are seen in 10 to 55 percent of adults with psoriasis. They are less common in children (7 to 13 percent). Psoriasis limited to the nails is quite frequent.

The following nail abnormalities are highly suggestive for a diagnosis of psoriasis: irregular pitting, salmon patches of the nail bed, and onycholysis. All these nail abnormalities are almost exclusively found in the fingernails. Nail pitting results from the presence of easily detachable parakeratotic cells in the superficial layers of the nail plate. This nail abnormality indicates a disturbance in the maturation and keratinization of the proximal nail matrix. In psoriasis, pits are typically deep, large, irregular in size, and randomly distributed. Salmon patches appear as yellow or salmon-pink areas, irregular in size and shape, visible through the transparent nail plate. They result from a psoriatic involvement of the nail bed.

The term *onycholysis* describes the distal or lateral detachment of the nail plate from the nail bed. Onycholysis may be a consequence of inflammatory, traumatic, or neoplastic conditions that involve the nail bed. In psoriasis, the onycholytic area is characteristically surrounded by an erythematous margin that marks its proximal border (Fig. 72-8 and Fig. 72-20). In addition to these three clinical signs, which are very useful for diagnosis, psoriasis of the nail produces other nail abnormalities that are not diagnostic, including splinter hemorrhages, nail bed hyperkeratosis, thickening and crumbling of the nail plate, and chronic paronychia. In the absence of skin lesions or typical nail signs, the differential diagnosis of nail psoriasis includes the disorders listed in Table 72-2.

FIGURE 72-20 Nail psoriasis. Onycholysis and salmon patches of the nail bed.

Contact dermatitis
Inflammatory linear verrucous epidermal nevus
Keratoderma
Keratoderma blennorrhagica
Keratotic scabies
Lichen planus
Onychomycosis
Parakeratosis pustulosa
Pityriasis rubra pilaris
Reiter's disease

TABLE 72-2 **Differential Diagnosis of Nail Psoriasis**

When psoriasis is limited to the toenails, the differential diagnosis from onychomycosis may be very difficult, because toenail psoriasis most commonly produces massive subungual hyperkeratosis and onycholysis clinically indistinguishable from those of onychomycosis (Fig. 72-21). Psoriasis and onychomycosis actually are also frequently associated because psoriatic nails are more susceptible to fungal invasion than healthy nails.

FIGURE 72-21 Toenail psoriasis showing massive nail bed hyperkeratosis.

Nail psoriasis is difficult to treat. [3] Patients must be instructed to avoid traumas that may trigger or worsen their condition (Koebner's phenomenon). When onycholysis is present, the detached nail plate should be removed. Systemic

administration of methotrexate or cyclosporin A may improve the nail changes, but these drugs are not recommended in the absence of extensive skin psoriasis. Intralesional steroid injections (10 mg/mL) are effective but very painful. Retinoids and PUVA are scarcely effective and may even worsen the nail changes. Topical application of creams containing steroids and salicylic acid, and/or topical application of calcipotriol ointment may be useful. Because nail psoriasis is frequently associated with psoriatic arthropathy (Fig. 72-22), a rheumatological evaluation is advisable.

FIGURE 72-22 Nail psoriasis associated with psoriatic arthropathy.

PUSTULAR PSORIASIS/HALLOPEAU'S ACRODERMATITIS CONTINUA

This condition frequently involves the nails and the periungual tissues. The disease, which is most frequently localized to one digit (usually a finger), typically shows a chronic course with periodic episodes of painful acute inflammation. In the acute phase, the affected digit shows severe inflammatory changes with pustular lesions of the nail bed and periungual skin (Fig. 72-23). In the chronic phase, the nail bed and the periungual tissues show erythema and scaling. The nail plate is onycholytic or absent. The condition often improves with topical calcipotriol. Systemic retinoids may be useful in severe cases. [4]

FIGURE 72-23 Hallopeau's acrodermatitis. Pustular lesions of the nail bed.

PARAKERATOSIS PUSTULOSA

This condition, which is exclusively seen in children, usually involves one finger, most commonly the thumb or the index finger. The affected nail shows subungual hyperkeratosis and onycholysis, which are usually more marked on one side of the nail (Fig. 72-24). Erythema and scaling of the fingertip is typical, but not always present. Parakeratosis pustulosa is possibly a variety of psoriasis and some children develop typical nail psoriasis later in life. The disease usually regresses spontaneously at puberty.

FIGURE 72-24 Parakeratosis pustulosa. This child has psoriasiform nail lesions associated with fingertip scaling of one digit.

LICHEN PLANUS

Nail involvement occurs in about 10 percent of patients with lichen planus. Lichen planus limited to the nails is uncommon but not exceptional. It may be observed in children. [5]

Lichen planus of the nail matrix is a harmful condition because it frequently produces diffuse nail scarring (Fig. 72-25). Nail abnormalities that are highly suggestive of lichen planus include dorsal pterygium and diffuse nail thinning and

splitting. Pterygium appears as an extension of the skin of the proximal nail fold that expands distally to adhere to the nail bed (Fig. 72-25). Although lichen planus is the most common cause of nail pterygium, this lesion may be a consequence of nail matrix destruction by other conditions, including trauma, digital ischemia, and bullous disorders. Nail thinning and splitting are consequences of diffuse and mild involvement of the nail matrix by lichen planus. The nail plate is diffusely or partially thinned and presents longitudinal ridging and splitting (Fig. 72-26). Nail bed lichen planus produces subungual hyperkeratosis and onycholysis. Yellow-nail–like changes are not uncommon in toenails and may also affect fingernails. In children, nail lichen planus may present with atypical features such as trachyonychia or idiopathic atrophy of the nails. [6] Differential diagnosis of these clinical features include traumatic nail lesions, tumors that compress the nail matrix, age-related nail changes, systemic amyloidosis, and lichen striatus.

FIGURE 72-25 Severe nail scarring due to lichen planus.

FIGURE 72-26 Diffuse nail thinning and onychorrhexis due to lichen planus.

The definitive diagnosis of nail matrix lichen planus requires a nail biopsy. Except for trachyonychia, treatment of nail lichen planus is mandatory, because if left untreated, it may produce diffuse nail scarring (Fig. 72-26). Systemic (triamcinolone 0.5 to 1 mg/kg IM every 30 days) or intralesional steroids are effective. Acitretin is also effective.

ALOPECIA AREATA

Nail abnormalities are frequent in patients with alopecia areata, particularly in children. They may precede or follow the onset of the disease and usually regress spontaneously. The changes include geometric pitting, mottled erythema of the lunulae, and trachyonychia. Pits are usually small, superficial, and regularly distributed in a geometric pattern.

Trachyonychia observed in 20-nail dystrophy describes nail roughness caused by excessive longitudinal striations. This nail sign is not exclusive to alopecia areata because it can also be a sign of other inflammatory disorders such as lichen planus, psoriasis, eczema, and pemphigus vulgaris. [7] The affected nails may be opaque (sandpapered nails) (Fig. 72-27) or, less frequently, have a shiny appearance (Fig. 72-28). Trachyonychia is more frequent in children, where it may be an isolated sign (idiopathic trachyonychia).

FIGURE 72-27 Trachyonychia. Sandpapered nails.

FIGURE 72-28 Shiny appearance in 20-nail dystrophy. Multiple superficial pits distributed in a regular pattern.

DARIER'S DISEASE

The nail abnormalities are diagnostic and consist of longitudinal subungual white and red streaks. White streaks are

associated with V-shaped distal notching due to wedge-shaped hyperkeratotic papules of the distal nail bed (Fig. 72-29).

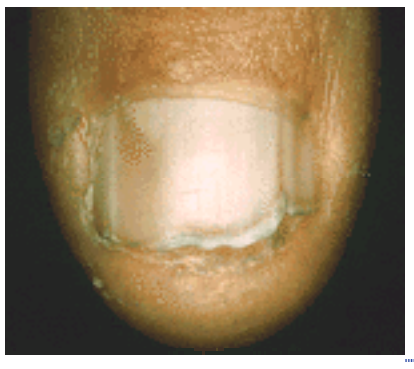

FIGURE 72-29 Darier's disease. Red and white streaks with distal V-shaped notches.

CONTACT DERMATITIS

Irritant and allergic contact dermatitis may occasionally be localized to the nail, where they most commonly affect the proximal nail fold and the hyponychium.

Contact dermatitis of the proximal nail fold is responsible for chronic paronychia and nail plate surface abnormalities, such as irregular pitting and Beau's lines. These are caused by mild involvement of the adjacent proximal nail matrix. Contact dermatitis of the hyponychium produces severe subungual hyperkeratosis and nail bed splinter hemorrhages (Fig. 72-30). The differential diagnosis includes onychomycosis, psoriasis, parakeratosis pustulosa, pityriasis rubra pilaris, and keratoderma.

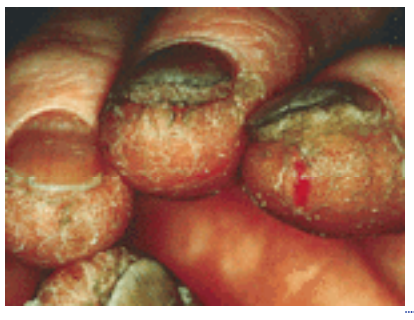

FIGURE 72-30 Contact dermatitis of the hyponychium and distal tip with severe subungual hyperkeratosis.

NAIL ABNORMALITIES ASSOCIATED WITH GENERAL MEDICAL CONDITIONS[7]

Examination of the nails may sometimes offer a clue for the diagnosis of systemic conditions. Nail signs that may indicate a systemic illness are listed in Table 72-3.

Beau's lines—onychomadesis	High fever
	Peripheral nerve injury
	Surgery
	Drugs
Koilonychia	Sideropenic anemia
Proximal splinter hemorrhages	Bacterial endocarditis
	Trichinosis
	Vasculitis
Periungual erythema	"Collagen" disease
	HIV infection
	HCV infection
Lichenoid nail changes with hemorrhages	Systemic amyloidosis

TABLE 72-3 **Nail Signs in Systemic Illness**

Collagen disorders

PROXIMAL NAIL FOLD CAPILLARY ABNORMALITIES Proximal nail fold capillaries can easily be examined using a portable ophthalmoscope. In systemic sclerosis and dermatomyositis, proximal nail fold capillaries are limited due to the presence of avascular areas. Enlarged capillary loops are present (Fig. 72-31).

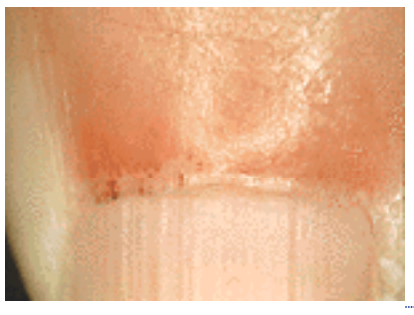

FIGURE 72-31 Systemic sclerosis. Avascular areas and enlarged capillaries.

In systemic lupus erythematosus, capillary density is normal, but capillary loops are tortuous and meandering.
CLUBBING Clubbing may be associated with joint effusion and periosteal bone formation. Clubbing or hypertrophic

osteoarthropathy may be a consequence of a large number of diseases that involve tissues with a vagus nerve supply (see Table 72-1).

ACROOSTEOLYSIS Destructive changes in the distal phalangeal bone may be associated with minimal skin changes or with ischemic skin lesions that may result in digital necrosis (Fig. 72-32). The affected digits usually show bulbous fingertips with soft tissue thickening and pseudo-clubbing. Shortening of the distal phalanges causes the nails to appear abnormally broad (acquired racquet nails). Acroosteolysis results from a wide variety of systemic and localized disorders that produce impaired phalangeal perfusion (Table 72-4).

FIGURE 72-32 Necrotic nail lesions and acroosteolysis in a patient with carpal tunnel syndrome.

Neurologic disorders	Peripheral neuropathies Diabetes Leprosy Carpal tunnel syndrome Cervical rib Myelopathies Tabes dorsalis Syringomyelia
Vascular disease	Atherosclerosis Pernicosis Buerger's disease Raynaud's disease Systemic sclerosis

TABLE 72-4 **Systemic Causes of Acroosteolysis**

ACROKERATOSIS PARANEOPLASTICA OF BAZEX This condition is characterized by psoriasiform changes of hands, feet, ears, and nose. Involvement of the nails and periungual tissues is characteristic, nail lesions being indistinguishable from nail psoriasis (Fig. 72-33). Acrokeratosis paraneoplastica of Bazex occurs in association with malignant epitheliomata of the upper respiratory or digestive tract and may precede the diagnosis of the tumor.

FIGURE 72-33 Psoriasiform nail lesions due to Bazex' syndrome.

YELLOW NAIL SYNDROME This condition is typically characterized by an arrest in the nail growth. Fingernails and toenails are hard and excessively curved from side to side and show a diffuse pale yellow to dark yellow-green discoloration. Cuticles are absent. Secondary onycholysis is frequent (Fig. 72-34). In typical cases, the nail changes are associated with lymphedema and respiratory tract involvement. Yellow nail syndrome may occasionally be a paraneoplastic sign. The nail changes may benefit from treatment with high dosages of vitamin E combined with systemic itraconazole or fluconazole.

FIGURE 72-34 Yellow nail syndrome. Transverse overcurvature with loss of cuticle.

PSEUDO-INFLAMMATORY CHANGES Digital ischemia frequently produces massive swelling, erythema, and pain of the nails and periungual tissues, which resemble acute paronychia. The affected digit, however, is cold. Digital metastases may also produce an acute paronychia-like picture.

MELANONYCHIA Multiple bands of longitudinal melanonychia may be a consequence of pharmacologic treatment and numerous systemic diseases including AIDS, Addison's disease, Cushing's syndrome, hyperthyroidism, folic acid or vitamin B_{12} deficiency (Fig. 72-35). Transverse melanonychia is frequently observed in patients undergoing anticancer chemotherapy.

FIGURE 72-35 Multiple bands on longitudinal melanonychia in a patient with AIDS.

DRUG-INDUCED NAIL CHANGES Drugs may produce a large number of nail abnormalities. [7], [8] Usually, several nails are simultaneously affected and the nail changes regress after withdrawal of the drug. Table 72-5 lists the most common nail changes induced by drugs.

Drugs	Symptom
Retinoids	Nail brittleness
	Pseudopyogenic granuloma
Azidothymidine (AZT)	Melanonychia
Indinavir	Paronychia/pyogenic granuloma
β-Blockers	Digital ischemia
Antineoplastic	Melanonychia
	Onycholysis/photoonycholysis
	Apparent leukonychia
	Beau's lines
	Onychomadesis
PUVA therapy	Melanonychia
	Photoonycholysis

TABLE 72-5 **Drug-Induced Nail Changes**

HEREDITARY AND CONGENITAL NAIL DISORDERS[9]

Nail defects occurring between the ninth and twentieth week of fetal life are called *embryopathies*. They include abnormalities of the nail matrix (absence, reduction, position, or function) and/or nail bed (hereditary partial onycholysis, pachyonychia congenita). *Fetopathies* occur after 20 weeks of gestation (malformations due to drugs).

The term *hereditary ectodermal dysplasia* is used to cover a heterogeneous group of primary epidermal disorders in which one of the following signs occur: hypotrichosis, hypodontia, onychodysplasia, and anhidrosis, plus at least one sign affecting other structures of epidermal origin (see Chap. 53).

In the *nail-patella syndrome,* there is an association of nail changes, triangular lunula, and usually partial nail loss (Fig. 72-36), with the severity of the defects decreasing from the thumb to the fifth finger. Skeletal abnormalities, such as an absent or hypoplastic patella, iliac horns, and kidney involvement with collagen-like fibrils in the glomerular basement membrane, are also found.

FIGURE 72-36 Partial nail loss in nail-patella syndrome.

In *pachyonychia congenita,* an autosomal dominant keratin disorder, thickening of the nail and subungual hyperkeratosis appear in infants up to 6 months of age, but late onset has also been reported. Jadassohn-Lewandowsky syndrome is characterized by hyperkeratosis of palms and soles, follicular keratosis, and oral leukoplakia, as well as a striking increase in thickness of the distal portion of the nail and yellow to brown discoloration with pinched margins and upward tilt of distal tips (Fig. 72-37). This may interfere with the coordination of finger movement, sometimes leading to ablation of the nail matrix and bed.

FIGURE 72-37 Pachyonychia congenita.

Nail changes in dystrophic and junctional forms of *epidermolysis bullosa (EB)* are common, but although they strongly suggest the disease, they are not pathognomonic. They result from abnormalities of the nail matrix and nail bed, associated with the pathogenetic alterations of the dermal-epidermal junction that occur in EB. In addition, secondary trauma in the areas of dermal-epidermal separation and chronic inflammation of the nail matrix are probably contributory factors, even in nonscarring forms of EB.

TUMORS INVOLVING THE NAIL AREA[10]

Epithelial Tumors

Warts are benign, fibroepithelial tumors that are caused by human papilloma viruses (HPV) of different types, most frequently HPV-1, HPV-2, and HPV-4, but other HPV types have also been isolated from the nail region. Periungual and

subungual warts are mildly contagious and probably caused by inoculation of HPV DNA into the skin after biting or picking. Periungual warts are circumscribed keratotic papules with a rough verrucous surface; they sometimes exhibit fissures and clefts that may cause pain and give rise to secondary bacterial infections. The warts may merge to form larger, plaquelike tumors. When extending under the nail plate, they may raise the plate, causing discoloration, loss of transparency, or splitting and breaking of the plate. Any pressure may then be painful. Even bone erosion from subungual warts has been observed. Injection of bleomycin is one of the best treatments.

Keratin implantation cysts (Fig. 72-38), which are lined with epidermis and filled with keratin, are occasionally observed under the nail. They are most commonly due to trauma that causes a laceration of the nail bed and start to grow after the patient has already forgotten the injury. Depending on the location in the nail apparatus, the keratin cyst may appear as a large subungual tumor raising the nail plate or causing a bulbous enlargement of the terminal phalanx. Intraosseous epidermal cysts may lead to spontaneous fracture and may mimic a bone tumor or intraosseous metastasis. An x-ray is mandatory and will show a sharply demarcated, round defect. Cysts lined with matrix epithelium and filled with keratin-like nail substance have been observed after incomplete removal of the lateral matrix horn.

FIGURE 72-38 Keratin implantation cyst following surgery for ingrown toenail.

Onychomatricoma (Fig. 72-39) is a recently described distinctive tumor of the nail matrix. [11] The clinical criteria for diagnosis include a longitudinal band of yellow thickening of the nail plate, increased transverse curvature of the nail, and splinter hemorrhages in the proximal portion of the nail. Histologically the tumor is characterized by filiform epithelial projections in the center of which traumatic clefts or parakeratotic columns are visible.

FIGURE 72-39 Onychomatricoma. Longitudinal xanthonychia.

Keratoacanthomas (Fig. 72-40) are benign, but rapidly growing, locally aggressive tumors, which sometimes occur on the nail apparatus. [12] Keratoacanthomas in this site differ from those of the skin. The most frequent location is the hyponychium or the lateral nail groove from which the lesion may grow under the nail plate. Keratoacanthomas usually start as small, painful nodules visible under the nail plate margin. They may achieve a diameter of 1 to 2 cm within 4 to 8 weeks. Whereas the typical dome shape is not usually seen, there is almost always a central keratotic plug that tends to be extruded upon pressure on the surrounding tissue. Pain is a very typical symptom of subungual keratoacanthoma. The subungual tumors reported in adolescents or young adults in incontinentia pigmenti are probably true keratoacanthomas.

FIGURE 72-40 Distal subungual keratoacanthoma.

Fibrous Tumors

Fibrous tumors encompass a wide spectrum of clinical manifestations although the histology is quite uniform.

ACQUIRED PERIUNGUAL FIBROKERATOMA (See Fig. 72-41)

FIGURE 72-41 Acquired fibrokeratoma causing a sharp longitudinal depression.

This presents as an asymptomatic nodule with a hyperkeratotic tip and a narrow base, occurring mostly in the periungual area. The fibrokeratoma often emerges from beneath the PNF, grows on the nail, and causes a sharp longitudinal depression. Such fibrokeratomas may present as double and even triple lesions. The hyperkeratotic tip is not present in the “garlic-glove” fibroma.

KOENEN'S TUMOR Koenen's periungual fibromas develop in 50 percent of tuberous sclerosis cases. They appear in patients between 12 and 14 years of age and increase progressively in size and number with age. The tumors may be either small, round, smooth, flesh-colored, and asymptomatic, or they may be slightly hyperkeratotic at the tip, resembling fibrokeratoma. Excessively large tumors involving the nail bed are often painful.

FIBROUS DERMATOFIBROMAS (See Fig. 72-42)

FIGURE 72-42 Distal subungual fibroma lifting up the nail plate.

Fibromas develop as painless slow-growing nodular tumors, spherical or oval in shape and firm or rubbery, in consistency, in any epidermal tissue. They may move freely or remain fixed. In the distal nail bed, they lift the nail plate. Nail dystrophy usually results in a longitudinal depression as pressure is exerted on the nail matrix.

INFANTILE DIGITAL FIBROMATOSIS (See Fig. 72-43)

FIGURE 72-43 Infantile digital fibromatosis.

These round, smooth, dome-shaped, shiny, firm, tense, reddish or livid red dermal nodules are usually located on the dorsal and axial surfaces of the fingers and toes, but spare the thumbs and the great toes. They may be present at birth or develop during infancy. Multiple lesions occur in 50 percent of patients. The tumors may cause considerable distortion of the distal digit, but spontaneous resolution is the rule, which may be hastened by cryosurgery.

EPIDERMOID CARCINOMAS (Bowen's disease and squamous cell carcinomas) (see Fig. 72-44). Bowen's disease is a carcinoma developing into frankly invasive squamous cell carcinoma. Because the clinical picture does not permit a distinction to be made between carcinoma in situ and invasive carcinoma, the term *epidermoid carcinoma* was coined for these lesions in the nail region. The etiology of epidermoid carcinomas has recently been linked to HPV-16, HPV-34, and HPV-35, but arsenic may also play a role.

FIGURE 72-44 Bowen's disease involving the lateral nail groove.

Bowen's disease occurs most frequently in males between 50 and 70 years of age. The fingers, mainly the first three, are most frequently affected. When a toe is involved, it is usually the great toe. The lesion grows slowly and is resistant to conservative therapy. In most cases, it presents as a circumscribed plaque, with a warty surface extending from the nail groove both under and around the nail. Nail dystrophy develops when the matrix is affected. Because involvement of the nail bed causes onycholysis, the overlying nail plate should be cut away to permit evaluation of the extent of nail bed involvement. Erosions, oozing, bleeding, and development of a tumor mass indicate malignant degeneration. Bowen's disease of the nail may be pigmented, causing longitudinal melanonychia. It may mimic ungual fibrokeratoma and occur on several digits. Carcinoma cuniculatum is a rare variant of squamous cell carcinoma, with low biologic malignancy. Diagnosis requires histologic examination of the entire surgical specimen.

METASTASES (See Fig. 72-45)

FIGURE 72-45 Bronchial carcinoma metastasis to the distal phalanx.

More than 120 cases of metastases to the nail apparatus and finger tip have been reported. Most lesions are bone metastases. Frequent symptoms are swelling, pseudo-clubbing, redness, nail dystrophy, pulsating pain, or acute paronychia-like symptoms, with pain being much less intense than expected from the clinical findings. Osteolysis is usually seen radiographically. Bronchial carcinoma is by far the most frequent to metastasize to the fingertip, with breast carcinoma being second.

Vascular Tumors

Pyogenic granuloma (Fig. 72-46) is an eruptive hemangioma that is usually seen following trauma. A small bluish-red nodule develops rapidly on the periungual skin. The lesion becomes necrotic, developing an oozing appearance with a collarette of macerated white epithelium. Onycholysis occurs when the hyponychium is involved. Injury penetrating the nail plate may cause pyogenic granuloma in the nail bed or even the matrix. Complete removal of the tumor should always be accompanied by histologic examination of the specimen to rule out amelanotic melanoma.

FIGURE 72-46 Pyogenic granuloma involving the nail bed.

Glomus tumor (Fig. 72-47) presents as a classic triad of symptoms: pain, tenderness, and temperature sensitivity. In typical cases, there is a reddish spot in the nail bed, sometimes with a distal fissured nail plate. Although the use of magnetic resonance imaging (MRI) [13] to detect small tumors is not necessary, MRI is most useful in recurrent tumors, not only because the original may have been missed by surgery, but also because multiple glomus tumors may occur in the

same digit.

FIGURE 72-47 Glomus tumor. Longitudinal red streak.

Osteocartilaginous Tumors

Exostosis (Fig. 72-48) and *osteochondroma* commonly occur on toes and rarely on fingers. Trauma appears to be the main cause of these reactive lesions. They are often painful and may elevate the nail plate or cause an ingrown nail, especially on the great toe. Palpation reveals a bone-hard tumor, which should be confirmed by x-ray (Fig. 72-49). Exostoses in the nail region are infrequently seen in the multiple exostosis syndrome. *Enchondroma* of the terminal phalanx is rare. It may result in a painful, bulbous enlargement of the finger tip, clubbing, nail deformation, and discoloration, or even an apparent paronychia. X-ray reveals a sharply delimited radiolucent defect.

FIGURE 72-48 Exostosis.

FIGURE 72-49 X-ray of patient with exostosis.

Degenerative Lesions

Myxoid cysts (see Fig. 72-7) are much more frequent on fingers than toes. The tumor begins as an asymptomatic smooth swelling that slowly enlarges to about the size of a bean. Its consistency varies from soft to firm, cystic to fluctuant. It is usually located on one side of the midline, but tumors may appear beneath the nail matrix and nail bed. A space-occupying lesion in the PNF may compress the matrix, thereby interfering with nail plate formation. This may result in a longitudinal depression running the length of the nail or in a series of irregular transverse grooves that suggest

alternating intermittent episodes of decompression and refilling of the cystic tumor. Heberden's nodes and osteoarthritis of distal joints are present in most cases. Transillumination reveals the cystic nature of the tumor and rules out a giant cell tumor on the dorsum of the distal digit. Surgical treatment involves exposure of the DIP joint, removal of all osteophytes with a rongeur, and preservation of the cyst wall. [14]

Melanocytic Lesions [15]

Isolated *longitudinal melanonychia* (Fig. 72-50) is a diagnostic problem because it may be of trivial etiology or represent a malignant melanoma, especially in white patients. The clinician should be suspicious and always take a proper biopsy when an area of longitudinal melanonychia suddenly becomes darker or wider; occurs in either the first, second, or third digits; demonstrates blurred borders; or is accompanied by nail dystrophy and/or periungual pigmentation (Hutchinson's sign) (Fig. 72-51). Multiple bands of longitudinal melanonychia may be a consequence of drug treatment or numerous systemic diseases including AIDS (Fig. 72-35). Addison's disease, Cushing's syndrome, or hyperthyroidism may result from folic acid or vitamin B_{12} deficiency. *Transverse melanonychia* is frequently observed in patients treated with cytotoxic drugs.

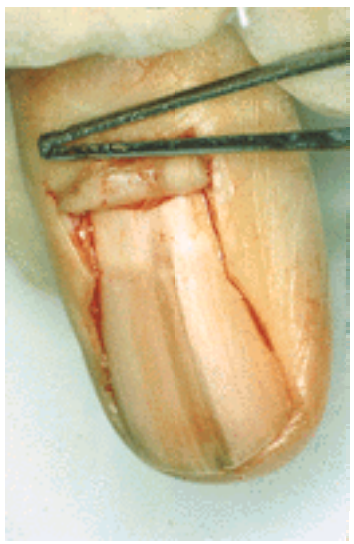

FIGURE 72-50 Isolated longitudinal melanonychia.

FIGURE 72-51 Melanonychia with distal fissure and pigmentation of the proximal nail fold (Hutchinson's sign).

Between 2 and 3 percent of *melanomas* in caucasians occur in the nail, whereas in blacks the figure is about 20 percent. About a quarter of melanomas of the nail are amelanotic, presenting initially as nail dystrophy, indolent tumor nodules, or chronic granulation tissue.

REFERENCES

1. Baran R et al: Physical signs, in *Baran & Dawber's Diseases of the Nails and Their Management,* 3rd ed, edited by R Baran, RPR Dawber, D De Berker, E Haneke, A Tosti. Oxford, Blackwell Scientific, 2001, p 48

2. Baran R: Significance and management of congenital malalignment of the big toenail. *Cutis* **58**:181, 1996

3. De Berker D: Management of nail psoriasis. *Clin Exp Dermatol* **25**:357, 2000

4. Piraccini BM et al: Pustular psoriasis of the nails: Treatment and long-term follow-up of 46 patients. *Br J Dermatol* **144**:1000, 2001

5. Tosti A et al: Nail lichen planus in children: Clinical features, response to treatment and long-term follow-up. *Arch Dermatol* **137**:1027, 2001

6. Tosti A et al: Idiopathic trachyonychia (twenty-nail dystrophy): A pathological study of 23 patients. *Br J Dermatol* **131**:866, 1994

7. Tosti A et al: The nail in systemic diseases and drug-induced changes, in *Baran & Dawber's Diseases of the Nails and Their Management,* 3rd ed, edited by R Baran, RPR Dawber, D De Berker, E Haneke, A Tosti. Oxford, Blackwell Scientific, 2001, p 223

8. Piraccini BM et al: Drug induced nail disorders, incidence, management and prognosis. *Drug Safety* **21**:187, 1999

9. Juhlin L et al: Hereditary and congenital nail disorders, in *Baran & Dawber's Diseases of the Nails and Their Management,* 3rd ed, edited by R Baran, RPR Dawber, D DE Berker, E Haneke, A Tosti. Oxford, Blackwell Scientific, 2001, p 370

10. Baran R et al: Tumours of the nail apparatus and adjacent tissues, in *Baran & Dawber's Diseases of the Nails and Their Management,* 3rd ed, edited by R Baran, RPR Dawber, D De Berker, E Haneke, A Tosti. Oxford, Blackwell Scientific, 2001, p 515

11. Perrin C et al: Onychomatricoma: Clinical and histopathologic findings in 12 cases. *J Am Acad Dermatol* **39**:560, 1998

12. Baran R et al: Distal digital keratoacanthoma. Two cases with a review of the literature. *J Dermatol Surg* **27**:5, 2001

13. Drapé JL et al: Imaging of tumors of the nail unit, in *Nail Surgery,* edited by E Krull, EG Zook, R Baran, E aneke. Philadelphia, Lippincott, Williams & Wilkins, 2001, p 319

14. De Berker D et al: Ganglion of the distal interphalangeal joint (myxoid cyst) therapy by identification and repair of the leak of joint fluid. *Arch Dermatol* **137**:607, 2001

15. Goettmann-Bonvallot S et al: Longitudinal melanonychia in children. A clinical and histopathologic study of 40 cases . *J Am Acad Dermatol* **41**:17, 1999

T>

Chapter 73

Diane Thiboutot John Strauss

Diseases of the Sebaceous Glands

ACNE VULGARIS
Anatomy of the Sebaceous Gland
Physiology of the Sebaceous Gland
Lipid Composition of Sebum
Factors Regulating Sebaceous Gland Size and Sebum Production
Androgens
Retinoids
Melanocortins
Peroxisome Proliferator Activated Receptors
Acyl-CoA:Diacylglycerol Acyltransferase (DGAT)
Epidemiology of Acne
Etiology and Pathogenesis of Acne
Clinical Manifestations of Acne
Diagnosis and Differential Diagnosis
Laboratory Findings
Pathology
Treatment
Course and Prognosis
MISCELLANEOUS TYPES OF ACNE
Neonatal Acne
Acne Excoriée des Jeunes Filles
Steroid Folliculitis
Halogen Acne
Miscellaneous Drugs
Occupational Acne
Tropical Acne
Acne Aestivalis
Acne Cosmetica
Pomade Acne
Acne Mechanica
Acne with Facial Edema
Acne Conglobata
Acne Fulminans
Steatocystoma Multiplex

REFERENCES

ACNE VULGARIS

Acne vulgaris is a self-limited disease, seen primarily in adolescents, involving the sebaceous follicles. Most cases of acne are pleomorphic, presenting with a variety of lesions consisting of comedones, papules, pustules, nodules, and, as sequelae to active lesions, pitted or hypertrophic scars. Although classically classified as a sebaceous gland disease, it is actually a process that involves the pilosebaceous unit.

Anatomy of the Sebaceous Gland

In the human fetus, sebaceous glands develop in the thirteenth to fifteenth week of gestation from bulges on the developing hair follicles. When fully formed, the glands remain attached to the hair follicles by a duct through which sebum flows into the follicular canal and eventually to the skin surface. Sebaceous glands are associated with hair follicles all over the body. Only the palms and soles, which have no hair follicles, are totally devoid of sebaceous glands. Sebaceous glands known as *Fordyce spots* are sometimes present in the oral epithelium. In this location, the sebaceous ducts open directly to the surface.

Sebaceous glands are unilobular or multilobular and vary considerably in size, even in the same individual and in the same anatomic area. Fordyce spots are visible to the unaided eye because of their large size (up to 2 to 3 mm) and the transparency of the oral epithelium. On the external body surface, most glands are only a fraction of a millimeter in size. The largest glands and the greatest density of glands are found on the face and scalp. The hairs associated with the large glands in these areas are often tiny, and it has been suggested that the total structures be more properly termed *sebaceous follicles* rather than hair follicles.

Physiology of the Sebaceous Gland

The sebaceous glands exude lipids by disintegration of entire cells, a process known as *holocrine secretion*. The stages of this process are evident in the histology of the gland (Fig. 73-1). [1] The outermost cells, just inside the basement membrane, are small, nucleated, and devoid of lipid droplets. This layer contains the dividing cells that replenish the gland as cells are lost in the process of lipid excretion. As cells are displaced into the center of the gland, they begin to

produce lipid, which accumulates in droplets. Eventually the cells become greatly distended with lipid droplets and the nuclei and other subcellular structures disappear. As the cells approach the sebaceous duct, they disintegrate and release their contents. Only neutral lipids reach the skin surface. Proteins, nucleic acids, and the membrane phospholipids are digested and apparently recycled during the disintegration of the cells. Sebaceous gland activity is high at birth but then declines to become almost nonexistent in children between ages 2 and 6 years. At about age 7, sebum secretion begins to increase and continues to do so well into the teens. [2] From the twenties on, there is a decline of approximately 23 percent per decade in men and approximately 32 percent per decade in women. [3] There is great individual variation and overlap between the sexes, although males have higher values, on average, than females.

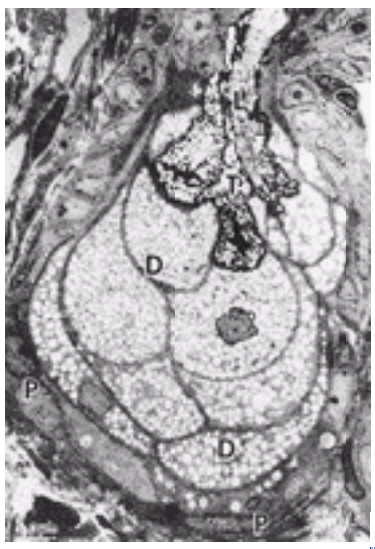

FIGURE 73-1 Electron micrograph of a rabbit sebaceous gland stained with uranyl acetate-lead citrate. The peripheral cells (P) contain ellipsoidal nuclei (NuP) and no lipid droplets. As the cells differentiate (D), lipid droplets accumulate and the nuclei (NuD) become irregularly shaped. In the terminally differentiated cells (T), near the lumen (L) of the sebaceous duct, all subcellular structures appear to break down. (*From Ito et al.,* [1] *with permission. Copyright by Williams & Wilkins, 1984.*)

Lipid Composition of Sebum

Human sebum, as it leaves the sebaceous gland, contains squalene, cholesterol, cholesterol esters, wax esters, and triglycerides (Fig. 73-2). During passage of sebum through the hair canal, bacterial enzymes hydrolyze some of the triglycerides, so that the lipid mixture reaching the skin surface contains free fatty acids and small proportions of mono- and diglycerides in addition to the original components. The wax esters and squalene distinguish sebum from the lipids of human internal organs, which contain no wax esters and little squalene. Squalene that is synthesized in internal tissues is quickly converted to lanosterol and eventually to cholesterol. Human sebaceous glands, however, appear to be unable to cyclize squalene to sterols.

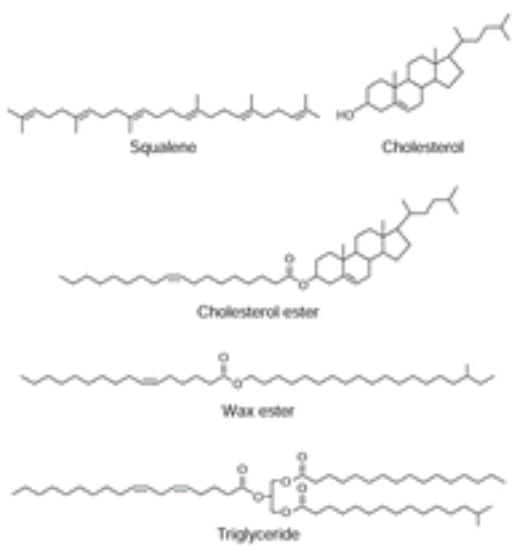

FIGURE 73-2 Human sebaceous gland lipids. The structures of the cholesterol ester, wax ester, and triglyceride are representative of the many species that are present. Two sebaceous-type unsaturated fatty acid moieties are shown: sapienic acid (16:1?6) (in the wax ester structure); and sebaleic acid (18:2?5,8) (in the triglyceride structure). Anteiso branching is shown in the alcohol moiety of the wax ester, and iso branching is shown in the triglyceride.

The patterns of unsaturation of the fatty acids in the triglycerides, wax esters, and cholesterol esters also distinguish human sebum from the lipids of other organs. The “normal” mammalian pathway of desaturation involves inserting a double bond between the ninth and tenth carbon of stearic acid (18:0) to form oleic acid (18:1?9). A ?6 double bond can be added only after the ?9 double bond is in place. However, in human sebaceous glands, the predominant pattern is the insertion of a ?6 double bond into palmitic acid (16:0). The resulting sapienic acid (16:1?6) (Fig. 73-2) is the major fatty acid of adult human sebum. Elongation of the chain by two carbons and insertion of another double bond between the fifth and sixth carbon gives sebaleic acid (18:2?5,8) (Fig. 73-2), a fatty acid thought to be unique to human sebum.

Sebaceous fatty acids and alcohols are also distinguished by chain branching. Methyl branches can occur on the next to last (penultimate) carbon of a fatty acid chain (iso branching), on the third from the last (antepenultimate) carbon (anteiso

branching), or on any even-numbered carbon (internal branching). Examples of these unusual unsaturated and branched-chain moieties are included in the lipid structures in Fig. 73-2.

Factors Regulating Sebaceous Gland Size and Sebum Production

The exact mechanisms underlying the regulation of human sebum production have not been defined. Clearly, sebaceous glands are regulated by androgens and retinoids, but recently, other factors, such as melanocortins, peroxisome proliferator-activated receptors (PPARs), and acyl-CoA:diacylglycerol acyl transferase (DGAT), have been postulated to play a role as well.

Androgens

It has long been recognized that sebaceous glands require androgenic stimulation to produce significant quantities of sebum. Individuals with a genetic deficiency of androgen receptors (complete androgen insensitivity) have no detectable sebum secretion. [4] However, there is still a question as to which androgen is physiologically significant. Although the most powerful androgens are testosterone and its end-organ reduction product dihydrotestosterone (DHT), levels of testosterone do not parallel the patterns of sebaceous gland activity. For example, testosterone levels are many-fold higher in males than in females, with no overlap between the sexes, while average rates of sebum secretion are only slightly higher in males than in females, with considerable overlap between the sexes. Also, sebum secretion starts to increase in children during adrenarche, a developmental event that precedes puberty by about 2 years.

The weak adrenal androgen, dehydroepiandrosterone sulfate (DHEAS), might be a significant regulator of sebaceous gland activity through its conversion to testosterone and dihydrotestosterone in the sebaceous gland. Levels of DHEAS are high in newborns, very low in 2- to 4-year-old children, and start to rise when sebum secretion starts to increase. In adulthood, DHEAS levels show considerable individual variation, but are only slightly higher in men than in women on the average. There is a decline in DHEAS levels in both sexes starting in early adulthood and continuing throughout life, this decline parallels the decline of sebum secretion. DHEAS is present in the blood in high concentration. The enzymes required to convert DHEAS to more potent androgens are present in sebaceous glands. [5] These include 3ß-hydroxysteroid dehydrogenase, 17ß-hydroxysteroid dehydrogenase and 5a-reductase. Each of these enzymes exists in two or more isoforms that exhibit tissue-specific differences in their expression. The predominant isozymes in the sebaceous gland include the type 1 3ß-hydroxysteroid dehydrogenase, the type 2 17ß-hydroxysteroid dehydrogenase and the type 1 5a-reductase.

Retinoids

Isotretinoin (13- *cis*-retinoic acid) is the most potent known pharmacologic inhibitor of sebum secretion. Significant reductions in sebum production can be observed as early as 2 weeks after use. [6] Histologically, sebaceous glands are markedly reduced in size and individual sebocytes appear undifferentiated lacking the characteristic cytoplasmic accumulation of sebaceous lipids. The mechanism by which 13- *cis*-retinoic acid lowers sebum secretion is unknown. It does not interact with any of the known retinoid receptors. Isotretinoin may serve as a prodrug for the synthesis of all- *trans*-retinoic acid or 9- *cis*-retinoic acid, which do interact with retinoid receptors, however, it has greater sebosuppressive action than do all- *trans*- or 9- *cis*-retinoic acid. [7] Unfortunately 13- *cis*-retinoic acid is teratogenic, so there is a continuing need for a nonteratogenic retinoid or retinoid-like compound that would inhibit human sebaceous glands.

Melanocortins

Melanocortins include melanocyte-stimulating hormone (MSH) and adrenocorticotropic hormone (ACTH). In rodents, melanocortins increase sebum production. Transgenic mice deficient in the melanocortin-5 receptor have hypoplastic sebaceous glands and reduced sebum production. [8] The melanocortin-5 receptor has been identified in human sebaceous glands where it may play a role in the modulation of sebum production. [9] Further experimentation however is required to test this hypothesis.

Peroxisome Proliferator Activated Receptors

Peroxisome proliferator activated receptors (PPARs) are orphan nuclear receptors that are similar to retinoid receptors in many ways. Each of these receptors form heterodimers with retinoid X receptors in order to regulate the transcription of genes involved in a variety of processes, including lipid metabolism and cellular proliferation and differentiation. Rat preputial cells serve as a model for human sebocytes. [10] In rat preputial cells, agonists of the PPAR-? receptor, such as drugs of the thiazolidinedione class, increase lipid accumulation. [11] The PPAR-? receptor is strongly expressed in human sebaceous glands, where it may play a role in mediating sebum production. [12]

Acyl-CoA:Diacylglycerol Acyltransferase (DGAT)

Acyl-CoA:diacylglycerol acyltransferase an enzyme involved in the final step of triglyceride synthesis, was recently shown to be important in sebaceous gland homeostasis in mice. [13] The absence of DGAT leads to sebaceous gland atrophy and changes in the composition of surface lipid. This effect does not appear to be mediated through androgens, and did not occur in the absence of leptin, a peptide hormone secreted by adipocytes. The importance of these findings in human sebaceous gland activity remains to be determined.

Epidemiology of Acne

Acne is sufficiently common that it often has been termed physiologic. Mild degrees of acne are often seen at birth,

probably resulting from follicular stimulation by adrenal androgens, and mild cases may continue in the neonatal period. However, it is not until puberty that acne becomes a common problem. Acne is often an early manifestation of puberty; in the very young patient the predominant lesions are comedones. In girls, the occurrence of acne may precede menarche by more than a year. The greatest number of cases is seen during the middle-to-late teenage period; subsequently, the incidence decreases. However, particularly in women, acne may persist through the third decade or even later. Acne seems to be familial, but owing to the high prevalence of the disease this has been extremely difficult to assess. Nodulocystic acne has been reported to be more common in white males than in black males, [14] and one group of investigators has found that acne is more severe in patients with the XYY genotype. [15]

Etiology and Pathogenesis of Acne

Although the basic cause of acne is unknown, there is considerable information on the various factors concerned in its pathogenesis. Acne is a multifactorial disease, developing in the sebaceous follicles. Its pathophysiology centers on the interplay of follicular hyperkeratinization, colonization with *P. acnes* bacteria, increased sebum production, and inflammation.

FOLLICULAR HYPERKERATINIZATION The primary change in the sebaceous follicle in acne is an alteration in the pattern of keratinization within the follicle. [16] Normally, the keratinous material in the follicle is loosely organized (Fig. 73-3A). On the ultrastructural level, there are many lamellar granules and relatively few keratohyaline granules. The initial changes in comedo formation are observed in the lower portion of the follicular infundibulum. The keratinous material becomes more dense, the lamellar granules are less numerous, keratohyaline granules are increased, and some of the cells contain amorphous material, which is probably lipid, generated during the process of keratinization (Fig. 73-3B). Kinetic studies demonstrate that there is an increase in cellular turnover in comedones.

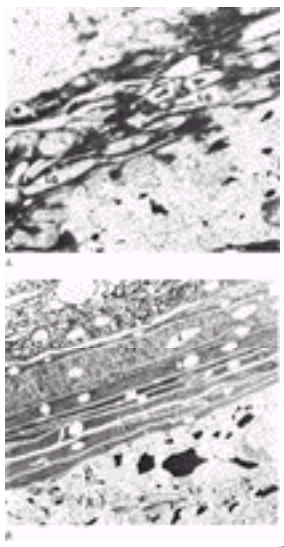

FIGURE 73-3 *A.* High magnification of the keratinized layer in the proximal infundibulum of a normal sebaceous follicle. The cornified cells are thin and filamentous, and the cell membranes are indistinct. Large clusters of lamellar granules (LG) fill the intracellular spaces. (×15,258) *B.* High magnification of the infundibular region of an early comedo from the face. The keratinized cells have thickened cell margins (*single arrows*), and many layers accumulate. In comparison with the normal follicle (see Fig. 73-3A), there are fewer small clusters of lamellar granules (*double arrows*) at the junction of the granular and cornified layers. Note intracellular lipid inclusions (L). (×8493). (*From Knutson,* [16] *with permission.*)

The initiating factor in comedo formation still has not been definitely identified. Follicular hyperkeratinization may relate to a local deficiency of linoleic acid, production of interleukin-1 within the follicle, or, possibly, the effects of androgens on follicular keratinization. Downing et al. [17] advanced the theory that the decreased concentrations of linoleic acid that accompany the high sebum secretion rate found in patients with acne result in a localized essential fatty acid deficiency of the follicular epithelium. This, in turn, theoretically induces follicular hyperkeratosis and decreased epithelial barrier function, both of which are characteristic of the essential fatty acid deficiency syndrome. Investigators have developed models using human infrainfundibular segments to study the process of follicular hyperkeratinization. Guy et al. found that the addition of 1 ng/mL of interleukin (IL)-1a to infrainfundibular segments caused hypercornification similar to that seen in comedones. [18] This could be blocked by addition of an IL-1 receptor antagonist. These authors suggest that changes in sebum secretion or composition could lead to the release of IL-1 by follicular keratinocytes, which, in turn, may stimulate comedogenesis. Androgens are known to regulate the development of the sebaceous gland and sebum production. In addition, androgens may play a role in the follicular hyperkeratinization seen in acne. Indirect evidence in support of this latter hypothesis includes these observations: (1) androgen receptors have been localized to the outer root sheath of the infrainfundibular region of follicles; [19] (2) the formation of follicular casts is reduced in patients treated with antiandrogens; [20] and (3) each of the key enzymes involved in androgen metabolism has been identified in follicles. [21] No direct effect of androgens on follicular hyperkeratinization has been demonstrated, however. Additional studies are needed to determine whether androgens modulate follicular hyperkeratinization.

PROPIONIBACTERIUM ACNES The predominant organism in the follicular flora is the anaerobic pleomorphic diphtheroid *Propionibacterium acnes*. In 11- to 15-year-olds, practically no *P. acnes* are found in individuals without acne, whereas in patients with acne, the geometric mean of *P. acnes* organisms is 114,800 per square centimeter. [22] Similar differences are found in 16- to 20-year-old groups, but in older individuals the number of organisms is the same in those with and without acne. It is generally accepted that *P. acnes* are important in the pathogenesis of acne. While the initial impression was that inflammation resulted from the production of free fatty acids, and it was shown that *P. acnes* was the main source of follicular lipases, *P. acnes* also produces other extracellular enzymes such as proteases and hyaluronidases, which may be important in the inflammatory process. Furthermore, there are other ways in which *P. acnes* may produce inflammation. [23] The organism has been shown to secrete chemotactic factors [24] and chemotactic activity has been found in comedones. [25] The dialyzable, low molecular weight chemotactic factor does not require serum complement for activation, and, because of its small size, it can probably escape from the follicle and attract polymorphonuclear leukocytes. If the polymorphonuclear leukocytes enter the follicle, they can ingest *P. acnes*

organisms, resulting in the release of hydrolytic enzymes, which, in turn, may be of importance in producing follicular epithelial damage. [26] In addition, the classical and alternative complement activation pathways are stimulated by *P. acnes,* possibly also contributing to the inflammatory response. [27] The host response may also be important. Circulating antibodies to *P. acnes* are elevated in patients with severe acne. [28] Whether this has a direct effect is not proved, but it has been shown that the *P. acnes* induction of lysosomal hydrolases by polymorphonuclear leukocytes is anti- *P. acnes* antibody dependent. [26] There is other evidence of changes in the immune response as demonstrated by increased response to *P. acnes* injections in patients with acne. [29]

SEBUM PRODUCTION A connection between acne and high rates of sebum secretion is supported by at least three types of evidence: (1) children do not get acne during the age range from approximately 2 to 6 years, when sebum secretion is extremely low; (2) average rates of sebum secretion are higher in individuals with acne than in those without acne; [30] and (3) treatments that reduce sebum secretion (such as estrogen or 13- *cis*-retinoic acid) improve acne. [31], [32] It is unclear, however, why elevated rates of sebum secretion lead to acne. The triglyceride fraction of sebum, which is unique to humans, is probably responsible for acne. The bacterial population of the follicle hydrolyzes triglycerides to fatty acids, which eventually appear on the skin surface. In the past, the free fatty acid fraction of sebum was considered to be important in the causation of inflammation, but in recent years, it has become evident that there are probably other more important causes of inflammation, as discussed below. Most studies have failed to detect any changes in the composition of sebum in patients with acne as compared to age-matched controls. However, there is a significant decrease in the levels of linoleic acid in patients with acne, and there is an inverse relationship between sebum secretion and the linoleic acid concentration of sebum. Linoleic acid cannot be synthesized in mammalian tissues, and so the linoleate concentration in human sebum depends on the quantity of this essential fatty acid with which each cell is endowed and the extent to which this initial endowment is diluted by subsequent endogenous lipid synthesis in sebaceous cells. In individuals with high rates of sebum secretion, the fatty acids of the skin surface may contain only about 0.5 percent linoleate. [2] During passage through the follicle, some of the linoleate-deficient fatty acids may percolate through the follicular wall and dilute the linoleate necessary for a healthy epithelium. Although this mechanism is speculative, the involvement of follicular bacteria and free fatty acids in acne is supported by the fact that when the bacterial population is reduced with oral antibiotics, free fatty acids are reduced and acne may thus be alleviated.

Clinical Manifestations of Acne

The primary site of acne is the face and to a lesser degree the back, chest, and shoulders. On the trunk, lesions tend to be numerous near the midline. The disease is characterized by a great variety of clinical lesions. Although one type of lesion may be predominant, close observation usually reveals the presence of several types of lesions (Fig. 73-4). The lesions may be either noninflammatory or inflammatory. The noninflammatory lesions are comedones, which may be either open (blackheads) or closed (whiteheads). The open comedo appears as a flat or slightly raised lesion with a central dark-colored follicular impaction of keratin and lipid. The closed comedones, in contrast to the open comedones, may be difficult to visualize. They appear as pale, slightly elevated, small papules and do not have a clinically visible orifice. Stretching of the skin is an aid in detecting the lesions. Because the closed comedones are potential precursors for the large inflammatory lesions, they are of considerable clinical importance. Although comedones are the primary lesions of acne, they are not unique in this disease as they may be seen under other conditions (e.g., so-called senile comedones, which are common, particularly in the periorbital area of older persons, and comedones that are seen in atrophic skin resulting from x-ray therapy).

FIGURE 73-4 Acne vulgaris, mild to moderate. *A.* Close-up of the lower face with comedones, papules, pustules, and scars. *B.* Close-up of the cheek, showing large open comedones, and inflammatory papules and pustules that become confluent, forming an erythematous plaque.

The inflammatory lesions vary from small papules with an inflammatory areola to pustules to large, tender, fluctuant nodules (Fig. 73-4, Fig. 73-5, and Fig. 73-6). Some of the large nodules were previously called “cysts” and the term *nodulocystic* has been used to describe severe cases of inflammatory acne. True cysts are rarely found in acne, and this term should be abandoned and the term *severe nodular acne* used instead (Fig. 73-6). Whether the lesion appears as a papule, pustule, or nodule depends on the extent and location of the inflammatory infiltrate in the dermis.

FIGURE 73-5 Acne vulgaris, nodular, moderate to severe. *A.* Many papules and nodules are seen on the forehead and cheeks with little scarring apparent at this time. *B.* Nodular acne with scars on the cheek. *C.* Larger nodules on the cheek and chin with significant scarring.

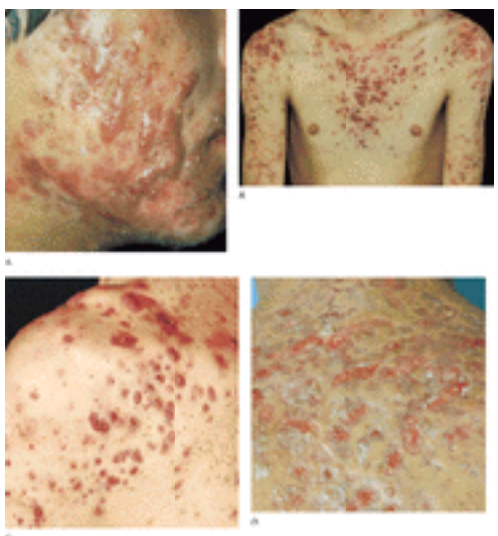

FIGURE 73-6 Acne vulgaris, nodular, severe. *A.* Large confluent nodules formed by confluence of smaller lesions with interconnecting channels, associated with atrophic and hyperplastic scars. *B.* Extensive nodules on the chest and arms with severe scarring. *C.* Close-up of nodules, crusted ulcers, and scars on the shoulder. *D.* Severe nodular acne of the back with little residual normal uninvolved skin.

In addition to the above-described lesions, patients may have scars of varying size (Fig. 73-7). The characteristic scar of acne is a sharply punched-out pit. These are ordinarily single, but where inflammation has been marked, the pits may have multiple openings. Less commonly, broader pits may occur, and in rare instances, especially on the trunk, the scars may be hypertrophic.

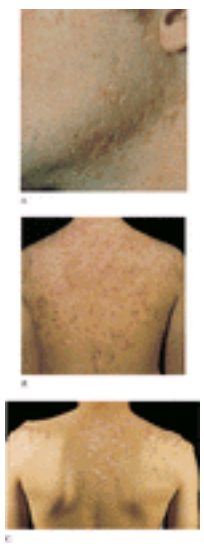

FIGURE 73-7 Acne vulgaris, scarring. *A.* “Punched out” and “ice-pick” scars are seen on the cheek as a residual of burned-out nodular acne. *B.* Extensive atrophic scarring of the back associated with recent nodular acne. *C.* Severe hypertrophic scarring of the back in a patient with history of nodular acne.

It has been mentioned that seborrheic dermatitis is commonly seen in association with acne, but there does not appear to be any relation between these two diseases.

Diagnosis and Differential Diagnosis

Although one type of lesion may predominate, the diagnosis of acne vulgaris is usually made from the finding of a mixture of lesions of acne (comedones, pustules, papules, and nodules) on the face, back, or chest. Diagnosis is usually easy, but acne may be confused with folliculitis, rosacea, and the various miscellaneous acneiform disorders that are

discussed subsequently. Lupus miliaris disseminatus faciei may also have a similar appearance.

Laboratory Findings

In general, laboratory workup is not indicated for patients with acne unless hyperandrogenism is suspected. There are numerous clinical studies relating acne to elevated serum levels of androgens in both adolescents and adults. Varying results have been obtained based on the patient population studied and the methodology used. Among 623 prepubertal girls followed over time, girls with acne had increased levels of DHEAS as compared to aged-matched controls without acne. [33] DHEAS can serve as a precursor for testosterone and dihydrotestosterone. Elevated serum levels of androgens have been found in cases of severe cystic acne [34] and in acne associated with a variety of endocrine conditions, including congenital adrenal hyperplasia (11ß- and 21ß-hydroxylase deficiencies), ovarian or adrenal tumors, and polycystic ovarian disease. In the majority of acne patients, however, serum androgens are within the normal range. Several studies indicate that the mean serum levels of DHEAS, testosterone, or dihydrotestosterone may be higher (but still within the normal range) in patients affected with acne as compared to normal controls. [35] It should be stressed that most of these studies involved older patients with treatment-resistant acne, and that other investigators, using a younger age group, either have not demonstrated increased androgens [36], [37] or have shown that if increased blood androgens are found, the levels, at most, are variable. At this time, a potential androgen excess should be considered, particularly in older female patients who have treatment-resistant acne. However, there is no evidence that there are endocrinologic changes in all patients with acne. For this reason, it is thought that the local production of androgens within the skin may correlate more directly with the development of acne, [38] and it has been shown that the skin possesses each of the enzymes required to convert precursor DHEAS into more potent androgens. [21], [39] Focus is also centering on the role of 5a-reductase in acne. Testosterone is converted to dihydrotestosterone by the action of 5a-reductase. Skin biopsies from men and women with acne have demonstrated increased 5a-reductase activity when compared to normal controls. [40] Two isozymes of 5a-reductase have been identified that differ in their tissue localization. [41] The type 1 isozyme is active in human sebaceous glands and is more active in glands from areas that are prone to acne such as the face, when compared to areas of the skin not predisposed to acne. [42]

Hyperandrogenism should be considered to be a contributing factor to the development of acne in female patients whose acne is severe, sudden in its onset, or associated with hirsutism or irregular menstrual periods. A medical history and physical examination directed toward eliciting any symptoms or signs of hyperandrogenism should be performed. The patient should be asked about the frequency and character of her menstrual periods and whether her acne flares with changes in her menstrual cycle. Hyperandrogenism can also result in deepening of the voice or an increase in libido. In addition to acne, other skin signs of endocrine diseases associated with hyperandrogenism include hirsutism, male pattern alopecia, acanthosis nigricans, and truncal obesity.

Acne can also result from the administration of exogenous androgens such as testosterone, other anabolic steroids, gonadotrophins, glucocorticoids, and ACTH. The latter two agents are the cause of steroid acne, an entity to be described later.

Many patients report that their acne flares during periods of stress. Although objective data are limited, stress is known to increase the output of adrenal steroids, which may affect the sebaceous gland. It has been shown that patients with acne have a greater increase in urinary glucocorticoid levels after corticotropin administration.

Excess androgens may be produced by either the adrenal gland or ovary. The laboratory workup should include measurement of serum DHEAS, total testosterone, free testosterone, and the luteinizing hormone (LH) to follicle-stimulating hormone (FSH) ratio. Testing should be obtained in the luteal phase of the menstrual cycle (within 2 weeks prior to the onset of menses), and patients on oral contraceptives will need to discontinue their medication for at least 1 month prior to testing. The above tests can be used to screen for the source of the hyperandrogenism. Values of DHEAS in the range of 4000 to 8000 ng/mL may be associated with congenital adrenal hyperplasia. Patients with a serum level of DHEAS > 8000 ng/mL could have an adrenal tumor and should be referred to an endocrinologist for further evaluation. An ovarian source of excess androgens can be suspected in cases where the serum total testosterone is > 150 ng/dL. Serum total testosterone in the range of 150 to 200 ng/dL or an increased LH/FSH ratio (greater than 2.0) can be found in cases of polycystic ovary disease. Greater elevations in serum testosterone may indicate an ovarian tumor, and appropriate referral should be made. There is a significant amount of variability in an individual's serum androgen levels. In cases in which abnormal results are obtained, it may be wise to repeat the test before proceeding with therapy or additional testing.

Pathology

As already stated, acne develops in the sebaceous follicles, and the primary lesion is the comedo. Comedo development starts in the midportion of the follicle as an expanding mass of lipid-impregnated keratinous material, resulting in thinning and ballooning-out of the follicular wall. Gradually, more keratinous material accumulates, and, as it does, further thinning and dilatation of the follicular wall occur. At the same time, the sebaceous glands begin to atrophy and are replaced by undifferentiated epithelial cells. The fully formed comedo has a thin wall and a minimal number of sebaceous cells, if they can be found at all. The open comedo has a patulous orifice, and the keratinous material is arranged in a lamellar concentric fashion (Fig. 73-8). With lipid stains, it can be shown that the keratin is permeated by lipid. Diphtheroid bacteria are also present. In cross section, the keratinous material consists of whorls of lamellar material centered on appendageal structures such as the hairs. In fact, most comedones contain multiple hairs. The closed comedo differs from the open comedo in that the keratinous material is not as compact and the follicular orifice is narrow and not distended (Fig. 73-9).

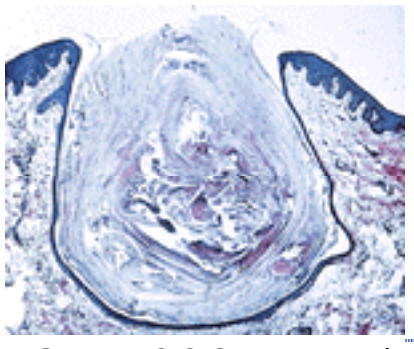

FIGURE 73-8 Open comedo. The mouth of the follicle is widely dilated. The comedo is composed of a lamellar keratinous mass impregnated with lipid. Bacteria are also present. The sebaceous glands have undergone atrophy. *(From Strauss and Kligman,* [80] *with permission.)*

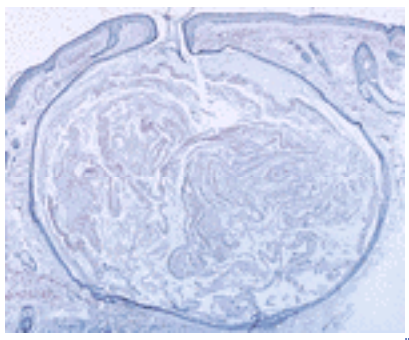

FIGURE 73-9 Closed comedo. The structure of the lesion is similar to that of the open comedo. However, the orifice is small, and the contents of the comedo are not as compact. (*From Strauss and Kligman,* [80] *with permission.*)

The fully developed open comedo is not usually the site of inflammatory changes, unless it is traumatized by the patient. The developing microcomedo and, to a lesser degree, the closed comedo are the major sites for the development of inflammatory lesions. The initial event appears to be escape of lipid through an edematous comedo wall, with the development of a cellular reaction in the adjacent dermis. Once complete rupture has occurred, the entire contents of the comedo are extruded into the dermis (Fig. 73-10). This reaction is much greater, and giant cells are common, reflecting the escape of the keratinous material. Within the inflammatory infiltrate, gram-positive diphtheroid bacteria with the morphologic characteristics of *P. acnes* may be observed free and within polymorphonuclear leukocytes. Depending upon the site and extent of inflammation, these ruptured lesions may appear as a pustule, a nodule, or as a nodule surmounted by a pustule.

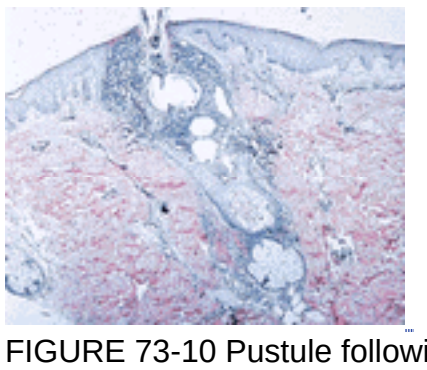

FIGURE 73-10 Pustule following rupture of a sebaceous follicle. The original walls of the follicle can be seen at the follicular orifice. New strands of epithelial cells are migrating from the epidermis to encapsulate the inflammatory mass, making the inflammatory material appear to be within the follicle.

It should be realized that the skin is always attempting to repair itself, and sheaths of cells will grow out from the epidermis or appendageal structures in an attempt to encapsulate the inflammatory reaction. This encapsulation may be complete so that the inflammatory infiltrate appears to be within the follicle, but often it is far from complete, and further rupture may occur leading to multichanneled tracts, as can be seen in many acne scars. Fibrous contraction also contributes to scar formation.

Treatment

There may be great fluctuations in the natural course of acne; furthermore, the response to placebo therapy is considerable. Therefore, the determination of the therapeutic efficacy of medications used in acne is not a simple task, and it is possible to find many favorable therapeutic reports for agents that are obviously of little value in the treatment of acne. In this section, no attempt is made to be all-inclusive; only the more commonly used or useful modalities are discussed.

In general, there are four major principles governing the therapy of acne, and the individual therapeutic modalities listed below are related to these principles, where possible. These principles are: (1) correct the altered pattern of follicular keratinization; (2) decrease sebaceous gland activity; (3) decrease the follicular bacterial population, particularly the *P. acnes* population, and inhibit the production of extracellular inflammatory products (either directly or indirectly) by inhibiting the bacterial organisms; and (4) produce an anti-inflammatory effect. The first of these treatment principles, namely, changing the altered pattern of follicular keratinization, should be the primary form of therapy in noninflammatory acne; the rest of the modalities are primarily designed for use in inflammatory acne. Nonetheless, because altered follicular keratinization is the starting point for the development of inflammatory acne, therapy directed at this abnormality

also should be of value in inflammatory acne.

LOCAL THERAPY

Cleansing There is no evidence that either surface sebum or surface bacteria aggravates acne. Therefore, in order for a soap or topical antibacterial agent to be of aid in the therapy of acne, the topical agent would have to remove the lipids or the bacteria (or both) from within the follicle. Certainly, the action of a soap will not remove open or closed comedones. Any dermatologist can readily describe cases of acne that he or she has seen in compulsive washers. It would appear that washing as a therapeutic measure is often overemphasized, but many acne patients do not have a pronounced seborrhea, and washing or cleansing to remove this excessive oil, if not overdone, provides subjective benefit.

Topical agents Topical therapy of acne has undergone periodic change. Many years ago, empirical reliance was placed on the use of sulfur- and resorcinol-containing products, and to a degree, they are still used in the over-the-counter market. Their mechanism of action has not been defined. Products containing salicylic acid, a keratolytic agent, have also enjoyed some popularity. However, the major topical agents now in use are retinoids and antimicrobials such as benzoyl peroxide and topical antibiotics. Topical retinoids, such as tretinoin and tazarotene, and agents with retinoid activity, such as adapalene, are used extensively for their comedolytic activity. These agents can be irritants; in general, the order of irritancy increases as one progresses from the use of cream preparations to gels to the solution. Most patients can use low-potency tretinoin or adapalene cream daily without developing an irritant reaction. Patients must also be cautioned about sun exposure, because an exaggerated burn may follow what previously was an easily tolerated sun exposure. Unlike tretinoin, adapalene and tazarotene are specific for a subset of retinoic acid receptors (RARs). These two drugs selectively activate RAR-ß and RAR-?, but not RAR-a receptors. The binding of these agents to nuclear retinoic acid receptors affects the expression of genes involved in cell proliferation, cell differentiation, and inflammation. At the cellular level, the result may be a modification of several acne pathogenic factors, including corneocyte accumulation and cohesion, and inflammation. Topical retinoids are comedolytic, and reversal of the altered pattern of follicular keratinization has been seen at an ultrastructural level. Epidermal cell turnover is increased in comedones. Salicylic acid is also comedolytic but is not as effective as topical retinoids. Benzoyl peroxide preparations are among the most common topical medications prescribed by dermatologists, and benzoyl peroxide is a major therapeutic agent in the over-the-counter acne market. Benzoyl peroxide is a powerful antibacterial agent, and its effect is probably related to a decrease in the bacterial population and an accompanying decrease in the hydrolysis of triglycerides. Benzoyl peroxide preparations are available in both lotion and gel forms, the latter generally being considered more active. The compound can produce significant dryness and irritation, and allergic contact dermatitis has occurred, but this is an uncommon event. Topical antibiotics are also used for the treatment of acne, the most popular preparations containing erythromycin or clindamycin. These two agents have also been used in combination preparations with benzoyl peroxide. Increased levels of *P. acnes* resistance have been reported in patients who are being treated with antibiotics. However, the development of resistance is less likely in patients who are treated with a combination of benzoyl peroxide/erythromycin or clindamycin. [43] Therefore, these combination products are preferable over topical antibiotics alone. Another topical agent is a cream containing 20% azelaic acid. Azelaic acid is a naturally occurring dicarboxylic acid found in cereal grains. It is available as a topical cream, which is effective in inflammatory and comedonal acne. The activity of azelaic acid against inflammatory lesions may be greater than its activity against comedones. Azelaic acid is applied twice daily and its use is reported to have fewer local side effects than topical retinoids. In addition, it may help to lighten postinflammatory hyperpigmentation. Because comedolytic agents, such as topical retinoids or salicylic acid, and antimicrobial agents, such as benzoyl peroxide or antibiotics, have different modes of action, they are often used together in an individual patient. However, they should be applied at separate times.

SYSTEMIC THERAPY Over the years, many different agents have been used systemically. The major systemic modalities that are currently being used include antibiotics and antibacterial agents, hormones, and an oral synthetic retinoid.

Antibiotics and antibacterial agents Currently, the broad-spectrum antibiotics are widely used in the treatment of acne. Although the oral administration of tetracycline does not alter sebum production, it does decrease the concentration of free fatty acids while the esterified fatty acid content increases. This decrease in free fatty acids is seen with dosages ranging from 250 mg/day to 1 g/day. The free fatty acids are probably not the major irritants in sebum, but their level is an indication of the metabolic activity of the organism and its secretion of other proinflammatory products. The decrease in free fatty acids may take several weeks to become evident. This, in turn, is reflected in the clinical course of the disease during antibiotic therapy, as several weeks are often required for maximal clinical benefit. The effect, then, is one of prevention; the individual lesions require their usual time to undergo resolution. However, the fact that a decrease in free fatty acids does occur strengthens the rationale for the use of tetracycline. Tetracycline may act through direct suppression of the number of *P. acnes,* but part of its action may also be due to its anti-inflammatory activity. Decreases in free fatty acid formation also have been reported with erythromycin, demethylchlortetracycline, clindamycin, and minocycline. Most studies support the efficacy of tetracycline and its derivatives in the treatment of acne. In clinical practice, tetracycline is usually given initially in dosages of 500 mg/day to 1000 mg/day. While the dose is often decreased as improvement occurs and may be continued at a level of 250 mg/day or less, there is increasing concern that this may generate resistant strains. Tetracycline should be taken on an empty stomach to promote absorption. Erythromycin has been used in the past in patients who have difficulty in taking tetracycline on an empty stomach, but there is increasing evidence of the development of erythromycin-resistant strains of *P. acnes* from both the topical and systemic use of erythromycin. Therefore, it is wise to limit the use of oral erythromycin to those cases where tetracyclines are contraindicated, that is, in pregnant women and young children. Increasingly, doxycycline and minocycline are being used as alternatives for tetracycline or in tetracycline-unresponsive cases. These two drugs appear to be more effective than tetracycline, and drug resistance is less likely to occur, especially with minocycline. Doxycycline should be administered in dosages of 50 to 100 mg twice daily. The major disadvantage of the use of doxycycline is that it can produce photosensitivity reactions, and patients should be switched to another antibiotic, if possible, during the summer months. Minocycline is given in divided dosages at a level of 100 mg/day to 200 mg/day. Patients on minocycline should be monitored carefully as the drug can cause blue-black pigmentation, especially in the acne scars, as well as the hard palate, alveolar ridge, and anterior shins. Minocycline-induced autoimmune hepatitis and a systemic lupus erythematosus-like syndrome have been reported during minocycline therapy, but to date, these side effects are very rare. [44], [45] Oral clindamycin has been used in the past, but because of the potential of pseudomembranous colitis, it is now rarely used for acne. Although long-term, low-dosage antibiotic therapy is often continued for many months, very few side effects have been observed. Tetracyclines have an affinity for rapidly mineralizing tissues and are deposited in developing teeth, where they may cause irreversible yellow-brown staining; also, tetracyclines have been reported to

inhibit skeletal growth in the fetus. Therefore, they should not be administered to pregnant women, especially after the fourth month of gestation, or to babies. The tetracyclines also should not be given to children younger than 8 years of age. The only safe antibiotic to administer to pregnant women or children is erythromycin. A rare complication, but one that can easily be missed, is the development of a gram-negative folliculitis. [46] With prolonged antibiotic therapy, gram-negative organisms may proliferate in the anterior nares and spread out onto the surrounding skin. The physician should be alerted to this diagnosis if there is a sudden flare with pustules or nodules in a patient who is otherwise improving. Two types of lesions are seen. Most commonly there are multiple pustules with an intense inflammatory areola. This type of lesion is often caused by *Enterobacter* or *Klebsiella*. The patient may also have deep indolent nodules from which *Proteus* organisms are most often isolated. Culture confirmation is necessary, and antibiotic therapy should be governed by the results of sensitivity studies. Ampicillin is often the antibiotic of choice. Patients who do not show a response to antibiotics should be treated with a full course of isotretinoin (see below). Tetracycline in dosages ranging from 1500 mg/day to 3500 mg/day has been used in patients with very severe acne. The results of this form of therapy are encouraging, particularly because the treated patients have otherwise been resistant to therapy. Patients under treatment with high-dose tetracycline should be carefully monitored with frequent laboratory evaluation. Trimethoprim-sulfamethoxazole combinations are also effective in acne. In general, because the potential for side effects is greater with their use, they should be used only in patients with severe acne who do not respond to other antibiotics. If trimethoprim-sulfamethoxazole is used, the patient must be monitored for potential hematologic suppression approximately monthly.

Hormonal therapy of acne Sebum secretion is increased by agents with androgenic activity, including synthetic anabolic steroids, and decreased by agents that counteract or interfere with androgen action, namely estrogens and antiandrogens. The goal of hormonal therapy is to counteract the effects of androgens on the sebaceous gland. This can be accomplished with the use of estrogens, antiandrogens, or agents designed to decrease the endogenous production of androgens by the ovary or adrenal gland, including oral contraceptives, glucocorticoids, or gonadotropin-releasing hormone (GnRH) agonists.

ESTROGENS Any estrogen given in sufficient amounts will decrease sebum production. The dose of estrogen required to suppress sebum production, however, is greater than the dose required to suppress ovulation. Although some patients will respond to lower-dose agents containing 0.035 to 0.050 µg of ethinyl estradiol or its esters, higher doses of estrogen are often required. [47] If estrogen therapy is indicated and if the physician is unfamiliar with its usage or side effects, it is best to work with a gynecologist. Breast examinations and Pap smears are recommended for women receiving estrogen therapy. The incidence of more serious side effects such as clotting and hypertension that follow the use of estrogens is, fortunately, rare in young healthy females. Nevertheless, the physician and patient should be aware of the possibilities, and the risk/benefit ratio should be carefully considered before undertaking estrogen therapy. Although the use of estrogen therapy for acne has decreased dramatically since oral isotretinoin has been available, there are specific patients in whom its use is still appropriate. As mentioned below, estrogens can be used in combination with glucocorticoids.

ORAL CONTRACEPTIVES With the use of estrogen-progestin-containing oral contraceptives rather than estrogen alone, side effects such as delayed menses, menorrhagia, and premenstrual cramps are uncommon. However, other side effects such as nausea, weight gain, spotting, breast tenderness, amenorrhea, and melasma can occur. The third-generation progestins, desogestrel, norgestimate, and gestodene (not available in the United States), have the lowest intrinsic androgenic activity. [48] Two oral contraceptives are currently FDA approved for the treatment of acne (Ortho Tri-Cyclen and Estrostep). Ortho Tri-Cyclen is a triphasic oral contraceptive comprised of a norgestimate-ethinyl estradiol (35 µg) combination. [49] In an effort to reduce the estrogenic side effects of oral contraceptives, preparations with lower doses of estrogen (20 µg) have been developed and are being studied for the treatment of acne. Estrostep contains a graduated dose of ethinyl estradiol (20 to 35 µg) in combination with norethindrone acetate. [50] An oral contraceptive containing a low dose of estrogen (20 µg) in combination with levonorgestrel (Alesse) has also demonstrated efficacy in acne. [51] Side effects from oral contraceptive use include nausea, vomiting, abnormal menses, weight gain, and breast tenderness. Rare but more serious complications include thrombophlebitis, pulmonary embolism, and hypertension.

GLUCOCORTICOIDS Because of their anti-inflammatory activity, high-dose systemic glucocorticoids may be of benefit in the treatment of acne. In practice, their use is usually restricted to the severely involved patient. Furthermore, because of the potential side effects, these drugs are ordinarily used for limited periods of time, and recurrences are common after therapy is discontinued. Prolonged use may result in the appearance of steroid acne. Glucocorticoids in low dosages are also indicated in those female patients who have an elevation in serum DHEAS associated with an 11- or 21-hydroxylase deficiency or in other individuals with demonstrated androgen excess. Low-dose prednisone (2.5 mg or 5 mg) or dexamethasone can be given orally at bedtime to suppress adrenal androgen production. [34] The combined use of glucocorticoids and estrogens has been used in recalcitrant acne in women, based upon the inhibition of sebum production by this combination. [52] The mechanism of action is probably related to a greater reduction of plasma androgen levels by combined therapy than is produced by either drug alone.

GONADOTROPIN-RELEASING HORMONE AGONISTS GnRH agonists act on the pituitary gland to disrupt its cyclic release of gonadotropins. The net effect is suppression of ovarian steroidogenesis in women. These agents are used in the treatment of ovarian hyperandrenogenism. GnRH agonists have demonstrated efficacy in the treatment of acne and hirsutism in females both with and without endocrine disturbance. [53] Their use, however, is limited by their side-effect profile, which includes menopausal symptoms and bone loss.

ANTIANDROGENS Cyproterone acetate is a progestational antiandrogen that blocks the androgen receptor. It is combined with ethinyl estradiol in an oral contraceptive formulation that is widely used in Europe for the treatment of acne. Cyproterone acetate is not available in the United States. Spironolactone functions both as an androgen receptor blocker and inhibitor of 5a-reductase. In doses of 50 to 100 mg twice a day, it has been shown to reduce sebum production and to improve acne. [54] Side effects include potential hyperkalemia, irregular menstrual periods, breast tenderness, headache, and fatigue. As an antiandrogen, there is a risk of feminization of a male fetus if this medication is taken by a pregnant female. Risk to a fetus and the symptoms of irregular menstrual bleeding can be alleviated by combining spironolactone treatment with an oral contraceptive. Flutamide, an androgen receptor blocker, has been used at doses of 250 mg twice a day in combination with oral contraceptives for treatment of acne or hirsutism in females. [55] Liver function tests should be monitored as cases of fetal hepatitis have been reported. [56] Pregnancy should be avoided. Use of flutamide in the treatment of acne may be limited by its side effect profile.

ENZYME INHIBITORS The development of 5a-reductase inhibitors, such as finasteride, that block the conversion of

testosterone to DHT in the prostate suggested the possibility of an approach to interfering with androgen action on the sebaceous glands that would be appropriate for use in males. However, finasteride does not inhibit sebum secretion. [4] Its lack of action is attributed to the existence of two different 5a-reductases, with the enzyme in the prostate being blocked by the drug while that in the skin is unaffected. [42], [57] Specific inhibitors of the type 1 5a-reductase are being developed. [58] If these agents reduce sebum production, they may be efficacious in the treatment of acne.

ISOTRETINOIN (See also Chap. 257) The use of the oral retinoid, isotretinoin, has revolutionized the management of severe treatment-resistant acne. [59] Isotretinoin, like vitamin A, produces side effects, but, as discussed below, these are not usually severe enough to necessitate interruption of therapy in most cases. The remarkable aspects of isotretinoin therapy are the completeness of the remission in almost all cases and the longevity of the remission, which lasts for months to years in the great majority of patients. Isotretinoin therapy, for all practical purposes, is always accompanied by side effects that may mimic those seen in the chronic hypervitaminosis A syndrome. [60] Thus, side effects related to the skin and mucous membranes are most common. Cheilitis of varying degrees is found in almost all cases. Other side effects that are likely to be seen in over 50 percent of patients are dryness of the mucous membranes, xerosis, conjunctivitis, and pruritus. Side effects seen with lesser degrees of frequency include bone and joint pain; thinning of hair; headache and accompanying symptoms associated with increased intracranial pressure; palmoplantar desquamation; and nausea and vomiting. The laboratory abnormalities that have occurred include elevations in triglycerides, erythrocyte sedimentation rate, platelet count, liver function tests, and white blood cells in the urine and decreases in red blood cell parameters, white cell counts, and high-density lipoprotein levels. The elevation of triglycerides, which is dose-related, is of particular concern because it is often accompanied by a decrease in the high-density lipoprotein levels, which may increase the risk of coronary artery disease. There are also reports of the development of bony hyperostoses after isotretinoin therapy, but these are more likely to be seen in patients who receive the drug for longer periods of time in higher dosages for diseases of keratinization. [61] The issue of isotretinoin and psychiatric effects has come to the forefront. From 1982 to May 2000, 37 cases of suicide, 110 cases of hospitalized depression, suicidal ideation or suicide attempt, and 284 cases of nonhospitalized depression in patients on isotretinoin were reported to the FDA's Adverse Event Reporting System. [62] In one population-based cohort study comparing isotretinoin users with oral antibiotic users, the relative risk for development of depression or psychosis was approximately 1.0, indicating no increased risk. [63] Further studies are needed to resolve this issue of causality. Until then, a careful review for signs and symptoms of depression and suicidal ideation should be performed in all patients for whom isotretinoin therapy is considered, and the patients must be carefully monitored during therapy. Studies show that some of the side effects are dosage related. These same studies demonstrate that clinical results can be obtained with dosages as low as 0.1 mg/kg per day. However, with such dosages, the incidence of relapses after therapy is greater. The recommended daily dosage of isotretinoin is in the range of 0.5 to 1 mg/kg per day. Because back and chest lesions show less of a response than facial lesions, dosages as high as 2 mg/kg per day may be necessary in those patients who have very severe trunk involvement. Patients with severe acne, particularly those with granulomatous lesions, will often develop marked flares of their disease when isotretinoin is started. Therefore, the initial dosing should be low, even below 0.5 mg/kg per day. These patients often need pretreatment for 1 to 2 weeks with prednisone (40 to 60 mg per day), which may have to be continued for the first 2 weeks of therapy. Isotretinoin is usually given for 20 weeks, but the length of the course of treatment is not absolute; in patients who have not shown an adequate response, therapy can be extended, if necessary. Some improvement is usually seen for 1 to 2 months after isotretinoin is discontinued, so that total clearing is not a necessary endpoint for determining when to discontinue therapy. Approximately 10 percent of patients treated with isotretinoin require a second course of the drug. The likelihood for repeat therapy is increased in patients younger than 16 to 17 years of age. It is best to allow at least 2 to 3 months between courses of isotretinoin. Studies suggest that the chances of inducing a long-term remission are greatest if the patient has received a total dose of 120 to 150 mg/kg of isotretinoin during a course of therapy. [64] Isotretinoin should be used only in those patients with severe acne. Furthermore, laboratory monitoring is indicated. It is appropriate to obtain a baseline complete blood count and liver function tests, but the greatest attention should be paid to following serum triglyceride levels. Baseline values for serum triglycerides should be obtained and repeated at 3 to 4 weeks and 6 to 8 weeks of therapy. If the values are normal at 6 to 8 weeks, there is no need to repeat the test during the remaining course of therapy unless there are risk factors. If serum triglycerides increase above 500 mg/dL, the levels should be monitored frequently. Levels above 700 to 800 mg/dL are a reason for interrupting therapy or treating the patient with a lipid-lowering drug such as gemfibrozil. Eruptive exanthemas or pancreatitis can occur at higher serum triglyceride levels. In rare instances, exuberant granulation tissue has appeared in some lesions. If this occurs, the dosage of drug may have to be decreased or the drug may have to be discontinued. Glucocorticoids may have to be administered either systemically or intralesionally to control the granulation tissue. The greatest concern during isotretinoin therapy is the risk of the drug being administered during pregnancy and thereby inducing teratogenic effects in the fetus. [65], [66] The drug is not mutagenic; its effect is on organogenesis. Therefore, the production of retinoic embryopathy occurs very early in pregnancy, with a peak near the third week of gestation. [65], [66] Theoretically, based on animal studies and the pharmacokinetics of the drug, there should be more safety in the use of isotretinoin than either vitamin A or etretinate. [67], [68] However, that is not the case, and a significant number of fetal abnormalities have been reported after the use of isotretinoin. For this reason, it should be emphasized that isotretinoin should be given only to patients who have not responded to other therapy. Furthermore, women who are of childbearing age must be fully informed of the risk of pregnancy. The patient must either avoid sexual exposure totally or should employ two highly effective contraception techniques such as the use of an oral contraceptive and condoms with a spermicidal jelly. Contraception must be started at least 1 month before isotretinoin therapy. The patient must have a negative serum pregnancy test at the time when therapy is decided upon and on the second or third day of the next menstrual period or 11 days after the last unprotected intercourse in a woman who is amenorrheic. The woman must thoroughly understand the contraception techniques she is using and continue them throughout the course of isotretinoin and for 1 month after stopping treatment. No more than 1 month's supply of drug should be given to a female patient so that she can be counseled on a monthly basis on the hazards of pregnancy during isotretinoin therapy. The pregnancy test should be repeated monthly to maintain patient awareness. The manufacturer and the FDA have recently instituted a verification process requiring that authorization stickers be affixed to prescriptions to insure that pregnancy-prevention procedures are followed. As stated above, retinoic acid embryopathy results from the effect of isotretinoin on early organogenesis. Therefore, because the drug is not mutagenic, there is no risk to a fetus conceived by a male who is taking isotretinoin. Although it may seem obvious, it is important to remind men who are taking isotretinoin not to give any of their medication to female companions under any circumstances. The mechanism of action of isotretinoin is not completely known. The drug produces profound inhibition of sebaceous gland activity, and this

undoubtedly is of great importance in the initial clearing. [69], [70] In some patients, sebaceous gland inhibition continues for at least a year, but in the majority of patients, sebum production returns to normal after 2 to 4 months. [69] Thus, this action of the drug cannot be used to explain the long-term remissions. The *P. acnes* population is also decreased during isotretinoin therapy, but this decrease is not often long lasting. [70], [71] Isotretinoin has no inhibitory effect on *P. acnes* in vitro. Therefore, the effect on the bacterial population is probably indirect, resulting from the decrease in intrafollicular lipids necessary for organism growth. Isotretinoin also has anti-inflammatory activity and probably has an effect on the pattern of follicular keratinization. Once again, it has not been demonstrated that these effects are long lasting. Thus, while the drug may influence the course of severe acne through several different mechanisms, the explanation for the long-term remissions remains obscure.

DIET Currently, there is little enthusiasm for the elimination of various foods such as shellfish, chocolate, sweets, milk, and fatty foods from the diet of patients with acne. There is no evidence to support the value of elimination of these foods, although some patients will attest to flares of their disease after ingestion of certain foods. This is especially true with chocolate. Because patients will cling to their beliefs, it is best to restrict those dietary agents that they feel produce flares.

PHYSICAL THERAPY Superficial x-ray therapy, ultraviolet light therapy, and cryotherapy have been used extensively in the past for the treatment of acne. Superficial x-ray therapy was helpful in that it produced temporary suppression of the sebaceous glands, but the hazards associated with this procedure, including thyroid carcinoma, far outweigh the gains, and it is rarely, if ever, used now. There is no proof that ultraviolet light therapy is effective, other than the masking produced by the tan, and cryotherapy is rarely used.

ACNE SURGERY This modality, used for the removal of comedones and superficial pustules, aids in bringing about involution of individual acne lesions. Acne surgery was a mainstay of therapy in the past. However, with the advent of comedolytic agents such as topical vitamin A acid, it is not needed as often. Its use is primarily restricted to those patients who do not respond to comedolytic agents. Even in those patients, the comedones are removed with greater ease and less trauma if the patient is treated first with topical vitamin A acid or a similar topical agent for 3 to 4 weeks. This pretreatment should be done in all patients who are going to undergo mechanical comedo removal. Acne surgery is helpful only when properly done, and inaccurate placement of the comedo extractor may serve only to push the inflammatory material further into the skin. Therefore, it is inadvisable to have the patient do acne surgery at home. The Unna type of comedo extractor, which has a broad flat plate and no narrow sharp edges, is preferable. The removal of open comedones does not materially influence the course of the disease because these lesions do not become inflammatory. However, it is desirable to remove them for cosmetic purposes. In contrast, closed comedones should be removed to prevent their rupture. Unfortunately, the orifice of closed comedones is often very small, and usually the material contained within the comedo can be removed only after the orifice is gently enlarged with a no. 25 needle or other suitable sharply pointed instrument.

INTRALESIONAL GLUCOCORTICOIDS Intralesional injection of glucocorticoids, either by the use of a syringe or by the use of an automatic needleless injector, usually dramatically decreases the size of deep nodular lesions. The injection of 0.05 to 0.25 mL per lesion of a triamcinolone acetate suspension (2.5 to 10 mg/mL) is recommended as the anti-inflammatory agent. This is a very useful form of therapy in the patient with nodular acne, but it often has to be repeated every 2 to 3 weeks. A major advantage is that it can be done without incising or draining the lesions, thus avoiding the possibility of scar formation.

Course and Prognosis

The age of onset of acne varies considerably. It may start as early as 6 to 8 years of age or it may not appear until the age of 20 or later. The course is one of several years' duration followed by spontaneous remission, the cause of which is unknown. While most patients will clear by their early twenties, some have acne extending well into the third or fourth decades. The extent of involvement varies, and spontaneous fluctuations in the degree of involvement are the rule rather than the exception. In the northern sections of the United States, where seasonal differences are great, relative clearing occurs in the summer for reasons that are not understood. Also, in women there is often a fluctuation in association with menses, with a flare just before the onset of menstruation. This flare is not due to a change in sebaceous gland activity as there is no increase in sebum production in the luteal phase of the menstrual cycle.

The prognosis of acne vulgaris is favorable, and almost all cases undergo spontaneous resolution as mentioned above. The only physical sequela is scarring which, with proper care, can often be minimized. Several different procedures are available to correct the scarring. Dermabrasion, laser resurfacing and deeper chemical peels seek to reduce the variability of the skin surface area and smooth out pitted complexions. The scar may be treated by superficial peeling with agents such as phenol or trichloroacetic acid, but it is unlikely that the technique will eliminate more than the most superficial scars. For discreet, depressed scars, soft tissue augmentation can be temporarily beneficial. Filler substances used include bovine collagen, autologous fat, silicone, and dermal grafts. Hypersensitivity to xenographic fillers should be ruled out prior to their use. For larger hypertrophic or aggregated pitted scars, full thickness surgical excision may result in improved scar placement and a better cosmetic outcome.

Many scars are erythematous, and the redness may be decreased by treatment with a pulsed dye laser. However, the most definitive treatment for scars is the use of deep abrasive therapy with motor-driven brushes or wheels to remove the epidermis and upper dermis down to the level of the scars. Potential patients for dermabrasive therapy must be carefully screened. Because the sebaceous glands are suppressed by the administration of isotretinoin, procedures such as dermabrasion or laser resurfacing, which are dependent upon intact appendageal structures for resurfacing, should be delayed at least 6 months. It should be noted that emotionally unstable individuals are poor risks because they likely will blame their appearance for their underlying difficulties. The improvement from dermabrasion is unlikely to solve these difficulties, and such patients are often not satisfied with the results. Persistent erythema, hyperpigmentation or hypopigmentation may follow dermabrasion or resurfacing, and, very rarely, hypertrophic scarring may occur. When deep scars exist, more than one dermabrasion may be necessary. For all these reasons, the patient must give considerable thought to the pros and cons before undertaking this surgical procedure. If there is no medical contraindication to dermabrasion, the decision to undergo the procedure should rest with the patient and not with the physician.

It is important, however, to look beyond the physical scarring, for, as has been stated, there is no disease that has

caused more insecurity and feelings of inferiority than acne. [72] Indeed, acne is perceived by adolescents as having negative personal and social consequences. [73] The psychiatric morbidity associated with acne can assume many varied forms, including impaired self-image and self-esteem, social impairment, depression, or even anger.

MISCELLANEOUS TYPES OF ACNE

In the past, acne was divided into various minor subgroups on the basis of the predominant lesions. Thus, there are references to, for example, comedonal, papular, and pustular acne. As stated earlier, this classification has limited value because close scrutiny usually discloses an admixture of lesions. Nevertheless, there are a few varieties of acne that warrant presentation as separate entities.

Neonatal Acne

An acneiform eruption may occur in newborns or infants. This is often seen on the nose and adjacent portions of the cheeks. The appearance of acne at this time is probably related to the glandular development that occurs during fetal life. Clearing usually occurs, even without treatment. Recent studies suggest that neonatal cephalic pustulosis, a condition confused with neonatal acne, may be due to an inflammatory reaction against Malassezia species. [74] Acne can also start after birth and persist for a few months. This is called *infantile acne*.

Acne Excoriée des Jeunes Filles

Mild acne may be accompanied by extensive excoriations. As a result of the depth of the lesions, linear scarring may occur in these patients. Because this is most frequently seen in young adult women, the above name has been used to describe these cases. Excoriated acne is usually very difficult to treat and may even require supportive psychotherapy.

Steroid Folliculitis

Following administration of glucocorticoids or corticotropin, a folliculitis may appear. This is very uncommon in children but may occur in any adult as early as 2 weeks after steroids are started. Similar lesions may follow the prolonged application of topical glucocorticoids to the face. For this reason, topical glucocorticoids have no place in the treatment of acne, and their use on the face, in general, should be limited. The pathology of steroid acne is that of a focal folliculitis with a neutrophilic infiltrate in and around the follicle. On histologic examination, hyperkeratinization is not a prominent feature, which is consistent with the clinical findings. This type of acne clearly differs from acne vulgaris in its distribution and in the type of lesions observed. The lesions, which are usually all in the same stage of development, consist of small pustules and red papules. In contrast to acne vulgaris, they appear mainly on the trunk, shoulders, and upper arms, with lesser involvement of the face. Postinflammatory hyperpigmentation may occur, but comedones, cysts, and scarring are unusual.

Halogen Acne

Iodides and bromides may induce an acneiform eruption similar to that observed with steroids. With iodides, in particular, inflammation may be marked. The iodine content of iodized salt is low and, therefore, it is extremely unlikely that enough iodized salt could be ingested to cause this type of acne. Rather, when it occurs, it is due to ingestion of halogen-containing sedatives, expectorants, drugs, vitamins, and the like.

Miscellaneous Drugs

Acne resembling steroid acne has been reported after the use of isonicotinic acid hydrazide, and there is a report that patients in whom inactivation of this drug is slow are prone to develop this type of acne. [75] Acne also occurs in patients taking diphenylhydantoin, and it has been reported in individuals taking lithium carbonate.

Occupational Acne

Several different groups of industrial compounds may cause acne. These include coal tar derivatives, insoluble cutting oils, and chlorinated hydrocarbons (chlornaphthalenes, chlordiphenyls, and chlordiphenyloxides). Acne from these agents tends to be quite inflammatory and, in addition to large comedones, is characterized by papules, pustules, large nodules, and true cysts. Tar acne is often accompanied by hyperpigmentation. The lesions of industrial acne are not restricted to the face and, in fact, are more common on covered areas where intimate contact with clothing saturated with the offending compound is maintained. Because the cutting oils are so widely used, they are the most common cause of industrial acne. However, the chlorinated hydrocarbons have posed a more difficult problem because of the severity of the disease induced with these compounds. Many cases have occurred as the result of massive exposure in industrial accidents. [76]

Tropical Acne

Acne vulgaris may flare, and a severe folliculitis may develop, in tropical climates. These skin conditions are a major cause of dermatologic disability in the Armed Forces. Tropical acne, which occurs mainly on the trunk and buttocks, has many deep, large, inflammatory nodules with multiple draining areas. It resembles acne conglobata (see below). The pathogenesis of this type of acne is unknown, although secondary infection with coagulase-positive staphylococci almost always ensues. Systemic antibiotics must be given, but often more important is the necessity to remove the patient to a cooler environment.

Acne Aestivalis

This monomorphous eruption consists of multiple, uniform, red, papular lesions and is reported to occur after sun exposure. It is referred to as *Mallorca acne* because it occurred in many Scandinavians after they had been in southern Europe. Almost all cases have occurred in women, mainly 20 to 30 years old. The lesions are common on the shoulders, arms, neck, and chest. Histologically, the lesions resemble steroid acne in that they show a focal follicular destruction with neutrophilic infiltrate. Comedones are not part of the clinical or histologic picture. The pathogenesis is unknown.

Acne Cosmetica

In the past, various cosmetic compounds were found to induce comedo formation when applied to the external ear canal of rabbits, and cosmetics were considered to be a major cause of adult acne in women. However, new guidelines for interpretation of assays using the rabbit ear model for comedogenesis are now available [77] and cosmetic companies are testing their compounds adequately for comedogenicity before marketing. Consequently, with the exception of very greasy, occlusive products, cosmetics are infrequent etiologic agents for acne.

Pomade Acne

This form of acne is seen most often in black men and women. Some of the pomade that is applied to the scalp is also applied to the forehead and is responsible for the development of multiple, closely packed comedones close to the hairline. If the pomade is spread over greater areas of the face, the lesions themselves may be more extensive and may appear on areas such as the cheek. Pomades are comedogenic in the rabbit ear canal model.

Acne Mechanica

Acneiform eruptions have been observed after repetitive physical trauma to the skin such as rubbing. This can occur from clothing (belts and straps) or sports equipment (football helmets and shoulder pads). It has been induced by occluding the skin with adhesive tape. These extrinsic factors probably produce flares of preexisting acne, and it is uncertain whether they can produce acne in otherwise uninvolved skin. Probably the most common location to see this form of acne is on the forehead and the chin area in those wearing football helmets.

Acne with Facial Edema

Acne may uncommonly be associated with a peculiar inflammatory edema of the mid-third of the face. The edema is unresponsive to high-dose oral antibiotics, but sometimes responds to oral glucocorticoids, often in combination with isotretinoin. However, recurrences are common when glucocorticoids are stopped.

Acne Conglobata

This is a highly inflammatory disease with comedones, nodules, abscesses, and draining sinus tracts. Healing occurs with severe scarring, which is often keloidal in nature. This type of acne is rare and usually starts in adult life.

EPIDEMIOLOGY Males predominate, but a few cases have been reported in females. There may be an antecedent history of acne vulgaris, but this is not invariable.
ETIOLOGY AND PATHOGENESIS Acne conglobata is generally considered to be a separate entity from acne vulgaris because of its occurrence at a later age and its chronic unremitting course. Its true pathogenesis is unknown, but because of the frequent recovery of coagulase-positive staphylococci, and sometimes ß-hemolytic streptococci, it is often considered to be a true pyoderma.
CLINICAL MANIFESTATIONS The patients with acne conglobata have a mixture of comedones, papules, pustules, nodules, abscesses, and scars on the back, buttocks, chest, and, to a lesser extent, on the abdomen, shoulders, neck, face, upper arms, and thighs. The comedones often have multiple openings. The inflammatory lesions are large, tender, and dusky-colored. The draining lesions discharge a foul-smelling serous, purulent, or mucoid material. Subcutaneous dissection with the formation of multichanneled sinus tracts is common. Healing results in an admixture of depressed and keloidal scars.
LABORATORY FINDINGS Although some lesions may be sterile or show only the presence of resident coagulase-negative staphylococci and anaerobic diphtheroids, is common to isolate coagulase-positive staphylococci. Occasionally, ß-hemolytic streptococci are found. The presence of a chronic infection may be reflected by the presence of a normochromic, normocytic anemia, an elevated white blood count with an increased percentage of polymorphonuclear leukocytes, and an increased sedimentation rate. There is no evidence that these patients have decreased ?-globulins; in fact, ?-globulins may be elevated. The fasting blood sugar and glucose tolerance tests are normal.
PATHOLOGY This disease is highly inflammatory, resulting in the destruction of the normal architecture of the appendageal structures. Where follicles can be identified, there is a dense perifollicular inflammatory infiltrate of lymphocytes, polymorphonuclear leukocytes, and plasma cells. Abscess formation is common. Many proliferating tongues of epithelial cells permeate the inflammatory masses, leading eventually to the formation of interconnecting sinus tracts.
DIAGNOSIS AND DIFFERENTIAL DIAGNOSIS The highly inflammatory nature of the lesions, their distribution on the trunk, and the usual age of onset are aids in establishing the diagnosis and differentiating this disease from cystic acne vulgaris. Acne conglobata may also be confused with tropical acne, acne fulminans, and chloracne. Because lesions may occur in the axillary and inguinal regions, the disease may resemble hidradenitis suppurativa. In fact, acne conglobata, hidradenitis suppurativa, and perifolliculitis capitis abscedens et suffodiens of the scalp are often seen in the same patient.
TREATMENT The management of these patients is very difficult and the effect of treatment is often temporary. Several medications have been used including intensive high-dose therapy with antibiotics governed by in vitro antibiotic

sensitivity studies, intralesional glucocorticoids, systemic glucocorticoids, x-ray therapy, surgical debridement, surgical incision, and surgical excision. The use of isotretinoin has produced dramatic results in some of these patients. In severe cases, dosages as high as 2 mg/kg per day for a 20-week course may be necessary. However, because severe flares may occur when isotretinoin is started, the initial dose should be 0.5 mg/kg per day or less, and systemic glucocorticoids are often required either before initiating isotretinoin therapy or as concomitant therapy.
COURSE AND PROGNOSIS This disease tends to run a recalcitrant, chronic course, and patients often have emotional disturbances. However, the prognosis is much better now as isotretinoin can be used to control the active disease, although in many instances significant scarring may remain. Slow-growing, well-differentiated squamous cell carcinoma has been reported in the lesions of acne conglobata. [78] To date, no metastases have been reported. Spondyloarthropathy has also been reported. [79]

Acne Fulminans

This catastrophic disease has also been called *acute febrile ulcerative acne*. It is characterized by the sudden appearance of massive, inflammatory, tender lesions of the back and chest that rapidly become ulcerative and heal with scarring. The disease is reported to occur exclusively in teenage boys. The face is often not involved. The patients are febrile, have a leukocytosis of 10,000 to 30,000/mm^3 white blood cells, and usually have polyarthralgia, myalgia, and other systemic symptoms. X-ray examination may disclose the presence of osteolytic areas in parts of bone tenderness. Although this disease is often classified with acne conglobata, there are basic differences. The onset of acne fulminans is more explosive; nodules and polyporous comedones are less common; the face is not involved as frequently and the neck is usually spared; ulcerative and crusted lesions are unique; and systemic symptoms are more common. Systemic glucocorticoid therapy, along with intensive use of oral antibiotics and intralesional glucocorticoids, is the treatment regimen required for these patients. Isotretinoin is also of benefit in these patients, but in order to prevent explosive flares, systemic glucocorticoids must be started before isotretinoin and continued during the first few weeks of isotretinoin therapy. The initial dosing of isotretinoin must also be small. The daily dose of glucocorticoids should be slowly decreased as tolerated.

Steatocystoma Multiplex

This is a disorder characterized by multiple, varying sized, cystic lesions of the trunk.

EPIDEMIOLOGY Both men and women may be affected. The disease starts in early adult life. It is familial and has been said to be inherited as a dominant characteristic.
ETIOLOGY AND PATHOGENESIS The exact pathogenesis of these lesions is unknown. It has been proposed that this is a cystic sebaceous nevus, and it has also been proposed that the lesions are a result of blockage of the follicular orifice. Relationship to the development of the sebaceous glands is indicated by their location in the midline and the appearance of the lesions at puberty.
CLINICAL MANIFESTATIONS The cutaneous lesions appear chiefly on the upper anterior trunk. They may also be found on the back, arms, forearms, thighs, and scrotum. The individual lesions vary from 1 to 2 mm up to 1 to 2 cm in diameter. They may be flesh-colored or distinctly yellow. The lesions are soft and freely movable. The contents may be either a clear oily liquid or a cheesy white material. There are no systemic manifestations. No laboratory abnormalities have been reported.
PATHOLOGY Serial sections will disclose the presence of a follicular duct that is filled with keratinous material. The cysts are filled with keratin and lipid. Usually, however, there is much less keratin than is found in keratinous cysts. The follicular wall is atrophic, but appendageal remnants may be visible. Some of the cells of the cyst walls may show lipid differentiation. Lanugo hairs may be seen. The surrounding dermis is compressed by the expanding lesions.
DIAGNOSIS AND DIFFERENTIAL DIAGNOSIS The appearance of the multiple cystic lesions, varying in size, particularly on the anterior chest, is essential for diagnosis. Any confusion with solid epithelial tumors or infiltrates into the skin can be eliminated by incising one of the lesions.
TREATMENT None is indicated, but the lesions can be drained by incision or aspiration. They may be excised, although the number of lesions usually precludes any significant overall improvement.
COURSE AND PROGNOSIS The number of lesions, as well as their size, may increase slowly. Except for the cosmetic appearance, this disease poses no threat to the person's health. Malignant degeneration has not been reported.

REFERENCES

1. Ito M: New findings on the proteins of sebaceous glands. *J Invest Dermatol* **82**:381, 1984

2. Stewart ME, Steele WA et al: Changes in the relative amounts of endogenous and exogenous fatty acids in sebaceous lipids during early adolescence. *J Invest Dermatol* **92**:371, 1989

3. Jacobsen E: Age-related changes in sebaceous wax ester secretion rates in men and women. *J Invest Dermatol* **85**:483, 1985

4. Imperato-McGinley J et al: The androgen control of sebum production. Studies of subjects with dihydrotestosterone deficiency and complete androgen insensitivity. *J Clin Endocrinol Metabol* **76**:524, 1993

5. Chen W et al: Cutaneous androgen metabolism: Basic research and clinical progress *J Invest Dermatol,* **119**:992, 2002

6. Stewart M et al: Effect of oral 13- *cis*-retinoic acid at three dose levels on sustainable rates of sebum secretion and on acne. *J Am Acad Dermatol* **8**:532, 1983

7. Hommel L et al: Sebum excretion rate in subjects treated with oral all- *trans*-retinoic acid. *Dermatology* **193**:127, 1996

8. Chen W et al: Exocrine gland dysfunction in MC5-R deficient mice: Evidence for coordinated regulation of exocrine gland function by melanocortin peptides. *Cell* **91**:789, 1997

9. Thiboutot D et al: The melanocortin-5 receptor is expressed in human sebaceous glands and rat preputial cells. *J Invest Dermatol* **115**:614,

2000

10. Laurent S et al: Growth of sebaceous cells in monolayer culture. *In Vitro Cell Dev Biol* **28A**:83, 1992

11. Rosenfield RL et al: Rat preputial sebocyte differentiation involves peroxisome proliferator-activated receptors. *J Invest Dermatol* **112**:226, 1999

12. Rosenfeld RK, Deplewski D, Greene ME: Peroxisome proliferator-activated receptors and skin development. *Horm Res* **54:**269, 2000

13. Chen H et al: Leptin modulates the effects of acyl CoA: diacylglycerol acyltransferase deficiency on murine fur and sebaceous glands. *J Clin Invest* **109**:175, 2002

14. Wilkins JWJ, Voorhees JJ: Prevalence of nodulocystic acne in white and Negro males. *Arch Dermatol* **102**:631, 1970

15. Voorhees JJ: Nodulocystic acne as a phenotypic feature of the XYY genotype. *Arch Dermatol* **105**:913, 1972

16. Knutson D: Ultrastructural observations in acne vulgaris: The normal sebaceous follicle and acne lesions. *J Invest Dermatol* **62**:288, 1974

17. Downing D, Stewart M et al: Essential fatty acids and acne. *J Am Acad Dermatol* **14**:221, 1986

18. Guy R, Green M et al: Modeling of acne in vitro. *J Invest Dermatol* **106**:176, 1996

19. Choudhry R, Hodgins M et al: Localization of androgen receptors in human skin by immunohistochemistry: Implications for the hormonal regulation of hair growth, sebaceous glands and sweat glands. *J Endocrinol* **133**:467, 1991

20. Cunliffe W, Forster R: Androgen control of the pilosebaceous duct? *Br J Dermatol* **116**:449, 1987

21. Hay JB, Hodgins MB: Distribution of androgen metabolizing enzymes in isolated tissues of human forehead and axillary skin. *J Endocrinol* **79**:29, 1978

22. Leyden JJ: Propionibacterium levels in patients with and without acne vulgaris. *J Invest Dermatol* **65**:382, 1975

23. Webster G: Mechanisms of *Propionibacterium acnes*-mediated inflammation in acne vulgaris. *Semin Dermatol* **1**:299, 1982

24. Puhvel SM, Sakamoto M: The chemoattractant properties of comedonal components. *J Invest Dermatol* **71**:324, 1978

25. Tucker SB: Inflammation in acne. Leukocyte attraction and cytotoxicity by comedonal material. *J Invest Dermatol* **74**:21, 1980

26. Webster GF: Polymorphonuclear leukocyte lysosomal release in response to *Propionibacterium acnes* in vitro and its enhancement by sera from inflammatory acne patients. *J Invest Dermatol* **74**:398, 1980

27. Webster GF: Complement activation in acne vulgaris. Consumption of complement by comedones. *Infect Immun* **26**:183, 1979

28. Puhvel SM: Study of antibody levels to Corynebacterium acnes. *Arch Dermatol* **99**:421, 1964

29. Kersey P: Delayed skin test reactivity to *Propionibacterium acnes* correlates with severity of inflammation in acne vulgaris. *Br J Dermatol* **103**:651, 1980

30. Harris HH: Sustainable rates of sebum secretion in acne patients and matched normal control subjects. *J Am Acad Dermatol* **8**:200, 1983

31. Strauss JS et al: The effect of androgens and estrogens on human sebaceous glands. *J Invest Dermatol* **39**:139, 1962

32. Farrell L et al: The treatment of severe cystic acne with 13- *cis*-retinoic acid. *Am Acad Dermatol* **3**:602, 1980

33. Lucky AW et al: Acne vulgaris in premenarchal girls. *Arch Dermatol* **130**:308, 1994

34. Marynick SP et al: Androgen excess in cystic acne. *N Engl J Med* **308**:981, 1983

35. Lucky A et al: Plasma androgens in women with acne vulgaris. *J Invest Dermatol* **81**:70, 1983

36. Levell MJ: Acne is not associated with abnormal plasma androgens. *Br J Dermatol* **120**:649, 1989

37. Sultan C: Free and total plasma testosterone in men and women with acne. *Acta Derm Venereol* **66**:301, 1986

38. Lookingbill DP et al: Tissue production of androgens in women with acne. *J Am Acad Dermatol* **12**:481, 1985

39. Simpson NB et al: The relationship between the in vitro activity of 3ß-hydroxysteroid dehydrogenase delta $^{4-5}$-isomerase in human sebaceous glands and their secretory activity in vivo. *J Invest Dermatol* **81**:139, 1983

40. Sansone G, Reisner RM: Differential rates of conversion of testosterone to dihydrotestosterone in acne and in normal human skin—A possible pathogenic factor in acne. *J Invest Dermatol* **56**:366, 1971

41. Jenkins EP, Andersson S et al: Genetic and pharmacological evidence for more than one human steroid 5a-reductase. *J Clin Invest* **89**:293, 1992

42. Thiboutot D, Harris G et al: Activity of the type 1 5a-reductase exhibits regional differences in isolated sebaceous glands and whole skin. *J Invest Dermatol* **105**:209, 1995

43. Eady E, Bojar R et al: The effects of acne treatment with a combination of benzoyl peroxide and erythromycin on skin carriage of erythromycin-resistant propionibacteria. *Br J Dermatol* **134**:107, 1996

44. Gough A: Minocycline-induced autoimmune hepatitis and systemic lupus erythematosus-like syndrome. *BMJ* **312**:169, 1996

45. Goulden V: Safety of long-term high-dose minocycline in the treatment of acne. *Br J Dermatol* **134**:693, 1966

46. Leyden JJ: Gram-negative folliculitis: A complication of antibiotic therapy in acne vulgaris. *Br J Dermatol* **88**:533, 1973

47. Strauss JS, Kligman AM: Effect of cyclic progestin-estrogen therapy on sebum and acne in women. *JAMA* **190**:815, 1964

48. Speroff L, DeCherney A: Evaluation of a new generation of oral contraceptives. *Obstet Gynecol* **81**:1034, 1993

49. Lucky AW et al: Effectiveness of norgestimate and ethinyl estradiol in treating moderate acne vulgaris. *J Am Acad Dermatol* **37**:746, 1997

50. Maloney M et al: Use of a low-dose oral contraceptive containing norethindrone acetate and ethinyl estradiol in the treatment of moderate acne vulgaris. *Clin J Women's Health* **1**:124, 2001

51. Thiboutot D et al: A randomized, controlled trial of a low-dose contraceptive containing 20 µg of ethinylestradiol and 100 µg of levonorgestrel for acne treatment. *Fertil Steril* **76**:461, 2001

52. Pochi P, Strauss J: Sebaceous gland inhibition from combined glucocorticoid-estrogen treatment. *Arch Dermatol* **112**:1108, 1976

53. Faloia E, Filipponi S et al: Treatment with a gonadotropin-releasing hormone agonist in acne or idiopathic hirsutism. *J Endocrinol Invest* **16**:675, 1993

54. Goodfellow A, Alaghband-Zadeh J et al: Oral spironolactone improves acne vulgaris and reduces sebum excretion. *Br J Dermatol* **111**:209, 1984

55. Cusan L: Treatment of hirsutism with the pure antiandrogen flutamide. *J Am Acad Dermatol* **23**:462, 1990

56. Wysowski D, Freiman J et al: Fatal and nonfatal hepatotoxicity associated with flutamide. *Ann Int Med* **118**:860, 1993

57. Russell DW, Wilson JD: Steroid 5a-reductase: Two genes/two enzymes. *Annu Rev Biochem* **63**:25, 1994

58. Chen W et al: The 5 alpha-reductase system and its inhibitors. Recent development and its perspective in treating androgen-dependent skin disorders. *Dermatology* **193**:177, 1996

59. Peck GL: Prolonged remissions of cystic acne with 13- *cis*-retinoic acid. *N Engl J Med* **300**:329, 1979

60. Windhorst DB, Nigra T: General clinical toxicity of oral retinoids. *J Am Acad Dermatol* **6**:675, 1982

61. Pittsley RA, Yoder FW: Retinoid hyperostosis: Skeletal toxicity associated with long-term administration of 13- *cis*-retinoic acid for refractory ichthyosis. *N Engl J Med* **308**:1012, 1983

62. Wysowski D et al: An analysis of reports of depression and suicide in patients treated with isotretinoin. *J Am Acad Dermatol* **45**:515, 2001

63. Jick S et al: Isotretinoin use and risk of depression, psychotic symptoms, suicide and attempted suicide. *Arch Dermatol* **136**:1231, 2000

64. Lehucher C, Weber-Buisset M: Isotretinoin and acne in practice: A prospective analysis of 188 cases over 9 years. *Dermatology* **186**:123, 1993

65. Stern RS: Isotretinoin and pregnancy. *J Am Acad Dermatol* **10**:851, 1984

66. Lammer EJ: Retinoic acid embryopathy. *N Engl J Med* **310**:1023, 1984

67. Kamm JJ: Toxicology, carcinogenicity, and teratogenicity of some orally administered retinoids. *J Am Acad Dermatol* **6**:652, 1982

68. Brazzell RK, Colburn WA: Pharmacokinetics of the retinoids isotretinoin and etretinate. A comparative review. *J Am Acad Dermatol* **6**:643, 1982

69. Strauss JS, Stranieri AM: Changes in long-term sebum production from isotretinoin therapy. *J Am Acad Dermatol* **6**:751, 1982

70. Leyden JJ, McGinley KJ: Effect of 13- *cis*-retinoic acid on sebum production and *Propionibacterium acnes* in severe nodulocystic acne. *Arch Dermatol* **272**:331, 1982

71. Weismann A: Reduction of bacterial skin flora during treatment with 13- *cis*-retinoic acid. *Arch Dermatol* **270**:179, 1981

72. Koo J: The psychological impact of acne: Patient's perceptions. *J Am Acad Dermatol* **32**:S26, 1995

73. Krowchuk D et al: The psychosocial effects of acne on adolescents. *Pediatr Dermatol* **8**:332, 1991

74. Niamba P et al: Is common neonatal cephalic pustulosis (neonatal acne) triggered by Malassezia sympodialis? *Arch Dermatol* **134**:995, 1998

75. Cohen LK: Isoniazid-induced acne and pellagra: Occurrence in slow inactivators of isoniazid. *Arch Dermatol* **109**:377, 1974

76. Dunagin WG: Cutaneous signs of systemic toxicity due to dioxins and related chemicals. *J Am Acad Dermatol* **10**:689, 1984

77. Strauss JS: American Academy of Dermatology Invitational Symposium on Comedogenicity. *J Am Acad Dermatol* **20**:272, 1989

78. Dillon JS, Spjut HJ: Epidermoid carcinoma occurring in acne conglobata. *Ann Surg* **159**:451, 1964

79. Ellis BI: Acne-associated spondyloarthropathy: Radiographic features. *Radiology* **162**:541, 1987

80. Strauss JS, Kligman AM: The pathologic dynamics of acne vulgaris. *Arch Dermatol* **82**:779, 1968

T>

Chapter 74

Gerd Plewig Thomas Jansen

Rosacea

OCCURRENCE
PATHOGENESIS
CLINICAL FINDINGS
Episodic Erythema (The Rosacea Diathesis)
Stage I
Stage II
Stage III
VARIANTS OF ROSACEA
Persistent Edema of Rosacea
Ophthalmic Rosacea (Ocular Rosacea)
Lupoid or Granulomatous Rosacea
Steroid Rosacea
Gram-Negative Rosacea
Rosacea Conglobata
Rosacea Fulminans
PHYMAS IN ROSACEA
Rhinophyma
Phymas in other locations
HISTOPATHOLOGY
DIFFERENTIAL DIAGNOSIS
TREATMENT
Topical
Systemic
Miscellaneous
Special Situations

REFERENCES

The disease was originally called *acne rosacea,* an inappropriate term that invites confusion with acne vulgaris and is best abandoned. Papules and pustules occur in the central region of the face against a livid erythematous background with telangiectases. Later, there may occur diffuse hyperplasia of connective tissue with enlarged sebaceous glands. The disease evolves in stages. The early signs are recurrent episodes of blushing that finally become persistent dark red erythema, particularly on the nose and cheeks, often before the age of 20 years. These persons are the so-called flushers and blushers. Rosacea is common in the third and fourth decades and peaks between the ages of 40 and 50 years. In the worst cases, nonpitting edema (fibrosis), particularly of the nose (rhinophyma), may develop after many years. Early diagnosis and appropriate management are required to minimize patient discomfort and psychological distress.

OCCURRENCE

Rosacea is a relatively common disease, especially in fair-skinned people of Celtic or northern European heritage, hence the term *curse of the Celts*. [1] It is rarer in dark-skinned people, particularly so with American and African blacks. [2] The disease is estimated to affect at least 5 percent of Americans, or some 13 million people. Although it is said that women are more often affected than men in earlier stages (3:1 ratio), men develop the tissue and sebaceous gland hyperplasia leading to rhinophyma much more frequently. Although rosacea tends to be milder in women, it can lead to severe emotional distress owing to its chronic course.

The importance of sun-damaged skin in rosacea cannot be stressed enough. [3] Rosacea is always associated with solar elastosis and often with heliodermatosis. This is a consistent background on which rosacea is superimposed. However, an increase in ultraviolet sensitivity has not been demonstrated in rosacea patients, nor is the disease more common in outdoor workers.

There is also a wide spectrum of rosacea manifestations. Especially in young patients there may be a history of acne giving rise to variants of two independent facial diseases that are difficult to recognize and treat. It is important to realize that rosacea and acne can coexist, though normally rosacea begins and reaches its peak incidence decades after acne declines.

PATHOGENESIS

Although the precise etiology of rosacea remains a mystery, various factors have been suspected to contribute to this condition. [4], [5] None of them, however, has been definitely confirmed. Rosacea patients are constitutionally predisposed to flushing and blushing. Migraine headaches have been shown to be two or three times more common in rosacea patients than among age- and sex-matched control subjects, suggesting the possibility of a more generalized vascular pathogenesis. The fact that vasomotor lability is especially pronounced during menopause and that a significant number of rosacea patients are perimenopausal women supports this hypothesis. [5] Experimental studies show that the involved skin responds normally to various vasoactive chemicals, with facial blood vessels maintaining their capacity for dilatation and constriction. The basic abnormality seems to be a microcirculatory disturbance of the function of the facial angular

veins directly involved in the brain-cooling vascular mechanism. [6]

An hypothesis holds that rosacea is preceded by degenerative changes of the perivascular, and possibly vascular, collagen and elastic tissues in inherently susceptible individuals exposed to climatic factors. [4] These dermal changes are believed to lead to small vessel dilatation resulting in flushing, telangiectases, and erythema. Eventually, the dilated vessels become incompetent with perivascular leakage of potentially inflammatory substances.

Different mediators, including the neurotransmitter peptide substance P, histamine, serotonin, and prostaglandins, have been proposed to be involved in the erythematous response. It is also possible that none of these is responsible but that the reaction is triggered by another, still unknown mechanism.

The presence of microorganisms has also been examined as a potential contributing factor to rosacea, but results have been inconclusive. *Demodex folliculorum* mites are merely commensals and do not, in contrast to former belief, play a significant part in the pathogenesis of rosacea, although an inflammatory reaction to the mites may be important in this condition. [7] This is different from *Demodex folliculorum* folliculitis (demodicosis, demodicidosis). Some reports suggest that patients with rosacea have an increased prevalence of *Helicobacter pylori* infection, although other reports fail to confirm this association. [8] Eradication of *H. pylori* has been occasionally associated with an improvement of rosacea symptoms. Study results are inconsistent, but it has been suggested that *H. pylori* synthesizes gastrin, which may stimulate flushing.

Rosacea is considered by some authors as a seborrheic disease. Many patients with rosacea, however, do not show signs of excessive sebaceous activity although others do. One report says that there is no significant association between rosacea and seborrhea. It is not a primary disease of sebaceous follicles in contrast to acne vulgaris. Comedones are absent and the initial findings are not related to follicles, though papulopustules are follicular bound.

No acceptable evidence of genetic predisposition has been reported so far, although more than one case in a family is often encountered.

CLINICAL FINDINGS

Rosacea is a centrofacial disease. It is principally localized on the nose, cheeks, chin, forehead, and glabella. Rarer localizations, which are usually overlooked, are the retroauricular areas, the V-shaped area of the chest, the neck, the back, the balded scalp, and even the limbs (extrafacial rosacea). [9]

The hallmarks of rosacea are livid red erythema and telangiectases, preceded by episodes of flushing, papules, and pustules. Comedones are notably absent. If present, they are of different origin, such as concomitant solar comedones (Favre-Racouchot's disease), acne vulgaris, or contact acne (acne cosmetica). In severe cases, papules are numerous enough to be confluent. Granulomatous changes can emerge in later stages, sometimes receiving special designations such as *lupoid rosacea*. Rhinophyma and other phymas are the ultimate tissue reaction, particularly in men.

For didactic as well as for therapeutic reasons, rosacea is classified into stages, which may develop successively (Table 74-1). [1] In some affected individuals, there is progression through all stages, but this succession does not necessarily occur.

Stages in rosacea
Episodic erythema: the rosacea diathesis
Stage I. Persistent moderate erythema with scattered telangiectases
Stage II. Persistent erythema, numerous telangiectases, papules, and pustules
Stage III. Persistent deep erythema, dense telangiectases forming sprays of vessel especially on the nose; papules, pustules, nodules with variable plaquelike edema
Variants of rosacea
Persistent edema of rosacea
Ophthalmic rosacea
Lupoid or granulomatous rosacea
Steroid rosacea
Gram-negative rosacea
Rosacea conglobata
Rosacea fulminans
Phymas in rosacea
Rhinophyma
Gnathophyma
Metophyma
Otophyma
Blepharophyma

TABLE 74-1 **Rosacea: Classification and Key Features**

Episodic Erythema (The Rosacea Diathesis)

Rosacea patients characteristically react with erythema on the central areas of the face, less often the neck and the V-shaped area of the chest. These individuals are constitutionally predisposed to flushing and blushing, evoked by numerous nonspecific stimuli such as ultraviolet radiation, heat, cold, chemical irritation, strong emotions, alcoholic beverages, hot drinks, and spices. Flushing is more intense and lasts longer than in those who tend to blush when embarrassed. Eventually flushing and blushing lead to permanent erythema.

Stage I

The erythema persists for hours and days, hence the old description *erythema congestivum*. Telangiectases become progressively more prominent, forming sprays on the nose, nasolabial folds, cheeks, and glabella. Most of these patients complain of sensitive skin that stings and burns after application of a variety of cosmetics, fragrances, and certain sunscreens. Trauma from abrasives and peeling agents readily induces long-lasting erythema.

Stage II

Dome-shaped inflammatory papules less than 0.5 to 1.0 mm in size, with or without pustules, crop up and persist for weeks. Some papules show a small pustule at the apex, justifying the term *papulopustular*. The lesions are always follicular in origin; vellus and sebaceous follicles are involved. Although patients with concomitant acne may exhibit comedones, comedones should be considered part of an acne process unrelated to rosacea. Spacious sebaceous follicles contain cheesy follicular filaments, which can easily be expressed as a pasty wormlike material. The deeper inflammatory lesions may heal with scarring, but scars are small and tend to be shallow. Facial pores become more prominent. If there has been much solar exposure for decades, the stigmata of photodamaged skin become superimposed, such as elastosis, solar comedones, and heliodermatosis. The papulopustular attacks become increasingly frequent. Finally, rosacea may extend over the entire face and also the scalp (Fig. 74-1). Itchy follicular pustules of the scalp are typical. These either contain the normal bacterial flora or are sterile.

FIGURE 74-1 *A.* Rosacea, stage II. Persistent erythema, telangiectases, numerous papules, pustules, and bulbous nose. Before therapy. *B.* After 12 weeks of isotretinoin treatment (0.5 mg/kg body weight per day, monotherapy). There was no recurrence in 2 years.

Stage III

A small proportion of the patients go on to develop the worst expressions of the disease, namely large inflammatory nodules, furunculoid infiltrations, and tissue hyperplasia. These derangements occur particularly on the cheeks and nose, less often on the chin, forehead, or ears (Fig. 74-2). The facial contours become coarse, thickened, and irregular. Although patients may not appreciate the coarsened appearance, the change becomes evident when photographs from previous years are reviewed. Finally, the patient shows inflamed and thickened edematous skin with large pores, resembling the surface of an orange (*peau d'orange*). These features are caused by inflammatory infiltration, connective tissue hypertrophy with masses of collagen deposition, diffuse sebaceous gland hyperplasia, and overgrowth of individual sebaceous glands forming dozens of yellowish umbilicated papules on cheeks, forehead, temples, and nose. Along with folds and ridges the appearance may mimic leonine facies in leprosy or leukemia. The ultimate deformities are the phymas, such as rhinophyma (Fig. 74-3 and Fig. 74-4).

FIGURE 74-2 Rosacea, stage III. Persistent erythema, papules, pustules, rhinophyma, plaquelike edema and phymas of the perinasal zone.

FIGURE 74-3 Rosacea, stage III. Persistent deep erythema, papules, rhinophyma, and persistent edema of cheeks. Ophthalmic rosacea with blepharitis and conjunctivitis.

FIGURE 74-4 Rosacea, stage III. Severe rhinophyma. Persistent, deep erythema and edema of the forehead (metophyma), cheeks, and chin (gnatophyma).

VARIANTS OF ROSACEA

Classic rosacea is easily recognized; the variants of rosacea are easily overlooked or misdiagnosed.

Persistent Edema of Rosacea

This feature is uncommon and the diagnosis is often missed. The literature hardly mentions this distressing condition referred as rosaceous lymphedema, chronic upper facial erythematous edema, or Morbihan's disease. [10] A hard nonpitting edema is found on the areas involved, mainly on the forehead, glabella, upper eyelids, nose, or cheeks (Fig. 74-5). Subjective complaints are slight, except for the deformed facial contours. This unusual manifestation may lead to other irrelevant diagnoses that delay proper treatment, such as streptococcal cellulitis. A similar edema, although rare, may occur in acne vulgaris and in Melkersson-Rosenthal's syndrome, or without any of these disorders. This edema develops on the background of chronic inflammation from any cause, including bacterial infection.

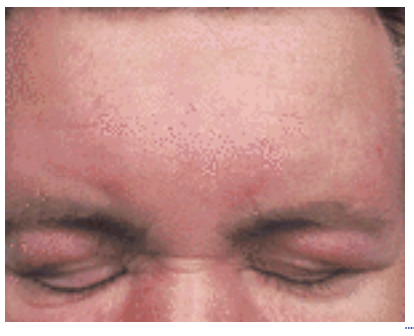

FIGURE 74-5 Persistent edema of rosacea. This patient had stage II rosacea, which quickly responded to oral tetracyclines, but the nonpitting edema on forehead, eyelids, and cheeks (not shown) did not respond.

Ophthalmic Rosacea (Ocular Rosacea)

The exact prevalence of ocular involvement in patients with rosacea is unknown, although it has been reported to be as low as 3 percent and as high as 58 percent. The disease may begin in the eye and escape diagnosis for a long time, even years, and be accompanied by inappropriate treatments. Ophthalmic manifestations may develop prior to cutaneous manifestations in up to 20 percent of patients with ophthalmic rosacea. Approximately half of these patients develop skin lesions first, and a minority develop both manifestations simultaneously. The ophthalmic complications are independent of the severity of facial rosacea. However, there is a strong correlation between the degree of eye

involvement and tendency to flushing.

The ophthalmic signs are variable including blepharitis, conjunctivitis, iritis, iridocyclitis, hypopyoniritis, and even keratitis (Table 74-2; Fig. 74-3). [11], [12] and [13] The term *ophthalmic rosacea* (ophthalmorosacea) covers all these signs, also discourteously referred to as rabbit eyes.

Lid	Blepharitis
	Chalazion, meibomian gland plugging
Conjunctiva	Conjunctival hyperemia
	Conjunctivitis
	Keratoconjunctivitis sicca
Sclera	Scleritis, episcleritis
Iris	Iritis, iridocyclitis, hypopyoniritis
Cornea	Superficial punctate keratopathy
	Corneal thinning, ulceration, perforation
	Corneal neovascularization, scarring
	Blindness

TABLE 74-2 **Ophthalmic Rosacea: Clinical Spectrum**

Rosacea keratitis has an unfavorable prognosis, and in extreme cases can lead to blindness because of corneal opacity. The most frequent eye sign, which may never progress, is chronically inflamed margins of the eyelids, with scales and crusts, quite similar to seborrheic dermatitis, with which it is often confused. Pain and photophobia may be present. It is instructive to ask rosacea patients how their eyes react to bright sunlight. All patients with progressive rosacea should be seen by an ophthalmologist for a thorough examination to detect other subclinical complications. Indeed, such rosacea patients are ideally managed by the cooperative efforts of the dermatologist and the ophthalmologist.

Lupoid or Granulomatous Rosacea

Some patients develop epithelioid (lupoid) granulomas in a diffuse pattern. [14] Clinically, dozens of brown-red papules or little nodules are seen on a diffusely reddened, thickened skin, frequently involving the lower eyelids. Diascopy with a glass spatula or slide reveals the infiltrations. Histopathologic examination reveals perifollicular and perivascular noncaseating epithelioid granulomas. These histopathologic features lead to earlier designations such as *rosacea-like tuberculid of Lewandowsky* and *micropapular tuberculid*.

The course is chronic and unremitting. The diagnosis is often missed. Differential diagnosis includes lupoid perioral dermatitis, lupoid steroid rosacea, small nodular sarcoidosis, and lupus miliaris disseminatus faciei.

Steroid Rosacea

When a rosacea patient is erroneously treated for a prolonged time with topical corticosteroids, the disorder may at first respond, but inevitably the signs of steroid atrophy emerge with thinning of the skin and marked increase in telangiectases. [15], [16] The complexion becomes dark red with a copper-like tone. Soon the surface becomes studded with follicular, round, deep-seated papulopustules, firm nodules, and even secondary comedones. The appearance is shocking with a flaming red, scaling, papule-covered face (Fig. 74-6). Steroid rosacea is a pitiable, avoidable condition that, in addition to disfigurement, is accompanied by severe discomfort and pain. Withdrawal of the steroid is inevitably accompanied by exacerbation of the disease, a trying experience for patient and physician.

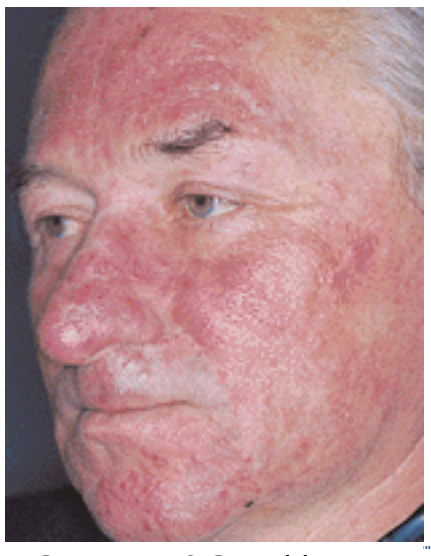

FIGURE 74-6 Steroid rosacea. The patient was treated for a long time with topical glucocorticoid preparations. Flaming red, atrophic facial skin, papulopustules, and edema. Withdrawal of the steroid caused an uncomfortable exacerbation of rosacea.

Gram-Negative Rosacea

The process has only recently been described among gram-negative infections, [17] and is not likely to be diagnosed unless one has been informed of its existence. Clinically it looks like stage II or III rosacea. Multiple tiny yellow pustules (type I) or deep-seated nodules (type II) on the perioral or perinasal region increase suspicion. Neither oral antibiotics nor topical metronidazole will control the disease. The diagnosis rests on demonstration of gram-negative organisms by culturing the contents of several pustules and the nares. The disease is analogous to gram-negative folliculitis, which sometimes develops on top of acne vulgaris as a result of long-term oral antibiotic administration. The organisms are the

same: *Klebsiella, Escherichia coli, Pseudomonas, Acinetobacter* (type I), and *Proteus* (type II), as well as others.

Rosacea Conglobata

Rarely a patient with severe rosacea shows a reaction which mimics acne conglobata with hemorrhagic nodular abscesses and indurated plaques (Fig. 74-7). [1] It may be provoked by the oral intake of halogen-containing preparations. The course is progressive and chronic. This variant seems to occur mainly in women. Diagnosis is based on recognizing preexisting rosacea, confinement to the face, and no other signs of acne conglobata on back, shoulders, chest, or extremities.

FIGURE 74-7 Rosacea conglobata. Purple red skin with intractable episodes of flushing and blushing. Hemorrhagic fluctuating nodules, papules, and pustules. The disease is limited to the face.

Rosacea Fulminans

This variant was first described by O'Leary and Kierland under the designation *pyoderma faciale*. It has been a matter of controversy ever since. [18] One can say with certainty that it is not a variant of acne conglobata; neither is it pyoderma. We interpret it as an extreme form of rosacea conglobata with sudden onset occurring almost exclusively in postadolescent women. In analogy to its acne-counterpart, acne fulminans, we opt to call it *rosacea fulminans.* [19]

This is a conglobate, nodular disease springing up abruptly on the face (Fig. 74-8). [20] Once seen, it is never forgotten. Large coalescent nodules and confluent draining sinuses occupy most of the face. The main locations are the chin, cheeks, and forehead. Ripe abscesses form with multiple pustules riding on top of the carbunculoid nodules. The face is diffusely reddened. Seborrhea is a constant feature but may be overlooked. When questioned closely, patients will often describe the development of extreme oiliness before or concomitant with the explosion. The disease is both embarrassing and debilitating.

FIGURE 74-8 Rosacea fulminans. Large coalescent nodules and abscesses limited to the face attacked this woman within a few weeks.

The history is uniform. The skin is ferociously attacked within a few weeks. Prior acne or rosacea is usually denied. However, we perceived a connection to rosacea because after the stormy blowup, signs of rosacea often make their appearance. Some patients, too, have been flushers and blushers.

Its etiology remains obscure. Often blamed, but unproven, is a severe emotional trauma, such as the death of a family member, divorce, loss of a lover, accidents, and the like. Other patients lack such stress situations. There is a definite association with pregnancy [19] and inflammatory bowel diseases (Crohn's disease, ulcerative colitis) [21], [22] in a significant number of patients.

The prognosis is excellent. Once the disease has been brought under control it does not recur, though the rosacea

diathesis or mild stages of rosacea become progressively more noticeable.

PHYMAS IN ROSACEA

Phyma is the Greek word for swelling, mass, or bulb. Phymas occur in various areas of the face and ears. Rhinophyma is the most common form; other phymas can cause difficulties in diagnosis.

Rhinophyma

It occurs almost exclusively in men. Fortunately, only a few rosacea patients develop this complication. The bulbous nose develops over many years as a result of progressive increase in connective tissue, sebaceous gland hyperplasia, ectatic veins, and chronic deep inflammation. Rhinophyma may accompany stage III rosacea; in other patients surprisingly the signs of rosacea in the rest of the face may be rather mild. Four variants of rhinophyma are recognizable. [23], [24]

GLANDULAR FORM The nose is enlarged mainly because of enormous lobular sebaceous gland hyperplasia. The surface is pitted, with deeply indented and mildly distorted follicular orifices. The tumorous expansions of the nose are often asymmetric and of varying size. Humps and sulci occur. Sebum excretion is increased. Compression by the fingers yields a white pasty substance consisting of an amalgam of corneocytes, sebum, bacteria, and *Demodex folliculorum* mites.
FIBROUS FORM Diffuse hyperplasia of the connective tissue dominates this picture. A variable amount of sebaceous gland hyperplasia may be seen.
FIBROANGIOMATOUS FORM The nose is copper-red to dark red, greatly enlarged, edematous, and covered by a network of large, ectatic veins. Pustules are frequently present.
ACTINIC FORM Nodular masses of elastic tissue distort the nose. These are rather similar to the elastomas that occur in older individuals who have markedly photodamaged skin as a result of overexposure to sunlight. This variety is mainly observed in subjects of Celtic origin who burn easily and tan poorly.

Phymas in other locations

- Gnathophyma (Greek *gnathos,* jaw) involves swelling of the chin.
- Metophyma (Greek *metopon,* forehead) refers to cushion-like swellings on the forehead above the saddle of the nose.
- Otophyma (Greek *ota,* ear) is a cauliflower-like swelling of one or both ears.
- Blepharophyma (Greek *blepharon,* lid) refers to chronic swelling of eyelids, mainly due to sebaceous gland hyperplasia.

HISTOPATHOLOGY

The histopathologic changes of rosacea vary according to the stage and quality of the disease. [25] They are often not diagnostic, resembling other chronic disorders. Skin damage by sunlight is a rather constant background feature, hence often severe elastosis is prominent and may be quite marked.

In stage I rosacea, there are mainly ectatic venules and lymphatics, slight edema, and sparse lymphatic perivascular infiltration. Moderate hyperplasia of the elastic tissue is present with increased curled, thickened elastic fibers.

In stage II rosacea, there is increasing lymphohistiocytic perivascular and perifollicular infiltration. Intrafollicular collections of neutrophils are often found, invariably when pustules are observed. The infiltrate likewise surrounds sebaceous ducts and glands. The veins are thickened and grossly dilatated. Elastosis is more advanced.

In stage III rosacea, there is diffuse expansion of the connective tissue, accompanied by hyperplasia of sebaceous follicles with long, distorted follicular canals, and large, irregular sebaceous lobules. Epithelialized tunnels undermine the hyperplastic tissue and are filled with inflammatory debris. The elastotic changes are prominent, often evident as amorphous masses of degenerated elastic tissue.

Demodex folliculorum mites are often found in all types of rosacea within the follicular infundibula and sebaceous ducts.

Epithelioid granulomas of the noncaseating type with multiple foreign body multinucleated cells are the histopathologic equivalent of lupoid rosacea. *Demodex folliculorum* mites may be involved in the pathogenesis of this condition.

Persistent edema of rosacea is characterized by mild edema in the middle and deep dermis, ectatic lymph vessels, and occasionally a sparse to dense lymphohistiocytic perivascular infiltrate. There are remarkably many mast cells throughout the fibrotic-thickened dermis.

Multiple abscesses with pseudoepitheliomatous hyperplasia, widespread necrosis, and lakes of granulocytes are characteristic of rosacea fulminans.

Immunofluorescence and immunohistochemical techniques have not contributed to the histopathologic identification of rosacea. In some studies, deposition of immunoglobulins and complement at the dermoepidermal junction has been observed by immunofluorescent staining.

DIFFERENTIAL DIAGNOSIS

Rosacea is a clinical diagnosis, because there is no specific laboratory test to confirm the diagnosis. Many disorders

share similar characteristics with rosacea, such as acne vulgaris, seborrheic dermatitis, lupus erythematosus, dermatomyositis, perioral dermatitis, sarcoidosis, polymorphous light eruption, and Haber's syndrome. The episodic facial flushing of the carcinoid syndrome may resemble that of rosacea, but the 24-h urinary excretion of 5-hydroxyindoleacetic acid is normal in rosacea.

TREATMENT

Rosacea is a treatable disease. Sometimes treatment is difficult. Caring for rosacea patients requires a dedicated clinician and a compliant patient. Treatment schedules are determined by the stage and severity of the disease. [1]

Topical

Rosacea patients have a skin that is unusually vulnerable to chemical and physical insults. All sources of local irritation, such as soaps, alcoholic cleansers, tinctures, astringents, abrasives, and peeling agents must be avoided. Only mild soaps or cleansers are advised. Protection against sunlight must be emphasized. [1], [5]

Antibiotics, as used in acne, are sometimes effective. Topical tetracyclines, clindamycin, and erythromycin, usually in concentrations from 0.5% to 2.0%, are commercially available. Erythromycin and clindamycin [26] seem to be superior. Tetracycline is effective orally, but a disappointment topically. An inhibition of chemotaxis or inflammatory cells or a direct effect on vascular endothelium may be responsible for its action.

Metronidazole has become an important addition to the antirosacea repertoire. The observation that topical metronidazole was comparable in its effects to oral tetracycline (250 mg bid) led to placebo-controlled double-blind clinical studies demonstrating its effectiveness. [27] In many countries throughout the world there is a 0.75% gel, cream, or lotion, as well as a 1% cream available. It is applied once or twice daily and has its greatest effect on papules and pustules, and reduces erythema to a lesser degree. It does not alter telangiectases or flushing. Topical metronidazole may be used as monotherapy or, in more severe forms, in combination with oral antibiotics. One study found that 0.75% metronidazole gel rapidly reduced inflammatory lesions during the first 3 weeks of treatment, potentially allowing quick tapering and discontinuation of oral medication. Long-term use of 0.75% metronidazole gel has been shown to keep rosacea in remission. A study involving 88 patients whose rosacea was initially controlled with a combination of oral tetracycline and metronidazole found that more than 80 percent of those patients given metronidazole remained in remission after 6 months, while 40 percent of those patients given placebo relapsed. [28] The mechanism by which metronidazole ameliorates the inflammatory lesions and erythema of rosacea may be related to anti-inflammatory or immunosuppressive actions of the drug.

Imidazoles are also gaining popularity with the treatment of rosacea. The authors' personal experience, although not substantiated by appropriate clinical trials, is best with ketoconazole cream applied once or twice daily. The imidazoles are anti-inflammatory agents, affect gram-positive bacteria, and, above all, are well tolerated by most rosacea patients with sensitive skin.

Old-time remedies should not be forgotten, even though their use is not supported by evidence-based trials. Drying lotions fall into this category, with a very thin application at night recommended. Lotions with 2% to 5% sulfur have been used successfully. [29] Because they are messy, we no longer use them. Other topical medications proven effective for treating rosacea include sulfacetamide sodium 10% lotion, as well as sulfacetamide sodium 10% and sulfur 5% lotion, which may be tinted or tint free. [30] They are used in a similar fashion and for the same purpose as metronidazole.

Retinoids are worth a trial. In an uncontrolled clinical study, women with rosacea used 0.025% tretinoin cream over a period of several months. [31] After a predictable early exacerbation of symptoms, the patients then appeared to develop hardening and side effects diminished. Gratifying long-term results were reported, including a reduction in erythema. Alternative topical retinoids may prove easier to use. There is preliminary evidence that 0.2% isotretinoin in a bland cream is helpful. It is less irritating than tretinoin, and suppresses inflammatory lesions in stage II and III rosacea. No data exist for adapalene, which seems to be the least irritating of all topical retinoids.

In a clinical study, 20% *azelaic acid* cream was more effective than its vehicle cream in reducing the number of inflammatory lesions and degree of erythema associated with rosacea. In a recent study, 20% azelaic acid cream gave results comparable to 0.75% metronidazole cream with the added benefit of increased patient satisfaction. [32] The efficacy of azelaic acid in rosacea may be due to the anti-inflammatory properties of this compound.

As stated earlier, *Demodex folliculorum* mites are not considered to play an etiologic role in rosacea, although massive infestation of *Demodex folliculorum* mites may sometimes aggravate the condition. Nevertheless, it is good to check for mites. This is best done with the skin-surface biopsy technique of placing a drop of cyanoacrylate on a glass slide that is covered with immersion oil and analyzed with the 10 or 20 × objective in the light microscope. [7] The mites are hard to control with any of the antiparasitic drugs such as lindane (?-hexachlorocyclohexane), crotamiton, permethrin, or benzyl benzoate. The effect of treatment on the mite population can be monitored by cyanoacrylate skin-surface biopsies.

Sunscreens, preferably of the broad spectrum UVA plus UVB and infrared type, with a skin protection factor (SPF) of 15 or higher are always recommended to rosacea patients and should be used every day of the year. The sunscreens with a base of micronized zinc oxide or titanium oxide are nonirritating and work well for anyone with the sensitive skin of rosacea, but they leave sometimes an opaque hue on the skin, especially in the spacious facial pores. For this reason patients often turn away from these products.

Glucocorticoids should never be used. The only exception is with rosacea conglobata and rosacea fulminans. In these patients, short courses of oral and topical glucocorticoids are a reasonable option because of their anti-inflammatory

properties.

Systemic

ANTIBIOTICS The most agreeable feature of rosacea is that it generally responds well to oral antibiotics. Tetracycline-HCl, oxytetracycline, doxycycline, and minocycline are usually quite effective in controlling papulopustular rosacea and even reducing erythema. [33] It is important to start with full doses, for example, 1.0 to 1.5 g tetracycline-HCl or oxytetracycline per day. Likewise 50 mg of minocycline (our own choice) or doxycycline twice daily can be given. If tetracyclines are ineffective or not tolerated, erythromycin or other macrolides such as clarithromycin [34] or azithromycin [35] may be used. As soon as full control of papulopustules is achieved, usually after 2 to 3 weeks, maintenance doses of 250 to 500 mg tetracycline-HCl or oxytetracycline, or 50 mg minocycline or doxycycline per day or every other day are generally sufficient. Rosacea patients often know how to titrate disease activity and vary dosage accordingly. Some get by with 250 mg tetracycline-HCl every other day. The patient's input should be encouraged and antibiotic usage should be carefully monitored. The disease has exacerbations and remissions and topical drugs may be sufficient during inactive periods. Some patients seem to become “addicted” to oral antibiotics and find ways to get them without prescription. Tetracycline therapy is mandatory for ophthalmic rosacea.
ISOTRETINOIN (13- *CIS*-RETINOIC ACID) This drug is exceptionally effective, although accompanied by far greater risks than tetracyclines (Fig. 75-1). [36] Before using it, one has to consider indications, contraindications, and all risks. Isotretinoin may be appropriate for all forms of severe or therapy-resistant rosacea, especially the variants which are unresponsive to antibiotics, such as lupoid rosacea, stage III rosacea, rosacea conglobata, gram-negative rosacea, [36] and rosacea fulminans. [19], [20] It is particularly helpful in patients who have oily, wide-pored skin and multiple, often many dozens of sebaceous gland hyperplasias. Furthermore, all forms of phymas are worthwhile indications. The dose required for the control of severe rosacea varies. Tailored doses are recommended. The standard dose of isotretinoin is lower than in acne, namely 0.2 to 0.5 mg/kg body weight per day. Side effects on the eyes make this low dose unbearable for some patients. Ophthalmic rosacea may get worse, complaints of dry eyes can increase, and so can blepharitis. This may lead to the inability to use contact lenses. The standard dose is only used in rosacea fulminans, or preoperatively for a couple of months to shrink rhinophyma before surgical reduction of the bulbous nose. More recent studies demonstrate the efficacy of low-dose isotretinoin in the treatment of rosacea. [37] In this schedule, initially 10 mg or 20 mg daily (not adjusted to body weight) are used. This dose is helpful in many forms of the disease, especially stage III rosacea, lupoid rosacea, and persistent edema in rosacea. After 1 to 2 months, this is further reduced to 10 mg every other day or even to two or three of seven days per week. Side effects on the eyes are minimal. Duration of therapy is longer as with the standard dose, for about 6 months. The cumulative dose, however, is very low. The usual precautions apply as in the therapy of acne. Isotretinoin is a teratogen and is contraindicated for women of childbearing age unless the patient meets all the requirements printed in detail in the package insert. Laboratory monitoring includes liver transaminases, bilirubin, cholesterol, and triglycerides before therapy and at monthly or bimonthly intervals thereafter.
METRONIDAZOLE This is a synthetic nitroimidazole-derivative antibacterial and antiprotozoal agent for the treatment of infections caused by *Trichomonas vaginalis, Entamoeba histolytica,* and several anaerobic organisms. The usual dose is 500 mg twice daily for 6 days. Oral metronidazole is generally effective in all types of rosacea, including stage II and III. [38] However, it may require 20 to 60 days to achieve control with a daily dose of 500 mg. The use of oral metronidazole is limited by concerns over adverse systemic effects and toxicity with long-term therapy, and it is not approved for rosacea treatment. Consequently, oral metronidazole is a second-line drug that may be tried when other methods are not working. It is very helpful for the treatment of *Demodex* folliculitis, even its worst form, such as *Demodex*-associated abscesses and furunculoid nodules. The dose is 750 to 1500 mg daily in divided doses for 10 to 14 days.
CLONIDINE In a limited clinical trial, the vasoconstrictor clonidine has been able to reduce flushing in rosacea, but subdepressor doses, which do not cause a decrease in blood pressure, have little or no effect. It is not our choice.
NADOLOL The betablocker nadolol has been used with variable success to reduce flushing in rosacea. It has significant side effects and is therefore best reserved for intractable cases. It is not our choice.
SPIRONOLACTONE An uncontrolled study of 13 male rosacea patients showed promising results. [39] There was improvement in itching and erythema from the low dose of 50 mg spironolactone daily given over a 4-week period. It is postulated that the observed improvement may be due to an inhibitory effect on epidermal cytochrome P_{450}. Further studies are required to confirm these observations. It is not our choice.

Miscellaneous

FACIAL MASSAGE This has long been recommended and is the so-called Sobye's massage with twice daily gentle circular massage given for several minutes to nose, cheeks, and forehead. Its value is uncertain, and controlled studies are lacking. The mechanism of action may be accelerated lymphatic drainage with reduction of edema. It is not our choice.
DIET IN ROSACEA There is no specific rosacea diet. Dietary limitations relate only to factors that provoke erythema, flushing, and blushing, such as alcoholic beverages, hot drinks, and spicy food. Patients should be encouraged to discover which dietary items are troublesome and to avoid them.
CAMOUFLAGE Women may benefit from the use of a coverup makeup that has a green tint to help mask the underlying telangiectatic erythema of the skin.
SURGICAL TREATMENT This is a very successful approach in rhinophyma. Excellent cosmetic results can be obtained, and the patients brought back into society. A variety of techniques are available, including scalpel or razor modeling; electrocoagulation; [40] cryosurgery; [41] elevation of the intact epidermis with débridement of excess tissue below it with the original epidermis used to cover the wound to maintain a most natural skin surface; argon laser; CO_2 laser; [40] Neodynium:YAG laser; [42] Erbium:YAG laser; [43] and others. Much depends on the training and preferences of the physician. Low-dose oral isotretinoin may be used successfully before the surgical procedure to shrink down the bulbous portions, and it can be continued postoperatively for many months. [44], [45] Unfortunately, information was published that isotretinoin causes unsightly hypertrophic scarring when used close to surgical techniques. We use oral isotretinoin directly before and after the surgical procedure. Obliteration of ectatic vessels, particularly on the nose, can be achieved by intravascular insertion of a fine diathermy needle or by argon or pulsed dye lasers. In expert hands, these physical modalities work satisfactorily.

Special Situations

OPHTHALMIC ROSACEA Management of the ophthalmic disease requires both systemic and topical treatment, including lid hygiene, lubrication, and, occasionally, short-term topical corticosteroids.

ROSACEA FULMINANS This variant requires special care. [19], [20] Treatment starts with oral glucocorticoids such as prednisolone 1.0 mg/kg body weight per day for 7 to 10 days to suppress the inflammatory process. Then isotretinoin is added at 0.2 to 0.5 mg, rarely 1.0 mg per kg body weight per day, with a slow tapering of the glucocorticoid over the next 2 to 3 weeks. Isotretinoin is continued until all inflammatory lesions have disappeared. This may require 3 to 4 months. Draining abscesses should not be incised. Concomitant treatment in the first 2 weeks may consist of warm compresses and topical application of a potent glucocorticoid cream. Besides rosacea conglobata, this is the only indication for topical and systemic glucocorticoids in the treatment of rosacea, and the steroids should never be used for more than 2 or 3 weeks.

PERSISTENT EDEMA OF ROSACEA Treatment has been highly unsatisfactory so far. Our tentative recommendation is low-dose isotretinoin, 0.1 to 0.2 mg/kg body weight per day over a period of 2 to 6 months. This drug is combined with ketotifen, 1 to 2 mg per day, which is a potent H_1-antagonist and possesses antiallergic activities by inhibition of mediator release from mast cells. Preliminary results are encouraging. [46] Clofazimine may be worth a trial, at a dosage of about 100 mg four times weekly.

REFERENCES

1. Jansen T: Rosacea, in *Acne and Rosacea,* edited by G Plewig, AM Kligman. 3rd ed. Berlin, Springer, 2000, p 455

2. Rosen T, Stone MS: Acne rosacea in blacks. *J Am Acad Dermatol* **17**:70, 1987

3. Logan RA, Griffiths WAD: Climatic factors and rosacea, in *Acne and Related Disorders,* edited by R Marks, G Plewig. London, Dunitz, 1989, p 311

4. Marks R: Rosacea: Hopeless hypotheses, marvelous myths and dermal disorganization, in *Acne and Related Disorders,* edited by R Marks, G Plewig. London, Dunitz, 1989, p 293

5. Wilkin JK: Rosacea: Pathophysiology and treatment. *Arch Dermatol* **130**:359, 1994

6. Brinnel H et al: Rosacea: Disturbed defense against brain overheating. *Arch Dermatol Res* **281**:66, 1989

7. Forton F, Seys B: Density of *Demodex folliculorum* in rosacea: A case-control study using standardized skin-surface biopsy. *Br J Dermatol* **128**:650, 1993

8. Jones M: *Helicobacter pylori* in rosacea: lack of an association. *Arch Dermatol* **134**:511, 1998

9. Dupont C: How common is extrafacial rosacea? *J Am Acad Dermatol* **14**:839, 1986

10. Jansen T, Plewig G: Morbus Morbihan. *Akt Dermatol* **22**:161, 1996

11. Akpek EK et al: Ocular rosacea: patient characteristics and follow-up. *Ophthalmology* **104**:1863, 1997

12. Meschig R et al: Ophthalmological complications of rosacea, in *Acne and Related Disorders,* edited by R Marks, G Plewig. London, Dunitz, 1989, p 321

13. Quarterman MJ et al: Ocular rosacea: Signs, symptoms, and tear studies before and after treatment with doxycycline. *Arch Dermatol* **133**:49, 1997

14. Helm KF et al: A clinical and histopathologic study of granulomatous rosacea. *J Am Acad Dermatol* **25**:1038, 1991

15. Jansen T et al: Steroidrosazea. *Akt Dermatol* **21**:129, 1995

16. Leyden JJ et al: Steroid rosacea. *Arch Dermatol* **110**:619, 1974

17. Neubert U et al: Bacteriologic and immunologic aspects of gram-negative folliculitis: A study of 46 patients. *Int J Dermatol* **38**:270, 1999

18. Jansen T, Plewig G: An historical note on pyoderma faciale. *Br J Dermatol* **129**:594, 1993

19. Plewig G et al: Pyoderma faciale: A review and report of 20 additional cases: Is it rosacea? *Arch Dermatol* **128**:1611, 1992

20. Jansen T et al: Diagnosis and treatment of rosacea fulminans. *Dermatology* **188**:251, 1994

21. Jansen T, Plewig G: Fulminating rosacea conglobata (rosacea fulminans) and ulcerative colitis. *Br J Dermatol* **137**:830, 1997

22. Romiti R et al: Rosacea fulminans in a patient with Crohn's disease: A case report and review of the literature. *Acta Derm Venereol (Stockh)* **80**:127, 2000

23. Aloi F et al: The clinicopathologic spectrum of rhinophyma. *J Am Acad Dermatol* **42**:468, 2000

24. Jansen T, Plewig G: Clinical and histological variants of rhinophyma, including nonsurgical treatment modalities. *Facial Plast Surg* **14**:241, 1998

25. Marks R et al: Histopathology of rosacea. *Arch Dermatol* **100**:683, 1969

26. Wilkin JK, DeWitt S: Treatment of rosacea: Topical clindamycin versus oral tetracycline. *Int J Dermatol* **32**:65, 1993

27. Dahl MV et al: Once-daily topical metronidazole cream formulations in the treatment of the papules and pustules of rosacea. *J Am Acad Dermatol* **45**:723, 2001

28. Dahl MV et al: Topical metronidazole maintains remissions of rosacea. *Arch Dermatol* **34**:679, 1998

29. Blom I, Hornmark AM: Topical treatment with sulfur 10 percent for rosacea. *Acta Derm Venereol (Stockh)* **64**:358, 1984

30. Lebwohl MG, Medansky RS: The comparative efficacy of sodium sulfacetamide 10% sulfur 5% (Sulfacet-R) lotion and metronidazole 0.75% (MetroGel) in the treatment of rosacea. *J Geriatr Dermatol* **3**:183, 1995

31. Kligman AM: Topical tretinoin for rosacea: A preliminary report. *J Dermatol Treat* **4**:71, 1993

32. Maddin S: A comparison of topical azelaic acid 20% cream and topical metronidazole 0.75% cream in the treatment of patients with papulopustular rosacea. *J Am Acad Dermatol* **40**:961, 1999

33. Wereide K: Long-term treatment of rosacea with oral tetracycline. *Acta Derm Venereol (Stockh)* **49**:176, 1968

34. Torresani C et al: Clarithromycin versus doxycycline in the treatment of rosacea. *Int J Dermatol* **36**:942, 1997

35. Elewski BE: A novel treatment for acne vulgaris and rosacea. *J Eur Acad Dermatol Venereol* **14**:424, 2000

36. Plewig G et al: Action of isotretinoin in acne, rosacea, and gram-negative folliculitis. *J Am Acad Dermatol* **6**:766, 1982

37. Erdogan FG et al: Efficacy of low-dose isotretinoin in patients with treatment-resistant rosacea. *Arch Dermatol* **134**:884, 1998

38. Saihan EM, Burton JL: A double-blind trial of metronidazole versus oxytetracycline therapy for rosacea. *Br J Dermatol* **102**:443, 1980

39. Aizawa H, Niimura M: Oral spironolactone therapy in male patients with rosacea. *J Dermatol* **19**:293, 1992

40. Greenbaum SS et al: Comparison of CO_2 laser and electrosurgery in the treatment of rhinophyma. *J Am Acad Dermatol* **18**:363, 1988

41. Sonnex TS, Dawber RP: Rhinophyma-treatment by liquid nitrogen spray cryosurgery. *Clin Exp Dermatol* **11**:284, 1986

42. Wenig BL, Weingarten RT: Excision of rhinophyma with Nd:YAG laser: A new technique. *Laryngoscope* **103**:101, 1993

43. Orenstein A et al: Treatment of rhinophyma with Er:YAG laser. *Lasers Surg Med* **29**:230, 2001

44. Irvine C et al: Isotretinoin in the treatment of rosacea and rhinophyma, in *Acne and Related Disorders,* edited by R Marks, G Plewig. London, Dunitz, 1989, p 301

45. Rödder O, Plewig G: Rhinophyma and rosacea: Combined treatment with isotretinoin and dermabrasion, in *Acne and Related Disorders,* edited by R Marks, G Plewig. London, Dunitz, 1989, p 335

46. Jansen T, Plewig G: The treatment of rosaceous lymphoedema. *Clin Exp Dermatol* **22**:57, 1997

T>

Chapter 75

Ronald Marks

Perioral Dermatitis

DEFINITION
HISTORICAL ASPECTS
CLINICAL FEATURES
COURSE AND PROGNOSIS
EPIDEMIOLOGY
PATHOLOGY
THE CAUSE OF PERIORAL DERMATITIS
MANAGEMENT OF PATIENTS WITH PERIORAL DERMATITIS

REFERENCES

DEFINITION

Perioral dermatitis (POD) is a relatively common inflammatory disorder of facial skin of unknown cause in young women in which small papules and pustules occur around the mouth.

HISTORICAL ASPECTS

This disorder seems to have appeared in the second half of the twentieth century, as the first reports of a disease with its characteristic clinical picture appeared in the 1950s. Unfortunately, the various names used and the lack of clinical criteria for inclusion of patients make some aspects of the history somewhat uncertain.

It is generally accepted that the report of Frumess and Lewis, in 1957, [1] of what they termed light-sensitive seborrhcid was the first description of the condition. Mihan and Ayres [2] subsequently gave the condition the name “perioral dermatitis”, which has stuck, although other names were used, such as “rosacea-like dermatosis.” [3] Definitive descriptions were presented by Cochran and Thomson [4] and Wilkinson et al. [5]

CLINICAL FEATURES

This disorder is consistent in its clinical presentation. Characteristically, t first appears around the external nares and the superior end of the nasolabial folds or around the lip commissures (Fig 75-1). The eruption then spreads around the mouth leaving a clear and uninvolved zone immediately adjacent to the lips. When severe and/or long-standing, the condition travels up at the sides of the nose and may even involve the glabella. A variant has been described in which the disorder occurs predominantly around the eyes. This is known as *periocular perioral dermatitis* (Fig 75-2). [6]

FIGURE 75-1 Typical perioral dermatitis: The eruption is confined to the nasolabial folds and the skin of the chin.

FIGURE 75-2 Periocular perioral dermatitis: There are a number of small papules and papular pustules around the eye.

The lesions of POD are typically small papules (or micropapules) but some lesions seem to be surmounted by tiny pustules, and pustules may occur independently. Unlike rosacea, there is little in the way of persistent erythema or telangiectasia, although there may be a background faint pink flush on the affected skin. The papules themselves are a shade of red. Generally, POD causes little in the way of symptoms apart from some mild soreness. The condition, nonetheless, causes considerable distress because of the perceived cosmetic disability.

POD is easily differentiated from rosacea because the latter disorder occurs on facial convexities and is characterized by persistent erythema and telangiectasia.

It is often confused with seborrheic dermatitis, but the scaling in this disease and the occurrence of dandruff, as well as affected areas occurring elsewhere over the skin in seborrheic dermatitis, should enable the distinction to be made from POD. The age group affected may also lead the dermatologist to consider the possibility of acne. However, the different distributions of rash over the face, and the presence in acne of lesions on the upper trunk, of comedones and seborrhea serve to distinguish these two conditions.

The term dermatitis is really a misnomer and it is important to differentiate forms of “true” dermatitis from POD. One form of dermatitis that is quite distinctive and sometimes mistaken for POD is “lip-licking cheilitis,” which is seen predominantly in the 7- to 15-year-old age group. In this disorder, the rash is caused by the repeated licking of the skin around the mouth and is marked by a scaling, pink band around the mouth. Curiously, there is often a spared 1 to 2 mm zone immediately adjacent to the vermilion of the lips just as in perioral dermatitis. Allergic contact dermatitis to lip cosmetic can also result in a “circumoral” dermatitis, [7] but this is quite uncommon.

COURSE AND PROGNOSIS

The condition usually arises spontaneously over the course of a week or two. In nearly every patient, there is a striking dependency on topical corticosteroids. A frequently heard story is that the patient presents with the earliest signs of the rash and is given a potent or moderately potent topical corticosteroid. The condition then shows some improvement but when an attempt is made to stop treatment the condition dramatically worsens after a few days. This happens every time the steroid preparation is stopped. In fact, the condition tends to be doggedly persistent and there does not seem to be any tendency to spontaneous remission. Fortunately, the correct treatment with antibiotics cures the condition (see below).

EPIDEMIOLOGY

The condition is mainly a disease of women aged 15 to 25 years, but occasionally it is seen in children. [8], [9], [10] and [11] There is no validated data on the frequency of the disease, and it may well be that the incidence varies in different countries. In the United Kingdom, it seemed at one time to be a very common disorder in routine dermatologic practice but then in the 1980s, it seemed to vanish and became quite uncommon. However, it showed a resurgence in the 1990s. The same sequence does not seem to have been the case in the United States and some other countries from which reports of studies and case reports continue to appear. [12]

PATHOLOGY

There have been few studies of the pathologic appearances of POD, presumably because of the reluctance of clinicians to biopsy facial skin of young women. However, a 3- or 4-mm diameter punch biopsy rarely produces a significant scar in inflamed facial skin if no sutures are inserted. Our study [13] of 26 patients demonstrated eczematous changes predominantly, with most of the spongiotic change being focused in the external root sheaths of the follicles. In this investigation, there did not appear to be any similarity to the pathologic changes noted in rosacea. Ramelet, [14] however, stated that in his series of 30 cases, the changes were most like those of rosacea. In one series of POD in children, [9] a granulomatous reaction was a consistent finding and this often appeared to emanate from follicular rupture.

THE CAUSE OF PERIORAL DERMATITIS

As yet no convincing explanation to account for the disease has emerged. The striking predominance in women, the relationship with topical corticosteroids, and the curious sudden appearance of the disorder in the 1960s and 1970s have been difficult to fit together into any rational hypothesis. The early view that it was light induced has not been sustained and most writers on the topic have focused on either an infective cause or the result of some form of topical application.

Both *Candida* and fusiform bacteria have been considered as etiological agents, but supporting evidence has not been forthcoming. [15], [16] The *Demodex* mite has also been accused of causing the eruption. [17] Cosmetics have been often considered as evocative agents of the condition. If this is the case, then physical occlusion [12] or some form of irritation may be responsible, as allergic contact dermatitis does not seem likely because patch tests to various cosmetic agents have been consistently negative. [18] Contact with bristly male chin stubble [15] has been discussed as a cause, but has been hotly denied as a possibility by some patients. Fluoride-containing toothpaste [19], [20], [21], [22] and [23] and/or fluoridation of water supplies has been blamed, but neither has received further support.

Most attention has been given to potent topical corticosteroids, particularly fluorinated topical corticosteroids as causative agents. [24], [25] It is certainly the case that many subjects develop a strange dependency on the use of these steroids and flare when they stop using them, but this is a long way from saying that they actually cause the disorders. It has to be borne in mind that a small number of patients vigorously deny ever having used topical corticosteroids.

MANAGEMENT OF PATIENTS WITH PERIORAL DERMATITIS

Most patients are anxious and depressed by the time they reach the dermatologist because of the succession of ineffective treatments they have had. Strong reassurance concerning the eventual successful outcome is needed. At the start of treatment, all topical corticosteroids should be stopped and the patient should be warned that a flare of the rash will almost certainly develop within a few days, but will only last for a few days. Some have suggested that a weak corticosteroid such as hydrocortisone should be given during this period, but this doesn't stop the flare or alleviate the symptoms in most patients. It is probably better to experience the flare “cold turkey” using just an emollient and

continuing to take oral tetracycline (see below).

Most patients respond to oral tetracycline, either tetracycline [18] itself or to one of the more recent analogues, such as minocycline, doxycycline or lymecycline. These drugs should be given in full dosage until the patient starts to respond—usually a 3- or 4-week period—and then reduced to half dosage until the rash has completely resolved. Usually treatment can be stopped after 8 to 10 weeks. Recurrences are very uncommon and, luckily, there are no sequelae. The mode of action of the tetracyclines does not appear to be purely antimicrobial and is yet another of the mysteries associated with POD.

Other oral antibiotics such as erythromycin have been used and have been claimed as successful. Topical metronidazole, [26], [27] topical erythromycin, and topical tetracycline [28] have all been used, but it is rare that such therapies are required.

REFERENCES

1. Frumess GM, Lewis HM: Light-sensitive seborrheid. *Arch Dermatol* **75**:245, 1957
2. Mihan R, Ayres S Jr: Perioral dermatitis. *Arch Dermatol* **89**:803, 1964
3. Weber G: Rosacea-like dermatitis: Contraindication or intolerance to strong steroid. *Br J Dermatol* **86**:253, 1972
4. Rosacea-like dermatitis [editorial]. *BMJ* **3**:545, 1969
5. Wilkinson DS et al: Perioral dermatitis. *Br J Dermatol* **101**:245, 1979
6. Fisher AA: Periocular dermatitis akin to the perioral variety. *J Am Acad Dermatol* **15**:642, 1986
7. Hayakawa R et al: Lipstick dermatitis due to C18 aliphatic compounds. *Contact Dermatitis* **4**:215, 1987
8. Bruyngeel DP: A child with perioral dermatitis. *Contact Dermatitis* **1**:43, 1987
9. Frieden IJ et al: Granulomatous perioral dermatitis in children. *Arch Dermatol* **125**:369, 1989
10. Gianotti F et al: Particuliere dermatitie peri-orale infantile. Observation su 5 cas. *Bull Soc Fr Dermatol Syphiligr* **77**:341, 1970
11. Manders M, Lucky AW: Perioral dermatitis in childhood. *J Am Acad Dermatol* **27**:688, 1992
12. Malik R, Quirk CJ: Topical applications and perioral dermatitis. *Australas J Dermatol* **41**:54, 2000
13. Marks R, Black MM: Perioral dermatitis: A histopathological study of 26 cases. *Br J Dermatol* **84**:242, 1971
14. Ramelet AA, Delacretaz J: Histopathological study of perioral dermatitis. *Dermatologica* **47**:163, 361, 1981
15. Buck A, Kalkoff KW: Zur Nachweis von Fusobakterien aus Effloreszenzen der perioralen dermatitis. *Hautarzt* **22**:433, 1971
16. Beetz HM et al: Uber die bedeutung von bakterien bei den sogenannter periorale dermatitis. *Hautarzt* **24**:220, 1973
17. Ayres S Jr, Ayres S III: Demodectic eruptions (demodicidosis) in the human. *Arch Dermatol* **83**:816, 1961
18. Marks R: Perioral dermatitis, in *Common Facial Dermatoses*. Bristol, England, John Wright, 1976, p 25
19. Epstein E: Fluoride toothpastes as a cause of acne-like eruptions. *Arch Dermatol* **112**:1033, 1976
20. Saunders MA: Fluoride toothpastes: A cause of acne-like eruptions. *Arch Dermatol* **111**:793, 1975
21. Kocsard E, King RH: Perioral dermatitis. *Australas J Dermatol* **13**:49, 1972
22. Sainio EL, Kanerva L: Contact allergens in toothpaste. *Contact Dermatitis* **33**:100, 1995
23. Ferlito TA: Tartar control toothpastes and perioral dermatitis. *J Clin Orthod* **26**:43, 1992
24. Sneddon IB: Iatrogenic dermatitis. *BMJ* **4**:49, 1969
25. Verbov J, Abell E: Iatrogenic dermatitis. *BMJ* **4**:621, 1969
26. Veien NK et al: Topical metronidazole in treatment of perioral dermatitis. *J Am Acad Dermatol* **24**:258, 1991
27. Miller SR, Shalita AR: Topical metronidazole gel for the treatment of perioral dermatitis in children. *J Am Acad Dermatol* **31**:847, 1994
28. Wilson RG: Topical tetracycline in the treatment of perioral dermatitis. *Arch Dermatol* **115**:637, 1979

T>

Chapter 76

Lowell Goldsmith

Disorders of the Eccrine Sweat Glands

IN VIVO METHODS OF STUDYING SWEAT GLAND FUNCTION
Visualization of Sweat
VISUAL EXAMINATION OF THE SKIN
HYPERHIDROSIS OF RELATIVELY LARGE AREAS
Hyperhidrosis Associated with Past Spinal Cord Injuries
Hyperhidrosis Associated with Peripheral Neuropathies
Hyperhidrosis Associated with Brain Lesions
Hyperhidrosis Associated with Intrathoracic Neoplasms or Lesions
Generalized Hyperhidrosis Associated with Systemic Medical Problems
Hyperhidrosis Associated with Drugs or Poisoning
Compensatory Hyperhidrosis
LOCALIZED HYPERHIDROSIS
Idiopathic Unilateral Circumscribed Hyperhidrosis
Localized Hyperhidrosis Associated with Cutaneous Diseases
Gustatory Sweating
Lacrimal Sweating
Harlequin Syndrome
EMOTIONAL SWEATING
Hyperhidrosis of the Palms and Soles
Hyperhidrosis of the Axillae
HYPOHIDROSIS (ANHIDROSIS) OF RELATIVELY LARGE AREAS
Hypo- or Anhidrosis due to Poral Occlusion
Hypohidrosis due to Atrophy, Paucity, or Dysfunction of the Sweat Gland
Hypohidrosis due to Impaired Autonomic Function
LOCALIZED HYPOHIDROSIS
SWEAT RETENTION SYNDROMES
Miliaria
Tropical Anhidrotic Asthenia
Transient Acantholytic Dermatosis (Grover's Disease)
Eccrine Hidradenitis
Heat Hyperpyrexia and Heat Stroke

REFERENCES

Disorders of sweating can occur for many different reasons, including dysfunction of the sweat centers; changes in preganglionic efferent sympathetic pathways; alterations in sympathetic ganglia or postganglionic sympathetic fibers; responses to pharmacologic receptors; and abnormalities in the secretory function of the sweat gland or the sweat duct. Generalized hypohidrosis results in heat intolerance in adults and fever “of unknown etiology” in infants. Acquired generalized hypohidrosis can result in compensatory hyperhidrosis in the areas of the skin with normal sweat gland function. Very frequently it is the compensatory hyperhidrosis, not the underlying hypohidrosis, that brings the patient to the physician's office.

Table 76-1 and Table 76-2 summarize the differential diagnoses of patients with hyperhidrosis and anhidrosis, both generalized and localized.

Hyperhidrosis of a relatively large area (>100 cm^2 or generalized)
In patients with a past history of spinal cord injuries
Autonomic dysreflexia
Orthostatic hypotension
Posttraumatic syringomyelia
Associated with peripheral neuropathies
Familial dysautonomia (Riley-Day syndrome)
Congenital autonomic dysfunction with universal pain loss
Exposure to cold
Associated with probable brain lesions
Episodic with hypothermia (Hines and Bannick syndromes)
Episodic without hypothermia
Olfactory
Associated with intrathoracic neoplasms or lesions
Associated with systemic medical problems
Pheochromocytoma, Parkinson's disease, thyrotoxicosis, diabetes mellitus, congestive heart failure, anxiety, menopausal state, etc.
Due to drugs or poisoning
Night sweats
Compensatory
Hyperhidrosis of relatively small area (<100 cm^2)
Idiopathic unilateral circumscribed hyperhidrosis
Reported association with blue rubber bleb nevus, glomus tumor,
POEMS syndrome, burning feet syndrome
(Goplan's), causalgia, pachydermoperiostosis, pretibial myxedema
Gustatory sweating associated with
Encephalitis, syringomyelia
Diabetic neuropathies, herpes zoster
Parotitis, parotid abscesses, thoracic sympathectomy
Auriculotemporal or Frey's syndrome
Miscellaneous
Lacrimal sweating
Harlequin syndrome
Palm, sole, and axillary hyperhidrosis (emotional)

TABLE 76-1 **Generalized and Localized Hyperhidrosis**

Hypohidrosis or anhidrosis (AH) of relatively large area
Due to poral occlusion
Papulosquamous, dermatitic, or ichthyosiform lesions
Xerosis (incl. xerosis of atopics)
Acquired generalized AH (= tropical anhidrotic asthenia?)
Sweat retention syndrome
Due to absence of the sweat gland
Anhidrotic ectodermal dysplasia (Christ-Siemens-Touraine syndrome)
Due to paucity, atrophy, or dysfunction of the sweat gland
Systemic sclerosis
Fabry disease
Due to impaired autonomic function
Congenital sensory neuropathy type IV (= congenital insensitivity to pain with AH)
Progressive segmental AH with Adie's tonic pupils (Ross's syndrome)
Progressive isolated segmental AH without tonic pupils
Autonomic insufficiency syndrome (postural hypotension and AH)
Chronic idiopathic anhidrosis—diabetic neuropathy
Others: Guillain-Barré, Fabry
Anhidrosis or hypohidrosis of relatively small area
Damage to the glands by infection, trauma, tumors, morphea, scars, or inflammatory infiltrate
Denervation
Incontinentia pigmenti
Dermatomal vitiligo
Miscellaneous
Follicular atrophoderma (Buzen syndrome)
Hypomelanosis of Ito

TABLE 76-2 **Generalized and Localized Anhidrosis**

IN VIVO METHODS OF STUDYING SWEAT GLAND FUNCTION

Visualization of Sweat

Sweat (actually the water in sweat) is readily visualized by an iodine-starch reaction. [1] The one-step method involves applying iodinated starch powder (prepared by adding 0.5 to 1 g of iodine crystals to 500 g of soluble starch in a tightly capped bottle) to the skin with large cotton balls, a body powder applicator, or an atomizer. In addition, iodine-impregnated imprint papers can be made by exposing about 100 sheets of ordinary copy machine paper to 1 g of iodine crystals in an airtight jar for 1 week or longer. The imprints can be photocopied for storage.

The most informative measure of sweat gland function that can be determined in vivo is the maximal sweat rate. Higher sweat rates are associated with larger sweat glands and greater pharmacologic sensitivity. [2] Methods for determining the maximal sweat rate include using a water vapor analyzer, collecting the sweat under mineral oil, and using an anaerobic bag method.

VISUAL EXAMINATION OF THE SKIN

When sweat from patients with cystic fibrosis is dried, it forms fernlike crystals, whereas sweat from healthy individuals does not have this characteristic. Similarly, the skin of an infant with cystic fibrosis is much saltier than normal skin, as detected when the infant is kissed.

The urea content of sweat increases with increasing serum levels of urea. In uremia, the evaporation of sweat with high concentrations of urea results in the deposition of urea in the solid state on the skin. This is commonly referred to as "uremic frost."

Chromhidrosis is the secretion of colored sweat. Several dyes, when injected intravenously, are secreted in eccrine sweat. [3] Colored eccrine sweat has been described in various situations, but in all probability, the sweat is colorless when secreted but immediately becomes colored after reaching the surface, for example, blue sweat noted in copper workers and in those exposed to dye powders (e.g., bromophenol blue or quinazarin).

HYPERHIDROSIS OF RELATIVELY LARGE AREAS (See Table 76-1)

Hyperhidrosis Associated with Past Spinal Cord Injuries

Some patients with a past history of spinal cord injuries experience episodes of profuse sweating months or years after the injuries. The areas of hyperhidrosis are not explained by the sensory or sympathetic dermatomes. The episodes include hyperhidrosis associated with autonomic dysreflexia, [4], [5] hyperhidrosis triggered by orthostatic hypotension, [5] and posttraumatic syringomyelia. [6], [7]

HYPERHIDROSIS ASSOCIATED WITH AUTONOMIC DYSREFLEXIA This syndrome occurs in paraplegic patients with spinal cord lesions at or above T6. Following stimuli such as distention of the bowel or bladder, visceral inflammation, or skin irritation, there is episodic profuse sweating (on the face, neck, and upper trunk), vasodilatation (flushing of the face and congestion of the nasal passages), and throbbing headaches and other signs of sympathetic hyperactivity, such as piloerection and hypertension, and of hyperparasympathetic hyperactivity, such as bradycardia with vasodilatation. [4] The mechanism of hyperhidrosis in autonomic dysreflexia (usually but not always above the spinal cord lesions) is not well understood. The beneficial effect of oral propoxyphene-HCl and propantheline bromide on hyperhidrosis in autonomic dysreflexia has been reported in a few patients. [4] A similar condition occurs in quadriplegic patients. Upon switching from a supine to a tilted or upright position, a sudden spell of dizziness due to orthostatic hypotension is followed within 5 to 10 min by rising blood pressure; profuse sweating on the face, neck, upper chest, and arms; chattering of teeth; piloerection; blurred vision; and agitation. Fludrocortisone acetate, 0.3 mg daily, may control sweating in such patients. [5]
HYPERHIDROSIS DUE TO POSTTRAUMATIC SYRINGOMYELIA The patients may or may not be paraplegic due to injuries to the spinal cord. In most cases, hyperhidrosis may be the only initial symptom. [7] The onset of hyperhidrosis lags months to many years behind trauma. Because the syrinx (a fluid-filled cavity in the spinal cord) develops above and/or below the level of transaction, hyperhidrosis can occur above and/or below the lesion.

Hyperhidrosis Associated with Peripheral Neuropathies

FAMILIAL DYSAUTONOMIA (RILEY-DAY SYNDROME OR HEREDITARY SENSORY NEUROPATHY TYPE III) Hyperhidrosis has been reported in some patients with familial dysautonomia and is caused by mutations in the *IKAP* gene (the IKK complex associated protein forms a scaffold for the complex which includes the NF?B-inducing complex). [7], [8] Riley-Day syndrome, a recessively inherited disorder is usually seen in Ashkenazi Jews. Hyperhidrosis is probably due to the increased excitability of the sweat center [9] and is usually episodic. The diagnostic criteria include the lack of an axon reflex flare following intradermal histamine injection (indicating peripheral panneuropathy); the absence of fungiform papillae on the tongue; miosis of the pupil following instillation of 2.5% methacholine (normal subjects do not respond; miosis means hypersensitivity of the parasympathetic nerves); diminished deep-tendon reflexes; a lack of overflow tears; failure to thrive; a generalized reduction in pain sensation; mild mental retardation; and an erythematous mottling of the skin upon heat exposure. [10] Congenital autonomic dysfunction with universal pain loss is a similar syndrome in those not of Ashkenazi Jewish descent.

PERIPHERAL MOTOR NEUROPATHY WITH AUTONOMIC DYSFUNCTION The onset of profuse sweating in the neck and the thorax was reported in two sisters with this condition. [11] Sweating is aggravated by cold weather or nervousness. These patients also noted slowly progressive muscular weakness and muscular hypertrophy (due to demyelination of motor nerves), distal cyanosis, orthostatic hypotension, and esophageal achalasia, but they lacked sensory neuropathy.

Hyperhidrosis Associated with Brain Lesions

A variety of lesions in the brain can cause episodes of profuse sweating; they may be separated into two major groups: those associated with hypothermia and those not associated with hypothermia.

EPISODIC HYPOTHERMIA WITH HYPERHIDROSIS (HINES AND BANNICK SYNDROME) Hyperhidrosis in the Hines and Bannick syndrome [12] begins at anytime from 9 months to 38 years of age. Episodes of profuse sweating are triggered on awakening or standing up and are preceded by a feeling of warmth, tingling, and flushing of the face, during which time the body temperature decreases to between 24° to 31°C (75° to 88°F). Sweating lasts only 5 min in some patients, but it may persist for as long as several hours in others. Hyperhidrosis in these patients is most likely due to the episodic decrease of the hypothalamic temperature set point (diencephalic epilepsy or hypothalamic storm) by diencephalic lesions or malformations such as agenesis of the corpus callosum, heterotopias, microgyria, parencephalia, malformation of cranial nerves and brainstem nuclei, cholesteatoma, lipoma, or surgical manipulation of the anterior hypothalamus. [13] Anticonvulsants and oxybutynin have been used for control of hypothermia and hyperhidrosis with variable success.

GENERALIZED HYPERHIDROSIS NOT ASSOCIATED WITH HYPOTHERMIA Hyperhidrosis has been reported in rare patients with episodic hypertension and hypothalamic-pituitary dysfunction after a brain injury and after a cerebrovascular accident in the region of the hypothalamus.

OLFACTORY HYPERHIDROSIS Profuse facial sweating precipitated by perfume smells, but not by gustatory or mental stimuli, was reported in a 42-year-old woman [14] and was successfully treated with amitriptyline.

Hyperhidrosis Associated with Intrathoracic Neoplasms or Lesions

PAROXYSMAL UNILATERAL HYPERHIDROSIS ASSOCIATED WITH INTRATHORACIC NEOPLASMS Abnormal thoracic sympathetic activity due to encroachment of tumors (pulmonary adenocarcinoma, bronchial carcinoma, mesothelioma, etc.), osteomas, or cervical ribs on the sympathetic trunk, or postganglionic fibers can cause ipsilateral hyperhidrosis. [15] Sweating is usually spontaneous and profuse on the face, neck, and chest.

Generalized Hyperhidrosis Associated with Systemic Medical Problems

Increased sweating has been reported in diabetes mellitus, hypoglycemia, congestive heart failure, thyrotoxicosis, hyperpituitarism, anxiety, dumping syndrome, carcinoid, alcohol and drug withdrawal, and the menopausal state. At 34°C (93°F) a significantly higher rate of sweating than normal is seen in patients with thyrotoxicosis. Sweating is a feature of growth hormone excess and is decreased in growth hormone deficiency in males. [16] Growth hormone administered to adults with growth hormone deficiency did not increase sweating. [16] In Parkinson's disease, an increase in pharmacologic sweating was reported, and other studies [17] have noted a combination of patchy areas of anhidrosis and areas of hyperhidrosis. The symptomatic triad of excessive and inappropriate paroxysmal sweating, tachycardia, and pounding headaches (associated with increased blood pressure), almost assures the diagnosis of pheochromocytoma. [18]

Hyperhidrosis Associated with Drugs or Poisoning

Excessive diaphoresis has also been reported as a side effect of antidepressants such as cyclobenzapine and fluoxetine. Acrodynia, a form of mercury poisoning, occurred in a child exposed to paint fumes in a home recently painted with a brand of house latex paint containing mercury. [19]

NIGHT SWEATS (NOCTURNAL DIAPHORESIS) Night sweats are occasionally associated with tuberculosis; endocarditis; lymphoma; hyperthyroidism; diabetes mellitus; hypoglycemia due to insulinoma; systemic vasculitis; pheochromocytoma; carcinoid syndrome; drug withdrawal; dysautonomic states; other chronic infectious diseases; acromegaly; and Prinzmetal's angina pectoris.

NIGHT SWEATS ASSOCIATED WITH HODGKIN'S DISEASE Hodgkin's disease is characterized by the triad of fever, sweating, and weight loss; in many patients, night sweats may be the only symptom. [20] The increased sweating in this disease may be due to a fluctuating fever and instability of the thermoregulatory hypothalamic center. In fact, the sudden drop of body temperature was found to coincide with the onset of profuse night sweats. The excessive production of interleukin-1 (IL-1) by activated macrophages is implicated as the cause of the temperature instability. [20] IL-1 is known to induce an abrupt increase in the synthesis of prostaglandin E_2 in the preoptic anterior hypothalamic region, causing an

elevation of the temperature “set point.”

Compensatory Hyperhidrosis

Compensatory hyperhidrosis describes the occurrence of hyperhidrosis on the trunk and legs after thoracic sympathectomy for the treatment of palmar hyperhidrosis, facial hyperhidrosis in patients with generalized sweat retention syndrome, or distal anhidrosis due to diabetic neuropathy (Fig. 76-1). Sweating in such a patient is usually triggered by thermal stimuli or by physical exercise and is presumably due to the increased thermoregulatory need for the remaining functional sweat glands. The most frequent causes of anhidrosis in such patients include diabetes mellitus, lesions in the spinal cord or sympathetic trunk, and widespread poral occlusion in atopic dermatitis or in extensive miliaria.

FIGURE 76-1 Compensatory hyperhidrosis in a patient with herniation of intervertebral disk at L1–L2 with subsequent partial sensory and motor neuropathy of the buttock and legs. The patient complained of excessive spontaneous sweating on the trunk and face, and although his skin was dry in our clinic, brief exposure to a sauna induced sweating on the trunk but not on the buttock and legs. The dark areas are hyperhidrotic areas visualized by the one-step iodinated starch method. Note that the buttock and legs are completely anhidrotic with a sharp cut-off line.

LOCALIZED HYPERHIDROSIS

Idiopathic Unilateral Circumscribed Hyperhidrosis

The involved area in unilateral circumscribed hyperhidrosis is usually sharply demarcated and no larger than 10 × 10 cm^2. It occurs mainly on the face and upper extremities of otherwise healthy individuals [21] (see Fig. 76-2). Profuse sweating, which is usually precipitated by heat, lasts 15 to 60 min. In some patients, mental or gustatory (in the case of facial hyperhidrosis) stimulation also triggers sweating. There is no accompanying sensory or motor neuropathy, flushing of the face, headaches, excessive salivation, lacrimation, vasodilation, or piloerection. The pathogenesis of circumscribed hyperhidrosis is unknown. Sweating may be partially controlled by local application of 25% aluminum salts or topical anticholinergic agents or by systemic clonidine (which inhibits central sympathetic outflow). Local injections of botulism toxin to the affected area may also control the sweating (see Chap. 276). As a last resort, total excision of the affected area should be considered.

FIGURE 76-2 Idiopathic unilateral circumscribed hyperhidrosis in a 7-year-old boy visualized by the conventional Minor's iodine starch method (the skin was painted with tincture of iodine, air-dried, and sprayed with starch). Hyperhidrosis was precipitated by heat. Over the following 2 years, the hyperhidrosis gradually improved without treatment.

Localized Hyperhidrosis Associated with Cutaneous Diseases

Localized hyperhidrosis has been reported to occur in the skin over a blue rubber bleb nevus (presumably due to axon-reflex sweating after manipulation of the painful lesion), in the perilesional skin of a glomus tumor (presumably due to increased local temperature and/or pain), and in POEMS (polyneuropathy, organomegaly, endocrinopathy, M protein, and skin changes) syndrome, Goplan's disease (burning-feet syndrome), causalgia, pachydermoperiostosis, and painful pretibial myxedema.

Gustatory Sweating

GUSTATORY SWEATING DUE TO HYPERACTIVITY OF SYMPATHETIC FUNCTION Gustatory sweating on the face and neck can occur in association with encephalitis or syringomyelia or the invasion of the cervical sympathetic trunk by a tumor. [22] Gustatory sweating occurs in 73 percent of patients after an upper dorsal sympathectomy and is explained by pre- and postganglionic sympathetic regeneration with collateral sprouting into, or aberrant synapsing with, the superior cervical ganglion. [23] Thus ipsilateral gustatory sweating can occur in the presence of other signs of Horner's syndrome (full Horner's syndrome includes ipsilateral anhidrosis, ptosis, miosis, and enophthalmos), but sweating is more intense in their absence. [24] Gustatory sweating rarely occurs in diabetic neuropathy.

AURICULOTEMPORAL (OR FREY'S) SYNDROME Frey's syndrome occurs in 37 to 100 percent of patients 1 month to 5 years after parotid gland surgery or injury to the preauricular region. This syndrome most frequently results from injury to the auriculotemporal nerve, which carries sensory fibers from the skin, parasympathetic fibers to the salivary glands, and sympathetic fibers to the sweat glands in the preauricular region (Fig. 76-3). According to the misdirection hypothesis, the severed parasympathetic fibers in the auriculotemporal nerve regenerate and migrate into the postganglionic sympathetic fibers to reach the sweat glands as well as the blood vessels in the preauricular region. When the greater auricular nerve is damaged together with the parotid gland, the parasympathetic fibers regenerating from the damaged parotid gland migrate into the distal segment of the greater auricular nerve to innervate the sweat glands in the infraauricular area. Gustatory sweating in Frey's syndrome is usually mild, i.e., only 10 percent of the patients may require treatment. Topical scopolamine cream (3 to 5%) and 20% aluminum chloride in ethanol have been used with variable success. Injecting alcohol around the auriculotemporal nerve may eliminate symptoms for several months. Tympanic neurectomy and an interpositional fascial graft may offer permanent relief. Gustatory sweating secondary to parotitis or parotid abscess is a variant of Frey's syndrome.

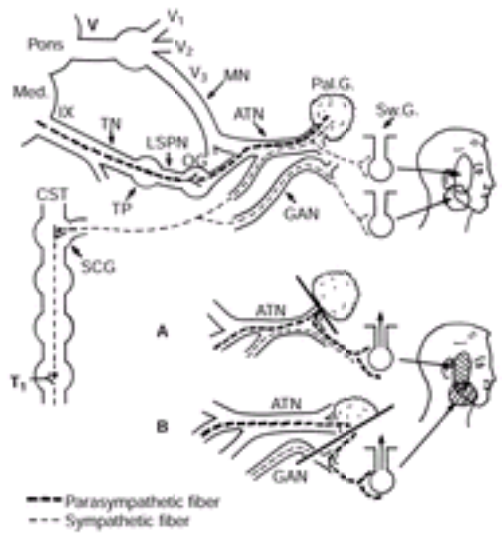

FIGURE 76-3 Illustration of parotid secretomotor and sudomotor neural pathway. ATN, auriculotemporal nerve; CST, cervical sympathetic trunk; GAN, greater auricular nerve; IX, glossopharyngeal nerve; LSPN, lesser superficial petrosal nerve; Med., medulla oblongata; MN, mandibular nerve; OG, otic ganglion; Pal. G, parotid gland; SCG, superior cervical ganglion; Sw.G, sweat gland; T1, first thoracic nerve; TN, tympanic nerve (or Jacobson's nerve); TP, tympanic plexus; V, trigeminal nerve. *A* and *B.* The most widely held “misdirection” hypothesis on the pathogenesis of Frey's syndrome, i.e., injury to the parotid gland and/or auriculotemporal nerve (as indicated by a diagonal line), causes misdirection of its parasympathetic fibers toward the sweat glands in the preauricular area (*A*). When both the greater auricular nerve (GAN) and the parotid gland are severed, the regenerating parasympathetic fibers from the ATN migrate into the GAN to reach the sweat glands, causing gustatory sweating in the infraauricular area. (*From Sato et al.,* [1] *with permission.*)

Lacrimal Sweating

Lacrimal sweating refers to continuous profuse sweating in the right supraorbital region associated with Raeder's syndrome (Horner's syndrome plus temporal and frontal headache). [25] The etiology of this rare condition is unknown, but the nature of Horner's syndrome suggests that it is due to the localized neuropathy of sympathetic fibers supplying the orbital area.

Harlequin Syndrome

Five patients, aged 27 to 64 years, suddenly developed onset of unilateral facial flushing and sweating. [26] Brainstem infarct was suspected in one patient; occlusion of the anterior radicular artery due to strenuous exertion (with consequent damage to the third thoracic segment) was suspected in the other four patients. The flushing side showed increased sympathetic activity (which was abolished by ipsilateral stellate ganglionectomy), whereas contralateral sympathetic activity was found to be deficient. Sweating was aggravated by heat or exercise in all the patients, but in four of the five patients, gustatory stimuli also triggered sweating. Thus, the contralateral anhidrotic side with absent sympathetic activity may be the primary abnormality, and the ipsilateral hyperhidrosis (with sympathetic hyperactivity) may be compensatory in nature.

EMOTIONAL SWEATING

Hyperhidrosis of the Palms and Soles

Excessive sweating of the palms and soles occurs during mental stress and may be associated with tachycardia and vasomotor instability. Palmar hyperhidrosis interferes with occupations in which instruments and tools are handled. Increased moisture may be an accessory factor in contact dermatitis by leaching out sensitizing chemicals from solid objects in contact with the skin.

The hypothalamic sweat center controlling the palms and soles (and the axillae in some patients) is distinct from the rest of the hypothalamic sweat centers and receives nervous inputs from the cerebral cortex but not from the thermosensitive elements and is activated predominantly by emotional stimuli. Thus, sweating on the palms and soles does not occur during sleep or sedation, nor is it augmented in a warm environment. Patients with hyperhidrosis of the palms and soles show electroencephalographic (EEG) abnormalities such as sharp wave bursts when challenged by hyperventilation, and their frontal cortexes are hyperperfused. [27] These patients have less reflex bradycardia than control subjects in response to the Valsalva maneuver or facial immersion, but a higher degree of cutaneous vasoconstriction in response to finger immersion in cold, suggesting that they have increased sympathetic outflow passing through the T2–T3 ganglia. [28]

Excessive palmoplantar sweating lowers the skin temperature of the hands and fingers by excessive evaporative cooling, which further increases the sympathetic outflow and aggravates the hyperhidrosis. Successful treatment of the palmoplantar hyperhidrosis elevates the palmar skin temperature by 2.5°C (4.5°F) which may also help to alleviate the vicious cycle of sympathetic reflex.

Tap water iontophoresis is an effective, safe, and inexpensive therapeutic modality for palmoplantar hyperhidrosis (Fig. 76-4). [29] Local injection of botulinum toxin is an effective treatment for palmar hyperhidrosis [30] and for axillary hyperhidrosis as measured in a double-blind placebo trial. [31] This therapy shows measurable improvement in the quality of life of the infected individual. [32] The biology of botulinum toxin is discussed in Chap. 8 and its clinical use is reviewed in Chap. 276.

FIGURE 76-4 Successful treatment of hyperhidrosis with tap water iontophoresis. The right palm was treated for 30 min daily for 7 days at 20 mA by anodal current, whereas the left palm was only immersed in water. The right foot was connected to a cathodal electrode. The sweat prints were taken using an iodine-impregnated paper.

Hyperhidrosis of the Axillae

Patients with excessive axillary sweating rarely emit a pungent axillary odor, supporting the notion that the apocrine glands but not the apoeccrine glands are responsible for the axillary odor. The important role of the axillary apoeccrine sweat glands to the overall axillary wetness is discussed in Chap. 8. The emotional nature of the axillary sudomotor function (supplied mainly by the fourth thoracic ganglion) is similar to that on the palms and soles except that axillary sweat glands also respond to thermal stimuli to varying extents. Only 25 percent of patients with axillary hyperhidrosis also have palmoplantar hyperhidrosis. Unlike palmar sweating, axillary sweating is relatively well controlled by topical application of 25% aluminum chloride in alcohol solution applied at bedtime, with or without subsequent occlusion with a plastic film. [33] Botulinum toxin is also an effective treatment. Thoracic sympathectomy (usually second through fourth thoracic ganglia) should be considered only as the last resort. Treatment with systemic anticholinergic (atropine-like) drugs should be discouraged because of the excessive side effects (e.g., excessive dryness of the mouth, failure of accommodation). Local application of anticholinergics has been disappointing.

HYPOHIDROSIS (ANHIDROSIS) OF RELATIVELY LARGE AREAS

Anhidrosis can result from poral occlusion, congenital or acquired absence of sweat glands, damage to sweat gland function by inflammation of the skin, or dysfunction of sympathetic nerves in neuropathies. Anhidrosis can involve relatively large areas or very small areas of the skin (Table 76-2). The anhidrotic ectodermal dysplasias are discussed in Chap. 53.

Hypo- or Anhidrosis due to Poral Occlusion

Delivery of sweat to the skin surface is hindered to varying extents in papulosquamous lesions, dermatophytosis, ichthyosiform erythroderma, and the xerotic skin of atopic patients. [34] Following sunstroke, patients may suddenly develop generalized anhidrosis and heat intolerance that may last as long as 6 years. Biopsy revealed atrophic and vacuolar changes of the sweat secretory cells. This disorder may be a variant of tropical anhidrotic asthenia.

Hypohidrosis due to Atrophy, Paucity, or Dysfunction of the Sweat Gland

Atrophy of the sweat gland is seen in systemic sclerosis, systemic lupus erythematosus, or Sjögren's syndrome.

Hypohidrosis due to Impaired Autonomic Function

CONGENITAL INSENSITIVITY TO PAIN WITH ANHIDROSIS (HEREDITARY SENSORY NEUROPATHY TYPE 4 WITH ANHIDROSIS) This autosomal recessive disorder is characterized by generalized anhidrosis, mental retardation, self-mutilation, painless ulcers, fractures, and episodes of high fever. Skin bruises may suggest a diagnosis of child abuse. In the skin, there is a lack of unmyelinated fibers and a marked reduction in the number of myelinated nerves in sweat glands. The glands are unresponsive to local injection of pilocarpine. Mutations in the high affinity tyrosine kinase receptor for nerve growth factors is the molecular etiology of the syndrome. [35]

PROGRESSIVE SEGMENTAL ANHIDROSIS WITH TONIC PUPILS (ROSS SYNDROME OR HOLMES-ADIE SYNDROME WITH ANHIDROSIS) Ross syndrome affects both males and females, with the age of onset ranging from 3 to 50 years. [36] Patients usually present with heat intolerance and irregular segmental areas of anhidrosis on the trunk and/or the extremities and hyporeflexia. Examination shows tonic pupils, anisocoria, sluggish reaction to light, and abnormal constriction by 2.5% methacholine. The symptoms are generally ascribed to postganglionic denervation of the parasympathetic fibers that travel with the third cranial nerve. The absence of deep-tendon reflexes in the extremities is also seen consistently. The mechanism of anhidrosis in these patients is unknown.

PROGRESSIVE ISOLATED SEGMENTAL ANHIDROSIS One patient had anhidrosis without tonic pupils, sensory

neuropathy, or areflexia. [37] The anhidrotic areas remained responsive to intradermal cholinergic agents for several months but became unresponsive 2 years later. The authors concluded that the anhidrosis in their patient was due to denervation of preganglionic sympathetic fibers.

CHRONIC IDIOPATHIC ANHIDROSIS Eight patients reported by Low et al. [38] showed generalized anhidrosis of from 1 to 10 years duration without orthostatic hypotension. Some of these patients showed mild anisocoria, sluggish pupillary response to light and accommodation, and an abnormal pupillary response to cocaine (indicative of mild postganglionic sympathetic failure). Five of them showed electrophysiologic evidence of mild peripheral somatic sensory nerve involvement. Recovery from anhidrosis occurred in one patient. The age of onset of their symptoms ranged from 18 to 60 years. The histology of the sweat glands was apparently normal. Thus, chronic idiopathic anhidrosis could be a forme fruste or stage of acute panautonomic neuropathy. Fisher and Maibach [39] reported five patients with postural hypotension, of whom two had generalized anhidrosis and one had localized anhidrosis.

DIABETIC NEUROPATHY WITH ANHIDROSIS Autonomic neuropathy is a frequent complication of diabetes mellitus that often accompanies, or even precedes, the first signs of more commonly recognized sensorimotor polyneuropathy. [40] Diabetic neuropathy commonly involves distal sensorimotor neuropathy, painful thoracolumbar monoradiculopathy, and polyradiculopathy. Of 51 patients with diabetic neuropathy, 48 presented with unequivocal abnormalities of thermoregulatory sweating. [41] Compensatory hyperhidrosis may accompany diabetic anhidrosis.

OTHER ANHIDROSIS DUE TO NEUROPATHIES Anhidrosis of the lower limbs is seen in 12 percent of patients with Guillain-Barré syndrome. [42] In Fabry's disease, extensive deposition of ceramide trihexoside in the peripheral and central autonomic nerves, the dorsal root ganglia, and the peripheral sensory nerves results in pandysautonomia and sensory neuropathy [43] and deposition of lamellar lipid granules in the ductal and secretory cells. Thus, whether the sweat gland itself is rendered inactive by the lipid deposition or whether the anhidrosis is secondary to peripheral and central autonomic dysfunction remains to be determined.

LOCALIZED HYPOHIDROSIS

Localized hypohidrosis can occur whenever sweat glands are damaged by surgery or trauma, scar formation, cutaneous neoplasms, irradiation, infection, inflammation of the skin, granulomatous lesions, scleroderma, or vasculitis. Delivery of sweat to the skin surface may be impaired in a variety of dermatoses and papulosquamous diseases, presumably because of poral occlusion. Blister formation with sweat gland necrosis has been reported during intoxication with barbiturates, methadone, diazepam, carbon monoxide, amitriptyline, and clorazepate. [44] Moss and Ince [45] observed the absence of sweating in the hypopigmented streaks and patches on the legs, arms, and scalp of 10 women with incontinentia pigmenti. Skin biopsy revealed a lack of eccrine sweat glands and hair follicles in the anhidrotic, hypopigmented lesions. Koga [46] reported that hypohidrosis occurs only in dermatomally distributed vitiligo and not in the nondermatomal type. Anhidrosis of the face and neck has been reported in members of a family with “follicular atrophoderma, basal cell carcinoma, and hypotrichosis,” a rare X-linked, dominantly inherited syndrome. [47] The hypomelanotic regions in hypomelanosis of Ito are anhidrotic. [47] Disorders with congenital absence of sweat glands may not have active cutaneous vasodilatation that can contribute to poor heat transfer to the skin and increased core temperature.

SWEAT RETENTION SYNDROMES (See Table 76-3)

Miliarias
Miliaria crystallina (sudamina)
Miliaria rubra (prickly heat)
Miliaria pustulosa
Miliaria profunda
Tropical anhidrotic asthenia
? Transient acantholytic dermatosis (Grover's)
? Dyshidrosis (pompholyx)

TABLE 76-3 **Sweat Retention Syndromes**

Miliaria

When the free flow of eccrine sweat to the skin surface is obstructed and sweat is retained within the skin, a variety of signs and symptoms result. [48], [49] Based on clinical and histopathologic findings, miliaria is subdivided into four groups: (1) miliaria crystallina; (2) miliaria rubra; (3) miliaria pustulosa; and (4) miliaria profunda. Every clinical type of miliaria has been produced experimentally in the laboratory. [48], [49]

Miliaria crystalline (sudamina) consists of superficial, subcorneal, noninflammatory vesicles (Fig. 76-5) that easily rupture when rubbed with a finger.

FIGURE 76-5 Miliaria crystallina. Note the delicate, droplike vesicles without erythema.

Miliaria rubra (prickly heat) results when obstructed sweat migrates into the living layers of the epidermis as well as the

upper dermis, causing pruritic inflammatory papules around the sweat pores. This disorder is especially common in infants, but also occurs in adults after repeated episodes of sweating in a hot, humid environment. The eruption usually subsides within a day after the patient moves to a cool environment. Anhidrosis associated with miliaria, however, takes 2 weeks (the time needed to repair the affected epidermal sweat duct unit by epidermal turnover) to recover completely. Some of the eruptions of miliaria rubra become pustular, resulting in miliaria pustulosa. A recent epidemic called miliaria rubra occurred in miners working underground in a metalliferous mine in Australia. The miners were exposed to groundwater and had lesions on the lower legs; in addition one-quarter of the miners had folliculitis. [50]

Miliaria profunda results when the sweat leaks into the dermis. During exposure to intense heat or after local injection of cholinergic agents, the affected skin can be uniformly covered with multiple discrete, flesh-colored papules that resemble gooseflesh. Ductal blockade at various levels is the immediate cause of miliaria. However, investigators do not agree on why the sweat escapes the duct at different levels (causing different subgroups of miliaria) nor on what causes the ductal blockade and/or ductal leakage at different levels. It is puzzling that the morphologic evidence of ductal blockade—such as keratin rings, PAS-positive proteins, or clusters of microorganisms—is rarely seen by light microscopic observation of miliarial lesions. Thus, Holzle and Kligman [49] speculated that the keratin rings and PAS-positive proteins are the consequence but not the cause of ductal damage. The role of resident organisms has long been suspected as the leading predisposing factor in miliaria. [51] Indeed, there was a linear correlation between the severity of miliaria rubra and the number of cocci in experimental miliaria under a plastic film. The development of experimental miliaria could be markedly suppressed by pretreatment of the skin with hexachlorophene or pyrithione. [49]

Tropical Anhidrotic Asthenia

Tropical anhidrotic asthenia, [51] which is frequently seen in military troops engaged in hot, humid environments, is a postmiliarial hypohidrosis. [52] Upon deployment in tropical theaters, most troops first develop extensive miliaria. However, a few weeks later, some troops develop persistent widespread hypohidrosis and heat intolerance without clinically visible miliaria. Keratin plugs are noted in the sweat pores. Their sweating recovers partially after a week in a cool environment or after desquamation by exposure to ultraviolet light. This condition may lead to the chronic extensive form of miliaria profunda.

Transient Acantholytic Dermatosis (Grover's Disease) (See Chap. 55)

The edematous and excoriated papules and vesicles that appear predominantly on the trunk often occur after excessive heat, heavy sweating, or sweating accompanying malignancy. [53]

Eccrine Hidradenitis

Neutrophilic infiltration of sweat glands occurs after treatment with several chemotherapeutic agents [54] and occurs on the palms and soles associated with local pseudomonas infection. [55]

Heat Hyperpyrexia and Heat Stroke

Heat hyperpyrexia and heat stroke are states of thermoregulatory failure of sudden onset that are characterized by general anhidrosis, hyperpyrexia [rectal temperature greater than 40.5°C (105°F)], and disturbances of the central nervous system. The exact cause of this disorder is unknown. The picture is generally one of environmental stress too severe for the thermoregulatory system, which suddenly collapses. Whether the anhidrosis is primary and the central nervous system pathology is secondary to the hyperpyrexia or vice versa is unclear. In some cases, dehydration, with its depression of the sweat rate, appears to be an initiating factor. The presence of local defects of the sweat glands (e.g., miliaria, profunda, ectodermal dysplasia) that interfere with thermoregulation may be a contributory factor. It appears, however, that the syndrome can occur as a result of hyperpyrexia per se—from heat stress too severe to be compensated for—without any primary defect of the sweat glands or any significant alteration of body fluids. Destructive lesions of the hypothalamus have been described in some cases coming to autopsy. In the late stages, there may also be petechial hemorrhages in many organs in association with thrombocytopenia; in some cases, other coagulation defects such as fibrinogenopenia are present. Destructive lesions in the brain outside the hypothalamus, hepatic and renal changes, as well as adrenal hemorrhages have been noted. In the early stages, sweating may still be present and the patient rational, but the rectal temperature may be greater than 40.5°C (105°F). Within minutes, anhidrosis, mental confusion, coma, and/or seizures may appear. The diagnosis should be suspected from the clinical setting of activity in extreme heat and rectal temperature greater than 40.5°C (105°F); it should be accepted with the additional presence of anhidrosis, hot, dry skin, and any degree of central nervous system manifestations. If untreated, the disorder is uniformly fatal. In treated cases, the mortality is approximately 35 percent.

Heat stroke is an acute medical emergency. Primary attention should be given to lowering the body temperature by any means available, ideally by immersion in ice or very cold water. Because some cutaneous vasoconstriction will occur with vigorous cooling, even in the presence of hyperpyrexia, chlorpromazine, which inhibits this response, has been advised by many. In view of possible adrenal hemorrhages, the administration of adrenal steroids is probably desirable. Rectal temperature should be lowered to less than 39°C (102°F) before efforts are reduced. The patient should then be placed in a relatively cool environment. General medical management of possible renal or hepatic disorders should be maintained. Some instability of thermoregulation may persist for several days to weeks. Mental and neurologic aberrations may persist and improve slowly only after several months. Permanent sequelae such as ataxia are not infrequent.

REFERENCES

1. Sato K et al: Biology of the eccrine sweat gland: II. Hyperhidrosis and hypohidrosis. *J Am Acad Dermatol* **20**:713, 1989

2. Sato K, Sato F: Individual variations in structure and function of human eccrine sweat gland. *Am J Physiol* **245**:R203, 1983

3. Hurley H, Witkowski J: Dye clearance and eccrine sweat secretion in human skin. *J Invest Dermatol* **36**:259, 1961

4. Canaday BR, Stanford RH: Propantheline bromide in the management of hyperhidrosis associated with spinal cord injury. *Ann Pharmacother* **29**:489, 1995

5. Khurana RK: Orthostatic hypotension-induced autonomic dysreflexia. *Neurology* **37**:1221, 1987

6. Ottomo M, Heimburger RF: Alternating Horner's syndrome and hyperhidrosis due to dural adhesions following cervical spinal cord injury: Case report. *J Neurosurg* **53**:97, 1980

7. Slaugenhaupt SA et al: Tissue-specific expression of a splicing mutation in the IKBKAP gene causes familial dysautonomia. *Am J Hum Genet* **68**:598, 2001

8. Anderson SL et al: Familial dysautonomia is caused by mutations of the IKAP gene. *Am J Hum Genet* **68**:753, 2001

9. Green M, Behrendt H: Sweat gland reactivity to local thermal stimulation in dysautonomia. *Am J Dis Child* **130**:816, 1976

10. Axelrod FB, Pearson J: Congenital sensory neuropathies. Diagnostic distinction from familial dysautonomia. *Am J Dis Child* **138**:947, 1984

11. Lisker R et al: Peripheral motor neuropathy associated with autonomic dysfunction in two sisters: new hereditary syndrome? *Am J Med Genet* **9**:255, 1981

12. Hines EA, Bannick EG: Intermittent hypothermia with disabling hyperhidrosis: Report of a case with successful treatment. *Mayo Clin Proc* **9**:705, 1935

13. LeWitt PA et al: Episodic hyperhidrosis, hypothermia, and agenesis of corpus callosum. *Neurology* **33**:1122, 1983

14. Eedy DJ, Corbett JR: Olfactory facial hyperhydrosis responding to amitriptyline. *Clin Exp Dermatol* **12**:298, 1987

15. Pleet DL et al: Paroxysmal unilateral hyperhidrosis and malignant mesothelioma. *Arch Neurol* **40**:256, 1983

16. Sneppen SB et al: Sweat secretion rates in growth hormone disorders. *Clin Endocrinol (Oxf)* **53**:601, 2000

17. Aminoff MJ, Wilcox CS: Assessment of autonomic function in patients with a Parkinsonian syndrome. *Br Med J* **4**:80, 1971

18. Bravo EL, Gifford RW: Current concepts. Pheochromocytoma: Diagnosis, localization and management. *N Engl J Med* **311**:1298, 1984

19. Agocs MM et al: Mercury exposure from interior latex paint. *N Engl J Med* **323**:1096, 1990

20. Gobbi PG et al: Night sweats in Hodgkin's disease. A manifestation of preceding minor febrile pulses. *Cancer* **65**:2074, 1990

21. Cunliffe WJ et al: Localized unilateral hyperhidrosis—A clinical and laboratory study. *Br J Dermatol* **86**:374, 1972

22. McGibbon BM, Paletta FX: Further concepts in gustatory sweating. *Plast Reconstr Surg* **49**:639, 1972

23. Kurchin A et al: Gustatory phenomena after upper dorsal sympathectomy. *Arch Neurol* **34**:619, 1977

24. Bronshvag MM: Spectrum of gustatory sweating, with especial reference to its presence in diabetics with autonomic neuropathy. *Am J Clin Nutr* **31**:307, 1978

25. van Weerden TW et al: Lacrimal sweating in a patient with Reader's syndrome. *Clin Neurol Neurosurg* **81**:119, 1979

26. Lance JW et al: Harlequin syndrome: The sudden onset of unilateral flushing and sweating. *J Neurol Neurosurg Psychiatr* **51**:635, 1988

27. Momose T et al: *N*-isopropyl I-123 p-iodoamphetamine brain scans with single photon emission computed tomography: Mental sweating and EEG abnormality. *Radiat Med* **4**:46, 1986

28. Shih CJ et al: Autonomic dysfunction in palmar hyperhidrosis. *J Auton Nerv Syst* **8**:33, 1983

29. Levit F: Simple device for treatment of hyperhidrosis by iontophoresis. *Arch Dermatol* **98**:505, 1968

30. Shelley WB et al: Botulinum toxin therapy for palmar hyperhidrosis. *J Am Acad Dermatol* **38**:227, 1998

31. Naumann M, Lowe NJ: Botulinum toxin type A in treatment of bilateral primary axillary hyperhidrosis: Randomised, parallel group, double-blind, placebo-controlled trial. *BMJ* **323**:596, 2001

32. Swartling C et al: Botulinum A toxin improves life quality in severe primary focal hyperhidrosis. *Eur J Neurol* **8**:247, 2001

33. Brandrup F, Larsen PO: Axillary hyperhidrosis: Local treatment with aluminum chloride hexahydrate 25% in absolute ethanol. *Acta Derm Venereol* **58**:461, 1978

34. Sulzberger MB, Hermann F: *The Clinical Significance of Disturbances in the Delivery of Sweat*. Springfield, IL, CC Thomas, 1954

35. Mardy S et al: Congenital insensitivity to pain with anhidrosis (CIPA): Effect of TRKA (NTRK1) missense mutations on autophosphorylation of the receptor tyrosine kinase for nerve growth factor. *Hum Mol Genet* **10**:179, 2001

36. Heath PD et al: Ross syndrome and skin changes. *Neurology* **32**:1041, 1982

37. Faden AI et al: Progressive isolated segmental anhidrosis. *Arch Neurol* **39**:172, 1982

38. Low PA et al: Chronic idiopathic anhidrosis. *Ann Neurol* **18**:344, 1985

39. Fisher DA, Maibach HI: Postural hypotension and anhidrosis. The autonomic insufficiency syndrome. *Arch Dermatol* **102**:527, 1970

40. Kennedy WR, Navarro X: Sympathetic sudomotor function in diabetic neuropathy. *Arch Neurol* **46**:1182, 1989

41. Fealey RD et al: Thermoregulatory sweating abnormalities in diabetes mellitus. *Mayo Clin Proc* **64**:617, 1989

42. Singh NK et al: Assessment of autonomic dysfunction in Guillain-Barré syndrome and its prognostic implications. *Acta Neurol Scand* **75**:101, 1987

43. Cable WJ et al: Fabry disease: Impaired autonomic function. *Neurology* **32**:498, 1982

44. Herschthal D, Robinson MJ: Blisters of the skin in coma induced by amitriptyline and clorazepate dipotassium. Report of a case with underlying sweat gland necrosis. *Arch Dermatol* **115**:499, 1979

45. Moss C, Ince P: Anhidrotic and achromians lesions in incontinentia pigmenti. *Br J Dermatol* **116**:839, 1987

46. Koga M: Vitiligo: A new classification and therapy. *Br J Dermatol* **97**:255, 1977

47. Steijlen PM et al: Sweat testing in hypomelanosis of Ito: Divergent results reflecting genetic heterogeneity. *Eur J Dermatol* **10**:217, 2000

48. Lobitz WC, Dobson RL: Miliaria. Sweat retention syndrome. *Pediatr Clin North Am* **3**:791, 1965

49. Holzle E, Kligman AM: The pathogenesis of miliaria rubra. Role of the resident microflora. *Br J Dermatol* **99**:117, 1978

50. Donoghue AM, Sinclair MJ: Miliaria rubra of the lower limbs in underground miners. *Occup Med (Lond)* **50**:430, 2000

51. O'Brien JP: The etiology of poral closure: An experimental study of miliaria rubra, bullous impetigo and related diseases of the skin. I: An histological review of the causation of miliaria. *J Invest Dermatol* **15**:95, 1950

52. Sulzberger MB, Griffin TB: Induced miliaria, postmiliarial hypohidrosis, and some potential sequelae. *Arch Dermatol* **99**:145, 1969

53. Hu CH et al: Transient acantholytic dermatosis (Grover's disease). A skin disorder related to heat and sweating. *Arch Dermatol* **121**:1439, 1985

54. Fitzpatrick JE: The cutaneous histopathology of chemotherapeutic reactions. *J Cutan Pathol* **20**:1, 1993

55. Fiorillo L et al: The pseudomonas hot-foot syndrome. *N Engl J Med* **345**:335, 2002

T>

Chapter 77

Mazen Daoud Charles Dicken

Disorders of the Apocrine Sweat Glands

APOCRINE BROMHIDROSIS
Epidemiology
Etiology and Clinical Features
Pathology
Diagnosis
Treatment
Course and Prognosis
APOCRINE CHROMHIDROSIS
Historical Aspects
Epidemiology
Etiology and Pathogenesis
Clinical Manifestations
Pathology
Diagnosis and Differential Diagnosis
Treatment and Course
FOX-FORDYCE DISEASE
Epidemiology
Etiology and Pathogenesis
Clinical Manifestations
Pathology
Diagnosis and Differential Diagnosis
Treatment
Course and Prognosis
HIDRADENITIS SUPPURATIVA
Epidemiology
Etiology and Pathogenesis
Clinical Manifestations
Pathology
Diagnosis and Differential Diagnosis
Treatment
Course and Prognosis

REFERENCES

The apocrine sweat glands are members of the apocrine system, which also includes the mammary glands, ceruminous (wax) glands of the ear canal, and glands of Moll in the eyelid. The apocrine sweat glands are usually found in the axillae, anogenital area, and mammary areola, and are scattered over the skin of trunk, face, and scalp. Four disorders of the apocrine sweat glands are considered in this chapter: apocrine bromhidrosis, apocrine chromhidrosis, Fox-Fordyce disease, and hidradenitis suppurativa.

APOCRINE BROMHIDROSIS

Apocrine bromhidrosis, also known as bromidrosis or osmidrosis, is a disorder characterized by excessive or abnormal body odor arising from the apocrine glands. [1] It should be differentiated from the less common eccrine bromhidrosis, which may be keratinogenic, metabolic, or exogenous.

Epidemiology

The disease usually affects young adults after puberty; blacks more than whites or Asians. There is no occupational or geographic predisposition. The problem is more intense in the summer because of increased eccrine sweating that augments apocrine sweating. Poor personal hygiene may aggravate the problem. Axillary hyperhidrosis may actually cause a decrease in the odor because the eccrine sweat flushes away the apocrine sweat. A positive family history is present in the majority of cases reported from the Far East.

Plantar bromhidrosis is seen in young males and middle-aged adults. There is no racial or sexual predisposition. The process is not seasonal, because volar sweating is induced by emotional not thermal stimulation. Intertriginous eccrine bromhidrosis is more prominent in the summer.

Etiology and Clinical Features

In males, the most abundant odor component is known to be e-3-methyl-2-hexenoic acid, which is liberated from nonodorous apocrine secretions by axillary bacteria. Other materials include short-chain fatty acids and ammonia, e-3-Methyl-2-hexenoic acid is carried to the skin surface bound to two proteins, apocrine secretion odor-binding proteins-1 (ASOB1) and -2 (ASOB2). Both male and female subjects appear to have the same proteins. Partial sequence data obtained from the N-terminus of ASOB1 suggested that it shares homology with the a chain of apolipoprotein J. [2] Local bacterial flora in the axillary area, whose growth is supported by warmth and moisture, increase apocrine odor

production. Leyden et al. demonstrated that aerobic diphtheroids are capable of producing axillary odor. [1] However, bacterial contamination of apocrine sweat may not be the sole cause of apocrine bromhidrosis. Not all family members of a person afflicted with bromhidrosis have the disease, even when they harbor axillary bacteria and live in the same environment. Increased apocrine sweat production as documented by increased number and size of apocrine glands in affected versus normal individuals has been suggested as a possible cause. [3]

The role of androgens is also important. High levels of 5a-reductase has been detected in apocrine glands, and the concentration of dihydrotestosterone has been found to be higher than that of testosterone in the nuclear fraction of the skin of patients with osmidrosis. [4] Apocrine glands express type I 5a-reductase mRNA almost exclusively.

Patient complaints vary based on cultural and geographic location. In the Far East, patients complain of the apocrine odor (bromhidrosis) rather than the excessive sweating, because odorous sweat is considered the greater social embarrassment. In much of the Western world, both hyperhidrosis and bromhidrosis are usually equal complaints. The appearance of axillary skin in patients with bromhidrosis is normal. No laboratory abnormalities are reported.

Eccrine bromhidrosis results from bacterial action on keratin softened by sweating. The soles of the feet are the most common location affected. A similar mechanism is responsible for odor production in other intertriginous areas. Physical examination is essentially normal in these areas except when intertrigo, erythrasma, or candidiasis develop.

Pathology

In these patients, increased numbers of apocrine glands have been found as compared to controls, and the apocrine to eccrine ratio is significantly higher. [3] The apocrine glands are several times larger than the eccrine glands, a feature not seen in patients without excessive sweating. No significant inflammation in the apocrine glands is seen.

Diagnosis

The diagnosis of bromhidrosis is a clinical one. The definition of “normal” odor is a subjective and poorly defined term that varies among races. Hurley reported that the presence of axillary odor is a normal finding in all postpubertal individuals, and bromhidrosis is an accentuation of the axillary odor. [5] In the Asian population, the presence of even a faint odor is considered diagnostic of bromhidrosis. [3] Furthermore, although recognizing an odor-producing chemical is possible using chromatographic or spectroscopic methods, these methods cannot differentiate normal odor from one caused by bromhidrosis. Some individuals may have olfactory limitations to the perception of a single or a broad range of odors, and hence the definition of cutaneous odor is highly variable.

Trimethylaminuria gives rise to a “fishy” odor. It affects patients who have deficient trimethylamine oxidase in the liver or a defective demethylation mechanism; they are unable to metabolize the absorbed trimethylamine produced by intestinal bacteria after ingestion of choline- and lecithin-containing food such as fish, eggs, liver, and kidney. Accumulation of trimethylaminuria in the urine, sweat, and mucosa of the mouth and respiratory tract gives rise to the characteristic odor.

Treatment

The control of axillary bromhidrosis may be accomplished by reducing bacterial flora and apocrine sweat of the axilla. Cleansing with antibacterial soap and the use of topical antibacterial agents, deodorants, perfumes, and antiperspirants should always be recommended. Careful, regular axillary hygiene should be followed. Systemic antibiotics are not helpful. Attention should be paid to odor arising from dried sweat on clothing.

Reduction of eccrine sweating using aluminum chloride may help reduce the local bacterial flora but will not reduce apocrine sweat production. One useful treatment is 20% aluminum chloride in anhydrous ethanol applied at bedtime, with or without occlusion; it may be used on two consecutive nights, then every three to seven nights thereafter. Local radiation treatment and adrenergic nerve sympathectomy are not justifiable.

A variety of surgical techniques have been described in the treatment of bromhidrosis. Excision of subcutaneous tissue, with preservation of the overlying skin, provides good clinical response and minimal complications and avoids contraction of the skin. [6]

Surgical removal of axillary skin and subcutaneous tissue by simple excision can also be done; however, tightness of the axillary fossa may develop.

Ultrasonic surgical aspiration of axillary apocrine glands with endoscopic confirmation is highly effective. [7] Ultrasound energy liquefies fat and sweat glands via cavitation, but minimally affects blood vessels and nerves, which minimizes side effects. Superficial ultrasound-assisted lipoplasty removes the apocrine glands located in the dermis and dermosubcutaneous junction. [8] The frequency-doubled, Q-switched Nd:YAG laser has been reported to be an effective, noninvasive treatment for axillary bromidrosis. [9]

Similar therapeutic measures are used for treatment of eccrine bromhidrosis. Iontophoresis of tap water produces an antiperspirant effect on volar skin when used two to three times a week until there is reduction in sweating, after which maintenance treatment is employed every 3 to 4 weeks. Treatment of secondary intertrigo, candidiasis, and erythrasma is essential.

Course and Prognosis

The course of bromhidrosis is chronic, and spontaneous resolution is not likely. It should be emphasized that patients

with bromhidrosis may find it a most distressing and embarrassing problem; if untreated, these patients may develop significant psychological symptoms.

APOCRINE CHROMHIDROSIS

Apocrine chromhidrosis refers to the secretion of colored sweat by the apocrine glands. It is a localized disease affecting apocrine-bearing skin and may be of two clinical varieties, axillary and facial. Areolar involvement has also been described. [10] The responsible pigment is produced inside the apocrine glands, in contrast to false or extrinsic chromhidrosis, in which local bacteria, fungi, or dyes may color apocrine sweat.

Historical Aspects

Yonge first described facial chromhidrosis in 1709. The apocrine origin of the secretion was established in 1954 by Shelley and Hurley, [11] who also described axillary apocrine chromhidrosis in detail, surveyed the world literature, and designated the lipofuscins as the responsible pigment.

Epidemiology

Apocrine chromhidrosis is not seen until after puberty, when apocrine secretory function is activated. Slow regression of the disease is noted with advanced age, in parallel with the regression of apocrine glands. The disease is more common in blacks than whites. There is no sexual, occupational, or geographic predisposition, and seasonal or climatic variations exert little or no influence on these conditions.

Etiology and Pathogenesis

The pigment responsible is apparently one or more of the lipofuscins, which are found in chromhidrotic apocrine sweat in higher concentrations or in a higher state of oxidation than in the normal secretion. No systemic or acquired metabolic or dietary alteration has been detected that could account for the production of these colored apocrine lipofuscins. Dietary restriction or overloading of carotenoids does not seem to alter the pigment production. No other systemic or pathologic findings accompany the disease.

Clinical Manifestations

Apocrine chromhidrosis is usually seen in one of two major skin areas, the axillae or the face (Fig. 77-1). Axillary apocrine chromhidrosis is rarely a clinical problem, and it is often observed only by the affected person. Staining of the undershirt is the usual complaint, the most common color being yellow; much less frequently, it is green, blue, blue-black, or brown-black. The quantities of apocrine sweat seen are comparatively small, with each droplet at a follicular orifice representing 0.001 mL or less. The droplets are odorless, dry quickly, and fluoresce under UV radiation (360 nm). In general, very light- or very dark-colored apocrine sweat does not fluoresce. Emotional and local physical stimuli appear to excite apocrine sweat.

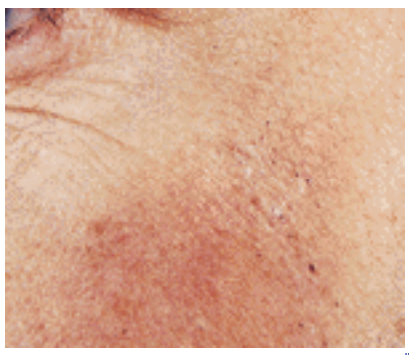

FIGURE 77-1 Black sweat produced in a patient with facial apocrine chromhidrosis after gentle squeezing of the cheeks.

Facial apocrine chromhidrosis is a rare variant; it is seen on the cheeks and malar eminences most commonly but the forehead and eyelids may also be involved. Concomitant chromhidrosis in other apocrine-bearing skin areas is not present. Onset of colored sweating may be preceded by an aura of warmth or a prickling sensation and is usually prompted by emotional excitation such as anger, fear, or pain. Local physical stimulation will induce the appearance of these colored droplets. Most patients will be able to express the secretion mechanically. The color is usually dark blue or black and is situated at follicular orifices. When dried, the secretion results in adherent, deeply colored flecks. The skin of the affected region is otherwise normal. No pertinent laboratory abnormalities are present.

Pathology

The apocrine glands are normal in size and morphology. Increased numbers of lipofuscin granules are seen in the cytoplasm of the secretory cells. Many granules are seen on unstained slides. Schmorl stain may be positive. Autofluorescence of an unstained paraffin-embedded histologic section has been demonstrated microscopically using a UV excitation wavelength of 360 nm (as used in routine immunofluorescence microscopy). [12] A yellow-green color is seen by examining clothing fibers from an area of staining. The staining is much less intense than the blue-green staining from normal clothing fibers. [12]

Diagnosis and Differential Diagnosis

The history and physical examination suggest the diagnosis of apocrine chromhidrosis. Induction of apocrine sweat by emotional, pharmacologic, or mechanical stimulation confirms the diagnosis. The presence of lipofuscin granules in apocrine cells and the characteristic fluorescence usually also confirm the diagnosis. Patients with ochronosis may have brown-colored sweat. Confirmation by qualitative urinalysis for homogentisic acid is recommended in all patients with chromhidrosis. Contamination of sweat from *Corynebacteria, Piedraia* organisms, or from paint or clothing dye should be ruled out.

Treatment and Course

There is no satisfactory therapy for apocrine chromhidrosis. Capsaicin depletes the neuron of substance P, an important transmitter in apocrine sweat production, and has been used successfully in the treatment of chromhidrosis. [10] The disease is chronic and tends to fade gradually but slowly with age.

FOX-FORDYCE DISEASE

Fox-Fordyce disease is a chronic, pruritic, papular eruption, mainly in women, with a strict localization to areas bearing apocrine glands. Synonyms that have been used for this condition include apocrine miliaria and chronic itching papular eruption of the axillae and pubes. The disease was first described by Fox and Fordyce in 1902. [13]

Epidemiology

The exact incidence of the disease is not known. The majority of patients are women (90 percent), usually between the ages of 15 and 35 years. The disease does not occur before puberty, and cases after menopause are rare. No racial predilection is known. Seasonal, geographic, climatic, and occupational influences are of no significant importance in the development of the disease.

Etiology and Pathogenesis

The fundamental etiologic factors in Fox-Fordyce disease are unknown. The distribution, clinical course, and histopathologic findings clearly indicate a disease of apocrine glands. Since its description, many theories have attributed the disease to emotional, hormonal, and structural factors. Keratinous obstruction of the distal portion of the apocrine duct seems an early finding. Retention of sweat results in rupture of the intraepidermal portion of the apocrine duct, producing a microvesicle. A localized inflammatory reaction around the vesicle then becomes prominent. Dilatation of the apocrine duct results from accumulation of sweat in the distal parts. The reason for the rupture of the intraepidermal duct is unknown. A genetic predisposition for the development of the disease is possible; and the disease has been reported in family members of affected patients and in identical twins. Although clinical improvement is seen in pregnant women during the third trimester of pregnancy, a documented endocrine dysfunction has never been established.

Clinical Manifestations

Fox-Fordyce disease is characterized by discrete, flesh-colored, perifollicular papules with a dome-shaped contour and an occasional central punctum. The process often affects the axillae (Fig. 77-2), pubic area, labia, perineum, areola, presternal skin, umbilicus, and medial thighs. The eruption is usually pruritic and worse in the summer, and it improves with the use of oral contraceptives. Paroxysmal exacerbations are seen after emotional or physical stimulation of the apocrine glands. In a few cases where the majority of the apocrine glands are affected, the apocrine sweat odor may disappear.

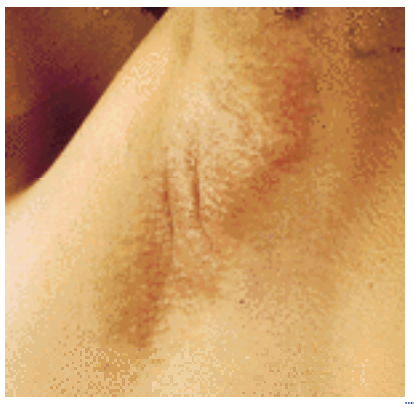

FIGURE 77-2 Classic follicular papules in axilla of a patient with Fox-Fordyce disease.

Pathology

Obstruction of the outer portion of the apocrine duct and follicular orifice is seen. Dilatation of the proximal portion of the duct causes spongiosis and vesiculation of the intraepidermal portion of the duct and spongiosis of the adjacent epidermis. An inflammatory reaction is seen, composed of lymphocytes and occasional histiocytes and rare eosinophils. Epidermal acanthosis and mucinous deposition in the follicular epithelium are not uncommon. A lymphocytic

inflammatory infiltrate is often seen in the upper dermis.

Because serial sectioning is often necessary to see the characteristic pathologic changes of Fox-Fordyce disease, transverse serial sectioning of biopsy specimens seems to be more effective and efficient in establishing the diagnosis. [14]

Diagnosis and Differential Diagnosis

The diagnosis of Fox-Fordyce disease is often made based on the clinical features, morphology, and distribution of the lesions. The lesions are perifollicular papules, confined to the “apocrine areas” of the body, and commonly associated with reduction in sweat odor. Pruritus, often exacerbated with emotional, physical, or pharmacologic stimuli, is often characteristic and this aids in establishing the diagnosis. A 2- or 3-mm punch biopsy will confirm the diagnosis. Serial sectioning may be needed to show the characteristic findings. The differential diagnosis includes lichen planus, lichen nitidus, infective folliculitis, chronic dermatitis, and syringomas. These disorders can be excluded based on the clinical and certainly the pathologic features.

Treatment

The treatment of Fox-Fordyce disease is often difficult. Temporary relief is seen during treatment; however, flares are noted after discontinuation. Clindamycin solution twice a day has been associated with reduction of burning and itching and should be considered as the initial step. Tretinoin cream 0.1% is safe and occasionally effective in reducing the associated pruritus. However, it has minimal effect on the papules themselves. Destructive methods have been used, such as the use of an epilation needle inserted into the superficial part of the follicular orifice and short pulses of electrodesiccation current to destroy the obstructing epithelium. Estrogens and oral contraceptives are occasionally efficacious; however, the response may be slow. Topical glucocorticoid gels may be tried. Systemic glucocorticoids may bring immediate, but temporary, relief to the pruritus. X-ray therapy and surgical excision are not justified.

Course and Prognosis

Fox-Fordyce disease is a chronic, rarely remitting disease that may improve spontaneously during pregnancy. Complications such as folliculitis may develop secondary to intense pruritus. Hidradenitis suppurativa may be associated with the disease.

HIDRADENITIS SUPPURATIVA

Hidradenitis suppurativa is a chronic, inflammatory, scarring disease of the apocrine sweat gland–bearing skin. The disease is characterized by the presence of multiple abscesses, fibrosis, and sinus tracts. A number of synonyms are used to indicate hidradenitis suppurativa such as apocrinitis, hidradenitis axillaris, and abscess of the apocrine sweat gland.

Hidradenitis suppurativa was first described by Velpeau in 1839. Verneuil suggested that the etiology was abscess formation of sweat glands. [15] Histologic features of hidradenitis suppurativa were first described in 1939. [16]

Epidemiology

The disease occurs in both sexes, usually in the second or third decade, and affects women more than men. The disease is rare before puberty. No racial predilection is described. The prevalence of hidradenitis suppurativa is estimated at 4 percent of women in the general population. The prevalence was 1 percent in the general Danish population and 4 percent in a selected group of young adults attending a sexually transmitted diseases clinic. [17] The different age groups examined and differences in diagnostic specificities may account for the variable prevalence estimates.

Etiology and Pathogenesis

The pathogenesis of hidradenitis suppurativa is unknown. The anatomic location of the disease in the axilla, groin, perianal, and inframammary areas suggests a disorder of apocrine glands. It has been suggested that occlusion of the apocrine duct may lead to severe dilatation and apocrine gland inflammation, with ensuing bacterial growth and neutrophilic inflammation of the duct and surrounding tissue, and later fibrosis and sinus tract formation.

Follicular occlusion is another possibility. [18] The clinical similarity of hidradenitis suppurativa to, and its frequent association with, the follicular occlusion–related diseases, such as acne conglobata and dissecting cellulitis of the scalp, suggests that hidradenitis suppurativa may share the same pathogenesis. Follicular occlusion is a prominent feature in all biopsy specimens from patients with hidradenitis suppurativa. [19] At a later stage, apocrine glands may become inflamed due to direct continuity of the apocrine glands to the follicular infundibulum. Apoeccrine glands, whose secretory coils show decapitation secretion with a straight intradermal duct opening directly onto the surface of the skin, remain intact until dermal fibrosis distorts the opening duct, causing irritation by the apocrine sweat. [19]

The role of androgens or other hormones in hidradenitis seems unclear. Obesity, a common finding in hidradenitis suppurativa, is known to alter sex hormone metabolism, leading to an androgen-excess state. Excess androgens can lead to coarsening of the hair shaft and hence to follicular occlusion. [19] Women with hidradenitis suppurativa tend to have a shorter menstrual cycle and a longer duration of menstrual flow, suggesting a possible hormonal influence. However, the incidence of acne, hirsutism, and irregular menstrual periods—signs of a hyperandrogenic state—is not different from that in the general population. There is no difference in the levels of plasma androgens between hidradenitis suppurativa patients and controls. [20] However, cyclic variations during the menstrual cycle, with amelioration of the disease during the estrogen-elevation phase and flares during the estrogen-fall phase, have been reported. [20] Furthermore, improvement is

noted during pregnancy, and flares may be seen postpartum. A familial form of hidradenitis suppurativa with autosomal dominant inheritance may exist. An insufficiently sensitive disease definition, a variable degree of gene penetrance and possibly a hormonal influence on gene expression may explain the reduced risk to first-degree relatives, which falls short of the expected 50 percent mark. [21]

The significance of bacterial findings in hidradenitis suppurativa is controversial. In one study, bacterial culture was positive in all cases for at least one bacterial species. [22] This motivates a reevaluation of the significance of bacteria in the progress of hidradenitis suppurativa. It is of interest to note that cigarette smoking was found to be a major triggering factor. [23]

Clinical Manifestations

Patients with hidradenitis suppurativa are usually otherwise healthy. Obesity is common, as are follicular occlusive diseases, such as acne conglobata, and dissecting cellulitis of the scalp. The early lesion is a tender, red dermal abscess measuring about 0.5 to 2 cm. The lesion may resemble an inflamed epidermoid cyst. The abscess gradually increases in size and may open to the surface, discharging purulent or seropurulent material, if untreated. The inflammation subsides gradually; however, recurrent episodes of inflammation in the same abscess or others is the rule. Inflammatory abscesses may appear at other anatomic areas at the same time. Fibrosis eventually becomes prominent, and healing appears incomplete (Fig. 77-3). In advanced stages, bands of scar tissue and bridging fibrosis develop that may restrict the mobility of the tissue (Fig. 77-4). Three clinical stages of hidradenitis suppurativa were described by Hurley [24] and are summarized in Table 77-1.

FIGURE 77-3 Multiple abscesses in the axilla of a patient with stage I hidradenitis suppurativa. No fibrosis is yet present in the involved area.

FIGURE 77-4 Multiple interconnected sinus tracts with severe fibrosis representing end-stage hidradenitis suppurativa. A new abscess is present at the edge of the axilla.

Stage I	Solitary or multiple isolated abscess formation without scarring or sinus tracts
Stage II	Recurrent abscesses, single or multiple widely separated lesions, with sinus tract formation and cicatrization
Stage III	Diffuse or broad involvement across a regional area with multiple interconnected sinus tracts and abscesses

Adapted and reprinted with permission from Hurley.[27]

TABLE 77-1 **Clinical Staging of Hidradenitis Suppurativa**

The axillae, buttocks, inguinal, perianal, mammary, and inframammary areas are the most commonly affected. The abdominal wall, chest, scalp, and lower extremities may also be involved. Although apocrine sweating is absent in chronic cases, the lesions have a foul smell secondary to bacterial overgrowth and colonization. Sinus tracts are often seen, draining minimal purulent discharge. Perianal hidradenitis can extend to involve the anus and rectum. Sinus tract formation and anal canal fibrosis can lead to stricture formation. Urethral and vaginal fistulas may develop with deep vaginal involvement. Mild arthritis of axial and peripheral type may be seen in acute flares. Laboratory evaluation reveals occasional elevation of white blood cells. Staphylococcus aureus and coagulase-negative staphylococci are the most common species cultured from skin lesions. [22] Other aerobic bacteria include *Streptococcus pyogenes, Pseudomonas aeruginosa,* and *Escherichia coli*. The most frequently isolated anaerobes are *Peptostreptococcus* and *Prevotella*

species. [25]

Pathology

The histologic findings in hidradenitis suppurativa cover a wide spectrum of changes. Follicular plugging and poral occlusion are prominent features. Occasionally, large cystic spaces are seen, filled with keratin material and hair shafts and lined by stratified squamous epithelium, resembling epithelial cysts. Fibrosis is often seen in the dermis and may occasionally extend to the subcutaneous tissue. Various degrees of inflammation and fibrosis are seen, according to the stage of the disease. Folliculitis and perifollicular inflammation are common and seen in approximately two-thirds of cases, with or without follicular occlusion. The inflammatory cells are composed of neutrophils, lymphocytes, plasma cells, and occasional eosinophils. Areas of frank dermal abscess are seen. Active inflammation around sweat glands is less common than that around hair follicles. Apocrine gland destruction by neutrophilic infiltrates is seen occasionally in the axilla. [19] Apocrinitis, originally suggested as the typical histologic appearance of hidradenitis suppurativa, is seen in a minority of cases. [26] Foreign body-type granulomas around hair follicles and sinus tracts are occasionally seen. The presence of epithelioid granulomas in the dermis away from areas of inflammation is a rare finding (5 percent) and should alert the clinician to the possibility of coexisting Crohn's disease or sarcoidosis.

Diagnosis and Differential Diagnosis

Any inflammatory, abscess-like swelling of the apocrine gland–bearing skin should be regarded as possible hidradenitis suppurativa. A solitary abscess in the early stages resembles a carbuncle, lymphadenitis, or an infected epidermoid cyst. In the vaginal area, it resembles an infected Bartholin cyst. Multiple abscesses in different apocrine gland–bearing skin areas should present no difficulty in establishing the diagnosis. The distribution and characteristic scarring, sinus tracts, and partial healing of infected abscesses are usually diagnostic. Other dermatoses that produce fistulas and sinuses should be included in the differential diagnosis, such as tuberculosis, actinomycosis, tularemia, and cat-scratch disease. In the inguinal area, lymphogranuloma venereum, granuloma inguinale, Crohn's disease, and ulcerative colitis should be excluded.

Treatment

Treatment of hidradenitis suppurativa is very difficult. Medical management is recommended in early stages; however, a surgical approach is preferred if scarring and sinus tract formation have developed.

For early disease, intralesional triamcinolone acetonide (5 to 10 mg/mL) may help. Incision and drainage are helpful if spontaneous rupture is imminent. In these situations, drainage and intralesional glucocorticoid injections can be done simultaneously. Bacterial culture of the drained material should be done, and antibiotics should be selected based on sensitivity. Concomitant use of antibiotics is recommended. Minocycline, ciprofloxacin, cephalosporins, clindamycin, or semisynthetic penicillins can be used in the usual doses for soft tissue infections. Isotretinoin may be helpful in some patients. The dose is 1 mg/kg/day as in acne patients; however, higher dosages or longer duration may be needed. The response rate is less than 50 percent. Once significant fibrosis ensues, retinoids are less effective. If inflammation is severe, a short course of systemic glucocorticoids (daily prednisone 40 to 60 mg to be tapered over 2 to 3 weeks) is often needed.

A regimen of 100 mg of cyproterone acetate from days 5 to 14 and 50µg of ethinylestradiol from days 5 to 25 of each menstrual cycle can be helpful. [27]

Local care includes gentle cleansing with antiseptic soaps or cleansers and application of warm compresses with saline or Burow's solution. Some have advocated the use of 6.25% aluminum chloride hexahydrate in absolute ethanol as an antiperspirant and antibacterial agent. Also suggested are avoidance of tight fitting clothing and roll-on antiperspirant deodorants, which can produce frictional trauma and exacerbation of the disease. Topical clindamycin is often used between flare ups.

If scarring develops in conjunction with inflammation, exteriorization is preferred. The aim of the procedure is to destroy the tracts and drain the abscessed area. Fibrotic tracts are explored by soft probes, and complete destruction of granulation tissue and epithelial cells is attempted, even from the smallest pockets. Curettage and electrofulguration of the base are used to destroy residual infected tissue. The wound is then covered with sterile gauze and cleaned twice daily with warm compresses and topical antibiotic ointments. The use of oral antibiotics is recommended on an individual basis. The wound usually heals in 4 to 8 weeks, and the scar is usually smooth and acceptable. This procedure can be performed in all locations except the perianal area, where the risk of traumatizing the anal sphincter is high. Simple excision and primary closure can be done for smaller lesions, but recurrences are more likely.

In severe, stage III disease, complete removal of the affected area is often required. Wide local excision and healing by second intention is considered the surgical treatment of choice. [28] Large wounds in the genital area are best covered with synthetic dressings, with healing by second intention. Negative pressure dressing can secure skin grafts firmly to the wound bed after radical excision. These dressings are simple to apply and are highly effective. [29] Large defects of the axilla can be repaired by advancement or transposition of an island flap from the lateral thoracic wall, pedicled on two or three nourishing vessels arising from the lateral thoracic or thoracodorsal vessels. [30] The use of CO_2 laser ablation of lesions, by vaporizing the tissue in layers until all of the macroscopically abnormal tissue has been removed, could spare normal tissue. [31]

Course and Prognosis

Hidradenitis suppurativa is a chronic disease that progresses relentlessly despite treatment, but the early stages may be curable with proper diagnosis and treatment. The psychological impact of the disease exceeds the systemic

complications. Patients with advanced disease are often depressed and socially isolated. [32] Secondary infection of the lesions, which causes a foul smelling odor, adds to the misery of some patients. Septicemia is a rare event. Restricted mobility, secondary to extensive scarring, and fistula formation are common complications. Urethral and rectal fistulas and strictures are uncommon, and squamous cell carcinoma is a rare complication of long-standing disease. The majority of cases develop on the buttocks and perianal areas. Squamous cell carcinoma arising from hidradenitis suppurativa usually behaves aggressively, with local invasion, distant metastasis, and high mortality. Other rare complications include amyloidosis, interstitial keratitis, and anemia.

REFERENCES

1. Leyden JJ et al: The microbiology of human axilla and its relationship to axillary odor. *J Invest Dermatol* **77**:413, 1981

2. Spielman AL et al: Identification and immunohistochemical location of protein precursors to human axillary odors in apocrine glands and secretion. *Arch Dermatol* **134**:813, 1998

3. Bang YH et al: Histopathology of apocrine bromhidrosis. *Plast Reconst Surg* **98**:288, 1996

4. Sato T et al: Predominance of type I 5-alpha-reductase in apocrine sweat glands of patients with excessive or abnormal odour derived from apocrine sweat (osmidrosis). *Br J Dermatol* **139**:806, 1998

5. Hurley HJ: Diseases of the apocrine sweat glands, in *Dermatology,* 3d ed, vol 2, edited by SL Moschella, HJ Hurley. Philadelphia, Saunders, 1992, p 1495

6. Wang HJ et al: Surgical management of axillary bromidrosis—a modified Skoog procedure by an axillary bipedicle flap approach. *Plast Reconstr Surg* **98**:524, 1996

7. Chung S et al: Ultrasonic surgical aspiration with endoscopic confirmation for osmidrosis. *Br J Plast Surg* **53**:212, 2000

8. Park S: Very superficial ultrasound-assisted lipoplasty for the treatment of axillary osmidrosis. *Aesth Plast Surg* **24**:275, 2000

9. Kunachak S et al: Noninvasive treatment of bromidrosis by frequency-doubled Q-switched Nd:YAG laser. *Aesth Plast Surg* **24**:198, 2000

10. Saff DM et al: Apocrine chromhidrosis involving the areola in a 15-year-old amateur figure skater. *Pediatr Dermatol* **12**:48, 1995

11. Shelley WB, Hurley HJ Jr: Localized chromhidrosis: Survey. *Arch Dermatol* **69**:449, 1954

12. Cox NH et al: Autofluorescence of clothing as an adjunct in the diagnosis of apocrine chromhidrosis. *Arch Dermatol* **128**:275, 1992

13. Fox GH, Fordyce JA: Two cases of a rare papular disease affecting the axillary region. *J Cutan Genitourinary Dis* **120**:1, 1902

14. Stashower ME et al: Fox-Fordyce disease: Diagnosis with transverse histologic sections. *J Am Acad Dermatol* **42**:89, 2000

15. Verneuil AS: Etudes sur les tumours de la peau: De quelque maladies des glands sudoripares. *Arch Gen Med* **94**:693, 1854

16. Brunsting HA: Hidradenitis suppurativa: Abscess of the apocrine sweat glands. *Arch Dermatol Syphil* **39**:108, 1939

17. Jemec GBE et al: The prevalence of hidradenitis suppurativa and its potential precursor lesions. *J Am Acad Dermatol* **35**:191, 1996

18. Yu CCW, Cook MG: Hidradenitis suppurativa: A disease of follicular epithelium, rather than apocrine glands. *Br J Dermatol* **122**:763, 1990

19. Attanoos RL: The pathogenesis of hidradenitis suppurativa: A closer look at apocrine and apoeccrine glands. *Br J Dermatol* **133**:254, 1995

20. Barth JH et al: Endocrine factors in pre- and postmenopausal women with hidradenitis suppurativa. *Br J Dermatol* **134**:1057, 1996

21. Von Der Werth JM et al: The clinical genetics of hidradenitis suppurativa revisited. *Br J Dermatol* **142**:947, 2000

22. Lapins J et al: Coagulase-negative staphylococci are the most common bacteria found in cultures from the deep portions of hidradenitis suppurativa lesions, as obtained by carbon dioxide laser surgery. *Br J Dermatol* **140**:90, 1999

23. Konig A et al: Cigarette smoking as a triggering factor of hidradenitis suppurativa. *Dermatol* **198**:261, 1999

24. Hurley HJ: Axillary hyperhidrosis, apocrine bromhidrosis, hidradenitis suppurativa and familial benign pemphigus: Surgical approach, in *Dermatologic Surgery, Principles and Practice,* edited by RA Roenigk, HH Roenigk Jr. New York, Marcel Dekker, 1989, p 735

25. Brook I, Frazier EH: Aerobic and anaerobic microbiology of axillary hidradenitis suppurativa. *J Med Microbiol* **48**:103, 1999

26. Jemec GBE: Histology of hidradenitis suppurativa. *J Am Acad Dermatol* **34**:994, 1996

27. Sawers RS et al: Control of hidradenitis suppurativa in women using combined antiandrogen (cyproterone acetate) and oesterogen therapy. *Br J Dermatol* **115**:269, 1986

28. Banerjee AK: Surgical treatment of hidradenitis suppurativa. *Br J Dermatol* **79**:863, 1992

29. Elwood ET, Bolitho DG: Negative pressure dressings in the treatment of hidradenitis. *Ann Plastic Surg* **46**:49, 2001

30. Schwabegger AH et al: The lateral thoracic fasciocutaneous island flap for treatment of recurrent hidradenitis axillaris suppurativa and other axillary skin defects. *Br J Plast Surg* **53**:676, 2000

31. Lapins J et al: Surgical treatment of chronic hidradenitis suppurativa: CO_2 laser stripping–secondary intention technique. *Br J Dermatol* **131**:551, 1994

32. Von der Werth JM, Jemec GB: Morbidity in patients with hidradenitis suppurativa. *Br J Dermatol* **144**:809, 2001

T>

Chapter 78

Peter Fritsch

Follicular Syndromes with Inflammation and Atrophy

CLASSIFICATION
HISTORICAL ASPECTS
Keratosis Pilaris Atrophicans Faciei
Keratosis Follicularis Spinulosa Decalvans
Atrophoderma Vermiculatum
EPIDEMIOLOGY
ETIOLOGY AND PATHOGENESIS
CLINICAL FEATURES
Keratosis Pilaris Atrophicans Faciei (MIM 604093)
Keratosis Follicularis Spinulosa Decalvans (MIM 308800)
Atrophoderma Vermiculatum (MIM 209700)
PATHOLOGY
DIFFERENTIAL DIAGNOSIS
TREATMENT, COURSE, AND PROGNOSIS

REFERENCES

Follicular keratosis is a characteristic reaction pattern of the ostioinfundibular portion of the hair follicles. It is defined by orthohyperkeratotic follicular plugs that distend the ostia and may protrude from the orifices, rendering the skin surface rough to touch, at times even “nutmeg-grater–like.” This phenomenon is exceedingly common, and it may be found either as an isolated symptom or associated with a broad spectrum of pathologic conditions. Clinical expression is highly variable, ranging from very subtle to conspicuous; this may explain the very discrepant data on the prevalence which range from 1 percent [1] to 44 percent. [2] Several overlapping clinical entities have been described. Ordinarily, the horny plugs do not impair hair growth or lead to follicular atrophy; those few entities in which they do are classified under the term *keratosis follicularis atrophicans* (see below).

Keratosis pilaris (synonym: keratosis follicularis, lichen pilaris) (KP) is the most common type of follicular keratosis. [3] KP is a harmless but fairly stable eruption of grouped keratotic follicular papules which may be localized to the predilection sites (extensor and lateral aspects of the proximal extremities, buttocks, less often face, neck and trunk) or, infrequently, generalized. A subtle erythema may rim the affected follicle, particularly in skin damaged by chronic exposure to cold (chilblain, cutis marmorata). KP arises in the first decade of life, reaches a peak at adolescence and tends to ameliorate or to subside in the subsequent decades. [4] In a mild form, KP may be found in up to half of the population, thus it is often viewed as a “physiological” condition. KP is of unknown cause; there is no racial predilection, and it appears to be transmitted in an autosomal dominant mode.

Association of KP is most often found with autosomal dominant ichthyosis vulgaris (up to 75 percent [2]) and the ichthyosis-like phenotype that often accompanies dry skin and atopy. [2], [5] Interestingly, KP is not a feature of patients with atopic dermatitis who lack the ichthyosis-like phenotype. [2] Association with other disorders of keratinization is less common. KP can also be caused or aggravated by a number of metabolic disturbances such as malnutrition, [6] scurvy, [7] hypovitaminosis B_2 and A (phrynoderma), hypothyroidism, hyperandrogenism, hypercorticism, diabetes and obesity, [8] renal insufficiency, and others. It may also be found in Noonan's and Down's syndrome. [3]

Lichen spinulosus is an uncommon variant of KP that is characterized by sudden appearance of patches of spiny follicular keratoses in children that tend to resolve spontaneously. Another rare variant is erythromelanosis follicularis faciei et colli.

Keratosis pilaris atrophicans (KPA), in contrast, includes a group of phenotypically related, rare disorders that show keratotic follicular papules like KP but, in addition, have nonpurulent inflammation of variable degree, and atrophic end stages characterized by irreversible hair loss and/or atrophic depressions similar to pitted scars. [9], [10] All of these disorders appear to be hereditary, to have their onset early in life, and to have disease activity that tends to relent after puberty while atrophy remains. KPA most conspicuously affects the face and scalp, but KP of the ordinary type is a common associated finding on the rest of the body (which then often proves more persistent than the usual type KP). In most cases, KPA is a disorder of the skin only and is mainly of cosmetic relevance, but rare associations with a variety of developmental defects have been reported.

CLASSIFICATION

Attempts at classification are still predominantly based on clinical criteria. Three categories of KPA are generally accepted: the more localized entities of keratosis pilaris atrophicans faciei (KPAF) and atrophoderma vermiculatum (AV) and the generalized keratosis follicularis spinulosa decalvans (KFSD) of Siemens. It has been a matter of debate whether these categories are manifestations or stages of a single process, [9], [11] or, instead, independent clinical entities. [12] Heterogeneity of KPA is most likely in view of the different modes of inheritance, significant clinical differences, and the results of gene mapping hitherto available.

Both KPAF and AV are fairly well defined entities with little overlap. Early stage KFSD, however, is similar to KPAF and differs only by its tendency for more widespread expansion and involvement of the scalp later on. Confusion has arisen

because KFSD has variously been lumped with similar but different genodermatoses such as the keratosis-ichthyosis-deafness (KID) syndrome [13], [14] and the ichthyosis follicularis-alopecia-photophobia (IFAP) syndrome. [15], [16] Moreover, KFSD may be heterogeneous in itself; most patients in published cases were members of several large kinships in which the disease phenotype appears fairly homogenous. [17], [18], [19], [20] and [21] Many of the unrelated cases, however, do not conform to this "classic" type of KFSD (e.g., see Refs. [9] and [11]). According to Oranje et al, [12] a more intensely inflammatory phenocopic variant should be distinguished, which they term *folliculitis spinulosa decalvans*.

HISTORICAL ASPECTS

Keratosis Pilaris Atrophicans Faciei

In 1878, Erasmus Wilson described a syndrome characterized by erythematous follicular papules of the eyebrows, cheeks, back, and arms, which began in childhood and eventually led to complete alopecia of the eyebrows; he called it *folliculitis rubra*. [22] Later, several other synonyms were introduced to describe the same condition, including ulerythema ophryogenes (from the Greek *ule,* "scar," and *ophrys,* "eyebrow"), [23] *lichen pilaire ou xerodermie pilaire symmetrique de la face,* [24] and others.

Keratosis Follicularis Spinulosa Decalvans

This name was given by Siemens, in 1926, to an inflammatory follicular syndrome in a Bavarian family, that included scarring alopecia of the scalp, specific eye symptoms, and hyperkeratosis of the palms and soles. [17] X-linked dominant inheritance was proposed. This pedigree was later traced by Thelen. [25] In 1950, Jonkers [18] traced the pedigree of a family in the Netherlands with this disease, which had been briefly described by Lameris in 1905. [26] This latter kinship is now the largest one published so far. [19] Other large kinships with KFSD have been reported from Finland [20] and from Great Britain. [21]

Atrophoderma Vermiculatum

In 1896, Unna introduced the term *ulerythema acneiforme* to describe follicular red papules of the cheeks that eventually progress to reticulate atrophy. [27] Synonyms introduced later include *acne vermoulante,* [28] *atrophodermie vermiculée des joues avec kératoses folliculaires,* [29] *honeycomb atrophy,* [30] and others.

EPIDEMIOLOGY

All categories of KPA are rare, AV and KFSD exceedingly so. KPAF is the most common, but no estimates on its prevalence are available. Familial incidence in all types of KPA has been documented (besides many sporadic cases, particularly in AV). For KPAF and AV, no sex predilection is apparent, and autosomal dominant transmission is likely. KFSD is an X-linked trait; thus most patients are males, but female carriers may also be severely affected. [11], [12], [31]

ETIOLOGY AND PATHOGENESIS

The disorders that make up KPA are genodermatoses of unknown etiology. In the Dutch pedigree, the gene for KFSD has been mapped to Xp22.13-p22.2, in the region of the genes for X-linked juvenile retinoschisis, the Coffin-Lowry syndrome, and hypophosphatemic rickets. [32] Linkage to the same locus was confirmed for the English family, [33] but in a smaller kinship reported by Harth, [31] the gene could not be tracked to the candidate region, suggesting genetic heterogeneity of KFSD. [34] The gene loci of KPAF and AV are still unknown. KPAF has been observed associated with deletions of 18p in a number of cases, [35], [36] and [37] and an involvement of the *LAMA1* (laminin a $_1$ chain) gene has been hypothesized. [38]

The pathogenesis is not well understood. The primary pathogenetic event appears to be abnormal keratinization of the ostioinfundibulum of the hair follicle, resulting in horny plugs that dilate the follicular ostium and may protrude in a spinelike manner. From early stages on, inflammatory infiltrates appear around the follicle. These later mediate perifollicular fibrosis, atrophy, and destruction of the hair bulb. Inflammation, fibrosis, and shrinkage are deeper and more intense in AV, leading to a scarlike reticulate remodeling of the skin surface that is absent in KPAF and KFSD.

Atrophy and inflammation may not be caused simply by pressure from the horny plugs and, later on, by a foreign-body reaction to keratin. The size of follicular horny plugs in common type KP is not necessarily smaller but still does not lead to intense inflammation and scarring. More specific pathomechanisms may thus be anticipated. [11] It is likely that this undefined atrophogenic property of KPA (or at least of KFSD) is common to all hair follicles, even though alopecia becomes apparent first and most conspicuously in the face and scalp, and KP of the rest of the body is indistinguishable from that of the nonscarring type. Follicular atrophy is slow to develop; it does not usually affect all follicles of the face and scalp even in full-blown cases of KFSD; on the other hand, body hair is typically sparse in these cases, and inflammation can on occasion also be found in the seemingly common type of KP. [3], [11]

Inflammation is of varying degree in all categories of KPA. In some instances, it is a purely histopathologic sign; in others, it manifests as a visible erythema.

CLINICAL FEATURES

Keratosis Pilaris Atrophicans Faciei (MIM 604093)

In KPAF, the process begins in the lateral third of the eyebrows a few months after birth, with follicular papules surrounded by an erythematous halo (Fig. 78-1). The skin of the eyebrows may appear diffusely inflamed. There is a gradual loss of hair from the follicles during childhood that may eventually involve the entire eyebrow. The follicular pores appear dilated; their number diminishes over the years. Pitlike scarring and remodeling of the skin surface is absent. The process may progress to involve the cheeks and forehead, where it is less conspicuous because hair loss is not readily detected. KPAF is often accompanied by KP of the extensor sites of the extremities. Progression appears to cease after puberty. The likely mode of inheritance is autosomal dominant.

FIGURE 78-1 Keratosis pilaris atrophicans faciei (KPAF) (ulerythema ophryogenes) in an 11-year-old boy. Note follicular papules of eyebrows, cheek, and neck; sparsity of lateral eyebrow; and perifollicular erythema.

KPAF has been seen with other ectodermal defects or with multiple congenital abnormalities. [39], [40] Mertens studied 15 patients from 5 families with KPAF and found most patients to have an atopic diathesis. [41] Five cases of Noonan's syndrome associated with KPAF were described by Pierini, [10] and woolly hair may be found in patients with KPA with and without Noonan's syndrome. [42], [43]

Keratosis Follicularis Spinulosa Decalvans (MIM 308800)

KFSD is more widespread but morphologically similar to KPAF. It begins in infancy with numerous horny follicular plugs and milia on the nose and cheeks and later on the eyebrows, scalp, neck, and body (Fig. 78-2A). Erythema is variable and often very faint. [12] Scarring alopecia of the scalp, eyebrows, and eyelashes becomes apparent in childhood and progresses until puberty. It is often restricted to patches and rarely proceeds to full baldness. Remnant hairs of the eyelashes typically protrude in different directions. Facial lanugo hair is absent. There is KP of the body that resembles that of the nonatrophic type, but many hair follicles appear empty (Fig. 78-2B). Axillary and pubic hair thinning is frequently observed. Patches of eczema, particularly of the scalp, may be seen. Ichthyosiform scaling of the interfollicular epidermis is typically absent. After puberty, progression slowly subsides.

FIGURE 78-2 Keratosis follicularis spinulosa decalvans (KFSD) in a 25-year-old female. *A*. Scarring alopecia, generalized follicular papules, and diffuse erythema of the face. *B*. Keratosis pilaris of the thighs.

Associated features include palmoplantar keratoderma, with predilection for the calcaneal region, and the unusual sign of high cuticles. [19] Photophobia is a regular feature caused by subepithelial opacities in the Bowman's membrane. [44] Conjunctivitis and corneal vascularization (circular pannus) are infrequently combined. Another cause of corneal dystrophy may be hardened secretions of the meibomian glands forming hard prickles. Photophobia is found predominantly in children; it improves after puberty, similar to the skin symptoms. Visual prognosis is good. KFSD is not associated with other physical or mental disturbances. As rare exceptions, combinations have been described with

aminoaciduria [45] and with Noonan's syndrome. [46] There are no abnormalities of the cutaneous microbial flora. [11]

X-linked dominant mode of inheritance has been shown. Therefore, the most severe manifestations are found in males. Female carriers mostly show only dry skin and KP. Not infrequently, however, they may present the full clinical picture, [9], [21], [31] which is interpreted as nonrandom X-chromosome inactivation. [12]

Variant cases published as KFSD, [9], [10] and [11] and put together by Oranje et al. [12] under the tentative term *folliculitis spinulosa decalvans,* are also characterized by KPA but differ in several aspects: more pronounced inflammation and extensive erythema, pustule formation particularly of the scalp, crusting, and desquamation. An increased incidence of atopic dermatitis has been reported. [11] After puberty, the process fails to ameliorate; but rather, it gets worse. The mode of inheritance is likely to be autosomal dominant. This disorder must be distinguished from folliculitis decalvans.

Atrophoderma Vermiculatum (MIM 209700)

AV is set apart clinically from KPAF and KFSD by its later age of onset (between 5 and 12 years; some cases have been noted to begin at puberty or in adulthood) and by its morphologic hallmark, which is scarlike atrophic pits of the cheeks. It begins with erythematous follicular keratotic plugs, papules, and milia, which transform into conspicuous pitlike depressions separated by narrow epidermal ridges, lending the area a reticulate “honeycomb-like” or “worm-eaten” aspect. The pits are irregular in shape—approximately 1 mm in depth and up to 2 mm^2 in size. At times, they may extend to the upper lip, ears, and forehead (Fig. 78-3). Through the thinned epidermis of the pits, an erythematous blush may be seen. Eyebrows, eyelashes, and scalp are notably spared. The cheeks appear to be waxy and shiny and firmer on palpation than the surrounding skin. AV is typically symmetric, but unilateral occurrence has been reported. [47] Again, the progression of AV subsides after puberty. Most authors favor an autosomal dominant trait, [48] but autosomal recessive inheritance has also been considered. [12]

FIGURE 78-3 Atrophoderma vermiculatum (AV) in a 10-year-old girl. Note multiple confluent, atrophic, pitlike depressions of the cheek.

Associations of AV have occasionally been reported with various minor or major developmental anomalies such as epidermal cysts and folliculitis decalvans, birefringent hairs, mongolism, Eisenmenger complex and intraauricular septal defect, [49] and the Rombo syndrome (an autosomal dominant condition similar to the Bazex syndrome, with milia, hypotrichosis, basal cell carcinomas). [50]

PATHOLOGY

The histologic picture [11], [51] depends on the stage of the process, which may be different in neighboring hair follicles. Early inflammatory papules reveal acanthotic, hypergranulotic infundibula dilated by compact keratin plugs that contain dystrophic or twisted hairs. There is a lymphocytic infiltrate with neutrophils around the upper (in AV also the lower) portions of the appendages. More advanced stages show mixed lymphohistiocytic infiltrates with multinucleated giant cells, often around keratinous debris or naked hair particles; atrophy or absence of the hair bulbs; and deposition of collagen. End-stage biopsies exhibit the nonspecific findings of cicatricial alopecia: sclerosis of dermal collagen and atrophy of rete ridges and sebaceous glands. In the only electron-microscopic study of KFSD hitherto published, an increase of abnormally rounded keratohyalin granules, precocious appearance of the cornified envelope, and delayed desmosome dissolution were found in the infundibular epithelium. [52] Immunofluorescence was reported negative by Maroon et al. [53]

DIFFERENTIAL DIAGNOSIS

All types of KPA must principally be distinguished from the nonatrophic KP. Early KPAF may be misinterpreted as patches of seborrheic or atopic dermatitis. KFSD must be distinguished from atopic dermatitis associated with lichen pilaris and thinning of the lateral eyebrow (Hertoghe's sign).

The KID syndrome is similar to KFSD because of its extensive horny plugs in hair follicles and sweat gland pores, sparse hair, and variable degree of erythema. It is distinguished by the absence of follicular scarring and by its associated features: neurosensory deafness, vascularizing keratitis, and reticulated palmoplantar hyperkeratosis obliterating the

dermatoglyphics.

The IFAP syndrome (described in 1909 by MacLeod as “ichthyosis follicularis” [54]) shares several features with KFSD: generalized keratosis pilaris, eye symptoms, hair loss, and an X-linked inheritance. [16], [55] In contrast, the alopecia is nonscarring and universal, and keratosis pilaris is noninflammatory and exhibits extensive spiny horn plugs; there is also ichthyosis of the interfollicular epidermis in some body regions, and associated features such as severe photophobia and failure to thrive.

Atrichia with papular lesions is a developmental defect of the pilosebaceous system characterized by complete loss of hair in the first months of life and formation of extensive papules and horny plugs that histologically resemble trichoepitheliomas.

AV may resemble acne infantum (but does not have pustules) and acneiform eruptions such as those found in children exposed to the chloracnegen 2,3,7,8-tetrachlorodibenzo- *p*-dioxin in the industrial accident in Seveso, Italy. [56] After puberty, AV may be indistinguishable from acne scars (although these are rarely as localized as AV). Nevus comedonicus may be morphologically similar but is usually unilateral and follows the Blaschko lines.

TREATMENT, COURSE, AND PROGNOSIS

No effective therapy is available for reversing the course of these syndromes. Temporary symptomatic treatment, including emollients, topical steroids, tretinoin, and keratolytic agents, may be of limited value. Topical and systemic antibiotics are ineffective. Hair transplantation may be helpful in scalp alopecia. Dermabrasion and/or collagen implants may prove useful in treatment of the facial pits. Pulsed tunable dye laser treatment was found to improve the erythematous component of KPAF but not the follicular keratoses. [57] Systemic retinoids were found to be ineffective in KFSD by some authors [11], [52] but helpful by others. [58], [59] and [60] At any rate, possible therapeutic benefits must be weighed against the toxicity of chronic therapy.

REFERENCES

1. Fung WK, Lo KK: Prevalence of skin disease among school children and adolescents in a student health service center in Hong Kong. *Pediatr Dermatol* **17**:440, 2000

2. Mevorah B et al: The prevalence of accentuated palmoplantar markings and keratosis pilaris in atopic dermatitis, autosomal dominant ichthyosis and control dermatological patients. *Br J Dermatol* **112**:679, 1985

3. Lateef A, Schwartz RA: Keratosis pilaris. *Cutis* **63**:205, 1999

4. Poskitt L, Wilkinson JD: Natural history of keratosis pilaris. *Br J Dermatol* **130**:711, 1994

5. Yosipovitch G et al: High body mass index, dry scaly leg skin and atopic conditions are highly associated with keratosis pilaris. *Dermatology* **201**:34, 2000

6. Forman L: Keratosis pilaris. *Br J Dermatol* **66**:279, 1954

7. Hilty N et al: Skorbut bei Trisomie 21. *Hautarzt* **42**:464, 1991

8. Yosipovitch G et al: The prevalence of cutaneous manifestations in IDDM patients and their association with diabetes risk factors and microvascular complications. *Diabetes Care* **21**:506, 1998

9. Rand R, Baden H: Keratosis follicularis spinulosa decalvans. Report of two cases and literature review. *Arch Dermatol* **119**:22, 1983

10. Pierini DO, Pierini AM: Keratosis pilaris atrophicans faciei (ulerythema ophryogenes): A cutaneous marker in Noonan's syndrome. *Br J Dermatol* **100**:409, 1979

11. Baden HP, Byers HR: Clinical findings, cutaneous pathology and response to therapy in 21 patients with keratosis pilaris atrophicans. *Arch Dermatol* **130**:469, 1994

12. Oranje AP et al: Keratosis pilaris atrophicans. One heterogeneous disease or a symptom in different clinical entities? *Arch Dermatol* **130**:500, 1994

13. Britton H et al: Keratosis follicularis spinulosa decalvans: An infant with failure to thrive, deafness and recurrent infections. *Arch Dermatol* **114**:761, 1978

14. Morris J et al: Generalized spiny hyperkeratosis, universal alopecia, and deafness: A previously undescribed syndrome. *Arch Dermatol* **100**:692, 1969

15. Martino F et al: Child with manifestations of dermotrichic syndrome and ichthyosis follicularis-alopecia-photophobia (IFAP) syndrome. *Am J Med Genet* **44**:233, 1992

16. Hamm H et al: Further delineation of the ichthyosis follicularis, atrichia, and photophobia syndrome. *Eur J Pediatr* **150**:627, 1991

17. Siemens HW: Keratosis follicularis spinulosa decalvans. *Arch Dermatol Syphilol* **151**:384, 1926

18. Jonkers GH: Hyperkeratosis follicularis en cornea degenerative. *Ned Tijdschr Geneeskd* **94**:1464, 1950

19. van Osch LDM et al: Keratosis follicularis spinulosa decalvans: A family study of seven male cases and six female carriers. *J Med Genet* **29**:36, 1992

20. Kuokkanen K: Keratosis follicularis spinulosa decalvans in a family from northern Finland. *Acta Derm Venereol Suppl (Stockh)* **51**:146, 1971

21. Herd RM, Benton EC: Keratosis follicularis decalvans: Report of a new pedigree. *Br J Dermatol* **134**:138, 1996

22. Wilson E: *Lectures on Dermatology*. London, J & A Churchill, 1878, p 217

23. Taenzer P: Ueber das Ulerythema ophryogenes, eine noch nicht beschriebene hautkrankheit. *Monatsschr Prakt Dermatol* **8**:197, 1889

24. Brocq L: Lichen pilaire ou xérodermie pilaire symetrique de la face. *Ann Dermatol Syphiligr (Paris)* **10**:339, 1889

25. Thelen L: Keratosis folliculitis spinulosa decalvans (Siemens). *Z Haut Geschlechtskr* **66**:56, 1940

26. Lameris HJ: Ichthyosis follicularis. *Ned Tijdschr Geneeskd* **41**:1524, 1905

27. Unna PG: Ulerythema acneiforme, in *Histopathology of Diseases of the Skin,* translated from German by N Walker. Edinburgh, Clay, 1896, p 1084

28. Thieberge G: Acne vermoullante, in *La Pratique Dermatologique,* vol 1, edited by E Besnier, Brocq L, Jacquet L. Paris, Masson et Cie, 1900, p 207

29. Darier J: Atrophodermie vermiculée des joues avec kératoses folliculaires. *Bull Soc Fr Dermatol Syphiligr* **27**:345, 1920

30. Savatard L: Honeycomb atrophy. *Br J Dermatol* **55**:259, 1943

31. Harth W et al: Keratosis follicularis spinulosa decalvans: The complete syndrome in a female. *Z Hautkr* **67**:1080, 1992

32. Oosterwijk JC et al: Refinement of the localization of the X-linked keratosis follicularis spinulosa decalvans (KFSD) gene in Xp22.13-p22.2. *J Med Genet* **32**:736, 1995

33. Porteous M et al: Keratosis follicularis spinulosa decalvans: Confirmation of linkage to Xp22.13-p22.2. *J Med Genet* **35**:336, 1998

34. Oosterwijk JC et al: Molecular genetic analysis of two families with keratosis follicularis spinulosa decalvans: Refinement of gene localization and evidence for genetic heterogeneity. *Hum Genet* **100**:520, 1997

35. Zouboulis CC et al: Ulerythema ophryogenes and keratosis pilaris in a child with monosomy 18p. *Pediatr Dermatol* **11**:172, 1994

36. Nazarenko SA et al: Keratosis pilaris and ulerythema ophryogenes associated with an 18p deletion caused by a Y/18 translocation. *Am J Med Genet* **95**:179, 1999

37. Horsley SW et al: Del(18p) shown to be a cryptic translocation using a multiprobe FISH assay for subtelomeric chromosome rearrangements. *J Med Genet* **35**:722, 1998

38. Zouboulis C et al: Keratosis pilaris/ulerythema ophryogenes and 18p deletion: Is it possible that the LAMA1 gene is involved? *J Med Genet* **38**:127, 2001

39. Davenport DD: Ulerythema ophryogenes: Review and report of a case: Discussion of relationship to certain other skin disorders and association with internal abnormalities. *Arch Dermatol* **89**:74, 1964

40. Burnett JW et al: Ulerythema ophryogenes with multiple congenital abnormalities. *J Am Acad Dermatol* **18**:437, 1988

41. Mertens RLJ: Ulerythema ophryogenes and atopy. *Arch Dermatol* **97**:662, 1968

42. McHenry PM et al: The association of keratosis pilaris atrophicans with hereditary woolly hair. *Pediatr Dermatol* **7**:202, 1990

43. Snell JA, Mallory SB: Ulerythema ophryogenes in Noonan syndrome. *Pediatr Dermatol* **7**:77, 1990

44. Franceschetti A et al: Manifestations cornéennes dans la keratosis follicularis spinulosa decalvans (Siemens). *Ophthalmologica* **133**:259, 1957

45. Grosshans E et al: Keratosis follicularis spinulosa decalvans et aminoacidurie. *Ann Dermatol Venereol* **105**:433, 1978

46. Grob JJ et al: Les signes cutanées du syndrome de Noonan. A propos d'une observation avec ulérythème ophryogène, kératose pilaire et sudorale disséminée et alopécie progressive. *Ann Dermatol Venereol* **115**:303, 1988

47. Arieta E, Milgram-Sternberg Y: Honeycomb atrophy on the right cheek. *Arch Dermatol* **124**:1001, 1988

48. Frosch PJ, Brumage MR: Atrophoderma vermiculatum. Case reports and review. *J Am Acad Dermatol* **18**:538, 1988

49. Kooij R, Venter J: Atrophodermia vermiculata with unusual localization and associated congenital anomalies. *Dermatologica* **118**:161, 1959

50. Michaelsson G et al: The Rombo syndrome: A familial disorder with vermiculate atrophy, milia, hypotrichosis, trichoepitheliomas, basal cell carcinomas, and peripheral vasodilation with cyanosis. *Acta Derm Venereol Suppl (Stockh)* **61**:497, 1981

51. Brazelli V, Borroni G: Aspetti istologici e tardivi dell'atrophodermia vermiculata. *G Ital Derm Venereol* **125**:185, 1990

52. Puppin D et al: Keratosis follicularis spinulosa decalvans: Report of a case with ultrastructural study and unsuccessful trial of retinoids. *Dermatologica* **184**:133, 1992

53. Maroon M et al: Keratosis pilaris and scarring alopecia. *Arch Dermatol* **128**:397, 1992

54. MacLeod JMH: Three cases of “ichthyosis follicularis” associated with baldness. *Br J Dermatol* **21**:165, 1909

55. Konig A, Happle R: Linear lesions reflecting lyonization in women heterozygous for IFAP syndrome (ichthyosis follicularis with atrichia and photophobia). *Am J Med Genet* **85**:365, 1999

56. Gianotti F: Chloracné au tétrachloro-2,3,7,8-dibenzo- *p*-dioxide chez les enfants. *Ann Dermatol Venereol* **104**:825, 1977

57. Clark SM et al: Treatment of keratosis pilaris atrophicans with the pulsed tunable dye laser. *J Cutan Laser Ther* **2**:151, 2000

58. Richard G, Harth W: Keratosis follicularis spinulosa decalvans. Therapie mit Isotretinoin und Etretinat im entzündlichen Stadium. *Hautarzt* **44**:529, 1993

59. Fritsch P, Sidoroff A: Safety of retinoids and indications for use. *Curr Opin Dermatol* **1**:207, 1993

60. Layton AM, Cunliffe WJ: A case of ulerythema ophryogenes responding to isotretinoin. *Br J Dermatol* **129**:945, 1993

T>

Chapter 79

Karynne Duncan David Leffell

Epithelial Precancerous Lesions

ACTINIC KERATOSES
Epidemiology
Etiology and Pathogenesis
Prevention
Clinical Manifestations
Pathology
Diagnosis and Differential Diagnosis
Prognosis and Treatment
ARSENICAL KERATOSES
History and Epidemiology
Etiology and Pathogenesis
Clinical Manifestations
Histopathology
Diagnosis and Differential Diagnosis
Prognosis and Treatment
THERMAL KERATOSES
Clinical Manifestations
Histopathology
Diagnosis and Differential Diagnosis
Prognosis and Treatment
HYDROCARBON KERATOSES
Etiology and Pathogenesis
Clinical Manifestations
Histopathology
Diagnosis and Differential Diagnosis
Prognosis and Treatment
CHRONIC RADIATION KERATOSES
Clinical Manifestations
Pathology
Prognosis and Treatment
CHRONIC SCAR KERATOSES
History and Epidemiology
Etiology and Pathogenesis
Clinical Manifestations
Pathology and Diagnosis
Prognosis and Treatment
REACTIONAL KERATOSES
PUVA KERATOSES
VIRAL KERATOSES
Bowenoid Papulosis
Epidermodysplasia Verruciformis
HPV and Cutaneous Malignancy in Immunosuppressed and Immunocompetent Hosts
BOWEN'S DISEASE
Epidemiology
Etiology and Pathogenesis
Clinical Manifestations
Pathology
Diagnosis and Differential Diagnosis
Prognosis and Treatment
ERYTHROPLASIA OF QUEYRAT
ERYTHROPLAKIA (ERYTHROPLASIA)
Clinical Manifestations
Pathology and Diagnosis
Differential Diagnosis
Prognosis and Treatment
LEUKOPLAKIA
Clinical Manifestations
Pathology
Diagnosis and Differential Diagnosis
Prognosis and Treatment

REFERENCES

A precancerous or premalignant lesion is one that has a strong likelihood of transforming into a malignancy. There is much debate about the validity of the concept of “precancerous” lesions. [1], [2], [3] and [4] The lesions discussed in this chapter are those that clinically have a demonstrated potential to become invasive carcinomas and that histopathologically demonstrate atypia confined to the epidermis. The focus is only on the precancerous keratinocyte lesions and not on those of other epithelial cells such as the melanocyte, Merkel, and appendageal cells. Discussion of malignancies and premalignancies associated with these cells can be found in Chap. 92, Chap. 93, Chap. 86, and Chap. 85, respectively.

A common feature of all premalignant epithelial tumors listed in Table 79-1 is that they all have the potential to become invasive squamous cell carcinoma (SCC). These precancerous lesions and SCC are considered by many to represent a continuum of disease with dysplasia at one end of the spectrum and invasive carcinoma at the other. [5]

Actinic keratoses
Arsenical keratoses
Thermal keratoses
Hydrocarbon keratoses
Chronic radiation keratoses
Chronic scar keratoses
Reactional keratoses
PUVA keratoses
Viral keratoses
Bowenoid papulosis
Epidermodysplasia verruciformis
Bowen's disease
Erythroplasia of Queyrat
Erythroplakia
Leukoplakia

TABLE 79-1 **Precancerous Keratinocytic Lesions**

ACTINIC KERATOSES

Actinic keratoses (AKs) are cutaneous neoplasms consisting of proliferations of cytologically aberrant, epidermal keratinocytes that develop in response to prolonged exposure to ultraviolet radiation. The concept of a precancerous keratosis was first presented by Dubreuilh in the late 1800s. [5] AKs were first identified and named “keratoma senilis” by Freudenthal in 1926. [6] In 1958, Pinkus further characterized these lesions and coined the term *actinic keratosis*. [7] These lesions have also been called solar keratoses and senile keratoses. *Actinic keratosis* literally means a condition (- *osis*) of excessive horny (*kerat*-) tissue induced by a ray of light (*aktis*), presumably ultraviolet light. AKs have historically been considered precancerous or premalignant lesions, with a potential for developing into squamous cell carcinomas. In recent years, however, there has been an effort to redefine AKs as malignant neoplasms, as these lesions are essentially intraepithelial squamous cell carcinomas in evolution. Although not all AKs become SCCs, AKs are essentially the initial lesion in a disease continuum that progresses to squamous cell carcinoma. This concept of a progression along a spectrum is analogous to that of cervical carcinoma, where cervical intraepithelial neoplasia is the initial, “precancerous” lesion.

Actinic keratoses are clinically important lesions, not only because of their potential to develop into SCC, but because they are one of the strongest predictors that an individual may subsequently develop SCC or basal cell carcinoma (BCC) of the skin. [8], [9] With the increasing incidence and prevalence of these nonmelanoma skin cancers (NMSCs), as discussed in Chap. 80 and Chap. 81, persons with AKs are the perfect candidates for close longitudinal observation for prevention and early treatment.

Epidemiology

Actinic keratoses are lesions commonly encountered in dermatology practice. After acne vulgaris and dermatitis, AKs are the third most common reason for patients to see a dermatologist. [10] In a recent survey of outpatient visits between 1990 and 1994, it was estimated that of 127 million office visits, 14.6 million (11.5 percent) were for the evaluation and management of AKs. [11] Data on the prevalence of AKs (proportion of people in a population who have at least one AK) come primarily from studies in Australia, where AKs and NMSCs are more common than anywhere else in the world. [12] Studies outside of Australia are more limited and have reported AK prevalence rates ranging from 11 percent in persons older than age 21 in County Galway, Ireland, to 25 percent in a high-risk group of outdoor workers in Maryland, USA. [13], [14] Studies of the incidence (proportion of people in a population who develop a new AK in a specific time period) of AKs are even more limited, with one such study from Australia reported to date. [15] In that study, 59 percent of the people had at least one AK and 41 percent were lesion free. At the 12-month visit, 60 percent of people from the former group had developed new AKs, whereas only 19 percent of people from the latter group had developed new AKs.

Various risk factors have been identified for the expression of AKs, with the two major groups being individual susceptibility and cumulative ultraviolet radiation exposure. One of the most important susceptibility risk factors is age, as all the epidemiologic studies indicate that AKs increase in prevalence with increasing age, ranging from <10 percent in white adults aged 20 to 29 years to 80 percent in similar adults aged 60 to 69 years. Males appear to have more AKs than females in most epidemiologic studies, reflecting assumed greater cumulative sun exposure in males compared to females. [12] This sex differential is more pronounced at younger ages. Other individual susceptibility risk factors include a phenotype of fair skin that easily burns and freckles, while rarely tans; blue or light-colored eyes; and red or blond hair. [10], [12] Another individual risk factor is immunosuppression, as it is well known that organ transplant recipients are at increased risk of developing AKs and SCCs. Lastly, individuals with certain genetic syndromes are at greater risk of developing AKs, namely albinism and xeroderma pigmentosum, and possibly Rothmund-Thomson and Bloom's syndromes.

Cumulative exposure to ultraviolet radiation, including tanning beds, is the other major risk factor for developing AKs. Evidence that sun exposure plays a role in the development of AKs is seen in the fact that over 80 percent of all AKs are distributed on chronically sun-exposed areas of the body, such as the scalp, head, neck, forearms, and dorsal hands. [12] Variables that affect a person's cumulative ultraviolet radiation exposure include one's age, gender, occupation, recreational activities, and place of residence. As stated above, AKs increase in prevalence the older the individual. Intuitively, the older the individual, the greater is the cumulative exposure to ultraviolet radiation. In addition to this factor, the age at which a person received the greatest amount and intensity of exposure to ultraviolet radiation appears to be a risk factor, with such exposure in childhood apparently posing the greatest risk. In migration studies from Australia,

British immigrants who moved to Australia before the age of 20 had fewer AKs than the native white Australians early in life, but they equaled the native Australians in later years. British immigrants who moved to Australia after the age of 20 years never developed the same number of AKs as the native Australians or the early British immigrants. [16]

Etiology and Pathogenesis

In the past decade tremendous strides have been made in understanding the scientific basis of AKs and nonmelanoma skin cancer. Although genetic and environmental factors may play a role in the development of AKs and SCC, it has long been recognized that the most important contributing factor is chronic exposure to ultraviolet radiation, namely sunlight exposure. Ultraviolet radiation is responsible for the development of AK, and eventually SCC, in two ways: first, it causes mutations in cellular DNA that, when unrepaired, lead to unrestrained growth and tumor formation, and, second, it acts as an immunosuppressant to prevent tumor rejection. [17] Carcinogenesis is discussed in great depth in Chap. 36, Chap. 37 and Chap. 38.

It has become evident with recent studies involving the molecular biology of skin cancer that ultraviolet radiation–induced mutations in the tumor-suppressor gene *p53* play a pivotal role in the initiation of AKs and their development into SCC. *p53,* in general, is the most commonly mutated tumor-suppressor gene and is present in greater than 50 percent of all human cancers. [17] Ziegler et al. identified mutation hot spots in the *p53* gene in human NMSCs and demonstrated that the *p53* mutations, which are present in more than 90 percent of SCCs, are also present in AKs. [18] Normal *p53* gene activity produces a protein that is a transcription factor whose targets include genes that regulate the cell cycle. This protein acts to ensure that cells do not proliferate uncontrollably and to ensure that abnormal, mutated cells are destroyed so that they cannot divide and continue to pass along the mutation to daughter cells. This latter process of controlled cell suicide is also known as apoptosis, and it is one of the most important mechanisms by which cancer cells are kept in check in the human body. Several animal and human-based experiments have proven the role of ultraviolet radiation in causing unique mutations in *p53,* and in causing apoptosis in the skin. [19] While keratinocytes with normal functioning *p53* are undergoing apoptosis in the presence of repeated exposure to sunlight, the *p53*-mutated clone of keratinocytes is dividing and expanding into the space left behind by these dying cells. At some point, repeated exposure to sunlight may result in a second UVB-induced mutation in the *p53* gene (second hit or progression) with resultant malignant transformation and the development of the AK clone into SCC (Fig. 79-1).

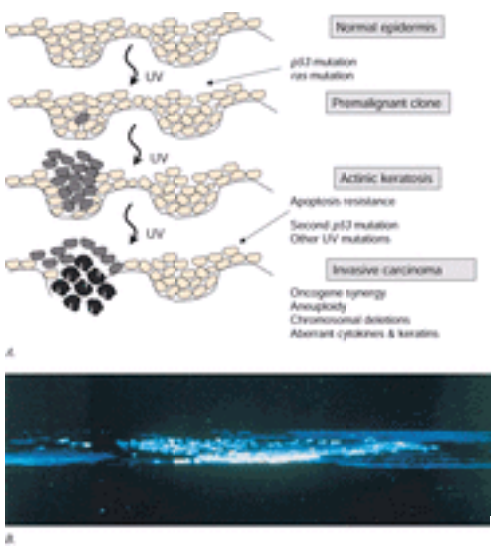

FIGURE 79-1 *A.* Diagram demonstrating the development of clonal expansion of ultraviolet-mutated p53 gene in epithelium. In the multistage model of carcinogenesis, UV-induced mutations provide selective growth advantage of neighboring cells leading to clonal expansion. *(Adapted from Grossman D, Leffell DJ: The molecular basis of nonmelanoma skin cancer. Arch Dermatol 133:1263, 1997). B.* Confocal microscopy revealing expansion of UV-induced clone of abnormal keratinocytes in sun-damaged skin. (*Courtesy Jonason et al: Frequent clones of p53-mutated keratinocytes in normal human skin. Proc Natl Acad Sci USA 93:1402, 1996*)

Prevention

It is widely believed that, because most AKs are related to exposure to ultraviolet radiation, preventive measures aimed at limiting the amount and intensity of sun exposure, especially in childhood and adolescence, should prove effective in decreasing their prevalence. The best prevention is avoidance of the sun, especially mid-day when the intensity is greatest. As this is often impractical, the next best preventive measures are wearing protective clothing, such as tightly woven, long-sleeved pants and shirts, and wide-brimmed hats, and the use of a high sun protection factor (SPF) sunscreen. Sunscreens reduce the frequency of tumors induced experimentally in animals exposed to ultraviolet radiation and reduce the development of AKs in humans. [20]

There is some evidence that adhering to a diet low in fat may decrease the incidence of AKs. [21] Oral retinoids are effective in preventing NMSC and AKs, especially in high-risk patients such as organ transplant recipients and patients with xeroderma pigmentosum, but they are only effective as long as the patient is taking the medication. The combination of low dose 13- *cis*-retinoic acid (10 mg every other day) with topical tretinoin has been advocated as prophylaxis of both AKs and NMSC in renal transplant recipients. [22]

Clinical Manifestations

The typical person who presents with AKs is an elderly, fair-skinned, light-eyed individual who has a history of significant sun exposure, who burned and freckled rather than tanned, and who has significant solar elastosis on examination (Fig.

79-2). AKs, however, can be seen in younger individuals if they have sustained sufficient sun exposure over their lives. As mentioned earlier, AKs (80 percent) are typically found on chronically sun-exposed sites of the body, such as the head, neck, forearms, and dorsal hands. [10] The majority are found on the upper limbs (approximately 65 percent). [12] The typical AK lesion, sometimes called the erythematous AK, presents most commonly as a 2- to 6-mm erythematous, flat, rough or scaly papule. It is usually easier felt than seen. AKs can vary in size, and sometimes reach up to several centimeters in diameter. They are most often found amongst a background of solar elastosis, with dyspigmentation, yellow discoloration, ephelides, telangiectases, and sagging skin being prominent. At times the number and confluence of AKs is so great that the patient appears to have a rash.

FIGURE 79-2 Severe solar damage of the face revealing telangiectasias as well as actinic keratoses at different stages in development, including the flat, pink macules and hyperkeratotic papules.

In addition to the typical erythematous AK, there are several other clinical subtypes. The hypertrophic AK (HAK) presents as a thicker, scaly, skin-colored, gray or erythematous, rough papule or plaque (Fig. 79-3). It can be found on any chronically sun-exposed site on the body, but has a propensity for the dorsal hands and arms. A typical erythematous AK can progress into a HAK. At times, it is difficult to clinically distinguish a HAK from a SCC and a biopsy is necessary.

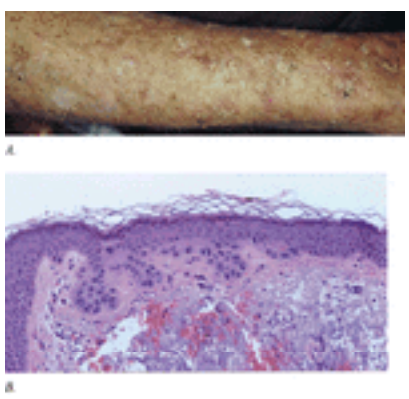

FIGURE 79-3 *A.* Severe solar damage of the dorsal arm demonstrating hypertrophic actinic keratoses and AKs. *B.* Histopathology of actinic keratoses demonstrates atypical cells along basal layer with sparing of adnexal epithelium.

Cutaneous horn, also known as cornu cutaneum, refers to a reaction pattern and not a particular lesion (Fig. 79-4). In reference to AKs, a cutaneous horn is a type of HAK that presents with a conical hypertrophic protuberance emanating from a skin-colored to erythematous papular base. In classic definitions of a cutaneous horn, the height is at least one-half of its largest diameter. Thirty-eight to 40 percent of all cutaneous horns represent AKs. [23] In fact, on examination of biopsy specimens, the base of a cutaneous horn can be a number of different lesions, such as AK, SCC, seborrheic keratosis, filiform verruca vulgaris, trichilemmoma, keratoacanthoma, or BCC. The most common underlying lesion in elderly, fair-skinned persons is a HAK.

FIGURE 79-4 *A.* Cutaneous horn of the ear. Only biopsy will confirm whether this is an actinic keratosis or a squamous cell carcinoma. *B.* Cutaneous horn of the cheek.

Actinic cheilitis represents confluent AKs on the lips, most often the lower lip (Fig. 79-5). Persons with this condition present with red, scaly, chapped lips, and at times erosions or fissures may be present. The vermilion border of the lip is

often indistinct, and focal hyperkeratosis and leukoplakia may also be seen. Individuals with this condition often complain of persistent dryness and cracking of the lips, and the diagnosis of actinic cheilitis should always be suspected in elderly patients with such complaints. Persistent ulcerations or indurated areas on the lip require biopsy to ensure that SCC is not present.

FIGURE 79-5 Actinic cheilitis of the lower lip in a young man with a marine occupation. The patient is at risk for developing SCC of the lip. Preventative treatment of the actinic cheilitis can include laser, cryosurgery, and topical treatment.

Unusual variants of AK include the pigmented AK, spreading pigmented AK, proliferative AK, and conjunctival AK. The pigmented AK presents as a flat, tan to brown-colored, scaly papule. Clinically, it is difficult to distinguish from a solar lentigo. Spreading pigmented AK is a particular lesion that is often found on the face or scalp. It is typically a large lesion, often reaching greater than 1 cm in diameter, and presents as scaly, verrucous or smooth plaque with variable colors. Proliferative AK is seen as an expanding, red, oval, scaly plaque that often reaches a up to 4 cm in diameter. It has poorly defined borders. Conjunctival AK is classified as a type of pinguecula or pterygium. It appears as a wedge-shaped, opaque thickening near the limbus, and it may extend onto the cornea from the scleral conjunctiva.

Pathology

The typical erythematous AK has characteristic architectural and cytologic histopathologic features. All of the abnormalities are confined to the epidermis, although dermal solar elastosis is usually present and an inflammatory dermal infiltrate may also be seen. The classic histopathologic findings include foci of atypical, pleomorphic keratinocytes in the basal cell layer, protruding as buds into the papillary dermis. The basal cell layer appears more basophilic because of the crowding of the atypical keratinocytes. Overlying these foci of abnormal cells one sees irregular acanthosis, hyperkeratosis, and parakeratosis. There is notable sparing of the adnexal epithelium, with orthokeratosis overlying these structures, thus giving rise to the characteristic pattern of alternating orthokeratosis and parakeratosis. Cytologically, there is an increased nuclear to cytoplasmic ratio in the atypical keratinocytes.

Just as there are clinical variants of AKs, there are histopathologic variants as well. These histopathologic variants all share the classic features of the AK as described above, but with some additional findings. In HAK, the hypertrophic areas consist of solid hyperkeratosis and parakeratosis. Cutaneous horns that represent AKs demonstrate similar but more exaggerated changes than the HAK with massive tiers of hyperkeratosis and parakeratosis. The base of such a cutaneous horn shows the typical histopathologic changes of an AK. An atrophic AK has very mild hyperkeratosis and a thinned epidermis that is devoid of rete ridges. Bowenoid AK is a histopathologic variant that demonstrates full epidermal dysplasia, but unlike true Bowen's disease or SCC in situ, there is no involvement of the adnexal epithelium. In proliferative AK there is exaggerated proliferation of the budlike downgrowths of atypical keratinocytes into the papillary dermis. Although difficult to distinguish from SCC at times, these proliferative budlike downgrowths are contiguous with the epidermis in the proliferative AK, unlike in true SCC.

In the pigmented AK one sees excessive amounts of melanin, especially in the basal cell layer. In the spreading pigmented AK variant, in addition to the typical AK histopathologic findings, one may see increased melanin in melanocytes and in the atypical keratinocytes. Lichenoid AKs are characterized by a dense, bandlike lymphohistiocytic infiltrate at the dermal–epidermal junction with basal cell liquefactive degeneration and occasional Civatte bodies. In the acantholytic AK variant there are clefts of lacunae directly above the atypical keratinocytes, reminiscent of the changes seen in Darier's disease. The acantholysis in an acantholytic AK is a result of the anaplastic changes occurring in the lower epidermis. Separation of cells and acantholytic cells within the clefts are also seen. The clear cell variant of AK results from an excess of cytoplasmic glycogen, resulting histopathologically in marked vacuolation of the epidermis.

Two different histopathologic reaction patterns may be seen in AKs, namely epidermolytic hyperkeratosis (EHK) and the pattern known as intraepidermal epithelioma of Borst-Jadassohn. In an otherwise classic histopathologic AK, one may find incidental changes consistent with EHK. The findings of EHK in these AKs most commonly are focal and isolated and have no clinical importance. Some authors consider the intraepidermal epithelioma of Borst-Jadassohn to be a specific lesion, [24] but other authors [25] believe this entity actually represents a type of reaction pattern found in a variety of lesions, such as AK, Bowen's disease, clonal seborrheic keratosis, intraepidermal malignant eccrine poroma, mammary and extramammary Paget's disease, intraepidermal junctional nevus, and malignant melanoma in situ. The pattern so-named is that of an intraepidermal neoplasm characterized by nests of different types of typical or atypical cells.

An important point to remember about making the diagnosis of AK histopathologically is that if the physician has a strong clinical suspicion of SCC or BCC and the initial cuts reveal AK, it is prudent to section more deeply into the block of tissue to ensure that an SCC or BCC is not missed. A recent study found that additional diagnostic findings were present on step sections in 23 of 69 specimens (33 percent) initially diagnosed histopathologically as AK. Of these additional findings, 13 percent were that of Bowen's disease, 4 percent basal cell carcinoma, and 3 percent invasive SCC. Three variables that correlated with the discovery of malignancy on step sections were ulceration on the first level, a clinical diagnosis of skin cancer, and a history of skin cancer confirmed previously by biopsy examination. [26]

Diagnosis and Differential Diagnosis

The diagnosis of AK is accurately made by clinical examination in most instances when the examiner is familiar and skilled in making such diagnoses. In practice, very few AKs are histopathologically confirmed, hence little data exist on the accuracy of clinical diagnosis. In a clinical referral setting, accurate clinical diagnosis is greater than that found in the general community setting. One study from a referral setting revealed a diagnostic accuracy of 94 percent, based on the correct histopathologic diagnosis of 34 of 36 clinically suspect, typical AKs. [27] Two studies out of community-based settings reported a diagnostic accuracy of only 80 percent when random clinically diagnosed AKs were confirmed histopathologically. [12], [20]

The clinical features of typical erythematous AKs are not unique to these lesions. The differential diagnosis includes other common lesions, such as benign lichenoid keratosis, seborrheic and irritated seborrheic keratoses, verruca vulgaris, Bowen's disease, SCC, keratoacanthoma, basal cell carcinoma, porokeratosis, discoid lupus erythematosus, large cell acanthoma, psoriasis, and other variants of cheilitis. Of the clinical AK variants, pigmented AKs are difficult to distinguish from solar lentigos, spreading pigmented AKs from lentigo maligna or a large seborrheic keratosis, HAK from SCC, and cutaneous horns from the many entities they may represent.

Clinically, the greatest dilemma is in trying to distinguish an AK from a SCC, as the latter portends a more serious prognosis and requires different treatment from an AK. There are no reliable criteria for distinguishing between the two entities, but findings of induration, larger size, ulceration, bleeding, rapid growth, and recurrence or persistence after treatment should make the diagnosis of SCC more suspect.

Histopathologically, actinic keratoses can be confused with benign lichenoid keratoses, as both can show vacuolar alteration of the basal cell layer. Closer inspection, however, reveals that in benign lichenoid keratoses there is no cellular atypia of the keratinocytes as seen in AKs. An atrophic AK can be mistaken for cutaneous lupus erythematosus, as both can demonstrate epidermal thinning and basal cell liquefaction. In cutaneous lupus, however, other classic features of the disease should also be present, such as follicular plugging and a patchy periappendageal infiltrate. Lastly, a pigmented AK may be confused histopathologically with lentigo maligna, but the latter usually has more flattening of the epidermis, an increased number of melanocytes, atypical melanocytes, and normal keratinocytes.

Prognosis and Treatment

In discussing the prognosis of AKs, there are basically three outcomes to consider. An AK can persist, regress, or undergo malignant transformation to invasive SCC. Which path any given AK may take is impossible to predict. The relative risk of progression to SCC depends upon factors related to the AK itself, in addition to individual patient characteristics, such as immune status. Several studies have attempted to determine the risk for the progression of AKs to SCC, but most of them are inadequate in one respect or another. The range of risk for progression of AK to SCC in the literature varies from <1 percent [28] up to 20 percent. [29] The problems with these studies are that they did not predict the malignant transformation risk for an individual AK, the follow-up periods were relatively short, patients were younger than the average person with SCC, and the initial diagnoses of AK were made clinically rather than being confirmed histopathologically.

Another way to approach this question of malignant transformation risk is to look at the percentage of SCCs that arise from preexisting AKs. One such study estimated that 60 percent of SCCs arose from a previous AK, [28] while others have found that in 100 percent of histopathologically confirmed SCCs, an AK was found at the periphery or within the confines of the existing SCC. [30] In terms of which AKs will spontaneously regress, clinical prediction is again impossible for an individual lesion. One study found that up to 25 percent of AKs remitted over a 1-year period, especially if sun exposure was limited during that time. [15] Another study found that more AKs regressed in individuals who routinely wore sunscreen. [20]

In addition to these three basic outcomes for an individual lesion, AKs are also sensitive clinical markers for predicting the future development of NMSC in a given person. The presence of AKs on an individual serves as a marker for chronic sun damage and identifies a high-risk group of people who are at risk for developing SCC, BCC, and, to a lesser extent, melanoma.

The estimate of metastases arising from actinically derived SCC has ranged from 1 to 2 percent up to 6 percent. The risk of metastases is much higher in actinically derived SCC of the lip, perhaps up to 20 percent. [31]

The inability to predict which AK will persist, regress, or become malignant makes treatment of these lesions equally confusing. Although some clinicians have argued that because of the low malignant transformation risk, treatment of AKs is unnecessary, most dermatologists now advocate the treatment of these lesions to avoid any chance of progression to invasive SCC. [32]

There are many available treatments that are extremely effective in eliminating AKs; in fact, cure rates of greater than 90 percent are not uncommon with many of these treatments. Which treatment a physician chooses depends on individual patient characteristics as well as size, location, and number of AKs present.

The most common treatment method for AKs in the United States is cryosurgery, with liquid nitrogen (-195.8°C [-320.4°F]) being the most common cryogen (see Chap. 278). When liquid nitrogen is applied to the affected skin, the temperature of the treated area is lowered to approximately -50°C (-58°F) and the atypical keratinocytes of the AK are destroyed. Liquid nitrogen can be applied in several ways, most commonly via cotton tip application or by using a spray device. Cure rates of up to 98.8 percent have been reported when employing liquid nitrogen cryosurgery for the treatment

of AKs.

Curettage, with or without electrosurgery, is another commonly used treatment for AKs. This approach and cryosurgery, account for roughly 80 percent of all treatments for AKs in the United States. [33] A curette is used to mechanically scrape away the atypical keratinocytes of the AK. Electrosurgery may or may not be employed to further destroy atypical cells and to provide hemostasis. Minimal use of cautery enhances the final cosmetic result and optimizes healing. A local anesthetic is needed for this procedure, and other hemostatic agents, such as aluminum chloride and ferric subsulfate, can be used to stop the bleeding if electrosurgery is not used. Patients can expect some discomfort with injection of the local anesthetic, and the treated area will take a few weeks to completely heal. Typically, the patient will have to care for the treated lesion at home by keeping it clean and covered with a small bandage and antibiotic ointment. This technique is ideal for patients with relatively few AK lesions. It is also beneficial for treatment of lesions after biopsy and for the treatment of hypertrophic AKs. Potential side effects include infection, scarring, and dyspigmentation.

Another frequently employed treatment for AKs is the use of the topical chemotherapy agent 5-fluorouracil (5-FU) (see Chap. 249). Its use has been estimated at 3.6 percent of office visits for AKs. [33] This agent blocks the methylation reaction of deoxyuridylic acid to thymidylic acid, and thus interferes with the synthesis of DNA and RNA. [34] Although many different treatment regimens have been used with topical 5-FU, the standard, FDA-approved method consists of twice-daily application of 5-FU to the entire affected region, typically for 2 to 4 weeks. Spot treatment of specific lesions is not recommended. There is also some evidence that concurrent or pretreatment with topical tretinoin for AKs on the forearms and dorsal hands is more effective than topical 5-FU alone in these areas. Treatment should be continued until the treated area demonstrates erythema, erosion, crusting, and necrosis, according to the treatment guidelines. Different strengths (1%, 2%, 5%) and vehicles (gel or cream base) for topical 5-FU are available, and the choice of which one to use depends on physician preference, individual patient characteristics, and the number and location of AKs being treated.

Physicians who prescribe topical 5-FU should spend time with the patient educating him or her about the proper application and the expected outcomes. Written handouts with similar information are also quite helpful for the patient to take home. Patients should expect discomfort, pruritus, and burning at the sites of application, as well as erythema, erosion, crusting, and ulceration (Fig. 79-6). These and other adverse reactions to 5-FU are discussed in Chap. 249. Regions of the skin that seemingly had no visible evidence of AKs may also become quite inflamed during treatment, as the 5-FU is uncovering incipient AKs in these treated areas. If such outcomes are achieved with good patient compliance, cure rates of greater than 90 percent can be expected. Much lower cure rates are seen when patient compliance is poor and the expected end points are not reached. Thus, topical 5-FU therapy is best reserved for those patients who can tolerate the normal, expected effects of the medication. It is ideal for compliant patients who have numerous AKs in a given region of the body, such as the face or arms. It is not very effective for treating hypertrophic AKs. Recurrence of AKs following treatment with 5-FU is commonly reported in the literature, with recurrence rates of 25 to 75 percent being seen with follow-up periods extending beyond 12 months.

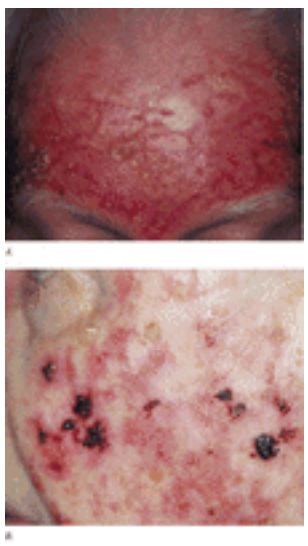

FIGURE 79-6 *A.* Erythema and crusting secondary to treatment with 5-fluorouracil *B.* Superficial hemorrhage in patient on Coumadin who was treated with 5-FU.

Less-common treatments for AKs include dermabrasion, chemical peels, cryopeels, laser therapy, and photodynamic therapy (PDT). These techniques are also highly effective in curing AKs when performed by skilled clinicians. Dermabrasion is an older technique that is quite effective in the treatment and prophylaxis of AKs. It is not a widely used modality because it is more difficult to learn than other, previously discussed alternative treatments. There also is the risk of exposure to blood splatter for the practitioner. Local anesthetics are necessary and the healing time can be prolonged (several weeks) if large areas are treated. Persistent erythema, activation of herpes simplex infection, scarring, dyspigmentation, and bacterial infection are potential side effects. It is ideal for patients with severe photodamage and multiple AKs, who frequently require repeated treatments of their AKs.

Medium-depth chemical peels with Jessner's solution and 35% trichloroacetic acid have reported efficacy rates of 75 percent at 1-month follow-up in one study, with equal efficacy to topical 5-FU therapy at 12-month and 32-month follow-ups. [35], [36] Such medium-depth chemical peels typically require a one-time application with minimal discomfort for the patient. Local anesthetics are not routinely administered prior to the peel. Patients can expect erythema and mild desquamation lasting up 1 to 2 weeks following the procedure. Prolonged erythema and activation of herpes simplex infection are potential side effects, and scarring and infection are rare in the hands of skilled clinicians. This treatment modality is ideal for patients with diffuse solar damage and numerous AKs, but it is not effective for treating hypertrophic AKs. As with treatment with 5-FU, recurrence of AKs 1 or more years following treatment is common, with efficacy rates

of 25 percent (1-year follow-up) [35] and 75 percent (3-year follow-up). [36]

Cryopeeling consists of extensive liquid nitrogen cryosurgery to the areas of discrete AKs as well as to the surrounding normal-appearing skin. Like dermabrasion, chemical peels, laser, and PDT, it requires further training to master the technique, but once mastered is quite easy to perform. Cryopeeling is a one-time application procedure, in which patients experience mild discomfort and burning. Topical and local anesthetics are often used. Postprocedure erythema, swelling, blistering, and peeling can be expected, and at-home care of the skin with daily cleanings and the application of topical petrolatum is necessary for 1 to 2 weeks. Efficacy has been reported to be equal to or slightly better than 5-FU for extensive AKs.

This procedure is ideal for patients with widespread actinic damage and for diffuse actinic cheilitis.

Laser therapy for the treatment and prophylaxis of AKs is a recently explored option. The carbon dioxide (CO_2) laser in preliminary, small series studies has been reported to be effective in clearing multiple facial AKs, with no recurrence reported at 6 to 24 months in one study. [37] Operation of the CO_2 laser requires training and experience for adequate results with minimal complications. It requires local or general anesthesia and sedation and the recovery time is longer than the other treatment modalities previously discussed. Persistent erythema is a common problem, often lasting up to 3 months following the procedure. Dyspigmentation, scarring, and infection are also potential complications. A pilot study [38] evaluated the erbium:YAG laser for the treatment of diffuse AKs in five patients, noting that clearance rates of 86 to 96 percent were found at 3 months' follow-up. In general, laser therapy is best reserved for patients with diffuse AKs and for the treatment of actinic cheilitis. Thicker lesions can also be treated with CO_2 laser because of its ability to make several, deeper passes in the skin.

PDT of AKs is another treatment modality that is gaining popularity in the treatment of AKs. Topical PDT was approved by the FDA in 1999. With PDT, topical 5-aminolevulinic acid (5-ALA) is applied directly to targeted AKs on the skin. It accumulates preferentially in the more rapidly proliferating, dysplastic cells and is converted to the photosensitizer, protoporphyrin IX (PP IX) via enzymes involved in the heme biosynthetic pathway. When the 5-ALA treated skin is then exposed to a light source that includes the absorption spectrum of PP IX (400 to 730 nm), PP IX is photoactivated with the resultant generation of reactive oxygen intermediates, which leads to the destruction of the cells. Both laser and nonlaser light sources have been used in studies of PDT for the treatment of AKs. Cure rates of 88 percent have been reported after a single cycle of PDT using a nonlaser blue light source, [39] and cure rates equivalent to 3 weeks of topical 5-FU have also been reported. [40] This technique requires a one- or two-time application of the topical 5-ALA followed by exposure to the light source several hours later. Patients experience some discomfort, including burning and stinging of the treated areas, primarily during exposure to the light source. This discomfort is tolerable and dissipates completely within 72 h, in most cases. Precise indications for PDT in the treatment of AKs have not been established, and longer-term follow-up studies with this therapy are lacking. Nonetheless, it may prove to be a viable treatment option in patients with multiple, non-HAKs who cannot tolerate or be compliant with topical 5-FU.

Uncommon treatments for AKs include excision, interferon, topical immune response modifiers, oral and topical retinoids, a-hydroxy acids, and salicylic acid. Excision can be completely curative, but such a procedure involving full-thickness excision is rarely needed and may be considered therapeutically excessive. Interferon is also highly effective, but costly. Topical immune response modifiers, such as imiquimod, were recently investigated as potential treatment options for AKs. [41] Topical retinoids, a-hydroxy acids, and salicylic acid are questionably effective as sole modalities for the treatment of AKs, but agents such as topical tretinoin have been advocated as adjuncts to other treatment approaches and as prophylaxis against the recurrence of AKs following treatment. Topical masoprocol is rarely used because of concerns about sensitization.

ARSENICAL KERATOSES

Arsenical keratoses (ArKs) are precancerous lesions found in association with chronic arsenicism. These lesions have the potential to develop into invasive SCC. Arsenic is a ubiquitous element that has no color, taste, or odor. It has the potential to cause characteristic acute and chronic syndromes in persons exposed to it, and such exposures are typically obscure because of medicinal, occupational, and environmental sources. Detecting acute and chronic arsenicism is important, because the acute form can be fatal and the chronic form is associated with a variety of cutaneous and internal malignancies. ArKs are associated with chronic arsenicism.

History and Epidemiology

The medicinal benefits and poisoning potential of arsenic date back to ancient times. Arsenic was introduced into the United States Pharmacopoeia in 1850 and, prior to its discontinuation around 1965, it was used medicinally in the United States and Europe in the form of Fowler's solution, Donovan's solution, and Asiatic pills for various illnesses such as psoriasis, asthma, and syphilis. Medicinal exposure is now basically limited to the treatment of tropical diseases, such as African trypanosomiasis. Arsenic in opium has been and is still used for medicinal and pleasure purposes in India, and inorganic arsenic is still found in some traditional Chinese herbal preparations. [42]

Arsenic exposure can occur in a variety of occupations, either by direct exposure to arsenic or through indirect exposure via contaminated water and landfills. In 1973, it was estimated that more than 1.5 million workers in the United States were potentially exposed to arsenic in the workplace. [43] Occupations that are at risk for exposure include the mining, smelting, agricultural, computer microchip, forestry, electroplating, semiconductor, and glassmaking industries. Environmental exposure is often obscure and insidious, as latent periods of up to 50 years may occur before manifestations of chronic arsenicism appear. Arsenic is routinely found in soil, and it is found in much higher levels in the well water of certain regions where smelting and mining activities predominate, such as Taiwan, Sweden, and Argentina. [42] Other routes of environmental exposure include some illegally produced alcoholic beverages and the burning of

pressure-treated lumber that has been pretreated with chromium-copper-arsenate. In all forms of medicinal, occupational, and environmental exposures, longer duration of exposure and higher cumulative doses are associated with a higher risk for the development of ArKs.

The association between arsenic exposure and skin cancer was first noted by Paris in 1822. [44] Arsenical keratoses were first described on the palms and soles of individuals in the late 1800s. In 1898, Dubreuilh categorized ArKs as precancerous lesions. [5] The relationship of arsenic ingestion to palmar and plantar ArKs and to skin cancer has been documented in several studies that involved wide-scale exposure to known sources of arsenic. [15] In particular, chronic arsenicism and an increased risk of skin cancer has been attributed to drinking water that contains greater than 0.6 mg of arsenic per liter. [43] The United States Environmental Protection Agency has set a maximum arsenic contaminant level at 50 µg/L. [45] Ingestion of as little as 400 mL of Fowler's solution is associated with signs of chronic arsenicism. [42] A compilation of the results of 12 reports that linked malignancy with the ingestion of inorganic arsenic found that skin cancer occurred in 70 percent and an internal malignancy in 6.3 percent of ingesters. [46]

Etiology and Pathogenesis

Arsenic is present as either organic or inorganic compounds as well as in three potential oxidative states: metalloid, trivalent, or tetravalent. Trivalent arsenicals are the most common and hazardous to humans. The toxicity of these compounds depends on the accumulation of arsenic in target tissues and its metabolism and elimination. Organic arsenicals are excreted rapidly and trivalent inorganic arsenicals are the most acutely and chemically toxic compounds. Because arsenic is metabolized and detoxified in the liver via methylation, those patients with preexisting liver disease may be at greater risk for arsenic-related toxicity.

The mechanisms of arsenic-induced ArKs and malignancy are not fully understood. Arsenic reacts with the sulfhydryl groups in certain tissue proteins and subsequently affects many different enzymes that are essential to cellular metabolism. Arsenic has been found to cause chromosomal mutations, chromosomal breaks, sister chromatid exchanges, and mutations in *p53*. [47], [48]

Clinical Manifestations

Arsenical keratoses typically begin as pinpoint papules that are easier felt than seen. They develop into small, 2 to 10 mm, punctate, yellow, keratotic papules most commonly seen on the palms and soles in areas of constant pressure or repeated trauma (Fig. 79-7). They preferentially arise on the thenar and lateral borders of the hands, the sides of fingers, and sometimes on the dorsal aspects of the fingers, overlying the joints. Although unusual, ArKs can be found on more widespread body areas such as the trunk, extremities, eyelids, and genitalia. ArKs may also present as slightly elevated, erythematous, scaly or pigmented plaques. ArKs on the palms and soles are more likely to be seen in individuals with chronic arsenicism caused by medicinal exposure, in comparison to occupational exposure. Also, individuals with arsenical-related cancer are more likely to have palmar and plantar ArKs. The mean latency periods for ArKs varies considerably from 9 to 30 years. [49]

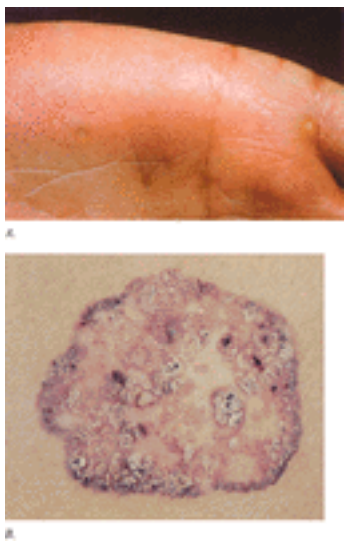

FIGURE 79-7 *A.* Arsenical keratoses of the palm. (*Courtesy of James E. Fitzpatrick, MD, University of Colorado, Deptartment of Dermatology.*) *B.* Arsenical in situ squamous cell carcinoma.

Other cutaneous neoplasms associated with chronic arsenicism include Bowen's disease, BCC, and SCC. Mean latency periods for the development of Bowen's disease and SCC can also be as long as 40 years. [49] With arsenic as the carcinogen rather than ultraviolet radiation, these neoplasms, like the ArKs, are distributed in a more widespread, random, and nonphotodamaged distribution. Arsenical Bowen's disease often begins as a small flesh- to pink-colored papule with a thick horny layer or crust. When this crust is removed, the underlying skin appears erythematous and oozing. Over time, unlike the relatively stable ArKs, these lesions increase in size, forming nodular and plaquelike lesions that often group together. Approximately one-third of patients have multiple lesions of Bowen's disease. [42]

Arsenic-induced BCCs are also usually multiple and the majority are of the superficial type, although small nodular BCC are sometimes seen. These BCCs are found in a random, scattered distribution, primarily on the trunk and in hair-bearing regions. Clinically, the superficial BCCs are often indistinguishable from Bowen's disease. Arsenic-related SCC can arise de novo or from malignant transformation of ArKs and Bowen's disease. In one study, 55 percent of SCCs arose from preexisting ArKs or Bowen's disease. [49] Patients with SCC are more likely to have been exposed to arsenic later in life as

compared to those without SCC. [49] They also are more likely to have multiple lesions of Bowen's disease and more numerous palmar and plantar ArKs. The majority of SCCs have been found on the distal extremities of the hands and feet, and it has been hypothesized that irritation and trauma in these areas may increase the risk of malignant transformation. Clinically, ArKs that show progression to SCC often present with pain, bleeding, fissuring, and later ulceration. They tend to gradually expand in diameter, forming a large erosion or ulceration, and they sometimes reach sizes up to 20 cm.

Other signs of chronic arsenicism include hyperpigmentation primarily affecting the nipples, axillae, groin, and other pressure points. Within these hyperpigmented patches, one often sees small areas of hypopigmentation, resembling raindrops. Diffuse alopecia of the scalp may be present. Longer term, patients may develop “blackfoot disease,” which is a peripheral vascular disease affecting the lower extremities that eventually results in gangrene. Hepatic cirrhosis can also be seen. A variety of internal malignancies have also been associated with chronic arsenicism, with long lag periods of 20 to 50 years reported. The internal malignancies linked with chronic arsenicism include lung, urinary tract, hepatic, hepatic angiosarcoma, leukemia, and lymphoma.

Histopathology

The histopathology of ArKs is essentially the same as for actinic keratoses. No reliable histopathologic criteria can distinguish between the two. Some cases of ArKs are characterized by marked vacuolation of the epithelial cells and keratin horn formation. Also, solar elastosis is usually absent and a chronic dermal lymphocytic infiltrate is commonly seen. Likewise, arsenic-related Bowen's disease, BCC, and SCC are histopathologically similar to their non–arsenic-induced counterparts.

Diagnosis and Differential Diagnosis

Arsenical keratoses may be mistaken for other types of punctate keratoses, such as disseminated punctate keratoderma, Darier's disease, corns, and verruca vulgaris. Disseminated punctate keratoderma usually appears earlier in life. It has also been reported that on removal of the keratinous plugs in punctate keratoderma, small crater-like pits are left behind, whereas no pits are seen on removal of the keratin plugs in ArKs. Darier's disease presents with characteristic lesions elsewhere. Corns are usually not so numerous and not so common on the hands. Warts often demonstrate evidence of thrombosed capillaries on removal of the surface keratin.

A diagnosis of ArKs and chronic arsenicism should be considered when numerous characteristic keratoses are seen on the palms and soles or when multiple lesions of Bowen's disease, SCC, or BCC are found on an individual, especially when these lesions are in non–sun-exposed regions of the body. In most patients with such neoplasms, palmar and plantar keratoses will also be present. Such patients should be questioned about previous occupations, living conditions, environmental, and medicinal exposures to elicit a history of potential arsenic exposure anywhere from 10 to 40 years previously. One should biopsy any changing ArK or erythematous nodule or plaque on the body to ensure that Bowen's disease, BCC, or progression to SCC are not present.

Prognosis and Treatment

Arsenical keratoses and arsenical-induced Bowen's disease tend to persist for many years, and the chance of progression into invasive SCC is believed to be relatively rare. Invasive SCC that arises in ArK, however, is more locally aggressive and has a greater chance of metastases when compared to SCC arising in AK. [42] In lesions of arsenical-induced Bowen's disease, locally invasive SCC has been seen histopathologically in up to 20 percent of cases. Once invasive SCC has occurred in Bowen's disease, it is said that at least one-third will demonstrate evidence of metastases unless adequate treatment is provided. [50]

Management of patients with chronic arsenicism and ArKs should include regularly scheduled total-body skin examinations and general physical examinations, possibly on an every 6-month basis. [49] Because the exact incidence of internal malignancies associated with chronic arsenicism is unknown, there is no standard protocol for the evaluation of potential internal malignancies. Exhaustive evaluations for such malignancies have not been recommended. Biannual detailed history taking and physical examinations, yearly chest radiographs, and selective tests when clinically indicated are probably reasonable recommendations.

Treatment of ArKs likewise is not standard and not mandatory, and treatment of these lesions is sometimes initiated to relieve the associated discomfort hat some patients experience. Available localized treatment options include surgical excision, cryosurgery, electrodesiccation and curettage, CO_2 laser, and topical chemotherapy with 5-FU, although success with 5-FU in treating ArKs is less than the success with AKs. [42] PDT with 5-ALA has also been used to treat these lesions. Oral retinoids may be useful in reducing the hyperkeratosis associated with ArKs.

THERMAL KERATOSES

Thermal keratoses (TKs) are keratotic lesions produced in the skin by exposure to infrared radiation. They have the potential to develop into SCC. Various sources of heat are implicated in causing these lesions and several classic syndromes have been reported. Most notable are the kangri basket cancers in Kashmir, the kang cancers in China, the railway cancers in Britain, and the peat fire cancers in Ireland. The kangri is a pot that contains a type of fuel, such as charcoal, that is held against the thigh or lower abdomen as a source of warmth. In Kashmir, the malignancies arose in the skin over the lower abdomen and thighs, where the baskets were in contact with the body. The skin overlying the greater trochanters is where the cancers developed in the Chinese and Tibetans. Heat was reported to be responsible for cancer of the skin overlying the shins of railway-engine drivers in England. In Ireland, more than 150 women were reported to have lesions of erythema ab igne and SCC on the lower legs. These women all reported many years of sitting close to an open fire of burning peat to stay warm. Because peat is a less-efficient fuel than coal, these women had to sit

closer to the source to attain adequate warmth. The men did not experience the same cutaneous effects because they primarily wore thick, longer trousers. In the United States, TKs, Bowen's disease, and the development of SCC have been noted in persons exposed long-term to coal and wood-burning stoves used as sources for heat and cooking. [51] The incidence and prevalence of thermal keratoses is not known. Likewise, the pathogenesis of these lesions is not fully understood and the percentage of TKs that will progress to invasive SCC is also unknown.

Clinical Manifestations

Prolonged exposure to infrared radiation and to sources of heat can clinically produce the characteristic lesion of erythema ab igne that manifests as an erythematous to brownish, fixed, thick, reticulated patch on the skin overlying the area that has been chronically exposed to heat. It differs from livedo reticularis in that it is more brownish in color, usually nonblanchable, and fixed. The sites of predilection are the back and abdomen from exposure to hot water bottles and heating pads or blankets, and the lower legs from exposure to fires or heating units as sources of warmth. After many years of such exposures, thermal keratoses may appear within these patches of erythema ab igne. SCC in situ within such patches has also been reported, and like solar-induced AKs, progression to invasive SCC from TKs can also occur. Clinically, TKs present as hyperkeratotic papules and plaques.

Histopathology

The histopathology of thermal keratoses is similar to that of AKs, including alternating hyperkeratosis and parakeratosis, keratinocyte atypia, sparing of the appendageal units, and interestingly, even dermal elastosis and vascular ectasia. In one study, biopsy specimens from erythema ab igne without apparent TKs showed evidence of keratinocyte atypia. [52] Merkel cell carcinoma has also been reported to arise alongside SCC within a patch of erythema ab igne.

Diagnosis and Differential Diagnosis

Hyperkeratotic papules or plaques that develop within a long-standing patch of erythema ab igne should be biopsied to confirm the diagnosis and to rule-out progression to SCC. Erythema ab igne should be distinguished from acute burn scars, the latter of which may also harbor scar keratoses and SCC. Potentially, erythema ab igne and ulcerated TKs or SCC on the lower extremities could be confused with periarteritis nodosa, which presents most often on the lower extremities with livedo reticularis, nodules, and ulceration.

Prognosis and Treatment

There is a paucity of information in the literature regarding the risk of progression of TK to invasive SCC and the general prognosis of thermal SCC. Similarly, little is written about the treatment of these lesions. Surgical excision, electrodesiccation and curettage, cryosurgery, and possibly laser therapy appear to be reasonable therapeutic options. Patients with erythema ab igne should be counseled about the need to discontinue exposure to whatever heat source they have been in contact with and they should be followed long-term with physical examinations to identify early changes suggestive of TK or SCC.

HYDROCARBON KERATOSES

Hydrocarbon keratoses (HKs), also known as tar keratoses, pitch keratoses, and tar warts, are precancerous keratotic skin lesions that occur primarily in persons who are exposed occupationally to polycyclic aromatic hydrocarbons (PAHs). SCC and keratoacanthomas have also been linked to such exposures. PAHs are produced by the incomplete combustion and distillation of coal, natural gas, and oil shale. They are found in tar, fuel oils, lubricating oils, oil shale, and bitumen. [44] Workers at risk for exposure to such compounds include workers in tar distillation, shale extraction, and workers exposed to creosotes, which are one of the main distillate fractions of coal tars and coal tar pitches. [53] Creosotes are used extensively as wood preservatives. Roofers, asphalt workers, road pavers, and highway maintenance workers are exposed to PAHs from fumes formed during the heating of bitumen. [53] Other groups of workers at risk for exposure to coal tar products include railway workers, brick masons, and diesel engineers. [44] Lastly, persons exposed to mineral oils, cutting oils, and coolants also are at risk for the development of HKs and SCC. [53]

The most infamous occupational exposure to PAHs was that of the chimney sweeps who developed scrotal SCC. [54] Mule spinners have also been reported to develop SCC of the scrotal skin. [44] Mule spinners frequently have their thighs and scrotum in contact with an oil-covered bar on the mule, which is a machine used to spin cotton.

Etiology and Pathogenesis

Hydrocarbon keratoses, SCCs, and keratoacanthomas develop in persons whose skin is exposed to PAHs over long periods of time. The risk of these precancerous and cancerous lesions is associated with dermal exposure to PAHs; inhalation of PAHs is not associated with skin cancers, although lung cancer is noted with such exposures. [53] /SUP>PAHs are known carcinogens that damage DNA and potentially cause mutations in the *p53* gene, at least in lung cancers. [54] Ultraviolet radiation exposure has been considered a cofactor in the development of HKs and related skin cancers, but a recent study found that the majority of HKs and SCC in a large group of tar refinery workers developed in non–sun-exposed regions of the body, thus questioning this belief. [55] The duration of exposure before the development of HKs ranges from 2.5 to 45 years. [56]

Clinical Manifestations

Hydrocarbon keratoses present as small, oval to round, gray, flat papules that are easily removed without residual bleeding. These papules can then become larger in size, more verrucous in appearance, and eventually may develop into invasive SCC. Sites of predilection include the face,

nostril rims, upper lip, forearms, volar wrists, dorsal feet, lower legs, vulva, and scrotum. [55] Of note, the lesions on the nostril rims, upper lip, genitalia, and forearms are not the typical sun-exposed sites of the body. Thus, keratoses or malignancies in these regions should prompt the physician to inquire about potential occupational hazardous exposures. Other cutaneous findings related to PAH skin exposure include patchy hyperpigmentation, acne, and telangiectases in sites of exposure. The presence of acneiform lesions on the forearms and thighs should alert one to the possibility of PAH exposure. Facial features associated with long-term tar exposure include periocular fibromas, brownish or slate-gray discoloration, comedones, and hair follicle plugs. [55]

PAHs have also been reported to cause internal malignancies, such as lung and bladder cancers. [53]

Histopathology

Hydrocarbon keratoses histopathologically appear similar to AKs and ArKs, as previously described. Often, in HKs, there is more of a progression to full-thickness atypia, or a bowenoid form. In early HKs, it has been said that distinction between benign and malignant epidermal changes can be difficult.

Diagnosis and Differential Diagnosis

Hydrocarbon keratoses, with their grayish keratotic appearance, may be mistaken for verruca vulgaris lesions, stucco keratoses, or even ArKs. A high index of suspicion is needed to make the diagnosis of HKs, as histopathologically they are difficult to distinguish from AKs and ArKs. The distribution of the lesions and other cutaneous findings of tar skin can aid in the diagnosis and lead one to further, pointed questioning of the patient. Once a diagnosis of HK has been made, closer examination for SCC or KAs should ensue and a good history and physical examination to detect signs of internal malignancy may be warranted, based on the type of occupational exposure. Examination of the scrotal and vulvar regions is essential.

Prognosis and Treatment

The exact risk of a HK progressing to SCC is unknown. Most recommendations in the literature are for biopsy and surgical removal of HKs, especially on the vulvar and scrotal regions and mucosal surfaces, where the risk of early metastasis from SCC is greater. Cryosurgery and electrodesiccation with curettage are probably reasonable treatment options for HKs on other cutaneous sites. Prevention is the key for workers exposed to PAHs in their occupations. Long-term follow-up of individuals with previous known PAH exposures is essential for early diagnosis and treatment of lesions and for the potential early detection of internal malignancy if at risk.

CHRONIC RADIATION KERATOSES

Chronic radiation keratoses (CRKs) are precancerous keratotic lesions that may arise on the skin many years after exposure to ionizing radiation. They have been described in persons exposed to x-ray therapy, including grenz-ray therapy for benign skin disorders, such as acne vulgaris and tinea capitis; medical personnel, dentists, and physicians who have administered x-rays over many years; [44] other professionals who handle radioactive materials in their workplace; on the fingers of persons who unknowingly wore gold rings contaminated by radioactivity (Fig. 79-8); [57] survivors of the atomic bomb in Japan; [58] and in the unfortunate victims of nuclear accidents such as the one in Chernobyl, Ukraine. [59] For the purpose of the following discussion, radiation refers to ionizing radiation, thus excluding the ultraviolet and infrared spectrums of radiation.

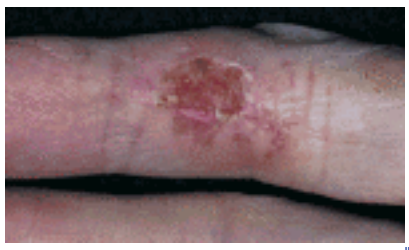

FIGURE 79-8 Chronic radiation keratoses on finger of an older dentist.

Clinical Manifestations

The primary neoplasms resulting in the skin from ionizing radiation include CRK, BCC, and SCC. Cutaneous sarcomas rarely occur. Chronic radiation keratoses and BCC are more commonly seen than SCC, but any given CRK can potentially evolve into invasive SCC. The site and penetration of the ionizing radiation determine which type of tumor develops, as palms, soles, and mucosal surfaces are said to favor CRK. The neoplasms that develop are often multiple, healing poorly and frequently recurring. [44] CRKs usually develop within areas of chronic radiation dermatitis or in persistent ulcerations arising in such chronically damaged areas of the skin. They appear as hyperkeratotic papules or plaques. The latency period from time of exposure to the development of CRKs and radiation-induced skin cancers is typically long, having been reported to range up to 56 years. The development of these tumors is inversely proportional to the radiation dose. Patients exposed to ionizing radiation are also at risk for the development of other internal malignancies, such as breast, bone, soft tissue, uterus, larynx, pharynx, thyroid, and maxillary sinus. [44]

Pathology

Chronic radiation keratoses histopathologically display keratinocyte dyskeratosis with hyperchromatic nuclei and abnormal mitoses. The dermis often demonstrates findings consistent with chronic radiation changes, such as hyalinization of the collagen bundles, thickening and occlusion of

deep dermal blood vessels, and destruction of the pilosebaceous units.

Prognosis and Treatment

The development of CRKs should be taken seriously, as they have the potential to develop into invasive SCC. Once radiation-induced invasive SCC develops, it has the ability to be quite aggressive with a higher potential for metastasis than does actinically induced SCC. The percentage of CRKs that will develop into SCC is unknown. It is recommended that CRKs be removed promptly and that surgical excision is often the recommended treatment of choice. Persons with ionizing radiation exposure should be followed with skin examinations at regular intervals for the rest of their life, as the latency period for the development of cutaneous neoplasms is quite long, and the number of skin cancers in such patients tends to increase with time after irradiation. Evaluation for the development of other high-risk internal malignancies should also be considered in the long-term follow-up of these patients. Lastly, these patients should be counseled regarding the avoidance of other potential carcinogens, such as ultraviolet radiation.

CHRONIC SCAR KERATOSES

Chronic scar keratoses (CSKs), also known as chronic cicatrix keratoses, are precancerous keratotic lesions that arise in long-standing scars. Chronic scar keratoses can arise in a number of different chronic scarring processes, such as chronic ulcers, burn scars, pilonidal sinuses, draining sinuses, chronic osteomyelitis, vaccination scars, chronic hidradenitis suppurativa, old frostbite scars, and scarring acne vulgaris.

History and Epidemiology

In 1828, Jean-Nicholas Marjolin described chronic ulcers that arose from scar tissue, without referring to them as malignant. [60] Today, the term Marjolin's ulcer is synonymous with malignant transformation of chronic ulcers, sinus tracts, and burn scars, although the term is used most frequently to describe malignant changes within burn scars. It is estimated that 2 percent of burn scars will undergo malignant degeneration. Most burn scar carcinomas are SCCs, but cases of BCC, melanoma, sarcoma, and malignant fibrous histiocytoma have also been reported. [61] Two types of Marjolin's ulcer have been described: an acute form and a chronic form. The acute type develops within 1 year from the time of injury, while the chronic form develops more than 1 year after the injury. [62] The average latency period from injury to onset of malignancy for the chronic form is 36 years, with a range of 1 to 75 years. [63] The latency period is inversely proportional to the patient's age at the time of the burn injury.

Etiology and Pathogenesis

The pathogenesis of a premalignant keratosis or a carcinoma arising in a chronic scar is not known. Proposed mechanisms for malignant degeneration within a burn scar include production of a carcinogenic toxin with the burn injury; immunologic privilege within scarred tissue allowing unchecked tumor growth; chronic irritation leading to malignancy; multistep carcinogenesis involving initiation, promotion, and progression; and burn-induced DNA damage leading to malignant transformation. Characteristics of the burn scar that predispose to malignant transformation include a prolonged healing phase, repetitive trauma, and rejected graft site.

Clinical Manifestations

Chronic scar keratoses present as hyperkeratotic papules, plaques, or erosions within the scarred skin. In terms of burn scars, two clinical types of carcinoma have been described. The more common presentation is of a flat, ulcerative, indurated lesion with elevated borders and surrounding induration. The less-common type is the exophytic, papillomatous lesion resembling granulation tissue. [62] Bleeding, pain, and a foul odor may also be present. Typically, chronic and recurrent ulcerations have been present in the burn scar prior to malignant degeneration and the malignancy often develops at an ulcer margin. One important fact about burn scar carcinomas is that usually only a portion of the ulcer undergoes malignant transformation. The remaining ulcer persists as a nonhealing wound, and thus false-negative results from biopsies of the ulcer are quite high. [61] Sites of predilection for burn scar carcinomas are the extremities and in areas overlying joints, presumably because of repeated trauma in these areas.

Pathology and Diagnosis

Histopathologically, most scar keratoses range in pattern from several atypical keratinocytes to full epidermal thickness atypia or in situ SCC. The majority of burn scar carcinomas are of the well-differentiated squamous cell type. Histopathologic diagnosis may be confused with pseudoepitheliomatous hyperplasia, a benign reactionary process. Any persistent lesion, erosion, or ulceration within a scar should be biopsied. In addition, in terms of burn scar carcinomas, because only a portion of the ulcer may be malignant, multiple biopsies or excisional biopsies are recommended if the suspicion of carcinoma is high, so as not to miss the diagnosis.

Prognosis and Treatment

Chronic scar keratoses may show a gradual progression to in situ carcinoma and frank SCC. Prompt diagnosis of these lesions is important because once overt, invasive SCC develops in a scar, it can quickly become aggressive and the risk for metastasis is high. In terms of burn scar carcinoma, the metastatic rate is estimated at approximately 35 percent, much higher than actinically induced SCC. [62] Lesions occurring on the lower extremities have the highest rates of metastases, averaging 50 percent, [64] while those on the head, neck, and upper extremities fare better. Lymph node metastasis on presentation is the single most important prognostic indicator.

Burn scar carcinoma may be prevented by meticulous burn wound care, early skin grafting, prompt treatment of infections, avoiding contractures, and by early excision of any degenerative changes within the scarred area. Large full-thickness burns are also probably best managed surgically, and not allowed to heal by secondary intention. Treatment of chronic scar keratoses should include prompt destruction of the lesion or excision of the entire area, with step sections through the specimen to ensure a malignancy has not been missed. Excision with wide margins (at least 2 cm) is the treatment of choice for burn scar carcinoma. [62], [64] Initial skin grafting is preferred over the use of a skin flap to cover the wound defect. If

the latter is to be used, a waiting period of 12 months is recommended so as not to obscure the possibility of a recurrence. [64] Radiation therapy and topical chemotherapy have not been beneficial in the treatment of these lesions. [52, 64]

REACTIONAL KERATOSES

Reactional keratoses (RKs) are premalignant keratotic lesions that may arise in a variety of long-standing, nonscarring, inflammatory processes such as cutaneous lupus erythematosus, necrobiosis lipoidica, porokeratosis, erythema elevatum diutinum, granuloma inguinale, epidermolysis bullosa variants, pemphigus vulgaris, lichen sclerosis, lichen planus, and chronic deep fungal infections. Clinically, RKs present as hyperkeratotic papules or plaques. As with other precancerous keratotic lesions, a continuum from RK to SCC in situ to invasive SCC may be seen. Once invasive SCC has developed, there is a significant risk of metastatic disease developing, similar to that of scar keratoses. The main diagnosis to consider in the clinical and histologic differential is pseudoepitheliomatous hyperplasia.

PUVA KERATOSES

PUVA keratoses are precancerous keratotic lesions that arise in individuals exposed to psoralen plus ultraviolet A (UVA) light therapy for the treatment of a variety of cutaneous conditions. Although UVA on its own does not appear to be significantly mutagenic to humans, the combination of UVA with psoralen is associated with a dose-dependent increased risk of premalignant keratoses and other cutaneous malignancies, such as SCC, melanoma, and possibly Merkel cell carcinoma (see Chap. 265).

VIRAL KERATOSES

Viral keratoses, otherwise known as warts, are one of the most common keratotic lesions in humans. These lesions are caused by infection with the human papillomavirus (HPV).

Bowenoid Papulosis

Bowenoid papulosis is characterized clinically by the presence of pigmented verrucous papules and plaques primarily on the genitalia of predisposed individuals, and histopathologically by the presence of SCC in situ–like changes (Fig. 79-9). Genital lesions that histopathologically resembled SCC in situ were first described by Lloyd, in 1970, as multicentric pigmented Bowen's disease of the groin. [65] In 1977, Kopf et al. [66] described multiple bowenoid papules of the penis. In 1979, Wade et al. coined the term *bowenoid papulosis of the genitalia*. [67] Other terms used for this condition include pigmented penile papules with carcinoma in situ changes, genital keratinocytic dysplasia, and penile carcinoma in situ associated with HPV infection.

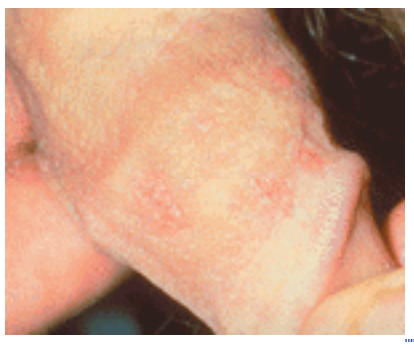

FIGURE 79-9 Bowenoid papulosis of the penis. (*Courtesy of James E. Fitzpatrick, MD, University of Colorado, Deptartment of Dermatology.*)

Bowenoid papulosis (BP) is caused by infection with HPV and numerous HPV types have been linked to BP, including types 16, 18, 31 to 35, 39, 42, 48, and 51 to 54 (see Chap. 223). HPV 16 is the most common, and types 16, 18, and 33 are considered the most oncogenic. Typically, BP presents in sexually active young males and females with multiple reddish-brown to violaceous-colored papules. Many are verrucous and, at times, the small papules coalesce into larger plaques. Sites of predilection include the penis in males and the external genitalia in females. Several reports of extragenital locations have also been described, typically on the neck and chin. The clinical differential diagnosis includes condyloma acuminata and, in fact, most lesions of BP are clinically diagnosed as condyloma acuminata. Unlike BP, typical anogenital Bowen's disease presents as a slowly enlarging pink plaque in most cases. Seborrheic keratoses and melanocytic nevi may sometimes be confused clinically with BP.

Histopathologically, the epidermis is usually hyperplastic with atypia, disordered maturation, scattered mitotic figures, and dyskeratotic keratinocytes. BP and Bowen's disease can usually be distinguished histopathologically by the fact that BP usually lacks the full-thickness epidermal atypia that is present in Bowen's disease. In BP, the atypical keratinocytes are randomly scattered throughout the epidermis and the acrotrichia are typically spared. In Bowen's disease the acrotrichia are usually involved.

The course of BP is variable, ranging from spontaneous regression to persistence of lesions to transformation into Bowen's disease and invasive SCC. Patients with BP and their sexual partners should be followed and examined periodically because of the risk of developing SCC and cervical and vulvar neoplasia. [68] Patients with persistent disease should probably undergo testing for an altered immune status. Treatment of BP is recommended and it typically responds well to local therapy, although recurrences are common. Therapeutic options include local destructive measures such as electrodesiccation and curettage, CO_2 laser, neodymium:YAG laser, cryosurgery, and excision. Topical tretinoin, topical 5-FU and low-dose interferon-a have also been beneficial.

Epidermodysplasia Verruciformis

Epidermodysplasia verruciformis (EV) is an autosomal recessive genetic disease that manifests in childhood with disseminated flat, wartlike papules. These patients also appear to have a defect in their cellular immunity (see Chap. 223). Histopathologically, the wartlike lesions of EV display hyperkeratosis, hypergranulosis, and acanthosis. The keratinocytes are vacuolated and appear pale blue-gray on staining with hematoxylin and eosin. This blue-gray pallor is most pronounced in the granular layer of the epidermis, and the vacuolated keratinocytes are typically arranged in clusters or columns. As the lesions progress to atypia, the nuclei of the keratinocytes become larger, more hyperchromatic, and cellular maturation is disordered. Changes of in situ SCC and SCC may eventually be seen.

HPV and Cutaneous Malignancy in Immunosuppressed and Immunocompetent Hosts

The role of HPV as an etiologic agent in the development of premalignant and malignant neoplasms in immunosuppressed and immunocompetent individuals is less clear (see Chap. 223).

BOWEN'S DISEASE

Bowen's disease (BD) is a form of squamous cell carcinoma in situ that was originally described in 1912 by John T. Bowen, a Boston dermatologist. [69] It affects both skin and mucous membranes and has the potential to progress into invasive SCC.

Epidemiology

Bowen's disease may occur at any age in adults, but it is rarely seen in individuals before the age of 30 years. The typical patient with BD is older than 60 years of age. The disease is said to occur with an equal incidence in men and women, although most studies report a slight preponderance in women. [70] Bowen's disease can be found on any body site, including both sun-exposed and non–sun-exposed regions of the body, and it appears to have a predilection for sun-exposed surfaces such as the head and neck, and for the lower legs of women, in particular. The exact incidence of BD in the United States is unknown, but in one population study from Hawaii, the incidence was estimated at 142 per 100,000 persons. [71] Lesions of BD are usually solitary but may be multiple in up to 10 to 20 percent of individuals.

Etiology and Pathogenesis

A number of different factors have been implicated in the etiology of BD, including a history of significant sun exposure, arsenic exposure, ionizing radiation, immunosuppression, and certain types of HPV. The age group and sites of predilection of BD suggest the association with sun exposure. Bowen's disease is also rare in more heavily pigmented individuals and it has been described with increased frequency in patients undergoing PUVA therapy. The association with arsenic exposure has already been discussed and it is seen commonly in organ transplant recipients after years of immunosuppression from medication. Infection with HPV has been implicated in causing certain subtypes of BD. In particular, HPV 16 has been detected in many cases of anogenital BD and in some cases of finger and periungual BD. [72]

Clinical Manifestations

Bowen's disease typically presents as a discrete, slowly enlarging, pink to erythematous, thin plaque with well-demarcated, irregular borders and overlying scale or crust (Fig. 79-10). Hyperkeratotic and verrucous surface changes may be seen, and a pigmented variant of BD has been reported in less than 2 percent of cases. [73] Individual lesions may measure up to several centimeters in diameter, and multiple lesions are not uncommon. As previously mentioned, sites of predilection include sun-exposed areas such as the head and neck and lower legs in women, although any body site may be affected.

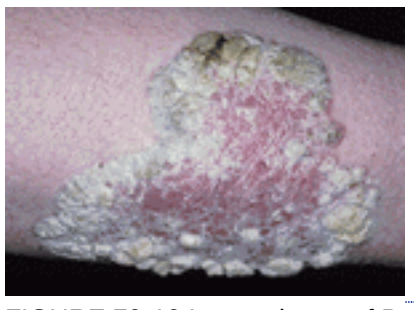

FIGURE 79-10 Large plaque of Bowen's disease of the leg.

A few clinical variants of BD deserve special mention. Intertriginous BD can present as an oozing, erythematous, dermatitic plaque or as a pigmented patch or plaque. Bowen's disease involving the periungual region may appear as an erythematous, scaly, thin plaque around the cuticular margin, a crusted erosion, nail discoloration or onycholysis, a verrucous plaque, or as destruction of the nail plate. Bowen's disease of mucosal surfaces can present as verrucous or polypoid papules and plaques, erythroplakia, or as a velvety erythematous plaque. These last two entities are discussed separately below.

Pathology

The epidermis displays full-thickness atypia, including the intraepidermal portions of the adnexal structures. Involvement spans from the stratum corneum down through the basal cell layer, although the basement membrane remains intact (Fig. 79-11). Characteristically, parakeratosis and

hyperkeratosis are present as is acanthosis with complete disorganization of the epidermal architecture. At times the hyperkeratosis and parakeratosis are so pronounced that a cutaneous horn is present. Throughout the epidermis are numerous, atypical, pleomorphic, hyperchromatic keratinocytes producing the characteristic “wind-blown” appearance. These cells are sometimes vacuolated and have a prominent pale-staining cytoplasm, reminiscent of the cells in Paget's disease. There is loss of maturation and polarity of these cells, in addition to numerous mitotic figures. Individually keratinized cells with large, rounded, eosinophilic cytoplasm and hyperchromatic nuclei can be found in the epidermis, as can multinucleated cells. These atypical cells also are seen throughout the pilosebaceous units, within the acrotrichia, follicular infundibula, and sebaceous glands. The upper dermis is typically infiltrated by numerous chronic inflammatory cells, including lymphocytes, plasma cells, and histiocytes.

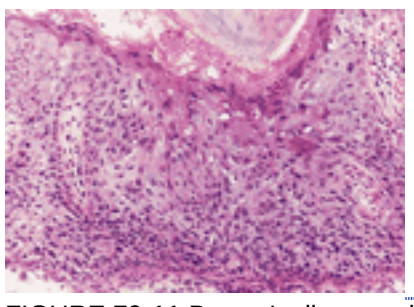

FIGURE 79-11 Bowen's disease showing full-thickness atypia of epithelium.

Several histopathologic subtypes of BD can be seen. Psoriasiform BD displays parakeratosis and marked acanthosis with broad, sometimes fused, epidermal rete ridges. Atrophic BD, like the atrophic AK, demonstrates a thinned epidermis, but in addition there is full-thickness atypia and lack of maturation, as well as adnexal involvement. The acantholytic BD shows marked acantholysis in the epidermis. Epidermolytic BD has changes of incidental EHK present. The phenomenon of intraepidermal epithelioma of Borst-Jadassohn, namely nesting of the atypical cells within the epidermis, can also be seen.

Diagnosis and Differential Diagnosis

Clinically, BD is most often mistaken for superficial BCC, patches of dermatitis, psoriasis or lichen planus, AK, benign lichenoid keratosis, irritated seborrheic keratosis, or amelanotic melanoma. More hyperkeratotic or verrucous lesions of BD may be difficult to clinically distinguish from viral warts, seborrheic keratoses and SCC, and pigmented BD lesions can be mistaken for melanoma. Superficial BCC can usually be distinguished by its raised, subtle, translucent border.

Histopathologically, BD must be differentiated from Paget's disease, pagetoid melanoma in situ, bowenoid papulosis, and podophyllin-induced changes of a wart. Both Paget's disease and BD may share the findings of vacuolated cells, but in contrast with BD, Paget's disease shows no dyskeratosis. Also, the material present in the Paget's cells is PAS-positive and diastase resistant, while the PAS-positive material sometimes present in the BD cells is glycogen and therefore PAS-labile. Lastly, staining for carcinoembryonic antigen is positive in Paget's disease but negative in BD. Pagetoid melanoma in situ can be difficult at times to histopathologically distinguish from BD. In BD, the intercellular desmosomal bridges should be identifiable between the atypical keratinocytes, and S-100 staining is positive in melanoma cells but negative in BD and Paget's disease. Bowenoid papulosis lacks the full-thickness epidermal atypia present in BD. Podophyllin applied topically to skin lesions causes metaphase arrest with resultant bizarre keratinocyte formation and sometimes a pattern of pseudoepitheliomatous hyperplasia. These changes typically resolve after a few days to a week. [74]

Prognosis and Treatment

The risk of BD progressing to invasive SCC has been estimated at approximately 5 percent. [75], [76] Once invasive SCC occurs in BD, it has also been estimated that approximately 33 percent may metastasize unless adequate therapy is initiated. [76] These risk estimates were drawn from retrospective case series, and are far in excess of the experience of the senior author of this chapter.

The presence of BD on any given individual is a marker for the high risk of developing a subsequent NMSC. [77] In studies addressing the association between BD and the risk of other NMSCs, approximately 30 to 50 percent of patients had either previous or subsequent NMSC. Another recent study estimated the incidence ratio for subsequent NMSC to be 4.3. [77] Previous studies have also purported that the presence of BD is a marker for internal malignancy, although a significant number of other studies have been unable to uphold this association. Critical analysis and meta-analysis of these past studies do not support the routine investigation for internal malignancy in persons with BD. The one exception to this position is in cases of BD related to previous arsenic exposure, in which the possibility of internal malignancy is real, as previously discussed. Also, BD involving the vulvar region in females has been associated with an increased risk of uterine, cervical, and vaginal cancer. [50], [78]

A number of different modalities are available for the treatment of BD including excision, Mohs micrographic surgery, electrodesiccation and curettage, cryosurgery, topical chemotherapy with 5-FU, topical immune response modifiers, laser therapy, radiotherapy, and PDT. Although some of these modalities have better reported cure rates than others, no one treatment is right for all forms of BD. Therapy has to be guided by the size and location of the BD, in addition to individual patient characteristics, such as age and healing capability.

Surgical excision is generally regarded as the treatment of choice for most BD lesions if the lesion's size and location permit such a procedure. The rationale for recommending excision is twofold: first, to remove the entire lesion for histopathologic confirmation in order to rule-out invasive SCC; and second, to ensure complete removal of the lesion, including appendageal involvement. One retrospective study compared excision with a cure rate of 95 percent, to standard cryosurgery (34 percent cure rate) and topical 5-FU (14 percent cure rate). [50] Mohs micrographic

surgery is regarded by many as the treatment of choice for BD of the nail bed and periungual region. [79]

Cure rates of 60 to 95 percent have been reported for curettage alone, with cure rates of 80 to 90 percent achieved with combination curettage and cautery regimens. [80] The length of follow-up in many of these studies was not reported. Curettage for superficial or extensive lesions of BD is ideal because of the avoidance of wound closure issues and the relative simplicity and speed of the procedure. Lower cure rates are expected with this procedure, however, because of the possibility of missing BD involving the appendages.

Properly administered cryosurgery can be quite effective in treating BD, especially in difficult to excise lesions, and in elderly individuals who may not tolerate more time-consuming surgery. It is a convenient, cost-effective, and widely available procedure. Two sets of investigators reported cure rates of 96 to 97 percent with cryosurgery, although their techniques used were not clearly defined (see Chap. 278).

Topical 5-FU chemotherapy has been used to treat BD in several studies, although most of these studies were small case series of 10 to 20 patients. Cure rates of 66 to 92 percent have been reported, with the highest cure rates being achieved when treatment included a margin of normal skin around the lesion and the treatment continued for 6 to 16 weeks. [80], [81] Recurrences are not uncommon, with one study finding a 14 percent recurrence rate. [50] This treatment modality may play a role in cases of multiple, small, thin lesions of BD, when surgery is not an option.

Another topical agent that was recently explored as a treatment for BD is the immune response modifier drug imiquimod. A recent study investigating the daily application of 5% imiquimod cream on clinically noninfiltrated patches of BD for 16 weeks reported a cure rate of 93 percent, with no clinical recurrence at a 6-month follow-up. [82] Local irritation and bacterial superinfection were the most significant side effects. Further studies on imiquimod as a treatment for BD need to be undertaken before it is accepted as mainstream therapy for this disease.

Lasers used to treat BD include the CO_2 argon, and Nd:YAG lasers. Laser ablation of BD appears to be most beneficial for lesions in difficult to treat sites, such as the finger or genitalia. These modalities are of little use if deep follicular involvement with BD is present. Published results with these modalities are limited. Radiotherapy using various techniques and regimens report cure rates of 89 to 100 percent with average follow-up between 6 months and 6 years. [80] It is advantageous for managing large or multiple lesions, especially in elderly patients who may not tolerate surgical procedures or in patients who tend to form hypertrophic scars or keloids. The main drawback of ionizing radiation therapy of BD is the problem with healing. In fact, healing after radiotherapy of BD lesions on the lower legs is so poor, that it is not recommended at these sites.

PDT, which was previously discussed under treatment modalities for AKs, is another newer, currently investigational treatment option for BD. Initial clinical clearance rates of approximately 90 percent have been reported in multiple studies, with recurrence rates of 0 to 11 percent being reported at 12-month follow-ups. [83] Longer term follow-up is needed with this modality, but it may ultimately play a role in treating larger or multiple lesions of BD, especially in difficult areas, such as the lower legs, where healing with other modalities is generally poor.

ERYTHROPLASIA OF QUEYRAT

Erythroplasia of Queyrat (EQ) is an in situ SCC (Bowen's disease) affecting the mucosal surfaces of the penis in uncircumcised males. This condition was described by Queyrat, in 1911, as “erythroplasie du gland.” [84] The term *erythroplasia of Queyrat*, rather than simply SCC in situ or BD, is preferred for this condition because it is clinically distinct, presenting as a well-demarcated, shiny, velvety, bright-red plaque. EQ occurs in uncircumcised males between the ages of 20 and 80, although the majority of cases are seen between the third and sixth decades. Risk factors for developing this condition in uncircumcised males include poor hygiene, smegma, heat, friction, trauma, and genital herpes simplex virus infection. [85] HPV subtypes 16 and 8 have also been identified in a number of EQ lesions. [85]

Clinically, EQ presents as a glistening, red, velvety plaque on the glans penis, the prepuce, or the urethra (Fig. 79-12). It begins as a solitary plaque in approximately 50 percent of cases, and as multiple plaques in the remainder of cases. [50] Affected males complain of localized pain, pruritus, difficulty retracting the foreskin over the glans, bleeding, and crusting. Histopathologically, EQ is similar to BD as previously described. In addition, there may also be epidermal hypoplasia and many more plasma cells in the dermal infiltrate, as often seen in other processes affecting mucosal surfaces. The clinical differential diagnosis includes other benign inflammatory conditions such as psoriasis, lichen planus, lichen sclerosus, candidiasis, plasma cell balanitis (Zoon's balanitis), lymphogranuloma venereum, granuloma inguinale, syphilis, and drug eruptions. If the diagnosis of EQ is under consideration, a biopsy should be performed.

FIGURE 79-12 Erythroplasia of Queyrat. (*Courtesy of James E. Fitzpatrick, MD, University of Colorado, Department of Dermatology.*)

Lesions of EQ persist and enlarge slowly, and they typically have been present for several years (an average of 3.4 years in one study [86]) before a biopsy is taken. Progression of EQ to invasive SCC is more common than in other lesions of BD, and is said to occur in up to 33 percent of

cases.[85] Once invasive SCC has occurred, approximately 20 percent of patients will display evidence of regional lymph node or more distant metastases.[50] Prevention of EQ in uncircumcised males may be maximized by adhering to good personal hygiene regimens, and early circumcision may also reduce the incidence of this disease. Several treatment options are available, including excision, Mohs micrographic surgery, CO_2 laser, and topical 5-FU.

ERYTHROPLAKIA (ERYTHROPLASIA)

Erythroplakia, also known as erythroplasia, is a clinical term used to describe a red macule or patch on a mucosal surface that cannot be clinically or histopathologically categorized as any other known disease entity caused by inflammatory, vascular, or traumatic factors. Histopathologically, it typically displays either findings of SCC in situ or focal areas of invasive SCC, and thus is considered a precancerous lesion in most instances. Erythroplakia can involve any mucosal surface, but most commonly, in more than half of all cases, it refers to lesions in the oral mucosa. Of all oral precancerous lesions, it is considered to be the most dangerous, carrying the greatest risk of progressing to or harboring invasive carcinoma.

Erythroplakia is an uncommon lesion in the oral cavity, and it is said to be one of the least commonly diagnosed lesions among the group of oral lesions that may or may not become malignant.[87] Typically, erythroplakia is found in males who have a history of tobacco use and/or alcohol use. In fact, more than 80 percent of patients with intraoral carcinoma in situ are males, the majority of whom are older than 50 years of age.[88] It is not known precisely how alcohol and tobacco together induce carcinoma, but the synergistic effect of the two substances in causing intraoral carcinoma is well regarded.

Clinical Manifestations

Erythroplakia of the oral mucosa is found either intraorally or on the vermilion surface of the lower lip. Intraorally, the most common sites involved include the lateral and ventral tongue, floor of the mouth, and soft palate. Erythroplakia presents as a subtle, asymptomatic, erythematous macule or patch. Most often it is less than 1.5 cm in its widest diameter, but lesions up to 4 cm in diameter have been described.[87] It characteristically is sharply demarcated from the surrounding pink mucosa, and its surface is most often smooth and homogeneous in color. On occasion lesions of erythroplakia demonstrate a pebbled or stippled surface change. On palpation it is said to have a velvety feel. Erythroplakia is commonly seen in association with leukoplakia, termed erythroleukoplakia. Overwhelmingly, it is the red patches of erythroleukoplakia that most likely contain or will develop into a malignancy.

Pathology and Diagnosis

Histopathologic examination of a lesion of erythroplakia usually reveals findings of SCC in situ (Bowen's disease), occasionally with areas of focal dermal invasion. Partial or sampling biopsies of erythroplakia may unfortunately miss these focal areas of invasive SCC. The use of toluidine blue to aid in the diagnosis and to help in choosing the best site for biopsy can be quite helpful. Mashberg and Samit's technique is the most widely used one.[89] This metachromatic dye selectively stains areas of dysplastic epithelium, and its topical administration to subtle lesions can help outline the lesion. Because inflammatory lesions can give false-positive results with this technique, potential irritants should be eliminated at least 2 weeks prior to the staining. Sites that stain positively on two successive visits should be biopsied, as should all clinically suspicious lesions regardless of the results of staining. In general terms, any erythroplakia lesion should be biopsied if the etiology is not obvious or if it does resolve over a period of several weeks.

Differential Diagnosis

Erythroplakia is a diagnosis of exclusion, so the onus is on the clinician to rule out all other erythematous oral lesions before the term erythroplakia can be applied. Other entities that should be considered in the differential diagnosis include acute and chronic mechanical trauma, thermal or chemical injury, candidiasis, lichen planus, chronic contact or allergic dermatitis, submucosal hemorrhage, and various forms of glossitis.

Prognosis and Treatment

The rate at which in situ carcinoma of the oral cavity progresses to invasive SCC is not known. The transformation rate for treated cases has ranged from 14 to 50 percent, with an average of 26 percent.[87] In high-risk individuals, such as heavy smokers or drinkers, up to 80 percent of erythroplakia lesions on biopsy may contain focal areas of invasive carcinoma.[89] The definitive treatment is controversial. For early dysplastic or in situ carcinoma lesions of erythroplakia, simple excision or Mohs micrographic surgery is ideal because the entire lesion can be removed with histopathologic confirmation of the diagnosis. Other modalities, such as laser ablation, cryosurgery, and electrocoagulation, have also been used. Regardless of the treatment method used to remove the lesion, all patients should be followed at regular intervals to evaluate for the development of a second primary lesion in the oral cavity or aerodigestive tract. Carcinogenic stimuli, such as tobacco and alcohol, should be discontinued.

LEUKOPLAKIA

Leukoplakia is a fixed, predominantly white lesion of the mucosa, which cannot be clinically or histopathologically characterized as any other disease. Leukoplakia is most often seen on the oral and anogenital mucosal surfaces. Some lesions are benign and others will transform into cancer. Like erythroplakia, leukoplakia should be considered a clinical diagnosis until a definitive histopathologic diagnosis has been determined following biopsy. It, too, is associated with alcohol and tobacco use, in addition to chronic trauma and infection. Leukoplakia with premalignant and malignant potential is also seen in the genetic disease dyskeratosis congenita. Because of the various factors contributing to the formation of the process, it can affect any age range.

Clinical Manifestations

Leukoplakia associated with carcinogenesis typically occurs in an older male, in the fifth to seventh decades of life. A history of long-standing tobacco use and/or alcohol abuse is not uncommon. Premalignant or malignant leukoplakia lesions are most likely to be found on the floor of the mouth, lateral and ventral tongue, and soft palate. Lesions in these sites are much less likely to be caused by trauma or infection, and they carry a higher risk of premalignancy and malignancy. In fact, it has been estimated that leukoplakic lesions in these anatomic sites have an approximate 40 percent risk of being malignant or premalignant. [90] As a general group, oral leukoplakias carry a 5 to 25 percent risk of harboring some form of dysplasia or malignancy. [90]

Clinically, leukoplakia presents as an asymptomatic, asymmetric white plaque. It cannot be easily rubbed off. It may have overlying roughness or a granular surface or it may be soft and smooth. Some lesions that also have concomitant areas of redness are termed *erythroleukoplakia*. This latter lesion carries a more ominous prognosis, because the risk of premalignancy or malignancy being present in the erythematous portion of the lesion is much greater.

Pathology

As previously mentioned, the majority of leukoplakic lesions, unlike the erythroplakias, do not show malignant or premalignant histopathologic changes. These more common, reactive leukoplakias exhibit hyperkeratosis, acanthosis or epithelial atrophy, and chronic inflammation. [90] Focal areas of candidiasis may also be seen. Some of the leukoplakias, however, do reveal histopathologic dysplasia, SCC in situ, or frank invasive SCC.

Diagnosis and Differential Diagnosis

In general, leukoplakia should be biopsied to determine the true histopathologic diagnosis. As mentioned earlier, leukoplakia on the floor of the mouth, lateral and ventral tongue, and soft palate carry a much greater risk of being malignant or premalignant and thus should be carefully evaluated, biopsied, and probably removed completely regardless of the histopathologic diagnosis. [90] Other conditions that may present with oral or mucosal white plaques include oral white sponge nevus, lichen planus, candidiasis, syphilis, lichen sclerosus, leukoedema, smoker's keratosis, Darier's disease, and cheek biting.

Prognosis and Treatment

In general, the prognosis for reactive leukoplakias is quite good. For all leukoplakias the risk of progression to malignant SCC is approximately 4 percent, and even higher in the high-risk anatomic sites. [91] In a series of 782 patients with oral or lip leukoplakia followed on a regular basis, 2.4 percent developed SCC in 10 years and 4 percent developed SCC in 20 years. [90] Patients should be followed closely, at regular intervals, and reevaluated should the leukoplakia persist or recur following adequate intervention. Treatment depends on the site. Lesions at low-risk sites, such as the buccal mucosa, hard palate, and gingival mucosa can be followed closely if the histopathologic features are benign or reactive. Lesions on high-risk sites, such as the floor of the mouth, lateral and ventral tongue, and soft palate should be removed completely. Surgical excision or Mohs micrographic surgery are treatment options. Other therapeutic approaches for known premalignant lesions include topical 5-FU, laser ablation, and cryosurgery. Patients should also be advised to discontinue tobacco use and alcohol consumption.

REFERENCES

1. Cockerell CJ: Histopathology of incipient intraepidermal squamous cell carcinoma ("actinic keratosi *J Am Acad Dermato* **42**:S11, 2000
2. Freeman RG et al: What is the boundary that separates a thick actinic keratosis from a thin squamous cell carcinor *Am J Dermatopatho* **6**:301, 1984
3. Yantsos VA et al: Incipient intraepidermal cutaneous squamous cell carcinoma: A proposal for reclassifying and grading solar (actinic) kerat *Semin Cutan Med Surg* **18**:3, 1999
4. Heaphy MR, Ackerman AB: The nature of solar keratosis: A critical review in historical perspect *J Am Acad Dermato* **43**:138, 2000
5. Dubreuilh W: Des hyperkeratoses circonscrites, i *Third International Congress of Dermatology. Official Transactio*, edited by JJ Pringle. London, Waterlow and Sons, 1898, p 125
6. Freudenthal W: Verruca senilis und keratoma senile *Arch f Dermat u Syph (Berlin* **158**:529, 1926
7. Pinkus H: Keratosis senilis: A biologic concept of its pathogenesis and diagnosis based on the study of normal epidermis and 1730 seborrheic and senile kerat *Am J Clin Patho* **29**:193, 1958
8. Marks R et al: The relationship of basal cell carcinomas and squamous cell carcinomas to solar keratos *Arch Dermato* **1224**:1039, 1988
9. Green A, Battistutta D: Incidence and determinants of skin cancer in a high-risk Australian populati *Int J Cancer* **46**:356, 1990
10. Salasche SJ: Epidemiology of actinic keratoses and squamous cell carcinon *J Am Acad Dermato* **42**:S4, 2000
11. Feldman SR et al: Most common dermatologic problems identified by internists, 1990–19 *Arch Intern Med* **158**:726, 1998
12. Frost CA, Green AC: Epidemiology of solar keratose *Br J Dermato* **131**:455, 1994
13. O'Beirn SF et al: Skin cancer in county Galway, Ireland, *Proceedings of the Sixth National Cancer Conferenc* Philadelphia, JB Lippincott, 1970, p 2811
14. Vitasa BC et al: Association of nonmelanoma skin cancer and actinic keratosis with cumulative solar ultraviolet exposure in Maryland wate *Cancer* **65**:2811, 1990
15. Marks R et al: Spontaneous remission of solar keratoses: The case for conservative managem *Br J Dermato* **115**:649, 1986

16. Marks R et al: The role of childhood sunlight exposure in the development of solar keratoses and nonmelanoma skin ca *Med J Aus* **152**:62, 1990

17. Grossman D, Leffell DJ: The molecular basis of nonmelanoma skin canc *Arch Dermato* **133**:1263, 1997

18. Ziegler A et al: Sunburn and p53 in the onset of skin cance *Nature* **372**:773, 1994

19. Leffell DJ: The scientific basis of skin cancer *J Am Acad Dermato* **42**:S18, 2000

20. Thompson SC et al: Reduction of solar keratoses by regular sunscreen us *N Engl J Med* **329**:1147, 1993

21. Black HS et al: Effect of a low-fat diet on the incidence of actinic keratos *N Engl J Med* **330**:1272, 1995

22. Rook AH et al: Beneficial effect of low-dose systemic retinoid in combination with topical tretinoin for the treatment and prophylaxis of premalignant and malignant skin lesions in renal transplant recipients. *Transplantatior* **59**:714, 1995

23. Yu RCH et al: A histopathological study of 643 cutaneous horn *Br J Dermato* **24**:449, 1991

24. Cruces Prado MJ, de la Torre C: Jadassohn's intraepidermal epithelion *Dermatologica* **168**:10, 1984

25. Steffan C, Ackerman AB: Intraepidermal epithelioma of Borst-Jadassol *Am J Dermatopatho* **7**:5, 1985

26. Carag HR et al: Utility of step sections: Demonstration of additional pathological findings in biopsy samples initially diagnosed as actinic kera *Arch Dermato* **136**:471, 2000

27. Ponsford MW et al: The prevalence and accuracy of diagnosis of non-melanotic skin cancer in Victo *Australas J Dermato* **24**:79, 1983

28. Marks R et al: Malignant transformation of solar keratosis to squamous cell carcinon *Lance* **1**:795, 1988

29. Montgomery H, Dörffel J: Verruca senilis und keratoma senil *Arch f Dermatol u Syphilol (Berlir* **166**:286, 1932

30. Lober BA et al: Actinic keratosis is squamous cell carcinom *J Am Acad Dermato* **43**:881, 2000

31. Boddie AW Jr et al: Squamous carcinoma of the lower lip in patients under 40 years of a *South Med J* **70**:711, 715, 1977

32. Drake LA et al: Guidelines for the care of actinic keratose *J Am Acad Dermato* **32**:95, 1995

33. Feldman SR et al: Destructive procedures are the standard of care for treatment of actinic keratos *J Am Acad Dermato* **40**:43, 1999

34. Eaglstein WH et al: Fluorouracil: Mechanism of action in human skin and actinic keratoses, I: Effect on DNA synthesis in v *Arch Dermato* **101**:132, 1970

35. Lawrence N et al: A comparison of the efficacy and safety of Jessner's solution and 35% trichloroacetic acid vs 5% fluorouracil in the treatment of widespread facial actinic keratoses. *Arch Dermato* **131**:176, 1995

36. Witheiler DD et al: Long-term efficacy and safety of Jessner's solution and 35% trichloroacetic acid vs 5% fluorouracil in the treatment of widespread actinic kerat *Dermatol Surg* **23**:191, 1997

37. Trimas SJ et al: The carbon dioxide laser: An alternative for the treatment of actinically damaged s *Dermatol Surg* **23**:885, 1997

38. Jiang B et al: YAG laser for the treatment of actinic keratose *Dermatol Surg* **26**:437, 2000

39. Jeffes EW et al: Photodynamic therapy of actinic keratoses with topical aminolevulinic acid hydrochloride and fluorescent blue *J Am Acad Dermato* **45**:96, 2001

40. Kurwa HA et al: A randomized paired comparison of photodynamic therapy and topical 5-fluorouracil in the treatment of actinic kera *J Am Acad Dermato* **41**:414, 1999

41. Stockfleth E et al: Successful treatment of actinic keratosis with imiquimod cream 5%: A report of 6 cas *Br J Dermato* **144**:1050, 2001

42. Schwartz RA: Arsenic and the skin *Int J Dermato* **36**:241, 1997

43. Blejer HP, Wagner W: Case study 4: Inorganic arsenic-ambient level approach to the control of occupational cancerigenic expos *Ann N Y Acad Sc* **271**:179, 1976

44. Travis LB, Arndt KA: Occupational skin cance *Postgrad Med* **79**:211, 1986

45. Col M et al: Arsenic-related Bowen's disease, palmar keratosis, and skin canc *Environ Health Perspec* **107**:687, 1999

46. Jackson R Grainge JW: Arsenic and cancer *Can Med Assoc J* **113**:396, 1975

47. Pershagen G: The carcinogenicity of arsenic *Environ Health Perspec* **40**:93, 1981

48. Hsu C-H et al: Mutational spectrum of p53 gene in arsenic-related skin cancers from the blackfoot disease endemic area of Tai *Br J Can* **80**:1080, 1999

49. Wong SS et al: Cutaneous manifestations of chronic arsenicism: Review of 17 cas *J Am Acad Dermato* **38**:179, 1998

50. Graham JH: Selected precancerous skin and mucocutaneous lesions, *Neoplasms of Skin and Malignant Melanom*. Chicago, Year Book Medical Publishers, 1976, p 69

51. Arrington JH III, Lockman DS: Thermal keratoses and squamous cell carcinoma in situ associated with erythema ab ig *Arch Dermato* **115**:1226, 1979

52. Shahrad P, Marks R: The wages of warmth: Changes in erythema ab igr *Br J Dermato* **97**:179, 1977

53. Boffetta P et al: Cancer risk from occupational and environmental exposure to polycyclic aromatic hydrocarb *Cancer Causes Contro* **8**:444, 1997

54. Pott P: Chirurgical works of Percivall Pott, i *Cancer Scrot*. Dublin, James Williams, 1775, p 403

55. Letzel S, Drexler H: Occupationally related tumors in tar refinery worke*J Am Acad Dermato* **39**:712, 1998

56. Götz H: Tar keratosis, ir*Cancer of the Skin: Biology-Diagnosis-Manageme*, edited by Andrade R, Gumport SL, Popkin GL, Rees TD. Philadelphia, WB Saunders, 1976, p 492

57. Helm KF et al: Radiation keratosis associated with exposure to a gold ri*Cutis* **57**:435, 1996

58. Yamada M et al: Prevalence of skin neoplasms among the atomic bomb survivc*Radiat Res* **146**:223, 1996

59. Peter RU et al: Chronic cutaneous damage after accidental exposure to ionizing radiation: The Chernobyl experie*J Am Acad Dermato* **30**:719, 1994

60. Marjolin JN: Ulcere, ir*Dictionnaire de Medecine* vol 21. Paris, Bechet, 1828, p 31

61. Phillips TJ et al: Burn scar carcinoma*Dermatol Surg* **22**:561, 1998

62. Dupree MT et al: Marjolin's ulcer arising in a burn sca*Cutis* **62**:49, 1998

63. Arons MS et al: Scar tissue carcinoma: A clinical study with special references to burn scar carcinor*Ann Surg* **161**:170, 1965

64. Novick M et al: Burn scar carcinoma: A review and analysis of 46 case*J Trauma* **17**:809, 1977

65. Lloyd KM: Multicentric pigmented Bowen's disease of the groi*Arch Dermato* **101**:48, 1970

66. Kopf AW, Bart RS: Tumor conference. No 11. Multiple bowenoid papules of the penis: A new enti*J Dermatol Surg Onco* **3**:265, 1977

67. Wade TR et al: Bowenoid papulosis of the genitali*Arch Dermato* **115**:306, 1979

68. Obalek S et al: Bowenoid papulosis of the male and female genitalia: Risk of cervical neopla*J Am Acad Dermato* **14**:433, 1986

69. Bowen JT: Precancerous dermatoses. A study of two cases of chronic atypical epithelial proliferati*J Cutan Dis* **30**:241, 1912

70. Kossard S, Rosen R: Cutaneous Bowen's disease: An analysis of 1001 cases according to age, sex, and s*J Am Acad Dermato* **27**:406, 1992

71. Reizner GT et al: Bowen's disease (squamous cell carcinoma in situ) in Kauai, Hawaii: A population-based incidence re*J Am Acad Dermato* **31**:596, 1994

72. McGrae JD et al: Multiple Bowen's disease of the fingers associated with HPV type *Int J Dermato* **32**:104, 1993

73. Ragi G et al: Pigmented Bowen's disease and review of 420 Bowen's disease lesio*J Dermatol Surg Onco* **14**:765, 1988

74. Civatte J: Pseudo-carcinomatous hyperplasi*J Cutan Patho* **12**:214, 1985

75. Peterka ES et al: An association between Bowen's disease and canc*Arch Dermato* **84**:623, 1961

76. Kao GF: Carcinoma arising in Bowen's diseas*Arch Dermato* **122**:1124, 1986

77. Jaeger AB et al: Bowen disease and risk of subsequent malignant neoplasms. A population-based cohort study of 1147 pati*Arch Dermato* **135**:740, 1999

78. Ragnarsson B et al: Carcinoma in situ of the vulva: Long-term prognos*Acta Onco* **26**:277, 1987

79. Sau P et al: Bowen's disease of the nail bed and periungual area. A clinicopathologic analysis of seven ca*Arch Dermato* **130**:204, 1994

80. Ball SB, Dawber RPR: Treatment of cutaneous Bowen's disease with particular emphasis on the problem of lower leg lesi*Australas J Dermato* **39**:63, 1998

81. Sturm HM: Bowen's disease and 5-fluorouraci*J Am Acad Dermato* **1**:1513, 1979

82. Mackenzie-Wood A et al: Imiquimod 5% cream in the treatment of Bowen's disea*J Am Acad Dermato* **44**:462, 2001

83. Morton CA et al: Photodynamic therapy for large or multiple patches of Bowen disease and basal cell carcinc*Arch Dermato* **137**:319, 2001

84. Queyrat L: Erythroplasie du glanc*Bull Soc Fr Dermatol Syphilig* **22**:378, 1911

85. Wieland U et al: Erythroplasia of Queyrat: Coinfection with cutaneous carcinogenic human papillomavirus type 8 and genital papillomaviruses in a carcinoma i*J Invest Dermato* **115**:396, 2000

86. Graham JH, Helwig EB: Erythroplasia of Queyrat: A clinicopathologic and histochemical stu*Cancer* **32**:1396, 1973

87. Bouquot JE, Ephros H: Erythroplakia: The dangerous red mucos*Pract Periodontics Aesthet Den* **7**:59, 1995

88. Bouquot JE: Epidemiology, ir*Pathology of the Head and Nec*, edited by DR Gnopp. New York, Churchill Livingstone, 1987, p 263

89. Mashberg A, Samit A: Early detection, diagnosis, and management of oral and oropharyngeal can*Cancer* **39**:67, 1989

90. Summerlin DJ: Precancerous and cancerous lesions of the oral cavi*Dermatol Cli* **14**:205, 1996

91. Silverman S Jr et al: Oral leukoplakia and malignant transformation. A follow-up study of 257 patie*Cancer* **53**:563, 1984

T>

Chapter 80

Douglas Grossman David Leffell

Squamous Cell Carcinoma

HISTORICAL ASPECTS
EPIDEMIOLOGY
Incidence
Demographics
ETIOLOGY AND PATHOGENESIS
Predisposing Factors
Molecular Aspects
PREVENTION
Sun Protection
Treatment of Precursor Lesions
Other Preventive Measures
CLINICAL MANIFESTATIONS
Development from Precursor Lesions
SCC Morphologies
Oral SCC
Lower Lip
Genital SCC
Scar SCC
Keratoacanthoma
Verrucous Carcinoma
Metastatic SCC
HISTOPATHOLOGY
GENERAL CONSIDERATIONS
Basic Features
Grading
Histologic Subtypes
DIAGNOSIS AND DIFFERENTIAL DIAGNOSIS
Making the Diagnosis
Differential Diagnosis
RECURRENCE AND METASTASIS
High-Risk Lesions
TREATMENT
Surgical Excision
Radiation
Recurrence Rates
Treatment of High-Risk Lesions
Patient Follow-up

REFERENCES

Cutaneous squamous cell carcinoma (SCC) is a malignant neoplasm derived from suprabasal epidermal keratinocytes. These and basal cell cancers are the nonmelanoma skin cancers that represent the most common malignancies in humans. While basal cell carcinoma (BCC) (discussed in Chap. 81) is thought to arise de novo, SCC probably evolves in most cases from precursor lesions of actinic keratosis (AK) and Bowen's disease (SCC in situ) (see Chap. 79). This chapter focuses on clinical aspects of invasive SCC. Cutaneous SCC represents a broad spectrum of disease ranging from easily managed, superficially invasive cancer to highly infiltrative, metastasizing tumors that can result in death. The clinical presentation can be variable despite the existence of easily identified typical lesions. The cellular and molecular aspects of SCC carcinogenesis are discussed elsewhere (see Chap. 36, Chap. 37 and Chap. 38).

HISTORICAL ASPECTS

Recognition of nonmelanoma skin cancer dates back to biblical times. Although precise clinical descriptions were documented centuries ago, distinctions between SCC and BCC were not fully appreciated until the late nineteenth century with advances in tissue preparation, staining, and microscopy. Percivall Pott was likely the first to describe the malignant nature of SCC in 1775. [1] His descriptions of “soot warts” in adolescent British chimney sweeps led to the early appreciation of an occupational carcinogen and the promulgation of the original occupational safety laws. Additional occupational associations with SCC were later revealed, most of which involved chronic exposure of factory workers to hydrocarbons in the form of coal tar or lubricating oils. [2] So-called mule spinner's disease was named for the oiled turning axle of the cotton spinning machine (mule) straddled by workers who later developed genital SCC. [3] The French surgeon Jean-Nicholas Marjolin, in 1828, first described SCC arising in traumatic scars, and subsequently SCC associated with burn scars was termed *Marjolin's ulcer*. [4] Arsenic, once commonly found in drinking water and fumes released in copper smelting, was recognized as a significant skin carcinogen in the early 1800s. [5] Sir Jonathan Hutchinson, in 1887, famously reported that medicinal arsenic in the form of potassium arsenite (Fowler's solution), then a treatment for psoriasis and asthma, caused skin tumors. [6] X-ray exposure was associated with SCC in the early 1900s in technicians operating roentgen machines, [7] and later in patients treated with grenz rays for a variety of benign conditions including psoriasis, acne, and hirsutism. [8] Today, it is ultraviolet (UV) radiation, rather than these occupational hazards, that is the predominant factor in the development of SCC (see Chap. 38). [9]

In light of these associations, the precursor lesions of SCC were initially called hydrocarbon keratoses, scar keratoses, burn keratoses, arsenical keratoses, radiation keratoses, and solar keratoses, among other names. These terms are generally of historical interest and seldom used today, with the exception of solar (actinic) keratosis (AK) because it is the most common.

EPIDEMIOLOGY

Incidence

The precise incidence of BCC and SCC is unknown because these cutaneous malignancies are generally not documented by the National Cancer Institute or most state registries. Conservative estimates for the year 2001 are well over 1 million cases in the United States, including approximately 200,000 cases of SCC. [10] Although less common than BCC, SCC carries a risk of metastasis and thus accounts for the majority of the several thousand deaths attributable to nonmelanoma skin cancer each year. By comparison, cutaneous melanoma accounts for only 50,000 cases, but approximately 10,000 deaths, annually. [11] Similar trends for SCC have been noted in Australia [12] and the Caribbean. [13]

SCC is strongly associated with *advanced age,* with a sharp increase in incidence after age 40. [14] Today, the lifetime risk of SCC among whites is approximately 15 percent, almost double that of two decades ago. Increased exposures to UV radiation (through increased use of tanning salons, more time spent outdoors, changes in clothing style, and ozone depletion) and increased longevity have been suggested as possible causes for the increase in disease. It is likely that this trend will continue as a result of further depletion of the ozone layer and the increasing age of the US population. The increased incidence of SCC over the past several decades has been paralleled by a 20 percent decrease in mortality, attributed largely to increased public awareness and aggressive treatment of high-risk lesions. [15] Following a diagnosis of SCC, patients have a 44 to 50 percent cumulative risk of developing another nonmelanoma skin cancer (18 to 30 percent risk of SCC) in the subsequent 3 to 5 years. [16] In addition, these patients are at increased risk for extracutaneous cancers. [17]

Demographics

Squamous cell cancer is twice as common in men than in women, probably a result of greater lifetime UV exposure in men. Similarly, longer hairstyle and use of lipstick may account for less-frequent SCC on the ears and lips of women. There is an inverse relationship between *skin pigmentation* and SCC incidence, largely because of the protective effect of eumelanin. Thus, persons with white skin, blue eyes, fair complexion, red hair, and Celtic ancestry who tan poorly are at greatest risk. Increased pigmentation is not only associated with a lower incidence of SCC, but also an inversion in the BCC to SCC ratio. When American blacks are compared with whites, the incidence of SCC decreases 30-fold and the BCC to SCC ratio falls to 0.8 to 1. [14] Tanzanian albinos all develop SCC by young adulthood, and the ratio of BCC to SCC is only 0.2 to 1. Asians and Polynesians, with intermediate skin pigmentation, have correspondingly intermediate levels of SCC. A gene involved in melanogenesis, encoding melanocortin-1 receptor (MC1R), is a major determinant of skin pigmentation and hair color. The MC1R gene is highly polymorphic, with more than 20 variants described. [18] Several variant MC1R alleles are associated with increased risk of SCC that was independent of skin type and hair color.

ETIOLOGY AND PATHOGENESIS

Predisposing Factors

There are a number of factors, including both acquired and genetic skin conditions, that may predispose to SCC (Table 80-1). Patients often demonstrate a multiplicity of factors that together are sufficient to induce SCC development. Thus, a given skin site may be exposed to both UV radiation and another environmental carcinogen.

Precursor lesions (AK, Bowen's disease)
UV exposure
Ionizing radiation
Environmental carcinogens
Immunosuppression
Scars
Burns or chronic heat exposure
Chronic scarring or inflammatory dermatoses
Human papilloma virus
Genodermatoses (albinism, xeroderma pigmentosum, porokeratosis, epidermolysis bullosa)

TABLE 80-1 **Predisposing Factors for SSC**

PRECURSOR LESIONS Most SCCs develop from precursor lesions such as AKs or Bowen's disease (see Chap. 79).
UV EXPOSURE UV radiation is considered the predominant risk factor for SCC. Importantly there is a linear correlation between the incidence of SCC and UV exposure. The incidence of SCC has been reported to double with each 8- to 10-degree decline in geographic latitude, and is highest at the equator. [19] World War II veterans stationed in the Pacific developed much higher rates of SCC than did their colleagues who served in Europe. [20] Similarly, SCC is more prevalent in Japanese people who emigrated to Hawaii than in those who remained in Japan. [21] Excessive UV radiation appears to be more related to the development of SCC than BCC. Rates of SCC rise more rapidly than those of BCC with increasing UV exposure, [22] and UV-induced skin cancers in mice are almost exclusively SCCs rather than BCCs. [23] Moreover, in patients receiving long-term PUVA for psoriasis there is an associated 30-fold increase in nonmelanoma skin cancer, most of which are SCCs. [24]
IONIZING RADIATION There is a strong association of SCC with ionizing radiation (Fig. 80-1), as described above. In a recent survey of SCC patients, the association with radiotherapy was observed only among those whose skin was likely to sunburn (see Chap. 79).

FIGURE 80-1 Papular SCC of the ear. The differential diagnosis includes chondrodermatitis nodularis helicis, which, unlike SCC, is associated with pain.

ENVIRONMENTAL CARCINOGENS There are numerous occupational and environmental carcinogens, such as arsenic and aromatic hydrocarbons, that predispose to SCCs. With the exception of 3-methylcholanthrene and anthramine, chemical carcinogens generally produce SCCs rather than BCCs. [25] Exposures to insecticides and herbicides have also been associated with SCCs. In addition, smoking and alcohol use are strongly associated with SCCs of the oral cavity.
IMMUNOSUPPRESSION Chronic immunosuppression may lead to an increase in SCCs, primarily on sun-exposed sites. [26] An 18-fold increase in SCC has been reported in renal transplant patients; [27] these tend to appear 3 to 7 years after the onset of chronic immunosuppressive therapy, with corticosteroids, azathioprine, and cyclosporine most frequently implicated. With the increase in the total number of organ transplant patients, management of SCCs in this population is becoming more important. In patients with leukemia and lymphoma, SCCs are both increased and more aggressive. [28] Although multiple SCCs have been described in HIV patients, advanced HIV infection has generally not been associated with an increased incidence of SCC, possibly because many patients do not live long enough to develop them.
SCARS AND UNDERLYING DISEASES Historically, SCC has been associated with both burn scars and chronic ulcers as noted above, although this is seldom seen today. Also rare but reported is the development of SCCs in the context of *chronic infections,* particularly those associated with draining sinuses and scarring, such as perianal pyoderma, osteomyelitis, chromomycosis, hyalohyphomycosis, granuloma inguinale, lupus vulgaris, and leprosy. Chronic *inflammatory processes,* particularly those associated with scarring, such as venous ulcer, snake-bite ulcer, discoid lupus erythematosus, oral lichen planus, morphea, lichen sclerosis et atrophicus, pilonidal cyst, acne conglobata, hidradenitis suppurativa, Hailey-Hailey disease, dissecting folliculitis of the scalp, and necrobiosis lipoidica, can all give rise to SCCs. An exception is vaccination scars, which are associated with BCCs rather than SCCs. SCCs have also been observed in transplanted skin, epidermal cyst, dental cyst, and dermoid cyst.
THERMAL FACTORS Chronic heat exposure can lead to SCCs. The role of thermal radiation in the development of skin cancer has long been recognized in many cultures, where common practices include placing hot ashes under the clothes to keep warm in winter or smoking opium while lying on heated beds. SCCs are increased in persons who habitually sit in front of heating stoves, and at sites of erythema ab igne (see Chap. 79).
HUMAN PAPILLOMA VIRUS There is a role for human papilloma virus (HPV) infection in some types of SCC. Verrucous carcinoma appears to be associated with several HPV types, as noted below. Head and neck and periungual SCCs are frequently associated with HPV type 16. Patients with epidermodysplasia verruciformis are chronically infected with HPV, most commonly type 5, and one-third of these patients ultimately develop SCCs (see Chap. 79 and Chap. 223).
GENODERMATOSES A variety of heritable diseases predispose to SCC development. Patients with oculocutaneous albinism develop predominantly SCCs (rather than BCCs) at an early age. Xeroderma pigmentosum, a disorder of DNA repair, is also characterized by early onset development of SCCs. SCCs have been reported to develop in the Mibelli, disseminated superficial actinic, and palmaris et plantaris disseminata forms of porokeratosis (see Chap. 56), and in oral lesions of dyskeratosis congenita. As noted above, lesions of epidermodysplasia verruciformis can degenerate into SCCs. Finally, patients with the dystrophic form of epidermolysis bullosa are at increased risk for SCC.

Molecular Aspects

Like most cancers, the development of SCC from normal keratinocytes begins with mutations in the cellular DNA and genomic instability. Alterations in gene expression lead to loss of growth controls, penetration of the basement membrane and ultimately invasion into surrounding tissue. Along the pathway to SCC, keratinocytes become resistant to apoptosis (programmed cell death) and immune attack.

GENETIC ALTERATIONS Most analyses of genetic alterations in SCCs have been performed in cases of oral or head and neck SCCs. Chromosomal deletions (loss of heterozygosity) commonly involve chromosomes 3, 9, 11, and 17; the regions most commonly identified include 9p21 and 17p13 where the p16 I ^{NK4A} and p53 tumor suppressors are respectively located. [29] Similar genetic lesions were found in a study of young patients (younger than 40 years old). [30] It is unclear whether these genetic markers will serve as useful prognostic indicators.
p53 IN THE DEFENSE AGAINST SKIN CANCER Apoptosis of keratinocytes that have sustained UV-induced DNA damage, termed *sunburn cells,* requires the *p53 tumor suppressor* and represents a key protective mechanism against skin cancer by removing premalignant cells that have acquired mutations. [31] In keratinocytes, UV radiation upregulates p53, [32] which delays cell-cycle progression until DNA damage can be repaired, or facilitates cell elimination by apoptosis. [33] Compromise of p53 function could undermine this apoptosis-based defense mechanism, giving UV-damaged cells a selective advantage to survive additional cycles of UV exposure. [34] Further impairment of p53 and other genes through additional UV-induced mutations may then lead to even greater resistance to apoptosis, increased proliferation, and ultimately development of SCC. The increased susceptibility of p53-deficient mice to UV-induced SCC [35] highlights this protective role of p53.
***p53* MUTATIONS IN SCC** Consistent with this scenario, mutations in the *p53* gene are a common finding in SCC. In

most cases, these are C?T single base and CC?TT tandem transition mutations at dipyrimidine sequences, that is, “UVB signature” mutations. [36] Most SCCs exhibit loss of heterozygosity with respect to *p53* and isolated mutations on the remaining allele. In one study, the *p53*-apoptosis pathway was disrupted in 50 percent of oral SCC. [37] With respect to SCC precursors, *p53* mutations have been found in up to 75 percent of AKs and SCCs in situ [38] lesions. Interestingly, while different *p53* mutations were found in separate AKs, all cells within a single precursor lesion have the same mutation. [31] *p53* mutations can also be detected in keratinocytes from clinically normal sun-exposed skin. [39] *p53*-mutated keratinocytes occur in clonal patches that are larger and more frequent in sun-exposed skin. [40] These findings substantiate a clonal basis for UV-induced SCC and suggest that *p53* mutation is an early event in the development of SCC. In addition to mutation, p53 can be compromised in keratinocytes infected with HPV. The E6 protein encoded by oncogenic HPV types binds p53 and targets it for rapid degradation, disabling the p53-apoptosis pathway. This is a primary mechanism by which HPV infection predisposes to SCC (see Chap. 223).

OTHER APOPTOTIC REGULATORS IN SCC In addition to p53, dysregulation of other apoptotic regulatory proteins has been described in SCC. In a study of vulvar SCC, expression of the apoptotic inhibitor *Bcl-2* correlated with metastasis. [41] Similarly, in esophageal SCC, expression of the apoptotic inhibitor *Bcl-XL* correlated with tumor invasion and metastasis. [42] In SCC of the tongue, low apoptotic index and decreased expression of the proapoptotic *Bax* correlated significantly with poor prognosis, whereas low *Bcl-2* expression was associated with a favorable clinical outcome. [43] Expression of the antiapoptotic *BAG-1* was associated with nodal metastasis in oral SCC. [44] Consistent with these observations, transgenic mice expressing Bcl-2 and Bcl-XL in the skin exhibit increased susceptibility to chemical-induced tumorigenesis. In addition to these Bcl-2 family members, the inhibitor of apoptosis protein *survivin* is expressed both in SCC and precursor lesions, [45] and in one study its expression correlated with aggressive tumor phenotype. [46]

IMMUNE EVASION Working with UV-induced SCCs in mice, Kripke and colleagues first demonstrated the importance of immunosuppression in UV-induced SCC in the 1970s (see Chap. 38). They found that while UV-induced SCC was promptly rejected when transplanted into genetically identical recipient mice, the transplanted tumors grew rapidly and rejection did not occur if recipient mice were first treated with a subcarcinogenic dose of UV. These experiments suggested that UV radiation not only induced SCC, but also impaired the ability of host animals to mount protective immune responses against foreign tumor antigens. While immunosuppressed patients are at great risk for SCC, as discussed above, the development and progression of SCC in all individuals requires some level of continuous local and perhaps systemic immunosuppression to prevent tumor rejection.

PREVENTION

Those at risk for SCC, namely persons with a prior history of nonmelanoma skin cancer or any of the predisposing conditions discussed above, should be monitored closely. They should receive complete skin examinations on a regular basis.

Sun Protection

The most effective preventive measure is protection from sun exposure. It is likely that adequate sun protection beginning in early childhood could prevent most SCCs. [47] This requires establishing patterns of behavior, at an early age, such as repeated application of sunscreen, wearing hats and protective clothing, and avoiding the sun during the hours of peak intensity. However, the role of sun prevention in childhood should not be construed to mean that sun protection later in life will be of no benefit. There is evidence that aggressive sun protection throughout life can prevent the development of SCC precursor lesions and cancers themselves.

Treatment of Precursor Lesions

Treatment of precursor lesions is expected to reduce the incidence of SCC. Several options are available for treatment of AK (see Chap. 79). Isolated lesions can often be effectively removed by liquid nitrogen cryotherapy. For patients with many AKs, or areas of skin with a multitude or confluence of lesions, topical chemotherapy using 5-fluorouracil is an option. More information on this topic can be found in Chap. 79.

Other Preventive Measures

A number of additional preventive measures can be taken that may reduce the incidence of SCC in individual patients. For example, the use of condoms can prevent transmission of HPV and may thereby reduce the risk of genital SCC. Decreased alcohol consumption and smoking cessation is likely to reduce the risk of oral SCC. Several years ago there was great interest in both retinoids and interferons as systemic chemopreventive agents. Low-dose etretinate (10 mg per day) has been used successfully in renal transplant patients. [48] A more recent recommendation is Accutane (10 mg every day or every other day) in addition to topically applied tretinoin. [49] Topical application of a DNA repair enzyme in liposomes was recently shown in an experimental trial to reduce the incidence of new AK in xeroderma pigmentosum patients. [50] Finally, topical immunologic modifiers are showing promise as a new class of agents that may stimulate the endogenous cutaneous immune system to destroy malignant cells.

CLINICAL MANIFESTATIONS

In white men and women, the majority of SCCs arise on sun-exposed areas such as the head, neck, and dorsal hands. SCC of the legs is more common in women. [51] In blacks, on the other hand, SCC tends to be distributed equally on sun-protected and exposed areas. [52] SCC typically presents in solitary fashion, arising from precursor lesions as noted above. An exception is in immunosuppressed patients, who may manifest eruptive SCCs.

Development from Precursor Lesions

AKs often occur as a multiplicity of lesions, ranging in size from pinpoint to over 2 cm, and the borders are usually ill

defined. A dry adherent scale gives them a rough gritty texture. By contrast, lesions of *Bowen's disease* are usually solitary, sharply demarcated scaling papules or plaques, often initially mistaken for eczema, psoriasis, or lichen simplex. These disorders are often pruritic, whereas Bowen's disease is usually not. In sun-protected sites, Bowen's disease may have a noneczematous appearance. For example, it may appear verrucous in the anogenital area, nail bed, and eyelid, and as a dark patch or oozing erythematous plaque in intertriginous areas. These precursor lesions are usually asymptomatic, and the development of tenderness, induration, erosion, increased scale, or enlarging diameter may herald evolution into SCC. Typically a patient with multiple AKs may present with a single lesion that gradually becomes more prominent than the rest (Fig. 80-1), or with a solitary, persistent, nonpruritic, scaling patch that is unresponsive to topical steroids.

SCC Morphologies

A firm, flesh-colored or erythematous, keratotic papule or plaque is most common (Fig. 80-1), but SCCs may also be pigmented. Other presentations include an ulcer (Fig. 80-2), a smooth nodule (Fig. 80-3), and a thick cutaneous horn. SCC may also be verrucous or present as an abscess, particularly if in a periungual location. The margins may be indistinct. With enlargement, there is usually increased firmness and elevation. Progressive tumor invasion ultimately results in fixation to underlying tissues. Especially in the head and neck region, an enlarged lymph node nearby that is firm and nontender may indicate tumor metastasis (Fig. 80-4).

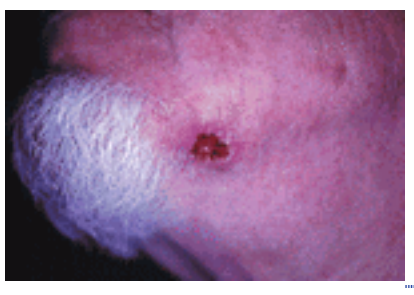

FIGURE 80-2 Ulcerative SCC of the jaw. In this region, extension of the cancer can invade the marginal mandibular nerve.

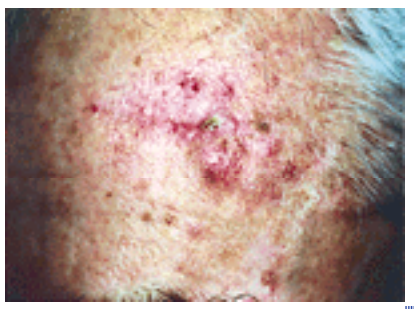

FIGURE 80-3 Nodular SCC of the forehead. This lesion is recurrent and can be seen arising in the previous surgical scar. It should be considered high risk.

FIGURE 80-4 Preauricular mass resulting from metastasis of cutaneous SCC. Involvement of the parotid gland can result from metastasis of SCC in the temple and ear region.

Oral SCC

SCC of the oral cavity usually occurs in patients with a long history of cigarette smoking, chewing tobacco, or alcohol use, but recently it has been documented in younger adults without these traditional risk factors. There is a male predominance, and the palate and tongue are the most common sites. Oral SCC most commonly evolves from lesions of erythroplakia and is usually asymptomatic (see Chap. 79). Distinct patterns include a persistent rough red patch or granular velvety red plaque that ultimately becomes firm and nodular. Surprisingly, the risk of transformation to SCC does not appear to correlate with the degree of epithelial dysplasia. [53] The floor of the mouth, ventrolateral tongue, and soft palate are considered high-risk sites. It may also present as a peritonsillar abscess.

Lower Lip

SCC of the lower lip begins as a roughened papule of actinic cheilitis or scaly leukoplakia, with slow progression to a tumor nodule (Fig. 80-5). Clinical clues associated with evolving SCC include persistent lip chapping with localized scale or crust, red and white blotchy atrophic vermillion lip, indistinct or “wandering” vermillion border, and small fissuring or ulceration within an area of indurated actinic cheilitis. Symptoms of underlying pain or altered sensation should be investigated as a potential sign of perineural invasion.

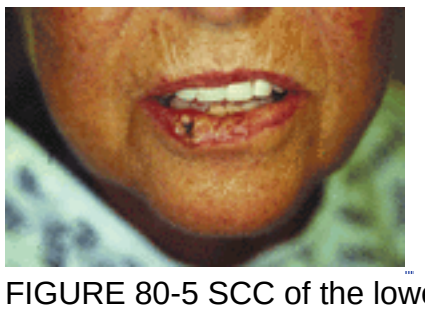

FIGURE 80-5 SCC of the lower lip develops in the setting of chronic solar exposure and actinic cheilitis. Metastasis to draining lymph nodes can occur.

Genital SCC

SCC of the *vulva* most commonly occurs on the anterior labia majora, beginning as a small warty nodule or an erosive erythematosus plaque. These lesions may be asymptomatic, but more often are associated with pruritus or bleeding. Lesions of lichen sclerosus are another common precursor of SCC of the vulva. SCC of the *cervix* is associated with HPV, most commonly type 16. SCC of the *scrotum* begins as a small pruritic verrucous lesion that becomes friable with increasing size. SCC of the *penis* usually occurs in uncircumcised males, and, although very uncommon in Western countries, may account for 10 percent of cancers in places where genital hygiene is poor. A distinct precursor of penile SCC is erythroplasia of Queyrat, characterized by a velvety red plaque. In addition to lack of circumcision, penile SCC has also been associated with history of condyloma and phimosis and lichen sclerosus et atrophicus. Once thought to be a common location for SCC following long-term PUVA therapy, this complication can be avoided by shielding the genitalia during treatment, and this association is rarely seen today. Perianal SCC may also occur (Fig. 80-6).

FIGURE 80-6 Perianal SCC in situ. Identification of these lesions requires thorough proctoscopic exam and monitoring for invasive SCC.

Scar SCC

SCCs arising in scars typically begin decades after injury with skin breakdown and persistent erosion. Most commonly this occurs on the lower extremities at sites of chronic pyogenic or venous stasis ulcers. Gradually there is acquisition of nodularity, although detection is often delayed because of concealment by surrounding indurated scar tissue. In the case of SCC developing in chronic sinuses, however, nodularity may not be present. The development of increased pain, drainage, or bleeding alone should raise concern and warrant further investigation.

Keratoacanthoma

The hallmark of this tumor is rapid growth, up to several centimeters in weeks, and then gradual involution over a period of months in most cases (see Chap. 83). The typical presentation is in an elderly patient on a sun-exposed site, particularly an extremity. Morphologically, keratoacanthoma is usually a large, smooth, dome-shaped, verrucous nodule with a central keratotic crater. Although historically viewed as a benign neoplasm because of its tendency toward spontaneous resolution, the keratoacanthoma can be locally destructive and aggressive and must be viewed as a clinical subtype of SCC. This tumor may occur in association with sebaceous neoplasms and gastrointestinal malignancies in the Muir-Torre syndrome.

Verrucous Carcinoma

This form of SCC encompasses several clinical entities all characterized by slow-growing exophytic tumors with cauliflower-like appearance that develop at sites of chronic irritation. [54] They may be clinically mistaken for giant warts. Four subtypes are recognized based on site of occurrence. Type I consists of oral tumors on the buccal mucosa of elderly male tobacco chewers, and have been referred to as *oral florid papillomatosis*. Representing 2 to 12 percent of all oral cancers, they are most commonly found on the buccal mucosa, tongue, gingiva, and floor of the mouth. Type II is the *anogenital type,* as described by Buschke and Loewenstein. It occurs on the glans penis of young uncircumcised males, the scrotum, perianally in both sexes, and, less commonly, on the female genitalia. Type III, also known as *epithelioma cuniculatum,* is a malodorous tumor often found on the plantar feet of elderly men (Fig. 80-7). It usually involves the skin underlying the first metatarsal head and tends to form draining sinuses that are caniculated (like rabbit burrows) in appearance. Finally, type IV occurs at other sites including the scalp, trunk and extremities. Detection of HPV type 6, 11, 16, and 18 sequences in epithelioma cuniculatum and type 11 sequences in oral verrucous carcinoma raises the possibility that these tumors evolve from verruca vulgaris.

FIGURE 80-7 Epithelioma cuniculatum, verrucous carcinoma of foot.

Metastatic SCC

Metastatic SCC in the skin can have a variety of presentations. It may be signaled by a palpable lymph node near the treatment site of a prior SCC. On the other hand, it may present as large keratotic papules or nodules resembling the primary lesion (Fig. 80-8). Metastatic SCC on the skin may be the first sign of internal malignancy, initially presenting in the skin as clusters of firm pink or red papules that may be keratotic centrally.

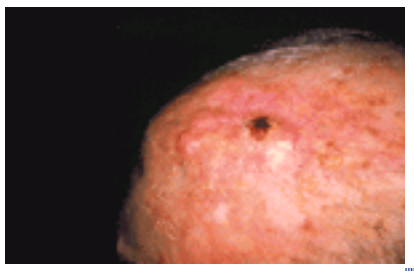

FIGURE 80-8 SCC metastatic to skin.

HISTOPATHOLOGY

GENERAL CONSIDERATIONS

The hallmark of invasive SCC is the extension of atypical keratinocytes beyond the basement membrane and into the dermis (Fig. 80-9). The absence of a connection between tumor cells and the epidermis should raise concern for metastatic SCC, although this may simply reflect undermining from adjacent tumor. In every case, it is important to note clues that may indicate a precursor lesion or particular etiology. For example, the presence of solar elastosis and keratinocyte atypia at the margins would suggest that the SCC is actinically derived. On the other hand, the presence of scar tissue may indicate recurrent disease or a sinister scar-associated SCC. These considerations have important implications for treatment and prognosis, as discussed below.

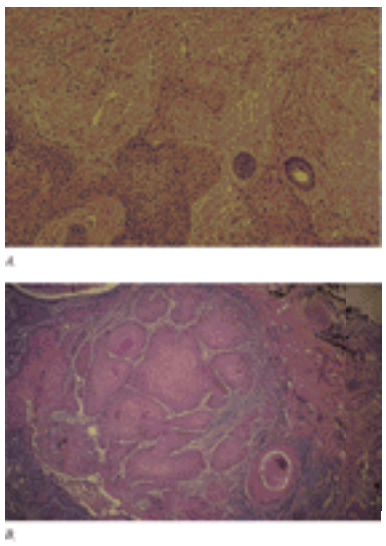

FIGURE 80-9 *A.* Low-power magnification of SCC demonstrating invasive cancer. *B.* SCC demonstrating atypical keratinocytes and foci of keratinization.

Basic Features

The tumor may appear as single cells, small groups or nests of cells, or a single mass. The inferior border may broadly impose on the dermis, or be represented by individual foci of microinvasion. Invasive tumor is usually confined to the dermis, and subcutaneous involvement is unusual. There are typically varying proportions of normal-appearing and atypical squamous cells, the latter characterized by increased mitoses, aberrant mitotic figures, nuclear hyperchromasia, and loss of intercellular bridges. Squamous differentiation is seen as foci of keratinization in concentric rings of squamous cells called *horn pearls*. Loss of differentiation is associated with decreased keratin production.

Grading

Histologic grading of SCC is based on degree of cellular differentiation. Low-grade tumors are comprised of uniform cells, resembling mature keratinocytes, with intracellular bridges and keratin production. High-grade SCC, by contrast, is characterized by atypical cells, loss of intracellular bridges, and minimal or absent keratin production. Another feature of higher-grade tumors is a less-distinct demarcation between malignant cells and adjacent normal stroma. In 1932, Broders [55] introduced a formal grading system based on keratinocyte differentiation that is still used today. Tumors are graded on a scale of 1 to 4 based on increasing percentages of undifferentiated cells (Table 80-2). In addition to grade, the depth of penetration, tumor thickness, and hair follicle involvement should also be reported.

Grade	% Undifferentiated Cells	Other Features
1	<25	Keratinization
2	<50	
3	<75	
4	>75	Atypia, loss of intracellular bridges

TABLE 80-2 **Broders' Grading System for SSC**

Histologic Subtypes

There are many histologic subtypes of SCC. [56] In the *adenoid* (or pseudoglandular) SCC, there is a tubular microscopic pattern and keratinocyte acantholysis. In *clear cell* SCC, the keratinocytes appear clear as a result of hydropic cytoplasmic swelling and accumulation of lipid vacuoles. *Spindle cell* SCC reveals spindle-shaped atypical cells. *Signet-ring cell* SCC is a rare variant characterized by concentric rings composed of keratin and large vacuoles corresponding to markedly dilated endoplasmic reticulum. In addition, a *basaloid* variant has been described. In *verrucous carcinoma,* the superficial component resembles verruca vulgaris with prominent acanthosis and papillomatosis, while the deeper component extends downward, displacing collagen bundles. Finally, *keratoacanthoma* reveals a symmetric keratin-filled crater, with the epidermis on each side extending over to form a distinct lip.

DIAGNOSIS AND DIFFERENTIAL DIAGNOSIS

Making the Diagnosis

The diagnosis of SCC is always made by skin biopsy. Any persistent, enlarging or nonhealing lesion, particularly if on a sun-exposed site, warrants biopsy evaluation. It is important that the biopsy be of sufficient depth so that invasive SCC can be distinguished from in situ disease. If a lesion is flat or minimally elevated (less than 1 mm), the superficial shaving technique minimizes wound size and scarring, and is usually adequate. For elevated lesions, the punch technique or a deep shave excision should be used to ensure that a specimen of adequate depth is taken. Because the diagnosis of keratoacanthoma depends largely on overall architecture, excisional biopsy or an incisional ellipse through the entire lesion is recommended. A tangential excision through the deep dermis also usually suffices.

Differential Diagnosis

Clinically, the differential diagnosis of SCC is long, but can be narrowed based on lesion morphology. For verrucous or scaly lesions, benign considerations include wart, seborrheic keratosis, AK, melanocytic nevus, pyogenic granuloma, eccrine poroma, and deep fungal infections such as chromomycosis. The entity “erosive pustular dermatosis of the scalp” is a benign condition often initially mistaken for SCC. Other malignant verrucous lesions include atypical fibroxanthoma,

BCC, Bowen's disease, verrucous melanoma, Merkel cell carcinoma, and, of course, metastatic SCC. Pigmented SCC in particular may mimic melanoma. For ulcerative lesions, additional diagnoses include trauma, BCC, and herpes virus infection (either herpes simplex virus or varicella-zoster virus).

Histologically, the differential diagnosis of well-differentiated SCC includes verruca vulgaris and inverted follicular keratosis. In addition, reactive epidermal hyperplasia (pseudoepitheliomatous hyperplasia) secondary to mycosis, halogenated drug eruptions (bromoderma and iododerma), and even mechanical trauma can mimic SCC. In these hyperplasias, however, the keratinocytes usually remain well differentiated; the margins of the proliferating epidermis are often pointed or irregular, rather than bulbous; there is leukocyte invasion with occasional keratinocyte disintegration; and granulomas or intraepidermal abscesses may be present. [57] Some adenoid SCC may demonstrate a pseudovascular pattern, with erythrocytes in pseudovascular spaces, and may be confused with angiosarcoma; these tumors do not express factor VIII antigens or bind ulex agglutinin. Clear cell SCC may simulate adnexal tumors with sebaceous differentiation or sebaceous carcinoma. Distinguishing spindle cell SCC from atypical fibroxanthoma is difficult. The differential diagnosis of poorly differentiated SCC also includes fibrosarcoma, Merkel cell carcinoma, and melanoma. In most cases, SCC can be distinguished from these others by special stains for various cytokeratins, but, in difficult cases, electron microscopy may be needed to establish the diagnosis. [56] In general, SCC does not stain for melanocyte (S-100, HMB-45) or smooth muscle (vimentin, actin) markers.

RECURRENCE AND METASTASIS

SCC, like BCC, may cause local tissue destruction, but it also has significant potential for metastasis. Metastases, when they occur, are generally to regional lymph nodes, and are detected 1 to 3 years after initial diagnosis and treatment. [19] In many cases, metastasis is preceded by local recurrence at the site of the primary lesion. Historically, the reported rate of metastasis for SCC ranges from 0.5 to 6 percent, [58], [59] and tends to occur with tumors that are large, recurrent, and involve deep structures or cutaneous nerves (Fig. 80-10).

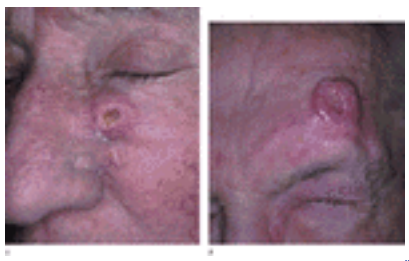

FIGURE 80-10 *A.* Infiltrative SCC demonstrating retraction of underlying tissue of the left cheek, where extension might involve infraorbital nerve. *B.* SCC of left side of forehead, where extension to bone with invasion might lead to death.

High-Risk Lesions

In a classic study, Rowe et al. [60] reviewed all major series of SCC dating back to 1940 to determine risk factors associated with recurrence and metastasis. Table 80-3 summarizes the characteristics of “high-risk” lesions. With respect to *size,* tumors less than 2 cm in diameter are low-risk, with an overall metastatic rate of roughly 1 percent. In one study, [61] the metastatic rate increased to 9.2 percent and 14.3 percent for tumors of 2 to 5 cm and greater than 5 cm, respectively. With respect to *depth and invasion,* tumors less than 4 mm deep and Clark levels I to III have limited metastatic potential, while close to half of those greater than 4 mm and Clark levels IV or V were metastatic in some series. [61], [62] Tumor involvement of bone, nerve, or muscle tissue is highly associated with metastasis. With respect to *anatomic site,* SCC of the ear has the highest rate of recurrence (18.7 percent), while lip SCC has the highest rate of metastasis (13.7 percent), with half of lip metastases present at time of initial diagnosis. [60] All SCCs *arising in scars* are high-risk, with metastatic rates approaching 40 percent in some series. [63] By contrast, SCCs arising in actinically damaged skin are of considerably lower risk, with an average metastatic rate of 5.2 percent. [60] *Poorly differentiated* SCCs (Broders' grade 3 or 4) demonstrate a recurrence rate of 28.6 percent and metastatic rate of 32.8 percent, as compared to 13.6 percent and 9.2 percent, respectively, for well-differentiated tumors. [60] The prognosis is particularly poor for spindle cell SCCs. [64] *Immune status* is another important consideration, as one study [65] found that 23 percent of patients with metastatic SCC were immunosuppressed. A heavy *inflammatory response* appears to be a favorable prognostic sign, as absence of infiltrate has been correlated with higher rates of recurrence and metastasis.

Diameter greater than 2 cm
Depth greater than 4 mm and Clark level IV or V
Tumor involvement of bone, muscle, nerve
Location on ear, lip
Tumor arising in scar
Broders grade 3 or 4
Patient immunosuppression
Absence of inflammatory infiltrate

TABLE 80-3 **High-Risk SSC**

TREATMENT

Table 80-4 summarizes the variety of treatment modalities available for SCCs. Treatment selection is largely directed by assessment of tumor risk for recurrence and metastasis, as discussed above. Ablative techniques such as electrodesiccation and curettage, liquid nitrogen cryotherapy, carbon dioxide laser, intralesional chemotherapy, and photodynamic therapy are superficial, do not allow histologic margin control, and thus are generally inappropriate for

invasive SCCs. An exception may be the use of topical 5-fluorouracil for conjunctival SCCs. [66]

Nonexcisional ablative techniques (in situ disease only, or special circumstances)
Mohs surgery
Conventional surgical excision
Radiation

TABLE 80-4 **Treatment of SCC**

Surgical Excision

Conventional surgical excision is viewed by most as the treatment of choice for primary SCCs. Recommended margins are 4 mm for low-risk lesions or SCCs with a depth less than 2 mm; for lesions with depth greater than 6 mm or diameter greater than 1 cm, margins of 6 mm or Mohs microscopically controlled surgery (MMCS) are recommended. [67] MMCS is recommended in specific circumstances when the highest cure rate and minimal tissue destruction are desired (Table 80-5). Specifically, cases involving deeply infiltrative tumor; history of radiation at the site; involvement of underlying structures (nerve, bone, muscle); immunosuppression; recurrent or large tumor; poorly defined clinical margins; sites with high recurrence rates (lip, ear, nail bed); and sites important for tissue preservation (nasal tip, lip, eyelid, ear, genitalia) should strongly be considered for Mohs surgery. [68] Additional indications include verrucous carcinomas and high-risk SCCs such as those arising from chronic scarring conditions.

Infiltrative SCC
Poorly defined clinical margins
Lip, ear, nail bed, nasal tip, eyelid, genitalia
History of radiation at site
Involvement of nerve, bone, muscle
Immunosuppressed patient
Recurrent or large SCC
Verrucous carcinoma
SCC arising from chronic scarring conditions

TABLE 80-5 **Indications of Mohs Surgery**

Radiation

Radiation can be used for superficially invasive to moderate-risk lesions, and serves as an important adjuvant to excisional surgery in treating residual microscopic disease and prophylaxis against metastatic disease. It has been shown to be particularly useful for SCCs of the external auditory canal. [69] Radiotherapy is not advised for verrucous carcinoma, in which there is an associated low rate of anaplastic transformation. Radiation may also be used as adjuvant therapy in cases where perineural SCC was identified on surgical pathology specimens but treatment failures occur.

Recurrence Rates

In their extensive review noted above, Rowe et al. [60] also assessed responses to treatment. They reported increasing combined rates of recurrence with each of the following treatment modalities (for primary cancers): MMCS (3.1 percent), electrodesiccation and curettage (3.7 percent), excisional surgery (8.1 percent), and radiation (10 percent). A recent review of MMCS for SCC with 4-year follow-up reported a cure rate of 92 percent. [70] The surprisingly low rate of recurrence for electrodesiccation and curettage likely reflects its judicious use for low-risk lesions. Similarly, the recurrence rates for both MMCS and excisional surgery may be somewhat skewed by their use for high-risk lesions. For lip SCC, the overall recurrence rate was 2.3 percent for Mohs surgery as compared to 10.5 percent for other modalities; for ear SCC, the recurrence rates were 5.3 percent and 18.7 percent, respectively. [60] For all recurrent tumors, cure rates were 76.7 percent with excision, as compared to 90 percent with Mohs surgery. [60] For low-risk SCCs, overall recurrence rates were 1.9 percent with Mohs surgery versus 16.5 percent with all other modalities. [60] Overall 5-year survival rates for metastatic SCCs were 26.8 percent, [60] with poorer outcomes among patients with lip lesions [71] and those treated with surgery alone (and no radiation).

Treatment of High-Risk Lesions

Management of high-risk lesions is reviewed elsewhere. [72] Oral 5-fluorouracil has been used for aggressive lesions refractory to conventional treatments. [73] Additional treatments, including beta-carotene, interferon, and retinoids, have been employed with variable results. High-risk lesions may require formal staging. Computed tomography or magnetic resonance imaging may be useful in the detection of advanced perineural involvement of head and neck SCC. [74] Sentinel lymphadenectomy has been combined with MMCS. [75] Involvement of lymph nodes may warrant radical lymph node dissection and radiation therapy. Elective cervical lymphadenectomy may be indicated for high-risk lesions of the lip. [76] In cases of negative clinical lymph node examination, further intervention may still be indicated if the tumor is considered sufficiently high-risk.

Patient Follow-up

Following a diagnosis of SCC, all patients should be considered at high risk for developing additional lesions of SCC as well as BCC. They should be seen at regular intervals, ranging between 3 and 12 months, depending on the degree of prior lesion risk, status of precursor lesions, and individual patient compliance. A complete skin examination should be performed at each visit, including examination of the oral mucosa. In addition, sites of previous lesions and treatments

should be assessed for signs of recurrence. Finally, a lymph node exam is indicated to monitor for metastatic disease.

REFERENCES

1. Pott P: *Chirurgical Observations Relative to the Cataract, the Polypus of the Nose, the Cancer of the Scrotum, and Different Kinds of Ruptures, and Mortification of the Toes and Feet.* London: Hawes, Clark & Collins, 1775

2. Waterhouse JA: Cutting oils and cancer. *Ann Occup Hyg* **14**:161, 1971

3. Waldron HA et al: Scrotal cancer in the West Midlands 1936–76. *Br J Indus Med* **41**:437, 1984

4. Horton CE et al: The malignant potential of burn scars. *Plast Reconstr Surg* **22**:348, 1958

5. Neubauer O: Arsenical cancer: A review. *Br J Cancer* **1**:192, 1947

6. Hutchinson J: Arsenic cancer. *Br Med J* **2**:1280, 1887

7. Traenkle HL: X-ray-induced skin cancer in man. *Natl Cancer Inst Monogr* **10**:423, 1963

8. Dabski K, Stoll HL Jr: Skin cancer caused by grenz rays. *J Surg Oncol* **31**:87, 1986

9. Alam M, Ratner D: Cutaneous squamous-cell carcinoma. *N Engl J Med* **344**:975, 2001

10. Boring CC et al: Cancer statistics, 1994. *CA Cancer J Clin* **44**:7, 1994

11. Jemal A et al: Recent trends in cutaneous melanoma incidence among whites in the United States. *J Natl Cancer Inst* **93**:678, 2001

12. Marks R: Epidemiology of non-melanoma skin cancer and solar keratoses in Australia: A tale of self-immolation in Elysian fields. *Australas J Dermatol* **38**(Suppl 1):S26, 1997

13. Kennedy C, Bajdik CD: Descriptive epidemiology of skin cancer on Aruba: 1980–1995. *Int J Dermatol* **40**:169, 2001

14. Miller DL, Weinstock MA: Nonmelanoma skin cancer in the United States: Incidence. *J Am Acad Dermatol* **30**:774, 1994

15. Weinstock MA: Nonmelanoma skin cancer mortality in the United States, 1969 through 1988. *Arch Dermatol* **129**:1286, 1993

16. Marcil I, Stern RS: Risk of developing a subsequent nonmelanoma skin cancer in patients with a history of nonmelanoma skin cancer: A critical review of the literature and meta-analysis. *Arch Dermatol* **136**:1524, 2000

17. Hemminki K, Dong C: Subsequent cancers after in situ and invasive squamous cell carcinoma of the skin. *Arch Dermatol* **136**:647, 2000

18. Rees JL, Healy E: Melanocortin receptors, red hair, and skin cancer. *J Investig Dermatol Symp Proc* **2**:94, 1997

19. Johnson TM et al: Squamous cell carcinoma of the skin (excluding lip and oral mucosa). *J Am Acad Dermatol* **26**:467, 1992

20. Ramani ML, Bennett RG: High prevalence of skin cancer in World War II servicemen stationed in the Pacific theater. *J Am Acad Dermatol* **28**:733, 1993

21. Chuang TY et al: Nonmelanoma skin cancer in Japanese ethnic Hawaiians in Kauai, Hawaii: An incidence report. *J Am Acad Dermatol* **33**:422, 1995

22. Vitaliano PP, Urbach F: The relative importance of risk factors in nonmelanoma carcinoma. *Arch Dermatol* **116**:454, 1980

23. Winkleman RK et al: Squamous cell carcinoma produced by ultraviolet light in hairless mice. *J Invest Dermatol* **40**:217, 1963

24. Stern RS, Lange R: Non-melanoma skin cancer occurring in patients treated with PUVA five to ten years after first treatment. *J Invest Dermatol* **91**:120, 1988

25. Miller SJ: Etiology and pathogenesis of basal cell carcinoma. *Clin Dermatol* **13**:527, 1995

26. Markey AC: Etiology and pathogenesis of squamous cell carcinoma. *Clin Dermatol* **13**:537, 1995

27. Gupta AK et al: Cutaneous malignant neoplasms in patients with renal transplants. *Arch Dermatol* **122**:1288, 1986

28. Weimar VM et al: Aggressive biologic behavior of basal- and squamous-cell cancers in patients with chronic lymphocytic leukemia or chronic lymphocytic lymphoma. *J Dermatol Surg Oncol* **5**:609, 1979

29. Scully C et al: Genetic aberrations in oral or head and neck squamous cell carcinoma 3: Clinicopathological applications. *Oral Oncol* **36**:404, 2000

30. Jin YT et al: Genetic alterations in oral squamous cell carcinoma of young adults. *Oral Oncol* **35**:251, 1999

31. Ziegler A et al: Sunburn and p53 in the onset of skin cancer. *Nature* **372**:773, 1994

32. Wang Y et al: Differential regulation of p53 and Bcl-2 expression by ultraviolet A and B. *J Invest Dermatol* **111**:380, 1998

33. Vogelstein B, Kinzler KW: p53 function and dysfunction. *Cell* **70**:523, 1992

34. Leffell DJ, Brash DE: Sunlight and skin cancer. *Sci Am* **275**:52, 1996

35. Li G et al: Induction of squamous cell carcinoma in p53-deficient mice after ultraviolet irradiation. *J Invest Dermatol* **110**:72, 1998

36. Wikonkal NM, Brash DE: Ultraviolet radiation induced signature mutations in photocarcinogenesis. *J Investig Dermatol Symp Proc* **4**:6, 1999

37. Stoll C et al: Prognostic significance of apoptosis and associated factors in oral squamous cell carcinoma. *Virchows Arch* **436**:102, 2000

38. Campbell C et al: p53 mutations are common and early events that precede tumor invasion in squamous cell neoplasia of the skin. *J Invest Dermatol* **100**:746, 1993

39. Nakazawa H et al: UV and skin cancer: Specific p53 gene mutation in normal skin as a biologically relevant exposure measurement. *Proc Natl Acad Sci U S A* **91**:360, 1994

40. Jonason AS et al: Frequent clones of p53-mutated keratinocytes in normal human skin. *Proc Natl Acad Sci U S A* **93**:14025, 1996

41. Hantschmann P, Kurzl R: Regulation of apoptosis in squamous cell carcinoma of the vulva. *J Reprod Med* **45**:633, 2000

42. Matsumoto M et al: Clinical significance and prognostic value of apoptosis related proteins in superficial esophageal squamous cell carcinoma. *Ann Surg Oncol* **8**:598, 2001

43. Xie X et al: The prognostic value of spontaneous apoptosis, Bax, Bcl-2, and p53 in oral squamous cell carcinoma of the tongue. *Cancer* **86**:913, 1999

44. Shindoh M et al: BAG-1 expression correlates highly with the malignant potential in early lesions (T1 and T2) of oral squamous cell carcinoma. *Oral Oncol* **36**:444, 2000

45. Grossman D et al: Expression of the apoptosis inhibitor, survivin, in nonmelanoma skin cancer and gene targeting in a keratinocyte cell line. *Lab Invest* **79**:1121, 1999

46. Lo Muzio L et al: Expression of the apoptosis inhibitor survivin in aggressive squamous cell carcinoma. *Exp Mol Pathol* **70**:249, 2001

47. Marks R et al: The role of childhood exposure to sunlight in the development of solar keratoses and non-melanocytic skin cancer. *Med J Aust* **152**:62, 1990

48. Rook AH et al: Beneficial effect of low-dose systemic retinoid in combination with topical tretinoin for the treatment and prophylaxis of premalignant and malignant skin lesions in renal transplant recipients. *Transplantation* **59**:714, 1995

49. Rook AH, Shapiro M: Cutaneous squamous-cell carcinoma. *N Engl J Med* **345**:296, 2001

50. Yarosh D et al: Effect of topically applied T4 endonuclease V in liposomes on skin cancer in xeroderma pigmentosum: A randomised study. Xeroderma Pigmentosum Study Group. *Lancet* **357**:926, 2001

51. Bernstein SC et al: The many faces of squamous cell carcinoma. *Dermatol Surg* **22**:243, 1996

52. Mora RG, Perniciaro C: Cancer of the skin in blacks. I. A review of 163 black patients with cutaneous squamous cell carcinoma. *J Am Acad Dermatol* **5**:535, 1981

53. Saito T et al: Development of squamous cell carcinoma from pre-existent oral leukoplakia with respect to treatment modality. *Int J Oral Maxillofac Surg* **30**:49, 2001

54. Schwartz RA: Verrucous carcinoma of the skin and mucosa. *J Am Acad Dermatol* **32**:1, 1995

55. Broders AC: Practical points on the microscopic grading of carcinoma. *N Y State J Med* **32**:667, 1932

56. Lohmann CM, Solomon AR: Clinicopathologic variants of cutaneous squamous cell carcinoma. *Adv Anat Pathol* **8**:27, 2001

57. Freeman RG: On the pathogenesis of pseudoepitheliomatous hyperplasia. *J Cutan Pathol* **1**:231, 1974

58. Katz AD et al: The frequency and risk of metastases in squamous cell carcinoma of the skin. *Cancer* **10**:1162, 1957

59. Lund HZ: How often does squamous cell carcinoma of the skin metastasize? *Arch Dermatol* **92**:635, 1965

60. Rowe DE et al: Prognostic factors for local recurrence, metastasis, and survival rates in squamous cell carcinoma of the skin, ear, and lip. Implications for treatment modality selection. *J Am Acad Dermatol* **26**:976, 1992

61. Breuninger H et al: Microstaging of squamous cell carcinomas. *Am J Clin Pathol* **94**:624, 1990

62. Friedman HI et al: Prognostic and therapeutic use of microstaging of cutaneous squamous cell carcinoma of the trunk and extremities. *Cancer* **56**:1099, 1985

63. Novick M et al: Burn scar carcinoma: A review and analysis of 46 cases. *J Trauma* **17**:809, 1977

64. Petter G, Haustein UF: Histologic subtyping and malignancy assessment of cutaneous squamous cell carcinoma. *Dermatol Surg* **26**:521, 2000

65. Dinehart SM et al: Immunosuppression in patients with metastatic squamous cell carcinoma from the skin. *J Dermatol Surg Oncol* **16**:271, 1990

66. Midena E et al: Treatment of conjunctival squamous cell carcinoma with topical 5-fluorouracil. *Br J Ophthalmol* **84**:268, 2000

67. Brodland DG, Zitelli JA: Surgical margins for excision of primary cutaneous squamous cell carcinoma. *J Am Acad Dermatol* **27**:241, 1992

68. Drake LA et al: Guidelines of care for Mohs micrographic surgery. American Academy of Dermatology. *J Am Acad Dermatol* **33**:271, 1995

69. Hashi N, et al: The role of radiotherapy in treating squamous cell carcinoma of the external auditory canal, especially in early stages of disease. *Radiother Oncol* **56**:221, 2000

70. Turner RJ et al: A retrospective study of outcome of Mohs' micrographic surgery for cutaneous squamous cell carcinoma using formalin fixed sections. *Br J Dermatol* **142**:752, 2000

71. Veness MJ et al: Squamous cell carcinoma of the lip. Patterns of relapse and outcome: Reporting the Westmead Hospital experience,

1980–1997. *Australas Radiol* **45**:195, 2001

72. Salasche SJ, Cheney ML: Recognition and management of the high-risk cutaneous squamous cell carcinoma. *Curr Probl Dermatol* **5**:141, 1993

73. Cartei G et al: Oral 5-fluorouracil in squamous cell carcinoma of the skin in the aged. *Am J Clin Oncol* **23**:181, 2000

74. Williams LS et al: Perineural spread of cutaneous squamous and basal cell carcinoma: CT and MR detection and its impact on patient management and prognosis. *Int J Radiat Oncol Biol Phys* **49**:1061, 2001

75. Weisberg NK et al: Combined sentinel lymphadenectomy and Mohs micrographic surgery for high-risk cutaneous squamous cell carcinoma. *J Am Acad Dermatol* **43**:483, 2000

76. Zitsch RP 3rd et al: Cervical lymph node metastases and squamous cell carcinoma of the lip. *Head Neck* **21**:447, 1999

T>

Chapter 81

John Carucci David Leffell

Basal Cell Carcinoma

EPIDEMIOLOGY
ETIOLOGY AND PATHOGENESIS
CLINICAL MANIFESTATIONS
Presentation
Basal Cell Carcinoma Subtypes
BIOLOGICAL BEHAVIOR
Local Invasion
Perineural Invasion
Metastasis
DIAGNOSIS
HISTOPATHOLOGY
Nodular BCC
Pigmented BCC
Superficial BCC
Morpheaform BCC
Fibroepithelioma of Pinkus
TREATMENT
Mohs Micrographic Surgery (see Chap. 279)
Standard Excision
Curettage and Desiccation
Cryosurgery
Topical Treatment
SPECIAL MANAGEMENT ISSUES
Incompletely Excised Basal Cell Carcinoma
Neurotropic Basal Cell Carcinoma
Metastatic Basal Cell Carcinoma
COURSE AND PROGNOSIS

REFERENCES

Basal cell carcinoma (BCC) is a malignant neoplasm derived from nonkeratinizing cells that originate in the basal layer of the epidermis. If left untreated, BCC can become invasive and may result in substantial tissue damage. Metastasis is a rare event.

EPIDEMIOLOGY

BCC is the most common cancer in humans. It is estimated that 900,000 new cases occur per year in the United States. [1] BCC is more common in elderly individuals, but is becoming increasingly common in people younger than 50 years of age. [2], [3] The malignancy accounts for approximately 75 percent of all nonmelanoma skin cancers and almost 25 percent of all cancers diagnosed in the United States. [4] The tumor characteristically develops on sun-exposed skin of lighter skinned individuals with 30 percent occurring on the nose. [3] Men are affected slightly more often than are women. Levi et al. report that the incidence of BCC rose steadily in the Swiss Canton of Vaud between 1976 and 1998 to levels in males of 75.1/100,000 and in females 66.1/100,000. [5] A recent study of nonmelanoma skin cancers in Aruba supports these findings. [6] In that study, BCC was the most common type of skin cancer diagnosed between 1980 and 1995. Tumors were more frequent in patients older than 60 years of age and 57% were in men. The greatest percentage of cases occurred on the nose (20.9 percent) followed by other sites on the face (17.7 percent).

Risk factors for BCC have been well characterized and include ultraviolet light (UVL) exposure, light hair and eye color, northern European ancestry, and inability to tan. [7] Although some investigators suggested a potential link between BCC and internal malignancies, this relationship remains to be defined. [8], [9] Bower et al. [10] recently reported that individuals with BCC had a threefold increased risk for melanoma, but no increased risk for any other type of cancer. Conversely, an increased risk for BCC has been reported in patients with a history of melanoma. [11]

ETIOLOGY AND PATHOGENESIS

The pathogenesis of BCC involves exposure to UVL, particularly the ultraviolet B (UVB) spectrum (290 to 320 nm) that induces mutations in tumor-suppressor genes. [3], [7]. [12], [13] and [14] Other studies indicate that intermittent brief holiday exposures may place patients at higher risk than occupational exposure. [15] Ramani and Bennett reported a significant increased incidence of BCCs in World War II servicemen stationed in the Pacific theater as compared to those stationed in Europe. [16] This suggests that several months or years of intense exposure to UVL may have deleterious long-term effects. Other factors that appear to be involved in the pathogenesis include mutations in regulatory genes, [17] exposure to ionizing radiation, [18] and alterations in immunosurveillance. [14]

The observation that BCC incidence is increased following radiation therapy (XRT) for conditions including neuroblastoma, tinea capitis, and acne vulgaris, suggests a role for this type of radiation in the etiology of some forms of this cancer. [18], [19] Although XRT is no longer used in the treatment of benign conditions, it is notable that the latency

period between treatment and recurrence may be as long as 40 years. Ron et al. [19] studied more than 10,000 patients radiated for tinea capitis and found a fourfold increase in skin cancers over nonirradiated controls. BCC accounted for 98 percent of tumors observed in this study.

The propensity to develop multiple BCCs may be inherited. Included among heritable conditions predisposing to the development of this epithelial cancer are the nevoid basal call carcinoma syndrome (NBCCS), [20] Bazex syndrome, [21] Rombo syndrome, [22] and unilateral basal cell nevus syndrome. [23] Patients with NBCCS may develop hundreds of BCCs and may exhibit a broad nasal root, borderline intelligence, jaw cysts, palmar pits, and multiple skeletal abnormalities (see Chap. 82). Recent studies indicate an association with mutations in the *PTCH* regulatory gene, which functions as a tumor-suppressor gene. [24] Mutations in the same gene, have been identified in sporadic nonfamilial BCC.

Bazex syndrome is transmitted in an x-linked dominant fashion. [21] Patients present with multiple BCCs, follicular atrophoderma, dilated follicular ostia with ice-pick scars, hypotrichosis, and hypohidrosis. In contrast, Rombo syndrome is transmitted in an autosomal dominant fashion. [22] Patients present with vermiculate atrophoderma, milia, hypertrichosis, trichoepitheliomas, BCCs, and peripheral vasodilation. Hypohidrosis is not a feature of Rombo syndrome. Linear basal cell nevus has been described including congenital, unilateral comedones and epidermoid cysts with basal cell proliferations that are thought to be basaloid follicular hamartomas. [23]

The role of the immune system in the pathogenesis of skin cancer is not completely understood. Immunosuppressed patients with lymphoma or leukemia, [25] and patients who have received an organ transplant, [26] have a marked increase in the incidence of squamous cell carcinoma (SCC), but only a slight increase in the incidence of BCC. Interestingly, Bastiaens et al. [27] found that transplant recipients developed more BCCs on the trunk and arms than did nonimmunosuppressed patients. Patients with HIV develop BCCs at the same rate as immunocompetent individuals, based on similar risk factors. [28] Immunosuppressed chronic alcoholics tend to develop infiltrative BCCs with increased frequency. [29]

A potential link between UVL and immunosurveillance has been suggested by Nickoloff and colleagues who demonstrated that UVL-induced BCC tumor cells express Fas ligand (CD95L). [14] They further showed that these cells were associated with CD95-bearing T cells undergoing apoptosis. This represents a potential mechanism by which UVL might facilitate the avoidance by the tumor cells of cytotoxic T lymphocytes.

CLINICAL MANIFESTATIONS

Presentation

The presence of any friable, nonhealing lesion should raise the suspicion of skin cancer. Frequently, BCC is diagnosed in patients who state that the lesion bled briefly, then healed completely only to recur. BCC usually develops on sun exposed areas of the head and neck but can occur anywhere on the body. Features include translucency, ulceration, telangiectasias, and the presence of a rolled border. Characteristics may vary according to clinical subtypes, which include nodular, superficial, morpheaform, and pigmented BCC and fibroepithelioma of Pinkus.

Basal Cell Carcinoma Subtypes

NODULAR BCC Nodular BCC is the most common clinical subtype of BCC (Fig. 81-1A and Fig. 81-1B). It occurs most commonly on the sun-exposed areas of the head and neck [30] and appears as a translucent papule or nodule depending on duration. There are usually telangiectasias and often a rolled border. Larger lesions with central necrosis are referred to by the historical term of “rodent ulcer” (Fig. 81-2). The differential diagnosis of nodular BCC includes dermal nevus and amelanotic melanoma.

FIGURE 81-1 *A.* Basal cell carcinoma, nodular type. *B.* An ulcerated nodular basal cell carcinoma.

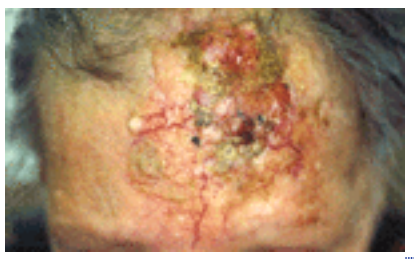

FIGURE 81-2 Basal cell carcinoma, rodent ulcer type. Extensive local tissue destruction is seen in this lesion.

PIGMENTED BCC Pigmented BCC is a subtype of nodular BCC that exhibits increased melanization. Pigmented BCC appears as a hyperpigmented, translucent papule which may also be eroded (Fig. 81-3). The differential diagnosis includes nodular melanoma.

FIGURE 81-3 Pigmented basal cell carcinoma. This lesion may resemble a malignant melanoma.

SUPERFICIAL BCC Superficial BCC occurs most commonly on the trunk [30] and appears as an erythematous patch (often well-demarcated) that resembles eczema (Fig. 81-4). An isolated patch of eczema that does not respond to treatment should raise suspicion for superficial BCC.

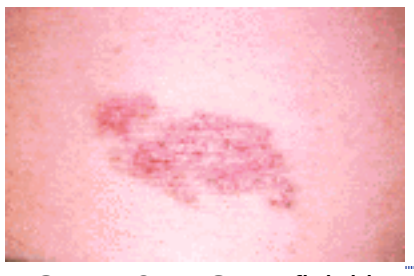

FIGURE 81-4 Superficial basal cell carcinoma. The well-demarcated plaque with a rolled edge characteristically occurs on the trunk.

MORPHEAFORM BCC Morpheaform BCC is an aggressive growth variant of BCC with a distinct clinical and histologic appearance. Lesions of morpheaform BCC may have an ivory white appearance and may resemble a scar (Fig. 81-5). Thus, the appearance of scar tissue in the absence of trauma or previous surgical procedure or the appearance of atypical appearing scar tissue at the site of a previously treated skin lesion should alert the clinician to the possibility of morpheaform BCC and the need for biopsy.

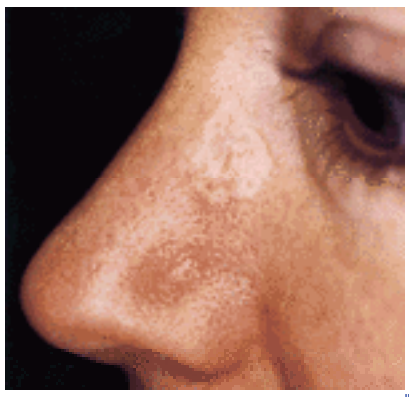

FIGURE 81-5 Morpheaform basal cell carcinoma. This lesion may resemble a scar and may be difficult to detect. It may, therefore, attain a considerable size before diagnosis.

FIBROEPITHELIOMA OF PINKUS Fibroepithelioma of Pinkus (FEP) classically presents as a pink papule, usually on the lower back. [31] It may be difficult to distinguish from amelanotic melanoma.

BIOLOGICAL BEHAVIOR

Local Invasion

The greatest danger of BCC results from local invasion. In general, BCC is a slow-growing tumor that invades locally rather than metastasizes. [32] The rate of doubling is estimated to be between 6 months and 1 year. [32] If left untreated, the tumor will progress to invade subcutaneous tissue, muscle, and even bone. Anatomic fusion planes appear to provide a low resistance path for tumor progression. Tumors along the nasofacial or retroauricular sulcus may be extensive. In one informative case, a patient documented the progression of his own tumor with photographs over a 27-year period. [33] The lesion, which encompassed an entire side of the face, including the maxillary sinus, apparently doubled over a 10-year period and grew rapidly in the 2 years prior to admission. This scenario occurs in the context of physical or psychiatric disability that interferes with judgment or access to health care. In another case, [34] a 35-cm BCC on the back of a 65-year-old man recurred after wide local excision and XRT, and compressed the spinal cord. There have been two other reported cases of BCC causing spinal cord compression. Extension to the central nervous system (CNS) has been described by Schroeder et al. [35] who report cerebral invasion from BCC on the scalp in a 51-year-old woman 4 years after

resection of a recurrent parietal BCC that had extended to bone and dura mater.

Perineural Invasion

Perineural invasion is uncommon in BCC and occurs most often in histologically aggressive or recurrent lesions. In one series, Niazi and Lamberty identified perineural invasion in less than 0.2% of cases. [36] In that series, perineural BCC was seen most often with recurrent tumors located in the preauricular and malar areas. Ratner et al. [37] showed a higher incidence in their study (3.8 percent). Perineural spread may present with pain, paresthesias, weakness, or paralysis. Cranial nerve involvement has been reported. [38] The presence of focal neurologic symptoms at the site of a previously treated skin cancer should raise concern about nerve involvement.

Metastasis

Metastasis of BCC occurs only rarely with rates varying from 0.0028 to 0.55 percent. [39], [40] and [41] Involvement of lymph nodes and lungs were most common. Domarus et al. [42] reported five cases of metastatic BCC in which perineural or intravascular invasion had been noted in three of the five cases. Squamous differentiation was not observed in the primary tumors in the cases they presented, but was noted in two of five cases of metastatic cancer. Overall, squamous differentiation was present in 15 percent of the primary or metastatic tumors from the 170 cases reviewed. Perineural invasion was present in 5 of 12 cases of metastatic BCC reported by Lo et al. [43]

DIAGNOSIS

Diagnosis of BCC is accomplished by accurate interpretation of the skin biopsy. The preferred biopsy methods include shave biopsy, which is often sufficient, and punch biopsy. The use of a sterilized razor blade, which can be precisely manipulated by the operator to adjust the depth of the biopsy is often superior to the use of a no. 15 scalpel for shave biopsies. A punch biopsy may be useful for flat lesions of morpheaform BCC or for diagnosis of recurrent BCC occurring in a scar.

HISTOPATHOLOGY

Histopathology varies somewhat with subtype, but most BCCs share some common histologic features. [44] The malignant basal cells have large nuclei and relatively little cytoplasm. Although the nuclei are large they may not appear atypical. Usually, mitotic figures are absent. Frequently, retraction of stroma from tumor islands is present, creating peritumoral lacunae that are helpful in histopathologic diagnosis.

Nodular BCC

Nodular BCC accounts for half of all BCCs and is characterized by nodules of large, basophilic cells and stromal retraction (Fig. 81-6). [44] The term micronodular BCC is used to describe tumors with multiple microscopic nodules less than 15 µm in size.

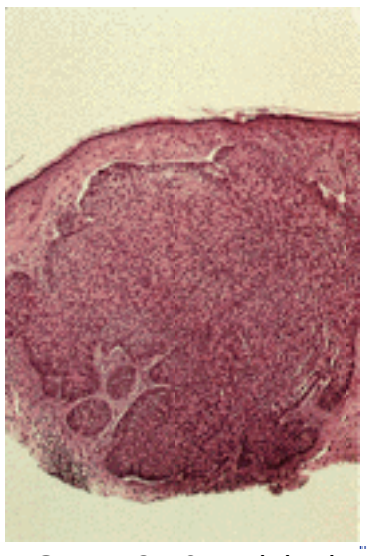

FIGURE 81-6 Nodular basal cell carcinoma. Palisading is evident at the periphery of tumor nodules.

Pigmented BCC

Pigmented BCC shows histologic features similar to nodular BCC but with the addition of melanin. [44] Approximately 75 percent of BCCs contain melanocytes but only 25 percent contain large amounts of melanin. The melanocytes are interspersed between tumor cells and contain numerous melanin granules in their cytoplasm and dendrites. Although the tumor cells contain little melanin, numerous melanophages populate the stroma surrounding the tumor.

Superficial BCC

Superficial BCC is characterized microscopically by buds of malignant cells extending into the dermis from the basal layer of the epidermis. [44] The peripheral cell layer shows palisading. There may be epidermal atrophy and dermal invasion is usually minimal. This histologic subtype is encountered most often on the trunk and extremities, but may also

appear on the head and neck. There may be a chronic inflammatory infiltrate in the upper dermis.

Morpheaform BCC

Morpheaform or infiltrative BCC consists of strands of tumor cells embedded within a dense fibrous stroma. [44] Tumor cells are closely packed and in some cases, only one cell thick. Strands of tumor extend deeply into the dermis. The cancer is often larger than the clinical appearance indicates (Fig. 81-7). Recurrent BCC may also demonstrate infiltrating bands and nests of cancer cells embedded within the fibrous stroma of scar (Fig. 81-8).

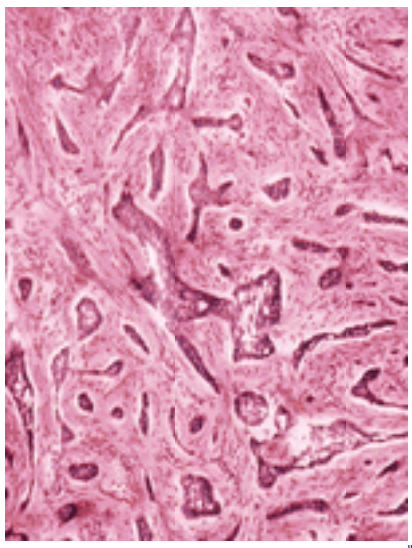

FIGURE 81-7 Infiltrative basal cell carcinoma. Small, spiky groups of cells are suggestive of aggressive behavior.

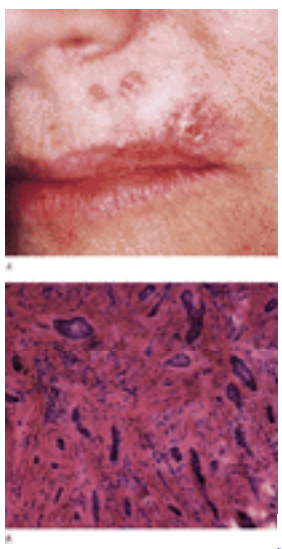

FIGURE 81-8 Recurrent basal cell carcinoma. *A*. Recurrence within a scar may be difficult to detect clinically and may be widely infiltrative. *B*. Recurrent basal cell carcinoma demonstrates deeply infiltrative nests of tumor cells.

Fibroepithelioma of Pinkus

In FEP, long strands of interwoven basiloma cells are embedded in fibrous stroma. [31] Histologically, FEP shows features of reticulated seborrheic keratoses and superficial BCC.

TREATMENT

Management is guided by anatomic location and histology. Approaches include Mohs micrographic surgery (MMS), standard surgical excision, destruction by various modalities, and topical chemotherapy. The best chance to achieve cure is through adequate treatment of primary BCC because recurrent tumors are more likely to recur and to cause further local destruction.

Mohs Micrographic Surgery (see Chap. 279)

MMS offers superior histologic analysis of tumor margins while permitting maximal conservation of tissue, when compared to standard excisional surgery. [45] In a series reviewed by Rowe et al., the recurrence rate for primary BCCs treated by MMS was approximately 1 percent. [46] This was superior to other modalities including standard excision (10 percent), curettage and desiccation (C&D) (7.7 percent), XRT (8.7 percent), and cryotherapy (7.5 percent). Recurrent BCC treated by MMS recurred with a rate of 5.6 percent, which was again superior to other modalities including excision (17.6 percent), XRT (9.8 percent), and C&D (40 percent). MMS is the treatment of choice for morpheaform, poorly delineated, incompletely removed, and otherwise high-risk primary BCC. It is the preferred treatment for recurrent BCC [47] and for any BCC that occurs at a site where tissue conservation is desired. MMS is particularly useful in high-risk anatomic sites including the embryonic fusion planes represented by the nasofacial junction and retroauricular sulcus (Table 81-1).

Recurrent tumor
Primary tumor
With aggressive histologic pattern
In site with high risk of recurrence (perioral, periorbital, nasolabial, nasal ala)
>2 cm diameter
With ill-defined clinical margin
Where tissue conservation is important (nasal tip and alae, lips, eyelid, fingers and toes, genitalia)

TABLE 81-1 **Indications for Mohs Micrographic Surgery in Basal Cell Carcinoma**

Standard Excision

Compared with nonexcisional techniques, standard surgical excision offers the advantage of histologic evaluation of the removed specimen. Although standard excision is appropriate for many BCCs, cure rates for standard excisional surgery are inferior to MMS in cases of primary morpheaform BCC, recurrent BCC, and tumors located in high-risk anatomic sites. [46], [47] Wolf and Zitelli [48] demonstrated that margins of 4 mm were adequate in 95 percent of nonmorpheaform BCC less than 2 cm in diameter when treated by standard excision. Johnson et al. [49] reported a 96.7 percent cure rate when the excision included a 2-mm margin beyond the area defined by curettage. Tumor was present in 64 of 403 curette margins and in 12 of 403 excision margins. The histologic subtype was aggressive in 11 of 12 cases with positive excision margins. Margins of 5 mm are necessary for primary morpheaform BCC or recurrent BCC. Excision of primary BCC should extend to fat to ensure adequate tumor removal.

Curettage and Desiccation

C&D is one of the most frequently used treatment modalities for BCC. That C&D is operator dependent was shown by Kopf et al., who identified a significant difference in cure rate between patients treated by private practitioners (94.3 percent) and those treated by residents (81.2 percent). [50] Spiller and Spiller showed a cure rate of 97 percent in 233 patients. [51] Cure rate decreased as a function of primary lesion size: for lesions less than 1.0 cm the cure rate was 98.8 percent; 95.5; for lesions between 1.0 and 2.0 cm; and 84 percent for lesions greater than 2.0 cm. Recurrences were noted most often on the forehead, temple, ears, nose, and shoulders. C&D is not recommended for large primary BCC, morpheaform BCC, or recurrent BCC.

Cryosurgery

Cryosurgery is another destructive modality that has been used in the treatment of BCC. [52] Two freeze-thaw cycles with a tissue temperature of -50°C (-58°F) are required to destroy BCC. In addition, a margin of clinically normal tissue must be destroyed to eradicate subclinical extension. Cryosurgery lacks the benefit of histologic confirmation of tumor removal. Kuflik and Gage [53] reported 99 percent cure rates in 628 patients followed for 5 years. Complications of cryosurgery may include hypertrophic scarring and postinflammatory pigmentary changes. Another serious potential adverse outcome is tumor recurrence obscured by fibrous scar tissue. Any recent change in a cryosurgery scar after normal healing is completed should raise the suspicion of recurrent BCC.

Topical Treatment

IMIQUIMOD Imiquimod is a recent addition to the nonsurgical options for treating BCC. It is a biologic response modifier that elicits local cytokine production including interferon (IFN)-a and interleukin (IL)-12. It is currently indicated for the treatment of condyloma. Beutner et al. [54] showed clearing of BCC with 10 to 16 weeks of treatment. In a phase II study by Marks et al., clearance rates of 69.7 percent, 73.3 percent, 87.9 percent, and 100 percent were achieved with once daily application three times per week, twice daily application three times per week, and once daily and twice daily application of imiquimod over 6 weeks. [55] Severe local reactions, including erythema, edema, pain, vesicles, ulceration, and scabbing, were observed frequently (up to 100 percent with twice daily treatment). Importantly, no patients discontinued therapy. Follow-up studies are necessary to determine the correct role of this modality.
5-FLUOROURACIL 5-Fluorouracil (5-FU), a topically applied chemotherapeutic agent used in the treatment of actinic keratoses, has also been used to treat BCCs. In one series, Epstein showed a 5-year recurrence rate of 21 percent, which was reduced to 6 percent when curettage was performed initially. [56] 5-FU is metabolized by dihydropyrimidine dehydrogenase (DHD) and is contraindicated in patients deficient in that enzyme. [57] The use of 5-FU to treat BCC should be carefully considered and should include an evaluation of the risk of recurrence and treatment failure.
PHOTODYNAMIC THERAPY Photodynamic therapy (PDT) involves the activation of a photosensitizing drug by visible light to produce activated oxygen species that destroy the constituent cancer cells. [58] Exogenous d-aminolevulinic acid increases intracellular production of the endogenous photosensitizer protoporphyrin type IX, which preferentially accumulates in tumor cells. Morton et al. [59] reported an 88 percent initial clearance of 40 large (>2 cm) BCCs after 1 to 3 treatments. The range of follow up was between 12 and 60 months. Clearance rates of 95 percent were reported by Varma et al. when tumors larger than 1.5 cm were excluded. [60]
RADIATION THERAPY In cases in which surgery is contraindicated, XRT can be considered. XRT may be useful in the treatment of primary BCC or in cases where postsurgical margins are positive for cancer. [61] Advantages include minimal patient discomfort and avoidance of an invasive procedure in a patient unwilling or unable to undergo surgery. Potential disadvantages include lack of histologic verification of tumor removal, prolonged treatment course, cosmesis that may worsen over time, and predisposition to aggressive and extensive recurrences. Local control rates of 93 to 97 percent have been reported; [62] however, cosmesis has been rated inferior to results achieved surgically. [63]

SPECIAL MANAGEMENT ISSUES

Incompletely Excised Basal Cell Carcinoma

Based on data from the 1960s suggesting that 50 to 70 percent of incompletely excised BCCs do not recur, some physicians adopted a “wait and see” approach. [64] In some cases, flap and graft repair may have been performed prior to confirmation of negative margins, thus distorting the anatomy. This confounds identification of positive margins for definitive treatment. Incomplete resection was addressed by Robinson and Fisher, [65] who reported on 994 consecutive patients referred for treatment of recurrent BCC that had been incompletely excised. Of these, only 32 were referred for MMS for complete tumor removal at the time the original operating surgeon received the pathologic confirmation of positive excision margins. Of the remaining 962 recurrent BCCs, the nose was the most common anatomic site (43 percent) and flap repair was the most common form of reconstruction (52 percent). Based on the potentially lengthy interval to definitive therapy for recurrence, it seems prudent to recommend MMS for the treatment of incompletely excised BCC. Patients unable to undergo reexcision should be evaluated for XRT.

Neurotropic Basal Cell Carcinoma

Perineural invasion by BCC is a rare event (<0.2 percent). [36] When perineural invasion is detected, every effort should be made to clear the tumor, preferably by MMS. We suggest that patients with microscopic evidence of perineural invasion be evaluated for adjunctive XRT after surgery. Control rates of 50 percent were reported by McCord et al. in patients with gross perineural disease treated with XRT alone or in combination with surgery. [66] Five-year control rates of 78 percent were achieved in patients with microscopic perineural disease treated by XRT alone or in combination with surgery. [67]

Metastatic Basal Cell Carcinoma

Although exceedingly rare, the possibility of metastatic disease exists and may need to be addressed. [32], [42], [43] If nodal disease is suspected on surgical exam, lymph node biopsy and imaging studies, as well as evaluation by medical and surgical oncologists, are indicated. Suspicion for distant metastatic disease must be followed up with appropriate imaging studies and consultation. Platinum-based chemotherapy has been used with modest results in metastatic BCC. [68]

COURSE AND PROGNOSIS

When treated appropriately the prognosis for most patients with BCC is excellent. Control rates as high as 99 percent have been achieved by MMS. [46] Although tumor control rates for primary tumors are high, patients must be monitored for recurrence and development of new primary BCCs. The risk for development of a second primary BCC ranges from 36 to 50 percent. [69] We recommend periodic full-body skin examinations and counseling about sun protection for any patient with a history of BCC. This is especially important because patients with a history of BCC are at increased risk for melanoma.

The prognosis for patients with recurrent BCC is still favorable, although recurrent tumors are more likely to recur again and to behave aggressively. Patients with a history of recurrent disease must be monitored more frequently for the development of further recurrences and new primary tumors. For the rare patient with metastatic disease prognosis is poor with mean survival of 8 to 10 months from diagnosis.

REFERENCES

1. Miller DLW, Weinstock MA: Nonmelanoma skin cancer in the United States: Incidence. *J Am Acad Dermatol* **30**:744, 1994

2. Roudier-Pujol C et al: Basal cell carcinoma in young adults: Not more aggressive than in older patients. *Dermatology* **199**:119, 1999

3. Gloster HM Jr, Brodland DG: The epidemiology of skin cancer. *Dermatol Surg* **22**:217, 1996

4. Strom SS, Yamamura Y: Epidemiology of nonmelanoma skin cancer. *Clin Plast Surg* **24**:627, 1997

5. Levi F et al: Trends in skin cancer incidence in Vaud: An update, 1976–1998. *Eur J Cancer Prev* **10**:371, 2001

6. Kennedy C, Bajdik CD: Descriptive epidemiology of skin cancer in Aruba: 1980–1995. *Int J Dermatol* **40**:169, 2001

7. Van Dam R et al: Risk factors basal cell carcinoma of the skin in men: Results from the health professionals follow up study. *Am J Epidemiol* **150**:459, 1999

8. Levi F et al: Incidence of invasive cancers following basal cell skin cancer. *Am J Epidemiol* **135**:722, 1998

9. Karagas MR et al: Occurrence of other cancers among patients with prior basal cell and squamous cell skin cancer. *Cancer Epidemiol Biomarkers Prev* **7**:157, 1998

10. Bower CPR et al: Basal cell carcinoma and risk of subsequent malignancies: A cancer registry based study in southwest England. *J Am Acad Dermatol* **42**:988, 2000

11. Kroumpouzos G et al: Risk of basal and squamous cell carcinoma in persons with prior cutaneous melanoma. *Dermatol Surg* **26**:547, 2000

12. Lindgren G et al: Basal cell carcinoma of the eyelids and solar ultraviolet radiation exposure. *Br J Ophthalmol* **82**:1412, 1998

13. Gailani MR et al: Relationship between sunlight exposure and a key genetic alteration in basal cell carcinoma [see comments]. *J Natl Cancer Inst* **88**:349, 1996

14. Gutierrez-Steil C et al: Sunlight-induced basal cell carcinoma tumor cells and ultraviolet-B–irradiated psoriatic plaques express Fas ligand (CD95L). *J Clin Invest* **101**:33, 1998

15. Naldi L et al: Host-related and environmental risk factors for cutaneous basal cell carcinoma: Evidence from an Italian case control study. *J*

Am Acad Dermatol **42**:446, 2000

16. Ramani ML, Bennett RG: High prevalence of skin cancer in World War II servicemen stationed in the Pacific theater. *J Am Acad Dermatol* **28**:733, 1993

17. Gailani MR et al: The role of the human homologue of *Drosophila* patched in sporadic basal cell carcinomas [see comments]. *Nat Genet* **14**:78, 1996

18. Karagas MR et al: Risk of basal cell and squamous cell skin cancers after ionizing radiation therapy. For The Skin Cancer Prevention Study Group. *J Natl Cancer Inst* **88**:1848, 1996

19. Ron E et al: Radiation induced carcinomas of the head and neck. *Radiat Res* **125**:318, 1991

20. Gorlin RJ: Nevoid basal cell carcinoma syndrome. *Dermatol Clin* **13**:113, 1995

21. Goeteyn M et al: The Bazex-Dupre-Christol syndrome. *Arch Dermatol* **130**:337, 1994

22. Ashinoff R et al: Rombo syndrome: A second case report and review. *J Am Acad Dermatol* **28**:1011, 1993

23. Bleiberg J, Brodkin RH: Linear basal cell nevus with comedones. *Arch Dermatol* **100**:187, 1969

24. Wicking C et al: Mutations of the human homolog of *Drosophila* patched in the nevoid basal cell carcinoma syndrome. *Cell* **85**(6):841, 1996

25. Ramsay HM et al: Multiple basal cell carcinomas in a patient with acute myeloid leukaemia and chronic lymphocytic leukaemia. *Clin Exp Dermatol* **24**:281, 1999

26. Espana A et al: Skin cancer in heart transplant recipients. *J Am Acad Dermatol* **32**:458, 1995

27. Bastiaens MT et al: Differences in age, site distribution, and sex between nodular and superficial basal cell carcinoma indicate different types of tumors. *J Invest Dermatol* **110**:880, 1998

28. Lobo DV et al: Nonmelanoma skin cancers and infection with the human immunodeficiency virus. *Arch Dermatol* **128**:623, 1992

29. Oram Y et al: Histologic patterns of basal cell carcinoma based upon patient immunostatus. *Dermatol Surg* **21**:611, 1995

30. McCormack C et al: Differences in age and body site distribution of the histological subtypes of basal cell carcinoma. A possible indicator of differing causes. *Arch Dermatol* **133**:593, 1997

31. Pinkus H: Epithelial and fibroepithelial tumors. *Arch Dermatol* **91**:24, 1963

32. Miller SJ: Biology of basal cell carcinoma (Part I). *J Am Acad Dermatol* **24**:1, 1991

33. Sherman JE, Talmor M: Slow progression and sequential documentation of a giant basal cell carcinoma of the face. *Surgery* **130**:90, 2001

34. Fogarty GB, Ainslie J: Recurrent basal cell carcinoma causing spinal cord compression. *Aust N Z J Surg* **71**:129, 2001

35. Schroeder M et al: Extensive cerebral invasion of a basal cell carcinoma of the scalp. *Eur J Surg Oncol* **27**:510, 2001

36. Niazi ZB, Lamberty BG: Perineural infiltration in basal cell carcinomas. *Br J Plast Surg* **46**:156, 1993

37. Ratner D et al: Perineural spread of basal cell carcinomas treated with Mohs micrographic surgery. *Cancer* **88**:1605, 2000

38. Carlson KC, Roenigk RK: Know your anatomy: Perineural involvement of basal and squamous cell carcinoma on the face. *J Dermatol Surg Oncol* **16**:827, 1990

39. Raszewski RL, Guyuron B: Long-term survival following nodal metastases from basal cell carcinoma. *Ann Plast Surg* **24**:170, 1990

40. Christian MM et al: Metastatic basal cell carcinoma presenting as unilateral lymphedema. *Dermatol Surg* **24**:1151, 1998

41. Berti JJ, Sharata HH: Metastatic basal cell carcinoma to the lung. *Cutis* **63**:165, 1999

42. Domarus H, Stevens PJ: Metastatic basal cell carcinoma. *J Am Acad Dermatol* **10**:1043, 1984

43. Lo JS et al: Metastatic basal cell carcinoma: Report of twelve cases with a review of the literature [see comments]. *J Am Acad Dermatol* **24**:715, 1991

44. Rippey JJ: Why classify basal cell carcinomas? *Histopathology* **32**:393, 1998

45. Vuyk H, Lohuis PJ: Mohs micrographic surgery for facial skin cancer. *Clin Otoloaryngol* **26**:265, 2001

46. Rowe DE et al: Long-term recurrence rates in previously untreated (primary) basal cell carcinoma: Implications for patient follow-up. *J Dermatol Surg Oncol* **15**:315, 1989

47. Rowe DE et al: Mohs surgery is the treatment of choice for recurrent (previously treated) basal cell carcinoma. *J Dermatol Surg Oncol* **15**:424, 1989

48. Wolf DJ, Zitelli JA: Surgical margins for basal cell carcinoma. *Arch Dermatol* **123**:340, 1987

49. Johnson TM, Swanson NA: Combined curettage and excision: A treatment method for primary basal cell carcinoma. *J Am Acad Dermatol* **24**:613, 1991

50. Kopf AW et al: Curettage-electrodesiccation treatment of basal cell carcinomas. *Arch Dermatol* **113**:439, 1977

51. Spiller W, Spiller RF: Treatment of basal cell epithelioma by curettage and electrodesiccation. *J Am Acad Dermatol* **11**:808, 1984

52. Kuflik EG: Cryosurgery updated. *J Am Acad Dermatol*; **31**:925, 1994

53. Kuflik E, Gage AA: The five-year cure rate achieved by cryosurgery for skin cancer. *J Am Acad Dermatol* **26**:283, 1992

54. Beutner KR et al: Therapeutic response of basal cell carcinoma to the immune response modifier imiquimod 5% cream. *J Am Acad Dermatol* **41**:1002, 1999

55. Marks R et al: Imiquimod 5% cream in the treatment of superficial basal cell carcinoma: Results of a multicenter 6-week dose-response trial. *J Am Acad Dermatol* **44**:807, 2001

56. Epstein E: Fluorouracil paste treatment of thin basal cell carcinomas. *Arch Dermatol* **121**:207, 1985

57. Johnson MR et al: Life-threatening toxicity in a dihydropyrimidine dehydrogenase deficient patient after treatment with topical 5-fluorouracil. *Clin Cancer Res* **8**:2006, 1999

58. Fritsch C et al: Photodynamic therapy in dermatology. *Arch Dermatol* **134**:207, 1998

59. Morton CAWC et al: Photodynamic therapy for large or multiple patches of Bowen disease and basal cell carcinoma. *Arch Dermatol* **137**:319, 2001

60. Varma SWH et al: Bowen's disease, solar keratoses, and superficial basal cell carcinomas treated by photodynamic therapy using a large-field incoherent light source. *Br J Dermatol* **144**:567, 2001

61. Halpern JN: Radiation therapy in skin cancer. A historical perspective and current applications. *Dermatol Surg* **23**:1089, 1997

62. Morrison WHGA, Kian Ang K: Radiation therapy for nonmelanoma skin carcinomas. *Clin Plast Surg* **24**:719, 1997

63. Petit JYAM et al: Evaluation of cosmetic results of a randomized trial comparing surgery and radiotherapy in the treatment of basal cell carcinoma of the face. *Plast Reconstr Surg* **105**:2544, 2000

64. Gooding CAWG, Yatsuhashi M: Significance of marginal extension in excised basal cell carcinoma. *N Engl J Med* **273**:923, 1965

65. Robinson JKFS: Recurrent basal cell carcinoma after incomplete resection. *Arch Dermatol* **136**:1318, 2000

66. McCord MW et al. Skin cancer of the head and neck with clinical perineural invasion. *Int J Radiat Oncol Biol Phys* **47**:89, 2000

67. McCord MW et al: Skin cancer of the head and neck with incidental microscopic perineural invasion. *Int J Radiat Oncol Biol Phys* **43**:591, 1999

68. Moeholt K et al: Platinum-based cytotoxic therapy in basal cell carcinoma—A review of the literature. *Acta Oncol* **35**:677, 1996

69. Czarnecki D: The prognosis of patients with basal and squamous cell carcinoma of the skin. *Int J Dermatol* **37**:656, 1998

T>

Chapter 82

Ervin Epstein

Basal Cell Nevus Syndrome

ETIOLOGY AND PATHOGENESIS
Genetic Abnormality[4]
PTCH1 Function
CLINICAL FEATURES
PATHOLOGY
DIAGNOSIS
Differential Diagnosis
TREATMENT

REFERENCES

The basal cell nevus syndrome (BCNS; nevoid basal cell carcinoma syndrome, Gorlin syndrome, [*MIM* 109400]) is a rare autosomal dominant abnormality with a panoply of phenotypic abnormalities that can be divided into developmental anomalies and postnatal tumors, especially basal cell carcinomas (BCCs). [1] Although individual aspects had been reported previously, their syndromic association was appreciated widely first in the late 1950s. [2], [3] As in many dominant conditions, new mutations are common, and so patients frequently have no affected ancestors or siblings.

ETIOLOGY AND PATHOGENESIS

Genetic Abnormality [4]

The BCNS is caused by mutations in the *PATCHED1* (*PTCH1*) gene. [5], [6] This gene is the human homologue of the *Drosophila patched* (*ptc*) gene, which is essential for the establishment of normal body and limb patterning in the developing fly embryo. Efforts to identify this gene began in the mid-1980s when it became apparent that (1) the appearance of BCCs in small numbers at an older age in sporadic cases and in larger numbers at a younger age in patients with BCNS is reminiscent of differences in sporadic and hereditary cases of retinoblastoma; [7] (2) BCCs follow the Knudson “two-hit” model for familial cancers; and (3) a tumor-suppressor gene important in the common sporadic BCCs might be identified by study of the rare BCNS. Numerous laboratories participated in efforts to identify the BCNS gene, and its cloning enabled verification of the prediction that the same gene is mutated in BCCs by two somatic “hits” in sporadic cases or by one somatic hit plus the inheritance of one defective allele in BCNS patients. Mutations in *PTCH1* have been identified in other sporadic tumors as well, including those known to be present in greater-than-expected numbers in BCNS patients (e.g., medulloblastomas and meningiomas). Screening has identified *PTCH1* somatic mutations in a minority of BCCs and constitutional mutations in less than 100 percent of BCNS patients, but it is likely that much or all of at least the latter “failure” is due simply to insensitivity/incompleteness of the screening methods used thus far. The *PTCH1* gene resides on chromosome 9q, and no family with BCNS has been reported in which the causative gene does not map to this site.

PTCH1 Function

The best-investigated function of the PTCH1 protein is its role as a participant in the hedgehog signaling pathway. Genetic and biochemical evidence indicates that PTCH1 protein inhibits this signaling pathway by inhibiting the function at the cell periphery of smoothened (SMO) protein and that the extracellular ligand hedgehog alleviates this inhibition. Signaling by SMO results in the activation of the GLI family (particularly GLI1 and GLI2) of transcription factors. SMO signaling proceeds through interacting proteins including the serine kinase FUSED, suppressor of FUSED, protein kinase A, and Costal 2 (no vertebrate homologue identified). Both the predicted 7-transmembrane protein structure and more direct biochemical evidence indicate that SMO can function as a G protein-coupled receptor. [8] Classically (i.e., circa mid-1990s), PTCH1 inhibition of SMO function was considered to be mediated by direct binding of PTCH1 protein to SMO protein, and, indeed, PTCH1, SMO, and hedgehog proteins all can be found bound to each other. [9], [10] More recently, however (i.e., since circa 2000), the alternative view that PTCH1 protein controls SMO functioning by indirect means has gained more credence. Indeed, both PTCH1 and SMO protein appear, in large measure, not to be present at the cell surface, and abrogation of PTCH1 inhibition may be accompanied by activating changes (e.g., in phosphorylation) and translocation of SMO to the cell surface, where it is active in signaling. [11], [12] and [13] Binding of hedgehog (HH) to PTCH1 protein, on the other hand, removes PTCH1 from the cell surface, with internalization of HH–PTCH1 complexes.

Activation of GLI, likely controlled in part by proteolytic processing and its inhibition and by localization to the nucleus, enhances the expression of hedgehog target genes. Clearly these include PTCH1 protein itself, so that there is a negative feedback loop in which decreased PTCH1 protein function leads to increased PTCH1 mRNA expression and, if the mRNA is of normal sequence, increased PTCH1 protein and dampening of the pathway signaling. Also upregulated are mRNA species encoding HIP (hedgehog-interacting protein, a cell surface protein that binds hedgehog protein with an avidity equal to that of PTCH1 but of currently unknown function) and GLI1. BCCs essentially all have increased mRNA for these three genes, providing evidence that hedgehog signaling dysregulation is pivotal to BCC carcinogenesis. However, it is far from certain how hedgehog signaling dysregulation causes the failure of differentiation and continued proliferation that characterize this tumor. One candidate for part of that mechanism is the upregulation of platelet-derived growth factor receptor (PDGFR)-a expression with consequent activation of ras and of the

mitogen-activated protein kinase (MAPK) pathway. [14]

One paper also reports a separate and novel function of PTCH1 protein—its binding of cyclin B1. [15] This sequestration would be expected to keep the cyclin out of the nucleus, and binding of hedgehog to PTCH1 appears to prevent this interaction and hence to allow progression of the cell cycle from S to G1. Similarly, loss of PTCH1 protein function might in part abrogate the S/G2 checkpoint and help to account for cell-cycle abnormalities in BCCs. [16]

Mutations of SMO protein have been identified in approximately 10 percent of BCCs, and these mutations appear to render SMO protein resistant to PTCH1 inhibition. Indeed, experimental transfection of cells with mutant SMO sequences can transform them to a malignant phenotype. [17] This finding that BCCs may have upregulation of HH target gene expression due to mutations in either PTCH1 or in SMO argues that it is the upregulation of hedgehog signaling rather than the specific mutation that is crucial to BCC formation. Consistent with this is the finding that mutations in the gene encoding SUFU, an intracellular inhibitor of hedgehog signaling that helps keep GLI out of the nucleus, have been reported to underlie formation of medulloblastomas. [18]

The identification of these molecular abnormalities in BCCs for the first time has permitted the development of mouse models of this tumor. Previous insults to mouse skin—ultraviolet or ionizing radiation or carcinogenic chemicals—have produced papillomas and carcinomas of the squamous, but not basal cell, lineage. Models in which mice spontaneously develop BCC-like tumors include those with epidermal overexpression of hedgehog, [19] of mutant SMO, [17] or of GLI1 [20] or GLI2. [21] In addition, *ptc1*+/- mice, which, like BCNS patients, have one instead of two functioning alleles of *PTCH1*, develop not only BCCs and related tumors but also develop plantar pits, medulloblastomas, and rhabdomyosarcomas, as do BCNS patients. The mouse BCCs (mimicking BCCs in BCNS patients) occur spontaneously in low numbers and in small sizes but in much higher numbers and of greater size in mice exposed to ultraviolet or ionizing radiation. [22], [23]

PTCH1 normally is expressed not only postnatally but also, in vertebrates as well as in insects, during development. Experimental models with abnormalities of the hedgehog signaling pathway cause significant developmental anomalies in mice and flies. The resemblance of some of these anomalies to those characteristic of BCNS implies that aberrant prenatal activation of the hedgehog signaling pathway is a sufficient explanation for the developmental anomalies of the BCNS, even if the precise pathogenic mechanisms have yet to be elucidated.

CLINICAL FEATURES

Patients with BCNS sustain multiple abnormalities, none of which are unique to this syndrome. [1], [24], [25] and [26] The three abnormalities traditionally considered to be most characteristic of the syndrome are BCCs, pits of the palms and soles, and cysts of the jaw.

BCCs in patients with the BCNS cannot be distinguished individually from those in sporadic cases, which is not surprising in view of the similar pathogenesis in familial and sporadic cases. What is distinguishing is their appearance in large numbers starting at an early age. They may be banal-appearing and confused grossly with nevocytic nevi—hence the name *basal cell nevus*. They may also have a translucent, papulonodular appearance more characteristic of sporadic basal cell carcinomas and may invade locally, and even, rarely, metastasize, causing the patient's death. Although the ratio of sun-protected to sun-exposed BCCs may be higher in BCNS than in sporadic cases, sunlight clearly accelerates BCC formation in BCNS patients, and darkly pigmented BCNS patients may have few to no BCCs (Fig. 82-1, Fig. 82-2, Fig. 82-3 and Fig. 82-4).

FIGURE 82-1 Face of man with severe scarring from growth and treatment of multiple BCCs. Note multiple outlined new BCCs despite extensive and frequent surgery.

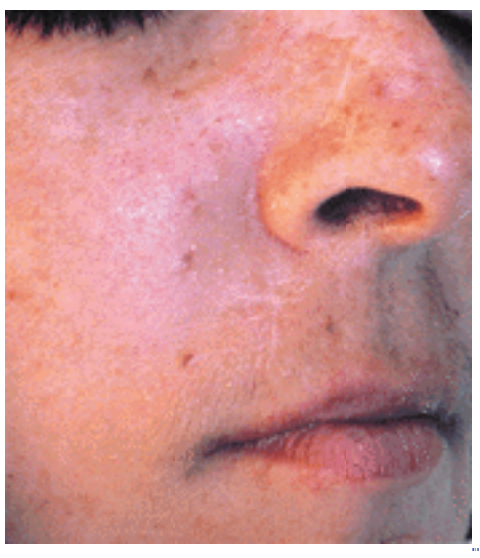

FIGURE 82-2 Face of woman with BCNS with less severe scarring with multiple milia.

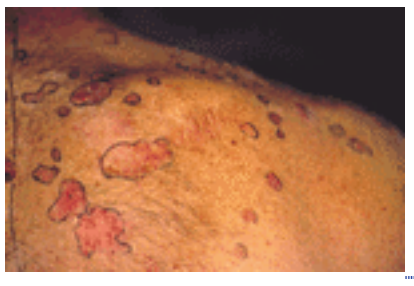

FIGURE 82-3 Upper back of man with BCNS with innumerable BCCs, some of which are nodular and most of which are flat, erythematous patches.

FIGURE 82-4 BCC on toe of a patient with BCNS, illustrating that the whole skin surface of BCNS patients is susceptible to BCC formation.

Palmoplantar pits are small defects in the stratum corneum and may be pink or, if dirt has accumulated, dark in color (Fig. 82-5). Jaw cysts often are the first detectable abnormality, and they may be asymptomatic and therefore diagnosed only radiologically. However, they also may erode enough bone to cause pain, swelling, and loss of teeth (see Chap. 112).

FIGURE 82-5 Unusually florid palmar pits in a patient with BCNS.

Tissue overgrowth, which also is a feature of hedgehog signaling pathway activation in *Drosophila*, often is manifested by an overall body size larger than that of other family members; limbs may be particularly long, giving a marfanoid appearance, and a large head circumference (at least in probands) and frontal bossing are often described.

Table 82-1 lists the phenotypic abnormalities that have been reported often enough that they probably are true components of the syndrome. Variation in clinical severity is typical even within a single kindred, and this heterogeneity is likely due to both environmental differences (e.g., exposure to ultraviolet and ionizing radiation) and genetic background differences.

TABLE 82-1 **Diagnostic Findings in Adults with Basal Cell Nevus Syndrome**

PATHOLOGY

Histologic examination cannot differentiate abnormalities that arise sporadically from those that arise in the context of BCNS.

DIAGNOSIS

Because the individual abnormalities are not unique to BCNS patients, it is possible to diagnose the BCNS clinically only when multiple, typical defects are present. The severity of abnormalities may differ markedly among members of a single kindred, and diagnostic certainty may be difficult for individuals even if they belong to a kindred with known BCNS. Generally, the diagnosis is suggested to the dermatologist in a patient with multiple BCCs arising at an unexpectedly early age and in unexpectedly large numbers. Further evaluation should include (1) questions about whether other family members have had abnormalities consistent with the BCNS (although perhaps 25 to 30 percent of patients with BCNS have no affected ancestors) and whether the patient is taller and heavier than his or her relatives; (2) examination for palmoplantar pits and skin cysts and assessment of body and head size; and (3) radiologic evaluation for jaw cysts (which often appear around the start of the second decade and which frequently recur following surgery [27]), calcification of the falx (which occurs in nearly all adults with BCNS [28] and which may be present in early childhood in BCNS patients, thus suggesting the diagnosis of BCNS in patients with early onset medulloblastomas [29]), and abnormalities of the ribs, spine, and phalanges (flame-shaped lucencies), each of which are present in one-third to one-half of BCNS patients (Fig. 82-6). Kimonis and colleagues have proposed a set of major and minor criteria for presumptive diagnosis of BCNS (Table 82-2). [25] Identification of *PTCH1* gene mutations eventually should become the “gold standard” for diagnosis.

TABLE 82-2 **BCNS Diagnostic Criteria**

FIGURE 82-6 Basal cell nevus syndrome. *A.* Short fourth, metacarpal (Albright's sign). A line drawn through the distal ends of the fifth and fourth metacarpals intersects the third metacarpal proximal to its end. *B.* Lamellar calcification of the flax (*arrow*).

Differential Diagnosis

Several very rare syndromes that include the development of multiple BCCs have been described. These include Bazex-Dupre-Christol syndrome, [30] the Rombo syndrome, [31] and a family with BCCs, milia, and coarse, sparse hair. [32] Hair abnormalities are present in all three syndromes; a finding of interest in view of the often-repeated suggestion that BCCs arise from hair follicles rather than from interfollicular epidermis. The exact nosologic relationships among these three syndromes are uncertain, but patients with the BCNS have normal hair, and all three syndromes seem quite different from the BCNS.

Patients with chronic arsenic ingestion may have multiple BCCs; their dyschromia and lack of other phenotypic abnormalities differentiate them from BCNS patients (Chap. 81). Patients with xeroderma pigmentosa develop multiple BCCs but are readily differentiated from BCNS patients by their severe photosensitivity and other phenotypic abnormalities (Chap. 155). Finally, patients with a marked propensity to develop multiple BCCs, sometimes sporadically and rarely following therapeutic irradiation (e.g., for Hodgkin's disease), occasionally produce diagnostic confusion, and it is not known whether their defect is related to the hedgehog pathway, to DNA repair, to an unknown toxin, and/or to undescribed mechanisms.

TREATMENT

Therapy must be directed at the individual lesions as they arise, and the most important aspect of management is frequent examination, enthusiastic counseling about avoidance of sun exposure, and early treatment of small tumors. Clinicians caring for BCNS patients generally become confident enough of their clinical acumen that they treat tiny BCCs,

for example, with cryotherapy, without histopathologic confirmation, because obtaining tissue for the latter produces more scarring. Other nonsurgical approaches often of real benefit are topical treatment with 5-fluorouracil (with or without occlusion, depending upon the degree of inflammation produced) or with imiquimod. [33] Oral therapy with retinoids also may be of real therapeutic value, but often only at a dose that causes severe side effects. Because the key is to convince the patient to accept frequent treatments, minimization of discomfort and of scarring is a major concern.

X-irradiation of BCCs should be avoided if possible, because enhanced radiation-induced carcinogenesis (e.g., in the skin of the portals of irradiation of childhood medulloblastomas) is characteristic of BCNS (Fig. 82-7).

FIGURE 82-7 Basal cell nevus syndrome. Multiple, large, fungating basal cell carcinomas arising in a portion of the lower back treated years earlier with superficial x-ray for therapy of basal cell carcinomas.

Genetic counseling is appropriate. Half of the children of affected individuals are expected to develop the BCNS, and prenatal diagnosis is potentially achievable for many families if they desire this option.

REFERENCES

1. Gorlin RJ: Nevoid basal cell carcinoma syndrome. *Medicine* **66**:98, 1987

2. Howell JB, Caro MR: Basal cell nevus: Its relationship to multiple cutaneous cancers and associated anomalies of development. *Arch Dermatol* **79**:67, 1959

3. Gorlin RJ, Goltz RW: Multiple nevoid basal-cell epithelioma, jaw cysts and bifid ribs: A syndrome. *N Engl J Med* **262**:908, 1960

4. Bale AE, Yu K-P: The hedgehog pathway and basal cell carcinomas. *Hum Mol Genet* **10**:757, 2001

5. Hahn H et al: Mutations of the human homologue of *Drosophila* patched in the nevoid basal cell carcinoma syndrome. *Cell* **85**:841, 1996

6. Johnson RL et al: Human homologue of *patched*, a candidate gene for the basal cell nevus syndrome. *Science* **272**:1668, 1996

7. Howell JB: Nevoid basal cell carcinoma syndrome: Profile of genetic and environmental factors in oncogenesis. *J Am Acad Dermatol* **11**:98, 1984

8. DeCamp DL et al: Smoothened activates Galphai-mediated signaling in frog melanophores. *J Biol Chem* **275**:26322, 2000

9. Stone D et al: The tumour-suppressor gene *patched* encodes a candidate receptor for Sonic hedgehog. *Nature* **384**:129, 1996

10. Marigo V et al: Biochemical evidence that Patched is the hedgehog receptor. *Nature* **384**:176, 1996

11. Ingham PW et al: Patched represses the hedgehog signaling pathway by promoting modification of the smoothened protein. *Curr Biol* **10**:1315, 2000

12. Denef N et al: Hedgehog induces opposite changes in turnover and subcellular localization of patched and smoothened. *Cell* **102**:521, 2000

13. Alcedo J et al: Posttranscriptional regulation of smoothened is part of a self-correcting mechanism in the hedgehog signaling system. *Mol Cell* **6**:457, 2000

14. Xie J et al: A role of PDGFR alpha in basal cell carcinoma proliferation. *Proc Natl Acad Sci U S A* **98**:9255, 2001

15. Barnes EA et al: Patched1 interacts with cyclin B1 to regulate cell cycle progression. *EMBO J* **20**:2214, 2001

16. Fan H, Khavari PA: Sonic hedgehog opposes epithelial cell cycle arrest. *J Cell Biol* **147**:71, 1999

17. Xie J et al: Activating SMOOTHENED mutations in sporadic basal-cell carcinoma. *Nature* **391**:90, 1998

18. Taylor MD et al: Mutations in *SUFU* predispose to medulloblastoma. *Nat Genet* **31**:302, 2002

19. Oro AE et al: Basal cell carcinomas in mice overexpressing Sonic hedgehog. *Science* **276**:817, 1997

20. Nilsson M et al: Induction of basal cell carcinomas and trichoepitheliomas in mice overexpressing GLI-1. *Proc Natl Acad Sci U S A* **97**:3438, 2000

21. Grachtchouk M et al: Basal cell carcinomas in mice overexpressing GLI2 in skin. *Nat Genet* **24**:216, 2000

22. Aszterbaum M et al: Ultraviolet and ionizing radiation enhance the growth of BCCs and trichoblastomas in patched heterozygous knockout mice. *Nat Med* **5**:1285, 1999

23. Hahn H et al: Rhabdomyosarcomas and radiation hypersensitivity in a mouse model of Gorlin syndrome. *Nat Med* **4**:619, 1998

24. Shanley S et al: Nevoid basal cell carcinoma syndrome: Review of 118 affected individuals. *Am J Med Genet* **50**:282, 1994

25. Kimonis VE et al: Clinical manifestations in 105 persons with nevoid basal cell carcinoma syndrome. *Am J Med Genet* **69**:299, 1997

26. Lo Muzio L et al: Nevoid basal cell carcinoma syndrome. Clinical findings in 37 Italian affected individuals. *Clin Genet* **55**:34, 1999

27. Meara JG et al: The odontogenic keratocyst: A 20-year clinicopathologic review. *Laryngoscope* **108**:280, 1998

28. Ratcliffe JF et al: The diagnostic implication of falcine calcification on plain skull radiographs of patients with basal cell naevus syndrome and the incidence of falcine calcification in their relatives and two control groups. *Br J Radiol* **68**:361, 1995

29. Stavrou T et al: Intracranial calcifications in childhood medulloblastoma: Relation to nevoid basal cell carcinomas syndrome. *Am J Neuroradiol* **21**:790, 2000

30. Goeteyn M et al: The Bazex-Dupre-Christol syndrome. *Arch Dermatol* **130**:337, 1994

31. Ashinoff R et al: Rombo syndrome: A second case report and review. *J Am Acad Dermatol* **28**:1011, 1993

32. Oley CA et al: Basal cell carcinomas, coarse sparse hair, and milia. *Am J Med Genet* **43**:799, 1992

33. Kagy MK, Amonette R: The use of imiquimod 5% cream for the treatment of superficial basal cell carcinomas in a basal cell nevus syndrome patient. *Dermatol Surg* **26**:577, 2000

T>

Chapter 83

Lorenzo Cerroni Helmut Kerl

Keratoacanthoma

HISTORICAL ASPECTS
EPIDEMIOLOGY
RELATIONSHIP TO SQUAMOUS CELL CARCINOMA
ETIOLOGY AND PATHOGENESIS
CLINICAL MANIFESTATIONS
Systemic Associations
Variants
PATHOLOGY
HISTOPATHOLOGIC VARIANTS
DIAGNOSIS AND DIFFERENTIAL DIAGNOSIS
TREATMENT AND PROGNOSIS
Prognosis

REFERENCES

Keratoacanthoma is a common epithelial tumor of the skin characterized by rapid growth, histopathologic features similar to those of cutaneous squamous cell carcinoma, and a tendency toward spontaneous regression in absence of treatment. The exact nosology and classification of keratoacanthoma are a matter of debate. Some authors regard keratoacanthoma as a benign cutaneous tumor that is the prototype of the “pseudomalignant” tumors of the skin, whereas others maintain that it truly represents a malignant neoplasm and should be regarded as a peculiar variant of cutaneous squamous cell carcinoma.

HISTORICAL ASPECTS

The first description of solitary keratoacanthoma was provided by Sir Jonathan Hutchinson in 1889, who called this tumor “crateriform ulcer of the face.” [1] Based on histopathologic features, he classified the lesion as a form of epithelial cancer. MacCormac and Scarff, in 1936, underlined the peculiar clinical features of this rapidly growing, self-healing tumor. [2] The term *keratoacanthoma* was officially first adopted in 1950 by Rook and Whimster. [3] They acknowledged that the designation keratoacanthoma was used by G.B. Dowling in London since the 1940s, and that Walter Freudenthal had coined the term keratoacanthoma in 1936, in order to underline its remarkable histopathologic aspects. [4]

Several other terms have been used to define lesions showing identical clinicopathologic features—molluscum sebaceum; molluscum pseudocarcinomatosum; kyste sébacé atypique; tumor-like keratosis; keratocarcinoma; self-healing primary squamous cell carcinoma; verrucome aveque adenite; button epithelioma; and idiopathic cutaneous pseudoepitheliomatous hyperplasia are some of the many names proposed in the past for keratoacanthoma. [4], [5]

In addition to the solitary type of keratoacanthoma, a number of other variants have been described in the literature. Ferguson-Smith, in 1934, reported on a young patient presenting with multiple self-healing squamous cell carcinomas of the skin, a condition that later would be renamed as “multiple keratoacanthomas of the Ferguson-Smith type.” [6] The occurrence of thousands of lesions in a single patient, today known as “multiple keratoacanthomas of the Grzybowski type,” was reported by Grzybowski in 1950. [7] In 1961, Fisher published the first report on digital keratoacanthoma, pointing at the destructive features of the disease. [8] Another rare variant, today described as “keratoacanthoma centrifugum marginatum,” a term that was coined in 1962 by Miedzinski and Kozakiewicz, [9], [10] was first described by Puente Duany in 1958. [10]

EPIDEMIOLOGY

Keratoacanthoma is a relatively common neoplasm, but its exact incidence is unknown. The tumor is more frequent in light-skinned persons, and rarer in dark-skinned persons and in Japanese. The relative frequency in comparison with squamous cell carcinoma of the skin is controversial, but most studies show a lower incidence of keratoacanthoma than of squamous cell carcinoma. Discordant results may be explained, at least in part, by differences in classification of these lesions.

Studies on gender distribution reveal that both sexes are affected equally, possibly with a slight predilection for men. Keratoacanthoma occurs mostly in adult life, with a peak between ages 55 and 65 years; it has been observed rarely in younger patients. The familial type of keratoacanthoma occurs often during adolescence, and a neonatal case has been reported. [11] Although the incidence was thought to remain stable after a peak in the sixth decade, a study conducted in a defined population in Hawaii revealed that keratoacanthoma increases with age, in a fashion similar to that observed for cutaneous basal and squamous cell carcinomas. [12]

RELATIONSHIP TO SQUAMOUS CELL CARCINOMA

The authors of earlier reports considered keratoacanthoma to be a form of epithelial cancer of the skin, and named it accordingly. However, since the introduction of the concept of keratoacanthoma as a benign, self-healing neoplasm distinct from squamous cell carcinoma, the relationship between these two epithelial tumors has been the subject of debate. In their paper published in 1950, Rook and Whimster wrote, “This disease is evidently not cancerous or

precancerous." [3] On the other hand, Kwittken, in 1975, stated, "I have come to the firm conclusion that all of these lesions are malignancies and that the formerly accepted concept of a self-healing squamous cell carcinoma of the skin is a correct one," [13] and in 1979, even Rook amended his initial concept by writing, "… transformation from keratoacanthoma to squamous cell carcinoma occurs frequently." [4] Cases of typical keratoacanthoma with metastases have been observed, [14] and four possible explanations for this phenomenon have been suggested: an initial misdiagnosis of keratoacanthoma; the presence of both keratoacanthoma and squamous cell carcinoma in the same lesion; the malignant transformation of keratoacanthoma into squamous cell carcinoma; and, finally, the possibility that keratoacanthoma may be a peculiar variant of squamous cell carcinoma. [15] The debate is not settled yet, and some authors still maintain that keratoacanthoma represents a benign epithelial tumor, distinct from squamous cell carcinoma, [16] whereas others hold that it is a variant of squamous cell carcinoma with tendency to spontaneous regression, but with the potential for giving distant metastases and killing the patients. [17] Two recent studies based on large numbers of cases underlined the impossibility of reliably differentiating keratoacanthoma from squamous cell carcinoma using histopathologic criteria alone. [18], [19] Other investigations pointed at similarities among squamous cell carcinoma and keratoacanthoma in the expression of oncogenetic and cell-cycle–regulating proteins as well as regarding the presence of trisomy 7 in a subset of tumors in both groups, thus suggesting a close relationship between these two entities. [20], [21], [22] and [23] On the other hand, recent publications on loss of heterozygosity, and on expression of angiotensin type 1 receptor and of desmogleins 1 and 2 showed clear-cut differences among keratoacanthomas and squamous cell carcinomas, revealing different phenotypes of the two tumors. [24], [25] and [26] In short, at present, and in spite of the great amount of clinical and experimental data collected over the decades, the exact nosology of keratoacanthoma is not clear.

The authors of this chapter believe that keratoacanthoma represents a peculiar variant of squamous cell carcinoma, based on the rare but well known potential for distant metastases, and the capability for local destruction of important structures.

ETIOLOGY AND PATHOGENESIS

Different etiologic factors are probably involved in the development of keratoacanthomas in different patients, and it seems likely that these different factors act synergistically to induce the onset of a lesion in a given patient. The role of chronic UV light exposure in the etiology of keratoacanthoma is well documented by the frequent occurrence on sun-exposed areas, as well as by the presence of keratoacanthomas in patients with xeroderma pigmentosum and after prolonged PUVA treatment. In patients with multiple keratoacanthomas, PUVA treatment accelerates the development of the tumors, [27] but the risk for keratoacanthoma after therapy with PUVA seems lower than that for squamous or basal cell carcinoma. [28] An etiologic link to UV light has been confirmed also by experimental studies in mice.

The relationship of keratoacanthoma to chemical carcinogens has been well documented in humans and in several animals. [29] In fact, the incidence of keratoacanthoma is higher in industrial towns, and among industrial workers coming in contact with pitch, mineral oils, and tar. Chemical carcinogens may act in conjunction with UV rays to induce the onset of keratoacanthomas. Smokers seem also to be more affected than nonsmokers. [29]

Keratoacanthomas have been reported at the site of injury, thus suggesting an infectious etiology, at least in some cases. The association with trauma is also documented by the report of cases occurring after skin grafting, at both the donor and the recipient sites, and at the site of arterial puncture and vaccination. [5], [30] The role of human papilloma virus (HPV) remains controversial. Recently, evidence of HPV infection was documented by the highly sensitive polymerase chain reaction (PCR) technique, [31] but other studies failed to detect viral material within lesions of keratoacanthoma. [32] Some studies found an association with HPV type 25, and HPV-19 and HPV-48 have been isolated in a lesion arising in a HIV-patient. [33], [34] Several other types of HPV have been linked to keratoacanthoma, including types 6, 9, 14, 16, 19, 35, 37, 58, and 61.

Genetic factors probably play a major role in the familial type of keratoacanthoma. In the other variants of keratoacanthoma, it seems likely that genetic aspects interplay with other etiologic factors (i.e., UV rays, trauma, infections) by providing the genetic predisposition for the development of keratoacanthoma, in a fashion similar to that documented for basal and squamous cell carcinomas of the skin. Keratoacanthomas are commonly observed in patients with Muir-Torre syndrome, suggesting that the genetic defect(s) of this syndrome also plays a role in the development of keratoacanthoma. [35], [36] In addition, keratoacanthomas have been observed in patients affected by a variety of skin diseases including psoriasis, lupus erythematosus, lichen planus, atopic dermatitis, herpes zoster, acne conglobata, and pemphigus foliaceus, among others. [5]

Keratoacanthomas also have been observed in patients under immunosuppression as a result of bone marrow transplantation, cyclosporine treatment, or infection with HIV, thus suggesting that immunosuppression may play an etiologic role in some cases. In these patients, most lesions of keratoacanthoma tested for presence of HPV proved positive, suggesting that immunosuppression may contribute by decreasing the immune response against possible causative agents. [37] Similarly, UV light may act not only by direct carcinogenesis, but also by virtue of the local immunosuppression caused by sun exposure (see Chap. 38).

Clinical and experimental evidence indicates that most keratoacanthomas derive from the epithelium of the hair follicles. In 1961, Ghadially suggested that type 1 tumors derive from the upper part of the hair follicle and give rise to lesions with a bud-shaped pattern, whereas types 2 and 3 tumors derive from the more proximal portion of the hair follicle or from the hair bulb (see below), thus giving rise to lesions that are characterized by a dome-shaped or a berry-shaped morphology. [30] Although it seems likely that most, if not all, keratoacanthomas on hair-bearing skin derive from hair follicles, keratoacanthomas may occur at times on mucous membranes and in the subungual region, suggesting that the presence of hair follicles is not essential for their development. The onset of keratoacanthomas on the oral mucosa has been explained by the association with ectopic sebaceous glands, but it seems much more reasonable to postulate that in

non–hair-bearing skin, keratoacanthomas derive from surface epithelium, as was suggested by Eversole et al. [38] It must be added, however, that some authors, based on differences in keratoacanthoma behavior (tendency to persist, local destructiveness), suggested that keratoacanthomas arising on the oral mucosa and ungual bed may represent a different tumor altogether, rather than a variant of keratoacanthoma.

Little is known about the pathogenesis of keratoacanthoma, and about the exact mechanisms inducing regression in the absence of any treatment. Studies on p53 oncoprotein expression and p53 gene mutations revealed expression of p53 oncoprotein in the great majority of tested cases, and association with a point mutation in the p53 gene in slightly more than 10 percent of these cases, suggesting a possible role of p53 gene in the development of some keratoacanthomas. [21] Cyclins regulating the cell cycle and mitotic activity may also play a role in the evolution of keratoacanthoma. [23] Microsatellite instability has been detected in about 30 percent of keratoacanthomas in Muir-Torre syndrome, but in less than 10 percent of cases of sporadic keratoacanthoma, suggesting that microsatellite instability does not play a role in this variant of the disease. [35], [39] The rapid growth and regression of keratoacanthoma suggested to some an analogy to the normal cycle of the hair follicle, in which rapid growth is followed by slow involution. [30] However, it seems likely that regression in keratoacanthoma is not only due to its follicular derivation, but is also related to tumor and host factors. [40] Activated T-helper lymphocytes and increased numbers of Langerhans cells are present within the reactive inflammatory infiltrate of keratoacanthomas. Recently, the antiapoptotic *bcl-2* protein, the growth regulatory cytokine oncostatin M, and the cyclin-dependent kinase inhibitor p27 have been suggested to play a role in the regression of keratoacanthoma. [22], [41], [42]

No genetic markers have been identified for solitary keratoacanthoma, the most common form of the disease. Multiple keratoacanthomas of the Ferguson-Smith type show a familial distribution, and are transmitted in an autosomal dominant fashion. The gene responsible for this syndrome is localized to chromosome 9q. The majority of the cases have been described in some Scottish families, and in these patients, the syndrome is thought to be caused by a single genetic mutation that occurred before 1790. [43]

CLINICAL MANIFESTATIONS

Keratoacanthomas occur mostly on sun-exposed skin of the face, forearms, and dorsal aspects of the hands (Fig. 83-1). Actinic damage is commonly found in the surrounding skin. In most instances, they are located on hairy skin, but lesions with similar clinicopathologic aspects have been described in the oral cavity, the subungual region, the genital mucosa, and the conjunctiva.

FIGURE 83-1 Keratoacanthoma on the forehead of a 64-year-old woman.

The stereotypic example of keratoacanthoma is represented by a solitary lesion growing rapidly within a few weeks, and subsequently showing a slow involution over a period of a few months. Three clinical stages have been described: proliferative, mature, and resolving. [5] Lesions in the proliferative stage are rapidly enlarging erythematous papules that grow up to a dimension of 1 to 2 cm or more. In this stage the lesions are symmetric, firm, and show a smooth surface. In the mature stage there are symmetric, firm, erythematous or skin-colored nodules with a central keratotic core (Fig. 83-2). The central part can appear crateriform if the keratotic core is removed. Ghadially divided mature keratoacanthomas into three main morphologic types: type 1, or bud-shaped; type 2, or dome-shaped; and type 3, or berry-shaped. [30] Regressing lesions are characterized by a keratotic, partly necrotic nodule that becomes progressively flat upon elimination of the keratotic plug, eventually leaving an hypopigmented scar (Fig. 83-3).

FIGURE 83-2 Mature keratoacanthoma on the temple of a 93-year-old woman. Note central keratotic core giving a white-yellowish appearance to the superficial part of the lesion.

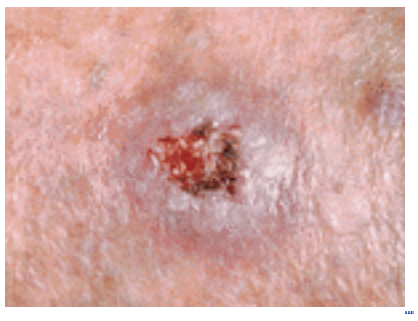

FIGURE 83-3 Regressing keratoacanthoma on the lower leg of a 59-year-old man. There is a whitish flattened plaque with superficial ulceration in the center.

Systemic Associations

Keratoacanthomas may be associated with multiple internal cancers in patients with Muir-Torre syndrome and the related hereditary nonpolyposis colorectal cancer syndrome. Patients with multiple keratoacanthomas should always be evaluated for the presence of typical traits of Muir-Torre syndrome where cutaneous sebaceous tumors and low-grade visceral malignancies can be observed (most commonly carcinomas of the gastrointestinal tract, but also carcinomas of the lung and genitourinary system, and, occasionally, colonic polyps). It has been suggested that at least some of the patients with multiple keratoacanthomas of the Ferguson-Smith type may have an incomplete form of the Muir-Torre syndrome.

Keratoacanthomas may also occur in patients with xeroderma pigmentosum (see Chap. 155), and rarely in patients with lymphomatoid papulosis (see Chap. 159).

Variants

Several variants of keratoacanthoma have been described, and different morphologic types of keratoacanthoma have been observed in a single patient. [44]

GIANT KERATOACANTHOMA In some instances, keratoacanthomas may reach dimensions of several centimeters (Fig. 83-4), and even a tumor reaching 15 cm in its diameter has been observed. Giant keratoacanthomas show a predilection for the nose and the dorsum of the hands. In some cases, the growth of the tumor may be associated with destruction of underlying tissues (Fig. 83-5).

FIGURE 83-4 Giant keratoacanthoma on the cheek of a 91-year-old man. The tumor is asymmetric and reveals ulceration with necrosis.

FIGURE 83-5 Giant keratoacanthoma on the tip of the nose of a 52-year-old man. Note the destructive appearance of the tumor.

KERATOACANTHOMA CENTRIFUGUM MARGINATUM Keratoacanthoma centrifugum marginatum is characterized by multiple tumors growing on a localized area, usually on the face, trunk, or extremities (Fig. 83-6). Tumors are annular, polycyclic, or circular in morphology. The area affected may reach 20 cm in diameter, and resolution may be slower than in solitary keratoacanthoma.

FIGURE 83-6 Multiple keratoacanthomas with an annular arrangement and central, keratin-filled craters on the back of the hand (keratoacanthoma centrifugum marginatum). This 42-year-old male patient also had lupus erythematosus.

MULTIPLE KERATOACANTHOMAS OF THE FERGUSON-SMITH TYPE This is a familial form of keratoacanthoma that

affects both sexes with approximately equal severity, which is characterized by the appearance of multiple, sometimes hundreds of keratoacanthomas, each with the clinicopathologic aspects of a solitary keratoacanthoma. The disorder is inherited in an autosomal dominant manner, and the majority of the cases have been described in a few Scottish families. Patients develop keratoacanthomas during adolescence and early adulthood, but onset during childhood is not infrequent. It has been suggested that at least some of these patients may have an incomplete form of the Muir-Torre syndrome.

GENERALIZED ERUPTIVE KERATOACANTHOMAS OF GRZYBOWSKI This variant is characterized by the presence of hundreds to thousands of tiny follicular keratotic papules disseminated all over the body, with predominance on sun-exposed areas. Facial involvement is usually severe, and coalescence of lesions around the eyes may cause ectropion. The mucosal regions (oral, genital) may be affected, whereas palms and soles are usually not involved. The age of onset is similar to that of solitary keratoacanthoma, and clustering in families has not been observed.

SUBUNGUAL KERATOACANTHOMA Subungual keratoacanthoma (Fig. 83-7) differs from the other types of keratoacanthoma by being persistent and often causing destruction of the underlying bone. The tumor originates in the distal nail bed separating the nail plate from the nail bed, and can grow rapidly causing destruction of the entire phalanx. The predilection sites are the thumb, index, and middle fingers. Pain is a common symptom. Many authors consider subungual keratoacanthoma to be distinct from solitary keratoacanthoma because of the absence of hair, the common lack of tendency to spontaneous regression, and the destructive growth pattern. However, in patients with multiple keratoacanthomas at other sites, tumors involving the nails have been observed, suggesting a relationship between the two types.

FIGURE 83-7 Subungual keratoacanthoma in a 38-year-old woman. A small keratotic tumor can be observed on the distal portion of the nail bed.

KERATOACANTHOMA OF THE MUCOSAL REGIONS Keratoacanthomas have been described in the oral mucosa, the conjunctiva, the nasal mucosa, and the genital mucosa. In fact, involvement of the oral and genital mucosa is common in the generalized eruptive keratoacanthomas of the Grzybowski type. Keratoacanthomas arising on mucosal regions, especially on the oral mucosa, present clinically as slowly growing crateriform lesions that tend to persist for many months or years.

PATHOLOGY

The histopathologic diagnosis of keratoacanthoma rests mainly on the silhouette of the tumor as assessed at scanning magnification; inadequate specimens (i.e., punch biopsies, shaving biopsies, curettage) do not allow a diagnosis and differentiation from squamous cell carcinoma. Two large studies on the histopathologic criteria for diagnosis of keratoacanthoma recently emphasized the overlapping features between this tumor and squamous cell carcinoma, which render differentiation very difficult or even impossible in given cases. [18], [19]

The histopathologic features of keratoacanthoma depend on the stage of evolution of the tumor. In early, proliferative lesions, the epithelium is markedly hyperplastic, and the central keratotic plug is not as pronounced as in fully developed lesions. The lesion has an overall symmetrical aspect (Fig. 83-8). Although atypical cells do not represent the majority of the cells in typical keratoacanthoma, there may be atypical keratinocytes and mitoses, especially at the lower margin of the tumor. Nests of epithelial cells may detach from the main tumor mass and be found in the superficial reticular dermis. Fully developed, mature lesions are characterized by a large central core of keratin surrounded by a well-differentiated proliferation of squamous epithelium that in some cases may resemble squamous cell carcinoma (Fig. 83-9A). The epidermis at both sides of the central core extends over the keratotic area in a fashion that has been described as “lipping” or “buttressing,” giving a distinct crateriform appearance to the lesion. Nests and strands of keratinocytes may be found apart from the main bulk of the tumor, but usually do not extend lower than the level of sweat glands. Especially in keratoacanthomas originating from the epithelium of the hair follicles, intraepithelial microabscesses are often present. Cytomorphologically, large keratinocytes with eosinophilic cytoplasm are commonly observed, together with atypical cells and mitoses (Figure 83-9B). An inflammatory infiltrate containing lymphocytes, plasma cells, histiocytes, eosinophils, and neutrophils is a common feature, and in some instances may be conspicuous. Neurotropism and even vascular invasion can be observed in otherwise typical keratoacanthomas, but the prognosis does not seem to be affected by these histopathologically worrisome features (Fig. 83-9C). [16] In resolving lesions, the thickness of the epithelial proliferation decreases, and the tumor becomes more flattened and less crateriform (Fig. 83-10A). Atypical cells and mitoses are usually not observed at this stage. Granulomatous inflammation and fibrosis of the superficial dermis, eventually resulting in a scar, are a common feature of resolving lesions (Fig. 83-10B).

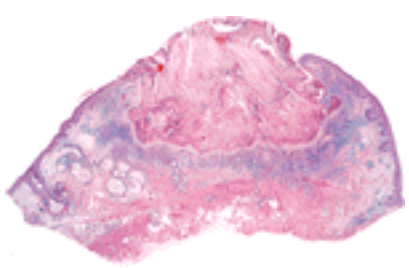

FIGURE 83-8 Keratoacanthoma (earlier stage) showing a symmetric epithelial tumor with a central keratotic crater surrounded by epithelial lipping.

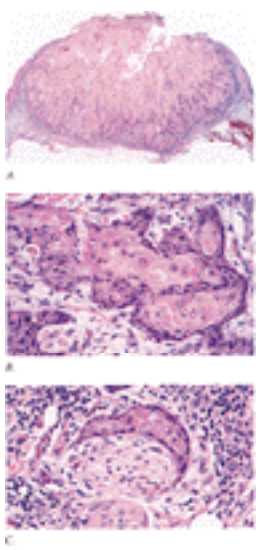

FIGURE 83-9 Mature keratoacanthoma. *A.* Low-power magnification revealing a symmetric lesion with a central keratotic core. *B*. Tumor complexes with large eosinophilic cells admixed with atypical cells and a few mitoses. *C*. Perineural growth of tumor cells (neurotropism).

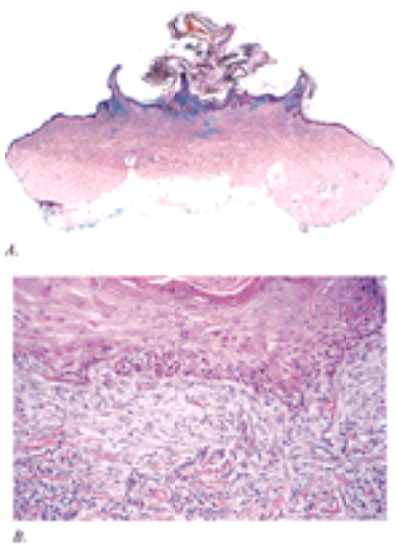

FIGURE 83-10 Regressing keratoacanthoma. *A.* Low-power magnification showing a symmetric, flattened lesion with inflammatory infiltrate and fibrosis. *B*. Proliferation of fibroblasts in the papillary dermis.

HISTOPATHOLOGIC VARIANTS

Subungual keratoacanthomas often are more vertically oriented and do not show the typical epithelial “lipping” over the central keratotic plug, and reveal a greater number of dyskeratotic cells. Neutrophils within the epithelium are not observed, and there is no fibrosis. The absence of fibrosis also characterizes keratoacanthomas arising on mucous membranes. Keratoacanthomas in patients with Muir-Torre syndrome may show the concomitant presence of sebaceous proliferation. Multiple keratoacanthomas of the Ferguson-Smith type differ in that the lateral demarcation is less definite, the cells may be more pleomorphic and atypical, and the amount of central keratin may be less pronounced than in solitary keratoacanthoma.

DIAGNOSIS AND DIFFERENTIAL DIAGNOSIS

Diagnosis and differential diagnosis of keratoacanthoma rest on clinicopathologic features of the lesions. The clinical differential diagnosis of fully developed keratoacanthomas includes mainly squamous cell carcinoma, and it may be impossible to tell these two entities apart on clinical grounds only. Rarely, differential diagnosis includes other cutaneous lesions such as common warts, molluscum contagiosum, and prurigo nodularis. Lesions located at the tip of the nose may clinically resemble metastatic carcinoma. Subungual lesions should be differentiated from subungual warts and from other tumors arising on the nail bed. Regressing tumors may simulate clinically a regressing lesion of lymphomatoid papulosis and/or anaplastic large cell lymphoma.

Histopathologic differential diagnosis mainly includes squamous cell carcinoma and differentiation among the two neoplasms may be impossible in a given case. Features in favor of a diagnosis of keratoacanthoma are the presence of a relatively symmetric, flasklike epithelial neoplasm with a central core of keratin and epithelial “lipping,” as well as the lack of prominent atypia and mitotic figures. Although several immunohistochemical stains may be helpful in the differential diagnosis of keratoacanthoma versus squamous cell carcinoma, the utility of immunohistologic markers for differentiation of keratoacanthoma from squamous cell carcinoma is controversial. Staining for proliferative cells with the antibody MIB-1 (Ki-67 antigen) shows a peripheral pattern in keratoacanthoma, as opposed to a more diffuse pattern in squamous cell carcinoma.

TREATMENT AND PROGNOSIS

Keratoacanthomas show a tendency to spontaneous regression, and in typical cases, an acceptable therapeutic option may be to adopt the so-called watchful waiting strategy. However, because of the uncertainty regarding the exact

nosology of this tumor, as well as the difficulty to differentiate it clinically from squamous cell carcinoma, complete conservative excision is advisable in most cases, especially in those of solitary keratoacanthoma. Biopsies by shaving or curettage are being increasingly performed for keratoacanthoma. If done so that architecture is preserved, these techniques are acceptable. These surgical methods, however, in most instances do not allow a definitive histopathologic diagnosis because the complete architectural features of the lesion are missed. Punch biopsies never allow differentiation of keratoacanthoma from well-differentiated squamous cell carcinoma, and should be avoided. For diagnostic purposes, a longitudinal biopsy that includes normal skin at both margins of the lesion as well as the underlying fat tissues is acceptable. However, whenever possible, a simple complete surgical excision should be performed. Special surgical techniques, such as Mohs micrographic surgery, have been adopted for difficult cases, for instance for recurrent lesions, giant lesions, or lesions of keratoacanthoma centrifugum marginatum, that may cover a large area of the body. [45] Therapy by laser vaporization, electrodesiccation, and cryosurgery with liquid nitrogen do not allow the histopathologic verification of the clinical diagnosis. Curettage followed by electrodesiccation or cryosurgery has been used in many instances, with a relative low rate of recurrences. [46]

Keratoacanthomas have been treated by radiotherapy with excellent results. [47] This type of treatment is particularly indicated for lesions that can be difficult to manage surgically, and for lesions of large dimensions. Several different types of radiotherapy have been employed, including electron beam, orthovoltage radiation, and superficial x-ray. Intralesional application of chemotherapeutic agents has also proven therapeutically successful. [5], [48] Methotrexate, bleomycin, and 5-fluorouracil have been used with success by intralesional injection, and 5-fluorouracil has been applied also topically. Some keratoacanthomas have been treated by intralesional injection of interferon alfa-2a, [49] and others have been successfully treated with intralesional application of triamcinolone. Successful topical treatment has been performed with podophyllin, either alone or in combination with other treatment modalities. However, podophyllin is also capable of inducing keratoacanthomas. Multiple keratoacanthomas have been treated successfully with oral retinoids in several cases, but larger studies have not been performed. [50] Systemic treatments include chemotherapy with methotrexate, cyclophosphamide, or 5-fluorouracil.

A new, promising treatment option for keratoacanthoma of both solitary and multiple types is represented by photodynamic therapy with d-aminolevulinic acid (see Chap. 266). The treatment is simple, and has been shown to achieve good therapeutic and cosmetic results. [51], [52] Topical imiquimod is presently being evaluated.

Preventive measures against the development of keratoacanthomas are similar to those applied for basal and squamous cell carcinoma of the skin. In predisposed subjects (i.e., fair skin, history of multiple actinic keratoses, basal and/or squamous cell carcinomas, Muir-Torre syndrome), avoidance of direct sun exposure should be achieved, and skin protection creams applied.

Prognosis

Solitary keratoacanthoma behaves as a benign tumor in the majority of the cases, but lymph node and visceral metastases have been observed in a small number of patients. There are no clear-cut features to predict the biologic behavior of a given tumor, but persistent and recurrent lesions should be managed by complete surgical excision. Histopathologic features that are associated with a poor prognosis in common squamous cell carcinoma, such as neurotropism and vascular invasion, do not seem to have prognostic implications in keratoacanthomas. [16] Ungual keratoacanthomas do not show a tendency to spontaneous regression, and often are the cause of massive bone destruction. [53] In spite of aggressive local behavior, however, distant metastases have not been observed in ungual and mucosal types of keratoacanthoma.

REFERENCES

1. Hutchinson J: The crateriform ulcer of the face: a form of acute epithelial cancer. *Trans Pathol Soc London* **40**:275, 1889

2. MacCormac H, Scarff RW: Molluscum sebaceum. *Br J Dermatol* **48**:624, 1936

3. Rook A, Whimster I: Le Kerato-Acanthome. *Arch Belg Dermatol Syphiligr* **6**:137, 1950

4. Rook A, Whimster I: Keratoacanthoma: A thirty-year retrospect. *Br J Dermatol* **100**:41, 1979

5. Schwartz RA: Keratoacanthoma. *J Am Acad Dermatol* **30**:1, 1994

6. Ferguson-Smith J: A case of multiple primary squamous celled carcinomata of the skin in a young man, with spontaneous healing. *Br J Dermatol Syph* **46**:267, 1934

7. Grzybowski MA: A case of peculiar generalized epithelial tumours of the skin. *Br J Dermatol Syph* **62**:310, 1950

8. Fisher AA: A distinctive destructive digital disease. *Arch Dermatol* **83**:1030, 1961

9. Miedzinski F, Kozakiewicz J: Das Keratoakanthoma centrifugum—eine besondere Varietät des Keratoakanthoms. *Hautarzt* **13**:348, 1962

10. Puente Duany N: Squamous cell pseudoepithelioma (keratoacanthoma): A new clinical variety, gigantic, multiple, and localized. *Arch Dermatol* **91**:505, 1958

11. Kumar V et al: Multiple keratoacanthoma with neonatal onset in a girl. *Pediatr Dermatol* **16**:411, 1999

12. Chuang TY et al: Keratoacanthoma in Kauai, Hawaii. The first documented incidence in a defined population. *Arch Dermatol* **129**:317, 1993

13. Kwittken JA: A histologic chronology of the clinical course of the keratocarcinoma (so-called keratoacanthoma). *Mt Sinai J Med* **42**:127, 1975

14. Hodak E et al: Solitary keratoacanthoma is a squamous-cell carcinoma: Three examples with metastases. *Am J Dermatopathol* **15**:332,

1993

15. Goldenhersh MA, Olsen TG: Invasive squamous cell carcinoma initially diagnosed as a giant keratoacanthoma. *J Am Acad Dermatol* **10**:372, 1984

16. Godbolt AM et al: Keratoacanthoma with perineural invasion: a report of 40 cases. *Australas J Dermatol* **42**:168, 2001

17. Choonhakarn C, Ackerman AB: Keratoacanthomas: a new classification based on morphologic findings and on anatomic site. *Dermatopathol Pract Concept* **7**:7, 2001

18. Sanchez-Yus E et al: Solitary keratoacanthoma: A self-healing proliferation that frequently becomes malignant. *Am J Dermatopathol* **22**:305, 2000

19. Cribier B et al: Differentiating squamous cell carcinoma from keratoacanthoma using histopathological criteria. Is it possible? A study of 296 cases. *Dermatology* **199**:208, 1999

20. Cheville JC et al: Trisomy 7 in keratoacanthoma and squamous cell carcinoma detected by fluorescence in situ hybridization. *J Cutan Pathol* **22**:546, 1995

21. Perez MI et al: p53 oncoprotein expression and gene mutations in some keratoacanthomas. *Arch Dermatol* **133**:189, 1997

22. Tran TA et al: Comparison of oncostatin M expression in keratoacanthoma and squamous cell carcinoma. *Mod Pathol* **13**:427, 2000

23. Tran TA et al: Comparison of mitotic cyclins and cyclin-dependent kinase expression in keratoacanthoma and squamous cell carcinoma. *J Cutan Pathol* **26**:391, 1999

24. Waring AJ et al: Loss of heterozygosity analysis of keratoacanthoma reveals multiple differences from cutaneous squamous cell carcinoma. *Br J Cancer* **73**:649, 1996

25. Takeda H, Kondo S: Differences between squamous cell carcinoma and keratoacanthoma in angiotensin type-1 receptor expression. *Am J Pathol* **158**:1633, 2001

26. Krunic AL et al: Immunohistochemical staining for desmogleins 1 and 2 in keratinocytic neoplasms with squamous phenotype: actinic keratosis, keratoacanthoma and squamous cell carcinoma of the skin. *Br J Cancer* **77**:1275, 1998

27. Penmetcha M et al: Failure of PUVA in lichen myxedematosus: Acceleration of associated multiple keratoacanthomas with development of squamous carcinoma. *Clin Exp Dermatol* **12**:220, 1987

28. Henseler T et al: Skin tumors in the European PUVA study. Eight-year follow-up of 1643 patients treated with PUVA for psoriasis. *J Am Acad Dermatol* **16**:108, 1987

29. Ghadially FN et al: The etiology of keratoacanthoma. *Cancer* **16**:603, 1963

30. Ghadially FN: The role of the hair follicle in the origin and evolution of some cutaneous neoplasms of man and experimental animals. *Cancer* **14**:801, 1961

31. Hsi ED et al: Detection of human papillomavirus DNA in keratoacanthomas by polymerase chain reaction. *Am J Dermatopathol* **19**:10, 1997

32. Lu S et al: Known HPV types have no association with keratoacanthomas. *Arch Dermatol Res* **288**:129, 1996

33. Payne D et al: Human papillomavirus DNA in nonanogenital keratoacanthoma and squamous cell carcinoma of patients with HIV infection. *J Am Acad Dermatol* **33**:1047, 1995

34. Gassenmaier A et al: Human papillomavirus 25-related DNA in solitary keratoacanthoma. *Arch Dermatol Res* **279**:73, 1986

35. Honchel R et al: Microsatellite instability in Muir-Torre syndrome. *Cancer Res* **54**:1159, 1994

36. Burgdorf WH et al: Muir-Torre syndrome. Histologic spectrum of sebaceous proliferations. *Am J Dermatopathol* **8**:202, 1986

37. Stockfleth E et al: Identification of DNA sequences of both genital and cutaneous HPV types in a small number of keratoacanthomas of nonimmunosuppressed patients. *Dermatology* **198**:122, 1999

38. Eversole LR et al: Intraoral and labial keratoacanthoma. *Oral Surg Oral Med Oral Pathol* **54**:663, 1982

39. Langenbach N et al: Assessment of microsatellite instability and loss of heterozygosity in sporadic keratoacanthomas. *Arch Dermatol Res* **291**:1, 1999

40. Ramselaar CG, van der Meer JB: The spontaneous regression of keratoacanthoma in man. *Acta Derm Venereol* **56**:245, 1976

41. Hu W et al: Expression of the cyclin-dependent kinase inhibitor p27 in keratoacanthoma. *J Am Acad Dermatol* **42**:473, 2000

42. Sleater JP et al: Keratoacanthoma: a deficient squamous cell carcinoma? Study of bcl-2 expression. *J Cutan Pathol* **21**:514, 1994

43. Ferguson-Smith MA et al: Multiple self-healing squamous epithelioma. *Birth Defects* **7**:157, 1971

44. Schaller M et al: Multiple keratoacanthomas, giant keratoacanthoma and keratoacanthoma centrifugum marginatum: Development in a single patient and treatment with oral isotretinoin. *Acta Derm Venereol* **76**:40, 1996

45. Larson PO: Keratoacanthomas treated with Mohs' micrographic surgery (chemosurgery). A review of forty-three cases. *J Am Acad Dermatol* **16**:1040, 1987

46. Kingman J, Callen JP: Keratoacanthoma: a clinical study. *Arch Dermatol* **120**:736, 1984

47. Donahue B et al: Treatment of aggressive keratoacanthomas by radiotherapy. *J Am Acad Dermatol* **23**:489, 1990

48. Melton JL et al: Treatment of keratoacanthomas with intralesional methotrexate. *J Am Acad Dermatol* **25**:1017, 1991

49. Somlai B, Hollo P: Die Anwendung von Interferon alpha (IFN alpha) in der Keratoakanthombehandlung. *Hautarzt* **51**:173, 2000

50. Street ML et al: Multiple keratoacanthomas treated with oral retinoids. *J Am Acad Dermatol* **23**:862, 1990

51. Calzavara-Pinton PG: Repetitive photodynamic therapy with topical delta-aminolevulinic acid as an appropriate approach to the routine treatment of superficial non-melanoma skin tumours. *J Photochem Photobiol B* **29**:53, 1995

52. Radakovic-Fijan S et al: Efficacy of topical photodynamic therapy of a giant keratoacanthoma demonstrated by partial irradiation. *Br J Dermatol* **141**:936, 1999

53. Baran R, Goettmann S: Distal digital keratoacanthoma: A report of 12 cases and a review of the literature. *Br J Dermatol* **139**:512, 1998

T>

Chapter 84

Shane Silver Vincent Ho

Benign Epithelial Tumors

SEBORRHEIC KERATOSIS
Etiology
Clinicopathologic Variants
Skin Cancer Association
The Sign of Leser-Trélat
Treatment
EPIDERMAL NEVUS
Epidemiology
LICHEN STRIATUS
Etiology and epidemiology
Clinical features
Course and complications
Pathology
Differential diagnosis
Treatment
CLEAR CELL ACANTHOMA
Etiology and pathogenesis
Epidemiology
Clinical features
Pathology
Differential diagnosis
Treatment, course, and prognosis
WARTY DYSKERATOMA
Etiology and pathogenesis
Epidemiology
Clinical features
Pathology
Treatment, course, and prognosis
ACANTHOMA FISSURATUM
Clinical features
Pathology
Differential diagnosis
Treatment, course, and prognosis
CYSTS OF EPIDERMAL ORIGIN
EPIDERMOID CYST
TRICHILEMMAL CYST
MILIUM
STEATOCYSTOMA MULTIPLEX
DERMOID CYST
BRANCHIAL CYST
PREAURICULAR CYST AND SINUS
CHONDRODERMATITIS NODULARIS HELICIS*
Etiology and Pathogenesis84,85
Epidemiology86
Clinical Features
Pathology84,85
Treatment

REFERENCES

Benign epithelial tumors are exceedingly common. Unfortunately, a good classification for these tumors is lacking. For discussion purposes, we have divided the benign epithelial tumors into various groups based upon their histology (Table 84-1). Although lesions grouped in this manner represent seemingly divergent clinical entities, such a classification helps us with our understanding of these diseases by linking possible common etiologic factors and aberrant cellular mechanisms.

Seborrheic keratosis
Common seborrheic keratosis
Reticulated seborrheic keratosis
Stucco keratosis
Clonal seborrheic keratosis
Irritated seborrheic keratosis
Seborrheic keratosis with squamous atypia
Melanoacanthoma (pigmented seborrheic keratosis)
Dermatosis papulosa nigra
Sign of Leser-Trélat
Epidermal nevi
Linear verrucous epidermal nevus (localized, systematized)
Nevus unius lateris
Ichthyosis hystrix
Inflammatory linear verrucous epidermal nevus (ILVEN)
Nevus sebaceous of Jadassohn
Nevus comedonicus
Eccrine nevus
Apocrine nevus
Becker's nevus
White sponge nevus
Epidermal nevus syndrome
Lichen Striatus
Clear cell acanthoma
Warty dyskeratoma
Acanthoma fissuratum
Cysts of epithelial origin
Epidermoid cyst
Trichilemmal cyst
Milium
Steatocystoma multiplex
Dermoid cyst
Branchial cyst
Preauricular cyst and sinus

TABLE 84-1 **Overview**

SEBORRHEIC KERATOSIS

Synonyms: Senile wart, senile keratosis, seborrheic verruca, basal cell papilloma. Seborrheic keratoses are benign skin tumors. They are exceedingly common and most people will develop at least one such lesion in their lifetime. Seborrheic keratoses are most commonly found in the over-30 age group. These lesions can appear on any part of the body except the mucous membranes. When multiple and occurring on the trunk, seborrheic keratoses can be seen in a “Christmas tree” pattern, lying with their long axis along skin folds, or Blaschko's lines.

Seborrheic keratoses typically begin as flat, sharply demarcated, brown macules. As they progress, they become polypoidal, with an uneven surface. The usually dull or lackluster surface commonly shows a “warty” topography with multiple plugged follicles and fronds (Fig. 84-1). Follicular prominence is one of the hallmarks of seborrheic keratoses. This can either be caused by pale follicular plugs within a darker lesion, or by black or brown plugs within a pale lesion. Seborrheic keratoses typically have a “stuck-on” appearance secondary to their somewhat polypoidal morphology (Fig. 84-2). Colors of these lesions can vary from a pale brown with pink tones to dark brown or black. Some seborrheic keratoses can be almost white (see “ Stucco Keratosis” later in this chapter).

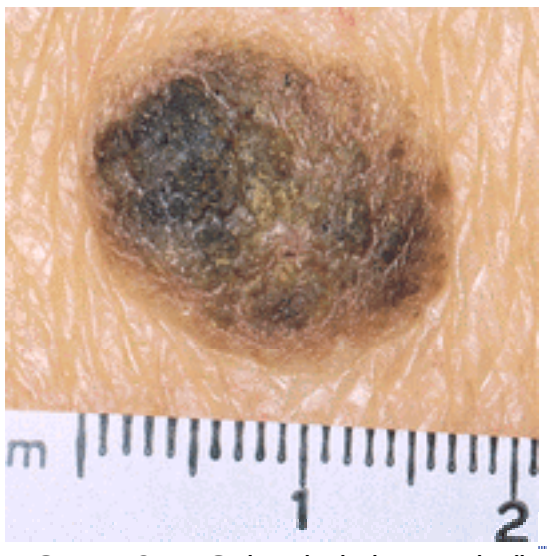

FIGURE 84-1 Seborrheic keratosis (basal cell papilloma) showing lackluster surface and “stuck-on” appearance.

FIGURE 84-2 Multiple small seborrheic keratoses.

A clinical variant of the typical seborrheic keratosis described above is the small polypoidal lesion commonly called *skin tags*. Distinct from smooth skin tags, these small, furrowed, rough-surfaced polyps appear most commonly around the neck, under the breast, or in the axillae. They seem to have a predilection for points of chronic trauma. They show a surface morphology, similar to that of the classic seborrheic keratosis, but their diameter is frequently only 1 to 2 mm,

with a height above the skin of sometimes more than 3 mm. These lesions may spontaneously disappear by dropping off.

Seborrheic keratoses are an annoyance. Lesions around the neck can catch on clothing, as can lesions around the waist. Others can grow to become cosmetically undesirable, whether on the face or on the trunk. Many can cause concern because of confusion with nevi, and the thought that the lesion is becoming a malignant melanoma. Conversely, dysplastic nevi or malignant melanomas can lurk in a forest of seborrheic keratoses and be undetected until a late stage, posing a significant danger.

Etiology

The etiology of seborrheic keratoses is unknown. In patients with a great number of seborrheic keratoses, there may be a positive family history. This may well reflect a genetic propensity. Seborrheic keratoses have sometimes been blamed on sun exposure. Yeatman et al. reported a higher prevalence of seborrheic keratoses on sun-exposed areas when taking into account skin surface area. [1] There is a propensity for the large type of seborrheic keratoses to develop in areas of intermittent sun exposure, such as the back and anterior chest.

Because of the verrucous appearance of seborrheic keratoses, human papilloma virus (HPV) has also been suggested as a possible etiology. In a study, 173 seborrheic keratoses were compared with 173 normal skin samples from nongenital sites for the presence of HPV. All specimens derived from normal skin were negative, whereas 34 of 173 seborrheic keratoses specimens were positive for HPV. [2]

Epidermal growth factors (EGF) are implicated in the development of seborrheic keratoses. The eruptive appearance of multiple seborrheic keratoses (the sign of Leser-Trélat) in association with various internal malignancies and with concomitant acanthosis nigricans, another epidermal hyperplastic phenomenon, suggests the possibility that a tumor-derived circulating growth factor or humoral factor may be involved in the pathogenesis of these lesions. Ellis et al. [3] described a patient with cutaneous melanoma, acanthosis nigricans, and the sign of Leser-Trélat. This patient had increased EGF receptors and urinary transforming growth factor (TGF)-a. After excision of the melanoma, TGF-a and EGF receptors decreased to normal. [3], [4] Melanocytic hyperplasia is commonly seen in seborrheic keratoses. It has been suggested that melanocytes or melanocyte-derived growth factors may have a role in the development of seborrheic keratoses. However, a causal relationship has not been determined.

Clinicopathologic Variants

There are several histologic and sometimes clinically distinct forms of seborrheic keratoses. [5]

COMMON SEBORRHEIC KERATOSIS *Synonyms:* Basal cell papilloma, solid seborrheic keratosis. This is considered the classic lesion. The configuration is mushroom-like, with sharply demarcated hyperplastic epidermis overhanging the surrounding skin. The tumor consists of uniform basaloid cells. Keratin cysts are often prominent, and may be follicular or extrafollicular (Fig. 84-3). Melanocytes are often present in considerable numbers, and their pigment production results in the color of the darker lesions. Pigment transfer to the keratinocytes appears to be fairly normal.

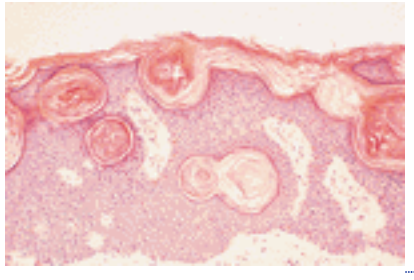

FIGURE 84-3 Seborrheic keratosis (basal cell papilloma) showing a papillomatous acanthotic epidermis consisting of basaloid cells.

RETICULATED SEBORRHEIC KERATOSIS *Synonym:* Adenoid seborrheic keratosis. Thin cords of basaloid cells descend from the base of the epidermis. Keratin cysts are embraced by these thin strands of cells (Fig. 84-4). A fine eosinophilic collagen stroma wraps these cords and can form much of the lesion.

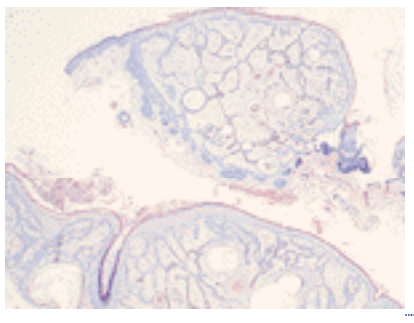

FIGURE 84-4 Reticulated seborrheic keratosis showing reticulated cords of basaloid cells descending from the base of the epidermis.

STUCCO KERATOSIS *Synonyms:* Hyperkeratotic seborrheic keratosis, digitate seborrheic keratosis, serrated seborrheic keratosis, verrucous seborrheic keratosis. Stucco keratoses present as multiple 3- to 4-mm skin-colored or gray-white papules presenting symmetrically on the lower legs. Church-spire–like projections of the epidermal cells around a collagen core thrust upward into a basket-weave type of hyperkeratosis. The vacuolated keratinocytes seen in verruca vulgaris are not seen in this lesion, although clinically it can resemble a small viral wart.
CLONAL SEBORRHEIC KERATOSIS Nests, usually but not always well defined, of round, loosely packed cells, are present within the epidermis (Fig. 84-5). Although the predominant cell is the keratinocyte, the nests may contain large numbers of melanocytes. The keratinocytes vary in size.

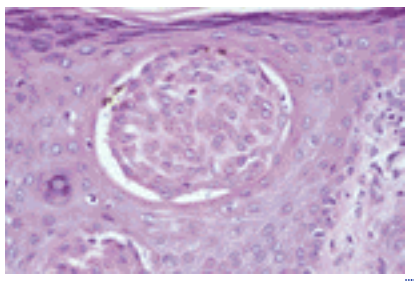

FIGURE 84-5 Clonal seborrheic keratosis showing round nests of keratinocytes and some elanocytes.

IRRITATED SEBORRHEIC KERATOSIS *Synonym:* Inflamed seborrheic keratosis, basosquamous cell acanthoma. Eczematous changes can occur in and around an otherwise typical seborrheic keratosis. The cause of this eczematous reaction is unknown. Trauma may play a role, but in most instances there is no apparent antecedent event. Histologically, an irritated seborrheic keratosis shows, apart from inflammatory changes, many whorls or eddies of eosinophilic flattened squamous cells arranged in an onionskin fashion. These resemble poorly differentiated keratin pearls in squamous cell carcinoma, but can be distinguished by their large number, small size, and circumscribed configuration. Keratinocytes within an irritated seborrheic keratosis show a higher degree of keratinization or more complete maturation as compared with the common seborrheic keratosis; the mechanism for this phenomenon is unknown.
SEBORRHEIC KERATOSIS WITH SQUAMOUS ATYPIA Cellular atypia and dyskeratosis can be seen in some seborrheic keratoses. These lesions can closely mimic Bowen's disease or invasive squamous cell carcinoma. It is not known what causes these changes, whether they are a result of irritation/activation, or whether they are precursors of squamous cell carcinoma. It seems prudent to completely remove these lesions.
MELANOACANTHOMA *Synonym:* Pigmented seborrheic keratosis. Melanoacanthoma is more than a darkly pigmented seborrheic keratosis. Within the lesion there is a striking proliferation of dendritic melanocytes. These melanocytes are engorged with melanin, whereas the surrounding keratinocytes contain hardly any melanin. The melanocytes may proliferate as nests, extending from the basal layer into the superficial layers of the epidermis. This lesion has no malignant potential.
DERMATOSIS PAPULOSA NIGRA These small facial papules, originally described in African Americans, but seen in darker-skinned people of many other races, appears to be a variant of seborrheic keratosis. They resemble tiny melanoacanthomas. They have the histologic appearance of a common seborrheic keratosis but are smaller.

Skin Cancer Association

Basal cell carcinomas and other common skin cancers have been reported, rarely, in association with seborrheic keratoses. [6], [7] In a study of 4310 tumors clinically diagnosed as seborrheic keratoses, 60 (1.4 percent) proved to be squamous cell carcinoma in situ. [7] In another study of 108 seborrheic keratoses, a 4.6 percent incidence of associated squamous cell carcinoma was reported. [6] Malignant melanoma in association with seborrheic keratoses has rarely been reported. [8] It has been suggested that basal cell carcinoma, squamous cell carcinoma, and melanomas associated with seborrheic keratoses may arise from the basaloid cells, spinous cells, and melanocytes that comprise seborrheic keratoses. [9] Most likely, however, malignant associations with seborrheic keratoses represent a collision phenomenon. Prudence, however, dictates that seborrheic keratoses that have undergone rapid growth or are clinically atypical be biopsied and that lesions demonstrating cellular atypia be completely removed.

The Sign of Leser-Trélat

Multiple eruptive seborrheic keratoses, also known as the *sign of Leser-Trélat,* have been mentioned in association with multiple internal malignancies. [10] The most frequent associations are adenocarcinoma of the stomach, colon, and breast. This sign has also been reported with a variety of other tumors, including lymphoma, leukemia, and melanoma. [10] It has also been mentioned in associations with hyperkeratosis of the palms and soles associated with malignant disease [11] and with acanthosis nigricans. [3], [10] Evidence to support the presumed relationship of seborrheic keratoses to malignant disease is meager. Most of the cancers described in association with seborrheic keratoses are common cancers. Seborrheic keratoses are also common. Proving an uncommon causal relationship between a common cancer and a common skin sign is difficult.

The phenomenon of eruptive seborrheic keratoses, may represent an inflammatory dermatosis centered around skin papillomas and seborrheic keratoses making them suddenly more prominent. Indeed, it is common clinical experience to see an increase in the prominence of seborrheic keratoses in patients with generalized dermatitis from any cause. Chemotherapy, in particular cytarabine, can cause inflammation of seborrheic keratoses, especially when associated with the sign of Leser-Trélat (Fig. 84-6). [12] Malignant acanthosis nigricans is present in 35 percent of patients with the sign of Leser-Trélat, suggesting a similar mechanism of action. [3], [4] However, the true relationship of multiple eruptive seborrheic keratoses to internal malignant disease remains to be defined.

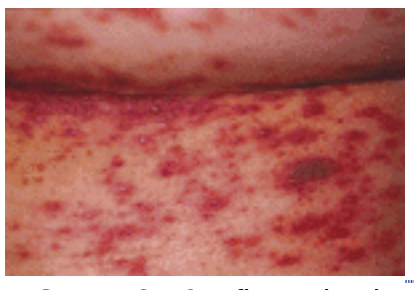

FIGURE 84-6 Inflamed seborrheic keratoses occurring during cytarabine therapy.

Treatment

Lesions that are symptomatic or cosmetically bothersome to the patient can be treated. Cryotherapy is probably the treatment of choice for the majority of lesions. A freeze to a 1-mm diameter around the lesion using either a cotton applicator or spray usually produces an excellent response. Should there be a residual lesion, or should the lesion recur, repeat treatment may be given. Following cryotherapy, postinflammatory hypopigmentation or hyperpigmentation may develop. Although usually temporary, these pigmentary changes may persist in darker-skinned patients and can be most disturbing.

Other treatment modalities include electrodesiccation followed by the easy removal of the lesion with a curette, or curettage followed by light electrodesiccation. Laser therapy using a pigmented lesion laser is also effective, and when used to treat flat seborrheic keratoses, may carry a lower risk of postinflammatory pigmentation or scarring as compared to cryotherapy or electrodesiccation. Surgical excision is also effective, but is usually not the treatment of choice in view of the adverse effect of scarring. Less-common treatment modalities used for giant seborrheic keratoses include topical fluorouracil and dermabrasion. [13], [14]

One of the greatest dangers posed by treating a “seborrheic keratosis” other than by surgical excision is that the treated lesion could be a dysplastic melanocytic lesion or a malignant melanoma. It is strongly recommended that if the lesion is not absolutely typical of a seborrheic keratosis, it should be submitted for histologic examination.

EPIDERMAL NEVUS

Epidermal nevi, are hamartomatous proliferations developing from embryonic ectoderm, which gives rise to many structures in the skin, including keratinocytes, apocrine glands, eccrine glands, hair follicles, and sebaceous glands. Therefore, epidermal nevi may be classified into a number of variants depending on the clinical appearance (morphology), extent of involvement, and the predominant epidermal structure in the lesion (Table 84-2). [15] There is considerable overlap between these variants and rigid categorization is not advisable. The term nevus is used here to denote a developmental defect; there is no proliferation of nevocellular nevus cells (melanocytes) in the lesion.

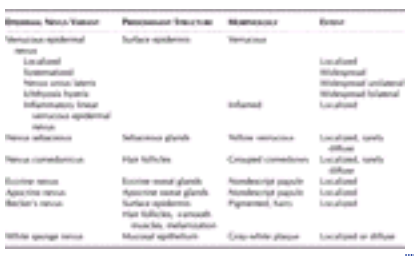

TABLE 84-2 **Classification of Epidermal Nevi**

Epidemiology

The incidence of epidermal nevi is estimated to be 1 per 1000 live births. [16] The majority occur sporadically and affect both sexes equally; familial cases have been described. [16] Most epidermal nevi are present at birth or infancy, but rarely do they appear as late as puberty. [16] In one study of 131 cases, [15] 60 percent were present at birth, and more than 80 percent had onset of their epidermal nevi in the first year of life; the remainder developed the lesion between the ages of 1 and 7 years with the exception of one patient whose onset was at 14 years; all the epidermal nevi on the head were present at birth. There are rare reports of adult onset of epidermal nevi, with the oldest patient being a 60-year-old woman. [17] Such late-developing epidermal nevi probably represent lesions that have always been present subclinically, but recent growth resulted in clinical recognition.

VERRUCOUS EPIDERMAL NEVUS *Synonyms:* Linear verrucous epidermal nevus, linear epidermal nevus.
Clinical features Verrucous epidermal nevi are characterized by closely set, skin-colored, brown, or gray-brown verrucous papules, which may coalesce to form well-demarcated papillomatous plaques (Fig. 84-7). A linear configuration is common, especially for lesions on a limb (Fig. 84-8). Such lesions may appear to follow skin tension lines, or Blaschko's lines.

FIGURE 84-7 Verrucous epidermal nevus.

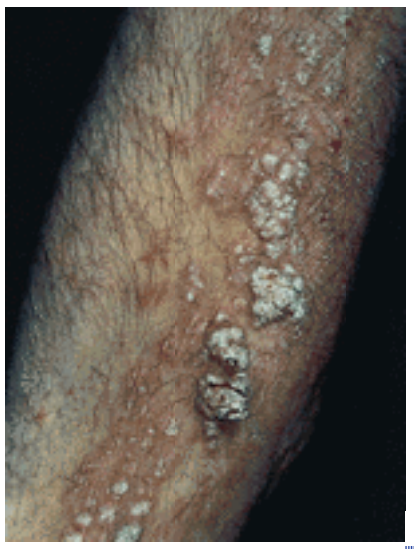

FIGURE 84-8 Verrucous epidermal nevus showing linear configuration.

Verrucous epidermal nevi may be localized or diffuse. An epidermal nevus with diffuse or extensive distribution is called a *systematized epidermal nevus*. When the lesions are distributed on one-half of the body, it is termed *nevus unius lateris* (Fig. 84-9). *Ichthyosis hystrix* refers to an epidermal nevus with extensive bilateral distribution. In these systematized nevi, the lesions on the limbs are usually linear in configuration, while those on the trunk tend to form wavy, transverse bands.

FIGURE 84-9 Nevus unius lateris. Epidermal nevus affecting one-half of body.

Inflammatory linear verrucous epidermal nevus (ILVEN), as the name implies, is an inflammatory variant of epidermal nevus. The lesion is pruritic and shows clinical signs of inflammation, namely, erythema, scaling, and crusting (Fig. 84-10).

FIGURE 84-10 Inflammatory linear verrucous epidermal nevus (ILVEN) showing erythema and scaling.

Course and complications A verrucous epidermal nevus may enlarge slowly during childhood. By adolescence, the lesion usually reaches a stable size and further extension is unlikely. [16] In Rogers' series of 131 cases, only 16 percent of the epidermal nevi present at birth showed extension, as compared to 65 percent of lesions of later onset; extension rarely lasts for more than 2 years. [15] Epidermal nevi may be associated with other cutaneous lesions, most commonly, café au lait macules, congenital hypopigmented macules, and congenital nevocellular nevi. [15] Epidermal nevi, especially if extensive, may be associated with developmental abnormalities in other systems (see later discussion on epidermal nevus syndrome). Rarely, basal cell and squamous cell carcinomas have been reported to develop in an epidermal nevus; this malignant transformation should be suspected when sudden localized growth, nodules or ulcers appear. [18] Malignant transformation of verrucous epidermal nevi usually occurs in long-standing, extensive lesions in middle-aged to elderly patients. The youngest reported case of malignant transformation was in a 17-year-old woman. Epidermal nevi in intertriginous areas may become macerated and secondarily infected. There have been isolated reports of generalized epidermolytic hyperkeratosis developing in offspring of parents with epidermal nevi. [19] Paller et al. investigated three patients with the rare subgroup of segmental epidermal nevi displaying histopathologic features of epidermolytic hyperkeratosis (see below), each of whom had offspring with generalized epidermolytic hyperkeratosis. [20] Affected parents demonstrated mutations in one of the two K10 (keratin) alleles from lesional, but not normal, skin. The identical K10 mutation was found in each of their offspring. Each parent demonstrated genetic mosaicism, defined as the presence of two genetically distinct cell lines arising from a postzygotic mutation during embryogenesis. [21] Therefore, mosaicism is exemplified by epidermal nevi displaying epidermolytic hyperkeratosis and offspring of such patients may develop generalized epidermolytic hyperkeratosis.

Pathology There is hyperkeratosis, acanthosis and papillomatosis with (Fig. 84-11) elongated rete ridges. The histologic picture is essentially that of a benign papilloma. Epidermolytic hyperkeratosis, characterized by compact hyperkeratosis, vacuolization of the upper and middle prickle cell layer, and large keratohyaline granules within or outside the cells may be seen, most frequently in ichthyosis hystrix but also in localized epidermal nevi. The ILVEN lesion shows a dermal chronic inflammatory infiltrate in the dermis in addition to the above findings. Furthermore, the

characteristic feature of alternating areas of hyperkeratosis with a thickened granular layer and parakeratosis without a granular area may be present. [22]

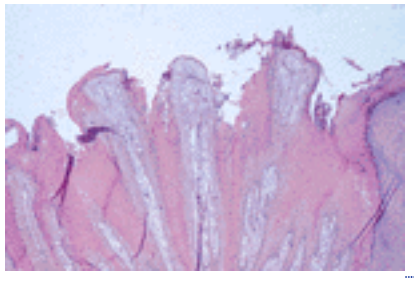

FIGURE 84-11 Epidermal nevus showing hyperkeratosis, acanthosis, papillomatosis, and elongation of rete ridges.

Differential diagnosis Verrucous epidermal nevi should be differentiated from other linear hyperkeratotic or verrucous lesions, namely, incontinentia pigmenti (verrucous stage), lichen striatus, linear porokeratosis, linear Darier's disease, linear lichen planus, and linear psoriasis. The latter two conditions are considered by some authors to be lichenoid and psoriasiform variants of linear epidermal nevus. [23] Linear porokeratosis is distinguished by its pathognomonic cornoid lamellae. The history of an antecedent vesicular stage and the transient nature of the linear verrucous lesions of incontinentia pigmenti allow differentiation of this condition from an epidermal nevus; histologically, incontinentia pigmenti shows eosinophilic exocytosis, dyskeratosis, basal layer vacuolization, and pigment incontinence, which are absent in an epidermal nevus. Lichen striatus may be difficult to exclude clinically and histologically from ILVEN. Their differentiation is important from a prognostic point of view as lichen striatus is self-limited, whereas ILVEN persists indefinitely. Lichen striatus is asymptomatic, whereas ILVEN is usually pruritic; histologically, lichen striatus shows little or no acanthosis and may have a lichenoid inflammatory infiltrate.
Treatment Excision is the most reliable treatment. However, this may not be practical or advisable if the epidermal nevus is very extensive or at sites not amenable to simple surgery. The excision should extend to the deep dermis, otherwise, the lesion will recur. Therefore, the patient should be advised that scarring is to be expected. Alternative treatments include laser, [24] electrofulguration, cryotherapy, dermabrasion, and chemical peels with trichloroacetic acid or phenol. These treatments usually remove the superficial portion of the nevus and recurrence is common. Topical treatments include podophyllin, retinoic acid, anthralin, calcipotriol, or alpha-hydroxy acids, and are relatively ineffective. [25], [26] Occasionally, using combination topical therapy will lead to higher efficacy. [25] Systemic retinoids can produce a partial but usually temporary response in some patients with extensive disease. Success with antipsoriatic treatments is not surprising as some argue that ILVEN represents true linear psoriasis or superimposed psoriasis. [27] Because epidermal nevi are associated with a small risk of malignant transformation, suspect areas of any lesion should be biopsied. If malignancy is confirmed, the entire lesion must be excised.
NEVUS SEBACEOUS *Synonym:* Nevus sebaceous of Jadassohn, organoid nevus.
Clinical features This usually presents as a solitary lesion at birth or early childhood. It has a predilection for the scalp where it presents as a solitary patch or a slightly elevated yellowish plaque with alopecia. Less commonly, nevus sebaceous may be found on the face, neck, or trunk, or, rarely, in the oral cavity. [28] The well-developed lesion, with its characteristic yellow or yellow-brown color, linear configuration and verrucous surface is quite distinctive (Fig. 84-12). However, in early childhood, the lesion may be quite flat and inconspicuous; the characteristic appearance may not develop until puberty. Nevus sebaceous occurs sporadically; familial nevus sebaceous has been described but is exceedingly rare. [29]

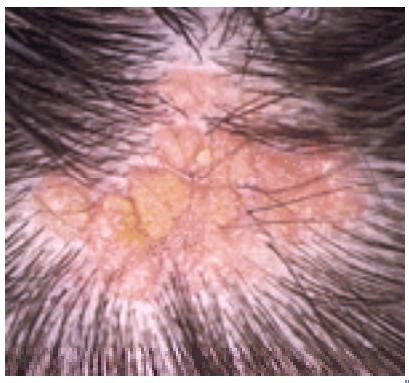

FIGURE 84-12 Nevus sebaceous.

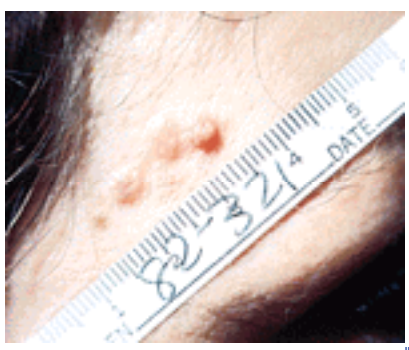

FIGURE 84-13 The development of basal cell carcinoma in a nevus sebaceous.

Course and complications Nevus sebaceous appears to be under some hormonal control and frequently enlarges during puberty. The lesion can be raised at birth, flatten in childhood, and become raised again during puberty. Further extension after puberty is uncommon. Systemic abnormalities may develop in association with a nevus sebaceous (see “ Epidermal Nevus Syndrome” below). This is more common in patients with multiple or extensive lesions. Another significant complication is the development of secondary benign and malignant tumors. It is believed that nevus sebaceous arises from pluripotential primary epithelial germ cells and these cells have the capacity to differentiate into various epithelial tumors. Early reports indicate an increased risk of basal cell carcinomas (6.5 to 50.0 percent)

developing within lesions of nevus sebaceous (Fig. 84-13). [30] However, two recent studies of 596 and 154 patients found the incidence of basal cell carcinoma to be quite low (0.0 to 0.8 percent) and it appears that most lesions diagnosed as basal cell carcinoma were most likely trichoblastomas. [31], [32] Mutations in the patched gene within nevus sebaceous has been postulated to be the cause of the increased incidence of basal cell carcinoma. [33] The patched gene mutation is also associated with both sporadic basal cell carcinomas and the basal cell nevus syndrome. In studies in which trichoblastoma was not discussed, syringocystadenoma papilliferum proved to be the most common benign neoplasm developing in lesions of nevus sebaceous (8 to 19 percent). [31], [32] Less-common associations include sebaceous epithelioma, hidradenoma, syringoma, chondroid syringoma, trichilemmoma, and desmoplastic trichilemmoma, proliferating trichilemmal tumor. [34], [35] The development of squamous cell carcinoma, apocrine carcinoma, and malignant eccrine poroma has been reported but is rare. [30]

Pathology The epidermis shows papillomatous hyperplasia. In the dermis, there are increased numbers of mature sebaceous glands and apocrine glands are often found in the deep dermis (Fig. 84-14). Frequently, small hair follicles and buds of basaloid cells that may represent malformed hair germs are present. In early childhood, the sebaceous glands in nevus sebaceous are underdeveloped and the histologic finding may only consist of immature hair structures.

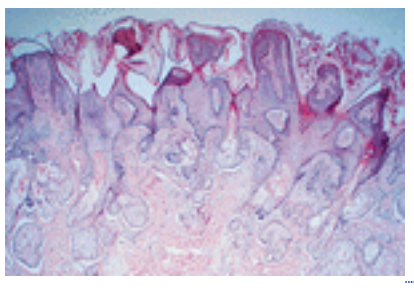

FIGURE 84-14 Nevus sebaceous showing epidermal hyperplasia and increased numbers of sebaceous glands and apocrine glands in the dermis.

Differential diagnosis In a well-developed lesion, nevus sebaceous is easy to diagnose and should not be confused with other conditions. Although some authors make a distinction between an epidermal nevus with a predominant sebaceous component and a nevus sebaceous, this may well be a matter of semantics. In early childhood, when the lesion is not well developed, the differential diagnosis should include other congenital causes of localized alopecia such as aplasia cutis and congenital triangular alopecia.

Treatment Prophylactic surgical excision of a nevus sebaceous is controversial as a consequence of recent articles demonstrating a low incidence of basal cell carcinoma and other tumors. [31], [32] Some investigators feel that nevus sebaceous should be excised because of malignant potential and cosmetic considerations. Others suggest that surgical excision should only be performed when clinical signs suggestive of a secondary tumor develop. [31], [32]

NEVUS COMEDONICUS Synonym: Comedo nevus.

Clinical features Many authors believe that nevus comedonicus is a hamartoma of the pilosebaceous follicle, with normal development of keratin but incomplete development of terminal hair and sebaceous glands. [36] As with other epidermal nevi, nevus comedonicus may be present at birth or develop in early childhood. It is characterized by closely set papules that have in their centers dilated follicular orifices, which are filled with keratotic plugs, thus resembling comedones (Fig. 84-15). The lesion most commonly occurs on the face, neck, upper arm, and chest, often in a linear configuration. Nevus comedonicus is usually a solitary, circumscribed plaque; rarely, the nevus may be systematized. [36]

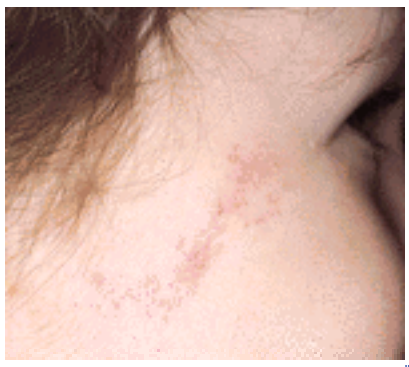

FIGURE 84-15 Nevus comedonicus consisting of closely set comedone-like papules.

Course and complications Spontaneous resolution has not been reported. Nevus comedonicus is usually asymptomatic but may become inflamed. Pustules, cysts, and scarring may develop, resembling acne vulgaris. Rarely, developmental defects of the central nervous system, eyes, bone, and skin have been associated with nevus comedonicus syndrome. This is considered a variant of the epidermal nevus syndrome.

Pathology There are multiple dilated pilosebaceous follicles filled with keratinous plugs. Occasionally, the follicular epithelial wall may show epidermolytic hyperkeratosis.

Differential diagnosis Acne vulgaris, acne neonatorum, nevus sebaceous, and linear Darier's disease are included. Nevus comedonicus is differentiated from acne vulgaris by its circumscribed (unilateral) distribution and its early onset and persistence.

Treatment Nevus comedonicus is usually treated for aesthetic purposes or because of recurrent inflammation. Topical retinoic acid treatment may be helpful in some cases. A patient with extensive nevus comedonicus responded dramatically within 1 month to a once-daily application of 12% ammonium lactate lotion. Individual comedones may be manually extracted. Lesions with recurrent inflammation and cyst formation may be treated with intralesional corticosteroids, incision and drainage, or systemically with antibiotics and isotretinoin. Destructive treatment methods include laser resurfacing and dermabrasion. Definitive treatment by surgical excision may offer good cosmetic results.

ECCRINE NEVUS Eccrine nevus is very rare. There are three types of presentation: the first is a circumscribed area of hyperhidrosis; [37] the second is a solitary pore that discharges a mucoid substance; [38] the third is a small skin colored plaque that often has a linear configuration. [39] Histologically, eccrine nevi may show an increase in size or number of eccrine secretory coils. In some cases, there is eccrine duct hyperplasia consisting of thickening of the walls and dilatation of the lumina. The epidermis overlying the lesion may show basaloid proliferation. [5] A variant of eccrine nevus, known as eccrine angiomatous hamartoma, presents as skin-colored or violaceous nodules or plaques; hyperhidrosis

may not be apparent. Histologically, there are increased numbers of eccrine structures and increased capillaries. [5] Treatment is by excision if desirable.

APOCRINE NEVUS Apocrine nevus is an extremely rare lesion that is composed of hyperplastic mature apocrine glands. Apocrine nevi do not show uniform clinical appearance. Clinical presentations have included solitary nodules on the scalp, [40] bilateral soft axillary masses, and multiple small firm papules on the chest. Histologically, numerous mature apocrine glands extend from the reticular layer of the dermis to the subcutis. Basaloid proliferation of the epidermis resembling basal cell carcinoma may be seen. [40] Treatment is by excision if desirable.

EPIDERMAL NEVUS SYNDROME *Synonyms:* Schimmelpenning's syndrome, Feuerstein and Mims syndrome, Solomon's syndrome. Epidermal nevus syndrome refers to a disease complex consisting of the association of an epidermal nevus with various developmental abnormalities of the skin, eyes, nervous, skeletal, cardiovascular, and urogenital systems. As mentioned earlier, epidermal nevi are classified according to their predominant component, which includes *nevus sebaceous* (sebaceous glands), *nevus comedonicus* (hair follicles), and *nevus verrucous* (keratinocytes). Therefore, the generic term *epidermal nevus syndrome* traditionally refers to any one of these entities, when associated with abnormalities in other organ systems. [41] However, some authors present strong arguments that *epidermal nevus syndrome* encompasses several distinct syndromes (see below). [42]

Epidemiology Epidermal nevus syndrome is believed to occur sporadically, but there have been some reports of autosomal dominant transmission, which has not been substantiated. [16] Both sexes are affected equally. Ages of diagnosis ranges from birth to 40 years. [16] Although the exact incidence of epidermal nevus syndrome is unknown, a study of 119 cases of epidermal nevi showed that 33 percent of patients showed one or more extracutaneous abnormalities, 16 percent showed two or more abnormalities, 10 percent showed three or more abnormalities, and 5 percent showed five or more abnormalities. [15]

Clinical features Solomon and Esterly [16] provided a detailed account of the spectrum of epidermal nevi seen in the epidermal nevus syndrome. They described seven types of lesions. The majority of patients had nevus unius lateris; 20 percent of patients had ichthyosis hystrix; and another 20 percent had what the authors termed the *acanthotic form* of epidermal nevus. These lesions presented as large, unilateral, brown, slightly scaly patches. About 10 percent of patients had linear nevus sebaceous involving the scalp and face. Localized linear verrucous nevus and a velvety epidermal nevus in the axilla similar to acanthosis nigricans were seen in a minority of cases. Some patients had a mixture of several types of lesions. Table 84-3 lists the mucocutaneous changes other than epidermal nevus that may be seen in patients with epidermal nevus syndrome. [15], [16], [43] Hemangiomas and pigmentary changes are found in 10 to 20 percent of patients. Less-common findings are hair abnormalities, dental abnormalities in association with mucosal epidermal nevi, and dermatomegaly. This last condition involves an increase in skin thickness, warmth, and hairiness. As discussed earlier, various cutaneous tumors may develop within the epidermal nevus.

Epidermal nevus	Cutaneous malignancies
Hemangioma	Keratoacanthoma
Pigmentary changes	Basal cell carcinoma
Café-au-lait spots	Squamous cell carcinoma
Hypopigmentation	Syringocystadenoma papilliferum
Melanocytic nevi	Other adnexal tumors
Dermatomegaly	

TABLE 84-3 **Cutaneous Findings in Epidermal Nevus Syndrome**

A wide range of skeletal abnormalities has been reported (Table 84-4). [15], [16], [43], [44] The incidence of skeletal changes have ranged from 15 to 70 percent. Solomon and Esterly classified the osseous changes into primary and secondary effects. Primary changes include bone deformities and cysts, and secondary bone changes include atrophies and hypertrophies. In several patients, bone deformities have resulted from hypophosphatemic vitamin D-resistant rickets, thought to be induced by epidermal nevi producing a potent phosphaturic factor. In one such case report, after excision of the epidermal nevus the hypophosphatemia resolved. [45]

Bone cysts
Bone hypergplasia or hypertrophy
Chondroblastoma
Asymmetry of skull
Short stature
Brachydactylia
Kyphosis
Scoliosis
Spina bifida
Syndactyly, polydactyly, clinodactyly
Vitamin D-resistant rickets

TABLE 84-4 **Skeletal Findings in Epidermal Nevus Syndrome**

Neurologic abnormalities occur in 15 to 50 percent of cases (Table 84-5). [15], [16], [43] Mental retardation, seizures, and cognitive development delay are the most common findings. These may be associated with cerebrovascular malformations, cortical atrophy, hydrocephalus, and intracranial calcifications. Central nervous system abnormalities are reported to be associated with epidermal nevi on the head, [46] but this has been disputed. [15]

Cerebrovascular accidents	Encephalocele
Cerebrovascular malformations and neoplasias	Hemiparesis
Cortical atrophy	Hydrocephalus
Cortical blindness	Mental retardation
Cranial nerve palsies	Seizures (generalized local infantile spasms)
Delayed milestones	Spinal cord stenosis
Macrocephaly	

TABLE 84-5 **Neurologic Findings in Epidermal Nevus Syndrome**

From 9 to 30 percent of patients with epidermal nevus syndrome have ocular abnormalities (Table 84-6); [15], [16], [43], [47] the most common abnormalities are colobomas and choristomas. A coloboma is defined as an absence or functional defect of ocular tissue; most commonly, the iris, ciliary body, or choroid. A choristoma is a congenital overgrowth of normal tissue in an abnormal location. Choristomas include dermoid, lipodermoid, single-tissue choristoma and complex choristoma. Table 84-7 lists the other uncommon abnormalities associated with this syndrome. [15]

Astigmatism
Lipodermoid
Bilateral cataracts
Blocked tear duct
Choristomas
Coloboma of lid, iris, choroid retina
Corneal opacity and pannus formation
Cortical blindness
Ectopic lacrimal glands
Extension of epidermal nevus to eyelid, conjunctiva, or sclera
Micro- or macrophthalmia
Nystagmus
Oculomotor dysfunction
Optic nerve hypoplasia
Ptosis
Strabismus

TABLE 84-6 **Ocular Findings in Epidermal Nevus Syndrome**

Urogenital	Others
Horseshoe kidneys	Teratoma
Undescended testes	Choanal atresia
Testicular adenomas	Pyloric stenosis
Double ureters	Hernia
Vascular	
Aneurysms	
Arteriovenous malformations	
Coarctations	
Patent ductus arteriosus	
Renal artery stenosis	

TABLE 84-7 **Miscellaneous Abnormalities Associated with the Epidermal Nevus Syndrome**

As in isolated epidermal nevi, malignant transformation may occur within the epidermal nevi in patients with epidermal nevus syndrome. This occurrence is most common in those with nevus sebaceous. Perhaps less well known is the association of visceral malignancies with the epidermal nevus syndrome. The following tumors are reported to occur at a higher frequency and at an earlier age in patients with epidermal nevus syndrome: tumors of the genitourinary system (Wilm's tumor, nephroblastoma, metastatic transitional cell carcinoma of the bladder, and rhabdomyosarcoma of the bladder); tumors of the gastrointestinal tract (hepatic adenoma, salivary gland adenocarcinoma, and carcinoma of the esophagus and stomach); and tumors of the central nervous system (astrocytoma, mixed glioma, and meningioma). Breast carcinoma, mandibular ameloblastoma, chondroma, odontoma, and endometrioma are other tumors associated with epidermal nevus syndrome. [41] However, these associations have not been confirmed by case-controlled studies. Recently, Happle [42], [48] proposed that the epidermal nevus syndrome is not a single entity; rather, it consists of at least six distinct diseases that differ in genetic origin but which share the common feature of mosaicism, including Schimmelpenning's syndrome; nevus comedonicus syndrome; pigmented hairy epidermal nevus syndrome; Proteus syndrome; congenital hemidysplasia, ichthyosiform dermatitis, and limb defects (CHILD) syndrome; and phacomatosis pigmentokeratotica (see Chap. 188 for more information).

Management Patients with extensive epidermal nevi or those with epidermal nevi and systemic abnormalities should be suspected of having the epidermal nevus syndrome. Evaluation and management of patients with epidermal nevus syndrome requires a multidisciplinary team approach involving the dermatologist, pediatrician, ophthalmologist, neurologist, plastic surgeon, and orthopedic services. These patients require a careful history with particular attention given to developmental history, attainment of milestones, history of seizures, and abnormalities of the bones, eyes, and urinary tract. Thorough mucocutaneous, neurologic, ophthalmologic, and orthopedic examinations are necessary. Depending on the findings on history and physical examination, further investigations may be indicated. These may include biopsy of the epidermal nevus, electroencephalography, computed tomography, magnetic resonance imaging, intravenous pyelography, and radiographic evaluation of bones. A regular follow-up program should be set up for the patient.

LICHEN STRIATUS

Synonym: BLAISE (Blaschko linear acquired inflammatory skin eruption). Lichen striatus is a self-limited linear dermatosis most commonly seen in children.

Etiology and epidemiology

Lichen striatus commonly presents in children between 5 to 15 years of age. However, a study of 61 children by Kennedy et al. found the mean age to be 3 years. [49] Lichen striatus is rarely present in adults. Females are more commonly affected than males, with a ratio of 2:1. The etiology of lichen striatus is unknown but reports of its occurrence in siblings, atopic individuals, and in the spring and summer support genetic, infectious, and environmental factors. [49], [50] and [51]

Clinical features

Lichen striatus presents as a sudden eruption of discrete pink, red, or skin-colored 1- to 3-mm flat-topped papules distributed in a linear configuration commonly following the lines of Blaschko. Individual papules are either smooth or have a very fine scale. The papules coalesce into a 1- to 3-cm wide band, which gradually, over a few weeks, progresses unilaterally on an upper or lower extremity with occasional extension onto the trunk. It is usually asymptomatic but some patients may experience mild pruritus. Nail involvement of lichen striatus is uncommon and presents as nail plate thinning with longitudinal ridging and splitting. It is usually associated with typical skin lesions; however, rarely, lichen striatus may be limited to the nails. [52]

Course and complications

Lichen striatus may progress over a few weeks, and then remain stable for months, eventually regressing within 1 year. Postinflammatory hypopigmentation or hyperpigmentation may persist for years. Nail involvement also improves spontaneously.

Pathology

Epidermal changes consists of hyperkeratosis, focal parakeratosis, mild spongiosis with lymphocyte exocytosis, and a

few necrotic keratinocytes. Within the dermis there is a superficial and deep perivascular infiltrate, with either focal or lichenoid patterns at the dermal–epidermal junction and appendageal involvement. Colloid bodies are present in 50 percent of cases. [53]

Differential diagnosis

Lichen striatus is diagnosed based on history and physical exam. Other dermatoses presenting in a linear configuration are lichen planus, psoriasis, porokeratosis, lichen nitidus, Darier's disease and ILVEN. ILVEN may be distinguished from lichen striatus by its appearance at birth or early infancy, associated pruritus, lack of spontaneous regression, and histologically having alternating parakeratosis and orthokeratosis with acanthosis and mild superficial lymphocytic infiltrate.

Treatment

Treatment is not necessary as lichen striatus undergoes spontaneous regression and is usually asymptomatic. For patients with mild pruritus, topical steroids may be useful.

CLEAR CELL ACANTHOMA

Synonyms: Degos' acanthoma, pale cell acanthoma. Clear cell acanthoma is a benign epidermal tumor characterized histologically by clear, glycogen-containing epidermal cells.

Etiology and pathogenesis

It was postulated that clear cell acanthoma was of sweat duct origin, but Penneys et al., found no carcinoembryonic antigen (CEA) positivity and felt that a sweat duct origin was unlikely. [54] The expression of involucrin and epithelial membrane antigen suggests that clear cell acanthoma is derived from surface epithelium. [55] The etiology of clear cell acanthoma, however, remains unknown. Ohnishi and Watanabe [56] suggest that the pattern of cytokeratin expression is similar to that found in inflammatory dermatosis, suggesting that there is a relationship with psoriasis, lichen planus, or discoid lupus. Finch et al. reported a case of clear cell acanthoma developing within a psoriatic plaque, which supports this theory. [57]

Epidemiology

Clear cell acanthoma is an uncommon tumor occurring in adults, most commonly presenting between 50 and 70 years of age. There is no sexual predilection.

Clinical features

The typical lesion is a slowly growing, sharply marginated, dome-shaped nodule or small plaque, with a “stuck on” appearance. There is frequently a wafer-like peripheral collarette scale. The color varies from pink to brown; a rare, pigmented variant has been reported. [58] The surface is often moist and may show red vascular puncta giving an erythematous appearance. Blanching is almost complete with pressure. It is usually approximately 1 to 2 cm in diameter, but a variant named *giant clear cell acanthoma* may be as large as 5 cm. Clear cell acanthoma is usually solitary; multiple lesions ranging in number from several to more than 100 have been reported but are rare. The most common location is the legs, although it has been reported to occur on the trunk, face, and back. [59]

Pathology

This exo-endophytic epidermal tumor is sharply circumscribed. The acanthotic epidermis consists of slightly enlarged malpighian cells with strikingly clear cytoplasm (Fig. 84-16). The “clear cell” appearance is due to glycogen deposition in the cells as verified by PAS staining. The epidermis is commonly infiltrated by abundant numbers of neutrophils, which may form microabscesses in the parakeratotic stratum corneum. A well-formed granular layer is absent. There are dilated superficial capillaries accounting for the characteristic red color and red puncta of this lesion.

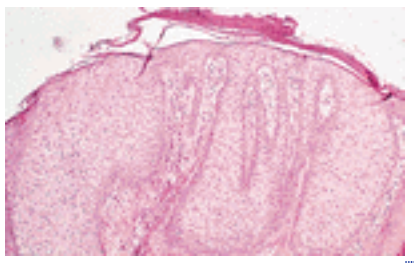

FIGURE 84-16 Clear cell acanthoma showing a well-circumscribed epidermal tumor composed of clear (glycogen-rich) cells.

Differential diagnosis

The clinical differential diagnosis may include an irritated seborrheic keratosis, hemangioma, dermatofibroma, basal cell carcinoma, squamous cell carcinoma, amelanotic melanoma, and pyogenic granuloma.

Treatment, course, and prognosis

Clear cell acanthoma does not show spontaneous regression. This benign tumor can be removed by simple excision or curettage and electrofulguration. Complete resolution with good cosmetic results following liquid nitrogen cryotherapy has been reported. [60] This mode of therapy may be suitable for patients with large lesions, multiple lesions, or lesions over bony prominences or for patients on anticoagulant therapy for whom surgery may be difficult.

WARTY DYSKERATOMA

Synonym: Isolated dyskeratosis follicularis. Warty dyskeratoma is a benign, usually solitary tumor characterized clinically as a crateriform keratotic nodule and histologically by acantholytic dyskeratosis.

Etiology and pathogenesis

The etiology and pathogenesis of warty dyskeratoma are unknown. Its derivation from the pilosebaceous unit has been proposed, but the observation that warty dyskeratoma can occur on the oral mucosa argues against this proposal. Smoking may be a predisposing factor to warty dyskeratoma.

Epidemiology

The exact incidence of this lesion is unknown. It is not common. There is no sexual predisposition.

Clinical features

Warty dyskeratoma usually occurs as a solitary papule or nodule with a central keratotic plug. Rarely, multiple warty dyskeratomas have been reported. [61] The lesion may be skin-colored to red-brown. It most commonly occurs on the face, scalp, or neck; lesions on other locations, including the oral mucosa, have been reported. The lesion grows slowly and, after reaching the usual size of 1 to 2 cm, persists indefinitely.

Pathology

The tumor is well circumscribed and appears as a cup-shaped invagination of the acanthotic epidermis (Fig. 84-17). The center of this invagination is filled with a keratotic plug. Within this cavity are many acantholytic dyskeratotic cells. Numerous pseudovilli (dermal papillae lined with basal cells) project up from the base of the invagination. Corps ronds (acantholytic dyskeratotic cells with central basophilia, pyknotic nuclei surrounded by a clear halo) and grains (parakeratotic cells surrounded by homogeneous eosinophilic material) are commonly found.

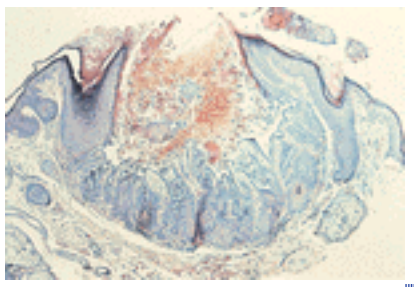

FIGURE 84-17 Warty dyskeratoma showing cup-shaped invagination of the acanthotic epidermis and acantholysis.

Treatment, course, and prognosis

This benign tumor may be treated by saucerization or elliptical excision, which allows for histologic examination of the entire lesion. Untreated, the lesion persists indefinitely.

ACANTHOMA FISSURATUM

Synonyms: Granuloma fissuratum, spectacle frame acanthoma. Acanthoma fissuratum is a localized thickening of the skin in response to pressure caused by an eyeglass frame.

Clinical features

Acanthoma fissuratum is usually unilateral and may occur on any of the pressure points of the eyeglass frame: retroauricular fold, superior auricular crease, or bridge of the nose. The lesion is a red-brown nodule with a central depressed groove where the eyeglass frame rests on the skin [62] (Fig. 84-18): This groove may be fissured, ulcerated, and crusted; it may or may not be tender.

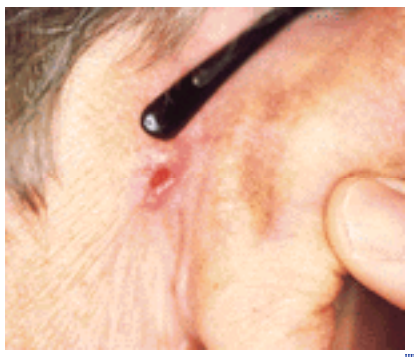
FIGURE 84-18 Acanthoma fissuratum due to excessive pressure from eyeglasses.

Pathology

The epidermis is acanthotic and may even show pseudoepitheliomatous hyperplasia. In the center, the epidermis may be atrophic or degenerated, beneath which the collagen appears hyalinized. There is a variable degree of perivascular infiltration of plasma cells, histiocytes, and lymphocytes.

Differential diagnosis

The common clinical differential diagnosis includes basal cell carcinoma, squamous cell carcinoma, and chondrodermatitis nodularis helicis. Recognition that the lesion is related to external pressure should lead to the correct diagnosis. If in doubt, histologic examination provides easy distinction.

Treatment, course, and prognosis

The lesion can be expected to slowly resolve if the excessive pressure on the affected area caused by ill-fitting spectacle frames can be relieved. Otherwise, the lesion may become thicker or pressure necrosis and ulceration may ensue.

CYSTS OF EPIDERMAL ORIGIN

EPIDERMOID CYST

Synonyms: Epidermal cyst, epithelial cyst, keratin cyst, sebaceous cyst (a misnomer). An epidermoid cyst is a keratin-containing cyst lined by surface epidermis.

Etiology and pathogenesis An epidermoid cyst is the result of the proliferation of surface epidermal cells within the dermis. Production of keratin within a circumscribed space results in a cyst. Epidermoid cysts may arise from occlusion of pilosebaceous follicles, from implantation of epidermal cells into the dermis following penetration injury, and from trapping of epidermal cells along embryonal fusion planes. The first mechanism is the most common, and it is widely believed that the epidermal lining of the cyst is derived from the follicular infundibulum. Ohnishi et al. [63] have recently confirmed that the cytokeratin profile of epidermal cysts is the same as the follicular infundibulum. The theory of epidermal cells trapped along fusion planes explains reports of intracranial, intraabdominal, and testicular epidermoid cysts. [64], [65] Several reports show the presence of human papillomavirus types 57 and 60 in palmoplantar epidermoid cysts. [66]
Epidemiology Epidermoid cysts are rare in children but common in adults. Both sexes are affected equally. Patients with Gardner's syndrome and nevoid basal cell carcinoma syndrome may have many lesions.
Clinical features An epidermoid cyst presents as a 1- to 5-cm intradermal or subcutaneous, dome-shaped protuberance, which is freely mobile over underlying structures (Fig. 84-19). Some cysts may be tethered to the epidermis, and there may be a central punctum from which cheesy keratinous material may be expressed, representing the plugged orifice of the pilosebaceous follicle. Cysts that are superficially located may appear yellowish or white. Epidermoid cysts are most commonly found on the face, neck, chest, and upper back, where the sebaceous glands are most numerous and active. Cysts secondary to traumatic implantation usually occur on the palms or soles or on the buttocks.

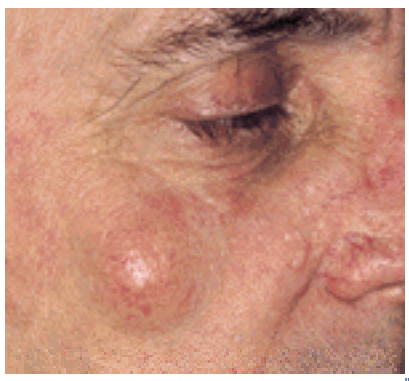
FIGURE 84-19 Epidermoid cyst presenting as a dome-shaped protuberance of the skin.

Complications Epidermoid cysts are slow-growing and are usually not symptomatic. Some cysts may become inflamed and secondarily infected. This occurs most frequently on the face and neck in association with acne vulgaris. Rupture of an inflamed epidermoid cyst induces a foreign-body inflammatory response in the dermis. Dystrophic calcification of the cyst contents may also occur, but this is rarely detected clinically. In a study of the microbiology of infected epidermal cysts Brook [67] found 192 of 231 clinically infected epidermoid cysts yielded bacterial growth, of which 44 percent had aerobic organisms, 30 percent had anaerobic organisms, and 26 percent had mixed growth. The predominant aerobic bacteria were *Staphylococcus aureus* (81 isolates), group A *Streptococcus* (9 isolates), and *Escherichia coli* (7 isolates). The predominant anaerobic organisms were *Peptostreptococcus* species (85 isolates) and *Bacteroides* species (55

isolates). Anaerobic organisms were isolated more frequently in perirectal, vulvovaginal, and head infections and less frequently in trunk and extremity lesions. This study highlights the polymicrobial nature and the predominance of anaerobes in cyst abscesses. There have been rare reports of basal cell carcinoma, [68] Bowen's disease, [69] and squamous cell carcinoma [70] developing in epidermoid cysts. Some of these reported cases may represent pseudoepitheliomatous hyperplasia or a proliferating trichilemmal tumor rather than malignant transformation.
Pathology The cyst is lined by a true epidermis composed of several layers of stratified squamous epithelium and a granular layer. Within the cyst is keratinous material arranged in laminated layers (Fig. 84-20). An epidermal cyst may contain melanocytes; as a result pigmentation is more commonly seen in dark-skinned individuals. A foreign body-type reaction with multinucleated giant cells may be found in the dermis surrounding the cyst in response to spillage of cyst contents.

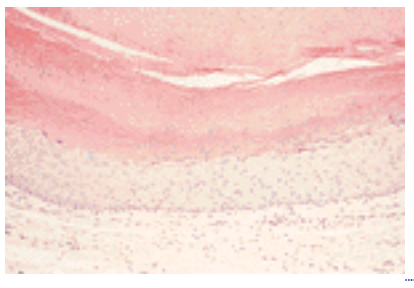
FIGURE 84-20 Epidermoid cyst lined by stratified epithelium with a granular layer. Within the cyst, the keratinous material is arranged in laminated layers.

Differential diagnosis The typical epidermoid cyst can usually be diagnosed clinically with confidence, especially if there is a central punctum through which the characteristic cheesy keratinous material can be expressed. Epidermoid cysts are clinically indistinguishable from pilar cysts; cysts on the trunk are usually epidermoid while those on the scalp are pilar in origin. Steatocystoma, especially the simplex variant, may cause diagnostic confusion, but typically it contains a yellow oily fluid rather than the cheesy-white keratinous debris seen in an epidermoid cyst. A lipoma may resemble an epidermoid cyst but may be differentiated by its soft consistency.
Treatment An inflamed noninfected cyst can be treated by intralesional triamcinolone 5 mg/mL. A fluctuant, probably infected cyst should be incised, drained, and cultured; if there is no improvement, antibiotic treatment should be started. The initial antibiotic therapy should be directed against *S. aureus,* as this is the most common pathogen; the antibiotic treatment can be modified according to culture and sensitivity results. Removal of the cyst is usually best deferred until the inflammation and infection have subsided. A cyst that has never been inflamed can usually be easily enucleated through a simple incision. A cyst with a history of previous inflammation and scarring as a result may need to be carefully dissected out. To prevent recurrence, the entire epidermal lining should be removed or destroyed.

TRICHILEMMAL CYST

Synonym: Pilar cyst. A trichilemmal cyst is a keratin-containing cyst, most commonly located on the scalp, which is derived from the lower portion of the hair follicle.

Etiology and pathogenesis The trichilemmal cyst wall is derived from the outer root sheath from the lower portion of the isthmus of the hair follicle located between the arrector pili muscle and the orifice of the sebaceous duct. As a result of this origin, the squamous epithelium undergoes abrupt homogeneous keratinization without the interposition of a granular layer. Leppard et al. illustrated features of an autosomal dominant mode of inheritance from pedigrees of patients with trichilemmal cysts. [71]
Epidemiology Trichilemmal cysts account for 10 to 20 percent of keratinous cysts seen in surgical pathology. They are reportedly more common in women and usually present in middle age. They occur in 5 to 10 percent of the population.
Clinical features Trichilemmal cysts are smooth, mobile, firm dermal nodules. They are located in areas of dense hair follicle concentrations; therefore, 90 percent occur on the scalp (Fig. 84-21). [71] Occasionally, lesions may form on the face, neck, and trunk. Patients usually have multiple lesions; more than 70 percent of patients have several lesions and 10 percent of patients have more than 10 lesions. [71]

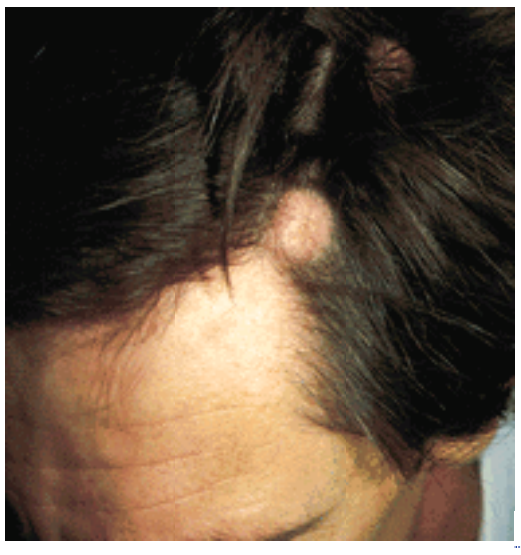
FIGURE 84-21 A trichilemmal (pilar) cyst on the scalp.

Complications Trichilemmal cysts may become inflamed and may suppurate, but this is uncommon. Rarely, the cyst may fuse with the epidermis to form a marsupialized cyst. Proliferating trichilemmal cyst (also known as proliferating trichilemmal tumor) may develop from an ordinary trichilemmal cyst. [71] This condition is usually seen in elderly women and is clinically recognized as a progressively enlarging lobulated mass that may ulcerate and resemble a squamous cell carcinoma. Although considered biologically benign, it may be locally aggressive. Very rarely, malignant transformation (malignant proliferating trichilemmal cyst) may occur, and this is heralded by rapid enlargement of a nodule. [72], [73]

Pathology A trichilemmal cyst is lined by epidermal cells that tend to be cuboidal, with indistinct intercellular bridges. The peripheral cell layer often shows palisading. There is no granular layer (Fig. 84-22). The cyst contains homogeneous eosinophilic keratinous material; foci of calcification may develop. A proliferating trichilemmal cyst shows a well-demarcated lobular squamous epithelial tumor. Characteristically, the epithelium in the center of the lobule changes abruptly into eosinophilic amorphous keratin, indicating trichilemmal keratinization. Infiltrative margins with a loss of a periodic acid-Schiff–reactive basement membrane and stromal desmoplasia suggest malignant transformation. [73]

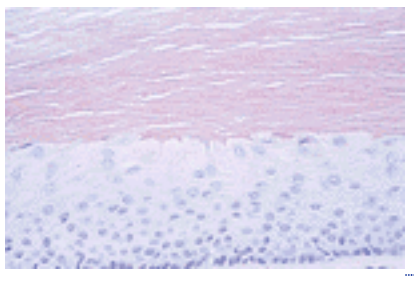

FIGURE 84-22 Trichilemmal cysts showing an epithelial lining that lacks a granular layer.

Differential diagnosis See " Epidermoid Cyst," above.
Treatment Treatment is the same as that for an epidermoid cyst. An uncomplicated trichilemmal cyst can usually be removed easily. A proliferating trichilemmal cyst must be excised with a narrow margin to ensure complete removal.

MILIUM

A milium is a small, superficial keratin cyst.

Etiology and pathogenesis Milia are common skin tumors classified as either primary or secondary. Primary milia are believed to be derived from the lowest portion of the infundibulum of vellus hairs. Secondary milia may represent retention cysts following injury to the skin and are believed to be derived from a hair follicle, sweat duct, sebaceous duct, or epidermis. Secondary milia may be seen in blistering dermatoses, after dermabrasion or 5-fluorouracil treatment, and in areas of chronic glucocorticoid-induced atrophy. [74]
Epidemiology Milia are very common and most of the time are not brought to medical attention. They are commonly found on the skin and mucosa of term infants. They also commonly occur in adults and show no sexual predisposition.
Clinical features Milia are clinically distinct. They are superficial, pearly white, globoid papules, generally only 1 to 2 mm in diameter (Fig. 84-23). Primary milia arise most commonly on the face, especially on the eyelids and cheeks. Milia in the newborn also have a predilection for the face, especially the nose. They may also appear elsewhere on the body and on mucosae (palate and gingiva). Milia on the palate are known as Epstein's pearls. A rare subtype of primary milia, called milia en plaque, occurs in middle-aged individuals and consists of grouped milia on an erythematous, indurated plaque, commonly located around the ears. Secondary milia are morphologically identical to primary milia; they are scattered within the affected areas. Rare cases of eruptive milia in which large numbers of lesions develop acutely on the face and trunk have been reported. [75]

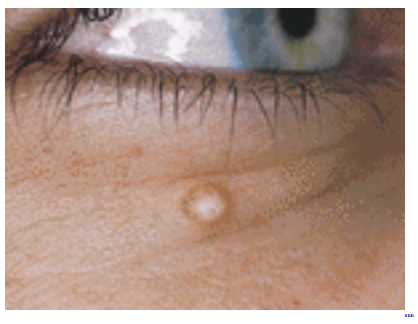

FIGURE 84-23 Primary milium. A 3.0-mm, hard, seedlike white papule.

Pathology The pathology of milia is identical to that of an epidermoid cyst, differing only in size. On serial section, a primary milium may be connected to a vellus hair follicle by an epithelial pedicle. Similarly, a secondary milium may show connection to its "parent" epithelial structure.
Treatment Spontaneous resolution of congenital milia is common and they do not require treatment. Milia arising later in life persist and can easily be expressed with a comedone extractor after incision with a no. 11 scalpel blade or a needle. When there are many lesions, they may be treated by light electrodesiccation of the surface of the lesions; the keratin core may extrude after the charred epidermal surface sloughs off.

STEATOCYSTOMA MULTIPLEX

Synonyms: Sebocystomatosis, epidermal polycystic disease. Steatocystoma multiplex is characterized by the presence of multiple dermal cysts that contain sebum and are lined by an epithelium containing sebaceous follicles.

Etiology and pathogenesis This is an autosomal dominant disorder; however, in some cases, no familial pattern can be established. Steatocystoma also occurs as a solitary lesion known as steatocystoma simplex, which has no hereditary tendency.
Epidemiology Both steatocystoma multiplex and simplex are uncommon. The condition usually begins in adolescence or early adulthood and persists indefinitely. Both sexes are affected equally.
Clinical features Patients present with many smooth, firm, dermal cystic papules and nodules adherent to the overlying skin (Fig. 84-24). The trunk and proximal extremities are most commonly involved, but lesions may appear anywhere, including the scrotum. Lesions vary from a few millimeters to several centimeters in diameter. The deeper lesions are skin-colored; superficial ones often appear yellow. When punctured, the cysts discharge a characteristic oily or creamy fluid. The lesions are usually asymptomatic; some may become inflamed, suppurate, and heal with scarring. Multiple lesions can be associated with pachyonychia congenita.

FIGURE 84-24 Steatocystoma multiplex. Multiple yellow cystic lesions on the trunk.

Pathology The cyst is situated in the mid-dermis. The cyst wall is convoluted with a peripheral layer of palisaded basal cells. The luminal surface of the wall is lined by a thick, homogeneous, eosinophilic layer (Fig. 84-25). There is no granular layer. Sebaceous glands are characteristically present in the cyst wall. The cystic cavity may contain small hairs.

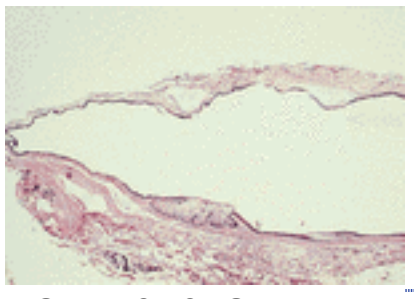

FIGURE 84-25 Steatocystoma multiplex. Sebaceous glands are present in the cyst wall.

Differential diagnosis The main differential diagnoses include “epidermoid cyst” (discussed earlier) and eruptive vellus hair cysts. Eruptive vellus hair cyst, which can be clinically indistinguishable from steatocystoma multiplex, are of both sporadic and autosomal dominant inheritance, most commonly presenting in adolescents as asymptomatic smooth papules and nodules on the anterior chest and extremities. It is histologically distinctive from steatocystoma multiplex. In a vellus hair cyst the cyst wall has several layers of mature squamous cells with a well-defined granular layer. The lumen is filled with laminated and amorphous keratinous material and numerous fragments of vellus hair. Sebaceous glands are situated close to the cyst, but rarely within the cyst wall. There are reports demonstrating that steatocystoma multiplex and eruptive vellus hair cysts may be variants of one entity. [76]

Treatment The multiplicity of lesions of steatocystoma multiplex usually precludes surgical excision. Recent reports of 1- to 3-mm incisions at the domes of lesions and removal of cyst walls with artery forceps have offered both excellent cosmetic results and long lasting remissions. [77] Inflamed lesions may be excised or treated with incision and drainage and/or intralesional glucocorticoids. Other attempts of treatment with aspiration, isotretinoin, cryotherapy, and CO_2 laser have had variable success.

DERMOID CYST

A dermoid cyst is a cyst that is lined by an epidermis containing various epidermal appendages.

Etiology and pathogenesis Dermoid cysts develop from sequestration of epithelium along lines of embryonic fusion.

Epidemiology Dermoid cysts are rare, the estimated incidence is about 0.002 to 0.005 percent of births. [78] They may first be noted at birth or in early childhood. The sexes are affected equally.

Clinical features As expected, these lesions are found along embryonal fusion planes. The most common locations are the lateral third of the eyebrows, the nose, and the scalp. Nasal dermoid cysts may have a sinus tract that opens on the skin of the nose anywhere between the base of the columella and the glabella, with the distal one-third of the nasal dorsum being the most common site. A cheesy material may be expressed from the sinus, and tufts of hair may project from it. [79] Cystic swellings may appear anywhere along the sinus tract. Uncommon locations include the neck, sternum, scrotum, perineal raphe, and sacrum. [79] The cysts are usually subcutaneous and freely mobile, although they may occasionally be fixed to the periosteum. They are smooth and firm in consistency. They enlarge slowly and may reach sizes ranging from 1 to 4 cm or more in diameter.

Complications Dermoid cysts can become inflamed and infected. Infection may be introduced iatrogenically through aspirations or biopsies. This may lead to serious complications if there is intracranial communication. [80] Periocular dermoids usually do not extend intracranially, but dermoids in the midline frontal (including nasal dermoids), temporal-parietal, and occipital regions frequently have intracranial extensions. [81]

Pathology The cyst is lined by epidermis and the cyst wall contains various mature skin appendages; namely, hair follicles, sweat glands, and sebaceous glands. Hairs are often present within and projecting into the cyst cavity.

Differential diagnosis The differential diagnosis includes other cysts of epithelial origin, glioma, encephalocele, hemangioma, rhabdomyosarcoma, and fibrosarcoma. The early onset of the lesion and the location should help distinguish a dermoid cyst from other cysts of epithelial origin. [81] A hemangioma has a purple to bluish hue. Rhabdomyosarcomas and fibrosarcomas are hard and rapidly growing. When the lesion is located on the neck, thyroglossal duct cyst, bronchial cyst, and ectopic thyroid should be considered. It is important to differentiate a nasal dermoid cyst from an extranasal glioma or an encephalocele because the latter two lesions may connect with the subarachnoid space. Extranasal glioma is a rare benign tumor of heterotopic brain tissue thought to arise from abnormal sequestration of normal elements during development. It may present at birth as a firm, red-to-purple protrusion at the root of the nose. A useful differentiating feature is that glioma is almost always eccentric and not midline. An

encephalocele is a herniation of cranial contents through a skull defect; it may show size fluctuation or spontaneous pulsation; hypertelorism is frequently seen.
Treatment Treatment of a dermoid cyst is by excision. [82] Any possible underlying sinus tract should be explored and excised to prevent recurrence. Careful preoperative evaluation is essential to delineate any intracranial extension. When appropriate, consultations with otolaryngology or facial plastic surgery and neurosurgery services should be obtained. Imaging studies include magnetic resonance imaging or computed tomography as well as polytomography of the base of the skull. [81], [82]

BRANCHIAL CYST

Synonym: Branchial cleft cyst. A branchial cyst is an epithelial cyst that arises from incomplete obliteration of the branchial clefts in embryologic development.

Etiology and pathogenesis Branchial cysts usually arise from incomplete closure of the second branchial cleft and rarely from the third branchial clefts. The cysts are derived from the sequestrated remains of the cleft membrane. Most appear to be sporadic cases, but pedigrees showing autosomal dominant inheritance have been reported.
Epidemiology This is a rare disorder.
Clinical features Asymptomatic sinuses or fistulas present in infancy, drain internally to the pharynx and/or externally through the skin of the neck along the middle to lower third of the anterior edge of the sternocleidomastoid muscle. Branchial cleft cysts occur in childhood or early adulthood as a result of occlusion of the sinus tract. They most frequently present after an upper respiratory tract infection as a painful, warm, erythematous inflammatory mass, deep to the anterior border of the sternocleidomastoid muscle. Most are unilateral, but 10 percent are bilateral. They may have a mucoid discharge and may become infected.
Pathology The cysts and sinuses are lined by stratified squamous epithelium. The wall commonly contains lymphoid tissue with germinal centers.
Treatment Complete excision is recommended at diagnosis, as recurrent infections are common. Infected cysts and sinus tracts should be treated with warm compresses and systemic antibiotics.

PREAURICULAR CYST AND SINUS

Synonyms: Ear pits, congenital auricular fistula. A preauricular cyst or sinus is an epithelial cyst or sinus in the preauricular region; it arises from incomplete fusion of the first two branchial arches.

Etiology and pathogenesis During Embryonic development, six tubercles from the first two branchial arches produce the tragus and pinna. Their incomplete fusion results in epithelium-lined pouches. These become epithelial cysts known as preauricular cysts. The cysts tunnel to the surface of the skin, forming preauricular sinuses.
Epidemiology Preauricular cysts and sinuses are common, occurring in 1 percent of the population. Familial cases with autosomal dominant inheritance have been described.
Clinical features Most cases are asymptomatic and bilateral, and the lesions are noted incidentally as bilateral cystic swellings or pits just anterior to the superior auricular crease; the pits represent the openings of the preauricular sinuses. Sometimes, the lesions may present as infected cysts draining pus through the preauricular sinuses to the surface of the skin.
Complications The majority of preauricular cysts and sinuses are uncomplicated. Sometimes, secondary infection may occur. Rarely, other developmental anomalies of the ear and branchial arches may coexist. Deafness has been associated with this disorder. [83]
Pathology The cysts and sinus tracts are lined by stratified squamous epithelium.
Treatment Asymptomatic lesions require no treatment. Secondarily infected lesions should be treated with antibiotics. Excision should be delayed until the infection has subsided.

CHONDRODERMATITIS NODULARIS HELICIS*

Chondrodermatitis nodularis helicis (CNH) usually occurs as a single, less than 1 cm diameter, exquisitely tender eroded nodule on the free border of the helix of the ear.

Etiology and Pathogenesis [84], [85]

The pinnae are exposed to constant mechanical and environmental trauma (e.g., pressure, sun, wind, and extremes of temperature), leading to thinning of the skin and cartilage, to loss of elastic tissue, and to degenerative vascular and connective tissue changes. Anatomically, there is no subcutaneous tissue in the lateral ear for thermal or mechanical protection; the blood supply to the pinna is through relatively small blood vessels. Minor trauma may precipitate damage and inadequate blood supply may prevent tissue repair.

Goette suggested that CNH represents an actinically induced, necrobiotic granuloma with secondary epithelial changes leading to transepidermal elimination of degenerated connective tissue. [85] Factors supporting this concept include: CNH is most common in the middle-aged and the elderly, darkly pigmented patients are affected less frequently, and often there is solar elastosis at the periphery of the lesion. Biopsies frequently show transepidermal elimination of necrobiotic material through overlying epidermal channels, slits, or erosions.

Whether inflammation proceeds outward from primarily damaged perichondrium or inward from injured epidermis or dermis is unknown.

Epidemiology [86]

CND is most common in adult males over 50 years old. Women account for approximately 10 percent of the total cases.

Clinical Features

CNH nodules usually appear spontaneously, enlarge quickly to less than 1 cm, and then remain stationary unless altered by infection or trauma. Lesions are firm, well-defined, round to oval with sloping margins, either embedded in the skin or elevated several millimeters. They range from 3 to 20 mm in diameter (average 4 to 7 mm) and have a flat or dome-shaped surface covered with an adherent scale (Fig. 84-26). The surrounding skin is gray-white, or waxy and translucent. A narrow inflammatory areola may surround the nodule. The right ear is more commonly involved than the left and helical lesions are more common in women.

FIGURE 84-26 Painful nodule of the ear: a typical lesion of chondrodermatitis nodularis helicis.

Spontaneous pain or tenderness is almost always the initial presenting complaint, but is often intensified by pressure or cold. The discomfort is described as intense and stabbing, paroxysmal or continuous, and is momentary or lasts several hours. The pain may be temporarily relieved by removal of the crust. A history of ulceration or drainage is frequent. There is no relation to systemic disease.

Elderly women often have multiple lesions that are only slightly, if at all, painful. These resolve spontaneously and may be a variant of CNH. The nodules are larger, more rounded, and always directly attributable to trauma such as from the constant friction of a nun's headpiece.

Spontaneous remission is rare. With treatment, remissions of months to years may occur, but the disease generally continues to be active indefinitely unless adequately treated.

Basal cell and squamous cell carcinomas are commonly confused with CNH. Actinic keratosis, keratoacanthoma, and warts may present a similar appearance, as, to a lesser degree, do clavus, tophus, rheumatoid or rheumatic nodules, and discoid lupus erythematosus. Relapsing polychondritis presents painful areas on the ears but is otherwise dissimilar.

Pathology [84], [85]

The epidermis shows well-localized acanthosis with either a central depression or an erosion covered by a hyperkeratotic parakeratotic scale. The acanthotic region is often penetrated by a channel filled with necrotic dermal debris. In the dermis there is intense edema, fibrinoid degeneration, necrolysis of the collagen, and ingrowth of richly vascularized granulation tissue. Lymphocytes, plasma cells, and histiocytes are present, as are epithelioid cells. Elastic tissue is diminished or absent in areas of inflammation. The thickened and layered perichondrium shows an infiltrate continuous with granulation tissue in the dermis. Cartilage may be altered but is frequently normal. Calcification and ossification of the distal chondral laminae have been described.

Treatment

Relief of pressure with custom or commercially available foam rubber pillows, with a depression for the ear, is often effective for symptomatic relief. High-potency topical corticosteroids are occasionally effective and should be tried first. Single or multiple intralesional injections of corticosteriods will often cause lesions to regress or disappear (triamcinolone acetonide, 10 to 40 mg/mL, 0.2 to 0.5 mL). [87] Carbon dioxide laser surgery is useful in clearing lesions. [88] Ablation of lesions with a defocused carbon dioxide laser beam may lead to smooth asymptomatic scars that remain painless for long periods of time. The definitive treatment, excisional surgery or cartilage excision, eliminates the mechanical squeezing of the dermis by removing the pathologic tissue, relieves pain by cutting the nerves, and reduces the amount of projecting rim of helical cartilage, although recurrence occurs. [89], [90]

*Portions of this chapter are modified from the chapter by K. Arndt in the fourth edition of this text.

REFERENCES

1. Yeatman JM et al: The prevalence of seborrhoeic keratoses in an Australian population: Does exposure to sunlight play a part in their

frequency? *Br J Dermatol* **137**:411, 1997

2. Tsambaos D et al: Detection of human papillomavirus DNA in nongenital seborrhoeic keratoses. *Arch Dermatol Res* **287**:612, 1995

3. Ellis DL et al: Melanoma, growth factors, acanthosis nigricans, the sign of Leser-Trélat, and multiple acrochordons. A possible role for alpha-transforming growth factor in cutaneous paraneoplastic syndromes. *N Engl J Med* **317**:1582, 1987

4. Heaphy MR Jr et al: The sign of Leser-Trélat in a case of adenocarcinoma of the lung. *J Am Acad Dermatol* **43**:386, 2000

5. Lever W, Schaumberg-Lever G: *Histopathology of the Skin*. Philadelphia, Lippincott, 1997

6. Sloan JB, Jaworsky C: Clinical misdiagnosis of squamous cell carcinoma in situ as seborrheic keratosis. A prospective study. *J Dermatol Surg Oncol* **19**:413, 1993

7. Rao BK et al: The relationship between basal cell epithelioma and seborrheic keratosis. A study of 60 cases. *J Dermatol Surg Oncol* **20**:761, 1994

8. Zabel RJ et al: Malignant melanoma arising in a seborrheic keratosis. *J Am Acad Dermatol* **42**:831, 2000

9. Cascajo CD et al: Malignant neoplasms associated with seborrheic keratoses. An analysis of 54 cases. *Am J Dermatopathol* **18**:278, 1996

10. Schwartz RA: Sign of Leser-Trélat. *J Am Acad Dermatol* **35**:88, 1996

11. Millard LG, Gould DJ: Hyperkeratosis of the palms and soles associated with internal malignancy and elevated levels of immunoreactive human growth hormone. *Clin Exp Dermatol* **1**:363, 1976

12. Williams JV et al: Chemotherapy-induced inflammation in seborrheic keratoses mimicking disseminated herpes zoster. *J Am Acad Dermatol* **40**:643, 1999

13. Tsuji T, Morita A: Giant seborrheic keratosis on the frontal scalp treated with topical fluorouracil. *J Dermatol* **22**:74, 1995

14. Pepper E: Dermabrasion for the treatment of a giant seborrheic keratosis . *J Dermatol Surg Oncol* **11**:646, 1985

15. Rogers M et al: Epidermal nevi and the epidermal nevus syndrome. A review of 131 cases. *J Am Acad Dermatol* **20**:476, 1989

16. Solomon LM, Esterly NB: Epidermal and other congenital organoid nevi . *Curr Probl Pediatr* **6**:1, 1975

17. Adams BB, Mutasim DF: Adult onset verrucous epidermal nevus . *J Am Acad Dermatol* **41**:824, 1999

18. Ichikawa T et al: Squamous cell carcinoma arising in a verrucous epidermal nevus. *Dermatology* **193**:135, 1996

19. Reddy BS et al: Generalized epidermolytic hyperkeratosis in a child born to a parent with systematized epidermolytic linear epidermal nevus. *Int J Dermatol* **36**:198, 1997

20. Paller AS et al: Genetic and clinical mosaicism in a type of epidermal nevus. *N Engl J Med* **331**:1408, 1994

21. Happle R: Mosaicism in human skin. Understanding the patterns and mechanisms. *Arch Dermatol* **129**:1460, 1993

22. Dupre A, Christol B: Inflammatory linear verrucose epidermal nevus. A pathologic study. *Arch Dermatol* **113**:767, 1977

23. Brownstein MH et al: Lichenoid epidermal nevus: “Linear lichen planus.” *J Am Acad Dermatol* **20**:913, 1989

24. Baba T et al: Successful treatment of dark-colored epidermal nevus with ruby laser. *J Dermatol* **22**:567, 1995

25. Kim JJ et al: Topical tretinoin and 5-fluorouracil in the treatment of linear verrucous epidermal nevus. *J Am Acad Dermatol* **43**:129, 2000

26. Bohm I et al: Successful therapy of an ILVEN in a 7-year-old girl with calcipotriol [in German]. *Hautarzt* **50**:812, 1999

27. Ozkaya-Bayazit E et al: Pustular psoriasis with a striking linear pattern. *J Am Acad Dermatol* **42**:329, 2000

28. Morency R, Labelle H: Nevus sebaceus of Jadassohn: A rare oral presentation. *Oral Surg Oral Med Oral Pathol* **64**:460, 1987

29. Sahl WJ Jr: Familial nevus sebaceus of Jadassohn: Occurrence in three generations. *J Am Acad Dermatol* **22**:853, 1990

30. Chun K et al: Nevus sebaceus: Clinical outcome and considerations for prophylactic excision. *Int J Dermatol* **34**:538, 1995

31. Cribier B et al: Tumors arising in nevus sebaceus: A study of 596 cases. *J Am Acad Dermatol* **42**:263, 2000

32. Jaqueti G et al: Trichoblastoma is the most common neoplasm developed in nevus sebaceus of Jadassohn: A clinicopathologic study of a series of 155 cases. *Am J Dermatopathol* **22**:108, 2000

33. Xin H et al: The sebaceous nevus: a nevus with deletions of the PTCH gene. *Cancer Res* **59**:1834, 1999

34. Hunt SJ et al: Desmoplastic trichilemmoma: Histologic variant resembling invasive carcinoma. *J Cutan Pathol* **17**:45, 1990

35. Rahbari H, Mehregan AH: Development of proliferating trichilemmal cyst in organoid nevus. Presentation of two cases. *J Am Acad Dermatol* **14**:123, 1986

36. Cestari TF et al: Nevus comedonicus: Case report and brief review of the literature. *Pediatr Dermatol* **8**:300, 1991

37. Parslew R, Lewis-Jones MS: Localized unilateral hyperhidrosis secondary to an eccrine naevus. *Clin Exp Dermatol* **22**:246, 1997

38. Herzberg J: Ekkrines syringocystadenoma. *Arch Klin Exp Dermatol* **214**:600, 1962

39. Imai S, Nitto H: Eccrine nevus with epidermal changes. *Dermatologica* **166**:84, 1983

40. Civatte J et al: Apocrine nevus. Study of 2 cases . *Ann Dermatol Syphiligr* **101**:251, 1974

41. Hodge JA et al: The epidermal nevus syndrome. *Int J Dermatol* **30**:91, 1991

42. Happle R: Epidermal nevus syndromes. *Semin Dermatol* **14**:111, 1995

43. Eichler C et al: Epidermal nevus syndrome: Case report and review of clinical manifestations. *Pediatr Dermatol* **6**:316, 1989

44. Chow MJ, Fretzin DF: Epidermal nevus syndrome: Report of association with chondroblastoma of bone. *Pediatr Dermatol* **6**:358, 1989

45. Ivker R et al: Hypophosphatemic vitamin D-resistant rickets, precocious puberty, and the epidermal nevus syndrome. *Arch Dermatol* **133**:1557, 1997

46. Baker RS et al: Neurologic complications of the epidermal nevus syndrome. *Arch Neurol* **44**:227, 1987

47. Mansour AM et al: Ocular choristomas. *Surv Ophthalmol* **33**:339, 1989

48. Happle R et al: Phacomatosis pigmentokeratotica: A melanocytic-epidermal twin nevus syndrome. *Am J Med Genet* **65**:363, 1996

49. Kennedy D, Rogers M: Lichen striatus. *Pediatr Dermatol* **13**:95, 1996

50. Di Lernia V et al: Lichen striatus and atopy. *Int J Dermatol* **30**:453, 1991

51. Patrizi A et al: Simultaneous occurrence of lichen striatus in siblings. *Pediatr Dermatol* **14**:293, 1997

52. Tosti A et al: Nail lichen striatus: Clinical features and long-term follow-up of five patients. *J Am Acad Dermatol* **36**:908, 1997

53. Zhang Y, McNutt NS: Lichen striatus. Histological, immunohistochemical, and ultrastructural study of 37 cases. *J Cutan Pathol* **28**:65, 2001

54. Penneys NS et al: Clear cell acanthoma: Not of sweat gland origin. *Acta Derm Venereol* **61**:569, 1981

55. Hashimoto T et al: Two cases of clear cell acanthoma: An immunohistochemical study. *J Cutan Pathol* **15**:27, 1988

56. Ohnishi T, Watanabe S: Immunohistochemical characterization of keratin expression in clear cell acanthoma. *Br J Dermatol* **133**:186, 1995

57. Finch TM, Tan CY: Clear cell acanthoma developing on a psoriatic plaque: Further evidence of an inflammatory aetiology? *Br J Dermatol* **142**:842, 2000

58. Langer K et al: Pigmented clear cell acanthoma. *Am J Dermatopathol* **16**:134, 1994

59. Langtry JA et al: Giant clear cell acanthoma in an atypical location. *J Am Acad Dermatol* **21**:313, 1989

60. Betti R et al: Successful cryotherapic [sic] treatment and overview of multiple clear cell acanthomas. *Dermatol Surg* **21**:342, 1995

61. Griffiths TW et al: Multiple warty dyskeratomas of the scalp. *Clin Exp Dermatol* **22**:189, 1997

62. Cerroni L et al: Acanthoma fissuratum. *J Dermatol Surg Oncol* **14**:1003, 1988

63. Ohnishi T, Watanabe S: Immunohistochemical observation of cytokeratins in keratinous cysts including plantar epidermoid cyst. *J Cutan Pathol* **26**:424, 1999

64. Walsh C, Rushton HG: Diagnosis and management of teratomas and epidermoid cysts. *Urol Clin North Am* **27**:509, 2000

65. Talacchi A et al: Assessment and surgical management of posterior fossa epidermoid tumors: Report of 28 cases. *Neurosurgery* **42**:242, 1998

66. Egawa K et al: Human papillomavirus 57 identified in a plantar epidermoid cyst. *Br J Dermatol* **138**:510, 1998

67. Brook I: Microbiology of infected epidermal cysts. *Arch Dermatol* **125**:1658, 1989

68. Delacretaz J: Keratotic basal-cell carcinoma arising from an epidermoid cyst. *J Dermatol Surg Oncol* **3**:310, 1977

69. Shelley WB, Wood MG: Occult Bowen's disease in keratinous cysts. *Br J Dermatol* **105**:105, 1981

70. Lopez-Rios F et al: Squamous cell carcinoma arising in a cutaneous epidermal cyst: Case report and literature review. *Am J Dermatopathol* **21**:174, 1999

71. Leppard BJ, Sanderson KV: The natural history of trichilemmal cysts. *Br J Dermatol* **94**:379, 1976

72. Sau P et al: Proliferating epithelial cysts. Clinicopathological analysis of 96 cases. *J Cutan Pathol* **22**:394, 1995

73. Lopez-Rios F et al: Proliferating trichilemmal cyst with focal invasion: Report of a case and a review of the literature. *Am J Dermatopathol* **22**:183, 2000

74. Tsuji T et al: Milia induced by corticosteroids . *Arch Dermatol* **122**:139, 1986

75. Cairns ML, Knable AL: Multiple eruptive milia in a 15-year-old boy. *Pediatr Dermatol* **16**:108, 1999

76. Kiene P et al: Eruptive vellus hair cysts and steatocystoma multiplex. variants of one entity? *Br J Dermatol* **134**:365, 1996

77. Adams BB et al: Steatocystoma multiplex: a quick removal technique. *Cutis* **64**:127, 1999

78. Nocini PF et al: Dermoid cyst of the nose: A case report and review of the literature. *J Oral Maxillofac Surg* **54**:357, 1996

79. Brownstein MH, Helwig EB: Subcutaneous dermoid cysts. *Arch Dermatol* **107**:237, 1973

80. Crawford R: Dermoid cyst of the scalp: intracranial extension. *J Pediatr Surg* **25**:294, 1990

81. Thomson HG: Common benign pediatric cutaneous tumors: Timing and treatment. *Clin Plast Surg* **17**:49, 1990

82. Fornari M et al: Surgical treatment of intracranial dermoid and epidermoid cysts in children. *Childs Nerv Syst* **6**:66, 1990

83. Fourman P, Fourman J: Hereditary deafness in a family with ear-pits. *Br Med J* **2**:1354, 1955

84. Shuman R, Helwig EB: Chondrodermatitis nodularis chronica helicis. *Am J Clin Pathol* **24**:126, 1954

85. Goette DK: Chrondrodermatitis nodularis chronica helicis: A perforating necrobiotic granuloma. *J Am Acad Dermatol* **2**:148, 1980

86. Newcomer VD et al: Chondrodermatitis nodularis chronica helicis: Report of 94 cases and survey of literature, with emphasis on pathogenesis and treatment. *Arch Dermatol Syphilol* **68**:241, 1953

87. Cox NH, Denham PF: Intralesional triamcinolone for chondrodermatitis nodularis: A follow-up study of 60 patients. *Br J Dermatol* **146**:712, 2002

88. Taylor MB: Chondrodermatitis nodularis chronca helicis. Successful treatment with the carbon dioxide laser. *J Dermatol Surg Oncol* **18**:862, 1992

89. Zimmerman MC: Chondrodermatitis nodularis chronica helicis: A nondeforming surgical cure for painful nodules of the ear. *Arch Dermatol* **78**:41, 1958

90. Hudson-Peacock MJ et al: The long-term results of cartilage removal alone for the treatment of chondrodermatitis nodularis. *Br J Dermatol* **141**:703, 1999

T>

Chapter 85

Steven Kaddu Helmut Kerl

Appendage Tumors of the Skin

GENERAL CONSIDERATIONS
PRINCIPLES OF DIAGNOSIS
PRINCIPLES OF CLASSIFICATION
PRINCIPLES OF THERAPY
APPENDAGE TUMORS WITH APOCRINE DIFFERENTIATION
Cysts
Hamartomas
Hyperplasia
Benign Neoplasms
Malignant Neoplasms
APPENDAGE TUMORS WITH ECCRINE DIFFERENTIATION
Cyst
Hamartoma
Hyperplasias
Benign Neoplasms
Malignant Neoplasms
APPENDAGE TUMORS WITH FOLLICULAR DIFFERENTIATION
Cysts
Hamartomas
Benign Neoplasms
Malignant Neoplasms
APPENDAGE TUMORS WITH SEBACEOUS DIFFERENTIATION
Cyst
Hamartomas
Hyperplasia
Benign Neoplasms
Malignant Neoplasms

REFERENCES

GENERAL CONSIDERATIONS

Appendage tumors of the skin show differentiation toward epithelial components of normal (embryonal or mature) adnexal structures (i.e., apocrine, eccrine, hair follicle, and sebaceous units) (Table 85-1). [1], [2], [3], [4], [5] and [6] They may occur as solitary or multiple lesions. Solitary lesions generally reveal no distinctive clinical features. Their anatomic distribution, however, often reflects areas with high densities of corresponding normal cutaneous adnexa. Appendage tumors arising as multiple lesions frequently display a characteristic distribution. They are often inherited as autosomal dominants and may be associated with other cutaneous and extracutaneous pathology.

TABLE 85-1 **Classification of Appendage Tumors of the Skin**

Histopathology is the most important tool for diagnosis and classification of appendage skin tumors. Diagnosis is based mainly on assessment of architectural and cytomorphologic characteristics as well as estimation of the predominant direction and level of differentiation towards normal adnexa. [1], [2], [3], [4], [5] and [6] Diagnostic criteria are apparent in the vast majority of cases on routine hematoxylin and eosin (H&E)-stained sections, although they may be absent or less prominent in different areas of the same tumor. A careful and adequate sampling of the specimen is, therefore, essential.

Immunohistologic analyses are occasionally necessary for interpretation of the tumors (Table 85-2). Interestingly, there is a significant overlap of immunohistologic features among tumors with ductal differentiation (apocrine and eccrine tumors), and certain visceral malignancies. In our experience, ultrastructural studies are of limited value in routine diagnosis of these tumors.



TABLE 85-2 **Immunohistochemical Findings in Appendage Tumors of the Skin**

Recently, cytogenetic and molecular studies have shed some light on the pathogenesis of several cutaneous appendage tumors. For instance, *p53* mutations have been detected in a number of neoplasms, suggesting a possible etiologic role for UV light exposure. [7] Mutation of the human homologue of *Drosophila patched (PTC)* gene is considered to be the molecular defect in follicular appendage tumors arising in patients with the basal cell nevus (Gorlin) syndrome (i.e., trichoblastoma and basal cell carcinoma; see Chap. 82). [8] Germ-line mutations have consistently been reported in other familial syndromes, suggesting a role of these aberrations in pathogenesis. For example, mutations of *PTEN,* a tumor-suppressor gene, have been identified in tumors from patients with Cowden's (multiple hamartoma) syndrome [9] (see Chap. 184). Microsatellite instability as well as mutations of the *hMSH2* and *hMLH1* mismatch repair genes have also been detected in neoplasms from patients with Muir-Torre syndrome [10] (see Chap. 184).

PRINCIPLES OF DIAGNOSIS

Apocrine and eccrine tumors are characterized histopathologically by the presence, at least focally, of features of ductal differentiation. The ductal structures in apocrine neoplasms display “apocrine” secretion (“decapitation” or “pinching”), while those of eccrine tumors are lined by a flattened epithelium. [1] Follicular tumors show a range of morphologic features that recapitulate specific portions of normal hair and hair follicle [3] such as the infundibulum, isthmus, stem, and bulb (see Chap. 71). The finding of matrical cells reflects differentiation towards follicular bulbs. Trichohyalin granules and blue-gray corneocytes indicate differentiation towards the inner root sheath. Differentiation toward the outer root sheath is manifested by the presence of either clear columnar cells aligned in a palisade (outer root sheath differentiation at the bulb), subtly cornified cells with pink cytoplasm (outer root sheath differentiation at the stem), or fully cornified cells with red cytoplasm (“tricholemmal keratinization”) which corresponds to outer root sheath differentiation at the isthmus. Sebaceous tumors reveal areas with sebocytes and tubular structures. [2] Notably, some tumors may display one or more lines of differentiation.

Determination of whether an appendage neoplasm is benign or malignant requires assessment of architectural and cytomorphologic characteristics. Great care is, however, necessary when applying traditional morphologic criteria of malignancy such as asymmetry, poor circumscription, and presence of epithelial aggregations with prominent atypia and mitotic activity. Some malignant and aggressive neoplasms (e.g., microcystic adnexal carcinoma) show deceptively bland appearances. Furthermore, there are certain neoplasms whose malignant potential is not always predictable on morphologic grounds.

PRINCIPLES OF CLASSIFICATION

The number of current classifications of appendage tumors of the skin indicate how little consensus exists about their grouping and their etiology and pathogenesis. [1], [2], [3], [4], [5] and [6] There is also no unanimity among authors as to whether particular tumors are truly neoplasms, hyperplasias or hamartomas. In this chapter, we have categorized appendage tumors of the skin as cysts, hamartomas, hyperplasias, and benign or malignant neoplasms, and have arranged them alphabetically (Table 85-1). A *cutaneous cyst* is defined as an epithelium-lined, round or oval sac-like lesion. The term *cutaneous hamartoma* refers to a possibly embryologic malformation characterized by an abnormal arrangement of “normal” cutaneous tissues. *Cutaneous hyperplasia* represents an increase in number of normal cells but with relatively normal arrangement in the skin. A *benign* neoplasm has no potential to metastasize. A *malignant* neoplasm possesses the potential for local destruction and metastasis.

PRINCIPLES OF THERAPY

A diagnostic biopsy of a suspicious lesion and a correct diagnosis is usually the first step in appropriate management of patients with appendage skin tumors. A number of tumor-related and patient-related factors influence the choice of treatment. Tumor-related factors include the type, size, and anatomic location. Patient-related factors include life expectancy, comorbid conditions, and cosmetic concerns.

Specific treatment of benign appendage tumors is sometimes unnecessary. In some cases, removal of the tumor is indicated for cosmetic reasons only. Treatment of choice for the majority of benign appendage tumors and relatively nonaggressive, malignant appendage neoplasms is excisional surgery. A variety of superficial ablative techniques (electrodesiccation and curettage and cryotherapy) have proved to be effective in selected patients. A number of other alternative treatment options, including the use of systemic retinoids, laser, and photodynamic therapy, have also been advocated for use in some cases. However, these alternative therapies are still considered investigational because of lack of sufficient data regarding their efficacy and side effects.

Treatment of malignant appendage tumors aims mainly at eradication of the cancer, and preservation or restoration of normal function, as well as cosmesis. High-risk patients with tumors known to have a high rate of recurrence or metastasis most frequently require wide excisional surgery, Mohs micrographic surgery, and/or radiotherapy. Notably, sentinel node biopsy is sometimes valuable in staging of patients with eccrine and apocrine carcinomas.

APPENDAGE TUMORS WITH APOCRINE DIFFERENTIATION

Appendage tumors with ductal differentiation (sweat gland tumors) have traditionally been divided into apocrine and eccrine. However, over the years, it has become increasingly recognized that distinction between apocrine and eccrine is

not always possible, as classic features of apocrine differentiation are sometimes observed in tumors traditionally categorized as eccrine.

Generally, the anatomic distribution of apocrine tumors reflects that of normal glands manufacturing apocrine secretion which are confined to the head and neck, axillae, and genital or perianal skin. The vast majority of apocrine tumors are benign. [1] Malignant neoplasms show varied and diverse morphologic features and biologic potential.

Cysts

HIDROCYSTOMA Hidrocystoma (cystadenoma) is a relatively common cystic lesion that shows features of either apocrine (apocrine type) or eccrine (eccrine type) differentiation. It presents mostly in middle-aged or elderly individuals as a solitary, small- to medium-sized, skin-colored, reddish or bluish cystic nodule situated on the head or neck, especially around the eyes [1], [4], [5] and [6], [11] (Fig. 85-1A). Men and women are equally affected. Unusual presentations include multiple lesions, giant tumors (up to 7 cm), and lesions occurring in childhood. Hidrocystoma occasionally develops within a nevus sebaceus (see Chap. 84). Multiple hidrocystomas localized to borders of the upper and lower eyelids bilaterally may represent a feature of ectodermal dysplasia.

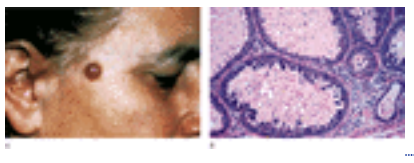

FIGURE 85-1 Apocrine hidrocystoma. *A.* Reddish-brown to bluish cystic nodule. *B.* Multilocular tumor with papillary projections (“apocrine secretion”).

Histopathology There is an unilocular or occasionally a multilocular cyst located in the dermis. The epithelial lining displays either features of apocrine (decapitation secretion) or eccrine (single or double layered, cuboid often flattened epithelium) differentiation. [1] Prominent papillations protruding into the lumen are noted in a subset of cases (Fig. 85-1B). Secretory products contain lipofuscin, melanin, and/or hemosiderin. Treatment of choice in solitary lesions is simple surgical excision. Multiple lesions may be removed using a carbon dioxide laser, electrodesiccation, or surgery with blepharoplasty.

MOLL'S GLAND CYST Moll's gland cyst is a cystic dilatation of Moll's glands, which are modified apocrine glands located on the eyelids. The lesion presents mainly as a solitary, dome-shaped cystic tumor located on the inner or outer canthus of the eyelid. [1]

Histopathology The histology is essentially similar to that of apocrine hidrocystoma.

Hamartomas

APOCRINE NEVUS Apocrine nevus is a rare hamartoma that consists of proliferation in the dermis of normal appearing apocrine glands. Two variants are recognized: a type occurring as a part of nevus sebaceus and an extremely rare type arising independently (pure apocrine nevus). Pure apocrine nevus presents as a unilateral or bilateral, soft, lobulated dermal mass in the axilla or as a circumscribed area on the scalp. [1], [4], [5] and [6], [11] Cases of apocrine nevus occurring as multiple, firm papules on the chest have been reported. [12]

Histopathology There are numerous, discrete, closely spaced tubular structures in the dermis and/or the subcutaneous fat. The tubules are lined by typical apocrine glandular epithelium and contain a homogeneous or vacuolated pink material (apocrine secretion). An apocrine nevus developing within a preexisting nevus sebaceus usually arises in the deeper portion, sometimes in association with a syringocystadenoma papilliferum or trichoblastoma. [13]

SUPERNUMERARY NIPPLE This condition is characterized by the presence of solitary or multiple rudimentary nipples developing along the embryonal milk line. Lesions present mainly in young individuals. [1] Males and females are equally affected. Most cases are sporadic but some lesions show a genetic transmission. Supernumerary nipples occur commonly as solitary, asymptomatic, soft, brown papules with a dimple, resembling dermatofibromas, fibromas, or melanocytic nevi. Less frequently, patients show supernumerary nipples with an appearance of an areola (polythelia areolaris), a patch of hair (polythelia pilosa), or a subcutaneous mass with or without areola. Rare cases present as a pedunculated or dermal mass in the axilla or vulva. Supernumerary nipples have also been reported in association with adenoma of the nipple (erosive adenomatosis) [1], [14] and with renal abnormalities, including renal cell carcinoma.

Histopathology There is usually an exophytic or dome-shaped lesion consisting of variable components of a normal nipple, including sebaceous lobules and ducts (Montgomery's tubercles). A rudimentary vellus follicle, various lactiferous ducts, dilated venules, and fascicles of smooth muscle can be observed. Treatment is by simple surgical excision.

Hyperplasia

FIBROADENOMA Fibroadenoma represents the most common cause of a breast mass in women younger than 25 years of age. Rarely, the tumor arises along the embryonic milk line or in other locations. [1], [15] Although previously generally considered to be a benign neoplasm, fibroadenoma is now widely regarded as a form of hyperplasia of normal breast lobules. The etiology is unknown, but the condition probably results from a proliferation of breast tissue in response to excessive circulating estradiol over progesterone. Lesions commonly present as single or multiple firm, rubbery, smooth, mobile, painless infiltrates ranging up to 2 cm in diameter. Patients occasionally show bilateral tumors. Smaller lesions are being increasingly discovered on routine mammography. A subset of cases presents as large or giant tumors measuring 15 to 20 cm in diameter. These lesions represent mainly a distinctive juvenile type that arises in teenage females and grows rapidly, often leading to extensive stretching of the skin and distortion of the nipple.

Histopathology Histopathologic examination reveals a variably hyalinized or mucinous, fibrous stroma surrounding a proliferation of ductal structures with apocrine secretion. Treatment is by complete local surgical excision. Conservative management without surgery has also been proposed. [15]

Benign Neoplasms

ADENOMA OF THE NIPPLE Adenoma of the nipple (florid papillomatosis, erosive adenomatosis, papillary adenoma) is a rare, benign neoplasm currently thought to originate from terminal lactiferous ducts and subareolar breast tissue. Peak incidence is in the fifth decade in women; however, the lesion may present at any age. Men are occasionally affected. Patients sometimes complain of pain or an itchy, burning sensation within the lesion. Clinically, there is usually a unilateral enlargement and/or induration of the nipple which contains a palpable, firm, subareolar nodule. [1], [5], [6], [11] The surface is occasionally erythematous, ulcerated or crusted, and may ooze a serous, serosanguineous or bloody discharge. The overall clinical appearance is often indistinguishable from that of mammary Paget's disease. Bilateral tumors have been reported. The lesion has also been observed to develop in association with a supernumerary nipple. [14]
Histopathology An endophytic proliferation of tubular structures in the dermis with a verrucous or ulcerated surface is usually found. Some of the tubular structures exhibit cystic dilations with discrete papillations. They are lined by an inner apocrine secretory epithelium and an outer myoepithelial layer, and are separated by a fibrous stroma. Treatment of choice is complete surgical excision. Persistence or recurrences are common. Mohs micrographic surgery and cryosurgery may be useful in the treatment of some patients.
HIDRADENOMA PAPILLIFERUM Hidradenoma papilliferum (papillary hidradenoma) is a relatively uncommon benign neoplasm, which usually occurs as a unilateral, small (up to 1 cm in diameter), asymptomatic, skin-colored nodule on the vulva or perineum of adult women. [1], [4], [5] and [6], [11] There are, however, a few reports of similar neoplasms arising on the eyelid [16] and external auditory canal.
Histopathology Histopathologic examination reveals a partly solid or solid-cystic lesion, usually without an epidermal connection. The tumor shows a complex pattern with anastomosing papillary structures and tubules as well as some glandular areas (Fig. 85-2). The papillary structures are interconnected with each other resulting in a trabecular pattern. The epithelial lining consists of an inner layer of tall and columnar cells with an eosinophilic cytoplasm and features of decapitation secretion. A thin, outer myoepithelial layer is frequently present.

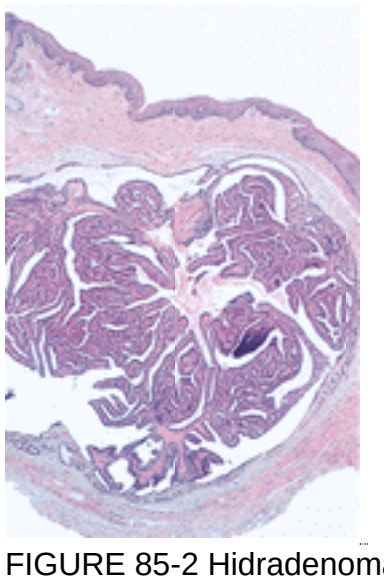

FIGURE 85-2 Hidradenoma papilliferum. Cystic tumor with papillary and glandular areas.

Treatment is by simple surgical excision. In perianal tumors, consultation with a colorectal surgeon is advised to assure preservation of a normal sphincter function. One patient with a fatal, metastasizing squamous carcinoma arising in a hidradenoma papilliferum has been reported. [17]
MIXED TUMOR OF THE SKIN Mixed tumor of the skin (chondroid syringoma) represents a group of adnexal neoplasms with ductal differentiation and a fibromyxochondroid stroma. [1], [4], [5] and [6], [11] Features of either apocrine (apocrine type) or eccrine (eccrine type) differentiation predominate in individual cases. Skin lesions present usually as solitary, firm, nonulcerated nodules measuring from 2 mm to several centimeters in diameter, situated on the head and neck [18] (Fig. 85-3A). They commonly show a shiny or a waxy surface. Middle-aged and elderly individuals, and preferentially men, are commonly affected. Mixed tumors may occasionally develop on a variety of other anatomic sites, including genitalia.

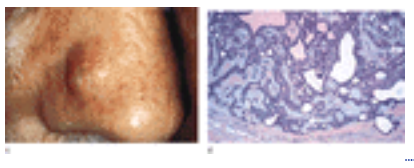

FIGURE 85-3 Mixed tumor. *A.* Mixed tumor on the nose. *B.* Solid cords and tubular structures in a background of a fibromyxoid stroma.

Histopathology There is a well-circumscribed dermal and/or subcutaneous lesion composed of elongated, partly ramifying tubular structures and/or complex solid nests as well as cords (Fig. 85-3B). The epithelial component is typically embedded in a stroma consisting of a variable admixture of spindled and stellate cells, mucin, as well as chondroid material. The apocrine type reveals, at least focally, small tubular lumina and cystic structures with apocrine secretion. A homogenous material is sometimes noted within the cystic cavities. Foci of polygonal, plasmacytoid, pale and clear cells may be observed. Occasional cases display follicular and sebaceous differentiation, fat metaplasia, and/or collagenous spherulosis. [1], [19] The eccrine type is characterized by tubulocystic spaces attached to solid elements, resembling the tadpole configuration seen in syringomas. Notably, some mixed tumors reveal atypical histologic features, including an infiltrative margin, satellite tumor nodules, and tumor necrosis. These atypical histologic appearances do not generally correspond with aggressive potential. Treatment is by complete surgical excision. To date, there are no convincing reports of malignant transformation of benign mixed tumor in the literature. [1], [5]
RETICULATED ACANTHOMA The term *reticulated acanthoma* was recently suggested for a group of benign tumors that histopathologically show a reticulated pattern and an epithelial component with multidirectional differentiation toward folliculosebaceous, apocrine, and sometimes eccrine units. [1] In the past, similar tumors have been described under a number of different names, including “poroma with follicular, sebaceous, and apocrine differentiation,” “complex

poroma-like adenoma," "combined polymorphic epidermal and adnexal tumor," "benign cutaneous adnexal tumor with combined folliculosebaceous, apocrine, and eccrine differentiation," and "sebocrine adenoma." [1] Reticulated acanthomas with prominent sebaceous differentiation are probably identical to tumors previously termed "superficial epithelioma with sebaceous differentiation" or "benign sebaceous neoplasm with prominent epidermal component." [2] The clinical appearance of reticulated acanthoma is not distinctive. Lesions occur as solitary, asymptomatic hyperkeratotic plaques and nodules on the face, trunk, and extremities. They are often suspected to be seborrheic keratosis or basal cell carcinoma.

Histopathology Usually, a broad superficial lesion confined to the papillary dermis and composed of cords and anastomosing columns of epithelial cells with a distinctive reticulated pattern is observed. Epithelial columns in individual lesions reveal variable features of apocrine, sebaceous, and/or follicular differentiation, and occasionally eccrine differentiation. Treatment is by simple surgical excision.

SYRINGOCYSTADENOMA PAPILLIFERUM The exact nosologic status of syringocystadenoma papilliferum among tumors with ductal differentiation is still debatable. Most authors consider it to be a benign tumor, [5], [6] while others categorize it as a hamartoma. [1] The lesion develops either independently or arises in association with a nevus sebaceus. [13] Solitary syringocystadenoma papilliferum occurs as a single, papillomatous, verrucous, sometimes erosive plaque or nodule measuring 1 to 3 cm in diameter, situated on the head and neck of adults [1], [4], [5] and [6], [11] (Fig. 85-4A). A small fistula discharging a clear, bloody or malodorous fluid may be noted. Less common presentations include childhood tumors, lesions located on unusual anatomic sites (e.g., chest, upper arms, and thighs) and lesions arising as multiple or linearly arranged cutaneous nodules.

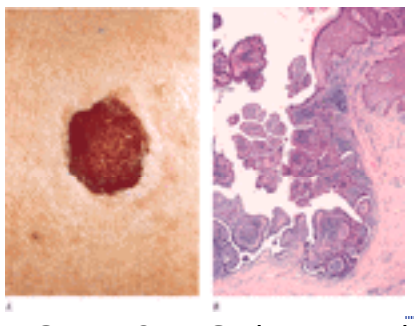

FIGURE 85-4 Syringocystadenoma papilliferum. *A.* Erosive nodule on the forehead. *B.* Epidermal invagination with papilliferous projections.

Histopathology There is a crateriform epidermal invagination with the upper portion lined by squamous epithelium and the lower portion lined by apocrine epithelium (Fig. 85-4B). The surrounding epidermis usually reveals papillomatosis, hypergranulosis and hyperkeratosis. Foci with variously sized papillations covered by a squamous epithelium are frequently observed within the epidermal invagination. In the dermis, cystic structures with villous projections exhibiting apocrine secretion may be present. The lesion is often surrounded by a variable lymphoplasmacytic infiltrate. Syringocystadenoma papilliferum arising in nevus sebaceus sometimes coexists with trichoblastomas. [13] Treatment of choice is surgical excision. Carbon dioxide laser may be effective in removing tumors on anatomic sites unfavorable to surgical excision. Syringocystadenocarcinoma papilliferum may develop from long-standing syringocystadenoma (see below).

Malignant Neoplasms

ADENOID CYSTIC CARCINOMA Adenoid cystic carcinoma occurs as either a primary cutaneous neoplasm or as an extracutaneous tumor, especially in the salivary glands. Primary cutaneous adenoid cystic carcinoma presents in adults as a solitary, slowly growing, asymptomatic or slightly painful, firm, papule or nodule, with predilection for the scalp. [1], [4], [5] and [6], [11], [20] Rare patients show multiple nodules. The tumor has occasionally been reported on other anatomic sites, including the trunk and upper extremities.

Histopathology Lesions consist of irregularly shaped, variously sized, asymmetric aggregations of basaloid neoplastic cells arranged in solid, tubular, and/or sieve-like patterns within the dermis. Extension to the subcutis is sometimes noted. Some areas of the tumor reveal cystic spaces with mucin. Foci with authentic tubules exhibiting apocrine secretion are noted in sections. Neoplastic cells are mainly monomorphous, and display round, hyperchromatic nuclei with inconspicuous nucleoli. Mitotic figures are rare. Perineural involvement is a common finding. Treatment is by surgical excision with adequate margins. The tumor sometimes recurs after excision and rarely metastasizes.

APOCRINE ADENOCARCINOMA Apocrine adenocarcinoma (apocrine carcinoma) is a rare, poorly documented, aggressive adnexal neoplasm. Lesions present predominantly in adults as either solitary or multiple nodules and plaques measuring 2 to 8 cm in diameter, situated in the axilla or anogenital area. [1], [4], [11] Occasional cases may involve the fingers, nipples, or chest. Lesions occasionally develop in association with nevus sebaceus, apocrine hamartoma or extramammary Paget's disease. [1], [21]

Histopathology Histopathologic examination reveals a dermal/subcutaneous nonencapsulated tumor with infiltrative margins. The epithelial component shows variable papillary, solid or mixed, patterns. Foci of partly anastomosing tubular structures exhibiting apocrine (decapitation) secretion and infiltrating cords of neoplastic cells can be observed. Neoplastic cells display variable pleomorphism and mitotic activity, as well as abundant, sometimes granular or vacuolated, eosinophilic cytoplasm. It is particularly important to differentiate apocrine adenocarcinoma from cutaneous metastases from other organs, especially from the breast. Treatment is by surgical excision with adequate margins. Regional lymph node metastases and fatal visceral metastases have been recorded. [22]

DUCTAL CARCINOMA The term *ductal carcinoma* has been suggested to denote a rare type of malignant sweat gland carcinoma characterized by prominent, closely packed tubular structures with either apocrine or eccrine features. [1], [23] Tumors present usually as solitary, asymptomatic nodules in the axilla of elderly individuals, preferentially of men. [23] Occasional cases arise as multiple lesions or are situated on unusual sites, including face, scalp, sternal region, and nipple. Tumors developing within a preexisting nevus sebaceus have been reported. [21]

Histopathology There is a deep dermal and/or subcutaneous proliferation composed of numerous, closely packed, tubular structures, sometimes with cystic and solid aggregations of neoplastic cells. The tubular and solid elements are composed of atypical neoplastic cells with abundant eosinophilic cytoplasm, hyperchromatic nuclei and frequent mitotic

figures. Features of apocrine or eccrine differentiation can be observed in individual cases. [1], [23] Treatment is by surgical excision with adequate margins. Recurrences are common. Metastases especially to regional lymph nodes, lungs, and to other organs can be found.

EXTRAMAMMARY PAGET'S DISEASE See Chap. 87.

HIDRADENOCARCINOMA PAPILLIFERUM This is a rare malignant appendage tumor that most often arises from a preexisting, usually long-standing, benign hidradenoma papilliferum. [1], [24] It presents mainly in middle-aged women as a solitary, small, often ulcerated nodule in the anogenital region, and rarely in the axilla. Most lesions are asymptomatic, but a few patients complain of slight pain or a brownish, watery discharge. Lesions have occasionally been observed in association with extramammary Paget's disease. [25]

Histopathology Histopathologically, unlike hidradenoma papilliferum, this malignant tumor often shows asymmetry and high cellularity. It consists of tubules and cystic cavities with features of apocrine differentiation, surrounded by compressed fibrous stroma. Papillations with a central fibrovascular tissue core are noted projecting in the cyst cavities. Treatment is by local surgical excision. Fatal metastases, often initially involving lymph nodes, have been recorded. Sentinel node biopsy may be valuable in staging of these patients.

MALIGNANT MIXED TUMOR This malignant counterpart of benign mixed tumor appears mainly to develop de novo. [1], [5], [26] Moreover, it also shows predilection for the trunk and extremities, [1], [5], [27] anatomic sites not usually involved by benign mixed tumors. Malignant mixed tumor presents in middle-aged adults, preferentially women, as a solitary, occasionally painful, firm or cystic, nonulcerated cutaneous or subcutaneous nodule measuring 2 to 10 cm in diameter. [1], [4], [5] and [6], [11], [27]

Histopathology The tumor shows lobulated epithelial aggregations with tubular structures, cords and solid elements. The epithelial component is surrounded by a fibrous stroma with myxomatous and cartilaginous areas. Neoplastic cells display polygonal, plasmacytoid, or cuboidal appearances with variable pleomorphism and scattered mitotic figures. Tubular structures show either apocrine (apocrine type) or eccrine differentiation (eccrine type). The apocrine type is characterized by foci of elongated tubules lined by two or more layers of epithelial cells displaying apocrine (decapitation) secretion. The eccrine type reveals small, round tubules lined by a single layer of flattened, atypical epithelial cells. Foci of ossification may be noted. A recognizable component of a benign mixed tumor is usually not present. Treatment of choice is total surgical excision. Local and distant metastases, especially to lymph nodes are common. Some authors advocate prophylactic removal of regional lymph node chains. [5] Adjuvant radiotherapy may facilitate long-term survival.

MUCINOUS CARCINOMA Primary mucinous carcinoma of the skin (colloid, gelatinous, or adenocystic carcinoma) is a rare, low-grade carcinoma with close morphologic resemblance to mucinous carcinoma of the breast. It presents as a solitary, slowly growing, soft to firm, grayish, reddish, or bluish, smooth-surfaced nodule measuring up to 3 cm in diameter. [1], [4], [5] and [6], [11], [28] Lesions tend to occur in older adults on the head, and particularly around the eyelids. [28] Men are more commonly affected than women. Occasional tumors arise on the scalp, axilla, and trunk. Scalp tumors may occur as a patch of alopecia.

Histopathology There are solid and cystic aggregations of neoplastic cells within the dermis, often with extension to the subcutis, embedded in large pools of mucin. Mucinous areas are typically separated by fibrous septae. Focal areas with a cribriform pattern, and tubular as well as glandular structures may be noted. Neoplastic cells are usually round, oval, or polygonal. They show abundant, often eosinophilic and/or vacuolated, cytoplasm and small, moderately pleomorphic nuclei. Malignant satellites may be found in adjacent tissues. Occasional cases reveal signs of neuroendocrine differentiation or show features mimicking mammary carcinoma and Paget's disease. Mucinous areas stain positive with PAS, mucicarmine, and colloidal iron. Tumor cells express low molecular weight cytokeratin, S-100 protein, and carcinoembryonic antigen (CEA). Treatment is by wide surgical excision. Recurrences have been reported in about 28 percent of cases. [28] Metastases are rare, and involve mostly regional lymph nodes.

SIGNET-RING CELL CARCINOMA Primary carcinoma of the skin with signet-ring cell morphology occurs either as an eyelid lesion or as an expression of mammary or extramammary Paget's disease. [1], [4], [5], [11], [29] Signet-ring cell carcinoma of the eyelid presents mainly in older adults, preferentially in males as a solitary nodule or a as diffuse eyelid swelling. [29] The lower eyelids are most commonly involved.

Histopathology Histopathologic examination shows closely packed, variably shaped dermal/subcutaneous aggregations of atypical neoplastic cells arranged in solid nests, and sometimes in cords and strands. They reveal, at least focally, neoplastic cells with eccentric nuclei and vacuolated cytoplasm (signet-ring cells). The cytoplasm of these cells stains positive for sialic acid-containing mucins (PAS, Alcian blue, and mucicarmine stains). Apart from signet-ring cells, a subset of neoplastic cells display abundant foamy cytoplasm, reminiscent of lipidized histiocytes. Sections of the lesions occasionally show small tubular structures. An inflammatory infiltrate composed of lymphocytes is usually noted within the tumor. A fibrotic or partially sclerotic stroma commonly surrounds the lesion. Treatment of choice is total surgical excision. Tumors frequently recur locally. Fatal metastases have been reported. [29]

SYRINGOCYSTADENOCARCINOMA PAPILLIFERUM This rare neoplasm usually arises in a long standing syringocystadenoma papilliferum, and occasionally in a nevus sebaceus. [1], [11], [30], [31] The tumor preferentially involves the scalp of adult women. A few cases have been reported on the chest. Patients may give a history of sudden enlargement of long-standing clusters of skin-colored or yellowish, sometimes ulcerated, papules or nodules. [31]

Histopathology Syringocystadenocarcinoma papilliferum superficially resembles syringocystadenoma papilliferum on scanning magnification. However, the malignant tumor is characteristically asymmetric and poorly circumscribed, and frequently shows extension deeply into the subcutis. It consists mainly of papillations which project above the skin surface into cystic cavities. The cystic cavities are lined by two layers of epithelium with crowded atypical cells and numerous mitotic figures. Tubular structures with apocrine secretion are noted in some sections. Treatment of choice is surgical excision. The neoplasm occasionally gives rise to regional lymph node metastases. [31]

APPENDAGE TUMORS WITH ECCRINE DIFFERENTIATION

Eccrine tumors show a wider anatomic distribution than do apocrine tumors. [32] This is due to the broader distribution of normal eccrine glands in virtually all topographic sites, in contrast to normal apocrine glands, which are confined to the head and neck, axillae, genital, and perineal skin.

Histopathologically, eccrine tumors comprise a large spectrum of lesions with differentiation to various portions of normal

eccrine apparatus, including intraepidermal (acrosyringium), dermal, and secretory ducts. [32] There are no uniform criteria for diagnosis. The most important feature is the tendency to form lumina with a flattened epithelium. Distinction from apocrine tumors is not always straightforward as the ducts of each gland type are similar and “decapitation” can be observed in certain tumors traditionally classified as “eccrine.”

Cyst

HIDROCYSTOMA See appendage tumors with apocrine differentiation.

Hamartoma

ECCRINE HAMARTOMA The term *eccrine hamartoma* is employed for a number of conditions characterized by an increase in size and/or number of normal intradermal eccrine ducts and coils, including eccrine nevus, eccrine angiomatous hamartoma, and porokeratotic eccrine ostial and dermal duct nevus. [11], [32] Eccrine nevus usually presents as a solitary, well-circumscribed area of hyperhidrosis. A few cases occurring as linear papules and multiple plaques have been reported. Eccrine angiomatous hamartoma commonly shows a solitary, flesh-colored, hyperhidrotic, painful papule or plaque appearing at birth or during childhood. [33], [34] A few cases arising as multiple, symmetrically located lesions have been reported. Porokeratotic eccrine ostial and dermal duct nevus typically presents as congenital, keratotic papules and plaques located on the distal extremities. Lesions may show a linear arrangement.
Histopathology There is an increase in size and/or number of normal eccrine ducts and coils in the dermis. Eccrine angiomatous hamartoma, in addition, reveals a proliferation of small blood vessels, sometimes with an admixture of nerve fibers and/or fatty tissue. Porokeratotic eccrine ostial and dermal duct nevus displays a comedo-like dilatation and hyperplasia of the acrosyringium, as well as parakeratotic cornoid lamella-like plugs within the sweat gland pores and ducts. Most patients require no specific treatment. Surgical excision is indicated for painful eccrine angiomatous hamartomas. Carbon dioxide laser therapy has been employed in some cases of porokeratotic eccrine ostial and dermal duct nevus. [33]

Hyperplasias

MUCINOUS SYRINGOMETAPLASIA Mucinous syringometaplasia is a rare benign, presumably reactive condition. Lesions present as slowly growing verrucous plaques on acral sites, particularly on palms and soles. [32] They commonly resemble viral warts. [35]
Histopathology There is an epidermal invagination with one or several ductlike structures that are lined by a stratified squamous epithelium alternating with mucin-containing goblet cells. A prominent papillary dermis commonly surrounds the lesion. Treatment is by surgical excision.
SYRINGOLYMPHOID HYPERPLASIA Syringolymphoid hyperplasia is a chronic skin condition that may present either as an isolated lesion or in association with cutaneous T-cell lymphoma. [36] Patients usually show patches of hairless, anhidrotic, reddish-brown papules with pseudofollicular hyperkeratosis. Males are preferentially affected.
Histopathology Hyperplastic eccrine structures are surrounded by a dense lymphocytic infiltrate with “syringotropism.” Lesions associated with mycosis fungoides occasionally reveal a perifollicular lymphocytic infiltrate and follicular mucinosis. Careful follow-up with biopsy of persistent lesions is recommended in apparently idiopathic cases in order to exclude lymphoma.

Benign Neoplasms

CYLINDROMA Two main clinical forms of cylindroma are recognized, namely a common, solitary type and a less-frequent form showing multiple lesions. Solitary cylindromas occur as slowly growing, asymptomatic or painful, skin-colored, reddish or bluish papules, nodules, or tumors on the head and neck region of adults. [4], [5] and [6], [11], [32] Women are more commonly affected than men. Multiple cylindromas are often familial and inherited as an autosomal dominant trait, mainly in the setting of Brooke-Spiegler syndrome (familial cylindromatosis). Multiple cylindromas occur as numerous papules, nodules, or variously sized tumors distributed mostly on the scalp, and sometimes on the face or trunk. They show a tendency to confluence, and may cover the entire scalp (so-called turban tumors; Fig. 85-5A) or display a linear arrangement. Rarely, patients reveal widespread nodules, a clinical picture that mimics neurofibromatosis. Patients with Brooke-Spiegler syndrome show multiple cylindromas and trichoepitheliomas, occasionally in association with multiple basal cell adenomas of the parotid glands, milia, organoid nevi, basal cell carcinomas, and spiradenomas. The susceptibility gene has been mapped to chromosome 16q12-q13 and has features of a recessive oncogene/tumor-suppressor gene. [37]

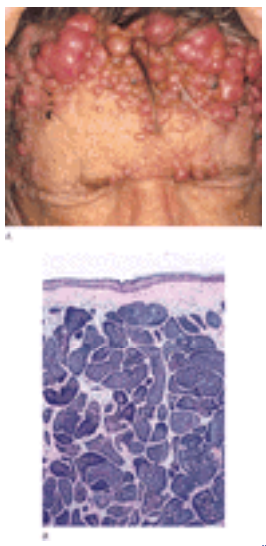

FIGURE 85-5 *A.* Cylindroma or turban tumor. *B.* Cylindroma with irregularly shaped aggregations of basaloid cells arranged in a “jigsaw puzzle” pattern.

Histopathology There is usually a well-circumscribed dermal and/or subcutaneous lesion composed of irregularly shaped tumor islands and cords of basaloid cells arranged in a jigsaw puzzle-like pattern (Fig. 85-5B). Islands of basaloid cells are surrounded by a prominent rim of uniformly thickened PAS-positive basement membranes. They consist of two types of basaloid cells, namely, a central population with large nuclei and abundant cytoplasm and a periphera1 population with smaller nuclei, arranged in a palisade at the periphery. Cylindromas may recur if incompletely excised. Local aggressive behavior and malignant transformation has occasionally been observed, especially in long standing turban tumors of the scalp. [38]

ECCRINE SYRINGOFIBROADENOMA Eccrine syringofibroadenoma (acrosyringeal nevus) is a rare, benign tumor that usually presents as a solitary, slowly growing, skin-colored to reddish nodule or plaque on the face, trunk, and distal extremities of adults. [11], [32], [39] Rarely, familial cases have been recorded. A few patients show confluent lesions ("syringofibradenomatosis"), especially in association with venous insufficiency. Some lesions arise in association with diabetes mellitus, hidrotic ectodermal dysplasia, or periocular, and ocular, abnormalities.

Histopathology Histopathologic examination reveals interconnected cords and columns of predominantly basaloid cells, extending from beneath the epidermis into the upper dermis. Foci with tubular structures resembling eccrine ducts are frequently observed. A highly vascular, edematous stroma commonly surrounds the epithelial component. Surgical removal is often not necessary except for cosmetic reasons.

HIDRADENOMA Hidradenoma (eccrine acrospiroma) presents mainly in adults, preferentially in women as a slowly growing, firm, solitary, smooth-surfaced, usually bluish-red, movable dermal and/or subcutaneous papule or nodule. [4], [5] and [6], [11], [32] Lesions are located mostly on the scalp, face, trunk, and abdomen, and occasionally on the extremities (Fig. 85-6A). Unusual presentations include childhood neoplasms, large or rapidly growing lesions, [40] painful and/or ulcerated lesions, as well as pedunculated tumors.

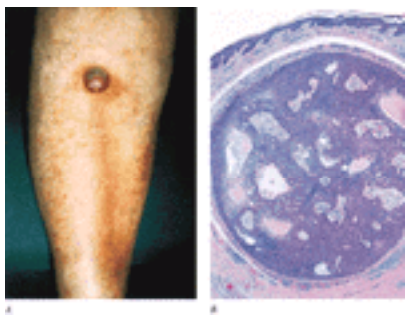

FIGURE 85-6 Hidradenoma. *A.* Dome-shaped nodule on the leg. *B.* Well-circumscribed, dermal nodule composed of two cell types.

Histopathology A nodular, solid or solid-cystic lesion in the dermis, sometimes with extension to the subcutis can be observed (Fig. 85-6B). The epithelial component consists of closely packed aggregations of round, fusiform or polygonal cells with either eosinophilic or clear cytoplasm. Individual lesions show a variable cellular composition. Clear cells predominate in about one-third of cases. Mitotic figures are sometimes noted within the epithelial component, a feature that does not generally indicate malignancy. The cystic spaces are often filled with mucin. Lesions frequently show some ductal structures with features of either eccrine or apocrine differentiation. The tumors are commonly surrounded by a variably fibrous, vascularized, or hyalinized stroma, occasionally with myxoid or chondroid changes. Unusual findings include the presence of mucinous syringometaplasia, oncocytic cells, squamoid cells, melanin pigmentation, and an increased number of melanocytes. Treatment is by complete surgical excision. Hidradenoma shows a high rate of local recurrence and may rarely undergo malignant transformation. [41]

POROMA The term *poroma* refers to a group of cutaneous appendage tumors composed of cells (cuticular and poroid cells) similar to those of the acrosyringium. Poromas are traditionally subcategorized histopathologically based on their location in relation to the epidermis into three main variants, namely, hidroacanthoma simplex, eccrine poroma, and dermal duct tumor. [4], [5] and [6], [32] Some authors add poroid hidradenoma to this group. [32] There are also reports of "poromas" with differentiation towards the folliculosebaceous–apocrine unit. Clinically, hidroacanthoma simplex presents mostly in middle-aged and elderly individuals, preferentially in women as a solitary, hyperkeratotic plaque, with predilection for the extremities. Eccrine poroma occurs commonly as a solitary, slowly growing, skin-colored or pigmented, sometimes bright red, itchy or painful, pedunculated, sessile papule or nodule, situated mostly on the soles and palms of adults. Unusual presentations of eccrine poroma include trunk, head, and neck lesions, and rapidly growing giant tumors. Eccrine poromas may occasionally arise in association with a variety of cutaneous conditions, including hypohidrotic ectodermal dysplasia, chronic radiation dermatitis, and Bowen's disease. Dermal duct tumor is usually observed in adults, revealing a solitary, skin-colored or pigmented papule or plaque on the head and neck region.

Histopathology Hidroacanthoma simplex shows sharply demarcated aggregations of cuboid to ovoid cells confined to the epidermis. Eccrine poroma reveals aggregations of uniform basaloid cells that radiate from the basal layer of the epidermis into the dermis (Fig. 85-7). Dermal duct tumor consists of several, sharply circumscribed, mainly dermal nodules composed of poroid and cuticular cells. Ductal structures are frequently observed. Poroid hidradenoma is characterized by intradermal, solid, and cystic aggregations of poroid cells.

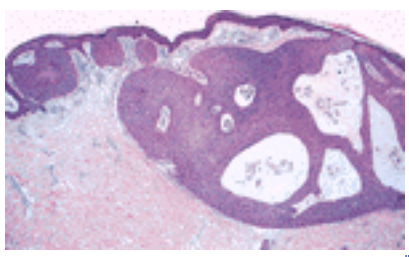

FIGURE 85-7 Eccrine poroma. Nodular aggregations of basaloid cells extend from the epidermis into the superficial dermis.

Treatment of choice is total surgical excision. Eccrine poroma is rarely observed to precede the development of porocarcinoma.

SPIRADENOMA Spiradenoma presents usually as a solitary, slowly growing, sometimes painful, reddish-brown,

intradermal or deeply subcutaneous nodule on the head and trunk of young and middle-aged adults [4], [5] and [6], [11], [32], [42] (Fig. 85-8A). A subset of lesions arises in the setting of Brooke-Spiegler syndrome, in association with multiple cylindromas and trichoepitheliomas. Unusual presentations include childhood neoplasms, relatively large or giant tumors, pedunculated tumors, ulcerated lesions, and cutaneous nodules arranged in a linear or zosteriform pattern.

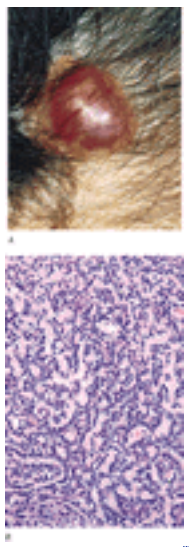

FIGURE 85-8 Spiradenoma. *A.* Reddish-brown tumor on the scalp. *B.* Tumor cells arranged in a trabecular pattern. Note hyaline material in the background.

Histopathology There are one or several, well-circumscribed, basophilic nodules in the dermis, sometimes with extension to the subcutis. Nodules show epithelial cell aggregates arranged in sheets and cords or in a trabecular pattern (Fig. 85-8B). They consist of two types of cells, namely small, dark-staining basaloid cells located at the periphery, and larger cells with a pale nucleus situated mostly in the center. Tubular or cystic structures are occasionally noted within the epithelial aggregations. Some areas of the tumor contain a PAS-positive hyaline material. The surrounding fibrous stroma occasionally reveals prominent vessels with telangiectasia and edematous or hemorrhagic changes. Additional findings in individual cases include squamous eddies, small cysts, and a variable lymphocytic infiltrate within tumor nests. Cylindromatous areas are observed in a subset of lesions. Treatment of choice is complete surgical excision. Malignant transformation has been reported in a few patients. [38]

SYRINGOMA Syringoma is a benign neoplasm with differentiation toward eccrine acrosyringium. It presents as numerous, small, firm, smooth, skin-colored, or slightly yellowish papules situated on the face, particularly around the lower eyelids of adults [4], [5] and [6], [11], [32] (Fig. 85-9A). Women are more commonly affected. Lesions sometimes develop in other anatomic sites, including the vulva and penis, the dorsum of the fingers, axillae, lower abdomen, umbilicus, and buttocks, as well as scalp. Scalp lesions often present as nonscarring alopecia. Syringomas occasionally show a unilateral, linear, or bathing-trunk type distribution. Familial cases have been recorded. There appears to be an increased frequency of syringomas in patients with Down's syndrome. Eruptive syringomas represent a distinctive, occasionally familial form presenting mainly in pubescent or adolescent girls as successive crops of numerous, disseminated, sometimes confluent papules. These lesions tend to involve the upper half of the body, particularly the anterior aspect of the neck, chest, trunk, axillae, inner aspects of the upper arms, and umbilical area.

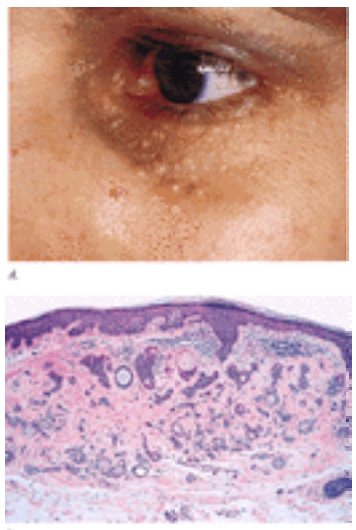

FIGURE 85-9 Syringoma. *A.* Multiple, small papules on the periorbital skin of a young woman. *B.* Solid, tubular, and cystic structures in the upper dermis. Note “tadpole”-like morphology of tumor lobules.

Histopathology Numerous epithelial aggregations of small, solid nests, cords, and tubular structures focally with a tadpole shape in the upper half of the dermis can be observed (Fig. 85-9B). The epithelial areas are commonly surrounded by thickened, closely packed collagen bundles. Tubular structures show an inner layer of luminal cells with one or two rows of peripheral cells. They sometimes contain a homogenous or eosinophilic, PAS-positive and diastase-resistant material. Sections of the lesions sometimes reveal cystic structures filled with cornified cells. A distinctive clear cell variant with an epithelial lining consisting of cells having large amounts of cytoplasmic glycogen has been described. This variant is most commonly found in patients with diabetes mellitus. Treatment is usually unnecessary. Some patients seek removal of the lesions because of cosmetic concerns. Surgery generally produces less-satisfactory cosmetic results. Alternative therapeutic approaches may include dermabrasion, electrodesiccation with curettage, and laser resurfacing. [43]

TUBULAR ADENOMA The term *tubular adenoma* defines a group of benign appendage tumors histopathologically characterized mainly by numerous cystic, dilated, and branching tubular structures in the dermis surrounded by a compressed fibrous stroma. [11], [32], [44] Lesions show either eccrine (tubular eccrine adenoma) or apocrine (tubular apocrine adenoma) differentiation. They are found in middle-aged adults as solitary, slowly growing, well-circumscribed nodules, situated mostly on the extremities. Black women appear to be preferentially affected. Unusual presentations include their occurrence during childhood, large tumors, and lesions with verrucous or eroded surfaces. Some cases

arise in association with a preexisting nevus sebaceus or a syringocystadenoma papilliferum.
Histopathology There is a relatively well-circumscribed dermal nodule consisting of numerous cystic, dilated and branching tubules, surrounded by compressed or focally hyalinized fibrous tissue. The tubules usually display an inner layer with intraluminal papillations. Tubular lumina are often filled with homogeneous, eosinophilic material or necrotic debris. Features of apocrine or eccrine differentiation are observed in individual cases. Occasional lesions reveal areas with clear or squamous cell changes. Treatment is by simple surgical excision. Tubular adenomas sometimes recur after surgical excision but malignant transformation has not been observed.

Malignant Neoplasms

AGGRESSIVE DIGITAL PAPILLARY ADENOMA AND ADENOCARCINOMA Aggressive digital papillary adenoma and adenocarcinoma are rare neoplasms characterized mainly by an acral localization and a tendency to recur after excision. [1], [4], [11], [45] Aggressive digital papillary adenoma represents the less-aggressive end of the spectrum. *Aggressive digital papillary adenocarcinoma* is the term reserved for more aggressive tumors with a potential for metastasis. The neoplasms present mainly in middle-aged adults, preferentially white males, as single, painless, flat or slightly elevated, often ulcerated, crusted or bleeding nodules measuring up to 2 cm in diameter. The volar surface of the fingers and toes and the adjacent parts of the palms and soles are predominantly involved. Adherence to underlying deeper tissues is often apparent.
Histopathology There is usually a dermal/subcutaneous lobular proliferation of ductal and glandular structures with focal solid and cribriform zones. [45] Epithelial components are separated by a fibrocollagenous stroma. Ductal structures show variable dilatations forming cystic spaces in which several intraluminal papillary projections are present. Solid and ductal structures are composed mainly of polygonal cells. Additional findings in individual cases include areas of squamous metaplasia and spindle cells, as well as features of apocrine as well as sebaceous differentiation. An inflammatory infiltrate consisting predominantly of lymphocytes and plasma cells is sometimes noted. Aggressive digital papillary adenocarcinoma commonly reveals cellular atypia, pleomorphism, and focal necrosis, as well as an infiltrative growth with involvement of deeper soft tissues, blood vessels, and sometimes bone. Immunohistochemical studies have shown positivity of neoplastic cells for CEA, S-100, and cytokeratins, [45] and in the malignant variant for ferritin. Treatment is by surgical excision. Approximately 50 percent of aggressive digital papillary adenomas recur locally. In one study, metastases were recorded in 7 of 17 cases of aggressive digital papillary adenocarcinoma. [45] Metastases involve mainly the lungs (71 percent of cases), but have occasionally been observed in other tissues such as lymph nodes, brain, skin, bone, and kidney.
CYLINDROCARCINOMA Cylindrocarcinoma is a very rare malignant appendage tumor with a tendency for local destructive growth and the potential to metastasize. It presents in middle-aged and elderly individuals (mean age 66 years) as a rapidly growing ulcerated or bleeding nodule on the scalp. [27], [32], [46] Women are more commonly affected than men. There is often a family history of cylindromas or a history of previous excision of a benign cylindroma.
Histopathology The vast majority of cylindrocarcinomas show a remnant of a benign cylindroma (see above). The cylindrocarcinomatous areas consist of irregularly shaped, poorly circumscribed, focally confluent nests and cords of atypical basaloid cells. Neoplastic cells reveal two distinctive populations, namely, small cells located mostly at the periphery and solid nests of larger cells in the center. Unlike benign cylindromas, cylindrocarcinomas reveal only small foci of the jigsaw puzzle-like arrangement, and sometimes show no thickened basement membrane. Tumors often display areas of geographic necrosis. Treatment is by surgical excision. Local recurrences are sometimes observed. Metastases, particularly to lymph nodes and occasionally to other internal organs, including liver, lung, and bone, have occasionally been reported.
ECCRINE CARCINOMA Eccrine carcinoma is a term used for a group of rare, malignant eccrine neoplasms with a great diversity in histomorphologic features and wide differences in biologic behavior. [5], [11], [23], [32] The common histopathologic denominator is the presence of variable areas of basaloid cells with tubular structures. These tumors have previously been described under different names, including basal cell tumor with eccrine differentiation (eccrine epithelioma), syringoid carcinoma, and eccrine syringomatous carcinoma. Lesions show no distinctive clinical features. They present as slowly growing, solitary, nodules, plaques, and tumors on the scalp, extremities, or trunk of older adults.
Histopathology There is a wide spectrum of histopathologic features. Some tumors show confinement to the dermis, whereas others reveal involvement of the subcutis and deeper soft tissues. Lesions may display relatively well-differentiated features with areas of clear-cut ductal differentiation. A subset of lesions exhibit anaplastic features with only subtle signs of ductal differentiation. Relatively well-differentiated tumors are characterized by basaloid aggregations arranged in strands, solid nests, and dilated or branching tubular structures (Fig. 85-10). Foci with syringomatous features may be present. Perineural invasion is a common finding.

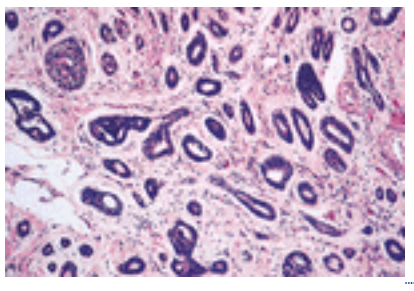
FIGURE 85-10 Eccrine carcinoma with nests and tubular structures. Note focal syringomatous features.

Treatment is by wide surgical excision. Local recurrences are common. Lymph node and distant metastases are observed in some patients. Sentinel node biopsy may be valuable in diagnosis of lymph node metastases.
HIDRADENOCARCINOMA Hidradenocarcinoma (clear cell hidradenocarcinoma, malignant clear cell hidradenoma, solid-cystic hidradenocarcinoma, malignant acrospiroma, malignant clear cell myoepithelioma, clear cell eccrine carcinoma) is an exceedingly rare tumor. It presents as an ulcerated nodule on the head/neck, trunk, and extremities of middle-aged or elderly individuals [1], [11], [32], [41] (Fig. 85-11). Many cases are probably malignant from inception, but exceptional hidradenocarcinomas have been associated with a component of a benign hidradenoma.

FIGURE 85-11 Hidradenocarcinoma. Large ulcerated tumor.

Histopathology There is usually a nonencapsulated dermal/subcutaneous nodule consisting of irregularly shaped lobules of predominantly large, atypical, polygonal cells with eosinophilic cytoplasm. Foci of clear cells are frequently observed. Sections of the lesions often reveal cords and nests of tumor cells infiltrating the surrounding tissues. Mitotic figures are frequent. Individual lesions show ductal structures with either eccrine or apocrine differentiation. Areas with basaloid or squamoid features are noted in some cases. Tumors arising within long-standing nodular hidradenomas reveal a separate, distinctive component of a “benign” nodular hidradenoma. Treatment of choice is wide surgical excision. Local recurrences are frequent. Lymphatic spread and distant metastases have been recorded.

MICROCYSTIC ADNEXAL CARCINOMA Microcystic adnexal carcinoma (syringomatous carcinoma, sclerosing sweat duct carcinoma) is a rare, locally aggressive tumor with a high potential for local recurrences. It presents usually in elderly individuals as a solitary, slowly growing, firm, indurated plaque on the face, particularly around the upper lip and orbit. [1], [4], [5], [11] For reasons that are unclear, the tumor tends to occur on the left side of the face. Lesions may occasionally be found on extrafacial locations, including the nipple, axilla, and lower extremities. Patients sometimes complain of a burning sensation and numbness within the lesion, probably as a result of perineural involvement. The skin surface is often normal, atrophic or scaly. Unusual presentations include tumors arising in relatively young individuals, and ulcerated lesions. A few cases have developed in previously therapeutically irradiated facial areas.

Histopathology There is a large, ill-defined dermal-subcutaneous component composed of islands of basaloid keratinocytes, some of which contain horn cysts. The epithelial aggregates are focally embedded in a desmoplastic stroma. In the superficial portion, ducts and glandlike structures lined by a two-cell layer, sometimes filled with homogeneous, eosinophilic material, predominate. The deeper portion reveals individual, thin strands of cells with a tendency to dissect collagen bundles and skeletal muscle, and to involve perineural spaces. Despite these findings, cytologic atypia and mitotic figures are only rarely noted. Lesions sometimes show involvement of underlying fascia or skeletal muscle. Sections in some cases may display foci with clear cells, sebaceous differentiation, and/or amyloid deposition. Treatment of choice is wide surgical excision. Local recurrences are common (about 50 percent of cases), and may develop several years after initial diagnosis and therapy. Prolonged follow-up is therefore usually necessary. A more favorable cure rate (up to 89 percent) has been achieved with Mohs micrographic surgery. Regional and distant metastases are rare. [47]

POLYMORPHOUS SWEAT GLAND CARCINOMA This is a rare tumor characterized by a distinct, but varied, morphologic appearance, and a low-grade malignant behavior. [11], [48] Patients are usually middle-aged women (mean age, 60 years) presenting a single, slowly growing, or long-standing nodule situated on the extremities.

Histopathology There is a highly cellular proliferation of epithelial cells with a variety of growth patterns, including solid, trabecular, tubular, pseudopapillary, and cylindromatous. The lesion is often surrounded by a stroma with hemorrhagic, hyalinized, and/or cystic changes. Treatment is by surgical excision. Recurrences and metastases, especially to regional lymph nodes, have been observed.

POROCARCINOMA Porocarcinoma, the malignant counterpart of eccrine poroma, is a rare, potentially aggressive neoplasm. It presents in elderly individuals as a partially ulcerated, verrucous plaque or polypoid tumor on the lower extremities. [4], [5] and [6], [11], [32], [49], [50] Patients may show lesions on other anatomic sites, including the head and neck, [49] trunk, upper extremities, and vulva. There is frequently a history of a long-standing nodule, suggesting malignant transformation of an eccrine poroma or hidroacanthoma simplex. Occasional cases present as multiple cutaneous nodules or rapidly growing tumors. Rarely, porocarcinoma arises in a nevus sebaceus. Some cases have been observed in association with a range of unrelated cutaneous and systemic conditions including, extramammary Paget's disease, chronic radiation, sarcoidosis, pernicious anemia, chronic lymphocytic leukemia, Hodgkin's disease, and visceral carcinomas. Of note is a peculiar presentation of epidermotropic and nonepidermotropic cutaneous metastases of porocarcinoma as numerous, skin-colored to reddish/purple, papules or nodules. These may be accompanied by lymphedema caused by lymphatic involvement.

Histopathology Histopathologically, primary porocarcinoma reveals either a carcinomatous area with an adjacent benign eccrine poroma or a hidroacanthoma simplex component, or a carcinomatous area only. The lesion is characterized by sharply circumscribed nests and islands of atypical basaloid cells within the epidermis. The underlying dermis is variably involved by irregularly shaped nests with neoplastic cells displaying striking atypia and mitotic activity. Epithelial aggregations reveal, at least focally, features of ductal differentiation ranging from variably mature eccrine ducts to focal intracytoplasmic lumina. [50] Areas of necrosis, perineura1, and lymphatic/vascular invasion are occasionally present. Some cases reveal clear cell, squamous cell, and/or spindle cell differentiation. A small subset of cases (up to 15 percent) occurs as “in situ” porocarcinoma. Additional findings may include foci of cornification, melanin pigmentation, and colonization by melanocytes. Immunohistologic studies show positivity of tumor cells for CEA, cytokeratin, and epithelial membrane antigen (EMA), and negativity for S-100. Treatment is by wide local surgical excision. Previous studies suggest a generally poor prognosis with frequent local recurrences (up to 20 percent of cases), lymph node metastases, and occasionally distant metastases. Distant metastases have been observed in a number of internal organs, including the lung, breast, mediastinum, peritoneum, and liver. Metastatic porocarcinoma is very resistant to adjunctive chemotherapy or radiation, and such patients have a high mortality rate (up to 67 percent). [49] However, there is now mounting evidence that porocarcinoma may not be as aggressive as previously thought. [50]

SPIRADENOCARCINOMA Spiradenocarcinoma is a rare, malignant, appendage tumor that usually arises on long-standing benign spiradenoma and sometimes behaves aggressively. [11], [32], [51] It presents mainly in middle-aged and elderly individuals as a single, large, nodule on the extremities, trunk, or abdomen. Occasional lesions arise on the head and neck. Patients sometimes give a history of a long-standing cutaneous nodule that had grown slowly for several years, but that recently rapidly enlarged in size with a change in color, ulceration, or bleeding. One case of spiradenocarcinoma developing in a scar after a previous excision of a benign spiradenoma has been recorded. [52]

Histopathology The tumor usually shows a carcinomatous area, representing spiradenocarcinoma, in association with a

typical, benign spiradenoma. The carcinomatous area is characterized by aggregations of atypical basaloid or squamous cells focally arranged in sheets and showing an infiltrative pattern. [52] Unlike the benign spiradenoma component, spiradenocarcinoma exhibits a less-conspicuous two-cell population. Neoplastic cells display nuclear hyperchromasia and pleomorphism, and an increased mitotic activity. Areas of *necrosis en masse* are often present. Additional findings in individual cases include foci with features of ductal, clear cell, rhabdomyoblastic, and osteosarcomatous differentiation. Immunohistologically, tumor cells show positivity for epithelial markers, and occasionally for S-100. Treatment is by wide surgical excision. Patients sometimes develop local recurrences and/or lymph node involvement. Fatal metastases have been reported in about 20 percent of cases. [27] Radiation, systemic chemotherapy, and hormonal treatment with tamoxifen have been used for metastatic disease.

APPENDAGE TUMORS WITH FOLLICULAR DIFFERENTIATION

The follicular cysts, hamartomas, and neoplasms reviewed in this section show predominantly histopathologic features that resemble different portions of a normal hair follicle, hair shaft and/or perifollicular fibrous sheath. They exhibit a wide range of morphologic features and may display variable degrees of differentiation. Consequently, uniform diagnostic criteria do not exist for a number of entities. [3], [4], [5] and [6], [11]

Cysts

EPIDERMAL CYST Epidermal (epidermoid, infundibular, epithelial) cyst is the most common type of follicular cyst. It presents usually as a solitary, mobile, skin-colored, white or yellowish nodule on the head and neck or trunk of young and middle-aged adults. [53] It is discussed in Chap. 84. Multiple epidermal cysts may be a feature of Gardner's syndrome. [4], [5], [53] Gardner's syndrome, caused by mutations in the *adenomatous polyposis coli (APC)* gene, is a rare, inherited autosomal dominant trait characterized by multiple epidermal cysts and pilomatricomas, soft-tissue proliferations (fibromatosis, lipomas, leiomyomas), multiple craniofacial osteomas, bilateral pigmented ocular fundus lesions (congenital hypertrophy of the retinal epithelium), and intestinal (colorectal) polyposis. If intestinal (colorectal) polyposis is undetected or untreated, virtually all patients develop colonic carcinoma at a young age. The cutaneous cysts frequently predate the intestinal polyps.

HYBRID CYST Hybrid cysts present usually as solitary, cystic nodules situated on the head and neck. [4], [54] Tumors occur in all age groups.

Histopathology There is a cystic lesion displaying a mixed type of epithelial lining with a stratified squamous epithelium in its upper portion and outer sheath differentiation with tricholemmal cornification in its lower portion.

KERATOCYST Cutaneous keratocysts present typically in patients with basal cell nevus syndrome [53], [55] (see Chap. 82). The cutaneous keratocysts show similar histopathologic features to the jaw keratocysts of patients with this syndrome. They have been observed on the trunk and extremities.

Histopathology Histopathologic examination shows a cystic structure with a corrugated or festooned configuration. The epithelial lining reveals several layers of squamous epithelium without a granular zone. A lanugo hair is observed within the cyst cavity of some lesions.

PIGMENTED FOLLICULAR CYST Pigmented follicular cyst shows differentiation toward the infundibular portion of the hair follicle. It presents usually as a solitary, relatively small (0.4 to 1.5 cm), pigmented papule/nodule situated on the head and neck region of adult males. [4], [53], [56]

Histopathology There is a cystic structure filled with numerous, heavily pigmented hair shafts. The cyst is lined by a stratified squamous epithelium.

TRICHOLEMMAL CYST Tricholemmal (sebaceous, trichilemmal, isthmus-catagen, pilar) cyst is a relatively common lesion characterized by outer root sheath differentiation at the level of the follicular isthmus and tricholemmal cornification. [4], [5] and [6], [53] Lesions present as solitary, cutaneous/subcutaneous nodules on the scalp of adults, preferentially of women. Some patients show multiple, occasionally familial tumors. Familial tricholemmal cysts are inherited in an autosomal dominant fashion. [57] The lesion is discussed in detail in Chap. 84.

VELLUS HAIR CYST Vellus hair cysts show differentiation toward the infundibular portion of the hair follicle and typically contain numerous vellus hairs. Lesions are either sporadic or inherited in an autosomal dominant fashion. Multiple, small (1- to 3-mm), asymptomatic, pigmented, reddish or grayish papules distributed on the chest, abdomen, and axilla (eruptive vellus hair cysts) may be observed. [5], [6], [53] The face, neck, and extremities are occasionally involved. Familial cases present most commonly at birth or in early infancy. Sporadic lesions tend to develop in the first or second decades of life. Eruptive vellus hair cysts may be associated with steatocystoma multiplex, trichostasis spinulosa, anhidrotic ectodermal dysplasia, [58] and pachyonychia congenita, as well as some neurologic disorders.

Histopathology Histopathologic examination reveals a cystic structure located in the middle or upper dermis. It is lined by a stratified squamous epithelium with focal features of outer root sheath differentiation at the level of the follicular isthmus and tricholemmal cornification. Several transversely and obliquely sectioned vellus hair shafts and keratin material are present within the cystic lumen. Eruptive vellus hair cysts are difficult to treat surgically. Patients may benefit from therapy with isotretinoin, pulsed carbon dioxide and erbium: YAG-laser ablation. [59] Spontaneous regression has occasionally been observed.

Hamartomas

BASALOID FOLLICULAR HAMARTOMA Basaloid follicular hamartoma occurs either as a solitary, nonhereditary tumor or as multiple, hereditary lesions. [60], [61] Familial, multiple, basaloid follicular hamartomas manifest as numerous, small (1 to 2 mm in diameter), flesh-colored papules located predominantly over the central face, and occasionally on the scalp, neck, and shoulders. Lesions have been reported in association with myasthenia gravis, alopecia, hypohidrosis, facial sclerosis, or cystic fibrosis. [60], [61] Solitary forms of basaloid follicular hamartoma are commonly found on the face and scalp. Localized linear and unilateral variants have also been documented. The exact nature of solitary and multiple basaloid follicular hamartomas and their relationship to basal cell carcinoma is still controversial. Some authors believe these lesions represent a distinctive type of basal cell carcinoma. [3]

Histopathology Histopathologic examination shows anastomosing strands of basaloid cells with numerous epidermal connections. Central areas of epithelial aggregations occasionally reveal cells with a squamoid appearance. Features of

follicular differentiation including horn cysts, rudimentary germs, and follicular papillae are variably present.

HAIR FOLLICLE NEVUS Hair follicle nevi have been reported in all age groups. [3], [11], [62] They occur as slightly dome-shaped, skin-colored papules and nodules on hair-bearing skin, particularly on the face. [62] Cases with a linear arrangement have been documented. A number of specific conditions have been included as variants of hair follicle nevus by different authors, namely the so-called faun-tail, a cutaneous lesion characterized by the presence of a patch of hairs arising over the lower sacral area, hair follicles arising on the palms and soles, and Becker's pigmented hairy nevus. [11], [63] There is currently disagreement as to whether “hair follicle nevus” (“congenital vellus hamartoma”) represents a distinct entity or a variant of trichofolliculoma. [3]

Histopathology The upper dermis reveals a well-circumscribed area with numerous closely packed mature vellus follicles. Hair follicles are surrounded by prominent sheaths of perifollicular connective tissue. Clefts are usually observed bordering the perifollicular connective tissue. Some lesions display sebaceous lobules. Treatment of choice is surgical excision.

LINEAR UNILATERAL BASAL CELL NEVUS Linear unilateral basal cell nevus presents at birth or in infancy as numerous, cutaneous papules or nodules distributed unilaterally, sometimes in a zosteriform fashion. Lesions often show comedone plugs and closely resemble nevus comedonicus. One patient with diffuse osteoma cutis, unilateral anodontia, and abnormal bone mineralization has been reported. [64]

Histopathology Histopathologic features simulate those of basal cell carcinoma. Lesions are characterized by a lattice-like pattern of basaloid cells attached to the undersurface of the epidermis. Hints of follicular differentiation are usually present.

NEUROFOLLICULAR HAMARTOMA Neurofollicular hamartoma is a rare hamartoma characterized by a proliferation of spindle cells and hyperplastic pilosebaceous units. Lesions present as solitary, small (up to 7 mm in diameter), pale papules on the face, particularly around the nose, of children and adults. [65]

Histopathology There are hyperplastic pilosebaceous units in the dermis surrounded by a stroma composed of spindle cells. The spindle cells are arranged mainly in broad, haphazard fascicles. Immunohistologically, the spindle cells show variable positivity for S-100.

NEVUS COMEDONICUS Nevus comedonicus is a follicular hamartoma characterized by contiguous structures that resemble aberrant infundibula. [3] Patients show grouped, unilateral, linear, or segmentary arranged dark papules with keratin-plugs situated on the face and neck. [3], [6], [11] The condition is fully discussed in Chap. 84.

NEVUS SEBACEUS Nevus sebaceus (organoid nevus, pilosyringosebaceous nevus) is a hamartoma that presents mostly at birth or in early childhood as a yellowish plaque on the scalp, face, neck, and trunk. [3], [4], [5] and [6], [11], [13], [66] Nevus sebaceus is discussed in Chap. 84.

Benign Neoplasms

DESMOPLASTIC TRICHOEPITHELIOMA Desmoplastic trichoepithelioma (sclerosing epithelial hamartoma) is a relatively uncommon tumor that presents as a small (up to 1 cm in diameter), asymptomatic firm, oval, oblong, or annular papule or plaque on the face (Fig. 85-12), particularly around the angle of the lip. [3], [4], [5] and [6], [11] Plaques often reveal a raised border and depressed center. The tumor shows a predilection for young and middle-aged adults. Women are about three times more commonly affected than men. Familial cases of solitary or multiple lesions have been reported.

FIGURE 85-12 Desmoplastic trichoepithelioma located on the infraorbital region.

Histopathology Histopathologic examination reveals a relatively well circumscribed lesion in the upper two-thirds of the dermis, rarely with extension to the lower dermis and subcutis. It is composed of basaloid aggregations arranged predominantly in columns and cords and admixed with infundibulocystic structures, surrounded by a dense, hypocellular desmoplastic stroma. A focal connection to the epidermis is usually observed. Additional features in some lesions include foci of sebaceous cells, shadow (“ghost”) cells, foreign-body granulomas, calcification, and ossification. A subset of cases are associated with a dermal melanocytic nevus. Treatment is by local surgical excision.

DILATED PORE OF WINER Although classified as a neoplasm in this section, there is currently some debate as to whether dilated pore represents a type of follicular (infundibular) cyst or a neoplastic process. [3], [5], [6], [67] The lesion presents usually as a solitary, comedo-like, keratin-filled structure on the head and neck of elderly individuals. [67] In some cases lesions arise in the setting of cystic acne or actinic damage.

Histopathology A single or several contiguous, markedly dilated infundibula are observed in the upper dermis, sometimes with extension to the lower dermis. The epithelial lining reveals focal acanthosis and finger-like projections radiating into the surrounding dermis. Dilated infundibula contain cornified cells arranged in basket-weave and laminated patterns. Heavy pigmentation of the epithelium can be observed in some cases. Treatment is by local surgical excision.

FIBROFOLLICULOMA Fibrofolliculoma is a rare tumor that presents usually as multiple, small papules measuring 2 to 4 mm in diameter, situated on the head and neck, upper trunk, and arms. [3], [5], [6] Fibrofolliculomas commonly develop in middle-aged individuals. Multiple, familial fibrofolliculomas occurring in association with trichodiscomas, perifollicular fibromas, and skin tags are a feature of Birt-Hogg-Dubé syndrome. [68] Patients with this syndrome show a tendency to develop colonic polyposis and a range of internal neoplasms (e.g., renal carcinoma). Rare examples of fibrofolliculoma occur as solitary lesions. Regarding pathogenesis, fibrofolliculoma has traditionally been considered to represent a distinct follicular adnexal neoplasm. However, some authors recently suggested that this lesion may indeed be a type of hamartoma with sebaceous differentiation, closely related to trichodiscoma. [3] This hypothesis is based on chronological considerations and frequent occurrence of both fibrofolliculomas and trichodiscomas in patients with Birt-Hogg-Dubé syndrome. According to these authors, both fibrofolliculoma and trichodiscoma represent temporal stages in the development of a single pathologic tumor, called “mantleoma.” The term *mantleoma* reflects the likely derivation of this tumor from the sebaceous mantle, a well-described but little known part of the sebaceous gland cycle (see below).

Histopathology Fibrofolliculoma is characterized by a dome-shaped lesion with a central, relatively well-formed hair follicle displaying a single or several, contiguous, dilated, keratin-filled infundibula. The infundibula are connected to several thin, focally anastomosing epithelial strands that extend in a radial fashion into the connective tissue. The lesion is often surrounded by a well-circumscribed fibrillary collagenous or mucinous stroma with scant or no elastic tissue. Treatment of choice in solitary lesions is by surgical excision. Carbon dioxide laser can be useful in removal of multiple lesions. Patients should be screened for other features of Birt-Hogg-Dubé syndrome.

FIBROUS PAPULE Fibrous papule (perifollicular fibroma) presents mainly as a solitary papule or as several dome-shaped, skin-colored, pigmented, or reddish lesions situated on the face, particularly around the nose of adults. [3], [5], [6], [11] Multiple fibrous papules occurring in association with fibrofolliculomas and trichodiscomas are a feature of Birt-Hogg-Dubé syndrome. [68] Currently, there is some disagreement as to whether fibrous papule represents a neoplastic process or a hamartoma. [3]

Histopathology A dome-shaped or polypoid lesion consisting of one or more poorly formed hair follicles, surrounded by cellular fibrous stroma is observed in the upper dermis. The epidermis sometimes reveals an increased number of large, single melanocytes located along the dermal–epidermal junction. There is usually a proliferation of small vessels within the dermis. Spindle- and stellate-shaped, sometimes multinucleated fibrocytes can be found within the stroma. Treatment of choice is surgical excision. Carbon dioxide laser is useful in removing multiple lesions.

INVERTED FOLLICULAR KERATOSIS Inverted follicular keratosis presents as an asymptomatic, small (3 to 10 mm in diameter), solitary papule or nodule on the face of middle-aged and older individuals. [3], [4], [5] and [6], [11] Most lesions are located around the cheek and upper lip. Males are two to three times more commonly affected than females. Because of the wartlike morphology, it was recently suggested that inverted follicular keratosis may represent a manifestation of human papillomavirus infection rather than a true neoplasm. [3]

Histopathology Histopathologic examination reveals an endophytic or exophytic–endophytic lesion consisting of several large epithelial lobules extending into the dermis. Four distinctive histopathologic patterns are recognized, namely, papillomatous, keratoacanthoma-like, solid, and cystic. The center of the epithelial lobules is composed of squamous cells focally arranged in a whorled pattern (squamous eddies). The periphery is sometimes occupied by basaloid cells. Additional features in some lesions include foci of tricholemmal differentiation, mucinous areas with spongiosis, and melanin pigmentation. A mild lymphohistiocytic inflammatory infiltrate often surrounds the lesion. Treatment is by surgical excision.

LYMPHADENOMA Cutaneous lymphadenoma (adamantinoid trichoblastoma) is a rare appendage tumor that is currently classified as a peculiar variant of trichoblastoma. [3] The neoplasm presents mainly in adults in the fourth to fifth decades as a solitary, skin-colored nodule situated on the head and neck. [3], [4], [11], [69] The usual clinical diagnosis is basal cell carcinoma.

Histopathology There are multiple, variably sized lobules in the dermis composed of basaloid cells, surrounded by a fibrous stroma. The basaloid lobules display focal palisading of nuclei at the periphery. An infiltrate of T and B lymphocytes is typically observed within the basaloid lobules, with focal sprinkling of the lymphocytes in the stroma (Fig. 85-13). Some cases reveal adamantinoid features. Epithelial aggregations in individual lesions display variable signs of follicular and sebaceous differentiation.

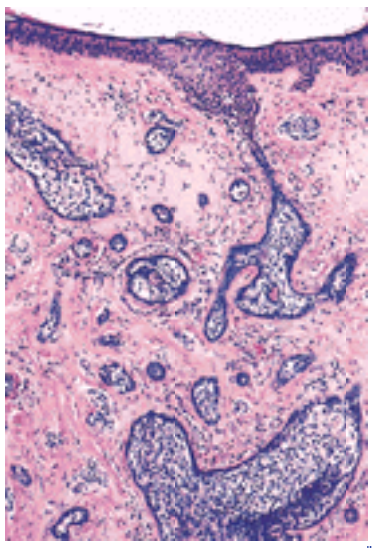

FIGURE 85-13 Lymphadenoma. Multiple, variably sized basaloid lobules in the dermis. Note the prominent palisading of nuclei at the periphery and the lymphoid cells within the lobules.

Treatment is by surgical excision. Local recurrences or metastases have not been observed.

PANFOLLICULOMA This is a recently described benign neoplasm that shows differentiation toward portions of both the upper and lower segments of a normal hair follicle. [3] The tumor reveals several morphologic similarities to trichoblastoma. Clinically, cystic, skin-colored or reddish, dome-shaped papules, situated on the head, trunk, and lower limbs of adults can be found.

Histopathology The tumor is characterized by several closely packed, solid, solid-cystic, or cystic aggregations of epithelial cells in the dermis, sometimes extending into the subcutis. They are surrounded by a fibrous stroma with focal clefts between the stroma and adjacent “normal” dermis or subcutaneous fat. Neoplastic cells reveal a spectrum of morphologic features reflecting bulbar, stem, isthmic, and infundibular differentiation. These include the presence of germinative and matrical cells (bulb), cells with trichohyline granules and blue-gray corneocytes (inner root sheath), and cells with abundant pale and clear cytoplasm (outer root sheath). Cystic structures are lined by infundibular epithelium with a granular zone and filled with blue-gray corneocytes arranged in basket-weave, laminated, and compact patterns. Treatment is by surgical excision.

PILAR SHEATH ACANTHOMA Pilar sheath acanthoma is characterized by a small (5 to 10 mm in diameter), solitary, skin-colored papule situated on the head and neck, particularly around the upper lip. [3], [4], [5] and [6], [70] A central, occasionally keratin plugged pore is often present. Middle-aged and elderly individuals are commonly affected.

Histopathology There is a crateriform depression in the epidermis representing a widely dilated, keratin-filled infundibulum or closely set infundibula, contiguous at the base with numerous epithelial lobules of pink keratinocytes. The epithelial lobules radiate into the dermis, sometimes with involvement of the subcutis. They are surrounded by a narrow rim of fibrous tissue. The epithelium shows similar features to those of the isthmus of a normal hair follicle. Small

infundibulocystic structures, tubular structures and foci of sebaceous differentiation (ducts or sebaceous lobules) are variably observed in individual cases. Treatment is by surgical excision.

PILOMATRICOMA Pilomatricoma (calcifying epithelioma of Malherbe) is a relatively common appendage tumor that predominantly shows differentiation towards the matrical portion of a normal hair follicle at the level of the bulb. Lesions present usually as solitary, skin-colored or pigmented cystic or firm nodules on the head and neck (Fig. 85-14A) and upper extremities of children and young persons. [3], [4], [5] and [6], [11] Some tumors arise in older adults. Unusual clinical features include rapidly growing tumors, lesions associated with overlying striae or anetodermic changes, and neoplasms arising in a nevus sebaceus. A few patients present with multiple lesions (usually fewer than five in number). Multiple pilomatricomas have also been reported in patients with Gardner's syndrome. [4], [53] Gardner's syndrome is described in the earlier section on epidermal cysts.

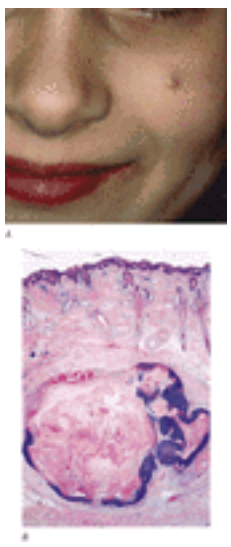

FIGURE 85-14 Pilomatricoma. *A.* A tumor in a young girl. *B.* Cystic lesion lined focally at the periphery by basaloid epithelium and filled with masses of eosinophilic, cornified material with shadow cells.

Histopathology Pilomatricoma shows a spectrum of morphologic features which mainly reflect different evolutionary stages. [71] Early and well-developed pilomatricomas reveal variably sized, round to oval cystic lesions lined by a basaloid epithelium at the periphery and filled in the center with masses of eosinophilic, faulty hair matrix material containing “shadow” (“ghost”) cells (Fig. 85-14B). Basaloid (matrical) cells show monomorphous round nuclei with one or more distinctive nucleoli, and variable numbers of mitotic figures. Foci of squamoid epithelium are sometimes noted within the epithelial lining. Regressing pilomatricomas display haphazardly arranged foci of basaloid cells and shadow cells, as well as an inflammatory infiltrate with multinucleated histiocytic giant cells. Granulation tissue is sometimes noted. Old pilomatricomas reveal no basaloid component but show irregularly shaped, partially confluent masses of shadow cells with foci of calcification or ossification. Melanin deposition, transepidermal elimination, and extramedullary hematopoiesis have been described in some pilomatricomas. A peculiar variant with relatively large areas of basaloid cells and small foci of shadow cells (“proliferating pilomatricoma”) is occasionally observed in older adults. Treatment of choice is surgical excision. Some lesions show spontaneous regression. Local recurrences may occasionally develop after surgical excision. A case of malignant transformation has been described. [72]

PROLIFERATING PILAR TUMOR Proliferating pilar tumor was previously reported under different names including proliferating trichilemmal cyst, pilar tumor, proliferating trichilemmal tumor, invasive pilomatrixoma, trichochlamydocarcinoma, giant hair matrix tumor, trichilemmal pilar tumor, and proliferating follicular cystic neoplasm. Clinically, lesions present as solitary, slowly growing, cystic or lobulated nodules and tumors on the scalp and trunk, as well as on the extremities of older adults. [3], [5], [11] Women are approximately two times more commonly affected than men. A few patients show multiple, sometimes familial, lesions. Occasional tumors may be ulcerated or occur as relatively large extracranial masses (up to 25 cm in diameter) (Fig. 85-15). Rarely, the neoplasm has been reported in association with nevus sebaceus or basaloid follicular hamartoma.

FIGURE 85-15 Proliferating pilar tumor. Ulcerated giant nodule on the scalp.

The exact nature of proliferating pilar tumor is still debatable. Traditionally, the tumor has been regarded as a benign follicular neoplasm. There are, however, several well-documented reports demonstrating that proliferating pilar tumor is capable of undergoing frank carcinomatous transformation, even with development of distant metastases. This has prompted some authors to advance the view that proliferating pilar tumor represents a low-grade type of squamous cell carcinoma (“proliferating tricholemmal cystic squamous carcinoma”). [3]

Histopathology Histopathologic examination usually reveals a sharply circumscribed, round or oval, cystic neoplasm occupying the lower dermis and subcutis. There is an epithelial component lining nearly the whole lesion, and extending within it in a radial fashion. The epithelium forms several partially interconnecting solid and cystic lobules. A zone of fibrous stroma with clefts between the stroma and surrounding normal tissue encompasses the tumor. Tumor nests are

composed mainly of squamous cells with some areas of clear cells containing glycogen. A characteristic feature is the presence, in the center of lobules, of tricholemmal cornification; that is, abrupt formation of compact eosinophilic keratin without granular layer interposition. Foci with keratohyaline granules, small horn pearls and squamous eddies, calcification, stromal calcium deposition, ossification, and shadow cells, as well as a palisading arrangement of the nuclei at the periphery of the lobules are observed in individual tumors. Some lesions reveal a lymphohistiocytic inflammatory infiltrate with foreign-body granulomas. A small subset of cases exhibits rather “atypical” features with numerous mitoses and dyskeratotic cells, edema and cystic degeneration, tumoral necrosis, and local infiltration of tumor cells into the stroma and galea, as well as underlying cranium. These changes are mainly suggestive of aggressive behavior. Treatment is by complete excision. Local recurrences and metastatic spread have been observed even in histopathologically typical cases. Accurate follow-up is recommended in all patients.

TRICHOADENOMA Trichoadenoma (of Nikolowski) is a rare follicular tumor that some authors consider a neoplastic process, while other authors consider it a malformation. [3], [4], [5] and [6], [11] Lesions are commonly found in adults and present as solitary, slowly growing, grayish nodules measuring up to 1.5 cm in diameter. They are mainly situated on the face and trunk.

Histopathology A dome-shaped, sharply defined, nodule composed of numerous, round to oval, infundibulocystic structures is observed in the dermis. Involvement of the subcutis may be noted in some cases. Infundibulocystic structures are lined by a squamous epithelium with a clear-cut basal layer, spinous zone and granular layer. They contain corneocytes arranged in a laminated pattern. A conspicuous collagenous stroma often surrounds the tumor cell nests. A subset of cases shows prominent verrucous hyperplasia of the epidermis. Treatment is by surgical excision.

TRICHOBLASTOMA Headington first introduced the name “trichoblastoma” in 1970, in a classification of neoplasms of the hair germ. [73] In his classification, tumors of the hair germ were divided into trichoblastomas, trichoblastic fibromas, and trichogenic trichoblastomas, based on their stromal characteristics. Ackerman et al. now suggest using the term *trichoblastoma* to embrace all benign appendage tumors whose common histopathologic denominator is the presence of an epithelial component consisting predominantly of follicular germinative (basaloid) cells. [3] Trichoblastomas are best subdivided according to the predominant morphologic pattern into large nodular (including pigmented), small nodular (including adamantinoid or lymphadenoma), retiform (giant solitary trichoepithelioma), cribriform (classic trichoepithelioma), racemiform (nonclassic trichoepithelioma), and columnar (desmoplastic trichoepithelioma) variants. [3] Exact subclassification is difficult in some lesions because of the presence of more than one predominant morphologic pattern. Here we focus mainly on “conventional” trichoblastomas. Other specific variants, including lymphadenoma and trichoepitheliomas, are discussed elsewhere in this chapter. Clinically, trichoblastomas present as solitary, nonulcerated, skin-colored to brown or bluish-black papules/nodules situated mostly on the head and neck, particularly on the scalp and face of adults. Lesions sometimes develop on extremities or trunk. They are frequently initially suspected to be basal cell carcinomas or dermal nevi. Trichoblastomas are also commonly observed in association within a preexisting nevus sebaceus [13], [74] (Fig. 85-16A), or may occasionally coexist with a basal cell carcinoma. [3]

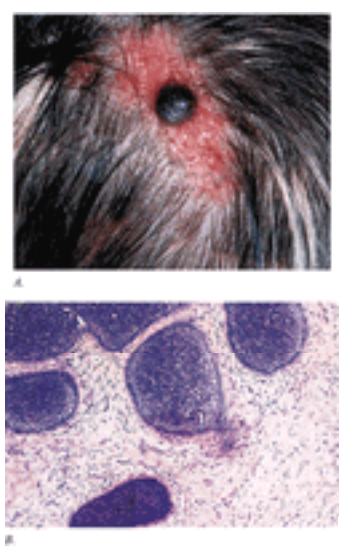

FIGURE 85-16 Trichoblastoma. *A.* Pigmented type arising in a nevus sebaceous. I>B. Nodular aggregations of basaloid cells surrounded by abundant fibrous stroma. Note prominent peripheral palisading of nuclei and a focus with a follicular germ and papilla.

Histopathology Lesions are characterized by several, dermal/subcutaneous, smooth-bordered aggregations of basaloid (germinative) cells arranged in different morphologic patterns including, cribriform, nodular, racemiform, and retiform. Epithelial aggregations are surrounded by a variable sclerotic or partly hyalinized stroma. They typically reveal peripheral palisading and several foci with rudimentary follicular papillae and germs (Fig. 85-16B). The basaloid cells are relatively monomorphous and exhibit dark-staining nuclei with large prominent nucleoli and scanty, pale, or eosinophilic cytoplasm. A few mitotic figures and single necrotic cells are sometimes noted. Additional findings in some cases include heavy melanin pigmentation, horn cysts, and amyloid deposits. Treatment is by complete excision. [3]

TRICHODISCOMA Trichodiscoma is a rare tumor that presents as multiple, asymptomatic, small, skin-colored papules situated on the face, arms, trunk, and sometimes the legs. [3], [5], [6], [11] Multiple, trichodiscomas may be inherited in an autosomal dominant fashion in the setting of Birt-Hogg-Dubé syndrome [68] (see above). Recently, the cutaneous lesions in this syndrome (fibrofolliculomas and trichodiscomas) have been interpreted as different developmental stages of one single tumor with sebaceous differentiation, called “mantleoma.”

Histopathology Histopathologic examination reveals a well-circumscribed, nonencapsulated, dome-shaped nodule in the dermis consisting of a zone of loose, finely fibrillar connective tissue with bundles of collagen, fibrocytes, and venules. The lesion is encircled by collarettes of infundibular epithelium that are focally continuous with epithelial cords radiating into the stroma. The epithelial cords sometimes contain sebaceous cells. A hair follicle or nerve fibers may be noted at the edge. Treatment of choice in solitary lesions is by surgical excision. Carbon dioxide laser is useful in removal of multiple lesions. Patients should be screened for other features of Birt-Hogg-Dubé syndrome.

TRICHOEPITHELIOMA Trichoepithelioma shows a spectrum of histopathologic features reflecting mainly differentiation toward hair and hair follicle, particularly follicular germs. [3], [4], [5] and [6], [11] These include aggregations of basaloid (follicular germinative) cells arranged in a cribriform or lacelike reticular pattern, conspicuous germs and follicular papillae, small horn cysts, and fibrotic stroma. This neoplasm is therefore best regarded as a distinct variant of trichoblastoma described

above. Three distinctive forms of trichoepitheliomas are recognized, namely solitary, multiple, and desmoplastic. [3] Desmoplastic trichoepithelioma was discussed earlier. Solitary trichoepithelioma occurs mainly as a small (5 to 8 mm in diameter), skin-colored papule situated on the face, especially around the nose, upper lip, and cheeks of adults. [3], [4], [5] and [6], [11] Occasional lesions develop on the trunk, neck, scalp, and lower extremities. Multiple trichoepitheliomas present usually in adolescents as numerous, small papules distributed on the face, with predilection for the area around the nasolabial folds, forehead, chin, and preauricular area (Fig. 85-17A). A few patients reveal plaques, nodules, or tumors due to coalescing of several lesions. Multiple trichoepitheliomas are mostly transmitted as an autosomal dominant trait in patients with Brooke-Spiegler (epithelioma adenoides cysticum) syndrome. In this syndrome, patients show predisposition for developing multifocal cylindromas, spiradenomas, and milia. [75] Multiple trichoepitheliomas have also rarely been associated with a number of other systemic conditions, including Rombo's syndrome (atrophoderma, milia, hypotrichosis, basal cell carcinomas, and peripheral vasodilatation), [76] systemic lupus erythematosus, and myasthenia gravis.

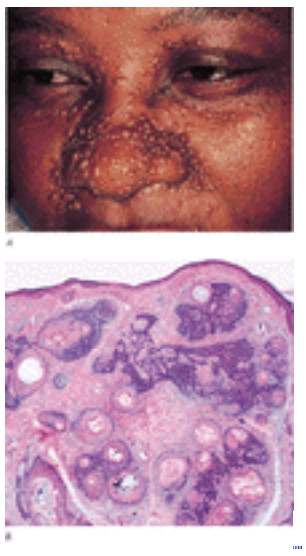

FIGURE 85-17 Trichoepithelioma. *A.* Multiple familial type. *B.* Well-circumscribed, multilobular dermal tumor consisting of solid and branching basaloid aggregations admixed with horn cysts, surrounded by abundant fibrous stroma. Note a focal cribriform pattern.

Histopathology There is a dome-shaped, sharply circumscribed lesion composed of aggregations of relatively monomorphic basaloid (germinative) cells in the upper dermis, surrounded by abundant fibrous stroma with intrastromal clefts (Fig. 85-17B). The basaloid aggregations are mainly arranged in a cribriform pattern, but may show other architectural patterns, including nodular, racemiform, and retiform. They typically reveal peripheral palisading and several foci with rudimentary follicular papillae and germs. In some lesions, other findings include infundibulocystic structures, shadow cells, sebaceous glands, amyloid, calcification, melanin pigmentation, and mucin deposition. A lymphohistiocytic infiltrate with small foreign-body granulomas is sometimes present. Surgery is usually effective in removing solitary lesions. However, surgical treatment of multiple trichoepitheliomas is generally disappointing. Alternative therapies have included cryotherapy, electrodesiccation, and carbon dioxide laser.

TRICHOFOLLICULOMA Trichofolliculoma is a rare tumor which presents mainly in adults as a small, solitary, dome-shaped papule or nodule situated on the face, particularly around the nose. [3], [4], [5] and [6], [11] A central, dilated keratin plugged ostium with vellus hair(s) is often present (Fig. 85-18). Trichofolliculoma has been regarded by different authors either as a neoplastic process or as a hamartoma (hair follicle nevus).

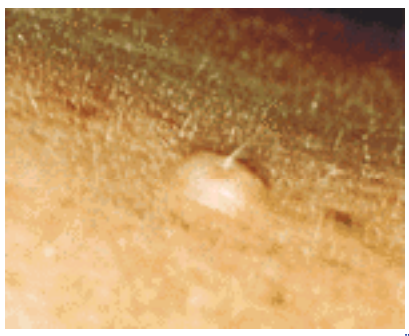

FIGURE 85-18 Trichofolliculoma. Papule on the forehead with a hair emanating from its central pore.

Histopathology The lesion is basically centered on one, or less frequently on several contiguous, variably dilated, primary follicles lined by infundibular and isthmus type epithelium and opening to the skin surface. Numerous, smaller, secondary (vellus) follicles bud from the wall of the central follicle in a radial fashion. The central follicle is commonly filled with cornified cells and sometimes contains vellus hairs. The secondary follicles often reveal differentiation toward germinative epithelium or formation of hair. They are surrounded by a prominent fibrous stroma. Individual tumors display variable features of outer root sheath differentiation at the isthmus with tricholemmal cornification and basaloid matrical, as well as sebaceous, differentiation. Sebaceous trichofolliculoma represents a distinctive variant with large sebaceous follicles connecting to the central cavity. Treatment is by surgical excision.

TRICHOLEMMOMA Tricholemmoma (trichilemmoma) shows mainly differentiation toward the outer root (tricholemmal) sheath of a normal hair follicle at the level of the bulb. Lesions present usually in adults as solitary, small (3 to 8 mm in diameter), asymptomatic, keratotic, or smooth-surfaced papules on the face, particularly around the nose and upper lip. [3], [4], [5] and [6], [11] Some cases arise in association with nevus sebaceus. [74] Multiple facial tricholemmomas represent an important cutaneous marker for Cowden's syndrome, which is discussed in Chap. 184. Patients with Cowden's syndrome show a tendency to develop particular internal malignancies, especially involving the breast, colon and thyroid. A tumor-suppressor gene (designated *PTEN/MMAC1*) has been demonstrated to play a causative role. [9] Recently, based mainly on the wartlike morphology, some authors have proposed tricholemmoma to represent an old viral wart. [3]

Histopathology Lesions show a lobular, folliculocentric, exo-endophytic proliferation of polygonal, pale-staining, glycogen-containing squamoid cells. The epidermal surface often reveals parakeratosis with scale crusts, and sometimes a cutaneous horn (tricholemmal horn). The periphery of the lobules is bordered by columnar cells arranged in a palisade.

Foci with small squamous eddies are occasionally observed within the center of tumor lobules. A conspicuous basement membrane usually surrounds the lesions. Desmoplastic tricholemmoma represents a special variant with prominently hyalinized or desmoplastic stroma. [77] Treatment is by surgical excision.

TUMOR OF THE FOLLICULAR INFUNDIBULUM Despite its name, tumor of the follicular infundibulum shows mainly differentiation toward the isthmus of a normal hair follicle, rather than the infundibulum. Lesions present as solitary, small (5 to 10 mm in diameter), asymptomatic, smooth or keratotic papules on the head and neck of middle-aged and elderly individuals. [3], [5], [11] A small subset of cases occur as multiple lesions (infundibulomatosis, eruptive infundibulomas). Tumors developing in association with Cowden's syndrome or with a preexisting nevus sebaceus have been reported.

Histopathology There is a horizontally oriented, platelike tumor in the upper dermis with an epithelial component showing multifocal connections to the epidermis or hair follicles. The epithelium typically reveals a fenestrated pattern with interconnecting cords and columns. Infundibulocystic structures are focally present. Cells display small, monomorphic nuclei and abundant, pale to pink-staining cytoplasm. The tumors are sometimes surrounded by a collagenous stroma with a network of elastic fibers. Variable areas with single necrotic cells, clear cells, rudimentary papillae and germs, ductal structures, and features of sebaceous differentiation are observed in some cases. Treatment is by surgical excision.

Malignant Neoplasms

BASAL CELL CARCINOMA WITH FOLLICULAR DIFFERENTIATION See Chap. 81.

PILOMATRICAL CARCINOMA Pilomatrical carcinoma (matrical carcinoma) is rare tumor that is found in older adults on the head and neck, and occasionally on the trunk. [3], [4], [5] and [6], [11] Clinical appearances are generally not distinctive. Most cases probably develop de novo, but malignant transformation from a benign pilomatricoma has been reported. [72]

Histopathology Histopathologic examination shows irregularly sized and variously shaped cutaneous/subcutaneous epithelial islands of basaloid (matrical and supramatrical) cells with conspicuous foci of shadow cells (Fig. 85-19). The basaloid cells reveal nuclear atypia and mitoses, as well as areas of geographic necrosis. Involvement of vascular lumina, subjacent deep soft tissues, and bone may be observed.

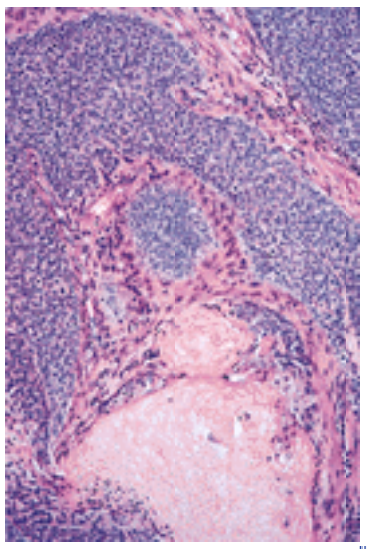

FIGURE 85-19 Pilomatrical carcinoma. Irregular aggregations of atypical basaloid cells continuous with an area of cornified material containing shadow cells.

Treatment of choice is surgical excision with adequate margins. [72] Pilomatrical carcinoma is mainly locally aggressive, but distant metastases, especially to lungs, bones, and lymphatics have rarely been reported.

TRICHOLEMMAL CARCINOMA This is an extremely rare tumor that presents mainly in elderly individuals as a solitary, slowly growing, sometimes indurated, papule, plaque, or nodule situated on sun-exposed, hair-bearing areas. [5], [11] Lesions are mostly located on the face, scalp, auricular skin, and extremities. They are most frequently initially suspected to be basal cell carcinomas or squamous cell carcinomas.

Histopathology There is a predominantly dermal tumor composed of several epithelial aggregations arranged in various growth patterns including solid, lobular, and trabecular. Focal connections to the epidermis and pilosebaceous structures are noted in some sections. Most lesions show prominent atypia and a high mitotic activity. Epithelial aggregations exhibit, at least focally, features of outer root sheath differentiation, including neoplastic cells with abundant, clear cytoplasm, and focal tricholemmal cornification. Peripheral nuclear palisading may be observed in some tumor nests. Treatment of choice is surgical excision with adequate margins. The tumor usually behaves in an indolent fashion, but a few patients have shown local recurrences. So far, no cases of distant metastases have been reported.

APPENDAGE TUMORS WITH SEBACEOUS DIFFERENTIATION

Apart from sebaceus hyperplasia, sebaceous tumors appear to be less common and to show less morphologic diversity than other types of appendage tumors. Terminology is still controversial. Benign sebaceous neoplasms were conventionally divided into sebaceous hyperplasia, sebaceous adenoma, and sebaceous epithelioma, and malignant sebaceous neoplasms into basal cell carcinoma with sebaceous differentiation and sebaceous carcinoma. [5], [6] Recently, the existence of sebaceous epithelioma as a distinctive neoplasm was challenged. [2] The term *sebaceoma* has been recommended for the most common benign neoplasm with sebaceous differentiation, whose malignant counterpart is sebaceous carcinoma. Furthermore, it has been proposed that sebaceous adenoma represents a superficial sebaceous carcinoma rather than a benign neoplasm. This section adopts this classification.

Cyst

STEATOCYSTOMA See Chap. 84.

Hamartomas

FOLLICULOSEBACEOUS CYSTIC HAMARTOMA Folliculosebaceous cystic hamartoma is a cutaneous hamartoma that is comprised of follicular, sebaceous, and mesenchymal elements. Lesions present as solitary, long-standing, asymptomatic papules or nodules measuring 0.5 to 2 cm or more in diameter, situated on the head and neck. [11], [78] The face, especially the region around the nose, is mainly involved. Some lesions show a slightly depressed area with a centrally located crateriform pore.
Histopathology A dome-shaped nodule with a mature infundibular structure to which numerous rudimentary hair follicles and/or sebaceous units are attached is observed. The follicular structure is typically surrounded by abundant fibrous and elastic tissue. Adipocytes, nerves, and blood vessels are frequently found within the stroma. Treatment is by simple surgical excision.
FORDYCE'S SPOTS (FORDYCE'S DISEASE) AND MONTGOMERY'S TUBERCLES Fordyce's spots and Montgomery's tubercles represent the occurrence of sebaceous glands on the lips and buccal mucosa, and on breast areola, respectively. [2] Despite the ectopic locations, both conditions reveal sebaceous glands with a “normal” histopathologic appearance and are therefore best regarded as hamartomas. Clinically, Fordyce's spots present as tiny white or yellowish, focally grouped papules on the lip near the vermilion or on a bucca1 mucosa of adults. Rare lesions develop on the genital mucosa. Montgomery's tubercles arise as tiny papules distributed in a circle near the periphery of the breast areola of adult women. They have not been described in men.
Histopathology Fordyce's spots show similar features to those in Montgomery's tubercles. They consist of a single sebaceous gland or lobule located in the upper submucosa or dermis, respectively. Some lesions reveal no accompanying sebaceous duct.
NEVUS SEBACEUS See Chap. 84.

Hyperplasia

SEBACEOUS HYPERPLASIA AND RHINOPHYMA Sebaceous hyperplasia presents commonly as solitary or multiple, small (less than 3 mm in diameter), yellowish, papules on the face, particularly on the forehead of middle-aged individuals. [2], [4], [5] and [6], [11] Lesions often reveal a central dell. Males are more commonly affected than females. Clinically, lesions are often suspected to be basal cell carcinomas. Unusual presentations of sebaceous hyperplasia include linear and zosteriform lesions, giant and diffuse tumors, and lesions confined to the areola or genital (vulva) region. Rare cases show a familial pattern. Rhinophyma is currently widely considered to represent a special form of sebaceous hyperplasia [2] and is discussed in Chap. 74.
Histopathology Both sebaceous hyperplasia and rhinophyma reveal large mature sebaceous lobules clustered around discrete, often dilated, infundibula and located mainly in the upper dermis. The infundibulum is sometimes filled with debris and bacteria, and may contain a vellus hair. In addition, rhinophyma often reveals striking telangiectases in the upper dermis and features of folliculitis as well as granulomatous perifolliculitis. Old rhinophyma lesions are characterized by severe dermal fibrosis and scarring. Treatment of choice is surgical excision. However, a variety of treatment options have previously been tried, including oral isotretinoin, electrodesiccation, CO_2 laser surgery, cryosurgery, and shave excision with curettage.

Benign Neoplasms

MANTLEOMA Mantleoma (see also fibrofolliculoma discussed earlier) is a recently described benign tumor that shows differentiation toward the sebaceous mantle. [3] The sebaceous mantle is a well-recognized, but poorly documented, part of the sebaceous gland cycle. In the resting phase, the sebaceous mantle represents cords of undifferentiated cells that project from the infundibulum of a hair follicle and droop down aside the follicle. Cyclically, vacuolated sebocytes appear at the terminus of these cords, singly, then in groups, and finally as fully developed sebaceous lobules and glands. Sebaceous glands probably involute to become undifferentiated mantles. Mantleomas occur either as solitary or as multiple tumors. [3], [11] Solitary mantleomas appear to be sporadic. They present as small papules on the face, frequently mimicking basal cell carcinomas or dermal nevi. As far as multiple mantleomas are concerned, it was recently proposed that both fibrofolliculomas and trichodiscomas arising in patients with Birt-Hogg-Dubé syndrome actually represent different developmental stages of mantleoma. Multiple mantleomas in these patients occur as numerous, small papules located mainly on the head and neck, as well as the trunk.
Histopathology Mantleomas show various histopathologic features. Some lesions consist only of cords and columns of undifferentiated epithelial cells that radiate from an infundibulum. Other lesions reveal interconnected cords with sebocytes and sebaceous ductal structures. Treatment of solitary lesions is by surgical excision. Management of multiple mantleomas is that of multiple fibrofolliculomas and trichodiscomas.
RETICULATED ACANTHOMA See the earlier section on tumors with apocrine differentiation.
SEBACEOMA Sebaceoma represents the most common benign neoplasm with sebaceous differentiation. It presents usually as a solitary, slowly growing, asymptomatic, yellowish papule or small nodule on the face and scalp of older individuals [2], [75] (Fig. 85-20A). Women appear to be more commonly affected than men. Occasional tumors arise in association with nevus sebaceus or seborrheic keratosis.

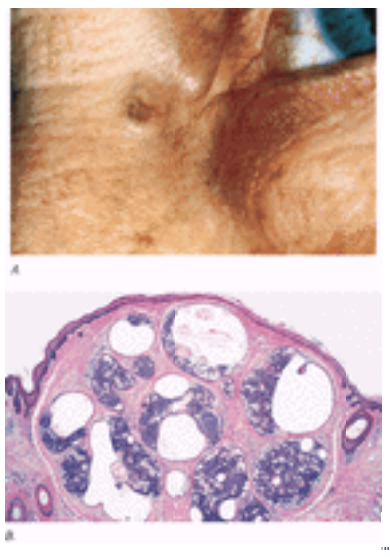

FIGURE 85-20 Sebaceoma. *A.* Yellowish nodule near the inner canthus of the eye. *B.* Well-circumscribed tumor composed of basaloid aggregations, admixed with sebocytes and ductal, as well as cystic structures.

Histopathology Lesions are centered in the dermis and consist of relatively symmetric, well-circumscribed, and smoothly bordered lobular aggregations of epithelial cells with focal connections to preexisting infundibula. [2], [79] Involvement of the subcutis is observed in some cases. Epithelial aggregations are composed of basaloid cells with relatively monomorphous nuclei, admixed with variable foci of discernible sebocytes and sebaceous ductal structures (Fig. 85-20B). Some cases reveal entirely immature sebocytes, that is, cells with small monomorphous nuclei and scant cytoplasm, but without vacuoles. Other cases display a variable mixture of immature and mature sebocytes with highly vacuolated abundant cytoplasm and nuclei exhibiting scalloped borders. Scattered mitoses are observed in some cases. Additional features may include a “ripple-like” pattern, and cystic as well as ductlike structures containing sebaceous secretion. Treatment of choice is simple surgical excision. Electrodesiccation, curettage, and cryotherapy are effective in some cases.

Malignant Neoplasms

SEBACEOUS CARCINOMA AND NEOPLASMS IN MUIR-TORRE SYNDROME Sebaceous carcinoma represents a spectrum of rare malignant appendage tumors with sebaceous differentiation and with a potential for aggressive behavior. [2], [4], [5] and [6], [11], [79] They have traditionally been divided into ocular and extraocular types. Of these, the ocular type is the commonest. Ocular type of sebaceous carcinoma usually presents in older adults as a small, solitary, papule or nodule on the eyelid, particularly around the Meibomian glands and glands of Zeiss of the upper eyelid. [2] Women are more commonly affected than men. Patients may give a history of radiation. Lesions are often suspected to be chalazions. Rare cases have been observed in young individuals infected with human immunodeficiency virus. Extraocular sebaceous carcinoma occurs mostly as a yellowish, firm, often ulcerated nodule on the head and neck of elderly individuals. Other anatomic sites, such as the foot and genital regions (labia and penis), may occasionally be involved. Lesions often mimic pyogenic granuloma, hemangioma, or squamous cell carcinoma. Sebaceous carcinoma represents an important cutaneous marker of Muir-Torre syndrome [80] (see Chap. 184). In this syndrome, the tumors occur as single or multiple, skin-colored, yellowish or reddish-brown, sometimes ulcerated papules with the appearance of sebaceus hyperplasia and nodules, situated commonly on the face. They may coexist with keratoacanthomas and/or epidermal cysts. There is still controversy regarding the nature of sebaceous tumors arising in patients with Muir-Torre syndrome. Previous examples have mostly been considered as benign neoplasms (“sebaceous adenomas” or sebaceomas) and less commonly as sebaceous carcinomas. Based mainly on morphology, some authors recently proposed that the vast majority of sebaceous tumors arising in these patients are, in fact, sebaceous carcinomas. [79]
Histopathology Sebaceous carcinoma is characterized by an asymmetric lesion centered in the dermis, and consisting of variously sized and irregularly shaped aggregations of neoplastic cells. [2], [79] Involvement of the subcutaneous tissue and/or underlying muscle is observed in some cases. Neoplasms may be relatively well-differentiated with prominent sebaceous lobules and/or sebaceous ductal structures or show undifferentiated features with neither readily discernible cytoplasmic vacuoles nor ductal differentiation. The nuclei of the neoplastic cells, especially along the periphery of the tumor nests tend to be crowded and pleomorphic, and may exhibit marked atypia, as well as increased mitotic figures. Sections often reveal areas with geographic necrosis. A peculiar variant with cystic features may be difficult to differentiate from sebaceoma. Treatment of choice is surgical excision with adequate margins. Radiation therapy may be effective in some patients with eyelid neoplasms. Up to one-third of patients with ocular type of sebaceous carcinoma show lymph node metastases, particularly to the preauricular and cervical nodes, and the 5-year mortality rate is about 20 percent. Histopathologic features suggestive of a poor prognosis include the presence of vascular and lymphatic invasion, orbital extension, poor differentiation, an infiltrative growth pattern, and large tumor size. In contrast to ocular tumors, extraocular sebaceous carcinoma very rarely reveals nodal or visceral metastases. Sebaceous carcinomas arising in Muir-Torre syndrome, like visceral malignancies in these patients, also seem to be less aggressive than their ocular counterpart, which is unassociated with the syndrome. [80]

REFERENCES

1. Requena L et al: *Neoplasms with Apocrine Differentiation.* Philadelphia, Lippincott-Raven, Ardor Scribendi, 1997

2. Steffen C, Ackerman AB: *Neoplasms with Sebaceous Differentiation.* Philadelphia, Lea & Febiger, 1994

3. Ackerman AB et al: *Neoplasms with ollicular Differentiation.* New York Ardor Scribendi, 2001

4. Hurt MA, Santa Cruz DJ: Adnexal tumors, in *Diagnostic Histopathology of Tumors*, 2d ed, edited by CDM Fletcher. Edinburgh, Churchill Livingstone, 2000, p 1378

5. Wick MR, Swanson PE: *Cutaneous Adnexal Tumors: A Guide to Pathologic Diagnosis.* Chicago, ASCP Press, 1991

6. Maize JC et al: Adnexal tumors, in *Cutaneous Pathology*, edited by JC Maize. Philadelphia, Churchill-Livingstone, 1998, p 483

7. Biernat W et al: p53 Mutations in sweat gland carcinomas. *Int J Cancer* **76**:317, 1998

8. Aszterbaum M et al: Ultraviolet and ionizing radiation enhance the growth of BCCs and trichoblastomas in patched heterozygous knockout mice. *Nat Med* **5**:1285, 1999

9. Stambolic V et al: Negative regulation of PKB/Akt-dependent cell survival by the tumor suppressor PTEN. *Cell* **95**:29, 1998

10. Kruse R et al: Is the mismatch repair deficient type of Muir-Torre syndrome confined to mutations in the hMSH2 gene? *Hum Genet* **98**:747, 1996

11. Weedon D: Tumors of cutaneous appendages, in *Skin Pathology*. New York, Churchill-Livingstone, 1997, p 713

12. Vakilzadeh F et al: Fokale dermale Hypoplasie mit apokrinen Naevi und streifenfoermiger Anomalie der Knochen. *Arch Dermatol Res* **256**:189, 1976

13. Cribier B et al: Tumors arising in nevus sebaceus: A study of 596 cases. *J Am Acad Dermatol* **42**:263, 2000

14. Civatte J et al: Adenomatose érosive sur mamelon surnuméraire. *Ann Dermatol Venereol* **104**:777, 1977

15. Wilkinson S et al: Fibroadenoma of the breast: A follow-up of conservative management. *Br J Surg* **76**:390, 1989

16. Santa Cruz DJ et al: Hidradenoma papilliferum of the eyelid. *Arch Dermatol* **117**:55, 1981

17. Shenoy YMV: Malignant perianal papillary hidradenoma. *Arch Dermatol* **83**:965, 1961

18. Hirsch P, Helwig EB: Chondroid syringoma. Mixed tumor of the skin, salivary gland type. *Arch Dermatol* **84**:835, 1961

19. Requena L et al: Apocrine type of cutaneous mixed tumor with follicular and sebaceous differentiation. *Am J Dermatopathol* **14**:186, 1992

20. Cooper PH et al: Primary cutaneous adenoid cystic carcinoma. *Arch Dermatol* **120**:774, 1984

21. Domingo J, Helwig EB: Malignant neoplasms associated with nevus sebaceus of Jadassohn. *J Am Acad Dermatol* **1**:545, 1979

22. Warkel RL: Selected apocrine neoplasms. *J Cutan Pathol* **11**:437, 1984

23. Urso C et al: Histologic spectrum of carcinomas with eccrine ductal differentiation (sweat-gland ductal carcinomas). *Am J Dermatopathol* **15**:435, 1993

24. Bannatyne P et al: Vulvar adenosquamous carcinoma arising in a hidradenoma papilliferum with rapidly fatal outcome: Case report. *Gynecol Oncol* **35**:395, 1989

25. Weilburg RD et al: Paget's disease of the vulva associated with adenocarcinoma developing in a hidradenoma papilliferum. *Am J Obstet Gynecol* **98**:294, 1967

26. Metzler G et al: Malignant chondroid syringoma: Immunohistopathology. *Am J Dermatopathol* **18**:83, 1996

27. Santa Cruz DJ: Sweat gland carcinomas: A comprehensive review. *Semin Diagn Pathol* **4**:38, 1987

28. Wright JD, Font RL: Mucinous sweat gland adenocarcinoma of eyelid: A clinicopathologic study of 21cases with histochemical and electron microscopic observations. *Cancer* **44**:1757, 1979

29. Jakobiec FA et al: Primary infiltrating signet ring carcinoma of the eyelids. *Ophthalmology* **90**:291, 1983

30. Ishida-Yamamoto A et al: Syringocystadenocarcinoma papilliferum: Case report and immunohistochemical comparison with its benign counterpart. *J Am Acad Dermatol* **45**:755, 2001

31. Numata M et al: Syringadenocarcinoma papilliferum . *J Cutan Pathol* **12**:3, 1985

32. Abenoza P, Ackerman AB: *Neoplasms with Eccrine Differentiation*. Philadelphia, Lea & Febiger, 1990

33. Leung CS et al: Porokeratotic eccrine ostial and dermal duct naevus with dermatomal trunk involvement: Literature review and report on the efficacy of laser treatment. *Br J Dermatol* **138**:684, 1998

34. Morrell DS et al: Eccrine angiomatous hamartoma: A report of symmetric and painful lesions of the wrists. *Pediatr Dermatol* **18**:117, 2001

35. Trotter MJ et al: Mucinous syringometaplasia: A case report and review of the literature. *Clin Exp Dermatol* **20**:42, 1995

36. Tannous Z et al: Syringolymphoid hyperplasia and follicular mucinosis in a patient with cutaneous T-cell lymphoma. *J Am Acad Dermatol* **41**:303, 1999

37. Biggs PJ et al: The cylindromatosis gene (cyld1) on chromosome 16q may be the only tumour-suppressor gene involved in the development of cylindromas. *Oncogene* **12**:1375, 1996

38. Galadari E et al: Malignant transformation of eccrine tumors . *J Cutan Pathol* **14**:15, 1987

39. Mehregan AH et al: Eccrine syringofibroadenoma (Mascaro). Report of two cases. *J Am Acad Dermatol* **13**:433, 1985

40. Hunt SJ et al: Giant eccrine acrospiroma. *J Am Acad Dermatol* **23**:663, 1990

41. Hernandez-Perez E, Cestoni-Parducci R: Nodular hidradenoma and hidradenocarcinoma. A 10-year review. *J Am Acad Dermatol* **12**:15, 1985

42. Mambo NC: Eccrine spiradenoma: Clinical and pathologic study of 49 tumors. *J Cutan Pathol* **10**:312, 1983

43. Frazier CC et al: The treatment of eruptive syringomas in an African American patient with a combination of trichloroacetic acid and CO laser destruction. *Dermatol Surg* **27**:489, 2001

44. Rulon DB, Helwig EB: Papillary eccrine adenoma . *Arch Dermatol* **113**:596, 1977

45. Kao GF et al: Aggressive digital papillary adenoma and adenocarcinoma. A clinicopathological study of 57 patients, with histochemical, immunopathological, and ultrastructural observations. *J Cutan Pathol* **14**:129, 1987

46. Gerretsen AL et al: Cutaneous cylindroma with malignant transformation. *Cancer* **72**:1618, 1993

47. Carroll P et al: Metastatic microcystic adnexal carcinoma in an immunocompromised patient. *Dermatol Surg* **26**:531, 2000

48. Suster S, Wong TY: Polymorphous sweat gland carcinoma. *Histopathology* **25**:31, 1994

49. Snow SN, Reizner GT: Eccrine porocarcinoma of the face. *J Am Acad Dermatol* **27**:306, 1992

50. Robson A et al: Eccrine porocarcinoma (malignant eccrine poroma): A clinicopathologic study of 69 cases. *Am J Surg Pathol* **25**:710, 2001

51. Fernandez-Acenero MJ et al: Malignant spiradenoma: Report of two cases and literature review. *J Am Acad Dermatol* **44**:395, 2001

52. Granter SR et al: Malignant eccrine spiradenoma (spiradenocarcinoma): A clinicopathologic study of 12 cases. *Am J Dermatopathol* **22**:97, 2000

53. Weedon D: Cysts and sinuses, in *Skin Pathology*. New York, Churchill-Livingstone, 1997, p 425

54. Brownstein MH: Hybrid cyst: A combined epidermoid and trichilemmal cyst. *J Am Acad Dermatol* **9**:872, 1983

55. Barr RJ et al: Cutaneous keratocysts of nevoid basal cell carcinoma syndrome. *J Am Acad Dermatol* **14**:572, 1986

56. Requena CL, Sanchez Yus E: Pigmented follicular cyst. *J Am Acad Dermatol* **21**:1073, 1989

57. Leppard BJ et al: Hereditary trichilemmal cysts. Hereditary pilar cysts. *Clin Exp Dermatol* **2**:23, 1977

58. Kose O et al: Anhidrotic ectodermal dysplasia with eruptive vellus hair cysts. *Int J Dermatol* **40**:401, 2001

59. Kageyama N, Tope WD: Treatment of multiple eruptive hair cysts with erbium: YAG laser . *Dermatol Surg* **25**:819, 1999

60. Shimizu H et al: A case of generalized hair follicle hamartoma associated with diffuse sclerosis of the face . *Br J Dermatol* **143**:1103, 2001

61. Brownstein MH: Basaloid follicular hamartoma: Solitary and multiple types. *J Am Acad Dermatol* **27**:237, 1992

62. Davis DA, Cohen PR: Hair follicle nevus: case report and review of the literature. *Pediatr Dermatol* **13**:135, 1996

63. Headington JT: Tumors of the hair follicle. A review. *Am J Pathol* **85**:479, 1976

64. Aloi FG et al: Unilateral linear basal cell nevus associated with diffuse osteoma cutis, unilateral anodontia, and abnormal bone mineralization. *J Am Acad Dermatol* **20**:973, 1989

65. Sangueza OP, Requena L: Neurofollicular hamartoma. A new histogenetic interpretation. *Am J Dermatopathol* **16**:150, 1994

66. Mehregan A, Pinkus H: Life history of organoid nevi: Special references to nevus sebaceus of Jadassohn. *Arch Dermatol* **91**:574, 1965

67. Steffen C: Winer's dilated pore: the infundibuloma. *Am J Dermatopathol* **23**:246, 2001

68. Toro JR et al: Birt-Hogg-Dubé syndrome: A novel marker of kidney neoplasia. *Arch Dermatol* **135**:1195, 1999

69. Santa Cruz DJ et al: Cutaneous lymphadenoma. *Am J Surg Pathol* **15**:101, 1991

70. Smolle J, Kerl H: Das “pilar sheath acanthoma”: Ein gutartiges follikulaeres Hamartom. Dermatologica **167**:335, 1983

71. Kaddu S et al: Morphological stages of pilomatricoma. *Am J Dermatopathol* **18**:333, 1996

72. Sassmannshausen J, Chaffins M: Pilomatrix carcinoma: A report of a case arising from a previously excised pilomatrixoma and a review of the literature. *J Am Acad Dermatol* **44**:358, 2001

73. Headington JT: Differentiating neoplasms of hair germ. *J Clin Pathol* **23**:464, 1970

74. Kaddu S et al: Basaloid neoplasms in nevus sebaceus. *J Cutan Pathol* **27**:327, 2000

75. Weyers W et al: Spiradenomas in Brooke-Spiegler syndrome. *Am J Dermatopathol* **15**:156, 1993

76. Ashinoff R et al: Rombo syndrome: A second case report and review. *J Am Acad Dermatol* **28**:1011, 1993

77. Hunt SJ et al: Desmoplastic trichilemmoma: Histologic variant resembling invasive carcinoma. *J Cutan Pathol* **17**:45, 1990

78. Templeton SF: Folliculosebaceous cystic hamartoma: A clinical pathologic study. *J Am Acad Dermatol* **34**:77, 1996

79. Ackerman AB et al: Sebaceoma versus sebaceous carcinoma, in *Differential Diagnosis in Dermatopathology,* edited by AB Ackerman. Philadelphia, Ardor Scribendi, 2001, p 134

80. Schwartz RA, Torre DP: The Muir-Torre syndrome: A 25-year retrospect. *J Am Acad Dermatol* **33**:90, 1995

T>

Chapter 86

Helmut Kerl Rainer
Hofmann-Wellenhof

Cutaneous Neuroendocrine Carcinoma: Merkel Cell Carcinoma

CLINICAL FEATURES
HISTOLOGIC FEATURES
ULTRASTRUCTURAL FEATURES
IMMUNOHISTOLOGIC, BIOCHEMICAL, AND MOLECULAR FEATURES
DIFFERENTIAL DIAGNOSIS
HISTOGENESIS
PROGNOSIS AND TREATMENT

REFERENCES

In 1875, Friedrich S. Merkel (1845–1919) discovered unusual clear-staining cells at the dermal–epidermal junction and in the basal epidermis that were intimately associated with myelinated nerve fibers. He named these previously undescribed cells, which later became known as Merkel cells, “Tastzellen” (touch cells).

In 1972, Toker [1] reported five cases of skin neoplasms with a prominent “trabecular” architectural pattern. Subsequent reports [2] pointed out that the cells of trabecular carcinomas displayed striking ultrastructural similarities to the Merkel cell. Further immunocytochemical and biochemical investigations indicated that this group of skin carcinomas expressed features of neuroendocrine and epithelial differentiation [3], [4] and [5] and the term *cutaneous neuroendocrine carcinoma* (neuroendocrine skin carcinoma) was proposed. [6]

In recent years, numerous publications dealing with cutaneous neuroendocrine carcinomas have appeared under various designations. Cases termed *primary neuroepithelial tumor of the skin, primary small cell carcinoma of the skin, primary cutaneous carcinoid, cutaneous*

APUD-oma, and *adult neuroblastoma* seem to represent cutaneous neuroendocrine carcinomas.

CLINICAL FEATURES

More than 50 percent of cutaneous neuroendocrine carcinomas arise in the head (face) and neck region, followed by the extremities, buttocks, and trunk. The patients range in age from 15 to 97 years. Most patients, however, are in their seventh or eighth decade, with an average of 65 years at diagnosis. The sex distribution is approximately equal. [5], [7], [8] and [9]

Clinically, pink, bluish-red, or reddish-brown cutaneous-subcutaneous nodules are observed. The overlying skin is usually intact (Fig. 86-1A). The tumors range in size from 0.5 to 5 cm, but sometimes large ulcerated masses are found (Fig. 86-1B and Fig. 86-1C. The majority of cutaneous neuroendocrine carcinomas are solitary. In a few reports multifocal or even disseminated lesions have been described. The neoplasms grow rapidly within 1 year, but there may be a longer duration of the lesions before diagnosis.

FIGURE 86-1 Clinical features of cutaneous neuroendocrine carcinoma. *A*. Erythematous nodule on the cheek. *B*. Ulcerated tumor on the right upper arm. *C*. Large ulcerated masses with involvement of lymph nodes on the neck.

The association of cutaneous neuroendocrine carcinoma with squamous cell carcinoma, adnexal neoplasms, basal cell carcinoma, actinic keratosis, and Bowen's disease in the same anatomic area has been documented. [5]

A relationship between cutaneous neuroendocrine carcinoma and concomitant clinical endocrinopathies [increased levels of adrenocorticotropic hormone (ACTH) and calcitonin in the serum] has been found, but this is extremely rare. The tumors have also been described in young patients with congenital ectodermal dysplasia, Cowden's disease, and in

patients with B cell lymphoma. [7], [9] The cause of cutaneous neuroendocrine tumors is still unknown. Some authors postulate that UV radiation may lead to the development of these tumors. Two cases developed in an area of erythema ab igne, and one case occurred in an irradiation site. [8], [9] Merkel cell carcinomas have been found to have an increased incidence among immunosuppressed patients. [10], [11]

HISTOLOGIC FEATURES

The histologic features of cutaneous neuroendocrine carcinomas are variable. [2], [12] Two main architectural patterns are found: (1) a nodular and/or diffuse pattern mimicking malignant lymphoma (Fig. 86-2); (2) sheets of cells forming nests, cords, and trabeculae (Fig. 86-3). Frequently, a mixed pattern with features of both the nodular/diffuse and trabecular forms is observed. The epidermis is usually spared. Rarely, epidermotropism with pagetoid growth of tumor cells can be present. The tumors involve the dermis and extend into the subcutaneous fat.

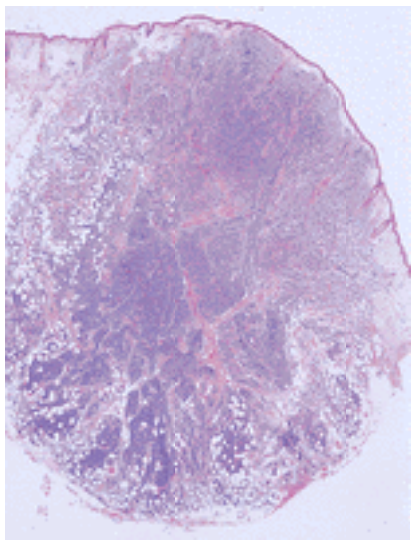

FIGURE 86-2 Histologic features of cutaneous neuroendocrine carcinoma. The scanning magnification illustrates a nodule with deep extension into the subcutaneous fat (H&E).

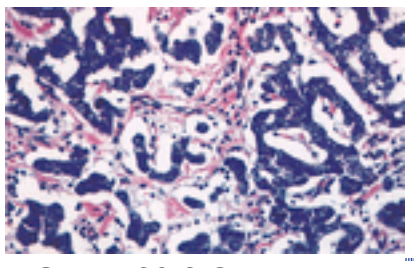

FIGURE 86-3 Cutaneous neuroendocrine carcinoma. Trabecular pattern (H&E).

The neoplastic cells are uniform in size with round or oval nuclei and have evenly dispersed chromatin, small nucleoli, and sharply defined nuclear membranes. Cytoplasm is scanty and amphophilic (Fig. 86-4). The cells show various degrees of intercellular adhesion. Necrotic areas, scattered pyknotic nuclei, and numerous mitotic figures are frequently evident. Occasionally, pseudorosettes or Homer-Wright rosettes (Fig. 86-5A), myxoid stroma, spindle cell proliferation, eccrine differentiation, or the collision of cutaneous neuroendocrine and squamouscell carcinoma (Fig. 86-5B) are found. [5] A dense lymphocytic infiltrate can also often be observed. Some authors described the Azzopardi phenomenon (DNA-deposition in intratumoral blood vessels) in cutaneous neuroendocrine carcinoma. [13] Gould et al. [6] have recognized three variants of cutaneous neuroendocrine carcinoma: a trabecular, an intermediate, and a small cell type that mimics oat-cell carcinoma of the lung at other sites.

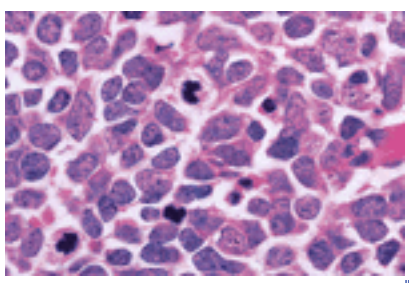

FIGURE 86-4 Cutaneous neuroendocrine carcinoma. Cytomorphologic details. Loosely cohesive monomorphic cells with frequently round nuclei and a narrow cytoplasm. Note the scattered pyknotic nuclei and mitotic figures (H&E).

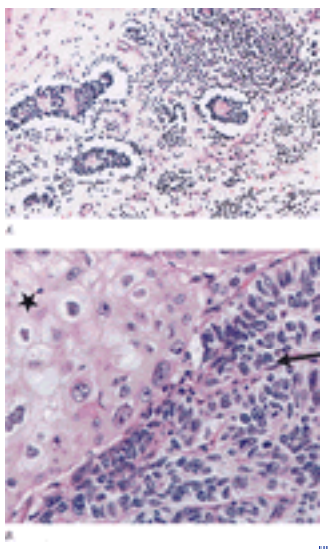

FIGURE 86-5 *A*. Cutaneous neuroendocrine carcinoma. Area of a tumor containing Homer-Wright neural rosettes with central fibrillary cores (H&E). *B*. Coexistence of cutaneous neuroendocrine carcinoma (*arrow*) and squamous-cell carcinoma (*star*) (H&E).

ULTRASTRUCTURAL FEATURES

Electron microscopy plays a key role in the recognition of cutaneous neuroendocrine carcinoma. [2], [6], [14] The tumor cells exhibit variable numbers of peripherally arranged, membrane-bound, dense-core neurosecretory granules (Fig. 86-6) measuring 80 to 150 nm in diameter. The neurosecretory granules are frequently concentrated in cytoplasmic processes. Further typical ultrastructural features are bundles in concentric configuration or bundles of 10-nm intermediate-sized filaments in juxtanuclear location (fibrous bodies). Intercellular junctions resembling primitive desmosomes or adherent-type junctions are occasionally present.

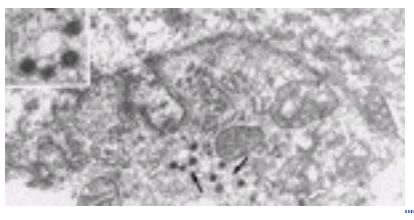

FIGURE 86-6 Electron micrograph of cutaneous neuroendocrine carcinoma. Cytoplasm of neoplastic cell displaying abundant organelles. The arrows denote neurosecretory granules. 38,000×. Inset: Higher magnification to better illustrate the dense-core neurosecretory granules.

IMMUNOHISTOLOGIC, BIOCHEMICAL, AND MOLECULAR FEATURES

Neuron-specific enolase is the most constant marker found in cutaneous neuroendocrine carcinoma. The tumor cells have epithelial and neural properties because coexpression of cytokeratin filaments (simple epithelial cytokeratins 8, 18, 19, and 20) and neurofilaments (neurofilament L- and M-polypeptides) can be observed [3], [4], [5] and [6] (Fig. 86-7). The characteristic staining pattern displays a ringlike appearance or paranuclear discoid, plaque- and ball-like profiles that correlate well with the electron microscopically detectable perinuclear accumulations of intermediate-sized filaments. Further evidence for epithelial differentiation of cutaneous neuroendocrine carcinomas is represented by positive reactions for epithelial membrane antigen and desmoplakin. Chromogranin A/B, synaptophysin, and peripherin, which are very important markers for the diagnosis of neuroendocrine tumors, are also present in cutaneous neuroendocrine carcinomas. [5] The tumors can contain several neuropeptides including calcitonin, bombesin, gastrin, met-enkephalin, substance P, ACTH, vasoactive intestinal polypeptide, neural cell adhesion molecule, and protein gene product 9.5. The expression of these substances is, however, inconstant. S-100 protein, glial fibrillary acidic protein, actin, and vimentin are usually not detectable in cutaneous neuroendocrine carcinomas. [12]

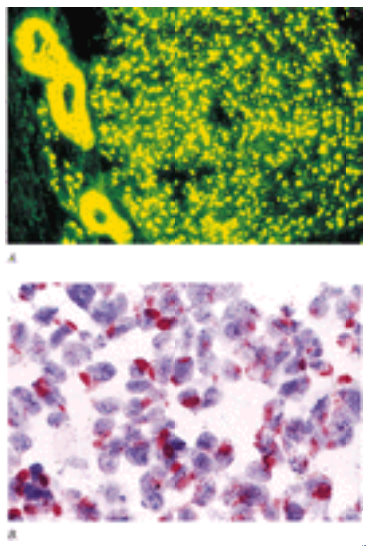

FIGURE 86-7 Immunohistologic features of cutaneous neuroendocrine carcinoma. *A*. Strong fluorescence of paranuclear cytokeratin accumulations in tumor cells. Note the positive reaction in epithelial structures (eccrine glands). Indirect immunofluorescence. *B*. Tumor cells staining with monoclonal antibodies against neurofilaments. Note the discoid

pattern. PAP-technique.

The bcl-2 protein, which may assume oncogenic function by blocking apoptosis, is expressed in cutaneous neuroendocrine tumors, whereas the p53 protein and the cell adhesion protein CD44 are only found in some cases. [15], [16], [17] and [18]

Cytogenetic analysis of neuroendocrine tumors revealed changes in chromosome 1 most frequently. Genes located on chromosomes 3, 6, 18, and 20 may also play an important role in the development of these tumors. [19]

The diagnosis of cutaneous neuroendocrine carcinoma can be made reliably by the immunohistologic demonstration of neuron-specific enolase, chromogranin A, and the characteristic paranuclear globular coexpression of the simple epithelial cytokeratins and neurofilament proteins.

DIFFERENTIAL DIAGNOSIS

Several primary and metastatic neoplasms should be considered in the differential diagnosis of cutaneous neuroendocrine carcinomas, namely, amelanotic malignant melanoma, malignant lymphoma (especially lymphoblastic type), neuroblastoma, Ewing's sarcoma, peripheral neuroepithelioma, adnexal neoplasms, lymphoepithelioma-like carcinoma of the skin, and skin metastases. Malignant melanoma is S-100- and HMB-45–positive, whereas malignant lymphomas react positively with common leukocyte antigen. Neuroblastomas are neurofilament- and neuron-specific enolase-positive, but, in contrast to cutaneous neuroendocrine carcinoma, they are keratin-negative. Adnexal neoplasms reveal keratin positivity and are neurofilament- and neuron-specific enolase-negative. Problems arise in the differential diagnosis of skin metastases from neuroendocrine tumors of internal origin, especially pulmonary neuroendocrine neoplasms. Cytokeratin 20 (Fig. 86-8) and thyroid transcription factor-1 are useful markers to distinguish between primary cutaneous neuroendocrine carcinoma and a metastatic pulmonary neuroendocrine tumor. [20] The characteristic paranuclear ring- or plaquelike neurofilament- and cytokeratin-staining pattern in cutaneous neuroendocrine carcinoma may provide an additional clue in the differential diagnosis.

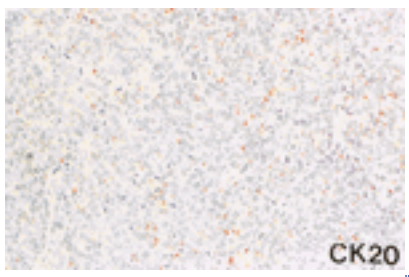

FIGURE 86-8 Cutaneous neuroendocrine carcinoma. Anticytokeratin 20 is a useful antibody to distinguish between cutaneous neuroendocrine carcinoma and metastatic small cell carcinoma of the lung in which CK 20 is usually absent. PAP-technique.

Integrin expression may help to distinguish cutaneous neuroendocrine carcinomas of the skin from primitive peripheral neuroectodermal tumors. [21]

HISTOGENESIS

The histogenesis of cutaneous neuroendocrine carcinomas remains unresolved. [4], [5] and [6], [12], [13] Merkel cells and cutaneous neuroendocrine carcinomas have similar ultrastructural features. Furthermore, Merkel cells and the cells of cutaneous neuroendocrine carcinomas both express neuron-specific enolase, low molecular weight cytokeratins, neurofilaments, and other markers.

On the other hand, cutaneous neuroendocrine carcinomas possibly may have no histogenetic relationship to Merkel cells, and the arguments for this assumption are that (1) most cases of cutaneous neuroendocrine carcinoma arise in the dermis and subcutaneous tissue without obvious epidermal involvement or contact with the outer root sheath of hair follicles where Merkel cells are normally located; (2) Merkel cells seem to predominate in the skin of palms, digits, and dorsa of the feet, a distribution that is completely different from that of cutaneous neuroendocrine carcinoma; and (3) proliferating Merkel cells are absent in normal skin.

Cutaneous neuroendocrine carcinomas may be of epithelial origin, having undergone neuroendocrine differentiation, or the neoplasms may be derived from pluripotent epidermal stem cells. [5], [12] Alternatively, cutaneous neuroendocrine carcinomas could also arise from or differentiate toward dermal neuroendocrine cells. There is some similarity between cutaneous neuroendocrine carcinomas and gastrointestinal carcinoids, which probably originate from subepithelial stromal cells that have migrated downward into the stroma from the epithelial layer. [4]

PROGNOSIS AND TREATMENT

Cutaneous neuroendocrine carcinomas are aggressive high-grade malignant tumors with local recurrences and metastases as common features. The overall survival rates are: 1 year, 88 percent; 2 years, 72 percent; and approximately 55 percent at 3 years. The 5-year survival rate varies between 64 and 30 percent. [8], [9] Depending on the length of follow-up, 40 percent of patients develop local recurrences following surgical excision. Recurrent tumor can be observed in the previous excisional scar and surrounding it in a satellite-like fashion. Regional nodal metastases are

found in 50 to 60 percent of patients, and distant metastases develop in 30 to 40 percent of patients. Sites for distant metastases are lungs, liver, bones, brain, deep lymph node groups (retroperitoneum), and other locations. Spontaneous regression of cutaneous neuroendocrine carcinoma has been rarely documented.

Management of cutaneous neuroendocrine carcinoma is based on a thorough clinical evaluation for evidence of distant metastases, careful palpation of regional lymph nodes, and a close, regular follow-up for evidence of recurrent tumor or regional lymphadenopathy. No standard treatment protocol for cutaneous neuroendocrine carcinoma exists. [22]

Different therapeutic regimens are appropriate according to the clinical presentation, and patients can be categorized into various stages of tumor spread (Table 86-1).

Stage I: Localized disease	Surgery Sentinel lymph node biopsy Radiotherapy
Stage II: Regional lymph node metastases	Surgery Radiotherapy Chemotherapy
Stage III: Disseminated disease	Chemotherapy Innovative: α-interferon, cytokines, Bcl-2 antisense oligonucleotides

TABLE 86-1 **Treatment of Cutaneous Neuroendocrine Carcinoma**

For primary treatment, wide local excision (1- to 2-cm margin) of the tumor and sentinel lymph node biopsy should be performed. [23] In addition, radiation therapy should be administered to the surgical bed and the draining lymph nodes. [24] Radiation therapy can be used prophylactically as well as for recurrent disease and nodal metastases. Chemotherapy has been used especially for patients with metastatic cutaneous neuroendocrine carcinoma. [22], [25] The combination of drugs that are active against small cell carcinoma of the lung is recommended. [25] Other treatment possibilities include local hyperthermia, hyperthermic limb perfusion chemotherapy, the somatostatin analogue octreotide, blood stem cell transplantation, cytokines, direct intralesional administration of recombinant human tumor necrosis factor, or perhaps, in the future, Bcl-2 antisense oligonucleodides. [8], [26], [27] and [28]

REFERENCES

1. Toker C: Trabecular carcinoma of the skin. *Arch Dermatol* **105**:107, 1972

2. Frigerio B et al: Merkel cell carcinoma of the skin: The structure and origin of normal Merkel cells. *Histopathology* **7**:229, 1983

3. Kerl H et al: New immunocytochemical observations in cutaneous neuroendocrine carcinoma (Merkel cell tumor). *J Invest Dermatol* **84**:541, 1984

4. Höfler H et al: The intermediate filament cytoskeleton of cutaneous neuroendocrine carcinoma (Merkel cell tumour). Immunohistochemical and biochemical analyses. *Virchows Arch* **406**:339, 1985

5. Walsh NMG: Primary neuroendocrine (Merkel cell) carcinoma of the skin: Morphologic diversity and implications thereof. *Hum Pathol* **32**:680, 2001

6. Gould VE et al: Neuroendocrine (Merkel) cells of the skin: Hyperplasias, dysplasias, and neoplasms. *Lab Invest* **52**:334, 1985

7. Ratner D et al: Merkel cell carcinoma. *J Am Acad Dermatol* **29**:143, 1993

8. Haag ML et al: Merkel cell carcinoma. Diagnosis and treatment. *Dermatol Surg* **21**:669, 1995

9. Tai PT et al: Merkel cell carcinoma of the skin. *J Cutan Med Surg* **4**:186, 2000

10. Penn I et al: Merkel's cell carcinoma in organ recipients: Report of 41 cases. *Transplantation* **68**:1717, 1999

11. An KP et al: Merkel cell carcinoma in the setting of HIV infection. *J Am Acad Dermatol* **45**:309, 2001

12. Moll I: Merkelzellkarzinom, in *Histopathologie der Haut,* edited by H Kerl, C Garbe, L Cerroni, HH Wolff. Berlin, Springer, 2002

13. Sibley RK et al: Primary neuroendocrine (Merkel cell?) carcinoma of the skin. *Am J Surg Pathol* **9**:95, 1985

14. Mount SL et al: Neuroendocrine carcinoma of the skin (Merkel cell carcinoma). An immunoelectron-microscopic case study. *Am J Dermatopathol* **16**:60, 1994

15. Moll I et al: Differences of bcl-2 protein expression between Merkel cells and Merkel cell carcinoma. *J Cutan Pathol* **23**:109, 1996

16. Penneys NS et al: CD44 expression in Merkel cell carcinoma may correlate with the risk of metastasis. *J Cutan Pathol* **21**:22, 1994

17. Van Gele M et al: Mutation analysis of P73 and TP53 in Merkel cell carcinoma. *Br J Cancer* **82**:823, 2000

18. Feinmesser M et al: Expression of the apoptosis-related oncogenes bcl-2, bax, and p53 in Merkel cell carcinoma: Can they predict treatment response and clinical outcome? *Hum Pathol* **30**:1367, 1999

19. Leonard JH et al: Deletion mapping on the short arm of chromosome 1 in Merkel cell carcinoma. *Cancer Detect Prev* **24**:620, 2000.

20. Leech SN et al: Merkel cell carcinoma can be distinguished from metastatic small cell carcinoma using antibodies to cytokeratin 20 and thyroid transcription factor 1. *J Clin Pathol* **54**:727, 2001

21. Perrin C et al: VLA and alpha $_6$beta $_4$ integrin expression in neuroendocrine carcinomas of the skin (their xenografts on nude mice and a corresponding primary culture). *J Cutan Pathol* **23**:223, 1996

22. Medina-Franco H et al: Multimodality treatment of Merkel cell carcinoma: Case series and literature review of 1024 cases. *Ann Surg Oncol* **8**:204, 2001

23. Rodrigues LK et al: Early experience with sentinel lymph node mapping for Merkel cell carcinoma. *J Am Acad Dermatol* **45**:303, 2001

24. Meeuwissen JA et al: The importance of postoperative radiation therapy in the treatment of Merkel cell carcinoma. *Int J Radiat Oncol Biol Phys* **31**:325, 1995

25. Voog E et al: Chemotherapy for patients with locally advanced or metastatic Merkel cell carcinoma. *Cancer* **85**:2589, 1999

26. Olieman AF et al: Hyperthermic isolated limb perfusion with tumor necrosis factor alpha, interferon gamma, and melphalan for locally advanced nonmelanoma skin tumors of the extremities: a multicenter study. *Arch Surg* **134**:303, 1999

27. Waldmann V et al: Transient complete remission of metastasized Merkel cell carcinoma by high-dose polychemotherapy and autologous peripheral blood stem cell transplantation. *Br J Dermatol* **143**:837, 2000

28. Schlagbauer-Wadl H et al: Bcl-2 antisense oligonucleotides (G3139) inhibit Merkel cell carcinoma growth in SCID mice. *J Invest Dermatol* **114**:725, 2000

T>

Chapter 87

S. Connolly

Mammary and Extramammary Paget's Disease

HISTORICAL ASPECTS
EPIDEMIOLOGY
ETIOLOGY AND PATHOGENESIS
CLINICAL MANIFESTATIONS
LABORATORY FINDINGS
PATHOLOGY
IMMUNOHISTOCHEMISTRY
DIAGNOSIS AND DIFFERENTIAL DIAGNOSIS
TREATMENT AND PROGNOSIS

REFERENCES

Mammary and extramammary Paget's disease are rare intraepidermal adenocarcinomas with similar clinical features that mimic inflammatory or infectious conditions. Whereas mammary Paget's disease is most often associated with an underlying carcinoma of the breast, extramammary Paget's disease is a heterogenous condition representing either an intraepidermal adenocarcinoma in situ with potential to become invasive, or pagetoid spread of an underlying adnexal tumor or of a regional internal malignancy.

HISTORICAL ASPECTS

In 1874, Sir James Paget described 15 women with a chronic eczematous eruption of the nipple and areola in whom carcinoma developed in the underlying mammary gland. Almost all cases of mammary Paget's disease (MPD) are associated with an underlying intraductal breast carcinoma. In 1889, Crocker described extramammary Paget's disease (EMPD), involving the penis and scrotum with histologic features similar to the cases defined by Paget. The origin of the tumor cells was thought to be from underlying adnexal structures. Although the clinical and histologic features of MPD are generally accepted and the frequent association with underlying breast carcinoma recognized, the source of the neoplastic cells in EMPD has been controversial.

EPIDEMIOLOGY

MPD accounts for 2 to 3 percent of neoplastic conditions affecting the breast and presents at the median age of 56 years, which is 5 to 10 years higher than the overall peak age of incidence of invasive breast carcinoma. [1], [2] The average duration of symptoms prior to diagnosis is 6.5 months but may be many years, which reflects an inappropriate delay in diagnosis. Males rarely develop MPD.

EMPD is rare and usually develops in the seventh decade. [3] There is a predilection for areas with a high density of apocrine glands, including the vulva, perianal region, male genitalia, and axillae. Vulvar involvement is most common, yet accounts for only 2 percent of all primary vulvar neoplasms. Occurrence in sites with modified apocrine glands, such as the eyelid and external auditory canal, and rare ectopic or mucosal cases have been noted. [3] Simultaneous anogenital and axillary involvement can occur, as can MPD and EMPD. [2], [3], [4] and [5]

ETIOLOGY AND PATHOGENESIS

The proportion of cases of MPD in which an associated in situ or invasive ductal breast carcinoma can be identified is high (82 to 92 percent) and supports the epidermotropic theory of origin. The in situ transformation theory was proposed to explain those cases in which there is no underlying mammary carcinoma or when there is cancer remote from the nipple–areola complex. The Paget's cells are purported to arise as malignant cells in the nipple epithelium independent from any other pathologic process. [3], [6]

Heregulin-a is a motility factor produced and released by normal nipple epidermal keratinocytes. Heregulin receptors are expressed by Paget's cells. Binding of heregulin-a to the receptor complex on Paget's cells was recently shown to result in chemotaxis of the breast cancer cells, which migrate into the overlying epithelium. [7] There may be other mechanisms. A “field” effect in the duct system harboring intraductal carcinoma and the adjacent epidermis may play a role in the tumor cell spread in the epidermis as well as in the ductal system. [8]

Whereas MPD is highly associated with an underlying breast carcinoma, approximately 25 percent of EMPD cases are associated with neoplastic disease in adnexal structures or in organs with a contiguous lining. The current theory is that EMPD arises as an intraepithelial neoplasm in most cases. [2], [9] The origin of the cell is either from intraepidermal cells of the apocrine gland ducts or from pluripotent keratinocyte stem cells. These cases are often referred to as “primary” EMPD. “Secondary” EMPD refers to cases in which there is epithelial spread from an underlying neoplasm either arising in the adnexal structures or from an organ with a contiguous epithelium. [2] Most vulvar EMPD is of the primary type, but endometrial, endocervical, and vaginal, as well as vulvar, urethral, and bladder carcinoma can be associated. [2], [9] EMPD of the male genitalia is thought to be more frequently associated with internal malignancy of the genitourinary tract. [10] Perianal EMPD is less common than the vulvar form of the disease. It is associated with colorectal or anal adenocarcinoma in 70 to 80 percent of cases and is more often thought to be secondary. Although there are rare reports of distant tumors arising without direct epithelial connection to the affected epidermis such as ovarian, renal cell, breast,

or hepatocellular carcinoma, there is no clear evidence that the Paget's cells arise from these.

CLINICAL MANIFESTATIONS

MPD presents as a unilateral, sharply demarcated, erythematous or scaly patch on the nipple or areola with variable extension to surrounding skin (Fig. 87-1). It can be exudative with vesicles occurring as an early manifestation; bleeding, ulceration, or nipple invagination reflecting adherence to underlying tumor tend to be late findings. Pruritus, pain, and tenderness are early and prominent symptoms in approximately 25 percent of cases. In 82 to 92 percent of cases, tumor cells have spread to the skin of the nipple and areola from an underlying invasive or ductal carcinoma in situ. [2] A palpable breast mass is noted in approximately 50 percent of cases of MPD. [6] Although the carcinoma is more often centrally located, it may be peripheral. It is said to be more commonly multifocal. [11], [12] If palpable, the carcinoma is more often invasive (90 to 94 percent) and axillary metastases are present in one-half to two-thirds of these. If it is not palpable, ductal carcinoma in situ is more likely.

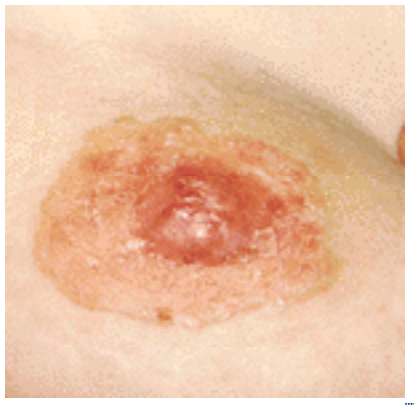

FIGURE 87-1 Paget's disease of the nipple. On the nipple and the areola mammae is a sharply demarcated erythematous area with scaling and an erosive moist surface. There is slight superficial induration.

Bilateral MPD with underlying intraductal carcinoma identified in one breast, development of MPD in a supernumerary nipple associated with an underlying intraductal carcinoma in the ectopic breast, MPD in a supernumerary nipple without associated carcinoma, and MPD developing after conservative management of breast cancer are among the unusual presentations of MPD.

EMPD also presents as moist superficially eroded or erythematous scaly patches. Gray-white eczematous patches are also a common presentation; hypopigmented macules, ulceration, crusting, or a palpable tumor may be present (Fig. 87-2). Pruritus is frequently present in EMPD; bleeding, oozing, tenderness, or a burning sensation can occur. Symptoms may be present for months to many years.

FIGURE 87-2 Perianal Paget's disease presenting as a moist superficially eroded patch. (*Courtesy of Robert Spencer, M.D.*)

LABORATORY FINDINGS

Evaluation of MPD or EMPD begins with cutaneous biopsy to establish the diagnosis. Mammography is indicated in all cases of MPD but may be normal. The incidence of abnormal radiographic findings varies from 24 to 97 percent. [1] Mammography does not discriminate between ductal carcinoma in situ and invasive disease; it is more likely to detect changes suggestive of malignancy if there is a palpable mass (97 percent) as compared to cases without a palpable mass (50 percent). The tumor may be a significant distance from the nipple and multifocal disease may not be appreciated radiographically. [6], [9], [11], [12] Occasionally, a lesion invisible on mammography may be identified by ultrasonography or by magnetic resonance imaging; ^{99m}Tc MIBI prone scintimammography may be useful. [6]

Because EMPD of the female and male genitalia or perianal skin may be associated with underlying neoplasms of the genitourinary or gastrointestinal tracts, a thorough general physical examination, along with laboratory and radiographic testing, with emphasis on the region adjacent to the site of EMPD, is indicated. Evaluation of the breasts is indicated

because of the rare association of EMPD and MPD. Examination of the axillae should not be overlooked because of the rare simultaneous occurrence of axillary and anogenital EMPD.

PATHOLOGY

MPD and EMPD are characterized by distinctive intraepithelial neoplastic proliferative cells with abundant pale-staining cytoplasm and large atypical nuclei apparent on routine hematoxylin and eosin histologic sections (Fig. 87-3). Mitoses are often present and Paget cells may be distributed singly or in clusters in the epithelium with variable extension into hair follicles and sweat gland ducts. Intercellular bridges are not appreciated on light microscopy. The epithelium is variably hyperkeratotic or hypokeratotic, acanthotic, or eroded and ulcerated. A dermal mixed inflammatory infiltrate is usually present.

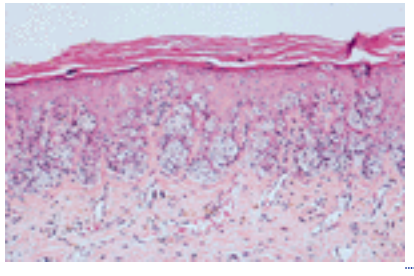

FIGURE 87-3 Neoplastic Paget's cells are randomly dispersed throughout the epidermis and readily appreciated on this hematoxylin and eosin section. Paget's cells have distinctive pale-staining cytoplasm when compared to surrounding keratinocytes.

In MPD, Paget's cells do not invade the dermis from the epidermis but can extend into the outer root sheath; underlying lactiferous ducts often show adenocarcinoma, which can invade the surrounding stroma. In primary EMPD, Paget's cells may be present in the outer root sheath but are also found in sebaceous, apocrine, or eccrine gland structures; they can form glandular and ductal structures in the epidermis and adnexal epithelium. Unless there is disruption of the basement membrane with extension of Paget's cells into the dermis, EMPD is in situ. In secondary EMPD, Paget's cells extend from an underlying adenocarcinoma arising in the adnexal structures or from a local organ with contiguous epithelium. Careful histologic examination is key and immunohistochemistry may assist in identification of secondary EMPD.

Sialomucin, a nonsulfated acid mucopolysaccharide, is found in the cytoplasm of Paget's cells. It stains with colloidal iron, Alcian blue at a pH of 2.5, and mucicarmine, PAS, and aldehyde fuchsin at a pH of 1.7. It is resistant to diastase and bovine testicular hyaluronidase. Mucin stains more frequently and more extensively in EMPD than in MPD, but mucin stains can be negative because of patchy distribution of mucin and skip areas.

IMMUNOHISTOCHEMISTRY

Immunohistochemistry is helpful in the diagnosis of Paget's disease and may clarify the cellular origin. [2] Certain markers may be helpful in determining whether an internal malignancy might be associated with EMPD. Immunohistochemistry has not permitted differentiation of intraepidermal in situ disease from that arising from an adnexal structure.

Cytokeratins are fibrous proteins present in almost all epithelia. Cytokeratin 7 is a sensitive marker for MPD and EMPD. [13] It is not specific; some mammary gland-related clear cells (Toker cells) and Merkel cells are stained. [14] It is an excellent marker for intraepithelial and invasive Paget's cells and distinguishes hyperplastic and malignant squamous cells. Cytokeratin 20, which is present in gastrointestinal and urothelial carcinoma, is found more frequently in EMPD from pagetoid spread of extracutaneous carcinoma than in primary EMPD; immunophenotypes other than cytokeratin 7+/cytokeratin 20- in Paget's cells suggest underlying regional internal malignancy. [15]

Gross cystic disease fluid protein-15 (GCDFP-15), a marker of apocrine epithelial cells is strongly expressed in vulvar and perianal Paget's disease without an underlying internal malignancy, and less frequently in those with a malignancy. [16], [17] and [18] Normal, metaplastic, and carcinomatous apocrine epithelium is stained and, hence, GCDFP-15 does not exclude a dermal apocrine tumor.

Most cases of EMPD stain strongly for carcinoembryonic antigen, whereas MPD is positive in approximately 35 percent of cases. S-100 may be expressed in 25 percent of MPD, and, rarely, in EMPD. It is best used along with HMB-45 to differentiate Paget's disease from malignant melanoma. MPD and EMPD are HMB-45 negative. [2]

The histologic differential diagnosis of Paget's cells includes those conditions characterized by spread of cells singly or in clusters throughout the epithelial layers. Thus, superficial spreading malignant melanoma, Bowen's disease, mycosis fungoides, Langerhans cell histiocytosis, pagetoid Spitz nevus, clear cell papulosis, Merkel cell carcinoma with pagetoid intraepidermal invasion, eccrine porocarcinoma, sebaceous carcinoma, clear cells of Toker, and pagetoid dyskeratoses are other considerations. [19]

DIAGNOSIS AND DIFFERENTIAL IAGNOSIS

The key to diagnosis of MPD or EMPD is a high index of suspicion and confirmation with skin biopsy. Any eczematous or thickened area in regions with a high density of apocrine glands that does not resolve promptly with what is deemed appropriate therapy must be considered as possible Paget's disease. The clinical differential diagnosis of MPD includes dermatitis, benign intraductal papilloma, frictional hyperkeratosis of the nipple, erosive adenomatosis, Hailey-Hailey

disease, and pemphigus. Fungal, viral, or bacterial infections are frequent misdiagnoses. Identification of MPD in individuals who have other active dermatoses, such as psoriasis, is difficult. Bowen's disease, basal cell carcinoma, metastatic carcinoma, malignant melanoma, mammary duct ectasia with chronic nipple discharge associated with eczematoid nipple-areola changes, hyperplasia of Toker cells, and leiomyomas of the nipple are other considerations that might arise. [4], [5] and [6]

The differential diagnosis in the anogenital area is similarly broad and includes candidiasis, dermatitis, psoriasis, seborrheic dermatitis, lichen sclerosus et atrophicus, lichen simplex chronicus, lichen planus, necrolytic migratory erythema, histiocytosis, erythroplasia of Queyrat, malignant melanoma, and periorificial tuberculosis. [3] Axillary EMPD may be mistaken for dermatitis, psoriasis, or candidiasis. Histochemical and immunohistochemical techniques have improved our ability to differentiate Paget's disease.

TREATMENT AND PROGNOSIS

Mastectomy has been the standard therapy for MPD. [6] In patients with a palpable mass there is a higher risk of axillary node metastasis as the mass is often invasive and mastectomy remains the standard. Pathologic findings of the mass and axillary staging direct therapy. [12] Patients with MPD with a palpable mass have a greater incidence of invasive carcinoma, multifocal lesions, and nodal metastases and worse survival. [11]

Controversy exists in cases in which disease is apparently confined to the nipple. Breast-conserving therapies currently considered include nipple excision alone, central segmentectomy alone, or radiation with or without resection. [2], [6], [20], [21] and [22] However, selecting patients with disease amenable to these approaches without mastectomy is difficult and can be associated with understaging and high rates of recurrence. [11]

Patients with MPD and no palpable mass have 5- and 10-year survival rates of 90 to 100 percent following mastectomy as compared to survival rates of 20 to 60 percent at 5 years and 9 to 40 percent at 10 years for those with palpable disease. [1] MPD in the male breast has a poor prognosis with a 20 to 30 percent 5-year survival rate. [23]

Primary EMPD is managed at any site by surgical excision. Other modalities that have been employed include radiation, electrodesiccation and curettage, cryosurgery, Mohs micrographic technique, topical 5-fluorouracil, photodynamic therapy (PDT), and CO_2 laser. Because this condition can often be multifocal and extend beyond the visible clinical margin, recurrence or residual disease are frequently seen. Long-term follow-up is required because of this and the associated risk of late progression to invasive disease. Recurrence rates for vulvar EMPD range from 15 percent with vulvectomy, 27 percent with the Mohs technique, and 43 percent with wide local excision; perianal disease recurs in 28 percent of patients after Mohs and in 50 percent of patients after wide local excision. [24]

Efforts to better define the extent of disease in EMPD have included preoperative topical 5-fluorouracil application to delineate extent of disease prior to Mohs micrographic surgery. Multiple punch biopsies prior to therapy to define margins have also been used. PDT has been used to guide margins of the involvement prior to destruction by CO_2 laser or as an adjunctive therapy for residual disease after radiation or wide local excision. [24], [25], [26] and [27] PDT has also been combined with the Mohs technique to minimize tissue loss and decrease risk of recurrence in EMPD. [24] The multimodal approach of PDT, Mohs technique, and cytokeratin 7 staining of Mohs sections holds the promise of lower recurrence rates. (O'Connor WJ, personal communication).

Prognosis for primary intraepithelial EMPD is excellent; patients require long-term follow-up because of the multifocal nature of the condition and high recurrence rate. In a large series of cases of vulvar EMPD, there was a 12 percent prevalence rate of invasive disease and a 4 percent prevalence rate of associated vulvar adenocarcinoma. [9] EMPD at any site has a worse prognosis in the presence of dermal invasion. Depth of invasion may be a prognostic factor but requires further confirmation. [17], [18], [27] If there is lymphatic invasion with lymph node metastases present, the prognosis is poor. [22] If EMPD is associated with an underlying regional internal malignancy, the prognosis and therapy are directed by the underlying carcinoma.

REFERENCES

1. Jamali FR et al: Paget's disease of the nipple-areola complex. *Surg Clin North Am* **76**:365, 1996

2. Lloyd J, Flanagan AM: Mammary and extramammary Paget's disease. *J Clin Pathol* **53**:742, 2000

3. Lupton GP, Graham JH: Mammary and extramammary Paget's disease, in *Cancer of the Skin*, edited by RJ Friedman DS Rigel, AW Kopf, MN Harris, D Baber. Philadelphia, WB Saunders, 1991, p 217

4. Heyman WR: Extramammary Paget's disease. *Clin Dermatol* **11**:83, 1993

5. Popiolek DA et al: Synchronous Paget's disease of the vulva and breast *Gynecol Oncol* **71**:17, 1998

6. Sakorafas GH et al: Paget's disease of the breast. *Cancer Treat Rev* **27**:9, 2001

7. Schelfout VRJ et al: Pathogenesis of Paget's disease: Epidermal heregulin-a, motility factor, and the HER receptor family. *J Natl Cancer Inst* **92**:622, 2000

8. Mai KT: Morphological evidence for field-effect as a mechanism for tumor spread in mammary Paget's disease. *Histopathol* **35**:567, 1999

9. Fanning J et al: Paget's disease of the vulva: Prevalence of associated vulvar adenocarcinoma, invasive Paget's disease, and recurrence after surgical excision. *Am J Obstet Gynecol* **180**:24, 1999

10. Allen SJR et al: Paget's disease of the scrotum: A case exhibiting positive prostate specific antigen staining and associated prostatic

adenocarcinoma. *Br J Dermatol* **4**:689, 1998

11. Yim JH et at: Underlying pathology in mammary Paget's disease. *Ann Surg Oncol* **4**:287, 1997

12. Kollmorgen DR et al: Paget's disease of the breast: A 33-year experience. *J Am Coll Surg* **187**:171, 1998

13. Smith KJ et al: Cytokeratin 7 staining in mammary and extramammary Paget's disease. *Mod Pathol* **10**:1069, 1997

14. Lundquist K et al: Intra-epidermal cytokeratin 7 expression is not restricted to Paget's cells but is also seen in Toker cells and Merkel cells. *Am J Surg Pathol* **23**:212, 1999

15. Ohnishi T, Watanabe S: The use of cytokeratins 7 and 20 in the diagnosis of primary and secondary extramammary Paget's disease. *Br J Dermatol* **142**:243, 2000

16. Kohler S, Smoller BR: Gross cystic disease fluid protein-15 reactivity in extramammary Paget's disease without associated internal malignancy. *Am J Dermatopathol* **18**:118, 1996

17. Goldblum JR, Hart WR: Vulvar Paget's disease: A clinicopathologic and immunohistochemical study of 19 cases. *Am J Surg Pathol* **21**:1178, 1997

18. Goldblum JR, Hart WR: Perianal Paget's disease—A histologic and immunohistochemical study of 11 cases with and without associated rectal carcinoma. *Am J Surg Pathol* **22**:170, 1998

19. Kohler S et al: The differential diagnosis of Pagetoid cells in the epidermis. *Mod Pathol* **11**:79, 1998

20. Bijker N et al: Breast-conserving therapy for Paget disease of the nipple: A prospective European Organization for Research and Treatment of cancer study of 61 patients. *Cancer* **91**:472, 2001

21. Pierce LJ et al: The conservative management of Paget's disease of the breast with radiotherapy. *Cancer* **80**:1065, 1997

22. DeVita VT Jr: Cancers of the skin, in *Cancer, Principles and Practice of Oncology* edited by VT DeVita, Jr, S Hellman, SA Rosenberg. New York, Lippincott Raven, 1997, p 1565

23. Desai DC et al: Paget's disease of the male breast. *Am Surgeon* **62**:1068, 1996

24. Zollo JD, Zeitouni NC: The Roswell Park Cancer Institute experience with extramammary Paget's disease. *Br J Dermatol* **142**:59, 2000

25. Becker-Wegerich PM et al: Carbon dioxide laser treatment of extramammary Paget's disease guided by photodynamic therapy. *Br J Dermatol* **138**:169, 1998

26. Henta T et al: Photodynamic therapy for inoperable vulval Paget's disease using delta-aminolevulinic acid: Successful management of a large skin lesion. *Br J Dermatol* **141**:347, 1999

27. Crawford D et al: Prognostic factors in Paget's disease of the vulva; a study of 21 cases. *Intl J Gynecol Pathol* **18**:351, 1999

T>

Chapter 88

Thomas Fitzpatrick Jean-Paul Ortonne

Normal Skin Color and General Considerations of Pigmentary Disorders

SKIN COLOR
Constitutive and Facultative Skin Color and Skin Phototype
Melanin Pigmentation and Ultraviolet Radiation
Eumelanin, Pheomelanin, and Neuromelanin
Hormonal Control of Melanin Pigmentation
Melanocytes and the Epidermal Melanin Unit
Melanin in Perspective
DIAGNOSIS OF MELANIN PIGMENTARY DISORDERS
Classification of Disorders of Melanin Pigmentation
Clinicopathologic Classification based on the Number of Melanocytes and/or the Amount of Melanin (see also Chap. 90)
Clinical History in Diagnosis of Melanin Pigmentary Disorders
Physical Examination in Diagnosis of Melanin Pigmentary Disorders
The Wood's Light in Diagnosis of Melanin Pigmentary Disorders
Histology and Transmission Electron Microscopy as Diagnostic Tools

REFERENCES

SKIN COLOR

The varieties of normal skin color in humans range from people of “no color” (pale white) to “people of color” (light brown, dark brown, and black). Skin color is a blend resulting from the skin chromophores *red* (oxyhemoglobin), *blue* (deoxygenated hemoglobin), *yellow-orange* (carotene, an exogenous pigment), and *brown* (melanin). Melanin, however, is the major component of skin color (Fig. 88-1); it is the presence or absence of melanin in melanosomes in melanocytes and melanin in keratinocytes that is responsible for *epidermal* pigmentation, and the presence of melanin in macrophages or melanocytes in the dermis (Fig. 88-2) that is responsible for *dermal* pigmentation. A scholarly treatise on skin has been published that [1] integrates the various aspects of skin color from an historical standpoint.



FIGURE 88-1 Components of normal skin color include red (oxyhemoglobin), blue (deoxyhemoglobin), brown (melanin), and yellow (carotene).



FIGURE 88-2 Expressions of abnormalities of melanin pigmentation: white (hypopigmentation); brown (epidermal hyperpigmentation); and blue (dermal pigmentation).

Melanocytes are the sole site of melanin formation; they are specialized dendritic cells present in normal skin only in the hair matrix and at the epidermal-dermal junction (see Chap. 11). All melanocytes are derived from the neural crest (melanoblasts), with the single exception of melanocytes in the retinal pigment epithelium (RPE); these do not migrate

from the neural crest but arise from the outer layer of the optic cup. Melanocytes are normally found in humans in the skin (hair matrix and at the dermal-epidermal junction), in all the mucous membranes, the uveal tract, the RPE, and in the stria vascularis of the inner ear. In certain peoples, such as Asians, American Indians, African Americans, and some Caucasians, melanocytes are normally present at birth in the dermis, usually located in the lumbosacral areas in the so-called Mongolian spot (see Chap. 90). Melanocytes in the epidermis are not equally distributed throughout the skin, but there are essentially equal numbers of melanocytes in skin of various colors (Fig. 88-3).

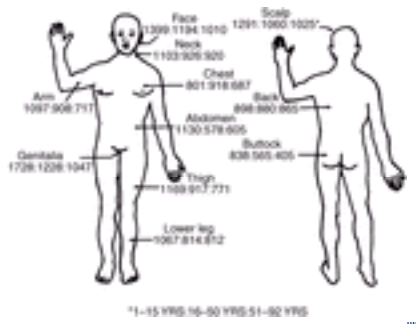

FIGURE 88-3 Comparison of average number of melanocytes in the epidermal skin of various body surfaces in three age groups (per mm ^{2}).

Constitutive and Facultative Skin Color and Skin Phototype

Two types of normal melanin pigmentation form the basis for normal skin color. *Constitutive* skin color (also called basic skin color) is the genetically determined color (light brown, medium brown, and dark brown) or absence of color (white) in skin unexposed to solar irradiation; this is found in habitually sun-shielded areas such as the buttocks and inner upper arms. *Facultative* skin color is the skin color that results from an increase in the intensity of skin color as a result of ultraviolet radiation (UVR) exposure and reflects the genetically predetermined capacity of the skin to darken in response to UVR (Fig. 88-4). “White” people are dissimilar in their capacity to tan. This is the basic premise of the system of *skin phototypes* (Table 88-1). The phenotype (hair and eye color) is not a reliable guide to *sunburn sensitivity* because the “white” population is a mix of various skin phototypes: although persons with white skin with freckling and red hair have a limited or no capacity to tan, this failure to tan can also be present in persons who have brown eyes and dark hair. Because of the unreliability of the phenotype, a system of *skin phototypes* (SPT) was developed, in 1975, [2], [3] to provide a basis for estimating the dose of UVA in the use of psoralen photochemotherapy.

FIGURE 88-4 Impact of sun exposure on skin color; tanned Egyptian male reflects considerable sun exposure (facultative color), while Egyptian woman who remains indoors remains pale (constitutive color).

SPT	Reaction To Moderate* Sun Exposure	Skin Color
	MELANOCOMPROMISED	
I	Burn and no tan	Pale white
II	Burn and minimal tan	Pale white
III	Burn then tan well	White
	MELANOCOMPETENT	
IV	Tan, no burn	Light brown
V	Tan, no burn	Brown
VI	Tan, no burn	Dark brown

*Dose estimates assume brief sun exposure, i.e., without sunscreens, at peak season (spring or summer) depending on the latitude.

TABLE 88-1 **Classification of Skin Phototypes (SPT)**

The term “fair” skin is frequently used by epidemiologists to describe white skin. This can be very misleading because, in fact, persons with SPTs I, II, and II are regarded together as “fair” and have virtually the same degree of “whiteness,” yet this term would include three very different SPTs, each with a different capacity to tan; a “fair” skin person with SPT III can become very tanned, while “fair” persons with SPT I cannot tan at all, even after multiple exposures, and persons with SPT II can tan only minimally. This is truly a spectrum of skin pigment. At one end of the spectrum are persons with oculocutaneous albinism and SPTs I and II who have limited tanning potential who are, in fact, melanocompromised. At the other end of the spectrum are persons who are melanocompetent (SPT IV) who have a full tanning potential without sunburn (Table 88-1).

Skin phototyping can used to counsel these persons about risk of sun exposure; skin phototypes I, II, and III are at risk for developing photodamage of all types: dermatoheliosis (wrinkling, solar lentigo, actinic keratosis), nonmelanoma skin cancer, and cutaneous malignant melanoma. For example, the *p-16 Leiden* (Holland) carriers in the familial atypical mole malignant melanoma (FAMMM) with skin phototype I run the highest risk of developing melanoma.

The degree of tanning response is genetically determined and is the logical basis for the division of normal skin into SPTs. Once UVR exposure is discontinued, the facultative color spontaneously recedes to constitutive levels until further

melanogenic influences are introduced. Although the degree of facultative skin color is genetically determined, endocrine changes that occur in pregnancy and in Addison's disease may also result in facultative pigmentation. Thus, the fluctuation in skin color is a combined result of genetics, UV irradiation, and hormonal influences; disorders of melanin pigmentation must always be considered against this background.

The extent of genetic control of facultative skin color change is unknown. However, the degree of facultative color change is not directly related to constitutive skin color because the constitutive skin colors for SPTs I to III are quite similar and there is considerable variability in the intensity of the tanning response that can be induced in white persons. This variation in response can be graded by personal history.

The additive interaction of three or four genic pairs is probably adequate to account for the variation in skin color between the very fair-skinned individual and the very dark. These few interacting loci may be responsible for the variation in constitutive skin color over the globe.

Besides the polygenic series responsible for constitutive skin color, there are other genes that, as in albinism, act individually partly or completely to dilute melanin pigmentation. There appear to be two basic genetic influences: (1) those responsible for the phenotype of melanoblasts programmed to undergo differentiation, and (2) those responsible for the capability of melanoblasts to survive and to differentiate in embryonic life. The genetic influences in humans may well be as complex as those in mice, in which more than 100 genes at about 62 loci influence skin and hair color (see also Chap. 11). If one envisions a scheme in which an increasing number of genes are operative in the process of melanoblast migration and differentiation with the final controlling genes expressed in specific cutaneous zones (dermatomes), one may view the numerous melanin disorders as expressions of different genic defects operative at various levels; many such chromosomal defects have been identified (e.g., albinism, piebaldism, and Waardenburg's syndrome; see Chap. 89 and Chap. 90).

Melanin Pigmentation and Ultraviolet Radiation

Ultraviolet radiation (UVR) is, at the same time, a powerful stimulus to melanin pigmentation and a destructive agent on the melanocytes. UVR can stimulate skin melanocytes to increase epidermal melanin content, which then functions as a very effective density photoprotective filter of UVR. In contrast, mutations caused by UVR (principally UVB) result in disfiguring changes related to pigmentation (actinic leukoderma, solar lentigo) and induce fatal malignancies (malignant melanoma in white persons). Visible melanin pigmentation in human skin is directly related to the number of, melanization of, transfer of, and degradation of the metabolic unit and specific organelle of melanocytes, the melanosome (see Chap. 11). The production, size, degree of melanization, and transfer to keratinocytes of melanosomes are all under genetic control. UVR (both UVB and UVA) elicits a response in direct relation to the tanning potential of the epidermal melanin unit (the melanocyte and its cluster of keratinocytes.)

In cultured melanocytes from different skin phototypes, melanin content is five times higher in SPTs IV to VI than in SPTs I to III, and the melanocytes maintain their phenotype according to their original skin phototype. [4] After UVB irradiation a stronger induction of endonuclease sensitive sites was found for melanocytes with a lower level of total melanin and a high content of pheomelanin. By measuring the clone-forming ability in different melanocyte cultures after UVB irradiation, significant better survival was found in case of the cells with the higher melanin content. [4]

Visibly equivalent UVB and UVA tans are not equally protective; the UVA tan is much less protective. This is because while UVA increases melanin pigmentation, it is virtually limited to the basal cell layer; UVB results in melanin that is distributed throughout the epidermis. A UVA tan is photoprotective, however, against vascular damage and inflammation. UVA tanning but not UVB tanning is prevented by vascular occlusion, presumably because it is oxygen dependent. Most interesting is the observation that the action spectra for delayed tanning and erythema differ on the basis the SPT. In SPTs I and II, the action spectra for erythema and tanning are the same, while in SPTs III and IV, the action spectra separate in the longer UV-wave range (UVA) and it is therefore possible using UVA to develop tanning without burning. [5]

Eumelanin, Pheomelanin, and Neuromelanin (See also Chap. 11)

Melanocytes produce two chemically distinct types of melanin pigments: *eumelanin* and *pheomelanin*. These pigments can be quantitatively analyzed by acidic permanganate oxidation or by reductive hydrolysis with hydriodic acid to form pyrrole-2,3,5-tricarboxylic acid or aminohydroxyphenylalanine, respectively. About 30 coat color genes in mice have been cloned, and functions of many of those genes have been elucidated. However, little is known about the interacting functions of these loci.

Three types of melanin in humans have been demonstrated. *Eumelanin* (brown-black melanin) is found in ellipsoidal melanosomes, which impart brown-black color to skin, eye, and hair. *Pheomelanin* (yellow-red melanin), found in spherical melanosomes, is the basis for yellow-red hair and has also recently been found in basal layer melanocytes. *Neuromelanin* is the black pigment formed within nerve cells (e.g., the substantia nigra) that is formed by an enzymatic pathway different from that responsible for eumelanin or pheomelanin synthesis; therefore, in albinism, the pigment in the substantia nigra is unchanged. The concept of mixed melanins (eumelanin and pheomelanin) arises from evidence that melanins cannot be easily characterized as purely eumelanin or purely pheomelanin. For example, small amounts of pheomelanin are probably present in most melanocytes; red hair, however, may only contain pheomelanin.

The melanocortin-1 receptor (MC1R), a seven-pass transmembrane G protein coupled receptor, is a control site in melanogenesis and skin pigmentation. It has been ascertained that variants of the *MC1R* gene are common in individuals with red hair and fair skin. Loss-of-function mutations in *MC1R* result in a switch from eumelanin to pheomelanin production. The shade of red hair frequently differs in heterozygotes from that in homozygotes/compound heterozygotes, and there is also evidence for a heterozygote effect on beard hair color, SPT, and freckling. There appears to be evidence for a dosage effect of *MC1R* variants on hair as well as skin color. [6] This area of research is expanding rapidly and recently it was shown that *MC1R* has a clear heterozygote effect on SPT, with up to 30 percent containing

loss-of-function mutations. [7]

Hormonal Control of Melanin Pigmentation

Tsatmali et al. [8] have summarized the role of hormones in melanin pigmentation. They state that melanin pigmentation of the skin is regulated by locally produced MSH-a rather than that of pituitary origin. MSH-a acts as a paracrine and/or autocrine mediator of UV-induced pigmentation. However, the predominant MSH-a in human skin is desacetyl MSH-a and, compared to the acetylated form, is a relatively weak agonist at the human MC1R. By acting as a partial agonist desacetyl MSH-a may even oppose the actions of acetylated MSH-a and other MC1R agonists. The most abundant MC1R agonist in human epidermis is adrenocorticotropic hormone (ACTH)1-17. This proopiomelanocortin (POMC) peptide, which is produced by keratinocytes, is more potent than acetylated MSH-a in stimulating melanogenesis in human melanocytes and, in contrast to the latter, produces a biphasic dose-response curve. This is probably a consequence of its activation of both the CAMP and inositol 1,4,5-triphosphate (IP_3)/diacylglycerol (DAG) signaling pathways. MSH-a peptides, on the other hand, selectively activate the CAMP pathway. Compared with MSH-a, ACTH1-17 could have a more important role as a paracrine mediator of melanogenesis and other melanocytic processes. However, ACTH1-17 is not the only POMC peptide in the skin and may interact with related peptides at the MC1R. These interactions are likely to represent important determinants of melanocyte function and skin pigmentation. For example, Bastiaens et al. [9] have reported that nearly all individuals with ephelides (freckles) are carriers of at least one *MC1R* gene variant and suggest that *MC1R* gene variants are necessary to develop ephelides.

Melanocytes and the Epidermal Melanin Unit

Melanin pigment is synthesized in specialized cytoplasmic organelles called *melanosomes,* which contain the principal pigment-synthesizing enzyme *tyrosinase* (see Chap. 11). It is the presence of melanized melanosomes within the keratinocytes that imparts skin color. The number, melanin content, and location of these melanosomes determine the various hues of human skin and hair color. Melanosomes are synthesized in melanocytes, transferred to keratinocytes, and transported to the epidermal surface. Melanin formation cannot occur in melanosomes that have been transferred to keratinocytes.

The *epidermal melanin unit* (Fig. 88-5) is the functional unit responsible for the orderly process of melanin synthesis. This multicellular unit is composed of a melanocyte and an associated cluster of about 36 keratinocytes and is the focal point for the control of melanin metabolism within the mammalian epidermis. When melanosomes are confined to the melanocytes at the epidermal-dermal junction and the melanosomes are not transferred to keratinocytes, a dilution of the normal skin color results (hypomelanosis secondary to “transfer block” as in postinflammatory hypomelanosis).

FIGURE 88-5 Epidermal melanin unit. This multicellular unit is composed of a melanocyte and a cluster of approximately 36 keratinocytes to which melanosomes are transferred. In melanocompetent individuals, there is a higher density of melanosomes, which are distributed as single large organelles (*A*), whereas in melanocompromised skin, melanosomes are smaller, occur as multiples in membrane-limited vesicles (melanosome complexes), and undergo gradual degradation (*B*).

Melanin in Perspective

Melanin is not biodegradable, similar to plastic polymers, and it is surprising that the world is not covered with melanin! Nature in its economy must have regarded melanin as an important polymer, most probably because of its role in protection of the skin and the eye, from damaging radiant energy, especially ultraviolet. Certainly the earliest hominids did not have a use for melanin in photoprotection as their skin was white and the protection against radiant energy was provided by dark pigmented hair. As the hair was lost early in the evolution of *Homo sapiens*, the naked white skin developed a melanized epidermis as a shield against damaging UVR. Quevedo et al. summarized the evolution of melanin pigmentation and the role of climate and sunlight. [10] It was suggested that melanin pigmentation was related to human fitness, acting in natural selection during evolution. Before man used clothing, pigment protected the skin against solar radiation in a particular environment. The variations in skin color can be regarded as adaptive and related to the level of ultraviolet. As hominids moved outside of the tropics, melanin depigmentation decreased to permit synthesis of previtamin D_3. [11] There is a strong correlation between absolute latitude and UV radiation levels.

Melanized epidermis acts as a shield for vulnerable cells of the epidermis and dermis, reducing the penetration of UVB and UVA radiation into the skin. There is an inverse relationship between melanin density of the skin and sun-induced skin damage: skin cancer and dermatoheliosis (photoaging). Melanin absorbs UVR, acts as a biologic electron exchange polymer, quenching free radicals that are generated by UVR, and preventing the inactivation of superoxide dismutase. [12] The protective role of melanin against skin cancer is the basis of the marked reduction in photoaging and skin cancer (basal cell carcinoma, squamous cell carcinoma, and malignant melanoma) in populations with high levels of constitutive melanin pigmentation such as SPTs IV, V, and VI. We call these *melanocompetent* in contrast to light SPTs I, II, and III that we call *melanocompromised*. Not only is there a higher melanin density in the melanocompetent but the melanosomes remain as single large organelles while in melanocompromised skin the melanosomes are smaller, occurring in membrane-limited vesicles and undergo gradual degradation into small, electron-dense particles (see Fig.

88-5); this aggregation in keratinocytes is related to the size of the melanosomes; small melanosomes are aggregated and large melanosomes that occur in heavily melanized skin are nonaggregated, and thus provide a better shield against penetration of ultraviolet. [13] Norlund et al. [14] recently produced a summary of the pigmentary system.

DIAGNOSIS OF MELANIN PIGMENTARY DISORDERS

Classification of Disorders of Melanin Pigmentation

There are three categories of melanin pigmentary disturbances: (1) hypomelanosis (*leukoderma,* white or lighter than the individual's normal color); [14] (2) brown hypermelanosis (*melanoderma*); and (3) gray, slate, or blue hypermelanosis (*ceruloderma*). Figure 88-6 provides a visual example of these and gives selected examples in certain general categories, based on the number of melanocytes and/or the amount of melanin.

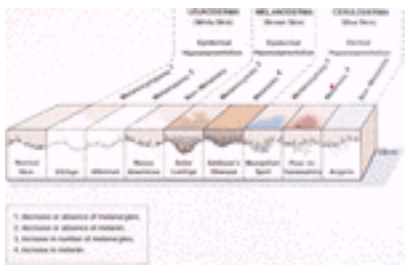

FIGURE 88-6 Clinicopathologic classification of pigmentary disorders.

Clinicopathologic Classification based on the Number of Melanocytes and/or the Amount of Melanin (see also Chap. 90)

Hypomelanoses or leukodermas may be subdivided based on the increase, reduction, or absence of melanocytes and/or melanin. Vitiligo is an example of a *melanocytopenic* disorder in which melanocytes are absent. This stands in contrast to albinism, which is one of the *melanopenic* disorders, in which a normal number of melanocytes is present but the melanin content of melanosomes is reduced. Nonmelanotic disorders are those pigmentary aberrations in which melanin pigmentation is unaffected but rather the pigmentary abnormality is caused by a chromophore other than melanin (minocycline, chlorpromazine). Disorders of hyperpigmentation may be called *melanotic* when the number of melanocytes is normal but the amount of melanin is increased (e.g., Addison's disease, melasma), or *melanocytotic* when the number of melanocytes is increased (oculodermal melanocytosis nevus of Ota). The intent of this classification is to categorize the pigmentary disorders according to an increase or decrease of melanin or of melanocytes.

Diseases with alterations in melanin pigmentation are not as common as the most frequent skin disorders (e.g., acne, psoriasis, eczema, verrucae), so that physicians are generally less familiar with pigmentary disorders. Furthermore, many pigmentary disorders are difficult to identify, as the diagnosis requires specialized knowledge and the use of special techniques. In parts of the world where the majority of the indigenous population has brown or black skin, pigmentation disorders (especially vitiligo, melasma, and postinflammatory hyperpigmentation) are a major reason for seeking a dermatologic consultation.

Establishing the correct diagnosis requires a good history, a detailed physical examination, the use of special lighting techniques, and sometimes a biopsy of the abnormally pigmented skin as well as of the normally pigmented skin.

Clinical History in Diagnosis of Melanin Pigmentary Disorders

Variations in normal skin color often confound the recognition of melanin disorders; diffuse brown hypermelanosis in SPTs II or III may be fairer than diffuse hypopigmentation of SPTs V or VI (see Chap. 90). The intensity of coloration in the normal skin of a white person originating ethnically from one of the Mediterranean countries may be no different from that in abnormally pigmented skin of an Anglo-Saxon with Addison's disease. There are two clues, however, that suggest abnormal diffuse brown hypermelanosis: (1) change in the intensity of skin color and (2) the appearance, for the first time, of pigmentation in sites that are normally pigmented in some persons with dark brown or black skin, such as the axillae, the palmar creases, and, especially, the mucous membranes (buccal mucosa and gums). In addition, the patient may observe that his or her summer tan has not faded over the winter so that persons who see the patient only from time to time may observe that the skin has darkened abnormally. The determination of normal pigmentation involves consideration of many factors. This requires knowledge of the patient's basic or constitutive skin color. A certain degree of pigmentary dilution obvious in the darker-skinned white persons may not identifiable in the light-skinned white persons such as the Celtic people (Scotland, Ireland, Wales, Cornwall, French Briton). Proper assessment depends upon history and physical examination, often aided by established and newer auxiliary investigational techniques.

History of onset and evolution of the pigmentary change are also important. Are the lesions congenital, as in piebaldism or nevus depigmentosus, or are they acquired, as in vitiligo or hypomelanosis of Ito? Not all congenital pigmentary disorders, particularly hypomelanoses, are obvious at birth. In a fair-skinned child not exposed to sunlight in the first year or years of life, hypopigmented lesions, which are, in fact, congenital, may be thought to be acquired, inasmuch as a white infant born in the late fall may not become tanned for at least a year. For example, the white macules in tuberous sclerosis may not be apparent until the skin is tanned after sun exposure, providing contrast between normal tanned skin and the hypomelanotic macule.

Physical Examination in Diagnosis of Melanin Pigmentary Disorders (See Chap. 90)

In examination of the skin for hypo- or hyperpigmented macules, it is helpful to view the patient in a slightly darkened room in order to accentuate the contrast. Furthermore, it is important that the examiner take the few moments required to become dark adapted.

Distribution of lesions may be useful; vitiligo and piebaldism have typical distribution patterns. Furthermore, segmental or dermatomal distribution of hypomelanosis suggests segmental vitiligo, nevus depigmentosus, or, rarely, tuberous sclerosis. The *size* of lesions may be useful, as very small or confetti macules, for example, may occur with chemical leukoderma, tuberous sclerosis, tinea versicolor, vitiligo, or idiopathic guttate hypomelanosis. The presence of sharp, discrete margins in vitiligo macules distinguishes vitiligo from pityriasis alba and postinflammatory hypermelanosis. *Scales* on white lesions, although minimal in pityriasis alba and in tinea versicolor, may be a clue to the disease. History of an antecedent or concomitant eruption may suggest a postinflammatory hyper- or hypomelanosis. The presence of other cutaneous abnormalities, such as a shagreen patch and adenoma sebaceum in a patient with the typical lance-ovate hypomelanotic macules of tuberous sclerosis, may provide additional clues. In patients from areas with endemic leprosy, including the southern United States, all hypomelanotic macules should be tested for hypesthesia.

Diagnosis of more diffuse and widespread, ill-defined melanin disorders may be particularly difficult. The patient with Addison's disease may be unaware of the pigment darkening, especially of axillae, palmar creases, may only complain that their summer tan did not fade.

The Wood's Light in Diagnosis of Melanin Pigmentary Disorders

The use of the Wood's lamp facilitates diagnosis of epidermal pigmentary disorders because it helps to define the extent and level (dermal or epidermal) of the pigmentary change (Fig. 88-7). Hypomelanoses appear whiter; epidermal hypermelanoses become accentuated, but dermal melanoses (which in visible light can be brown, gray, or blue) are not enhanced and, in fact, may become less apparent. Furthermore, Wood's lamp examination facilitates distinction of melanocytopenic disorders that are amelanotic (such as vitiligo or piebaldism) from melanopenic macules that are off-white to tan, as found in tuberous sclerosis, pityriasis alba, or postinflammatory hypomelanosis. To use the Wood's light in assessing hypermelanoses, it is useful to *first* grade the hyperpigmentation in visible light, and then to estimate the grade of pigmentary change under the Wood's lamp. A café au lait macule or ephelide will be graded 2 in visible light but will increase to grade 3 under the Wood's lamp (Fig. 88-7); by contrast, a Mongolian spot will be grade 2 in visible light and will remain grade 2 or less with the Wood's lamp (Fig. 88-8). The use of infrared film makes it possible to detect whether the pigmentation is dermal. An important caveat is that this technique is not useful in persons with brown skin because of optical factors that vitiate dermal melanin. Because this technique requires the use of a camera and special equipment, it is not as practical as the Wood's lamp.

FIGURE 88-7 *A*. Photograph taken with conventional lighting. *B*. Accentuation of epidermal changes (freckling in this case) under examination with a Wood's lamp.

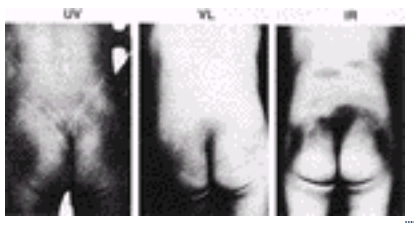

FIGURE 88-8 Infrared (IR) photography for dermal pigmentation. With dermal melanoses, there is no accentuation with UV light as compared to room or visible (VL) light; however, accentuation is apparent with special IR photography.

Histology and Transmission Electron Microscopy as Diagnostic Tools (See Table 88-2)

TABLE 88-2 **Investigation of Melanin Pigmentary Disorders**

Histologic study provides several levels of information. Standard hematoxylin and eosin (H&E) preparations may confirm the presence or absence of melanocytes; it is also possible to assess the amount of pigment that has been transferred to the keratinocytes and thereby to identify the “transfer-block” hypomelanoses. Split-dopa preparations are used to count the number of melanocytes. The dopa histochemical test also provides information about the number, size, and dendritic quality of identifiable melanocytes. Study of abnormalities of the melanin pathway is facilitated with the electron microscope. Some melanin disturbances have typical if not characteristic electron microscopic features. For example, melanin pigmentary disorders may result from or be associated with (1) decreased or absent melanocytes (vitiligo), (2) abnormal formation or melanization of melanosomes (as in albinism), or (3) failure of transfer of melanosomes from melanocytes to keratinocytes (eczematous dermatitis).

REFERENCES

1. Holubar K, Schmidt C: *Sun and Skin.* Vienna, Verlag der Osterreichischen Ärztekammer, 1994, p 47

2. Fitzpatrick TB: Soleil et peau. *J Med Esthet* **2**:33, 1975

3. Pathak MA, Fitzpatrick TB: Preventative treatment of sunburn, dermatoheliosis and skin cancer with sun-protective agents, in *Dermatology in General Medicine,* 4th ed, edited by TB Fitzpatrick, AZ Eisen, K Wolff, IM Freedberg, KF Austen. New York, McGraw Hill, 1993, p 1689

4. De Leeuw SM, et al: Melanin content of cultured human melanocytes and UV-induced cytotoxicity. *J Photochem Photobiol B* **61**:106, 2001

5. Parrish JA et al: Erythema and melanogenesis action spectrum of normal human skin. *Photochem Photobiol* **36**:187, 1982

6. Flanagan N et al: Pleiotropic effects of the melanocortin 1 receptor (MC1R) gene on human pigmentation. *Hum Mol Genet* **9**:2531, 2000

7. Rees JL: The melanocortin 1 receptor (MC1R): More than just red hair. *Pig Cell Res* **13**:135, 2000

8. Tsatmali M et al: Skin POMC peptides: Their actions at the human MC-1 receptor and roles in the tanning response. *Pig Cell Res* **13:**125, 2000

9. Bastiaens M et al: The melanocortin-1-receptor gene is the major freckle gene *J Hum Mol Genet,* **10:**1701, 2001

10. Quevedo et al: Role of light in human skin color variation. *Am J Phys Anthropol* **43:**393, 1975

11. Jablonski NG, Chaplin G: The evolution of human coloration. *J Hum Evol* **39:**57, 2000

12. Pathak MA: Functions of melanin and photoprotection by melanin in melanin: Its role in human photoprotection, in *Melanin Its Role in Human Photoprotection,* edited by L Zeise, MR Chedekel, TB Fitzpatrick. Overland Park, KS, Valdenmar Publishing, 1995, p 125

13. Wolff K et al: Experimental pigment donation in vivo. *J Ultrastruct Res* **47**:400, 1974

14. Nordlund JJ et al: *The Pigmentary System*. New York, Oxford University Press, 1998, p 1025

T>

Chapter 89

Philippe Bahadoran Jean-Paul Ortonne Richard King William Oetting

Albinism

OCULOCUTANEOUS ALBINISM
Classification of Albinism
Inheritance of OCA
Prevalence of OCA
Oculocutaneous Albinism Type 1
Oculocutaneous Albinism Type 2
Oculocutaneous Albinism Type 3
Oculocutaneous Albinism Type 4
Autosomal Dominant OCA
TYPES OF OCA IN WHICH THE PRIMARY DEFECT IS NOT LIMITED TO THE MELANOCYTE
Hermansky-Pudlak Syndrome
Chediak-Higashi Syndrome
OCULAR ALBINISM
OA1: X-Linked Recessive OA
Molecular Pathogenesis of OA1
DIAGNOSIS OF ALBINISM
MANAGEMENT OF ALBINISM

REFERENCES

Albinism refers to genetic abnormalities of melanin synthesis associated with a normal number and structure of melanocytes. [1], [2] Reduced melanin synthesis in the melanocytes of the skin, hair, and eyes is termed *oculocutaneous albinism* (OCA), and hypopigmentation primarily involving the retinal pigment epithelium of the eyes is termed *ocular albinism* (OA). [1] The precise definition of albinism includes specific changes in the development and function of the eyes and the optic nerves, and the ocular changes are necessary to make the diagnosis. [3] Changes in the auditory system are also found in the brain in albinism, but they produce no hearing loss. [4] A generalized reduction in skin pigment without ocular changes should be referred to as *cutaneous hypopigmentation* rather than albinism or cutaneous albinism.

The characteristic changes in the development and function of the eyes and optic nerves, common to all types of OCA and OA, include nystagmus, [3] reduced melanin in the retinal pigment epithelium associated with foveal hypoplasia, reduced visual acuity, and misrouting of the optic nerves at the chiasm [3], [5] (Table 89-1). These ocular changes are present only in individuals with albinism with one exception. In X-linked OA, 80 to 90 percent of obligate female heterozygotes without skin changes do have observable changes in ocular pigment that are related to X-chromosome inactivation. [6]

Reduction in iris pigment
Reduction in retinal pigment
Foveal hypoplasia
Misrouting of the optic fibers at the chiasm
Nystagmus
Alternating strabismus

TABLE 89-1 **Ocular System Changes in Albinism**

OCULOCUTANEOUS ALBINISM

Classification of Albinism

Classification of OCA should be based on the genetic locus involved. Indeed, there is a range of phenotypes of OCA associated with mutations at each of the responsible loci. On the other hand, mutations at different loci can result in closely related, if not similar, phenotypes. This classification will be used in this chapter and is summarized in Table 89-2 and Table 89-3.

Type	Subtype	Clinical Phenotype
OCA1	OCA1A	Tyrosinase-negative OCA
	OCA1B	Minimal pigment OCA
		Platinum OCA
		Yellow OCA
		Temperature-sensitive OCA
		Autosomal recessive OA (some)
OCA2		Tyrosinase-positive OCA
		Brown OCA (most cases)
		Autosomal recessive OA (some)
		Prader-Willi's and Angelman's syndromes
OCA3		Rufous/red OCA
		Brown OCA (one case)
OCA4		
HPS	HPS1	Hermansky-Pudlak syndrome
	HPS2	
	HPS3	
	HPS4	
CHS		Chediak-Higashi syndrome
OA1		X-linked OA, Nettleship-Falls type

Abbreviations: OCA, oculocutaneous albinism; OA, ocular albinism.

TABLE 89-2 **Classification of Albinism: Clinical Phenotypes**

TABLE 89-3 **Classification of Albinism: Genetic Loci**

Inheritance of OCA

All types of OCA characterized to date are autosomal recessive in inheritance. There are no phenotypic changes with obligate heterozygotes except as noted earlier. Rare families with OCA having dominant inheritance have been described. X-linked OA is produced by mutations of a gene on the short arm of the X chromosome.

Prevalence of OCA

Oculocutaneous albinism is the most common inherited disorder of generalized hypopigmentation, with an estimated frequency of 1:20,000 in most populations. [1] Four different types of OCA have been described up to now. OCA1 and OCA2 are the most frequent types and account for approximately 40 and 50 percent, respectively, of OCA worldwide. OCA3 and OCA4 are far less frequent.

Oculocutaneous Albinism Type 1

Oculocutaneous albinism type 1 (OCA1; MIM 203100), one of the two most common types of albinism, is produced by loss of function of the melanocytic enzyme tyrosinase resulting from mutations of the *TYR* gene. Classic OCA, with a total absence of melanin in the skin, hair, and eyes, is the most obvious type of OCA1, but the spectrum of OCA1 is broad and includes the development of moderate to nearly normal amounts of cutaneous melanin over time (Fig. 89-1). Null mutations are associated with a total loss of function and no pigment formation (OCA1A), whereas “leaky” mutations result in an enzyme that retains some function and is associated with some pigment formation (OCA1B). Most individuals affected with a type of OCA1 have white hair, milky white skin, and blue eyes at birth, and this helps distinguish this type from other OCA types.



FIGURE 89-1 Pigment spectrum in OCA1 related to tyrosinase gene mutations that are associated with different amounts of residual enzyme function.

OCA1 PHENOTYPES (See Table 89-2)

OCA1A In OCA1A, or the classic tyrosinase-negative OCA, there is a complete inability to synthesize melanin in skin, hair, and eyes, resulting in the characteristic “albino” phenotype. Affected individuals are born with white hair and skin and blue eyes, and there are no changes as they mature. [2] The phenotype is the same in all ethnic groups and at all ages (Fig. 89-2). The hair may develop a slight yellow tint due to denaturing of the hair protein related to sun exposure and/or shampoo use. The irides are translucent, appear pink early in life, and often turn a gray-blue color with time. No pigmented lesions develop in the skin, although amelanotic nevi can be present. The architecture of skin and hair bulb melanocytes is normal. The melanosomes show a normal surrounding membrane and normal internal matrix ormation (stage 1 and II premelanosomes) (see Chap. 11).

FIGURE 89-2 OCA1A with no hair or skin pigment, demonstrating iris translucency.

OCA1B The OCA1B phenotype is produced by mutations that result in an enzyme that retains some function. The variation in the phenotype of OCA1B can be from minimal hair pigment to near-normal skin and hair pigment. [5] Mutations coding for enzyme with differing amounts of residual activity are the primary cause of this variation, and a moderate amount of residual activity can lead to near-normal cutaneous pigmentation and the mistaken diagnosis of OA. The original OCA1B phenotype was called “yellow albinism” because the affected individuals had this hair color. The hair color is the result of pheomelanin synthesis. OCA1B includes several previously described OCA types, including minimal-pigment OCA, [7] platinum OCA, [2] temperature-sensitive OCA, [8] and autosomal recessive ocular albinism (AROA). Most individuals with OCA1B have very little or no pigment at birth and develop varying amounts of melanin in the hair and skin in the first or second decade of life (see Fig. 89-1 and Fig. 89-3). In some cases the melanin develops within the first year. The hair color changes to light yellow, light blond, or golden blond first and eventually can turn dark blond or brown in adolescents and adults. The irides can develop light-tan or brown pigment, sometimes limited to the inner third of the iris, and iris pigment can be present on globe transillumination. Some degree of iris translucency, as demonstrated by slit-lamp examination, is usually present. Many individuals with OCA1B will tan with sun exposure, although it is more common to burn without tanning. Pigmented lesions (nevi, freckles, lentigines) develop in the skin of individuals who

have developed pigmented hair and skin.

FIGURE 89-3 OCA1B with golden blond scalp hair and tan.

One of the more interesting variations of OCA1B is the temperature-sensitive phenotype. [8] Scalp hair color is white at birth and remains white or slightly yellow. Axillary hair remains white, whereas arm and leg hair pigments. The skin remains white and does not tan. Analysis of tyrosinase from scalp and leg hair bulbs of the originally described proband showed that the enzyme was temperature-sensitive, losing activity above 35°C. [8] As a result, melanin synthesis occurred in the cooler but not the warmer areas of the body, such as the arms and legs, in a pattern similar to the Siamese cat and the Himalayan mouse.

MOLECULAR PATHOGENESIS OF OCA1 (See Table 89-3) Analyses of DNA from individuals with OCA1A have shown a large number of different mutations in the *TYR* gene. These mutations include missense, nonsense, frameshift, splice site, and deletion mutations. [5], [9], [10] Most individuals with OCA1 are compound heterozygotes with different mutant maternal and paternal alleles. Missense mutations in the *TYR* gene are distributed into four clusters of the coding region, suggesting functional domains of the encoded protein. Two of the clusters are in the copper-binding regions, a third cluster is 3' of the copper B–binding region, and a fourth cluster is near the amino-terminus of the protein. Missense mutations in the copper-binding regions would be expected to cause hypopigmentation through impairment or loss of enzymatic activity of tyrosinase. [9], [10] Frameshift mutations have been identified in OCA1, and analysis of the flanking sequences shows that these mutations tend to occur in repetitive sequences, as in other mammalian genes. The identified frameshift mutations lead to a premature stop codon, and the abnormal protein would be expected to have reduced stability, altered processing, or loss of enzyme function. [9], [10] Recently it was shown that different types of mutant tyrosinase, including deletion mutants that destroy catalytic function, and missense mutants that have a temperature-sensitive phenotype, were retained and degradated in the endoplasmic reticulum compartment. This suggests that regardless of the type of mutation, most *TYR* gene mutants may not be transported properly to melanosomes. [11], [12] and [13] Considering the large variety of *TYR* gene mutations observed in OCA1, more work is required to assess the relative, contribution of the aforementioned mechanisms, e.g., loss of enzymatic activity or lack of transport to melanosomes, in the genesis of hypopigmentation in OCA1.

Oculocutaneous Albinism Type 2

Individuals with albinism who have pigmented hair and eyes have long been identified, particularly in the African and African American populations, and have been described with a variety of terms such as *partial albinism, incomplete albinism,* or *imperfect albinism*. [14] The identification of mutations of the *P* gene in humans has now provided a molecular basis of this type of albinism, which is called *oculocutaneous albinism type 2* (OCA2; MIM 203200). [15], [16] From the standpoint of melanin synthesis, the defect in OCA2 appears to involve a reduction in eumelanin synthesis primarily, with less effect on pheomelanin synthesis. [17] OCA2 is the most common type of OCA in the world primarily because of its high frequency in equatorial Africa. [18], [19] OCA2 has been described in most populations.

OCA2 PHENOTYPES (See also Table 89-2) In Caucasian individuals, the amount of hair pigment present at birth or developing with time varies from minimal in northern Europeans (particularly Scandinavians) to moderate in southern European or Mediterranean individuals. The hair can be very lightly pigmented at birth, having a light yellow or blond color, or more pigmented with a definite blond, golden blond, or even red color. Furthermore, the normal delayed maturation of the pigment system and sparse hair early in life in many normally pigmented northern European individuals (i.e., very blond children who develop dark blond or brown hair with maturation) can make the distinction between OCA1 and OCA2 difficult in the first few months of life. Many such persons would not be recognized as having albinism if the visual changes were absent. The skin is creamy white and does not tan. The iris color is blue-gray or lighted pigmented, and the amount of translucency correlates with the development of iris pigment. With time, pigmented nevi and lentigines may develop, and pigmented freckles are seen in areas with repeated sun exposure. The hair in Caucasian individuals may slowly turn darker through the first two or more decades of life. In African and African American individuals, there is a distinct OCA2 phenotype [14], [18] (Fig. 89-4). Hair is yellow at birth and remains so throughout life, although the color may turn darker. Hair color can turn lighter in older individuals, and this probably represents the normal graying with age. The skin is creamy white at birth and changes little with time. No generalized skin pigment is present, and no tan develops with sun exposure, but pigmented nevi, lentigines, and freckles often develop. The irides are blue-gray or lightly pigmented. This phenotype may be related to the existence of a single common deletion mutation of the *P* gene in Africans and African Americans with OCA2. [14], [18], [19] The development of lentigines or ephelides, well-demarcated pigmented patches usually on sun-exposed areas of the skin, may be evidence of a separate genetic susceptibility because these lesions only develop in some OCA2 families and not in others. The presence of ephelides is associated with a lower risk of skin cancer in South African individuals.

FIGURE 89-4 OCA2 with yellow hair, white skin, and freckles in an African individual (classic tyrosinase-positive OCA phenotype).

BROWN OCA Brown OCA has been described in the African and African American populations in which the amount of eumelanin in the skin and hair is reduced but not absent. [20] Recent studies have shown that brown OCA is associated with heterozygosity for *P* gene alleles, one of which is null and the other having partial function. [19], [21] In African and African American individuals with the brown OCA phenotype, the hair and skin color are light brown and the irides are gray to tan at birth [19], [21] (Fig. 89-5). With time, there is little change is skin color, but the hair may turn darker, and the irides may accumulate more tan pigment. The skin generally does not burn but may darken with sun exposure. Affected individuals are recognized as having albinism rather than a variation in normal pigmentation because of the ocular changes present. The iris has punctate and radial translucency, and moderate retinal pigment is present. Visual acuity ranges from 20/60 to 20/150. The brown OCA phenotype has not been described in Caucasian individuals and is most likely part of the OCA2 phenotypic range that is being recognized.

FIGURE 89-5 OCA2 with brown hair and skin in an African individual (brown OCA phenotype).

PRADER-WILLI'S AND ANGELMAN'S SYNDROMES While it is clear that the *P* gene is not involved directly in these syndromes, Prader-Willi's and Angelman's syndromes often are associated with hypopigmentation, and this appears to be related to OCA2 and the *P* gene, at least to a certain extent.

Prader-Willi's Syndrome Prader-Willi's syndrome is a developmental syndrome that includes neonatal hypotonia, hyperphagia and obesity, hypogonadism, small hands and feet, and mental retardation associated with characteristic behavior. Approximately 70 percent of individuals with Prader-Willi's syndrome have an interstitial deletion on the long arm of the paternal chromosome 15, and most of those without a deletion of the paternal chromosome 15 have uniparental disomy for the maternal chromosome. Many individuals with Prader-Willi's syndrome are hypopigmented but do not have the typical ocular features of albinism [23]; however, individuals with Prader-Willi's syndrome can have typical features of OCA. [24], [25] For those without OCA, the hypopigmentation is characterized by having hair and skin that are lighter than unaffected family members. Childhood nystagmus and strabismus are common but often do not persist into adult life. The irides are pigmented with some translucency on globe transillumination, and retinal pigment is reduced in amount. Foveal hypoplasia usually is not present, but the fovea may not appear entirely normal. [26] Visual evoked potential studies have revealed optic tract misrouting similar to that found in albinism in some individuals with Prader-Willi's syndrome and hypopigmentation, [26] but this is not a universal finding. Some individuals with Prader-Willi's syndrome have typical OCA2 with cutaneous hypopigmentation and all ocular features of albinism. [15], [24]

Angelman's Syndrome Angelman's syndrome is a complex developmental disorder with developmental delay and severe mental retardation, microcephaly, neonatal hypotonia, ataxic movements, and inappropriate laughter. Approximately 70 percent of individuals with Angelman's syndrome have an interstitial deletion of the long arm of the maternal chromosome 15. Many without a deletion have uniparental disomy for the paternal chromosome 15. In Angelman's syndrome, the hypopigmentation is characterized by light skin and hair. [22] Nystagmus or strabismus may be present early in life, and iris translucency and reduced retinal pigment may be present. No analysis of optic nerve formation is available. As in Prader-Willi's syndrome, individuals with Angelman's syndrome who have typical OCA2 features have been described. [19]

MOLECULAR PATHOGENESIS OF OCA2 (See also Table 89-3) Mutations of the *P* gene, which maps to chromosome 15q, are responsible for OCA2. [16], [19], [25] Mutations of mouse pink-eyed dilution (*p*) gene, the murine homologue of the human *P* gene, result in hypopigmentation of the coat and the eyes, and many alleles have been identified at this locus. As expected, a number of mutations of the human *P* gene are associated with human OCA2. [15], [19], [24], [27] In sub-Saharan Africa, a single 2.7-kb deletion allele accounts for 60 to 90 percent of mutant *P* alleles and is associated with a common haplotype, suggesting a common founder. It has been estimated that this single mutation is associated with 25 to 50 percent of all mutant *P* alleles in African Americans. However, other diverse mutant alleles have been described in this population and in Africans. In an American group with African heritage, the Brandywine, Maryland isolate, 1 in 85 individuals has OCA2 and is homozygous for the 2.7-kb deletion allele of the *P* gene. Thus it is likely that this 2.7-kb deletion allele accounts for the distinct OCA2 phenotype in Africans and African Americans. [19] OCA2 also has been reported at high frequencies in specific Native American groups. Individuals within this population presumably have mutations in the *P* gene. However, it cannot be excluded that mutations in another gene lead to a similar phenotype in individuals and groups for which no molecular data are yet available. Many diverse mutations in the *P* gene have been reported in individuals with OCA2 from diverse ethnic backgrounds. The missense mutations described to date in the *P* gene do not seem to cluster in any specific region, as observed for tyrosinase. [19] A model system in which to test for *P* allele function has been described. The assay for this system is complementation of the hypopigmentation of *P* mutant melanocytes by the expression of a transfected copy of the human *P* gene. A normal *P* gene restores pigmentation,

whereas the expression of a transfected copy of an OCA2 allele does not. [28] There has been considerable progress in the last few years in understanding of the *P* gene product function. It was suggested, based on the observation that melanocytes from mice lacking expression of the p protein pigmented in the presence of high concentrations of tyrosine, that the p protein may play a role in tyrosine transport. However, it has been demonstrated clearly that tyrosine transport is normal in *P* mutant melanocytes. These data, though apparently conflicting, are consistent with the possibility that the p protein mediates conditions favorable for tyrosinase activity. Recently it has been shown that melanosomes from p protein–deficient melanocytes have an abnormal pH. Melanosomes in cultured melanocytes derived from wild-type mice are typically acidic, whereas melanosomes from p protein–deficient mice are nonacidic. In light of these observations, it is likely that the p protein regulates the acidic pH of melanosomes. Whether or not acidic conditions directly enhance tyrosinase activity in mammalian melanosomes in vivo is still an open question. An alternate possibility is that the acidic conditions mediated by the p protein favor the normal biogenesis of melanosomes, including the correct targeting of other melanosomal proteins such as tyrosinase. [19] The mechanism for the hypopigmentation in Prader-Willi's and Angelman's syndromes has not been fully explained. Most patients who are hemizygous for the *P* gene in the context of a large deletion of 15q are hypopigmented regardless of their remaining *P* gene allele. [19], [20] These observations are difficult to resolve with the recessive nature of both human *P* and mouse *p* mutations. Thus hypopigmentation in hemizygous Prader-Willi's or Angelman's syndrome may reflect the presence of other genetic determinants of pigmentation in the chromosome 15 region of the *P* gene rather than an altered maternal *P* allele. Further analysis of this phenomenon will be easier now that the function of the gene product of the *P* locus is being determined. Patients with Prader-Willi's syndrome or Angelman's syndrome truly associated with OCA2 have been found to have a typical deletion of one homologue of the *P* gene in the context of Prader-Willi's syndrome or Angelman's syndrome and inheritance of a mutation on the another homologue, making them compound heterozygotes for *P* gene mutations, which result in their albinism. [19]

AUTOSOMAL RECESSIVE OCULAR ALBINISM Families in which male and female children of normally pigmented parents had the ocular features of albinism but did not appear to have significant cutaneous hypopigmentation were identified as having AROA. It now appears that the designation AROA is not correct. The affected individuals may have nearly normal cutaneous pigmentation, but their albinism is associated with mutations of the *tyrosinase* or *P* genes and actually represents part of the spectrum of OCA1B and OCA2 (see Table 89-2).

Oculocutaneous Albinism Type 3

The human phenotypic variations associated with genetic alterations of the *TYRP1* gene, which encodes tyrosinase-related protein 1, have been identified. Individuals with oculocutaneous albinism type 3 (OCA3; MIM 203290) present with minimal pigment reduction in the skin, hair, and eyes. This form of albinism was referred to previously as rufous and possibly some forms of brown albinism. The function of Tyrp1 in the human melanocyte is not well characterized yet.

OCA3 PHENOTYPES (See also Table 89-2) An African-American newborn twin boy with a mutation of the *TYRP1* gene had light brown skin, light brown hair, and blue/gray irides, whereas his fraternal twin brother had normal pigmentation. [30] The affected twin also had nystagmus, and the clinical presentation of this patient was felt to be consistent with brown OCA. Melanocyte cultures from the patient had only 7 percent of the amount of insoluble melanin as a result of compromised tyrosinase activity. [30] This family was lost to follow-up, so the ultimate phenotype of the affected child was unknown. Meanwhile, it has been shown that brown-African OCA is a subtype of OCA2. Thus the aforementioned patient represents the brown OCA phenotype classified under OCA3. Mutations of the *TYRP1* gene also were found in a substantial number of individuals with rufous OCA in the South African population. [31], [32] The rufous OCA phenotype in South African individuals includes red or reddish brown skin, ginger or reddish hair, and hazel or brown irides. [33] The ocular changes are not always present, and many do not have iris translucency, nystagmus, strabismus, or foveal hypoplasia. Furthermore, no misrouting of the optic nerves has been demonstrated by a visual evoked potential, suggesting either that this is not a true type of albinism, as strictly defined in this chapter, or that the hypopigmentation is not sufficient to consistently alter optic nerve development. [33] Hair bulb and skin melanocytes show eumelanosomes and pheomelanosomes in various stages of melanization. This is consistent with the red color coming from pheomelanin synthesis, since pheomelanosomes are absent in normally pigmented black skin and hair bulbs. [33] The described phenotype in New Guinea includes reddish brown skin, deep mahogany hair, reddish brown to brown irides with some translucency, and normal retinal pigment and foveal development. [34] Congenital nystagmus is present in this population but does not segregate specifically with the red phenotype. The phenotype for *TYRP1*-related OCA in the Caucasian and the Asian populations is unknown.

MOLECULAR PATHOGENESIS OF OCA3 (See also Table 89-3) The *TYRP1* gene was mapped to chromosome 9p. The first *TYRP1* gene mutation, identified both in the twin boy described as having brown OCA and in South African individuals with rufous OCA, was a single-base deletion at codon 368 (1104delA) producing a frameshift and a premature stop codon in exon 6 and a slightly truncated TYRP1 molecule. The second *TYRP1* mutation, identified in the rufous OCA population, was a single-base substitution at codon 166 (S166X) resulting in the alteration of a serine to a premature stop codon in exon 3 and a truncated Tyrp1 molecule. Two additional nonpathologic mutations also were identified. [30], [31] and [32] In the African population, the *TYRP1* and *P* gene mutations appear to be responsible, respectively, for the rufous and brown OCA phenotypes. [19], [21], [30], [31] and [32] This suggests that the African American individual first described with the 1104delA *TYRP1* gene mutation [30] actually has rufous rather than brown OCA. Alternatively, the phenotypic similarity between *P* mutant and *TYRP1* mutant brown OCA may result from modification by genetic background and/or mixed ancestry between the two types. A more comprehensive analysis to identify polymorphisms of the human *TYRP1* gene was performed to determine the role of variation in *TYRP1* sequences and resulting variation in amino acids to changes in pigmentary phenotype. However, evaluation of 100 Caucasian individuals of varying hair color did not result in identification of amino acid variations in the *TYRP1* gene. [32] The pathogenesis of OCA3 is poorly understood because the normal role of Tyrp1 in human melanocytes is still unclear. It is now generally accepted that in the murine system, the Tyrp1 protein functions as DHICA oxidase. However, this enzymatic activity should be interpreted cautiously because in a recent study it has not been observed for human Tyrp1 protein. Besides, it has been demonstrated that human tyrosinase itself, in contrast to mouse tyrosinase, has DHICA oxidase activity. Therefore, though logical, the role of human Tyrp1 as a DHICA oxidase cannot be stated unequivocally. Tyrosinase,

Tyrp1, and Dct are type 1 membrane-bound melanosomal glycoproteins with similar structural features. All three are believed to interact with one another in melanosomes to form a melanogenic protein complex; it was shown that Tyrp1 has an important function of stabilizing tyrosinase in melanosomes. Very recently it was demonstrated that Tyrp1 and tyrosinase also form a complex in the endoplasmic reticulum and that a mutation in each of them results in the retention and degradation of both in the endoplasmic reticulum and markedly slows down their transport to melanosomes. This suggests that abnormal trafficking of wild-type tyrosinase elicited by mutant Tyrp1 could be an important etiologic factor of OCA3. [31], [35]

Oculocutaneous Albinism Type 4

Oculocutaneous albinism type 4 (OCA4; MIM 606574) is a new clinical form of oculocutaneous albinism that has been described very recently in a patient of Turkish descent presenting with generalized hypopigmentation and ocular abnormalities within the phenotypic range commonly associated with OCA2. No mutations were detected in the *P* gene alleles, but a splice-acceptor-site mutation was found in exon 2 of a gene called *MATP* (membrane-associated transporter protein) located on chromosome 5p. 100 The murine orthologue of the *MATP* gene is the *uw* (underwhite) gene. [36], [37] *uw/uw* mice have a light-beige outer fur, very white underfur, and pink eyes at birth, which darken with age. [38] The severity of hypopigmentation among *uw* alleles is correlated with melanosomal size, shape, melanin content, and maturity. [36] Mutations in the fish orthologue of mouse and human *MATP* genes have been detected in the medaka fish, [39] which has a generalized hypopigmentation.

The human, murine, and fish *MATP* genes share several common features. The encoded proteins are predicted to span the membrane 12 times. They contain a conserved sucrose transporter signature sequence, suggesting an important functional role for this motif. In addition, melanosome anomalies have been observed in the medaka fish and in the *uw* mouse. These data indicate that Matp plays a critical role in vertebrate pigmentation and suggest that Matp may be a component of the melanosomal membrane, presumably mediating the transport of a molecule required for melanogenesis or for another melanosome function. [36] /SUP>, [37], [38] and [39]

Autosomal Dominant OCA

Several families have been described with autosomal dominant expression of OCA or cutaneous hypopigmentation, but characterization is incomplete, and most do not meet the strict criteria for albinism. [40] The characterization of dominant OCA must await the careful evaluation of families with a clear autosomal dominant expression of OCA.

TYPES OF OCA IN WHICH THE PRIMARY DEFECT IS NOT LIMITED TO THE MELANOCYTE

The two disorders included in this section, the Hermansky-Pudlak syndrome (HPS; MIM 203300) or, more correctly, syndromes and the Chediak-Higashi syndrome (CHS; MIM 214500), are now considered hallmark disorders of the biogenesis of lysosome-related organelles/secretory lysosomes (LROs/SOs). LROs/SOs, a newly recognized type of intracellular vesicle, play an important role in different cell types, Melanosomes in melanocytes and dense bodies in platelets are typical examples of LROs/SOs. [41], [42] This concept is fully consistent with the multiple clinical manifestations of HPS and CHS. It also explains the locus heterogeneity of HPS because many different gene products are required for LRO/SO biogenesis. Consequently, these diseases and their causative genes have become of immense interest to researchers in cellular biology.

Hermansky-Pudlak Syndrome (See also Table 89-2)

HPS is a complex disorder that presents with OCA, a bleeding diathesis, and a ceroid lipofuscin–like lysosomal storage in a variety of tissues. [43], [44] HPS is autosomal recessive in inheritance. Although HPS reflects a process that affects not only melanocytes but also platelets and other tissues, the pigmentry disorder is similar to the primary OCA types described earlier, and ocular features of HPS are the same as those found with other types of OCA. HPS is rare in most populations, except in the Caribbean island of Puerto Rico, particularly in the northwestern region, where the majority of patients are found with an incidence of 1:1800. HPS is not found on other Caribbean islands but is frequent in one long-isolated mountain village in the Swiss Valais. [43], [44]

HPS PHENOTYPES The clinical manifestations of HPS are colored by the ethnic background of affected patients, as well as by the causative locus. HPS is a pigmenting type of OCA in that cutaneous and ocular pigments develop in many affected individuals, and the amount of pigment that forms is quite variable. [43], [44], [45] and [46] (Fig. 89-6).

FIGURE 89-6 Hermansky-Pudlak syndrome in Puerto Rican individual.

In Puerto Rico, affected individuals have hair color that varies from white to yellow to brown. [43], [44], [45], [46] and [47] Skin color is creamy white and definitely lighter than in normally pigmented individuals in this population. Albinism in HPS is associated with quantitatively reduced and qualitatively abnormal melanosomes in skin and hair melanocytes. [43], [44], [45], [46] and [47] Freckles can be present in the sun-exposed regions, often

coalescing into large areas that look like normal dark skin pigment, but tanning does not occur. Pigmented nevi are common. Iris color varies from blue to brown, and all the ocular features of albinism are present. [47] Typically, HPS patients are legally blind, with a visual acuity of 20/200 or worse, but occasionally, a patient has an acuity as high as 20/50. [47] The presence of OCA may not be obvious in a Puerto Rican individual with brown hair, skin pigment in exposed areas, and brown eyes unless the cutaneous pigmentation is compared with that of unaffected family members, who generally are darker in pigment, and unless the ocular features of albinism are recognized. Affected individuals have been identified in other populations, and the phenotype shows the same degree of variation in pigmentation as is found in Puerto Ricans. Hair color varies from white to brown, and this correlates somewhat with the ethnic group. The skin is white and does not tan. Eye color varies from blue to pigmented. The bleeding diathesis in HPS usually produces mild hemorrhagic episodes. The first sign in HPS patients usually consists of excess bruising beginning at the time of ambulation Episodes of epistaxis are frequent but offen remit during adolescence. Other events that result in excess bleeding include dental extractions, surgeries, acute colitis, menstrual periods, and child birth. Fatalities due to bleeding are rare. [47] The cause of bleeding is absence of platelet dense granules, making the disease a platelet storage pool deficiency. Dense granules are intracellular LROs/SOs that contain ADP, ATP, serotonin, calcium and polyphosphates and disgorge their contents on stimulation. Released components, ADP in particular, cause aggregation of surrounding platelets, contributing to clot formation. HPS patients have a normal or increased platelet count but an attenuated secondary aggregation response. The bleeding time is often but not always prolonged. Absence of dense bodies, which confirms the diagnosis of HPS, is demonstrable by wet-mount electron microscopy. The most severe clinical manifestations of HPS are related to the pulmonary and intestinal changes. Interstitial pulmonary fibrosis has been described in many individuals with HPS; in particular, patients with HPS1 disease (see below) are at increased risk for developing pulmonary fibrosis. The etiology of the fibrosis is unknown. [47] Approximately 15 percent of HPS patients, whether Puerto Rican or non–Puerto Rican, suffer from granulomatous colitis. [47] The distal colon is involved most often by this complication, and the colitis of HPS resembles Crohn's disease. The etiology of the colitis is unknown. [43], [44], [47] HPS is associated with accumulation of ceroid lipofuscin–like materials in the lysosomes of many cell types, suggesting lysosomal dysfunction. [43], [44] Average survival of HPS patients is 30 to 50 years, with death usually resulting from restrictive lung disease or, less frequently, hemorrhage or colitis.

MOLECULAR PATHOGENESIS OF HPS (See also Table 89-3) HPS can be caused by mutations in any one of four genes *HPS1, HPS2, AP3B1, or HPS4.* This reflects, in part, the situation in mice, where at least 15 different genes cause hypopigmentation and platelet storage pool deficiency. Consequently, the identification of additional genes in HPS patients is possible. [43], [44], [45] and [46]

Hermansky-Pudlak syndrome type 1 (HPS1; MIM 604982) The *HPS1* gene (chromosome 10q23) is the first identified HPS gene [43], [44] and a major cause of HPS in Puerto Rican patients. The *HPS1* gene codes for a 79.3-kDa protein with no significant homology to any other known proteins. It has been proposed that the Hps1 complex is involved in the biogenesis of early melanosomes, but its specific role remains to be determined. In melanotic cells, the Hps1 protein is contained in two distinct high-molecular-weight complexes distributed between uncoated vesicles, early stage melanosomes, and the cytosol. The Hps1 protein does not seem to be associated with lysosomes, consistent with the mild and indirect lysosomal defects observed in HPS1 patients cells. The mouse pale-ear (*ep*) locus is the homologue to the human *HPS1* locus. [43], [44], [48]

Hermansky-Pudlak syndrome type 2 (HPS2; MIM 603401) Mutations in the *AP3B1* gene (chromosome 15q15), causing HPS2 disease, have been found in three individuals in two families. [49], [50] Patients with HPS2 display characteristic clinical findings. They have mild OCA, a mild bleeding diathesis, persistent neutropenia, and possibly recurrent childhood infections. Pulmonary function tests are borderline low. *AP3B1* codes for the $ß_{3A}$ subunit of adaptor complex 3 (AP-3), one of four known adaptor complexes. AP-3 interacts with tyrosinase, and tyrosinase is not targeted properly to melanosomes in *AP3B1*-deficient melanocytes. [44] These data suggest that in melanocytes, AP-3 mediates the trafficking of tyrosinase, and presumably other melanosomal proteins, from an intracellular site to melanosomes. The same may stand true for the transport of transmembrane proteins to LROs/SOs in the other cell types involved in HPS2. The mouse pearl (*pe*) locus is the homologue to the human *HPS2* locus. [43], [44]

Hermansky-Pudlak syndrome type 3 (HPS3; MIM 606118) Recently, a third HPS-causing gene, *HPS3* (chromosome 3q24), was isolated in a population of HPS patients from central Puerto Rico who were devoid of mutations in *HPS1*. [45] Among these patients, one Puerto Rican–Italian patient inherited the common Puerto Rican 3904-bp deletion from his father, whereas no mutation was detected in the coding region of his maternal allele. In the other non–Puerto Rican patients, however, other *HPS3* mutations gave rise to HPS3 disease. Five patients were Ashkenazi Jews, three of whom were homozygous for a 1303+1G?A splice-site mutation that causes skipping of exon 5 and decreases the amount of mRNA. The other two were heterozygous for the 1303+1G? A mutation and for either a 1831+2T? G or a 2621-2 *A?*G splicing mutation. The finding of a common mutation in *HPS3* among patients of Ashkenazi Jewish descent is important because it suggests a founder effect in this population and shows a need for a heightened awareness of the possibility of HPS among Ashkenazi Jews, particularly those with some degree of albinism or platelet storage pool deficiency. Another patient, of German-Swiss descent, was a compound heterozygous for a 2729+1G?C splicing mutation removing exon 14 and decreasing HPS3 mRNA and an R397W missense mutation involving an arginine residue conserved from mice to humans. The last patient, of Irish-English descent, was heterozygous for an 89-bp insertion between exons 16 and 17 resulting from abnormal splicing and a yet unidentified mutation. The HPS3 disease associated with severe *HPS3* mutations, such as splicing mutations, is relatively mild. Hence it cannot be excluded that the diagnosis of HPS3 is overlooked in some patients, and additional studies are needed to assess the exact importance of the *HPS3* locus in non–Puerto Rican patients. Patients with less severe mutations, such as missense mutations, may be indistinguishable from normal individuals. [51]

Hermansky-Pudlak syndrome type 4 (HPS4: MIM 606118) Very recently, a fourth HPS-causing gene, *HPS4,* was isolated in a number of non–Puerto Rican individuals and thus appears potentially as an important HPS locus in this subset of patients. The Hps4 protein is a 72.7-kDa polypeptide unrelated to any known proteins. Preliminary data suggest that Hps4 functions in the same pathway of organelle biogenesis as Hps1, but its specific function is currently unknown. The mouse light ear (*le*) locus is the homologue to the human *HPS4* locus. [46]

Chediak-Higashi Syndrome

CHS PHENOTYPE Chediak-Higashi syndrome (CHS; MIM 214500) is a rare autosomal recessive disorder characterized by severe immunologic

defects, hypopigmentation, bleeding tendency, progressive neurologic dysfunction, and the presence of giant peroxidase-positive lysosomal granules in peripheral blood granulocytes. [52] As with HPS, the hypopigmentation is the result of a primary defect that affects many other cell types than the melanocyte. The skin, hair, and eye pigments are reduced or diluted in CHS. The affected individuals often do not have obvious albinism, and the hypopigmentation may be noted only when compared with that of other family members. Hair color is light brown to blond, and the hair has a metallic silver-gray sheen. The skin is creamy white to slate gray. Iris pigment is present, and nystagmus and photophobia may be present or absent. Histologic studies of the eye in CHS have shown reduced iris pigment, a marked reduction in retinal pigment granules, and infiltration of the choroid with reticuloendothelial cells. Visual evoked potential studies show misrouting of the optic fibers in a pattern that is similar to that seen in individuals with OCA1 and OCA2. It should be noted that children with CHS have many serious medical problems and that the hypopigmentation is usually not a medical concern. Most patients with CHS die young unless they undergo allogenic bone marrow transplantation because of the so-called accelerated phase, consisting of a lymphoproliferative syndrome with hemophagocytosis and infiltration of most tissues by activated T lymphocytes. About 10 to 15 percent of patients exhibit a much milder clinical phenotype and survive to adulthood but develop progressive and often fatal neurologic dysfunction. Very rare patients exhibit an intermediate adolescent CHS phenotype, presenting with severe infections in early childhood but a milder course by adolescence and no accelerated phase. Cells from patients with CHS and from beige mice contain giant intracellular vesicles that cluster around the nucleus. Affected vesicles are lysosomes and LROs/Sos, such as melanosomes, platelet dense granules, and cytolytic granules. The susceptibility to bacterial infections appears to be the result of the abnormal granules in the neutrophils and other cells. [52] The hypopigmentation also arises from the formation of abnormal granules. Giant melanosomes form in the melanocyte. As a result, the melanosomes (and their contained melanin) stay centralized in the cell and do not transfer to surrounding keratinocytes, the result being hypopigmentation of the skin and hair. The pigment granules in the hair shaft are large and have an irregular shape when compared with those in normally pigmented hair from an unaffected individual, and this observation has been used to make a prenatal diagnosis of CHS.

MOLECULAR PATHOGENESIS OF CHS (See also Table 89-3) The beige (*bg*) mouse was proposed as a model of CHS. The mouse *beige* gene [53] and its human orthologue, the *LYST* (lysosomal regulator trafficking) gene (chromosome 1q) [52], [53] have now been identified and cloned. [52], [54] It has been hypothesized that the Beige/CHS protein is involved in vesicular transport, and this would explain the defective vesicular transport to and from lysosomes and the aberrant compartmentalization of lysosomal and granular enzymes. Most *LYST* gene alterations published so far result in a truncated protein because of frameshift or nonsense mutations, suggesting that missense substitutions in the *LYST* gene may result in a milder phenotype. [55], [56] Indeed, very recently, mutation analysis of 21 unrelated patients with the childhood, adolescent, and adult forms of CHS showed that patients with severe childhood CHS had only functionally null mutant *CHS1* alleles, whereas patients with the adolescent and adult forms of CHS also had missense mutatnt alleles that likely encode Chs1 polypeptides with partial function. These results suggest an allelic genotype-phenotype relationship among the various clinical forms of CHS. [57] The *beige* gene encodes a 400-kDa cytosolic protein that is expressed in most mouse tissues. Most data available to date on the function of the Lyst protein arise from immunologic studies. Cultured mouse fibroblasts in which the Beige protein is overexpressed have smaller than normal lysosomes, suggesting that the Beige protein could control lysosomal fission. [58] CHS T cells have defective peptide loading and MHC class II molecules, endosomal sorting, and altered surface expression of cytotoxic T lymphocyte–associated antigen 4 (CTLA-4). These data suggest alternatively that the Lyst protein could control membrane targeting of the proteins present in LROs/SOs. [59], [60] However, in cytotoxic T lymphocyte (CTL) clones derived from CHS patients, it was shown that the initial steps of secretory lysosome formation are normal but that these organelles subsequently fuse together during cell maturation to form the giant secretory lysosomes. [61] Additional studies are needed to shed more light on these apparently conflicting data.

OCULAR ALBINISM

OA, albinism in which the hypopigmentation is primarily localized to the eye, is less common than OCA. It is important to note that the hypopigmentation in OA is clinically limited to the eye, but changes in the cutaneous pigment system also may be present when the ultrastructure of these tissues is analyzed.

OA1: X-Linked Recessive OA

OA1 PHENOTYPES (See also Table 89-2) Ocular albinism type 1 (OA1, X-linked ocular albinism of the Nettleship-Falls type; MIM 300500) is the most common form of OA, with an estimated prevalence of about 1:50,000. Affected males have normal generalized skin and hair pigment. The irides are blue to brown, and all the optic system changes of albinism are present. [62] In African American males, iris color is brown, and iris translucency can be minimal. The skin of Caucasian individuals with OA1 appears normally pigmented, whereas that of African American individuals with darker skin may have scattered hypopigmented macules; these are rarely seen in the skin of Caucasian individuals. Approximately 80 percent of obligate heterozygous females can be detected clinically because of ocular pigment changes that result from X inactivation. These include a variegated pattern of retinal pigment and punctate areas of iris transluency. A small number of heterozygous females have ocular changes of albinism, including nystagmus and reduced acuity, that are thought to be the result of nonrandom patterns of X inactivation. In OA1 melanocytes in the skin and hair follicles, as well as those of the iris and retina, contain large melanosomes called *giant melanosomes, macromelanosomes,* or *melanin macroglobules* along with normal melanosomes. [63] The giant melanosomes are also found in the tissues of obligate heterozygous females.

Molecular Pathogenesis of OA1

The gene for OA1 was mapped to the Xp22.3-Xp22.2 region. The analysis of mutations in patients with OA1 indicates that approximately 50 percent of independent mutations responsible for the disorder are represented by partial or complete deletions of the *OA1* gene, frameshift, splice site, and nonsense mutations. All these mutations presumably lead to gene inactivation. Numerous missense mutations also have been identified along the coding region of the gene. [60], [61], [62], [63], [64] and [65] Recent data indicate that many missense mutations of the *OA1* gene observed in OA1 determine endoplasmic reticulum retention and altered glycosylation of the OA1 protein, thus impairing its proper targeting to melanosomes.

[66] Conformational changes in the tertiary structure, rather than lack of *N*-glycosylation per se, are likely to be the cause of this misrouting. [67]

The *OA1* gene sequence predicts a protein of 404 amino acids with several transmembrane domains and several potential *N*-glycosylation sites. It has been confirmed that the *OA1* gene product is an integral membrane glycoprotein. [68], [69] In human pigment cells, the OA1 protein was localized to melanosomes. [68] However, in a murine system oa1 was localized to late endosome/lysosomes rather than to melanosomes. [69] It was found that OA1 displays structural homology with G protein–coupled seven transmembrane domain receptors (GPCR) and interacts with heterotrimeric G proteins. [70] Since the other known members of the GPCR family are localized to the plasma membrane, OA1 would be the first example of intracellular GPCR identified in a mammalian system. It was proposed that this putative OA1 receptor may represent a “sensor” of a yet unidentified intramelanosomal ligand regulating organelle biogenesis and maturation through activation of heterotrimeric G proteins on the cytoplasmic side of the melanosomal membrane. [70]

DIAGNOSIS OF ALBINISM

The determination of the specific type of albinism can be made with the family history and clinical examination. For OCA, the family history is usually negative, or there is an affected sibling of either sex, indicative of autosomal recessive inheritance.

Children with OCA1 are almost always born with white hair. Many develop pigmented hair, skin, and irides with time (OCA1B), whereas many have white hair and skin with blue eyes all their lives (OCA1A). If hair pigment is present at birth, then the most likely diagnosis is OCA2. For both OCA1 and OCA2, the child is often identified because of the lack of visual attention and the concern for vision. In northern European families, the cutaneous hypopigmentation at birth or early in life is often similar to that of the parents and relatives, and the first concern is raised when it appears that the child is not tracking well or has developed nystagmus.

The presence of strabismus and nystagmus is sufficient to indicate misrouting of the optic fibers at the chiasm. Specialized hematologic tests such as a platelet count, bleeding time, and platelet aggregation or ultrastructure analysis are reserved for individuals with albinism who have a bleeding problem such as easy bruising, recurrent expistaxis, or heavy menstrual bleeding (HPS).

Molecular testing is available in several laboratories and does allow a precise diagnosis to be made at the gene level. In general, this is not necessary for the proper care of a child or adult with albinism. However, it has been proposed recently to screen for HPS among patients who have some degree of hypopigmentation. The rationale for this is that (1) the phenotype of HPS can be extremely mild with respect to both pigmentation and bleeding, (2) as the genotype-phenotype relationship in HPS is becoming clearer, strategies for the molecular diagnosis of patients with HPS are becoming better defined, and (3) identification of patients with a bleeding diathesis among those with hypopigmentation could improve the proper care of these patients. Finally, all patients should be encouraged to participate in research protocols when available because a great deal of the new information on albinism has come from these studies. A mutation database for genes involved in OCA and OA is available at http://www.cbc.umn.edu/ifpcs/micemut.htm .

MANAGEMENT OF ALBINISM

All individuals with albinism should be under the care of an ophthalmologist and should have annual examinations until adult life. Most are hyperopic or myopic, and many have significant astigmatism; refractive correction aids in their visual attentiveness and performance.

Protection from ultraviolet radiation of the sun and care by a dermatologist are necessary for individuals with OCA who have little or no skin and hair pigment. This care is the same as that necessary for individuals without albinism who have type I or II skin and includes the use of sunscreens, hats, and long sleeves, as well as sun avoidance.

REFERENCES

1. King RA et al: Albinism, in *The Metabolic and Molecular Bases of Inherited Diseas* 7th ed, edited by CR Scriver, AL Beaudet, WS Sly, D Valle. New York, McGraw-Hill, 1995, p 4353

2. Witkop CJ Jr: Inherited disorders of pigmentatior *Clin Dermato* **3:**70, 1985

3. Creel DJ et al: Visual anomalies associated with albinisr *Ophthal Pediatr Gene* **11**:193, 1990

4. Garber SR et al: Auditory system abnormalities in human albinc *Ear Hea* **3**:207, 1982

5. Summers CG et al: Diagnosis of oculocutaneous albinism with molecular analys *Am J Ophthalmo* **121**:724, 1996

6. Schnur RE et al: Phenotypic variability in X-linked ocular albinism: Relationship to linkage genoty *Am J Hum Gene* **55**:484, 1994

7. King RA et al: Minimal pigment: A new type of oculocutaneous albinis *Clin Gene* **29**:42, 1986

8. King RA et al: Temperature-sensitive tyrosinase associated with peripheral pigmentation in oculocutaneous albin *J Clin Inves* **87**:1046, 1991

9. Oetting WS, King RA: Molecular basis of albinism: Mutations and polymorphisms of pigment genes associated with albini *Hum Muta* **13**:99, 1999

10. Oetting WS: The tyrosinase gene and oculocutaneous albinism type 1 (OCA1): A model for understanding the molecular biology of melanin form *Pigment Cell Res* **13**:320, 2000

11. Berson JF et al: A common temperature-sensitive allelic form of human tyrosinase is retained in the endoplasmic reticulum at the nonpermissive temper *J Biol Chem* **275**:12281, 2000

12. Halaban R et al: Endoplasmic retioulum retention is a common defect associated with tyrosinase-negative albin *Proc Natl Acad Sci USA* **97**:5889, 2000

13. Toyofuku K et al: The molecular basis of oculocutaneous-albinism type 1 (OCA1): Sorting failure and degradation of mutant tyrosinases results in a lack of pigmen *Biochem J*

355:259, 2001

14. Okoro AN: Albinism in Nigeria: A clinical and social stud *Br J Dermato* **92**:485, 1975

15. Rinchik EM et al: A gene for the mouse pink-eyed dilution locus and for human type II oculocutaneous albini *Nature* **361**:72, 1993

16. Gardner JM et al: The mouse pink-eyed dilution gene: Association with human Prader-Willi and Angelman syndron *Science* **257**:1121, 1992

17. Barsh GS: The genetics of pigmentation: From fancy genes to complex trai *Trends Genet* **12**:299, 1996

18. King RA et al: Albinism in Nigeria with delineation of new recessive oculocutaneous ty *Clin Gene* **17**:259, 1980

19. Brilliant MH: The mouse *p* (*pink-eyed dilution*) and human *P* genes, oculocutaneous albinism type 2 (OCA2), and melanosomal p *Pigment Cell Res* **14**:86, 2001

20. King RA et al: Brown oculocutaneous albinism: Clinical, ophthalmological, and biochemical characterization. Ophthalmo **92**:1496, 1985

21. Kerr R et al: Identification o *P* gene mutations in individuals with oculocutaneous albinism is sub-Saharan Afric *Hum Mutat* **15**:166, 2000

22. King RA et al: Hypopigmentation in Angelman syndrom *Am J Med Genet* **46**:40, 1993

23. Wiesner GL et al: Hypopigmentation in the Prader-Willi syndrom *Am J Hum Genet* **40**:431, 1987

24. Lee S-T et al: Mutations of the *P* gene in oculocutaneous albinism, ocular albinism, and Prader-Willi Syndrom *N Engl J Med* **330**:529, 1994

25. Rinchik EM et al: A gene for the mouse pink-eyed dilution locus and for human type II oculocutaneous albini *Nature* **361**:72, 1993

26. Creel DJ et al: Abnormalities of the central visual pathways in Prader-Willi syndrome associate with hypopigmenta *N Engl J Med* **314**:1606, 1986

27. Stevens G et al: An intragenic deletion of th *P* gene is the common mutation causing tyrosinase-positive oculocutaneous albinism in southern African Negro *Am J Hum Genet* **56**:586, 1995

28. Sviderskaya EV et al: Complementation of hypigmentation *p* mutant (*pink-eyed dilution*) mouse melanocytes by normal huma *P* cDNA, and defective complementation b *OCA2* mutant sequences. *J Invest Dermato* **108**:30, 1997

29. Spritz RA et al: Hypopigmentation in the Prader-Willi syndrome correlates w *P* gene deletion but not with haplotype of the hemizygo *P* allele. *Am J Med Genet* **71**:57, 1997

30. Boissy RE et al: Mutation in and lack of expression of tyrosinase-related protein 1 (TRP-1) in melanocytes from an individual with brown oculocutaneous albinism: A new subtype of albinism classified as OCA3. *Am J Hum Genet* **48**:1145, 1996

31. Manga P et al: Rufous oculocutaneous albinism in southern African blacks is caused by mutations *TYRP1* gene. *Am J Hum Genet* **61**:1095, 1997

32. Sarangarajan R, Boissy RE: Tyrp1 and oculocutaneous albinism type *Pigment Cell Res* **14**:437, 2001

33. Kromberg JGR et al: Red or rufous albinism in southern Afric *Ophthal Pediatr Gene* **11**:229, 1990

34. Hornabrook RW et al: Congenital nystagmus among the red-skins of the highlands of Papua New Guin *Br J Ophthalmo* **64**:375, 1980

35. Toyofuku K et al: Oculocutaneous albinism types 1 and 3 are ER retention diseases: Mutation of tyrosinas *TYRP1* can affect the processing of both mutant and wild-type proteins. *FASEB J* **15**:2149, 2001

36. Newton JM et al: Mutations in the human orthologue of the mou *underwhite* gene (*uw*) underlie a new form of oculocutaneous albinism, OCA *Am J Hum Genet* **69**:981, 2001

37. Du J, Fisher DE: Identification o *Aim-1* as the *underwhite* mouse mutant and its transcriptional regulation by MITF *J Biol Chem* **277**:402, 2002

38. Lehman A et al: The *underwhite* (*uw*) locus acts autonomously and reduces the production of melani *J Invest Dermato* **115**:601, 2000

39. Fukamachi S et al: Mutations in the gene encoding B, a novel transporter protein, reduces melanin content in med *Nature* Genet **28**:381, 2001

40. Fitzpatrick TB et al: Dominant oculocutaneous albinism *Br J Dermato* **91**(suppl 10):23, 1974

41. Marks MS, Seabra MC: The melanosome: Membrane dynamics in black and whi *Nature Rev Mol Cell Bio* **2**:738, 2001

42. Blott EJ, Griffiths GM: Secretory lysosomes *Nature Rev Mol Cell Bio* **3**:122, 2002

43. Spritz RA: Hermansky-Pudlak syndrome and pale-ear: Melanosome making for the millenni *Pigment Cell Res* **13**:15, 2000

44. Huizing M et al: Hermansky-Pudlak syndrome and related disorders of organelle formati *Traffic* **1**:823, 2000

45. Anikster Y et al: Mutations of a new gene causes a unique form of Hermansky-Pudlak syndrome in a genetic isolate of central Puerto *Nature Genet* **28**:376, 2001

46. Suzuki T et al: Hermansky-Pudlak syndrome is caused by mutations *HPS4,* the human homolog of the mouse light-ear gen *Nature Genet* **30**:321, 2002

47. Gahl WA et al: Genetic defects and clinical characteristics of patients with a form of oculocutaneous albinism (Hermansky-Pudlak syndro *N Engl J Med* **338**:1258, 1998

48. Gardner JM et al: The mouse pale ear *ep*) mutation is the homologue of Hermansky-Pudlak syndrome (HPS *Proc Natl Acad Sci USA* **94**:9238, 1997

49. Dell'Angelica E et al: Altered trafficking of lysosomal proteins in Hermansky-Pudlak syndrome due to mutations in the beta3A subunit of the AP-3 ad *Mol Cell* **3**:11, 1999.

50. Shotelersuk V et al: A new variant of Hermansky-Pudlak syndrome due to mutations in a gene responsible for vesicle form *Am J Med* **108**:423, 2000

51. Huizing M et al: Hermansky-Pudlak syndrome type 3 in Ashkenazi Jews and other non–Puerto Rican patients with hypopigmentation and platelet storage-pool defi *Am J Hum*

Genet **69**:1022, 2001.

52. Spritz RA: Molecular genetics of Hermansky-Pudlak and Chediak-Higashi syndrome. *Platelets* **9**:21, 1998

53. Barbosa MDFS et al: Identification of the homologous beige and Chediak-Higashi syndrome ger *Nature* **382**:262, 1996

54. Nagle DL et al: Identification and mutation analysis of the complete gene for Chediak-Higashi syndro *Nature Genet* **14**:307, 1996

55. Barbosa MD et al: Identification of mutations in two major isoforms of mRNA of the Chediak-Higashi syndrome gene in humans and mc *Hum Mol Genet* **6**:1091, 1997

56. Certain S et al: Protein truncation test c *LYST* reveals heterogeneous mutations in patients with Chediak-Higashi syndron *Blood* **95**:979, 2000

57. Karim MA et al: Apparent genotype-phenotype correlation in childhood, adolescent, and adult Chediak-Higashi syndr *Am J Med Genet* **108**:16, 2002

58. Perou CM: The Beige/Chediak-Higashi protein encodes a widely expressed cytosolic prot *J. Biol Chem* **272**:29790, 1997

59. Faigle W et al: Deficient peptide loading and MHC class II endosomal sorting in a human genetic immunodeficiency syndrome: The Chediak-Higashi syndr *J Cell Bio* **141**:1121, 1998

60. Barrat FJ et al: Defective CTLA-4 cycling pathway in Chediak-Higashi syndrome: A possible mechanism for deregulation of T lymphocyte activ *Proc Natl Acad Sci USA* **96**:8645, 1999

61. Stinchcombe JC et al: Secretory lysosome biogenesis in cytotoxic T lymphocytes from normal and Chediak-Higashi syndrome pati *Traffic* **1**:435, 2000

62. O'Donnell FE, Green WR: The eye in albinism, i *Clinical Ophthalmology* vol 4, edited by TD Duane. Philadelphia, Lippincott, 1989, p 1

63. Garner A, Jay BS: Macromelanosomes in X-linked ocular albinis *Histopathology* **4**:243, 1980

64. Rosenberg T, Schwarz M: X-linked ocular albinism: Prevalence and mutations—a national stu *Eur J Hum Genet* **6**:570, 1998

65. Schnur R et al: OA1 deletions and mutations in X-linked ocular albinis *Am J Hum Genet* **62**:800, 1998

66. d'Addio M et al: Defective intracellular transport and processing of OA1 is a major cause of ocular albinism typ *Hum Mol Genet* **9**:3011, 2000

67. Shen B, Orlow SJ: The ocular albinism type 1 gene product is *N*-glycoprotein but glycosylation is not required for its subcellular distributic *Pigment Cell Res* **14**:485, 2001

68. Schiaffino MV et al: The ocular albinism type 1 gene is a membrane glycoprotein localized to melanosor *Proc Natl Acad Sci USA* **93**:9055, 1996

69. Samaweera P et al: The mouse ocular albinism 1 gene product is an endolysosomal prot *Exp Eye Res* **72**:312, 2001

70. Schiaffino MV et al: Ocular albinism: Evidence for a defect in an intracellular signal transduction syst *Nature Genet* **23**:108, 1999

T>

Chapter 90

Jean-Paul Ortonne Philippe Bahadoran Thomas Fitzpatrick David Mosher Yoshiaki Hori

Hypomelanoses and Hypermelanoses

HYPOMELANOSES
Clinicopathologic Correlation in Hypomelanoses
Generalized Hypomelanoses Attributed to Heritable/Congenital Factors
Circumscribed Melanocytopenic Hypomelanoses Attributed to Heritable/Congenital Factors
Hypomelanosis Associated with Nutritional Disorders
Hypomelanosis Associated with Endocrinopathies
Hypomelanosis Secondary to Physical Trauma30
Hypomelanoses Resulting from Chemical Exposure
Hypomelanosis Associated with Infection35
Hypomelanosis Associated with Tumors
Hypomelanoses—Idiopathic, Circumscribed
Confetti Leukoderma
Miscellaneous Types of Hypomelanosis
Hypomelanosis of Hair Alone (Canities)
Hypopigmentation Unrelated to Melanin Pigmentation
HYPERMELANOSES
Epidermal Hypermelanoses
Dermal Hypermelanoses
Dermal Melanoses from Chemical or Pharmacologic Agents
Dermal Hypermelanosis Secondary to Infectious Diseases
Idiopathic Circumscribed Dermal Melanoses
Diffuse Dermal Melanotic Hypermelanoses
Nonmelanin Dermal Hyperpigmentation
Mixed Hypermelanoses and Leukomelanodermas
XANTHODERMAS (YELLOW SKIN COLOR)

REFERENCES

HYPOMELANOSES

Pigmentary disturbances (Table 90-1) may be congenital or acquired, circumscribed or generalized, and partially or completely hypomelanotic (having reduced melanin pigmentation). The term *hypomelanosis* refers to reduction in melanin compared with that individual's normal skin, whereas *amelanosis* signifies total absence of melanin. The term *depigmentation* implies loss of preexisting melanin pigmentation. History and physical examination usually can quickly establish the diagnosis or at least limit the differential. A congenital generalized hypomelanosis may only be appreciated by comparison with unaffected first-generation family members; an acquired generalized amelanosis results from the progressive destruction of melanocytes characteristic of vitiligo and chemical leukoderma. Morphologic and metabolic pathways leading to hypomelanosis and amelanosis are shown in Fig. 90-1. Circumscribed or localized hypomelanoses represent islands of disease amidst clinically normal skin. These also may be amelanotic and progressive (vitiligo, chemical leukoderma); amelanotic, congenital, and stable [piebaldism, Waardenburg's syndrome (WS)]; hypomelanotic and progressive (tinea versicolor, postinflammatory); or hypomelanotic and stable (tuberous sclerosis, nevus depigmentosus).

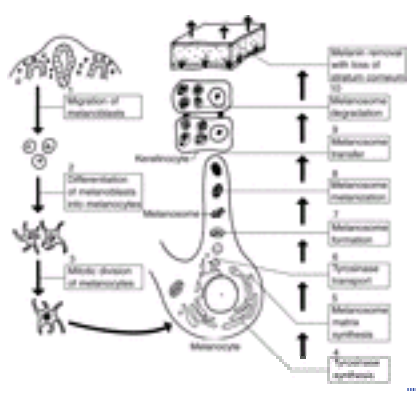

FIGURE 90-1 Morphologic and metabolic pathway of melanin hypopigmentation.

TABLE 90-1 **Hypopigmentation: Clinicopathologic Classification of Disorders**

Circumscribed hypomelanotic macules may have certain features that facilitate diagnosis; these include size, shape, hue, array, and additional features. Confetti or 1- to 2-mm macules may be seen in vitiligo, chemical leukoderma, and tuberous sclerosis. The lesions of pityriasis alba and postinflammatory leukoderma are larger but have fuzzy, indistinct margins, unlike the sharp margins observed with idiopathic guttate melanosis and often tinea versicolor. Scalloped or convex borders are seen in vitiligo or chemical leukoderma. The lance-ovate shape is characteristic of the white macule of tuberous sclerosis. Vitiligo and piebald macules are milk- or chalk-white as opposed to the off-white color seen with nevus depigmentosus, tuberous sclerosis, or postinflammatory leukoderma. A dermatomal, quasi-dermatomal to segmental array of macules can be caused by vitiligo (milk-white), nevus depigmentosus (off-white), tuberous sclerosis (usually with fairly discrete macules), hypermelanosis of Ito. Vitiligo, tinea versicolor, and chemical depigmentation typically involve numerous macules, whereas nevus depigmentosus and tuberous sclerosis are usually characterized by only a few scattered lesions. Vitiligo typically involves extensor surfaces, periorificial skin, anterior shins, flexor wrists, and lower back, whereas piebaldism involves the central forehead and the midarms and legs, sparing the dorsal spine in a cephalocaudal direction. Symmetry is often found with vitiligo, piebaldism, WS, and chemical leukoderma. Isolated hypomelanotic macules with raised erythematous borders suggest tinea versicolor or inflammatory vitiligo, anesthesia suggests leprosy, telangiectasia suggests lupus erythematosus, and hyperpigmented macules suggest piebaldism, pinta, or repigmenting vitiligo. Other features may be observed. Scaling is typical of pityriasis alba and tinea versicolor.

Thus, with attention to the variability of extent of hypomelanosis, history of evolution, attention to hue, and awareness of ancillary features, the differential diagnosis usually can be quickly narrowed down. In fair-skinned individuals, the Wood's lamp is always useful.

Clinicopathologic Correlation in Hypomelanoses

The color or hue of the hypomelanotic macules has a limited clinicopathologic correlation with the defect in melanization (see Fig. 90-1). Melanocytopenic (brilliant or milk-white due to the reflection of incident light) macules may arise because of absence or loss of melanocytes. Melanopenic disorders arise because of failure of normal melanocyte or epidermal melanin unit function.

MELANOCYTOPENIC DISORDERS

1. Failure of migration of melanoblasts to the skin (piebaldism, WS)
2. Failure of differentiation and/or survival of melanoblasts into melanocytes (piebaldism, WS)
3. Failure of mitotic division of melanocytes (? vitiligo)

MELANOPENIC DISORDERS

1. Defect of synthesis of functional tyrosinase (albinism)
2. Failure of biogenesis of melanosomal matrix
3. Defect in tyrosinase transport
4. Failure of normal melanosome formation [tuberous sclerosis, Chédiak-Higashi syndrome (CHS)]
5. Failure of melanization of melanosomes (albinism, hypomelanosis of Ito, idiopathic guttate hypomelanosis, tinea versicolor)
6. Defective transport or transfer of melanosomes [CHS, pityriasis alba, postinflammatory hypomelanosis, Griscelli's syndrome (GS)]
7. Alteration in degradation of melanosomes (CHS, nevus depigmentosus, pityriasis alba, postinflammatory hypomelanosis, tinea versicolor)
8. Alteration in melanin removal related to loss of stratum corneum

In time it is expected that there will be more specificity between a particular pathophysiologic defect and a certain hypomelanotic disorder.

Generalized Hypomelanoses Attributed to Heritable/Congenital Factors

ALBINISM (See Chap. 89)

HISTIDINEMIA Histidinemia is characterized by fair skin, blue eyes, and fair to reddish hair. [1]
HOMOCYSTINURIA (See Chap. 147) Reversible hypopigmentation in homocystinuria is the result of tyrosinase

inhibition by homocyst(e)ine; this likely results from the interaction of homocyst(e)ine with copper at the active site of tyrosinase. Affected individuals with classic homocystinuria have fine blond hair, blue eyes, and fair skin; however, fewer than half the reported patients have blond hair, [1] and there are even rare reports of patients with black or dark brown hair. Reversal of hypopigmentation of hair has been reported with pyridoxine supplementation in some patients with cystathionine synthetase deficiency. [2]

MENKES' SYNDROME (See Chap. 71) Decreased cutaneous pigmentation has been noted in some patients and is due to tyrosinase deficiency. The hair is sparse, wiry, and depigmented. Normally colored hair at birth fades to an ivory-white by 6 weeks of age.

PHENYLKETONURIA (See Chap. 147) *Phenylketonuria* (PKU) is an autosomal recessive disorder characterized by pigmentary dilution involving skin, hair, and eyes and attributed to a large number of mutations at the phenylalanine hydroxylase locus. Mental retardation is the most significant consequence of untreated or undertreated PKU.

Clinical features PKU is characterized by blond hair, blue eyes, and fair skin; these changes may be so subtle that they become apparent only by comparison with other unaffected family members. While hair color may vary from light blond to dark brown, in most series blond hair predominates. In the Japanese, however, PKU is associated with dark brown hair, clearly lighter in color than the black hair normally found in this race. Between 64 and 93 percent of patients have blue eyes, and most PKU patients have such fair skin that they sunburn easily, though some patients tan mildly. Melanocytes are present in normal to increased numbers; however, there is a reduction in the number of mature melanosomes.

Pathogenesis of hypomelanosis PKU results from a deficiency in *phenylalanine hydroxylase* (PAH), which is the enzyme that catalyzes the conversion of phenylalanine to tyrosine. Hypomelanosis in PKU patients has been attributed to impaired tyrosine metabolism due to hyperphenylalaninemia. Tyrosinase, the key enzyme in the melanogenesis pathway is competitively inhibited by increased amounts of L-phenylalanine, thus reducing melanin production. In addition, phenylalanine competitively inhibits tyrosine uptake by melanocytes in a melanoma cell line. Hypomelanosis of skin and hair can be prevented by a strict low-phenylalanine diet from early infancy. Phenylketonuria is caused by deficiency of phenylalanine hydroxylase, resulting in a decreased conversion of phenylalanine into tyrosine. A mouse model of PKU has been developed. These mice show behavioral abnormalities and pronounced hypomelanosis. Reversal of hypopigmentation by adenovirus-mediated transfer of human PAH cDNA, suggests the feasibility of gene therapy for PKU and demonstrates that the correction of hyperphenylalaninemia and the increased conversion of phenylalanine into tyrosine reverse hypomelanosis.

Treatment Dietary therapy with a low-phenylalanine diet is the treatment of choice. Hair color normally darkens with dietary restriction and again lightens if the dietary restrictions are relaxed.

GRISCELLI's SYNDROME Griscelli's syndrome is an uncommon disorder transmitted as an autosomal recessive trait and characterized by hypomelanosis of the skin and hair and immunodeficiency. [3] Although pigmentary dilution of the skin may be seen, hypomelanosis in GS may be limited to an abnormal appearance of the hair, described as silvery gray or grayish golden. Histologic and ultrastructural studies show large pigment clumps within hair shafts and an accumulation of melanosomes in melanocytes with poorly pigmented adjacent keratinocytes. Numerous mature melanosomes are arranged in a perinuclear distribution in melanocytes, whereas few or no melanosomes are observed at the tips of dendrites. Frequent pyogenic infections and acute episodes of fever, hepatosplenomegalia, neutropenia, and thrombopenia are common features of GS. Immune deficiency in GS is associated with a profound impairment of B cell and T cell immunity and with impaired natural killer (NK) cell function. Early death is the usual outcome. Many GS patients have neurologic involvement, including intracranial hypertension, cerebellar signs, bulbar poliomyelitis, encephalopathy, hemiparesis, hypotonia, seizures, and psychomotor retardation, with or without immune abnormalities. A hemophagocytic syndrome and uncontrolled T lymphocyte and macrophage activation syndrome leading to death has been observed. Mutations in the *myosin Va* gene have been identified in GS patients exhibiting primarily neurologic impairment without immune defects (GS1). In contrast, mutations in another gene, *RAB27A,* have been found in patients with immune defects (GS2). These findings demonstrate that GS consists of at least two different disorders. Rab27a protein is not expressed in brain tissue. Direct interaction between Rab27a and myosin Va have been demonstrated. Several other syndromes may be closely related to GS. [4] *Elejalde's syndrome,* also called *melanosomal disease,* is characterised by silvery hair and severe dysfunction of the central nervous system (seizures, severe hypotonia, mental retardation). The pigmentary abnormality in Elejalde's syndrome seems different from that of GS. In Elejalde's syndrome, melanosomes are apparently transferred to basal keratinocytes. Mutations analysis of the *MYO Va* gene in Elejalde's patients would be extremely interesting.

Circumscribed Melanocytopenic Hypomelanoses Attributed to Heritable/Congenital Factors

VITILIGO Vitiligo is a specific, common, often heritable, acquired disorder characterized by well-circumscribed milky-white cutaneous macules devoid of identifiable melanocytes. It carries a risk for ocular abnormalities, particularly iritis. [1], [5], [6]

Psychosocial implications of vitiligo Vitiligo, particularly in brown and black peoples and in Caucasian persons who can tan deeply [*skin phototype* (SPT) IV; see Chap. 88] may be a psychosocial disaster.

Incidence Across the globe, vitiligo is a relatively common cause of leukoderma; although studies have demonstrated an incidence of 0.14 to 8.8 percent, the likely incidence is between 1 and 2 percent. All races are affected. Both sexes are affected equally; the female prevalence in some studies probably can be attributed to greater concern (and greater willingness to express concern) about a cosmetic defect. Vitiligo appears to be observed more commonly in sun-exposed areas and in darker skin types. About 85 percent of patients tan well, and only 15 percent sunburn in constitutively normal skin. SPT IV is the prevalent skin type among Caucasian vitiligo patients. Normal hair color may be black, brown, blond, or red, and the eyes may be blue, hazel, or brown. Black to dark-brown hair and brown iris color seem more common than expected. Vitiligo may develop at any age; onset has been reported from birth to 81 years of age. Congenital vitiligo is very rare, however. The peak age of onset in all series was between 10 and 30 years; in 50 percent of cases, the age of onset fell within the first two decades of life.

Etiology Although vitiligo is generally recognized as a single entity, the etiology is complex. There appears to be a certain genetic predisposition and a number of potential precipitating causes.

Heritability (Fig. 90-2)

FIGURE 90-2 Vitiligo (familial vitiligo). Vitiligo in mother and daughter. The daughter has typical generalized vitiligo, but the mother's condition has evolved to vitiligo universalis.

Familial cases of vitiligo are common, strongly suggesting a genetic basis for this disorder. It is likely, however, that vitiligo is not transmitted in a simple Mendelian autosomal dominant or recessive pattern. The transmission is more complex, most likely polygenic with variable expression. Many studies on the relationship between the human leukocyte antigen (HLA) system and vitiligo showed variable findings. An association between the catalase gene (*CAT*) and vitiligo has been suggested. [7] A novel gene named *VIT1*, possibly associated with vitiligo, has been identified recently by differential display. The involvement of the GTP cyclohydrolase I gene (*GTPCH*), which encodes a key enzyme of the biopterin pathway, has been ruled out. The exact genetic defects in vitiligo remain to be elucidated, and the vitiligo susceptibility genes have not yet been identified.

Precipitating factors Vitiligo patients often can attribute the onset of their disease to a specific life event, crisis, or illness. Many can relate it to loss of a job, death of a close family member, an accident, or a severe systemic disease. In some, the onset follows a physical injury such as a cut or abrasion; this development of vitiligo congruent with a site of injury is referred to as the *Koebner phenomenon* and is characteristic of at least a third of vitiligo patients. Many patients related onset to sun exposure; this may cause koebnerization in predisposed individuals. In darker-skinned individuals who have lost their previous summer tans, a single sun exposure may darken normally pigmented skin to reveal amelanotic macules not previously apparent. Gradual tanning of normal skin also reveals previously inapparent preexisting vitiligo macules that no longer tan.

Clinical features

TYPICAL MACULE OF VITILIGO The typical vitiligo macule has a chalk- or milk-white color, is round to oval in shape, has slightly brushed to fairly distinct, often scalloped margins, measures from several millimeters or many centimeters in diameter, and usually lacks other epidermal changes (Fig. 90-3). There are several variations on the typical vitiligo macule, however. *Trichrome vitiligo* (Fig. 90-4) refers to the presence of an intermediate color; this is a uniform tan coloration that is a narrow to broad interface between the normally pigmented skin and the typical vitiligo macule. An occasional vitiligo macule may be entirely off white to tan (tan being the third color). A trichrome lesion naturally evolves to a typical white vitiligo macule, albeit not at a predictable rate.

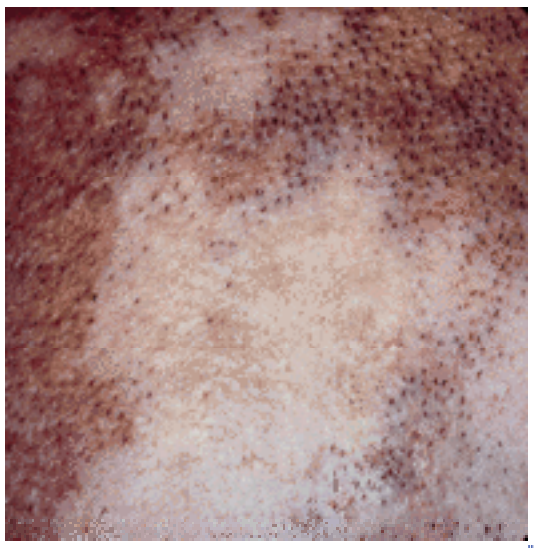

FIGURE 90-3 Vitiligo. Scalloping of the border of the remaining normal pigmentation suggests that the evolving hypopigmentation is invading the normally pigmented skin. Note that in this case (beard area) vitiligo is associated with alopecia areata.

FIGURE 90-4 Vitiligo. Trichrome vitiligo displays three colors—white, light tan, and normal brown. The light tan area is metastable and will evolve to the amelanosis typical of vitiligo.

Quadrichrome refers to the fourth color; this is a macular perifollicular or marginal hyperpigmentation seen in some cases of repigmenting vitiligo (especially in darker skin phototypes). The macules of hyperpigmentation vary from one to several millimeters in diameter. *Pentachrome vitiligo* (white, tan, brown hyperpigmented, blue-gray hyperpigmented, and normal) also may be observed. Blue vitiligo corresponds to vitiligo macules occurring in sites of postinflammatory hypermelanosis. *Inflammatory vitiligo* has an erythematous, raised border similar to that seen in tinea versicolor. Erythema of the entire macule of vitiligo occurs following sun exposure, but a vitiligo macule itself does not clinically resemble an inflammatory dermatosis. *Confetti macules,* which are typical in color but only 1 to 2 mm in diameter, may occur randomly or may be perifollicular. There may be one, several, or up to hundreds of macules that may be small to

large in size, even in a single patient. As vitiligo naturally evolves over time, the macules enlarge, coalesce, and impart a scalloped appearance to the interface of the normal and vitiligo skin. When vitiligo becomes very extensive so that little normal pigment remains, the remaining islands of normal pigmentation have concave borders (as if the whole process were evolving) (see Fig 90-4), which is a diagnostic clue that distinguishes this process from hyperpigmented macules on normal, extremely fair skin. In actively repigmenting vitiligo, the margins lose their impressionistic character and become surrealistically sharp and again convex (representing foci of melanocytes migrating into vitiligo skin).

TYPES OF VITILIGO The following types represent the most characteristic patterns of vitiligo: focal, segmental, generalized, and universal. *Focal vitiligo* (see Fig. 90-3) is an isolated macule or a few scattered macules; by vague convention, the macules are limited in both size and number. Twenty percent of children with vitiligo have the focal pattern. *Segmental vitiligo* (Fig. 90-5) is characterized by unilateral macules in a dermatomal or quasi-dermatomal distribution. This should be considered a special type of vitiligo that has a stable course and is unlikely to be associated with thyroid disease or with other vitiligo-associated diseases. Segmental vitiligo tends to be earlier in onset and more stable than generalized vitiligo and is not familial. Involved patients are unlikely to develop remote or contralateral lesions. Koebnerization is not characteristic. Five percent of adults but more than 20 percent of children with vitiligo are found to have this pattern. The trigeminal area is the most common single site of involvement (>50 percent); the neck and trunk are involved in 23 and 17 percent, respectively. Up to 13 percent may have multiple sites of involvement. Nearly half are associated with poliosis (white hairs; see below). In various studies, from 5 to 28 percent of patients have been noted to have the segmental pattern.

FIGURE 90-5 Segmental vitiligo. Distribution is unilateral and quasidermatomal. Evolution is very unusual outside the generally involved dematome(s): rarely generalized vitiligo develops at a later date.

Generalized vitiligo (Fig. 90-6) is the most common type of vitiligo and is characterized by few to many widespread macules. These macules are often symmetrically placed (Fig. 90-7A) and involve extensor surfaces; the most common extensor surfaces include interphalangeal joints, metacarpal/metatarsal interphalangeal joints, elbows, and knees. Other surfaces involved include volar wrists, malleoli, umbilicus, lumbosacral area, anterior tibia, and axillae. Vitiligo macules may be periorificial and involve the skin around the eyes, nose, ears, mouth, and anus. Periungual involvement may occur alone or with certain mucosal surfaces (lips, distal penis, nipples); the latter is lip-tip vitiligo (Fig. 90-7B). Acrofacial vitiligo involves distal digits and periorificial facial areas. Universal vitiligo (vitiligo universalis) (Fig. 90-8) describes such widespread vitiligo that there are few remaining normal macules of pigmentation; this type has been associated with the multiple endocrinopathy syndrome.

FIGURE 90-6 Vitiligo. Generalized vitiligo in a patient with very extensive involvement. Note symmetry.

FIGURE 90-7 Vitiligo. Characteristic types and features. *A.* Symmetry. There is often nearly mirror-image symmetry as in this 14-year-old Indian girl. *B.* Lip-tip vitiligo. The coexistent involvement of the distal digits and the lips is a common

subtype of vitiligo that also includes involvement of the areolae and the penis.

FIGURE 90-8 Vitiligo (vitiligo universalis). This patient, who developed total body vitiligo at the age of 9, also has Addison's disease, hypothyroidism, and cutaneous moniliasis. (Note onychomycosis of fingernails.)

The general array of macules in generalized vitiligo is often remarkably symmetric, sometimes seemingly mirror image, but asymmetry is not unusual. An artifactual or atypically shaped macule may represent koebnerization and is a macule of vitiligo that corresponds exactly to the area of injury; a laceration will leave a macule of linear depigmentation, and a burn will leave an amelanotic lesion conforming to the exact area burnt. Shoulder-strap, waistband, and collar areas—areas frequently rubbed by clothing—seem particularly common sites. Involvement of bony prominences also may represent koebnerization. Mucosal involvement is not infrequent; the genitalia, nipples, lips, and gingiva may be involved. Involvement of the palms and soles, once considered rare, can now be said to be rather common, although often unapparent without Wood's lamp examination, particularly in a fair-skinned individual.

OTHER CUTANEOUS ABNORMALITIES Vitiligo may be associated with leukotrichia, prematurely gray hair, halo nevi, and alopecia areata. Depigmented hairs are found commonly in isolated vitiligo macules; leukotrichia (poliosis) has been reported in 9 to 45 percent of vitiligo patients. From one to all of the hairs in a macule may be white. Depigmented scalp hair occurs with or without an underlying vitiligo macule. Extensive white hair may be a marker for poor prognosis in repigmentation, but this may not apply for very small macules. Aside from macular leukotrichia, premature graying of hair (canities) occurs in up to 37 percent (see Chap. 91). Halo nevi appear relatively commonly. There may be one to many halo nevi. Confluence of these lesions in the stage of disappearance of the nevus leaves a typical vitiligo-like macule with scalloped borders. Alopecia areata has been reported in up to 16 percent of vitiligo patients (see Fig. 90-3).

OCULAR ABNORMALITIES Vitiligo patients normally have no ophthalmologic complaints (except for the Vogt-Koyanagi-Harada syndrome, see below), but may have iris and retinal pigmentary abnormalities. Careful examination has revealed choroidal abnormalities in up to 30 percent and evidence of iritis in 5 percent. Visual acuity is normally unaffected.

OTIC ABNORMALITIES Clinically significant hearing difficulties are not observed. However, deafness has been described in a cluster of patients on a small island where inbreeding and vitiligo are very common. In an audiometric study, no abnormalities implicating ear melanocytes could be found in a group of 93 vitiligo patients.

SYSTEMIC DISEASE ASSOCIATIONS Many authors have reported an association of vitiligo and thyroid dysfunction, either hyper- or hypothyroidism. Taking into account the high incidence of thyroid disease in the population, it is difficult to draw definitive conclusions about the association of vitiligo with thyroid dysfunction or the presence of thyroid antibodies in vitiligo patients, and this association is now questioned. Also, the validity of an association of vitiligo and diabetes mellitus is not obvious from the available data. Incidental association of vitiligo and Addison's disease, pernicious anemia, lymphomas, leukemias, and HIV infections has been reported. An increased incidence (13 percent) of vitiligo in patients with autoimmune polyendocrinopathy, candidiasis–ectodermal dystrophy (APECED), has been established. The gene mutated in this syndrome is called *AIRE* (autoimmune regulator). This association suggests that vitiligo, at least in a subset of patients, is an autoimmune disease. Diabetes mellitus, both juvenile- and adult-onset types, occurs in 1 to 7.1 percent of vitiligo patients, and conversely, vitiligo occurs in 4.8 percent of diabetic patients. The incidence of Addison's disease in vitiligo is said to be 2 percent but is likely much less common. Adrenal cortical and steroid cell antibodies do not appear increased in vitiligo patients. Pernicious anemia, although uncommon, occurs with increased frequency in vitiligo patients. The multiple endocrinopathy syndrome is found particularly among those with extensive vitiligo.

Histology The current consensus is that no identifiable melanocytes are present in vitiligo macules. A recent report that melanocytes are not absent in lesional skin of long-duration vitiligo illustrates the dynamic nature of the melanocyte loss in vitiligo. The number of melanocytes in trichrome vitiligo, decreased in light-brown skin compared with perilesional normal skin and in vitiligo skin compared with light-brown skin, confirms the centrifugal progression of vitiligo lesions. In the dermis, few lymphocytes may be present in the upper dermis in involved macules and in inflammatory vitiligo with raised and erythematous borders. Melanin may be present in dermal macrophages in darker skin types. [8] Vitiligo affects the entire epidermal melanin unit. Indeed, cytoplasmic vacuolization and/or the presence of extracellular granular material that may be derived from the cytoplasm of altered keratinocytes has been reported in the adjacent normal-appearing skin but also in the perilesional skin and rarely in the lesional hypomelanotic skin. The Langerhans' cell (LC) density in vitiligo macules has been variably reported as increased, normal, or decreased. The differences in the density of epidermal LCs in the various zones of trichrome vitiligo strongly suggest the involvement of LCs in the pathogenesis of this disorder. In addition, functional impairment of LCs has been documented in vitiligo skin. Repigmentation with PUVA is characterized by activation of inactive melanocytes from the middle and lower outer root sheath; this is followed by proliferation, division, migration, and maturation of melanocytes along with movement from the surface of the outer root sheath to the dermal-epidermal junction, where these appear as active melanocytes.

Pathogenesis An undisputable fact in the pathogenesis of vitiligo is that there are no melanocytes present in the fully evolved white macules. Theories on the pathogenesis therefore center on mechanisms for the destruction of melanocytes. Traditionally, there have been three hypotheses to explain vitiligo [9]: the neural hypothesis, the self-destruct

hypothesis, and the immune hypothesis.

NEURAL HYPOTHESIS The neural hypothesis [10] was based initially on anecdotal observations suggesting that stress and severe emotional trauma may initiate or precipitate vitiligo. The common embryologic origin of melanocytes, the nervous system, and the dermatomal distribution of segmental vitiligo are additional arguments put forward to support this view. Local physiologic abnormalities reflecting possible neuromediated aberrations have been reported in vitiligo patients. Direct contact between cutaneous free nerve endings and epidermal melanocytes has been demonstrated in vitiligo. The discovery of a wide range of neuropeptides in the skin and the demonstration that some of them are able to regulate melanocyte differentiation (melanogenesis, dendricity) have given more strength to the neural hypothesis. An increased immunoreactivity of neuropeptide Y (NPY) or an altered balance of nerve growth factor receptors and calcitonin gene–related peptide have been observed in vitiligo skin. Alterations of the catecholamine pathway, increased catechol- *o*-ethyltransferase and monoamino oxidase activities, and increased expression of ß $_2$-adrenoreceptors have been described in vitiligo skin. These alterations are said to induce melanocyte dysfunction and melanocyte injury by promoting the production of melanocytotoxic compounds and by decreasing the natural detoxification-decreasing systems of melanocytes. At present, however, the role of the nervous system in vitiligo, if any, is poorly defined. Clinical evidence is misleading, since the so-called dermatomal or polydermatomal distribution of segmental vitiligo is, in fact, pseudodermatomal.

THE SELF-DESTRUCT HYPOTHESIS According to the self-destruct hypothesis initially put forward by A. B. Lerner, melanocytes in vitiligo have lost an intrinsic protective mechanism that eliminates toxic intermediates or metabolites in the melanogenesis pathway. This pathway is still not identified. The toxic potential of a large number of melanin precursors is well established. Chemicals such as monomethyl- and monobenzyl-ether of hydroquinone induce vitiligo-like hypomelanosis that is clinically and histologically indistinguishable from vitiligo. It has been suggested that the melatonin receptor and melatonin could play a key role in vitiligo. Indeed, melatonin is known to stimulate the melanogenic pathway without production of melanins, leading to an accumulation of toxic intermediate metabolites of the melanogenesis pathway. According to this hypothesis, these toxic products lead to melanocyte and keratinocyte injury with release of specific cellular proteins that initiate a secondary autoimmune reaction. However, this interesting theory is without any substantial experimental basis. The presence of melatonin receptors on melanocytes has not been demonstrated, and the role of melatonin in melanogenesis, if any, is unknown. Several reports provide evidence for increased oxidative stress in the entire epidermis of vitiligo patients. [11] The presence of high epidermal H_2O_2 levels in vitiligo has been demonstrated, and low epidermal catalase levels in involved and uninvolved skin of vitiligo patients have been found. These findings suggest a major stress arising from increased epidermal H_2O_2 generation in vitiligo. Indeed, normal human melanocytes show an increased sensitivity to hydroperoxide in vitro. Protection of these cells against H_2O_2 cytotoxicity can be achieved in vitro by adding catalase to the culture medium. Several pathways could be involved in the overproduction of H_2O_2 in vitiligo. The first is an abnormality in tetrabiopterin metabolism leading to an overproduction of metabolites of this pathway, $6BH_4$ (6 *R*)-L-erythro-5,6,7,8-tetrahydro- and $7BH_4$ (7 *R*)-L-erythro-5,6,7,8-tetrahydrobiopterin. This accumulation of 6- and 7-BH_4 is detectable clinically by a characteristic yellow-green or bluish fluorescence on Wood's light examination. The defective recycling of 6-BH_4 in vitiligo skin may lead to the formation of H_2O_2. Overproduction of H_2O_2 in vitiligo is claimed to result also from increased catecholamine biosynthesis in association with increased levels of monoamine oxidase A from inhibition of thioredoxin/thioredoxin reductase by calcium and increased nitric oxide synthase activities.

THE AUTOIMMUNE HYPOTHESIS The putative association of vitiligo with autoimmune diseases has suggested an immunologic basis for vitiligo. [12] This concept is now strongly supported by many recent studies. Involvement of humoral immunity was first demonstrated by the findings of circulating antibodies to melanocytes. The vitiligo antibodies are predominantly directed to various melanocyte antigens, including tyrosinase, tyrosinase-related protein 1, and tyrosinase-related protein 2. More recently, autoantibodies to a transcription factor called *SOX10* have been found in vitiligo associated with polyglandular dysfunction (APECED) and in a small number of patients with isolated vitiligo. The level of these antibodies has been claimed to correlate with the disease activity and the extent of the cutaneous involvement. These vitiligo antibodies have the ability to kill human melanocytes in vitro. The best evidence that vitiligo antibodies play a role in melanocyte destruction is the observation of the disappearance of melanocytes from normal human skin engrafted onto nude mice injected with vitiligo patient sera. Evidence for a role of cellular immunity in vitiligo is even stronger. In marginal skin from progressing lesions of inflammatory and generalized vitiligo, an infiltrate of skin-homing (CLA+) cytotoxic T cells expressing granzyme/perforin is often found close to the remaining melanocytes. This infiltrate is composed of CD8+ T cells, CD4+ T cells, and subsets of macrophages, and this correlates with the increased numbers of CLA+ MART-1–reactive CD8+ T cells in the peripheral blood of patients with progressive vitiligo. In vitro, direct analysis of cutaneous T cells from margins of vitiligo macules demonstrates that they have a T_H1 phenotype with a secretory repertoire including interferon-? and tumor necrosis factor a (TNF-a). These specific cytotoxic T cells react against the melanocyte differentiation antigens Melan-A/MART-1, tyrosinase, and gp100 in vitiligo patients. These CD4+ and particularly CD8+ T cells are associated with the destruction of melanocytes during active disease. [13] It is still unknown whether these specific immune abnormalities are a cause or an effect of the disease, whether they damage melanocytes or aggravate melanocyte injury initiated by other causes, or are an irrelevant epiphenomenon. However, the presence of HLA-A2–restricted melanocyte-specific CLA+ CD8+ T lymphocytes is related to disease activity. Furthermore, melanocyte-associated vitiligo-like depigmentation is observed following successful immunotherapy of melanoma patients, with peptide-pulsed dendritic cells triggering tumor peptide–specific cytotoxic T cell responses.

OTHER THEORIES Besides these three prevailing hypothesis, other possible pathomechanisms have been proposed: an intrinsic defect of the structure and function of the rough endoplasmic reticulum in vitiligo melanocytes, [14] a deficiency in a melanocyte growth factor, a viral origin, a dysregulation of melanocyte apoptosis, and a primary disturbance of T lymphocytes resulting in the development of “forbidden” clones of autoreactive lymphocytes in the epidermis. [9]

ANIMAL MODELS Several animal models of vitiligo have been identified in horses, swine, and mice. [15] The most interesting model is the Smyth chicken. These birds develop a delayed partial or total feather hypomelanosis. They also express many of the associated disorders presented by patients with vitiligo, including ocular depigmentation and uveitis, alopecia areata–like trait, autoimmune thyroiditis, and sometimes spontaneous repigmentation. The etiology of hypomelanosis in the Smyth chicken appears to include an inherent defect in the melanocytes followed by an autoimmune reaction involving antibody-producing B cells. Indeed, elimination of the humoral immune system in the Smyth chicken by neonatal bursectomy results in a significant decrease in the expression and severity of the feather amelanosis. From the available data, it is likely that the loss of epidermal and follicular melanocytes in vitiligo may be the

result of several different pathogenic mechanisms. A convergence theory suggests that genetic factors, stress, accumulation of toxic compounds, infection, autoimmunity, mutations, altered cellular environment, and impaired melanocyte migration and proliferation can all contribute to the phenomenon. [16] Present knowledge strongly suggests an immune pathogenesis, at least in a subgroup of vitiligo patients. However, the concept that the disorder we call vitiligo does not represent a single entity but constitutes a syndrome composed of a variety of different diseases is still valid. [6]

Diagnosis The diagnosis of generalized vitiligo in a patient with progressive, acquired chalk-white macules in typical sites is normally straightforward. Few such acquired conditions are so patterned and symmetric as vitiligo can be. Wood's lamp examination may be required to visualize macules in patients with lighter SPTs and to identify macules in sun-protected areas. The differential diagnosis of generalized vitiligo includes the following: *Chemical leukoderma:* History of exposure to certain phenolic germicides, confetti macules
Leprosy: Endemic area, anesthetic macules, off-white color
Lupus erythematosus: Atypical distribution, inflammation, atrophy, positive immunofluorescence
Melanoma-associated leukoderma: Different distribution, may disappear completely, may have melanocytes
Piebaldism: Congenital, white forelock, stable, large hyperpigmented macules, different distribution
Pityriasis alba: Slight scaling, fuzzy margins, off-white color, ill-defined border
Postinflammatory hypomelanosis: Off-white macules, ill-defined border, history of psoriasis, eczema in same areas
Tinea versicolor: Fine scales with fluorescence under Wood's lamp, positive KOH
Tuberous sclerosis: Congenital, white macules, occasional segmental and confetti macules, stable
Waardenburg's syndrome: Widely spaced inner canthi, heterochromia, broadened nasal root, deafness
Segmental vitiligo is confined to one unilateral quasi-dermatomal distribution, and the following should be excluded:
Nevus depigmentosus: Unusually congenital, stable to progressive, hypomelanotic as opposed to amelanotic
Tuberous sclerosis: Usually associated with typical white ash-leaf macules or confetti macules elsewhere; hypomelanotic, not amelanotic
Idiopathic guttate hypomelanosis: Porcelain-white macule, discrete margins, may be slightly depressed
A solitary white macule or several white to off-white macules often present a challenge because they may be the presenting stage in the evolution of any of the processes listed above. In some instances, a biopsy may be helpful, but standard histologic studies cannot distinguish a vitiligo macule from one of chemical leukoderma, piebaldism, or WS. Biopsy is useful to establish diagnoses such as lupus erythematosus, leprosy, and tinea versicolor. The presence of melanin or melanocytes in a biopsy cannot be assumed to exclude a diagnosis of vitiligo because trichrome vitiligo, marginal (vitiligo) skin, and repigmenting macules of vitiligo also demonstrate melanocytes. Once the diagnosis has been established, testing for vitiligo-associated diseases is indicated.

Natural course The natural course of vitiligo is unpredictable. Focal vitiligo, although stable for a time, may be a precursor of generalized vitiligo. The natural course of common vitiligo is often one of abrupt onset, followed by progression for a time; then a period of stability follows and may last for some time, even decades. This may be followed later by a period of more rapid evolution. Total spontaneous regression is rare, and evolution to vitiligo universalis is unusual, although not rare. The most common course is one of gradual evolution of existing macules and periodic development of new ones. Segmental vitiligo, on the other hand, is usually very stable. The period of evolution is often less than a year, after which there is little extension or regression; significant spontaneous repigmentation is unusual.

Treatment While there are several options in the management of vitiligo, most patients require reassurance and an understanding of their affliction. In an increasingly sophisticated world, many patients present with a certain level of knowledge of their options. All patients should be encouraged to use sunscreens to protect the vitiliginous areas, reassured that the use of cosmetic coverup is perfectly acceptable, and educated about the benefits and risks of attempts at repigmentation and depigmentation. [17], [18] Additional information is available through support groups, printed brochures, and the Internet. Professional counseling should be offered to those particularly distressed over their appearance. Patients suffering untoward life disruption in personal or professional relationships particularly should be encouraged to seek help. *Sunscreens* offer both protection from sunburn reaction with possible resulting koebnerization and attenuation of facultative tanning of normally pigmented skin; were the latter successful, the contrast between vitiligo macules and normal skin remains minimal, as is the case in the winter months or on habitually unexposed areas of skin. Opaque sunblocks with a *sun protection factor* (SPF) of over 30, containing ZnO and/or TiO_2, are most suited for this purpose (see Chap. 247). Daily use of opaque sunscreens alone may be adequate management for those who are melanodeficient (tan weakly). *Cosmetics,* including conventional makeups, dyes, and “self-tanning” preparations, provide quick and practical solutions that are perfectly adequate for many patients. Certain specialized, thicker cosmetics are readily available and can be custom mixed to match most skin colors. Because cosmetics do rub off, they may be of limited value for the lower neck and wrists (rub off on clothing) and hands (because of handshaking). These areas may be better covered with dyes or self-tanning agents or one of the many cosmetic stains, respectively. A formulation containing 5% dihydroxyacetone in an oil-in-water emulsion base is practical and well accepted in vitiligo patients. However, the stains are usually modestly satisfactory at best and do tend to wash off. Patients need to be reassured that none of these preparations will cause their vitiligo to progress, nor will they preclude success of other options.
Repigmentation involves any attempt to reverse the depigmentation and to reestablish normal pigmentation in established macules of vitiligo. Systematic review of the literature reveals that only a few randomized clinical trials have been performed on vitiligo therapies. All current attempts should be viewed as treatments or quasi-remissive techniques and not as a cure. Current available options include topical glucocorticoids for limited vitiligo, topical PUVA for focal and segmental types, PUVA-grafting (see below) for refractory segmental vitiligo or stable vitiligo, narrow-band ultraviolet B (UVB) therapy and oral PUVA for segmental or generalized vitiligo. All forms of treatment require a certain commitment from patients and should be undertaken with the full understanding of the advantages and limitations of each approach (discussed below). A meta-analysis of the literature concludes that class 3 glucocorticoids and UVB therapy are the most effective and safest therapies for localized and generalized vitiligo, respectively. [18] *Topical glucocorticoids* have proven effective for isolated macules in some cases, but overall results tend to be disappointing. Hydrocortisone may be used for isolated macules in sensitive areas such as the face and axillae and for children. More potent topical steroids generally are more successful. However, with the most potent topical steroids, the approach should be daily application for 3 weeks, skip a week, and repeat to avoid local glucocorticoid side effects. If there has been no response after 2 months, treatment should be abandoned. If treatment is to be continued, monitoring every 2 months for signs of atrophy is prudent; irreversible striae may develop on the legs after as little as 4 months of continuous treatment. Topical steroids may be used in conjunction with other modalities. *PUVA* is indicated in patients for whom no other option is satisfactory and in patients who understand its limitations (see Chap. 266 and Fig. 90-9). Concurrent topical calcipotriol potentiates the efficacy of PUVA in the treatment of vitiligo whereas calcipotriol monotherapy is uneffective.

FIGURE 90-9 PUVA treatment of vitiligo. *A.* Typical symmetric periorificial vitiligo with characteristic involvement of the skin overlying the interphalangeal joints. *B.* After treatment there is marked hyperpigmentation, often seen in darker skin types. *C.* After discontinuation of treatment, the hyperpigmentation has faded, but the facial macules have remained filled in. A remarkable amount of repigmentation was also noted on the hands.

Narrow-band UVB is presently considered a treatment of choice for vitiligo. [19] Narrow-band fluorescent tubes (e.g., Philips TL-01/100 W) with an emission spectrum of 311 nm are used for this therapy. For a detailed discussion of PUVA and narrow-band UVB for vitiligo, see Chap. 266 and Chap. 265, respectively. *Focused microphototherapy* delivers UVB light with a spectrum of 280 to 315 nm only on the hypomelanotic skin. About 25percent of patients have excellent results. Unfortunately, this therapy requires expensive equipment and trained personal and therefore will not be available for many patients. Numerous *surgical techniques* have been reported to be successful in repigmentation, [20] but it should be noted that no controlled studies are available. Regardless of the surgical technique, segmental vitiligo is the best candidate for surgical intervention. Vitiligo, which always carries the risk of koebnerization, may be considered suitable for surgical interaction in those cases in which the vitiligo is limited in area and has been stable for some time (2 years). In most cases, pretreatment with PUVA will establish those islands of inapparent melanocytes capable of repigmenting and define sites that have no ability to repigment. The minigrafting test described by Falabella and colleagues is particularly useful in predicting success (or failure) in minigrafting of stable vitiligo; in all patients, the results demonstrate to the patient the expected cosmetic appearance of the graft and donor sites. The patient and the physician together then may decide if proceeding with extensive grafting will likely be satisfactory. Various surgical techniques have been described. Transplantation of cultured autologous melanocytes to depigmented macules has led to excellent results, but the method is tedious. Up to 6 to 8 months are required for an excellent color blend. The grafts are generally stable over the 1 to 2 years of follow-up. Falabella reported that even the dorsal hands can be grafted successfully. [20] Cryostorage of excess cultured melanocytes is a source of melanocytes for future procedures. Minigrafting with 1- to 2-mm punch grafts or split-skin grafts may be most practical for isolated small macules. Placement of four 1.5-mm grafts per square centimeter is a practical technique; pigment spread beyond the graft site should be visible within a month. PUVA may be required to complete the repigmentation (Fig. 90-10). Hyperpigmentation and pebbling may be observed but generally will reverse over time. Patients with stable vitiligo without koebnerization seem to be the best surgical candidates; reversal of leukotrichia also has been observed. Permanent dermal micropigmentation using a nonallergic iron oxide pigment can be used to cover recalcitrant areas of vitiligo. [21]

FIGURE 90-10 Vitiligo. Treatment with grafting. *A.* Vitiligo macule unresponsive to PUVA. *B.* Same macule after grafts have been placed; pigmentation begins to spread outward from the graft site. *C.* Repigmentation of the macule. PUVA may sometimes be required after grafting to complete the repigmentation. (*Courtesy of WL Morison, MD, and J. Skouge, MD.*)

OTHER THERAPIES *Multivitamin therapy* (folic acid/vitamin B_{12}/ Vitamin C) has been reported to show repigmentation, particularly in children. *Melagenina* (placental therapy) generally has proven disappointing outside of Cuba, where it was first described. Likewise, *phenylalanine/UVA* (PAUVA) generally has been inconsistent. The combination of *calcium, pseudocatalase,* and *UVB* has been reported to result in repigmentation even of such refractory areas as the dorsal hand; this improved response plus the relevance of this therapy to new understanding of the disease makes this approach particularly exciting. However, this open study has not yet been confirmed. Oral administration of compounds such as ubiquinone, tocopherol, selenium, and methionine in vitiligo patients is common practice among dermatologists. No controlled study demonstrating the efficacy of antioxidant therapy is yet available. *Depigmentation* is another option (Table 90-2) for those with extensive vitiligo and/or in those who have failed PUVA, for whom PUVA is not an option, or who have rejected it (Fig. 90-11). Bleaching, which implies destruction of residual melanocytes with *monobenzylether of hydroquinone* (MBEH) 20% cream is a permanent, irreversible process. Application of MBEH may be associated with satellite depigmentation; therefore, MBEH cannot be used selectively to bleach just limited areas of normal pigmentation; the risk of distant and remote macules of depigmentation is very real. The patient may elect to treat all residual pigmentation or just selected cosmetically bothersome areas. Successful bleaching with MBEH requires twice-daily application for 2 to 3 months before improvement is observed and 9 to 12 months before complete depigmentation is achieved. Up to 50 percent of patients may complain of erythema, dryness, burning, and pruritus, particularly on the face; these symptoms may be diminished by reducing the frequency of use or by mixing the MBEH with an emollient. Contact dermatitis restricted to normally melanized skin occurs in nearly 15 percent of users. [22] Between 90 and 95 percent of patients will be fully bleached in a year. Maintenance applications are not required. However, although this

depigmentation is normally considered to be irreversible, an occasional patient will observe focal repigmentation following sun exposure, which requires reapplication of MBEH for a month or more. Assiduous avoidance of midday sun and routine use of high-SPF opaque sunblocks usually minimize this risk. There have been no long-term untoward effects from the use of MBEH.

FIGURE 90-11 Vitiligo. Treatment of “normal” skin by depigmentation with 20% monobenzylether of hydroquinone. *A.* Dark-skinned patient with extensive vitiligo before therapy. *B*. Permanent depigmentation after a year of application of 20% monobenzylether of hydroquinone cream. The patient has remained uniformly depigmented for over 15 years.

Criteria for selection
Absolute
PUVA failure (or unable/unwilling to treat with PUVA)
Patients who can accept the expected irreversible, universal nature of treatment
Dark-skinned patients who are prepared to become totally white
Patients who will use effective sunblock and avoid midday sunlight
Relative
Older than 40 years
Extensive vitiligo (often > 40%)
Fair-skinned (melanodeficient) skin types
Side effects of therapy
Acute
Cutaneous irritation
Satellite depigmentation
Remote depigmentation
Contact dermatitis
Focal resistant macules (unusual)
Rare rapid repigmentation following cessation of use
Chronic
None expected
Occasional focal repigmentation in sun-interactive skin

TABLE 90-2 **Monobenzylether of Hydroquinone Therapy of Vitiligo**

Some patients who have bleached may wish to attenuate the chalk-white appearance of their skin; this may be achieved by daily ingestion of 30 to 60 mg of beta-carotene; the intensity of the color may be adjusted by increasing or decreasing the dose.

TREATMENT OF VITILIGO IN CHILDREN There is a particular challenge in the treatment of vitiligo in children, for the complex parent-child relationship may bear heavily on what is asked of the dermatologist. The compelling principle is to segregate the needs of the child from those of the parent. Often it is the parent, not the child, who is concerned; in this case it is the parental worries that must be addressed. In some regions, support groups are available and can be quite helpful. Sunscreens and cover-up are the initial steps. The next is topical steroids, which may take weeks to be effective. In certain cases of limited vitiligo, topical psoralens may be considered. Narrow-band UVB therapy is the treatment of choice for children (over 6 years). Oral psoralens may be considered after maturity of the ocular lens can be reasonably assured (about age 10). The specifics of each approach are the same as for adults.

VOGT-KOYANAGI-HARADA SYNDROME (VKHS) VKHS is a rare multisystem disease characterized by vitiligo, poliosis, uveitis, dysacousia, and alopecia. While Vogt-Koyanagi syndrome was associated with anterior uveitis and Harada with posterior uveitis and retina detachment, there is enough crossover of features that all these cases may be grouped as one syndrome, VKHS.

Clinical Features Classic VKHS appears in three phases. The first is the meningoencephalitic phase, which begins with the prodrome of fever, malaise, headache, nausea, and vomiting. The degree of involvement is variable, but confusion, psychosis, hemiparesis, paraplegia, aphasia, syncope, generalized muscle weakness, dysphagia, and nuchal rigidity follow. Personality changes and paresis have been known to persist, although neurologic sequelae are unusual. The second phase—the ophthalmic-auditory phase—may appear rapidly and last for 10 or more years. Common features include decreased visual acuity, photophobia, and eye irritation, as well as headache, eye pain, and low-grade fever. Anterior uveitis is usually accompanied by complaints of ocular pain, whereas posterior uveitis is usually less symptomatic but may be associated with retinal detachment, which can be permanent. Dysacousia, which is usually bilateral, occurs in 50 percent of patients. The convalescent phase starts as uveitis begins to abate and is characterized by alopecia, poliosis, and vitiligo. Up to 90 percent may have poliosis, 73 percent alopecia, and 63 percent or less have leukoderma. The macules of hypomelanosis appear with or after the eye symptoms and resemble vitiligo; these are symmetric, may enlarge centrifugally, and seem principally to involve the head, eyelids, neck, and shoulders. Poliosis is usually observed after the onset of alopecia, which is patchy or diffuse. The poliosis may affect the scalp, eyebrows, and eyelashes.

Histology In established macules the most consistent abnormality is absence of melanocytes, as in vitiligo. There are reports of edema and vasodilatation in the dermis, pigment-laden macrophages, and a lymphocytic infiltrate. Histopathologic studies of the skin taken a month after the onset of ocular symptoms reveal a mononuclear infiltrate of a slightly edematous dermis; these are mostly T lymphocytes, but a small number of B cells have been noted. The infiltrate is particularly concentrated around hair follicles and sweat glands. The CD4/CD8 ratio is 3:1.

Diagnosis Diagnosis is based on the presence of ocular and CNS abnormalities, the otic abnormalities being less common and more subtle. Vitiligo with poliosis or canities is the major diagnosis to be excluded. Diagnosis is critical because treatment of the eye abnormalities with steroids may prevent progression to blindness.

Treatment Systemic glucocorticoids are used for eye involvement. Treatment options for skin depigmentation are the same as for vitiligo; abundant poliosis remains an indicator of a poor prognosis for repigmentation.

ALEZZANDRINI'S SYNDROME Alezzandrini's syndrome has been reported in five patients; the syndrome includes facial vitiligo, poliosis, deafness, and unilateral tapetoretinal degeneration.

PIEBALDISM Piebaldism is an uncommon, autosomal dominant, congenital, stable leukoderma characterized by a white forelock and vitiligo-like amelanotic macules, usually containing a few normally pigmented or hyperpigmented macules. The incidence of piebaldism is estimated to be less than 1 in 20,000 persons. Both males and females are equally affected, and no race is spared. [23]

Clinical features The typical piebald macule is chalk or milk white like that of vitiligo and may have feathered margins. The classic pattern for piebaldism (Fig. 90-12) includes a central macule with a white forelock; the lateral trunk, sparing the dorsal spine; and the midarms and legs, sparing the hands, feet, and periorificial areas so characteristic of vitiligo. In up to 90 percent of cases of classic piebaldism, there is a congenital white forelock arising from a triangular, elongated, or diamond-shaped, midline, usually symmetric white macule of the forehead (see Fig. 90-12A). This white macule extends to the medial eyebrows, which are often white; the eyelashes also may be depigmented. Amelanotic macules are apparent elsewhere in characteristic symmetric patterns; in 10 to 20 percent of patients with piebaldism, these macules may be the only expression of the disorder. The most characteristic depigmented sites are the anterior abdomen extending to the chest and dorsally to the back with sparing of the midline (see Fig. 90-12B), mid-upper arms to wrists, midthighs to midcalves, occasionally the face, in addition to the typical macule associated with the white forelock. Mucosal involvement also has been observed. The hands, upper arms, shoulders, upper thighs, and feet to midcalves usually remain normally pigmented. Hyperpigmented macules within the amelanotic macules and on normally pigmented skin are characteristic of piebaldism. Most hyperpigmented macules are less than 1 cm in diameter, although larger macules have been described. These macules are darker than the normal skin color, are not uniformly pigmented, and have a characteristic electron microscopic appearance. They may appear over time or follow sun or artificial UVA exposure. Partial repigmentation of piebald macules has been reported, as has complete depigmentation.

FIGURE 90-12 Piebaldism. *A.* Autosomal dominant inheritance pattern is shown by involvement of a mother and two daughters, all of whom have the typical white forelock. *B.* Dorsal sparing of involvement with piebald macules is particularly apparent; the central back is normally unaffected.

Piebaldism variants Although patients with piebaldism are generally otherwise normal, occasional patients also have heterochromic irides or deafness. *Woolf's syndrome* is considered a distinct autosomal recessive syndrome characterized by piebaldism with deafness. Interstitial chromosome 4 deletions have been found in several piebald patients with mental retardation. Other variants of piebaldism include X-linked occipital white forelock, white forelock and osteopathic striae, and X-linked autosomal recessive white forelock with blue striae, ocular hypertelorism, epicanthal folds, high arched palate, atrial septal defect, syndactyly, and other problems.
Histology In established macules, the most consistent abnormality is absence of melanin, and melanocytes as in vitiligo.
Pathogenesis Animal model systems provide additional insight suggesting defective melanoblast differentiation or survival. Dominant white spotting, a mouse equivalent of human piebaldism, has been shown to result from deletions or point mutations of the *kit* proto-oncogene, which encodes the tyrosine kinase transmembrane cellular receptor for mast/cell stem growth factor. In piebaldism, the human homologue of this gene, located on chromosome 4q12.8, is mutated. This affects most patients, but those without *KIT* mutations have no abnormality of the gene encoding SLF itself. Phenotypic variations are a function of the site of the *KIT* gene mutation. [23]
Diagnosis Vitiligo is the major diagnosis to be excluded (Table 90-3). Congenital onset, stable typical pattern, hyperpigmented macules in normal and depigmented skin, and an autosomal dominant inheritance pattern establish the diagnosis of piebaldism. Uncommonly, heterochromia without deafness or lateral displacement of the inner canthus will suggest a variant of piebaldism instead of Waardenburg's syndromes (WS) (see below). Deafness and piebaldism without the other features of WS is Woolf's syndrome. Audiometry should be considered for patients with piebaldism.

TABLE 90-3 **Comparative Features of Vitiligo, Piebaldism, and Waardenburg's Syndrome**

Treatment Autologous minigrafts or use of autologous cultured melanocytes has potential because there is no risk of koebnerization in the donor sites as in vitiligo; however, the scope of potential grafting required is often daunting. Bleaching with MBEH has proved successful in several patients (personal observations), but the process appears to take much longer than the year usually required for vitiligo.
WAARDENBURG'S SYNDROME This is a rare autosomal dominant disorder that is characterized by lateral displacement of the inner canthi and of lacrimal puncta, prominence of the nasal root and of the medial eyebrows, congenital deafness, heterochromic irides, white forelock, and hypomelanotic macules (Fig. 90-13). Variable expression and penetrance create confusion about adequate criteria for the diagnosis of WS. Spontaneous occurrences of WS are seen and may not be unusual. WS has been reported widely; the incidence ranges from 1 in 20,000 in Kenya to 1 in 40,000 in the Netherlands. It may be the cause of deafness in up to 3 percent of the deaf. [23]

FIGURE 90-13 Waardenburg's syndrome. *A.* This 15-year-old boy displays the white forelock (which often disappears entirely), broadened nasal root, wide-spaced inner canthi, and hearing deficit. *B.* Heterochromia is particularly apparent in this woman (note one blue and one brown eye).

Four types of WS have been isolated. Type I (WS1) is associated with dystopia canthorum, and most commonly with cutaneous pigmentary changes and with white forelock. Type II (WS2) is associated with a high incidence of congenital sensorineural hearing loss (familial; 77 percent) and heterochromia (47 percent) but not with dystopia canthorum. WS1 and WS3 are caused by mutation of *PAX3* that encodes a transcription factor expressed during embryonic development of the melanocyte system. Type II WS or Klein-Waardenburg syndrome is heterogeneous, being caused by mutations in the microphthalmia (*MITF*) gene in some but not all affected families. Patients with WS4, also called *Waardenburg-Shah syndrome,* have mutations in *SOX10,* a gene encoding a transcription factor that plays an essential role in the development of neural crest–derived human cell lineages. A mutation in the endothelin-3 gene has been described in a patient with Waardenburg-Shah syndrome. Types I, II, and III WS are inherited in an autosomal dominant manner, whereas WS4 is an autosomal recessive condition. Molecular genetic analyses have shown that WS1 and WS3 are allelic variants, whereas WS2 and WS4 are distinct entities.

Clinical features A dappled appearance of the skin, white forelock, and premature graying of hair, eyebrows, and cilia are the pigmentary changes found in WS. White forelock, found in from 17 to 58 percent, is present at birth or appears soon thereafter but may disappear over time; it is usually associated with amelanosis. The hypopigmented macules resemble those of piebaldism but may be localized or generalized and symmetrically or asymmetrically arrayed. Forehead, neck, anterior chest, abdomen, anterior knees and arms, and dorsal hands are the most commonly involved sites. The hair within the white macules is usually white. The fundi may be hypopigmented.

Other features of WS (See also Chap. 188) Nearly all patients (99 percent) have laterally displaced medial canthi, but the interpupillary distance remains normal. Hypopigmented irides are seen in 87 percent of blacks and 81 percent of Caucasians. Waardenburg found a broad nasal root in 78 percent. Eyebrow hyperplasia with confluence of normally colored medial eyebrows is reported in 17 to 69 percent. Fundal pigmentary abnormalities may occur in about half of patients, but visual acuity is unaffected. Deafness is reported in 9 to 38 percent. Various other CNS and ocular abnormalities have been observed but may be incidental.

Variants of WS A few cases of pseudo-WS have been described, with congenital unilateral eyelid ptosis, heterochromia or isohypochromia, congenital deafness, fair hair with scattered white scalp hairs, dystopia canthorum, and broad nasal root. In another family, several features of WS (except dystopia canthorum) were associated with foveal hypoplasia, iris translucency, and hyperopia-extropia amblyopia. The association of cutaneous white hair, blue irides, macules of retinal depigmentation, a black temporooccipital lock, and aganglionosis of the gut has been reported as a new neural crest syndrome with autosomal recessive inheritance and likely represents an additional example of WS with some unusual clinical features.

Histology and electron microscopy of white macules Melanocytes are absent from the depigmented skin. Reduced numbers of melanocytes are found at the margins of the depigmented macules.

Pathogenesis WS is considered to be one of the neural crest disorders. Melanoblasts fail to migrate, fail to differentiate, and fail to survive. Since nerve cells also may fail to migrate properly, deafness may occur.

Diagnosis The presence of three or more of the classic features usually establishes the diagnosis. Woolf's syndrome (piebaldism with deafness) must be excluded (see above). Rozychi's syndrome is characterized by typical leukoderma, congenital deafness, muscle wasting, and achalasia. Fisch's syndrome includes deafness, early graying of hair, and sometimes partial heterochromia but not laterally displaced inner canthi. Tietz's syndrome is characterized by deaf-mutism, eyebrow hyperplasia, blue eyes, and a generalized cutaneous hypomelanosis characterized histologically by an absence of melanin. The hair is light blond and the eyes are blue, but other features of WS or of albinism are absent. An autosomal dominant inheritance pattern has been suggested.

Treatment No treatment of the pigmentary dilution is available. Spontaneous disappearance of the white forelock does occur, and spontaneous repigmentation and contraction of the white macules have been reported. Early diagnosis and management of the hearing defect is important for normal social and mental development and for genetic counseling.

ZIPRKOWSKI-MARGOLIS SYNDROME (ZMS) ZMS is a curious, rare, X-linked recessive syndrome that occurs in males. The ZMS gene has been localized at Xg26.3-q27.1. ZMS is characterized by deaf-mutism, heterochromic irides, and piebald-like hypomelanosis of the skin and hair. Although the skin appears totally amelanotic at birth, hyperpigmented macules, which are round, oval, or geographic, develop mainly on the extremities and trunk (Fig. 90-14) but rarely on the scalp, where the hair is usually white. Even in the pigmented macules, the hair remains white. The number of melanocytes is equal in the pigmented and amelanotic skin; the dopa reaction is strongly positive in the former and weakly positive in the latter.

FIGURE 90-14 Ziprkowski-Margolis syndrome. Round, oval, or geographic hyperpigmented macules develop in congenitally amelanotic skin. The scalp involvement seen here is unusual.

TUBEROUS SCLEROSIS (TS) (See also Chap. 189) White macules are found in 79 to 98 percent of tuberous sclerosis patients. Most lesions have been assumed to be present at birth but are relatively unapparent in fair-skinned individuals not examined with the Wood's lamp. However, delayed onset has been demonstrated in longitudinal studies; in one study of 479 Japanese patients, white spots were noted in 82 percent at 1 year and 100 percent at 2 years. Four types of hypopigmented macules are recognized: lance-ovate macules, polygonal macules, confetti spots, and hypomelanosis in dermatomal distribution. Poliosis may occur. The average lesion is 1 to 3 cm in diameter, but macules may vary from 4 mm to 12 cm; 89 percent are larger than 1 cm. The long axis of the lance-ovate macules (Fig. 90-15) is usually axial on the extremities and transverse on the trunk. Confetti macules (2 to 3 mm) (Fig. 90-16) occurr symmetrically from the wrists to the elbows and from the ankles to the knees. Dermatomal patterns (Fig. 90-17) also may occur zarely but usually only in conjunction with other typical macules. The margins of the lesions are usually fairly discrete, and the color of the lesions is dull to off-white or milk-white, unlike the pure white of vitiligo macules. Wood's lamp examination may be particularly useful to find hypomelanotic macules not readily apparent. The white macules may fade in adulthood. Poliosis also occurs with or independently of hypomelanotic macules. Macular hypopigmentation of the retina and of the iris also have been described. [24]

FIGURE 90-15 Tuberous sclerosis (TS). Ash-leaf spot. The lance-ovate macule in TS is exactly the shape of a mountain ash leaf. This type of white macule is the most typical of TS but not the most common.

FIGURE 90-16 Tuberous sclerosis (TS). Numerous ash-leaf spots in a mother and her son with TS. Note the myriad of scattered tiny white macules, 1 to 2 mm in diameter, on the legs. These are highly characteristic of TS; the “confetti-like” hypomelanotic macules are now regarded as a “presumptive” feature of TS and are an indication for performing imaging studies.

FIGURE 90-17 Tuberous sclerosis. Segmental hypomelanosis. This shoulder macule could be mistaken for nevus depigmentosus, which is similarly off-white.

Histology of hypopigmented macules The hypopigmented macules of tuberous sclerosis are characterized by a normal to reduced number of melanocytes, which have poorly developed dendrites and which contain small and poorly melanized melanosomes.

Other cutaneous manifestations Adenoma sebaceum is a misnomer because the lesions are angiofibromas that appear as small (up to 0.3 cm) reddish brown or flesh-colored, shiny papules located centrofacially, particularly on the sides of the nose and the medial portions of the cheeks and are dealt with in Chap. 189 and Chap. 102 (Fig. 102-8). In these lesions there is a proliferation of dense collagen surrounding appendages and ectatic blood vessels (see Fig. 102-9). Other lesions are shagreen patches, flat, slightly elevated, skin-colored, or brownish plaques present in up to 80 percent and usually appearing in childhood during the first 4 years. These lesions occur on the trunk and buttocks and are not present at birth. Angiofibromas also occur in the nail folds and at subungual sides, and these lesions are called *Koenen tumors*. These periungual fibromas develop in 50 percent of tumorous sclerosis cases, appear between the ages 12 and 14, and increase progressively in size and number with age. The tumors are small, round, and flesh-colored and may be hyperkeratotic, resembling fibrokeratoma (see Chap. 189).

Diagnosis A précis of the diagnosis of TS is given in Table 90-4. The diagnosis of TS is a clinical one based on primary, secondary, and tertiary criteria. Hypomelanotic macules are the earliest clinical sign of TS. They can be detected in patient of all ages including neonates and are identified most clearly with the use of a Wood's light. The ash-leaf shaped hypomelanotic macules is most characteristic of TS. Congenital confetti macules are also particularly significant but have been found in other disorders (multiple endocrine neoplasia type 1).

TABLE 90-4 **Precis of the Diagnosis of Tuberous Sclerosis**

In a patient with three or more typical white lance-ovate or “thumb-print” macules or confetti macules, seizures, and mental retardation, the diagnosis is readily apparent and a pediatric neurologist should be consulted. Diagnostic difficulties arise when there are fewer than three macules, where there are no other features of TS, or when the issue of subclinical TS must be resolved. If occurring alone, hypomelanotic macule are not sufficient for diagnosis. The true incidence of solitary white macules in the general population is uncertain. One study of 4412 neonates found no white macules. In another study, 98 percent of congenital white spots resolved. These lesions obviously did not represent TS, but the study did not incorporate use of Wood's lamp and there was no long-term follow-up. In a large series of babies, all of those with three or more hypomelanotic macules were mentally retarded, of the eight with two macules, one had seizures and two had frank TS. None of the 60 with a solitary white macules had other clinical features of TS. Whether or not a solitary white macule is an expression of heterogeneity remains unresolved; isolated hypomelanotic macules have been found in apparently unaffected parents of affected children. While hypopigmented macules may represent secondary or tertiary criteria for diagnosis, the presence of white macules with or without CNS findings may require exclusion of the diagnosis of TS. Cranial CT scan may diagnose calcified subependymal glial nodules, and MRI may show cerebral cortical and subcortical lesions, which are not always pathognomonic. Compared with CT scans, MRI findings more closely correlate with the severity of neurologic impairment. Echocardiograms are sensitive, especially in those under 2 years of age. Abdominal ultrasound identifies renal disease in infancy and adolescence. Distinguishing between spontaneous and heritable TS can be difficult. Examination of first-degree family members with the Wood's lamp is helpful if white macules are found, but since these macules may fade with time, the absence of adult white macules does not exclude familial TS. No consensus has emerged with regard to radiologic screening of first-degree relatives of affected patients.

Differential diagnosis The differential diagnosis is that of stable congenital hypomelanotic macules (Table 90-5). The difficulties are underscored by a recent study that found hypopigmented macules (resembling those of TS) such as streaks or round to oval off-white macules to be common in apparently normal individuals.

TABLE 90-5 **Comparative Features of Nevus Depigmentosus, Tuberous Sclerosis, and Hypomelanosis of Ito**

The diagnosis of TS should be considered in every newborn with seizures and/or mental retardation. Wood's lamp examination is essential, particularly in fair-skinned individuals.

Treatment There is no treatment for the white macules of TS.

HYPOMELANOSIS AND CUTANEOUS MOSAICISM These include two different entities, hypomelanosis of Ito (HI) and phylloid hypomelanosis.

Hypomelanosis of Ito [25], [26] This disorder is also termed *incontinentia pigmenti achromians* or *pigmentary mosaicism of the Ito type.* It is characterized by randomly distributed hypomelanotic macules with a bizarre whorled and streaked marble-cake configuration (Fig. 90-18). These lesions consist of bilateral or unilateral streaks corresponding to the lines of Blaschko. [27] On the back, the lesions resemble an inverted Christmas tree. Any part of the body, including the face, may be involved. The lesions present at birth become recognizable during the natal period or early childhood. Other types of pigmentary patterns such as a checkerboard arrangement likewise have been described. HI is often associated with extracutaneous anomalles (75 percent). They include CNS abnormalities (seizures, mental or motor retardation, microcephaly, hypotony, hyperkinesias, ataxia, and deafness), ophthalmologic abnormalities (ptosis, nonclosure of the upper lid, symblepharon, dacryostenosis, strabismus, nystagmus, corneal opacification, cataracts, myopia, amblyopia, microphthalmia, iridal heterochromia, scleral melanosis, patchy hypopigmented fundi, and retinal degeneration), enamel changes and other dental defects, and skeletal defects (short stature, pectus carinatum or excavatum, scoliosis, syndactyly, polydactyly, brachydactyly, clinodactyly, asymmetry of limbs, and facial asymmetry). HI is a cutaneous sign of many different forms of genomic mosaicism. Indeed, karyotypic abnormalities of different chromosomes are found in lymphocytes and fibroblasts and rarely kératinocytes. Mosaicism affecting melanocytes has not yet been demonstrated. Histologic and ultrastructural studies show rounded melanocytes with reduced or absent dendrites and slightly decreased epidermal melanin pigmentation.

FIGURE 90-18 Hypomelanosis of Ito. Over 75 percent of patients will have abnormalities of the eyes, musculoskeletal system, and/or nervous system. Swirls of hypomelanosis on the chest of an infant who had similar lesions on the back.

DIAGNOSIS The clinical picture is characteristic enough to suggest the diagnosis when the whorled pattern is present (see Table 90-5).

Phylloid hypomelanosis [28] This newly recognized disorder is characterized by round or oval hypomelanotic macules resembling the asymmetric leaves of a begonia or oblong lesions. A mosaic trisomy 13 or translocation trisomy 13 has been found in the peripheral blood lymphocytes of a majority of patients with this phylloid hypomelanotic pattern. All patients had CNS defects: mental retardation, absence of corpus callosum, conductive hearing loss, choroidal and retinal coloboma, craniofacial defects, as well as brachydactyly, camptodactyly, and other skeletal abnormalities. In contrast to HI which is a cutaneous sign of many different forms of genomic mosaicism, phylloid hypomelanosis appears to be a cytogenetically rather uniform neurocutaneous phenotype.

Nevus depigmentosus Whether nevus depigmentosus (ND) is a distinct entity or a manifestation of cutaneous mosaicism is still a matter of debate. ND occurs equally among males and females and can affect any ethnic group. Three clinical forms of ND are described: an isolated, circular or rectangular macule or, less commonly, a dermatomal or quasi-dermatomal pattern (Fig 90-19) or a systematized (unilateral whorls or streaks) form. The hypomelanotic lesions remains stable throughout life. ND occurs most commonly on the trunk and proximal extremities. ND typically does not cross the midline. Rare reports of associated findings (seizures, mental retardation, limb hypertrophy) have been reported. Several authors believe that HI and ND belong to cutaneous mosaicism. Cytogenetic abnormalities in ND patients have not yet demonstrated.

FIGURE 90-19 Nevus depigmentosus. This congenital nevoid off-white stable hypomelanosis, unlike segmental vitiligo, does not usually change in size or color over time. This linear nevus depigmentosus involves one leg posteriorly.

INCONTINENTIA PIGMENTI (IP) (See Chap. 143 and Chap. 188) IP is a syndrome characterized by skin lesions that are arranged in a linear pattern. [29] This uncommon X-linked dominant disorder, generally lethal in males, has three stages: vesiculobullous, verrucous, and hyperpigmented. However, in about 13 percent there is a fourth stage, that of swirls of hypopigmentation, consisting of atrophic hypo- or amelanotic bands of streaks that fail to tan with sun exposure.

In addition, these lesions are hypohydrotic and hairless. Hypomelanosis is a late manifestation of the disease, observed most commonly in adults. Hypomelanosis involves mainly the back but also the abdomen and the limbs. The pathogenesis of these lesions is not understood. Hypomelanotic lesions of IP share with HI the streaky distribution and the frequent occurrence of extracutaneous abnormalities. However in HI, hypomelanotic lesions are either recognized at birth or become visible during the neonatal period or early childhood. [29]

ATAXIA TELANGIECTASIA (See Chap. 191) Ataxia telangiectasia may be associated with premature graying of hair and with hypomelanotic macules. Vitiligo-like leukoderma has been reported in a few patients.

XERODERMA PIGMENTOSUM (See Chap. 155) Hypopigmented lesions 1 to 5 mm in diameter have been reported in patients with xeroderma pigmentosum. No melanocytes are present in the centers of the lesions, and decreased numbers of melanocytes are found at the margins. These melanocytes in both normally sun-exposed and unexposed areas of skin are bizarre in that they are characterized by melanin macroglobules, melanosomes aggregated in autophagic vacuoles, abnormal melanin deposition, and few melanosomes in upper-level keratinocytes alone.

PREUS SYNDROME The association of growth retardation, dolichocephaly, cataracts, high arched palate, small, widely spaced teeth, generalized hypopigmentation (tyrosinase positive), psychomotor retardation, and hypochromic anemia has been reported in two siblings of consanguineous parents. An additional patient has been reported with additional features (coxa valga, generalized osteoporosis). This disorder appears to be distinct from the oculocerebral hypopigmentation described by Cross. [4]

MISCELLANEOUS DISORDERS Circumscribed hypomelanosis also has been described in the focal dermal hypoplasia syndrome (linear or reticular pattern), in punctate keratosis of palms and soles, and in ectodermal dysplasia.

Hypomelanosis Associated with Nutritional Disorders

KWASHIORKOR (See Chap. 145) In kwashiorkor, the depigmentation, which may precede other features by weeks, begins on the face. A shiny erythema is followed by raised plaques that gradually darken until they assume a shiny black appearance. Exfoliation may be followed by depigmentation; the latter patches may repigment with hypermelanosis. The lesions are most common on sites of pressure. A generalized pallor also may occur. Red-brown to gray or golden hair is common. The hypopigmentation has been attributed to disruption of normal melanogenesis. The hypomelanosis and dyschromic hair are reversible with dietary correction.

SELENIUM DEFICIENCY Two children with selenium deficiency following long-term parenteral nutrition developed pigmentary dilution of the hair and skin. After 6 months of selenium replacement, the two children with decreased pigmentation became dark-skinned, and their hair color changed from blond to dark brown. A third child's hair, which had been blond, also became darker. The mechanism by which selenium contributes to hair and skin color changes is as yet unknown.

Hypomelanosis Associated with Endocrinopathies

Numerous endocrinopathies have been associated with pigmentary dilution (see Chap. 169).

Hypopituitarism is associated with reversible hypomelanosis secondary to decreased MSH and ACTH production. Depigmentation of the extensor hands and feet has been reported in a patient with adrenal insufficiency secondary to defective corticotropin-releasing factor; since ACTH levels were not increased, the pigmentary abnormality was attributed to presumed decreased MSH levels. Most cases of selective ACTH deficiency are not associated with hypopigmentation, however.

Hypogonadism may be associated with pallid skin. One male eunuch tanned poorly until after testosterone therapy; he then tanned deeply in sun-exposed areas. Orchiectomy has been reported to decrease melanin pigmentation of the skin in men.

Hypomelanosis Secondary to Physical Trauma [30]

Hypomelanosis may result from a multitude of types of trauma, including thermal injury, physical injury, hypothermia and freezing, and x-ray, ionizing, and UV irradiation. X-rays have long been known to cause depigmentation. Epilating doses of x-rays have been shown to result in regrowth of white hair. This appears to result from the loss of functioning melanocytes.

Hypomelanoses Resulting from Chemical Exposure

CHEMICAL LEUKODERMA [31], [32] Chemical leukoderma is an acquired hypomelanosis arising from repeated exposure to specific chemical compounds, particularly certain phenol derivatives and sulfhydryl compounds. Awareness of chemical leukoderma dates from a report of a vitiligo-like leukoderma appearing among tannery workers exposed to monobenzylether of hydroquinone (MBEH), which was being used as an antioxidant. Chemical compounds reported to cause chemical leukoderma are listed in Table 90-6. Exposure may be reasonably widespread. MBEH, for example, is found not only in disinfectants and germicides but also in rubber-covered wire dish trays, adhesive tape, hatbands, contraceptive diaphragms, rubber finger cots, rubber clothing, rubber aprons, powdered rubber condoms, rubber dolls, neoprene, and fabric-lined rubber gloves; all of the latter have been implicated in production of chemical leukoderma. Previously unsuspected by-products of rubber processing have been shown to be parasubstituted phenols, which may be implicated in chemical leukoderma. Certain medications may cause pigmentary dilution. Topical tretinoin can cause subtle hypomelanosis and reversal of hyperpigmentation. Intralesional cortiosteroids also can cause ill-defined hypomelanosis. Benzoyl peroxides (acne preparations) bleach hair. Cinnamic aldehyde, once in toothpaste, has been shown to cause a vitiligo-like leukoderma. Soymilk and two soymilk-derived proteins (soybean trypsin inhibitor and Bownran-birk protease inhibitor) inhibit the protease-activated receptor 2 (PAR-2) that regulates pigmentation via keratinocyte-melanocyte interactions. This inhibition of PAR-2 blocks melanosome transfer and thus induces skin depigmentation. The use of PAR-2 inhibitors could lead to new class of depigmenting agents. [33]

Phenols/catechols	Miscellaneous/unclassified
Alkyl phenol	Ammoniated mercury
Butylated hydroxytoluene	Arsenic
Catechol	Benzoyl peroxide
Dihydroxyphenylmethane	Brilliant lake red R
Hydroquinone	Carmustine (BCNU)
4-Isopropylcatechol	Chloroquine
Methylcatechol	Cinnamic aldehyde
Monobenzylether of hydroquinone	Dinitrochlorobenzene (DNCB)
Monoethylether of hydroquinone	Eserine
Monomethylether of hydroquinone	Fluorouracil
p-Tertiary amylphenol	Glucocorticoids
p-Tertiary butylcatechol	Guanonitrofuracin
p-Tertiary butylphenol	Thiotepa
Tretinoin	
Sulfhydryls	
β-Mercaptoethylamine HCl	
β-Mercaptoethylamine HCl	
β-Metcaptopropylamine HCl	
N-(2-Mercaptoethyl)-dimethylamine	
Sultanolic acid	

TABLE 90-6 **Chemicals Implicated in Causing Chemical Leukoderma**

Clinical features The leukoderma attributed to MBEH and other substances resembles that of vitiligo (Fig. 90-20). Hypomelanotic macules are milk-white and appear not only at the site of contact with the offending compound but also remotely. Remote or satellite lesions are guttate or confetti macules. A prior irritant or contact eruption is not required for the leukoderma to develop. In early stages, the leukoderma may be reversible if the chemical exposure is stopped.

FIGURE 90-20 Chemical leukoderma. *A.* O-Syl (a phenolic disinfectant)–induced chemical leukoderma that mimics vitiligo clinically. Repeated exposure is required to depigment, but antecedent clinical inflammation is not observed. *B.* Reversible hypomelanosis of the face in a South African woman after several weeks application of topical hydroquinone. Note color contrast of face to that of (untreated) hand. *C.* African American factory worker depigmented from repeated exposure to monobenzylether of hydroquinone.

In contrast to leukoderma due to MBEH, which is vitiligo-like and sharply defined, hypomelanosis due to hydroquinone usually does not have sharp margins (Fig. 90-20B) and is usually a more subtle, ill-defined hypomelanosis. Complete depigmentation and satellite depigmentation do not occur. Hydroquinone has been used for many years to lighten the skin to an acceptable cosmetic color.

Histology Chemical leukoderma has no typical diagnostic features to distinguish it from vitiligo; typically, melanocytes are absent, and there are no dermal or other epidermal changes in established macules. Histologic evidence of melanocyte disruption and destruction may be noted in evolving lesions.

Pathophysiology There are many possible mechanisms involved in cutaneous depigmentation induced by chemicals. These include selective action on the melanocyte through free-radical formation, competitive inhibition of tyrosinase, inhibition of oxidation of tyrosine to dopa synthesis, interference with premelanosome or melanosome synthesis, interference with tyrosinase synthesis by combining with melanocytic ribosomes, interference with transfer of melanosomes from melanocytes to keratinocytes by inhibition of arborization of melanocytic dendrites, and reduction of melanin present in melanosomes. Sulfhydryls may be cytotoxic agents that alter or block melanin formation through inhibition of tyrosinase or promote the production of phaeomelanins and their colorless metabolites rather than eumelanogenesis.

Diagnosis Chemical leukoderma always should be in the differential diagnosis of vitiligo (Table 90-7) or any other acquired, circumscribed, progressive amelanosis. The site of the initial leukoderma should correspond to the area of primary and repeated chemical exposure. A presumptive diagnosis may be made on the basis of history of repeated exposures to known or suspected leukoderma-producing agents (see Table 90-6); leukoderma that follows an untoward single exposure to a chemical may result in postinflammatory leukoderma or koebnerization in a patient with a vitiligo diathesis. Unfortunately, there is no definitive test or histology to distinguish vitiligo from chemical leukoderma. Despite isolated reports of abnormal thyroid studies or hepatosplenomegaly, most patients with chemical leukoderma are healthy.

TABLE 90-7 **Comparative Features of Chemical Leukoderma and Vitiligo**

Treatment Established chemical leukoderma is irreversible if the offending chemical is not eliminated soon enough. Early localized cases may be reversed by discontinuing the offending chemical and, if necessary, by topical or oral PUVA; as with vitiligo, established acral and mucosal macules are usually refractory to repigmentation. Discontinuation of the exposure is mandatory; surveillance of the environment to exclude others at risk is equally prudent. Hydroquinone-induced leukoderma is usually spontaneously reversible, particularly with small amounts of solar

irradiation. The subtle hypomelanosis secondary to topical tretinoin is also slowly reversible on discontinuation of the preparation. Hypopigmentation secondary to topical steroids is also usually spontaneously reversible, but that secondary to intralesional glucocorticoids may be amelanotic and persistent, particularly in patients of SPT V and VI.

POSTINFLAMMATORY HYPOMELANOSIS A number of inflammatory dermatoses may be associated with or may resolve to leave hypomelanotic macules corresponding to the cutaneous sites of involvement. This is seen commonly with atopic dermatitis, eczematous dermatitis, and psoriasis but also less commonly with chronic guttate parapsoriasis, pityriasis lichenoides chronica, alopecia mucinosa, mycosis fungoides, discoid lupus erythematosus, lichen planus, lichen striatus, and seborrheic dermatitis. [34]

Clinical features Most cases of postinflammatory hypomelanosis are clinically similar regardless of the preexisting inflammatory dermatosis. The macules are tan to off-white with indiscrete margins and always correspond to sites of prior eruption (Fig. 90-21). The hypomelanosis immediately follows resolution of the primary process and starts to fade over weeks to months, particularly in sun-exposed areas.

FIGURE 90-21 Postinflammatory hypomelanosis (psoriasis). The hypomelanotic lesions correspond exactly to the antecedent eruption. There is some residual psoriasis within the lesions.

Pathogenesis This process is considered to result from a melanosome transfer block. In eczema, the defect may result from edema, whereas markedly increased epidermal turnover may be responsible in psoriasis. In T cell lymphoma, there are degenerative changes in melanocytes and spherical melanosomes.

Diagnosis The diagnosis rests on the observation or the history of the associated dermatosis. When the diagnosis is unclear, biopsy of a hypomelanotic lesion may reveal histologic evidence of the underlying dermatosis.

Treatment Treatment is normally that of the underlying disorder. Once the inflammatory process has resolved, normally constitutive skin color is slowly reestablished. This may be facilitated by solar exposure; the color of macules will not normalize, however, so long as the inflammatory process is present.

MYCOSIS FUNGOIDES (See Chap. 157) Hypopigmentation in mycosis fungoides has been reported in patients of darker skin types. The eruption clinically resembles tinea versicolor, generalized pityriasis alba, postinflammatory hypopigmentation, or vitiligo (including trichrome vitiligo). Involvement tends to be more central than acral. Onset may, however, occur in the teens. Histologically, hypopigmented mycosis fungoides lacks epidermal atrophy and demonstrates moderate to marked exocytosis resembling pagetoid reticulosis. The number of melanocytes is generally reduced, and reduced numbers of melanosomes in keratinocytes suggested a transfer block. PUVA therapy is very effective. Topical nitrogen mustard and topical carmustine are also effective.

PITYRIASIS ALBA Pityriasis alba is a common hypomelanosis that occurs in all races, although it is considered more common, perhaps just more obvious, in blacks.

Clinical features Pityriasis alba is generally a disorder of young children and affects males and females equally. The typical macule is pale pink or light brown with very indistinct margins. The subtle erythema fades over weeks to leave an off-white to tan-white macule with a powdery scale (Fig. 90-22). The face, particularly the midforehead, malar ridges, and around the eyes and mouth, is the most commonly involved area, but macules on the neck, trunk, back, limbs, and scrotum do occur. Macules vary from 5 to 30 mm or larger. While only 2 or 3 lesions are usually present, from 1 to over 20 are possible. Usually pityriasis alba is asymptomatic, but some patients complain of burning or itching. The macules, once present, are usually stable and then gradually disappear with age; however, persistence into adulthood has been reported. *Pigmenting pityriasis alba* is a variant in which there is a central bluish coloration of involved macules. The histology is nonspecific.

FIGURE 90-22 Pityriasis alba. The lesions are typically hypomelanotic, finely scaling, and have indistinct borders. Spontaneous resolution is typical but slow.

Pathogenesis Pityriasis alba is probably an eczematous dermatosis with hypomelanosis resulting from postinflammatory changes and ultraviolet screening effects of the hyperkeratotic and parakeratotic epidermis.

Diagnosis The absence of a positive scraping readily excludes tinea versicolor. The tan color, indistinct margins, and appearance under Wood's lamp examination exclude vitiligo.

Treatment Treatment of pityriasis alba is often not satisfactory, but the condition is self-limited. Topical glucocorticoids are useful. PUVA has been found to be effective for extensive pityriasis alba.

Hypomelanosis Associated with Infection [35]

TINEA VERSICOLOR (See Chap. 206) Tinea versicolor is caused by the lipophilic yeast *Malassezia furfur*. The typical lesion is a round, scaling hypomelanotic macule that is occasionally raised and may have erythematous raised margins (Fig. 90-23). Individual macules are several millimeters to a centimeter in diameter. Macules may increase in number and in size so that they may become confluent; this imparts a scalloped appearance to the border. The macules occur typically on the upper back and chest but also may occur on the upper arms, neck, and face, especially in patients living in the tropics. Tan, hyperpigmented and erythematous macules may precede and/or coexist with hypopigmented macules; these have features otherwise similar to the white macules. The disease is chronic, although as the summer tan fades, the lesions may become less obvious. In contrast to vitiligo, tinea versicolor has fine, often barely perceptible, dustlike scales.

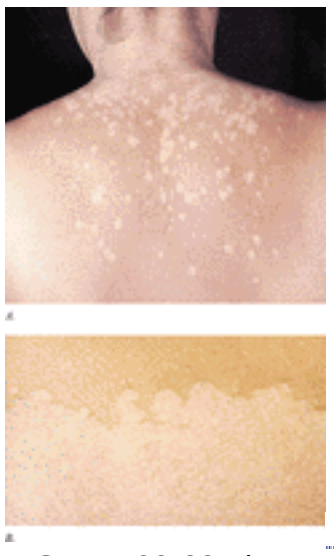

FIGURE 90-23 Tinea versicolor. *A.* Typical macules are round, very well circumscribed, have fine scale, and are off-white to tan in color. Typical distribution involves the upper back and upper chest. Involvement of the lower arms and legs and of the face is unusual. *B.* Confluent macules create scalloped borders. This is a characteristic pattern of macules of tinea versicolor.

Pathogenesis It has been suggested that the depigmentation in tinea versicolor results from inhibition of tyrosinase by C_9 and C_{11} dicarboxylic acids, such as azelaic acid, which are formed by cultures of this lipophilic yeast and which, in cultures, inhibit tyrosinase activity. For diagnosis and treatment, see Chap. 206.

TREPONEMATOSES (See Chap. 229)

Clinical features Hypochromia is commonly a late feature of pinta. Secondary lesions, or *pintides,* are usually erythematous or copper-colored, then slate-blue, and finally mottled with both hypo- and hyperpigmentation. Macules occur symmetrically over bony prominences, namely, elbows, knuckles, knees, ankles, and flexor wrists. The margins are distinct and may be outlined with peripheral hypermelanosis. Lesions are usually milk-white (Fig. 90-24). For histology, pathogenesis, diagnosis, and treatment, see Chap. 229.

FIGURE 90-24 Pinta. The hypomelanosis in pinta is a vitiligo-like hypomelanosis that occurs later in the disease and is associated with deep blue to slate-gray areas of hyperpigmentation.

Depigmentation in Bejel (nonvenereal syphilis) is an uncommon feature of the late stage and may resemble pinta. Early use of penicillin may result in repigmentation. The primary lesion of yaws, at the site of inoculation, may heal to leave atrophic hypochromic or achromic scars that occasionally have dark halos. Rarely, lenticular or hypochromic macules occur in secondary yaws. Most commonly, the hypomelanosis follows the tertiary stage of the disease; lesions are symmetrically placed and particularly involve the anterior wrists (with a triangular macule pointing dorsally), dorsal hands, small joints over the extensor hands, and less commonly, the feet. Lesions are depigmented and tend to enlarge centrifugally. Treatment in the infectious stages prevents the characteristic late leukoderma (see Chap. 229).

ONCHOCERCIASIS (See Chap. 236) The depigmentation is a late feature and usually involves the pretibial skin—usually bilaterally; the groin and the pelvic and axillary areas less commonly may become depigmented. This hypomelanosis gives the patient a leopard-like appearance. Repigmentation from the margins occurs in some cases. Melanocytes are absent in the later stages.

POST-KALA-AZAR (See Chap. 235) The lesions begin as pinpoint hypopigmented macules and gradually enlarge to a centimeter or so in diameter. The most common sites are the chest, back, arms, anterior thighs, and neck; the skin from the waist to the feet is conspicuously spared. In later stages, the lesions become raised. The lesions are asymptomatic. The hypomelanosis is generally irreversible, even with treatment.

LEPROSY (See Chap. 202) The presence of anesthetic hypomelanotic macules is virtually diagnostic. The numbers of

such lesions vary from a solitary lesion (Fig. 90-25) to a few in indeterminate and tuberculoid leprosy to many in borderline and lepromatous leprosy. Lesions are most common in the brachial and lumbar plexus areas of skin; they are usually small, except in the lepromatous type, which is characterized by large lesions. Tuberculoid lesions are well delineated, as may be the lesions in indeterminate leprosy, but borderline and lepromatous lesions have ill-defined margins.

FIGURE 90-25 A characteristic off-white hypomelanotic and anesthetic macule of leprosy.

Hypomelanosis Associated with Tumors

Tumors have been associated with leukoderma in two different instances, the halo nevus, and a much more insidious process, melanoma-associated leukoderma.

HALO NEVI (See Chap. 91) Halo nevus, also referred to as *Sutton's nevus* or *leukoderma acquisitum centrifigum,* is a nevus surrounded by a macule of leukoderma.
MELANOMA-ASSOCIATED LEUKODERMA (See Chap. 93) Several types of hypomelanosis may be associated with melanoma, and any type of melanoma may be associated with hypomelanosis. The first type, analogous to halo nevus, is associated with a primary melanoma; it has an eccentrically placed irregular halo. The second type is a remote leukoderma, well distant from the primary lesion. The third type is vitiligo-like (Fig. 90-26A). Halos also may develop around metastatic lesions (Fig. 90-26B). In addition, leukoderma may develop at sites distant from the tumor or its metastases. The prevalence has been suggested to be from 1.3 to 20 percent of melanoma patients. Among 42 reported cases, the time of onset of the melanoma and of the leukoderma were fairly close. In many, the depigmentation appeared between several months and 5 years after the appearance of the tumor, but usually in patients older than 40 years of age. In two cases, the leukoderma came first, and none of the patients had a family history of vitiligo. Most cases are associated with visceral or lymph node involvement.

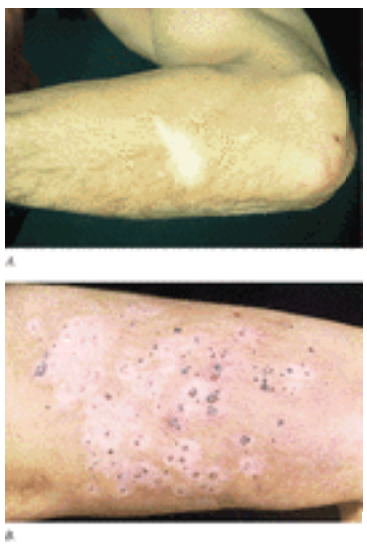

FIGURE 90-26 Melanoma-associated leukoderma. *A.* This hypomelanosis may resemble vitiligo clinically and be characterized by an absence of melanocytes. It may be associated with a favorable prognosis. *B.* These macules in a different patient developed after the patient developed metastases to the skin. They surround the individual metastases.

Clinical features Melanoma-associated leukoderma is a diffuse vitiligo-like macular hypomelanosis or depigmentation. It develops distant from the melanoma, is frequently first observed on the trunk, and may spread to the extremities. It may be symmetric or asymmetric. The hypomelanosis may be mottled (hypomelanotic) or milk-white, as in vitiligo (amelanotic) (see Fig. 90-26A). Spontaneous repigmentation may occur. Uveitis also may be observed. Histologically, there is an absence of melanocytes in established lesions or reduced numbers of melanocytes with very stubby dendrites in earlier lesions.
Pathogenesis Strong evidence suggests that melanoma-associated hypomelanosis is the visible consequence of a cellular antitumoral response. The hypomelanosis infiltrates lymphocytes and most exclusively T lymphocytes, and most are CD8+. These CD8+ T cells have a clonal or oligoclonal T cell receptor profile, and they specifically recognize differentiation antigens shared by normal melanocytes and melanoma cells. [36]

Hypomelanoses—Idiopathic, Circumscribed

IDIOPATHIC GUTTATE HYPOMELANOSIS (IGH) IGH is a common acquired, discrete hypomelanosis particularly affecting the extremities in darker-skinned individuals. [37]
Clinical features IGH is probably found in all races but is simply most apparent in darker-skinned ones. Males and

females are equally affected. Typical lesions are very discrete, well-circumscribed, porcelain-white macules (Fig. 90-27), occasionally containing black dots. The lesions are usually round but may be stellate; they average about 5 mm in diameter but may be from 1 mm to about 2 cm in diameter. The lesions number from few to many, may increase in number and in size with age, and are most common in sun-exposed areas of the extremities, particularly the anterior lower legs, but are not observed on the face. The lesions are asymptomatic and irreversible.

FIGURE 90-27 Idiopathic guttate hypomelanosis. Lesions on the leg of an African American individual.

Histology and electron microscopy The most consistent histologic abnormalities include flattening of the dermal-epidermal junction, a moderate to marked reduction of the melanin granules in the basal and prickle cell layers, epidermal atrophy, and basket-weave hyperkeratosis. Changes in collagen and elastic fibers are less common. There is a moderate reduction in the number of melanocytes, and they have stubby dendrites.
Pathogenesis There appear to be two general types of IGH. The first is the actinic type. The second is a nonactinic familial type, which does not necessarily occur on sun-exposed areas and is found particularly on the trunk, especially in individuals of SPT VI. A genetic predisposition is possible.
Diagnosis Clinically, the lesions must be distinguished from vitiligo, tinea versicolor, tuberous sclerosis, chemical depigmentation, and postinflammatory hypomelanosis. Careful examination with a hand lens reveals the very sharp, discrete margins and porcelain-colored smooth surface not found in entities other than IGH.
Treatment The cosmetic significance of lesions of IGH, particularly in darker-skinned individuals, should not be minimized. However, reports of successful treatment of IGH are few. Improvement may be achieved with intralesional triamcinolone, with or without small grafts in the center of the hypopigmented lesions; permanency remains to be established, however. Cryotherapy has given mixed results. PUVA has not proved successful.

Confetti Leukoderma

Confetti leukoderma refers to small, 1- to 3-mm hypopigmented cutaneous macules. These may be found as macular lesions in vitiligo, *leukoderma punctatum* in patients undergoing PUVA therapy (see below), tuberous sclerosis, chemical leukoderma, tinea versicolor, IGH, and photoaging. Perifollicular hypopigmentation may be observed in vitiligo, tinea versicolor, Grover's disease, and Darier's disease. A few patients with multiple endocrine neoplasia type 1 have been observed to have confetti-like hypomelanotic macules; these macules are more likely on the neck and trunk, whereas those of tuberous sclerosis are found on the extremities. Confetti hypomelanosis also may present as small raised papules in disseminated hypopigmented keratoses. *White lentiginosis* is a very unusual disorder characterized by flat to raised keratotic and depigmented macules of the trunk. Histologically, features include a lentiginous hyperplasia of the epidermis with elongated club-shaped rete ridges and a loss of epidermal pigmentation with abnormal keratinization.

Miscellaneous Types of Hypomelanosis

HEMODIALYSIS Widespread acquired hypopigmentation of the hair and skin has been described in uremia patients undergoing maintenance hemodialysis.
PIGMENTARY DEMARCATION LINES Futcher's or Voigt's lines, known as *pigmentary demarcation lines,* are abrupt transitions from deeply pigmented skin to lighter-pigmented skin (Fig. 90-28) commonly found in African Americans and darker-skinned Caucasians. Pigmentary demarcation lines have been noted in up to 10 percent of Caucasians and 4 percent of Japanese; they are often present at birth or develop in early childhood and tend to darken with time.

FIGURE 90-28 Pigmentary demarcation line. These lines are often barely perceptible and not unusual in darker-skinned phototypes.

PROGRESSIVE MACULAR HYPOMELANOSIS OF THE TRUNK A condition frequently observed in the West Indies is characterized by a progressively spreading macular hypomelanosis of the trunk and is found mainly in females from 18 to 25 years of age. Microscopic examination of the hypochromic macules reveals a slight reduction in epidermal melanin. Ultrastructural examination of the macules shows a switch from type IV single melanosomes to small, aggregated type I to III melanosomes. These findings suggest that this disorder may result from a variation in melanosome size and distribution. This disorder does not respond to treatment but does regress spontaneously within 3 to 4 years.
SARCOIDOSIS (See Chap. 183) Only a few cases have been described in the literature. Hypopigmented sarcoidosis appears to be more common in dark-skinned individuals. Spontaneous or PUVA-induced repigmentation of the hypopigmented macules of sarcoidosis may occur. [38]
SCLERODERMA [39] **(See Chap. 173)** A vitiligo-like hypomelanosis has been described with scleroderma. The lesions are located primarily on the upper trunk and distal extremities and are amelanotic with perifollicular sparing; this resembles repigmenting vitiligo except for the additional presence of atrophy.
VAGABOND'S LEUKODERMA Vagabond's leukoderma is actually a leukomelanoderma found in older, ill-kempt men and women with a history of poor hygiene, inadequate diet, and chronic alcohol abuse. Depigmented macules are found in diffuse, light-brown, hyperpigmented patches around the waist and groin, on the buttocks, in the axillae, over the back, and on the back of the neck. The arms, legs, and face are usually less dramatically involved. Vagabond's leukoderma has been attributed to multiple ectoparasitic infections. Dietary management and good hygiene usually reverse the pigmentary abnormalities.

Hypomelanosis of Hair Alone (Canities)

There are numerous entities, besides physiologic aging, associated with graying or whitening of the hair as a predominant pigmentary abnormality. This may be expressed as diffuse graying, or canities, or as focal hypomelanosis, or poliosis. The entities to be considered in this section are associated with canities and/or poliosis but not with hypomelanosis of the skin. They include many genetic syndromes such as Fanconi's syndrome, myotonia dystrophica, Rothmund-Thomson syndrome, Seckel's syndrome, Böö's syndrome (bicuspid aplasia, premature whitening of hair, and hyperhidrosis transmitted as an autosomal dominant trait), Fisch syndrome (early graying of hair and deafness without the typical features of WS), and premature aging syndromes (Werner's syndrome, progeria). Diffuse pigmentary dilution of hair may accompany acquired disorders such as nutritional deficiency, iron deficiency, zinc deficiency, kwashiorkor, pernicious anemia, celiac disease, ulcerative colitis, and necrotizing enterocolitis. Numerous medications and chemicals have been associated with hypomelanosis of hair. Both chloroquine and hydroxychloroquine may cause hypopigmentation of scalp hair, especially in blondes; eyelids and eyelashes also may be affected. Mephenesin also has been reported to cause reversible lightening of hair color. Triparanol and valproic acid have been associated with lightening of hair in isolated cases. [40]

PHYSIOLOGIC GRAYING OF HAIR Graying of hair is a normal concomitant of aging. While graying is more readily apparent in those with black hair, fair-haired individuals appear totally gray earlier. Clinically, graying begins at the temples, spreads to the vertex, and slowly involves the entire scalp. Beard and body hair become gray later, but axillary, pubic, and chest hair may remain pigmented even in old age. While graying is ultimately irreversible, temporary reversal even to darker than the preexisting hair color may follow inflammation, particularly folliculitis. Histochemically, there is a gradual loss of melanocytes. Animal models do provide some insight. Bcl-2–deficient mice demonstrate hypopigmented hair that turns gray during the second hair cycle. In these animals, an accelerated disappearance of follicular melanocytes by apoptosis mimics the loss of melanocytes in human senile gray and white hair. In the light mouse, a mutation in the tyrosinase-related protein gene (*Trp1*) results in hairs pigmented only at their tips. This phenotype is due to premature death of melanocytes, mediated through the inherent cytotoxicity of pigment production. Premature aging with early graying is observed in DNA repair and transcription abnormalities resulting from a mutation in *XPD,* a gene encoding a DNA helicase.
SUDDEN WHITENING OF HAIR There is no known physiologic mechanism to explain abrupt depigmentation of established hairs. Rather, this is an expression of alopecia areata in which the pigmented hairs are lost selectively. Regrowth also may be white and be characterized by a total absence of melanocytes or by reduced numbers of melanocytes with poorly developed dendritic processes. Degenerative melanocytes have been observed only in the presence of adjacent keratinocytes showing necrosis.

Hypopigmentation Unrelated to Melanin Pigmentation

NEVUS ANEMICUS (Fig. 90-29)

FIGURE 90-29 Nevus anemicus. This entity is a pharmacologic nevus; unlike melanocytic disorders, pressure over the lesion with a glass slide causes the lesion to become inapparent; nevus anemicus becomes invisible under the Wood's lamp but becomes more prominent after rubbing, which induces vasodilatation only in the adjacent uninvolved skin. (*Courtesy of RA Johnson, MD.*)

Nevus anemicus is an uncommon congenital, localized vascular malformation observed more frequently in women than in men. Most lesions occur on the chest, but involvement of the face and extremities also occurs. The typical macule appears to be off-white, not totally colorless, but is capable of exhibiting a delayed tanning reaction. Wood's lamp examination does not accentuate nevus anemicus, unlike true hypomelanoses. Pressure on the lesion from a glass slide makes the lesion inapparent. Finally, friction or cold or heat application fails to induce erythema in the leukoderma areas. The histology is normal, and the vascular structures are normal by electron microscopy. The defect of nevus anemicus may be at the motor endplate or at the smooth muscle effector cells of the blood vessels or arises from a focal increased blood vessel sensitivity to catecholamines.
BIER SPOTS Bier spots are small, light macules usually found on the arms and legs of young adults. The intervening skin may seem erythematous but blanches with pressure so that the light macules disappear. This is a benign physiologic vascular anomaly of no significance.
WORONOFF'S RING Woronoff's ring is a hypomelanotic ring surrounding psoriatic lesions under treatment secondary to vascular rather than melanin-related changes.

HYPERMELANOSES

Epidermal Hypermelanoses

Epidermal hypermelanosis refers to brown hyperpigmentation that results from increased melanin in the epidermis. This is generally caused by increased melanin production by existing melanocytes (melanotic hyperpigmentation) and less often by increased proliferation of active melanocytes (melanocytotic hyperpigmentation).

Epidermal hypermelanosis also may be categorized by pattern. There may be diffuse hypermelanosis or localized circumscribed lesions like café-au-lait macules, or the lesions may be multiple. Multiple lesions may be, scattered, isolated, discrete macules like ephelides, reticulated macules like Dowling-Degos disease, or ill-defined ones like postinflammatory lesions. Lesions may have particularly characteristic anatomic locations such as the face in melasma and hands in acral melanoses.

Some hypermelanoses can present with a banding pattern. These lesions are described with various terms such as *agminated, linear, segmental, zosteriform,* or *following Blaschko lines.* Typical examples include partial unilateral lentiginosis, linear whorled hypermelanosis, segmentary neurofibromatosis, McCune-Albright syndrome, speckled lentiginous nevus, or stage IV IP. Beyond these clinical aspects, there is growing evidence that most, if not all, entities that fall into this category are caused by a common mechanism of somatic mosaicism. The same concept probably stands true for hypomelanoses presenting with a banding pattern, such as hypomelanosis of Ito, nevus depigmentosus, or stage III incontinentia pigmenti (see above). A clinicopathologic classification of epidermal hypermelanoses is given in Table 90-8.

TABLE 90-8 **Epidermal Hypermelanoses: Clinicopathologic Classification of Disorders**

MELANOCYTOTIC EPIDERMAL HYPERMELANOSES Lentigines are small, usually less than 5 mm in diameter, circumscribed, brown to dark-brown to black, variegated to uniformly colored macules. They may be found as isolated macules in sun-exposed areas or as multiple lesions on any cutaneous surface, including the palms and soles. Lentigines are characterized histologically by basilar hyperpigmentation with melanocyte proliferation in elongated epidermal rete ridges. Syndromes with multiple lentigines in a characteristic nonrandom pattern are know *lentiginoses*. Some lentiginoses have a defined set of associated extracutaneous anomalies.
Lentigo simplex (See also Chap. 91) *Lentigo simplex* is the term applied to isolated lentigines found on any cutaneous site irrespective of UV exposure (Fig. 90-30). Apart from some lentiginoses, there is no known genetic predisposition for lentigo simplex. Lentigo simplex also can occur on the oral and genital mucosa. In the nail, lentigo simplex is a possible cause of melanonychia striata longitudinalis.

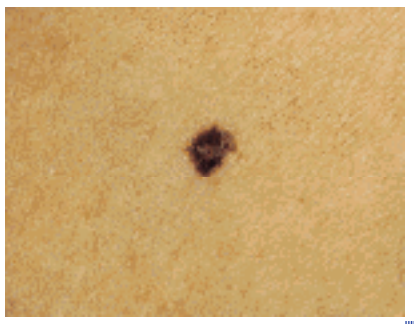

FIGURE 90-30 Lentigo simplex, a slightly irregular dark brown to black spot, level with the skin.

Lentigo senilis (actinica) (See also Chap. 91 and Chap. 134) *Lentigo senilis et actinica,* more commonly known as *senile* or *actinic lentigo* or *solar lentigo,* is the term applied to lentigines induced by UV radiation (Fig. 90-31). The prevalence of actinic lentigines is correlated with low-grade phototype and increasing age. They are present in 90 percent of Caucasians older than 60 years. Sun-exposed areas, especially the face and hands, are involved. Their diameters range from less than 1 mm to a few centimeters. They are usually light brown, occasionally black. They may persist with minimal or no fading in the absence of sun exposure. They differ from ephelides, which generally occur in Caucasian children and fade or disappear when sun exposure is discontinued. Specific variants include ink-spot lentigo, PUVA lentigo, sunbed lentigo. Ink-spot lentigo is a variant characterized by its jet-black color and reticulated border. PUVA lentigines are found in patients receiving extensive PUVA. Sunbed lentigines have been described after the use of UVA sunbeds.



FIGURE 90-31 Actinic or solar lentigines are induced by UV radiation. They are usually light brown, sharply defined, and irregular in outline, and occur on sun-exposed sites in light skin phototypes. Here they are shown on the shoulder of a 50-year old male who had sustained repeated sunburns during adolescence.

Eruptive lentiginosis Eruptive lentiginosis is the widespread occurrence of several hundred lentigines over a few months to years, usually in adolescents and young adults, in the absence of systemic abnormalities. This is different from *eruptive nevi*.

Partial unilateral lentiginosis Partial unilateral lentiginosis (PUL) is a rare pigmentary disorder characterized by numerous lentigines arranged in a group and involving one-half of the body. PUL is diagnosed mostly in young people, and it can even be present at birth. There is no known inheritance pattern. Histologically, most of the cases have a lentigo pattern, but some patients have a “jentigo” pattern (some small nests of melanocytes at the dermal-epidermal junction) in addition. It is generally admitted that PUL has no commonly associated abnormalities. Multiple hypotheses exist concerning the pathogenesis of PUL, with as yet no clear-cut answer. Some cases of PUL may be a form of segmental neurofibromatosis. In other cases, PUL may represent the incomplete expression of a lentiginosis syndrome. These possibilities are all consistent with the more general view that PUL reflects somatic mosaicism. [41]

Inherited-pattern lentiginosis in blacks Generalized lentiginosis has been described in 10 adult black patients with onset during infancy or early childhood and familial clustering in an autosomal pattern in patients, without somatic abnormalities. Face, lips, extremities, buttocks, and palmoplantar but not mucosal surfaces were involved.

Laugier-hunziker syndrome Laugier-Hunziker syndrome is characterized by early to midlife appearance of macular hyperpigmentation of the lips and buccal mucosa and often of the palms and soles. Other cutaneous surfaces may be involved, and hyperpigmented nail streaks may be present. Patients are otherwise healthy.

Leopard syndrome (See Chap. 166) LEOPARD syndrome (OMIM 151100, Moynahan's syndrome) is an uncommon autosomal dominant syndrome. The features of the full syndrome include lentigines, ECG conduction defects, ocular hypertelorism, pulmonary stenosis, abnormal genitalia, growth retardation, and deafness. Lentigines are first noted in infancy, evolve until adulthood, and are distributed with no particular pattern all over the body except mucous membranes. Variable expression is common, as illustrated by a family in which five of six members exhibited only lentigines, whereas the sixth member had lentigines with most other features. Linkage analysis suggests that the LEOPARD syndrome is not linked to the neurofibromatosis-1 (NF-1) gene. [42]

CARNEY COMPLEX (See Chap. 166) Carney complex (CNC; OMIM 160980) is an autosomal dominant disorder characterized by spotty pigmentation, cardiac and cutaneous myxomas, and endocrine hyperactivity Subjects with LAMB syndrome (*l*entigines, *a*trial myxoma, *M*ucocutaneous myxomas, *b*lue nevi) or NAME syndrome (*n*evi, *a*trial myxomas, *M*yxoid neurofibromata, *e*phelides) have the same characteristics that are now called CNC. The most common presentation of CNC is that of lentigines (see Fig. 166-3) with cardiac myxoma. Early appreciation of cutaneous lesions and their significance allows patients and primary relatives to be screened. Spotty skin pigmentation can be cutaneous and/or mucocutaneous. Lentigines and blue nevi usually predominate. Ephelides, if present, may be profuse in number. Junctional nevi and compound nevi also may be present. Myxomas affect the heart, skin, and breast; tend to be multiple in each affected organ; and recur commonly after excision. More than 65 percent of patients with the complex have cardiac myxomas. Skin myxomas are present in 33 percent of patients. An occult cardiac myxoma always should be suspected in the presence of multiple cutaneous myxomas. Breast myxoid mammary fibroadenomas occur in 25 percent of female patients. There are several manifestations of endocrine hyperactivity in CNC. Cushing's syndrome, due to the rare primary pigmented adrenocortical disease, is present in 20 percent of patients. Acromegaly, due to growth hormone–secreting pituitary adenomas, is present in 10 percent of patients. Testicular tumors, predominantly of the rare, large cell, calcifying Sertoli cell type, occur in 30 to 50 percent of affected males. Schwannomas, of the rare psamommatous melanotic type, are present in 14 percent of patients, of which approximately 10 percent are malignant, extensively metastatic, and fatal. The pigmented lesions in Peutz-Jeghers syndrome (PJS) (see below) are the same as in CNC, and both syndromes include the rare, large cell, calcifying Sertoli cell of the testis. However, PJS patients often have ovarian tumors and exhibit numerous blue nevi but lack cardiac and cutaneous myxomas. Conversely, ovarian tumors have been described in CNC, and blue nevi are commonly singular. [43] CNC is a disorder of neural crest, mesenchymal, and endocrine tissues. It was demonstrated tha *PRKAR1A* gene, located on 17q22-24, is mutated in about half of CNC kindreds. *PRKAR1A* is a tumor-suppressor gene, as demonstrated by loss of heterozygosity at the 17q22-24 locus in tumors associated with the complex. The *PRKAR1A* gene codes for the type 1 alpha regulatory subunit of PKA. A second locus, at chromosome 2p16, to which most but not all of the remaining kindreds map, is also involved in the molecular pathogenesis of CNC tumors. Despite the known genetic heterogeneity in the disease, phenotypic difference between patients with *PRKAR1A* mutations and those without has not been detected. [44]

Peutz-Jeghers syndrome Peutz-Jeghers syndrome (PJS; OMIM 175200) is an autosomal dominant disorder characterized by macular mucocutaneous pigmentation and hamartomatous polyps of the gastrointestinal tract. [45]

Hyperpigmentation is usually the first sign of the disorder and develops in infancy or childhood. Macules are most common on the buccal mucosa and are dark brown, blue, or blue-brown in color. They are usually 10 to 15 mm in diameter and may resemble freckles but may be larger and resemble café-au-lait macules. They are usually found on the face, dorsal hands and feet (Fig. 90-32A), and, around the mouth, eyes, umbilicus, and anus. Mucosal lesions typically occur on the lips, palate, and tongue (Fig. 90-32B). The diagnosis of PJS is important because of the presence of hamartomatous gastrointestinal polyps. Although most polyps are benign, there is a 2 to 3 percent risk for malignant transformation. In addition to gastrointestinal malignancies, which may arise from normal mucosa as well as from polyps, patients with PJS are predisposed to develop other types of cancer.

FIGURE 90-32 Peutz-Jeghers syndrome. *A.* Lentigines, which are dark brown to gray-blue, appear on the lips, around the mouth, and on the fingers. Lip macules may, over time, disappear. *B.* Macules of the buccal mucosa are blue to blue-black and are pathognomonic; unlike lip lesions, these do not tend to disappear with time.

Two acquired conditions that share features with PJS are Cronkhite-Canada syndrome and Laugier-Hunziker syndrome. In the former, there are hyperpigmented macules and gastrointestinal polyposis, but the macules affect the skin and not the mucosa. In addition, there is nail dystrophy and alopecia, and the onset is generally over age 50. In latter, there are hyperpigmented macules of the lips and oral mucosa but no gastrointestinal polyps. The *LKB1/STK11* gene, located on 19p13, is mutated in approximately half of PJS kindreds and codes for a novel serine threonine kinase. *LKB1/STK11* is a tumor-suppressor gene, more precisely a mediator of p53-dependent cell death. [46]

Centrofacial neurodysraphic lentiginosis Centrofacial neurodysraphic lentiginosis (OMIM 151000) is a rare neurocutaneous syndrome characterized by lentigines limited to the medial face, neuropsychiatric problems, and dysraphic malformations. There seems to have been no report of this syndrome for nearly 30 years. [47]

Arterial dissection with lentiginosis This familial syndrome of multiple lentigines and arterial dissection (OMIM 600459) was reported in two families. Cystic necrosis of the arterial media was found in some cases, an interesting finding considering that melanocytes and arterial media both originate from neural crest cells.

Bannayan-Riley-Ruvalcaba syndrome The term *Bannayan-Riley-Ruvalcaba* (BRR; OMIM 153480) *syndrome* has been proposed to encompass the clinical overlap of three conditions previously described as separate entities and each inherited in an autosomal dominant fashion. They are the Riley-Smith, Bannayan-Zonana, and Ruvalcaba-Myhre-Smith syndromes. BRR syndrome is a hamartoma syndrome, with macrocephaly, multiple lipomas, and vascular malformations as hallmark features. Pigmented lesions of the glans penis were noted in some patients and were presented as café-au-lait macules or lentigines. The latter diagnosis is supported by histology. As predicted by some clinical overlap between the two entities, it was demonstrated that BRR syndrome can result from mutations in the tumor-suppressor gene *PTEN,* implicated in Cowden's syndrome [47] (see Chap. 184). The genetic etiology of BRR syndrome is heterogeneous because many atients have no mutations in the *PTEN* gene.

Tay's syndrome This autosomal recessive disorder of multiple lentigines, vitiligo, café-au-lait macules, premature canities, growth and mental retardation, cirrhosis, hypersplenism, and multiple skeletal defects was reported in two Malaysian sisters.

Faces syndrome Faces syndrome, with unique facial features, anorexia, cachexia, and eye and skin anomalies affecting three family members, has been reported as a new hereditary condition. The cutaneous pigmentary changes include multiple lentigines and café-au-lait macules.

MELANOTIC EPIDERMAL HYPERMELANOSES Melanotic epidermal hyperpigmentation may be local, with isolated individual lesions such as café-au-lait macules or Becker's nevus, or occur in a widespread small (ephelides), patterned (periorbital melanosis, reticular melanosis, acromelanosis), or widespread and diffuse (postinflammatory, drug) distribution. Melanotic hypermelanoses are characterized histologically by increased epidermal melanin and a normal number of melanocytes.

Isolated melanotic epidermal hypermelanoses

CAFÉ-AU-LAIT MACULES Café-au-lait macules (CALMs) are discrete, uniformly pale brown, well-circumscribed, less than one to several centimeter large macules. They are characterized by serrated or irregular margins (Fig. 90-33). They appear at or soon after birth and tend to disappear with age. CALMs are common cutaneous findings. Isolated CALMs occur in up to 10 to 20 percent of the normal population. Their size usually ranges from 5 to 15 mm in adults. Ninety-eight percent of normal young adults who have CALMs have fewer than three. CALMS also can be markers for multisystem disease, in particular, neurofibromatosis (see Chap. 190), where they may be associated with intertrigmous “freckling” and neurofibromas. [48]

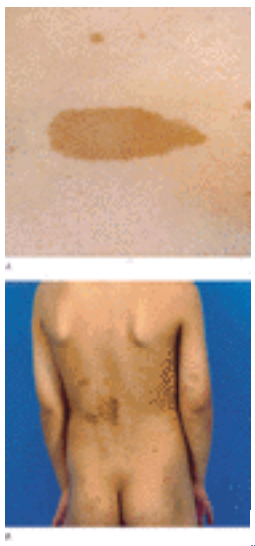

FIGURE 90-33 Café-au-lait macules (CALMs) are uniformely pale-brown, sharply defined macules. *A*. Isolated CALMs occur in up to 10 to 20 percent of the population. *B*. CALMs are also a marker for multisystem disease, in particular neurofibromatosis where they are associated with intertriginous freckling and neurofibromas.

Unless no adult relatives with CALMS and no other stigmata of NF-1 can be found in two generations, a young child with multiple CALMS should be evaluated thoroughly and followed closely because CALMS can be the only manifestation of NF-1 at this age.

MCCUNE-ALBRIGHT SYNDROME McCune-Albright syndrome (MAS; OMIM 174.800), also known as *Albright's syndrome*, is characterized in its complete form by the triad of bone lesions termed *polyostotic fibrous dysplasia,* a hyperfunctioning endocrine system, and cutaneous lesions of light-brown pigmentation. [50] Most cases of MAS are sporadic. The pigmented lesions may be present at birth, but most develop in infancy. Sites of predilection include the head, trunk, sacral area, and buttocks. The lesions are unilateral and do not cross the midline. They are usually large with irregular jagged borders, differing from the regular smooth-bordered macules usually observed in NF (Fig. 90-34). The bony lesions of polyostotic fibrous dysplasia and the pigmented macules often occur in the same distribution. Precocious puberty and hyperthyroidism are the most common endocrinopathies observed in MAS. Molecular genetics studies indicate that MAS is a disorder of mosaicism, resulting from postzygotic somatic mutations in the *GNAS1* gene that encodes for the alpha subunit of the stimulatory G proteins.

FIGURE 90-34 Albright's syndrome. The melanotic macules are indistinguishable from café-au-lait macules in neurofibromatosis.

BLOOM'S SYNDROME (See Chap. 155) Cardinal features of this syndrome include congenital facial telangiectatic erythema, photosensitivity, short stature, and predispositon to malignancy. Café-au-lait macules are present in roughly 50 percent of patients. The gene for Bloom's syndrome, *BLM,* encodes for a DNA helicase.

SILVER-RUSSELL SYNDROME Cardinal features of this syndrome include prenatal-onset growth restriction, small triangular face, body asymmetry, and a characteristic small triangular face. Café-au-lait macules are present in roughly 30 percent of patients; they are usually one or two in number. However, there can be considerable variability in the clinical expression of this syndrome. [51] The disorder is also genetically heterogeneous, but only chromosomes 7 and 17 have been consistently implicated in patients with a verified diagnosis. [52]

WATSON'S SYNDROME Watson's syndrome (OMIM 193520) is a rare autosomal dominant syndrome consisting of multiple CALMs, intertriginous freckling, short stature, mental deficiency, and pulmonary stenosis. Linkage analysis suggests that this disorder is an allelic variant of NF-1. [53]

WESTERHOF'S SYNDROME Congenital hypermelanotic and hypomelanotic macules were described in three generations of a family. The pattern suggested autosomal dominant inheritance. Some affected family members also showed growth and mental retardation.

BECKER'S NEVUS Becker's nevus is a common/acquired focal epidermal melanotic hypermelanosis. The reported incidence in males is 1 in 200, much less in females. The nevus typically appears at about the time of puberty as a unilateral, several centimeter large, hyperpigmented, irregular patch. It involves the upper part of the trunk, especially the shoulder, submammary area, and back (Fig. 90-35).

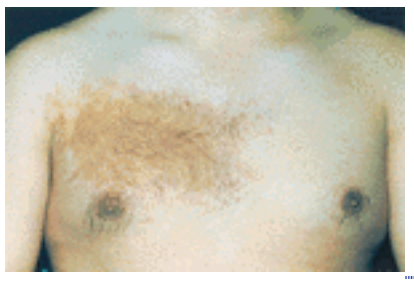

FIGURE 90-35 Becker's nevus (pigmented hairy hamartoma). This acquired reticulate lesion is usually flat or raised. Neck and trunk locations are common sites. Up to 50 percent demonstrate hypertrichosis.

The color, most often light brown, is uniform and rarely fades over time. The jagged margins are sharply demarcated. Although the lesion is macular, there is a palpable quality, particularly in the center. A variable amount of hypertrichosis occurs (see Fig. 90-35). The hairs are darker and coarser than normal. Tissue hypoplasia, such as shortening of an arm or reduced breast development, rarely may underlie Becker's nevus. Spina bifida also has been associated. In addition to epidermal melanotic hyperpigmentation, histology shows acanthosis, papillomatosis, thickening of the dermis, and smooth muscle hyperplasia. Becker's nevus is considered as an organoid nevus with epidermal melanocytic and dermal components. [54]

NEVUS SPILUS/SPECKLED LENTIGINOUS NEVUS Nevus spilus/ speckled lentiginous nevus (NS/SLN) presents as a circumscribed, usually lightly pigmented macule containing scattered, usually more darkly pigmented spots. The Greek root *spilos* means “spot,” hence the term of *nevus spilus*. NS/SLN can appear on any area of the body. Background pigmentation in NS/SLN is often 3 to 6 cm in diameter, but it can vary from 1 to over 60 cm. Histopathology is consistent with lentigo. There is a wide spectrum of clinical findings when it comes to the spots, including red to brown to blue to black macules and papules (Fig. 90-36). Their size is often 2 to 3 mm in diameter but can range from 1 to 9 mm. Accordingly, histopathology ranges from lentigines to junctional, compound, and dermal nevi to Spitz and blue nevi. Most commonly, the shape of an NS/SLN is oval, but there are clinical variants: blocklike with a sharp demarcation at the midline, linear (and the linear lesions may follow the lines of Blaschko), extensive over large areas of the body, and lastly, a divided form involving both eyelids. [55]

FIGURE 90-36 Nevus spilus. A café-au-lait macule sprinkled with melanotic macules that are either lentigines or common nevi.

LINEAR AND WHORLED HYPERMELANOSIS Linear and whorled hypermelanosis (LWH), also classified as a variety of other names such as *zebra-like hyperpigmentation,* is characterized by linear streaks of hyperpigmentation along Blaschko's lines. [56] The pigmentary anomalies become apparent in infancy or early childhood and usually remain stable, but they may either increase in extent or fade over time. Histopathology suggests melanotic hypermelanosis in most cases, but melanocytotic hypermelanosis and less often pigmentary incontinence also have been reported. Although the general opinion was that LWH is not typically associated with extracutaneous anomalies, there have been many case reports to suggest the contrary. The concept that LWH is a disorder of mosaicism has been supported recently by molecular genetics studies. [57], [58] Striking homologies exist between HI and LWH. In addition, several patients have been reported who display bands of both hypo- and hyperpigmentation, making the distinction between HI and LWH somewhat blurred. In some cases, it is difficult to know with certainty whether the cells producing the “background” skin tone or those producing the distinctly hued bands are the genetically abnormal ones, making the putative distinction between HI and LWH even less clear. Emerging opinion is that a revised nomenclature should group HI and LWH as a single entity including hypopigmentation or hyperpigmentation along the lines of Blaschko, possible association with extracutaneous anomalies in approximately 30 percent of patients, and somatic mosaicism in a yet-indetermined but probably several different genes involved in human pigmentation.

Widespread epidermal melanotic hyperpigmentation

EPHELIDES Ephelides, or freckles, are small, usually less than 0.5 cm in diameter, discrete brown macules that appear on sun-exposed skin (Fig. 90-37). They occur commonly in the Caucasian population, more frequently in fair-skinned individuals with red or light-blond hair. Ephelides appear early in childhood and partly vanish with age. Fair skin, red hair, and ephelides are indicators for an increased risk of melanoma and nonmelanoma skin cancer. The melanocortin-1 receptor gene is the major ephelide gene. [59] Ephelide-like pigmented macules may be found in neurofibromatosis, progeria, Moynahan's syndrome, and xeroderma pigmentosum.

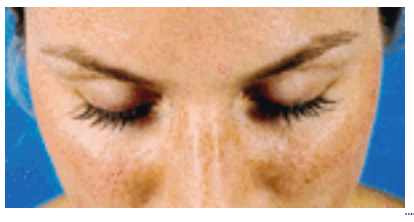

FIGURE 90-37 Ephelides. Typical small, flat, medium brown macules in sun-exposed areas of skin.

MELASMA Melasma is a common acquired symmetric hypermelanosis characterized by irregular light-brown to gray-brown macules and patches on sun-exposed areas of the skin (Fig. 90-38). It is far more common in women and in persons with high-grade phototype. The major etiologic factors in the pathogenesis of melasma include genetic influences, exposure to UV radiation, and female sex hormones. A melasma-like facial hyperpigmentation also has been described in relation with HIV infection. [60] Melasma is generally considered as an epidermal melanotic hyperpigmentation. However, it was suggested recently that an increased number of melanocytes may account for the epidermal hyperpigmentation of melasma. [61] The pathogeny of melasma is not yet fully understood. A recent study

suggests that a high expression of a-MSH in the lesional keratinocytes of melasma plays a key role in the hyperpigmentation of melasma skin. [62]

FIGURE 90-38 Melasma. *A.* Typical blotchy, macular pigmentation bilaterally on the cheeks, upper lip, and bridge of the nose. *B.* Excellent cosmetic result after 10 weeks of treatment with 4% hydroquinone and tretinoin.

Successful treatment of melasma involves the triad of sunblocks, bleach, and time (Fig. 90-38). The sunscreen must be an opaque formulation; however, use of a broad-spectrum formulation with an SPF of more than 30 plus coverup is adequate. Without daily use of opaque sunscreen, treatment will fail. Topical hydroquinone 2% to 4%, alone or in combination with tretinoin 0.05% to 0.1%, is an established bleaching treatment (see Fig. 90-38B). Possible side effects of hydroquinone are allergic sensitization and exogenous ochronosis. Topical azelaic acid 15% to 20% has also been used. Kojic acid, alone or in combination with glycolic acid or hydroquinone, has shown good results. [63] For epidermal melasma, normally up to 2 months are required to begin to initiate response and up to 6 months to complete the process. Dermal melasma does not respond to the preceding formulation and at the present time cannot be treated; coverup with opaque cosmetics is the only management option. Mixed-type melasma will improve only to the extent that there is a treatable epidermal component. Laser treatments do not offer promise. Patients taking oral ontraceptives should understand that successful treatment of their melasma may not be possible as long as the oral contraceptive is continued. Treatment of melasma during pregnancy or breast feeding is not advised.

ACQUIRED BRACHIAL CUTANEOUS DYSCHROMATOSIS Acquired brachial cutaneous dyschromatosis (ABCD) is a common acquired bilateral hypermelanosis characterized by gray-brown patches with geographic borders, occasionally interspersed with hypopigmented macules, on the dorsum of the forearms. It is observed most often in postmenopausal Caucasian women. Histologic findings are melanotic epidermal hyperpigmentation and dermal elastosis. Civatte's poikiloderma is observed in nearly 50 percent of patients. [64]

TAR MELANOSIS Tar melanosis also has been called *melanodermatitis toxica*. This is an entity found mainly in workers exposed to tar and other hydrocarbons, which also may be present in cosmetics. It likely follows a photosensitivity reaction. Erythema, edema, vesiculation, and pruritus are found most often on the face or dorsal hands. The late stage features a reticulate hyperpigmentation with hyperkeratosis. Histology shows edema, follicular hyperkeratosis, reduction of basal layer pigmentation, pigment-laden macrophages, and lymphocytic perivascular infiltrate.

PELLAGRA (See Chap. 145) Chronic pellagra may be characterized by eczema-like lesions, thickening, fissuring, and striking hyperpigmentation of the dorsal hands, neck area, nasal bridge, and scalp. These changes are most prominent over bony prominences. A leukomelanoderma also may be present. Niacin deficiency is associated with photosensitivity and susceptibility to mechanical trauma.

POSTINFLAMMATORY HYPERPIGMENTATION In many instances, hyperpigmentation follows resolution of specific eruptions. Certain rashes, such as contact dermatitis to poison ivy or primula, atopic dermatitis, etc., are particularly likely to result in postinflammatory hyperpigmentation. These pigmentary changes, which are characteristically discrete macules with hazy, feathered margins, correspond exactly with the primary eruption (Fig. 90-39) and may persist for months.

FIGURE 90-39 Postinflammatory hyperpigmentation. Epidermal hyperpigmentation corresponds to areas of resolved primary eruption.

TINEA VERSICOLOR (See Chap. 206) In tinea versicolor, hyperpigmented macules are not as common as the hypopigmented macules, but they are by no means unusual. The brown lesions are otherwise analogous to the white lesions in size, distribution, scaling, and in response to topical therapy.

PHOTOCONTACT DERMATITIS (See Chap. 136) Photocontact dermatitis is caused by application of photosensitising compounds such as psoralens. Psoralens can be found in plants or in perfumes. The first stage of photocontact dermatitis is an inflammatory bullous eruption 24 to 48 h after contact (Fig. 90-40B). It is mostly observed after contact with certain plants and subsequent sun exposure, hence the term *phytophotodermatitis* (see Chap. 136). The second stage is a macule of brown hyperpigmentation 7 to 10 days after the first stage, often with discrete margins and streaking. This is also called *berloque dermatitis* (see Fig. 90-40A).

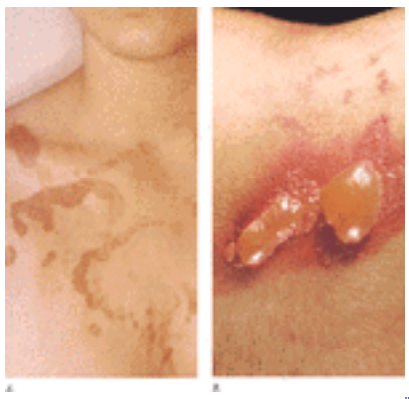

FIGURE 90-40 Berloque dermatitis. *A.* Cutaneous photosensitization developed following application of a 5-methoxypsoralen–containing perfume; after sun exposure, the hyperpigmentation developed. *B.* A similar reaction due to furocoumarin present in a plant (phytophotodermatitis). After inflammation and bullous eruption have subsided, pigmentation as in (*A*) will develop.

CRONKHITE-CANADA SYNDROME Cronkhite-Canada syndrome (CCS; OMIM 175.500), also known as *intestinal polyposis with hyperpigmentation,* is a rare sporadic syndrome mostly reported in Japanese patients. There are many cutaneous manifestations. A common feature is development of a diffuse hyperpigmentation affecting all parts of the integument. Patchy hair loss that progresses to almost complete alopecia is common. The fingernails become thin and brittle and later are shed from the ends of the fingers. The main extracutaneous features are polyps that form throughout the intestinal tract. Loss of fluid from the polyp results in diarrhea and malabsorption. [65]

DYSCHROMATOSIS UNIVERSALIS HEREDITARIA Dyschromatosis universalis hereditaria (DUH; OMIM) has been reported almost exclusively in Asian families. It shows an autosomal dominant pattern of inheritance. The pigmentary features of DUH generally appear during infancy or early childhood. Pinpoint to pea-sized hyperpigmented and hypopigmented macules form the striking reticulated pattern characteristic of this syndrome (Fig. 90-41). They are distributed over the entire integument, especially on the trunk, abdomen, and limbs. The face is involved rarely. Palms and soles are spared usually. Nails, hair, teeth, and mucous membranes are unaffected. [66]

FIGURE 90-41 Dyschromatosis universalis. (*Courtesy of Y Tomita, MD.*)

FAMILIAL PERIORBITAL HYPERPIGMENTATION Periorbital hyperpigmentation, or dark circles around the eyes, is a common finding in otherwise healthy people. This form of hyperpigmentation also was described as an autosomal dominant disorder. Clinical expression is variable. The hyperpigmentation usually starts during childhood in the lower eyelids and progresses with age to involve the entire periorbital area. [67]

FAMILIAL PROGRESSIVE HYPERPIGMENTATION This rare dermatosis, inherited mostly in an autosomal dominant manner, also was reported under different terms. The salient clinical finding is intense pigmentation that is variably described as jet black, dark brown, or bronze. Patchy hyperpigmentation occurs at birth or develops in early infancy. The initial site of involvement is usually the face or groin. Generally, the pigment becomes diffusely distributed due to coalescence of the pigmented macules. The pigmentation involves the palms, soles, lip, oral mucosa, and conjunctivae. The cornea may be affected as well. [68]

Reticular melanotic hypermelanoses

DOWLING-DEGOS DISEASE Dowling-Degos disease (OMIM 179.850), or reticular pigmented anomaly of the flexures, is a rare genodermatosis characterized by an acquired reticular macular hyperpigmentation that initially affects the axillae and groin and later involves intergluteal and inframammary folds, neck, trunk, and arms. Onset is in early adult life and is slowly progressive. Both sexes are involved. Histologically, there are pigmented filiform epidermal projections involving the follicular infundibulum as well as the epidermis. There is no increase in the number of melanocytes. The main concentration of melanin is in the keratinocytes of the elongated rete ridges, particularly near the lower tips. This entity is separate from acanthosis nigricans because Dowling-Degos disease has no papillomatosis, has elongation of the rete ridges that does not resemble that of acanthosis nigricans, and has a follicular anomaly not found in acanthosis nigricans.

DYSKERATOSIS CONGENITA Dyskeratosis congenita (DKC) is a rare genodermatosis characterized by reticulate hyperpigmentation, nail atrophy, hyperkeratosis and atrophy of palms and soles, and leukokeratosis of the mucosal surfaces. X-linked chromosomal pattern and autosomal dominant inheritance have been described. The complete syndrome, which also includes mucosal lesions and pancytopenia, is not apparent until the second or third decade of life. Mucosal lesions on the oral, vaginal, urethral, and conjunctival epithelia present as whitish plaques. Mucosal malignancy is a frequent complication. Pancytopenia occurs in over a third of patients and may be responsible for death. *DKC* is the gene responsible for X-linked dyskeratosis congenita. Dyskerin i *DKC1* gene product. The pathology of DKC is a defect in telomerase maintenance that may limit the proliferative capacity of epithelial and blood cells. [69] *TERC* is the gene responsible for autosomal DKC. The *TERC* gene product is known to interact with *DYSKERIN,* the gene mutated in X-linked DKC. [70] DKC may be confused with Fanconi's syndrome, which is associated with short stature, aplasia or hypoplasia of the thumbs, and a reduced number of carpal bones. In Fanconi's syndrome, the skin is hyperpigmented in multiple patches, particularly the trunk, neck, axillae, and groin. This pigmentation is present in the first few years of life—earlier than in dyskeratosis congenita.

Acromelanoses

DIFFUSE ACROMELANOSIS Diffuse acromelanosis consists of diffuse hyperpigmentation of the fingers that is not in a reticular pattern. It is found in many races, may be autosomal dominant, and is first expressed in early childhood. It evolves and may extend to the flexor creases of larger joints. This pigmentary pattern is particularly common in darker

races.

RETICULATED ACROPIGMENTATION OF DOHI Reticulate acropigmentation of Dohi is the localized form of dyschromatosis universalis hereditaria, hence the term *dyschromatosis symmetrica hereditaria.* This rare disorder is often familial and has been reported mostly in Asian and Brazilian populations. It presents generally during infancy or early childhood as symmetrical pinpoint to pea-sized hyperpigmented and hypopigmented macules on the back of the hands and feet. [71]

RETICULATE ACROPIGMENTATION OF KITAMURA Reticulate acropigmentation of Kitamura is an autosomal dominant pigmentary disorder that is characterized by reticulate freckle-like hyperpigmentation (which darkens over time) beginning on the dorsal hands and subsequently spreading over the body. These slightly depressed brown macules may be associated with palmar pits and breaks in the epidermal rete ridge pattern. Two-thirds of the cases reported have been from Japan, but other cases have been reported from Iran, Great Britain, western India, Ghana, and elsewhere. Unlike reticulate acropigmentation of Dohi, white macules are not observed. Histologic features include epidermal atrophy and an increased number of epidermal melanocytes. Increased melanocyte activity is also apparent.

Diffuse melanotic hypermelanoses *Diffuse* or *widespread epidermal melanotic hypermelanosis* refers to the marked accentuation of normal areas of melanin pigmentation all over but often with particular accentuation in certain areas, particularly over the pressure points (vertebrae, knuckles, elbows, knees, and the like), in the body folds, in the palmar creases, in recent scars, and in some cases in the mucous membranes. This also may be referred to as *addisonian hyperpigmentation* and may result from a number of factors. Because these pigmentary changes may reflect a variety of disease entities and may occur in normal persons of all races, comparative observations are required to identify any abnormality. A congenital, diffuse, mottling syndrome may occur rarely; it features many light- and dark-brown macules that are irregular in size and shape and up to 2 cm in diameter. Proximal nail beds are also partly pigmented.

ADDISON'S DISEASE (See Chap. 169) Addison's disease is rare (1 in 100,000), resulting from primary adrenocortical insufficiency and affecting all ages and both sexes equally. The disease becomes apparent after physical or metabolic stress. Weakness is the prominent symptom, first reported after stress; later on, patients report chronic weakness, fatigue, and weight loss. Nausea and vomiting are frequent complaints; there may be orthostatic hypotension with dizziness and syncope. Hyperpigmentation occurs as a change in the intensity of pigmentation in normally pigmented areas especially or as the development of new areas of pigmentation, e.g., gingival or buccal mucous membrane. Pigmentation also develops in new scars; around the eyes, nipples, and creases of the palms; over bony prominences; and in the linea nigra (abdomen), axillae, and the anogenital areas. Linear streaks of pigmentation are found in the nail plate (a normal finding in brown- and black-skinned persons). Gray scalp hair may darken as the disease progresses. Axillary hair may be decreased or absent. The hyperpigmentation results from the melanogenic action of a-MSH.

OTHER CAUSES OF ADDISONIAN-LIKE HYPERPIGMENTATION Other causes of addisonian-like hyperpigmentation are listed in Table 90-9. In Nelson's syndrome, involving adrenalectomized individuals with functioning pituitary adenomas, there are often darkening of hair, multiple lentigines, and pigmented nail bands. The hyperpigmentation in hyperthyroidism may spare mucosal surfaces and be associated with eyelid hyperpigmentation (see Chap. 169).

Addison's disease	Hyperthyroidism
ACTH administration	Lymphoma, particularly Hodgkin's disease
ACTH-producing tumors (Nelson's syndrome)	Pheochromocytoma
Acromegaly	POEMS syndrome
AIDS	Porphyria cutanea tarda
Carcinoid	Schilder's disease
Cirrhosis	Scleroderma
Cushing's syndrome	Siemerling-Creuzfeldt disease
Hepatolenticular degeneration	Still's disease

TABLE 90-9 **Diseases Associated with Addisonian-like Hyperpigmentation**

In Siemerling-Creuzfeldt disease (leukodystrophy, hyperpigmentation, and adrenal atrophy), which is inherited, unaffected carriers may show increased pigmentation at an early age. Death occurs in early life to the midfifties. The generalized hypermelanosis observed in 90 to 98 percent of cases of hemochromatosis (see also Chap. 164) may be bronze, blue gray, or brown black and may be accentuated in sun-exposed areas of skin. The changes are attributed to deposition of melanin (brown) and hemosiderin (blue black). Cutaneous and mucous membrane involvement, seen in 15 to 25 percent, may resemble Addison's disease and may precede cirrhosis and associated (diabetes mellitus by years. Hyperpigmentation also may involve genitalia, flexor folds, scars, and nipples. Other cutaneous signs include atrophy, ichthyosis-like changes, alopecia, koilonychia, onychonychia, palmar erythema, spider angiomas, and leukonychia. [72] Biopsy sections stained with potassium ferrocyanide demonstrate hemosiderin around sweat glands and cutaneous blood vessels. Color abnormalities increase with exacerbations and decrease with remissions. The siderosis is more likely to be affected by treatment than is the hypermelanosis.

UNIVERSAL ACQUIRED MELANOSIS—THE CARBON BABY Several such cases have been reported. In general, the hyperpigmentation begins between birth and 2 to 2½ years, is observed initially on the face or groin, and over the years spreads gradually over the entire body. The palms, soles, and mucous membranes display a mottled or homogeneous dark hyperpigmentation that gradually may become less uniform and mottled, even with white patches.

POEMS SYNDROME The POEMS syndrome is a rare plasma cell dyscrasia characterized by the combination of polyneuropathy, organomegaly (involving liver, spleen, lymph nodes), endocrinopathies (diabetes mellitus, gynecomastia, impotence, oligomenorrhea/ amenorrhea, and hyperthyroidism), M protein, and skin changes. Abnormal pigmentation of the skin, either generalized or localized, is observed in 98 percent of patients. The hyperpigmentation is diffuse, but there may be accentuation over extensor surfaces, the back, neck, and axillae. The hyperpigmentation may ameliorate with effective treatment of the plasmacytoma. [73]

MISCELLANEOUS CONDITIONS *Whipple's intestinal lipodystrophy* may be associated with hyperpigmentation in up to a third of cases. Cutaneous but not mucosal hyperpigmentation may be found in *primary biliary cirrhosis;* this occurs in sun-exposed areas, resembles a deep tan, and disappears as the cirrhosis improves (see also Chap. 164). *Porphyria cutanea tarda* is associated with a diffuse generalized brown hypermelanosis accentuated in sun-exposed areas; this is associated with facial hirsutism and other characteristic features (see Chap. 149). *Renal failure* is often associated with hyperpigmentation (see Chap. 165). *Hyperpigmentation in vitamin* B_{12} *deficiency* , in which hyperpigmentation is accentuated over the knuckles, is associated with loss of hair, and it reverses with vitamin B_{12} therapy. Folate deficiency also may be associated with hyperpigmentation (see Chap. 145). *Progressive systemic sclerosis* may give an intensely brown hyperpigmentation without significant induration of the skin. Hypermelanosis also may be associated with local scleroderma or morphea (see Chap. 173).

Hyperpigmentation due to drugs/chemical agents A number of drugs have been reported to cause epidermal hyperpigmentation in various patterns. These are listed in Table 90-10.

Generalized types of hyperpigmentation
Addisonian
ACTH
Busulfan (sun-exposed areas)
5-Fluorouracil
Diffuse
Carmustine
Clofazimine
Cyclophosphamide
Dibromomannitol
Mechlorethamine
Procarbazine
Tetracosactide (cosyntropin)
Patterned types of hyperpigmentation
Linear
Bleomycin
Zidovudine
Palms, soles (diffuse)
Cyclophosphamide
Dibromomannitol
Doxorubicin (also palmar creases)
Procarbazine
Around small joints
Bleomycin (knuckles)
Doxorubicin (interphalangeal joints)
Melasma-like
Estrogen
Estrogen-progesterone
Mephenytoin
Phenytoin

TABLE 90-10 **Drug-Induced Hyperpigmentation**

Dermal Hypermelanoses

Dermal hyperpigmentation, or ceruloderma, results from the presence of pigment in the dermis (Table 90-11). Because of the Tyndall effect, dermal pigment is perceived as blue, gray, blue gray, or gray brown and is distinctive from normal skin color in all skin phototypes. Unlike epidermal hypermelanosis, comparison with normal skin color is rarely required to establish that an abnormality exists. Although dermal pigment disorders are rather rare among Caucasians, they are observed commonly in East Indians and Asians. The Wood's lamp is not useful as a diagnostic tool; infrared photography accentuates dermal pigmentation but not epidermal pigmentation. Skin biopsy may be required to identify the presence of melanin, iron, or exogenous pigment in the dermis. Clinicopathologic classification of dermal hypermelanoses is given in Table 90-11.

TABLE 90-11 **Dermal Hypermelanoses: Clinicopathologic Classification of Disorders**

PATHOGENESIS OF DERMAL HYPERPIGMENTATION The pathogenesis of dermal hyperpigmentation is based on several possible mechanisms. Dermal hyperpigmentation may result from melanin in the dermis attributed to (1) *dermal melanotic hyperpigmentation,* that is, melanin formed in the epidermis by epidermal melanocytes and transferred to the dermis, (2) *dermal melanocytotic hyperpigmentation,* that is, melanin formed in dermal melanocytes, or (3) *nonmelanin dermal pigmentation,* attributed to pigment other than melanin deposited in the dermis. The phenomenon of epidermal melanin incontinence is a reaction pattern common to a number of diseases of diverse etiologies and associated with dermal melanosis. Although there may be slight variations, the common sequence in these diverse entities appears to be (1) a targeted attack on the melanosome-containing keratinocytes, (2) loss of nuclei from basal keratinocytes to form anucleate, aggregated, filamentous, eosinophilic masses (Civatte bodies), (3) movement of the Civatte bodies, often containing melanosomes, into the dermis either inside macrophages or in some unknown manner as free bodies to remain as extracellular masses in the dermal connective tissue or to be phagocytosed by macrophages.

CIRCUMSCRIBED DERMAL MELANOCYTOTIC HYPERPIGMENTATION Circumscribed dermal melanoses are generally developmental or heritable, localized to one area or general area of the body, and particularly common among Asians.

Mongolian spots or congenital dermal melanocytosis The term *Mongolian spot,* or *congenital dermal melanocytosis* (CDM), applies to specific blue-gray macules commonly observed among Asians and Polynesians, although occasionally they are seen in Caucasians and blacks.

CLINICAL FEATURES CDM is almost always located on the lumbosacral skin or on the buttocks. The lesions are macular with distinct margins and blue black in color, although with variations in intensity (Fig. 90-42). The lesions are characteristically a few centimeters in diameter but may be large enough to cover the entire lower back and buttocks. In typical CDM, the dermal melanocytes appear microscopically at the fetal age of 3 months, and the pigmentation appears at the fetal age of 7 months. The natural course of CDM is to disappear in childhood.

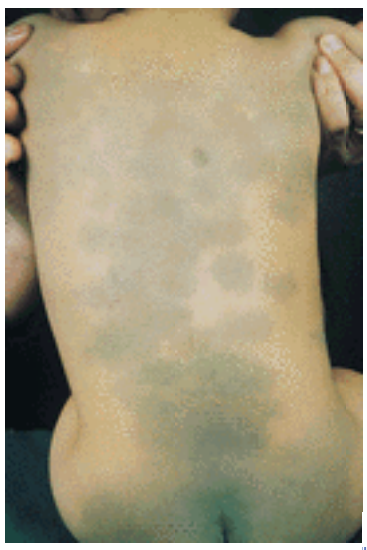

FIGURE 90-42 Classic Mongolian spot in the lumbosacral region, and aberrant or extrasacral Mongolian spots on the back.

CLINICAL VARIANTS Several variants of typical CDM appear to exist. The so-called persistent Mongolian spot is said to occur in 3 to 4 percent of Japanese adults. Aberrant Mongolian spots occur not on the common sites of the buttocks and lumbosacral areas but in less common regions such as the face or extremities; when they occur on the face, they may be confused with nevus of Ota (oculodermal melanocytosis). The latter almost always has a mottled appearance composed of blue-black, slate-gray, or brown macules and is acquired in early childhood or young adulthood, whereas CDM is congenital. Persistent aberrant Mongolian spots may be called *macular-type blue nevi*. The value of laser treatment is uncertain.

Nevus of Ota (oculodermal melanocytosis) (See Chap. 91) Nevus of Ota is usually congenital but may appear in early childhood or in puberty. It is usually characterized by unilateral, flat, blue-black or slate-gray macules intermingled with small, flat brown, spots occurring most characteristically in the skin innervated by the first and second branches of the trigeminal nerve (Fig. 90-43). Mucosa, conjunctivae, and tympanic membranes may be involved. This disorder, which is not hereditary, is said to occur in up to 0.8 percent of dermatologic outpatients in Japan but also occurs in Chinese, blacks, East Indians, and Caucasians. Women are affected five times as frequently as men.

FIGURE 90-43 Nevus of Ota. *A.* Nevus of Ota in an African American; this pigmentation is not usually congenital but rather develops at puberty and does not disappear. Both epidermal and dermal components may coexist. *B.* Bilateral type. *C.* Unilateral type with ocular involvement.

Hyperpigmentation in the involved areas of cornea, iris, optic nerve, fundus, extraocular muscles, retrobulbar fat, and periosteum may occur. Similar involvement may be located on the hard palate, pharynx, nasal mucosa, buccal mucosa, and tympanic membrane of the involved side.

COURSE AND TREATMENT Nevus of Ota does not improve with time. There have been a large number of reported cases of melanoma development in nevus of Ota. Selective photothermolysis with the Q-switched ruby laser is a safe and effective treatment. Multiple treatments increase the response rate.

Acquired circumscribed dermal facial melanocytosis Hori's nevus, or acquired circumscribed dermal melanocytosis of the face, is characterized by blue-brown macules that occur bilaterally on the forehead, temples, eyelids, malar areas, nasal alae, and nasal root of middle-aged Japanese women. These macules are clinically very similar to classic nevus of Ota. The lesions usually are noted in the fourth or fifth decade of life in Japanese women and do not extend to ocular or mucosal surfaces.

Nevus of Ito Initially described by Ito in 1954, nevus of Ito is analogous to nevus of Ota and may in fact coexist in the same patient. With nevus of Ito, the cutaneous involvement occurs in the distribution of the lateral supraclavicular and lateral brachial nerves. Except for the fact that the involvement is more diffuse and less mottled, the pigmentary change is the same as that of the nevus of Ota.

Diffuse dermal melanocytotic hyperpigmentation Extensive blue pigmentation of the skin involving the forehead, nose, lips iris, sclera, vestibule of the mouth, and trunk has been reported twice. [74]

CIRCUMSCRIBED DERMAL MELANOTIC HYPERPIGMENTATION Each of these disorders has characteristic features, some of which are presented in greater detail in other sections of this chapter or elsewhere in this book.

Incontinentia pigmenti (See above and Chap. 143 and Chap. 188) Of the three stages of evolution of IP, hyperpigmentation is observed only in the third stage and is characterized by whorls and streaks of hyperpigmentation over the trunk and extremities (Fig. 90-44). The pigmentary macules are bizarre, macular, brown, dirty brown to slate gray, and intensity in color up to age 2 and then begin to fade gradually through adolescence and early adulthood. Up to 14 percent of patients will develop hypopigmentation.

FIGURE 90-44 Incontinentia pigmenti. The pigmentary stage shows bizarre swirls of gray-brown hypermelanosis over the trunk and extremities.

Franceschetti-Jadassohn syndrome This condition, affecting a father and two daughters, is a distinct entity that has been described only in one Swiss family. The pigmentary anomaly, which occurs without antecedent inflammation, begins at 2 years of age and is characterized by reticular brown, dirty-brown, slate-gray, or gray-brown pigmentation on the trunk and upper extremities. Yellowing of teeth, hyperkeratosis of palms and soles, hyperhidrosis, and heat intolerance also have been observed.

Dermatophathia pigmentosa reticularis This is characterized by macular pigmentation that develops in infancy and forms a reticulate network, particularly on the trunk, neck, shoulders, and thighs. This may be a variant of the Franceschetti-Jadassohn syndrome. Nail dystrophy and alopecia, as well as palmoplantar keratoderma and ainhum-like constriction, have been described.

Macular amyloidosis (See Chap. 148) The macular variety of amyloidosis is characterized by brownish gray, reticulated pigmentation that may or may not be associated with pruritus. Macular amyloidosis is more common in females than in males and is frequently noted in individuals from Central or South America and from Mediterranean countries and in Asiatic peoples. There are occasional reports of non-Mediterranean Europeans and rare ones of blacks. The average age of onset is under 30 years. Clinically, the common sites of occurrence are the upper back (interscapular areas), buttocks, chest (over the clavicles, on the ribs), breast, and extremities (shins, forearms). The eruption is usually symmetric and is often observed to arise at sites where the skin comes in contact with clothing; the latter observation has given support to the theory that cutaneous amyloidosis is a postinflammatory process, possibly related to friction, or localized lichenification (see Chap. 148).

Dermal Melanoses from Chemical or Pharmacologic Agents

Numerous chemical or pharmacologic agents may result in dermal pigmentation of a local or widespread nature. Perhaps most fascinating is the very localized repetitive type, the fixed drug eruption.

FIXED DRUG ERUPTION (See Chap. 138) This is a reddish brown to slate-gray cutaneous macule that may be localized or generalized. The most typical cases flare repeatedly in the same area following ingestion or injection of a particular medication. The initial phase of erythema, edema, and/or desquamation may be followed by a spontaneously resolving vesiculobullous eruption and finally by hyperpigmentation.

WIDESPREAD/DIFFUSE DERMAL MELANOSES RELATED TO DRUGS Numerous medications have been implicated in diffuse blue-gray coloration of the skin; in some cases these represent drug bound to melanin and in others drug alone. Particularly implicated has been long-term use of chlorpromazine, other phenothiazines, hydrochlorothiazide, and minocycline. This blue-gray coloration may involve any normally sun-exposed area but occurs especially on the forehead, malar eminences, and nose. Although the initial color is brown, repeated sun exposure leads to a slate-gray or violaceous hue. With chlorpromazine (Fig. 90-45), blue-gray pigmentation has been reported in 1 to 15 percent of those taking 800 to 2000 mg daily for over a year. Pigment deposition also has been described in the kidney, heart, skeletal muscle, brain, eye, and reticuloendothelial system. The eye changes are restricted to the lens.

FIGURE 90-45 Chlorpromazine pigmentation. Purple pigmentation in a schizophrenic patient after prolonged high dosage of chlorpromazine.

There is evidence to implicate melanin in chlorpromazine-related hyperpigmentation. An additional chromophore, a polymer of chlorpromazine, also has been implicated. This stems from the discovery of electron-dense bodies without recognizable internal structure in endothelial cells in the dermis and alongside the melanosomes within the phagocytic lysosomes. Thiazides, tetracyclines, and amiodarone cause a photosensitivity-related hyperpigmentation. As with chlorpromazine, melanin is not the only pigment implicated. Amiodarone, a drug given for cardiac diseases, induces a low-grade photosensitivity. Clinical findings include dusky-red erythema and later slate blue-gray pigmentation in sun-exposed areas of the face and hands (Fig. 90-46). The course of evolution is subtle in that some patients gradually develop pigmentary changes without clinically apparent phototoxicity, whereas others express a dusky-red erythema of the face and dorsal hands within 30 to 120 min of sun exposure. This reaction lasts 1 to 2 days.

FIGURE 90-46 Amiodarone hyperpigmentation. This patient exhibits a striking amiodarone-induced, slate-gray pigmentation of the face. The blue color (ceruloderma) is due to the deposition of a brown pigment in the dermis, contained in macrophages and endothelial cells.

Histopathologic studies reveal a perivascular dermal lymphohistiocytic infiltrate. Brown granular pigment is noted in histiocytes, endothelial cells, and circulating neutrophils. Large amounts are found in dermal macrophages. The pigment occurs as electron-dense, compact, and lamellated granules in lysosomes. [75] The pathogenesis of the photosensitivity involves incorporation of amiodarone into cell membranes that then absorb UVA so as to induce a phototoxic injury to erythrocytes, macrophages, and lymphocytes. Systemic complications include pulmonary fibrosis, pneumonitis, hepatotoxicity, thyroid disturbances, neuropathy, and myopathy. The subtle phototoxicity may persist for 12 to 24 months after discontinuation of the drug as the drug is slowly eliminated from lysosomal membranes. Resolution of the pigmentation required 33 months in one patient who was followed very carefully. [75] Imipramine hyperpigmentation also has been described. In a reported case, the hyperpigmentation followed ingestion of 150 mg/day for 5 years, occurred in sun-exposed areas, and returned slowly to normal after discontinuation of the drug for a year. The color of the iris also was reported to be darkened. Histologic studies showed doubly refractile golden-yellow granules in the papillary dermis, and electron microscopy revealed many phagocytosed melanosomes and other separate electron-dense inclusions in histiocytes, phagocytes, fibroblasts, and dermal dendrocytes. The electron-dense granules were considered to be imipramine or its metabolites. [76]

Dermal Hypermelanosis Secondary to Infectious Diseases

Pinta is a treponematosis caused by *Treponema carateum;* it was first described in 1757 by Alzate y Raminez, who was a missionary priest who lived in the area of the volcano Jorulla and ministered to many people with blue spots on the skin. The blue-gray pigmentation arises in the third phase of pinta and generally in previously involved areas, particularly the face, waistline, and trochanteric areas (see Chap. 229 and Fig. 90-24).

Idiopathic Circumscribed Dermal Melanoses

Erythema dyschromicum perstans (EDP) is an idiopathic, acquired, generalized, macular, ashen–gray-blue hypermelanosis (Fig. 90-47) that occurs in otherwise healthy individuals. The lesions begin in the first or second decade as erythematous macules that gradually assume a slate-gray hue. Usually the lesions are flat, although there may be a thin, raised, erythematous border like “a thin piece of string.” The macules of EDP may vary in size from a few millimeters to many centimeters, may enlarge slowly, and may coalesce to be as large as half the trunk. No effective treatment is available.

FIGURE 90-47 Erythema dyschromicum perstans (ashy dermatosis). Eruption often begins with erythematous macules that rapidly evolve to blue-gray macules.

RIEHL'S MELANOSIS This is a reticular black to brown-violet pigmentation of the face (Fig. 90-48). Because most of the patients with Riehl's melanosis are middle-aged women, the term *female facial melanosis* also has been used. The pigmentary change occurs not only on the face but sometimes on the neck, dorsal hands, and forearms. Although the etiology remains unsettled, Riehl's melanosis may be a result of contact sensitivity or photocontact dermatitis related to a chemical, particularly fragrance, found in cosmetics. [77]

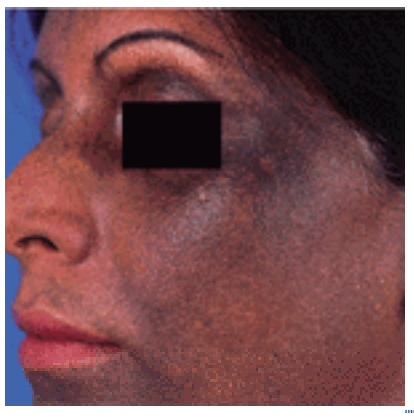

FIGURE 90-48 Riehl's melanosis. In this patient the mottled and disfiguring hyperpigmentation resulted from the chronic application of undefined cosmetics to the face.

ERYTHEMA AB IGNE (HEAT-INDUCED CIRCUMSCRIBED DERMAL MELANOSIS) Erythema ab igne is a reticular hypermelanosis that has a livedo reticularis pattern (Fig. 90-49). The process is thought to arise from repeated heat exposure, such as from a heating pad. There may be certain predisposing factors, particularly a combination of venous stasis, aging, and heat injury. [78]

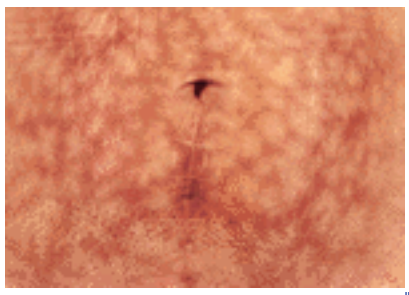

FIGURE 90-49 Reticular hyperpigmentation (erythema ab igne) resulting from repeated applications of a heating pad over several years.

Diffuse Dermal Melanotic Hypermelanoses

Widespread or diffuse slate-gray coloration may be secondary to chronic nutritional deficiency and to widespread metastatic melanoma. *Chronic nutritional deficiency* may give an ashen coloration accompanied by generalized scaling or eczematous or psoriasiform dermatitis. *Metastatic melanoma* and *melanogenuria* present with a generalized blue-gray cutaneous discoloration, sometimes accentuated in sun-exposed areas of skin (Fig. 90-50). The color varies from gray to brown with a metallic tint. This rare change is secondary to dermal melanin, and individually metastatic melanoma cells [79] and can develop in as little as 2 months.

FIGURE 90-50 Metastatic melanoma-associated, slate-gray, dermal pigmentation involving the entire body. There was melanogenuria and at autopsy all internal organs were found to be black.

Nonmelanin Dermal Hyperpigmentation

Drugs, heavy metals, and other exogenous agents may deposit in the dermis to give rise to a blue-gray pigmentation that clinically mimics dermal melanosis. Drugs that may lead to dermal pigmentation include minocycline, hydroquinone, and antimalarials. Heavy metals include mercury, silver, bismuth, arsenic, gold, and lead. Ochronosis, or alkaptonuria, is one disease entity that gives rise to nonmelanin ceruloderma.

CERULODERMA DUE TO OCHRONOSIS (See Chap. 147) Clinically alkaptonuria, or ochronosis, presents as faint, uniform blue or blue-gray color of the pinnae, tip of the nose, sclera, costochondral junctions, axillae, and overlying extensor tendons of the hands. A butterfly pattern on the face, involvement of the axillae and genitalia, and uncommonly, diffuse involvement may occur. The facial pigmentation actually may result from myriads of circumscribed blue macules. Fingernails may be affected, nevi may darken, the sclerae may have pigment granules, and the tympanic membranes may be involved.
PIGMENTATION DUE TO HEAVY METALS *Argyria* results from deposition of silver in the skin to give rise to blue to slate-gray coloration, particularly in sun-exposed areas (Fig. 90-51A). The degree of pigmentation is proportional more to the silver exposure than to sun exposure. Histologically, there are small, uniform, refractile granules scattered

throughout the dermis, particularly about the sweat glands and in the papillary dermis; melanin also may be increased in the epidermis and in dermal chromatophores (see Fig. 90-51B).

FIGURE 90-51 Argyria. *A.* Blue to slate-gray coloration, particularly in sun-exposed areas. Note that this is a mix of gray and tan. This patient had taken medication containing silver salts for chronic gastritis. *B.* Dark-field microscopy reveals refractile silver granules scattered throughout the dermis.

Arsenic gives a bronze color, prominent on the trunk; melanin is also implicated. Bismuth and lead may both give generalized pigmentation and a gingival pigment line. Bismuth also may pigment the conjunctivae and oral mucosa; small granules are found in the papillary and reticular dermis. *Chrysoderma* is a rare consequence of parenteral gold administration and is prominent around the eyes and in sun-exposed areas. Biopsy shows round to oval, black, irregularly sized granules in dermal histiocytes and around vessels. Isolated macules occasionally may be present over sites of intramuscular gold injection. Mercury exposure causes pigmentation of skin from topical administration and gingival hyperpigmentation from systemic administration. The pigment is present in the upper dermis around capillaries and associated with elastic fibers or collagen fibers; melanin also may be increased in the basal layer and be found in dermal macrophages. *Tattoos* result from the deliberate introduction of exogenous pigments into skin in a decorative fashion. Traumatic entry of foreign substances (e.g., graphite from a lead pencil) may result in permanent tattooing. Biopsy shows pigment-laden macrophages. Common sources of adventitial tattooing include abrasions induced by falls from bicycles and motorcycles (blacktop and asphalt) and chemicals such as gunpowder.

NONMELANIN PIGMENTATION DUE TO DRUGS Chloroquine, if taken for protracted periods of time, may be associated with ceruloderma, particularly on the shins. Clofazimine may cause both increased basilar melanin and brown pigment in dermal macrophages. Clinically, however, clofazimine-induced discoloration appears orange-red. Hydroxyurea may cause ceruloderma of the back and pressure points. Minocycline is a tetracycline derivative frequently used for acne vulgaris. Dermal pigmentation (Fig. 90-52) may follow ingestion of from 100 to 200 mg/day for 1 to 3 years, although cases have been described from lower doses and shorter courses. The blue-gray, dirty coloration develops in acne scars, on the anterior lower legs and feet, on the gingiva and hard palate, and around the eyes. Circumscribed lesions are the most common, but generalized and diffuse ceruloderma may occur, as can pigmentation of the conjunctivae and the teeth. The brown pigment in the dermal macrophages is composed of iron and sulfur. Gradual resolution over months to years follows discontinuation of the drug.

FIGURE 90-52 Minocycline pigmentation. Blue-gray coloration follows long-term moderate to high-dose ingestion and may first be observed in old scars, on the lateral face, anterior lower legs, or the gingiva.

Exogenous ochronosis secondary to phenol applied to a leg ulcer was first reported in 1912. Hydroquinone-induced ochronosis by topical application was reported in up to 35 percent of African blacks using a 6% to 8% preparation. The complication has been seen in American blacks allegedly using only 2% hydroquinone. Histopathologic studies reveal yellow-brown banana-shaped fibers in the papillary dermis. Colloid degeneration and elastosis are also seen. Also, the condition requires the presence of melanocytes because it does not occur in vitiligo skin. The course is chronic, and the treatment is disappointing.

Mixed Hypermelanoses and Leukomelanodermas

A number of different disorders are characterized clinically by features of both epidermal and dermal hyperpigmentation (mixed hypermelanoses) or by features of both hypo- and hyperpigmentation (leukomelanodermas).

MIXED HYPERMELANOSES In the following entities there may be a mixture of dermal (blue) and epidermal (brown) hyperpigmentation. In general, the changes are randomly mixed. These disorders have been discussed above.

- Dermatopathia pigmentosa reticularis
- Hemochromatosis
- Melasma. There is a dermal component, particularly in Latinos, Africans, and African-Americans.
- Nevus of Ota. The dermal component is usually clinically dominant.
- Postinflammatory hypermelanosis. The relative risk of a dermal component increases with increasing skin phototype.
- Tar melanosis. The dermal component is dominant.

HYPERMELANOSES WITH HYPOMELANOSIS The following are disorders associated primarily with hyperpigmentation but sometimes may have hypopigmentation as a feature. They have been discussed above.

- Acropigmentation of Dohi. Acral hypo- and hyperpigmented macules are found.
- Dyschromatosis. Hyper- and hypopigmented macules are intermixed.
- Linear inherited hypermelanosis. Mixed swirls of hyper- and hypopigmentation are found.
- Tay's syndrome. Vitiligo, café-au-lait macules, and lentigines are found.
- Tinea versicolor. Usually there are more hypopigmented than hyperpigmented macules, which are otherwise morphologically similar.
- Westerhof's syndrome. This is an autosomal dominant syndrome with congenital hyper- and hypopigmented macules.

HYPOMELANOSES (LEUKODERMAS) WITH HYPERPIGMENTATION The following entities are disorders associated primarily with hypopigmentation but sometimes may have also a hyperpigmentation feature. They have been discussed above or are dealt with in other chapters.

- Chemical leukoderma. Confetti macules are often found within a hyperpigmented background.
- Piebaldism. Thumbprint hyperpigmented macules appear in amelanotic macules and at times on normal skin.
- Pinta. Epidermal and dermal melanosis is characteristic of the late stage.
- Postinflammatory leukoderma. Particularly lupus erythematosus and lichen planus may be characterized by leukomelanoderma with the hyperpigmentation at the margins. In lichen planus, the hyperpigmentation may be dermal.
- Repigmenting vitiligo. Brown hyperpigmented macules may be found at the margins and around hair follicles.
- Scleroderma. Macules may resemble repigmenting vitiligo or postinflammatory leukoderma.
- Secondary syphilis. Leukomelanoderma may be postinflammatory.
- Tinea versicolor. Macules may be red, white, or brown, always in characteristic shapes and locations.
- Vagabond's leukoderma. Hyperpigmented macules are found particularly in the groin, buttocks, axillae, on the back of the neck, and over the back.
- Xeroderma pigmentosum. Hyperpigmented and hypopigmented macules are generally apparent in sun-exposed areas.
- Yaws. Dark halos may occur around achromic macules.
- Ziprkowski-Margolis syndrome. Hyperpigmented macules appear after birth within white macules.

XANTHODERMAS (YELLOW SKIN COLOR)

Xanthoderma, or yellow skin color, can arise from exogenous (quinacrine, beta-carotene, picric acid) or endogenous (secondary carotenemia, bilirubin) pigments. *Bronze baby syndrome* is a rare complication of phototherapy of icteric infants. During the treatment, the skin shows a grayish brown discoloration; direct hyperbilirubinemia develops, and urine and serum turn dirty gray. This syndrome is probably induced by the photooxidation products of bilirubin.

Carotenemia develops following ingestion of large amounts of fruits and vegetables that contain carotene (oranges, mangoes, apricots, carrots, and all green vegetables) and in patients taking synthetic beta-carotene. The yellow skin color is most prominent on the palms and soles and behind the ears. Carotenemia occurs in about 10 percent of patients with diabetes mellitus and in hypothyroidism. An idiopathic or benign essential carotenemia also has been described.

Jaundice arises from increased levels of bilirubin that deposits in the dermis and in the sclerae because of the affinity of bilirubin for elastic tissue. In patients with high levels of conjugated bilirubin, the skin color may assume a greenish hue because of the oxidation of bilirubin to green biliverdin. The sclerae are also yellow (see Chap. 164).

Quinacrine pigmentation produces a greenish yellow color that does not involve the sclerae. Because quinacrine does not produce retinopathy, as do chloroquine and hydroxychloroquine, it is used in the treatment of extensive discoid lupus erythematosus and polymorphous light eruption. Administration of beta-carotene simultaneously appears to produce a more cosmetically acceptable yellowing than quinacrine alone.

Xanthoma planum is a circumscribed, macular, yellow pigmentation found especially on the upper arms; widespread normolipemic generalized planar xanthoma may be associated with multiple myeloma (see Chap. 150).

REFERENCES

1. Ortonne JP et al: *Vitiligo and Other Hypomelanosis of Hair and Skin*. New York, Plenum, 1983

2. Nagasaki Y et al: Reversal of hypopigmentation in phenylketonuria mice by adenovirus-mediated gene transfer. *Pediatr Dermatol* **45**:465, 1999

3. Huizing M et al: Hermansky-Pudlak syndrome and related disorders of organelle formation. *Traffic* **1**:823, 2000

4. Bahadoran P et al: Hypomelanosis, immunity, central nervous system: No more “and,” not the end. *Am J Med Genet* **116A**:334, 2003

5. Hann SK, Nordlund JJ: Definition of vitiligo, in *Vitiligo,* edited by SK Hann, JJ Nordlund. London, Blackwell Science, 2000, p 3

6. Nordlund JJ, Ortonne JP: Vitiligo and depigmentation, in *Current Problems in Dermatology,* St Louis, edited by WL Weston et al. Mosby–Year Book, 1992

7. Bradley CA et al: Genetic association of the catalase gene (CAT) with vitiligo susceptibility. *Pigment Cell Res* **15**:62, 2002

8. Boissy RE: Histology of vitiliginous skin, in *Vitiligo,* edited by SK Hann, JJ Nordlund. London, Blackwell Science, 2000, p 23

9. Ortonne JP, Bose SK: Vitiligo: Where do we stand? *Pigment Cell Res* **6**:61, 1993

10. Orecchia GE: Neural pathogenesis, in *Vitiligo,* edited by SK Hann, JJ Nordlund. London, Blackwell Science, 2000, p 142

11. Schallreuter KU et al: Biochemical theory of vitiligo: A role of pteridines in pigmentation, in *Vitiligo,* edited by SK Hann, JJ Nordlund. London, Blackwell Science, 2000, p 151

12. Bystryn JC: Theories on the pathogenesis of depigmentation: Immune hypothesis, in *Vitiligo,* edited by SK Hann, JJ Nordlund. London, Blackwell Science, 2000, p 129

13. Das PK et al: A symbiotic concept of autoimmunity and tumour immunity: Lessons from vitiligo. *Trends Immunol* 22:130, 2001

14. Boissy RE: The intripsic (genetic) theory for the cause of vitiligo, in *Vitiligo,* edited by SK Hann, JJ Nordlund. London, Blackwell Science, 2000, p 123

15. Lamoureux L, Boissy RE: Animal models, in *Vitiligo,* edited by SK Hann, JJ Nordlund. London, Blackwell Science 2000, p 281

16. Le Poole IC et al: Review of the etiopathomechanism of vitiligo: A convergence theory. *Exp Dermatol* **2**:145, 1993

17. Njoo MD, Westerhof W: Vitiligo: Pathogenesis and treatment. *Am J Clin Dermatol* **2**:167, 2001

18. Njoo MD et al: Management of vitiligo: Results of a questionnaire among dermatologists in the Netherlands. *Int J Dermatol* **38**:866, 1999

19. Westerhof W, Nieuweboer-Krobotova L: Treatment of vitiligo with UV-B radiation vs topical psoralen plus UV-A. *Arch Dermatol* **133**:1525, 1997

20. Falabella R: Surgical therapies for vitiligo, in *Vitiligo,* edited by SK Hann, JJ Nordlund. London, Blackwell Science, 2000, p 193

21. Halder RM: Micropigmentation, in *Vitiligo,* edited by SK Hann, JJ Nordlund. London, Blackwell Science, 2000, p 202

22. Mosher DB et al: Monobenzylether of hydroquinone: A retrospective study of treatment of 18 vitiligo patients and a review of the literature. *Br J Dermatol* **97**:669, 1977

23. Spritz RA: Piebaldism, Waardenburg syndrome, and related disorders of melanocyte development. *Semin Cutan Med Surg* **16**:15, 1997

24. Jimbow K: Tuberous sclerosis and guttate leukodermas. *J Cutan Med Surg* **16**:30, 1997

25. Ruiz Maldonado R et al: Hypomelanosis of Ito: Diagnostic criteria and report of 41 cases. *Pediatr Dermatol* **9**:1, 1992

26. Küster W et al: Hypomelanosis of Ito and mosaicism, in *The Pigmentary System: Physiology and Pathophysiology,* edited by JJ Nordlund, RE Boissy, VJ Hearing, RA King, J-P Ortonne. New York, Oxford University Press, 1998, p 594

27. Loomis CA: Linear hypopigmentation and hyperpigmentation including mosaicism. *J Cutan Med Surg* **16**:44, 1997

28. Happle R: Phylloid hypomelanosis and mosaic trisomy 13: A new etiologically defined neurocutaneous syndrome. *Hautarzt* **52**:3, 2001

29. Francis JS, Sybert VP: Incontinentia pigmenti. *J Cutan Med Surg* **16**:54, 1997

30. Lacour JP: Physical agents, in *The Pigmentary System: Physiology and Pathophysiology,* edited by JJ Nordlund, RE Boissy, VJ Hearing, RA King, J-P Ortonne. New York, Oxford University Press, 1998, p 627

31. Jimbow K, Jimbow M: Chemical and pharmacologic agents, in *The Pigmentary System: Physiology and Pathophysiology,* edited by JJ Nordlund, RE Boissy, VJ Hearing, RA King, J-P Ortonne. New York, Oxford University Press, 1998, p 621

32. Miyamoto L, Taylor JS: Chemical leukoderma, in *Vitiligo,* edited by SK Hann, JJ Nordlund. London, Blackwell Science, 2000, p 269

33. Paine C et al: An alternative approach to depigmentation by soybean extracts via inhibition of the PAR-2 pathway. *J Invest Dermatol* **116**:587, 2001

34. Ruiz Maldonado R, Orozco-Covarrubias M: Postinflammatory hypopigmentation and hyperpigmentation. *Semin Cutan Med Surg* **16**:36, 1997

35. Lacour JP: Infectious hypomelanoses, in *The Pigmentary System: Physiology and Pathophysiology,* edited by JJ Nordlund, RE Boissy, VJ Hearing, RA King, J-P Ortonne. New York, Oxford University Press, 1988, p 629

36. Le Gal FA et al: Direct evidence to support the role of antigen-specific CD8+ T cells in melanoma-associated vitiligo. *J Invest Dermatol* **117**:1464, 2001

37. Ortonne JP, Perrot H: Idiopathic guttate hypomelanosis. *Arch Dermatol* **116**:664, 1980

38. Mitchell IC et al: Ulcerative and hypopigmented sarcoidosis. *J Am Acad Dermatol* **15**:1062, 1986

39. Ortonne JP, Perrot H: Scleroderma: Ultrastructural study of the melanin pigmentary disturbances of the skin. *Clin Exp Dermatol* **5**:13, 1980

40. Castanet J, Ortonne JP: Hair pigmentation, in *Hair and Its Disorders: Biology, Pathology and Management,* edited by FM Camacho, VA

Randall, VH Price. Amsterdam, Martin Dunitz, 2000, p 49

41. Trattner A, Metzker A: Partial unilateral lentiginosis. *J Am Acad Dermatol* **29**:963, 1993

42. Cullen MK: Leopard syndrome, in *The Pigmentary System: Physiology and Pathophysiology,* edited by JJ Nordlund, RE Boissy, VJ Hearing, RA King, JP Ortonne. New York, Oxford University Press, 1998, p 770

43. Cullen MK: Carney complex, in *The Pigmentary System: Physiology and Pathophysiology,* edited by JJ Nordlund, RE Boissy, VJ Hearing, RA King, JP Ortonne. New York, Oxford University Press, 1998, p 781

44. Stratakis CA et al: Clinical and molecular features of Carney complex: Diagnostic criteria and recommendations for patient evaluation. *J Clin Endocrinol Metab* **86**:4041, 2001

45. Esterly NB et al. Peutz-Jeghers syndrome, in *The Pigmentary System: Physiology and Pathophysiology,* edited by JJ Nordlund, RE Boissy, VJ Hearing, RA King, JP Ortonne. New York, Oxford University Press, 1998a, p 790

46. Karuman P et al: The Peutz-Jegher gene product is a mediator of p53-dependent cell death. *Mol Cell* **7**:1307, 2001

47. Marsh DJ et al: *PTEN* mutation spectrum and genotype-phenotype correlations in Bannayan-Riley-Ruvalcaba syndrome suggest a single entity with Cowden syndrome. *Hum Mol Genet* **8**:1461, 1999

48. Esterly NB et al: Neurofibromatosis, in *The Pigmentary System: Physiology and Pathophysiology,* edited by JJ Nordlund, RE Boissy, VJ Hearing, RA King, JP Ortonne. New York, Oxford University Press, 1998, p 741

49. Ruggieri M, Huson SM: The clinical and diagnostic implications of mosaicism in the neurofibromatoses. *Neurology* **56**:1433, 2001

50. Esterly NF et al: Polyostotic fibrous dysplasia (McCune-Albright syndrome), in *The Pigmentary System: Physiology and Pathophysiology,* edited by JJ Nordlund, RE Boissy, VJ Hearing, RA King, JP Ortonne. New York, Oxford University Press, 1998, p 748

51. Price SM et al: The spectrum of Silver-Russell syndrome: A clinical and molecular genetic study and new diagnostic criteria. *J Med Genet* **36**:837, 1999

52. Hitchins MP et al: Silver-Russell syndrome: A dissection of the genetic aetiology and candidate chromosomal regions. *J Med Genet* **38**:810, 2001

53. Esterly NF et al: Watson's syndrome, in *The Pigmentary System: Physiology and Pathophysiology,* edited by JJ Nordlund, RE Boissy, VJ Hearing, RA King, JP Ortonne. New York, Oxford University Press, 1998, p 753

54. Happle R, Koopman RJ: Becker nevus syndrome. *Am J Med Genet* **68**:357, 1997

55. Bolognia JL: Speckled lentiginous nevus, in *The Pigmentary System: Physiology and Pathophysiology,* edited by JJ Nordlund, RE Boissy, VJ Hearing, RA King, JP Ortonne. New York, Oxford University Press, 1998, p 958

56. Loomis CA: Linear hypopigmentation including mosaicism. *Semin Cutan Med Surg* **16**:44, 1997

57. Verghese S et al: Mosaic trisomy 7 in a patient with pigmentary anomalies. *Am J Med Genet* **87**:371, 1999

58. Komine M et al: Linear and whorled nevoid hypermelanosis: A case with systemic involvement and trisomy 18 mosaicism. *Br J Dermatol* **146**:500, 2000

59. Bastiaens M et al: The melanocortin-1-receptor gene is the major freckle gene. *Hum Mol Genet* **10**:1701, 1975

60. Bahadoran P: Hyperpigmentation associated with human immunodeficiency virus infection, in *The Pigmentary System: Physiology and Pathophysiology,* edited by JJ Nordlund, RE Boissy, VJ Hearing, RA King, JP Ortonne. New York, Oxford University Press, 1998, p 859

61. Kang WH et al: Melasma: Histopathological characteristics in 56 Korean patients. *Br J Dermatol* **146**:228, 2002

62. Im S et al: Increased expression of a melanocyte-stimulating hormone in the lesional skin of melasma. *Br J Dermatol* **146**:165, 2002

63. Perez Bernal A et al: Management of facial hyperpigmentation. *Am J Clin Dermatol* **1**:261, 2000

64. Rogioletti F, Rebora A: Acquired brachial cutaneous dyschromatosis: A common pigmentary disorder of the arm in middle-aged women. *J Am Acad Dermatol* **42**:680, 2000

65. Nordlund JJ: Cronkhite-Canada syndrome, in *the Pigmentary System: Physiology and Pathophysiology,* edited by JJ Nordlund, RE Boissy, VJ Hearing, RA King, JP Ortonne. New York, Oxford University Press, 1998, p 865

66. Im S: Dyschromatosis universalis hereditaria, in *The Pigmentary System: Physiology and Pathophysiology,* edited by JJ Nordlund, RE Boissy, VJ Hearing, RA King, JP Ortonne. New York, Oxford University Press, 1998, p 724

67. Esterly NB et al: Periorbital hyperpigmentation, in *The Pigmentary System: Physiology* and Pathophysiology, edited by JJ Nordlund, RE Boissy, VJ Hearing, RA King, JP Ortonne. New York, Oxford University Press, 1998, p 804

68. Esterly NB et al: Familial progressive hyperpigmentation, in *The Pigmentary System: Physiology and Pathophysiology,* edited by JJ Nordlund, RE Boissy, VJ Hearing, RA King, JP Ortonne. New York, Oxford University Press, 1998, p 713

69. Mitchell JR et al: A telomerase component is defective in the human disease dyskeratosis congenital. *Nature* **402**:551, 1999

70. Vulliany T et al: The RNA component of telomerase is mutated in autosomal dominant dyskeratosis congenita. *Nature* **413**:432, 2001

71. Im S et al: Reticulated acropigmentation of Dohi, in *The Pigmentary System: Physiology and Pathophysiology,* edited by JJ Nordlund, RE Boissy, VJ Hearing, RA King, JP Ortonne. New York, Oxford University Press, 1998, p 733

72. Chevrant-Breton J et al: Cutaneous manifestations of idiopathic hemochromatosis. *Arch Dermatol* **113**:161, 1977

73. Fedderson RM et al: Plasma cell dyscrasia: A case of POEMS syndrome with a unique dermatologic presentation. *J Am Acad Dermatol* **21**:1061, 1989

74. Bashito HM et al: General dermal melanocytosis. *Arch Dermatol* 117:791, 1981

75. Rappersberger K et al: Morphological changes in peripheral blood cells and skin in amiodarone-treated patients. *Br J Dermatol* **114**:189, 1986

76. Hashimoto K et al: Imipramine hyperpigmentation: A slate-gray discoloration caused by long-term imipramine administration. *J Am Acad Dermatol* **25**:357, 1991

77. Nakayama H et al: Pigmented cosmetic dermatitis. *Int J Dermatol* **15**:673, 1976

78. Sharood P, Marks R: The wages of warmth: Changes in erythema ab igne. *Br J Dermatol* **97**:179, 1977

79. Kourad K, Wolff K: Pathogenesis of diffuse melanosis secondary to malignant melanoma. *Br J Dermatol* **91**:635, 1974

T>

Chapter 91

James Grichnik Arthur Rhodes Arthur Sober

Benign Hyperplasias and Neoplasias of Melanocytes

HYPERPLASIAS
Lentigo Simplex
Combined Lesions of Lentigo Simplex
Agminated Lentigines
Nevus Spilus
Solar Lentigo
NEOPLASIAS
Common Acquired Nevomelanocytic Nevus
Halo Nevomelanocytic Nevus
Epithelioid Cell and/or Spindle Cell Melanocytic Nevus
Blue Nevus
Congenital Nevomelanocytic Nevus

REFERENCES

Benign melanocytic proliferative lesions form a spectrum of disorders ranging from a simple increase in epidermal melanocyte number to extensive cutaneous infiltration of melanocytic cells exhibiting various states of differentiation. In this chapter these lesions will be separated into the *melanocytic hyperplasias,* a term used to indicate increased normal melanocytes in the basal layer of the epidermis *melanocytic neoplasias,* a term used to describe the presence of melanocytic cells in epidermal nests within the dermis or in other tissues.

The specific molecular events causing melanocytic hyperplasias and neoplasias remain poorly defined. Simple hyperplasias are likely to be the result of an alteration of normal melanocytic homeostatic mechanisms leading to the accumulation of increased numbers of differentiated melanocytes in the epidermis. These alterations could be due to a primary melanocytic defect (such as an ultraviolet-induced mutation) or to homeostatic signaling changes in the local environment. Melanocytic neoplasias may be the result of aberrant melanocytic differentiation due to the presence of melanocytic cells lacking normal melanocytic differentiation (referred to as *nevomelanocytes*). Normal melanocytic differentiation occurs in a stepwise manner from a subpopulation of neural crest–derived cells. It is possible that aberrant differentiation from this population of neural crest cells is responsible for the diverse variety of melanocytic neoplasias.

The extent of melanocytic hyperplasia can be quite variable, ranging from lesions in which the increased melanin content is notable but the increase in melanocyte number is marginal to lesions in which accumulation of melanocytes is marked. The point at which a melanocytic hyperplasia becomes a neoplasia is artificially defined as the point at which three or more melanocytic cells form a nest (or theque) in the epidermis or defined as clonally derived based on genetic composition. The presence of melanocytic cells in the dermis also is sufficient to define a melanocytic neoplasia. The extent of melanocytic proliferation, spectrum and type of differentiation, location of cells, and age of the lesion may all affect the clinical and histopathologic features.

Until discrete molecular markers are defined, definitive subclassification of these melanocytic lesions is not possible. This heterogeneous group of disorders is currently loosely subgrouped based on clinical features, time of appearance, and microscopic characteristics. The benign melanocytic hyperplasias described in this chapter include lentigo simplex, combination lesions with lentigo simplex (agminated lentigines and nevus spilus), and solar lentigines. The neoplasias described include common acquired nevomelanocytic nevi (including halo nevi and excluding dysplastic/atypical nevi), epithelioid/spindle cell nevomelanocytic nevi, blue nevi, and congenital nevomelanocytic nevi.

HYPERPLASIAS

A well-defined hyperpigmented lesion with an increased number of individual melanocytes confined to the epidermal compartment is a lentigo (plural, lentigines, derived from Latin *lens,* meaning “lentil”). Although separated into simplex and solar lentigines, a number of subtypes exist with varying degrees of melanocytic and/or keratinocytic abnormalities. While the primary defect may be melanocytic in some lentigines, it is possible that the melanocytic hyperplasia is merely a secondary response to abnormal keratinocytic function (or some other local abnormality) in others. Other lesions in which epidermal melanocytic hyperplasia may be noted and some overlap may exist with lentigines include café-au-lait macules, seborrheic keratoses, melasma, and inflammatory/cytokine-induced proliferation.

Lentigo Simplex

Lentigo simplex (Fig. 91-1) is an acquired or congenital hyperpigmented macule consisting of intraepidermal melanocytic hyperplasia and increased melanin formation. Lentigo simplex lesions may be isolated or multiple and present on skin, nails, and mucous membranes. Multiple lentigines may be associated with systemic disorders.

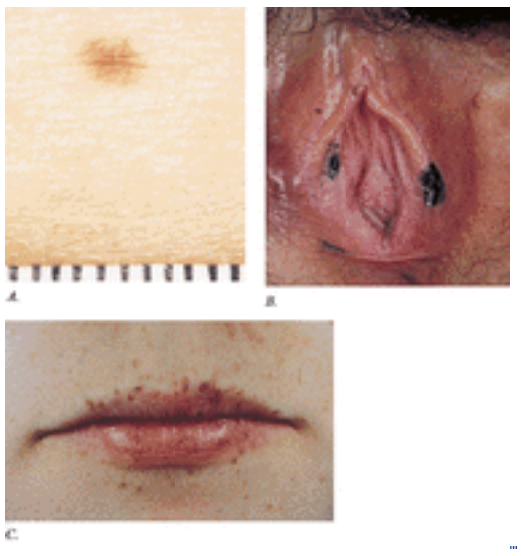

FIGURE 91-1 Lentigo simplex. *A.* Isolated acquired lentigo simplex on the abdomen of a 42-year-old white man who has dysplastic nevi and a family history of melanoma. *B.* Acquired darkly pigmented lentigines on the vulva of a 13-year-old white girl who has LAMB (myxoma syndrome). *C.* Multiple lentigines on the lips of the same patient.

HISTORICAL ASPECTS There has been a continual debate regarding the nosologic differentiation between lentigo and nevomelanocytic nevus. Early treatises by Darier, Scholtz, and Kissmeyer included lentigo among the nonelevated nevi. Zeisler and Becker in 1936 and Lund and Kraus in 1962 defined lentigo as an entity separate and distinct from nevomelanocytic nevus.

EPIDEMIOLOGY The frequency of lentigo simplex in children and adults has not been determined. Lentigo simplex is the most common histopathologic pattern of darkly pigmented lesions excised from acral sites of darkly pigmented races. [1] Pigmented nail bands in up to 20 percent of Japanese may have histopathologic features of lentigo simplex. [2]

ETIOLOGY AND PATHOGENESIS The increased density of melanocytes in lentigines is presumably due to an underlying developmental or intrinsic defect in melanocyte homeostasis. In some lentigines, the presence of melanin macroglobules in melanocytes and keratinocytes suggests that defects affecting melanization pathways are also involved. The presence of lentigo simplex in association with somatic abnormalities in such diverse conditions as Peutz-Jeghers syndrome, LEPOARD syndrome, and LAMB/myxoma syndrome suggests that lentigo development may be influenced by a number of different genetic factors.

CLINICAL MANIFESTATIONS Lentigo simplex usually is a sharply circumscribed, light-brown or dark-brown macule (see Fig. 91-1). There appears to be no relation between sun exposure and appearance of lentigo simplex. Lentigo simplex may appear as early as the first decade and may occur anywhere on skin or mucous membranes. Generalized lentigines may occur as an isolated phenomenon without known familial aggregation and present at birth, during infancy, or during adulthood. Familial clustering in an autosomal pattern also has been noted. A number of syndromes are recognized (reviewed in Chap. 90). In Moynahan's (LEOPARD) syndrome, lentigines are present at birth or shortly thereafter and may increase in number during childhood; they occur on both sun-exposed and sun-protected sites, including genitalia, conjunctiva, oral mucosa, palms, and soles. In Peutz-Jeghers syndrome, numerous lentigines may be present at birth or appear during early childhood. Oral mucosa is almost always involved. Other common sites of involvement in Peutz-Jeghers syndrome include lips, nose, eyelids, anus, nail bed, and dorsal and ventral surfaces of hands and feet. Oral pigmentation usually persists in Peutz-Jeghers syndrome, whereas cutaneous lentigines usually fade after puberty. The myxoma syndromes (also referred to as LAMB and NAME syndromes) are also associated with mucocutaneous lentigines (see also Chap. 90 and Chap. 166). Lentigines in this syndrome occur mainly on the face and genitalia as tan to black macules (see Fig. 91-1). In centrofacial lentiginosis, the presence of pigmented macules is restricted to a horizontal band across the central face. The lesions appear in the first year of life, increase in number during the first decade, and then fade in later life.

PATHOLOGY Lentigo simplex consists of intraepidermal melanocytic hyperplasia in the basal layer of elongated epidermal rete ridges without nest formation (Fig. 91-2). At one end of the lentigo spectrum are lesions more similar to café-au-lait lesions, in which the melanocyte number may not be significantly increased but pigmentary differences are marked, and at the other end of the spectrum the increased number of melanocytes is sufficient to begin forming nests bordering on a junctional nevus. Further, depending on the degree of keratinocytic hyperplasia, distinct separation from solar lentigo may not be possible in some lesions based on histopathologic interpretation. Giant pigment granules (melanin macroglobules) may occur in lentigo simplex in isolation and in association with multiple-lentigines (LEOPARD) syndrome.

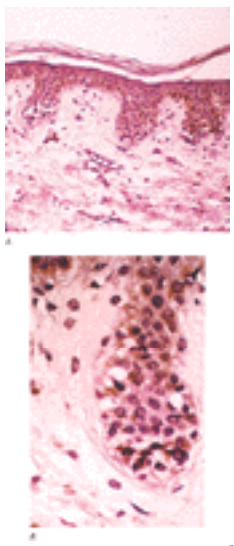

FIGURE 91-2 Histopathologic features of lentigo. Lentigo simplex (*A*) and higher magnification (*B*). There is hyperpigmentation and increased numbers of melanocytes without nest formation. The solar lentigo also demonstrates keratinocytic hyperplasia and bulbous rete pegs.

DIAGNOSIS AND DIFFERENTIAL DIAGNOSIS Lentigo simplex should be differentiated from solar lentigines, junctional

nevomelanocytic nevi, dysplastic melanocytic nevi, café-au-lait macules, and melanoma (Table 91-1).

Benign Macules	Benign Papules
Lentigo simplex	Lentigo simplex
Café-au-lait macule	Café-au-lait macule
Solar lentigo	Solar lentigo
PUVA lentigo	Becker's melanosis
Solar lentigines in xeroderma pigmentosum	Atypical lentigo simplex
Sulfiad lentigines	Lentigo maligna
Carotid lentiginosis	Nevus spilus*
LEOPARD syndrome	Benign pigmented keratosis*
Cardiac myxoma syndrome (LAMB, NAME)	Large cell acanthoma*
Peutz-Jeghers syndrome	Melanoma on acral and mucosal sites*
Agminated lentigines	Nevomelanocytic nevus, junctional type*
Centrofacial lentiginosis	Dysplastic melanocytic nevus*
Generalized lentigines	
Scar lentigo	
Atypical lentigo simplex	
Lentigo maligna	
Nevus spilus*	
Pigmented actinic keratosis*	
Melanoma on acral and mucosal sites*	
Nevomelanocytic nevus, junctional type*	
Dysplastic melanocytic nevus*	

*May have elevated compared quadrilateral.

TABLE 91-1 **Differential Diagnosis of Brown Macule/Patch**

TREATMENT There is no need to treat benign-appearing lentigo simplex. However, lesions that are significantly unusual, irregular, asymmetric, or changing in shape should be examined histopathologically for melanocytic dysplasia or melanoma. Wood's lamp examination is useful in defining margins of lentigo simplex.
COURSE AND PROGNOSIS The natural history of isolated lentigo simplex is not known. Once developed, the lesions are presumed to be relatively stable. There is no convincing evidence that lentigo simplex evolves to a nevomelanocytic nevus. As with any process in which melanocytes are present (including normal skin), it is possible for melanoma to evolve in a lentigo, but an elevated risk has not been demonstrated conclusively.

Combined Lesions of Lentigo Simplex

Multiple lentigines may appear in localized patches of skin, suggesting an underlying developmental abnormality. Two patterns will be reviewed that may represent different ends of a similar spectrum: numerous lentigines appearing together as an isolated group on otherwise normal-appearing skin (agminated lentigines) and a patch with features consistent with lentigo or café-au-lait macule with internal nevomelanocytic and/or melanocytic hyperplastic foci (nevus spilus).

Agminated Lentigines

Agminated lentigines may be defined as a circumscribed grouping of small pigmented macules arranged in a small or large group, often in a segmental pattern, each macule consisting of a lentiginous epidermal proliferation of melanocytes. Other names for this entity include *unilateral lentigines, partial unilateral lentiginosis, lentiginous mosaicism, segmental lentiginosis,* and *zosteriform lentiginous nevus.* Cases reported under the name of *zosteriform lentiginous nevus* also include examples of nevus spilus.

HISTORICAL ASPECTS A segmental distribution of lentigines was reported by McKelway in 1904. Since then, at least 11 cases of this pigmentary anomaly have been reported under the various names listed earlier.
EPIDEMIOLOGY The population prevalence of this disorder is unknown, but it is believed to be rare. There does not appear to be a racial or gender predilection.
ETIOLOGY AND PATHOGENESIS Chromosomal mosaicism confined to neural crest melanoblasts may have some role in this disorder.
CLINICAL MANIFESTATIONS Agminated lentigines first become manifest at birth or early childhood as small, circumscribed, light-brown macules, 2 to 10 mm in diameter, confined to a localized area of the body, often in a segmental distribution (Fig. 91-3) and frequently in a curvilinear or swirled pattern. While there are usually no associated disorders, agminated lentigines may occur with somatic abnormalities, including cerebrovascular hypertrophy, neuropsychiatric disturbance, rigid cavus foot, epidermal nevus, and ocular involvement.

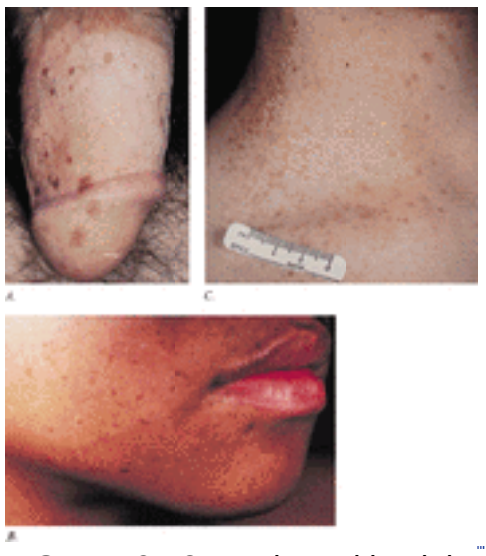

FIGURE 91-3 Agminated lentigines. *A.* Grouping of small light brown macules, present since age 14 years, on the right side of the shaft and glans penis of a 17-year-old healthy white male. *B.* Grouping of small, light brown macules, present for at least 6 years, on the right cheek of a healthy 10-year-old African-American male. *C.* Grouping of small light brown macules, present since age 2 years, on the right neck and supraclavicular area of a 13-year-old healthy white female.

PATHOLOGY Histopathologic studies reveal increased numbers of melanocytes in elongated epidermal rete ridges, similar to lentigo simplex, without nests of nevomelanocytes or cellular inflammation.
DIAGNOSIS AND DIFFERENTIAL DIAGNOSIS Agminated lentigines may be confused with nevus spilus and other varieties of pigmented macules (see Table 91-1). Wood's lamp examination may be required to differentiate agminated lentigines from nevus spilus because it can help differentiate the background pigmentation in the latter and its absence in the former.
TREATMENT Until the long-term course of agminated lentigines is known, it may be prudent to recommend periodic examinations to detect the earliest signs of possible atypical evolution.
COURSE AND PROGNOSIS The long-term course and malignant potential of agminated lentigines are unknown.

Nevus Spilus

Nevus spilus (derived from Greek *spilos,* meaning “spot”) is defined as a circumscribed macule/patch of tan pigmentation including scattered, more darkly pigmented melanocytic or nevomelanocytic macular and/or papular elements. Cases fitting the gross and microscopic description of nevus spilus have been called *speckled lentiginous nevus* and *zosteriform lentiginous nevus.*

HISTORICAL ASPECTS In older terminology, *nevus spilus* referred to a solitary, hairless, melanotic macule that was not associated with von Recklinghausen's neurofibromatosis or McCune-Albright syndrome. This term is still being used by some authors to describe uncharacterized macular hyperpigmentation. Nevus spilus was redefined by Ito and Hamada in 1952 [3] and reemphasized by Cohen et al. in 1970 [4] to be a circumscribed tan macule in which more darkly pigmented, raised and/or flat, melanocytic or nevomelanocytic elements are distributed. This clinical and microscopic definition of nevus spilus has been illustrated in multiple case reports under the same or different names.
EPIDEMIOLOGY Nevus spilus occurs in less than 0.2 percent of newborns, 1 to 2 percent of white school children, and 2 percent of white adults. There are no prevalence data in darkly pigmented persons. There does not appear to be a gender predilection. [5]
ETIOLOGY AND PATHOGENESIS Nevus spilus may be postulated to represent a localized defect in neural crest melanoblasts. Genetic and environmental factors also may play a role. Hypothetically, the development of a nevus spilus may be a multistep process involving a primary genetic defect creating the hyperpigmented macule/patch coupled with a secondary intrinsically (growth factor) or extrinsically (UV light) mediated event leading to the development of focal individual melanocytic neoplasms.
CLINICAL MANIFESTATIONS Rarely, nevus spilus may be present at birth. More commonly, the lesion becomes evident during infancy or early childhood. More darkly pigmented, flat or raised speckles are usually present when the lesion is first recognized, but new speckles may appear over time. The tan macular background pigmentation ranges from less than 1 cm to greater than 10 cm in diameter (Fig. 91-4). Although nevus spilus may occur anywhere, lesions have been noted primarily on the torso and extremities. A divided nevus spilus of the eyelid has been reported. [6] Lesions may be localized or have a segmental distribution. Giant varieties of nevus spilus may occur. Nevus spilus has been associated with other anomalies of vascular, central nervous system, or connective tissue origin. Multiple granular tumors and nevus flammeus have been associated with a giant nevus spilus.

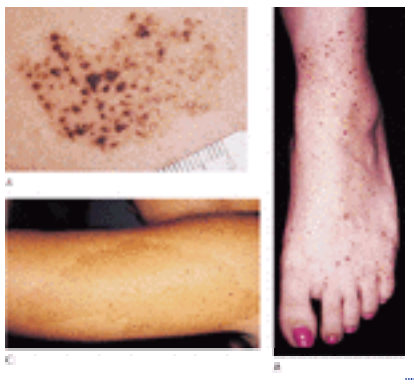

FIGURE 91-4 Nevus spilus. *A.* Acquired nevus spilus of indeterminate duration on the abdomen of a 29-year-old white woman. *B.* Nevus spilus appearing first at age 3 years on the ankle and foot of a 25-year-old white woman *C.* Congenital nevus spilus on the arm of a 10-year-old white male.

PATHOLOGY The tan background pigmentation usually consists of increased numbers of melanocytes in a lentiginous epidermal pattern. Routine and electron microscopic studies of nevus spilus may demonstrate melanin macroglobules in some cases. The flat, dark speckles of nevus spilus usually demonstrate lentiginous melanocytic hyperplasia, whereas the raised elements usually contain collections of nevomelanocytes in the epidermis and/or dermis. The speckled elements of nevus spilus also may consist of epithelioid and/or spindle cell nevi, nevi with dysplastic features, or blue nevi.
DIAGNOSIS AND DIFFERENTIAL DIAGNOSIS Nevus spilus can be differentiated from simple café-au-lait macules, relatively flat and hairless varieties of large congenital nevi, Becker's melanosis, and other varieties of lentigines (see Table 91-1) largely based on clinical features. The internal hyperpigmented or occasionally hypopigmented foci of nevus spilus may require biopsy to determine the nature of the associated melanocytic proliferation, which could be lentigo, junctional or compound nevus, epithelioid/spindle cell nevus, blue nevus, dysplastic nevus, or melanoma.
TREATMENT No standard guidelines for management of patients with nevus spilus exist. Clinical appearance (typical or atypical), history of stability or instability of pigmented elements, congenital or noncongenital onset, perceived risk of developing melanoma, and cosmetic concerns are considerations when determining whether to excise or recommend periodic clinical evaluation. Atypical-appearing new and/or unstable elements in nevus spilus should be evaluated by histopathologic examination to exclude melanoma. A nevus spilus with dysplastic or congenital features may have a greater risk of developing melanoma. [7], [8]
COURSE AND PROGNOSIS There are insufficient data to be certain of the natural history of nevus spilus or to comment specifically about its malignant potential; however, caution must be exercised for affected individuals. There are at least 12 well-documented cases of melanoma developing in contiguity with nevus spilus, some cases ending in metastatic disease and death. When viewed as a risk marker for melanoma, nevus spilus shows a trend for being more common in melanoma cases than in controls. Kopf et al. [5] detected nevus spilus in 5 (4.8 percent) of 105 white adults with melanoma compared with 14 (2.3 percent) of 601 dermatology outpatients, but overmatching bias in the control group could not be excluded.

Solar Lentigo

Solar lentigo is a circumscribed pigmented macule occurring singly or as multiple lesions induced by natural or artificial sources of ultraviolet (UV) radiation (Fig. 91-5 and Fig. 91-6). Outdated synonyms for solar lentigo include *sun-induced freckle, lentigo senilis,* and *senile lentigo.* Solar lentigines are separated from simplex lentigines based on the clinical

characteristics suggesting UV light as the precipitating factor and histopathologic characteristics suggesting a pronounced keratinocytic proliferative response. Specific defects involved are not yet known, but the primary defects could be either melanocytic or keratinocytic.

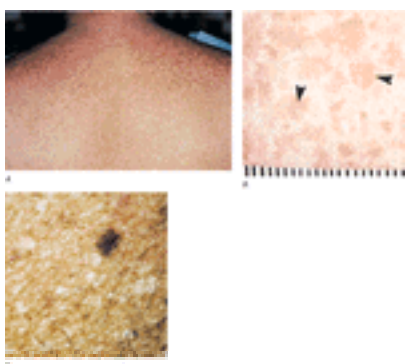

FIGURE 91-5 Solar lentigo. *A.* Uncountable solar lentigines on the back of a 30-year-old white man, appearing initially during early childhood following multiple sunburns. *B.* High magnification of lentigines in (*A*) showing light-brown macules with markedly irregular outlines. *C.* Solar lentigines on sun-damaged dorsal hand skin (hypopigmentation, wrinkling, and telangiectasia) of an elderly white man.

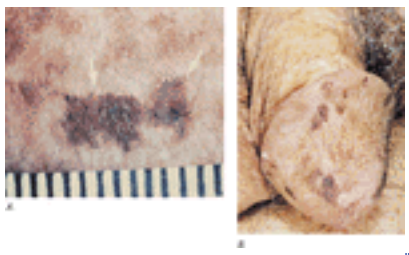

FIGURE 91-6 Photochemotherapy (PUVA)–induced lentigines on the buttock (*A*) and penis (*B*) of a 57-year-old white man who had received PUVA for psoriasis several times per week for 5 years. The PUVA lentigines appeared between 1 to 2 years after PUVA therapy was begun. The current recommendation is to shield the male genitalia during PUVA therapy to prevent epithelial tumors of the penis and scrotum.

A distinction is made between a freckle (ephelis) and a solar lentigo. Freckle (derived from Middle English, *freken*) and ephelis (plural, ephelides; derived from the Greek) also refer to circumscribed, pigmented macules on sun-exposed skin. Freckles are common on the central face and often first noted in early childhood, presumably developing after significant sun-exposure. Ephelides are said to fade or even disappear when sun exposure is discontinued. Unfortunately, there are no longitudinal studies of ephelides or solar lentigines that document gross morphologic or time-course differences that would reliably allow a clinical distinction between ephelides and solar lentigines. According to dopa studies on epidermal sheets, ephelides were reported to show increased melanogenesis but decreased melanocyte number, which infers a different pathologic basis. [9], [10] Studies in dopa-incubated tissue sections suggest that melanocytes are increased in ephelides in children and young adults, similar to solar lentigines. [11], [12]

HISTORICAL ASPECTS In 1950, Cawley and Curtis [13] called attention to solar lentigo as a unique lesion that appears mostly in older individuals and consists of a localized proliferation of intraepidermal melanocytes in elongated epidermal rete ridges. In 1963, Hodgson [14] confirmed the proliferation of melanocytes in solar lentigo using routine and dopa histochemical studies. Montagna et al. [15] emphasized the concurrent proliferation of melanocytes and keratinocytes in solar lentigo in the elderly. Solar lentigines also may occur in healthy white children and young adults even in the first several decades of life.

EPIDEMIOLOGY The prevalence of solar lentigines is correlated directly with increasing age, and they are present in 90 percent of white people over 60 years of age. [14] Solar lentigines are common in individuals who sunburn easily and fail to tan, whereas they are uncommon among people who have darkly pigmented skin. [16] Lentigines may be induced by photochemotherapy (PUVA lentigo), occurring in 40 to 50 percent of patients an average of 5.7 years after starting therapy, their frequency and severity directly attributable to the total number of treatments [16] (Fig. 91-6) (see also Chap. 266). Darkly pigmented skin is associated with the lowest risk for PUVA-induced or solar-induced lentigines. [16] Lentigines have been associated with UVA tanning bed use. [17] Lesions similar in gross and microscopic appearance to solar lentigo occur in children and young adults. They may appear within the first 5 years of life, tend to aggregate in families, and are significantly associated with red hair; their location and density correlate with sun sensitivity and sun exposure. The presence of freckles has been associated with a 2.5-fold increase in the rate of sunburn susceptibility and poor tanning response and a 3-fold greater likelihood of a lower minimal erythema dose in people who mostly burn and tan minimally or not at all. [18] The presence of dense sun-induced freckling increases the estimated risk for melanoma by three- to fourfold [19] (Table 91-2).

Risk Factor	Relative Risk*
1. New mole or mole that has changed or is changing	Very high†
2. Adulthood (≥15 years vs. <15 years)	88
3. Unique mole and/or prominent mole pattern	
a. Dysplastic mole(s), prior melanoma, and familial melanoma	500
b. Dysplastic mole(s) and familial melanoma, no prior melanoma	148
c. Dysplastic mole(s), no familial melanoma or prior melanoma	7–27
d. Congenital mole	2–21
e. Lentigo maligna	10
f. 50 moles ≥2 mm diameter	4–54
g. 12 moles ≥5 mm diameter	41
h. 5 moles ≥5 mm diameter	7–10
4. Caucasian race vs. black	20
5. Prior cutaneous melanoma	9
6. Cutaneous melanoma in first-degree blood relative	8
7. Immunosuppression	4
8. Sun-induced freckles (marked)	4
9. Sun sensitivity	3

*Degree of estimated increased risk for people who have the risk factor compared to people who do not have the risk factor. A relative risk of 1.0 implies no increased risk.
†Risk estimated roughly to be increased tenfold to four hundredfold based on theoretical prevalence of a "new mole or a mole that has changed or is changing" in the general population compared with the same risk factor in the population of patients who have melanoma.
SOURCE: Adapted from Rhodes,[109] modified with additional data from text.

TABLE 91-2 **Risk Factors for the Development of Cutaneous Melanoma**

ETIOLOGY AND PATHOGENESIS Solar lentigines are thought to represent a marker of intermittent high-intensity UV radiation, cumulative UV radiation, and/or a unique susceptibility to the proliferative, stimulatory, and/or mutagenic effects of UV radiation. Sun-exposed skin consistently reveals a twofold greater melanocytic density compared with nonexposed skin. In addition, experimental repeated UV radiation exposure is known to increase epidermal melanocyte number. [20] However, the acute hyperplastic response normally decreases by 2 months after UV radiation is discontinued. [20] It is possible that a mutation in a UV radiation–induced lentigo results in proliferation and enhanced pigment production in response to UV radiation, but this lesion remains persistent, unlike normal skin. It is possible that there is a genetic susceptibility to the development of solar lentigo in response to acute or chronic UV radiation and that melanocytes in these circumscribed proliferations are permanently altered. The minimal *freckling dose* to single exposures of experimental UVB radiation (320 mm) is 6 to 10 times the minimal erythema dose, and susceptibility to experimental induction of freckles appears to be restricted to people who already have the freckling tendency. [10] Phototoxic doses of photochemotherapy may lead to the development of lentigines 6 to 8 months later. [21] Lentigines that develop in patients receiving chronic photochemotherapy for psoriasis may persist 1 to 2 years or longer after therapy is discontinued, [16] and cellular atypia of epidermal melanocytes in these lentigines also may persist. In addition to the total dose of UV radiation received during photochemotherapy, individual susceptibility factors to lentigo development include race, age, and burning/tanning response to sunlight. [16] Disorders with increased sensitivity to UV light such as xeroderma pigmentosum (XP), in which the melanoma incidence rate in the first two decades of life is several orders of magnitude greater than expected, is associated with hyperpigmented macules on light-exposed skin within the first 5 years of life (see Chap. 155). These lesions demonstrate hyperplasia of variably atypical epidermal melanocytes (i.e., atypical lentigines) and persist despite sun avoidance. The lesions in XP are presumed to reflect hypermutability of melanocytes related to an impaired capacity to repair UV radiation–induced damage. [22] Lentigo maligna melanoma was the predominant melanoma type in one series of XP patients from Japan, [23] suggesting an association between this tumor subtype, sensitivity to UV radiation, and the presence of UV radiation–induced atypical solar lentigines.

CLINICAL MANIFESTATIONS Solar lentigo occurs as a circumscribed pigmented macule on skin exposed to natural sunlight or artificial sources of UV radiation, usually in the presence of similar lesions in the same location (see Fig. 91-5). Lesions may be tiny (<1 mm) or large (up to a few centimeters in diameter), with a tendency to confluence in severely sun-damaged skin and with smooth or markedly irregular outlines. Lesions are usually light brown, but varieties of solar lentigo are jet black, similar to an ink stain. When examined by dermoscopy (epiluminescence microscopy), the pigmented pattern in solar lentigo is reticulated. [12] Lentigines in patients receiving photochemotherapy and in individuals who have XP are often darkly and/or irregularly pigmented. Although solar lentigo usually occurs on sun-exposed skin, identical-appearing lesions may occur on sun-protected sites (including the penis and buttocks) that have been exposed to photochemotherapy (see Fig. 91-6). The oral-labial melanotic macule has gross morphologic characteristics similar to solar lentigo (Fig. 91-7), but its relation to a sun-sensitive phenotype or excessive sun exposure has not been well documented.

FIGURE 91-7 Labial melanotic macule, appearing 5 years earlier, on the lower lip of a 26-year-old white woman.

PATHOLOGY Solar lentigo shows elongated epidermal rete ridges with club-shaped or budlike extensions, frequent branching and fusing of rete ridges, a thinned or atrophic epidermis between rete ridges, and increased numbers of epidermal melanocytes without nesting (see Fig. 91-2). The microscopic appearance suggests a concurrent proliferation of keratinocytes and melanocytes. [15] There is a scant to moderate perivascular mononuclear cell infiltrate in the dermis, usually associated with scattered melanin-laden macrophages. Electron microscopic studies of solar lentigo reveal abundant melanosome complexes in keratinocytes, the complexes being generally larger than complexes in keratinocytes in adjacent skin. [15] Compared with melanocytes in sun-protected skin, melanocytes in solar lentigo reveal increased activity manifested by marked dopa reactivity (suggesting increased tyrosinase activity), elongated dendrites, large numbers of normal-appearing melanosomes, enlarged perikarya with well-developed rough endoplasmic reticula, numerous mitochondria, and hypertrophic Golgi complexes. [24] Melanin macroglobules also have been noted. [25] Pathologic features of photochemotherapy-induced lentigo (PUVA lentigo) include increased numbers of melanocytes in elongated epidermal rete ridges, with large cell bodies and sometimes atypical cellular morphologic features, dendrites often extending high into the epidermis, and melanocytes frequently residing above the epidermal basal unit. [12] Melanocytes in PUVA lentigo occasionally manifest autophagocytosis, sharply invaginated nuclear contours, nuclear

pseudoinclusions, double nuclei, striking melanosomal alterations, and melanin macroglobules; melanosomes in keratinocytes of PUVA lentigines are often large and single instead of small and compound as in solar lentigines. [24] Cosmetic UVA tanning also induces lentigines, and cellular atypia has been reported. Histopathologic characteristics of the labial melanotic macule (labial lentigo) are similar to those of solar lentigo, showing melanocytic hyperplasia but without cellular atypia. The presence of melanocytic hyperplasia in labial melanotic macule is not a uniform finding in all studies.

DIAGNOSIS AND DIFFERENTIAL DIAGNOSIS Other lesions that may be confused with solar lentigo include relatively "flat" varieties of seborrheic keratosis, lentigo simplex, junctional nevomelanocytic nevus, pigmented actinic keratosis, and large-cell acanthoma (see Table 91-1). Solar lentigines not apparent in visible light may be visualized using Wood's lamp illumination in a completely darkened examination room.

TREATMENT Solar lentigo usually requires no therapy, but more important, its presence indicates sensitivity and/or excessive exposure to UV radiation. Cosmetically displeasing lesions may resolve for as long as a year after light application of liquid nitrogen or other superficial destructive techniques. Bleaching creams containing hydroquinone are usually not effective. It may be possible to prevent further solar lentigines by reducing sun exposure. This may be accomplished through avoidance, protective clothing, and sunscreens. Optimally, these measures should be initiated during early childhood and continued throughout life.

COURSE AND PROGNOSIS Solar lentigines may appear at any time of life. A solar lentigo may enlarge, darken, and become stable over time, but longitudinal studies of solar lentigines are lacking. It is possible that once formed, solar lentigines may persist indefinitely or fade slightly with time. Solar lentigines may be a heterogeneous population that includes lesions that fade and lesions that do not fade after UV radiation avoidance. It has been proposed that some varieties of lichenoid keratosis (see Chap. 79) evolve from solar lentigo and that spontaneous resolution of lichenoid keratosis may cause regression of the associated lentigo. [26] This hypothesis has not been confirmed in longitudinal studies. The long-term course of atypical varieties of PUVA lentigo is unknown, but it is clear that PUVA lentigines (see Fig. 91-6) may persist 1 to 2 years or longer after therapy is discontinued [16] and that cellular atypia of epidermal melanocytes in these lesions may persist as well. It is also clear that these patients may be at increased risk for melanoma [27] and should be followed periodically for life. The presence of dense solar lentigines in adults is associated with an estimated two- to fourfold increased risk for epithelial skin cancer and two- to sixfold increased risk for melanoma. [24] Lentigo maligna (see Chap. 93) may masquerade as a lentigo early in its development or, alternatively, may evolve from a preexisting solar lentigo. A solar lentigo not matching the patient's other lentigines and/or enlarging/darkening out of step should be examined histopathologically or followed closely.

NEOPLASIAS

The benign melanocytic neoplasias include lesions in which nevomelanocytes are noted to be present in nests in the epidermis and/or present in locations other than the epidermis. The nevomelanocytes forming these lesions often do not demonstrate normal melanocytic differentiation and hence thei *nevomelanocytes*. The extent of melanocytic proliferation, spectrum and type of differentiation, location of cells, and age of the lesion all may influence clinical and histopathologic features. This section will focus on the spectrum of benign melanocytic neoplasias, excluding atypical (dysplastic) melanocytic nevi, nevus of Ota/Ito, and dermal melanocytosis (Mongolian spot) (see Chap. 90 and Chap. 92). Cutaneous melanoma is covered separately in Chap. 93.

Common Acquired Nevomelanocytic Nevus

Nevomelanocytic nevus is a collection of nevomelanocytes in the epidermis (junctional), dermis (intradermal), or both areas (compound). Other names include *nevus cell nevus, nevocellular nevus, nevocytic nevus, soft nevus, neuronevus, pigmented nevus, pigmented mole, common mole, melanocytic nevus, hairy nevus, cellular nevus,* and *benign melanocytoma. Dysplastic* melanocytic nevi usually are acquired nevi (see Chap. 92).

EPIDEMIOLOGY Common (also called *typical*) acquired nevomelanocytic nevi (Fig. 91-8) develop after birth, slowly enlarge symmetrically, stabilize, and persist or regress later in life. The majority of common acquired nevi appear to develop during the second and third decades of life, although some lesions may appear in the first 6 to 12 months of life.

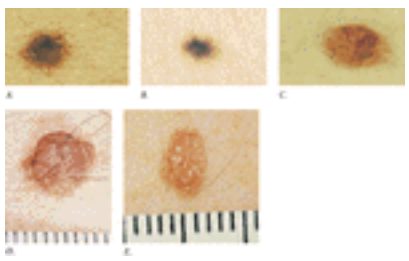

FIGURE 91-8 Typical acquired nevomelanocytic nevi. *A.* Junctional nevus on the chest of a 25-year-old white woman. *B.* Junctional nevus, present and stable for 6 years but darkening and enlarging in the past 6 months, on the left thigh of a 27-year-old Chinese woman. *C.* Dermal nevus on the abdomen of a 27-year-old white woman. *D.* Compound nevus (primarily dermal) on the shoulder of a 32-year-old white man. *E.* Compound nevus on the back of a 22-year-old white man. Scale in millimeters.

A number of studies have quantitated the number of typical acquired nevi in different age groups. In 432 European whites between the ages of 4 days and 96 years, nevi that were 3 mm in diameter or larger were detected in females and males, respectively, at median numbers of 0 and 2 in the first decade, 16 and 10 in the second decade, 24 and 16 in the third decade, 19 and 10 in the fourth decade, 12 and 15 in the fifth decade, 12 and 4 in the sixth decade, and 3.5 and 2 in the seventh through the ninth decades. [28] In a series of Australian whites, the average number of nevi per person peaked at 43 for males and 27 for females during the second and third decades, respectively, and decreased to very few in the sixth and seventh decades. [29] A similar age-related prevalance rate for nevi has been documented in other countries. A difference in frequency distribution of nevi according to gender is not clear, although most series show a close to equal prevalence in males and females. The prevalence of nevi varies according to race. In blacks, the overall prevalence of nevi (regardless of size) tends to be higher in those with lighter skin versus those with darker skin. [1] When prepubertal

whites were examined for nevi, a significant association for excess nevi was documented for pale skin, blue or green eyes, blond or light-brown hair, and a tendency to sunburn, but not a tendency to freckle. [30] Other studies show variable relationships to these same parameters. Environmental exposure to UV light appears to be a critical exacerbating factor for the development of melanocytic nevi. In an Australian study, mole density has been shown to increase with increasing sun intensity in the northern parts of the continent. [31] Further, the use of UV blocking sunscreens has been shown to decrease the number of new moles in children. [32] Genetics plays a role in nevus development. There is evidence that the size, frequency, and distribution patterns of acquired nevi tend to aggregate in families. This observation is well documented for atypical nevi in the setting of familial cutaneous melanoma (see Chap. 92) and congenital nevi. Correlation coefficients for total nevus counts were significantly higher in 153 monozygotic versus 199 dizygotic twin pairs in Australia (0.94 versus 0.64). [33] In studies of children younger than 12 years of age in Queensland, a history of melanoma in a child's first- or second-degree relative was associated with an increase in total nevi and an increase in large nevi (>5 mm). [30]

ETIOLOGY AND PATHOGENESIS There has been a continual debate as to the origin of nevi. Although many theories have been proposed and some supporting data are available, the critical events leading to nevus development remain a mystery. A number of hypotheses have been proposed. These include (1) transformation from epidermal melanocytes and subsequent deposition/migration into the dermis, (2) dual origin, i.e., nevomelanocytes in the epidermis and upper dermis being derived from epidermal melanocytes, and nevomelanocytes in the lower dermis being derived from Schwann cells of nerves, (3) hamartomatous change affecting many cell types, and (4) benign neoplastic proliferation originating from a defect in melanoblast/neural crest cells. Evidence for the first hypothesis includes the demonstration of basement membrane around nevomelanocytes in the dermis based on routine, ultrastructural, and immunohistologic features, suggesting structural contiguity of dermal nevomelanocytes with epidermis. [34] These studies would suggest that nevomelanocytes extend down from the epidermis along with the basement membrane. Evidence for the second hypothesis is based on differences in differentiation of nevomelanocytes. This includes positive staining by a monoclonal antibody to the Schwann cell–associated antigen for nevomelanocytes in the lower dermis and negative staining for nevomelanocytes in the epidermis and upper and middle dermis. Moreover, nevomelanocytes in the epidermis and papillary dermis commonly resemble epithelioid cells, aggregate in nests, demonstrate tyrosinase activity but not cholinesterase activity, stain weakly for neuron-specific enolase, and contain melanin. Nevomelanocytes in the deep dermis tend to resemble fibroblasts or Schwann cells or form concentrically arranged and loosely layered structures becoming nevic corpuscles that resemble Meissner corpuscles, are usually disposed as single cells, demonstrate minimal tyrosinase activity, have abundant cholinesterase activity, and commonly stain positively for neuron-specific enolase. This hypothesis would suggest that the phenotypic differences in the nevomelanocytes are due to different origins (melanocytes and Schwann cells). Evidence for the third hypothesis includes changes in the associated epidermis, including lentiginous, seborrheic, or epidermal nevus type patterns, and aberrations of appendageal and neurovascular structures, particularly in congenital nevi. These findings reinforce the notion that nevomelanocytic nevi are benign hamartomas involving multiple tissue elements. The fourth hypothesis is based on the existence of defective melanoblasts that may lead to defective differentiation. Neural crest–derived melanoblasts migrate to the dermis and basal layer of the epidermis before 40 days of estimated gestational age. These cells are thought to take up residence in the epidermis and/or superficial dermis (or the deep dermis, panniculus, and adnexal structures in the case of congenital nevi). Melanocytic “precursor” cells have been shown to be present in adult human skin. [35] Theoretically, these cells could aberrantly proliferate and differentiate, giving rise to melanocytic neoplasms. Depending on the defect, timing, and local tissue influences, a variety of different melanocytic neoplasias could be created. This fourth hypothesis is supported by data showing that human acquired nevi are clonal. [36], [37] and [38]

CLINICAL MANIFESTATIONS Common acquired nevi vary considerably in their gross appearance. In general, appearance to the naked eye is orderly; i.e., lesions have a homogeneous surface and coloration pattern, round or oval shape, regular outlines, and relatively sharp border (Fig. 91-8). Common acquired nevi may be papillomatous, dome-shaped, pedunculated, or flat-topped and usually are flesh-colored, pink, or brown. More elevated acquired nevi tend to be more lightly pigmented, and flatter acquired nevi tend to be more darkly pigmented. More elevated and less pigmented lesions tend to have a prominent intradermal nevus component, whereas flatter and darker lesions have a more prominent junctional melanocytic or nevomelanocytic component and a less prominent dermal component. Very dark brown and black are unusual colors for common acquired nevi in lightly pigmented people. In contrast, dark pigmentation is usual for common acquired nevi in people who have darkly pigmented skin. Very dark brown and black in nevi on acral and mucosal surfaces and nail apparatus should be viewed with suspicion regardless of constitutive skin color. Blue, gray, red, and white areas in a nevus are not typical features and ought also to be viewed with suspicion. The surfaces of nevi may reveal hair that is less than, equal to, or greater than that of surrounding skin. Hair in nevi may be coarser, longer, and darker than that in surrounding skin. Lesions on palms and soles are usually hairless. Size, shape, skin markings, and hair quality of nevi in darkly pigmented races are similar to those in whites. Pigmented nevi of the nail apparatus may be a dark or light brown, extending from the nail matrix to the distal edge of the nail plate (Fig. 91-9); extension of the pigmentation onto the skin of the nail fold or beyond the distal nail groove should be considered suspicious for melanocytic dysplasia or melanoma. Nevi on palms and soles, even compound nevi, may not distort the skin surface, perhaps because of a thickened stratum corneum in these sites.

FIGURE 91-9 Acquired melanocytic nevus of the nailbed in a 32-year-old white man. Note the lack of involvement of proximal nail fold.

Relatively large and numerous nevi are common in Turner's syndrome and Noonan's syndrome and in persons who have atypical nevi. Multiple studies demonstrate that prominent numbers of nevi indicate an increased melanoma risk. Tucker et al. [39] noted a 3.4 (95% CL: 2.0–5.7) adjusted relative risk for melanoma in patients with 100 nevi or more (>2 mm and <5 mm) compared with those with fewer than 25 nevi. The relative risk was increased to 12 (95% CI: 4.4–31) for patients with 10 or more atypical nevi compared with patients without atypical nevi. Absence of direct site specificity of nevi and melanoma suggests that nevus proneness per se indicates a general melanoma risk, [40] largely independent of hair and eye color and overall sun exposure. [41] Other traits, including skin color and freckles, may be multiplicative to the number of nevi in increasing melanoma risk. [42]

PATHOLOGY Nevomelanocytes in the epidermis have a nuclear size similar to or larger than nuclei of epidermal melanocytes. Nevomelanocytes are arranged in nests surrounded by a smooth perimeter of epidermis and separated from nevomelanocytes by a retraction artifact (Fig. 91-10). Nevomelanocytes have abundant pale-staining eosinophilic cytoplasm and may have pseudopodic or dendritic extensions that are more evident when dopa histochemistry is used for visualization. Nuclei of nevomelanocytes are pale-staining, characterized as vacuolated or reticulated; a nucleolus is usually visible. [43] Epidermal melanocytes between junctional theques of nevomelanocytes in typical nevomelanocytic nevi are disposed as single cells, with overall numbers and cell size equal to or slightly greater than that in adjacent sun-exposed skin [11] (see Fig. 91-10). The overlying epidermis is often normal in appearance but may be thickened in a lentiginous pattern (elongated and club-shaped rete ridges), with an appearance similar to seborrheic keratosis complete with horn cysts or epidermal verrucous hyperplasia similar to epidermal nevus.

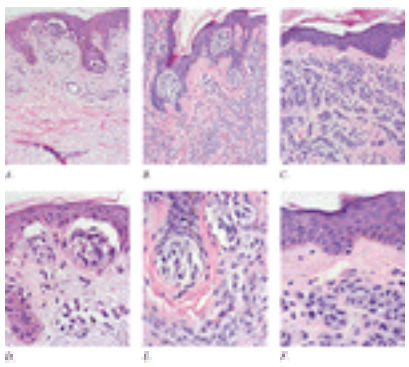

FIGURE 91-10 Histopathologic features of acquired nevi. Junctional nevus (*A*) and higher magnification (*D*). Compound nevus (*B*) and higher magnification (*E*). Intradermal nevus (*C*) and higher magnification (*F*). Well-formed nests of nevomelanocytes are present in the junctional and compound nevi. Sheets and cords of nevocytes are present in the dermis of the compound and intradermal nevi. A Grenz zone free of nevomelanocytes is present just below the epidermis in the intradermal nevus (*C* and *F*).

The dermal component of nevi has an orderly progression from top to bottom, with larger epithelioid cells above (epidermis and superficial papillary dermis) blending into a pattern of smaller cells in the deeper dermis. Nevomelanocytes in epidermis and upper papillary dermis frequently resemble epithelial cells, with an oval or cuboidal shape, a well-outlined cytoplasm that is homogeneous in character, a nucleus not much larger than nuclei of basal keratinocytes, and a visible nucleolus. Nevomelanocytes in the epidermis and superficial dermis frequently contain melanin, but the dopa histochemical reaction in nevomelanocytes in the epidermis and dermis is usually minimal. [11] Nevomelanocytes in the middle or deep dermis are usually smaller than nevomelanocytes in the superficial dermis or epidermis and frequently resemble lymphoid cells. Nevomelanocytes in the deep dermis may be round or oval and often resemble Schwann cells or fibroblasts when they are singly disposed and may be difficult to differentiate from fibroblasts unless they are disposed in sheets, cords, or patchy aggregates [44] (see Fig. 91-10). Usually, dermal nevomelanocytes are interposed among collagen bundles, and there is no distinct rim of collagen or retraction artifact between surrounding collagen and cellular aggregates. Features that suggest atypicality of nevomelanocytes in the dermis are nests or fascicles “pushing” and compressing collagen in the reticular dermis, lack of maturation with descent into the deep dermis, persistence of pigment production in the deep dermis, irregularity of size and shape of cells, frequent mitotic figures, and desmoplasia or fibrosis in the dermis. Nevomelanocytes in the dermis of typical acquired nevi have a monotonous similarity one to another within the same anatomic level and an overall symmetry of architecture from top to bottom and side to side. Inflammatory cellular infiltrates in typical, stable acquired nevi are usually scanty [43] or absent. Melanin-laden macrophages are usually apparent in the superficial papillary dermis of nevi, their number usually proportional to degree of melanin production. [43] Blood vessel proliferation, eosinophilic fibrosis, and lamellar fibroplasia (features frequently seen in atypical melanocytic nevi) are usually not prominent in typical acquired nevi. Langerhans cell density overlying typical acquired nevi and atypical nevi is increased compared with adjacent skin. Intradermal nevi that have few or no junctional nests frequently have a Grenz zone relatively free of nevomelanocytes just below the epidermis (see Fig. 91-10). Multinucleated nevomelanocytes occur occasionally and may be interpreted as a sign of benignity. Nevomelanocytes in the deep dermis may be disposed within a collagenous framework that is loose, pale, and wavy in formations called *neuroid tubes,* similar to a neurofibroma; they may be disposed in concentrically arranged whorls resembling Meissner's tactile corpuscles; and they may be spindle-shaped and embedded in loosely arranged connective tissue (neural nevi). Both neural nevi and neurofibromas show nonspecific cholinesterase activity. Myelin basic protein is detected in various neural tumors but not in melanocytic or nevomelanocytic tumors, and melanosomes are present in nevomelanocytes but not in neurofibromas or nerve tissue. Cutaneous neural lesions may be distinguished from melanocytic tumors by the presence of myelin basic protein and neurofilaments and the absence of vimentin. The balloon cell nevus is composed of peculiar foam cells comprising a portion or all of a given lesion. In addition to clear cells with single basophilic nuclei, multinucleated balloon cells and multinucleated giant cells are seen frequently. Electron microscopic studies suggest that the vacuolization of the nevomelanocytes is due to enlargement and destruction of melanosomes. There appears to be no distinguishing gross features of balloon cell nevi. The *combined nevus* refers to the in-contiguity association of different types of melanocytic nevi. These lesions include the combined compound nevus (acquired or congenital)–blue nevus and compound nevus–spindle cell and/or epithelioid cell nevus. *Recurrent melanocytic nevus* (pseudomelanoma) is the name given to recurrent lesions following incomplete removal of a benign

nevomelanocytic nevus. [45] Pseudomelanoma is said to be relatively common after superficial destructive procedures (i.e., shave biopsy or dermabrasion). A markedly atypical clinical and histopathologic appearance may accompany this recurrence, making these lesions worrisome for possible melanoma. Clinically, the recurrent nevus is confined to the scar but may be markedly irregular. Histopathologically, the recurrent lesions often demonstrate the presence of melanocytic hyperplasia in a lentiginous or junctional pattern (often to a greater extent than the original nevus). Moderate nuclear atypia may be present in 12 percent of recurrent nevi, mitotic figures in 8 percent, and pagetoid scattering in 3 percent, raising concern about the potential biologic behavior of some recurrent lesions. Other studies suggest that deliberate trauma to benign nevi in the form of incisional biopsy was not associated with atypical melanocytic changes. [46] Various findings have been identified in nevi that may suggest modes of regression or elimination of melanocytic elements. Some of the findings include neuroid, fibrous, mucinous, and fatty degeneration. [47] The presence of nevomelanocytes in the stratum corneum [48] suggests transepidermal elimination. Psamomma bodies and amyloid bodies, present occasionally in nevi, also may be related to degeneration or regression. Fibrosis may occur as an age-related phenomenon, whereas true desmoplasia appears to be a reactive process or functional transformation by the nevomelanocytes. Follicular mucinosis has been reported in nevi in at least two cases. Spicules of bone are observed occasionally in nevi, possibly related to reactive metaplasia, trauma, or infection. There may be histopathologic artifacts in nevomelanocytic nevi. Shrinkage clefts may resemble lymphatics or vascular spaces, prominent in the midportion of nevi and particularly in areas with hemorrhage. Separation of sheets of nevomelanocytes into parallel rows may be caused by improper cutting. Local anesthesia injection directly into the nevus also may be associated with artifactural changes.

DIAGNOSIS AND DIFFERENTIAL DIAGNOSIS It may be difficult to differentiate relatively flat nevomelanocytic nevi that are pale brown from solar lentigo, lentigo simplex, or café-au-lait macules without resorting to oblique lighting, which usually will reveal at least some skin surface distortion in nevomelanocytic nevi. Dermoscopy also may be useful and may reveal a number of diagnostic patterns in nevi, including reticular, globular, cobblestone, and parallel patterns. [49], [50] Clinically, a nevomelanocytic nevus must be differentiated from melanoma, blue nevus, pigmented fibrous histiocytoma (dermatofibroma), Kaposi's sarcoma, pigmented basal cell carcinoma, pigmented actinic keratosis, benign pigmented keratosis, mastocytoma, seborrheic keratosis, epidermal nevus, Becker's melanosis, common wart, molluscum contagiosum, subungual hematoma, supernumerary nipple, pigmented spindle cell and/or epithelioid cell nevus, sclerosing hemangioma, appendage tumor, pyogenic granuloma, and large cell canthoma. Nevus spilus has melanocytic or nevomelanocytic pigmented elements within a lighter background of lentigo simplex. The differentiation between typical acquired nevomelanocytic nevus and acquired atypical melanocytic nevus (or cutaneous melanoma) is discussed in Chap. 92 and Chap. 93. Nevomelanocytic nevi that are nonpigmented or pink must be distinguished from other nonpigmented tumors, such as basal cell carcinoma, fibrous papule, wart, dermal mucinosis, clear cell acanthoma, and a variety of appendageal tumors.

TREATMENT The vast majority of acquired nevomelanocytic nevi require no treatment. Indications for removal of benign-appearing lesions may include cosmetic concerns or continual irritation that could be mistaken for a changing mole. Lesions with features worrisome for melanoma need to be excised. These features are addressed in detail in Chap. 92 and Chap. 93. Dermoscopy may be used to differentiate benign and potentially malignant features. A photographic medical record can play a critical role in identifying changes that might not have been detected otherwise. [51] Complete removal of nevi is best accomplished by elliptical excision. Leaving a partially excised nevus, regardless of the initial pathology, is fraught with potentially alarming consequences of repigmentation and/or regrowth (pseudomelanoma). [45] Incisional biopsy, even for melanoma, is necessary at times, particularly for lesions that cannot be excised easily and that require histopathologic diagnosis. Destructive modes of therapy (electrodesiccation, cryotherapy, dermabrasion, and laser) should be considered very carefully if used in the management of melanocytic and nevomelanocytic nevi. They have the definite disadvantage of not providing tissue for histopathology. Although dermabrasion has been used to eliminate pigmentation of nevomelanocytic nevi, residual nevus cells in the dermis are to be expected, cosmetic outcome is often unpredictable, and recurrence with worrisome clinical features may complicate future management. Laser treatment of melanocytic and nevomelanocytic lesions has the theoretical risk of malignant transformation, but there is no proof for this.

COURSE AND PROGNOSIS Typical acquired nevi have not been followed systematically from their inception to resolution or regression. Therefore, dynamic evolution of acquired nevi must be surmised from static information or short-term follow-up studies. It has been stated that during the early years of life, virtually all nevomelanocytic nevi are composed primarily of junctional theques, [52] that nevomelanocytes in these junctional theques eventually push their way to the dermis and finally lose their epidermal contact as they continue to grow into the dermis and become intradermal nevi, and that in the intermediate stage of this process there are junctional theques in the epidermis and sheets and nests of nevomelanocytes in the dermis (i.e., compound nevi). [53] This argument suggests that because nevi in adults are primarily of the dermal type and because nevi in children are primarily of the junctional type, nevi evolve by a process of nevus cells from the epidermis “dropping down” into the dermis (*Abtropfung*). [52] The precise nature of the “dropping down” process has not been defined. It is likely that acquired nevi evolve through a life cycle, first becoming apparent after infancy in the vast majority of cases, peaking in number during the second and third decades of life, and then disappearing by the seventh to ninth decades. [28], [29], [47] Regression of nevi is believed to occur by neuroid, fibrous, mucinous, or fatty degeneration. [47] The formation of cylindrical neuroid structures in aging nevi suggests an end stage in differentiation and not a source of origin of intraepidermal nevi. Transepidermal elimination of nevomelanocytes occurs rarely, [48] in 0.13 percent of cases in one study. [54] Rarely, nevomelanocytes have been documented to show spontaneous disappearance. Nevi also may involute during the course of inflammatory halo depigmentation (halo nevi). There may be relatively sudden changes in nevi that are unrelated to malignant transformation. Any single nevus that is noted to suddenly change independently should be cause for concern. Causes of sudden changes in a nevus (color, surface, or size, with or without pain, itching, ulceration, or bleeding) over days or weeks include cystic dilatation of a hair follicle, epidermal cyst formation, folliculitis, abscess formation, trauma, hemorrhage, and, in the case of a pedunculated nevus, strangulation and thrombosis. These benign causes of sudden change may require close observation until resolution occurs over the course of 7 to 10 days (in the case of trauma or inflammation) or histopathologic examination. Cases have been described of the eruptive appearance of nevi after blistering skin disease, immunosuppression, or chemotherapy. The vast majority of acquired nevi are harmless, growing in proportion to body growth, with physiologic spurts of enlargement during early childhood and puberty. Melanoma risk appears to be related to the number and size of nevi; patients with numerous nevi, atypical nevi, and a personal or family history of melanoma should be considered for periodic surveillance examinations (see Table 91-2).

Halo Nevomelanocytic Nevus

The halo nevus is defined as a nevomelanocytic nevus surrounded by a halo of depigmentation (Fig. 91-11 and Fig. 91-12). This lesion should not be considered a unique melanocytic neoplasia but rather a reaction pattern that may occur around any melanocytic neoplasm. This phenomenon often, but not always, indicates the onset of involution and subsequent regression of the melanocytic nevus. Other names for this phenomenon include *leukoderma acquisitum centrifugum, Sutton's nevus, leukopigmentary nevus, perinevoid vitiligo, and perinevoid leukoderma.* The halo phenomenon may be associated with acquired and congenital nevomelanocytic nevi as well as with melanoma and nonmelanocytic tumors.

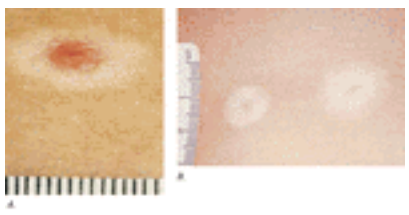

FIGURE 91-11 Acquired halo nevomelanocytic nevus. *A.* Acquired halo nevus on the chest of a 16-year-old white boy whose maternal grandmother had melanoma. *B.* Acquired halo nevi on the back of a 6-year-old white boy who has dysplastic nevi in the hairy scalp and a history of melanoma in his maternal grandmother. Scale in millimeters.

FIGURE 91-12 Halo congenital nevomelanocytic nevus on the neck of a 4-year-old female of a black African-American mother and white father. This child also had scattered areas of vitiligo-like depigmentation in other sites. A 3-year follow-up after excision of the nevus revealed almost total repigmentation of the widely scattered previously depigmented areas.

EPIDEMIOLOGY Of 8298 whites aged 12 to 16 years, there were 51 males (1.2 percent) and 22 females (0.5 percent) who had one or more halo nevi, for an overall prevalence rate of 0.9 percent. [56] In one large series of halo nevus, [57] individuals ranged in age from 3 to 42 years (mean age 15 years), the vast majority of cases occurring before age 20 years. No race is spared. The most common condition associated with halo nevus is vitiligo, occurring in 18 to 26 percent of patients. Halo nevus may be associated with poliosis, Vogt-Koyanagi-Harada syndrome (see Chap. 90), pernicious anemia, and a personal or family history of melanoma (including ocular melanoma). Halo nevus has been reported after exposure to external depigmenting agents.

ETIOLOGY AND PATHOGENESIS Pathogenesis of the halo phenomenon is poorly understood. Available evidence suggests that both humoral and cellular factors may be responsible for nevus destruction. Lymphocytes isolated from patients with halo nevus or melanoma, but not patients with vitiligo or normal controls, show enhanced cell killing of human melanoma cells in culture. [58] A cytoplasmic antibody has been demonstrated against melanoma in patients with resolving halo nevus but not in patients who have vitiligo without halo nevus or in patients with Spitz or ordinary nevi. [59] These lymphocyte and serologic abnormalities do not indicate the exact sequence of events in the halo phenomenon, nor whether these abnormalities are primary or secondary. Reed et al. [60] postulate atypicality of nevomelanocytes as the initiating factor for the immune response, which may cross-react with normal epidermal melanocytes and typical nevomelanocytes. Sinclair swine may provide an animal model for halo nevus because melanocytic tumors associated with metastatic disease in these animals are similar to human melanoma, and regression of tumors is associated with surrounding depigmentation as a concomitant event that follows an inflammatory cellular infiltrate in the tumors. A second process that may provide some insight into factors involved in melanocytic interactions with the immune system is a process that results in the development of an eczematous dermatitis presenting as a red halo around nevi (halo dermatitis). Unlike halo nevi, regression of the nevus does not usually occur, and the eczematous changes clear over the course of several months.

CLINICAL MANIFESTATIONS The typical halo nevus has a pink or brown central nevomelanocytic nevus surrounded by a symmetric round or oval halo of depigmented skin. The central nevus may be small, in the case of typical acquired nevus, or large, in the case of acquired dysplastic or congenital nevus (see Fig. 91-11 and Fig. 91-12). The halo of depigmentation is variable in size, usually a radial zone 0.5 to 5 cm around the central lesion. Under Wood's lamp, which may be required to visualize depigmentation in lightly pigmented individuals, the perinevic halo is seen as depigmented with sharply defined borders. White hairs may be seen in hair-bearing depigmented areas. Alopecia areata surrounding halo nevus has been reported. The number of halo nevi per person may be one or many, multiple lesions occurring in 25 to 50 percent of patients. For patients who have multiple lesions, only a few nevi are usually affected, but as many as 90 halo nevi have been reported in a single person. Any nevus in any anatomic site may be involved, but the posterior torso is involved most commonly. Lesions are usually asymptomatic. UV radiation may cause redness and even blistering in the perinevic halo. The typical history for halo nevus is that depigmentation appears around a preexisting nevus. Time for full evolution to depigmentation of the halo is not known, but patients report the phenomenon occurring over days to weeks, with little change occurring in the halo thereafter. A trichrome appearance of the halo has been reported. Occasionally, the depigmented halo may show transient redness as the initial manifestation. The central nevus may remain unchanged, or it may change from one or more shades of brown to variegations of brown and red or totally red or pink. The central nevus may persist or eventually flatten and disappear. Disappearance may take months to years. Areas of depigmentation that remain after the central nevus disappears may remain stationary for many years or repigment after months to years. There are nevi in which the nevus fails to involute, and repigmentation of the depigmented halo may

occur. Occasionally, congenital nevi associated with halo phenomenon may show clinical regression of surface pigmentation overlying the nevus.

PATHOLOGY The usual histopathologic findings in a halo nevus are the central nevomelanocytic nevus, a dermal lymphocytic infiltrate associated with the nevus, and a depigmented zone totally or almost totally devoid of epidermal basal unit dopa-reactive melanocytes. In early-regressing lesions, the nevus is associated with a marked cellular infiltrate, but there is little or no destruction of nevomelanocytes. In later lesions, there is cytolysis of nevomelanocytes, portions of which are evident in macrophages. In the most regressed lesions, there is vitiligo-like loss of pigmentation, total absence of nevomelanocytes, and few or no inflammatory cells. The histopathologic appearance of a given halo nevus depends on the stage of evolution. Epidermal melanocytes in the depigmented halo initially show detachment from the basal layer, autophagocytosis of preformed melanosomes, vacuolization of melanosomes, pyknotic nuclei, and abnormal cytoplasmic features. Remaining melanocytes in the depigmented halo show only a few melanosomes in very early stages of formation. In the completely depigmented halo, epidermal melanocytes are absent, and numerous Langerhans cells occupy the epidermal basal layer. Epidermal keratinocytes in the depigmented halo are devoid of melanosomes, degenerative changes are sometimes seen, and the epidermis also may be infiltrated by a few lymphocytes and nerve fibers. The dermis below the depigmented halo is usually devoid of inflammation. The central nevus may be purely junctional or purely dermal, but the most common pathology is compound. The inflammatory infiltrate is usually located in a bandlike pattern beneath the nevus and/or intermixed with dermal nevomelanocytes. Immunohistochemical staining for S100 protein (or other melanocytic markers) may help to identify the nevomelanocytes in the inflammatory infiltrate. The inflammatory infiltrate is composed mainly of lymphocytes, plasma cells, and histiocytes. Mast cells are scarce, and eosinophils and neutrophils are not usually evident. The lymphocytes appear to be antigenically stimulated, and 80 percent are T lymphocytes, whereas B lymphocytes are scarce or absent. The T cells appear to belong to the CD8+ population. [61]

DIAGNOSIS AND DIFFERENTIAL DIAGNOSIS Diagnosis of halo nevus is usually clinical, based on the presence of an acquired or congenital nevus surrounded by macular depigmentation. The halo phenomenon may be associated with nevi exhibiting a wide spectrum of histopathologic cellular atypia. Tumors associated with the halo phenomenon include congenital nevomelanocytic nevus, atypical melanocytic nevus, melanoma, Spitz nevus, histiocytoma, molluscum contagiosum, flat wart, seborrheic keratosis, basal cell epithelioma, neurofibroma, congenital dermal melanocytosis (Mongolian spot), and miscellaneous conditions such as blue nevus, lichen planus, sarcoidosis, psoriasis, and angioma. An atypical gross appearance of the central nevus or an asymmetric halo of depigmentation around a suspicious nevus, particularly in adults, should raise suspicion for melanocytic dysplasia or melanoma. The depigmented halo associated with melanoma tends to be irregular and surrounds the tumor asymmetrically, but this is not always the case.

TREATMENT Patients who have benign-appearing, centrally placed nevi within a symmetric halo of depigmentation should have a mucocutaneous examination in visible and Wood's light to exclude melanoma, dysplastic melanocytic nevi, and vitiligo. Although a benign-appearing nevus associated with halo depigmentation need not be removed, it is reasonable to recommend periodic examination of affected individuals for dysplastic melanocytic nevi, vitiligo, and melanoma. Atypical-appearing central nevi, presence of an asymmetric halo, eccentric placement of a melanocytic lesion in the halo, or the setting of atypical melanocytic nevi and/or melanoma (personal or family) should suggest the need for histopathologic examination for melanoma. Coverup or sunscreens should be recommended for sun-exposed areas of depigmentation to prevent acute burn, chronic actinic damage, and carcinogenesis.

COURSE AND PROGNOSIS For a given halo nevus, the central tumor may persist unchanged, become less pigmented over time, or flatten and disappear totally. Areas of depigmentation may persist unchanged for months or years or repigment totally. New halo nevi may appear over time. Dysplastic nevi, melanoma, and vitiligo may occur more frequently in individuals with halo nevus.

Epithelioid Cell and/or Spindle Cell Melanocytic Nevus

Epithelioid cell and/or spindle cell (EC-SC) melanocytic nevi are unique, usually acquired, usually benign melanocytic tumors differing grossly and histopathologically from typical acquired nevomelanocytic nevi; they are often alarming in their clinical presentation and sufficiently bizarre histopathologically as to cause diagnostic confusion for melanoma. Other terms for EC-SC nevus include *Spitz tumor, nevus prominens et pigmentosus, pseudomelanoma, spindle and epithelioid cell nevus, nevus of large spindle and/or epithelioid cells, and compound melanocytoma.* The previously used terms *Spitz's juvenile melanoma, benign juvenile melanoma,* and *prepubertal melanoma* should not be employed. Use of the adjective *juvenile* (i.e., juvenile melanoma) is misleading because EC-SC nevi are not restricted to children. Use of the term *melanoma* to describe the EC-SC nevus is unfortunate because EC-SC nevi usually (although not always) have a benign course. The term *benign,* when applied to melanoma, is likely to confuse both patients and physicians. The term *epithelioid cell* and/or *spindle cell melanocytic nevus* characterizes these tumors as melanocytic in origin, usually composed of epithelioid cells and/or spindle cells, not confined to children, and not guaranteeing a benign course.

HISTORICAL ASPECTS Examples of melanocytic tumors having gross and microscopic features resembling melanoma but behaving in a benign manner were described by Darier and Civatte in 1910 and Miescher in 1933. The tumor was named *juvenile melanoma* by Spitz in 1948, [62] *benign juvenile melanoma* by Kopf and Andrade in 1966, [63] and *EC-SC nevus* by Helwig in 1975. [64] The pigmented spindle cell tumor was reported as a variant of EC-SC nevus by Reed et al. [60] in 1975 and Sagebiel et al. [65] in 1984.

EPIDEMIOLOGY An annual incidence rate of 1.4 cases per 100,000 individuals in Australia for EC-SC nevus has been estimated compared with 25.4 per 100,000 individuals for cutaneous melanoma during the same time interval. [66] Among melanocytic nevi excised in children, 1 to 8 percent of cases are interpreted as EC-SC nevus. [65] In a case series of 308 patients with EC-SC nevi reported by Allen, [67] 15 percent of lesions occurred in adolescents and adults, the oldest patient being 56 years of age. There appears to be no gender predilection for EC-SC nevus. Published cases have been described primarily in whites. EC-SC nevus may be pigmented more frequently in adults than in children.

ETIOLOGY AND PATHOGENESIS It may be presumed that EC-SC nevi are derived from the same progenitor cells giving rise to epidermal melanocytes and nevomelanocytes. Except for a single report of multiple tumors in identical twin boys, [63] genetic factors have not been investigated systematically. The role of trauma in the histogenesis of EC-SC nevi is speculative. One case is reported to have arisen at the site of bacille Calmette-Guérin (BCG) vaccination. There are unique aberrations of genes occurring on chromosome 11 in some cases of EC-SC nevi. [68]

CLINICAL MANIFESTATIONS EC-SC nevus may present in one of the following ways: (1) a pink or tan,

smooth-surfaced elastic papule that flattens easily with external pressure (Fig. 91-13), (2) a lightly pigmented blue papule, often with telangiectasias on the surface, resembling a fibrous histiocytoma or keloid, (3) a darkly pigmented, usually smooth-surfaced, firm papule (Fig. 91-14), (4) multiple agminated lesions consisting of red, red-brown, brown, or dark-brown papules or nodules, with a fine stippled surface (Fig. 91-15), often occurring in the early years of life within a background of congenital (sometimes acquired) macular pigmentation or occasionally a hypopigmented plaque, (5) single or multiple lesions developing in a large congenital nevomelanocytic nevus, or (6) eruptive widespread lesions in the absence of background macular pigmentation or large congenital nevomelanocytic nevus.

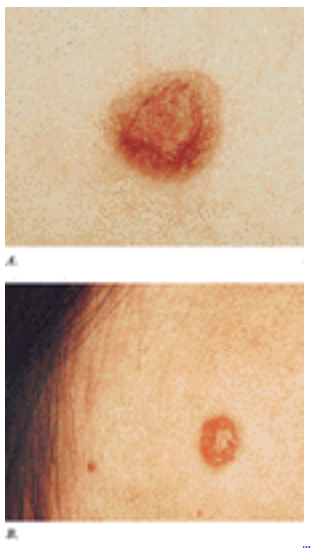

FIGURE 91-13 Acquired epithelioid cell and/or spindle cell nevus, predominantly epithelioid cell type. *A.* Pink plaque, which appeared de novo over an 8-week period, becoming more elevated with time, in the preauricular area of a 4-year-old white boy. *B.* Dome-shaped pink papule, which appeared de novo over a 2-week interval 4 months before, on the forehead of a 5-year-old white boy.

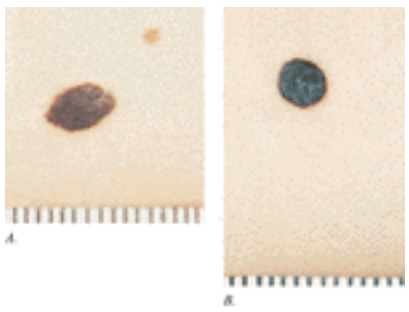

FIGURE 91-14 Acquired epithelioid cell and/or spindle cell nevus, predominantly pigmented spindle cell type. *A.* Very dark brown plaque appearing over several weeks on the posterior thigh of a 22-year-old white woman. *B.* Very dark bluish plaque appearing de novo 3 months previously on the back of an 8-month-old white (Hispanic) boy. Scale in millimeters.

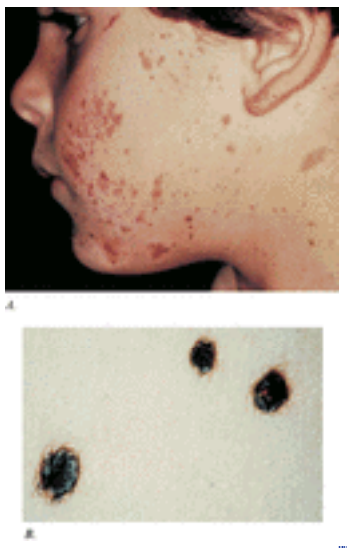

FIGURE 91-15 Agminated (grouped) epithelioid cell and/or spindle cell nevi. *A.* Numerous grouped pink papules and plaques, appearing at age 6 months, on the face of a 4-year-old white boy. *B.* Multiple black papules, appearing suddenly several years before, on the anterior torso of a 13-year-old white girl.

The most common variety of EC-SC nevus is the solitary, asymptomatic, pink or red, hairless, firm, dome-shaped, verrucous, or smooth-surfaced telangiectatic papule or nodule (see Fig. 91-13). Infrequently, lesions may have a polypoid or pedunculated shape. Borders may be indefinite and/or irregular or smooth and sharply demarcated. Although the surface is commonly smooth or verrucous, lesions may have a scaly, stippled, crusted, or (rarely) eroded surface. Translucent varieties of EC-SC nevus have been described. Very darkly pigmented lesions constitute a minority of EC-SC nevi, up to 7 percent of cases. [62], [63], [69] EC-SC nevi are usually asymptomatic, but pruritus, tenderness, and/or bleeding may occur. [63] A halo of depigmentation has been associated with several cases of EC-SC nevus. [57], [70] The diameter of EC-SC nevi ranges from several millimeters to several centimeters, the average being 8 mm in one series. [63] In 73 percent of patients in one series, [66] the tumor was 6 mm or less in greatest diameter, and in 94 percent of patients, the tumor was less than 10 mm in diameter. Most cases are described as superficial papules or nodules, although subcutaneous involvement may occur. [62] The duration of solitary EC-SC nevus before presentation is usually less than 9 months. Lesions usually show an increase in radial size over time, some gradual and others rapid. [62] In one series of 43

patients, [63] the anatomic location included the head or neck in 18, upper extremities in 9, torso in 9, and lower extremities in 7. The EC-SC nevus tends to spare palms, soles, and mucous membranes. The *deep penetrating nevus* may be considered a variety of EC-SC nevus, combined nevus, or a unique dermal nevomelanocytic dysplasia. These lesions are said to be darkly pigmented, blue-black papules or nodules. Lesions are mostly on the head and neck or upper extremities, 2 to 9 mm in diameter, and occurring predominantly in the first four decades of life, including childhood.

PATHOLOGY Although the bizarre histopathologic features and frequent occurrence of dermal inflammation may cause diagnostic confusion, EC-SC nevus usually can be differentiated from melanoma. EC-SC nevus in children and adults is histopathologically similar. Although EC-SC nevus usually has nested melanocytic elements in the epidermis and dermis (Fig. 91-16), the tumor may be restricted to either anatomic zone. Melanocytic elements are usually arranged in well-circumscribed nests, although there may be permeation of the epidermis by single cells or small groups of cells. In those cases with epidermal nests, artifactual clefts are usually seen above the nests in half the cases, a finding rarely observed in melanoma. [66] The epidermis is usually hyperplastic, with elongated and bulbous pegs and knobs extending into the dermis, although thinning and even ulceration may occur rarely. The dermal inflammatory cell infiltrate may be slight or marked, bandlike, and mainly at the base or patchy around blood vessels and/or intermixing with tumor cells. Although melanin was observed in all 13 patients described by Spitz, [62] in other studies melanin was moderate in 10 percent of patients and heavy in 5 percent. [70] Subtypes of EC-SC nevus may be heavily pigmented.

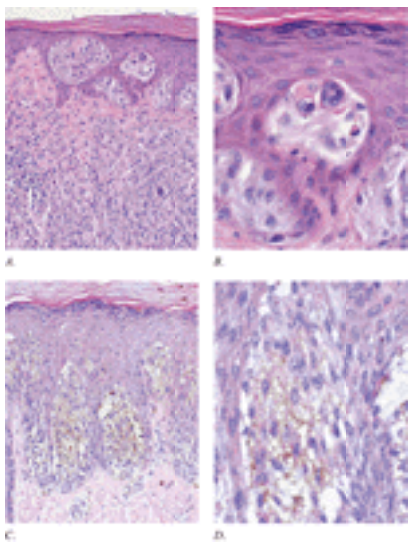

FIGURE 91-16 Histopathologic features of acquired epithelioid and/or spindle cell nevi. Epithelioid Spitz nevus (*A*) and higher magnification of the intraepidermal component revealing eosinophilic cytoplasmic changes in several cells (*B*). Pigmented spindle cell nevus (*C*) and higher magnification of the intraepidermal component (*D*) revealing pigmented spindle shaped cells.

Spindle cells predominate in 45 to 54 percent of EC-SC nevi, epithelioid cells in 21 percent, and a relatively equal combination of cell types in 24 to 34 percent. [70], [71] The pigmented spindle cell nevus described by Reed et al. [60] and later by others [65], [72] as a variant of EC-SC nevus is usually a sharply circumscribed, uniformly darkly pigmented papule or plaque (see Fig. 91-14) consisting of compact and aggregated spindle-shaped, pigment-producing melanocytes (see Fig. 91-16), distinguished from melanoma by its uniform nuclei, uniform cellular detail, and distinctive pattern of growth. In a review of 91 pigmented spindle cell nevi by Sagebiel et al., [65] cells were predominantly spindle in 74 percent and mixed spindle cell and epithelioid cell in 26 percent of patients. Almost all cases of pigmented spindle cell nevus have a lymphohistiocytic host response. Spindle cells extend down eccrine ducts in 40 percent and involve hair follicles in 22 percent of patients. [65] There are atypical variants of pigmented spindle cell nevi in which there are architectural alterations and striking cellular atypia. [72] Unlike ordinary nevi and melanomas, melanocytic cells in EC-SC nevi are large, often twice the size of epidermal basal keratinocytes, [62] with prominent mononuclear or multinucleated giant cells in the epidermis and/or dermis (see Fig. 91-16). Mitoses, usually few in number, are detected in half the cases, [70] whereas atypical mitoses are uncommon in EC-SC nevus. In contrast to melanoma, the melanocytic cells in EC-SC nevi show progressive maturation with increasing depth, becoming smaller and more similar to ordinary nevomelanocytes, [62], [70] with the overall distribution of cells in the dermis being wedge-shaped, with narrowing of the wedge toward the subcutaneous fat. Coalescent eosinophilic globules (Kamino bodies), PAS-positive and diastase-resistant (resembling colloid bodies), have been reported in 60 percent of EC-SC nevi [73] (see Fig. 91-16). Similar globules may be detected in 2 percent of melanomas and 0.9 percent of typical acquired nevi, but the globules are smaller in size, more difficult to find, single rather than coalescent, and commonly PAS-negative. [73] A histopathologic diagnosis of EC-SC nevus depends on the presence of multiple histopathologic features, none of which have been subjected to systematic testing for predictive value. Features believed to distinguish EC-SC nevi from melanomas include presence in the former of bizarre mononuclear and multinucleated giant cells, maturation of tumor cells with increasing depth (as reflected in mean nuclear size and DNA content), prominent coalescent eosinophilic globules, and artifactual clefts of junctional nests and absence of atypical mitoses, nuclear pleomorphism, prominent upward spread of nevomelanocytes as single cells or small nests in the epidermis, or hyperchromasia of tumor cells. Favoring the diagnosis of melanoma (and a potential for metastasis) are deep dermal invasion, intense melanin production in the dermis, arrangement of epithelioid cells in contiguous aggregates, atypical mitoses, and lack of cellular maturation with increasing tumor depth.

DIAGNOSIS Nonpigmented varieties of EC-SC nevi (see Fig. 91-13) may resemble amelanotic melanoma, juvenile xanthogranuloma, hemangioma, pyogenic granuloma, molluscum contagiosum, dermal nevomelanocytic nevus, solitary mastocytoma, granuloma, clear cell acanthoma, insect bite reaction, and dermatofibroma. Pigmented varieties of EC-SC nevus (see Fig. 91-14 and Fig. 91-15) may appear similar to melanoma, dysplastic melanocytic nevus, fibrous histiocytoma, sclerosing hemangioma, appendage tumor, keloid, and unusual varieties of acquired junctional and compound nevus called *hypermelanotic nevus.* [74] Warty variants of EC-SC nevi may be confused for verrucca vulgaris, seborrheic keratosis, and epidermal nevus.

TREATMENT Complete excision with a clear margin of normal skin is generally sufficient treatment for EC-SC nevi. Given the difficulty of confidently excluding the possibility of melanoma, a wider margin of normal skin may be prudent for histopathologically worrisome lesions. [75] Incompletely excised lesions may recur in as many as 7 to 16 percent of patients. Management of patients who have numerous EC-SC nevi requires individual judgment and periodic examination

for new or unstable lesions.
COURSE AND PROGNOSIS The natural history of the EC-SC nevus is unknown because lesions are usually singular, and histopathologic confirmation is required to establish the diagnosis. It is possible that some lesions regress spontaneously. A concern is that some varieties of EC-SC nevus may progress to melanoma or represent melanoma at the outset. [75] Tumors believed to have histopathologic features similar to EC-SC nevus occasionally may metastasize. [75] The pigmented spindle cell nevus variant of EC-SC nevus is said to have a benign course in most cases but prospective studies of intact lesions are not available.

Blue Nevus

The blue nevus consists of an acquired or congenital blue, blue-gray, or blue-black papule, nodule, or plaquelike aggregate of aberrant dermal melanocytes actively producing melanin. Three types of blue nevus are recognized: (1) common blue nevus, (2) cellular blue nevus, and (3) combined blue nevus–nevomelanocytic nevus. The cellular blue nevus differs from the common blue nevus in that it is usually larger, more elevated, more aggressive locally, and occasionally associated with lymph node "benign metastasis." Melanoma may develop in a cellular blue nevus. Other names for blue nevus include *benign mesenchymal melanoma, blue neuronevus, chromatophoroma, melanofibroma, blue nevus of Jadassohn-Tieche, pilar neurocristic hamartoma,* and *dermal melanocytoma.*

HISTORICAL ASPECTS The blue nevus was described by Tieche in 1906, but similar lesions had been described earlier as chromatophoromas by Riecke and as melanofibromas by Kreibich. The cellular blue nevus was classified originally as a variant of melanoma by Darier in 1925 and reclassified as a variant of blue nevus by Allen in 1949. [54] A malignant variant of cellular blue nevus has been described as an entity separate from both melanoma and cellular blue nevus. Tuthill et al. [76] defined a unique presentation of grouped blue nevi with peripilar arrangement of pigment-laden cells called *pilar neurocristic hamartoma.* An atypical variant of peripilar blue nevus has been called *bizarre blue nevus.*
EPIDEMIOLOGY Blue nevi are present in fewer than 1 in 3000 newborns, in about 1 in 1000 during the first 5 years of life, and in 1 to 2 percent of white school children, 3 percent of Japanese adults, and 0.5 to 4 percent of healthy white adults. They are said to be uncommon in darkly pigmented persons. The vast majority of blue nevi are single, small, deep-blue macules or papules about 1 to 2 mm in diameter. Multiple blue nevi may be associated with lentigines, cardiac myxoma, and mucocutaneous myxomas (LAMB syndrome). Blue nevi have been associated with nodular mastocytosis, and a histogenic relationship has been claimed for melanocytes and mast cells. Blue nevi have been reported to occur in oral mucosa, uterine cervix, vagina, spermatic cord, prostate, and lymph nodes.
ETIOLOGY AND PATHOGENESIS Although a Schwann cell or endoneural origin is postulated for blue nevi based on ultrastructural features and cholinesterase activity, a melanocytic origin is suggested by the presence of obvious melanin synthesis in common blue nevi and ultrastructural evidence of melanin synthesis in cellular blue nevi. The common blue nevus is believed to represent an ectopic accumulation of melanin-producing melanocytes in the dermis during their migration from the neural crest to sites in the skin, i.e., a normal melanocyte with an abnormal location and abnormal function. An origin from melanocytes in hair follicles is also believed possible. An additional hypothesis is that common blue nevi and cellular blue nevi represent benign neoplasms, each resulting from an abnormal melanoblast derived from the neural crest. The causative factor in eruptive blue nevi has been attributed to sun exposure, [77] although other etiologies are possible.
CLINICAL MANIFESTATIONS Common blue nevi are usually acquired, solitary, asymptomatic blue, blue-gray, or blue-black papules, usually less than 10 mm in diameter (Fig. 91-17). The blue-gray color of blue nevi is an optical effect of dermal melanin viewed through the overlying skin. The longer wavelengths of visible light penetrate the deep dermis and are absorbed by black dermal melanin, but the shorter (blue) wavelengths do not penetrate deeply enough to be absorbed by melanin and are thus reflected back to the observer's eye, giving a blue-gray cast to the deeply situated melanin. Common blue nevi occur anywhere, but about half the reported cases present on the dorsa of hands and feet. Usually, the common blue nevus is singular, but rarely, lesions may be multiple and agminated or arranged in large plaques consisting of multiple solitary papules or nodules with intervening areas of blue discoloration. The large plaque blue nevus (pilar neurocristic hamartoma) may be apparent at birth or later in childhood and occasionally is associated with a background of lentigo simplex (nevus spilus). The common blue nevus occasionally may have a target-like appearance, with a blue-gray central nodule, a flesh-colored or hypopigmented surrounding area, and a blue-black rim. The target blue nevus occurs mostly on the hands and feet but also on the back and perianal area. Hypopigmented blue nevi with only minimal identifiable melanin pigment have been reported. Common blue nevi occasionally may have satellite lesions that may be mistaken for melanoma metastasis. [78]

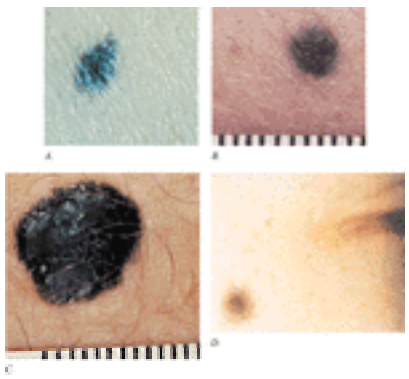

FIGURE 91-17 Blue nevus. *A.* Common blue nevus appearing as an acquired blue-gray papule on the shoulder of an 18-year-old white woman. *B.* Common blue nevus appearing as an acquired blue-gray papule on the buttock of an 62-year-old white man. *C.* Cellular blue nevus appearing as a congenital blue papule on the low back of a 30-year-old white man. *D.* Combined common blue nevus–nevomelanocytic nevus appearing as a brown papule with a blue-gray center on the cheek of a 12-year-old white boy, beginning as a pinpoint dot at age 1 year and enlarging slowly over time. Scale in millimeters.

Cellular blue nevi are blue-gray or blue-brown nodules or plaques 1 to 3 cm in diameter, occasionally larger (see Fig. 91-17). Their surface is usually smooth but may be irregular. About half the cases are located on the buttocks or sacrum. Rare giant varieties of congenital blue nevus occur, often with multiple satellite lesions. Cellular blue nevi may develop in

association with congenital nevomelanocytic nevi, occasionally with target appearance. Combined blue nevus–nevomelanocytic nevus (see Fig. 91-17) and a compound variant of blue nevus are usually diagnosed clinically as atypical nevi or suspected melanomas. These lesions are blue brown and/or blue black, variable in size, and have a smooth or slightly irregular elevated surface. Malignant blue nevus may develop in contiguity with a cellular blue nevus, nevus of Ota (see Chap. 90), combined congenital blue nevus–nevus of Ota, or de novo. Malignant blue nevus presents as an expanding dermal nodule with or without ulceration. There is some dispute as to whether malignant blue nevus should be considered a separate entity from melanoma or simply referred to as a melanoma developing in a blue nevus.

PATHOLOGY In common blue nevi, dermal melanocytes appear as melanin-containing fibroblast-like cells grouped in irregular bundles admixed with melanin-containing macrophages, ultimately associated with excessive fibrous tissue in the middle or upper reticular dermis, occasionally extending downward to subcutaneous fat or upward to papillary dermis (Fig. 91-18). Elongated melanin-producing dermal melanocytes in common blue nevi usually lie with their long axis parallel to the epidermis. Except in the case of combined blue nevus–nevomelanocytic nevus, the epidermis in common blue nevi appears normal. In the combined blue nevus–nevomelanocytic nevus, there is a blue nevus associated with a typical nevomelanocytic nevus or EC-SC nevus. A close histopathologic association between blue nevi and nevomelanocytic nevi has been noted in 1 percent of melanocytic nevi excised for histopathologic examination. The compound variant of blue nevus is remarkable for hyperplasia of dendritic melanocytes in the epidermis and common blue nevus in the dermis.

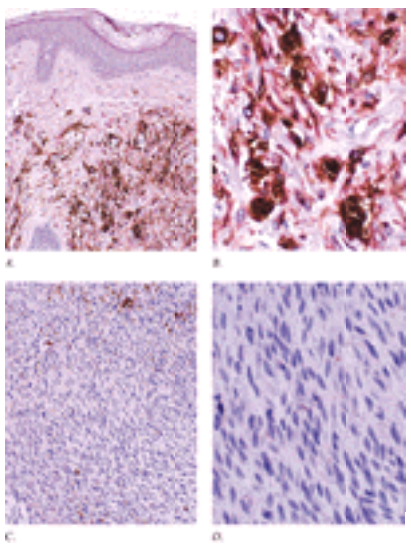

FIGURE 91-18 Histopathologic features of common and cellular blue nevi. Common blue nevus (*A*) and higher magnification of the dermal component (*B*) revealing heavily pigmented, elongated melanocytes. Cellular blue nevus (*C*) and higher magnification (*D*) revealing sheets of melanocytes with ovoid nuclei.

Pathology of the plaquelike blue nevus (pilar neurocristic hamartoma) reveals a peripilar grouped arrangement of mostly spindle cells containing varying amounts of melanin, patterns of a common blue nevus and a Mongolian spot, and presence of abnormal (granular) melanosomes. There are other varieties of plaquelike blue nevi with subcutaneous cellular nodules with a range of histologic appearances from dermal melanosis to common blue and cellular blue nevi. [79] In cellular blue nevi, there is usually a component of a common blue nevus plus fascicles of spindle-shaped cells with ovoid nuclei and abundant pale cytoplasm with little or no melanin, and often epithelioid cells, present in the dermis and often in subcutaneous fat in nests, bundles, and neuroid forms with little or no intervening stroma (see Fig. 91-18). Epithelioid cell and amelanotic varieties of the cellular blue nevus have been described. Epithelioid blue nevi have been reported with [80] or without [81] an association with cardiac myxoma. Histopathologic diagnosis may be difficult when the common blue nevus component and melanin production are sparse or inapparent. Ultrastructural studies combined with dopa histochemistry demonstrate that cells of cellular blue nevi are capable of melanin production, and therefore, the cells are melanocytes and not Schwann cells. Atypical melanosomes may be seen in cellular blue nevi. Some varieties of cellular blue nevi stain for CD-34, suggesting an origin from cells derived from the neural crest. [82] Differentiation between a cellular blue nevus and a melanoma that has developed in a cellular blue nevus may be difficult. Occasionally, small groups of well-differentiated melanocytes are present in the marginal sinus or parenchyma of lymph nodes draining the anatomic site of the cellular blue nevus, making it difficult to differentiate true metastasis from pseudometastasis. It is believed that “inert” deposits of melanocytes in the capsules and peripheral sinuses of lymph nodes draining some varieties of cellular blue nevus are transported passively. An alternative hypothesis is that these cellular deposits represent ectopic embryologic rests. The malignant blue nevus may be regarded as a variant of melanoma, distinguished from cellular blue nevus by invasiveness, cellular atypia, pleomorphism, atypical mitoses, and areas of necrosis. There are atypical variants of cellular blue nevi that are intermediate in histopathologic appearance between typical cellular blue nevi and melanoma. [83]

DIAGNOSIS AND DIFFERENTIAL DIAGNOSIS Blue nevus may be confused clinically with sclerosing hemangioma, dermatofibroma, histiocytoma, glomus tumor, primary or metastatic melanoma, pyogenic granuloma, pigmented spindle cell nevus, and traumatic tattoo. There are acquired variants of macular dermal melanocytosis that may cause confusion for blue nevus. Mongolian spots, nevus of Ota, and nevus of Ito are also accumulations of melanin-producing melanocytes, but unlike typical blue nevus, these forms of dermal melanocytosis are usually broad in extent and macular.

TREATMENT A common blue nevus that is stable for many years in an adult usually requires no therapy. Sudden appearance of a blue nodule, expansion of a preexisting blue nodule, a congenital blue nodule, or a relatively large blue nodule or plaque greater than 10 mm in diameter demands histopathologic examination. Excision should include subcutaneous fat to ensure complete removal of deep dermal melanocytes, which are frequently present in the subcutaneous tissue of cellular blue nevus. The large plaque blue nevus (pilar neurocristic hamartoma) requires consideration for excision or periodic evaluation for suspicious change. Cellular blue nevus should be evaluated for excision because of its malignant potential.

COURSE AND PROGNOSIS The natural evolution has not been studied for common blue nevi or cellular blue nevi. It is likely that once established, blue nevi remain unchanged or possibly regress over time. More than a dozen cases of melanoma have been noted to evolve in cellular blue nevus.

Congenital Neyomelanocytic Nevus

Congenital nevomelanocytic nevi (CNNs; synonyms: *garment nevus, nevus pigmentosus et pilosus, giant nevus, verrucous nevus,* and *giant pigmented nevus*) are nevomelanocytic nevi apparent at birth. However, there are also rare varieties of relatively large nevomelanocytic nevi (>1.5 cm) that appear for the first time between 1 month and 2 years of life, according to parental observations and corroborated by photographs (tardive congenital nevi).

HISTORICAL ASPECTS In 1832, a giant “waist coat and drawers” nevus was described by Alibert. In 1861, Rokitansky described a patient with a giant CNN and leptomeningeal hyperpigmentation. The malignant potential of giant CNN was documented as early as 1879 by Jablokoff and Klein, and there were at least 53 cases by 1959. [84] The malignant potential of smaller varieties of CNN was illustrated in 1982 based on historic and histopathologic association compared with expected association based on chance and body-surface-area considerations. [85] Staged excisions of very large CNNs were reported by Baker in 1878 and later by Morestin in 1915 and Roy in 1925. The histopathologic appearance of very large CNNs was reviewed in detail by Reed et al. [86] in 1965. Microscopic similarities between large and small varieties of CNN and differences from acquired nevi have been noted. [44]

EPIDEMIOLOGY Some 2.5 percent of newborns have pigmented lesions, [87] but only 1 percent have a biopsy-confirmed nevomelanocytic nevus. The most reliable prevalence rate for CNN in a homogeneous racial group was obtained by biopsying all pigmented lesions in 841 white infants examined within 72 h of birth; of 21 infants with pigmented lesions, 7 babies (0.83 percent of 841) had a biopsy-confirmed nevomelanocytic nevus. [87] Many other series have yielded equivalent results. The vast majority of CNNs noted at birth are small and singular, and no gender predilection has been demonstrated.

ETIOLOGY AND PATHOGENESIS The congenital divided nevus of the eyelid (Fig. 91-19) is an important natural experiment, for it reflects the probable time of development of CNN in utero. [88] Because of the contiguous nature of this lesion on the upper and lower eyelids, [5] it may be presumed that the nevus was already in place during or after eyelid fusion but before the eyelids split. The eyelids form at between 5 and 6 weeks in utero, begin to fuse at about 8 to 9 weeks, and reopen during the sixth uterine month. Because melanocytes begin to appear in fetal skin before 40 days' estimated gestational age, it is likely that CNNs form after that time but before the sixth uterine month. Familial aggregation has been demonstrated for both large and small varieties of CNN (Fig. 91-20). This observation is remarkable considering that CNNs of 99 mm or more in diameter occur in only 1 of every 20,000 newborns, and CNNs with a garment distribution occur in only 1 of every 500,000 newborns. Discordance for giant CNNs has been demonstrated for identical twins in at least three cases and for nonidentical twins in two cases. It is likely that developmental and genetic mechanisms play some role in CNN development.

FIGURE 91-19 Congenital divided nevomelanocytic nevus of the eyelid. The nevus is contiguous when the eyelids are closed, suggesting that the lesion was formed in the developing fetus before the eyelids split, i.e., before 24 weeks.

FIGURE 91-20 Familial aggregation of small congenital nevomelanocytic nevi. Note small congenital nevus on the thigh of a 3-year-old white boy and on the back of his 5-year-old male sibling.

CLINICAL MANIFESTATIONS Although CNNs are on average larger than acquired nevi, there is no specific size limitation that can be used to predict reliably wheather a given nevus is congenital or acquired for lesions less than 1.5 cm in diameter. Nevi attaining a diameter of 1.5 cm or more are likely to be congenital, atypical, or melanomas. There is no completely satisfactory way to separate CNNs as small or large. Definitions based on ease of removal and absolute size are most popular. CNNs may be defined as small if they can be excised easily and the wound defect closed primarily without significant deformity and without using skin flaps or grafts (see Fig. 91-20). Based on these practical definitions, otherwise “small” CNNs in noncritical sites (such as the torso or buttocks) might be regarded as “large” in critical anatomic sites (such as the face, digits, or genitalia). Arbitrary size criteria to categorize CNNs as small, large, or giant also have been based on the diameter or surface area of a given lesion. *Giant* has been variously defined as a lesion as large as the patient's palm for the face or neck (and twice that area for other anatomic sites), 30 percent of the body surface (Fig. 91-21), or 900 cm^2 in adults (or smaller if it involves a major anatomic area). Others have arbitrarily divided CNNs according to the largest diameter as small (<1.5 cm), medium (1.5–19.9 cm), and large (= 20 cm). Lesions

that are regarded as small or medium in the newborn period may be designated medium or large, respectively, by late childhood or adulthood, given that CNNs appear to grow in proportion to the affected anatomic site. [89]

FIGURE 91-21 Small congenital nevomelanocytic nevus, 12 mm in diameter. Note regular configuration, heavy regular pigmentation, and slightly corrugated surface.

The overall appearance of CNNs and acquired nevi is similar (see Fig. 91-12, Fig. 91-19, Fig. 91-20 and Fig. 91-21). In general, CNNs are usually round or oval, and skin markings distort the skin surface at least slightly when assessed by oblique lighting. The outlines of CNNs are usually smooth, regular, and sharply demarcated (see Fig. 91-12 and Fig. 91-21). At birth, some CNNs have coarse and long hairs, whereas others are relatively hairless; coarse, long, darkly pigmented hair may appear within the first year or two of life or be delayed for several years. Lesions may have a smooth, pebbly, rugose, verrucous, cerebriform, or grossly lobular surface (see Fig. 91-21). CNNs with a cerebriform appearance may present as cutis verticis gyrata. CNNs usually have a uniform pigmentation pattern consisting of medium- or dark-brown speckles symmetrically disposed in a tan or light-brown field or a reticular pattern when assessed by dermoscopy. Other patterns are similar to those described for acquired nevi. Unique varieties of CNNs may have an atypical appearance, striking for their haphazard, very dark-brown, black, or blue-black pigmentation or discontinuous pigmentation and poorly demarcated and/or irregular outlines, often associated with atypical histopathologic features. Very darkly pigmented CNNs are distinctly uncommon in whites and should suggest the possibility of atypical histopathologic features. In darkly pigmented infants, CNNs are usually even more darkly pigmented. While small CNNs usually occur as single lesions, giant CNNs often present as single, very large lesions or multiple smaller CNNs (Fig. 91-22). CNNs may have a delayed onset, often appearing during infancy and as late as early childhood. Histopathologically, these late lesions nonetheless show all the features of CNNs (see below). In giant CNNs nevomelanocytes have been found in regional lymph nodes without further evidence of progressive metastatic disease.

FIGURE 91-22 Giant congenital nevomelanocytic nevus. The lesion involves the entire back; the surface is pebbly; rugose, in areas even cerebriform, and there is hypertrichosis in the sacral region. There are also multiple smaller CNNs on the buttocks, thighs, and elsewhere on the body. Most of these were not present at birth but developed during infancy.

There is a significant association between neurofibromatosis and giant CNNs. In a study by Crowe et al., [90] 3 of 223 patients with neurofibromatosis had extensive CNNs. In his monograph on neurofibromatosis, von Recklinghausen described 1 of 28 patients as having a giant CNN. Tumors indistinguishable from neurofibroma in the absence of von Recklinghausen's neurofibromatosis may develop in association with giant varieties of CNN. CNNs of the head or neck area or posterior midline may be associated with underlying cranial and/or spinal leptomeningeal melanocytosis. This phenomenon may be asymptomatic or may give rise to communicating or noncommunicating hydrocephalus, seizures, focal neurologic deficits, mental retardation, or even melanoma. CNNs need not be giant to be associated with this underlying disorder. Symptomatic leptomeningeal melanocytosis carries a poor prognosis, even in the absence of malignant degeneration. Both small and large varieties of CNNs have been associated with loss of pigmentation, halo depigmentation (see Fig. 91-12), and even regression. The relationship between melanoma and large CNNs is well documented. The risk of melanoma development is proportional to the size of the congenital nevus, [91] with clear evidence of increased risk in patients with congenital nevi that involve over 5 percent of the body surface. [41] The cumulative 5-year risk has been calculated to be 2.3 percent [93] and 5.7 percent. [94] The lifetime risk of melanoma for patients with very large CNNs has been estimated to be at least 6.3 percent, based on a questionnaire follow-up study of 151 persons with CNNs examined between 1915 and 1973 in Denmark. [95] Melanoma may develop in large CNNs at any time, but the diagnosis of melanoma was established in the first 3–5 years of life in about half of published cases in which patients ultimately developed melanoma in association with giant CNN. Malignant degeneration of large CNNs may be associated with the relatively sudden appearance of a dermal or subcutaneous nodule, very dark pigmentation, itching, pain, bleeding, or ulceration. Often, CNN-associated melanomas appear to have evolved in nonepidermal locations. [86] Therefore, early detection of melanoma in association with a giant CNN may be difficult and not recognized until a dermal nodule or metastatic disease appears. The prognosis for patients who develop melanoma in association with giant CNNs is usually grave. [86] Unlike melanoma in general, there is no racial predilection for melanoma developing in a giant CNN. There have been multiple cases of lethal melanoma developing in association with giant CNNs in black children. A causal association between small CNNs and melanoma is more difficult to establish than for large CNNs. When histopathologic features were studied, 6 to 8 percent of primary melanomas were found to be in contiguity with nevi that had microscopic

features characteristic of CNN. [96], [97] These findings support the concept of melanoma evolution even in small congenital nevi, given the expected chance association based on body-surface-area considerations. [85]

PATHOLOGY CNNs are characterized by the presence of nevomelanocytes in the epidermis as well-ordered theques and/or nevomelanocytes in the dermis as sheets, nests, cords, and/or single cells. Although histopathologic features are cited as being useful in distinguishing nevi as congenital or acquired, there are no known features with absolute specificity and sensitivity. The histopathologic features of very large CNNs may be divided into nevomelanocytic, neuroid, epithelioid cell and/or spindle cell, dermal melanocytic, and mixed types. In the nevomelanocytic type of large CNN, the histopathologic appearance may be identical to typical acquired nevi, with nevomelanocytes in the epidermis as well-defined theques and/or nevomelanocytes in the papillary dermis as sheets, cords, or nests. CNNs are more likely than acquired nevi to have nevomelanocytes in the lower two-thirds of the reticular dermis or deeper and to be associated with nevomelanocytes in appendageal and neurovascular structures in the reticular dermis (Fig. 91-23). There may be preferential involvement of one or more epithelial structures in CNN, such as eccrine ducts, and these structures may be abundant and malformed. Veins may be preferentially involved, with an “inflammatory” appearance showing nevomelanocytes within and around blood vessel walls. Subendothelial protrusion by nevomelanocytes in lymphatic vessels may be prominent. Arrector pili may be malformed, large, and infiltrated by nevomelanocytes. Hair follicles are often quite large and frequently associated with abundant melanin in the hair bulb. Nevomelanocytes in the deep reticular dermis may be distributed as single cells or as a single-file array insinuating among collagen bundles, sheets of cells, or combinations of patterns.

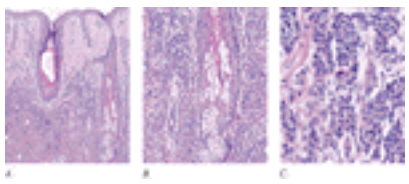

FIGURE 91-23 Histopathologic features of congenital nevomelanocytic nevus. Nevomelanocytes in the low-magnification image (*A*) reveal dense accumulation in the lower two-thirds of the dermis; at medium magnification (*B*), these cells encroach on dermal adnexal structures (follicular and eccrine); and (*C*) higher magnification reveals dense collections of small nevomelanocytic cells.

In the neuroid type of giant CNN, melanocytic elements take on the appearance of Wagner-Meissner corpuscles (lames foliacée), a palisaded arrangement of cells around a cellular mass of homogeneous material (Verocay body), and sheathing of nerves by neuroid tissue (neuroid tubes). The neuroid type of nevus may be responsible for lobulation and redundancy of tissue (pachydermatous or cerebriform appearance) due mainly to the production of connective tissue elements, reticulin, collagen, and sometimes mucinous stroma. The neuroid type of giant CNN may take on the appearance of a pigmented neurofibroma and may be associated with congenital anomalies of bone (club foot, spina bifida, and atrophy) as well as with a “neurosarcomatous” morphologic variant of melanoma. In the spindle cell and/or epithelioid cell type of giant CNN, the dermis may be infiltrated in whole or in part by nests or sheets of epithelioid cells and/or spindle cells. Unlike the usual variety of acquired epithelioid cell and/or spindle cell nevus, the epithelioid and spindle cell elements in CNN may involve deep reticular dermis, often intermixing with neuroid elements and ordinary nevomelanocytes. The epithelioid cell and/or spindle cell elements in giant CNN may have atypical cellular and architectural features, making differentiation from melanoma extremely difficult. In some cases, large epithelioid cells may comprise superficial papillary zones of the nevus, and smaller nevomelanocytes may appear in the same lesion in deeper zones of the reticular dermis, with a Grenz zone separating the two elements. In the dermal melanocytic type of giant CNN, the appearance may be that of a giant blue nevus, or the lesion may have elements of blue nevus (either common or cellular type). Heavily pigmented spindle-shaped melanocytes may occur alone or may be intermixed with nevomelanocytes in the reticular dermis or deeper. Unique to the very large CNN is the occasional presence of nevomelanocytes within the substance of muscle, bone, placenta, umbilical cord, cranium, and dura mater. Very extensive CNN may be intermixed with elements of vascular malformation, hemangiomas, increased numbers of mast cells, cartilage, calcification, and even bone. There may be sparse mononuclear cell infiltrates associated with some giant CNNs. In addition to melanoma, associated tumors developing in CNN include schwannoma, neuroid tumor, lipoma, rhabdomyosarcoma, neurofibroma, sebaceous nevus, blue nevus, epithelioid cell and/or spindle cell nevus, hemangioma, lymphangioma, and mastocytoma. A possible explanation of mixed neoplasms containing melanocytic and neuronal elements in CNN is that the neural crest is the origin not only of melanoblasts, Schwann cells, and sensory ganglia but also of bone, muscle, blood vessels, and fat. Small CNNs may have a histopathologic appearance similar to large CNNs. When CNNs are compared with acquired nevi, CNNs are significantly more likely to show nevomelanocytes in the lower reticular dermis and to involve dermal appendages and neurovascular structures. The positive predictive value of nevomelanocytes in the midreticular dermis or deeper for diagnosing nevi as congenital may be estimated to be 76 to 97 percent based on available sensitivity and specificity data and a prevalence rate for CNNs of 50 percent of melanocytic tumors selected for excision at a pediatric hospital. [44] However, some CNNs cannot be distinguished microscopically from acquired nevi.

DIAGNOSIS AND DIFFERENTIAL DIAGNOSIS The differential diagnosis of CNN includes other pigmented lesions apparent at birth, including Mongolian spot, café-au-lait macule, lentigo simplex, nevus spilus, epidermal nevus, nevus sebaceous, arrector pili (smooth muscle) hamartoma, and “congenital” Becker's nevus. To experienced examiners, congenital pigmented lesions that are not melanocytic usually can be distinguished from CNN based on clinical examination alone. In some cases, a small biopsy may be required to confirm the presence of nevomelanocytes, particularly in relatively lightly pigmented and flat varieties of CNN. In lightly pigmented individuals, very dark pigmentation or haphazard pigmentation in a nevus (with or without irregular and/or poorly demarcated outlines) should suggest the possibility of intraepidermal melanocytic dysplasia, pigmented spindle cell nevus, or melanoma. An ulcerated surface, a nodule, or discontinuous pigmentation in a CNN should suggest the possibility of intraepidermal melanocytic dysplasia or melanoma. Any nevomelanocytic lesion that is 1.5 cm or greater in diameter (and is not a dysplastic melanocytic nevus or melanoma) is likely to be a CNN.

TREATMENT The treatment of CNNs, large and small, depends on the perceived risk of melanoma plus cosmetic and functional considerations. Strongly stated positions on both sides of the issue are reflected in clinical practice. The results from a questionnaire survey of academic and nonacademic dermatologists in 1984 [98] revealed that (1) a clear majority referred their patients with very large CNNs for plastic surgical evaluation, (2) infants with very large CNNs usually were treated by 12 months of age, (3) an incidence of conversion to melanoma of 0.1 percent or greater

warranted prophylactic removal of small CNNs, (4) about half the respondents excised small varieties of CNN in children and adults, and (5) fewer than 40 percent of dermatologists stated that they observe small CNNs rather than excise. The most important consideration of CNN management relates to the perceived malignant potential. While there is disagreement about the exact frequency of association between CNN and melanoma, most students of the controversy would agree that at least some melanomas develop in CNNs, large and small. Melanoma may arise in very large CNNs even in the first several years of life. Therefore, excision of very large CNNs should be considered as early as possible, but it is probably prudent to wait until after the first 6 months of life to reduce surgical and anesthetic risks. Management of patients with very large CNNs must be individualized. Extensive involvement of the body surface, with little or no normal skin available for graft sites, may necessitate abandoning efforts at prophylactic excision and accepting lifelong surveilance to detect the earliest signs of malignant change. It may be impossible to remove every nevomelanocyte in very large CNNs, particularly when there is involvement of vital structures or deep anatomic zones. The treatment goal is to remove as much of the nevus as possible while preserving function and improving cosmetic appearance. Tissue expansion and artificial skin replacement are invaluable in repairing large wound defects. Other indications for surgical excision of very large CNNs include chronic pruritus, ulceration, and infection. In at least one case, infection of a puritic giant CNN resulted in sepsis and death. Unlike surgical excision, dermabrasion and other modes of destructive therapy do not address the malignant potential of CNN; nevomelanocytes may still be left behind in the dermis (if present initially), and the cosmetic results associated with destructive therapy are unpredictable. Melanoma has been reported following dermabrasion of large CNNs. Partial excision of a giant CNN resulting in “pseudomelanoma” has been described after laser treatment of a CNN. The approach to small CNNs needs to be considered carefully. It appears that the risk of melanoma development depends on CNN size, and therefore, smaller lesions appear to have less risk. However, due to the smaller size, complete excision of small congenital nevi may be relatively straightforward, resulting in excellent cosmetic results. The risks and benefits need to be weighed carefully. The following considerations should be made when managing patients who have small CNNs. First, all CNNs should be documented at birth, preferably in the form of high-quality photographs that can be used to aid follow-up by parents and physicians. Follow-up will be complicated by the natural evolutionary changes that take place in a nevus during body growth (i.e., surface, size, color, and hair). Therefore, periodic updates of photographs may be warranted. A physician experienced in gross morphologic examination and histopathologic correlation should help to determine management decisions. Second, small CNNs should be considered for prophylactic excision. However, given the risk of general anesthesia for lesions perceived to be at low risk during the first decade of life, it is appropriate to consider waiting until the child is old enough to tolerate local anesthesia. Careful surveillance without excision may be an option depending on gross appearance, size, location, cosmetic and functional deficits (or improvement) resulting from excision, and general health issues. Third, atypical-appearing CNNs should be considered for immediate prophylactic excision because even small CNNs may give rise to melanomas during infancy and early childhood. Fourth, during follow-up, suspicious changes in color, surface, or size would require urgent evaluation.

COURSE AND PROGNOSIS CNNs do not remain static after their appearance at birth. Lesions in fully grown individuals should remain stable, but CNNs have a dynamic evolution during body growth. [99] With few exceptions, CNNs generally expand in direct proportion to growth of a given anatomic zone, although disproportionately rapid area expansion of some congenital nevi may occur during early infancy. [89] In a 12-year follow-up of seven CNNs observed (and biopsied) in the newborn period, Nickoloff et al. [99] confirmed a two- to eightfold increase in size in five patients and no increase in size in two. CNNs at birth usually distort the skin surface at least slightly when assessed by oblique lighting and may become more elevated over time. Surface pigmentation also may change. Lightly pigmented CNNs may become more darkly pigmented, and darkly pigmented CNNs eventually may become less pigmented. Relatively hairless CNNs at birth may develop long, dark, coarse hair or may maintain a relatively normal hair density. Very large CNNs may demonstrate fading of surface pigmentation over time. CNNs also may develop a halo of depigmentation (see Fig. 91-12), potentially heralding spontaneous regression. Loss of pigmentation has been associated with regression of underlying nevomelanocytes and the replacement with sclerosis in some cases. Although acquired nevi are believed to regress with old age, there are no natural history studies to document this phenomenon for CNNs or acquired nevi.

REFERENCES

1. Coleman WP et al: Nevi, lentigines, and melanomas in blacks. *Arch Dermatol* **116**:548, 1980

2. Tasaki K: On band or linear pigmentation of the nails. *Jpn J Dermatol* **33**:568, 1983

3. Ito M, Hamada Y: Nevus spilus en nappe. *Tohoku J Exp Med* **55**:44, 1952

4. Cohen HJ et al: Nevus spilus. *Arch Dermatol* **102**:433, 1970

5. Kopf AW et al: Congenital nevus-like nevi, nevi spili, and cafe-au-lait spots in patients with malignant melanoma. *J Dermatol Surg Oncol* **11**:275, 1985

6. Sato S et al: Divided nevus spilus and divided form of spotted grouped pigmented nevus. *J Cutan Pathol* **6**:507, 1977

7. Rhodes AR, Mihm MC Jr: Origin of cutaneous melanoma in a congenital dysplastic nevus spilus. *Arch Dermatol* **126**:500, 1990

8. Grinspan D et al: Melanoma on dysplastic nevus spilus. *Int J Dermatol* **36**:499, 1997

9. Breathnach AS: Melanocyte distribution in forearm epidermis of freckled human subjects. *J Invest Dermatol* **29**:253, 1957

10. Wilson PD, Kligman AM: Experimental induction of freckles by ultraviolet-B. *Br J Dermatol* **106**:401, 1982

11. Rhodes AR et al: Increased intraepidermal melanocyte frequency and size in dysplastic melanocytic nevi and cutaneous melanoma: A comparative quantitative study of dysplastic melanocytic nevi, superficial spreading melanoma, nevocellular nevi, and solar lentigines. *J Invest Dermatol* **80**:452, 1983

12. Rhodes AR et al: The PUVA-induced pigmented macule: A lentiginous proliferation of large, sometimes cytologically atypical, melanocytes. *J Am Acad Dermatol* **9**:47, 1983

13. Crawley EP, Curtis AC: Lentigo senilis. *Arch Dermatol Syphilol* **62**:635, 1950

14. Hodgson C: Senile lentigo. *Arch Dermatol* **87**:197, 1963

15. Montagna W et al: A reinvestigation of solar lentigines. *Arch Dermatol* **116**:1151, 1980

16. Rhodes AR et al: The PUVA lentigo: An analysis of predisposing factors. *J Invest Dermatol* **81**:459, 1983

17. Kadunce DP et al: Persistent melanocytic lesions associated with cosmetic tanning bed use: "Sunbed lentigines." *J Am Acad Dermatol* **23**:1029, 1990

18. Azizi E et al: Skin type, hair color, and freckles are predictors of decreased minimal erythema ultraviolet radiation dose. *J Am Acad Dermatol* **19**:32, 1988

19. Mackie-RM: Personal risk-factor chart for cutaneous melanoma. *Lancet* **2**:487, 1989

20. Szabo G: Photobiology of melanogenesis: Cytological aspects with special reference to differences in racial coloration, in *Advances in Biology of the Skin,* vol 8, edited by W Montagna, F Hu. Oxford, England, Pergamon, 1967, p 379

21. Konrad K et al: Ultrastructure of poikiloderma-like pigmentary changes after repeated experimental PUVA overdosage. *J Cutan Pathol* **4**:219, 1977

22. Kraemer KH et al: Reduced DNA repair in cultured melanocytes and nevus cells from a patient with xeroderma pigmentosum. *Arch Dermatol* **125**:263, 1989

23. Takebe H et al: Melanoma and other skin cancers in xeroderma pigmentosum patients and mutation in their cells. *J Invest Dermatol* **92**:236S, 1989

24. Nakagawa H et al: Morphologic alterations of epidermal melanocytes and melanosomes in PUVA lentigines: A comparative ultrastructural investigation of lentigines induced by PUVA and sunlight. *J Invest Dermatol* **82**:101, 1985

25. Rhodes AR et al: Sun-induced freckles in children and young adults: A correlation of clinical and histopathologic features. *Cancer* **67**:1990, 1991

26. Barranco VP: Multiple benign lichenoid keratosis simulating photodermatoses: Evolution from senile lentigines and their spontaneous resolution. *J Am Acad Dermatol* **13**:201, 1985

27. Stern RS: The risk of melanoma in association with long-term exposure to PUVA. *J Am Acad Dermatol* **44**:755, 2001

28. MacKie RM et al: The number and distribution of benign pigmented moles (melanocytic naevi) in a healthy British population. *Br J Dermatol* **113**:167, 1985

29. Nicholls EM: Development and elimination of pigmented moles, and the anatomical distribution of primary malignant melanoma. *Cancer* **32**:191, 1973

30. Green A et al: Melanocytic nevi in schoolchildren in Queensland. *J Am Acad Dermatol* **20**:1054, 1989

31. Kelly JW et al: Sunlight: A major factor associated with the development of melanocytic nevi in Australian schoolchildren. *J Am Acad Dermatol* **30**:40,1994

32. Gallagher RP et al: Broad-spectrum sunscreen use and the development of new nevi in white children: A randomized controlled trial. *JAMA* **283**:2955, 2000

33. Zhu G et al. A major quantitative trait locus for mole density is linked to the familial melanoma gene CDKN2A: A maximum likelihood combined linkage and association analysis in twins and their sibs. *Am J Hum Genet* **65**:483, 1999

34. Lea PJ, Pawlowski A: Human melanocytic naevi. *Acta Derm Venereol (Stockh)* 127(suppl):5, 1986

35. Grichnik JM et al: KIT expression reveals a population of precursor melanocytes in human skin. *J Invest Dermatol* **106**:967, 1996

36. Robinson WA et al: Human acquired naevi are clonal. *Melanoma Res* **8**:499, 1998

37. Harada M et al: Clonality in nevocellular nevus and melanoma: An expression-based clonality analysis at the X-linked genes by polymerase chain reaction. *J Invest Dermatol* **109**:656, 1997

38. Hui P et al: Assessment of clonality in melanocytic nevi. *J Cutan Pathol* **28**:140, 2001

39. Tucker MA et al: Clinically recognized dysplastic nevi: A central risk factor for cutaneous melanoma. *JAMA* **277**:1439, 1997

40. Weinstock MA et al: Moles and site-specific risk of nonfamilial cutaneous malignant melanoma in women. *J Natl Cancer Inst* **81**:948, 1989

41. Swerdlow AJ et al: Benign melanocytic nevi as a risk factor for malignant melanoma. *Br Med J* **292**:1555, 1986

42. Seykora J, Elder D: Dysplastic nevi and other risk markers for melanoma. *Semin Oncol* **23**:682, 1996

43. Rhodes AR et al: Dysplastic melanocytic nevi: A reproducible histologic definition emphasizing cellular morphology. *Mod Pathol* **2**:306, 1989

44. Rhodes AR et al: A histologic comparison of congenital and acquired nevomelanocytic nevi. *Arch Dermatol* **121**:1266, 1985

45. Kornberg R, Ackerman AB: Pseudomelanoma: Recurrent melanocytic nevus following partial surgical removal. *Arch Dermatol* **111**:1588, 1975

46. Curley RK et al. Effect of incisional biopsy on subsequent histology of melanocytic nevi. *Br J Dermatol* **123**:503, 1990

47. Stegmaier OC: Natural regression of the melanocytic nevus. *J Invest Dermatol* **23**:413, 1959

48. Kantor GR, Wheeland RG: Transepidermal elimination of nevus cells: A possible mechanism of nevus involution. *Arch Dermatol* **123**:1371, 1987

49. Pehamberger H et al: In vivo epiluminescence microscopy of pigmented skin lesions: I. Pattern analysis of pigmented skin lesions. *J Am Acad Dermatol* **17**:571, 1987

50. Steiner A et al: In vivo epiluminescence microscopy of pigmented skin lesions: II. Diagnosis of small pigmented skin lesions and early detection of maligant melanoma. *J Am Acad Dermatol* **17**:584, 1987

51. Kelly JW et al: A high incidence of melanoma found in patients with multiple dysplastic naevi by photographic surveillance. *Med J Aust* **167**:191, 1997

52. Unna PG: *Histopathology of the Diseases of the Skin,* 1st ed, translated by N Walker. New York, MacMillan, 1896, p 1129

53. Allen AC: A reorientation on the histogenesis and clinical significance of cutaneous nevi and melanomas. *Cancer* **2**:28, 1949

54. Gartmann H: Transepidermale Ausscheidung von Nävus- und Melanomzellen. *Hautarzt* **33**:495, 1982

55. Richert S et al: Widespread eruptive dermal and atypical melanocytic nevi in association with chronic myelocytic leukemia: case report and review of the literature. *J Am Acad Dermatol* **35**:326, 1996

56. Larsson P-A, Liden S: Prevalence of skin disease among adolescents 12–16 years of age. *Acta Derm Venereol (Stockh)* **60**:415, 1980

57. Kopf AW et al: Broad spectrum of leukoderma acquisitum centrifugum. *Arch Dermatol* **92**:14, 1965

58. Mitchell MS et al: Comparison of cell-mediated immunity to melanoma cells in patients with vitiligo, halo nevi, or melanoma. *J Invest Dermatol* **75**:144, 1980

59. Copeman PS et al: Immunologic associations of the halo nevus with cutaneous melanoma. *Br J Dermatol* **88**:127, 1973

60. Reed RJ et al: Common and uncommon melanocytic nevi and borderline melanomas. *Semin Oncol* **2**:119, 1975

61. Zeff RA et al: The immune response in halo nevi. *J Am Acad Dermatol* **37**:620, 1997

62. Spitz S: Melanomas of childhood. *Am J Pathol* **3**:591, 1948

63. Kopf AW, Andrade R: Benign juvenile melanoma, in Yearbook of Dermatology 1965–1966, edited by AW Kopf, R Andrade. Chicago, Year Book, 1966, p 7

64. Helwig EB: Malignant melanoma in children, in *Neoplasms of the Skin and Malignant Melanoma.* Chicago, Year Book, 1976, p 11

65. Sagebiel RW et al: Pigmented spindle cell nevus: Clinical and histologic review of 90 cases. *Am J Surg Pathol* **8**:645, 1984

66. Weedon D, Little JH: Spindle and epithelioid cell nevi in children and adults: A review of 211 cases of Spitz nevus. *Cancer* **40**:217, 1977

67. Allen AC: Juvenile melanomas. *Ann NY Acad Sci* **100**:29, 1963

68. Bastian BC et al. Chromosomal gains and losses in primary cutaneous melanomas detected by comparative genomic hybridization. *Cancer Res* **58**:2170, 1998

69. Kernan JA, Ackerman LV: Spindle cell nevi and epithelioid cell nevi (so-called juvenile melanomas) in children and adults. *Cancer* **13**:612, 1960

70. Harvell JD et al: Spitz's nevi with halo reaction: A histopathologic study of 17 cases. *J Cutan Pathol* **24**:611, 1997

71. Gartmann H, Ganser M: Der Spitz-Naevus: Spindelzellen- und/oder Epitheloidzellnaevus-eine klinishe Analyse von 652 Tumoren. *Z Hautkr* **60**:22, 1984

72. Barnhill RS et al: The histologic spectrum of pigmented spindle cell nevus: A review of 120 cases with emphasis on atypical variants. *Hum Pathol* **22**:52, 1991

73. Kamino H et al: Eosinophilic globules in Spitz's nevus: New findings and a diagnostic sign. *Am J Dermatopathol* **1**:319, 1979

74. Cohen LM et al: Hypermelanotic nevus: Clinical histopathologic, and ultrastructural features in 316 cases. *Am J Dermatopathol* **19**:23, 1997

75. Barnhill RL et al: Atypical Spitz nevi/tumors: Lack of consensus for diagnosis, discrimination from melanoma, and prediction of outcome. *Hum Pathol* **30**:513, 1999

76. Tuthill RJ et al: Pilar neurocristic hamartoma: Its relationship to blue nevus and equine melanotic disease. *Arch Dermatol* **118**:592, 1982

77. Betti R et al: Agminate and plaque-type blue nevus combined with lentigo, associated with follicular cyst and eccrine changes: A variant of speckled lentiginous nevus. *Dermatology* **195**:387, 1997

78. Kang DS, Chung KY: Common blue perivascular dissemination resulting in clinical resemblance to malignant melanoma. *Br J Dermatol* **141**:992, 1999

79. Busam KJ et al: Large plaque-type blue nevus with subcutaneous cellular nodules. *J Cuttan Pathol* **24**:92, 2000

80. Carney JA, Ferreiro JA: The epithelioid blue nevus. A multicentric familial tumor with important associations, including cardiac myxoma and psammomatous melanotic schwannoma. *Am J Surg Pathol* **20**:259, 1996

81. Moreno C et al: Epithelioid blue nevus: A rare variant of blue nevus not always associated with the Carney complex. *J Cutan Pathol* **27**:218, 2000

82. Smith K et al: CD-34 positive cellular blue nevi. *J Cutan Pathol* **28**:145, 2001

83. Tran TA et al: Cellular blue nevus with atypia (atypical cellular blue nevus): A clinicopathologial study of nine cases. *J Cutan Pathol* **25**:252, 1998

84. Russel JL, Reyes RC: Giant pigmented nevi. *JAMA* **171**:2083, 1959

85. Rhodes AR et al: The malignant potential of small congenital nevocellular nevi: An estimate of association based on a histologic study of 234 primary cutaneous melanomas. *J Am Acad Dermatol* **6**:230, 1982

86. Reed WB et al: Giant pigmented nevi, melanoma, and leptomeningeal melanocytosis: A clinical and histopathological study. *Arch Dermatol* **91**:100, 1965

87. Walton RG et al: Pigmented lesions in newborn infants. *Br J Dermatol* **95**:389, 1976

88. Ribuffo D et al: Divided nevus of the eyelid: A case report. *Ophthalmic Plast Reconstr Surg* **12**:186, 1996

89. Rhodes AR et al: Congenital nevomelanocytic nevi: Proportionate area expansion during infancy and early childhood. *J Am Acad Dermatol* **34**:51, 1996

90. Crowe FW et al: *A Clinical, Pathological, and Genetic Study of Multiple Neurofibromatosis.* Springfield, IL, Charles C Thomas, 1956, p 181

91. Marghoob AA et al: Large congenital melanocytic nevi and the risk for the development of malignant melanoma: A prospective study. *Arch Dermatol* **132**:170, 1996

92. Swerdlow AJ et al: The risk of melanoma in patients with congenital nevi: A cohort study. *J Am Acad Dermatol* **32**:595, 1995

93. Bittencourt FV et al: Large congenital melanocytic nevi and the risk for development of malignant melanoma and neurocutuaneous melanosis. *Pediatrics* **106**:736, 2000

94. Egan CL et al: Cutaneous melanoma risk and phenotypic changes in large congenital nevi: A follow-up study of 46 patients. *J Am Acad Dermatol* **39**:923, 1998

95. Lorentzen M et al: The incidence of malignant transformation in giant pigmented nevi. *Scand J Plast Reconstr Surg* **11**:163, 1977

96. Harly S, Walsh N: A new look at melanomas. Am J Dermatopathol **18**:137, 1996

97. Betti R: Small congenital nevi associated with melanoma: Case reports and considerations. *J Dermatol* **27**:583, 2000

98. Sweren RJ: Management of congenital nevocytic nevi: A survey of current practices. *J Am Acad Dermatol* **11**:629, 1984

99. Nickoloff BJ et al: Immunohistologic patterns of congenital nevocellular nevi. *Arch Dermatol* **122**:1263, 1986

100. Rhodes AR: Public education and cancer of the skin: What people need to know about melanoma and nonmelanoma skin cancer. *Cancer* **75**:613, 1995

T>

Chapter 92

Hensin Tsao Arthur Sober

Atypical Melanocytic Nevi

HISTORICAL ASPECTS
EPIDEMIOLOGY
ETIOLOGY AND PATHOGENESIS
CLINICAL MANIFESTATIONS
PATHOLOGY
CLINICAL-PATHOLOGIC CORRELATION
DIFFERENTIAL DIAGNOSIS
ATYPICAL MELANOCYTIC NEVI AND MELANOMA RISK
MANAGEMENT

REFERENCES

Recognition of nonmalignant melanocytic and nevomelanocytic tumors is important because of their pathogenic relationship to cutaneous melanoma. A history of a preexisting pigmented lesion at the site of primary melanoma may be elicited in 18 to 85 percent of patients, while histologic remnants of nevus cells can be observed in 18 to 72 percent of melanoma cases. [1] Because the majority of adults have one or more pigmented lesions, it is important to identify melanocytic and nevomelanocytic hyperplasias that have an increased risk of developing melanoma from those pigmented lesions that carry little or no enhanced melanoma risk.

Atypical melanocytic nevi (AMN) are acquired, usually irregular-appearing, melanocytic tumors (Fig. 92-1 and Fig. 92-2), characterized histologically by architectural and/or cytologic atypia. AMN are important because they are potential histiogenic precursors of melanoma and markers of increased melanoma risk. Other names that have been used for AMN include atypical nevus, atypical mole, B-K mole (B and K represent family names of two kindreds in which atypical nevi aggregated with familial melanoma), Clark's nevus (after the late Dr. Wallace H. Clark, Jr.), and dysplastic nevus.

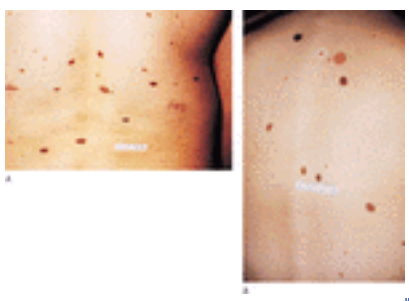

FIGURE 92-1 Multiple acquired atypical melanocytic nevi on the back of a healthy 30-year-old white man who has no personal or family history of melanoma (*A*), and on the back of a 13-year-old white female who has no personal or family history of melanoma but whose father has multiple atypical nevi (*B*). Note associated halo nevus in (*B*). (*Courtesy of Arthur R. Rhodes, MD.*)

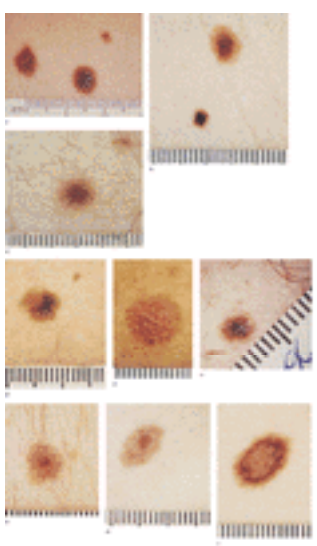

FIGURE 92-2 Acquired atypical melanocytic nevi. Atypical compound nevi (*A* to *E* and *G* to *I*) and atypical junctional nevus (*F*). These nevi are striking for irregular and/or dark pigmentation or “fried-egg” appearance, irregular and/or sharp or poorly demarcated outlines, relatively large size, and relatively “flat” surface relative to breadth. Scale in millimeters. (*Courtesy of Arthur R. Rhodes, MD.*)

The older designation for AMN—“dysplastic nevus”—is derived from the Greek roots *dys* and *plasis* and refers to abnormal tissue development. Although the term *dysplasia* is frequently used in the cancer context, it can also refer to abnormally formed states with no tendency for neoplasia (e.g., ectodermal dysplasia, enamel dysplasia). Given

ambiguities in its definition, a 1992 National Institutes of Health Consensus Development Panel recommended against the use of dysplastic nevus as a diagnosis. [2] The clinical lesions should be described as *atypical moles* while the microscopic patterns should be designated *nevi with architectural disorder* with varying amounts of cellular atypia. Although the diagnosis of AMN is suspected for atypical-appearing melanocytic lesions, histologic confirmation is encouraged to establish the diagnosis because not all atypical-appearing melanocytic lesions have an atypical histology. Table 92-1 delineates some clinical characteristics that can help to distinguish acquired typical between atypical nevi.

TABLE 92-1 **Comparison of Acquired Typical Nevomelanocytic Nevus and Acquired Atypical Melanocytic Nevus (AMN) in White Adults†**

HISTORICAL ASPECTS

Although the concept of AMN as a precursor to melanoma has been popularized as an entity sui generis only in the last several decades, [3], [4], [5] and [6] reports of such lesions date back to the 1800s when Norris [7] described a family in which two members developed cutaneous melanoma and other family members had “many moles on various parts of their bodies.” The numerous moles in the family described by Norris may very well have been AMN. Munro [8] showed the gross and microscopic appearance of what we now know to be AMN as early as 1974, in association with a family history of melanoma. Formerly, AMN were described grossly and histologically by other names, including “intraepidermal melanoma” and “atypical” or “active” junctional nevi. [9] The first published reports formally delineating the presence of AMN as a marker for and precursor of cutaneous melanoma were described in the setting of familial cutaneous melanoma–B-K mole syndrome and familial atypical multiple mole melanoma (FAMMM) syndrome. [3], [10], [11]

EPIDEMIOLOGY

Earlier reports suggested that approximately 30,000 people in the United States belong to AMN/familial melanoma kindreds. [12] Although AMN were originally described in these melanoma-prone kindreds, subsequent studies have documented its presence in the general population. In Australia and New Zealand, the prevalence rate is approximately 5 to 9 percent. [13], [14] In Germany, 2.2 percent of 500 white males aged 16 to 25 years had histologically documented AMN. [15] In Sweden, clinically identified AMN were detected in 69 of 379 white adults (18 percent) aged 30 to 50 years, while only 30 of these or 8 percent of the total had histopathologically determined AMN. [16] In the United States, up to 17 percent of the healthy population is reported to harbor at least one AMN. [17], [18] In France, 63 out of 295 healthy individuals (24 percent) had at least one “clinically atypical nevus” but only 5 had “clinically very atypical nevus.” [19] The marked variation in prevalence among various populations and the extraordinarily high rates in some groups may relate to true population heterogeneity, the marked variation of gross and/or microscopic definitions used for ascertainment, or differences in the amount of sun exposure in various regions of the world.

ETIOLOGY AND PATHOGENESIS

Intraepidermal melanocytic dysplasia in AMN has been interpreted by some as a block in nevocellular differentiation. [20] Evidence for this abnormal differentiation in AMN includes the relatively large clinical lesions, deranged melanogenesis associated with increased pheomelanin content and abnormal melanosomes, enlarged cell bodies, increased dopa-positivity, and the associated disordered proliferation of melanocytes, inflammatory host response, and unique mesenchymal features. [20], [21], [22] and [23] As with most neoplastic processes, AMN most likely result from an interaction between genetics and the environment.

Many advances have been made in the molecular characterization of FAMMM kindreds. Initial genetic analysis of these families suggested an autosomal dominant mode of inheritance with a possible locus on chromosome 1. [24] Subsequent mapping of the FAMMM locus by using the National Cancer Institute kindreds suggested a locus for familial cutaneous melanoma and AMN on chromosome 1p36. [25] This localization, however, could not be confirmed in other melanoma-prone kindreds around the world. [26], [27] and [28] Cannon-Albright et al. eventually identified a melanoma susceptibility locus on chromosome 9p21, [29] thereby setting the groundwork for the isolation of *CDKN2A* (also designated p16) as a melanoma predisposition gene from this chromosomal region. [30], [31] Subsequent genetic analysis of *CDKN2A* in chromosome 9p–linked families showed a high rate of germ-line mutations. [32] In this study, [32] the mutations appeared to cosegregate with the melanoma phenotype, but not with the atypical mole phenotype. Thus, other unidentified loci may be responsible for AMN susceptibility. Somatic analyses of sporadic AMN have shown evidence of allelic deletion on chromosomes 1 and 9, [33], [34] and [35] although confirmation of deleterious mutations of any specific gene in AMN is still lacking. Inconsistencies between the localization data and phenotype point to significant genetic heterogeneity among the FAMMM kindreds. Evidence suggests that the chromosome 1p36 locus may contribute to both cutaneous melanoma and AMN, while the chromosome 9p locus only determines melanoma susceptibility. [36], [37]

Although strong epidemiologic data support an association between cutaneous melanoma and excessive ultraviolet radiation (UVR) exposure (reviewed in Ref. 38), the role of sunlight in the induction of AMN is not well established. Many studies report a higher mole density on intermittently sun-exposed sites (upper arms, upper back) as compared to sun-protected (lower back, buttocks) and chronically irradiated (head and neck) sites. [39], [40], [41] and [42] For total mole development, these anatomic patterns argue against a direct dose effect by the sun. Furthermore, the prevalence of AMN and anatomic distribution of AMN appear to be even less sun-related than common acquired nevi. [40], [43], [44] The direct effects of ultraviolet exposure on AMN nevomelanocytes are also unclear. Stierner et al. irradiated 11 AMN patients and 22 healthy subjects with UVB irradiation over 17 days and found no abnormal melanocytic UV response in the AMN patients. [45] However, Noz et al. observed a higher rate of DNA damage after UVB irradiation in nevus cells from AMN when compared with nevus cells from common acquired nevi and melanocytes from neonatal foreskin. [46] On the other hand, cyclobutane thymine dimers, a marker of genomic UV injury, do not occur with increased frequency in UV-irradiated AMN melanocytes when compared with UV-irradiated neonatal foreskin melanocytes. [47] Thus, the role of UVR in the pathogenesis of AMN remains speculative.

Analyses of nonmelanocytes from patients with AMN have revealed genetic instability in response to genotoxic stress. In fibroblast cultures, excision repair of UVR-induced thymine dimers was altered adversely within the first hour after UVR (but was normal by 90 min) in seven of eight patients who had AMN (with or without a personal or family history of melanoma). [48] In response to ?-irradiation, skin fibroblasts from members of FAMMM kindreds with AMN show significantly more chromatid breaks and gaps. [49] Based on an analysis of Giemsa-banded karyotypes of peripheral blood lymphocytes, there appears to be a significant excess of apparently random chromosome abnormalities (major and minor structural and numerical abnormalities, i.e., general chromosomal instability) in subjects with AMN in the presence or absence of a personal history of melanoma, as compared to spouse controls and unaffected blood relatives. [50]

Other carcinogens besides UVR have been used to create models of AMN progression in animals. Topical application of 7,12-dimethyl-benzanthracene (DMBA) elicits intraepidermal melanocytic hyperplasia and cutaneous melanomas in both Weiser-Maple guinea pigs [51] and albino guinea pigs. [52] The biological relationship, however, of these hyperplastic lesions to AMN is unknown.

In summary, the etiology of AMN remains elusive. Although no recurrent mutational targets have been detected in these melanocytic lesions, there is some indication that cells from AMN patients may be genetically unstable. Moreover, the interaction between AMN and melanomas within FAMMM kindreds is complex; that is, melanoma patients within these families may lack AMN and vice versa. At the current time, the extant information does not support the involvement of a single gene in both AMN and cutaneous melanoma or a direct effect by UVR.

CLINICAL MANIFESTATIONS

Reliable clinical criteria are not available to predict with absolute certainty the presence of intraepidermal melanocytic dysplasia in a given melanocytic nevus, although general characteristics may be helpful in distinguishing dysplastic nevi from typical nevi (see Table 92-1 and Fig. 92-1, Fig. 92-2, and Fig. 92-3). Because the term “dysplastic nevus” is still frequently used by dermatopathologists, it is not uncommon for clinicians to designate moles with atypical features as AMN and for pathologists to define lesions with melanocytic dysplasia as “dysplastic nevi.”

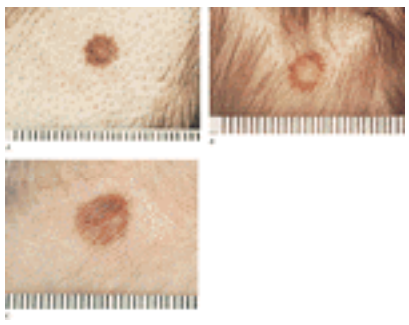

FIGURE 92-3 Acquired atypical compound nevi on the scalp (*A* to *C*). (*Courtesy of Arthur R. Rhodes, MD.*)

The 1992 NIH Consensus Panel defined atypical moles as “acquired pigmented lesions of the skin whose clinical and histologic appearances are different from those of typical common moles.” [2] In general, AMN are larger than common moles, have macular and/or papular components, have ill-defined or irregular borders, and exhibit variegation in color that ranges from tan to dark brown or black. These lesions tend to occur on the trunk, although they can also appear on sun-protected areas such as the buttocks. Maiweg et al. found that 96 percent of AMN have at least one of the following four criteria: irregular border, irregular pigmentation, greatest diameter >5mm, and black-colored areas. [53] Although these features can also be found in melanomas, pigmented lesions that lack at least one of these features are unlikely to be AMN.

AMN are often different from one another in the same individual, and AMN in different people may have a variable appearance. Lesions may barely distort the skin surface or have obvious “cobblestoning” of the surface when viewed with oblique lighting. Some lesions have a “fried-egg” appearance, with a central raised component and a more macular pigmented flare that blends imperceptibly into adjacent skin. Other varieties of AMN are very darkly pigmented throughout, distorting the skin surface minimally, and sharply demarcated or blending into surrounding skin. Some lesions are sharply demarcated with an irregular border, distorting the skin surface as an obviously raised plaque (Fig. 92-2 and Fig. 92-3). Atypical histologic features should be suspected in melanocytic tumors that have very dark pigmentation and/or haphazard disposition of multiple hues (shades of brown, pink, and flesh tone) or a target

appearance, irregular and/or poorly demarcated outlines, and relatively large size (5 mm or larger) (Fig. 92-2 and Fig. 92-3). The presence of pink hue with or without pigmentation in a relatively large nevus correlates with the presence of epithelioid cell dysplasia. [54]

Surface topography and size are useful parameters in assessing AMN. Although AMN usually distort the skin surface to some degree when assessed by oblique lighting and a macular component is usually present, melanocytic dysplasia in a given lesion cannot be excluded based on topographic features. For instance, lentigo maligna and melanocytic dysplasias on acral and mucosal surfaces need not distort the skin surface. Although nevi less than 4 mm in greatest diameter rarely exhibit melanocytic dysplasia, [54] size alone cannot be used to exclude melanocytic dysplasia. Likewise, location also cannot be used to exclude melanocytic dysplasia. In melanoma-prone families (or in any patient with AMN or melanoma), hidden areas such as the scalp (Fig. 92-3) must be examined carefully for AMN, for such sites may be the source of lethal melanoma, even in children. [55] There are also several case reports of AMN disposed in quadrant distribution. [56], [57]

People with AMN may have a few to hundreds of lesions (Fig. 92-1). Population-based AMN counts in different countries have yielded varying results. For instance, Augustsson et al. found that more than 15 percent of residents from the city of Gothenburg, Sweden, had more than 100 AMN, [16] whereas Grob et al. found that only 5 percent of a French health-center population had more than 1 AMN. [19] There are several possibilities for these discrepancies. The stringency of criteria used to diagnose AMN is often different between studies. The Swedish study defined AMN as a nevus = 5 mm plus at least two of the following: an ill-defined or irregular border, speckled pigmentation, erythema, or a pebbled surface, [16] whereas the French investigators defined AMN as a nevus with any three of the following: ill-defined border, irregular border, irregularly distributed pigmentation, diameter 5 mm or greater, background erythema, and accentuated skin markings. [19] Moreover, there is limited interobserver agreement as to the presence of these atypical clinical features. In one study, four physicians (two oncologists, one internist, one dermatologist) were asked to evaluate a fixed panel of 156 AMN lesions and to identify AMN features within these lesions. Among the clinical features assessed, the examiners noted macular components in 86 to 96 percent of lesions, asymmetry in 47 to 80 percent of lesions, irregular borders in 55 to 80 percent of lesions, ill-defined borders in 40 to 84 percent of lesions, and haphazard color in 41 to 74 percent of lesions. [58] This wide range of values suggests that different observers have different interpretations of “irregular borders” and “irregular pigment.” Because of the low concordances, some clinicians have advocated using more quantitative measures, such as total numbers or maximal sizes of nevi, rather than the subjective determinations of atypia, [59] when assessing melanoma risk. Finally, the AMN individuals participating in these various studies originated from clinics in a single institution [17], [19], [60], [61] and [62] or from multiple institutions [18] to randomly selected individuals in a given location. [16] A healthy control population in a case-controlled series is different from a residential population because the latter would also include melanoma patients and persons at high risk for developing cutaneous melanoma.

Although the characteristic appearance of AMN may not be evident until puberty, AMN may occur in young children. [55] Significantly more lesions with a histologically confirmed diagnosis of AMN occur in individuals 20 years of age or older. Children who have a prominent mole pattern but without obvious AMN should be reexamined periodically until at least age 20 years. If AMN are not apparent by age 20 years and prominent moles are not evident, it is unlikely that an individual has the AMN trait, at least in the setting of familial melanoma. [63] Unlike common acquired nevi, AMN remain dynamic throughout adult life. New AMN develop in about 20 percent of individuals over 50 years of age, while nearly 50 percent of all AMN undergo some kind of change. The change may represent an increase or decrease in extent of clinical atypia or a disappearance of the mole altogether. [64]

Given the relatively ill-defined criteria for AMN and the dynamic nature of these lesions, adjunctive measures have been added to clinical practice for surveillance of AMN. One such tool is dermoscopy (i.e., epiluminescence microscopy). Although many dermoscopic features of melanoma have been described (see Chap. 93), dermoscopic features of AMN are not quite as straightforward and are not equally well delineated. [65] However, they are distinct enough to make a diagnosis in most cases. [65] There is usually some distortion of the dermoscopic pigment network in AMN, but other dermoscopic features of melanoma are lacking. In melanoma, the pigment pattern is widely spaced and associated with black globular pigment accumulations, pigment streaming and pseudopods, gray haze, gray-blue areas, and areas of pigment loss. [65] Recently, a dermoscopic classification of AMN was devised based on 829 AMN from 23 patients (Fig. 92-4A, Fig. 92-4B, Fig. 92-4C, Fig. 92-4D, Fig. 92-4E, Fig. 92-4F, Fig. 92-4G, Fig. 92-4H, Fig. 92-4I, Fig. 92-4J, Fig. 92-4K and Fig. 92-4L). The utility of this classification scheme will ultimately depend upon the reproducibility of these results and the correlation between dermoscopic findings and histology. [66]

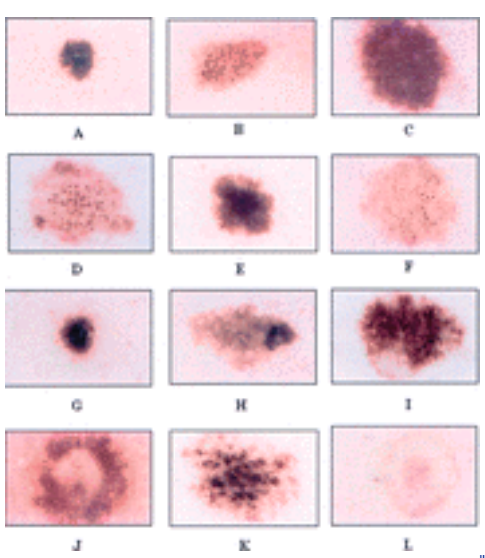

FIGURE 92-4 Dermoscopic patterns of atypical melanocytic nevi. The (*A*) reticular pattern with pigment network; (*B*)

globular pattern showing numerous globules or dots; (*C*) homogeneous pattern with homogeneous brown pigmentation; (*D*) reticular-globular pattern with =3 meshes of pigment network with =3 globules or dots; (*E*) reticular-homogeneous pattern with =3 meshes of pigment network with homogeneous brown pigmentation in at least one quarter of the lesion; (*F*) globular-homogeneous pattern with =3 globules or dots with homogeneous brown pigmentation in at least one quarter of the lesion (*L*) unclassified pattern. Dermoscopic classification of AMN showing (*G*) central hyperpigmentation; (*H*) eccentric peripheral hyperpigmentation; (*J*) central hypopigmentation; (*I*) eccentric peripheral hypopigmentation; (*K*) multifocal hyperpigmentation and hypopigmentation. (*Courtesy of R. Hofmann-Wellenhof, MD.*)

There are also no agreed upon clinical criteria for classifying individuals with AMN. At least three different, but related, systems exist. The NIH Consensus Panel defined the FAMMM syndrome as (1) occurrence of melanoma in one or more first- or second-degree relatives, (2) large numbers of moles (often >50), some of which are atypical and often variable in size, and (3) moles that demonstrate certain distinct histologic features. [2] The *classic atypical moles syndrome* is defined by the presence of (1) more than 100 nevi, (2) one or more nevi = 8 mm in greatest diameter, and (3) one or more nevi with clinically atypical features. [67] The *atypical mole syndrome* has also been scored on a point system. One point is assigned for each of these features: (1) two or more pigmented lesions of the iris; (2) more than 100 nevi larger than 2 mm in diameter (or >50 nevi in patients older than 50 years or younger than 20 years); (3) two or more clinically atypical moles; (4) moles on the anterior aspect of the scalp; and (5) moles abnormally distributed (e.g., one on the buttocks or two or more on the dorsum of the foot). Affected individuals are said to have the “atypical mole syndrome” phenotype if they score 3 or more points. [68] All of these systems are arbitrary and have not been fully tested for melanoma risk.

PATHOLOGY

Histologic features required to diagnose AMN have not been tested sufficiently for sensitivity, specificity, and predictive value. Therefore, diagnostic criteria are not universally accepted. Nevertheless, sufficient data are available to make a histologic diagnosis until universally accepted criteria are available.

Elder et al. [69] outlined diagnostic features for AMN as *absolute* (necessary for the diagnosis) and *relative* (frequently associated). These criteria have been modified slightly as follows: *Absolute* histologic criteria include (1) a proliferation of intraepidermal melanocytes disposed singly and/or in irregular nests in the epidermal basal unit or slightly above, in a lentiginous epidermal pattern (elongated, club-shaped, and/or fused rete ridges), and (2) variable and discontinuous cellular atypia of melanocytes (Fig. 92-5A, Fig. 92-5B and Fig. 92-53). *Relative* histologic criteria include (1) lymphohistiocytic infiltrates in the dermis, with or without melanin-laden macrophages; (2) a dermal mesenchymal response consisting of concentric eosinophilic fibrosis (condensed papillary dermal collagen abutting epidermal rete ridges), lamellar fibroplasia (delicate collagen fibrils and elongated fibroblasts parallel to the epidermal surface, situated at the tips of epidermal rete ridges), and/or neovascularization (blood vessel proliferation); (3) a proliferation of ellipsoidal and irregularly nested melanocytes disposed at the epidermal basal unit, frequently bridging epidermal rete ridges; (4) nevus cells in the dermis, often associated with impairment of maturation and synthesis of pigment; and (5) extension of intraepidermal melanocytic hyperplasia beyond the shoulders of the dermal nevus component (if a dermal nevus is present).

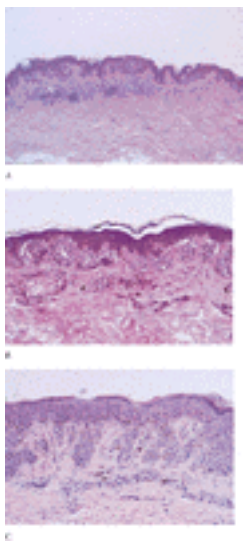

FIGURE 92-5 Histopathologic features of a compound dysplastic nevus. *A*. The lesion is asymmetric with centrifugal proliferation of junctional nests which extend well beyond the dermal component (“shoulder phenomenon”). This shoulder results clinically in the irregular macular flare at the border of an atypical mole. *B*. Closer examination reveals an abnormal nesting pattern of melanocytes with moderate epithelioid atypia, concentric eosinophilic fibroplasia, and focal lymphocytic host response. *C*. The presence of cytologic atypia, which is a hallmark of dysplastic nevi, can be appreciated with cells exhibiting marked nuclear pleomorphism and hyperchromasia. (*Photographs courtesy of Artur Zembowicz, MD, PhD.*)

These criteria [69] have been adopted and modified slightly into two major and four minor criteria recently outlined in a paper by pathologists convened by the World Health Organization (WHO) Melanoma Program to test concordance of interpretation of melanocytic lesions. [70] Diagnosis of AMN by this scheme requires both major criteria and two of the four minor criteria. The major criteria are (1) basilar proliferation of atypical nevomelanocytes, extending three rete ridges beyond a dermal melanocytic component (if a dermal component is present), and (2) a pattern of intraepidermal melanocytic proliferation as one of two types, namely, lentiginous or epithelioid cell. The minor criteria are (1) concentric eosinophilic fibrosis or lamellar fibroplasia, (2) neovascularization, (3) dermal inflammatory response, and (4) fusion of rete ridges. In the WHO Melanoma Program, these predetermined criteria for diagnosis permitted a mean percent

concordance of diagnosis for benign acquired nevi, AMN, and radial growth phase melanoma to be 95, 88, and 95 percent, respectively. [70]

The degree of cellular atypia in AMN is often difficult to reproducibly measure. On the one hand, AMN with clear architectural disorder may harbor scant or no melanocyte nuclear atypia. On the other hand, the melanocytic atypia may be so severe that distinction from melanoma is nearly impossible. Cellular atypia of melanocytes is characterized by nuclear enlargement and usually expansion of cell cytoplasm, and expanded retraction artifact (for spindle cells), nuclear hyperchromasia and pleomorphism, often a prominent nucleolus, and expansion of eosinophilic cytoplasm in spindle cells or finely pink and granular cytoplasm in epithelioid cells. [71] Most nevi that exhibit cellular atypia also possess concomitant architectural changes associated with AMN, including atypical localization of melanocytes in the epidermis, irregular distribution of melanocytes in the junctional zone, and atypical nests of melanocytes. [72] In a multivariate analysis, other histologic features of AMN that were significantly associated with melanocytic nuclear atypia included basal melanocytic hyperplasia, junctional nest disarray, prominent vascularity, and large melanin granules. [73] In another study, dustlike melanin in the cytoplasm of melanocytes, irregular nevoid nests, markedly increased junctional activity, and enlarged melanocytic nuclei were found in half of the AMN and in none of the common typical nevi. [74]

CLINICAL-PATHOLOGIC CORRELATION

Suspecting melanocytic dysplasia in a given melanocytic tumor requires a high index of suspicion and experience correlating gross appearance with microscopic patterns of architecture and cellular morphology of melanocytes. With individual lesions clinically, some investigators have found that ill-defined border, macular component, pink color, and especially size (in mm) and irregular border correlate most closely with AMN histology, [75] while others have reported ill-defined border and irregularly distributed pigmentation to be most predictive. [76] However, if histologic criteria of AMN were strictly applied to nevus pathology specimens, a high percentage of benign nevi also exhibit characteristics of AMN. Klein and Barr found that 88 percent of small, clinically benign junctional and compound nevi manifest at least one histologic feature of AMN, [77] while Piepkorn et al. estimated the prevalence of histologic dysplasia in nevi to range from 7 to 32 percent, depending on the observer. [78] As yet, there is no uniform, reproducible consensus to the grading of atypia in AMN.

DIFFERENTIAL DIAGNOSIS

AMN must be differentiated from a common nevomelanocytic nevus; intraepidermal (in situ) melanoma; pigmented spindle cell and/or epithelioid cell nevus; blue nevus; combined melanocytic nevus-blue nevus; darkly pigmented solar lentigo; darkly pigmented varieties of lentiginous nevomelanocytic nevi without significant cellular atypia; seborrheic keratosis; pigmented actinic keratosis; pigmented basal cell carcinoma; pigmented varieties of Bowen's disease; traumatic hematoma; pyogenic granuloma; sclerosing hemangioma; and dermatofibroma.

The gross and microscopic features of AMN may not be sufficiently evolved to clearly establish the diagnosis before puberty. However, AMN can develop before puberty, particularly in the familial melanoma setting. [55] It may also be difficult to diagnose nonpigmented varieties of AMN in persons who are relatively deficient in their ability to make melanin.

ATYPICAL MELANOCYTIC NEVI AND MELANOMA RISK

Familial, population, and pathologic studies all document an increased risk of cutaneous melanoma among individuals with AMN. Historically, Kraemer initially devised a classification of these families in order to estimate melanoma risk. [12] Persons with sporadic AMN have the lowest risk of developing melanoma, although the risk is still 27 times greater than that for the general population. On the other hand, individuals with familial AMN and a strong family history of cutaneous melanoma have a cumulative risk of melanoma approaching 100 percent by age 75 years; [79] this was approximately 148 times that of the general white population [63] in 1986.

Over the past 20 years, many population- and clinic-based case-controlled studies have reproducibly established an elevated melanoma risk among individuals with atypical nevi. [17], [18], [60], [61] and [62], [80], [81] Because these studies were performed in different parts of the world, the overall impact is unlikely to be biased by specific populations. Patients with a few atypical nevi (<3 to 5 lesions) have an adjusted relative risk of approximately 4 or less. However, individuals with a moderate-to-large number of atypical moles (>5 to 10 lesions) harbor up to a tenfold risk for developing melanoma. More recently, Tucker et al. reported that the presence of even a single AMN conferred a 2.3-fold increase in the risk for melanoma. [18] Prospective cohort studies also consistently show an increased observed-to-expected ratio for developing melanomas among cohorts of patients with atypical nevi. [82], [83], [84] and [85]

The presence of AMN remnants in histologically confirmed cutaneous melanomas has also been promulgated as evidence for the histiogenic evolution from AMN to malignancy. A contiguous association between melanoma and melanocytic dysplasia has been reported in 6.6 to 70.3 percent of cutaneous melanomas in different case series. [20], [63], [86], [87], [88], [89], [90], [91], [92] and [93] Variations in the percentages of precursor AMN reported in the literature most likely reflect differences in the definition of dysplastic nevi and differences in the thoroughness of the histopathologic search (e.g., availability of serial sections). Furthermore, because benign fragments of nevi have also been observed in many studies, the relative rates of transformation to melanoma for AMN and other types of melanocytic hyperplasias are currently unknown.

MANAGEMENT

The proper management of people who have AMN, with or without a personal or family history of melanoma, has not been universally established. In general, pathologic confirmation of the clinical diagnosis provides a more solid basis for

making additional management recommendations. However, histopathologic examination is not necessary to define an individual at high risk if there are obviously atypical nevi (but none suspicious enough to warrant removal) or prominent nevi (see Table 92-1). It is prudent to offer periodic follow-up to persons who have slightly irregular AMN and/or a prominent nevus pattern, whether or not histopathologic confirmation of the diagnosis of AMN is available. For individuals who have AMN and/or prominent nevi, the goal over time is to excise lesions raising clinical suspicion of melanoma—either new nevi with suspicious features or preexisting nevi that have changed.

Recently, it was suggested that monitoring with digital dermoscopy might be offered to patients with multiple AMN. The potential benefit of this technique is that identification of structural modifications over time enables early detection of melanoma, while decreasing the need for excision of suspicious benign lesions. In a recent study by Kittler et al., 1862 melanocytic skin lesions drawn from 202 patients with multiple AMN were monitored with digital dermoscopy. [94] During follow-up 75 (4%) lesions showed substantial modifications over time and were referred to excision. Eight of the 75 excised lesions were histologically diagnosed as early melanomas. These melanomas initially had not displayed clinical or dermoscopic features of melanoma and the decision to excise relied solely on evidence of morphologic change. Although the value of short-term monitoring with digital dermoscopy is still a matter of ongoing research, it may become a useful procedure for selected patients with multiple AMN, where wholesale removal of all AMN is neither necessary, desirable, nor feasible.

For people who have only one or two lesions suspicious for being AMN, complete excision is reasonable, but periodic examination by a health care provider should be offered for a lifetime. Affected people may be expected to develop new lesions over time. In melanoma-prone families, AMN are usually evident by age 20 years for people destined to have them. [63] Prophylactic removal of every AMN is unnecessary for people who have numerous AMN because most will be benign, few will change over time, and the risk of melanoma cannot be eliminated with such an approach. Lesions that are difficult to monitor (i.e., hairy scalp, perianal area) should be considered for prophylactic excision. Other scenarios requiring consideration for surgical excision include AMN that are extremely atypical in gross appearance, nevi that are documented to be changing or new, and AMN in patients for whom medical follow-up is deemed likely to be inadequate. Despite these approaches, one study reported that in patients with nonfamilial melanoma, only 18 percent of the clinically most atypical nevi show histologic evidence of AMN. [95] Adjunctive measures, such as total-body photography, dermoscopy, patient self-examination, and digital dermoscopy (see above) may improve our ability to identify lesions for surgery.

Although persons who have AMN and a personal and/or family history of melanoma appear to have a greater risk for developing melanoma than do those persons with AMN who do not have a personal or family history of melanoma, the overall management is similar. Those who have AMN should practice self-examination at least once every 1 to 2 months, using full-length mirrors and hand-held mirrors for difficult-to-examine sites. Relatives or spouses should be enlisted to assist in these examinations, particularly the posterior torso and hairy scalp. Affected individuals should be made aware of the signs of early melanoma. Patients who have AMN should be examined by a physician every 3 to 12 months, depending on the history of malignancy and number of AMN, and digital dermoscopy, where available, should be performed. Particular attention should be given to those affected patients during periods of puberty and pregnancy, because nevi may develop or change during these times. For patients who have AMN or melanoma, with or without a family history of melanoma or AMN, it is prudent to recommend examination of first-degree bloodline relatives for AMN and melanoma starting before or around puberty. Early development of melanoma has also been described in the setting of FAMMM. [96], [97] and [98] In a study of melanoma patients from 23 pedigrees, Goldstein et al. found a mean age of diagnosis to be 36 years [97] as compared to 55 years for the general melanoma population. [99]

Although visual surveillance is universally accepted as part of an ongoing melanoma prevention strategy, there are little data to document its effectiveness. In a Connecticut-based population analysis, skin self-examination, although practiced by only 15 percent of 1159 subjects, was associated with a lower rate of advanced melanoma. [100] Moreover, cutaneous melanomas detected by physicians are thinner, and presumably less life-threatening, than those detected by the patient. [101] Together, these preliminary findings suggest that surveillance of individuals with AMN, either by self-examination or by physician-directed examination, may be beneficial.

In patients with numerous AMN, it should be presumed that excessive UVR exposure, to either artificial or natural sources, may promote cellular alterations that permit the formation of new AMN, de novo melanoma, or cause progression of preexisting AMN to melanoma. Persons who have AMN should avoid sunbathing or getting red in the sun. Cover-up with tightly woven clothing and maximum sunscreen protection to body sites that cannot be covered easily should be used daily for exposed sites during any sun exposure.

Eye care given to people who have AMN is controversial. Although there are case reports and small case series reporting associations between ocular nevi and/or ocular melanoma with AMN and/or cutaneous melanoma, [102], [103], [104], [105] and [106] formal ophthalmologic recommendations do not currently exist for patients with AMN. Until there is more conclusive information, however, people who have AMN, whether or not there is a personal or family history of cutaneous melanoma, should receive the same level of eye care as that recommended for the general population.

There has also been some recent evidence that individuals from FAMMM kindreds, particularly families with germline *CDKN2A* mutations, have an increased risk of developing pancreatic cancer. [107], [108] and [109] Moreover, in a population-based analysis, Schenk et al. calculated a twofold risk in pancreatic cancer among patients who developed cutaneous melanoma prior to age 50 years. [110] These findings are still considered preliminary and currently there are no formal recommendations for pancreatic cancer screening among individuals with either familial or sporadic AMN.

Surgical excision is currently the recommended method of removing AMN. Lateral excision margins of 2 to 3 mm should be taken to ensure complete removal of AMN. Because melanoma can arise within lesions, complete histologic examination is essential to rule out melanoma. For lesions with a poorly demarcated outline, dermoscopy or a Wood's lamp (long-wave ultraviolet light) may be useful in defining borders. Incompletely excised AMN may recur and possibly

become histologically more atypical over time. Therefore, incompletely excised AMN should be considered for re-excision or close periodic examination for recurrence, depending on degree and quantity of cellular atypia. The deep excision margin of AMN should extend to below the deepest component of the lesion, which for most acquired AMN is the papillary or upper reticular dermis. Destructive modes of therapy for any melanocytic tumor will obfuscate histopathologic confirmation of a benign, intermediate, or malignant lesion.

REFERENCES

1. Elder DE et al: Acquired melanocytic nevi and melanoma, in *Pathology of Malignant Melanoma,* edited by AB Ackerman. New York, Masson, 1981, p 185

2. NIH Consensus conference: Diagnosis and treatment of early melanoma. *JAMA* **268**:1314, 1992

3. Clark WH Jr et al: Origin of familial malignant melanomas from heritable melanocytic lesions: The B-K mole syndrome. *Arch Dermatol* **114**:723, 1978

4. Lynch HT et al: Familial atypical multiple mole-melanoma (FAMMM) syndrome: Segregation analysis. *J Med Genet* **20**:342, 1983

5. Elder DE et al: Dysplastic nevus syndrome: A phenotypic association of sporadic cutaneous melanoma. *Cancer* **46**:1787, 1980

6. Reimer RR et al: Precursor lesions in familial melanoma: A genetic preneoplastic syndrome. *JAMA* **239**:744, 1978

7. Norris W: Case of fungoid disease. *Edinburgh Med Surg J* **16**:562, 1820

8. Munro DD: Multiple active junctional naevi with family history of malignant melanoma. *Proc R Soc Med* **67**:594, 1974

9. Allen AC et al: Histogenesis and clinicopathologic correlation of nevi and malignant melanomas. *Arch Dermatol Syphilol* **69**:150, 1954

10. Frichot BC 3rd et al: New cutaneous phenotype in familial malignant melanoma. *Lancet* **1**:864, 1977

11. Lynch HT et al: Familial atypical multiple mole-melanoma syndrome. *J Med Genet* **15**:352, 1978

12. Kraemer KH et al: Dysplastic naevi and cutaneous melanoma risk. *Lancet* **2**:1076, 1983

13. Nordlund JJ et al: Demographic study of clinically atypical (dysplastic) nevi in patients with melanoma and comparison subjects. *Cancer Res* **45**:1855, 1985

14. Cooke KR et al: Dysplastic naevi in a population-based survey. *Cancer* **63**:1240, 1989

15. Sander C et al: Epidemiology of dysplastic nevus [in German]. *Hautarzt* **40**:758, 1989

16. Augustsson A et al: Prevalence of common and dysplastic naevi in a Swedish population. *Br J Dermatol* **124**:152, 1991

17. Holly EA et al: Number of melanocytic nevi as a major risk factor for malignant melanoma. *J Am Acad Dermatol* **17**:459, 1987

18. Tucker MA et al: Clinically recognized dysplastic nevi. A central risk factor for cutaneous melanoma. *JAMA* **277**:1439, 1997

19. Grob JJ et al: Count of benign melanocytic nevi as a major indicator of risk for nonfamilial nodular and superficial spreading melanoma. *Cancer* **66**:387, 1990

20. Clark WH Jr et al: A study of tumor progression: the precursor lesions of superficial spreading and nodular melanoma. *Hum Pathol* **15**:1147, 1984

21. Salopek TG et al: Dysplastic melanocytic nevi contain high levels of pheomelanin: Quantitative comparison of pheomelanin/eumelanin levels between normal skin, common nevi, and dysplastic nevi. *Pigment Cell Res* **4**:172, 1991

22. Takahashi H et al: Fine structural characterization of melanosomes in dysplastic nevi. *Cancer* **56**:111, 1985

23. Rhodes AR et al: Melanosomal alterations in dysplastic melanocytic nevi. A quantitative, ultrastructural investigation. *Cancer* **61**:358, 1988

24. Greene MH et al: Familial cutaneous malignant melanoma: Autosomal dominant trait possibly linked to the Rh locus. *Proc Natl Ac ad Sci U S A* **80**:6071, 1983

25. Bale SJ et al: Mapping the gene for hereditary cutaneous malignant melanoma–dysplastic nevus syndrome to chromosome 1p. *N Engl J Med* **320**:1367, 1989

26. Nancarrow DJ et al: Exclusion of the familial melanoma locus (MLM) from the PND/D1S47 and MYCL1 regions of chromosome arm 1p in 7 Australian pedigrees. *Genomics* **12**:18, 1992

27. Cannon-Albright LA et al: Evidence against the reported linkage of the cutaneous melanoma–dysplastic nevus syndrome locus to chromosome 1p36. *Am J Hum Genet* **46**:912, 1990

28. Gruis NA et al: Locus for susceptibility to melanoma on chromosome 1p. *N Engl J Med* **322**:853, 1990

29. Cannon-Albright LA et al: Assignment of a locus for familial melanoma, MLM, to chromosome 9p13-p22. *Science* **258**:1148, 1992

30. Kamb A et al: A cell cycle regulator potentially involved in genesis of many tumor types. *Science* **264**:436, 1994

31. Nobori T et al: Deletions of the cyclin-dependent kinase-4 inhibitor gene in multiple human cancers. *Nature* **368**:753, 1994

32. Hussussian CJ et al: Germline p16 mutations in familial melanoma. *Nat Genet* **8**:15, 1994

33. Lee JY et al: Genetic alterations of p16INK4a and p53 genes in sporadic dysplastic nevus. *Biochem Biophys Res Commun* **237**:667, 1997

34. Park WS et al: Allelic deletion at chromosome 9p21(p16) and 17p13(p53) in microdissected sporadic dysplastic nevus. *Hum Pathol* **29**:127,

1998

35. Boni R et al: Loss of heterozygosity detected on 1p and 9q in microdissected atypical nevi. *Arch Dermatol* **134**:882, 1998

36. Goldstein AM et al: Two-locus linkage analysis of cutaneous malignant melanoma/dysplastic nevi. *Am J Hum Genet* **58**:1050, 1996

37. Goldstein AM et al: Linkage of cutaneous malignant melanoma/dysplastic nevi to chromosome 9p, and evidence for genetic heterogeneity. *Am J Hum Genet* **54**:489, 1994

38. Tsao H et al: Ultraviolet radiation and malignant melanoma. *Clin Dermatol* **16**:67, 1998

39. Nicholls EM: Development and elimination of pigmented moles, and the anatomical distribution of primary malignant melanoma. *Cancer* **32**:191, 1973

40. Augustsson A et al: Regional distribution of melanocytic naevi in relation to sun exposure, and site-specific counts predicting total number of naevi. *Acta Derm Venereol* **72**:123, 1992

41. Gallagher RP et al: Anatomic distribution of acquired melanocytic nevi in white children. A comparison with melanoma: The Vancouver Mole Study. *Arch Dermatol* **126**:466, 1990

42. Harrison SL et al: Body-site distribution of melanocytic nevi in young Australian children. *Arch Dermatol* **135**:47, 1999

43. Rampen FH et al: Prevalence of common “acquired” nevocytic nevi and dysplastic nevi is not related to ultraviolet exposure. *J Am Acad Dermatol* **18**:679, 1988

44. Stierner U et al: Regional distribution of common and dysplastic naevi in relation to melanoma site and sun exposure. A case-control study. *Melanoma Res* **1**:367, 1992

45. Stierner U et al: UVB-induced melanocyte proliferation and 5-S-cysteinyldopa excretion in dysplastic nevus syndrome. *Photodermatol* **5**:218, 1988

46. Noz KC et al: Comet assay demonstrates a higher ultraviolet B sensitivity to DNA damage in dysplastic nevus cells than in common melanocytic nevus cells and foreskin melanocytes. *J Invest Dermatol* **106**:1198, 1996

47. Noz KC et al: UV induction of cyclobutane thymine dimers in the DNA of cultured melanocytes from foreskin, common melanocytic nevi and dysplastic nevi. *Photochem Photobiol* **59**:534, 1994

48. Roth M et al: Thymine dimer repair in fibroblasts of patients with dysplastic naevus syndrome (DNS). *Experientia* **44**:169, 1988

49. Sanford KK et al: Hypersensitivity to G2 chromatid radiation damage in familial dysplastic naevus syndrome. *Lancet* **2**:1111, 1987

50. Caporaso N et al: Cytogenetics in hereditary malignant melanoma and dysplastic nevus syndrome: Is dysplastic nevus syndrome a chromosome instability disorder? *Cancer Genet Cytogenet* **24**:299, 1987

51. Clark WH Jr et al: The developmental biology of induced malignant melanoma in guinea pigs and a comparison with other neoplastic systems. *Cancer Res* **36**:4079, 1976

52. Gomez S et al: Melanocytic carcinogenesis in albino guinea pigs. *Pigment Cell Res* **1**:390, 1988

53. Maiweg C et al: The usefulness of single and combined clinical characteristics for the diagnosis of dysplastic naevi. *Melanoma Res* **1**:377, 1992

54. Roush GC et al: Correlation of clinical pigmentary characteristics with histopathologically-confirmed dysplastic nevi in nonfamilial melanoma patients. Studies of melanocytic nevi IX. *Br J Cancer* **64**:943, 1991

55. Tucker MA et al: Dysplastic nevi on the scalp of prepubertal children from melanoma-prone families. *J Pediatr* **103**:65, 1983

56. Sterry W et al: Quadrant distribution of dysplastic nevus syndrome. *Arch Dermatol* **124**:926, 1988

57. Misago N et al: Unilateral dysplastic nevi associated with malignant melanoma. *J Dermatol* **18**:649, 1991

58. Barnhill RL et al: Interclinician agreement on the recognition of selected gross morphologic features of pigmented lesions. Studies of melanocytic nevi V. *J Am Acad Dermatol* **26**:185, 1992

59. Meyer LJ et al: Interobserver concordance in discriminating clinical atypia of melanocytic nevi, and correlations with histologic atypia. *J Am Acad Dermatol* **34**:618, 1996

60. Marghoob AA et al: Risk of developing multiple primary cutaneous melanomas in patients with the classic atypical-mole syndrome: A case-control study. *Br J Dermatol* **135**:704, 1996

61. Kang S et al: Melanoma risk in individuals with clinically atypical nevi. *Arch Dermatol* **130**:999, 1994

62. Garbe C et al: Markers and relative risk in a German population for developing malignant melanoma. *Int J Dermatol* **28**:517, 1989

63. Greene MH et al: High risk of malignant melanoma in melanoma-prone families with dysplastic nevi. *Ann Intern Med* **102**:458, 1985

64. Halpern AC et al: Natural history of dysplastic nevi. *J Am Acad Dermatol* **29**:51, 1993

65. Pehamberger H et al: In vivo epiluminescence microscopy of pigmented skin lesions. I. Pattern analysis of pigmented skin lesions and early detection of malignant melanoma. *J Am Acad Dermatol* **17**:584, 1987

66. Hofmann-Wellenhof R et al: Dermoscopic classification of atypical melanocytic nevi (Clark nevi). *Arch Dermatol* **137**:1575, 2001

67. Kopf AW et al: Atypical mole syndrome. *J Am Acad Dermatol* **22**:117, 1990

68. Newton-Bishop JA et al: Family studies in melanoma: Identification of the atypical mole syndrome (AMS) phenotype. *Melanoma Res* **4**:199, 1994

69. Elder DE et al: The dysplastic nevus syndrome: Our definition. *Am J Dermatopathol* **4**:455, 1982

70. Clemente C et al: Histopathologic diagnosis of dysplastic nevi: Concordance among pathologists convened by the World Health Organization Melanoma Programme. *Hum Pathol* **22**:313, 1991

71. Rhodes AR et al: Dysplastic melanocytic nevi: A reproducible histologic definition emphasizing cellular morphology. *Mod Pathol* **2**:306, 1989

72. Balkau D et al: Architectural features in melanocytic lesions with cellular atypia. *Dermatologica* **177**:129, 1988

73. Barnhill RL et al: Correlation of histologic architectural and cytoplasmic features with nuclear atypia in atypical (dysplastic) nevomelanocytic nevi. *Hum Pathol* **21**:51, 1990

74. Steijlen PM et al: The efficacy of histopathological criteria required for diagnosing dysplastic naevi. *Histopathology* **12**:289, 1988

75. Barnhill RL et al: Correlation of clinical and histopathologic features in clinically atypical melanocytic nevi. *Cancer* **67**:3157, 1991

76. Kelly JW et al: Clinical diagnosis of dysplastic melanocytic nevi. A clinicopathologic correlation. *J Am Acad Dermatol* **14**:1044, 1986

77. Klein LJ et al: Histologic atypia in clinically benign nevi. A prospective study. *J Am Acad Dermatol* **22**:275, 1990

78. Piepkorn MW et al: A multiobserver, population-based analysis of histologic dysplasia in melanocytic nevi. *J Am Acad Dermatol* **30**:707, 1994

79. Kraemer KH et al: Risk of cutaneous melanoma in dysplastic nevus syndrome types A and B. *N Engl J Med* **315**:1615, 1986

80. Rhodes AR et al: Risk factors for cutaneous melanoma. A practical method of recognizing predisposed individuals. *JAMA* **258**:3146, 1987

81. Augustsson A et al: Common and dysplastic naevi as risk factors for cutaneous malignant melanoma in a Swedish population. *Acta Derm Venereol* **71**:518, 1991

82. Halpern AC et al: A cohort study of melanoma in patients with dysplastic nevi. *J Invest Dermatol* **100**:346S, 1993

83. Rigel DS et al: Dysplastic nevi. Markers for increased risk for melanoma. *Cancer* **63**:386, 1989

84. Tiersten AD et al: Prospective follow-up for malignant melanoma in patients with atypical-mole (dysplastic-nevus) syndrome. *J Dermatol Surg Oncol* **17**:44, 1991

85. Schneider JS et al: Risk factors for melanoma incidence in prospective follow-up. The importance of atypical (dysplastic) nevi. *Arch Dermatol* **130**:1002, 1994

86. Rhodes AR et al: Dysplastic melanocytic nevi in histologic association with 234 primary cutaneous melanomas. *J Am Acad Dermatol* **9**:563, 1983

87. Cook MG et al: Melanocytic dysplasia and melanoma. *Histopathology* **9**:647, 1985

88. McGovern VJ et al: Histogenesis of malignant melanoma with an adjacent component of the superficial spreading type. *Pathology* **17**:251, 1985

89. Black WC: Residual dysplastic and other nevi in superficial spreading melanoma. Clinical correlations and association with sun damage. *Cancer* **62**:163, 1988

90. Duray PH et al: Dysplastic nevus in histologic contiguity with acquired nonfamilial melanoma. Clinicopathologic experience in a 100-bed hospital. *Arch Dermatol* **123**:80, 1987

91. Gruber SB et al: Nevomelanocytic proliferations in association with cutaneous malignant melanoma: A multivariate analysis. *J Am Acad Dermatol* **21**:773, 1989

92. Marks R et al: Do all melanomas come from “moles”? A study of the histological association between melanocytic naevi and melanoma. *Aust J Dermatol* **31**:77, 1990

93. Hastrup N et al: The presence of dysplastic nevus remnants in malignant melanomas. A population-based study of 551 malignant melanomas. *Am J Dermatopathol* **13**:378, 1991

94. Kittler H et al: Follow-up of melanocytic skin lesions with digital epiluminescence microscopy: Patterns of modifications observed in early melanoma, atypical nevi, and common nevi. *J Am Acad Dermatol* **43**:467, 2000

95. Grob JJ et al: Dysplastic naevus in non-familial melanoma. A clinicopathological study of 101 cases. *Br J Dermatol* **118**:745, 1988

96. Kopf AW et al: Familial malignant melanoma. *JAMA* **256**:1915, 1986

97. Goldstein AM et al: Age at diagnosis and transmission of invasive melanoma in 23 families with cutaneous malignant melanoma/dysplastic nevi. *J Natl Cancer Inst* **86**:1385, 1994

98. Lucchina LC et al: Familial cutaneous melanoma. *Melanoma Res* **5**:413, 1995

99. Chang AE et al: The national cancer database report on cutaneous and noncutaneous melanoma. *Cancer* **83**:1664, 1998

100. Berwick M et al: Screening for cutaneous melanoma by skin self-examination. *J Natl Cancer Inst* **88**:17, 1996

101. Epstein, DS et al: Is physician detection associated with thinner melanomas? *JAMA* **281**:640, 1999

102. Rodriguez-Sains RS: Coexistent primary ocular and cutaneous melanoma. *Arch Dermatol* **130**:660, 1994

103. Bataille V et al: Five cases of coexistent primary ocular and cutaneous melanoma. *Arch Dermatol* **129**:198, 1993

104. McCarthy JM et al: Conjunctival and uveal melanoma in the dysplastic nevus syndrome. *Surv Ophthalmol* **37**:377, 1993

105. Rodriguez-Sains RS: Ocular findings in patients with dysplastic nevus syndrome. An update. *Dermatol Clin* **9**:723, 1991

106. Vink J et al: Ocular melanoma in families with dysplastic nevus syndrome. *J Am Acad Dermatol* **23**:858, 1990

107. Goldstein AM et al: Increased risk of pancreatic cancer in melanoma-prone kindreds with p16 ^{INK4} mutations. *N Engl J Med* **333**:970, 1995

108. Vasen HF et al: Risk of developing pancreatic cancer in families with familial atypical multiple mole melanoma associated with a specific 19 deletion of p16 (p16-Leiden). *Int J Cancer* **87**:809, 2000

109. Hille ETM et al: Excess cancer mortality in six Dutch pedigrees with the familial atypical multiple mole-melanoma syndrome from 1830 to 1994. *J Invest Dermatol* **110**:788, 1998

110. Schenk M et al: The risk of subsequent primary carcinoma of the pancreas in patients with cutaneous malignant melanoma. *Cancer* **82**:1672, 1998

T>

Chapter 93

Richard Langley Raymond Barnhill Martin Mihm Thomas Fitzpatrick Arthur Sober

Neoplasms: Cutaneous Melanoma

DEFINITION
EPIDEMIOLOGY AND RISK FACTORS
Incidence and Mortality Rates (Table 93-1)
Risk Factors
TUMORIGENESIS AND CAUSATION
Tumor Progression
PRECURSOR LESIONS
TYPES OF PRIMARY MELANOMA OF THE SKIN
Lentigo Maligna
Lentigo Maligna Melanoma
Superficial Spreading Melanoma
Nodular Melanoma
Acral Lentiginous Melanoma
Other Melanoma Variants
MELANOMA ARISING IN CONGENITAL NEVI
MELANOMA AND PREGNANCY
MELANOMA IN CHILDHOOD AND ADOLESCENCE
METASTATIC AND RECURRENT MELANOMA
Local Recurrences
In-Transit and Satellite Metastases
Regional Lymph Node Metastases
Distant Metastases
Late Recurrences
METASTATIC MELANOMA WITH UNKNOWN PRIMARIES
CLINICAL DETECTION OF MELANOMA
Practical Aspects
Noninvasive Clinical Techniques
Future Developments
ESTABLISHING A HISTOLOGIC DIAGNOSIS
Excision
Incisional Biopsy
Histopathologic Criteria for the Diagnosis of Melanoma
IMMUNOHISTOCHEMISTRY IN THE DIAGNOSIS OF MELANOMA
STAGING OF MELANOMA
CLINICAL AND HISTOPATHOLOGIC PARAMETERS OF POSSIBLE PROGNOSTIC SIGNIFICANCE IN MELANOMA (Table 93-7)
Prognostic Factors for Stages I and II Melanoma
Prognostic Factors for Stage III Melanoma
Prognostic Factors for Stage IV Melanoma
Melanoma and Hypopigmentation
EVALUATION FOR SUSPECTED OR NEWLY DIAGNOSED MELANOMA
History
Physical Examination
Laboratory Evaluation and Staging
MANAGEMENT
Therapy for Primary Melanoma (Table 93-9)
Elective Lymph Node Dissection
Sentinel Lymph Node Biopsy
Therapy for Regional Metastases (Table 93-10)
Therapy for Distant Metastases (Stage IV Melanoma) (Table 93-10)
FOLLOW-UP EVALUATION
REFERENCES

Cutaneous melanoma is an increasingly common, enigmatic, and potentially lethal malignancy of melanocytes. The salient challenge for clinicians is to detect and excise melanoma in its earliest stage, as tumor thickness remains the most important prognostic indicator for primary cutaneous melanoma. [1], [2] and [3] Early diagnosis and surgical excision of in situ or early invasive melanomas are curative in most patients. Despite advances in chemotherapy and immunotherapy, the success in the treatment of advanced melanoma remains limited, and the prognosis of metastatic disease is guarded.

DEFINITION

Melanoma results from the malignant transformation of melanocytes. Melanocytes are derived from the neural crest and produce melanin (see Chap. 11). During embryonic life, precursor cells, known as melanoblasts, migrate to the basal-cell layer of the epidermis and, less frequently, to the dermis and sebaceous glands. Melanoma can arise from melanocytes located in these sites and from altered melanocytes called nevus cells in certain precursor lesions.

EPIDEMIOLOGY AND RISK FACTORS

Incidence and Mortality Rates (Table 93-1)

Melanoma represents 5% of all cancers by incidence in males and 4% in females.
Estimated number of new cases in the United States for 2002: invasive melanoma: 53,600; melanoma in situ: 34,300
US lifetime risk of developing invasive melanoma: 1935:1/500; 1961:1/600; 1980:1/150; 1992:1/105; 1996:1/88; 2000:1/75; 2010:1/50. Estimated new melanoma deaths in US, 2002: 7400
Most frequent sites in whites, male: back, upper extremities
Most frequent sites in whites, female: back, lower legs
Most frequent sites in blacks and Asians: soles, mucous membranes, palms, nail beds
Frequency of melanoma by type of tumor: superficial spreading melanoma: 70%; nodular melanoma: 15%; lentigo maligna melanoma: 5%; acral and unclassified melanoma: 10%
Important features in recognition: A = symmetry; B = irregularity of borders, presence of notching; C = variegation in color and pigmentation pattern (mixtures of colors in addition to brown and tan); D = diameter >6 mm

TABLE 93-1 **Cutaneous Melanoma: Data and Facts**

The incidence of melanoma has been steadily increasing in the past several decades. This increased frequency of newly diagnosed melanomas has been seen worldwide and is in the order of 3 to 8 percent per year. This increase in incidence of melanoma has been sustained over time: in the United States, the lifetime risk of invasive melanoma developing was only 1 in 1500 in 1935; in 1960, 1 in 600; in 1992, 1 in 105; in 1996, 1 in 88; and 1 in 75 in 2000 and could reach 1 in 50 by the year 2010. [4] The American Cancer Society estimates that in 2002 alone melanoma will have developed in 87,800 Americans: 53,500 of these tumors will have been invasive and 34,300 will have been in situ. [5] Cutaneous melanoma currently represents 5 percent of all types of newly diagnosed cancer in men, and skin is the fifth most frequent site for cancer to occur overall. Cutaneous melanoma is the leading fatal illness arising in the skin; it is estimated that it will have been the cause of 7400 deaths in the year 2002. [5]

Mortality rates have also been rising over much of this century, but more slowly than incidence rates. The Surveillance, Epidemiology, and End Results Program (SEER) has documented a 32.7 percent increase in mortality rates over the period 1973 to 1995. [6] On the other hand, the overall survival rate has been improving for melanoma in the past 5 decades as a consequence of early detection. In 1940, the 5-year overall survival rate for melanoma was 40 percent. By 1975, the 5-year rate was 67 percent and data from the SEER program indicates this has increased to 88.2 percent for the period 1989 to 1994. [6]

Risk Factors

SUN EXPOSURE There is convincing evidence from epidemiologic studies that exposure to solar radiation is the major cause of cutaneous melanoma in light-pigmented populations and plays a role in the increasing incidence of this malignancy. There are at least four basic lines of evidence that support this relationship, including anatomic differences by sex, migration studies, differences by latitude of residence, and racial differences. [7] Plotting melanoma cases on anatomic models (Fig. 93-1) illustrates the concentration of melanoma on sites of sun exposure with virtual sparing of consistently covered areas. The pattern of sun exposure appears important because the distribution of melanoma by body site is not consistently related to the areas of maximal ultraviolet radiation exposure in whites, but appears to involve areas intermittently exposed. In men, the trunk, particularly the upper back, is the most common site for melanoma, whereas in women, the most frequent sites are the lower legs and the upper back (Fig. 93-1). Involvement of the head and neck is less frequent for all subtypes of melanoma apart from lentigo maligna melanoma, for which the link between long-term sun exposure and its development has been more widely accepted. Preferential involvement of sites of intermittent sun exposure has, in part, led to the supposition that for melanoma, intermittent exposure to sunlight is more carcinogenic than continuous exposure. In a critical review of the world's literature, Elwood identified 39 case-control studies involving more than 10,000 melanoma patients investigating the role of melanoma and sun exposure: 20 of these studies examined the role of intermittent exposure to sunlight, with 14 finding a significant positive association; 5 studies failed to show a major association, and 1 study identified a protective effect. [7]

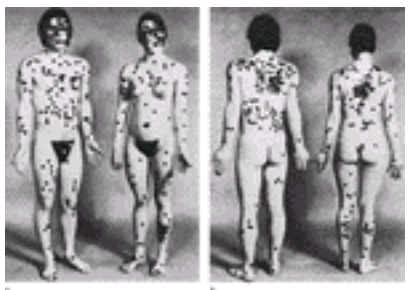

FIGURE 93-1 Anatomic site distribution of melanoma by sex in 731 males and females. (*Courtesy of the Melanoma Cooperative Group*).

Studies of immigrants to areas with higher levels of ambient solar radiation demonstrate increased rates of melanoma in the immigrants to such areas when compared with similar individuals in their native lands. [8], [9] Younger migrants to sunny climates have an increased risk for melanoma as compared with adult migrants. Holman and Armstrong noted that immigrants who migrated to western Australia prior to age 10 years have a fourfold increase in the risk of melanoma as compared with those arriving after the age of 15 years. [10] A study by Holly et al. of women with cutaneous melanoma from the western United States confirmed the importance of intense sun exposure at an early age, but also extended the risk to older ages. [11] Children who sustained frequent severe sunburns before age 12 years had a 3.6 elevated risk of developing melanoma, but sunburns even within the 10 years preceding the diagnosis of melanoma also resulted in a twofold elevation of risk. [11] Melanoma incidence and mortality among whites correlate inversely with latitude of residence and dose of ultraviolet radiation. This effect has been termed the “latitude gradient,” and increased rates of melanoma have been documented when comparing regions of different proximity to the equator in essentially similar populations such as Australia and New Zealand, the United States, and Norway. In these diverse geographic areas, the incidence of melanoma has ranged from being three- to tenfold greater in regions closer to the equator. In one Australian study higher rates were reported in the southwest as compared with the north. [9] This apparent paradoxical relationship to latitude can be resolved after controlling for racial and phenotypic features of the population. The final line of evidence in support of a role of solar radiation as a cause of melanoma arises from the differences seen between racial groups. Cutaneous

melanoma is a greater problem in light-skinned whites, [8] with the incidence of melanoma in blacks living within a similar geographic region roughly one-tenth to one-twentieth that of whites. Among whites, higher rates of melanoma occur among those who are less pigmented. Two reasons cited for the decreased rate of melanoma in darker-pigmented races are the protective effect of melanin against solar radiation and the fewer numbers of nevi that may serve as precursor lesions for melanoma. Exposure to psoralen and ultraviolet A radiation (PUVA) increases the risk of developing melanoma. The PUVA Follow-up Study is a multicenter, prospective study that evaluated a cohort of 1380 patients who first received PUVA in 1975 to 1976. In the initial report, Stern et. al. [12] documented 11 melanomas in 9 patients who had received PUVA. The relative risk increased over time: it was 1.1 in the study group from 1975 to 1990, but increased to 5.4 for the period 1991 to 1996. An update was recently published, [13] indicating that 23 patients have developed 26 invasive or in situ cutaneous melanomas since 1975. The risk increases in patients exposed to high doses of PUVA. [13] Taken together, there is compelling epidemiologic evidence that solar radiation is causally related to a significant proportion of cutaneous melanoma. Although the exact quantitative and qualitative nature of this exposure is not clear, it is probable that intermittent exposures and intense exposures with consequent sunburns in a high-risk phenotype are important. While the exact nature of the relationship remains to be precisely defined, it is certain that preventive measures regarding exposure to the sun should be recommended. Exposures to ultraviolet (UV) radiation from early in life should be reduced.

PHENOTYPE Case-control studies have identified certain phenotypic features that are associated with an elevated risk for melanoma [10] (Table 93-2). Such phenotypic features include light skin pigmentation, ease of sun burning, blond or red hair color, pale or light skin, prominent freckling tendency, and blue or green eyes.

Pigmentary characteristics
Blue eyes
Blond, fair, or red hair
Light complexion
Response to sun exposure
Freckling tendency
Inability to tan
Tendency to sunburn
Upper socioeconomic status
Family history of melanoma
p16 mutation; *BRAF* mutation
Nevi
Melanocytic nevi
Dysplastic nevi
Changing mole
Congenital nevus
History of prior melanoma
Immunosuppression

TABLE 93-2 **Risk Factors for Cutaneous Melanoma**

REACTION OF SKIN TO SUNLIGHT The manner of reaction of the skin to sun exposure (or skin phototype) is an important indicator of melanoma risk. Increased melanoma risk is associated with erythema or a tendency to sunburn on acute exposure and little or no tendency to tan with long-term exposure [10] (see Chap. 88).

OCCUPATION AND SOCIAL STATUS Multiple case-control studies have documented a relationship between higher socioeconomic status and risk for melanoma. [7] This association may be confounded by factors such as race, degree of pigmentation, greater leisure time, and tendency to take vacations in sunny locations. Elwood [7] reviewed the evidence for an increased relative risk for occupational exposure, noting conflicting results in the 18 studies reported up to 1996. In these studies, a significant increase in the risk of melanoma developing was seen in 4 of 18 cases, with a significant reduction in risk seen in 4 of 18, and no significant difference in the remainder.

FAMILIAL MELANOMA Patients with familial melanoma are estimated to account for 10 to 15 percent of all patients with melanoma. It is important to inquire about family history for relatives with melanoma, as recognition of such cases constitutes an identifiable high-risk group. Patients with at least two first-degree relatives with melanoma are at particular elevated risk. Patients with familial melanoma typically have disease onset at an earlier age, and have an increased frequency of multiple primary melanomas and of dysplastic nevi as compared with nonfamilial melanoma. Dysplastic nevi are markers for individuals at an increased risk for melanoma both in the sporadic and familial settings (see Chap. 92). Patients with familial melanoma appear to have a more favorable prognosis because of higher awareness, as they may have thinner tumors on average at the time of diagnosis. More intensive follow-up may also contribute to earlier melanoma diagnoses in familial cases. A family history of melanoma should increase the suspicion that melanoma will develop in other relatives, and reported skin examinations should be recommended for all first-degree relatives to facilitate early diagnosis. It is important to inform high-risk persons of the clinical features of early melanoma so that they will be able to recognize suspicious pigmented lesions in themselves and in family members. Genetic linkage studies have identified a familial melanoma gene on chromosome 9p21. A cyclin-dependent kinase inhibitor, p16 ^{INK4a}, has been implicated as candidate tumor-suppressor gene, and has been documented in approximately 40 percent of familial melanoma patients (see below). Future studies to determine the melanoma gene precisely may enable identification of susceptible individuals, and may identify family members who lack the gene, with different counseling, preventive, and follow-up regimens implied.

MELANOCYTIC NEVI Congenital and acquired melanocytic nevi are potential, although infrequent, precursors of cutaneous melanoma. Approximately one-third of melanomas are associated with a nevus remnant. Multiple case-control studies have documented an increased risk developing melanoma, and it is evident that there is both a quantitative and qualitative risk associated with nevi. Quantitative measures of nevi correlate directly with magnitude of melanoma risk. [14] There is also evidence that qualitative abnormalities of nevi are linked to elevated melanoma risk. [14], [15] It has been shown that the presence of clinically atypical nevi (dysplastic nevi) in individuals with familial melanoma indicates substantial risk (lifetime relative risk of 148) for melanoma (see Chap. 92). At present, the relative importance of these quantitative versus qualitative factors has not been resolved. A multicenter prospective case-control study of 716 patients with newly diagnosed melanoma and 1014 controls examined the risk of melanoma according to the number and type of nevi [15] (Table 93-2). An increased risk of melanoma was determined according to the number of nondysplastic and dysplastic nevi. In this study, the presence of a solitary dysplastic nevus doubled the risk of melanoma developing, while having 10 or more dysplastic nevi was associated with a 12-fold elevation of risk. The number of small and large

nondysplastic nevi was also associated with an increased risk of melanoma, with the presence of 50 to 99 small nevi or more than 10 large nevi conferring a doubling of risk for the development of melanoma. [15]

GENDER AND HORMONAL FACTORS The possible influence of both endogenous and exogenous hormones on the clinical course of melanoma has been a topic of long-standing interest. Much of this interest stems from several clinical observations unique to melanoma. First, melanoma is rare before puberty, suggesting that development of greater melanoma risk correlates with onset of hormonal changes. Even after adjustment for site and thickness, women still manifest a better prognosis than do men for primary cutaneous melanoma [American Joint Committee on Cancer (AJCC) stages I and II]. [16] The biologic basis of potential hormonal effects on melanoma include the well-known hyperpigmentation associated with pregnancy; elevation of many endogenous hormones during pregnancy [e.g., estrogens, androgens, melanocyte-stimulating hormone (MSH), follicle-stimulating hormone (FSH), and luteinizing hormone (LH)]; induction of melasma by oral contraceptives; and stimulation of melanoma growth in animals after administration of estrogens. There is conflicting evidence on the presence of estrogen receptors on melanoma, as studies employing specific monoclonal antibodies have either failed to verify the presence of estrogen receptors in melanoma or have detected estrogen receptors only to 30 percent of specimens. Because of the influence of sex and other hormonal factors on the course of melanoma, there has been concern about the effects of oral contraceptives on melanoma risk. Review of the studies published so far indicates that there is little, if any, evidence to indicate significant risk for the vast majority of women who have been diagnosed with melanoma and who continue to use oral contraceptives. [17]

TUMORIGENESIS AND CAUSATION

Tumor Progression

Cancer may be viewed as an inherently genetic disease with multiple stages resulting from progressive changes in DNA. These genetic alterations may result from activating mutations of proto-oncogenes, mutations or deletions in tumor-suppressor genes, gross structural changes of chromosomes, and often from all three mechanisms. [18] Aberrations of DNA may contribute not only to tumor progression, but also to alterations in expression and differentiation. Thus, in the evolutionary process from benign cells to fully malignant cells, there are likely to be many causative factors, both endogenous and exogenous, that interact and influence tumorigenesis in a cumulative fashion.

Five stages of tumor progression in the melanocytic system have been suggested based on clinical, histopathologic, immunopathologic, cytogenetic, and in vitro properties: [19] (1) benign melanocytic nevi; (2) dysplastic nevi; (3) primary malignant melanoma, radial growth phase; (4) primary malignant melanoma, vertical growth phase; and (5) metastatic malignant melanoma. It is believed that with each successive step of tumorigenesis, a new clone of cells emerges with growth advantages over the surrounding tissue, resulting in “clonal expansion.” Clark and associates postulated that a critical step in tumor progression of melanoma may be the transition from radial to vertical growth phases. [19] The radial growth phase consists of invasion of the papillary dermis by small numbers of melanoma cells that have gained a growth advantage. These cells are thought to have the capacity for autonomous proliferation in this location, but not for aggregative growth. The vertical growth phase is signaled by this property of aggregative growth, resulting in the formation of expansile nests or nodules of cells. It must be emphasized that because the metastatic cascade comprises a complex range of biochemical events, the vertical growth phase is likely to be an oversimplified correlate for the metastatic phenotype.

A discussion of tumorigenesis of melanoma must take into account several important clinical observations: (1) the association between nevi and melanoma in at least 30 percent of cases (an apparent absence of nevi in 70 percent of melanoma); (2) the role of sunlight in the pathogenesis of melanoma; (3) pigmentary phenotype of patients in whom melanoma develops; and (4) family history of melanoma and other genetic factors. In addition, the latter observations are closely related or have complex interactions. When the above observations are considered in light of the multistep process of tumor progression of melanoma, at least two major pathways of tumorigenesis can be envisaged. [20] In the first pathway, melanomas, particularly superficial spreading melanomas (SSMs), develop in association with melanocytic nevi. According to this model, nevi may represent the first stage of tumor progression of melanoma or an initiated clonal proliferation. The most likely initiating agent would be sunlight exposure, perhaps at an early age. There is epidemiologic evidence that sun exposure in the second decade may result in larger numbers of nevi. The number of precursor nevi may be important as greater numbers of initiated cells would increase the target population for another mutational event. Because UV is believed to be a complete carcinogen, sunlight exposure, perhaps of intermittent nature, could lead to this second promotional event of tumor progression. [20]

Another pathway of melanoma development is that of lentigo maligna melanoma (LMM). According to this model, this form of melanoma results from cumulative sun exposure and a corresponding cumulative insult to the DNA of melanocytes of sun-exposed skin. Lentigo maligna (LM) shows the least common association with nevi (3 percent of cases) and the most direct relationship with sun exposure among the different types of melanoma. The age-incidence rates show a steady increase with age, consistent with continuous exposure (initiation) to a carcinogenic agent such as sunlight.

GENETICS Based on the first comprehensive analysis of 22 kindreds of familial melanoma in 1967, Anderson et al. concluded that melanoma appeared to be inherited by an autosomal mechanism, possibly dominant, based on the observed frequent transmission from parent to child, irrespective of sex. [21] However, because of the variation in this mode of transmission, they also observed that inheritance was probably more complex and could involve more than one gene. A formal segregation analysis was conducted by Greene on 401 members of 14 melanoma-prone families and the results were interpreted as consistent with an autosomal dominant mechanism. [22] These studies identified a melanoma susceptibility gene on the short arm of chromosome 1 that was linked to the rhesus blood group locus. By using linkage analysis, Bale et al. later implicated the *1p36* gene on the short arm of chromosome 1p in the pathogenesis of cutaneous melanoma. [23] Subsequently, other researchers worldwide have failed to reproduce linkage to chromosome 1p, leading to controversy regarding the linkage to chromosome 1p. A tumor-suppression gene, *p16,* has been localized on

chromosome 9p [24], [25] and was identified as the possible candidate for melanoma susceptibility. This promising information was initiated by cytogenetic studies detecting homozygous and heterozygous deletions of the 9p21-p22 region in melanoma cell lines, [26] and in a patient with multiple primary melanomas and multiple atypical nevi in which cytogenetic rearrangements involving chromosome 5p and 9p were determined. [27] Linkage studies in 11 kindreds with multiple cases of primary melanoma were able initially to link genetic markers to chromosome 9p13-p22. [28] This linkage study identifying markers to the melanoma susceptibility locus to chromosome 9p was subsequently confirmed by investigators studying kindreds from Australia, Holland, Britain, and the United States. These studies were able to identify the locus to within a 2- to 3-Mb region on chromosome 9p21. Nobori et al. [25] and Kamb et al. [24] discovered by positional cloning studies that the gene *p16* is likely the tumor-suppressor gene locus on chromosome 9p21. The current nomenclature for the gene is *CDKN2A (cyclin-dependent kinase inhibitor 2A),* and the protein is referred to as p16 ^{INK4a} or INK4a (inhibitor of kinase 4a), although both the gene and protein are often referred to as p16. [29] The p16 locus encodes two gene products: *p16* and an *alternative reading frame (ARF)*. The cyclin-dependent kinase inhibitors bind and inhibit cyclin-dependent kinases, CDK4 and CDK6, which are involved in entry into the cell cycle. p16 thus functions in cell-cycle regulation, because it can bind to CDK4 or CDK6, inhibiting progression of cells through the G1 phase of the cell cycle. Mutations in p16 could allow cells to progress into S phase and result in abnormal proliferation, and ultimately neoplasia. Germ-line mutations in the p16 gene have been identified in approximately 40 percent of melanoma-prone families. [29] Penetrance studies estimate that 53 percent of individuals with a mutant allele will develop melanoma by the age of 80. [30] Other candidate melanoma susceptibility loci include 3p, 6q, 10q, 11q, and 17p. [29] Deletions in chromosome 10q are believed to be important in melanoma progression with up to 48 percent of metastatic melanomas exhibiting such deletions. Davies et al. have reported a mutation in the signaling pathway gene *BRAF,* in 66 percent of malignant melanomas. [31] This somatic missense mutation identified a new oncogene likely to play a critical role in our understanding of malignant melanoma. The high frequency of *BRAF* mutations in malignant melanoma may be related to crucial regulations of melanocytes; alpha-melanocyte–stimulating hormone and proopiomelanocortin-derived peptides. These peptides bind to melanocortin receptor I and upregulate CAMP, leading to increased proliferation and melanogenesis in response to UVB radiation. [32] This signaling cascade activates *BRAF,* thus linking a principal melanocyte signaling pathway controlling proliferation and differentiation that operates through activation of *BRAF*. The product of the mutated *BRAF* gene has elevated kinase activity and is transformed in NIH3T3 cells. Inhibiting the kinase may be an important new strategy in the treatment of metastatic melanoma. [31]

PRECURSOR LESIONS

Cutaneous melanoma may arise in a preexisting melanocytic lesion or de novo, in previously normal skin. A preexisting lesion is considered a precursor, implying a temporal and spatial relationship. [33] Such a lesion may occur prior to and at the site of a malignancy. Dysplastic nevi may be precursors and markers of increased risk for cutaneous melanoma (see Chap. 92). Recognition of precursors can facilitate surveillance of a high-risk population for early diagnosis of curable melanomas.

TYPES OF PRIMARY MELANOMA OF THE SKIN

Melanoma can be classified into four main growth patterns, which are defined by their gross and microscopic characteristics and correlated with their life history (Table 93-3). The four major growth patterns of melanoma are termed *lentigo maligna, superficial spreading, nodular,* and *acral lentiginous melanoma*.

TABLE 93-3 **Comparisons of Clinical Features of Cutaneous Melanoma**

Lentigo Maligna

CLINICAL CHARACTERISTICS LM is a type of melanoma in situ with a prolonged radial growth phase that may eventuate into invasive melanoma. Once invasive, LM can be lethal. LM is a macular, freckle-like lesion of irregular shape, with differing shades throughout that occurs on sun-exposed surfaces, most often in elderly patients with sun-damaged atrophic skin (Fig. 93-2A). Irregular mottling or flecking may appear as the lesion enlarges. LM grows by spreading radially, increasing in size, and assuming a variety of irregular shapes (Fig 93-2B). The exact percentage of LM that progress to LMM is unknown. [34] The lifetime risk of LMM developing from LM is estimated to be 4.7 percent at 45 years of age and 2.2 percent for a person 65 years old. [35]

FIGURE 93-2 Lentigo maligna and lentigo maligna melanoma. *A.* Lentigo maligna displays prominent asymmetry with irregular borders and variegation of pigmentation. *B.* Extensive lentigo maligna melanoma with large nodules (vertical growth phase) on the face of a patient.

HISTOPATHOLOGY The histopathology of LM is characterized by an atrophic epidermis with thinning and loss of rete ridges, containing increased numbers of atypical basilar melanocytes (Fig. 93-3). These melanocytes vary in appearance, size, and shape, and have nuclei of different sizes that are variably hyperchromatic. The cytoplasm of these cells, which is usually retracted about the nucleus leaving a space between the cell borders and adjacent melanocytes, is pink to purple to red-brown and irregularly granular. These cells may extend down hair follicles and skin appendages, making the lesion difficult to eradicate by superficial therapies. A mononuclear cell infiltrate is characteristically present in the superficial lesions below the proliferated melanocytes. The dermis shows elastotic changes of the connective tissue from long-term sun damage. Diagnosis can usually be established by biopsy of the darkest portion. Occasionally, the histopathology will not be diagnostic, and either rebiopsy or repeat biopsy over time with close observation will be necessary.

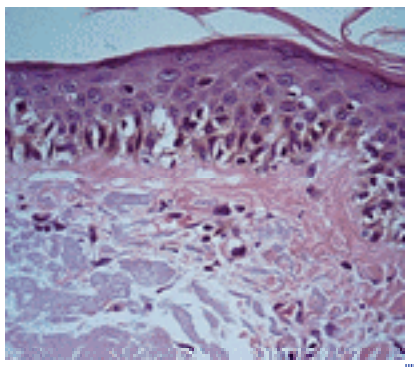

FIGURE 93-3 Lentigo maligna. This is a proliferation of pleomorphic melanocytes in the basal cell layer of an atrophic epidermis in sun-damaged skin.

Lentigo Maligna Melanoma

CLINICAL CHARACTERISTICS (Table 93-3) LMM is the least-common type of melanoma (usually 4 to 15 percent of all melanoma patients), although a rising incidence has been reported. [34] LMM is almost exclusively located on sun-exposed skin of the head and neck, with the nose and cheeks the most common sites. Occasionally, LMM may be found on the dorsal aspect of the hands, the lower legs, or, rarely, at other sites. LMM occurs in an older age group, with a median age at diagnosis of approximately 65 years old; it is uncommon before the age of 40 years (Fig. 93-4). [36] Frequently the lesion is quite large (3 to 6 cm or larger), although its nodular portion may vary from only a few millimeters to 1 to 2 centimeters in width (Fig 93-2B). The colors in flat areas include tan, brown, black, and, at times, opalescent blue-gray and white. Brown areas may exhibit dark flecks in a black reticular pattern. Regression may be present in blue-gray or white areas (Fig 93-2B). Rarely, LM and LMM can be amelanotic. LMM can have extremely convoluted borders with prominent notching. LMM is usually flat, especially in early lesions, and palpability usually indicates invasive melanoma, although clinical examination may be unreliable in early invasive LMM (<1 mm) (Fig. 93-2A).



FIGURE 93-4 Age distribution by type of melanoma. Superficial spreading (SSM), nodular (NM), and lentigo maligna (LMM) melanomas. (*Melanoma Clinical Cooperative Group data, 1978.*)

HISTOPATHOLOGY LMM is characterized histologically by extensive variation in the morphologic features of the intraepidermal melanocytes in the tan, brown, and flat black portions of the lesion. Tan areas demonstrate an increased number of melanocytes, some normal, others larger than normal, and others frankly atypical and bizarre, all distributed along the basal layer (Fig. 93-5). In the flat black areas, numerous melanocytes, with variable morphologic character, apparently replace the basal layer and form a sheet along the dermal–epidermal interface, with keratinocytes above it and the papillary layer of the dermis below it. Marked hyperpigmentation and some atrophy of the keratinocytic epidermis accompany the extensive hyperplasia of atypical melanocytes along the dermal–epidermal interface. The papillary dermis usually contains a dense infiltrate of lymphocytes and macrophages laden with melanin. At certain places in the dermis, invading malignant melanocytes are present and form large nests; these nests correspond to clinically detectable

nodules (Fig. 93-6).

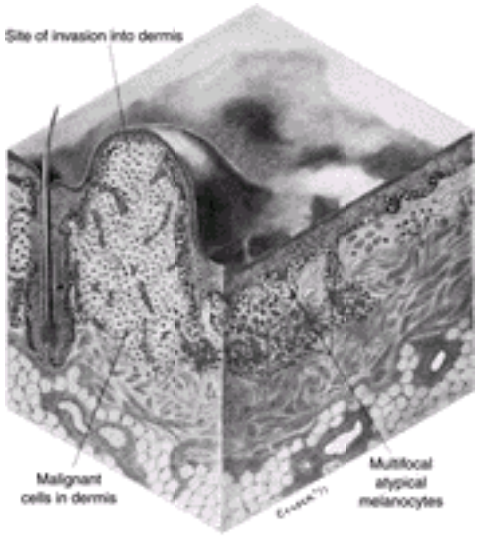

FIGURE 93-5 Lentigo maligna melanoma. Illustrated is a large, variegated, freckle-like macule (not elevated above the plane of the skin) with irregular borders; the tan areas show increased numbers of melanocytes, usually atypical and bizarre, and distributed single file along the basal layer; at certain places in the dermis, malignant melanocytes have invaded and formed prominent nests. At the left is a large nodule that is composed of epithelioid cells in this illustration; the nodules of all four types of melanoma are indistinguishable from each other.

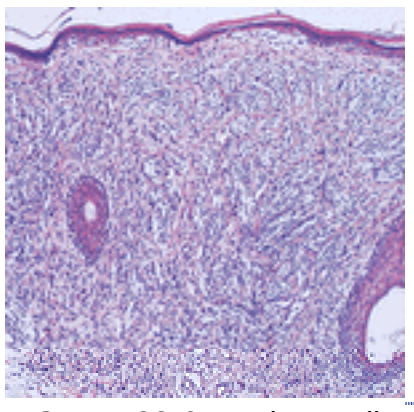

FIGURE 93-6 Lentigo maligna melanoma. Extending from the epidermis into the dermis are numerous elongated melanocytes. In LMM these cells are frequently spindle-shaped.

Superficial Spreading Melanoma

CLINICAL CHARACTERISTICS (Table 93-3) SSM represents approximately 70 percent of all melanomas and is the most common type of cutaneous melanoma. SSM most commonly occurs on the legs of women and the upper backs of men, although it can occur at any site. SSM is diagnosed most commonly in the fourth and fifth decades. Various clinical presentations of SSM are shown in Fig. 93-7, Fig. 93-8, and Fig. 93-9. SSM may present as a deeply pigmented macule or barely raised plaque, and initially the fine skin markings may remain intact. The earliest change in a SSM may be a discrete, focal area of darkening within a preexisting nevus. Pigment variegation of SSM involves a mixture of colors, ranging from a dark brown to black to dark blue-gray to a pink or gray-white color (Fig. 93-7 and Fig. 93-8). The placement of the different colors is haphazard. The absence of pigmentation within a SSM may represent regression and can be more readily identified with a Wood lamp (long-wave ultraviolet) as a hypopigmented area. As the lesion grows, the surface may appear glossy. The borders of SSM may be irregular with angular indentations (notches) or scalloping (Fig. 93-7 and Fig. 93-8), particularly with enlargement of the SSM. The lesion throughout varies from slightly to definitely elevated (Fig. 93-7, Fig. 93-8, and Fig. 93-9).

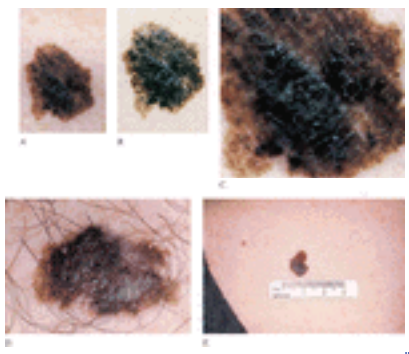

FIGURE 93-7 Superficial spreading melanoma. Photographs illustrate the importance of close examination of cutaneous lesions. *A.* One sees the lesion as it would appear to an examiner standing far enough from the patient to include a substantial portion of the body in his or her visual field. Note the notch at 6:30 o'clock. *B.* Close-up view, still with the naked eye, in which pigmentation becomes more obvious. *C.* Under a handheld lens (× 7), bluish coloration and irregular surface typical of melanoma becomes obvious. (*From Hospital Practice, January 1982, with permission*.) *D.* De novo SSM on the back of the thigh, level III (0.49 mm). A classic presentation: There is a pigmented plaque in which all the borders of the lesion are elevated with a central thicker portion. The lesion has the five cardinal features of a superficial spreading melanoma: asymmetry, irregular and scalloped border, mottled color, large diameter, and elevation with surface distortion. *E.* The upper tan portion of the lesion is a dysplastic nevus, and on the lower portion is a blue-black plaque, which is the superficial spreading melanoma.

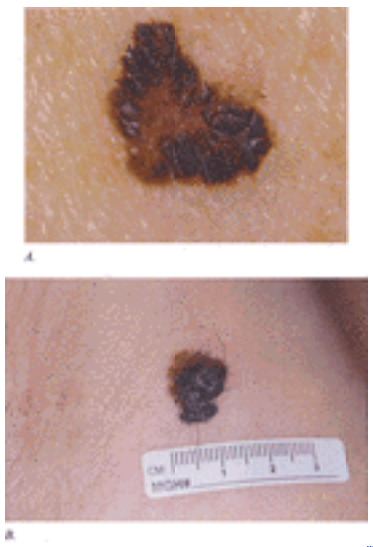

FIGURE 93-8 “ABCD's” of melanoma. The two lesions (*A* and *B*) shown here are SSMs: *A, asymmetry:* the melanoma is not symmetrical. Also note the irregular border. *B, border:* note the highly irregular, uneven, and notched border. *C,* color: the color is variegated with different shades of brown, black, tan. *D, diameter:* the diameter is usually >6 mm in melanomas. This does not mean that a melanoma cannot be smaller but, except for atypical (dysplastic) nevi, acquired nevi are usually not >5 mm in diameter.

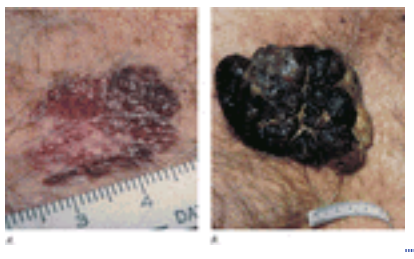

FIGURE 93-9 Superficial spreading melanoma. *A.* Lesion had been documented 4 years earlier with biopsy; patient refused treatment. *B.* Three years later, shortly before patient died of metastatic melanoma.(*Courtesy of HC Maguire, Jr, MD.*)

HISTOPATHOLOGY SSM is characterized by a population of melanocytes appearing uniformly atypical; the striking melanocytic pleomorphism so characteristic of LMM is not usually seen. Biopsy of a slightly raised, hyperpigmented portion of SSM reveals a “pagetoid” distribution of large melanocytes throughout the epidermis (Fig. 93-10 and Fig. 93-11). The large cells may occur singly or in nests and have a monomorphous appearance. On microscopic examination, biopsies of markedly nodular areas of SSM reveal dense accumulations of malignant cells in the dermis. In areas of invasion, large melanocytes are observed. These large cells have an abundance of cytoplasm containing regularly dispersed, fine particles of melanin; the dusty appearance of the cells, when viewed with the microscope, is the result of these numerous granules.

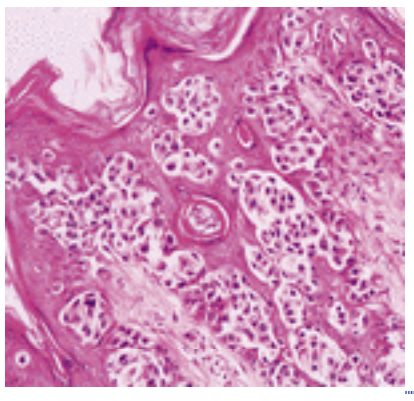

FIGURE 93-10 Superficial spreading melanoma. This tumor shows intraepidermal growth. In this photomicrograph, the pagetoid distribution is evident in the epidermis. The cells are relatively uniform and have an abundance of dusty, fine pigment. These relatively large melanoma cells are frequently referred to as epithelioid cell type.

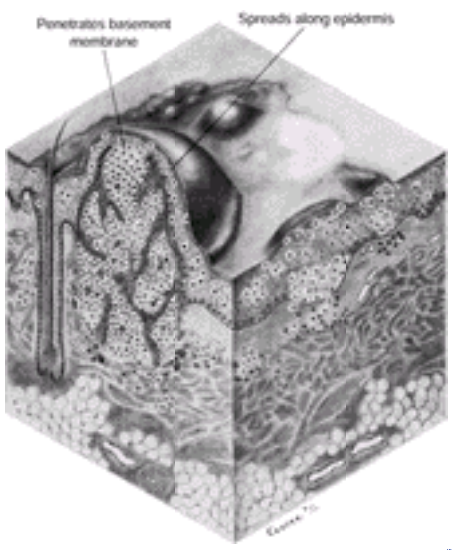

FIGURE 93-11 Superficial spreading melanoma. The border is irregular and the lesion is elevated throughout its entirety; biopsy of the area surrounding the large nodule shows a “pagetoid” distribution of large melanocytes and are occurring singly or in nests, and uniformly atypical. On the left is a large nodule, and scattered throughout the surrounding portion of the nodule are smaller papular and nodular areas. The nodule on the left shows malignant melanocytes that are very

large, have an abundance of cytoplasm, and often have regularly dispersed fine particles of melanin. The nodules may also show spindle cells or small malignant melanocytes as in lentigo maligna melanoma and nodular melanoma.

Nodular Melanoma

CLINICAL CHARACTERISTICS (Table 93-3) The second most common subtype of melanoma is nodular melanoma, with a frequency of 15 to 30 percent of all types. The trunk, head, and neck are the most frequent anatomic sites for nodular melanoma (NM). NM is remarkable for its rapid evolution, often arising over several weeks or months. NM lacks an apparent radial growth phase. It is more common for NM to begin de novo in uninvolved skin than to arise in a preexisting nevus. NM typically appears as a uniform dark blue-black, bluish-red, or amelanotic papule or nodule, but can present as a polypoid lesion with a stalk. [36] NM may appear as a blueberry-shaped nodule with a thundercloud-gray appearance (Fig. 93-12A). Early recognition of NMs can be difficult because they lack many of the conventional clinical features of melanoma. In certain cases, it may be difficult to discriminate between NM and hemangioma, pyogenic granulomas, blue nevus, eccrine poroma, and pigmented basal cell carcinoma on clinical examination (see Fig. 93-12B and Fig. 93-12C).

FIGURE 93-12 Nodular melanoma. *A.* The lesion consists of a blue-black nodule with scale crust on the surface. *B.* This is a mushroom-shaped 1.5-cm, partially red, otherwise brown, firm tumor, round and sharply demarcated. *C.* This 69-year-old patient presented with an asymptomatic red papule on her right pretibial area. This lesion is an amelanotic nodular melanoma, 2.9 mm in depth, invasive to anatomic level IV. (*From Langley RGB et al.,* [36] *with permission.*)

HISTOPATHOLOGY NM demonstrates little tendency for intraepidermal growth. The epidermis lateral to the areas of invasion do not contain atypical melanocytes. Consequently, invasion of the dermis conjointly with any area of intraepidermal invasion is inherent in the concept of NM (Fig. 93-13). This tumor may show large epithelioid cells, spindle cells, small cells, or mixtures of the different cells (Fig. 93-14).



FIGURE 93-13 Nodular melanoma. This tumor arises at the dermal–epidermal junction and extends vertically into the dermis; intraepidermal growth is present only in a small group of tumor cells that conjointly are also invading the underlying dermis. The epidermis lateral to the areas of this invasion does not demonstrate atypical melanocytes. As in lentigo maligna melanoma and superficial spreading melanoma, the tumor may show large epithelioid cells, spindle cells, small malignant melanocytes, or mixtures of all three.

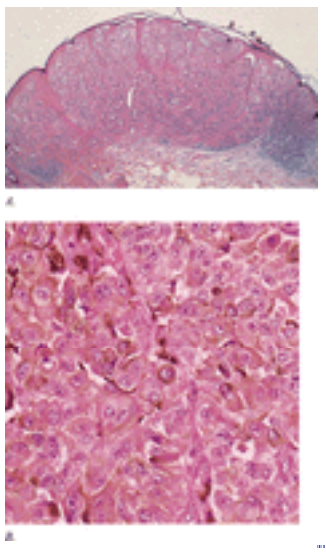

FIGURE 93-14 Nodular melanoma. *A.* Low-power photomicrograph demonstrating a dome-shaped expansile tumor located in the upper dermis. *B.* High-power photomicrograph reveals nests of anaplastic epithelioid cells in the tumor.

Acral Lentiginous Melanoma

CLINICAL CHARACTERISTICS (Table 93-3) Distinct differences in the frequency of acral lentiginous melanoma (ALM) are seen between racial groups. ALM is relatively infrequent in light-skinned whites (only 2 to 8 percent of melanomas) but represents the most common form in darker-complected individuals (constitutes 60 to 72 percent in blacks, and 29 to 46 percent in Asians [36]. Although darker-pigmented patients have a greater proportion of ALM than other types of melanoma, the incidence of ALM is similar between different ethnic groups. ALM occurs on the palms, soles, or beneath the nail plate, with the sole being the most common site. Not all plantar or palmar melanomas are ALMs; a minority are SSMs or NMs. This subtype is usually diagnosed in older age groups, with a median age at onset of 65 years. ALM is characterized by a tan, brown to black flat lesion with variegations in color and with irregular borders (Fig. 93-15 and Fig. 93-16). Papules or nodules are often present. ALMs that have a flesh-colored appearance can be misdiagnosed as a benign lesion such as a clavus, verruca, or pyogenic granuloma (Fig. 93-16B). ALM is considered more aggressive with an associated poorer prognosis; however, this may be a result of late diagnosis of more advanced disease rather than a true difference in biologic nature of the tumor. Early biopsy of suspected lesions is recommended to avoid such delays in the diagnosis.

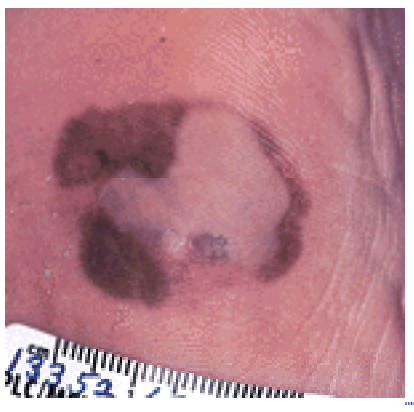

FIGURE 93-15 Acral lentiginous melanoma. The lesion is almost entirely macular and exhibits marked irregularity of color. A large confluent central area has a bluish-gray appearance, indicating regression.

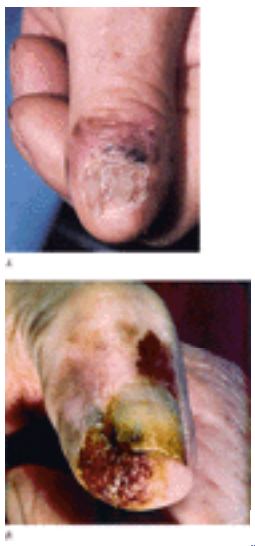

FIGURE 93-16 ALM on the thumb. *A.* Extensive involvement of periungual skin (Hutchinson's sign). There is dystrophy and loss of the nail plate secondary to the tumor. *B.* Subungual melanoma. The initial radial growth phase is evident in the periungual skin with blotchy, cloudy macules of various shades of light to dark brown, some ill-, some sharply defined and with irregular borders. There is white, blue, and black close to the ulcerated, nonpigmented subungual tumor (vertical growth phase).

Subungual melanoma is an uncommon type of cutaneous melanoma and is often considered a variant of the acral lentiginous subtype. The majority of subungual melanomas involve the great toe or the thumb (Fig. 93-16). An early subungual melanoma may be recognized as a brown to black discoloration in the nail bed, usually at a proximal location. Hutchinson's sign is the finding of pigmentation of the posterior nail fold and has been considered an ominous finding associated with advanced subungual melanoma (Fig. 93-16A). Benign lesions that can mimic subungual melanoma include longitudinal melanonychia, subungual hematoma, onychomycosis, paronychia, ingrown toenail, nevus, or

pyogenic granuloma. Subungual hematomas may appear as sharply localized, black, maroon, or multicolored lesions, often within the nail bed or matrix. These lesions are often acutely painful, and a history of trauma at the site can usually be obtained. If the diagnosis is uncertain and the lesion is of recent onset, a diagnostic and therapeutic procedure involves piercing the nail with a large-bore needle to release the blood.

HISTOPATHOLOGY The macular areas exhibit basilar proliferation of large melanocytes with large nuclei showing atypical chromatin patterns. The cytoplasm is filled with melanin granules, and there are elongated dendrites that may extend to the granular cell layer (Fig. 93-17). In the papular or nodular areas, malignant melanocytes are frequently spindle-shaped and extend into the dermis. As discussed below, desmoplastic–neurotropic patterns of the invasive component are frequently associated with ALM.

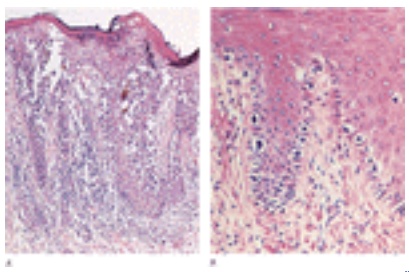

FIGURE 93-17 Acral lentiginous melanoma. *A.* Photomicrograph showing hyperkeratosis associated with plantar location of this melanoma. Fibrosis and patchy host response are noted in the dermis. *B.* High-power photomicrograph showing lentiginous proliferation of abnormal melanocytes along the dermal–epidermal junction.

Other Melanoma Variants

MELANOMA OF THE MUCOSA Melanoma infrequently can arise from mucosal surfaces. The most common sites are the mucosal surfaces of the head and neck (typically involving the nasal and oral cavity) and vulva or anorectal mucosa. Patients may present with bleeding at these sites or with a mass lesion but most often with a deeply pigmented, irregular mucosa. Melanoma of the mucosa may occur with or without a radial growth phase. The intraepithelial growth phases of malignant melanomas of the vulva and of the conjunctiva can be divided into three subtypes: a pagetoid pattern, which shows the typical characteristics of SSM of the skin; a lentiginous pattern, which shares some features with LM and ALM; and a mixed pattern, in which a profusion of nests of malignant, often ovoid, cells is admixed with a lentiginous proliferation. LM of the eyelid can involve the conjunctiva and is similar to lentiginous melanocytic hyperplasia of the conjunctiva, without LM, occurring on the palpebral or cutaneous surface. The two lesions, therefore, cannot be distinguished histologically.

DESMOPLASTIC–NEUROTROPIC MELANOMA Desmoplastic melanoma is a rare subtype of melanoma that is locally aggressive with high rates of local recurrence. Desmoplastic melanoma most commonly develops in sun-exposed skin of the head and neck region of elderly individuals, usually in the sixth or seventh decade. Desmoplastic melanomas are variants of invasive melanoma that may arise in association with LM, ALM, and mucosal lentiginous melanoma, as well as de novo. Thus, on clinical examination, one may observe a pigmented macule with or without a nodular component, or a flesh-colored nodule without any surrounding pigmentation. Typically, the latter lesions have a firm, sclerotic or indurated quality. Histologically, desmoplastic melanoma appears as a nodule of fibrous tissue containing hyperchromatic cells that either are scattered singly, lie in fascicles, or aggregate in nests. Variable degrees of mucin deposition may also be present. Interspersed throughout a dense collagenous tissue are fascicles of hyperchromatic melanoma cells, most often spindle-shaped. Many resemble irregularly shaped fibroblasts. Macrophages filled with melanin may be scattered throughout the dense collagenous tissue. In general, desmoplastic melanomas have a propensity to infiltrate the perineurium and endoneurium of the cutaneous nerves. The large nerves may have thickened perineurium populated by hyperchromatic cells. Endoneurial involvement usually consists of hypercellularity, with an increase in the size and pleomorphism of the cells. The term *neurotropic melanoma* applies to a subset of desmoplastic melanomas in which the constituent cells, in addition to showing prominent infiltration of nerves, form patterns that resemble nerves or neuroidal structures. [36] The result is a florid proliferation of cells, often with wavy configurations, running parallel to one another, associated with a fibrous response. The differential diagnosis includes morpheaform (desmoplastic) basal cell carcinoma, desmoplastic nevus, sclerosing variants of blue nevus, scar, fibrous histiocytoma, fibromatosis, atypical fibroxanthoma, malignant fibrous histiocytoma, neurothekeoma, and malignant peripheral nerve sheath tumors (see Chap. 102 and Chap. 107). Helpful features in recognizing desmoplastic malignant melanoma are the usual clinical setting: sun-exposed skin of the head and neck of an elderly individual, an intraepidermal lentiginous melanocytic proliferation, and the presence of cytologic atypia of dermal spindle cells with mitoses. Immunohistochemistry (see below) is usually quite helpful as the tumors are almost always immunoreactive with S-100 protein and vimentin. However, many tumors are negative for HMB-45. Electron microscopy may not be useful because the spindle cells frequently do not contain melanosomes and may have characteristics of fibroblasts or peripheral-nerve sheath cells. Most desmoplastic melanomas are deeply invasive at the time of diagnosis. The natural history of these tumors is that of a propensity to local recurrence, frequently multiple, followed by regional metastasis in a smaller subset of cases. The lesions may also exhibit deep local invasion and, when located on the head, even into the skull, result in death.

MELANOMA ARISING IN CONGENITAL NEVI

Congenital nevi are recognized potential precursors of melanoma, although the degree of risk is contentious depending on the size of the lesion (see Chap. 91). Specifically, there is convincing evidence that large congenital melanocytic nevi (LCMN) have a significant risk of malignant transformation. Many series arbitrarily define large congenital nevi as greater than 20 cm; however, they have also been defined by area or by ease of surgical excision (inability to close the surgical defect primarily and requiring a skin graft).

Exact quantification of the risk of melanoma developing within a congenital nevus is problematic in that there are a number of methodologic shortcomings of many of the studies reported thus far. Current estimates are in the order of 5 to 42 percent; however, a figure of 6 percent is widely quoted based on a study that estimated the risk from a questionnaire follow-up of patients from the Danish Registry of patients with congenital nevi. [37] A prospective study examining patients

from the New York University Registry of LCMN, [38], [39] including a review of the world's literature, identified 34 patients with primary cutaneous melanoma in 289 cases of LCMN. [38] Primary cutaneous melanoma developed in 50 percent (17 of 34) of patients before 5 years of age, and 62 percent (21 of 34) died from the disease at a median age of 7.1 years. In general, about half of melanomas developing in giant nevi reportedly do so in the first 3 to 5 years of life compared to malignant transformation after puberty for smaller nevi. In addition to the 34 patients in whom melanoma developed within LCMN, 21 patients had primary melanoma in the central nervous system, and 10 had primary cutaneous melanoma outside the LCMN. In an update of the New York University series, 160 patients were followed prospectively for an average of 5.5 years, with 3 melanomas developing in extracutaneous sites (2 in the central nervous system and 1 retroperitoneally). [39] The cumulative 5-year life table risk for developing melanoma was 2.3 percent, and the relative risk was 101. No melanomas were reported within a LCMN. Four patients developed neurocutaneous melanosis, two of whom had central nervous system melanoma.

MELANOMA AND PREGNANCY

The impact of pregnancy on the clinical course of melanoma, whether melanoma is diagnosed concomitantly with, after, or prior to a pregnancy, is uncertain and a source of controversy in the literature. Initial case reports documented a precipitation of melanoma during pregnancy and an overall deleterious effect on the tumor and a fulminant course. Other reports have documented a favorable or protective influence of previous or multiple pregnancies on melanoma. These studies have a number of methodologic shortcomings: many of the previous studies were small; included heterogeneous assortments of patients (e.g., women pregnant before, in some instances many years before, during, or after melanoma); had failed to control for thickness and anatomic site; or were uncontrolled altogether. Critical reviews of the literature on this subject have examined those studies in which the data fulfill more stringent criteria. [40] Driscol et al. [40] noted that of five controlled studies examining this issue none demonstrated a deleterious effect on survival. Two of the studies, however, identified a shorter disease-free survival in pregnant patients. The effect of prior pregnancies on the prognosis of melanoma has also been examined, and there appears to be no adverse effect on prognosis of patients in whom melanoma developed after the woman completed a pregnancy. In fact, one study found an improved survival rate of women with five or more pregnancies after controlling for major prognostic factors. A limited number of controlled studies also suggest that a melanoma developing prior to a pregnancy does not effect the prognosis of a women subsequently diagnosed with melanoma in comparison with controls. [40]

Thus, accumulating data suggest that pregnancy does not affect outcome from melanoma. Based on the evidence to date, women considering pregnancy after melanoma develops should be counseled on prognosis based on standardized microstaging of melanoma (i.e., with tumor thickness and ulceration as the predominant determinant of prognosis for primary cutaneous melanoma). Many authors advise that women delay pregnancy for at least 2 years in order to avoid the period of greatest risk for recurrence. Such advice, however, should be tailored to the risk of recurrence and is most appropriate for women with higher risk primary (thick or ulcerated) lesions, or those with more advanced disease. We do not routinely recommend avoiding pregnancy for any period in women with thin primary melanomas.

MELANOMA IN CHILDHOOD AND ADOLESCENCE

Melanoma in childhood and adolescence is rare, accounting for approximately 1 to 4 percent of all newly diagnosed melanomas in patients younger than 20 years of age, and 0.3 to 0.4 percent in prepubertal children. [41] Melanoma can develop in a congenital setting due to transplacental spread, or melanomas may arise de novo or in association with a large congenital nevus. A rare but grave presentation of congenital melanoma is that of neurocutaneous melanosis, which is characterized by multiple nevi with meningeal melanosis and melanoma. Particular risk factors for melanoma in childhood include the presence of congenital nevi (Chap. 91), dysplastic nevi (Chap. 92), xeroderma pigmentosum (frequency of melanoma in children is 2000 times greater than it is in children without xeroderma pigmentosum; see Chap. 155), hereditary melanoma, and neurocutaneous melanosis. Immunosuppression may also be relevant in elevating the risk for melanoma.

METASTATIC AND RECURRENT MELANOMA

Approximately 15 to 36 percent of patients with stages I and II melanoma have some form of recurrence or metastasis during their clinical course. Melanoma typically recurs or metastasizes in a stepwise manner. These steps consist of local recurrences, regional metastases, and, finally, distant metastases.

Local Recurrences

A local recurrence is currently defined as any recurrence in close proximity to the surgical scar for primary cutaneous melanoma. A lack of uniformity of a definition exists in the literature: some authors define local recurrence as occurring within the scar, while others include recurrence within 2 cm of the site of the definitive surgical excision scar, recurrences up to 5 cm, and even regional metastatic disease.

Restricting the definition to the distance from the surgical scar is based on the understanding that there is a biologic difference between a local recurrence, which is believed to develop as a result of a failure of the initial local treatment to remove tumor, from that of local metastasis with intralymphatic spread. Based on such understandings of the pathophysiology of recurrent melanoma, a case can be made to restrict the definition to recurrences within the scar. It is difficult to estimate the incidence and prognosis in local recurrences from the literature because of the lack of a consistent definition in the past. The reported frequency of local recurrence is approximately 3 percent, and is related to tumor thickness, with increased rates in patients with thicker primary lesions. Karakousis et al. reported in a multi-institutional randomized surgical trial a local recurrence rate of 2.3 percent for melanomas between 1.0 and 2.0 mm thickness, and 11.7 percent ($p = .001$) in tumors 3.01 to 4.0 mm in thickness. [42] Lesions without ulceration had a local recurrence rate of 1.5 percent, whereas higher local recurrence rates were seen with the presence of ulceration in 10.6 percent ($p = .001$). Local recurrence has historically been associated with a poorer prognosis, and has been considered

an indicator of disseminated disease. Karakousis et al. reported that 82 percent of patients with local recurrence died from their disease. [42] A population-based study from Sweden that used strict diagnostic criteria for local recurrence, including only those cases with recurrence in the scar, identified a lower frequency of recurrences: only 1.3 percent (48 of 3706) of patients followed over a period of approximately 20 years. [43] The 5-year disease-free survival rate in patients with local recurrence in this study was 69 percent and the melanoma-specific survival rate was 83 percent, which is favorable in comparison with those reported in the literature. [43] The relatively favorable prognosis reported in this study is likely a result of the strict definition of local recurrence, including only those cases with recurrence in the surgical scar and discriminating such cases from in-transit metastases, which biologically represent intralymphatic spread and potentially more widespread disease.

In-Transit and Satellite Metastases

In-transit metastases are currently defined as small tumor emboli within the dermal and subdermal lymphatics between the primary tumor and the regional lymph node basin. In the revised AJCC staging system (see below) in-transit and satellite metastases have been grouped in the same subclassification (N2c). [44] Patients with intralymphatic metastases but no nodal metastases are recognized as having a similar prognosis, and are thus grouped together. Clinically, the lesions are generally multiple, relatively small dermal or subcutaneous nodules, bluish in color or amelanotic. Large lesions are frequently ulcerated.

Regional Lymph Node Metastases

The presence of regional nodal disease is highly predictive of visceral metastases. The risk of regional node metastasis varies by primary tumor thickness (see below): patients with melanomas that are <0.76 mm, 0.76 to 1.49 mm, 1.5 to 4.0 mm, and >4.0 mm have nodal metastases at 3 years in 2 to 3 percent, 25 percent, 57 percent and 62 percent, respectively.

Distant Metastases

Melanoma is well known for its propensity to metastasize to virtually any organ and also for its highly variable clinical course. Nevertheless, melanoma does have certain patterns of metastasis that enable the clinician to manage the disease with some degree of confidence. Melanoma spreads most frequently to nonvisceral sites: skin, subcutaneous tissue, and distant lymph nodes in about 42 to 57 percent of cases. Visceral metastases to the lungs (18 to 36 percent), liver (14 to 20 percent), brain (12 to 20 percent), bone (11 to 17 percent), and intestines (1 to 7 percent) are the next most common sites. [46]

Late Recurrences

The incidence of late recurrence (10 or more years after initial diagnosis and treatment) among melanoma patients is approximately 0.93 to 6.7 percent. The largest series to date involved 7104 patients with melanoma, including 168 patients with late recurrences. [47] This study reported that most of the primary tumors were in the intermediate thickness category (mean thickness, 1.6 mm; range, 0.34 to 6.3 mm) with very few lesions <0.70 mm or >3.0 mm. The mean time to recurrence was 14.3 years for patients having recurrences after 10 years. Another retrospective review of 2766 melanoma patients identified 20 patients with “ultra late” recurrence, defined as recurrences after at least 15 years of disease-free survival. [48] Virtually all tumors were between 0.8 and 2.3 mm in thickness and Clark levels III to IV, and recurred an average of 19 years after initial diagnosis and treatment.

METASTATIC MELANOMA WITH UNKNOWN PRIMARIES

Metastatic melanoma with no known primary site is defined by the presence of histologically confirmed regional lymph node or distant metastases in an individual without a history or evidence of a primary cutaneous, mucosal, or ocular melanoma. This situation occurs in approximately 2 to 6 percent of all melanoma cases. Such metastases involve the lymph nodes in approximately two-thirds of cases, and one-third spread to distant sites, typically the subcutaneous tissue, lung, or brain. In one large series, such patients comprised 4.8 percent of all cases of melanoma, and patients presented with regional lymph node metastases (64 percent) versus distant spread to visceral (21 percent) or nonvisceral (e.g., subcutaneous) sites (15 percent). Most regional lymph node metastases involved the axillae followed by the inguinal nodes. The most frequent sites of visceral metastasis were the lung (54 percent), brain (20 percent), and gastrointestinal tract (13 percent). [49]

The evaluation of such a patient must involve a complete history and a physical examination that includes a thorough Wood lamp examination of the entire skin surface for hypopigmented areas that might suggest a regressed primary lesion, particularly in the areas of regional lymph node drainage. In patients presenting with regional node involvement, particular attention should be focused on areas that drain to that node basin. Any suspicious lesion should be excised to look for residual melanoma or histologic regression (see below). The patient should also have an eye, ear, nose, throat, rectal, and proctoscopic examination; women should also have a gynecologic examination. Staging investigations should also be performed, depending on the clinical presentation. In general, all previously removed melanocytic and other skin lesions should be reviewed histologically to exclude melanoma.

Historically, there has been considerable confusion in the literature about the prognosis of patients with unknown primaries. Early reports indicated that patients had reduced survival compared to a similar group of patients with known primary sites. When controlled for stage of disease, however, subsequent authors have found similar or even improved survival in patients with occult primary melanomas. In the largest study to date, Chang and Knapper observed survival rates of 46 and 41 percent at 5 and 10 years, respectively, in patients with unknown primary and stage III (lymph node) disease. [50] A German study reported that the prognosis of patients with melanoma of unknown primary origin is similar to that of patients with metastasis from a known primary origin if clinical stages of disease are compared. [51] In a review of

3258 melanomas diagnosed over approximately 20 years, 75 cases of melanoma with unknown primary origin were detected. Patients with cutaneous or subcutaneous metastases had a 5-year survival rate of 83 percent, which was significantly better than patients with primary cutaneous melanoma with in-transit metastases in which the 5-year survival rate was 50 percent ($p = .02$). [51] The 5-year survival rate for patients with an unknown primary and lymph node metastases was 50 percent, which compared favorably with patients with a known primary and subsequent lymph node metastasis of 36 percent ($p = 0.14$). The number of nodes involved was not documented in this study, however, which is a significant prognostic indicator, and a key staging criterion in the revised AJCC classification (see below). Finally, the median survival was similar in patients with visceral metastasis with unknown primary or known primary origin of 6 versus 5 months, respectively. [51]

CLINICAL DETECTION OF MELANOMA

Because cutaneous melanoma arises on a readily accessible site, the health professional and patient have a unique and challenging opportunity to diagnose this malignancy at an early, curable time. This is an important challenge given that tumor thickness remains the most critical prognostic indicator in primary cutaneous melanoma. [1], [2] and [3] Despite the importance of early diagnosis of melanoma, however, there are several reasons why this objective has not yet been fulfilled. Patients with suspicious lesions may delay medical assessment due to lack of knowledge, fear, or denial. [52] In addition, the physician's diagnostic accuracy of melanoma is not perfect, with the sensitivity of diagnosis on the order of 47 to 97 percent. [52]

It must be emphasized that no single clinical feature ensures or excludes a diagnosis of melanoma. Even among expert clinicians, the clinical diagnosis of melanoma can be made in only about 80 to 90 percent of cases, with the remainder being diagnosed only by histologic examination. The clinical diagnosis of melanoma relies on a history of sustained change and assessing a constellation of gross morphologic features, but in essence, is related to the overall degree of order or symmetry of a lesion. In general, the gross morphologic features used in assessing melanocytic lesions include size, coloration, border characteristics, surface topography on tangential or side lighting, and symmetry. For practical purposes the *ABCD rule* can be applied for diagnosis of all types of melanoma, except for NM: *A*, asymmetry of the lesion; *B*, border characteristics (notched, scalloped, irregular); *C*, color (mottled, haphazard display of all shades of brown, black, gray, pink, white, blue); *D*, diameter >6 mm (greater than a pencil eraser) (see Fig. 93-7, Fig. 93-8, Fig. 93-9A for examples).

Malignant melanomas have an initial pattern of growth in the skin and mucosa, the radial growth phase, common to all types of melanoma with the exception of NM. This stage of proliferation is characterized by a relatively flat or slightly papular surface and horizontally extending growth. In general, irregularity of borders (B) with notching, variation and complexity of color pattern, and asymmetry are present at this stage (see Fig. 93-8). When diagnosed, melanomas are usually >10 mm in largest diameter. Less frequently, they are diagnosed when >6 mm in size (D). There may be obliteration or loss of skin cleavage lines when the lesion is observed with tangential lighting. Pattern of coloration is perhaps the single most important attribute for detection of melanoma (C). Although varying shades of brown typify most melanocytic lesions, striking aspects of black, blue, gray, white, pink, and red coloration may be found in melanoma (Fig. 93-7C, Fig. 93-7D; Fig. 93-8 and Fig. 93-9A). In fact, the presence of blue-black, red, and white hues is particularly suggestive of the diagnosis. Focal black areas, particularly if newly developed, are suspicious for melanoma. Changes of regression usually correspond to foci of white, gray, and pink.

The most suspicious sign suggesting melanoma is a persistently changing pigmented lesion, which should prompt immediate attention. The most frequent signs suggesting early melanoma are changes in size (D) and color (C). Not only darkening, particularly focally, but also lightening (regression) may occur. Loss of pigmentation may involve the lesion in question and take the form of a halo or occur in distant locations, resulting in a process known as melanoma-associated leukoderma. Other findings, such as elevation, ulceration, and bleeding, generally signify more-advanced primary melanoma. These changes typically occur over the course of weeks to months. An alteration of a pigmented lesion within days can usually be attributed to external insult, as from trauma, or an inflamed hair follicle within the lesion. [36]

The development of a new pigmented lesion, particularly in an individual beyond the age of 30 to 40 years and on an anatomic site of the body without similar lesions, is also worthy of close inspection. Also, the development of multiple halo nevi in mid- to late-adult life should lead to a careful inspection of the patient for melanoma (see Chap. 91). The hypopigmented halos in such patients appear around benign pigmented lesions, the melanoma being surrounded by skin of normal color (see below).

Practical Aspects

The skin examination should encompass the entire skin surface, including the scalp and genitalia. The examination should be conducted under optimal lighting, ideally daylight, and with access to a source of side lighting. A magnifying lens, usually handheld, also facilitates the examination. A Wood lamp is useful for accentuation of epidermal hyper- or hypopigmentation, such as in mapping the extent of LM or the detection of a regressed primary melanoma.

Noninvasive Clinical Techniques

The importance of making an early diagnosis of primary melanoma to increase the detection of curable melanomas and the need for improvement in the clinical diagnostic accuracy of melanoma has stimulated interest in the development of noninvasive clinical techniques in the assessment of pigmented skin lesions such as dermoscopy and computerized image analysis.

DERMOSCOPY Dermoscopy [epiluminescence microscopy (ELM)] is a noninvasive in vivo clinical examination technique in which immersion oil is applied to the pigmented lesion and examined with a lens or a handheld device (dermatoscope). More sophisticated stereo microscopes or computerized digital imaging systems can be used.

Morphologic structures are observed using this technique that are otherwise not visible to the unaided eye. A new terminology and set of criteria have subsequently been developed based on this subsurface morphology for application in the assessment of pigmented lesions. Dermoscopy improves the clinical diagnosis of melanoma and facilitates the differentiation of other benign and malignant pigmented skin lesions in experienced hands. [53], [54], [55], [56], [57], [58] and [59] Soyer et al. have thoroughly reviewed the subject. [56] The pigment network is one of the most recognizable and important structures to identify, to facilitate accurate diagnosis when examining a pigmented skin lesion with dermoscopy (Fig. 93-18, Table 93-4). A pigment network appears on dermoscopy as a series of pigmented lines, because of pigmentation along the rete ridges, and clear holes, which represent the apex of the dermal papillae. [56] Identification of the pigment network invariably indicates that the pigmented lesion is melanocytic, and its absence usually indicates a nonmelanocytic lesion. The pigmented network should be examined closely to determine whether a benign or malignant pattern exists. A benign pigment network pattern, as seen in dermal nevi, has regular, delicate lines with gradual thinning at the margin, whereas melanomas may have a malignant pattern with an irregular, variable, and widened pigment network that ends abruptly at the periphery. [53], [54] and [55] Lists of many of the important dermoscopy features with clinical pathologic correlations and significance have been published in several studies. Figure 93-18 shows the salient features and Table 93-4 summarizes them.



TABLE 93-4 **Dermascopic Features of Pigmented Lesions**

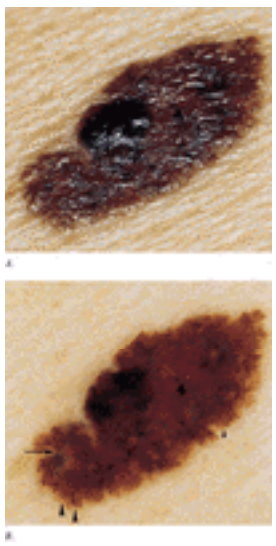

FIGURE 93-18 A superficial spreading melanoma as viewed by close inspection with a handheld lens (*A*) and by ELM (i.e., with immersion oil) (*B*). Here new features become apparent, such as the pigment network, brown globules (*small arrowhead*), pseudopods (*large arrowheads*), and depigmentation, extending irregularly to the periphery of the lesion (*arrow*). (*Courtesy of Michael Binder, MD.*)

Different approaches have been developed to facilitate the interpretation of dermoscopy findings, including the pattern analysis method proposed by Pehamberger et al., [53] the ABCD method, [57] and various others that have been tested and compared to each other in a large multicenter trial. [56] The pattern analysis method has been the most extensively tested method to date, including examination and analysis of over 7000 pigmented lesions. [53], [54] and [55] In the pattern analysis method, an algorithm is applied in which the dermoscopic features are classified into specific patterns characteristic of different pigmented skin lesions. By using this method, significant improvements were documented in overall diagnostic accuracy: from 60 percent with clinical examination alone to 85 percent with dermoscopy. [54], [56] Although dermoscopy can enhance the diagnostic accuracy of those experienced in using this technique, there is some evidence that dermatologists who are not formally trained in this technique may not benefit by using this technique and that the sensitivity of diagnosis may be lower. [59] Such studies emphasize the need for specific instruction in application of the technique and the need for extensive experience in using the technique if the potential gains in diagnostic accuracy are to be reached. It should be emphasized that the technique is not absolute, and that the presence or absence of dermoscopic features has not been reliably shown to be 100 percent sensitive or specific for the diagnosis of melanoma. Dermoscopy is an aid in the clinical diagnosis of melanoma, however, and dermoscopic examination provides important additional information and affords the opportunity to study and analyze lesional features not visible to the naked eye, particularly in lesions that are small and have not yet developed the full complement of features diagnostic for melanoma. Dermoscopy facilitates a rigorous examination of pigmented lesion morphology and is an important advance in the scientific approach to clinical assessment of pigmented skin lesions. [60]

IMAGE ANALYSIS Computerized digital imaging is another noninvasive in vivo technique currently being investigated for the assessment, diagnosis, and monitoring of pigmented skin lesions. Such images can be retrieved and examined at a later date to permit comparisons, qualitatively or quantitatively, to detect changes over time. Digital dermoscopy [digital epiluminescent microscopy (DELM)] is a significant advance in this field because it enables an enhanced discrimination of melanoma from other pigmented skin lesions. DELM uses computer image analysis programs, which provide objective measurement of changes in pigmented lesions over time (Fig. 93-19), storage and rapid retrieval at low operating cost, transmission of images to experts for further discussion, and extraction of morphologic features for numeric analysis. [60] Such systems even allow the employment of artificial neural networks and can assist screening for melanomas for those untrained in the complexities of dermoscopy or in general dermatology. [60] A recent four-center validation study that used an automated multispectral digital dermatoscope was promising in this regard. [61]

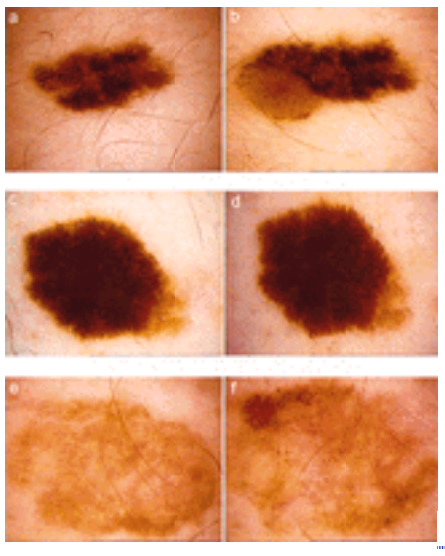

FIGURE 93-19 Monitoring of dysplastic nevi (DN) by digital epiluminescence microscopy. All lesions are from patients with the multiple atypical (dysplastic) nevus syndrome. *A.* Image of DN at time of presentation. The lesion shows features of a DN and because the patient has multiple such lesions, clinical monitoring at 6-month intervals was scheduled. *B.* Follow-up of the same lesion after 8 months. The lesion has changed. There is an asymmetrical increase in size and the appearance of a new hypopigmented structure in the periphery on the left. The lesion was excised and histology revealed DN in the right portion of the lesion and SSM <0.75 mm on the left. *C.* This DN is more difficult to evaluate. Typical DN at baseline (*C.*) but after 6 months, (*D*) subtle changes have occurred. There is an increase in size, albeit symmetrical, of the lesion, but the pigment network at the upper and lower margin has transformed into a fringe of fine pseudopods suggesting SSM. Histology confirmed SSM <0.75 mm. *E.* Another DN at baseline. *F.* Follow-up image of the same lesion at 6 months. The most prominent changes are asymmetrical increase in size, appearance of a new irregular pigment network, dots, and globules at the upper left margin of the lesion. Histology revealed SSM <0.75 mm. (*Courtesy of Harald Kittler, MD.*)

Future Developments

The continued advances in optical imaging technology should translate into improvements in the discrimination of benign pigmented lesions from malignant ones. Ultrasonography, including 20-MHz ultrasound and, more recently, higher frequency (40 to 60 MHz) ultrasound, and magnetic resonance imaging have also been used as noninvasive techniques; however, their value remains to be determined.

The first clinical studies in pigmented lesions using a confocal scanning laser microscope have been reported. [62] The confocal scanning laser microscope (CSLM) allows in vivo visualization of cellular level structures within the epidermis and papillary dermis, including circulating erythrocytes and leukocytes in the superficial plexus. Preliminary analysis of this technique has provided high-resolution in vivo images of pigmented skin lesions. [62] With the technique, melanocytic nevi have cohesive nests of uniformly monomorphic circular cells and increased microvascular blood flow. Melanomas have a polymorphous cytologic structure, containing atypical, pleomorphic cells in disarray and irregular dendritic cells. In this pilot project, CSLM enabled identification of distinct patterns and cytologic features of benign and malignant pigmented skin lesions in vivo.

Continued development of technology for noninvasive imaging of the skin could lead to enhanced diagnostic accuracy of pigmented skin lesions. Improved recognition of benign lesions may result in avoiding unnecessary biopsies while facilitating the diagnosis of early curable melanomas.

ESTABLISHING A HISTOLOGIC DIAGNOSIS

Excision

Patients with lesions clinically suspect for melanoma should, whenever possible, undergo prompt excisional biopsy with narrow margins.

Incisional Biopsy

An incisional biopsy is acceptable, although less desirable, if it is not possible to perform an excisional biopsy because of large size. An incisional or punch biopsy may be obtained through what is considered to be the thickest (most elevated) portion of the clinical lesions. In the case of flat lesions, the darkest (e.g., black) area should be sampled. It must be emphasized that shave biopsies are to be avoided because they usually yield inadequate specimens, frequently disrupt the tumor, and preclude conventional microstaging. There is no evidence that biopsy or incision of a melanoma leads to “seeding” of tissue and adversely affects survival.

Histopathologic Criteria for the Diagnosis of Melanoma

The histologic diagnosis of melanoma is based on the assessment of a constellation of findings with no single feature, particularly architectural, being diagnostic.

Fully evolved cytologic atypia is considered necessary for a diagnosis of melanoma. Although precise definitions are lacking, this degree of atypia generally refers to pronounced cellular enlargement, nuclear enlargement, variations in nuclear size and shape (anisokaryosis), hyperchromasia of nuclei with irregular clumping and distribution of chromatin, and enlarged nucleoli. In melanoma, large epithelioid cells are usually characterized by abundant granular, eosinophilic, or “dusty” cytoplasm; spindle cells have less cytoplasm, which is frequently basophilic or amphophilic, with high

nucleus-to-cytoplasm ratios. Architectural features suggestive of melanoma include large size (>5 to 6 mm), asymmetry, and pagetoid spread or intraepidermal upward migration of melanocytes. Also, there is loss of a nevic growth pattern; that is, loss of elongated epidermal rete with variation in the junctional nesting pattern and confluence of nests with dyshesion of cells in nests. Substantial zones of regression and expansile nodule formation in the dermal component are commonly present. Pagetoid spread is usually considered diagnostic of melanoma. However, this finding should be assessed cautiously because of the frequent occurrence of upward migration of cells in acral nevi of children, pigmented spindle-cell nevi, Spitz nevi, and epithelioid cell dysplasia (see Chap 91). In the benign lesions, the upwardly migratory cells have benign cytologic features. The histologic differential diagnosis of melanoma commonly includes Spitz tumor, pigmented spindle-cell nevus, dysplastic nevus, halo nevus, combined nevus, recurrent nevus (see Chap. 91 and Chap. 92), and cellular blue nevus. Emphasis should be placed on having sufficient architectural and cytologic atypicality in the proper clinical context before rendering a diagnosis of melanoma.

IMMUNOHISTOCHEMISTRY IN THE DIAGNOSIS OF MELANOMA

Immunohistochemistry is used for the diagnosis of melanoma in these situations: primary or metastatic, poorly differentiated malignant neoplasms containing little or no pigment; spindle-cell tumors; tumors with pagetoid epidermal patterns that are not obvious melanoma (e.g., sebaceous carcinoma); and small cell malignant tumors suggesting melanoma, lymphoma, or neuroendocrine carcinoma. The antisera used most often for the routine evaluation of paraffin-embedded specimens include S-100 protein and HMB-45. S-100 protein is expressed by virtually all malignant melanomas and melanocytic nevi, as well as by a variety of other tumors, including peripheral-nerve sheath tumors, cartilaginous tumors, osteosarcomas, eccrine and visceral carcinomas, and Langerhans cell tumors. HMB-45 is a monoclonal antibody with high specificity for malignant melanoma: in general, it is not immunoreactive with carcinomas, lymphomas, or sarcomas. HMB-45 is frequently negative in spindle-cell and desmoplastic melanomas; however, these tumors commonly exhibit vimentin and S-100 protein positivity. In general, these two reagents should be used in concert with a panel of antibodies against other tumor markers, such as cytokeratins, vimentin, and leukocyte common antigen, depending on the clinical and histologic features.

STAGING OF MELANOMA

Accurate documentation of the extent of melanoma is essential for determining the optimal treatment of patients and for assessing prognosis. In addition, melanoma clinical trial design must account for such prognostic factors and stratify patients accordingly to permit comparison of results across institutions and to establish a treatment effect.

The AJCC and the International Union Against Cancer (UICC) tumor node metastasis (TNM) committees have approved a new melanoma staging system, which was implemented in 2002. [44] The changes incorporate information in prognostic variables that have enabled clinicians and pathologists to more accurately stage patients. Specific advances in melanoma staging involve more accurate analysis of primary melanoma tumors (ulceration), regional nodes (sentinel node biopsy), and metastases [site and serum lactic dehydrogenase (LDH)] for determining prognosis of patients. The previous (1997) version of the AJCC staging system did not incorporate this information, prompting the revision of the staging system by a panel of melanoma experts and approval of the current system by the AJCC and UICC TNM committees. Table 93-5 presents the TNM categories and Table 93-6 lists the stage groupings.

TABLE 93-5 **Melanoma TNM Classification***

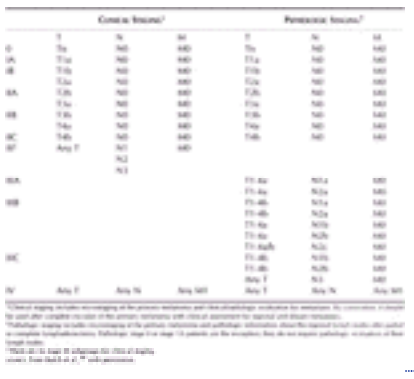

TABLE 93-6 **Proposed Stage Groupings for Cutaneous Melanoma**

In general, approximately 85 percent of patients have localized disease (stages I and II) on presentation, and prognosis and treatment are related to the assessment of the characteristics of the primary tumor, so-called microstaging, as discussed below. Approximately 15 percent of patients have regional nodal disease (stage III), and prognosis is related to evaluating extent of this nodal disease and the presence of ulceration in the primary tumor. Only approximately 2 percent of patients have distant metastases (stage IV) at initial presentation.

CLINICAL AND HISTOPATHOLOGIC PARAMETERS OF POSSIBLE PROGNOSTIC SIGNIFICANCE IN MELANOMA (Table 93-7)



TABLE 93-7 **Prognostic Factors for Clinical Stage I Melanoma**

More than 50 multivariate studies have been conducted in an effort to identify clinical and histologic parameters of prognostic significance in melanoma. The factors generally assessed in most studies include age, sex, tumor site, tumor thickness in millimeters (Breslow, see below), anatomic level (Clark, see below), tumor subtype, ulceration, regression, mitotic rate, host response, microscopic satellites, and vascular invasion (Table 93-7). Almost all of these studies have overwhelmingly confirmed the fundamental importance of tumor thickness as predicting the outcome in stages I and II melanoma.

Prognostic Factors for Stages I and II Melanoma

A multicenter AJCC melanoma database was created to validate the new AJCC staging system, and the largest prognostic factor analyses performed to date was conducted. [1] Staging and survival data from 30,450 melanoma patients were contributed from thirteen institutions and cooperative groups. Complete data was available for 17,600 melanomas and a multivariate prognostic factor analysis was performed to validate the new AJCC staging system that included age, sex, site, thickness, Clark's level of invasion, and ulceration. In the examination of the nodal metastases, the prognostic factors examined included the number of metastatic nodes, tumor burden, and the factors examined in the multivariate analysis of the primary tumor. In the analysis of distant metastases, the site of the metastases and the clinical and pathologic features used for the other stages were included. [1] The results are presented in Fig. 93-20, Fig. 93-21, Fig. 93-22, and Fig. 93-23, and are discussed below.

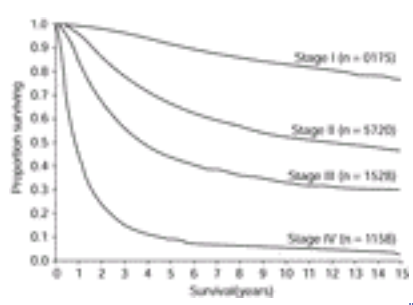

FIGURE 93-20 Fifteen-year survival curves comparing localized melanoma (stages II and I), regional metastases (stage III), and distant metastases (stage IV). The numbers in parentheses are patients from the AJCC melanoma staging database used to calculate the survival rates. The differences between the curves are significant ($p < .0001$). (*From Balch CM et al: Final version of the American Joint Committee on Cancer Staging System for Cutaneous Melanoma. J Clin Oncol 1p: 3635, 2001*)

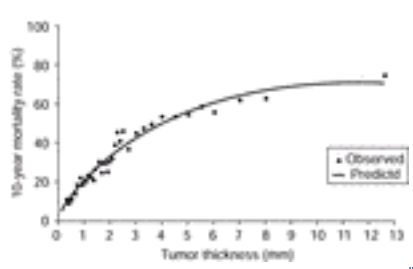

FIGURE 93-21 Observed and predicted 10-year mortality rate of 15,320 patients with clinically localized melanoma based on a mathematical model $f(t) = 1 - 0.988e^{(-211t + 0.0091\ 2)}$ derived from the AJCC melanoma database. T is the measured tumor thickness (mm) and f(t) is 10-year melanoma-specific mortality rates. $p < .0001$. (*From Balch et al* [1])

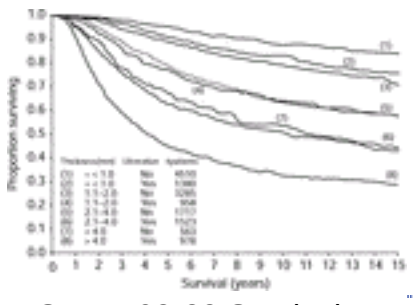

FIGURE 93-22 Survival curves of 14,914 patients with localized melanoma stratified by melanoma thickness and presence or absence of ulceration. The correlation of the sub-groups used for defining melanoma TNM staging with melanoma-specific survival is significant ($p < .0001$). (*From Balch et al* [1])

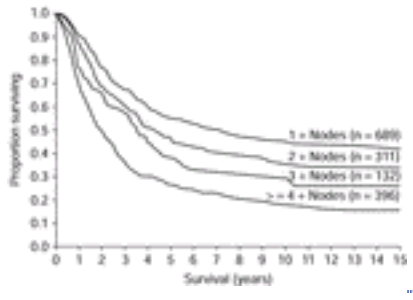

FIGURE 93-23 Survival curves of 1528 melanoma patients with lymph node metastases subgrouped by the actual number of metastatic nodes. The correlation is significant ($p < .0001$). (*From Balch et al* [1])

PROGNOSTIC FACTORS INCLUDED IN AJCC STAGING

Tumor thickness Melanoma thickness as measured from the granular layer of the epidermis to the greatest depth of tumor invasion by using an ocular micrometer, as originally described by Breslow (Fig. 93-24), has proved to be the single most important predictor of survival in primary cutaneous melanoma. Survival diminishes with increasing tumor thickness and, in general, there appears to be a linear relationship between tumor thickness and survival. In the new staging system, tumor thickness is classified by thresholds that correlate with clinical management (see later) and prognosis of melanoma patients. Tumors are classified by thickness of =1.0 mm (T1), 1.01 to 2.0 mm (T2), 2.01 to 4.0 mm (T3), and >4.0 mm (T4). [63], [64] In the AJCC melanoma validation study, tumor thickness was the most powerful independent prognostic factor for patients with primary cutaneous melanoma. No natural breakpoints were noted for tumor thickness in the analyses.

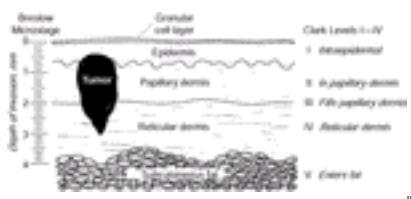

FIGURE 93-24 Breslow thickness and anatomic levels of invasion. When using the method described by Breslow, the greatest thickness of melanoma is measured in the vertical dimension from the granular layer (or top of an ulcerated surface) to the point of deepest tumor invasion. The anatomic level of invasion (Clark) refers to the extent of melanoma incursion into the papillary dermis, reticular dermis, and subcutaneous fat.

Ulceration Ulceration was the second most powerful factor in the AJCC validation study and was highly correlated with survival; consequently, ulceration of the tumor was added to the new staging system. Ulceration is an independent risk factor and portends a higher risk of developing advanced disease. The presence of ulceration “upstages” all patients with stages I to III disease. In a given T grouping, the new system subclassifies patients as “a” for tumors without ulceration and “b” for tumors with ulceration. [44]

Level of invasion Anatomic level of invasion originally described by Clark [2] refers to progressive penetration of certain anatomic barriers in the skin by melanoma [46] (see Fig. 93-24). Level I indicates melanoma is confined to the epidermis. Level II indicates breaching the epidermal–dermal basement membrane by tumor cells extending into the papillary dermis. Level III signifies a further accumulation of tumor cells in the papillary dermis such that the papillary dermis is expanded or distended by a cohesive nodule or plaque of cells or nests of cells. With level IV there is clear-cut extension of tumor cells into the reticular dermis. Finally, level V indicates invasion of the subcutaneous fat. Recognition of these levels provided one of the first objective correlates of survival in stages I and II melanoma. [2] After the description of Breslow's method of measuring tumor thickness, [3] anatomic levels have assumed a less-significant place in the microstaging of melanoma. Much of this has to do with the ease, reproducibility, and objectivity of measuring tumor depth. Assessing anatomic levels can also be cumbersome at certain sites, such as acral skin, and can lack reproducibility in certain instances, for example, level III versus early level IV. In the AJCC validation study, the level of invasion had a significant impact on survival only within thin melanomas (<1.0 mm). As a result, Clark's levels are incorporated into the revised AJCC staging of thin melanomas only (<1.0 mm or category T1). [44]

PROGNOSTIC FACTORS NOT INCLUDED IN AJCC STAGING Although the following prognostic factors also significantly correlate with survival, they have been determined to be less-powerful prognostic factors in multivariate regression models and are not included in the revised 2002 AJCC staging classifications.

Sex A large number of studies have reported women with melanoma as having improved survival rates when compared to men, even after adjustment for tumor thickness and anatomic site (Table 93-7).

Tumor site Multivariate analyses confirm site as an independent predictor of survival. [16] In general, extremity lesions (other than hands and feet) are associated with a better prognosis than tumors located on the trunk, head and neck, and palmar/plantar/subungual sites. [16] In addition, extremity melanomas are associated with a higher proportion of local and regional (in-transit and nodal) recurrences (85.6 percent versus systemic metastases) than are melanomas located on the trunk (77.3 percent local/regional recurrences), and head and neck (62.5 percent local/regional recurrences). Because local and regional recurrences are associated with greater survival than are systemic metastases, the improved survival of patients with extremity lesions appears related to pattern of recurrence. Nonetheless, site has not been

confirmed as an independent prognostic factor in many studies. Melanomas of intermediate thickness (0.69 to 1.69 mm) that are localized to the so-called BANS area (back, posterior arm, posterior neck, scalp) have been reported to have a worse prognosis than non-BANS melanomas. [65] However, these findings have not been confirmed in other data bases [16] with the exception of scalp melanomas.

Age Single-factor and multivariate analysis indicate that advanced age portends a poorer prognosis for patients diagnosed with primary cutaneous melanoma. [16]

Phase of tumor progression The radial and vertical growth phases correlate with thickness and level of invasion. Clark and his colleagues suggested that the vertical growth phase, defined as the presence of an expansile nodule in the papillary dermis, may indicate competence for metastasis, whereas the radial growth phase is associated with no metastatic potential (in the absence of regression). [16] According to these investigators, the generally excellent prognosis of tumors <1.0 mm thick and anatomic level II (almost 100 percent survival at 8 years) is primarily related more to the growth phase than to thickness itself (see below). Other studies, however, have not confirmed the validity of growth phase as an independent prognostic factor. [63]

Histogenetic type For some time after the delineation of histogenetic subtypes of melanoma by Clark, it was reported that LMM had a better prognosis than SSM, and that SSM had a better prognosis than NM. Differences in prognosis among histogenetic subtypes do not remain after controlling for thickness.

Regression There are conflicting reports on the significance of regression on the prognosis of melanoma. Some of the problems in evaluating the contribution of regression can be attributed to lack of standardized definitions of regression and thresholds for recording this phenomenon.

Host response (Table 93-7) There is some evidence that the presence of a lymphoid infiltrate at the base of a melanoma is a favorable prognostic factor indicating a host response to the melanoma. [16] Lymphocytic infiltrates at the tumor base may diminish with increasing tumor thickness. Thus, lymphoid response may be inversely correlated with tumor thickness and have no independent predictive value. The presence of tumor-infiltrating lymphocytes (TILs) is a significant prognostic factor, even after adjustment for other variables, including thickness. TILs were defined as “brisk” if lymphocytes permeated the vertical growth phase nodule and infiltrated the entire base of the vertical growth phase. The presence of “brisk” TILs was one of the most significant prognostic parameters in Clark's model.

Mitotic Rate There is a significant relationship between mitotic activity, usually measured in mitoses/mm ^{2}, and prognosis, particularly in tumors of intermediate thickness. [16] Nonetheless, some investigators have demonstrated an independent effect after adjustment for thickness. One significant problem related to recording mitoses is sampling error. Because of heterogeneity of mitotic activity in most tumors, hot spots or areas with the highest mitotic activity must be assessed for recording purposes. The prognostic index (PI), defined as *mitoses/mm* ^{2} × *thickness,* has been suggested as a better prognostic indicator than thickness alone. Kopf and associates demonstrated that patients with tumors 1.5 to 3.99 mm thick and a PI > 19 had a worse survival rate than patients with comparable tumors and a PI < 19. [64] The effect of PI as an independent variable has not been corroborated in other studies.

Tumor cell type Recognition of melanoma cell type other than spindle- versus non–spindle-cell type has not proved a useful prognostic indicator. [16] In general, the limiting factors in evaluating cell type are the lack of standardized definitions and heterogeneity of tumors.

Vascular invasion This parameter, which is closely related to microscopic satellites, is a strong predictor of nodal metastasis. The usefulness of the finding is limited because of frequent false-positive results (a consequence of tissue-shrinkage artifacts) and the rarity of true positive results.

Prognostic Factors for Stage III Melanoma

The presence of regional lymph node metastasis portends a poorer prognosis for patients with an overall 5-year survival rate of approximately 37 percent and 10-year survival rate of 32 percent. [65] The number of positive lymph nodes is the most important prognostic factor in patients with nodal metastasis. Patients with nodal micrometastases (clinical stages I and II, pathologic stage III) have considerably better survival than clinical stage III (palpable nodes).

In the AJCC melanoma validation study, 1528 melanoma patients with lymph node metastases were analyzed, and the number of metastatic nodes was the most powerful predictor of survival (P <0.00001). Increasing numbers of lymph nodes involved portends a poorer prognosis (Fig. 93-23). [1] The second most significant predictor of outcome was the tumor burden as determined by whether microscopic/clinically occult or macroscopic/clinically apparent disease was present. The only feature of the primary tumor that was a significant predictor of outcome once lymph node involvement was present was tumor ulceration.

Prognostic Factors for Stage IV Melanoma

Once metastases to distant sites have developed, median survival is approximately 6 months. The only variables of prognostic significance are number of metastatic sites, surgical resectability, duration of remission, and location of metastases (Table 93-8). Survival is longer for one metastatic site versus two, and two sites are more favorable than three or more. Solitary resectable metastases in sites such as the lungs, brain, or bowel may be associated with significantly prolonged survival. [46] Patients also have improved survival with nonvisceral sites (skin, subcutaneous tissue, distant lymph nodes) versus visceral (lung, liver, bone, brain).

Prognostic Variable	Effect on Prognosis
Number of metastatic sites	Worse prognosis with increasing number of sites
Location of metastases	Worse prognosis for visceral sites (lung, liver, brain, bone) versus nonvisceral sites (skin, subcutaneous tissue, distant lymph nodes)
Presence of "resectable" metastases	Better prognosis for solitary resectable metastases
Sex*	Worse outcome for males
Duration of remission	Shorter duration of remission associated with worse prognosis

*Not confirmed in all studies.

TABLE 93-8 **Prognostic Factors for Clinical Stage IV Melanoma**

Site of metastases was the most important prognostic factor in the AJCC melanoma validation study with patients with visceral metastases having a relatively poorer prognosis than nonvisceral (skin, subcutaneous, and distant lymph nodes) sites.

Melanoma and Hypopigmentation

Both primary and metastatic melanoma may be associated with vitiligo-like hypopigmentation. For details, see Chap. 90.

METASTATIC MELANOMA AND DIFFUSE HYPERMELANOSIS Advanced metastatic melanoma may be associated with diffuse hypermelanosis and melanogenuria. For details, see Chap. 90.

EVALUATION FOR SUSPECTED OR NEWLY DIAGNOSED MELANOMA

History

A patient with suspected or newly diagnosed melanoma should have an appropriate history taken including risk factor assessment as outlined earlier. (Dr. T.B. Fitzpatrick has proposed an acronym that summarizes the important risk factors for melanoma and is remembered as MMRISK: M = Moles: atypical; M = Moles: common; R = Red hair and freckling; I = Inability to tan: skin phototypes I and II; S = Sunburn: severe sunburn before age 14 years; K = Kindred: family history of melanoma) (see also Chap. 88). The history should also include the details concerning the lesion in question: how long has the lesion been present; has the lesion changed and how has it changed (e.g., enlargement in area or elevation, change in color, change in borders, ulceration, bleeding, tenderness, itching); duration of changes; how changes were detected or reason for seeking medical attention; occupational exposures; history of other medical conditions; medications; and history of nevi previously removed.

Physical Examination

The patient should have a complete physical examination, including comprehensive examination of the skin. The characteristics of the lesion in question and other relevant pigmented lesions should be assessed with optimal illumination, a source of side-lighting, a hand lens, a Wood lamp, and dermoscopy, as needed. Other gross morphologic parameters such as overall symmetry, regularity of coloration, number of colors, and topography (macular, papular, accentuation or obliteration of skin cleavage lines, ulceration, crusting) should be noted. In general, numbers of nevi and clinically atypical nevi should be recorded because they are markers of increased risk for melanoma. The primary site should be palpated, and the patient examined for evidence of lymphadenopathy and hepatosplenomegaly.

Laboratory Evaluation and Staging

Further evaluation of the patient is aimed at determining the extent of the disease process so that prognosis and therapy are appropriate. In general, additional investigations are directed by symptoms and signs. For example, headache or development of seizures would prompt imaging of the head. Performance of such studies without any clear clinical indication has proved to be of little practical value. As a general rule, individuals with primary cutaneous melanoma may need only a baseline chest x-ray examination as part of an initial evaluation. Patients with melanomas >1.0 mm in thickness may be considered for sentinel lymph node studies (see below).

The presence of lymphadenopathy (clinical stage III disease) generally requires intervention to verify the presence of tumor. Such intervention usually takes the form of a complete lymph node dissection, but lymph node biopsy or fine-needle aspiration may be employed as the first diagnostic maneuver. Additional evaluation of the patient for distant metastases includes liver enzymes, LDH, and CT scans of the chest and abdomen.

MANAGEMENT

This malignancy attracts the interest and requires the expertise of several disciplines. Although there have been significant advances in the management of melanoma, currently the only standard treatment for cutaneous melanoma is early recognition and surgical excision of the primary tumor. The advances in management and evolving treatments are reviewed below.

Therapy for Primary Melanoma (Table 93-9)

Tumor Thickness (mm)	Margins of Surgical Resection (cm)	Closure	Sentinel Node Mapping
In situ	0.5	Primary	No
≤1.0	1	Primary	No[1]
1.0–2.0	1–2	Primary	+
2.0–4.0	2	Primary; graft or flap	+
>4.0	2–3	Primary; graft or flap	+

*The treatment of each patient is individualized. It may not be possible to achieve the recommended margin of excision in certain anatomic sites, such as on the face or distal extremities. Also, skin grafts or flaps may be necessary for surgic defects in the latter locations.
[1]Standard node mapping may be considered for melanoma <1.0 mm if ulcerated, Clark's level IV/V.

TABLE 93-9 **Guidelines for Surgical Management of Patients with Clinical Stage I and II Melanoma***

The only standard treatment in primary cutaneous melanoma is the complete surgical excision of the primary lesion. The principal debate in the management of primary cutaneous melanoma involves the surgical margin that should be taken. Traditionally, a wide local excision involving a margin of 5 cm was considered the standard of care. The recommendation

of a 5-cm margin has been attributed to W. Sampson Handley who, in the 1907 Hunterian lectures, based this recommendation on a single autopsy examination of a 34-year-old patient who had “centrifugal lymphatic spread” of the melanoma cells at a site of cutaneous metastasis. On the basis of this anatomic study, Handley recommended a 2.5-cm surgical margin extending to the subcutaneous fat and to 5 cm of the fascial layer. [66] The surgical practice of performing a wide local excision was challenged in 1977, when Breslow and Macht presented a series of 35 patients safely treated with narrower surgical margins. [67] Subsequently, a large number of retrospective and nonrandomized trials have also supported a narrower surgical margin.

Two prospective, randomized surgical trials have provided solid evidence for the safety of narrower excision margins in the surgical management of primary cutaneous melanoma. The World Health Organization (WHO) randomized 612 patients, with melanomas <2 mm thick, to undergo excision with 1- or 3-cm margins. [68] At a mean follow-up of 55 months, there was no significant difference in disease-free survival and survival rates between the groups. An update of this trial was published with a mean follow-up of 90 months, and reported that the 8-year actuarial survival and disease-free survival were similar. [69] The WHO study concluded that margins of 1.0 cm were safe for melanomas 1.0 mm and less in thickness. Based on the trend to local recurrences in the 1.1- to 2.0-mm group, these authors recommended that longer follow-up is needed in this group before issuing a final recommendation.

The Intergroup Melanoma Surgery Trial conducted by Balch et al. prospectively enrolled 486 patients to undergo 2-cm versus 4-cm margins for intermediate-thickness melanomas (between 1 and 4 mm thick). [70] At a median follow-up of 72 months, no statistically significant difference was noted in local recurrence or survival between the study groups. An update has been reported with a median follow-up of 91 months, which update confirmed the effectiveness and safety of a 2-cm margin for intermediate-thickness melanomas. [42] In addition, the local recurrence rate was not significantly different (p = .72) groups. The conclusion of these investigators was that a 2-cm margin is satisfactory for eliminating residual disease at the site of primary intermediate-thickness melanomas, and that local recurrences and survival would not be significantly affected by a further 2-cm margin.

Taken together, these well-designed high-quality surgical trials provide strong evidence that 1-cm margins are safe and efficacious for invasive melanomas less than 1 mm in thickness. For melanomas >1 mm in thickness, there remains controversy regarding optimal excision margins. Based on the trend to local recurrences in the 1.1- to 2.0-mm group from the WHO study, and the lack of benefit to any wider excision as determined in the Intergroup study, some centers recommend 2.0-cm margins for intermediate-thickness melanomas, where feasible. The current American Academy of Dermatology (AAD) guidelines of care for cutaneous melanoma recommend a 1.0-cm margin for invasive melanomas <2 mm thick, and 2-cm margins for melanomas >2 mm thick. [71] The lack of a difference in survival or local recurrence with wider margins has led some authors to recommend 1-cm margins for all invasive melanomas, [72] but there are no prospective randomized, controlled surgical trials that support this recommendation.

Prospective randomized studies have not yet evaluated the optimal excision margin for in situ or thick melanomas (>4 mm). A National Institutes of Health consensus conference recommended 0.5-cm margins for melanomas in situ. [73] Despite a lack of good evidence, many surgeons prefer to take margins >3 cm for thick primaries (>4 mm).

It is important to note that strict guidelines should not be routinely recommended in the surgical management of cutaneous primary melanoma, and that each case should be evaluated individually. Primary melanomas near a vital structure may require a reduction in the margin, whereas poor histologic prognostic factors may suggest a biologically more aggressive melanoma and support a wider margin. Melanoma excision at special sites, such as the fingers, toes, sole of the foot, and ear, also require separate surgical and functional considerations. Table 93-9 summarizes current recommendations for surgical margins, based on an evidenced-based approach, and current guidelines.

Elective Lymph Node Dissection

The removal of regional lymph nodes draining the site of a primary cutaneous melanoma in the absence of any clinical evidence of metastasis to those nodes is termed *elective lymph node dissection* (ELND). The decision to perform ELND is a very controversial aspect in the surgical management of melanoma. The debate focuses primarily on the role of ELND in intermediate-thickness melanomas, because thin melanomas (<0.75 mm) have an excellent 5-year survival rate, in the order of 96 to 99 percent with excision of the primary alone, and thick primaries (>4.0 mm) have an elevated risk of systemic metastases, thus reducing any potential survival benefit of prophylactic lymphadenectomy.

The principal rationale for ELND is based on the biologic presumption that melanoma metastasizes in a predictable manner to a regional nodal basin first before spreading to distant organs. Proponents of ELND maintain that by removing regional nodes, draining a primary melanoma, it is possible to eradicate subclinical micrometastases in a timely and potentially curative manner. In further support of early surgical intervention is the recognition that the prognosis is worse with increasing nodal tumor burden. Additional cited benefits of ELND include the accurate staging for prompt initiation of adjuvant therapy and the avoidance of future palliative node dissection.

Opponents of ELND counter that the presumption of regional metastasis may not be valid in melanoma as nodal involvement can be a reflection of systemic metastasis, and that melanoma can metastasize hematogenously, bypassing regional nodes. In addition, it is suggested that removal of regional nodes also reduces the immune response to micrometastasis. Furthermore, in patients with intermediate-thickness melanomas, only approximately 30 percent are expected to have nodal micrometastases, thus subjecting the remaining group to the morbidity of this procedure without any benefit. Additional arguments against prophylactic lymphadenectomy include the morbidity of the procedure, including lymphedema, nerve damage, surgical wound infection, and hematoma, and the chance (although low) of mortality associated with the procedure.

The evidence cited by these groups to support or refute the respective arguments involves the interpretation of both retrospective and prospective studies. Proponents of ELND cite retrospective studies that demonstrate improved

prognosis for patients, particularly those with intermediate-thickness lesions. Critics of ELND point to two prospective, randomized trials from WHO and the Mayo Clinic that failed to demonstrate a statistically significant difference in survival from ELND. [74], [75] and [76] These prospective studies, however, have been criticized on methodologic grounds. Two further randomized, prospective trials that address some of the methodologic shortcomings were subsequently initiated. The Intergroup Melanoma study has been reported with a median follow-up of 7.4 years. [77] This study involved a prospective randomized surgical trial of 740 AJCC stages I and II patients with intermediate-thickness melanomas (1 to 4 mm) of the trunk or extremity. Patients were randomly selected to receive excision of the primary melanoma (with a 2-cm or 4-cm margin) and to receive ELND or observation. This trial failed to show a statistically significant overall 5-year survival benefit from ELND (86 percent) as compared with the observation group (82 percent). A subset analysis did identify a survival benefit in patients who were younger than 60 years of age who had ELND, and in those subgroups having ELND that had nonulcerated lesions, and in melanomas between 1 and 2 mm thick. This trial has been criticized for analyzing subpopulations in this manner, as the trial was not designed to answer this question, and raises the potential of false-positive results. Cascinelli et al. reported for the WHO Melanoma Program that ELND did not significantly improve 5-year survival in patients with trunk melanomas 1.5 mm or greater in thickness. [78] This prospective randomized study in 252 patients determined 5-year survival rates with ELND of 61.7 percent when compared to the rate for delayed node dissection of 51.3 percent ($p = 0.09$). Patients who had occult regional node metastases at the time of ELND had an improved survival rate of 48.2 percent as compared to a rate of 28.6 percent ($p = 0.04$) for those whose nodal dissection was delayed until the appearance of regional node metastases.

Recently, a systematic review and meta-analysis of randomized controlled trials comparing elective lymph node dissection with delayed lymphadenectomy at the time of clinical recurrence was conducted. [79] Three randomized controlled trials comprising 1533 participants met the inclusion criteria. The pooled odds ratio for overall mortality for the 3 trials was 0.86 (95 percent confidence interval, 0.68 to 1.09), and the results were statistically nonsignificant. No significant overall survival benefit for patients undergoing elective lymph node dissection was determined; however, the trials were recognized to contain significant bias. These investigators advised that further research would be required to exclude the possibility that some subgroups may benefit from elective lymph node dissection.

Sentinel Lymph Node Biopsy

Traditionally, staging of regional nodal basins has relied on clinical examination or ELND. A more rational approach to staging nodal basins in patients with melanoma is lymphatic mapping and sentinel lymph node biopsy. [80] This technique is minimally invasive and has decreased morbidity when compared to ELND, particularly in view of the lack of survival benefit from large prospective randomized surgical trials with ELND as outlined in the previous section. This technique is based on the anatomic understanding that the first node draining a lymphatic basin, [80] named the *sentinel node,* would be expected to predict the presence or absence of melanoma in that basin. Preoperative lymphoscintigraphy is typically used to assist operative planning to precisely “map” or locate the nodal basin draining the primary melanoma. Either isosulfan blue or patent blue V is injected around the lesion to permit intraoperative localization of the sentinel node, to which the primary melanoma drains. This allows subsequent histopathologic examination to determine the presence or absence of tumor in the blue sentinel node. Frozen section analysis of sentinel lymph nodes has been reported to have a low sensitivity, and it is recommended that conventional permanent sections be performed. Using sentinel lymph node biopsy, it is possible to identify patients who have subclinical micrometastases to the sentinel node in a minimally invasive way and target them for therapeutic lymph node dissection, without subjecting those patients who lack metastases to the morbidity of ELND. In the original studies, Morton et al. [80] were able to identify a sentinel node in 82 percent of the lymphatic basins, and metastases were detected in 21 percent of lymphadenectomy specimens. The accuracy of the procedure was confirmed as complete lymphadenectomy was performed in all cases, and metastases were present exclusively in 2 of 3079 nonsentinel nodes (1 percent false-negative rate). A single sentinel node was found in 72 percent of the basins, two sentinel nodes were found in 20 percent of the basins, and three or more sentinel nodes were found in 8 percent of the basins.

To facilitate intraoperative identification of the sentinel node, radioactive colloidal tracer may be used for intraoperative mapping. One difficulty of the blue-dye technique is that surgically locating the blue-labeled sentinel node may require considerable surgical dissection, with a success rate in the order of 80 percent. [81] A refinement of the blue-dye technique involves the injection of a radioactive tracer, Technetium (Tc)-99 sulfur colloid, at the site of the primary with intraoperative localization with a handheld gamma probe to help identify the sentinel node. [81] A “hot spot” is identified with the gamma probe, and an incision in the skin over the site of peak transcutaneous counts is made. The sentinel lymph node (SLN) is identified by the radioactivity and the blue staining of the lymphatic channel and the node, with ex vivo correlation. Krag et al. were able to identify 98 percent (118/121) of sentinel nodes with this technique, and with less tissue dissection than with the conventional blue-dye method. [81]

Further refinements of the sentinel node procedure have involved attempts to improve the detection of micrometastases in the sentinel node after it is removed for examination. Conventional pathologic evaluation of lymph nodes, involving sectioning and hematoxylin and eosin staining, underestimates melanoma present in nodes with false negatives occurring. Investigators at the M.D. Anderson Cancer Center examined a consecutive cohort of patients that underwent lymphatic mapping and sentinel node biopsy to determine the patterns of recurrence and causes for failure. It was determined that 11 percent of patients with a histologically negative SLN (AJCC stages I and II) developed recurrence at a median follow-up of 35 months. Serial sectioning and immunohistochemistry, of the 10 patients who developed nodal recurrence in a previously mapped basin, identified occult metastases in 80 percent of these cases. [82] Currently, the assessment of the sentinel node involves careful evaluation of multiple sections of the node with H&E and immunohistochemistry focused on tumor-associated markers (S-100, HMB-45, and Melan-A/MART-1). Attempts to compare PET-FDG (positron emission tomography with [^{18}F]-labeled fluorodeoxyglucose) scanning with SLN biopsy indicate that PET scans are not reliable for detecting micrometastatic melanoma, and that SLN biopsy is superior in identifying metastases in regional basins.

Serial sectioning with standard histopathologic and immunohistologic examination may still fail to detect submicroscopic

melanoma metastases in lymph nodes. Reverse transcriptase-polymerase chain reaction (RT-PCR) for tyrosinase is being studied as an adjunct to conventional histopathology and immunohistochemistry to reduce sampling error and to increase sensitivity. Several studies have used RT-PCR to determine that histologically negative SLNs have occult metastases. [83] Nevus cells can be present in lymph nodes and result in false-positive results with this technique. Correlation with conventional histology can reduce this source of error. The significance of micrometastatic melanoma detected by RT-PCR has yet to be definitively determined. One objective of the Sunbelt Melanoma Trial is to determine the survival of patients that have occult metastases in sentinel nodes that are RT-PCR positive, but negative by conventional histopathology. The survival of RT-PCR–positive patients that are observed will be compared to those who undergo node dissection alone, or who undergo node dissection and adjuvant therapy with interferon.

Although the sentinel lymph node procedure provides an elegant method of sampling lymph nodes to determine the presence of subclinical micrometastases, a rigorous, prospective, randomized surgical trial has not yet reported a survival benefit for this procedure. Proponents of this procedure have also advocated this procedure to stage patients for adjuvant interferon therapy. This rationale for performing this procedure is now in question in light of the most recent studies on the use of adjuvant therapy with interferon (see below). As a result, widespread acceptance of this procedure as a standard of care is lacking [83] despite many leading centers and the WHO designation of this procedure as such. [84] The most recent AAD guidelines of care for melanoma note that the value of sentinel node biopsy is “undetermined,” and it is neither included nor addressed in the management of primary cutaneous melanoma. [71] The Multicenter Selective Lymphadenectomy Trial (MSLT) is a prospective randomized trial that will examine the impact of SLN on survival. This trial has accrued 1800 patients, and is now closed to enrollment with long-term follow-up results pending. Until the MSLT results are available, current evidence supports the use of the sentinel node biopsy procedure as a staging procedure only, and is generally considered for patients with a melanoma more than 1 mm thick (see Table 93-9 for special consideration).

Therapy for Regional Metastases (Table 93-10)

TABLE 93-10 **General Guidelines for Treatment Sequences in Metastatic Melanoma***

SURGERY Regional metastases include regional lymph node and in-transit metastases. Treatment for patients with regional node involvement consists of therapeutic lymph node dissection and consideration of adjuvant therapy. The management of in-transit metastases is related to the number of lesions, location, and possible presence of distant metastases. In general, isolated or small numbers of lesions may be surgically excised.
ISOLATED LIMB PERFUSION The technique of isolated limb perfusion (ILP) is principally used to treat locoregional disease of the extremity (in-transit metastases and satellitosis) and for palliation with significant regional disease. The procedure is frequently used in conjunction with surgical excision of in-transit metastases and regional lymph node dissection. The method involves perfusing an isolated extremity with oxygenated blood from an extracorporeal source. Chemotherapeutic agents, especially melphalan (L-phenylalanine mustard), are perfused in high doses to the limb surgically isolated from systemic circulation under hyperthermic conditions [usually 40°C to 41°C (104°F to 105.8°F)] in order to achieve greater tumor destruction. TNF in combination with melphalan compared to melphalan alone is currently the focus of ongoing clinical trial research. This technique has also been used as adjuvant therapy for high-risk (>1.5 mm) melanomas of the extremities, including acral lentiginous and subungual melanomas. Retrospective series and a recent major prospective multicenter randomized trial failed to demonstrate a benefit of prophylactic ILP, and current evidence does not support this technique as adjuvant therapy in high-risk extremity lesions. Under the auspices of the WHO, North American Perfusion Group, and the European Organization for Research and Treatment of Cancer (EORTC), 832 patients with melanoma greater than 1.5 mm in thickness were randomized to have wide local excision or wide local excision plus ILP with melphalan and hyperthermia. [85] No survival benefit was determined at a median follow-up of 6.4 years. A marginal benefit was noted in patients with melanoma of 1.5- to 2.99-mm thickness, as in-transit metastasis was reduced from 6.6 to 3.3 percent and regional lymph node metastasis was reduced from 16.7 to 12.6 percent. [85]
ADJUVANT THERAPY Adjuvant therapy involves the treatment of a patient after all visible tumor is removed, but the patient is considered at high risk for relapse. The current AJCC staging system helps to define patients at high risk of recurrence (AJCC stages IIb and III) who could be considered for adjuvant therapy. There have been numerous adjuvant trials in patients with melanoma that involved the use of radiotherapy, chemotherapy, regional limb perfusion, and biologic response modifiers and that failed to establish a standard regimen for melanoma in an adjuvant setting. Three randomized trials [86], [87] and [88] comparing levamisole with placebo in patients with Clark levels II to V or positive nodes, failed to demonstrate a significant difference in survival. One trial conducted by the National Cancer Institute of Canada did show a significant difference in the 5-year survival rates (74 percent in levamisole versus 62 percent in the placebo group, $p = .027$). [89] This improvement in survival, however, was not significant after the multivariate analysis was adjusted for known prognostic factors (sex, age, stage of disease). The first study to fulfill stringent methodologic criteria and to demonstrate a statistically significant difference in survival in the adjuvant treatment of melanoma was reported by Kirkwood et al. of the Eastern Cooperative Oncology Group (ECOG) 1684 study [90] using interferon alpha-2b (IFN-a2b) conducted under the auspices of the National Cancer Institute. This trial randomized 287 patients who were to receive 52 weeks of IFN-a2b [high-dose interferon (HDI)] or observation. An induction phase for 4 weeks (20 million units/m^2, intravenous, five times weekly) was followed by 48 weeks of maintenance therapy (10 million units/m^2 subcutaneously, three times weekly). Patients selected were at high risk of recurrence, with either thick primaries (>4 mm; AJCC stage IIb,

T4N0M0) or presented initially with nodal involvement (AJCC stage III) at ELND or clinically. Patients were also enrolled that had recurrent lymph node metastases after treatment for a primary melanoma. All patients underwent elective lymph node dissection, and those with extracapsular invasion of the lymph nodes were excluded. With a median follow-up of 6.9 years, this trial demonstrated a statistically significant increase in the 5-year survival rate of 11 percent (37 percent for the treatment group as compared with 26 percent for the observation group, $p = .005$), and an increase in the median overall survival by approximately 1 year (3.82 years for the treatment group as compared with 2.78 years for the observation group, $p = .047$). This study led to the FDA approval of IFN-a2b for adjuvant therapy of melanoma in patients with deep primary melanomas (T4), and node-positive patients. Other randomized trials using interferon in an adjuvant setting in the treatment of melanoma have failed to report a statistically significant benefit. These studies differ from the ECOG study by including patients with extracapsular node involvement, mode of administration (intramuscular/subcutaneous versus intravenous in the induction and subcutaneous in the maintenance phases), dose (lower and shorter course versus high dose), and type of interferon (? versus a). The regimen used in the HDI-ECOG-1684 study was associated with significant toxicity, the most frequent being flulike symptoms in almost all patients (fatigue, fever, myalgias, anorexia, headache). Severe (grade 3) and life-threatening (grade 4) reactions were less frequent, but they still occurred in 43 percent (59 of 137) and 14 percent (20 of 143), respectively. While 60 percent of patients were able to complete >80 percent of dosing, adverse effects required discontinuation of interferon in 24 percent of patients. There were two treatment-related deaths caused by hepatotoxicity that occurred early in the trial and prior to close monitoring of liver enzymes. A subsequent study performed a quality-of-life-adjusted survival analysis to compare the interferon treatment group with the observation group after accounting for the decreased quality of life associated with treatment toxicity and that associated with relapse of melanoma. [91] This study determined that the interferon-treated group had more quality-of-life-adjusted time than the observation group even after adjusting for toxicity. This difference was statistically significant, however, only for certain patients who were willing to undergo toxicity in exchange for the increased survival and decreased chance of relapse. The HDI regimen was reevaluated in the intergroup E1690/S9111/ C9190 study, as well as a lower dose of IFN-a2b [low-dose interferon (LDI)] in an effort to administer therapy over a longer period but with less toxicity. [92] Six hundred forty-two patients were treated with wide local excision and randomized to HDI (1684 regimen), LDI (3 million units three times weekly subcutaneously for 2 years), or observation. At a median follow-up of 52 months, no significant benefit in overall survival was reported with HDI, LDI, or observation. HDI did improve disease-free survival (44 percent versus 35 percent; $p = 0.05$) when compared to observation, although LDI did not (40 percent versus 35 percent). Proponents of adjuvant IFN-a2b therapy maintain that the lack of significance of HDI on overall survival in this trial may be a result of confounding factors. In comparing E1684 and E1690, the median survival for the observation arm in 1684 was significantly worse than the observation arm in 1690 (2.8 years versus 6 years in 1690; $p = 0.001$). It was noted that 31 percent of the patients in the observation arm of the 1690 trial who relapsed received “salvage therapy” with interferon. In a post hoc analysis, patients receiving salvage therapy with interferon had an improved overall survival (2.2 years versus 0.8 years; $p = 0.0024$). Still, such post hoc analyses have methodologic flaws, with the possibility of selection bias in a nonrandomized, unblinded setting. A recent intergroup phase III study (E1694/S9512/C509801) with HDI or GMK vaccine provided evidence in support of a biologic effect of HDI. [93] In this trial, 880 patients were randomized to HDI or GMK vaccine. An interim analysis revealed the HDI arm had significantly improved disease-free survival (62 percent versus 49 percent) and 2-year overall survival (78 percent versus 73 percent). This trial had prespecified early stopping rules; consequently, it was closed by the external safety monitoring committee because of the improved disease-free survival in the interferon-treated arm. Several studies have also been conducted in LDI, particularly for node-negative patients at high risk of recurrence due to thick, high-risk primary lesions. Pehamberger et al. reported for the Austrian Malignant Melanoma Cooperative Group [94] that adjuvant IFN-a2a treatment diminishes the occurrence of metastases and thus prolongs disease-free survival in patients with resected primary stage II cutaneous melanoma. The prospective randomized study included 311 patients with melanoma who had a Breslow thickness of >1.5 mm who were assigned either to adjuvant IFN-a2a treatment (or observation) after excision of the primary tumor. IFN-a2a was given in a low-dose regimen (3 million international units) subcutaneously. Prolonged disease-free survival was observed in patients treated with IFN-a2a versus those who underwent surgery alone. The difference was significant ($p = .02$) for all patients enrolled in the study (intention-to-treat analysis) at a mean observation time of 41 months. A French multicenter randomized trial of LDI was also conducted in patients with >1.5-mm thick primary melanomas. Four hundred eighty-nine patients received excision alone with clinical staging of the nodal basins only (no ELND or sentinel node biopsy), and were randomized to LDI (3 million units subcutaneously three times a week for 18 months) or observation. At a median follow-up of 5 years, a significant improvement was reported in disease-free survival ($p = 0.035$) but not overall survival ($p = 0.059$). [95] Lens and Dawes recently performed a systematic review of randomized controlled trials that compared regimens with or without IFN-a adjuvant therapy in melanoma patients. [96] Eight trials comprising 3178 patients were analyzed to assess the effect of IFN-a therapy on overall survival, disease-free survival, melanoma recurrences, and toxicity. The authors concluded that no clear benefit of IFN-a therapy on overall survival in patients could be demonstrated. It was proposed that a large randomized controlled trial would be required to answer whether a full regimen of IFN-a therapy is effective and to identify the subgroups of patients who might benefit from IFN-a treatment. [96]

Therapy for Distant Metastases (Stage IV Melanoma) (Table 93-10)

The treatment of the patient with distant metastatic melanoma must take into account several important factors: average survival for such patients is only 6 months and chemotherapy, immunotherapy, and chemoimmunotherapy have complete responses in a minority of patients that is usually short-lived, although randomized controlled trials are currently evaluating new agents. The aims of therapy in stage IV melanoma must be clearly defined and generally include one or more of the following: (1) to relieve symptoms of a life-threatening problem, (2) to increase length of survival, or (3) to evaluate new therapies.

Therapy should be individualized and should consider the age, underlying medical condition of the patient, number and site(s) of metastasis, previous treatments, and the wishes of the patient and family. Conservative treatment with observation and no active treatment is reasonable in certain patients (asymptomatic, elderly, poor underlying medical condition), particularly given the low probability of cure and potential toxicity associated with certain regimens.

SURGERY Surgical excision (metastasectomy) of isolated metastases in certain sites such as the skin and subcutis,

lymph nodes, lung, brain, and gastrointestinal tract can prolong survival. [46] The number of metastatic lesions has prognostic importance, with patients having a solitary lesion performing relatively better than those with two or more sites. Excision of metastatic lesions can achieve significant palliation. For example, resection of a gastrointestinal tract metastasis may relieve life-threatening obstruction or hemorrhage.

RADIATION THERAPY Radiation therapy is indicated in certain patients with stage IV disease with palliative intent. Specific indications include brain metastases, pain associated with bone metastases, and skin and subcutaneous metastases that are superficially located. [46] Spinal cord compression and localized unresectable visceral deposits are special situations in which radiation therapy is also indicated.

CHEMOTHERAPY Chemotherapy is primarily indicated for stage IV, nonresectable metastatic melanoma. A variety of chemotherapy agents have shown activity against melanoma, and have been used as single agents, combination chemotherapy, and chemoimmunotherapy (biochemotherapy) regimens.

Single-agent chemotherapy Dacarbazine (DTIC) has shown the greatest effectiveness as a single agent in most series. The overall response rate in 1936 patients treated with DTIC was 20 percent (382 of 1936). [97] Complete responses occur in approximately 5 percent of patients and are not sustained in the majority of patients. Other agents used as single therapy that have shown activity against melanoma include nitrosoureas [carmustine (BCNU) and lomustine (CCNU)] and vinca alkaloids (cisplatin and carboplatin), which have had response rates of 10 to 20 percent. Fotemustine is a new class of nitrosourea with a reported response rate in up to 20 percent of patients with metastatic melanoma to the central nervous system (CNS). Temozolomide is a new oral agent with CNS penetration that has also had promising preliminary results in cases of brain metastasis. [98] Other investigational drugs include taxanes and betulinic acid. The use of high-dose chemotherapy with or without autologous bone marrow transplantation (experimental) has also yielded higher response rates, but has not prolonged survival; however, current trials are evaluating this option. Crosby et al. performed a recent Cochrane Review involving a systematic analyses of all prospective randomized trials using systemic therapy in metastatic cutaneous melanoma. [99] These authors could not find any randomized controlled trials comparing systemic therapy with placebo in metastatic melanoma. No support was found for a “gold standard” therapy in the treatment of metastatic melanoma. The authors noted that DTIC has been used as a control arm in more than 20 prospective randomized clinical trials, and the response rate is in the order of 9.1 to 29 percent. Given the lack of evidence from randomized clinical trials for any systemic therapy versus supportive care, it was proposed that systemic treatments (simple or combination) be compared to single-agent DTIC.

Combination chemotherapy A number of combination chemotherapy regimens have been used in patients with stage IV disease. Most regimens have included agents that have shown efficacy as single therapy and have included various combinations of DTIC, nitrosoureas (BCNU), vinca alkaloids, cisplatin, dactinomycin, hormonal therapy (tamoxifen), and, more recently, fotemustine. One of the more promising regimens is a chemohormonal combination therapy, known as the “Dartmouth regimen” or DBDT. This regimen includes the combination of DTIC, BCNU, cisplatin (DDP), and tamoxifen (TAM). This regimen has been tested predominantly in phase II single-institution studies. A review of all reported clinical experience with this regimen included 384 patients with an overall response in 44 percent, a complete response in 14 percent, and a partial response in 30 percent. [100] The first prospective, randomized placebo-controlled trial conducted under the auspices of the National Cancer Institute of Canada has been reported; it failed to demonstrate a statistically significant difference between groups in response or survival. [101] Such results demonstrate the difficulty in analyzing small uncontrolled studies and support the continued comparison of new agents to single-agent DTIC, which remains the standard chemotherapy agent for stage IV disease.

CHEMOIMMUNOTHERAPY The disappointing results of most chemotherapy regimens in metastatic melanoma have led to clinical investigation using combinations of chemotherapy and immunotherapy (see below), which are believed to have different mechanisms of action, in hopes of a synergistic effect. A number of studies have examined the use of IFN-a in combination with chemotherapy. A review of five phase III randomized trials comparing DTIC/IFN to DTIC ± TAM indicates that IFN may increase response duration, but in view of added toxicity and absence of improved survival to date, the combination should be restricted to clinical trial investigation. [102] The use of interleukin 2 (IL-2) and IFN-a with the Dartmouth regimen was studied in 42 patients and reported to have an overall response rate of 57 percent, with 24 percent complete responses and 33 percent partial responses. Significant toxicity accompanies such protocols, however, and the duration of response was short-lived. There is some evidence that cisplatin-based biochemotherapy regimens may have improved response rates with some durable remissions.

BIOLOGIC THERAPY The role of the immune system in inducing spontaneous regression of melanoma has stimulated considerable interest in the use of biologic therapy in melanoma. Various strategies for modulating or stimulating the immune response against melanoma have been devised over the years. Principal treatments that have been investigated include interferons, IL-2, adoptive immunotherapy techniques that use IL-2 in combination with lymphokine-activated killer cells (LAKs) or TILs, monoclonal antibodies, and tumor vaccines.

Interferon Interferon is believed to have activity against melanoma based on its antiproliferative effect and the ability to cause upregulation of human leukocyte antigen (HLA) and tumor antigen expression as well as other immunomodulatory effects. Interferon as adjunct treatment was discussed earlier. For advanced disease, IFN-a has been used as a single agent or in combination with chemotherapy. The response rate is on the order of 10 to 20 percent, with a minority of these complete responses. Response duration is typically less than 6 months, and nonvisceral sites have the best response.

Interleukin IL-2 has been used as a single agent in a variety of doses and regimens in metastatic melanoma. Rosenberg et al. published follow-up data for 134 patients treated with high-dose IL-2 from the NCI Surgery branch. [103], [104] An overall response was seen in 17 percent, a complete response was seen in 7 percent, and a partial response was seen in 10 percent. Of interest, the complete responses were durable, with patients remaining disease-free for as long as 8 years after initiating therapy. High-dose IL-2 therapy is associated with significant toxicity, including deaths caused by myocardial infarction, arrhythmia, capillary leak syndromes, nephrotoxicity, respiratory distress, and sepsis. Early studies involving IL-2 plus LAK cells suggested increased activity compared to IL-2 alone. Follow-up data, however, fail to demonstrate any significant benefit over IL-2 alone. [105] Another category of IL-2 therapy consists of harvesting TILs, expanding these cells in vitro, and readministering the TILs plus IL-2 to the patient. Summary results of the NCI Surgery branch experience involving 86 patients treated with bolus IL-2 and TIL therapy, determine an overall response rate of 34 percent with 5 complete responses and 24 partial responses. [106] Combinations of IL-2 with IFN results in increased toxicity without significant benefit. [106]

Monoclonal antibodies Murine and human monoclonal antibodies (MAbs) are experimental therapies of potential use in melanoma. MAbs recognize melanoma-associated antigens, such as peptidoglycans, transferrin receptor-related

antigens, glycoproteins, high-molecular-weight melanoma-associated antigens, sialoglycoproteins, and gangliosides. [106] MAbs are being developed as direct therapeutic agents to elicit a host immune response, as well as conjugating MAbs to a radioactive isotope for diagnostic imaging of metastases, or to a cytotoxic or other agent for therapeutic effect. Clinical trials using unconjugated murine MAbs have demonstrated clinical responses, particularly using monoclonal antibodies against GD2 and GD3 gangliosides. [106]

Melanoma vaccines Melanoma vaccines have been developed in an attempt to stimulate a specific immune response against melanoma-associated antigens. [107], [108] Initial strategies in vaccine therapy included the use of tumor-cell vaccines either using autologous tumor cells or allogeneic melanoma cell lines. Several thousand patients have been treated with such tumor-cell vaccines with an overall response rate of 10 to 20 percent. Attempts to increase immunogenicity of tumor vaccines include treating melanoma cells with viruses (e.g., Newcastle, vaccina), using mechanical lysates, and as using nonspecific immunologic adjuvants such as BCG or DETOX. [108] Evolving strategies include the use of vaccines using defined melanoma antigens known to be immunogenic (gangliosides such as GM2), the development of melanoma-derived peptide antigen vaccines (e.g., MART-1, gp-100), and the development of gene therapy to transfect and genetically alter melanoma cells to secrete cytokines of interest or increase immunogenicity by enhanced antigen expression. The latter approach is based on studies demonstrating that vaccination of mice with cytokine-secreting melanoma cells can protect them from an otherwise lethal challenge with wild-type cancer cells, and can lead to the regression of melanoma cell deposits. Studies have been conducted to test safety, tolerability and, immunostimulatory potency of such cancer vaccines in patients with advanced melanoma. [109] More recently, knowledge of the potent antitumor activity of dendritic cells led to development of dendritic cell vaccines. These vaccines are produced by pulsing autologous dendritic cells with melanoma tumor epitopes to stimulate host antitumor activity. [110] Such novel but exciting therapies remain investigational and are currently the subject of ongoing and future clinical trial research. Table 93-11 reviews the major types of melanoma vaccines and the advantages and disadvantages of each.

TABLE 93-11 **Advantages and Disadvantages of Melanoma Vaccine Preparations**

FOLLOW-UP EVALUATION

Periodic examination of patients with melanoma is aimed both at detecting recurrence of melanoma and at the development of a second primary. Standardized follow-up schedules have been generated based on the frequency of recurrence for various melanoma thickness categories (Table 93-12). Based on data for 3171 patients with stage I melanoma followed for a mean of almost 10 years, McCarthy and his associates observed that thicker melanomas (>3.0 mm) recurred about eight times more frequently and much more rapidly (50 percent of recurrences within 1 to 1.5 years) than did thin tumors (>0.7 mm). [111] Thus, patients with thick tumors, particularly >1.5 mm, require close surveillance in the first 2 years of follow-up. Thin tumors (<0.76 mm) may be followed less frequently as the risk of recurrence is only approximately 1 percent per year. In general, after 5 years all patients should be followed on a yearly schedule unless they have dysplastic nevi, in which case visits should be every 6 months. The risk of a second primary is significantly increased in patients with dysplastic nevi and a family history of melanoma. Annual examination should continue for a minimum of 10 years and probably for life, as late recurrences develop in about 3 percent of patients. Continued follow-up is also advised for patients with dysplastic nevi.



TABLE 93-12 **Guidelines for Follow-up of Patients with Clinical Stages I and II Melanoma**

The history and physical examination are fundamental for the detection of recurrent melanoma. The history should emphasize new or persistently changing lesions and pertinent review of symptoms such as development of cough, headache, or bone pain. The physical examination should include a comprehensive skin examination with attention to the previous primary excision site for local recurrence, regional lymphatic drainage route, and lymph nodes, liver, and spleen. Patients with dysplastic nevi must be carefully evaluated for changing lesions or nevi sufficiently atypical to require histologic evaluation. Photography is useful for following clinically atypical nevi.

REFERENCES

1. Balch CM et al: Prognostic factors analysis of 17,600 melanoma patients: Validation of the American Joint Committee on Cancer melanoma staging system. *J Clin Oncol* **19**:3622, 2001

2. Clark WH Jr et al: The histogenesis and biologic behavior of primary human malignant melanomas of the skin. *Cancer Res* **29**:705, 1969

3. Breslow A: Thickness, cross-sectional areas and depth of invasion in the prognosis of cutaneous melanoma. *Ann Surg* **172**:902, 1970

4. Rigel DS: Melanoma update: 2001. *Skin Cancer Found J* **19**:13, 2001

5. Ahmedin J et al: Cancer statistics, 2002. *CA Cancer J Clin* **52**:23, 2002

6. Cosary CL et al: SEER Cancer Statistics Review, 1973–1992. Bethesda, MD, National Cancer Institute, NRH Pub. No. 96-2789, 1995

7. Elwood JM: Melanoma and sun exposure. *Semin Oncol* **23**:650, 1996

8. Langley RGB, Sober AJ: A clinical review of the evidence for the role of ultraviolet radiation in the etiology of cutaneous melanoma. *Cancer Invest* **15**:561, 1997

9. Holman CD et al: Epidemiology of pre-invasive and invasive malignant melanoma in western Australia. *Int J Cancer* **25**:317, 1980

10. Holman CD, Armstrong BK: Cutaneous malignant melanoma and indicators of total accumulated exposure to the sun: An analysis separating histogenetic types. *J Natl Cancer Inst* **73**:75, 1984

11. Holly EA et al: Cutaneous melanoma in women: I. Exposure to sunlight, ability to tan, and other risk factors related to ultraviolet light. *Am J Epidemiol* **141**:923, 1995

12. Stern RS et al: Malignant melanoma in patients treated for psoriasis with methoxsalen (psoralen) and ultraviolet A radiation (PUVA). *N Engl J Med* **336**:1041, 1997

13. Stern RS: The risk of melanoma in association with long-term exposure to PUVA. *J Am Acad Dermatol* **44**:755, 2001

14. Holly EA et al: Number of melanocytic nevi as a major risk factor for malignant melanoma. *J Am Acad Dermatol* **17**:459, 1987

15. Tucker MA et al: Clinically recognized dysplastic nevi: A central risk factor for cutaneous melanoma. *JAMA* **277**:1439, 1997

16. Clark WH Jr et al: Model predicting survival in stage I melanoma based on tumor progression. *J Natl Cancer Inst* **81**:1893, 1989

17. Mackie RM: Pregnancy and exogenous female sex hormones in melanoma patients, in *Cutaneous Melanoma,* 3d ed, edited by CM Balch, AN Houghton, AJ Sober, SJ Soong. St Louis, Quality Medical Publishing, 1998, p 187

18. Herlyn M et al: Biology of tumor progression in human melanocytes. *Lab Invest* **56**:461, 1987

19. Clark WH Jr et al: A study of tumor progression: The precursor lesions of superficial spreading and nodular melanoma. *Hum Pathol* **15**:1147, 1984

20. Holman CDJ et al: A theory of the etiology and pathogenesis of human cutaneous malignant melanoma. *J Natl Cancer Inst* **71**:651, 1983

21. Anderson DE et al: Hereditary aspects of malignant melanoma. *JAMA* **200**:741, 1967

22. Greene MH: Familial cutaneous malignant melanoma: Autosomal dominant trait possibly linked to the Rh locus. *Proc Natl Acad Sci U S A* **80**:6071, 1983

23. Bale SJ et al: Mapping the gene for hereditary cutaneous melanoma-dysplastic nevus to chromosome 1p. *N Engl J Med* **320**:1367, 1989

24. Kamb A et al: A cell cycle regulator potentially involved in genesis of many tumor types. *Science* **264**:436, 1994

25. Nobori T et al: Deletions of the cyclin-dependent kinase-4 inhibitor gene in multiple human cancers. *Nature* **368**:753, 1994

26. Fountain JW et al: Homozygous deletions within human chromosome band 9p21 in melanoma. *Proc Natl Acad Sci U S A* **89**:10557, 1992

27. Petty EM et al: Molecular definition of a chromosome 9p21 germ-line deletion in a woman with multiple melanomas and a plexiform neurofibroma: Implications for 9p tumor suppressor gene(s). *Am J Hum Genet* **53**:96, 1993

28. Cannon-Albright LA et al: Assignment of a locus for familial melanoma, MLM, to chromosome 9p13-p22. *Science* **258**:1148, 1992

29. Piepkorn M: Melanoma genetics: An update with focus on the CDKN2A (p16)/ARF tumor suppressors. *J Am Acad Dermatol* **42**:705, 2000

30. Cannon-Albright LA et al: Penetrance and expressivity of the chromosome 9p melanoma susceptibility locus (MLM). *Cancer Res* **54**:6041, 1994

31. Davies et al: Mutations in the BRAF gene in human cancer. *Nature* **9**:1, 2002

32. Halaban R: The regulation of normal melanocyte proliferation. *Pigment Cell Res* **13**:4, 2000

33. Tsao H et al: Precursor lesions and markers of increased risk for melanoma, in *Cutaneous Melanoma,* 3d ed, edited by CM Balch, AN Houghton, AJ Sober, SJ Soon. St. Louis, Quality Medical Publishing, 1998

34. Cohen LM: Lentigo maligna and lentigo maligna melanoma. *J Am Acad Dermatol* **33**:923, 1995

35. Weinstock MA, Sober AJ: The risk of progression of lentigo maligna to lentigo maligna melanoma. *Br J Dermatol* **116**:303, 1987

36. Langley RGB et al: Clinical characteristics, in *Cutaneous Melanoma,* 3d ed, edited by CM Balch, AN Houghton, AJ Sober, SJ Soong. St Louis, Quality Medical Publishing, 1998, p 81

37. Rhodes AR et al: Nonepidermal origin of malignant melanoma associated with a giant congenital nevocellular nevus. *Plast Reconstr Surg* **67**:782, 1981

38. DeDavid M et al: A study of large congenital melanocytic nevi and associated malignant melanomas: Review of cases in the New York University Registry and the world literature. *J Am Acad Dermatol* **36**:409, 1997

39. Bittencourt FV et al: Large congenital melanocytic nevi and the risk for development of malignant melanoma and neurocutaneous melanocytosis. *Pediatrics* **106**:736, 2000

40. Driscol MS et al: Does pregnancy influence the prognosis of malignant melanoma? *J Am Acad Dermatol* **29**:619, 1993

41. Ceballus PI et al: Melanoma in children. *N Engl J Med* **332**:656, 1995

42. Karakousis CP et al: Local recurrence in malignant melanoma: Long-term results of the multi-institutional randomized surgical trial. *Ann Surg Oncol* **3**:446, 1996

43. Cohn-Cedermark G et al: Outcomes of patients with local recurrence of cutaneous malignant melanoma. *Cancer* **80**:1418, 1997

44. Balch CM et al: Final version of the American Joint Committee on Cancer staging system for cutaneous melanoma. *J Clin Oncol* **19**:3635, 2001

45. Balch CM: Surgical management of regional lymph node metastases in cutaneous melanoma. *J Am Acad Dermatol* **3**:511, 1980

46. Meyers ML et al: Diagnosis and treatment of metastatic melanoma, in *Cutaneous Melanoma,* 3d ed, edited by CM Balch, AN Houghton, AJ Sober, SJ Soong. St Louis, Quality Medical Publishing, 1998, p 325

47. Crowley NJ, Seigler HF: Late recurrence of malignant melanoma. *Ann Surg* **212**:173, 1990

48. Tsao H et al: Ultra-late recurrence (15 years or longer) of cutaneous melanoma. *Cancer* **79**:2361, 1997

49. Reintgen DS et al: Metastatic malignant melanoma with an unknown primary. *Surg Gynecol Obstet* **156**:335, 1983

50. Chang P, Knapper WH: Metastatic melanoma of unknown primary. *Cancer* **49**:1106, 1982

51. Schlagenhauff B et al: Metastatic melanoma of unknown primary origin shows prognostic similarities to regional metastatic melanoma: Recommendations for initial staging examinations. *Cancer* **80**:60, 1997

52. Langley RGB, Sober AJ: Causes for the delay in the diagnosis of melanoma, in *Epidemiology, Causes and Prevention of Skin Diseases,* edited by JJ Grob, RS Stern, RM MacKie, WA Weinstock. Cambridge, UK, Blackwell, 1997, p 177

53. Pehamberger H et al: In vivo epiluminescence microscopy of pigmented skin lesions: I. Pattern analysis of pigmented skin lesions. *J Am Acad Dermatol* **17**:571, 1987

54. Steiner A et al: In vivo epiluminescence microscopy of pigmented skin lesions: II. Diagnosis of small pigmented skin lesions and early detection of malignant melanoma. *J Am Acad Dermatol* **17**:584, 1987

55. Pehamberger H et al: In vivo epiluminescence microscopy: Improvement of early diagnosis of melanoma. *J Invest Dermatol* **100**:356S, 1993

56. Soyer HP et al: *Dermoscopy of Pigmented Skin Lesions*. Milan, EDRA Med Publishing and New Media, 2001

57. Nachbar F et al: The ABCD rule of dermatoscopy: High prospective value in the diagnosis of doubtful melanocytic skin lesions. *J Am Acad Dermatol* **30**:551, 1994

58. Langley RGB, Sober AJ: *New Techniques in the Early Diagnosis of Melanoma: Melanogenesis and Malignant Melanoma: Biochemistry, Cell Biology, Molecular Biology, Pathophysiology, Diagnosis, and Treatment*. (International Congress Series 1096.) Excerpta Medica, St Louis, MO 1996, p 233

59. Binder M et al: Epiluminescence microscopy: A useful tool for the diagnosis of pigmented skin lesions for formally trained dermatologists. *Arch Dermatol* 131:286, 1995

60. Wolff K: Why is epiluminescence microscopy important?, in *Cancers of the Skin,* edited by R Dumer, FO Nestle, G Burg. Berlin, Springer, 2002, p 125

61. Elbaum M et al: Automatic differentiation of melanoma from melanocytic nevi with multispectral digital dermoscopy: A feasibility study. *J Am Acad Dermatol* **44**:207, 2001

62. Langley RG et al: Confocal scanning laser microscopy of benign and malignant skin lesions in vivo. *J Am Acad Dermatol* **45**:365, 2001

63. Barnhill RL et al: Predicting five-year outcome for patients with cutaneous melanoma in a population-based study. *Cancer* **79**:423, 1997

64. Kopf AW et al: Prognostic index for malignant melanoma. *Cancer* **59**:1236, 1987

65. Day CL et al: Prognostic factors for melanoma patients with lesions 0.76 mm–1.69 mm in thickness: An appraisal of “thin” level IV lesions. *Ann Surg* **195**:30, 1982

66. Buzzell RA et al: Favorable prognostic factors in recurrent and metastatic melanoma. *J Am Acad Dermatol* **34**:798, 1996

67. Breslow A, Macht SD: Optimal size of resection margin for thin cutaneous melanoma. *Surg Gynecol Obstet* **145**:691, 1977

68. Veronesi U et al: Thin stage I primary cutaneous malignant melanoma. *N Engl J Med* **318**:1159, 1988

69. Veronesi U, Cascinelli N: Narrow excision (1 cm margin). *Arch Surg* **126**:438, 1991

70. Balch CM et al: Efficacy of 2 cm surgical margins for intermediate-thickness melanomas (1 to 4 mm). *Ann Surg* **218**:262, 1993

71. Sober AJ et al: Guidelines of care for primary cutaneous melanoma. *J Am Acad Dermatol* **45**:579, 2001

72. Piepkorn M, Barnhill RL: A factual, not arbitrary, basis for choice of resection margins in melanoma. *Arch Dermatol* **132**:811, 1996

73. NIH Consensus Conference: Diagnosis and treatment of early melanoma. *JAMA* **268**:1314, 1992

74. Veronesi U et al: Inefficacy of immediate node dissection in stage I melanoma of the limbs. *N Engl J Med* **297**:627, 1977

75. Veronesi U et al: Delayed regional node dissection: Delayed regional lymph node dissection in stage I melanoma of the skin of the lower extremities. *Cancer* **49**:2420, 1982

76. Sim FH et al: Lymphadenectomy in the management of stage I malignant melanoma: A prospective randomized study. *Mayo Clin Proc*

61:697, 1986

77. Balch CM et al: Efficacy of an elective regional lymph node dissection of 1 to 4 mm thick melanomas for patients 60 years of age and younger. *Ann Surg* **224**:255, 1996

78. Cascinelli N et al: Immediate or delayed dissection of regional nodes in patients with melanoma of the trunk: A randomized trial (WHO melanoma programme). *Lancet* **351**:793, 1998

79. Lens MB et al: Elective lymph node dissection in patients with melanoma: Systematic review and meta-analysis of randomized controlled trials. *Arch Surg* **137**:458, 2002

80. Morton DL et al: Technical details of intraoperative lymphatic mapping for early stage melanoma. *Arch Surg* **127**:392, 1992

81. Krag DN et al: Minimal-access surgery for staging of malignant melanoma. *Arch Surg* **130**:654, 1995

82. Gershenwald JE et al: Patterns of recurrence following a negative sentinel lymph node biopsy in 243 patients with stage I or II melanoma. *J Clin Oncol* **16**:2253, 1998

83. Thomas JM, Patocskai EJ: The argument against sentinel node biopsy for malignant melanoma. *BMJ* **321**:3, 2000

84. McMasters et al: Sentinel lymph node biopsy for melanoma: Controversy despite widespread agreement. *J Clin Oncol* **19**:2851, 2001

85. Koops HS et al: Prophylactic isolated limb perfusion for localized, high-risk limb melanoma: Results of a multicenter randomized phase III trial. European Organization for Research and Treatment of Cancer Malignant Melanoma Cooperative Group Protocol 18832, the World Health Organization Melanoma Program Trial 15, and the North American Perfusion Group Southwest Oncology Group-8593. *J Clin Oncol* **16**:2906, 1998

86. Lejeune FJ et al: An assessment of DTIC versus levamisole or placebo in the treatment of high risk stage I patients after surgical removal of a primary melanoma of the skin: A phase III adjuvant study (EORTC protocol 18761). *Eur J Cancer* **24**(suppl 2):81, 1988

87. Loutfi A et al: Double blind randomized prospective trial of levamisole/placebo in stage I cutaneous malignant melanoma. *Clin Invest Med* **10**:325, 1987

88. Spitler LE: A randomized trial of levamisole versus placebo as adjuvant therapy in malignant melanoma. *J Clin Oncol* **9**:736, 1991

89. Quirt IC et al: Improved survival in patients with poor prognosis malignant melanoma treated with adjuvant levamisole: A phase III study by the National Cancer III Trial by the National Cancer Institute of Canada clinical trials group. *J Clin Oncol* **9**:729, 1991

90. Kirkwood JM et al: Interferon alfa-2b adjuvant therapy of high-risk resected cutaneous melanoma: The Eastern Cooperative Oncology Group Trial EST 1684. *J Clin Oncol* **14**:7, 1996

91. Cole BF et al: Quality-of-life-adjusted survival analysis of interferon alfa-2b adjuvant therapy of high-risk resected cutaneous melanoma: The Eastern Cooperative Oncology Group Trial EST 1684. *J Clin Oncol* **14**:2666, 1996

92. Kirkwood JM et al: High- and low-dose interferon alfa-2b in high-risk melanoma: First analysis of intergroup trial E1690/S9111/C9190. *J Clin Oncol* **18**:2444, 2000

93. Kirkwood JM et al: High-dose interferon alfa-2b significantly prolongs relapse-free and overall survival compared with the GM2-KLH/QS-21 vaccine in patients with resected stage IIB-III melanoma: Results of intergroup trial E1694/S9512/C509801. *J Clin Oncol* **19**:2370, 2001

94. Pehamberger H et al: Adjuvant interferon alpha-2a treatment in resected primary stage II cutaneous melanoma. *J Clin Oncol* **16**:1425, 1998

95. Grob JJ et al: Randomized trial of interferon alpha-2a as adjuvant therapy in resected primary melanoma thicker than 1.5mm without clinically detectable node metastases. *Lancet* **351**:1905, 1998

96. Lens MB, Dawes M: Interferon alfa therapy for malignant melanoma: A systematic review of randomized controlled trials. *J Clin Oncol* **20**:1818, 2002

97. Balch CM et al: Cutaneous melanoma, in *Cancer Principles and Practice of Oncology,* 5th ed, edited by VT Devita, S Hellman, SA Rosenberg. Philadelphia, Lippincott Raven, 1997, p 1947

98. Biasco G et al: Treatment of brain metastases of malignant melanoma with temozolomide. *N Engl J Med* **345**:621, 2001

99. Crosby T et al: Systemic treatments for metastatic cutaneous melanoma (Cochrane Review). The Cochrane Library 1, 2002. Oxford: Update Software.

100. McClay MC, McClay MT: Systemic chemotherapy for the treatment of metastatic melanoma. *Semin Oncol* **23**:744, 1996

101. Rusthoven J et al: Randomized, double-blind, placebo-controlled trials comparing the response rates of carmustine, dacarbazine, and cisplatinum with and without tamoxifen in patients with metastatic melanoma. *J Clin Oncol* **14**:2083, 1996

102. Buzaid AC et al: Systemic chemotherapy and biochemotherapy, in *Cutaneous Melanoma,* 3d ed, edited by CM Balch, AN Houghton, AJ Sober, SJ Soong. St Louis, Quality Medical Publishing, 1998, p 405

103. Rosenberg SA et al: Treatment of 283 consecutive patients with metastatic melanoma or renal cell cancer using high dose bolus interleukin-2. *JAMA* **271**:907, 1994

104. Rosenberg SA et al: A progress report on the treatment of 157 patients with advanced cancer using lymphokine-activated killer cells and interleukin-2 or high-dose interleukin-2 alone. *N Engl J Med* **316**:889, 1987

105. Chapman PB et al: Biologic therapy, in *Cutaneous Melanoma,* 3d ed, edited by CM Balch, AN Houghton, AJ Sober, SJ Soong. St Louis, Quality Medical Publishing, 1998, p 419

106. Leong SP: Immunotherapy of malignant melanoma. *Surg Clin North Am* **76**:1355, 1996

107. Fearon ER et al: Interleukin-2 production by tumor cells bypasses T helper function in the generation of an ntitumor response. *Cell* **60**:397, 1990

108. Livingston P, Sznol M: Vaccine therapy, in *Cutaneous Melanoma,* 3d ed, edited by CM Balch, AN Houghton, AJ Sober, SJ Soong. St

Louis, Quality Medical Publishing, 1998, p 437

109. Schreiber S et al: Immunotherapy of metastatic malignant melanoma by a vaccine consisting of autologous IL-2 transfected cancer cells-outcome of a phase I study. *Proc Nat Acad Sci, USA* **10**:983, 1999

110. Nestle FO et al: Vaccination of melanoma patients with peptide- or tumor lysate-pulsed dendritic cells. *Nat Med* **4**:328, 1998

111. McCarthy WH et al: Time and frequency of recurrence of cutaneous stage I malignant melanoma with guidelines for follow-up study. *Surg Gynecol Obstet* **166**:497, 1988

T>

Chapter 94

Herbert Hönigsmann Philip Cohen Klaus Wolff

Acute Febrile Neutrophilic Dermatosis (Sweet's Syndrome)

INCIDENCE
ETIOLOGY
CLINICAL FEATURES
LABORATORY FINDINGS
PATHOLOGY
IMMUNOFLUORESCENCE
ASSOCIATED DISEASES
DIAGNOSIS AND DIFFERENTIAL DIAGNOSIS
TREATMENT
COURSE AND PROGNOSIS

REFERENCES

In 1964, Robert Douglas Sweet [1] described eight women who had a distinct, previously unrecognized condition that he termed *acute febrile neutrophilic dermatosis.* This dramatic skin disease is characterized by recurrent painful plaque-forming inflammatory papules or nodules, fever, peripheral leukocytosis, a diffuse dermal neutrophilic infiltrate, and prompt resolution of symptoms and lesions with glucocorticoid therapy. Since Sweet's original paper, several hundred cases of Sweet's syndrome have been reported. [2], [3]

INCIDENCE

Sweet's syndrome has a worldwide distribution and no racial predilection. [2], [3] The disease presents in three clinical settings (Table 94-1): (1) classic or idiopathic Sweet's syndrome, which may be associated with infection (upper respiratory tract or gastrointestinal tract), inflammatory bowel disease, or pregnancy, (2) malignancy-associated or paraneoplastic Sweet's syndrome, in which the onset and/or recurrence of the dermatosis is temporally associated with the presence of cancer, and (3) drug-induced Sweet's syndrome, which occurs most frequently in patients who are receiving granulocyte colony-stimulating factor (G-CSF) but also may develop during treatment with antibiotics, antiepileptic drugs, antihypertensive agents, oral contraceptives, or retinoids. [4], [5]

TABLE 94-1 **Clinical Features in Patients with Sweet's Syndrome**

Idiopathic and drug-induced Sweet's syndrome predominantly affects women. Patients typically range between 30 and 50 years of age, but younger adults and children may be affected. [6], [7] The youngest patient recognized was a 7-week-old infant. [6] Malignancy-associated Sweet's syndrome does not have a female predominance (see Table 94-1). In this setting, the dermatosis is usually associated with a hematologic malignancy—most commonly acute myelogenous leukemia. [8] Carcinomas of the genitourinary organs, breast, and gastrointestinal tract are the most frequently occurring cancers in Sweet's syndrome patients with solid tumors. [9] Medications that have been implicated in causing drug-induced Sweet's syndrome are listed in Table 94-2. [5], [10]



TABLE 94-2 **Medications Associated with Drug-Induced Sweet's Syndrome***

ETIOLOGY

There is no known cause of Sweet's syndrome. Fever and peripheral leukocytosis suggest a septic process, but antibiotics usually do not influence the course of disease. Although there is no conclusive evidence that a bacterial

infection has a causative role, most patients have a febrile upper respiratory tract infection, tonsillitis, or influenza-like illness that precedes their skin lesions by 1 to 3 weeks. Sweet's syndrome reportedly improved with systemic antibiotics in patients who had culture- and serology-confirmed intestinal infection with *Yersinia enterolitica.* [11], [12] A case of exclusively photoinduced Sweet's syndrome has been reported; in this patient, an eruption recurred 1 or 2 days after prolonged exposure to the sun every summer for 8 years. [13]

The clinical appearance, course, and histopathology indicate that Sweet's syndrome may represent a form of hypersensitivity reaction to a bacterial, viral, or perhaps tumor antigen. [14] Several characteristics of the skin lesions (clinical appearance, course, and histopathology) support this hypothesis. Also consistent with this concept is the favorable response of the symptoms and lesions to systemic glucocorticoids.

Massive tissue leukocytosis strongly implies a pathogenic role for leukotactic mechanisms. [14] However, contradictory findings have been reported on leukocyte function and their response to chemotactic stimuli. [3], [4], [15], [16] Complement does not appear to be essential to the disease process. Some investigators postulate that dermal dendrocytes may have a prominent role in the pathogenesis of Sweet's syndrome. [17]

A possible role for circulating autoantibodies, [4], [18] immune complexes, [8] or cytokines [19], [20] has been postulated. Although an increased frequency of HLA-BW54 has been described in Japanese patients with Sweet's syndrome, a subsequent study was unable to demonstrate a significant association between Sweet's syndrome and certain HLA-ABC antigens in Caucasians. [21], [22] Antibodies to neutrophilic cytoplasmic antigens (ANCAs) have been observed in some patients, [23] but they likely represent an epiphenomenon. [2], [3]

Cytokines that possibly may cause the symptoms and lesions of this disease include G-CSF, granulocyte-macrophage colony-stimulating factor (GM-CSF), interferon-? (IFN-?), interleukin l (IL-1), IL-3, IL-6, IL-8. [5], [19], [24], [25] and [26] GM-CSF was detected in the intraarticular synovial and fluid of an 8-month-old boy with Sweet's syndrome–associated acute arthritis. [27] In a patient with myelodysplastic syndrome–associated, non-G-CSF-induced Sweet's syndrome, the levels of G-CSF and IL-6 were elevated. [26]

In a recent study, the patients' serum levels of IL-1a, IL-1ß, IL-2, and IFN-? were significantly elevated, whereas the IL-4 level was within the normal range. It was suggested therefore that the pathogenesis of Sweet's syndrome may be mediated through helper T cell type 1 cytokines (IL-2, IFN-?) rather than helper T cell type 2 cytokines (IL-4). [28]

CLINICAL FEATURES

The typical skin lesions are red or bluish red papules or nodules that show a strong tendency to coalesce and to form irregular, sharply bordered plaques (Fig. 94-1A). Such lesions have been compared with a “relief of a mountain range” [12] (see Fig. 94-1B). The pronounced inflammatory edema is often responsible for a transparent vesicular appearance of the lesions, although they are solid on palpation [14] (Fig. 94-2). This phenomenon has been described as an “illusion of vesiculation.” [1] In later stages, the tops of the papules occasionally may become studded with tiny pustules, and central clearing may lead to annular or arcuate patterns. The lesions are tender and often painful, tend to enlarge over a period of days or weeks, and resolve eventually without scarring after weeks or months. The eruption may present with a single lesion or multiple lesions, characteristically in an asymmetric distribution (Fig. 94-3). Most commonly, the upper extremities, face, and neck are involved, but lesions also develop on the trunk and lower limbs (see Table 94-1); leg lesions can mimic a panniculitis such as erythema nodosum. Widespread or even generalized forms have been reported (see Fig. 94-2), particularly in the malignancy-associated form, which generally exhibits more severe symptoms of the disease. Involvement of the oral mucosa is uncommon in the idiopathic form; however, it does occur—particularly in patients with hematologic disorders [8] (see Table 94-1). Skin hypersensitivity (cutaneous pathergy) may be present; lesions have occurred at the sites of stimuli such as biopsies, cat scratches, insect bites, intravenous catheter placement sites, and venipuncture sites. [2], [3], [8] About half of patients experience recurrences, often at previously involved sites.

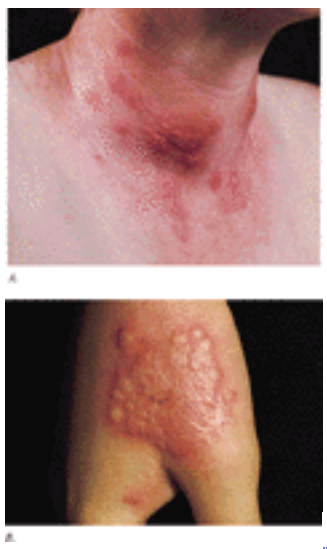

FIGURE 94-1 Acute febrile neutrophilic dermatosis. Typical lesions consisting of coalescing, plaque-forming papules. *A.* Bright-red lesions on the neck. *B.* Lesion on the dorsum of the right hand exhibiting the “relief of a mountain range” feature. (*From Hönigsmann and Wolff* [14] *with permission.*)

FIGURE 94-2 Multiple confluent papules and plaques that at first sight give the illusion of vesiculation but are solid on palpation. (*From Hönigsmann et al: Akute febrile neutrophile Dermatose. Wien Klin Wochenschr 91:842, 1979, with permission*.)

FIGURE 94-3 Unilateral lesions around the eye and upper lip consisting of plaques and pseudovesicular papules suggesting herpes simplex.

The systemic symptoms that accompany the skin eruption are fever and leukocytosis, and patients often appear dramatically ill. However, not all patients with Sweet's syndrome express the whole spectrum of symptoms, [4] and fever, neutrophilia, or both may be absent [4], [14] (see Table 94-1). A period of fever may precede the skin disease by several days or weeks and may be present throughout the entire course. Additional symptoms that may occur to varying degrees are headache, arthralgia, myalgia, and general malaise. Ocular manifestations such as conjunctivitis and episcleritis may be present; less commonly, conjunctival hemorrhage, glaucoma, iritis, limbal nodules, and ocular congestion have been observed. [2], [3], [8], [29], [30]

Extracutaneous manifestations may affect the bone, central nervous system, gastrointestinal tract, kidney, liver, and lung. Dermatosis-related sterile osteomyelitis has been described in children. [2] Neurologic involvement has presented with aseptic meningitis, neurologic and psychiatric symptoms, and neutrophils in the cerebrospinal fluid. [6], [31], [32] Renal involvement manifests most commonly as proteinuria, less often as hematuria and mesangiocapillary glomerulonephritis. [8], [33] Hepatic involvement was shown by liver biopsy, which revealed infiltration of the portal triad and tracts [8], [33]; hepatic enzyme abnormalities have been observed in other patients. [2], [3] Pulmonary features of Sweet's syndrome were glucocorticoid-responsive, culture-negative infiltrates on chest x-rays and/or neutrophilic infiltrates on open lung biopsies. [3], [34]

LABORATORY FINDINGS

An elevated erythrocyte sedimentation rate and peripheral leukocytosis with neutrophilia are the most consistent laboratory findings (see Table 94-1). White blood cell counts range from 10,000 to 20,000/mm [3]. However, not all patients with biopsy-confirmed Sweet's syndrome exhibit leukocytosis. [8] In patients with malignancy-associated Sweet's syndrome, anemia, a normal or low neutrophil count, and an abnormal platelet count may be present. [4] Proteinuria occurs in patients with renal involvement.

PATHOLOGY

The most prominent histopathologic features are edema of the dermal papillae and a dense infiltrate of mature leukocytes in the dermis (Fig. 94-4). In some patients with hematologic malignancy–associated Sweet's syndrome, concurrent leukemia cutis has been demonstrated in the lesion. [35] The infiltrate is usually diffuse, with occasional eosinophils and lymphocytes. Fragmented neutrophil nuclei (leukocytoclasia or karyorrhexis) are quite common and, at low magnification, may suggest vasculitis (Fig. 94-5). In some lesions of Sweet's syndrome, secondary vasculitis (occurring as an epiphenomenon in which the affected vessel is most frequently an “innocent bystander” within moderate to extensive, diffuse or bandlike dermal inflammation) has been observed. [36], [37] Usually, the epidermis is normal. Spongiosis and exocytosis have been reported, and rarely there may be a subcorneal pustule. In deep-seated nodular lesions, the neutrophilic infiltrates may be confined to the subcutaneous tissue (in the lobules, the septa, or both) or localized within both the dermis and the subcutaneous fat. [14], [35], [37]

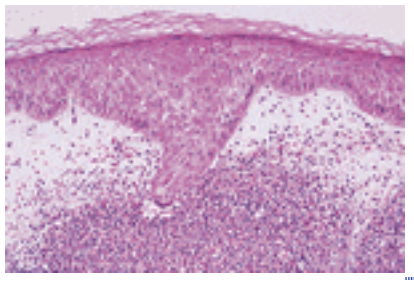

FIGURE 94-4 Histopathologic presentation of massive edema of the papillary dermis and a dense diffuse infiltrate of mature neutrophils throughout the upper dermis (hematoxylin and eosin stain). (*From Cohen et al.* [9] *with permission.*)

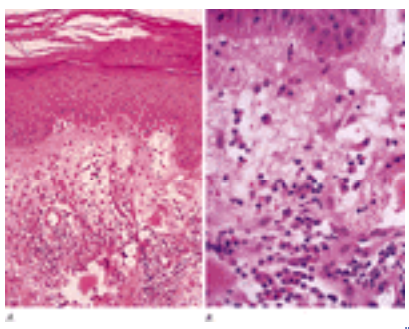

FIGURE 94-5 Characteristic histopathologic features of Sweet's syndrome are observed at low (*A*) and high (*B*) magnification: papillary dermal edema, swollen endothelial cells, and a diffuse infiltrate of predominantly neutrophils with leukocytoclasia, yet no evidence of vasculitis (hematoxylin and eosin stain). (*From Cohen et al.* [24] *with permission.*)

Electron microscopy does not reveal endothelial cell damage but rather signs of metabolic activation, as indicated by the abundance of endoplasmic reticulum, mitochondria, and multiple Golgi areas in the endothelial cells. [14] The vessels are separated from the cellular infiltrate by a relatively broad electron-lucent zone occupied by multiple concentrically arranged basal laminae and a finely fibrillar and vesicular material consisting of plasma constituents and cell debris, which also may be found in the vascular lumen. Such findings are consistent with endothelial repair and regeneration after endothelial damage.

IMMUNOFLUORESCENCE

Direct immunofluorescence of lesional skin is noncontributory. Deposits of IgG, IgM, C3, and fibrin are diffusely distributed in a perivascular arrangement, but this distribution may represent only a nonspecific inflammatory exudate. [28], [36]

ASSOCIATED DISEASES

Various other conditions have been observed in patients with Sweet's syndrome (Table 94-3). Some of them appear to have a possible etiologic role in the pathogenesis of Sweet's syndrome, [2], [3] and [4], [12], [38], [39] but others are likely to be coincidental. [10]

Probably bona fide associated conditions
Cancer: hematologic malignancies (most commonly acute myelogenous leukemia) and solid tumors (most commonly carcinomas of the genitourinary organs, breast, and gastrointestinal tract)
Infections: most commonly of the upper respiratory tract (streptococcosis) and the gastrointestinal tract (yersiniosis)
Inflammatory bowel disease: Crohn's disease and ulcerative colitis
Medications: most commonly granulocyte-colony-stimulating factor
Pregnancy
Possibly bona fide associated conditions
Behçet's disease
Erythema nodosum
Rheumatoid arthritis
Sarcoidosis
Thyroid disease: Grave's disease and Hashimoto's thyroiditis
Validity of associated conditions remains to be established
Autoimmune disorders: dermatomyositis, lupus erythematosus, relapsing polychondritis, Sjögren's syndrome
Bronchiolitis obliterans and organizing pneumonia
Chronic granulomatous disease
Cirrhosis (cryptogenic)
Common bile duct and intrahepatic duct stones
Complement deficiency
Congenital dyserythropoietic anemia
Cutis lysa
Dressler's syndrome (postmyocardial infarction syndrome)
Fanconi's anemia
Immunizing agent: BCG vaccination
Infections: atypical mycobacteria, bartholinitis, chlamydia, cholecystitis, cytomegalovirus, hepatitis (chronic active), histoplasmosis, human immunodeficiency virus, lepromy, lymphadenitis (subacute necrotizing), otitis media, pancreatitis, pyelonephritis, salmonellosis, tonsillitis, toxoplasmosis, tuberculosis, zygomycosis, urinary tract, vulvovaginitis
POEMS syndrome: polyneuropathy, organomegaly, endocrinopathy, M protein, and skin changes
Psoriasis vulgaris
Ureter obstruction
Urticaria pigmentosa

TABLE 94-3 **Sweet's Syndrome and Associated Conditions**

More than 85 percent of patients with malignancies have a hematologic disorder, most commonly acute myeloid leukemia. [4], [8], [9] In most cases, the skin lesions either precede the diagnosis of leukemia (by up to several months or even years) or appear concurrently with the discovery of malignancy. Because recurrent episodes often herald cancer recurrence, periodic hematologic follow-up of patients with Sweet's syndrome is recommended. [4]

DIAGNOSIS AND DIFFERENTIAL DIAGNOSIS

Diagnostic criteria for classic (idiopathic and malignancy-associated) and drug-induced Sweet's syndrome are summarized in Table 94-4. [2], [5] The clinical differential diagnosis of Sweet's syndrome is listed in Table 94-5. [2], [8], [9]

Conditions characterized microscopically by neutrophilic dermatosis are in the histologic differential diagnosis of Sweet's syndrome (Table 94-6). [37], [39], [40]

TABLE 94-4 **Diagnostic Criteria for Classic Sweet's Syndrome versus Drug-Induced Sweet's Syndrome**

Cutaneous conditions	Neoplastic conditions
Acral erythema	Chloroma
Drug eruptions	Leukemia cutis
Granuloma faciale	Lymphoma
Haloagnoderma	Metastatic tumor
Infectious and inflammatory	Reactive erythemas
disorders	Erythema multiforme
Bacterial sepsis	Erythema nodosum
Cellulitis	Urticaria
Erysipelas	Systemic diseases
Leprosy	Behçet's disease
Lymphangitis	Bowel bypass syndrome
Panniculitis	Dermatomyositis
Pyoderma gangrenosum	Familial Mediterranean fever
Syphilis	Lupus erythematosus
Systemic mycosis	Vasculitis
Thrombophlebitis	Erythema elevatum diutinum
Tuberculosis	Leukocytoclastic vasculitis
Viral exanthem	Periarteritis nodosa

TABLE 94-5 **Clinical Differential Diagnosis of Sweet's Syndrome**

TABLE 94-6 **Histologic Differential Diagnosis of Sweet's Syndrome**

Early Sweet's syndrome clinically may resemble erythema multiforme, but the asymmetric distribution pattern, the usual absence of oral and genital mucosal involvement, the pronounced tenderness of the lesions, the absence of target-like lesions, and the typical histopathology permit the correct diagnosis.

The differential diagnosis of deep-seated lesions also includes erythema nodosum, which can present either concurrently or sequentially in patients with Sweet's syndrome. [24] Solitary lesions of Sweet's syndrome clinically may mimic herpes simplex because of their peculiar transparent, pseudovesicular appearance, but palpation will reveal their solid consistency. Although pyoderma gangrenosum should not give rise to confusion because of its characteristic ulceration, the lesions may be difficult to differentiate clinically in patients with Sweet's syndrome with hematologic malignancies.

TREATMENT

Although the symptoms, fever, and leukocytosis suggest a septic process, the dermatosis usually persists after treatment with antibiotics. Systemic therapy directed toward *Staphylococcus aureus* may result in slight improvement of skin lesions that have become impetiginized secondarily. There are isolated reports of Sweet's syndrome that resolved after treatment with metronidazole in patients with Crohn's disease [41] and after treatment with doxycycline, [11], [42] minocycline, [12] or tetracycline [43] in patients with or without an associated *Yersinia* infection.

Prompt relief of cutaneous and systemic symptoms is obtained with systemic prednisone in doses of 30 to 60 mg daily; the dose is tapered to 10 mg within 4 to 6 weeks. In some patients, prolonged treatment with lower doses (10–30 mg on alternate days) for 2 or 3 months may be necessary to suppress recurrences. Localized lesions also respond to either high-potency topical glucocorticoids (0.05% clobetasol propionate) or intralesional glucocorticoids (starting at a dose of approximately 3.0 mg/mL of triamcinolone acetonide). [3], [9], [44]

A dramatic response to oral potassium iodide (900 mg daily for 2 weeks) was reported in 1980 [45] and was confirmed subsequently. [9], [46] If potassium iodide tablets are unavailable, an oral saturated solution of potassium iodide (SSKI or Lugol's solution) can be used with either increasing doses [3 drops (in juice) three times each day and increased by 1 drop per day up to a final dose of 10 drops three times each day [14]] or a high dose initially (20 or 30 drops three times each day [39]. Potential drug-induced side effects of potassium iodide include vasculitis and hypothyroidism. [2], [47]

Oral colchicine (1.5 mg daily for 7 days with gradual reduction to 0.5 mg daily over 3 weeks) also has been shown to induce rapid regression of Sweet's syndrome. [15], [48] However, a common drug-limiting side effect is diarrhea. [39] Other agents, [49] used alone or in combination with glucocorticoids, have been reported (predominantly in case reports) to be effective in the treatment of Sweet's syndrome, including chlorambucil, [50] clofazimine, [2] cyclophosphamide, [51] cyclosporine, [2], [52], [53] dapsone, [3], [16] indomethacin, [54] interferon-a, [44] naproxen, [55] and sulfapyridine. [3]

COURSE AND PROGNOSIS

Acute febrile neutrophilic dermatosis is a benign condition, but it may be the sign of malignancy, especially a hematologic disorder. Without treatment, the eruption may persist for weeks or even months and then involute without leaving scars.

Recurrences occur at various intervals after therapy-induced or spontaneous remission in approximately 30 percent of patients and somewhat more frequently in patients with cancer. In the latter group, a recurrence may be the presenting manifestation of recurrent malignancy.

REFERENCES

1. Sweet RD: An acute febrile neutrophilic dermatosis. *Br J Dermatol* **76**:349, 1964

2. von den Driesch: Sweet's syndrome (acute febrile neutrophilic dermatosis). *J Am Acad Dermatol* **31**:535, 1994

3. Fett DL et al: Sweet's syndrome: Systemic signs and symptoms and associated disorders. *Mayo Clin Proc* **70**:234, 1995

4. Cohen PR, Kurzrock R: Sweet's syndrome and cancer. *Clin Dermatol* **11**:149, 1993

5. Walker DC, Cohen PR: Trimethoprim-sulfamethoxazole–associated acute febrile neutrophilic dermatosis: Case report and review of drug-induced Sweet's syndrome. *J Am Acad Dermatol* **34**:918, 1996

6. Dunn TR et al: Sweet's syndrome in a neonate with aseptic meningitis. *Pediatr Dermatol* **9**:288, 1992

7. Boatman BW et al: Sweet's syndrome in children. *South Med J* **87**:193, 1994

8. Cohen PR et al: Malignancy-associated Sweet's syndrome: Review of the world literature. *J Clin Oncol* **6**:1887, 1988

9. Cohen PR et al: Sweet syndrome in patients with solid tumors. *Cancer* **72**:2723, 1993

10. Cohen PR, Kurzrock R: Sweet syndrome: A neutrophilic dermatosis classically associated with acute onset and fever. *Clin Dermatol* **18**:265, 2000

11. Escallier F et al: Sweet's syndrome and *Yersinia enterocolitica* infection. *Ann Dermatol Venereol* **117**:858, 1990

12. Neau D et al: Sweet syndrome and *Yersinia enterocolitica* infection. 2 cases. *Rev Med Interne* **16**:919, 1995

13. Bessis D et al: Photoinduced Sweet syndrome. *Arch Dermatol* **137**:1106, 2001

14. Hönigsmann H, Wolff K: Acute febrile neutrophilic dermatosis (Sweet's syndrome), in *Major Problems in Dermatology*, vol 10, *Vasculitis*, edited by K Wolff, RK Winkelmann, consulting editor A Rook. London, Lloyd-Luke, 1980, p 307

15. Suehisa S et al: Colchicine in the treatment of acute febrile neutrophilic dermatosis (Sweet's syndrome). *Br J Dermatol* **180**:99, 1983

16. Aram H: Acute febrile neutrophilic dermatosis (Sweet's syndrome): Response to dapsone. *Arch Dermatol* **120**:245, 1984

17. Misery L et al: Are neutrophilic dermatoses during granulocytopenia really neutrophilic? (letter). *Arch Dermatol* **132**:832, 1996

18. von den Driesch P, Weber MFA: Are antibodies to neutrophilic cytoplasmic antigens (ANCA) a serologic marker for Sweet's syndrome? (letter). *J Am Acad Dermatol* **29**:666, 1993

19. Cohen PR, Kurzrock R: The pathogenesis of Sweet's syndrome (letter). *J Am Acad Dermatol* **25**:734, 1991

20. Eghrari-Sabet JS, Hartley AH: Sweet's syndrome: An immunologically mediated skin disease? *Ann Allergy* **72**:125, 1994

21. von den Driesch P et al: Analysis of HLA antigens in Caucasian patients with febrile neutrophilic dermatosis (Sweet's syndrome). *J Am Acad Dermatol* **37**:276, 1997

22. Mizoguchi M et al: Human leukocyte antigen in Sweet's syndrome and its relationship to Behçet's syndrome. *Arch Dermatol* **124**:1069, 1988

23. Kemmett D et al: Antibodies to neutrophil cytoplasmic antigens: A serologic marker for Sweet's syndrome. *J Am Acad Dermatol* **24**:967, 1991

24. Cohen PR et al: Concurrent Sweet's syndrome and erythema nodosum: A report, world literature review and mechanism of pathogenesis. *J Rheumatol* **19**:814, 1992

25. Reuss-Borst MA et al: The possible role of G-CSF in the pathogenesis of Sweet's syndrome. *Leukemia Lymphoma* **15**:261, 1994

26. Reuss-Borst MA et al: Sweet's syndrome associated with myelodysplasia: Possible role of cytokines in the pathogenesis of the disease. *Br J Haematol* **84**:356, 1993

27. Tuerlinckx D et al: Sweet's syndrome with arthritis in an 8-month-old boy. *J Rheumatol* **26**:440, 1999

28. Giasuddin AS et al: Sweet's syndrome: Is the pathogenesis mediated by helper T cell type 1 cytokines? *J Am Acad Dermatol* **39**:940, 1998

29. Davies R: Limbal nodules in Sweet's syndrome. *Aust NZ J Ophthalmol* **20**:263, 1992

30. Cohen PR: Sweet's syndrome presenting as conjunctivitis. *Arch Ophthalmol* **111**:587, 1993

31. Furukawa F et al: Neutrophils in cerebrospinal fluid of a patient with acute febrile neutrophilic dermatosis (Sweet's syndrome) (letter). *Int J Dermatol* **31**:670, 1992

32. Chiba S: Sweet's syndrome with neurologic signs and psychiatric symptoms (letter). *Arch Neurol* **40**:829, 1983

33. Matta M, Kurban AK: Sweet's syndrome: Systemic association. *Cutis* **12**:561, 1973

34. Cohen PR, Kurzrock R: Extracutaneous manifestations of Sweet's syndrome: Steroid-responsive culture-negative pulmonary lesions (letter). *Am Rev Respir Dis* **146**:269, 1992

35. Cohen PR: Skin lesions of Sweet's syndrome and its dorsal hand variant contain vasculitis: An oxymoron or an epiphenomenon? (editorial).

Arch Dermatol **138**:400, 2002

36. Cohen PR: Subcutaneous Sweet's syndrome: A variant of acute neutrophilic dermatosis that is included in the histopathologic differential diagnosis of neutrophilic lobular panniculitis (letter). *J Am Acad Dermatol* (in press)

37. Jordaan HF: Acute febrile neutrophilic dermatosis: A histopathological study of 37 patients and a review of the literature. *Am J Dermatopathol* **11**:99, 1989

38. Cohen PR: Pregnancy-associated Sweet's syndrome: World literature review. *Obstet Gynecol Surv* **48**:584, 1993

39. Su WPD et al: Sweet syndrome: Acute febrile neutrophilic dermatosis. *Semin Dermatol* **14**:173, 1995

40. Cohen PR: Paraneoplastic dermatopathology: Cutaneous paraneoplastic syndromes. *Adv Dermatol* **11**:215, 1995

41. Rappaport A et al: Sweet's syndrome in association with Crohn's disease: Report of a case and review of the literature. *Dis Colon Rectum* **44**:1526, 2001

42. Joshi RK et al: Successful treatment of Sweet's syndrome with doxycycline. *Br J Dermatol* **128**:584, 1993

43. Purdy MJ, Fairbrother GE: Case reports: Acute febrile neutrophilic dermatosis of Sweet. *Australas J Dermatol* **12**:172, 1971

44. Brodkin RH, Schwartz RA: Sweet's syndrome with myelofibrosis and leukemia: Partial response to interferon. *Dermatology* **190**:160, 1995

45. Horio T et al: Treatment of acute febrile neutrophilic dermatosis (Sweet's syndrome) with potassium iodide. *Dermatologica* **160**:341, 1980

46. Myatt AE et al: Sweet's syndrome: A report on the use of potassium iodide. *Clin Exp Dermatol* **12**:345, 1987

47. Cohen PR, Kurzrock R: Treatment of Sweet's syndrome (letter). *Am J Med* **89**:396, 1990

48. Maillard H et al: Colchicine for Sweet's syndrome: A study of 20 cases (letter). *Br J Dermatol* **140**:565, 1999

49. Cohen PR, Kurzrock R: Sweet's syndrome: A review of current treatment options. *Am J Clin Dermatol* **3**:117, 2002

50. Case JD et al: The use of pulse methylprednisolone and chlorambucil in the treatment of Sweet's syndrome. *Cutis* **44**:125, 1989

51. Feliu E et al: Neutrophilic pustulosis associated with chronic myeloid leukemia: A special form of Sweet's syndrome. Report of two cases. *Acta Haematol* **88**:154, 1992

52. Sharpe GR, Leggat HM: A case of Sweet's syndrome and myelodysplasia: Response to cyclosporin. *Br J Dermatol* **127**:538, 1992

53. von den Driesch P et al: Sweet's syndrome: Therapy with cyclosporin. *Clin Exp Dermatol* **19**:274, 1994

54. Jeanfils S et al: Indomethacin treatment of eighteen patients with Sweet's syndrome. *J Am Acad Dermatol* **36**:436, 1997

55. Bello Lopez JL et al: Sweet's syndrome during the chronic phase of chronic myeloid leukemia. *Acta Haematol* **84**:207, 1990

T>

Chapter 95

Stephen Katz

Erythema Elevatum Diutinum

HISTORICAL ASPECTS
ETIOLOGY AND PATHOPHYSIOLOGY
CLINICAL FEATURES AND COURSE
HISTOPATHOLOGY
LABORATORY FINDINGS
DIFFERENTIAL DIAGNOSIS
TREATMENT

REFERENCES

Erythema elevatum diutinum is a rare, chronic skin disease that is characterized by red, purple, and yellowish papules, plaques, and nodules that are usually distributed acrally and symmetrically over extensor surfaces. It is characterized histologically by a leukocytoclastic vasculitis.

HISTORICAL ASPECTS

In 1894, Radcliffe-Crocker and Williams [1] described a 6-year-old patient with persistent pink and purple nodules over the hands, elbows, knees, and buttocks and reviewed the small number of clinically similar cases reported by Hutchinson [2] and Bury. [3] Inasmuch as the patients could be collectively characterized as having red, raised lesions with a strong tendency toward persistence of lesions rather than toward involution, they suggested the descriptive term *erythema elevatum diutinum*. In that report, Radcliffe-Crocker and Williams distinguished the Bury type of erythema elevatum diutinum, occurring in young females with a family history of gout or “rheumatism,” from the Hutchinson type, occurring in elderly males with gout. Radcliffe-Crocker and Williams felt that the two types of erythema elevatum diutinum might be phases of one disease; however, any distinction between these two types has long been abandoned. Although for many years cases of erythema elevatum diutinum were confused with what was later described by Radcliffe-Crocker to be granuloma annulare, [4] these diseases can be clearly differentiated. In the 1930s, extracellular cholesterosis [5] was introduced as a new entity, but it cannot be distinguished from erythema elevatum diutinum [6] and should not be separated nosologically.

ETIOLOGY AND PATHOPHYSIOLOGY

Although the cause of erythema elevatum diutinum is unknown, the finding of C1q binding activity in the sera of some patients, the exacerbation of disease with spontaneous streptococcal infections or with streptokinase-streptodornase skin tests, the Arthus-like histology of all spontaneous and streptokinase-streptodornase-induced lesions, and the positive 4-h streptokinase-streptodornase skin test reactivity in many patients suggest an immune complex etiology. [7] It may be, as Jensen and Esquenazi [8] have proposed from animal studies, that chemoattraction occurs as a direct result of an immune reaction taking place between the chemotactic stimulus and the surface of the responding cell. In the case of erythema elevatum diutinum, the neutrophil surface would have to be coated with a substance that binds bacterial cell products (streptokinase-streptodornase or perhaps others), and the resultant immune complex reaction results in the movement of these neutrophils to the site of antigenic deposition. Others have reported an enhanced response in vitro of neutrophils from patients with erythema elevatum diutinum to interleukin (IL)-8 and increased random migration of neutrophils as well as marked integrin expression in the lesions themselves. [9]

CLINICAL FEATURES AND COURSE

Erythema elevatum diutinum most frequently appears in adults, but may occur at any age. [7] The lesions are multiple and often progress from papules to plaques or nodules. Coalescence of lesions may result in gyrate or irregular forms. The early lesions are often pink or yellowish and may later become red or purple. Early lesions are soft and may be tender, whereas older lesions may become doughy or hard.

The distribution of lesions is highly characteristic. They are usually distributed symmetrically on the extensor surfaces and have a striking predilection for the skin overlying joints, especially on the hands and knees (Fig. 95-1, Fig. 95-2, and Fig. 95-3). However, lesions may cover large areas of skin (Fig. 95-4). They also have a predilection for the buttocks (Fig. 95-4) and for the skin overlying the Achilles tendon. The face and ears may be affected, but the trunk is generally spared, as are the mucous membranes. Lesions may be round or oval, and their surface is usually smooth with the occasional presence of scale. They are usually freely movable from the underlying tissues. Petechiae or purpura are sometimes seen in early lesions (especially after discontinuation of dapsone therapy). Bulla formation or hemorrhagic crusting with ulceration may also occur, especially in very edematous lesions. Some old nodules or plaques may become fibrotic and may resemble xanthomas. Occasionally, lesions involute spontaneously and often leave atrophic, wrinkled hyper- or hypopigmented areas with loss of underlying collagen.

FIGURE 95-1 Erythema elevatum diutinum. Nodular lesions on dorsa of hands and on wrists. Each lesion had been present for several years.

FIGURE 95-2 Erythema elevatum diutinum. Papular and nodular lesions on knee.

FIGURE 95-3 Erythema elevatum diutinum. Papules, nodules, and plaques on dorsa of hands.

FIGURE 95-4 Erythema elevatum diutinum. Papules and nodules on buttocks and thighs.

Symptoms vary; lesions are totally asymptomatic in some and very painful in others. The lesions are sometimes characterized as aching or burning. Often there is an associated systemic abnormality, the most common of which is arthralgia of varying severity. [7] Some patients have had associated rheumatoid arthritis, [10] while others have had ulcerative keratitis. [11] Patients with a long history of recurrent pharyngeal and sinopulmonary infections, most commonly streptococcal, have been described. [7] Several patients have been reported as having associated inflammatory bowel disease with exacerbations in the skin disease at the time of flares in Crohn's disease. [12]

During the past several years, patients infected with HIV have been reported to have erythema elevatum diutinum or a close facsimile to it. [13] Whether lesions occur as a direct result of the virus or as a result of associated bacterial infections is unknown.

The course of the disease is highly variable; there are few well-documented instances of spontaneous long-term

resolution. A follow-up study of five patients who were reported in 1977 [7] revealed that four of them had disease that had persisted from 24 to 39 years. The fifth patient was lost to follow-up. One of these patients developed an IgA myeloma and another died because of lupus pericarditis. There are periods of waxing and waning; some patients have only one or two lesions or crops of new lesions every 2 to 3 weeks, and others have new lesions once every month or two. Streptococcal infections have been reported to exacerbate the disease. [7] Changes in temperature, and especially cold weather, have also been said to aggravate lesions or to be associated with the eruption of new lesions.

HISTOPATHOLOGY

Erythema elevatum diutinum was one of the first skin diseases designated to be a form of necrotizing vasculitis. Weidman and Besancon [14] felt that the vasculitis with prominent neutrophils along with the marked hyalinization of vessel walls were the outstanding features of this disease, which they clearly differentiated from granuloma annulare. Histologically, the lesions are highly characteristic and are easily differentiated from the other clinical considerations, but they may be difficult to differentiate from other types of leukocytoclastic vasculitis. [7], [15] Most small, upper, and mid-dermal blood vessels show endothelial swelling as well as a significant number of neutrophils and their fragments in and around their walls (Fig. 95-5). Fibrinoid degeneration, referred to as toxic hyalin of the vessel walls, is usually present (see Fig. 95-5). An admixture of lymphocytes and a smaller number of eosinophils may be seen perivascularly. Neutrophils and their fragments are also commonly strewn throughout the upper and mid-dermis and may appear in large numbers between collagen bundles. There may be an unaffected zone of collagen just beneath the epidermis as in granuloma faciale. However, the epidermis may be affected as a result of the dermal infiltrate and edema and may show varying degrees of injury from slight acanthosis to frank necrosis. Older lesions may show a fibrotic replacement of the dermis accompanied by capillary proliferation. Even when the dermis appears to be totally replaced by these changes, there can be small foci of the leukocytoclastic vasculitis. In the older lesions, there may be varying amounts of extracellular cholesterol deposits, especially in lesions that have a yellowish xanthomatous appearance clinically. This particular histologic variant of erythema elevatum diutinum, formerly called *extracellular cholesterosis,* [5] is unassociated with disturbances of lipid metabolism. It probably occurs as a result of the heavily damaged tissue with extracellular and intracellular deposits consisting of cholesterol esters. Ultrastructural studies demonstrate that the lipid deposits are mainly intracellular. [16] None of the histologic findings cited is pathognomonic for erythema elevatum diutinum, although the constellation of histologic findings in both recently erupted and older lesions of erythema elevatum diutinum may serve to distinguish this entity from other forms of leukocytoclastic vasculitis. There are occasional solitary cutaneous lesions with histologic features resembling erythema elevatum diutinum in patients who have no other features of the disease. [17]

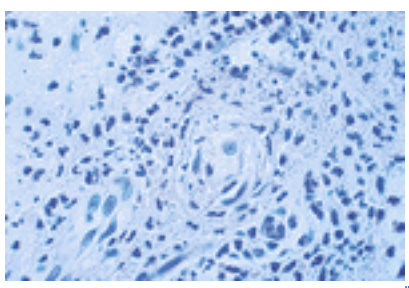

FIGURE 95-5 Erythema elevatum diutinum. High-power view showing endothelial swelling, fibrinoid necrosis of the vessel wall (“toxic hyalin”), and neutrophilic fragments in the vessel wall.

LABORATORY FINDINGS

Most patients have elevated erythrocyte sedimentation rates. In addition, in most patients tested, there are markedly positive 4- and 24-h skin test reactions to intradermally injected streptokinase-streptodornase, extracellularly elaborated products of Lancefield group C strains of streptococci. [7], [18] Biopsy specimens obtained 4 or 6 h after the skin test show most of the histologic features of leukocytoclastic vasculitis. In addition to the markedly positive skin test reactions, many patients develop satellite lesions peripheral to the skin reactions. These lesions also show the histopathologic features of erythema elevatum diutinum.

Many patients who have IgA (mainly) or IgG or IgM monoclonal gammopathies, or even myeloma, have been reported. [7], [19] Elevated levels of IgA in other patients with erythema elevatum diutinum, [7], [19], [20], [21] and [22] and the rarity of both erythema elevatum diutinum and IgA monoclonal gammopathy would suggest that this association may be more than chance. In addition, C1q binding activity (indicative of IgG- or IgM-containing circulating immune complexes) has been identified in the sera of three of five patients. [7] Altered neutrophil chemotaxis has been detected in several patients. [7], [9] IgA antineutrophilic antibodies have also been detected in a few patients. [23]

Direct immunofluorescence or immunoperoxidase studies of lesional skin of patients with erythema elevatum diutinum occasionally reveal immunoglobulin and complement deposition in and around blood vessels. [16], [24]

DIFFERENTIAL DIAGNOSIS

Although for many years there was confusion between erythema elevatum diutinum and granuloma annulare, there is now little difficulty in differentiating the two clinically and histologically. Recurrent febrile neutrophilic dermatosis of Sweet, characterized by painful red plaques accompanied by fever and neutrophilic leukocytosis, can usually be distinguished from erythema elevatum diutinum by the distribution and character of lesions. Also, although Sweet's syndrome is characterized histologically by the presence of a dense neutrophilic infiltrate, which may be diffuse or, at times, perivascular, there is no leukocytoclastic vasculitis. Xanthomas can easily be distinguished histologically, as can

multicentric reticulohistiocytosis. There is occasional difficulty in differentiating erythema elevatum diutinum from granuloma faciale histologically (not clinically); however, the latter lesion usually shows far less vascular involvement, more eosinophilia, and regular sparing of the overlying epidermis. Extracellular cholesterosis of Urbach [5] should be regarded as a variant of erythema elevatum diutinum. Other forms of leukocytoclastic vasculitis may be very difficult to distinguish from erythema elevatum diutinum, especially histologically; the distribution, character, and chronicity of individual lesions is highly suggestive of erythema elevatum diutinum.

TREATMENT

Case reports [18], [20], [22], [25], [26] and a study of a series of patients [7] indicate the regularity with which a dramatic response is obtained when patients with erythema elevatum diutinum are treated with dapsone or sulfapyridine. The prompt recurrence of skin lesions and systemic symptoms after sulfone withdrawal is evidence of the suppressive but not curative effect of sulfones in this disease. It seems that the disease exacerbations are more severe with each subsequent withdrawal of medication. A few prior case reports stated that dapsone was ineffective in treating erythema elevatum diutinum, perhaps because of extensive fibrosis in some patients. Dosage, however, varies considerably and is probably crucial. In addition to its beneficial effect in erythema elevatum diutinum, dapsone therapy is occasionally beneficial in other forms of leukocytoclastic vasculitis. Reportedly, niacinamide suppresses erythema elevatum diutinum effectively. [27] Systemic glucocorticoids are generally not effective. However, intralesional and topical high-potency glucocorticoids may be very effective in decreasing the size of lesions, and these glucocorticoids are the preferred treatment for patients with very limited disease.

REFERENCES

1. Radcliffe-Crocker H, Williams C: Erythema elevatum diutinum. *Br J Dermatol* **6**:1, 1894

2. Hutchinson J: On two remarkable cases of symmetrical purple congestion of the skin in patches, with induration. *Br J Dermatol* **1**:10, 1888

3. Bury JS: A case of erythema with remarkable nodular thickening and induration of the skin associated with intermittent albuminuria. *Illus Med News* **3**:145, 1889

4. Radcliffe-Crocker H: Granuloma annulare. *Br J Dermatol* **14**:1, 1902

5. Urbach E et al: Extrazellulare cholesterinose. *Arch Dermatol Syphilol (Berlin)* **166**:243, 1932

6. Herzberg JJ: Die extracellulare Cholesterinose (Kerl-Urbach), eine Variante des Erythema elevatum diutinum . *Arch Klin Exp Dermatol* **205**:477, 1958

7. Katz SI et al: Erythema elevatum diutinum—Skin and systemic manifestations, immunologic studies, and successful treatment with dapsone. *Medicine (Baltimore)* **56**:443, 1977

8. Jensen JA, Esquenazi V: Chemotactic stimulation by cell surface immune reactions. *Nature* **256**:213, 1975

9. Grabbe J et al: Erythema elevatum diutinum-evidence for disease-dependent leucocyte alterations and response to dapsone. *Br J Dermatol* **143**:415, 2000

10. Nakajima H et al: Erythema elevatum diutinum complicated by rheumatoid arthritis. *J Dermatol* **26**:452, 1999

11. Takiwaki H et al: Peripheral ulcerative keratitis associated with erythema elevatum diutinum and a positive rheumatoid factor: A report of three cases. *Br J Dermatol* **138**:893, 1998

12. Elsner J et al: Erythema elevatum and diutinum in Crohn disease. *Hautartz* **47**:701, 1996

13. Muratori S et al. Erythema elevatum diutinum and HIV infection: A report of five cases. *Brit J Dermatol* **141**:335, 1999

14. Weidman FD, Besancon JH: Erythema elevatum diutinum: Role of streptococci, and relationship to other rheumatic dermatoses. *Arch Dermatol Syphilol* **20**:593, 1929

15. Sangueza OP et al: Erythema elevatum diutinum: A clinicopathological study of eight cases. *Am J Dermatopathol* **19**:214, 1997

16. Kanitakis J et al: Ultrastructural study of chronic lesions of erythema elevatum diutinum: “Extracellular cholesterosis” is a misnomer. *J Am Acad Dermatol* **29**:363, 1993

17. Carlson JA, LeBoit PE: Localized chronic fibrosing vasculitis of the skin: An inflammatory reaction that occurs in settings other than erythema elevatum diutinum and granuloma faciale. *Am J Surg Pathol* **21**:698, 1997

18. Cream JJ et al: Erythema elevatum diutinum: An unusual reaction to streptococcal antigen and response to dapsone. *Br J Dermatol* **84**:393, 1971

19. Yiannias JA et al: Erythema elevatum diutinum: A clinical and histopathologic study of 13 patients. *J Am Acad Dermatol* **26**:38, 1992

20. Abdel-Aziz AHM, Robertson DEH: Erythema elevatum diutinum: Immunoglobulin, bacterial skin tests and response to dapsone. *Cutis* **12**:549, 1973

21. Chowdhury MMU et al: Erythema elevatum diutinum and IgA paraproteinaemia: ‘A preclinical iceberg’. *Int J Dermatol* **41**:368, 2002

22. Vollum DI: Erythema elevatum diutinum: Vesicular lesions and sulfone response. *Br J Dermatol* **80**:178, 1968

23. Rovel-Guitera P et al: IgA antineutrophilic antibodies in cutaneous vasculitis. *Br J Dermatol* **143**:99, 2000

24. Wolff HH et al: Erythema elevatum diutinum. *Arch Dermatol Res* **261**:17, 1978

25. Fort S, Rodman OG: Erythema elevatum diutinum: A review and report of a case. *Arch Dermatol* **113**:819, 1977

26. Kalkoff KW: Zur Behandlung des Erythema elevatum diutinum mit 3-Sulfanilamido-methox-pyridazin (Lederkyn). *Dermatol Wochenschr* **142**:788, 1960

27. Kohler IK, Lorincz AL: Erythema elevatum diutinum treated with niacinamide and tetracycline. *Arch Dermatol* **116**:693, 1980

T>

Chapter 96

Kristin Leiferman Margot Peters Gerald Gleich

Eosinophils in Cutaneous Diseases

STRUCTURE AND FUNCTION OF EOSINOPHILS
Granule Proteins
Membrane Proteins
Oxidative Products
Eosinophil Infiltration of Tissues
Effects of IL-3, IL-5, and GM-CSF
CUTANEOUS DISEASES ASSOCIATED WITH INCREASED EOSINOPHILS AND/OR EOSINOPHIL DEGRANULATION
Syndromes Associated with Edema
Onchocercal Dermatitis, Atopic Dermatitis, and Prurigo Nodularis
Eosinophils and Blistering
Eosinophilic Diseases Associated with Fibrosis
Hypereosinophilic Syndrome
Angiolymphoid Hyperplasia with Hypereosinophilia and Kimura's Disease
Eosinophilic Pustular Folliculitis and Other Pustular Dermatoses
Granuloma Faciale

REFERENCES

The eosinophil is a conspicuous cell in cutaneous lesions because of its intense avidity for eosin. Eosinophils are prominent in many skin diseases and often constitute part of the diagnostic histologic patterns (Table 96-1). [1], [2] In addition, eosinophils, even when not identifiable in tissue, may participate in the pathogenesis of the disease through the deposition of potently bioactive granule proteins (Table 96-2).

Diseases with peripheral and/or tissue eosinophilia
Atopic diseases
Parasitic diseases
Bullous diseases
Drug reactions
Hypereosinophilic syndrome
Eosinophilia myalgia syndrome
Toxic oil syndrome
Eosinophilic fasciitis
Urticaria and angioedema
Mastocytosis
Cutaneous T cell lymphoma
Eosinophilic panniculitis
Reactions to arthropod bites and stings
Diseases histologically characterized by tissue eosinophilia
Kimura's disease and angiolymphoid hyperplasia with eosinophilia
Wells' syndrome (eosinophilic cellulitis)
Eosinophilic pustulosis (Ofuji's disease and erythema toxicum neonatorum)
Granuloma faciale
Eosinophilic ulcer of the tongue

SOURCE: Adapted from Peters.[1]

TABLE 96-1 **Eosinophils and Cutaneous Diseases**

Urticarial and edematous lesions
Chronic urticaria[3]
Solar urticaria[4]
Delayed pressure urticaria[5]
IgE-mediated late-phase reaction[6]
Episodic angioedema with eosinophilia[7,8]
Facial edema with eosinophilia[9]
GM-CSF reactions[10]
IL-2 capillary leak syndrome[11]
Eosinophilic cellulitis[12,13]
Eczematoid dermatitis
Atopic dermatitis[14–16]
Onchocercal dermatitis[17]
Pachydermatous eosinophilic dermatitis[18]
Prurigo nodularis[19,20]
Blistering disorders
Herpes (pemphigoid) gestationis[21]
Bullous pemphigoid[22]
Bullous morphea[23]
Incontinentia pigmenti[24]
Vasculitis
Recurrent cutaneous necrotizing eosinophilic vasculitis[25]
Eosinophilic vasculitis in connective tissue disease[26]
Churg-Strauss syndrome[27]

TABLE 96-2 **Deposition of Eosinophil Granule Proteins in Cutaneous Disease**

STRUCTURE AND FUNCTION OF EOSINOPHILS

In 1879, Ehrlich named this cell the eosinophil because of the intense staining of its cytoplasmic granules with the acidic dye eosin. [28] By electron microscopy, these distinctive specific granules show an electron-dense core and a less-dense matrix. Because the crystalloid-containing granules are characteristic of eosinophils, their contents have been investigated as a means of understanding eosinophil functions. [29], [30] Four cationic proteins comprise the bulk of the granule: major basic protein (MBP), eosinophil peroxidase (EPO), eosinophil-derived neurotoxin (EDN), and eosinophil cationic protein (ECP). MBP constitutes the core of the eosinophil granule; EPO, EDN, and ECP are present in the

granule matrix. All the eosinophil granule proteins are cytotoxins, partly because of their basicity.

Granule Proteins

MAJOR BASIC PROTEIN MBP has been localized to the eosinophil granule core by biochemical analyses and by immunoelectron microscopy. MBP is a single polypeptide chain of 117 amino acids, 17 of which are arginines, and it has a calculated isoelectric point (pI) of 10.9. It is a potent toxin against helminths, protozoa, bacteria, tumor cells, and many mammalian cells. The cDNA indicates that MBP is translated as a larger preproprotein with an acidic propiece. Because MBP is a potent toxin, its translation as proMBP with an anionic propiece may serve as a mechanism to neutralize the molecule and to protect the cell while MBP is transferred to its sequestered site in the granule core. Of interest is the finding that proMBP is markedly elevated during pregnancy, is produced by the placenta, and serves as an inhibitor for the enzyme, pregnancy-associated plasma protein A (PAPP-A); PAPP-A degrades insulin-like growth factor binding protein 4 and releases insulin-like growth factor activity. The cationic charge of MBP causes it to bind avidly to the anionic surface of target cells; the apolar residues may then insert into and disrupt the lipid milieu, causing nonspecific cell membrane damage and death of target cells. In a noncytotoxic manner, MBP also induces histamine release from human basophils and rat mast cells, activates neutrophils, and is a strong and unique platelet agonist. After instillation into the lungs of primates, MBP increases both respiratory resistance and sensitivity to methacholine. A related protein, MBP homologue, has been identified in eosinophil granules. Its soelectric point is almost three magnitudes of order less than MBP, but it also has cytotoxic activity. [31] The genes for both MBP and the homologue are localized to chromosome 11q12. [31]

EOSINOPHIL CATIONIC PROTEIN ECP is located in the eosinophil granule matrix and is a strongly basic single polypeptide chain of 133 amino acids, 19 of which are arginines. [29], [30] ECP is an enzymatically active member of the ribonuclease supergene family. It also has cytotoxic activity, most likely as a function of its cationic charge. In contrast to MBP, which may increase the permeability of target membranes without formation of transmembrane channels, ECP forms channels across membranes similar to those formed during membrane-complement interactions. ECP is a potent toxin against helminths, protozoa, bacteria, and mammalian cells; it also has neurotoxic activity and antiviral activity. [30]

EOSINOPHIL-DERIVED NEUROTOXIN EDN, contained in the matrix of the eosinophil granule, is a powerful neurotoxin with the ability to damage myelinated neurons. [29], [30] The amino acid sequence of EDN has approximately 70 percent identity with that of ECP; the nucleotide sequences of these proteins have an 89 percent similarity index. Like ECP, EDN possesses ribonuclease activity, although it is approximately 100 times more potent, and it has antiviral activity. It is also a member of the ribonuclease supergene family, which includes angiogenin and ribonuclease itself. Both EDN and ECP genes have been localized to the q24-q31 region of human chromosome 14. [29], [30]

EOSINOPHIL PEROXIDASE EPO is localized to the matrix of eosinophil granules, and is strongly basic. It consists of two subunits, a heavy chain of 53.0 kDa and a light chain of 12.7 kDa. [29], [30] The amino acid sequence of EPO has a high content of arginine, leucine, and aspartic acid. In combination with hydrogen peroxide and a halide, EPO kills bacteria, helminths, and tumor cells. EPO binds to mast cells, and the EPO–mast cell complex catalyzes iodination of proteins in killing microorganisms. At low concentrations, EPO in combination with hydrogen peroxide and halide also causes mast cell degranulation and histamine release in a noncytotoxic reaction. With hydrogen peroxide and halide, EPO inactivates leukotrienes (LT) C_4, D_4, and E_4. Bromide is preferred over chloride in the eosinophil peroxidase reaction, whereas chloride is preferred in the myeloperoxidase reaction. Bromide is present in biologic fluids at concentrations that EPO can use; EPO, hydrogen peroxide, and bromide generate hypobromous acid and the corresponding ion OBr^-, both of which are potent oxidants.

Membrane Proteins

Eosinophils express various membrane receptors that enable communication with the extracellular environment. [29], [30] Membrane proteins expressed by eosinophils include receptors for adhesion molecules, chemokines, the Fc portion of immunoglobulins, complement fragments, and soluble substances such as cytokines and lipid mediators. [29], [30], [32] The presence of IgG and complement receptors is linked to effector functions of the eosinophil toward parasitic and cellular targets. In addition, hypodense eosinophils may possess low-affinity IgE receptors that participate in mediating damage to parasites. Secretory IgA appears to be particularly effective in causing eosinophil degranulation, suggesting that eosinophils possess IgA receptors and participate in mucosal immunity. Based on the activity of the corresponding cytokines, eosinophils possess receptors for interleukin (IL)-3, IL-5, interferon (IFN)-a, IFN-?, tumor necrosis factor (TNF)-a, and granulocyte-macrophage colony-stimulating factor (GM-CSF). In addition, membrane eceptors for leukotriene B_4 (LTB_4) and platelet-activating factor (PAF) are present. [29], [30], [32]

Oxidative Products

Although eosinophils can ingest and kill microorganisms, their primary role in host defense may be against targets such as helminths and tumor cells. The phagocytic activity of eosinophils is less than that of neutrophils, but the respiratory burst to most stimuli is greater than that of neutrophils. Stimulation of eosinophils results in degranulation with a respiratory burst that forms superoxide anions, hydrogen peroxide, and the hydroxyl radical. Oxygen does not appear to be required for phagocytosis by eosinophils but is used for the generation of toxic oxygen metabolites. In addition, EPO in combination with hydrogen peroxide and a halide generates toxic hypohalous acid. [29], [30], [32]

Eosinophil Infiltration of Tissues

The factors determining eosinophil infiltration of tissues involve at least three interrelated signals: chemoattractants; adhesion molecules; and activating cytokines such as GM-CSF, IL-3, and IL-5. [33] Several members of the C-C chemokine gene superfamily are chemotactic for eosinophils. [34] These chemoattractants include eotaxin and RANTES (regulated on activation normal T cell-expressed and secreted). Eotaxin is specifically chemotactic for eosinophils, and its activity in inflammation is being delineated. RANTES is potently chemotactic for eosinophils and is also chemotactic for monocytes, T lymphocytes, natural killer (NK) cells, and basophils, but not for neutrophils. In addition to their chemotactic properties,

RANTES and eotaxin induce production of reactive oxygen species by eosinophils, indicating that they have both chemotactic and functional activation effects. As an eosinophil chemoattractant, eotaxin is similar in potency to RANTES, but is stronger in inducing reactive oxygen species by eosinophils. Both RANTES and eotaxin are produced by dermal fibroblasts; RANTES is also produced by keratinocytes.

For eosinophils to migrate from the peripheral blood into tissues, the cells must cross blood vessel barriers. Three gene superfamilies contribute to the signaling needed for transmigration. Selectins are involved in the early, high-sheer-force stage of leukocyte adhesion to endothelium, and integrins are cell-surface proteins that recognize counterreceptor members of the immunoglobulin gene superfamily. Together, the integrin-immunoglobulin family interactions promote flattening and migration of cells onto and through the endothelium. [35] After eosinophils migrate through vessels into the extracellular matrix, integrins on the cell surface interact with counterligands such as the fibrous proteins fibronectin, laminin, and collagen, and the glycosaminoglycans hyaluronic acid and chondroitin sulfate. Ongoing studies suggest that integrin expression is critical for the effector functions of eosinophils, including degranulation. [29]

Several lines of investigation indicate that eosinophils are recruited to and activated in tissues by cytokines from a subset of T cells, the T_H2 cells, which produce IL-4, IL-5, IL-10, and IL-13, in addition to some cytokines common to T_H1 cells. Mast cell cytokines may also contribute to eosinophil activation. [36] In addition, human NK cells, which respond to some of the same C-C chemokines as eosinophils, also produce IL-5. [37] Eosinophils themselves elaborate important inflammatory and regulatory cytokines; these include IL-1a, transforming growth factor-a and $ß_1$, GM-CSF, IL-3, IL-5, IL-6, IL-8, TNF-a, and macrophage inhibitory protein-1a. [38] Through expression of major histocompatibility complex (MHC) class II molecules and IL-1a production, eosinophils may act as specialized antigen-presenting cells. The functional diversity of the eosinophils, therefore, may have multiple ramifications in tissues.

Effects of IL-3, IL-5, and GM-CSF

A current model for eosinophil differentiation suggests that totipotent hematopoietic stem cells give rise to pluripotent cells that, in turn, give rise to the cells committed to one or two lines of differentiation. [39] Studies of purified eosinophils from patients with eosinophilia show that eosinophils exist as populations of varying densities, which may reflect their levels of activation. Hypodense eosinophils appear to be activated and generate significantly more superoxide and discharge more granule products than normodense cells. At least three factors are thought to influence eosinophil differentiation in the bone marrow and activation in tissues: GM-CSF, IL-3, and IL-5. Both GM-CSF and IL-3 act by inducing more eosinophil precursors, whereas IL-5 acts later in eosinophil differentiation and regulates cell maturation. IL-5 is also chemotactic for eosinophils. GM-CSF, IL-3, and IL-5 all enhance eosinophil survival. Along with IFN-? and TNF-a, GM-CSF, IL-3, and IL-5 are cytoprotective and also activate eosinophils, as judged by surface receptor expression and enhancement of the respiratory burst, production of inflammatory mediators, cytotoxicity, and degranulation stimulated by secretory IgA. In vitro exposure to IL-3, IL-5, or GM-CSF alone, or to GM-CSF in association with fibroblasts or endothelial cells can convert normodense eosinophils into hypodense cells.

CUTANEOUS DISEASES ASSOCIATED WITH INCREASED EOSINOPHILS AND/OR EOSINOPHIL DEGRANULATION

Syndromes Associated with Edema

Several cutaneous syndromes show an association between edema and local eosinophilia. Although the etiologic mechanisms are incompletely understood, the ability of eosinophils to elaborate LTC_4 and PAF, to induce histamine release from mediator-containing cells, and to elicit a cutaneous wheal-and-flare reaction in human skin, along with the presence of cationic granule proteins in lesions, support a role for the eosinophil as a primary participant in the inflammation and edema associated with certain cutaneous diseases.

IgE-MEDIATED LATE-PHASE REACTION The mast cell-mediated wheal-and-flare cutaneous reaction is characteristic of IgE-mediated hypersensitivity. In sensitive patients, an intradermal challenge with a particular concentration of allergen elicits a wheal-and-flare followed by a late inflammatory reaction that becomes apparent at 3 to 4 h, peaks at 6 to 12 h, and resolves by 24 to 72 h. At its height, the late-phase reaction is characterized by erythema, warmth, edema, pruritus, and tenderness. Histologic examination of the cutaneous late-phase reaction shows edema; dermal infiltration with mononuclear cells, neutrophils, basophils, and eosinophils; and mast-cell degranulation. The extracellular deposition of neutrophil elastase and MBP indicates that both eosinophil and neutrophil degranulation occur in the late-phase reaction beginning 1 to 3 h after challenge. [6] Electron microscopy confirms that eosinophils degranulate in the tissue and lose their morphologic integrity in the late-phase response. This sequence is considered pertinent to some clinical urticarial diseases, as discussed below.

URTICARIAL REACTIONS Eosinophils are commonly present in urticarial skin lesions, but the histologic patterns are nonspecific. Between 43 and 60 percent of urticarial skin lesions demonstrate prominent extracellular deposition of eosinophil granule proteins. [35] Extracellular granule protein deposition occurs around small blood vessel walls, with granules dispersed in the dermis, and on connective tissue fibers. Autologous serum skin-testing sites in patients with chronic urticaria may also show extracellular MBP deposition. [40] Based on the activities of eosinophil granule proteins, eosinophil degranulation in lesions of chronic urticaria could be of pathogenetic importance. Sequential biopsy specimens of wheals elicited by either a solar simulator or a dermographometer in patients with solar and delayed pressure urticaria demonstrate a pattern of eosinophil and neutrophil degranulation similar to that seen in the IgE-mediated late-phase reaction with both neutrophil elastase and MBP deposition.

EDEMATOUS SYNDROMES Episodic angioedema associated with eosinophilia was first described in 1984; it is characterized by recurrent angioedema, urticaria, fever, and elevated IgM levels. [7] During attacks, leukocyte counts increase to levels as high as 100,000/mm [3] with up to 90 percent eosinophils, and patients gain up to 31 percent of their body weight in edema fluid (Fig. 96-1). The disease activity waxes and wanes in concert with the number of peripheral eosinophils. Staining of skin biopsy specimens with hematoxylin and eosin shows few eosinophils; but by

immunofluorescence, extracellular deposition of MBP can be seen around collagen bundles and blood vessels. Electron microscopy shows alteration of cytoplasmic granules in peripheral blood eosinophils and a spectrum of changes in dermal eosinophils, ranging from abnormal cytoplasmic granules in intact cells to complete cellular disruption, with loss of organelles, including granules, into the spaces among collagen bundles. Analyses of peripheral helper T cells and infiltrating dermal T cells in lesions of episodic angioedema and eosinophilia showed increased activated, HLA-DR+ helper T cells. IL-5 levels are elevated in the serum of patients with this syndrome. [8] The disease responds favorably to prednisone therapy and INF-a therapy (unpublished observations), which may be steroid-sparing in patients with this disease. A variant of episodic angioedema includes recurrent facial edema associated with eosinophilia. Peripheral blood eosinophilia is seen during attacks of localized facial edema; levels of both MBP and Charcot-Leyden crystal protein are elevated in peripheral blood during attacks, and extracellular deposition of MBP is seen in the skin. [9]

FIGURE 96-1 Episodic angioedema with eosinophilia. Facial appearance during an attack, showing marked edema (*left*) and normal appearance (*right*) between episodes. (*From Katzen et al. Hypereosinophilia and recurrent angioneurotic edema in a 2½-year-old girl. Am J Dis Child 140:62, 1986 with permission*.)

An association between T cell activation, eosinophilia, and angioedema has been observed in patients with advanced malignancies undergoing treatment with recombinant IL-2 who experience a capillary leak syndrome with weight gain and peripheral blood eosinophilia. MBP is strikingly elevated in serum and urine, and immunofluorescence analyses of skin specimens show extracellular MBP deposition. [11] IL-5 is elevated in patients undergoing IL-2 therapy. [8], [11] Eosinophil degranulation may also be found in skin lesions that develop during GM-CSF therapy. [10]

WELLS' SYNDROME OR EOSINOPHILIC CELLULITIS This entity is characterized by recurrent cutaneous swelling. After prodromal burning or itching, lesions begin with redness and swelling, then evolve in a few days into large areas of edema with violaceous borders; bullae may develop over the surface. Individual lesions persist for days to weeks, and gradually change from bright red to brown-red and, finally, to blue-gray, resembling morphea (Fig. 96-2). The lesions may be single or multiple, may occur in any cutaneous location, and may recur. Familial cases have been reported, and the disease occurs in childhood. [13] The edematous and infiltrative plaques of Wells' syndrome are characterized histologically by dermal foci of amorphous eosinophilic material called *flame figures*. When examined for MBP by immunofluorescence, the flame figures show bright extracellular staining, suggesting that extensive eosinophil degranulation has occurred. [12] Further support for the participation of eosinophils in the formation of flame figures is provided by electron microscopic observations of free eosinophil granules coating collagen fibers in flame figures.

FIGURE 96-2 Wells' syndrome. Late lesion resembling morphea.

Onchocercal Dermatitis, Atopic Dermatitis, and Prurigo Nodularis

An association between peripheral blood eosinophilia and helminth infection was established before 1900, and considerable evidence suggests that eosinophils are important in defense against parasitic diseases. [29] Infection with *Onchocerca volvulus* causes a dermatitis associated with pruritus and lichenification. Slight cutaneous eosinophilia and extensive deposition of eosinophil granule proteins throughout the dermis are found in untreated lesions. After treatment, the extracellular deposition of eosinophil granule proteins is located to the areas around degenerating microfilaria in the dermis. [17]

Although eosinophils are rarely a prominent histologic feature of atopic dermatitis, extensive dermal deposition of eosinophil granule proteins, including MBP, EDN, and ECP, is seen in lesions, but not in unaffected skin. [1], [14], [15] and [16] In contrast, neutrophil elastase is absent or minimally present in atopic dermatitis. These observations suggest that composite inflammatory factors differ for atopic dermatitis and urticaria, even though eosinophil involvement is common to both.

A pattern of dermal extracellular eosinophil granule protein deposition similar to that in atopic dermatitis and onchocercal dermatitis is found in prurigo nodularis. [19] Eosinophil granule proteins are deposited in the presence of increased numbers of mast cells but in the absence of neutrophil granule elastase. Comparable extracellular eosinophil granule protein deposition is present in pachydermatous eosinophilic dermatitis. [18] Similar to asthma, [41] eosinophil granule proteins are deposited around cutaneous nerves in both atopic dermatitis (unpublished observations) and prurigo nodularis. [20] The localization of eosinophil granule proteins in these diseases suggests that the eosinophil has deposited its toxic molecules in the tissue, contributing to the cutaneous pathophysiology.

Eosinophils and Blistering

Deposition of eosinophil granule proteins is prominently associated with blister formation in bullous pemphigoid, [22] herpes

gestationis, [21] bullous morphea, [23] incontinentia pigmenti, [24] and in blisters developing in Churg-Strauss syndrome. [27] Additionally, eosinophil-active cytokines are found in blister fluid from bullous pemphigoid [22] and Churg-Strauss lesions. [27] These findings imply a connection between eosinophil activation and the pathologic process of blister formation.

Eosinophilic Diseases Associated with Fibrosis

Eosinophils are found in association with fibrotic reactions in a number of diseases, including parasitic infections, pulmonary and hepatic drug-sensitivity reactions, and the hypereosinophilic syndrome. Eosinophils elaborate collagenase that degrades type I and type III collagen; eosinophil extracts stimulate dermal fibroblast DNA synthesis and matrix production. EDN is mitogenic for fibroblasts, and ECP inhibits proteoglycan degradation in fibroblasts. Eosinophil degranulation is prominent in retroperitoneal fibrosis and in the fibrotic areas of orbital pseudotumor. [42] Therefore, eosinophils may be important in the pathogenesis of fibrosis.

EOSINOPHILIC FASCIITIS Eosinophilic fasciitis may be preceded by an episode of marked exertion. The disease commonly presents with pain, erythema, swelling, and induration of the extremities. Lesions are typically confined to the extremities, although truncal and generalized involvement may occur. Peripheral blood eosinophilia, an elevated erythrocyte sedimentation rate, and hypergammaglobulinemia also accompany the disease. [43] Contractures may occur early because of fascial involvement. In addition, fascial involvement may cause separation of muscle groups by a line of demarcation (groove sign), and the veins may appear depressed (sunken veins). Rippling of the skin may develop (Fig. 96-3) as the disease progresses. Histologic findings include thickening of the deep fascia with infiltration of lymphocytes, plasma cells, mast cells, and eosinophils. Later in the course of the disease, the fascia becomes fibrotic. Several features overlap with progressive systemic sclerosis, and the ultimate histologic changes are indistinguishable from those of scleroderma. Eosinophilic fasciitis often responds promptly to systemic glucocorticoids, especially if therapy is initiated early. Cimetidine and methotrexate reportedly are beneficial in treating the process. The pathophysiology of the sclerosing diseases, including eosinophilic fasciitis, is not understood.

FIGURE 96-3 Eosinophilic fasciitis. Puckered skin changes involving the thighs.

EOSINOPHILIA-MYALGIA SYNDROME The eosinophilia-myalgia syndrome (EMS) is characterized by marked peripheral eosinophilia with a spectrum of signs and symptoms, including disabling generalized myalgias, pneumonitis, myocarditis, neuropathy, encephalopathy, and fibrosis. [43] The name derives from the two consistent features of the disease, peripheral blood eosinophilia and myalgias. The clinical picture may progress to one indistinguishable from that of eosinophilic fasciitis. The disease has been related to the ingestion of certain lots of L-tryptophan; epidemiologic studies indicate that the L-tryptophan ingested by the patients was traced to a single manufacturer. The etiology and pathogenesis are unknown, but the implicated lots of L-tryptophan contained a contaminant that was identified as 1,1'-ethylidene *bis* [L-tryptophan]. This contaminant may be the cause of the disease or a marker for another active substance in the preparation that provokes the syndrome. Cutaneous symptoms associated with EMS include edema, pruritus, a faint erythematous rash, hair loss, and changes suggestive of fasciitis with peau d'orange and morphea-like skin lesions. Several other organ systems have been involved in the disease, including the lungs, heart, and nervous system. Histologic studies of deep-muscle biopsies show a prominent inflammatory cell infiltrate in the perimysium and fascia. Inflammatory cells are scattered diffusely or form sheets or clusters surrounding and often infiltrating the walls of small blood vessels. Some affected vessels have narrow lumina and appear to be occluded, but fibrinoid necrosis of vessel walls is absent; fibrin or platelet thrombi are absent. Perimysial tissue is thickened, and, in some areas, perimysial connective tissue is separated by edema. Striking evidence of eosinophil granule protein deposition is found in areas of skin and around muscle bundles. Most patients improve with prednisone; however, many of the symptoms, especially painful myalgias and those related to eosinophilic fasciitis, persist. Multiple forms of therapy have been tried, including plasma exchange, methotrexate, and hydroxychloroquine, but a consistently beneficial intervention for refractory signs and symptoms has not been achieved.

TOXIC OIL SYNDROME A condition similar to EMS was described in Spain, in May 1981, and has been termed *toxic oil syndrome* (TOS). [44] Patients presented with acute respiratory symptoms followed by intense myalgias, thromboembolism, weight loss, sicca syndrome, and, lastly, a chronic phase characterized by eosinophilic fasciitis-like lesions, peripheral neuropathy, muscle atrophy, and pulmonary hypertension. The epidemic of TOS was linked to the consumption of adulterated rapeseed oil distributed in the industrial belt around Madrid. The initial clinical manifestation of TOS was pneumonitis along with a nonspecific pruritic, erythematous rash that persisted up to 4 weeks. During the next 2 months, patients developed subcutaneous edema, predominantly in legs, ankles, forearms, face, and hands. The edema was accompanied by myalgias, arthralgias, contractures, and peripheral blood eosinophilia. Histopathologic studies of the skin showed mainly a lymphocytic inflammatory infiltrate in the dermis, fascia, and small vessels of the dermis. The edema was eventually replaced by shiny, indurated skin that adhered to the deep tissues. Years after the onset of the disease, the patients had thin, atrophied, hyperpigmented skin with indurated plaques persisting in pretibial areas and occasionally on the forearms and abdomen. [44] Histologic examination revealed fibrosis and atrophy of sweat glands and hair follicles with extension of the fibrosis into subcutaneous fat. In some tissues, marked hyperplasia of the vessel intima was noted, and the lumina of blood vessels were partially obliterated. Subsequent studies showed eosinophil infiltration and degranulation in tissues, especially during the acute phase of TOS, and serum MBP levels were elevated during all phases, implicating a role for eosinophils in the disease. TOS was most severe during its first 10 months. Joint contractures were among the most disabling and persistent features; several factors may have contributed to their

development, including edema, neuropathy, myositis, and fibrosis of soft tissues. Renal involvement and malabsorption have been reported in only a few patients with TOS. Long-term follow-up studies of TOS patient cohorts at 8 and 12 years showed variable clinical manifestations. The disease had generally improved; however, the most prominent persisting features were muscle cramps, musculoskeletal pain, soft tissue tenderness, Raynaud's phenomenon, carpal tunnel syndrome, chronic lung disease, fatigue, and subjective cognitive impairment. Identification of the triggering agent(s) in TOS and EMS will likely increase understanding of both these multisystem scleroderma-like diseases as well as the effects of eosinophils in tissues.

Hypereosinophilic Syndrome

The hypereosinophilic syndrome is a multisystem disease characterized by peripheral blood eosinophilia and infiltration of eosinophils into many organs, including the skin. [45] Cutaneous involvement occurs in more than 50 percent of patients as either pruritic macular, papular, and nodular lesions over the trunk and extremities or as urticaria and angioedema. Dermographism is reported in over 75 percent of patients. While the hypereosinophilic syndrome is associated with a significant mortality rate, a variant of the disease characterized by mucosal ulcers (Fig. 96-4) carries an unusually grave prognosis—five of seven patients with this subset of hypereosinophilic syndrome died within 2 years of diagnosis. The mucosal ulcers frequently precede or appear concurrently with peripheral blood eosinophilia and are resistant to therapy.

FIGURE 96-4 Hypereosinophilic syndrome. Mucosal erosions and ulcers of mouth (*A*) and glans penis (*B*), with conjunctival irritation (*C*).

Criteria for the diagnosis of hypereosinophilic syndrome include persistent peripheral blood eosinophil counts greater than 1500/mm [3] for more than 6 months; failure to diagnose parasitic, allergic, or other known causes of eosinophilia; and presumptive signs and symptoms of organ involvement. Patients satisfying the criteria likely have a constellation of diseases. Recently, a subset of patients with the hypereosinophilic syndrome were found to have unusual T cell clones, CD3- and CD4+, that express T_H2 cytokines, particularly IL-5. [46]

Other organs that may be involved include the bone marrow, sometimes associated with eosinophilic leukemia; the heart, leading to subendocardial fibrosis and restrictive cardiomyopathy; the liver and spleen, with organomegaly; the lung with infiltrates; and the nervous system. The histopathology of skin lesions is nonspecific but frequently shows a heavy dermal infiltrate of eosinophils. Serum MBP levels are usually elevated in patients with the hypereosinophilic syndrome, and eosinophil degranulation is noted in tissues such as the endocardium and the myocardium. Eosinophils from patients with the hypereosinophilic syndrome are hypodense, implying a more activated state.

Glucocorticoids have been used as initial and maintenance therapy for the hypereosinophilic syndrome and are continued until the eosinophilia is under control. In patients unresponsive to prednisone, hydroxyurea is added. Improvement in peripheral eosinophilia correlates with improved cardiac status. Vincristine also has been tried as a therapeutic agent. INF-a therapy has been successfully used to control the disease, including the variant with mucosal ulcerations. [47] Recently, imatinib mesylate (Gleevec), a tyrosine kinase inhibitor useful for treatment of chronic myelogenous leukemia, was found to be remarkably effective for certain patients with hypereosinophilic syndrome, namely those without elevation of IL-5. [48]

The hypereosinophilic syndrome predominantly affects men, and the 5-year survival rates are reported at 80 percent or better. Treatment limits organ involvement and extends survival. The cause of death in patients with the hypereosinophilic syndrome is frequently related to cardiovascular disease, most commonly congestive heart failure.

Angiolymphoid Hyperplasia with Hypereosinophilia and Kimura's Disease

Angiolymphoid hyperplasia with eosinophilia and Kimura's disease are characterized by persistent, recurrent dermal and/or subcutaneous nodules, primarily in the head and neck area. Lesions of both diseases are infiltrated with masses of eosinophils, and peripheral blood eosinophilia is common. Controversy exists as to whether angiolymphoid hyperplasia with eosinophilia and Kimura's disease represent separate disease entities or are part of a single disease spectrum. [49] The features of the two diseases are compared in Table 96-3. Because of the associated tissue and peripheral blood eosinophilia, both syndromes are thought to be hypersensitivity responses; serum IgE is elevated in many cases of Kimura's disease. The pathogenic stimulus for the hypersensitivity response is unknown. Angiolymphoid hyperplasia with eosinophilia has been described in the Occident, and Kimura's disease has been described mainly in the Orient. Compared with Kimura's disease, angiolymphoid hyperplasia with eosinophilia is more varied in its clinical and immunohistologic findings. [50]

TABLE 96-3 **Comparison of Angiolymphoid Hyperplasia with Eosinophilia and Kimura's Disease**

Eosinophilic Pustular Folliculitis and Other Pustular Dermatoses

Eosinophilic pustular folliculitis, first described by Ofugi, is characterized by recurrent crops of pruritic follicular papules and pustules that occur mainly on the face, trunk, and extremities. Histologically, the most striking feature is the infiltration of eosinophils, mixed with mononuclear cells, into the epidermis and dermis. Chemotactic factors for neutrophils and eosinophils have been found in stratum corneum extracts from eosinophilic pustular folliculitis lesions. Other studies revealed an epidermal antibody directed against the intercellular substance in the lower epidermis. There are high titers of circulating IgG and IgM directed against the cytoplasm of the epidermal basal cells in the outer sheath of hair follicles. The pathogenesis of eosinophilic pustular folliculitis is unknown, but the disease occurs in conjunction with immunologic disorders including the acquired immunodeficiency syndrome. When bacterial or fungal organisms are cultured, a response to antimicrobial therapy has been demonstrated. Nonsteroidal anti-inflammatory drugs, diaminodiphenylsulfone (dapsone), and topical glucocorticoids may be beneficial. Indomethacin has been suggested as first-line therapy, and improvement is associated with decreases in peripheral blood eosinophils. [51] Other studies suggest that IFN-? therapy may effectively control the disease. [52]

Granuloma Faciale

Granuloma faciale is characterized by single or multiple brown-red, asymptomatic, indurated facial nodules with prominent follicular orifices and occasional telangiectasias. The lesions never ulcerate and tend to be progressive. Peripheral blood eosinophilia may accompany the disease. Intranasal and laryngeal lesions with similar histopathologic features have been reported. Histologically, granuloma faciale is distinctive: a dense dermal accumulation of neutrophils, eosinophils, monocytes, lymphocytes, plasma cells, and histiocytes is separated from the epidermis by a narrow band of uninvolved dermis. Lesions may contain increased numbers of mast cells. The degree of eosinophil infiltration is variable, from lesions dominated by eosinophils to those with only a few identifiable cells. Evidence for eosinophil degranulation includes extracellular MBP deposition. [53] A vasculitis characterized by vessel wall damage and nuclear dust may be seen. Direct immunofluorescence has shown IgG, IgM, and IgA along the basement membrane zone and striking perivascular fibrin deposition. The disease is resistant to most treatments; surgical excision may be curative, but lesions recur. Diaminodiphenylsulfone (dapsone) therapy has been reported to be helpful. [54]

REFERENCES

1. Leiferman KM: Eosinophils, interleukin-5, and cutaneous disease, in *Interleukin-5: From Molecule to Drug Target For Asthma. Lung Biology in Health and Disease*, vol 125, edited by CJ Sanderson. New York, Marcel Dekker, 1999, pp 95–118

2. Peters MS: The eosinophil, in *Advances in Dermatology*, vol 2, edited by JP Callen et al. Chicago, Year Book, 1987, p 192

3. Peters MS et al: Localization of eosinophil granule major basic protein in chronic urticaria. *J Invest Dermatol* **81**:39, 1983

4. Leiferman KM et al: Evidence for eosinophil degranulation with deposition of granule major basic protein in solar urticaria. *J Am Acad Dermatol* **21**:75, 1989

5. McEvoy MT et al: Immunohistological comparison of granulated cell proteins in induced immediate dermographism and delayed pressure urticaria. *Br J Dermatol* **133**:853, 1995

6. Leiferman KM et al: Extracellular deposition of eosinophil and neutrophil granule proteins in the IgE-mediated cutaneous late phase reaction. *Lab Invest* **62**:579, 1990

7. Gleich GJ et al: Episodic angioedema associated with eosinophilia. *N Engl J Med* **310**:1621, 1984

8. Butterfield JH et al: Elevated serum levels of interleukin-5 in patients with the syndrome of episodic angioedema and eosinophilia. *Blood* **79**:688, 1992

9. Songsiridej V et al: Facial edema and eosinophilia: Evidence for eosinophil degranulation. *Ann Intern Med* **103**:503, 1985

10. Mehregan DR et al: Cutaneous reactions to granulocyte monocyte colony stimulating factor. *Arch Dermatol* **128**:1055, 1992

11. van Haelst-Pisani CM et al: Administration of IL-2 results in increased plasma concentrations of IL-5 and eosinophilia in patients with cancer. *Blood* **78**:1538, 1991

12. Peters MS et al: Immunofluorescence identification of eosinophil granule major basic protein in the flame figures of Wells' syndrome. *Br J Dermatol* **109**:141, 1983

13. Davis MDP et al: Familial eosinophilic cellulitis, dysmorphic habitus and mental retardation. *J Am Acad Dermatol* **38**:919, 1998

14. Leiferman KM et al: Dermal deposition of eosinophil-granule major basic protein in atopic dermatitis: Comparison with onchocerciasis. *N Engl J Med* **313**:282, 1985

15. Leiferman KM: A role for eosinophils in atopic dermatitis. Proceedings of the International Consensus Conference on Atopic Dermatitis. *J Am Acad Dermatol* **45**:S21, 2001

16. Leiferman KM, Plager DA, Gleich GJ. Eosinophils and atopic dermatitis, in *Atopic Dermatitis*, edited by T Bieber, DYM Leung. New York, Marcel Dekker, 2002, p 327

17. Ackerman SJ et al: Eosinophil degranulation: An immunologic determinant in the pathogenesis of the Mazzotti reaction in human onchocerciasis. *J Immunol* **144**:3961, 1990

18. Jacyk WK et al: Pachydermatous eosinophilic dermatitis. *Br J Dermatol* **134**:469, 1996

19. Perez GL et al: Mast cells, neutrophils and eosinophils in prurigo nodularis. *Arch Dermatol* **129**:861, 1993

20. Johansson O, et al: Eosinophil cationic protein- and eosinophil-derived neurotoxin/eosinophil protein X-immunoreactive eosinophils in

prurigo nodularis. *Arch Dermatol Res* **292**:371, 2000

21. Scheman AJ et al: Evidence for eosinophil degranulation in the pathogenesis of herpes gestationis. *Arch Dermatol* **125**:1079, 1989

22. Borrego L et al: Deposition of eosinophil granule proteins precedes blister formation in bullous pemphigoid: Comparison with neutrophil and mast cell granule proteins. *Am J Pathol* **148**:897, 1996

23. Daoud MS et al: Bullous morphea: Clinical, pathologic and immunopathologic evaluation of thirteen cases. *J Am Acad Dermatol* **30**:937, 1994

24. Thyresson NH et al: Localization of eosinophil granule major basic protein in incontinentia pigmenti. *Pediatr Dermatol* **8**:102, 1991

25. Chen K-R et al: Recurrent cutaneous necrotizing eosinophilic vasculitis: A novel eosinophil mediated syndrome. *Arch Dermatol* **130**:1159, 1994

26. Chen K-R et al: Eosinophilic vasculitis in connective tissue disease. *J Am Acad Dermatol* **35**:173, 1996

27. Drage LA et al: Evidence for pathogenic involvement of eosinophils and neutrophils in Churg-Strauss Syndrome. *J Am Acad Dermatol* **47**:209, 2002

28. Hirsch JG, Hirsch BI: Paul Ehrlich and the discovery of the eosinophil, in *The Eosinophil in Health and Disease*, edited by AAF Mahmoud, KF Austen. New York, Grune & Stratton, 1980, p 3

29. Kita H: Biology of eosinophils, in *Allergy: Principles & Practice,* Middleton E Jr, Reed CE, Ellis EF, Adkinson NF Jr, Yunginger JW, Busse WW (eds). St. Louis, Mosby, 5th ed, Vol. 1, Ch. 19, 1998, pp 242–260

30. Gleich GJ: Mechanisms of eosinophil-associated inflammation. *J Allergy Clin Immunol* **105**:651, 2000

31. Plager DA et al: A novel human homolog of eosinophil major basic protein. *Immunol Rev* **179**:192, 2001

32. Weller PF: Human eosinophils. *J Allergy Clin Immunol* **100**:283, 1997

33. Broide D, Sriramarao P: Eosinophil trafficking to sites of allergic inflammation. *Immunol Rev* **179**:163, 2001

34. Elsner J, Kapp A. The chemokine network in eosinophil activation. *Allergy Asthma Proc* **22**:139, 2001

35. Bochner BS, Schleimer RP: Mast cells, basophils, and eosinophils: Distinct but overlapping pathways for recruitment. *Immunol Rev* **179**:5, 2001

36. Bradding P et al: Interleukin-4, -5, and -6 and tumor necrosis factor-alpha in normal and asthmatic airways: Evidence for the human mast cell as a source of these cytokines. *Am J Respir Cell Mol Biol* **10**:471, 1994

37. Warren HS et al: Production of IL-5 by human NK cells and regulation of IL-5 secretion by IL-4, IL-10, and IL-12. *J Immunol* **154**:5144, 1995

38. Lacy P, Moqbel R: Eosinophil cytokines. *Chem Immunol* **76**:134, 2000

39. Sehmi R, Denburg JA: Differentiation of human eosinophils. *Chem Immunol* **76**:29, 2000

40. Gratten CEH et al: Eosinophil major basic protein in autologous serum and saline skin tests in chronic idiopathic urticaria [letter]. *Br J Dermatol* **136**:141, 1997

41. Jacoby DB, Costello RM: Eosinophil recruitment to the airway nerves. *J Allergy Clin Immunol* **107**:211, 2001

42. Noguchi H et al: Tissue eosinophilia and eosinophil degranulation in syndromes associated with fibrosis. *Am J Pathol* **140**:521, 1992

43. Varga J, Kahari VM: Eosinophilia-myalgia syndrome, eosinophilic fasciitis, and related fibrosing disorders. *Curr Opin Rheumatol* **9**:562, 1997

44. Diggle GE: The toxic oil syndrome: 20 years on. Int J Clin Prac 55:371, 2001.

45. Leiferman KM: Hypereosinophilic syndrome, in *Cutaneous Medicine and Surgery*, edited by KA Arndt, PE Leboit, JK Robinson, BU Wintroub. Philadelphia, Saunders, 1996, p 352

46. Simon HU et al:: Abnormal clones of T cells producing interleukin-5 in idiopathic eosinophilia. *N Engl J Med* **341**:1112, 1999

47. Butterfield JH, Gleich GJ: Interferon-alpha treatment of six patients with the idiopathic hypereosinophilic syndrome. *Ann Intern Med* **121**:648, 1994

48. Gleich GJ et al: Treatment of the hypereosinophilic syndrome with imatinib mesylate. *Lancet* **359**:1577, 2002

49. Kung ITM et al: Kimura's disease: A clinicopathological study of 21 cases and its distinction from angiolymphoid hyperplasia with eosinophilia. *Pathology* **16**:39, 1984

50. Helander SD et al: Kimura's disease and angiolymphoid hyperplasia with eosinophilia: New observations from immunohistochemical studies of lymphocyte markers, endothelial antigens and granulocyte proteins. *J Cutan Pathol* **22**:319, 1995

51. Ota T et al: Eosinophilic pustular folliculitis (Ofugi's disease): Indomethacin as a first choice of treatment. *Clin Exp Dermatol* **26**:179, 2001

52. Fushimi M et al: Eosinophilic pustular folliculitis effectively treated with recombinant interferon-gamma: Suppression of mRNA expression of interleukin 5 in peripheral blood mononuclear cells. *Br J Dermatol* **134**:766, 1996

53. Dinneen AM et al: Granuloma faciale: Immunohistopathologic study and evidence for eosinophil degranulation [abstract]. *J Invest Dermatol* **96**:568, 1991

54. van de Kerkhof PC: On the efficacy of dapsone in granuloma faciale. *Acta Derm Venereol* **74**:61, 1994

T>

Chapter 97

Walter Burgdorf

Granuloma Faciale

HISTORICAL ASPECTS
ETIOLOGY AND PATHOGENESIS
CLINICAL MANIFESTATIONS
LABORATORY EXAMINATION
PATHOLOGY
DIAGNOSIS AND DIFFERENTIAL DIAGNOSIS
TREATMENT

REFERENCES

Granuloma faciale is an uncommon disease of unknown origin characterized by single or multiple cutaneous nodules, usually occurring on the face.

HISTORICAL ASPECTS

Although a variety of skin lesions have been called eosinophilic granuloma, the case that Wigley described as eosinophilic granuloma may be the first example of what is now known as granuloma faciale. [1] This rare disease had been lost among the common infectious granulomas and became better recognized only as the latter decreased in number with increasing antibiotic use. Cobane and colleagues used the phrase *facial granuloma with eosinophilia* and separated this entity from other eosinophilic infiltrates of skin and other tissues; [2] Pinkus suggested the name of granuloma faciale. [3]

ETIOLOGY AND PATHOGENESIS

The etiology of granuloma faciale remains a mystery. The literature does not even include any attractive speculations.

CLINICAL MANIFESTATIONS

Granuloma faciale occurs as cutaneous nodules or plaques that are usually solitary. [4] Occasionally, patients have multiple or disseminated lesions. Most often, lesions occur on the face, but they may appear anywhere. [5] Because the disease favors light-exposed areas and sunlight makes some lesions worse, actinic exposure may play a role in the pathogenesis. The disease may appear at any age, but becomes evident primarily in middle life. It seems to be more common in males. Although most have occurred in Caucasians, Lesions have been identified in blacks and Japanese.

The lesions are soft, elevated, well-circumscribed nodules, ranging in size from a few millimeters to several centimeters (Fig. 97-1). Due to sinking of their centers, some lesions become annular. Their color varies; they are seldom bright red, but rather are shades of dull red, brown, blue, and purple. After sun exposure, they may darken. The surface is smooth, but the follicular orifices are accentuated. Lesions are never ulcerated but may be covered by telangiectases (Fig. 97-2). They are usually asymptomatic and chronic or slowly progressive; occasionally, they involute.

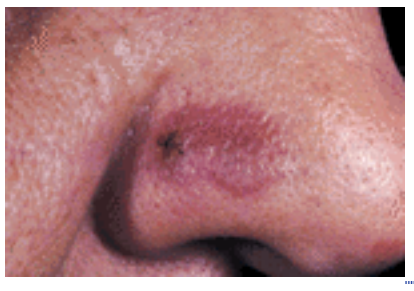

FIGURE 97-1 Granuloma faciale. Large reddish brown nodule on the nose.

FIGURE 97-2 Granuloma faciale. Close-up view of the chin, showing reddish brown nodule with prominent pores and telangiectases.

Extracutaneous involvement is most rare. There have been isolated reports of granuloma faciale–like lesions of the oral

mucosa and upper airway, known as eosinophilic angiocentric fibrosis. [6] In one case, the patient had cutaneous granuloma faciale and a histologically similar process in her nasal mucosa, which was causing obstruction. [7] One patient with myelodysplastic syndrome had granuloma faciale, Sweet syndrome, and pyoderma gangrenosum. [8] Even in patients with widespread cutaneous disease, no other internal involvement has been reported.

LABORATORY EXAMINATION

The findings of the laboratory evaluation are normal except for occasional mild blood eosinophilia.

PATHOLOGY

Biopsy of the skin is the most important method of diagnosis, because the histologic changes associated with granuloma faciale are usually distinctive. The epidermis is unaffected except where it is thinned and flattened by the underlying infiltrate. There is usually a narrow Grenz zone of uninvolved dermis between the epidermis and the dense dermal accumulation of inflammatory cells (Fig. 97-3), including neutrophils, eosinophils, monocytes, and lymphocytes. Some cases show a considerable number of mast cells as well. Extravasated red blood cells, hemosiderin, and melanin probably all contribute to the brown color seen clinically. The number of eosinophils varies widely. In some cases, they constitute the largest part of the infiltrate; in others, only a few are seen.

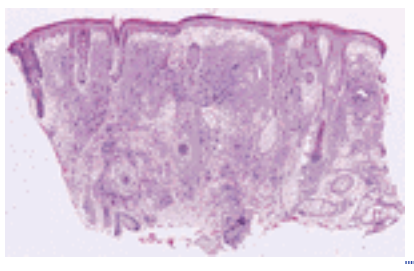

FIGURE 97-3 Granuloma faciale. There is a normal epidermis separated from a perivascular infiltrate of lymphocytes and eosinophils by a Grenz zone.

The infiltrate is usually distributed diffusely throughout the involved dermis. At its depth and periphery, it is predominantly perivascular. At times, true vasculitis occurs, causing vessel wall damage and nuclear dust. In other cases, there is fibrinoid or hyaline material within and about the affected blood vessels. In older lesions, considerable fibrosis may occur. Immunofluorescence studies and electron microscopic studies support the vascular involvement and presence of eosinophils. The benign appearance of the cells, as well as the mixed composition, serves to differentiate granuloma faciale from malignant processes.

DIAGNOSIS AND DIFFERENTIAL DIAGNOSIS

Clinically, the reddish brown nodules of granuloma faciale must be differentiated from those associated with a wide variety of other diseases. Many cutaneous infiltrates are similar in appearance, including that of lupus erythematosus, polymorphic light eruption, fixed drug eruption, leukemic infiltrate, and the whole spectrum of benign and malignant lymphoid proliferations. Granulomatous processes ranging from sarcoidosis, granuloma annulare, and foreign body reactions to infections such as tinea faciale, leprosy, and tuberculosis also enter the differential. In children, juvenile xanthogranuloma, mastocytoma, and Spitz nevus are additional possibilities, although one must remember that granuloma faciale is extremely rare in children. The clinical appearance and history usually help to eliminate most of the choices, but histologic findings determine the final diagnosis.

Granuloma faciale and erythema elevatum diutinum appear to be related. Erythema elevatum diutinum is characterized by persistent plaques on the extremities. Histologically, it has more epidermal and vascular involvement with fewer eosinophils.

Several other benign and malignant skin lesions have significant numbers of eosinophils in their infiltrates. Angiolymphoid hyperplasia with eosinophilia also presents as a reddish facial nodule rich in eosinophils, but the prominent endothelial cells and lymphoid proliferation, usually including germinal center formation, allow ready identification on biopsy. Also similar are arthropod bites with both lymphoid and pseudoepitheliomatous hyperplasia and nodular scabies, which usually has less epidermal change. When histiocytosis X involving the skin is rich in eosinophils, differentiation is still possible because its atypical histiocytes exhibit epidermotropism and contain Langerhans granules, which may be identified by immunohistochemical staining or electron microscopy.

TREATMENT

Facial granulomas are notorious for their stubborn resistance to treatment. Surgical excision may be curative, but both the recurrence of old lesions and the appearance of new lesions are common. Destruction with the 585-nm pulsed dye laser seems promising. [9] Other lasers, electrosurgery, cryosurgery, and dermabrasion have also produced acceptable results. [10] It seems that any destructive treatment may ablate a lesion, but ablation requires treatment deep enough to risk scarring.

Thus, nonscarring intervention is attractive. Local injection of triamcinolone suspension in concentrations of 2.5 to 5 mg/mL with either a fine-gauge needle or pressure injector may be helpful. This approach has been effectively combined with cryotherapy. [11] Several orally administered medications are potentially beneficial. Dapsone in doses of 50 to 150 mg

daily has been effective. [12] Although many other therapies have been the topic of case reports, none has proven consistently successful.

Because of its poor response to therapy and apparent harmlessness, granuloma faciale may be left untreated. However, its facial location and unsightly appearance cause most physicians or patients to at least try some of these remedies.

REFERENCES

1. Wigley JEM: Sarcoid of Boeck? Eosinophilic granuloma. *Br J Dermatol* **57**:68, 1945

2. Cobane JH et al: Facial granulomas with eosinophilia: Their relation to other eosinophilic granulomas of the skin and to reticulogranuloma. *Arch Dermatol Syphilol* **61**:442, 1950

3. Pinkus H: Granuloma faciale. *Dermatologica* **105**:85, 1952

4. Pedace FJ, Perry HO: Granuloma faciale. *Arch Dermatol* **94**:387, 1966

5. Roustan G et al: Granuloma faciale with extrafacial lesions. *Dermatology* **198**:79, 1999

6. Thompson LD, Heffner DK: Sinonasal tract eosinophilic angiocentric fibrosis: A report of three cases. *Am J Clin Pathol* **115**:243, 2001

7. Roberts PF, McCann BG: Eosinophilic angiocentric fibrosis of the upper respiratory tract: A mucosal variant of granuloma faciale? A report of three cases. *Histopathology* **9**:1217, 1985

8. Vazquez Garcia J et al: Multiple neutrophilic dermatoses in myelodysplastic syndrome. *Clin Exp Dermatol* **26**:398, 2001

9. Ammirati CT, Hruza GJ: Treatment of granuloma faciale with the 585-nm pulsed dye laser. *Arch Dermatol* **135**:903, 1999

10. Dinehart SM et al: Granuloma faciale: Comparison of different treatment modalities. *Arch Otolaryngol Head Neck Surg* **116**:849, 1990

11. Dowlati B et al: Granuloma faciale: Successful treatment of nine cases with a combination of cryotherapy and intralesional corticosteroid injection. *Int J Dermatol* **36**:548, 1997

12. van de Kerkhof PC: On the efficacy of dapsone in granuloma faciale. *Acta Derm Venereol* **74**:61, 1994

T>

Chapter 98

Klaus Wolff Georg Stingl

Pyoderma Gangrenosum

ETIOLOGY AND PATHOGENESIS
CLINICAL MANIFESTATIONS
CLINICAL VARIANTS
EXACERBATING FACTORS
LABORATORY FINDINGS
PATHOLOGY
ASSOCIATION WITH SYSTEMIC DISEASE
Ulcerative Colitis and Crohn's Disease
Arthritis
Monoclonal Gammopathy
Myeloproliferative Disorders
Other Conditions
Relationship to Other Neutrophilic Dermatoses
DIFFERENTIAL DIAGNOSIS
TREATMENT
Glucocorticoids
Sulfa Drugs
Cyclosporine
Other Immunosuppressive Agents
Clofazimine
Anti–Tumor Necrosis Factor-a
Miscellaneous Treatments
COURSE AND PROGNOSIS
REFERENCES

Pyoderma gangrenosum is a rare, destructive inflammatory skin disease in which a painful nodule or pustule breaks down to form a progressively enlarging ulcer. Lesions may occur either in the absence of any apparent underlying disorder or in association with systemic disease, such as ulcerative colitis, Crohn's disease, polyarthritis, gammopathy, and other conditions. Pyoderma gangrenosum belongs to the group of neutrophilic dermatoses in which the common cellular denominator is the neutrophil.

ETIOLOGY AND PATHOGENESIS

When Brunsting, Goeckerman, and O'Leary described pyoderma gangrenosum in 1930, [1] they implicated streptococci and staphylococci as causative agents because of the inflammatory and purulent nature of the condition. Seventy years later, the etiology of pyoderma gangrenosum is still unknown, but in all likelihood bacteria do not directly cause the disease, nor is it infectious in nature.

Pyoderma gangrenosum, cystic acne, and pyogenic, aseptic arthritis (PAPA syndrome) have been reported in a three-generation kindred with autosomal dominant transmission and mapped to the long arm of chromosome 15. [2]

A key to the etiologic and pathogenic background of pyoderma gangrenosum may be found in its frequent association with systemic disease, but, because pyoderma gangrenosum exists both as a disease sui generis and in association with a systemic disorder, the cause-effect relationship of such associations is not clear. The phenomenon of pathergy, which describes the development of new lesions or the aggravation of existing ones after trivial trauma and is frequently present in pyoderma gangrenosum, suggests altered, exaggerated, and uncontrolled inflammatory responses to nonspecific stimuli.

The preeminent cell in pyoderma gangrenosum pathology is the neutrophil. Indeed, the condition responds to sulfa drugs, which have an antineutrophilic action (see Chap. 254). Pyoderma gangrenosum has occurred as a side effect of treatment with granulocyte-macrophage colony-stimulating factor (GM-CSF), [3] following treatment with interferon-a2b, [4] and in cases in which IL-8 is overexpressed in the tissue. [5] By contrast, GM-CSF has been successfully used in the treatment of pyoderma gangrenosum. [6] There have been reports of abnormalities of neutrophil function, but no consistent patterns have emerged. Some in vitro studies showed impaired neutrophil chemotaxis, [7] but neutrophil accumulation at a Rebuck skin window was normal [8]; moreover, neutrophils do accumulate at sites of pyoderma gangrenosum. Human skin engrafted to mice with severe combined immunodeficiency and then injected with recombinant adenovirus expressing DNA that encoded human IL-8, which induces a 200-fold increase in IL-8 expression of infected human fibroblasts in vitro, developed massive neutrophilic inflammation and ulceration clinically and histologically resembling pyoderma gangrenosum. [5] A streaking leukocyte factor that enhances migration of leukocytes without altering their chemotactic activity, aberrant neutrophil trafficking, and metabolic oscillations of leukocytes have been observed. [9], [10] Impairment of microbicidal activation of leukocytes and impaired neutrophil functions associated with hyperimmunoglobulinemia E have been isolated findings. [11] IgA of multiple myeloma can impair neutrophil chemotaxis in vitro, and IgA gammopathies are not infrequent in pyoderma gangrenosum. Circulating immunoglobulins can affect neutrophil functions, and monoclonal or polyclonal hyperglobulinemia frequently occurs in pyoderma gangrenosum.

The evidence implicating a disturbance of cellular immune functions in pyoderma gangrenosum is insufficient to explain the pathogenesis of the disease. Certainly, the strongest piece of evidence indicating a disturbed immune response is

the fact that pyoderma gangrenosum responds to cyclosporine, but no consistent pattern of a disturbed cellular immune response has emerged. Findings include anergy to recall antigens, [12] impairment of both antigen-specific and mitogen-induced lymphocyte proliferation, [13] inhibition of allogeneic and autologous mixed lymphocyte proliferation, [14] and defective monocyte phagocytosis linked to an IgG paraprotein that inhibits Fc-dependent phagocytosis of normal monocytes. [15] All these findings have appeared in some individual patients, but not in others. Thus, although evidence suggests that disturbances of immunoregulation and immunologic effector functions occur in some patients with pyoderma gangrenosum, these disruptions are not detectable in others; it is unclear whether they are epiphenomena.

CLINICAL MANIFESTATIONS

The salient feature of pyoderma gangrenosum is an ulcer with a raised inflammatory border and a boggy, necrotic base. It starts as a deep-seated, painful nodule or as a superficial hemorrhagic pustule (Fig. 98-1A), either de novo or after minimal trauma. The lesions break down and ulcerate, discharging a purulent and hemorrhagic exudate (Fig. 98-1B). The irregular, crenated border is elevated and is dusky red or purplish; it is undermined, soggy, and often perforated so that pressure releases pus (Fig. 98-1C and Fig. 98-1D.

FIGURE 98-1 Lesions of pyoderma gangrenosum in various stages of development. *A*. A small, hemorrhagic pustule with an extremely painful red base. *B*. Three rapidly spreading hemorrhagic, bullous lesions that have broken down in the center, revealing a necrotic and purulent base. *C*. A rapidly progressive ulcerative lesion with a soggy, pustular, and partially undermined margin; a granulating necrotic base; and a red inflammatory halo. *D*. A larger ulcerating lesion with undermined bullous margins; a necrotic, purulent base; and a deep ulcer in the center.

A halo of bright erythema surrounds the margin of an advancing ulceration (Fig. 98-1B, Fig. 98-1C, and Fig. 98-2B), which may expand rapidly in one direction and more slowly in another so that a serpiginous configuration results (Fig. 98-2B). The base of such an ulcer is partially covered with necrotic material (Fig. 98-3A) and studded with small abscesses (see Fig. 98-1C and Fig. 98-3A). Ulcers may be confined to the dermis, but they often extend into the fat and even down to the fascia (see Fig. 98-1D, Fig. 98-2B, and Fig. 98-3).

FIGURE 98-2 *A*. Multiple lesions of pyoderma gangrenosum in a patient who later died of Wegener's granulomatosis. Note multiple, atrophic scars that have resulted from previous flareups of pyoderma gangrenosum. *B*. Rapidly enlarging pyoderma gangrenosum triggered by laparotomy. The lesion spread to involve the entire lower abdomen within 5 days.

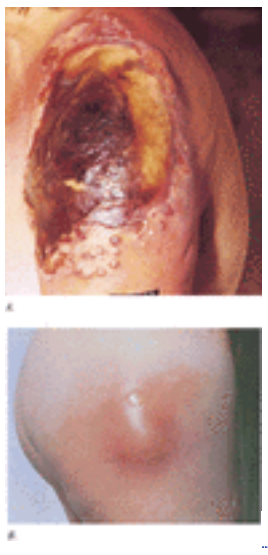

FIGURE 98-3 Lesions of pyoderma gangrenosum. *A*. An acute, necrotic ulcer with an elevated purulent border studded with pustules. *B*. Lesion that started in the subcutaneous fat and thus presented as acute, purulent panniculitis. Bullous lesions have developed on the surface. When this lesion broke down, an ulcer similar to that shown in Fig. 98-1D developed, extending all the way down to the fascia.

Lesions are usually solitary, but may arise in clusters that then coalesce to form multicentric, irregular ulcerations. Multiple lesions may arise simultaneously or consecutively in different parts of the body (see Fig. 98-2A). Any area of the body may be involved. Mucous membranes are usually spared, but aphthous lesions are sometimes seen in the oral mucosa. Massive ulcerative involvement of the oral cavity, larynx and pharynx, vulva, cervix, and eyes occasionally occurs.

Pyoderma gangrenosum may occur at any age. Its clinical course may follow one of two patterns: (1) an explosive onset with rapid spread of lesions or (2) a slow, indolent progression. Pain, signs of a toxic reaction and fever, hemorrhagic blisters and suppuration, extensive necrosis, and soggy ulcer margins with a highly inflammatory halo characterize the first type of pyoderma gangrenosum (see Fig. 98-1, Fig. 98-2, and Fig. 98-3). The slow, indolent form clinically exhibits massive granulation within the ulcer from the onset, crusting, and even hyperkeratosis at the margins; it spreads gradually, grazing over large areas of the body for months. Spontaneous regression and healing in one area and progression in another are characteristic of the slow form (Fig. 98-4A and Fig. 98-4B. In both forms, healing occurs spontaneously at some time in the disease process, resulting in thin, atrophic, usually cribriform scars.

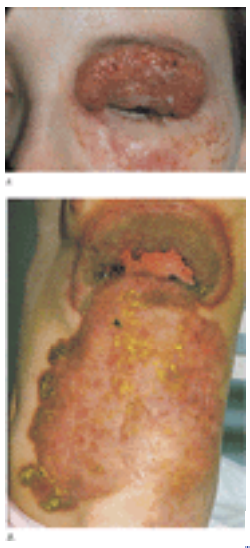

FIGURE 98-4 *A*. Chronic form of pyoderma gangrenosum involving the upper eyelid. The ulcer has an elevated granulating base with multiple small abscesses. *B*. Lesion of chronic pyoderma gangrenosum that slowly spread over months to involve almost the entire trunk. The lesion is less inflammatory than the one shown in *A*; it is progressive at the margins on the abdomen and the lateral chest, while it has spontaneously healed in the center, the hip, and the back.

Rarely, pyoderma gangrenosum may start in the subcutaneous fat, presenting as an extremely painful, suppurative panniculitis (Fig. 98-3B). Breakdown of the lesion and the centrifugal spread of the resulting ulcer eventually reveal the true nature of the process.

CLINICAL VARIANTS

A localized, vegetative form of pyoderma gangrenosum with verrucous and ulcerative lesions and a more granulomatous histology has been identified and designated superficial granulomatous pyoderma. [16] Most authors consider this condition, originally described as malignant pyoderma, [17] to be a variant of pyoderma gangrenosum, [18] although some of these cases may have actually been a form of Wegener's granulomatosis. [19] Pyostomatitis vegetans, a pustular, vegetative process of the oral mucous membranes often associated with ulcerative and vegetating skin lesions and inflammatory bowel disease, is now also considered a variant of pyoderma gangrenosum.

An atypical, bullous form of pyoderma gangrenosum appears to herald preleukemic or leukemic states. [20], [21] It has an acute onset, is more superficial than the typical pyoderma gangrenosum, and is characterized by steadily enlarging, soft purple papules and blue-gray, hemorrhagic bullous lesions. This condition is similar to the bullous form of acute febrile neutrophilic dermatosis (Sweet's syndrome; see Chap. 94). [22], [23]

EXACERBATING FACTORS

Intradermal skin testing or injections (including even the injection of saline), pricks, insect bites, biopsies, and operations may induce new lesions of pyoderma gangrenosum. This phenomenon is called pathergy. The lesions shown in Figure 98-2B arose after laparotomy for a gynecologic problem. However, pathergy occurs in only 20 percent of patients, [24] and, because some individuals with the disease tolerate even major surgery well, the significance of pathergy is difficult to assess. Pathergy may also be the reason for the rejection of autologous skin grafts and the development of new lesions in donor sites, but again, patients with pyoderma gangrenosum do not always reject skin grafts. Potassium iodide can induce an exacerbation of pyoderma gangrenosum, [1] as can GM-CSF and interferon, [3], [4] but, as is true for pathergy after trauma, this exacerbation does not always occur.

LABORATORY FINDINGS

No laboratory findings are specific and thus diagnostic of pyoderma gangrenosum. A high erythrocyte sedimentation rate and leukocytosis are invariably present. The level of C-reactive protein may be raised; there may be anemia and a low level of serum iron. Both hyper- and hypoglobulinemia occur. Specific autoantibodies are not known; the complement system is not altered, and circulating immune complexes have not been detected regularly. [7], [13], [25] HLA typing has not revealed a consistent pattern. [7]

PATHOLOGY

The histopathologic features of pyoderma gangrenosum are not diagnostic. They include edema, massive neutrophilic inflammation, engorgement and thrombosis of small- and medium-sized vessels, necrosis, and hemorrhage. The extremely dense infiltrate of polymorphonuclear leukocytes leads to abscess formation and liquefaction necrosis of the tissue with secondary thrombosis of venules. Lesions further evolve to suppurative granulomatous dermatitis and regress with prominent fibroplasia. [26]

The occurrence of necrotizing vasculitis in lesions of pyoderma gangrenosum was controversial in the past, but a number of authors have now described fibrinoid necrosis, leukocytoclasia, [27], [28] and intramural deposition of C3 in vessels of pyoderma gangrenosum lesions [29], [30] that are indistinguishable from those associated with immune complex vasculitis. There also exist reports on the concomitant occurrence of pyoderma gangrenosum and necrotizing vasculitis, [28], [31], [32] and [33] and patients with pyoderma gangrenosum have been reported to develop Wegener's granulomatosis. [34] However, the ultimate proof for a pathogenic role of immune complex vasculitis has yet to be provided. When pyoderma gangrenosum is associated with Crohn's disease, lesions may contain granulomatous foci with giant cells. [35] When localized in the fat, it presents as subcutaneous abscess. [36]

ASSOCIATION WITH SYSTEMIC DISEASE

Pyoderma gangrenosum may occur as a disease confined to the skin in 40 to 50 percent of cases (idiopathic pyoderma gangrenosum), [37], [38] but it may sometimes manifest itself in extracutaneous sites. Peripheral ulcerative keratitis is an inflammatory keratitis characterized by cellular infiltration, corneal thinning, and ulceration. [39] Cavitating pulmonary infiltrates may also occur in pyoderma gangrenosum. [40], [41] Among the systemic diseases sometimes associated with pyoderma gangrenosum are inflammatory large- and small-bowel disease, arthritis, paraproteinemia and myeloma, myeloproliferative disease, and Behçet's syndrome. The heterogeneity of these conditions makes pinpointing a common denominator difficult. Common and less common disease associations are listed in Table 98-1.

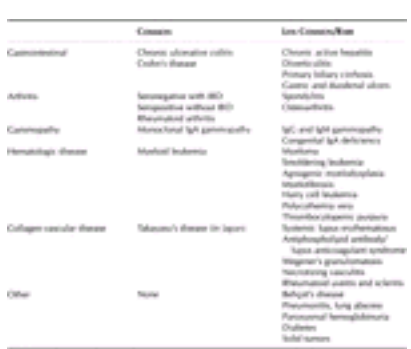

TABLE 98-1 **Systemic Disease Associations with Pyoderma Gangrenosum**

Ulcerative Colitis and Crohn's Disease

In its original description, pyoderma gangrenosum was associated with ulcerative colitis in four of five cases, [1] and subsequent series have found a frequency ranging from 30 to 60 percent. [42] These figures are probably too high, for other studies have found a frequency of up to only 15 percent. [43] Also, pyoderma gangrenosum occurs only rarely in ulcerative colitis, with a reported prevalence ranging from 0.6 to 5 percent. [44] Nonetheless, together with erythema nodosum, pyoderma gangrenosum represents the most common dermatologic disorder accompanying ulcerative colitis. In most patients, symptoms of ulcerative colitis precede pyoderma gangrenosum, and exacerbations of the bowel disease frequently correlate with a worsening of the skin lesions. However, pyoderma gangrenosum may persist for long periods while the bowel disease is quiescent.

Pyoderma gangrenosum is also associated with Crohn's disease. In one series, 16.3 percent of patients with pyoderma gangrenosum had Crohn's disease, [45] but the overall prevalence is low (1.2 percent). [46] In inflammatory bowel disease, the most frequent localization of pyoderma gangrenosum is on the lower legs and around a stoma [47] (see Chap. 129).

Arthritis

Arthritis is frequently associated with pyoderma gangrenosum and usually precedes it. In one review, [24] arthritis was found in 30 percent of patients with pyoderma gangrenosum. In a study of 86 patients from the Mayo Clinic, arthritis was the most frequently associated disorder. [45] Some patients have classic seropositive rheumatoid arthritis [48]; others have the arthritis associated with inflammatory bowel disease, which is seronegative, acute, oligoarticular, and nondestructive; others have a seronegative rheumatoid-like arthritic syndrome; still others have spondylitis. An association of pyoderma

gangrenosum with the synovitis, acne, pustulosis, hyperostosis, and osteitis (SAPHO) syndrome [49], [50] and with psoriatic arthritis (see Chap. 43) has been described. In addition, pyoderma gangrenosum is a clinical manifestation of the autosomal dominant PAPA syndrome characterized by pyogenic arthritis, pyoderma gangrenosum, and cystic acne. [2], [51]

Monoclonal Gammopathy

Pyoderma gangrenosum is often associated with paraproteinemia, mostly of the IgA type, but also of the IgG and IgM types. In one series, [52] monoclonal gammopathy was found in 5 of 21 patients, and in 4 of the 5 it was of the IgA type. In another series, a monoclonal gammopathy was present in 10 percent of those studied. [45] Although patients with a monoclonal gammopathy do not show progression to malignancy over the short term, some patients with pyoderma gangrenosum have myeloma at presentation or develop it subsequently. [7], [24]

Myeloproliferative Disorders

Pyoderma gangrenosum occurs in myelodysplasia, [53] as well as in acute myeloblastic, myelomonocytic, and chronic myeloid leukemia. [42], [54], [55] A few cases have been associated with smoldering leukemia, hairy cell leukemia, polycythemia vera, erythroid hypoplasia, autoimmune hemolytic anemia, myelofibrosis, and Hodgkin's disease. The features of “atypical bullous” pyoderma gangrenosum overlap with those of Sweet's syndrome presenting as an association with acute leukemia (see Chap. 94).

Other Conditions

Several studies have documented patients with pyoderma gangrenosum and Behçet's syndrome. [56], [57] and [58] The two diseases share certain features, such as arthritis, pustulation, aphthous lesions of the mucous membranes, and the phenomenon of pathergy. Pyoderma gangrenosum has occurred in association with other purulent diseases, such as acne conglobata and fulminans [59], [60] (see Chap. 73), the PAPA syndrome, [2], [51] vasculitis, [32], [33] erythema elevatum diutinum [61] (see Chap. 95), and Wegener's granulomatosis. [34], [62] Figure 98-2A shows multiple lesions of pyoderma gangrenosum in a patient who, during the course of the disease, developed necrotizing vasculitis and eventually died of Wegener's granulomatosis. There is an increased frequency (up to 30 percent) of pyoderma gangrenosum in patients with Takayasu's disease in Japan, [63] but not in Europe where such associations are rare. [64] Additional, probably fortuitous, associations are listed in Table 98-1.

Relationship to Other Neutrophilic Dermatoses

The predominant cell in lesions of pyoderma gangrenosum is the neutrophil. This, together with the absence of any sign of infection and the response of pyoderma gangrenosum to sulfa drugs, places pyoderma gangrenosum into the group of etiologically ill-understood neutrophilic dermatoses, such as Sweet's syndrome (see Chap. 94), subcorneal pustular dermatosis (see Chap. 69), Behçet's syndrome (see Chap. 192), neutrophilic eccrine hidradenitis, and rheumatoid neutrophilic dermatitis (see Chap. 179). In the past, pyoderma gangrenosum has been reported in association with generalized, vesiculopustular eruptions, which in retrospect appear to have been subcorneal pustular dermatosis (Sneddon-Wilkinson disease). Indeed, the syndrome consisting of pyoderma gangrenosum, subcorneal pustular dermatosis, and IgA gammopathy, which was first described in 1971, [65] now appears established by a number of case reports. [66], [67] and [68] Subcorneal pustular dermatosis can be associated with ulcerative colitis and IgA myeloma, and it responds to sulfa drugs (see Chap. 69). These findings also hold true for pyoderma gangrenosum. Generalized pustular eruptions occur in patients with ulcerative colitis; whereas some of these pustular lesions progress to frank pyoderma gangrenosum in some patients, others do not.

DIFFERENTIAL DIAGNOSIS

Because there is no specific laboratory test for pyoderma gangrenosum and the histopathology is only suggestive, the diagnosis rests entirely on the clinical presentation and course. Differential diagnoses include postoperative gangrene, ecthyma gangrenosum, atypical mycobacterial and clostridial infection, deep mycoses, amebiasis, tropical ulcers, bromoderma, North American blastomycosis, and pemphigus vegetans. Stasis ulcers are easily excluded, but artifacts and brown recluse spider bites may occasionally cause problems in early, developing lesions. Wegener's granulomatosis includes involvement of the upper respiratory tract and histopathologically displays necrotizing and granulomatous vasculitis; as mentioned previously, however, the two diseases may occur together.

TREATMENT

In patients with underlying disease, therapy should focus not only on pyoderma gangrenosum, but also and primarily on the systemic disorder. In milder forms and those not associated with systemic disease, a trial of local or topical treatment may be appropriate. Some authorities have advocated the intralesional injection of glucocorticoids into the active border of the lesions; the use of hyperbaric oxygen; or topical treatment with disodium cromoglycate, cyclosporine, or tacrolimus. With the possible exception of the topical use of tacrolimus, [69], [70] topical treatment alone is usually insufficient both in patients with associated systemic disease and in most of those having purely cutaneous pyoderma gangrenosum. Although measures directed at cleaning the ulcer and preventing bacterial overgrowth are important, more invasive surgical debridement is generally unwise as it may trigger new lesions. This caveat applies also to excision and grafting, unless systemic treatment has controlled the pyoderma gangrenosum. There have as yet been no enrolled clinical trials for any of the treatments.

Glucocorticoids

The systemic administration of glucocorticoids is the most effective treatment of pyoderma gangrenosum. They dramatically halt the progression of existing ulcerations and prevent the development of new lesions. [43] A high dosage of prednisone, such as 100 to 200 mg/day, may be necessary initially; the dosage is reduced as the inflammatory component of pyoderma gangrenosum disappears and is tapered slowly to discontinuation after the condition has completely resolved. Pulse therapy with suprapharmacologic doses of methylprednisolone (1 g/day for 5 consecutive days) most effectively halts progressive pyoderma gangrenosum, [59], [71], [72] and it is still the first-line treatment for severe pyoderma gangrenosum in many institutions. However, it is necessary to continue suppressing the inflammatory process after pulse therapy by administering prednisolone or sulfa drugs. [43] Unfortunately, long-term oral therapy with glucocorticoids produces side effects in up to 50 percent of the patients.

Sulfa Drugs

Dapsone, sulfapyridine, and sulfasalazine (Azulfidine) are beneficial drugs for pyoderma gangrenosum, but not all patients respond equally well to them. Initial daily doses of sulfasalazine range from 4 to 6 g; the dosage is gradually reduced to maintenance levels of 0.5 to 1 g/day. It may be necessary to administer sulfa drugs in combination with glucocorticoids (given systemically), particularly in the initial phases of therapy, but there have been patients who have failed to respond to this regimen as well.

The mechanism of action of the sulfa drugs in pyoderma gangrenosum is unknown, but may be related to a stabilizing effect on lysosomes, to their interference with the myeloperoxidase-halide system of polymorphonuclear leukocytes, or to a decrease of glycosaminoglycan viscosity in this condition (see Chap. 254). Dapsone is effective in a host of cutaneous disorders that are all characterized by the abnormal accumulation of polymorphonuclear leukocytes, such as erythema elevatum diutinum, dermatitis herpetiformis, Sneddon-Wilkinson disease, Sweet's syndrome, and pyoderma gangrenosum.

Cyclosporine

The oral administration of cyclosporine [73], [74], [75], [76] and [77] and tacrolimus [9], [78] is very effective in the treatment of pyoderma gangrenosum. In severe cases, cyclosporine given intravenously has been successful. [77] Significant improvement occurs within weeks of the start of oral therapy with cyclosporine in doses that range from 6 to 10 mg/kg per day, and healing is likely to take place within 1 to 3 months. Some patients require low-dose maintenance therapy, but others can tolerate complete withdrawal of the drug. Also, patients may require concomitant medium- to low-dose glucocorticoid therapy. As with other immunosuppressive treatments, patients who use cyclosporine require careful monitoring for side effects.

Other Immunosuppressive Agents

Although not universally successful, 6-mercaptopurine, azathioprine, and methotrexate have been beneficial for some patients. Cyclophosphamide has induced dramatic remissions in some patients, [79], [80] and chlorambucil has demonstrated a glucocorticoid-sparing effect. [81], [82] Mycophenolate mofetil, either alone or in combination with cyclosporine, has also been useful. [83], [84] and [85]

Clofazimine

Reports have stressed the efficacy of clofazimine (Lamprene) in pyoderma gangrenosum. [86], [87] Dosages of 200 to 300 mg/day supposedly stop progression of lesions within 1 to 2 weeks and lead to complete or partial healing within 2 to 5 months. However, clofazimine may have adverse effects, and some patients do not respond to this drug at all.

Anti–Tumor Necrosis Factor-a

There is no laboratory evidence that tumor necrosis factor-a (TNF-a) plays a pathogenic role in pyoderma gangrenosum. However, monoclonal antibodies to TNF-a are beneficial in Crohn's disease and ulcerative colitis, and such antibodies (infliximab) have also been used in the treatment of pyoderma gangrenosum, apparently with success. [88], [89]

Miscellaneous Treatments

Pyoderma gangrenosum has been reported to respond to minocycline, colchicine, and heparin, as well as to the intravenous administration of vancomycin and mezlocillin; although, as indicated by worldwide experience, it is usually unresponsive to any kind of antibiotic. It has been reported to improve with a combination of sulfasalazine and isotretinoin and to respond to interferon-a. [90], [91] However, it has also been reported that interferon triggers pyoderma gangrenosum. [4] Plasmapheresis has been successfully used in the treatment of patients with pyoderma gangrenosum. [92], [93] Immunoglobulin [94] (given intravenously) and thalidomide are of benefit to patients with pyoderma gangrenosum, both with and without an association with Behçet's disease. [56], [57], [95]

COURSE AND PROGNOSIS

Pyoderma gangrenosum behaves in an unpredictable way. It may have a dramatic onset with pustular and bullous lesions rapidly breaking down to form ulcers, which progressively enlarge (see Fig. 98-1, Fig. 98-2, and Fig. 98-3) until arrested by treatment; in these cases, there may be signs of toxicity, fever, and considerable pain. More chronic forms of the disease show ulcers that extend slowly in a creeping fashion (see Fig. 98-4), expanding in one direction and healing spontaneously in another or in the center. In both forms, spontaneous healing can occur, but as old lesions resolve, new

lesions may arise. The disease may come to a spontaneous halt for no apparent reason; remain quiescent for months and even years; and exacerbate again after minimal trauma, surgery, or no apparent triggering cause. When associated with ulcerative colitis, the disease activity of pyoderma gangrenosum may parallel that of the bowel disease, but not always. The same is true for patients with associated hematologic disease, in which the underlying condition determines the final prognosis. The overall prognosis of pyoderma gangrenosum per se is good, particularly in those patients who readily respond to treatment, but considerable scarring and disfigurement may occur.

REFERENCES

1. Brunsting LA et al: Pyoderma (ecthyma) gangrenosum: Clinical and experimental observations in five cases occurring in adults. *Arch Dermatol* **22**:655, 1930

2. Yeon HB et al: Pyogenic arthritis, pyoderma gangrenosum, and acne syndrome maps to chromosome 15q. *Am J Hum Genet* **66**:1443, 2000

3. Johnson ML, Grimwood RE: Leukocyte colony-stimulating factors: A review of associated neutrophilic dermatoses and vasculitides. *Arch Dermatol* **130**:77, 1994

4. Montoto S et al: Pyoderma gangrenosum triggered by alpha2b-interferon in a patient with chronic granulocytic leukemia. *Leuk Lymphoma* **30**:199, 1998

5. Oka M et al: Interleukin-8 overexpression is present in pyoderma gangrenosum ulcers and leads to ulcer formation in human skin xenografts. *Lab Invest* **80**:595, 2000

6. Shapiro D et al: Pyoderma gangrenosum successfully treated with perilesional granulocyte-macrophage colony stimulating factor. *Br J Dermatol* **138**:368, 1998

7. Holt PJA et al: Pyoderma gangrenosum: Clinical and laboratory findings in 15 patients with special reference to polyarthritis. *Medicine (Baltimore)* **59**:114, 1980

8. Shore RN: Pyoderma gangrenosum, defective neutrophil chemotaxis, and leukemia. *Arch Dermatol* **112**:792, 1976

9. Abu-Elmagd K et al: Resolution of pyoderma gangrenosum in a patient with streaking leukocyte factor disease after treatment with tacrolimus (FK 506). *Ann Intern Med* **119**:595, 1993

10. Adachi Y et al: Aberrant neutrophil trafficking and metabolic oscillations in severe pyoderma gangrenosum. *J Invest Dermatol* **111**:259, 1998

11. Berbis P et al: Hyperimmunoglobulin E and impaired neutrophil functions in a case of pyoderma gangrenosum: Effect of clofazimine. *Am Acad Dermatol* **18**:574, 1988

12. Lazarus GS et al: Pyoderma gangrenosum, altered delayed hypersensitivity, and polyarthritis. *Arch Dermatol* **105**:46, 1972

13. Breathnach SM et al: Idiopathic pyoderma gangrenosum and impaired lymphocyte functions: Failure of azathioprine and corticosteroid therapy. *Br J Dermatol* **104**:567, 1981

14. Greenberg SJ et al: Pyoderma gangrenosum: Occurrence with altered cellular immunity and circulating serum factor. *Arch Dermatol* **188**:498, 1982

15. Jones RR et al: Defective monocyte function in pyoderma gangrenosum with IgG kappa paraproteinaemia. *Clin Exp Immunol* **82**:685, 1983

16. Wilson Jones E, Winkelmann RK: Superficial granulomatous pyoderma: A localized vegetative form of pyoderma gangrenosum. *Am Acad Dermatol* **18**:511, 1988

17. Perry HO et al: Malignant pyoderma. *Arch Dermatol* **98**:561, 1968

18. Callen JP: Pyoderma gangrenosum and related disorders. *Adv Dermatol* **4**:51, 1989

19. Gibson LE et al: Malignant pyodermas revisited. *Mayo Clin Proc* **72**:734, 1997

20. Perry HO, Winkelmann RK: Bullous pyoderma gangrenosum and leukemia. *Arch Dermatol* **196**:901, 1972

21. Lewis JE et al: Atypical pyoderma gangrenosum with leukemia. *JAMA* **239**:935, 1980

22. Burton JL: Sweet's syndrome, pyoderma gangrenosum, and acute leukemia. *Br J Dermatol* **102**:239, 1980

23. Caughman W et al: Neutrophilic dermatosis of myeloproliferative disorders: Atypical forms of pyoderma gangrenosum and Sweet's syndrome associated with myeloproliferative disorders. *Am Acad Dermatol* **9**:751, 1983

24. Van der Sluis I: Two cases of pyoderma (ecthyma) gangrenosum associated with the presence of an abnormal serum protein (beta2A-paraprotein): With a review of the literature. *Dermatologica* **132**:409, 1966

25. Fernandez Bussy R et al: Evaluation of circulating immune complexes in cutaneous diseases associated with immune disorders. *Allergol Immunopathol (Madr)* **18**:47, 1990

26. Hurwitz RM, Haseman JH: The evolution of pyoderma gangrenosum: A clinicopathologic correlation. *Am Dermatopathol* **15**:28, 1993

27. Benci M et al: Pyoderma gangrenosum, an unusual aspect of cutaneous vasculitis. *Clin Dermatol* **17**:581, 1999

28. Calabrese LH: Cutaneous vasculitis, hypersensitivity vasculitis, erythema nodosum and pyoderma gangrenosum. *Curr Probl Rheumatol* **2**:66, 1990

29. Su WP et al: Histopathologic and immunopathologic study of pyoderma gangrenosum. *J Cutan Pathol* **13**:323, 1986

30. Powell FC et al: Direct immunofluorescence in pyoderma gangrenosum. *Br J Dermatol* **108**:287, 1983

31. English JSC et al: Pyoderma gangrenosum and leukocytoclastic vasculitis in association with rheumatoid arthritis: A report of two cases.

Clin Exp Dermatol **9**:270, 1984

32. Wong E, Greaves MW: Pyoderma gangrenosum and leukocytoclastic vasculitis. *Clin Exp Dermatol* **10**:72, 1985

33. Callen JP: Cutaneous vasculitis and other neutrophilic dermatoses. *Curr Opin Rheumatol* **5**:33, 1993

34. Thomas RHM et al: Wegener's granulomatosis presenting as pyoderma gangrenosum. *Clin Exp Dermatol* **7**:523, 1982

35. Sanders S et al: Giant cells in pyoderma gangrenosum. *J Cutan Pathol* **28**:97, 2001

36. Hara H et al: Subcutaneous abscesses in a patient with ulcerative colitis. *J Am Acad Dermatol* **42**:363, 2000

37. Hickman JG, Lazarus GS: Pyoderma gangrenosum: A reappraisal of associated systemic diseases. *Br J Dermatol* **110**:235, 1980

38. Powell FC et al: Pyoderma gangrenosum: Classification and management. *J Am Acad Dermatol* **34**:395, 1996

39. Wilson DM et al: Peripheral ulcerative keratitis—An extracutaneous neutrophilic disorder: Report of a patient with rheumatoid arthritis, pustular vasculitis, pyoderma gangrenosum, and Sweet's syndrome with an excellent response to cyclosporine therapy. *J Am Acad Dermatol* **40**:331, 1999

40. Brown TS et al: Cavitating pulmonary infiltrate in an adolescent with pyoderma gangrenosum: A rarely recognized extracutaneous manifestation of a neutrophilic dermatosis. *J Am Acad Dermatol* **43**:108, 2000

41. Kruger S et al: Multiple aseptic pulmonary nodules with central necrosis in association with pyoderma gangrenosum. *Chest* **119**:977, 2001

42. Perry HO: Pyoderma gangrenosum. *South Med J* **62**:899, 1969

43. Hickman JG, Lazarus GS: Pyoderma gangrenosum: New concepts in etiology and treatment, in *Dermatology Update: Review for Physicians*, edited by SL Moschella. New York, Elsevier, 1979, p 325

44. Greenstein AJ et al: The extraintestinal complications of Crohn's disease and ulcerative colitis: A study of 700 patients. *Medicine (Baltimore)* **55**:401, 1976

45. Powell FC et al: Pyoderma gangrenosum: A review of 86 patients. *Am J Med* **55**:173, 1985

46. Bernstein CN et al: The prevalence of extraintestinal diseases in inflammatory bowel disease: A population-based study. *Am J Gastroenterol* **96**:1116, 2001

47. Lyon CC et al: Parastoma pyoderma gangrenosum: Clinical features and management. *J Am Acad Dermatol* **42**:992, 2000

48. Ko CB et al: Pyoderma gangrenosum: Associations revisited. *Int J Dermatol* **31**:574, 1992

49. Claudepierre P et al: SAPHO syndrome and pyoderma gangrenosum: Is it fortuitous? *J Rheumatol* **23**:400, 1996

50. Beretta-Piccoli BC et al: Synovitis, acne, pustulosis, hyperostosis, osteitis (SAPHO) syndrome in childhood: A report of ten cases and review of the literature. *Eur J Pediatr* **159**:594, 2000

51. Lindor NM et al: A new autosomal dominant disorder of pyogenic sterile arthritis, pyoderma gangrenosum, and acne PAPA syndrome. *Mayo Clin Proc* **72**:611, 1997

52. Prystowsky J et al: Present status of pyoderma gangrenosum. *Arch Dermatol* **125**:57, 1989

53. Avivi I et al: Myelodysplastic syndrome and associated skin lesions: A review of the literature. Leuk Res **23**:323, 1999

54. Asai M et al: Pyoderma gangrenosum associated with biphenotypic acute leukemia. *J Am Acad Dermatol* **44**:530, 2001

55. Beele H et al: Pyoderma gangrenosum as an early relevator of acute leukemia. *Dermatology* **200**:176, 2000

56. Munro CS, Cox NH: Pyoderma gangrenosum associated with Behçet's syndrome: Response to thalidomide. *Clin Exp Dermatol* **13**:408, 1988

57. Rustin MHA et al.: Pyoderma gangrenosum associated with Behçet's disease: Treatment with thalidomide. *J Am Acad Dermatol* **23**:941, 1990

58. Lee LA: Behçet disease. *Semin Cutan Med Surg* **20**:53, 2001

59. Velez A et al: Pyoderma gangrenosum associated with acne conglobata. *Clin Exp Dermatol* **20**:496, 1995

60. Kurokawa S et al: Acne fulminans with pyoderma gangrenosum–like eruptions and posterior scleritis. *Dermatol* **23**:37, 1996

61. Wayte JA et al: Pyoderma gangrenosum, erythema elevatum diutinum and IgA monoclonal gammopathy. *Australas J Dermatol* **36**:21, 1995

62. Handfield JS et al: Wegener's granulomatosis presenting as pyoderma gangrenosum. *Clin Exp Dermatol* **117**:197, 1992

63. Kobayashi K et al: A case of pyoderma gangrenosum with Takayasu's arteritis. *J Transpl Med* **42**:181, 1988

64. Frances C et al: Cutaneous manifestations of Takayasu arteritis: A retrospective study of 80 cases. *Dermatologica* **181**:266, 1990

65. Wolff K: Subkorneale pustulöse Dermatose (Sneddon-Wilkinson): Pyoderma gangraenosum mit IgA-Paraproteinämie. *Dermatol Monatsschr* **157**:842, 1971

66. Fraire Murgueytio P et al: Gangrenous pyoderma associated with subcorneal pustular dermatosis (Sneddon-Wilkinson disease). *Med Cutan Iber Lat Am* **17**:105, 1989

67. Marsen JR, Millard LG: Pyoderma gangrenosum, subcorneal pustular dermatosis, and IgA paraproteinemia. *Br J Dermatol* **114**:125, 1986

68. Stone MS, Lyckholm LJ: Pyoderma gangrenosum and subcorneal pustular dermatosis: Clues to underlying immunoglobulin A myeloma. *Am*

J Med **100**:663, 1996

69. Reich K et al: Topical tacrolimus for pyoderma gangrenosum. *Br J Dermatol* **139**:755, 1998

70. Petering H et al: Pyoderma gangrenosum—Erfolgreiche toische Therapie mit Tacrolimus (FK 506). *Hautarzı* **52**:47, 2001

71. Johnson RB, Lazarus GS: Pulse therapy, therapeutic efficacy in the treatment of pyoderma gangrenosum. *Arch Dermatol* 118: **76**, 1982

72. Chow RK, Ho VC: Treatment of pyoderma gangrenosum. *J Am Acad Dermatol* **34**:1047, 1996

73. Curley RK et al: Pyoderma gangrenosum treated with cyclosporin A. *Br J Dermatol* **113**:601, 1985

74. Gupta AK et al: Oral cyclosporine in the treatment of inflammatory and noninflammatory dermatoses. *Arch Dermatol* **126**:339, 1990

75. Capella GL et al: The simultaneous treatment of inflammatory bowel disease and associated pyoderma gangrenosum with oral cyclosporin A. *Scand J Gastroenterol* **34**:220, 1999

76. Ho VC et al: Cyclosporine in the treatment of dermatologic disease: An update. *Mayo Clin Proc* **71**:1182, 1996

77. Friedman S et al: Intravenous cyclosporine in refractory pyoderma gangrenosum complicating inflammatory bowel disease. *Inflamm Bowel Dis* **7**:1, 2001

78. Jolles S et al: Combination oral and topical tacrolimus in therapy-resistant pyoderma gangrenosum. *Br J Dermatol* **140**:564, 1999

79. Zonana-Nacach A et al: Intravenous cyclophosphamide pulses in the treatment of pyoderma gangrenosum associated with rheumatoid arthritis. *J Rheumatol* **21**:1352, 1994

80. Reynoso-von Drateln C et al: Intravenous cyclophosphamide pulses in pyoderma gangrenosum: an open trial. *J Rheumatol* **24**:689, 1997

81. Burns JB et al: Chlorambucil is an effective corticosteroid-sparing agent for recalcitrant pyoderma gangrenosum. *J Am Acad Dermatol* **35**:720, 1996

82. Resnik BI et al: Successful treatment of aggressive pyoderma gangrenosum with pulse steroids and chlorambucil. *J Am Acad Dermatol* **27**:635, 1992

83. Hohenleutner U et al: Mycophenolate mofetil and cyclosporin treatment for recalcitrant pyoderma gangrenosum. *Lancet* **350**:1748, 1997

84. Nousari HC et al: The effectiveness of mycophenolate mofetil in refractory pyoderma gangrenosum. *Arch Dermatol* **134**:1509, 1998

85. Gilmour E, Stewart DG: Severe recalcitrant pyoderma gangrenosum responding to a combination of mycophenolate mofetil with cyclosporin complicated by a mononeuritis. *Br J Dermatol* **144**:397, 2001

86. Mensing H: Clofazimine in dermatitis ulcerosa (pyoderma gangrenosum): Open clinical trial. *Dermatologica* **177**:232, 1988

87. Arbeiser JL, Moschella SL: Clofazimine: A review of its medical uses and mechanisms of action. *J Am Acad Dermatol* **32**:241, 1995

88. Tan MH et al: Improvement of pyoderma gangrenosum and psoriasis associated with Crohn disease with anti-tumor necrosis factor alpha monoclonal antibody. *Arch Dermatol* **137**:930, 2001

89. Arnott ID et al: Clinical use of Infliximab in Crohn's disease: The Edinburgh experience. *Aliment Pharmacol Ther* **15**:1639, 2001

90. Smith JB et al: Pyoderma gangrenosum in a patient with cryoglobulinemia and hepatitis C successfully treated with interferon alfa. *J Am Acad Dermatol* **34**:901, 1996

91. Sanchez-Roman J et al: The treatment of cyclosporine A-resistant pyoderma gangrenosum with recombinant interferon alfa-2 [Letter]. *Med Clin (Barc)* **104**:517, 1995

92. Gerard JA et al: Pyoderma gangrenosum: Traitement par exchanges plasmatiques (4 cas). *Ann Med Interne (Paris)* **139** (suppl 1):29, 1988

93. Baumbauer R et al: Drug resistant pyoderma gangrenosum successfully treated with therapeutic plasma exchange. *Transfus Sci* **10**:349, 1989

94. Dirschka T et al: Successful treatment of pyoderma gangrenosum with intravenous human immunoglobulin. *J Am Acad Dermatol* **39**:789, 1998

95. Federman GL, Federman DG: Recalcitrant pyoderma gangrenosum treated with thalidomide. *Mayo Clin Proc* **75**:842, 2000

T>

Chapter 99

Walter Burgdorf

Erythema Annulare Centrifugum and Other Figurate Erythemas

ERYTHEMA ANNULARE CENTRIFUGUM
Historical Aspects
Etiology and Pathogenesis
Clinical Manifestations
Pathology
Diagnosis and Differential Diagnosis
Treatment
FAMILIAL ANNULAR ERYTHEMA
Historical Aspects
Clinical Manifestations

REFERENCES

The figurate erythemas include a variety of eruptions characterized by annular and polycyclic lesions; some are fixed, but most are migratory. Many of these conditions appear related to hypersensitivity, be it to drugs, neoplasms, infections, arthropod bites, or self. Classification of the figurate erythemas has always been controversial; the literature about them abounds with contradictions, uncertainties, and a bewildering array of synonyms. The figurate erythemas and other disorders to be considered in their differential diagnosis are listed in Table 99-1.

TABLE 99-1 **Figurate Erythemas**

ERYTHEMA ANNULARE CENTRIFUGUM

Erythema annulare centrifugum (EAC) denotes an eruption with slowly migrating annular and configurate erythematous lesions.

Historical Aspects

Darier first used the term *erythema annulare centrifugum* in 1916, [1] although similar lesions had been described previously under other names.

Etiology and Pathogenesis

Both the annularity and the peripheral spread of EAC have attracted speculation as to a possible mechanism. Most hypotheses have centered about interactions among inflammatory cells, their mediators, and ground substance as foreign antigens diffuse through the skin. [2] The cause of most cases of EAC is unknown. In one series, the conditions of 24 patients were closely evaluated, and in none of the cases was any clear evidence of causality found. [3] There are occasional reports of EAC associated with malignant neoplasms, with the eruption disappearing after treatment of the tumor and often recurring as the tumor recurs. [4], [5] Many different infections, inhalants, and medications have been identified as causes of EAC in case reports. Bacterial or candidal infections are most often suspected as triggers. [6], [7] Sometimes a true infection can spread peripherally to create an annular pattern; in an immunosuppressed host, there may be no signs of systemic toxicity. [8]

Clinical Manifestations

Erythema annulare centrifugum presents as one or more lesions that begin as erythematous macules or urticarial papules and enlarge by peripheral extension to form ringed, arcuate, or polycyclic figures. They spread gradually to form large rings with central clearing, the edges of the lesions often advancing several millimeters a day. After a variable period of time, the lesions disappear, often to be replaced by new ones. Erythema annulare centrifugum appears to have no predilection for either sex or any age group.

Bressler and Jones have suggested dropping the term *erythema annulare centrifugum* and instead referring either to (1) deep gyrate erythema that has a firm yet indurated border, lacks scale, and is rarely pruritic (Fig. 99-1) or to (2) superficial gyrate erythema that has an indistinct border, has trailing scale, and is more often pruritic (Fig. 99-2). [9] Although this subdivision is reasonable, it does not help in identifying possible etiologic agents.

FIGURE 99-1 Deep figurate erythema. Annular lesions very similar to urticaria are seen without any scale.

FIGURE 99-2 Superficial figurate erythema. A large annular patch has trailing scale behind the advancing erythematous edge.

Pathology

The typical deep figurate erythemas lack epidermal damage and have intense lymphohistiocytic cuffing about both the superficial and deep vessels. There is minimal papillary dermal edema and no spongiosis (Fig. 99-3). On the other hand, the more superficial figurate erythemas may demonstrate epidermal changes of parakeratosis and spongiosis, with a superficial perivascular infiltrate.

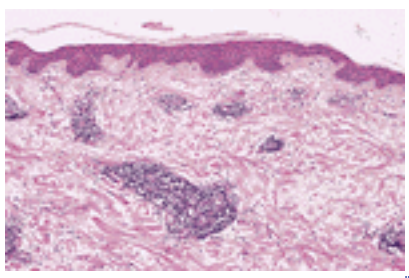

FIGURE 99-3 Figurate erythema. Normal epidermis overlies a dermis in which there is tight lymphocytic perivascular cuffing.

Occasionally, both peripheral blood and tissue eosinophilia occur in EAC. In such cases, EAC may represent an early manifestation of the hypereosinophilic syndrome. The pathologic evaluation may produce other surprises, requiring a new diagnosis. Sometimes a leukocytoclastic vasculitis may be found. A metastatic tumor may occasionally be identified; in this case, the annular lesions usually expand slowly and are permanent. [10]

Diagnosis and Differential Diagnosis

The main differential diagnostic points are summarized in Table 99-1. It is most helpful to observe patients with figurate erythema over a period of weeks to see how they progress and how their rashes evolve. Cases of annular or figurate erythemas may not fit easily into any classification. Patients may be approached with the following schema:

1. Are there signs or symptoms suggesting a systemic disorder such as a malignancy, infection, or other problems? Many authors feel that there is no distinction between EAC and erythema gyratum repens; since erythema gyratum repens is more often a marker for malignant disease, separation appears valid. Erythema gyratum repens tends to be scalier and move more rapidly than EAC. In addition, erythema gyratum repens often mimics the grain of wood, whereas EAC appears more annular and urticarial.
2. Is there a history of tick bite, or are other manifestations of Lyme disease present? Usually, erythema migrans

appears before the rheumatologic or cardiologic problems. In Lyme disease, there are generally one or two annular lesions centered about tick bites. Erythema migrans often evolves into a plaque, which is uncommon for EAC. In EAC, multiple lesions are more common.

3. Are there urticarial or angioedematous lesions elsewhere? Urticaria is more pruritic than EAC and more short-lived.
4. Are bullous lesions present elsewhere? If so, it is wise to consider the annular urticarial phase of bullous pemphigoid or linear IgA disease. An immunofluorescence study of perilesional skin may be helpful.
5. Are the lesions predominantly oral or acral? Are blisters present? An acral distribution is uncommon in EAC and should raise the question of erythema multiforme if it occurs.
6. Is the KOH examination positive?
7. Is the rash psoriasiform? If so, both psoriasis and subacute lupus erythematosus warrant consideration. The clinician should search for psoriasis elsewhere; pustular psoriasis is more likely to present with annular lesions. In Asians and, rarely, in Caucasians, Sjögren's syndrome may present with annular lesions that probably reflect an overlap with subacute lupus erythematosus. [11] Thus, it is helpful to measure antibodies against Ro/La (SS-A, SS-B).
8. Are there other stigmata of rheumatic fever or other rheumatic diseases? Erythema marginatum is more transient than any other figurate erythema.
9. Are the lesions accompanied by desquamative oral and intertriginous changes or biochemical evidence of excessive glucagon production? These findings suggest necrolytic migratory erythema.
10. Is there a family history of similar lesions or of chronic granulomatous disease? Is phagocytic function normal? In one form of chronic granulomatous disease, the carrier females may have an annular eruption.
11. Is the patient an infant? The approach to figurate erythemas in this age group is slightly different from that used for older age groups. First of all, neonatal lupus erythematosus is usually annular and often occurs in conjunction with congenital heart block. Despite its rarity, it should be excluded first. Second, while there are many discussions of familial annular erythema in the literature, it is extremely rare and not often the correct diagnosis. Third, while dermatophytes and tinea versicolor are most uncommon in infants, it is necessary to exclude such infections. Finally, there are patients meeting none of these criteria who have self-limited annular erythemas, sometimes with atrophy. [12]

Treatment

Although an assiduous search for the underlying cause is the primary goal of treatment, only symptomatic help is truly available. The systemic administration of glucocorticoids usually suppresses EAC, but recurrence is common when these drugs are stopped. Systemic therapy with antipruritics may help, but topical therapy has little effect. Empirical use of antibiotic, antifungal, or anticandidal agents has sometimes been useful. In general, most of the therapeutic approaches employed for chronic urticaria can also be tried for EAC.

FAMILIAL ANNULAR ERYTHEMA

Sometimes associated with other developmental anomalies, familial annular erythema has its onset at an early age.

Historical Aspects

Colcott Fox originally described familial annular erythema in 1881 as erythema gyratum repens. [13] A small number of similar cases have since been described. Beare and colleagues provided a detailed description with color photographs. [14] The disease appears to be inherited in an autosomal dominant fashion and is extremely rare. As EAC can be familial, the diagnosis of familial annular erythema probably can be dropped.

Clinical Manifestations

The eruption appears early, perhaps only a few days after birth. The lesions are similar to those of EAC, but they are more transitory (although the patient is rarely free of them). The eruption persists for many years; the grandfather in one pedigree seems to have outlived his disease.

REFERENCES

1. Darier J: De l'érythème annulaire centrifuge. *Ann Dermatol Syphiligr* **6**:57, 1916

2. Lobitz WC et al: The anergy of annularity. *J Dermatol (Tokyo)* **11**:425, 1984

3. Mahood JM: Erythema annulare centrifugum: A review of 24 cases with special reference to its association with underlying disease. *Clin Exp Dermatol* **8**:383, 1983

4. Yaniv R et al: Erythema annulare centrifugum as the presenting sign of Hodgkin's disease. *Int J Dermatol* **32**:59, 1993

5. Ural AU et al: Erythema annulare centrifugum as the presenting sign of CD 30 positive anaplastic large cell lymphoma—Association with disease activity. *Haematologia (Budap)* **31**:81, 2001

6. Borbujo J et al: Erythema annulare centrifugum and *Escherichia coli* urinary infection. *Lancet* **347**:897, 1996

7. Schmid MH et al: Erythema annulare centrifugum and intestinal *Candida albicans* infection—Coincidence or connection? *Acta Derm Venereol* **77**:93, 1997

8. Czechowicz RT et al: *Pseudomonas aeruginosa* infection mimicking erythema annulare centrifugum. *Australas J Dermatol* **42**:57, 2001

9. Bressler GS, Jones RE Jr: Erythema annulare centrifugum. *J Am Acad Dermatol* **4**:597, 1981

10. Reichel M, Wheeland RG: Inflammatory carcinoma masquerading as erythema annulare centrifugum. *Acta Derm Venereol* **73**:138, 1993

11. Haimowitz JE et al: Annular erythema of Sjögren's syndrome in a white woman. *J Am Acad Dermatol* **42**:1069, 2000

12. Herbert AA, Esterly NB: Annular erythema of infancy. *J Am Acad Dermatol* **14**:339, 1986

13. Colcott Fox T: Erythema gyratum repens. *Trans Clin Soc Lond* **14**:67, 1881

14. Beare JM et al: Familial annulare erythema. *Br J Dermatol* **78**:59, 1966

T>

Chapter 100

Mark Dahl

Granuloma Annulare

EPIDEMIOLOGY
ETIOLOGY AND PATHOGENESIS
CLINICAL MANIFESTATIONS
Types of Granuloma Annulare
Relationship to Internal Disease
LABORATORY AND SPECIAL EXAMINATION
PATHOLOGY
DIFFERENTIAL DIAGNOSIS
TREATMENT
COURSE AND PROGNOSIS

REFERENCES

Granuloma annulare is a benign, usually self-limited dermatosis of unknown cause, characterized by necrobiotic dermal papules that often assume an annular configuration. Colcott Fox first described this dermatosis under the name of ringed eruption of the fingers. [1] Radcliffe-Crocker gave it its present title. [2]

EPIDEMIOLOGY

Although it can start at any age, granuloma annulare is predominantly a disease of children and young adults. In a series of 208 patients, the onset was prior to age 30 in more than two-thirds. [3] The disorder affected females twice as often as males. However, most patients with HIV-associated granuloma annulare have been men.

ETIOLOGY AND PATHOGENESIS

Granuloma annulare usually appears for no known reason. It has been reported to follow insect bites; sun exposure; tuberculin skin tests; ingestion of allopurinol; trauma; and viral infections, including Epstein-Barr, HIV, hepatitis C, and herpes zoster. An adenovirus was isolated from a patient with AIDS and granuloma annulare, but the presence of this virus could represent a secondary, unrelated infection in an immunocompromised host. [4] None of 34 consecutive HIV-positive patients with granuloma annulare had the Epstein-Barr virus. [5] Granuloma annulare has occurred in identical twins and siblings and in more than one generation, suggesting hereditary predisposition. [6] Whatever the cause, granuloma annulare evokes a peculiar sort of inflammatory reaction. Most experts believe the reaction is an immunologically mediated one in which inflammation surrounds blood vessels and alters collagen and elastic tissues. [7]

Necrotizing changes suggesting vasculitis are present in dermal blood vessels, although obvious acute leukocytoclastic vasculitis is uncommon. [8] Clinical purpura is rare, but extravasated red blood cells appear in biopsy specimens of about one-third of patients. Immunoglobulins, complement, and fibrinogen are occasionally found in dermal blood vessels in or near the necrobiotic zone. [8], [9] The nature of the antigen eliciting the vasculitis is unknown, and the type of immune reaction is debatable. Possible antigens include viruses, altered collagen, altered elastic fibers, or antigens in saliva or infectious agents introduced by arthropod vectors. Vasculitis might result from the deposition of circulating immune complexes, as these complexes have been found in patients with granuloma annulare. [10] The vasculitis also might arise from cytotoxic mediators secreted by cells linked with cell-mediated immunity. Endothelial cells in the dermal capillaries of patients with generalized granuloma annulare contain mysterious rod-shaped bodies resembling Birbeck granules, but their role, if any, in vessel injury is unknown. [11]

The evidence linking cell-mediated immune reactions to granuloma annulare is scantier. The leukocytes of patients with granuloma annulare have produced macrophage inhibitory factor. [12] Activated lymphocytes or lymphoblasts have been noted in the inflammatory infiltrate, but they are widely scattered and not usually prevalent or even evident in 1-mm thick sections. Helper-inducer lymphocytes are common (as they are in most inflammatory skin diseases), [13], [14] and fibrin is present within the area of necrobiosis (as it is in many inflammatory disorders). [8], [9] Most lymphocytes in the infiltrate are activated and express class II HLA antigens and receptors for interleukin 2 (IL-2). [15] Lesions with histology similar to that of granuloma annulare have occurred in delayed hypersensitivity reactions to intradermally injected bovine collagen. [16] If cell-mediated immunity is important, the granuloma annulare–like lesions that occur in patients with AIDS and sarcoidosis, who have deficiencies of cell-mediated immunity, are difficult to explain.

Vascular damage could also result from non-immune mechanisms. Factor VIII–related antigen circulates in the blood of patients with widespread granuloma annulare. [17] Excessive binding of factor VIII antigen to blood vessels could lead to blood vessel thickening and damage, with secondary deposition of immunoreactants in the vessel walls and a surrounding inflammatory infiltrate.

Blood monocyte function is normal, [18] but tissue monocytes may act abnormally. Release of lysosomal enzymes from macrophages may lead to necrobiosis. Macrophages in lesions of granuloma annulare contain abundant lysozyme, [19] acid phosphatase, and nonspecific esterase, and they abundantly express metaloelastase mRNA in lesional skin. [20] Their epithelioid appearance suggests an active secretory role. Perhaps cytokines from monocytes could activate fibroblasts; this would explain the four- to fivefold increase in Pro alpha 1(I) collagen mRNA, [21] the high activity of prolyl hydroxylase,

and the deposition of type III procollagen and fibronectin in the granulomas. [22]

Trauma sometimes resolves the problem of granuloma annulare. Probably every dermatologist has seen the adjacent sides of an annular lesion disappear after biopsy. Just how this happens is speculative, but this phenomenon likely provides an important clue to pathogenesis. Perhaps trauma restores normality to an otherwise disordered inflammatory cascade.

The tendency to develop granuloma annulare may be inherited. In addition to at least 15 reports of familial granuloma annulare, generalized granuloma annulare has been found more frequently among persons who are HLA phenotypes BW35 and A29. [23]

CLINICAL MANIFESTATIONS

Types of Granuloma Annulare

Clinically, granuloma annulare can be divided into a number of more or less distinct types.

LOCALIZED LESIONS The most common type of granuloma annulare occurs primarily in children and young adults. An annular plaque may be skin-colored, erythematous, or violaceous. Sometimes, dome-shaped papules are arranged in a complete or half circle (Fig. 100-1). Lesions are usually asymptomatic. The epidermal surface is most often undisturbed, but occasionally telangiectatic vessels may appear over individual papules, or epidermal markings may be lost. Centrally, the surface may be slightly hyperpigmented and subtly depressed below the level of surrounding skin. Solitary papules or nodules may also be present. Sometimes these are umbilicated, especially on the fingers.

FIGURE 100-1 Typical lesion of granuloma annulare demonstrating the elevated rolled border without epidermal change, as well as the frequent violaceous color of the central patch and associated atrophy.

Localized granuloma annulare most commonly appears on the dorsa of the hands and feet, but it may appear on the forearms, arms, legs, and thighs. It only rarely affects the face and scalp. In about half of the patients, only one ring is present.

GENERALIZED LESIONS About 15 percent of all patients with granuloma annulare have more than 10 lesions. These patients are usually either younger than 10 years old or older than 40. Hundreds or even thousands of individual, 1- to 2-mm, usually skin-colored papules arise anywhere on the cutaneous surface and may form small annular plaques (Fig. 100-2A). In contrast to other forms, generalized granuloma annulare usually involves the trunk, and lesions are especially common on the neck, forearms, legs, and extensor surfaces of the elbows. Typically, the rings are less than 5 cm in diameter. They may enlarge centrifugally over the course of weeks or months. Uneven development, skin biopsy, or spontaneous resolution of one side of a lesion may convert annular into arcuate forms (see Fig. 100-2A). Sometimes, all the lesions are annular, while at other times, most or all lesions are small papules (Fig. 100-2B). They may be slightly violaceous in color, but they are occasionally waxlike and pink, tan, yellow, or dusky gray. Violaceous patches with raised edges, but without epidermal change, are less common. Symmetry is a usual feature. Lesions on the face, palms, soles, and mucous membranes are rare.

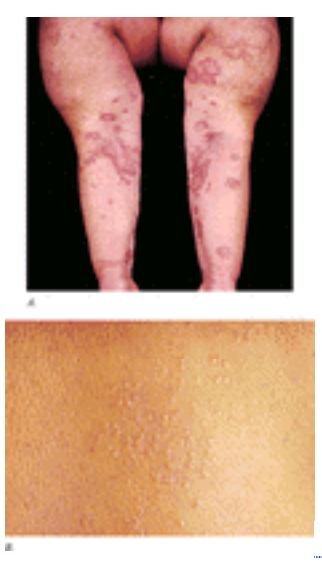

FIGURE 100-2 Generalized granuloma annulare. *A*. Numerous annular pink plaques scattered over the arms. *B*. Small papular lesions of generalized granuloma annulare. These lesions are too small to exhibit an annular configuration.

SUBCUTANEOUS LESIONS Subcutaneous granuloma annulare consists of large, painless, skin-colored, deep dermal or subcutaneous nodules. [8] Lesions usually occur in children or young adults. [24] About 75 percent of patients develop lesions on the leg or foot, but lesions may also appear on the palms, buttocks, fingers, toes, eyelids, or scalp. They may be solitary or multiple. Occasionally, the skin over the nodules may ulcerate (Fig. 100-3). When near the joints, they may be confused with rheumatoid nodules or nodules of rheumatic fever. However, nodules are not associated with arthritis, and rheumatoid factor is not present in serum. Some patients with these “pseudorheumatoid nodules” subsequently develop more ordinary granuloma annulare lesions elsewhere. Diabetes and abnormal glucose tolerance may be more

common among patients with this nodular variant.

FIGURE 100-3 Nodular (subcutaneous) granuloma annulare, with perforation. The necrobiotic granulomas here are large and extend into the subcutaneous fat.

PERFORATING LESIONS Superficial, small papules may develop central umbilication, plugs, or crusts. [25] This occurs most frequently in lesions on the hands and fingers. Frank ulceration with discharge of creamy fluid is rare. In one series, 30 percent of patients with this form had diabetes. [26]
PATCH LESIONS Some patients with granuloma annulare develop subtly pink patches without induration or scale. Most of these patients are women, and most of these lesions occur on the proximal extremities. Both localized and generalized forms are recorded. [27]
ARCUATE DERMAL ERYTHEMA Annular or circinate erythematous lesions that resemble erythema multiforme, erythema migrans, or erythema annulare centrifugum may occur. In such patients, the papular quality is less obvious than the erythema. As in other forms of granuloma annulare, rings may spread centrifugally, and central hyperpigmentation may be present. This form of granuloma annulare, which is uncommon, usually occurs on the trunk. Biopsy rather than clinical inspection generally confirms the diagnosis.
ACTINIC GRANULOMA Sometimes, one or more large annular plaques develop on the face or other actinically damaged skin area. [28] These lesions can become quite large and/or very elevated.

Relationship to Internal Disease

In general, patients with granuloma annulare are in good health. A relationship of granuloma annulare to diabetes mellitus, [26] necrobiosis lipoidica diabeticorum, and rheumatoid nodules has been widely discussed, but not firmly established. Necrobiosis lipoidica coexists with granuloma annulare quite commonly, despite the small number of reported cases. Similarly, some patients with rheumatoid arthritis have developed granuloma annulare. Occasionally, patients with granuloma annulare have arthritis that may worsen when new lesions of granuloma annulare appear. Some of these patients have rheumatoid nodules rather than granuloma annulare. Such patients will nearly always have detectable rheumatoid factor in their sera.

Granuloma annulare may rarely involve fascia and tendons, causing sclerosis, carpal tunnel syndrome, lymphedema, and deformities. [29] Ankylosis of a joint may occur. In one instance, a man with insulin-dependent diabetes, Addison's disease, myxedema, and ulcerative colitis developed small nodules of granuloma annulare in the skin, bowel, mesentery, and peritoneum. [30]

Active vasculopathy or extravascular neutrophilic infiltrates in a skin biopsy specimen showing granuloma annulare is more likely to be associated with underlying systemic disease, particularly in patients with granuloma annulare atypical in location and appearance.

Patients with AIDS have developed granuloma annulare. Painful lesions in atypical locations have been associated with malignant lymphomas. [32]

LABORATORY AND SPECIAL EXAMINATION

The results of laboratory tests are usually normal, although there have been reports of glucose tolerance abnormalities, particularly in patients with the nodular granuloma annulare and in patients with the widespread, disseminated type. [33] Rarely, circulating antithyroid and antinuclear antibodies have been found in the serum of some patients. Levels of complement are normal, but levels of heparin-precipitable cryofibrinogen, [34] fibronectin, [35] serum lysozyme, [36] and benzylamine monoamine oxidase [37] may be elevated, especially in patients with active generalized disease. Serum angiotensin-converting enzyme levels are usually normal.

PATHOLOGY

The chief aid in the diagnosis of granuloma annulare is biopsy. [38], [39] The diagnosis is best made at low magnifications (Fig. 100-4). At the level of the subpapillary plexus of blood vessels, or occasionally somewhat deeper, are single or multiple foci of granulomatous inflammation. These foci have a central core of incomplete and mostly reversible change (necrobiosis) of the connective tissue, surrounded by a wall of palisaded histiocytes. The necrobiotic centers are usually oval in outline, slightly basophilic, devoid of nuclei, and marked by a loss of outline of collagenous and elastic tissue fibers. Characteristically, the necrobiotic foci are not so large or deeply situated as those of rheumatoid nodules or as broad and diffuse as those of necrobiosis lipoidica (diabeticorum). Histochemically, they demonstrate varying amounts of mucinous, PAS-positive, diastase-resistant material and small amounts of lipids. The zone around the necrobiotic focus is composed of palisades of histiocytes intermingled with a few acute inflammatory cells, including neutrophils and eosinophils. Sometimes, histiocytes are large enough to resemble epithelioid cells. Multinucleated giant cells may be present. In some lesions, lines of histiocytes may transverse the necrobiotic focus (the so-called interstitial type). Normal areas of collagen may be found between areas of necrobiosis.

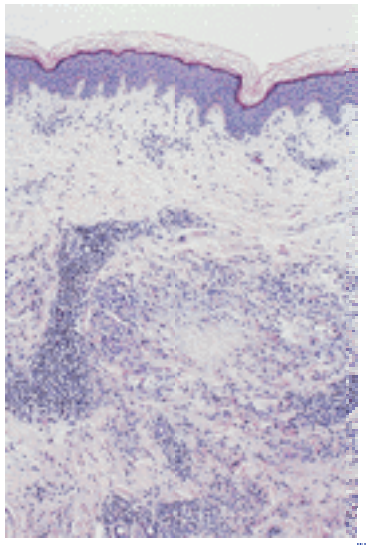

FIGURE 100-4 Granuloma annulare. Disease affects the connective tissue of the reticular dermis, characterized by a central area of altered collagen (so-called necrobiosis of collagen) that is surrounded by an inflammatory zone separating altered from normal collagen.

In early lesions, or at the edge of the granuloma, only histiocytic cells may be evident. In these cases, the character of the cellular reaction leads the experienced dermatopathologist to consider the diagnosis of granuloma annulare.

Within the palisading granuloma, inflammation often appears to center around blood vessels, with endothelial swelling and thickening of vessel walls. [12] Vessels may contain PAS-positive, diastase-resistant material. Changes associated with acute leukocytoclastic vasculitis are usually not present, but at times microscopic purpura or a small amount of nuclear dust may be present around one or more blood vessels. [40]

Immunofluorescence examination of biopsied tissue from some lesions of granuloma annulare often reveals C3, IgM, and fibrinogen in some dermal blood vessels and at the dermal-epidermal junction. [8], [9], [40] Deposits usually occur in only a few vessels, suggesting that complexes may be detectable only at one stage of the indolent pathologic process that causes granuloma annulare. Although deposits of immunoreactants in blood vessels are uncommon, massive deposits of fibrinogen regularly appear throughout the area of necrobiosis. This finding rapidly identifies the areas of necrobiosis, but is not specific.

In subcutaneous forms of granuloma annulare, the foci of necrobiosis are larger and lie in the deep dermis or even the panniculus adiposus. Microscopic differentiation from the more common rheumatoid nodules may be impossible, although mucin deposits are more regularly associated with granuloma annulare. Central ulceration and communication between the area of necrobiosis and the surface characterize perforating granuloma annulare, but serial sections may be necessary to demonstrate the necrobiotic plug.

DIFFERENTIAL DIAGNOSIS

The annular configuration of granuloma annulare often leads to the incorrect diagnosis of tinea corporis, but the lack of epidermal surface change and the failure to detect fungi in scrapings and cultures in tissues taken from patients with granuloma annulare serve to readily distinguish these disorders. Erythema migrans of Lyme disease mimics granuloma annulare, especially the arcuate dermal erythema form. Biopsy helps to distinguish these conditions. Other annular granulomatous eruptions, such as sarcoidosis, cat-scratch disease, or late secondary or tertiary syphilis, may cause some confusion. The clinical differential diagnosis also includes annular lichen planus, tuberculous granulomas, insect bites, xanthomas, lipoid proteinosis, erythema multiforme, erythema annulare centrifugum, subacute cutaneous lupus erythematosus, granuloma multiforme, amyloidosis, creeping eruption, drug reaction (e.g., from angiotensin-converting enzyme inhibitors), and erythema elevatum diutinum.

Annular elastolytic giant-cell granuloma can be confused both clinically and histologically, although the central hypopigmentation, zonal infiltrate, asteroid bodies, giant cells, and absence of true necrobiosis are usually distinctive. Elastic tissue is destroyed in granuloma annulare, and sometimes the result may be secondary anetoderma. [41] Occasionally, as noted earlier, subcutaneous granuloma annulare may simulate rheumatoid nodules both clinically and histologically. Epithelioid sarcoma has necrobiotic features. At times, microscopic and clinical differentiation of granuloma annulare from necrobiosis lipoidica may also be difficult. Lysozyme is abundant in histiocytes of granuloma annulare, but absent or sparse in necrobiosis lipoidica. [19] Interstitial granulomatous drug reactions can cause histologic confusion as well. [42]

Familial granulomatous arthritis, iritis, and skin granulomas (Blau syndrome) comprise an autosomal dominantly inherited syndrome that overlaps both sarcoidosis and granuloma annulare. [43]

TREATMENT

Granuloma annulare is a cosmetic disease in that it is rarely symptomatic and usually has no medical consequence. The cosmetic disfigurement may be severe or mild. Although the disease is usually self-limited, clinicians have used a wide array of treatment methods to hasten resolution. These include the topical application of vitamin E and x-ray therapy, cryotherapy, laser destruction, or intralesional injection of triamcinolone acetonide. Of these, the last seems the most effective. Potent topical glucocorticoids suppress the disease. Glucocorticoids applied topically under occlusion or incorporated into tape may also be beneficial, but side effects such as atrophy may occur. Intralesional injections of

recombinant human interferon-? induced remission in three patients within 3 weeks. [44]

Psoralen plus ultraviolet A (PUVA) therapy may improve the eruption and apparently even cure it. [45] This approach is probably the treatment of choice for patients with widespread disease, because it is quite effective and relatively safe—at least over a short term of treatment. Topical applications of psoralens followed by ultraviolet A radiation can also be effective. [46]

Retinoids given systemically either alone or during PUVA treatments may be effective. [47] Systemic treatment with pentoxifylline, nicotinamide, niacinamide, isotretinoin, salicylates, chlorpropamide, potassium iodide, thyroxine, aspirin, dipyridamole, dapsone, or antimalarials has been advocated and sometimes seems efficacious, but spontaneous resolution makes the evaluation of such treatments difficult. The systemic use of glucocorticoids improves appearance, but risks almost always outweigh benefits. Treatment with low doses of chlorambucil is probably effective, but only very rarely justified because of the severe side effects, including the induction of leukemia and bone marrow depression.

COURSE AND PROGNOSIS

The lesions of granuloma annulare tend to resolve spontaneously. In more than half of 208 cases, cutaneous lesions had disappeared in 2 years. [3] In 40 percent of these, there was recurrence, usually at the original site. Recurrent lesions often disappeared more rapidly than the original ones, and 80 percent of them resolved within 2 years. Although a retrospective study indicates that the prognosis for patients with generalized disease is no worse than the prognosis for those with localized disease, [3] most dermatologists believe that resolution is less likely in middle-aged patients with widespread, generalized granuloma annulare.

REFERENCES

1. Colcott Fox T: Ringed eruption of the fingers. *Br J Dermatol* **7**:91, 1895

2. Radcliffe-Crocker H: Granuloma annulare. *Br J Dermatol* **14**:1, 1902

3. Wells RS, Smith MA: The natural history of granuloma annulare. *Br J Dermatol* **75**:199, 1963

4. Coldiron BM et al: Isolation of adenovirus from a granuloma annulare–like lesion in the acquired immunodeficiency syndrome–related complex. *Arch Dermatol* **124**:654, 1988

5. Toro JR et al: Granuloma annulare and human immunodeficiency virus infection. *Arch Dermatol* **135**:1404, 1999

6. Rubin M, Lynch FW: Subcutaneous granuloma annulare: Comment on familial granuloma annulare. *Arch Dermatol* **93**:416, 1966

7. Dahl MV: Speculations on the pathogenesis of granuloma annulare. *Australas J Derm* **26**:49, 1985

8. Dahl MV et al: Vasculitis in granuloma annulare: Histopathology and direct immunofluorescence. *Arch Dermatol* **113**:463, 1976

9. Thyresson HN et al: Granuloma annulare: Histopathologic and direct immunofluorescent study. *Acta Derm Venereol (Stockh)* **60**:261, 1980

10. Dahl MV et al: Circulating immune complexes in granuloma annulare [Abstract]. *Clin Res* **27**:712A, 1979

11. Kohn S, Friedman-Birnbaum R: Rod-shaped bodies resembling Birbeck granule-like structures in endothelial cells of dermal capillaries in generalized granuloma annulare. *J Dermatol* **28**:5, 2001

12. Baba T et al: Monocyte-modulating activities in the sera of patients with granuloma annulare. *J Dermatol* **15**:248, 1988

13. Buechner SA et al: Identification of T-cell subpopulations in granuloma annulare. *Arch Dermatol* **119**:125, 1983

14. Modlin RL et al: Granuloma annulare: Identification of cells in the cutaneous infiltrate by immunoperoxidase techniques. *Arch Pathol Lab Med* **108**:379, 1984

15. Modlin RL et al: Immunopathologic demonstration of T lymphocyte subpopulations and interleukin 2 in granuloma annulare. *Pediatr Dermatol* **2**:26, 1984

16. Rapaport MJ: Granuloma annulare caused by injectable collagen. *Arch Dermatol* **120**:837, 1984

17. Majewski BBJ et al: Increased factor VIII–related antigen in necrobiosis lipoidica and widespread granuloma annulare without associated diabetes. *Br J Dermatol* **107**:641, 1982

18. Cherney KJ et al: Leukocyte function in granuloma annulare. *Br J Dermatol* **101**:23, 1979

19. Padilla RS et al: Differential staining pattern of lysozyme in palisading granulomas: An immunoperoxidase study. *J Am Acad Dermatol* 121:624, 1985

20. Vaalamo M et al: Enhanced expression of human metalloelastase (MMP-12) in cutaneous granulomas and macrophage migration. *J Invest Dermatol* **112**:499, 1999

21. Tasanen K et al: Quantitation of Pro alpha 1(I) collagen mRNA in skin biopsy specimens: Levels of transcription in normal skin and granuloma annulare. *J Invest Dermatol* **107**:314, 1996

22. Oikarinen A et al: Biochemical and immunohistochemical comparison of collagen in granuloma annulare and skin sarcoidosis. *Acta Derm Venereol (Stockh)* **69**:277, 1989

23. Friedman-Birnbaum R et al: A study of HLA antigen associated in localized and generalized granuloma annulare. *Br J Dermatol* **115**:329, 1986

24. Grogg KL, Nascimento AG: Subcutaneous granuloma annulare in childhood: Clinicopathologic features in 34 cases. *Pediatrics* **107**:E42,

2001

25. Samlaska CP et al: Generalized perforating granuloma annulare. *J Am Acad Dermatol* **27**:319, 1992

26. Castro A et al: Glucose, insulin HGH, and cortisol plasma levels in granuloma annulare patients during glucose tolerance and cortisone glucose tolerance test. *Clin Biochem* **7**:150, 1974

27. Mutasim DF, Bridges AG: Patch granuloma annulare: Clinicopathologic study of 6 patients. *J Am Acad Dermatol* **2**:417, 2000

28. Boneschi V et al: Annular elastolytic giant cell granuloma. *Am J Dermatopathol* **10**:224, 1988

29. Kossad S, Winkelmann RK: Response of generalized granuloma annulare to alkylating agents. *Arch Dermatol* **114**:216, 1978

30. Thomas DJ et al: Visceral and skin granuloma annulare, diabetes, and polyendocrine disease. *Br Med J* **293**:977, 1986

31. Magro CM et al: Granuloma annulare and necrobiosis lipoidica tissue reactions as a manifestation of systemic disease. *Hum Pathol* **27**:50, 1996

32. Barksdale SK et al: Granuloma annulare in patients with malignant lymphoma: Clinicopathologic study of thirteen new cases. *J Am Acad Dermatol* **31**:42, 1994

33. Haim S et al: Carbohydrate tolerance in patients with granuloma annulare. *Br J Dermatol* **88**:447, 1973

34. Dahl MV et al: Elevated heparin precipitable fraction of plasma in granuloma annulare. *Arch Dermatol* **115**:1059, 1979

35. Koh MS et al: Increased plasma fibronectin in diabetes mellitus, necrobiosis lipoidica and widespread granuloma annulare. *Clin Exp Dermatol* **9**:293, 1984

36. Padilla RS et al: Serum lysozyme in patients with localized and generalized granuloma annulare. *Arch Dermatol* **121**:624, 1985

37. Yuen CT et al: Increased activity of serum amine oxidases in granuloma annulare necrobiosis lipoidica and diabetes. *Br J Dermatol* **116**:643, 1987

38. Friedman-Birnbaum R et al: A comparative histopathologic study of generalized and localized granuloma annulare. *Am J Dermatopathol* **11**:144, 1989

39. Dabski K, Winkelmann RK: Generalized granuloma annulare: Histopathology and immunopathology. Systematic review of 100 cases and comparison with localized granuloma annulare. *J Am Acad Dermatol* **20**:28, 1989

40. Bergman R et al: Localized granuloma annulare: Histopathological and direct immunofluorescence study of early lesions, and the adjacent normal-looking skin of actively spreading lesions. *Am J Dermatopathol* **15**:544, 1993

41. Ozkan S et al: Anetoderma secondary to generalized granuloma annulare. *J Am Acad Dermatol* 42:335, 2000

42. Perrin C et al: Interstitial granulomatous drug reaction with a histologic pattern of interstitial granulomatous dermatitis. *Am J Dermatopathol* **23**:295, 2001

43. Blau EB: Familial granulomatous arthritis, iritis, and rash. *J Pediatr* **107**:689, 1985

44. Weiss JM et al: Treatment of granuloma annulare by local injections with low-dose recombinant human interferon gamma. *J Am Acad Dermatol* **39**:117, 1998

45. Hindson TC et al: PUVA therapy of diffuse granuloma annulare. *Clin Exp Dermatol* **13**:26, 1988

46. Grundmann-Kollmann M et al: Cream psoralen plus ultraviolet A therapy for granuloma annulare. *Br J Dermatol* 144:996, 2001

47. Harth W, Richard G: Retinoids in therapy of granuloma annulare disseminatum. *Hautarzt* **44**:693, 1993

T>

Chapter 101

Louis Dubertret

Malignant Atrophic Papulosis (Degos' Disease)

PATHOGENESIS
CLINICAL FEATURES
Cutaneous Manifestations22,23
Gastrointestinal Manifestations 22,23
Neurologic Manifestations27,28
Other Visceral Manifestations
Other Disease Associations
HISTOPATHOLOGY
LABORATORY FINDINGS
DIFFERENTIAL DIAGNOSIS
TREATMENT
PROGNOSIS

REFERENCES

Köhlmeier first described malignant atrophic papulosis (Degos' disease) in 1941, [1] and Degos recognized it as a specific entity in 1942. [2] This rare disorder, of which fewer than 200 cases have been reported to date, is a multisystem lymphocytic vasculitis characterized by widespread thrombosis of small vessels not only in the skin, but also, with decreasing frequency, in the gastrointestinal tract and in the ocular and central nervous systems. Local ischemia may also involve the lungs, heart, kidneys, liver, bladder, and prostate gland. Of the patients with documented disease, one-half have died, primarily from intestinal perforations or central nervous system infarcts.

PATHOGENESIS

The pathogenesis of malignant atrophic papulosis is unknown. The occlusion of blood vessels seems to be the consequence of endothelial cell swelling and lymphocytic vasculitis, leading to thrombosis. [3] Besides these constant histologic observations, other physiopathologic phenomena occur, although they have not been uniformly verified in all patients. From time to time, fibrinolytic activity seems to decline within the lesion, [4], [5] and a decrease in blood fibrinolytic activity seems to be present in most of the studied patients. [6], [7] Some cases have suggested that anticardiolipin antibodies and the lupus anticoagulant play a role in this condition, [8] but a study of 15 patients did not confirm such an association. [9]

By electron microscopy, so-called confronting cylindrical cysternae have been observed in endothelial cells; [10], [11] and [12] these are now considered products of a cellular reaction to viral infection. An increased content of von Willebrand factor in Weibel-Palade granules has been observed by immunoelectron microscopy, suggesting a secretion defect. [7]

An extract of brain tissue obtained from a surgeon who died of malignant atrophic papulosis produced an extensive subacute spongiform encephalopathy in a chimpanzee and a squirrel monkey. [13] The symptoms of the induced disease were similar to those of Creutzfeldt-Jakob disease. This observation suggests that malignant atrophic papulosis could result from a transmissible agent; however, injections of tissue from other patients' skin lesions into nonhuman primates have not induced the disease. [14]

Four familial cases of malignant atrophic papulosis have been described: (1) a mother and her daughter, [14] (2) a son and his mother, [15] (3) a mother and her five children, [16] and (4) members of three generations in a single family. [17] This emphasizes the possibility of genetic contributing factors in this disease or of slow virus infection and transmission. Findings of an association with AIDS [18] and an exacerbation during immunosuppression [19] also suggest the possible role of an infectious agent.

CLINICAL FEATURES

Malignant atrophic papulosis has been described mainly in Europe and the United States. It nearly always occurs in Caucasians, but two cases have been observed in African American patients and three cases have been reported in Japan. Sixty-one percent of patients are male. Although the disease has occurred in patients of many ages, it is rare in young children. [20], [21] Typically, it occurs in young adults.

Cutaneous Manifestations [22], [23]

The cutaneous lesions of malignant atrophic papulosis, which pass through progressive stages, are pathognomonic. They can be few in number, but are usually multiple—up to 600 lesions on the same patient. Lesions predominate on the trunk and upper limbs. The disease does not affect the scalp and usually spares the palms, soles, and face.

The evolution of the lesion is characteristic. In the early phase, a small, firm papule from 2 to 5 mm in diameter appears. Its color may be pink, gray, or yellow, and a normal epidermis covers it. Dermal edema may be evident. Within a few days, the papule becomes umbilicated, and a typical central white, porcelain-like zone of atrophy appears (Fig. 101-1). A scale may cover this central zone, and an erythematous border, generally 1 to 2 mm in width and sometimes slightly

raised, may encircle it. This border may be pink or violaceous and is covered by telangiectasia. With time, the border disappears, leading to a varicelliform scar.

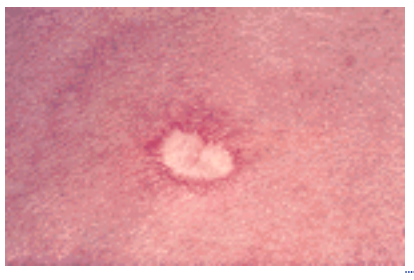

FIGURE 101-1 Malignant atrophic papulosis. Characteristic evolution of papules into typical porcelain-white atrophic lesions.

Crops of new elements occur from time to time, and lesions of different ages can be evident in the same patient. Skin lesions are asymptomatic or slightly pruritic. Usually, the lesions are separated from each other, but they may coalesce, leading to polycyclic atrophic areas or to skin ulcerations.

Gastrointestinal Manifestations [22], [23]

In general, gastrointestinal lesions occur a few months after the onset of skin lesions, but they may not occur until many years later. Thus, it is difficult to determine the percentage of patients with gastrointestinal manifestations. According to the published cases without long-term follow-up, 61 percent of patients with malignant atrophic papulosis suffer from gastrointestinal lesions. Gastrointestinal tract involvement may remain unsymptomatic and may be discovered only at autopsy of patients who died of encephalitis. [24] Sometimes, patients suffer only from dyspepsia, but there is usually an abdominal emergency such as vomiting, acute abdominal pain, hematemesis, or melena that reveals the intestinal involvement. Symptomatic gastrointestinal involvement signifies a poor prognosis, even though the results of a radiologic examination of the intestine remain normal.

Laparoscopy or laparotomy reveals white, avascular patches scattered on the surface of the small intestine, colon, or stomach, sometimes with perforation leading to peritonitis. The rectum can also be involved.

Among mucosal lesions, ocular involvement is predominant. It is present in one-third of patients, [25], [26] occurring mainly on the conjunctiva but also on the sclera, episclera, retina, choroid, and the optic nerves. Lesions appear as avascular patches on the conjunctiva (Fig. 101-2) or on chorioretinal sites, sometimes with depigmentation. Telangiectasia with microaneurysms has also been observed. Involvement of the buccal mucosa and of the genitalia is rare.

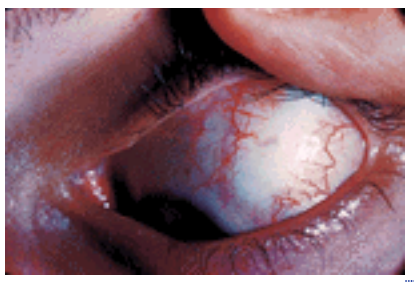

FIGURE 101-2 Ocular involvement in malignant atrophic papulosis: a typical avascular patch on the conjunctiva surrounded by injected collateral vessels.

In most cases, cutaneous manifestations precede visceral symptoms. When gastrointestinal or neurologic manifestations precede those of the skin, the diagnosis is hardly possible clinically and requires the histologic examination of specimens obtained by abdominal surgery or at autopsy.

Neurologic Manifestations [27], [28]

Twenty percent of patients experience neurologic manifestations of malignant atrophic papulosis. These symptoms are polymorphic and include hemiparesis, aphasia, multiple cranial nerve involvement, monoplegia, sensory disturbances, and seizures. The cerebrospinal fluid is usually abnormal, with pleocytosis and increased protein content. Neuropathologic findings are multiple infarcts, with or without hemorrhage, in the brain, cerebellum, and spinal cord. The meningeal vessels can also be occluded.

Neurologic manifestations usually occur in the course of the acute form of malignant atrophic papulosis, where the prognosis is dependent mainly on the intestinal involvement. However, progressive neurologic involvement sometimes leads to death. This has been the case in some rare cases of malignant atrophic papulosis occurring in children. [29]

Other Visceral Manifestations

Postmortem examination reveals infarcts in many organs (heart, kidneys, bladder, lungs, pleura, liver, pancreas). These lesions are rarely symptomatic during life. However, pleuritis and pericarditis have been observed, and death has occasionally resulted from respiratory insufficiency (five patients). In one infant, death resulted from disseminated

myocardial infarcts. [20]

Other Disease Associations

Malignant atrophic papulosis–like lesions have been described in collagen vascular disease, [30] and lesions have been reported in one patient who also had AIDS. [18]

HISTOPATHOLOGY

The histologic lesions of malignant atrophic papulosis are characteristic. [2] Classically, there is a definite area of dermal necrosis situated just below an atrophic epidermis, with or without hyperkeratosis (Fig. 101-3). The first histologic description of typical lesions emphasized the absence of adnexae, vessels, and inflammatory cells in the necrobiotic zone. Just beneath the necrobiotic zone, there is considerable vascular pathology with endothelial cell swelling, proliferation, and thrombosis. The vessel walls are thickened, and fibrinoid necrosis is often present (Fig. 101-4). Vascular damage occurs predominantly in the arterioles, but it may also occur in the small, deep venules.

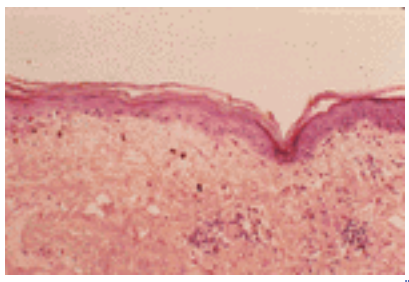

FIGURE 101-3 Early lesion of malignant atrophic papulosis with the beginning of ischemic necrolysis of the epidermis and dermis on the left and sparse superficial lymphocytic infiltrates on the right. (*Courtesy of Olivier Verola, MD*)

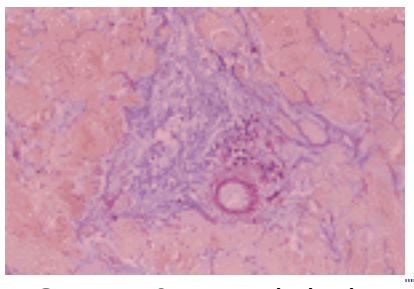

FIGURE 101-4 Early lesion of malignant atrophic papulosis showing fibrinoid necrosis of an arteriole, a sparse inflammatory infiltrate, and mucin deposition. (*Courtesy of Bernard Cribier, MD*)

The classical abscence of inflammatory cells [2] is a questionable criterion for diagnosis as it is characteristic only for old lesions. Most of the early lesions show features of lymphocytic vasculitis associated with the alterations of endothelial cells of arterioles and venules (see Fig. 101-4). [3], [31] Demyelination and degenerative alterations of small nerves may occur. Fibrin deposits are frequently evident within and around the skin vessels. Mucin deposits are common in the dermis. [32]

Immunofluorescence studies have not detected immunoglobulin or complement deposits in the lesions. Circulating immune complexes have not been found. [33]

Electron microscopy indicates that the essential features of malignant atrophic papulosis are focal endothelial cell degeneration and hypertrophy with fibrin deposits. Paramyxovirus-like inclusions have appeared in the endothelial cells and fibroblasts of some patients. [11], [12] These structures are now called confronting cylindrical cysternae and are considered products of a cellular reaction to an unknown, possibly infectious agent; they are a not uncommon sequela of certain viral infections and/or virus-induced neoplasms in different species. [34] These structures, which can be induced in vitro by interferon, [34], [35] are commonly found in association with Kaposi's sarcoma. [36]

LABORATORY FINDINGS

Patients with malignant atrophic papulosis have a normal CBC and a normal erythrocyte sedimentation rate; hypergammaglobulinemia can be observed in a few patients. Some abnormalities in blood coagulation have been reported: an increase in plasma fibrinogen level, [37], [38], [39], [40], [41], [42] and [43] increased platelet aggregation, [7], [9], [38], [40] and a decrease of local [4] and systemic fibrinolytic activity. [6], [7] Thus, the possibility of consumption coagulopathy has been entertained. [40] Antiarterial antibodies have been observed in a few patients. [41], [42] and [43] The results of skin tests to common recall antigens are normal.

DIFFERENTIAL DIAGNOSIS

The clinical and histologic patterns of the skin lesions are diagnostic of malignant atrophic papulosis. As noted earlier, however, when visceral lesions precede the skin lesions, diagnosis may be impossible. Similar skin lesions have appeared in patients with systemic lupus erythematosus. [44] Individual lesions of atrophie blanche can mimic the disease, but the topography of the lesions and the absence of papules excludes the diagnosis. [45] A skin biopsy can exclude

allergic necrotizing vasculitis, acute parapsoriasis, or lymphomatoid papulosis, when necessary.

TREATMENT

Proposed therapies for malignant atrophic papulosis are unfortunately not based on controlled studies because of the rarity of the disease and its unpredictable and variable evolution. Glucocorticoids not only seem to be inefficient, but also may increase the risk of intestinal perforation.

Anticoagulants, mainly heparin, have been used without demonstrable effect. [46] Therapy with dipyridamole (50 mg three times a day) and aspirin (325 mg daily) has been beneficial in some patients who demonstrate increased platelet aggregation. [38], [39] Fibrinolytic therapy with phenformin and ethylestrenol has been useful in some cases, [47] but ineffective in others. [48] Ethylestrenol has been used as an anabolic steroid; like danazol, it has fibrinolytic activity, but danazol has not been tested in malignant atrophic papulosis. Pentoxifyllin plus aspirin has been reported beneficial in one case. [49] Dextran perfusion has not proved useful. Surgery of intestinal lesions is usually ineffective.

PROGNOSIS

Classically, the prognosis is poor, and death usually occurs after a few years as the consequence of intestinal lesions or neurologic involvement. However, some patients have survived for 15 years with only skin lesions. [50] Thus, as more observations are made, the spectrum of the disease seems more and more polymorphic with both acute and chronic forms, with lesions either limited to the skin or associated with visceral involvement, and with or without the presence of detectable coagulation abnormalities. When platelet aggregation is increased, treatment to inhibit the aggregation seems logical and useful.

REFERENCES

1. Köhlmeier W: Multiple Hautnekrosen bei Thrombangiitis obliterans. *Arch Dermatol Syphilol* **181**:783, 1941

2. Degos R et al: Dermatite papulo-squameuse atrophiante. *Bull Soc Fr Dermatol Syphiligr* **49**:148, 281, 1942

3. Soter NA et al: Lymphocytes and necrosis of the cutaneous microvasculature in malignant atrophic papulosis: A refined light microscope study. *J Am Acad Dermatol* **7**:620, 1982

4. Black MM et al: The role of dermal blood vessels in the pathogenesis of malignant atrophic papulosis (Degos' disease): A study of two cases using enzyme histochemical, fibrinolytic, electron-microscopical and immunological techniques. *Br J Dermatol* **83**:213, 1973

5. Muller SA, Landry M: Malignant atrophic papulosis (Degos disease): A report of two cases with clinical and histological studies. *Arch Dermatol* **112**:357, 1976

6. Daniel F et al: Papulose atrophiante maligne avec insuffisance de la fibrinolyse sanguine. *Ann Dermatol Venereol* **109**:763, 1982

7. Caux F et al: Anomalies de la fibrinolyse dans la maladie de Degos. *Ann Dermatol Venereol* **121**:537, 1994

8. Englert HJ et al: Degos' disease: Association with anticardiolipin antibodies and the lupus anticoagulant. *Br Med J* **289**:576, 1984

9. Assier H et al: Absence of antiphospholipid and anti-endothelial cell antibodies in malignant atrophic papulosis: A study of 15 cases. *J Am Acad Dermatol* **33**:831, 1995

10. Olmos L, Laugier P: Ultrastructure de la maladie de Degos (Apport d'un nouveau cas et revue de la littérature). *Ann Dermatol Venereol* **104**:280, 1977

11. Olmos L et al: Microcylinders of endoplasmic reticulum in histiocytes in patients suffering from Degos' syndrome and dermatomyositis. *Br J Dermatol* **100**:137, 1979

12. Bioulac P et al: La papulose atrophiante maligne de Degos: Étude ultrastructurale d'un nouveau cas. *Ann Anat Pathol (Paris)* **25**:111, 1980

13. Gajdusek DC et al: Transmission of subacute spongiform encephalopathy to the chimpanzee and squirrel monkey from a patient with papulosis atrophicans maligna of Köhlmeier-Degos. *Proceedings of the Tenth International Congress of Neurology*, Series 319, edited by A Subirana, JM Espadaler, EH Burrows. Amsterdam, Excerpta Medica, 1973–1974, p 390

14. Moulin G et al: Papulose atrophiante de Degos familiale (mère-fille). *Ann Dermatol Venereol* **111**:149, 1984

15. Hall-Smith R: Malignant atrophic papulosis (Degos' disease): Two cases occurring in the same family. *Br J Dermatol* **81**:817, 1969

16. Kisch LS, Bruynzeel DP: Six cases of malignant atrophic papulosis (Degos' disease) occurring in one family. *Br J Dermatol* **111**:469, 1984

17. Katz SK et al: Malignant atrophic papulosis (Degos' disease) involving three generations of a family. *J Am Acad Dermatol* **37**:480, 1997

18. Requena L et al: Degos disease in a patient with acquired immunodeficiency syndrome. *J Am Acad Dermatol* **38**:852, 1998

19. Powell J et al: Benign familial Degos disease worsening during immunosuppression. *Br J Dermatol* **141**:524, 1999

20. Cabré J et al: Papulose atrophiante maligne de Degos chez un nourrisson. *Bull Soc Fr Dermatol Syphiligr* **81**:652, 1974

21. Enjolras O et al: Un cas juvenile de maladie de Degos. *Bull Soc Fr Dermatol Syphiligr* **81**:205, 1974

22. Degos R: Malignant atrophic papulosis. *Br J Dermatol* **100**:21, 1979

23. Barrière H: Papulose atrophiante maligne (maladie de Degos). *Ann Dermatol Venereol* **105**:733, 1978

24. Huriez CL et al: Forme à prédominance cérébrale d'une maladie de Degos. *Bull Soc Fr Dermatol Syphiligr* **82**:276, 1975

25. Henkind P, Clark WE: Ocular pathology in malignant atrophic papulosis Degos' disease. *Am J. Ophthalmol* **65**:164, 1968

26. Sibillat M et al: Papulose atrophiante maligne (maladie de Degos): Revue clinique. *J Fr Ophthalmol* **9**:299, 1986

27. Petit WA Jr et al: Degos' disease: Neurologic complications and cerebral angiography. *Neurology* **32**:1305, 1982

28. Label LS et al: Myelomalacia and hypoglycorrhachia in malignant atrophic papulosis. *Neurology* **33**:936, 1983

29. Rosemberg S et al: Childhood Degos' disease with prominent neurological symptoms: Report of a clinicopathological case. *J Child Neurol* **3**:42, 1988

30. Tsao H et al: Lesions resembling malignant atrophic papulosis in a patient with dermatomyositis. *J Am Acad Dermatol* **36**:317, 1997

31. Thiers H et al: Papulose atrophiante de Degos: Particularités histologiques. *Bull Soc Fr Dermatol Syphiligr* **75**:657, 1968

32. Feuerman EJ et al: Malignant atrophic papulosis with mucin in dermis: A clinical and pathological study including autopsy. *Arch Pathol* **90**:310, 1970

33. Tribble K et al: Malignant atrophic papulosis: Absence of circulating immune complexes or vasculitis. *J Am Acad Dermatol* **15**:365, 1986

34. Luu J et al: Tubular structures and cylindrical confronting cisternae: A review. *Hum Pathol* **20**:617, 1989

35. Orenstein JM et al: The relationship of serum alpha-interferon and ultrastructural markers in HIV-seropositive individuals. *Ultrastruct Pathol* **11**:673, 1987

36. Rappersberger K et al: Endemic Kaposi's sarcoma in human immunodeficiency virus type-1 seronegative persons: Demonstration of retrovirus-like particles in cutaneous lesions. *J Invest Dermatol* **95**:371, 1990

37. Roenigk HH, Farmer RG: Degos' disease (malignant papulosis): Report of three cases with clues to etiology. *JAMA* **206**:1508, 1968

38. Stahl D et al: Malignant atrophic papulosis: Treatment with aspirin and dipyridamole. *Arch Dermatol* **114**:1687, 1978

39. Drucker CR: Malignant atrophic papulosis: Response to antiplatelet therapy. *Dermatologica* **180**:90, 1990

40. Dastur DK et al: CNS involvement in malignant atrophic papulosis (Köhlmeier-Degos disease): Vasculopathy and coagulopathy. *J Neurol Neurosurg Psychiatry* **44**:156, 1981

41. Degos R et al: Papulose atrophiante maligne avec présence d'anticorps anti-artère. *Bull Soc Fr Dermatol Syphiligr* **74**:715, 1967

42. Basset A et al: Papulose atrophiante maligne de Degos avec atteinte du système nerveux central et présence d'anticorps anti-artères. *Bull Soc Fr Dermatol Syphiligr* **76**:333, 1969

43. Repay VI: Über das Krankheitsbild “Papulose atrophiante maligne Degos.” *Dermatol Wochenschr* **155**:325, 1969

44. Dubin HV, Stawiski MA: Systemic lupus erythematosus resembling malignant atrophic papulosis. *Arch Intern Med* **134**:321, 1974

45. Black MM, Hudson PM: Atrophie blanche closely resembling malignant atrophie papulosis (Degos' disease) in systemic lupus erythematosus. *Br J Dermatol* **95**:649, 1976

46. Rivoire J: Papulose atrophiante maligne de Degos. Evolution après 28 mois de traitement aux anticoagulants. *Bull Soc Fr Dermatol Syphiligr* **78**:18, 1971

47. Delaney TJ, Black MM: Effect of fibrinolytic treatment in malignant atrophic papulosis. *Br Med J* **3**:415, 1975

48. Howsden SM et al: Malignant atrophic papulosis of Degos: Report of a patient who failed to respond to fibrinolytic therapy. *Arch Dermatol* **112**:1582, 1976

49. Victor C, Schulz-Ehrenburg U: Malignant atrophic papulosis (Uëhlweier-Degos): Diagnosis, therapy and course. *Hautarzt* **52**:734, 2001

50. Su WPD et al: Clinical and histologic findings in Degos' syndrome (malignant atrophic papulosis). *Cutis* **35**:131, 1985

T>

Chapter 102

Christopher Shea Victor Prieto

Fibrous Lesions of Dermis and Soft Tissue

THE FIBROMATOSES
CHILDHOOD FIBROMATOSES
Solitary Lesions
Multifocal Lesions
FIBROMATOSES MAINLY OF ADULT ONSET
Dupuytren's Contracture (Palmar Fibromatosis)
Peyronie's Disease (Induratio Penis Plastica)
Knuckle Pads
Pachydermodactyly
Progressive Nodular Fibrosis of the Skin
DESMOID TUMOR
REACTIVE AND DEGENERATIVE FIBROUS LESIONS
Hypertrophic Scars and Keloids
Nodular Fasciitis
Elastofibroma Dorsi
Degenerative Collagenous Plaques of the Hands (Synonyms: Keratoelastoidosis Marginalis, Digital Papular Calcific Elastosis)
Pachydermoperiostosis (Primary Hypertrophic Osteoarthropathy)
Acrokeratoelastoidosis of Costa
Fibroepithelial Polyp (Synonyms: Acrochordon, Skin Tag, Soft Fibroma)
HAMARTOMAS AND RELATED SYNDROMES
Fibrous Hamartoma of Infancy
Connective Tissue Nevus
BENIGN NEOPLASMS
Angiofibroma
Fibrofolliculoma
Sclerotic Fibroma (Circumscribed Storiform Collagenoma, Plywood Fibroma)
Giant Cell Collagenoma
Pleomorphic Fibroma
Desmoplastic Fibroblastoma (Collagenous Fibroma)
Solitary Fibrous Tumor
Dermatofibroma (Cutaneous Benign Fibrous Histiocytoma)
Dermatomyofibroma
Superficial Acral Fibromyxoma
INTERMEDIATE-GRADE NEOPLASMS (OF LOW METASTATIC POTENTIAL)
Dermatofibrosarcoma Protuberans
Giant Cell Fibroblastoma
Atypical Fibroxanthoma (AFX)
MALIGNANT NEOPLASMS
Malignant Fibrous Histiocytoma (MFH)
Epithelioid Sarcoma

REFERENCES

Lesions characterized by (1) proliferations of fibroblasts or myofibroblasts and/or (2) increased or altered extracellular deposits of collagen or elastic tissue are discussed in this chapter. Classification into traditional nosologic categories is problematic. Fibrous lesions often are composed predominantly of stroma, and only in certain high-grade sarcomas is the neoplastic nature of the lesion obvious. The presence of defined chromosomal abnormalities suggests a neoplastic status for some fibrous lesions traditionally considered to be reactive.

THE FIBROMATOSES

Fibromatoses are proliferations composed of fibrous tissue with varying degrees of cellularity, often exhibiting myofibroblastic differentiation. Lesions in childhood often remit spontaneously, whereas in adults fibromatoses tend to be locally aggressive but nonmetastatic. Fibromatoses of most interest to the dermatologist may arise in fascia (e.g., palmoplantar fibromatosis) or musculoaponeuroses (e.g., fibromatosis colli); a few are dermal (e.g., infantile digital fibromatosis). While most fibromatoses are considered nonmalignant, lesions affecting vital viscera (e.g., abdominal desmoid tumors) can be fatal through local complications. The nosologic status of fibromatoses is disputed. Clonal chromosome aberrations (e.g., trisomies 8 and 20 and loss of 5q material) occur in 46 percent of desmoid tumors and in 10 percent of superficial types. [1]

CHILDHOOD FIBROMATOSES

Solitary Lesions

FIBROMATOSIS COLLI (STERNOMASTOID TUMOR OF INFANCY) This benign proliferation of fibrous tissue infiltrating the lower third of the sternocleidomastoid or shoulder region is the most common cause of neonatal torticollis. Possibly a consequence of birth trauma, it usually is present at birth and remits spontaneously. Fine-needle aspiration reveals clusters of spindled fibroblasts with plump, ovoid nuclei. [2]

INFANTILE DIGITAL FIBROMATOSIS (INCLUSION BODY FIBROMATOSIS, REYE TUMOR) This lesion usually occurs as a small, asymptomatic, nodular, dermal fibrous proliferation at the extensor or lateral surface of a finger or toe (Fig. 102-1) but occasionally is seen at other sites, such as breast or tongue. Typically, onset is in the first year of life, and the lesion may involute spontaneously without scarring after several years. Recurrence after local excision is common; thus management by observation is usually the best approach. Histologically, myofibroblasts in poorly circumscribed, interlacing bundles contain pathognomonic, eosinophilic, paranuclear inclusion bodies that stain red with Masson's trichrome stain and purple with phosphotungstic acid–hematoxylin. [3]

FIGURE 102-1 Infantile digital fibromatosis (Reye's tumor) in a 2-year-old child.

CALCIFYING APONEUROTIC FIBROMA This lesion usually presents as a painless, solitary, deep fibrous nodule, often adherent to tendon, fascia, or periosteum, on the hands and feet. [4] Histologically, fascicles of spindled fibroblasts and scattered epithelioid cells border chondroid areas with or without calcification. This lesion is best managed by conservative local excision.

Multifocal Lesions

AGGRESSIVE INFANTILE FIBROMATOSIS This lesion is characterized by rapidly growing nodules on the trunk that infiltrate skeletal muscle and only rarely regress spontaneously. [5] The pathologic appearance varies from immature mesenchymal cells to collagenous and desmoid patterns. Treatment is by complete local excision, but this often cannot be accomplished because of muscular involvement. Distant metastases, e.g., to lungs, can occur.

INFANTILE MYOFIBROMATOSIS This lesion is usually solitary (solitary infantile myofibroma), but patients with multicentric presentation (congenital generalized fibromatosis) often also have visceral involvement, and in these there may be a 75 percent mortality rate. Occasionally, familial cases are reported. Most lesions present at or soon after birth as rubbery masses in skin or muscle in the head and neck, upper extremity, or trunk; they may simulate hemangiomas clinically. Similar lesions occur rarely in adults. [6] This biphasic tumor is composed of (1) interlacing fascicles or whorled nodules of eosinophilic spindle cells in a collagenous or myxoid stroma and (2) centrally, vascular proliferation resembling hemangiopericytoma admixed with primitive-appearing round to spindle cells. Mitotic figures, vascular invasion, and tumor necrosis may be seen and are not evidence of malignancy. The cells express vimentin and muscle actin. Because solitary lesions of skin and bone usually regress spontaneously, surgical excision is limited to lesions interfering with function.

JUVENILE HYALINE FIBROMATOSIS This very rare, possibly autosomal recessive disease occurs from early childhood to adulthood. It presents as slow-growing, pearly white or skin-colored dermal or subcutaneous papules or nodules on the face, scalp, and back that may be confused clinically with neurofibromatosis. The course generally progresses to ulceration, joint contractures, deformities, and lytic bone lesions. Associated clinical features include gingival hyperplasia, growth retardation, and papillomatous perianal lesions. Histologically, cords of spindled myofibroblasts, often with cytoplasmic vacuoles, occur in a hyalinized or chondroid stroma. Infantile systemic hyalinosis shows similar features affecting viscera. [7]

FIBROMATOSES MAINLY OF ADULT ONSET

Dupuytren's Contracture (Palmar Fibromatosis)

This bilateral, progressive fibrosis of the palmar fascia usually presents as nodules over the fourth or fifth metacarpal head and progresses to flexion deformity of the fingers. While most lesions are asymptomatic, about one-fifth of patients have tingling, edema, changes in temperature sensation, sweating, or pain. Dupuytren's disease predominantly affects males of northern European descent. Some patients have associated plantar fibrosis (Ledderhose's disease), usually over the medial side of the sole and rarely associated with contractures. [8] These two processes share the same histologic and ultrastructural features. [9] Knuckle pads are also associated (see below).

Chronic trauma appears an unlikely etiology. Decreases in conduction velocity of the ulnar nerve occur in some patients, as do abnormal cervical vertebrae. The disease has a hereditary component, and there is an association with alcoholic liver disease, epilepsy, diabetes mellitus, and smoking. [10] Histologically, the palmar aponeurosis and adipose tissue exhibit nodules of fibroblasts in a dense reticulin network. In older lesions, thick, acellular collagen bundles predominate. [11] Early lesions contain fibroblasts and collagen type III, intermediate lesions have myofibroblasts, and late lesions contain fibrocytes and collagen type I. [12] Basic fibroblast growth factor and transforming growth factor alpha are overexpressed, [13] as is epidermal growth factor receptor, suggesting a possible autocrine stimulatory loop. [14]

The early, nodular lesions may respond to intralesional steroids or colchicine. [15] Older lesions usually require partial fasciectomy. Recurrence is more common in highly cellular lesions in which mitotic figures can be seen, as opposed to the more mature, hypocellular lesions. [16]

Peyronie's Disease (Induratio Penis Plastica)

This fibrosing condition involves the dorsum of the penis and, in particular, the fibrous septa between the corpus spongiosum and corpora cavernosa. It is occasionally associated with Dupuytren's contracture. The etiology is unknown.

Propranolol has been suspected as an inciting agent, [17] but the condition existed long before propanolol was used as a drug. Over several years, most patients have spontaneous regression. [18] The histology is very similar to that of Dupuytren's fibromatosis.

Knuckle Pads

These are circumscribed, keratotic, fibrous growths over the dorsa of the interphalangeal joints. [19] Many patients have coexisting fibromatosis of the palmar, plantar, or penile aponeurosis or fascia. [20] Pathologically, there is intradermal fibroblastic and myofibroblastic proliferation without atypia or inflammation, eventuating in fibrosis. *False knuckle pads* are caused by repetitive mechanical trauma or factitious injury such as chewing or gagging in bulemics.

Pachydermodactyly

This superficial dermal fibromatosis presents as poorly circumscribed symmetric, infiltrative, asymptomatic soft-tissue hypertrophy of the proximal fingers, typically sparing the thumbs and fifth fingers and rarely extending proximally to the wrists or occurring distally. [21] Most cases occur in young men. It may be associated with tuberous sclerosis, atrophia maculosa varioliformis cutis, and carpal tunnel syndrome. Histologically, it exhibits a thickened, fibrotic dermis entrapping eccrine glands.

Progressive Nodular Fibrosis of the Skin

This lesion presents with progressive dermal nodules of fibroblasts in a collagenous stroma. In vitro, increased synthesis of procollagen and decreased synthesis of collagenase suggest expansion of a clone of fibroblasts having these reciprocal abnormalities. [22]

DESMOID TUMOR

This rare mesenchymal tumor may develop anywhere on the body, most often on the anterior abdominal wall and shoulder girdle (Fig. 102-2). More frequent in women, desmoids may develop following childbirth or in abdominal scars. Injury precedes a minority of cases. [23] The desmoids slowly, relentlessly invade surrounding structures, sometimes causing fatality. Retroperitoneal desmoids occur in Gardner's syndrome, especially after intraabdominal operations. Rarely, desmoid tumors transform into classic fibrosarcomas. [24] Desmoid tumors have chromosomal abnormalities, such as trisomies 20 and 8. The latter may behave less aggressively. [25]

FIGURE 102-2 Desmoid tumors involving upper chest and epigastric region. These represent recurrences after multiple surgical interventions. This patient also had intraabdominal desmoid tumors.

Histologically, a poorly circumscribed growth of mature fibrous tissue arises from a musculoaponeurosis. Regarding differential diagnosis, in contrast with fibrosarcomas, desmoids tend to be less cellular and more monomorphous. In contrast with nodular fasciitis, desmoids lack significant myxoid background or mitotic figures.

Due to diffuse infiltration, surgical excision is very difficult. When feasible, aggressive wide resection is the treatment of choice because the lesions recur often (see Fig. 102-2), and death may result from local infiltration. Metastases do not occur. Radiotherapy can be used to control recurrent disease and may be the primary therapy to avoid a mutilating resection, particularly of extraabdominal desmoids. Antiestrogens can be used when surgery is not possible or in recurrent disease. [26] Chemotherapy with doxorubicin, dacarbazine, and carboplatin can be used for recurrent extraabdominal desmoid tumors where surgery is contraindicated. [27]

REACTIVE AND DEGENERATIVE FIBROUS LESIONS

Hypertrophic Scars and Keloids

Both are abnormal growths of fibrous tissue following cutaneous injury. A hypertrophic scar remains confined to the site of original injury, whereas a keloid grows beyond it. Keloids and hypertrophic scars are most common around the shoulders (Fig. 102-3), upper back, and chest (Fig. 102-4), where the skin is thick and under tension, and on the earlobe following piercing. Hypertrophic scars are usually linear following surgical trauma and papular or nodular

following inflammatory and ulcerating lesions, as in cystic acne or burns (see Fig. 102-3). Both hypertrophic scars and keloids are disfiguring and can produce contractures. A keloid appears as a firm, mildly tender, irregular nodule or plaque (see Fig. 102-4). The overlying epidermis is thin, and there may be focal ulceration. The borders are well demarcated but irregular. The color is pink to purple and may be accompanied by hyperpigmentation. Both lesions may be pruritic; in addition, keloids are often painful and hyperesthetic.

FIGURE 102-3 Hypertrophic keloidal scars following cystic acne.

FIGURE 102-4 Two keloids in the presternal region, a typical location.

Hypertrophic scars occur at any age. Keloids usually present in the third decade. Although both sexes are affected, more females seek help for keloids, especially when the lesions appear in the face, such as after ear piercing. Dark-skinned and blood group A individuals are more susceptible to keloid formation. Growth of a keloid may be stimulated by pregnancy. Surgical resection of a keloid may be followed by recurrence of a larger growth; if a skin graft has been used, a keloid may occur in the donor site as well.

Early scars show a proliferation of fibroblasts running parallel to the epidermis in an edematous, myxoid stroma. Blood vessels are prominent. After a few weeks to months, cellularity and edema are replaced by mature collagen. In a hypertrophic scar, areas of eosinophilic collagen are admixed haphazardly with areas of myxoid stroma. In addition to the immature stroma, a keloid has thick, eosinophilic, acellular bands of collagen (Fig. 102-5). Mast cells and plasma cells are seen in increased numbers [28]; mast cells are degranulated and closely apposed to myofibroblasts, suggesting a pathogenic role. [28] However, the differences in mast cell numbers are not significant between the scarred area and the surrounding dermis. [29] Elastin is usually absent, in contrast to a normal mature scar, which does contain elastin. Electron microscopy confirms the presence of fibroblasts and myofibroblasts. [30] The collagen bundles are dense and homogeneous. The intercellular ground substance is increased, with a fibrillar appearance instead of the normal globular deposits.

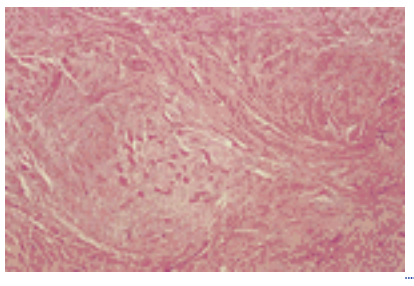

FIGURE 102-5 Photomicrograph showing whorls of collagen characteristic of hypertrophic scar. The thick eosinophilic bundles of collagen on the left are typical of keloid.

Hypertrophic scars are associated with HLA-DRß16, [31] perhaps explaining the predisposition to keloid formation in certain individuals. In most studies, keloids and scars show the same biochemical and pathologic abnormalities. In contrast, some studies have identified antinuclear antibodies in keloids but not in scars. Keloids express increased levels of the gli-1 protein, an oncogene product also present in neoplasms such as basal cell carcinoma. [32] Collagen synthesis and collagenase activity are increased in both keloids and hypertrophic scars. Alpha $_1$ globulin (a collagenase inhibitor usually not present in normal scars) may contribute to increased collagen deposits. Hypertrophic scars have increased levels of the profibrotic agent tumor necrosis factor. [31] Keloids contain tenascin C, a protein associated with inflammation and wound healing. [33] Fibroblasts from keloid-prone patients have altered cytokine patterns [34] and increased sensitivity to transforming growth factor ß1 (TGF-ß1), [35] TGF-ß2, [36] and epidermal growth factor. [37] Along these lines, CO_2 laser treatment reduces TGF-ß1 levels in keloids. [38] At least part of the fibroblast stimulation may be secondary to infiltration of the scar by activated T cells. [39] Also, there seem to be decreased levels of apoptosis (as shown by TUNEL technique)

and increased bcl-2 and p53 expression in keloid-associated fibroblasts. [40] Electron-microscopic studies show partially or totally occluded blood vessels in granulation tissue, hypertrophic scars, and keloids. Blood vessel occlusion may be due primarily to endothelial cell proliferation, resulting in anoxia and stimulation of growth of fibroblasts. [41] However, this theory is difficult to accept because constant pressure on a hypertrophic scar flattens the lesion, presumably due to anoxia. Hypertrophic scars and, even more so, keloids appear to be proliferative lesions based on quantitation of silver-stained nucleolar organizer regions (AgNORs).

Intralesional steroids (e.g., triamcinolone acetonide, 10–40 mg/mL) given every few weeks will stop growth of the keloid or hypertrophic scar, and continued use leads to significant flattening in most instances. Cryotherapy immediately before injection softens the tumor thus allowing easier instillation of the steroid. Leakage of steroid into tissues surrounding the keloid/hypertrophic scar likely will cause atrophy; therefore, steroids should be injected into the center of the lesion. Too superficial an injection leads to visible collections of chalky material, which can be removed surgically. Other side effects of steroid injections include hypopigmentation and occasional sloughing of the keloid. Adrenal suppression is very rare.

Larger keloids are best treated by excision combined with steroid infiltration at the edges of the lesion, immediate skin grafting, and pressure bandaging. After such treatment, there is a reduction in pro-alpha $_1$ type I collagen gene expression. [42] Pressure should be applied to both the resected area and the donor site. Pressure (around 24 mmHg) alone often will prevent hypertrophic scars in burn patients and, if used in early hypertrophic scars, may induce regression.

Radiation therapy may prevent keloid formation and decrease recurrence when used in the early postoperative period (24–48 h). [43] However, it is sometimes difficult to find a radiotherapist willing to use this modality for a benign indication. Laser therapy results have been mixed, but one study did show a decrease in collagen production after therapy, as well as clinical improvement. [44] The 585-nm flashlamp and pulsed-dye lasers are effective in the treatment of keloids and hypertrophic scars. In contrast, the recurrence rate is fairly high when CO_2 lasers are used.

Retinoids decrease fibroblast proliferation and collagen synthesis. Topical retinoid creams have been partially effective in treating keloids. [45] Intralesional interferon alpha 2b also has decreased both collagen production and glycosaminoglycans in keloidal fibroblasts, both in vivo and in vitro. [46] Intralesional interferon alpha 2b does not improve mature keloids [47] but reduces recurrence after treatment with carbon dioxide laser ablation. [48] Silicone oil has been used as a silicone cream or silicone gel sheet in the treatment of both keloids and hypertrophic scars. [49], [50] The mechanism of action is still unclear; however, hydration and occlusion rather than the silicone itself are felt to play an important role. Since it is painless and noninvasive, this silicone solution appears especially useful in the treatment of children. In summary, a combined surgical and medical therapeutic approach may be the best approach to treatment and prevention of keloid recurrence.

Nodular Fasciitis

Nodular fasciitis typically occurs after trauma and is probably a reactive proliferation rather than a neoplasm. It usually presents as a very rapidly growing, firm, variably painful mass in the subcutis, fascia, or muscle of the forearm, upper arm, or thigh, with onset in the third and fourth decade. Involvement of the head and neck (*cranial fasciitis*) is most common in children. The dermal analogue of this lesion has been designated *postoperative/posttraumatic spindle cell nodule of the skin.* Despite its somewhat alarming clinical presentation (and histology; see below), nodular fasciitis is self-limiting and rarely recurs (1–2 percent); any recurrent lesion warrants careful scrutiny because it might represent a misdiagnosed sarcoma. Local excision is the treatment of choice, although some cases have been reported to regress spontaneously.

Histologically, there is a poorly circumscribed nodule in the subcutis, fascia, or occasionally dermis composed of spindled fibroblasts and myofibroblasts in a loose, myxoid, highly vascular stroma resembling granulation tissue, often with associated hemorrhage and infiltrates of lymphocytes, plasma cells, and mast cells. The cellularity and stromal quality (myxoid, fibrotic) vary from area to area. The cells have a feathery “tissue culture fibroblast” appearance and vesicular nuclei. Mitotic figures are often prominent, but atypical forms or nuclear pleomorphism are not present. Besides these classic features, the spectrum includes granulation tissue–like areas, solid and whorled myofibroblastic proliferations with multinucleated cells, mucoid cysts, and “ancient” forms with dense, refractile strands of keloidal collagen. [51] Occasionally, giant cells resemble osteoclasts. Related lesions include *proliferative fasciitis*, [52] distinguished by the presence of ganglion-like giant cells; *proliferative myositis*, of intramuscular location; *ischemic fasciitis*, on pressure points, often in bedridden patients; and *intravascular fasciitis*, involving veins. These variants tend to occur in older patients than classic nodular fasciitis. Immunohistochemically, nodular fasciitis expresses smooth muscle and muscle-specific actins, vimentin, and CD68, consistent with dual myofibroblastic and “histiocytic” differentiation. The lesions are negative for cytokeratin, S-100 protein, and desmin. [51]

Elastofibroma Dorsi

The lesion may be a reparative phenomenon or perhaps a degenerative end-stage response to chronic trauma. A subcutaneous, tender nodule, up to several centimeters in diameter, typically occurs in women in the sixth to the eighth decade. It is often attached to ribs and fascia on the back and tends to protrude from beneath the tip of the scapula. Occasionally, it arises around other articular bursae. Radiology shows a poorly circumscribed soft-tissue mass; signal intensity on MRI is similar to that of muscle interlaced with linear areas of fat. [53] Histologically, fibrous tissue and fat are admixed with thick globules and strands of dense eosinophilic elastic tissue. Ultrastructural and immunohistochemical studies suggest abnormal elastogenesis. [54]

Degenerative Collagenous Plaques of the Hands (Synonyms: Keratoelastoidosis Marginalis, Digital Papular

Calcific Elastosis)

Progressive, firm, glistening, linear plaques are located symmetrically on the medial and lateral aspects of the fingers and thumbs. [55] They are probably due to actinic damage, possibly in concert with repetitive mechanical trauma. Histologically, the epidermis is hyperkeratotic, and the reticular dermis has a bandlike deposition of dense collagen. Solar elastosis is prominent, and calcification is characteristic.

Pachydermoperiostosis (Primary Hypertrophic Osteoarthropathy)

Digits are enlarged from pachydermia, periostosis, and clubbing related to altered proteoglycan synthesis. [56] The lesion is commonly associated with arthralgia and other cutaneous signs, including cutis verticis gyrata and seborrhea, and is familial.

Acrokeratoelastoidosis of Costa

This familial condition is characterized by multiple keratotic papules on the dorsum of hands and feet, palms, and soles. Electron microscopy shows rarified, abnormal elastic tissue; fibroblasts contain dense granules at the periphery of their cytoplasm without elastic extracellular fibers, suggesting abnormal secretion of elastic material. [57]

Fibroepithelial Polyp (Synonyms: Acrochordon, Skin Tag, Soft Fibroma)

These flesh-colored, pedunculated papules or nodules have an irregular or smooth surface (Fig. 102-6). They occur mostly on eyelids, neck, and axillae. Usually asymptomatic, they may undergo infarction if the pedicle twists. The larger lesions that occur on the groin and thighs sometimes are associated with diabetes. The clinical differential diagnosis includes wart, nevus, neurofibroma, and seborrheic keratosis.

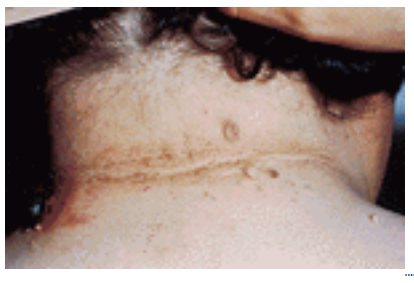

FIGURE 102-6 Soft fibromas or skin tags on the neck of a female patient who also had (endocrine) acanthosis nigricans.

These exophytic or pedunculated lesions may have a flattened, acanthotic-hyperpigmented, or folded and frondlike epidermis. The stroma has loose connective tissue with dilated blood vessels resembling the papillary dermis. [58] Nerves are reduced or absent, and no appendages are present. Pseudosarcomatous fibroepithelial polyps show scattered, bizarre stromal cells similar to those seen in degenerating angiofibroma and vaginal pseudosarcomatous polyp. [59] Lesions containing adipose tissue in addition to the loose fibrous stroma are called *lipofibromas* or *dermatolipomas* and may be associated with diabetes mellitus (N. S. McNutt, personal communication). Similar lesions occurring in a dermatomal or other patterned distribution are seen in nevus lipomatosus superficialis.

If requested, simple snipping with curved scissors, cryotherapy, and electrodesiccation are all appropriate treatments. Simple excision may be needed in the larger lesions.

HAMARTOMAS AND RELATED SYNDROMES

Fibrous Hamartoma of Infancy

This rapidly growing, painless, ill-defined subcutaneous or intradermal nodule is generally solitary and less than 5 cm in size [60]; rarely, multiple lesions occur synchronously. Onset is almost always within the first or second year of life and is congenital in 20 percent of cases. Boys are affected twice as often as girls. The axilla, upper arm, shoulder, groin, and external genitalia are involved most often. Histopathologically, a triphasic pattern comprises (1) orderly interlacing fascicles of fibroblasts and myofibroblasts embedded in a densely collagenous stroma, (2) primitive mesenchymal cells in organoid nests, concentric whorls, and bands, often in a myxoid stroma, and (3) mature adipose tissue intimately admixed with the other components; some cases include disorganized, immature-appearing adipocytes. [61] The treatment of choice is local excision, but recurrence may follow partial excision.

H4>Connective Tissue Nevus

These may be present at birth or appear within the first few years. They are elevated, soft to firm, vary from 0.5 to several centimeters in diameter, and may be grouped, linear, or irregularly distributed. The overlying epithelium is usually smooth. Lesions often are centered on hair follicles and form irregular aggregates (“cobblestones”). They may be flesh-colored, brown, or hypopigmented; a yellow color usually reflects high elastic tissue content. *Familial cutaneous collagenoma* is an autosomally inherited symmetric eruption of nodules and plaques (Fig. 102-7) occurring predominantly over the upper back in adolescents. The autosomal dominant *Buschke-Ollendorf syndrome* (dermatofibrosis lenticularis disseminata) is asymmetric, occurs on the lower trunk and extremities, is composed of papules of elastin tissue, and is associated with osteopoikilosis, i.e., multiple round or oval densities of long bones, pelvis, hands, and feet. [62], [63] Connective tissue nevi also may occur in focal dermal hypoplasia (Goltz syndrome),

macrodactyly, and hemihypertrophy, as well as the shagreen patches of tuberous sclerosis. Histologically, the dermis may contain abnormally compact collagen, adipose tissue, or increased or decreased elastic fibers. [64] However, because the cellularity is normal, routine histology may be unremarkable.

FIGURE 102-7 Cutaneous collagenoma, a connective tissue nevus involving almost the entire back.

BENIGN NEOPLASMS

Angiofibroma (See also Chap. 189)

These lesions are small, reddish brown or even flesh-colored, smooth, shiny, 0.1- to 0.3-cm papules present over the sides of the nose and the medial portions of the cheeks (Fig. 102-8). They are usually associated with the tuberous sclerosis complex and are dealt with in detail in Chap. 189. However, solitary lesions are quite common and clinically resemble small basal cell carcinomas. In the penile coronal sulcus, similar lesions are called *pearly penile papules.* Histopathologically, there is a proliferation of dense collagen surrounding appendages and ectatic blood vessels (Fig. 102-9).

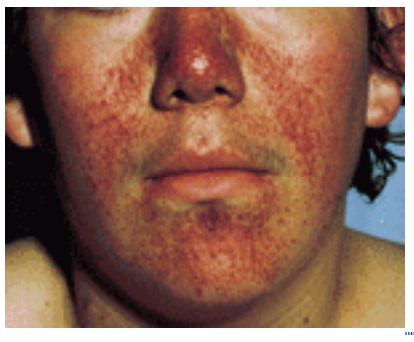

FIGURE 102-8 Multiple angiofibromas in a patient with tuberous sclerosis complex.

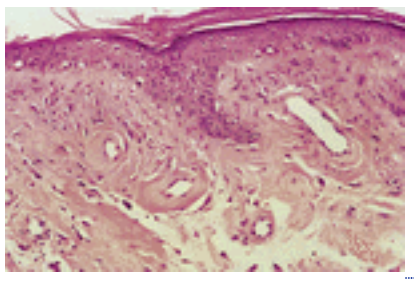

FIGURE 102-9 Solitary angiofibroma of the face. The upper dermis shows fibrosis and an increased number of stellate and dendritic cells. Telangiectatic vessels are also present, and so are melanophages in the superficial portion of the dermis.

Fibrofolliculoma (See also Chap. 85)

Fibrofolliculomas are 2 to 4 mm in diameter, dome-shaped, yellowish or skin-colored papules usually located on the head, neck, and upper trunk. Multiple lesions usually are inherited in an autosomal dominant pattern. The association with trichodiscomas and skin tags constitutes the Birt-Hogg-Dubé syndome. [65]

Sclerotic Fibroma (Circumscribed Storiform Collagenoma, Plywood Fibroma)

This uncommon benign neoplasm occurs as an isolated lesion in healthy individuals. [66] Multiple lesions are a cutaneous marker for the multiple hamartoma (Cowden's) syndrome (see Chap. 184). This autosomal dominant syndrome involves the *PTEN /MMAC1* gene (chromosome 10q) [67] and leads to multiple organ involvement, including trichilemmoma, oral papillomatosis, gastrointestinal polyps and carcinoma, thyroid goiter and carcinoma, fibrocystic disease/gynecomastia, leukemia, lymphoma, and Lhermitte-Duclos disease (dysplastic cerebellar gangliocytoma).

Histologically, sclerotic fibromas reveal dermal hypocellularity and stromal sclerosis with eosinophilic, hyalinized collagen bundles in a parallel or whorled (“plywood”) arrangement. Occasional patients express CD34, raising the possibility of misdiagnosis with hypocellular areas of dermatofibrosarcoma protuberans. There is a striking microscopic similarity between sclerotic fibroma and perineurinoma. The latter can express CD34, but in contrast to sclerotic fibroma, it also expresses epithelial membrane antigen (EMA).

Giant Cell Collagenoma

This rare, solitary, slowly growing, symmetric, well-circumscribed, dome-shaped nodule occurs on the trunk, upper extremities, and face of young and middle-aged individuals. Histologically, it has hyalinized collagen bundles in a whorled, storiform pattern that is indistinguishable from sclerotic fibroma; however, it also contains a population of plump, bizarre, multinucleated giant cells expressing vimentin. [68]

Pleomorphic Fibroma

This presents as a polypoid to dome-shaped dermal fibrous lesion on the torso, extremities, or face of adults. [69] Histologically, it is sparsely cellular but has striking nuclear atypia and rare mitotic figures. Immunohistochemical staining for vimentin and actin supports fibroblastic differentiation. The lesion is biologically benign, and the atypia may be a degenerative phenomenon akin to that seen in an “ancient” schwannoma. Lesions otherwise resembling sclerotic fibromas but with a similar high degree of atypia also have been described. [70] It has been proposed that there is a spectrum between sclerotic fibroma and pleomorphic fibroma based on the occurrence of cases showing transition between these poles. [71]

Desmoplastic Fibroblastoma (Collagenous Fibroma)

A painless, slowly growing mass, often of long duration, typically involves the arm, shoulder girdle, posterior neck, upper back, feet, ankles, leg, hand, abdominal wall, or hip in middle-aged men. [72] It is a relatively well-circumscribed lesion that predominantly involves subcutaneous tissue but may involve fascia or skeletal muscle. Microscopically, it is composed of bland, stellate or spindled myofibroblasts in a hypovascular fibrous or fibromyxoid stroma; mitotic figures are minimal. Simple conservative excision suffices.

Solitary Fibrous Tumor

This lesion most often involves the pleura but also may occur in the skin (among other organs). [73] It is a well-circumscribed, nonencapsulated tumor composed of uniform spindle cells expressing CD34. [74] Histologically, it exhibits alternating hypercellular and hypocellular areas, often with prominent hemangiopericytoma-like (stag-horn vessels) regions.

Dermatofibroma (Cutaneous Benign Fibrous Histiocytoma)

The concept of fibrohistiocytic lesions is attended by long-standing controversy. Originally, the notion was based on apparent features of both fibroblastic and histiocytic morphology of neoplastic cells when cultured in vitro. However, it is now recognized that the cytologic features of these differentiation pathways are not specific. Even the term *histiocyte* is controversial, and some authors [75] have proposed to rename those cells by more specific terms, e.g., interdigitating dendritic cells in lymph nodes or dermal dendrocytes (dendritic cells) in the skin. However, most authors still use the term *histiocyte,* putatively of monocyte-macrophage lineage, to describe cells with prominent evidence of phagocytosis. Such cells usually have abundant eosinophilic cytoplasm and vesicular, irregular nuclei. The specificity of histiocytic markers is also challenged. For example, the CD68 antigen seems to be present in lysosomes and therefore could be detected in any lesion formed by cells with significant numbers of lysosomes, including granular cell tumors, [76] neural neoplasms, [77] and even melanomas. [78] For all these reasons, the concept of fibrous histiocytoma has been criticized (and especially in regard to the malignant fibrous histiocytoma; see below). However, most clinicians are familiar with this term, and it is still used in the World Health Organization (WHO) classification of mesenchymal neoplasms. Accordingly, this terminology is retained here for convenience.

Some authors distinguish between a fibrous form (*dermatofibroma*) with spindled cells in a collagenous stroma and a *fibrous histiocytoma* form rich in histiocytes. However, many lesions show different areas with varying degrees of these two basic patterns, so they are best considered to represent poles of one entity that exhibits both myofibroblastic and histiocytic differentiation. [79]

Dermatofibroma is perhaps the most common mesenchymal growth of the skin. It has a predilection for the lower legs of women in their early twenties. The surface may be shiny or keratotic, and the color is usually brown, sometimes with a play of colors (Fig. 102-10). Characteristically, a dermatofibroma is firm and mobile and measures from 0.5 mm to 1 cm in diameter. Lateral compression produces a dimple-like depression in the overlying skin. Generalized lesions have been described, as have occasional unusual tumors confined to the palms and soles. Usually asymptomatic, they occasionally are pruritic and may ulcerate following trauma. Some tumors grow very rapidly, whereas others remain static for many years. Regression may leave hypopigmentation. Dermatofibromas arising on the face are uncommon but require special mention. They are more often of cellular type, extend into the subcutaneous fat or muscle, and frequently recur; therefore, a wider initial excision is recommended. [80]

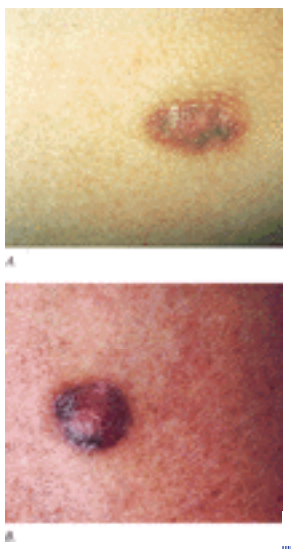

FIGURE 102-10 Dermatofibroma. *A.* This is a firm, flat nodule with a variegated yellowish to brown color. Lateral compression will produce a dimple-like depression in the center of the overlying skin. *B.* This dermatofibroma is also variegated in color, with a red center and a brownish to black periphery. In contrast to melanoma, it is hard and shows the dimple-like depression on lateral compression.

Trauma, such as insect bites, has been thought to induce some lesions. For this reason, some authors classify these as reactive/reparative lesions rather than as neoplasms. However, the recent demonstration of chromosome abnormalities in at least some cases of dermatofibroma supports a neoplastic nature. [81] Of note, the karyotypic changes identified are different from those in dermatofibrosarcoma. A viral etiology also has been considered.

Histologically, the epidermis is usually hyperplastic and hyperpigmented (“dirty fingernail” sign). There is sometimes a curious induction phenomenon, whereby the basilar epidermis proliferates to form basaloid aggregates. While these may simulate superficial basal cell carcinoma, they more often resemble an early stage in fetal development of a hair follicle and lack the myxoid stroma and retraction effect usually seen in basal cell carcinoma. Regardless, rarely basal cell carcinoma has been reported to arise in a dermatofibroma, but this diagnosis should be reserved for unequivocal cases showing deep nodular growth or necrosis. The dermis has haphazardly arranged fascicles of plump spindle cells that lack atypia in most cases. The edges of the lesion are poorly defined, with individual cells infiltrating between collagen bundles that are often thickened and hyalinized (“keloidal”). Mitotic figures may be present, but atypical forms are not a feature.

A cellular variant characterized by increased cellularity, storiform arrangement, larger size, and location in the deep dermis, often with extension into the superficial subcutaneous tissue, may be difficult to differentiate from dermatofibrosarcoma protuberans. In such circumstances, immunohistochemical expression of factor XIIIa rather than CD34 is often helpful. Because about 20 percent of cellular dermatofibromas recur after simple biopsy, a conservative complete excision may be indicated. There is a report of two cellular dermatofibromas that underwent metastasis to lymph nodes and lungs. [82] Notably, both original lesions were two cm in diameter, an unusually large size for dermatofibroma, and had recurred locally prior to metastasis.

Several other histologic variants exist, more than one of which may be present in a single lesion, so-called combined dermatofibroma. [83] A vascular variant, rich in endothelial-lined spaces and hemosiderin pigment, formerly was termed *sclerosing hemangioma.* The epithelioid histiocytoma [84] is characterized by large, angulated cells and presents clinically as a solitary raised vascular nodule resembling pyogenic granuloma. A granular cell variant of dermatofibroma is described. [85] Dermatofibroma with monster cells is an interesting lesion in which many of the cells have notable nuclear enlargement and prominent nucleoli. [86], [87] This morphologic change generally is considered a degenerative phenomenon of little clinical import.

There is a rare group of atypical fibrous histiocytomas [88] characterized by pleomorphic, plump, spindle, or polyhedral cells with large, hyperchromatic, irregular, or bizarre nuclei set in a background of classic features of fibrous histiocytoma, including a storiform pattern and keloidal collagen. Some lesions attained a diameter of more than 2 cm, invaded the superficial subcutis, or exhibited geographic necrosis. Atypical mitotic figures have been noted, as have local recurrence and distant metastases. Thus lesions with such atypical features must be excised completely and the patients followed up carefully.

A different lesion is the indeterminate histiocytic lesion of skin, [89] which has several features intermediate between dermatofibroma and dermatofibrosarcoma protuberans. These include overlying acanthosis and densely cellular fascicles with focal storiform areas. Prominent cytologic atypia has been observed. All lesions have keloidal dermal collagen, infiltrate the subcutis in a honeycomb pattern, and have low mitotic counts without atypical forms. All are diffusely immunoreactive for factor XIIIa as well as CD34. However, double immunolabeling shows no significant coexpression of these two antigens by individual cells. A single recurrence was documented. These indeterminate fibrohistiocytic lesions of skin suggest a possible spectrum between dermatofibroma and dermatofibrosarcoma protuberans. Their potential for local recurrence suggests that performing a complete conservative excision may be prudent.

Immunolabeling for factor XIIIa is usually positive in dermatofibroma [90] but not in dermatofibrosarcoma protuberans. [91] In addition, the more cellular forms of dermatofibroma tend to express alpha-smooth-muscle actin, whereas the lesions with more epithelioid cells and giant cells tend to express histiocytic markers. [92]

Dermatomyofibroma

This benign lesion [93] occurs typically on the shoulder area of young women, presenting as a firm, asymptomatic, intradermal 1- to 2-cm plaque. Histologically, it forms a well-circumscribed platelike lesion in the middermis that is arranged parallel to the epidermal surface and composed of elongated fascicles of spindle cells lacking atypia or mitotic figures. The neoplastic cells express vimentin and muscle-specific actin; initially, expression of alpha-smooth-muscle actin was reportedly negative, but in our experience, it is usually positive. By electron microscopy, the cells have typical features of myofibroblasts, including prominent rough endoplasmic reticulum, pinocytotic vesicles, and subplasmalemmal linear densities.

Superficial Acral Fibromyxoma

This recently described lesion [94] presents as a solitary dermal or subcutaneous mass of the toe, finger, or palm, and it often involves the nail region. Histologically, it is composed of spindled and stellate-shaped cells with random, loose storiform or fascicular growth patterns embedded in a myxoid/collagenous stroma. There is generally only slight nuclear atypia, and mitotic figures are infrequent. There is expression of CD34, epithelial membrane antigen, and CD99.

INTERMEDIATE-GRADE NEOPLASMS (OF LOW METASTATIC POTENTIAL)

Dermatofibrosarcoma Protuberans

Dermatofibrosarcoma protuberans (DFSP) is a locally aggressive dermal and subcutaneous mesenchymal neoplasm that typically occurs during the third and fourth decades of life on the trunk and proximal extremities of patients. It often grows to several centimeters in diameter and may form large tumors (Fig. 102-11). The clinical morphology is variable. The most common presentation is as an indurated plaque with firm, bosselated, flesh-colored to red-brown nodules (see Fig. 102-11). It also can present as a nonprotuberant, atrophic, violaceous lesion (Fig. 102-12) simulating sclerosing basal cell carcinoma, anetoderma, or scar. Large nodular tumors occur (Fig. 102-13). The epidermis is often atrophic and may ulcerate focally. Local recurrences even following wide excision are common; metastases are extremely rare, [95] being hematogenous in two-thirds of cases and nodal in one-third of cases.

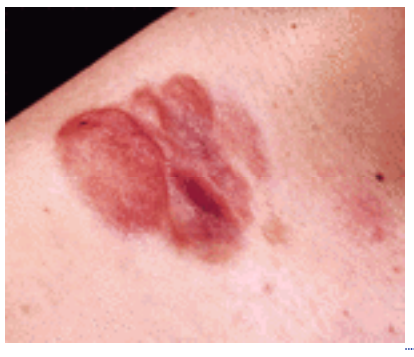

FIGURE 102-11 Dermatofibrosarcoma protuberans presenting as reddish brown confluent flat nodules.

FIGURE 102-12 Atrophic variant of dermatofibrosarcoma protuberans.

FIGURE 102-13 Large nodular dermatofibrosarcoma protuberans. This is a recurrence after the primary tumor had been excised.

DFSP is a poorly circumscribed dermal proliferation of monomorphous, slender or slightly plump spindle cells with little pleomorphism arranged in a storiform pattern (Fig. 102-14). The proliferation commonly infiltrates the subcutaneous fat, isolating adipocytes to form lucencies (“honeycomb” or “Swiss cheese” pattern). In contrast to dermatofibroma, the tumor is much more cellular and usually does not have mature collagen interspersed between fascicles of spindle cells.

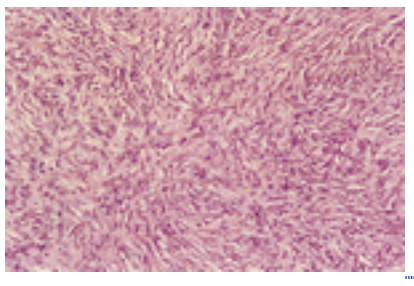

FIGURE 102-14 Dermatofibrosarcoma protuberans showing fibroblastic spindle cells that are arranged in interlacing fascicles. These intersect and bend at acute angles producing a starburst (storiform) pattern.

Variable histologic patterns described include myxoid, neuroid, fibrosarcomatous, myoid, [96] and granular cell types. The tumor may be relatively monomorphous or show combinations of various patterns within the original tumor or in the recurrences. As discussed below, some lesions show overlap between giant cell fibroblastoma and DFSP. [97] The fibrosarcomatous variant has basic features of DFSP but focal areas in which the cells exhibit a high grade of atypia and are arranged in long fascicles in a herringbone (fibrosarcoma-like) pattern. Several series indicate an increased biologic aggressiveness of this type compared with ordinary DFSP; thus in a series from Memorial Sloan Kettering Cancer Center, patients with the fibrosarcomatous variant versus classic DFSP had a 5-year recurrence-free survival rate of 81 and 28 percent, respectively. [98] On the other hand, in a series from the Cleveland Clinic, patients with sarcomas arising in DFSP did not have an increased risk of distant metastasis within a 5-year follow-up period, provided they were treated by wide local excision with negative margins. [99]

The histogenesis of DFSP is uncertain; fibrohistiocytic, purely fibroblastic, and neural-related differentiation have all been hypothesized. A very sensitive, although nonspecific, marker for DFSP is CD34. A distinctive cell population within normal nerves has been shown to express CD34, consistent with a neural-related histogenesis of DFSP. CD34 can help distinguish between DFSP and scar tissue in reexcision specimens because scars are CD34-negative. [79] However, myxoid or fibrosarcomatous areas may be negative [100]; therefore, a focally negative CD34 immunostain does not rule out DFSP. Another interesting marker is low-affinity nerve growth receptor (p75), reported to be positive in DFSP but negative in dermatofibroma. [101] This antigen is also consistently expressed in many neural neoplasms and in embryonal and alveolar rhabdomyosarcoma, synovial sarcoma, and spindle cell hemangioendothelioma, as well as in a variable number of cases of fibrosarcoma variants, solitary fibrous tumor, hemangiopericytoma, spindle cell lipoma, Ewing's sarcoma, mesenchymal chondrosarcoma, and malignant melanoma.

At the molecular level, DFSP exhibits the reciprocal translocation t(17;22)(q22;q13), producing a fusion of the collagen type I alpha 1 gene (I>COL1A1) and the platelet-derived growth factor B-chain gene (*PDGFB*). Current techniques permit sensitive and specific detection of these fusion transcripts in paraffin-embedded DFSP tumor specimens by reverse transcription polymerase chain reaction (PCR). [102] Both fibrosarcomatous transformation of DFSP and some cases of superficial fibrosarcoma have been shown to harbor these fusion transcripts, suggesting a close affinity between DFSP and fibrosarcoma. [103]

DFSP is a low-grade malignant tumor, often infiltrating diffusely through the dermis and into the subcutaneous fat but seldom metastasizing. Increased age, high mitotic index, and increased cellularity are predictors of poor clinical outcome. [98] About 30 to 50 percent of DFSPs recur locally after simple excision, so it is generally recommended that a wide excision with at least 2-cm free margins be performed (see Fig. 102-13). Pathologic examination of margins during surgery is helpful in delineating the extent of the tumor. Mohs surgery has shown good results in some practitioners' hands. [104] Adjuvant radiation therapy may help decrease the local recurrence rate. [105]

Giant Cell Fibroblastoma

This rare tumor, commonly considered a juvenile variant of DFSP, occurs occasionally in adults. [106] It usually presents as a dermal or subcutaneous mass on the back, inguinal, or thigh areas. Tumors with a DFSP component have been described, suggesting that giant cell fibroblastoma is a variant of DFSP. [107] Recurrences are common (50 percent); metastases have not been reported. Treatment is adequate surgical excision.

Spindle cells with moderate nuclear atypia are seen in a loose fibrous or mucinous stroma infiltrating the dermis and subcutis. Angiectoid spaces lined by multinucleated tumor giant cells are prominent in the deeper portions of the tumor. Immunohistochemically, the cells are positive for CD34 and occasionally alpha $_1$ antichymotrypsin and negative for factor VIII and S-100. Ultrastructural studies are compatible with fibrohistiocytic differentiation.

Atypical Fibroxanthoma (AFX)

This relatively common rapidly growing but low-grade neoplasm occurs mainly on sun-exposed skin (face, neck, and hands) of elderly individuals (Fig. 102-15). The anatomic distribution and the presence of cyclobutane pyrimidine dimers support a pathogenic role for ultraviolet radiation. [108] Some tumors occur 10 to 15 years after local ionizing irradiation. The lesion usually presents as a solitary nodule, often ulcerated, and usually less than 3 cm in diameter. Metastases are rare [109]; vascular invasion, necrosis, and deep subcutaneous invasion may be associated with greater metastatic potential. Recurrences are common, predominantly those involving the subcutaneous tissue. Mohs' micrographic surgery may lead to a better outcome than conventional wide local excision. [110] AFX is now considered a subtype of malignant fibrous histiocytoma (MFH) that, because of its small size and superficial location, behaves in a much less aggressive fashion. Additionally, it has been suggested that unlike deep MFH, AFX may lack some mutations in *ras* oncogenes, possibly also contributing to its more favorable biologic course. [111]

FIGURE 102-15 Atypical fibroxanthoma presenting as a flat, bosselated tumor on the forehead of an elderly woman. Note the yellowish to reddish color.

Specimens often are partially exophytic tumors with ulceration of the overlying epidermis. A Grenz zone may be present, but usually the tumor abuts onto the dermal-epidermal junction. However, evidence for true origin from the epidermis is lacking. A poorly circumscribed hypercellular tumor often extends deeply into the reticular dermis or subcutis. It consists of spindle cells in a collagenous or occasionally myxoid stroma admixed with multinucleated giant cells and epithelioid cells (Fig. 102-16). The neoplastic cells display pronounced atypia, with bizarre, large, round or ovoid hyperchromatic nuclei with numerous mitotic figures (some of them atypical); large, prominent eosinophilic nucleoli; and abundant, occasionally vacuolated cytoplasm. Some cells may contain fine droplets of lipid, demonstrable by oil red O stains on frozen tissue. The spindle cell subtype of AFX occurs in the same clinical setting as an ulcerated tumor and is characterized by a monomorphous proliferation of spindle cells with very little pleomorphism. Immunohistochemically, AFX has variable profiles, but cells usually express vimentin and histiocytic markers such as alpha $_1$-antitrypsin, alpha $_1$-antichymotrypsin, HAM-56 antigen, and CD68. A few express factor XIIIa. Recently, expression of CD99 has been proposed to be a relatively sensitive (73 percent of cases) and, in context, specific marker for these tumors. [112] Expression of S-100A6 also appears to be a sensitive marker for AFX. [113]

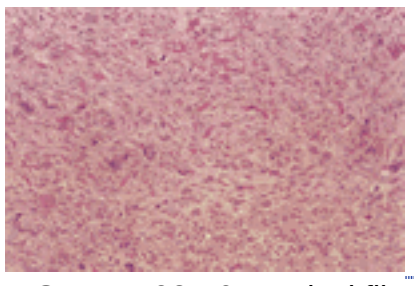

FIGURE 102-16 Atypical fibroxanthoma showing atypical plump spindle cells and multinucleated giant cells.

By electron microscopy, the tumor cells differentiate along histiocytic (multiple phagolysosomes), fibroblastic (abundant rough endoplasmic reticulum), or myofibroblastic (subplasmalemmal condensations of intermediate filaments, pinocytosis) lines. Tumor cells lack features of epithelial (desmosomes or tonofilaments) or melanocytic (melanosomes) differentiation.

The histologic differential diagnosis includes squamous cell carcinoma and malignant melanoma and some types of sarcoma. Some pathologists argue that all AFX cases are actually dedifferentiated (sarcomatoid) squamous cell carcinomas, but we prefer to designate as squamous cell carcinoma only those lesions having expression of epithelial markers such as cytokeratin, showing histologic evidence of keratinization, or arising in the setting of squamous cell carcinoma in situ. Most melanomas exhibit at least focal areas of melanoma in situ and express S-100 protein, gp100 (with HMB-45), and MART-1 (see Chap. 93). In AFX, in contrast, the neoplastic cells are S-100–negative, although scattered S-100–positive dendritic cells may infiltrate the tumor. Diagnosis of specific histogenic types of sarcoma requires immunohistochemical or ultrastructural evidence for a particular pathway of differentiation.

MALIGNANT NEOPLASMS

Malignant Fibrous Histiocytoma (MFH)

This tumor is presently considered to be the most common malignant soft tissue tumor, having replaced fibrosarcoma in that position some years ago. However, the future of this entity is in doubt. Some authorities deride the concept of MFH, considering it to be a diagnostic wastebasket. According to this view, MFH is merely a morphologic pattern rather than a defined pathologic entity. [114] Moreover, this school argues that, in most cases, careful immunohistochemical and ultrastructural examination permits probable or definite classification into defined histogenetic subtypes of sarcoma; the remaining minority might be better designated as pleomorphic sarcoma not otherwise classified rather than using an ambiguous and potentially misleading term such as MFH. It has been questioned whether an exhaustive attempt to subclassify pleomorphic sarcomas into defined histogenetic categories is clinically significant or worthwhile. However, MFH tumors reclassified as myogenic sarcoma had a worse prognosis and a shorter interval before metastasis compared with nonmyogenic tumors of the same stage. [115] Accordingly, there is much merit in the attacks on MFH as a term and

entity. However, most pathologists and clinicians are familiar with this term and use it to describe mesenchymal proliferations of markedly atypical cells that lack any more definitive differentiation. Accordingly, we shall continue to use this terminology, but without implying a defined fibrohistiocytic differentiation of such lesions.

MFH occurs mainly in the deep soft tissue (skeletal muscle) of the limbs or retroperitoneum, but virtually any anatomic site, including the heart, gall bladder, and other viscera, can be affected. It rarely occurs in children except for the dermal/subcutaneous angiomatoid variant. Recurrences occur in half of patients, and at least one-third of deep tumors metastasize within 2 years, primarily to lung, lymph nodes, liver, and bone. As with several other soft tissue tumors (leiomyosarcoma, liposarcoma), MFH originating in the dermis or subcutis (atypical fibroxanthoma) is associated with a better prognosis than when the deep soft tissue is involved.

The predominant pattern may be storiform, myxoid, giant cell, or inflammatory. Large size, histologic grade, and positive surgical margins are all significantly negative prognostic factors for survival. [115] The most common appearance is of spindle cells in a storiform pattern. The stroma may be finely fibrillary, myxoid, or densely collagenous. Bizarre epithelioid and giant cells may be present and may contain small amounts of lipid. Many mitotic figures, bizarre giant cells, and necrosis are common. Ultrastructurally, the neoplastic cells have features consistent with fibroblastic, myofibroblastic, and histiocytic differentiation. Immunohistochemistry using a broad antibody panel is required to rule out metastatic carcinoma, lymphoma, leiomyosarcoma, melanoma, and similar lesions.

Complete surgical resection at presentation offers the best chance for survival. Radiation therapy plays an important role in combination with surgery for better local control, particularly in high-grade lesions and in patients with positive surgical margins after wide complete gross excision. Adjuvant chemotherapy is investigational. [116]

Epithelioid Sarcoma

This aggressive sarcoma [117] occurs most often on the hands and fingers of young males (mean age 27 years). Proximally located tumors (e.g., groin, thigh, vulva, and axilla) have a much worse prognosis. [118] Because the classic location on distal extremities often discourages early deep biopsy, and because epithelioid sarcoma may closely mimic various nonneoplastic lesions histologically such as granuloma annulare, it often evades diagnosis at an early, localized stage. The etiology is obscure; possibly trauma plays some a role. Epithelioid sarcoma usually presents as a firm dermal or subcutaneous nodule, sometimes with ulceration or sinus formation (Fig. 102-17). Linear subcutaneous nodules due to progressive multifocal spread along tendons, nerves, and fascia may give a sporotrichoid appearance. The tumor has recurrence rates of 50 to 77 percent and nodal or hematogenous metastasis in 40 to 50 percent of patients. The lung and pleura are the most common sites of metastatic disease; local recurrence (size of 5 cm or larger) and regional metastasis events are predictive of worse distant-metastasis-free survival. [119]

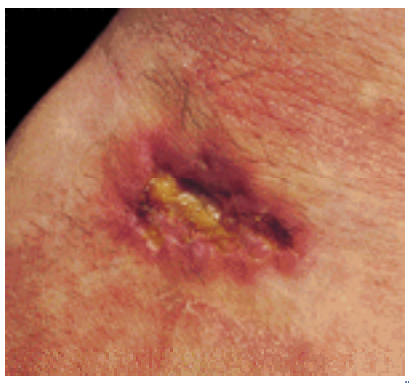

FIGURE 102-17 Epithelioid sarcoma typically occurring over the wrist. Note ulceration and granuloma-like border.

Radical excision traditionally has been the treatment of choice, but recurrences occur even with amputation. Recently, conservative (limb-sparing) surgery combined with pre- or postoperative radiation therapy has been tried, with results comparable with those reported with radical amputation. [120] Chemotherapeutic regimens have not been successful. Surgical excision of a solitary metastasis is occasionally helpful.

Most lesions occur in fascia, tendon, or subcutaneous septa; approximately 25 percent arise in the dermis. The tumor usually presents as a multinodular mass composed of epithelioid cells with abundant eosinophilic, often vacuolated, cytoplasm admixed with spindle cells in a collagenous and myxoid stroma. Characteristically, there is central necrosis with a surrounding palisade of tumor cells. A high mitotic rate, large areas of necrosis, vascular invasion, and size greater than 5 cm are associated with worse prognosis. Proximal tumors often have a rhabdoid appearance. [118] Other histologic variants include spindle cell (fibroma-like) [121] and angiomatoid types.

The cell of origin is uncertain. Tumor cells express vimentin and epithelial markers. In a large series, epithelial membrane antigen was present in 96 percent of patients, and muscle-specific actin and CD34 were noted in 41 and 52 percent of the patients, respectively. The angiomatoid, fibroma-like, and large cell–rhabdoid variants had immunohistochemical profiles similar to the classic cases. S-100 protein is usually absent. Ultrastructural findings suggest myofibroblastic differentiation, but others conclude that the tumor is composed of immature mesenchymal tissue.

The pathologic differential diagnosis includes necrobiosis lipoidica, granuloma annulare, rheumatoid nodule, and necrotizing infectious granuloma. In addition, other malignant neoplasms include epithelioid forms of angiosarcoma, malignant peripheral nerve sheath tumor (malignant schwannoma), malignant melanoma, synovial sarcoma, and fibrosarcoma. Deep biopsy, immunohistochemical workup, and review of all previous material may be necessary before

the correct diagnosis is reached.

REFERENCES

1. De Wever I et al: Cytogenetic, clinical, and morphologic correlations in 78 cases of fibromatosis: A report from the CHAMP study group. Chromosomes and morphology. *Mod Pathol* **13**:1080, 2000

2. Kurtycz DF et al: Diagnosis of fibromatosis colli by fine-needle aspiration. *Diagn Cytopathol* **23**:338, 2000

3. Fringes B et al: Identification of actin microfilaments in the intracytoplasmic inclusions present in recurring infantile digital fibromatosis (Reye tumor). *Pediatr Pathol* **6**:311, 1986

4. Fetsch JF, Miettinen M: Calcifying aponeurotic fibroma: A clinicopathologic study of 22 cases arising in uncommon sites. *Hum Pathol* **29**:1504, 1998

5. Hoffman CD et al: Aggressive infantile fibromatosis: Report of a case undergoing spontaneous regression. *J Oral Maxillofac Surg* **51**:1043, 1993

6. Guitart J et al: Solitary cutaneous myofibromas in adults: Report of six cases and discussion of differential diagnosis. *J Cutan Pathol* **23**:437, 1996

7. Landing BH, Nadorra R: Infantile systemic hyalinosis: Report of four cases of a disease, fatal in infancy, apparently different from juvenile systemic hyalinosis. *Pediatr Pathol* **6**:55, 1986

8. Classen DA, Hurst LN: Plantar fibromatosis and bilateral flexion contractures: A review of the literature. *Ann Plast Surg* **28**:475, 1992

9. de Palma L et al: Plantar fibromatosis: An immunohistochemical and ultrastructual study. *Foot Ankle Int* **20**: 253, 1999

10. Frey M: Risks and prevention of Dupuytren's contracture. *Lancet* **350**:1568, 1997

11. Ushijima M et al: Dupuytren-type fibromatoses: A clinicopathologic study of 62 cases. *Acta Pathol Jpn* **34**:991, 1984

12. Meister P et al: Palmar fibromatosis, “Dupuytren's contracture”: A comparison of light electron and immunofluorescence microscopic findings. *Pathol Res Pract* **164**:402, 1979

13. Berndt A et al: TGF beta and bFGF synthesis and localization in Dupuytren's disease (nodular palmar fibromatosis) relative to cellular activity, myofibroblast phenotype and oncofetal variants of fibronectin. *Histochem* **27**:1014, 1995

14. Margo G et al: Myofibroblasts of palmar fibromatosis coexpress transforming growth factor-alpha and epidermal growth factor receptor. *J Pathol* **181**:213, 1997

15. Dominguez-Malagon HR et al: Clinical and cellular effects of colchicine in fibromatosis. *Cancer* **69**:2478, 1992

16. Rombouts JJ et al: Prediction of recurrence in the treatment of Dupuytren's disease: Evaluation of a histologic classification. *J Hand Surg* **14A**:644, 1989

17. Coupland WW: Fibrosing conditions and propranolol. *Med J Aust* **2**:137, 1977

18. Williams G, Green NA: The non-surgical treatment of Peyronie's disease. *Br J Urol* **52**:392, 1980

19. Guberman D et al: Knuckle pads—a forgotten skin condition: Report of a case and review of the literature. *Cutis* **57**:241, 1996

20. Caroli A et al: Epidemiological and structural findings supporting the fibromatosis origin of dorsal knuckle pads. *J Hand Surg* **168**:258, 1991

21. Tompkins SD et al: Distal pachydermodactyly. *J Am Acad Dermatol* **38**:359, 1998

22. Bauer EA et al: Progressive nodular fibrosis of the skin: Altered procollagen and collagenase expression by cultured fibroblasts. *J Invest Dermatol* **87**:210, 1986

23. Ben-Izhak O et al: Fibromatosis (desmoid tumor) following radiation therapy for Hodgkin's disease. *Arch Pathol Lab Med* **118**:815, 1994

24. Lowy M et al: Desmoid tumor: Transformation into fibrosarcoma (author's translation). *Dermatologica* **163**:125,1981

25. Fletcher JA et al: Chromosome aberrations in desmoid tumors: Trisomy 8 may be a predictor of recurrence. *Cancer Genet Cytogenet* **79**:139, 1995

26. Wilcken N, Tattersall MH: Endocrine therapy for desmoid tumors. *Cancer* **68**:1384, 1991

27. Hamilton L et al: Chemotherapy for desmoid tumours in association with familial adenomatous polyposis: A report of three cases. *Can J Surg* **39**:247, 1996

28. Lee YS, Vijayasingam S: Mast cells and myofibroblasts in keloid: A light microscopic, immunohistochemical and ultrastructural study. *Ann Acad Med Singapore* **24**:902, 1995

29. Beer TW et al: Mast cells in pathological and surgical scars. *Br J Ophthalmol* **82**:691, 1998

30. Kischer CW: Contributions of electron microscopy to the study of the hypertrophic scar and related lesions. *Scanning Microsc* **7**:921, 1993

31. Castagnoli C et al: TNF production and hypertrophic scarring. *Cell Immunol* **147**:51, 1993

32. Kim A et al: Are keloids really “gli-loids”? High-level expression of *gli-1* oncogene in keloids. *J Am Acad Dermatol* **45**:707, 2001

33. Dalkowski A et al: Increased expression of tenascin C by keloids in vivo and in vitro. *Br J Dermatol* **141**:50, 1999

34. McCauley RL et al: Altered cytokine production in black patients with keloids. *J Clin Immunol* **12**:300, 1992

35. Younai S et al: Modulation of collagen synthesis by transforming growth factor-beta in keloid and hypertrophic scar fibroblasts. *Ann Plast Surg* **33**:148, 1994

36. Smith P et al: TGF-beta2 activates proliferative scar fibroblasts. *J Surg Res* **82**:319, 1999

37. Kikuchi K et al: Effects of various growth factors and histamine on cultured keloid fibroblasts. *Dermatology* **190**:4, 1995

38. Nowak KC et al: The effect of superpulsed carbon dioxide laser energy on keloid and normal dermal fibroblast secretion of growth factors: A serum-free study. *Plast Reconstr Surg* **105**:2039, 2000

39. Castagnoli C et al: Characterization of T-cell subsets infiltrating post-burn hypertrophic scar tissues. *Burns* **23**:565, 1997

40. Ladin DA et al: p53 and apoptosis alterations on keloids and keloid fibroblasts. *Wound Repair Regen* **6**:28, 1998

41. Kischer CW et al: Perivascular myofibroblasts and microvascular occlusion in hypertrophic scars and keloids. *Hum Pathol* **13**:819, 1982

42. Kauh YC et al: Major suppression of pro-alpha1(I) type I collagen gene expression in the dermis after keloid excision and immediate intrawound injection of triamcinolone acetonide. *J Am Acad Dermatol* **37**:586, 1997

43. Sallstrom KO et al: Treatment of keloids with surgical excision and postoperative x-ray radiation. *Scand J Plast Reconstr Surg Hand Surg* **23**:211, 1989

44. Sherman R, Rosenfeld H: Experience with the Nd:YAG laser in the treatment of keloid scars. *Ann Plast Surg* **21**:231, 1988

45. Daly TJ, Weston WL: Retinoid effects on fibroblast proliferation and collagen synthesis in vitro and on fibrotic disease in vivo. *J Am Acad Dermatol* **15**:900, 1986

46. Berman B, Duncan MR: Short-term keloid treatment in vivo with human interferon alpha-2b results in a selective and persistent normalization of keloidal fibroblast collagen, glycosaminoglycan, and collagenase production in vitro. *J Am Acad Dermatol* **21**:694, 1989

47. Wong TW et al: Intralesional interferon alpha-2b has no effect in the treatment of keloids. *Br J Dermatol* **130**:683, 1994

48. Conejo-Mir JS et al: Carbon dioxide laser ablation associated with interferon alpha-2b injections reduces the recurrence of keloids. *J Am Acad Dermatol* **39**:1039, 1998

49. Tilkorn H et al: The protruding scars: Keloids and hypertrophic diagnosis and treatment with silicon-gel sheeting. *Polim Med* **24**:31, 1994

50. Fulton JE Jr: Silicone gel sheeting for the prevention and management of evolving hypertrophic and keloid scars. *Dermatol Surg* **21**:947, 1995

51. Montgomery EA, Meis JM: Nodular fasciitis. Its morphologic spectrum and immunohistochemical profile. *Am J Surg Pathol* **15**:942, 1991

P>52. Kiryu H et al: Proliferative fasciitis. Report of a case with histopathologic and immunohistochemical studies. *Am J Dermatopathol* **19**:396, 1997

53. Naylor MF et al: Elastofibroma dorsi: Radiologic findings in 12 patients. *AJR* **167**:683, 1996

54. Fukuda Y et al: Histogenesis of unique elastinophilic fibers of elastofibroma: Ultrastructural and immunohistochemical studies. *Hum Pathol* **18**:424, 1987

55. Jordaan HF, Rossouw DJ: Digital papular calcific elastosis: A histopathological, histochemical and ultrastructural study of 20 patients. *J Cutan Pathol* **17**:358, 1990

56. Wegrowski Y et al: Alteration of matrix macromolecule synthesis by fibroblasts from a patient with pachydermoperiostosis. *J Invest Dermatol* **106**:70, 1996

57. Masse R et al: Costa's acrokerato-elastoidosis: Ultrastructural study (author's translation). *Ann Dermatol Venereol* **104**:441, 1977

58. Brodell RT, Pokorney DR: Fibroepithelial polyps and pathologic evaluation. *Arch Dermatol* **133**:915, 1997

59. Williams BT et al: Cutaneous pseudosarcomatous polyp: A histological and immunohistochemical study. *J Cutan Pathol* **23**:189, 1996.

60. Dickey GE, Sotelo-Avila C: Fibrous hamartoma of infancy: Current review. *Pediatr Dev Pathol* **2**:236, 1999

61. Groisman G, Lichtig C: Fibrous hamartoma of infancy: An immunohistochemical and ultrastructural study. *Hum Pathol* **22**:914, 1991

62. Schirren H et al: Papular elastorrhexis: A variant of dermatofibrosis lenticularis disseminata (Buschke-Ollendorff syndrome)? *Dermatology* **189**:368, 1994

63. Assmann A et al: Buschke-Ollendorff syndrome—differential diagnosis of disseminated connective tissue lesions. *Eur J Dermatol* **11**:576, 2001

64. DePadova-Elder S et al: Multiple connective tissue nevi. *Cutis* **42**:222, 1988

65. Lindor NM et al: Birt-Hogg-Dubé syndrome: An autosomal dominant disorder with predisposition to cancers of the kidney, fibrofolliculomas, and focal cutaneous mucinosis. *Int J Dermatol* **40**:653, 2001

66. Donati P et al: Sclerotic (hypocellular) fibromas of the skin. *Br J Dermatol* **124**:395, 1991

67. Steck PA et al: Identification of a candidate tumour suppressor gene, *MMAC1,* at chromosome 10q23.3 that is mutated in multiple advanced cancers. *Nature Genet* **15**:356, 1997

68. Brito H et al: Giant cell collagenoma: Case report and review of the literature. *J Cutan Pathol* **29**:48, 2002

69. Kamino H et al: Pleomorphic fibroma of the skin: A benign neoplasm with cytologic atypia. A clinicopathologic study of eight cases. *Am J*

Surg Pathol **13**:107, 1989

70. Garcia-Doval I et al: Pleomorphic fibroma of the skin, a form of sclerotic fibroma: An immunohistochemical study. *Clin Exp Dermatol* **23**:22, 1998

71. Chen TM et al: Pleomorphic sclerotic fibroma: A case report and literature review. *Am J Dermatopathol* **24**:54, 2002

72. Miettinen M, Fetsch JF: Collagenous fibroma (desmoplastic fibroblastoma): A clinicopathologic analysis of 63 cases of a distinctive soft tissue lesion with stellate-shaped fibroblasts. *Hum Pathol* **29**:676, 1998

73. Okamura JM et al: Solitary fibrous tumor of the skin. *Am J Dermatopathol* **19**:515, 1997

74. Westra WH et al: Solitary fibrous tumor: Consistent CD34 immunoreactivity and occurrence in the orbit. *Am J Surg Pathol* **18**:992, 1994

75. Headington JT: The histiocyte: In memoriam. *Arch Dermatol* **122**:532, 1986

76. Tsang WY, Chan JK: KP1 (CD68) staining of granular cell neoplasms: Is KP1 a marker for lysosomes rather than the histiocytic lineage? *Histopathology* **21**:84, 1992

77. Tos AP et al: KP1 (CD68) expression in benign neural tumours: Further evidence of its low specificity as histiocytic/myeloid marker. *Histopathology* **23**:185, 1993

78. Banerjee SS, Harris M: Morphological and immunophenotypic variations in malignant melanoma. *Histopathology* **36**:387, 2000

79. Prieto VG et al: CD34 immunoreactivity distinguishes between scar tissue and residual tumor in re-excisional specimens of dermatofibrosarcoma protuberans. *J Cutan Pathol* **21**:324, 1994

80. Mentzel T et al: Benign fibrous histiocytoma (dermatofibroma) of the face: Clinicopathologic and immunohistochemical study of 34 cases associated with an aggressive clinical course. *Am J Dermatopathol* **23**:419, 2001

81. Vanni R et al: Cytogenetic evidence of clonality in cutaneous benign fibrous histiocytomas: A report of the CHAMP study group. *Histopathology* **37**:212, 2000

82. Colome-Grimmer MI, Evans HL: Metastasizing cellular dermatofibroma. Report of two cases. *Am J Surg Pathol* **20**:1361, 1996

83. Zelger BG et al: Combined dermatofibroma: Co-existence of two or more variant patterns in a single lesion. *Histopathology* **36**:529, 2000

84. Jones EW et al: Epithelioid cell histiocytoma: A new entity. *Br J Dermatol* **120**:185, 1989

85. Soyer HP et al: Granular cell dermatofibroma. *Am J Dermatopathol* **19**:168, 1997

86. Rudolph P et al: Differential expression of CD34 and Ki-M1p in pleomorphic fibroma and dermatofibroma with monster cells. *Am J Dermatopathol* **21**:414, 1999

87. Goodman WT et al: Giant dermatofibroma with monster cells. *Am J Dermatopathol* **24**:36, 2002

88. Kaddu S et al: Atypical fibrous histiocytoma of the skin: Clinicopathologic analysis of 59 cases with evidence of infrequent metastasis. *Am J Surg Pathol* **26**:35, 2002

89. Horenstein MG et al: Indeterminate fibrohistiocytic lesions of the skin: Is there a spectrum between dermatofibroma and dermatofibrosarcoma protuberans? *Am J Surg Pathol* **24**:996, 2000

90. Cerio R et al: Identification of factor XIIIa in cutaneous tissue. *Histopathology* **13**:362, 1988

91. Kutzner H: Expression of the human progenitor cell antigen CD34 (HPCA-1) distinguishes dermatofibrosarcoma protuberans from fibrous histiocytoma in formalin-fixed, paraffin-embedded tissue. *J Am Acad Dermatol* **28**:613, 1993

92. Prieto VG et al: Immunohistochemistry of dermatofibromas and benign fibrous histiocytomas. *J Cutan Pathol* **22**:336, 1995

93. Kamino H et al: Dermatomyofibroma: A benign cutaneous, plaque-like proliferation of fibroblasts and myofibroblasts in young adults. *J Cutan Pathol* **19**:85, 1992

94. Fetsch JF et al: Superficial acral fibromyxoma: A clinicopathologic and immunohistochemical analysis of 37 cases of a distinctive soft tissue tumor with a predilection for the fingers and toes. *Hum Pathol* **32**:704, 2001

95. Lal P et al: Dermatofibrosarcoma protuberans metastasizing to lymph nodes: A case report and review of literature. *J Surg Oncol* **72**:178, 1999

96. Calonje E, Fletcher CD: Myoid differentiation in dermatofibrosarcoma protuberans and its fibrosarcomatous variant: Clinicopathologic analysis of 5 cases. *J Cutan Pathol* **23**:30, 1996

97. Sigel JE et al: A morphologic study of dermatofibrosarcoma protuberans: Expansion of a histologic profile. *J Cutan Pathol* **27**:159, 2000

98. Bowne WB et al: Dermatofibrosarcoma protuberans: A clinicopathologic analysis of patients treated and followed at a single institution. *Cancer* **88**:2711, 2000

99. Goldblum JR et al: Sarcomas arising in dermatofibrosarcoma protuberans: A reappraisal of biologic behavior in eighteen cases treated by wide local excision with extended clinical follow up. *Am J Surg Pathol* **24**:1125, 2000

100. Orlandi A et al: Myxoid dermatofibrosarcoma protuberans: Morphological, ultrastructural and immunohistochemical features. *J Cutan Pathol* **25**:386, 1998

101. Fanburg-Smith JC, Miettinen M: Low-affinity nerve growth factor receptor (p75) in dermatofibrosarcoma protuberans and other nonneural tumors: A study of 1150 tumors and fetal and adult normal tissues. *Hum Pathol* **32**:976, 2001

102. Wang J et al: Detection of *COL1A1-PDGFB* fusion transcripts in dermatofibrosarcoma protuberans by reverse transcription-polymerase chain reaction using archival formalin-fixed, paraffin-embedded tissues. *Diagn Mol Pathol* **8**:113, 1999

103. Wang J et al: *COL1A1-PDGFB* fusion transcripts in fibrosarcomatous areas of six dermatofibrosarcomas protuberans. *J Mol Diagn* **2**:47, 2000

104. Huether MJ et al: Mohs' micrographic surgery for the treatment of spindle cell tumors of the skin. *J Am Acad Dermatol* **44**:656, 2001

105. Sun LM et al: Dermatofibrosarcoma protuberans: Treatment results of 35 cases. *Radiother Oncol* **57**:175, 2000

106. Shmookler BM et al: Giant cell fibroblastoma: A juvenile form of dermatofibrosarcoma protuberans. *Cancer* **64**:2154, 1989

107. Galinier P et al: Giant-cell fibroblastoma and dermatofibrosarcoma protuberans: The same tumoral spectrum? Report of two cases of association in children. *Eur J Pediatr Surg* **10**:390, 2000

108. Sakamoto A et al: Immunoexpression of ultraviolet photoproducts and *p*53mutation analysis in atypical fibroxanthoma and superficial malignant fibrous histiocytoma. *Mod Pathol* **14**:581, 2001

109. Sankar NM et al: Metastasis from atypical fibroxanthoma of skin. *Med J Aust* **168**:418, 1998

110. Davis JL et al: A comparison of Mohs' micrographic surgery and wide excision for the treatment of atypical fibroxanthoma. *Dermatol Surg* **23**:105, 1997

111. Sakamoto A et al: *H*-, *K*-, and *N-ras* gene mutation in atypical fibroxanthoma and malignant fibrous histiocytoma. *Hum Pathol* **32**:1225, 2001

112. Monteagudo C et al: CD99 immunoreactivity in atypical fibroxanthoma: A common feature of diagnostic value. *Am J Clin Pathol* **117**:126, 2002

113. Fullen DR et al: S100A6 expression in fibrohistiocytic lesions. *J Cutan Pathol* **28**:229, 2001

114. Hollowood K, Fletcher CD: Malignant fibrous histiocytoma: Morphologic pattern or pathologic entity? *Semin Diagn Pathol* **12**:210, 1995

115. Fletcher CD et al: Clinicopathologic reevaluation of 100 malignant fibrous histiocytomas: Prognostic relevance of subclassification. *J Clin Oncol* **19**:3045, 2001

116. Belal A et al: Malignant fibrous histiocytoma: A retrospective study of 109 cases. *Am J Clin Oncol* **25**:16, 2002

117. Chase DR, Enzinger FM: Epithelioid sarcoma: Diagnosis, prognostic indicators, and treatment. *Am J Surg Pathol* **9**:241, 1985

118. Hasegawa T et al: Proximal-type epithelioid sarcoma: A clinicopathologic study of 20 cases. *Mod Pathol* **14**:655, 2001

119. Spillane AJ et al: Epithelioid sarcoma: The clinicopathological complexities of this rare soft tissue sarcoma. *Ann Surg Oncol* **7**:218, 2001

120. Callister MD et al: Epithelioid sarcoma: Results of conservative surgery and radiotherapy. *Int J Radiat Oncol Biol Phys* **51**:384, 2001

121. Tan SH, Ong BH: Spindle cell variant of epithelioid sarcoma: An easily misdiagnosed tumor. *Australas J Dermatol* **42**:139, 2001

T>

Chapter 103

Suzanne Grevelink John Mulliken

Vascular Anomalies and Tumors of Skin and Subcutaneous Tissues

A BIOLOGIC CLASSIFICATION
TRANSLATION OF TERMINOLOGY
TUMORS
Hemangioma of Infancy
Other Vascular Tumors of Infancy
VASCULAR MALFORMATIONS
Cutis Marmorata
Fading Macular Stain
Capillary Malformation
Phakomatosis Pigmentovascularis
Telangiectases
Cutis Marmorata Telangiectasia Congenita (CMTC)
Lymphatic Malformation
Capillary-Lymphatic Malformation (CLM)
Venous Malformation
Blue Rubber Bleb Nevus Syndrome
Glomuvenous Malformations (GVMs)
Arteriovenous Malformation and Fistula
Combined Malformations
Genetics of Vascular Malformations

REFERENCES

Proper diagnosis of vascular anomalies has been hampered by contradictory and confusing descriptive nomenclature. The old terminology derives from the appearance of the anomaly and/or the concept of maternal impressions, as expressed in such terms as *strawberry hemangioma, cherry angioma, port-wine stain,* and *Salmon patch*. The first histopathologic classification by Virchow categorized vascular anomalies into three main types: *angioma simplex, angioma cavernosum,* and *angioma racemosum*. Variations on this confusing terminology persist in modern textbooks and are still used. Thus the generic term *hemangioma* is applied to lesions that predictably grow and involute and also to acquired vascular lesions in adults that do not regress and often progress. The nineteenth-century descriptive term *port-wine stain* applies to a permanent vascular abnormality that unfortunately is often called *capillary hemangioma*. Virchow's term, *cavernous hemangioma,* has been used mistakenly to describe deep cutaneous vascular anomalies and vascular anomalies of bone, muscle, and viscera that never regress. These categorizations of cutaneous anomalies based on descriptive terms or histopathologic terms, without clinical correlations, are confusing and lead to incorrect diagnosis and therapy and misdirected research efforts. [1]

A BIOLOGIC CLASSIFICATION

In 1982, Mulliken and Glowacki proposed a classification system for vascular birthmarks that correlated natural history and physical examination with cellular features. [2] This schema divided vascular lesions of infancy and childhood into two major types: *hemangiomas,* which exhibit endothelial hyperplasia *malformations,* which have normal endothelial turnover (Table 103-1). The terminological key is the Greek suffix *oma* that originally meant “swelling or tumor.” Today, this suffix should be appended to terms describing lesions that grow by cellular proliferation, such as the common hemangioma. Most hemangiomas of infancy are not present at birth but appear postnatally. They grow rapidly during the first year (*proliferating phase*), undergo slow, spontaneous regression during childhood (*involuting phase*), and remain stable thereafter (*involuted phase*). Histologically, the proliferating phase is characterized by increased mitotic activity, whereas the involuting phase is characterized by apoptosis, gradual fibrosis, and variable fatty infiltration.

	Tumors	Malformations
Present at birth	Usually postnatal, 30 percent nascent, rarely fully grown	100 percent (presumably), not always obvious
Male/female ratio	1.3:1-1.5	1:1
Incidence	1-2.6 percent at birth; 10-12 percent at 1 year	0.3-0.5 percent "port-wine" stain
Natural history	Phases: Proliferating, involuting, and involuted	Proportionate growth, can expand
Cellular	Endothelial hyperplasia	Normal endothelial turnover
Skeletal changes	Occasional mass effect on adjacent bone; rare hypertrophy	Slow flow: distortion, hypertrophy, or hypoplasia Fast flow: destruction, distortion, or hypertrophy

SOURCE: Modified from Mulliken and Young.[7]

TABLE 103-1 **Distinguishing Features of Vascular Tumors (Hemangiomas) and Vascular Malformations**

Vascular malformations are errors of morphogenesis that are presumed to occur between the fourth and tenth weeks of intrauterine life. Most vascular malformations are present at birth, although they may not be apparent; others do not appear until years later. Once manifest, they grow proportionately with the patient; however, rapid enlargement can occur

as a result of trauma, hormonal changes (puberty, pregnancy, oral contraceptive), thrombosis, infection, or surgical intervention. Histologically, vascular malformations are characterized by dilated channels with abnormal walls lined by normal, quiescent endothelium.

This binary biologic classification has gained wide acceptance and has required only minor modifications to incorporate new information. Rather than specify all vascular birthmarks as either *hemangioma malformation,* it is more appropriate to use the categorical terms *vascular tumors* and *vascular malformations* (Table 103-2). Vascular malformations are subclassified according to the basic structural components into capillary, venous, lymphatic, arterial, and combined forms. In addition, it is clinically useful to separate rheologically vascular anomalies into *slow-flow* (capillary, lymphatic, venous, combined) and *fast-flow* (arterial, combined) types. Abbreviated designations are formed by the first letter of the major anomalous channel(s).

Congenital*
Hemangioma
Kaposiform hemangioendothelioma
Tufted angioma
Hemangiopericytoma
Acquired*
Pyogenic granuloma
Acquired tufted angioma
Targetoid hemosiderotic hemangioma
Unilateral nevoid telangiectasia
Angiolymphoid hyperplasia with eosinophilia
Intravascular papillary endothelial hyperplasia
Spindle-cell hemangioendothelioma
Kaposi's sarcoma
Endovascular papillary angioendothelioma
Epithelioid hemangioendothelioma
Retiform hemangioendothelioma
Angiosarcoma
Macular stain†
Cutis marmorata†
Capillary malformation (CM)
Port-wine stain
Phakomatosis pigmentovascularis
Telangiectasia
Spider angioma
Cutis marmorata telangiectatica congenita
Lymphatic malformation (LM)
Localized, diffuse, macro- or microcystic
Venous malformation (VM)
Venous lake
Blue rubber bleb nevus
Glomangioma
Arterial
Arterial malformation (AM)
Arteriovenous fistula (AVF)
Arteriovenous malformation (AVM)
Combined
Slow-flow: capillary-lymphaticovenous malformation (CLVM)
Fast-flow: capillary-arteriovenous malformation (CAVM)

*"Congenital" by definition means present at birth. "Acquired" is used variably, often to describe lesions that manifest after 1 year of age. However, the index of any vascular birthmark may be present at birth but not clinically evident.
†These common lesions tend to fade completely over time. There is little evidence they are dermatopathologic lesions.

TABLE 103-2 **Classification of Vascular Anomalies**

TRANSLATION OF TERMINOLOGY

The old descriptive nomenclature can be translated into the current biologic classification. For example, *strawberry, cherry, and capillary* hemangiomas are all forms of superficial hemangioma of infancy. The term *cavernous hemangioma* should be abandoned; it has been used to refer both to a deep hemangioma and to a venous malformation. *Nevus flammeus,* stork bite, and salmon patch should not be used interchangeably for a capillary malformation because they are minor dermal capillary ectasias that usually fade. In contrast, capillary malformation (port-wine stain) is a permanent vascular anomaly. All of the rare vascular anomalies, such as unilateral nevoid telangiectasia and "acquired" lymphangioma circumscriptum, fit comfortably into this biologic schema. This classification also accommodates various eponymous malformation syndromes, such as Sturge-Weber and Klippel-Trenaunay, Parkes Weber, and Maffucci syndromes by delineation of the various slow-flow or fast-flow channel types.

TUMORS

Hemangioma of Infancy

EPIDEMIOLOGY Hemangioma is the most common tumor of infancy. The incidence in the newborn nursery is between 1.0 and 2.6 percent [3], [4] in white, black [3] and Japanese infants. [5] An incidence of 10 to 12 percent has been reported in white children by 1 year of age. [6] Hemangiomas develop in premature infants weighing between 1500 and 2500g at a frequency equal to that in full-term babies, whereas 23 percent of premature infants weighing less than 1000 g manifest a hemangioma. [7] Females are affected more commonly than males in a 3:1 ratio. [8] Approximately 30 percent of hemangiomas are nascent at birth; two-thirds become apparent during the first to fourth weeks of life. A family history of hemangioma can be elicited in 10 percent of children, but this may be more related to the frequency in whites rather than to an inheritable predisposition. [9] The hemangioma's initial proliferative phase of rapid postnatal growth lasts for 3 to 9 months; rarely beyond 18 months (Fig. 103-1 and Fig. 103-2). Proliferative-phase hemangiomas express high levels of angiogenic molecules, specifically basic fibroblast growth factor (bFGF) and vascular endothelial growth factor/vascular permeability factor (VEGF/VPF). Enzymes involved in remodeling of extracellular matrix, e.g., type IV collagenase, urokinase, proteases, and metalloproteinases, are also present in the proliferative phase. There is also evidence for diminished levels of an endogenous inhibitor of angiogenesis, interferon-ß (IFN-ß). [10] Hemangiomas represent clonal expansions of endothelial cells that may result from somatic mutations in one or more genes regulating endothelial cell proliferation. [11]

FIGURE 103-1 Natural history of hemangioma. *A*. Age 11 months, at peak of proliferating phase. *B*. Age 2 years, involuting phase, apoptosis is maximal. *C*. Age 4 years, some further involution expected.

FIGURE 103-2 Congenital hemangioma. *A*. Fetal ultrasonography reveals tumor on right parietal scalp with fast-flow vessels and cranial deformation. *B*. Fully grown tumor as seen at birth. *C*. Rapid involution at age 1 month; color faded before 1 year.

The phase of involution occurs gradually over 2 to 6 years and is complete by the age of 7 to 10 years [1], [12] (Fig. 103-2 and Fig. 103-3). The rate of involution varies greatly between children and does not correlate with the size, location, or appearance of the lesion. An increase in cellular apoptosis during the second year of life is associated with the initiation of the involuting phase. [13] During regression, levels of IFN-ß return to normal. Mast cells are prominent in the involuting phase, along with upregulation of tissue inhibitor of metalloproteinase (TIMP), clusterin, and mitochondrial cytochrome. [14] About 50 percent of children have normal skin after involution, whereas the remainder have variable telangiectasias, atrophy, fibrofatty residuum, or scarring (particularly if there was ulceration during infancy).

FIGURE 103-3 Congenital hemangioma on left thigh. *A*. Note central ulceration, violaceous color, and pale periphery. Fast-flow vessels detected on Doppler examination. *B*. Rapid regression at age 2 months.

DESCRIPTION The initial signs of a nascent hemangioma can be a hypopigmented blanched macule with or without telangiectasia (similar in appearance to a *nevus anemicus*) or an erythematous to ecchymotic patch that is superficial, [5] often with an irregular surface and borders. Several large draining veins typically radiate from the tumor. Most hemangiomas grow to between 0.5 and 5.0 cm in diameter, whereas some involve large areas of the face, trunk, or extremities (see Fig. 103-1 and Fig. 103-3). Eighty percent of affected infants have a single lesion, most commonly located on the head and neck (60 percent), followed by the trunk (25 percent), and the extremities (15 percent). [8] Multiple hemangiomas occur in 20 percent of affected infants. Often these cutaneous tumors are tiny, dome-shaped lesions associated with hemangiomas in visceral organs such as the liver.

ATYPICAL PRESENTATIONS There are several unusual presentations, including deep (subcutaneous) hemangioma, telangiectatic hemangioma, arteriovenous malformation (AVM)–like hemangioma, multiple cutaneous hemangiomas, and congenital hemangioma.

Deep hemangioma Deep hemangiomas (old term, *cavernous hemangioma*) proliferate in the lower dermis and subcutaneous tissue without penetration of the papillary dermis. They present as a localized, firm, rubbery subcutaneous mass that can be slightly raised with a bluish color or with telangiectasias involving the overlying skin, or they may be deep enough that the overlying skin is completely flat and of normal hue (Fig. 103-4). Hemangiomas that involve the papillary dermis, and deeper tissues have the typical bright-red surface as well as a subcutaneous component and can be called *superficial* and *deep hemangiomas*.

FIGURE 103-4 Natural history of a deep hemangioma, right cheek/parotid. *A*. Age 1 year, peak of proliferation. *B*. Age 3 years, involuting phase.

Telangiectatic hemangioma Telangiectatic hemangiomas are flat or slightly elevated and deep red with an array of superficial dilated capillaries radiating over the surface (Fig. 103-5). This tumor resembles a port-wine stain but involutes spontaneously with the usual time course of all postnatal hemangiomas, leaving telangiectasias and occasionally a minor fibrofatty residuum. Extensive telangiectatic hemangiomas can be associated with fast flow, congestive heart failure, and ulcerations.

FIGURE 103-5 Telangiectatic hemangioma, left foot. This lesion could be confused with a port-wine stain. *A*. Reticulated stain and minor soft-tissue hypertrophy. *B*. Only fine telangiectasias remain at age 11 years (involuted phase).

AVM-like hemangioma There can be a localized hemangioma with shunting, sometimes referred to as *AVM-like hemangioma*. Reported complications include episodic bleeding, venous thrombosis, and increased cardiac output and failure. [15] Involution is slow, often these tumors can be resected. Histologic examination reveals endothelial proliferation within arteries and venous walls indicative of persistent fast flow.
Multiple infantile hemangiomas Hemangiomas also can present as multiple small (1 to 20 mm) lesions involving the skin alone (called *benign cutaneous hemangiomatosis*) or involving both the skin and viscera (called *diffuse neonatal hemangiomatosis*) (Fig. 103-6). It is unknown whether *hemangiomatosis* represents multifocal involvement or metastatic spread. Visceral hemangiomas have been reported in the lymph nodes, liver, spleen, brain and meninges, iris, retina, salivary glands, heart, thymus, gastrointestinal tract, lung, urinary bladder, kidney, gallbladder, pancreas, and adrenal gland. [16] Hepatic hemangiomas can be solitary or multiple and can be associated with a mortality as high as 30 to 40 percent because of high-output cardiac failure. Involution of multiple cutaneous hemangiomas often begins after just 3 to 6 months and is complete within 1 to 2 years—much sooner than with the more common solitary lesions. [16]

FIGURE 103-6 Infant with multiple dome-shaped cutaneous hemangiomas, hepatic hemangiomas, and high-output congestive heart failure. Tumors and cardiac failure responded to systemic glucocorticoid therapy.

Congenital hemangioma Hemangiomas can develop in fetal life, proliferate in utero and present as fully formed tumors at birth. This is the definition of a congenital hemangioma. Congenital hemangiomas can be subdivided according to natural history into rapidly involuting congenital hemangiomas (RICH) and noninvoluting congenital hemangiomas (NICH). It is not clear whether or not these two subtypes are really the same vascular tumor that behaves differently because of prenatal and postnatal influences. The important observation is that there is no rapid proliferation in the neonate. Curiously, neither RICH nor NICH have the marked female preponderance of common infantile hemangiomas.
RAPIDLY INVOLUTING CONGENITAL HEMANGIOMAS RICH present as violaceous hemispheric nodules with overlying telangiectasia, pale dusky borders, and large veins at the periphery (see Fig. 103-2). Alternatively, they may appear as firm, erythematous to violaceous plaques infiltrating the dermis or subcutaneous tissue. Regression becomes obvious in early infancy, resulting in disappearance of these lesions more rapidly than common hemangiomas that regress postnatally (by 14 months versus 5 to 9 years). Approximately 50 percent of RICHs involute prior to 7 months of age. [12]
NONINVOLUTING CONGENITAL HEMANGIOMAS NICH are uncommon vascular lesions that grow proportionately with the child and do not regress. NICH have many similar features to RICH in appearance, size, and location. Characteristic features of NICH include coarse overlying telangiectasia, pale halos at the rims, and intermingled areas of pallor (Fig. 103-7). Lesions have an average diameter of 5 cm and are located (in order of frequency) on the head/neck, extremities, and trunk. Radiologic studies, specifically Doppler and arteriography, demonstrate fast flow. Histologically, NICH differ from common involuting hemangiomas in several ways, including larger and more irregular intralobular vessels, higher cellularity, and multiple microscopic arteriovenous fistulas. Excision is generally the treatment of choice. [17]

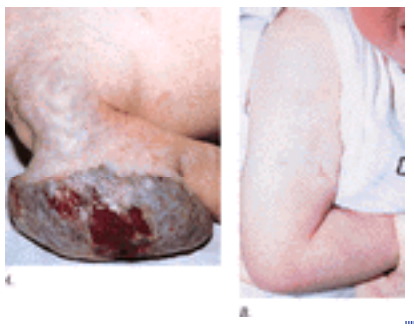

FIGURE 103-7 Noninvoluting congenital hemangioma (NICH). Hemangioma with persistent fast flow. *A*. Girl at 1 year of age with pedunculated tumor right upper limb with rapid flow, ulceration, and bleeding. *B*. Two years after resection, large draining veins have regressed.

ASSOCIATED STRUCTURAL ANOMALIES Hemangiomas are rarely associated with underlying anomalies, and in these unusual cases, a marked female preponderance has been documented. Large cervicofacial hemangiomas may present with (1) ocular abnormalities such as microphthalmia, congenital cataract, and optic nerve hypoplasia, (2) sternal nonunion and supraumbilical raphe, (3) arterial abnormalities such as persistent embryonic intra- and extracranial embryonic arteries, absence of ipsilateral carotid/vertebral vessels, and coarctation of a right-sided aortic arch, and (4) posterior fossa malformations, including the Dandy-Walker malformation. The acronym *PHACE* has been proposed as an mnemonic for these associations: posterior fossa malformations, hemangioma (especially a segmental lesion), arterial abnormalities, coarctation of the aorta, and eye abnormalities. [18] However, this term does not include other structural anomalies that can be associated with hemangiomas. For example, lumbosacral hemangiomas may signal the presence of spinal dysraphism and should be evaluated by magnetic resonance imaging (MRI). These hemangiomas are often

clinically distinctive, being telangiectatic, macular, or diffuse, sometimes with an acrochordon. Pelvic and perineal hemangiomas may be associated with urogenital and anorectal anomalies (e.g., anterior or vestibular anus, hemiclitoris, atrophy or absence of the labia minora, and hypospadias).

DIAGNOSIS Hemangiomas almost always can be diagnosed accurately by clinical presentation and history alone. The hemangioma is nonblanching and is firm to rubbery on palpation. In some infants with ambiguous, atypical, or deep lesions, observation of change over time or radiologic investigation is necessary to confirm the diagnosis. Biopsy of any vascular lesion is indicated whenever there is the slightest suspicion of malignancy. Ultrasonography with color flow imaging is, in experienced hands, a useful and cost-effective method, [19] but it does not portray the extent of the lesion or its relation to adjacent structures. MRI provides the most useful information, including exact localization, extent of involvement, and with midline lesions the presence of associated cranial or spinal dysraphism. MRI is also useful for differential diagnosis of an atypical lesion, since hemangiomas have an appearance on MRI distinct from vascular malformations, dermoid cysts, meningoceles, and other benign and malignant infantile tumors. Computed tomography (CT) is less informative than MRI because it cannot distinguish between fast-flow and slow-flow lesions, although it does display skeletal abnormalities. These noninvasive imaging techniques have essentially replaced arteriography. High endothelial immunoreactivity for the erythrocyte-type glucose transporter protein GLUT1 is observed in hemangiomas of infancy in all phases as well as in other microvessels of blood-tissue barrier function, including brain and placenta. Vascular malformations do not exhibit any GLUT1 immunoreactivity. [20] GLUT1 may provide a diagnostic tool to differentiate hemangioma from vascular malformation. RICH and NICH do not stain with antibodies to GLUT1, however.

COMPLICATIONS Potential problems in the proliferative phase include ulceration; bleeding; infection; distortion of the cornea; obstruction of the visual axis, nasal passages, larynx, or auditory canals; congestive heart failure; skeletal distortion; and rarely, skeletal overgrowth. Spontaneous ulceration, bleeding, and secondary infection occur in approximately 5 percent of superficial lesions and are seen most often in hemangiomas involving the lips and genital areas, where abrasion is common. Rarely, ulceration and subsequent infection can result in extensive necrosis and destruction of facial soft tissues and the cartilaginous framework of the nose or ear. Hemangiomas in the upper eyelid can obstruct the visual axis, resulting in deprivation amblyopia and failure to develop binocular vision (Fig. 103-8). Obstruction need be present for only 1 to 2 weeks to cause blindness. More important, even a small hemangioma in the upper eyelid or supraorbital region can distort the cornea, leading to refractive errors, both astigmatic and myopic. Periorbital hemangiomas require prompt consultation with a pediatric ophthalmologist. Another ocular complication is strabismus, an abnormal alignment of the eyes due to amblyopia or to infiltration of the extraocular muscles by the hemangioma.

FIGURE 103-8 Vision-endangering hemangioma treated with systemic glucocorticoids. *A*. No premonitory signs of tumor seen on infant's photograph. *B*. By age 3 months, extensive hemangioma has infiltrated upper lid and surrounding tissue, causing blocked vision. *C*. Eyelid opened within 2 weeks of glucocorticoid therapy. *D*. Involuted tumor, age 6 years.

Blockage of the nasal passages typically develops so gradually that the infant adapts by breathing through the mouth. However, subglottic obstruction can be life-threatening. It develops insidiously, manifesting as biphasic stridor with or without respiratory distress. A child with a subglottic hemangioma often presents with a mistaken diagnosis of laryngotracheitis or multiple episodes of croup. Half of infants with subglottic hemangiomas have an associated cutaneous tumor in the cervicofacial skin. [1] Furthermore, infants with a cutaneous hemangioma in a beard distribution (preauricular areas, chin, anterior neck, and lower lip) are at increased risk for upper airway or subglottic involvement. [21] High-output failure is another potentially life-threatening complication. It is usually associated with multiple hepatic hemangiomas; however, it also can occur with a single large cutaneous hemangioma. The proliferation of a hemangioma within the vascular hepatic parenchyma produces the hemodynamic changes characteristic of a large left-to-right shunt. Hepatic hemangiomas can be single or multiple; the latter are often associated with multiple small (2 to 15 mm in diameter) hemispherical cutaneous hemangiomas. Liver hemangiomas can also occur in the absence of cutaneous lesions. Infants with multiple hepatic tumors present within the first 16 weeks of life with a clinical triad of hepatomegaly, congestive heart failure, and anemia. [22] The rare infant with a hepatic arteriovenous malformation or a single large hepatic hemangioma typically presents at birth with the same triad.

TREATMENT The decision to treat a hemangioma is based on many factors, including size and location of the lesion, psychosocial implications, and risks and benefits of the proposed therapy. For the majority of small hemangiomas, active nonintervention is the most appropriate approach. This does not mean doing nothing. The parents need a thorough explanation of the natural history of their child's hemangioma, including photographs of the likely outcome for a similar lesion. The infant should be seen frequently, and the parents must be reassured constantly. Over the past decade, there has been an increase in parental pressure for intervention. Treatment is probably indicated in about 25 percent of hemangiomas—the 5 percent that ulcerate; the 20 percent that compress, distort, or obstruct vital structures such as the eyes, nose, ears, or larynx; and the less than 1 percent of truly life-threatening tumors. Ulceration is managed with gentle cleansing and application of topical antibiotics and barrier creams. Bioocclusive dressings may be helpful, especially in the anogenital area, where the tumor is frequently contaminated. Systemic antibiotics are used for infection. Other modalities for treatment of ulcerated hemangioma include intralesional and systemic corticosteroids, excision, and interferon-a. Pain may be controlled with topical lidocaine ointment and oral acetominophen with or without codeine.

Ulcerations generally heal within 2 to 3 weeks with topical care, leaving a scar. Treatment with the pulsed-dye laser may reduce healing time and pain; one study reported that 50 percent of ulcerated hemangiomas treated with pulsed-dye laser showed a definite improvement, but 18 percent showed no change, and one hemangioma showed definite worsening. [23]

Pharmacologic therapy Intralesional glucocorticoids can be used for small hemangiomas (1 to 2 cm) localized to critical sites such as the lip, nasal tip, cheek, or ear. Triamcinolone is injected slowly and at low pressure at a dose of 3 to 5 mg/kg every 4 to 6 weeks for 1 to 5 total injections. Injection into an upper eyelid hemangioma carries a slight risk of retrobulbar hematoma, and there are two case reports of microvascular embolism causing blindness due to occlusion of the central retinal artery. [24], [25] Glucocorticoid injections also can be effective in the treatment of minor ulceration. The response rate for intralesional steroid injections is the same as for systemic steroid therapy. [26] The high-potency topical steroid clobetasol propionate may be used to treat small superficial lesions. [27] Systemic glucocorticoids are the first-line pharmacologic treatment for deforming, endangering, or life-threatening hemangiomas. Prednisone or prednisolone is given at a dose of 2 to 3 mg/kg per day for 4 to 6 weeks, after which time the dosage is tapered gradually for several months. If the drug dosage is lowered or stopped before the age of 8 to 10 months, rebound growth often occurs. The response to oral glucocorticoids is excellent, with approximately 84 percent showing accelerated involution or cessation of growth (response rate) with a mean prednisone equivalent daily dose of 2.9 mg/kg given over 1.8 months [28] (see Fig. 103-8). The optimal dosage is controversial. Response is 75 percent with a dosage of prednisone between 2 and 3 mg/kg per day, whereas a dosage higher than 3 mg/kg results in a response as high as 94 percent but greater adverse effects. Dosages lower than 2 mg/kg per day result in a 69 percent response rate, but the rebound rate (enlargement after tapering after response occurred) is 70 percent. If there is no response after 2 to 3 weeks of therapy, the tumor is unlikely to respond to a higher dose, and the glucocorticoids should be discontinued. Short-term complications of glucocorticoid therapy include cushingoid facies (71 percent), personality changes (29 percent), gastric irritation (21 percent), fungal infection (oral or perineal, 6 percent), and diminished gain of height (35 percent) and weight (42 percent) during treatment. Over 90 percent of children with diminished gain of height return to their pretreatment growth curve for height by 24 months of age. [29] Interferon-a2a and -2b are indicated in the treatment of endangering and life-threatening hemangiomas, specifically for tumors unresponsive to glucocorticoids. The drug is given subcutaneously at a dose of 3 million U/m ^{2} daily for 6 to 12 months. [30], [31] Side effects include transient fever, neutropenia, and minor elevations in liver enzymes. Spastic diplegia develops in approximately 5 to 10 percent of infants treated with interferon. [32] The neurologic signs are reversible after stopping the drug. Obviously, periodic neurologic examination is indicated during treatment.

Laser therapy Treatment of hemangiomas with the flash-lamp pulsed-dye laser has been a subject of considerable controversy over the past decade. This laser uses a wavelength of 585 nm, specific for the absorption of oxyhemoglobin, the treatment target. In addition, the pulse duration is extremely short (400 ms), allowing for effective coagulation of vessels without extensive thermal diffusion to surrounding tissue that could result in scarring. Histologically, the flash-lamp pulsed-dye laser produces selective intravascular and perivascular coagulation necrosis, seen clinically as purpura. On resolution of the purpura, histologic examination shows an absence of dermal ectatic vessels and an otherwise normal unaltered epidermis and dermis. With darker skin types, laser treatment can cause damage to melanocytes in the basal cell layer, resulting in hypopigmentation. It is generally accepted that the pulsed-dye laser is the treatment of choice for residual telangiectasias during or after involution. More controversial is the treatment of a proliferating hemangioma or a precursor lesion in an effort to prevent or diminish growth. Laser treatment of the superficial dermal component of the tumor has no effect on proliferation of the deeper component. [33] Thus laser treatment is ineffective in reducing the bulk of deep hemangiomas. [34] Some authors think that laser treatment can accelerate involution and diminish the growth phase if therapy is begun early enough; however, this has not been substantiated by controlled trials. Laser treatment is most effective in telangiectatic-type hemangiomas, and it typically results in complete clearing of the lesion after a mean of two laser sessions. [34] However, it is important to remember that telangiectatic hemangiomas are generally macular or slightly elevated—the very tumors that tend to regress spontaneously leaving minimal to no residua. [35] Potential side effects of pulsed-dye laser treatment include ulceration with scarring and hypopigmentation that becomes evident only after regression. The pulsed-dye laser should be considered in the treatment of ulcerated hemangiomas. One small pilot study showed that 6 of 10 ulcerations healed after a single laser treatment, and pain was subjectively decreased in all patients within 2 to 3 days after one treatment. [36] Controlled trials are needed to confirm these findings.

Surgical therapy Surgical resection may be indicated at any time during the life cycle of a hemangioma. Excision is often necessary for fibrofatty tissue and abnormal skin after involution (when the child is 8 to 12 years old). Surgical intervention in early childhood should be considered for special situations. For example, a localized pedunculated hemangioma on the upper eyelid unresponsive to pharmacologic therapy sometimes can be totally excised, thereby quickly correcting astigmatism. An ulcerated hemangioma that bleeds frequently and is largely necrotic can take as long as 4 to 8 weeks to heal and is often associated with significant pain. Such tumors may be excised, leaving a scar that is likely to be more cosmetically acceptable than the scar resulting from natural regression. [35] Surgical excision should be considered during the preschool age, before the child begins to manifest a facial or body image. A spheroidal hemangioma in the nasal tip usually causes cutaneous expansion and splayed alar cartilages. For psychosocial reasons, subtotal excision to improve nasal contour should be considered during early childhood. Hemangiomas of the vermilion border, glabella, eyebrow, and eyelid (Fig. 103-9) often are excised prior to the child's entry into school. In some instances, it is best to wait until regression is nearly complete before resecting the fibrofatty residuum or atrophic skin. In summary, excision in early childhood is indicated (1) if it is obvious that resection is inevitable (because of postulcerative scarring unalterably expanded skin, or likely fibrofatty residuum), (2) if the scar would be the same length or appearance if excision were postponed, and (3) if the scar can be easily concealed. [35]

FIGURE 103-9 Surgical correction of involuting-phase hemangioma. *A*. Three-year-old girl with protuberant tumor on upper eyelid. *B*. Age 9 years, after staged surgical resection, including vertical shortening of eyelid, repair of

blepharoptosis, and formation of tarsal crease.

Other Vascular Tumors of Infancy

KASABACH-MERRITT PHENOMENON/KAPOSIFORM HEMANGIOENDOTHELIOMA The association of a giant capillary hemangioma with thrombocytopenia was first reported in 1940 by Kasabach and Merritt. In addition to thrombocytopenia, there is a superimposed disseminated intravascular coagulation manifested by anemia, prolongation of the prothrombin and partial thromboplastin times, low fibrinogen level, and elevated levels of D-dimers and fibrin split products. This disorder is not a true syndrome; it is best termed *Kasabach-Merritt phenomenon* because it is pathogenically heterogeneous.

Clinical manifestations Hemangiomas of infancy are not associated with Kasabach-Merritt coagulopathy. Usually the tumor is a kaposiform hemangioendothelioma (KHE), a more aggressive vascular lesion that is distinctive histologically, clinically, and radiographically. [37], [38] Approximately 50 percent of KHEs are congenital; the remainder appear during the first year of life. The tumor grows rapidly to a large size (5 cm) and is characterized by a deep-red to violaceous color, induration, and a centrifugally advancing rim of ecchymosis (Fig. 103-10). The anatomic distribution of KHE is retroperitoneum (52 percent), proximal lower limb (19 percent), upper limb (19 percent), and the cervicofacial region (10 percent). [38]

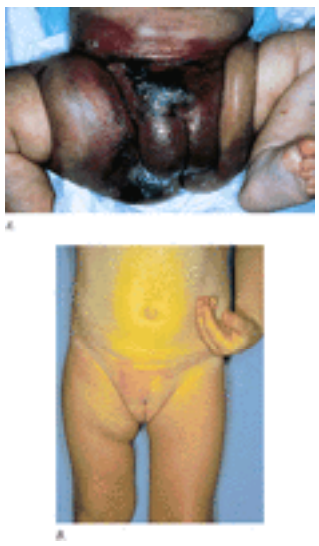

FIGURE 103-10 Kasabach-Merritt phenomenon (KMP) secondary to KHE. *A*. Indurated, purpuric tumor appeared at age 3 months, seen here at age 8 months. KHE confirmed by MRI and biopsy. Platelet count less than 5000/mm3. *B*. Age 2 years, after successful treatment with interferon alfa-2a for 6 months and a 3-day course of cyclophosphamide.

Pathology The histopathology of this vascular neoplasm shows remarkable similarity to Kaposi sarcoma with infiltrating interconnecting sheets of slender endothelial cells lining slitlike vessels interspersed with nests of epithelioid endothelial cells with a prominent eosinophilic cytoplasm.

Diagnosis and treatment MRI shows distinctive findings, i.e., diffuse enhancement with poorly defined margins, cutaneous thickening, edema, and stranding of subcutaneous fat. The mortality is high (30 to 40 percent) despite a variety of treatments, e.g., blood products, antifibrinolytic agents, compression, embolization, glucocorticoids, and chemotherapy. In one review, interferon-a2a accelerated tumor regression and corrected coagulopathy in 6 of 14 infants; the mortality rate was 19 percent (4 of 21). [38] Vincristine is also effective and is currently the first-line drug if there is no response to corticosteroids. Spontaneous regression can occur from 1 to 5 years of age; however, residual dormant KHE is common after the resolution of thrombocytopenia and coagulopathy. [39] There are some rare examples of recrudescence of thrombocytopenia in late childhood and adolescence.

PYOGENIC GRANULOMA

Clinical manifestations Pyogenic granuloma is a rapidly developing vascular lesion that often arises at sites of minor trauma; it may represent a reactive phenomenon. Pyogenic granuloma is common. Lesions are solitary, small (average size 6.5 mm), eroded papules or nodules that bleed spontaneously or after trauma (Fig. 103-11). Common locations include the face, fingers, toes, and trunk. Pyogenic granuloma rarely appears prior to 6 months of age; mean age at presentation in children is 6.7 years. [40] Pyogenic granuloma frequently presents in adults. The lesions can appear within an existing capillary malformation (port-wine stain), but most commonly there is no history of a preexisting dermatologic condition.

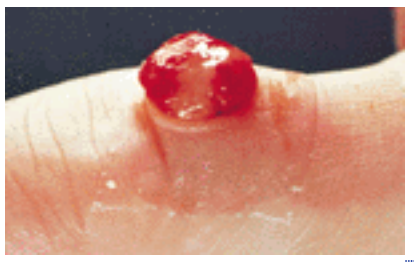

FIGURE 103-11 Pyogenic granuloma. An early lesion. An ulcerated, glistening, reddish papule is surrounded by a collarette.

Pathology Histopathology reveals well-circumscribed lobular aggregates of proliferating capillaries within an edematous stroma infiltrated by numerous neutrophils. The epidermis is often eroded.

Treatment Treatment is by surgical excision or curettage with electrodesiccation of the base. Smaller lesions (<5mm) in cosmetically important areas can be treated with the pulsed-dye laser. Other rare vascular proliferations [41], [42], [43], [44], [45], [46] and [47] are summarized in Table 103-3.

Name	Clinical Manifestations	Histopathology	Recent Review
[illegible]	[illegible]	[illegible]	[illegible]
[illegible]	[illegible]	[illegible]	[illegible]
[illegible]	[illegible]	[illegible]	[illegible]
[illegible]	[illegible]	[illegible]	[illegible]
[illegible]	[illegible]	[illegible]	[illegible]
[illegible]	[illegible]	[illegible]	[illegible]
[illegible]	[illegible]	[illegible]	[illegible]
[illegible]	[illegible]	[illegible]	[illegible]
[illegible]	[illegible]	[illegible]	[illegible]

TABLE 103-3 **Other Vascular Tumors**

FIGURE 103-12 Tufted angioma, acquired tumor in an adolescent girl. The tumor failed to respond to pulsed-dye laser therapy.

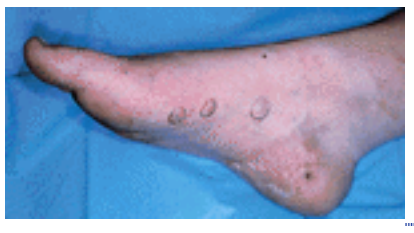

FIGURE 103-13 Spindle-cell hemangioendotheliomas on the foot of a young woman with Maffucci syndrome.

FIGURE 103-14 *A*. An advanced lesion of angiosarcoma. The tumor has infiltrated the jaw, maxillary bone and sinus, and neck. Note pronounced accompanying edema. *B*. Six-month-old girl with congenital lymphedema, left lower extremity. Ecchymotic, firm area appeared below the medial knee and biopsy confirmed angiosarcoma. Congenital lymphedema as well as acquired lymphedema can presage angiosarcoma (Stewart-Treves syndrome).

VASCULAR MALFORMATIONS

There are two common vascular phenomena in infants that are characterized by transient, macular, blotchy, erythematous staining. Because they typically fade and disappear, these are not true vascular malformations but rather a transitory phenomenon related to vasodilatation.

Cutis Marmorata

Cutis marmorata is a marbled, bluish discoloration of the skin that occurs in a netlike pattern on the trunk and extremities of an infant. It occurs as a physiologic response to cooling and resolves on rewarming of the child. This typically resolves during the first year of life, and treatment is usually unnecessary. Cutis marmorata may persist in patients with the De Lange syndrome, Down syndrome, and trisomy. [22]

Fading Macular Stain

Fading macular stain (old terms, *stork bite, salmon patch, angel's kiss, nevus flammeus neonatorum*) consists of a faint pink, blanchable patch with irregular borders. Studies document an incidence of 42 percent in white neonates, 31 percent in blacks, [3] and 23.4 percent in Chinese and Malaysian infants. [48] These stains are located most commonly on the nape of the neck (81 percent), the eyelids (45 percent), and the glabella (33 percent). [4] The macular stain becomes more obvious during crying or when the infant is febrile. They typically fade slowly and usually disappear completely after 1 year of age. Nuchal lesions fade more slowly and less completely than facial lesions; if they persist in this location, the term *nevus of Unna* has been applied. A fading macular stain is often listed as a dermatologic finding in various syndromes, including Beckwith-Wiedemann and Rubenstein-Taybi syndromes. However, the high incidence of these macular stains argues against any true association with such syndromes.

True vascular malformations are subdivided according to the rate of flow and predominant vessel type. *Slow-flow* anomalies include capillary malformation (CM), lymphatic malformation (LM), and venous malformation (VM), whereas *fast-flow* anomalies include arterial malformation (AM), arteriovenous fistula (AVF), and arteriovenous malformation (AVM).

Capillary Malformation

CLINICAL MANIFESTATIONS *Port-wine stain* is the nineteenth-century term for the most common type of CM. It is a light-pink to deep-red macule occurring in 0.3 percent of neonates. [4] The lesion can be small or can cover extensive areas of the body in a geographic pattern or a dermatomal distribution (Fig. 103-15). The color deepens gradually with time, becoming dark red during adolescence and violaceous during middle age. In addition, with age, the surface thickens, slowly becoming raised and nodular. CM is usually considered sporadic, but there are well-documented pedigrees showing autosomal dominant inheritance. A CM can be associated with combined vascular anomalies (see Table 103-4).



TABLE 103-4 **Vascular Syndromes**

FIGURE 103-15 Capillary malformation (port-wine stain) involving V_1–V_2 dermatomes, left face; patients with CM in the V_2 distribution are at risk for the Sturge-Weber syndrome.

PATHOLOGY Microscopy reveals dilated ectatic vessels in the papillary and upper reticular dermis lined by normal-appearing, flat endothelial cells. Stains for factor VIII, fibronectin, and basement membrane proteins fail to show any difference between a CM and normal dermal vessels. However, a paucity of nerves was documented by S100 staining; decreased perivascular neural elements could account for altered modulation of vascular tone and subsequent gradual ectasia. [49]

TREATMENT Many therapeutic methods have been used for CM, including scarification, electrocautery, cosmetic tattooing, dermabrasion, cryosurgery, and cosmetic makeup. These methods are no longer used because of ineffectiveness and scarring; however, camouflage using either Dermablend or Covermark remains an option for some patients. Laser therapy is the treatment of choice for most patients with facial CM. The flash-lamp, pumped, pulsed-dye laser was introduced in the late 1970s for treatment of CM. [50] This system differs from the argon laser in that it uses a wavelength of 585 nm, specific for the absorption of oxyhemoglobin. In addition, as discussed earlier, the pulse duration is extremely short (400 ms), allowing for effective coagulation of vessels without extensive thermal diffusion to surrounding tissue (i.e., selective photothermolysis). [51] The pulsed-dye laser (PDL) offers effective treatment for infants and children with a very low risk of hypopigmentation (1.4 percent) or scarring (atrophic, 4.3 percent; hypertrophic, 0.7 percent). [52] Approximately 65 percent of patients treated with PDL will achieve between 50 and 90 percent lightening, and

15 percent will have more than 90 percent lightening of their lesion. [53] Multiple treatment sessions (6 to 12) are often needed to obtain optimal lightening of lesions, and lesions may recur several years after treatment. [53] General anesthesia is safe and significantly less traumatic for infants and small children, [54] but precautions must be taken to avoid flash fires resulting from ignition of oxygen from the endotracheal tube. Refinements of PDL include the use of longer pulses and longer wavelengths that penetrate more deeply, thereby producing greater lightening. In addition, the use of a dynamic cooling device to cool the epidermis allows the use of higher fluences, effectively producing greater lightening and reducing the number of treatments needed. [55]

Phakomatosis Pigmentovascularis

Phakomatosis pigmentovascularis refers to the coexistence of a CM (port-wine stain) with various melanocytic lesions, including dermal melanocytosis (Mongolian spots), nevus spilus, and nevus of Ota. Fewer than 100 cases have been reported since the original description in 1947 [56]; most reports are in the Japanese literature. Phakomatosis pigmentovascularis is categorized into four types, each of which is further subclassified according to the presence or absence of associated systemic findings (Table 103-5). Developmental abnormalities of neural crest–derived vasomotor nerves and melanocytes are thought to be involved in the pathogenesis. Aberrant neural regulation of blood vessels coupled with abnormal migration of melanocytes could explain the coexistence of CM and melanocytic lesions.

Type	CM	Dermal Melanocytosis	Nevus Anemicus	Nevus Spilus	Other
I a,b	+	–	–	–	Nevus pigmentosus et verrucosus
II a,b	+	+	±	–	
III a,b	+	–	±	+	
IV a,b	+	+	±	+	

*+ = cutaneous involvement only; b = cutaneous and systemic involvement. Systemic involvement includes: + = present; – = not present; ± = may or may not be present; nevus anemicus = localized pale macule with irregular borders that usually presents at birth and is most often located on the upper trunk. The lesion is a pharmacologic anomaly rather than a structural one; the involved vessels exhibit increased reactivity to catecholamines resulting in persistent vasoconstriction.

TABLE 103-5 **Classification of Phakomatosis Pigmentovascularis***

Telangiectases

These lesions are composed of dilated capillaries that manifest clinically as tiny erythematous to violaceous cutaneous vessels. These may blanch but do not tend to fade with time. They may be sporadic or associated with several syndromes (Table 103-6).

Disease	Systemic Involvement or Manifestations	Associated Features
Familial hereditary hemorrhagic telangiectasia (Osler-Rendu-Weber disease)	Nasal septum Face, tongue, lips, nasal and oral mucous membranes, conjunctiva, palmar fingers, nail beds, rectal mucous membranes	Skin Telangiectasia, hemangioma, nodules, little or none; small size, few average
Hereditary hemorrhagic telangiectasia (Rendu, 1896)	Nasal and pharyngeal bleeding, conjunctivitis, tract, neck, upper chest, Rare lesions	Cerebellar ataxia, progressive neurosensory hypoacusis, endocrine dysfunction, chronic/acute inability, growth retardation, chronic/acute infection, lymphoreticular malignancy

TABLE 103-6 **Syndromes with Telangiectasia**

Familial telangiectasia (Osler-Rendu-Weber disease) This process, a vascular anomaly transmitted as a simple dominant trait, affects the skin, the mucous membranes, the gastrointestinal and genitourinary tracts, and occasionally the nervous system (see Chap. 188). The basic lesion is probably a defect in the vessel wall. The lesions range from the size of a pinhead to 3 mm or more, are of bright-red or violaceous color, and blanch under pressure (see Fig. 166-6). Some of them form small vascular papules 2 to 3 mm in diameter. Located sparsely in the skin of any part of the body, they first appear during childhood, enlarge during adolescence, and may assume spidery forms, resembling, in late adult life, the cutaneous telangiectases of cirrhosis. The lesions cause trouble only because of their tendency to hemorrhage. During adult years, they may give rise to severe and repeated epistaxis or gastric, intestinal, or urinary tract hemorrhages. Chronic blood loss may result in an iron-deficiency anemia. Lesions may form in either the spinal cord or brain and produce apoplectic syndromes, or an intermittently progressive cerebral syndrome may result from a succession of small hemorrhages. Diagnosis of an unexplained gastrointestinal, genitourinary, intracranial, or intraspinal hemorrhage warrants a search for these small cutaneous lesions, which are easily overlooked. Pulmonary fistulas constitute another important feature of the generalized vascular dysplasia. Such patients are subject to brain abscesses, like the patient with congenital heart disease (see Chap. 166). Although cautery eradicates a bleeding lesion, satellites tend to re-form. Prophylaxis has proved to be unsatisfactory. The pulmonary arteriovenous malformation can be excised, if not too large, and the common hepatic vascular malformation as well.

SPIDER ANGIOMA Spider angioma is a localized network of dilated capillaries radiating from a central feeding arteriole. Lesions appear most often on the face, forearms, and hands and occur in approximately 40 percent of children. They can fade spontaneously, but more commonly they persist. Pulsed-dye laser treatment usually can eradicate these lesions completely (Fig. 103-16).

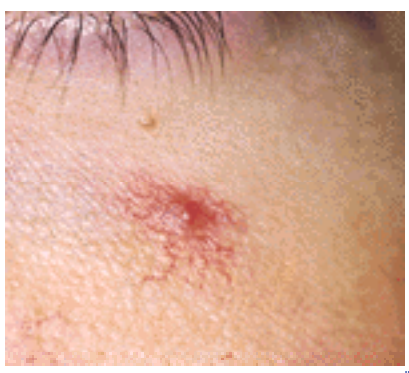

FIGURE 103-16 Spider hemangioma. A red lesion with a central papular punctum at the site of the feeding arterial vessel, with macular, radiating, telangiectatic vessels. On diascopy, the central arterial vessels can be seen to pulsate.

Cutis Marmorata Telangiectasia Congenita (CMTC)

Old terms for CMTC include *congenital generalized phlebectasia, nevus vascularis reticularis, congenital livedo reticularis,* and *van Lohuizen syndrome*.

CLINICAL MANIFESTATIONS CMTC, first described in 1922 by van Lohuizen, is characterized by a distinct, deeply erythematous to violaceous, reticulate vascular network that can be localized or generalized. Lesions are often segmental and unilateral and are present, in order of decreasing frequency, on the extremities (Fig. 103-17), trunk, face, and scalp. [56] CMTC is present at birth. Approximately 75 percent of children will show improvement of the marbled vascular pattern over time, with the most significant change occurring during the first 2 years of life. The skin within the reticulated network can be normal in color or erythematous to violaceous. The reticulated pattern is always present and is enhanced by crying, exercise, or cold temperatures. With time, the dilated veins become more prominent as the overlying skin becomes increasingly atrophic.

FIGURE 103-17 Cutis marmorata telangiectasia congenita, right lower limb in a young boy.

Associated findings have been reported in approximately 27 percent of patients; however, it is unknown whether these findings occur more frequently in CMTC patients compared with the normal population. [57] The most frequent findings include ulceration, cutaneous atrophy, and hypertrophy or atrophy of the affected limb. Other findings in association with CMTC include (1) craniofacial abnormalities such as cleft palate, high arched palate, micrognathia, dytrophic teeth, congenital glaucoma, macrocephaly, dolichocephaly, optic nerve atrophy, facial asymmetry, and frontal bossing; (2) neurologic abnormalities such as mental retardation, delayed motor development, and hypotonia; (3) vascular anomalies such as CM; (4) cutaneous abnormalities such as hyperelastic skin and aplasia cutis; (5) syndactyly of the toes; and (6) hypospadias. [58] CMTC is considered to be a sporadic disorder; however, two sisters with CMTC have been reported. [56]
PATHOLOGY Histopathologic examination reveals dilated capillaries and veins, as well as vascular fibrosis. Hyperkeratosis, dilated lymphatics, and venous thrombosis also can be seen. In some biopsies, there are few to no histologic changes. Diagnosis is generally made by the characteristic clinical features.
TREATMENT Management begins with careful evaluation of the child for possible associated abnormalities. Ulcerations may require topical or systemic antibiotics. PDL treatment potentially could help to lighten areas of CMTC.

Lymphatic Malformation

Old terms for LM include *lymphangioma circumscriptum, lymphangioma,* and *cystic hygroma*.

CLINICAL MANIFESTATIONS LM are composed of micro-to macroscopic vesicles and channels filled with clear or serosanguinous fluid or soft, subcutaneous nodules or large masses composed of dilated ectatic lymphatic channels (Fig. 103-18). Lesions typically present at birth or prior to 2 years of age. Occasionally, LMs may not manifest until childhood or adulthood. LMs very rarely involute spontaneously; they usually expand or contract according to changes in the flow of lymphatic fluid and the presence of inflammation or intralesional bleeding. They are subcategorized as microcystic (*lymphangioma*), macrocystic (*cystic hygroma*), or combined.

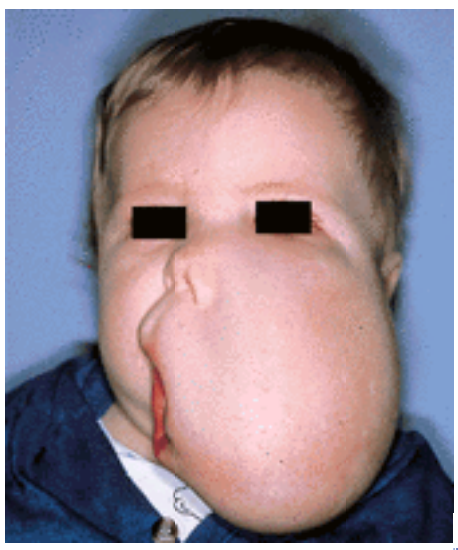

FIGURE 103-18 Macro-/microcystic lymphatic malformation involving soft tissues on the left face. This patient has had multiple bouts of cellulitis.

LM is often associated with bony hypertrophy, especially in the face or extremity. Difficulty in differentiating LM from VM

is due to spontaneous intralesional bleeding or blood flow within LM and the fact that many lesions at their onset are a combined lymphaticovenous malformation (LVM). Lymphedema is caused by LM in an extremity.
TREATMENT Intralesional bleeding causes pain and is managed with rest and analgesics. Bacterial infection should be treated promptly with antibiotics; often prolonged administration is necessary. Long-term management involves sclerotherapy and resection for appearance and functional problems.

Capillary-Lymphatic Malformation (CLM)

Old terms for CLM include *hypertrophic nevus flammeus*, *verrucous hemangioma, hemangiolymphangioma,* and *angiokeratoma circumscriptum*.

CLINICAL MANIFESTATIONS CLM is a well-demarcated, pink to bluish red, raised lesion consisting of dilated protuberant vascular and lymphatic channels (Fig. 103-19A). These lesions are commonly located on the lower extremities, but CLM may be found also on the chest, abdomen, and arms. If the surface is rough, hyperkeratotic, and wartlike, lesions are called angiokeratomas (see Fig. 103-19B).

FIGURE 103-19 *A*. Capillary-lymphatic malformation, right forearm; treated by resection. *B*. Angiokeratoma circumscriptum. Keratotic violaceous plaques whose edges are jagged.

All the angiokeratomas can be considered as variations of CLM, including angiokeratoma of Mibelli, angiokeratoma of Fordyce, angiokeratoma circumscriptum, angiokeratoma corporis diffusum universale (Fabry disease, see Chap. 151), and fucosidosis (Table 103-7).

TABLE 103-7 **The "Angiokeratomas"**

PATHOLOGY CLMs are composed of dilated vessels with deficient elastic fibers in the dermis and subcutaneous tissues. The caliber of vessels ranges from capillary to large venule. Larger ectatic lymphatic vessels also can be present, containing proteinaceous material. There may be reactive epidermal hyperkeratosis and parakeratosis.

Venous Malformation

CLINICAL MANIFESTATIONS VM is present at birth but may not be evident clinically until childhood or adulthood. Typical lesions are violaceous to blue in color and consist of patches or soft, compressible papules, plaques, or nodules. They may be localized or more extensive, involving an entire anatomic region. VMs are located most frequently on the face (Fig. 103-20), trunk, or extremities but may be present in the oronasopharynx and any of the viscera, as well as in bone. Typically, VMs are solitary; however, multiple cutaneous and visceral lesions may occur. Multifocal VM suggests an inheritable disorder or syndrome (see Table 103-4).

FIGURE 103-20 Nine-year-old girl with extensive cutaneous-intramuscular VM of upper lip and cheek.

VMs are easily compressible and swell when the affected part is dependent. Patients often complain of intermittent pain in the VM, particularly on wakening in the morning. Presumably this is due to stasis and possibly thrombosis within this slow-flow vascular anomaly. Phleboliths, noted by either palpation or radiographically, are the hallmark of VMs. Skeletal alterations can occur with VMs. Craniofacial VMs typically cause facial asymmetry and gradual progressive distortion of

facial features. Intraorbital VMs are associated with expansion of the orbital cavity, and oral VMs cause dental malalignment. An extremity VM may induce bony hypertrophy, resulting in length discrepancy, although undergrowth due to disuse may also occur.

DIAGNOSIS Ultrasonography is the easiest way to confirm the diagnosis of a deep VM and to differentiate the lesion from a deep hemangioma versus lymphatic malformation. However, MRI is considered the gold standard for diagnosis of VMs and for documentation of their extent and involvement of surrounding tissues. Patients with an extensive VM should be evaluated for the possibility of localized intravascular coagulopathy caused by stasis within the interstices of the VM; this is a different bleeding disorder than that seen in Kasabach-Merritt phenomenon. A coagulation profile may reveal a slightly low platelet count (100,000 to 150,000/mm^3 range), low fibrinogen (150 to 200 mg/dL), and increased D-dimers, with normal prothrombin and partial thromboplastin times.

TREATMENT Indications for treatment of VM include appearance, pain, and functional impairment. Conservative management involves the use of custom-made elastic support, especially for extremity VMs. Episodes of painful thrombosis may be minimized with low-dose aspirin (80 mg qd to qod). Small cutaneous VMs at any site may be injected with a sclerosant such as 1% sodium tetradecyl sulfate. Patients with a large VM, either cutaneous or intramuscular, also may be sclerosed, but they require general anesthesia with real-time fluoroscopic monitoring. The most commonly used sclerosant in the United States is absolute ethanol (100%), whereas Ethibloc (a corn protein, ethanol, and contrast medium) is used commonly in Europe. Possible complications include blistering, hemoglobinuria, deep ulceration, nerve damage, renal toxicity, and cardiac arrest. [59] Multiple therapeutic sessions may be necessary because VM has a tendency for recanalization and reexpansion. Surgical excision is best done after sclerotherapy to decrease tissue bulk or to improve function.

Blue Rubber Bleb Nevus Syndrome

Blue rubber bleb nevus syndrome (BRBNS) is composed of the constellation of multiple cutaneous and gastrointestinal venous malformations. The first description of this entity was in 1860 by Gascoyen, and in 1958, Bean reported two cases and coined the term *blue rubber bleb nevus syndrome*. [56] Cutaneous lesions may be present at birth or appear during early childhood and, once present, remain unchanged. The lesions are soft, compressible, 0.1- to 5.0-cm blue nodules commonly located on the trunk and extremities, but they can be located anywhere on the skin and mucosa. Lesions are usually asymptomatic but can be tender, and occasionally, patients have pain in the lesions (likely secondary to thromboses). Most cases are sporadic, but there are several reports suggesting autosomal dominant inheritance.

BRBNS lesions are the most common type of intestinal venous anomaly. Gastrointestinal lesions occur most commonly in the small intestine; however, any portion of the gastrointestinal tract can be involved, including the oral and anal mucosa. In contrast to cutaneous lesions, the gastrointestinal lesions are friable and often bleed, causing iron-deficiency anemia. Acute gastrointestinal hemorrhage, intussusception, volvulus, bowel infarction, and rectal prolapse have been described. The VMs that constitute blue rubber bleb nevus syndrome also can involve other organ systems, including the eye, nasopharynx, brain, meninges, heart, lung, liver, spleen, gallbladder, kidney, adrenal gland, uterus, muscle and joints. [56]

PATHOLOGY Histopathologic examination reveals ectatic vessels of various sizes in the deep dermis and subcutaneous fat.

TREATMENT Treatment options for cutaneous lesions include excision, sclerotherapy, and laser (pulsed-dye or CO_2) for the smaller new lesions. Treatment of these patients should include periodic stool guaiac examinations, complete blood count, and endoscopic cauterization or sclerosis or bowel resection, if necessary.

Glomuvenous Malformations (GVMs)

Old term *glomangiomas.*

CLINICAL MANIFESTATIONS GVM arise from the arterial segment of the cutaneous glomus, the Suquet-Hoyer canal. Glomus cells are of smooth muscle origin and are polyhedral in shape, in contrast to the usual elongated form. These cells comprise specialized vascular structures, called *glomus formations,* that are present in abundance in the distal pads and nail beds of the fingers and to a lesser degree on the volar aspect of the hands and feet, in the skin of the ears, and on the central face. Glomus formations are special arteriovenous shunts that appear to play a role in thermoregulation. GVM are distinct from the more common glomus tumors, which present as solitary, painful papules that are a few millimeters in diameter on the extremities, especially in the nail bed. GVM is a type of slow-flow vascular malformation consisting of multiple, nontender vascular lesions that may reach a size of several centimeters. They are usually scattered over the body but may be localized to one area such as the face. [60] GVMs are generally asymptomatic, although paroxysmal attacks of pain have been described, occasionally related to menstruation or pregnancy. GVMs arise during childhood or during the second decade of life. Men are more commonly affected than women. In many cases of GVM, a strong family history has been reported, with incomplete to complete penetrance. [61] Gastrointestinal involvement, so common in the blue rubber bleb nevus syndrome, has not been described.

TREATMENT Treatment options include excision, electrosurgery, sclerotherapy, electron-beam irradiation, and laser therapy with the CO_2, argon, and pulsed ruby lasers.

Arteriovenous Malformation and Fistula

CLINICAL MANIFESTATIONS *Arterial malformation* (AM) is a general term for embryonic vascular anomalies, such as aneurysm, coarctation, hypoplasia, and stenosis. AVM is the most common fast-flow anomaly in children. AVMs are present at birth but may not be evident clinically until later. The most common location for an AVM is intracranial, followed by extremities, trunk, and viscera. The initial presentation may be a faint or ill-defined area of macular erythema resembling a port-wine stain (Fig. 103-21). Expansion of an AVM often occurs in puberty or following trauma or infection and results in an altered clinical appearance: a deeply erythematous to violaceous color, an underlying subcutaneous mass (possibly pulsatile), warmth, a thrill, and a bruit. End-stage lesions are characterized by ulceration, intractable pain, bleeding and multiple violaceous papules and nodules—pseudo Kaposi sarcomatous changes (Fig. 103-22).

FIGURE 103-21 Stage I arteriovenous malformation on the left face. Cheek is warm; only tiny dermal blush seen on MRI.

FIGURE 103-22 Teenage girl with stage III AVM in her left foot, with pseudo-Kaposi cutaneous changes.

DIAGNOSIS Diagnosis of AVM is primarily clinical and is confirmed by ultrasonography and color Doppler examination. MRI is superior for evaluation of the extent of an AVM. Diagnostic angiography is usually done at the same time as embolization or sclerotherapy. The Schobinger staging system has been proposed to facilitate clinical research and outcome studies [62]: stage I (quiescence): stain and warmth; stage II (expansion): enlargement, tortuous, tense veins, pulsations, thrill, and bruit; stage III (destruction): dystrophic changes, ulceration, bleeding, and persistent pain; and stage IV (decompensation): cardiac failure.
TREATMENT Intervention for AVM is considered whenever endangering signs or symptoms develop—Schobinger stage III or IV. Early intervention for a quiet AVM (stages I to II) is debatable but should be considered if resection is achieved easily without disfigurement. Palliative embolization can be done but almost never will cure an AVM, in contrast to closure of an AVF by embolization. The concept for cure is to obliterate and resect the nidus or epicenter of the AVM. This requires embolization or sclerotherapy followed by resection (whenever possible). Following combined embolization-resection, the patient must be followed for years by clinical examination, ultrasonography, and/or MRI. There are extensive AVMs for which only palliative embolization is possible. Pharmacologic treatment of such AVMs is evolving.

Combined Malformations

Combined vascular malformations (CVMs) include, CLM, CLVM, and CLAVM and are also subdivided as either slow flow or fast flow (Fig. 103-23, Fig. 103-24, and Fig. 103-25). There is often associated soft tissue and skeletal hypertrophy. Many of the combined malformations are known by well-worn eponyms (see Table 103-4).

FIGURE 103-23 Capillary-lymphaticovenous malformation (CLVM) (old term, *Klippel-Trenauney syndrome*), lower limb.

FIGURE 103-24 Lymphaticovenous anomalies (LVM) of hands; radiographs show enchondromas (Maffucci syndrome).

FIGURE 103-25 Capillary-arteriovenous malformation (CAVM) (old term, *Parkes-Weber syndrome*), left lower limb and trunk.

Genetics of Vascular Malformations

Advances in molecular genetics have led to the discovery of the genes and/or chromosomal locations for many inheritable vascular anomalies. Genetic information regarding several well-known vascular disorders is listed in Table 103-8 and in references 64, 65, 66, 67, 68, 69, 70 and 71.



TABLE 103-8 **Genetic Information for Selected Vascular Anomalies**

REFERENCES

1. Mulliken JB, Young AE: *Vascular Birthmarks: Hemangiomas and Malformations*. Philadelphia, Saunders 1988

2. Mulliken JB, Glowacki J: Hemangiomas and vascular malformations in infants and children: A classification based on endothelial characteristics. *Plast Reconstr Surg* **69**:412, 1982

3. Pratt AG: Birthmarks in infants. *Arch Dermatol* **67**:302, 1953

4. Jacobs AH, Walton RG: The incidence of birthmarks in the neonate. *Pediatrics* **58**:218, 1976

5. Hidano A, Nakajima S: Earliest features of the strawberry mark in the newborn. *Br J Dermatol* **87**:138, 1972

6. Holmadahl K: Cutaneous hemangiomas in premature and mature infants. *Acta Paediatr* **44**:370, 1955

7. Amir J et al: Strawberry hemangioma in preterm infants. *Pediatr Dermatol* **3**:331, 1986

8. Finn MC et al: Congenital vascular lesions: Clinical application of a new classification. *J Pediatr Surg* **18**:894, 1983

9. Cheung DS et al: Hemangioma in twins. *Ann Plast Surg* **38**:269, 1997

10. Bielenberg DR et al: Progressive growth of infantile cutaneous hemangiomas is directly correlated with hyperplasia and angiogenesis of adjacent epidermis and inversely correlated with expression of the endogenous angiogenesis inhibitor, IFN-beta. *Int J Oncol* **14**:401, 1999

11. Boye E et al: Clonality and altered behavior of endothelial cells in hemangiomas. *J Clin Invest* **107**:665, 2001

12. Enjolras O, Mulliken JB: The current management of vascular birthmarks. *Pediatr Dermatol* **10**:311, 1993

13. Razon MJ et al: Increased apoptosis coincides with onset of involution in infantile hemangioma. *Microcirculation* **5**:189, 1998

14. Hasan Q et al: Altered mitochondrial cytochrome *b* gene expression during the regression of hemangioma. *Plast Reconstr Surg* **108**:1471, 2001

15. Martinez-Perez D et al: Not all hemangiomas look like strawberries: Uncommon presentations of the most common tumor of infancy. *Pediatr Dermatol* **12**:1, 1995

16. Esterly NB et al: The management of disseminated eruptive hemangiomata in infants. *Pediatr Dermatol* **1**:312, 1984

17. Enjolras O et al: Noninvoluting congenital hemangioma: A rare cutaneous vascular anomaly. *Plast Reconstr Surg* **107**:1647, 2001

18. Frieden IJ et al: PHACE syndrome: The association of posterior fossa brain malformations, hemangiomas, arterial anomalies, coarctation of

the aorta and cardiac defects, and eye abnormalities. *Arch Dermatol* **132**:307, 1996

19. Paltiel HJ et al: Soft-tissue vascular anomalies: Utility of US for diagnosis. *Radiology* **214**:747, 2000

20. North PE et al: GLUT1: A newly discovered immunohistochemical marker for juvenile hemangiomas. *Hum Pathol* **31**:11, 2000

21. Orlow SJ et al: Increased risk of symptomatic hemangiomas of the airway in association with cutaneous hemangiomas in a “beard” distribution. *J Pediatr* **131**:643, 1997

22. Boon LM et al: Hepatic vascular anomalies in infancy: A twenty-seven year experience. *J Pediatr* **129**:346, 1996

23. Kim HJ et al: Ulcerated hemangiomas: Clinical characteristics and response to therapy. *J Am Acad Dermatol* **44**:962, 2001

24. Ellis PO: Occlusion of the central retinal artery after retrobulbar corticosteroid injection. *Am J Ophthalmol* **85**:352, 1978

25. Deans RM et al: Surgical dissection of capillary hemangiomas: An alternative to intralesional corticosteroids. *Arch Ophthalmol* **110**:1743, 1992

26. Sloan GM et al: Intralesional corticosteroid therapy for infantile hemangiomas. *Plast Reconstr Surg* **83**:459, 1989

27. Elsas FJ, Lewis AR: Topical treatment of periocular capillary hemangioma. *J Pediatr Ophthalmol Strabismus* **31**:153, 1994

28. Bennett ML et al: Oral corticosteroid use is effective for cutaneous hemangiomas: An evidence-based evaluation. *Arch Dermatol* **137**:1208, 2001

29. Boon LM et al: Complications of systemic corticosteroid therapy for problematic hemangioma. *Plast Reconstr Surg* **104**:1616, 1999

30. Ezekowitz RA et al: Interferon-a2a therapy for life-threratening hemangiomas of infancy. *New Engl J Med* **326**:1456, 1992

31. Tamayo L et al: Therapeutic efficacy of interferon-a2b in infants with life-threatening giant hemangiomas. *Arch Dermatol* **133**:1567, 1997

32. Barlow CF et al: Spastic diplegia as a complication of interferon-a2a treatment of hemangiomas of infancy. *J Pediatr* **132**:527, 1998

33. Ashinoff R, Geronemus RG: Failure of the flashlamp-pumped pused-dye laser to prevent progression to a deep hemangioma. *Pediatr Dermatol* **10**:77, 1993

34. Scheepers JH, Quaba AA: Does the pulsed tunable dye laser have a role in the management of infantile hemangiomas: Observations based on 3 years' experience. *Plast Reconstr Surg* **95**:305, 1995

35. Mulliken JB: Management of hemangiomas. *Pediatr Dermatol* **14**:60, 1997

36. Morelli JG et al: Treatment of ulcerated hemangiomas with the pulsed tunable dye laser. *Am J Dis Child* **145**:1062, 1991

37. Enjolras O et al: Infants with Kasabach-Merritt syndrome do not have “true” hemangiomas. *J Pediatr* **130**:631, 1997

38. Sarkar M et al: Thrombocytopenic coagulopathy (Kasabach-Merritt phenomenon) is associated with kaposiform hemangioendothelioma and not with common infantile hemangioma. *Plast Reconstr Surg* **100**:1377, 1997

39. Enjolras O et al: Residual lesions after Kasabach-Merritt phenomenon in 41 patients. *J Am Acad Dermatol* **42**:225, 2000

40. Patrice SJ et al: Pyogenic granuloma (lobular capillary hemangioma): A clinicopathologic study of 178 cases. *Pediatr Dermatol* **8**:267, 1991

41. Jones EW, Orkin M: Tufted angioma (angioblastoma): A benign progressive angioma, not to be confused with Kaposi's sarcoma or low-grade angiosarcoma. *J Am Acad Dermatol* **20**:214, 1989

42. Suarez SM et al: Response of deep tufted angioma to interferon-a. *J Am Acad Dermatol* **33**:124, 1995

43. Pitluk HC, Conn JJ: Hemangiopericytoma: Literature review and clinical presentations. *Am J Surg* **137**:413, 1979

44. Enzinger FM, Smith BH: Hemangiopericytoma: An analysis of 106 cases. *Hum Pathol* **7**:61, 1976

45. Santa Cruz DJ, Aronberg J: Targetoid hemosiderotic hemangioma. *J Am Acad Dermatol* **19**:550, 1988

46. Vion B, Frenk E: Targetoid hemosiderotic hemangioma. *Dermatology* **184**:300, 1992

47. Hynes LR, Shenefelt PD: Unilateral nevoid telangiectasia: Occurrence in two patients with hepatitis C. *J Am Acad Dermatol* **36**:819, 1997

48. Tan KL: Nevus flammeus of the nape, glabella, and eyelids: A clinical study of frequency, racial distribution, and association with congenital anomalies. *Clin Pediatr* **11**:112, 1972

49. Smoller BR, Rosen S: Port-wine stains: A disease of altered neural modulation of blood vessels? *Arch Dermatol* **122**:177, 1986

50. Anderson RR, Parrish JA: Microvasculature can be selectively damaged using dye lasers: A basic theory and experimental evidence in human skin. *Lasers Surg Med* **1**:263, 1981

51. Anderson RR, Parrish JA: Selective photothermolysis: Precise microsurgery by selective absorption of pulsed radiation. *Science* **220**:524, 1983

52. Seukeran DC et al: Adverse reactions following pulsed tunable dye laser treatment of port-wine stains in 701 patients. *Br J Dermatol* **36**:725, 1997

53. Orten SS et al: Port-wine stains: An assessment of 5 years of treatment. *Arch Otolaryngol Head Neck Surg* **122**:1174, 1996

54. Grevelink JM et al: Pulsed laser treatment in children and the use of anesthesia. *J Am Acad Dermatol* **37**:75, 1997

55. Waldorf HA et al: Effect of dynamic cooling on 585-nm pulsed dye laser treatment of port-wine stain birthmarks. *Dermatol Surg* **23**:657,

1997

56. Requena L, Sangueza OP: Cutaneous vascular anomalies: Hamartomas, malformations, and dilatation of preexisting vessels. *J Am Acad Dermatol* **37**:523, 1997

57. Picascia DD, Esterly NB: Cutis marmorata telangiectasia congenita: Report of 22 cases. *J Am Acad Dermatol* **20**:1098, 1989

58. Ben-Amitai D et al: Cutis marmorata telangiectatica congenita and hypospadias: Report of 4 cases. *Am Acad Dermatol* **45**:131, 2001

59. Berenguer B et al: Sclerotherapy of craniofacial venous malformations: Complications and results. *Plast Reconstr Surg* **104**:1, 1999

60. Mounayer C et al: Facial “glomangiomas”: Large facial venous malformations wit glomus cells. *J Am Acad Dermatol* **45**:239, 2001

61. Rudolph B: Familial multiple glomangiomas. *Ann Plast Surg* **30**:183, 1993

62. Kohout MP et al: Arteriovenous malformations of the head and neck: Natural history and management. *Plast Reconstr Surg* **102**:643, 1998

63. Cragg H et al: Fucosidosis: Genetic and biochemical analysis of eight cases. *J Med Genet* **34**:105, 1997

64. Guttmacher AE et al: Hereditary hemorrhagic telangiectasia. *New Engl J Med* **333**:918, 1995

65. Savitsky K et al: A single ataxia-telangiectasia gene with a product similar to PI-3 kinase. *Science* **268**:1749, 1995

66. Vikkula M et al: Vascular dysmorphogenesis caused by an activating mutation in the receptor tyrosine kinase TIE2. *Cell* **87**:1181, 1996

67. Boon LM et al: A gene for inherited cutaneous venous anomalies (“glomangiomas”) localizes to chromosome 1p21–22. *Am J Hum Genet* **65**:125, 1999

68. Eerola I et al: KRIT1 is mutated in hyperkeratotic cutaneous capillary-venous malformation associated with cerebral capillary malformation. *Hum Mol Genet* **22**:1351, 2000

69. Finegold DN et al: Truncating mutations in *FOXC2* cause multiple lymphedema syndromes. *Human Molecular Genetics* **10**:1185, 2001

70. Vikkula M et al: Molecular genetics of vascular malformations. *Matrix Biology* **20**:327, 2001

71. Zhou X et al: Germline and germline mosaic PTEN mutation associated with a Proteus-like syndrome of hemohypertrophy, lower limb asymmetry, arteriovenous malformations, and lipomatosis. *Hum Mol Genet* **9**:765, 2000

T>

Chapter 104

Klemens Rappersberger Georg Stingl Klaus Wolff

Kaposi's Sarcoma

GENERAL CONSIDERATIONS
EPIDEMIOLOGY AND CLINICAL MANIFESTATIONS
Classic KS
African Endemic KS
KS in Iatrogenically Immunocompromised Patients
Epidemic HIV-Associated KS
PATHOLOGY
HISTOGENESIS
ETIOLOGY
Human Herpesvirus-8/Kaposi's Sarcoma-Associated Herpesvirus
PATHOGENESIS
TREATMENT
Ionizing Radiation
(Poly)chemotherapy
Interferon and Antiretroviral Drugs
Experimental Therapy
REFERENCES

GENERAL CONSIDERATIONS

In 1872, the Austro-Hungarian dermatologist Moriz Kaposi described five patients with multicentric cutaneous and extracutaneous neoplasms that primarily affected older individuals. This disease, originally described as “idiopathic, multiple, pigment sarcoma” was later eponymously designated *Kaposi's sarcoma* (KS) and is now called *classic KS* (CKS). In the 1950s, endemic KS was described in certain areas of central Africa (endemic African KS) and subsequently in iatrogenically immunosuppressed patients (immunosuppression KS). This disease, however, raised little interest in the general medical community until its epidemic spread among young male homosexuals was recognized as a hallmark of the new disease AIDS (AIDS-associated KS). While these different clinical and epidemiologic variants run rather distinct clinical courses, the phenotypic features of the proliferating vascular elements are quite uniform. The discovery of the presence of a new human herpesvirus [human herpesvirus (HHV)-8, alternatively designated Kaposi's sarcoma-associated herpesvirus (KSHV)] in all KS-variants and the identification of a humoral immune response against this putative infectious agent, has shed new light onto the postulated infectious etiology of the disease. Subsequently, various molecular mechanisms were identified as to how HHV-8 initiates and sustains KS cell growth and proliferation. However, it remains to be seen whether HHV-8 is the sole etiologic agent and how genetic, social, immunologic, and endocrine factors influence the pathogenesis and course of this disease.

EPIDEMIOLOGY AND CLINICAL MANIFESTATIONS

Classic KS

The annual incidence of CKS in the United States is estimated to be 0.02 to 0.06 percent of all malignant tumors. Among those afflicted, there is a distinct preponderance of people of either Jewish or Mediterranean descent. [1] Recent epidemiologic studies in Sweden and Denmark, countries with very small nonclustered Jewish populations, indicate a twofold increase in the incidence of classic KS in the late 1960s (Sweden), and incidence rates of 0.40 and 0.22 per 1,000,000 population among men and women, respectively. [2], [3], [4] and [5] Although the clustered occurrence of CKS in the Mediterranean (Sardinia, Peloponnesos) and the preponderance of KS in several Jewish populations suggest a critical role for genetic factors, no disease-defining human leukocyte antigen (HLA) marker has yet been identified. [6] Although previously reported to have a very high male:female ratio, current studies indicate that there is a slight preponderance for males with a male:female ratio of approximately 3:1, the mean age of onset is 65 years.

CKS usually starts as single or multiple pea-sized bluish-red macules on the distal portions of the lower extremities (Fig. 104-1). In most instances, the lesions progress very slowly and may coalesce to form large plaques and, subsequently, nodules and tumors. Unilateral involvement, seen at the onset of the disease, changes to a bilateral and later to a more disseminated, multicentric pattern spreading in a centripetal fashion (Fig. 104-2). As the lesions age, they become brownish in color and may display a verrucous and hyperkeratotic surface. KS may show eczematous changes, and the lesions can erode and even ulcerate. In severe cases, there are large, partly eroded and ulcerated plaques or tumors involving the feet, hands, and even an entire extremity. Early, angiomatous lesions are soft and spongy to the touch, but older tumors are firm. An initially pitting edema of the surrounding tissue is often present, particularly on the lower extremities, where it may evolve into a fibrotic swelling of the limb that causes considerable discomfort.

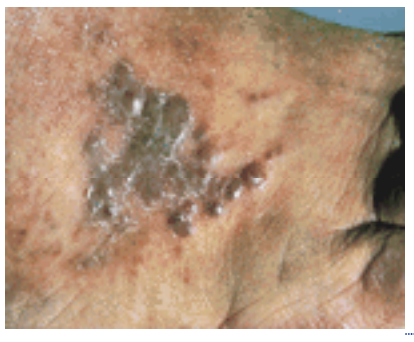

FIGURE 104-1 Classic variant. Multiple papules and nodules are localized on the dorsum of the foot, a site of predilection of classic KS.

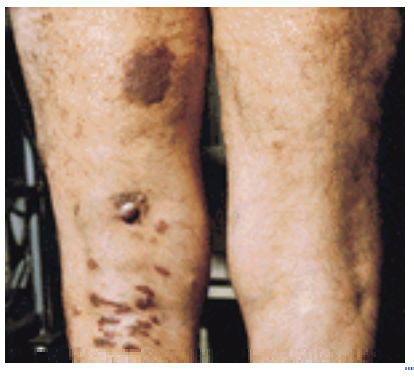

FIGURE 104-2 Mediterranean variant. Involvement of extremities by KS lesions at different stages of development. As is usually seen in non-AIDS cases, the disease started on both feet and evolved in a centripetal fashion.

CKS may develop on various mucous membranes, especially in the oral cavity and within the gastrointestinal tract. [5] Gastrointestinal lesions mostly evolve without any clinical symptoms and are often found only at autopsy. Upon thorough examination (e.g., gastroscopy, x-ray, and tests for occult blood), one may detect gastrointestinal involvement in up to 90 percent of patients. CKS usually develops very slowly and therefore runs a rather benign course (mean duration, 3 to 8 years), however, rapid courses with involvement of the lungs, spleen, heart, and gastrointestinal tract may occur. [7]

African Endemic KS

KS is a common tumor in black Africans and accounts for up to 9 percent of all malignancies in central Africa. [8] Its endemic occurrence was first noted in the 1950s, thus antedating the outbreak of the AIDS pandemic by several decades. Epidemiologic studies indicate a clear-cut prevalence of male patients, with ratios ranging from 3 to 1 in children and up to 18 to 1 in adults. The mean age at onset is 36 years for females and 48 years for males. The disease runs a faster course with earlier generalization in females as compared to males. In children, fulminant courses with rapid dissemination to the visceral organs are seen.

According to clinicopathologic features African endemic KS (AKS) is classified into four subvariants: nodular-, florid-, infiltrative-, and lymphadenopathic-type (for review, see Ref. 8). Nodular KS runs a rather benign course, with a mean duration of 5 to 8 years, and resembles CKS. The florid/vegetating and infiltrative variants are characterized by a more aggressive biologic behavior and may extend deeply into the dermis, subcutis, muscle, and bone. Lymphadenopathic AKS predominantly affects children and young adults; skin and mucosa are affected to a lesser degree. Ninety percent of AKS patients develop asymptomatic gastrointestinal involvement that is found at autopsy only.

KS in Iatrogenically Immunocompromised Patients

With the development of immunosuppressive therapy, KS has been described with increasing frequency in organ-transplant recipients. [9] It has also been reported in individuals who had undergone chronic immunosuppressive therapy for autoimmune diseases and, sporadically, in cancer patients having received cytotoxic chemotherapy. The risk of developing KS in association with cyclosporin A immunosuppression is four times higher than with conventional immunosuppressive therapy (e.g., glucocorticoids and azathioprine) and the onset of the disease is much earlier. [9] Males are more frequently affected than females (ratios range from 3:1 to 7:1). A particularly high KS frequency has been documented in a transplantation center in Tel Aviv, where it was found in 2.5 percent of all kidney transplant recipients. This observation further strengthens the hypothesis of a genetic predisposition in KS. KS in immunocompromised patients is strikingly dependent on the dose of the immunosuppressive drug employed. Complete regression of KS lesions can be achieved by reduction/withdrawal of the immunosuppression and, vice versa, rapid tumor progression may occur after increase of the dosage. [10]

Epidemic HIV-Associated KS

In the late 1970s, clusters of KS cases were observed in the New York and San Francisco areas among young homosexual men with signs of a profound immunosuppression. [11], [12] Subsequently, it became clear that KS occurred almost exclusively in homo- or bisexual men and, to a lesser degree, in female partners of the latter, and in women from certain regions of Africa and the Caribbean, who had heterosexually acquired HIV infection. [13] In contrast, in other AIDS risk groups (i.e., intravenous drug users of both sexes, hemophiliacs, blood transfusion recipients, and children born to HIV-positive mothers) the occurrence of KS is rare. Recent epidemiologic studies clearly have shown that homosexual men with KS tend to be sexually more active, frequently report histories of sexually transmitted diseases and are more likely to have partners from areas with a high frequency of AIDS-associate KS. Moreover, this population practices sexual contacts such as “rimming” (oral-anal contacts) and “fisting” (insertion of the hand into the partner's rectum). The

hypothesis that AIDS-KS is caused by a sexually transmissible infectious agent that is cotransmitted with HIV was subsequently supported by a steady decline in its incidence, paralleled by a decrease in the incidence of HIV-1 seroconversion in male homosexuals. This trend has been attributed to an increased use of condoms and avoidance of a high-risk sexual behavior of the male homosexual population. [13]

In pediatric AIDS patients in the United States, KS is a rare event: among 4954 children it was found in 8 patients, much less frequently than other AIDS-defining tumors such as lymphomas that accounted for 102 cases. [14] However, in Africa, KS is the most frequent tumor among children suffering from AIDS, and even occurs more frequently than Burkitt's lymphoma. Among 318 children with AIDS, KS was diagnosed in 36 patients and Burkitt's lymphoma was diagnosed in 33 cases. [15]

Early AIDS-KS lesions appear either as small round or oval pink to reddish macules, mimicking insect bites or as dermatofibroma-like small, tense, brownish papules. In contrast to other variants of KS, the initial lesions in AIDS patients frequently develop on the face, especially on the nose, eyelids, and ears, and on the trunk, where the lesions follow the lines of cleavage (Fig. 104-3). In prolonged courses, KS lesions may be disseminated over the entire face, head, and trunk, often coalescing to form large plaques. Involvement of the deep subcutaneous tissue, skeletal muscle, or bone is usually absent. A pronounced lymphedema is observed when tumors arise on the eyelids or in acral areas.

FIGURE 104-3 Epidemic variant. Multiple lesions at all stages of development (macules, papules, nodules) are located on the trunk. Note that the lesions follow the lines of cleavage.

The oral mucosa, primarily the palate, is the initial site of localization in 10 to 15 percent of all HIV-KS patients (Fig. 104-4) and severe involvement of the epipharynx and larynx are not uncommon. These localizations may cause considerable discomfort, interfere with eating and speech, may lead to respiratory distress and carry the risk of life-threatening bleeding.

FIGURE 104-4 Epidemic variant. The localization of KS macules on the hard palate is a typical finding in AIDS patients.

Extracutaneous KS is most frequently encountered in the lymph nodes, gastrointestinal tract, and lungs. Gastrointestinal KS is found in up to 80 percent of AIDS patients, especially when extensive cutaneous lesions are present; however, patients with exclusively gastrointestinal involvement have been described. [16] Although KS can be found throughout the gastrointestinal tract, the stomach and duodenum represent predilection sites. The lesions frequently cause clinical symptoms (e.g., nausea, ulceration, bleeding, perforation, and ileus). Visible by gastroscopy, such lesions are underdiagnosed histologically because they are located in the submucosa and may escape the biopsy forceps. Pulmonary KS can cause such diverse symptoms as bronchospasm, intractable coughing, and progressive respiratory insufficiency. These symptoms are very similar to those described in *Pneumocystis carinii* pneumonia. Although chest x-ray generally reveals diffuse interstitial infiltrates in both diseases, pulmonary nodules and pleural effusions are more common in KS. Bronchoscopy with bronchoalveolar lavage is the most appropriate diagnostic tool to explore pulmonary KS. The prognosis of pulmonary KS is poor and justifies aggressive systemic chemotherapy.

PATHOLOGY

Like other skin neoplasms, KS evolves through stages of macules, papules/plaques, and nodules/tumors. Early patchlike lesions exhibit rather discrete histopathologic changes, which consist of a proliferation of oval or spindle-shaped cells

within the interstitium around the superficial vascular plexus. [17] These neoplastic cells outline irregular, tiny, bizarre slits and clefts that may display features of lymphangioma. KS papules and plaques show multiple dilated and angulated vascular spaces outlined by an attenuated endothelium. These structures dissect the collagen bundles of the entire dermis, leaving a spongy network of collagen tissue. A characteristic sign of KS papules is the presence of solid cords and fascicles of spindle cells arranged between the jagged vascular channels (Fig. 104-5). This biphasic angiomatous and solid tumor morphology changes to a clear-cut sarcomatous morphology with progression of the disease. Tumorous lesions almost exclusively consist of spindle cells arranged in bundles and interlacing fascicles. Advanced lesions may display pronounced pleomorphism, nuclear atypia, and mitotic figures. At the periphery of solid tumors, (lymph) angiomatous-like portions of KS with bizarre vascular lumina and intravascular and extravasated erythrocytes, as well as siderophages, may be preserved. Erythrocytes, which appear as eosinophilic globules, are trapped within the slits and clefts formed by the spindle cells and occasionally erythrophagocytosis is observed. A moderate inflammatory infiltrate of lymphocytes, histiocytes, plasma cells, and, sporadically, neutrophils is always present in all stages of KS.

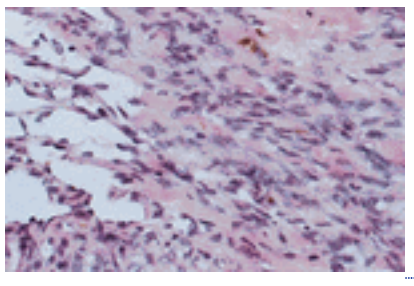

FIGURE 104-5 Histopathology of KS (biopsy taken from a KS papule). The neoplastic process follows a biphasic growth pattern: angiomatous portions, reminiscent of a lymphangioma, as well as solid, sarcomatous fascicles are present.

Considerable controversy still exists whether KS is a reversible proliferative disorder or a true malignant neoplasia. Assessing the methylation pattern of the human androgen receptor gene (*HUMARA*), several investigators showed that KS can be both, a clonal and polyclonal proliferation, respectively. Moreover, multiple lesions that arise in an individual patient may develop independently from distinct transformed cells and later acquire clonal characteristics. [18] Studies of HHV-8 terminal repeat sequences in KS-lesions support these findings and indicate that KS starts as a polyclonal disease with subsequent evolution to a monoclonal process. [19]

HISTOGENESIS

The histogenetic derivation of the KS cells, the cell lining the irregular vascular-like spaces of angiomatous lesions and composing the bundles and interlacing fascicles of solid tumors, has been the subject of considerable controversy: the histopathologic features of KS lesions and the immunophenotype of the proliferating cell (e.g., CD31+, CD34+, vimentin+, collagen type 4+/-, laminin+/-, vWF+/-) strongly favored the concept of an endothelial origin. However, because KS cells do not react with PAL-E, a specific marker for blood endothelial cells, but express markers for smooth muscle cells, macrophages, and dendritic cells, other authors suggest that KS cells may derive from a pluripotent mesenchymal precursor or represent a heterogeneous cell population. [20], [21] Recent immunomorphologic and ultrastructural studies show that KS cells express vascular endothelial growth factor (VEGF) receptor-3 and podoplanin, proteins that are specific for lymphatic endothelial cells. [22], [23] Moreover, there are significant morphologic similarities between KS cells and the endothelium of dermal lymphatic capillaries. Thus, KS cells are considered to be most closely related to or are even derived from the lymphatic endothelial cell lineage. [24] However, because cultured spindle cells, derived from peripheral blood mononuclear cells (PBMCs) of patients with or at risk for KS, displayed both, common endothelial cell antigens and macrophage markers, the mere possibility remains that the KS is derived from a circulating progenitor/endothelial stem cell/angioblast. [25], [26]

ETIOLOGY

Human Herpesvirus-8/Kaposi's Sarcoma-Associated Herpesvirus

In 1994, Chang and colleagues identified DNA sequences in AIDS-KS coding for amino acids that shared a striking homology (30 to 50 percent) with two lymphotropic, oncogenic gamma-herpesviruses: Epstein-Barr virus and herpesvirus saimiri. [27] These findings were confirmed and extended by several molecular studies of all clinical variants of KS, suggesting that a new human herpesvirus, designated HHV-8, might be causally related to KS. [28], [29] The subsequent observation that KSHV can be also detected in PBMCs in more than 50 percent of AIDS-KS patients, and, moreover, that the detection may precede the onset of KS lesions by months, further corroborated the hypothesis that HHV-8 represents the causative agent of KS. [30], [31]

Currently, four HHV-8 subtypes—A, B, C, and D— are known, and each has a close association with the geographic and ethnic backgrounds of the infected individuals. [8] Subtype A is present in western Europe and North America, B is found almost exclusively in Africans, and subtype C in Middle East and Mediterranean Europe. Subtype D has been described in individuals from the Pacific islands. Another subtype (E) has been described in PBMC and saliva of Amerindians in Brazil in whom KS was not reported. [32] Molecular studies have localized the HHV-8-DNA to the nuclei of KS tumor cells but not to regular endothelial cells in KS lesions. [33] These findings were corroborated by immunomorphologic studies that used monoclonal antibodies against the major viral latency-associated nuclear antigen (LANA-1/LNA-1), that is expressed in virtually all HHV-8 infected cells. [34] During the development of KS lesions there is a steady increase of spindle cells positive for LANA-1: in early patchlike lesions HHV-8 is present only in approximately 10 percent of spindle cells, whereas in nodular lesions, more than 90 percent of spindle cells are positive. [34] Evidence that HHV-8 may induce productive/lytic infection was provided by Renne, who established HHV-8+ cell lines from body cavity-based lymphomas

(BCBLs). [35] Stimulation of HHV-8–harboring cells with the phorbol ester 12- *O*-tetradecanoyl phorbol-13-acetate induced a dramatic inhibition of cell growth accompanied by widespread transcription of the viral genome, including the gene for the viral capsid protein that is expressed only late in the viral life cycle. Electron microscopic studies revealed the presence of lytic cells that displayed mature herpesvirus-like particles within their nuclei and cytoplasm, and also within the cell-free supernatant of the cultures. Further evidence for production and transmission of mature (infectious) viral particles came from coculture experiments using a BCBL cell line and the CD19+ cell fraction of umbilical cord blood mononuclear cells. [36] The assumption that a lymphoid cell may serve as the original site of HHV-8 replication was also supported by the observation that KS tissue harbors intact HHV-8, but in a latent, circular-episomal form, whereas the linear form of HHV-8/DNA indicative of replication occurs in PBMCs. [37] Moreover, the observation of virus replication in vivo, confined to CD34+ cells localized within the lumen of KS slits and in CD34+ circulating PBMCs, also points to a lymphoid (precursor) cell as the target for original HHV-8 infection/replication. [38], [39] This is further supported by the occurrence of HHV-8 in Castleman's disease and pleural effusion lymphoma. [34] One would thus expect that KSHV may undergo a continuous infectious life cycle also in vivo, as it has already been shown in vitro by the production of DNAse-resistant filterable viruses transmitted into and released from kidney embryonic epithelial cells. [40]

Infections with human herpesviruses are ubiquitous, usually occur during infancy and childhood, and result in the persistence of the viral genome throughout life.

Several seroepidemiologic studies support the hypothesis that HHV-8 is the causative agent of KS and suggest various routes of virus transmission: HHV-8 DNA is present in all types of KS lesions and all patients with KS, independent of their HIV-status, have HHV-8 antibodies. [41] Seroconversion seems to reflect a primary infection with HHV-8, because viremia is detectable close to the point of seroconversion. [42] The persistence of HHV-8 antibodies indicates that continuous antigen presentation is taking place. This suggests that the virus remains present in a latent or lytic form of replication somewhere in the body. [42] As best exemplified in HIV-positive individuals, the time from seroconversion to overt KS may last up to 15 years (median 63.5 months), with a higher incidence of KS when HIV-infection was acquired before HHV-8 seroconversion. [43] This phenomenon may be due to inadequate immune responses to HHV-8 in HIV-infected individuals, with subsequent higher HHV-8 virus loads. [44], [45] Moreover, there is now clear epidemiologic evidence of a prevalence of HHV-8 seropositivity in people who have acquired HIV more likely via sexual contacts than via clotting-factor concentrates or other blood products. These observations support previous epidemiologic data suggesting an association of KS with promiscuity and risky sexual behavior, [13] and are also true for HIV-seropositive and high-risk HIV-seronegative women, especially those who are engaged in commercial sex and have a history of sexually transmitted disease (syphilis, gonorrhea). [46] Nevertheless, the prevalence of HHV-8 seropositivity in females is much lower than in males.

A direct correlation apparently exists between human herpesvirus-8 seroprevalence and the incidence of the Mediterranean- and Jewish-variant of classic KS. [47], [48] Seroprevalence for HHV-8 is also increased among family members. The most important risk factors for adult individuals to test positive for HHV-8 were place of birth and seropositivity of spouses; in children, maternal seropositivity was the discriminating factor. [48] These observations also confirm what several HHV-8 seroepidemiologic studies in Africa indicate: the familial aggregation of HHV-8 seroprevalence in the population of endemic KS areas in Africa indicates early infection in childhood and adolescence, mostly from mother to child or between siblings. [49] Thus, nonsexual routes of infection, that is, “casual/household infections,” are obviously of major importance in endemic areas.

It is interesting in this context that HHV-8 DNA is frequently detectable in saliva/nasal secretions, but only rarely in genitourinary secretions (i.e., semen, prostate secretion, and cervicovaginal fluids) of KS-patients and individuals at risk for the development of KS. [50], [51] and [52] Recent investigations in homosexual men identified the oral mucosa as the major site of HHV-8 shedding. Thus, one can assume that oral exposure to infectious saliva (oro-penile contact, deep kissing) is a potential risk factor for the acquisition of HHV-8 and one can easily imagine that casual, nonsexual transmission of the virus via infectious saliva also occurs in close familial contacts, among siblings, spouses and between mother and child. [53]

Because circulating CD34+ cells may serve as HHV-8 carriers, there exists a certain risk to transmit HHV-8 through blood. Several studies have shown an increased risk among needle-sharing IV drug users. [45] Vertical transmission from a mother to her newborn can occur, albeit as an exceedingly rare event. [54] However **,** the risk of acquiring HHV-8 by transfusion of white blood cell (WBC)-depleted blood components seems to be negligible. [55] In contrast, HHV-8 seroconversions in organ transplant recipients are frequently observed and occur more often in liver, than in renal, transplant recipients. Renal transplant recipients have a higher risk of developing KS, whereby reactivation of a preexisting HHV-8 infection seems to play a greater role than incident infection. Therefore, there is a need to perform routine screening for HHV-8 antibodies in organ transplant donors and recipients. [56], [57]

PATHOGENESIS (See Fig. 104-6)

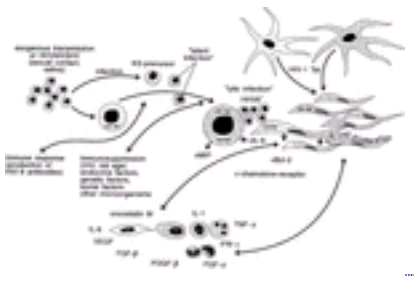

FIGURE 104-6 The etiopathogenesis of KS: a hypothesis. EC, endothelial cell; FB, fibroblast; LC, lymphocyte; MC,

monocyte.

Several in vivo and in vitro studies indicate that KS results from a mutual, cytokine-driven, autocrine and paracrine stimulation of KS cells and passenger leucocytes (for review, see Ref. 8, Ref. 58, and Ref. 59). KS cells express a wide array of various proinflammatory cytokines, such as intercellular adhesion molecule (ICAM)-I, platelet-activating factor, monocyte chemotactic protein 1/2, IL-6, and IL-8, that may attract and activate leucocytes. Attracted inflammatory cells then exert growth stimulatory effects through the secretion of, for example, oncostatin-M, IL-1, tumor necrosis factor (TNF)-a, interferon (IFN)-?, and granulocyte macrophage colony-stimulating factor. In addition, KS cells express receptors for potent endothelial cell mitogens such as platelet-derived growth factor (PDGF)-ß, IL-1, and VEGF (e.g., VEGF-KDR and -flt-1). VEGF production is upregulated by PDGF and IL-1. The observation that VEGF-stimulated microvascular endothelial cells injected into mice induced KS-like angiogenic lesions, led to the speculation that these cytokines regulate angiogenesis in KS in vivo.

Because AIDS-KS displays a much more aggressive biology, several investigators have speculated that HIV-gene products could account for this phenomenon. This was first exemplified by the demonstration that male, HIV-tat transgenic mice develop KS-like angiomatous skin lesions. [60] Interestingly, tat-expression in these animals was essentially confined to the epidermis. Because epidermal Langerhans cells in humans are the major cutaneous target of HIV-1 [61] it is conceivable that tat production in these cells and subsequent release into the dermis may provide the appropriate mitogenic stimulus required for cutaneous endothelial cells to progress to KS-like angiomatous tumors. [8], [58], [59] Alternatively, growth-stimulating mechanisms might be initiated by HIV-expressing leucocytes (monocytes/macrophages, dendritic cells) present in KS lesions in situ that produce high levels of HIV-tat and cytokines mentioned above, thereby stimulating the proliferation of a certain responder cell, most likely the KS-precursor, that then becomes autonomous. These inflammatory cytokines induce normal endothelial cells to acquire characteristics as KS cells, stimulate the constitutive synthesis and release of bioactive ß-fibroblast growth factor (FGF), and enhance their ability to form angiogenic KS-like lesions in athymic nude mice. Moreover, after exposure to cytokine-rich supernatants of T cell cultures from AIDS patients, normal endothelial cells express the receptors for tat, $a_v ß_1$- and $a_v ß_3$-integrins and become responsive to the mitogenic effects of tat protein. Subsequently, they start proliferation and migration and even degrade basement membrane collagen type IV, indicative of the acquisition of an invasive potential.

Together, these studies indicate that chronic immune stimulation via the release of inflammatory cytokines may contribute to the pathogenesis of KS, an effect that is dramatically increased by tat protein in AIDS-KS.

What is the connection, if any, between these events and HHV-8 infection? There is now clear evidence that HHV-8 encodes for various genes that may directly contribute to the pathogenesis of KS. [58], [59] Several factors have been identified that promote KS-cell growth, for example, vIL-6, viral interferon regulatory factor (vIRF) and v-cyclin; others inhibit KS cell apoptosis, such as vFLIP, LANA, vBcl-2, K15/LAMP, and vIRF. Additional factors, such as K1, vGPCR, Kaposin, and vIRF, may guarantee a limitless replicative potential of KS cells. Moreover, HHV-8 possibly encodes for paracrine factors that promote leucocytes attraction, for example, vIL-6, MIP-1, -2, and -3. The genes for some of these factors can be upregulated by the addition of phorbol esters, indicating their expression during virus replication in the lytic phase. [62]

In summary, current data suggest that HHV-8, exogenously acquired (e.g., from saliva, sexual contact, organ transplant), initially most likely infects a B lymphoid precursor, or, alternatively, the KS precursor cell, integrates and subsequently enters a latent phase of infection. Upon activation of the virus through immunosuppression (AIDS, iatrogenic) or various other endocrine, metabolic, microbiologic, and social stimuli (sexual practices), as well as a genetic predisposition (Jews and Mediterranean People), HHV-8 genes are activated and transcribed. Robust activation allows HHV-8 to enter a productive/lytic life cycle. Full transcriptive activity is achieved and cytokine homologues, proteins that stimulate inflammation and cell proliferation or inhibit apoptosis, are produced. Concomitantly, inflammatory cells attracted by HHV-8 gene products provide additional proliferative stimuli to maintain and support the proliferation of KS-cells, which then increases the release of appropriate tumor-promoting mediators. Most likely, these circumstances also result in the replication and release of mature, infectious HHV-8, which subsequently may infect other host cells. However, if this mutual stimulation is perturbed, for example, by reconstitution of immune competence [highly active antiretroviral therapy (HAART)], the cascade of pathobiologic events would be adversely influenced resulting in delayed tumor growth or even tumor regression (see Fig. 104-6).

TREATMENT

The choice of treatment of KS depends on the extent and the localization of lesions as well as on the clinical type of the disease. Solitary lesions of all KS variants may be excised or subjected to laser irradiation. Superficial and flat lesions can be successfully treated with liquid nitrogen and photodynamic therapy. [63], [64]

Ionizing Radiation

Radiation therapy plays a major role in the management of solitary and disseminated mucocutaneous KS. [65] Types of radiation, dosage and application-form depend on the extent and size of lesions. Flat lesions are usually irradiated with superficial x-ray; high-energy beams, including cobalt therapy, are commonly used in the treatment of large tumors. Other possibilities are (un)fractionated half-body irradiation with electron beams and/or photon beams. High-dose microelectron brachytherapy has fewer adverse effects than external beam radiotherapy. [66]

(Poly)chemotherapy

Patients with rapidly progressive disease require (poly)chemotherapy with cytotoxic drugs. Good efficacy has been reported for liposomal-doxorubicin, and liposomal-daunorubicin. [67] Paclitaxel has been used as a single agent with

moderate success, and the vinca alkaloids are currently preferred in combination with adriamycin and bleomycine. [68]

Interferon and Antiretroviral Drugs

INF-a has been widely used in the treatment of KS and it has yielded quite contradictory results. However, there seem to be some beneficial effects, especially when the immunosurveillance is, at least partially, intact. [69] It is now well established that the treatment of HIV-infected individuals with antiretroviral agents may prolong survival and improve the quality of life. Most important was the introduction of HAART into the management of HIV infection, which has dramatically decreased the incidence of AIDS-KS. These observations have been explained by supportive effects of HAART on the immune system. However, recent investigations clearly demonstrate direct antiangiogenic properties of HIV protease inhibitors in vitro and in vivo. [70], [71] and [72]

Experimental Therapy

The establishment of long-term KS spindle cell cultures and of KS mouse models has enabled us to test new therapeutic concepts. Some of these concepts were assessed for safety, tolerability, and efficacy in experimental trials in KS patients. Such studies were performed with substances that interact with neoangiogenesis, matrix metalloproteinase inhibitors, as well as topical retinoic acid and “immunomodulators.” Treatment with the ß chain of human chorionic gonadotropin did not keep its early promise. [73] Large clinical trials are needed to ultimately determine the efficacy and, thus, the future applicability of these experimental treatment modalities.

REFERENCES

1. Safai B: Kaposi's sarcoma: An overview of classical and epidemic forms, in *AIDS, Modern Concepts and Therapeutic Challenges,* edited by S Broder. New York, Marcel Dekker, 1987, p 205

2. Fenig E et al: Classic Kaposi's sarcoma: Experience at Rabin Medical Center in Israel. *Am J Clin Oncol* **21**:498,1998

3. Bendsöe N: Increased incidence of Kaposi's sarcoma in Sweden before the AIDS epidemic. *Eur J Cancer* **26**:699, 1990

4. Hjalgrim H et al: Epidemiology of classic Kaposi's sarcoma in Denmark between 1970 and 1992. *Cancer* **77**:1373, 1996

5. Rappersberger K et al: Endemic Kaposi's sarcoma in human immunodeficiency virus type 1-seronegative persons: Demonstration of retrovirus-like particles in cutaneous lesions. *J Invest Dermatol* **95**:371, 1990

6. Brunson M et al: HLA and Kaposi's sarcoma in solid organ transplantation. *Hum Immunol* **29**:56, 1990

7. Iscovich J et al: Classic Kaposi's sarcoma: Epidemiology and risk factors. *Cancer* **88**:500, 2000

8. Boshoff C, Weiss RA: Epidemiology and pathogenesis of Kaposi's sarcoma-associated herpesvirus. *Phil Trans R Soc Lond B* **356**:517, 2001

9. Penn I: The changing pattern of posttransplant malignancies. *Transplant Proc* **23**:1101, 1991

10. Wijnveen AC et al: Disseminated Kaposi's sarcoma—Full regression after withdrawal of immunosuppressive therapy: Report of a case. *Transplant Proc* **19**:3735, 1987

11. Centers for Disease Control: Kaposi's sarcoma and *Pneumocystis carinii* pneumonia among homosexual men—New York City and California. *MMWR Morb Mortal Wkly Rep* **25**:305, 1981

12. Centers for Disease Control: Special report: Epidemiologic aspects of the current outbreak of Kaposi's sarcoma and opportunistic infections. *N Engl J Med* **306**:258, 1982

13. Beral V et al: Is risk of Kaposi's sarcoma in AIDS patients in Britain increased if sexual partners come from the United States or Africa? *BMJ* **324**:624, 1991

14. Biggar RJ et al: Risk of cancer in children with AIDS. AIDS-cancer Match registry study group. *JAMA* **284**:205, 2000

15. Newton R et al: A case-control study of human immunodeficiency virus infection and cancer in adults and children residing in Kampala, Uganda. *Int J Cancer* **92**:622, 2001

16. Ioachim HL et al: Kaposi's sarcoma of internal organs: A multiparameter study of 86 cases. *Cancer* **75**:1376, 1995

17. Ackerman AB: Subtle clues to diagnosis by conventional microscopy: The patch stage of Kaposi's sarcoma. *Am J Dermatopathol* **1**:165, 1979

18. Gil PS et al: Evidence for multiclonality in multicentric Kaposi's sarcoma. *Proc Natl Acad Sci USA* **95**:8257, 1998

19. Judde JG et al: Monoclonality or oligoclonality of human herpesvirus 8 terminal repeat sequences in Kaposi's sarcoma and other diseases. *J Natl Cancer Inst* **92**:729, 2000

20. Regezi JA et al: Human immunodeficiency virus-associated oral Kaposi's sarcoma: A heterogeneous cell population dominated by spindle-shaped endothelial cells. *Am J Pathol* **143**:240, 1993

21. Uccini S et al: Kaposi's sarcoma cells express the macrophage-associated antigen mannose receptor and develop in peripheral blood cultures of Kaposi's sarcoma patients. *Am J Pathol* **150**:929, 1997

22. Weninger W et al: Expression of vascular endothelial growth factor receptor-3 and podoplanin suggests a lymphatic endothelial cell origin of Kaposi's sarcoma tumor cells. *Lab Invest* **79**:243, 1999

23. Kriehuber E et al: Isolation and characterization of dermal lymphatic and blood endothelial cells reveal stable and functionally specialized cell lineages. *J Exp Med* **194**:797, 2001

24. Sauter B et al: Immunoelectronmicroscopic characterization of human dermal lymphatic microvascular endothelial cells. Differential

expression of CD31, CD34 and type IV-collagen with lymphatic endothelial cells versus blood capillary endothelial cells in normal human skin, lymphangioma and hemangioma, in situ. *J Histochem Cytochem* **46**:165, 1998

25. Browning PF et al: Identification and culture of Kaposi's sarcoma-like spindle cells from the peripheral blood of human immunodeficiency virus-1–infected individuals and normal controls. *Blood* **84**:2711, 1994

26. Sirianni MC et al: Circulating spindle cells: Correlation with human herpesvirus-8 (HHV-8) infection and Kaposi's sarcoma. *Lancet* **349**:255, 1997

27. Chang Y et al: Identification of herpesvirus-like DNA sequences in AIDS-associated Kaposi's sarcoma. *Science* **266**:1865, 1994

28. Moore PS, Chang Y: Detection of herpesvirus-like DNA sequences in Kaposi's sarcoma in patients with and those without HIV infection. *N Engl J Med* **332**:1181, 1995

29. Huang YQ, Li JJ, Kaplan MH et al: Human herpesvirus-like nucleic acid in various forms of Kaposi's sarcoma. *Lancet* **345**:759, 1995

30. Whitby D et al: Detection of KS associated herpesvirus in peripheral blood of HIV-infected individuals and progression to Kaposi's sarcoma. *Lancet* **346**:799, 1995

31. Parry JP, Moore PS: Corrected prevalence of Kaposi's sarcoma (KS)-associated herpesvirus infection prior to onset of KS. *AIDS* **11**:127, 1997

32. Biggar R et al: Human herpesvirus 8 in Brazilian Amerindians: A hyperendemic population with a new subtype. *J Infect Dis* **181**:1562, 2000

33. Boshoff C et al: Kaposi's sarcoma associated herpesvirus infects endothelial cells and spindle cells. *Nat Med* **1**:1274, 1995

34. Dupin N et al: Distribution of human herpesvirus-8 latently infected cells in Kaposi's sarcoma, multicentric Castleman's disease and primary effusion lymphoma. *Proc Natl Acad Sci USA* **96**:4546, 1999

35. Renne R et al: Lytic growth of Kaposi's sarcoma-associated herpesvirus (human herpesvirus 8) in culture. *Nat Med* **2**:342, 1996

36. Mesri EA et al: Human herpesvirus-8/Kaposi's sarcoma associated herpesvirus is a new transmissible virus that infects B cells. *J Exp Med* **183**:2385, 1996

37. Decker LL et al: The Kaposi's sarcoma associated herpesvirus (KSHV) is present as an intact latent genome in KS tissue but replicates in the peripheral blood mononuclear cells of KS patients. *J Exp Med* **184**:283, 1995

38. Orenstein JM et al: Visualization of human herpesvirus type 8 in Kaposi's sarcoma by light and transmission electron microscopy. *AIDS* **11**:F35, 1997

39. Henry M et al.: Infection of circulating CD34+ cells by HHV-8 in patients with Kaposi's sarcoma. *J Invest Dermatol* **113**:613, 1999

40. Foreman KE et al: Propagation of a human herpesvirus from AIDS associated Kaposi's sarcoma. *N Engl J Med* **336**:163, 1997

41. Katano H et al: Identification of antigenic proteins encoded by human herpesvirus 8 and seroprevalence in the general population and among patients with and without Kaposi's sarcoma. *J Virol* **74**:3478, 2000

42. Goudsmit J et al: Human herpesvirus 8 infections in the Amsterdam Cohort Studies (1984–1997): Analysis of seroconversion to ORF65 and ORF73. *Proc Natl Acad Sci USA* **97**:4383, 2000

43. O'Brien TR et al: Evidence for concurrent epidemics of human herpesvirus 8 and human immunodeficiency virus type 1 in US homosexual men: rates, risk factors, and relationship to Kaposi's sarcoma. *J Infect Dis* **180**:1010, 1999

44. Renwick N et al.: Seroconversion for human herpesvirus 8 during HIV infection is highly predictive of Kaposi's sarcoma. *AIDS* **12**:2481, 1998

45. Cannon MJ et al: Blood-borne and sexual transmission of human herpesvirus 8 in women with a risk for human immunodeficiency virus infection. *N Engl J Med* **344**:637, 2001

46. Greenblatt RM et al.: Human herpesvirus 8 infection and Kaposi's sarcoma among human immunodeficiency virus-infected and uninfected women. *J Infect Dis* **183**:1130, 2001

47. Santarelli R et al: Direct correlation between human herpesvirus-8 seroprevalence and classic Kaposi's sarcoma incidence in northern Sardinia. *J Med Virol* **65**:368, 2001

48. Davidovici B et al: Seroepidemiology and molecular epidemiology of Kaposi's sarcoma associated herpesvirus among Jewish population groups in Israel. *J Natl Cancer Inst* **93**:194, 2001

49. Plancoulaine Sabel L et al: Human herpesvirus-8 transmission from mother to child and between siblings in an endemic population. *Lancet* **356**:1062, 2000

50. Gessain A et al: Human herpesvirus 8 primary infection occurs during childhood in Cameroon, Central Africa. *Int J Cancer* **81**:189, 1999

51. Koelle DM et al: Frequent detection of Kaposi's sarcoma-associated herpesvirus in saliva of human immunodeficiency virus-infected men: Clinical and immunological correlates. *J Infect Dis* **176**:94, 1997

52. Calabro ML et al: Detection of human herpesvirus 8 in cervicovaginal secretions and seroprevalence in human immunodeficiency virus type 1-seropositive and seronegative women. *J Infect Dis* **179**:1534, 1999

53. Pauk K et al: Mucosal shedding of human herpesvirus 8 in men. *N Engl J Med* **343**:1369, 2000

54. Mantina H et al: Vertical transmission of Kaposi's sarcoma associated herpesvirus. *Int J Cancer* **94**:749, 2001

55. Challine D et al: Seroprevalence of human herpes virus 8 antibody in populations at high or low risk of transfusion, graft, or sexual transmission of virus. *Transfusion* **41**:1120, 2001

56. Milliancourt C et al: Human herpesvirus-8 seroconversion after renal transplantation. *Transplantation* **72**:1319, 2001

57. Andreoni M et al.: Prevalence, Incidence and correlates of HHV-8/KSHV infection and Kaposi's sarcoma in renal and liver transplant recipients. *J Infect* 43:195, 2001

58. Stürzl, M et al: Human herpesvirus-8 and Kaposi's sarcoma: Relationship with the multistep concept of tumorigenesis. *Adv Cancer Res* **81**:125, 2001

59. Moore PS, Chang Y: Molecular virology of Kaposi's sarcoma-associated herpesvirus. *Philos Trans R Soc Lond B Biol Sci* **356**:499, 2001

60. Vogel J et al: The HIV tat gene induces dermal lesions resembling Kaposi's sarcoma in transgenic mice. *Nature* **335**:606, 1988

61. Rappersberger K et al: Langerhans cells are an actual site of HIV-1 replication. *Intervirology* **29**:185, 1988

62. Montaner S et al: The Kaposi's sarcoma-associated herpesvirus G protein coupled receptor promotes endothelial cell survival through the activation of Akt/protein kinase B. *Cancer Res* **61**:2641, 2001

63. Lenz P et al: Treatment of HIV-Kaposi's sarcoma. *Derm Therapy* **12**:77, 1999

64. Mitsuyasu RT: Update no the pathogenesis and treatment of Kaposi sarcoma. *Curr Opin Oncol* **12**:174, 2000

65. Kirova YM et al: Radiotherapy in the management of epidemic Kaposi's sarcoma: A retrospective study of 643 cases. *Radiother Oncol* **46**:19, 1998

66. Syndikus I et al: High dose rate microselectron radiation for Kaposi's sarcoma of the palate. *Radiother Oncol* **42**:167, 1997

67. Nunez M et al: Response to liposomal doxorubicin and clinical outcome of HIV-1–infected patients with Kaposi's sarcoma receiving highly active antiretroviral therapy. *HIV Clin Trials* **2**:429, 2001

68. von Roenn J et al: Management of AIDS associated Kaposi's sarcoma: A multidisciplinary perspective. *Oncology* **12**(suppl 3):1, 1998

69. Krown SE: Interferon-alpha: Evolving therapy for AIDS-associated Kaposi's sarcoma. *J Interferon Cytokine Res* **18**:1112, 1998

70. Holkova B et al: Effect of highly active antiretroviral therapy on survival in patients with AIDS-associated pulmonary Kaposi's sarcoma treated with chemotherapy. *J Clin Oncol* **19**:3848, 2001

71. Jones JL et al: Incidence and trends in Kaposi's sarcoma in the era of effective antiretroviral therapy. *J Acquir Immune Defic Syndr* **24**:270, 2000

72. Sgadari C et al: HIV protease inhibitors are potent anti-angiogenic molecules and promote regression of Kaposi sarcoma. *Nat Med* **8**:225, 2002

73. Gill PS et al: The effects of preparations of human chorionic gonadotropin on AIDS-related Kaposi's sarcoma. *N Engl J Med* **335**:1261, 1996

T>

Chapter 105

Walter Burgdorf

Anetoderma and Other Atrophic Disorders of the Skin

HISTORICAL ASPECTS
ETIOLOGY AND PATHOGENESIS
CLINICAL MANIFESTATIONS
PATHOLOGY
RELATED DISORDERS
DIAGNOSIS AND DIFFERENTIAL DIAGNOSIS
TREATMENT

REFERENCES

Anetoderma is a localized laxity of the skin with herniation or outpouching resulting from abnormal dermal elastic tissue. Because atrophy is not an essential component of this process, the term *anetoderma* (Greek *anetos,* relaxed; *derma,* skin) more accurately describes the phenomenon than does the alternative name, macular atrophy.

HISTORICAL ASPECTS

Far too many proper names have been associated with anetoderma. The idiopathic version without preceding lesions is named after Schweninger and Buzzi, while the postinflammatory form is attributed to Jadassohn, Pellizari, and others.

ETIOLOGY AND PATHOGENESIS

The key defect is damage to the dermal elastic fibers. However, the exact mechanisms of damage remain a mystery. Both cell-mediated and humoral damage have been postulated, but specific antielastin reactivity has not been shown. The occurrence of anetoderma with acrodermatitis chronica atrophicans, a proven borreliosis (see Chap. 203), suggests that anetoderma may have an infectious cause in some cases. Anetoderma may occur as an early finding in HIV infections, sometimes without clinically apparent inflammation [1] but more often secondary to well-characterized eruptions. [2] In addition, a variety of autoimmune phenomena have been reported in patients with anetoderma; most common appears to be the presence of antiphospholipid antibodies, [3] sometimes associated with systemic lupus erythematosus [4] or HIV infection. Rare familial cases have been described.

The mechanism of elastin destruction remains unclear, but there are multiple ways in which the structures can be altered. Electron microscopy may show fragmented and irregular elastic fibers, occasionally engulfed by macrophages. [5] Many different inflammatory and enzymatic pathways have been studied, but no unifying concept has emerged. When anetoderma is secondary to an obvious dermatosis or tumor, the whole spectrum of inflammatory processes as well as simple pressure combine to produce diminished elastic fibers. In adults, the capacity for repair of elastin is limited. Attempts to unequivocally separate anetoderma from other forms of scarring are futile, as ordinary scars from any cause may also be atrophic and lack elastin.

CLINICAL MANIFESTATIONS

All forms of anetoderma are characterized by a circumscribed loss of normal skin elasticity. As a result, a soft bladder-like pouch is created. The examining finger can press this pouch into the dermis and sometimes seems to fall through into the subcutaneous layer without meeting resistance. The sensation is similar to palpating an inguinal hernia. When the finger is removed, the skin pushes outward again. The epidermis is wrinkled, thinned, and often depigmented with telangiectases apparent. Despite the thinness, ulceration is uncommon (Fig. 105-1 and Fig. 105-2).

FIGURE 105-1 Anetoderma. Patulous herniations are seen on the lower back.

FIGURE 105-2 Anetoderma. A closer view.

Attempts to distinguish between Schweninger-Buzzi and Jadassohn-Pellizari types of anetoderma are artificial. Clearly all anetoderma must have a precursor phase with inflammation and elastic fiber damage; whether one can recognize this feature or not is an individual variable, not a disease-defining feature. Patients often have several types of lesions simultaneously, some inflammatory, some noninflammatory, some spontaneous, and some secondary to minor trauma. [6] The best established causes of primary anetoderma are the antiphospholipid syndrome and HIV/AIDS.

Many dermatoses produce a true secondary anetoderma in which the pouched lesions develop at the sites of inflammation; the most common causes today are probably acne and varicella. Anetoderma following secondary syphilis was formerly common. Persistent irritation and inflammation, such as with prurigo nodularis, may also evolve into anetoderma. [7] Anetoderma can also appear with acrodermatitis chronica atrophicans, especially at the periphery of such lesions. In some forms of granulomatous inflammation, dermal elastolysis and anetoderma may be seen. Anetoderma may also follow the resolution of cutaneous tumors such as juvenile xanthogranulomas, [8] pilomatricomas, [9] or lymphomas. [10], [11] Finally, in Sicily, leech application appears to be a common cause; here there is no mystery as to the origin of the trauma. [12]

Children may be affected with anetoderma; they are similar in every way to adult cases. [13] In contrast, in premature infants a distinct type of anetoderma may be seen, clearly suspected to be caused by electrocardiographic electrodes or adhesives. [14], [15]

PATHOLOGY

The predominant defect resides in the elastic fibers, which are fragmented, shortened, and, in some lesions, have almost completely disappeared (Fig. 105-3). In a study of 45 biopsies from 17 patients with anetoderma, the elastin was generally absent, but the fine microfibrils were still present. [16] Presumably the weakening of the elastic network leads to flaccidity and herniation. The collagen fibers appear normal. Mononuclear inflammatory cells have been found in all types of anetoderma, regardless of whether the lesions were thought to be clinically inflamed.

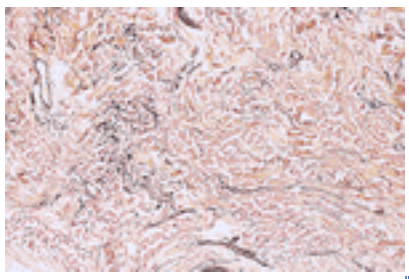

FIGURE 105-3 Anetoderma. The section of skin is stained with an elastin stain and viewed at high power. There are far more elastin fibers visible as black strands on the left, or normal, side than on the right, or anetodermic, side.

RELATED DISORDERS

A number of other defects of elastin that have been described are similar to anetoderma. For example, endocrine disorders may produce changes in dermal connective tissue resulting in localized loss of elasticity. Perhaps related to anetoderma are the common striae of pregnancy, puberty, Cushing disease, and long-term glucocorticoid therapy. Transverse striae of the back [17] also have many similarities.

The ophthalmologic literature contains a number of reports of eyelid laxity following chronic and recurrent lid dermatitis, as well as that developing spontaneously. Idiopathic lid laxity can exist alone or associated with redundancy of the upper lip (Ascher's syndrome) or with cutis laxa. Lid laxity is also part of the aging process.

Penicillamine is the only drug that produces anetoderma. It is plausible that penicillamine produces this process by interfering with lysyl oxidase, a copper-dependent enzyme essential to normal manufacture of elastin fibers. There is no other evidence of abnormal copper metabolism in patients with the disease.

Diffuse damage to elastic tissue, whether congenital or acquired, is designated cutis laxa (see Chap. 154), but overlaps

between anetoderma and cutis laxa exist. Postinflammatory elastosis and cutis laxa has been described primarily in African children who experience apparent insect bites that heal with atrophic scars resembling anetoderma. At the same time, the children develop more diffuse atrophy without a clear preceding event. A similar case has been reported in a North American child. [18]

While changes in elastin are a well-known part of both aging and actinic damage, occasionally such changes occur in localized areas in relatively young patients. Some young women develop focal loss of mid-dermal elastin, leading to wrinkling and protrusion of tiny papules of nonfollicular skin known as mid-dermal elastolysis. [19] The same process is also associated with systemic lupus erythematosus. [20] A similar clinical and histologic appearance has been described in a patient with pancreatic carcinoma. Presumably, elastases from the tumor caused the dermal damage. [21]

Sometimes the elastin changes are localized about hair follicles, producing perifollicular elastolysis. A similar process may produce the common papular acne scars, which also lack elastin. [22] Elastolysis in aging skin may produce both pseudoxanthoma elasticum–like changes and white fibrous papules of the neck, which seem to combine fibrosis and elastolysis. [23]

DIAGNOSIS AND DIFFERENTIAL DIAGNOSIS

Lesions of anetoderma must be distinguished from other forms of localized loss of substance or circumscribed protrusion of the skin. Atrophic conditions include scars, discoid lupus erythematosus, lichen sclerosus et atrophicus, and more esoteric cutaneous atrophies. The following conditions are included in this list:

1. Atrophoderma of Pasini and Pierini is a major source of confusion both etymologically and clinically. Patients have larger lesions with a sharp peripheral border dropping into a depression with no outpouching. It may be a nonsclerotic variant of morphea, more common in adolescent females. On biopsy, elastin is normal, while collagen may be thickened, but this finding is difficult to quantify. Patients have been identified who clinically best fit atrophoderma but have clear-cut elastolysis; the term *atrophoderma elastolytica discreta* has been proposed for this variant. [24]
2. Patients with atrophia maculosa varioliformis cutis are typically young with subtle, slightly depressed lesions on the temples and cheeks. [25] While the clinical impression is that of pits and scars, perhaps following varicella, no supporting history is obtained. Familial cases have been described. Histologic studies are limited, but in some cases elastic fibers have been damaged.
3. Glucocorticoid-induced atrophy occurs typically over the triceps or buttocks. The lesions resemble atrophoderma, but patients have a history of injection of glucocorticoids. Polarization may show the steroid crystals in the dermis; at other times only dermal atrophy and inflammation are seen. [26] One should be most reluctant to diagnose idiopathic atrophoderma at sites where injections are usually given.
4. Perifollicular atrophoderma is most prominent on the backs of the hands and is often associated with multiple basal cell carcinomas and hair abnormalities in the Bazex syndrome. It is also a feature of the Conradi-Hünermann syndrome, better designated as X-linked dominant ichthyosis or X-linked dominant chondrodysplasia punctata. Perifollicular atrophy has also been described in extreme forms of keratosis pilaris, in which large keratin plugs may produce a dilated patulous follicle. This condition, usually found on the cheeks of young children, has been given a variety of long names. Both of these lesions mimic perifollicular anetoderma but lack elastin changes.

Other protuberant lesions are neurofibromas, connective tissue nevi, lipomatous nevus of Hoffman and Zurhelle, and the adipose herniations in focal dermal hypoplasia. In the last condition, thinning or absence of the dermis, rather than changes in elastin fibers, accounts for the proximity of the subcutis to the epidermis.

TREATMENT

Cosmetically objectionable areas of anetoderma may be excised. No other therapy is of value. Appropriate treatment of inflammatory conditions might forestall later development of atrophy.

REFERENCES

1. Ruiz-Rodriguez R et al: Anetoderma and human immunodeficiency virus infection. *Arch Dermatol* **128**:661, 1992

2. Lindstrom J et al: Increased anticardiolipin antibodies associated with the development of anetoderma in HIV-1 disease. *Int J Dermatol* **34**:408, 1995

3. Stephansson EA, Niemi KM: Antiphospholipid antibodies and anetoderma: Are they associated? *Dermatology* **191**:204, 1995

4. Montilla C, Alarcon-Segovia D: Anetoderma in systemic lupus erythematosus: Relationship to antiphospholipid antibodies. *Lupus* **9**:545, 2000

5. Zaki I et al: Primary anetoderma: Phagocytosis of elastic fibres by macrophages. *Clin Exp Dermatol* **19**:388, 1994

6. Venencie PY et al: Anetoderma: Clinical findings, associations, and long-term follow-up. *Arch Dermatol* **120**:1032, 1984

7. Hirschel-Scholz S et al: Anetodermic prurigo nodularis (with Pautrier's neuroma) responsive to arotinoid acid. *J Am Acad Dermatol* **25**:437, 1991

8. Ang P, Tay TK: Anetoderma in a patient with juvenile xanthogranuloma. *Br J Dermatol* **140**:541, 1999

9. Shames BS et al: Secondary anetoderma involving a pilomatricoma. *Am J Dermatopathol* **16**:557, 1994

10. Child FJ et al: Multiple cutaneous immunocytoma with secondary anetoderma: A report of two cases. *Br J Dermatol* **143**:165, 2000

11. Kasper RC et al: Anetoderma arising in cutaneous B-cell lymphoproliferative disease. *Am J Dermatopathol* **23**:124, 2001

12. Siragusa M et al: Anetoderma secondary to the application of leeches. *Int J Dermatol* **35**:227, 1996

13. Karrer S et al: Primary anetoderma in children: Report of two cases and literature review. *Pediatr Dermatol* **13**:382, 1996

14. Prizant TL et al: Spontaneous atrophic patches in extremely premature infants. Anetoderma of prematurity. *Arch Dermatol* **132**:671, 1996

15. Colditz PB et al: Anetoderma of prematurity in association with electrocardiographic electrodes. *J Am Acad Dermatol* **41**:479, 1999

16. Venencie PY, Winkelmann RK: Histopathologic findings in anetoderma. *Arch Dermatol* **120**:1040, 1984

17. Burket JM et al: Linear focal elastosis (elastotic striae). *J Am Acad Dermatol* **20**:633, 1989

18. Lewis PG et al: Postinflammatory elastolysis and cutis laxa. A case report. *J Am Acad Dermatol* **22**:40, 1990

19. Kim JM, Su WP: Mid-dermal elastolysis with wrinkling. Report of two cases and review of the literature . *J Am Acad Dermatol* **26**:169, 1992

20. Boyd AS, King LE Jr: Mid-dermal elastolysis in two patients with lupus erythematosus. *Am J Dermatopathol* **23**:136, 2001

21. Slater DN, Messenger A: Eruptive elastolysis: A new manifestation of pancreatic carcinoma. *J R Soc Med* **79**:237, 1986

22. Wilson BB et al: Papular acne scars. *Arch Dermatol* **126**:797, 1990

23. Rongioletti F, Rebora A: Fibroelastolytic patterns of intrinsic skin aging: Pseudoxanthoma elasticum-like papillary dermal elastolysis and white fibrous papulosis of the neck. *Dermatology* **191**:19, 1995

24. Carrington PR et al: Atrophoderma elastolytica discreta. *Am J Dermatopathol* **18**:212, 1996

25. Dall'Oglio F et al. Familial atrophia maculosa varioliformis cutis: An ultrastructural study. *Pediatr Dermatol* **18**:230, 2001

26. Schetman D et al: Cutaneous changes following local injection of triamcinolone. *Arch Dermatol* **88**:820, 1963

T>

Chapter 106

Walter Burgdorf

Ainhum and Pseudoainhum

AINHUM
Epidemiology
Etiology and Pathogenesis
Clinical Manifestations
Pathology
Treatment
PSEUDOAINHUM
Clinical Manifestations
Pathology
Treatment

REFERENCES

AINHUM

The name *ainhum* is derived from a word in the Nagos language of East Africa meaning “to saw.” It aptly describes the development of constricting bands about digits that then undergo autoamputation. In the United States, more attention has been focused on the other constricting bands that may mimic ainhum and have been designated *pseudoainhum*.

Epidemiology

Ainhum is traditionally a disease of middle-aged African males accustomed to going barefoot, [1] although it occurs throughout the world in both sexes and all races. In one series it was present in 2 percent of all patients admitted to University Hospital in Ibadan, Nigeria. [2] Occasional isolated cases are reported in North America. [3] Ainhum has been reported in children, but these cases most likely represent a postinfectious or posttraumatic process.

Etiology and Pathogenesis

Chronic trauma, infection, hyperkeratosis, decreased vascular supply, and impaired sensation may alone or in combination produce excessive fibroplasia in a susceptible host. As they tend to form keloids, some blacks appear to respond to relatively minor damage with an excessive fibroblastic reaction. But keloids are not a problem in the scarred digital stumps of ainhum. Impaired blood supply to the little toe has been identified in four patients with ainhum. [4] All had attenuation of the posterior tibial artery and absence of the plantar arterial arch; perhaps poor perfusion predisposed the toe to mechanical trauma.

Clinical Manifestations

Ainhum usually affects the fifth toe (Fig. 106-1); it may be unilateral, but 75 percent of the cases are bilateral. In the beginning, a groove or sulcus appears at the plantar junction of the toe with the sole. The formation of the sulcus has been blamed on rotational stress applied to the bare, mechanically unstable foot, perhaps comparable to the way a piece of plastic is damaged by repeated flexing. As this sulcus deepens, edema develops distally and roentgenographic examination shows resorption of the underlying bone. Slowly and often painfully, the process of autoamputation proceeds, until the digit is dangling by a twisted piece of soft tissue. Eventually, this tenuous connection necroses and amputation is complete. Accompanying problems other than infection and gangrene are uncommon. The entire process is usually slowly progressive, and the disease may require many years to run its full course.

FIGURE 106-1 Ainhum in an African male. (*Courtesy of Wayne M. Meyers, MD.*)

Pathology

The constricting bands consist of fibrous tissue density resembling scar tissue. The band usually extends deep into the subcutaneous layers and may impinge upon underlying skeletal and vascular structures. In addition, there may be moderate inflammation and the overlying epidermis may be hyperplastic or verrucous. [5]

Treatment

Surgery is the mainstay of therapy, for in most cases of ainhum, prompt amputation may allow the patient to escape pain and infection. Early cases may respond to conservative plastic repair with a Z-plasty or similar relaxing closure.

PSEUDOAINHUM

Pseudoainhum or constricting bands are far more common than ainhum outside of Africa and constitute the only differential diagnostic consideration. There are three main categories of pseudoainhum: (1) congenital constricting bands; (2) constricting bands secondary to hyperkeratosis, trauma, chronic infections, and a variety of other conditions; and (3) constriction by external forces, such as hairs or threads.

Clinical Manifestations

Congenital constricting bands are usually caused by the umbilical cord. They usually involve more than one part of the body and frequently encircle large structures such as limbs or even the trunk. They persist throughout life and interfere with normal growth of the involved segment unless surgically treated [6] (Fig. 106-2).

FIGURE 106-2 Congenital constricting bands about two digits. No etiology was identified.

Acquired constricting bands are seen in a variety of conditions. When associated with chronic trauma and infection of the extremities, they blend with ainhum. In general, pseudoainhum is more likely to involve any of the toes or even the hands, rather than being confined to the little toes. In children, chronic dermatophyte infection can be identified and appropriately treated, with apparent complete reversal of the constriction. Pseudoainhum has been seen in a number of seemingly unrelated diseases with vascular abnormalities (Raynaud's disease, diabetes mellitus, linear scleroderma), systemic sclerosis, sensory changes (leprosy, tertiary syphilis, syringomyelia), or scar formation (burns, frostbite, trauma).

Hyperkeratosis is also associated with constricting bands and subsequent loss of digits. This sequence is common in the verrucous hyperkeratotic plantar lesions of yaws. Rarer hereditary forms include Vohwinkel's syndrome or keratoderma hereditaria mutilans, in which palmar and plantar hyperkeratoses as well as starfish-like and linear keratoses on the extremities are seen with the constricting bands. Genetic studies have provided surprising insight into the etiology of Vohwinkel's syndrome. Two different genes are involved. Mutations in the gene for loricrin (1q21), a major component of the epidermal differentiation complex forming the cornified cell envelope lead to Vohwinkel's syndrome with ichthyosis [7], [8] or progressive symmetric erythrokeratoderma. [9] On the other hand, mutations in connexin 26 (GJB2) (13q11-q13) lead to Vohwinkel's syndrome with neurosensory deafness. Connexin 26 is a crucial protein in the formation of gap junctions and docking with adjacent cells. [10], [11] Other less-distinctive palmar and plantar keratodermas have also been reported to be accompanied by constricting bands (see Chap. 52).

Even a disease as common as psoriasis may present with pseudoainhum. For example, a 68-year-old black woman presented with constricting casts about her fingers and an acute pustular hand dermatitis but shortly thereafter she developed typical psoriasis elsewhere. [12] Pseudoainhum was also described in a Caucasian woman with erythropoietic protoporphyria, which generally is not considered a cause of acral scarring. [13]

Artifactitious pseudoainhum may prove to be a most challenging diagnosis. Strands of hair, fibers, or threads may be wrapped around digits or other body parts. This phenomenon is encountered in children or mentally deranged adults. Because of soft-tissue swelling, the ligating band may not be visible and the true cause of the condition not immediately recognized. [14]

Pathology

The constricting bands in all these conditions tend to be more superficial than in ainhum but are otherwise similar. There may be histologic clues to the associated disorder, such as dermatophytosis, foreign bodies, or distinct patterns of keratinization.

Treatment

Constricting bands can be treated with a Z-plasty or similar relaxing closure. Early surgery may avoid further disease progression and damage to underlying structures. [14]

Impending amputation in Vohwinkel's syndrome can sometimes be aborted by therapy with oral etretinate. When chronic fungal or bacterial infections are diagnosed in the early phase of band formation, treatment may reverse the threat to the digit. Other predisposing causes of underlying diseases should be treated aggressively in the hope of preventing loss of a digit.

REFERENCES

1. Browne SG: True ainhum: Its distinctive and differentiating features. *J Bone Joint Surg Br* **47**:52, 1965

2. Cole GJ: Ainhum: An account of fifty-four patients with special reference to etiology and treatment. *J Bone Joint Surg Br* **47**:43, 1965

3. Greene JT, Fincher RM: Case report: Ainhum (spontaneous dactylolysis) in a 65-year-old American black man. *Am J Med Sci* **303**:118, 1992

4. Dent DM et al: Ainhum and angiodysplasia. *Lancet* **2**:396, 1981

5. Kerhisnik W: The surgical pathology of ainhum (dactylolysis spontanea). *J Foot Surg* **25**:95, 1986

6. Ray M et al: Amniotic band syndrome. *Int J Dermatol* **27**:312, 1988

7. Camisa C, Rossana C: Variant of keratoderma hereditaria mutilans (Vohwinkel's syndrome): Treatment with orally administered isotretinoin. *Arch Dermatol* **120**:1323, 1984

8. Maestrini E et al: A molecular defect in loricrin, the major component of the cornified cell envelope, underlies Vohwinkel's syndrome. *Nat Genet* **13**:70, 1996

9. Ishida-Yamamoto A et al: The molecular pathology of progressive symmetric erythrokeratoderma: A frameshift mutation in the loricrin gene and perturbations in the cornified cell envelope. *Am J Hum Genet* **61**:581, 1997

10. Solis RR et al: Vohwinkel's syndrome in three generations. *J Am Acad Dermatol* **44**:376, 2001

11. Maestrini E et al: A missense mutation in connexin 26, D66H, causes mutilating keratoderma with sensorineural deafness (Vohwinkel's syndrome) in three unrelated families. *Hum Mol Genet* **8**:1237, 1999

12. McLaurin CI: Psoriasis presenting with pseudoainhum. *J Am Acad Dermatol* **7**:132, 1982

13. Christopher AP et al: Pseudoainhum and erythropoietic protoporphyria. *Br J Dermatol* **118**:113, 1988

14. Pickus EJ et al: Digital constriction bands in pseudoainhum: Morphological, radiographic, and histological analysis. *Ann Plast Surg* **47**:194, 2001

T>

Chapter 107

Steffen Albrecht

Neoplasias and Hyperplasias of Neural and Muscular Origin

TUMORS OF SKELETAL MUSCLE
Neuromuscular Hamartoma
Rhabdomyomatous Mesenchymal Hamartoma
Rhabdomyoma
Rhabdomyosarcoma
TUMORS OF SMOOTH MUSCLE
Congenital Smooth Muscle Hamartoma
Leiomyoma
Leiomyosarcoma
BENIGN PROLIFERATIONS OF NERVES—NEUROMAS
Morton's Neuroma
Hyperplastic/Hypertrophic Pacinian Corpuscle (“Pacinian Neuroma”)
Traumatic (Amputation) Neuroma
Palisaded Encapsulated Neuroma
Multiple Endocrine Neoplasia Syndrome Type 2B (Multiple Mucosal Neuromas)
BENIGN NERVE SHEATH NEOPLASMS
Schwannoma
Neurofibroma
Neurothekeoma
Perineurioma
MALIGNANT TUMORS OF NERVE
Malignant Peripheral Nerve Sheath Tumor
Primitive Neuroectodermal Tumor
MISCELLANEOUS TUMORS
Granular Cell Tumor
Cutaneous Lesions with Meningothelial Cells
Myxopapillary Ependymoma
Cutaneous Ganglioneuroma and Ganglion Cell Tumor
Cerebral Heterotopia

REFERENCES

TUMORS OF SKELETAL MUSCLE

This group of lesions includes the nonneoplastic neuromuscular and rhabdomyomatous mesenchymal hamartomas, as well as neoplasms with striated muscle differentiation, that is, benign rhabdomyomas and malignant rhabdomyosarcomas. Contrary to most other classes of mesenchymal tumors where benign neoplasms are more frequent than malignant ones, rhabdomyosarcomas far outnumber rhabdomyomas. Interestingly, both types of neoplasms have been described in patients with Gorlin's nevoid basal cell carcinoma syndrome. [1]

Neuromuscular Hamartoma

This is a very rare entity of which less than 20 cases have been reported in the English language literature; [2] it is also known as *neuromuscular choristoma* or *benign triton tumor*. Most reported cases involved large nerves; dermal location is unusual. Histologically, the lesion is composed of bundles of nerves and fascicles of mature skeletal muscle fibers, all of which are intimately intermingled to the point where some muscle fibers actually grow within the nerve fascicles. This very unusual growth pattern along with the lack of other mesenchymal elements distinguish the neuromuscular hamartoma from the rhabdomyomatous mesenchymal hamartoma described below.

Rhabdomyomatous Mesenchymal Hamartoma

Rhabdomyomatous mesenchymal hamartoma (RMH) is a rare entity; only about two dozen cases have been described. [3] It is also known as *striated muscle hamartoma, hamartoma of cutaneous adnexa and mesenchyma,* or *congenital midline hamartoma*. It presents as a pedunculated nodule (“skin tag”), usually on the face around the eyes, nose, or mouth. Most are solitary; rare patients with multiple lesions have been described. Although most are congenital, a few have been noted only in adults. Histologically, the dermis contains randomly oriented, mature, striated muscle fibers with admixed mesenchymal elements (adipose tissue, vessels, collagen) and prominent nerves. Skin appendages are also prominent. Excision is curative. Patients with RMH of the ocular adnexa invariably have ocular malformations [3] and some patients with nonocular RMH have other malformations, including cerebral ones. In fact, as reviewed elsewhere, [3] some patients with RMH and multiple associated malformations fulfill the criteria for Delleman's oculocerebrocutaneous syndrome or Goldenhar's oculoauriculovertebral syndrome, which may be related. A diagnosis of RMH in a patient thus should prompt further investigations, especially to rule out brain malformations.

Rhabdomyoma

Cardiac rhabdomyomas occur in about 30 to 50 percent of patients with tuberous sclerosis (TS) and, conversely, a similar proportion of patients with cardiac rhabdomyoma have TS. [4] Sporadic examples are usually solitary, whereas

TS-associated cases are often multiple. A minority becomes symptomatic by obstructing cardiac flow or by causing dysrhythmias. Because it is now well established that many cardiac rhabdomyomas regress spontaneously with age, surgical removal is reserved for patients with severe hemodynamic compromise or refractory dysrhythmias. [4]

Extracardiac rhabdomyomas are not associated with TS. [5] They are subdivided into three types: adult, fetal, and genital. [5] The designation as “adult” or “fetal” refers to the tumor's resemblance to adult or fetal skeletal muscle, not to the age of the patient. While the adult type is indeed seen mostly in adults, many fetal rhabdomyomas also occur in older children and adults. [5] Both types occur predominantly in male patients and usually arise in the soft tissues or mucosal surfaces of the head and neck region. As such, they are unlikely to come to the attention of a dermatologist. The fetal type, however, has been repeatedly associated with Gorlin's syndrome. [5] Genital rhabdomyomas usually occur as small polypoid vaginal or vulvar lesions in middle-aged women. [5]

Rhabdomyosarcoma

Rhabdomyosarcomas are aggressive sarcomas occurring most commonly in children. There are four histologic types: embryonal, alveolar (ARMS—alveolar rhabdomyosarcoma), pleomorphic, and undifferentiated. ARMS is characterized at the molecular level by novel fusion genes combining the forkhead (*FKHR*) gene with either the *PAX3* or the *PAX7* gene, producing a t(2;13) or t(1;13), respectively. [6] Rhabdomyosarcoma is the most frequent soft tissue sarcoma of childhood and involves predominantly the head and neck region, the genitourinary tract, and the extremities. [7] Only about 0.7 percent occur as primary skin lesions; [7] nevertheless, in one series, rhabdomyosarcoma was the most frequent primary malignant pediatric skin tumor, making up about one-third of such cases [8] and very rare cases of primary cutaneous rhabdomyosarcoma have been reported in adults. [9] Some of these cases arose in giant congenital nevi either pure or as part of a mixed malignant neoplasm. [10] A deep soft tissue rhabdomyosarcoma can also extend into the overlying skin and present as a cutaneous nodule. Metastases to the skin also occur. [7] In fact, in children, rhabdomyosarcoma is the most common nonhematological cutaneous metastatic tumor. [11]

About a dozen cases of congenital ARMS have been reported. [6], [7], [12] Roughly half of these patients presented as a “blueberry muffin baby” with multiple cutaneous and subcutaneous metastases. Prognosis has been dismal, with all patients dying in spite of aggressive therapy, usually within a few weeks to months after diagnosis. Interestingly, none of four cases examined for the typical ARMS-associated fusion genes was positive, [6], [12] leading one group to postulate that congenital ARMS is a clinically and genetically distinct entity with very poor prognosis. [6] Rhabdomyosarcoma has been reported in association with Gorlin's syndrome [1] and an embryonal rhabdomyosarcoma has been described in a patient with cardiofaciocutaneous syndrome. [13] There is also definitely an increased incidence of rhabdomyosarcoma in type 1 neurofibromatosis (NF1). [14]

TUMORS OF SMOOTH MUSCLE

The dermis contains smooth muscle fibers in the arrectores pilorum muscles, in the walls of dermal blood vessels, and in the dartos muscle of the scrotum, vulva, nipple, and areola. As with striated muscle tumors, there are three types of cutaneous smooth muscle lesions: hamartomas, leiomyomas, and leiomyosarcomas. Whether neoplastic or not, smooth muscle cells are recognized histologically by their spindle cell shape, their eosinophilic, fibrillary cytoplasm, and their blunt ended, oval (“cigar-shaped”) nuclei. By immunohistochemistry, they express smooth muscle actin (also called a-actin) and the muscle-specific intermediate filament desmin, but are negative for S-100 protein and epithelial membrane antigen (EMA).

Congenital Smooth Muscle Hamartoma

First described by Stokes in 1923, [15] congenital smooth muscle hamartoma (CSMH) has been increasingly recognized during the last two decades. Most cases are congenital; a prevalence of up to 0.2 percent in children has been reported. [16] Notwithstanding the name, some cases appear to be acquired. [16], [17] CSMH usually arises on the trunk or an extremity and may take one of several forms: a solitary patch or plaque with or without a follicular pattern, multiple lesions (rarely with a linear distribution), and diffuse skin involvement producing a “Michelin-tire baby.” [18], [19] Vellus hairs may be prominent. Clinically, most lesions cause concern because of their congenital nature or for cosmetic reasons. Some can produce worm-like movements (“vermiculation”) and stroking may induce transient induration with piloerection (pseudo-Darier's sign).

Histologically, there is a marked increase of smooth muscle fibers in the dermis, especially in its deeper portions. The fibers are grouped in sharply circumscribed bundles that are arranged haphazardly and are not necessarily attached to hair follicles. There may be basal hyperpigmentation, as well as acanthosis and papillomatosis of the overlying epidermis. The grouping of the smooth muscle fibers into discrete bundles and the fact that these bundles do not intermingle with the dermal collagen fibers distinguish smooth muscle hamartomas from pilar leiomyomas. Smooth muscle hamartoma shares some clinical and histologic features with Becker's nevus; some authors consider these lesions as part of a spectrum, [16] while others prefer to keep them separate. [17], [20] No specific treatment is indicated. Although the localized form is usually not associated with other malformations, [16] some of the children with the generalized form did have multiple associated congenital malformations [21] and growth, as well as psychomotor retardation. [21], [22]

Leiomyoma

Leiomyomas of the skin are generally divided into three categories: (1) solitary or multiple pilar leiomyomas arising from the arrectores pilorum muscles; (2) angioleiomyomas, which are thought to arise from vascular smooth muscle; and (3)

dartoic leiomyomas originating in the dartos muscles of the genitalia, areola, and nipple. Most are acquired.

Pilar leiomyomas range in size from several millimeters to a centimeter and are fixed to the skin but freely moveable with it over underlying structures. The skin often has a reddish brown color (Fig. 107-1). The tumors can coalesce to form plaques. The extensor surfaces of limbs, trunk, and sides of face and neck are most commonly involved. The lesions are often sensitive to touch or cold and may be spontaneously painful. Angioleiomyomas are mostly seen on the legs in women and can reach a size of several centimeters. Dartoic leiomyomas are usually solitary, deep, and occasionally pedunculated. Leiomyomas involving the nipple are surprisingly rare. [23] Smooth muscle proliferations resembling pilar leiomyomas have been reported in some cases of nevus sebaceous. [24]

FIGURE 107-1 Clinical photograph showing multiple leiomyomas involving the back.

Histologically, pilar leiomyomas are made up of a poorly circumscribed proliferation of haphazardly arranged smooth muscle fibers located in the dermis that appear to infiltrate the surrounding tissue and may extend into the subcutis (Fig. 107-2). They are usually separated from the epidermis by a thin grenz zone. On the other hand, angioleiomyomas are well circumscribed, richly vascularized dermal or subcutaneous nodules composed of well-differentiated smooth muscle fibers (Fig. 107-3). Occasionally, the vessel of origin can be identified. Dartoic leiomyomas resemble pilar leiomyomas which are distinctive lesions, not easily confused with other tumors. Angioleiomyoma should be distinguished from schwannoma; this is discussed in the latter section. Excision is the treatment of choice for solitary leiomyomas if pain is a problem or because of cosmetic concern.

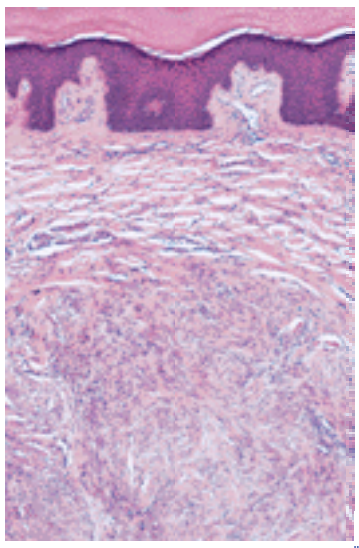

FIGURE 107-2 Histologic appearance of a pilar leiomyoma. The tumor has an irregular outline. It is composed of fascicles of smooth muscle fibers with intermingled dermal collagen and is separated from the epidermis by a grenz zone of uninvolved dermis. (H&E, ×40.)

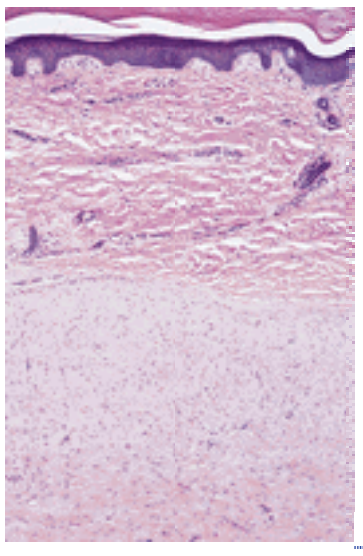

FIGURE 107-3 Histologic appearance of an angioleiomyoma. Compared to the pilar leiomyoma, this tumor is more sharply circumscribed (but not encapsulated). Furthermore, the smooth muscle fibers form a solid nodule with little, if any, intervening collagen. (H&E, ×40.)

Special mention should be made of patients with multiple pilar leiomyomas. Starting in early adulthood, these patients develop increasing numbers of tumors and can have hundreds to thousands of them; transmission appears to be autosomal dominant with variable penetrance. [25] One patient with multiple leiomyomas was also mentally retarded and had craniofacial dysmorphism (and a similarly affected sister); the patient's karyotype showed anomalies of chromosomes 9 and 18. [26] However, other workers found normal karyotypes in three patients with multiple leiomyomas without other lesions. [27] Women affected by the condition may also have uterine smooth muscle tumors, an entity named *familial leiomyomatosis cutis et uteri* or *Reed's syndrome*. [25] Pain may be a major problem in these patients and excision of all lesions is obviously not feasible. The pain may respond to treatment with nitroglycerin, phenoxybenzamine, or nifedipine. [25], [28] Trials assessing the effect of a given medication on cold-induced pain may be helpful in selecting an agent effective for a particular patient. Occasionally, the tumors are associated with polycythemia and erythropoietin-like activity has been demonstrated in tumor extracts. [29] Recently, an association between familial cutaneous leiomyomas and a peculiar histological variant of renal cell carcinoma with linkage to chromosome arm 1q has been reported. [30]

Leiomyosarcoma

Leiomyosarcomas are malignant mesenchymal tumors usually found in the uterus, the retroperitoneum, gastrointestinal tract, or deep soft tissue. They do, however, rarely occur as primary skin tumors. The legs are the favored site. Some cases arise in fields of prior radiotherapy or at sites of previous trauma. [31] They may be painful or tender. Some patients have multiple lesions; four of seven such patients in one series had a previous retroperitoneal leiomyosarcoma, [32] raising the possibility that the cutaneous lesions could be metastases. Cutaneous (or “superficial”) leiomyosarcomas are divided into either a dermal or subcutaneous type, based on their origin. [31] Dermal lesions usually present as small (<2 cm) nodules that are fixed to the epidermis and can be ulcerated. Subcutaneous tumors tend to be larger and are usually not associated with epidermal changes.

Histologically, the tumor cells are still identifiable as having smooth muscle differentiation. However, their malignant character is evidenced by nuclear hyperchromasia, prominent nucleoli, mitotic activity, and possibly necrosis. The cells are arranged in irregular, intersecting bundles and fascicles. The tumors may be more or less circumscribed or frankly infiltrative. *Granular cell, epithelioid cell, myxoid,* and *sclerosing* (or *desmoplastic*) variants have been described. [33] Leiomyosarcomas have to be distinguished from other malignant spindle cell tumors of the skin, such as spindle cell melanoma, spindle cell squamous cell carcinoma, or atypical fibroxanthoma. Immunohistochemistry and electron microscopy can be very useful in this regard.

As reviewed elsewhere, [31] the most important prognostic factor is the origin of the tumor: although both dermal and subcutaneous lesions may recur locally in up to one-third to one-half of cases, the risk of metastasis is about 5 to 10 percent for the former versus up to 50 to 60 percent for the latter. [31] Standard therapy for either type consists of wide local excision and reexcision for recurrent lesions. [31] Especially in acral locations, complete excision may require amputation. [31] Alternative treatment modalities that may be applicable to selected patients include the Mohs technique, cryosurgery, and isolated limb perfusion with chemotherapeutic agents. [31], [34]

BENIGN PROLIFERATIONS OF NERVES—NEUROMAS

Quite literally, neuromas are tumors composed of a proliferation of nerves; that is, they contain both Schwann cells and axons. This is not to say, however, that they constitute true neoplasms; on the contrary, these lesions appear to represent nonneoplastic overgrowths of preexisting neural structures. The first three lesions in this section are mentioned mostly for sake of completeness because they are usually not seen by dermatologists.

Morton's Neuroma

This lesion is not a neuroma in the strict sense, but rather a chronic compressive neuropathy typically involving the third digital plantar nerve along its course through its intermetatarsal space. [35] Repeated microtrauma to the nerve causes epi- and perineurial fibrosis, leading to nerve enlargement, which makes the nerve still more susceptible to trauma. Middle-aged women are predominantly affected; “nonsensible” footwear (i.e., pointed high-heeled shoes) may be partly to blame. Conservative measures include a metatarsal pad or steroid injections; surgical removal is curative. [35]

Hyperplastic/Hypertrophic Pacinian Corpuscle (“Pacinian Neuroma”)

Pacinian corpuscles are the largest sensory corpuscles in the body, [36] normally measuring 1 to 2 mm on average. They are mechanoreceptors involved in deep touch and vibrational sense. More than 30 cases of hyperplasia and/or hypertrophy of pacinian corpuscles (“pacinian neuroma”) have been reported. [36], [37] This presents clinically as an extremely painful and exquisitely tender nodule or swelling of the digital pulp. (Their painfulness is somewhat surprising, given that normal pacinian corpuscles are not thought to be involved in pain perception.) A history of preceding local trauma is present in about half the patients. Treatment is by excision. These lesions should not be confused with rare cases of true nerve sheath neoplasms such as neurofibromas and schwannomas that can occasionally have structures resembling pacinian or meissnerian corpuscles.

Traumatic (Amputation) Neuroma

When a nerve is partially or completely severed, the axons distal to the point of transection undergo Wallerian degeneration, whereas the axons and Schwann cells of the proximal stump proliferate. If the two nerve segments are reapproximated, and if the Schwann cells and the endoneurium of the distal segment remain intact, it can be reinnervated. However, if there is interposition of tissue between the two segments (e.g., because of scarring) or if the distal segment is lost (e.g., by amputation), axons and Schwann cells will still grow out of the proximal stump but will fail to reach their target and form instead a disorganized tangle of nerve twiglets extending into the surrounding soft tissue, thus forming a traumatic neuroma. The pain associated with traumatic neuromas may be caused by contraction of the scar tissue leading to nerve compression or ischemia. [38] The nerve proliferation typical of accessory digits may also represent an example of traumatic neuroma. Treatment can be conservative or surgical; the latter aims either at preventing axonal growth or at isolating the nerve from injury. [38]

Palisaded Encapsulated Neuroma

This lesion was initially described by Reed et al. in 1972, [39] and although by no means uncommon, it received relatively little attention until the last decade or so. [40], [41], [42], [43], [44] and [45] Palisaded encapsulated neuroma (PEN) presents in adults, mostly in their third to fifth decade, as an asymptomatic papule, usually less than 6 mm in diameter, located on the face in approximately 80 percent of cases. [42], [43] and [44] The sex distribution is roughly equal. Although it makes up approximately a quarter of benign cutaneous neural lesions, [44] PEN is almost never diagnosed clinically; the most common misdiagnoses are nevus, basal cell carcinoma, and adnexal tumor.

Histologically, there is a well-demarcated dermal nodule composed of fascicles of Schwann cells (Fig. 107-4). Contrary to what the name implies, the capsule is rarely complete and the palisading typical of schwannomas is often indistinct at best. This has led one author to propose rechristening these tumors *circumscribed solitary neuromas of skin*. [41] Special stains demonstrate variable numbers of axons within the lesion. A dermal nerve twig is often seen in continuity with the neuroma and its perineurium merges with the tumor capsule. Immunohistochemical data [40], [41], [43] also support a perineurial phenotype of the tumor capsule as opposed to the Schwannian phenotype of the cells making up the lesion proper. In fact, some PENs may actually be small dermal schwannomas that contain a few residual entrapped axons. [45]

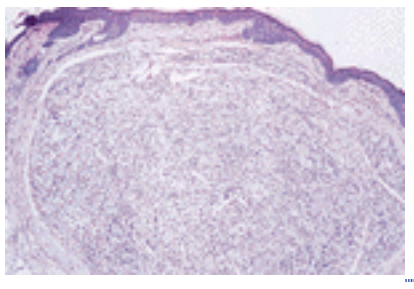

FIGURE 107-4 Histologic appearance of a typical palisaded encapsulated neuroma. The tumor is composed of fascicles of Schwann cells and surrounded by a delicate capsule best seen on the left. There is a suggestion of nuclear palisading but this is not as pronounced as that seen in a schwannoma. (The axons that are normally also present cannot be seen on this stain.) (H&E, ×40.)

Excision is the treatment of choice. There is no evidence of an association between PEN and neurofibromatosis, and although the individual lesions may be histologically quite similar, there is also no evidence linking PEN to the multiple endocrine neoplasia syndrome type 2B (multiple mucosal neuroma syndrome).

Multiple Endocrine Neoplasia Syndrome Type 2B (Multiple Mucosal Neuromas)

Multiple endocrine neoplasia syndrome type 2 (MEN2) is an autosomal dominant disease associated with hyperplasia and/or tumors of the calcitonin-producing cells of the thyroid gland (C cells), the adrenal medulla, the parathyroids, and the enteric autonomic nervous system. MEN2A is characterized by the triad of medullary carcinoma of the thyroid gland, pheochromocytoma, and parathyroid hyperplasia. The neoplastic spectrum of MEN2B is similar, but in addition, these patients have malformations (marfanoid habitus, facial dysmorphism) and overgrowth of mucosal nerves giving rise the so-called mucosal neuromas. MEN2A and 2B are caused by different germ-line mutations of the *RET* proto-oncogene located on chromosome 10q11.2. [46]

The neuromas appear by 2 years of age and thus serve as an important clinical marker for identifying affected individuals in MEN2B families. [46] They involve all mucosal surfaces; those accessible to clinical examination (oral mucosa, lips, tongue, conjunctivae), appear as pink, pedunculated nodules. The lips become enlarged and bulging, and the eyelids may be everted. Histologically, there is hypertrophy of the mucosal nerves; some lesions may resemble palisaded encapsulated neuromas. Other cutaneous lesions include café-au-lait spots, facial lentigines and hyperpigmentation of the hands and feet.

The main threat to these patients is the development of tumors. Virtually all will have a medullary carcinoma of the thyroid by early adulthood and about half will develop pheochromocytomas. The thyroid carcinoma is highly aggressive. Early detection and prophylactic thyroidectomy by 5 years of age are essential. [46]

BENIGN NERVE SHEATH NEOPLASMS

Cells that make up the nerve sheath include the Schwann cells and the endo- and perineurial fibroblasts. Benign nerve sheath tumors used to be simply divided into neurofibromas and schwannomas. In recent years, however, several new

subtypes as well as two “new” lesions have been added. Unfortunately, the nomenclature is at times quite confusing with identical lesions receiving different names and identical names referring to different lesions.

Schwannoma

Schwannomas are also called *neurinomas, neurolem(m)omas,* or *neurilem(m)omas*. They usually arise in cranial nerves, especially the vestibular nerve (the so-called acoustic neuromas are actually schwannomas of the vestibular division of the eighth cranial nerve); they also occur in other peripheral nerves and spinal roots. Therefore, most schwannomas are either intracranial, intraspinal, or deep soft-tissue lesions; dermal location is uncommon. Schwannomas occur sporadically or in association with NF2, which is discussed in greater detail in Chap. 190. Briefly, the hallmark of NF2 is the presence of bilateral vestibular schwannomas. Patients with NF2 also frequently develop meningiomas, schwannomas of the spinal roots, and gliomas. The NF2 gene is located on the long arm of chromosome 22 (22q12). It codes for a protein that is variously called merlin or schwannomin and which has tumor-suppressor activity. [47]

In the skin, schwannomas present as rather nondescript, asymptomatic papules or nodules. Because a schwannoma is a neoplastic proliferation composed only of Schwann cells and devoid of axons, it grows as an eccentric nodule, displacing its nerve of origin. This growth pattern and its cellular composition distinguish schwannoma from neurofibroma (Fig. 107-5). Histologically, schwannomas are well encapsulated; in fact, the capsule is derived from the epineurium of the schwannoma's nerve of origin. The tumor cells are typically slender, spindled, elongated, and “wavy” in appearance. Areas of high cellularity (Antoni A) alternate with areas of hypocellularity (Antoni B), which can have a myxoid quality. In the cellular A areas, adjacent cells have a tendency to align, creating stacks of nuclei known as palisades. These palisades are separated by an anuclear area made up of stacked cytoplasmic extensions; these stacks of nuclei and cell processes form the so-called Verocay bodies (Fig. 107-6). Tumor blood vessels are characteristically thick and hyalinized. By immunohistochemistry, schwannomas are strongly positive for S-100 protein and negative for EMA and smooth muscle markers (desmin, a-actin), which distinguishes them from perineuriomas (S-100 negative, EMA positive, desmin and a-actin negative) and leiomyomas (S-100 and EMA negative, desmin and a-actin positive).

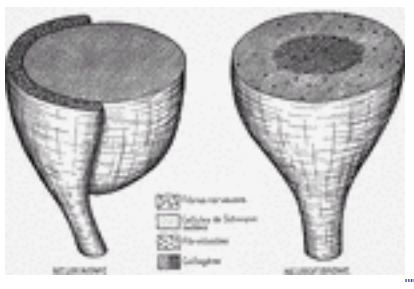

FIGURE 107-5 Diagram illustrating the difference between a schwannoma and a neurofibroma. A schwannoma (*left*) is a circumscribed tumor composed only of Schwann cells which arises eccentrically from a nerve. A neurofibroma (*right*), on the other hand, is a segmental hyperplasia of all the nerve's constituent elements. This also illustrates why a schwannoma can often be resected without sacrificing its nerve of origin whereas resection of a neurofibroma always requires transection of that nerve. (*Reproduced from Escourolle R, Poirier J: Manuel élémentaire de neuropathologie, 2nd ed. Paris, Masson Publishing, 1977, p 36, with permission*.)

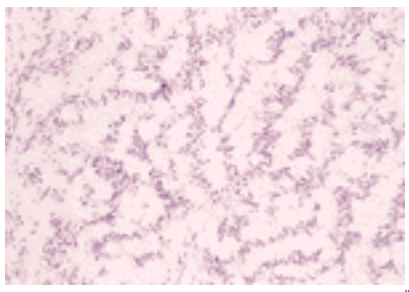

FIGURE 107-6 Photomicrograph of a schwannoma showing orderly arrangement of tumor cells into palisades and Verocay bodies. (H&E, ×100.)

Several histological variants of schwannoma are recognized. Some tumors have extensive degeneration with cyst formation, old hemorrhage, and marked hyalinization (*ancient schwannoma*). This may be accompanied by bizarre nuclear morphology that does not imply malignancy. Other schwannomas are quite cellular and poor in hypocellular areas with few palisades or Verocay bodies. These tumors have been called *cellular schwannomas;* [48] they may have significant mitotic activity but behave in a benign fashion. This type only rarely involves subcutaneous tissue. Some schwannomas are melanotic. A rare and unusual variant is melanotic and also contains concentrically lamellated microcalcifications called psammoma bodies. [49] Although this *psammomatous melanotic schwannoma* only rarely involves the skin, it is noteworthy that roughly half the affected patients have Carney's syndrome and that about 10 percent of cases metastasize. [49]

In recent years, attention has been drawn to the *plexiform* variant of schwannoma. As the name implies, this tumor grows within a nerve, forming an agglomeration of small nodules and interconnected cords. Contrary to ordinary schwannomas, plexiform schwannomas have a distinct predilection for the dermis and subcutaneous tissue. The relationship between plexiform schwannoma and neurofibromatosis is somewhat ill defined, because of confusing nomenclature and because some authors do not distinguish between NF1 and NF2. Judging from the literature, most plexiform schwannomas are not associated with either type of NF, [50], [51], [52] and [53] especially if they are solitary. Some solitary, and especially multiple, plexiform schwannomas, however, are definitely associated with NF2. [52], [53]

Finally, there is an entity called *neurolemmomatosis* or *schwannomatosis* in which patients present with multiple cutaneous, soft tissue, or spinal schwannomas, but without vestibular schwannomas or other central nervous system (CNS) tumors typical of NF2 (such as meningiomas or ependymomas); this entity is usually sporadic but can rarely be familial. Based on the literature, it may well represent more than one entity. Some of these patients probably have unrecognized NF2, either because they have had insufficient cranial imaging to exclude small vestibular schwannomas or because they are still too young to exclude the eventual growth of such tumors. [54] Among those in whom vestibular schwannomas have been definitively excluded, a minority do nevertheless carry germ-line mutations of the NF2 gene. [54], [55] Some patients are in fact somatic mosaics, which could explain the limited extent of their disease. [56], [57] However, the majority of schwannomatosis patients (including those with the familial form) do not have germ-line mutations of NF2, even though their schwannomas do harbor the typical somatic mutations seen in NF2-associated schwannomas. [56] This intriguing finding led the authors of the study to surmise that this type of schwannomatosis is due to an inheritable predisposition to somatic NF2 mutations. [56] Finally, a last group of patients has neither germline nor somatic NF2 mutations; [56] in these individuals, an as yet unknown gene may be involved.

Excision is the treatment of choice for schwannoma. Plexiform schwannomas may recur, but this probably reflects incomplete excision due to their multifocal nature rather than true recurrence.

Neurofibroma

Neurofibroma can be seen as a sporadic lesion or in the context of NF1 which is covered in detail in Chap. 190. At this point, suffice it to say that patients with NF1 have multiple cutaneous and noncutaneous neurofibromas as well as café-au-lait spots, axillary and/or inguinal freckling, iris hamartomas (Lisch nodules), and certain bony malformations. They may also develop other tumors, especially pilocytic astrocytomas of the optic pathways, malignant nerve sheath neoplasms, rhabdomyosarcoma, and pheochromocytoma as well as myeloid leukemia. [14] The gene for NF1 is located on the long arm of chromosome 17 (17q11.2). At least one of the functions of the NF1 protein, which is called *neurofibromin,* appears to be regulation of the *ras* oncogene. [14]

Neurofibromas arise in nerves, and, consequently, are found wherever nerves are found. Those likely come to the attention of the dermatologist are the ones located in the dermis and subcutaneous tissue. Cutaneous neurofibromas present as protuberant to pedunculated, flesh-colored papules or nodules that are typically quite soft on palpation, contrary to what the term “fibroma” might imply. They can be very pruritic. Subcutaneous neurofibromas are usually larger than dermal ones and consist of a fusiform swelling involving a larger nerve. In patients with NF1, the tumors start appearing in early childhood and may be quite variable in size. NF1 has a highly variable expressivity, even among patients from the same kindred who have identical germ-line mutations. [58] Patients may therefore have from a few to thousands of lesions with corresponding degrees of disfigurement and functional impairment. A special type of neurofibroma is the *plexiform* variant, which involves an entire large nerve and its branches (Fig. 107-7), forming a mass of tangled, ropelike structures that feel like a “bag of worms” on palpation and that can reach an enormous size and be associated with massive soft tissue overgrowth leading to significant functional impairment. A plexiform neurofibroma is considered to be pathognomonic of NF1.

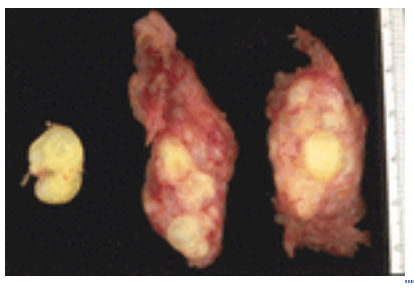

FIGURE 107-7 Cross-sections of a plexiform neurofibroma of the facial nerve in a child with NF1. The main nerve is on the left. Note its massive enlargement and involvement of its branches.

Neurofibromas are polyclonal proliferations [59] and can be regarded as hyperplasias of all the nerve's elements (see Fig. 107-5). Histologically, a neurofibroma is composed of Schwann cells, fibroblasts, endothelial cells, perineurial fibroblasts, mast cells, and axons, all arranged haphazardly in a matrix that contains collagen and myxoid ground substance in various proportions (Fig. 107-8). Dermal neurofibromas are circumscribed but unencapsulated nodules. A rare subtype of neurofibroma is the *diffuse* variant that involves the skin and subcutaneous tissue in a plaquelike fashion, surrounding rather than displacing preexisting structures such as skin appendages. Plexiform neurofibromas have the same histologic appearance as ordinary neurofibromas but instead of involving merely a segment of a nerve, they involve an entire nerve and its branches; they also infiltrate the surrounding soft tissue. Rarely, neurofibromas can contain structures resembling meissnerian or pacinian corpuscles. A variant with a very unusual histologic appearance was recently described as *dendritic cell neurofibroma with pseudorosettes*. [60] Finally, some neurofibromas are melanotic.

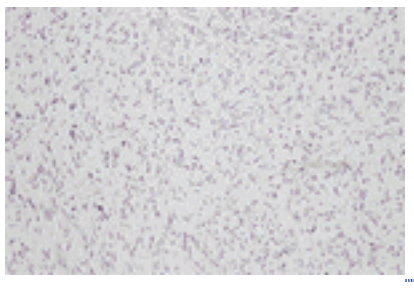

FIGURE 107-8 Histology of a neurofibroma. Neurofibromas lack the orderly arrangement of cells that is typical of schwannomas. (H&E, ×100.)

Solitary dermal neurofibromas can be simply excised. Resection of a neurofibroma involving an identifiable nerve by definition implies sacrificing the nerve. Management of patients with NF1 is discussed in Chap. 190.

Neurothekeoma

As is often the case with rare lesions, this one goes under a disturbing variety of names, including *nerve sheath myxoma* (the most frequently used alternate name), *benign myxoid tumor of nerve sheath, perineurial myxoma, bizarre cutaneous neurofibroma,* and *pacinian neurofibroma,* the last two being real misnomers. Two large series established it as an entity; [61], [62] most of the literature concerning this lesion has been reviewed recently. [63]

Three-fourths of these tumors arise in the dermis of the head, neck, shoulder, or arm where they present as nondescript, asymptomatic papules. The “classical” neurothekeoma is hypocellular, very myxoid, with a distinctly lobulated growth pattern, and immunohistochemical evidence of nerve-sheath derivation. [63] The tumor expands the dermis, leaving a grenz zone. Variants of neurothekeoma that are more cellular and lack the myxoid matrix have been reported as *cellular neurothekeoma,* but these tumors often lack evidence of nerve sheath differentiation and may be more closely related to fibrohistiocytic tumors. [63], [64] Neurothekeomas are clinically benign and there is no recurrence after complete excision. There is no evidence at this point that they are associated with NF1, NF2, or other types of phakomatosis.

Perineurioma

There are two forms of perineurioma. One is *intraneural* and presents as a fusiform swelling of a major nerve, often with signs of mononeuropathy. Histologically, the tumor is confined to the nerve and composed of very delicate, elongated spindle cells that grow around axons, forming whorls composed of multiple concentric layers. [65] These whorls are similar to the “onion bulbs” seen in certain types of hypertrophic neuropathy and especially in the older literature, intraneural perineurioma is often called *localized hypertrophic neuropathy*. However, the cells in perineurioma clearly differentiate along perineurial lines, as shown by ultrastructure and immunohistochemistry, [65] whereas the “onion bulbs” of hypertrophic neuropathy are composed of Schwann cells. Furthermore, cytogenetic evidence indicates that intraneural perineurioma is a true neoplasm. [65] The other form of perineurioma is *extraneural*. It usually arises in soft tissue, but recently, cutaneous examples are increasingly being reported, possibly due to more routine use of immunohistochemistry for the diagnosis of cutaneous spindle cells tumors. This clearly identifies tumors with perineurial differentiation (EMA positive; S-100 protein, a-actin, and desmin negative) and has already led to the description of several histological variants. [66], [67], [68], [69] and [70] Excision is curative. Neither intra- nor extraneural perineuriomas appear to be associated with NF1 or NF2, but chromosome 22 deletions have been described in one intraneural and two cutaneous perineuriomas. [65], [66], [71] Analysis of these tumors for somatic NF2 mutations would clearly be of interest.

MALIGNANT TUMORS OF NERVE

Malignant Peripheral Nerve Sheath Tumor

Malignant peripheral nerve sheath tumor (MPNST) is also known as *neurofibrosarcoma, neurogenic sarcoma,* and *malignant schwannoma,* but because its histogenesis is uncertain, the noncommittal term MPNST is preferred. These neoplasms arise mostly in the deep soft tissues; primary cutaneous MPNSTs are rare but are being increasingly recognized. [72], [73] MPNSTs often have a relatively nonspecific “spindle-cell sarcoma” histology; the classical features of Schwannian differentiation are only seldom seen. Often, the major reason for calling such a tumor MPNST is that it shows some (often very focal) immunoreactivity for S-100 protein and arises within a nerve or a neurofibroma; origin from either of these can be demonstrated in many cases. [74] Plexiform neurofibromas and neurofibromas involving medium-sized to large nerves are the ones most likely to undergo malignant degeneration, which does not occur in cutaneous neurofibromas. [74] Benign schwannomas on the other hand almost never undergo malignant transformation; one recent compilation presents only nine well-documented cases reported in the last six decades. [75] MPNSTs can contain (malignant) heterologous components such as bone, cartilage, glandular or squamous epithelium, and skeletal muscle; an MPNST with a rhadbomyosarcomatous component is called a *malignant triton tumor*. In some MPNSTs, the tumor cells have an epithelioid appearance and this variant must be distinguished from (metastatic) melanoma. [76] Recently, perineurial rather than Schwannian differentiation has been described in a minority (<5 percent) of MPNTs. [77]

Depending on the series, about 20 to 70 percent of MPNSTs occur in patients with NF1. [10] These are aggressive tumors with a tendency to recur and metastasize. Outcome is guarded with reported 5-year survival rates of no more than 50 percent in spite of aggressive therapy; [10] however, primary cutaneous MPNSTs may have a better prognosis. [72], [73] A low-grade plexiform MPNST of infancy and childhood has been proposed as a distinct clinicopathologic entity, [78] but its malignant nature has been disputed. [79]

Primitive Neuroectodermal Tumor

Several types of peripheral primitive neuroectodermal tumors (PNETs) seen mostly in children, such as neuroblastoma and Ewing's sarcoma, can metastasize to the skin. [11] Especially with neuroblastoma, cutaneous metastases can be very numerous and involve multiple sites. In about half the patients with such metastases, they were the initial clinical presentation. [11] Somewhat paradoxically, neuroblastoma patients with multiple skin, liver, and bone marrow lesions (without any other involved organs) actually have a good prognosis with their tumors often undergoing spontaneous regression; this stage is called IV-S (for “special”). Extremely rare cases of peripheral PNETs arising as primary cutaneous or subcutaneous tumors have also been reported. [80]

MISCELLANEOUS TUMORS

Granular Cell Tumor

Granular cell tumors (GCTs) are neoplasms of uncertain histogenesis, but with a typical histological appearance, that have been reported in (almost) every anatomic site but are most often seen in the tongue and skin. [81] Multiple GCTs are seen in approximately 10 to 25 percent of patients. [81] Most cutaneous GCTs are asymptomatic papules or nodules less than 3 cm in diameter; they can be verrucous.

The classical histologic picture is that of an ill-defined, dermal, nonencapsulated nodule composed of large, polyhedral cells, that grow in a sheetlike fashion, with distinct cell borders; small, round, central nuclei; and abundant, granular cytoplasm. The cytoplasmic granules stain strongly with the PAS stain and retain this characteristic after diastase digestion. By immunohistochemistry, the granular cells are strongly positive for S-100 protein (Fig. 107-9). Ultrastructurally, the granules consist of phagolysosomes containing granular and membranous debris. [81] An unusual plexiform variant has been described. [82] Cutaneous and mucosal lesions typically have pseudoepitheliomatous hyperplasia of the overlying epithelium. Few tumors have created as much controversy about their “cell of origin” as granular cell tumors and this debate has created a body of literature far out of proportion to the importance of the problem. Suffice it to say that current opinion favors neural crest origin. [81]

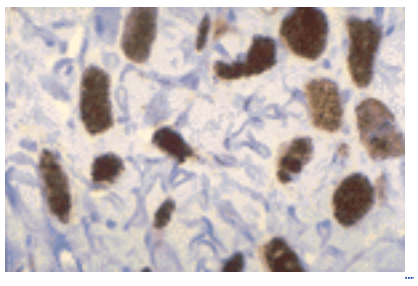

FIGURE 107-9 Granular cell tumor stained immunohistochemically with an antibody against S-100 protein. Note strong positivity of the granular cells. (Hematoxylin counterstain, ×400.)

Excision is the treatment of choice. The major threat to the patient lies in overdiagnosing the pseudoepitheliomatous hyperplasia as carcinoma, a possibility especially with superficial biopsies or excisions that contain only epidermis and miss the underlying dermal tumor.

Only 1 to 2 percent of granular cell tumors are malignant. [81] Clinical findings that should raise concern are a size greater than 4 to 5 cm, location in deep soft tissue (as opposed to dermis), and recurrence. [81] Histological warning signs are the presence of increased cellularity, cytological atypia, and especially mitotic figures and necrosis. [81] However, some clinically malignant GCTs were small and/or histologically innocuous. [81] Therefore, the only definite proof of malignancy is metastasis. Other malignant cutaneous tumors that can contain a subpopulation of cells with granular cytoplasm, such as leiomyosarcoma, melanoma, or angiosarcoma, have to be excluded pathologically.

Cutaneous Lesions with Meningothelial Cells

Meningiomas are neoplasms that arise from meningothelial (arachnoid) cells and usually grow on the inner surface of the cranial or spinal dura. Multiple intracranial and/or intraspinal meningiomas are seen in patients with NF2. Cutaneous lesions containing meningothelial cells also exist. In adults, these usually represent the cutaneous or subcutaneous extension of an aggressive intracranial meningioma that invades through the skull into the pericranial soft tissues and scalp. The meningioma itself may cause surprisingly few neurologic symptoms and patients may actually present because of a growing “lump” on their scalp. In children, skin nodules composed of fibrous tissue and islands of meningothelial cells occur mostly in the scalp over the midline or more rarely along the spine. They are variously called *rudimentary* or *acoelic meningocele, meningeal hamartoma,* or *cutaneous heterotopic meningeal nodules*. These are most likely developmental defects related to meningoceles, which would explain their locations and their invariably congenital nature, along with the fact that some contain a central lumen and may be connected to the dura by a fibrous band running through a skull or vertebral defect. [83] This possibility should be kept in mind at the time of surgical excision and preoperative imaging is indicated to exclude it. Rare familial cases have been reported. [84], [85] Exceptionally, a skull or facial bone fracture may cause a tear in the dura with entrapment of meningeal cells in the overlying skin and subsequent development of a posttraumatic cutaneous meningioma. [86]

Myxopapillary Ependymoma

Myxopapillary ependymoma (MPE) is a peculiar variant of ependymoma that typically arises intradurally from the filum terminale of the spinal cord. However, histologically identical lesions also rarely occur as primary extradural tumors of the sacrococcygeal soft tissue, where they present as subcutaneous masses. They are thought to arise from subcutaneous ependymal rests, which are quite common in this region. [87]

These tumors generally present in young patients as a sacrococcygeal or more rarely gluteal mass that is asymptomatic in most cases and can reach a size of several centimeters. Histologically, they are composed of papillae covered by ependymal cells. The cores of the papillae contain abundant myxoid ground substance, hence the name. While intradural MPEs are usually benign, the subcutaneous type is more aggressive with a significant risk of local recurrence and even metastasis. [87]

Cutaneous Ganglioneuroma and Ganglion Cell Tumor

Ganglioneuromas are neoplasms composed of large mature neurons (ganglion cells) growing in a Schwann cell stroma. Pure ganglion cell tumors (or gangliocytomas) do not contain the Schwann cell component. Although they are usually seen as tumors of the autonomic nervous system, some very rare examples have been encountered in the skin or subcutis where they presented as small papules or nodules. Of the half dozen or so reported cases, [88], [89] only one was congenital. [88] These lesions have to be distinguished from cutaneous metastases from a neuroblastoma, which can mature into ganglioneuroma. Furthermore, some plexiform neurofibromas in patients with neurofibromatosis arise in autonomic ganglia and can therefore contain residual, entrapped ganglion cells. [90]

Cerebral Heterotopia

Cutaneous cerebral heterotopias arise from CNS tissue that is entrapped in dural diverticula. This can occur during craniofacial development and sometimes fail to regress. [91] In other words, these lesions are now considered as malformations related to encephaloceles, [92] and not as neoplasms as the older designation, “nasal glioma,” implied. They occur most often in or on the nose but are also seen on the face, scalp, lip, tongue, as well as in the oro- and nasopharynx, and orbit. [92] Histologically, there are various admixtures of neurons, astrocytes, oligodendrocytes, ependyma, and choroid plexus. There may be significant fibrosis, which can obscure the neuroglial component. [92] Treatment is by excision. Preoperative CT and/or MRI of the head is imperative to determine whether the lesion is connected to the CNS, because this will determine the surgical approach. [91]

REFERENCES

1. Gorlin RJ: Nevoid basal-cell carcinoma syndrome. *Medicine (Baltimore)* **66**:98, 1987

2. Tiffee JC, Barnes EL: Neuromuscular hamartomas of the head and neck. *Arch Otolaryngol Head Neck Surg* **124**:212, 1998

3. Read RW et al: Rhabdomyomatous mesenchymal hamartoma of the eyelid. Report of a case and literature review. *Ophthalmology* **108**:798, 2001

4. Freedom RM et al: Selected aspects of cardiac tumors in infancy and childhood. *Pediatr Cardiol* **21**:299, 2000

5. Weiss SW, Goldblum JR: *Enzinger and Weiss's Soft Tissue Tumors*. St. Louis, Mosby, 2001, p 769

6. Grundy R et al: Congenital alveolar rhabdomyosarcoma. Clinical and molecular distinction from alveolar rhabdomyosarcoma in older children. *Cancer* **91**:606, 2001

7. Schmidt D et al: Rhabdomyosarcomas with primary presentation in the skin. *Pathol Res Pract* **189**:422, 1993

8. Orozco-Covarrubias M et al: Malignant cutaneous tumors in children. Twenty years of experience at a large pediatric hospital. *J Am Acad Dermatol* **30**:243, 1994

9. Colleoni M et al: Primary cutaneous rhabdomyosarcoma in adults—description of an uncommon aggressive disease. *Acta Oncol* **35**:494, 1996

10. Wong T-Y, Suster S: Primary cutaneous sarcomas showing rhabdomyoblastic differentiation. *Histopathology* **26**:25, 1995

11. Wesche A et al: Non-hematopoietic cutaneous metastases in children and adolescents: Thirty years experience at St. Jude Children's Research Hospital. *J Cutan Pathol* **27**:485, 2000

12. Godambe SV, Rawal J: Blueberry muffin rash as a presentation of alveolar cell rhabdomyosarcoma in a neonate. *Acta Paediatr* **89**:115, 2000

13. Bisogno G et al: Rhabdomyosarcoma in a patient with cardio-facio-cutaneous syndrome. *J Pediatr Hematol Oncol* **21**:424, 1999

14. Korf BR: Malignancy in neurofibromatosis type 1. *Oncologist* **5**:477, 2000

15. Stokes JH: Nevus pilaris with hyperplasia of nonstriated muscle. *Arch Dermatol Syphil* **7**:479, 1923

16. De la Espriella J et al: Hamartome musculaire lisse: Caractères anatomo-cliniques et limites nosologiques. *Ann Dermatol Venereol* **120**:879, 1993

17. Darling TN et al: Acquired cutaneous smooth muscle hamartoma. *J Am Acad Dermatol* **28**:844, 1993

18. Gerdsen R et al: Congenital smooth muscle hamartoma of the skin: Clinical classification. *Acta Derm Venereol* **79**:408, 1999

19. Jang HS et al: Linear congenital smooth muscle hamartoma with follicular spotted appearance. *Br J Dermatol* **142**:138, 2000

20. Gagné EJ, Su WPD: Congenital smooth muscle hamartoma of the skin. *Pediatr Dermatol* **10**:142, 1993

21. Schnur RE et al: Variability in the Michelin tire syndrome. A child with multiple anomalies, smooth muscle hamartoma, and familial paracentric inversion of chromosome 7q. *J Am Acad Dermatol* **28**:364, 1993

22. Oku T et al: Folded skin with an underlying cutaneous smooth muscle hamartoma. *Br J Dermatol* **129**:606, 1993

23. Tsujioka K et al: Cutaneous leiomyoma of the male nipple. *Dermatologica* **170**:98, 1985

24. Burden PA et al: Piloleiomyoma arising in an organoid nevus: A case report and review of the literature. *J Dermatol Surg Oncol* **13**:1213, 1987

25. Fernández-Pugnaire MA, Delgado-Florencio V: Familial multiple cutaneous leiomyomas. *Dermatology* **191**:295, 1995

26. Fryns JP et al: 9p trisomy/18p distal monosomy and multiple cutaneous leiomyomata. Another specific chromosomal site (18pter) in dominantly inherited multiple tumors? *Hum Genet* **70**:284, 1985

27. Turleau C et al: Etude cytogénétique de trois cas de léiomyomatose cutanée multiple [letter]. *Ann Dermatol Venereol* **115**:483, 1988

28. Tiffee JC, Budnick SD: Multiple cutaneous leiomyomas. Report of a case. *Oral Surg Oral Med Oral Pathol* **76**:716, 1993

29. Venencie PY et al: Multiple cutaneous leiomyomata and erythrocytosis with demonstration of erythropoietic activity in the cutaneous leiomyomata. *Br J Dermatol* **107**:483, 1982

30. Kiuru M et al: Familial cutaneous leiomyomatosis is a two-hit condition associated with renal cell cancer of characteristic histopathology. *Am J Pathol* **159**:825, 2001

31. Auroy S et al: Léiomyosarcomes cutanés primitifs: 32 cas. *Ann Dermatol Venereol* **126**:235, 1999

32. Dahl I, Angervall L: Cutaneous and subcutaneous leiomyosarcoma. A clinicopathologic study of 47 patients. *Pathol Europ* **9**:307, 1974

33. Diaz-Cascajo C et al: Desmoplastic leiomyosarcoma of the skin. *Am J Dermatopathol* **22**:251, 2000

34. Häffner AC et al: Complete remission of advanced cutaneous leiomyosarcoma following isolated limb perfusion with high-dose tumor necrosis factor-a and melphalan. *Br J Dermatol* **141**:935, 1999

35. Wu KK: Morton neuroma and metatarsalgia. *Curr Opin Rheumatol* **12**:131, 2000

36. Reznik M et al: Painful hyperplasia and hypertrophy of Pacinian corpuscles in the hand. Report of two cases with immunohistochemical and ultrastructural studies, and a review of the literature. *Am J Dermatopathol* **20**:203, 1998

37. Rinaldi P et al: Iperplasia paciniana digitale. Descrizione di un caso con associata reazione da corpo estraneo. *Pathologica* **92**:36, 2000

38. Whipple RR, Unsell RS: Treatment of painful neuromas. *Orthop Clin North Am* **19**:175, 1988

39. Reed RJ et al: Palisaded, encapsulated neuromas of the skin. *Arch Dermatol* **106**:865, 1972

40. Albrecht S et al: Palisaded encapsulated neuroma: an immunohistochemical study. *Mod Pathol* **2**:403, 1989

41. Fletcher CDM: Solitary circumscribed neuroma of the skin (so-called palisaded, encapsulated neuroma). A clinicopathologic and immunohistochemical study. *Am J Surg Pathol* **13**:574, 1989

42. Kutzner H et al: Das solitäre, umkapselte Neurom. *Hautarzt* **41**:620, 1990

43. Eckert F et al: Das umkapselte Neurom der Haut. Eine klinische, histologische und immunohistologische Studie. *Hautarzt* **41**:378, 1990

44. Dakin MC et al: The palisaded, encapsulated neuroma (solitary circumscribed neuroma). *Histopathology* **20**:405, 1992

45. Kossard S et al: Neural spectrum: Palisaded encapsulated neuroma and Verocay body poor dermal schwannoma. *J Cutan Pathol* **26**:31, 1999

46. Stratakis CA: Clinical genetics of multiple endocrine neoplasias, Carney complex and related syndromes. *J Endocrinol Invest* **24**:370, 2001

47. Pollack IF, Mulvihill JJ: Neurofibromatosis 1 and 2. *Brain Pathol* **7**:823, 1997

48. Casadei GP et al: Cellular schwannoma. A clinicopathologic, DNA flow cytometric, and proliferation marker study of 70 patients. *Cancer* **75**:1109, 1995

49. Carney JA: Carney complex: The complex of myxomas, spotty pigmentation, endocrine overactivity, and schwannomas. *Semin Dermatol* **14**:90, 1995

50. Fletcher CDM, Davies SE: Benign plexiform (multinodular) schwannoma: A rare tumour unassociated with neurofibromatosis. *Histopathology* **10**:971, 1986

51. Kao GF et al: Solitary cutaneous plexiform neurilemmoma (schwannoma): A clinicopathologic, immunohistochemical, and ultrastructural study of 11 cases. *Mod Pathol* **2**:20, 1989

52. Reith JD, Goldblum JR: Multiple cutaneous plexiform schwannomas. Report of a case and review of the literature with particular reference to the association with types 1 and 2 neurofibromatosis and schwannomatosis. *Arch Pathol Lab Med* **120**:399, 1996

53. Val-Bernal JF et al: Cutaneous plexiform schwannoma associated with neurofibromatosis type 2. *Cancer* **76**:1181, 1995

54. Pulst SM et al: Spinal scwannomatosis. *Neurology* **48**:787, 1997

55. Honda M et al: Neurofibromatosis 2 and neurilemmomatosis gene are identical. *J Invest Dermatol* **104**:74, 1995

56. Jacoby LB et al: Molecular analysis of the NF2 tumor-suppressor gene in schwannomatosis. *Am J Hum Genet* **61**:1293, 1997

57. MacCollin M et al: Schwannomatosis resulting from somatic mosaicism of the NF2 gene. *Ann Neurol* **42**:513, 1997

58. Zwarthoff EC: Neurofibromatosis and associated tumour suppressor genes. *Pathol Res Pract* **192**:647, 1996

59. Fialkow PJ et al: Multiple cell origin of hereditary neurofibromas. *N Engl J Med* **284**:298, 1972

60. Michal M et al: Dendritic cell neurofibroma with pseudorosettes. A report of 18 cases of a distinct and hitherto unrecognized neurofibroma variant. *Am J Surg Pathol* **25**:587, 2001

61. Gallager RL, Helwig EB: Neurothekeoma—a benign cutaneous tumor of neural origin. *Am J Clin Pathol* **74**:759, 1980

62. Pulitzer DR, Reed RJ: Nerve-sheath myxoma (perineurial myxoma). *Am J Dermatopathol* **7**:409, 1985

63. Laskin WB et al: The “neurothekeoma”: Immunohistochemical analysis distinguishes the true nerve sheath myxoma from its mimics. *Hum Pathol* **31**:1230, 2000

64. Zelger BG et al: Cellular “neurothekeoma”: An epithelioid variant of dermatofibroma? *Histopathology* **32**:414, 1998

65. Emory TS et al: Intraneural perineurioma. A clonal neoplasm associated with abnormalities of chromosome 22. *Am J Clin Pathol* **103**:696, 1995

66. Burgues O et al: Cutaneous sclerosing Pacinian-like perineurioma. *Histopathology* **39**:498, 2001

67. Fetsch JF, Miettinen M: Sclerosing perineurioma. A clinicopathologic study of 19 cases of a distinctive soft tissue lesion with a predilection for the fingers and palms of young adults. *Am J Surg Pathol* **21**:1433, 1997

68. Graadt van Roggen JF et al: Reticular perineurioma. A distinctive variant of soft tissue perineurioma. *Am J Surg Pathol* **25**:485, 2001

69. Michal M: Extraneural retiform perineuriomas. A report of four cases. *Pathol Res Pract* **195**:759, 1999

70. Robson AM, Calonje E: Cutaneous perineurioma: A poorly recognized tumour often misdiagnosed as epithelioid histiocytoma. *Histopathology* **37**:332, 2000

71. Sciot R et al: Cutaneous sclerosing perineurioma with a cryptic *NF2* gene deletion. *Am J Surg Pathol* **23**:849, 1999

72. Coady MSE et al: Cutaneous malignant peripheral nerve sheath tumour (MPNST) of the hand: A review of the current literature. *J Hand Surg* **18B**:478, 1993

73. Misago N et al: Malignant peripheral nerve sheath tumor of the skin: A superficial form of this tumor. *J Cutan Pathol* **23**:182, 1996

74. Woodruff JM: Pathology of tumors of the peripheral nerve sheath in type 1 neurofibromatosis. *Am J Med Genet* **89**:23, 1999

75. Woodruff JM et al: Schwannoma (neurilemoma) with malignant transformation. A rare, distinctive peripheral nerve tumor. *Am J Surg Pathol* **18**:882, 1994

76. King R et al: Metastatic malignant melanoma resembling malignant peripheral nerve sheath tumor: Report of 16 cases. *Am J Surg Pathol* **23**:1499, 1999

77. Hirose T et al: Perineurial malignant nerve sheath tumor (MPNST). A clinicopathologic, immunohistochemical, and ultrastructural study of seven cases. *Am J Surg Pathol* **22**:1368, 1998

78. Meis-Kindblom JM, Enzinger FM: Plexiform malignant peripheral nerve sheath tumor of infancy and childhood. *Am J Surg Pathol* **18**:479, 1994

79. Woodruff JM, Scheithauer BW: Nerve sheath tumors [letter]. *Am J Surg Pathol* **19**:608, 1995

80. Taylor GB, Chan YF: Subcutaneous primitive neuroectodermal tumour in the abdominal wall of a child: Long-term survival after local excision. *Pathology* **32**:294, 2000

81. Ordóñez NG: Granular cell tumor: A review and update. *Adv Anat Pathol* **6**:186, 1999

82. Lee J et al: Plexiform granular cell tumor. A report of two cases. *Am J Dermatopathol* **16**:537, 1994

83. El Shabrawi-Caelen L et al: Rudimentary meningocele: Remnant of a neural tube defect? *Arch Dermatol* **137**:45, 2001

84. Miyamoto T et al: Primary cutaneous meningioma on the scalp: Report of two siblings. *J Dermatol* **22**:611, 1995

85. Tron V et al: Familial cutaneous heterotopic meningeal nodules. *J Am Acad Dermatol* **28**:1015, 1993

86. Walters GA et al: Posttraumatic cutaneous meningioma of the face. *Am J Neuroradiol* **15**:393, 1994

87. Kline MJ et al: Extradural myxopapillary ependymoma: Report of two cases and review of the literature. *Pediatr Pathol Lab Med* **16**:813, 1996

88. Gambini C, Rongioletti F: Primary congenital cutaneous ganglioneuroma. *J Am Acad Dermatol* **35**:353, 1996

89. Hammond RR, Walton JC: Cutaneous ganglioneuromas: A case report and review of the literature. *Hum Pathol* **27**:735, 1996

90. Rios JJ et al: Cutaneous ganglion cell choristoma. *J Cutan Pathol* **18**:469, 1991

91. Pensler JM et al: Craniofacial gliomas. *Plast Reconstr Surg* **98**:27, 1996

92. Argenyi ZB: Cutaneous neural heterotopias and related tumors relevant for the dermatopathologist. *Semin Diagn Pathol* **13**:60, 1996

T>

Chapter 108

Mark Lebwohl

Acquired Perforating Disorders

DEFINITION AND HISTORICAL ASPECTS
ETIOLOGY AND PATHOGENESIS
CLINICAL MANIFESTATIONS
HISTOPATHOLOGY
ELASTOSIS PERFORANS SERPIGINOSA
Definition and History
Etiology and Pathogenesis
Clinical Manifestations
Histopathology
Therapy
Differential Diagnosis

REFERENCES

DEFINITION AND HISTORICAL ASPECTS

The acquired perforating disorders consist of a group of conditions characterized by transepithelial elimination of dermal material. Umbilicated papules with central white, keratotic crusts are the clinical hallmarks of the perforating disorders. Historically, reactive perforating collagenosis, Kyrle's disease, and perforating folliculitis have been differentiated from one another histologically. In 1982, reactive perforating collagenosis was described as associated with diabetes and renal disease. [1] In retrospect, cases of Kyrle's disease and perforating folliculitis had also been associated with diabetes and renal failure [2], [3] and reexamination of histologic sections in some of those cases revealed transepidermal elimination of collagen consistent with reactive perforating collagenosis. Because of the common association with diabetes and renal failure, one group of authors suggested that the diseases be called reactive perforating collagenosis of diabetes and renal failure. [4] More recently, another group of authors suggested the term acquired perforating dermatosis, [5] and similar terminology has been used by several authors over the past decade.

Elastosis perforans serpiginosa is a unique perforating disorder characterized by transepidermal elimination of elastic fibers and distinctive clinical lesions, which are serpiginous in distribution and can be associated with specific diseases. Consequently, the latter condition is dealt with separately.

In 1916, Kyrle described [6] hyperkeratosis follicularis et parafollicularis in cutem penetrans, the disorder reported in patients with liver disease, diabetes, or renal disease. Many authors now include it under the general term of acquired perforating dermatosis, although others still distinguish Kyrle's disease as a unique entity. Of interest, the original patient reported by Kyrle did not have diabetes, but developed it 8 years later. [7]

Perforating folliculitis was first described by Mehregan and Coskey in 1968. [8] As with Kyrle's disease, some now include this with the acquired perforating dermatoses but others maintain the term perforating folliculitis as a unique entity. Mehregan also described reactive perforating collagenosis in 1967, [9] and this condition has also been included by some in the acquired perforating disorders.

ETIOLOGY AND PATHOGENESIS

Although there are several theories that seek to explain the etiology of the perforating disorders, none have been proven. Several features in the pathogenesis of the disorder have been suggested, however. Components of the dermal extracellular matrix are extruded from the dermis through the epidermis to form the central keratotic crusts that are apparent in these skin lesions. It is clear that many patients exhibit the Koebner phenomenon and lesions can be produced experimentally by traumatizing the skin. [10] Noting a microvasculopathy in the dermis of affected patients, one study hypothesizes that perforating disorders are triggered by trauma to the skin that results in an abnormal cutaneous response due to the dermal vasculopathy. [11] Yet another group of investigators has shown increased serum or extracellular matrix fibronectin, suggesting that fibronectin may result in increased epithelial migration that ultimately results in perforation. [12] Other theories have attributed perforating disorders to elevated plasma silicon in patients on dialysis [13] or to vitamin A deficiency. [14], [15] One patient with perforating folliculitis, however, was found to have elevated serum levels of vitamin A. [16] While none of these theories concerning the etiology of the perforating disorders has been proven, all agree that affected patients have an abnormal cutaneous response to trauma.

Another study examined the evolution of skin lesions through light and electron microscopic examination of biopsies. Excoriations developed in a chronic mass containing collagen bundles that were contiguous with the reticular dermis. As lesions evolved, new epidermis regenerated between the necrotic mass and the reticular dermis with bundles of collagen connecting the necrotic mass with the reticular dermis through epithelial tunnels. The authors suggest that the regenerated epidermis forms a thick horny layer that lifts up the necrotic mass and its collagen bundles from the dermis through these epidermal channels. [17] Yet another author has demonstrated that at least some of the collagen being eliminated in reactive perforating collagenosis stains with antibodies against type IV collagen, suggesting that the collagen eliminated in this disorder may originate in the basement membrane. [18]

CLINICAL MANIFESTATIONS

The acquired perforating disorders are characterized by umbilicated papules with central white, keratotic crusts (Fig. 108-1). Lesions most often develop on the arms and legs, but any site on the cutaneous surface can be affected including trunk and scalp. Lesions have even been described on the conjunctiva and buccal mucosa of a patient with Kyrle's disease. [19] Virtually all patients complain of pruritus, and scratching can lead to a Koebner phenomenon, with linear umbilicated papules arising in excoriated skin.

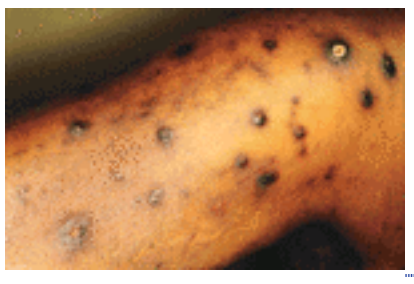

FIGURE 108-1 Acquired perforating dermatosis. Umbilicated, keratotic papules on the arm of a patient with diabetes and renal failure.

In the original description of reactive perforating collagenosis, renal failure and diabetes were not noted. [9] Nevertheless, most acquired perforating disorders are seen in association with kidney failure, diabetes, or both. Associations with hyperparathyroidism, hypothyroidism, and liver disorders, [20] as well as HIV infection [21] and primary sclerosing cholangitis, [22] have also been reported, but these may be coincidental.

HISTOPATHOLOGY

Histologically, the acquired perforating disorders are characterized by invagination of the epidermis with extrusion of dermal material through the cup-shaped epidermal depression into the necrotic basophilic tissue within the invaginated epidermis. In the classic description of reactive perforating collagenosis, collagen bundles were observed crossing from the reticular dermis through the epidermis (Fig. 108-2). More recently, one group of investigators found that elastic fibers accompanied the collagen in a small group of patients. [5]

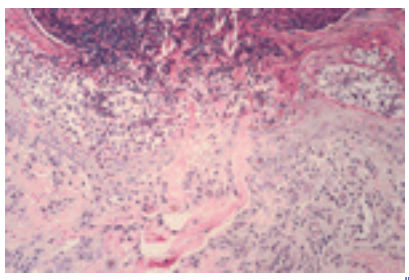

FIGURE 108-2 Reactive perforating collagenosis. Collagen bundles can be seen crossing from the reticular dermis through the epidermis into an epidermal depression containing necrotic debris (Hematoxylin and eosin stain).

In Kyrle's disease, an amorphous extracellular dermal material was extruded through the epidermis. Descriptions of Kyrle's disease report an invagination of the epidermis that is filled with a keratotic plug containing a parakeratotic column. Within the epidermal invagination, there is a focus of vacuolated dyskeratotic cells, which extends to the basal cell layer and eventually penetrates into the dermis, leaving fragments of parakeratotic keratin in the dermis with a surrounding inflammatory and granulomatous reaction. Subsequent studies using Masson trichrome stains have found bundles of collagen perforating through the epidermis into the base of the invagination.

Perforating folliculitis is characterized histologically by follicular perforation. There is a focal inflammatory infiltrate adjacent to areas of perforation of the follicular epithelium. Degenerating collagen and extracellular matrix tissues mixed with inflammatory cells and orthokeratotic and parakeratotic material fill the dilated hair follicle. Occasionally, a hair is seen. One author suggested that lesions begin as follicular pustules and develop into perforating folliculitis and, ultimately, into prurigo nodularis. [23]

ELASTOSIS PERFORANS SERPIGINOSA

Definition and History

After several clinical descriptions of the entity we now call elastosis perforans serpiginosa, Miescher described the histopathology of this condition in 1955, [24] and in 1958, the term *elastosis perforans serpiginosa* (EPS) was coined. [25] EPS is characterized by keratotic papules that are often, but not always distributed in a serpiginous pattern (Fig. 108-3). It is associated with Down's syndrome, [26] as well as with a number of inherited disorders of connective tissue (see below). It also occurs as a result of treatment with oral penicillamine. Histologically, lesions are characterized by transepidermal elimination of elastic fibers.

FIGURE 108-3 Elastosis perforans serpiginosa. Erythematous, hyperkeratotic papules in a serpiginous distribution on the arm.

Etiology and Pathogenesis

Alterations of elastic fibers have been described in patients with penicillamine-induced EPS and this condition has usually occurred after long-term therapy of Wilson's disease [27] or cystinuria, and has also been reported in a child treated with D-penicillamine for juvenile rheumatoid arthritis. [28] Abnormal elastic fibers have been found in the lungs as well as the skin of penicillamine-treated patients, [29] and abnormalities of collagen have also been described in patients with EPS. [30], [31] The precise mechanism by which penicillamine induces EPS is not entirely known, but the drug chelates copper, the cofactor for lysyl oxidase, which is the enzyme that cross-links elastin. The abnormal elastin is eliminated through the epidermis.

Familial cases of EPS have been reported with different modes of inheritance. In at least one family, autosomal dominant inheritance with variable expression of EPS was suggested. [32] Several inherited disorders of connective tissue have also been associated with EPS, suggesting that various pathways can lead to the abnormal elastin that results in this condition.

Clinical Manifestations

Skin lesions consist of hyperkeratotic papules raging from 2 mm to 1 cm in diameter in a serpiginous distribution. Skin within these serpiginous arcs is often atrophic. The most common site of involvement is the neck, but lesions can also occur on the extremities and, more rarely, on the trunk. In rare instances systemic involvement occurs with involvement of elastic tissue in the endocardium, bronchiolar walls, and arteries. Rupture of the aorta has been reported. [33]

Elastosis perforans serpiginosa is associated with numerous inherited disorders including osteogenesis imperfecta, [34] cutis laxa, [35] acrogeria, [36] Ehlers-Danlos syndrome, Marfan's syndrome, Rothmund-Thompson syndrome, [37] and Down's syndrome. [26] It is also associated with pseudoxanthoma elasticum, [38], [39] but at least one author has questioned that association, [40] believing that most reported cases of EPS in patients with pseudoxanthoma elasticum represent perforating pseudoxanthoma elasticum.

Histopathology

On pathologic examination of skin biopsy specimens, typical changes can be identified and consist of an inflammatory response around abnormal elastic tissue in the papillary dermis. The elastic tissue penetrates through channels in the acanthotic epidermis. The channels may be straight or tortuous, and there may be multinucleated giant cells in the surrounding inflammatory infiltrate. In addition to elastic tissue, the channels contain necrobiotic material with degenerated epithelial cells and parakeratotic nuclei of inflammatory cells. The top of the epidermal channels is also filled with keratotic material.

Therapy

While some have reported spontaneous disappearance of perforating disorders with stabilization of renal disease, [41] most of the perforating diseases continue for years unless treated. With renal transplantation, lesions can resolve. [42]

Both reactive perforating collagenosis [43], [44] and Kyrle's disease [45] are reported to respond to topical retinoids, but these are not always effective. In patients refractory to topical therapy, phototherapy with UVB [46] and PUVA [47] are reported to clear the disease.

In recent years, oral retinoids, including isotretinoin [48] and acitretin, [49] have been used effectively for Kyrle's disease, and phototherapy has also been used effectively for perforating folliculitis. [23] Because some authors attribute perforating disorders to low serum levels of vitamin A, it should not be surprising that oral retinoids are effective. In fact, there is one report of perforating folliculitis improving dramatically upon treatment with oral vitamin A. [15] Other treatments that have been used for perforating disorders include surgical removal, [50] transcutaneous electrical nerve stimulation, [51] oral antibiotics, and topical corticosteroids. [23] Most recently, there have been several reports of success in treating perforating

disorders with oral allopurinol. [52], [53] and [54]

Many of the treatments that have been applied to the other perforating disorders have also been used for EPS. In recent years, isotretinoin has been used to treat this disorder. [55] Destructive modalities such as cryotherapy have been effective, [56] and, most recently, lasers have been used for EPS. [57], [58]

Differential Diagnosis

Other perforating dermatoses can simulate the acquired perforating disorders. EPS is easily distinguished when characteristic serpiginous lesions are present and by the finding of elastic fibers in the perforating tissue on histology. In contrast to the other perforating dermatoses, which are usually associated with diabetes or renal failure, EPS has an entirely different group of disease associations as mentioned above.

Individual lesions of perforating pseudoxanthoma elasticum can simulate those of the acquired perforating dermatoses, but patients with pseudoxanthoma elasticum have characteristic yellow papules and plaques on the neck, axillae, and other flexural sites. Moreover, on skin biopsy, von Kossa stains show calcification of elastic fibers and Verhoeff van Gieson stains show fragmentation and clumping of elastic tissue. The lesions of perforating granuloma annulare can also simulate acquired perforating disorders, but on biopsy, palisading granulomas are seen. Flegel disease is characterized by keratotic papules, but these are smaller and usually involve the palms and soles. Histologically, this is not a perforating condition, but occasionally it has been confused with perforating disorders. [59]

EPS is easily distinguished from the acquired perforating disorders in that the latter conditions are often associated with diabetes and renal disease. There is a single case report of EPS in a patient with renal disease. [60] Histologically, however, the perforating elastic fibers of EPS usually allow differentiation although fragments of elastic fibers may be found in the necrobiotic plug of other perforating disorders. At least one study reports the transepidermal elimination of elastic fibers in follicular occlusion disease, distinguishing that disorder from EPS. [61] The differentiation of EPS from perforating pseudoxanthoma elasticum is easily accomplished because the eliminated elastic fibers in EPS are not calcified in contrast to the von Kossa–staining fibers of pseudoxanthoma elasticum.

REFERENCES

1. Poliak SC et al: Reactive perforating collagenosis associated with diabetes mellitus. *N Engl J Med* **306**:81, 1982

2. Harman M et al: Kyrle's disease in diabetes mellitus and chronic renal failure. *J Eur Acad Dermatol Venereol* **11**:87, 1998

3. Hurwitz RM et al: Perforating folliculitis in association with hemodialysis. *Am J Dermatopathol* **4**:101, 1982

4. Cochran RJ et al: Reactive perforating collagenosis of diabetes mellitus and renal failure. *Cutis* **31**:55, 1983

5. Rapini RP et al: Acquired perforating dermatosis. Evidence for combined transepidermal elimination of both collagen and elastic fibers. *Arch Dermatol* **125**:1074, 1989

6. Kyrle J: Über einen ungewöhnlichen fall von universeller folliculärer und parafollikulärer hyperkeratose (hyperkeratosis follicularis et parafollicularis in cutem penetrans). *Arch Dermatol Syph (Berlin)* **123**:466, 1916

7. Kren O: Keratosis follicularis in cutem penetrans (Kyrle). *Dermatology* **78**:57, 1924

8. Mehregan AH, Coskey RJ: Perforating folliculitis. *Arch Dermatol* **97**:394, 1968

9. Mehregan AH et al: Reactive perforating collagenosis. *Arch Dermatol* **96**:277, 1967

10. Bovenmyer DA: Reactive perforating collagenosis. Experimental production of the lesion. *Arch Derm* **102**:31, 1970

11. Kawakami T, Saito R: Acquired reactive perforating collagenosis associated with diabetes mellitus: Eight cases that meet Faver's criteria. *Br J Dermatol* **140**:521, 1999

12. Morgan MB et al: Fibronectin and the extracellular matrix in the perforating disorders of the skin. *Am J Dermatopathol* **20**:147, 1998

13. Saldanha LF et al: Silicon-related syndrome in dialysis patients. *Nephron* **77**:48, 1997

14. Neill SM et al: Phrynoderma and perforating folliculitis due to vitamin A deficiency in a diabetic. *J R Soc Med* **81**:171, 1988

15. Barr DJ et al: Bypass phrynoderma. Vitamin A deficiency associated with bowel-bypass surgery. *Arch Dermatol* **120**:919, 1984

16. Bardach HG: Generalized perforating folliculitis in chronic kidney insufficiency [in German]. *Hautarzt* **33**:584, 1982

17. Yanagihara M et al: The pathogenesis of the transepithelial elimination of the collagen bundles in acquired reactive perforating collagenosis. A light and electron microscopical study. *J Cutan Pathol* **23**:398, 1996

18. Herzinger T et al: Reactive perforating collagenosis—Transepidermal elimination of type IV collagen. *Clin Exp Dermatol* **21**:279, 1996

19. Alyahya GA et al: Ocular changes in a case of Kyrle's disease. 20-year follow-up. *Acta Ophthalmol Scand* **78**:585, 2000

20. Faver IR et al: Acquired reactive perforating collagenosis. Report of six cases and review of the literature. *J Am Acad Dermatol* **30**:575, 1994

21. Rubio FA et al: Perforating folliculitis: Report of a case in an HIV-infected man. *J Am Acad Dermatol* **40**:300, 1999

22. Kahana M et al: Perforating folliculitis in association with primary sclerosing cholangitis. *Am J Dermatopathol* **7**:271, 1985

23. Hurwitz RM: The evolution of perforating folliculitis in patients with chronic renal failure. *Am J Dermatopathol* **7**:231, 1985

24. Miescher G: Elastoma intrapapillare perforans verruciform. *Dermatologica* **110**:254, 1955

25. Dammet K, Putkonen T: Keratosis follicularis serpiginosa Lutz. *Dermatologica* **116**:143, 1958

26. Siragusa M et al: Localized elastosis perforans serpiginosa in a boy with Down syndrome. *Pediatr Dermatol* **14**:244, 1997

27. Hill VA et al: Penicillamine-induced elastosis perforans serpiginosa and cutis laxa in Wilson's disease. *Br J Dermatol* **142**:560, 2000

28. Sahn EE et al: D-Penicillamine–induced elastosis perforans serpiginosa in a child with juvenile rheumatoid arthritis. Report of a case and review of the literature. *J Am Acad Dermatol* **20**:979, 1989

29. Bardach H et al: “Lumpy-bumpy” elastic fibers in the skin and lungs of a patient with a penicillamine-induced elastosis perforans serpiginosa. *J Cutan Pathol* **6**:243, 1979

30. Ludatscher RM et al: Structural alterations of collagen fibrils in the reactive type of elastosis perforans serpiginosa. *Arch Dermatol Res* **280**:319, 1988

31. Holbrook KA, Byers PH: Structural abnormalities in the dermal collagen and elastic matrix of patients with inherited connective tissue disorders. *J Invest Dermatol* **79**:7s, 1982

32. Langeveld-Wildschut EG et al: Familial elastosis perforans serpiginosa. *Arch Dermatol* **129**:205, 1993

33. Eide J: Elastosis perforans serpiginosa with widespread arterial lesions: A case report. *Acta Derm Venereol* **57**:533, 1977

34. Relias A et al: Lutz-Miescher elastosis perforans serpiginosa and osteogenesis imperfecta. *Ann Dermatol Syph (Paris)* **95**:491, 1968

35. Korting GW: Elastosis perforans serpiginosa as an ectodermal border symptom in cutis laxa. *Arch Klin Exp Dermatol* **224**:437, 1966

36. Tafelkruyer J, Mees R: Acrogeria and elastosis perforans serpiginosa [proceedings] *Dermatologica* **156**:309, 1978

37. Mehregan AH: Elastosis perforans serpiginosa: A review of the literature and report of 11 cases. *Arch Dermatol* **97**:381, 1968

38. Katagiri K et al: Heterogeneity of clinical features of pseudoxanthoma elasticum: Analysis of thirteen cases in Oita Prefecture from a population of 1,240,000. *J Dermatol* **18**:211, 1991

39. Caro I et al: Pseudoxanthoma elasticum and elastosis perforans serpiginosa. Report of two cases. *Dermatologica* **150**:36, 1975

40. Lund HZ, Gilbert CF: Perforating pseudoxanthoma elasticum. Its distinction from elastosis perforans serpiginosa. *Arch Pathol Lab Med* **100**:544, 1976.

41. Chang P, Fernandez V: Acquired perforating disease: Report of nine cases. *Int J Dermatol* **32**:874, 1993

42. White CR Jr et al: Perforating folliculitis of hemodialysis. *Am J Dermatopathol* **4**:109, 1982

43. Cullen SI: Successful treatment of reactive perforating collagenosis with tretinoin. *Cutis* **23**:187, 1979

44. Berger RS: Reactive perforating collagenosis of renal failure/diabetes responsive to topical retinoic acid. *Cutis* **43**:540, 1989

45. Petrozzi JW, Warthan TL: Kyrle disease. Treatment with topically applied tretinoin. *Arch Dermatol* **110**:762, 1974

46. Vion B, Frenk E: Acquired reactive collagen disease in the adult: Successful treatment with UV-B light [in German]. *Hautarzt* **40**:448, 1989

47. Serrano G et al: Reactive perforating collagenosis responsive to PUVA. *Int J Dermatol* **27**:118, 1988

48. Saleh HA et al: Kyrle's disease. Effectively treated with Isotretinoin. *J Fla Med Assoc* **80**:395, 1993

49. Baumer FE et al: The Kyrle disease entity and its therapeutic modification by acitretin (etretin) [in German]. *Z Hautkr* **64**:286, 289, 1989.

50. Ford TC et al: Kyrle's disease. A rare case report and surgical treatment. *J Am Podiatr Med Assoc* **80**:151, 1990

51. Chan LY et al: Treatment of pruritus of reactive perforating collagenosis using transcutaneous electrical nerve stimulation. *Eur J Dermatol* **10**:59, 2000

52. Querings K et al: Treatment of acquired reactive perforating collagenosis with allopurinol. *Br J Dermatol* **145**:174, 2001

53. Munch M et al: Treatment of perforating collagenosis of diabetes and renal failure with allopurinol. *Clin Exp Dermatol* **25**:615, 2000

54. Kruger K et al: Acquired reactive perforating dermatosis. Successful treatment with allopurinol in 2 cases [in German]. *Hautarzt* **50**:115, 1999

55. Ratnavel RC, Norris PG: Penicillamine-induced elastosis perforans serpiginosa treated successfully with isotretinoin. *Dermatology* **189**:81, 1994

56. Tuyp EJ, McLeod WA: Elastosis perforans serpiginosa: treatment with liquid nitrogen. *Int J Dermatol* **29**:655, 1990

57. Kaufman AJ: Treatment of elastosis perforans serpiginosa with the flashlamp pulsed dye laser. *Dermatol Surg* **26**:1060, 2000

58. Abdullah A et al: Localized idiopathic elastosis perforans serpiginosa effectively treated by the Coherent Ultrapulse 5000C aesthetic laser. *Int J Dermatol* **39**:719, 2000

59. Price ML et al: Flegel's disease, not Kyrle's disease. *J Am Acad Dermatol* **18**:1366, 1988

60. Schamroth JM et al: Elastosis perforans serpiginosa in a patient with renal disease. *Arch Dermatol* **122**:82, 1986

61. Hyland CH, Kheir SM: Follicular occlusion disease with elimination of abnormal elastic tissue. *Arch Dermatol* **116**:925, 1980

T>

Chapter 109

Michael Camilleri W.P. Su

Panniculitis

PANNICULITIS IN CONNECTIVE TISSUE DISORDERS
Lupus Panniculitis
Deep Morphea
Other Connective Tissue Disease–Associated Panniculitides
VASCULAR DISORDERS
Nodular Vasculitis
Calciphylaxis
Oxalosis
Sclerosing Panniculitis
OTHER PANNICULITIDES ASSOCIATED WITH SYSTEMIC DISORDER
Pancreatic Panniculitis
a1-Antitrypsin Deficiency–Associated Panniculitis
CYTOPHAGIC HISTIOCYTIC PANNICULITIS
HISTORICAL ASPECTS
EPIDEMIOLOGY
ETIOLOGY AND PATHOGENESIS
CLINICAL MANIFESTATIONS
LABORATORY FINDINGS
PATHOLOGY
TREATMENT AND PROGNOSIS
NONINFECTIOUS GRANULOMATOUS PANNICULITIDES
Erythema Nodosum
INFECTIOUS PANNICULITIS
ETIOLOGY AND PATHOGENESIS
CLINICAL MANIFESTATIONS
PATHOLOGY
TREATMENT AND PROGNOSIS
PHYSICAL PANNICULITIDES
Traumatic Panniculitis
Cold Panniculitis
CHEMICAL/FOREIGN BODY PANNICULITIS
ETIOLOGY AND PATHOGENESIS
CLINICAL MANIFESTATIONS
PATHOLOGY
TREATMENT AND PROGNOSIS
CHILDHOOD PANNICULITIS
Sclerema Neonatorum
Subcutaneous Fat Necrosis of the Newborn
Poststeroid Panniculitis
DIAGNOSTIC APPROACH TO PANNICULITIS

REFERENCES

The subcutaneous fat or panniculus adiposus is the cushioning tissue that lies between the dermis and the fascia. The subcutaneous fat has two important functions: a protective function from thermal and mechanical injuries and a metabolic function, acting as a depot of energy in the form of stored fat. The subcutaneous fat is composed of adipocytes and fibrocytes, which are embryologically derived from primitive mesenchymal cells. Mature adipocytes are characterized by polygonal-shaped cells that have a small dark eccentric nucleus and a large cytoplasmic lipid vacuole. Small cohesive collections of adipocytes form the primary microlobules, which aggregate into secondary lobules that are separated from each other by discernible fibrous septa or trabeculae. The pannicular fibrous septa contain blood vessels (arteries and veins), lymphatics, and nerves. Arteriolar branches from the septal arteries, which traverse between the pannicular lobules, give off a capillary network that surrounds each adipocyte [1], [2] (see Chap. 6).

The panniculitides are a diverse group of cutaneous disorders that are characterized by an inflammatory process that predominantly affects the subcutaneous fat. A wide range of etiological factors may result in panniculitis [3] (Table 109-1). Weber-Christian disease (synonyms: idiopathic nodular panniculitis, nodular panniculitis, and relapsing febrile nonsuppurative nodular panniculitis) was formerly described as an idiopathic type of lobular panniculitis with mixed inflammation characterized by erythematous subcutaneous nodules, often accompanied by systemic involvement. Most authorities now agree that this type of panniculitis should no longer be considered as a distinctive entity, because an alternative specific cause of the lobular panniculitis is detected in most cases. [4], [5] Lipoatrophy is characterized by atrophy of subcutaneous fat and may represent either an end-stage result of various inflammatory panniculitides or may be a primary process not associated with inflammation, also known as lipodystrophy. [5]



TABLE 109-1 **Etiologic Classification of the Panniculitides** [1], [3]

PANNICULITIS IN CONNECTIVE TISSUE DISORDERS

Lupus Panniculitis (See Chap. 171)

Lupus panniculitis (LP), also known as lupus profundus or Kaposi-Irgang disease, is an uncommon form of chronic cutaneous lupus erythematosus that is characterized by chronic, recurrent pannicular inflammation. [6]

HISTORICAL ASPECTS LP was first described by Kaposi in 1883, and the term lupus erythematosus profundus was coined by Irgang in 1940. [6]
EPIDEMIOLOGY LP is seen in 1 to 5 percent of patients with lupus erythematosus, with a mean age incidence of 40 years (age range: 30 to 60 years). Females are more commonly affected, with a 4:1 female-to-male ratio. [7]
CLINICAL MANIFESTATIONS The cutaneous lesions of LP are characterized by multiple, deep, symmetric, painful subcutaneous nodules or plaques that characteristically heal with persistent, large areas of depression or delling secondary to lipoatrophy (Fig. 109-1A). LP may be associated with an overlying chronic discoid lupus erythematosus (CDLE) lesion and may ulcerate. LP commonly affects the proximal upper and lower extremities, trunk, and head, but may also involve unusual sites, including the breast, orbital, and periparotid tissue. [3], [6], [7] Aggravating factors for LP include trauma (scars and injections) and ultraviolet radiation. LP may rarely present as morphea-like lesions, in a linear arrangement, or in association with neonatal lupus erythematosus (LE). [5]

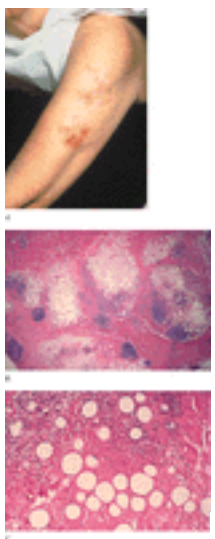

FIGURE 109-1 Lupus panniculitis. *A*. Erythematous nodules with central delling (lipoatrophy) involving the lateral arm. Histopathologic features of (*B*) early lupus panniculitis with lobular lymphocytic pannicular inflammation and lymphoid follicle formation and (*C*) more advanced lupus panniculitis with the characteristic hyaline fibrosis of pannicular lobules.

LP may precede, occur simultaneous with, or follow discoid LE in 33 percent of LP. [7] In 10 percent of cases, LP may be associated with systemic LE. [7] The LE tends to be less severe and includes arthralgias, Raynaud's phenomenon, lymphadenopathy, pleurisy, and livedo reticularis. [6] Other autoimmune disorders associated with LP include Hashimoto's thyroiditis, chronic ulcerative colitis, and autoimmune hepatitis. [7]
LABORATORY FINDINGS Patients with LP may have a positive low-titer antinuclear antibody (65 percent), anti–double-stranded DNA antibody (15 percent), rheumatoid factor (12 percent) and anti-RNP (ribonucleoprotein) (14 percent). Leukopenia, an elevated sedimentation rate, a low total hemolytic complement activity (CH50), and a low C2 and C4 level have also been reported. [7]
PATHOLOGY The main histopathologic characteristic of LP is a predominantly lobular panniculitis without any vasculitis. In the early stages of LP, there is marked lobular (usually periseptal) inflammation composed of lymphocytic aggregates that are often arranged as lymphoid follicles with central germinal centers (Fig. 109-1B). The inflammatory infiltrate may also extend into the pannicular septa. Lymphocytic vasculitis, lymphocytic nuclear dust, and eosinophils are also frequently noted. In more advanced stages of LP, there is hyaline fibrosis of the pannicular lobules and septa (Fig. 109-1C) with calcification, increased mucin deposition and a decrease in the degree of inflammation. Associated overlying epidermal and dermal changes of discoid lupus may also be observed. [5], [6] Direct immunofluorescence demonstrates granular deposition of IgM, IgG, and C3 at the dermoepidermal junction (lupus band) in 70 percent of cases. [6]
TREATMENT AND PROGNOSIS The treatment of LP includes bed rest, avoidance of trauma, photoprotection, and the use of immunosuppressive agents. [6], [7] Potent topical corticosteroids under occlusion, [8] intralesional and systemic corticosteroids, [7] antimalarials, [7] dapsone, [9] thalidomide, [10] cyclophosphamide, [7] and cyclosporine [11] have all been used with success. LP follows a chronic, recurrent course. Evidence exists supporting the possibility that some cases of LP may exhibit phenotypic and genomic abnormalities suggesting a subcuticular T cell lymphoid dyscrasia in which subcutaneous T cell lymphoma forms part of the spectrum. [12]

Deep Morphea (See Chap. 173)

Deep morphea (DM), also known as scleroderma panniculitis, is a fibrosing inflammatory process primarily involving the subcutaneous fat, with variable involvement of the deep dermis, fascia, and muscle. Various types of DM are described,

[13] including:

- Subcutaneous morphea characterized by predominant involvement of the panniculus.
- Morphea profunda characterized by predominant involvement of both the panniculus and fascia.
- Eosinophilic fasciitis characterized by predominant involvement of the fascia with extension into the panniculus and muscle (see Chap. 173).
- Pansclerotic morphea of childhood, characterized by involvement of the deep dermis, panniculus, fascia, muscle and bone (see Chap. 173).

ETIOLOGY AND PATHOGENESIS Most cases of DM are idiopathic, although a number of specific factors have been observed in some variants of DM. In eosinophilic fasciitis, prior physical exertion has been observed in 50 percent of cases. [13] Toxins such as L-tryptophan in eosinophilia-myalgia syndrome, and ingestion of adulterated rapeseed oil in toxic-oil syndrome, are also implicated. Other etiologic agents for DM variants include infections (acute brucellosis [14] and Lyme disease), malignancies (lymphoproliferative malignancies, breast and prostate carcinoma) in cancer-associated fasciitis panniculitis, [15] radiation (postirradiation pseudosclerodermatous panniculitis [16], and the late stage of graft-versus-host disease.
CLINICAL MANIFESTATIONS The cutaneous manifestations of DM include stable or progressively enlarging, bound down, indurated plaques or nodules, which heal with atrophy and hyperpigmentation. The sites of involvement vary with the clinical subtype, predominantly involving the proximal upper extremities and trunk in subcutaneous morphea and morphea profunda (Fig. 109-2A), bilateral forearms and legs in eosinophilic fasciitis, and generalized in pansclerotic morphea of childhood. [13]

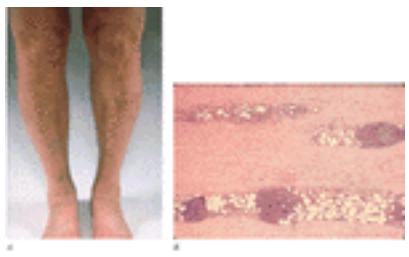

FIGURE 109-2 Deep morphea. *A*. Bilateral, bound down, indurated plaques with atrophy and hyperpigmentation involving the legs. Histopathologic features of deep morphea with fibrous thickening of the pannicular septa and lymphoplasmacytic aggregates at the septal–lobular junction.

PATHOLOGY The main histopathologic manifestations of DM include a predominantly septal panniculitis without vasculitis. The histologic hallmark of the disease is marked fibrous thickening of the pannicular septa with lymphoplasmacytic inflammatory aggregates at the septal–lobular junction (Fig. 109-2B). The homogenous, eosinophilic, thickened collagen bundles replace the fat surrounding adnexal structures, which also become atrophic. Calcification may also be seen. [13]
TREATMENT AND PROGNOSIS Therapeutic modalities for the treatment of DM include intralesional corticosteroids, systemic corticosteroids, antimalarials, penicillamine, and methotrexate. Usually, DM's response to treatment is poor with progressive sclerosis and atrophy of the affected areas. [13]

Other Connective Tissue Disease–Associated Panniculitides

Dermatomyositis is rarely associated with either a lobular lipophagic panniculitis secondary to subcutaneous calcification or a lymphoplasmacytic lobular panniculitis with hyaline sclerosis, similar to LP. [17]

Sjögren's syndrome is rarely associated with a lobular panniculitis, characterized by a granulomatous, lymphocytic or plasma cell–rich inflammatory infiltrate. [18]

Mixed connective tissue disease is also associated with a lobular lipophagic panniculitis secondary to subcutaneous calcification. [19]

VASCULAR DISORDERS

Nodular Vasculitis

Nodular vasculitis (NV), is a reactive inflammatory lobular panniculitis associated with vasculitis.

HISTORICAL ASPECTS Erythema induratum was first described in 1861 by Bazin, and in 1900, French dermatologists linked this condition to tuberculosis, including it with the tuberculids. In 1905, Whitfield described cases of erythema induratum without any associated tuberculosis and in 1945, Montgomery, O'Leary, and Barker proposed the term *nodular vasculitis* for these cases of erythema induratum. A consensus has been reached considering erythema induratum of Bazin, erythema induratum of Whitfield, and nodular vasculitis as the same entity. [5]
EPIDEMIOLOGY NV is an uncommon condition that mainly affects obese middle-aged females, [3] who also have venous insufficiency. The incidence of NV has risen with the reemergence of tuberculosis due to the HIV pandemic. [20]
ETIOLOGY AND PATHOGENESIS NV is a reactive, probably immune complex-mediated vasculitis, which results in ischemic injury of fat with secondary pannicular necrosis and inflammation. The most common cause of NV is tuberculosis, but cases without any evidence of a tuberculous focus have also been described (see Chap. 200). Most nontuberculous cases are idiopathic, but case reports of NV associated with underlying hepatitis C infection [21] and propylthiouracil [22] have been described. Rheumatoid arthritis rarely has been associated with a lobular panniculitis with vasculitis similar to NV (neutrophilic lobular panniculitis or pustular panniculitis associated with rheumatoid arthritis). [23]
CLINICAL MANIFESTATIONS The main cutaneous manifestations of NV include recurrent, bilateral, painful,

erythematous subcutaneous nodules and plaques that commonly affect the posterior legs, but which also may affect the thighs, as well as other sites of the body. The lesions characteristically become bluish-red in color and break down into slowly healing ulcers with violaceous margins, eventually resulting in atrophic scars (Fig. 109-3A). The condition tends to occur in cold, winter months and has a prolonged recurrent course, with new crops of lesions occurring at irregular intervals, and it may last for many years. Associated erythrocyanosis, cutis marmorata, perifollicular erythema, features of venous insufficiency, and swollen, column-like calves may be observed. Individuals with NV tend to have no systemic involvement. [3], [5]

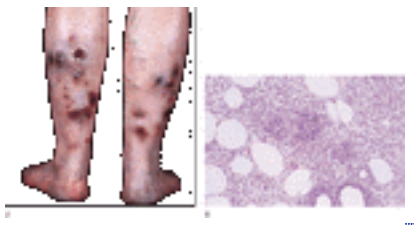

FIGURE 109-3 Nodular vasculitis. *A*. Note overall configuration of the legs, deep-seated erythematous and bluish nodules, ulceration, and scarring. *B*. Histopathologic features of nodular vasculitis with a mixed lobular panniculitis and neutrophilic vasculitis.

LABORATORY FINDINGS Patients with NV should be evaluated for tuberculosis with a chest x-ray and a tuberculin test.
PATHOLOGY NV is characterized histopathologically by a predominantly lobular panniculitis with vasculitis. There is an intense neutrophilic vasculitis of blood vessels (both arteriolar and venular) of different sizes in both the septa and lobules (Fig. 109-3B). In early lesions, there is a neutrophil-rich inflammatory infiltrate with extensive fat necrosis. In later lesions, there is a granulomatous inflammatory infiltrate composed of foamy histiocytes, epithelioid histiocytes and multinucleated giant cells in association with caseation necrosis, The inflammatory infiltrate may extend to the dermis and results in epidermal ulceration. In advanced cases, the inflammatory infiltrate is replaced by fibrosis. [5] In those cases associated with tuberculosis, *Mycobacterium tuberculosis* complex DNA may be demonstrated by polymerase chain reaction (PCR) within the cutaneous biopsy specimen. [24]
TREATMENT AND PROGNOSIS All cases of NV require bed rest and nonsteroidal anti-inflammatory agents for pain. Further treatment of NV depends on the underlying cause. Triple-agent antituberculous therapy is indicated in NV associated with evidence of a tuberculous infection. NV not associated with tuberculosis may be treated with systemic steroids, tetracycline, or potassium iodide. [25]

Calciphylaxis

Calciphylaxis, also known as calcifying panniculitis and vascular calcification-cutaneous necrosis syndrome, is a necrotic and ulcerative form of panniculitis resulting from ischemia secondary to calcification of the cutaneous vessel walls.

HISTORICAL ASPECTS In 1962, Selye [26] described the pathogenic factors leading to calciphylaxis in an animal experimental model. He observed that two requirements were needed: a critical period of sensitization by a variety of factors (parathyroid hormone, vitamin D, and a high calcium and phosphorus diet, all potentiated by nephrotoxic agents) followed by exposure to a challenging agent (trauma, metal salts, glucocorticoids, albumin, and mast cell degranulators).
EPIDEMIOLOGY Calciphylaxis occurs in about 4 percent of patients on hemodialysis. The mean age affected is 50 years and there is a predilection in females and whites. [27]
ETIOLOGY AND PATHOGENESIS Ischemic necrosis and ulceration of the skin in calciphylaxis occurs as a result of medial calcification, intimal hyperplasia and occlusion of the small cutaneous arterioles. [27] The most common cause of calciphylaxis is end-stage chronic renal failure (ESRF), with associated secondary hyperparathyroidism and raised calcium-phosphorus product. Precipitating factors for calciphylaxis in ESRF include arterial hypertension, obesity, diabetes mellitus, trauma, corticosteroids, immunosuppression, posthemodialysis metabolic alkalosis, and hypercoagulable defects, especially protein C and S deficiency. [27] Calciphylaxis may occur in patients with ESRF and normal calcium and phosphorus levels. Calciphylaxis may rarely occur in individuals with normal renal function, including patients with primary hyperparathyroidism, [28] malignancies (metastatic breast carcinoma, [29] cholangiocarcinoma, [30] and multiple myeloma [31] and end-stage liver disease. [32]
CLINICAL MANIFESTATIONS The early lesions of calciphylaxis include symmetric, violaceous, mottled to reticulated patches and plaques (livedo reticularis-like) with occasional bullae. The lesions most commonly involve the lower extremities (especially the thighs), but other less-common sites of involvement include the upper extremities, trunk, and penis. As the lesions evolve, they become indurated, necrotic plaques that break down into very painful, large, deep, nonhealing ulcers covered with black eschar [33] (Fig. 109-4A). Associated ischemic digital pain and gangrene has also been described. Calciphylaxis may rarely affect extracutaneous sites, particularly the eyes and the tracheal mucosa (tracheopathia chondro-osteoplastica). [5], [27]

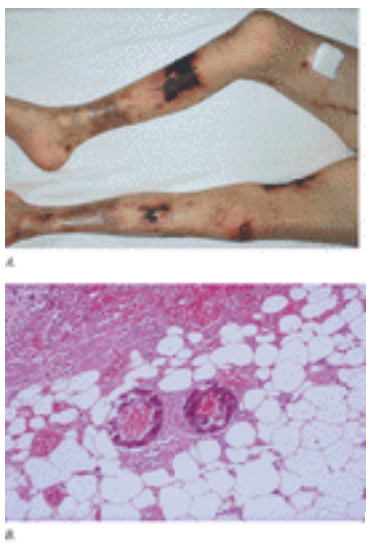

FIGURE 109-4 Calciphylaxis. *A*. Bilateral necrotic, ulcerating plaques with black eschar. *B*. Histopathologic features of calciphylaxis with lobular inflammation and medial vascular wall calcification.

LABORATORY FINDINGS Patients with calciphylaxis often have end-stage renal failure with elevated creatinine, BUN, and parathyroid hormone, as well as elevated calcium and phosphorus levels. Radiographs of affected areas may demonstrate vascular calcification.
PATHOLOGY Calciphylaxis is characterized by a predominantly lobular panniculitis without any vasculitis. Vascular wall calcification, capillary congestion, prominent fat necrosis, and lobular calcification accompany a sparse lobular inflammatory infiltrate composed of lymphocytes, neutrophils and foamy histiocytes. The vascular wall calcification (Fig. 109-4B) is the histopathologic hallmark of calciphylaxis and usually consists of segmental or circumferential calcium depositions in the media of small- to medium-sized arteries/arterioles in the reticular dermis and pannicular septa. Associated overlying dermal and epidermal necrosis is usually seen. Pseudoxanthoma elasticum-like elastic fiber calcification in the lower dermis and pannicular septa has also been observed in some cases of calciphylaxis. [5]
TREATMENT AND PROGNOSIS Calciphylaxis has a poor prognosis with a mortality rate of up to 60 to 70 percent, this being mainly caused by sepsis that results from secondary infection of the necrotic ulcers. Proximal extremity and truncal involvement are poor prognostic factors as compared to distal extremity involvement. Supportive therapy is of utmost importance in the treatment of calciphylaxis and includes wound care, control of the ESRF and the prevention and treatment of secondary hyperparathyroidism. [27] Parathyroidectomy [34], [35] and hyperbaric oxygen therapy [36], [37] reportedly are effective in the treatment of calciphylaxis. Studies are underway to assess the therapeutic efficacy of hyperbaric oxygen therapy with subcutaneous fractionated heparin. [27]

Oxalosis

Oxalosis is a rare crystal deposition disorder characterized by the accumulation and deposition of calcium oxalate crystals, which may result in histopathologic features similar to calciphylaxis: a lobular panniculitis with both vascular and extravascular calcification. There are two main types of oxalosis: primary and secondary oxalosis. Primary oxalosis, which presents with miliary, palmar deposits, is an autosomal recessive genetic disorder. Secondary oxalosis, which presents with livedo reticularis and digital gangrene, occurs in association with chronic renal failure, intestinal disease, excessive oxalate/glycolic acid ingestion, methoxyflurane anesthesia, and ethylene glycol poisoning. Both forms of oxalosis may result in a crystal deposition arthropathy and renal failure. [5]

Sclerosing Panniculitis

Sclerosing panniculitis (SP), also known as hypodermatitis sclerodermiformis, lipodermatosclerosis, lipomembranous change in chronic panniculitis, venous stasis panniculitis, and sclerous atrophic cellulitis, is a chronic form of lower extremity panniculitis associated with venous insufficiency [38] (see Chap. 167).

EPIDEMIOLOGY SP is a common cause of panniculitis most commonly affecting obese middle-aged to elderly females. [39]
ETIOLOGY AND PATHOGENESIS SP results from venous insufficiency of the lower extremity, this leading to decreased venous return with sludging of the blood in the lobular capillaries, thus resulting in pannicular ischemia, fat necrosis, and fibrosis. Venous insufficiency commonly results from varicose veins or deep venous thrombosis.
CLINICAL MANIFESTATIONS The cutaneous manifestations of SP are characterized by a clinical spectrum with an acute inflammatory phase at one end and a chronic fibrotic stage at the other end. [40] Progressive, symmetric, erythematous, woodlike, indurated plaques that involve the lower extremities in a stocking distribution characterize the acute phase. Associated features of lower extremity stasis including edema, telangiectasia, hyperpigmentation, dermatitis, and ulceration commonly accompany the acute phase of SP. As the disease advances there is extensive sclerosis and atrophy of the subcutaneous tissue resulting in an inverted champagne bottle deformity [5], [38] (see Chap. 167).
LABORATORY FINDINGS Venous Doppler ultrasound studies will reveal incompetence of the lower extremity veins.
PATHOLOGY The main histopathologic finding of SP is a predominantly lobular panniculitis without any vasculitis. There is septal thickening and sclerosis with atrophy of the fat lobules surrounded by a lipophagic granulomatous inflammatory infiltrate composed of lymphocytes, plasma cells and foamy histiocytes. The atrophic fat lobules are characterized by fatty microcysts lined by an amorphous, PAS-positive, eosinophilic corrugated membrane, known as lipomembranous or membranocystic change. [5], [39] Although the latter finding is characteristic for SP, it is not diagnostic because it is seen as a late feature in other panniculitides. [39] Overlying dermal angioplasia and fibrosis are also observed.
TREATMENT AND PROGNOSIS The management of SP includes treating venous insufficiency with leg elevation, elastic compression stockings (20 to 40 mmHg); in some difficult cases, the condition may be improved with the additional use of the fibrinolytic agent, stanozol. [5], [38]

OTHER PANNICULITIDES ASSOCIATED WITH SYSTEMIC DISORDER

Pancreatic Panniculitis

Pancreatic panniculitis (PP) is a panniculitis that results from the saponification of fat as a result of the release of pancreatic enzymes in pancreatic disease.

EPIDEMIOLOGY PP is rare, occurring in 2 to 3 percent of all patients with pancreatic disorders. [41] The average age incidence of PP is 60 years and males are affected more commonly than females, especially in cases associated with pancreatic carcinoma (5:1), but also, to a lesser extent, in cases associated with pancreatitis (3:1). [42]
ETIOLOGY AND PATHOGENESIS The most common pancreatic disorders associated with PP are acute or chronic pancreatitis (especially alcohol-related) and pancreatic carcinoma (usually the acinar cell type and less frequently the islet cell type). Rarely, other pancreatic disorders may be associated with PP, including pancreatic pseudocysts, pancreas divisum (unfused ducts of Wirsung and Santorini), and vascular-pancreatic fistulas. [5], [42] The released

pancreatic enzymes (particularly lipases) are thought to result in pannicular fat necrosis by saponification and secondary pannicular inflammation.

CLINICAL MANIFESTATIONS The cutaneous lesions of PP include multiple, variably painful, erythematous, fluctuant subcutaneous nodules that tend to ulcerate and exude a brown oily material (Fig. 109-5A). The most common sites of involvement of PP are the distal extremities (knees and ankles), although the proximal lower extremities, abdomen, and arms may also be affected. PP associated with a pancreatic carcinoma tends to be more extensive, more persistent, more recurrent, and more ulcerative than cases associated with pancreatitis. [5], [42] Systemic manifestations of PP include periarticular fat necrosis with secondary acute arthritis, especially of the ankles (60 percent) polyserositis (pleuritis, peritonitis, and pericarditis), fat necrosis of the bone marrow, and mesenteric thrombosis. [42]

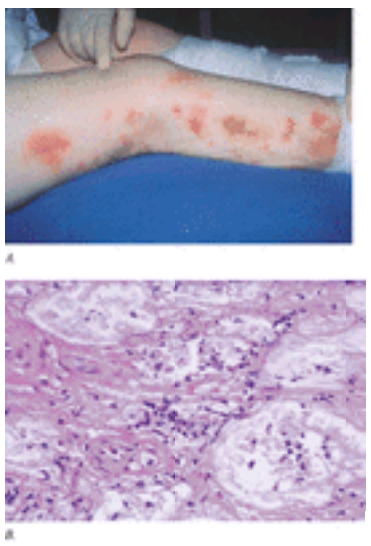

FIGURE 109-5 Pancreatic panniculitis. *A*. Erythematous, ulcerating nodules in lower extremity. *B*. Histopathologic features of pancreatic panniculitis with saponification necrosis and neutrophilic pannicular inflammation.

LABORATORY FINDINGS Diagnostic findings that demonstrate pancreatic disease include elevated serum pancreatic enzymes (amylase and lipase) and pancreatic imaging (ultrasonography or computed tomographic scan). A leukemoid reaction and eosinophilia are common findings in association with PP. [42]

PATHOLOGY The main histopathologic feature of PP is a predominantly lobular panniculitis without any vasculitis. A predominantly neutrophilic lobular inflammatory infiltrate is seen surrounding a characteristic type of fat necrosis—saponification of fat (Fig. 109-5B). This pancreatic fat necrosis is characterized by a collection of ghost adipocytes, which are anucleate and contain intracytoplasmic fine, basophilic granular material (calcification) from saponification of the fat secondary to the action of the pancreatic enzymes. In more advanced lesions, the infiltrate is more granulomatous (foamy histiocytes and multinucleated giant cells) and fewer ghost cells are observed. [5], [42]

TREATMENT AND PROGNOSIS The mainstay of treatment of PP is treatment of the underlying pancreatic disorder, which may include surgery. [43] The prognosis is worse for cases of PP associated with pancreatic carcinoma.

a $_1$-Antitrypsin Deficiency–Associated Panniculitis

a $_1$-Antitrypsin deficiency–associated panniculitis (a $_1$-ATDP) is a rare form of panniculitis that results from the uncontrolled activity of proteases on the subcutaneous tissue as a result of a deficiency in the serine proteinase inhibitor, a $_1$-antitrypsin (a $_1$-AT).

EPIDEMIOLOGY a $_1$-ATDP is a rare type of panniculitis that is usually seen in adults. It has no sexual predilection.

ETIOLOGY AND PATHOGENESIS a $_1$-ATDP results from a deficiency of the serine proteinase inhibitor a $_1$-AT (a $_1$ proteinase inhibitor). This hepatic-derived enzyme normally inhibits the activity of a number of serine proteases including trypsin, chymotrypsin, plasmin, thrombin, neutrophilic elastase, pancreatic elastase, collagenase, factor VII, and kallikrein. It is thought that the unchecked overactivity of these enzymes, particularly elastases and collagenase, will result in damage to the skin, as well as activation of lymphocytes and phagocytes, thus resulting in severe inflammation and necrosis. Trauma is a common precipitant of a $_1$-ATDP. [44]

GENETICS a $_1$-AT deficiency is inherited in an autosomal codominant fashion. There are 33 different alleles for the gene for a $_1$-AT, the commonest being the M, S, and Z alleles. Individuals with the phenotype, PiMM have normal levels of a $_1$-AT, whereas those individuals with the PiZZ phenotype have a severe deficiency. [44] The PiMS and PiMZ heterozygote phenotypes are associated with a moderate deficiency of a $_1$-AT. a $_1$-ATDP usually occurs in individuals with the homozygous phenotype PiZZ, although reports of a $_1$-ATDP occurring in association with other phenotypes (PiMZ, PiSS, [45] PiSZ [46] have also been described.

CLINICAL MANIFESTATIONS The cutaneous lesions of a $_1$-ATDP are characterized by ill-defined, subcutaneous, erythematous nodules or plaques (similar to cellulitis) commonly seen on the lower extremities, arms, trunk, and face. The lesions commonly ulcerate, exuding an oily material (derived from necrotic adipocytes), [44], [45], [47] and heal with atrophic scars. They are commonly seen in sites of trauma (Fig. 109-6A). Other cutaneous manifestations of a $_1$-ATDP include vasculitis, acquired angioedema, severe psoriasis, and Marshall's syndrome (Sweet's syndrome and acquired cutis laxa). [5] Systemic manifestations of a $_1$-AT deficiency include emphysema, hepatitis (commonly neonatal) and cirrhosis. [5]

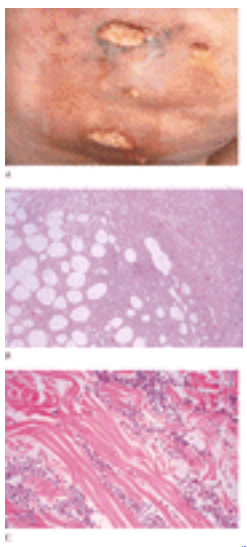

FIGURE 109-6 a $_1$-Antitrypsin deficiency–associated panniculitis. *A*. Subcutaneous, erythematous, ulcerating nodules exuding an oily material. Histopathologic features include neutrophilic lobular pannicular inflammation (*B*) and splaying of collagen in the pannicular septa (*C*).

LABORATORY FINDINGS Low levels of a $_1$-AT and an abnormal phenotype are the key tests for the diagnosis of this form of panniculitis.
PATHOLOGY a $_1$-ATDP is characterized histopathologically by a predominantly lobular panniculitis without vasculitis. Early lesions consist of focal areas of severe fat necrosis associated with a predominantly neutrophilic lobular inflammatory infiltrate (Fig. 109-6B), surrounded by large areas of normal adipose tissue. Within the overlying reticular dermis of early lesions, there is splaying of the collagen bundles by an interstitial neutrophilic inflammatory infiltrate (Fig. 109-6C). [5], [44], [48] Late lesions are characterized by replacement of fat lobules by an infiltrate of lymphocytes and foamy histiocytes and fibrosis.
PROGNOSIS AND TREATMENT Effective therapies that have been used for a $_1$-ATDP include dapsone, [49] systemic corticosteroids, [44] doxycycline, [46] minocycline, [50] intravenous infusions of exogenous a $_1$-protease inhibitor concentrate [44], [45], [51] (60 mg/kg per week), and liver transplantation. [52] Trauma or surgical débridement should be avoided, as well as smoking and exposure to potential hepatotoxins. The prognosis of a $_1$-ATDP is poor when there is associated pulmonary and hepatic involvement.

CYTOPHAGIC HISTIOCYTIC PANNICULITIS

Cytophagic histiocytic panniculitis (CHP) is a biologically aggressive, autonomous cellular proliferation affecting the panniculus and is characterized by a cytokine-driven histiocytic cytophagocytosis. [53]

HISTORICAL ASPECTS

Winkelmann and Bowie first described CHP in 1980. [54]

EPIDEMIOLOGY

CHP is a rare form of panniculitis that is most commonly seen in middle-aged to elderly individuals. [55]

ETIOLOGY AND PATHOGENESIS

The current concept of CHP is that it represents a spectrum of lymphoproliferative disorders that characteristically induce secondary histiocytic cytophagocytosis. Histiocytes are stimulated to undertake cytophagocytosis by a number of cytokines, especially interferon-? and macrophage inflammatory protein-1a (MIP-1a). Nonneoplastic and neoplastic lymphocytes, endothelial cells, and macrophages themselves elaborate these cytokines.

Studies suggest that CHP represents an early stage of a lymphoproliferative disorder, where the underlying lymphoid clone is difficult to detect, but in which there is a natural progression to develop into a lymphoma. [20], [56] In most cases, this non-Hodgkin's lymphoma is a subcutaneous panniculitic T cell lymphoma (SPTL), with either the a/ß or the ?/d cytophenotypes. Rarely, natural killer cell lymphoma (NKL) or some B cell lymphomas have also been described. Epstein-Barr virus infection is associated with CHP, especially those cases associated with SPTL or NKL. [53] Exogenous interferon therapy and the altered immunologic milieu in bone marrow transplantation are associated with CHP [53] (see Chap. 158).

CLINICAL MANIFESTATIONS

The main cutaneous manifestations of CHP are multiple, large erythematous, subcutaneous plaques and nodules, which commonly have associated overlying ecchymoses and spontaneous ulcerations. The main sites of involvement include the upper and lower extremities (Fig. 109-7A) and, to a lesser extent, the trunk and face. Associated features of the hemophagocytic syndrome (HPS) include pyrexia, weight loss, lymphadenopathy, hepatosplenomegaly, pancytopenia, and a consumptive coagulopathy. [3], [5], [20], [55], [57]

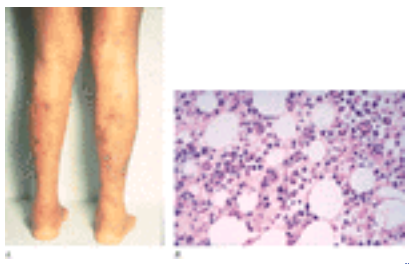

FIGURE 109-7 Cytophagic histiocytic panniculitis. *A*. Multiple, ulcerating erythematous nodules and plaques involving the lower extremities. *B*. Histopathologic features with mixed lobular pannicular inflammation and the pathognomonic feature of cytophagocytosis—“bean-bag” cells.

LABORATORY FINDINGS

CHP is characterized by the laboratory findings of HPS—characterized by pancytopenia, elevated liver enzymes, and a consumptive coagulopathy.

PATHOLOGY

The main histopathologic manifestation of CHP is a predominantly lobular panniculitis without vasculitis. The inflammatory infiltrate is composed of lymphocytes and histiocytes, the latter exhibiting the pathognomonic finding of cytophagocytosis that is characterized by intrahistiocytic intact and fragmented erythrocytes, leukocytes, and lymphocytes—“bean-bag” cells (Fig. 109-7B). The lymphocytes have a benign morphology in CHP, while they are atypical in SPTL, usually forming a ring around the necrotic adipocytes. [3], [5], [55]

TREATMENT AND PROGNOSIS

The prognosis and treatment of CHP depends on two main poor prognostic factors: (1) the presence of HPS and (2) the presence of an underlying lymphoma. In cases of CHP not associated with these poor prognostic factors, prednisone, potassium iodide, and cyclosporine have been used with success. Multiagent chemotherapy with CHOP (cyclophosphamide, doxorubicin, vincristine, and prednisone) combined with cyclosporine is used in cases of CHP associated with HPS or an underlying lymphoma. [57]

NONINFECTIOUS GRANULOMATOUS PANNICULITIDES

Erythema Nodosum

Erythema nodosum (EN) is a reactive dermatosis that occurs in response to a myriad of conditions, characterized by tender, erythematous subcutaneous nodules primarily affecting the lower extremities.

HISTORICAL ASPECTS Willan, in 1798, with further contributions by Wilson in 1842 and Hebra in 1866, first described EN. Several variants of EN were described: erythema nodosum migrans by Bafverstedt in 1954, and acute nodular migratory panniculitis by Vilanova and Pinol in 1956, and by Perry and Winkelmann in 1964. The term *chronic erythema nodosum* was coined by Fine and Meltzer, in 1969, to encompass both erythema nodosum migrans and acute nodular migratory panniculitis. [1]
EPIDEMIOLOGY EN is the most common type of panniculitis, with a peak age incidence of 20 to 30 years. Females are three to six times more commonly affected than males. However, any age may be affected, and in children, there is less of a female predominance. [1], [3]
ETIOLOGY AND PATHOGENESIS EN is a reactive hypersensitivity reaction that may occur in response to a number of antigenic stimuli. Table 109-2 presents an extensive list of the various reported causes of EN. [1] Streptococcal infections are the leading cause of EN in children, while in adults, the most common causes of EN include drugs, sarcoidosis, and inflammatory bowel disease. The underlying cause of EN may also be idiopathic. [1]



TABLE 109-2 **Causes of Erythema Nodosum** [1], [3]

CLINICAL MANIFESTATIONS EN is characterized by the sudden onset of symmetric, painful, erythematous, warm, nonulcerating nodules and plaques commonly affecting the knees, shins, and ankles (Fig. 109-8A), but they may also be seen on the thighs, arms, face, and neck. As the lesions of EN advance, they become flat and undergo color changes similar to a bruise, becoming purple after a few days and then acquiring a greenish-yellow hue. EN lesions finally resolve without any scarring or atrophy. Associated systemic manifestations include pyrexia, malaise, headache, cough, arthralgias, conjunctivitis, and gastrointestinal upset. Recurrent episodes of EN frequently occur. [1], [3]

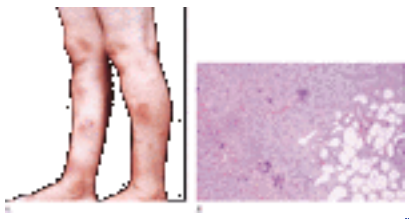

FIGURE 109-8 Erythema nodosum. *A*. Bilateral erythematous nodules in lower extremities. *B*. Histopathologic features of

erythema nodosum with a granulomatous septal panniculitis.

A variant of EN is chronic erythema nodosum (synonyms: erythema nodosum migrans and subacute nodular migratory panniculitis) that is characterized by unilateral subcutaneous nodules or plaques, which are fewer, less tender, and more persistent than those in classic EN. The individual lesions of chronic EN tend to extend peripherally with central clearing. [58]

LABORATORY FINDINGS An elevated sedimentation rate and a leukocytosis commonly accompany an acute episode of EN. Diagnostic tests to search for an underlying cause of EN depend on the geographic location, age, and clinical presentation of the patient. All patients should have a chest roentgenogram and complete blood count.

PATHOLOGY EN is characterized histopathologically by a predominantly septal panniculitis without any vasculitis. The histopathologic features vary with the stage of the disease, but are characterized throughout all the stages of the lesion by pannicular septal thickening containing Miescher's radial granulomas, which are small aggregates of histiocytes, surrounding a stellate-shaped cleft. The septal widening in the early stages is due to edema, hemorrhage, and predominantly neutrophilic inflammatory infiltrate surrounding the Miescher's radial granulomas, while in late-stage lesions, there is septal fibrosis and a predominantly granulomatous inflammatory infiltrate with multinucleated giant cells and lymphocytes (Fig. 109-8B). As the lesions advance, there is a sparser inflammatory infiltrate with granulation tissue at the dermal–pannicular interface. The septal pannicular inflammation is associated with some peripheral lobular inflammation and a superficial and deep dermal lymphocytic inflammatory infiltrate. [1], [3]

TREATMENT AND PROGNOSIS The treatment of EN depends upon identifying and treating any underlying associated condition. In most cases, EN resolves spontaneously within a few weeks, and bed rest and a nonsteroidal anti-inflammatory agent (aspirin, indomethacin, or naproxen) [59] for analgesia are all that is required. In more chronic or recurrent cases of EN, potassium iodide [25] (400 to 900 mg daily) or oral prednisone [20] may be used.

INFECTIOUS PANNICULITIS

ETIOLOGY AND PATHOGENESIS

The process occurs commonly in immunosuppressed patients [3], [5] and a large variety of microorganisms may cause the subcutaneous infections [60], [61], [62] and [63] (Table 109-3). The source of infection may be local or hematogenous. Local infection may result from direct inoculation (e.g., most subcutaneous mycoses), or at sites of an occlusive dressing (e.g., aspergillosis), or from direct extension from lymph nodes or viscera (e.g., actinomycosis, amebiasis, and tuberculosis). Hematogenous spread of infection usually, but not always, occurs in immunosuppressed individuals (e.g., candidiasis, opportunistic fungal infections, pseudomonas infections, and atypical mycobacterial infections).



TABLE 109-3 **Microorganisms that May Cause an Infectious Panniculitis** [60], [61], [62] and [63]

CLINICAL MANIFESTATIONS

The cutaneous lesions of an infectious panniculitis are characterized by erythematous subcutaneous nodules and plaques, some of which ulcerate and discharge a necrotic and/or pustular material. The site of involvement varies with the type of infection. [3], [5]

PATHOLOGY

The characteristic histopathologic features of an infectious panniculitis may be a predominantly lobular or predominantly septal, or a mixed lobular and septal panniculitis, usually being accompanied by dermal involvement. Fat necrosis and vascular thrombosis usually accompanies a variably mixed inflammatory infiltrate of neutrophils, plasma cells, histiocytes, and multinucleated giant cells. Microorganism may be seen within the inflammatory infiltrate or necrotic debris. [3], [5] Special stains (Gram's, Fite, PAS with and without diastase, and Gomori methenamine stains) may be needed to identify the microorganisms. In subcutaneous Whipple's disease, a predominantly septal panniculitis with foamy histiocytes containing pathognomonic PAS-positive, diastase-resistant intracytoplasmic granular material is seen. [63] Anti-BCG immunostaining may be used as a highly sensitive screen for bacterial or fungal microorganisms. [64] PCR techniques for specific organisms may also be used to identify the specific DNA of the causative microorganism.

TREATMENT AND PROGNOSIS

The therapy of an infectious panniculitis involves antimicrobials dictated by the causative microorganism. The prognosis depends mainly on other sites of involvement and the immune status of the patient. [5]

PHYSICAL PANNICULITIDES

Traumatic Panniculitis

ETIOLOGY AND PATHOGENESIS Traumatic panniculitis (TP) usually results from blunt trauma to the subcutaneous fat resulting in fat necrosis and inflammation. A number of situations may result in physical trauma to the subcutaneous fat

and may be accidental, factitial, or secondary to a procedure.

CLINICAL MANIFESTATIONS TP is clinically characterized by subcutaneous nodules or plaques, which may or may not be erythematous. TP may involve any site of the body. The most common sites of involvement of accidental TP are the lower extremities (shins; anterolateral thighs in females who repeatedly knock them against a desk at work—lipoatrophia semicircularis), elbows, and breasts (especially in obese 20- to 60-year-old females with large breasts—traumatic fat necrosis of the breast). Factitial TP is commonly seen following self-inflicted blunt trauma to the distal extremities—l'oedeme bleu. TP has also been seen following cupping or acupuncture. Mobile encapsulated lipoma (synonyms: nodular-cystic fat necrosis and encapsulated fat necrosis) is an end stage of TP, characterized by a persistent, well-demarcated, mobile nodule at sites of injury. [3], [5]

PATHOLOGY TP is characterized histopathologically by a predominantly lobular panniculitis without vasculitis. Variably sized and variably shaped cystic spaces of fat necrosis are surrounded by various degrees of fibrosis, hemorrhage, and a lipophagic inflammatory infiltrate. In later stages, there may be lipomembranous change, extracellular and intracellular hemosiderin, and encapsulation of lipocytes (both normal and necrotic) by a fibrous capsule—mobile encapsulated lipoma. [3] /SUP>, [5], [65]

TREATMENT AND PROGNOSIS TP is usually self-limited often resulting in a residual subcutaneous nodule (mobile encapsulated lipoma), which may be surgically excised.

Cold Panniculitis

Cold panniculitis (CP) is a form of traumatic panniculitis that results from cold injury to the subcutaneous fat.

HISTORICAL ASPECTS In 1966, Duncan et al. reproduced a lymphohistiocytic lobular panniculitis 49 to 72 hours after application of ice cubes on the skin. [5]

EPIDEMIOLOGY This is an uncommon cause of panniculitis that is commonly seen in infants and, to a lesser extent, adult females.

ETIOLOGY AND PATHOGENESIS The main risk factor for cold injury to the subcutaneous fat is age, where it is seen most commonly in infants, who have a higher content of saturated fat that solidifies more rapidly at low temperatures. CP is seen in the cheeks of infants following sucking of ice cubes, ice packs, or ice popsicles—popsicle panniculitis. CP may also occur in adults following activities that involve prolonged exposure to cold temperature—sledding, motorcycling, and horseback riding (equestrian panniculitis). [3], [5] Contributing risk factors for CP in adults are the female sex, tight fitting or noninsulating clothing, a chilblain type of circulation, paralysis and cold agglutinin disease. [66] Adult CP especially occurs in the buttocks and lateral thighs of females. CP involving the scrotum may also be seen in prepubertal males.

CLINICAL MANIFESTATIONS The cutaneous manifestations of CP are indurated, erythematous plaques with ill-defined margins that occur on the face and extremities in winter. The plaques slowly soften and resolve after a few days with temporary hyperpigmentation but no scarring. [3], [5]

PATHOLOGY Cold panniculitis is characterized by a predominantly lobular panniculitis without vasculitis. Fat necrosis usually accompanies a lymphohistiocytic pannicular inflammatory infiltrate. Papillary dermal edema and a superficial and deep perivascular dermal lymphocytic infiltrate are also seen. [3], [5]

TREATMENT Cold panniculitis usually resolves with avoidance of cold exposure. In equestrian panniculitis, looser-fitting trousers are helpful.

CHEMICAL/FOREIGN BODY PANNICULITIS

Panniculitis may result from the introduction of a variable number of different chemicals within the subcutaneous fat—chemical/foreign body panniculitis (CFBP).

ETIOLOGY AND PATHOGENESIS

In CFBP, the introduction of a variety of chemicals in the subcutaneous fat may be either for factitial or therapeutic/cosmetic reasons [67], [68], [69] and [70] (Table 109-4).

Factitial	Therapeutic/Cosmetic
Acids/alkalis	Meperidine
Mustard	Vitamin K_1
Oils	Povidone
Urine/feces	Paraffin
Microbiologically contaminated material	Silicone
	PMMA-microspheres (Artecoll)
	Polymethylsiloxane (Bioplastique)

TABLE 109-4 **Causes of Chemical/Foreign Body Panniculitis** [67], [68], [69] and [70]

CLINICAL MANIFESTATIONS

The main cutaneous manifestations of CFBP are subcutaneous nodules or plaques, which may or may not be erythematous or ulcerated.

PATHOLOGY

The main histopathologic feature of CFBP is usually a predominantly lobular panniculitis without vasculitis. The inflammatory infiltrate is predominantly neutrophilic in early lesions, becoming predominantly granulomatous in more advanced lesions. The inciting foreign material (commonly polarizable) may be identified and, sometimes, specific features that help identify the injected material may also be observed (Table 109-5). Spectroscopic analysis also helps to identify the injected material. [3], [5]

Material Injected	Characteristic Features on Histopathologic
Paraffinoma	Sclerosing lipogranuloma: Granulomatous inflammation and fibrosis surrounding multiple variably sized spaces (Swiss cheese) that replace the fat lobules
Silicone	Granulomatous inflammation surrounds polygonal translucent angulated foreign bodies
Polymethylmethacrylate (Bioplastique)	Granulomatous inflammation surrounding irregularly sized and shaped spaces containing jagged, translucent nonbirefringent foreign bodies

TABLE 109-5 **Pathognomonic Histopathologic Findings of Injectable Materials in Chemical/Foreign Body Panniculitis** [5], [67], [68], [69] and [70]

TREATMENT AND PROGNOSIS

Treatment of CFBP depends on the underlying cause. In cases that are factitial, psychiatric advice should be sought and any associated underlying secondary infection should be appropriately treated. In cases associated with material injected for cosmetic purposes such as silicone, the material should be removed.

CHILDHOOD PANNICULITIS (See also Chap. 143)

Sclerema Neonatorum

EPIDEMIOLOGY Sclerema neonatorum (SN) is a rare form of panniculitis, mainly affecting seriously ill, low birth weight and/or premature neonates, usually in their first days of life.

ETIOLOGY AND PATHOGENESIS The high ratio of saturated to unsaturated fatty acids in the adipose tissue of low birth weight or premature neonates predisposes them to the changes in the adipose tissue that result in SN.

CLINICAL MANIFESTATIONS The characteristic cutaneous manifestations of SN are diffuse yellow-white, woody, indurated plaques that start on the buttocks and thighs and rapidly expand to involve large areas of the body with immobility of the extremities. SN occurs in association with a serious underlying systemic illness such as an infection or congenital heart disease or any other major developmental anomaly. [5]

PATHOLOGY The main histopathologic characteristics of SN include a predominantly lobular panniculitis with a sparse to absent lymphohistiocytic inflammatory infiltrate with a few multinucleated giant cells. The characteristic histopathologic findings are radial needle-shaped clefts within the adipocytes and the few multinucleated giant cells. Fat necrosis is not present in SN and the pannicular septa are thickened and bandlike. [5]

TREATMENT AND PROGNOSIS The management of SN is usually treatment of the underlying systemic illness. Exchange transfusions may help to decrease mortality, while corticosteroids are ineffective in this disorder. [5] The prognosis if SN is very poor, with infants dying within a few days of the onset of disease. [71] Survivors of this disorder usually have normal skin without any long-term complications or calcification.

Subcutaneous Fat Necrosis of the Newborn

EPIDEMIOLOGY Subcutaneous fat necrosis of the newborn (SFNN) is a rare form of neonatal panniculitis that is mainly seen in the first days of the neonatal period, but rarely are lesions present at birth. [72]

ETIOLOGY AND PATHOGENESIS Various etiologic factors are associated with SFNN, including hypercalcemia, obstetric trauma, induced hyperthermia for cardiac surgery, prostaglandin E administration, brown fat deficiency, serum lipid/lipoprotein abnormalities, use of cocaine by the mother during pregnancy, and intrapartum administration of calcium-channel blockers, and in association with thrombocytopenia. It is felt that the large surface-area-to-weight ratio and the greater ratio of saturated to unsaturated fatty acids in the neonate favor release of hydrolases, induced by minor trauma, resulting in the breakdown of unsaturated fatty acids. [5], [72]

CLINICAL MANIFESTATIONS The cutaneous manifestations of SFNN consist of indurated, erythematous subcutaneous nodules or plaques mainly affecting the buttocks, thighs, shoulders, and cheeks. Although many underlying conditions are associated with SFNN, this form of panniculitis is usually seen in healthier individuals. [5], [72]

LABORATORY FINDINGS Hypercalcemia is a common associated laboratory finding in SFNN. [5], [72]

PATHOLOGY The histopathologic characteristics of SFNN are a lobular panniculitis without any vasculitis. Fat necrosis occurs in association with a dense inflammatory infiltrate, composed of lymphocytes, histiocytes, foamy histiocytes, multi-nucleated giant cells and eosinophils. Characteristic of SFNN are needle-shaped clefts (triglyceride crystals) that are present within both lipocytes and histiocytes. Advanced lesions will have septal fibrosis and calcification. [5], [72]

TREATMENT AND PROGNOSIS SFNN has an excellent prognosis, regressing within a few days without any sequelae.

Poststeroid Panniculitis

Poststeroid panniculitis (PSP) is a rare type of childhood panniculitis that occurs in children who are withdrawn from high doses of systemic steroids.

EPIDEMIOLOGY PSP is very rare and has only been seen in children.

ETIOLOGY AND PATHOGENESIS PSP is most commonly seen 1 to 10 days following rapid withdrawal of high doses of systemic corticosteroids used in infants for several conditions, including rheumatic fever, leukemia, nephrotic syndrome, and cerebral edema. [73], [74] The exact pathogenesis of this type of panniculitis is unclear, although it may result from lipocyte injury secondary to the accelerated removal of the excess fat gained during corticosteroid use.

CLINICAL MANIFESTATIONS The characteristic cutaneous lesions of PSP are erythematous, 1 to 4 cm, occasionally pruritic subcutaneous nodules that develop up to 2 weeks following cessation of high-dose corticosteroids. The most common sites of involvement are the cheeks,

arms, and trunk. Although no extracutaneous manifestations are usually seen with poststeroid panniculitis, a fatal case of intestinal fat necrosis has been reported. [5, 73, 74]

PATHOLOGY The main histopathologic feature of PSP includes a lobular panniculitis without vasculitis. The inflammatory infiltrate is composed of lymphocytes and foamy histiocytes that contain intracytoplasmic needle-shaped clefts similar to subcutaneous fat necrosis of the newborn. [5]

TREATMENT AND PROGNOSIS Mild cases of poststeroid panniculitis do not usually require any treatment, because there is gradual resolution over a period of a few weeks. In more severe cases, where ulceration and scarring of the cheeks may occur, readministration of high-dose systemic corticosteroids followed by a gradual tapering of the dose is indicated. [5]

DIAGNOSTIC APPROACH TO PANNICULITIS

The diagnosis of the etiology of panniculitis can be made in most cases after careful clinical assessment (Table 109-6) and appropriate diagnostic testing (Table 109-7). The diagnosis of the cause of a panniculitis is usually established on assessment of a number of dermatopathologic parameters, which include the location of the inflammatory infiltrate (septal or lobular), the presence or absence of vasculitis, and the nature of the inflammatory infiltrate [75] (Table 109-8 and Table 109-9).

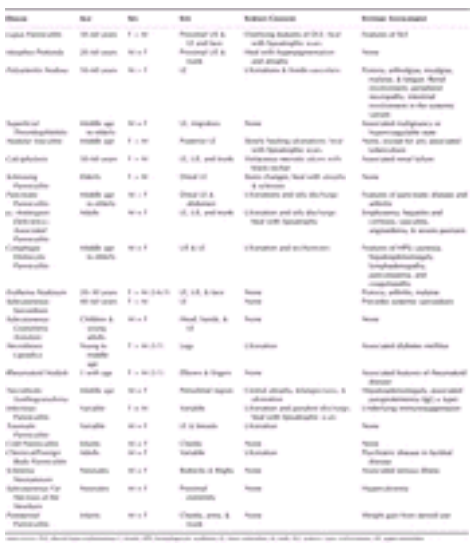

TABLE 109-6 **Clinical Clues to the Diagnosis of the Etiology of Panniculitis**



TABLE 109-7 **Diagnostic Tests for the Etiology of Panniculitis**

TABLE 109-8 **Histopathologic Differential Diagnosis of Predominantly Septal Panniculitides**

TABLE 109-9 **Histopathologic Differential Diagnosis of Predominantly Lobular Panniculitides**

REFERENCES

1. Raquena L, Sanchez Yus E: Panniculitis. Part I. Mostly septal panniculit *J Am Acad Dermato* **45**:163, 2001

2. Ackermann AB et al: *Histologic Diagnosis of Inflammatory Skin Disease: An Algorithmic Method Based on Pattern Analy* 2nd ed. Baltimore, Williams and Wilkins, 1997, p 31

3. Peters MS, Su WPD: Panniculitis. *Dermatol Cli* **10**:37, 1992

4. White JW, Winkelmann RK: Weber-Christian panniculitis: A review of 30 cases with this diagnosi *J Am Acad Dermato* **39**:56, 1998

5. Requena L, Sanchez Yus E: Panniculitis. Part II. Mostly lobular panniculi *J Am Acad Dermato* **45**:325, 2001

6. Peters MS, Su WPD: Lupus erythematosus panniculitis *Med Clin North Am* **73**:1113, 1989

7. Martens PM et al: Lupus panniculitis: Clinical perspectives from a case serie *J Rheumato* **26**:68, 1999

8. Yell JA, Burge SM: Lupus erythematosus profundus treated with clobetasol propionate under hydrocolloid dress *Br J Dermato* **128**:103, 1993

9. Yamada Y et al: Lupus erythematosus profundus: Report of a case treated with dapso *J Dermatol* **16**:379, 1989

10. Burrows NP et al: Lupus erythematosus profundus with partial C4 deficiency responding to thalidomi *Br J Dermato* **125**:62, 1991

11. Saeki Y et al: Maintaining remission of lupus erythematosus profundus (LEP) with cyclosporin *Lupus* **9**:390, 2000

12. Magro CM et al: Lupus profundus, indeterminate lymphocytic lobular panniculitis and subcutaneous T-cell lymphoma: A spectrum of subcuticular T-cell lymphoid dysc *J Cutan Patholo* **28**:235, 2001

13. Peterson LS et al: Classification of morphea (localized scleroderm *Mayo Clin Proc* **70**:1068, 1995

14. Zuckerman E et al: Fasciitis-panniculitis in acute brucellosi *Int J Dermato* **33**:57, 1994

15. Naschitz JE et al: Cancer-associated fasciitis panniculitis *Cancer* **73**:231, 1994

16. Winkelmann RK et al: Pseudosclerodermatous panniculitis after irradiation: An unusual complication of megavoltage treatment of breast carcin *Mayo Clin Proc* **68**:122, 1993

17. Chao YY, Yang LJ: Dermatomyositis presenting as panniculiti *Int J Dermato* **39**:140, 2000

18. Tait PT et al: Sjögren's syndrome and granulomatous panniculiti *Aust J Dermato* **41**:187, 2000

19. Itoh O et al: Mixed connective tissue disease with severe pulmonary hypertension and extensive subcutaneous calcific *Intern Med* **37**:421, 1998

20. Phelps RG, Shoji T: Update on panniculitis *Mt Sinai J Med* **68**:262, 2001

21. Cardinali C et al: Hepatitis C virus: A common triggering factor for both nodular vasculitis and Sjögren's syndrom *Br J Dermato* **142**:187, 2000

22. Wolf D et al: Nodular vasculitis associated with propylthiouracil therap *Cutis* **49**:253, 1992

23. Tran TA et al: Neutrophilic lobular (pustular) panniculitis associated with rheumatoid arthritis: A case report and review of the litera *Am J Dermatopatho* **21**(3):247, 1999

24. Yen A et al: Detection o *Mycobacteria tuberculosis* in erythema induratum of Bazin using polymerase chain reactio *Arch Dermato* **133**:532, 1997

25. Hori T et al: Potassium iodide in the treatment of erythema nodosum and nodular vascul *Arch Dermato* **117**:29, 1981.

26. Selye H: *Calciphylaxis*. Chicago, IL, University of Chicago Press, 1962, pp 1–100

27. Mathur RV et al: Calciphylaxis *Postgrad Med J* **77**:557, 2001

28. Mirza I et al: An unusual presentation of calciphylaxis due to primary hyperparathyroidi *Arch Pathol Lab Med* **125**:1351, 2001

29. Mastruserio DN et al: Calciphylaxis associated with metastatic breast carcinon *J Am Acad Dermato* **41**:295, 1999

30. Riegert-Johnson DL et al: Calciphylaxis associated with cholangiocarcinoma treated with low-molecular-weight heparin and vitan *Mayo Clin Proc* **76**:749, 2001

31. Raper RD, Ibels LS: Osteosclerotic myeloma complicated by diffuse arteritis, vascular calcification and extensive cutaneous necr *Nephron* **39**:389, 1985

32. Fader DJ, Kang S: Calciphylaxis without renal failur *Arch Dermato* **132**:837, 1996

33. Dahl PR et al: The vascular calcification: cutaneous necrosis syndrom *J Am Acad Dermato* **33**:53, 1995

34. Hafner J et al: Uremic small-artery disease with medial calcification and intimal hyperplasia (so-called calciphylaxis): A complication of chronic renal failure and benefit from parathyroidectomy *J Am Acad Dermato* **33**:954, 1995

35. Girotto JA et al: Parathyroidectomy promotes wound healing and prolonged survival in patients with calciphylaxis from secondary hyperparathyro *Surgery* **130**:645, 2001

36. Vassa N et al: Hyperbaric oxygen therapy in calciphylaxis-induced skin necrosis in a peritoneal dialysis pat *Am J Kidney Dis* **23**:878, 1994

37. Podymow T et al: Hyperbaric oxygen in the treatment of calciphylaxis: A case seri *Nephrol Dial Transplan* **16**:2176, 2001

38. Jorizzo JL et al: Sclerosing panniculitis: A clinicopathological assessmen *Arch Dermato* **127**:554, 1991

39. Snow JL, Su WPD: Lipomembranous (membranocystic) fat necrosis: Clinicopathological correlation of 38 cas *Am J Dermatopatho* **18**:151, 1996

40. Kirsner RS et al: The clinical spectrum of lipodermatosclerosi *J Am Acad Dermato* **28**:623, 1993

41. Sibrack LA, Goutermann IH: Cutaneous manifestations of pancreatic disease *Cutis* **21**:763, 1978

42. Dahl PR et al: Pancreatic panniculitis *J Am Acad Dermato* **33**:413, 1995

43. Lambiase P et al: Resolution of panniculitis after placement of pancreatic duct stent in chronic pancreat *Am J Gastroentero* **91**:1835, 1996

44. Su WPD et al: a_1-Antitrypsin deficiency panniculitis: A histopathological and immunopathological study of 4 cas *Am J Dermatopatho* **9**:483, 1987

45. Pittelkow MR et al: Alpha$_1$-antitrypsin deficiency and panniculitis: Perspectives on disease relationship and replacement ther *Am J Med* **84**:80, 1988

46. Ching WJ, Henderson CA: Suppurative panniculitis associated with alpha$_1$-antitrypsin deficiency (PiSZ phenotype) treated with doxycyclin *Br J Dermato* **144**:1261, 2001

47. Smith KC et al: Clinical and pathologic correlations in 96 patients with panniculitis, including 15 patients with deficient levels $_1$-antitrypsin. *J Am Acad Dermato* **21**:1192, 1989

48. Geller JD, Su WPD: A subtle clue to the histopathological diagnosis of early$_1$-antitrypsin deficiency panniculitis *J Am Acad Dermato* **31**:241, 1994

49. Smith KC et al: Panniculitis associated with severe $_1$-antitrypsin deficiency: Treatment and review of the literatur *Arch Dermato* **123**:1655, 1987

50. Ginarte M et al: Treatment of alpha$_1$-antitrypsin-deficiency panniculitis with minocycline *Cutis* **68**(2):86, 2001

51. Furey NL et al: Treatment of alpha$_1$-antitrypsin deficiency, massive edema and panniculitis with alph$_1$protease inhibitor. *Ann Intern Med* **125**:699, 1996

52. O'Riordan K et al: Alpha$_1$-antitrypsin deficiency-associated panniculitis: Resolution with intravenous alph$_1$-antitrypsin administration and liver transplantatio *Transplantatior* **63**:480, 1997

53. Wick MR, Patterson JW: Cytophagic histiocytic panniculitis—A critical reapprais *Arch Dermato* **136**:922, 2000

54. Winkelmann RK, Bowie EJ: Hemorrhagic diathesis associated with benign histiocytic cytophagic panniculitis and systemic histiocyt *Arch Intern Med* **140**:1460, 1980

55. Chin-Yao EW, Su WPD: Subcutaneous panniculitic T-cell lymphoma *Int J Dermato* **35**:1, 1996

56. Marzano AV et al: Cytophagic histiocytic panniculitis and subcutaneous panniculitis-like T-cell lymphoma. Report of 7 ca *Arch Dermato* **136**:889, 2000

57. Weenig RH et al: Subcutaneous panniculitis-like T-cell lymphoma. An elusive case presenting as lipomembranous panniculitis and a review of 72 cases in the liter *Am J Dermatopatho* **23**:206, 2001

58. De Almeida Prestes C et al: Septal granulomatous panniculitis: Comparison of the pathology of erythema nodosum migrans (migratory panniculitis) and chronic erythema noc *J sum. Am Acad Dermato* **22**:477, 1990

59. Ubogy Z, Persellin RM: Suppression of erythema nodosum by indomethac *Acta Derm Venereol (Stockh)* **107**:209, 1982

60. Patterson JW et al: Infection-induced panniculitis *J Cutan Patho* **16**:183, 1989

61. Bartralot R et al: Cutaneous infections due to non-tuberculous mycobacteria: Histopathological review of 28 cases. Comparative study between lesions observed in immunosuppressed patients and normal hosts *J Cutan Patho* **27**:124, 2000

62. Rosenberg AS, Morgan MB: Disseminated acanthamoebiasis presenting as lobular panniculitis with necrotizing vasculitis in a patient with A *J Cutan Patho* **28**:307, 2001

63. Tarroch X et al: Subcutaneous nodules in Whipple's diseas *J Cutan Patho* **28**:368, 2001

64. Byrd J et al: Utility of anti-bacillus Calmette-Guerin antibodies as a screen for organisms in sporotrichoid infecti *J Am Acad Dermato* **44**:261, 2001

65. Kiryu H et al: Encapsulated fat necrosis: a clinicopathological study of 8 cases and a literature revi *J Cutan Patho* **27**:19, 2000

66. De Silva BD et al: Equestrian perniosis associated with cold agglutinins: A novel findi *Clin Exp Dermato* **25**:285, 2000

67. Kossard S et al: Povidone panniculitis. Polyvinylpyrrolidone panniculi *Arch Dermato* **116**:704, 1980

68. Palestine RF et al: Skin manifestations of pentazocine abus *J Am Acad Dermato* **2**:47, 1980

69. Delage C et al: Mammary silicone granulom *Arch Dermato* **108**:104, 1973.

70. Rudolph CM et al: Foreign body granulomas due to injectable aesthetic microimplar *Am J Surg Patho* **23**:113, 1999

71. Warwick W et al: Sclerema neonatorum: A sign not a diseas *JAMA* **184**:680, 1963

72. Burden AD, Krafchik BR: Subcutaneous fat necrosis of the newborn: A review of 11 cas *Pediatr Dermato* **16**:384, 1999

73. Silverman RA et al: Poststeroid panniculitis *Pediatr Dermato* **5**:92, 1988

74. Saxena AK, Nigam PK: Panniculitis following steroid therap *Cutis* **42**:341, 1988

75. Cascajo CD et al: Panniculitis: Definition of terms and diagnostic strate *Am J Dermatopatho* **22**:530, 2000

T>

Chapter 110

Ervin Epstein

Lipodystrophy

CLASSICAL PARTIAL LIPODYSTROPHY
Etiology
Clinical Features
Histopathology
Laboratory Findings and Associated Internal Disease
Treatment
DUNNIGAN TYPE OF LIPODYSTROPHY
Etiology and Pathogenesis
Clinical Features, Laboratory Findings, and Associated Internal Disease
Treatment
HIV-ASSOCIATED LIPODYSTROPHY26,27
Etiology and Pathogenesis
Clinical Features
Histopathology
Laboratory Findings and Associated Internal Disease
Treatment
GENERALIZED LIPODYSTROPHY
Etiology and Pathogenesis
Clinical Features
Laboratory Findings and Associated Internal Disease
Treatment

REFERENCES

The syndromes of partial lipodystrophy (PL) and generalized lipodystrophy (GL) are a heterogeneous group of diseases characterized by the absence of subcutaneous fat over part or all of the body surface. [1]

CLASSICAL PARTIAL LIPODYSTROPHY

Etiology

The causes of most instances of PL, the more common of the syndromes, are unknown. There are conflicting data regarding a possible genetic predisposition to the usual cephalothoracic type. For example, in two instances one identical twin had PL with glomerulonephritis, decreased C3, and the presence of C3 nephritic factor, but her twin sister had none of these abnormalities. [2] By contrast, one family was reported in which an affected mother had two normal and two affected children.

Clinical Features

Over several years, patients with “classical” acquired (Barraquer-Simons) PL gradually lose their subcutaneous fat in clearly demarcated, generally symmetric areas of the body. The wasting usually begins on the face, spreads downward, and may stop at any level, most often above or at the middle of the thighs. Occasionally, the lower portion of the body may be affected while the upper portion remains uninvolved. The unaffected part of the body often appears obese, partly because of the contrast with the gaunt appearance of the thin portion. Excess fat deposition over the hips and thighs frequently occurs in postpubertal women with PL. Eighty percent of patients are female, and the disease develops in most patients before the age of 15 years. A clinically apparent inflammatory phase does not precede the fat loss, but patients often correlate the onset with some acute febrile illness.

The face appears cachectic. Buccal fat pads disappear, leaving a relative prominence of the chin and zygomas (Fig. 110-1). With loss of retroorbital and periorbital tissue, the eyes may sink deeply into the sockets. Smiling produces many wrinkles and a prematurely aged expression. Unshielded by the usual blanket of fat, the veins and muscles of the trunk and upper extremities appear hypertrophied. The overlying skin itself is of normal color, texture, and elasticity. Visceral fat stores underlying the thin areas also are absent.

FIGURE 110-1 Partial lipodystrophy. Emaciated facies results from a loss of buccal fat pads. (*Courtesy of John Reeves, MD.*)

Patients with the clinically quite separate syndrome of localized lipodystrophy, or lipoatrophy, have one or more scattered areas of loss of subcutaneous fat. There may be myositis underlying these areas, and the loss may represent the end stage of lymphocytic panniculitis (see Chap. 109). Lipoatrophia semicircularis is a bandlike depression of the skin mainly on the lower extremities and caused by pressure and trauma. [3]

Histopathology

Subcutaneous fat cells may be detected microscopically but in markedly decreased number. [4]

Laboratory Findings and Associated Internal Disease

The most common laboratory abnormality in patients with PL is decreased serum complement: C3 was diminished in 70 percent of unselected PL patients, and this may be due both to decreased synthesis and to increased catabolism. Associated with this is the presence of C3 nephritic factor, an immunoglobulin that binds to factor H (an inhibitor of C3) and hence allows uncontrolled activation of C3. Many PL patients have glomerulonephritis. These serologic abnormalities may be found in patients with glomerulonephritis without PL, and currently the weight of evidence, albeit it mostly circumstantial, favors the hypothesis that the nephritic factor predisposes to glomerulonephritis via direct toxicity and/or via hypocomplementemia. [5], [6] Furthermore, there is experimental evidence that serum that contains nephritic factor is toxic to adipocytes in vitro, leading to the suggestion that this factor contributes directly to the loss of fat. [7] Patients with these complement abnormalities may have histologically detectable glomerulonephritis before renal disease is apparent clinically. [8] The percentage of patients who eventually develop significant renal disease is not known. In some patients with PL, resistance to infection is decreased, possibly because of the C3 deficiency. [9] Some of the patients have had pancreatitis with eosinophilia. [10] Women with PL may be at increased risk for third-trimester intrauterine death. [11] Development of diabetes is common.

Treatment

Effective therapy for the underlying defect is not available. Because fat may be resorbed rapidly, implantation of fat from unaffected areas is of inconsistent benefit, but one patient had good cosmetic results more than a year following subcutaneous implantation of muscle harvested from the abdomen. [12] Subcutaneous lipectomy and liposuction may improve the appearance of lower extremities in which excessive subcutaneous fat is deforming. [13] Patients with uremia have had successful renal transplants.

DUNNIGAN TYPE OF LIPODYSTROPHY

Etiology and Pathogenesis

More rarely, patients lose subcutaneous fat only from the limbs with maintenance of fat on the trunk and face or they lose fat from both the limbs and trunk and maintain fat on the face. In some families, this syndrome is inherited as an autosomal dominant trait, the Dunnigan-Kobberling syndrome (D-PL; MIM #151660). [14], [15], [16] and [17] Mutations in *LMNA,* the gene that encodes lamins A and C, underlie D-PL. [18], [19] and [20] Other mutations in the same gene can cause autosomal forms of muscular dystrophy, dilated cardiomyopathy, Charcot-Marie-Tooth neuropathy, and mandibuloacral dysplasia, in which affected individuals have not only lipodystrophy but also several other abnormalities including mottled hyperpigmentation and alopecia. [21] The nuclear lamins belong to the family of intermediate filament proteins and are attached to the inner surface of the nuclear envelope. This localization contrasts with that of other intermediate filament proteins such as the keratins, which are cytoplasmic and are attached to the inner surface of the plasma membrane. One report suggested association of lamin A/C gene polymorphisms and obesity in non-PL individuals. [22] In a unique mother and son with insulin-resistance, hypocalcemia, and PL, similar clinically to that of the Dunnigan type, there was a missense mutation in a calcium-sensing receptor at the cell surface. [23]

Clinical Features, Laboratory Findings, and Associated Internal Disease

In patients with D-PL, the fat loss of the extremities and trunk begins at puberty and is accompanied by fat deposition on the face and upper back as well as by maintenance of fat within the truncal cavities and bone marrow. [24] Despite

maintenance of some fat, the acanthosis nigricans (see Chap. 185) and metabolic problems of insulin resistant diabetes of these patients resemble more those of patients with GL, rather than PL. These metabolic abnormalities are more common in women than in men with D-PL. [25]

Treatment

Thus far, the recent insights into the genetic basis of this disease have yet to produce new therapeutic options.

HIV-ASSOCIATED LIPODYSTROPHY [26], [27] (See also Chap. 225)

Etiology and Pathogenesis

Soon after the introduction in the mid-1990s of highly active antiretroviral therapy (HAART) for the treatment of patients with HIV disease, redistribution of body fat—analogous to PL—in treated patients was reported. The incidence of this complication increases with duration of therapy and may affect one-third to two-thirds of patients treated for 2 years or longer. Although the incidence of PL clearly increased markedly after the introduction of protease inhibitors (PI), several reports document the development of PL in patients who had not received PI. Evidence for several disparate mechanisms of action of HAART components in causing PL has been reported, [28], [29] but a unifying hypothesis is lacking. For now, it appears that different classes of anti-HIV drugs may contribute and that within each class different drugs may be more or less associated with PL. Although some of the changes may be long-term effects of HIV infection, unmasked by HAART prolongation of life, patients treated early after HIV infection also may develop PL, suggesting more direct drug effects.

Clinical Features

Starting as soon as several months after institution of HAART, patients notice loss of subcutaneous fat from their limbs (both upper and lower) (Fig. 110-2) and from their face. Fat increases at the posterior neck/upper back (a “buffalo hump” similar to that in patients with Cushing's disease), in the abdomen (with increased waist:hip ratio, and with feelings of bloating and distention), and on the breasts (sometimes with marked pain).

FIGURE 110-2 Partial lipodystrophy associated with HIV and HAART. Note protruding veins and excessive skin folds over knees and loss of fat of the buttocks in this 35-year-old patient. Also note increased fat on the hips. *(Courtesy of Armin Rieger MD.)*

Histopathology

Subcutaneous fat is atrophic and adipocyte apoptosis is present. [30]

Laboratory Findings and Associated Internal Disease

Patients generally have insulin resistance and hyperglycemia, progressing in some cases to frank non-insulin-dependent diabetes mellitus, hypertriglyceridemia, and hypercholesterolemia. This constellation of metabolic abnormalities clearly is associated in the non-HIV population with accelerated atherosclerosis, and these patients, too, may be at increased risk for cardiovascular disease. [31] The development of HIV-PL may be more common in those with a better therapeutic response to HAART, as measured by recovery of peripheral blood CD4+ lymphocytes. [32]

Treatment

Some patients find the cosmetic and symptomatic changes of HIV-PL to be so debilitating as to require changes in their HIV treatment. Changes between or within a class of drugs may ameliorate the disease as may treatment with recombinant human growth hormone (rhGH), metformin, dehydroepiandrosterone plus nonsteroidal anti-inflammatory drugs, or PPAR-? agonists. [33], [34] However, although they may be associated with improvement in both the metabolic abnormalities and in the intraabdominal fat deposition, these therapies have not led to cosmetically-significant reaccumulation of facial or limb subcutaneous fat. Statins may be helpful in reducing the hyperlipidemia and, hopefully, in reducing the risk of accelerated atherosclerosis. Liposuction of the upper back may reduce the cosmetic disfigurement of

the “buffalo hump.” [35]

GENERALIZED LIPODYSTROPHY

Etiology and Pathogenesis

Patients with congenital GL (MIM #269700) cluster in consanguineous families, most of whom have linkage evidence of abnormalities at the BSCL 1 locus on chromosome 9q34, [36] or the BSCL 2 locus on chromosome 11q13. The mutated gene at the latter site is the G-protein seipin. [37] Patients with later onset GL appear not to have seipin mutations. Seipin's strong expression in normal brain and absent expression in normal adipose tissue are consistent with the earlier hypotheses of a primary hypothalamic dysfunction with secondary adipose and other tissue effects. [38] Transgenic mice engineered to have specific loss of white adipose tissue have metabolic abnormalities that are reversed by transplantation of normal fat, indicating the likelihood of a causal effect of the fat loss. [39], [40] Therefore, the most likely pathogenesis is that hypothalamic abnormalities cause loss of adipose tissue, which, in turn, causes the metabolic abnormalities.

Clinical Features

Patients with GL lack both subcutaneous fat and extracutaneous adipose tissue. This condition may be congenital (Berardinelli-Seip syndrome) or acquired later in life (Seip-Lawrence syndrome), in which patients' loss of fat may be extremely rapid. [41] Acanthosis nigricans (see Chap. 185), hypertrichosis, generalized hyperpigmentation, and unusually thick, curly scalp hair (*cf.* the development of curly hair coincident with the onset of HIV-associated PL [42] often are present. During infancy and childhood linear growth is accelerated, and adult height may be greater than that predicted by the height of the parents. Daily energy consumption is increased noticeably; patients eat voraciously, perspire excessively, and may be heat-intolerant despite normal thyroid function; and the basal metabolic rate is elevated. In infants, hepatosplenomegaly causes abdominal protuberance. This may resolve in later childhood. Because of generalized absence of fat, the muscles appear hypertrophic; however, usually the age at which the child sits and walks is normal, and muscle strength is not increased. [43] The external genitalia often are enlarged, with the large clitoris or penis and rippling muscles suggesting precocious puberty. Moderate mental retardation is frequent but not uniform. [44]

Laboratory Findings and Associated Internal Disease

The characteristic laboratory abnormality is decreased glucose tolerance, and the syndrome is often termed *lipoatrophic diabetes*. Diabetes may become apparent clinically only in the second or third decade, but insulin resistance can be detected earlier. Hyperglycemia (reportedly due mostly to increased glucose production), glycosuria, and insulin resistance are often marked, but life-threatening ketoacidosis does not develop. Nonetheless, renal, retinal, and neuropathic diabetic changes may occur. Patients' endogenous insulin is normal biologically, immunologically, and in its proportion of proinsulin. [45] Conflicting findings of decreased or normal binding of insulin to cell receptors have been reported in patients with congenital GL. Fasting reduces the serum insulin and increases cell surface binding of insulin by peripheral blood leukocytes, and it is uncertain whether the putative decreased binding in vivo is a primary cause of insulin resistance or is a result of the high circulating insulin. Some believe the insulin resistance to be the result of a postreceptor defect. [46] A separate group of patients without lipodystrophy but with insulin resistance, acanthosis nigricans, hirsutism, and accelerated early growth have a definitely decreased number of insulin receptors, but insulin binding does not increase with fasting. [47], [48] Also, patients with various other syndromes with associated insulin resistance and acanthosis nigricans have been reported, some of whom have insulin-receptor gene mutations. [49]

Nearly all patients with GL have hepatomegaly, resulting initially from increased fat; the liver may shrink with fasting. As with fatty liver resulting from other causes, cirrhosis may develop and the patient may die of hepatic failure. [50]

Significant kidney disease (without hypocomplementemia), mental retardation, and crippling schizophrenia have occurred in patients with GL. In one patient with diabetic nephropathy, a transplanted kidney was damaged acutely by massive lipid deposition. [51] Several women with GL have had frank virilization with polycystic ovarian disease, [52], [53] but several affected patients have had normal children. [54]

Reduced fat around the viscera and increased fat in the liver can be detected by abdominal computed tomography (CT) scan and ultrasonography. [55] Enlarged cerebral ventricles have been reported, but cerebral CT scans are usually normal. [56] Radiographic changes of bony sclerosis and cystic changes have been described frequently. [55] Hyperlipoproteinemia occurs with a rapid turnover of plasma free fatty acids, presumably derived from peripheral lipolysis of triglycerides [57] and with overproduction of very-low-density lipoproteins. [58], [59] Eruptive xanthomas may occur (see Chap. 150). Patients with GL, thickened dermis, frank scleroderma, and Hodgkin's disease have been reported. [60]

Treatment

There is no treatment confirmed to restore the storage of fat or to forestall the sequelae of long-term diabetes. Although the hyperglycemia persists despite therapy with very large doses of insulin, hyperglycemia and hyperinsulinemia both fall following treatment with insulin-like growth factor 1 (IGF-1). [61], [62] Whether this will be helpful or harmful [44] for the patients is unknown. Reduction of food intake, for example, by treatment with fenfluramine or simply by caloric restriction alone, may reduce the hypermetabolic state, but the long-term benefits are unproven, [44] and fenfluramine may cause significant morbidity. Etretinate caused clearing of acanthosis nigricans in one patient. [63] One group found improvement in the metabolic abnormalities and some regain of subcutaneous fat in patients with various forms of lipodystrophy treated with the PPAR-? agonist troglitazone. This drug has been removed from the US market because of hepatotoxicity but has been succeeded by pioglitazone and rosiglitazone, which are expected to be similarly beneficial. [64] Leptin infusion can

reverse metabolic abnormalities in murine transgenic lipoatrophic mice but the sensitivity to this agent depends on the model used. [65], [66] Combination therapy of lipoatrophic mice with leptin plus adiponectin may be more effective. [67] Nine women treated with leptin for 4 months had significant amelioration of their metabolic and endocrine abnormalities and reduction in liver hypertrophy and abnormal transaminases. [68], [69]

REFERENCES

1. Garg A: Lipodystrophies. *Am J Med* **108**:143, 2000

2. Bier DM et al: Cephalothoracic lipodystrophy with hypocomplementemic renal disease: Discordance in identical twin sisters. *J Clin Endocrinol Metab* **46**:800, 1978

3. Nagore E et al: Lipoatrophia semicircularis—A traumatic panniculitis: Report of seven cases and review of the literature. *J Am Acad Dermatol* **39**:879, 1998

4. Bernstein RS et al: Adipose cell morphology and control of lipolysis in a patient with partial lipodystrophy. *Metabolism* **28**:519, 1979

5. Mathieson PW, Peters K: Are nephritic factors nephritogenic? *Am J Kidney Dis* **24**:964, 1994

6. Williams DG: C3 nephritic factor and mesangiocapillary glomerulonephritis. *Pediatr Nephrol* **11**:96, 1997

7. Mathieson PW et al: Complement-mediated adipocyte lysis by nephritic factor sera. *J Exp Med* **177**:1827, 1993

8. Bennett WM et al: Mesangiocapillary glomerulonephritis type II (dense-deposit disease): Clinical features of progressive disease. *Am J Kidney Dis* **13**:469, 1989

9. Alper CA et al: Increased susceptibility to infection in a patient with type II essential hypercatabolism of C3. *N Eng J Med* **288**:601, 1973

10. Smith PM et al: Lipodystrophy, pancreatitis, and eosinophilia. *Gut* **16**:230, 1975

11. Fitch N, Tulandi T: Progressive partial lipodystrophy and third-trimester intrauterine fetal death. *Am J Obstet Gynecol* **156**:1195, 1987

12. Coessens BC, Van Geertruyden JP: Simultaneous bilateral facial reconstruction of a Barraquer-Simons lipodystrophy with free TRAM flaps. *Plast Reconstr Surg* **95**:911, 1995

13. Ketterings C: Lipodystrophy and its treatment. *Ann Plast Surg* **21**:536, 1988

14. Kobberling J, Dunnigan MG: Familial partial lipodystrophy: Two types of an X linked dominant syndrome, lethal in the hemizygous state. *J Med Genet* **23**:120, 1986

15. Lloyd J et al: Subtotal lipodystrophy with autosomal dominant inheritance. *J R Soc Med* **86**:477, 1993

16. Johansen K et al: An unusual type of familial lipodystrophy. *J Clin Endocrinol Metab* **80**:3442, 1995

17. Jackson SN et al: Dunnigan-Kobberling syndrome: An autosomal dominant form of partial lipodystrophy. *QJM* **90**:27, 1997

18. Cao H, Hegele RA: Nuclear lamin A/C R482Q mutation in Canadian kindreds with Dunnigan-type familial partial lipodystrophy. *Hum Mol Genet* **9**:109, 2000

19. Shackleton S et al: LMNA, encoding lamin A/C, is mutated in partial lipodystrophy. *Nat Genet* **24**:153, 2000

20. Speckman RA et al: Mutational and haplotype analyses of families with familial partial lipodystrophy (Dunnigan variety) reveal recurrent missense mutations in the globular C-terminal domain of lamin A/C. *Am J Hum Genet* **66**:1192, 2000

21. Novelli G et al: Mandibuloacral dysplasia is caused by a mutation in LMNA-encoding lamin A/C. *Am J Hum Genet* **71**:426, 2002

22. Hegele RA et al: Genetic variation in LMNA modulates plasma leptin and indices of obesity in aboriginal Canadians. *Physiol Genomics* **3**:39, 2000

23. Vigouroux C et al: A new missense mutation in the calcium-sensing receptor in familial benign hypercalcaemia associated with partial lipoatrophy and insulin resistant diabetes. *Clin Endocrinol* **53**:393, 2000

24. Garg A et al: Adipose tissue distribution pattern in patients with familial partial lipodystrophy (Dunnigan variety). *J Clin Endocrinol Metab* **84**:170, 1999

25. Garg A: Gender differences in the prevalence of metabolic complications in familial partial lipodystrophy (Dunnigan variety). *J Clin Endocrinol Metab* **85**:1776, 2000

26. John M et al: Antiretroviral therapy and the lipodystrophy syndrome. *Antivir Ther* **6**:9, 2001

27. Strawford A, Hellerstein MK: Metabolic Complications of HIV and AIDS. *Curr Infect Dis Rep* **3**:183, 2001

28. Murata H et al: The mechanism of insulin resistance caused by HIV protease inhibitor therapy. *J Biol Chem* **275**:20251, 2000

29. Caron M et al: The HIV protease inhibitor indinavir impairs sterol regulatory element-binding protein-1 intranuclear localization, inhibits preadipocyte differentiation, and induces insulin resistance. *Diabetes* **50**:1378, 2001

30. Domingo P et al: Subcutaneous adipocyte apoptosis in HIV-1 protease inhibitor-associated lipodystrophy. *AIDS* **13**:2261, 1999

31. Hadigan C et al: Metabolic abnormalities and cardiovascular disease risk factors in adults with human immunodeficiency virus infection and lipodystrophy. *Clin Infect Dis* **32**:130, 2001

32. Wurtz R, Ceaser S: The possible benefits of the improved CD4 response outweigh the metabolic and cosmetic problems associated with lipodystrophy is not known. *Clin Infect Dis* **31**:1497, 2000

33. Hadigan C et al: Metformin in the treatment of HIV lipodystrophy syndrome. *JAMA* **284**:472, 2000

34. Smith KJ, Skelton HG: Peroxisomal proliferator-activated ligand therapy for HIV lipodystrophy. *Clin Exp Dermatol* **26**:155, 2000

35. Chastain MA et al: HIV lipodystrophy: Review of the syndrome and report of a case treated with liposuction. *Dermatol Surg* **27**:497, 2001

36. Garg A et al: A gene for congenital generalized lipodystrophy maps to human chromosome 9q34. *J Clin Endocrinol Metab* **84**:3390, 1999

37. Magre J et al: Identification of the gene altered in Berardinelli-Seip congenital lipodystrophy on chromosome 11q13. *Nat Genet* **28**:365, 2001

38. Corbin A et al: Diencephalic involvement in generalized lipodystrophy: Rational and treatment with the neuroleptic agent, pimozide. *Acta Endocrinol (Copenh)* **77**:209, 1974

39. Shimomura I et al: Insulin resistance and diabetes mellitus in transgenic mice expressing nuclear SREBP-1c in adipose tissue: Model for congenital generalized lipodystrophy. *Genes Dev* **12**:3182, 1998

40. Gavrilova O et al: Surgical implantation of adipose tissue reverses diabetes in lipoatrophic mice. *J Clin Invest* **105**:271, 2000

41. Andreelli F et al: Normal reproductive function in leptin-deficient patients with lipoatrophic diabetes. *J Clin Endocrinol Metab* **85**:715, 2000

42. Colebunders R et al: Curly hair and lipodystrophy as a result of highly active antiretroviral treatment? *Arch Dermatol* **136**:1064, 2000

43. Garg A et al: Skeletal muscle morphology and exercise response in congenital generalized lipodystrophy. *Diabetes Care* **23**:1545, 2000

44. Seip M, Trygstad O: Generalized lipodystrophy, congenital and acquired (lipoatrophy). *Acta Pediatr Suppl* **413**:2, 1996

45. Sovik O, Oseid S: Studies in congenital generalized lipodystrophy. VI. Suppressible and non-suppressible insulin-like activities of plasma. *Acta Endocrinol (Copenh)* **79**:720, 1975

46. Sovik O et al: Studies of insulin resistance in congenital generalized lipodystrophy. *Acta Pediatr Suppl* **413**:29, 1996

47. Kahn CR et al: The syndromes of insulin resistance and acanthosis nigricans: Insulin-receptor disorders in man. *N Engl J Med* **294**:739, 1976

48. Podskalny JM, Kahn CR: Cell culture studies on patients with extreme insulin resistance: 1. Receptor defects on cultured fibroblasts. *J Clin Endocrinol Metab* **54**:261, 1982

49. Moller DE et al: Prevalence of mutations in the insulin receptor gene in subjects with features of the type A syndrome of insulin resistance. *Diabetes* **43**:247, 1994

50. Case records of the Massachusetts General Hospital: Case 1-1975. *N Engl J Med* **292**:35, 1975

51. Casali RE et al: Renal Transplantation in a patient with lipoatrophic diabetes. *Transplantation* **26**:174, 1978

52. Huseman CA et al: Congenital lipodystrophy. II. Association with polycystic ovarian disease. *J Pediatr* **95**:72, 1979

53. Penney LL et al: Congenital lipodystrophy and polycystic ovarian disease. *J Reprod Med* **26**:145, 1981

54. Catalano PM et al: Successful pregnancy outcome in association with lipoatrophic diabetes mellitus. *Obstet Gynecol* **76**:978, 1990

55. Westvik J: Radiological features in generalized lipodystrophy. *Acta Pediatr Suppl* **413**:44, 1996

56. Wilson TA et al: Cerebral computed tomography in lipodystrophy. *Arch Neurol* **39**:733, 1982

57. Boucher BJ et al: Plasma free fatty acid turnover in total lipodystrophy. *Clin Endocrinol (Oxf)* **4**:83, 1975

58. Chait A et al: Lipodystrophy with hyperlipidaemia: The role of insulin in very low density lipoprotein over-synthesis. *Clin Endocrinol (Oxf)* **10**:173, 1979

59. Rossini AA et al: Metabolic and endocrine studies in a case of lipoatrophic diabetes. *Metabolism* **26**:637, 1977

60. Hall SW et al: Generalized lipodystrophy, scleroderma, and Hodgkin's disease. *Arch Intern Med* **138**:1303, 1978

61. Kuzuya H et al: Trial of insulin-like growth factor I therapy for patients with extreme insulin resistance syndromes. *Diabetes* **42**:696, 1993

62. Moses AC et al: Insulin-like growth factor I (rhIGF-I) as a therapeutic agent for hyperinsulinemic insulin-resistant diabetes mellitus. *Diabetes Res Clin Pract* **28**(Suppl):S185, 1995

63. Mork NJ et al: Treatment of acanthosis nigricans with etretinate (Tegison) in a patient with Lawrence-Seip syndrome (generalized lipodystrophy). *Acta Derm Venereol (Stockh)* **66**:173, 1986

64. Arioglu E et al: Efficacy and safety of troglitazone in the treatment of lipodystrophy syndromes. *Ann Intern Med* **133**:263, 2000

65. Shimomura I et al: Leptin reverses insulin resistance and diabetes mellitus in mice with congenital lipodystrophy. *Nature* **401**:73, 1999

66. Ebihara K et al: Transgenic overexpression of leptin rescues insulin resistance and diabetes in a mouse model of lipoatrophic diabetes. *Diabetes* **50**:1440, 2001

67. Yamauchi T et al: The fat-derived hormone adiponectin reverses insulin resistance associated with both lipoatrophy and obesity. *Nat Med* **7**:941, 2001

68. Oral EA et al: Leptin-replacement therapy for lipodystrophy. *N Engl J Med* **346**:570, 2002

69. Oral EA et al: Effect of leptin replacement on pituitary hormone regulation in patients with severe lipodystrophy. *J Clin Endocrinol Metab*

87:3110, 2002

T>

Chapter 111

Karl Anders

Neoplasms of the Subcutaneous Fat

LIPOMA
- Clinical Features
- Histopathologic Findings

MULTIPLE LIPOMA SYNDROMES
ANGIOLIPOMA
- Clinical Features
- Histopathologic Findings

SPINDLE CELL LIPOMA
- Clinical Features
- Histopathologic Findings

PLEOMORPHIC LIPOMA
- Clinical Features
- Histopathologic Findings

CHONDROID LIPOMA
- Clinical Features
- Histopathologic Findings

MYOLIPOMA
- Clinical Features
- Histopathologic Findings

ANGIOMYOLIPOMA
- Clinical Features
- Histopathologic Features

FIBROHISTIOCYTIC LIPOMA
- Clinical Features
- Histopathologic Findings

HEMOSIDEROTIC FIBROHISTIOCYTIC LIPOMATOUS LESION
- Clinical Features
- Histopathologic Findings

HIBERNOMA
- Clinical Features
- Histopathologic Findings

LIPOBLASTOMA/LIPOBLASTOMATOSIS
- Clinical Features
- Histopathologic Findings

LIPOSARCOMAS
- Clinical Features
- Histopathologic Findings

REFERENCES

Benign lipomatous tumors of the subcutaneous fat are very common, whereas cutaneous liposarcomas are exceptionally rare. The recently described variants of lipomas are encountered infrequently, [1], [2], [3] and [4] but recognition of their characteristics is important so as to avoid erroneous diagnoses and excessive surgery.

In general, lipomas and all their variations are grossly and microscopically symmetric, well circumscribed, and smooth bordered. In contrast, malignant neoplasms of adipocytes (lipocytes) and of lipoblasts, the embryonic precursors of lipocytes (i.e., liposarcomas), are asymmetric and infiltrative. Usually lipomas do not persist at the local site once they have been completely excised. This is equally true for most liposarcomas, although their poor circumscription often precludes complete resection.

Benign and malignant lipomatous tumors often demonstrate repeatable karyotypic abnormalities, thereby offering a potential, albeit usually impractical, diagnostic tool for their elucidation. A discussion of these chromosomal aberrations is beyond the scope of this chapter, and the interested reader is referred elsewhere. [1], [2], [5]

LIPOMA

Clinical Features

Lipomas are the most common mesenchymal neoplasms.[1] They may be found at any subcutaneous site but are especially frequent on the neck and trunk. Although lipomas usually are solitary, they may be multiple. Most lipomas are small, mobile, slowly growing, and asymptomatic, but some may be large (>15 cm). Lipomas may occur at any age but usually become evident in middle age. Characteristically, they are disk-shaped, round or ovoid, lobulated, yellow masses, usually within the subcutaneous tissue, with a doughy consistency. Lipomas are easily “shelled out” surgically because they are well demarcated. Recurrences are uncommon. Lipomas practically never eventuate in liposarcoma.

Histopathologic Findings

Subcutaneous lipomas tend to be well-circumscribed neoplasms surrounded by a thin, fibrous capsule. They are composed of sheets of mature, uniform adipocytes (i.e., large clear cells), spherical to polygonal, characterized by a

single, large, lipid vacuole that compresses and displaces the nucleus to the periphery of the cell (Fig. 111-1). Adipocytes in a lipoma are indistinguishable from those in the adjacent subcutaneous fat and, like them, are encircled by capillaries. Thin strands of fibrous tissue intersect the sheets of adipocytes, but they are not arranged in the fenestrated pattern characteristic of fibrous septa in the normal subcutaneous fat.

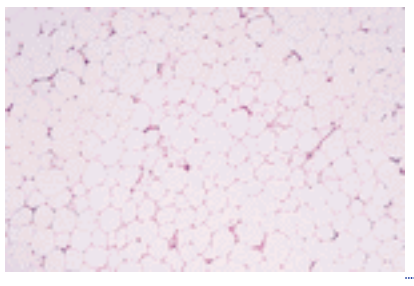

FIGURE 111-1 Lipoma.

Lipomas may extend into or arise within skeletal muscle (*intramuscular lipomas*), a phenomenon usually seen on the trunk [6] (Fig. 111-2). Intramuscular lipomas are often poorly delineated and thus more prone to recur because their excision often is incomplete. *Adenolipomas* are characterized by the presence of eccrine glands and ducts within a lipoma. [7]

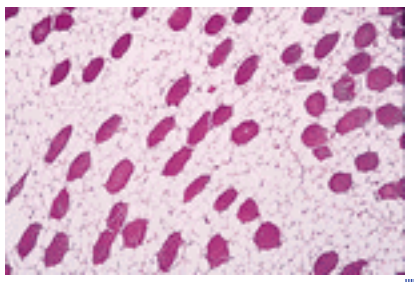

FIGURE 111-2 Intramuscular lipoma.

Some lipomas contain mesenchymal elements other than fat. For example, *fibrolipomas* exhibit many thick bundles of collagen (Fig. 111-3). *Sclerotic lipomas* demonstrate primarily thickened collagen bundles, with few persisting adipocytes, and mimic sclerotic fibromas. [4], [8] *Myxolipomas* show extensive stromal deposits of mucopolysaccharides (Fig. 111-4) and may mimic myxoma. *Myelolipomas* manifest ectopic hematopoietic bone marrow elements; *osteolipomas* display metaplastic bone.

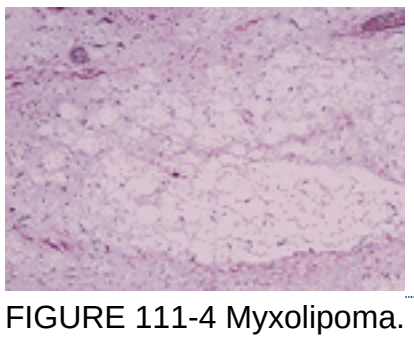

FIGURE 111-4 Myxolipoma.

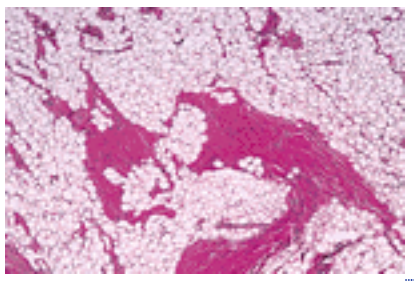

FIGURE 111-3 Fibrolipoma.

Trauma and ischemia can cause necrosis en masse of adipocytes. *Infarcted lipomas* demonstrate necrotic fat surrounded by multinucleate histiocytic giant cells, lipophages, lymphocytes, and extravasated erythrocytes (Fig. 111-5). Pseudocysts may form consequent to absorption of necrotic adipocytes, and fibrosis and dystrophic calcification are late sequelae.

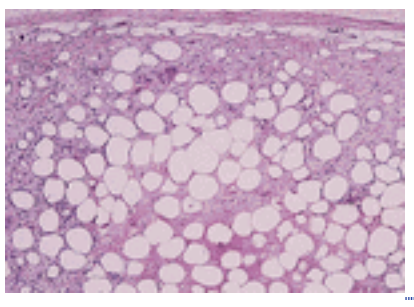
FIGURE 111-5 Infarcted lipoma.

MULTIPLE LIPOMA SYNDROMES

Some patients bear numerous subcutaneous lipomas. [1] These neoplasms are microscopically indistinguishable from the solitary lipomas just described but are of clinical interest.

Familial multiple lipomas are transmitted in autosomal dominant fashion, with incomplete penetrance, and usually have become apparent by the third decade of life. [9] Patients may have hundreds of discrete, slowly growing, asymptomatic, subcutaneous lipomas of various sizes and in widespread distribution (Fig. 111-6). The lesions are often more pronounced on the extremities, especially the forearms.

FIGURE 111-6 Multiple, symmetric lipomas of variable size on the forearms of a middle-aged man.

Diffuse lipomatosis is characterized by widespread, noncircumscribed overgrowth of mature adipocytes. [1] The lesions usually are situated on the trunk or proximal extremity. They may be huge and cosmetically disfiguring. Persistence at the local site is common because resection of these lesions is often incomplete; they may be treated with suction lipectomy.

Symmetric lipomatosis (Madelung's disease) is an uncommon disorder characterized by numerous, symmetrically distributed, nontender, poorly demarcated fatty tumors in the subcutaneous and deeper tissues. These masses are situated mostly in the neck, suboccipital region, proximal (but not distal) extremities, and upper part of the trunk [10] (Fig. 111-7). Confluence of these lesions results in a disfiguring “horse collar” appearance that, when severe, may interfere with mobility of the neck and with respiration. This idiopathic condition is not hereditary and usually afflicts middle-aged alcoholic men.

FIGURE 111-7 Symmetric lipomatosis.

Adiposis dolorosa (Dercum's disease) is a rare idiopathic disorder that favors middle-aged, obese, menopausal women. [11] In this condition, many slowly growing, exquisitely tender lipomas are present, especially on the arms, trunk, and periarticular soft tissues. Pain is episodic and may be debilitating. Sustained therapy with analgesics may be required for symptomatic relief of painful paroxysms. Weight loss is reputed to be beneficial, and surgical excision may eliminate pain at a local site.

Congenital lipomatosis is usually diagnosed during the first few months of life, presenting as large, irregular, subcutaneous masses of adipose tissue. [12] These masses are found mostly on the chest, where they permeate skeletal

muscle (i.e., *infiltrating lipomas*). Since their resection is often incomplete, the lesions frequently persist at the local site.

Congenital lipomatosis may also be a manifestation of the *Proteus syndrome* [13], [14] (see Chap. 188), in which, in addition to lipomas, there are partial gigantism of the hands or feet, hemihypertrophy, exostoses, scoliosis, melanocytic nevi, and other cutaneous neoplasms (i.e., hemangiomas, lymphangiomas, mesenchymomas). The disorder may be sporadic or inherited in autosomal recessive fashion. It is now thought that the “Elephant Man” was afflicted with the Proteus syndrome.

The *Bannayan-Zonana syndrome,* an autosomal dominant disorder manifest in children, consists of multiple lipomas, hemangiomas, lymphangiomas, and macrocephaly without ventricular enlargement. [14] Patients with the Bannayan-Zonana syndrome often demonstrate delayed motor and speech development and motor dysfunction.

ANGIOLIPOMA

Clinical Features

Angiolipomas resemble lipomas clinically but tend to develop in young adults and are less prevalent (representing about 5 percent of fatty tumors). They are usually numerous, frequently painful or tender on palpation, and sometimes surprisingly mobile. [1] The forearms and trunk are favored sites. Angiolipomas tend to be small (<5 cm), firm, well-circumscribed, yellow to red subcutaneous tumors. Rarely, these neoplasms present as large, ill-defined masses with jagged extensions into skeletal muscle (i.e., *infiltrating angiolipomas*). Familial angiolipomatosis is uncommon but does occur. [15]

Histopathologic Findings

Angiolipomas are usually sharply circumscribed neoplasms composed of a mixture of adipocytes and small blood vessels (Fig. 111-8). Blood vessel proliferation is most pronounced at the periphery of the neoplasm, and the vascular component comprises at least 10 percent of the tumor's volume. Some angiolipomas, however, contain very few vessels, in contrast to others that are richly vascular in a lobular pattern that mimics a hemangioma. Intraluminal spaces are often filled with erythrocytes or fibrin thrombi. Oval-shaped pericytes, mast cells, and fibrous tissue also may be present.

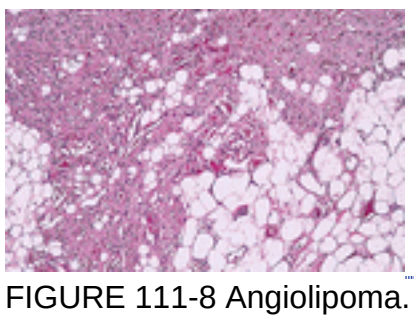

FIGURE 111-8 Angiolipoma.

Angiolipomas that exhibit a prominent vascular pattern and little fat are often highly cellular (i.e., *cellular angiolipoma*), and when they are poorly circumscribed or removed in fragmented fashion, they have been confused with Kaposi's sarcoma and hemangioendothelioma. [16] Endothelial cells in angiolipomas are small and monomorphous; no mitotic figures are detectable.

SPINDLE CELL LIPOMA

Clinical Features

Spindle cell lipomas comprise about 1.5 percent of neoplasms of adipocytes. They usually are small (< 5 cm), firm, subcutaneous masses that become apparent in middle-aged men. [1], [17] Generally only one spindle cell lipoma is present, but patients with multiple tumors—including familial clusters—have been reported. [18] The lesions are slowly growing, painless nodules situated principally on the upper part of the back, shoulders, or lower posterior neck, although they may present at almost any site. On gross inspection, they are yellow to gray-white.

Histopathologic Findings

Spindle cell lipomas consist of mature adipocytes, oval to spindle-shaped cells, and a stroma replete with collagen and mucin within which mast cells are scattered (Fig. 111-9). The relative proportion of these elements varies markedly, even within a particular lesion. Most tumors are subcutaneous and well circumscribed, but some are intradermal and poorly delineated. [3], [19] Spindle cell lipomas rarely are dominated by mucinous stroma and may be diagnosed incorrectly as a myxoma or myxoid liposarcoma. An entity described as *dendritic fibromyxolipoma* appears to be a variant of spindle cell lipoma that is replete with mucinous stroma and stellate mesenchymal cells. [4], [19]

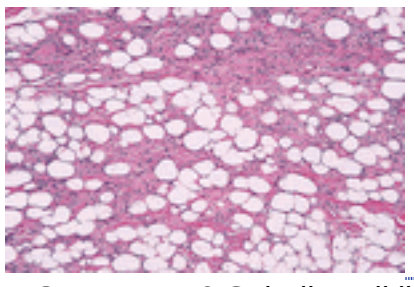
FIGURE 111-9 Spindle cell lipoma.

The “spindle” cells characteristic of spindle cell lipoma usually have small, oval, monomorphous nuclei and pale cytoplasm. In some foci, there are only a few oval cells among numerous adipocytes; in others, there are sheets of oval cells that may obscure the fundamental adipose character of the neoplasm. Rarely, the oval cells exhibit pleomorphism and multinucleation, analogous to changes seen in “ancient schwannomas.” Mitotic figures are hardly ever seen. Some spindle cell lipomas demonstrate large, irregular clefts and slitlike spaces that resemble blood vessels, described as the *pseudoangiomatous variant* of spindle cell lipoma. [4], [21]

Although the origin of the oval cells has yet to be elucidated, electron microscopy reveals them to display features consistent with fibroblasts or prelipoblastic mesenchymal cells. [17], [20], [22] Unlike myolipomas, no evidence of smooth muscle differentiation is found within the oval cells of spindle cell lipoma, which are desmin- and actin-negative but strongly positive for CD34. [1] Spindle cell lipoma may be confused with dermatofibrosarcoma protuberans, fibrosarcoma, and liposarcoma but can be differentiated from those malignant neoplasms by its sharply circumscribed border, monomorphous nuclei, and absence of mitotic figures and of lipoblasts. [17]

PLEOMORPHIC LIPOMA

Clinical Features

Pleomorphic lipomas are uncommon neoplasms that cannot be distinguished clinically from spindle cell lipomas. [1], [23] Because of their similarity clinically and ultrastructurally, [23] and because of identical chromosomal alterations, [5] these tumors are now generally accepted as pleomorphic variants of spindle cell lipomas.

Histopathologic Findings

In the overall setting of a spindle cell lipoma, there are bizarre, multinucleate giant cells, termed *floret cells* (Fig. 111-10). These cells, which also may be seen in pleomorphic fibroma and fibroepithelial papillomas, have abundant eosinophilic cytoplasm and many crowded, overlapping dark nuclei that resemble, vaguely, the petals of a flower. Floret cells in a particular pleomorphic lipoma may be few or many, localized or diffuse. The precise nature of floret cells has yet to be established, but they are probably prelipoblastic mesenchymal cells. [22] Occasional lipoblast-like cells may be scattered throughout a pleomorphic lipoma, and the adipocytes may show nuclear hyperchromasia.

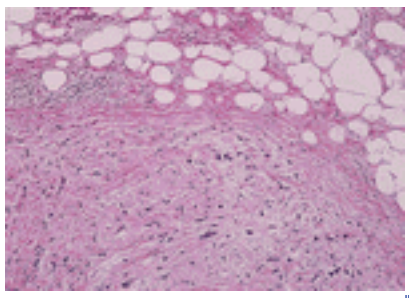
FIGURE 111-10 Pleomorphic lipoma.

Although pleomorphic lipomas are benign, they may be misinterpreted histopathologically as a sarcoma, especially liposarcoma, because of the presence of the peculiar floret cells. Pleomorphic lipomas can be differentiated from liposarcomas by their circumscription, infrequent (nonatypical) mitotic figures, only rare lipoblasts, absence of necrosis, and distinct cytogenetic alterations. [5]

CHONDROID LIPOMA

Clinical Features

This neoplasm is extremely uncommon and found mostly in women. [14], [24], [25] It usually appears in the subcutaneous fat or in muscles of the hips and extremities. Chondroid lipomas are small (<5 cm) lesions with a rubbery, yellow, cut surface.

Histopathologic Findings

The neoplasm is sharply circumscribed and composed of lobules of eosinophilic, vacuolated cells that resemble chondroblasts or lipoblasts admixed with a variable number of mature adipocytes. [24], [25] and [26] The vacuolated cells are often arranged in sheets, nests, or cords and are situated in a collagenous and mucinous stroma that resembles cartilage. The vacuolated cells contain hyperchromatic nuclei that sometimes have scalloped borders and are replete

with cytoplasmic fat, as demonstrated by oil-red O stains [25], [26]; they are S-100 protein positive. In some foci, the tumor appears mostly chondroid; in other regions, adipocytes predominate, and it is there that the lipomatous nature of the neoplasm is apparent. Blood vessels are prominent, and hemorrhage and hemosiderin are common. Ultrastructurally, most chondroid lipomas show features consistent with origin from white fat. [26]

While clinically benign, chondroid lipoma may be misinterpreted histopathologically as extraskeletal myxoid chondrosarcoma or myxoid liposarcoma, but it is distinguished from these malignant neoplasms by its sharp circumscription and absence of nuclear atypia and mitotic figures.

MYOLIPOMA

Clinical Features

Sometimes known as *lipoleiomyomas,* these rare neoplasms clinically resemble large lipomas. [1], [4], [27] They usually arise in subcutaneous or deeper abdominal tissues of adults. Grossly, they are generally large (>15 cm) and well demarcated, with a soft to slimy yellow-white cut surface.

Histopathologic Findings

Myolipomas are biphasic neoplasms that consist of a mixture of mature adipocytes and smooth muscle cells, the latter demonstrating immunoreactivity with actin and desmin but not CD34, features that are useful in differentiating these tumors from spindle cell lipomas. [27] In some fields the smooth muscle cells may predominate, and the lesions may mimic leiomyomas, but thorough study always reveals many adipocytes. The prominent vascular component so characteristic of angiomyolipoma is not seen. There is no nuclear atypia or mitotic activity, a feature useful in distinguishing myolipoma from dedifferentiated liposarcoma.

ANGIOMYOLIPOMA

Clinical Features

Angiomyolipomas (*angiolipoleiomyomas*) occur mostly in the kidneys, generally in patients with tuberous sclerosis. Rarely, these neoplasms appear in the dermis or subcutis, usually in acral skin or in skin near the elbows and ears. Cutaneous angiomyolipomas usually arise in adult men and are not associated with tuberous sclerosis or with renal angiomyolipomas. [28], [29] They are slowly growing, usually asymptomatic, circumscribed neoplasms. Clinically, they are often confused with cysts, conventional lipomas, and giant cell tumors of tendon sheath.

Histopathologic Features

Like their more common renal counterparts, cutaneous angiomyolipomas contain a variable admixture of thick-walled blood vessels, smooth muscle bundles, and mature adipocytes. The smooth muscle cells are desmin- and actin-positive and may show atypia that is of no prognostic significance. Unlike renal angiomyolipomas, smooth muscle cells in cutaneous angiomyolipomas do not stain with HMB-45. Stromal mucin may be present and is accompanied by mast cells.

FIBROHISTIOCYTIC LIPOMA

Clinical Features

Fibrohistiocytic lipomas are uncommon benign neoplasms that arise in the subcutaneous tissues of young men, especially on the anterior torso. [4], [30] These tumors are small (<5 cm), solitary, and well circumscribed; complete excision is curative.

Histopathologic Findings

Fibrohistiocytic lipomas are smooth bordered and are characterized by an admixture of mature adipocytes and spindle cells that resemble those seen in fibrous histiocytoma. Fibrohistiocytic lipomas lack atypia, mitotic activity, xanthoma cells, and inflammation; their spindle cells are CD34- and calponin-positive.

The differential diagnosis of fibrohistiocytic lipoma includes spindle cell lipoma, fibrous histiocytoma, and dermatofibrosarcoma protuberans. Spindle cell lipoma has a different clinical presentation and demonstrates no calponin staining but very strong CD34 positivity. Unlike fibrohistiocytic lipoma, fibrous histiocytoma demonstrates no adipocytes, no calponin positivity, and the presence of inflammatory cells. Dermatofibrosarcoma protuberans has a distinctive infiltrative growth pattern and lacks calponin immunoreactivity.

HEMOSIDEROTIC FIBROHISTIOCYTIC LIPOMATOUS LESION

Clinical Features

Hemosiderotic fibrohistiocytic lipomatous lesions are extremely rare, usually occurring around the ankle or feet of middle-aged women. [31] There is often a history of prior trauma at the site, suggesting that they are reactive or reparative proliferations. Hemosiderotic fibrohistiocytic lipomatous lesions are subcutaneous, well circumscribed, and yellow-brown.

Histopathologic Findings

The morphology of hemosiderotic fibrohistiocytic lipomatous lesions overlaps with that of fibrohistiocytic lipoma, in that both contain mature adipocytes and a proliferation of spindle cells. Hemosiderotic fibrohistiocytic lipomatous lesions also demonstrate numerous plump fibroblastic cells, some with atypia and multinucleation, abundant hemosiderin pigment, and the presence of mixed inflammatory cell infiltrates.

HIBERNOMA

Clinical Features

Hibernomas are uncommon benign neoplasms that clinically resemble common lipomas. [1], [32] They are solitary and reside in the subcutaneous tissues of the interscapular, lower cervical, or axillary region of young adults. Hibernomas tend to be small, mobile, and tan to reddish brown.

Histopathologic Findings

Hibernomas are distinguished by their similarity to embryonic brown fat. The neoplasms are formed by lobules of plump, round or oval vacuolated cells that resemble mulberries (Fig. 111-11). “Mulberry cells” have large, round central nuclei, often with prominent nucleoli, and abundant granular eosinophilic cytoplasm. Small intracytoplasmic lipid vacuoles are numerous in mulberry cells. Larger univacuolar adipocytes, i.e., white fat cells, are often present in these lesions, especially at the periphery. In some neoplasms, there are features of both conventional lipomas and hibernomas. Electron microscopy reveals numerous large mitochondria that account for the granular cytoplasm of the cells and the brown gross appearance of these neoplasms. [32]

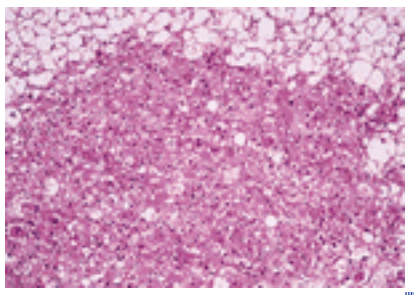

FIGURE 111-11 Hibernoma.

LIPOBLASTOMA/LIPOBLASTOMATOSIS

Clinical Features

Lipoblastomas are uncommon neoplasms that appear only in infants and children, usually in the first 5 years of life. [1], [33], [34] They are solitary subcutaneous masses, usually situated on the trunk or limbs, that may be present at birth. Growth of the neoplasm is slow, but in time it may become large, i.e., >12 cm.

Two variants of lipoblastoma are recognized, i.e., the benign and the diffuse, terms that are confusing because they are not contrasting. *Benign lipoblastomas* are subcutaneous, discrete, and suggestive clinically of lipoma. *Diffuse lipoblastomas (lipoblastomatosis)* are seated more deeply and infiltrate skeletal muscle and other soft tissues. Diffuse lipoblastomas are more likely to persist because their resection tends to be incomplete. The cut surface of lipoblastomas reveals pale-yellow lobulated tissue, often with mucinous stroma.

Histopathologic Findings

Lipoblastomas consist of a variable admixture of mature adipocytes, lipoblasts, and primitive stellate mesenchymal cells situated in a myxoid stroma (Fig. 111-12). The lipoblasts are separated into small lobules by fibrovascular septa. Most lipoblasts demonstrate a single cytoplasmic fat vacuole that causes the nucleus to be compressed to the periphery of the cell, resulting in a “signet ring” appearance. Some lipoblasts have numerous cytoplasmic vacuoles and scalloped nuclear contours. Scattered mature adipocytes are present in variable numbers and sometimes predominate; rarely, hibernoma-like brown fat cells are noted.

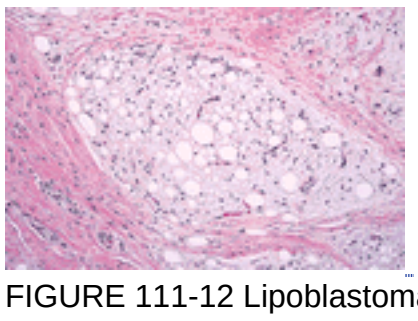

FIGURE 111-12 Lipoblastoma.

Histopathologically, lipoblastomas are easily confused with myxoid liposarcomas. Lipoblastomas occur only in children, in contrast to liposarcomas, which practically never affect children. There are few mitotic figures, no bizarre lipoblasts, and no giant cells in lipoblastomas. At times, however, the histopathologic distinction between lipoblastoma and myxoid liposarcoma may be nearly impossible. Cytogenetic studies can be a useful diagnostic aid, if they have been submitted, because they show characteristic genetic abnormalities that allow these entities to be distinguished. [1], [5]

Biologically, lipoblastomas are benign. With the passage of time, the lipoblasts of a lipoblastoma mature to become adipocytes, and the microscopic appearance then becomes that of a conventional lipoma.

LIPOSARCOMAS

Clinical Features

Liposarcomas are among the most common soft tissue malignancies. They are discovered mostly in middle-aged and elderly adults, practically never in children and young adults. Almost always, liposarcomas arise de novo rather than in a preexisting lipoma. [35], [36], [37] and [38] Most liposarcomas present in the deep soft tissues, but they may involve the skin.

Liposarcomas that arise primarily in the dermis or subcutaneous tissues are very rare but well-documented and have a predilection for the scalp. [3], [36], [37] and [38] Their superficial location generally allows them to be detected and treated when they are relatively small. Primary cutaneous liposarcomas may recur at the local site, but metastases are uncommon, even if the tumor is of high histologic grade. [3], [38] As with other cutaneous sarcomas, e.g., leiomyosarcoma, atypical fibroxanthoma, and dermatofibrosarcoma protuberans, their superficial location seems to impart a favorable prognosis.

Usually when liposarcoma involves the skin it is by secondary extension—or metastatic spread—from a deep-seated primary site. These tumors present themselves as nonmobile, often rapidly enlarging masses that cause pain by compression or infiltration of nerves. The skin above such liposarcomas may be stretched, inflamed, ulcerated, or infiltrated by tumor. Successful management requires wide and deep complete resection, in conjunction with local radiation and/or chemotherapy for higher-grade lesions.

Histopathologic Findings

Several types of liposarcomas are recognized on the basis of their characteristic biology, cytogenetic, and histopathologic changes. Common to all are abnormal lipoblasts. The various types of liposarcoma are as follows:

1. *Well-differentiated liposarcomas* have highly variable histopathologic patterns, all of which imply a favorable prognosis. *Lipoma-like liposarcomas* closely resemble, and are often misdiagnosed as, lipomas, especially at scanning magnification (Fig. 111-13). There is greater variation, however, in the size of adipocytes, some of which have enlarged, hyperchromatic nuclei. Abnormal primitive mesenchymal cells are present in thickened fibrous septa. Lipoblasts are also seen occasionally. These neoplasms are sometimes incorrectly classified as *atypical lipomas* [2], [35] but, unlike lipomas, frequently recur following surgical resection and may dedifferentiate into higher-grade sarcomas capable of metastasis. *Sclerosing liposarcoma* is typified by abundant dense and fibrillary collagen that contains bizarre, hyperchromatic (sometimes multinucleate) mesenchymal cells and only rare lipoblasts. When a dense infiltrate of lymphocytes and plasma cells is present in the setting of a well-differentiated liposarcoma, a diagnosis of *inflammatory liposarcoma* can be rendered. *Spindle cell liposarcoma* is a recently recognized variant of well-differentiated liposarcoma found in the subcutaneous tissues, generally on the shoulder and upper limbs of middle-aged adults. It is characterized by a slightly atypical spindle cell proliferation demonstrating mitotic activity and associated with adipocytes and lipoblasts. Like other low-grade liposarcomas, spindle cell liposarcoma will recur if excised incompletely and may dedifferentiate. [4], [39] With the passage of time and repeated local recurrences, well-differentiated liposarcomas may evolve to become *dedifferentiated liposarcoma,* [35], [40] a higher-grade tumor of variable histologic pattern that is capable of metastasis and of causing death.

   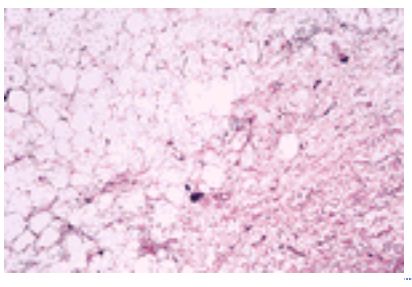
   FIGURE 111-13 Well-differentiated lipoma-like liposarcoma.

2. *Myxoid and round cell liposarcomas* have in common a reciprocal translocation between chromosomes 12 and 16. *Myxoid liposarcomas* are the most common variant of liposarcoma (Fig. 111-14), resembling fetal fat, with abundant mucinous stroma, a complex capillary network, and variable numbers of abnormal lipoblasts and stellate cells. Like well-differentiated liposarcomas, myxoid liposarcomas have a favorable prognosis; they often recur following incomplete resection but only rarely metastasize. *Round cell liposarcomas* (Fig. 111-15) are now generally considered to be the most malignant of myxoid liposarcomas, consisting of sheets of primitive, round or oval neoplastic cells that often house a single cytoplasmic lipid vacuole (“signet ring” lipoblasts) and scattered multivacuolated lipoblasts. Stroma is scant but mucinous. It is not uncommon to see evolution focally of an otherwise low-grade myxoid liposarcoma into a round cell liposarcoma.

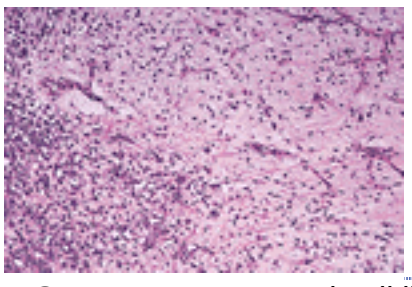

FIGURE 111-15 Round cell liposarcoma.

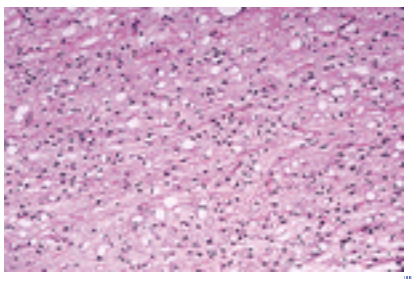

FIGURE 111-14 Myxoid liposarcoma.

3. *Poorly differentiated (pleomorphic) liposarcomas* exhibit bizarre, markedly abnormal lipoblasts intermingled with smaller pleomorphic cells. The cellularity of the tumor is high, with plentiful mitosis (often atypical) and extensive necrosis. Stroma is usually scant. The neoplasm may be difficult to diagnose as liposarcoma by conventional microscopy alone; electron microscopy may be necesary. Like round cell liposarcoma, these tumors are highly malignant and capable of widespread metastases.

REFERENCES

1. Weiss SW, Goldblum JR: Benign lipomatous tumors, in *Soft Tissue Tumors,* 4th ed. St Louis, Mosby, 2001, p 571

2. Mentzel T, Fletcher CDM: Lipomatous tumors of soft tissues: An update. *Virchows Arch* **427**:353, 1995

3. Mentzel T: Cutaneous lipomatous neoplasms. *Semin Diagn Pathol* **18**:250, 2001

4. Guillou L, Coindre JM: Newly described adipocytic lesions. *Semin Diagn Pathol* **18**:238, 2001

5. Fletcher CDM et al: Correlation between clinicopathological features and karyotype in lipomatous tumors: A report of 178 cases from the chromosomes and morphology (CHAMP) collaborative study group. *Am J Pathol* **148**:623, 1996

6. Fletcher CDM, Bates EM: Intramuscular and intermuscular lipoma: Neglected diagnoses. *Histopathology* **12**:275, 1988

7. Hitchcock MG et al: Adenolipoma of the skin: A report of nine cases. *J Am Acad Dermatol* **29**:82, 1993

8. Zelger BH et al: Sclerotic lipoma: Lipomas simulating sclerotic fibroma. *Histopathology* **31**:174, 1997

9. Leffell DJ, Braverman IM: Familial multiple lipomatosis: Report of a case and a review of the literature. *J Am Acad Dermatol* **15**:275, 1986

10. Uhlin SR: Benign symmetric lipomatosis. *Arch Dermatol* **115**:94, 1979

11. Held JL et al: Surgical amelioration of Dercum's disease: A report and review. *J Dermatol Surg Oncol* **15**:1294, 1989

12. Nixon HH, Scobie WG: Congenital lipomatosis: A report of four cases. *J Pediatr Surg* **6**:742, 1971

13. Viljoen DL et al: Cutaneous manifestations of the Proteus syndrome. *Pediatr Dermatol* **5**:14, 1988

14. Bialer MG et al: Proteus syndrome versus Bannayan-Zonana syndrome: A problem in differential diagnosis. *Eur J Pediatr* **148**:122, 1988

15. Kumar R et al: Autosomal dominant inheritance in familial angiolipomatosis. *Clin Genet* **35**:202, 1989

16. Hunt SJ et al: Cellular angiolipoma. *Am J Surg Pathol* **14**:75, 1990

17. Fletcher CDM, Martin-Bates E: Spindle-cell lipoma: A clinicopathological study with some original observations. *Histopathology* **11**:803, 1987

18. Fanburg-Smith JC et al: Multiple spindle cell lipomas: A report of 7 familial and 11 nonfamilial cases. *Am J Surg Pathol* **22**:40, 1998

19. French CA et al: Intradermal spindle cell/pleomorphic lipoma: A distinct subset. *Am J Dermatopathol* **22**:496, 2000

20. Suster S et al. Dendritic fibromyxolipoma: Clinicopathologic study of a distinctive benign soft tissue lesion that may be mistaken for a sarcoma. *Ann Diagn Pathol* **2**:111, 1998

21. Hawley IC et al: Spindle cell lipoma: A pseudoangiomatous variant. *Histopathology* **24**:565, 1994

22. Pitt MA et al: Spindle cell and pleomorphic lipoma: An ultrastructural study. *Histopathology* **19**:475, 1995

23. Shmookler BM, Enzinger FM: Pleomorphic lipoma: A benign tumor simulating liposarcoma. A clinicopathologic analysis of 48 cases. *Cancer* **47**:126, 1981

24. Meis JM, Enzinger FM: Chondroid lipoma: A unique tumor simulating liposarcoma and myxoid chondrosarcoma. *Am J Surg Pathol* **17**:1103, 1993

25. Thomson TA et al: Cytogenetic and cytologic features of chondroid lipoma of soft tissue. *Mod Pathol* **12**:88, 1999

26. Kindblom LG, Meis-Kindblom JM: Chondroid lipoma: An ultrastructural and immunohistochemical analysis with further observations regarding its differentiation. *Hum Pathol* **26**:706, 1995

27. Meis JM, Enzinger FM: Myolipoma of soft tissue. *Am J Surg Pathol* **17**:121, 1991

28. Fitzpatrick JE et al: Cutaneous angiolipoleiomyoma. *J Am Acad Dermatol* **23**:1093, 1990

29. Argenyi ZB et al: Cutaneous angiomyolipoma: A light-microscopic, immunohistochemical, and electron-microscopic study. *Am J Dermatopathol* **13**:497, 1991

30. Marshall-Taylor C, Fanburg-Smith JC: Fibrohistiocytic lipoma: Twelve cases of a previously undescribed benign fatty tumor. *Ann Diagn Pathol* **4**:354, 2000

31. Marshall-Taylor C, Fanburg-Smith JC: Hemosiderotic fibrohistiocytic lipomatous lesion: Ten cases of a previously undescribed fatty lesion of the foot/ankle. *Mod Pathol* **13**:1192, 2000

32. Fleishman JS, Schwartz RA: Hibernoma: Ultrastructural observations. *J Surg Oncol* **23**:285, 1983

33. Mentzel T et al: Lipoblastoma and lipoblastomatosis: A clinicopathological study of 14 cases. *Histopathology* **23**:527, 1993

34. Collins MH, Chatten J: Lipoblastoma/lipoblastomatosis: A clinicopathologic study of 25 tumors. *Am J Surg Pathol* **21**:1131, 1997

35. Weiss SW, Goldblum JR: Liposarcoma, in *Soft Tissue Tumors,* 4th ed. St Louis, Mosby, 2001, p 641

36. Weitzner S, Kornblum S: Subcutaneous liposarcoma of forearm. *Am Surg* **38**:176, 1972

37. McKee PH et al: Subcuteaneous liposarcoma. *Clin Exp Dermatol* **8**:593, 1983

38. Dei Tos AP et al: Primary liposarcoma of the skin: A rare neoplasm with unusual high grade features. *Am J Dermatopathol* **20**:332, 1998

39. Dei Tos AP et al: Spindle cell liposarcoma, a hitherto unrecognized variant of liposarcoma: Analysis of six cases. *Am J Surg Pathol* **18**:913, 1994

40. McCormick D et al: Dedifferentiated liposarcoma: Clinicopathologic analysis of 32 cases suggesting a better prognostic subgroup among pleomorphic sarcomas. *Am J Surg Pathol* **18**:1213, 1994

T>

Chapter 112

Jonathan Ship Joan Phelan A. Kerr

Biology and Pathology of the Oral Mucosa

BIOLOGY OF THE ORAL MUCOSA
Anatomy and Histology of the Oral Mucosa
Oral Physiology
PATHOLOGY OF THE ORAL MUCOSA
Leukoplakic Lesions
Leukoplakic and/or Erythemic Lesions
Pigmented and Vascular Lesions
Papillary and Verrucous Lesions
Submucosal Nodules
Salivary Gland Diseases
Ulcerative, Vesicular, and Bullous Oral Lesions

REFERENCES

The mucosal tissues that extend from the vermilion border of the lips to the posterior border of the oral pharynx play a critical role in the protection and maintenance of oral and systemic health. The oral mucosa is a unique tissue that is designed to protect the host; to provide oral-facial sensory feedback to the brain; to facilitate mastication, deglutition, and chemosensory function; and to assist in phonation. Impaired oral mucosal health may lead to numerous oral and systemic complications, including pain, malnutrition, infection, compromised immune function, and exacerbation of medical disorders. Many systemic conditions appear initially in the oral cavity, and prompt diagnosis and management can help minimize disease progression and organ destruction. Further, the oral and systemic implications of oral mucosal diseases can have deleterious consequences for a person's health and quality of life. [1], [2], [3] and [4] The diagnosis, management, and prevention of oral mucosal diseases are a joint responsibility of dental and medical health care professionals.

BIOLOGY OF THE ORAL MUCOSA

Anatomy and Histology of the Oral Mucosa

The two major functional roles of the oral mucosa are (1) to cover and protect the tissues beneath it and (2) to convey sensory information from the surface. As a covering layer, it provides resistance to insult and protects against infection and toxic substances. In its specialized sensory role, the oral mucosa provides taste sensation and transmits pain, touch, and temperature information. The oral mucosa is classified into three functional types: lining mucosa, masticatory mucosa, and specialized mucosa.

Orthokeratinized stratified squamous epithelium covers the vermilion of the lips. An abrupt interface with the labial oral mucosa occurs just inside the oral cavity. Lining mucosa includes the labial and buccal mucosa, the mucosa covering the ventral surface of the tongue and floor of the mouth, and the mucosa covering the soft palate and the alveolar processes that extend to the gingiva (Fig. 112-1). The lining epithelium is moderately thicker than that of skin and is usually nonkeratinized, but it may be orthokeratinized in areas subject to persistent friction, such as the buccal mucosal tissues adjacent to the occlusal plane (i.e., the interface between the maxillary and the mandibular teeth). The trenchlike configurations that form where the buccal and labial mucosae attach to the maxilla and mandible are called maxillary and mandibular, buccal and labial vestibules.

FIGURE 112-1 Normal teeth and anterior floor of the mouth. The patient is raising the tongue toward the upper incisor teeth. Visible are the lingual frenum, dark-colored veins on the ventrum of the tongue, and the ridges corresponding to the submandibular (Wharton's) duct.

The second type of oral mucosa, the masticatory mucosa, includes the mucosa covering the hard palate and gingiva. The surface of these areas is orthokeratinized stratified squamous epithelium. The free gingiva occurs where the oral mucosa meets the surface of a tooth and is just a few millimeters in thickness. The mucosa covering the alveolar bone of the maxilla and mandible is called the attached gingiva, and the lining mucosa that extends from the attached gingiva to the buccal and labial mucosa is called the alveolar mucosa. When teeth have been extracted, the resulting area is called the alveolar ridge.

The third type of oral mucosa is the specialized mucosa. This type of mucosa consists primarily of two types of papillae

(filiform and fungiform) that cover the dorsal surface of the tongue (Fig. 112-2). The filiform papillae are located on the anterior portion of the tongue and consist of fronds of keratinized epithelium covering thin connective tissue cores. Fungiform papillae are scattered among the filiform papillae. Dark pink in color, they consist of thin nonkeratinized squamous epithelium covering well-vascularized fibrous connective tissue cores. The specialized mucosa of the tongue also includes circumvallate papillae and rudimentary foliate papillae. Circumvallate papillae are located on the posterior dorsal surface of the tongue and are arranged in a V-shaped pattern with the apex of the V at the foramen cecum (Fig. 112-3). These appear as round (4 mm in diameter), erythematous, and slightly exophytic structures. Foliate papillae appear as vertical ridges or folds of tissue on the posterior lateral borders of the tongue.

FIGURE 112-2 Normal tongue. Note the rough surface, with filiform papillae, and the red, punctate, fungiform papillae scattered, especially in the anterior and lateral regions.

FIGURE 112-3 Normal dorsal tongue, with circumvallate papillae. A white coating makes the papillae stand out in sharp relief.

Several different specialized structures lie in the oral cavity. The most numerous of these are the minor salivary glands. The majority occur in the mucosa of the lower lip and junction of the hard and soft palate, but these glands also appear in many other locations, including the upper lip, the buccal mucosa, and the tongue. The vast majority are mucus-secreting glands. Serous minor salivary glands are found on the tip of the tongue and bilaterally on the posterior lateral aspect of the tongue.

Taste buds are in the mucosa of the tongue, the soft palate, and the pharynx. Three types of lingual papillae contain taste buds: fungiform (anterior two-thirds of the tongue), foliate (lateral borders of the tongue), and circumvallate (posterior border of the tongue). Also commonly found in the oral mucosa, sebaceous glands appear as yellowish-white, slightly raised, granule-appearing structures located on labial and buccal mucosal surfaces. They are referred to as Fordyce's granules and are true sebaceous glands, but have no identified function in the oral cavity.

Three major pairs of salivary glands secrete saliva into the oral cavity: parotid, submandibular, and sublingual glands. The orifice of the excretory duct of the parotid glands (Stenson's duct) is visible on a raised papilla on the buccal mucosa opposite the maxillary molars. The submandibular gland saliva enters the oral cavity through ducts with orifices that open into the floor of the mouth (Wharton's duct; see Fig. 112-1). The sublingual gland is composed of collections of mucous glands; the majority share the same excretory duct as the submandibular gland, while others excrete saliva directly into the floor of the mouth through individual ducts.

Finally, there are dendritic and lymphoid cells located in the oral mucosal tissues. The dendritic Langerhans cells and melanocytes are present in multiple layers of the oral mucosal epithelium. Aggregates of lymphoid tissue, referred to collectively as Waldeyer's ring, are located in the posterior oral pharynx. This tissue forms the lingual (soft, yellowish-red, nodular tissue on the posterior lateral aspect of the tongue), palatine, and pharyngeal tonsils.

Oral Physiology

The oral cavity serves three essential functions in human physiology: (1) the production of speech and communication, (2) the initiation of alimentation, and (3) the protection of the host from pathogens and trauma. Many specialized oral-facial tissues have evolved to carry out these vital functions. The teeth, the periodontium (Fig. 112-4), and the muscles of mastication prepare food for deglutition. The tongue, besides occupying a central role in communication, is a key participant in food bolus preparation and translocation. Salivary glands provide a secretion with multiple functions. In addition to lubricating all oral mucosal tissues to keep them intact and pliable, saliva moistens the developing food bolus, permitting it to be fashioned into a swallow-acceptable form. All these activities are finely coordinated, and a disturbance in any one function can significantly compromise speech and/or alimentation and diminish the quality of a person's life.

FIGURE 112-4 Normal teeth, gingival tissues, and periodontium. The mucogingival line, between the pink attached gingiva and red vestibular mucosa, is well demonstrated.

Because of its exposure to the external world, the oral cavity is potentially vulnerable to a limitless number of environmental insults. Extensive mechanisms have evolved to protect the mouth and permit normal oral function. The oral cavity is richly endowed with sensory systems that not only contribute to the enjoyment of food, but also alert an individual to potential problems. These systems include mechanisms for taste (and its inextricable relationship with smell); thermal, textural, and tactile sensations; and pain discrimination. Also, saliva plays an important protective role through its broad spectrum of antimicrobial proteins that modulate oral microbial colonization. Other proteins maintain the functional integrity of the teeth by keeping saliva supersaturated with calcium and phosphate salts and, in effect, repairing incipient caries (tooth decay) by a remineralization process.

Many of these functions and tissues can remain remarkably intact throughout the aging process in healthy persons. Conversely, numerous systemic diseases and their treatment (e.g., medications, surgery, head and neck radiation) can cause significant impairments to oral health, particularly in older adults. These problems can subsequently lead to impaired communication, malnutrition, and diminished host immunity.

PATHOLOGY OF THE ORAL MUCOSA

Leukoplakic Lesions

Leukoplakic, or white, lesions are among the most prevalent oral mucosal conditions found in people of all ages. They range from benign to malignant, and all require appropriate diagnosis.

LEUKOPLAKIA A white plaque that cannot be wiped off and cannot be diagnosed as any other distinct lesion is called leukoplakia. [5] The histologic appearance of leukoplakia varies, ranging from hyperkeratosis and epithelial hyperplasia to epithelial dysplasia and squamous cell carcinoma. When the diagnosis of a white lesion is definitive, the term *leukoplakia* is no longer appropriate. The histologic diagnosis of the lesion determines the appropriate treatment of clinical leukoplakia.

LEUKOEDEMA A variant of normal, leukoedema appears as a grayish-white opalescence of the buccal mucosa, more frequently observed in blacks. The mucosa attains a normal pink color if stretched. Histologically, the epithelium of leukoedema exhibits acanthosis, and the cells of the spinous layer appear larger and more transparent than those of normal epithelium. Because leukoedema is a variant of normal, no treatment is required.

FRICTIONAL KERATOSIS Chronic friction against another surface may result in a white lesion called frictional keratosis. There is a marked thickening of the keratin on the epithelial surface that may be accompanied by acanthosis. Identification and elimination of the cause of the friction (e.g., sharp tooth, rough or overextended denture border) should resolve the lesion. If not, biopsy and histologic examination are warranted.

CHRONIC LIP, TONGUE, AND CHEEK CHEWING Individuals who chronically chew their lip, tongue, and cheek may develop a white lesion that is a form of frictional keratosis. The surface appears rough, and a clinician can easily remove keratin scales from the surface. When this occurs on the buccal mucosa, a wedge-shaped configuration is observed that is broader at the anterior aspect and narrower at the posterior aspect.

LINEA ALBA Forming most commonly on the buccal mucosa at the edge of the teeth (occlusal plane), linea alba is a white, raised line. The line follows the pattern of the teeth at the occlusal plane and may extend onto the labial mucosa as well. In some patients with a teeth-clenching habit, linea alba becomes prominent. Histologically, the white raised line is due to epithelial hyperplasia with overlying hyperkeratosis. No treatment is indicated.

NICOTINE STOMATITIS In response to pipe, cigar, and cigarette smoking, nicotine stomatitis may develop. [6] With this condition, the keratin surface of the hard palate thickens. Because the increase in the surface keratin obstructs the minor salivary gland ducts on the palatal surface, the ducts become inflamed. They appear as raised, erythemic dots, 2 to 5 mm in diameter, representing the opening of the minor salivary glands on the posterior hard palate and the soft palate. The white appearance will resolve with cessation of smoking; however, it may take several weeks for a change in the lesion to become noticeable. Diagnosis is based upon signs and symptoms, and it is not considered to be a premalignant lesion. Except for cessation of smoking, there is no successful treatment.

TOBACCO CHEWER'S WHITE LESION Individuals who chew tobacco may develop a white lesion in the area where they habitually place tobacco. [7] The mucosa appears granular or wrinkled, and lesions are most commonly located in the mucobuccal fold. Long-standing lesions have a more opaque and corrugated appearance than newer lesions do. Histologically, these white lesions show epithelial hyperplasia and hyperkeratosis. Long-term exposure to smokeless tobacco has been associated with an increased risk of intraoral squamous cell carcinoma. Lesions usually resolve when the individual no longer places tobacco in the area. If resolution does not occur, biopsy and histologic examination are warranted.

HAIRY TONGUE A condition characterized by elongation of the filiform papillae on the dorsal surface of the tongue, hairy tongue may be white, black, or brown; in fact, it can be stained almost any color by candies or lozenges dissolved in the mouth (Fig. 112-5). The color of black hairy tongue is attributed to chromogenic bacteria, whereas the color of brown hairy tongue is associated with tobacco smoking. The etiology is unknown, although chemical mouth rinses (e.g., hydrogen peroxide), radiation-induced xerostomia, and systemic antibiotic and glucocorticoids have all been proposed. Gentle brushing of the tongue may be helpful in decreasing the length of the papillae.

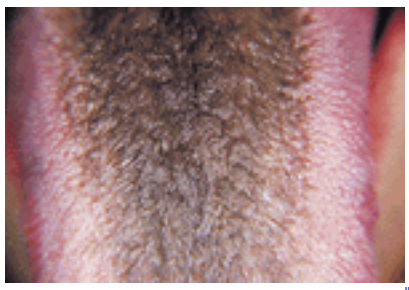

FIGURE 112-5 Hairy tongue. There is hyperplasia of the filiform papillae of the dorsum of the tongue. The pigmentation results from overgrowth of pigment-producing strains of microbial flora as a result of antibiotic therapy.

ASPIRIN/CHEMICAL BURN An aspirin burn of the oral mucosa occurs when a patient with a toothache places an aspirin tablet directly on the painful tooth instead of swallowing the tablet. As a result, the nearby mucosal tissues become necrotic. The necrotic tissue in this white and painful lesion is loosely adherent to the underlying connective tissue and easily sloughs off. Phenol is a component of some nonprescription products advertised for the relief of oral pain. When these products contact oral mucosa, they destroy tissue in a way that appears identical to aspirin burns. Diagnosis is usually established from patient history, signs, and symptoms.

OTHER WHITE LESIONS Keratoacanthoma and squamous acanthoma have occurred in the oral cavity. Submucous fibrosis, a potentially premalignant condition, has a generalized white appearance of the oral mucosa that has been attributed to betel nut chewing, seen in India and Southeast Asia. [8] White sponge nevus, a white lesion of the oral mucosa that follows an autosomal dominant inheritance pattern, is usually diagnosed from family history (Fig. 112-6). Lichen planus and candidiasis (described below) may also appear as white lesions.

FIGURE 112-6 White sponge nevus. These lesions appeared in a nonsmoking young adult with a family history of white sponge nevus.

Leukoplakic and/or Erythemic Lesions

DYSPLASIA AND SQUAMOUS CELL CARCINOMA Lesions with erythroplakic components appear red because of inflammation, hemorrhage, increased angiogenesis, epithelial atrophy, acantholysis, or ulceration. Among the most significant erythroplakic conditions of the oral cavity are dysplasia and squamous cell carcinoma. [9], [10] In their early stages, the lesions are generally unilateral and asymptomatic, appearing as white (leukoplakic), red/white (erythroleukoplakic), or red (erythroplakic) lesions. Suspicious lesions have erythroplakic components with poorly defined borders, nonhomogenous coloration, and ulcerations (Fig. 112-7). [11]

FIGURE 112-7 A squamous cell carcinoma involving the alveolar ridge, gingiva, floor of the mouth, and buccal mucosal tissues.

High-risk sites for developing oral cancer are the lower lip, lateral border of the tongue, oropharynx, and floor of the mouth (Fig. 112-8). High-risk factors are age greater than 50 years, and excessive tobacco and/or alcohol use. It is important not to rely on clinical appearance alone, and all lesions that persist for longer than 3 weeks without a definitive diagnosis should undergo biopsy with either scalpel [12] or transepithelial brush, [13] followed by histopathologic examination. Toluidine blue staining is helpful for facilitating biopsy site selection. [14]

FIGURE 112-8 Invasive oral squamous cell carcinoma on the floor of the mouth of an edentulous patient.

Treatment of dysplastic lesions involves complete excision (i.e., by scalpel or CO_2 laser), risk reduction, and close follow-up for recurrences. Recurrent lesions may respond to antioxidant micronutrients. [15] Treatment of squamous cell carcinoma begins with tumor staging. [16] Surgery is the treatment of choice for accessible localized disease, while tumors with lymph node involvement usually require surgery followed by external beam head and neck radiotherapy.

ORAL CANDIDIASIS The commensal fungus *Candida albicans* is the primary cause of candidiasis (see Chap. 206). The

condition develops as a result of compromised oral and systemic immune function (e.g., salivary hypofunction, HIV infection, diabetes), and immunosuppressant drugs or broad-spectrum antibiotics. [17], [18] Oral fungal infections are common beneath removable prostheses, especially in the presence of poor oral and denture hygiene. There are four clinical manifestations showing a range of white, red/white, or red appearances:

1. *Pseudomembraneous candidiasis* (thrush) is asymptomatic and has a diagnostically characteristic appearance of curdlike white patches that can easily be wiped off to reveal an underlying erythema (Fig. 112-9 and Fig. 112-10).

FIGURE 112-9 Pseudomembraneous candidiasis, the most common intraoral manifestation of *Candida albicans,* on the hard palate.

FIGURE 112-10 Pseudomembraneous oral candidiasis of the buccal mucosa and tongue dorsum.

2. *Erythematous candidiasis* may manifest as (a) a generalized oral erythema (Fig. 112-11) with symptoms of burning (e.g., atrophic candidiasis secondary to antibiotic therapy), (b) a sharply defined erythematous area under dentures (denture stomatitis), and (c) a midline dorsal tongue atrophy and erythema (median rhomboid glossitis).

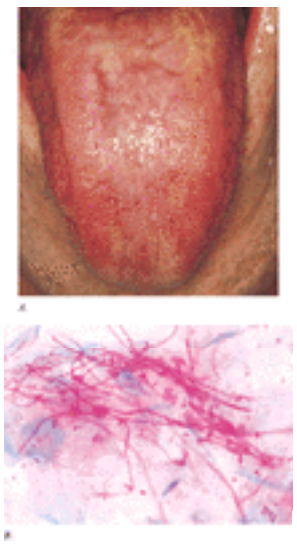

FIGURE 112-11 Erythematous candidiasis. *A*. Papillary atrophy on the dorsum of the tongue of a patient with AIDS. *B*. Cytologic smear showing yeast cells and pseudomycelia of *Candida* (periodic acid–Schiff stain).

3. *Angular cheilitis,* not exclusively attributed to candidiasis, manifests as erythema with cracking and crusting of the labial commissures. It is commonly seen concomitant with other forms of candidiasis (Fig. 112-12).

FIGURE 112-12 Angular cheilitis resulting from *Candida albicans* infection of the bilateral labial commissures.

4. *Hyperplastic candidiasis,* a relatively uncommon form, is a thickened and firm nonremovable white lesion. It affects smokers and sites of friction, such as the anterior buccal mucosa.

Diagnosis of candidiasis is initially based on the clinical presentation, positive findings on a KOH examination, and a favorable response to antifungal therapy. When the clinical signs are less obvious, smears or biopsies stained with periodic acid–Schiff (PAS) or cultures to identify candidal species are required (see Fig. 112-11B). The clinical circumstances dictate the choice of antifungal therapy (Table 112-1). [19] Topical antifungals are the first line of treatment, delivered as troches, rinses, or creams. Systemic antifungals are indicated for refractory and more extensive lesions, but their use increases the risk for drug interactions and adverse effects.



TABLE 112-1 **Treatment of Oral Fungal Infections**

GEOGRAPHIC TONGUE Also known as benign migratory glossitis, geographic tongue is a very common oral inflammatory condition affecting approximately 2 percent of the population. Lesions manifest as mixed red/white annular areas of dorsal tongue depapillation, sharply demarcated by a whitish rim (Fig. 112-13). Geographic tongue intermittently recurs and is associated with fissured tongue. Lesions migrate around the tongue dorsum, revealing an ever-changing maplike or “geographic” appearance. Lesions may occasionally occur on sites other than the tongue in a condition known as areata migrans. Treatment with topical steroid ointments is reserved for symptomatic patients.

FIGURE 112-13 Geographic tongue. Irregular linear white lesions enclose areas of erythema and mucosal atrophy.

RADIOTHERAPY- AND CHEMOTHERAPY-INDUCED MUCOSITIS Oral and pharyngeal mucositis is one of the most common short-term complications of head and neck radiotherapy and some chemotherapeutic regimens. [20] Causes are direct tissue damage by radiotherapy and chemotherapy, resulting in mucosal ulceration, pain, and epithelial cell death. Radiation mucositis begins after 1 to 2 weeks of radiotherapy with mucosal erythema. Ulcerations develop with pseudomembranes that can hemorrhage readily, with associated stomatodynia and dysphagia. Ulcers form readily in areas where trauma is unavoidable (e.g., buccal/labial mucosa, tongue dorsum). Healing begins after completion of radiotherapy. Chemotherapy-induced mucositis has a similar clinical appearance. Radiotherapy- and chemotherapy-induced salivary hypofunction frequently accompanies the mucositis, which increases pain and mucosal friability (Fig. 112-14). Desiccated lips and oral mucosal surfaces, dental caries, oral fungal infections, and poorly fitting dentures are common signs of salivary hypofunction.

FIGURE 112-14 Salivary hypofunction and xerostomia, which frequently occur after external beam radiotherapy (for head and neck cancers), chemotherapy, and multiple prescription and nonprescription medications.

Palliative therapies include avoidance of mucosal irritation by careful oral care and application of water-based lubricants, oral rinsing with saline or bicarbonate solutions, oral cooling with ice chips, topical coating agents (e.g., kaolin-pectin, aluminum or magnesium hydroxide, sucralfate), topical anesthetic agents, and analgesics. [21] Dietary counseling can help avoid dehydration and nutritional disorders.

ORAL LICHEN PLANUS A common epithelial immune-mediated condition, oral lichen planus affects 1 to 2 percent of adults. [22] It has many forms (leukoplakic, erosive, atrophic) that reflect the degree of epithelial damage and the host's capacity for repair. Lesions affect the buccal mucosa most frequently, although the tongue, palate, gingiva, or lips are also involved (Fig. 112-15). The reticular form of oral lichen planus has a predominant network of lace-like white striae and, on occasion, plaques or papules (Fig. 112-16). Atrophy, erosion, ulceration, and rarely, the formation of bullae mark the epithelial destruction, as seen in the erosive form. Typically, erosive oral lichen planus is painful, particularly following the ingestion of acidic or spicy foods. Tissue biopsy establishes the diagnosis.

FIGURE 112-15 Irregular white striae of classic oral lichen planus on the buccal mucosa, right side.

FIGURE 112-16 Erosive lichen planus and reticular lichen planus of the posterior buccal mucosa. The leukoplakic striations are referred to as “Wickham's striae.”

Oral lichenoid drug reactions, contact sensitivities, and oral graft-versus-host disease all have an almost identical clinical and histologic presentation. All patients, particularly those with erosive disease, need long-term follow-up care to identify early signs of dysplastic change. [23] Treatment begins with the removal of local traumatic factors (e.g., sharp teeth) and rigorous oral hygiene. Topical treatment and/or intralesional injections with immunosuppressants are reserved for patients with symptomatic disease, and systemic treatment with immunosuppressants should be used in patients with significant oral and/or cutaneous lesions [24], [25] (Table 112-2).



TABLE 112-2 **Treatment of Common Oral Vesiculobullous and Erosive Diseases**

LUPUS ERYTHEMATOSUS Both discoid and systemic lupus erythematosus may produce oral lesions similar in appearance to those of oral lichen planus or lichenoid drug reactions (Fig. 112-17). The course of oral lesions frequently parallels that of systemic manifestations. A biopsy may be required for accurate diagnosis.

FIGURE 112-17 Discoid lupus erythematosus. Painful ulcers with inflammation are evident on the palate.

Pigmented and Vascular Lesions

MELANOCYTIC LESIONS

Melanin pigmentation In general, melanin pigmentation is a variant of normal seen in patients with more deeply pigmented skin. [26] Any areas of the oral mucosal tissues can appear brown and pigmented. Edentulous patients may present with melanin pigmentation on the alveolar ridge. Histologically, melanin pigment is visible in the basal layer of the epithelium and in the subjacent connective tissue. Focal areas of melanin pigmentation may follow inflammation, and increased melanin pigmentation of the anterior attached gingiva may be associated with smoking (referred to as smoker's melanosis or smoking-associated melanosis).

Oral melanotic macule Flat, small (<1 cm in diameter), well-circumscribed, brown lesions, oral melanotic macules are of unknown etiology. The lesions exhibit a focal increase in melanin deposition in the basal layer of the epithelium, as well as in the subjacent connective tissue and normal stratified squamous epithelium. [27] A labial melanotic macule is a similar lesion occurring on the vermilion of the lips. The labial melanotic macule darkens with exposure to sunlight. Lesions may require biopsy and histologic examination to confirm the diagnosis. No treatment is necessary once the diagnosis has been established.

Melanocytic nevi Intraoral melanocytic nevi are uncommon, yet junctional, compound, intramucosal, and blue nevi have all been reported to occur in the oral cavity. [28] Most melanocytic nevi arise on the palate or gingiva, although they may appear on any oral mucosal site. Biopsy and histologic examination are required, as early oral malignant melanoma can mimic a melanocytic nevus.

Malignant melanoma A rare oral disease, malignant melanoma affects adults in the sixth to seventh decade of life. Most oral melanomas occur on the hard palate or maxillary gingiva. Early oral melanomas appear as brown to black macules with irregular borders. The macules thicken, enlarge, and ulcerate. Diagnosis requires biopsy, and treatment involves complete surgical removal. The prognosis for oral melanoma is extremely poor.

Peutz-Jeghers syndrome Freckle-like lesions of the skin are a characteristic of Peutz-Jeghers syndrome. They frequently involve the perioral area and occasionally the intraoral mucosa. These melanocytic lesions do not darken with exposure to sunlight. The syndrome is inherited (autosomal dominant), but new mutations also occur. Components of the syndrome include hamartomatous intestinal polyposis and tumors of the pancreas, breast, and ovaries; there also is an increased risk of gastrointestinal carcinoma.

EXOGENOUS PIGMENTED LESIONS The deposition of amalgam particles causes the amalgam tattoo, a flat, bluish-gray lesion. The introduction of amalgam particles into the mucosa can occur during the placement or removal of an amalgam restoration or during a tooth extraction if a piece of amalgam fractures and remains in the extraction site tissue. The metal particles disperse in the connective tissue and produce a permanent pigmentation. Amalgam tattoos most commonly occur on the gingiva or on an edentulous alveolar ridge, with occasional lesions in the mandibular vestibule, floor of the mouth, and buccal mucosa. The identification of the metal particles in the tissue on a dental radiograph often can confirm the diagnosis. Biopsy and histologic examination are occasionally required for diagnosis. No treatment is necessary. A blue-gray line along the free gingival margin has been reported to occur with lead and bismuth toxicity.

VASCULAR LESIONS

Varicosities/varices Oral varicosities are multiple, asymptomatic, bluish-purple elevated nodules that are most commonly found on the ventral and lateral aspects of the tongue and lips in individuals more than 45 years of age. Oral mucosal varices are not associated with systemic disease, and generally, no treatment is indicated. Biopsy and histologic examination are required to confirm the diagnosis if thrombi and phleboliths are associated with oral varices.

Hemangioma Oral mucosal hemangiomas are benign proliferations of blood vessels that appear as raised, bluish-red nodular lesions. They may be either capillary or cavernous. Capillary hemangiomas contain a proliferation of

capillary-sized blood vessels, whereas cavernous hemangiomas exhibit larger dilated blood vessels. Thromboses and phleboliths may form in hemangiomas. Oral hemangiomas are primarily tumors of childhood, although they may also occur in adults. When they occur in infants and children, they tend to regress with time. Treatment for adults includes surgical removal, laser therapy, and injection with sclerosing agents.

Kaposi's sarcoma Oral Kaposi's sarcoma is rare except in association with HIV infection. [29] Histologically, Kaposi's sarcoma consists of a proliferation of spindle-shaped cells mixed with slitlike vascular spaces. Lesions are usually bluish-red and vary from single to multiple and from flat to nodular. [30] The most common locations are the gingiva and the hard palate. A viral etiology has been proposed for Kaposi's sarcoma, in particular human herpesvirus type 8. The use of highly active antiretroviral therapy (HAART) has reduced the prevalence of HIV-associated Kaposi's sarcoma. Because treatment is not curative, its purpose is to reduce the size of lesions via surgical debulking, radiation therapy, and chemotherapy.

BLEEDING DIATHESES

Oral mucosal petechiae, ecchymoses, hematomas, and spontaneous gingival bleeding Oral mucosal lesions such as petechiae, ecchymoses, hematomas, and spontaneous gingival bleeding may occur in patients with blood dyscrasias, including severe thrombocytopenia and coagulation defects. [31] The etiology includes a variety of medical disorders (e.g., hemolytic anemia, von Willebrand's disease) and medications (e.g., chemotherapy, anticoagulants). Thrombocytopenia-associated oral lesions do not usually become evident until the platelet level falls below 100,000/mm [3] , and they resolve when platelet levels increase.

Polycythemia The oral mucosa in individuals with primary or secondary polycythemia appears deeper red in color than normal and may resemble the mucosa seen in erythematous candidiasis. A history of polycythemia or a serologic bleeding profile confirms the diagnosis.

Hereditary hemorrhagic telangiectasia (Rendu-Osler-Weber syndrome) An autosomal dominant syndrome, hereditary hemorrhagic telangiectasia involves multiple telangiectasias of the mucosa and skin. Oral mucosal telangiectasias are most frequently found on the vermilion of the lips, tongue, and buccal mucosa. Frequent episodes of epistaxis because of telangiectasias of the nasal mucosa often lead to the initial diagnosis. However, the oral mucosal telangiectasias may be the most easily recognized component of the syndrome.

GINGIVAL AND PERIODONTAL DISEASES

Drug-induced gingival enlargement Characterized by an increase in free and attached gingiva, particularly involving the interdental papillae (gingival tissue between teeth), [32] gingival enlargement results from the use of certain medications: phenytoin, calcium channel blockers (nifedipine, diltiazem, felodipine, nitrendipine, verapamil), other dihydropyridines, and cyclosporine (Fig. 112-18). [33] When the patient has used two drugs known to cause gingival enlargement concurrently, the enlargement may be more severe. Signs and symptoms establish the diagnosis. Management includes meticulous oral hygiene, and moderate to severe cases require surgical removal of the enlarged tissue (gingivectomy). Recurrences are frequent, especially if the patient continues to use the causative drug.

FIGURE 112-18 Gingival hyperplasia caused by phenytoin.

HIV/AIDS-associated gingival and periodontal disease When associated with HIV infection and AIDS, gingival disease appears as a distinct linear gingival erythema (Fig. 112-19). [30] The etiology is unknown, and the prevalence remains unclear. Necrotizing, ulcerative gingivitis and more extensive periodontitis with bone involvement may also occur in conjunction with HIV infection and AIDS. Bacterial species commonly associated with inflammatory periodontal diseases are generally responsible. The signs and symptoms establish the diagnosis. Treatment involves debridement of the necrotic tissue, the administration of antibiotics (e.g., metronidazole, tetracycline), and meticulous oral hygiene.

FIGURE 112-19 AIDS-related periodontitis, with painful erosions of the marginal gingiva and exudate from the gingival sulcus.

Cyclic neutropenia A cyclic decrease in the number of circulating neutrophils characterizes cyclic neutropenia, an autosomal dominant disease. Cycles are usually at intervals of 21 to 27 days and persist for 2 to 3 days. Oral manifestations of cyclic neutropenia include ulcerative gingivitis and oral mucosal ulcers. With repeated cycles of neutropenia, gingivitis progresses into periodontal disease and bone loss. Oral lesions usually improve when the neutrophil count returns to normal. Antibiotic therapy is occasionally used to prevent the development of alveolar bone loss.

Langerhans cell disease Formerly called histocytosis X, Langerhans cell disease is characterized by the proliferation of Langerhans cells accompanied by eosinophils. The etiopathogenesis is unclear. Ulcerating or proliferating gingival lesions with bone destruction may be evident in chronic disseminated disease (Hand-Schuller-Christian disease) and in solitary eosinophilic granuloma. Diagnosis requires tissue biopsy, and treatment involves curettage of the affected tissue and/or low doses of external beam radiation.

Papillary and Verrucous Lesions

REACTIVE PAPILLARY HYPERPLASIA Mechanical trauma from dentures and/or *Candida albicans* colonization may cause reactive papillary hyperplasia. An erythemic and papillary hyperplastic condition, the disease typically affects the palate beneath an ill-fitting removable prosthesis. Symptoms range from none to soreness and burning. The palatal mucosa covered by the prosthesis is bright red, with short papillary projections that may appear either packed together or scattered. The clinical appearance and fungal culture indicate the diagnosis. If initial therapy is ineffective, definitive diagnosis requires tissue biopsy. Therapy begins with antifungal treatment of both prosthesis and palatal mucosa (see Table 112-1). Ill-fitting dentures require relining with temporary and permanent materials and, possibly, reconstruction.
ORAL HAIRY LEUKOPLAKIA Epstein-Barr virus infection of mucosal keratinocytes is associated with oral hairy leukoplakia, a proliferative epithelial lesion. Originally, reports of the disorder involved almost exclusively homosexual men infected with HIV-1, but now the disorder also affects immunodeficient and HIV-negative adults, typically after organ transplant therapy or chemotherapy. Oral hairy leukoplakia appears as an accentuation of the normal vertical folds at the lateral border of the tongue, with elongation of the papillae (Fig. 112-20). It is homogenously leukoplakic, and as the lesion progresses, it coalesces and thus takes on a shaggy appearance.

FIGURE 112-20 Oral hairy leukoplakia. White corrugated folds occur on the lateral aspects of the tongue. Rubbing with gauze cannot remove the lesion.

The condition is asymptomatic unless infected with *Candida albicans,* which may cause pain and burning. The clinical appearance is the basis for the diagnosis of oral hairy leukoplakia. If certain risk factors are present (e.g., HIV-1 infection, immunodeficiency, smoking, alcohol use), then tissue biopsy can help rule out dysplastic or neoplastic conditions. Frictional keratosis, another benign mucosal proliferative condition, shares many of the clinical attributes of oral hairy leukoplakia, but it has no HIV-1/immunodeficiency association. Oral hairy leukoplakia rarely requires treatment, unless the clinical appearance is bothersome to the patient. Surgical removal is helpful in the short term, but the lesion will recur. If oral hairy leukoplakia is associated with candidiasis, then appropriate antifungal therapy must be initiated (see Table 112-1). A few symptomatic patients have benefited from the application of podophyllum resin solution.
VERRUCOUS CARCINOMA Also referred to as verrucous hyperplasia and proliferative verrucous leukoplakia, verrucous carcinoma is a mucosal proliferation condition commonly affecting older adults, particularly those who use tobacco. Lesions present as thickened, rough, white areas; diagnosis is a challenge, because the lesions have clinical and microscopic features intermediate between those of frictional or reactive keratosis and squamous cell carcinoma (Fig. 112-21). The buccal mucosa is a common location, but the disorder may involve any oral site. Early lesions may be relatively inconspicuous, but become more prominently thick, rough, and leukoplakic over time. Tissue biopsy confirms the diagnosis, although the fact that many specimens show intermediate features of hyperplasia and neoplasia complicates the diagnostic process.

FIGURE 112-21 Verrucous squamous cell carcinoma.

Treatment consists of eliminating tobacco and alcohol use, and removing irrevocably altered mucosa by surgery, laser, cautery, or cryotherapy. Patients require frequent reevaluation and episodic treatment in order to identify and eliminate potentially preneoplastic tissue.
SQUAMOUS PAPILLOMA Although squamous papilloma is a small, exophytic, papillary mucosal growth that can occur on any oral mucosal surface, it occurs most frequently on the palate, tongue, lips, and gingiva. Most papillomas are small (less than 1 cm in diameter), asymptomatic pedunculated growths, with a similar color to that of the surrounding mucosa (Fig. 112-22). The etiology of these lesions is unknown, although there is a strong association with human papillomavirus. Tissue biopsy establishes the diagnosis, and treatment requires complete excision (preferably, by scalpel), including the base of the lesion. Failure to remove the entire lesion may result in recurrence.

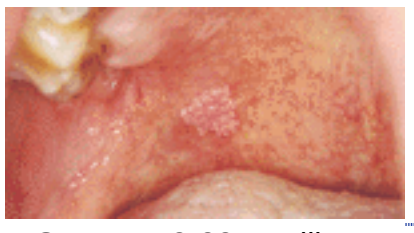

FIGURE 112-22 Papilloma on the soft palate.

VERRUCA VULGARIS The lesions of verruca vulgaris are small, sessile, finely papillated, and exophytic epithelial proliferations that are etiologically associated with human papillomavirus (particularly types 2 and 4). They can occur singly or in small clusters, which is suggestive of autoinoculation. Lesions more commonly occur on the masticatory mucosa, the lips, and the perioral skin. Tissue biopsy establishes the diagnosis, and treatment requires complete excision. Recurrence is possible if there are lesions elsewhere that can serve as sources for reinoculation of the virus.

CONDYLOMA ACUMINATUM Another papillary epithelial hyperplasia with a human papillomavirus as a contributing factor (most commonly type 6 or 11) is condyloma acuminatum. These lesions frequently affect the anogenital mucosa, but can also occur in the oral cavity, primarily as a result of sexual activity. The clinical appearance is nearly identical to that of verruca vulgaris or squamous papilloma, and lesions can occur on any oral mucosal tissue. Tissue biopsy is necessary for diagnosis, yet recurrence or growth of new lesions at different oral sites occurs, possibly because of reinoculation or different latency periods in lesions that were initiated at the same time.
VERRUCIFORM XANTHOMA A small (less than 2 cm), asymptomatic, sessile, rough-surfaced growth, verruciform xanthoma appears white or yellow in color. It affects any oral mucosal site, most commonly in older adults. The etiology is uncertain, but it is hypothesized that the cause may be low-grade epithelial damage resulting from irritation or minor trauma, with the accumulation of lipid from the damaged cells. Diagnosis is made by tissue biopsy. This is an innocuous lesion that seldom recurs after conservative excision; it is necessary to distinguish the lesions from dysplastic epithelial proliferations, which require more aggressive treatment.
UNCOMMON PAPILLARY AND VERRUCOUS ORAL LESIONS Among the uncommon papillary and veruccous lesions that occur in the oral cavity are warty dyskeratoma (focal acantholytic dyskeratosis), focal epithelial hyperplasia (Heck's disease), acanthosis nigricans, and focal dermal hypoplasia (Gorlin-Goltz syndrome).

Submucosal Nodules

SOLITARY NODULES
Parulis Found at the distal opening of an intraoral sinus tract, a parulis is a mass of inflamed granulation tissue related to an abscess associated with the root of a tooth. The parulis is asymptomatic, as the abscess has already drained. Diagnosis involves dental radiographs and identification of the tooth involved. Treatment involves endodontic therapy, dental-alveolar surgery, or extraction of the tooth.
Irritation fibroma A tumor-like lesion, an irritation fibroma contains dense fibrous connective tissue with a surface of intact stratified squamous epithelium. Most fibromas are sessile lesions, but pedunculated fibromas also occur. Chronic irritation of the fibroma may result in a thicker keratin surface, and acute trauma may result in surface ulceration. This type of fibroma is not a true tumor, but rather a reactive lesion resulting from local irritation or trauma. Diagnosis requires tissue biopsy. Treatment involves conservative surgical excision, and irritation fibromas generally do not recur.
Giant cell fibroma Another fibrous lesion, the giant cell fibroma, can occur on any oral mucosal surface with distinct histopathologic features: well-vascularized fibrous connective tissue covered by stratified squamous epithelium. In the superficial connective tissue, there are numerous large, stellate-shaped, and multinucleated fibroblasts. The giant cell fibroma may be sessile or pedunculated, and the surface may appear nodular; it is asymptomatic. There is no known etiology. Diagnosis requires tissue biopsy, treatment involves conservative surgical excision, and lesions generally do not recur.
Pyogenic granuloma Characteristic of this commonly occurring lesion is a proliferation of granulation tissue infiltrated by neutrophils, lymphocytes, and plasma cells. There is no known cause. The lesion appears as an ulcerated and pedunculated mass, most often on the gingiva. It is more common in children and young adults than in older adults. Diagnosis requires tissue biopsy, and treatment involves conservative surgical excision. If not treated, fibrosis may occur, resulting in an oral mucosal fibroma. The term *pyogenic granuloma* is a misnomer, because the lesion is neither pyogenic nor a granuloma. Pyogenic granulomas that develop on the gingiva in pregnant women are often called *pregnancy tumors*. These may resolve, decrease in size, or undergo fibrosis after pregnancy.
Peripheral giant cell lesion (granuloma) Occurring only on the gingiva or edentulous alveolar ridge, the peripheral giant cell lesion (peripheral giant cell granuloma) contains multinucleated giant cells, extravasated red blood cells, hemosiderin, and inflammatory cells, with osteoid and bone formation. The peripheral giant cell lesion is thought to be a reactive lesion, not a true tumor. Diagnosis requires tissue biopsy, and treatment involves conservative surgical excision. Recurrence of these lesions has been reported. A lesion exhibiting the same histologic appearance also occurs within the bone of the maxilla and mandible. In this location, it is called a central giant cell lesion or central giant cell granuloma. In addition, the “brown tumor” of hyperparathyroidism is histologically indistinguishable from the central giant cell lesion.
Peripheral ossifying fibroma Only the gingiva is affected by a peripheral ossifying fibroma. It is composed of a cellular, fibrous proliferation with formation of calcified material that consists of osteoid and bone trabeculae, rounded cementoid calcifications, or dystrophic calcifications. The peripheral ossifying fibroma is a reactive lesion, most commonly occurring in teenagers and young adults, that presents as an ulcerated, sessile or pedunculated gingival mass. Diagnosis requires tissue biopsy, treatment involves conservative surgical excision, and the condition may recur.
Lipoma A benign tumor of fat, a lipoma occasionally develops in the oral cavity. A well-circumscribed mass of mature fat cells, sometimes in a lobular arrangement, makes up the lipoma. Microscopic variants of oral lipomas include fibrolipoma, angiolipoma, myxoid lipoma, spindle cell lipoma, and pleomorphic lipoma. Oral lipomas present as soft, yellowish-pink nodules that can occur on any oral mucosal surface. Diagnosis requires tissue biopsy, treatment involves conservative surgical excision, and recurrences are rare.
Neurogenic lesions Benign neurogenic lesions occur in the oral cavity, although all are uncommon (see Chap. 107). Oral neurogenic lesions require tissue biopsy for diagnosis, and treatment involves conservative surgical excision. There are several types:

- A traumatic neuroma is a reactive proliferation of nerve tissue that develops when the proximal portion of a peripheral nerve attempts to regenerate after it has been damaged. Such neuromas appear as nonulcerated nodules, most commonly in the mental foramen area, that are occasionally painful.
- The neurofibroma is an asymptomatic mass, most commonly located on the tongue or buccal mucosa, that exhibits a well-delineated diffuse proliferation of spindle-shaped Schwann cells. Malignant transformation of a solitary neurofibroma has been reported.
- The neurilemoma (Schwannoma) is another benign tumor of Schwann cell origin that presents as a slow-growing, occasionally painful mass.
- The granular cell tumor is a benign mesenchymal tumor also of Schwann cell origin, that infiltrates regional striated muscle. It presents as an asymptomatic, sessile mass most commonly located on the dorsal tongue.

MULTIPLE NODULES Several different oral mucosal conditions can produce multiple submucosal nodules. For example, multiple neurofibromas or neurolemomas are evident in neurofibromatosis. Multiple mucosal neuromas are a common component of multiple endocrine neoplasia, type III. Multiple oral mucosal fibroepithelial nodules occur in multiple

hamartoma syndrome (Cowden's disease). Finally, primary and secondary amyloidosis may present as multiple oral mucosal nodules.

Salivary Gland Diseases

BENIGN SALIVARY GLAND DISEASES Common problems affecting salivary glandular tissue result from the obstruction of salivary secretions from either fluid-producing acinar cells or ductal cells. The most common lesion is a mucocele, occurring on the lower lip or floor of the mouth (Fig. 112-23). It is a smooth-surfaced, exophytic, fluid-containing recurrent lesion, which is caused by a traumatic rupture of the minor salivary gland duct. Long-term fibrosis can develop if chronic draining and refilling occurs.

FIGURE 112-23 Mucocele: a smooth-surfaced, exophytic, fluid-containing, recurrent lesion caused by a traumatic rupture of the minor salivary gland duct.

Lesions affecting the main excretory duct of the submandibular or sublingual gland are called ranulas. Usually larger than mucoceles, ranulas produce a fluctuant mass covered by translucent mucosa, causing an elevation of the tongue. Diagnosis and treatment of a minor gland mucocele requires complete excision. Complete excision is also necessary in the treatment of a ranula, and the required excision may also involve the submandibular or sublingual gland. Glandular obstructions can also result from the formation of mucous plugs or sialoliths (salivary gland stones). The cause is a reduced salivary output (see Fig. 112-14), which may be due to numerous medications (e.g., antihypertensives, antipsychotics, anticholinergics), dehydration, head and neck radiotherapy, or certain medical disorders (e.g., Sjögren's syndrome, diabetes). Signs and symptoms include painful swellings of the major salivary gland regions, and palpation of the glands produces either viscous or no salivary secretions. Excision of swellings may be necessary to restore salivary gland function if stimulation is not successful and to exclude the possibility of a glandular neoplasm.
SALIVARY GLAND NEOPLASMS Fewer than 10 percent of all oral malignancies are salivary gland neoplasms, but they can affect all major and minor glands located in the palate, labial and buccal mucosa, retromolar areas, floor of the mouth, and the base of the tongue. [16], [34] Common findings are a swelling, with or without pain, with surface morphology ranging from smooth to ulcerated. Pleomorphic adenomas, adenoid cystic carcinomas, and polymorphous low-grade adenocarcinomas affect minor as well as major glands, whereas acinic cell carcinomas and mucoepidermoid carcinomas affect major glands. Pleomorphic adenomas are the most common benign salivary gland neoplasm; they grow slowly and respond well to conservative excision. Mucoepidermoid carcinomas are the most common malignant tumors of salivary glands and frequently require aggressive therapies, including excision of tumors and surrounding lymph nodes and postoperative external beam radiotherapy. Adenoid cystic carcinomas are aggressive tumors that invade the perineural areas. Diagnosis of all salivary gland tumors requires tissue biopsy. If a neoplasm is suspected, then incisional/excisional biopsy with a margin of uninvolved tissue is the preferred diagnostic procedure. However, highly suspicious tumors warrant referral to an oncologic surgeon who will eventually participate in the definitive care of the patient.

Ulcerative, Vesicular, and Bullous Oral Lesions

Ulcerative and vesiculobullous lesions of the oral mucosa can be subdivided into four groups: (1) traumatic, (2) immune-mediated, (3) infectious, and (4) neoplastic. In general, treatment starts with removal of any possible source of trauma (e.g., sharp teeth or restorations), particularly in a patient with diminished salivary flow or with an oral movement disorder, and/or pharmacologic therapy based on the clinical appearance of the lesion. If no resolution occurs within 2 to 3 weeks, then reevaluation with consideration of tissue biopsy for histopathologic diagnosis is necessary.

RECURRENT APHTHOUS STOMATITIS The most common immune-mediated oral ulcerative condition is recurrent aphthous stomatitis (RAS). There are three types of RAS (minor, major, and herpetiform) that all produce acute, painful, and recurring ulcers, usually involving nonkeratinized oral mucosa. [35], [36] Minor RAS (canker sores) have a high prevalence in healthy adults (5 to 25 percent) and manifest as one or more small shallow ulcers (5 to 10 mm in diameter) with a necrotic gray center and an erythematous halo (Fig. 112-24 and Fig. 112-25). The ulcer lasts 7 to 10 days, with recurrences averaging two to three times a year. Not only are major RAS ulcers less common, but also they are larger (>10 mm in diameter), penetrate deeper, can last up to 6 weeks, and often scar after healing (Fig. 112-26). Herpetiform RAS ulcers (unrelated to herpes infection) are the least common, characterized by multiple small painful ulcers (1 to 3 mm in diameter) on nonkeratinized oral mucosa; they coalesce to produce large irregular ulcers.

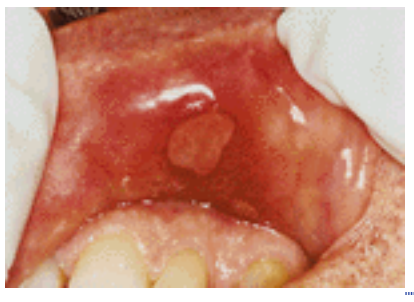

FIGURE 112-24 A minor recurrent aphthous stomatitis lesion on the inner aspect of the lower lip. This well-circumscribed lesion has a characteristic erythematous halo with a gray pseudomembranous and necrotic center.

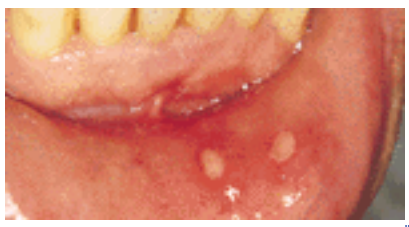

FIGURE 112-25 Minor aphthous stomatitis ulcers of the labial mucosa and vestibule. A pair of aphthae, each exhibiting a well-circumscribed, flat, erythematous border, surround an ulcer with a fibrin-covered base.

FIGURE 112-26 Major aphthous stomatitis ulcer of the lateral border of the tongue.

The etiology of RAS includes heredity, allergy to certain foods or drugs, hematologic and immunologic disorders, emotional stress, and tissue trauma. In addition, RAS is an oral manifestation of several systemic diseases, such as HIV infection; Behçet's syndrome; Reiter's syndrome; Crohn's disease; cyclic neutropenia; nutritional and hematinic deficiencies; gluten-sensitive enteropathy; and periodic fever, aphthous stomatitis, pharyngitis, and adenitis (FAPA). History and clinical appearance form the basis for diagnosis. In patients with frequently occurring outbreaks, systemic diseases should be ruled out. Treatment is supportive for minor RAS, and the topical or intralesional administration of glucocorticoids is beneficial for major RAS, as well as for frequently recurring and painful minor RAS [37] (see Table 112-2). Ulcers refractory to topical medications may require the use of systemic glucocorticoids and immunosuppressants. Second-line systemic therapy includes dapsone, thalidomide (particularly in HIV-associated aphthous), colchicine, and pentoxyfylline.

ERYTHEMA MULTIFORME An acute immune-mediated ulcerative mucocutaneous disease, erythema multiforme commonly affects healthy young adults (see Chap. 58). The cause is often unestablished, although there is an association with emotional stress, infections (herpes simplex and *Mycoplasma*), and medications (especially antibiotics and antiepileptics). Erythema multiforme may involve only lip and oral mucosal sites, or it may affect multiple sites on the skin and other mucous membranes (i.e., Stevens-Johnson syndrome). The oral presentation depends on the severity of the disorder; it may range from lip swelling and erythematous, target-like erosions to widespread ulcerations with bleeding and crusting. Lesions are usually painful, causing difficulty with chewing and swallowing. They will resolve within 14 days. Chronic erythema multiforme is rare, but recurrence is possible. The most severe forms of erythema multiforme (i.e., Stevens-Johnson syndrome and toxic epidermal necrolysis) can be fatal. Treatment is palliative with topical anesthetics and analgesics, yet may require hospitalization in severely dehydrated and nutritionally depleted patients. Severe forms of erythema multiforme require the systemic administration of glucocorticoids and other immunosuppressants.

CICATRICIAL PEMPHIGOID Another chronic immune-mediated ulcerative condition is cicatricial pemphigoid (see Chap. 62). This disorder has a predilection for females in the sixth decade and results in the deposition of autoimmune complexes, leading to subepithelial separation, bulla formation, desquamation of the epithelium, and significant discomfort. [38] Oral lesions involve gingival tissues (referred to as desquamative gingivitis), and the tongue, palate, buccal mucosa, and oropharynx (Fig. 112-27). Ocular involvement warrants an ophthalmologic evaluation, because mucosal scarring can lead to blindness. Diagnosis is predicated on tissue biopsy for histopathologic study (characteristic appearance of subepithelial separation) and examination by direct immunofluorescence (IgG and C3 deposition at the basement membrane).

FIGURE 112-27 Cicatricial pemphigoid lesions on the maxillary and mandibular attached gingival. The erythemic and fragile mucosa on the gingival tissues (desquamative gingivitis) was tender and bled easily.

Treatment of cicatricial pemphigoid depends on the severity and location of the involvement. Improved oral hygiene and the use of high-potency topical glucocorticoids are indicated for mild disease (see Table 112-2), while the systemic administration of glucocorticoids, with or without steroid-sparing drugs (e.g., azathioprine and cyclophosphamide), dapsone, sulfonamides, and tetracyclines, have been shown to be effective for more extensive disease.

PEMPHIGUS VULGARIS The presentation of pemphigus vulgaris is similar to that of cicatricial pemphigoid (see Chap. 59). [39] It affects male and female adults in the fifth to seventh decades, particularly Ashkenazi Jews. The oral mucosa, where it appears as shallow irregular ulcerations of gingival and buccal mucosal tissues (Fig. 112-28), is the first site of involvement in the majority of cases. Disease progression leads to involvement of skin and other mucosal sites. Untreated, pemphigus vulgaris can lead to high rates of morbidity and mortality. The basis for diagnosis is tissue biopsy for histopathologic study (finding of acantholysis) and direct immunofluorescence examination (finding of intraepithelial spider-web deposition of IgG and C3).

FIGURE 112-28 Pemphigus vulgaris lesions on the maxillary and mandibular gingival and labial vestibular tissues. Multiple eroded areas are visible on both masticatory and lining mucosa.

Topical glucocorticoids are helpful for limited oral lesions. Disseminated pemphigus vulgaris requires the systemic administration of glucocorticoids, often in conjunction with steroid-sparing drugs (e.g., azathioprine, cyclophosphamide), and other immunosuppressants (e.g., mycophenolate mofetil).

HERPES SIMPLEX VIRUS INFECTIONS The most common viral infection producing oral ulcerations is the herpes simplex viral (HSV) infection (see Chap. 214). [40] Primary HSV infection occurs frequently as a subclinical infection during childhood, resulting in a lifelong latent condition. However, some patients develop acute primary herpetic gingivostomatitis, with fever, malaise, lymphadenopathy, and generalized painful ulcers of gingival and oral mucosal tissues (Fig. 112-29). The signs and symptoms establish the diagnosis.

FIGURE 112-29 Primary herpetic gingivostomatitis.

Reactivation of the HSV occurs in patients of all ages and follows triggering events (e.g., stress, tissue trauma, sunlight) and/or immunosuppression. The most common recurrence manifests as herpes labialis (known as a cold sore): several painful vesicles form on the lip, coalesce, and then produce a crusted scab in 5 to 7 days (Fig. 112-30). Intraoral recurrent HSV infection produces a painful focal eruption of vesicles on keratinized tissues (e.g., hard palate, gingivae) that coalesce into a poorly defined ulceration.

FIGURE 112-30 Recurrent herpes labialis of the lower lip. Small fluid-filled vesicles are early characteristics of the condition; they will coalesce and form a scab within 7 days.

In the immunocompetent patient, treatment is palliative. The topical use of antiviral medications (e.g., penciclovir, acyclovir) produces limited relief, and the systemic administration of antivirals (e.g., acyclovir, valacyclovir) provides prophylactic benefit to patients who experience frequent recurrences. In immunocompromised patients, HSV infections can produce extensive and long-lasting oral ulcerations that lead to significant morbidity. [30] Diagnosis is by viral culture, and treatment requires high doses of antiviral drugs.

VARICELLA ZOSTER VIRUS INFECTIONS The primary infection of varicella zoster virus is chicken pox, which causes oral ulcers in children (see Chap. 215). The secondary infection, herpes zoster (shingles), represents a reactivation of the varicella zoster virus and frequently involves the trigeminal nerve in adults. Involvement of the maxillary branch of the trigeminal nerve manifests intraorally as unilateral palatal ulcerations. The signs and symptoms indicate the diagnosis, and a smear or viral culture confirms it. Early treatment with the systemic administration of high-dose antivirals (e.g., famciclovir, valacyclovir) minimizes the risk for developing postherpetic neuralgia. [41] Other viral infections that can cause oral ulcerations include cytomegalovirus, measles, and coxsackievirus (causing herpangina and hand, foot, and mouth disease).

BACTERIAL AND DEEP FUNGAL INFECTIONS Rarely do the bacterial and deep fungal infections that cause oral ulceration occur in the immunocompetent patient, with the exception of the sexually transmitted bacterial diseases. [42] Syphilis produces oral mucosal ulcers as the primary chancre, but most often as the secondary mucous patch (Fig. 112-31) or the tertiary gumma. Gonorrhea has a greater predilection for the nasopharynx than for the oral cavity. Tuberculosis has also been reported to occur in the mouth. Deep fungal infections (e.g., histoplasmosis, cryptococcosis) are seen almost exclusively in the immunocompromised patient. [43]

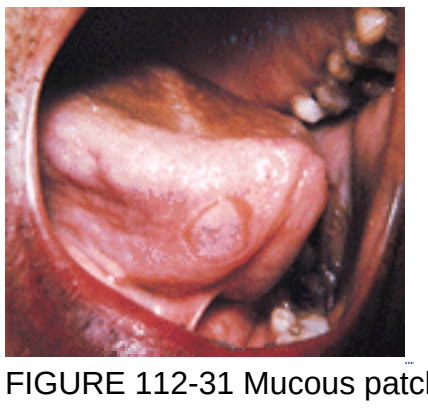

FIGURE 112-31 Mucous patch of the anterior-lateral border of the tongue. It may be the only sign of secondary syphilis.

This patch is a large painless erosion simulating an aphthous lesion.

OTHERS Neoplastic diseases, such as oral squamous cell carcinoma (see above), and oral lymphomas can present as ulcers in the oral cavity.

REFERENCES

1. Greenberg M, Glick M: *Burket's Oral Medicine: Diagnosis and Treatment,* 10th ed. Hamilton, Ontario, Canada; BC Decker, 2003

2. Neville BW et al: *Oral and Maxillofacial Pathology*. Philadelphia, WB Saunders, 1995

3. Regezi JA, Sciubba JJ: *Oral Pathology: Clinical Pathological Correlations*. Philadelphia, WB Saunders, 1999

4. Silverman S Jr et al: *Essentials of Oral Medicine,* 1st ed. Hamilton, Ontario, Canada, BC Decker, 2001

5. Scully C, Porter S: ABC of oral health: Swellings and red, white, and pigmented lesions. *BM J* **321**:225, 2000

6. Hoffmann D, Djordjevic MV: Chemical composition and carcinogenicity of smokeless tobacco. *Adv Dent Res* **11**:322, 1997

7. Johnson GK et al: Development of smokeless tobacco-induced oral mucosal lesions. *J Oral Pathol Med* **27**:388, 1998

8. Zain RB et al: Oral mucosal lesions associated with betel quid, areca nut and tobacco chewing habits: Consensus from a workshop held in Kuala Lumpur, Malaysia, November 25–27, 1996. *J Oral Pathol Med* **28**:1, 1999

9. Silverman SJ: *Oral Cancer,* 4th ed. Hamilton, Ontario, Canada, The American Cancer Society, 1998

10. Ship JA et al: Evaluation and management of oral cancer. *Home Health Care Consult* **6**:2, 1999

11. Axell T et al: Oral white lesions with special reference to precancerous and tobacco-related lesions: Conclusions of an international symposium held in Uppsala, Sweden, May 18–21, 1994. International Collaborative Group on Oral White Lesions. *J Oral Pathol Med* **25**:49, 1996

12. Golden DP, Hooley JR: Oral mucosal biopsy procedures: Excisional and incisional. *Dent Clin North Am* **38**:279, 1994

13. Sciubba JJ: Improving detection of precancerous and cancerous oral lesions: Computer-assisted analysis of the oral brush biopsy. U.S. Collaborative Oral CDx Study Group. *J Am Dent Assoc* **130**:1445, 1999

14. Epstein JB et al: The utility of toluidine blue application as a diagnostic aid in patients previously treated for upper oropharyngeal carcinoma. *Oral Surg Oral Med Oral Pathol Oral Radiol Endod* **83**:537, 1997

15. Anderson WF et al: Secondary chemoprevention of upper aerodigestive tract tumors. *Semin Oncol* **28**:106, 2001

16. Million RR, Cassisi NJ: *Management of Head and Neck Cancer,* 2nd ed. Philadelphia, JB Lippincott, 1994

17. Reichart PA et al: Pathology and clinical correlates in oral candidiasis and its variants: A review. *Oral Diseases* **6**:85, 2000

18. Farah CS et al: Oral candidosis. *Clin Dermatol* **18**:553, 2000

19. Meis JF, Verweij PE: Current management of fungal infections. *Drugs* **61**(suppl 1):13, 2001

20. Scully C, Epstein JB. Oral health care for the cancer patient. *Oral Oncol* **32B**:281, 1996

21. Plevova P: Prevention and treatment of chemotherapy- and radiotherapy-induced oral mucositis: A review. *Oral Oncol* **35**:453, 1999

22. Sugerman PB et al: Oral lichen planus. *Clin Dermatol* **18**:533, 2000

23. Silverman S Jr: Oral lichen planus: A potentially premalignant lesion. *J Oral Maxillofac Surg* **58**:1286, 2000

24. Eisen D: The therapy of oral lichen planus. *Crit Rev Oral Biol Med* **4**:141, 1993

25. McCreary CE, McCartan BE: Clinical management of oral lichen planus. *Br J Oral Maxillofac Surg* **37**:338, 1999

26. Batsakis J et al: The pathology of head and neck tumors: Mucosal melanomas. *Head Neck Surg* **4**:404, 1982

27. Buchner A, Hansen L: Melanotic macule of the oral mucosa: A clinical pathologic study of 105 cases. *Oral Surg Oral Med Oral Pathol* **48**:244, 1979

28. Buchner A, Hansen L; Pigmented nevi of the oral mucosa: A clinical pathologic study of 36 new cases and review of 155 cases from the literature. Part II: Analysis of 191 cases. *Oral Surg Oral Med Oral Pathol* **63**:676, 1987

29. Ficarra G et al: Kaposi's sarcoma of the oral cavity: A study of 134 patients and a review of the pathogenesis, epidemiology, clinical aspects, and treatment. *Oral Surg Oral Med Oral Pathol* **66**:543, 1988

30. Patton LL, van der Horst C: Oral infections and other manifestations of HIV disease. *Infect Dis Clin North Am* **13**:879, 1999

31. Patton LL, Ship JA: Treatment of patients with bleeding disorders. *Dent Clin North Ar* **38**:465, 1994

32. Meraw SJ, Sheridan PJ: Medically induced gingival hyperplasia. *Mayo Clin Proc* **73**:1196, 1998

33. Ship JA, Crow HC: Diseases of periodontal tissues in the elderly: Description, epidemiology, aetiology, and drug therapy. *Drugs Aging* **5**:346, 1994

34. Lopes MA et al: A clinicopathologic study of 196 intraoral minor salivary gland tumours. *J Oral Pathol Med* **28**:264, 1999

35. Porter SR et al: Recurrent aphthous stomatitis. *Clin Dermatol* **18**:569, 2000

36. Ship JA et al: Recurrent aphthous stomatitis. *Quintessence Int* **31**:95, 2000

37. Ship JA, Mohammad AR: *Clinician's Guide to Oral Health in Geriatric Patients,* 1st ed. Baltimore, American Academy of Oral Medicine, 1999

38. Scully C et al: Update on mucous membrane pemphigoid: A heterogeneous immune-mediated subepithelial blistering entity. *Oral Surg Oral Med Oral Pathol Oral Radiol Endod* **88**:56, 1999

39. Sirois D et al: Oral pemphigus vulgaris preceding cutaneous lesions: Recognition and diagnosis. *J Am Dent Assoc* **131**:1156, 2000

40. Birek C. Herpesvirus-induced diseases: Oral manifestations and current treatment options. *J Calif Dent Assoc* **28**:911, 2000

41. Johnson R. Herpes zoster—Predicting and minimizing the impact of post-herpetic neuralgia. *J Antimicrob Chemother* **47**(suppl T1):1, 2001

42. Siegel MA. Syphilis and gonorrhea. *Dent Clin North Am* **40**:369, 1996

43. Scully C et al: The deep mycoses in HIV infection. *Oral Diseases* **3**(suppl 1): S200, 1997

T>

Chapter 113

Richard Johnson

Diseases and Disorders of the Male Genitalia

DISEASES AND DISORDERS OF THE PENIS AND SCROTUM RELATING TO ITS SPECIALIZED ANATOMY AND FUNCTION
BALANITIS AND BALANOPOSTHITIS
BALANITIS XEROTICA OBLITERANS (BXO)
PEARLY PENILE PAPULES (PPPs)
PLASMA CELL BALANITIS (BALANITIS CIRCUMSCRIPTA PLASMACELLULARIS OR ZOON'S BALANITIS)
LICHEN SCLEROSUS (LS)
PSEUDOEPITHELIOMATOUS, KERATOTIC, AND MICACEOUS BALANITIS (PEKMB)
PEYRONIE'S DISEASE (PENILE FIBROMATOSIS)
CUTANEOUS DISORDERS INVOLVING THE MALE GENITALIA
PSORIASIS VULGARIS
Epithelial Precancerous and Cancerous Lesions of the Penis and Scrotum
Benign Epithelial and Appendegeal Tumors
Disorders of Melanocytes: Disorders of Pigmentation
Disorders of Melanocytes: Benign Neoplasias, Hyperplasias, and Dysplasias of Melanocytes
Epidermal-Dermal Inflammatory Conditions of Unknown Etiology
Neoplasms, Pseudoneoplasms, Hyperplasias, and Mucinoses of Supporting Tissue Origin
Vascular Neoplasms, Pseudoneoplasms, and Hyperplasias
Eczematous Dermatitis
Photomedicine
ADVERSE CUTANEOUS DRUG REACTIONS (ACDRs)
FIXED DRUG ERUPTIONS (FDEs)
GLUCOCORTICOID-INDUCED ATROPHY
TOPICAL 5-FLUOROURACIL
INTRAVENOUS DRUG USE
ORAL RETINOIDS
SYSTEMIC DISEASES INVOLVING THE MALE GENITALIA
LEUKEMIA CUTIS
CUTANEOUS CHANGES IN PERIPHERAL VASCULAR DISEASE
LYMPHATIC DISORDERS
SCROTAL AND/OR PENILE EDEMA
SYSTEMIC VASCULITIS
REITER'S SYNDROME
SARCOIDOSIS
GLUCAGONOMA SYNDROME
METASTATIC CANCER TO THE PENIS/SCROTUM
BEHCET'S SYNDROME
INFECTIOUS DISEASES OF MALE GENITALIA
Bacterial Diseases
Fungal Diseases
Viral Diseases
Sexually Transmitted Diseases
Infestations
Bites and Stings
DISEASES AND DISORDERS OF THE PERINEUM AND ANUS
PRURITUS ANI
PSORIASIS VULGARIS
HIDRADENITIS SUPPURATIVA
PILONIDAL CYSTS AND SINUSES
PERIANAL STREPTOCOCCAL CELLULITIS (PSC)

REFERENCES

The male genital skin is markedly varied in its anatomy, microecology, and physiology. Anatomically, the glans penis and inner surface of the prepuce (i.e., the preputial sac) are covered with nonkeratinized epithelium. This sac is continually moist and may accumulate smegma, the product of mucosal turnover and adnexal gland secretion, unless daily hygiene is performed. Smegma provides an excellent growth substrate for various infectious agents that are capable of causing balanoposthitis. Amputation of the prepuce, i.e., circumcision, eliminates the preputial sac and thus prevents many types of acute and chronic balanoposthitis and reduces the risk for many sexually transmitted infections (STDs), [1] as well as penile squamous cell carcinoma (SCC). [2]

DISEASES AND DISORDERS OF THE PENIS AND SCROTUM RELATING TO ITS SPECIALIZED ANATOMY AND FUNCTION

BALANITIS AND BALANOPOSTHITIS

Balanitis is an inflammatory condition of the glans penis; posthitis is an inflammation of the foreskin; and balanoposthitis is an inflammation of the contiguous and opposing mucosa of the glans penis and prepuce. Balanoposthitis does not occur in an adequately circumcised male. In young males, the incidence of balanoposthitis is highest in those 2 to 5

years of age, in whom the foreskin is either partly or completely nonretractable; characteristic findings include erythema, swelling, discharge, dysuria, bleeding, and ulceration of the glans. In most cases, no single infectious agent is the cause; bacterial cultures of the exudate in the space commonly produce a mixed growth, but, at times, *Staphylococcus aureus* and group A (GAS) or group B ß-hemolytic *Streptococcus* (GBS) can be recovered alone. At times, perianal streptococcal cellulitis, cause by GAS, can be accompanied by acute balanoposthitis.

In adult uncircumcised males, balanoposthitis most commonly occurs as an intertrigo, with no specific etiologic agent identifiable. Diabetes mellitus with glucosuria is a common predisposing disease. Sexually transmissible agents that can cause balanoposthitis include *Candida albicans,* GBS, gonococcus, *Gardnerella vaginalis,* and *Trichomonas vaginalis*. Clinical findings include “rash,” itching, burning sensation, erythema, erosion/ulceration, pseudomembrane, and/or subpreputial exudate. Invasive infection can complicate balanoposthitis (penile cellulitis), especially in the immune-compromised host. The differential diagnosis of balanoposthitis includes trauma, allergic or irritant contact dermatitis, psoriasis (inverse pattern), plasma cell balanitis, balanitis circinata (Reiter's syndrome), fixed drug eruption, squamous cell carcinoma in situ, and extramammary Paget's disease.

Management of acute balanoposthitis is based on elimination of any predisposing factors in the pathogenesis, identification of a specific etiologic agent, and retraction of the foreskin, if possible, to eliminate the preputial sac, allowing the opposing epithelial surfaces to dry out. Castellani's paint applied daily is effective in acute symptomatic cases. In some cases of recurrent balanoposthitis, the sexual partner also must be treated to prevent recolonization of the specific infectious agent; circumcision is indicated in some cases, especially if phimosis exists.

BALANITIS XEROTICA OBLITERANS (BXO)

This is the end stage of some cases of chronic balanoposthitis. [3] The most common disorder associated with BXO is lichen sclerosus (LS); however, BXO also occurs in males with chronic nonspecific balanoposthitis. The onset and evolution of BXO is insidious, evolving over many years. Patients usually seek medical consultation because of a reduced urinary stream or an acute, painful exacerbation of balanoposthitis with resulting phimosis or paraphimosis. Clinically, the prepuce is thickened, contracted, fissured, and fixed over the glans and cannot be retracted even with moderate tension, i.e., phimosis (Fig. 113-1). Patients with LS may have associated urethral narrowing and stricture. BXO may respond to potent topical corticosteroids. [4] Circumcision is curative in patients with phimosis secondary to chronic balanoposthitis. Invasive SCC has been reported to arise in LS with long-standing BXO.

FIGURE 113-1 Balanitis xerotica obliterans with phimosis. The prepuce is fixed, covering the glans, and cannot be retracted.

PEARLY PENILE PAPULES (PPPs)

These are common, normal anatomic structures located on the proximal glans penis. The papules are asymptomatic but often arouse some anxiety when first noticed by patient or physician. Clinically, PPPs appear as skin-colored 1- to 2-mm, discrete, domed papules evenly distributed circumferentially around the corona and extending proximally on each side of the frenulum (Fig. 113-2). Histologically, the lesions are angiofibromas with dense connective tissue and a rich vascular complex. No treatment other than reassurance is indicated.

FIGURE 113-2 Pearly penile papules. Pink (skin-colored), 1- to 2-mm papules are seen regularly spaced along the corona of the glans penis. These structures, which are part of the normal anatomy of the glans, are commonly mistaken for condylomata or molluscum contagiosum.

PLASMA CELL BALANITIS (BALANITIS CIRCUMSCRIPTA PLASMACELLULARIS OR ZOON'S BALANITIS)

This presents as a solitary, persistent plaque on the glans of uncircumcised, middle-aged to older men. The etiology and pathogenesis are unknown. The duration of the lesion prior to presentation ranges from several months to a decade or more. The clinical presentation is usually an erythematous, shiny, moist, and glistening macular to slightly raised plaque(s) (Fig. 113-3) on the glans penis. At times, the coronal sulcus and the inner surface of the prepuce may be involved. The color of the lesion is usually bright red, but it may be the color of cayenne pepper due to microhemorrhage and hemosiderin deposition. Solitary lesions are more common, but multiple lesions may occur in some patients. Clinical variants including erosive and vegetative types have been reported. The differential diagnosis includes psoriasis, eczema, lichen simplex chronicus, lichen planus, lichen sclerosus, SCC, balanitis circinata, fixed drug eruption, HPV infections (external genital warts, SCC in situ or invasive), and extramammary Paget's disease. Histologic features include a thinned epidermis showing “lozenge” keratinocytes (i.e., diamond-shaped acanthocytes), an occasional dyskeratotic keratinocyte, and mild spongiosis. Dermal findings include a dense bandlike or lichenoid mixed infiltrate with a predominance of plasma cells and vascular proliferation. There is poor response to all local modalities of therapy [5]; circumcision is curative.

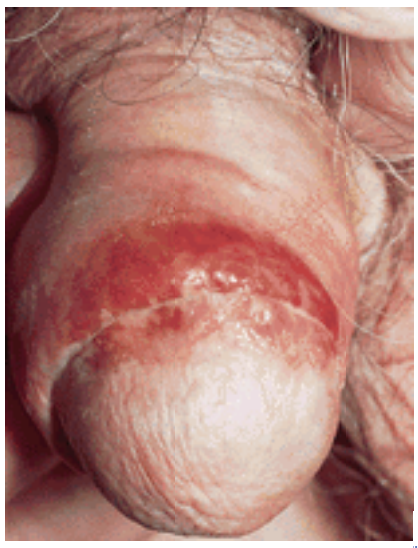

FIGURE 113-3 Plasma cell (Zoon's) balanitis. A single red, glistening plaque is seen on the glans penis, extending onto the adjacent prepuce.

LICHEN SCLEROSUS (LS)

This is a chronic idiopathic dermatosis characterized by white papules or plaques occurring most commonly on the anogenital skin. Penile LS is diagnosed most commonly in middle age. Penile LS is often asymptomatic; some men are aware of subtle visual changes occurring over months to years. Symptomatic individuals report itching, burning with urination, painful erections, diminished sensation of the glans, or diminution in the caliber and force of the urinary stream. In uncircumcised males, a sclerotic, constricting band forms 1 to 2 cm from the distal end of the prepuce; in time, phimosis may occur. Obstruction of urinary flow may occur if the urethral orifice is involved or if phimosis becomes severe. BXO occurs if the sclerotic process progresses untreated.

Clinically, ivory- or porcelain-white macules and plaques (Fig. 113-4) are noted in all patients; the anemic color is caused by a loss of dermal vasculature with or without depigmentation. The surface of lesions is usually smooth but in some patients may be hyperkeratotic and may be elevated above or in the same plane as normal skin.

FIGURE 113-4 Lichen sclerosus, chronic. A white sclerotic plaque is seen on the glans and prepuce.

Hemorrhage may occur beneath the surface of macules and plaques, resulting in ecchymotic sites or hemorrhagic bullae within the lesions. The epidermis of atrophic lesions may sheer off, resulting in eroded or ulcerated loci within the lesions. LS occurs most commonly on the glans and inner aspect of the prepuce; in some individuals, it may occur circumferentially around the urethral meatus, resulting in varying degrees of stricture and obstruction of urinary flow. BXO

is usually associated with phimosis and paraphimosis (once retracted, the prepuce cannot be replaced over the glans). A rare complication of LS and/or BXO is the development of SCC of the penis arising in involved sites. [6] The differential diagnosis of LS includes vitiligo, postinflammatory hypopigmentation, and posttraumatic or surgical scar. Clobetasol ointment has proven very effective for treatment of early disease. [7] Circumcision is helpful in LS-induced phimosis. [8] Patients should be monitored on a regular basis; focal persistent hyperkeratotic or ulcerated sites within the involved sites should be biopsied to rule out evolution to SCC.

PSEUDOEPITHELIOMATOUS, KERATOTIC, AND MICACEOUS BALANITIS (PEKMB)

This is a rare, idiopathic, papulosquamous dermatosis occurring on the glans penis that may represent a premalignancy or low-grade SCC. PEKMB is usually asymptomatic but may be associated with pain during intercourse. Clinically, a solitary, well-demarcated, laminated (micaceous) hyperkeratotic plaque is seen on the circumcised glans penis; the surface is thick, often resembling a sheet of mica from which thin folia can be peeled. Invasive SCC should be considered in nodular lesions arising within the plaque, whether hyperkeratotic or erosive.

PEYRONIE'S DISEASE (PENILE FIBROMATOSIS)

This is an idiopathic disorder of the penis that leads to distortion or angulation of the erect penis. Onset is usually in middle age. Dupuytren's contracture of the hand and plantar fibromatosis may present concurrently. Symptomatically, erection may be associated with pain, especially in the early stages of the disease, caused by fibrosis of the tunica albuginea, the covering sheaths of the corpora cavernosa. The inflammatory plaque begins in the dorsal midline connective tissue near the base and extends to the adjacent tissue. Reduction in the normal erectile property of the dorsal penis results in an upward painful curvature when the penis is erect. Progressive fibrosis and curvature preclude coitus. Intralesional injection of corticosteroid into the fibrotic plaque may be helpful in some patients. Anti-inflammatory agents have been used, and surgical procedures have been developed.

CUTANEOUS DISORDERS INVOLVING THE MALE GENITALIA

PSORIASIS VULGARIS (See Chap. 42)

This is the most common noninfectious dermatosis occurring on the penis. In circumcised males, penile psoriasis presents most commonly as a well-demarcated erythematous plaque(s) with varying degrees of scale (Fig. 113-5), similar to psoriasis at other nonoccluded sites. In uncircumcised individuals, psoriatic plaques occur on both the glans and the inner aspect of the foreskin and lack any scale (inverse psoriasis) (Fig. 113-6). Genital psoriasis is frequently accompanied by asymptomatic, unrecognized intertriginous psoriasis, perianally and in the intergluteal cleft, which appears as an elongated, well-demarcated, erythematous plaque(s). The diagnosis usually can be made on the local clinical findings, assisted by findings of psoriasis at other sites such as the scalp or intergluteal cleft and of nail changes. In that the differential diagnosis includes human papilloma virus (HPV) infections [genital warts, squamous intraepithelial lesion (SIL), and invasive SCC], the diagnosis may be confirmed by lesional biopsy in older uncircumcised males with preputial lesions. The course of anogenital psoriasis tends to wax and wane for years and is usually minimally symptomatic. Topical corticosteroids are effective, but their use should be minimized to avoid atrophy. Newer topical agents such as vitamin D preparations (calcipotriol), tacrolimus, and pimecrolimus may be effective and appear to be safe for long-term use.

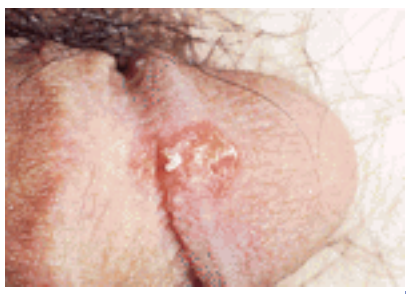

FIGURE 113-5 Psoriasis vulgaris. A scaling plaque is seen on the glans penis of this circumcised male.

FIGURE 113-6 Psoriasis vulgaris, “inverse pattern.” A well-demarcated nonscaling plaque is seen under the prepuce and on the proximal glans of this uncircumcised male.

Epithelial Precancerous and Cancerous Lesions of the Penis and Scrotum (See Chap. 79)

SQUAMOUS CELL CARCINOMA IN SITU (SCCIS) Several presentations of penile SCCIS occur. One is a solitary lesion arising on the epithelium of the glans/inner surface of the prepuce known as *erythroplasia of Queyrat* (EQ). EQ occurs in those not circumcised in infancy and with poor hygiene, i.e., associated chronic low-grade balanoposthitis. Another presentation is HPV-associated high-grade squamous intraepithelial lesions (HSIL), which usually occur as multiple lesions on the penis and may be associated with lesions at other anogenital sites. [9] In addition, SCCIS occurs in chronic inflammatory dermatoses such as lichen sclerosus, lichen planus, BXO, etc. HPV-B has been detected recently in EQ and may be a factor in oncogenesis. [10], [11] Non-EQ penile SCCIS is associated with HPV-16 and -18. Additional etiologic factors include immunocompromised patients (HIV disease, solid-organ transplantation) and PUVA therapy. Clinically, EQ presents as a well-defined, irregularly bordered, red patch with a glazed to velvety surface (Fig. 113-7); a nodule or ulcer within EQ usually represents invasive SCC arising within the SCCIS. Histologically, approximately 10 percent of EQ lesions show invasion. Effective modalities of therapy for EQ include electrosurgery, cryosurgery, laser surgery, photodynamic therapy, and topical application of 5-fluorouracil. [12], [13]

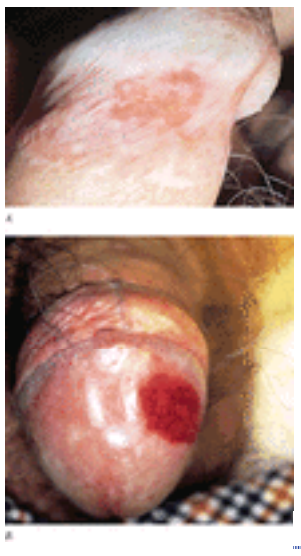

FIGURE 113-7 *A.* Squamous intraepithelial lesion (SIL) of the prepuce. Pink plaque on the prepuce. A circumcision had been performed recently because of “chronic balanitis.” Histology of the excised specimen showed high-grade SIL. The lesion cleared following topical 5-fluorouracil therapy. *B.* Squamous cell carcinoma in situ of the glans penis (erythroplasia of Queyrat). A solitary red plaque on the glans of this uncircumcised male must be differentiated from plasma cell balanitis and psoriasis. (*Courtesy of Alfred Eichmann, MD.*)

INVASIVE SCC OF THE PENIS (See Chap. 80) This is an uncommon cancer in the United States, accounting for 2 percent of all male genital cancers, having a mean age at diagnosis of 59 years. Geographically, penile SCC is 10 times greater in certain regions of Africa than in industrialized countries. Invasive penile SCC usually arises within SCCIS, i.e., EQ, HPV-induced SIL, or inflammatory dermatoses. The tumor usually presents as a warty, exophytic papule or nodule, erythematous compared with the normal color of the penis, and it usually feels indurated, often arising in an area of SCCIS (Fig. 113-8 and Fig. 113-9). Less commonly, lesions may be flat and ulcerative. The tumor arises most commonly on the glans, prepuce, or coronal sulcus. Inguinal lymphadenopathy is indicative of secondary bacterial infection of the tumor or metastatic disease.

FIGURE 113-8 Invasive squamous cell carcinoma of the penis arising in chronic lichen sclerosus. A large eroded tumor is seen arising on the prepuce.

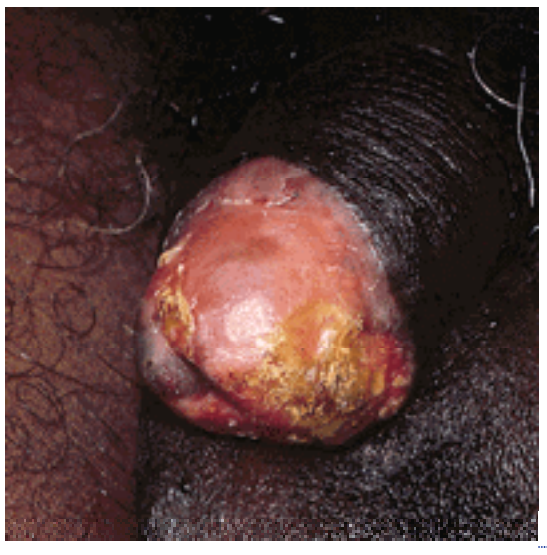

FIGURE 113-9 Invasive squamous cell carcinoma of the penis arising in pseudoepitheliomatous keratotic and micaceous balanitis of Civatte. The superior aspect of the glans shows micaceous balanitis with a large nodule inferolaterally.

SCC OF THE SCROTUM (see Chap. 80) This is much less common than SCC of the penis. Industrial carcinogens such as tar have long been implicated in the pathogenesis ("soot warts," chimney sweeps' disease); other agents include inorganic arsenic and HPV. Clinically, early scrotal SCC presents as a slowly growing, painless nodule; older, more advanced lesions tend to be indurated, ulcerated, and/or painful, in some cases with unilateral inguinal adenopathy.
GENITAL VERRUCOUS CARCINOMA (GVC) (See Chap. 80) This is a slowly growing SCC, accounting for up to 25 percent of penile cancers. Etiologic factors include HPV infection. GVC arises most frequently on the glans penis and prepuce and less often on the scrotum and perianal regions; it often presents as a large, chronic fungating tumor mass. With continuing growth, the tumor erodes exophytically through the prepuce; however, at times, it may erode inwardly into the urethra and corpora cavernosa with subsequent compression and destruction. Areas of more aggressive SCC may exist within a GVC. Because of the low-grade aggressive nature of GVC, the prognosis is usually excellent. [14], [15] However, in long-standing tumors, more aggressive behavior can develop and regional and distant lymphatic metastasis occur.
BASAL CELL CARCINOMA (BCC) OF THE PENIS AND SCROTUM (See Chap. 81) BCC, the most common malignancy in geographic regions populated by fair-skinned individuals, rarely arises in the penis or scrotum. [16] Ultraviolet radiation exposure, which is a major etiologic factor in BCC at other sites, is an uncommon factor in the pathogenesis of anogenital lesions. As with other skin cancers, BCC of the genital skin is much more common in fair-skinned than heavily melanized males. Clinically, the most common presentation of penile and scrotal BCCs is a pearly papule with surface telangiectases, but ulcerative, cicatricial, and superficial multicentric variants also occur.
EXTRAMAMMARY PAGET'S DISEASE (EMPD) This is a rare neoplasia that arises most commonly within apocrine glands present in the anogenital, anorectal, and axillary regions. [17] Rarely, it is associated with rectal or urothelium carcinoma. EMPD of the glans penis associated with a urethral or bladder carcinoma may present up to 7 years after treatment of the primary malignancy. Clinically, EMPD appears as a macular to slightly raised plaque with well-demarcated borders (Fig. 113-10) that is pink, red, to tan or brown; the surface may appear glistening red or scaly. Secondary changes of excoriations and lichen simplex chronicus from scratching may be a prominent part of the clinical appearance. A nodular area within a plaque of EMPD may represent a site of deeper invasion into the dermis. In males, the most common sites for EMPD are the perianal, scrotal, penile, and axillary regions. Perianal EMPD may extend up to the anal canal. Scrotal lesions tend to extend to the thigh or onto the shaft of the penis. A shiny red patch of EMPD occurring periurethrally on the glans penis may herald carcinoma of the urethra, periurethral gland, or bladder. Metastasis to regional inguinal or femoral lymph nodes or to distant lymph nodes may occur late in the course of the disease. The most common underlying primary carcinomas found in association with male anogenital EMPD are adenocarcinoma of the sweat glands and rectal carcinoma.

FIGURE 113-10 Extramammary Paget's disease. A large brown-pink plaque at the base of the penis and the pubic region.

Benign Epithelial and Appendegeal Tumors

The most common benign nonviral tumor of the anogenital regions is seborrheic keratosis. These lesions usually can be distinguished from external genital warts on clinical findings.

VERRUCIFORM XANTHOMA This occurs on the male genitalia as well as in the mouth. [18] Clinically, the presentation is of hyperkeratotic plaques occurring at the coronal sulcus which, if large, can cause phimosis. The pathogenesis is unknown but is thought to represent an initial epidermal irritation or degeneration followed by a dermal histiocytic response. SCC may arise within the lesion.
SCROTAL CYSTS These are a relatively common occurrence, whereas those arising on the penis are infrequent. Epidermal inclusion cysts may arise in a circumcision or other scars. Medical raphe cysts lined with epithelium of combined epidermal and urothelial origin occur on the shaft. *Sebaceous glands* occur normally on the shaft of the penis in association with hair follicles. *Syringomas,* benign tumors of the eccrine sweat duct, occur on the penis, presenting as discrete, skin-colored, dome-shaped papules 1 to 3 mm in diameter located on the dorsal and lateral aspects of the shaft. The differential diagnosis of appendageal tumors includes normal sebaceous glands, lichen nitidus, condylomata acuminata, and mollusca contagiosa.

Disorders of Melanocytes: Disorders of Pigmentation (See Chap. 90)

HYPERPIGMENTATION Postinflammatory hyperpigmentation commonly occurs following various inflammatory disorders of the genitalia, more frequently in individuals with darker skin types. Following a fixed drug eruption, a violaceous-brown macule persists for many months after the acute lesion has resolved. Recurrences of the eruption at the same site leave the skin progressively darker. A similar pigmentation occurs during the course of lichen planus, associated with pigment incontinence. Epidermal hyperpigmentation occurs following many genital infections such as genital herpes.
LEUKODERMA Penile postinflammatory hypopigmentation occurs commonly following recurrent episodes of genital

herpes, especially in individuals with darker skin types. LS often presents with macular white areas on the glans and shaft that are caused by decreased dermal vasculature rather than decreased melanin pigmentation. Depigmentation is seen most commonly with vitiligo but also as a chemical or occupational leukoderma or following exposure to rubber-containing devices such as condoms and pessaries. The isomorphic phenomenon occurs in vitiligo, i.e., depigmentation at sites of injury; as such, an individual with vitiligo may develop depigmentation on the genital skin following infections such as genital herpes or gonorrhea or inflammatory disorders. Vitiligo, either idiopathic or chemically induced, appears as sharply demarcated, macular white lesions. The entire cutaneous surface should be examined, looking for other depigmented areas, using a Wood's lamp; hypopigmented areas show little accentuation of pigmentary differences.

Disorders of Melanocytes: Benign Neoplasias, Hyperplasias, and Dysplasias of Melanocytes (See Chap. 92 and Chap. 93)

PENILE MELANOSIS This condition is characterized clinically by large size, irregular borders, multifocality, and variegated pigmentation and histologically by basalar hyperpigmentation without melanocytic hyperplasia. [19] The condition is usually idiopathic but has been associated with ultraviolet A irradiation with or without psoralens. The macules may be solitary or multiple, tan to brown in color, with variation in the pigmentation from macule to macule. Borders are regular with round or oval shapes. However, melanosis on the glans penis may show some variegation of color and/or irregularity of the borders. Genital lentigines may be part of systemic disorders such as the LAMB syndrome (vulvar and other mucocutaneous lentigines, atrial myoxoma, and blue nevi) and multiple lentigines syndrome (lentigines and hypertrophic cardiomyopathy). Penile melanosis must be differentiated from in situ malignant melanoma, Peutz-Jeghers syndrome, and Ruvalcaba-Myhre-Smith syndrome (pigmented penile macules, macrocephaly, hamartomatous intestinal polys, and a unique lipid storage myopathy).
MALIGNANT MELANOMA This tumor arising on the male genitalia is rare, accounting for 0.1 to 0.2 percent of all nonocular melanomas and 1 percent of all penile carcinomas; the most common histologic type is acrolentiginous melanoma. As with melanoma at other sites, that occurring on genital skin can arise either from a preexisting pigmented lesion or de novo from epidermal melanocytes. Penile melanomas appear as macules or papules with variegation of brown-black color, irregular borders, and often with an area of ulceration averaging 1 cm in diameter at time of diagnosis (Fig. 113-11). The most common sites are the glans, prepuce, urethral meatus, penile shaft, and coronal sulcus. The prognosis of penile melanoma is poor because of late presentation, delay in treatment, early metastases via lymphatic vessels, and anatomic constraints regarding surgical excision; the majority of patients die within 1 to 3 years. [20], [21] and [22]

FIGURE 113-11 Malignant melanoma arising on the penis. A large, highly variegated plaque on the penis with an eroded invasive nodule.

Epidermal-Dermal Inflammatory Conditions of Unknown Etiology

LICHEN PLANUS (LP) (See Chap. 49) LP of the penis may be the sole manifestation of the condition, but it is more often part of a more widespread eruption. Clinically, violaceous flat-topped papules with a lacy white surface pattern are seen, most commonly on the glans (Fig. 113-12). Older lesions may have a grayish hue associated with melanin incontinence into the dermis. Annular lesions occur on the glans and penile shaft. In some individuals, the epithelium may slough, resulting in eroded portions of lesions (erosive LP). SCC is a rare complication of chronic LP. [23] In the majority of cases, penile LP undergoes spontaneous remission after several years with residual postinflammatory hyperpigmentation in darker-skinned individuals. Erosive penile LP, as with the oral involvement, may persist for decades. Papular lesions can be treated with mild topical corticosteroid ointment; erosive lesions respond to intralesional triamcinolone injection. Topical tacrolimus or pimecrolimus may be effective without the risk of cutaneous atrophy.

FIGURE 113-12 Lichen planus. Small papules with a follicular pattern resemble lichen nitidus; however, the lesions are larger than those seen in lichen nitidus, and typical findings of lichen planus were present at other sites. Flattopped violaceous papules are also seen on the glans.

LICHEN NITIDUS (See Chap. 50) This is an uncommon, asymptomatic cutaneous disorder characterized by the appearance of small, discrete, skin-colored papules occurring most commonly on the penis, abdomen, and arms. Clinically, shiny, 1- to 2-mm, well-demarcated, domed, skin-colored papules are seen on the shaft of the penis. The lesions remain discrete and usually are not grouped or confluent; however, a linear arrangement may be seen with the isomorphic or Koebner phenomenon. The course of penile lichen nitidus is chronic, extending over years.

Neoplasms, Pseudoneoplasms, Hyperplasias, and Mucinoses of Supporting Tissue Origin

SCROTAL CALCINOSIS This is characterized by variable numbers of subcutaneous, hard, marble-like, scrotal nodules (Fig. 113-13) that probably arise from epidermoid cysts. [24] The nodules are of varying diameters and are attached neither to the underlying structures nor to the overlying epidermis. Soft tissue radiologic examination shows calcified nodules. Histologically, accretions of homogeneous material that stains for calcium are seen scattered throughout the dermal connective tissue, with an inflammatory infiltrate composed of lymphocytes, histiocytes, and giant cells; cyst walls can be seen in some cases. Scrotal calcinosis slowly progresses throughout life; the lesions remain discrete and do not become confluent. Symptomatic single or groups of nodules can be excised surgically.

FIGURE 113-13 Idiopathic calcification of the scrotum. *A*. White nodule on the scrotum. *B*. The contents of one cyst, a white chalky material, seen after incision and expression.

Vascular Neoplasms, Pseudoneoplasms, and Hyperplasias (See Chap. 103)

ANGIOKERATOMAS Angiokeratomas of the scrotum and penis are common genital lesions characterized by ectasia of superficial dermal blood vessels and hyperkeratosis. Lesions occur on the scrotum or periurethral glans, may be solitary or multiple, and increase in number with age. Penile angiokeratomas are thin-walled and occasionally bleed spontaneously with trauma. Clinically, the lesions are soft and compressible, purple, 1- to 5-mm papules. Angiokeratomas are occasionally solitary but are more commonly multiple with up to 50 to 100 caviar-like scrotal papules (Fig. 113-14). The differential diagnosis includes angiokeratoma corporis diffusum of Fabry's disease, which appears as multiple, 1- to 4-mm lesions concentrated in the bathing-trunk area but also on the gentalia. Symptomatic lesions can be eradicated by electrodesiccation or laser surgery.

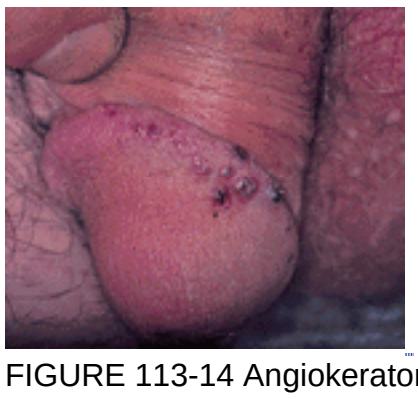

FIGURE 113-14 Angiokeratomas of Fordyce. Multiple violaceous and red papules on the glans.

DARTOIC LEIOMYOMA This is a smooth muscle tumor arising in the dartoic muscle within the scrotal sac; its occurrence

is rare, accounting for only 0.1 percent of scrotal tumors. Like other types of leiomyomas, this solitary, pink, firm dermal nodule may be painful and may contract following touch or cold stimulus. Multiple lesions can occur.

APHTHOUS ULCERS (AUs) (See Chap. 112) These arise on the scrotum and penis, less commonly than vulvovaginal involvement in females. Genital ulcers, indistinguishable from AUs, occur during the course of the acute retroviral syndrome (HIV disease), resolving within a few weeks. When chronic AUs occur, the diagnosis of Behçet's syndrome always should be considered; genital aphthae are a major diagnostic criterion for the syndrome and occur in 60 to 90 percent of cases. Lesions are usually painful and solitary, with a gray, necrotic, fibrin-filled base surrounded by a halo of erythema (Fig. 113-15). Unlike AUs of the mouth, the diagnosis of AUs of the genitalia must be made by ruling out other causes of genital ulcer disease. Intralesional triamcinolone is quite effective in treatment.

FIGURE 113-15 Aphthous ulcer. A sharply marginated ulcer with a red rim is seen on the glans; the diagnosis is made by ruling out other causes of genital ulcer disease. Identical lesions occur in Behçet's syndrome.

Eczematous Dermatitis

ALLERGIC CONTACT DERMATITIS (ACD) (See Chap. 121) This occurs on the penis and scrotum and often is more florid and symptomatic than on other sites. In nonsensitized individuals, a minimum of 5 to 7 days elapses from the time of contact to onset of symptoms. In a previously sensitized individual, however, the time varies with the quantity of allergen and the individual reactivity but can be as short as 4 to 6 h. The extreme reactivity and tremendous vascularity of the penis maximize the intensity of the ACD. Sensitizing haptens make contact with the penis in three ways: hand-to-penis contact occurs in phytodermatitis (poison ivy or oak); during sexual intercourse, a sensitizing agent may be applied directly to the penis or from a sexual partner; and as involvement in a generalized contact dermatitis. Symptomatically, acute ACD is heralded by intense pruritus and a burning sensation at times prior to any visible changes. Clinically, gential ACD presents with erythema and marked edema and, in time, with microvesiculation and exudation (Fig. 113-16). Older lesions may become crusted. Intense pruritus often causes the patient to scratch, resulting in excoriations and larger erosions. Finding eczematous dermatitis on the inguinal area, thighs, perianal area, axillae, hands, or face is helpful in making a diagnosis of an ACD. The differential diagnosis includes atopic dermatitis, seborrheic dermatitis, genital herpes, cellulitis, inguinal dermatophyte infection, balanoposthitis, intertrigo, psoriasis, lichen planus, and balanitis circinata. Untreated and with no further exposure to the contactant, ACD of the penis usually resolves in 2 weeks or less. Reexposure to the hapten can result in repeated flares of the dermatitis even months or years later. Most cases of acute dermatitis respond to short courses of potent topical corticosteroids. Prednisone (70 mg initially tapered by 10 mg per day) is indicated for severe symptomatic involvement.

FIGURE 113-16 Allergic contact dermatitis; neomycin. Striking skin-colored edema of the distal penile shaft was attributed to neomycin application. (The red color on the glans is Castellani's paint.)

ATOPIC DERMATITIS (See Chap. 122) Individuals with atopic dermatitis frequently have involvement of the penis or scrotum as part of either flexural or generalized dermatitis. Atopic patients can have the dermatitis confined to a single area of lichen simplex chronicus on the scrotum (Fig. 113-17) for years or decades. Lichen simplex chronicus is best treated with intralesional triamcinolone (3–5 mg/mL), combined with the application of a corticosteroid ointment for a limited time. Topical macrolides (tacrolimus or pimecrolimus) may be useful.

FIGURE 113-17 Lichen simplex chronicus. Lichenification, erythema, and hypopigmentation on the scrotum have been present for 20 years. The pruritus and lichen simplex chronicus resolved following intralesional triamcinolone injection.

SEBORRHEIC DERMATITIS (See Chap. 124) This occurs in the pubic area or scrotum, usually associated with involvement of the scalp, retroauricular area, face (eyebrows and nasolabial fold), presternal chest, and axillae. Genital involvement can occur in isolation, characterized by mild erythema, mild scaling, and at times, follicular involvement only. Individuals with psoriasis may have more erythema and scaling, i.e., seborrhiasis of the pubic and scrotal skin; inverse pattern psoriasis also may be present. Symptomatic patients can be treated with a mild topical corticosteroid or a topical macrolide (tacrolimus or pimecrolimus).

Photomedicine

EFFECT OF PUVA THERAPY ON THE MALE GENITALIA (See Chap. 265) Neither natural sunlight nor artificial ultraviolet B exposure on the male genital skin appears to be an etiologic factor in photodamage or precancerous or cancer lesions at this site. Photochemotherapy (oral psoralen plus ultraviolet A; PUVA) has been used to treat extensive refractory psoriasis for two decades and has been implicated occasionally in the etiology of genital malignancies in males. [25], [26] PUVA-induced ultraviolet damage can be avoided easily by covering the penis and scrotum with clothing during therapy.

ADVERSE CUTANEOUS DRUG REACTIONS (ACDRs)

ACDRs such as urticarial and exanthematous types are systemic reactions. Genital involvement is usually minor and part of the generalized cutaneous reaction.

FIXED DRUG ERUPTIONS (FDEs)

These follow ingestion of a sensitizing drug, occurring most commonly in males on the penis, with or without lesions at other mucocutaneous sites. Patients often give a history of having identical lesions occurring at the same site. Because of the recurrent nature of an FDE, many patients are misdiagnosed as having genital herpes. Common drugs causing fixed eruptions include phenazones, tetracyclines, sulfonamides, dapsone, barbiturates, griseofulvin, and carbamazepine. Clinically, FDEs occur initially as inflammatory plaque(s) 2 to 3 cm in diameter that become bullous in some cases (Fig. 113-18). The most common site is on the glans and distal shaft. The lesion may be solitary or associated with similar lesions at other cutaneous or oral sites. Patients with previous FDEs often have macular violaceous to brown hyperpigmentation at the site that persists for many months after the previous outbreak. Phosphonoformate, used in the treatment of cytomegalovirus and acyclovir-resistant HVS infections, causes erosive and ulcerative penile lesions (Fig. 113-19), an irritant effect from high concentration of the drug in urine, which should be differentiated from FDE.

FIGURE 113-18 Adverse cutaneous drug reaction. Fixed drug eruption: phenolphthalein. Bright-red erosions on the glans and scrotum and a red plaque on the wrist were associated with extensive oral erosions following self-administration of phenolphthalein in a laxative. The patient had a history of three identical reactions following ingestion of the drug.

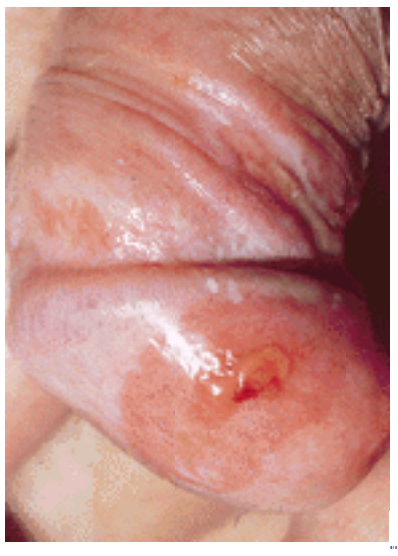

FIGURE 113-19 Adverse cutaneous drug reaction: erosions secondary to foscarnet. Erosion and ulceration are seen on the glans associated with foscarnet therapy of cytomegalovirus retinitis in an individual with advanced HIV disease.

GLUCOCORTICOID-INDUCED ATROPHY

Prolonged used of moderate to potent glucocorticoids may result in epithelial and dermal atrophy. Clinically, chronic corticosteroid application to the penis is characterized by an atrophic appearance to the skin, prominent blood vessels, spontaneous ecchymoses, and striae on the glans and shaft. Corticosteroid-induced atrophy occurs more commonly in the inguinal region than the genitalia (Fig. 113-20).

FIGURE 113-20 Adverse cutaneous drug reaction: topical glucocorticoid-induced atrophy and striae. The scrotum and inguinal area show erythema, telangiectasias, and striae formation follow chronic application of a class III glucocorticoid cream.

TOPICAL 5-FLUOROURACIL

This has been used in the treatment of HPV-induced lesions (external genital warts, squamous intraepithelial lesion). An irritant dermatitis occurs most commonly on the intertriginous skin between the anterior scrotum and the underside of the penis. Clinically, the dermatitis can begin within 3 to 5 days after onset of application and may present as mild dermatitis to extensive erosive lesions.

INTRAVENOUS DRUG USE

Intravenous injections into penile veins or soft tissue result in venous thrombosis, thrombophlebitis, cellulitis, lymphangitis, and abscess formation. Localized gangrene of the scrotum and penis can follow injection of heroin into the femoral artery. Injection of particulate matter into the microcirculation of the genitalia results in arterial thrombosis, ischemia, and subsequent gangrene.

ORAL RETINOIDS

Isotretinoin can cause erythema and stickiness of the epithelium, including the glans penis and urethral meatus. At times, the opposing surfaces of the distal urethral mucosa may adhere together, resulting in a diverted stream of urine flow.

SYSTEMIC DISEASES INVOLVING THE MALE GENITALIA

LEUKEMIA CUTIS

This can present on the scrotum, heralding the relapse of acute myelogenous or chronic lymphocytic leukemia. [27] Chronic herpetic ulcers occur commonly in individuals with hematologic malignancies. Priapism also has been reported to occur with both acute and chronic types of leukemia. Multiple myeloma, when associated with hyperglobulinemia and hyperviscosity, also has been reported to cause priapism. An exophytic, ulcerative penile lesion may occur as the initial presentation of Langerhans' cell histiocytosis. A yellow or red-brown papular eruption in the diaper and inguinal areas, at

times with nodules within the eruption, may be the only manifestation of Langerhans' cell histiocytosis in male infants.

CUTANEOUS CHANGES IN PERIPHERAL VASCULAR DISEASE

Severe Raynaud's phenomenon associated with progressive systemic sclerosis can reduce penile arterial blood flow and cause impotence. In diabetics, occulsion of arterioles commonly results in neuropathy and erectile dysfunction and, rarely, infarction/gangrene of the penis. Penile gangrene can be associated with penile calciphylaxis, occurring in diabetes mellitus with renal failure. Phlebothrombosis and thrombosis of the penile veins are rare and, when present, are attributed to trauma, infection, internal malignancy, or injecting drug use. Clinically, they present as a subcutaneous cord that is usually nontender and lacks any signs of inflammation. Lymphangitis and thrombophlebitis cannot be distinguished on clinical grounds.

LYMPHATIC DISORDERS

Sclerosing lymphangitis of the penis (nonvenereal sclerosing lymphangitis) represents a thrombosed or sclerosed lymphatic vessel. The etiology is unknown but often follows vigorous sexual activity. Clinically, a painless, firm, at times nodular, translucent cord appears suddenly, usually parallel to the corona or on the glans. The lesion resolves spontaneously in a period of weeks to months.

SCROTAL AND/OR PENILE EDEMA

This is characteristically painless, nontender, and nonerythematous and may be acute or chronic and occur as a result of local or distant disorders of lymphatic vessel inflammation, fibrosis, or obstruction. Because of the loose connective support and the abundant vasculature of the genitalia, lymphedema is often confined to the penis and scrotum and does not involve the abdominal wall. The most common etiologies of acute edema are allergic contact dermatitis, angioedema, parenteral fluid overload, and peritonitis. Penile venereal edema is associated with gonorrhea (“bull-headed clap”), *Chlamydia trachomatis, Ureaplasma urealyticum, Mycoplasma genitalium,* and HSV infections. Reversible, iatrogenic genital edema occurs in patients with parenteral fluid overload and in 10 percent of patients with renal failure treated with peritoneal dialysis. Chronic lymphedema may be idiopathic or secondary to inflammation, postoperative state, neoplasms, radiation, hypoproteinemia, injection of foreign material such as silicone or paraffin, and other medical conditions. In countries where endemic filariasis is common, genital lymphedema is much more common and may be associated with massive lymphedema, i.e., elephantiasis.

SYSTEMIC VASCULITIS (See Chap. 174)

Henoch-Schönlein purpura (HSP) can present with tender edema and hemorrhage of the penis and/or scrotum in boys and may herald the onset of other, more typical cutaneous and systemic signs and symptoms. Scrotal swelling occurs in 15 percent of young male patients with HSP, at times associated with pain that mimics testicular torsion; scrotal swelling and pain may be the presenting symptom of HSP. [28] Polyarteritis nodosa (PAN) also can present with scrotal swelling that is painful. Vasculitis of the testicle or epididymis may be the sole manifestation of the PAN early in its course and often results in ischemic damage to the skin with subsequent infarction and ulceration, Testicular biopsy showing large-vessel vasculitis is often helpful in making the diagnosis of PAN. Wegner's granulomatosisis is a systemic vasculitis that has been associated with penile necrosis secondary to large-vessel vasculitis.

REITER'S SYNDROME (See Chap. 182)

This is characterized by an episode of peripheral arthritis and urethritis and frequently is accompanied by circinate balanitis (CB) (25 percent), conjunctivitis, stomatitis, and keratoderma blenorrhagica. In noncircumcised males with CB, superficially erosive plaques with ragged margins occur around the corona, with smaller satellite lesions on the glans and prepuce. In circumcised males, balanitis circinata sicca is seen, the lesions resembling those seen in psoriasis. A mucoid urethral discharge with periurethral erythema is frequently present.

SARCOIDOSIS (See Chap. 183)

Rarely, this can be limited to the penis and scrotum. [29] Penile involvement is reportedly characterized by tender, erythematous induration of the distal shaft and yellow-tan plaques on the dorsum of the glans. There may be associated urethral obstruction.

GLUCAGONOMA SYNDROME

Glucagonoma syndrome with superficial migratory necrolytic erythema (MNE) presents with inflammatory plaques that occur in the anogenital region. [30] The lesions enlarge with central clearing, resulting in confluence and a geographic pattern; borders may show vesiculation to bulla formation, crusting, and scaling. In addition to the anogenital region, axillae, umbilicus, perioral skin, and fingertip lesions, glossitis, angular cheilitis, and blepharitis are also seen.

METASTATIC CANCER TO THE PENIS/SCROTUM

Despite the rich vascularization of the penis, metastasis of distant carcinomas to the region is rare; metastatic scrotal tumors are even rarer. [31] Sites of origin of penile or scrotal metastases include adenocarcinoma of the prostate (30 percent), transitional cell carcinoma of the bladder (30 percent), rectosigmoid tumors (16 percent), and renal cell carcinoma (11 percent). The presentation is either as dermal or subcutaneous nodule(s), gangrene, carcinoma erysipelatodes, penile pain, or priapism.

BEHÇET'S SYNDROME (See Chap. 192)

In Turkish males with Behcet's syndrome, 89 percent had experienced scrotal ulceration, 6 percent epididymitis, and 3 percent sterile urethritis. In a report from Korea, 99 percent had oral ulcers, 83 percent genital ulcers, and 84 percent skin lesions. [32] Large, painful, deep aphthous-type ulcerations occur commonly on the scrotum and penis (Fig. 113-21). MAGIC syndrome (mouth and genital ulcers with inflamed cartilage) is an overlap syndrome of Behçet's syndrome with relapsing polychondritis.

FIGURE 113-21 Behçet's syndrome with aphthous ulcer of scrotum. A chronic scrotal ulcer was associated with oral aphthous ulcers and central nervous system symptoms.

INFECTIOUS DISEASES OF MALE GENITALIA

Bacterial Diseases (See Chap. 194)

STAPHYLOCOCCUS AUREUS This organism causes primary infections in the anogenital region (folliculitis, impetigo, bullous impetigo, furuncles, carbuncles), secondary infection of dermatoses (atopic dermatitis, lichen simplex chronicus, and at times, psoriasis), or superinfection (genital herpes, chancres, or *Candida* intertrigo). Group A (GAS) and group B ß-hemolytic *Streptococcus pyogenes* (GBS) colonize the anogenital region and may cause a superficial erosive intertrigo, e.g., perianal streptococcal “cellulitis.” *Erythrasma* presents as a uniformly colored, pink to tan, well-demarcated plaque on the medial thigh, most commonly with symmetric bilateral involvement; the adjacent scrotum and penis are usually uninvolved. *Trichomycosis pubis* presents on the pubic area, with hair appearing to be thicker than the normal and with a yellow, red, or black layer coating.

CELLULITIS OF THE SCROTUM AND PENIS This is an uncommon condition probably because of the rich vasculature of the tissue. In the immunocompetent host, aggressive pathogens such as groups GAS, GBS, or *S. aureus* can enter a break in the epithelium, i.e., normal skin, underlying dermatosis such as psoriasis or at the site of a superficial infection such as a balanoposthitis with resulting cellulitis. GBS is the most common bacterial pathogen in the neonatal period and can cause cellulitis following circumcision. In the immune compromised host, pathogens such as *Pseudomonas aeruginosa,* especially in the setting of neutropenia, can cause soft tissue infections such as ecthyma gangrenosum. Symptomatically, early infection is associated with local pain and fever. Clinically, the genital skin is red, hot, and tender and may be associated with an obvious portal of entry.

FOURNIER'S GANGRENE This process is a necrotizing soft tissue infection of the genital and anorectal regions characterized by tissue necrosis (cellulitis, fasciitis, and myositis), rapid progression, lack of frank suppuration, severe systemic toxicity. [33] Major etiologic factors included diabetes mellitus, periurethritis with urinary extravasation, indwelling catheter placement, after instrumentation, after genitourinary surgery, after traumatic injury, injecting drug use into the dorsal vein of the penis, and infiltration of the urethra from a bladder tumor. In the majority of cases the infection was polymicrobial; *S. aureus,* GAS, or *Escherchia coli* may be the sole isolate in some cases. The onset can be insidious, with a discrete area of necrosis on the scrotum that progresses to advanced skin necrosis rapidly over 1 to 2 days. The infection tends to be superficial, limited to skin and subcutaneous tissue, and extending to the base of the scrotum; the testes, glans penis, and spermatic cord usually are spared in that they have a separate blood supply. The infection may extend to the perineum and the anterior abdominal wall through fascial planes. Symptomatically, patients with urogenital necrotizing infection show marked systemic toxicity, urinary retention, abdominal discomfort, and peroneal pain out of proportion to the physical findings. Clinically, local findings of Fournier's gangrene involving the scrotum and penis universally include edema, erythema, skin necrosis, crepitus, and bulla formation. Fever and leukocytosis are seen in nearly all patients.

TUBERCULOSIS OF THE PENIS This is a rare problem even in developing countries, where the prevalence of tuberculosis remains relatively high. Tuberculosis of the penis may be a primary infection acquired through sexual contact with genital or oral tuberculosis or may be associated with coexisting infection at some other site. Penile tuberculosis presents as subacute or chronic, painful, usually multiple ulcers; there may be associated inguinal lymphadenopathy.

ACUTE LYME BORRELIOSIS (SEE CHAP. 203) This disease can present with either erythema migrans, which occurs at the site of the tick bite, often the groin or pubic area, and lymphocytoma cutis, which also occurs at the bite site, often on the scrotum. Lymphocytoma cutis is characterized by an inflammatory nodule, usually solitary but occasionally multiple, occurring on the scrotum; it is part of the clinical spectrum of European Lyme borreliosis but very uncommon in North American Lyme borreliosis. Young males are most commonly infected, the lesion occurring at the site of the tick bite. There may be coexisting systemic symptoms.

Fungal Diseases

DERMATOPHYTOSIS (See Chap. 205) This commonly involves the inguinal area, i.e., tinea cruris, but rarely causes superficial infection of the scrotum or penis. Tinea cruris is always associated with tinea pedis, the dermatophyte being transferred by the hand from the feet to the crural area. Clinically, tinea cruris presents as an erythematous to tan plaque with well-demarcated, scalloped borders advancing inferiorly down the anterior thigh. Chronic scratching may induce an eczematous dermatitis or lichen simplex chronicus on the scrotum or, less commonly, on the penis. Chronic application of topical corticosteroids can mask the clinical presentation (tinea incognito).
CANDIDIASIS (See Chap. 206) *C. albicans* is often a resident flora of the bowel and can be cultured from the intertriginous skin of the preputial sac, the inguinal folds, and the perineal area. Etiologic factors for intertriginous candidiasis include uncontrolled diabetes mellitus, impaired immunity during the course of a disease or immunosuppressive therapy, and severe debilitating illness. Candidal intertrigo in males usually represents overgrowth of endogenous *C. albicans*. With recurrent balanoposthitis, the source is exogenous from the sexual partner. Clinically, the primary lesions of candidal intertrigo are small papules and pustules that quickly increase in number, merging to form erosive patches and plaques. The central eroded area has ragged edges and is surrounded by satellite pustules. The most common sites are the preputial sac (balanoposthitis) and the inguinal regions. Bacterial superinfection with *S. aureus* or *Streptococcus* is associated with more pain and exudation than with candidal infection alone.
PITYRIASIS (TINEA) VERSICOLOR This occurs uncommonly as an asymptomatic scaling hypo- or hyperpigmented macular eruption on the shaft of the penis. This superficial fungal infection may occur only on the penis but is usually present on the upper trunk as well.

Viral Diseases

HERPES SIMPLEX VIRUS (HSV) (See Chap. 214) Genital herpes is a recurrent infection caused by herpes HSV-2 more commonly than HSV-1. Primary genital HSV infection is most commonly asymptomatic. Symptomatic males note fragile grouped vesicles on a red base that soon rupture and leave superficial erosions. Unilateral tender lymphadenitis often accompanies symptomatic primary infection but not recurrences. Headache associated with aseptic meningitis occurs in some patients with primary HSV infection and less often with each recurrence. Recurrent genital herpes is often heralded by a tingling, burning, or sensitivity 24 h prior to the appearance of vesicles. Groups of vesicles (Fig. 113-22) appear and are quickly eroded; the size of recurrent lesions is usually much less than that of primary infection. Genital herpes occurs more commonly on the prepuce, glans penis, and shaft and least commonly on the scrotum. Uncommonly, herpetic urethritis associated with a scant discharge and dysuria may occur with few lesions on the external penile epithelium. Primary and recurrent HSV proctitis or lesions in the anal canal or perianal area may follow receptive anal intercourse. Chronic herpetic ulcers (CHUs) occur in immunocompromised individuals. HIV disease is the most common underlying disorder associated with CHUs; other underlying disorders include cancer chemotherapy, hematologic malignancies, and bone marrow and solid-organ transplantation. CHUs appear as painful erosions or ulcerations that may have rolled borders and are located most commonly on the penis, scrotum, and inguinal areas (Fig. 113-23). Older ulcers may become crusted or hyperkeratotic. Giant ulcers may occur in patients with acyclovir-resistant strains of HSV.

FIGURE 113-22 Herpes simplex virus infection: recurrent. Clusters of small vesicles on the penile shaft.

FIGURE 113-23 Herpes simplex virus infection: chronic. Larger ulcers on the penis and scrotum caused by an acyclovir-resistant HSV strain resolved with intravenous cidofovir.

HERPES ZOSTER (See Chap. 215) Herpes zoster infection of the third or fourth sacral sensory nerves involves the penis, scrotum, and perianal skin. Symptomatically, zoster is often associated with varying degrees of neuritic pain. Pain prior to the appearance of any cutaneous findings can be confused with an acute surgical problem. Clinically, zoster is characterized by grouped vesicles in a dermatomal distribution.
MOLLUSCUM CONTAGIOSUM (MC) (See Chap. 221) This is a poxvirus skin infection characterized by clustered 1- to 5-mm domed papules with central umbilication. The clusters evolve at sites of primary inoculation following autoinoculation. The anogenital area is a common site in children. In adult men, the penis is a common site for sexually

transmitted MC. Commonly, MC varies from this classic description following trauma or spontaneous involution, becoming hyperkeratotic and/or inflamed, such that the skin-colored, centrally umbilicated dome becomes a red scaling papule. As such, MC becomes clinically indistinguishable from condylomata acuminata.

HUMAN PAPILLOMAVIRUS (HPV) (See Chap. 223) HPV infects the moist epithelium of the anogenital region and gives rise to a spectrum of lesions in males ranging from genital warts, squamous intraepithelial lesions (SIL), and invasive SCC. More than 60 HPV types have been detected; however, types 6 and 11 most commonly infect anogenital epithelium, as well as types 16, 18, 31, and 33. Types 16, 18, 31, and 33 are linked etiologically to intraepithelial neoplasia and invasive SCC. Anogenital HPV infections/genital warts are the most common sexually transmitted diseases, infecting 30 to 40 million individuals in the United States. The majority of cases of genital HPV infection are subclinical; i.e., no clinical lesions can be detected on routine examination.

External genital warts (EGWs) The majority of anogenital HPV infections are subclinical. When clinically detectable, EGWs appear as papules, condyloma acuminatum (cauliflower floret–like papules), flat-topped plaques, and hyperkeratotic papules/nodules (Fig. 113-24). The color is that of the normal genital skin but may be pink or hyperpigmented. Lesions much darker in color than the normal genital skin may be SIL. The most common sites for genital warts to occur in males are the frenulum corona, glans, prepuce, shaft, scrotum, urethral meatus, and urethra. Perineal, perianal, and anal canal genital warts are associated with receptive anal intercourse. EGWs cannot be distinguished on clinical findings from SIL; lesional biopsy is indicated in immunocompromised individuals. EGWs recur after appropriate therapy in a high percentage of patients due to persistence of latent HPV in normal-appearing perilesional skin. The major significance of HPV infection is the oncogenic potential. HPV types 16, 18, 31, and 33 are the major etiologic factors for SIL and invasive SCC of the cervix, anus, and external genitalia. Subclinical genital infection persists for months to years. The current approach is to treat visible lesions with a variety of destructive modalities, the most commonly used of which is cryosurgery with liquid nitrogen. Topical imiquimod 5% cream is an immunomodulatory molecule that upregulates T_H1 cytokine response, causing specific immune response to HPV.

FIGURE 113-24 Human papillomavirus infection: condylomata acuminata. Multiple skin-colored papules on the shaft and glans penis.

Squamous intraepithelial lesions (SIL) SIL of the anogenital skin are characterized by multifocal maculopapular lesions occurring on the cervix, anus, and external anogenitalia. Intraepithelial neoplasia is caused by HPV type 16 most commonly but also by types 18, 31, and 33. Commonly, patients have a prior history of EGWs or female sexual partners with cervical or anal SIL. Immunosuppression associated with HIV disease, [34] iatrogenically induced immunosuppression in solid-organ transplantation, [35] and prolonged immunosuppressive therapy have been linked with an increased incidence. Clinically, SIL appears as erythematous macules and lichenoid (flat-topped) or pigmented papules (several millimeters) occurring as solitary lesions, scattered lesions, or confluent larger plaques (Fig. 113-25). The surfaces of lesions are usually smooth or velvety; the color is tan, brown, pink, red, violaceous, or white. Patients with SIL should be followed frequently, and new lesions should be treated to minimize the risk of progression to invasive SCC. HAART does not appear to have reduced the incidence of SIL. [36] Long-term survivors with immune compromise continue to be at risk for invasive SCC.

FIGURE 113-25 Human papillomavirus infection: squamous cell carcinoma in situ. A huge cobblestoned plaque composed of confluent brown and pink papules on the penis, scrotum, inguinal folds, and perineum in an individual with advanced HIV disease.

HUMAN IMMUNODEFICIENCY VIRUS DISEASE(See Chap. 225)

Sexually Transmitted Diseases

SYPHILIS (See Chap. 228) Syphilis is manifested by anogenital lesions during the primary, secondary, tertiary, and congenital stages of the infection. A syphilitic chancre develops at the site of entry of the treponeme, beginning as a button-like papule/nodule that often erodes and ulcerates centrally. The lesion, which is usually not painful or tender on palpation, feels like a firm dermal lozenge, varying in size from 1 or 2 cm. Chancres are most often solitary but may occur as “kissing” lesions. The most common sites of anogenital chancres are on the inner prepuce, coronal sulcus of the glans, penile shaft and base, anus, and rectum. In secondary syphilis, condylomata lata appear as soft, flat-topped, moist, red to pale papules, nodules, or plaques that may become confluent, occurring in the anogenital region. Uncommonly, lesions of secondary syphilis and a chancre of primary syphilis may coexist. Annular polycyclic lesions may occur, especially in dark-skinned individuals.
CHANCROID (See Chap. 230) Chancroid is characterized clinically by a painful ulcer at the site of inoculation, often associated with painful inguinal lymphadenitis. The initial lesion, a papule, occurs at the site of inoculation 4 to 7 days after exposure, evolving into an ulcer with sharp, often undermined borders and a friable base of granulation tissue, often covered with a gray to yellow exudate. The most common sites of ulceration are the prepuce, frenulum, coronal sulcus, glans, and shaft. Edema of the prepuce and penis is common. Multiple lesions may occur due to autoinoculation. Inguinal lymphadenitis (usually unilateral), occurring in approximately half of patients within 1 to 2 weeks after the appearance of the primary lesion, is common in untreated patients. Abscess formation may occur within the infected lymph nodes with bubo formation; these have erythema of the overlying epidermis and may drain spontaneously with formation of a sinus tract.
LYMPHOGRANULOMA VENEREUM (LGV) (See Chap. 231) LGV is manifested by an infrequent primary genital lesion, secondary lymphadenitis with bubo formation and/or proctitis, and late infrequent sequelae of fibrosis, edema, and fistula formation. Clinically, primary infection is characterized by a papule, shallow erosion, ulcer, grouped small erosions, or ulcers (herpetiform) on the coronal sulcus, frenulum, prepuce, penile shaft, urethra, glans, or scrotum at the portal of entry. Lymphatic infection is manifested by a cordlike lymphangitis of the dorsal penis or lymphangial nodule (bubonulus); complications of lymphatic involvement include rupture, formation of sinuses and fistulas of the urethra, and deforming scars of the penis. When the inoculation site occurs intraurethrally, the presentation is of a nonspecific urethritis with a thin, mucopurulent discharge. Subacute or chronic LGV is manifested by the inguinal syndrome, anogenitorectal syndrome, and genital edema. In the inguinal syndrome, bubo formation occurs in the inguinal lymph nodes, more commonly unilaterally, with edema, erythema of the overlying skin, and rupture in one-third of cases. The inflammatory mass of femoral and inguinal nodes separated by a depression or groove made by Poupart's ligament is called the *groove sign*. In the anogenitorectal syndrome, proctocolitis, as well as hyperplasia of intestinal and perirectal lymphatic tissue, occurs with formation of perirectal abscesses, ischiorectal and rectovaginal fistulas, anal fistulas, or rectal stricture. Overgrowth of lymphatic tissue results in lymphorrhoids (resembling hemorrhoids) or perianal condylomata. Genital edema can occur years after the primary infection.
DONOVANOSIS (GRANULOMA INGUINALE) (See Chap. 232) Granuloma inguinale is characterized by ulceration and epitheliomatous hyperplasia. This STD is endemic in some developing geographic areas (Papua New Guinea, India, and South America) and is infrequently diagnosed in the industrialized nations of North America or Europe. The primary lesion is a relatively painless, button-like papule or subcutaneous nodule that ulcerates within a few days of appearance, occurring on the prepuce, glans, penile shaft, or scrotum. Ulcers have a beefy-red granulation tissue base with sharply defined edges. Ulcerations may enlarge by direct extension or autoinoculation to the inguinal and perineal regions. Fibrosis occurs concurrently with extension of the ulcer. Long-standing, untreated infection is associated with chronic lymphedema, which, if severe, may result in elephantiasis of the penis and scrotum. Variants of chronic donovanosis include ulcerovegetative with large, spreading exuberant ulcers, nodular with soft, red nodules that eventually ulcerate with bright red granulating bases, hypertrophic with formation of large vegetating masses, and cicatricial with spreading scar tissue formation associated with spread of infection. Regional lymph node enlargement is uncommon: however, a large subcutaneous nodule may mimic an enlarged lymph node, i.e., pseudobubo.
GONORRHEA (See Chap. 233) This is most commonly manifested as an acute urethritis in males associated with a purulent urethral discharge usually within 5 days after exposure. Clinically, the most common presentation of gonorrhea in males is a urethral discharge, which may be scanty or copious, clear or purulent. Uncircumcised individuals are more likely to experience meatal edema, balanoposthitis, erosion or ulceration of the glans, or penile edema. Untreated patients may experience a deeper infection of the urothelium with infection of the sebaceous glands of Tyson, periurethral glands, Littré's glands, lacunae of Morgagni, subepithelial and periurethral tissue of the urethra, median raphe, and Cowper's ducts and glands. Uncommonly, abscess of a periurethral gland may point and drain on the glans penis with formation of a small fistula. Rarely, gonococcal periprosthetic infection of a penile implant has been reported. The differential diagnosis of gonococcal urethritis is that of urethritis. A serious complication of gonococcal infection is disseminated gonococcal infection (DGI), which occurs more commonly in homosexual men with asymptomatic rectal or pharyngeal gonorrhea.

Infestations (See Chap. 236)

LYMPHATIC FILARIASIS (TROPICAL ELEPHANTIASIS) This is caused by the filarial worms *Wuchereria bancrofti, Brugia malayi,* and *B. timori,* which are estimated to infect approximately one-quarter of a billion individuals in tropical climes. In some geographic areas, up to 25 percent of the adult male population have lymphatic filariasis with thickened scrotal skin and hydrocele. The adult worms lodge in lymphatic vessels, resulting in a chronic inflammation, lymphatic obstruction, and chronic lymphedema. Clinically, early signs of infection include swelling, erythema, and tenderness of the scrotum. Long-standing disease may result in orchitis, hydrocele, thickening of the scrotal skin, scrotal elephantiasis, secondary bacterial cellulitis or lymphangitis, and a verrucous epidermal hypertrophy.
CUTANEOUS LARVA MIGRANS (CREEPING ERUPTION) This is caused by nematodes, which do not normally infest humans, and is characterized by serpiginous tracks on the skin overlying the path of migrating parasites. Larvae tunnel within the subcutaneous tissue. An inflammatory response is mounted with a resulting pruritic urticarial lesion over the larvae; as the parasites wander, a serpiginous track is created about the sites of penetration, i.e., the groin or buttocks.
SCHISTOSOMIASIS (BILHARZIASIS) Shistosomiasis with paragenital granulomas and fistulous tracts occurs in highly endemic areas and is caused by a variety of schistosomal blood flukes. The presence of adult flukes within the vasculature results in granulomatous inflammatory masses, which form condylomata, sinuses, and fistulas on the genitalia, perineum, groin, and buttocks.
AMEBIASIS Caused by *Entamoeba histolytica,* this is a common infestation is South America and Southeast Asia. Genital and perianal ulcers occur either at the site of penetration of the ameba, most commonly on the penis of

homosexual males, or as a consequence of enteric amebiasis. Ulcers associated with enteric amebiasis begin about the anus or buttocks and enlarge to form large, deep, very painful ulcerations with serpiginous borders.

Bites and Stings (See Chap. 237)

Scabies presents with pruritus associated with small serpiginous tunnels on the penis and/or scabetic nodules on the scrotum and penis; eczematous dermatitis occurs secondary to scratching. Hyperkeratotic scabies occurs in immune-compromised individuals, presenting with hyperkeratotic and crusted lesions of the penis, extremities, and other sites. *Pediculosis pubis* (crabs, crab lice, pubic lice) is most commonly manifested in the pubic hair. Clinical findings include adult lice, appearing as 1- to 2-mm brownish gray specks in the pubic, scrotal, and inguinal hairy sites, eggs (nits) attached to the hair, papular urticaria (small erythematous papules at bite sites), secondary changes of lichenification, excoriations, impetiginized excoriations, and maculae caeruleae (tache bleues), slate-gray or bluish gray macules 0.5 to 1.0 cm in diameter on the lower abdominal wall, buttocks, and upper thighs.

DISEASES AND DISORDERS OF THE PERINEUM AND ANUS

PRURITUS ANI

This is a common symptom, defined as an unpleasant cutaneous sensation that induces the desire to scratch the skin around the anal orifice, occurring in the absence of any identifiable dermatologic disorder, more common in males than in females (4:1 ratio). The onset occurs throughout life but is more common in the fifth and sixth decades. The pathogenesis is multifactorial in the majority of patients: fecal contamination and irritation [aggravated by poor hygiene, anorectal disease (fissures, hemorrhoids, chronic diarrhea, fistulas, impaction, or partial obstruction), diet (excessive liquids, spicy foods), drugs (mineral oil, colchicine, quinidine)] and anal sphincter dysfunction. The normal pH of the perianal skin and feces is acidic; factors that make it more alkaline may cause pruritus. Secondary infection (*S. aureus,* GAS, GBS, erythrasma, dermatophytosis, candidiasis, and HSV) may be a factor in some cases.

Symptomatically, pruritus ani is characterized by local itching. Clinically, the perianal skin may show erosions, excoriations, and lichenification. Erythema is more pronounced with secondary infection. Treatment should be directed at identifying and correcting local factors such as infection and anorectal anatomic disorders and eliminating irritant foods or drugs. All mechanical traumas should be minimized. Zinc oxide ointment is helpful in protecting the perianal skin from irritants. Castellani's paint is effective in reducing exudation from inflamed skin acutely. Topical macrolides (tacrolimus, pimecrolimus) may be effective and appear to be safe with long-term use. Fluorinated corticosteroid preparations should be avoided because of the possibility of atrophy with prolonged usage. Intralesional injection of triamcinolone is helpful in patients with lichen simplex chronicus. Oral antihistamines are helpful at controlling nocturnal rubbing and scratching.

PSORIASIS VULGARIS (See Chap. 42)

This commonly occurs in the intergluteal cleft and perianal regions. In these sites, psoriasis is often asymptomatic, although some persons (atopics) may experience pruritus. Clinically, perianal psoriasis presents as very well demarcated linear erythema in the intergluteal cleft that may extend perianally. It is often helpful to examine the intergluteal cleft for, psoriasis to confirm the diagnosis in those with minimal disease.

HIDRADENITIS SUPPURATIVA (See Chap. 77)

This may present with involvement in the perianal region and buttocks with inflammatory nodules, abscesses, fistulas, and sinus tracts, often accompanied by involvement of the axillae and inguinocrural region. In the absence of hidradenitis suppurativa at other sites, diagnosis of the disorder with involvement of the perineum and buttocks is often missed. The differential diagnosis includes acne, *S. aureus* folliculitis, furuncles, pilonidal infection, and inflammatory bowel disease with fistulas.

PILONIDAL CYSTS AND SINUSES

These present as midline inflammatory nodules overlying the sacrum or coccyx. Secondary infection may occur, resulting in deeper infection and cellulitis. Rarely, a chronically inflamed pilonidal cyst may give rise to SCC.

PERIANAL STREPTOCOCCAL CELLULITIS (PSC)

This is a superficial infection (intertrigo) caused by GAS and characterized symptomatically by perianal pruritus and mild pain and clinically by a ring of perianal erythema and edema. It is most common in prepubertal children but also occurs in adults. Several members of one family may be infected simultaneously, some with streptococcal pharyngitis and others with perianal cellulitis. [37] In some patients, a coexisting GABHS proctocolitis and vulvovaginitis may occur. Subjective findings include pruritus, painful defecation, fecal hoarding behavior, and blood staining the underpants in these children. A well-demarcated erythematous plaque is seen perianally.

REFERENCES

1. Auvert B et al: Male circumcision and HIV infection in four cities in sub-Saharan Africa. *AIDS* **15** (suppl 4):S31, 2001

2. Mallon E et al: Circumcision and genital dermatoses. *Arch Dermatol* **136**:350, 2000

3. Das S, and Tunuguntla HS: Balanitis xerotica obliterans: A review. *World J Urol* **18**:382, 2000

4. Kiss A et al: The response of balanitis xerotica obliterans to local steroid application compared with placebo in children. *J Urol* **165**:219, 2001

5. Tang A et al: Plasma cell balanitis of Zoon: Response to Trimovate cream. *Int J STD AIDS* **12**:75, 2001

6. Dillner J et al: Etiology of squamous cell carcinoma of the penis. *Scand J Urol Nephrol Suppl* **205**:189, 2000

7. Riddell L et al: Clinical features of lichen sclerosus in men attending a department of genitourinary medicine. *Sex Transm Infect* **76**:311, 2000

8. Aynaud O et al: Incidence of preputial lichen sclerosus in adults: Histologic study of circumcision specimens. *J Am Acad Dermatol* **41**:923, 1999

9. von Krogh G, Horenblas S: Diagnosis and clinical presentation of premalignant lesions of the penis. *Scand J Urol Nephrol Suppl* **205**:201, 2000

10. Wieland U et al: Erythroplasia of Queyrat: Coinfection with cutaneous carcinogenic human papillomavirus type 8 and genital papillomaviruses in a carcinoma in situ. *J Invest Dermatol* **115**:396, 2000

11. Rubin MA et al: Detection and typing of human papillomavirus DNA in penile carcinoma: Evidence for multiple independent pathways of penile carcinogenesis. *Am J Pathol* **159**:1211, 2001

12. van Bezooijen BP et al: Laser therapy for carcinoma in situ of the penis. *J Urol* **166**:1670, 2001

13. Stables GI et al: Erythroplasia of Queyrat treated by topical aminolaevulinic acid photodynamic therapy. *Br J Dermatol* **140**:514, 1999

14. Cubilla AL et al: Warty (condylomatous) squamous cell carcinoma of the penis: A report of 11 cases and proposed classification of “verruciform” penile tumors. *Am J Surg Pathol* **24**:505, 2000

15. Bezerra AL et al: Clinicopathologic features and human papillomavirus dna prevalence of warty and squamous cell carcinoma of the penis. *Am J Surg Pathol* **25**:673, 2001

16. Gibson GE, Ahmed I: Perianal and genital basal cell carcinoma: A clinicopathologic review of 51 cases. *J Am Acad Dermatol* **45**:68, 2001

17. Park S et al: Extramammary Paget's disease of the penis and scrotum: Excision, reconstruction and evaluation of occult malignancy. *J Urol* **166**:2112, 2001

18. Mohsin SR et al: Cutaneous verruciform xanthoma: A report of five cases investigating the etiology and nature of xanthomatous cells. *Am J Surg Pathol* **22**:479, 1998

19. Barnhill RL et al: Genital lentiginosis: A clinical and histopathologic study. *J Am Acad Dermatol* **22**:453, 1990

20. Oldbring J, Mikulowski P: Malignant melanoma of the penis and male urethra: Report of nine cases and review of the literature. *Cancer* **59**:581, 1987

21. Larsson KB et al: Primary mucosal and glans penis melanomas: The Sydney Melanoma Unit experience. *Aust NZ J Surg* **69**:121, 1999

22. Honda S et al: Six cases of metastatic malignant melanoma with apparently occult primary lesions. *J Dermatol* **28**:265, 2001

23. Leal-Khouri S, Hruza GJ: Squamous cell carcinoma developing within lichen planus of the penis: Treatment with Mohs micrographic surgery. *J Dermatol Surg Oncol* **20**:272, 1994

24. Dini M, Colafranceschi M: Should scrotal calcinosis still be termed idiopathic? *Am J Dermatopathol* **20**:399, 1998

25. Stern RS: Genital tumors among men with psoriasis exposed to psoralens and ultraviolet A radiation (PUVA) and ultraviolet B radiation: The Photochemotherapy Follow-up Study. *N Engl J Med* **322**:1093, 1990

26. Aubin F et al: Genital squamous cell carcinoma in men treated by photochemotherapy: A cancer registry-based study from 1978 to 1998. *Br J Dermatol* **144**:1204, 2001

27. Gatto-Weis C et al: Ulcerative balanoposthitis of the foreskin as a manifestation of chronic lymphocytic leukemia: Case report and review of the literature. *Urology* **56**:669, 2000

28. Ben-Sira L, Laor T: Severe scrotal pain in boys with Henoch-Schonlein purpura: Incidence and sonography. *Pediatr Radiol* **30**:125, 2000

29. Wei H et al: Multiple indurated papules on penis and scrotum *J Cutan Med Surg* **4**:202, 2000

30. Alkemade JA et al: Delayed diagnosis of glucagonoma syndrome. *Clin Exp Dermatol* **24**:455, 1999

31. Fujimoto N et al: Metastasis to the penis in a patient with squamous cell carcinoma of the lung with a review of reported cases. *Lung Cancer* **34**:149, 2001

32. Bang D et al: Epidemiologic and clinical survey of Behcet's disease in Korea: The first multicenter study. *J Korean Med Sci* **16**: 615, 2001

33. Basoglu M et al: Fournier's gangrene: Review of fifteen cases. *Am Surg* **63**:1019, 1997

34. Aboulafia DM, Gibbons R: Penile cancer and human papilloma virus (HPV) in a human immunodeficiency virus (HIV)–infected patient. *Cancer Invest* **19**:266, 2001

35. Penn I: Cancers of the anogenital region in renal transplant recipients: Analysis of 65 cases. *Cancer* **58**:611, 1986

36. Palefsky JM et al: Effect of highly active antiretroviral therapy on the natural history of anal squamous intraepithelial lesions and anal human papillomavirus infection. *J AIDS* **28**:422, 2001

37. Barzilai A, Choen HA: Isolation of group A streptococci from children with perianal cellulitis and from their siblings. *Pediatr Infect Dis J* **17**:358, 1998

T>

Chapter 114

Libby Edwards

Diseases and Disorders of the Anogenitalia of Females

THE VAGINA
COMMON NORMAL VARIANTS
INFLAMMATORY DERMATOSES
Eczema/Lichen Simplex Chronicus
Irritant Contact Dermatitis
Allergic Contact Dermatitis
Psoriasis
Candida Vulvovaginitis
Lichen Sclerosus (et Atrophicus)
Vulvar Fissures
BULLOUS AND EROSIVE DISEASES
Lichen Planus
Stevens-Johnson Syndrome, Toxic Epidermal Necrolysis (Bullous Erythema Multiforme)
Cicatricial Pemphigoid
Pemphigus Vulgaris
Fixed Drug Eruption
ULCERS
Aphthae
Crohn's Disease
Hidradenitis Suppurativa
VULVODYNIA (VULVAR DYSESTHESIA)
PRURITUS VULVAE

REFERENCES

The diagnosis of vulvar skin disease and the management of women with such conditions require modification of some dermatologic principles, evaluation for and correction of vaginitis, and careful patient education regarding expectations and therapy. In general, women with vulvovaginal symptoms assume that their problems are produced by a curable infectious disease, particularly a yeast infection. Patients require reassurance and an explanation that dermatoses generally are controllable, although not curable. These women cannot be evaluated and treated in a 10-minute office visit; rather, they require adequate time for reassurance and education.

Vulvar skin disease, even more than skin disease in other areas of the body, is often multifactorial with subtle clinical abnormalities sometimes causing significant symptoms. Vulvar skin disease is often accompanied and driven by a secondary yeast infection or bacterial colonization, even in the absence of obvious clincal findings. The infection can be purely cutaneous, purely vaginal, or both. Thus vaginal secretions should be examined microscopically or cultured. Irritant contact dermatitis from multiple applied topical agents often exacerbates the symptoms.

Extremely severe itching and pain of the vulva are sometimes associated with unimpressive physical findings. Lichenification manifested only by a slight texture change can be associated with excruciating pruritus deserving of and responsive to aggressive therapy. Many clinicians make the mistake of overlooking or dismissing subtle physical findings.

The warm, moist environment of the vulva produces an altered morphology of some diseases. For example, scaling dermatoses may lack clinically obvious scale, and diseases that usually exhibit well-demarcated plaques may be less well formed. In addition, diseases that normally do not produce scarring of keratinized skin or oral mucosa can induce agglutination (resorption) of the labia minora, narrowing of the introitus, and scarring of the clitoral hood. Thus vulvar scarring can occur from any inflammatory condition, including lichen sclerosus, lichen planus, pemphigus vulgaris, and even a single episode of a blistering form of erythema multiforme.

THE VAGINA

Vulvar symptoms cannot be divorced from vaginal abnormalities. Irritating or infected vaginal secretions are a common cause of vestibulular (introital) symptoms. Vaginal cultures sometimes yield surprises such as a nonalbicans *Candida* infection, a pathogen that can be responsible for significant symptoms but is difficult to see on microscopic smears. However, a microscopic evaluation of vaginal smears can be extremely helpful and generally is more important than an examination of the vaginal mucosa. In addition to an inspection for *Candida albicans, Trichomonas,* and bacterial vaginosis, a microscopic examination for other abnormalities such as an increased number of white blood cells or the presence of immature epithelial cells is important. These abnormalities may be markers for inflammatory skin diseases such as lichen planus or other causes of desquamative inflammatory vaginitis, for estrogen deficiency, for a foreign body, or for a pyogenic bacterial infection.

Normal women of childbearing age and postmenopausal women on adequate estrogen-replacement therapy exhibit moist, pink mucous membranes with prominent vaginal rugae. Normal vaginal secretions show mature, differentiated epithelial cells that are large, flattened, and cuboidal with small nuclei. Immature epithelial cells are rounded basaloid cells that are shed from erosions or from thin, fragile, poorly estrogenized epithelium. Immature epithelial cells serve as a sign of erosions, extreme inflammatory disease, or estrogen deficiency. Epithelial cells that are stippled with surface bacteria and have borders obscured by these bacteria (clue cells) are markers for bacterial vaginosis.

Scattered white blood cells are usual, in a ratio of one or fewer leukocytes to one epithelial cell. Significantly more white blood cells suggest bacterial vaginitis, *Trichomonas,* or noninfectious inflammation. Abundant lactobacilli in the form of long rods are normally present and produce an acidic vaginal pH. Lactobacilli are often absent when vaginal inflammation is intense, and lactobacilli are always lacking when estrogen levels are low.

Group B *Streptococcus* (*Streptococcus agalactiae*) is often cultured from the asymptomatic vagina and generally is regarded as colonizing bacteria. More recently, there is evidence that this organism is sometimes associated with vulvovaginal inflammation. [1]

COMMON NORMAL VARIANTS

Erythema of varying degrees is present in most asymptomatic premenopausal women, but this redness is rarely noticed before the onset of discomfort. Several normal structures can resemble genital warts. Vulvar papillae, a common normal variant, are monomorphous, soft, tubular papillae with rounded tips seen in up to half of premenopausal women. These differ from warts by their monomorphous, symmetric distribution. Some patients demonstrate a variant of vulvar papillae characterized by diffuse plaques of short, dome-shaped, discrete but closely set papules that form a monotonous, cobblestoned texture.

Some physicians presume that whitening of the epithelium after the application of 5% acetic acid (white vinegar) to the vulva (*acetowhitening*) is diagnostic of genital warts or epithelial dysplasia. However, this is a nonspecific sign that occurs with any inflamed, acanthotic, or hyperkeratotic skin, as well as in the normal skin of many women. Acetowhite skin should be biopsied before making a diagnosis of wart, although some pathologists overcall human papillomavirus infection because of the presence of pseudokoilocytes.

Fordyce spots are prominent sebaceous glands that occasionally are confused with genital warts. These occur as normal findings on the modified mucous membranes of most premenopausal women. Although Fordyce spots were once believed to produce itching, they are now known to be common, normal findings.

The labia minora exhibit a wide range of asymmetry and size, which is usually obvious to the examiner. However, normal but very small labia minora may be difficult to differentiate from agglutination produced by inflammatory skin disease.

Although a wide range in color, consistency, and volume of vaginal secretions is normal, any changes are likely to be interpreted by the patient as infection, particularly yeast. The quantity of vaginal secretions varies among women both by time of the menstrual recycle and as a result of other poorly understood factors unrelated to infection or disease. Some women experience copious secretions that are otherwise normal. Vaginal secretions that have an acid pH of less than 5.0, mature epithelial cells, normal numbers of leukocytes, no yeast forms, no *Trichomonas,* no clue cells, multiple lactobacilli, and a negative culture indicate an absence of pathology. This diagnosis of a physiologic discharge is unpopular with patients, and some of these patients can be irritated by the ever-present moisture. However, careful patient education can end an ongoing search for diagnosis. Sometimes excess wetness from a “vaginal discharge” is actually perspiration from the groin area, and the problem can be controlled by an antiperspirant.

Some patients also complain of unpleasant odor. Although bacterial vaginosis is the classic cause, some patients are unaware that vulvovaginal odor is normally present in varying degrees. Sometimes perceived vaginal odor is actually skin odor, and this can be controlled by the application of a deodorant.

INFLAMMATORY DERMATOSES

Clinically subtle inflammation of the vulva sometimes produces remarkable symptoms. Therefore, a very careful examination with a high index of suspicion for a dermatosis is required.

Eczema/Lichen Simplex Chronicus

The most common inflammatory but noninfectious dermatosis is eczema (atopic dermatitis, lichen simplex chronicus). The morphologic manifestations of this disease when it occurs on the vulva vary from remarkable lichenification, edema, and even elephantiasis nostra verrucosum to minimal hyperpigmentation and dullness of texture of the modified mucous membranes (Fig. 114-1 and Fig. 114-2). Erythema can be subtle on the labia majora because hair obscures the skin, and the modified mucous membranes are normally pink. Sometimes, hydrated, thickened eczema appears white, mimicking lichen sclerosus or premalignant leukoplakia of intraepithelial neoplasia (Fig. 114-3). Excoriations and fissures within skin folds are common but heal quickly and may not be seen in the office.

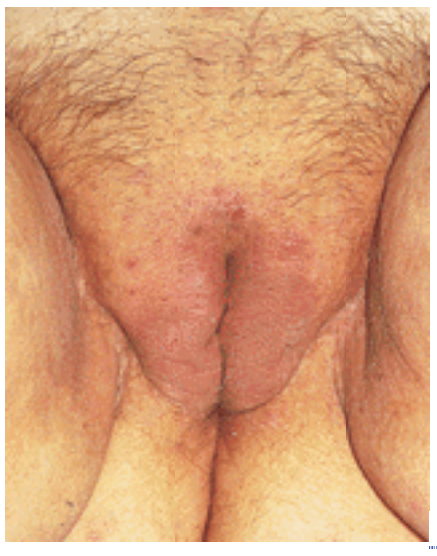

FIGURE 114-1 Dusky erythema, lichenification, excoriations, and loss of hair from rubbing are classic findings of skin eczema. Staphylococcal folliculitis as seen in this patient demonstrates the frequent occurrence of a secondary infection that often drives pruritus.

FIGURE 114-2 Often clinical findings in patients with very symptomatic eczema are minimal, with lichenification of the inner right labium majus most notable when the texture of the left modified mucous membrane is compared to that of the right.

FIGURE 114-3 When occurring in moist areas such as the vulva, the acanthosis of eczema frequently appears white, mimicking the clinical findings of lichen sclerosus or lichen planus.

Although the histology, differential diagnosis, and therapy are the same for vulvar eczema as for eczema on other parts of the body, there are several notable modifications in the management of vulvar eczema. Subtle skin and vaginal infections are extremely common and often drive eczema. Therefore, a vaginal culture should be performed on any patient who does not improve as expected or who requires ongoing middle- or high-potency topical glucocorticoid therapy for control. A negative microscopic examination of a vaginal smear is an inadequate evaluation. As with eczema in other areas, nighttime sedation is crucial to interrupt the itch-scratch cycle. However, moisturization is not needed because of the occluded, naturally moist nature of the skin. In fact, the occlusive property of lubricants sometimes can increase pruritus.

Topical glucocorticoid therapy is a mainstay in the treatment of eczema, but prompt alleviation of symptoms often requires a higher-potency preparation than is standard for intertriginous skin. Although a low-potency glucocorticoid usually is recommended for genital skin, most patients with vulvar eczema are much better served with a high-potency glucocorticoid initially. Those with significant lichenification do well with an ultrapotent preparation such as clobetasol propionate for the first few weeks. However, these patients should be reevaluated monthly and warned about side effects in the surrounding areas where atrophy is especially likely to occur, such as the inguinal crease, proximal medial thighs, and perianal skin. The potency or frequency can be decreased as the patient improves.

Although tacrolimus or pimecrolimus can be used on vulvar skin, there is little experience with these medications. Stinging can occur with initial application, although this is generally well tolerated.

Patients with eczema that is not intensely inflamed or excoriated generally prefer medications in a cream base because an ointment can be too occlusive. However, inflamed or eroded vulvar skin often stings when treated with a cream or a gel.

Irritant Contact Dermatitis

Irritant contact dermatitis is a common complicating factor in vulvar symptoms. A patient with vulvar symptoms will have tried multiple local therapies by the time she sees a dermatologist. Topical medications, washing, soaps, and home remedies are the most common causes of a chronic irritant contact dermatitis. Because soap and water, douches, disinfectants, and very hot or cold water often are not considered relevant, the use of these home remedies frequently is not volunteered by patients, and very careful questioning is warranted.

The resulting chronic irritant contact dermatitis is characterized by poorly demarcated erythema or hyperpigmentation that can be difficult to appreciate because the vulva normally is pink or dusky. Lichenification, scale, and pruritus are suggestive of either this diagnosis, chronic allergic contact dermatitis, or eczema. Often the skin appears nearly normal.

Acute irritant dermatitis occurs most often in response to caustic therapies such as fluorouracil or podophyllum resin for genital warts. In addition, some topical antifungal creams can produce an immediate and brisk reaction, as can topical gentian violet therapy, a medication used by some gynecologists for unusually recalcitrant vulvovaginal yeast infections. An acute irritant contact dermatitis is essentially a chemical burn, so the diagnosis is relatively easy because the patient experiences immediate burning on contact with the offending substance. Deeper erythema is common; vesiculation can occur on keratinized skin, whereas erosion is usual on modified mucous membranes.

An irritant contact dermatitis also can obscure underlying disease, and women with chronic symptoms often are well served by discontinuing all topical therapies. Cleansing can be a accomplished by gentle flushing of the area once a day with clear water (or mild soap and water) and patting the area dry. Triamcinolone ointment 0.1% applied twice daily can hasten improvement. Reevaluation 1 or 2 weeks later may reveal the underlying process.

Allergic Contact Dermatitis

Vulvar dermatoses can be complicated by allergic contact dermatitis. This is true in part because of exposure to multiple allergens in the form of medications and cleansers applied to alleviate symptoms and in part because the vulvar skin is thin, damp, and permeable. Although the British have found allergic contact dermatitis to be a common finding on the vulva, American physicians report few relevant positive patch tests on patients with eczematous vulvar skin. [2], [3] However, women with refractory vulvar symptoms should be evaluated clinically and historically for allergic contact dermatitis.

Allergic contact dermatitis of the genital area often presents somewhat differently than allergic contact dermatitis of dry, keratinized skin. The classic confluent vesicles that normally result from acute allergic contact dermatitis often erode as quickly as they form on the vulva, producing exudative, painful plaques. Chronic allergic contact dermatitis is manifested more often by erythema, which is often mild, and edema, which can be subtle in this area with loose connective tissue. Scale is frequently inapparent. More severe chronic disease can produce lichenification and secondary changes due to itching and scratching, causing the physician to make a diagnosis of eczema and to overlook an underlying allergic contact dermatitis.

Common allergens include topical medications such as diphenhydramine, neomycin, polymyxin, sulfonamides, some anesthetics, some antifungal creams, spermacides, glucocorticoids, some antiseptics, and preservatives and fragrances. As can occur with eyelid dermatitis, allergens can be carried inadvertently from fingertips to the vulva during the course of scratching or wiping. In addition, the habits of sexual partners can be important. For example, a woman allergic to latex can experience symptoms caused by a rubber condom (*consort dermatitis*).

The therapy for vulvar allergic contact dermatitis is the same as for this disease occurring in other areas.

Psoriasis (See Chap. 42)

Although vulvar psoriasis generally is accompanied by psoriasis in other typical locations, the vulva is a common site of initial involvement. Vulvar psoriasis usually affects only fully keratinized skin, sparing the modified mucous membrane of the inner labia majora and the labia minora. Vulvar psoriasis typically exhibits dusky red, well-demarcated, scaling plaques. Most often the scale is not typical psoriasiform scale but is more likely to exhibit the moistness of inverse psoriasis or a glazed, shiny surface texture. Extension of erythema into the gluteal cleft is characteristic of psoriasis.

Therapy for genital psoriasis is difficult. First-line therapy consists of a topical glucocorticoid. A middle- or high-potency glucocorticoid generally is required for significant clinical or symptomatic improvement. Glucocorticoid atrophy is surprisingly uncommon on the modified mucous membranes of the vulva, but the proximal medial thighs, the crural crease, and the perianal skin become atrophic quite easily. Calcipotriene ointment can be tried as well, but some patients find this too irritating. Some clinicians suggest topical tar as a useful therapy, but this medication should be used carefully because of irritation in skin folds of some patients. Tar can be used in a bath or as a 5% liquor carbonis detergens mixed with topical glucocorticoid cream applied twice daily. Most often vulvar psoriasis is controlled adequately by a topical glucocorticoid, but otherwise, systemic medications such as methotrexate, oral retinoids, and cyclosporine are required.

Of paramount importance to the comfort of women with psoriasis is control of local factors. The thickened epithelium, scale, warmth, and moisture promote infection and maceration. Yeast infections are especially common, particularly when patients are treated with topical glucocorticoids. The identification of infection on red, scaling, and often exudative skin can be difficult and should be pursued actively in patients with recalcitrant symptoms. Patients with recurrent documented yeast infections can be maintained free of *Candida albicans* with fluconazole 150 mg by mouth each week.

Candida Vulvovaginitis

Although most *Candida* infections produce mild or no erythema of the vulva, this infection is occasionally accompanied by deeply erythematous plaques with scale and peripheral erosions, pustules, or collarettes. Because warm, damp skin folds are a good environment for yeast, skin fold fissures are especially common. Vulvar candidiasis is often prominent in women who have treated their *Candida* vaginitis with an intravaginal topical antifungal medication, neglecting the vulva.

Candida vulvitis can be treated effectively in any of several ways. Topical azole creams applied two to four times a day are the most commonly prescribed therapies. However, cream vehicles sometimes produce unacceptable stinging on very inflamed vulvar skin. Nystatin is available in a soothing ointment base. The vagina generally also requires treatment when topical medications are used. Oral fluconazole is effective for the vulva and vagina in a single 150-mg dose.

Lichen Sclerosus (et Atrophicus)

Lichen sclerosus et atrophicus, its name now shortened to *lichen sclerosus* by the International Society for the Study of Vulvovaginal Disease, is a skin disease that occurs most often on vulvar skin. Other names include *kraurosis vulvae* and *hypoplastic dystrophy*. The disease usually occurs on the vulva, although occasionally it can be found on the glans penis and on other keratinized skin surfaces. Previously, lichen sclerosus was believed to occur most often in postmenopausal women, but it is now known that this disease occurs in all ages but tends to be most symptomatic in a setting of the estrogen deficiency of early or late life.

A likely but unproven etiology is that of an autoimmune mechanism. [4] Lichen sclerosus clusters with other autoimmune diseases, and histologic similarities exist between lichen sclerosus and several other immunologically mediated skin diseases, including lichen planus, graft-versus-host diseases, and lupus erythematosus. Other theories include abnormalities of keratin synthesis and defects in androgen metabolism or receptor function. [5] Abnormal keratins, decreased collagenase, increased collagen inhibitors, and an increase in elastase activity all have been reported as well. [6] Although an association of both lichen sclerosus and morphea with serologic evidence of past *Borrelia bergdorferi* infection, has been documented in some areas, women in the United States with vulvar lichen sclerosus have not exhibited increased seropositivity to this organism. [7] Finally, there is a known but small hereditary predisposition for this disease.

Lichen sclerosus begins asymptomatically in most patients. Many women, by the time they are seen with the classic symptoms of itching or pain, exhibit late signs of lichen sclerosus, including remarkable textural changes and scarring. Often women tolerate their disease comfortably until they develop a superimposed complicating event, such as candidiasis or atrophic vaginitis, that produces itching followed by scratching, and the process becomes self-perpetuating.

The most common symptom is that of pruritus. Itching can be mild or severe. Because vulvar skin affected by lichen sclerosus is fragile, scratching often produces painful erosions. With late scarring and narrowing of the introitus, pain with, and even an inability to tolerate, intercourse may occur.

Lichen sclerosus begins with white papules or plaques that often occur first on the anterior vulva and periclitorally. Although these papules and plaques are sometimes smooth and somewhat waxy, especially when occurring on moist skin, the classic presentation is one of a hypopigmented, well-demarcated plaque with a crinkled or cellophane paper–like texture (Fig. 114-4). Although other diseases such as lichen planus can produce hypopigmentation and scarring, this characteristic crinkled texture occurs only in lichen sclerosus. Generally, the skin is quite fragile and thin, with erosions and purpura being common manifestations. Some women, particularly those who are excruciatingly itchy, exhibit thickened, hyperkeratotic skin and accompanying changes of eczema.

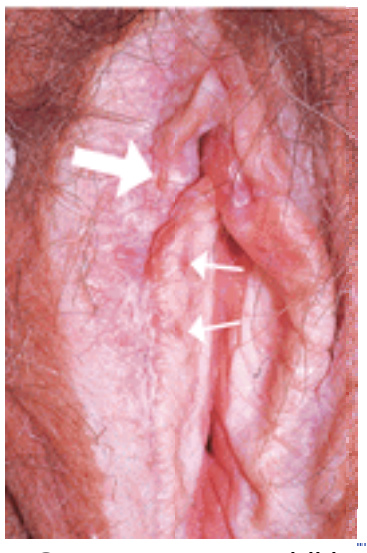

FIGURE 114-4 In addition to the well-demarcated, white vulvar plaque that is classic for lichen sclerosus, the waxy or crinkled texture, purpura (*small arrows*), and erosions (*large arrow*) are diagnostic.

Many patients with lichen sclerosus experience progressive scarring. Resorption of the labia minora and scarring of the clitoral hood, which buries the clitoris, are common in long-standing disease (Fig. 114-5). Although this end result is classic for lichen sclerosus, it is a nonspecific scarring caused also by lichen planus, cicatricial pemphigoid, and other chronic, inflammatory dermatoses that affect the modified mucous membranes of the vulva.

FIGURE 114-5 Late lichen sclerosus results in resorption of the labia minora and clitoral hood and narrowing of the introitus. A thickened, white hyperkeratotic squamous cell carcinoma at the posterior fourchette (*arrow*) required a conservative vulvectomy in this elderly woman with recalcitrant disease.

Unfortunately, lichen sclerosus is sometimes subtle or a mimic of other diseases. Superimposed changes of eczema and hyperkeratosis can obscure underlying pathognomonic texture changes. Because an ultrapotent glucocorticoid dramatically improves both eczema and lichen sclerosus, diagnostic changes of lichen sclerosus may not be obvious clinically. Occasionally, lichen sclerosus lacks the characteristic white color or texture. These patients deserve a skin biopsy, although in this circumstance initial biopsies are sometimes nondiagnostic.

Lichen sclerosus never affects the vagina. Published reports of oral lesions of lichen sclerosus exist but are extremely uncommon. [8] However, some clinicians report caring for a number of patients with oral lesions clinically and histologically typical for lichen sclerosus. Oral lesions morphologically and microscopically characteristic of lichen planus also have been described in women with lichen sclerosus, and the coexistence of vulvar lichen sclerosus and vulvar lichen planus is reported. Extragenital lichen sclerosus of keratinized skin occurs in a minority of women with vulvar lichen sclerosus, and lesions most often are located on the upper trunk and arms. Usually, extragenital lesions are asymptomatic.

Although an association of lichen sclerosus with circulating autoantibodies has been reported, there are no associations with autoimmune diseases sufficient to prompt laboratory testing. Well-developed lichen sclerosus has an easily recognized histologic picture, although very early or late disease may be quite subtle. Thinning and effacement of the epidermis with hyperkeratosis is usual, although acanthosis is present occasionally. A chronic inflammatory infiltrate is present in early lesions in the upper dermis, abutting the epidermis. Vacuolar degeneration of the basal cell layer occurs, and a characteristic homogenization of the upper dermis is characteristic and pathognomonic. With later lesions, this zone of edematous and homogenized dermis displaces the inflammatory response from the upper dermis into the middermis.

Fully developed lichen sclerosus with hypopigmentation and distinctive shiny or crinkled texture changes is easily recognized. However, lichen sclerosus often is obscured by and mistaken for secondary lichen simplex chronicus. Also, disease with more subtle texture changes can be mistaken for vitiligo. Lichen planus occasionally exhibits uniform white papules or plaques and scarring that resembles lichen sclerosus, although vulvar lichen planus usually is accompanied by oral or vaginal disease. Also, lichen planus and lichen sclerosus occur together more often than predicted by chance. Scarring identical to that produced by lichen sclerosus also occurs with immunobullous disease and by any intensely inflammatory process. When doubt of the diagnosis exists, a biopsy is indicated because the course and long-term management of lichen sclerosus differ from those of these other diseases.

The management of patients with lichen sclerosus has become far easier in the past few years since the effectiveness of ultrapotent topical glucocorticoids such as clobetasol propionate has been realized. [9] Although midpotency topical glucocorticoids reduce symptoms, they do not normalize the skin texture or prevent scarring. The application of an ultrapotent topical preparation such as clobetasol propionate once or twice a day alleviates symptoms within a few days, but several months of therapy are required for reversion of the clinical texture and color changes to normal (Fig. 114-6 and Fig. 114-7). Patients should be followed monthly to monitor the skin for steroid side effects and for improvement so that the frequency of application can be decreased.

FIGURE 114-6 Prepubertal girls can develop lichen sclerosus, and this 11-year-old child has secondarily lichenified the area from rubbing despite the use of a midpotency topical glucocorticoid.

FIGURE 114-7 After 4 months of daily application of the ultrapotent glucocorticoid clobetasol propionate, the skin appears nearly normal. Although symptoms resolved within 1 week, prolonged therapy is required for adequate control.

Most patients require 3 to 5 months of once- or twice-daily application reach maximal improvement. Chronic maintenance therapy is required, but there is no proven optimal schedule. [10] Most patients do well with the chronic application of an ultrapotent glucocorticoid thrice weekly on an ongoing basis. Although this therapy eliminates itching and pain, restores a normal texture and resiliency to the skin, and usually eliminates hypopigmentation, any preexisting scarring of vulvar structures remains unchanged.

Most women very quickly experience dramatic relief from itching or pain with a superpotent glucocorticoid. However, women with especially severe itching or pain, patients with significant secondary eczematous changes or hyperkeratosis, and estrogen-deficient females, such as prepubertal children and postmenopausal women, often improve more quickly with additional therapy for the first 2 weeks to control scratching and secondary infection. Nighttime therapy with sedating doses of an antihistamine or a tricyclic antidepressant helps to control scratching and hasten healing. Women with hyperkeratosis, lichenification, and excoriation are likely to experience secondary bacterial infection with the addition of a topical glucocorticoid. This risk is also increased for patients whose skin is further thinned by low estrogen levels. Patients who appear to have secondary infection or who may be at high risk for this are best treated for the first 2 weeks with an oral antistaphylococcal antibiotic such as cephalexin, dicloxacillin, or erythromycin. Because the combination of antibiotics and glucocorticoids is particularly likely to allow for the development of a yeast infection, the clinician should seriously consider the addition of 150 mg of oral fluconazole weekly to prevent this occurrence during antibiotic therapy. Estrogen deficiency in postmenopausal women should be corrected with topical therapy, achieved by insertion of an estrogen cream or estradiol vaginal tablet three nights a week.

No other treatments for lichen sclerosus produce the striking and prompt benefit of ultrapotent glucocorticoid, and other therapies generally have shown benefit only in open-label series. Oral retinoids have been reported to be useful for some. [11] Beneficial effects have been reported with topical progesterone and topical estrogen, but the benefit is minimal and equivalent to that of lubrication alone. Topical tretinoin 0.025% sometimes produces improvement, but its usefulness is limited by its remarkable irritant properties. [12] An unduplicated report of benefit with oral potassium aminobenzoate also has been published. One case report describes a good outcome following treatment with the 585-nm flashlamp-pumped dye laser. The Chinese literature abounds with reports of benefit with traditional Chinese herbs and acupuncture for lichen sclerosus.

Although topical testosterone is a time-honored therapy for lichen sclerosus, its effectiveness has been substantiated almost exclusively by open trials rather than by placebo-controlled, double-blind studies. [13] Recent controlled trials have shown that topical testosterone and placebo are equally effective, producing a significant improvement in 66.6 and 75 percent of women, respectively. [14] Also, another study compared testosterone, its vehicle, and the ultrapotent glucocorticoid clobetasol propionate. [15] This trial showed that topical testosterone and vehicle produced similar improvement in patients but that clobetasol propionate exerted a far superior effect when compared with either. In addition, topical testosterone does not control lichen sclerosus after clearing by an ultrapotent corticosteroid, but the addition of this hormone tends to increase irritation. [16] At this time, there is no place for topical testosterone in the

treatment of any vulvar dermatosis.

In the past, surgical therapy, including cryotherapy, vulvectomy, and carbon dioxide laser vaporization, had been advocated for lichen sclerosus. Ablation of lichen sclerosus is regularly followed by recurrence. However, surgical intervention is required for patients who develop a secondary squamous cell carcinoma and for those whose lichen sclerosus is well controlled but who experience scarring that results in dysfunction. Surgery for scarring should never be performed before the skin disease has been controlled with glucocorticoid therapy. Surgery is also advocated by some physicians for the rare patient whose lichen sclerosus is not adequately treated medically. Although recurrence is expected, recurrent disease is sometimes better controlled with the early reinstitution of medical therapy.

Sometimes patients with lichen sclerosus who are treated with an ultrapotent glucocorticoid either fail to improve or experience a relapse following initial improvement. These women should be reexamined to evaluate them specifically for several events: (1) the possibility of an intercurrent bacterial or yeast infection, (2) the occurrence of contact dermatitis to the topical medication, cleansers, topical anesthetics, etc., (3) the presence of a secondary squamous cell carcinoma, and (4) the possibility of a different or additional diagnosis; e.g., erosive lichen planus can produce white plaques and scarring but often does not respond well to therapy.

Lichen sclerosus is not eliminated permanently by therapy, and disease recurs gradually when medication is discontinued. However, the disease generally can be controlled chronically with the twice- or thrice-weekly application of ultrapotent glucocorticoid, although this conclusion is supported only by anecdotal experience. Despite earlier reports that childhood vulvar lichen sclerosus generally remits spontaneously, more recent series show that most patients continue to exhibit signs but not necessarily symptoms of lichen sclerosus. [17]

Reports published before the advent of topical glucocorticoid therapy show that about 5 percent of patients develop a local squamous cell carcinoma in the natural course of lichen sclerosus. [18] Squamous cell carcinomas occur primarily in patients with chronic hyperkeratosis or erosions. Although the likelihood of intercurrent squamous cell carcinoma theoretically will decline as more patients receive topical glucocorticoid therapy, this is not yet supported by data, and patients should continue to be followed carefully.

Vulvar Fissures

Small, linear fissures on the vulva are common causes of dyspareunia, itching, and stinging. Sometimes these fissures present clinically as painful, erythematous lines in skin folds and at other times as obvious linear erosions.

Most well recognized are fissures at the posterior fourchette that split during intercourse (Fig. 114-8). These produce tearing pain initially, followed by burning and stinging when alkaline semen touches the area. The skin heals quickly, but splits recur with intercourse. The cause is unknown, although some patients exhibit tight, inelastic skin at the posterior fourchette, and others simply may have fragility of the area. The condition usually occurs suddenly, after years of comfortable coitus. Adequate lubrication and the woman positioned on top can minimize tearing. Otherwise, surgical excision is required, with the vertical fissure excised and the skin closed front to back with advancement of the vaginal mucosa to cover the area.

FIGURE 114-8 A posterior fourchette fissure is a painful, recurring split that occurs with intercourse.

Recurrent fissuring within skin folds of the vulva rather than the posterior fourchette is a much less well recognized but common cause of stinging and irritation of the vulva. Women typically complain of a sensation of “paper cuts.” Intercourse and tight clothing often are precipitating events. Clinically, subtle fissures or linear erythema occur within skin folds, especially in the interlabial sulci. Skin fold fissures result from any inflammatory dermatosis, including eczema, psoriasis, seborrhea, and lichen sclerosus. Isolated fissuring is associated most often with bacterial (especially group B *Streptococcus*) or *Candida* colonization or infection. When one of these factors is identified, treatment obviously is directed toward correction of infection or skin disease. When no specific underlying cause is found, a topical glucocorticoid ointment combined with an oral antibiotic and anticandidal medication usually eliminates this fissuring. However, almost immediate recurrence is common, and prolonged therapy may be required to break this cycle.

BULLOUS AND EROSIVE DISEASES

Lichen Planus (See Chap. 49)

Symptomatic vulvovaginal lichen planus is generally of the erosive form. Although formerly believed to be rare, an increased awareness of this disease has shown that it is actually very common, although exact numbers are not known. [19] Lichen planus is believed to be a disease of cell-mediated autoimmunity.

Vulvovaginal lichen planus presents with symptoms of itching, burning, rawness, and dyspareunia. Occurring most often in postmenopausal women, this disease has a very wide variety of clinical manifestations. Although vulvar lichen planus

usually is associated with oral and/or vaginal disease, accompanying lesions on keratinized skin are unusual. White, lacy, reticulate striae resembling papular oral lichen planus sometimes occur on the modified mucous membranes the vulva (Fig. 114-9). Less easily recognized are solid, uniformly hypopigmented, flat white plaques that mimic lichen sclerosus except for the absence of crinkled cellophane paper–like texture. Finally, erosive lichen planus sometimes is manifested by red, painful erosions that are either nonspecific or surrounded by typical white epithelial changes (Fig. 114-10).

FIGURE 114-9 Lichen planus of the modified mucous membranes of the vulva sometimes appears identical to lichen planus of the buccal mucosa, exhibiting white, lacy striae.

FIGURE 114-10 Lichen planus of the vulva also can show white, solid plaques that resemble lichen sclerosus, although the texture does not show the crinkled or waxy changes of lichen sclerosus. Erosive lichen planus is often manifested by nonspecific erosions, but a biopsy of any white surrounding epithelium, when present, is diagnostic.

Lichen planus, especially when erosive, produces remarkable scarring. Resorption of the labia minora and obliteration of the clitoris under an agglutinated clitoral hood are very common. Narrowing of the introitus occurs more often and more severely than with lichen sclerosus, and vaginal adhesions can close the vagina, preventing intercourse and introduction of the speculum. Rectal and perianal diseases are common and often produce pain.

Although nonerosive lichen planus of the vulva may appear bland, significant and symptomatic accompanying erosive vaginal disease is often present. Irritating inflammatory vaginal secretions can produce symptoms of introital burning and stinging due to an irritant contact dermatitis. Vaginal erosions are often obvious, appearing as bright-red patches, but sometimes equally painful disease can be more subtle and show only mild erythema on a speculum examination. However, an examination of vaginal smears is a sensitive test for the presence of a vaginal inflammation. Large, flat, cuboidal mature desquamated vaginal epithelial cells are replaced by smaller, rounded basal cells shed from erosions and rapidly proliferative inflamed vaginal epithelium (Fig. 114-11). Often vaginal secretions exhibit sheets of leukocytes as well.

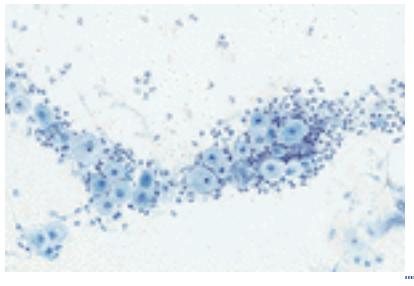

FIGURE 114-11 Although the vaginal erosions of lichen planus can be difficult to visualize, a microscopic examination of vaginal secretions can detect disease. An abundance of neutrophils and immature, rounded squamous epithelial cells shed from the base of erosions, rather than the usual large, flat, cuboidal mature surface cells, is characteristic.

Vulvovaginal lichen planus is usually accompanied by erosive oral disease. In addition to the more common buccal mucosa disease, erosive gingival lichen planus is likely to occur.

A biopsy normally shows irregular acanthosis, hyperkeratosis, hypergranulosis, and a lichenoid infiltrate with basal cell degeneration. Cytoid bodies are usual. On mucous membrane and modified mucous membrane skin, epidermal thinning and effacement are common, and parakeratosis rather than hypergranulosis may be seen.

The diagnosis of lichen planus is made either by the identification of classic lacy lesions in association with other typical mucous membrane lesions or by biopsy. Lichen planus is confused most often with lichen sclerosus because both produce hypopigmentation and scarring. However, lichen planus does not exhibit the characteristic texture changes of lichen sclerosus, and purpura is absent. In addition, lichen sclerosus essentially never affects the vagina or the mouth.

Mucosal immunobullous diseases can be indistinguishable from erosive lichen planus, as can blistering erythema multiforme and fixed drug eruptions. These diseases are differentiated by biopsy and onset.

Pruritic, noneroded, papular vulvar lichen planus is usually quite well managed simply by the application of a potent topical glucocorticoid. Unfortunately, severe erosive vulvovaginal lichen planus can be an extraordinarily difficult therapeutic problem.

The treatment of vaginal lichen planus is crucial for patient comfort. Standard therapy includes the use of an antibiotic for its anti-inflammatory effects. A common choice is oral clindamycin or doxycycline or topical clindamycin vaginal cream. Hydrocortisone acetate 25-mg rectal suppositories can be inserted nightly into the vagina as well. Any vulvar patient receiving both an antibiotic and a glucocorticoid should receive prophylactic anticandidal therapy such as oral fluconazole 150 mg each week.

Although topical cyclosporine has been found effective for oral lichen planus, its usefulness in vulvovaginal lichen planus is limited by its cost, its tendency to burn with application, and its minimal effectiveness. Other medications that have been reported primarily in open trials as useful for erosive mucous membrane lichen planus include hydroxychloroquine, oral retinoids, azathioprine, and cyclophosphamde. [20], [21] Although topical tacrolimus has been reported to be useful for vulvar lichen planus, this medication is irritating and, when inserted into the vagina, produces significant blood levels of medication. [22] Case reports suggest that some patients may improve with oral thalidomide, although some clinicians describe disappointing results in their patients. [23]

Meticulous local care with early treatment of infection, minimization of external irritants, and attention to superimposed atrophy of estrogen deficiency are important measures that enhance patient comfort. Emotional support and careful patient education regarding the nature disease, its prognosis, and its therapy are vital.

There is little tendency for erosive vulvovaginal lichen planus to remit. The severity tends to wax and wane, sometimes as a result of secondary infections, irritants, or stress but more often for no identifiable cause. Bursts of oral prednisone can be helpful for flares.

Finally, squamous cell carcinoma has been well described in patients with erosive genital lichen planus. The magnitude of this risk is not known, but patients should be evaluated for this regularly.

Stevens-Johnson Syndrome, Toxic Epidermal Necrolysis (Bullous Erythema Multiforme) (See Chap. 58)

Blistering erythema multiforme nearly always affects mucous membranes, with the vulva and vagina frequently involved. Although the diagnosis is often obvious, many physicians do not specifically examine for or address complications of bullous erythema multiforme that are unique to the vulva and vagina.

Sometimes manifestations of blistering erythema multiforme are limited to oral and vulvovaginal erosions. In these patients, vulvar erosions generally are smaller than 1 cm, well demarcated, and sparing of surrounding hair-bearing skin. Frequently, surrounding inflammation is minimally apparent. With more severe disease, vulvovaginal blistering and erosions are often extensive. Secondary vulvovaginal infection is common, and permanent scarring including vaginal adhesions sometimes occurs. One retrospective survey of 40 women with toxic epidermal necrolysis revealed 28 with vulvovaginal involvement, of whom 5 experienced permanent scarring. [24] These patients were unable to engage in intercourse, even after corrective surgery.

Unfortunately, patients with severe disease at risk for significant sequelae are women who are extremely ill and little attention is given to their genitalia. However, as with eye involvement, local care during the serious phase of this illness can prevent long-term dysfunction arising from scarring. Prompt treatment of secondary bacterial or candidal infection may be important. In addition, daily insertion of a vaginal dilator or syringe cover can ensure patency.

Cicatricial Pemphigoid (See Chap. 62)

Cicatricial pemphigoid regularly produces multiple erosions, often without accompanying blisters on keratinized skin. Surrounding epithelium is sometimes white from hydrated hyperkeratotic skin. The nonspecific, painful erosions of the vulva and surrounding epithelium can be clinically indistinguishable from lichen planus and lichen sclerosus. Vulvar erosions generally are accompanied by nonspecific vaginal erosions that can, like lichen planus, eventuate in significant vaginal scarring. Like lichen planus, desquamative gingivitis and other oral mucosal erosions are usual. Eye involvement is much more common in cicatricial pemphigoid than in erosive lichen planus. A high index of suspicion and characteristic biopsies are required for this diagnosis in patients without blistering of keratinized skin.

Management consists of both local glucocorticoid therapy and traditional systemic treatments. Recently, intravenous immunoglobulin therapy has shown promise in the therapy of this disease. [25] Again, local care, the use of vaginal dilators, and secondary infection control are important factors in management.

Pemphigus Vulgaris (See Chap. 59)

Because pemphigus vulgaris often presents with mucosal erosions before the appearance of blisters or erosions on keratinized skin, this disease sometimes can be confused with erosive lichen planus, erythema multiforme, or cicatricial pemphigoid. The fragility of vulvovaginal epithelium results in deepening erosions that mimic those of cicatricial pemphigoid. In addition, although pemphigus vulgaris usually is considered to be a nonscarring disease, ulvovaginal involvement can eventuate in scarring, with obliteration of vulvar architecture and vaginal adhesions. As for cicatricial pemphigoid, a high index of suspicion and confirmatory biopsies are important in the correct diagnosis.

The mainstay of therapy is oral glucocorticoids, with antimetabolites conferring possible steroid-sparing effects. More recently, pulse intravenous cyclophosphamide therapy and oral mycophenolate have been reported beneficial. [26], [27]

Fixed Drug Eruption

Erosions due to fixed drug eruption sometimes occur on the vulva. Common offenders include acetaminophen, allopurinol, barbiturates, nonsteroidal anti-inflammatory medications, tetracyclines, penicillin, sulfa drugs, oral contraceptives, and furosemide. [28] These are most often located in the vestibule or on the modified mucous membranes of labia minora or medial labia majora. Unlike the classic, round, edematous plaques or blisters seen on keratinized skin, the erosions of a fixed drug eruption on the vulva are often irregular, sometimes with a slightly shaggy border (Fig. 114-12). Often there are one or a few typical lesions on keratinized skin, or there are oral erosions. The deepening hyperpigmentation seen on keratinized skin affected by recurrent fixed drug eruptions is usually absent on the modified mucous membranes of the vulva. This condition generally can be differentiated from other erosive diseases by the history of ingestion of a potentially causitive medication, the sudden onset, and the pattern of involvement.

FIGURE 114-12 A fixed drug eruption of the vulva occurs most often on the modified mucous membranes and may be round in shape, as seen here, or more irregular.

ULCERS

Aphthae (See Chap. 112)

The most common noninfectious ulcers of the vulva are aphthae. These usually occur in women who have a history of oral aphthae, although oral and genital ulcers may not be present concomitantly. These recurrent ulcerations occur most often on the modified mucous membrane of the vulva but are larger, more irregular, and deeper than oral aphthae (Fig. 114-13). Often, as with oral aphthae, the base of a vulvar lesion is covered with white fibin debris. Unlike oral aphthae, significant scarring may occur on the vulva. Some women experience only one episode of genital ulceration, whereas others develop frequently recurrent or chronic crops of ulcerations.

FIGURE 114-13 Aphthae of the vulva usually are larger and more irregular than those on the oral mucosa, and the base may show either the classic white fibrin or red granulation tissue.

The diagnosis is made after ruling out infectious causes of ulceration as well as sterile inflammatory diseases such as

Crohn's disease and hidradenitis suppurativa. Women without a typical history of recurrent aphthae or with atypical lesions should undergo biopsy. The treatment of vulvar aphthae is the same as when these ulcers occur in the mouth. A burst of oral prednisone is indicated when outbreaks are occasional. Topical potent glucocorticoid ointments can hasten healing of mild aphthae. Daily dapsone alone or with colchicine often suppresses or decreases the frequency and severity of aphthae, and thalidomide is very beneficial but toxic. [29], [30]

Crohn's Disease

Although this sterile disease of granulomatous inflammation primarily involves the bowel, vulvar and perianal skin sometimes are affected. Draining sinus tracts and fistulas from the bowel to the overlying skin are classic manifestations. However, cutaneous ulcers that do not extend to the bowel occur at times. These ulcers characteristically are linear, resemble lacerations, and lie in skin folds. Nonspecific painless, firm edema and erythema also can represent Crohn's disease. The diagnosis is made on the basis of a characteristic granulomatous biopsy and identification of the bowel disease. The primary disease to be differentiated from anogenital Crohn's disease is hidradenitis suppurativa (see below), and treatment consists of systemic therapy for underlying intestinal Crohn's disease. In addition to systemic glucocorticoids, infliximab and oral tacrolimus have been shown to be effective in some patients with Crohn's disease. [31], [32] Topical and intralesional glucocorticoids and local care can help to induce healing of ulcerations.

Hidradenitis Suppurativa (See Chap. 77)

Hidradenitis suppurativa, sometimes called *apocrine acne* or *inverse acne,* generally is manifested by red papules and nodules that suppurate and drain, sometimes causing ulcerations. Not only is the clinical presentation similar to that Crohn's disease, but these two conditions reportedly coexist more often than predicted by chance.

One manifestation of hidradenitis suppurativa is that of chronic ulceration as inflamed cysts break down. This can occur on keratinized, hair-bearing areas of the vulva but also can occur on the modified mucous membranes. Ulcerations are especially likely to occur in the setting of chronic edema.

The diagnosis is made by the setting and by the elimination of infectious causes. Ulcerations usually heal with long-term suppressive antibiotic therapy for the underlying disease. Although oral retinoids are useful in the short term, long-term results are poor. [33] Surgical excision is a treatment of choice, and removal of individual lesions is often practical and beneficial. [34], [35] More recently, cyclosporine and finasteride have been reported beneficial for some. [36], [37]

VULVODYNIA (VULVAR DYSESTHESIA)

Vulvodynia is the symptom of chronic vulvar burning, soreness, stinging, or rawness in the absence of objective physical signs. By definition, whenever a specific etiology is defined, the name of the causitive disease is substituted for the term *vulvodynia*. For example, pain produced by vaginal lichen planus is not referred to as *vulvodynia* but rather as *vaginal lichen planus*. Vulvodynia previously was held to be a rare occurrence, but this symptom now is known to be quite common. In the past, vulvodynia was believed to be a psychosomatic disease. By the 1980s, candidiasis (or hypersensitivity to colonizing yeast) was believed to cause vulvodynia, but the poor response of patients to antifungal therapy and recent evidence have shown yeast to be a minor factor in most patients. [38] Subclinical human papillomavirus infection is believed by some to produce vulvodynia, but this concept also has been shown to be unlikely in other studies. [39], [40] When all other causes of pain are ruled out, the cause of vulvodynia is believed to be neuropathic pain, especially complex regional pain syndrome. [41] Associated with and complicating neuropathy as a cause of vulvodynia is pelvic floor muscle dysfunction. [42]

Patients with vulvodynia describe burning, irritation, rawness, or soreness, often associated with self-perceived redness and swelling. Many of these women present with a presumed diagnosis of chronic yeast infections. Although an occasional patient with vulvodynia describes itching, this is a minor aspect of the symptomatology. She denies both scratching and pleasure with scratching. Usually, women report dyspareunia and pain with constrictive clothing. Women with vulvodynia are uniformly depressed, often anxious, and usually have experienced significant disruption in their lives and relationships.

There are no characteristic laboratory findings, and biopsies reveal only nonspecific chronic perivascular inflammation, sometimes with mild squamous hyperplasia. However, patients are likely to report an increased frequency of headaches, interstitial cystitis, irritable bowel syndrome, chronic fatigue syndrome, fibromyalgia, poor sleeping, and low energy levels.

Patients with vulvodynia should be examined carefully for any underlying skin disease or infection. Very subtle findings sometimes can produce very significant symptoms. Irritant contact dermatitis, vulvar fissures (see above), and lichen planus are the most common skin diseases to be mistaken for vulvodynia. A significant proportion of women with symptoms of vulvar dysesthesia are found to have a sterile, inflammatory vaginitis manifested by grossly and microscopically purulent vaginal secretions and immature epithelial cells similar to those seen with lichen planus. Biopsies are nonspecific, and a relationship of this inflammation to symptoms is sometimes tenuous.

Nonalbicans *Candida* infections such as *C. glabrata, C. krusei,* and *Saccharomyces cerevisiae* and vaginal group B streptococcal infection or colonization are the most common infections that can account for chronic vulvovaginal pain. These infections are easily missed without a culture and can be resistant to therapy. Often, when these infections are cleared, symptoms remit. However, these infections not infrequently are coincidental rather than causitive.

Women with vulvar dysesthesia fall into two major groups: those who experience provoked pain only at the introitus (pain only when touched and only in this localized area) and those who experienced unprovoked, spontaneous symptoms in

any area, not necessarily worsened by touch. [43] Pain limited to touch in the introitus is referred to as *vulvar vestibulitis,* whereas more generalized or migratory pain that is not necessarily provoked by touch is called *dysesthetic vulvodynia.* [44], [45] The primary importance of a distinction between these two groups is the management option of surgical excision in those women with introital, well-localized, provoked pain.

The management of women with vulvar dysesthesias first includes attention to depression and sexual dysfunction. Most patients benefit from referral for counseling to help these women cope with such debilitating symptoms. Local care and topical anesthetics improve day-to-day quality of life. The elimination of irritants, including overwashing and topical medications, can improve symptoms significantly. Topical lidocaine jelly 2% is useful for many patients.

Tricyclic antidepressants such as amitriptyline or desipramine, beginning at very low doses and increasing up to 150 mg or until the patient is comfortable, is a first-line treatment for neuropathic pain. [45] For women who do not tolerate tricyclic antidepressants or who experience suboptimal improvement, gabapentin has been used. [46]

Most women with vulvar pain syndrome exhibit abnormal pelvic floor muscle function that can contribute to their symptoms. These patients are more likely than symptom-free women to show abnormally high resting pelvic floor tension, fasiculations, but poor contractile strength on surface electromyography. These women benefit remarkably from pelvic floor rehabilitation and subsequently are able to engage in comfortable sexual activity. [47], [48] However, improvement is slow, and trial-and-error therapy with support by the physician is required frequently. Other anecdotal therapies include a low-oxalate diet with calcium citrate supplementation, topical estrogen, topical capsaicin, and chronic suppressive antifungal therapy. Acupuncture has been useful in a small open study as well. [50]

PRURITUS VULVAE

Like the burning of vulvar pain or irritation, itching can occur with minimal physical findings. The most common cause of acute itching is an infection, usually caused by *C. albicans*. Otherwise, even in the absence of significant physical findings, itching is often caused by eczema and responds well to empirical therapy with a topical corticosteroid, nighttime sedation, and control of infection.

A small proportion of women have itching and no clinical findings and do not respond to treatment for eczema. Additionally, these patients generally do not respond to topical doxepin, anesthetics, or tacrolimus. Some of these patients may have pruritus on the basis of neuropathy and respond to therapy directed toward this. In other women, depression and anxiety play a major role, and this must be addressed.

REFERENCES

1. Honig E et al: Can group B streptococcus cause symptomatic vaginitis? *Infect Dis Obstet Gynecol* **7**:206, 1999

2. Marren P et al: Allergic contact dermatitis and of vulvar dermatoses. *Br J Dermatol* **126**:52, 1992

3. Bauer A et al: Allergic contact dermatitis and patients with anogenital complaints. *J Reprod Med* **45**:649, 2000

4. Gross T et al: Identification of TIA+ and granzyme B+ cytotoxic T cells in lichen sclerosus et atrophicus. *Dermatology* **202**:198, 2001

5. Neill SM et al: The cytokeratin profile of normal vulval epithelium and vulval lichen sclerosus. *Br J Dermatol* **123** (suppl 37):62, 1990

6. Ridley CM: Lichen sclerosus. *Dermatol Clin* **10**:309, 1992

7. Fugiwara H et al: Detection of *Borrelia burgorferi* DNA (*B. garinii* or *B. afzelii*) in morphea and lichen sclerosus et atrophicus tissues of German and Japanese but not of U.S. patients. *Arch Dermatol* **41**:1133, 1997

8. de Araujo VC et al: Lichen sclerosus at atrophicus. *Oral Surg Oral Med Oral Pathol* **60**:655, 1985

9. Dalziel KL et al: The treatment of vulval lichen sclerosus with a very potent topical steroid (clobetasol propionate 0.05%) cream. *Br J Dermatol* **124**:461, 1991

10. Dalziel KL, Wojnarowski F: Long-term control of vulva lichen sclerosus after treatment with a topical steroid cream. *J Reprod Med* **38**:25, 1993

11. Bousema MT et al: Acetretin in the treatment of severe lichen sclerosus at atrophicus of the vulva: A double-blind, placebo-controlled study. *J Am Acad Dermatol* **30**:225, 1994

12. Virgili A et al: Open study of topical 0.025% tretinoin in the treatment of lichen sclerosus: One year of therapy. *J Reprod Med* **40**:614, 1995

13. Joura EA et al: Short-term effects of topical testosterone in vulvar lichen sclerosus. *Obstet Gynecol* **89**:297, 1997

14. Sideri M et al: Topical testosterone in the treatment of vulvar lichen sclerosus. *Int J Gynaecol Obstet* **46**:53, 1994

15. Bornstein J et al: Clobetasol dipropionate 0.05% versus testosterone propionate 2 topical application for severe vulvar lichen sclerosus. *Am J Obstet Gynecol* **178**:80, 1998

16. Cattaneo A et al: Testosterone maintenance therapy: Effects on vulvar lichen sclerosus treated with clobetasol propionate. *J Reprod Med* **41**:99, 1996

17. Ridley CM: Genital lichen sclerosus (lichen sclerosus at atrophicus) in childhood and adolescents. *J R Soc Med* **86**:68, 1998

18. Scurry JP, Vanin K: Vulvar squamous cell carcinoma and lichen sclerosus. *Australas J Dermatol* **38**(suppl 1):S20, 1997

19. Eisen D: The vulvovaginal gingival syndrome: The clinical characteristics of two patients. *Arch Dermatol* **130**:1379, 1994

20. Eisen D: Hydroxychloroquine sulfate (Plaquenil) improves oral lichen planus: An open trial. *J Am Acad Dermatol* **28**:609, 1993

21. Lear JT, English JS: Erosive and generalized lichen planus responsive to azathioprine. *Clin Exp Dermatol* **21**:56, 1996

22. Lener EV et al: Successful treatment of erosive lichen planus with topical tacrolimus. *Arch Dermatol* **137**:411, 2001

23. Camisa C, Popovski JL: Effective treatment of oral erosive lichen planus with thalidomide. *Arch Dermatol* **136**:1442, 2000

24. Meneux L et al: Vulvovaginal sequelae in toxic epidermal necrolysis. *J Reprod Med* **42**:153, 1997

25. Urcelay ML et al: Cicatricial pemphigoid treated with intravenous immunoglobulin. *Br J Dermatol* **137**:467, 1997

26. Fleischli ME et al: Pulse intravenous cyclophosphamde therapy in pemphigus. *Arch Dermatol* **135**:57, 1999

27. Enk AH et al: Mycophenolate is effective in the treatment of pemphigus vulgaris. *Arch Dermatol* **135**:54, 1999

28. Litt J: Drugs responsible for 100 common reaction patterns, in *Drug Eruption Reference Manual 2001,* edited by J Litt. New York, Parthenon Publishing Group, 2001, p 373

29. Rosen T, Brown TJ: Genital ulcers: Evaluation and treatment. *Dermatol Clin* **16**:673, 1998

30. Moraes M, Russo G: Thalidomide and its dermatologic uses. *Am J Med Sci* **34**:159, 1995

31. Panaccione R: Canadian Consensus Group on the use of infliximab in Crohn's disease. *Can J Gastroenterol* **15**:371, 2001

32. Ierardi E et al: Oral tacrolimus (FK 506) in Crohn's disease complicated by fistulae of the perineum. *J Clin Gastroenterol* **30**:200, 2000

33. Boer J, van Gemert MJ: Long-term results of isotretinoin in the treatment of 68 patients with hidradenitis suppurativa. *J Am Acad Dermatol* **41**:73, 1999

34. Endo Y et al: Perianal hidradenitis suppurativa: Early surgical treatment gets good results in chronic or recurrent cases. *Br J Dermatol* **139**:906, 1998

35. Golcman R: Subcutaneous fistulectomy in bridging hidradenitis suppurativa. *Dermatol Surg* **25**:795, 1999

36. Buckley DA, Rogers S: Cyclosporin-responsive hidradenitis suppurativa. *J Soc Med* **88**:289P, 1998

37. Farrell AM et al: Finasteride as a therapy for hidradenitis suppurativa. *Br J Dermatol* **141**:1138, 1999

38. Bornstein J et al: Pure versus complicated vulvar vestibulitis: A randomized trial of fluconazole treatment. *Gynaecol Obstet Invest* **50**:194, 2000

39. Bornstein J et al: A repetitive DNA sequence that characterizes human papillomavirus integration site into the human genome is present in vulvar vestibulitis. *Eur J Obstet Gynecol Reprod Biol* **89**:173, 2000

40. Orgoni M at al: Human papillomavirus with coexisting vulvar vestibulitis syndrome and vestibule or papillomatosis. *Int J Gynaecol Obstet* **64**:259, 1999

41. Cox JT: Deconstructing vulval pain. *Lancet* **345**:53, 1995

42. Glazer HI et al: Electromyographic comparisons of the pelvic floor in women with dysesthetic vulvodynia and asymptomatic women. *J Reprod Med* **43**:959, 1998

43. McKay M: Vulvodynia: Diagnostic patterns. *Dermatol Clin* **10**:423, 1992

44. Marinoff S, Turner MLC: Vulvar vestibulitis syndrome: An overview. *Am J Obstet Gynecol* **165**:1228, 1991

45. McKay M: Dysesthetic (“essential”) vulvodynia: Treatment with amitriptyline. *J Reprod Med* **38**:9, 1993

46. Ben-David B, Friedman M: Gabapentin therapy for vulvodynia. *Anesth Analg* **89**:1459, 1999

47. Bergeron S: A randomized comparison of group-behavioral therapy, surface electromyographic biofeedback, and vestibulodynia in the treatment of dyspareunia resulting from vulvar vestibulitis. *Pain* **91**:297, 2001

48. Glazer HI: Dysesthetic vulvodynia: Long-term follow-up after treatment with surface electromyography-assisted pelvic floor muscle rehabilitation. *J Reprod Med* **45**:798, 2000

49. McCormick WM, Spence MR: Evaluation of the surgical treatment of vulvar vestibulitis. *Eur J Obstet Gynecol Reprod Biol* **86**:135, 1999

50. Powell J, Wojnarowska F: Acupuncture for vulvodynia. *J R Soc Med* **92**:579, 1999

T>

Chapter 115

Amy Paller

Genetic Immunodeficiency Diseases

SIGNS OF IMMUNODEFICIENCY
ANTIBODY-DEFICIENCY DISORDERS
X-Linked Hypogammaglobulinemia
Common Variable Immunodeficiency
Selective Immunoglobulin Disorders
X-Linked Lymphoproliferative Disease (Duncan's Disease)
COMBINED ANTIBODY AND T CELL DEFICIENCY
Wiskott-Aldrich Syndrome
Ataxia-Telangiectasia
SEVERE COMBINED IMMUNODEFICIENCY
SELECTIVE T LYMPHOCYTE DISORDERS
Chronic Mucocutaneous Candidiasis
Di George Syndrome
Cartilage-Hair Hypoplasia Syndrome
Nezelof Syndrome
DISORDERS OF PHAGOCYTIC CELLS
Chronic Granulomatous Disease
Hyperimmunoglobulinemia E Syndrome
Leukocyte Adhesion Deficiency
Chédiak-Higashi Syndrome
Griscelli Syndrome
COMPLEMENT-DEFICIENCY DISORDERS
Leiner's Disease

REFERENCES

Immunodeficiency disorders may be associated with a variety of cutaneous abnormalities, and recognition of these clinical features may allow an early diagnosis of primary immunodeficiency. Cutaneous abnormalities may include cutaneous infections, atopic- or seborrheic-like dermatitis, macular erythemas, alopecia, poor wound healing, purpura, petechiae, telangiectasias, pigmentary dilution, cutaneous granulomas, angioedema, and lupus-like changes (Table 115-1). Other clinical consequences of impaired immunocompetence often include failure to thrive, visceral infection, autoimmune disorders, allergic reactions, and neoplasia.

TABLE 115-1 **Cutaneous Manifestations of Immunodeficiency Disorders**

The classification of genetic immunodeficiency disorders includes (1) disorders of lymphocytes, including antibody-deficiency disorders, severe combined immunodeficiency, partial combined immunodeficiency, and predominantly T cell defects; (2) disorders of phagocytic cells; and (3) disorders of complement proteins. The characteristic clinical signs of each group suggest proper classification, and laboratory tests may be employed to confirm the diagnosis. In the past decade, great advances have been made in the prenatal diagnosis of immunodeficiency, the elucidation of the underlying molecular basis of several immunodeficiencies, and early gene therapy.

SIGNS OF IMMUNODEFICIENCY

In general, immunodeficiency should be suspected when patients have recurrent infections of increased duration and severity, particularly with unusual organisms. Incomplete clearing of infections or poor response to antibiotics may be associated. Affected infants often grow poorly (failure to thrive). The most common noncutaneous abnormalities are infections, diarrhea, vomiting, hepatosplenomegaly, arthritis, adenopathy or lack of nodes where they would be expected, and hematologic abnormalities. The clinical characteristics of each group of immunodeficiency disorders are outlined in Table 115-2.

Features of antibody deficiency disorders
Recurrent infections with pathogenic extracellular encapsulated bacteria
Chronic sinopulmonary infections
Normal handling of fungal and viral infections, except enterovirus infections
Minimal growth retardation
Paucity of palpable lymphoid tissue (XLH)
Compatible with survival for many years except if persistent enteroviral infections, malignancy, or autoimmune disease
Features of cellular (T lymphocyte) immunodeficiency
Recurrent infections with low-grade or opportunistic infections, particularly with fungi, *Pneumocystis carinii*, and viruses
Growth retardation, wasting, diarrhea
Susceptible to graft-versus-host disease, fatal infections from live vaccines
High incidence of malignancy
Shortened life span
Features of neutrophil disorders
Recurrent skin and pulmonary infections
Lymphadenopathy, hepatosplenomegaly
Ulcerative stomatitis
Features of complement deficiency disorders (see Chaps. 33 and 117)
Autoimmune disorders (early components)
Bacterial infections, especially neisserial (alternative, late components)
Angioedema (C1 esterase inhibitor deficiency)

TABLE 115-2 **Classification of Genetic Immunodeficiency Disorders by Clinical Characteristics**

ANTIBODY-DEFICIENCY DISORDERS

X-Linked Hypogammaglobulinemia

X-linked hypogammaglobulinemia (XLH, Bruton's disease) is characterized by recurrent pyogenic infections that often begin approximately 9 months after birth with the disappearance of maternal immunoglobulins. [1], [2] Recurrent otitis, sinusitis, bronchitis, and staphylococcal pneumonitis are the earliest infectious manifestations and usually are caused by pneumococci, staphylococci, or *Haemophilus.* Untreated pulmonary infections may lead to chronic progressive bronchiectasis. Other common bacterial infections include conjunctivitis, osteomyelitis, septic arthritis, and meningitis. Protracted diarrhea may be due to infection, particularly with *Giardia, Salmonella, Campylobacter,* or *Cryptosporidium* spp.

Skin infections, especially furunculosis and impetigo, occur in 28 percent of patients and often surround body orifices. An atopic-like eczematous eruption that fails to improve with immunoglobulin therapy has been described in many affected children. Pyoderma gangrenosum and cutaneous granulomas have been reported. Childhood exanthematous disorders are handled appropriately, but the infections may recur owing to a failure to develop specific antibodies. Three virus groups cause problems: enterovirus, hepatitis B virus, and rotavirus. Patients have developed paralysis after administration of polio vaccine. A rheumatoid-like arthritis, characterized by chronic inflammation and swelling of the large joints, may develop in as many as one-third to one-half of boys with XLH and is often due to mycoplasmal infection (*Ureaplasma urealyticum*). Disseminated echovirus infection has caused meningoencephalitis and a dermatomyositis-like disorder with brawny edema, induration of the muscles with accompanying weakness, muscle contractures, and poikiloderma.

The underlying defect in XLH is a failure of maturation of the pre-B cell to a differentiating B cell; B cell precursors are found in the bone marrow in normal numbers. Serum concentrations of IgG, IgA, and IgM are far below the 95 percent confidence limits for appropriate controls (usually less than 100 mg/dL total immunoglobulin). Cell-mediated immunity is normal. Early intravenous immunoglobulin replacement markedly reduces the risk of infections, although it may not be helpful in diminishing the risk and morbidity of chronic enterovirus infection or of lymphoreticular malignancy (as high as 6 percent).

The gene for XLH encodes Btk (Bruton's or B cell tyrosine kinase). [3], [4] The *btk* gene is expressed early in B cell development but not in T cells or plasma cells; it is likely to be required for B cell maturation. Several mutations in all parts of the *btk* gene have been identified. Carrier detection is possible by analyzing the patterns of X-chromosome inactivation, with selective inactivation of the abnormal X chromosome in B lymphocytes from female carriers.

Common Variable Immunodeficiency

Common variable immunodeficiency (CVID) commonly presents in young adults, but 45 percent of cases are diagnosed before the age of 21 years. [5] Patients have infections similar to those in patients with XLH, particularly sinopulmonary infections, but are less susceptible to enteroviral infections and more susceptible to *Giardia* infections. Many patients with CVID have malabsorption syndromes; and noncaseating granulomas of skin (Fig. 115-1), lungs, liver, and spleen have been reported. Lymphoid tissues often are enlarged, and splenomegaly with hypersplenism is found in 25 percent of patients. Autoimmune disorders are especially frequent (22 percent), particularly autoimmune thrombocytopenia, autoimmune hemolytic anemia, rheumatoid arthritis, sicca syndrome, and pernicious anemia. Alopecia areata and lupus also have been described. In 11 percent of patients, other family members also are immunodeficient (hypogammaglobulinemia, IgA deficiency). The incidences of lymphoreticular malignancy and gastric carcinoma are markedly increased, particularly in the fifth and sixth decades of life. [6]

FIGURE 115-1 Noncaseating granulomas on the legs of a child with common variable immunodeficiency. Cultures and special stains showed no organisms.

Immunoglobulin levels may be as low as or lower than those in X-linked hypogammaglobulinemia probably because of intrinsic abnormalities in B cells. The numbers of circulating T and B lymphocytes are usually normal. Approximately one-half of patients have T cell dysfunction as well (Fig. 115-2), with the incidence increasing with advancing age. Molecular genetic studies have suggested that both CVID and IgA deficiency are linked to the same susceptibility gene, the complement 4A (C4A) locus on chromosome 6 in the class III major histocompatibility complex (MHC) region. [7]

FIGURE 115-2 Flat warts on the hands of a girl with CVID. The warts were widespread, including face, trunk, and extremities, and did not respond to therapy during a 3-year treatment period.

Selective Immunoglobulin Disorders

IgA deficiency occurs in approximately 1 in 600 persons, and most of those affected are healthy. However, affected individuals tend to have an increased incidence of upper respiratory tract infections (especially viral), allergies and atopic dermatitis, chronic gastroenteritis, and autoimmune disorders with circulating autoimmune antibodies. [8] Approximately one-third of patients with IgA deficiency have IgE anti-IgA antibody and risk transfusion reactions if immunoglobulin is given. Selective IgM deficiency is associated with an increased risk of pneumococcal and neisserial infections, warts, and eczema.

Patients with hypogammaglobulinemia associated with elevated IgM levels have recurrent respiratory tract infections, eczematous dermatitis, an increased incidence and severity of warts, and oral ulcerations, sometimes in association with neutropenia. [9], [10] The disorder usually occurs in males, with X-linked inheritance in approximately 70 percent of affected individuals. In addition to pyogenic and opportunistic infections, including *Pneumocystis carinii,* patients tend to develop autoimmune disorders of the hematopoietic system. Uncontrolled proliferation of IgM-producing plasma cells often occurs during the second decade of life, at times resulting in potentially fatal, massive infiltration of the gastrointestinal tract, liver, and gallbladder. Patients with hyper-IgM syndrome also have an increased risk of abdominal cancer. The sera of patients with hyper-IgM syndrome have very low amounts of IgG, IgA, and IgE but normal or high concentrations of IgM and IgD. The condition is treated prophylactically with intravenous gamma globulin; the autoimmune neutropenia also may respond well to granulocyte-macrophage colony-stimulating factor. Allogeneic bone marrow transplantation may correct the disorder.

Hyper-IgM syndrome is caused by a defect of B cell differentiation. [11] Normally, the humoral immune response begins with production of IgM and IgD antibodies. Subsequently, IgG, then IgA, and finally IgE antibodies are produced. The sequential production of different classes of immunoglobulins is called *class switching.* This mechanism enables the immune system to produce antibodies with different effector functions while retaining variable region specificity. In hyper-IgM syndrome, B cells are unable to switch from IgM/IgD secretion to the production of other immunoglobulin isotypes.

Normally, isotype switching in B cells requires a contact-dependent signal from T cells. B cells have on their surface CD40, a glycoprotein. This molecule interacts with CD40 ligand on activated T cells. The hyper-IgM syndrome is caused by a defect in the gene that encodes for the CD40 ligand. T cells from patients with the syndrome cannot synthesize CD40 ligand, or in some cases a nonfunctional ligand is produced. B cells respond to antigen and produce specific antibodies; however, they are restricted to the IgM isotype, and there is no memory response. In contrast to the case in X-linked hypogammaglobulinemia, female carriers of the hyper-IgM syndrome have random inactivation of the X chromosome in T lymphocytes because the CD40 ligand is not required for the normal development of T lymphocytes.

X-Linked Lymphoproliferative Disease (Duncan's Disease)

X-linked lymphoproliferative (XLP) disease, or Duncan's disease, is characterized by an abnormal immune response to Epstein-Barr virus (EBV) infection. [12] Before EBV infection, patients with XLP have normal immunologic responses. With

EBV infection, however, patients respond abnormally to the antigen and fail to develop EBV-specific serologic responses. Clinical features include fever, maculopapular rash, pharyngitis, lymphadenopathy, hepatosplenomegaly with jaundice, and purpura. Most patients die early because of severe hepatitis, liver necrosis, and hepatic failure. Patients who survive the acute EBV infection (25 percent) tend to develop acquired dysgammaglobulinemia and chronic infectious mononucleosis, progressing to malignant lymphoma and marked T lymphocyte depletion of lymph nodes, thymus, and spleen. Overall, 70 percent of affected boys die by 10 years of age. XLP disease results from mutations in the gene encoding SH2D1A, which affects intracellular signaling. [13]

COMBINED ANTIBODY AND T CELL DEFICIENCY

Wiskott-Aldrich Syndrome

The Wiskott-Aldrich syndrome (WAS) is an X-linked recessive disorder characterized by hemorrhage due to thrombocytopenia and platelet dysfunction, recurrent pyogenic infections, and recalcitrant dermatitis, although this classic triad appears in only 27 percent of patients. [14], [15] WAS usually manifests initially during the first weeks or months of life with bleeding, especially with bloody diarrhea. Epistaxis, hematemesis, hematuria, mucocutaneous petechiae, and intracranial hemorrhage also may occur. Recurrent bacterial infections begin in infancy as levels of placentally transmitted maternal antibodies diminish. These infections include furunculosis, conjunctivitis, otitis media and externa, pansinusitis, pneumonia, meningitis, and septicemia. Infections with encapsulated bacteria such as pneumococcus, *H. influenzae,* and *Neisseria meningitidis* predominate. With advancing age, T cell function deteriorates progressively, and patients become increasingly susceptible to infections due to herpes and other viruses and to *P. carinii.*

The atopic dermatitis associated with WAS, which occurs in approximately 80 percent of patients, usually develops during the first few months of life and may be quite severe. The face, scalp, and flexural areas are the most severely involved, although patients commonly have widespread involvement with progressive lichenification. The rash is often more exfoliative than that of atopic dermatitis in individuals without WAS, and excoriated areas frequently have serosanguineous crusts (Fig. 115-3). Secondary bacterial infection of eczematous lesions is common, as are eczema herpeticum (Fig. 115-4) and molluscum.

FIGURE 115-3 Severe atopic dermatitis in a patient with Wiskott-Aldrich syndrome. Note the serosanguineous crust.

FIGURE 115-4 Herpetic infection with pustules on the ear of a patient with Wiskott-Aldrich syndrome. The patient was blind in his left eye owing to previous ocular involvement with herpes simplex. Following the pictured infection, the patient was administered prophylactic oral acyclovir and had no subsequent herpetic infections during 5 years of follow-up. (*From Paller AS: Hereditary immunodeficiency disorders, in* Genetic Disorders of the Skin, *edited by JC Alper. Chicago, Mosby–Year Book, 1991, pp 105–123.*)

Hepatosplenomegaly is common, and lymphadenopathy, transient arthritis with joint effusions, nephropathy, and nodular vasculitis with arteritis are present occasionally. IgE-mediated allergic problems such as urticaria, food allergies, and asthma are seen in addition to the atopic dermatitis.

The thrombocytopenia of WAS is persistent, and platelet counts may range from 1000 to 80,000 platelets per microliter. The platelets are small, and platelet aggregation is defective. Patients also may have Coombs-positive hemolytic anemia, leukopenia, lymphopenia, and eosinophilia. Levels of IgM and sometimes IgG are low, and isohemagglutinins are absent. IgA, IgE, and IgD levels usually are elevated. Delayed hypersensitivity skin test reactivity is diminished, and patients fail to respond to polysaccharide antigens. The number of T lymphocytes and the response in vitro to mitogens may be

normal in early life but often decrease with advancing age.

Many patients with WAS die during infancy, usually as a result of severe infections, especially of the respiratory and central nervous systems, or as a result of severe hemorrhage, especially intracranial. Twenty percent of patients with WAS develop lymphoreticular malignancies, especially non-Hodgkin's lymphoma, with a predominance of extranodal and brain involvement. Ten percent of patients die from these malignancies, usually as adolescents or young adults.

Appropriate antibiotics and transfusions of platelets and plasma decrease the risk of fatal infections and hemorrhage. Intravenous infusions of gamma globulin are useful in some patients. Splenectomy has been advocated to ameliorate the bleeding abnormality in patients with recurrent severe hemorrhage, but this procedure increases the risk of infection from encapsulated bacterial organisms in these patients who cannot mount a response to vaccination. Bone marrow transplantation is the treatment of choice for patients with recurrent problems. Full engraftment results in normal platelet numbers and functions, normal immunologic status, and clearance of the dermatitis (T lymphocyte engraftment). Topical glucocorticoid preparations and systemic gamma globulin may improve the dermatitis, and chronic administration of oral acyclovir is appropriate for patients with recurrent eczema herpeticum.

Lymphocytes from patients with WAS lack microvilli formed by actin bundles. Additionally, sialoglycoproteins (e.g., CD43 and others) are not stably expressed by WAS lymphocytes and platelets. The defective gene is *WAS,* which encodes WASP, a 53-kDa protein that functions in signaling and cytoskeletal organization. [16]

Female carriers of *WAS* mutations may be detected by the selective inactivation of the abnormal X chromosome in T and B cells and in platelets. Studies of maternal X-chromosome inactivation also have been used to diagnose boys with atypical WAS. Prenatal diagnosis has been achieved in the first trimester with DNA markers. [17]

Ataxia-Telangiectasia

Ataxia-telangiectasia (AT) is an autosomal recessive disorder characterized by ataxia, oculocutaneous telangiectases, sinopulmonary infections, immunodeficiency, and the development of lymphoreticular malignancies. [18] The gene for AT (*ATM*) encodes a protein that resembles phosphoinositol-3 kinases and is involved in DNA repair and cell-cycle control. [19] Ataxia-telangiectasia is covered in detail in Chap. 191.

SEVERE COMBINED IMMUNODEFICIENCY

Severe combined immunodeficiency (SCID) includes a group of heterogeneous disorders characterized by similar clinical manifestations and immunologic deficiencies of both humoral and cell-mediated immunity. [20], [21] and [22] Most patients with SCID are boys (95 percent) with an X-linked recessive inheritance pattern (50–60 percent), but autosomal recessive and sporadic modes have been described. The overall incidence of SCID is from 1 in 100,000 to 500,000 live births.

Infants with SCID usually fail to gain weight by 3 to 6 months of age, following the onset of recurrent infections. Persistent mucocutaneous candidiasis is often present at the time of diagnosis, and systemic candidal infections occur occasionally. Patients with SCID also may have chronic diarrhea and malabsorption caused by viral infections. *P. carinii* pneumonia is often a presenting feature. Although bacterial infections usually respond to systemic antibiotics, viral infections tend to be fatal. Infants with SCID lack palpable lymphoid tissue despite recurrent infections.

In addition to cutaneous bacterial and candidal infections, the most common cutaneous eruptions are morbilliform or resemble seborrheic dermatitis. In some infants with SCID, biopsy sections show graft-versus-host disease (GVHD). GVHD may result from the in utero exposure to maternal lymphocytes or from transfusion with nonirradiated blood products, or it may follow bone marrow transplantation.

All patients with SCID share most clinical features and have abnormalities of both cell-mediated and humoral immunity, although the extent of deficiency is variable. However, the underlying bases of SCID are quite heterogeneous. The genetic defect in X-linked SCID is a mutation in ? $_c$ chain of the interleukin 2 (IL-2) receptor, which is shared with several other interleukin receptors, thus explaining the severity of the immunodeficiency. Several of these receptors are required for the early development of T cells, so female carriers with the mutation have nonrandom inactivation of T cells, which do not survive if the mutated allele is activated.

The most common forms of autosomal recessive SCID result from mutations in the genes for the purine-degradation enzymes adenosine deaminase and purine nucleoside phosphorylase and account for 20 percent of cases of SCID. SCID also may result from deficiency of MHC class I or MHC class II molecules (HLA-DP, -DQ, -DR). [23] MHC class I deficiency is due to mutations in TAP1 or TAP2, proteins that transport peptides to assemble the class I molecule. Affected children have a deficiency of CD8 and natural killer (NK) cells. The pathogenesis of MHC class II deficiency is complex and relates to defects in transactivating factors (e.g., class II transactivator, RFX5, RFXAP, or RFX-B). Patients with MHC class II deficiency have insufficiency of CD4 and not CD8 cells, and their T cells do not react to specific antigens. Affected children have hypogammaglobulinemia, although the B cell number is normal. Patients with SCID also may have defects in lymphocyte activation, including defects in the CD3 T cell receptor, in cytokine production (especially IL-2 production), and in signal transduction (e.g., ZAP-70 deficiency).

SCID must be differentiated from acquired immunodeficiency syndrome (HIV infection). In addition to the lack of HIV antigen and anti-HIV antibodies in patients with SCID, other features help to differentiate the disorders. Despite the lymphopenia of SCID, the inverted CD4/CD8 ratio of HIV infection is not found. Most patients with SCID have low levels of immunoglobulins, in contrast to the hypergammaglobulinemia of infants with HIV infection. The subtype of SCID is determined generally by DNA analysis, although detection of cells by fluorescence-activated cell sorting (e.g., T, B, and NK cells) and by analysis for the presence of surface markers is confirmatory.

In families with a previously affected sibling of a known phenotype, prenatal detection of SCID is possible by DNA analysis if the specific gene defect is known, by fluorescence-activated cell sorting of fetal blood with monoclonal antibodies, or by analysis of enzyme levels in cultured amniocytes. Carrier mothers of boys with X-linked SCID may be detected by the selective inactivation of the abnormal X chromosome in T and B cells.

The definitive treatment of choice for SCID is bone marrow transplantation. [24] Affected children with most forms of SCID rarely survive beyond 2 years without transplantation. Removal of postthymic cells from parental marrow may diminish the risk of GVHD in patients with SCID without an HLA-identical donor. In utero transfer of haploidentical CD34 cells [25] and gene therapy [26] have been successful for patients with ? $_c$- and adenosine deaminase (ADA)–deficient forms of SCID. Patients with IL-2 deficiency have been treated with IL-2 injections. Enzyme replacement therapy with polyethylene glycol modified bovine ADA administered subcutaneously once weekly has resulted in clinical and immunologic improvement in patients with ADA deficiency.

SELECTIVE T LYMPHOCYTE DISORDERS

Chronic Mucocutaneous Candidiasis

Patients with chronic mucocutaneous candidiasis (CMC) have recurrent, progressive infections of the skin, nails, and mucous membranes most commonly due to *Candida albicans* and in some cases due to dermatophytes as well. [27] The clinical features of CMC may be seen in a variety of immunologic disorders, all characterized by ineffective defense mechanisms against *Candida.* In general, the patients with greater severity and an earlier onset of cutaneous candidal infections have more severe immunologic alterations.

The clinical presentation ranges from recurrent, recalcitrant thrush (Fig. 115-5) to mild erythematous scaling plaques with a few dystrophic nails to severe generalized, crusted granulomatous plaques (Fig. 115-6). The cutaneous plaques occur most commonly in intertriginous and on periorificial sites and the scalp, but they may be more generalized. The nails are thickened, brittle, and discolored, and the paronychial areas are often erythematous, swollen, and tender. Scalp infections may lead to scarring and alopecia. Although the oral mucosa is the most frequent site of mucosal alteration, esophageal, genital, and laryngeal mucosae may be affected. Patients with CMC rarely develop systemic candidiasis but may develop recurrent or severe infections other than candidal, including bacterial septicemia, particularly if other immune defects are present. Concomitant dermatophyte infections are not uncommon.

FIGURE 115-5 Recurrent thrush and candidal cheilitis in a patient with chronic mucocutaneous candidiasis.

FIGURE 115-6 Cutaneous candidal infections with a hyperkeratotic candidal granuloma. The child responded to oral ketoconazole but not to topical agents.

Many patients with CMC have *a*utoimmune *p*oly *e*ndocrinopathy- *c*andidiasis- *e*ctodermal *d*ysplasia (APECED) syndrome, [28] owing to mutations in the *a*uto *i*mmune *r* *e*gulator (*AIRE*) gene. The candidal infections tend to begin by 5 years of age, although the endocrinologic dysfunction may not be apparent until 12 to 13 years of age. Associated endocrinopathies have been described. Most common are hypoparathyroidism (88 percent) and hypoadrenocorticism (60 percent). One-third of patients have candidiasis, hypoparathyroidism, and defective adrenal function. Other associated endocrinopathies or autoimmune disorders include gonadal insufficiency (45 percent), alopecia areata (20 percent), pernicious anemia (16 percent), thyroid abnormalities (12 percent), chronic active hepatitis or juvenile cirrhosis (9 percent), vitiligo, diabetes mellitus, and hypopituitarism. Chronic diarrhea and malabsorption have been reported in 25 percent of patients and usually are associated with hypoparathyroidism. Some affected patients also have pulmonary fibrosis, dental enamel hypoplasia, and keratoconjunctivitis. Patients with APECED often have autoimmune antibodies, including antithyroglobulin, antimicrosomal antibodies, antiadrenal and antimelanocyte antibodies, and rheumatoid factor. Autoantibodies also have been found in patients with CMC who do not have clinical endocrinologic disease.

Scrapings and cultures from cutaneous or mucosal lesions demonstrate candidal organisms. Most patients with CMC have defective cell-mediated immunity, although no uniform alteration is found. [29], [30] Some 25 to 35 percent of patients with CMC have no demonstrable immunologic defects.

Candidal lesions in patients with CMC generally respond to systemically administered azole antifungal agents (itraconazole, fluconazole). [31] Ketoconazole is no longer used becaused of the risk of hepatitis. Cutaneous granulomas often are less responsive despite clearance of infection. Recurrences are common, and the antifungal agents must be used intermittently. The drugs have no effect on the abnormal cell-mediated immunity. Patients who are resistant usually respond to amphotericin B with or without flucytosine.

Di George Syndrome

Di George syndrome (congenital thymic aplasia) is a member of a group of disorders that result from deletion of chromosome 22q11 (catch 22/Di George/velocardiofacial syndrome). [32] The disorder results from developmental defects of the third and fourth pharyngeal pouches due to haploinsuffienciency of Tbx1, a member of the t-box transcription factor. [33] Although most patients have T cell defects, some have only mild T cell abnormalities, whereas others have SCID with B cell immunodeficiency as well, presumably due to the effect of T cells on B cell function. The thymic shadow is absent or reduced at birth. Infants often have neonatal tetany with hypocalcemia due to the aplastic parathyroid glands. The cardiac anomalies are most commonly truncus arteriosus, septal defects, and abnormal aortic arch vessels. Characteristic facial features of Di George syndrome include a short philtrum, low-set malformed ears, and hypertelorism.

Many patients have recurrent mucocutaneous candidal infections as neonates, as well as increased susceptibility to viral infections, *P. carinii,* and other fungal infections. GVHD may develop in infants given nonirradiated blood products.

Cartilage-Hair Hypoplasia Syndrome

Cartilage-hair hypoplasia syndrome is an autosomal recessive disorder that is most common in Amish and Finnish individuals. [34] Patients have fine, sparse, hypopigmented hair (Fig. 115-7) and metaphyseal dysostosis that results in short-limbed dwarfism. Patients may have soft, doughy skin with degenerated elastic tissue. Associated pleiotropic features include Hirschsprung's disease, deficient erythrogenesis, and an increased risk of malignancies, [35] particularly non-Hodgkin's lymphoma and basal cell carcinomas. The disorder results from mutations in the RNA component of a ribonucleoprotein endoribonuclease, [36] RNase MRP, that in mitochondria cleaves RNA primers responsible for DNA replication and in the nucleolus processes pre-rRNA. Most patients have defective cell-mediated immunity, and patients may be particularly susceptible to severe disseminated varicella. [37] A subset of patients who have additional defective humoral immunity has been described.

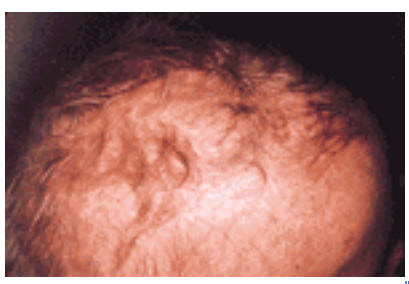

FIGURE 115-7 Sparse hypopigmented hair in a patient with the cartilage-hair hypoplasia syndrome. (*From Brennan and Pearson* [34] *with permission.*)

Nezelof Syndrome

Most patients with Nezelof syndrome present later in infancy or childhood with infections similar to those of patients with SCID. Gram-negative sepsis and pneumonia are common, as are candidal infections of the mouth, perianal area, skin (Fig. 115-8), esophagus, and gastrointestinal tract that do not respond to topical therapy. Severe viral and *P. carinii* infections also may occur. Patients characteristically have lymphopenia, but other leukocyte counts are normal. T cells are deficient, but immunoglobulin levels are normal or near normal. Despite the presence of immunoglobulin, antibody production is suboptimal or absent. A subgroup of patients with Nezelof syndrome has purine nucleoside phosphorylase (PNP) deficiency, an autosomal recessive disorder that is due to absence of an enzyme of the purine salvage pathway (see discussion of SCID earlier). Between 10 and 15 percent of children with ADA deficiency have a less severe form of Nezelof syndrome with the onset of T cell immunodeficiency after 6 months of age and normal immunoglobulin levels.

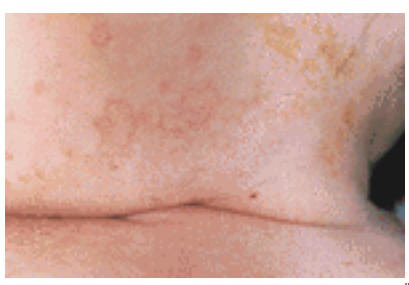

FIGURE 115-8 Cutaneous candidal infection in an infant with Nezelof syndrome.

DISORDERS OF PHAGOCYTIC CELLS

Chronic Granulomatous Disease

Chronic granulomatous disease (CGD) is a heterogeneous group of X-linked and autosomal recessive disorders characterized by severe recurrent infections due to an inability of phagocytic leukocytes to kill intracellular organisms by generation of oxidative metabolites. [38], [39] Ninety percent of patients with the disorder are male, and the overall incidence is 1 in 250,000 to 500,000 persons. The recurrent infections of patients with CGD usually begin during the first year of life. Pyodermas with associated regional lymphadenopathy and dermatitis, especially periorificial, may occur during infancy. Staphylococcal abscesses are common, particularly of the perianal area. Cutaneous granulomas occur less frequently than cutaneous infections and are nodular and often necrotic. The granulomas can occlude vital structures, especially of the gastrointestinal and genitourinary systems. Intraoral ulcerations resembling aphthous stomatitis, chronic gingivitis, perioral ulcers, scalp folliculitis, and seborrheic dermatitis have been described in many patients.

The lymph nodes, lungs, liver, spleen, and gastrointestinal tract are the most frequent areas of noncutaneous involvement. Suppurative lymphadenitis with abscess and fistula formation usually affects cervical nodes. Pneumonia occurs in almost all affected children and may lead to abscess formation, cavitation, and empyema. Hepatosplenomegaly has been reported in 80 to 90 percent of patients; more than 30 percent of patients develop hepatic abscesses, and hepatic granuloma formation is common.

Normal bactericidal activity after phagocytosis requires the nicotinamide adenine dinucleotide (NADPH) oxidase system, which consists of NADPH, an unusual phagocyte cytochrome b, and several cytosolic proteins. Patients with CGD have deficient killing because this membrane-associated NADPH oxidase system fails to produce superoxide and other toxic oxygen metabolites. In X-linked kindreds (60–76 percent of patients), the gene encoding the gp91 ^{phox} (*ph*agocyte *o*xidase) subunit of cytochrome b $_{558}$ is mutated. Patients with autosomal recessive CGD (40 percent) are deficient in NADPH oxidase cytosolic factors (p47 ^{phox} or p67 ^{phox}); occasionally the p22 ^{phox}(? subunit of cytochrome b $_{558}$) is deficient. It is thought that cytochrome b $_{558}$ is the membrane attachment site for these cytosolic factors that translocate from the cytosol to the plasma membrane, assembling oxidase components to allow activation of the oxidase.

The types of microbial organisms that cause infections in patients with CGD are usually catalase-positive and require intracellular killing; such organisms include *Staphylococcus aureus, Klebsiella, Pseudomonas, Escherichia coli, Serratia,* and *Aspergillus.* The intensive humoral and granulomatous responses can be explained as compensatory reactions. The screening test for CGD is the nitroblue tetrazolium (NBT) reduction assay. Quantitative NBT tests and chemiluminescence assays also may be performed. Immunoblot analysis confirms the absence of the phagocyte oxidase component; because deficiency of one component of cytochrome b $_{558}$ leads to absence of the other, sequencing of the *gp91* ^{phox} or *p*22 ^{phox} genes is necessary if absence is noted by immunoblot analysis. Patients frequently have leukocytosis, anemia, elevated sedimentation rate, and hypergammaglobulinemia, but immune function is otherwise normal. Heterozygous carriers for X-linked CGD do not have the increased risk of infections but may have discoid or systemic lupus erythematosus, severe aphthous stomatitis, or granulomatous cheilitis.

Therapy of CGD includes antimicrobial agents for infections and debridement and drainage of abscesses. Long-term prophylactic trimethoprim-sulfamethoxazole therapy decreases the incidence of bacterial infection without increasing the incidence of fungal infection, whereas itraconazole therapy effectively lowers the risk of *Aspergillus* infection. [40], [41] Leukocyte transfusions have been used for rapidly progressive, life-threatening infections. Bone marrow transplantation has been performed in some patients with CGD. Interferon-? induces the mRNA that codes for the defective cytochrome b, and it has been shown to increase the functional cytochrome b, superoxide generation, and bactericidal activity. [42] Patients with both X-linked CGD and autosomal recessive CGD showed clinical improvement after receiving interferon-?. Systemic glucocorticoids have been helpful for patients with obstructive visceral granulomas. Stem cell gene therapy has been used for patients with the p47 ^{phox}-deficient form. [43] Prenatal diagnosis has been performed by the NBT slide test and now can be based on molecular analysis.

Hyperimmunoglobulinemia E Syndrome

The hyperimmunoglobulinemia E (HIE) syndrome is characterized by (1) markedly increased levels of IgE, (2) recurrent cutaneous and systemic pyogenic infections, (3) atopic-like dermatitis, (4) peripheral eosinophilia, and (5) defective neutrophil chemotaxis. Buckley's syndrome and Job's syndrome are subsets of the HIE syndrome. The disorder is thought to be autosomal dominant with variable expressivity; many patients show a partial phenotype. [44], [45] The gene has been mapped to chromosome 4q, although it has not yet been identified. [46]

The dermatitis of HIE syndrome begins in infancy and resembles atopic dermatitis, often with extensive lichenification (Fig. 115-9). Many patients have other manifestations of atopy. Early skin manifestions may include vesicular lesions and cutaneous candidal infections. *Candida* also may affect mucosal sites and nails. Patients develop progressive coarsening of facial features (Fig. 115-10). Staphylococcal skin infections include impetigo, furunculosis, paronychia, cellulitis, and characteristic abscesses (“cold” abscesses; see Fig. 115-10) that do not demonstrate the anticipated degree of erythema, warmth, and purulence. The abscesses occur most commonly on the head and neck and in intertriginous areas. Pulmonary bacterial pneumonia, abscesses, and empyema are the most frequent systemic infections and may result in pneumatoceles that become the nidus for further bacterial and fungal infections. The most common infecting organisms are *S. aureus* and *H. influenza.* Osteopenia is common, and 57 percent of patients have had at least three fractures, especially of the long bones, ribs, and pelvis. Scoliosis occurs in 76 percent of adult patients and hyperextensibility of joints in 68 percent of patients. Dental anomalies include retention of primary teeth and lack of eruption of secondary teeth.

FIGURE 115-9 Extensive lichenification in a patient with hyperimmunoglobulinemia E syndrome and severe atopic dermatitis.

FIGURE 115-10 Coarse facial features and “cold” abscess and furuncle in a patient with hyperimmunoglobulinemia E syndrome.

Elevated serum IgE levels (>2000 IU; may be considerably lower in infancy but still markedly elevated from standard levels) are characteristic and may be related to defective T suppressor cell function. Cell-mediated immunity is often abnormal. The most common functional defect in host resistance is defective neutrophil chemotaxis, particularly during severe infections. Mononuclear cells from patients with HIE syndrome fail to exhibit the normal stimulation of IgE production by IL-4 [47] and cannot produce normal levels of interferon-? even after cells are stimulated by IL-12. [48]

Antistaphylococcal antibiotics are effective for most cutaneous infections in patients with HIE. Ascorbic acid and cimetidine have decreased the number of infections and the chemotactic defect in some patients. Isotretinoin has been reported to eliminate the recurrent staphylococcal abscesses in an isolated patient without any change in immunologic status. Gamma globulin and interferon-? also have been used successfully; the former may decrease IgE levels without altering IgG or IgM levels, whereas the latter improves the chemotactic response. The cutaneous and pulmonary abscesses often require incision and drainage and may require partial lung resections.

Leukocyte Adhesion Deficiency

Leukocyte adhesion deficiency (LAD) is a rare autosomal recessive disorder that affects the adherence of neutrophils, lymphocytes, and monocytes. [49] Patients have frequent skin infections, mucositis, and otitis. The skin infections often present as necrotic abscesses that resemble pyoderma gangrenosum (Fig. 115-11), [50] but the inflammatory response and production of purulent material are impaired. Patients may have delayed separation of the umbilical cord. Cellulitis of the face and perirectal area is common. Gingivitis with periodontitis results in loss of teeth. Life-threatening severe bacterial or fungal infections may occur. Poor wound healing leads to paper-thin or dysplastic cutaneous scars.

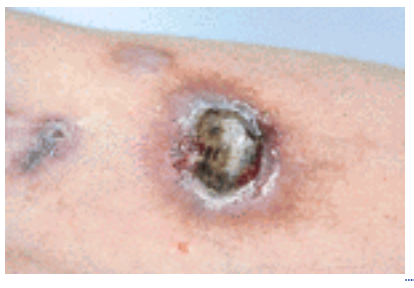

FIGURE 115-11 A necrotic ulcer on the leg of a boy with leukocyte adhesion deficiency type 1. Note the presence of heaped-up edges of the ulcer and extensive crusting. Biopsies showed essentially no neutrophils invading.

Adherence of leukocytes relates in part to a group of cell surface glycoproteins (ß $_2$ integrins) that share a common 95-kDa ß $_2$ subunit (CD18) encoded on the distal portion of the long arm of chromosome 21. This ß $_2$ subunit may be linked to three distinct a chains to form three different surface glycoproteins. These glycoproteins—the iC3b receptor (CR3), LFA-1, and p150,95 (CR4)—are absent or deficient in affected patients with LAD1. As a result, neutrophil and monocyte chemotaxis and phagocytosis are impaired. The severity of clinical involvement is proportional to the degree of glycoprotein deficiency. Death usually occurs by 2 years of age unless successful bone marrow transplantation is performed. The normal CD18 subunit gene has been introduced into hematopoietic stem cells and may provide the basis for gene therapy. [51] Another adhesion molecule deficiency (LAD2) that results from absence of the neutrophil sialyl-Lewis X ligand of E-selectin on vascular endothelium has been described. Clinical features and markedly decreased neutrophil motility resemble that of LAD1. [52] Oral fucose administration has been helpful in some patients. [53]

Chédiak-Higashi Syndrome

This rare autosomal recessive disorder is characterized by incomplete oculocutaneous albinism and severe recurrent infections.[54],[55] Parental consanguinity is often reported. Pigmentary dilution is present in 75 percent of patients. Ocular hypopigmentation may cause photophobia, and strabismus and nystagmus are common. The skin is typically fair, but slate-colored areas of pigmentation may be present. The hair frequently has a silvery sheen (Fig. 115-12A). Infections most commonly involve the skin, lungs, and respiratory tract and usually are due to *S. aureus, Streptococcus pyogenes,* and *Pneumococcus.* Deep ulcerations resembling pyoderma gangrenosum have been described. Seizures and progressive neurologic deterioration, with muscle weakness and cranial and peripheral neuropathy, occur in some patients in early childhood.



FIGURE 115-12 Chédiak-Higashi syndrome. *A.* Silvery sheen to hair in a black infant; patient had darkly pigmented eyes and skin. *B.* Clumped pigment granules in hairs. *C.* Larger aggregates of clumped pigmentation in hairs of a patient with Griscelli syndrome.

An accelerated phase that resembles lymphoma occurs by late childhood and is characterized by widespread visceral infiltration by atypical lymphoid and histiocytic cells. This lymphoma-like stage is precipitated by viruses, particularly by EBV infection. Hepatosplenomegaly, lymphadenopathy, pancytopenia, jaundice, a leukemia-like gingivitis, and pseudomembraneous sloughing of the buccal mucosa are associated. The thrombocytopenia and depletion of coagulation factors lead to petechiae, bruising, and gingival bleeding. The mean age of death for patients with Chédiak-Higashi syndrome is 6 years, usually from overwhelming infection or hemorrhage during the lymphoma-like accelerated phase.

Giant granules typically are found in circulating neutrophils, melanocytes, renal tubular cells, and neurons. Hair shafts have finely clumped pigment granules (see Fig. 115-12B), in contrast to the larger pigmentary clumping of Griscelli syndrome (see Fig. 115-12C). The granules are thought to result from markedly delayed discharge of lysosomal and peroxidative enzymes from cells, perhaps because of a defective protein involved in membrane fusion. Diminished chemotaxis of neutrophils and decreased antibody-dependent cellular cytotoxicity and NK cell function are often associated.

The gene that is mutated in the Chédiak-Higashi syndrome is the lysosomal trafficking regulator (*LYST*).[56] The protein appears to regulate the secretion of intracellular lysosomal vesicles and melanosomes. Cytotoxic T lymphocyte–associated antigen is trapped in abnormally large vesicles rather than on the cell surface and thus may be unable to regulate T cell activation, increasing the risk of lymphoproliferative disease.[57]

Prenatal diagnosis has been achieved by examination of hair from fetal scalp biopsies and of leukocytes from fetal blood samples. The treatment of choice for patients with Chédiak-Higashi syndrome is bone marrow transplantation, which corrects the immunologic status but does not affect pigment dilution. Acyclovir, high-dose intravenous gamma globulin, vincristine, cyclosporine, and prednisone have been used to control the accelerated phase. Ascorbic acid corrects the microtubular defects in vitro but has no clinical ameliorative effect. Interferon has been demonstrated by some authors to partially restore NK cell function.

Griscelli Syndrome

As in Chédiak-Higashi syndrome, patients with Griscelli syndrome have pigmentary dilution with silver-gray hair, recurrent systemic and cutaneous pyogenic infections, and cutaneous abscesses.[58] Early hepatosplenomegaly, progressive neurologic deterioration, lymphohistiocytosis, and neutropenia and thrombocytopenia may occur. Large clumps of pigment are present in the hair shaft (see Fig. 115-12C), and melanosomes accumulate in melanocytes. Patients with Griscelli syndrome also have hypogammaglobulinemia and defective cell-mediated immunity. Polymorphonuclear leukocytes do not show giant granules. Mutations that lead to Griscelli syndrome occur in either *myosin Va*[59] or *RAB27a.*[60] Griscelli syndrome has been uniformly fatal but now can be reversed by successful bone marrow transplantation. Prenatal diagnosis has been achieved by examination of hair from fetal scalp biopsies and of leukocytes from fetal blood samples.

COMPLEMENT-DEFICIENCY DISORDERS (See also Chap. 33 and Chap. 117)

Leiner's Disease

Leiner's disease is characterized by severe seborrheic dermatitis, diarrhea, failure to thrive, and recurrent gram-negative and candidal infections during infancy. Although originally reported as a disorder due to defective yeast opsonization from dysfunctional C5, it is now clear that so-called Leiner's syndrome describes a constellation of clinical findings that may be manifestations of a variety of immunodeficiency disorders, including defective yeast opsonization, C3 deficiency, severe combined immunodeficiency, hypogammaglobulinemia, and hyperimmunoglobulinemia E. [61]

REFERENCES

1. Rosen FS et al: The primary immunodeficiencies. *N Engl J Med* **333**:431, 1995

2. Minegishi Y et al: Recent progress in the diagnosis and treatment of patients with defects in early B-cell development. *Curr Opin Pediatr* **11**:528, 1999

3. Vetrie D et al: The gene involved in X-linked agammaglobulinaemia is a member of the *src* family of protein-tyrosine kinases. *Nature* **361**:226, 1993

4. Tsukada S et al: Deficient expression of a B cell cytoplasmic tyrosine kinase in human X-linked agammaglobulinemia. *Cell* **72**:279, 1993

5. Cunningham-Rundles C, Bodian C: Common variable immunodeficiency: Clinical and immunological features of 248 patients. *Clin Immunol* **92**:34, 1999

6. Cunningham-Rundles C et al: Incidence of cancer in 98 patients with common varied immunodeficiency. *J Clin Immunol* **7**:294, 1987

7. Schaffer FM et al: Individuals with IgA deficiency and common variable immunodeficiency share complex polymorphisms of major histocompatibility complex class III genes. *Proc Natl Acad Sci USA* **86**:8015, 1989

8. Sennhauser FH et al: Anti-IgA antibodies in IgA-deficient children. *J Clin Immunol* **8**:356, 1988

9. Schneider LC: X-linked hyper IgM syndrome. *Clin Rev Allergy Immunol* **19**:205, 2000

10. Chang MW et al: Mucocutaneous manifestations of the hyper-IgM immunodeficiency syndrome. *J Am Acad Dermatol* **38**:191, 1998.

11. DiSanto JP et al: CD40 ligand mutations in X-linked immunodeficiency with hyper-IgM. *Nature* **361**:541, 1993

12. Seemayer TA et al: X-linked lymphoproliferative disease: Twenty-five years after the discovery. *Pediatr Res* **38**:471, 1995

13. Sylla B et al: The X-linked lymphoproliferative syndrome gene product SH2D1A is associated with p62 ^{dok} (Dok1) and activates NF-?B. *Proc Natl Acad Sci USA* **97**:7470, 2000

14. Ochs HD: The Wiskott-Aldrich syndrome. *Semin Hematol* **35**:332, 1998

15. Thrasher AJ, Kinnon C: The Wiskott-Aldrich syndrome. *Clin Exp Immunol* **120**:2, 2000

16. Snapper SB, Rosen FS: The Wiskott-Aldrich syndrome protein (WASP): Roles in signaling and cytoskeletal organization. *Annu Rev Immunol* **17**:905, 1999.

17. Giliani S et al: Prenatal molecular diagnosis of Wiskott-Aldrich syndrome by direct mutation analysis. *Prenat Diagn* **19**:36, 1999

18. Gatti RA: Ataxia-telangiectasia. *Dermatol Clin* **13**:1, 1995

19. Savitsky K et al: A single ataxia telangiectasia gene with a product similar to PI-3 kinase. *Science* **268**:1749, 1995

20. Fischer A: Severe combined immunodeficiencies (SCID). *Clin Exp Immunol* **122**:143, 2000

21. Gaspar HB et al: Severe combined immunodeficiency: Molecular pathogenesis and diagnosis. *Arch Dis Child* **84**:169, 2001

22. Gennery AR, Cant AJ: Diagnosis of severe combined immunodeficiency. *J Clin Pathol* **54**:191, 2001

23. DeSandro A et al: The bare lymphocyte syndrome: Molecular clues to the transcriptional regulation of major histocompatibility complex class genes. *Am J Hum Genet* **65**:279, 1999

24. Haddad E et al: Long-term immune reconstitution and outcome after HLA-nonidentical T-cell depleted bone marrow reconstitution for SCI: A European retrospective study of 116 patients. *Blood* **91**:3636, 1998

25. Buckley RH et al: Hematopoeietic stem cell transplantation for the treatment of severe combined immunodeficiency. *N Engl J Med* **340**:508, 1999

26. Cavazzana-Calvo M et al: Gene therapy of human severe sombined immundeficiency (SCID)-X1 disease. *Science* **288**:669, 2000

27. Kirkpatrick CH: Chronic mucocutaneous candidiasis. *Pediatr Infect Dis J* **20**:197, 2001

28. Ahonen P et al: Clinical variation of autoimmune polyendocrinopathy-candidiasis-ectodermal dystrophy (APECED) in a series of 68 patients. *N Engl J Med* **322**:1829, 1990

29. Lilic D, Gravenor I: Immunology of chronic mucocutaneous candidiasis. *J Clin Pathol* **54**:81, 2001 /P>

30. de Moraes-Vasconcelos D et al: Characterization of the cellular immune function of patients with chronic mucocutaneous candidiasis. *Clin Exp Immunol* **123**:247, 2001

31. Tosti A et al: Itraconazole in the treatment of two young brothers with chronic mucocutaneous candidiasis. *Pediatr Dermatol* **14**:146, 1997

32. Hong R: The Di George anomaly. (catch 22, Di George/velocardiofacial syndrome). *Semin Hematol* **35**:282, 1998

33. Merscher S et al: TBX1 is responsible for cardiovascular defects in velocardiofacial/Di George syndrome. *Cell* **104**:619, 2001

34. Brennan T, Pearson R: Abnormal elastic tissue in cartilage-hair hypoplasia. *Arch Dermatol* **124**:1411, 1988

35. Makitie O et al: Increased incidence of cancer in patients with cartilage-hair hypoplasia. *J Pediatr* **134**:315, 1999

36. Ridanpaa M et al: Mutations in the RNA component of RNase MRP cause a pleiotropic human disease, cartilage-hair hypoplasia. *Cell* **104**:195, 2001

37. Makitie O et al: Deficiency of humoral immunity in cartilage-hair hypoplasia. *J Pediatr* **137**:487, 2000

38. Winkelstein JA et al: Chronic granulomatous disease: Report on a national registry of 368 patients. *Medicine* **79**:155, 2000

39. Segal BH et al: Genetic, biochemical, and clinical features of the chronic granulomatous disease. *Medicine* **79**:170, 2000

40. Margolis DM et al: Trimethoprim-sulfamethoxazole prophylaxis in the management of chronic granulomatous disease. *J Infect Dis* **162**:723, 1990

41. International Chronic Granulomatous Disease Cooperative Study Group: A controlled trial of interferon gamma to prevent infection in chronic granulomatous disease. *N Engl J Med* **324**:509, 1991

42. Mouy R et al: Long-term itraconazole prophylaxis against *Aspergillus* infections in thrity-two patients with chronic granulomatous disease. *J Pediatr* **125**:998, 1994

43. Malech HL: Progress in gene therapy for chronic granulomatous disease. *J Infect Dis* **2**:S318, 1999

44. Grimbacher B et al: Hyper-IgE syndrome with recurrent infections: An autosomal dominant multisystem disorder. *N Engl J Med* **340**:692, 1999

45. Borges WG et al: The face of Job. *J Pediatr* **133**:303, 1998

46. Grimbacher B et al: Genetic linkage of hyper-IgE syndrome to chromosome 4. *Am J Hum Genet* **65**:735, 1999

47. Garraud O et al: Regulation of immunoglobulin production in hyper-IgE (Job's) syndrome. *J Allerg Clin Immunol* **103**:333, 1999

48. Borges WG et al: Defective interleukin-12/interferon-? pathway in patients with hyperimmunoglobulinemia E syndrome. *J Pediatr* **136**:176, 2000

49. Arnaout MA: Leukocyte adhesion molecule deficiency: Its structural basis, pathophysiology and implications for modulating the inflammatory response. *Immunol Rev* **114**:145, 1990

50. Paller AS et al: Leukocyte adhesion deficiency: Recurrent childhood skin infections. *J Am Acad Dermatol* **31**:316, 1994

51. Hibbs M et al: Transfection of cells from patients with leukocyte adhesion deficiency with an integrin beta subunit (CD18) restores lymphocyte function associated antigen-1 expression and function. *J Clin Invest* **85**:674, 1990

52. Marquardt T et al: Leukocyte adhesion deficiency II syndrome, a generalized defect in fucose metabolism. *J Pediatr* **134**:681, 1999

53. Marquardt T et al: Correction of leukocyte adhesion deficiency type II with oral fucose. *Blood* **94**:3976, 1999

54. Blume RS, Wolff SM: The Chédiak-Higashi syndrome: Studies in four patients and review of the literature. *Medicine* **51**:247, 1972

55. Anderson LL et al: Chédiak-Higashi syndrome in a black child. *Pediatr Dermatol* **9**:31, 1992

56. Introne W et al: Clinical, molecular, and cell biological aspects of Chédiak-Higashi syndrome. *Mol Genet Metab* **68**:283, 1999

57. Barrat FJ et al: Defective CTLA-4 cycling pathway in Chédiak-Higashi syndrome: A possible mechanism for deregulation of T lymphocyte activation. *Proc Natl Acad Sci USA* **96**:8645, 1999

58. Mancini A et al: Partial albinism with immunodeficiency: Griscelli syndrome. Report of a case and review of the literature. *J Am Acad Dermatol* **38**:295, 1998

59. Pastural E et al: Griscelli disease maps to chromosome 15q21 and is associated with mutations in the *myosin-Va* gene. *Nature Genet* **16**:289, 1997

60. Menasche G et al: Mutations in RAB27A cause Griscelli syndrome associated with haemophagocytic syndrome. *Nature Genet* **25**:173, 2000

61. Glover M et al: Syndrome of erythroderma, failure to thrive and diarrhea in infancy: A manifestation of immunodeficiency. *Pediatrics* **81**:66, 1988

T>

Chapter 116

Nicholas Soter Allen Kaplan

Urticaria and Angioedema

HISTORICAL ASPECTS
EPIDEMIOLOGY
PATHOGENESIS
CLINICAL MANIFESTATIONS
Immunologic IgE- and IgE Receptor–Dependent Urticaria/Angioedema
Urticaria/Angioedema Mediated by the Complement System and Other Plasma Effector Systems
Urticaria/Angioedema after Direct Mast Cell Degranulation
Urticaria/Angioedema Relating to Abnormalities of Arachidonic Acid Metabolism
Idiopathic Urticaria/Angioedema
LABORATORY FINDINGS
PATHOLOGY
DIAGNOSIS AND DIFFERENTIAL DIAGNOSIS
TREATMENT (Table 116-4)

REFERENCES

Urticaria and angioedema occur as clinical manifestations of immunologic and inflammatory mechanisms, or they may be idiopathic. They may develop after IgE- or IgE receptor–dependent reactions, in association with abnormalities of the complement system and other plasma effector systems, after direct mast cell degranulation, and in relation to activation of cellular arachidonic acid metabolic pathways (Table 116-1). In addition to the skin and mucous membranes, the respiratory and gastrointestinal tracts as well as the cardiovascular system may be involved in any combination.

Immunologic IgE- and IgE receptor-dependent urticaria/angioedema
Atopic diathesis
Specific antigen sensitivity (foods, drugs,therapeutic agents, aeroallergens, animal danders, Hymenoptera venom, helminths)
Physical urticaria/angioedema
Contact urticaria
Autoimmune urticaria
Urticaria/angioedema mediated by the complement system and other plasma effector systems
Hereditary angioedema
Acquired angioedema with C$\bar{1}$NH deficiency and malignant disorders or autoantibody
Urticarial venulitis
Serum sickness
Reactions to blood products
Infections
Angiotensin-converting enzyme inhibitors
Urticaria/angioedema after direct mast cell degranulation
Opiate analgesics
Polymyxin B
Curare, D-tubocurarine
Radiocontrast media
Urticaria/angioedema relating to abnormalities of arachidonic acid metabolism
Aspirin and nonsteroidal anti-inflammatory agents
Azo dyes and benzoates
Idiopathic urticaria/angioedema
Cyclic episodic angioedema

TABLE 116-1 **Classification of Urticaria/Angioedema**

HISTORICAL ASPECTS

In China, cutaneous lesions thought to be urticaria have been recognized since about 1000 B.C. Hippocrates (460–377 B.C.) described pruritic lesions caused by nettles and mosquitoes that he termed *knidosis,* which is derived from the Greek word for nettle (*knide*). Plinius (A.D. 32–79) used the term *uredo* (burning), Zedler in 1740 used the word *urticatio,* and William Cullen in 1769 introduced the word *urticaria.* Some physical urticarias initially were recognized in the eighteenth century. Angioedema was described by Donato in 1586, and hereditary angioedema was reported by Osler in 1888.

EPIDEMIOLOGY

Urticaria and angioedema are common. Age, race, sex, occupation, geographic location, and season of the year may be implicated in urticaria and angioedema only insofar as they may contribute to exposure to an eliciting agent. Of a group of college students, 15 to 20 percent reported having experienced urticaria, and 1 to 3 percent of the patients referred to hospital dermatology clinics in the United Kingdom noted urticaria and angioedema. In the National Ambulatory Medical Care Survey data from 1990 to 1997 in the United States, women accounted for 69 percent of patient visits. There was a bimodal age distribution in patients aged birth to 9 years and 30 to 40 years. [1]

Urticaria/angioedema is considered to be acute if it lasts less than 6 weeks. Most acute episodes are due to adverse reactions to foods in children or to viral illnesses. Episodes of urticaria/angioedema persisting beyond 6 weeks are considered chronic and most likely represent idiopathic urticaria or urticaria that is autoimmune. Physically induced urticaria/angioedema is not included in the definition. Various types of physical urticaria/angioedema may last for years, but the individual lesions last fewer than 2 h and are intermittent. Whereas 85 percent of children experience only urticaria, approximately 50 percent of adult patients with urticaria also experience angioedema.

About 50 percent of patients with urticaria alone are free of lesions within 1 year, 65 percent within 3 years, and 85

percent within 5 years; fewer than 5 percent have lesions that last for more than 10 years. Angioedema alters the natural history, and only 25 percent of patients experience resolution of lesions within 1 year.

PATHOGENESIS

The mast cell (see Chap. 32) is the major effector cell in most forms of urticaria and angioedema, although other cell types may be involved. Cutaneous mast cells adhere to fibronectin and laminin through the very late activation (VLA) $ß_1$ integrins VLA-3, VLA-4, and VLA-5 and to vitronectin through the $avß_3$ integrin. Cutaneous mast cells, but not those from other sites, release histamine in response to compound 48/80, C5a, morphine, and codeine. The neuropeptides substance P (SP), vasoactive intestinal peptide (VIP), and somatostatin, but not neurotensin, neurokinins A and B, bradykinin, and calcitonin gene–related peptide (CGRP), activate mast cells for histamine secretion. Dermal microdialysis studies of the application of SP on skin indicate that it induces histamine release only at 10^{-6} M, which suggests that after physiologic nociceptor activation, SP does not release histamine. [2] Not all potential biologic products are produced when cutaneous mast cells are stimulated. For example, SP releases histamine from cutaneous mast cells but does not generate prostaglandin D_2 (PGD_2). Vascular permeability in skin is produced predominantly by H_1 histamine receptors, although H_2 histamine receptors sometimes may participate.

The participation of the mast cell in vivo in urticaria and angioedema has been studied by analysis of morphologic alterations of mast cells and by identification and quantitation of mast cell products in tissues or biologic fluids. Aspirates of experimental suction blisters generated over lesional and control skin have provided biologic fluid for analysis. The skin chamber model has been useful particularly because the presentation of antigen into the chamber is controlled, and the mast cell products appearing in the fluid can be assessed quantitatively and serially. Scanning laser Doppler imaging has been used to study dermal blood perfusion, and dermal microdialysis has been used to detect the presence of biochemical mediators and the consequences of their actions. A current hypothesis suggests that the release of mast cell products leads to alterations in vasopermeability with the appearance of adhesion molecules on endothelial cells and the subsequent rolling and attachment of blood leukocytes that enter the cutaneous microenvironment.

Various forms of physical urticaria/angioedema have provided experimental models to study urticaria/angioedema by allowing the observation of the elicited clinical response, examination of lesional and normal skin biopsy specimens, assay of chemical mediators released into the blood or tissues, and characterization of peripheral leukocyte responses. The intracutaneous injection of specific antigen in sensitized individuals has provided an experimental model for analysis of the role of IgE and its interaction with the mast cell. In some subjects, the challenged cutaneous sites demonstrate a biphasic response, with a transient, pruritic, erythematous wheal-and-flare reaction followed by a tender, deep, erythematous, poorly demarcated area of swelling that persists for up to 24 h.

In a study of the histamine-induced wheal-and-erythema reaction with dermal microdialysis and scanning laser Doppler imaging, the wheal began to develop at 1 to 2 min and reached a maximum at 10 min. The flare reached a steady state between 7 and 10 min. Although the rate of development of the flare was independent of the histamine concentration, the steady-state flare area at 10 min was concentration-dependent. The fact that histamine was detected in the wheal but not in the flare implies that the flare is a neurogenic reflex. [3]

The possibility that chronic idiopathic urticaria may be an autoimmune disorder arose from data that suggested an association of chronic idiopathic urticaria with autoimmune thyroiditis and, more specifically, with the presence of IgG autoantibodies to thyroglobulin and peroxidase. [4] In the original studies, the incidence of such antibodies was 12 to 14 percent in patients with chronic idiopathic urticaria; more recently, the incidence of antibodies to either antigen or to both of them is 24 percent.

It was demonstrated subsequently that approximately 10 percent of patients with chronic idiopathic urticaria had circulating IgG anti-IgE antibodies. Then IgG antibodies to the a subunit of the high-affinity IgE receptor FceRIa were detected in about 30 percent of patients with chronic idiopathic urticaria. Autologous serum injected into their skin induced a wheal-and-flare reaction.

The autoantibodies to FceRIa and IgE are associated with IgG_1 and IgG_3. [5], [6] Consistent with the latter subclass distribution are data that demonstrate a role for complement in the degranulation of basophils or cutaneous mast cells. IgG alone is effective at plasma concentrations, but the reaction is augmented in the presence of C5a in serum. [7] Blocking antibody to the C5a receptor inhibits the ability of serum to augment basophil histamine release caused by the patient's IgG autoantibodies; therefore, the complement agonist is C5a. [8] The circulating basophils of patients with chronic idiopathic urticaria behave as if they are nonspecifically desensitized, with reduced histamine release in response to challenge with anti-IgE; there is a peripheral basopenia.

Immunoblot analysis initially was thought to be a method to screen patients for the FceRIa autoantibody and to seek evidence of serum IgG binding to a cloned a subunit after sodium dodecylsulfate (SDS) gel electrophoresis. However, there are both false-positive and false-negative reactions when this assay is used, [7] and a functional assay is required to demonstrate the presence of the autoantibody. Although the autologous serum skin test can be used as a screening method that identifies some patients, serum is injected and clotting leads not only to bradykinin formation but also to enzymatic cleavage of C5 to release C5a, which may result in false-positive reactions.

The autoantibody to FceRIa has been detected in 35 to 40 percent of patients with chronic idiopathic urticaria and in some individuals with dermatomyositis, systemic lupus erythematosus, pemphigus vulgaris, and bullous pemphigoid; it has not been detected in patients with atopic dermatitis or psoriasis. Sera obtained from patients with chronic idiopathic urticaria but not from those with other autoimmune diseases released histamine from peripheral blood basophils and cutaneous mast cells. [5], [6] The explanation for the observation that the autoantibodies to either IgE or FceRIa can be present but not functional is unclear. Considerations are antibody affinity, subclass distribution, and differences in

epitope recognition. In addition to patients with chronic idiopathic urticaria, autoantibodies to IgE that are not functional also may be found in 5 to 10 percent of sera from patients with atopic dermatitis and from normal control subjects.

Some patients with chronic urticaria and thyroid autoimmunity have IgG autoantibodies to thyroglobulin and peroxidase. [4] In a study of 116 patients with chronic idiopathic urticaria, 19.8 percent exhibited IgG autoantibodies to peroxidase, and 88 percent of these individuals also exhibited IgE autoantibodies to peroxidase. [9] These IgE autoantibodies were functional and released ß-hexosaminidase from mouse mast cells. This finding has not been corroborated, however. [10]

Partially characterized histamine-releasing factors obtained from sera of patients with chronic idiopathic urticaria and from mononuclear cells, neutrophils, and platelets suggest that cytokines or chemokines may provide alternative mechanisms.

HLA-DRB1*04, HLA-DQB1*0302, HLA-DRB1*15, and HLA-DQB1*06 are present with increased frequency in patients with chronic idiopathic urticaria as compared with a control population. [11] In patients with FceRIa autoantibody, HLA-DRB1*04, HLA-DQB1*0301/4, and HLA-DQB1*0302 are present with increased frequency.

CLINICAL MANIFESTATIONS

Circumscribed, raised, erythematous, usually pruritic, evanescent areas of edema that involve the superficial portion of the dermis are known as *urticaria* (Fig. 116-1); when the edematous process extends into the deep dermis and/or subcutaneous and submucosal layers, it is known as *angioedema* (Fig. 116-2). Urticaria and angioedema may occur in any location together or individually. Angioedema commonly affects the face or a portion of an extremity, may be painful but not pruritic, and may last several days. Involvement of the lips, cheeks, and periorbital areas is common, but angioedema also may affect the tongue and pharynx. The individual lesions of urticaria arise suddenly, rarely persist longer than 24 to 48 h, and may continue to recur for indefinite periods.

FIGURE 116-1 Urticaria. This patient has urticaria occurring on the face, neck, and upper trunk with angioedema about the eyes.

Immunologic IgE- and IgE Receptor–Dependent Urticaria/Angioedema

ATOPIC DIATHESIS Episodes of acute urticaria/angioedema that occur in individuals with a personal or family history of asthma, rhinitis, or eczema are presumed to be IgE-dependent. In clinical practice, however, urticaria/angioedema infrequently accompanies an exacerbation of asthma, rhinitis, or eczema. The prevalence of chronic urticaria/angioedema is not increased in atopic individuals.
SPECIFIC ANTIGEN SENSITIVITY Common examples of specific antigens that provoke urticaria/angioedema include foods, such as shellfish, nuts, and chocolate; drugs and therapeutic agents, notably penicillin; aeroallergens; and Hymenoptera venom. Urticaria in patients with helminthic infestations has been attributed to IgE-dependent processes; however, proof of this relationship is often lacking. Specific allergens and nonspecific stimuli may activate local reactions, termed *recall urticaria,* at sites previously injected with allergen immunotherapy.
PHYSICAL URTICARIA/ANGIOEDEMA[12], [13] **(Table 116-2)**

Mechanical	
Acute brisk trauma	
Dermographism	Erythema, wheal, pruritus
Delayed dermographism	Erythema, wheal, nodules, pruritus
Pressure	
Immediate pressure urticaria	Erythema, angioedema
Delayed pressure urticaria	Erythema, angioedema, tenderness or pain, fever, chills, arthralgia, myalgia, leukocytosis
Vibration	Erythema, angioedema, flushing (may be familial)
Temperature	
Cold	
Primary acquired	Erythema, wheal, angioedema, pruritus, headache, hypotension, syncope, wheezing, shortness of breath, palpitations, nausea, vomiting, diarrhea
Familial	Erythema, macules, wheals, burning, fever, headache, conjunctivitis, arthralgia, leukocytosis (dominantly inherited
Delayed	Erythema, deep local swelling (dominantly inherited)
Heat	
Cholinergic	Erythema, small wheals, pruritus, dizziness, headache, syncope, flushing, wheezing, shortness of breath, nausea, vomiting, diarrhea (may be familial)
Local	Erythema, wheal, pruritus (may be familial)
Light	
Solar	Erythema, wheal, angioedema, pruritus, headache, syncope, dizziness, wheezing, nausea
Exercise	
Exercise-induced anaphylaxis	Erythema, wheal, angioedema, hoarseness, difficulty swallowing, syncope
Stress	
Adrenergic	Erythema, wheal with halo, pruritus
Water	
Aquagenic	Erythema, small wheals, pruritus (may be familial)

TABLE 116-2 **Physical Urticaria/Angioedema**

Dermographism Dermographism is the most common form of physical urticaria. It appears as a linear wheal with a flare at a site in which the skin is briskly stroked with a firm object. A transient wheal appears rapidly and usually fades within 30 min; however, normal skin is typically pruritic so that an itch-scratch sequence may appear. The prevalence of dermographism in the general population was 1.5 and 4.2 percent, respectively, in two studies, and its prevalence in patients with chronic idiopathic urticaria is 22 percent. It is not associated with atopy. The peak prevalence occurs in the second and third decades. In one study, the duration of dermographism was greater than 5 years in 22 percent of individuals and greater than 10 years in 10 percent. Elevations in blood histamine levels have been documented in some

patients after experimental scratching, and increased levels of histamine, tryptase, SP, and VIP, but not CGRP, have been detected in experimental suction-blister aspirates. The dermographic response has been passively transferred to the skin of normal subjects with serum or IgE.

FIGURE 116-2 Hereditary angioedema. Extensive involvement (*A*) is to be contrasted with this patient's normal facies (*B*).

Delayed dermographism Delayed dermographism develops 3 to 6 h after stimulation, either with or without an immediate reaction, and lasts 24 to 48 h. The eruption is composed of linear red nodules. This condition may be associated with delayed pressure urticaria. Cold-dependent dermographism is a condition that occurs only after cold exposure. Cholinergic dermographism is a rare form that develops as punctate wheals in patients with cholinergic urticaria.

Pressure urticaria Delayed pressure urticaria appears as erythematous, deep, local swellings, often painful, that arise from 0.5 to 6 h after sustained pressure has been applied to the skin. Spontaneous episodes are elicited after sitting on a hard chair, under shoulder straps and belts, on the feet after running, and on the hands after manual labor. The peak prevalence occurs in the third decade. Delayed pressure urticaria may be associated with fever, chills, arthralgias, and myalgias, as well as with an elevated erythrocyte sedimentation rate and leukocytosis. In one study, it occurred in 37 percent of patients with chronic idiopathic urticaria plus dermographism. An IgE-mediated mechanism has not been demonstrated; however, histamine and interleukin 6 (IL-6) have been detected in lesional experimental suction-blister aspirates and in fluid from skin chambers, respectively; leukotriene B_4 (LTB_4), 12- and 15-hydroxyeicosatetraenoic acids, and IL-1 were absent. Immediate pressure urticaria is a rare idiopathic disorder. It has been described in patients with the hypereosinophilic syndrome.

Vibratory angioedema Vibratory angioedema may occur as an acquired idiopathic disorder, in association with cholinergic urticaria, or after several years of occupational exposure to vibration. It has been described in a family with an autosomal dominant pattern of inheritance. The heritable form often is accompanied by facial flushing. An increase in the level of plasma histamine was detected during an experimental attack in patients with the hereditary form and in patients with acquired disease.

Cold urticaria There are both acquired and inherited forms of cold urticaria/angioedema. The acquired forms are more common. Idiopathic or primary acquired cold urticaria may be associated with headache, hypotension, syncope, wheezing, shortness of breath, palpitations, nausea, vomiting, and diarrhea. Attacks occur within minutes after exposures that include changes in ambient temperature and direct contact with cold objects. The elicitation of a wheal after the application of ice has been called a *diagnostic cold contact test.* If the entire body is cooled, as in swimming, hypotension and syncope, which are potentially lethal events, may occur. In rare instances, acquired cold urticaria has been associated with underlying cryoglobulins, cryofibrinogens, cold agglutinins, and cold hemolysins, especially in children with infectious mononucleosis. Passive transfer of cold urticaria with serum or IgE to the skin of a normal recipient has been documented. Histamine, chemotactic factors for eosinophils and neutrophils, PGD_2, cysteinyl leukotrienes, platelet-activating factor, and tumor necrosis factor a (TNF-a) have been released into the circulation after experimental challenge. Histamine, SP, and VIP, but not CGRP, have been detected in experimental suction-blister aspirates. Histamine has been released in vitro from chilled skin biopsy specimens that have been rewarmed. Neutrophils harvested from the blood of an experimentally cold-challenged arm manifested an impaired chemotactic response. Whereas complement has no role in primary acquired cold urticaria, the challenge of patients with cold urticaria who have circulating immune complexes, such as cryoglobulins, can provoke a cutaneous necrotizing venulitis with complement activation. Rare forms of acquired cold urticaria that have been described mainly in case reports include systemic cold urticaria, localized cold urticaria, cold-induced cholinergic urticaria, cold-dependent dermographism, and localized cold reflex urticaria. Two forms of dominantly inherited cold urticaria have been described. *Familial cold urticaria,* which also has been termed *familial cold autoinflammatory syndrome* and is considered a type of periodic fever, [14] is an autosomal dominant disorder with a genetic linkage to chromosome 1q44. The responsible gene has been identified as *CIAS1,* which codes for a protein involved in regulation of inflammation and apoptosis. [15] The eruption occurs as erythematous macules and infrequent wheals and is associated with burning or pruritus. Fever, headaches, conjunctivitis, arthralgias, and a neutrophilic leukocytosis are features of attacks. The delay between cold exposure and onset of symptoms is 2.5 h, and the average duration of an episode is 12 h. Renal disease with amyloidosis occurs infrequently. Skin biopsy specimens show mast cell degranulation and an infiltrate of neutrophils. The cold contact test and passive transfer with serum have been negative. Serum levels of IL-6 and granulocyte colony-stimulating factor (G-CSF) were elevated in one patient. *Delayed cold urticaria* occurs as erythematous, edematous, deep swellings that appear 9 to 18 h after cold challenge. Lesional biopsy specimens show edema with minimal numbers of mononuclear cells; mast cells are not degranulated; and complement proteins, immunoglobulins, and fibrin are not detected. Cold immersion does not release histamine, and the condition cannot be passively transferred.

Cholinergic urticaria Cholinergic urticaria develops after an increase in core body temperature, such as during a warm bath or shower, exercise, or episodes of fever. The highest prevalence is observed in individuals aged 23 to 28 years. The eruption appears as distinctive, pruritic, small, 1- to 2-mm wheals that are surrounded by large areas of erythema (Fig. 116-3); occasionally, the lesions may become confluent, or angioedema may develop. Systemic features include dizziness, headache, syncope, flushing, wheezing, shortness of breath, nausea, vomiting, and diarrhea. An increased

prevalence of atopy has been reported. The intracutaneous injection of cholinergic agents, such as methacholine chloride, produces a wheal locally in approximately one-third of patients. Alterations in pulmonary function have been documented during experimental exercise challenge or after the inhalation of acetylcholine. Familial cases have been reported only in men in four families. This observation suggests an autosomal dominant pattern of inheritance. One of these individuals had coexisting dermographism and aquagenic urticaria. After exercise challenge, histamine and factors chemotactic for eosinophils and neutrophils have been released into the circulation. Tryptase has been detected in lesional suction-blister aspirates. The urticarial response has been passively transferred on one occasion; however, most other attempts to do so have been unsuccessful.

Local heat urticaria Local heat urticaria is a rare form of urticaria in which wheals develop within minutes after exposure to locally applied heat. An increased incidence of atopy has been reported. Passive transfer has been negative. Histamine, neutrophil chemotactic activity, and PGD_2 have been detected in the circulation after experimental challenge. In two individuals, there were alterations in factor B levels, which suggested activation of the alternative complement pathway. A familial delayed form of local heat urticaria in which the urticaria occurred 1 to 2 h after challenge and lasted up to 10 h has been described.

Solar urticaria Solar urticaria occurs as pruritus, erythema, wheals, and occasionally angioedema that develop within minutes after exposure to sun or artificial light sources. Headache, syncope, dizziness, wheezing, and nausea are systemic features. Most commonly, solar urticaria appears during the third decade. [16] In one study, 48 percent of patients had a history of atopy. Although solar urticaria may be associated with systemic lupus erythematosus and polymorphous light eruption, it is usually idiopathic. The development of skin lesions under experimental conditions in response to specific wavelengths has allowed classification into six subtypes; however, individuals may respond to more than one portion of the light spectrum. In type I, elicited by wavelengths of 285 to 320 nm, and in type II, elicited by wavelengths of 400 to 500 nm, the responses have been passively transferred with serum. In type I, the wavelengths are blocked by window glass. Type VI, which occurs in erythropoietic protoporphyria and is due to ferrochelatase deficiency, has been reported in a single patient.

FIGURE 116-3 Cholinergic urticaria showing small wheals with surrounding erythema.

Histamine and chemotactic factors for eosinophils and neutrophils have been identified in blood after exposure of the individuals to ultraviolet A (UVA), UVB, and visible light. In some individuals, uncharacterized serum factors with molecular weights ranging from 25 to 1000 kDa, which elicit cutaneous wheal-and-erythema reactions after intracutaneous injection, have been implicated in the development of lesions.

Exercise-induced anaphylaxis Exercise-induced anaphylaxis is a clinical symptom complex consisting of pruritus, urticaria, angioedema (cutaneous, laryngeal, and intestinal), and syncope that is distinct from cholinergic urticaria. In most patients, the wheals are not punctate but are normal in size. There is a high prevalence of an atopic diathesis. Various types of this syndrome have been described, including exercise-induced anaphylaxis requiring exercise alone as a stimulus, food-dependent exercise-induced anaphylaxis requiring both exercise and food as stimuli, and a variant form in which punctate wheals appear after exercise. The administration of aspirin before the ingestion of food allergens induced urticaria in some patients with food-dependent exercise-induced anaphylaxis. [17] Analysis of a questionnaire study of individuals with exercise-induced anaphylaxis for more than a decade [18] disclosed that the frequency of attacks had decreased in 47 percent and had stabilized in 46 percent. Forty-one percent had been free of attacks for one year. Rare familial forms have been described. In exercise-induced anaphylaxis, pulmonary function tests are normal, biopsy specimens show mast cell degranulation, and histamine and tryptase are released into the circulation.

Adrenergic urticaria Adrenergic urticaria occurs as wheals surrounded by a white halo that develop during emotional stress. The lesions can be elicited by the intracutaneous injection of norepinephrine.

Aquagenic urticaria and aquagenic pruritus Contact of the skin with water of any temperature may result in pruritus alone or, more rarely, urticaria. The eruption consists of small wheals that are reminiscent of cholinergic urticaria. Aquagenic urticaria has been reported in more than one member in five families. [19] Aquagenic pruritus without urticaria is usually idiopathic but also occurs in elderly persons with dry skin and in patients with polycythemia vera, Hodgkin's disease, the myelodysplastic syndrome, and the hypereosinophilic syndrome. Patients with aquagenic pruritus should be evaluated for the emergence of a hematologic disorder. After experimental challenge, blood histamine levels were elevated in subjects with aquagenic pruritus and with aquagenic urticaria. Mast cell degranulation was present in lesional tissues. Passive transfer was negative.

CONTACT URTICARIA Urticaria may occur after direct contact with a variety of substances. It may be IgE-mediated or nonimmunologic. The transient eruption appears within minutes, and when it is IgE mediated, it may be associated with systemic manifestations. Passive transfer has been documented in some instances. Proteins from latex products are a prominent cause of IgE-mediated contact urticaria. Latex proteins also may become airborne allergens, as demonstrated by allergen-loaded airborne glove powder used in inhalation challenge tests (see Chap. 137). These patients may manifest cross-reactivity to fruits, such as bananas, avocado, and kiwi. Associated manifestations include rhinitis, conjunctivitis, dyspnea, and shock. The risk group is dominated by biomedical workers and individuals with frequent contact with latex, such as children with spina bifida. Agents such as stinging nettles, arthropod hairs, and chemicals may release histamine directly from mast cells. Papular urticaria occurs as episodic, symmetrically distributed, pruritic, 3- to 10-mm urticarial papules that result from a hypersensitivity reaction to insect bites, such as mosquitoes, fleas, and bedbugs. This condition appears mainly in children. The lesions tend to appear in groups on exposed areas, such as the extensor aspects of the extremities.

AUTOIMMUNE URTICARIA Circulating autoantibodies have been recognized in the sera of some patients with chronic idiopathic urticaria, leading to the term *autoimmune urticaria.* These antibodies are estimated to be present in at least 35 to 40 percent of patients with chronic idiopathic urticaria and are discussed under “Pathogenesis” above. A positive autologous serum skin test is defined as a red wheal with a diameter that is 1.5 mm greater than the saline-induced

response at 30 min. [20] Patients with autoantibodies have a greater number of wheals with a wider distribution, more severe pruritus, and systemic features of nausea, abdominal pain, diarrhea, and flushing. [21]

Urticaria/Angioedema Mediated by the Complement System and Other Plasma Effector Systems

HEREDITARY AND ACQUIRED ANGIOEDEMA Hereditary angioedema is a dominantly inherited disorder that is characterized by recurrent attacks of angioedema that involve the skin and mucous membranes of the respiratory and gastrointestinal tracts (see Chap. 117). Urticaria is not a manifestation. There is a functional deficiency of the inhibitor of the activated first component of the complement system ($C\overline{1}$1INH). Acquired angioedema with depletion of $C\overline{1}$1INH has two forms. One is associated with malignant disorders, notably B cell lymphomas and autoantibody to paraproteins. The other form is associated with an autoantibody directed against the $C\overline{1}$1INH molecule. A clinical symptom complex that resembles hereditary angioedema and has an X-linked pattern of inheritance was described in women with angioedema without urticaria and with laryngeal edema and abdominal pain. C4 and $C\overline{1}$1INH levels and function are normal. [22] An estrogen-dependent form of angioedema that resembles hereditary angioedema has been reported in a single family with seven affected individuals in three generations, suggesting an autosomal dominant pattern of inheritance. [23] Clinical features include angioedema without urticaria, laryngeal edema, and abdominal pain with vomiting. Attacks occur during pregnancy and with the administration of exogenous estrogens. Although the molecular mechanism is unknown, $C\overline{1}$1INH levels and function are normal, and the 5' flanking region of the gene encoding factor XII, which contains an estrogen response element, is normal.

URTICARIAL VENULITIS Chronic urticaria and angioedema may be manifestations of cutaneous necrotizing venulitis, which is known as *urticarial venulitis.* [24] Associated features include fever, malaise, arthralgia, abdominal pain, and less commonly, conjunctivitis, uveitis, diffuse glomerulonephritis, obstructive and restrictive pulmonary disease, and benign intracranial hypertension (see Chap. 175). Serum complement abnormalities have been reported in some patients with this disorder. The term *hypocomplementemic urticarial vasculitis syndrome* is used in patients with more severe clinical manifestations of urticarial venulitis with hypocomplementemia and a low-molecular-weight 7S C1q-precipitin that has been identified as an IgG autoantibody directed against the collagen-like region of C1q. Urticarial venulitis also may occur in individuals with serum sickness, connective tissue disorders, hematologic malignant conditions, an IgM $_{K}$M component, and infections and as an idiopathic disorder.

SERUM SICKNESS Serum sickness, which was defined originally as an adverse reaction that resulted from the administration of heterologous serum to humans, may occur after the administration of drugs. Serum sickness occurs 7 to 21 days after the administration of the offending agent and is manifested by fever, urticaria, lymphadenopathy, myalgia, arthralgia, and arthritis. Symptoms are usually self-limited and last 4 to 5 days. More than 70 percent of patients with serum sickness experience urticaria, which may be pruritic or painful. The initial manifestation of urticaria may appear at the site of injection. It is not clear whether the urticaria is due to IgE antibodies to the offending allergen or to immune complexes that activate the complement system leading to C5a or both.

REACTIONS TO THE ADMINISTRATION OF BLOOD PRODUCTS Urticaria/angioedema may develop after the administration of blood products. It usually is the result of immune complex formation and complement activation that leads to direct vascular and smooth muscle alterations and indirectly, via anaphylatoxins, to mast cell mediator release. This mechanism has been delineated clearly in the case of urticarial or anaphylactic reactions to blood, plasma, or immunoglobulin in patients with antibodies to IgA, which may arise after transfusion or by placental transfer. These antibodies form complexes with donor IgA and may activate the complement system. Urticarial or anaphylactic reactions to the administration of immunoglobulin do not, however, always depend on antibody to IgA. Aggregates of IgG may activate mast cells by binding to Fc?RIII or by activating complement. The intradermal administration of aggregated IgG to humans leads within 10 min to swelling and erythema that becomes tender and persists up to 24 to 48 h. Biopsy specimens of these reactions show neutrophilic infiltrates at 6 and 24 h, with a mononuclear infiltrate appearing at 24 h. The implication that aggregated IgG is responsible for most human reactions is strengthened by the fact that the administration of IgG from which aggregates have been removed is not associated with urticaria or anaphylaxis. An uncommon mechanism for the development of urticaria after the administration of blood products is the transfusion of IgE of donor origin directed toward an antigen to which the recipient is subsequently exposed. Another mechanism may be the transfusion of a soluble antigen present in the donor preparation into a previously sensitized recipient.

INFECTIONS Episodes of acute urticaria can be associated with upper respiratory tract viral infections, most commonly in children. The acute urticaria resolves within 3 weeks. Hepatitis B virus infection has been associated with episodes of urticaria lasting up to 1 week that are associated with fever and arthralgias as part of the prodrome.

ANGIOTENSIN-CONVERTING ENZYME INHIBITORS Angioedema has been associated with the administration of angiotensin-converting enzyme (ACE) inhibitors. [25] The frequency of angioedema occurring after ACE inhibitor therapy is 0.1 to 0.7 percent. Angioedema develops during the first week of therapy in up to 72 percent of affected individuals and usually involves the head and neck, including the mouth, tongue, pharynx, and larynx. Urticaria occurs only rarely. Cough and angioedema of the gastrointestinal tract are associated features. It has been suggested that therapy with ACE inhibitors is contraindicated in patients with a prior history of idiopathic angioedema, hereditary angioedema, and acquired $C\overline{1}$1INH deficiency. [25] The mechanism is believed not to be immunologic because the angioedema may occur within hours of the first dose and may develop after the administration of ACE inhibitors of various structures. The pathobiologic mechanism is believed to be related to the kallikrein-kinin plasma effector system. One hypothesis is that bradykinin, which is normally degraded in part by ACE, accumulates in tissues when an ACE inhibitor is given.

Urticaria/Angioedema after Direct Mast Cell Degranulation

Various therapeutic and diagnostic agents have been associated with urticaria/angioedema. Up to 8 percent of patients receiving radiographic contrast media experience such reactions, which occur most commonly after intravenous administration. Opiate analgesics, polymyxin B, curare, and D-tubocurarine release histamine from mast cells and basophils. Decreased serum alternative pathway complement protein levels and increased serum histamine levels have been detected in patients receiving radiocontrast media. A greater risk for urticaria/angioedema and anaphylactic-like reactions in women is suggested by one study in which 70 percent of those experiencing such a reaction were women.

Urticaria/Angioedema Relating to Abnormalities of Arachidonic Acid Metabolism

Intolerance to aspirin manifested as urticaria/angioedema occurs in otherwise normal individuals or in patients with allergic rhinitis and/or bronchial asthma. Urticaria/angioedema in response to aspirin and nonsteroidal anti-inflammatory drugs (NSAIDs) occurred in approximately 10 to 20 percent of individuals referred to a hospital dermatology clinic in the United Kingdom. Patients intolerant of aspirin also may react to indomethacin and to other NSAIDs.

Reactions to aspirin are shared with other NSAIDs because they reflect inhibition of prostaglandin endoperoxide synthase 1 (PGHS-1, cyclooxygenase 1) rather than inhibition of the inducible PGHS-2 (cyclooxygenase 2). Sodium salicylate and choline salicylate generally are well tolerated because of their weak activity against PGHS-1. In a single-blind, placebo-controlled oral provocation study with PGHS-2 inhibitors in 82 patients with urticaria and angioedema who were intolerant to NSAIDs, 74.5 percent were cross-reactors. [26] The reaction rates were 33.3 percent for celecoxib, 21.3 percent for nimesulide, 17.3 percent for meloxicam, and 3.0 percent for rofecoxib. Reactions to NSAIDs increase the levels of cysteinyl leukotrienes, [27] which may relate to the appearance of urticaria, although their role in NSAID-induced asthma is better characterized. Prick skin tests are of no diagnostic value, passive transfer reactions are negative, and neither IgG nor IgE antibodies have been associated with clinical disease. The clinical manifestations elicited by aspirin challenge of aspirin-intolerant patients are blocked when such patients are protected with a cysteinyl leukotriene receptor blocker or biosynthetic inhibitor; this finding confirms a pathobiologic role for the cysteinyl leukotrienes rather than acetylation of PGHS-2 by aspirin. However, in two patients with aspirin-induced urticaria, the administration of a cysteinyl leukotriene receptor 1 antagonist provoked urticaria. [28]

Idiopathic Urticaria/Angioedema

In at least 70 percent of individuals with chronic idiopathic urticaria/angioedema, the cause is unknown. Because this clinical entity is common, has a capricious course, and is recognized easily, it is frequently associated with concomitant events. Such attributions must be interpreted with caution. Although infections, metabolic and hormonal abnormalities, malignant conditions, and emotional factors have been claimed as causes, proof of their etiologic relationship often is lacking. In a meta-analysis of chronic idiopathic urticaria and *Helicobacter pylori* infection, [29] resolution of the urticaria was four times more likely when the *H. pylori* infection was eradicated successfully by antibiotic therapy than when it was not. However, only one-third of patients with chronic urticaria will undergo remission with successful eradication of infection. The hypothesis that urticaria is associated with internal malignant disease has been based primarily on anecdotal reports. There is no convincing evidence to support a causal relationship.

Although idiopathic urticaria/angioedema is the most prevalent form, the diagnosis remains one of exclusion. Cyclic episodic angioedema with urticaria/angioedema has been associated with fever, weight gain, absence of internal organ damage, a benign course, and peripheral blood eosinophilia. [30] Biopsy specimens of tissues show eosinophils, eosinophil granule proteins, and CD4 lymphocytes exhibiting HLA-DR. Blood levels of IL-1, soluble IL-2 receptor, and IL-5 are elevated.

LABORATORY FINDINGS

The evaluation of patients (Table 116-3) with urticaria/angioedema begins with a comprehensive history, with particular emphasis on the recognized causes, and a physical examination. Some varieties of urticaria may be identified by their characteristic appearance, such as the small wheals with a large erythematous flare of cholinergic urticaria, the linear wheals in dermographism, and the localization of lesions to exposed areas in light- or cold-induced urticaria. If suggested by the history, the physical examination in all patients with urticaria should include tests for physical urticaria, such as a brisk stroke to elicit dermographism, the use of a weight to elicit delayed pressure urticaria, and application of a cold or warm stimulus for cold-induced urticaria and localized heat urticaria, respectively. Exercise, such as running in place, may elicit cholinergic urticaria and, in some instances, exercise-induced anaphylaxis. Phototests to elicit solar urticaria usually are performed in referral centers, as are challenges for exercise-induced anaphylaxis.

In all patients
History and physical examination
Provocative tests for physical urticarias
In selected patients
Complete blood count with differential analysis
Erythrocyte sedimentation rate
Urinalysis
Blood chemistry profile
Stool examination for ova and parasites
Hepatitis B virus surface antigen and hepatitis B and C antibodies
Thyroid microsomal and peroxidase antibodies
Antinuclear factor
Cryoproteins
Skin tests for IgE-mediated reactions
Radioallergosorbent test (RAST) for specific IgE
Skin biopsy

TABLE 116-3 **Investigation of Chronic Idiopathic Urticaria/Angioedema**

In most patients with chronic urticaria/angioedema, no underlying disorders or causes can be discerned. Diagnostic studies should be based on findings elicited by the history and physical examination. There is no recommended diagnostic laboratory evaluation for chronic urticaria/angioedema, and routine screening laboratory tests are of no value. [31] Serum hypocomplementemia is not present in chronic idiopathic urticaria, and mean levels of serum IgE are normal.

Cryoproteins should be sought in patients with acquired cold urticaria. An antinuclear antibody test should be obtained in patients with solar urticaria. Autoantibodies to thyroglobulin and peroxidase may be present in individuals with autoimmune thyroid disease and urticaria/angioedema; routine screening in patients with chronic urticaria for thyroid autoimmunity is suggested by some investigators but not by others. Assessment of serum complement proteins may be

helpful in identifying patients with urticarial venulitis, as well as those with hereditary and acquired forms of C $\overline{1}$1INH deficiency.

Skin biopsy of chronic urticarial lesions should be undertaken only to identify urticarial venulitis.

There is little role for routine prick skin testing or the radioallergosorbent test (RAST) in the diagnosis of specific IgE-mediated antigen sensitivity in chronic urticaria/angioedema. Inhalant materials are uncommon causes of urticaria/angioedema, and food skin tests may be difficult to interpret. The tests for drugs are limited to penicillin but cannot be performed in patients with dermographism. The RAST should be reserved for those in whom skin testing is contraindicated, unavailable, or unrevealing despite a highly suspected history. Use of the autologous serum skin test to seek autoantibodies to FceRIa or IgE remains a research technique.

The release of histamine from peripheral basophilic leukocytes has supported the diagnosis of anaphylactic sensitivity to a variety of antigens, which include pollens and insect venom, and may suggest the presence of a FceRIa autoantibody, but this assay also remains a research technique.

PATHOLOGY

Edema involving the superficial portion of the dermis is characteristic of urticaria, whereas angioedema involves the deeper dermis and subcutaneous tissue. Both disorders are associated with dilation of the venules. Mast cell numbers are comparable in lesional and nonlesional skin of patients with chronic idiopathic urticaria and are not different from the numbers in control skin of unaffected individuals, although in a few studies mast cell numbers were observed to be increased in the lesional skin of patients with chronic idiopathic urticaria.

In chronic idiopathic urticaria, the dermal infiltrating inflammatory cells may be sparse or dense in amount and include more CD4 than CD8 T lymphocytes, neutrophils, eosinophils, and basophils [32], [33] without B lymphocytes or natural killer (NK) cells. In some specimens, neutrophils are the predominant cell type. Increased expression of TNF-a and IL-3 on endothelial cells and perivascular cells was detected in the upper dermis of patients with acute urticaria, chronic idiopathic urticaria, and delayed-pressure urticaria and in one patient with cold urticaria. [34] TNF-a also was detected on epidermal keratinocytes in lesional and nonlesional biopsy specimens. In chronic idiopathic urticaria, CD11b and CD18 cells were detected about the blood vessels in the superficial and deep dermis. Direct immunofluorescence tests for immunoglobulins and complement proteins were negative.

Major basic protein and eosinophil cationic protein (ECP), which are derived from the eosinophil granule, are present around blood vessels and are dispersed in the dermis in lesions of acute urticaria, chronic idiopathic urticaria, delayed-pressure urticaria, cholinergic urticaria, and solar urticaria. In chronic idiopathic urticaria, free eosinophil granules in the dermis were increased in wheals of greater than 24 h duration as compared with wheals lasting fewer than 24 h. The secreted form of ECP and eosinophil-derived neurotoxin were detected on cells in greater amounts in biopsy specimens from patients with chronic idiopathic urticaria without autoantibodies as compared with those with autoantibodies. P-selectin, E-selectin, intercellular adhesion molecule 1 (ICAM-1), and VCAM-1 have been demonstrated on the vascular endothelium of patients with chronic idiopathic urticaria and dermographism. Major histocompatability complex (MHC) class II antigen also is upregulated on the endothelial cells of patients with chronic idiopathic urticaria, and the peripheral blood lymphocytes have increased CD40 ligand expression and higher Bcl-2 expression; these observations suggest an augmentation of autoimmune phenomena. [35]

In papular urticaria, the epidermis is thick, with intercellular edema and lymphocytes. In the dermis, there is edema with an infiltrate containing T lymphocytes, macrophages, eosinophils, and neutrophils without B lymphocytes or the deposition of immunoglobulins, fibrin, and C3.

DIAGNOSIS AND DIFFERENTIAL DIAGNOSIS

Urticaria and angioedema are easily recognizable disorders. Urticarial eruptions are episodic and evanescent, with multiple lesions occurring in various stages of evolution and resolution. Seldom do individual urticarial lesions persist for more than 48 h except in patients with urticarial venulitis. Angioedema may persist for several days. Several disorders are included in the differential diagnosis. Edematous, papulovesicular, or bullous eruptions with mucosal involvement and typical iris, or target, lesions characterize erythema multiforme. One or more annular, edematous plaques that may expand in diameter (erythema migrans) occur in Lyme borreliosis. Edematous and erythematous plaques that are indolent with or without bullae are features of bullous pemphigoid. Urticaria pigmentosa is a generalized, red-brown, macular, papular, or nodular mast cell infiltration in which the skin lesions become edematous when rubbed. The syndrome of perceptive deafness, fever with urticaria, and renal insufficiency consequent to amyloidosis is readily excluded.

Cellulitis, congestive heart failure, renal insufficiency, myxedema, thrombophlebitis, the superior vena cava syndrome, and the Melkersson-Rosenthal syndrome should be considered as causes for edematous processes resembling angioedema.

TREATMENT (Table 116-4)

Identification and removal of precipitating cause when possible
Administration of H_1 antihistamines with empirical trials of each pharmacologic subclass
Various combination of H_1 antihistamines
Administration of H_1 and H_2 antihistamines
Addition of a β-adrenergic agonist to an H_1 antihistamine
Avoidance of epinephrine except in instances of respiratory tract compromise or cardiovascular collapse
Alternate-day systemic glucocorticoids and trials of novel and anecdotal therapeutic agents in refractory disease

TABLE 116-4 **An Approach to the Management of Chronic Urticaria/Angioedema**

The pathobiologic areas at which the treatment of urticaria and angioedema are directed include the initiating stimulus, effector cells and their inflammatory mediators, and receptor sites on target tissues. Therapy directed at mast cells involves blocking the release or generation of mediators or the effects of released mediators. Release can be blocked by stabilizing the membrane and by modulating cyclic nucleotide levels or calcium flux. Therapy also can be directed at other effector cells, such as lymphocytes. In one study, allergists and dermatologists were demonstrated to have more expertise in caring for patients with urticaria/angioedema than other specialists. Allergists were the least likely to use a systemic glucocorticoid (6 percent of visits), whereas internists were the most likely (29 percent of visits). [1]

The ideal treatment for urticaria/angioedema is identification and removal of its cause. Many patients with acute urticaria and angioedema probably are not treated by physicians because the cause is identified by the individual or the course is limited. Treatment of chronic idiopathic urticaria focuses on measures that provide symptomatic relief. The physician should provide not only medications but also support and reassurance. In a questionnaire study, patients with chronic idiopathic urticaria considered the worst aspects to be pruritus and the unpredictable nature of the attacks. [36] Affected individuals reported sleep disturbances, diminished energy, social isolation, and altered emotional reactions as well as difficulties in relation to work, home activities, social life, and sex life. Another study showed a correlation between the severity of chronic idiopathic urticaria and depression. In a questionnaire study, individuals with delayed-pressure urticaria and cholinergic urticaria had the most quality-of-life impairment. [37] Those with cholinergic urticaria suffered in relation to their sporting activities and sexual relationships. Although urticaria/angioedema may be a source of frustration to both physicians and patients, most individuals can achieve acceptable symptomatic control of their disease without identification of the cause. In some individuals it is important to avoid aspirin and other NSAIDs. Antipruritic lotions, cool compresses, and ice packs may provide temporary relief.

H_1-type antihistaminic drugs are the mainstays in the management of urticaria/angioedema (see Chap. 258). The older H_1-type antihistamines are known as classic, traditional, or first-generation H_1-type antihistamines. Newer, low-sedating, or second- and third-generation H_1-type antihistamines with reduced sedative and anticholinergic side effects have become the initial therapeutic agents of choice. Antihistaminic agents should be administered initially at a low dose and increased to tolerance. The drug should be taken on a regular basis and not as needed. If the initial drug chosen is ineffective, an agent from a different pharmacologic class should be used. If the initial drug chosen is partially beneficial, an agent from a different pharmacologic class can be added. Thus combinations of agents from different classes may be used. The combination of H_1- and H_2 antihistamines may benefit a few patients with chronic idiopathic urticaria. The tricyclic antidepressant doxepin, which has activity against both H_1 and H_2 histamine receptors, may be useful. Terbutaline, a ß-adrenergic agonist, in combination with an H_1-type antihistamine, has been reported to benefit a few patients with chronic idiopathic urticaria. Although clinical trials have been carried out with many of the H_1-type antihistamines, in many instances the therapeutic approaches are based on clinical experience.

For patients with refractory, chronic idiopathic urticaria who have failed to benefit from conventional therapy, novel and anecdotal therapeutic measures may be considered. Nifedipine has been shown in a double-blind crossover study to be useful as an adjunctive therapeutic agent with H_1 antihistamines. In open trials, zafirlukast and montelukast had beneficial responses, [38] and zileuton was used successfully in some patients. In a double-blind, placebo-controlled trial, the combination of montelukast and cetirizine was of benefit to patients with intolerance to food additives or acetylsalicylic acid. [39] In a study of 18 patients with chronic idiopathic urticaria, the addition of zafirlukast or montelukast to an H_1 antihistamine was beneficial. [40] In a single female who experienced urticaria after treatment with piroxicam, zafirlukast prevented a flare of urticaria on subsequent use of piroxicam. [41] Stanozolol and sulfasalazine [42] have been of benefit in some patients with chronic idiopathic urticaria. One report suggested that colchicine in combination with an H_1 antihistamine was of value to 5 of 7 patients with chronic idiopathic urticaria, in which the dermal infiltrate is rich in neutrophils and eosinophils. Cyclosporine was effective in chronic idiopathic urticaria in a randomized, double-blind study [43]; however, the appropriate dose has not yet been determined. [44] Methotrexate was used in 3 patients with benefit. Plasmapheresis was of value in patients with circulating autoantibodies, but relapse occurred as the antibody formed again. Intravenous immunoglobulin was of limited benefit in a few patients. [45] In one study, the use of narrow-band UVB phototherapy achieved improvement in 71 percent and resolution in 28 percent of patients with chronic idiopathic urticaria. [46] The subcutaneous administration of interferon a in two controlled trials was of no benefit. In one study of 7 euthyroid patients with thyroid autoantibodies and chronic idiopathic urticaria, all experienced resolution within 4 weeks after the administration of thyroxine. In 5 of the 7 patients, the urticaria recurred after the treatment was discontinued. In a few individuals, hypnosis may be useful. Acupuncture has been reported to be of benefit in the treatment of urticaria in Asia.

The use of prednisone in the management of acute urticaria has been advocated in emergency rooms, but this form of therapy should not be routine. Epinephrine is used widely, particularly in hospital emergency departments, but its use is indicated only in cases of laryngeal edema or cardiovascular collapse. Systemic glucocorticoids have no place in the regular therapy of chronic idiopathic urticaria. When glucocorticoids are used, alternate-day administration is recommended. Prednisone is used at a dose of 15 to 20 mg every other day and is tapered gradually by 2.5 to 5.0 mg every 3 weeks, depending on the patient's response. At that rate, it often can be discontinued in a 4- to 5-month period. The alternate-day dose rarely exceeds 20 mg of prednisone or its equivalent. Side effects are minimized with dietary discretion and exercise. Patients requiring alternate-day glucocorticoids beyond this period should be examined annually

by an ophthalmologist for cataracts or glaucoma, and a bone density scan is obtained to seek osteoporosis.

In the treatment of the physical urticarias, patient education and avoidance of the inciting stimulus are important. Most forms of physical urticaria are treated with antihistamines. Induction of refractoriness has been achieved in some patients with primary acquired cold urticaria, solar urticaria, and local heat urticaria. In cholinergic urticaria, hydroxyzine and cetirizine are the initial agents of choice. In anecdotal reports and in small numbers of patients in open trials, delayed-pressure urticaria may respond to NSAIDs, dapsone, cetirizine, sulfasalazine, and systemic glucocorticoids but not to colchicine and uncommonly to H_1 antihistamines. During hypothermic cardiopulmonary bypass, cold urticaria was managed successfully with the administration of H_1 and H_2 antihistamines. Plasmapheresis has been used successfully in patients with solar urticaria with a circulating photoallergen. Propranolol hydrochloride may prevent attacks of adrenergic urticaria. A few patients with some forms of physical urticaria have responded to treatment with broadband UVB phototherapy and PUVA photochemotherapy. In exercise-induced anaphylaxis, there are no controlled therapeutic trials. Although treatment for acute exercise-induced anaphylaxis is the same as that for anaphylaxis of any cause, an important aspect of therapy is modification of exercise programs and food intake.

In hereditary angioedema, therapy is directed toward treatment of the acute attack, to preoperative and dental prophylaxis, and to chronic prophylactic suppression of attacks (see Chap. 117).

The role of dietary manipulation in urticaria/angioedema is difficult to assess. Information gained from the routine trial of elimination diets may be confusing due to the placebo effect and the variability of the course of urticaria. It is generally thought that if a food is truly responsible for exacerbation of urticaria, its ingestion should be followed routinely by lesions within 2 h. In addition to foods, ingested preservatives, food colorings, and natural salicylates in foods may be responsible for the genesis or aggravation of chronic idiopathic urticaria, although these associations may be spurious.

REFERENCES

1. Henderson RL Jr et al: Allergists and dermatologists have far more expertise in caring for patients with urticaria than other specialists. *J Am Acad Dermatol* **43**:1084, 2000

2. Weidner C et al: Acute effects of substance P and calcitonin gene-related peptide in human skin: A microdialysis study. *J Invest Dermatol* **115**:1015, 2000

3. Petersen LJ et al: Histamine is released in the wheal but not the flare following challenge of human skin in vivo: A microdialysis study. *Clin Exp Allergy* **27**:284, 1997

4. Turktas I et al: The association of chronic urticaria and angioedema with autoimmune thyroiditis. *Int J Dermatol* **36**:187, 1997

5. Ferrer M et al: Comparative studies of functional and binding assays for IgG anti-FceRIa (a-subunit) in chronic urticaria. *J Allergy Clin Immunol* **101**:672, 1998

6. Fiebiger E et al: Anti-FceRIa autoantibodies in autoimmune-mediated disorders: Identification of a structure-function relationship. *J Clin Invest* **101**:243, 1998

7. Kikuchi Y, Kaplan AP: Mechanisms of autoimmune activation of basophils in chronic urticaria. *J Allergy Clin Immunol* **107**:1056, 2001

8. Kikuchi Y, Kaplan AP: A role for C5a in augmenting IgG-dependent histamine release from basophils in chronic urticaria. *J Allergy Clin Immunol* **109**:114, 2002

9. Hanau A et al: Functional thyroid peroxidase autoantibodies of IgE class in patients with chronic urticaria. *J Invest Dermatol* **117**:776, 2001

10. Tedeschi A et al: Anti-thyroid peroxidase IgE in patients with chronic urticaria. *J Allergy Clin Immunol* **108**:467, 2001

11. O'Donnell BF et al: Human leukocyte antigen class II associations in chronic idiopathic urticaria. *Br J Dermatol* **140**:853, 1999

12. Gorevic PD, Kaplan AP: The physical urticarias. *Int J Dermatol* **19**:417, 1980

13. Soter NA: Physical urticaria/angioedema. *Semin Dermatol* **6**:302, 1987

14. Hoffman HM et al: Familial cold autoinflammatory syndrome: Phenotype and genotype of an autosomal dominant periodic fever. *J Allergy Clin Immunol* **108**:615, 2001

15. Hoffman HM et al: Mutation of a new gene encoding a putative pyrin-like protein causes familial cold autoinflammatory syndrome and Muckle-Wells syndrome. *Nature Genet* **29**:301, 2001

16. Uetsu N et al: The clinical and photobiological characteristics of solar urticaria in 40 patients. *Br J Dermatol* **142**:32, 2000

17. Harada S et al: Aspirin enhances the induction of type I allergic symptoms when combined with food and exercise in patients with food-dependent exercise-induced anaphylaxis. *Br J Dermatol* **145**:336, 2001

18. Shadick NA et al: The natural history of exercise-induced anaphylaxis: Survey results from a 10-year follow-up study. *J Allergy Clin Immunol* **104**:123, 1999

19. Luong KV, Mguyen LT: Aquagenic urticaria: Report of a case and review of the literature. *Ann Allergy Asthma Immunol* **80**:483, 1998

20. Sabroe RA et al: The autologous serum skin test: A screening test for autoantibodies in chronic idiopathic urticaria. *Br J Dermatol* **140**:446, 1999

21. Sabroe RA et al: Chronic idiopathic urticaria: Comparison of the clinical features of patients with and without anti-FceRI or anti-IgE autoantibodies. *J Am Acad Dermatol* **40**:443, 1999

22. Bork K et al: Hereditary angioedema with normal C1-inhibitor activity in women. *Lancet* **356**:213, 2000

23. Binkley KE, Davis A III: Clinical, biochemical, and genetic characterization of a novel estrogen-dependent inherited form of angioedema. *J*

Allergy Clin Immunol **106**:546, 2000

24. Soter NA: Urticarial venulitis. *Derm Ther* **13**:400,2000

25. Sabroe RA, Kobza Black A: Angiotensin-converting enzyme (ACE) inhibitors and angio-oedema. *Br J Dermatol* **136**:153, 1997

26. Sanchez Borges M et al: Tolerability to new COX-2 inhibitors in NSAID-sensitive patients with cutaneous reactions. *Ann Allergy Asthma Immunol* **87**:201, 2001

27. Israel E et al: The pivotal role of 5-lipoxygenase products in the reaction of aspirin-sensitive asthmatics to aspirin. *Am Rev Respir Dis* **148**:1447, 1993

28. Ohnishi-Inoue Y et al: Aspirin-sensitive urticaria: Provocation with a leukotriene receptor antagonist. *Br J Dermatol* **138**:483, 1998

29. Federman DG et al: The effect of antibiotic therapy for *H. pylori*–infected patients with chronic urticaria. *J Am Acad Dermatol* (in press)

30. Gleich GJ et al: Episodic angioedema associated with eosinophilia. *New Engl J Med* **310**:1621, 1984

31. Kozel MMA et al: The effectiveness of a history-based diagnostic approach in chronic urticaria and angioedema. *Arch Dermatol* **134**:1575, 1998

32. Hoskin SL et al: Basophil infiltration of wheals in chronic idiopathic urticaria. *J Allergy Clin Immunol* **109**:587, 2002

33. Ying S et al: T_H1/T_H2 cytokines and cell infiltration in skin from chronic idiopathic urticaria: Comparison with allergen-induced skin late-phase reactions and normal controls. *J Allergy Clin Immunol* **109**:S88, 2002

34. Hermes B et al: Upregulation of tumor necrosis factor a and interleukin-3 expression in lesional and uninvolved skin in different types of urticaria. *J Allergy Clin Immunol* **103**:307, 1999

35. Toubi E et al: Immune aberrations in B and T lymphocytes derived from chronic urticaria patients. *J Clin Immunol* **20**:371, 2000

36. O'Donnell BF et al: The impact of chronic urticaria on the quality of life. *Br J Dermatol* **136**:197, 1997

37. Poon E et al: The extent and nature of disability in different urticarial conditions. *Br J Dermatol* **140**:667, 1999

38. Nettis E et al: Comparison of montelukast and fexofenadine for chronic idiopathic urticaria. *Arch Dermatol* **137**:99, 2001

39. Pacor ML et al: Efficacy of leukotriene receptor antagonist in chronic urticaria: A double-blind, placebo-controlled comparison of treatment with montelukast and cetirizine in patients with chronic urticaria with intolerance to food additive and/or acetylsalicylic acid. *Clin Exp Allergy* **31**:1607, 2001

40. Bensch G, Borish L: Leukotriene modifiers in chronic urticaria. *Ann Allergy Asthma Immunol* **83**:348, 1999

41. Asero R: Leukotriene receptor antagonists may prevent NSAID-induced exacerbations in patients with chronic urticaria. *Ann Allergy Asthma Immunol* **85**:156, 2000

42. Jaffer AM et al: Sulfasalazine in the treatment of chronic urticaria (CU). *J Allergy Clin Immunol* **109**:S127, 2002

43. Grattan CEH et al: Randomized double-blind study of cyclosporine in chronic “idiopathic” urticaria. *Br J Dermatol* **143**:365, 2000

44. Toubi E et al: Low-dose cyclosporin A in the treatment of severe chronic idiopathic urticaria. *Allergy* **52**:312, 1997

45. O'Donnell BF et al: Intravenous immunoglobulin in autoimmune chronic urticaria. *Br J Dermatol* **138**:101, 1998

46. Clark C et al: TI-01 phototherapy for chronic idiopathic urticaria: 14 years' experience. *Br J Dermatol* **145**(suppl.59):136, 2001

T>

Chapter 117

Irma Gigli Fred Rosen

Angioedema Associated with Complement Abnormalities

CLASSIFICATION AND CLINICAL MANIFESTATIONS (Table 117-1)
Hereditary Angioedema (Genetic C1INH Deficiency)
Acquired C1INH Deficiency
LABORATORY FINDINGS
DIFFERENTIAL DIAGNOSIS
TREATMENT
REFERENCES

Angioedema is a reaction characterized by swellings of the subcutaneous tissue that occurs in the skin and the mucosae, including those of the respiratory and gastrointestinal tracts. In certain patients, angioedema and urticaria may present with abnormalities of the serum complement system. This presentation is seen most often with an underlying cutaneous necrotizing venulitis or systemic lupus erythematosus, after the injection of blood products or the administration of diagnostic agents, or in the presence of a number of autoantibodies. Angioedema/urticaria without complement abnormalities may occur in association with antigen-initiated IgE-dependent reactions, anti-IgE, or anti-Fc $_e$ receptor 1 autoantibodies; with reactions to non-steroidal anti-inflammatory agents; or with contact and physical stimuli. It also may occur without apparent cause. [1] Less frequently, angioedema is caused by a genetic or acquired defect in the inhibitor of the activated first component of the complement system (C1INH). The genetic deficiency of C1INH results in the disease termed *hereditary angioedema* (HAE). A nonhereditary form of C1INH deficiency designated *acquired C1INH deficiency* (or acquired angioedema, AAE) may be due to a monoclonal B cell disease or to autoantibodies to C1INH. [2] Urticaria does not accompany the angioedema in patients with the genetic or acquired deficiency of C1INH.

CLASSIFICATION AND CLINICAL MANIFESTATIONS (Table 117-1)

Normal or elevated serum complement levels
IgE mediated (atopic, specific antigen, exercise)
Induced by physical agents (cold pressure)
Induced by aspirin and nonsteroidal anti-inflammatory agents
Dyes, contrast media
Opiates
Polyanionic antibiotics
Low serum complement levels
Low C1INH (protein, function, or both)
Genetic (HAE)
C1INH deficiency type I (no protein)
C1INH deficiency type II (dysfunctional protein)
Acquired (AAE)
Lymphoproliferative disorders (type I, low protein)
Anti-C1INH antibodies (type II, dysfunctional protein)
Normal C1INH
Serum sickness
Blood products reactions
Necrotizing vasculitis
Idiosyncratic
Dyes, contrast media

TABLE 117-1 **Classification of Angioedema**

Hereditary Angioedema (Genetic C1INH Deficiency)

HAE is a rare form of angioedema with life-threatening consequences. It was described initially by Robert Graves in 1843. In 1882, Quincke reported circumscribed swellings occurring in members of two consecutive generations of the same family. Osler pointed out that angioedema, in certain instances, seems to adhere to a clear pattern of inheritance; he named this entity *hereditary angioneurotic edema*. Landerman et al. [3] reported a biochemical abnormality in HAE, observing that individuals with this disease were unusually reactive to the intracutaneous injection of a kallikrein. Simultaneously, Donaldson and Evans [4] demonstrated that the sera of such patients lacked the protein C1INH. It was established subsequently that this inhibitor also was active against kallikrein. [5] Although HAE is believed to account for only a small fraction of all cases of angioedema, it is the most common disorder caused by the deficiency of a complement protein.

Clinically, HAE is characterized by recurrent, circumscribed, nonpruritic, nonpitting, subepithelial edema (see Fig 116-2). Cutaneous angioedema may develop over several hours at any given site and may be preceded by a faint macular or serpiginous erythema. Patients frequently are aware of a peculiar tingling or twitching sensation in the affected area. The skin swells progressively within hours, returning to normal in 24 to 72 hours. The lesions may involve an area a few centimeters in diameter or may evolve to include an entire extremity. Swelling of the face and lips may progress to involve the upper airways. The patients do not have urticaria associated with the angioedema. [6]

All patients with cutaneous manifestations report varying degrees of intestinal symptoms. Recurrent abdominal pain in multiple family members has been reported as the sole manifestation of HAE. [7] Angioedema of the small bowel frequently is associated with colicky, severe abdominal pain without fever or leukocytosis. When the large intestine is involved, copious watery diarrhea may ensue. Hemoconcentration is evidenced by an increased hematocrit and prerenal azotemia. During these abdominal crises, undiagnosed patients frequently are subjected to unnecessary exploratory laparotomies. Other associated symptoms frequently observed are urinary retention and central nervous system involvement, including severe headaches, transient aphasia, and hemiplegia.

The onset of HAE is extremely variable. Most patients date the initial appearance of their symptoms to early childhood and become dramatically worse at pubescence. However, symptoms can begin in the second decade of life and even later. Most commonly, the attacks decrease in frequency and severity after age 50 and may even disappear. [2] The precipitating factors are not clear. Patients state that attacks of angioedema follow minor trauma to any body part, and some recognize an association with extreme heat or cold, vigorous exercise, and infections. Some female patients note an increase in the frequency of attacks during menses and while they are taking birth control pills. In contrast, most women report a marked decrease in the frequency of attacks during the last two trimesters of pregnancy. Most menopausal females do not improve. The term *hereditary angioneurotic edema* was used because affected individuals are known to respond to stress with an episode of angioedema. Evaluation of a large number of these patients reveals no increase in psychiatric disorders. Systemic lupus erythematosus, lupus-like disorders, and Sjögron's syndrome have been diagnosed in members of families with HAE. [1], [8], [9] and [10]

GENETICS OF C1INH DEFICIENCY HAE is inherited as an autosomal dominant trait. Each patient is heterozygous for the defect; thus every affected individual has an affected and a normal parent. There is no linkage with the human leukocyte antigen system, and there is no sex preference. About 10 percent of patients have new mutations and two normal parents, but these mutations are transmitted to their offspring in a Mendelian dominant fashion. [11] There are two genetic variants of HAE. [12], [13] In the more common form (type I), between 5 and 30 percent of the normal antigenic and functional C1INH protein is present in the blood, whereas in the less common form (type II), a normal or increased amount of an abnormal, dysfunctional C1INH protein is found together with low levels of the normal protein. Of patients with HAE, 85 percent have type I and 15 percent have type II. [13] Patients with type I HAE have one normally expressed C1INH gene and one deleted or non-expressed abnormal gene. Patients with type II HAE have one normal gene and one expressed abnormal gene with missense mutations that result in the synthesis of a dysfunctional protein. One family has been identified in which the disease is transmitted as an autosomal recessive trait due to a mutation in the promoter region of the gene. [14] The gene encoding the C1INH maps to the long arm of chromosome 11.2-q13. [15], [16] It encodes a single-chain protein composed of 478 amino acid residues. The secreted protein is cleaved by various serum proteases at an arginine-threonine bond between residues 444 and 445. [16] The carboxyl-terminal 33 amino acids are set free, and this peptide has no known biologic function. Mutations are found throughout the 12 exons of the *C1INH* gene. In type II HAE, the mutations are almost exclusively at or around the bait site Arg^{444}–Thr^{445}. [17] Arginine is usually substituted by a histidine [18] or a cysteine [19] and renders the inhibitor nonfunctional. Other mutations have been found in the hydrophobic amino acid residues just amino-terminal to the arginine at position 444. [20] These mutations apparently distort the tertiary structure of the C1INH in a hydrophobic region that is critical for maintaining the binding site exposed and determining the substrate specificity. A mutant protein with a substitution at position 443 (Ala^{443}–Val) has diminished inhibitory activity toward C1r and C1s but normal activity toward contact system proteases. [21] One other mutation is due to deletion of a lysine codon at residue 251. The lysine deletion creates a glycosylation signal that appears to distort the conformation of the molecule. [22] In type I HAE there are nonsense mutations resulting in premature stop codons. Twenty percent of patients have unequal crossovers between Alu sequences in the introns. [23], [24] Deletions and duplications in the gene occur in other cases of HAE. [25] The sequence of the C1INH, as determined by the combination of protein and DNA sequence analysis, shows that it belongs to the superfamily of protease inhibitors called *serpins.* [15], [16] It has 40 to 50 percent amino acid sequence homology with antithrombin III and a $_1$-antitrypsin, but it differs from the other serpins in that it is heavily glycosylated. The functional role of this carbohydrate-rich domain is unknown. C1INH is synthesized mainly in hepatocytes, but it also can be synthesized in blood monocytes, skin fibroblasts, and umbilical endothelial cells. The expression of C1INH in vivo is enhanced by androgens, and in vitro synthesis can be upregulated greatly by interferon-? and interleukin 6 (IL-6). [26] As a result of the presence of a single functional gene, [22] the rate of synthesis of C1INH in cells of patients with HAE is only 30 to 40 percent of normal. [27] When the turnover of radiolabeled C1INH is measured in patients with HAE, the fractional catabolic rate is found to be almost twice normal. [28] Thus the decreased synthesis of C1INH is inadequate to maintain the equilibrium in the spontaneous activation of the complement system as well as other proteolytic enzymes. The activation of these enzymes results in increased C1INH consumption. For these reasons, patients with HAE have far less than the anticipated 50 percent of normal C1INH in their sera. Functionally, C1INH inhibits the activation of the first component of complement (C1) and the esteratic activity of two of its subcomponents, C1r and C1s. Although C1INH is the only serum inhibitor of these complement proteins, it also inhibits factors XIa, XIIa, and XIIf, kallikrein, and plasmin. [5], [29]

MECHANISM OF INCREASED VASCULAR PERMEABILITY IN HAE A number of studies have implicated the activation of the classical pathway of the complement system as the mechanism of angioedema. [2] During attacks, activated C1s can be detected in fluids from the involved area, and the natural substrates of C1, complement proteins C4 and C2, are cleaved, thus resulting in markedly reduced blood levels of these proteins. [30] Because this activation occurs in the body fluids rather than on antigen-antibody aggregates, the concentrations of C3 and the late-acting complement components (C5 to C9) usually are normal. The reason for the episodic activation of C1 during attacks remains unclear. C1 may be activated by enzymes such as factor XIIa and plasmin. [31] The capacity of C1INH to inhibit these enzymes suggests that the activation of factor XII in traumatized tissues may be responsible for the further activation of C1 (Fig. 117-1).

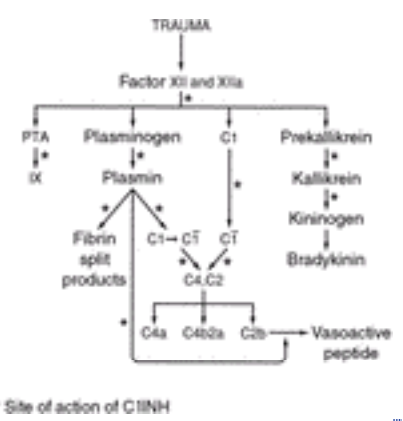

FIGURE 117-1 Sites of action of C1INH in the contact phase of coagulation, fibrinolysis, kinin generation, and

complement activation. PTA, plasma thromboplastin antecedent; $C\overline{1}1$, activated C1. Deficiency of C1INH leads to the generation of bradykinin and a complement-derived vasoactive peptide.

Multiple clinical studies support the view that uninhibited C1 can elicit angioedema. The intradermal injection of C1s into normal persons induces local edema that is not painful and does not itch. [32] The active site of C1s is required for this activity. Individuals deficient in C2 fail to respond, whereas one C3-deficient patient responded normally. Plasma obtained from patients with HAE during asymptomatic intervals spontaneously generates smooth muscle contracting activity during incubation; this activity is associated with a heat-stable kinin-like polypeptide. [33] The generation of this peptide is inhibited by addition to the plasma of purified C1INH, heparin, or antibodies to C4 and C2 but not by antibodies to C3. The polypeptide enhances vascular permeability when injected intradermally and causes histamine release from mast cells in vitro. [34] However, neither antihistamines nor histamine-depleting substances such as 48/80 inhibit the angioedema induced by the local injection of activated C1s or the polypeptide. Furthermore, a kinin-like peptide has been generated from mixtures of purified C1s, C4, C2, and plasmin; the requirement for C4 was abrogated by a large input of C2. Other studies have shown that plasmin releases several small peptides from C2 cleaved by C1s (C2b) with kinin activity and the ability to increase vascular permeability. [34] Moreover, a 38-amino-acid fragment released from the carboxyl terminal portion of C2b can cause angioedema. This peptide differs from bradykinin in size, electrophoretic mobility, isoelectric point, and susceptibility to trypsin. Other studies suggest that the source of the kinin-like activity in HAE plasma is bradykinin rather than C2. This hypothesis is based on the following observations: The levels of bradykinin and cleaved high-molecular-weight kininogen are elevated in the plasma of patients with angioedema, and plasma levels of factor XIIa are significantly increased during attacks. [35], [36] and [37] The intracutaneous injection of small amounts of factor XIIa (Hageman factor) induces a localized increase in vascular permeability. Blister fluid obtained from suction blisters induced in the skin of patients with HAE contain large amounts of kallikrein. [35] Moreover, members of a family with a mutant C1INH (Ala ^{443}–Val) that inhibits the proteases of the kinin-forming system but is a poor inhibitor of C1r and C1s have not developed angioedema. [20] Further evidence for the role of bradykinin in HAE has been obtained from studies with mice genetically deficient in the *C1INH* gene or in both the *C1INH* gene and the bradykinin 2 receptor (*Bk2R*) gene. [38] The C1INH deficiency results in increased vascular permeability that could be reversed with the infusion of C1INH, whereas the animals deficient in the *C1INH* and *Bk2R* genes did not display increased vascular permeability. Because bradykinin is the only known ligand for the bradykinin 2 receptor, these data strongly suggest that the symptoms of angioedema are mediated, at least in part, by bradykinin via the bradykinin 2 receptor. Although a receptor for C2 kinin has not yet been identified, it is possible that mediator(s) generated during activation of complement also may play a role. **PATHOLOGY OF HAE** Pathologic alterations in HAE have been described on the basis of studies of cutaneous and jejunal biopsies obtained at autopsies or laparotomies of affected individuals during attacks. Skin changes consisted primarily of subcutaneous edema. Laryngeal edema was characterized by spongiosis of the mucosal epithelial cells with cytoplasmic vacuole formation and submucosal edema with masking of fibrous structures. When edema and hemorrhage of the lungs were present, they were attributed to asphyxiation. Jejunal tissue showed edema of the lamina propria, particularly of the superficial portion of the villi, giving rise to a club-shaped appearance. No submucosal edema was present, nor were there any cellular infiltrates. The increased vascular permeability is due to the creation of gaps between the endothelial cells in the postcapillary venules. Under electron microscopy, the contraction of the endothelial cells is denoted by wrinkling and indentation of the nuclei. Degranulation of adjacent mast cells is also seen. However, the lesion is not mediated by histamine, and it cannot be aborted by antihistamines or by depleting the skin of its histamine content with compound 48/80 or polysorbate. [39]

Acquired C1INH Deficiency

An acquired form of C1INH deficiency with angioedema (AAE) has been observed in patients in the fifth and sixth decades of life without a family history of the disorder. The clinical manifestations of this form of angioedema resemble those of the hereditary type of C1INH deficiency, i.e., non-pruritic subcutaneous edema without urticaria and with upper respiratory and gastrointestinal tract involvement. There are two forms of AAE, type I and type II. [40] AAE type I was described initially as a clinical entity in association with lymphoproliferative disorders. Most, but not all, of these patients have monoclonal B cell disease such as myeloma, Waldenström's macroglobulinemia, B cell lymphoma, or chronic lymphocytic leukemia and, less commonly, other types of malignancies. In some patients, the immunochemical abnormalities and episodes of angioedema appear several years before the underlying malignancy of the lymphocytes (Table 117-2). When these patients are relieved of their tumor burden, the acquired C1INH deficiency improves. The immunoglobulin isotypes expressed in the abnormal B cells include gamma, mu, and alpha heavy chains, as well as both kappa and lambda light chains. Neither epsilon nor delta heavy-chain disease has been associated with acquired C1INH deficiency. It became apparent that these patients have anti-idiotypic antibodies to their monoclonal immunoglobulins. [41] A markedly decreased serum level of C1 distinguishes acquired C1INH deficiency from the hereditary form, in which the level of C1 is within the normal range. It is possible that the idiotype–anti-idiotype interaction fixes C1 and preferentially consumes C1INH. In AAE type II, autoantibodies to the C1INH are present in the sera of patients. [42] The antibodies to the C1INH usually are of the IgG_1 class and bind to the reactive center of the inhibitor at residues 448–459, with lower affinity to residues 438–449. The C1INH in the complex has lost its proteinase regulatory capacity. In some of these patients the anti-C1INH antibodies may be part of the serologic abnormalities associated with systemic lupus erythematosus, rheumatoid arthritis, and Sjögren's syndrome. Although C1INH synthesis is normal or increased in both types of AAE, in type I the levels of the inhibitor in blood are reduced, whereas in type II the inhibitor remains in the circulation as an inactive protein.

Pathologic Diagnosis	Presenting Symptom
IgA myeloma	Cutaneous angioedema, gastrointestinal symptoms
Chronic lymphatic leukemia	Cutaneous angioedema, laryngeal edema
Non-Hodgkin's B cell lymphoma	Cutaneous angioedema
Histiocytic lymphoma	Laryngeal edema
Chronic lymphatic leukemia	Cutaneous angioedema
Lymphosarcoma	Cutaneous angioedema
Lymphocytic lymphomas	Cutaneous angioedema
Undefined neoplastic lymphoproliferative disorder	Cutaneous angioedema
Waldenström's macroglobulinemia	Cutaneous angioedema
Essential cryoglobulinemia	Cutaneous angioedema
Monoclonal gammopathy	Cutaneous angioedema
Adenocarcinoma	Cutaneous angioedema
Myelofibrosis	Cutaneous angioedema
Autoimmunity	Cutaneous angioedema
Anti-C1INH autoantibodies	Cutaneous angioedema

TABLE 117-2 **Disease Association in Acquired C1INH Deficiency**

LABORATORY FINDINGS

The diagnosis of HAE is not straightforward. On immunochemical measurement of C1INH, 85 percent of patients with HAE are identified by decreased serum levels (type I), but 15 percent (type II) are missed because they have normal levels or increased levels of abnormal C1INH protein. C4 levels usually are measured at the same time because almost all patients with HAE have decreased serum levels of C4 (Table 117-3). However, some affected individuals, especially young children, may not exhibit this decrease; therefore, it may be necessary in some cases to assay C1INH functionally to be certain of the diagnosis. [2]

	C1INH						
	Antigenic	Functional	CH_{50}	C1	C4	C2*	C3
HAE type I	↓↓	↓↓	↓ or ↓	N	↓↓	↓	N
HAE type II	N	↓↓	↓ or ↓	N	↓↓	↓	N
AAE type I	↓↓	↓↓					
AAE type II	N†	↓↓	↓↓	↓↓	↓↓	↓↓	N

C1INH = C1 esterase inhibitor; ↓ = markedly depressed; N = normal
*↓ during attacks of hereditary angioedema
†Normal or depressed

TABLE 117-3 **Complement Abnormalities in Hereditary and Acquired Angioedema**

The acquired form of C1INH deficiency can be diagnosed readily because the serum level of C1 is markedly decreased in contrast to the normal level of C1 in sera from patients with HAE. C4 levels are not helpful because they are decreased in both the genetic and acquired forms of C1INH deficiency. The underlying cause for acquired C1INH deficiency must be investigated carefully. Patients with AAE are clinically and biochemically heterogeneous, and they have different responses to treatment. [2]

DIFFERENTIAL DIAGNOSIS

Complement-mediated angioedema, by definition, excludes clinically similar syndromes mediated by other pathways, such as those involving IgE or abnormalities in arachidonic acid metabolism uncovered by the administration of nonsteroidal anti-inflammatory agents. Acute IgE-mediated reactions in humans are characterized by respiratory symptoms, hypotension or vascular collapse, and angioedema/urticaria. These clinical manifestations begin within minutes of antigen exposure, and the diagnosis can be confirmed by the demonstration of specific IgE by in vitro techniques. The adverse reactions that occur after the ingestion of aspirin include angioedema/urticaria, rhinitis (with associated nasal polyps), and bronchial asthma. In each of these clinical settings, localized angioedema may occur without any other symptoms or signs.

Although angioedema usually is recognized easily because of its episodic and evanescent nature, several other disorders should be included in the differential diagnosis. Contact dermatitis may occur as recurrent episodes of swelling at sites of contact with the responsible antigen. Historical information, additional cutaneous changes, and patch tests are useful in establishing the diagnosis. Cellulitis or erysipelas may, at times, resemble angioedema. Lymphedema may occur after cutaneous pyoderma. Surgery, congestive heart failure, and obstruction of the superior vena cava may produce recurrent swelling.

TREATMENT

Acute attacks of HAE are potentially life-threatening; thus patients should be advised about prevention. Care should be taken to avoid trauma. Before dental or surgical procedures, appropriate prophylactic therapy should be given.

Airway obstruction is the most threatening event during an attack. It is a medical emergency, and a patent airway must be established. Epinephrine is of little value, as are antihistamines and glucocorticoids. Freshly reconstituted freeze-dried plasma has been used for acute attacks. [43] However, besides replacing the C1INH, the plasma provides the substrates of C1, C4, and C2. The intravenous injection of purified C1INH or recombinant C1INH is the most effective modality of treatment; however, neither has been approved for use in the United States. [44] Demerol compounds are effective in controlling the excruciating pain associated with abdominal attacks.

In 1960, testosterone was found to be effective in preventing attacks of angioedema. Subsequently, attenuated androgens with reduced virilizing effects but retained anabolic activity also were found to be prophylactic agents. [45] Stanozolol (0.5–2 mg daily) and danazol (50–400 mg daily) are now used widely to prevent attacks of angioedema. The optimal daily dose must be determined for each patient. [46] Because the latent period to achieve an effect is approximately 5 days, these agents are of little value in treating acute attacks. When surgical procedures or dental work is contemplated, it is prudent to give two to three times the doses stated earlier for 5 days before the anticipated trauma. Androgens are contraindicated in children except for short courses before surgery or dental work. This therapeutic approach may not be justified in patients with limited manifestations of the disease, and some patients prefer to live with their symptoms rather than take prophylactic androgens. The most common side effects of androgen treatment include

irregular menstruation but rarely amenorrhea and hirsutism and less frequently hepatic dysfunction.

The two types of acquired C1INH deficiency require distinct therapeutic approaches. Whereas patients with lymphoproliferative disorders (AAE type I) respond to attenuated androgens, those with anti-C1INH autoantibodies (AAE type II) respond to glucocorticoids. [40]

REFERENCES

1. Zuraw BL: Urticaria, angioedema, and autoimmunity. *Clin Lab Med* **17**:559, 1997

2. Cicardi M et al: Pathogenetic and clinical aspects of C1 inhibitor deficiency. *Immunobiology* **199**:366, 1998

3. Landerman NS et al: Hereditary angioneurotic edema: II. Deficiency of inhibitor for serum globulin permeability factor and/or plasma kallikrein. *J Allergy* **33**:330, 1962

4. Donaldson VH, Evans RR: A biochemical abnormality in hereditary angioneurotic edema: Absence of serum inhibitor of C'1-esterase. *Am J Med* **35**:37, 1963

5. Gigli I et al: Interaction of plasma kallikrein with the C1 inhibitor. *J Immunol* **104**:574, 1970

6. Winnewisser J et al: Type I hereditary angio-oedema: Variability of clinical presentation and course within two large kindreds. *J Int Med* **241**:39, 1997

7. Weinstock LB et al: Recurrent abdominal pain as the whole manifestation of hereditary angioedema. *Gastroenterology* **93**:1116, 1987

8. Kohler PF et al: Hereditary angioedema and “familial” lupus erythematosus in identical twin boys. *Am J Med* **56**:406, 1974

9. Donaldson VH et al: Lupus-erythematosus-like disease in three unrelated women with hereditary angioedema. *Ann Intern Med* **86**:312, 1977

10. Suzuki Y et al: Association of Sjögren's syndrome with hereditary angioneurotic edema: Report of a case. *Clin Immunol Immunopathol* **84**:95, 1997

11. Ariga T et al: A de novo deletion in the C1 inhibitor gene in a case of sporadic hereditary angioneurotic edema. *Clin Immunol Immunopathol* **69**:103, 1993

12. Oltvai ZN et al: C1 inhibitor deficiency: Molecular and immunologic basis of hereditary and acquired angioedema. *Lab Invest* **65**:381, 1991

13. Rosen FS et al: Genetically determined heterogeneity of the C1 esterase inhibitor in patients with hereditary angioneurotic edema. *J Clin Invest* **50**:2143, 1971

14. Verpy E et al: Exhaustive mutation scanning by fluorescence-assisted mismatch analysis discloses new genotype-phenotype correlations in angioedema. *Am J Hum Genet* **59**:289, 1996

15. Davis AE et al: Human inhibitor of the first component of complement, C1: Characterization of cDNA clones and localization of the gene to chromosome 11. *Proc Natl Acad Sci USA* **83**:3161, 1986

16. Bock SC et al: Human C1 inhibitor: Primary structure, cDNA cloning and chromosomal localization. *Biochemistry* **25**:4292, 1986

17. Davis AE et al: C1 inhibitor hinge region mutations may convert the inhibitor to a substrate or may result in diminished ability to interact with target proteases. *Nature Genet* **1**:354, 1992

18. Aulak KS et al: Dysfunctional C1 inhibitor (At), isolated from a type II hereditary angioedema plasma, contains a P1 “reactive center” (Arg ^{444}–His) mutation. *Biochem J* **253**:615, 1988

19. Skriver K et al: CpG mutations in the reactive site of human C1 inhibitor. *J Biol Chem* **264**:3066, 1989

20. Zahedi R et al: C1 inhibitor: Analysis of the role of amino acid residues within the reactive center loop in target protease recognition. *J Immunol* **167**:1500, 2001

21. Zahedi R et al: Role of the P2 residue of complement 1 inhibitor (Ala ^{443}) in determination of target protease specificity: Inhibition of complement and contact system proteases. *J Immunol* **159**:983, 1997

22. Parad RB et al: Dysfunctional C1 inhibitor Ta: Deletion of Lys-251 results in acquisition of an *N*-glycosylation site. *Proc Natl Acad Sci USA* **87**:6786, 1990

23. Stoppa-Lyonet D et al: Clusters of intragenic Alu repeats predispose the human C1 inhibitor locus to deleterious rearrangements. *Proc Natl Acad Sci USA* **87**:1551, 1990

24. Ariga T et al: Recombination between Alu repeat sequences that result in partial deletions within the C1 inhibitor gene. *Genomics* **8**:607, 1990

25. Bissler JJ et al: A cluster of mutations within a short triplet repeat in the C1 inhibitor gene. *Proc Natl Acad Sci USA* **91**:9622, 1994

26. Prada AE et al: Regulation of C1 inhibitor synthesis. *Immunobiology* **199**:377, 1998

27. Kramer J et al: Synthesis of C1 inhibitor in fibroblasts from patients with type I and type II hereditary angioneurotic edema. *J Clin Invest* **87**:1614, 1991

28. Quastel M et al: Behavior in vivo of normal and dysfunctional C1 inhibitor in normal subjects and patients with hereditary angioneurotic edema. *J Clin Invest* **7**:1041, 1983

29. Kaplan AP et al: The intrinsic coagulation/kinin-forming cascade: Assembly in plasma and cell surfaces in inflammation. *Adv Immunol* **66**:225, 1997

30. Donaldson VH et al: Action of complement in hereditary angioneurotic edema: Role of C1-esterase. *J Clin Invest* **43**:2204, 1964

31. Ratnoff OD et al: The conversion of C'1s to C'1 esterase by plasmin and trypsin. *J Exp Med* **125**:337, 1967

32. Klemperer MR et al: Effect of C'1 esterase on vascular permeability in man: Studies in normal and complement deficient individuals and in patients with hereditary angioneurotic edema. *J Clin Invest* **47**:604, 1968

33. Donaldson VH et al: Permeability-increasing activity in hereditary angioneurotic edema plasma: II. Mechanism of formation and partial characterization. *J Clin Invest* **48**:642, 1969

34. Strang CJ et al: Angioedema induced by a peptide derived from complement component C2. *J Exp Med* **168**:1685, 1988

35. Curd JG et al: Detection of active kallikrein in induced blister fluids of hereditary angioedema patients. *J Exp Med* **152**:742, 1980

36. Cugno M et al: Activation of factor XII and cleavage of high molecular weight kininogen during acute attacks in hereditary and acquired C1-inhibitor deficiencies. *Immunopharmacology* **33**:361, 1996

37. Cugno M et al: Activation of the coagulation cascade in C1-inhibitor deficiencies. *Blood* **89**:3213, 1997

38. Han ED et al: Enhanced vascular permeability in C1 inhibitor–deficient mice is mediated via the bradykinin type 2 receptor. *J Clin Invest* **109**:1007, 2002

39. Granerus G et al: Studies on the histamine metabolism and the complement system in hereditary angioneurotic edema. *Acta Med Scand* **182**:11, 1967

40. Markovic SN et al: Acquired C1 esterase inhibitor deficiency. *Ann Intern Med* **132**:144, 2000

41. Geha RS et al: Acquired C1-inhibitor deficiency associated with antiidiotypic antibody to monoclonal immunoglobulins. *N Engl J Med* **312**:534, 1985

42. Alsenz J et al: Autoantibody-mediated acquired deficiency of C1 inhibitor. *N Engl J Med* **316**:1360, 1987

43. Jaffe CJ et al: Hereditary angioedema: The use of fresh frozen plasma for prophylaxis in patients undergoing oral surgery. *J Allergy Clin Immunol* **155**:386, 1975

44. Waytes AT et al: Treatment of hereditary angioedema with a vapor-heated C1 inhibitor concentrate. *N Engl J ed* **334**:1630, 1996

45. Gelfand JA et al: Treatment of hereditary angioedema with danazol: Reversal of clinical and biochemical abnormalities. *N Engl J Med* **295**:1444, 1976

46. Cicardi M et al: Long-term treatment of hereditary angioedema with attenuated androgens: A survey of a 13-year experience. *J Allergy Clin Immunol* **87**:768, 1991

T>

Chapter 118

Thomas Horn

Graft-versus-Host Disease

ERUPTIONS OF LYMPHOCYTE RECOVERY
CUTANEOUS GRAFT-VERSUS-HOST REACTIONS AFTER ALLOGENEIC MARROW TRANSPLANTATION
Acute Cutaneous GVHR
Chronic Cutaneous GVHR
ACUTE CUTANEOUS GVHR AFTER AUTOLOGOUS AND SYNGENEIC MARROW TRANSPLANTATION AND PERIPHERAL STEM CELL TRANSPLANTATION
CLINICAL DESCRIPTION
HISTOPATHOLOGY
PATHOGENESIS
DIAGNOSIS
TREATMENT

REFERENCES

Dermatologists play an important role in the evaluation and management of patients at risk for or diagnosed with graft-versus-host disease (GVHD). Of all organ dysfunction associated with GVHD, the skin serves as the earliest and most frequent target. To evaluate patients, optimally, the dermatologist must know the type of marrow transplant, any manipulation of marrow before infusion, the preparative regimen used, the date of marrow infusion, the peripheral white blood cell count, medications administered, and the course of hospitalization.

The field of marrow transplantation has evolved greatly over the past several decades. Early observations of GVHD were made among patients who received their marrow transplants with little or no prophylaxis. The flagrant disease that ensued then no longer occurs, and dermatologists must evaluate patients in the setting of significant prophylactic immunosuppression that blunts the clinical and histologic expression of GVHD. Viewed most simply, a marrow transplant is merely a form of dose intensification. With the recognition that the development of GVHD partially protects against tumor relapse, interest in immunologic manipulations that allow or even induce GVHD (in the autologous setting) arose. The frontiers of marrow transplantation expand constantly, as evidenced by a xenograft between a human recipient of baboon marrow. [1] Recently, transplantation of actual marrow has diminished in favor of the use of peripheral blood stem cells for both allogeneic and autologous transplants.

The clinical manifestations, histopathology, treatment, and pathogenesis of GVHD with emphasis on the skin are considered in this chapter, and its organization follows the types of marrow transplants to highlight the fact that skin disease after marrow ablation varies with subsequent therapy. Table 118-1 provides definitions for several common terms used.

Term	Definition
Allogeneic	Between two individuals
Autologous	From the same person
Syngeneic	Between two individuals with identical genetic material
Xenograft	Transplanted tissue from another species
Graft-versus-host disease (GVHD)	The totality of organ dysfunction attributable to immunocompetent lymphocytes targeting recipient tissues
Graft-versus-host reaction (GVHR)	The expression of GVHD in a specific organ, e.g., cutaneous GVHR
Stage	A term referring to clinical findings
Grade	A term referring to histopathologic findings

TABLE 118-1 **Terms and Definitions**

ERUPTIONS OF LYMPHOCYTE RECOVERY

The concept of cutaneous eruptions developing at the time of peripheral recovery of lymphocytes after marrow ablative therapy unifies all diagnoses considered in this chapter. [2] As defined initially, the eruption of lymphocyte recovery occurred with the earliest return of lymphocytes to the peripheral circulation of patients with acute leukemia who did not receive a marrow transplant. [3] The eruptions consisted of erythematous coalescing macules, predominantly on the trunk and proximal extremities. Skin biopsy specimens revealed nonspecific changes, with an upper dermal perivascular infiltrate of lymphocytes and variable epidermal spongiosis but no significant epidermal cell necrosis. An acute elevation in temperature accompanied the cutaneous eruptions. Resolution of the eruption occurred with multiline hematologic recovery.

This concept of lymphocyte recovery eruption has application to the field of marrow transplantation because graft-versus-host reactions (GVHRs) develop at the time of peripheral lymphocyte recovery and represent this phenomenon with immunologic differences between donor and recipient or in the setting of some immunologic manipulation. Indeed, some histologically nonspecific cutaneous eruptions among patients at risk for GVHD may represent the eruption of lymphocyte recovery rather than a true GVHR, in the sense that the acute cutaneous GVHR requires the epidermis to be targeted for cytotoxic damage by an effector lymphocyte population.

CUTANEOUS GRAFT-VERSUS-HOST REACTIONS AFTER ALLOGENEIC MARROW

TRANSPLANTATION

Acute Cutaneous GVHR

CLINICAL DESCRIPTION Marrow ablative regimens vary. Combinations of cyclophosphamide, busulfan, total-body ionizing radiation, methotrexate, and thio-TEPA are employed. The acute cutaneous GVHR develops in 20 to 80 percent of patients, usually 10 to 30 days after marrow infusion. Factors that predispose to the occurrence of GVHD include mismatch in the major histocompatibility complex (MHC), transplantation between unrelated individuals (Table 118-2), older age, and prophylactic regimen, among others. Patients receive cyclosporine in high dose at the time of marrow infusion to promote engraftment and prevent maximal expression of GVHD. Other modalities used to diminish the severity of GVHD include counterflow centrifugal elutriation, a mechanism of sorting lymphocytes by size to remove smaller, mature effector cells, and application of various antibodies to the graft to remove putative effector cell populations.



TABLE 118-2 **Overview of Acute GVHD by Type of Transplant**

The eruption generally begins with faint erythematous macules on any skin surface but often the palms, soles, and pinnae (stage 1) (Fig. 118-1). The specificity of palmoplantar erythema in the diagnosis of a cutaneous GVHR is questionable because chemotherapy alone, in the absence of marrow support, may cause acral erythema. [4] Edema and tenderness often accompany the erythema regardless of cause. Pruritus is an uncommon complaint. As a GVHR evolves, the distribution of erythematous macules increases, becoming confluent over broad surfaces, commonly the upper back (stages 2 to 3). On the trunk, the erythematous macules may be observed in a perifollicular array at a very early stage (Fig. 118-2). At later stages, erythroderma may ensue (Fig. 118-3). Development of bullae (stage 4) portends a poor prognosis. These bullae are subepidermal with a necrotic roof, greatly resembling toxic epidermal necrolysis. The staging scheme is detailed in Table 118-3. This progression of the acute cutaneous GVHR generally occurs over several weeks. An explosive variant is described in which erythroderma evolves rapidly, with subsequent quick evolution to a lichen planus–like eruption resembling chronic disease. [5] Factors predisposing to this form of the acute cutaneous GVHR are not known.

FIGURE 118-1 Acute cutaneous GVHR. Erythematous macules involving the pinna (*A*), palms (*B*), and soles are typical in early stages of the cutaneous GVHR after allogeneic and autologous marrow transplantation.

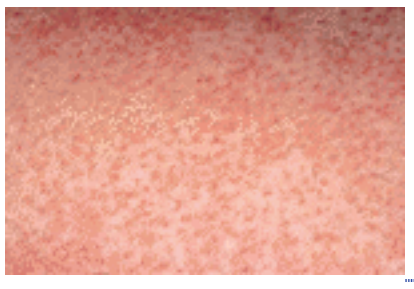

FIGURE 118-2 Follicular GVHR. In some patients, the earliest manifestation of the acute cutaneous GVHR is perifollicular erythema, as seen in this photograph at day 15 after marrow transplantation.

FIGURE 118-3 Acute cutaneous GVHR. Diffuse erythema may evolve in the acute cutaneous GVHR and is often faint.

Stage	Description
1	Cutaneous eruption involving less than 25% of surface area
2	Cutaneous eruption involving 25–50% of surface area
3	Erythroderma
4	Vesicles and bullae

SOURCE: Adapted from Glucksberg H et al: Clinical manifestations of graft-versus-host disease in human recipients of marrow from HLA-matched sibling donors. Transplantation 18:295, 1974.

TABLE 118-3 **Clinical Staging Scheme for the Acute Cutaneous GVHR**

While the skin is the earliest and most commonly involved organ in GVHD, liver and gastrointestinal disease are frequent; the presence of elevated total bilirubin levels and diarrhea often aids in establishing the diagnosis when skin findings are not specific. Isolated liver or gastrointestinal involvement is uncommon. Retrospective analysis of a large series of patients revealed that the extent of the cutaneous eruption, total bilirubin value, and stool output per day provided significant prognostic information when considered separately or in aggregate. [6] Ocular and oral involvement in the acute phase may occur but are less common than in chronic GVHD. With successful treatment, the eruption resolves with desquamation in the same general progression as its appearance. A brown-gray discoloration of the skin may evolve as a postinflammatory change with very slow or, in some cases, no resolution. Significant blister formation results in widespread denudation with exposed dermis, placing the patient at greater risk of sepsis as well as fluid and electrolyte imbalance. An acute cutaneous GVHR may arise after maternal-fetal transfer of lymphocytes, [7] as well as after blood transfusion [8] and solid organ transplant, most commonly a liver containing numerous immunocompetent lymphocytes. [9] The clinical differential diagnosis of the acute cutaneous GVHR includes drug hypersensitivity eruption, viral exanthem, transient acantholytic dermatosis, and in the presence of bullae, toxic epidermal necrolysis. As discussed below, findings in a skin biopsy specimen help to differentiate a GVHR from a drug eruption or a viral exanthem. Transient acantholytic dermatosis is an incidental finding in febrile patients receiving antineoplastic chemotherapy, with or without marrow support. [10], [11] Sampling more palpable lesions predisposes to obtaining this spurious diagnosis. Confident differentiation between a stage 4 acute cutaneous GVHR and toxic epidermal necrolysis generally is not possible, although dermatologists are often asked to try. Affected patients have received numerous medications known to cause toxic epidermal necrolysis, but rational criteria to exclude a GVHR in this setting do not exist.

HISTOPATHOLOGY The changes of an interface dermatitis appear in all phases of a cutaneous GVHR, including chronic sclerodermoid disease. The grading scheme for the histopathology of an acute cutaneous GVHR is given in Table 118-4. Minimal criteria for the diagnosis include an infiltrate of lymphocytes in the dermis, basal vacuolar alteration, and necrosis of epidermal cells at a frequency of at least four per linear millimeter of epidermis (grade 2). [12] Extension of lymphocytes into the epidermis is common (Fig. 118-4). The direct apposition of a lymphocyte to a necrotic keratinocyte is known as *satellite cell necrosis* and may occur in many types of interface dermatitis in which cell death is mediated by lymphocytes. Some quantitation of necrotic epidermal cells is advised because changes referable to the preparative regimen clearly include this finding, but in lower numbers than in a GVHR. [6], [12], [13] Other histologic findings attributable to marrow ablative measures include loss of polarity of keratinocytes, large and bizarrely shaped keratinocytes with unusual mitotic figures, and irregular nuclear forms. [14] This “dysmaturation” should be avoided when seeking to establish the diagnosis of a GVHR inasmuch as it may prevent adequate assessment of the specimen. Significant infiltration by lymphocytes typically does not accompany changes due to the preparative regimen, provided there is no erosion or ulceration.

Grade	Description
0	Normal skin or changes not referable to GVHD
1	Basal vacuolization of the dermal-epidermal junction
2	Basal vacuolization, necrotic epidermal cells, lymphocytes in the dermis and/or epidermis
3	Subepidermal cleft formation plus grade 2 changes
4	Separation of epidermis from dermis plus grade 2 changes

SOURCE: Adapted from Lerner KG et al: Histopathology of graft-versus-host reaction (GVHR) in human recipients of marrow from HLA-matched sibling donors. Transplantation 18:267, 1974.

TABLE 118-4 **Histologic Grading Scheme for the Acute Cutaneous GVHR**

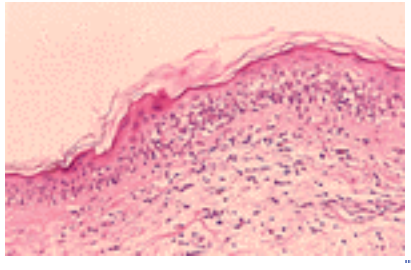

FIGURE 118-4 Histopathology of the acute cutaneous GVHR, grade 2. Inflammation of the upper dermis is evident with extension of lymphocytes into the epidermis and interface change.

In accordance with the clinical observation that the acute cutaneous GVHR begins around the hair follicle, early histopathologic changes also begin in a perifollicular array. At the follicular epithelium, evidence of interface changes is observed with necrosis of follicular keratinocytes and extension of lymphocytes into follicular epithelium. The pattern of inflammation seems to be along the entire follicular infundibulum, but evidence to suggest targeting of the bulge region, specifically the pleuripotent stem cells harbored there, does exist. [15] Grade 1 changes are not specific and may represent a GVHR in evolution, drug eruption, viral exanthem, or the eruption of lymphocyte recovery. Clinicians monitor patients at risk for GVHD closely and sample cutaneous eruptions very early in evolution. It is not surprising, then, that the histopathology is not fully manifest. Resampling is recommended as clinically indicated when diagnostic changes are absent. Evaluations of the immunologic changes in the skin during acute cutaneous GVHD document upregulation of keratinocyte expression of MHC class II and intercellular adhesion molecule 1. Inflammatory infiltrates contain a mixture of CD4+ (helper/inducer), CD8+ (cytotoxic/suppressor), and CD56+ natural killer (NK) cell lymphocytes with extension of all subsets into the epidermis. [16] CD8+ cells accumulate preferentially. [17] After the preparatory regimen, the number of Langerhans cells gradually diminishes over 1 to 4 weeks to undetectable levels. [18] Repopulating cells are derived from the donor. In a murine model, Langerhans cell number and function decreased more in animals developing GVHD than in those undergoing the preparative regimen alone. [19] Evidence of endothelial damage exists in GVHD, based on extravasation of anticoagulation factor VIII. Other findings correlating with the presence of GVHD include nuclear debris in the perivascular dermis and expression of endothelial LN3, an epitope on MHC class II. [20], [21]

PATHOGENESIS The precise pathophysiology of GVHD is not known. A distillation of many lines of evidence implicates allostimulation of donor lymphocytes by major and/or minor transplantation antigens, with subsequent targeting of host tissues, mostly epithelial, for cytotoxic damage. It is unclear whether direct lymphocyte-mediated damage occurs via molecules such as granzyme and perforin, whether cytokines are the main mediators of cell death, or whether both mechanisms are operative. [22] Epithelial cell death ensues by apoptosis, with evidence indicating T cell–mediated mechanisms as well as noncellular triggers. [23], [24] and [25] It is unlikely that a specific lymphocyte subset consistently mediates GVHD. Many epitopes on major and minor histocompatibility antigens are likely to promote allostimulation, resulting in numerous populations of effector lymphocytes in target organs. Indeed, several cytotoxic T cell clones have been isolated and identified from the skin of a single patient. [26] CD4+ and CD8+ cell lines are capable of mediating epidermal damage. In a murine model of GVHD, the effector population mediating the cutaneous GVHR varied with the strains used in the transplant, [27] suggesting that among humans each donor-recipient pair is nearly unique, with the potential to employ different lymphocyte subsets in subsequent GVHD. Evidence exists to implicate CD4+ T cells as major mediators of human disease. [28] These considerations are likely to explain the variability of disease expression, irrespective of MHC match or mismatch. Other cell types are likely involved in mediating GVHD. The presence of numerous NK cells in the dermal and epidermal infiltrates of cutaneous GVHRs suggests that these cells are recruited once the antigen-specific recognition phase of the immunologic reaction has occurred in a target tissue. [29] NK cells lack a hypermutable molecule such as the T cell receptor and are nonspecific mediators of epidermal damage. Mast cells and dermal dendrocytes increase in number in the superficial dermis during acute phases of the disease. [30], [31] Why cutaneous involvement in GVHD is so frequent and early compared with liver and gastrointestinal disease is unknown. Expression of the cutaneous lymphocyte antigen by lymphocytes returning to the peripheral circulation after marrow engraftment would explain homing to the skin.

DIAGNOSIS AND DIFFERENTIAL DIAGNOSIS The diagnosis of the acute cutaneous GVHR rests on the combination of clinical findings, including the onset of variably distributed erythematous macules and papules at the time of peripheral lymphocyte recovery (generally more than 10 to 14 days after transplantation), and a minimum of grade 2 histopathologic changes. Since stage 1 disease generally is not treated, eruptions with limited distribution may not warrant sampling. If eruptions persist or progress despite initial nonspecific histopathologic changes, resampling is very helpful because diagnostic changes evolve as the rash evolves. Emphasis on very early sampling of eruptions, while logical, promotes this dilemma. Despite some distinguishing clinical features, the acute allogeneic cutaneous GVHR lacks absolutely specific findings. Other considerations include a drug hypersensitivity reaction and a viral exanthem. Differentiation of a stage 4 cutaneous GVHR from toxic epidermal necrolysis was discussed earlier. In addition, in some patients a poorly characterized cutaneous eruption seems to occur at the time of marrow engraftment but before the appearance of peripheral lymphocytes. This eruption develops prior to day 14 after transplantation and consists of variably distributed erythematous macules. It should not be confused with a GVHR because this “engraftment” or “cytokine-release” eruption clearly occurs very early and without a discernible rise in peripheral leukocytes. What is the role of the biopsy specimen? There is more ability to establish the diagnosis of a GVHR than to exclude drug eruption and viral exanthem from consideration. The causes that may underlie grade 1 changes generally defy identification. It is sufficient to relate “not GVHD” rather than to speculate about the cause where objective criteria are lacking. Holding to the standard of an infiltrate of lymphocytes, basal vacuolization, and at least four necrotic epidermal cells per millimeter of epidermis helps to diminish the effects of the preparative regimen and heighten the specificity, and thus the significance, of the histologic changes. This standard should be employed in diagnostic dermatopathlogy as well as in prospective and retrospective investigations of the specificity of the histologic changes of the acute cutaneous GVHR. Although not documented in the literature, rare patients display early clinical and histologic features of a drug hypersensitivity reaction, including eosinophils in the tissue, only to have typical grade 2 GVHR histopathology 7 to 10 days later, after engraftment. Once allogeneic lymphocytes predominate and infiltrate the site of prior inflammation, effector function changes, allowing expression of GVHR.

TREATMENT Patients receiving allogeneic transplants are placed on cyclosporine, methotrexate, or both before marrow infusion. With the diagnosis of a cutaneous GVHR, usually greater than stage 1, typical therapy is systemic administration of glucocorticoids. In the face of worsening disease, additional immunosuppressive therapy may include FK-506, anti-thymocyte globulin, [32] or administration of monoclonal antibodies directed against effector cell populations or cytokines. [33], [34] Dosages and specific regimens vary among transplantation centers. As indicated earlier, manipulation of the marrow graft before transplantation reduces the incidence and severity of GVHD. Cutaneous and systemic disease both persist at some level, however. These maneuvers may lessen the incidence of GVHD but also may prevent prompt engraftment and the protection against tumor relapse afforded by GVHD (see below). Therapy directed specifically at the skin includes topical glucocorticoids and ultraviolet (UV) radiation. Psoralen plus UVA (PUVA) produces improvement in clinical features of the cutaneous GVHR, but whether this treatment improves survival is unknown. [35] UV radiation must be administered cautiously to avoid increasing the erythema of the GVHR and thereby inciting more inflammation. Extracorporeal photopheresis has reported benefit in acute disease, including steroid-refractory GVHD, possibly by

promoting a shift from a T_H1 to T_H2 lymphocyte distribution. [36], [37] Pretreatment of the graft with UVA prevents disease in a murine model of transfusion GVHD. [38]

Chronic Cutaneous GVHR

CLINICAL DESCRIPTION Traditionally, chronic GVHD is divided into lichenoid and sclerodermoid forms. The lichenoid phase generally develops earlier than the sclerodermoid phase, and both usually occur more than 60 days after transplantation. Some patients experience both forms of the disease sequentially or concurrently. The greatest predictor for the development of a chronic GVHR is prior acute GVHD. [39] The incidence of a chronic cutaneous GVHR is roughly 25 percent. Rare reports of a chronic GVHR after autologous transplantations exist. [40] The lichenoid form greatly resembles lichen planus, with erythematous to violaceous polygonal papules (Fig. 118-5) arising on flexor surfaces; subsequent greater distribution occurs in some patients. A keratotic variant with individual lesions resembling warts has been described. [41] Oral involvement is typical, with white lacy patches on the buccal mucosa. Rare patients display oral changes only. The lichenoid phase resolves with postinflammatory hyperpigmentation.

FIGURE 118-5 Lichenoid GVHR. These violaceous lichenoid papules developed approximately 100 days after allogeneic bone marrow transplantation.

The sclerodermoid phase greatly resembles scleroderma in that variably distributed plaques of thickened skin arise with a shiny, somewhat atrophic appearance and varied hyper- and hypopigmentation (Fig. 118-6A). The plaques display erythema and progressive loss of the pilosebaceous apparatus. Some patients develop very few sclerodermoid plaques and do not require therapy. Other patients develop widespread disease associated with joint contractures, chronic cutaneous ischemia with erosion (see Fig. 118-6B), alopecia, and a syndrome of general wasting. In certain patients, the main anatomic site of collagen alteration is fascial. This fasciitis is similarly debilitating and is suggested in patients in whom the skin seems supple but the deeper soft tissue is hard. Joint contracture is quite common in this group of patients. Bacterial skin infections recur, consonant with the general immunodeficiency that characterizes chronic GVHD. This immunocompromise promotes sepsis, a common cause of death in these patients. Sicca symptoms resembling Sjögren's syndrome often accompany the sclerodermoid phase due to diminished lacrimal and salivary output.

FIGURE 118-6 Sclerodermoid GVHR. A. Shiny bound-down skin with variable pigmentation is evident. B. The inflammation and collagen alteration combine to cause erosion and some crust formation, as seen in this photograph of a patient with overlap features of lichenoid and sclerodermoid disease.

The sharp separation of lichenoid and sclerodermoid phases of chronic GVHD is artificial. The two forms of disease clearly overlap in many patients. Furthermore, lichen planus–like forms of GVHD occur soon after transplantation. [42] Since immunomodulation and variability in histocompatibility are likely to result in differing clinical expression of all forms of the cutaneous GVHR, rigid adherence to the concept of time as an accurate discriminant of the phases of GVHD may not be appropriate.

HISTOPATHOLOGY Fully evolved histologic features of lichen planus may occur in the lichenoid chronic GVHR. In general, the degree of inflammation is less in the GVHR, but acanthosis, orthohyperkeratosis, wedge-shaped hypergranulosis, sharply pointed rete ridges, basal vacuolization, necrotic epidermal cells, and melanophages in the upper dermis characterize the fully evolved lesion (Fig. 118-7). The only distinction between a lichenoid chronic GVHR and the acute GVHR lies in recognition of the lichen planus–like epidermal changes, since both entities are considered to represent interface dermatitides.

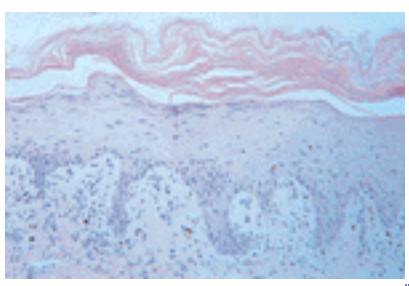

FIGURE 118-7 Histopathology of the lichenoid GVHR. Epidermal features of lichen planus are present with acanthosis,

hypergranulosis, hyperkeratosis, and pointed rete ridges. The inflammatory infiltrate in the upper dermis is less intense than the typical case of idiopathic lichen planus.

The sclerodermatous chronic GVHR displays thickened bundles of collagen with loss of interstices, entrapment of eccrine coils, and progressive loss of pilosebaceous units (Fig. 118-8). The dermal-epidermal junction is ill-defined with basal vacuolization and melanophages. Necrotic epidermal cells are rare. Unlike scleroderma, the progression of collagen alteration in the sclerodermatous GVHR is reportedly from the papillary dermis downward. [43] Panniculitis is an uncommon finding.

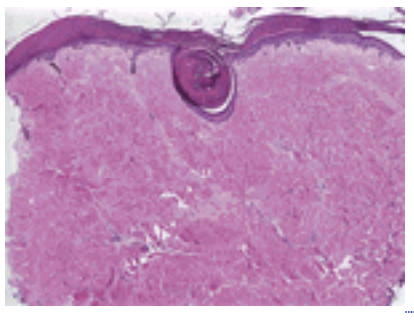

FIGURE 118-8 Histopathology of sclerodermoid GVHR. The epidermis shows mild, compact hyperkeratosis and keratotic plugging. There is hyalinization of the collagen throughout the dermis with loss of the appendageal structures.

Specimens of oral mucosa and minor salivary glands may aid in the diagnosis of chronic GVHD. [44] Interface changes along the epithelium may occur but generally without associated acanthosis and other epidermal features of the lichenoid chronic GVHR in the skin. Similar to the changes in Sjögren's syndrome, lymphocytes infiltrate glandular elements of the salivary glands, with progressive destruction and loss of acini. Lacrimal glands are sampled less often but show similar changes.

PATHOGENESIS Chronic GVHD in the skin bears great similarity to various diseases presumed to be autoimmune in origin. Empirical observation suggests the connection between lichen planus, scleroderma, and Sjögren's syndrome with phases of cutaneous GVHRs. Improper regulation of autoreactive elements of the immune system is proposed as an explanation for the development of these findings. [45] Strong evidence links transforming growth factor ß (TGF-ß) to the development of skin and visceral changes in sclerodermoid GVHD with neutralizing antibodies capable of reversing the fibrosis in a mouse model. [46] In women with scleroderma, persistent chimerism of male fetal tissue is identified. A fetal antimaternal immunologic reaction is proposed as the graft-versus-host–like (GVH-like) mechanism mediating the disease. [47] Cutaneous fibroblasts in sclerodermatous skin express MHC class II and make abnormally large amounts of type I collagen. As the use of peripheral blood stem cell transplantation increases, it is important to note a possible higher associated incidence of chronic GHVD. [48]

DIAGNOSIS The diagnosis of a sclerodermatous GVHR is generally apparent on the basis of the clinical and histologic findings detailed earlier. If superficial biopsy specimens fail to show changes consistent with sclerodermatous disease, then consideration should be given to fascial involvement, which requires incisional sampling. The distinction between the acute cutaneous GVHR and some cases of lichenoid chronic GVHR is more challenging. Rigid adherence to time after transplantation as a reliable discriminant between the two phases results in confusion. [42] Clinical and histologic features resembling lichen planus should lead to the diagnosis of “lichen planus–like GVHR,” with less emphasis placed on whether the disease is necessarily acute or chronic.

PROGNOSIS A graft-versus-tumor effect is recognized in patients who develop GVHD. [49] The incidence of tumor relapse is reduced, resulting in a dichotomous view of the disease. GVHD is the most common cause of morbidity and mortality after allogeneic marrow transplantation, yet mild disease modulated by immunosuppression increases the chance of cure. Systemic infection is the most common cause of death in patients with chronic GVHD. Patients with sclerodermatous disease demonstrate better survival than patients with lichenoid disease because they have overcome the earlier phases of acute and chronic GVHD and have lived longer, on average. Patients with skin biopsy specimens showing fully evolved features of lichenoid disease have a 5.6-fold increased risk for death due to GVHD. [42] No other histologic finding is known to correlate with outcome, specifically not in the early phases of GVHD.

TREATMENT Although most chronic GVHD is manifested only in the skin, oral immunosuppressive therapy is used because the disease is considered to be systemic. Thus glucocorticoids, cyclosporine, and azathioprine are given in various combinations. Thalidomide has received renewed interest as an immunomodulating agent due to its ability to ameliorate chronic GVHD. [50] The dermatologist is involved in treating chronic cutaneous infections, manifestations of lichenoid disease, and sclerodermatous disease. Intermittent cultures for bacteria and fungi should be taken as necessary. Chronic administration of antibiotics becomes necessary in cases of recurrent pyoderma. The incidence of cutaneous and oral mucosal squamous cell carcinoma is increased in long-term survivors with risk factors that include older age, treatment with cyclosporine, and prior administration of ionizing radiation. [51], [52] and [53] For the lichenoid manifestations, PUVA treatment generally controls widespread disease effectively. [54] Tapering PUVA is recommended after several months of clearance. Therapies claiming efficacy in the sclerodermatous GVHR are difficult to evaluate because the disease is relatively rare and remits spontaneously in some cases. It is unclear whether PUVA is able to reverse the cutaneous changes in sclerodermatous disease. Photopheresis has been reported as beneficial. [55] Etretinate has received attention as a treatment of the sclerotic GVHR. [56] Halofuginone, an inhibitor of collagen type I synthesis, has a reported beneficial effect. [57]

ACUTE CUTANEOUS GVHR AFTER AUTOLOGOUS AND SYNGENEIC MARROW TRANSPLANTATION AND PERIPHERAL STEM CELL TRANSPLANTATION

Protocols employing autologous marrow support are becoming increasingly popular as a means of dose intensification. Immunologic manipulations designed to enhance autoimmunity and hopefully to promote GVH-like phenomena are being investigated for potential graft-versus-tumor effect and improved survival.

Cutaneous eruptions simulating acute allogeneic GVHRs occur after autologous and syngeneic transplants in up to 10 percent of patients. [58] Prospective evaluation of eruptions in patients receiving peripheral stem cell transplants has not

been undertaken, but mild eruptions do occur at the time of peripheral lymphocyte recovery. Peripheral stem cells are harvested by selecting and concentrating CD34+ cells (hematopoietic progenitor antigen) with reinfusion after marrow ablative therapy. [59], [60]

The administration of chronic low-dose cyclosporine in the setting of autologous marrow transplants promotes a GVH-like eruption in roughly 60 percent of patients. Theoretically, cyclosporine, given in low dose, promotes escape from thymic and peripheral mechanisms regulating expression of self-targeted mechanisms, thus allowing expression of autoimmunity. [43] This autoimmunity resembles a mild acute cutaneous allogeneic GVHR. Again with the goal of enhancing graft-versus-tumor effect, protocols exist that add interferon-? (IFN-?) and interleukin 2 (IL-2) to cyclosporine regimens. These cytokines support general immunologic reactions and expand T cell populations, and it is hoped they will prime any graft-versus-tumor effect that may accrue with autologous transplants. Eruptions in this setting are more common and more severe, leading to erythroderma (stage 3 disease), an otherwise uncommon finding after autologous transplants. [61]

Whether these eruptions are truly GVHRs as seen after allogeneic transplants is uncertain. Because autologous marrow and peripheral stem cell transplant programs increasingly are performed outside university centers, dermatologists will encounter these eruptions more frequently. To assess clinical trial outcomes adequately, dermatologists and pathologists in academic centers must assess the occurrence of GVH-like reactions accurately.

CLINICAL DESCRIPTION

Erythematous macules and papules appear in variable locations and distributions at the time of peripheral lymphocyte recovery and are self-limited. Resolution with desquamation occurs without therapy. Stage 1 and stage 2 disease is most common after the administration of cyclosporine, whereas stage 3 disease is common after the addition of IFN-? and is accompanied by significant pruritus. Stage 4 disease, manifestations of chronic GVHD, and extracutaneous involvement are exceedingly rare.

HISTOPATHOLOGY

Unmodified autologous transplants result in eruptions that are histologically indistinguishable from that of lymphocyte recovery. [62] The administration of cyclosporine results in some cutaneous eruptions that histopathologically resemble grade 2 acute cutaneous GVHR after allogeneic transplantation, but the findings are usually mild without evolution to grade 3 or grade 4. Transplants modified by the administration of cyclosporine and IFN-? result in eruptions that combine the histologic features of a GVHR and eczematous dermatitis, as evidenced by more marked exocytosis and intercellular edema. [61]

PATHOGENESIS

In rodents and humans, evidence exists that autoimmunity is directed against an epitope(s) on the MHC class II molecule. [63] Since IFN-? upregulates MHC class II expression (ideally on tumor cells), and since cyclosporine promotes MHC class II–reactive T lymphocytes, this therapy combined with the dose intensification of autologous marrow transplants leads to enhanced GVH-like cutaneous reactions and possibly the beneficial graft-versus-tumor effect.

DIAGNOSIS

Separation of autologous GVHRs from the eruption of lymphocyte recovery may be difficult. Applying the same histologic criteria as for the acute allogeneic GVHR is recommended.

TREATMENT

No significant morbidity is associated with autologous GVHD, and the cutaneous eruptions resolve without therapy. Patients with erythroderma after autologous marrow transplants modified by cyclosporine and IFN-? may require systemic glucocorticoids to control the intense itching that accompanies the eczematous changes seen histologically.

REFERENCES

1. Fricker J: Baboon xenotransplant fails but patient improves. *Lancet* **347**:457, 1996

2. Horn TD: Acute cutaneous eruptions after marrow ablation: Roses by other names? *J Cutan Pathol* **21**:385, 1994

3. Horn TD et al: Cutaneous eruptions of lymphocyte recovery. *Arch Dermatol* **105**:1512, 1989

4. Blaack BR, Burgdorf WHC: Chemotherapy-induced acral erythema. *J Am Acad Dermatol* **24**:457, 1991

5. Vogelsang GB et al: Explosive graft-versus-host disease. *Blood* **82**:422a, 1993

6. Darmstadt GL et al: Clinical, laboratory, and histopathologic indicators of the development of progressive acute graft-versus-host disease. *J Invest Dermatol* **99**:397, 1992

7. Grogan TM et al: Graft-versus-host reaction (GVHR): A case report suggesting GVHR occurred as a result of maternofetal cell transfer. *Arch Pathol* **99**:330, 1975

8. Tanei R et al: Transfusion-associated graft-versus-host disease: An in situ hybridization analysis of the infiltrating donor-derived cells in the cutaneous lesion. *Dermatology* **199**:20,1999

9. Schmuth M et al: Cutaneous lesions and the presenting sign of acute graft-versus-host disease following liver transplantation. *Br J Dermatol*

141:901,1999

10. Horn TD, Groleau GE: Transient acantholytic dermatosis in immunocompromised febrile patients with cancer. *Arch Dermatol* **123**:238, 1987

11. Harvell JD et al: Grover's-like disease in the setting of bone marrow transplantation and autologous peripheral blood stem cell infusion. *Am J Dermatopathol* **20**:179, 1998

12. Horn TD et al: Reappraisal of histologic features of the acute cutaneous graft-versus-host reaction based upon an allogeneic rodent model. *J Invest Dermatol* **100**:546a, 1993

13. LeBoit PE: Subacute radiation dermatitis: A histologic imitator of acute cutaneous graft-versus-host disease. *J Am Acad Dermatol* **20**:236, 1989

14. Horn TD: Antineoplastic chemotherapy, sweat and the skin. *Arch Dermatol* **133**:905, 1997

15. Murphy GF et al: Cytotoxic folliculitis in GvHD: Evidence of follicular stem cell injury and recovery. *J Cutan Pathol* **18**:309, 1991

16. Horn TD, Haskell J: The lymphocyte infiltrate in acute cutaneous allogeneic graft-versus-host reactions lacks evidence for phenotypic restriction in donor-derived cells. *J Cutan Pathol* **25**:210, 1998

17. Paller AS et al: T-lymphocyte subsets in the lesional skin of allogeneic and autologous bone marrow transplant patients. *Arch Dermatol* **124**:1795, 1988

18. Murphy GF et al: Depletion and repopulations of epidermal dendritic cells after allogeneic bone marrow transplantation in humans. *J Invest Dermatol* **84**:210, 1985

19. Breathnach SM et al: Immunologic aspects of acute cutaneous graft-versus-host-disease: Decreased density and antigen-presenting function of Ia+ Langerhans cells and absent antigen-presenting capacity of Ia+ keratinocytes. *J Invest Dermatol* **86**:226, 1986

20. Sviland L et al: Endothelial changes in cutaneous graft-versus-host disease: A comparison between HLA matched and mismatched recipients of bone marrow transplantation. *Transplantation* **7**:35, 1991

21. Synovec MS et al: LN-3: A diagnostic adjunct in cutaneous graft-versus-host disease. *Mod Pathol* **3**:643, 1990

22. Graubert TA et al: Perforin/granzyme-dependent and independent mechanisms are both important for the development of graft-versus-host disease after murine BMT. *J Clin Invest* **100**:904, 1997

23. Gilliam AC et al: Apoptosis is the predominant form of epithelial target cell injury in acute experimental graft-versus-host disease. *J Invest Dermatol* **107**:377, 1996

24. Yoo YH et al: Experimental induction and ultrastructural characterization of apoptosis in murine acute cutaneous graft-versus-host disease. *Arch Dermatol Res* **289**:389, 1997

25. Jerome KR et al: Keratinocyte apoptosis following bone marrow transplantation: Evidence for CTL-dependent and -independent pathways. *Bone Marrow Transplant* **22**:359, 1998

26. Gaschet J et al: Acute graft-versus-host disease due to T lymphocytes recognizing a single HLA-DPB1*0501 mismatch. *J Clin Invest* **98**:100, 1996

27. Murphy GF et al: Characterization of target injury of murine acute graft-versus-host disease directed to multiple minor histocompatibility antigens elicited by either CD4+ or CD8+ effector cells. *Am J Pathol* **183**:983, 1991

28. Nikaein A et al: Characterization of skin-infiltrating cells during acute graft-versus-host disease following bone marrow transplantation using unrelated marrow donors. *Hum Immunol* **40**:68, 1994.

29. Acevedo A et al: Identification of natural killer (NK) cells in lesions of human cutaneous graft-versus-host disease: Expression of a novel NK-associated surface antigen (Kp43) in mononuclear infiltrates. *J Invest Dermatol* **97**:659, 1991

30. Stuart SP et al: Kinetics of mast cell, fibroblast, and epidermal cell proliferation during acute graft-versus-host disease in the neonatal rat. *J Invest Dermatol* **88**:369, 1987

31. Yoo YH et al: Dermal dendrocytes participate in the cellular pathology of experimental actue graft-versus-host disease. *J Cutan Pathol* **25**:426, 1998

32. Durrant S et al: Combination therapy with tacrolimus and anti-thymocyte globulin for the treatment of steroid-resistant acute graft-versus-host disease developing during cyclosporine prophylaxis. *Br J Haematol* **113**:217, 2001

33. Hiscott A, McLellan DS: Graft-versus-host disease in allogeneic bone marrow transplantation: The role of monoclonal antibodies in prevention and treatment. *Br J Biomed Sci* **57**:163, 2000.

34. Herve P et al: Phase I–II trial of a monoclonal anti-tumor necrosis factor alpha antibody for the treatment of refractory severe acute graft-versus-host disease. *Blood* **79**:3362, 1992

35. Wiesmann A et al: Treatment of acute graft-versus-host disease with PUVA (psoralen and ultraviolet irradiation): Results of a pilot study. *Bone Marrow Transplant* **23**:151, 1999

36. Klosner G et al: Treatment of peripheral blood mononuclear cells with 8-methoxypsoralen plus ultraviolet A radiation induces a shift in cytokine expression from a Th1 to a Th2 response. *J Invest Dermatol* **116**:459, 2001

37. Greinix HT et al: Extracorporeal photochemotherapy in the treatment of severe steroid-refractory acute graft-versus-host disease: A pilot study. *Blood* **96**:2426, 2000

38. Grass JA et al: Prevention of transfusion associated graft versus-host disease by photochemical treatment. *Blood* **93**:3140, 1999

39. Loughran TP et al: Value of day 100 screening studies for predicting the development of chronic graft-versus-host disease after allogeneic bone marrow transplantation. *Blood* **76**:228, 1990

40. Pimpinelli N: Localized scleroderma-like lesions in autologous bone marrow transplantation. *Eur J Dermatol* **2**:12, 1992

41. Kossard S, Ma DD: Acral keratotic graft-versus-host disease simulating warts. *Australas J Dermatol* **40**:161, 1999

42. Horn TD et al: Lichen planus–like histopathologic characteristics in the cutaneous graft-versus-host reaction. *Arch Dermatol* **133**:961, 1997

43. Bos GMJ et al: Chronic cyclosporine-induced autoimmune disease in the rat: A new experimental model for scleroderma. *J Invest Dermatol* **93**:610, 1989

44. Horn TD et al: The significance of oral mucosal and salivary gland pathology after allogeneic bone marrow transplantation. *Arch Dermatol* **131**:964, 1995

45. Hess AD et al: Effector mechanisms in cyclosporin-induced syngeneic graft-versus-host disease. *J Immunol* **145**:526, 1990

46. McCormick LL et al: Anti-TGF-beta treatment prevents skin and lung fibrosis in murine sclerodermatous graft-versus-host disease: A model for human scleroderma. *J Immunol* **163**:5693, 1999

47. Artlett CM et al: Identification of fetal DNA and cells in skin lesions from women with systemic sclerosis. *N Engl J Med* **338**:1186, 1998

48. Storek J et al: Allogeneic peripheral blood stem cell transplantation may be associated with a high risk of chronic graft-versus-host disease. *Blood* **90**:4705, 1997

49. Weiden PL et al: Anti-leukemic effect of chronic graft-versus-host disease: Contribution to improved survival after allogeneic bone marrow transplantation. *N Engl J Med* **304**:1529, 1981

50. Vogelsang GB et al: Thalidomide therapy of chronic graft-versus-host disease. *N Engl J Med* **326**:1055, 1992

51. Kolb HJ et al: Malignant neoplasms in long-term survivors of bone marrow transplantation. *Ann Intern Med* **131**:738, 1999

52. Bhatia S et al. Solid cancers after bone marrow transplantation. *J Clin Oncol* **19**:464, 2001

53. Gmeinhart B et al. Anaplastic squamous cell carcinoma (SCC) in a patient with chronic cutaneous graft-versus-host disease (GVHD). *Bone Marrow Transplant* **23**:1197, 1999

54. Vogelsang GB et al: Treatment of chronic graft-versus-host disease with ultraviolet radiation and psoralen (PUVA). *Bone Marrow Transplant* **17**:1061, 1996

55. Dippel E et al: Long-term extracorporeal photoimmunotherapy for treatment of chronic cutaneous graft-versus-host disease: Observations in four patients. *Dermatology* **198**:370, 1999.

56. Marcellus DC et al: Etretinate therapy for refractory sclerodermatous chronic graft-versus-host disease. *Blood* **93**:66, 1999

57. Nagler A, Pines M: Topical treatment of cutaneous chronic graft-versus-host disease with halofuginone: A novel inhibitor of collagen type I synthesis. *Transplantation* **68**:1806, 1999

58. Hood AF et al: Acute graft-versus-host disease: Development following autologous and syngeneic bone marrow transplantation. *Arch Dermatol* **123**:745, 1987

59. Kessinger A: Autologous transplantation with peripheral blood stem cells: A review of clinical results. *J Clin Apheresis* **5**:97, 1990

60. Watanabe T et al: Peripheral blood stem cell transplantation: An update. *J Med Invest* **44**:25, 1997

61. Horn TD et al: Erythroderma after autologous bone marrow transplantation modified by administration of cyclosporine and interferon gamma for breast cancer. *J Am Acad Dermatol* **34**:413, 1996

62. Bauer DJ et al: Histologic comparison of autologous graft-versus-host reaction and cutaneous eruption of lymphocyte recovery. *Arch Dermatol* **129**:855, 1993

63. Geller RB et al: Successful in vitro graft-versus-tumor effect against an Ia-bearing tumor using cyclosporine-induced syngeneic graft-versus-host disease in the rat. *Blood* **74**:1165, 1989

T>

Chapter 119

Andrew Blauvelt

Mucocutaneous Manifestations of the Non-HIV-Infected Immunosuppressed Host

INFECTIONS
Fungal Infections
Viral Infections
Bacterial Infections
Parasitic Infections
CANCERS
Nonmelanoma Skin Cancer
Kaposi's Sarcoma
Other Cancers
MISCELLANEOUS CONDITIONS

REFERENCES

This chapter is focused on dermatologic manifestations of patients with acquired immunodeficiency when the cause is not HIV infection. The changes associated with HIV infection are described in Chap. 225. Most individuals included in this group have cancer, have received an organ transplant, and/or are receiving immunosuppressive therapy. Some have diabetes mellitus or are transiently immunosuppressed following surgery. Since relatively few skin diseases manifest exclusively in an immunosuppressed host, many conditions discussed in this chapter also can occur in immunocompetent individuals. However, salient clinical features particularly associated with immunosuppression are emphasized here.

Like those infected with HIV, other immunosuppressed patients commonly present with skin disease characterized by unusual presentations of common dermatoses, as well as by infections with atypical or opportunistic pathogens. These features make both diagnosis and treatment of cutaneous disease difficult in this population. Prompt clinical evaluation, judicious use of skin biopsy and culture, and aggressive treatment often are necessary to alleviate significant morbidity and mortality.

Individuals with cancer often have immune system defects prior to aggressive cytotoxic, radiation, or surgical therapy. [1] Environmental exposures and systemic defects in tumor immune surveillance that induce the primary cancer can make individuals more vulnerable to opportunistic pathogens as well. In addition, tumors from patients with established malignancy often secrete immunosuppressive factors, e.g., transforming growth factor ß (TGF-ß), that help evade normal immune responses and lead to further systemic immunosuppression. Ravaging side effects of cancer therapies debilitate cancer patients further. Primary cutaneous infections and systemic infections with secondary skin involvement are common complications in this setting. [2]

Solid-organ transplantation is a therapeutic option for many human diseases. Unfortunately, however, individuals who have received grafts often require lifelong immunosuppressive drugs to maintain function of the transplanted organ. Cyclosporine, tacrolimus, prednisone, and azathioprine are the drugs used most commonly to prevent graft-versus-host disease, predominately by impairing cell-mediated immunity, i.e., T cell function. [3] Humoral immunity, i.e., B cell function, remains relatively intact in these patients. Thus opportunistic diseases are dominated by viral and fungal infections, intracellular bacterial infections, and viral-associated malignancies, [4], [5] conditions that are controlled predominantly by cell-mediated immune mechanisms in immunocompetent hosts. As with cancer patients, the skin is a commonly affected organ in posttransplant patients.

Graft-versus-host disease, the cutaneous manifestations of HIV disease, skin signs associated with primary immunodeficiency disorders, and side effects of cancer chemotherapeutic agents and cytokines are covered in other chapters (see Chap. 118, Chap. 140, Chap. 225, and Chap. 256). Idiopathic CD4+ lymphocytopenia, which occurs in the absence of HIV infection, is a recently described rare condition that immunologically and clinically resembles AIDS. The cutaneous manifestations of these patients are very similar to those experienced by AIDS patients [6] (see Chap. 225) and will not be further discussed in this chapter.

INFECTIONS

The diversity of cutaneous infections that occurs in immunosuppressed patients can pose a significant diagnostic challenge. To aid in the evaluation of these patients, it is helpful to know and understand the underlying immune defects that are associated with the medical condition(s) of the patient (Table 119-1). This helps to focus the history and physical examination toward skin manifestations of specific pathogens. In particular, the skin can be critical in the evaluation of immunosuppressed patients who are ill because the initial diagnosis of systemic infection often can be established by careful examination and biopsy of cutaneous lesions.



TABLE 119-1 **Opportunistic Infections That Are Commonly Associated with Specific Underlying Immune Defects**

Fungal Infections

CANDIDIASIS (See Chap. 206) Candidiasis is the most common fungal infection in immunosuppressed patients. [2], [4], [5] Medical conditions that cause defects in cell-mediated immunity or neutropenia, chronic immunosuppressive drug or broad-spectrum antibiotic therapy, hyperglycemia, intravenous catheterization, and prolonged hospitalization all can predispose to candidal infection [7] (see Table 119-1). Neutropenic patients and those with indwelling catheters are particular susceptible. Importantly, disseminated candidiasis should be suspected when evaluating acutely ill patients with one of these predisposing conditions. The classic triad of fever, myalgias, and erythematous skin lesions in a septic patient not responding to antibiotic therapy is highly suggestive of disseminated candidiasis. Fungus may seed numerous organs, causing myositis, meningitis, endocarditis, pneumonitis, cerebritis, esophagitis, bursitis, osteomyelitis, arthritis, and endophthalmitis. Accordingly, prognosis is poor, and mortality rates range as high as 75 percent. Cutaneous lesions are present in only 5 to 10 percent of persons with disseminated candidiasis. [8] Lesions are characteristically nonpainful, nonblanching, discrete, erythematous macules, papules, or nodules (Fig. 119-1) that may become purpuric, pustular, or necrotic within the centers of the lesions. They are usually generalized, but occasionally patients may present with a few lesions limited to the proximal extremities. The major clinical differential diagnosis includes infections caused by other opportunistic pathogens and drug eruptions. Histologically, periodic acid–Schiff-positive yeast forms are seen in the dermis, usually associated with vascular damage and mild inflammation.

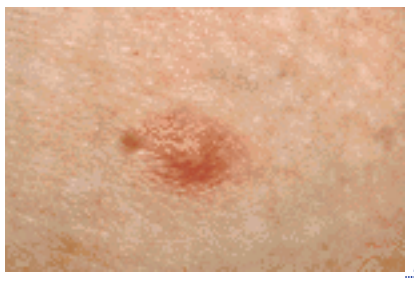
/A>

FIGURE 119-1 Early cutaneous lesion of disseminated candidiasis in a neutropenic patient following chemotherapy for non-Hodgkin's lymphoma.

Candida can be grown from skin lesions in approximately 50 percent of patients, and success correlates with the ability to isolate organisms from blood. *C. albicans* is isolated in over 50 percent of patients; other pathogenic species include *C. tropicalis* (25 percent), *Torulopsis glabrata* (8 percent), *C. parapsilosis* (7 percent), and *C. kruzei* (4 percent). [9] *C. tropicalis* is more likely than the other strains to cause skin lesions (up to 25 percent of patients). In general, less common strains are less virulent than *C. albicans,* although they are more likely to demonstrate fluconazole resistance. The treatment of choice for disseminated candidiasis is intravenous amphotericin B, with or without oral flucytosine; oral or intravenous fluconazole may be used as alternative treatment. Although less serious than disseminated candidiasis, candidiasis confined to mucosal and skin surfaces is also a very common complication observed in immunosuppressed hosts. [10] The conditions that predispose to mucocutaneous disease are the same that predispose to systemic infection. Approximately 10 percent of organ transplant patients exhibit oral candidiasis. [11] In patients receiving immunosuppressive therapy or broad-spectrum antibiotics, oral and/or vaginal candidiasis can develop within 1 month of initiating therapy. Patients with chronic mucocutaneous candidiasis have specific underlying immune deficits in fighting candidal infections and usually have chronic widespread disease (without systemic involvement). Patients with oral mucosal candidiasis most commonly present with pseudomembranous, white, friable plaques that are removed easily by scraping (see Chap. 112 and Chap. 206). Less common oral lesions include erythematous or atrophic plaques, as well as angular cheilitis. Esophageal involvement should be suspected in any patient with oral candidiasis complaining of pain or difficulty in swallowing. Women with vaginitis secondary to *Candida* present with pruritus, irritation, and a thick, white discharge. Cutaneous candidiasis commonly occurs in moist intertriginous areas as tender erythematous papules and satellite pustules. Onychomycosis and paronychia also may be caused by *Candida* and are common in patients with chronic mucocutaneous candidiasis. For mucocutaneous disease, topical therapy with nystatin or clotrimazole and oral fluconazole are the treatments of choice. Prophylactic treatment with fluconazole is often recommended in patients at high risk for infection, such as patients who have recently undergone organ transplant surgery.

ASPERGILLOSIS (See Chap. 207) Aspergillosis is caused by ubiquitous saprophytes found in soil and water. *Aspergillus fumigatus* is the most common cause of disseminated infections, whereas *A. flavus* is associated most commonly with primary cutaneous disease. [12] After candidiasis, aspergillosis is the second most common opportunistic fungal infection in immunosuppressed patients [2], [4], [5]; disease is rare in immunocompetent hosts. In organ transplant recipients, aspergillosis accounts for 20 percent of all opportunistic fungal infections. Normal functioning of both neutrophils and macrophages is required to prevent infection. Thus neutropenic patients (e.g., individuals with leukemia or those receiving chemotherapy) and patients receiving high-dose glucocorticoids (which impair macrophage function) are at high risk for aspergillosis. Environmental factors also contribute to the development of disease, including hospital construction (which increases spore counts in ventilation systems), indwelling catheters (which provide portals of entry for organisms), and contaminated tape and arm boards used to secure catheters. Primary infection usually occurs by inhalation of spores. Patients with disseminated aspergillosis often present with unremitting fever despite antibiotic use, necrotizing pneumonia, and sinusitis. The central nervous system, heart, kidneys, and gastrointestinal tract also may be involved. Cutaneous manifestations of disseminated aspergillosis are uncommon, occurring in 5 to 10 percent of patients. [12] Lesions begin as single or multiple, painful, erythematous papules, nodules, or plaques. They rapidly expand and develop central hemorrhagic vesicles or bullae, which in turn rapidly progress to central ulcers with black eschars (Fig. 119-2). Lesions of primary cutaneous aspergillosis that develop at indwelling catheter sites appear initially as cellulitis

and progress quickly to necrotic ulcers with black eschars. In patients with *Aspergillus* sinusitis, necrotic ulcers with black eschars can occur in the anterior nares, nasal septum, palate, and skin overlying the nasal bridge. Cutaneous necrosis caused by *Aspergillus* is secondary to invasion of fungi within deep blood vessels.

FIGURE 119-2 Primary cutaneous aspergillosis at an intravenous catheter site in a child with leukemia. (*Courtesy of Alexa Boer-Kimball, M.D., Stanford University.*)

Primary pulmonary, cutaneous, or sinus infection commonly leads to disseminated disease, and the prognosis is very poor (usually greater than 90 percent mortality). In tissue sections, diagnosis can be made by demonstration of nonpigmented septated hyphae that branch at acute angles. Blood cultures often are not positive or reliable because *Aspergillus* is found commonly as a laboratory contaminant. The treatment of choice is high-dose intravenous amphotericin B; oral itraconazole is used as alternative treatment. Surgical removal of isolated lesions of primary cutaneous aspergillosis can be attempted, although this may not necessarily prevent secondary disseminated infection in patients with persistent neutropenia. Laminar flow rooms, low-dose amphotericin B, and aerosolized amphotericin B nasal spray have been used in attempts to prevent infection.

MUCORMYCOSIS (See Chap. 207) Mucormycosis is the third most common opportunistic fungal infection in immunosuppressed hosts, accounting for 5 to 15 percent of all fungal infections. [2], [4], [5] The causative agents are "bread molds" of the phylum Zygomycetes, order Mucorales, and include species of *Mucor, Rhizopus, Absidia, Mortierella,* and *Cunninghamella.* Like aspergillosis, mucormycosis is rare in individuals without underlying immunodeficiency or predisposing conditions, which include neutropenia, organ transplantation, high-dose systemic glucocorticoid or cytotoxic therapy, cancer (especially leukemia), diabetes, intravenous drug use, hepatic or renal disease, anemia, burns, and severe malnutrition. Primary infection in these individuals can occur by inhalation, by direct inoculation into damaged skin, or by ingestion. In particular, diabetes and metabolic acidosis predispose patients to primary rhinocerebral and pulmonary infection, wounds and burn injuries predispose to primary cutaneous infection, and malnutrition and gastrointestinal disease predispose patients to primary gastrointestinal tract infection. Each type of primary infection can lead to hematogenous spread and disseminated infection of numerous organs (especially the brain). In such patients, prognosis is poor. The clinicopathologic hallmarks of cutaneous mucormycosis are vascular invasion, ischemic infarction, and necrosis, resulting in painful erythematous nodules and plaques that ulcerate rapidly and form central black eschars. [13] Rhinocerebral mucormycosis typically begins with facial edema and erythema (Fig. 119-3), bloody nasal discharge, and ulceration of the palate or nasal septum. Within a few days, necrotic skin lesions, headache, focal neurologic defects, exophthalmos, and altered vision develop and can progress to seizures, stupor, coma, and death. Primary cutaneous mucormycosis, which can develop rapidly in burn wounds, indwelling catheter sites, diabetic ulcers, and surgical wounds, manifests as necrotic ulcers with profuse, malodorous, purulent exudate. Diagnosis of mucormycosis usually is made by demonstration of nonseptated hyphae (with branching at right angles) within infected tissue. The treatment of choice for disseminated disease is intravenous amphotericin B and surgical debridement. If possible, reversal or removal of underlying predisposing conditions always should be attempted.

FIGURE 119-3 Rapidly progressing mucormycosis in a man with diabetes.

FUSARIOSIS *Fusarium* is a filamentous mold found in soil and plants. Leukemic patients with prolonged neutropenia are particularly susceptible to infection. [14] Primary infection usually occurs by inhalation of spores, although primary cutaneous infection can occur at indwelling catheter sites. Other than the lungs, disseminated infection commonly involves the sinuses and skin (75 percent of patients have skin lesions). Cutaneous lesions caused by *Fusarium* resemble lesions caused by *Aspergillus* and appear as painful, erythematous nodules and plaques that ulcerate rapidly and form black eschars. Unlike *Aspergillus, Fusarium* can be cultured readily from skin and blood of infected patients. Prognosis is poor because no effective therapy is available.

TRICHOSPORONOSIS *Trichosporon beigelii,* a yeastlike organism that causes white piedra in the tropics, may produce acute systemic infection in immunosuppressed patients, most commonly in the setting of neutropenia. [15] As with disseminated candidiasis, persons with disseminated trichosporonosis are acutely ill. They may have fever, hypotension, pulmonary infiltrates, renal involvement, and hepatosplenomegaly. Skin lesions occur in 30 percent of patients and appear similar to cutaneous lesions of disseminated candidiasis. Definitive diagnosis is made by culture, and the treatment of choice is fluconazole; amphotericin B resistance is not uncommon.

CRYPTOCOCCOSIS (See Chap. 207) *Cryptococcus neoformans* is a yeastlike encapsulated fungus that is ubiquitous and is found commonly in soil enriched with pigeon feces. Primary infection is acquired via the respiratory tract by inhalation of airborne spores and usually is asymptomatic. However, immunosuppressed patients, particularly those receiving high-dose systemic glucocorticoids, are susceptible to hematogenous spread and disseminated infection. [16], [17] In fact, 70 percent of individuals with disseminated cryptococcosis have some form of underlying immune defect. The central nervous system is involved most commonly, although infection may occur throughout the body, including the lungs, bone marrow, heart, liver, spleen, kidneys, thyroid, lymph nodes, and adrenal glands. Cutaneous lesions occur in 10 to 15 percent of patients with disseminated infection and may be protean. [10] In transplant patients, erythematous, edematous, warm, painful plaques (clinically indistinguishable from bacterial cellulitis) have been reported commonly.

Umbilicated papules (resembling molluscum contagiosum), nodules, pustules, vesicles, and ulcers also may occur (Fig. 119-4). Oral mucosal cryptococcal nodules and ulcerations also have been described. Lesions may be isolated or multiple and can be quite painful. Although any area of the skin and oral mucosa may be involved, there is a predilection for disseminated disease to involve the head and neck region. Localized cryptococcal cellulitis is most common on the extremities.

FIGURE 119-4 Cryptococcal cellulitis with ulceration in a woman receiving long-term high-dose glucocorticoids for systemic lupus erythematosus.

Although primary skin disease may occur in the absence of pulmonary infection, diagnosis of cutaneous cryptococcosis always warrants an investigation for systemic infection, especially since disseminated disease may not always be evident clinically. This is usually accomplished by examining cerebrospinal fluid for cryptococcal polysaccharide antigens. For evaluating skin lesions, budding encapsulated yeasts can be identified readily in tissue biopsies, as well as in purulent material obtained from skin lesions. They stain red with periodic acid–Schiff and mucicarmine stains and black with methenamine silver stain. *Cryptococcus* also can be isolated in culture from cutaneous tissue. The treatment of choice for cryptococcosis is intravenous amphotericin B with or without flucytosine. Fluconazole is used as alternative primary treatment. However, fluconazole is the treatment of choice for prophylaxis in individuals at high risk for primary or recurrent infection.

HISTOPLASMOSIS (See Chap. 207) *Histoplasma capsulatum* is a dimorphic fungus that is found commonly in soil in central and eastern regions of the United States. Endemic foci also exist in South America, Africa, and Asia. As with cryptococcosis, inhalation of airborne spores causes primary pulmonary infection that usually leads to self-limited disease in otherwise healthy individuals. However, disseminated disease may occur, particularly in individuals with deficiencies in cell-mediated immunity. [18] In addition to pneumonia, immunosuppressed hosts may present with fever, renal failure, central nervous system involvement, hepatosplenomegaly, lymphadenopathy, and myelosuppression. With disseminated infection, skin lesions occur in 5 to 25 percent of patients and may be an initial sign of disease. [10] Mucocutaneous lesions commonly manifest as painful nodules or plaques that progress to ulcers with indurated borders. However, numerous other morphologies have been described, including molluscum-like papules, acneiform papules and pustules, and cellulitis. In addition, as with cryptococcosis, the head and neck region is involved most commonly. In fact, the oropharynx is the most common site for lesions of mucocutaneous histoplasmosis. Because the organism grows very slowly in culture, histoplasmosis is best diagnosed by direct examination of tissue. Numerous small, oval, yeastlike fungi can be seen within the cytoplasm of dermal macrophages. The treatment of choice for disseminated histoplasmosis in an immunosuppressed host is intravenous amphotericin B. For patients who are not acutely ill, oral itraconazole may be used; itraconazole is also recommended for immunosuppressed patients to prevent recurrent disease.

COCCIDIOIDOMYCOSIS (See Chap. 207) *Coccidioides immitis,* the causative agent of coccidioidomycosis, is endemic to soil in the southwestern United States, and primary pulmonary infection is acquired through inhalation of spores. [19] Although progressive primary infection may occur in immunosuppressed patients, reactivation of prior, clinically inapparent infection appears to be more common. The risks of dissemination and fatal infection are greater among pregnant women, non-Caucasians, and immunosuppressed patients with defects in cell-mediated immunity, e.g., transplant patients receiving cyclosporine. Thus disseminated coccidioidomycosis can occur in any immunocompromised patient who lives or has lived previously in an endemic area. Immunosuppressed patients with disseminated disease may present with fever, pneumonia, bone involvement, and meningitis. Mortality is high. Cutaneous lesions are common and appear as reddish brown papules and nodules, pustules, abscesses, or ulcers. Lesions occur most commonly on the face. Definitive diagnosis of coccidioidomycosis is made by demonstrating characteristic endosporulating spherules in smears or biopsy specimens or by culture of infected tissue. For disseminated infections in immunosuppressed hosts, treatments include intravenous amphotericin B and oral fluconazole.

BLASTOMYCOSIS (See Chap. 207) *Blastomyces dermatiditis* is endemic to the soil of the Ohio and Mississippi river valleys. Infection is acquired through inhalation of spores. Immunosuppressed patients are prone to disseminated disease involving the lungs, bone, genital tract, and skin. [18] The most common lesion appears as a verrucous or crusted plaque with serpiginous borders located on the head, neck, or distal extremities. Subcutaneous nodules and ulcers are also not uncommon. Diagnosis is made on demonstration of broad-based, budding, thick-walled yeasts in pus or skin scrapings from the edges of lesions or by tissue culture. In life-threatening disseminated infection, intravenous amphotericin B is the treatment of choice; however, less severe disease is treated with oral itraconazole.

DERMATOPHYTOSIS (See Chap. 205) Dermatophytes commonly infect normal hosts and typically cause superficial scaly annular plaques and onychomycosis. However, immunosuppressed patients may have widespread, aggressive infection that can be resistant to topical and systemic therapy. [10] The morphology of individual lesions in immunosuppressed patients is usually similar to lesions seen in normal individuals. However, both white superficial onychomycosis and proximal subungual onychomycosis are types of fungal nail infections that are uncommon in immunocompetent hosts. In the former, the surfaces of affected nails have a white chalky appearance (Fig. 119-5), and hyphae are observed readily in superficial nail plate scrapings. These conditions should prompt a search for underlying immune deficiency.

FIGURE 119-5 White superficial onychomycosis in a renal transplant patient receiving cyclosporine.

OTHER FUNGAL INFECTIONS *Penicillium marneffei* is a dimorphic fungus that has emerged as an opportunistic pathogen in immunosuppressed patients (most but not all AIDS patients) who live in or who have traveled to Southeast Asia. [20] Initial infection is acquired through inhalation or ingestion of spores. Patients with disseminated disease develop fever, weight loss, anemia, pneumonia, hepatosplenomegaly, lymphadenopathy, and molluscum-like papules on the head and upper body (70–80 percent of patients). The mold *Scedosporium prolificans* can cause asymptomatic colonization, localized infection related to trauma or surgery, and disseminated infection. [21] The latter is particularly common in patients with neutropenia secondary to hematologic malignancies. *Alternaria* is a common saprophytic fungus that can cause opportunistic infection in the setting of hypercorticism (e.g., glucocorticoid treatment, Cushing's disease) and skin fragility. [22] *Paecilomyces lilacinus,* a fairly new opportunistic fungal pathogen, has been reported to contaminate topical preparations and cause deep-seated cutaneous nodules in immunosuppressed patients. [23] A number of dematiaceous fungi cause primary cutaneous phaeohyphomycosis. Immunosuppressed patients are particularly susceptible to infection and present with subcutaneous abscesses or cysts at sites of inoculation. [24] Chromomycosis, which typically occurs in patients in tropical and subtropical areas, is caused by dematiaceous fungi and can develop in immunosuppressed patients from other geographic areas. Typical lesions occur as scaly verrucous or crusted plaques on the extremities. Immunosuppressed patients may develop disseminated sporotrichosis, although this is not common. Tinea versicolor and folliculitis caused by *Pityrosporum ovale* (also known as *Malassezia furfur*) may be widespread and persistent in immunosuppressed hosts. [25] In addition, *Malassezia* has been reported to cause indwelling catheter–associated fungemia in immunosuppressed hosts.

Viral Infections

HERPESVIRUSES There are eight known human herpesviruses, including herpes simplex viruses (HSV) 1 and 2, varicella-zoster virus (VZV), Epstein-Barr virus (EBV), cytomegalovirus (CMV), human herpesviruses (HHV) 6 and 7, and Kaposi's sarcoma–associated herpesvirus (KSHV). As a family, herpesviruses are large DNA viruses that infect their hosts for life, typically remaining dormant in nuclei of latently infected cells. Clinical manifestations of primary infection, which generally occurs in childhood (except for HSV-2 and KSHV), are discussed in other chapters (see Chap. 214 and Chap. 215). Acquired defects in cell-mediated immunity often lead to herpesvirus reactivation (i.e., a latent to lytic switch) and recurrent or chronic disease. Interestingly, decreasing or stopping immunosuppressive drug therapy can improve or prevent recurrent herpesvirus-associated disease. Recurrent HSV-1, HSV-2, and VZV infections occur commonly in cancer and posttransplant patients. [26], [27] As many as 70 to 80 percent of these persons will experience reactivation with at least one of these three viruses. Eczema herpeticum, which is HSV infection involving previously damaged skin, can occur in patients with less obvious immune dysfunction, including individuals with atopic or other forms of dermatitis, cutaneous T cell lymphoma, or burns. Typical recurrent mucocutaneous lesions are grouped (for HSV) or dermatomal (for VZV) vesicles and crusted erosions, although lesions are commonly atypical in morphology and distribution. For example, recurrent lesions due to HSV or VZV in immunosuppressed hosts may be isolated, nondermatomal, disseminated, necrotic, ulcerative, or verrucous (Fig. 119-6 and Fig. 119-7). In the mouth, chronic recurrent HSV infection can form white plaques and can be confused clinically with candidiasis. Severe pain often is associated with both skin and oral lesions, and postherpetic neuralgia (for VZV) occurs commonly. Protracted clinical courses of recurrent HSV or VZV infection are also more common in the setting of immunosuppression. In short, any painful, eroded lesion in an immunocompromised patient, regardless of its distribution or age, should be evaluated for both HSV and VZV by Tzanck preparation, viral antigen detection by immunofluorescence, polymerase chain reaction (PCR), and viral culture. Importantly, systemic infection involving the lungs, central nervous system, liver, heart, and gastrointestinal tract may occur. Treatment with systemic acyclovir or a related newer antiherpesvirus drug is always necessary, whereas prophylactic treatment to prevent recurrent episodes should be considered for individual patients if warranted. Foscarnet is the drug of choice for acyclovir-resistant viruses.

FIGURE 119-6 Severe chronic herpes simplex 2 infection in a patient receiving long-term high-dose glucocorticoids for autoimmune disease.

FIGURE 119-7 Severe recurrent varicella-zoster virus infection in a child with acute lymphocytic leukemia.

Reactivation and recurrent disease associated with CMV (see also Chap. 216) are major causes of morbidity and mortality in patients with marked immunosuppression, occurring in up to one-third of transplant patients. [28] This is not as common in cancer patients. In patients with transplants, most disease is caused by reactivation of preexisting CMV, although CMV may be transmitted from donor to host via the transplanted organ. Cytomegalovirus retinitis, gastroenteritis, hepatitis, and pneumonitis are the most common clinical disease manifestations. Mucocutaneous lesions caused by CMV are indicative of systemic disease. [28] Oral ulcers caused by CMV are common, particularly on the lateral aspects of the tongue. However, skin involvement with CMV is unusual, the lesions are nonspecific, and it is difficult to prove that they actually are caused by the virus. Cytomegalovirus skin lesions have been described as ulcers, macules, papules, vesicles, petechiae, and purpura. [28] Painful punched-out perianal ulcers have been reported frequently and are probably the most specific type of skin lesion attributable to CMV infection. Tzanck preparation from the bases of ulcers may show multinucleated giant cells, and CMV-infected dermal endothelial cells may be seen in tissue sections by routine microscopy, appearing as large cells with intranuclear inclusions surrounded by clear halos (owl-eye nuclei). In addition, CMV can be cultured from infected skin. Ulcers containing both CMV and HSV also have been reported. The treatment of choice for systemic CMV disease is intravenous ganciclovir, although intravenous foscarnet, cidofovir, or CMV immunoglobulin also may be effective. Human herpesvirus 6 and HHV-7, herpesviruses most closely related to CMV, also can cause widespread multiorgan infection in immunosuppressed individuals. [29] Epstein-Barr virus and KSHV (see also Chap. 217) infections are distinguished from the other herpesviruses infections in that they are associated with malignancies in the setting of immunosuppression. Specifically, chronic reactivated EBV infection is associated with non-Hodgkin's lymphoma and other lymphoproliferative disorders, [30] whereas chronic KSHV infection is associated with Kaposi's sarcoma (discussed below), primary effusion lymphoma, and the plasmablastic variant of Castleman's disease. [29] In addition, reactivation of EBV within oral mucosal epithelial cells causes oral hairy leukoplakia in immunosuppressed individuals (see also Chap. 225). Between 10 and 15 percent of transplant patients have this disease. [11] Lesions appear as adherent, white, corrugated plaques on the lateral aspects of the tongue. By contrast, oral candidiasis, which clinically can appear similar to oral hairy leukoplakia, is removed easily by scraping. Histologically, there is hyperkeratosis and vacuolated suprabasal epithelial cells. Oral hairy leukoplakia may respond to topical podophyllin or high-dose acyclovir; however, it is usually asymptomatic and does not require treatment. Although it has been regarded as a poor prognostic indicator in HIV-infected individuals, the clinical significance of oral hairy leukoplakia in transplant patients is not known.

HUMAN PAPILLOMAVIRUSES (See Chap. 223) Warts caused by human papillomavirus (HPV) infection are a common problem in posttransplant patients and in others receiving long-term immunosuppressive drug therapy. [31] Cyclosporine-based regimens are associated with a higher prevalence of warts compared with immunosuppressed patients not taking cyclosporine. [32] In addition, the prevalence of warts increases with a longer duration of immune compromise, with up to 80 percent of individuals affected 5 years following transplant surgery. In this setting, lesions are numerous, persistent, and difficult to eradicate. The morphology of the lesions may be typical or atypical. The atypical lesions appear as scaly macules and plaques, occur more commonly in sun-exposed areas, and are associated with HPV types observed in patients with epidermodysplasia verruciformis, e.g., HPV types 5 and 8. Several recent studies have reported that systemic retinoids, i.e., isotretinoin or acitretin, can prevent or decrease wart formation and prevent a variety of premalignant and malignant cutaneous lesions in posttransplant patients. [33], [34], [35] and [36] In these patients, the association between HPV infection and cutaneous genital and nongenital squamous cell carcinoma is complex, as discussed below.

OTHER VIRAL INFECTIONS Molluscum contagiosum (see also Chap. 221) infection also can be a problem in individuals with non-HIV-associated immune deficiency. [37] In patients who have received organ transplants, however, molluscum lesions are not nearly as common as warts. Lesions typically manifest as numerous umbilicated papules that are difficult to eradicate in the setting of immunosuppression. Measles (see also Chap. 210), a paramyxovirus, can occur in immunocompromised patients and is associated with a very high mortality rate. [38] Specifically, individuals with defects in cell-mediated immunity, as opposed to those with humoral immune deficits, are particularly susceptible to severe infection. Patients may present without classic maculopapular lesions or with widespread and purpuric lesions. Secondary complications, including otitis media, pneumonia, and encephalitis, are common in this setting. Treatment may include intravenous ribavirin or immunoglobulin, as well as aggressive supportive care to prevent and treat secondary complications.

Bacterial Infections

***PSEUDOMONAS* (See Chap. 197)** Patients with neutropenia, cystic fibrosis, or extensive burns are particularly susceptible to systemic *Pseudomonas aeruginosa* infection. [2] Skin lesions occur in approximately 30 percent of individuals with *Pseudomonas* bacteremia. [8] Ecthyma gangrenosum is the most characteristic lesion, and classically, it appears as a painful erythematous nodule or plaque that rapidly develops a central pustule or hemorrhagic vesicle, followed by a central area of necrosis (Fig. 119-8). The groin, perianal area, and axillae are the most common locations for this condition. There may be one or many lesions. Usually, ecthyma gangrenosum is a manifestation of *Pseudomonas*

septicemia, although rarely it can represent a primary focus cutaneous infection. Other organisms are also capable of causing ecthyma gangrenosum–like lesions, including *Staphylococcus aureus, Aeromonas hydrophilia, Serratia marcescens, Aspergillus* spp., and Mucorales. Other cutaneous manifestations of *Pseudomonas* septicemia may present initially as grouped vesicles, cellulitis, subcutaneous nodules, petechiae, purpura, or folliculitis. All these types of lesions can progress to destructive ulcerative lesions more characteristic of ecthyma gangrenosum. Necrosis is secondary to underlying focal vasculitis, which can be observed on skin biopsy. Diagnosis is made by culture of the organism from skin or blood. The treatment of choice is an intravenous antipseudomonal penicillin combined with an aminoglycoside.

FIGURE 119-8 Early lesion of *Pseudomonas aeruginosa* sepsis (ecthyma gangrenosum) in a neutropenic cancer patient following chemotherapy.

NOCARDIOSIS (See Chap. 201) *Nocardia asteroides* is a filamentous rod found in soil that is a fairly common opportunistic pathogen. [39] Transplant recipients are particularly susceptible. The mean onset of infection in these patients is 9 months (although it can occur as early as 1 month) following transplantation. A history of local trauma or occupational exposure is elicited often in healthy individuals but usually is absent in immunosuppressed patients. The most common sites of infection are the lungs, central nervous system, and skin. Several types of skin lesions have been described, including abscesses with sinus tract formation, subcutaneous nodules with pustules (Fig. 119-9), mycetoma, sporotrichoid nodules, and cellulitis. [40] Cutaneous nocardiosis may represent primary skin infection or foci of infection in 30 percent of patients with disseminated disease. Thus a diagnosis of cutaneous nocardiosis always requires a search for systemic infection. Diagnosis is based on demonstration of gram-positive, partially acid-fast, branching bacilli in tissue or tissue exudate or is based on tissue culture, although it often takes several weeks for organisms to grow. The treatment of choice is trimethoprim-sulfamethoxazole; numerous other antibiotics have been reported to be efficacious as well. Transplant patients may require long-term prophylactic therapy to prevent recurrent disease. In addition, incision and drainage of cutaneous abscesses should be performed.

FIGURE 119-9 Nocardiosis in a man with glioblastoma.

MYCOBACTERIAL INFECTIONS (See Chap. 200) Atypical mycobacteria are ubiquitous organisms found in soil and water. The most common organisms in this group include *Mycobacterium marinum, M. chelonei, M. fortuitum, M. kansasii, M. haemophilum,* and *M. avium-intracellulare*. Postoperative patients, individuals with neutropenia or defects in cell-mediated immunity, and persons with interleukin-12 receptor or interferon-? receptor deficiency are prone to infection, particularly with non- *marinum* species. [41] Atypical mycobacterial infections in the skin are characterized by diverse morphologies, including reddish brown nodules and plaques (Fig. 119-10), abscesses (Fig. 119-11), and ulcers. [42] *M. avium-intracellulare* and *M. haemophilum* commonly cause disseminated infection that can involve the lungs, lymph nodes, liver, spleen, bone marrow, and skin. Organisms can be identified with special stains or by culture from affected skin. Specific antimycobacterial antibiotic treatment regimens are complex and depend on the mycobacterial species, sensitivity results, extent and severity of disease, and the presence or absence of underlying immune defects. [43]

FIGURE 119-10 Cutaneous *Mycobacterium avium-intracellulare infection in a child with an inherited interleukin 12 receptor deficiency*.

FIGURE 119-11 *Mycobacterium chelonei* in a patient receiving long-term high-dose glucocorticoid treatment.

M. tuberculosis infection is a common worldwide problem, especially in individuals with impaired immunity. For example,

individuals receiving high-dose glucocorticoids are prone to active pulmonary tuberculosis. Cutaneous tuberculosis is usually more common in the setting of immunosuppression. Specifically, scrofuloderma (tuberculous lymphadenitis with extension to overlying skin) and numerous cutaneous lesions of miliary tuberculosis may occur more commonly in patients with underlying immune defects. [44], [45]

BACILLARY ANGIOMATOSIS (See Chap. 198) Bacillary angiomatosis is caused by infection with the rickettsia-like organisms *Bartonella henselae* or *B. quintana* and usually occurs in immunocompromised hosts. [46] Cutaneous lesions appear as painful, dome-shaped vascular papules and nodules (resembling pyogenic granulomas). Disseminated infection may occur and involve the liver, spleen, bone marrow, and brain. Patients often have a istory of scratches or bites by cats, the natural reservoir for *B. henselae* and *B. quintana*. Diagnosis is made by demonstration of pleomorphic bacilli in tissue specimens with Warthin-Starry or silver stain. Preferred treatments include oral erythromycin or doxycycline.

***STAPHYLOCOCCUS* AND *STREPTOCOCCUS* (See Chap. 194 and Chap. 196)** Staphylococcal and streptococcal infections in posttransplant patients occur most commonly within 1 month of transplant surgery and are most commonly the result of poor aseptic surgical techniques or inadequate wound care. [47] Other immunocompromised hosts are prone to wound-associated cutaneous infections with common gram-positive organisms as well. Folliculitis, furunculosis, and cellulitis are additional manifestations of local staphylococcal or streptococcal infections. Importantly, cellulitis caused by *Streptococcus pyogenes, S. pneumoniae,* or *Staphylococcus aureus* may progress rapidly and cause necrotizing fasciitis in immunosuppressed patients (Fig. 119-12). Solid-organ recipients also may develop recurrent cellulitis of the elbow, a condition termed *transplant elbow,* that has been attributed to staphylococcal infection. Bone marrow transplant patients and other patients with neutropenia are prone to streptococcal bacteremia and may develop facial flushing, a widespread erythematous maculopapular eruption, and desquamation of the palms and soles. Staphylococcal scalded skin syndrome, which typically occurs in children (see Chap. 195), can occur in immunosuppressed adults. [48]

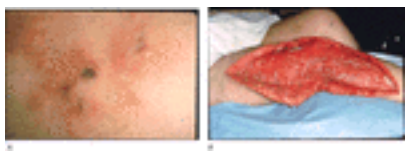

FIGURE 119-12 Early (*A*) and late (after surgical debridement, (*B*) lesions of necrotizing fasciitis caused by *Streptococcus pyogenes* in an intravenous drug abuser with underlying Job's syndrome.

NECROTIZING SOFT-TISSUE INFECTIONS Patients with neutropenia, diabetes, or peripheral vascular disease, as well as postoperative patients and intravenous drug users, are prone to cellulitis and necrotizing fasciitis. [49] Both aerobic and anaerobic bacteria have been implicated in these infections, most commonly *S. pyogenes, S. aureus, Clostridium perfringens, S. pneumoniae, Peptostreptococcus* spp., *Bacteroides fragilis,* and *Escherichia coli.* Patients present with rapidly evolving cellulitis and require aggressive surgical debridement and intravenous antibiotics to control spread of infection.

OTHER BACTERIAL INFECTIONS (See Chap. 197) Individuals with underlying complement deficiencies (loss of late phase components C5–C9) or alcoholism are susceptible to infection with *Neisseria meningitidis*. [50] Patients present with acute septicemia, meningitis, disseminated intravascular coagulation, and widespread petechiae and purpura (Fig. 119-13). Persons with underlying hepatic disease (commonly alcoholic cirrhosis or hemochromatosis) are prone to infection with *Vibrio vulnificus,* a gram-negative bacillus commonly found in seawater, shellfish, clams, and oysters. [51] Infection occurs by ingestion of contaminated seafood or by direct cutaneous inoculation after contact with contaminated seawater, and patients classically present with rapidly evolving septicemia and painful cellulitis, bullae, or ulcers on the lower extremities (Fig. 119-14). *Capnocytophaga canimorsus* is a commensal bacterium found in the saliva of dogs and cats that is transmitted to humans by bites or scratches. [52] Immunosuppressed hosts (postsplenectomy patients, alcoholics) are particularly susceptible to septicemia and widespread organ involvement. Skin lesions occur commonly and include macules, papules, purpura, and gangrene. In immunosuppressed patients, *Salmonella enteritidis* has been associated with cutaneous abscesses of the head and neck. [53]

FIGURE 119-13 Acute meningococcemia in a man with acquired complement deficiency.

FIGURE 119-14 *Vibrio vulnificus* infection in an alcoholic patient following minor trauma sustained while swimming in the ocean.

Parasitic Infections

NORWEGIAN SCABIES (See Chap. 238) Keratotic (or Norwegian) scabies infection typically occurs in the settings of mental deficiency, malnutrition, or immunosuppression. [54] Clinically, patients present with multiple, widespread, thick, gray or yellowish scaly plaques (Fig. 119-15), with numerous mites present within lesions. Unlike common scabies, pruritus may be minimal. Several courses of treatment with topical lindane or permethrin, as well as keratolytics, may be necessary to cure patients. Oral ivermectin is useful in these patients.

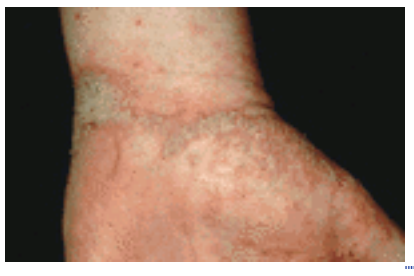

FIGURE 119-15 Norwegian scabies in a man with non-Hodgkin's lymphoma.

DEMODEX In immunosuppressed hosts, overgrowth of *Demodex* mites as well as abnormal immune responses triggered by *Demodex* mites may lead to rosacea-like disease [55] and eosinophilic folliculitis, [56] respectively. Topical permethrin, sometimes on a chronic basis, is required to treat these patients.

OTHER PARASITIC DISEASES (See Chap. 235 and Chap. 236) Individuals with defects in cell-mediated immunity are more likely to develop parasitic infections. [57] Cutaneous lesions of amebiasis include painful ulcers in the genital or perianal area (due to direct extension for intestinal foci of infection), urticaria, and pruritus. [58] Trypanosomiasis caused by *Trpanosoma cruzi,* or Chagas' disease, can lead to severe heart disease that requires cardiac transplantation. Paradoxically, immunosuppressive therapy required to maintain the transplanted heart may lead to reactivation of Chagas' disease. [59] Cutaneous lesions appear as subcutaneous nodules. In immunocompromised individuals, strongyloidiasis caused by *Strongyloides stercoralis* may be severe and cause pneumonia, severe gastrointestinal symptoms, urticaria, generalized pruritus, and larva currens (rapidly moving larvae under skin of covered areas). [60]

CANCERS

Nonmelanoma Skin Cancer (See also Chap. 80 and Chap. 81)

Individuals who have received a solid-organ transplant are at high risk for developing nonmelanoma skin cancers. [61], [62] The risk for developing skin cancer in other immunosuppressed populations is probably increased as well, but this group of individuals is not nearly as well studied. In posttransplant Caucasian patients, the incidence and prevalence of both squamous cell carcinomas and basal cell carcinomas are staggering, occurring in up to 40 and 70 percent of patients within 5 and 20 years following transplant surgery, respectively [63]; initial cancers usually occur within 2 to 3 years of surgery. [64] At a minimum, these numbers represent a 20-fold increase in nonmelanoma skin carcinoma incidence when compared with immunocompetent Caucasians. In addition, renal transplant patients have a 100-fold increase in anogenital carcinomas compared with the general population. [65] In skin, most studies show that squamous cell carcinomas occur more commonly than basal cell carcinomas (approximately 2:1 ratio). The incidence of other epidermal proliferative diseases is greatly increased as well, including actinic keratoses, keratoacanthomas, porokeratosis, and Bowen's disease.

The pathogenesis of nonmelanoma skin cancers in posttransplant patients is multifactorial and has been studied extensively. Sun exposure is probably the most important factor. Epidemiologically, patients with fair skin types, those living near the equator (e.g., Australians), and those with documented histories of significant sun exposure (e.g., farmers) are at highest risk. [64] In addition, mutations in the tumor suppressor gene *p*53 within nonmelanoma skin cancers from transplant patients suggest gene inactivation by ultraviolet light. [35], [66] The next most important factor in skin cancer development in immunosuppressed hosts is HPV infection. Clinically, squamous cell carcinomas have been reported to arise from common warts. Epidermodysplasia verruciformis–associated HPV (types 5, 8, and many others) also is detected commonly in tumors from these patients. [67] Although known oncogenic HPV (types 16, 18, 31, and 33) is not involved in cutaneous cancers in transplant patients, such types do contribute to the development of anogenital carcinomas in this population [65] (see Chap. 223). Genetically, certain HLA types (e.g., HLA-B27 or HLA-DR7) may predispose to development of nonmelanoma skin cancer. [68] Immunosuppressive drugs required for maintenance of solid-organ grafts also probably contribute to cancer development by impairing immune surveillance of tumor cells. In summary, cumulative effects of sunlight, HPV infection, genetics, and systemic immunosuppression contribute to the high incidence of skin cancer in posttransplant patients.

Squamous cell and basal cell carcinomas occur most commonly on sun-exposed areas of the body. Importantly, these cancers (especially squamous cell carcinomas) can be particularly aggressive. Local invasion, recurrence following primary treatment, and distant metastases are not uncommon. Fatalities caused by metastatic squamous cell carcinoma in immunocompromised patients also have been reported. Thus careful and regular examination of skin is required for all Caucasian posttransplant patients, with an emphasis on monitoring all potential premalignant lesions (e.g., actinic keratoses, porokeratosis) for morphologic changes. Recently, the use of topical or oral retinoids has been advocated in the prophylaxis of nonmelanoma skin cancers following transplantation surgery. Regular use of topical tretinoin, oral etretinate, and oral acitretin has been shown to decrease the incidence of both benign and malignant epidermal

diseases. [33], [34], [35] and [36]

Kaposi's Sarcoma (See also Chap. 104)

Kaposi's sarcoma (KS) is a multifocal inflammatory and proliferative disease that (in most cases) is probably not a true malignancy. It typically occurs in distinct populations, including patients receiving immunosuppressive therapy. [69] This form of KS is commonly called *iatrogenic KS.* Interestingly, Chang and Moore first identified KSHV in KS lesions from AIDS patients in 1994, [70] and subsequently, this virus was detected within tumor spindle cells of all clinical forms of KS. [71], [72] Although KSHV is now generally believed to be the etiologic agent for KS, exact mechanisms involved in KS pathogenesis remain unclear. [29]

KS accounts for approximately 0.5 percent of new neoplasms in organ transplant patients. Lesions appear soon after transplantation and more commonly in patients with liver transplants compared with those with renal transplants. In addition, individuals on cyclosporine-based immunosuppressive regimens are affected more commonly than individuals not taking cyclosporine. Because cyclosporine potently suppresses T cell function, this finding suggests that T cells are involved in normal immune surveillance and control of KS tumors. Epidemiologically, iatrogenic KS occurs more commonly in individuals of Mediterranean, Arabic, Jewish, and African descent compared with persons of northern European descent. [69] This pattern of clinical disease correlates with the incidence and distribution of KSHV seroprevalence, [29] again providing further evidence for a role of KSHV in the pathogenesis of KS.

Clinically, skin lesions of iatrogenic KS are identical to other forms of KS. Typically, early KS lesions are deep red to violaceous macules or patches. With time, lesions develop into papules, plaques, nodules, or tumors. Surface characteristics vary and may be smooth, crusted, necrotic, verrucous, or scaly. Significant edema may be associated with lower leg lesions. KS lesions are found most commonly on the lower legs and feet, although the groin and oral cavity are also common locations. In general, iatrogenic KS is a more aggressive disease than classic (Mediterranean type) KS but usually not as severe as cases of epidemic (HIV-associated) KS and endemic (African) KS. Systemic KS involvement can occur in up to 40 percent of cases in immunosuppressed individuals. The most common sites for internal disease include the lymph nodes, gastrointestinal tract, and lungs.

The first line of treatment for iatrogenic KS is to remove or decrease immunosuppressive therapy. This can lead to complete clearing of KS in up to 30 percent of patients. However, these patients remain at risk for developing KS at later times if immunosuppressive therapy is reinstituted. The decision to decrease or stop immunosuppressive drugs can be complex and should take into consideration the severity and extent of KS, as well as the importance of the immunosuppressive medications in maintaining overall health, e.g., in maintaining a potentially lifesaving transplanted organ. Otherwise, guidelines for KS therapy are no different from those for other forms of KS. Options include local excision or radiation, intralesional therapy, or systemic chemotherapy.

Other Cancers

The incidence of malignant melanoma and widespread atypical melanocytic nevi may be increased in transplant recipients and in other immunosuppressed patients. [73], [74] Most melanomas arise from precursor nevi in these patients. Fatal Merkel cell carcinoma has been reported in a renal transplant patient. [75] Oral mucosal leukoplakia and oral carcinoma also occur more commonly in immunocompromised individuals. [76] Lip lesions are particularly common, suggesting a pathogenic role for sunlight in lesion formation. Finally, cutaneous lesions secondary to non-Hodgkin's lymphoma or other lymphoproliferative processes may occur in the setting of iatrogenic immunosuppression. [30] Disease is nearly always linked with EBV infection and is tightly controlled by the immune system; e.g., lesions may resolve following reductions in immunosuppressive drug therapy.

MISCELLANEOUS CONDITIONS

Acute neutrophilic febrile dermatosis (see Chap. 94), or Sweet's syndrome, has been reported in association with malignancies, especially acute myeloid leukemia [77], [78] (see also Chap. 184). Lesions can occur prior to the onset of both initial and recurrent leukemic episodes (Fig. 119-16). There is not a female preponderance with malignancy-associated Sweet's syndrome (as there is with idiopathic Sweet's syndrome). Pyoderma gangrenosum (see Chap. 98) has been associated with a wide variety of diseases, including individuals with underlying leukemia. [77], [78] Both Sweet's syndrome and pyoderma gangrenosum may represent manifestations of abnormal neutrophil function.

FIGURE 119-16 Sweet's syndrome in a man with new-onset acute myeloid leukemia.

Multiple dermatofibromas and multiple lesions of porokeratosis can occur in association with immunosuppressive therapy for autoimmune disease or in the posttransplant setting, although the reasons for this are unclear. [79] Pseudo–hairy leukoplakia is described as adherent, white, corrugated plaques on the lateral aspects of the tongue, [76] clinical features

that are identical to EBV-associated oral hairy leukoplakia, as described earlier. Histologic features of these two conditions are also identical. However, EBV and other known viruses cannot be detected in these lesions; thus the etiology is unknown. Although this condition has been reported in transplant patients, its clinical significance in these patients is unclear. [76] Trichomegaly of the eyelashes has been reported in AIDS patients, patients taking cyclosporine, and cancer patients [80] (Fig. 119-17). The etiology is unclear, but it appears to be a manifestation of severe underlying immunodeficiency.

FIGURE 119-17 Acquired trichomegaly of the eyelashes in a child with advanced rhabdomyosarcoma.

REFERENCES

1. Kavanaugh DY, Carbone DP: Immunologic dysfunction in cancer. *Hematol Oncol Clin North Am* **10**:927, 1996

2. Emmanouilides C, Glaspy J: Opportunistic infections in oncologic patients. *Hematol Oncol Clin North Am* **10**:841, 1996

3. Yocum DE: Cyclosporine, FK-506, rapamycin, and other immunomodulators. *Rheum Dis Clin North Am* **22**:133, 1996

4. Kontoyiannis DP, Rubin RH: Infection in the organ transplant recipient: an overview. *Infect Dis Clin North Am* **9**:811, 1995

5. Patel R, Paya CV: Infections in solid-organ transplant recipients. *Clin Microbiol Rev* **10**:86, 1997

6. Kurwa HA, Marks R: Protracted cutaneous disorders in association with low CD4+ lymphocyte counts. *Br J Dermatol* **133**:625, 1995

7. Wright WL, Wenzel RP: Nosocomial *Candida:* Epidemiology, transmission, and prevention. *Infect Dis Clin North Am* **11**:411, 1997

8. Bodey GP: Dermatologic manifestations of infections in neutropenic patients. *Infect Dis Clin* **8**:655, 1994

9. Wingard JR: Importance of *Candida* species other than *C. albicans* as pathogens in oncology patients. *Clin Infect Dis* **20**:115, 1995

10. Conant MA: Fungal infections in immunocompromised individuals. *Dermatol Clin* **14**:155, 1996

11. King GN et al: Prevalence and risk factors associated with leukoplakia, hairy leukoplakia, erythematous candidiasis and gingival hyperplasia in renal transplant recipients. *Oral Surg Oral Med Oral Pathol Radiol Endod* **78**:718, 1994

12. Isaac M: Cutaneous aspergillosis. *Dermatol Clin* **14**:137, 1996

13. Adam RD et al: Mucormycosis: Emerging prominence of cutaneous infections. *Clin Infect Dis* **19**:67, 1994

14. Boutati EI, Anaissie EJ: *Fusarium,* a significant emerging pathogen in patients with hematologic malignancy: Ten years' experience at a cancer center and implications for management. *Blood* **90**:999, 1997

15. Hajjeh RA, Blumberg HM: Bloodstream infection due to *Trichosporon beigelii* in a burn patient: Case report and review of therapy. *Clin Infect Dis* **20**:913, 1995

16. White MH, Armstrong D: Cryptococcosis. *Infect Dis Clin* **8**:383, 1994

17. Pema K et al: Disseminated cutaneous cryptococcosis: Comparison of clinical manifestations in the pre-AIDS and AIDS eras. *Arch Intern Med* **154**:1032, 1994

18. Bradsher RW: Histoplasmosis and blastomycosis. *Clin Infect Dis* **22**:S102, 1996

19. Stevens DA: Coccidioidomycosis. *N Engl J Med* **332**:1077, 1995

20. Duong TA: Infection due to *Penicillium marneffei,* an emerging pathogen: Review of 155 reported cases. *Clin Infect Dis* **23**:125, 1996

21. Berenguer J et al: Deep infections caused by *Scedosporium prolificans*: A report on 16 cases in Spain and a review of the literature. *Medicine* **76**:256, 1997

22. Machet L et al: Cutaneous alternariosis: Role of corticosteroid-induced cutaneous fragility. *Dermatology* **193**:342, 1996

23. Itin PH et al: Cutaneous manifestations of *Paecilomyces lilacinus* infection induced by a contaminated skin lotion in patients who are severely immunosuppressed. *J Am Acad Dermatol* **39**:401, 1998

24. Rinaldi MG: Phaeohyphomycosis. *Dermatol Clin* **14**:147, 1996

25. Assaf RR, Weil ML: The superficial mycoses. *Dermatol Clin* **14**:57, 1996

26. Whitley RJ et al: Herpes simplex viruses. *Clin Infect Dis* **26**:541, 1998

27. Cohen JI et al: Recent advances in varicella-zoster virus infection. *Ann Intern Med* **130**:922, 1999

28. Drago F et al: Cytomegalovirus infection in normal and immunocompromised humans: A review. *Dermatology* **200**:189, 2000

29. Blauvelt A: Skin diseases associated with human herpesvirus 6, 7, and 8 infection. *J Investig Dermatol Symp Proc* **6**:197, 2001

30. Nalesnik MA: Posttransplantation lymphoproliferative disorders (PTLD): Current perspectives. *Semin Thorac Cardiovasc Surg* **8**:139, 1996

31. Bouwes JNB, Berkhout RJ: HPV infections and immunosuppression. *Clin Dermatol* **15**:427, 1997

32. Barba A et al: Analysis of risk factors for cutaneous warts in renal transplant recipients. *Nephron* **77**:422, 1997

33. Rook AH et al: Beneficial effect of low-dose systemic retinoid in combination with topical tretinoin for the treatment and prophylaxis of premalignant and malignant skin lesions in renal transplant recipients. *Transplantation* **59**:714, 1995

34. Bavinck JN et al: Prevention of skin cancer and reduction of keratotic skin lesions during acitretin therapy in renal transplant recipients: A double-blind, placebo-controlled study. *J Clin Oncol* **13**:1933, 1995

35. Gibson GE et al: *p*53 tumor suppressor gene protein expression in premalignant and malignant skin lesions of kidney transplant recipients. *J Am Acad Dermatol* **36**:924, 1997

36. Yuan ZF et al: Use of acitretin for the skin complications in renal transplant recipients. *N Z Med J* **108**:255, 1995

37. Birthistle K, Carrington D: Molluscum contagiosum virus. *J Infect* **34**:21, 1997

38. Kaplan LJ et al: Severe measles in immunocompromised patients. *JAMA* **267**:1237, 1992

39. Lerner PI: Nocardiosis. *Clin Infect Dis* **22**:891, 1996

40. Warren NG: Actinomycosis, nocardiosis, and actinomycetoma. *Dermatol Clin* **14**:85, 1996

41. deJong R et al: Severe mycobacterial and *Salmonella* infections in interleukin-12 receptor-deficient patients. *Science* **280**:1435, 1998

42. Weitzul S et al: Nontuberculous mycobacterial infections of the skin. *Dermatol Clin* **18**:359, 2000

43. Tartaglione T: Treatment of nontuberculous mycobacterial infections: Role of clarithromycin and azithromycin. *Clin Ther* **19**:626, 1997

44. Kawabata E et al: Bilateral inguinal scrofuloderma during steroid therapy in a patient with bullous pemphigoid. *J Dermatol* **22**:582, 1995

45. Libraty DH, Byrd TF: Cutaneous miliary tuberculosis in the AIDS era: Case report and review. *Clin Infect Dis* **23**:706, 1996

46. Spach DH, Koehler JE: *Bartonella*-associated infections. *Infect Dis Clin* **12**:137, 1998

47. Donnelly JP: Bacterial complications of transplantation: diagnosis and treatment. *J Antimicrob Chemother* **36**:59, 1995

48. Strauss G et al: Staphylococcal scalded skin syndrome in a liver transplant patient. *Liver Transplant Surg* **3**:435, 1997

49. Stone DR, Gorbach SL: Necrotizing fasciitis: The changing spectrum. *Dermatol Clin* **15**:213, 1997

50. Salzman MB, Rubin LG: Meningococcemia. *Infect Dis Clin* **10**:709, 1996

51. Kumamoto KS, Vukich DJ: Clinical infections of *Vibrio vulnificus*: A case report and review of the literature. *J Emerg Med* **16**:61, 1998

52. Lion C et al: *Capnocytophaga canimorsus* infections in humans: Review of the literature and cases report. *Eur J Epidemiol* **12**:521, 1996

53. Ray J et al: A rare case of *Salmonella* neck abscess. *J Laryngol Otol* **111**:489, 1997

54. Orkin M: Scabies: What's new? *Curr Probl Dermatol* **22**:105, 1995

55. Ivy SP et al: Demodicidosis in childhood acute lymphoblastic leukemia: An opportunistic infection occurring with immunosuppression. *J Pediatr* **127**:751, 1995

56. Evans TRJ et al: Eosinophilic folliculitis occurring after bone marrow autograft in a patient with non-Hodgkin's lymphoma. *Cancer* **73**:2512, 1994

57. Ambroise-Thomas P: Parasitic diseases and immunodeficiencies. *Parasitology* **122**:S65, 2001

58. Marshall MM et al: Waterborne protozoan pathogens. *Clin Microbiol Rev* **10**:67, 1997

59. Tomimori-Yamashita J et al: Cutaneous manifestation of Chagas' disease after heart transplantation: Successful treatment with allopurinol. *Br J Dermatol* **137**:626, 1997

60. Kramer MR et al: Disseminated strongyloidiasis in AIDS and non-AIDS immunocompromised hosts: Diagnosis by sputum and bronchoalveolar lavage. *South Med J* **83**:1226, 1990

61. Veness MJ et al: Aggressive cutaneous malignancies following cardiothoracic transplantation: The Australian experience. *Cancer* **85**:1758, 1999

62. Otley CC, Pittelkow MR: Skin cancer in liver transplant recipients. *Liver Transplant* **6**:253, 2000

63. Bouwes JNB et al: The risk of skin cancer in renal transplant recipients in Queensland, Australia: A follow-up study. *Transplantation* **61**:715, 1996

64. Espana A et al: Skin cancer in heart transplant recipients. *J Am Acad Dermatol* **32**:458, 1995

65. Wright TC, Sun XW: Anogenital papillomavirus infection and neoplasia in immunodeficient women. *Obstet Gynecol Clin North Am* **23**:861, 1996

66. McGregor JM et al: *p*53 mutations implicate sunlight in post-transplant skin cancer irrespective of human papillomavirus status. *Oncogene*

15:1737, 1997

67. Berkhout RJ et al: Nested PCR approach for detection and typing of epidermodysplasia verruciformis–associated human papillomavirus types in cutaneous cancers from renal transplant recipients. *J Clin Microbiol* **33**:690, 1995

68. Bouwes JNB et al: Relation between HLA antigens and skin cancer in renal transplant recipients in Queensland, Australia. *J Invest Dermatol* **108**:708, 1997

69. Gotti E, Remuzzi G: Post-transplant Kaposi's sarcoma. *J Am Soc Nephrol* **8**:130, 1997

70. Chang Y et al: Identification of herpesvirus-like DNA sequences in AIDS-associated Kaposi's sarcoma. *Science* **266**:1865, 1994

71. Moore PS, Chang Y: Detection of herpesvirus-like DNA sequences in Kaposi's sarcoma in patients with and those without HIV infection. *N Engl J Med* **332**:1181, 1995

72. Boshoff C et al: Kaposi's-sarcoma-associated herpesvirus in HIV-negative Kaposi's sarcoma. *Lancet* **345**:1043, 1995

73. Frezza EE et al: Non-lymphoid cancer after liver transplantation. *Hepatogastroenterology* **44**:1172, 1997

74. Richert S et al: Widespread eruptive dermal and atypical melanocytic nevi in association with chronic myelocytic leukemia: Case report and review of the literature. *J Am Acad Dermatol* **35**:326, 1996

75. Douds AC et al: Fatal Merkel-cell tumour (cutaneous neuroendocrine carcinoma) complicating renal transplantation. *Nephrol Dial Transplant* **10**:2346, 1995

76. Seymour RA et al: Oral lesions in organ transplant patients. *J Oral Pathol Med* **26**:297, 1997

77. Kurzrock R, Cohen PR: Mucocutaneous paraneoplastic manifestations of hematologic malignancies. *Am J Med* **99**:207, 1995

78. Huang W, McNeely MC: Neutrophilic tissue reactions. *Adv Dermatol* **13**:33, 1997

79. Herranz P et al: High incidence of porokeratosis in renal transplant recipients. *Br J Dermatol* **136**:176, 1997

80. Velez A et al: Acquired richomegaly and hypertrichosis in metastatic adenocarcinoma. *Clin Exp Dermatol* **20**:237, 1995

T>

Chapter 120

Donald Belsito

Allergic Contact Dermatitis

HISTORICAL ASPECTS
EPIDEMIOLOGY
Incidence and Prevalence of Disease
Age-Related Effects
Patterns of Exposure
Concomitant Disease
PATHOPHYSIOLOGY
The Allergens
Induction and Elicitation
Primary Sensitization
GENETIC FACTORS
Specific Allergens
Racial Differences
Gender
PREVENTION
Avoidance of Allergens
Induction Thresholds
CLINICAL MANIFESTATIONS
Physical Findings
A Geographic Approach
Systemic Manifestations
Noneczematous Variants of ACD
Allergic Contact Urticaria
LABORATORY FINDINGS
In Vivo Tests for ACD: The Patch Test
Relevance
False Positives and Negatives
In Vitro Tests for ACD
Computer Modeling
PATHOLOGY AND DIFFERENTIAL DIAGNOSES
Eczematous Dermatitis
Noneczematous Variants
TREATMENT
Allergic Contact Dermatitis
Allergic Contact Urticaria

REFERENCES

Allergic contact dermatitis (ACD) is one of the more frequent, vexing, and costly dermatologic problems. When the incidence of all occupationally related illness in the United States was last estimated, ACD accounted for 7 percent, at an annual cost of $250 million in lost productivity, medical care, and disability payments. [1] Given data suggesting that the actual annual incidence rate of ACD may be 10 to 50 times greater than reported in the US Bureau of Labor Statistics data, the total annual cost of occupational ACD alone may reach $1.25 billion. [1] It should be noted that these estimates were based on the assumption that 80 percent of occupational contact dermatitis (OCD) is irritant and 20 percent allergic. However, recent data from the United Kingdom [2] and the United States [3] suggest that the percentage of OCD due to allergy may be much higher, ranging between 50 and 60 percent, thus raising the economic impact of occupational ACD to greater than $3 billion annually. The additional costs of nonoccupational contact dermatitis are difficult to assess. In one study, nonoccupational ACD was found three times more frequently than occupational disease. [3] Furthermore, these estimates do not include the economic impact of retraining workers and “quality of life” issues.

HISTORICAL ASPECTS

Although ACD has probably plagued humans for millennia, the term *allergy* and its clinical recognition by patch testing are barely a century old. With the advent of experimental animal models for ACD in the 1920s, studies concerning its pathophysiology became possible. Despite all the clinical and scientific research since, a thorough understanding of the disease remains elusive.

EPIDEMIOLOGY

Incidence and Prevalence of Disease

The relatively few population-based studies assessing incidence and prevalence rates of ACD have primarily centered on specific allergens. Occupational data provide most of the available estimates. However, as previously noted, these data are subject to considerable underreporting. In one of the few population-based studies available, 86 (15.2 percent) of 567 randomly recruited adults had evidence of at least 1 allergic reaction to the 23 allergens tested. [4] Of note, more women (18.8 percent) were found to have contact allergies than men (11.5 percent) in this study. However, it must be understood that these numbers refer to the prevalence of ACD in the population (i.e., the number of individuals who have the capability to develop ACD when exposed to an allergen), and not to its incidence (i.e., number of individuals who

develop ACD over a defined period of time).

Age-Related Effects

Clinically, aged individuals have various defects in the induction and/or elicitation of ACD. [5] In studies on Rhus reactivity, younger (18 to 25 years) individuals had a quicker onset and a quicker resolution of the dermatitis than did older persons. [6] When sensitization rates to standard allergens were evaluated as a function of age, incidence rates dropped significantly in individuals older than 70 years. [6] For potent allergens such as dinitrochlorobenzene (DNCB), the effect of age on the induction of sensitization is more controversial. [7], [8] The precise reason for this age-related decline in contact sensitivity is unknown. Experiments in which contact-sensitized aged mice were reconstituted with naïve young T cells so that they subsequently demonstrated normal responses upon antigenic challenge suggest that a failure of T cell amplification signals and/or the generation of sufficient T effector cells may be the primary deficiencies in aged animals. [9]

The competency of T cell–mediated immune reactions in children is controversial. [5] It was believed that children rarely developed ACD because of an immature immune system. However, as suggested by Strauss [10] who was able to sensitize 35 of 48 infants (1 to 4 days old) to *Toxicodendron* oleoresin, the apparent hyporesponsiveness of children may be due to limited exposure and not to deficient immunity. Thus, documented allergic reactions are seen mostly in older pediatric patients and are secondary to topical medications, plants, nickel, fragrances, or shoe-related allergens. [5]

Patterns of Exposure

Allergen exposure, and, hence, the likelihood of sensitization, varies not only with age, but also with social customs, environmental factors, avocation, and occupation. Although most of the gender-related and geographic variations in ACD have been attributed to social and environmental factors, [5] avocation and occupation have more pronounced effects. Allergic reactions to thiurams (and other rubber constituents), topical medicaments (benzocaine and neomycin), and nickel are common among sports enthusiasts, who are frequently exposed to these materials. [11] Health care workers have high rates of sensitization to thiurams in gloves, while dental personnel and endoscopic technicians frequently react to glutaraldehyde, which is a rare allergen in the general population. [12] Finally, one must be constantly vigilant for the arrival of potentially new allergens into the environment. For example, the North American Contact Dermatitis Group recently added a number of amide anesthetics, once considered rare sensitizers, to its screening tray given the recent widespread use of topical anesthetic creams containing these agents.

Concomitant Disease

Impairment of cell-mediated immunity has been reported in certain diseases. In addition to the obvious disorders associated with immunologic deficiency, such as AIDS or severe combined immunodeficiency, diseases as diverse as lymphoma, sarcoidosis, lepromatous leprosy, and atopic dermatitis have been associated with diminished reactivity or anergy. However, while atopic individuals may be less-readily sensitized, the repeated application of topical preparations to their damaged skin can result in a significant incidence of ACD in this population. [13]

PATHOPHYSIOLOGY

The Allergens

Most environmental allergens are haptens, simple chemicals that must link to proteins to form a complete antigen before they can sensitize. These haptens are primarily small (= 500 kDa) electrophilic molecules that bind to carrier proteins via covalent bonds (Table 120-1). Although there are more than 3700 known environmental allergens, [15] not all electrophilic, protein-binding substances are haptens. The nature of the antigenic determinants, the type of binding that the hapten undergoes with the carrier, the final three-dimensional configuration of the conjugate, and a variety of unknown factors contribute to the antigenicity of a chemical. However, the importance of the carrier for the hapten cannot be underestimated because potent contact sensitizers, when complexed to nonimmunogenic carriers, can induce tolerance rather than sensitization. HLA-DR or class II antigens on the surface of the antigen-presenting Langerhans cells (LCs) act as the binding site (carrier) for contact allergens. The pathophysiologic basis of ACD, a type IV, cell-mediated, delayed hypersensitivity is reviewed in Chap. 23.

Allergen	No. of Patients Tested	Positive Reactions (%)	Positive Reactions Considered Relevant (%)
Nickel sulfate	3429	14.2	49.1
Neomycin sulfate	3436	13.1	46.2
Balsam of Peru	3439	11.8	82.9
Fragrance mix[†]	4095	11.7	86.9
Thimerosal	4087	10.9	16.8
Sodium gold thiosulfate	4101	9.5	40.6
Formaldehyde	3440	9.3	63.2
Quaternium-15	3436	9.0	88.7
Cobalt	4095	9.0	55.1
Bacitracin	4103	8.7	50.4
MDBGN/PE	4054	7.6	59.1
Carba mix[‡]	3437	7.3	71.7
ELMdF	4095	7.2	65.9
Thiuram mix[§]	3435	6.9	79.8
Para-phenylenediamine	3441	6.0	53.1
Propylene glycol	4095	3.8	82.8
Diazolidinyl urea	4095	3.7	91.5
Lanolin	3442	3.3	78.9
Imidazolidinyl urea	4094	3.2	91.7
2-Bromo-2-nitropropane-1,3,diol	4094	3.2	68.5
MCI/MI	4083	2.9	87.2
Potassium dichromate	3440	2.8	54.3
Ethylenediamine dihydrochloride	3439	2.6	23.9
DMDM hydantoin	4093	2.6	93.8
Glutaraldehyde	4094	2.6	68.1

[*]The population studied consisted of patients with suspected ACD referred for patch testing and is therefore not necessarily representative of the general population. ELMdF, dihydroacetamide/formaldehyde; MDBGN/PE, methyldibromoglutaronitrile/phenoxyethanol (Euxyl K400).
[†]Although formaldehyde releasers or potent nickel and sesquiterpene lactones in Compositae are frequent causes of ACD, they are not listed because they were not tested in this study.
[‡]Cinnamic alcohol 1%, cinnamic aldehyde 1%, hydroxycitronellal 1%, amylcinnamaldehyde 1%, geraniol 1%, eugenol 1%, isoeugenol 1%, coumarin alcohol 1%.
[§]1,3-Diphenylguanidine 1%, zinc dimethyldithiocarbamate 1%, zinc dibutyldithiocarbamate 1%.
[‖]Tetramethylthiuram disulfide 0.25%, tetramethylthiuram monosulfide 0.25%, tetraethylthiuram disulfide 0.25%, dipentamethylenethiuram disulfide 0.25%.
SOURCE: Data from Marks et al.[14]

TABLE 120-1 **The Twenty-five Most Frequent Allergens in the United States: 1996 to 1998*†**

Induction and Elicitation

In order for ACD to develop, a genetically susceptible individual must have biologically significant, and often repeated, contact with the allergen. As delineated by Friedmann [16] in his review of the dose/response induction of ACD to DNCB, “An apparently ineffective sensitizing stimulus is…registered immunologically…[and results in] enhanced subsequent responses to the same antigen.” This progressive subclinical induction of disease is consistent with the multitude of clinical observations that induction of allergy often takes months to years of exposure to low levels of the allergen. [17] Furthermore, a variety of endogenous and exogenous factors can influence both the induction and elicitation of allergic reactions (Table 120-2).

Endogenous	Exogenous
Application site	Vehicle
• State of stratum corneum	pH
• Follicular shunting	Exposure time
• Epidermal thickness	Exposure area
Immunologic state of the host	Occlusion
• Medications/disease states	Ambient temperature
• Sunlight exposure	Ambient humidity
• Concomitant exposure	Concomitant exposures

TABLE 120-2 **Endogenous and Exogenous Factors Affecting Thresholds for Allergic Contact Dermatitis**

The concentrations for inducing ACD are probably the same as those for eliciting the disease in “real life,” as opposed to the higher concentrations of allergen required to induce and elicit disease acutely in the laboratory. The point is reinforced by the data on incidence rates of occupational ACD, for example, to chromium in cement workers chronically exposed to low levels (10 to 50 ppm) of the sensitizing hexavalent form of this metal. [18] Because cement is diluted with water prior to use, chromium concentrations necessary for induction and elicitation of clinical disease in cement workers are significantly lower than the chromium concentrations typically used for inducing or eliciting the allergy by patch testing (2500 to 5000 ppm).

Primary Sensitization

The route of primary sensitization has a profound effect on the subsequent immunologic response. Tolerance induction has been reported after primary systemic injection or oral ingestion of allergens, and after primary epicutaneous application of allergens to areas deficient in HLA-DR–positive LCs. The exact mechanism by which tolerance ensues is controversial and partly depends on the route of exposure. In most instances, either induction of hapten-specific suppressor T cells or clonal deletion of the responding T cells seems responsible. Antibodies directed against the antigen recognition site of the T cell receptor (anti-idiotypic antibodies) may also play a role in tolerance. After tolerance is induced, it is long-lived and difficult to break. The mechanism(s) of tolerance induction is reviewed elsewhere. [19]

GENETIC FACTORS

Specific Allergens

Although animal studies show strain (presumably genetic) variation in cell-mediated immunity, the evidence for a genetic influence in humans is slight. Studies on the induction of ACD to DNCB and para-nitrosodimethylaniline (PNDA) suggest a genetic association. [20] However, attempts to correlate HLA haplotype with nickel sensitivity or other contact allergies have shown no association. Thus, definitive evidence of class II-related influences on ACD in humans has been meager, probably because of our diverse genetic pool and the limitations of technology.

Racial Differences

Whether African Americans develop significantly fewer reactions than do Caucasians to potent allergens such as DNCB, PNDA, or paraphenylenediamine (PPD) is controversial. [6] However, in the limited studies performed to date, the rate of sensitization to weaker allergens (e.g., nickel and neomycin) seem to be reduced in African Americans when compared to Caucasians. [6] This reduced rate of sensitization most likely relates to the greater compaction and lipid content in the stratum corneum of African American in contrast to white skin. This enhanced barrier function of African American skin, which is also thought to account for reduced rates of irritant contact dermatitis in this population, likely results in the observed differences in ACD, rather than any innate, genetically based, immunologic factors. [6]

Studies regarding ACD in other racial groups are very limited. In human “maximization tests” of cosmetic ingredients, Japanese individuals showed more severe allergic reactions than did Caucasians, although incidence rates for reactivity were the same. [21] Furthermore, Goh found no differences in the incidence of ACD among the indigenous (Malay, Chinese, and Indian) subpopulations in Singapore. [22] Additional studies evaluating racial influences on immunologic and nonimmunologic (e.g., barrier function) factors affecting ACD are needed.

Gender

The genetic effects of gender on ACD remain controversial because few studies have looked at induction of sensitization under similar circumstances in men and women. When the “human repeat insult patch testing” method was used to assess induction rates to 10 common allergens, women were found to be more often sensitized to 7 of the 10 allergens studied. [23] However, in “maximization studies” looking at allergens of different potencies, women reacted more frequently only to the weakest sensitizers. [24] Nonetheless, when challenged with the potent allergen DNCB, women had significantly more severe reactions at lower doses than did men. [25] Thus, female gender seems to correlate with higher rates of

sensitization and frequently more severe reactivity, at least for some allergens. Notwithstanding this, most gender differences in ACD seem to relate to cultural patterns and/or exposures in the workplace. [5]

PREVENTION

Avoidance of Allergens

In most cases, “prevention” of ACD has been through avoidance of allergen(s) once the individual has become sensitized. However, for some chemicals (such as the metals nickel and chromium), avoidance once sensitization has occurred does not necessarily result in symptomatic improvement. Burrows [18] found that more than 70 percent of chromium-sensitive workers in Northern Ireland had persistence of their skin disease for greater than 10 years. The persistence of ACD to metals, especially nickel and chrome, may partly be related to their trace levels in foods. Investigators have demonstrated that levels of nickel and/or chromium similar to those in foods are capable of eliciting allergic reactions in some sensitized individuals. [26]

Overall, the prognosis for occupationally acquired allergy is poor. In an Australian study of nearly 1000 workers with occupational skin disease, 54.7 percent had persistent problems, including many of the >40 percent who changed jobs. [27] Thus, allergen avoidance once sensitization occurs is inadequate prevention. Furthermore, advising workers with ACD to leave their current positions may not be the best advice, especially if a job change will result in a significantly negative economic impact.

Induction Thresholds

True prevention of ACD lies in the determination of thresholds for induction of disease. Armed with this information, products can be marketed and workplaces designed that contain allergens at levels below these thresholds. Led by Denmark, the European Economic Community (EEC) has restricted nickel content in metals that can contact the skin to = 0.5 µg nickel per cm^2 of skin per week. A decreased rate of nickel dermatitis has been noted. [28] Recently, some authors have argued for restrictions on chromium content in consumer products to =5 ppm to reduce rates of nonoccupational chromate dermatitis. [29] Already, many European countries add ferrous sulfate to cement to lessen the concentration of hexavalent chromium below the 10 to 50 ppm range, and hence reduce the sensitizing capacity of cements. As with nickel restriction, these occupational measures have significantly reduced the development of new cases of contact dermatitis to chromium in those countries where they have been instituted. Recently, European Economic Community (EEC) investigators have begun to focus on threshold induction levels for certain allergenic fragrances, such as isoeugenol.

In the US and EEC, labeling laws give the consumer access to the specific ingredients contained in cosmetics and over-the-counter/ prescription medicaments, but do not guarantee that these have been formulated to minimize sensitization by potential allergens. Although the safety of individual cosmetic ingredients is reviewed by the Cosmetic Ingredient Review's (CIR's) Expert Panel (Washington, DC), and although the panel has set limits on the use of specific ingredients based upon their ability to sensitize [e.g., parabens should not be used in products designed for use on damaged skin and the concentration of methylchloroisothiazolinone/methylisothiazolinone (MCI/MI) should be = 7.5 ppm in “leave on” products], the panel's findings are not binding upon manufacturers unless the US Food and Drug Administration (FDA) chooses to enforce its rulings. However, one might anticipate that manufacturers would not take the legal and/or financial risks of marketing a product that sensitizes a significant proportion of consumers, especially if the sensitizer has been restricted by CIR.

In workplaces in the US, individuals have less assurance regarding exposure to potential allergens. Although material safety data sheets (MSDS) should be available for materials handled occupationally, many times the contents are labeled proprietary. In addition, MSDS sheets do not need to list chemicals present in amounts <1 percent, unless they are carcinogenic. Unfortunately, many common sensitizers, such as biocides, are present at =1 percent. Even latex, the cause of life-threatening urticarial reactions in some individuals, is labeled on medical, but not nonmedical, products.

Currently, prevention requires postsensitization counseling and allergen avoidance. The success of such efforts after the diagnosis of ACD largely depends upon how rapidly the correct diagnosis is made. The longer the dermatitis persists before adequate treatment, the poorer the prognosis for complete resolution. Furthermore, patient education regarding allergen avoidance is crucial to improving outcome. In a study of 230 workers, [30] only one-third accurately recalled their diagnosis and treatment regimens and, among those workers who could not remember, persistent dermatitis was three times more likely.

CLINICAL MANIFESTATIONS

Physical Findings

The clinical appearance of ACD can vary depending on its location and duration. In most instances, acute eruptions are characterized by macular erythema and papules, vesicles, or bullae, depending on the intensity of the allergic response (Fig. 120-1). However, in acute ACD in certain areas of the body, such as the eyelids, penis, and scrotum, erythema and edema usually predominate rather than vesiculation. In contrast, chronic ACD of nearly all cutaneous sites presents as a lichenified, scaling, occasionally fissured dermatitis, with or without accompanying papulovesiculation (Fig. 120-2 and Fig. 120-3).

FIGURE 120-1 Acute dermatitis due to poison ivy. Note the linear arrangement of the lesions typical of phytodermatitis acquired by inadvertent contact with the plant. The severe vesiculobullous reaction is typical for urushiol, the pentadecylcatechol of *Toxicodendron* spp.

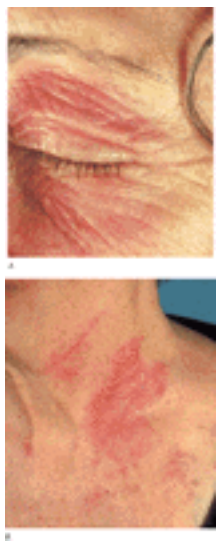

FIGURE 120-2 Chronic dermatitis of (*A*) the eyelids and (*B*) the neck, but not the hands, from an allergen in nail-care products. The patient was allergic to tosylamide/formaldehyde resin in her nail polish. Similar reactions caused by tosylamide/epoxy resin in nail polish, or to cyanoacrylate-containing nail glue and other acrylic products used about the nails, can be observed. The absence of an associated dermatitis of the fingers or hands is not unusual.

FIGURE 120-3 Chronic dermatitis of the hands. *A*. ACD involving the dorsal aspects of the hands and the distal forearms, but with minimal involvement of the palms, due to thiuram present in rubber gloves prescribed for treatment of an irritant hand dermatitis. *B*. ACD involving primarily the palms in a florist allergic to Tuliposide A, the allergen in *Alstroemeria* spp. Note the more prominent involvement of the dominant hand.

At its inception, ACD usually involves the cutaneous site of principal exposure. However, as it evolves, it can spread to other more distant sites either by inadvertent contact or, under certain circumstances, by autosensitization (see Chap. 121). Of note, the scalp, palms, and soles are relatively resistant to ACD; these areas may exhibit little pathology despite contact with an allergen that produces significant dermatitis in adjacent areas.

A Geographic Approach

While the failure of an eczematous dermatitis to respond to standard treatments may suggest the possibility of ACD, the shape and location(s) of the eruption provide the most important clues, especially to the causal allergen. ACD due to plants (e.g., poison ivy, poison oak, *Primula obconica,* and English ivy) is often characterized by linear lesions (Fig. 120-1). Aeroallergens, such as the sesquiterpene lactones in Compositae, involve the more exposed areas of skin with relative sparing of clothed areas (Fig. 120-4). In contrast, textile-related allergens (azoaniline dyes or urea formaldehyde resins) produce dermatitis of clothed areas with accentuation about the posterior neck, upper back, lateral thorax, waistband, flexor surfaces, and periaxillary areas with relative sparing of the axillary vault and undergarment areas. This

pattern of textile-related ACD points out the importance of such nonimmunologic factors as pressure, friction, heat, and perspiration on the ultimate clinical response.

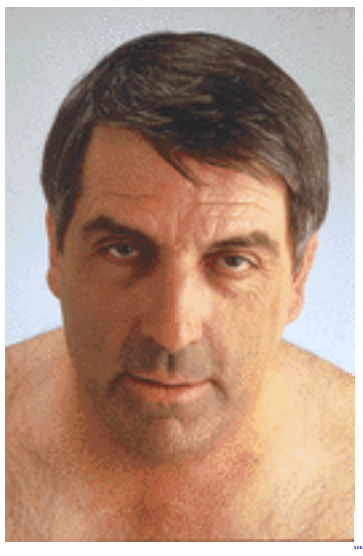

FIGURE 120-4 Airborne ACD to sesquiterpene lactones in ragweed (Ambrosia). This outdoorsman had annually developed increasingly more severe outbreaks of dermatitis about the face, neck, upper chest, and forearms beginning in late summer and lasting through the fall. The involvement of the submental area/upper neck and posterior auricular areas helps to differentiate airborne contact from photocontact. Although he reacted strongly to the crushed leaf and stem of native ragweed, he did not react to the commercially available sesquiterpene lactone mix. The failure to react to the commercial mix is not unusual and testing to the plant (as is) should be undertaken, if possible. Although some authors feel that ragweed dermatitis can be photo-accentuated, this was not the case for this patient.

A careful clinical assessment of the patient is required before any diagnostic tests to correctly identify causal allergens. Krasteva et al. [31] have published on the most frequently encountered causes of ACD in the major anatomic areas of the body. Summarized below is an overview of regional contact dermatitis.

HEAD AND NECK ACD of the head and neck can present particular difficulties in determining the causative allergen(s) because many substances could potentially be responsible. One must consider not only the components of facial cosmetics (vehicles, preservatives, emulsifiers, fragrances), airborne allergens (plant resins, fragrances), or photocontact allergens (see Chap. 136), but also grooming aids such as eyelash curlers (nickel, rubber) or make-up applicators (rubber). In addition, allergy to chemicals applied to the scalp, which has a greater resistance to ACD, may manifest itself on the face, ears, and neck while sparing the scalp (e.g., ACD from para-phenylenediamine in hair dyes). Finally, the hands can be an unwitting source of transmission of allergens to the face, ear, and neck, yet manifest no evidence of dermatitis themselves. Indeed, in women, a frequent cause of patchy ACD over the eyelids, face, and neck, but not the hands, are allergens in nail-care products (see Fig. 120-2).
HANDS Dermatitis of the hands, especially when chronic, is the bane of patients and practitioners alike. A history of atopy is frequently seen in many of these patients. In occupationally induced skin diseases, the hand is involved in one-third or more of cases. Among certain “wet work” occupations (health care, food handlers, cosmetologists, etc.), the number of cases of hand dermatitis is even higher. [1] The etiology of hand dermatitis is complex because multiple factors, in addition to atopy, contribute to its development. In some patients, an acute allergic or irritant contact dermatitis unmasks an endogenous disease (dyshidrosis, psoriasis, etc.) that otherwise might not have produced clinical symptoms. Not unusually, a secondary ACD of the hands will develop in a patient with an underlying, nonallergic hand dermatitis who begins using rubber gloves and/or topical creams and who becomes sensitized to a chemical in these products (see Fig. 120-3A). Significantly greater involvement of the finger webs and dorsa of the hands, rather than the palms, suggests ACD if the allergen contacts all areas of the hand equally (Fig. 120-3A). However, the floral worker who snaps the stems and leaves of Peruvian lilies (*Alstroemeria* spp.) with the palmar aspects of the dominant hand and fingers may present with dermatitis restricted primarily to these areas (Fig. 120-3B). When seeking an allergic cause for hand dermatitis, one must pay particular attention to those chemicals, listed in standard texts, [32], [33] that are encountered in the occupation(s) and hobbies of the patient. In addition, the many household and cosmetic products used must be identified.
FEET ACD of the feet is usually recognizable because, like the palms of the hands, the soles of the feet are relatively resistant to the manifestations of ACD. Thus, the typical picture is a dermatitis over the dorsal feet that is frequently accentuated over the joints of the toes. When the plantar aspects of the feet are involved, ACD typically spares the arch, toe creases, and webs. Nonetheless, despite a clinical picture suggesting allergy, the clinician must consider other diseases (psoriasis, dyshidrosis, juvenile plantar dermatosis, etc.), even when dermatitis is confined only to the feet. When allergic, the principal allergens are rubber accelerators (present in rubber-based liners and/or glues), isocyanates (present in foam rubber), *p*-tert-butylphenol formaldehyde resin (glue), or potassium dichromate (tanned leather) present in shoes. [34] Dyes (in either shoes or socks) are a rare cause of ACD of the feet. Because the range of potential allergens in shoes frequently goes beyond that in standard testing kits (e.g., dithiodimorphilone and isocyanates), [34] patch testing with materials taken from the shoe can be helpful. When testing with pieces of the shoe, the length of adhesion of the patch to the skin often must be exaggerated beyond 48 hours, perhaps as long 1 week. Before testing, it is important to rule out underlying fungal disease, because at least one investigator has transmitted dermatophyte infection with such patch testing (William P. Jordan, Jr., MD, personal communication). Finally, when evaluating dermatitis of the feet, it is important to note that many cases of secondary ACD develop in individuals applying topical antibiotics (neomycin/bacitracin) and/or topical steroids to an underlying nonallergic dermatitis. [34] As with hand dermatitis, the clinical picture can be confusing.
IATROGENIC Iatrogenic ACD must always be suspected when the primary dermatitis does not respond to usual therapies. A secondary ACD of the hands can develop in a patient with nonallergic hand dermatitis who uses rubber gloves to protect the hands (Fig. 120-3A). Iatrogenic contact dermatitis can also develop from the various topical preparations, including prescriptions, that patients apply. In a recent study, 9 of 70 (12.9 percent) individuals with

suspected ACD of the foot had iatrogenic disease secondary to topical steroids (1 of 9), topical antifungals (1 of 9), or topical antibiotics (7 of 9). [34] It can be particularly difficult to identify the allergic nature of iatrogenic ACD because the eczematous quality can be muted by the underlying disease for which the topical preparation was used.

MUCOSAL AND OTHER INTERNAL EXPOSURES ACD of the mucosa is rare. [20], [35] Patients allergic to flavorings such as cinnamic aldehyde in toothpastes or mouthwashes frequently present not with intraoral complaints but with a perioral dermatitis extending onto, but not past, the vermilion border of the lips. The unusual individual reacting to nickel, mercury, palladium, or gold in dental amalgams may present with a localized stomatitis and/or systemic contact dermatitis (see below). Given the widespread exposure of the oral mucosa to allergens, the scarcity of reports in the literature makes it obvious that patients only rarely react to allergens intraorally. Thus, one should be wary to ascribe cutaneous symptoms beyond the perioral area to contact with known intraoral allergens (e.g., a patient with scalp dermatitis, nickel allergy and dental amalgams containing nickel most likely has seborrhea or psoriasis and probably will not experience relief of the scalp disease following removal of the amalgams). The paucity of intraoral ACD has frequently been ascribed to the dilutional effects of saliva. Similarly, tearing of the eyes has been thought to explain why ACD to preservatives, such as thimerosal, in eye drops presents as pronounced erythema and edema of the eyelids with only mild injection of the conjunctiva. Although the dilutional effects of mucosal secretions in modifying ACD cannot be discounted, other unknown factors peculiar to mucosal surfaces are likely to account for the diminished responsiveness. The rectal mucosa, where chemicals are unlikely to be diluted or necessarily promptly swept away, is rarely involved in allergic reactions. ACD from medications and other materials administered per rectum presents as a perianal dermatitis and/or systemic contact dermatitis with little or no rectal pathology (Fig. 120-5).

FIGURE 120-5 Systemic contact dermatitis due to balsam of Peru. The patient had a history of chronic constipation and used a variety of suppositories. For 7 months she had been bothered by pruritus ani but only recently developed this generalized eruption unresponsive to glucocorticoids and light therapy. The multiple areas of excoriation are indicative of the intense pruritus. The rash was particularly severe about the anus and, for unknown reasons, about the lower torso, buttocks, and genital areas. Her dermatitis cleared when suppositories were discontinued and she was placed on a balsam-free diet. Colonoscopic examination revealed only minimal irritation of the sigmoid colon and rectum compatible with spastic colitis.

Although mucosal exposure to allergens infrequently causes symptoms, other internal exposures are even rarer causes of dermatitis. Given the frequency of nickel and cobalt sensitivity in the population, and given the large number of orthopedic implants performed worldwide, the very small number of reports linking dermatitis to intraarticular metals makes it unlikely, although not impossible, that the nickel or cobalt allergic individual with a dermatitis and an artificial joint is reacting to metals in the orthopedic appliance. The literature linking metals in cardiac pacemakers and other implantable devices to dermatitis is even scarcer than that for orthopedic appliances. In a recent controversial article that suggested an increased risk of cardiac stent stenosis in individuals with ACD to nickel and/or molybdenum, none of the 10 patients with metal allergies exhibited evidence of active dermatitis, although one had a history of metal intolerance. [36] Similarly, intramuscular administration of small amounts of an allergen is unlikely to generate a cutaneous reaction. For example, it has been shown that >90 percent of thimerosal-allergic individuals can be safely vaccinated intramuscularly with thimerosal-containing vaccines. The small percentage of reactors develop a dermatitis about the vaccination site, most likely secondary to accidental skin contamination. [37] Although not as well studied, the same is likely true for neomycin-sensitive individuals exposed to neomycin in vaccines.

Systemic Manifestations

Systemic contact dermatitis is an uncommon condition that highlights one of the poorly understood aspects of ACD: the potential for long-lasting immunologic memory in previously sensitized areas of skin. The phenomenon occurs in an individual who has been sensitized topically to an allergen and is subsequently exposed systemically. Although the clinical reaction is typically a dermatitis limited to the site of the original sensitization (recall reaction), a more pronounced eruption ranging from an extensive, bizarre-appearing dermatitis (Fig. 120-5) to erythroderma may rarely occur.

GENERALIZED DERMATITIS Generalized and/or bizarre patterns of dermatitis are not only caused by systemic exposures, but can also follow topical exposure to allergens that are ubiquitous in the environment. Nickel is a frequent offender as it is present not only in jewelry, but also in hair and eyelash curlers, hooks and buttons, eyelets of shoes, dental amalgams, some of our coinage, and a multitude of other products. [38] Indeed, nickel is also found in food and water and is believed by many Scandinavian dermatologists to cause recurrent, vesicular hand dermatitis (pompholyx) in some patients. Fortunately, most patients are aware of contact with metal-based products. This is not true of other common environmental allergens. Formaldehyde is not only ubiquitous but is frequently present in materials in which it is not suspected. Among these many products are insulating materials, rugs, paper products (including sanitary napkins and toilet tissue), and even smoke. [38] Many preservatives used in cosmetics, pharmaceuticals, and industry can release formaldehyde, such as 2-bromo-2-nitropropane-1,3-diol (Bronopol), quaternium-15 (Dowicil), DMDM hydantoin (Glydant), *tris*-(hydroxy-methyl)-nitro-methane (Tris Nitro), imidazolidinyl urea (Germal I), and diazolidinyl urea (Germal II). The urea formaldehyde resins used to impart color-fastness and wrinkle resistance to clothing can also release free formaldehyde. Thus, ACD to formaldehyde can present with a variety of clinical pictures, which can be confusing to the practitioner. Furthermore, although many wash-off products (e.g., shampoos and liquid soaps) are preserved with formaldehyde or its releasers, they are rarely problematic because the material is rapidly diluted and quickly rinsed off. Nonetheless, in areas where the product can be trapped (ear canals, under rings), or in the exquisitely formaldehyde-sensitive patient, such

wash-off products can cause ACD. Balsam of Peru or its cross-reacting allergens can, like formaldehyde, be present but unsuspected in a variety of products. The allergen is itself a mixture of many chemicals derived from wounding the bark of *Myroxolon pereirae,* a tree native to El Salvador. Approximately two-thirds of the native balsam consists of a volatile oil containing cinnamic acid, cinnamyl cinnamate, benzyl benzoate, benzoic acid, and benzyl alcohol, among other ingredients. The remaining one-third, which is thought to harbor the principal allergen, contains esterified polymers of coniferyl alcohol with benzoic acid and cinnamic acid. [38] Peruvian balsam is used as a “tacking” agent in cosmetics, topical medications, suppositories, and dental liquids/cements. Furthermore, as might be expected of a substance containing numerous constituent chemicals, balsam of Peru can cross-react with many other substances including benzoic acid, benzoin, benzyl alcohol, benzyl benzoate, cinnamic acid, cinnamon, clove, eugenol, and isoeugenol, among others. The balsam itself or, more typically, modified fractions are frequently used as fragrance and flavoring additives. In a recent publication, [39] 47 percent of balsam of Peru- and/or fragrance-allergic patients required dietary modification to control their dermatitis, while 18 percent of patients who failed to modify their diet had persistent disease and only 36 percent improved without some form of dietary modification. Thus, the patient allergic to balsam of Peru can present with a spectrum of clinical symptoms ranging from limited dermatitis at the site of application of a cosmetic product to a more generalized dermatitis bordering on erythroderma (see Fig. 120-5). Both natural and synthetic rubber are also ubiquitous. ACD to rubber products can therefore produce patchy dermatitis in various areas of the body. Among the sites most frequently involved are the face (make-up sponges), ear canals (ear plugs), periocular area (goggles), brassiere and/or waistline areas (elasticized undergarments), genital areas (condoms, diaphragms, pessaries), hands (gloves), feet (shoes), and/or joints (orthopedic braces). The allergens are typically either the accelerants (thiurams, carbamates, guanidines, and/or benzothiazoles) or the antioxidants (para-phenylenediamine derivatives) that are found in both natural and synthetic rubber. [38]

Noneczematous Variants of ACD

ACD need not be eczematous in appearance. [20] Noneczematous variants (Table 120-3) include lichenoid contact, erythema multiforme (EM), the cellulitic-like appearing dermal contact hypersensitivity, contact leukoderma, contact purpura, and erythema dyschromicum perstans, among others. Of these, the lichenoid and EM-like variants are seen most frequently.

TABLE 120-3 **Etiologic Factors in Noneczematous Allergic Contact Dermatitis**

Metals are the most likely cause of lichenoid allergic contact reactions, and have been linked to some cases of oral lichen planus. Many drugs can also cause a systemic lichenoid hypersensitivity, [20] the most notorious being the quinine derivatives, hydroxyurea, angiotensin-converting enzyme inhibitors, beta blockers, and antiepileptic agents. EM-like ACD is most frequently seen following contact with exotic woods, common plants, and topical medications. The other noneczematous variants of ACD are rare, most likely because they have many fewer causal agents. Of note, most cases of contact leukoderma are due to either postinflammatory hypopigmentation or direct chemical toxicity (e.g., hydroquinones, catechols, phenols, mercaptoamines). [40]

Allergic Contact Urticaria

As noted above, chemicals in rubber, especially those contained in black rubber mix, can cause a variety of noneczematous ACD, which includes not only those patterns delineated in Table 120-3, but also rarely plantar pustulosis, pitted keratolysis, and pyoderma gangrenosum. However, in addition to contact dermatitis, natural rubber latex (but not synthetic rubber) is responsible for a currently ongoing epidemic of allergic contact urticaria (ACU), an IgE-mediated phenomenon pathophysiologically distinct from the T cell–mediated ACD reactions discussed earlier in this chapter. Since 1979, when Nutter first called attention to ACU induced by latex, thousands of cases have been reported worldwide.

There are few good studies designed to look at the prevalence of immediate hypersensitivity to latex in the US. In 1996, Ownby et al. [41] evaluated 1000 volunteer blood donors in southeastern Michigan. They specifically targeted donors at mobile workplace sites and excluded all health facility sites. These authors found that, overall, 6.4 percent of their population was latex allergic. While this study revealed a remarkably high incidence rate of latex allergy in the general population, it may have underestimated the true rate because health care workers were specifically excluded, as were certain (but unknown) proportions of systemically medicated atopic patients. Both of these excluded populations have high incidence rates of latex urticaria. Among hospital workers most likely to be exposed to natural rubber latex gloves, the rate of latex ACU has been reported to range from a low of 5.5 percent [42] to as high as 38 percent. [43]

Atopic dermatitis predisposes to the development of ACU, as does mucosal xposure to latex. In one study, three of seven patients developed ACU following mucosal exposure. [44] In two of these individuals, anaphylactic reactions developed within minutes of contact. Thus, in addition to hospital personnel, paraplegics (especially patients with spina bifida), sexually active individuals exposed to latex condoms, and others with repeated mucosal exposure to latex must be considered high-risk groups for development of ACU. The failure to detect ACU to latex can have grave consequences in the allergic patient.

The presentation of ACU from latex is varied. For many patients, the symptoms are immediate burning, stinging, or itching with or without localized urticaria upon contact with latex. In some, symptoms include disseminated urticaria,

allergic rhinitis, asthma, and/or anaphylaxis. The respiratory symptoms are frequently a result of the latex allergen binding to, and being aerosolized by, glove powder. Patients with latex ACU may also present with an eczematous-appearing dermatitis. This clinical pattern is usually due to concomitant ACD to a rubber additive, which, in many cases, precedes the development of ACU. [44] However, some patients presenting with an eczematous pattern may have protein contact dermatitis, an IgE-mediated reaction to proteins (especially in foods) that clinically has the appearance of ACD.

In contrast to those with ACD from rubber gloves, many patients with ACU from latex gloves present with the palmar aspects of the hands as involved as, or more involved than, the dorsal surfaces. This may relate to the lipid composition of the palmar epidermis, which allows it to be more easily penetrated by the water-soluble protein allergens of latex. Urticarial reactions can occur to any combination of at least 10 different water-soluble proteins within latex (termed Hev b 1 through Hev b 10) rather than to just one, or a few, proteins. This makes the diagnosis very difficult. However, with cloning of these allergens (except Hev b 4) as recombinant proteins, more precise diagnostic tools may soon be available. [45]

Among the commercially available in vitro tests for IgE-mediated latex allergy, the CAP system, a solid-phase immunoassay (Kabi-Pharmacia, Uppsala, Sweden), seems to perform better than Ala STAT, the liquid-phase immunoassay (DPC, Los Angeles, California). For CAP, the sensitivity is 94 percent and the specificity is 82 percent; for Ala STAT, the sensitivity is 74 percent and the specificity is 92 percent. [46] Recently, an in-office serum dipstick method (Allergodip, Allergopharma, Reinbek, Germany) has been tested against the CAP assay and found to have nearly equivalent sensitivity and specificity. [47] However, the Allergodip is not yet FDA-approved. Furthermore, these in vitro tests do miss some individuals with ACU to latex. Therefore, in vivo prick and/or use testing are necessary if the in vitro tests are negative and ACU to latex remains a consideration.

When performing in vivo tests, one would ideally want the purified allergens extracted from natural latex; however, although cloned, these are not yet commercially available. Instead, one can leach out the responsible allergen(s) by soaking the rubber material in water at room temperature for 30 min. [48] In most, but not all, cases, use of such an eluate for prick testing is sufficient for detecting ACU. Whenever in vivo testing for latex is performed, the investigator must be aware of the potential for life-threatening anaphylactic reactions, especially in patients whose symptoms suggest prior systemic reactions to latex products. Such reactions may even follow prick testing.

LABORATORY FINDINGS

In Vivo Tests for ACD: The Patch Test

The only useful and reliable method for the diagnosis of ACD remains the patch test. Only 23 commercially prepared allergens are currently available in the United States (Table 120-4). A comparison of Table 120-1 with Table 120-4 makes it apparent that some, but not all, of the common allergens in the environment are contained on this tray. Therefore, given the fact that there are more than 3700 potential environmental allergens, practitioners interested in fully evaluating patients with ACD must be prepared to perform tests with other materials. For physicians compounding their own allergens, texts detailing appropriate concentrations and vehicles are available. [15]

TABLE 120-4 **Allergens Currently Available in the United States***

Relevance

As with any in vivo assay, patch testing is subject to pitfalls. A primary concern is that even when a chemical is found to be allergenic for a given patient, it cannot de facto be assumed to be the cause of ACD. As Table 120-1 shows, the relevance of presumably true-positive reactions to episodes of ACD ranges from as low as 16.8 percent for thimerosal to as high as 93.4 percent for DMDM hydantoin. This lack of relevance does not mean that patients are not allergic to the chemical in question, but rather that the specific allergen is not responsible for the current dermatitis. The temptation to “force” relevance for an irrelevant allergen can frustrate and disappoint the patient. This is particularly true for allergens that historically have low relevance, such as thimerosal. Many patients with positive patch tests to thimerosal have been asymptomatically sensitized by vaccines. [49]

To determine the relevance of a positive patch test requires correlation with the materials encountered by the involved areas of skin. Furthermore, even in some instances when patients are allergic to chemicals in products they are using, the allergen may be present in only minimal amounts and may not be responsible for the dermatitis. In this regard, “repeat open application testing” (ROAT), in which the patient applies the commercial product to normal skin several times daily for 1 to 2 weeks, can be helpful. With use of such provocative tests, members of the North American Contact Dermatitis Group (NACDG) found that 5 of 10 individuals who tested positive to MCI/MI at 100 ppm in water did not react

to a generic skin care lotion preserved with 15 ppm MCI/MI. [50] This is of particular note given the CIR's recommendation that MCI/MI not be used in “leave on” cosmetics above 7.5 ppm.

False Positives and Negatives

Physicians performing patch tests must also be concerned with the possibility of false-positive and false-negative reactions. False-positive reactions due either to the use of allergens at irritant concentrations or to the “excited skin syndrome” have received much attention in the literature. [51] In addition, metal allergens can produce irritant pustular reactions and cobalt is notorious for producing a “cayenne pepper” appearance to the skin, which represents deposition of cobalt in the pores and is not an allergic reaction. [35] The “false” nature of these reactions can usually be resolved by repeating the patch tests individually and/or in lower concentrations, or by ROAT. In contrast, false-negative reactions require high levels of suspicion and diligence to uncover.

One common and easily correctable cause of false-negative reactions is the failure to perform a second reading of the test sites after the initial 48-h inspection. This second reading, sometime between 3 and 7 days after application of the patches, is particularly important for elderly patients, who take longer o mount an allergic reaction. [8] A second reading is also important in detecting positive reactions to allergens such as neomycin, more than half of which are not evident until 96 h after application of the patch test. [52] False-negative reactions can also occur when the allergen is used in too low a concentration for patch testing, as can happen when cosmetic products are used as is. Therefore, if clinical suspicion warrants, and despite a negative patch test, additional testing such as ROAT with the suspect product can unmask the cause of ACD. In doing so, one must be aware of the “paraben paradox” and “lanolin paradox”: [53] neither chemical seems to be a potent allergen when applied to intact skin; however, when they are applied to dermatitic skin (e.g., stasis dermatitis), ACD may ensue.

With more than 3700 potential allergens, [15] negative reactions may simply indicate that the responsible chemical has not been tested. There is a particular problem in the US, where only 23 allergens have been FDA-approved (Table 120-4). Contrasting this table with Table 120-1 reveals that 40 percent of the 25 most common allergens in the US are not readily available for testing!

Although it has been widely quoted that 70 to 80 percent of patients with ACD can be diagnosed with use of screening trays such as the TRUE Test (Kabi Pharmacia Service A/S, Hillerød, Denmark), these numbers have recently been questioned. In an analysis of the 1994–1996 NACDG data on 3120 patients, [54] it was found that 62 percent had at least one positive reaction to an allergen present on the TRUE Test, of which 45 percent were relevant to the current dermatitis. However, by expanding the panel from 23 to 50 allergens, additional allergens of potential relevance were identified in 31 percent. In their study of 732 patients over 5.5 years, Cohen et al. [55] found that only 23 percent of patients reacted exclusively to allergen(s) on a similar (but not identical) standard series, 37 percent reacted to allergens on both the standard series and other supplementary tests, and 40 percent reacted only to supplementary allergens. Thus, to maximally benefit patients, practitioners must use allergens beyond those present on “standard” trays. In the case of fragrance allergens, Larsen et al. [56] found that the addition of a “natural mix” of 2% jasmine absolute, 2% ylang-ylang oil, 2% narcissus absolute, 2% sandalwood oil, and 2% spearmint oil increased the sensitivity of detecting fragrance allergy to 95 percent from the 81 percent detected by using only the “standard” allergens, fragrance mix and balsam of Peru.

In Vitro Tests for ACD

In vitro and animal tests for the diagnosis of ACD have received much attention in the past decade. Laboratory studies such as lymphocyte transformation or macrophage migration inhibition have been evaluated as measurements of ACD in both humans and animals. A major problem in developing in vitro systems is the lack of knowledge about what constitutes the antigenic moiety of a particular chemical. Nonetheless, these assays are now being extensively studied and reliably standardized. In a review of 209 chemicals, the accuracy of the local mouse lymph node assay (LLNA, a lymphocyte transformation test) versus all guinea pig tests (GPTs) was 86 percent and versus human data was 72 percent, whereas that of all GPTs versus human tests was 73 percent. [57] In terms of accuracy, sensitivity, specificity, and positive/negative predictability, the performance of the LLNA was similar to that of the GPT. Equally important, the performance of the LLNA and the GPT were similar when each was compared with human data.

In vitro predictive methodologies have been hampered by the lack of LC lines. Recent advances in culturing LC-like dendritic cells from CD34+ precursors under appropriate cytokine conditions and the development of stable LC-like cell lines should enhance the utility of in vitro methodologies. Based upon current data, a chemical that enhances CD86 expression and interleukin (IL)-1ß production, downregulates E-cadherin, causes endocytosis of surface major histocompatibility complex (MHC) class II, and induces tyrosine phosphorylation in LC cultures will likely be sensitizing. [57] However, given the variability in these assays among individuals, more work needs to be done in this area. Finally, studies are continuing in order to improve the predictive capabilities of LC/T cell cocultures and skin equivalent/reconstituted epidermal cultures. Thus, although in vivo patch testing, in which the skin can process the allergen for presentation, currently remains the “gold standard,” there are exciting prospects for in vitro testing in the future.

Computer Modeling

Quantitative structure–activity relationships (QSAR) represent a chemistry-based predictive approach that uses computer modeling. DEREK (“deductive estimation of risks from existing knowledge”) has been tested extensively for its ability to predict allergenicity. Based upon data from animal studies, DEREK uses a set of =50 rules describing chemical substructures responsible for sensitization. Although the predictive capabilities of DEREK are high (=80 percent), [58] further refinements in the scope of existing rules and the generation of new rules based on a chemical's biological activity

are needed to enhance its validity. Data derived from the LLNA should enhance the capabilities of QSAR.

PATHOLOGY AND DIFFERENTIAL DIAGNOSES

Eczematous Dermatitis

For most episodes of ACD, the end result of the exquisitely orchestrated interplay of cytokines and adhesion molecules is the entrance into the skin of T helper (T_H)-1 cells secreting IL-2 and interferon (IFN)-? (Chap. 23). IFN-? acts in a number of ways to amplify the immune response. [59] It activates cytotoxic T cells, natural killer (NK) cells, and macrophages. In addition, the induction of interferon-inducible protein 10 on keratinocytes adds to the recruitment of monocytes/macrophages, as does the IL-1- and tumor necrosis factor (TNF)-a–enhanced production of monocyte chemoattractant-1, monocyte chemotactic and activating factor, and macrophage inflammatory protein-2 by keratinocytes. This collection of monocytes/macrophages and proliferating T cells, along with their chemical mediators, is responsible for the epidermal spongiosis (intercellular edema) and superficial, perivascular, lymphohistiocytic dermal infiltrate that are the histologic hallmarks of ACD (Fig. 120-6). The clinicopathologic differential diagnoses include irritant contact, atopic, nummular, dyshidrotic, and autosensitization dermatitis.

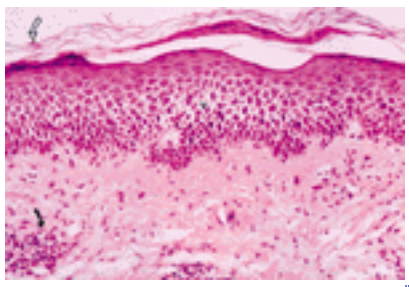

FIGURE 120-6 Histopathology of acute allergic contact dermatitis. The biopsy shows epidermal intercellular edema and microvesiculation (*v*), which are characteristic of an allergic response, as well as other eczematous dermatitides. The superficial perivascular infiltrate (*solid arrow*) consists of lymphocytes, macrophages, and, occasionally, eosinophils. The orthokeratotic stratum corneum (*open arrow*) is indicative of the acute nature of this eruption. In subacute to chronic allergic reactions, the stratum corneum is parakeratotic.

Noneczematous Variants

The pathologic findings of the noneczematous variants of ACD are nearly identical to the diseases they simulate. Lichenoid ACD does have some features that help to distinguish it from idiopathic lichen planus (Chap. 49), including a less-intense lichenoid infiltrate with more eosinophils and neutrophils, less epidermal hyperplasia with fewer necrotic keratinocytes, and some degree of epidermal spongiosis. [60] In contrast, EM-like ACD has no epidermal spongiosis and the findings are indistinguishable from other causes of EM (Chap. 58). Dermal contact hypersensitivity also lacks spongiosis, but has the characteristic lymphohistiocytic, perivascular infiltrate that often goes deeper in the dermis (mid-dermal) than eczematous ACD. [61] The histopathology of acute allergic contact leukoderma has not been studied. In the best-documented cases, [62] eczematous patch test reactions to PPD subsequently depigmented, at which time the biopsy was indistinguishable from chemically induced vitiligo (Chap. 90). Allergic contact purpura is pathologically similar to the eczematous variant of ACD, but with a capillaritis that results in extravasated red blood cells. [63] It is difficult to separate from the other pigmented purpuric dermatoses (Chap. 176).

In all of the noneczematous and eczematous variants of ACD, patch testing is the only means for accurate diagnosis. The history, physical examination, and/or pathology are not diagnostic. For example, it has been reported that 46 percent of patients with a clinically apparent nickel-induced dermatitis are, in fact, not allergic to nickel. [64]

TREATMENT

Allergic Contact Dermatitis

ALLERGEN AVOIDANCE The treatment of ACD lies in identifying its cause and thoroughly instructing the patient to avoid the responsible allergen(s). For certain allergens (e.g., vehicles, preservatives, stabilizers, and emulsifiers) found in topical preparations, it is important to impress upon patients the need to read labels. In addition, a recurrently updated, electronic database of ingredients in cosmetics and over-the-counter/prescription topical preparations (CARD: Contact Allergen Database) is available on the Internet (http://www.contactderm.org/) and allows practitioners to generate a unique list of topical preparations appropriate for the individual with specified allergies. Patients with allergies to preservatives must be aware that these materials can be found in any water-based formulation, such as latex paint. Furthermore, the name given a chemical used in a cosmetic or pharmaceutical product is frequently changed when it is used in a commercial product. For instance, the cosmetic preservative quaternium-15, when used in industry, is referred to as Dowicil 100 or Dowicil 200. Practitioners guiding patients through the synonymic jungle of these chemicals are advised to consult standard texts on the subject. [33], [38] Unfortunately for patients and physicians, the allergenic component of many materials will almost never be labeled. Rubber-, textile-, and metal-related allergens are but a few examples. In counseling patients with reactions to these materials, the physician must provide information about what kinds of products are likely to contain the allergen, as well as appropriate replacements. Such information can be found in standard texts. [33], [38], [65] Furthermore, some allergens are incompletely labeled. Given the proprietary nature of a fragrance's formulation, the individual fragrances that have been combined in the product are never listed. Patients with an allergic reaction to a fragrance should be advised to use fragrance-free materials, which include not only topical preparations but also a variety of other products such as toilet paper and sanitary napkins. [38], [65] It is important to realize

that products labeled “unscented” contain masking fragrances, although they are usually present in very low concentrations and do not cause problems. Because many allergens may share common antigenic moieties, the patient must be instructed not only about the known allergen, but also about possible cross-reacting allergens. For example, the individual allergic to benzocaine must be aware of the many potentially cross-reacting substances, which include agents as diverse as other anesthetics (e.g., procaine), certain medications (e.g., sulfonamides), hair dyes (e.g., para-phenylenediamine), textile dyes (e.g., aniline dyes), some sunscreens (e.g., para-aminobenzoic acid), and other products. [38] Because cross-reactions are not always evident to the nonchemist (e.g., benzoyl peroxide with cocaine), physicians must consult standard texts [38], [65] when instructing their patients.

SYMPTOMATIC THERAPY In addition to avoidance of further contact with the allergen and its cross-reactants, treatment of ACD should be directed to amelioration of symptoms. Acute vesicular, weeping eruptions benefit from drying agents such as topical aluminum sulfate/calcium acetate; chronic, lichenified eruptions are best treated with emollients. Pruritus can be controlled with topical antipruritics or oral antihistamines; topical antihistamines or anesthetics are best avoided because of the risk of inducing a secondary allergy in already dermatitic skin. Treatment with physicochemical agents that downregulate responsiveness may also be required. Glucocorticoids, macrolactams, and ultraviolet radiation are most widely used. A variety of other pharmacologic agents have been reported to interfere with the induction and/or elicitation of ACD in mouse models. [66] These include calcium channel blockers, amiloride, pentoxifylline, pentamidine, clonidine, spiperone, *N*-acetylcysteine, and flavonoids. Of these, only pentoxifylline has been evaluated in humans, where it was found to induce a slight reduction in responsiveness, perhaps by an effect on TNF-a. Whether the other pharmacologic agents exert any effect on the human response remains to be determined. Of note, with the possible exception of azelastine, [66] H_1-antihistamines do not affect the induction or elicitation of ACD. H_2-antihistamines enhance induction, but have no effect on elicitation. [67] Topical glucocorticoids or macrolactams (pimecrolimus or tacrolimus) usually suffice for treating most patients with ACD. However, individuals with involvement of greater than 25 percent of their body surface area and/or those exposed to certain allergens [such as *Toxicodendron (Rhus)* oleoresin, which may persist locally in the skin for weeks after exposure] may require treatment with systemic glucocorticoids. In those patients in whom systemic steroid therapy is inappropriate, phototherapy with UVB or PUVA can be beneficial. Individuals with occupational ACD who are economically unable to discontinue working with the offending allergen and who are also unable to work with gloves or effective barrier creams may also benefit from chronic maintenance therapy with UVB or PUVA. The advent of topical macrolactams, which do not cause cutaneous atrophy, are another option for these chronically exposed workers. In the future, inhibitors of cellular metabolic activity, inhibitors of cell adhesion molecules, targeted skin application of regulatory cytokines, and neutralization of proinflammatory cytokines with antisense oligonucleotides, anticytokine antibodies, or soluble cytokine receptors, may also be added to the therapeutic armamentarium.

PHYSICOCHEMICAL BARRIERS While prevention of ACD rests with avoidance of the allergen, for various reasons, principally economic, this is not always possible. Many chemicals, especially organic molecules, can rapidly penetrate vinyl and synthetic or natural latex rubber gloves, and exposed workers may be unable to avoid daily contact with the allergen. These individuals may benefit from a plastic glove made of a proprietary laminate (4H, North Safety Products, Cranston, Rhode Island). In clinical trials, the 4H glove, which is only 0.07 mm thick, was impervious to more than 90 percent of all randomly selected organic chemicals for 4 h at 35°C (95°F). [68] However, this glove is not form-fitting and is thought by many professionals to impede the fine dexterity needed in their work. In the future, barrier creams may be available to help such patients. Now, however, barrier creams are available for only a limited number of allergens (principally poison ivy and poison oak), are effective only if the protected area is washed within several hours of contact with the allergen, and are objectionable to many patients because of their thick tack and greasy consistency.

HYPOSENSITIZATION Although the possibility of hyposensitization for ACD has intrigued dermatologists for decades, it remains a nonviable alternative. Despite early encouraging work, Kligman [69] concluded that “complete desensitization of the highly sensitive subject by oral or intramuscular administration is impossible,” a statement later echoed by others. In these studies, months of treatment with *Toxicodendron* oleoresin resulted in a temporary lessening of the intensity, but not ablation, of the allergic response. Of the topical desensitization programs, only that for mechlorethamine hydrochloride (nitrogen mustard) has shown any success in a limited number of patients. [70] However, this success has been contested by others, as has the nature of the reaction (allergic or irritant) to mechlorethamine hydrochloride. [71]

TOLERANCE INDUCTION One theoretical possibility for prevention of occupational ACD is the induction of tolerance to known occupational allergen(s) before employment. When an antigen to which an individual has not yet been sensitized is administered either systemically or topically to areas deficient in functional LCs, long-lived tolerance rather than sensitization often ensues. However, because allergic reactions to otherwise apparently innocuous materials, such as nickel, persist in the human genotype, one must question on a Darwinian basis whether there is selective advantage to the trait. In the absence of information concerning the antigenic moieties of many simple chemicals and how they might relate to antigenically more complex viruses and malignancies, one cannot assume that simple chemical allergens do not cross-react with viral- or tumor-related antigens. At present, it is a matter of debate whether it is ethical to induce tolerance to even the most problematic environmental allergens given the theoretical risk of enhancing susceptibility to potentially more life-threatening diseases.

Allergic Contact Urticaria

The treatment of latex allergy, and other contact urticarial reactions, is straightforward: avoid the allergen. However, this can be difficult. Regarding latex, Yunginger et al. [72] have shown a 3000-time variation in allergen levels among gloves produced by different manufacturers. In general, nonsterile, examination gloves had significantly more latex than sterile surgical gloves. Powered gloves also had much higher latex levels because the glove powder tends to concentrate the allergen and because nonpowdered gloves are typically treated with chlorine (which reduces protein levels) during their manufacture. Among “hypoallergenic gloves,” 11 of 24 brands had significant levels of latex allergen; [72] this is because “hypoallergenic” refers to the absence of delayed-type hypersensitivity without concern for IgE-mediated urticaria.

Various methods exist to decrease the allergenicity of latex by removing residual protein. Those which have been shown to be most beneficial include: distilled water washing with or without agitation at 60°C (140°F), chlorination, 0.59 M ammonia, 0.28 M trichloroacetic acid, and steam autoclaving. [73] In contrast, methods such as wet-gel leaching, surface swabbing, autoclaving in dry air, and variations in vulcanization have produced clinically insignificant decreases in

protein levels. [73] The use of powder-free gloves also results in lower allergen levels, as described above. In countries such as Finland, where there has been a shift to low-protein natural latex products, there appears to be a decline in the incidence of new cases of ACU.

Given that there is no movement to label nonmedical latex, avoidance can be quite frustrating to the consumer. Fortunately, there is a significant amount of information on allergen alternatives available through the Internet. Table 120-5 lists some of the more valuable Internet sites for alternative materials and other information related to latex allergy. In addition to avoiding latex, it is important that latex-allergic individuals wear a medical alert tag and, depending upon their symptomatology, carry oral antihistamines and/or injectable epinephrine. If these individuals suffer respiratory symptoms, a search must be performed for potential airborne exposures. Finally, these patients need to be aware of the potential for cross-reactivity with the various foods that have been reported to be problematic for individuals with latex allergy (Table 120-6).

OSHA–General
http://www.osha-slc.gov/SLTC/latexallergy/index.html
Spina Bifida Association of America–Home and Hospital
http://www.sbaa.org/html/sbaa.latex.html
Alert, Inc.–Dental Products
http://www.execpc.com/~alert/dentprod.html
Elastic Inc.–Latex-Free Alternatives for the Home
http://www.latex-allergy.org/resources.html#when

TABLE 120-5 **Latex Alternative and Other Information**

Fruits	Banana,* kiwi,* avocado,* peach, mango, plum, cherry, papaya, fig, melon, apple, and pear
Vegetables	Tomato, celery, and potato
Nuts	Chestnuts, hazelnuts, and other tree nuts

*Most frequently reported cross-reacting food allergens.

TABLE 120-6 **Problematic Foods for Patients with Allergy to Latex**

REFERENCES

1. Burnett CA et al: Occupational dermatitis causing days away from work in US private industry, 1993. *Am J Ind Med* **34**:568, 1998

2. Meyer J et al: Occupational contact dermatitis in the UK: A surveillance report from EPIDERM and OPRA. *Occup Med* **50**:265, 2000

3. Kucenic MJ, Belsito DV: Occupational allergic contact dermatitis is more prevalent than irritant contact dermatitis: A five-year study. *J Am Acad Dermatol* **46**:695, 2002

4. Nielsen NH, Menne T: Allergic contact sensitization in an unselected Danish population. The Glostrup Allergy Study, Denmark. *Acta Derm Venereol* **72**:456, 1992

5. Kwangsukstith C, Maibach HI: Effect of age and sex on the induction and elicitation of allergic contact dermatitis. *Contact Dermatitis* **33**:289, 1995

6. Robinson MK: Population differences in skin structure and physiology and the susceptibility to irritant and allergic contact dermatitis: Implications for skin safety testing and risk assessment. *Contact Dermatitis* **41**:65, 1999

7. Schwartz M: Eczematous sensitization in various age groups. *J Allergy* **24**:143, 1952

8. Przybilla B et al: Evaluation of the immune status in vivo by the 2,4-dinitro-1-chlorobenzene contact allergy time (DNCB-CAT). *Dermatologica* **167**:1, 1983

9. Belsito DV, Possick LE: Age-related changes in allergic contact hypersensitivity: Functional T cell deficiencies are primarily responsible. *J Invest Dermatol* **90**:546, 1988

10. Strauss HW: Artificial sensitization of infants to poison ivy. *J Allergy* **2**:137, 1931

11. Ventura MT et al: Contact dermatitis in students practicing sports: Incidence of rubber sensitization. *Br J Sports Med* **35**:100, 2001

12. Shaffer MP, Belsito DV: Allergic contact dermatitis to glutaraldehyde in health-care workers. *Contact Dermatitis* **43**:150, 2000

13. Whitmore SE: Should atopic individuals be patch tested? *Dermatol Clin* **12**:491, 1994

14. Marks JG et al: North American Contact Dermatitis Group Patch Test Results, 1996–1998. *Arch Dermatol* **136**:272, 2000

15. de Groot AC: *Patch Testing: Test Concentrations and Vehicles for 3700 Allergens,* 2nd ed. Amsterdam, Elsevier, 1994

16. Friedman PS: The immunology of allergic contact dermatitis: The DNCB story. *Adv Dermatol* **5**:175, 1990

17. Wilkinson JD, Shaw S: Contact dermatitis: Allergic, in *Rook/Wilkinson/Ebling Textbook of Dermatology,* 6th ed, edited by RH Champion, JL Burton, DA Burns, and S.M. Breathnach. London, Blackwell Science, 1998, p 769

18. Burrows D: Adverse chromate reactions on the skin, in *Chromium: Metabolism and Toxicity,* edited by D. Burrows. Boca Raton, FL, CRC Press, 1983, p 137

19. Sosroseno W: A review of the mechanisms of oral tolerance and immunotherapy. *J R Soc Med* **88**:14, 1995

20. Belsito DV: The diagnostic evaluation, treatment, and prevention of allergic contact dermatitis in the new millennium. *J Allergy Clin Immunol* **105**:409, 2000

21. Rapaport MJ: Patch testing in Japanese subjects. *Contact Dermatitis* **11**:93, 1984

22. Goh CL: Prevalence of contact allergy by sex, race and age. *Contact Dermatitis* **14**:237, 1986

23. Jordan WP Jr, King SE: Delayed hypersensitivity in females. The development of allergic contact dermatitis in females during the comparison of two predictive patch tests. *Contact Dermatitis* **3**:19, 1977

24. Leyden JJ, Kligman AM: Allergic contact dermatitis: Sex differences. *Contact Dermatitis* **3**:333, 1977

25. Rees JL et al: Sex differences in susceptibility to development of contact hypersensitivity to initrochlorobenzene (DNCB). *Br J Dermatol* **120**:371, 1989

26. Sertoli A et al: Effetto della somministrazione orale de apteni in soggetti sensibilizzati affetti de eczema allergico de contatto. *Giorn It Derm Vener* **120**:212, 1985

27. Wall LM, Gebauer KA: A follow-up study of occupational skin disease in western Australia. *Contact Dermatitis* **24**:241, 1991

28. Liden C: Legislative and preventive measures related to contact dermatitis. *Contact Dermatitis* **44**:65, 2001

29. Basketter D et al: Investigation of the threshold for allergic reactivity to chromium. *Contact Dermatitis* **44**:70, 2001

30. Holness DL, Nethercott JR: Is a worker's understanding of their diagnosis an important determinant of outcome in occupational contact dermatitis? *Contact Dermatitis* **25**:296, 1991

31. Krasteva M, Nicolas JF: Eczéma de contact: Perspectives thérapeutiques. *Objectif Peau* **4**:442, 1996

32. Adams RM ed: *Occupational Skin Disease,* 3rd ed. Philadelphia, WB Saunders, 1999

33. Kanerva L et al: *Handbook of Occupational Dermatology*. Berlin, Springer-Verlag, 2000

34. Shackelford KE, Belsito DV: The etiology of foot dermatitis: A five-year retrospective study. *J Am Acad Dermatol* **47**:715, 2002

35. Storrs FJ: All the things I knew were true about contact dermatitis that aren't. *Cutis* **52**:301, 1993

36. Köster R et al: Nickel and molybdenum contact allergies in patients with coronary in-stent restenosis. *Lancet* **356**:1895, 2000

37. Audicana M et al: Allergic contact dermatitis from mercury antiseptics and derivatives. Study protocol of tolerance to intramuscular injections of thimerosal. *Am J Contact Dermatitis* **13**:3, 2002

38. Rietschel RL, Fowler JF Jr: *Fisher's Contact Dermatitis,* 5th ed. Philadelphia, Lippincott, Williams & Wilkins, 2001

39. Salam TN, Fowler JF Jr: Balsam-related systemic contact dermatitis. *J Am Acad Dermatol* **45**:377, 2001

40. Fisher AA: The differential diagnosis of contact chemical leukoderma. *Am J Contact Dermatitis* **8**:52, 1997

41. Ownby DR et al: The prevalence of anti-latex IgE antibodies in 1000 volunteer blood donors. *J Allergy Clin Immunol* **97**:1188, 1996

42. Kaczmarek RG et al: Prevalence of latex-specific IgE antibodies in hospital personnel. *Ann Allergy Asthma Immunol* **76**:51, 1996

43. Yassin MS et al: Latex allergy in hospital employees. *Ann Allergy* **72**:245, 1994

44. Belsito DV: Contact urticaria caused by rubber: An analysis of seven cases. *Dermatol Clin* **8**:61, 1990

45. Yip L et al: Skin prick test reactivity to recombinant latex allergens. *Int Arch Allergy Immunol* **121**:292, 2000

46. Grüber C et al: Is there a role for immunoblots in the diagnosis of latex allergy? Intermethod comparison of in vitro and in vivo IgE assays in spina bifida patients. *Allergy* **55**:476, 2000

47. Niggemann B, Wahn U: A new dipstick test (Allergodip) for in vitro diagnosis of latex allergy—Validation in patients with spina bifida. *Pediatr Allergy Immunol* **11**:56, 2000

48. Turjanmaa K et al: Comparison of diagnostic methods in latex surgical glove contact urticaria. *Contact Dermatitis* **19**:241, 1988

49. Suneja T, Belsito DV: Thimerosal in the detection of clinically relevant allergic contact reactions. *J Am Acad Dermatol* **45**:23, 2001

50. Marks JG Jr et al: Methylchloroisothiazolinone/methylisothiazolinone (Kathon CG) Biocide—United States multicenter study of human skin sensitization. *Am J Contact Dermatitis* **1**:157, 1990

51. Mitchell JC: Multiple concomitant positive patch test reactions. *Contact Dermatitis* **3**:315, 1975

52. Belsito DV et al: Reproducibility of patch tests: A US multicenter study. *Am J Contact Dermatitis* **3**:193, 1992

53. Wolf R: The lanolin paradox. *Dermatology* **192**:198, 1996

54. Marks JG Jr et al: North American Contact Dermatitis Group patch test results for the detection of delayed-type hypersensitivity to topical allergens. *J Am Acad Dermatol* **38**:911, 1998

55. Cohen DE et al: Utility of a standard allergen series alone in the evaluation of allergic contact dermatitis: A retrospective study of 732 patients. *J Am Acad Dermatol* **36**:914, 1997

56. Larsen W et al: A study of new fragrance mixtures. *Am J Contact Dermatitis* **9**:202, 1998

57. Ryan CA et al: Approaches for the development of cell-based in vitro methods for contact sensitization. *Toxicol In Vitro* **15**:43, 2001

58. Barratt MD, Langowski JJ: Validation and subsequent development of the DEREK skin sensitization rule base by analysis of the BgVV list of contact allergens. *J Chem Inf Comput Sci* **39**:294, 1999

59. Tau G, Rothman P: Biologic functions of the IFN-? receptors. *Allergy* **54**:1233, 1999

60. West AJ et al: A comparative histopathologic study of photodistributed and non-photodistributed lichenoid drug eruptions. *J Am Acad Dermatol* **23**:689, 1990

61. Hogan KP, Wyre HW: Dermal contact dermatitis to a disposable electrode plate. *Cutis* **27**:157, 1981

62. Taylor JS et al: Contact leukoderma associated with the use of hair colors. *Cutis* **52**:273, 1993

63. Calnan CD, Peachey RDG: Allergic contact purpura. *Clin Allergy* **1**:287, 1971

64. Kieffer M: Nickel sensitivity: Relationship between history and patch test reaction. *Contact Dermatitis* **5**:398, 1979

65. Guin JD: *Practical Contact Dermatitis*. New York, McGraw-Hill, 1995

66. Belsito DV: Patch-testing: After 100 years, still the gold standard in diagnosing cutaneous delayed-type hypersensitivity, in *Regulatory Control and Standardization of Allergenic Extracts: The Eighth International Paul-Ehrlich-Seminar,* edited by R Kurth YL Devries, and U Wagner. Stuttgart, Germany, Gustav Fischer, 1997, pp 195–202

67. Belsito DV et al: Cimetidine-induced augmentation of allergic contact hypersensitivity reactions in mice. *J Invest Dermatol* **94**:441, 1990

68. Henriksen HR et al: *Beskyttelsesklaeder mod Kemikalier, Oplosnings-parametre og Taethed*. Lyngby, Denmark, Instituttet for Kemiindustri, 1986

69. Kligman AM: Hyposensitization against *Rhus* dermatitis. *Arch Dermatol* **78**:47, 1958

70. Waldorf DS et al: Cutaneous hypersensitivity and desensitization to mechlorethamine in patients with mycosis fungoides lymphoma. *Ann Intern Med* **67**:282, 1967

71. Leshaw S et al: Failure to induce tolerance to mechlorethamine hydrochloride. *Arch Dermatol* **113**:1406, 1977

72. Yunginger JW et al: Extractable latex allergens and proteins in disposable medical gloves and other rubber products. *J Allergy Clin Immunol* **93**:836, 1994

73. Dalrymple SJ, Audley BG: Allergenic proteins in dipped products: Factors influencing extractable protein levels. *Rubber Develop* **45**:51, 1992

T>

Chapter 121

Donald Belsito

Autosensitization Dermatitis

CLINICAL MANIFESTATIONS
ETIOLOGY
HISTOPATHOLOGY
DIAGNOSIS AND TREATMENT

REFERENCES

CLINICAL MANIFESTATIONS

Autosensitization dermatitis refers to a phenomenon in which an acute dermatitis develops at cutaneous sites distant from an inflammatory focus and where the secondary acute dermatitis is not explained by the inciting cause of the primary inflammation. The term was coined in 1921 by Whitfield to describe reaction patterns ranging from a generalized, erythematous, morbilliform, and urticarial eruption following blunt trauma to a generalized, petechial, papulovesicular dermatitis after the acute irritation of chronic stasis dermatitis. [1] Over the next several decades, the cutaneous, vesicular "id" reactions associated with infections caused by tuberculosis, [2] dermatophytes, [3] and bacteria [4] were considered to be pathophysiologically equivalent phenomena. [5], [6] and [7] During this time, the concept that the process involves an urticarial component was dismissed, and the term was limited to a secondary papulovesicular eruption. [5], [6] and [7] In the more recent past, the precipitating factors for this phenomenon have been broadened to include the application of irritant or sensitizing chemicals [8] and ionizing radiation. [9] The "excited skin syndrome," [10] an entity well described by Mitchell, [11] could also be included under this rubric.

The classic presentation of autosensitization is that seen in patients with venous stasis disease [12] where, in the past, as many as 37 percent of patients have been reported to develop autosensitization. [13] Although still observed (Fig. 121-1), the incidence of autosensitization in stasis dermatitis is probably much lower today, given the dearth of reports in the current literature. Typically, 1 to 2 weeks after an acute inflammation of the lower leg, an extremely pruritic, symmetric, scattered, erythematous, eruption with macules, papules, and vesicles develops. The eruption involves the forearms, thighs, legs, trunk, face, hands, neck, and feet in descending order of frequency. [7], [13] The rash often persists and spreads until the underlying causative primary site of inflammation is treated. During the evolution of the dermatitis, its morphology may change in a manner consistent with the chronicity (i.e., vesicles to scale).

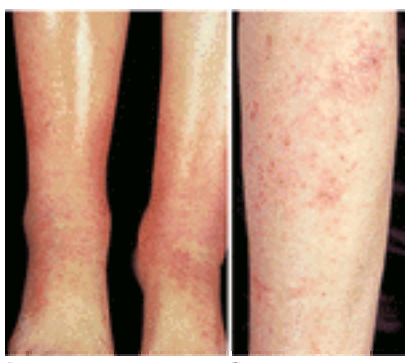

FIGURE 121-1 Stasis dermatitis with autosensitization. An elderly woman with a long-standing history of stasis dermatitis presented with gradual worsening of the edema; pruritus; and multiple, punctate, superficial, excoriated ulcers overlying the medial malleoli (*A*). Nine days after the ulcers appeared, she developed an acute, extremely pruritic, erythematous, papulovesicular eruption over the forearms (*B*), which progressively involved the upper arms, upper torso, and hands. The acute papulovesicular dermatitis also involved the lower extremities and can be noted overlying the chronic stasis dermatitis (*A*).

ETIOLOGY

Although the disease was originally thought to be due to autosensitization to epidermal antigens, [1] this concept has not been experimentally verified. In murine studies designed to determine whether keratinocyte-derived proteins can serve as antigenic carriers for hapten, Fehr et al. [14] derived major histocompatibility complex (MHC)-restricted, T cell receptor (TCR) a/ß, CD4+ T cell clones that proliferated in response to keratinocyte extracts unconjugated to hapten. In these studies, such autoreactive T cell clones could not be derived following treatment with irritants. These authors speculated that T cells autoreactive to keratinocyte antigens may be generated during the course of contact hypersensitivity and lead to the development of an "id" reaction. However, they could not exclude the possibility that the derived T cell clones were reacting to an inherently antigenic substance or a tumor antigen present on the keratinocytes (PAM 212, a line derived from a murine squamous cell carcinoma) used to sensitize the mice. Furthermore, they did not inject the mice with the putative autoreactive clones to determine whether a dermatitis similar to autosensitization could be induced. Finally, this model would not explain the development of id reactions following irritant contact dermatitis.

In the most extensive study to date, [12] only 4 of 81 patients with autosensitization dermatitis had serum antibodies

cytotoxic to autologous or homologous skin. However, the role of such autoantibodies in mediating the disorder, even in these four patients, must be interpreted cautiously, given the high frequency of epidermal autoantibodies in the normal adult population. [15] Unfortunately, this study was performed before the technology to evaluate autoreactive T cells was widely available.

One problem in defining the etiology of autosensitization is the lack of an accepted experimental model. In an experiment in which guinea pigs were injected with autologous skin, Wilhelmj et al. [16] reported cutaneous disease characterized by hair loss in 3 of 11 and dermatitis in 2 of 11 guinea pigs, but it was not clear whether these reactions were immunologic and, if so, what the causal allergen(s) was. Indeed, other investigators using similar techniques have been unable to induce cutaneous disease in animals by means of epidermal extracts. [17] These results in animals are in contrast to those in humans, where intradermal challenge with water-soluble extracts of autologous epidermal scale precipitated some form of reaction in 19 of 24 patients with active autosensitization. [18]

The term autosensitization may be a misnomer, and the disease could be due not to an allergy to one's own skin but to a conditioned hyperirritability of the skin induced by either immunologic or nonimmunologic stimuli. Thus, animal studies, in which acute skin irritation lowered the irritancy threshold to the same irritant chemical at remote sites, may be relevant. [19] In 2 percent of chronically irritated animals, antibodies to epidermis could be found; [20] this proportion is comparable to that reported for patients experiencing autosensitization [12] and enhances the validity of the model. Furthermore, states akin to autosensitization can be triggered in animals, as in humans, not only by irritant chemicals, but also by acute allergic dermatitis or chronic ulceration of the skin. [19] Although cytotoxic antibody to skin does not appear to be responsible, the factor(s) involved remains elusive.

In 1933, Turck proposed that hematogenous dissemination of “cytosts” released from inflamed tissues could induce damage in distant organs. [21] In 1939, Brown proposed that these “cytosts” might be responsible for autosensitization. [5] Currently, “cytosts” are more properly termed *cytokines*. Indeed, factors such as irritation, sensitization, infection, and wounding, which are known to precipitate autosensitization, have been reported to release a variety of epidermal cytokines. [22], [23] Once hematogenously disseminated in sufficient amounts, these cytokines could heighten the sensitivity of skin to a variety of nonspecific, but otherwise innocuous, stimuli, producing a pattern of “spillover” reactions [24] that have been classically termed *autosensitization*. Such an hypothesis would account for (1) the results in humans of delayed-type hypersensitivity testing with autologous epidermal scale, [18] (2) the histopathologic findings noted in the disease (see below), and (3) the activated T lymphocytes observed in the blood of one patient with autosensitization. [25] The characteristic distribution of the disease might perhaps be explained if the skin overlying the arms and legs was found to contain increased numbers of, or more avid receptors for, various cytokines than the skin of the face or hands. Such a geographic variation in the distribution of bullous pemphigoid antigen has been observed and hypothesized to account for the clinical patterns of this truly autoimmune disease. [26] Application of modern biotechnological tools should provide insight into the mysteries of autosensitization.

HISTOPATHOLOGY

The lesions of autosensitization are characterized by spongiotic epidermal vesicles associated with a superficial, perivascular lymphohistiocytic infiltrate, which may contain scattered eosinophils. [27] Immunophenotypic studies of skin from experimental models have revealed that most of the lymphohistiocytic cells are CD3+, that is, T lymphocytes. [24] Those T cells present in the epidermal vesicles are primarily CD8+ (cytotoxic/suppressor cells), whereas those in the dermal infiltrate are primarily CD4+ (helper cells). Consistent with earlier reports that cytotoxic antibodies could not be found in the majority of individuals with autosensitization, [12] deposition of antibody or complement in affected skin was not detected. Thus, the histopathologic findings in autosensitization are not pathognomonic, but can be seen in other conditions including allergic or irritant contact dermatitis, nummular dermatitis, and dyshidrosis. [27] In addition, vesicular dermatophytic infections can have a similar appearance, although the presence of hyphae in the stratum corneum helps to distinguish this entity. [27]

DIAGNOSIS AND TREATMENT

The diagnosis of autosensitization remains one of exclusion. As clinically indicated, patients with an underlying focus of inflammation who present with the acute onset of disseminated papulovesicular disease should be tested to exclude secondary allergic contact dermatitis and/or secondary bacterial, fungal, viral, or parasitic disease. After other potential underlying causes for the widespread dermatitis have been eliminated, treatment is best directed toward the inciting disease. Concomitantly, the frequently weeping, vesicular eruption of autosensitization benefits from drying agents such as aluminum sulfate and calcium acetate. Given the likely involvement of cytokines and inflammatory mediators sensitive to glucocorticoids [28] or macrolactams, [29], [30] systemic and/or topical treatment with glucocorticoids or macrolactams (cyclosporin A, tacrolimus, pimecrolimus) may be helpful. To prevent the secondary effects of excoriation, pruritus must be controlled with topical antipruritic agents or oral antihistamines. As in the case of treatment for allergic contact dermatitis (Chap. 120), one must remain alert to the possibility of inducing an allergy in existing dermatitic skin from such topical medicaments.

REFERENCES

1. Whitfield A: Lumelian lectures on some points in the aetiology of skin disease. *Lancet* **2**:122, 1921

2. Darier J: Des tuberculides cutanées. *Ann Dermatol Venereol* **7**:1431, 1896

3. Guth A: Uber lichenoide (Kleinpapulose, spinulost) Trichophytie. *Arch Dermatol Syphilis* **118**:856, 1914

4. Andrews GC et al: Recalcitrant pustular eruption of palms and soles. *Arch Dermatol* **29**:548, 1934

5. Brown WH: Some clinical manifestations of endogenous sensitization eruptions following local infection or injury. *Br J Dermatol* **51**:197, 1939

6. Hopkins HH, Burky EL: Cutaneous autosensitization: Role of staphylococci in chronic eczema of the hands. *Arch Dermatol* **49**:124, 1944

7. Smith SW: Eczema autolytica. *Br Med J* **1**:628, 1945

8. Bendl BS: Nummular eczema of stasis origin: The backbone of a morphologic pattern of diverse etiology. *Int J Dermatol* **18**:129, 1979

9. Roa WH et al: Generalized autosensitization to a localized eczematoid dermatitis induced by ionizing radiation. *J Am Acad Dermatol* **30**:489, 1994

10. Maibach HI: The E.S.S.—Excited skin syndrome (alias the "angry back"), in *New Trends in Allergy,* edited by J Ring, G Burg. New York, Springer, 1981, p 208

11. Mitchell JC: Multiple concomitant positive patch test reactions. *Contact Dermatitis* **3**:315, 1975

12. Parish WE et al: A study of auto-allergy in generalized eczema. *Br J Dermatol* **77**:479, 1965

13. Haxthausen H: Generalized "ids" ("autosensitization") in varicose eczema. *Acta Derm Venereol (Stockh)* **35**:271, 1955

14. Fehr BS et al: T cells reactive to keratinocyte antigens are generated during induction of contact hypersensitivity in mice. A model for autoeczematization in humans? *Am J Contact Dermat* **11**:145, 2000

15. Ackermann-Schopf C et al: Natural and acquired epidermal autoantibodies in man. *J Immunol* **112**:2063, 1974

16. Wilhelmj CM Jr et al: Production of hypersensitivity to skin of animals. *Arch Dermatol* **86**:161, 1962

17. Rosenthal SA et al: Failure to sensitize to autologous skin. *Proc Soc Exp Biol Med* **97**:279, 1958

18. Esplin BM, Cormia FE: Further studies in autoeczematization. *Arch Dermatol* **64**:31, 1951

19. Roper SS, Jones HE: An animal model for altering the irritability threshold of normal skin. *Contact Dermatitis* **13**:91, 1985

20. Parish WE: Autosensitization to skin, in *Progress in Biological Sciences in Relation to Dermatology,* edited by A Rook. Cambridge, England, Cambridge University Press, 1960, p 259

21. Turck FB: *The Action of the Living Cell*. London, Macmillan, 1933

22. Williams IR, Kupper TS: Immunity at the surface: Homeostatic mechanisms of the skin immune system. *Life Sci* **58**:1485, 1996

23. Uchi H et al: Cytokines and chemokines in the epidermis. *J Dermatol Sci* **24**(suppl 1):S29, 2000

24. Bruynzeel DP et al: Allergic reactions, "spillover" reactions, and T cell subsets. *Arch Dermatol Res* **275**:80, 1983

25. Cunningham MJ et al: Circulating activated (DR-positive) T lymphocytes in a patient with autoeczematization. *J Am Acad Dermatol* **14**:1039, 1986

26. Goldberg DJ et al: Bullous pemphigoid antibodies: Human skin as a substrate for indirect immunofluorescence assay. *Arch Dermatol* **121**:1137, 1985

27. Ackerman AB: *Histologic Diagnosis of Inflammatory Skin Disease: An Algorithmic Method Based on Pattern Analysis,* 2nd ed. Baltimore, MD, Williams & Wilkins, 1997

28. Almawi WY et al: Regulation of cytokine and cytokine receptor expression by glucocorticoids. *J Leukoc Biol* **60**:563, 1996

29. Paul C et al: Ascomycins: Promising agents for the treatment of inflammatory skin diseases. *Expert Opin Investig Drugs* **9**:69, 2000

30. Dumont FJ: FK506, an immunosuppressant targeting calcineurin function. *Curr Med Chem* **7**:731, 2000

T>

Chapter 122

Donald Leung Lawrence Eichenfield Mark Boguniewicz

Atopic Dermatitis (Atopic Eczema)

HISTORICAL ASPECTS
EPIDEMIOLOGY
ETIOLOGY AND PATHOGENESIS
The Systemic Response (Table 122-2)
Immunologic Triggers
Immune Response in AD Skin
Factors Controlling TH2 Cell Development
GENETICS
CLINICAL MANIFESTATIONS
Skin Reaction Patterns
Complications
LABORATORY FINDINGS
PATHOLOGY
DIAGNOSIS AND DIFFERENTIAL DIAGNOSIS
TREATMENT AND PROGNOSIS
Topical Therapy
Identification and Elimination of Triggering Factors
Pruritus
Tar Preparations
Phototherapy
Hospitalization
Phosphodiesterase Inhibitors
Systemic Therapy
Other Therapies
Prognosis

REFERENCES

Atopic dermatitis (AD) is a chronically relapsing skin disease that occurs most commonly during early infancy and childhood. It is frequently associated with elevated serum IgE levels and a personal or family history of AD, allergic rhinitis, and/or asthma. There is no single distinguishing feature of AD or a diagnostic laboratory test. Thus, the diagnosis is based on the constellation of clinical findings listed in Table 122-1.

Major features
- Pruritus
- Facial and extensor eczema in infants and children
- Flexural eczema in adults
- Chronic or relapsing dermatitis
- Personal or family history of atopic disease

Associated features
- Xerosis
- Cutaneous infections
- Nonspecific dermatitis of the hands or feet
- Ichthyosis, palmar hyperlinearity, keratosis pilaris
- Pityriasis alba
- Nipple eczema
- White dermatographism and delayed blanch response
- Anterior subcapsular cataracts, keratoconus
- Elevated serum IgE levels
- Positive immediate-type allergy skin tests
- Early age of onset
- Dennie-Morgan infraorbital folds, orbital darkening
- Facial erythema or pallor
- Perifollicular accentuation
- Course influenced by environmental and/or emotional factors

TABLE 122-1 **Clinical Features of Atopic Dermatitis**

HISTORICAL ASPECTS

This disorder was probably first reported by Robert Willan, [1] in 1808, as a *prurigo*-like condition. The term *disseminated neurodermatitis* was proposed by Brocq and Jacquet, in 1891, to emphasize that the disorder was emotionally based. In 1892, Besnier delineated the prurigo group of diseases and described the association of hay fever and asthma with AD. He suggested that these disorders tended to be familial and occurred in the constitutionally predisposed. Besnier also believed that pruritus played a primary role in the pathogenesis of AD and called the disorder *prurigo diathesique,* a term that was soon changed to Besnier's prurigo.

In 1923, Coca and associates [2] introduced the term *atopy* for [no(a)-place(top)-ness(y)] to describe some of the clinical manifestations of human hypersensitivity that characterized asthma and hay fever. Coca and Cooke later included patients with “the pruritic rash” in this group. In the 1930s, Sulzberger and associates [3] suggested the term *atopic dermatitis* to be used in place of disseminated neurodermatitis. The term AD has the advantage of connoting a close relationship among skin manifestations, asthma, and allergic rhinitis in patients with an atopic diathesis.

EPIDEMIOLOGY

Because there are no precise clinical definitions of AD, epidemiologic studies must be carefully interpreted as they can be plagued by problems of bias ascertainment. Despite these limitations, several well-designed studies suggest that

there has been at least a two- to threefold increase in the prevalence of AD during the past three decades (reviewed in Ref. [4]). Indeed, the most recent estimates indicate that AD is a major public health problem worldwide, with a prevalence in children of 10 to 20 percent in the United States, northern and western Europe, urban Africa, Japan, Australia, and other industrialized countries. [5] The prevalence of AD in adults is approximately 1 to 3 percent. Interestingly, the prevalence of AD is much lower in agricultural countries such as China and in eastern Europe, rural Africa, and Central Asia. There is also a female preponderance for AD, with an overall female/male ratio of 1.3:1.

The basis for this increased prevalence of AD is not well understood. However, wide variations in prevalence have been observed within countries inhabited by similar ethnic groups, suggesting that environmental factors are critical in determining disease expression. Some of the potential risk factors that have received attention as being associated with the rise in atopic disease include small family size, increased income and education both in whites and blacks, migration from rural to urban environments, and increased use of antibiotics, that is, the so-called Western lifestyle. [6] This has resulted in the "hygiene hypothesis," first proposed by Strachan, that allergic diseases might be prevented by "infection in early childhood transmitted by unhygienic contact with older siblings." [7] This hypothesis is supported by recent studies demonstrating that allergic responses are driven by T helper type (T_H) 2 immune responses whereas infections are induced by T_H1 immune responses. [8] T_H1 responses antagonize the development of T_H2 cells. Therefore, a decreased number of infections during early childhood could predispose to enhanced T_H2 allergic responses.

ETIOLOGY AND PATHOGENESIS

Complex interactions among genetic, environmental, skin barrier, pharmacologic, and immunologic factors contribute to the pathogenesis of AD. The development of new techniques for the study of naturally occurring and experimentally induced skin lesions have provided valuable new insights into the pathogenesis of AD. The concept that AD has an immunologic basis is supported by the observation that patients with primary T cell immunodeficiency disorders frequently have elevated serum IgE levels and eczematoid skin lesions indistinguishable from AD. In patients with Wiskott-Aldrich syndrome, clearing of the skin rash occurs following correction of their immunologic defect by successful bone marrow transplantation. [9] These data suggest that AD is not caused by a constitutive skin defect but is mediated by a bone marrow–derived cell(s).

The Systemic Response (Table 122-2)

Increased synthesis of IgE
Increased specific IgE to multiple allergens, including foods, aeroallergens, microorganisms, bacterial toxins, autoallergens
Increased expression of CD23 (low-affinity IgE receptor) on B cells and monocytes
Increased basophil histamine release
Impaired delayed-type hypersensitivity response
Eosinophilia
Increased secretion of IL-4, IL-5, and IL-13 by T_H2 cells
Decreased secretion of IFN-γ by T_H1 cells
Increased soluble IL-2 receptor levels
Elevated levels of monocyte CAMP-phosphodiesterase with increased IL-10 and prostaglandin-E_2

TABLE 122-2 **Systemic Immune Abnormalities in Atopic Dermatitis**

Most patients with AD have peripheral blood eosinophilia and increased serum IgE levels (reviewed in Ref. [10]). Nearly 80 percent of children with AD develop allergic rhinitis or asthma, suggesting that respiratory allergy and AD have a common systemic link. Because serum IgE levels are strongly associated with the prevalence of asthma, it suggests that allergen sensitization through the skin predisposes to respiratory disease due to its effects on the systemic allergic response (reviewed in Ref. [11]). Indeed, when mice are sensitized epicutaneously with protein antigen, it induces allergic dermatitis, elevated serum IgE, airway eosinophilia, and hyperresponsiveness to methacholine, suggesting that epicutaneous exposure to allergen in AD may enhance the development of allergic asthma. [12]

Peripheral blood mononuclear cells (PBMC) from AD patients have a decreased capacity to produce interferon-gamma (IFN-?). IFN-? generation ex vivo is inversely correlated with serum IgE concentrations in AD. There are also a number of studies demonstrating an increased frequency of allergen-specific T cells producing increased interleukin (IL)-4, IL-5, and IL-13, but little IFN-?, in the peripheral blood of patients with AD. [10] These immunologic alterations are important because IL-4 and IL-13 are the only cytokines that induce germ-line transcription at the Ce exon, thereby promoting isotype switching to IgE. IL-4 and IL-13 also induce the expression of vascular adhesion molecules such as vascular cell adhesion molecule (VCAM)-1 involved in eosinophil infiltration and downregulate T_H1 cell function. In contrast, IFN-? inhibits IgE synthesis as well as the proliferation of T_H2 cells and expression of the IL-4 receptor on T cells. Peripheral blood monocytes from AD patients are also activated, have an abnormally low incidence of spontaneous apoptosis, and are unresponsive to IL-4 induced apoptosis following stimulation. The likely cause of this inhibition of apoptosis is increased production of GM-CSF by circulating monocytes of AD patients. [13]

Immunologic Triggers

FOODS Well-controlled studies demonstrate that food allergens induce skin rashes in children with AD (reviewed in Ref. [14]). Based on double-blind, placebo-controlled food challenges, approximately 40 percent of infants and young children with moderate to severe AD have food allergy. Although the dermatology literature has frequently not supported a role for foods in AD, a study by Eigenmann et al. [15] reported that 37 percent of unselected children with moderate to severe AD followed at a university dermatology clinic had food allergy. Food allergies in AD patients may induce eczematous dermatitis in some patients, while in others urticarial reactions, contact urticaria, or other noncutaneous symptoms are elicited. In a study of 250 children with AD, Guillet and Guillet [16] found that increased severity of AD symptoms and younger age of patients was correlated directly with the presence of food allergy. Removal of food allergens from the

patient's diet can lead to significant clinical improvement but requires a great deal of education because most of the common allergens (e.g., egg, milk, wheat, soy, and peanut) contaminate many foods and are therefore difficult to avoid. [17] Laboratory studies support a role for food allergy in AD. Infants and young children with moderate to severe AD generally have positive immediate skin tests or serum IgE directed to various foods (even in the face of normal total serum IgE levels). Positive food challenges are accompanied by significant increases in plasma histamine levels and eosinophil activation. Children with AD who are chronically ingesting foods to which they are allergic have increased spontaneous basophil histamine release compared with children without food allergy. In mouse models of AD, oral sensitization with foods results in the elicitation of eczematous skin lesions on repeat oral food challenges. [18] In patients, however, immediate skin tests to specific allergens do not always indicate clinical sensitivity. Therefore, clinically relevant food allergy must be verified by controlled food challenges or carefully investigating the effects of a food elimination diet that is being done in the absence of other exacerbating factors. Importantly, food allergen-specific T cells have been cloned from the skin lesions of patients with AD. [19] In support of a role for food allergen-specific T cells in AD, patients with food-induced AD have been studied to analyze the relationship between tissue specificity of a clinical reaction to an allergen and expression of the skin homing receptor cutaneous lymphoid antigen (CLA) on T cells activated in vitro by the relevant allergen. [20] Casein-reactive T cells from patients with milk-induced eczema were found to have significantly higher levels of CLA than *Candida albicans*-reactive T cells from the same patients, casein- or *C. albicans*-reactive T cells from nonatopic controls, or noneczematous controls with milk-induced gastroenteropathy. Overall, these studies provide strong scientific evidence that foods can play a role in the pathogenesis of AD in young children. Most food allergic children, however, outgrow their food hypersensitivity in the first few years of life, so food allergy is not a common trigger factor in older patients with AD.

AEROALLERGENS Walker reported, in 1918, that several of his patients had exacerbation of AD following exposure to horse dander, timothy grass, or ragweed pollen. [21] In the 1950s, Tuft and co-workers reported that in patients with AD, pruritus and eczematoid skin lesions developed after intranasal inhalation challenge with either Alternaria or ragweed pollen, but not placebo. More recently, double-blind, placebo-controlled challenges have demonstrated that inhalation of house dust mites by bronchial challenge can result in new AD skin lesions and exacerbation of a previous skin rash. [22] Epicutaneous application of aeroallergens by patch test techniques on uninvolved atopic skin elicits eczematoid reactions in 30 to 50 percent of patients with AD (reviewed in Ref. [23]). Positive reactions have been observed to various aeroallergens, including dust mite, weeds, animal danders, and molds. In contrast, patients with respiratory allergy and healthy volunteers rarely have positive allergen patch tests. Several studies have examined whether avoidance of aeroallergens results in clinical improvement of AD. Most of these reports have involved uncontrolled trials in which patients were placed in mite-free environments, such as hospital rooms, through the use of acaricides or impermeable mattresses covers. Such methods have invariably led to improvement in AD. One double-blind, placebo-controlled study using a combination of effective mite-reduction measures, as compared to no treatment, in the home showed that a reduction in house dust mites is associated with significant improvement in AD. [24] Laboratory data supporting a role for inhalants include the finding of IgE antibody to specific inhalant allergens in most patients with AD. Indeed, a recent study found that 95 percent of sera from AD patients continued IgE to house dust mites as compared to 42 percent of asthmatic subjects. [25] The degree of sensitization to aeroallergens is directly associated with the severity of AD. [26] The isolation from AD skin lesions and allergen patch test sites of T cells that selectively respond to *Dermatophagoides pteronyssinus* and other aeroallergens provides further evidence that the immune response in AD skin can be elicited by aeroallergens. [23]

MICROBIAL PRODUCTS Patients with AD have an increased tendency to develop bacterial, viral, and fungal skin infections. Immune responses to the products of *Staphylococcus aureus* have provided insights into mechanisms underlying skin inflammation in AD. *S. aureus* is found in more than 90 percent of AD skin lesions. [10] In contrast, only 5 percent of normal subjects harbor this organism. The density of *S. aureus* on inflamed AD lesions without clinical superinfection can reach up to 10^7 colony-forming units per cm^2 on lesional skin. The importance of *S. aureus* is supported by the observation that even AD patients without overt infection show a greater reduction in severity of skin disease when treated with a combination of antistaphylococcal antibiotics and topical corticosteroids as compared to topical corticosteroids alone. [27] One strategy by which *S. aureus* exacerbates or maintains skin inflammation in AD is by secreting a group of toxins known to act as superantigens that stimulate marked activation of T cells and macrophages. The skin lesions of over half of AD patients contain *S. aureus* that secrete superantigens such as enterotoxins A and B, and toxic shock syndrome toxin-1. [28], [29] An analysis of the peripheral blood skin homing CLA^+ T cells from these patients, as well as T cells in their skin lesions, reveals that they have undergone a T cell receptor (TCR) Vß expansion consistent with superantigenic stimulation. [30], [31] Most AD patients make specific IgE antibodies directed against the staphylococcal superantigens found on their skin. [28], [29] Basophils from patients with IgE antibodies directed to superantigens release histamine on exposure to the relevant superantigen, but not in response to superantigens to which they have no specific IgE. [28] This raises the interesting possibility that superantigens induce specific IgE in AD patients and mast cell degranulation in vivo when the superantigens penetrate the disrupted epidermal barrier. This promotes the itch-scratch cycle critical to the evolution of skin rashes in AD. A correlation has also been found between the presence of IgE anti-superantigens and severity of AD. [29] Using a humanized murine model of skin inflammation, the combination of *S. aureus* superantigen plus allergen has been shown to have an additive effect in inducing skin inflammation. [32] Superantigens also augment allergen-specific IgE synthesis and induce corticosteroid resistance suggesting that several mechanisms exist by which superantigens could aggravate the severity of AD. [33], [34] Fulfilling Koch's postulates, application of the superantigen SEB to the skin can induce skin changes of erythema and induration accompanied by the infiltration of T cells that are selectively expanded in response to SEB. [35], [36] Furthermore, in a prospective study of patients recovering from toxic shock syndrome, it was found that 14 of 68 patients developed chronic eczematoid dermatitis, whereas no patients recovering from gram-negative sepsis developed eczema. [37] These investigators concluded that superantigens may induce an atopic process in the skin. It is therefore of interest that superantigens have been demonstrated to induce T cell expression of the skin homing receptor via stimulation of IL-12 production. [38] Aside from superantigens, staphylococci can produce other toxins that likely contribute to skin inflammation. [39] AD *S. aureus* isolates that do not secrete superantigenic toxins produce alpha-toxin. All staphylococcal strains also express staphylococcal protein A. There are significant differences in the action of these toxins on keratinocytes. Superantigenic toxins as well as protein A do not induce significant cytotoxic damage on keratinocytes but cause the delayed release of tumor necrosis factor (TNF)-a. In contrast, alpha-toxin induces profound keratinocyte cytotoxicity and immediate release

of TNF-a. Keratinocyte cytotoxicity induced by alpha-toxin demonstrates the morphologic and functional characteristics of necrosis, but not apoptosis. Increased binding of *S. aureus* to AD skin is likely related to underlying atopic skin inflammation. This concept is supported by several lines of investigation. First, it has been found that treatment with topical corticosteroids or tacrolimus will reduce *S. aureus* counts on atopic skin although they have no antibiotic actions. [40], [41] Second, acute inflammatory lesions have more *S. aureus* than chronic AD skin lesions or normal-looking atopic skin. Scratching likely enhances *S. aureus* binding by disturbing the skin barrier and exposing extracellular matrix molecules known to act as adhesins for *S. aureus,* for example, fibronectin and collagens. Finally, in studies of *S. aureus* binding to skin lesions of mice undergoing T_H1 versus T_H2 inflammatory responses, bacterial binding was significantly greater at skin sites with T_H2-mediated inflammation. [42] Importantly, this increased bacterial binding did not occur in IL-4 gene knockout mice, indicating that IL-4 plays a crucial role in the enhancement of *S. aureus* binding to skin. IL-4 appears to enhance *S. aureus* binding to the skin by inducing the synthesis of fibronectin, an important *S. aureus* adhesin. Interestingly in studies of human AD, a role for fibrinogen in the binding of *S. aureus* to atopic skin has been found. [43] Because acute exudative lesions likely have increased plasma-derived fibrinogen, this may provide a mechanism for further binding of *S. aureus* to acute AD lesions.

AUTOALLERGENS In the 1920s, several investigators reported that human skin dander could trigger immediate hypersensitivity reactions in the skin of patients with severe AD suggesting that they made IgE against autoantigens in the skin. [44] The potential molecular basis for these observations was recently demonstrated by Valenta et al. (reviewed in Ref. [45]) who reported that the majority of sera from patients with severe AD contain IgE antibodies directed against human proteins. One of these IgE-reactive autoantigens has been cloned from a human epithelial cDNA expression library and designated *Hom s 1,* which is a 55-kDa cytoplasmic protein in skin keratinocytes. [46] Such antibodies were not detected in patients with chronic urticaria, systemic lupus erythematosus (SLE), graft versus host disease (GVHD), or healthy controls. Although the autoallergens characterized to date have mainly been intracellular proteins, they have been detected in IgE immune complexes of AD sera, suggesting that release of these autoallergens from damaged tissues could trigger IgE- or T cell–mediated responses. These data suggest that while IgE immune responses are initiated by environmental allergens, allergic inflammation can be maintained by human endogenous antigens, particularly in severe AD.

Immune Response in AD Skin

ROLE OF CYTOKINES T_H2- and T_H1-type cytokines contribute to the pathogenesis of skin inflammation in AD. As compared with the skin of normal controls, unaffected skin of AD patients have an increased number of cells expressing IL-4 and IL-13, but not IL-5, IL-12, or IFN-?, mRNA. [47], [48] Acute and chronic skin lesions, when compared to normal skin or uninvolved skin of AD patients, have significantly greater numbers of cells that are positive for IL-4, IL-5, and IL-13 mRNA. However, acute AD does not contain significant numbers of IFN-? or IL-12 mRNA expressing cells. Chronic AD skin lesions have significantly fewer IL-4 and IL-13 mRNA-expressing cells, but increased numbers of IL-5, granulocyte-macrophage colony-stimulating factor (GM-CSF), IL-12, and IFN-? mRNA-expressing cells than does acute AD. Thus, acute T cell infiltration in AD is associated with a predominance of IL-4 and IL-13 expression, whereas maintenance of chronic inflammation is associated with increased IL-5, GM-CSF, IL-12, and IFN-? expression, and is accompanied by the infiltration of eosinophils and macrophages. The increased expression of IL-12 in chronic AD skin lesions is of interest as that cytokine plays a key role in T_H1 cell development and its expression in eosinophils and/or macrophages may initiate the switch to T_H1 or T_H0 cell development in chronic AD. This biphasic pattern of T cell activation has also been demonstrated after epicutaneous application of aeroallergens using patch-test techniques (reviewed in Ref. [49]). Twenty-four hours after allergen application to the skin, increased expression of IL-4 mRNA and protein is observed, after which IL-4 expression declines to baseline levels. In contrast, IFN-? mRNA expression is not detected in 24-h patch-test lesions, but is strongly expressed at the 48- to 72-h time points. Furthermore, T cell clones obtained from early time points of evolving allergen patch test sites secrete T_H2-type cytokines, whereas the majority of allergen-specific T cell clones derived from later patch-test sites (>48 h) exhibit a T_H1- or T_H0-type cytokine profile. Interestingly, the increased expression of IFN-? mRNA in atopic patch test lesions is preceded by a peak of IL-12 expression coinciding with the infiltration of macrophages and eosinophils. Activated T cells infiltrating the skin of AD patients have also been found to induce keratinocyte apoptosis contributing to the spongiotic process found in AD skin lesions. [50] This process is mediated by IFN-? released from activated T cells that upregulates Fas on keratinocytes. The lethal hit is delivered to keratinocytes by Fas-ligand expressed on the surface of T cells that invade the epidermis and soluble Fas-ligand released from T cells.

CHEMOATTRACTANT FACTORS IL-16, a chemoattractant for CD4+ T cells, is more highly expressed in acute than chronic AD skin lesions. [51] The C-C chemokines, RANTES (regulated on activation, normal T cell expressed and secreted), monocyte chemotactic protein-4, and eotaxin are also increased in AD skin lesions and likely contribute to the chemotaxis of eosinophils and T_H2 lymphocytes into the skin. [52], [53] Recent studies suggest a role for cutaneous T cell attractant chemokine (CTACK/CCL27) in the preferential attraction of CLA+ T cells to the skin. [54] The chemokine receptor CCR3, which is found on eosinophils and T_H2 lymphocytes and can mediate the action of eotaxin, RANTES, and MCP-4, has been reported to be increased in nonlesional and lesional skin of patients with AD. [53] Selective recruitment of CCR4 expressing T_H2 cells into AD skin may also be mediated by the chemokines MDC and TARC, which are increased in AD. [55]

PERSISTENT SKIN INFLAMMATION Chronic AD is linked to the prolonged survival of eosinophils and monocyte-macrophages in atopic skin. IL-5 expression during chronic AD likely plays a role in prolonging eosinophil survival and enhancement of their function. In chronic AD, the increased GM-CSF expression plays an important role in maintaining the survival and function of monocytes, Langerhans' cells and eosinophils. [13] Epidermal keratinocytes from AD patients express significantly higher levels of RANTES following stimulation with TNF-a and IFN-? than keratinocytes from psoriasis patients. [56] This may serve as one mechanism by which the TNF-a and IFN-? production during chronic AD enhances the chronicity and severity of eczema. Mechanical trauma can also induce the release of TNF-a and many other proinflammatory cytokines from epidermal keratinocytes. Thus, chronic scratching plays a role in the perpetuation and elicitation of skin inflammation in AD.

Factors Controlling T_H2 Cell Development

A number of determinants support T_H2 cell development early in the atopic skin process and provide opportunities for therapeutic intervention. These include the cytokine milieu in which T cell development is taking placing, the host's genetic propensity to produce T_H2-type cytokines, pharmacologic factors, the costimulatory signals used during T cell activation, the antigen-presenting cell, and skin barrier function (reviewed in Ref. [10]).

ROLE OF CYTOKINES IL-4 promotes T_H2 cell development, whereas IL-12, produced by macrophages, dendritic cells, or eosinophils, induces T_H1 cells. The IL-12 receptor (IL-12R) ß $_2$ subunit, which is the binding and signal transducing component of the IL-12R, is expressed on T_H1 but not T_H2 clones. Interestingly, IL-4 inhibits the expression of IL-12Rß $_2$ on T cells. In contrast, IL-12, IFN-a and IFN-? induce expression of the IL-12Rß $_2$ chain, thereby providing a basis by which these cytokines induce differentiation of T_H1 cells. IL-4 has also been demonstrated to inhibit IFN-? production and to downregulate the differentiation of T_H1 cells. Furthermore, mast cells and basophils also provide a source of T_H2-type cytokines that can be released upon cross-linking of their high affinity IgE receptor. Consequently, the increased systemic and local skin expression of IL-4 by T cells and mast cells/basophils in AD might promote T_H2 cell development.

PHARMACOLOGIC FACTORS Mononuclear cells from patients with AD have increased cyclic adenosine monophosphate (CAMP)-phosphodiesterase (PDE) enzyme activity. [57] This cellular abnormality contributes to the increased IgE synthesis by B cells and IL-4 production by T cells in AD as IgE and IL-4 production can be decreased in vitro by PDE inhibitors. The elevated CAMP PDE in atopic monocytes also contributes to the secretion of increased IL-10 and prostaglandin E_2. Both monocyte-derived IL-10 and PGE_2 inhibit IFN-? production by T cells and might contribute to the decreased IFN-? production by cultured AD PBMC. PDE inhibitors have also been found to reduce superantigen-induced, IL-12–dependent expression of the CLA skin homing receptor on T cells from patients with AD. [58]

COSTIMULATORY SIGNALS Complete activation of resting T cells requires costimulatory signals independent of the engagement of T cell receptors with the MHC plus peptide complex on antigen-presenting cells (APC). In mice, the generation of T_H2 cells depends on the interaction of CD28 with B7.2 (CD86). [59] The expression of B7.2 on B cells of AD patients is significantly higher than in normals or in patients with psoriasis. [60] In contrast, there was no significant difference in B7.1 (CD80) expression among the three subject groups. Importantly, total serum IgE from AD patients and normal subjects correlated significantly with B7.2 expression on B cells suggesting a role for B7.2+ B cells in IgE synthesis. Antihuman B7.2, but not B7.1, monoclonal antibody (MAb) significantly decreased IgE production by PBMC stimulated with IL-4 and anti-CD40 MAb. These data support the concept that B7.2 expression in AD promotes IgE synthesis. IL-4 and IL-13 also induce B7.2 expression on B cells, thereby providing an amplification loop for IgE synthesis in AD. Langerhans cells (LC) in the lesional skin of AD predominantly express B7.2 as compared to B7.1. [61] Furthermore, antibodies to B7.2 completely inhibited T cell proliferation stimulated with *D. pteronyssinus* (house dust mite antigen) in the presence of LC. These data suggest that CD86 expression on LC plays an important role as a costimulatory molecule for T cell activation and may account for the increased T_H2 responses that occur after repeated antigen presentation by LC.

ANTIGEN-PRESENTING CELLS AD skin contains an increased number of IgE-bearing LC that appear to play an important role in cutaneous allergen presentation to T_H2 cells (reviewed in Ref. [62]). In this regard, IgE bearing LC from AD skin lesions, but not LC which lack surface IgE, are capable of presenting house dust mite allergen to T cells. These results suggest that cell-bound IgE on LC facilitates capture and internalization of allergens into LC prior to their processing and antigen presentation to T cells. IgE-bearing LC that have captured allergen likely activate memory T_H2 cells in atopic skin but they may also migrate to the lymph nodes to stimulate naïve T cells there to further expand the pool of systemic T_H2 cells. Binding of IgE to LC occurs primarily via high affinity IgE receptors. The clinical importance of these IgE receptors on LC is supported by the observation that the presence of FceRI-expressing, LC-bearing IgE molecules is required to provoke eczematous skin lesions by application of aeroallergens on the skin of atopic patients. In contrast to mast cells and basophils, where the FceRI is a tetrameric structure constitutively expressed at high levels, this receptor on LC lacks the classical ß chain and its expression varies depending on the donor. Normal individuals and patients with respiratory allergy have low-level surface expression of FceRI on their LC, whereas FceRI is expressed at high levels in the inflammatory environment of AD. High-level FceRI expression not only enhances binding and uptake of allergens but the activation of LC upon receptor ligation. Surface expression of FceRI has been found to correlate with IgE serum levels. Furthermore, IL-4 strongly induces the cytoplasmic expression of the a chain of FceRI in dendritic cells and upregulates the expression of the skin homing structures, E-cadherin and CLA. In contrast, IFN-? inhibits FceRIa and E-cadherin expression.

DECREASED SKIN BARRIER FUNCTION AD skin has a marked decrease in barrier function associated with reduced ceramide levels and enhanced transepidermal water loss. [63] These epidermal changes likely contribute to increased antigen absorption into the skin. Because epicutaneous, as compared to systemic or airway, sensitization to allergen results in higher level T_H2 responses, decreased skin barrier function could lead to more vigorous systemic T_H2 responses, thereby acting as a sensitization site for allergic responses. [12], [64]

GENETICS

AD is familially transmitted with a strong maternal influence. Although many genes are likely to be involved in the development of allergic diseases, there has been particular interest in the potential role of chromosome 5q31-33 because it contains a clustered family of cytokine genes—IL-3, IL-4, IL-5, IL-13, and GM-CSF—which are expressed by T_H2 cells. [65] A case-control comparison has suggested a genotypic association between the T allele of the -590C/T polymorphism of the IL-4 gene promoter region with AD. Because the T allele is associated with increased IL-4 gene promoter activity when compared to the C allele, this suggests that genetic differences in transcriptional activity of the IL-4 gene influence AD predisposition. In addition, an association of AD with a gain-of-function mutation in the a subunit of the IL-4 receptor has been reported. These data support the concept that IL-4 gene expression plays a critical role in the expression of AD. A functional mutation in the promoter region of the C-C chemokine RANTES and an IL-13 coding region variant may

also be involved in the pathogenesis of AD. These candidate gene approaches have identified genes that suggest that AD has a common genetic basis with other atopic diseases.

A significant association between a specific polymorphism in the mast cell chymase gene and AD has been identified. It has no association with asthma or allergic rhinitis. This finding suggests that a genetic variant of mast cell chymase, which is a serine protease secreted by skin mast cells, may have organ-specific effects and contribute to the genetic susceptibility for AD. Two recent genome-wide linkage studies have also been performed to identify susceptibility loci for AD. A study by Lee et al. [66] suggested linkage for AD on chromosome 3q21, a region that encodes the costimulatory molecules CD80 and CD86. In contrast, Cookson et al. [67] reported linkage of AD to chromosome 1q21 and 17q25, identifying loci which closely coincide with regions linked to psoriasis. This suggests that AD is influenced by genes that modulate skin responses independent of allergic mechanisms.

CLINICAL MANIFESTATIONS

The diagnosis of AD is based on the constellation of clinical features summarized in Table 122-1. AD typically begins during infancy. Approximately 50 percent of patients develop this illness by the first year of life and an additional 30 percent between the ages of 1 and 5 years. Nearly 80 percent of patients with AD eventually develop allergic rhinitis or asthma later in childhood. Many of these patients outgrow their AD as they are developing respiratory allergy.

Skin Reaction Patterns

Intense pruritus and cutaneous reactivity are cardinal features of AD. Pruritus may be intermittent throughout the day but is usually worse in the early evening and night. Its consequences are scratching, prurigo papules (Fig. 122-1), lichenification (Fig. 122-2), and eczematous skin lesions. The pathogenesis of cutaneous pruritus is not well understood but is thought to be induced by various products of inflammatory effector cells including neuropeptides, histamine, leukotrienes, and proteolytic enzymes. Patients with AD also have a reduced threshold for pruritus. Clinically, this is supported by the observation that allergens, reduced humidity, excessive sweating, and low concentrations of irritants (e.g., wool, acrylic, soaps, and detergents) can exacerbate pruritus and scratching.

FIGURE 122-1 Prurigo papules in a patient with AD.

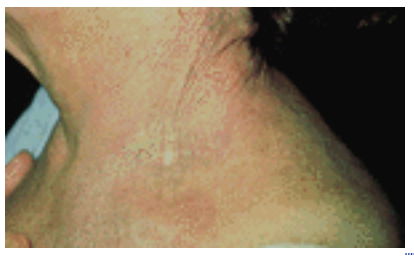

FIGURE 122-2 Lichenification of the neck and shoulders in an adult with AD.

Several skin reaction patterns are commonly seen in AD. Acute skin lesions are characterized by intensely pruritic, erythematous papules associated with excoriation, vesicles over erythematous skin, and serous exudate (Fig. 122-3). Subacute dermatitis is characterized by erythematous, excoriated, scaling papules (Fig. 122-4). Chronic AD is characterized by thickened plaques of skin, accentuated skin markings (lichenification), and fibrotic papules (prurigo nodularis) (Fig. 122-5). In chronic AD, all three stages of skin reactions frequently coexist in the same individual. At all stages of AD, patients usually have dry, lackluster skin (Fig. 122-6).

FIGURE 122-3 *A*. Pronounced weeping and crusting of eczematous lesions in childhood AD. *B*. Excoriated papules and crusting in an acute flare of AD.

FIGURE 122-4 Erythematous papules in a patient with subacute AD.

FIGURE 122-5 Severe lichenification and hyperpigmented prurigo papules seen in a patient with chronic AD.

FIGURE 122-6 Infiltrated, erythematous facial skin with scaliness in an adolescent with AD. Note lateral thinning of eyebrows and infraocular (Morgan's) fold.

The distribution and skin reaction pattern varies according to the patient's age and disease activity. During infancy, the AD is generally more acute and primarily involves the face, scalp, and the extensor surfaces of the extremities (Fig. 122-7). The diaper area is usually spared. In older children, and in those who have long-standing skin disease, the patient develops the chronic form of AD with lichenification and localization of the rash to the flexural folds of the extremities (Fig. 122-8). AD often subsides as the patient grows older, leaving an adult with skin that is prone to itching and inflammation when exposed to exogenous irritants. Chronic hand eczema may be the primary manifestation of many

adults with AD (Fig. 122-9). Other associated features of AD are listed in Table 122-1.

FIGURE 122-7 Itching infant with AD. (*Courtesy of Oholm Larsen, MD.*)

FIGURE 122-8 Childhood AD with lichenification of antecubital fossae and generalized severely pruritic eczematous plaques.

FIGURE 122-9 Typical papules and vesicles seen in atopic hand dermatitis.

Complications

OCULAR PROBLEMS Eye complications associated with severe AD can lead to significant orbidity. Eyelid dermatitis and chronic blepharitis are commonly associated with AD and may result in visual impairment from corneal scarring. Atopic keratoconjunctivitis is usually bilateral and can have disabling symptoms that include itching, burning, tearing, and copious mucoid discharge. Vernal conjunctivitis is a severe bilateral recurrent chronic inflammatory process associated with papillary hypertrophy, or cobblestoning of the upper eyelid conjunctiva. It usually occurs in younger patients and has a marked seasonal incidence, often in the spring. The associated intense pruritus is exacerbated by exposure to irritants, light, or sweating. Keratoconus is a conical deformity of the cornea believed to result from chronic rubbing of the eyes in patients with AD and allergic rhinitis. Cataracts were reported in the early literature to occur in up to 21 percent of patients with severe AD. However, it is unclear whether this was a primary manifestation of AD or the result of the extensive use of systemic and topical glucocorticoids, particularly around the eyes. Indeed, more recent studies suggest that routine screening for cataracts in patients with AD may not be productive unless there is concern about potential side effects from steroid therapy.
INFECTIONS AD can be complicated by recurrent viral skin infections that may reflect local defects in T cell function. The most serious viral infection is herpes simplex, which can affect patients of all ages, resulting in Kaposi's varicelliform eruption or eczema herpeticum. After an incubation period of 5 to 12 days, multiple, itchy, vesiculopustular lesions erupt in a disseminated pattern; vesicular lesions are umbilicated, tend to crop, and often become hemorrhagic and crusted (Fig. 122-10). Punched out and extremely painful erosions result. These lesions may coalesce to large, denuded and bleeding areas that can extend over the entire body.

FIGURE 122-10 Eczema herpeticum. Typical vesicles and crusting in a patient with disseminated disease.

Although smallpox infections have been eradicated worldwide since the late 1970s, threats of bioterrorism (with smallpox and other infectious agents) have made nations reconsider their policies toward initiating vaccination programs. In AD patients, smallpox vaccination (or even exposure to vaccinated individuals) may cause a severe widespread eruption (called eczema vaccinatum) that appears very similar to eczema herpeticum. Thus, in patients with AD, vaccination is contraindicated unless there is a clear risk of smallpox. In addition, decisions regarding vaccination of family members should take into consideration the potential of eczema vaccinatum in household contacts. Superficial fungal infections are also more common in atopic individuals and may contribute to the exacerbation of AD. Patients with AD have an increased prevalence of *Trichophyton rubrum* infections compared to nonatopic controls. There has been particular interest in the role of *Malassezia furfur* (*Pityrosporum ovale* or *P. orbiculare*) in AD. *M. furfur* is a lipophilic yeast commonly present in the seborrheic areas of the skin. IgE antibodies against *M. furfur* are commonly found in AD patients and most frequently in patients with head and neck dermatitis. In contrast, IgE sensitization to *M. furfur* is rarely observed in normal controls or asthmatics. Positive allergen patch test reactions to this yeast have also been demonstrated. The potential importance of *M. furfur* as well as other dermatophyte infections is further supported by the reduction of AD skin severity in such patients following treatment with antifungal agents. As discussed earlier, *S. aureus* is found in more than 90 percent of AD skin lesions. Honey-colored crusting, folliculitis, and pyoderma are indicators of secondary bacterial skin infection, usually due to *S. aureus* that requires antibiotic therapy. Regional lymphadenopathy is common in such patients. The importance of *S. aureus* in AD is supported by the observation that patients with severe AD, even those without overt infection, can show clinical response to combined treatment with antistaphylococcal antibiotics and topical glucocorticoids. Although recurrent staphylococcal pustulosis can be a significant problem in AD, deep-seated *S. aureus* infections occur rarely and should raise the possibility of an immunodeficiency syndrome such as hyper-IgE syndrome.

HAND DERMATITIS Patients with AD often develop a nonspecific, irritant hand dermatitis. It is frequently aggravated by repeated wetting and by washing of the hands with harsh soaps, detergents, and disinfectants. Atopic individuals with occupations involving wet work are prone to develop an intractable hand dermatitis in the occupational setting. This is a common cause of occupational disability.

EXFOLIATIVE DERMATITIS Patients with extensive skin involvement may develop exfoliative dermatitis. This is associated with generalized redness, scaling, weeping, crusting, systemic toxicity, lymphadenopathy, and fever (see Chap. 44). Although this complication is rare, it is potentially life-threatening. It is usually due to superinfection, for example, with toxin-producing *S. aureus* or herpes simplex infection, continued irritation of the skin, or inappropriate therapy. In some cases, the withdrawal of systemic glucocorticoids used to control severe AD may be a precipitating factor for exfoliative erythroderma.

LABORATORY FINDINGS

Serum IgE levels are elevated in the majority of patients with AD. Approximately 85 percent of patients have positive immediate skin tests or serum IgE antibody directed to a variety of food, inhalant, and microbial allergens. The majority of patients with AD also have peripheral blood eosinophilia. Unlike eosinophils from normal donors, peripheral blood eosinophils from AD patients are primed for chemotaxis and transendothelial transmigration. [11] Furthermore, serum levels of eosinophil cationic protein and urinary eosinophil protein X are elevated in AD and levels of these markers of eosinophil activation correlate with the severity of skin disease. Patients with AD also have increased spontaneous histamine release from basophils. These findings likely reflect a systemic T_H2 immune response in AD. Importantly, the peripheral blood skin homing CLA+ T cells in AD expressing either CD4 or CD8 spontaneously secrete IL-5 and IL-13, which functionally prolong eosinophil survival and induce IgE synthesis.

PATHOLOGY

Clinically unaffected skin of AD patients is not normal but reveals mild epidermal hyperplasia and a sparse perivascular T cell infiltrate. [47] Acute eczematous skin lesions are characterized by marked intercellular edema (spongiosis) of the epidermis. Dendritic APC (e.g., LC, macrophages) in lesional and, to a lesser extent, in nonlesional skin of AD exhibit surface-bound IgE molecules. A sparse epidermal infiltrate consisting primarily of T lymphocytes is also frequently observed. In the dermis of the acute lesion, there is a marked perivenular T cell infiltrate with occasional monocyte-macrophages. The lymphocytic infiltrate consists predominantly of activated memory T cells bearing CD3, CD4, and CD45 RO (suggesting previous encounter with antigen). Eosinophils, basophils, and neutrophils are rarely present in acute AD. Mast cells are found in normal numbers in different stages of degranulation.

Chronic lichenified lesions are characterized by a hyperplastic epidermis with elongation of the rete ridges, prominent hyperkeratosis, and minimal spongiosis. There is an increased number of IgE-bearing LC in the epidermis, and macrophages dominate the dermal mononuclear cell infiltrate. Mast cells are increased in number but are generally fully granulated. Increased numbers of eosinophils are observed in chronic AD skin lesions. These eosinophils undergo cytolysis with release of granule protein contents into the upper dermis of lesional skin. Eosinophil-derived extracellular major basic protein can be detected in a fibrillar pattern associated with the distribution of elastic fibers throughout the upper dermis. Eosinophils are thought to contribute to allergic inflammation by the secretion of cytokines and mediators that augment allergic inflammation and induce tissue injury in AD through the production of reactive oxygen intermediates and release of toxic granule proteins.

DIAGNOSIS AND DIFFERENTIAL DIAGNOSIS

Table 122-1 lists the clinical features of AD. Of the major features, pruritus and chronic or remitting eczematous dermatitis with typical morphology and distribution are essential for diagnosis. Other features, including exogenous allergy or elevated IgE are variable, and some of the “associated features” in the table may not be useful discriminators of individuals with AD from the unaffected general population. Various diagnostic criteria have been proposed to assist with clinical diagnosis, definition of patients for clinical studies, and epidemiologic population studies. [68] A refined list of diagnostic criteria suitable for epidemiologic studies has been derived and validated by workers in the United Kingdom. [69]

The sensitivity and specificity of these criteria have varied greatly in studies to date.

Table 122-3 lists a number of inflammatory skin diseases, immunodeficiencies, skin malignancies, genetic disorders, infectious diseases, and infestations that share symptoms and signs with AD. These should be considered and ruled out before a diagnosis of AD is made. Infants presenting in the first year of life with failure to thrive, diarrhea, a generalized scaling erythematous rash, and recurrent cutaneous and/or systemic infections should be evaluated for severe combined immunodeficiency syndrome. Wiskott-Aldrich syndrome is an X-linked recessive disorder characterized by cutaneous findings almost indistinguishable from AD. It is associated with thrombocytopenia, variable abnormalities in humoral and cellular immunity, and recurrent severe bacterial infections. The hyperimmunoglobulin-E syndrome is characterized by markedly elevated serum IgE levels, defective T cell function, recurrent deep-seated bacterial infections, including cutaneous abscesses due to *S. aureus* and/or pruritic skin disease due to *S. aureus* pustulosis, or by recalcitrant dermatophytosis. Although *S. aureus* is an important pathogen in this disorder, infection with other bacteria, viruses, and fungi may occur, particularly when patients are on chronic antistaphylococcal antibiotic prophylaxis. The pruritic dermatitis in this rare syndrome may be difficult to distinguish from AD.



TABLE 122-3 **Differential Diagnosis of Atopic Dermatitis**

It is important to recognize that an adult who presents with an eczematous dermatitis with no history of childhood eczema, respiratory allergy, or atopic family history may have allergic contact dermatitis (see Chap. 120). A contact allergen should be considered in any patient whose AD does not respond to appropriate therapy. Of note, topical glucocorticoid contact allergy has been reported increasingly in patients with chronic dermatitis on topical corticosteroid therapy. In addition, cutaneous T cell lymphoma must be ruled out in any adult presenting with chronic dermatitis poorly responsive to topical glucocorticoid therapy. Ideally, biopsies should be obtained from three separate sites, because the histology may show spongiosis and cellular infiltrate similar to AD. Eczematous dermatitis has been also reported with HIV as well as with a variety of infestations such as scabies. Other conditions that can be confused with AD include psoriasis, ichthyoses, and seborrheic dermatitis.

TREATMENT AND PROGNOSIS

Successful treatment of AD requires a systematic, multipronged approach that incorporates skin hydration, pharmacologic therapy, and the identification and elimination of flare factors such as irritants, allergens, infectious agents, and emotional stressors. [70] Many factors lead to the symptom complex characterizing AD. Thus, treatment plans should be individualized to address each patient's skin disease reaction pattern, including the acuity of the rash, and the trigger factors that are unique to the particular patient. In patients refractory to conventional forms of therapy, alternative anti-inflammatory and immunomodulatory agents may be necessary.

Topical Therapy

CUTANEOUS HYDRATION Patients with AD have reduced skin barrier function and dry skin (xerosis) contributing to disease morbidity by the development of microfissures and cracks in the skin, which serve as portals of entry for skin pathogens, irritants, and allergens. This problem can become aggravated during the dry winter months and in certain work environments. Lukewarm soaking baths for at least 20 min followed by the application of an occlusive emollient to retain moisture can give such patients excellent symptomatic relief. Use of an effective emollient combined with hydration therapy will help to restore and preserve the stratum corneum barrier, and may decrease the need for topical glucocorticoids. Moisturizers are available in the form of lotions, creams, or ointments. Lotions and creams may be irritating due to added preservatives, solubilizers, and fragrances. Lotions containing water may be drying due to an evaporative effect. Hydrophilic ointments can be obtained in varying degrees of viscosity according to the patient's preference. Occlusive ointments are sometimes not well tolerated because of interference with the function of the eccrine sweat ducts and the induction of folliculitis. In these patients, less occlusive agents should be used. Hydration, by baths or wet dressings, promotes transepidermal penetration of topical glucocorticoids. Dressings may also serve as an effective barrier against persistent scratching, allowing more rapid healing of excoriated lesions. Wet dressings are recommended for use on severely affected or chronically involved areas of dermatitis refractory to therapy. However, overuse of wet dressings may result in maceration of the skin complicated by secondary infection. Wet dressings or baths also have the potential to promote drying and fissuring of the skin if not followed by topical emollient use. Thus, wet dressing therapy is reserved for poorly controlled AD and should be closely monitored by a physician.
TOPICAL GLUCOCORTICOID TREATMENT Topical glucocorticoids are the cornerstone of treatment for anti-inflammatory eczematous skin lesions. Because of potential side effects, most physicians use topical glucocorticoids only to control of acute exacerbations of AD. However, recent studies suggest that once control of AD is achieved with a daily regimen of topical glucocorticoid, long-term control can be maintained with twice weekly applications of topical fluticasone to areas that have healed but are prone to developing eczema. [71] Patients should be carefully instructed in the use of topical glucocorticoids in order to avoid potential side effects. The potent fluorinated glucocorticoids should be avoided on the face, the genitalia, and the intertriginous areas. A low-potency glucocorticoid preparation is generally recommended for these areas. Patients should be instructed to apply topical glucocorticoids to their skin lesions and to use emollients over uninvolved skin. Failure of a patient to respond to topical glucocorticoids is sometimes due in part to an inadequate supply. It is important to remember that it takes approximately 30 g of cream or ointment to cover the entire skin surface of an adult once. To treat the entire body twice daily for 2 weeks requires approximately 840 g (2 lb) of

topical glucocorticoids. There are seven classes of topical glucocorticoids, ranked according to their potency based on vasoconstrictor assays (see Chap. 243). Because of their potential side effects, the ultrahigh-potency glucocorticoids should be used only for very short periods of time and in areas that are lichenified but not on the face or intertriginous areas. The goal is to use emollients to enhance skin hydration and low-potency glucocorticoids for maintenance therapy. Midpotency glucocorticoids can be used for longer periods of time to treat chronic AD involving the trunk and extremities. Glucocorticoids in gels are usually in a propylene glycol base and are irritating to the skin in addition to promoting dryness, thus limiting their use to the scalp and beard areas. Side effects from topical glucocorticoids are directly related to the potency ranking of the compound and the length of use, so it is incumbent on the clinician to balance the need for a more potent steroid with the potential for side effects. In addition, ointments have a greater potential to occlude the epidermis, resulting in enhanced systemic absorption when compared to creams. Side effects from topical glucocorticoids can be divided into local side effects and systemic side effects resulting from suppression of the hypothalamic-pituitary-adrenal axis. Local side effects include the development of striae and skin atrophy. Systemic side effects are related to the potency of the topical glucocorticoid, the site of application, the occlusiveness of the preparation, the percentage of the body surface area covered, and the length of use. The potential for potent topical glucocorticoid to cause adrenal suppression is greatest in infants and young children.

Topical Immunomodulators

Tacrolimus Topically applied FK-506 or tacrolimus, a calcineurin inhibitor that acts by binding to FK binding protein, has been successfully used in the treatment of AD (see Chap. 250). Tacrolimus inhibits the activation of a number of key cells involved in AD including T cells, Langerhans cells, mast cells, and keratinocytes. Atopic Dermatitis patients receiving this form of therapy can have markedly diminished pruritus within 3 days of initiating therapy. Skin biopsy results after treatment demonstrate markedly diminished T cell and eosinophilic infiltrates as well as decreased FceRI expression on both Langerhans cells and inflammatory dendritic epidermal cells. Multicenter, blinded, vehicle-controlled phase 3 trials with tacrolimus ointment, 0.03% and 0.1%, in both adults and children with AD have shown tacrolimus to be both safe and effective. [72], [73] A local burning sensation has been the only common adverse event. In adults, but not children, a dose-response effect was seen between 0.03% and 0.1% tacrolimus, particularly for patients with severe skin disease. Long-term open-label studies with tacrolimus ointment applied on up to 100 percent of body surface area have been performed for up to 12 months in adults and children with demonstrated sustained efficacy and no significant side effects; for example, no increased skin infections have been observed. Indeed, *S. aureus* colonization decreases during long-term therapy with tacrolimus ointment. [41] In addition, unlike topical corticosteroids, tacrolimus ointment does not cause cutaneous atrophy and has been used safely for facial and eyelid eczema. Tacrolimus ointment (Protopic) 0.03% is approved by the FDA for short-term and intermittent long-term use in moderate to severe AD for children 2 to 15 years of age; and 0.03%, as well as 0.1%, has been approved for adults.

Pimecrolimus Ascomycin compounds, which act by binding to macrophilin 12 to interfere with calcineurin action, have been developed in topical and oral forms that appear to have preferential drug distribution to the skin (see Chap. 250). Like tacrolimus, they inhibit T_H1 and T_H2 cytokine production and also inhibit mediator release from mast cells and basophils. Topical pimecrolimus (Elidel) 1% cream applied twice daily in a randomized, double-blind, placebo-controlled, right-and-left comparison trial in adult patients with moderate AD was significantly more effective than either a vehicle cream or once daily treatment over a 21-day period. [74] No significant drug-related adverse effects were noted. [75] In a vehicle- and betamethasone-17-valerate 0.1% cream-controlled dose-finding study of 260 adults with AD, pimecrolimus 1.0% cream was found to be the most effective concentration. Of note, the 0.1% betamethasone-17-valerate was more effective than the pimecrolimus creams tested in this study. However, the authors suggested that the efficacy plateau was not reached with the pimecrolimus creams during the 3 weeks of treatment. Further therapeutic trials are in progress with this new drug.

Identification and Elimination of Triggering Factors

GENERAL CONSIDERATIONS Patients with AD are more susceptible to irritants than are normal individuals. Thus, it is important to identify and eliminate aggravating factors that trigger the itch-scratch cycle. These include soaps or detergents, contact with chemicals, smoke, abrasive clothing, and exposure to extremes of temperature and humidity. Alcohol and astringents found in toiletries are drying. When soaps are used, they should have minimal defatting activity and a neutral pH. New clothing should be laundered prior to wearing to decrease levels of formaldehyde and other added chemicals. Residual laundry detergent in clothing may be irritating. Using a liquid rather than powder detergent and adding a second rinse cycle will facilitate removal of the detergent. Recommendations regarding environmental living conditions should include temperature and humidity control to avoid problems related to heat, humidity, and perspiration. Every attempt should be made to allow children to be as normally active as possible. Certain sports such as swimming may be better tolerated than other sports involving intense perspiration, physical contact, or heavy clothing and equipment, but chlorine should be rinsed off immediately after swimming and the skin lubricated. While ultraviolet light may be beneficial to some patients with AD, sunscreens should be used to avoid sunburn. However, because sunscreens can be irritants, care should be used to identify a nonirritating product.

SPECIFIC ALLERGENS Foods and aeroallergens such as dust mites, animal danders, molds, and pollens have been demonstrated to exacerbate AD. Potential allergens can be identified by taking a careful history and carrying out selective skin prick tests. Negative skin tests or serum tests for allergen-specific IgE have a high predictive value for ruling out suspected allergens. A normal total serum IgE level, however, does not rule out the possibility of allergen-specific IgE being present. Positive skin or in vitro tests, particularly to foods, often do not correlate with clinical symptoms and should be confirmed with controlled food challenges and elimination diets. Avoidance of foods implicated in controlled challenges results in clinical improvement. [14], [17] Extensive elimination diets, which in some cases can be nutritionally deficient, are rarely, if ever, required, because even with multiple positive skin tests, the majority of patients will react to three or fewer foods on controlled challenge. In dust mite–allergic patients with AD, prolonged avoidance of dust mites has been found to result in improvement of their skin disease. Avoidance measures include use of dust mite proof encasings on pillows, mattresses, and box springs; washing bedding in hot water weekly; removal of bedroom carpeting; and decreasing indoor humidity levels with air conditioning. Because there are many triggers contributing to the flares of AD, attention should be focused on identifying and controlling the flare factors that are important to the individual patient. Infants and young children are more likely to have food allergies, whereas older children and adults are more likely to be sensitive to environmental aeroallergens.

EMOTIONAL STRESSORS Although emotional stress does not cause AD, it often exacerbates the illness. AD patients often respond to frustration, embarrassment, or other stressful events with increased pruritus and scratching. In some

instances, scratching is simply habitual and less commonly associated with significant secondary gain. Psychological evaluation or counseling should be considered in patients who have difficulty with emotional triggers or psychological problems, contributing to difficulty in managing their disease. It may be especially useful in adolescents and young adults who consider their skin disease disfiguring. Relaxation, behavioral modification, or biofeedback may be helpful in patients with habitual scratching.

INFECTIOUS AGENTS Antistaphylococcal antibiotics are very helpful in the treatment of patients who are heavily colonized or infected with *S. aureus*. Erythromycin and the newer macrolide antibiotics (azithromycin and clarithromycin) are usually beneficial for patients who are not colonized with a resistant *S. aureus* strain. However, for macrolide-resistant *S. aureus,* a penicillinase-resistant penicillin (dicloxacillin, oxacillin, or cloxacillin) may be preferred. First-generation cephalosporins also offer effective coverage for both staphylococci and streptococci. Topical mupirocin offers some utility in the treatment of impetiginized lesions; however, in patients with extensive superinfection, a course of systemic antibiotics is most practical. Herpes simplex can provoke recurrent dermatitis and may be misdiagnosed as *S. aureus* infection. The presence of punched-out erosions, vesicles, and/or infected skin lesions that fail to respond to oral antibiotics should initiate a search for herpes simplex. This can be diagnosed by a Giemsa-stained Tzanck smear of cells scraped from the vesicle base or by viral culture. For infection suspected to be caused by herpes simplex, topical glucocorticoids are best discontinued, at least temporarily. Antiviral treatment for cutaneous herpes simplex infections is of critical importance in the patient with widespread AD because life-threatening dissemination has been reported. Acyclovir, 400 mg three times daily for 10 days or 200 mg four times daily for 10 days by oral administration (or an equivalent dosage of one of the newer antiherpetic medications), is useful in adults with herpes simplex confined to the skin. Intravenous treatment may be necessary for severe disseminated eczema herpeticum. The dosage should be adjusted according to weight in children. Dermatophyte infections can complicate AD and may contribute to exacerbation of disease activity. Patients with dermatophyte infection or IgE antibodies to *P. ovale* may benefit from a trial of topical or systemic antifungal therapy.

Pruritus

The treatment of pruritus in AD should be directed primarily at the underlying causes. Reduction of skin inflammation and dryness with topical glucocorticoids and skin hydration, respectively, will often symptomatically reduce pruritus. Inhaled and ingested allergens should be eliminated if documented to cause skin rash in controlled challenges. Systemic antihistamines act primarily by blocking the H_1 receptors in the dermis, thereby ameliorating histamine-induced pruritus. However, histamine is only one of many mediators that can induce pruritus of the skin. Therefore, certain patients may derive minimal benefit from antihistaminic therapy. Some antihistamines are also mild anxiolytics and may offer symptomatic relief through tranquilizing and sedative effects. Studies of newer nonsedating antihistamines show variable results in the effectiveness of controlling pruritus in AD, although they may be useful in the small subset of AD patients with concomitant urticaria.

Because pruritus is usually worse at night, the sedating antihistamines, for example, hydroxyzine or diphenhydramine, may offer an advantage with their soporific side effects when used at bedtime. Doxepin hydrochloride has both tricyclic antidepressant and H_1- and H_2-histamine receptor-blocking effects. It can be used in doses of 10 to 75 mg orally at night or up to 75 mg bid in adult patients. If nocturnal pruritus remains severe, short-term use of a sedative to allow adequate rest may be appropriate. Treatment of AD with topical antihistamines is generally not recommended because of potential cutaneous sensitization. However, short-term (1 week) application of topical 5% doxepin cream has been reported to reduce pruritus without sensitization. Of note, sedation is a side effect of widespread application of doxepin cream.

Tar Preparations

Coal tar preparations may have antipruritic and anti-inflammatory effects on the skin. The anti-inflammatory properties of tars, however, are not well characterized and are usually not as pronounced as those of topical glucocorticoids. Tar preparations may be useful in reducing the potency of topical glucocorticoids required in chronic maintenance therapy of AD. Newer coal tar products have been developed that are more acceptable with respect to odor and staining of clothes than some older products. Tar shampoos can be beneficial for scalp dermatitis and are often helpful in reducing the concentration and frequency of topical glucocorticoid applications. Tar preparations should not be used on acutely inflamed skin, because this often results in skin irritation. Side effects associated with tars include folliculitis and photosensitivity. There is a theoretical risk of tar being a carcinogen based on observational studies of workers using tar components in their occupations.

Phototherapy

Natural sunlight is frequently beneficial to patients with AD. However, if the sunlight occurs in the setting of high heat or humidity, thereby triggering sweating and pruritus, it may be deleterious to patients. Broad-band ultraviolet B, broad-band ultraviolet A, narrow-band ultraviolet B (311 nm), UVA-1 (340 to 400 nm), and combined UVAB phototherapy can be useful adjuncts in the treatment of AD. Investigation of the photoimmunologic mechanisms responsible for therapeutic effectiveness indicates that epidermal Langerhans cells and eosinophils may be targets of ultraviolet A phototherapy with and without psoralen, while UVB exerts immunosuppressive effects via blocking of function of antigen-presenting Langerhans cells and altered keratinocyte cytokine production. Photochemotherapy with PUVA may be indicated in patients with severe, widespread AD, although studies comparing it with other modes of phototherapy are limited. Short-term adverse effects with phototherapy may include erythema, skin pain, pruritus, and pigmentation. Long-term adverse effects include premature skin aging and cutaneous malignancies (see Chap. 265 and Chap. 266 for detailed discussion of phototherapy and photochemotherapy).

Hospitalization

AD patients who appear erythrodermic or who have widespread severe skin disease resistant to outpatient therapy should be hospitalized before considering systemic alternative therapies (see below). In many cases, removing the

patient from environmental allergens or emotional stresses, intense patient education, and assurance of compliance with therapy result in a sustained improvement in their AD. Clearing of the patient's skin during hospitalization also allows the patient to undergo allergen skin testing and appropriately controlled provocative challenges to correctly identify potential allergens.

Phosphodiesterase Inhibitors

Leukocytes from patients with AD have increased CAMP-PDE enzyme activity. This abnormality is most pronounced in atopic monocytes, which have a unique, highly active PDE isoenzyme. Monocytes from AD patients produce elevated levels of PGE_2 and IL-10, which both inhibit IFN-? production by T cells. Clinical studies using topical application of high-potency PDE inhibitors have demonstrated clinical benefit in AD. [57]

Systemic Therapy

SYSTEMIC GLUCOCORTICOIDS The use of systemic glucocorticoids, such as oral prednisone, is rarely indicated in the treatment of chronic AD. Some patients and physicians prefer the use of systemic glucocorticoids to avoid the time-consuming skin care involving hydration and topical therapy. However, the dramatic clinical improvement that may occur with systemic glucocorticoids is frequently associated with a severe rebound flare of AD following the discontinuation of systemic glucocorticoids. Short courses of oral glucocorticoids may be appropriate for an acute exacerbation of AD while other treatment measures are being instituted. If a short course of oral glucocorticoids is given, it is important to taper the dosage and to begin intensified skin care, particularly with topical glucocorticoids and frequent bathing followed by application of emollients, in order to prevent rebound flaring of AD.
ALLERGEN IMMUNOTHERAPY Unlike allergic rhinitis and extrinsic asthma, immunotherapy with aeroallergens is not proven to be efficacious in the treatment of AD. There are anecdotal reports of both disease exacerbation and improvement. Well-controlled studies are still required to determine the role for immunotherapy with this disease, and this form of treatment for AD should be reserved for individuals who have a clear-cut demonstrable history of aeroallergen-induced AD such as seasonal exacerbations to pollen.
INTERFERONS IFN-? is known to suppress IgE responses and downregulate T_H2 cell proliferation and function. Several studies of patients with AD, including a multicenter, double-blind, placebo-controlled trial, have demonstrated that treatment with recombinant IFN-? results in clinical improvement. Reduction in clinical severity of AD correlated with the ability of IFN-? to decrease total circulating eosinophil counts. Influenza-like symptoms are commonly observed side effects early in the treatment course. Recombinant IFN-a has also been used to treat patients with AD in several small, uncontrolled trials. Although a few reports suggest some clinical benefit using this immunomodulator, other studies have not confirmed this finding; however, a significant decrease in circulating eosinophils was noted. A single study of two patients with AD suggests improvement in their AD when recombinant IFN-? and IFN-a were used sequentially. Further controlled studies are required before any firm conclusion can be made regarding the role of interferon therapy in AD.
CYCLOSPORINE Cyclosporine is a potent immunosuppressive drug that acts primarily on T cells by suppressing cytokine transcription. The drug binds to cyclophilin, an intracellular protein, and this complex, in turn, inhibits calcineurin, a molecule required for initiation of cytokine gene transcription. Multiple studies demonstrate that both children and adults with severe AD, refractory to conventional treatment, can benefit from short-term cyclosporine treatment. Various oral-dosing regimens have been recommended: 5 mg/kg has generally been used with success in short-term and long-term (1 year) use, while some authorities advocate body-weight–independent daily dosing of adults with 150 mg (low dose) or 300 mg (high dose) daily of cyclosporine microemulsion. Treatment with cyclosporine is associated with reduced skin disease and an improved quality of life (see Chap. 262 for further discussion). However, discontinuation of treatment generally results in rapid relapse of skin disease. Elevated serum creatinine or more significant renal impairment and hypertension are specific side effects of concern with cyclosporine use.
ANTIMETABOLITES Mycophenolate mofetil (MMF) is a purine biosynthesis inhibitor used as an immunosuppressant in organ transplantation, that has been used for treatment of refractory inflammatory skin disorders (see Chap. 262). Open-label studies report that short-term oral MMF 2 g daily as monotherapy results in clearing of skin lesions in adults with AD resistant to other treatment including topical and oral steroids and PUVA. The drug has generally been well tolerated with the exception of one patient developing herpes retinitis that may have been secondary to this immunosuppressive agent. Dose-related bone marrow suppression has also been observed. Similar results were previously reported in another open study of 10 patients with a mean reduction in the SCORAD index of 68 percent in all 10 patients. Of note, not all patients benefit from treatment. Therefore the medication should be discontinued if patients do not respond within 4 to 8 weeks. Dose finding and well-controlled studies are needed for this drug. Methotrexate is an antimetabolite with potent inhibitory effects on inflammatory cytokine synthesis and cell chemotaxis. Methotrexate has been used for AD patients with recalcitrant disease, although controlled trials are lacking. Dosing is more frequent than the weekly dosing used for psoriasis. Azathioprine is a purine analogue with anti-inflammatory and antiproliferative effects; azathioprine has been used for severe AD, although no controlled trials have been reported. Myelosuppression is a significant adverse effect, and thiopurinemethyl transferase levels may predict individuals at risk.
EXTRACORPOREAL PHOTOPHERESIS This treatment consists of the passage of psoralen-treated leukocytes through an extracorporeal UVA light system. Clinical improvement in skin lesions associated with reduced IgE levels has been reported in a few patients with severe, resistant AD who were treated with extracorporeal photopheresis and topical glucocorticoids.

Other Therapies

Disturbances in the metabolism of essential fatty acids (EFA), involved in the generation of inflammatory mediators, has been suggested in patients with AD. Consequently, clinical trials have been conducted with either fish oil as a source of O-3 series EFA, or oil extracted from the seeds of *Oenothera biennis,* evening primrose, as a source of O-6 series EFA. Conflicting results were reported in earlier studies; however, recent better-controlled studies failed to demonstrate clinical benefit with either primrose oil or fish oil.

Several placebo-controlled clinical trials have suggested that patients with severe AD benefit from treatment with traditional Chinese herbal therapy. They had significantly reduced skin disease and decreased pruritus. The beneficial

response of Chinese herbal therapy, however, is often temporary, and effectiveness may wear off despite continued treatment. The possibility of hepatic toxicity, cardiac side effects, or idiosyncratic reactions remains a concern. The specific ingredients of the herbs also remain to be elucidated and some preparations have been found to be contaminated with corticosteroids. At present, Chinese herbal therapy for AD is considered investigational.

There are many different alternative therapies that could be efficacious in AD, but it is not possible to review them all. However, it is clear that AD is an illness associated with a multitude of immunoregulatory abnormalities. Future directions in therapy are likely to focus on a number of different immunologic targets in this illness.

Prognosis

The natural history of AD is not completely known because studies have been flawed in terms of inadequate sample size, an unclear definition of remission, inadequate length of follow-up, selection bias in the initial cohort, and excessive loss of patients to follow-up. Nevertheless, although the outcome of AD may be difficult to predict in any given individual, the disease generally tends to be more severe and persistent in young children. Periods of remission appear more frequently as the patient grows older. Spontaneous resolution of AD has been reported to occur after age 5 years in 40 to 60 percent of patients affected during infancy, particularly if their disease is mild. While earlier studies suggested that approximately 84 percent of children outgrow their AD by adolescence, more recent studies have reported that AD disappears in approximately 20 percent of children followed from infancy until adolescence, but becomes less severe in 65 percent. In addition, more than half of adolescents treated for mild dermatitis may experience a relapse of disease as adults.

Importantly for occupational counseling, adults whose childhood AD has been in remission for a number of years may present with hand dermatitis, especially if daily activities require repeated hand wetting. The following predictive factors correlate with a poor prognosis for AD: widespread AD in childhood; associated allergic rhinitis and asthma; family history of AD in parents or siblings; early age at onset of AD; being an only child; and very high serum IgE levels (Table 122-2).

REFERENCES

1. Willan R: *On Cutaneous Diseases,* Johnson, London, 1808

2. Coca AF et al: On the classification of the phenomena of hypersensitiveness. *J Immunol* **8**:163, 1923

3. Hill LW et al: Evolution of atopic dermatitis. *Arch Dermatol* **32**:451, 1935

4. Schultz-Larsen F, Hanifin JM: Epidemiology of atopic dermatitis. *Immunol Allergy Clin North Am* **22**:1, 2002

5. Williams H et al: Worldwide variations in the prevalence of symptoms of atopic eczema in the International Study of Asthma and Allergies in Childhood. *J Allergy Clin Immunol* **103**:125, 1999

6. von Mutius E: The environmental predictors of allergic disease. *J Allergy Clin Immunol* **105**:9, 2000

7. Strachan DP: Hay fever, hygiene, and household size. *BMJ* **299**:1259, 1989

8. Romagnani S: The role of lymphocytes in allergic disease. *J Allergy Clin Immunol* **105**:399, 2000

9. Saurat JH: Eczema in primary immune-deficiencies. Clues to the pathogenesis of atopic dermatitis with special reference to the Wiskott-Aldrich syndrome. *Acta Derm Venereol Suppl* **114**:125, 1985

10. Leung DYM: Atopic dermatitis: New insights and opportunities for therapeutic intervention. *J Allergy Clin Immunol* **105**:860, 2000

11. Beck LA, Leung DYM: Allergen sensitization through the skin induces systemic allergic responses. *J Allergy Clin Immunol* **106**:S258, 2000

12. Spergel JM et al: Epicutaneous sensitization with protein antigen induces localized allergic dermatitis and hyperresponsiveness to methacholine after single exposure to aerosolized antigen in mice. *J Clin Invest* **101**:1614, 1998

13. Bratton DL et al: Granulocyte macrophage colony-stimulating factor contributes to enhanced monocyte survival in chronic atopic dermatitis. *J Clin Invest* **95**:211, 1995

14. Sampson HA: Food allergy. Part 1: Immunopathogenesis and clinical disorders. *J Allergy Clin Immunol* **103**:717, 1999

15. Eigenmann PA et al: Prevalence of IgE-mediated food allergy among children with atopic dermatitis. *Pediatrics* **101**:E8, 1998

16. Guillet G, Guillet MH: Natural history of sensitizations in atopic dermatitis. A 3-year follow-up in 250 children: Food allergy and high risk of respiratory symptoms. *Arch Dermatol* **128**:187, 1992

17. Lever R et al: Randomised controlled trial of advice on an egg exclusion diet in young children with atopic eczema and sensitivity to eggs. *Pediatr Allergy Immunol* **9**:13, 1998

18. Li XM et al: Murine model of atopic dermatitis associated with food hypersensitivity. *J Allergy Clin Immunol* **107**:693, 2001

19. van Reijsen FC et al: T-cell reactivity for a peanut-derived epitope in the skin of a young infant with atopic dermatitis. *J Allergy Clin Immunol* **101**:207, 1998

20. Abernathy-Carver KJ et al: Milk-induced eczema is associated with the expansion of T cells expressing cutaneous lymphocyte antigen. *J Clin Invest* **95**:913, 1995

21. Walker IC: Causation of eczema, urticaria, and angioneurotic edema by proteins other than those derived from foods. *JAMA* **70**:897, 1918

22. Tupker RA et al: Induction of atopic dermatitis by inhalation of house dust mite. *J Allergy Clin Immunol* **97**:1064, 1996

23. Wheatley LM, Platts-Mills TAE: Role of inhalant allergens in atopic dermatitis, in *Allergic Skin Disease: A Multidisciplinary Approach,* edited by DYM Leung, MW Greaves. New York, Marcel Dekker, 2000, p 423

24. Tan BB et al: Double-blind controlled trial of effect of house dust-mite allergen avoidance on atopic dermatitis. *Lancet* **347**:15, 1996

25. Scalabrin DM et al: Use of specific IgE in assessing the relevance of fungal and dust mite allergens to atopic dermatitis: A comparison with asthmatic and nonasthmatic control subjects. *J Allergy Clin Immunol* **104**:1273, 1999

26. Schafer T et al: Association between severity of atopic eczema and degree of sensitization to aeroallergens in schoolchildren. *J Allergy Clin Immunol* **104**:1280, 1999

27. Leyden JJ, Kligman AM: The case for steroid–antibiotic combinations. *Br J Dermatol* **96**:179, 1977

28. Leung DYM et al: Presence of IgE antibodies to staphylococcal exotoxins on the skin of patients with atopic dermatitis. Evidence for a new group of allergens. *J Clin Invest* **92**:1374, 1993

29. Breuer K et al: Severe atopic dermatitis is associated with sensitization to staphylococcal enterotoxin B (SEB). *Allergy* **55**:551, 2000

30. Bunikowski R et al: Evidence for a disease-promoting effect of *Staphylococcus aureus*-derived exotoxins in atopic dermatitis. *J Allergy Clin Immunol* **105**:814, 2000

31. Strickland I et al: Evidence for superantigen involvement in skin homing of T cells in atopic dermatitis. *J Invest Dermatol* **112**:249, 1999

32. Herz U et al: A human-SCID mouse model for allergic immune response bacterial superantigen enhances skin inflammation and suppresses IgE production. *J Invest Dermatol* **110**:224, 1998

33. Hofer MF et al: Staphylococcal toxins augment specific IgE responses by atopic patients exposed to allergen. *J Invest Dermatol* **112**:171, 1999

34. Hauk PJ et al: Induction of corticosteroid insensitivity in human PBMCs by microbial super antigens. *J Allergy Clin Immunol* **105**:782, 2000

35. Strange P et al: Staphylococcal enterotoxin B applied on intact normal and intact atopic skin induces dermatitis. *Arch Dermatol* **132**:27, 1996

36. Skov L et al: Application of staphylococcal enterotoxin B on normal and atopic skin induces up-regulation of T cells by a superantigen-mediated mechanism. *J Allergy Clin Immunol* **105**:820, 2000

37. Michie CA, Davis T: Atopic dermatitis and staphylococcal superantigens. *Lancet* **347**:324, 1996

38. Leung DYM et al: Bacterial superantigens induce T cell expression of the skin-selective homing receptor, the cutaneous lymphocyte-associated antigen, via stimulation of interleukin 12 production. *J Exp Med* **181**:747, 1995

39. Ezepchuk YV et al: Staphylococcal toxins and protein A differentially induce cytotoxicity and release of tumor necrosis factor-alpha from human keratinocytes. *J Invest Dermatol* **107**:603, 1996

40. Nilsson EJ et al: Topical corticosteroids and *Staphylococcus aureus* in atopic dermatitis. *J Am Acad Dermatol* **27**:29, 1992

41. Remitz A et al: Tacrolimus ointment reduces staphylococcal colonization of atopic dermatitis lesions. *J Allergy Clin Immunol* **107**:196, 2001

42. Cho SH et al: Preferential binding of *Staphylococcus aureus* to skin sites of T_H2-mediated inflammation in a murine model. *J Invest Dermatol* **116**:658, 2001

43. Cho SH et al: Fibronectin and fibrinogen contribute to the enhanced binding of *Staphylococcus aureus* to atopic skin. *J Allergy Clin Immunol* **108**:269, 2001

44. Keller P: Beitrag zu den beziehungen von asthma und ekzem. *Arch Derm Syph Berl* **148**:82, 1924

45. Valenta R et al: Autoallergy: A pathogenetic factor in atopic dermatitis? *J Allergy Clin Immunol* **105**:432, 2000

46. Valenta R et al: Molecular characterization of an autoallergen, *Hom s* 1, identified by serum IgE from atopic dermatitis patients. *J Invest Dermatol* **111**:1178, 1998

47. Hamid Q et al: Differential in situ cytokine gene expression in acute versus chronic atopic dermatitis. *J Clin Invest* **94**:870, 1994

48. Hamid Q et al: In vivo expression of IL-12 and IL-13 in atopic dermatitis. *J Allergy Clin Immunol* **98**:225, 1996

49. Grewe M et al: A role for T_H1 and T_H2 cells in the immunopathogenesis of atopic dermatitis. *Immunol Today* **19**:359, 1998

50. Trautmann A et al: T cell-mediated Fas-induced keratinocyte apoptosis plays a key pathogenetic role in eczematous dermatitis. *J Clin Invest* **106**:25, 2000

51. Laberge S et al: Association of increased CD4+ T-cell infiltration with increased IL-16 gene expression in atopic dermatitis. *J Allergy Clin Immunol* **102**:645, 1998

52. Taha RA et al: Evidence for increased expression of eotaxin and monocyte chemotactic protein-4 in atopic dermatitis. *J Allergy Clin Immunol* **105**:1002, 2000

53. Yawalkar N et al: Enhanced expression of eotaxin and CCR3 in atopic dermatitis. *J Invest Dermatol* **113**:43, 1999

54. Morales J et al: CTACK, a skin-associated chemokine that preferentially attracts skin-homing memory T cells. *Proc Natl Acad Sci U S A* **96**:14470, 1999

55. Galli G et al: Macrophage-derived chemokine production by activated human T cells in vitro and in vivo: Preferential association with the production of type 2 cytokines. *Eur J Immunol* **30**:204, 2000

56. Giustizieri ML et al: Keratinocytes from patients with atopic dermatitis and psoriasis show a distinct chemokine production profile in

response to T cell-derived cytokines. *J Allergy Clin Immunol* **107**:871, 2001

57. Hanifin JM et al: Type 4 phosphodiesterase inhibitors have clinical and in vitro anti-inflammatory effects in atopic dermatitis. *J Invest Dermatol* **107**:51, 1996

58. Santamaria LF et al: Rolipram inhibits staphylococcal enterotoxin B-mediated induction of the human skin-homing receptor on T lymphocytes. *J Invest Dermatol* **113**:82, 1999

59. Kuchroo VK et al: B7-1 and B7-2 costimulatory molecules activate differentially the T_H1/T_H2 developmental pathways: Application to autoimmune disease therapy. *Cell* **80**:707, 1995

60. Jirapongsananuruk O et al: Enhanced expression of B7.2 (CD86) in patients with atopic dermatitis: A potential role in the modulation of IgE synthesis. *J Immunol* **160**:4622, 1998

61. Ohki O et al: Functional CD86 (B7-2/B70) is predominantly expressed on Langerhans cells in atopic dermatitis. *Br J Dermatol* **136**:838, 1997

62. Von Bubnoff D et al: Antigen-presenting cells in allergy. *J Allergy Clin Immunol* **108**:329–339, 2001

63. Imokawa G: Lipid abnormalities in atopic dermatitis. *J Am Acad Dermatol* **45**:S29, 2001

64. Herrick CA et al: T_H2 responses induced by epicutaneous or inhalational protein exposure are differentially dependent on IL-4. *J Clin Invest* **105**:765, 2000

65. Forrest S et al: Identifying genes predisposing to atopic eczema. *J Allergy Clin Immunol* **104**:1066, 1999

66. Lee YA et al: A major susceptibility locus for atopic dermatitis maps to chromosome 3q21. *Nat Genet* **26**:470, 2000

67. Cookson WO et al: Genetic linkage of childhood atopic dermatitis to psoriasis susceptibility loci. *Nat Genet* **27**:372, 2001

68. Williams HC: Diagnostic criteria for atopic dermatitis: Where do we go from here? *Arch Dermatol* **135**:583, 1999

69. Williams HC et al: The U.K. Working Party's Diagnostic Criteria for Atopic Dermatitis. I. Derivation of a minimum set of discriminators for atopic dermatitis. *Br J Dermatol* **131**:383, 1994

70. Hoare C et al: Systematic review of treatments for atopic dermatitis. *Health Technol Assess* **4**:1, 2000

71. Van Der Meer JB et al: The management of moderate to severe atopic dermatitis in adults with topical fluticasone propionate. The Netherlands Adult Atopic Dermatitis Study Group. *Br J Dermatol* **140**:1114, 1999

72. Hanifin JM et al: Tacrolimus ointment for the treatment of atopic dermatitis in adult patients: part I, efficacy. *J Am Acad Dermatol* **44**:S28, 2001

73. Paller A et al: A 12-week study of tacrolimus ointment for the treatment of atopic dermatitis in pediatric patients. *J Am Acad Dermatol* **44**:S47, 2001

74. Van Leent EJ et al: Effectiveness of the ascomycin macrolactam SDZ ASM 981 in the topical treatment of atopic dermatitis. *Arch Dermatol* **134**:805, 1998

75. Luger T et al: SDZ ASM 981: An emerging safe and effective treatment for atopic dermatitis. *Br J Dermatol* **144**:788, 2001

T>

Chapter 123

Nicholas Soter

Nummular Eczema and Lichen Simplex Chronicus/Prurigo Nodularis

NUMMULAR ECZEMA
Historical Aspects
Epidemiology
Etiology and Pathogenesis
Clinical Manifestations
Laboratory Findings
Pathology
Diagnosis and Differential Diagnosis
Treatment and Prognosis
LICHEN SIMPLEX CHRONICUS/PRURIGO NODULARIS
Historical Aspects
Epidemiology
Etiology and Pathogenesis
Clinical Manifestations
Laboratory Findings
Pathology
Diagnosis and Differential Diagnosis
Treatment and Prognosis

REFERENCES

NUMMULAR ECZEMA

Nummular eczema, which is also known as *discoid eczema,* is defined by its clinical appearance as coin-shaped, circular, or oval lesions with a definite border.

Historical Aspects

In 1845, Rayer described a condition with patches of vesicles and an illustration that resembled nummular eczema. Nummular eczema as a term was introduced by Devergie in 1857.

Epidemiology

Nummular eczema in adults occurs more frequently in men than in women. The peak age of onset in both sexes is between 55 and 65 years; in women, another peak is observed at 15 to 25 years. Nummular eczema is uncommon in children, rarely appears before one year of age, and its frequency tends to increase with age. [1]

Etiology and Pathogenesis

Although the cause is unknown, many factors, acting alone or in combination, have been proposed as etiologic agents. Staphylococci and micrococci have been incriminated both as a direct cause and through the mechanism of hypersensitivity; however, their pathogenic role remains unresolved. [2] Immediate skin test reactions have been elicited by intradermal injections of antigens prepared from *Staphylococcus aureus* and micrococci. Subjects aged 60 to 85 years showed more delayed-type contact sensitivity reactions as assessed by patch tests to *Candida albicans, Dermatophagoides farinae,* and house dust than did age-matched control subjects. [3] In other individuals, positive patch tests to rubber chemicals, formaldehyde, neomycin, chrome, and nickel have been thought to have clinical relevance. [4] Nummular eczema in adults is unrelated to the atopic disorders. In children, however, nummular lesions occur in atopic dermatitis.

There is a frequent association with dry skin, and the incidence of nummular eczema reaches a peak during the winter months. Patients with nummular eczema showed a low hydration state of the stratum corneum as assessed by high-frequency electrical conductors. [3] Of patients whose condition became worse in the summer months, men predominated with exacerbations after exertion in hot, humid situations. [5] Substances implicated with exacerbations include wool, soaps, water during frequent bathing, and topically applied medicaments. An association with emotional stress and with the ingestion of alcoholic beverages has been suggested.

Systemically administered drugs, notably gold, methyldopa, streptomycin, aminosalicylic acid, isoniazid, and isotretinoin, [6] as well as mercury in dental amalgam, [7] have been implicated in nummular eczema, but a direct association often is difficult to prove.

In cutaneous sensory nerves, increased amounts of substance P (SP), vasoactive intestinal polypeptide (VIP), and calcitonin gene–related peptide (CGRP) are present in the dermal fibers. Increased amounts of SP and CGRP are

present in epidermal fibers. [8] These observations implicate neuropeptides as a potential mechanism for mast cell degranulation.

Clinical Manifestations

The acute eruption appears as vesicles and papules that may enlarge by becoming confluent or by peripheral extension to form the characteristic, discrete, erythematous, coin-shaped areas (Fig. 123-1). Lesions that are more than 10 cm in diameter are seldom seen. Subsequently, there may be central clearing, which leads to morphologic configurations that resemble superficial fungal infections. Edema and exudation with crusts occur in acute lesions, whereas scale and lichenification are present in chronic lesions. Excoriations may be a prominent feature. Pruritus and occasionally burning occur in the lesional sites. The eruption occurs on the legs, the upper extremities including the dorsal surfaces of the hands, and the trunk; the lower extremities are the most commonly affected areas. The eruption may begin as a single lesion or several lesions that appear in episodes; individual lesions may persist for prolonged periods and commonly recur at previously affected sites.

FIGURE 123-1 Nummular eczema. Coin-shaped plaques composed of papules and vesicles on an erythematous base with some excoriations also present.

Laboratory Findings

If the history does not suggest an underlying cause for pruritus, no laboratory tests should be obtained. Scale may be examined for fungi. Patch tests at times may be of value. Serum IgE levels are normal. [9]

Pathology

The histopathologic alterations (Fig. 123-2) reflect the stage of evolution of the clinical lesion at the time of biopsy. In acute lesions, epidermal intercellular edema with vesicles of various sizes is associated with a dermal, perivenular infiltrate of lymphocytes and macrophages. In chronic lesions, hyperplasia of the epidermis with retention of the rete ridge pattern, hyperkeratosis, and an increase in the granular-cell layer are present. Minimal amounts of epidermal intercellular edema (spongiosis) may occur. Fibrosis of the papillary dermis may be present with lymphocytes and macrophages disposed about venules. The majority of the lymphocytes in the epidermis are CD8+ T lymphocytes. In the dermis, the lymphocytes are CD4+ T lymphocytes and exhibit CDw29.

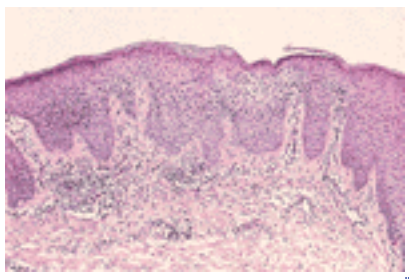

FIGURE 123-2 Parakeratosis containing plasma and neutrophils (scale crust) and psoriasiform epidermal hyperplasia with intercellular edema (spongiosis) are present with a superficial, dermal, perivascular infiltrate of lymphocytes, macrophages, and eosinophils. H&E 50×.

In the dermis, most of the mast cells are the MC_{TC} type, which contain tryptase and chymase. Some of the mast cells are the MC_{T} type, which contain only tryptase. This latter type of mast cell has increased contacts with the dermal–epidermal basement membrane zone. [10] Some of the mast cells contain interleukin-4 immunoreactivity. [11]

Diagnosis and Differential Diagnosis

Nummular eczema must be differentiated from the erythematous, annular areas with scale and erosions that may appear in dry skin. At times, nummular eczema may resemble dermatophyte infections or impetigo. Allergic contact dermatitis and atopic dermatitis should be considered.

Treatment and Prognosis

The skin should be hydrated by baths containing oil additives and the application of emollients. Topical anti-inflammatory agents include tar preparations, glucocorticoids, tacrolimus or pimecrolimus. Systemic antibiotics should be administered if a cutaneous infection is present. The humidity of the room should be regulated to avoid drying of the skin. If wool

garments are to be worn, they should be lined with nonirritating material. The pruritus may be treated with the administration of H_1 antihistamines. Both broad-band and narrow-band ultraviolet B phototherapy may be effective. The systemic administration of glucocorticoids should be reserved for severe, refractory cases and should be administered in short courses.

In one series of patients followed for various intervals up to 2 years, 22 percent were without disease, 25 percent had periods without lesions ranging from weeks to years, and 53 percent were never free of lesions except when using local therapy. [5] Furthermore, it was evident that the eruption would clear within 1 year after onset if it cleared at all; after that time, it tended to persist and recur for many years.

LICHEN SIMPLEX CHRONICUS/PRURIGO NODULARIS

Lichen simplex chronicus, which is also known as *circumscribed neurodermatitis,* and prurigo nodularis are alterations in the skin that result from repetitive rubbing, scratching, and picking of the skin, owing to a variety of pruritogenic stimuli.

Historical Aspects

The term *lichen simplex chronicus* initially was used by Vidal, and this condition was further characterized by Brocq in 1891. In 1880, Hardaway described a skin disease characterized by multiple tumors associated with pruritus. In 1909, this entity was named prurigo nodularis by Hyde.

Epidemiology

Lichen simplex chronicus is uncommon in childhood. The peak incidence occurs between 30 and 50 years of age. Women are affected more frequently than are men. Individuals with prurigo nodularis can be divided into an atopic and a nonatopic group. [12] Prurigo nodularis patients in the group associated with atopic dermatitis have a younger mean age of onset of 19 ± 5 years and a high incidence of reactivity to multiple environmental allergens. In contrast, those patients with prurigo nodularis without atopic dermatitis have an older mean age of onset of 48 ± 14 years without hypersensitivity to environmental allergens.

Etiology and Pathogenesis

The underlying stimulus for the development of lichen simplex chronicus and prurigo nodularis is pruritus. Hypotheses regarding the pruritus focus on underlying medical disorders, associated dermatologic disorders, proliferation of nerves, and psychological aspects with emotional tension. The underlying medical disorders include chronic renal failure, obstructive biliary disease, Hodgkin's lymphoma, polycythemia rubra vera, hyperthyroidism, gluten-sensitive enteropathy, and human immunodeficiency infection. The important pruritic dermatoses are atopic dermatitis, allergic contact dermatitis, insect bites, and stasis dermatitis.

In prurigo nodularis, eosinophils, which contain eosinophil cationic protein and eosinophil-derived neurotoxin/eosinophil protein X, are increased in the dermis. [13] The basic proteins possess the ability to degranulate mast cells. HLA-DR and S-100 Langerhans cells are more numerous in the dermis.

The number of nerves containing immunoreactive CGRP and SP are increased in the dermis in prurigo nodularis but not lichen simplex chronicus. [14] Depletion of SP as demonstrated by confocal laser scanning microscopy associated with clinical improvement of prurigo nodularis lends support for the role of neuropeptides. [15] The number of nerves showing immunoreactive somatostatin, VIP, peptide histidine-isoleucine, galanin, and neuropeptide Y were the same in lichen simplex chronicus, prurigo nodularis, and normal skin. It has been suggested that the nerve proliferation results from mechanical trauma, such as scratching. SP and CGRP may release histamine from mast cells, which further enhances the pruritus. Schwann cell membranes and perineurium cells show increased expression of p75 nerve growth factor, which perhaps results in neural hyperplasia. [16] In the dermal papillae and upper dermis, alpha-melanocyte–stimulating hormone (a-MSH)-like immunoreactivity was visualized in the endothelial cells of the capillaries. [17] Although the role of a-MSH in prurigo nodularis is unknown, it may function in immunosuppression to counter cutaneous inflammation.

Clinical Manifestations

Lichen simplex chronicus appears as circumscribed, erythematous plaques with lichenification and excoriations. Often there is a single lesion (Fig. 123-3A). Commonly involved sites include the posterior and lateral aspects of the neck, extensor aspects of the forearms, lower legs, vulva, scrotum, and perianal area. Localized variants are known lichen nuchae, pruritus vulvae, pruritus scroti, and pruritus ani.

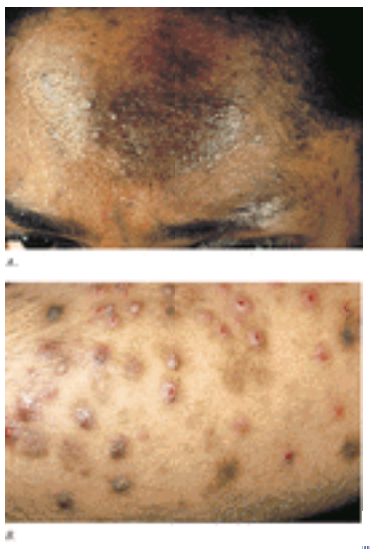

FIGURE 123-3 *A*. Lichen simplex chronicus. Lichenified plaque with erythema and excoriations. *B*. Prurigo nodularis. Several dome-shaped nodules, some with a depressed center.

Prurigo nodularis is a nodule that develops at a local site in which persistent picking and scratching occur. The lesions appear as dome-shaped nodules, which often have an eroded surface with scale and crusts (Fig. 123-3B). They range in size from several millimeters to 2 cm. Multiple lesions may be distributed on the extremities. The intervening skin may be normal or show changes such as erythema, scales, excoriations, lichenification, postinflammatory pigmentary changes, and scars.

Laboratory Findings

If an underlying systemic disease is suspected, a complete blood count with differential analysis, a blood chemistry profile that includes liver and renal function tests, thyroid function tests, and a chest radiograph may be obtained. Further laboratory studies depend on the history and on the results of the initial laboratory tests. Serum IgE levels may be elevated in atopic prurigo nodularis but are normal in those with nonatopic prurigo nodularis. [12]

Pathology

The histopathologic findings in lichen simplex chronicus include orthokeratosis, hypergranulosis, and epidermal hyperplasia with regular elongation of the rete ridges. A perivascular infiltrate of lymphocytes, macrophages, and fibroblasts may be present. The histopathologic features of prurigo nodularis are similar to those of lichen simplex chronicus; additional findings are a dome-shaped configuration, proliferation of Schwann cells, and neural hyperplasia.

Diagnosis and Differential Diagnosis

The diagnosis of lichen simplex chronicus or prurigo nodularis requires the elimination of primary dermatologic causes of pruritus and the search for underlying medical disorders. Lichen simplex chronicus must be differentiated from psoriasis, mycosis fungoides, dermatophyte infections, lichen planus, and lichen amyloidosis. Prurigo nodularis must be differentiated from keratoacanthomas, hypertrophic lichen planus, and perforating disorders.

Treatment and Prognosis

Lichen simplex chronicus and prurigo nodularis require similar therapeutic approaches. The traumatic perpetuation of the lesions should be explained to the patient. Treatment includes potent topical glucocorticoids, glucocorticoids under plastic-film occlusion, and intralesional injection of glucocorticoids. Doxepin cream can be used. Capsaicin cream has been used with clinical benefit in an open trial of 33 patients. [15] Oral H_1 antihistamines may be administered. Broad-band and narrow-band ultraviolet B phototherapy and psoralen plus ultraviolet A (PUVA) photochemotherapy may be of benefit. In some patients with prurigo nodularis, thalidomide, cyclosporine, azathioprine, and liquid nitrogen cryotherapy have been used. One patient with prurigo nodularis was successfully treated with a 585-nm pulsed dye laser.

The prognosis for lichen simplex chronicus and prurigo nodularis is variable, owing to the variety of causes of pruritus and the psychological status of the patient. When an underlying medical condition is present, improvement in pruritus may be achieved by treating the associated disorder.

REFERENCES

1. Goh CL, Akarapanth R: Epidemiology of skin disease among children in a referral skin clinic in Singapore. *Pediatr Dermatol* **11**:125, 1994

2. Krogh H-K: Nummular eczema: Its relationship to internal foci of infection. A survey of 84 case records. *Acta Derm Venereol Suppl (Stockh)* **40**:114, 1960

3. Aoyama H et al: Nummular eczema: An addition of senile xerosis and unique cutaneous reactivities to environmental aeroallergens. *Dermatology* **199**:135, 1999

4. Fleming C et al: Patch testing in discoid eczema. *Contact Dermatitis* **36**:261, 1997

5. Cowan MA: “Nummular eczema”: A review, follow-up and analysis of a series of 325 cases. *Acta Derm Venereol Suppl (Stockh)* **41**:453, 1961

6. Bettoli V et al: Nummular eczema during isotretinoin treatment. *Arch Dermatol* **16**:617, 1987

7. Adachi A et al: Mercury-induced nummular dermatitis. *J Am Acad Dermatol* **43**:383, 2000

8. Järvikallio A et al: Neuropeptides SP, VIP and CGRP are increased in lesions of atopic dermatitis and nummular eczema. *J Invest Dermatol* **106**:891, 1996

9. O'Loughlin S et al: Serum IgE in dermatitis and dermatosis: An analysis of 497 cases. *Arch Dermatol* **113**:309, 1977

10. Järvikallio A et al: Quantitative analysis of tryptase- and chymase-containing mast cells in atopic dermatitis and nummular eczema. *Br J Dermatol* **136**:871, 1997

11. Horsmanheimo L et al: Mast cells are one major source of interleukin-4 in atopic dermatitis. *Br J Dermatol* **131**:348, 1994

12. Tanaka M et al: Prurigo nodularis consists of two distinct forms: Early onset atopic and late-onset non-atopic. *Dermatology* **190**:269, 1995

13. Johansson O et al: Eosinophil cationic protein- and eosinophil-derived neurotoxin/eosinophil protein X-immunoreactive eosinophils in prurigo nodularis. *Arch Dermatol Res* **292**:371, 2000

14. Vaalasti A et al: Calcitonin gene-related peptide immunoreactivity in prurigo nodularis: A comparative study with neurodermatitis circumscripta. *Br J Dermatol* **120**:619, 1989

15. Ständer S et al: Treatment of prurigo nodularis with topical capsaicin. *J Am Acad Dermatol* **44**:471, 2001

16. Liang Y et al: Light and electron microscopic immunohistochemical observations of p75 nerve growth factor receptor-immunoreactive dermal nerves in prurigo nodularis. *Arch Dermatol Res* **291**:14, 2000

17. Liang Y et al: Endothelial cells express an a-melanocytic-stimulatory-hormone-like immunoreactivity in prurigo nodularis. *Br J Dermatol* **144**:1262, 2001

T>

Chapter 124

Gerd Plewig Thomas Jansen

Seborrheic Dermatitis

INCIDENCE
ETIOLOGY AND PATHOGENESIS
Seborrhea
Microbial Effects
Miscellaneous
IMMUNODEFICIENCY AND SEBORRHEIC DERMATITIS
PSORIASIS AND SEBORRHEIC DERMATITIS
PITYRIASIS AMIANTACEA
HISTOPATHOLOGY
EXFOLIATIVE CYTOLOGY
CLINICAL FINDINGS
Seborrheic Dermatitis in Infants
Erythroderma Desquamativum (Leiner's Disease)
Seborrheic Dermatitis in Adults
THERAPY
Infants
Adults
Antifungals
Metronidazole
Lithium Succinate
Vitamin D3 Analogues
Isotretinoin
Phototherapy

REFERENCES

Seborrheic dermatitis is a common chronic papulosquamous dermatosis that is usually easily recognized. It affects infants and adults and is often associated with increased sebum production (seborrhea) of the scalp and the sebaceous follicle-rich areas of the face and trunk. The affected skin is pink, edematous, and covered with yellow-brown scales and crusts. The disease varies from mild to severe, including psoriasiform or pityriasiform patterns and erythroderma. [1] Seborrheic dermatitis is one of the most common skin manifestations in patients with human immunodeficiency virus (HIV) infection. [2] Consequently, it is included in the spectrum of premonitory lesions and should be carefully evaluated in high-risk patients.

INCIDENCE

Seborrheic dermatitis has two age peaks, one in infancy within the first 3 months of life and the second around the fourth to the seventh decades of life. No data are available on the exact incidence of seborrheic dermatitis in infants, but the disorder is common. The disease in adults is believed to be more common than psoriasis, for example, affecting at least 3 to 5 percent of the population in the United States. [3] Men are affected more often than women in all age groups. There does not appear to be any racial predilection. Seborrheic dermatitis is found in up to 85 percent of patients with HIV infection. [2]

ETIOLOGY AND PATHOGENESIS

Although many theories abound, the cause of seborrheic dermatitis remains unknown.

Seborrhea

The disease is associated with oily-looking skin (seborrhea oleosa), although an increased sebum production cannot always be detected in these patients. [4] Even if seborrhea does provide a predisposition, seborrheic dermatitis is not a disease of the sebaceous glands. The high incidence of seborrheic dermatitis in newborns parallels the size and activity of the sebaceous glands at this age. It has been shown that newborns have large sebaceous glands with high sebum secretion rates similar to adults. [5] In childhood, sebum production and seborrheic dermatitis are closely connected. In adulthood, however, they are not, as the sebaceous gland activity peaks in early puberty and decades later seborrheic dermatitis may occur.

The sites of predilection—face, ears, scalp, and upper part of the trunk—are particularly rich in sebaceous follicles. Two diseases are prevalent in these regions: seborrheic dermatitis and acne. In patients with seborrheic dermatitis, the sebaceous glands are often particularly large on cross-sectional histologic specimens. In one study, skin surface lipids were not elevated but the lipid composition was characterized by an increased proportion of cholesterol, triglycerides, and paraffin, and a decrease in squalene, free fatty acids, and wax esters. [6] However, mild abnormalities in the skin surface lipids could well result from the ineffective keratinization, which is often demonstrable histopathologically. Seborrheic dermatitis seems to be more frequent in patients with parkinsonism, in whom sebum secretion is increased. Similarly, after reduction of sebum production induced by levodopa and by promestriene, seborrheic dermatitis may improve.

The synonym *eczéma flannelaire* stems from the idea that a retention of skin surface lipids by clothing and rubbing of the rough textiles on the skin—cotton (flannel), wool, or synthetic underwear in particular—promotes or aggravates seborrheic dermatitis.

Microbial Effects

Unna and Sabouraud, who were among the first to describe the disease, favored an etiology involving bacteria, yeasts, or both. This hypothesis has remained unsupported, although bacteria and yeast can be isolated in great quantities from affected skin sites.

In infancy, *Candida albicans* is often found in dermatitic skin lesions and in stool specimens. Although intracutaneous tests with candidin, positive agglutinating antibodies in serum, and positive lymphocyte-transformation tests in affected infants revealed sensitization to *C. albicans,* these observations cannot be convincingly linked to the pathogenesis.

Aerobic bacteria were recovered from the scalp of patients with seborrheic dermatitis (140,000 bacteria/cm^2 versus 280,000 in normal individuals and 250,000 in persons with dandruff). In contrast, *Staphylococcus aureus* was rarely seen in normal persons or those with dandruff. *Staphylococcus* was recovered in about 20 percent of patients with seborrheic dermatitis, accounting for an average of about 32 percent of the total skin flora. [7]

Propionibacterium acnes counts were low in patients with seborrheic dermatitis (7550 bacteria/cm^2 in those without dandruff). The small quantities of *P. acnes* in patients with seborrheic dermatitis may explain the low yield of free fatty acids from their skin surfaces.

The lipophilic yeast *Pityrosporum* is abundant in normal skin (504,000 organisms/cm^2 versus 922,000 in individuals with dandruff and 665,000 in patients with seborrheic dermatitis). [7] This organism has received particular attention in recent years. Some authors claim strong evidence in favor of a pathogenic role for these microbes, whereas others do not share this view. Their argument is that *Pityrosporum ovale* is not the causative organism, but is merely present in large numbers. In patients with pityriasis versicolor [8] and *Pityrosporum* folliculitis, [9] seborrheic dermatitis has been found in a higher percentage than expected. Clearing of seborrheic dermatitis by selenium sulfide and continued suppression of *P. ovale* with topical amphotericin B caused a relapse of the disease on inflamed scalp skin. [10] In seborrheic dermatitis, both normal and high levels of serum antibodies against *P. ovale* have been demonstrated. A cell-mediated immune response to *P. ovale* has been found in normal individuals using *Pityrosporum* extracts in lymphocyte-transformation studies. [11] Overgrowth of *P. ovale* may lead to inflammation, either through introduction of yeast-derived metabolic products into the epidermis or as a result of the presence of yeast cells on the skin surface. The mechanism of production of inflammation would likely then be through Langerhans cell and T lymphocyte activation by *Pityrosporum* or its by-products. When *P. ovale* comes into contact with serum, it can activate complement via the direct and alternative pathways and this may play some part in the introduction of inflammation. [12] A possible role for this yeast in the pathogenesis of seborrheic dermatitis is supported by the fact that seborrheic dermatitis–like lesions have been shown to be reproducible in animal models by inoculation of *P. ovale*. [13]

Miscellaneous

DRUGS Several drugs have been reported to produce seborrheic dermatitis–like lesions, including arsenic, gold, methyldopa, cimetidine, and neuroleptics.
NEUROTRANSMITTER ABNORMALITIES Seborrheic dermatitis is often associated with a variety of neurologic abnormalities, pointing to a possible influence of the nervous system. These neurologic conditions include postencephalitic parkinsonism, epilepsy, supraorbital injury, facial paralysis, unilateral injury to the ganglion of Gasser, poliomyelitis, syringomyelia, and quadriplegia. Emotional stress seems to aggravate the disease; a high rate of seborrhea is reported among combat troops in times of war.
PHYSICAL FACTORS It has been suggested that cutaneous blood flow and skin temperature may be responsible for the distribution of seb-orrheic dermatitis. [14] Seasonal variations in temperature and humidity are related to the course of the disease. Low fall and winter temperatures and low humidity in centrally heated rooms are known to worsen the condition. Seborrheic dermatitis of the face was observed in 8 percent of 347 patients receiving PUVA therapy for psoriasis and occurred within a few days to 2 weeks after the beginning of treatment; [15] the patients had no previous history of facial psoriasis or seborrheic dermatitis. Lesions were avoided by masking the face during irradiation.
ABERRANT EPIDERMAL PROLIFERATION Epidermal proliferation is increased in seborrheic dermatitis, like psoriasis, explaining why cytostatic therapeutic modalities may improve the condition. [16]
NUTRITIONAL DISORDERS Zinc deficiency in patients with acrodermatitis enteropathica and acrodermatitis enteropathica–like conditions may be accompanied by dermatitis mimicking seborrheic dermatitis of the face. Seborrheic dermatitis is, however, not associated with zinc deficiency nor does it respond to supplementary zinc therapy. Seborrheic dermatitis in infancy may have a different pathogenesis. Biotin deficiency, whether secondary to a holocarboxylase deficiency or a biotinidase deficiency, and abnormal metabolism of essential fatty acids have been proposed as possible mechanisms. [17]

IMMUNODEFICIENCY AND SEBORRHEIC DERMATITIS

The development of seborrheic dermatitis either de novo or as a flare of preexisting disease also may serve as a clue to the presence of HIV infection. The first report of this association in 1984 was followed by observations from all parts of the world. [2] The expression of the disease differs in several aspects from its classical form seen in HIV seronegative individuals (Fig. 124-1, Fig. 124-2, Fig. 124-3 and Fig. 124-4): the distribution is extensive, severity is marked, and treatment often difficult (Fig. 124-5). Even the histopathologic changes differ somewhat from those seen in commonly

encountered seborrheic dermatitis (Table 124-1).

FIGURE 124-1 Seborrheic dermatitis with involvement of nasolabial folds, cheeks, eyebrows, and nose.

FIGURE 124-2 Seborrheic dermatitis of forehead and scalp.

FIGURE 124-3 Seborrheic dermatitis of the ear lobe. The ear canal is also affected.

FIGURE 124-4 Seborrheic dermatitis of the upper back.

FIGURE 124-5 Widespread unusual distribution pattern of seborrheic dermatitis in a patient with AIDS. *A*. Moist patches

on the centrofacial region and hairy scalp. *B*. Moist lesions on the chest. In patients with AIDS, the disease responds poorly to conventional therapy.

AIDS-Associated Seborrheic Dermatitis	Classical Seborrheic Dermatitis
Epidermis	
Widespread parakeratosis	Limited parakeratosis
Many necrotic keratinocytes	Rare necrotic keratinocytes
Focal interface obliteration with clusters of lymphocytes	No interface obliteration
Sparse spongiosis	Prominent spongiosis
Dermis	
Many thick-walled vessels	Thin-walled vessels
Increased plasma cells	Rare plasma cells
Focal leukocytoclasis	No leukocytoclasis

SOURCE: From Sangueza OP et al: Seborrheic-like dermatitis of acquired immunodeficiency syndrome: A clinicopathologic study. J Am Acad Dermatol 14:242, 1986.

TABLE 124-1 **Histopathologic Differences Between AIDS-Associated Seborrheic Dermatitis and Classical Seborrheic Dermatitis**

The increased incidence and severity of seborrheic dermatitis in HIV seropositive individuals has led to speculation that unchecked growth of *Pityrosporum* in immunosuppressed patients is responsible. However, a study that compared quantitative *Pityrosporum* cultures in AIDS patients with and without seborrheic dermatitis failed to demonstrate increased yeast colonization in patients with seborrheic dermatitis. [18]

PSORIASIS AND SEBORRHEIC DERMATITIS

In patients with a psoriatic diathesis, particularly adults, seborrheic dermatitis is said to evolve into psoriasis. The term *sebopsoriasis* is sometimes used for these overlapping conditions. It should be used with caution because psoriasis, especially of the scalp, is clinically and histopathologically almost indistinguishable from seborrheic dermatitis.

PITYRIASIS AMIANTACEA

Pityriasis amiantacea (synonyms: tinea amiantacea, porrigo amiantacea, tinea asbestina, fausse teigne amiantacée, keratosis follicularis amiantacea) is the name given to a disease of the scalp in which heavy scales extend onto the hairs and separate and bind together their proximal portions.

Pityriasis amiantacea is a reaction of the scalp, often without evident cause, that may occur at any age. It may be observed as a complication or sequel of streptococcal infection, seborrheic dermatitis, atopic dermatitis, lichen simplex, and it also occurs in psoriasis, of which it may be the first clinical manifestation. [19]

The process may be circumscribed or diffuse. It is only slightly inflammatory with dry, micaceous scales, or markedly inflammatory with admixture of a crust (Fig. 124-6). Removal of the scales reveals normal or erythematous, edematous epidermis. The process is not followed by atrophy, scarring, or alopecia. If scarring alopecia occurs, it may be related to secondary infection. A common form complicates chronic or recurrent fissuring behind one or both ears mostly in young girls. The sticky scales extend several centimeters into the neighboring scalp. Another form extends from patches of lichen simplex and is seen mainly in middle-aged women.



FIGURE 124-6 Pityriasis amiantacea. Masses of sticky silvery scales adhere to the scalp and are attached in layers to the shafts of the hairs that they surround.

HISTOPATHOLOGY

The histopathologic picture varies according to the stage of the disease: acute, subacute, or chronic. [20], [21] In acute and subacute seborrheic dermatitis, there is a sparse superficial perivascular infiltrate of lymphocytes and histiocytes, slight to moderate spongiosis, slight psoriasiform hyperplasia, follicular plugging by orthokeratosis and parakeratosis, and scale-crusts containing neutrophils at the tips of the follicular ostia (see Table 124-1). In chronic seborrheic dermatitis, there are markedly dilated capillaries and venules in the superficial plexus, in addition to the above-mentioned features.

Clinically and histopathologically the lesions of chronic seborrheic dermatitis are psoriasiform and often difficult to distinguish from those of psoriasis. [20] Abortive forms of psoriasis share many features with seborrheic dermatitis. There are lesions that resemble psoriasis and may persist over many years before they finally turn into overt psoriasis. The most important diagnostic signs of seborrheic dermatitis are mounds of scale-crust containing neutrophils at the tips of the dilated horn-filled follicular infundibula. Acrosyringia and acroinfundibula may be plugged by corneocyte casts.

The most consistent findings in pityriasis amiantacea are spongiosis, parakeratosis, migration of lymphocytes into the epidermis, and a variable degree of acanthosis. [22] The essential features responsible for the asbestosis-like scaling are diffuse hyperkeratosis and parakeratosis together with follicular keratosis in which each hair is surrounded by a sheath of

corneocytes and debris.

EXFOLIATIVE CYTOLOGY

Cytologic abnormalities of superficial horny cells (corneocytes) including ortho- and parakeratotic (nucleated) cells, horny cells in different stages of nuclear decomposition (halo cells), and masses of leukocytes can be evaluated by exfoliative cytology. Seborrheic dermatitis and psoriasis, however, present similar findings compared with other conditions of the dermatitis-eczema group. [23]

CLINICAL FINDINGS

In all patients with seborrheic dermatitis there is a so-called seborrheic stage, which is often combined with a gray-white or yellow-red skin discoloration, prominent follicular openings, and mild to severe pityriasiform scales. Several forms can be distinguished (Table 124-2).

Infantile
Scalp (cradle cap)
Trunk (including flexures and napkin area)
Leiner's disease
Nonfamilial
Familial C5 dysfunction
Adult
Scalp
Face (may include blepharitis)
Trunk
Petaloid
Pityriasiform
Flexural
Eczematous plaques
Follicular
Generalized (may be erythroderma)

TABLE 124-2 **Clinical Patterns of Seborrheic Dermatitis**

Seborrheic Dermatitis in Infants

The disease occurs in infants predominantly within the first months of life as an inflammatory disease mainly affecting the hairy scalp and intertriginous folds with greasy-looking scales and crusts. Other regions such as the center of the face, chest, and neck may also be affected. Scalp involvement is fairly characteristic. The frontal and parietal scalp regions are covered with an oily-looking, thick, often fissured crust (*crusta lactea, milk crust* or *cradle cap*). Hair loss does not occur and inflammation is sparse. In the course of the disease, the redness increases and the scaled areas form clearly outlined erythematous patches topped by a greasy scale. Extension beyond the frontal hairline occurs. The retroauricular folds, the pinna of the ear, and the neck may also be involved. Otitis externa is often a complicating factor. Semiocclusive clothing and diapers favor moisture, maceration, and intertriginous dermatitis, particularly in the folds of the neck, axillae, anogenital area, and groins. Opportunistic infection with *C. albicans, S. aureus,* and other bacteria occurs. The clinical aspect reminds one of psoriasis vulgaris, hence the expressions *psoriasoid* or *napkin psoriasis.*

COURSE The disease is usually protracted over weeks to months. Exacerbation and, rarely, generalized erythroderma desquamativum may occur. The prognosis is good. There is no indication that infants with seborrheic dermatitis are more likely to suffer from the adult form of the disease.
DIFFERENTIAL DIAGNOSIS The differential diagnosis in seborrheic dermatitis of infancy includes atopic dermatitis (which usually starts after the third month of life); psoriasis in newborns, a rare disease; scabies; and Langerhans cell histiocytosis. The most useful distinguishing feature between atopic dermatitis and seborrheic dermatitis is the increased number of lesions on the forearms and shins in the former and in the axillae in the latter. The development of skin lesions solely in the diaper area favors a diagnosis of infantile seborrheic dermatitis. RAST (radioallergosorbent assay test) screening to egg white and milk antibodies or other geographically or ethnically relevant allergens (e.g., soybean), and, to a lesser extent, total IgE levels, may be useful in diagnosing atopic dermatitis at an early stage and distinguishing it from infantile seborrheic dermatitis. Absent to mild pruritus is considered a significant feature of infantile seborrheic dermatitis. Some authors believe that infantile seborrheic dermatitis is a clinical variant of atopic dermatitis rather than a separate entity. [24]

Erythroderma Desquamativum (Leiner's Disease)

This complication of seborrheic dermatitis in infants (dermatitis seborrhoides infantum) was described in 1908 by Leiner. [25] There is usually a sudden confluence of lesions, leading to a universal scaling redness of the skin (erythroderma). The young patients are severely ill with anemia, diarrhea, and vomiting. Secondary bacterial infection is common. The prognosis is very good unless proper intensive care and skin care are provided. The disease is both a familial and a nonfamilial form. The former is noted for having a functional deficiency of C5 complement, resulting in defective opsonization. These patients respond to antibiotics and infusions of fresh-frozen plasma or whole blood. The true nature of this disease remains obscure.

Seborrheic Dermatitis in Adults

The clinical picture and course of this disease differ in adults and infants.

Seborrheic eczematid is the mildest form of the disease (eczematid = eczema-like, dermatitis-like). It is associated with seborrhea, scaling, mild redness, and often pruritus of the scalp, eyebrows, nasolabial folds, and retroauricular area, as well as over the sternum and the shoulder blades (see Fig. 124-1 to Fig. 124-4). Asymptomatic fluffy, white dandruff of the scalp represents the mild end of the spectrum of seborrheic dermatitis and has been referred to as *pityriasis sicca*.

Erythema paranasale, more common in young women than men, may be part of this disease spectrum.

Patchy seborrheic dermatitis is the classical, well-known disease with chronic recurrent lesions. Lesions have a predilection for scalp, temples, retroauricular folds (see Fig. 124-3), external ear canals (see Fig. 124-3), inner parts of the eyebrows and glabella with nasolabial folds (see Fig. 124-2), and V-shaped areas of the chest and back (*eczema mediothoracicum*). Less frequently, intertriginous areas such as the side of the neck, axillae, submammary region, umbilicus, and genitocrural folds are involved.

Skin lesions are characterized by a yellow color, mild to severe erythema, mild inflammatory infiltrate, and oily, thick scales and crusts. This has occasionally been referred as *pityriasis steatoides*. Patients report pruritus, particularly on the scalp and in the ear canal. The lesions start with follicular and perifollicular redness and mounds; they spread until they form clearly outlined, round to circinate (petaloid) patches (Greek *petalon,* a thin plate or leaf). The pityriasiform type of seborrheic dermatitis is seen on the trunk and mimics the lesions of pityriasis rosea, producing oval scaly lesions whose long axes tend to parallel the ribs. In some individuals, only one or two sites are involved. Chronic otitis externa may be the sole manifestation of seborrheic dermatitis often mistaken for mycotic infections. Another possible manifestation is blepharitis with honey-colored crusts along the rim of the eyelid and casts of horny cell debris around the eyelashes. In men, a more follicular type of seborrheic dermatitis may extend over large parts of the back, flanks, and abdomen.

COURSE Usually the disease lasts for years to decades with periods of improvement in warmer seasons and periods of exacerbation in the colder months. Widespread lesions may occur as a result of improper topical treatment or sun exposure. The extreme variant of the disease is a generalized exfoliative erythroderma (seborrheic erythroderma).
DIFFERENTIAL DIAGNOSIS The differential diagnosis varies from site to site: *scalp:* dandruff, psoriasis, atopic dermatitis, impetigo; *ear canal:* psoriasis or contact dermatitis, irritant or allergic; *face:* rosacea, contact dermatitis, psoriasis, impetigo; *chest and back:* pityriasis versicolor, pityriasis rosea; *eyelids:* atopic dermatitis, psoriasis, *Demodex folliculorum* infestation (demodicosis, demodicidosis); *intertriginous areas:* psoriasis, candidiasis.

THERAPY

In general, therapy is directed toward loosening and removal of scales and crusts, inhibition of yeast colonization, control of secondary infection, and reduction of erythema and itching. Adult patients should be informed about the chronic nature of the disease and understand that therapy works by controlling the disease rather than by curing it. The prognosis of infantile seborrheic dermatitis is excellent because the condition is benign and self-limited.

Infants

SCALP Treatment consists of the following measures: removal of crusts with 3 to 5% salicylic acid in olive oil or a water-soluble base; warm olive oil compresses; application of low-potency glucocorticosteroids (e.g., 1% hydrocortisone) in a cream or lotion for a few days; topical antifungal agents such as imidazoles (in a shampoo); mild baby shampoos; proper skin care with emollients, creams, and soft pasts.
INTERTRIGINOUS AREAS Treatment measures include drying lotions, such as 0.2 to 0.5% clioquinol in zinc lotion or zinc oil. In cases of candidiasis, nystatin or amphotericin B lotion or cream can be applied followed by soft and stiff pastes. In cases of oozing dermatitis, application of 0.1 to 0.25% gentian violet where still available in combination with cotton or muslin diapers is often helpful. Imidazole preparations (e.g., 2% ketoconazole in soft pastes, creams, or lotions) may also be effective.
DIET Milk-free and high-protein, low-fat diets have not been shown to be of value nor has the efficacy of oral or intramuscular biotin, vitamin B complex, or essential fatty acids been established.

Adults

Because the disease runs an unpredictably long course, careful and mild treatment regimens are recommended. Anti-inflammatory agents and, when indicated, antimicrobial or antifungal agents have to be used.

SCALP Frequent shampooing with shampoos containing 1 to 2.5% selenium sulfide, imidazoles (e.g., 2% ketoconazole), zinc pyrithione, benzoyl peroxide, salicylic acid, coal or juniper tar where still available, or detergents is recommended. Crusts or scales can be removed by overnight application of glucocorticosteroids or salicylic acid in water-soluble bases or, when necessary, under occlusive dressings. Tinctures, alcoholic solutions, hair tonics, and similar products usually aggravate the inflammatory state and should be avoided. In pityriasis amiantacea, scales should be removed by the use of Oil of Cade ointment or a topical tar/salicylic ointment. Either preparation should be washed out of the scalp after 4 to 6 h with a suitable shampoo (e.g., tar or imidazole shampoo). Potent topical corticosteroid scalp creams or liquids may be beneficial in some cases, preferably under plastic occlusion in the initial phase. If topical treatment fails, systemic glucocorticosteroids (e.g., 0.5 mg prednisolone/kg body weight per day for approximately 1 week) in combination with topical treatment (steroid under occlusion, followed by open application) is worthwhile. Concomitant antimicrobial treatment (e.g., macrolides, sulfonamides) is reserved for stubborn cases, especially if bacterial coinfection of the scalp is proven or suspected. Of course, the underlying condition must be treated. Treatment remains difficult, and relapses occur frequently.
FACE AND TRUNK Patients should avoid greasy ointments and reduce or omit the use of soaps. Alcoholic solutions or pre- or aftershave lotions should not be recommended. Low-potency glucocorticosteroids (1% hydrocortisone is usually sufficient) are helpful early in the course of the disease. Uncontrolled long-term applications will lead to side effects such as steroid dermatitis, steroid rebound phenomenon, steroid rosacea, and perioral dermatitis.
SEBORRHEIC OTITIS EXTERNA Seborrheic otitis externa can be best treated with a low-potency glucocorticoid cream or ointment. Many otic preparations (solutions) that contain neomycin and other antibiotics, often in combination, are strong sensitizers and should be avoided. Once dermatitis is under control, the glucocorticoid should be discontinued and a solution containing aluminum acetate should be applied once or twice daily to maintain control. This acts as a drying agent and reduces the microbial flora. Basic ointments or plain petroleum jelly, gently applied into the ear canal (without cotton tips), are often helpful to maintain satisfaction of the patient.

SEBORRHEIC BLEPHARITIS Special consideration is given to the treatment of seborrheic blepharitis. The use of hot compresses with gentle débridement with a cotton-tipped applicator and baby shampoo one or more times daily is recommended. Stubborn cases may require the use of a topical antibiotic such as sodium sulfacetamide ophthalmic ointment. The use of ocular preparations containing glucocorticosteroids should be deferred to an ophthalmologist. If *D. folliculorum* mites occur in large numbers, they should be treated with antiparasitic drugs such as lindane (?-hexachlorocyclohexane), crotamiton, permethrin, or benzyl benzoate.

Antifungals

Good results are achieved with topical application of antifungal agents, especially imidazoles. Clinical studies have reported response rates ranging from 63 percent [26] up to 90 percent [27] after 4 weeks. In these trials, imidazoles such as itraconazole, miconazole, fluconazole, econazole, bifonazole, and ciclopiroxolamine were studied. The imidazole compound that has been mostly used is ketoconazole. In several clinical studies, 2% ketoconazole cream has been found as effective as glucocorticosteroid creams, and this often results in more prolonged remissions. [26], [28] Comparative studies of topical antifungal agents, however, are lacking. Personal experience, though based on open uncontrolled studies only, favors 2% ketoconazole cream. Other antifungal agents may also be effective. In a limited trial, 1% butenafine cream, a benzylamine derivative, demonstrated efficacy in the topical treatment of seborrheic dermatitis.

Oral antifungal agents such as ketoconazole and terbinafine are also effective, but because of potential side effects and pharmacoeconomic considerations, should probably be limited to severe or refractory cases. Antifungal agents have a wide spectrum of effects, including anti-inflammatory properties and inhibition of cell wall lipid synthesis. This efficacy is not proof of a causal relationship between *P. ovale* and seborrheic dermatitis.

Metronidazole

Topical metronidazole is a worthwhile alternative in the treatment repertoire of seborrheic dermatitis. It has been used successfully in patients with rosacea. Extemporaneous formulations (1 to 2% in a cream base) or commercial products (0.75% gel, cream, or lotion, 1% cream) are used once or twice daily. Recently, a significant benefit of using 1% metronidazole gel over placebo in the treatment of seborrheic dermatitis was demonstrated. [29]

Lithium Succinate

Another topical agent that is effective in the treatment of seborrheic dermatitis is lithium succinate, which possesses antifungal properties. [30]

Vitamin D_3 Analogues

Vitamin D_3 analogues (calcipotriol cream or lotion, calcitriol ointment, or tacalcitol ointment) are also recommended and useful in selected patients. [31] Their anti-inflammatory properties may be responsible for their efficacy in seborrheic dermatitis.

Isotretinoin

Oral isotretinoin (13- *cis*-retinoic acid) is a useful, although not officially approved, drug for this indication. Low to very-low doses (0.05 to 0.1 mg/kg body weight daily) given for several months clear stubborn seborrheic dermatitis in many cases. The lowest available dose (10 mg) is given daily with a fat-rich food for better absorption. The frequency can be reduced to 3 to 5 days per week. In women of child-bearing age, all precautions against pregnancy must be met.

Phototherapy

Narrow-band UVB phototherapy appears to be an effective and safe treatment option for patients with severe and refractory seborrheic dermatitis. [32] PUVA therapy has been used successfully in the erythrodermic form of the disease. [33]

REFERENCES

1. Fox BJ, Odom RB: Papulosquamous diseases: A review. *J Am Acad Dermatol* **12**:597, 1985

2. Soeprono FF et al: Seborrheic-like dermatitis of acquired immunodeficiency syndrome: A clinicopathologic study. *J Am Acad Dermatol* **14**:242, 1986

3. Johnson M, Roberts J: *Prevalence of dermatological diseases among persons 1–74 years of age.* Publication No. (PHS) 79-1660. Washington, DC, US Department of Health and Human Services, 1977

4. Burton JL, Pye PJ: Seborrhoea is not a feature of seborrhoeic dermatitis. *Br Med J* **286**:1169, 1983

5. Agache P et al: Sebum levels during the first year of life. *Br J Dermatol* **103**:643, 1980

6. Gloor M et al: Über Menge und Zusammensetzung der Haut-oberflächenlipide beim sogenannten seborrhoischen Ekzem. *Dermatol Monatsschr* **158**:759, 1972

7. McGinley K et al: Quantitative microbiology of the scalp in non-dandruff, dandruff, and seborrheic dermatitis. *J Invest Dermatol* **64**:401, 1975

8. Faergemann J, Fredriksson T: Tinea versicolor with reference to seborrhoeic dermatitis. *Arch Dermatol* **115**:966, 1979

9. Bäck O et al: *Pityrosporum* folliculitis: A common disease of the young and middle-aged. *J Am Acad Dermatol* **12**:56, 1985

10. Leyden JJ et al: Role of microorganisms in dandruff. *Arch Dermatol* **112**:333, 1976

11. Sohnle PG, Collins-Lech C: Relative antigenicity of *P. orbiculare* and *C. albicans*. *J Invest Dermatol* **75**:279, 1980

12. Sohnle PG, Collins-Lech C: Activation of complement by *Pityrosporum orbiculare*. *J Invest Dermatol* **80**:93, 1983

13. Faergemann J, Fredriksson T: Experimental infections in rabbits and humans with *Pityrosporum orbiculare* and *P. ovale*. *J Invest Dermatol* **77**:314, 1981

14. Hale EK, Bystryn JC: Relation between skin temperature and location of facial lesions in seborrheic dermatitis. *Arch Dermatol* **136**:559, 2000

15. Tegner E: Seborrhoeic dermatitis of the face induced by PUVA treatment. *Acta Derm Venereol Suppl (Stockh)* **63**:335, 1983

16. Shuster S: The aetiology of dandruff and the mode of action of therapeutic agents. *Br J Dermatol* **111**:235, 1984

17. Tollesson A et al: Essential fatty acids in infantile seborrheic dermatitis. *J Am Acad Dermatol* **28**:957, 1993

18. Wikler JR et al: Quantitative skin cultures of *Pityrosporum* yeasts in patients seropositive for the human immunodeficiency virus with and without seborrheic dermatitis. *J Am Acad Dermatol* **27**:37, 1992

19. Ring DS, Kaplan DL: Pityriasis amiantacea: A report of 10 cases. *Arch Dermatol* **129**:913, 1993

20. Braun-Falco O et al: Histologische Differentialdiagnose von Psoriasis vulgaris und seborrhoischem Ekzem des Kapillitium. *Hautarzt* **30**:478, 1979

21. Metz J, Metz G: Zur Ultrastruktur der Epidermis bei seborrhoischem Ekzem. *Arch Dermatol Forsch* **252**:285, 1975

22. Knight AG: Pityriasis amiantacea: A clinical and histopathological investigation. *Clin Exp Dermatol* **2**:137, 1977

23. Goldschmidt H, Thew MA: Exfoliative cytology of psoriasis and other common dermatoses: Quantitative analysis of parakeratotic horny cells in 266 patients. *Arch Dermatol* **106**:476, 1972

24. Podmore P et al: Seborrheic eczema—A disease entity or a clinical variant of atopic eczema? *Br J Dermatol* **115**:341, 1986

25. Leiner C: Über Erythrodermia desquamativa, eine eigenartige universelle Dermatose der Brustkinder. *Arch Dermatol Syphilol (Berlin)* **89**:65, 1908

26. Pari T et al: Randomised double blind controlled trial of 2% ketoconazole cream versus 0.05% clobetasol 17-butyrate cream in seborrheic dermatitis. *J Eur Acad Dermatol Venereol* **10**:89, 1998

27. Green CA et al: Treatment of seborrhoeic dermatitis with ketoconazole: II. Response of seborrheic dermatitis of the face, scalp and trunk to topical ketoconazole. *Br J Dermatol* **116**:217, 1987

28. Katsambas A et al: A double-blind trial of treatment of seborrheic dermatitis with 2% ketoconazole cream compared with 1% hydrocortisone cream. *Br J Dermatol* **121**:353, 1989

29. Parsad D et al: Topical metronidazole in seborrheic dermatitis—A double-blind study. *Dermatology* **201**:35, 2001

30. Cuelenaere C et al: Use of topical lithium succinate in the treatment of seborrheic dermatitis. *Dermatology* **184**:194, 1992

31. Nakayama J: Four cases of sebopsoriasis or seborrheic dermatitis of the face and scalp successfully treated with 1a-24 (R)-dihydroxycholecalciferol (tacalcitol) cream. *Eur J Dermatol* **10**:528, 2000

32. Pirkhammer D et al: Narrow-band ultraviolet B (ATL-01) phototherapy is an effective and safe treatment option for patients with severe seborrheic dermatitis. *Br J Dermatol* **143**:964, 2000

33. Dahl KB, Reymann F: Photochemotherapy in erythrodermic seborrheic dermatitis. *Arch Dermatol* **113**:1295, 1977

T>

Chapter 125

Alexa Kimball

Vesicular Palmoplantar Eczema

HISTORICAL ASPECTS
EPIDEMIOLOGY
ETIOLOGY AND PATHOGENESIS
EXACERBATING FACTORS
GENETICS
PREVENTION
CLINICAL MANIFESTATIONS
LABORATORY FINDINGS
PATHOLOGY
DIAGNOSIS AND DIFFERENTIAL DIAGNOSIS
Differential Diagnoses
TREATMENT AND PROGNOSIS
Topical Therapy
Systemic Therapy

REFERENCES

Vesicular palmoplantar eczema is an endogenous dermatitis of the hands and feet characterized clinically by small to large blisters and histologically by spongiotic vesicles. It can be present as an acute and/or as a chronic problem.

The nomenclature and the clinical presentations of the variants of hand dermatitis, including vesicular palmoplantar eczema, often overlap, rendering the diagnostic categories imprecise. Moreover, some variants are frequently caused or exacerbated by more that one factor. For example, patients with pompholyx, the most acute form of vesicular palmoplantar eczema, have been noted to have a higher incidence of both atopy and contact dermatitis than controls.

With the above caveat in mind, vesicular palmoplantar dermatitis can be divided into four categories: pompholyx, chronic vesiculobullous hand dermatitis (often mistermed *dyshidrotic hand dermatitis*), hyperkeratotic hand dermatitis, and id reactions. Some authors have grouped these conditions in the category of endogenous hand dermatitis, to distinguish them from dermatitis clearly caused by exogenous factors such as contact allergy or irritation. [1]

Pompholyx is a term best reserved for acute explosive outbreaks of small to large vesicles and bullae on the palms and soles. It tends to occur more often in the spring and fall and may be associated with stress. Other etiologic factors are less well established. Cheiropompholyx and podopompholyx are terms occasionally used to describe cases affecting the palms or soles, respectively.

Chronic vesiculobullous hand dermatitis, also known as *dyshidrotic hand eczema* or *dyshidrotic hand dermatitis,* is usually characterized by small vesicles on the inner aspects of the fingers. “Dyshidrosis,” a dysfunction of the sweat gland, is disproved as a cause, but the term, unfortunately, persists.

A third category is *chronic hyperkeratotic hand dermatitis,* an entity that generally occurs on the central palms. Although vesicles do not dominate the clinical presentation, spongiosis observed histologically is indistinguishable from the other forms.

An *id reaction* is a vesiculobullous process, generally appearing on the lateral aspects of the fingers, elicited by an infection elsewhere in the body. The most common cause is a fungal infection. Treatment of the underlying cause usually leads to resolution.

Endogenous hand dermatitis can, of course, be exacerbated by exogenous factors, most notably irritant dermatitis and allergic contact dermatitis. In addition, atopy may, in some cases, predispose to the development of vesicular palmoplantar eczema.

HISTORICAL ASPECTS

The clinical presentation of an acute blistering disorder confined to the palms and the soles was first described by Fox in 1873. [1] He attributed the blisters to a disorder of the sweat gland, giving rise to the term “dyshidrosis.” Not long thereafter, Hutchison [2] described acute explosive blisters on the hands, which he termed “pompholyx” from the Greek word meaning bubble.

EPIDEMIOLOGY

Differences in classification and definition have made it difficult to assess the true incidence of endogenous hand disorders and most studies have focused on the prevalence of allergic contact and irritant contact dermatitis in occupational settings.

Pompholyx is the least-common presentation of hand dermatitis; in one Swedish series, pompholyx accounted for 6 percent (51 of 827) of the cases of hand eczema. [3]

ETIOLOGY AND PATHOGENESIS

With the exception of the id reaction, a direct cause of vesicular palmoplantar hand dermatitis is rarely identified. Although previous theories about “dyshidrosis,” a dysfunction of the acrosyringium, have been debunked, hyperhidrosis may be an exacerbating factor. [4] An increased number of Langerhans cells has been observed, similar to that seen in other forms of dermatitis affecting the hands. [5], [6] Stress has been cited to be an exacerbating factor, and hot weather during the summer months worsens the condition. [7] Pompholyx has been reported after intravenous immunoglobulin therapy, [8], [9] ingestion of piroxicam, [10] and after ingestion of certain metals in predisposed or sensitized patients. [11] There has been one case report of pompholyx occurring after implantation of a nickel-containing pacemaker in a nickel-allergic patient. [12]

EXACERBATING FACTORS

Contact allergy is common in patients affected with vesicular palmoplantar eczema, especially the chronic type, but the causal relationship is not always clear. [13] There are cases where contact allergy has exacerbated preexisting dermatitis and reports that ingestion of certain metals, including nickel, cobalt, and chromium, have caused flares. However, in other cases, the causal relationship may be the reverse [4] so that the skin's impaired barrier function in vesiculobullous hand dermatitis might, in some cases, lead to sensitization and a higher prevalence of contact dermatitis.

Investigations into the role of atopy have yielded mixed results. Some studies show levels of personal or familial atopy as high as 50 percent in affected subjects, as compared to 11.5 percent of controls, [7] but other studies demonstrate no difference in the prevalence in people with vesiculobullous hand dermatitis versus controls. [13]

GENETICS

Genetics does not appear to play a major role in hand dermatitis, with the possible exception of the genetic tendency to atopy.

PREVENTION

Prevention is a critical part of therapy in most cases, especially when known exacerbating factors are present. Avoidance of commonly encountered allergens, such as foods and plants, and irritants such as soaps, detergents, solvents, acids, and alkalis can be helpful. Modification of environmental exposure to exacerbating factors, such as friction and cold air, may also help with persistent or refractory disease.

CLINICAL MANIFESTATIONS

Vesiculobullous attacks can range from the inconvenient to the severe; rarely, it can lead to hospitalization. In true acute pompholyx, there is an explosive outbreak of deep-seated vesicles on the palms, the lateral aspects of the fingers and sometimes the soles, usually in a symmetric pattern. (Fig. 125-1 and Fig. 125-2). Discomfort and itching usually precede the development of the blisters, which have been described as having a “tapioca” appearance (Figure 125-3). Blisters may coalesce, then desiccate and resolve without rupture. Large blisters can be drained but should not be unroofed.

FIGURE 125-1 Acute pompholyx (cheiropompholyx).

FIGURE 125-2 Podopompholyx.

This phase is generally followed by desquamation of the affected areas. Individual outbreaks are usually self-limited over 2 to 3 weeks, although they may recur. Secondary bacterial infection may occur and should be treated as it may evolve into cellulitis or lymphangitis. Attacks are most common among adolescents and young adults and seem to be more common in the spring and summer months.

Chronic vesiculobullous hand dermatitis is more common than true pompholyx and more difficult to manage because of its relapsing course. The clinical presentation includes small, 1- to 2-mm vesicles filled with clear fluid, on the lateral aspects of the fingers, palms, and soles (see Fig. 125-3). As the condition becomes more chronic, the clinical appearance may evolve and subsequently appear more fissured and hyperkeratotic. A clear history of vesicles or exacerbations characterized by blistering may help to narrow the classification of a given presentation of hand dermatitis.

FIGURE 125-3 Vesiculobullous eczematous dermatitis on the lateral fingers. Note the tapioca-like, deep-seated vesicles on the sides of the fingers.

Patients with hyperkeratotic hand dermatitis are usually male and generally present with a chronic keratotic pruritic plaques, sometimes with fissures on the central palm (Fig 125-4). This condition may be the end result of allergy, excoriation, and irritation, but generally the cause is not identifiable and contact allergy does not seem to play an important role. This type of eczema commonly occurs in middle-aged to elderly men and is normally very refractory to treatment. [14] Frictional factors or lichen simplex chronicus (neurodermatitis) may be an important factor in some cases. Plantar involvement is present in a minority of cases. In an ID reaction, erythematous vesicles usually are noted on the lateral aspects of the fingers and the palms in the setting of a distant inflammatory reaction (Fig 125-5). The vesicles are usually pruritic and resolve with treatment of the underlying condition.

FIGURE 125-4 Hyperkeratotic hand eczema.

FIGURE 125-5 Id reaction to tinea infection.

LABORATORY FINDINGS

There are no distinctive laboratory findings characteristic of vesicular palmoplantar eczema, although IgE levels may be elevated in atopic patients.

PATHOLOGY

The histology of these entities depends on the chronicity of the disease. The primary vesicle appears as an intraepidermal spongiotic vesicle that does not involve the acrosyringia [15] on both conventional and electron microscopy. Lymphocytic infiltration is common in the epidermis with a mixed infiltrate observed in the dermis. In more chronic cases, the epidermis may show hyperproliferation, hyperkeratosis, or even psoriasiform epidermal hyperplasia. PAS (periodic acid–Schiff) staining can be helpful in excluding fungal elements.

DIAGNOSIS AND DIFFERENTIAL DIAGNOSIS

The diagnosis of vesiculobullous hand dermatitis is usually made on the basis of clinical presentation, history, and, sometimes, histology. Patch testing may be useful in helping to distinguish this entity from other palmoplantar disorders or in eliminating other exacerbating factors such as irritant exposure and contact allergy.

There are many other skin conditions of the hands and feet that can be difficult to distinguish from vesiculobullous hand dermatitis. Several of these diagnoses may coexist.

Differential Diagnoses

Allergic contact dermatitis may be clinically indistinguishable from constitutional forms of hand eczema, and patch testing should always be performed in those with recurrent, atypical, or persistent forms of the disease. Common allergens include nickel, potassium dichromate, rubber, fragrances, formaldehyde, and lanolin.

Irritant contact dermatitis is by far the most common hand dermatitis and is often exacerbated by occupational exposures. It is usually symmetric, chronic, and affects the dorsal fingertips and web spaces.

Atopic hand dermatitis is associated with a number of factors: hand dermatitis before age 15 years, persistent eczema on the body, dry or itchy skin in adult life, and widespread atopic dermatitis in childhood. The backs of the hands, particularly the fingers are affected with erythema, vesiculation, crusting, excoriation, and scale.

Infections, most commonly from tinea, [16] can mimic endogenous hand dermatitis. In cases of asymmetric or atypical cases, or in cases of small vesicles confined to the feet, a potassium hydroxide exam may be useful in ruling out primary tinea infection.

In chronic cases of hand dermatitis, fungal and bacterial infections may be superimposed and treatment may result in improvement in clinical symptoms.

Herpes simplex may, in unusual cases, present as blisters on the hands. [17]

Bazex's acrokeratosis paraneoplastica is a rare, acute, erythematous, scaling vesiculobullous hand dermatitis with nail dystrophy associated with neoplasia, usually squamous carcinomas of the upper digestive and respiratory tracts, although there have been some reports of similar findings in patients with colon cancer and genitourinary tumors.

Psoriasis and *psoriasiform hand dermatitis* are most prominent over pressure points. Psoriasis can normally be distinguished by its sharply marginated, nummular, or circinate scaly plaques; the silvery scales; and the presence of psoriasis elsewhere. Psoriasiform hand dermatitis can occur without a family or personal history of psoriasis. It is a diagnosis made primarily on clinical and histologic presentation. At times, however, it appears as though eczematous, hyperkeratotic, and psoriatic diatheses coexist. Repeated pressure or friction may cause hyperkeratosis in some individuals.

Pustular hand dermatitis is generally easy to distinguish because, unlike the presentation of uninfected vesiculobullous hand dermatitis, pustules are the primary lesion. For example, in pustular psoriasis, the vesicles are cloudy and painful.

Keratolysis exfoliativa (recurrent focal palmar peeling), is a chronic asymptomatic noninflammatory peeling of the palms and soles, most commonly during the summer months. It is thought to occur more frequently in people with hyperhidrosis in these areas. Scaling usually starts from one to two fine points and expands outward to larger circular areas. The asymptomatic condition is usually self-limited, requiring only emollients.

Other blistering diseases, such as pemphigoid, pemphigus, or epidermolysis bullosa, may affect the hands and feet, but usually do so in the setting of blisters elsewhere on the body. [18]

TREATMENT AND PROGNOSIS

Treatment of vesiculobullous hand dermatitis should be based on the acuity of the condition, the severity of the disease, the prominence of blisters versus chronic changes, and any relevant history that reveals possible cofactors. There are few published, randomized, controlled therapeutic studies of hand dermatitis; thus, most therapy is empiric.

Topical Therapy

Topical glucocorticoids, usually of high potency, remain the mainstay of treatment. They are often more effective if used under occlusion, although this approach may increase the chance of infection. Topical drying agents such as Domeboro soaks, Burrow's solution (aluminum subacetate), or dilute potassium permanganate solution (1:8000) may be useful in acute forms with a predominance of vesicles. Newer therapies include topical tacrolimus and pimecrolimus.

For maintenance, frequent ointment applications and avoidance of irritants are generally helpful. Vinyl gloves, rather than latex, are recommended because of the risk of either having an underlying allergy or of developing one in the setting of impaired barrier function. Tap-water iontophoresis with pulsed direct current showed no benefit in time to improvement for subjects with hand dermatitis over controls, but those who were treated had much longer remissions by a factor of months. [19], [20] Hyperkeratotic palmar eczema is notoriously difficult to manage. In addition to potent topical glucocorticoids, intralesional glucocorticoids may prove to be of some benefit. Retinoids, keratolytics in high concentrations, and tar preparations are also used.

Systemic Therapy

For pompholyx, oral steroids may be required and are often effective. However, because of their side effects, they are inappropriate for long-term management. Large blisters may need to be drained and bacterial superinfection may require treatment with systemic antibiotics.

Other treatments for severe cases have included UVB, systemic, topical and bathwater PUVA, and UVA1. [21], [22] and [23]

For severe cases, systemic immunosuppressives have been tried, including low-dose methotrexate, [24] mycophenolate mofetil, [25] and cyclosporine [26] in doses ranging from 2.5 to 5.0 mg/kg. Superficial radiotherapy (Grenz ray) is still used at a few centers. This condition may be one of the last indications for this treatment modality, although there is controversy as to its efficacy in double-blind studies. [27], [28]

Disulfiram (200 mg per day for 8 weeks) was used in an open-label study to treat a small group of women with nickel allergy as chelation therapy and resulted in improvement in 10 women. [29] The role of ingested allergens in provoking vesicular hand eczema remains controversial. Patients with troublesome and persistent vesicular palmar eczema who are found to be allergic to substances that may be ingested may benefit from elimination diets.

For the hyperkeratotic variant of hand dermatitis, treatment can be exceedingly challenging. If topical glucocorticoid options fail, acitretin may be of benefit, and success with cyclosporine has been reported.

Two severity indices, the dyshidrosis area and severity index (DASI) [30] and the total sign and symptoms score (TSS), have been validated and may prove useful in clinical trials to better assess the effectiveness of some of these approaches.

For id reactions, treating the underlying condition is the most useful intervention, and should result in the resolution of the lesions. The same treatments described above may also be helpful.

Pompholyx tends to occur as intermittent explosive outbreaks, which fortunately, become less frequent with middle age. The more chronic forms of vesicular palmoplantar eczema, however, are much more persistent and frustrating to manage and often require multiple therapeutic approaches over time.

REFERENCES

1. Epstein E: Hand dermatitis: Practical management and current concepts. *J Am Acad Dermatol* **10**:395, 1984

2. Hutchinson J: Cheiropompholyx. *Lancet* **1**:630, 1876

3. Agrup GG: Hand eczema and hand dermatoses in south Sweden. *Acta Derm Venereol* **49**(suppl 61):1, 1969

4. Yokozeki H et al: The role of metal allergy and local hyperhidrosis in the pathogenesis of pompholyx. *J Dermatol* **19**:964, 1992

5. Rosen K: Pustulosis palmoplantaris and chronic eczematous hand dermatitis. Treatment, epidermal Langerhans cells and association with thyroid disease. *Acta Derm Venereol Suppl (Stockh)* **137**:1, 1988

6. Rosen K et al: Epidermal Langerhans' cells in chronic eczematous dermatitis of the palms treated with PUVA and UVB. *Acta Derm Venereol* **69**:200, 1989

7. Lodi A et al: Epidemiological, clinical and allergological observations on pompholyx. *Contact Dermatitis* **26**:17, 1992

8. Iannaccone S et al: Pompholyx (vesicular eczema) after i.v. immunoglobulin therapy for neurologic disease. *Neurology* **53**:1154, 1999

9. Ikeda K et al: Pompholyx after IV immunoglobulin therapy for neurologic disease. *Neurology* **54**:1879, 2000

10. Youn JI et al: Piroxicam photosensitivity associated with vesicular hand dermatitis. *Clin Exp Dermatol* **18**:52, 1993

11. Fisher AA: Hand dermatitis resembling pompholyx in nickel sensitive patients. *Cutis* **47**:157, 1991

12. Landwehr HA, Vanketel KG: Pompholyx after implantation of a nickel-containing pacemaker in a nickel-allergic patient. *Contact Dermatitis* **9**:147, 1983

13. Lehucher-Michel MP et al: Dyshidrotic eczema and occupation: A descriptive study. *Contact Dermatitis* **43**:200, 2000

14. Hersle K, Mobacken H: Hyperkeratotic dermatitis of the palms. *Br J Dermatol* **107**:195, 1982

15. Kutzner H et al: Are acrosyringia involved in the pathogenesis of “dyshidrosis”? *Am J Dermatopathol* **8**:109–116, 1986

16. Nakagawa T et al: Trichosporon cutaneum (*Trichosporon asahii*) infection mimicking hand eczema in a patient with leukemia. *J Am Acad Dermatol* **42**:929, 2000

17. Parker RK, Guin JD: Hand eczema herpeticum. *Cutis* **52**:227–228, 1993

18. Barth JH et al: Palmo-plantar involvement in auto-immune blistering disorders—Pemphigoid, linear IgA disease and herpes gestationis. *Clin Exp Dermatol* **13**:85, 1988

19. Wollina U et al: Therapy of hyperhidrosis with tap water iontophoresis. Positive effect on healing time and lack of recurrence in hand–foot eczema. *Hautarzt* **49**:109, 1998

20. Odia S et al: Successful treatment of dyshidrotic hand eczema using tap water iontophoresis with pulsed direct current. *Acta Derm Venereol* **76**:472, 1996

21. Behrens S et al: PUVA-bath photochemotherapy (PUVA-soak therapy) of recalcitrant dermatoses of the palms and soles. *Photodermatol Photoimmunol Photomed* **15**:47, 1999

22. Schmidt T et al: UVA1 irradiation is effective in treatment of chronic vesicular dyshidrotic hand eczema. *Acta Derm Venereol* **78**:318, 1998

23. Davis MD et al: Topical psoralen-ultraviolet A therapy for palmoplantar dermatoses: Experience with 35 consecutive patients. *Mayo Clin Proc* **73**:407, 1998

24. Egan CA et al: Low-dose oral methotrexate treatment for recalcitrant palmoplantar pompholyx. *J Am Acad Dermatol* **40**:612, 1999

25. Pickenacker A et al: Dyshidrotic eczema treated with mycophenolate mofetil. *Arch Dermatol* **134**:378, 1998

26. Granlund H et al: Comparison of cyclosporine and topical betamethasone-17,21-dipropionate in the treatment of severe chronic hand eczema. *Acta Derm Venereol* **76**:371, 1996

27. Lindelof B et al: A double-blind study of Grenz ray in chronic eczema of the hands. *Br J Drematol* **117**:77, 1987

28. Cartwright PH, Nowell NR: Comparison of Grenz rays versus placebo in the treatment of chronic hand eczema. *Br J Dermatol* **117**:73, 1987

29. Kaaber K et al: Antabuse treatment of nickel dermatitis. Chelation—A new principle in the treatment of nickel dermatitis. *Contact Dermatitis* **5**:221, 1979

30. Vocks E et al: The Dyshidrotic Eczema Area and Severity Index—A score developed for the assessment of dyshidrotic eczema. *Dermatology* **198**:265, 1999

T>

Chapter 126

Gérald Piérard Isabelle Fumal Claudine Piérard-Franchimont

Cold Injuries

PHYSIOLOGIC RESPONSE TO COLD
THERMOREGULATION AND HUNTING REACTION
COLD, WIND, AND HUMIDITY
BIOMETROLOGY APPLIED TO COLD EXPOSURE
CLASSIFICATION OF SKIN COLD INJURIES
FROSTBITE
NONFREEZING COLD INJURY AND DAMPNESS
WINTER XEROSIS
ACROCYANOSIS
ERYTHROCYANOSIS
CHILBLAINS
COLD URTICARIA AND POLYMORPHOUS COLD ERUPTION
COLD PANNICULITIS AND RELATED ENTITIES
SCLEREMA NEONATORUM AND SUBCUTANEOUS FAT NECROSIS OF THE NEWBORN
ERYTHROMELALGIA
RAYNAUD'S PHENOMENON
CRYOGLOBULINEMIA
LIVEDO RETICULARIS

REFERENCES

The human capacity for physiologic adaptation to cold is minimal. This may cause problems because seasonal changes in the outdoor environment are quite prominent even in the temperate zone of the world. In this context, skin is important in preserving homeostasis between the body and its environment. One of its main roles is thermoregulation, where cutaneous blood flow and the resulting skin temperature may vary widely in order to help preserve the core body temperature. [1], [2] There are physiologic, behavioral, and environmental factors that predispose to skin alterations following cold exposure.

PHYSIOLOGIC RESPONSE TO COLD

Core body temperature is maintained within a narrow range by thermoregulatory mechanisms that rely largely on control of the cutaneous blood flow. Arteriovenous anastomoses are abundant in acral areas, and they regulate the blood volume that passes through the skin. When the skin is cooled, there is usually an immediate acute shutdown in the amount of blood that flows to the surface. These events result in changes in skin temperature, heat loss, and color. Skin reactivity and the anatomic pattern of blood supply differ in the skin of newborns, adults, and older people. For instance, a reticulate appearance of cooled skin is a common finding in young infants (Fig. 126-1).

FIGURE 126-1 Reticulate appearance of cooled skin in the newborn due to the anatomic pattern of the blood supply and factors influencing flow, such as arteriolar vasoconstriction and the increased viscosity of cooled blood.

The parallel arrangement of large arteries and veins in the limbs allows countercurrent exchange of heat. Vasoconstriction due to cold results in shunting of blood from the superficial to the deep venous system, and heat is transferred from arteries to veins. Thus the blood going to the acral part of the limbs is precooled, and less heat is lost to the environment. With such thermoregulation, the body can maintain a constant core temperature of approximately 37ˆC over a range of external temperatures between 15 and 54ˆC.

Normally, the skin is to some extent adapted to a cooler environment than the 37ˆC of internal organs. With the presence of many cold-adapted enzymes, the skin may even function more effectively when slightly cooled. In the case of adipose tissue, mild chronic exposure to cooling may lead to a progressive better insulation. Chronically cold-exposed skin also develops a more efficient system for shunting blood away from the surface. These adaptive mechanisms are most flexible during the first years of life. Tissues in the aged are less able to develop new shunts.

The body fluid balance is affected by prolonged cold exposure, leading to hemoconcentration, extracellular fluid expansion, and diuresis. Increased sympathetic nerve activity and release of histamine can be observed. A reduction in plasma volume is, in part, due to venoconstriction and raised intracapillary pressure, which lead to enhanced filtration of intravascular fluid into the interstitium. In cold water, this is counteracted to some extent by hydrostatic forces. An interesting feature of winter swimmers is rapid rewarming of the interscapular region, providing circumstantial evidence that winter swimming may improve cold tolerance through nonshivering thermogenesis. The effect of cold water swimming following the extreme heating of the sauna [3] is somewhat comparable to the threat of accidental cold water immersion. Well-being in both groups and survival in the latter group largely depend on the degree of subcutaneous insulation. Overweight persons, as well as those who are well clothed, survive prolonged accidental cold water exposure.

[4]

Viscosity of fluids increases as temperature decreases. However, blood is a nonnewtonian fluid exhibiting thixotropy, by which it becomes less viscous with increasing flow velocity independent of temperature. This effect is strongly influenced by hematocrit and by packing of erythrocytes. Normally, rouleau formation maintains some flexibility of the erythrocyte columns, but defects in erythrocyte flexibility, such as are present in sickle cell anemia, can lead to severe disturbances of flow, especially in slow-flow conditions. Disordered erythrocyte flexibility can present as a decrease in the sedimentation rate. In persons who suffer from inflammatory diseases and a blood sedimentation rate lower than 2 mm/h, erythrocyte flexibility disorders should be considered. Such a situation is not uncommon in patients suffering from cold disorders. Macrophages also can block capillaries when developing pseudopods as a result of reduced flow. The combination of slow flow and leukocyte conformational changes is, in part, a physiologic process enabling these cells to migrate through the endothelial lining. [5] Other factors affecting blood viscosity include increased platelet adhesiveness, changes in concentrations of proteins, and the presence of abnormal proteins. Fibrinogen level is particularly important.

To some extent the skin becomes stiffer when cooled. The deformability and elasticity of the epidermis and dermis, and especially the capacity of the adipose tissue to dissipate the distorting forces of compression, are altered. These physical changes may influence the clinical signs of skin cold injuries. The interplay of these factors with a global depression of metabolism determines the normal skin response to cold and influences the related pathologic manifestations.

THERMOREGULATION AND HUNTING REACTION

Local and systemic thermoregulation is complex. A group of neurons of the hypothalamus responds directly to temperature. When the temperature decreases, the rate of discharges decreases. From this brain temperature-sensitive area, signals radiate to various other portions of the hypothalamus to control either heat production or heat loss. Stimuli that influence the autonomic nervous system, such as painful stimulation, mental stress, arousal stimuli, and deep breaths, can all produce cutaneous vasoconstriction in warm subjects but vasodilation in cold subjects. [6] The extent and direction of cutaneous vasomotor reflex responses depend therefore on skin temperature. Furthermore, the responses in the hands may differ from simultaneous responses in the feet, suggesting that there is spatial organization of vasomotor control. The response of the skin to cooling in atopic dermatitis and in disorders of sympathetic control often differ from normal. [7] Indeed, neuromediators synthesized and released by cutaneous cells play a prominent role in these regulations.

Cold exposure produces an initial massive cutaneous vasoconstriction, resulting in a fall in skin temperature. This change serves to maintain core temperature, but at the expense of the skin. Conversely, cold-induced vasodilation represents a protective mechanism against skin necrosis. This physiologic reflex, known as the *hunting reaction of Lewis,* involves transient cyclic vasodilation caused by the opening of arteriovenous anastomoses. [8] For instance, when a finger is immersed in water at 0ˆC, an initial drop in skin temperature to 2 to 4ˆC is followed by a rise of 7 to 13ˆC. With continued cold exposure, the temperature drops again, and the cycle is repeated over and over, especially in people acclimatized to cold, who have rapid cycling times and higher final skin temperatures. When core temperature is threatened, the hunting phenomenon ceases, and vasoconstriction persists. [7]

COLD, WIND, AND HUMIDITY

A cold environment can be a threat to the skin, with a subsequent fall in core body temperature. Many physiologic, behavioral, and environmental factors predispose to the global effects of cold injuries. Marked increases in convective, conductive, or radiant heat loss are responsible for the immediate effects of cold exposure. For instance, touching of metal objects considerably increases conductive cooling. Other predisposing factors increasing heat loss and/or decreasing heat production and clothing insulation make people especially susceptible to cold. [9]

There is ample evidence that the effect of low temperature on skin biology is, in part, a function of environmental humidity, wind speed, and altitude. In these respects, the wind chill index is indicative of the convective heat loss. Its value affects the gradients of temperature and water content across the stratum corneum, resulting in an imbalance in condition between outer and deeper epidermal layers. [10] High altitude, which reduces the oxygen supply to tissues, also contributes to increasing the skin damage induced by cold.

Environmental absolute humidity is a key factor for cold injuries. This parameter indicates the mass of water vapor present in a unit volume of the atmosphere, unlike relative humidity (RH), which is the ratio of the quantity of water vapor present in the atmosphere to the quantity that would saturate it at the actual temperature. An accurate representation of the amount of moisture in the air as a function of temperature is given by the calculation of the dew point, [11] which is defined as the temperature of the air at which the gaseous moisture begins to condense, i.e., when RH reaches 100 percent.

Poor clothing insulation is a common reason for cold injuries. The insulation can be insufficient when clothing is too light, wet, tight, permeable to wind, or inadequate to cover the cold sensitive body parts. Individual factors predisposing to cold injuries are physical injuries, leanness, inadequate behavior, low physical fitness, fatique, dehydration, previous cold injuries, sickness, trauma, poor peripheral circulation, tight constrictive clothing, and old age. [9] Newborns, the elderly, and individuals with impaired mental faculties remain the most vulnerable. Severity of damage is often increased by alcohol, smoking, and psychotropic drug intake.

Severe cold injuries have always represented a dramatic threat to human history. In particular, they have affected the outcome of battles and wars. [12], [13] American troops at Valley Forge during the winter of 1777 were endangered more by the cold than by the British army. During the Napoleonic wars, the Grand Army of France lost more than four-fifths of its troops in the Russian campaign primarily due to cold injuries. During World War I, the British recorded about 115,000 cases of frostbite and trench foot. The number of casualties declined after the winter of 1916 with the enforcement of

disciplinary measures including a second pair of dry socks, mandatory arrangements for drying socks, and time provided for sock changes. During World War II, American cold casualties were greater than 90,000 in the European theater alone, and only 15 percent of these soldiers returned to combat. Approximately one-third of these casualties had trench foot, and one-third had frostbite. In the Korean War, about 9000 cold casualties occurred, most of which were frostbite. Peacetime military operations also may be responsible for similar threats. [14]

Today, cold injuries are becoming more prevalent among the general population. [15] Many cases are associated with alcohol consumption, homelessness in urban centres, and car breakdown. Frostbite also prevails in winter sport enthusiasts, such as cross-country skiers and backpackers who get lost or trapped in a snowstorm. [2], [16], [17] and [18]

Adaptation to cold protects one from responding inappropriately, and a moderate degree of exposure to cooling might be health-promoting by stimulating a responsive and protective vasculature. In contrast, individuals who have experienced severe cold injury may have a profoundly delayed or abolished hunting reaction in the affected limbs. [19] They are rendered more susceptible to recurrent cold injury with pain, hyperesthesia, or paresthesia. [20] Some of these subjects also have coldness of the skin, which is very persistent and probably related to a functional imbalance in the sympathetic nervous system resulting from increased a-adrenergic receptor density or affinity for norepinephrine. [21] In addition, changes of vascular structure may cause reduced vasocompliance subsequent to cold exposure. In addition, there may be impairment of normal vascular reflexes to a series of stimuli including deep inspiration, venous occlusion, neck cooling, and ipsilateral skin cooling. [21]

BIOMETROLOGY APPLIED TO COLD EXPOSURE

Objective and quantitative assessments of the skin following cold exposure are possible using a series of biometrologic methods. Standardization of measuring conditions and procedures is required for skin temperature and blood flow assessments.

Thermography is the measurement and recording of the temperature at the skin surface. Contact and noncontact devices are available. The most popular methods are based on thermal conductance and infrared or microwave thermography. They suffer from relatively poor sensitivity.

The most widely used method to assess skin blood flow relies on laser-Doppler flowmetry. This method is designed to provide a continuous noninvasive measurement of microvascular perfusion in terms of relative changes in blood volume and velocity. The method is based on the effect of the light on moving erythrocytes and static components of a limited volume of tissue. Laser-Doppler imaging was designed to overcome contact measurements and spatial variability. These devices are based on the laser-Doppler principle, and data are collected without touching the skin. They generate a color-coded image of tissue perfusion. Photoplethysmography, using red or infrared emitting diodes, is well correlated with laser-Doppler velocimetry. It consists of a continuous recording of light intensity scattered by the skin. The signal is generated by the amount of blood present in a given skin area. The higher the hemoglobin content, the higher is the amount of light that is absorbed. Hence the method is sensitive to blood volume. The velocity of erythrocytes also may influence the readings through changes in the optical transmittance due to changes in their orientation relative to their speed.

CLASSIFICATION OF SKIN COLD INJURIES

Freezing and nonfreezing injuries basically can be distinguished according to the severity and duration of chilling. However, the nature of damage caused depends on many variables other than the actual temperature. Skin conditions caused by cold temperature are not uncommon. Recognition is generally easy at a clinical level, but awareness of the much less common underlying disorders is important. Treatment, both physical and pharmacologic, is aimed at keeping the body warm and maintaining vasodilation.

Frostbite is the consequence of extreme and prolonged freezing conditions. In addition, the whole body may cool down so much that life-threatening hypothermia may ensue. This condition can occur in many regions of the world. It is an especially important concern among people who enjoy cold weather sports, particularly in mountains and circumpolar regions. Prompt recognition and treatment are of paramount importance because many hypothermia victims can recover from very low body temperatures. Treatment in an adequate medical facility can make the difference between full recovery and lifelong problems. Even if someone appears to be dead from exposure to cold, resuscitative efforts should be started and continued until the proper core body temperature is reached. [15]

Extreme and often conductive heat loss at a given body site freezes the tissues and results in localized blistering and necrosis (Fig. 126-2). Several cutaneous disorders also occur when the tissue temperature is maintained just above freezing for long periods. These conditions include chilblains, cold urticaria, cold panniculitis, erythrocyanosis, and acrocyanosis, among others. This may be a consequence of impaired blood flow, reduced sensory perception, or a change in the physical properties of components of the tissues, such as may occur in adipose tissue.

FIGURE 126-2 Necrosis of the skin induced by freezing a wart with liquid nitrogen.

Minor but chronic cold exposure combined with environmental desiccation may have profound effects on the biology of the epidermis. As a result, winter xerosis develops. [22], [23] Persistent erythema of the face and the hands is not a rare finding (Fig. 126-3).

FIGURE 126-3 Facial redness in a person exposed to temperate climate with cold winters.

FROSTBITE

Frostbite occurs when tissue freezes after exposure to extreme cold air, liquids, or metals. The clinical effects of accidental injury that leads to death of tissues are similar to those caused by cryosurgery. [24] The components of tissue that may lead to damage when frozen are water, with formation of ice crystals at 0ˆC, and lipids such as fat globules or cell membrane constituents.

The rate of freezing determines the focus of freezing injury. [25] The extracellular formation of ice occurs most commonly with slow freezing, whereas fast freezing tends to produce intracellular ice. The formation of ice crystals in the extracellular space alters the osmotic properties of the tissues and disturbs the flow of water and electrolytes across the cell membranes. Thawing may be as damaging as the freezing itself, and repeated freeze and thaw cycles, as may occur in accidental injury, compound the injury, making available more water, which rapidly provides intracellular flooding. The rewarming rate is also important. In slow rewarming, ice crystals become larger and more destructive. Cells are also exposed to a high concentration of electrolytes for a longer period than with rapid rewarming.

As the body cools, there is a reflex constriction of the arteries and veins in the extremities. This results in increased venous pressure, decreased capillary perfusion, and sludging. Cooling also creates a left shift in the oxygen dissociation curve, and hemoglobin gives up its oxygen less readily. These two conditions result in hypoxia and damage to the capillaries and surrounding tissue. Oxygen tension is further decreased by thrombus formation in the microvasculature resulting in arteriovenous shunting. Arterial and arteriolar constriction, mediated by sympathetic outflow, initiates and probably maintains circulatory impairment. In addition, segmental vascular necrosis occurs in areas of erythrostasis, suggesting that ultimate damage may depend more on insufficient clearance of toxic substances than on initial vasoconstriction.

Cell types vary in their susceptibility to cold injury. Melanocytes are very sensitive to cold, and damage may occur at -4 to -7ˆC. This sensitivity explains the hypopigmentation that follows cryotherapy. In addition, it appears that black persons are more susceptible to frostbite than whites. Nerve axons are also easily damaged by cold, and nerve injury may occur with axonal degeneration of large myelinated fibers. Autonomic fibers are also affected, and this may account for the abnormal sweating and cold sensitivity that follow nonfreezing cold injury. [26], [27] Nerve sheaths are quite resistant to cold, as are bone and cartilage. [19] Desolidification of lipids in adipose tissue and disruption of endothelial cells lining blood vessels and lymphatics, with secondary disturbances of permeability and blood flow, are other consequences of severe cold. In the overall assessment, there are marked similarities in the pathologic processes to those seen in thermal burns and in ischemia-perfusion injuries.

Three stages of cooling are recognized. The first is massive vasoconstriction, which causes a rapid fall in skin temperature. In a second step, the hunting reaction follows with a cyclic rise and fall in skin temperature. If cold exposure continues, the third stage of freezing occurs as the skin temperature falls to approach ambient temperature. The events

that ensue in freezing and nonfreezing cold injuries are similar. [12], [28] They are listed in Table 126-1.

1. Arterial and arteriolar vasoconstriction
2. Excessive venular and capillary vasodilation
3. Increased endothelial leakage
4. Erythrostasis
5. Arteriovenous shunting
6. Segmental vascular necrosis
7. Massive thrombosis

TABLE 126-1 **Consequences of Cold Injuries**

Frosbite usually affects a finger, toe, ear, nose, or cheek. The clinical presentation of frostbite falls into three categories corresponding to mild frostbite or frostnip, superficial frostbite, and deep frostbite with tissue loss.

Frostnip involves only the skin and causes no irreversible damage. There is sensation of severe cold progressing to numbness followed by pain. Erythema is usually present on the cheeks, ears, nose, and extremities (Fig. 126-4). There is no edema or bleb formation. Frostnip is the only form of frostbite that can be treated safely in the field with first aid measures.

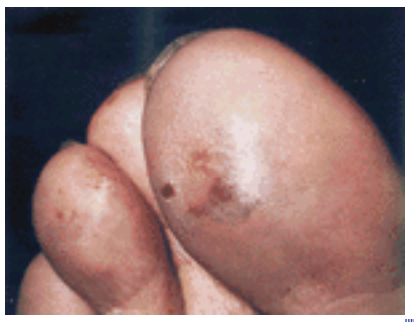

FIGURE 126-4 Frostnip.

Superficial frostbite involves the skin and immediate subcutaneous tissues. It includes the previously described signs but with progression of pain subsiding to feelings of warmth. This is a sign of severe involvement. The skin has a waxy appearance, but deeper tissues remain soft and resilient. Clear blebs form, accompanied by edema and erythema, within 24 to 36 h after thawing. Lesions may become eroded (Fig. 126-5).

FIGURE 126-5 Superficial frostbite.

Deep frostbite extends to the deep subcutaneous tissue. The injured skin becomes white or bluish white with a variable degree of anesthesia. Most often the affected skin becomes deceptively pain-free, and the discomfort of feeling cold vanishes. The tissue is totally numb, indurated with immobility of joints and extremities. Muscles may be paralyzed. Nerves, large blood vessels, and even bone may be damaged. Large blisters form 1 to 2 days after rewarming, and they can be classified according to depth, as in heat-induced burns. Frostbite blister fluid contains high amounts of prostaglandins, including prostaglandin F_{2a} and thromboxane A_2. These mediators may contribute to increased vasoconstriction, platelet aggregation, leukocyte adhesiveness, and ultimately progressive tissue injury. The blister fluid begins to be resorbed within 5 to 10 days, leading to formation of hard, black gangrene. Weeks later, a line of demarcation occurs, and the tissues distal to the line undergo autoamputation.

Preparation is the key to protecting individuals from the effects of cold weather; and frostbite, frostnip, and hypothermia always should be taken seriously. [25], [29] Prognostic factors are listed in Table 126-2. Nonmedicated ointments are traditionally used for protection against facial frostbite without evidence of their benefit. The thermal insulation they provide is indeed minimal. Protective emollients seem to cause a false sensation of safety, leading to an increased risk of frostbite, probably through neglect of efficient protective measures. [30], [31] However, in less extreme conditions, some specific topical formulations bring beneficial effects. [32]

Good prognostic signs	Large, clear blebs extending to the tips of the digits
	Rapid return of sensation
	Rapid return of normal (warm) temperature to the injured area
	Rapid capillary filling time after pressure blanching
	Pink skin after rewarming
Poor prognostic signs	Hard, white, cold, insensitive skin
	Cold and cyanotic skin without blebs after rewarming
	Dark hemorrhagic blebs
	Early evidence of mummification
	Constitutional signs of tissue necrosis, such as fever and tachycardia
	Cyanotic or dark red skin persisting after pressure
	Freeze-thaw-refreeze injury

SOURCE: From ref. 12 with permission.

TABLE 126-2 **Prognostic Signs of Frostbite**

The first consideration in frostbite treatment is to be aware that the victim may be suffering from hypothermia. [33] Because of the difficulty in assessing the depth of frostbite injury, conservative waiting after the frostbite episode is often encouraged to try to delineate the extent of tissue loss. Barring this, the main principles are to avoid trauma, friction, pressure, massaging with snow, and refreezing. Slow rewarming increases tissue damage, and therefore, rapid rewarming is the keystone of treatment. [14] It should be performed in a water bath no warmer than 40 to 42ˆC until the most distal part is flushed. Large amounts of analgesics may be required. The damaged part should be elevated, and blisters should be left intact. Surgical debridement is often delayed by 1 to 3 months after demarcation. However, triple-phase bone scans, magnetic resonnace imaging, and magnetic resonance angiography can be used to predict ultimate tissue loss and to assess the possibility of earlier surgical intervention. [28], [34], [35]

There is no uniformly accepted protocol for other measures allegedly beneficial in the treatment of frostbite injury. Intraarterial reserpine and sympathectomy have been used to reverse vasospasm, which may contribute to tissue loss. Their role is controversial, although some patients have benefited from the therapy. To counteract vasoconstriction caused by local release of inflammatory mediators, topical aloe vera, which inhibits thromboxane synthetase, and systemic ibuprofen, which inhibits cyclooxygenase, have been advocated. In addition, several adjunctive therapies, including vasodilators, thrombolysis, and hyperbaric oxygen, are sometimes useful. Tetanus toxoid should be given in case of open wounds.

Sequelae of frostbite include hypersensitivity to cold and hyperhidrosis. [26] Squamous cell carcinoma is a rare outcome, usually on the heel 20 to 30 years later. Epiphyseal plate damage or premature fusion may occur in children. Premature fusion can result in shortened digits, joint deviation, and dystrophic nails. In addition, frostbite arthritis, resembling osteoarthritis, may occur weeks to years later.

NONFREEZING COLD INJURY AND DAMPNESS

Nonfreezing cold injury occurs when tissues are cooled to temperatures between about 15ˆC and their freezing point for prolonged periods. This type of injury, which is exacerbated by dampness, has claimed numerous casualties in warfare. [12], [13] Nonfreezing cold injury may be followed by cold sensitivity and hyperhidrosis, which may persist for years.

During World War I, trench foot was identified as a separate entity. Wet conditions at temperatures above freezing and limb dependency due to immobility and constrictive footwear were important pathogenic factors. Three stages were described. Stage I consisted of initial erythema, edema, and tenderness. Stage II followed within 24 h with paresthesia, marked edema, numbness, and sometimes blisters. Stage III corresponded with progression to a usually superficial gangrene. Immersion foot was described in shipwreck survivors during World War II. It was similar to trench foot clinically and followed four phases corresponding to exposure, prehyperemia, hyperemia, and posthyperemia.

Tropical immersion foot was described during the Pacific campaign in World War II. Occurring after exposure to the warm, wet conditions of jungle warfare, this condition differed from classic trench foot and immersion foot by causing less tissue destruction, numbness, and anesthesia and by yielding quicker complete recovery. The role of temperature in tropical immersion foot is unclear and may not be important. [36] As with trench foot and immersion foot, prevention is most important.

Another specific condition known as “pulling-boat hands” was described as erythematous macules and plaques present on the dorsum of the hands and fingers of sailors aboard rowboats. [37] Small vesicles developed later, accompanied by itching, burning, and tenderness. These individuals were exposed to long periods of high humidity, cool air, and wind, an ideal setting for the development of nonfreezing cold injury. In addition, hours of vigorous rowing daily provided repetitive hand trauma.

WINTER XEROSIS

Many subjects present with dryness of the skin, particularly on the lower extremities, during wintertime. The hands, forearms, cheeks, lips, and trunk also may be affected. Itch, a dry appearance, chapping, and cracking of the stratum corneum are more or less prominent (Fig. 126-6). The condition is markedly influenced by cold environments, especially in combination with low humidity. [21], [22] Predisposing factors include atopic dermatitis, ichthyosis, and increasing age. Excessive washing exacerbates winter xerosis. Indeed, irritant dermatitis of the hands worsens in a cold and dry environment. [38] Emollients and improvement in the environmental temperature and humidity are helpful in controlling this skin condition.

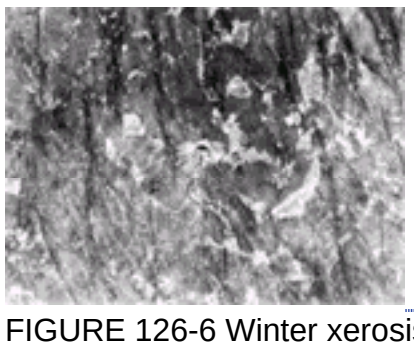
FIGURE 126-6 Winter xerosis observed under ultraviolet light.

ACROCYANOSIS

Acrocyanosis is a bilateral dusky, mottled discoloration of the entire hands, feet, and sometimes the face. It is persistent and accentuated by cold exposure. When the temperature is very low, the skin may be bright red. Trophic changes and pain do not occur, and pulses are present. This condition must be distinguished from Raynaud's phenomenon, which is clearly episodic and often segmental, as well as from obstructive arterial disease.

Acrocyanosis is genetically determined and usually starts in adolescence. Chronic vasospasm of small cutaneous arterioles or venules with a secondary dilatation of the capillaries and subpapillary venous plexus has been postulated. Stasis in the papillary loops with aneurysmal dilatation at the tips redistributes blood flow to the subpapillary venous plexus. The blood flow may be compromised by altered erythrocyte flexibility, increased platelet adhesiveness, and other plasma viscosity factors.

Acrocyanotic tissues are less sclerotic than in Raynaud's phenomenon. They contain twisted collagen fibrils and large pericytes. In cases developing for the first time late in life, a search for an underlying myeloproliferative disorder should be performed. Remittent necrotizing acrocyanosis is associated with enhanced susceptibility to cooling and pain, as well as ulceration and gangrene of the fingers. Arteriolar occlusion may occur by thrombi or intima proliferation.

There is no curative treatment for acrocyanosis. Supportive measures to keep the skin warm are helpful.

ERYTHROCYANOSIS

Erythrocyanosis is a dusky cyanotic discoloration, worse in winter, that occurs over areas with a thick layer of subcutaneous fat (Fig. 126-7). The condition is seen most often on the lower legs and thighs of adolescent girls and middle-aged women. Nodular lesions similar to chilblains may occur and have been described in women with severe erythrocyanosis and paraplegia. Keratosis pilaris, angiokeratomas, and telangiectases are commonly associated (Fig. 126-8). Spontaneous improvement often occurs after a few years. However, the disease may persist with long-standing edema and fibrosis.

FIGURE 126-7 Erythrocyanosis of plump upper arms of a woman.


FIGURE 126-8 Angiokeratomas occurring on the upper arm of erythrocyanotic skin of the patient shown in Fig. 126-7.

Warm clothes and weight reduction are important to decease the insulating effect of the subcutaneous fat, which is responsible for a chronically lower skin temperature. The outcome remains unpredictable.

CHILBLAINS

Chilblains, also called *pernio* or *perniosis* (Fig. 126-9A), are localized inflammatory lesions caused by continued exposure to cold above the freezing point. [39] Dampness and wind that increase cold conductivity and convection play a part. Absolute temperature is less important than cooling of nonadapted tissue. The condition shows a genetic predisposition. It has been described most often in temperate regions, where winters are occasionally cold and damp.

Chilblains are seen less often in very cold climates, where well-heated houses and warm clothing are essential. Both acrocyanosis and chilblains appear to be more common in children, women, and persons with low body mass. As such, anorexia nervosa is a predisposing factor. Spontaneous healing is common when spring arrives, and relapse is frequent on the following winters. However, chilblains do not always occur at the time of maximum cold.

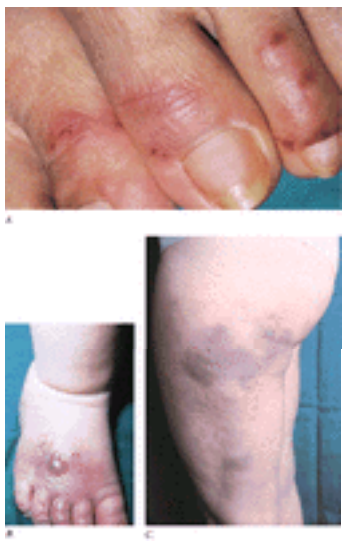

FIGURE 126-9 Chilblains are common at such sites as the hands and feet when they are exposed to both cooling and tight garments. *A.* Chilblains on the toes. *B.* Chilblains on the dorsum of the foot. Children and the elderly are most commonly affected, perhaps because they take less care to protect themselves from cooling. *C.* Equestrian chilblains from horse riding on a cold morning with inadequate clothing.

Chilblains develop acutely as single or multiple, burning, erythematous, or purplish swellings. Patients may complain of itching, burning, or pain. In severe cases, blisters (see Fig. 126-9B), pustules, and ulceration may occur. Characteristic locations include the proximal phalanges of the fingers and toes and the plantar surfaces of the toes, heels, nose, and ears. Lesions usually resolve in 1 to 3 weeks but may become chronic in elderly people with venous stasis. Tight garments such as gloves, stockings, and shoes are especially to be avoided where there is also peripheral vascular disease. A papular form of chilblains resembles erythema multiforme and occurs at all times of the year, usually as crops on the sides of the fingers, [40] often superimposed on a background of acrocyanosis.

A peculiar clinical presention may occur in young women riding horses for several hours daily during winter. [41], [42] Indurated red to violet tender plaques develop on the lateral calves and thighs (see Fig. 126-9C). The condition is quite similar to the nodular perniotic lesions described in adolescent girls with erythrocyanosis. With respect to prophylaxis, experienced riders usually wear baggy breeches that give insulation and are not tight enough to compromise the circulation.

Perniotic lesions have been described in association with myeloproliferative disorders, [43] probably as a consequence of blood flow changes, presence of cold agglutinins, and altered inflammatory response on cooling.

Idiopathic perniosis is characterized histologically by edema of the papillary dermis and by superficial and deep perivascular lymphocytic infiltrates. Necrotic keratinocytes and lymphocytic vasculitis also have been reported. Thickening of blood vessel walls with intimal proliferation may lead to obliteration of the vascular lumen. [44]

Chilblain lupus is a distinct disease similar to discoid lupus erythematosus. [45] Lupus pernio is a variant of sarcoidosis.

Unfamiliarity of physicians with chilblains sometimes gives rise to unnecessary hospital admissions with expensive laboratory and radiologic evaluations and, at times, hazardous therapy. The most important point in management is prophylaxis with adequate, loose, insulating clothing and appropriate warm housing and workplace. Maintaining the blood circulation by avoiding immobility is also helpful. A short course of ultraviolet light at the beginning of winter was a tradition that has been challenged. [46] Once chilblains occur, treatment is symptomatic with rest, warmth, and topical antipruritics. Calcium channel inhibiting drugs may be effective in the treatment of severe recurrent perniosis. [47] However, headache and flushing are troubling to some patients. In cases of crippling severity, thyrocalcitonin and hemodilution may be helpful.

COLD URTICARIA AND POLYMORPHOUS COLD ERUPTION

Cold urticaria (Fig. 126-10) occurs at sites of localized cooling, usually when the area is rewarmed. It may be idiopathic or associated with some serologic abnormality. [48] It accounts for about 2 percent of cases of urticaria.

FIGURE 126-10 Cold urticaria induced by the application of ice to the skin.

Most cases fall into the group of essential cold urticaria. They can be subdivided into a rare familial type and an acquired form. IgE and, more rarely, IgM have been implicated in the pathogenesis. The antigen is likely a normal metabolite produced on exposure to cold. Histamine is one of the most important mediators, but leukotrienes, platelet-activating factor, and others have been incriminated. In this disease, exposure to cold causes prolonged edematous swellings, often with headache, fever, arthralgia, and leukocytosis. Swelling of the oral mucosa and esophagus may occur on ingestion of cold liquids. A rather distinctive combination of cold urticaria with dermographism or with cholinergic urticaria is not uncommon. Alarming signs resembling histamine shock are responsible for loss of consciousness. Death may occur while swimming in cold water.

Familial cold urticaria is a rare autosomal dominant condition with onset at an early age. Urticaria develops when the patient is exposed to generalized cooling, particularly chilling wind, rather than local cold application. The delayed type of familial cold urticaria is characterized by localized angioedema developing 9 to 18 h after cold exposure.

Cold urticaria may occur in 3 to 4 percent of patients with cryoglobulinemia, and it also may be associated with cold agglutinins, cryofibrinogens, and cold hemolysins. Cold urticaria has been reported in cases of infectious mononucleosis in association with either cryoglobulins or cold agglutinins, but such occurrences are rare. *Helicobacter pylori* could be involved as a causative agent in some cases of acquired cold urticaria. [49]

Diagnosis of cold urticaria is confirmed by placing an ice cube wrapped in a plastic bag on the skin of the forearm for periods varying from 30 s to 10 min. Weals form on rewarming. Sometimes water at 7ˆC is more effective because it presumably causes less severe vasoconstriction.

Cold erythema seems to be a related disorder with erythema and pain but without urticaria. Familial polymorphous cold eruption is a rare autosomal dominant disease characterized by childhood-onset, non-pruritic, erythematous eruptions often accompanied by influenza-like symptoms after generalized exposure to cold, a negative ice-cube test, and leukocytosis. The pathogenesis remains unknown. The disease frequently has been referred to as familial cold urticaria, although the skin lesions are not urticarial. [50]

Avoiding cold wind exposure and swimming in cold water are important preventive measures. Antihistamines lower the clinical signs. Desensitization to cold is possible by immersing one arm on a daily basis into water at 15ˆC for 5 min.

COLD PANNICULITIS AND RELATED ENTITIES

Cold injuries may affect the subcutaneous tissue in different ways. The freezing injury in deep frostbite results in tissue gangrene. Nonfreezing injuries also can alter the hypodermis. Among them, cold panniculitis is more common in children than in adults. It affects the cheeks and legs most commonly. Tender erythematous subcutaneous nodules appear 1 to 3 days after exposure and subside spontaneously within 2 to 3 weeks. Ice-cube challenge to the child's skin for 10 min results in the develo pment of an erythematous plaque 12 to 18 h later.

A perivascular mixed infiltrate with neutrophils, lymphocytes, and histiocytes is present at the dermal subcutaneous junction after 24 h, followed by a well-developed panniculitis at 48 to 72 h. Some lipocytes are necrotic. They rupture to form cystic spaces, and the reaction subsides completely by 2 weeks. Infants have a higher content of saturated fatty acids in adipose tissue than do adults, and this may result in solidification at lower temperatures. [51] Cold panniculitis should be distinguished from other related disorders, including erythrocyanosis with nodules, sclerema neonatorum, and subcutaneous fat necrosis of the newborn.

SCLEREMA NEONATORUM AND SUBCUTANEOUS FAT NECROSIS OF THE NEWBORN

Sclerema neonatorum and subcutaneous fat necrosis of the newborn are distinct disorders involving the subcutaneous fat of the newborn. Infant fat differs from adult fat by having a higher saturated to unsaturated fatty acid ratio, resulting in solidification at a higher temperature. Prematurity and immature enzyme systems may result in a relative inability to desaturate fatty acids, altering the ratio further. Sepsis, dehydration, chilling, infection, and other stresses also may inhibit the enzyme system. Thus infants in general and premature or otherwise compromised newborns in particular are susceptible to such disorders.

Sclerema neonatorum is a rare disorder characterized by diffuse, rapidly spreading hardening of the skin and subcutaneous tissue of infants. It starts on the buttocks and trunk, usually in the first week of life. Palms, soles, and scrotum are spared. Fifty percent of affected infants are premature. They have difficulty feeding, are lethargic, and many are otherwise debilitated. Septicemia is frequent, and the prognosis is poor. Cold exposure does not seem to be important in the etiology of sclerema neonatorum; however, similar clinical findings have been seen in cases of primary cold injury. It seems likely that sclerema neonatorum results from the effect of severe illness and prematurity on the desaturating enzyme system in neonatal fat, resulting in an exaggeration of the usual saturated to unsaturated fatty acid ratio in infants. The subcutaneous layer is greatly thickened by enlarged fat cells and wide, fibrous bands. There is no fat necrosis, and many of the fat cells contain fine needle-like clefts. [52]

Treatment of sclerema neonatorum involves correcting dehydration and electrolyte imbalance and treating possible septicemia. The value of systemic glucocorticoids is controversial. Successful treatment with exchange transfusions has been reported. [53]

Subcutaneous fat necrosis of the newborn is characterized by discrete red to violaceous mobile plaques and nodules that usually appear within a few days of birth. The back, thighs, and cheeks are affected most commonly. Fat necrosis and crystallization are the hallmarks of the disease. There may be a granulomatous inflammatory response with foci of calcification. In most cases, the condition is benign and self-limited, although it has been associated with hypercalcemia

and death. [54]

As in sclerema neonatorum, there is no clear etiologic relationship to cold, and the etiology is likely multifactorial. It has been postulated that an underlying defect in fat composition, poor nutrition, and various physical stresses such as hypothermia may be important.

ERYTHROMELALGIA

Erythromelalgia is a rare chronic cutaneous disorder characterized by erythema, burning discomfort, and warmth of the extremities. Its pathogenesis and histopathologic characteristics have not yet been clearly identified. [55], [56], [57] and [58] Vasoconstriction apparently precedes reactive hyperaemia, similar to that seen in Raynaud's phenomenon. An early-onset type and an adult-onset type have been recognized. When the extremity is lowered or heat is applied, the pain is intensified. The application of cold or elevation of the extremity has the opposite effect of decreasing the pain. Idiopathic erythromelalgia may be due to increased thermoregulatory arteriovenous shunt flow. [56] Secondary erythromelalgia is associated commonly with myeloproliferative syndrome–related thrombocythemia and is mostly evident in the adult-onset condition.

Treatment for adults with erythromelalgia includes a single daily dose of acetylsalicylic acid, but children who have no associated underlying disorder find little to no relief with the drug.

RAYNAUD'S PHENOMENON

(See Chap. 173)

CRYOGLOBULINEMIA

(See Chap. 177)

LIVEDO RETICULARIS

(See Chap. 167)

REFERENCES

1. Page EH, Shear NH: Temperature-dependent skin disorders. *J Am Acad Dermatol* **18**:1003, 1988

2. Claes G et al: La peau, le froid et les sports d'hiver. *Rev Med Liege* **56**:257, 2001

3. Kauppinen K: Sauna and winter swimming. *Arct Med Res* **47**:71, 1989

4. Keatinge WR et al: Exceptional case of survival in cold water. *BMJ* **292**:171, 1986

5. Schmid Schoenlein GW: Activated leukocytes and endothelium in chronic venous insufficiency. *Phlebology* **10**(suppl 1):90, 1995

6. Oberle J et al: Temperature-dependent interaction between vasoconstrictor and vasodilator mechanisms in human skin. *Acta Physiol Scand* **132**:149, 1988

7. Hornstein OP, Heyer G: Responses of skin temperature to different thermic stimuli. *Acta Derm Venereol (Stockh)* **144**(suppl):149, 1989

8. Dana AS Jr et al: The hunting reaction. *Arch Dermatol* **99**:441, 1969

9. Rintamaki H: Predisposing factors and prevention of frostbite. *Int J Cicumpolar Health* **59**:114, 2000

10. Piérard-Franchimont C et al: Skin surface patterns of xerotic legs: The flexural and accretive types. *Int J Cosmet Sci* **23**:121, 2001

11. Paquet F et al: Sensitive skin at menopause: Dew point and electrometric properties of the stratum corneum. *Maturitas* **28**:221, 1998

12. Corbett DW: Cold injuries. *J Assoc Milit Dermatol* **8**:34, 1982

13. Francis TJR: Nonfreezing cold injury: A historical review. *J R Nav Med Serv* **70**:134, 1984

14. Taylor MS: Cold weather injuries during peacetime military training. *Mil Med* **157**:602, 1992

15. Murphy JV et al: Frostbite: Pathogenesis and treatment. *J Trauma Injury Infect Crit Care* **48**:171, 2000

16. Miller BJ, Chasmar LR: Frostbite in Saskatoon: A review of 10 winters. *Can J Surg* **23**:423, 1980

17. Fritz RL, Perrin DH: Cold exposure injuries: Prevention and treatment. *Clin Sports Med* **8**:111, 1989

18. Foray J: Mountain frosbite: Current trends in prognosis and treatment (from results concerning 1261 cases). *Int J Sports Med* **13**(suppl 1):193, 1992

19. Burge S et al: Effect of freezing the helix and rim or edge of the human and pig ear. *J Dermatol Surg Oncol* **10**:816, 1984

20. Cooke E et al: Reflex sympathetic dystrophy and repetitive strain injury: Temperature and microcirculatory changes following mild cold stress. *J R Soc Med* **86**:69, 1993

21. Arvesen A et al: Skin microcirculation in patients with sequelae from local cold injuries. *Int J Microcirc Exp* **14**:335, 1994

22. Middleton JB, Allen BM: The influence of temperature and humidity on stratum corneum and its relation to skin chapping. *J Soc Cosmet Chem* **24**:239, 1974

23. Piérard-Franchimont C, Piérard GE: Beyond a glimpse at seasonal dry skin: A review. *Exog Dermatol* **1**:3, 2002

24. Dawber RPR: Cold kills. *Clin Exp Dermatol* **13**:138, 1993

25. Gage AA: What temperature is lethal for cells? *J Dermatol Surg Oncol* **5**:459, 1979

26. Irwin MS et al: Neuropathy in non-freezing cold injury (trench foot). *J R Soc Med* **90**:433, 1997

27. Ervasti O et al: Sequelae of moderate finger frostbite as assessed by subjective sensations, clinical signs, and thermophysiological responses. *Int J Circumpolar Health* **59**:137, 2000

28. Kibbi AG, Tannous Z: Skin diseases caused by heat and cold. *Clin Dermatol* **16**:91, 1998

29. Hamlet MP: Prevention and treatment of cold injury. *Int J Circumpolar Health* **59**:108, 2000

30. Lehmuskallio E: Emollients in the prevention of frostbite. *Int J Circumpolar Health* **59**:122, 2000

31. Lehmuskallio E et al: Thermal effects of emollients on facial skin in the cold. *Acta Derm Venereol* (*stockh*) **80**:203, 2000

32. Claes G, Piérard GE: Biometrological assessment of skin protectors against moderate cold threat. *Exog Dermatol* **1**:92, 2002

33. Hirvonen J: Some aspects on death in the cold and concomitant frostbites. *Int J Circumpolar Health* **59**:131, 2000

34. Mehta RC, Wilson MA: Frostbite injury: Prediction of tissue viability with triple-phase bone scanning. *Radiology* **170**:511, 1989

35. Barker JR et al: Magnetic resonance imaging of severe frostbite injuries. *Ann Plast Surg* **38**:275, 1997

36. Taplin D et al: The role of temperature in tropical immersion foot syndrome. *JAMA* **202**:210, 1967

37. Toback AC et al: Pulling boat hands: A unique dermatosis from coastal New England. *J Am Acad Dermatol* **12**:649, 1985

38. Uter W et al: An epidemiological study of the influence of season (cold and dry air) on the occurrence of irritant skin changes of the hands. *Br J Dermatol* **138**:266, 1998

39. Goette DK: Chilbain (perniosis). *J Am Acad Dermatol* **23**:257, 1990

40. Wesagowit P et al: Papular perniosis mimicking erythema multiforme: The first case report in Thailand. *Int J Dermatol* **39**:527, 2000

41. Dowd PM et al: Nifedipine in the treatment of chilblains. *BMJ* **293**:923, 1986

42. Beacham BE et al: Equestrian cold panniculitis in women. *Arch Dermatol* **116**:1025, 1980

43. Kelly JW, Dowling JP: Pernio: A possible association with chronic myelomonocytic leukemia. *Arch Dermatol* **121**:1048, 1985

44. Wall LM, Smith NP: Perniosis: A histopathological review. *Clin Exp Dermatol* **6**:263, 1981

45. Doutre MS et al: Chilblain lupus erythematosus: Report of 15 cases. *Dermatology* **184**:26, 1992

46. Langtry JAA, Diffey BL: A double-blind study of ultraviolet phototherapy in the prophylaxis of chilblains. *Acta Derm Venereol* (*stockh*) **69**:320, 1989

47. De Silva BD et al: Equestrian perniosis associated with cold agglutinins: A novel finding. *Clin Exp Dermatol* **25**:285, 2000

48. Wanderer AA: Cold urticaria syndromes: Historical background, diagnostic classification, clinical and laboratory characteristics, pathogenesis, and management. *J Allergy Clin Immunol* **85**:965, 1990

49. Kranke B et al: *Helicobacter pylori* in acquired cold urticaria. *Contact Dermatitis* **44**:57, 2001

50. Urano Y et al: An unusual reaction to cold: A sporadic case of familial polymorphous cold eruption? *Br J Dermatol* **139**:504, 1998

51. Lowe LB Jr: Cold panniculitis in children. *Am J Dis Child* **115**:709, 1968

52. Kellum RE et al: Sclerema neonatorum. *Arch Dermatol* **97**:372, 1968

53. Fretzin DF, Arias AM: Sclerema neonatorum and subcutaneous fat necrosis of the newborn. *Pediatr Dermatol* **4**:112, 1987

54. Thomsen RJ: Subcutaneous fat necrosis of the newborn and idiopathic hypercalcemia. *Arch Dermatol* **116**:1155, 1980

55. Cohen JS. Erythromelalgia: New theories and new therapies. *J Am Acad Dermatol* **43**:841, 2000

56. Mork C et al: Microvascular arteriovenous shunting is a probable pathogenic mechanism in erythromelalgia. *J Invest Dermatol* **114**:643, 2000

57. Mork C, Kvernebo K: Erythromelalgia: A mysterious condition? *Arch Dermatol* **136**:406, 2000

58. Davis MD et al: Natural history of erythromelalgia: Presentation and outcome in 168 patients. *Arch Dermatol* **136**:330, 2000

T>

Chapter 127

Robert Sheridan

Evaluation and Management of the Thermally Injured Patient

NATURAL HISTORY AND PATHOPHYSIOLOGY
INITIAL EVALUATION OF THE BURNED PATIENT
INITIAL EVALUATION OF SPECIAL SITUATIONS
MANAGEMENT
Fluid Resuscitation
Initial Wound Excision and Biologic Closure
Definitive Wound Closure
Burn Critical Care
Rehabilitation, Reconstruction, Reintegration
ON THE HORIZON

REFERENCES

Despite increased awareness and focused prevention measures, burn injury remains a significant source of mortality and a major source of morbidity in the general population. The prognosis of those who do suffer serious burn injury has improved dramatically over the past 20 years, largely because of a recognition of the importance of early wound excision and biologic closure. [1], [2] The epidemiology of the injuries remains age specific in that the very young and the very old are at higher risk. Hot liquid is the injury agent in approximately 70 percent of pediatric burns, whereas a similar proportion of adults are injured by flame in the home or in the workplace. Although smoke alarms, tap water temperature limits, and other prevention strategies have had significant impact, the basic epidemiology has not changed over many years. This chapter provides a general overview of the management of the burned patient, with attention to our growing understanding of the pathophysiology of the injury.

NATURAL HISTORY AND PATHOPHYSIOLOGY

The development of an envelope of skin was a crucial component of the adaptation of aquatic sea animals to the land environment. The vapor and fluid barrier created by the epidermal layer facilitates the maintenance of fluid and electrolyte homeostasis within very narrow limits. The dermis provides strength and flexibility, and the reactive dermal vasculature facilitates control of internal body temperature within very narrow limits. The appendages provide lubrication and prevent desiccation. All of these critical functions are lost when substantial areas of the skin are burned.

There is both a local and a systemic response to the burn wound. The local response consists of coagulation of tissue with progressive thrombosis of surrounding vessels in the zone of stasis over the first 12 to 48 postinjury hours. An ability to truncate this secondary microvascular injury and its associated tissue loss is a major area of ongoing investigation. In larger burns, a systemic response develops that is driven initially by release of mediators from the injured tissue, with a secondary diffuse loss of capillary integrity and accelerated transeschar fluid losses. This systemic response is subsequently fueled by byproducts of bacterial overgrowth within the devitalized eschar.

Burn wounds are initially clean but are rapidly colonized by endogenous and exogenous bacteria. As bacteria multiply within the eschar over the days following injury, proteases result in eschar liquefaction and separation. This leaves a bed of granulation tissue or healing burn, depending on the depth of the original injury. In patients with large wounds involving 40 percent or more of the body surface, the local infectious challenge generally cannot be localized by the immune system with resulting systemic infection. This explains the rare survival of patients managed in an expectant fashion with burns of this size.

The systemic response to injury is characterized clinically by fever, a hyperdynamic circulatory state, increased metabolic rate, and muscle catabolism. This stereotypical response to injury has been retained by all mammalian species. It is effected by a complex cascade of mediators, including changes in hypothalamic function resulting in increases in glucagon, cortisol, and catecholamine secretions; deficient gastrointestinal barrier function with translocation of bacteria and their byproducts into the systemic circulation; bacterial contamination of the burn wound with systemic release of bacteria and bacterial byproducts; and some element of enhanced heat loss via transeschar evaporation. [3] It is likely that this response has significant survival value, but control of some of the adverse aspects of this response, particularly muscle catabolism, is an active area of ongoing investigation.

INITIAL EVALUATION OF THE BURNED PATIENT

The tendency to allow the burn wound to distract one from the performance of an organized and complete evaluation should be vigorously avoided, as many burn patients have sustained concurrent injuries. Ideally, the evaluation is done in a warm environment, as such patients are highly likely to become hypothermic. The most important component of the initial evaluation involves assessment and maintenance of airway patency. Airway resistance increases as the fourth power of the radius, and, particularly in small children, airway edema sufficient to cause obstruction can occur rapidly after the inhalation of noxious chemicals and superheated air. In equivocal cases, flexible bronchoscopy will allow for accurate assessment of the need for endotracheal intubation. Secure venous access, via the central or the peripheral approach, will allow for administration of adequate resuscitative fluids and reliable medication delivery. In children suffering from profound hypovolemia secondary to burn shock, intravenous access can be difficult, and temporary intraosseous access will allow for administration of initial resuscitative fluids. A functioning nasogastric tube will prevent acute gastric dilation, which can lead to emesis and aspiration. Placement of a bladder catheter permits accurate

assessment of the adequacy of urine output, an important guide to fluid resuscitation. The core temperature should be monitored frequently.

An organized and complete burn-specific secondary survey should follow the initial evaluation, again not allowing the wound to distract the examiner from a complete examination. This survey should include a complete history, vital signs, a detailed physical examination, and selected laboratory and radiographic studies. Often, an accurate history can be obtained in the emergency department only from the rescuing emergency medical personnel, highlighting the importance of attention to this detail during the initial evaluation. Important details of history include the mechanism of injury, past medical and surgical history, time of the last meal, status of tetanus immunization, medications, and allergies. Vital signs should be interpreted in an age-appropriate fashion.

Neurologic status should be carefully evaluated at first presentation. Patients with serious burns often become obtunded over the succeeding hours and days because of fluid shifts and the need for analgesics and sedatives. If the injury mechanism is consistent with a possible head injury, central nervous system imaging should be performed. The head and neck should be carefully inspected for other injuries. The corneal epithelium should be examined prior to the development of adnexal edema, which will make the examination more difficult. Topical fluorescein staining will facilitate an accurate evaluation of the corneal epithelium. Upper airway edema should be suspected if there are perioral or intraoral burns, carbonaceous sputum, or a hoarse voice. A clinical judgment must be made regarding the need for endotracheal intubation to guard the airway. Often, flexible bronchoscopy will facilitate this decision making.

The torso should be examined for the adequacy and symmetry of breath sounds and the presence of abdominal distention or tenderness. The abdomen should be imaged if the mechanism of injury is such that an intraabdominal injury is a possibility. Gastric distention is very common, particularly in smaller children, and nasogastric decompression should be performed at this time. Nasogastric tube position and functioning should be regularly verified during the subsequent hours. Gastric ulcer prophylaxis should be instituted at this time.

The status of peripheral perfusion should be verified at initial presentation and throughout the subsequent 48 h. Blood flow may be compromised by intracompartmental edema in patients with very deep thermal burns or electrical injuries, but more commonly it is compromised by overlying circumferential eschar that will not stretch as underlying soft tissue swells. Ideally, compromised perfusion is detected by monitoring the flow in low-pressure distal vasculature, such as the palmar arch or digital vessels, rather than by monitoring the presence of radial or pedal pulses. This is because the tissue pressure is lower than the mean arterial pressure in these large vessels, and it is possible to have flow detectable by Doppler in these higher pressure vessels with ischemic soft tissues distally. If peripheral perfusion is compromised by overlying eschar, escharotomies should be performed (Figure 127-1). It can be very difficult to detect the presence of intracompartmental pressure elevations in obtunded burn patients. When compartments become firm on serial examination, decompression should be done in the operating room. Selected patients may be followed with serial compartment pressure measurements, acknowledging the risk of seeding compartments by performing such measurements through burn. Most can be adequately evaluated with careful serial clinical examination.

FIGURE 127-1 If peripheral perfusion is compromised by overlying eschar, escharotomies should be performed.

The wound is evaluated after higher priority evaluations are complete. The wound should be assessed for depth, size, and circumferential components. It is difficult to estimate burn depth accurately on initial examination, as most injuries will become deeper in the 24 h following injury because of progressive microvascular thrombosis at the margins of the zone of coagulation. However, an exact determination of the burn depth is irrelevant to the initial resuscitation. Burn size in children is best estimated with an age-specific chart (Fig. 127-2) because body proportions change with growth. In adolescents and adults, the rule of nines facilitates accurate evaluation. Irregular burns can be estimated by remembering that the surface of the palm of the hand (excluding the digits) represents approximately 0.5 percent of the body surface area in all age groups. Patients with large burns, greater than 15 percent of the body surface area, are often best served by care in a specialized facility (Fig. 127-3).

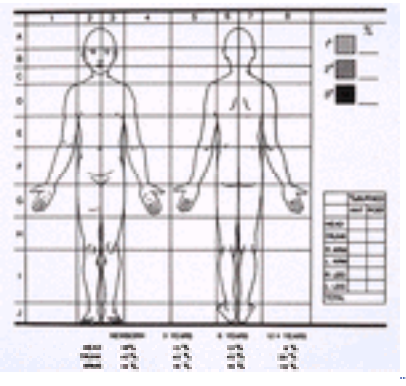

FIGURE 127-2 An age-specific burn diagram should be used to determine total burn size.

FIGURE 127-3 Patients with large burns, greater than 15 percent of the body surface area, are often best served by care in a specialized facility.

Selected laboratory and radiographic studies that are of value during the initial evaluation include a blood gas analysis with carboxyhemoglobin determination in those exposed to noxious fumes; routine hematology, chemistry, and coagulation studies; and urinalysis. Chest radiographs facilitate the documentation of proper position of resuscitative cannulae.

INITIAL EVALUATION OF SPECIAL SITUATIONS

There are certain patients who are referred to burn units routinely for care of specialized burns, nonburn injuries, and other conditions. [4] Such injuries include electrical, chemical, tar, or abuse-related burns that require unique evaluations. Nontraumatic conditions commonly referred to burn units include purpura fulminans, toxic epidermal necrolysis, staphylococcal scalded skin syndrome, and major soft tissue injuries. Such patients benefit from the unique combination of surgical, wound care, and critical care resources available in burn units. Unique aspects of the evaluation of these patients will be presented here.

Patients with electrical injuries can be conveniently divided into three exposure types: low voltage or household current, intermediate voltages between household and 1000 volts (V), and high voltage, which is defined as greater than 1000 V. Intermediate range and even low-voltage exposures, combined with a good quality electrical contact, can result in locally destructive injuries. A patient with high-voltage exposure often has multiple injuries and should be approached as a polytrauma patient. It is important to determine the presence of pigment in the urine promptly so that this can be appropriately treated with volume loading and judicious use of loop and osmotic diuretics. Involved extremities must be monitored carefully for subtle signs of evolving intracompartmental edema so that timely decompression can be performed in the operating room. Patients with serious tissue destruction should undergo all needed decompression operations within the first hours after injury and subsequently should be taken to the operating room within 72 h with a goal of definitive débridement and wound closure. Such is often facilitated by the use of local and distant flaps in addition to split-thickness autograft.

Patients sustaining chemical injury should undergo prompt irrigation at the scene, including dusting off dry chemicals and removing all clothing. Acidic wounds are generally well irrigated after 30 min of high-volume tap water irrigation. Alkaline injuries may require a longer time for adequate irrigation. The adequacy of irrigation of alkaline wounds can be evaluated by determining that the soapy feel on the fingers of a gloved hand has resolved or by checking the skin with litmus paper. Hydrofluoric acid exposures can be complicated by life-threatening hypocalcemia. [5] This should be suspected and treated appropriately with intravenous calcium supplementation and subeschar 10% calcium gluconate. It is important to contact poison control services to facilitate the proper management of patients exposed to one of the thousands of chemical agents in common industrial and home use.

Tar injuries should be cooled with tap water irrigation, and the tar removed later with appropriate lipophilic solvents. Underlying burns are generally very deep as these thermoplastic road materials are liquefied in the region of 300°C to 700°C (572°F to 1292°F).

Patients with purpura fulminans are often referred to burn units for definitive management. This is a condition, usually seen in a setting of meningococcal sepsis, that is thought to be induced by a transient protein C deficiency with diffuse microvascular thrombosis and soft tissue necrosis. These patients commonly develop organ failure secondary to the initial meningococcal sepsis and from infection of their deep wounds. Treatment requires management of organ failures and excision and grafting of the wounds, which are usually quite deep and have a characteristic “cookie cutter” appearance.

Toxic epidermal necrolysis is a variant of erythema multiforme major with a diffuse slough of the epidermis at the dermal–epidermal junction. Prominent mucous membrane and conjunctival involvement is common, and when particularly notable, the disease process is often called Stevens-Johnson syndrome (see Chap. 58). A differentiation from staphylococcal scalded skin syndrome is generally made on clinical grounds, but skin biopsy is diagnostic. Treatment

involves management of any sepsis-associated organ failures, prevention of wound desiccation and superinfection, topical antimicrobial use (generally 0.5% silver nitrate solution), and xenografting of large areas of confluent wound (Fig. 127-4). Ophthalmic evaluation is important as long-term sequelae often occur. Intense oropharyngeal involvement may make handling of secretions difficult, mandating intubation for airway protection and enteral feedings.

FIGURE 127-4 Large areas of open confluent wound in patients with toxic epidermal necrolysis should be dressed with a biologic membrane such as porcine xenograft.

Staphylococcal scalded skin syndrome is a staphylococcal exotoxin-induced separation of the epidermis at the granular layer (see Chap. 195). Mucous membrane and conjunctival involvement are not seen. These patients often have simply an area of colonization without an infection, but a careful search for focus of the staphylococcal infection is warranted while empiric antistaphylococcal antibiotics are initiated.

Epidermolysis bullosa consists of a group of diseases that result in epidermal loss over varying areas (see Chap. 65). If extensive, this may be complicated by sepsis. On occasion, children with particularly severe diffuse lesions are referred to burn units, particularly when these are complicated by sepsis. Management strategy requires prevention of desiccation and superinfection of wounds and support of failing organs system during septic episodes.

Finally, it is important to be sensitive to abuse as a possible etiologic agent. The index of suspicion should be raised when there is delay in the presentation for reasonable medical care or when there are conflicting histories of the event given by caregivers. Suspicious burn patterns include those demonstrating sharply demarcated margins or uniform depth; scald injuries without splash marks; flexor sparing (particularly in the antecubital or popliteal fossae); or sparing of areas in forced contact with the tub or sink. Also suspicious are localized, very deep contact or dorsal contact injuries. All suspicious cases should be reported to appropriate state authorities, and all such children should be admitted to the hospital regardless of the severity of their injuries. Imaging of the head and long bones should be considered (Fig. 127-5).

FIGURE 127-5 If the history or burn pattern is suggestive, children suffering injuries of abuse should be hospitalized, and their cases filed with state authorities for further investigation and intervention.

MANAGEMENT

The management of an acutely burned adult or child is a challenging task requiring the exercise of skills in critical care, surgery, physical and occupational therapy, nursing, and psychology. The following discussion outlines the management of such injuries by describing fluid resuscitation, initial wound excision and biologic closure, definitive wound closure, selected critical care issues, and reconstruction and reintegration.

Fluid Resuscitation

Patients with large burns will require fluid resuscitation. There are many fluid resuscitation formulas in common use. The

variability in their prediction of an individual burn patient's needs is a tribute to the inherent inaccuracy in any formula that attempts to predict individual needs in this group. A fluid resuscitation formula cannot therefore replace the bedside presence of a knowledgeable physician constantly reevaluating the physiologic effects of the fluid therapy and adjusting it appropriately. A commonly used consensus formula is the modified Brooke formula (Table 127-1). However, all such predictions are inherently inaccurate, and failure to adjust infusions based on the patient's physiology is fraught with hazard.

First 24 h
Adults and children weighing > 10 kg
Ringer's lactate: 2–4 mL/kg per % burn (half in first 8 h)
Colloid: none
Children weighing between 10 and 30 kg
Ringer's lactate: 2–3 mL/kg per % burn (half in first 8 h)
Ringer's lactate with 5% dextrose: calculated maintenance rate
Colloid: none
Second 24 h
All patients
Crystalloid: to maintain urine output. If silver nitrate is used, sodium leaching will mandate continued isotonic crystalloid. If other topicals are used, free water requirement is significant. Serum sodium should be monitored closely. Nutritional support should begin, ideally by the enteral route.
Colloid (5% albumin in Ringer's lactate graded with burn size):
0–30% burn: none
30–50% burn: 0.3 mL/kg per % burn
50–70% burn: 0.4 mL/kg per % burn
> 70% burn: 0.5 mL/kg per % burn

TABLE 127-1 **The Modified Brooke Formula**

The physiology behind the various resuscitation formulas is still very poorly understood, although it is thought that vasoactive mediators are released from injured tissue and result in a diffuse systemic capillary leak that is graded with burn size. This results in extravasation of both crystalloid and colloid for the first 18 to 24 h after injury. This physiologic reaction explains the enormous crystalloid requirements calculated by resuscitation formulas and the fact that most withhold colloid until 12 to 24 h has elapsed. To a certain extent, fluid requirements during this period are an artifact of the resuscitation end points chosen. Children are commonly thought to require fluid in excess of that predicted by various formulas, but this may be in part an artifact of setting 2 mL/kg of body weight per hour of urine output as a resuscitation end point. In infants and very young children, whose renal concentrating abilities are not completely mature, this is required. However, in older children, renal concentrating abilities are more fully developed and targeting urine flow of 0.5 to 1 mL/kg per hour results in overall resuscitative fluid requirements much closer to that of the adult patient. Patients who have suffered inhalation injury commonly require substantially more fluid than predicted for adequate resuscitation, and this may be secondary to the release of vasoactive mediators from injured pulmonary tissue.

During the first 24 h, Ringer's lactate is the primary resuscitative fluid. Young children can develop hypoglycemia if glucose is not administered, therefore Ringer's lactate or half-normal saline with 5% dextrose is infused at a maintenance rate. However, the primary resuscitation fluid should be Ringer's lactate without dextrose, because if dextrose-containing fluids are used as the primary resuscitation fluid, hyperglycemia and osmotic diuresis will occur. It is ideal to reevaluate the patient every 30 to 60 min during resuscitation and gradually increase or decrease infusions based on age-specific resuscitation end points.

If the resuscitation is not going as predicted, one should consider the early use of low-dose dopamine to facilitate renal perfusion, the early institution of colloid, and/or the insertion of a pulmonary artery catheter to facilitate monitoring and accurate fluid administration. Patients with obvious pigment in the urine, secondary to deep thermal or electrical burns, must be identified early, and the pigment cleared with additional intravenous crystalloid. Alkalinization of the urine is appropriate in selected patients. Occasionally, a forced diuresis with mannitol is beneficial.

During the second 24 h, colloid administration is appropriate as the capillary leak that characterizes the early postinjury period has abated. During this period, crystalloid requirements markedly diminish, and transeschar free water loss dominates the electrolyte situation except when an aqueous topical antimicrobial agent such as 0.5% silver nitrate is used. There is significant morbidity to rapid changes in serum sodium concentration, so diligent electrolyte monitoring during this period, with appropriate correction, is critical. Enteral nutritional support should start during this period as well.

Initial Wound Excision and Biologic Closure

Although most is written about patients with large, deep burns, the majority of patients have small, superficial burns, which can be very well managed, often in the outpatient setting, with a number of topical agents (Fig. 127-6). All topical care plans for such patients share the common goals of general cleanliness, prevention of wound desiccation, reduction of wound colonization, monitoring for infection, and minimizing mechanical trauma and pain. A wide variety of topical agents can be employed effectively to this end.

FIGURE 127-6 Patient with superficial burns that can be managed in an out-patient settting.

An essential element of modern care for patients with larger injuries is the prompt identification and removal of necrotic tissue with immediate biologic closure. This surgical maneuver modifies the natural history of burn injury by eliminating

the process of wound colonization, infection, liquefaction, and separation. Such expectant management of large burn wounds results in predictable sepsis of the host, with a resulting maximum survivable burn size of 40 to 50 percent of the body surface area. The policy of early burn wound excision and closure is now widely practiced in North America and is typically carried out as a series of staged excisions of all deep partial- and full-thickness components of the wound (except for the face, palms, soles, and genitals) over the first postinjury week. [6] This approach results in enhanced survival in patients with large injuries, truncated hospital stays, [7] decreased costs, and fewer painful dressing changes.

This policy of prompt definitive wound excision presupposes an ability to estimate burn depth accurately, which is still best judged by the eye of an experienced examiner. There is a rich history of efforts to quantify burn depth objectively by using devices such as laser Doppler flow meters, burn wound biopsy, intravenous fluorescence, thermography, light reflectance, and fluorescence of intravenous dyes. [8] However, nothing has yet surpassed the eye of an experienced examiner in accuracy, reliability, or practicality. If the patient presents with an overall wound size that is not large and there is a significant area of indeterminate depth, it is reasonable to treat this wound with topical antimicrobials for 3 to 5 days, at which time the full-thickness component becomes clear.

The topical wound care agents in general use have specific advantages and disadvantages that determine their use on the variety of wounds seen in clinical practice. The three most commonly used are silver sulfadiazine, mafenide acetate, and silver nitrate, the latter as an aqueous 0.5% solution. Silver sulfadiazine is painless on application, has relatively poor eschar penetration, has no metabolic side effects, and a broad antibacterial spectrum. Mafenide acetate is painful on application, penetrates eschar extremely well, is a carbonic anhydrase inhibitor, and has a broad antibacterial spectrum. Aqueous silver nitrate is painless on application, penetrates eschar poorly, and leaches electrolytes, yet it has a very broad spectrum of action, including against fungal organisms, which renders it quite useful.

The techniques of burn excision have evolved greatly since the initial reports, in the early 1970s, [9], [10] of conserving techniques of layered excision. These procedures should be done in a well-planned fashion in an operating room adequately heated and humidified to minimize evaporative heat loss. Keeping the patient euthermic during the procedure will greatly facilitate the effectiveness of innate clotting mechanisms.

Once necrotic eschar is excised to a bed of viable tissue, immediate biologic closure is essential. In most patients, immediate autografting is performed. However, when donor sites are insufficient for this purpose, temporary biologic closure is necessary. Such coverage will ideally prevent desiccation and superinfection and provide a vapor and bacterial barrier over the excised wound. Ideal to this purpose is cryopreserved human allograft, placed in a meshed, unexpanded fashion. There are a number of other temporary closure options available, and this is an area of ongoing investigation. A large, excised wound that is left open will become further desiccated and be a source of bacterial invasion and ongoing fluid and vapor loss.

Among the exciting new alternative biologic closure resources is a synthetic bilayered membrane that has an inner layer of homogenized bovine collagen, created so that the pore size forms an inviting lattice for fibrovascular ingrowth. Upon this layer is poured liquid silicone, which congeals into an outer membrane that bonds with the collagen. This bilaminar structure is laid upon freshly excised wounds, and fibrovascular ingrowth occurs. After 2 to 3 weeks, the outer membrane is removed and replaced with a very thin autograft. Initial experience with this procedure is encouraging. [11], [12]

Definitive Wound Closure

After the first postburn week, under ideal conditions, the patient has undergone near-complete wound excision, and permanent or temporary biologic cover has been achieved. Subsequently, it is predictable that the patient's physiology will normalize and the need for critical care will decrease. It is at this point that the definitive wound closure phase can be said to begin. It is during this phase of management that temporary covers are removed and replaced with autograft and areas of small physiologic surface area but high complexity, such as the face, hands, and genitals, are addressed surgically. In patients with extraordinarily extensive burns and very limited donor sites, there are a number of emerging technologies that will make a contribution to definitive wound closure. However, for the large majority of patients, split-thickness autografts continue to provide the most durable and reliable of covers.

Because of the thickness and well-developed skin appendages of the central face, relatively deep burns in this area will frequently heal with a good result. Therefore, unless burns in the central face are of extraordinary depth, they are treated with topical antimicrobial agents for 2 weeks. At that time, unhealed wounds are excised and autografted. Ideally, the face should be resurfaced in cosmetic units [13] by using sheet autografts of maximal thickness and of optimally matched pigmentation.

Burns of the ocular adnexa are quite common. The paramount concern during the acute phase of management is protection of the globe. During the initial few days after injury, adnexal edema generally results in complete coverage of the globe with excellent lubrication. As wound contracture occurs, exposure and desiccation can ensue and result in keratitis and corneal ulceration. If this is unresponsive to ocular lubrication, acute lid release should be performed. Tarsorrhaphy is an ineffective alternative, as wound contraction forces will disrupt the sutures and damage the lids. When the lid substance is destroyed but the globe is intact, a difficult wound problem ensues. However, in general, this can be successfully managed by mobilizing the remnant palpebral conjunctiva from the inferior and superior lids and closing them over the globe, placing split-thickness skin graft over this. Subsequently, the resulting membrane can be opened, creating an eyelid-like structure that, with difficulty, can provide a reasonable functional alternative.

Burns of the external ear are treated with topical mafenide acetate, as it will reliably penetrate the cartilage of the ear and prevent auricular chondritis. It is important to avoid pressure on the burned auricle. Deep burns of the external ear with full-thickness skin loss are resurfaced, carefully preserving underlying viable cartilage.

Management of hand burns is critical to a good outcome, and it is important to address this issue from the very beginning

of the hospital stay, no matter what the burn size. Critical components include a complete examination ruling out other injuries and ongoing attention to perfusion of the digits throughout the resuscitative period. As the mean arterial pressure in named vessels is much higher than tissue pressure, it is not enough to ensure that there is detectable flow in the ulnar or radial arteries. If the burned hand is cool and firm with decreased flow in the digital pulp, decompression should be performed to ensure adequate perfusion. In patients with very deep thermal burns or with high-voltage electrical injury, the need for urgent fasciotomy is predicted by progressive firmness of the compartments of the hands and forearm. The evaluation for the need for fasciotomy can be facilitated by documenting a compartment pressure of 30 mmHg; however, in most cases serial, physical examination is enough to make this determination. Even in the most obtunded patient, the burned hand should be taken through a complete range of passive motion twice a day and splinted in a functional position with the metacarpophalangeal joints at 70 to 90 degrees and the interphalangeal joints in extension. The only interruption in this program should be the time required to obtain sheet autograft closure of the wounds. Therapy is then advanced to an active and strength-enhancing program. Fourth-degree hand burns, with involvement of the underlying extensor mechanism, joint capsule, or bone, are significantly more difficult management problems. However, outcomes consistent with performing independent activities of daily living are the expectation in the large majority of these patients. [14]

Burn Critical Care

During the period of progressive wound closure, the burn patient often requires sophisticated life support to maintain homeostasis. Advanced techniques in burn critical care have played an important role in salvage of those patients with large injuries. The core components of this contribution are management of failing organ systems, support of the predictable hypermetabolic response to injury, nutritional support, and early detection and treatment of infectious foci.

The most common organ failure addressed in the burn unit is acute respiratory failure. This has multiple etiologies, including inhalation injury, pneumonia or other pulmonary infections, systemic sepsis, and as a component of multiorgan failure. The pathophysiology of inhalation injury is complex, but there are three major clinical components. The first is early upper airway obstruction secondary to edema. This is most likely to occur in smaller children with their decreased airway diameter, is generally a problem early during the course of injury, and is managed with endotracheal intubation for airway protection. Endotracheal tubes are removed when airway swelling has decreased, as manifested by decreased facial edema and an air leak around an appropriately sized endotracheal tube at a moderate pressure. The second problem is impaired gas exchange, which commonly becomes an increasing problem 3 to 5 days after injury. The degree of gas exchange dysfunction varies with the aerosolized toxins that the individual patient has inhaled and is difficult to predict, even when flexible bronchoscopy is used. Management of impaired gas exchange requires mechanical ventilation designed to minimize ventilator-induced lung injury. [15] The third problem, which is generally seen toward the end of the first postburn week, is pulmonary infection. This takes the form of either pneumonia or tracheobronchitis. Both present with fevers, impaired gas exchange, and purulent sputum. The management of pulmonary infection is with specific antibiotics and aggressive pulmonary toilet, often facilitated by toilet bronchoscopy.

Patients injured in structural fires may have been exposed to a hypoxic environment, high levels of carbon monoxide, and high levels of cyanide. These factors, combined with hemodynamic instability, may contribute to neurologic compromise. Such patients should be ventilated with 100% oxygen from the time of extrication. Selected patients with severe carbon monoxide exposures who are stable enough from a hemodynamic and pulmonary perspective to be managed safely in a monoplane hyperbaric chamber are appropriate candidates for hyperbaric oxygen treatment to facilitate more rapid clearance of carbon monoxide from hemoglobin and cellular enzyme systems. [16]

Nutritional support is a critically important component of burn critical care. The hypermetabolic response to injury is intense and lasts well beyond the time of complete wound closure, and this physiologic state must be supported if optimal outcomes are to be achieved. This response consists clinically of fever, a hyperdynamic circulatory state with high cardiac output and low afterload, increased gluconeogenesis and protein catabolism not suppressed with glucose infusion, decreased albumin synthesis, and increased acute-phase protein production. Accurate nutritional support is essential, because overfeeding is associated with hepatic steatosis and hepatic dysfunction as well as increased CO_2 production, which will exacerbate respiratory failure, while underfeeding results in poor wound healing. Patients with significant burns should be given a caloric load approximately 1.5 times their calculated basal metabolic rate and approximately 2.5 g/kg per day of protein. The accuracy of this program should be continually reassessed, ideally by indirect calorimetry and protein balance studies.

Throughout the intensive care course of the seriously burned patient, a vigilant search for the legion of predictable complications is an essential aspect of management, as prompt treatment markedly reduces morbidity and mortality associated with these problems (Table 127-2).

TABLE 127-2 **Complications after Burn Injury**

Rehabilitation, Reconstruction, Reintegration

With the increasing frequency with which patients suffering large burns survive, the importance of specific attention to the critical aspects of rehabilitation, reconstruction, and reintegration is increasing. It is clearly the duty of the burn unit team to place great importance on these aspects of care and to address these issues from the time of the initial burn management. Burn rehabilitation begins during burn resuscitation. This may initially be limited to splinting, antideformity positioning, and passive range of motion twice a day. As wound closure becomes complete, these activities expand to fill the bulk of the patient's day with active motion, ranging, strengthening, and work-hardening programs. These important activities are carefully planned to continue after discharge from the acute care hospital. It is ideal if the burn unit team can direct these activities after the patient has left inpatient status.

Psychosocial adaptation after severe burns can be very difficult. This is particularly true in patients with serious injury to the hands or face. The coordinated involvement of psychiatric, psychological, and social work staff will facilitate achieving the optimal emotional outcome. It is important to plan for funding for these activities.

Hypertrophic scar formation is a major source of long-term morbidity after burns (Fig. 127-7A). All healed and grafted burns will become hypervascular shortly after successful epithelization, but this neovascularity should involute between 9 and 13 weeks after the injury. [17] Additional collagen forms, and contraction occurs over the next 4 to 6 months in those wounds that go on to become hypertrophic. Typically, the hypervascular and erythematous nature of the wounds will become more prominent over the next months, peaking at 6 to 8 months after injury. Subsequently, this will involute, leaving a mature scar. The physiology of this reaction is very poorly understood. Wounds that are most commonly associated with scar hypertrophy are deep dermal burns that heal on their own over more than 3 weeks and full-thickness burns that heal by epithelial migration from the edges. Wounds across highly elastic surfaces, such as flexor surfaces and the anterior neck and submental area, are also highly prone to hypertrophic scar formation.

FIGURE 127-7 *A*. Hypertrophic scarring is a major source of morbidity in burn patients. *B*. Release and autografting of these injuries is an important component of ongoing care.

Our ability to influence the development of hypertrophic scars favorably is limited. Current methods include compression garments, topical silicone, wound massage, intradermal steroid injections, and surgery. The mechanism of action for these techniques has not been fully elucidated, and none is of enormous benefit; however, when used in appropriate combination they can be helpful. Carefully planned reconstructive surgery plays a critical role in these patients (Fig. 127-7B). Cosmetic or functionally limiting areas of hypertrophic scar are incised or excised, and the resulting wounds are replaced with sheet autograft. Tissue expanders are of great value in selected locations. Traditionally, it is considered ideal to wait for a fully mature scar prior to considering reconstructive surgery, but earlier surgery is indicated when function is threatened.

ON THE HORIZON

On the horizon are exciting potential adjuncts to current burn care; however, none will ever replace the sound practice of

clinical burn care. These adjuncts include permanent skin substitutes, critical care technologies, modifiers of the injury response, growth factors, and new modes of wound management and evaluation. Definitive wound closure that uses materials other than autograft remains the “holy grail” of burn care. It is an area of enormous interest and ongoing research. Multiple substitutes currently in early clinical trials include epidermal and dermal analogues and composite substitutes of either a temporary or permanent nature. Of the plethora of materials in trial, the most commonly described are cultured autologous epithelium, cryopreserved allograft dermis, and the synthetic bilaminar artificial skin of Yannas and Burke previously described. Cultured epidermal autografts can be of value in patients with massive burns in whom there are insufficient donor sites available for wound closure. However, the low initial engraftment rates, relatively poor quality of the resulting wound closure, and significant expense make this an imperfect solution to this difficult problem. Cryopreserved allograft dermis with overlying thin autograft is in initial clinical trials, and preliminary results are encouraging. However, this technology is also associated with significant additional expense. This area of research offers a major potential benefit to our patients.

Critical care technologies under development include newer modes of ventilation that allow for the complete avoidance of ventilator-induced lung injury, partial liquid ventilation, inhaled nitric oxide, and extracorporeal support. As these technologies are incorporated into burn care, our patients will gain the same benefits as other critically ill populations who suffer respiratory failure.

Better targeted nutritional support, provision of conditionally essential nutrients, and modifiers of the hypermetabolic response all offer potential advantages by improving the support of the response to injury. However, the complex cellular and subcellular biology involved should temper our blind enthusiasm for administration of powerful biologic substances without clear understanding of their effects.

Innovations in wound evaluation and management include the possible wider application of technologies that will allow us a better determination of burn depth, such as laser Doppler flow meters or fluorescence of intravenously administered dyes. The potential use of scanning CO_2 lasers and debriding enzymes for bloodless burn débridement are exciting technologies that may further improve burn care.

Epidermal growth factor and human growth hormone have been in clinical trials for some time and may be associated with shortened donor-site healing time in burn patients. Ongoing animal and clinical work with transforming growth factors, fibroblast growth factors, platelet-derived growth factor, and colony-stimulating factors may further enhance our understanding of the biology of wound healing and may ultimately lead to improvements in clinical care. However, caution must be exercised when giving large doses of these potent substances to our patients without a clear understanding of their complex biology.

Over the past 20 years, the field of burn care has changed dramatically. Regionalization of care, early surgery modifying the natural history of the disease process, and more focused attention on long-term outcomes has resulted in a much improved outlook for our patients. However, the disease process remains a very difficult one and requires an aggressive and multidisciplinary approach to achieve consistently favorable outcomes.

REFERENCES

1. Sheridan RL et al: Long-term outcomes of children surviving massive burns. *JAMA* **283**:69, 2000

2. Sheridan RL et al. Current expectations for survival in pediatric burns. *Arch Pediatrs Adolesc Med* **154**:245, 2000

3. Youn YK et al: The role of mediators in the response to thermal injury. *World J Surg* **16**:30, 1992

4. Sheridan RL et al: The burn unit as a resource for the management of acute nonburn conditions in children. *J Burn Care Rehabil* **16**:62, 1995

5. Sheridan RL et al: Emergency management of major hydrofluoric acid exposures. *Burns* **21**:62, 1995

6. Sheridan RL et al: Management of burn wounds with prompt excision and immediate closure. *J Intensive Care Med* **9**:6, 1994

7. Herndon DN et al: A comparison of conservative versus early excision. Therapies in severely burned patients. *Ann Surg* **209**:547, 1989

8. Heimbach D et al: Burn depth: A review. *World J Surg* 16:10, 1992

9. Janzekovic Z: A new concept in the early excision and immediate grafting of burns. *J Trauma* **10**:1103, 1970

10. Tompkins RG et al: Prompt eschar excision: A treatment system contributing to reduced burn mortality. A statistical evaluation of burn care at the Massachusetts General Hospital (1974–1984). *Ann Surg* **204**:272, 1986

11. Heimbach D et al: Artificial dermis for major burns. A multi-center randomized clinical trial. *Ann Surg* **208**:313, 1988

12. Sheridan RL: Skin substitutes in burns. *Burns* **25**:97, 1999

13. Gonzalez-Ulloa M: Restoration of the face covering by means of selected skin in regional aesthetic units. *Br J Plast Surg* **9**:212, 1956

14. Sheridan RL et al: The acutely burned hand: Management and outcome based on a ten-year experience with 1047 acute hand burns. *J Trauma* **38**:406, 1995

15. Sheridan RL et al: Permissive hypercapnia as a ventilatory strategy in burned children: Effect on barotrauma, pneumonia, and mortality. *J Trauma* **39**:854, 1995

16. Sheridan RL, Shank ES: Hyperbaric oxygen: A brief overview of a controversial topic. *J Trauma* **47**:426, 1999

17. Kischer CW: The microvessels in hypertrophic scars, keloids and related lesions. *J Submicrosc Cytol Pathol* **24**:281, 1992

T>

Chapter 128

Frederick Malkinson Renato Panizzon

Radiobiology and Radiotherapy of Skin Diseases

RADIOBIOLOGY OF THE SKIN
Mechanisms of Radiation Injury
Cellular Radiation Effects
DNA and Chromosome Damage
Cell Cycle Effects
Division Delay
Radiation Modifiers
Radiobiology of the Skin and Hair
Radiobiologic Effects on Melanocytes and Pigment Formation
Radiobiologic Effects on Langerhans Cells
RADIOTHERAPY OF SKIN DISEASES
Benign Skin Diseases
Psoriasis
Eczema/Dermatitis
Keloids
Lymphocytoma Cutis (Lymphocytoma Cutis Benigna, Lymphoid Hyperplasia)
Other Indications
Disseminated Actinic Keratoses
Bowen's Disease/Queyrat's Erythroplasia
Lentigo Maligna
Basal Cell Carcinoma, Squamous Cell Carcinoma, Keratoacanthoma
Melanoma of the Lentigo Maligna Type
Paget's Disease
Merkel Cell Tumor
Cutaneous Lymphomas
Kaposi's Sarcoma
Other Skin Tumors

REFERENCES

RADIOBIOLOGY OF THE SKIN

Radiobiologic events in the skin are best interpreted from a knowledge of the general responses of cells and tissues to ionizing radiation. These responses to electromagnetic radiation (x-rays, gamma-rays) and to particulate radiation (electrons, neutrons, protons, alpha particles, etc.) may be studied in the whole organism or at the tissue, cellular, or molecular levels.

Clinical and microscopic changes in skin and its appendages were among the first reactions seen after accidental or therapeutic exposure to x-rays. In the late 1890s, Becquerel and Pierre Curie both noted erythema and ulceration in their own radiation-exposed skin sites after accidental and deliberate exposure respectively. Our current knowledge of radiation responses in skin derives from clinical observations and animal studies. The latter sources are important, because certain data for humans can only be provided by accidental radiation exposure.

Mechanisms of Radiation Injury

Electromagnetic radiation with energies above 125eV (x-rays, ^{60}Co gamma rays) produce indirect ionization by ejecting orbital electrons from atoms in tissues or cells. These fast electrons ionize other atoms and break chemical bonds. The resultant free radicals (atoms or molecules carrying an unpaired electron in the outer orbital shell) have half-lives of 10^{-5} seconds, are largely formed from tissue water molecules and oxygen, and react with cell or tissue organic molecules, altering their structure and function. The activated cellular response pathways mediating cytoprotective and cytotoxic responses of cell survival or death [1] and the roles of cytokines in normal tissue radiation reactions have been reviewed. [2], [3] Resulting biological, biochemical, and/or metabolic changes appear within minutes, hours, days, weeks, or longer.

Cellular Radiation Effects

Although functional cell loss in nonproliferating cell systems may only follow large radiation doses (100 Gy; 1 Gy = 100 rad), reproductive integrity is usually lost after exposure to only 3 to 4 Gy. Cell death may occur within hours but usually occurs after one to five postradiation division cycles. Normal and malignant cells have similar radiation sensitivities. Chromosomal DNA is the main target for cell killing via chromosome and chromatid alterations. Cellular necrosis, reproductive failure, and apoptosis are the principal mechanisms of post-radiation cell death. Recent studies also suggest that microvascular endothelial cells may be a primary radiation target, contributing to consequent tissue or cell death. [4]

DNA and Chromosome Damage

Differences in numbers of chromosome sets (ploidy) affect radiation sensitivity. [5] Ionizing radiation impairs the synthesis of DNA, thymidine kinase, and DNA polymerase. Genetic damage from irradiation may occur in the gene at the molecular level or in the chromosome at the cellular level. Chromosome breaks may follow exposure to only 1 cGy (1 rad). Single strand breaks are common and readily repaired, but erroneous repair may induce mutation(s). Double-strand breaks, however, may be irreparable. Increased genome-wide instability in future cell generations may also occur. Chromosomal translocations or inversions may result in oncogene activation and malignancy.

Cell Cycle Effects

Cells in the division cycle are usually more radiosensitive than nondividing cells. In vitro and in vivo data reveal that radiosensitivity varies significantly in different phases of the cell cycle. [6] For most cell lines G_2- and M-phase cells are the most radiosensitive. Late S-phase and early G_1-phase cells are relatively radioresistant. Changes in DNA replication states and sulfhydryl compound content (radioprotectors) may affect cell cycle phase radiosensitivity. Overall, radiosensitivity varies by a factor of 2.5 to 3.0 among the various cell cycle phases.

Division Delay

Ionizing radiation produces cell division delay of 1 hour per Gy in a 2 to 10 Gy range. The delay is greatest for cells in G_2 phase. Molecular checkpoint genes arrest cells in G_2 phase to allow chromosomes to be checked for integrity and to be repaired before mitosis occurs. Cells lacking normal checkpoint genes will likely be more sensitive to radiation killing and malignant change. Shorter division delays occur in S cells and are least for G_1 cells.

Radiation Modifiers

There are two principal groups of radiation modifiers, radiosensitizers and radioprotectors, [7] both of which have been widely studied in skin and hair. For these agents, toxic effects, technological limitations, and, often, a lack of differential effects on tumors versus normal tissues, limit their usefulness. Only a few of these modifiers are discussed here.

OXYGEN AS A RADIOSENSITIZER The addition of oxygen to low prevailing pressures of 0 to 30 mmHg increases the effectiveness of sparsely ionizing radiation (x-rays, gamma-rays) up to threefold for a dose greater than 2 Gy. To produce this effect, mediated by free radical and H_2O_2 formation, oxygen must be present during the irradiation time. No further sensitization occurs after oxygen concentrations of 2 percent are reached. Oxygen enhancement ratios are least for densely ionizing radiations (neutrons, alpha particles). Hypoxic areas in tumors are best overcome by fractionation treatment schedules and use of densely ionizing radiation where feasible. Hyperbaric oxygen therapy is markedly compromised by sharp falls in oxygen levels during tissue and tumor diffusion.
ELECTRON-AFFINIC AGENTS AS RADIOSENSITIZERS Electron-affinic agents interact with radiation-damaged DNA, blocking repair of injury produced by free radicals. The agents are cytotoxic to hypoxic cells and bind to intracellular radioprotectors (glutathione), further enhancing radiosensitivity effects. Unlike oxygen, these agents diffuse over greater distances and are more slowly metabolized. The principal compounds used are nitroimidazoles, including metronidazole (Flagyl) and misonidazole. Cytotoxic effects (neuropathies) have limited their usefulness, but newer, less-lipophilic agents, have shorter tissue half-lives and display significantly enhanced sensitization potentials. Some of these agents also potentiate chemotherapeutic drug effects. Certain compounds have been evaluated in clinical trials. [8]
HYPERTHERMIA-INDUCED RADIOSENSITIZATION Heating skin before, during, or after irradiation enhances cutaneous reactions in mouse or human skin. At temperatures over 41.5°C (106.7°F) structural, chromosomal and/or repair proteins are damaged, and RNA, DNA, and protein synthesis are impaired. Above 43°C (109.4°F) cell survival curves are similar to those for ionizing radiation. Hyperthermia also induces apoptosis in some cell lines. Overall, normal and malignant cells have similar heat sensitivities. In the clinical and experimental use of hyperthermia with radiation, heat at temperatures of 43°C (109.4°F) or higher is usually administered within 4 hours before radiation. Thermal enhancement ratios range from 2 to 4 for single doses, but are lower for fractionated therapy. Combination treatment produces more partial and complete tumor responses than radiation alone, but the sole use of hyperthermia has little effect. Cooling reduces tissue oxygen tension through vasoconstriction, decreasing radiosensitivity.
RADIOPROTECTORS With sparsely ionizing radiation, dose reduction factors of 2 to 2.5 have been found with thiol and disulfide compounds (cysteine, glutathione) which scavenge free radicals. The most effective of these is WR-2721 (amifostine), [9] but toxicity (hypotension) may limit its effectiveness. Leukotrienes and, especially, prostaglandins are effective radioprotectors in microgram amounts, yielding dose reduction factors up to 6 for misoprostol, although their protective mechanism is not fully elucidated. Given before radiation, their efficacy depends on the presence of receptors for the individual agent. [10] Prostaglandins are radioprotective after local or systemic administration, greatly reducing, for example, experimental radiation-induced alopecia. [11] They also protect against chemotherapeutic agent toxicity as well, especially for doxorubicin and cyclophosphamide. [11], [12] Misoprostol holds clinical promise for the protection of normal tissues (hair, mucous membranes) lying in the path of a radiation beam, while experimentally it fails to protect tumors against radiation effects. [13], [14]

Radiobiology of the Skin and Hair

Within 2 to 3 weeks after exposure of human skin to high doses of fractionated radiation, acute erythema, moist desquamation, erosions, and epilation occur, followed by healing. The intensity of radiation erythema depends on age, gender, anatomic site, dose, and dose rate. These early changes reflect injury, apoptosis, and reproductive failure in germinative epidermal and hair matrix cells, reduced division rates in surviving cells, and vascular damage. [15] Epidermal cell replacement occurs from the third to the fifth week after radiation. Later chronic postradiation changes result largely from injury to dermal structures, particularly the vasculature, and fibrosis, which is actually an early (within 1 week) but progressive postradiation event that is cytokine mediated. [15], [16] and [17]

The character and magnitude of cutaneous responses to radiation depend on total dose and dose fractionation, radiation quality and ionization density, area or volume of tissue irradiated, anatomic site, and vascular supply. The responses of irradiated skin and the effects on postradiation skin changes of radioprotectors, radiosensitizers, and hyperthermia have been reviewed. [15], [18] The subjects of increased radiosensitivity and carcinogenesis in genetic disorders characterized by defective cellular and DNA repair processes have been summarized. [19]

Postradiation changes in the highly proliferative anagen hair matrix cells induce hair dysplasia and reduced hair lengths and growth rates. In humans, 3 Gy produces complete, reversible anagen alopecia; permanent alopecia begins to occur at 5 Gy. In mice, G_0 telogen matrix cells are 2.5 times more radioresistant than anagen cells. Differences in cell proliferation states and vascular supply between anagen and telogen hairs probably explain these differences. Altered matrix cell uptake of isotopically labeled amino acids, incidence of hair dysplasia, measurements of reduced hair shaft diameters, and quantitative assessments of surviving hairs or later regrown hairs have all been used as biologic end points to study general cellular radiation effects, as well as radioprotective or radiosensitizing actions of numerous pharmacologic or physical agents. [15], [20]

Radiobiologic Effects on Melanocytes and Pigment Formation

Low-dose radiation induces cutaneous hyperpigmentation after minimal inflammation. Pigmentation is directly related to dose rate and total dose, and is characterized by increased numbers of melanocytes with increased tyrosinase activity, and by enhanced melanin transfer to epidermal cells. Higher radiation doses destroy melanocytes with resultant depigmentation. Similar radiation effects occur in mid-anagen hair follicles. At higher dose rates, hair melanocytes are far more susceptible to radiation destruction than epidermal melanocytes. In mice, telogen melanocytes are much more radiosensitive than anagen melanocytes. Melanocyte survival in hair follicle squashes and depigmentation of hair in laboratory animals have both been used to quantitate combined drug-radiation effects.

Radiobiologic Effects on Langerhans Cells

Although Langerhans cells (LC) are relatively radioresistant, [21] in one study, single doses of 20 Gy in mice reduced LC numbers to 18 percent within 10 days; repopulation was complete 30 days later. Whole-body irradiation to the bone marrow delayed repopulation another 3 weeks. In mice, the effects of such radiation early in life markedly increased skin LC loss in aged animals, perhaps reflecting dermal fibrosis and reduced blood flow. [21] Loss of LCs and their immunologic functions may contribute to increased postradiation tumorigenesis and to reduced susceptibility to contact hypersensitivity in affected sites.

RADIOTHERAPY OF SKIN DISEASES

Soon after the discovery of x-rays by Röntgen in 1895, the therapeutic potential of radiation was recognized. The first patient treated for a squamous cell carcinoma of the nose was treated in 1900. Soon thereafter, radiation therapy was used empirically for a host of conditions, both benign and malignant. In many situations, in which no effective therapeutic alternatives existed, radiation therapy may have been one of the few treatment options available. This was true until the 1950s. Thereafter, radiation treatment declined for two major reasons: One reason was awareness of the deleterious late effects of radiation, including the potential for the induction of malignancy. In addition, advances in surgical techniques and the development of effective medical therapies such as corticosteroids and antibiotics provided effective alternatives to the use of ionizing radiation. Nonetheless, dermatologists should retain primary expertise in the indication and treatment with x-rays for skin diseases either benign or malignant. [22] There are situations in which ionizing radiation remains an accepted therapeutic alternative or even the treatment of choice for certain skin diseases. Dermatologists, often in collaboration with radiation oncologists, can assist the patient and referring physician in selecting the treatment regimen with the highest therapeutic ratio for a particular individual (Table 128-1). In many cases, the morbidity of radiation is low when compared to the morbidity or even mortality associated with alternative therapies, or with the complications associated with progressive or recurrent disease.

TABLE 128-1 **Radiation Qualities**

Benign Skin Diseases

The use of ionizing radiation for benign skin diseases has decreased considerably as new and better systemic and local treatments have become available. In some diseases, radiation treatment is a useful therapeutic alternative, for example, for keloids. In certain dermatoses, for example eczema, radiotherapy should be applied only after other therapeutic methods have failed. Improved x-ray technology, accurate dosimetry, and strict adherence to safety rules have reduced cutaneous and noncutaneous side effects to a minimum. [23] The use of x-rays for benign diseases in all medical specialties has been evaluated by the National Academy of Sciences and these recommendations are now endorsed by the Food and Drug Administration (FDA). [24] In addition, the following rules for the irradiation of benign skin diseases are emphasized by dermatologists and radiooncologists: [23]

- The diagnosis must be clearly established, if possible by biopsy.
- Radiotherapy should start at the earliest possible time, e.g., in keloids.
- There should be a reasonable expectation that radiotherapy will lead to an improvement.

- All patients should be questioned about previous irradiations (“passport”).
- No area of the skin should be subjected to more than 12 Gy of soft or superficial x-rays (20 to 150 kV) or 50 Gy of grenz rays per lifetime and radiation field.
- No local treatment should be applied prior to radiotherapy in order to avoid irritating effects (e.g., 5-fluorouracil) or a reduction of the x-ray effect (e.g., zinc preparations).

For very superficial skin conditions, especially epidermal processes, grenz-ray treatment (5 to 19 kV) is preferred. Lindelöf and colleagues conducted a large-scale investigation of grenz-ray therapy and concluded that even doses up to 100 Gy are not associated with any significant side effects. [25]

Most inflammatory dermatoses have their pathology in the first millimeter of the skin and the rest in the first 3 mm. Grenz-ray therapy may be expected to be beneficial because 50 percent of grenz radiation administered is absorbed by the first 0.5 mm of the skin. This form of radiation is extremely suitable if one considers the sparing effect on hair roots, sebaceous and sweat glands, as well as eyes and gonads. Grenz-ray therapy may be indicated for these dermatoses: [26]

- Psoriasis
- Lichen simplex chronicus
- Pruritus ani et vulvae
- Seborrheic dermatitis
- Nummular eczema or persistent eczematous conditions
- Lichen planus
- Hailey-Hailey disease

The possible side effects of grenz-ray therapy are qualitatively identical to those of conventional x-rays, the principal adverse effects being erythema and pigmentation. Grenz-ray erythema is relatively asymptomatic, and its latent period is shorter than that of conventional x-ray erythema. It is ordinarily not followed by sequelae other than pigmentation. For this reason, close shielding should be avoided in order to not produce a sharp line at the edge of the treated area. Pigmentation so induced varies with race, age, and body region, but is seldom permanent.

In the following paragraphs the specific indications for the x-ray treatment of benign skin diseases with grenz rays or superficial x-rays are reviewed.

Psoriasis

Once a widely used treatment modality, x-ray therapy is used as a last resort in recalcitrant localized legions, especially where other treatment modalities are not very effective, for example psoriasis of the scalp and psoriasis of the nails. If properly used, radiation therapy is not associated with any major side effects. In general, there is no difference between conventional superficial x-ray therapy and grenz-ray therapy in more than 70 percent of the patients. Some authors found that the effect of superficial x rays were longer lasting than grenz rays. [26] Although grenz rays may be tried in psoriatic nails of normal thickness, it has been shown that they are less effective in thickened, diseased nails. [23] In accordance with other reports in the literature, we recommend the dose schedule described in Table 128-2.

TABLE 128-2 **Recommended Doses: Dermatoses**

Eczema/Dermatitis

If superficial x-rays are used, the least-penetrating quality should be preferred; in most cases, grenz rays (5 to 19 kV) are suitable. [23] However, in some chronic, long-standing eczematous conditions, especially of the palms and soles, more penetrating radiation qualities, that is, soft x-rays (20 to 150 kV) are more effective. There were different studies performed, all with favorable response rates, for hyperkeratotic eczemas or chronic lichenified eczemas. The weekly doses range from 0.5 to 1 Gy. It has also been shown that under certain indications, especially hyperkeratotic eczemas, a total dose of 3 Gy of conventional superficial x-ray was superior to 9 Gy of grenz rays. In atopic dermatitis, ionizing radiation is rarely advisable because of its high tendency to recur, whereas lichen simplex chronicus responds quickly to radiation therapy, because the antipruritic effect of radiation in this dermatosis is striking. Recent surveys indicate that the group of eczematous disorders constitute the most frequent indication for radiotherapy of benign lesions, especially in older patients with contraindications to systemic steroids or to the continued use of topical steroids. Table 128-2 lists our dose recommendations.

Keloids

For unknown reasons, certain individuals have a predisposition to keloid formation after surgery or other skin injury. [27] Lesions appear to occur frequently among those of African or Asian ancestry. In addition to cosmetic problems, keloids can become painful, pruritic, or fibrotic, and can produce significant morbidity. A variety of treatment options have been described. The use of pressure postoperatively is important as an additional treatment as are injections of corticosteroids. Radiation therapy has been employed successfully in the treatment of keloids. In most series, external

kilovoltage or electron beam radiation is directed at the surgical bed within 24 to 72 hours after surgery. [23], [28]

It has been shown that recurrence rates after keloid irradiation are much lower if radiation is administered following excision (25 to 36 percent) than the recurrence rate without prior excision (63 to 74 percent). [23] Typical dose-fractionation schemes range from 9 to 16 Gy in 3 to 4 Gy fractions. There does not appear to be a significant dose–response relationship in this dose range. The technique for the treatment of keloids is relatively straightforward: the reexcision scar, plus a 1- to 2-cm margin is treated. All suture sites should be included. Superficial x-rays can be used. The overall profile of morbidity and efficacy compares favorably with that of other treatments for keloids. Table 128-2 lists dose recommendations.

Lymphocytoma Cutis (Lymphocytoma Cutis Benigna, Lymphoid Hyperplasia)

This entity represents a pseudolymphoma and occurs as a localized or disseminated type. Because there are different etiologic agents, a therapeutic trial with antibiotics may not induce quick resolution of the lesion. The localized and circumscribed type responds well to small doses of x-rays. [23], [29] Early lesions are more radiosensitive than older lesions. Cases of cutaneous lymphoid hyperplasia have also been reported in conjunction with the acquired immunodeficiency syndrome (AIDS), and progression to malignant lymphoma occurs in some cases. It is also possible to treat lymphomatoid papulosis with x-rays. [30] In general, the dose recommendations are similar to those for lymphomas (see below).

Other Indications

There are other rare indications for radiotherapy such as severely pruritic and refractory cases of the *verrucous type of lichen planus,* particularly on the legs. [23]

We earlier mentioned the possible indication of treating *Hailey-Hailey disease,* especially with grenz rays. These represent an excellent alternative to other treatment modalities and have a long-lasting effect. In rare cases, the treatment has to be repeated. [23] The dose schedule is the same as for eczema.

Another possible indication is *Peyronie's disease* (Induratio penis plastica), characterized by the development of penile plaques, arising from fibrosis of the corpus cavernosum. This disorder is characterized by a penile curvature during erection, and the presence of penile plaques or induration, often leading to pain during erection or intercourse. The disease may be self-limited in many cases. Indications and rationale for radiotherapy include the following: [31]

- There is a high rate of success when compared with other treatments: palliation of pain in approximately 80 percent of patients; decreased size of plaque in approximately 61 percent of patients; improvement of curvature in approximately 57 percent of patients.
- Treatment is painless, localized to the penis, without systemic side effects, and completed in 1 to 2 weeks.
- Failure of other therapies does not preclude a response to radiotherapy, and failure of radiotherapy does not preclude the use of other modalities.

Pain is the most reliable palliated symptom, with lesser rates of palliation achievable for induration and curvature.

Vasculitic painful leg ulcers are another potential indication for very-low-dose x-rays, that is, 0.2 Gy. [23], [32] The doses are applied daily and the pain relief is quite striking after a few sessions. Table 128-2 shows the treatment schedule.

Erythroderma [33] or *generalized senile pruritus* may also be treated with x-rays. [23]

There is no longer an indication for the treatment of acne, hemangiomas or verrucae with radiation therapy.

RADIATION THERAPY OF MALIGNANT SKIN DISEASES/TUMORS Carcinomas of the skin are the most accessible cancers, the diagnosis is readily made and the limits of the lesion are usually easy to define. No single treatment method is best for all cancers of the skin. If the sole criterion of success is eradication of the lesion, surgery and radiotherapy yield similar results. Most cutaneous cancers are sufficiently sensitive to radiation to be eradicated by doses that are well tolerated by the surrounding normal tissue. If appropriate principles are followed and precautions are taken, x-irradiation is a safe and effective method of therapy. [22] Our discussion is deliberately limited to radiotherapy of cutaneous cancers of moderate size that can be effectively treated with grenz rays, superficial x-rays, or contact therapy units (see Table 128-1). Larger and more complicated skin cancers should be referred to Mohs surgeons and/or radiation oncologists for treatment with higher kilovoltage, megavoltage, or electron-beam techniques, or for implants with radioactive isotopes. When treating skin cancer, the *advantages* of soft- or superficial x-ray therapy include:

- Performable on an outpatient basis
- Painless
- Usable for physically or psychologically handicapped patients (also patients over 90 years old [34]
- Usable for anticoagulated patients
- Usable in patients in whom there exists a contraindication for a surgical intervention
- Healthy tissue or certain organs can be protected
- Usually a wide margin of normal-appearing skin (wider than in surgical excisions)
- Atraumatic intervention

However, there also are *disadvantages* to radiation therapy about which the patient should be informed:

- The treatment cannot be done in one single session

- If the patient has already received full tumor doses in a radiation field, this particular field cannot be irradiated a second time
- Radiation treatment is followed by alopecia (except if treated by grenz rays)
- Chronic radiation dermatitis tends to be accentuated with time

What is the ideal indication for radiotherapy? Radiotherapy is particularly valuable for medium-sized tumors of 1 to 4 cm in diameter on the face of elderly people, because smaller tumors are mostly treated by surgery and larger lesions are mostly treated either by Mohs surgery or by a combination of surgery and megavoltage treatment.
What are the best areas to be treated by radiation therapy? The real superiority of irradiation over excision lies in its greater preservation of uninvolved tissue. In certain anatomic regions this may pose a problem for the surgeon but not for the radiotherapist who can easily adjust the size of the field to the required area of treatment. Therefore, radiation is often the treatment of choice in areas where tissue cannot be readily sacrificed for cosmetic and/or functional reasons. There is general agreement that ionizing radiation is often preferable to other methods of treatment for cutaneous tumors of the following areas: [22]

- Eyelids
- Medial or lateral canthi of the eyes
- Nose
- Ears
- Lips
- Nasolabial folds
- Preauricular areas
- Larger tumors of the cheek

On the other hand the skin of the trunk and extremities has a greater tendency to develop radiation sequelae, particularly telangiectasias and changes in pigmentation. [35] Before radiation therapy of a lesion is begun, the diagnosis must be confirmed by biopsy.
Why biopsy? The histologic examination determines

- the type of the tumor.
- the radiosensitivity of the tumor.
- the exact extension of the tumor.
- the depth of the tumor.
- the exclusion of an error.

Concerning the radiosensitivity of skin tumors, *four categories* are distinguishable (Table 128-3): (1) *Highly indicated* and unique advantage: Kaposi's sarcoma, mycosis fungoides, and other lymphomas of the skin. (2) *Good indication:* basal cell and squamous cell carcinomas, keratoacanthoma, Bowen's disease, Queyrat's erythroplasia, Merkel cell carcinoma. (3) *Sometimes indicated:* angiosarcoma, melanoma. (4) *Rarely indicated:* fibrosarcoma, carcinomas of the scrotum, soles, and palms.

Indication	Tumor
Highly indicated	Cutaneous T cell lymphomas (CTCL) Some B cell lymphomas Kaposi's sarcoma
Good indication	Basal cell carcinoma (BCC) Squamous cell carcinoma (SCC) Keratoacanthoma Bowen's disease Queyrat's erythroplasia Merkel cell tumor
Sometimes indicated	Angiosarcoma melanoma (LMM)
Rarely indicated	Carcinoma of the scrotum, or palms/soles fibrosarcoma

TABLE 128-3 **Indications/Radiosensitivity of Different Skin Tumors**

We also distinguish between *curative* radiotherapy in tumors such as basal cell carcinomas; squamous cell carcinomas; keratoacanthomas; precancerous lesions and melanomas of the lentigo maligna type; and *palliative* radiation therapy in tumors such as Merkel cell carcinoma, Kaposi's sarcoma, and most lymphomas. The contraindications for radiotherapy with soft x-rays include:

- Tumors penetrating into cartilage or bone
- Intraoral tumors
- Tumors penetrating into the nostrils
- Tumors in scars of osteomyelitis, burns, chronic ulcers, or in chronic radiodermatitis
- No retreatment of previously irradiated skin carcinomas
- Genodermatoses that are prone to neoplasms such as basal cell nevus syndrome or xeroderma pigmentosum

Which radiation quality? Since the work done in England, Germany, and United States, and with the introduction of the beryllium-windowed x-ray units, as a rule of thumb, radiation qualities with a half-value depth (HVD = $D_{1/2}$) corresponding to the depth of the tumor have been proposed. Most of the radiation will then be absorbed in the pathologic tissue and the possibility of undesirable radiation effects to underlying uninvolved tissue will be markedly reduced. The depth of the tumor can either be reasonably estimated by inspection and palpation or by an exact histopathologic description of the tumor depth, preferably by an experienced dermatopathologist. Several studies show that 50 percent of all basal cell and squamous cell cancers infiltrate to a depth of only 2 mm or less, and 75 percent of such tumors infiltrate to a depth of 5 mm or less. [22] With grenz and superficial x-ray machines, the kilovoltage is in a fixed combination with filters in order to avoid filter mistakes and thus application of faulty dosages. These x-ray machines have a kilovoltage between 10 and 50 kV, sometimes up to 100 or even 150 kV. With filter combinations, a HVD (= $D_{1/2}$) from 1 mm to 20 mm can be reached. For dermatologic purposes, it is rarely necessary to irradiate tumors thicker than 20 mm.
Why fractionated doses? Fractionation of radiation dosage is based on the assumptions that tissues recover at

different rates from the effects of radiation and that tumor tissue recovers more slowly than normal tissue. When a given dose of radiation is divided into several increments and delivered over a period of several days, the biological effect is usually less pronounced than that of the same radiation administered in a single dose. This lesser damage with fractionation appears to be related to cell recovery between increments and to the capabilities of recovering cells to adapt to radiation-induced alterations of the surrounding tissues. Small tumors and radiation fields support higher single doses than do large tumors with large irradiation fields that have to be irradiated with smaller single doses. In addition, in large irradiation fields, we have to consider an additional backscatter factor. Much work has been done in an attempt to define optimum time-dose-volume relationships for carcinomas of the skin. There is no consensus as to the total dose needed to eradicate a cutaneous cancer and when to terminate radiotherapy. Different authors have recommended different dosages. [22] The tendency is to use standardized schedules (Table 128-4).



TABLE 128-4 **Recommended Doses: Malignant Tumors**

It is still worthwhile to observe the patient's reaction during radiation therapy and to look for an exudative or erosive reaction in the irradiated margin. When larger individual doses are administered, the recommended total dose is usually smaller than in cases where smaller individual doses were used.

Disseminated Actinic Keratoses

Usually, there is agreement that small actinic keratoses are best treated by surgical excision or other equivalent methods. The problem arises in extensive and disseminated actinic keratoses as, for example, on the scalp. Here, again, there are possibilities with topical treatments such as 5-fluorouracil or imiquimod cream, but usually recurrence rates are higher or appear sooner than after treatment with radiotherapy. Because these lesions are intraepidermal and often in an atrophic epidermis, the ideal treatment is with grenz rays. The treatment consists of six sessions of 6 Gy twice weekly applied on one or several divided fields. [36] At the end of the treatment, an erythema or an exudative reaction will occur. If there is marked pruritus, topical glucocorticoid creams may be of help to the patient. One month after the end of treatment, the erythema has mostly gone. The patient has to be told to continue sun protection with a hat and application of a sunscreen. Rarely, it is necessary to perform a second treatment years later.

Table 128-4 shows the dose schedule.

Bowen's Disease/Queyrat's Erythroplasia

This carcinoma in situ is treated in a similar fashion to actinic keratosis, but histopathologically, these lesions are thicker. Even in elderly patients, it is possible to apply grenz rays with a $D_{1/2}$ of 1 mm. If the lesions are more infiltrated, soft x-rays with quality of 20 kV or more are necessary. The dose schedule can be adapted (see Table 128-4). Again fractions of single doses of 6 Gy up to total dose around 40 Gy may be used. Single doses with soft x-rays would be 4 Gy. Exudative reactions have to be expected a little earlier in the genitoanal area. Treatment results are excellent. [36]

Table 128-4 shows the dose schedule.

Lentigo Maligna

This is another precancerous lesion that is an excellent indication for radiation treatment. This treatment modality is not well known because it is always thought that it is not curative. Recent reports show that treatment results are at least as good as surgical procedures. [37], [38] and [39] As mentioned earlier, the inclusion of a wide enough margin is not a problem for the radiation therapist; consequently, large lentigo malignas are an excellent indication for radiotherapy. The classical treatment schedule is named after Miescher who proposed 5 to 6 doses of 20 Gy grenz rays for medium-sized lesions (around 2.5 cm in diameter). For larger lesions we prefer 10 to 12 doses of 10 Gy grenz rays (see Table 128-4). The epidermis in the elderly is atrophic, and with a HVD of 1 mm we reach even atypical melanocytes in the hair follicles. Figure 128-1 shows a grenz-ray treatment result.

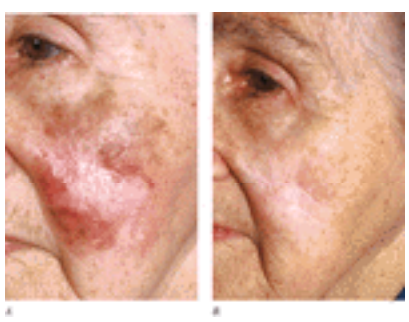

FIGURE 128-1 *A*. Extensive lentigo maligna on the left cheek of a 76-year-old female patient before and (*B*) 2 years after grenz ray treatment [10 times 10 Gy (100 Gy), twice per week].

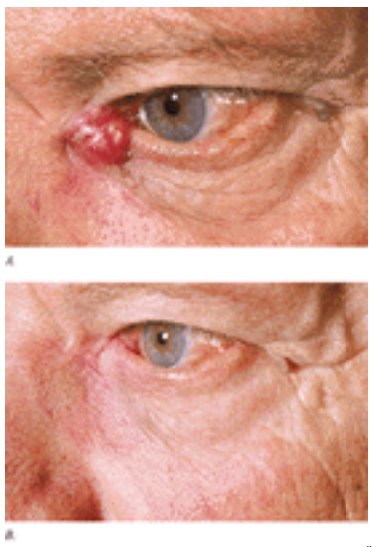

FIGURE 128-2 *A*. Basal cell carcinoma on the left inner canthus of a 64-year-old man before and (*B*) 6 months after soft x-ray treatment (40 kV) [12 times 4 Gy (48 Gy), twice per week].

Basal Cell Carcinoma, Squamous Cell Carcinoma, Keratoacanthoma

These tumors represent the classical indications for radiotherapy with soft x-rays or superficial x-rays, because most of these tumors are well circumscribed and rarely larger than 2.5 cm. In addition, 75 percent of these tumors are less than 5 mm thick. Some treatment centers use the same treatment schedules for basal cell carcinomas (BCCs) and squamous cell carcinomas (SCCs), although one could imagine that SCC should be treated with a higher total dose, because it represents a more aggressive tumor. [22] Elderly patients prefer not to come every day for the treatment sessions. Therefore, medium-sized lesions can be treated with, for example, a 4-Gy single dose in three fractions per week. There is even the possibility of applying a higher single dose, for example 6 to 8 Gy per fraction twice a week, to small lesions that cannot be excised. We agree that large lesions, (larger than 4 cm) are best treated with daily fractions of 2 or 3 Gy (see Table 128-4). Figure 128-2 shows the results of treating a BCC as described here.

We want to stress the importance of knowing the histopathology of BCC and SCC for the outcome of the treatment. A large study has shown that if the histopathology shows a sclerosing type rather than a nodular type of BCC or SCC, the recurrence rate rises immediately. [36] Consequently, the sclerosing histologic type is not well suited for treatment with soft x-rays. There are two possibilities: (1) if the patient is operable, Mohs surgery is the preferred method, or (2) if surgery is contraindicated, megavoltage therapy should be chosen.

For keratoacanthomas the same dose schedule is used as for SCCs. [40] Carcinomas of the skin appendages and carcinomas penetrating into cartilage or bone, localized in the mucous membranes, or arising in chronic scars, are not an indication for soft x-ray therapy.

Radiation treatment is possible for BCCs, SCCs, or keratoacanthomas that were not completely excised or were incompletely treated by electrodesiccation or cryotherapy. The techniques are the same as for primary tumors. The functional and the cosmetic results after irradiation of such treated tumors are usually satisfactory. [22]

Melanoma of the Lentigo Maligna Type

Since the time of Miescher, it has been well known that not only lentigo malignas (LMs), but also lentigo maligna melanomas (LMMs) respond well to radiation treatment. [37], [38] and [39] In contrast to lentigo malignas, LMMs penetrate into the dermal tissues. As a result, grenz-ray treatment is not recommended; instead, soft or superficial x-rays, that is, radiation qualities of at least 20 kV or more, are recommended. We want to stress that LM and LMM are not to be considered radioresistant; instead, they may be tumors with a *reduced radiosensitivity* for the following reasons: [41]

- High percentage of nonproliferating cells
- High percentage of hypoxic cells
- High probability of potentially lethal repair
- Subpopulations of cells with different radiosensitivity in the “shoulder” region of the survival curve
- Synthesis of the prostaglandins (radioprotectors) in the tumor cells
- Melanin is a scavenger of “radicals”

Therefore, higher doses per fractions are recommended, mostly situated around 6 Gy per fraction. Table 128-4 shows the proposed dose schedule.

Our results from treatment of 64 patients show a similar outcome for radiation treatment as for surgical treatment, with a cure rate of approximately 90 percent. [38] This rate is for both LM and LMM, especially for large lesions on the face of elderly patients, which lets these patients avoid major surgical procedures and scarring. From the cosmetic and functional point of view, the outcome is excellent.

Paget's Disease

Paget's disease of the nipple shows mostly an underlying carcinoma. In extramammary Paget's disease, seldom is an underlying carcinoma found. In these situations, we are dealing with a superficial lesion and thus grenz rays can be used. The dose schedule is similar to that used for Bowen's disease.

Merkel Cell Tumor

Merkel cell tumor is a rare primary skin tumor and occurs most frequently in the seventh and eighth decades. Tumors occur with greatest frequency in the head and neck region (50 percent). Tumors are characterized by a high rate of local recurrence after surgical excision (25 to 60 percent) and by frequent involvement of regional lymph nodes (45 to 79 percent); distant metastatic failure is common (22 to 48 percent). [42] Several series have shown promising results when radiation therapy is added to the initial surgical management of Merkel cell carcinoma. At the M.D. Anderson Cancer Center, 83 percent of patients showed disease control when they were treated with surgery and radiation therapy for palpable neck disease. Doses of 50 Gy at conventional fractionation appear adequate for the treatment of subclinical disease, but when microscopic or gross residual disease exists, boosting the doses to 60 to 70 Gy is indicated. [43]

Cutaneous Lymphomas

In general, the lesions of cutaneous lymphomas, that is, T cell or B cell lymphomas, are very radiosensitive. [44], [45] With the exception of certain circumscribed B cell lymphomas or localized CD30+ lymphomas where radiotherapy is curative, the radiation treatment for lymphomas is palliative. Total doses in the range of 20 to 30 Gy are commonly used and offer excellent palliation. Doses in this range may result in a relapse rate of up to 30 percent. Single doses of 2 Gy, either daily or three times per week, seem to offer the best local control. See also Table 128-4.

Because of the possible need for the subsequent treatment in adjacent areas, it is important to document the treated areas with photographs, accurate drawings, and, if feasible, tattooing of the corners of the fields with India ink. In most patients, the lesions will not clear during or at the completion of irradiation and it may take up to 6 to 8 weeks for complete response (Fig. 128-3). For individual skin lesions, energies may range from orthovoltage to electron beam. The depth of infiltration defines the energy of the beam required. Larger, bulkier lesions, such as deep ulcers or lymph nodes, may be treated by either Cobalt or 4 to 6 MeV photons. (see Table 128-1)

FIGURE 128-3 *A*. Mycosis fungoides in a 42-year-old woman before and (*B*) 1 month after soft x-ray treatment (40 kV) [6 times 2Gy (12 Gy), 3 times per week].

Kaposi's Sarcoma

NON–AIDS-ASSOCIATED KAPOSI'S SARCOMA Local irradiation of Kaposi's sarcoma (KS) includes the lesion plus a normal tissue border of approximately 1 to 2 cm. Thin, cutaneous lesions can be effectively treated either by superficial x-ray therapy (e.g., 20 to 150 kV) or relatively low-energy electron beams (e.g., 4 to 6 MeV). Thick nodules are best treated by electron beams that encompass the entire lesion homogeneously but spare underlying normal tissues. Lesions on the eyelids are treated most easily by superficial x-rays with protective shields over the optic lens. [36], [46] Based on the available evidence, both local therapy and elective regional therapy are effective techniques for the treatment of classical KS. The literature supports the use of a wide range of doses and fractionation patterns. As long as a sufficient dose is delivered (e.g., 20 to 30 Gy in 10 fractions or, for small lesions, 8 Gy in 1 fraction), a salutary outcome is likely. [47] Table 128-4 shows a treatment schedule.

AIDS-ASSOCIATED KAPOSI'S SARCOMA Usually, the same dose schedules are used and no difference is evident, although it may take 3 to 4 months for the tumors to resolve. Radiation-induced edema of the feet or face, as well as symptomatic mucositis, are more severe in patients with AIDS than in other patients. [47] Radiation therapy may be reserved for specific indications such as pain, ulceration, bleeding, functional impairment (e.g., on the legs), or improvement of the appearance of cosmetically disfiguring lesions (e.g., the eyelids). In the case of palliative radiation therapy for AIDS-associated Kaposi's sarcoma:

- Sufficient dose should be delivered to accomplish the desired goal and maintain that state for as long as possible.
- The treatment should be delivered as rapidly as possible.
- Distressing side effects should not be induced by the treatment.

Other Skin Tumors

Other possible indications for radiation therapy include: [26]

- Angiosarcoma

- Leukemic infiltrates of the skin (e.g., infiltrations of chronic myelogenous leukemia, or chronic lymphatic leukemia)
- Metastatic nodules of melanoma
- Metastatic nodules of breast carcinoma

REFERENCES

1. Schmidt-Ullrich RK et al: Signal transduction and cellular radiation responses. *Radiat Res* **153**:245, 2000

2. Herskind C et al: The role of cytokines in the development of normal-tissue reactions after radiotherapy. *Strahlenther Onkol* **174**(suppl 3):12, 1998

3. Rosen EM et al: The molecular and cellular basis of radiosensitivity: Implications for understanding how normal tissues and tumors respond to therapeutic radiation. *Cancer Invest* **17**:56, 1999

4. Davis ST et al: Prevention of chemotherapy-induced alopecia in rats by CDK inhibitors. *Science* **291**:134, 2001

5. Schwartz JL et al: The contribution of DNA ploidy to radiation sensitivity in human tumor cell lines. *Br J Cancer* **79**:744, 1999

6. Sinclair WK, Morton RA: X-ray sensitivity during cell generation cycle of cultured Chinese hamster cells. *Radiat Res* **29**:450, 1966

7. Maisin JR: Bacq and Alexander Award lecture—Chemical radioprotectors: Past, present, and future prospects. *Int J Radiat Biol* **73**:443, 1998

8. Lorimore SA et al: Oral (PO) dosing with RS 1069 or RB 6145 maintains their potency as hypoxic cell sensitizers and cytotoxics but reduces systemic toxicity compared with parenteral (IP) administration in mice. *Int J Radiat Oncol Biol Phys* **21**:387, 1991

9. Wasserman T: Radioprotective effects of amifostine. *Semin Oncol* **26**(2 suppl 7):89, 1999

10. Hanson WR et al: Prostaglandin-induced protection from radiation or doxorubicin is tissue specific in mice. *J Invest Dermatol* **104**:606, 1995

11. Geng L et al: Topical or systemic 16,16-dimethyl prostaglandin E_2 or WR-2721 (WR-1065) protects mice from alopecia after fractionated irradiation. *Int J Radiat Biol* **61**:533, 1992

12. Malkinson FD et al: Prostaglandins protect against murine hair injury produced by ionizing radiation or doxorubicin. *J Invest Dermatol* **101**(suppl):135, 1993

13. Hanson WR et al: The prostaglandin E_2 analog, misoprostol, a normal tissue protector, does not protect four murine tumors in vivo from radiation injury. *Radiat Res* **142**:281, 1995

14. Khan AM et al: A prospective randomized placebo-controlled double-blinded pilot study of misoprostol rectal suppositories in the prevention of acute and chronic radiation proctitis symptoms in prostate cancer patients. *Am J Gastroenterol* **95**:1961, 2000

15. Malkinson FD, Hanson WR: Radiobiology of the skin, in *Physiology, Biochemistry, and Molecular Biology of the Skin,* vol II, 2nd ed, edited by LA Goldsmith. Oxford, Oxford University Press, 1991, p 976

16. Panizzon RG et al: Ionizing radiation induces early, sustained increases in collagen biosynthesis: A 48-week study in mouse skin and fibroblast cultures. *Radiat Res* **116**:145, 1988

17. Randall K, Coggle JE: Expression of transforming growth factor-$ß_1$ in mouse skin during the acute phase of radiation damage. *Int J Radiat Biol* **68**:301, 1995

18. Archombeau JO et al: Pathophysiology of irradiated skin and breast. *Int J Radiat Oncol Biol Phys* **31**:1171, 1995

19. Malkinson FD: Radiobiology of the skin, in *Dermatology in General Medicine,* vol I, 5th ed, edited by IM Freedberg, AZ Eisen, K Wolff, KF Austen, LA Goldsmith, SI Katz, TB Fitzpatrick. New York, McGraw-Hill, 1999, p 1514

20. Kyoizumi S et al: Radiation sensitivity of human hair follicles in SCID-hu mice. *Radiat Res* **149**:11, 1998

21. Cole S et al: Langerhans cells: Quantitative indicators of x-ray damage in mouse skin? *Br J Cancer* **53**(suppl VII):75, 1986

22. Goldschmidt H: Treatment planning, in *Modern Dermatologic Radiation Therapy,* edited by H Goldschmidt, RG Panizzon. New York, Springer, 1991, pp 49–63

23. Goldschmidt H: Chronic radiation effects and radiation protection, in *Modern Dermatologic Radiation Therapy,* edited by H Goldschmidt, RG Panizzon. New York, Springer, 1991, pp 37–48

24. Goldschmidt H: FDA recommendations on radiotherapy of benign diseases. *J Dermatol Surg Oncol* **4**:619, 1978

25. Lindelöf B, Eklund G: Incidence of malignant skin tumors in 14,140 patients after grenz ray treatment for benign skin disorders. *Arch Dermatol* **122**:1391, 1986

26. Lindelöf B: Grenz ray therapy, in *Modern Dermatologic Radiation Therapy,* edited by H Goldschmidt, RG Panizzon. New York, Springer, 1991, pp 155–159

27. Luo S et al: Abnormal balance between proliferation and apoptotic cell death in fibroblasts derived keloid lesions. *Plast Reconstr Surg* **107**:87, 2001

28. Wagner W et al: Results of prophylactic irradiation in patients with resected keloids, a retrospective analysis. *Acta Oncol* **39**:217, 2000

29. Gillian AC, Wood GS: Cutaneous lymphoid hyperplasias. *Semin Cutan Med Surg* **19**:133, 2000

30. Kaufmann T et al: Lymphomatoid papulosis: Case report of a patient managed with radiation therapy an of the literature. *Am J Clin Oncol* **15**:412, 1992

31. Mira JG et al: The value of radiotherapy for Peyronie's disease: Presentation of 56 new case studies and review of the literature. *Int J Radiat Oncol Biol Phys* **6**:161, 1980

32. Trott KR: Therapeutic effects of low radiation doses. *Strahlenther Onkol* **170**:1, 1994

33. Holloway KB et al: Therapeutic alternatives in cutaneous T-cell lymphoma. *J Am Acad Dermatol* **27**:367, 1992

34. Mitsuhashi N et al: Cancer in patients aged 90 years or older: Radiation therapy. *Radiology* **211**:829, 1999

35. Panizzon RG, Goldschmidt H: Radiation reactions and sequels, in *Modern Dermatologic Radiation Therapy,* edited by H Goldschmidt, RG Panizzon. New York, Springer, 1991, pp 25–36

36. Panizzon RG: Radiotherapie des précancéroses et tumeurs malignes de la peau. *Med Hyg* **56**:461, 1998

37. Gaspar ZS, Dawber RP: Treatment of lentigo maligna. *Australas J Dermatol* **38**:1, 1997

38. Panizzon RG: Radiotherapy of lentigo maligna and lentigo maligna melanoma. *Skin Cancer* **14**:203, 1999

39. Schmid-Wndtner MH et al: Fractionated radiotherapy of lentigo maligna and lentigo maligna melanoma in 64 patients. *J Am Acad Dermatol* **43**:477, 2000

40. Caccialanza M, Sopelama N: Radiation therapy of keratoacanthomas: Results in 55 patients. *Int J Radiat Oncol Biol Phys* **16**:475, 1988

41. Panizzon RG. Radiation therapy of melanomas, in *Modern Dermatologic Radiation Therapy,* edited by H Goldschmidt, RG Panizzon. New York, Springer, 1991, pp 133–137

42. Pilotti S et al: Clinicopathologic correlations of cutaneous neuroendocrine Merkel cell carcinoma. *J Clin Oncol* **6**:1863, 1988

43. Wegmuller EA Jr et al: Merkel cell carcinoma of the ear. *Head Neck* **13**:68, 1991

44. Bekkenk MW et al: Treatment of multifocal primary cutaneous B-cell lymphoma: A clinical follow-up study of 29 patients. *J Clin Oncol* **17**:2471, 1999

45. Micaily B, Vonderheid EC: Cutaneous T-cell lymphoma in *Principles and Practice of Radiation Oncology,* edited by CA Perez, LW Brady. Philadelphia, Lippincott-Raven, 1997, p 763

46. Goldschmidt H Radiation therapy of other cutaneous tumors, in *Modern Dermatologic Radiation Therapy,* edited by H Goldschmidt, RG Panizzon. New York, Springer, 1991, pp 123–131

47. Cooper JS: Classic and acquired immunodeficiency syndrome (AIDS)-related Kaposi's sarcoma, in *Principles and Practice of Radiation Oncology,* edited by CA Perez, LW Brady. Philadelphia, Lippincott-Raven, 1997, p 745

T>

Chapter 129

Calum Lyon Michael Beck

Skin Problems in Amputees and Ostomates

PROBLEMS IN AMPUTEES*
Dermatoses Related to the Reasons for Amputation
Physical Dermatoses
Bacterial and Fungal Infections
Contact Dermatitis
Other Cutaneous Disorders
General Management Considerations
SKIN PROBLEMS IN PATIENTS WITH ABDOMINAL STOMAS (OSTOMATES)
Irritant Reactions
Contact Allergy
General Management

REFERENCES
Footnote

PROBLEMS IN AMPUTEES *

The skin of an amputation stump is not designed to withstand the physical insults it encounters within a prosthetic limb. While some adaptation will occur, for example to friction or pressure, some skin problems are inevitable. If these dermatoses cannot be prevented or rapidly resolved by prosthesis adjustment or medical intervention, they can incapacitate the patient, particularly those who have a lower-limb prosthesis. As a result, the patient may suffer social isolation, emotional distress, or even financial deprivation if the patient is unable to work.

Although modern limb prostheses allow many of today's amputees to lead an active life with good mobility, [1] as many as one-third of amputees will experience a skin problem that interferes with the normal use of their artificial limb. [2]

In most centers, artificial limbs are made by using a modular construction technique. The stump is placed in a thermoplastic socket that is then fitted into the main body of the limb. The bulk of the prosthesis comprises a metal frame with articulations and an outer casing of acrylic resin or carbon composite material. Before fitting the limb many patients place their stump in a liner designed to reduce friction on the skin. This may be an expanded plastic cup, a silicon/mineral oil sleeve, or a cotton sock. The prosthetic limb, once fitted, is held in position by one of a range of suspension elements. In above-knee (Fig. 129-1) or proximal arm amputations, this is usually a fabric belt arrangement worn around the waist or shoulders, respectively. Below-knee amputees require a different system using either a butyl rubber sleeve or corset to hold the appliance firmly onto the thigh (Fig. 129-2). Many patients with above-knee amputations now use a suction socket device that provides sufficient suspension, holding the prosthesis in place by negative pressure without the need for additional belts (Fig. 129-1).

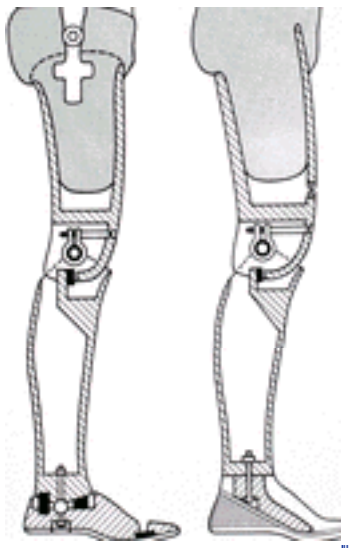

FIGURE 129-1 Above-knee prosthesis. Suction-socket prosthesis.

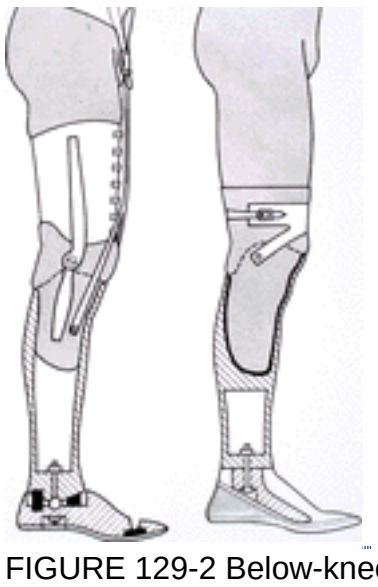

FIGURE 129-2 Below-knee prosthesis. Patellar–tendon-bearing cuff suspension.

Skin problems may occur because of allergy or chemical irritation to materials in contact with the skin, as well as from trauma and occlusion. Examples of physical stresses on the skin include shearing and friction from elements in the socket and pressure on load-bearing areas, especially on the tibial tuberosity in below-knee amputations and the ischial tuberosity, adductor region, or groin in above-knee amputations. In all cases, the occlusion results in increased humidity from trapped perspiration increasing the likelihood of irritation, allergy, and infection.

The great majority of artificial limb wearers are amputees, although a small proportion are people with congenital limb malformations. Lower-limb amputees are the most numerous and are also the group at greatest risk of skin problems. The reasons for this are clear when one considers the environmental stresses to which the stump skin is subjected. These stresses include heat, humidity, friction, shearing stress, and pressure, both positive and negative. In lower-limb prostheses, the greater load bearing and need for more secure attachment means that all these effects are amplified.

The common skin disorders in amputation stumps can be classified into diseases related to the reasons for the amputation, physical effects of a prosthesis, infection, contact dermatitis and other cutaneous disorders.

Dermatoses Related to the Reasons for Amputation

Several disorders resulting in the need for amputation can have a significant impact on skin integrity. In general, younger patients require artificial limbs because of traumatic amputations, congenital abnormalities, or malignancy, whereas in the older age group, arterial disease and vascular complications of diabetes mellitus predominate. Amputations following trauma or severe vasculitis may be associated with scarring that makes for a suboptimal prosthesis fit (Fig. 129-3). However, it is diabetes mellitus that is particularly associated with protracted skin problems as a result of impaired wound healing, susceptibility to infection, abnormal sensory nerve function, and disruption of normal tissue fluid balance. [3] Diabetic amputees as a group require more frequent clinical review in order to prevent complications. Treatment of the diabetic amputee not only requires good control of the blood glucose level but possibly a change of the stump environment through adjustment or redesign of the artificial limb. The diabetic amputee highlights the need for close links with a prosthetics department, which allow rapid referral of patients for assessment.

FIGURE 129-3 Scarring of the stump following amputation for severe postinfective vasculitis.

Physical Dermatoses

The physical effects of wearing a prosthesis are the commonest causes of skin problems. [2], [4] These can be divided into those resulting from repeated direct trauma and those secondary to disturbance of tissue fluid dynamics.

DIRECT PHYSICAL TRAUMA

Ulceration Ulceration and callus formation are seen where there is chronic pressure or repeated frictional forces on stump skin. Ulceration may also be caused by infection or poor cutaneous nutrition particularly secondary to diabetes mellitus (Fig. 129-4). Stump ulcers should be treated early as malignancy may develop in long-standing ulceration. With repeated infection and ulceration, an amputation scar on the distal stump skin can erode further. In some cases, the skin may become completely adherent to bone and develop thick, callus-like hyperkeratosis (Fig. 129-5), which may necessitate revision of the distal bony surface. In every instance, the cause of the ulceration must be determined in order to resolve a chronic process that can become totally disabling.

FIGURE 129-4 Chronic ulcer of stump skin.

FIGURE 129-5 Chronic ulceration resulting in thick hyperkeratosis and scab formation adherent to the underlying bone.

Physical dermatitis In some patients, eczema may be caused by a poorly fitted or misaligned prosthesis or by edema and congestion of the terminal portion of the stump; only with alleviation of these problems does the condition clear.
Epidermoid cysts and follicular keratoses These are two ends of a spectrum of the same disorder. They are a consequence of repeated pressure and friction from the prosthesis that appears to cause invagination of keratin around hair follicles, which then result in a foreign-body reaction. Follicular keratoses are therefore the earliest changes. [5] These are very common, often multiple, and distributed at sites of weight bearing such as the anterior tibial area, popliteal fossa, and the adductor or inguinal areas of the thigh (Fig. 129-6A). Fortunately, they cause little trouble in many cases, but they can become inflamed and painful, particularly if the patient picks at them to extract the keratin plug or if they become infected. Inflamed follicular keratoses can have an acneiform appearance leading some to suggest that they represent a form of acne mechanica. [6] When the continued pressure and friction causes the keratin to extend deeper into the dermis, larger cystic lesions, 1 to 3 cm in diameter, form; these are commonly termed *posttraumatic epidermoid cysts*. Deeper cysts can be very tender when compressed by the prosthesis. Some cysts have an obvious punctum and patients may express keratinous material from them. Large cysts can be so painful that the patient can no longer wear a weight-bearing prosthesis each day (Fig. 129-6B). Distention of the overlying epidermis can occur, followed by spontaneous rupture. A serous or purulent fluid, often mixed with blood, is then discharged. The resulting sinus is difficult to occlude and the discharge continues as long as the prosthesis is worn. Intercommunicating sinuses can appear and spontaneous ruptures may occur. In far-advanced cases, a granulomatous reaction occurs around the cyst, with considerable capillary dilation, vascularization, and a heavy inflammatory infiltrate progressing to abscess formation (see Fig. 129-6B).

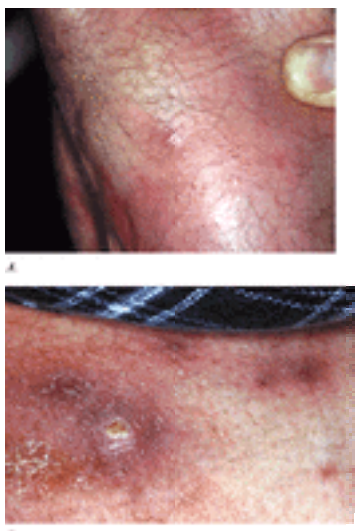

FIGURE 129-6 Epidermoid cysts in different stages. *A*. Early follicular keratoses in the popliteal fossa of a man with below-knee amputation. *B*. Hemorrhagic and inflamed large epidermoid abscess in a man with an above-knee prosthesis. Note the follicular hyperkeratosis.

Management of this condition can be difficult. Clearly, prevention is the ideal but is not always possible despite regular prosthetic assessments. The fit of the prosthesis is the single most important method of preventing cyst formation. The problem can sometimes be improved or successfully eliminated by proper fitting and aligning of the prosthesis and continued adjustment by the prosthetist. Rough surfaces in areas of increased contact pressure in the socket, particularly the suction socket, tend to catch the skin, increasing the shearing forces. For this reason, the lining of the socket should be kept smooth. With the idea of inserting a buffer between the skin and the socket, protective devices such as liners and stump socks are used. Various synthetic films and adhesives, such as Teflon, have been found satisfactory as liners. They allow for a smooth, gliding action of the prosthetic socket wall or brim against the skin. Applying a vapor-permeable adhesive membrane to the skin before fitting the appliance can also help to reduce frictional trauma. Topical glucocorticoids can be used at night to reduce inflammation and provide symptomatic relief. Intralesional injection of glucocorticoids into the cysts and their channels has also resulted in temporary improvement. Surgical intervention is useful in cases with a few lesions that are not infected. Lesions can be surgically incised and drained. In other instances, removal of the prosthesis is sufficient to cause the lesion to involute, provided that the cyst has not become too large.

However, spontaneous rupture, incision and drainage, and even spontaneous resorption of the lesion are of only temporary benefit. When the prosthesis is worn again, these cysts can recur so that surgical excision is not always the treatment of choice, especially in continually rubbed areas. In selected cases, systemic retinoid therapy may be appropriate to minimize hyperkeratosis. One author found oral isotretinoin to be effective in a patient described as having acne mechanica. [6]

DISTURBANCES OF TISSUE FLUID DYNAMICS

Edema Amputation of a lower extremity greatly disturbs the normal pattern of blood and lymph channels, as well as the relationship of pressure both inside the vessels and in the surrounding tissues of the stump. An important feature of care during convalescence after amputation is the reduction of edema and stabilization of new circulatory patterns in the stump. Swelling can be partially prevented by gradual compression of the stump tissues with an elastic bandage or "shrinker" sock before fitting the prosthesis and socket. When an amputee begins to wear a suction-socket prosthesis, the skin must adapt to an entirely new environment. The patient can expect edema, reactive hyperemia for days or weeks, a reddish-brown pigmentation resulting from capillary hemorrhage, and, occasionally, serous exudation and crusting of the skin of the distal portion of the stump. These changes are the almost inevitable result of the altered conditions forced on the skin and the subcutaneous tissues. They are relatively innocuous, usually short-lived, and do not usually require therapy. The extent to which edema may persist or recur in the healed stump depends on many factors. [7] Edematous portions of the skin of the distal part of the stump may become pinched and strangulated within the socket. Such areas may ulcerate if they catch in the spring-valve opening and become gangrenous as a result of the impaired blood supply. Therapy includes eliminating all mechanical factors contributing to the edema, such as choking by the socket and poor fitting and misalignment. Excessive negative pressure in a suction-socket prosthesis also contributes to circulatory congestion and edema. Treatment should be directed toward better support of the distal soft tissues. Occasional use of an oral diuretic sometimes allows the edema to resolve.

Verrucous hyperplasia This term refers to a reactive hyperplastic condition, characterized morphologically by numerous, coalescent warty papules (Fig. 129-7). It occurs when the chronic pressure effects of a poor prosthetic fit disrupt vascular and lymphatic channels resulting in chronic tissue edema. The same appearance is seen around long-standing leg ulcers where there is an element of lymphoedema (see Chap. 167). Histologic examination can show evidence of pseudoepitheliomatous hyperplasia, although the condition itself is benign and potentially reversible. However, in neglected cases, malignant change can occasionally occur (see Fig. 129-7). Bacterial infection may play a role in the development of pseudoverrucous hyperplasia, as secondary mixed flora infections are common because of the poor superficial blood flow and the convoluted surface. External compression is the best method of treatment, in combination with topical control of bacterial infection. In below-knee amputees, the distal part of the stump is edematous; the stump dangles freely in the socket or has no distal support or partial end-bearing. When the stump end is supported in the socket by a temporary cushion or platform, compression gradually reduces and slowly clears the verrucous condition. The greater the compression on the distal stump, the more immediate and lasting is the improvement. The use of compression bandaging, shrinker socks and other pads, and partial end-bearing all have a definite place in therapy and can be skillfully applied by the prosthetist. Short courses of oral diuretics may be indicated to reduce edema of the stump. The medication can be gradually decreased when the stump and its skin return to normal.

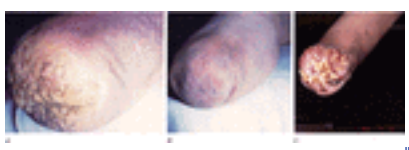

FIGURE 129-7 Verrucous hyperplasia of the distal stump skin. *A*. Before compression therapy. *B*. Total resolution after compression therapy. *C*. Malignant degeneration into squamous cell carcinoma.

Acroangiodermatitis This disorder occurs when the chronic pressure changes result in vessel proliferation in the upper and mid-dermis. There is also extravasation of red blood cells and these features combine to give a purplish hue to the papules and plaques that appear on a background of edematous skin. Some authors suggest that acroangiodermatitis occurs in above-knee amputees who use a suction socket prosthesis that exerts negative pressure. [8] However, there are reports of acroangiodermatitis in below-knee amputees, [9] and the same condition is seen in chronic venous insufficiency and in those patients with arteriovenous shunts (acroangiodermatitis of Mali). Management of this condition is the same as for stump edema and verrucous hyperplasia (above).

Bacterial and Fungal Infections

The bacterial flora of amputation stumps have been examined in small groups of patients, [10], [11] the commonest species encountered being *Staphylococcus epidermidis*, *S. aureus,* and *Streptococcus* species. The moist, occluded environment under a prosthesis is ideal for fungal and bacterial growth so that minor skin infections occur fairly frequently. In a study by the authors, *S. aureus* folliculitis or *Trichophyton rubrum* infection were identified in 3 percent of the study population. [2] Infections are more common during hot weather and in those amputees who pay insufficient attention to stump hygiene, partly because in these situations the skin becomes macerated more readily and follicular infections become more likely. Although folliculitis (Fig. 129-8) and furuncles are more common, superficial infections of the skin itself may also occur. Superficial dermatophyte and candidal infection are also common, and may be difficult to eradicate because of the ideal environment for fungal growth within a prosthesis.

FIGURE 129-8 Folliculitis of stump skin showing the typical distribution in the occluded area.

The diagnosis of infection is usually obvious when the rash extends onto skin not covered by the prosthesis. Underneath the prosthesis any superficial infection may present as a nonspecific scaling erythema indistinguishable from that caused, for example, by chronic irritation. All stump rashes should be swabbed for bacterial and fungal culture.

Superficial fungal infections respond to appropriate topical imidazole or terbinafine preparations. Infection can, however, be hard to completely eradicate because of the favorable conditions for fungal growth and because a widespread tinea corporis can occur. In this situation, systemic antifungal therapy is useful.

In the management of bacterial infections, oral antibacterial therapy should be directed by bacterial culture and sensitivity. Topical antiseptics or antibacterials can be used but some antiseptic preparations can cause irritation and there is also the potential for sensitization.

Contact Dermatitis (See also Chap. 120)

The clinical presentations of irritant and allergic contact dermatitis affecting amputation stumps are indistinguishable (Fig. 129-9), ranging from dry, scaling erythema to weeping eczema. [2] Indeed, the morphologic features may be the same as nonspecific eczematization where no irritant, allergic, or infectious cause is found, and where there is no history of eczema or atopy. Consequently, a careful history and examination is essential if one is to identify irritant or allergic causes. This includes accurate timing of the onset of dermatitis in relation to changes in the patient's appliance routine or the composition of the prosthesis. The distribution of rash typically matches the site of the contactant. To identify a primary irritant or allergen, it is particularly important for the dermatologist to observe the patient removing and refitting their limb, making note of the construction and any medicaments or other agents such as talcs and creams that the patient uses. Knowledge of the materials used in prosthesis manufacture and the patient's use of any topical agents is necessary when considering potential sensitizers and irritants. This is best achieved by liaison with one's local prosthetist, as different construction techniques may be used in different areas. In general, modern modular prostheses are fabricated with sockets, liners, and casings that may contain acrylic resins, carbon composites, and thermoplastics. Epoxy and, occasionally, polyester resins are still used by some manufacturers. Acrylate-based thread sealants are commonly used in socket bolts and metalwork. Butyl or black rubber material may be used to conceal access points to the metal frame. Rubber materials can also be found in some suction socket valves. Suspension elements often include leather in straps and sometimes have metal fastenings, rivets, or screws containing nickel. Glues containing *para*-tertiary butylphenol (PTBP) formaldehyde resins are often used.

FIGURE 129-9 Allergic contact dermatitis to formaldehyde-releasing biocides in a lubricating “baby oil.” Note the nonspecific dry eczematous appearance.

Repairs or adjustments to prostheses can introduce new irritants and allergens. For example, sockets sometimes have additional leather linings cemented to points of friction or pressure. Volatile solvents in these cements can be irritating and the resins potentially allergenic. Leather itself will often contain allergenic dichromates.

A proportion of patients regularly use an emollient cream or oil either as part of a skin care regimen or to lubricate the

stump when fitting a socket. Talc may also be used to dry the skin or to ease the fitting of a socket. These products may contain allergens such as fragrances or preservatives and patients should be advised to avoid such products. Colored stump socks may contain potentially allergenic nylon dyes.

Irritant dermatitis can be due to contact with volatile solvents in glues or resins, uncured monomers in a variety of resins, or from fragrances, preservatives, and emulsifiers in topical medicaments or lubricants. Soaps and other washing materials used to clean appliances can cause irritation if they are not removed by proper washing.

Contact allergy should always be considered as a cause of inflammatory and dermatitic disorders affecting the stump especially if there is secondary spread. In addition to standard series patch testing, we recommend an extra series of allergens to include components of plastics including acrylic, epoxy, and polyester resin systems, as well as an azo dyes series. It is important to test with pieces of the prostheses and all materials applied to the stump skin, including emollients, cleansers, powders, medicaments, and cosmetics. In our experience, the most common relevant allergens are nickel, acrylates, rubber, chromate (in leather), PTBP formaldehyde resin and components of topical applications. [2]

Other Cutaneous Disorders

Common skin diseases, for example, eczema and psoriasis, may affect amputation stumps by virtue of their typical distribution on limbs. Those diseases that exhibit the Koebner phenomenon, especially psoriasis or lichen planus, have been reported on amputation stumps with little involvement of other areas of skin.

Constitutional eczematous processes can also become localized to stump skin, as can acne vulgaris. In these cases, it is important to diagnose and treat the generalized skin condition. Atopic dermatitis with eczematization of the stump skin is often seen as a persistent, weeping or dry and scaly, itching area of dermatitis over the distal portion of the stump, as well as over the stump in general.

Temporary symptomatic topical therapy with glucocorticoid preparations can be effective, but the condition frequently recurs unless its cause can be eliminated. A short course of oral glucocorticoids may help control the process.

Benign keratoses, warts, nevi, and a variety of cutaneous papillomas may occur on stump skin and occasionally cause discomfort when a prosthesis is worn. Malignancies have also been described and squamous cell carcinoma may develop in nonhealing chronic stump ulcers or verrucous hyperplasia (Fig 129-7C). Patients who have amputations for lymphangiomas may develop the Stewart-Treves syndrome and metastatic lymphangiosarcoma.

Treatment of these benign and malignant tumors is the same as when they occur elsewhere on the skin. Healing after tumor excision may take weeks during which time the artificial limb may not be worn.

General Management Considerations

Many of the commoner skin problems can be prevented or controlled by adherence to an appropriate hygiene and skin-care regimen in conjunction with regular prosthetics reviews, which ensure that the prosthesis remains appropriate and correctly adjusted. To this end, it is important that good contacts exist between the dermatologist and prosthetist, which will allow rapid referrals of patients before skin disorders become established.

As a general routine, the stump skin should be washed at night rather than in the morning, because newly washed skin is hydrated and swollen, thereby increasing the likelihood of friction and shearing trauma. Nonperfumed soap should be used to minimize contact with potential sensitizers and fully removed with tepid water and gentle rubbing with a nonabrasive towel.

Soaps or washes containing hexachlorophene, triclocarban, or triclosan have a bacteriostatic effect in addition to their cleansing action and can reduce the possibility of infection. However, these antiseptic preparations can cause irritation or allergy in a small number of cases and patients should be warned about this.

If a stump sock is worn, it should be changed daily and washed and rinsed fully as soon as it is taken off, before perspiration is allowed to dry within it.

SKIN PROBLEMS IN PATIENTS WITH ABDOMINAL STOMAS (OSTOMATES)

A stoma is a surgically created opening onto the skin of an abdominal viscus. Stomas may be intended to be temporary or permanent. The most frequently performed stomas are ileostomies, colostomies, and ileal conduits (urostomies). The most common reasons for ileostomy and colostomy surgery are inflammatory bowel disease and malignancy. Urostomies are most frequently performed because of renal tract malignancy or for neurologic problems. A patient with a stoma is usually termed an “ostomist” or “ostomate.” There are more than one million ostomates in the United States and 100,000 in the United Kingdom. There have been considerable advances in the design of collecting devices for stoma effluent allowing for a high degree of comfort and convenience. Essentially, the device is a pouch or bag held in place over the stoma by an adhesive skin barrier made solely or partly from hydrocolloid (Fig. 129-10). Many ileostomists and urostomists use two-piece appliances where the barrier remains on the skin for 2 to 4 days and is detachable; disposable bags are changed as necessary. Appliances with convexity on the surface next to the skin are available for patients with short or buried stomas.



FIGURE 129-10 A typical drainable stoma bag.

At least two-thirds of ostomates experience skin problems that interfere with the normal use of their stoma appliance. [12] The majority of these problems are irritant reactions, usually dermatitis secondary to leaks from the stoma, however there are also a number of other well-defined irritant reactions. Common coincidental dermatoses, particularly psoriasis and constitutional eczema, account for around 15 percent of the diseases seen.

Irritant Reactions

DERMATITIS This most frequently results from the chronic leakage of effluent onto the skin because the patient is using an inappropriately shaped appliance or one with too large a hole for their stoma. The most common cause is the remodeling of the stoma and abdominal wall that occurs in the months after surgery, whereby a stoma usually becomes a little shorter and thinner, resulting in leaks unless a correctly fitting appliance is selected (Fig. 129-11). Leaks will also occur when patients gain a lot of weight after surgery and the effective length of their stoma diminishes because it becomes buried by subcutaneous fat. Irregular scarring after surgery or retraction of the stoma, may also be associated with chronic leakage. Chronically irritated skin can become markedly hyperkeratotic and acanthotic. These problems can be prevented and resolved by careful postsurgical follow-up by the enterostomal therapist (ET; stoma nurse specialist) to ensure that the correct appliance is being used. Severe, acute irritant dermatitis can be effectively treated with a short course of topical corticosteroid while longer-term appliance modifications are being undertaken.

FIGURE 129-11 Peristomal dermatitis due to fecal irritation. The skin beneath the stoma was chronically exposed to feces because a bag with too large an aperture was used.

In ileostomy patients with short bowel, the output may be very high and corrosive due to the enzyme content. In this situation, some leaks are inevitable, despite the use of proprietary barrier preparations or soothing lotions. Where the irritation has resulted in an eroded dermatitis, sucralfate powder applied at every stoma bag change can be very effective. In addition to forming a sticky barrier, the preparation is thought to promote healing. [13] Approximately 15 percent of ostomates with skin problems suffer from a chronic dermatitis for which no irritant, allergic, or infective cause can be found, and where primary skin disease is ruled out. [12] In the absence of a primary treatable cause, the authors have used topical corticosteroid lotions. Most patients require only occasional short courses for a maximum of 4 weeks duration. A small number of patients require intermittent applications longer term. Provided that the frequency of application is no more than once every 10 days, steroid atrophy of the skin appears to be unusual. Excessively frequent bag changing may cause an irritant dermatitis. This can be the result of patient anxiety concerning leaks. Whatever the cause of skin inflammation, a vicious cycle can develop when the damaged skin prevents proper bag adhesion necessitating more frequent bag changes. Careful counseling is usually necessary in order to reassure the patient regarding leaks.

CHRONIC PAPILLOMATOUS DERMATITIS This term refers to clinical appearance of warty excrescences around urostomies resulting from leaks and pooling of urine on the peristomal skin. Recurrent urinary tract infections appear to increase the likelihood of chronic papillomatous dermatitis (CPD) probably due to the presence of ammonia from urea-splitting bacteria. Histologically, there is massive hyperkeratosis and acanthosis. Pseudoepitheliomatous hyperplasia may also be a feature but is not universal. In severe cases, the lesions can encroach on the stoma and cause stenosis (Fig. 129-12). When the leaking of urine is caused by a receding stoma, CPD will resolve rapidly if a convex-backed appliance is used to increase the effective length of the urostomy and thereby stop leaks. Acetic acid soaks (10% domestic vinegar in water [14] at each bag change are effective in some cases. Larger excrescences may be shaved off under local anesthetic to allow a bag with a smaller aperture to be used. In severe cases, surgical revision of the stoma may be required.

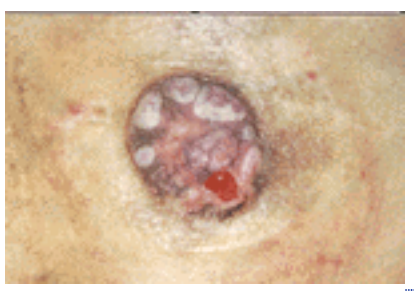

FIGURE 129-12 Chronic papillomatous dermatitis affecting a urostomy in a patient who is using a bag with too large an aperture. The red area is stoma and is becoming stenosed by the warty papules. The brown pigmentation is a typical finding in long-standing urostomies in all races. (Courtesy of Anita Eriksson, Karolinska Institute, Stockholm, Sweden)

GRANULOMAS The term *granuloma* is commonly used for a range of papular lesions, which are probably all secondary to irritation. The authors have only seen the condition affecting ileostomies or colostomies and not urostomies. They may affect the stoma itself (inflammatory colonic or ileal polyps) or the mucocutaneous junction, or may be found more widely, extending onto the peristomal skin (Fig. 129-13). The latter is more frequent in patients with colostomies, and in this situation, the papules may become very extensive. This occurs when the patient enlarges the stoma bag aperture to accommodate a papule, thereby exposing normal skin to fecal irritation. The irritation precipitates further lesions and prompts the patient to enlarge the aperture still further. In this way, progressively, areas several centimeters in diameter can become covered with these polyps. Histologically, the lesions contain a chronic inflammatory infiltrate, granulation tissue, and metaplastic bowel mucosa where the metaplasia is probably a response to fecal irritation.

FIGURE 129-13 “Granulomas” around a colostomy. The patient has cut the bag aperture larger to accommodate the original lesion and the area thus exposed is seen as a ring of postinflammatory hyperpigmentation in which new lesions developed.

Asymptomatic, solitary lesions can be left, although they may be painful and bleed easily, leading to poor stoma bag adhesion. In these cases, they can be destroyed by cautery (thermal or silver nitrate) or by cryotherapy, using a liquid nitrogen spray. Larger and proliferating lesions around colostomies are best removed by shave and cautery under local anesthetic and an appliance with a correctly sized aperture fitted in order to prevent massive proliferation.

PSORIASIS Psoriasis is a common cause of peristomal skin disease because it may appear in irritated and traumatized skin (Koebner's phenomenon). Peristomal psoriasis presents as a glazed erythema similar to flexural psoriasis and can be treated in the same way with topical corticosteroids although at the peristomal site, a nongreasy base should be selected. Resolution of psoriasis under hydrocolloid occlusion has been described, [15] which is of relevance to stoma patients because 50 percent of cases of peristomal psoriasis will resolve if a bag is selected with a thicker, hydrocolloid-only barrier. Where the patient can tolerate the stoma being temporarily unprotected from leaks, UV phototherapy is effective as for psoriasis elsewhere. The mucous membranes of the stoma should be protected from UV light. Although irritating topical psoriasis treatments are not usually tolerated, some patients have had success with creams containing hydrocortisone 1% and coal tar 3%, the application being left on the skin for 1 h each day before wiping off and applying a stoma bag. While the cream is in place, a nonadhesive bag can be worn, held in place with a waist belt, provided that the patient is sedentary during this time. Superficial x-ray (grenz-ray) therapy has been used in recalcitrant cases.

INFECTIONS The most frequent peristomal skin infection is staphylococcal folliculitis, usually, but not exclusively, in those individuals with hairy abdomens who shave regularly to help the bags to stick. It responds to oral antibiotics and to a reduction in shaving frequency to no more than once per week. Although antiseptic washes can be a useful additional therapeutic measure, they can cause irritant reactions if the skin is not correctly rinsed before being occluded by the stoma bag. Localized skin infections, usually staphylococcal or streptococcal, can produce a rash indistinguishable from irritant dermatitis or primary skin disease such as psoriasis or eczema. Furthermore, preexisting psoriasis or eczema can become secondarily infected under occlusion. Therefore, all peristomal rashes should be swabbed for microbiological investigation and appropriate antibiotics prescribed based on microbiological sensitivities. In tropical climates, cutaneous fungal infections are common, whereas in more temperate regions, *Candida albicans* is an occasional problem and dermatophyte infection is rare.

PYODERMA GANGRENOSUM This rare, inflammatory, ulcerative neutrophilic dermatosis (see Chap. 98) is more common in peristomal skin than would be expected from its frequency in the general population. [16] Clearly, this is partly due to its strong association with inflammatory bowel disease. There is some evidence, however, that the increased use of convex-backed appliances may contribute to the incidence via the pathergic effect of increased pressure on the skin. Although some cases of pyoderma gangrenosum (PG) are associated with active inflammatory bowel disease, the association is not universal; indeed, peristomal PG occurs in ostomates who have no history of inflammatory bowel disease. Small, superficial, and solitary ulcers respond to topical steroids. Because of the problems with greasy preparations causing lifting of stoma bags, alternative vehicles are usually necessary. These include triamcinolone in carmellose sodium paste, gauze soaked in aqueous prednisone, and scalp gels or lotions that do not contain oils or propylene glycol. Adhesive tapes impregnated with corticosteroids are useful in this and many of the other conditions. Larger ulcers, and those not responding to topical therapy, require topical tacrolimus or systemic treatment as for PG elsewhere (see Chap. 98).

Contact Allergy

Most patients and many health professionals regard contact hypersensitivity as an important cause of peristomal rashes. The authors have patch tested more than 100 ostomates with unexplained dermatitis and relevant positive allergic reactions were found in only two cases. Stoma bags are made largely from food-grade materials with a low potential for sensitization. Nonetheless, there are many case reports of sensitivities to individual ingredients including Gantrez resins, epoxy resins, and acrylate adhesives. Furthermore, there is a potential for contact allergy from deodorizers and topically applied preparations. Patch testing is indicated in patients with persisting problems where infection, irritation, and constitutional skin disease has been ruled out. [17]

General Management

The necessity for good adhesion between the skin and appliance presents problems for topical treatment of peristomal dermatoses. While some patients can apply therapies in a cream base, most patients find that any greasy preparation

will make the bag lift and cause leaks; consequently, they will not use them. Dressings under the bag to cover a greasy topical agent can be used in selected cases, but are not universally practical. Alternative vehicles are usually required and a number of alternatives can be tried. Adhesive tapes and lotions are a useful compromise, particularly for corticosteroids, and lotions are available as scalp applications formulated in 40% isopropyl alcohol. The alcohol can cause stinging on broken skin. In such cases, the lotion can be applied to the barrier and allowed to evaporate for 20 min before fitting to the skin.

REFERENCES

1. Marks LJ, Michael JW: Artificial limbs. *BMJ* **323**:732, 2001

2. Lyon CC et al: Skin disorders in amputees. *J Am Acad Dermatol* **42**:501, 2000

3. Feingold KE et al: Endocrine skin interactions: Diabetes mellitus. *J Am Acad Dermatol* **17**:921, 1987

4. Levy SW: Skin problems of the leg amputee. *Prosthet Orthot Int* **4**:37, 1980

5. Ibbotson SH et al: Follicular keratoses at amputation sites. *Br J Dermatol* **130**:770, 1994

6. Strauss RM, Harrington CI: Stump acne: A new variant of acne mechanica and a cause of immobility. *Br J Dermatol* **144**:647, 2001

7. Barnes GH et al: *Problems of the Amputee; Stump Edema. Illustrated Pamphlet*. University of California, Biomechanics Laboratory, 1964.

8. Suarez EC et al: Circulatory disorders in amputation stumps. *J Am Acad Dermatol* **44**:723, 2001

9. Gucluer H, et al: Kaposi-like acroangio-dermatitis in an amputee. *Br J Dermatol* **141**:380, 1999

10. Allende MF et al: The bacterial flora of the skin of amputation stumps. *J Invest Dermatol* **36**:165, 1961

11. Kohler P et al: Bacteria on stumps of amputees and the effect of antiseptics. *Prosthet Orthot Int* **13**:149, 1989

12. Lyon CC et al: The spectrum of skin disorders in abdominal stoma patients. *Br J Dermatol* **143**:1248, 2000

13. Lyon CC et al: Topical sucralfate in the management of peristomal skin disease. An open study. *Clin Exp Dermatol* **25**:584, 2000

14. Jeter KF. Hyperplasia or what? *J Enterostomal Ther* **10**:181, 1983

15. Griffiths CE et al: Prolonged occlusion in the treatment of psoriasis: A clinical and immunohistological study. *J Am Acad Dermatol* **35**:283, 1996

16. Lyon CC et al: Parastomal pyoderma gangrenosum: Clinical features and management. *J Am Acad Dermatol* **42**:992, 2000

17. Lyon CC, Beck MH, Smith A (eds): *Abdominal Stomas and Their Skin Disorders*. London, Martin Dunitz, 2001, pp 43–47

Footnote

*We wish to acknowledge S. William Levy, MD, the previous author of this chapter for his enormous contribution to the field of dermatoses in amputees and for stimulating our interest in the subject. T>

Chapter 130

Thomas DeLauro

Corns and Calluses

HISTORICAL ASPECTS
EPIDEMIOLOGY
ETIOLOGY AND PATHOGENESIS
GENETICS
PREVENTION
CLINICAL MANIFESTATIONS
LABORATORY FINDINGS
PATHOLOGY
DIAGNOSIS AND DIFFERENTIAL DIAGNOSIS
RELEVANCE TO THE DIABETIC FOOT
TREATMENT AND PROGNOSIS

REFERENCES

Every human being is vulnerable to the development of corns and calluses because our skin is subjected to regular mechanical stress. The prevalence of corns and calluses can be readily appreciated by the number of nonprescription products aimed at reducing or preventing them—a billion dollar annual market!

HISTORICAL ASPECTS

The earliest known discussion of these lesions can be found in the writings of Cleopatra, who authored a textbook on cosmetics. [1] Corns and calluses have plagued humankind since antiquity, affecting all socioeconomic levels.

EPIDEMIOLOGY

All human beings, with the exception of non–weight-bearing infants, are subject to the development of corns and calluses. As discussed below, certain foot types and regions are prone to mechanically induced skin thickening, regardless of race, gender, or age.

ETIOLOGY AND PATHOGENESIS

Corns (clavus or heloma, clavi or helomata) and calluses (tyloma, tylomata) are, respectively, keratotic papules and plaques that occur in response to chronic, excessive, mechanical shear or friction forces. In theory, these forces induce hyperkeratinization, leading to a thickening of the stratum corneum, although the precise mechanism by which this occurs remains unknown. If the abnormal forces are distributed over a broad area (i.e., more than one square centimeter), a callus occurs. In contrast, a corn will form if the same forces are applied to a focused location, wherein the lamellae of the stratum corneum become impacted to form a hard central core known as the radix or nucleus.

GENETICS

Mechanical keratoses are not determined genetically. Heredity does play a role, however, in configuring our skeletal architecture. A family history of bony abnormality or ligamentous laxity predisposes one to sites of increased cutaneous friction or shear.

PREVENTION

These lesions can only be prevented by reducing or eliminating the mechanical forces that created them. Usually, this is a daunting, if not impossible, task. Repetitive occupational motions are often unavoidable, patients are commonly reluctant to alter shoe styles, and osseous architecture is predetermined through heredity.

CLINICAL MANIFESTATIONS

Corns and calluses produce painful symptoms often described as burning in character, especially when weight-bearing and/or in shoe gear. This discomfort is thought to result from microtearing of the thickened, inflexible skin. The lesions occur in predictable pedal locations, corresponding to a structural deformity or biomechanical fault. Crookedness of the lesser toes leads to prominence of the proximal and/or distal interphalangeal joints. Keratoses can therefore form either dorsal to those joints, between the toes (Fig. 130-1), at the distal end of the toe, or on the lateral aspect of the fifth toe and/or toenail (the lateral toenail corn, aka Durlacher's corn, Fig. 130-2). Interdigital corns (those between toes) can be hard when adjacent to the interphalangeal joint(s), or soft when deep within the fourth interdigital space. The softness of this last corn results from trapped perspiration, leading to maceration of the keratotic tissue.

FIGURE 130-1 An interdigital corn at the medial aspect of the second distal interphalangeal joint.

FIGURE 130-2 A Durlacher's corn at the lateral nail groove of the fifth toe.

In patients with bunions (hallux valgus), a callus usually forms at the medioplantar aspect of the hallux. During gait, one rolls off that portion of the great toe due to its incorrect position. The skin is subsequently pinched to form a “pinch callus” (Fig. 130-3). In addition, the first metatarsal often does not bear its fair share of the weight-bearing load. Weight is therefore transferred laterally to the second metatarsal head, usually leading to an additional corn or callus beneath that bone.

FIGURE 130-3 A patient exhibiting both an exquisitely painful, intractable plantar keratosis (IPK) (beneath the second metatarsal head) and a “pinch” callus (at the medioplantar hallux).

Other favored locations for lesser metatarsal head keratosis include:

1. Beneath the first and fifth metatarsal heads in cavus foot types;
2. Beneath the fifth metatarsal head alone in cases with tailor's bunions (bunionette);
3. Beneath the second through fourth metatarsal heads when multiple hammertoes or an equinus deformity coexist; and
4. Erratic locations (e.g., subthird and fifth metatarsal heads, isolated third or fourth metatarsal head lesions, second and fourth metatarsal heads) in structural abnormalities such as brachymetatarsia or dislocated metatarsophalangeal joints as in rheumatoid arthritis or neuroarthropathy.

Another variant of corn is that referred to as heloma miliare, or seed corn. This title is derived from their clinical appearance: multiple guttate keratoses that are easily pared. When seamed nylon hosiery was fashionable, the garment was considered the etiologic factor. However, patients still present with seed corns even though they have never worn seamed stockings.

LABORATORY FINDINGS

Because corns and calluses are the result of mechanical friction and shear alone, there are no associated laboratory abnormalities.

PATHOLOGY

In contrast to nonmechanically induced keratoses, corns and calluses exhibit changes within the epidermis, dermis, and adipose layer. Corns demonstrate a parakeratotic plug within the stratum corneum, with a pressure-related loss of the stratum granulosum, as well as atrophy of the stratum malpighii. The dermis will display significant fibrosis, dilated eccrine ducts and blood vessels, hypertrophied nerves, and scar tissue replacement of subcutaneous fat. Overall, the histologic changes in calluses are less pronounced, and include a thickened stratum corneum but intact stratum

granulosum. The ratio of stratum corneum to stratum malpighii is commonly 1:1. [2]

DIAGNOSIS AND DIFFERENTIAL DIAGNOSIS

Corns and calluses are easily recognized by the finding of a thickened stratum corneum adjacent to a bony prominence. Patients who have undergone transmetatarsal amputation can develop corns and calluses at the stump's distal aspect when an Achilles tendon lengthening is not performed simultaneously. Charcot neuroarthropathy affecting the midfoot can lead to collapse and reversal of the longitudinal arch ("rocker bottom foot"), with corns or calluses forming midsole. In patients with flatfeet or who pronate excessively, it is common to find a diffuse keratotic ridge at the medioplantar aspect of the heel.

On occasion, one encounters patients with excruciatingly painful corns (Fig. 130-3). The central nucleus is deeper and wider, and mediolateral compression of the lesion elicits discomfort. A variety of terms have been used to describe such lesions, albeit interchangeably: neurofibrous or neurovascular corn, intractable plantar keratosis (IPK), or porokeratosis plantaris discretum. Treatment is the same as for other pressure-induced keratoses, which are described below.

Unlike verrucae, corns and calluses do not exhibit pinpoint hemorrhage, a papilliform surface, or interrupted skin lines when pared.

Corns and calluses *not* overlying a bony prominence should prompt a search for another etiology (e.g., genokeratosis, cutaneous neoplasm).

RELEVANCE TO THE DIABETIC FOOT

Lower extremity amputation is a dominant fear in most diabetic patients. These amputations are most often preceded by a history of foot ulceration. Although a number of comorbidities contribute to the development of ulceration (e.g., peripheral vascular disease, neuropathy, limited joint mobility), minor trauma via repetitive pressure is the pivotal precipitating event. As markers of repetitive friction and shear, corns and calluses in the diabetic foot are of special significance. Simple débridement of these hyperkeratotic lesions decreases peak plantar pressures by as much as 26 percent. [3] In a recent retrospective review of more than 200 diabetic foot ulcerations, patients who had their corns and calluses pared frequently experienced a statistically significant decrease in the incidence of foot ulceration, hospitalization, and surgical intervention. [4] Hemorrhage within a corn or callus is an especially ominous sign, indicating subcutaneous breakdown with a strong potential for ulceration.

TREATMENT AND PROGNOSIS

If left untreated, corns and calluses result in painful ambulation, and also in subhelomal bursitis and blistering that can rupture to the surface. Given the close proximity of some corns to joints and bone, septic arthritis and/or osteomyelitis can ensue. The mechanical forces that cause corns and calluses can also rupture portions of the subcutaneous vascular plexus, leading to hemorrhage within keratotic tissue. In healthy patients, these observations are of minor significance, but in other cases (e.g., in diabetics and patients with connective tissue disease), they may herald extensive skin ulceration or vasculitis.

Paring is the simplest treatment for corns and calluses. In the case of corns, the central radix or nucleus must also be débrided for pain to be relieved. Felt dispersion padding should be applied when paring is completed; the padding protects the tender underlying skin. Keratolytics may be employed by either the health care provider or patient, but must be used cautiously. Unmonitored usage is contraindicated in patients with comorbid peripheral neuropathy or arterial disease.

Soft corns and IPKs may also respond to biweekly infiltrations of a sclerosing solution of 4% alcohol mixed with local anesthetic. Typically, up to seven injections may be required with darkening and thrombosis of the lesion heralding a cure. [5], [6] Lastly, osseous surgical procedures designed to redistribute weightbearing pressures may be employed to eliminate corns and calluses. However, not all lesions can be cleared using this method.

REFERENCES

1. Block BH: *Foot Talk.* New York, Arbor House, 1984

2. Lemont H: Histologic differentiation of mechanical and non-mechanical keratoses of the sole. *Clin Dermatol* **1**:44, 1983

3. Young MJ, Cavanagh PR, Thomas G, et al: The effect of callus removal on dynamic plantar foot pressures in diabetic patients. *Diabet Med* **9**:55, 1992

4. Sage RA, Webster JK, Fisher SG: Outpatient care and morbidity reduction in diabetic foot ulcers associated with chronic pressure callus. *J Am Podiatr Med Assoc* **91**:275, 2001

5. Costello MJ, Gibbs RC: *The Palms and Soles in Medicine.* Springfield, IL, Charles C. Thomas, 1967

6. Dockery GL, Nilson RZ: Intralesional injections. *Clin Podiatr Med Surg* **3**:473, 1986

T>

Chapter 131

Dirk Elston

Sports Dermatology

SPORTS AND THE DERMATOLOGIST
Pyogenic Skin Infections
Prevention of Contagious Skin Infections
Heat and Cold Injury
Friction Blisters
Lime Burns
Calluses and Corns (Clavi)
Athlete's Nodules
Actinic Damage
Allergic Contact Dermatitis
SKIN PROBLEMS RELATED TO WATER SPORTS
Swimmer's Itch
Seabather's Eruption (Sea Lice)
Other Skin Problems Related to Sea Water
HISTAMINE-MEDIATED REACTIONS
ACNEIFORM LESIONS
OTHER SPECIAL DERMATOLOGIC PROBLEMS OF ATHLETES

REFERENCES
Footnote

SPORTS AND THE DERMATOLOGIST

Skin problems are extremely common among athletes. During an 8-week survey of university athletic teams, 40 percent reported skin problems. [1] In a recent study of mountain biking injuries, skin lesions accounted for 75 percent of all injuries. [2] Skin lesions account for 35 percent of all in-line skating injuries. [3] Minor skin injuries frequently become infected, and close physical contact during sports increases the risk of skin infection. As a result, skin infections are more prevalent in top athletes than in the general population. [4] The training environment is frequently the source of infection.

Skin-related complaints are especially common in warm, humid climates. During the 1993 Central American and Caribbean Games, held in Puerto Rico, 1 of every 100 athletes had a skin-related complaint severe enough to require medical care. [5] Similarly, sports that involve repeated immersion in water are associated with an increased incidence of skin injury and infection. [6]

Skin injuries frequently result in lost training time, and after months of dedication and training, an athlete may be disqualified from competition because of an infectious skin lesion. Thus, a knowledgeable dermatologist can be a great asset in the prevention and therapy of sports-related skin disease.

New treatments, including hydroactive wound dressings, have advanced the treatment of superficial wounds. Application of a hydroactive dressing can provide a protective barrier that allows the athlete to return to competition. Long used for deeper soft tissue injuries, nonsteroidal anti-inflammatory drugs may play a role in the treatment of skin and superficial soft tissue injuries, providing symptomatic relief to allow continued participation in competition.

Sports dermatology has produced some of the most vivid and alliterative diagnostic terms to be found in medicine. Table 131-1 lists some of the more memorable of these unique conditions.

Bikini bottom: bacterial folliculitis on the buttocks of swimmers
Jazz ballet bottom: buttock cleft abscess
Jogger's nipples: painful, swollen, eroded, or hyperkeratotic nipples
Karate cicatrices: linear scars on the dorsal aspects of the hands
Mogul skier's palm: traumatic hypothenar ecchymosis
Painful piezogenic pedal papules: transdermal fat herniations
Ping pong patches: traumatic ecchymotic patches
Pool palms: smooth, shiny, tender palms secondary to rough-pool surfaces
Pulling boat hands: friction and damp cold produce a pernio-like condition
Rower's rump: lichenification
Runner's nails: multiple Beau's lines or periodic shedding of a nail plate (Fig. 131-1)
Runner's rump: ecchymoses of the superior gluteal cleft
Stingray hickey: bite ecchymosis
Stretcher's scrotum: scrotal hematoma
Swimmer's shine: facial oiliness seen in swimmers
Swimmer's shoulder: abrasion of shoulder by beard during crawl stroke
Talon noir (black heal): intradermal hemorrhage.
Tennis toe: subungual hematoma with or without subungual hyperkeratosis or nail dystrophy (jogger's toe, hiker's toe, and skier's toe are similar)
Turf toe: metatarsophalangeal joint sprains.

TABLE 131-1 **Unique Sports-Associated Skin Conditions**

FIGURE 131-1 Runner's nail; in this case, multiple Beau's lines with onychoschizia.

Pyogenic Skin Infections

Outbreaks of furuncles may spread rapidly within an athletic team. Attack rates of approximately 25 percent have been described in high school athletic teams. Epidemiologic data implicate direct contact with infected individuals, rather than fomites, as the major route of transmission, [7] although fomites may play some role. Factors associated with the spread of furunculosis include the lack of readily available shower facilities, sharing of athletic pads, and sharing of towels. [8]

Group A streptococcal infections may also spread rapidly among team members. [9] Epidemic pyoderma with a nephritogenic streptococcus caused an epidemic of scrum kidney (glomerulonephritis) in a rugby team. [10] In addition to impetigo, streptococci may produce erysipelas and lymphangitis.

Pseudomonas infections are commonly associated with water. Type O:11 *Pseudomonas* is implicated most commonly. Other serotypes, including O:1, O:3, O:8, O:10, and O:16, have been reported. [11] Hot tub, whirlpool, and swimming pool folliculitis present with intensely pruritic papules and pustules involving intertriginous and “bathing suit” areas. Outbreaks are associated with both chlorine- and bromine-treated water. [12] Contamination of well water or bathroom components may result in *Pseudomonas* folliculitis related to bathing or showering. [13] Biopsy of a pruritic papule demonstrates suppurative folliculitis. Generally, organisms are not seen with special stains, but can be cultured from the lesions and from the source of infection. Loofah sponges enhance the growth of gram-negative organisms, and have been implicated as reservoirs of *Pseudomonas* organisms. [14] Most cases of *Pseudomonas* folliculitis resolve spontaneously; in cases requiring antibiotics, fluoroquinolones offer effective therapy. [15]

Diving suit dermatitis is an unusual manifestation of *Pseudomonas* folliculitis that presents as widespread crusted papules and pustules on the trunk and extremities. The lesions may be painful rather than pruritic, and are restricted to areas covered by the wetsuit. Diving suit dermatitis has been reported with both fresh and salt water diving. [16], [17]

Green nails are caused by *Pseudomonas* colonization in persons habitually exposed to water. Frequently, patients have preexisting hand eczema or psoriasis with distal onycholysis. *Candida* colonization can perpetuate and worsen the onycholysis, creating a deep, moist nidus for *Pseudomonas* growth. Effective treatment may require applications of an anticandidal agent, as well as topical antibiotic or acidic (acetic acid, aluminum acetate) measures against *Pseudomonas*. Chronic hand dermatitis and psoriasis often initiate the onycholysis and *Pseudomonas* colonization. Recurrences are common unless the underlying cause of onycholysis is addressed.

Pseudomonas is also a common cause of webspace infection and otitis externa in swimmers. [18] Webspace infection is commonly associated with occlusive footwear and preexisting interdigital tinea pedis. If not treated appropriately, prolonged disability may result. Topical aluminum acetate or dilute acetic acid may be helpful in this setting. Webspaces should be thoroughly dried with a fan or cool blow-dryer after each soak. Topical gentamicin or an oral fluoroquinolone may be required.

Severe contact dermatitis may occur as a result of treatment of otitis externa with a topical suspension containing neomycin, polymyxin B, and hydrocortisone. The offending agent is usually neomycin or thimerosal (a preservative present in the otic suspension but not the solution). Otic aluminum acetate solutions can be an effective alternative. Treatment of the contact dermatitis may require potent topical or oral steroids. Invasive *Pseudomonas* infections (malignant otitis externa) may be associated with sepsis and require parenteral antibiotics.

Pseudomonas keratitis may occur as a result of exposure to contaminated whirlpools. [19] This infection can have devastating consequences, and prompt consultation with an ophthalmologist is essential. *Pseudomonas* osteomyelitis has been associated with nail puncture wounds through tennis shoes. [20]

Prevention of Contagious Skin Infections

Herpes simplex virus (HSV) can be transmitted by skin to skin contact during any contact sport. Herpes gladiatorum (Fig. 131-2) is recognized as a major problem among wrestlers. Attack rates as high as 34 percent have been reported. [21] Ocular involvement is a serious complication. Wrestlers with active infections should be barred from participation. Because abrasive shirts may contribute to the spread of HSV infections among wrestlers, [22] they should be avoided. Oral antiviral drugs, such as acyclovir, valacyclovir, and famciclovir, can be used to shorten the course of an outbreak. It is likely that all three of these drugs will be shown to be useful in preventing outbreaks of herpes gladiatorum by means of

long-term or periodic prophylaxis, as they are used for prophylaxis against genital herpes outbreaks.

FIGURE 131-2 Herpes gladiatorum. (*Courtesy of Rita George, MD, Wilford Hall Air Force Medical Center.*)

Other infectious diseases, including pyogenic infections and tinea corporis can be spread by means of contact sports. Tinea pedis may be spread on floors around swimming pools. [23] Tinea infection is particularly common among wrestlers. [24] Prevalence among runners increases with age, and asymptomatic carriers are common. [25] Prompt identification and treatment of infected individuals, as well as use of protective clothing and footwear, reduces the incidence of infection. Periodic treatment of carriers with topical agents to prevent clinical disease may be possible. Intermittent doses of oral antifungal agents, such as itraconazole 200 mg bid for 1 day every 2 weeks, may be effective for prophylaxis against dermatophytosis in contact sports such as wrestling. [26]

There is growing concern about possible transmission of blood-borne pathogens during contact sports. Minor cuts and abrasions are both a source of contamination and a portal of entry for HIV and hepatitis viruses. Lacerations should be covered with self-adherent biosynthetic dressings to prevent blood transmission from minor wounds during contact sports. [27]

Heat and Cold Injury (See also Chap. 126)

Heat injury is a common cause of morbidity during sports. The skin serves as the major organ of thermal regulation. Regular exercise modifies the responsiveness of cutaneous vessels, increasing cutaneous perfusion during periods of activity. [28] The duration of exercise can be safely increased in hot environments if a volume of fluid at least equal to that lost in sweat is ingested within 60 min prior to and during exercise. [29] Adequate skin surface must be exposed during exercise in order to reduce the risk of heat stress injury. Evaporative cooling from forearm skin is more efficient than that from the upper trunk. [30] Short sleeve shirts are advisable when competing in a hot environment. Clothing should be lightweight and have high water permeability in order to facilitate evaporative cooling. [31] At high humidity, evaporative cooling from skin is inefficient and the risk of heat stress increases. Spraying of water on the skin during exercise can reduce skin temperature, but this results in vasoconstriction and does not reduce core body temperature. [32]

Younger athletes have a greater skin surface area, which places them at greater risk for hypothermia in cold environments. [33] Skin injury, such as frostbite and perniosis are seen in sports enthusiasts who engage in cold weather sports. The decreased oxygen tension at high altitudes contributes to peripheral vasoconstriction, and decreased peripheral blood flow increases the risk of frostbite. [34] Frostbite is also a problem among joggers, and may occur on the face, hands, feet, and penis. Clothing must remain dry in order to retain its insulating properties. Frequent changes of socks and periodic breaks in a warm environment are important safeguards. If frostbite occurs, rapid rewarming should be accomplished as soon as the individual is in a safe environment with no risk of refreezing. Rarely, frostbite may be related to the use of ice packs in a training environment. [35]

Friction Blisters

Friction blisters occur as a result of mid-epidermal necrosis and are a major cause of disability in athletes (Fig. 131-3). Proper fitting of footwear and the use of gloves and chalk can reduce the incidence of blistering. Heat, sweating, and maceration increase the risk of blistering. Antiperspirants have been used in an attempt to reduce the incidence of blistering, but results have been mixed and they may cause irritant dermatitis. Attempts to reduce the incidence of irritant dermatitis with the addition of emollients reduces the efficacy of the antiperspirant. [36] In a study of cross-country hikers, a 20% solution of aluminum chloride hexahydrate in anhydrous alcohol reduced the rate of blister formation from 48 percent to 21 percent, but the incidence of irritant dermatitis was high and noncompliance with the treatment regimen was common. [37] Closed-cell neoprene insoles, acrylic socks or thin polyester socks combined with thick wool, or polypropylene socks that maintain their bulk can reduce the incidence of blisters. [38] Mesh top footwear can decrease the risk of blistering by providing a cooler, dryer environment without the use of antiperspirants.

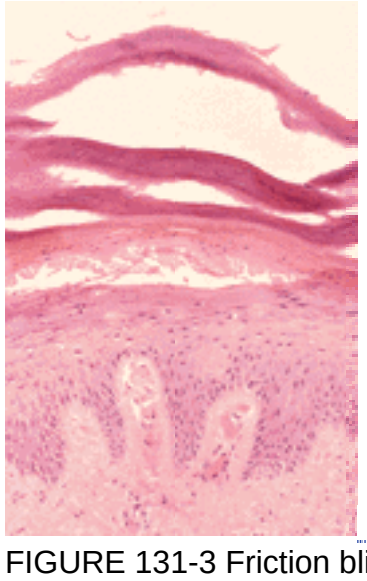

FIGURE 131-3 Friction blisters are a manifestation of intraepidermal necrosis.

Small blisters should be left intact to maintain sterility. An adhesive bandage or thin self-adhesive hydrocolloid dressing can be applied over the area, or a “doughnut” of moleskin can be applied around the blister to decrease discomfort. Larger blisters should be drained. The blister roof may be left in place as a biological dressing. A thin self-adhesive hydrocolloid dressing can be applied over the entire lesion. Antibiotics should be used if secondary infection is present.

Lime Burns

The use of calcium oxide (quicklime) or calcium hydroxide (slaked lime) instead of calcium carbonate (chalk) to line sports fields may result in chemical burns, especially in wet weather. In one report, 75 percent of football players developed chemical burns from lime used to mark a playing field. Such burns were predominantly located on the torso, buttocks and proximal lower extremities—areas occluded by football gear. Little reaction occurred on exposed skin. Second- and third-degree burns occurred, and the severity and extent of burns were related to the number of minutes played, and to delays in showering after the game. [39] Lime may also result in severe inhalation and ocular injuries. [40]

Soccer and rugby players may develop similar chemical burns. Calcium oxide (quicklime) converts to calcium hydroxide in wet environments. Calcium oxide is often used in Europe to mark soccer and rugby touchlines. Varying proportions of calcium compounds are often found in marking powders. [41] A lack of international regulations regarding marking materials has contributed to the problem. [42] Uniform regulations should be adopted by all sports federations.

Calluses and Corns (Clavi)

Callus formation is a physiologic protective mechanism. Large calluses can interfere with function, and may require treatment. Corns or clavi are particularly common in golfers, and can be treated with chemical or physical débridement. Liquid nitrogen and lasers can be useful in the treatment of corns. Prevention requires properly fitted footwear. Cushioning pads and metatarsal pads can be helpful.

Athlete's Nodules

Collagenous “surfer's nodules” are a well-described complication of surfboarding. [43] Boxers, marbles players, and football players are also prone to collagenous nodules. [44] These nodules occur at areas of pressure, trauma, and friction. Surgical excision may be required. [45]

Actinic Damage (See also Chap. 134 and Chap. 247)

Actinic irradiation can cause burns and a risk of skin cancer in later life. Even relatively short periods of exposure during sports is associated with an increase risk for basal cell carcinoma. [46] Sweating alters hydration of the stratum corneum and lowers the minimal erythema dose (MED) to ultraviolet B (UVB) by as much as 40.9 percent after just 15 min of jogging. [47] Participation in water sports is an independent risk factor for melanoma. [48] Professional cyclists experience intense ultraviolet exposure with a mean daily average exposure of 8.1 MED of UVB. During mountain segments, cyclists may have exposures of more than 17 MED. [49] Lifeguards have daily exposures from 3.6 to 9.5 MED, mountain guides have exposures from 4.4 to 17.1 MED, and ski instructors from 2.8 to 8.8 MED. [50]

Phototoxic reactions may occur in athletes treated with drugs such as tetracycline and sulfa. Actinic radiation in the UVA range is important in the induction of phototoxic reactions. Unfortunately, most currently available sunscreens do not block UVA well, although sunblocks with Parsol 1789 and “physical” sunblocks, such as titanium dioxide, offer better UVA protection. Application technique has a significant impact on the effectiveness of sunscreens. Sunblock should be applied evenly prior to sun exposure. Reapplication as often as every 2 h may be necessary after perspiration or water exposure.

Sun exposure may reactivate orolabial herpes infections. Although sunscreens are commonly recommended to decrease the risk of recurrence, a controlled trial did not confirm their effectiveness. [51] Oral antiviral drugs can be used effectively to prevent herpes reactivation following sun exposure. [52]

Allergic Contact Dermatitis

Rubber allergens are the most common cause of sports-associated allergic contact dermatitis. Rubber adhesives and

rubber chemicals in the box toe and cushioning materials of footwear can cause dermatitis (Fig. 131-4). Contact dermatitis also results from swimming goggles, diving equipment, swimming pool chemicals, bathing caps, nose clips, athletic tape, and topical creams and sprays that contain salicylates. The eruptions will respond to topical and systemic corticosteroids, but will recur unless the offending allergen is identified and eliminated. Patch testing can identify the allergen, and allow substitution of a suitable alternative.

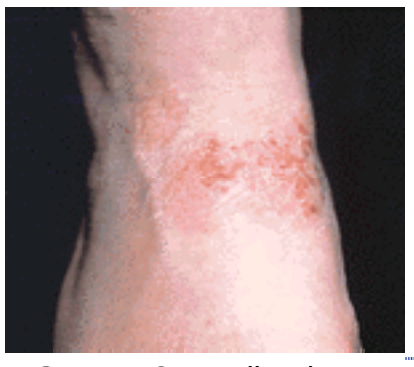

FIGURE 131-4 Allergic contact athletic shoe dermatitis.

SKIN PROBLEMS RELATED TO WATER SPORTS

Recreational swimming in lake water can result in significant transdermal absorption of water pollutants. [53] Hyperchlorinated rinsing pools may also cause cutaneous injury.

Water serves as a common source of infection, and an increased incidence of skin infections has been noted in swimmers exposed to polluted sea water. [54] Bathers are also at increased risk for gastroenteritis, acute febrile illness, and ear and eye infections. Illness is closely linked to contamination of water with domestic sewage. [55] Microscopic examination of formed stools found in swimming pools has demonstrated a significant rate of infestation with intestinal parasites. [56] Monitoring of water for fecal coliforms has been practiced for years, and has proved to be a better predictor of the risk of skin disease than of gastrointestinal disease. [57] Although many skin eruptions from recreational water probably go unreported, those that are reported account for almost half of all illness from recreational water. [58]

Storm run-off contaminating recreational waters results in a predominance of organisms linked to respiratory and skin infections. Current surveillance, which focuses on fecal contamination, may be inadequate to detect such contamination. [59] It has been suggested that monitoring for staphylococci could result in improved evaluation of the risk of skin disease.

Swimmers are prone to xerosis, especially during winter months. Contributing factors include loss of sebum and chlorine exposure while swimming, as well as long showers after swimming and the irritating liquid soap often supplied by the pool. Prevention and treatment include limiting showers, using mild soap and cooler water, and application of petrolatum before swim practice and a moisturizer after showering. [60]

Exposure to the rough surfaces of diving boards can result in a chronic plantar dermatosis. The fingers can also be affected (Fig. 131-5). Some of these individuals have a history of atopic dermatitis, psoriasis, or juvenile plantar dermatosis. The rough interior of swimming pools can result in “pool palms.” The skin appears taught, shiny, and erythematous with loss of dermatoglyphics. Avoidance of rough pool surfaces will result in healing, but divers and swimmers are seldom willing to give up their sport. Topical steroids and tars can occasionally be of some benefit.

FIGURE 131-5 Finger dermatitis in this diver paralleled the intensity of her training. It resolved during breaks from training.

Water slide alopecia has been described as symmetric alopecic patches of the posterolateral aspects of the calves. [61] The patches are associated with repeated frictional trauma to the areas.

Green hair is related to copper in pool water. Copper pipes or algicides may be the source of the high copper levels. Acidic pH, fluoridation of water, and swimming pool chlorination all contribute to the release of copper into pool water. [62] Previous damage to the hair shaft, frequent contact with chlorinated water, or the use of alkaline shampoos may predispose to the development of green hair. Hair damage induces cysteic acid and related sulfonate groups that adsorb copper. Green hair has been treated with hot vegetable oil, hydrogen peroxide, edetic acid (EDTA), [63] and 1-hydroxyethyl diphosphonic acid. [64] Penicillamine shampoo has also been used successfully.

Swimming pool water may be treated with chlorine, bromine, and ozone ionization. All three methods are acceptable, although bromine with ozone may be associated with a slightly lower risk of cutaneous reactions. Skin rashes with onset less than 24 h after swimming is reported by up to 8 percent of swimmers, while eye redness and itching is reported in up to 33 percent. [65] Swim goggles have a protective effect against eye irritation.

Swimmer's Itch (See also Chap. 237)

Swimmer's itch is generally produced by the penetration of avian schistosome cercariae through exposed skin. In endemic areas, a less-severe dermatitis is caused by penetration of the cercariae of human schistosomes. Eutrophication of lakes due to excessive nutrient input favors proliferation of schistosomes. Newly created bodies of water, such as recently abandoned quarries, have a lower incidence of swimmer's itch. Praziquantel, given to ducks inhabiting a lake, can reduce the incidence of swimmer's itch. [66] Chemical control or mechanical removal of snails can also be effective. The rash heals spontaneously in 2 to 3 weeks. Topical steroids and antihistamines may be beneficial.

Seabather's Eruption (Sea Lice) (See also Chap. 237)

Seabather's eruption occurs under the bathing suit area. Some outbreaks are caused by jellyfish larvae; [67] others are caused by sea anemone larvae. [68] The eruption runs its course in about 2 weeks. Topical corticosteroids and antihistamines may provide some relief, but are frequently ineffective. Of interest, topical thiabendazole and systemic thiabendazole have been reported as effective. [69] The mechanism for this reported effect in the treatment of what appears to be tiny coelenterate stings is unclear. During epidemics, children, people with a prior history of seabather's eruption, and surfers are at greatest risk. Length of time spent in the water is not a major risk factor. Showering with one's bathing suit off after seabathing reduces the incidence of the eruption. [70]

Other Skin Problems Related to Sea Water (See also Chap. 237)

Corals, especially fire coral, can produce contact dermatitis in divers. Their stinging cells produce a powerful irritant that can produce severe local reactions, including reactions that resemble full-thickness burns.

Sea urchin spines are brittle, and readily break off in the skin, potentially causing delayed contact sensitivity. Sarcoidal granulomas can occur.

Jellyfish stings cause both immediate pain and delayed allergic reactions (Fig. 131-6). Local reactions may be severe, and can result in gangrene and contractures. Delayed allergic reactions generally consist of local reactivation, but generalized reactions and erythema nodosum can also occur. Portuguese man-of-war (*Physalia physalis*) stings are more severe than those of most other jellyfish. Pacific box jellyfish (*Chironex fleckeri*) venom contains hemolytic, dermonecrotic, and myocardial toxins, and can cause severe cardiorespiratory reactions. Antivenin can neutralize cardiovascular effects of sea wasp envenomation in an animal model. In contrast, verapamil does not neutralize cardiovascular effects and increases mortality in the same animal model. [71] Vinegar is routinely used to inactivate undischarged box jellyfish nematocysts. It may also cause discharge of nematocysts of some other species of jellyfish, including some *Physalia*. [72] Cold packs provide effective analgesia during the acute painful stage of jellyfish stings.

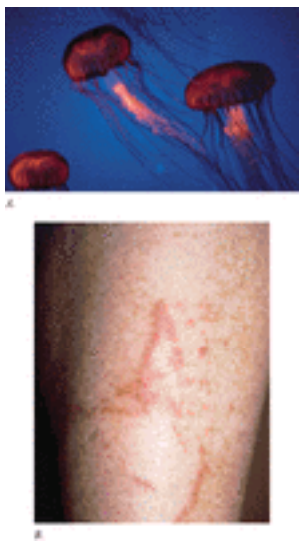

FIGURE 131-6 Free-floating jellyfish tentacles (*A*) may cause stings (*B*) identical to those caused by contact with an intact jellyfish. (*Photograph of clinical lesions is from the Wilford Hall Air Force Medical Center Dermatology teaching file.*)

Contact with seaweed has been implicated in vesiculobullous reactions. Algal organisms in seaweed can cause “stinging seaweed dermatitis” and pustular folliculitis.

Mycobacterium marinum (see Chap. 200) can cause epidemics of “swimming pool granuloma”. Mycobacterial infections are also commonly acquired in brackish coastal waters. Lesions can present as a smoldering tenosynovitis. Accurate diagnosis is essential because intralesional steroid injections for an “inflammatory joint” can cause severe sequelae.

Marine vibrio infections occur in brackish coastal waters. Many cases are related to ingestion of oysters, but skin and soft tissue injury in brackish water may also result in infection. Sepsis may occur, especially in those with preexisting liver disease (most commonly cirrhosis). Culture of wounds contaminated with sea water have a greater yield if

thiosulfate-citrate-bile-sucrose agar is used, and the cultures are performed both at room temperature and 30°C (86°F).[73]

Stingrays lash with their toxin-containing barbed tails when stepped on. Cutaneous and neurologic injury may result. Embedded barbs are associated with bacterial and deep fungal infection.

Decompression injury may affect the skin of divers, commonly causing livido reticularis. In a porcine model of decompression injury, vascular congestion and vasculitis were common skin biopsy findings.[74]

HISTAMINE-MEDIATED REACTIONS

Exercise-associated urticarial reactions include cholinergic urticaria, solar urticaria, symptomatic dermatographism, pressure-induced urticaria, cold urticaria, aquagenic urticaria, latex-induced contact urticaria, and exercise-induced anaphylaxis, which is the most severe of these reactions. In many cases, the reaction requires “priming” by an ingested allergen prior to exercise. These entities are discussed in more detail in Chap. 116.

ACNEIFORM LESIONS

Acne mechanica is common among athletes. It is caused by physical factors including pressure, occlusion, friction, and heat. It commonly occurs under chin straps, helmets, and shoulder pads. The lesions may respond better to keratolytics than to antibacterial agents.[75] They remit with the season's end.

Severe acne may be a sign of anabolic steroid use, which is widespread among athletes of all ages. Anabolic steroids cause enlargement of sebaceous glands, alter skin lipids and promote the growth of *Propionibacterium acnes*. Hirsutism and androgenic alopecia may also be present. Clinicians should be alert for skin signs of possible anabolic steroid use, as these drugs may have serious consequences, including peliosis hepatis.

OTHER SPECIAL DERMATOLOGIC PROBLEMS OF ATHLETES

Athletes with atopic eczema present special problems with exercise. Overheating may lead to bouts of pruritus. Individuals with atopic dermatitis demonstrate abnormal sweating and vasoconstriction patterns. However, there is evidence that the sweating[76] and vascular response improve with athletic training, and that athletics may not interfere with treatment of atopic dermatitis.[77] Application of an emollient after showering and short periods of rest can inhibit sweat-induced itching in atopic athletes, and regular moderate exercise does not cause deterioration in the condition of their skin.[78]

The athlete treated with oral retinoids also faces special problems. Arthralgia, staphylococcal colonization, photosensitization, and fatigue may result in lost training time or lost seasons. Retinoids cause disruption of epidermal integrity and skin fragility. The stratum corneum becomes loose and loses its barrier function. Greater trochanter enthesopathy (pain at the site of tendon insertion) may be a complication of short-term oral retinoid therapy in athletes.[79] For these reasons, when possible, retinoid treatment should be planned between seasons.

REFERENCES

1. Strauss RH et al: Illness and absence among wrestlers, swimmers, and gymnasts at a large university. *Am J Sports Med* **16**:653, 1988

2. Gaulrapp H et al: Injuries in mountain biking. *Knee Surg Sports Traumatol Arthrosc* **9**:48, 2001

3. Heitkamp HC et al: In-line skating: Injuries and prevention. *J Sports Med Phys Fitness* **40**:247, 2000

4. Brenner IK et al: Infection in athletes. *Sports Med* **17**:86, 1944

5. Perz-Perdomo R et al: Description of morbidity notified in the epidemiologic surveillance system of the XVII Central American and Caribbean Sport Games, Puerto Rico, 1993. *Puerto Rico Health Sci J* **13**:267, 1993

6. Shephard RJ: Science and medicine of canoeing and kayaking. *Sports Med* **4**:19, 1987

7. Sosin DM et al: An outbreak of furunculosis among high school athletes. *Am J Sports Med* **17**:828, 1989

8. Bartlett PC et al: Furunculosis in a high school football team. *Am J Sports Med* **10**:371, 1982

9. Falck G: Group A streptococcal infections after indoor association football tournament. *Lancet* **347**:840, 1996

10. Ludlam H et al: Scrum kidney: Epidemic pyoderma caused by a nephritogenic *Streptococcus pyogenes* in a rugby team. *Lancet* **2**:331, 1986

11. Maniatis AN et al: Pseudomonas aeruginosa folliculitis due to non-O:11 serotypes: Acquisition through the use of contaminated synthetic sponges. *Clin Infect Dis* **21**:437, 1995

12. Penn C et al: *Pseudomonas* folliculitis: and outbreak associated with bromine-based disinfectants. *Can Dis Wkly Rep* **16**:31, 1990

13. Zichichi L et al: *Pseudomonas aeruginosa* folliculitis after shower/bath exposure. *Int J Dermatol* **39**:270, 2000

14. Bottone EJ et al: Loofah sponges are reservoirs and vehicles in the transmission of potentially pathogenic bacterial species to human skin. *J Clin Microbiol* **32**:469, 1994

15. Rolston KV et al: *Pseudomonas aeruginosa* infection in cancer patients. *Cancer Invest* **10**:43, 1992

16. Lacour JP et al: Diving suit dermatitis caused by *Pseudomonas aeruginosa*: Tow cases. *J Am Acad Dermatol* **31**:1055, 1994

17. Saltzer KR et al: Diving suit dermatitis: A manifestation of *Pseudomonas* folliculitis. *Cutis* **59**:245, 1997

18. Agger WA: *Pseudomonas aeruginosa* infections of intact skin. *Clin Infect Dis* **20**:302, 1995

19. Insler MS et al: *Pseudomonas* keratitis and folliculitis from whirlpool exposure. *Am J Ophthalmol* **101**:41, 1986

20. Molina DN et al: Unusual presentation of *Pseudomonas aeruginosa* infections: A review. *Bol Asoc Med P R* **83**:160, 1991

21. Belogna EA et al: An outbreak of herpes gladiatorum at a high school wrestling camp. *N Engl J Med* **325**:906, 1991

22. Strauss RH et al: Abrasive shirts may contribute to herpes gladiatorum among wrestlers. *N Engl J Med* **320**:598, 1989

23. Bolanos B: Dermatophyte feet infection among students enrolled in swimming pool courses at a university pool. *Bol Asoc Med P R* **83**:181, 1991

24. Adams B: Tinea corporis gladiatorum: A cross-sectional study. *J Am Acad Dermatol* **43**:1039, 2000

25. Auger P et al: Epidemiology of tinea pedis in marathon runners: Prevalence of occult athlete's foot. *Mycoses* **36**:35, 1993

26. Hazen et al: Itraconazole in the prevention and management of dermatophytosis in competitive wrestlers. *J Am Acad Dermatol* **36**:481, 1997

27. Hazen PG et al: Management of lacerations in sports: The use of a biosynthetic dressing during competitive wrestling. *Cutis* **56**:301, 1995

28. Kvernmo HD et al: Enhanced endothelium-dependent vasodilatation in human skin vasculature induced by physical conditioning. *Eur J Applied Physiol Occup Physiol* **79**:30, 1998

29. Lindinger MI: Exercise in the heat: Thermoregulatory limitations to performance in humans and horses. *Can J Appl Physiol* **24**:152, 1999

30. Kato M et al: Thermophysiological effects of two different types of clothing under warm temperatures. *Appl Hum Sci* **14**:119, 1995

31. Gonzalez RR: Biophysiological integration of proper clothing for exercise. *Exerc Sport Sci Rev* **15**:261, 1987

32. Bassett DR, et al: Thermoregulatory responses to skin wetting during prolonged treadmill running. *Med Sci Sports Exerc* **19**:28, 1987

33. Squire DL: Heat illness. Fluid and electrolyte issues for pediatric and adolescent athletes. *Pediatr Clin North Am* **37**:1085, 1990

34. Fisher AA: Sports-related cutaneous reactions: Part 1. Dermatoses due to physical agents. *Cutis* **63**:134, 1999

35. O'Toole G, Rayatt S: Frostbite at the gym: A case report of an ice pack burn. *Br J Sports Med* **33**:278, 1999

36. Knapik JJ et al: Friction blisters. Pathophysiology, prevention, and treatment. *Sports Med* **20**:136, 1995

37. Knapik JJ et al: Influence of an antiperspirant on foot blister incidence during cross-country hiking. *J Am Acad Dermatol* **39**:202, 1998

38. Kawabata A et al: Effects of two kinds of sport shoes with different structure on thermoregulatory responses. *Ann Physiol Anthropol* **12**:165, 1993

39. Baker JG: Lime disease? *Arch Dermatol* **136**:1277, 2000

40. Potts A: Toxic responses of the eye, in, *Toxicology,* edited by M Amdur. New York, McGraw-Hill, 1993, p 524

41. Gelmetti C et al: Caustic ulcers caused by calcium hydroxide in 2 adolescent football players. *Contact Derm* **27**:265, 1992

42. Fisher AA: Sports-related cutaneous reactions: Part III. Sports identification marks. *Cutis* **63**:256, 1999

43. Erickson JG et al: Surfer's nodules and other complications of surfboarding. *JAMA* **201**:134, 1967

44. Cohen PR et al: Athlete's nodules: Sports-related connective tissue nevi of the collagen type (collagenomas). *Cutis* **50**:131, 1992

45. Cohen PR et al: Athlete's nodules. Treatment by surgical excision. *Sports Med* **10**:198, 1990

46. Rosso S et al: The multicenter south European study “Helios” II: Different sun exposure patterns in the aetiology of basal cell and squamous cell carcinomas of the skin. *Br J Cancer* **73**:1447, 1996

47. Moehrle M et al: Reduction of minimal erythema dose by sweating. *Photodermatol Photoimmunol Photomed* **16**:260, 2000

48. Herzfeld PM et al: A case-control study of malignant melanoma of the trunk among white males in upstate New York. *Cancer Detect Prev* **17**:601, 1993

49. Moehrle M et al: Extreme UV exposure of professional cyclists. *Dermatology* **201**:44, 2000

50. Moehrle M et al: *Bacillus subtilis* spore film dosimeters in personal dosimetry for occupational solar ultraviolet exposure. *Int Arch Occup Environ Health* **73**:575, 2000

51. Mills J et al: Recurrent herpes labialis in skiers. Clinical observations and effect of sunscreen. *Am J Sports Med* **15**:76, 1987

52. Spruance SL et al: Acyclovir prevents reactivation of herpes simplex labialis is skiers. *JAMA* **260**:1597, 1988

53. Moody RP et al: Dermal exposure to environmental contaminants in the Great Lakes. *Environ Health Perspect* **103**:103, 1995

54. von Schirnding YE et al: Morbidity among bathers exposed to polluted seawater. A prospective epidemiologic study. *S Afr Med J* **81**:543, 1992

55. Fleisher JM et al: Estimates of the severity of illnesses associated with bathing in marine recreational waters contaminated with domestic sewage. *Int J Epidemiol* **27**:722, 1998

56. Prevalence of parasites in fecal material from chlorinated swimming pools—United States. 1999. *MMWR Morb Mortal Wkly Rep* **50**:410, 2001

57. Zmirou D et al: Evaluation des indicateurs microbiens du risque sanitaire lie aux baignades en riviere. *Rev Epidemiol Sante Publique* **38**:101, 1990

58. Kramer MH et al: Surveillance for waterborne-disease outbreaks—United States, 1993–1994. *MMWR CDC Surveill Sum* **45**:1, 1996

59. O'Shea ML et al: Detection and disinfection of pathogens in storm-generated flows. *Can J Microbiol* **38**:267, 1992

60. Basler RS et al: Special skin symptoms seen in swimmers. *J Am Acad Dermatol* **43**:299, 2000

61. Adams B: Water-slide alopecia. *Cutis* **67**:399, 2001

62. Fisher AA: Green hair: Causes and management. *Cutis* **63**:317, 1999

63. Mascaro JM et al: Green hair. *Cutis* **56**:37, 1995

64. Melnik BC et al: Green hair: Guidelines for diagnosis and therapy. *J Am Acad Dermatol* **15**:1065, 1986

65. Kelsall HL, Sim MR: Skin irritation in users of brominated pools. *Int J Environ Health Res* **11**:29, 2001

66. Reimink RL et al: Efficacy of praziquantel in natural populations of mallards infected with avian schistosomes. *J Parasitol* **81**:1027, 1995

67. Wong DE et al: Seabather's eruption. Clinical, histologic, and immunologic features. *J Am Acad Dermatol* **30**:399, 1994

68. Freudenthal AR et al: Seabather's eruption. *N Engl J Med* **329**:542, 1993

69. Burnett JW: Seabather's eruption. *Cutis* **50**:98, 1992

70. Kumar S et al: Risk factors for seabather's eruption: a prospective study. *Public Health Rep* **112**:59, 1997

71. Tibballs J et al: The effects of antivenom and verapamil on the haemodynamic actions of *Chironex fleckeri* (box jellyfish) venom. *Anaesth Intensive Care* **26**:40, 1998

72. Fenner PJ et al: First aid treatment of jellyfish stings in Australia. Response to a newly differentiated species. *Med J Aust* **158**:498, 1993

73. Reed KC et al: Skin and soft-tissue infections after injury in the ocean: Culture methods and antibiotic therapy for marine bacteria. *Mil Med* **164**:198, 1999

74. Buttolph TB et al: Cutaneous lesions in swine after decompression: Histopathology and ultrastructure. *Undersea Hyperb Med* **25**:115, 1998

75. Basler R: Acne mechanica in athletes. *Cutis* **50**:125, 1992

76. Parkkinen MU et al: Sweating response to moderate thermal stress in atopic dermatitis. *Br J Dermatol* **126**:346, 1992

77. Salzer B et al: Gruppensport als adjuvante Therapie fur Patienten mit atopischem Ekzem. *Hautarzt* **45**:751, 1994

78. Heyer GR, Hornstein OP: Recent studies of cutaneous nociception in atopic and non-atopic subjects. *J Dermatol* **26**:77, 1999

79. Stitik TP et al: Greater trochanter enthesopathy: An example of “short course retinoid enthesopathy”: A case report. *Am J Phys Med Rehab* **78**:571, 1999

Footnote

The views expressed are those of the author and are not to be construed as official or as representing those of the Army Medical Department or the Department of Defense. This work is in the public domain. The work is original and has not been published or presented elsewhere. The author has no conflicts of interest to disclose. T>

Chapter 132

Joel Gelfand David Margolis

Decubitus (Pressure) Ulcers and Venous Ulcers

HISTORICAL ASPECTS
EPIDEMIOLOGY
Pressure Ulcers
Venous Leg Ulcers
ETIOLOGY AND PATHOGENESIS
Pressure Ulcers
Venous Leg Ulcers
Genetics
PREVENTION
Pressure Ulcers
Venous Leg Ulcers
CLINICAL MANIFESTATIONS
Pressure Ulcers
Venous Leg Ulcers
LABORATORY FINDINGS
PATHOLOGY
Pressure Ulcers
Venous Leg Ulcers
DIAGNOSIS AND DIFFERENTIAL DIAGNOSIS
TREATMENT AND PROGNOSIS
Pressure Ulcers
Venous Leg Ulcers
Other Therapies for Chronic Wounds
Pain Control

REFERENCES

Chronic wounds are a common medical problem that result in dramatic alterations in quality of life due to the associated pain, disability, and social isolation. Chronic wounds also result in excessive medical costs, health care provider visits, hospitalizations, and death. They disproportionately affect the elderly and, therefore, are increasing in incidence and prevalence as this segment of the population expands. Two of the most common types of chronic wounds are decubitus (pressure) ulcers and venous leg ulcers. Dermatologists are frequently involved in the care of patients with these problems.

Decubitus ulcers, preferably called pressure ulcers but also known as pressure sores and bedsores, are wounds that occur in areas of bony prominence as localized areas of necrosis of the skin and deeper soft tissues. These wounds tend to occur in individuals who are immobile. The pathophysiology involves unrelieved pressure, shearing, and frictional forces exerted on skin and subcutaneous tissues by bedding or seating surfaces. Pressure ulcers are initially evident as areas of blanchable or nonblanchable erythema, without a break in the continuity of the epidermis. They can progress to involve muscle, tendon, and bone. Treatment centers on relieving pressure.

Venous leg ulcers are wounds that occur on the lower extremity, most commonly in the gaiter area, which is located approximately between the lower half of the calf and 1 inch below the malleolus. The pathophysiology involves venous abnormalities of the lower extremity that result in ambulatory venous hypertension of the superficial venous system. The clinical diagnosis of venous leg ulcer is often made in any individual with a chronic wound in the gaiter area, with other signs of venous abnormalities (such as varicose veins, venous blush, lipodermatosclerosis), and an adequately functioning lower limb arterial system (e.g., an ankle brachial index of > 0.80, presence of a palpable distal limb pulse). [1] Venous leg ulcers frequently extend to the deep dermis and are often exudative wounds caused by the underlying abnormalities in venous circulation. Treatment centers on improving venous hemodynamics.

HISTORICAL ASPECTS

Management of chronic wounds dates back to one of the oldest known medical manuscripts, circa 2200 B.C. in which the need to wash the wound and bandage it are described. Pressure ulcers have been identified on a mummy of an elderly priestess of Amen. [2] Amboise Paré of the sixteenth century was one of the first to describe the significance of immobility and pressure in the cause of decubiti. He wrote of the importance of using a soft bed and local wound care; he also shunned the use of boiling oil to treat wounds, which was the routine at the time. Brown-Séquard believed that skin moisture was an important factor, while Charcot described the “neurotropic theory” of decubiti. Sir James Paget wrote about the importance of prevention of decubiti, particularly in those who are immobilized.

Writings on venous leg ulcers also date to antiquity. [3] Hippocrates wrote about the treatment of lower extremity varicosities. In the fourteenth century, Guy de Chauliac described the mechanical treatment of venous leg ulcers using lead plates. P.G. Unna developed the zinc paste bandage for treatment of venous leg ulcers in 1885. With the development of antiseptic techniques by Sir Joseph Lister, the use of surgical approaches increased with pioneering efforts by Friedrich Trendelenburg, Max Schede, Theodor Kocher, and William Babcock.

EPIDEMIOLOGY

Pressure Ulcers

Incidence and prevalence rates of pressure ulcers (Table 132-1) have varied with definition of incidence or prevalence used, study methodology, population studied, and imprecision due to small sample size. Pressure ulcers affect approximately 0.5 to 2.2 percent of the total population and in the United States, the cost is an estimated $1.335 billion dollars annually. [4], [5] The age distribution includes one peak in younger, mostly neurologically impaired (e.g., spinal cord injuries) individuals, and another peak in older, geriatric patients, with the elderly accounting for 70 percent of all pressure ulcers. [6] The incidence and prevalence is highly dependent on clinical setting (e.g., intensive care unit, nursing home, community settings) and patient factors, such as age, and related infirmities, such as hip fractures, spinal cord injuries, and other immobilizing conditions.

Population	Incidence	Prevalence
General	Unknown	0.5%
Acute care	0.4–38%	10–17%
Long-term care	2.2–23.9%	2.3–28%
Home care	0–17%	0–29%
Spinal cord injury patients	20–31%	10.2–30%
Elderly	0.18 to 3.36 per 100-person years	0.31–10%
Hip fracture patients	19.1–55%	Unknown

TABLE 132-1 **Incidence and Prevalence of Pressure Ulcers by Population**

The prevalence of pressure ulcers in the acute care setting in the late 1990s was estimated to be 10 to 17 percent, with 48 to 53 percent of these ulcers being acquired while in the hospital. [6] The majority of pressure ulcers in the acute care setting are stage I or II and are located on the sacrum and coccyx, followed by the heel. The incidence of pressure ulcers in the long-term care setting in the 1990s varied from 2.2 to 23.9 percent [6] and the prevalence ranged from 2.3 to 28 percent. [7] In the home care setting, incidence was 0 to 17 percent and prevalence was 0 to 29 percent. [6], [7]

Certain patient factors affect incidence and prevalence of pressure ulcers. The incidence and prevalence of pressure ulcers in patients with spinal cord injuries in the 1990s was 20 to 31 percent, and 10.2 to 30 percent, respectively. [6], [8] The overall prevalence rate in the elderly is estimated to be 5 to 10 percent. [6] Studies in elderly outpatients however, have found an annual prevalence between 0.31 and 0.70 percent with an incidence of 0.18 to 3.36 per 100-person years. [9] The incidence of pressure ulcers in patients with hip fractures varies from 19.1 to 55 percent. [6]

Venous Leg Ulcers

The epidemiology of venous leg ulcers has been investigated in several community-based population studies that are limited by the lack of a “gold standard” diagnostic for a large population sample. Therefore, data on venous leg ulcers are often extrapolated from studies of chronic ulcerations of the lower extremity. It is estimated that 40 to 70 percent of chronic lower extremity wounds are venous leg ulcers. [10] The prevalence of leg ulcers increases with age and disproportionately affects women with an observed female to male ratio of 1.6:1. [11] Chronic ulcerations of the leg occur in 0.8 percent of the general population, 1 percent of the adult population, and 3.6 percent of those older than 65 years of age, based on a mail survey of a Scottish community. [12] The prevalence of active ulcerations of the lower extremity is estimated to be 1.48/1000 [13] and the incidence of venous leg ulcers is estimated to be 18 per 100,000 person years. Chronic wounds of the lower extremity typically have a prolonged course with greater than 50 percent being present for more than a year. [14] Therefore, the prolonged course of venous leg ulcers results in a high prevalence of the disease relative to its incidence. Once healed, venous ulcers frequently recur with an annual recurrence rate of 33 to 42 percent. [15], [16] It is estimated that the annual cost of caring for a venous leg ulcer is $7460 with annual U.S. costs in excess of $1.9 billion. [11]

ETIOLOGY AND PATHOGENESIS

Pressure Ulcers

Central to the pathophysiology of the development of pressure ulcers is the interface of pressure between the skin and subcutaneous tissue, and the bedding or seating surface. Studies consistently find that pressures in excess of 32 mmHg are required to initiate skin breakdown. [17] Skin and subcutaneous tissue overlying bony prominences such as the occiput, sternum, scapulae, sacrum, coccyx, iliac crests, trochanters, patellae, malleoli, heel, and lateral edge of the foot, are particularly apt to develop high pressures. Certain subcutaneous tissues, such as muscle, are more sensitive to hypoxia than the overlying epidermis, and may undergo substantial injury prior to clinical signs of epidermal injury. [17]

Elevated cutaneous pressure results in tissue hypoxia, as a result of impairment in capillary flow. Pressure forces also lead to impairment in removal of toxic metabolites, such as free radicals, because of obstruction of venules. Initial tissue injury is physiologically responded to by vasodilation and resultant hyperemia (clinically seen as blanchable erythema), which may paradoxically lead to further tissue damage through further generation of free radicals. Elevated pressures result in hemorrhage into the tissues, clinically observed as nonblanchable erythema. An inverse relationship between amount of pressure and duration of pressure exists in terms of the force necessary to yield tissue necrosis. Low pressure over a long duration of time, however, results in greater tissue injury than does high pressure exerted over a short time period. [17]

Pressure alone is not the only cause of pressure ulcers. In humans, pressure ulcers occur when soft tissues are exposed to less pressure and time gradients than those required to create tissue necrosis in experimental models. Additional

forces involved are shear and friction. Forces that are parallel to an area are called shearing forces and can reduce, especially in deep tissues and blood vessels, the amount of pressure required to create necrosis by half. [18], [19] Frictional forces result in damage to the stratum corneum and epidermis resulting in an impairment of barrier function and a greater susceptibility to tissue necrosis. [17] Excessive moisture results in increased adhesiveness of the skin to bed linens, generating greater frictional and shearing forces. [17]

Venous Leg Ulcers

Chronic ambulatory venous hypertension is central to the pathophysiology of venous leg ulcers. [20] Venous return from the lower extremity involves the superficial veins, the communicating or perforator veins, and the deep veins. The superficial veins consist of the long and short saphenous veins and their tributaries. The superficial veins can enter directly into the deep veins or connect to the deep veins by small communicating or perforator veins. The deep veins are classified as either intramuscular or intermuscular. The deep venous system involves three sets of paired tibial veins, which merge to become the popliteal vein, which becomes the superficial femoral vein. The superficial femoral vein merges with the deep femoral vein in the femoral triangle to become the common femoral vein. Superficial, communicating, and deep veins have one-way bicuspid valves that allow flow only in the cephalad direction. Blood is returned to the heart primarily through the pumping action of leg muscles. [11], [21]

During ambulation, in an individual with a properly functioning venous system, the pressures in the superficial system fall toward zero. In an individual with venous disease, superficial venous pressure is elevated during ambulation to as high as 40 to 100 mmHg. [20] Venous hypertension may occur through four mechanisms: (1) dysfunction of valves in the superficial and/or communicating veins because of congenital or acquired (e.g., phlebitis, trauma) incompetence; (2) dysfunction in the valves of the deep system from congenital absence, inherent weakness, or thrombotic damage; (3) deep venous outflow obstruction from a mass or obesity; and (4) from muscle pump failure secondary to inflammatory conditions of the joints or muscles, fibrosis, or neuropathies. [11]

Why patients with ambulatory venous hypertension develop venous-associated wounds is not clear. The most popular theories concern the deposition of pericapillary fibrin in the small venules surrounding the ulcers, [20] the trapping of inflammatory cells within the venules surrounding the ulcers resulting in the liberation of proteolytic enzymes, and the trapping of essential growth factors by macroglobulins within the venules and dermis surrounding the ulcers. [22] None of these theories have been fully validated by experimental evidence. Central to all of these theories is an alteration in venous hemodynamics of the lower limb resulting in abnormally elevated ambulatory venous pressure. The importance of ambulatory venous hypertension in the pathophysiology of venous leg ulcers is validated by the centrality of lower-limb compression therapy in the treatment of these wounds.

Genetics

The role of genetics in the development of pressure ulcers and venous leg ulcers has not been clearly delineated. Factor V Leiden mutations resulting in resistance to activated protein C occur with increased prevalence in patients with postthrombotic venous leg ulcers relative to control subjects. [23], [24] Venous leg ulcers have also been reported in men with sex chromosome abnormalities, such as Klinefelter's syndrome.

PREVENTION

Pressure Ulcers

Prevention of pressure ulcers involves a multidisciplinary approach. Aggressive programs to prevent pressure ulcers may lower their incidence by 25 to 30 percent. [25], [26] The first step is the identification of individuals at risk for pressure ulcer development. Several scoring systems, including the Norton Scale, [27] the Waterlow Scale, [28] and the Braden Scale, [29] have been developed to identify such patients. These instruments evaluate variables such as mobility, moisture exposure, nutrition, and patient factors (e.g., health status, age, body weight). They have variable sensitivity and specificity, and are limited by poor predictive value because the incidence of pressure ulcers is relatively low in most settings, thus limiting the scale's clinical application. [4]

Relief of pressure is believed to be important in the prevention of pressure ulcers. Efforts to turn the patient, use of proper positioning, and improvement of passive activity, while important empirically, have not been validated by published data. Bioengineering advances have led to the development of alternating air mattresses and low-air-loss beds, which minimize the amount of pressure exerted on the skin. These specially designed pressure-reducing mattresses reduce the risk of pressure ulcers by 70 percent when compared to standard mattresses. [4] No dramatic advantage of type of pressure-reducing mattress (e.g., alternating air versus low-air-loss) has been demonstrated in clinical trials. [4] Therefore, the choice of pressure-reducing device in the prevention of pressure ulcers is based on cost, local availability, and patient factors.

The nutritional status of the patient is also believed to be important in the development of pressure ulcers. Patients who develop pressure ulcers frequently have low serum albumin, which is a marker of poor nutritional status. However, studies evaluating the use of oral and enteral feeding supplements have not demonstrated efficacy in the prevention of pressure ulcers. [4]

Venous Leg Ulcers

Efforts aimed at prevention of venous leg ulcers have centered on reversing ambulatory venous hypertension. Compression therapy is believed to prevent venous leg ulcers in patients with ambulatory venous hypertension, and to prevent recurrence of leg ulcers. [30], [31] Controlled data on the primary prevention of venous leg ulcers in those with

venous stasis, however are limited. Furthermore, the use of compression therapy in the prevention of the recurrence of venous leg ulcers has been evaluated by the Cochrane group, which found no controlled studies that demonstrate the efficacy of compression in this setting. [32] Preliminary data suggests that surgical correction of isolated superficial venous reflux may reduce the long-term recurrence rate of venous leg ulcers. [33] These data await confirmation by a controlled trial.

CLINICAL MANIFESTATIONS

Pressure Ulcers

The clinical appearance of a pressure ulcer depends on its stage of evolution (Table 132-2). The earliest sign of pressure ulcer is blanchable erythema. Stage I ulcers appear as nonblanchable erythema without breakdown of the epidermis (Fig. 132-1) and can be difficult to detect in patients with darkly pigmented skin. Stage II ulcers have partial-thickness skin loss involving the epidermis or the epidermis and dermis. Stage III ulcers demonstrate full-thickness skin loss that may extend to, but not include, the fascia. Stage IV ulcers show extensive necrosis with tissue destruction down to muscle, bone, or supporting structures (Fig. 132-2). [5] An overhanging border of epidermis may be seen in advanced pressure ulcers, masking the true extent of the tissue destruction. Pressure ulcers occur predominantly over areas of bony prominence such as the occiput, scapulae, elbows, sternum, sacrum, ischial tuberosities, iliac crest, trochanters, heels, and knees. They may also occur on the nose, ears, or lips. Pressure ulcers are often painful and can be particularly distressful to patients and families.

Stage	Definition
I	Nonblanchable erythema of intact skin
II	Partial-thickness skin loss involving epidermis, dermis, or both
III	Full-thickness skin loss involving damage or necrosis of subcutaneous tissue that may extend down to, but not through, underlying fascia
IV	Full-thickness skin loss with extensive necrosis, or damage to muscle, bone, or supporting structures

TABLE 132-2 **Staging of Pressure Ulcers**

FIGURE 132-1 Extensive stage I pressure ulcer of the sacral area.

FIGURE 132-2 Extensive stage IV pressure ulcer of the sacral area.

Venous Leg Ulcers

The early signs of venous hypertension include varicosities of the superficial veins, red brown hyperpigmentation of the leg resulting from red cell extravasation, and an eczematous dermatitis manifested as erythema, scaling, and, in some instances, a serosanguineous exudate. Lipodermatosclerosis, a sclerosing panniculitis, is seen in some patients with venous disease and is manifested by epidermal atrophy, yielding a shiny texture to the skin with a woody or indurated texture. The process often results in the lower leg resembling an inverted champagne bottle. An additional finding in some patients is atrophie blanche, which is manifested as porcelain-white atrophic lesions with telangiectasia that can be exquisitely painful.

Venous ulcers typically have a beefy red base with an edematous bluish border, termed *venous blush* (Fig. 132-3). Frank necrosis or eschar is rarely seen. The ulcers typically involve the middle to deep dermis, and rarely involve deeper tissue such as fascia, muscle, or bone. They can be large, exceeding 550 cm^2 in size, circumferential, commonly located between the lower half of the calf and 1 inch below the malleolus (gaiter area). The medial aspect of the leg is more commonly involved; however, venous ulcers can affect the lateral aspect. The calf has been reported to be involved in 5 percent of cases and the foot in 8 percent. [34] Pain is frequent and common features include burning, throbbing, cramping,

and aching pain. Pain is often relieved with leg elevation or ambulation. Foul smell may be present and socially isolating.

FIGURE 132-3 Venous stasis ulcer of the medial leg. Note the characteristic features of beefy red base, venous blush of wound edges, and varicosities.

Venous leg ulcers are often preceded by phlebitis and deep venous thrombosis (DVT) (e.g., postphlebitic syndrome) in some individuals. [21] Diagnosis and treatment of these conditions is important to help improve venous hemodynamics, as well as to prevent potential fatal sequelae of DVT such as pulmonary embolus. Venous leg ulcers are also associated with infection and contact dermatitis (particularly to topical steroids). Chronic wounds, such as pressure ulcers and venous leg ulcers, may also be complicated by the development of squamous cell carcinoma (Fig. 132-4).

FIGURE 132-4 Development of multiple squamous cell carcinomas in a patient with a history of venous leg ulcers and stasis dermatitis.

LABORATORY FINDINGS

There are no specific laboratory findings in patients with pressure ulcers or venous leg ulcers. As with any patient with a chronic wound, laboratory tests to evaluate nutritional status (e.g., serum albumin, total lymphocyte count), and infection (white blood count with differential) should be considered. In individuals with evidence of hypercoagulability (e.g., recurrent deep vein thrombosis) an appropriate hematologic workup should be considered.

For patients with suspected venous leg ulcers, function of the lower extremity superficial and deep venous system can be studied with venography, plethysmography, or ultrasound (duplex and continuous wave). These diagnostic tests confirm the diagnosis of venous leg ulcers (which is often made on a clinical basis), provide prognostic information (e.g., venous leg ulcers associated with deep venous reflux respond poorly to treatment), and help to localize the anatomic site of reflux for potential surgical correction. In addition, the clinician can perform the Trendelenburg test at the bedside to determine if the origin of the reflux is from the superficial or deep system. [35] To perform this maneuver, the patient's leg is elevated until the veins collapse. A tourniquet is then placed above the level of suspected reflux (typically just below the saphenofemoral junction at the groin). The patient then stands with the tourniquet in place. If the distal varicosity fills quickly, then the point of reflux has not been correctly identified or the deep veins or communicating veins are incompetent. If the veins fill very slowly, but then fill rapidly with removal of the tourniquet, the reflux originates from the superficial system (and therefore may be more amenable to treatment or surgical correction).

For ulcers on the lower extremity, arterial vascular disease should be assessed, particularly in patients that are treated with compression therapy. Options include physical examination (e.g. examination of pulses), determination of peak velocity ratio (PVR) by Doppler ultrasound, arteriography, or measuring the ankle-brachial index (ABI). The ABI is determined with the patient in the supine position. The systolic pressure is measured in both upper extremities by using Doppler measurement of the pulse and in the lower extremity with the pressure cuff around the calf. The dorsal pedal or posterior tibial pulse is determined with Doppler. A ratio (systolic ankle pressure divided by the higher of the two systolic brachial pressures) of >1 is normal, and a ratio of < 0.8 suggests lower extremity arterial disease.

PATHOLOGY

Pressure Ulcers

The pathologic findings in pressure ulcers depend on the stage of evolution. Witkowski and Parish studied the

pathological changes of pressure ulcers in 59 patients. [36] In blanchable erythema the histologic changes are primarily in the papillary dermis, where a mild perivascular lymphocytic infiltrate is seen. Occasionally, degenerative changes of adnexal structures and fibrin thrombi of deep dermal vessels are present. In stage I ulcers vessels are engorged with red blood cells and there is prominent hemorrhage. Degeneration of adnexal structures and subcutaneous fat is occasionally noted. In early ulceration, the epidermis is not present; however, the dermal papillae are seen. In addition to a perivascular lymphocytic infiltrate, neutrophils are seen. The necrotic changes in the appendages and fat are more pronounced. In ulcers with eschar the tissue appears basophilic with loss of the cellular details in the dermis. An inflammatory infiltrate is often not seen with this level of tissue destruction.

Venous Leg Ulcers

The histopathology of venous leg ulcer typically reveals absence of the epidermis with stigmata of venous stasis. The surrounding epidermis may show acanthosis, parakeratosis, and variable spongiosis. Hemosiderin deposition is notable. A superficial infiltrate of lymphocytes and, occasionally, both histiocytes and plasma cells surrounding thickened capillaries and venules with fibrin deposits are often seen, as well as dermal fibrosis. In some instances the vascular proliferation may resemble Kaposi's sarcoma. In lipodermatosclerosis, pathologic changes extend to the adipose tissue. In early lesions, there is a sparse lymphocytic infiltrate between the collagen bundles of the septae and necrosis of adipocytes in the center of the lobules. In later lesions, there is fibrosis and thickening of the septae with atrophy of the fat and a variable infiltrate of foamy macrophages, lymphocytes, plasma cells, and lipophagic granulomas.

DIAGNOSIS AND DIFFERENTIAL DIAGNOSIS

A pressure ulcer is any lesion caused by unrelieved pressure resulting in damage to the underlying tissue. The diagnosis is readily made in the proper clinical setting. The clinical diagnosis of venous leg ulcer is made in any individual with a chronic wound in the gaiter area, with other signs of venous abnormalities (such as varicose veins, venous blush, lipodermatosclerosis), and an adequately functioning lower-limb arterial system (e.g., an ankle brachial index of > 0.80, presence of a palpable distal limb pulse). [1] Venous ulcers have also been described on the upper leg and the foot. [34] The definitions of pressure ulcer and venous leg ulcer are broad and may actually represent syndromes of distinct disease entities that have not been delineated.

The differential diagnosis of a chronic wound is broad (Table 132-3). Common alternative etiologies to venous or pressure wounds of the lower extremity include arterial ulcers and diabetic foot (neuropathic) ulcers, which must be excluded by further diagnostic testing (e.g., Doppler ultrasound of arterial flow, ankle-brachial indexes, neurologic testing) because these disorders require different treatment. Furthermore, ulcers with an arterial component may be exacerbated by therapies for venous leg ulcers, such as compression. The reader is referred to Table 132-3 for a comprehensive differential diagnosis of chronic wounds. Biopsies and tissue culture of chronic wounds thought to be venous leg ulcers or pressure ulcers should be considered if they are not responding appropriately to treatment or if clinical signs indicate the potential for an alternative etiology.



TABLE 132-3 **Differential Diagnosis of Chronic Wounds**

TREATMENT AND PROGNOSIS

Pressure Ulcers

PROGNOSIS Pressure ulcers often have a prolonged course. About 80 percent will heal without surgery; however, 61 percent of patients will have ulcers for at least 6 months. [37] Pressure ulcers are frequently complicated by infections that play an important role in morbidity and mortality. The incidence of bacteremia from pressure ulcers is estimated to be 1.7 per 10,000 hospital discharges and osteomyelitis was found to occur in 38 percent of patients with infected ulcers. [4], [37], [38] Pressure ulcers are also associated with excess risk of mortality. Patients who developed a pressure ulcer in the acute care setting had a 67 percent risk of dying in a year as compared to a 15 percent mortality rate of patients who were at risk for development of a pressure ulcer but did not develop one. [4] In the long-term care setting, patients who developed a pressure ulcer within 3 months of admission had a 92 percent mortality rate as compared to a 4 percent mortality rate in patients who did not develop a pressure ulcer. [40] It appears, however, that pressure ulcers may be a marker of other comorbidities and not necessarily causally associated with death. Correction for comorbidities eliminates the association of pressure sores with death, [41] and the severity of pressure ulcer has not been linked to risk of death.

TREATMENT The majority of the treatment recommendations for pressure ulcers are based on clinical experience and have not been validated by rigorously controlled trials. Treatment of pressure ulcers involves assessment of the patient, management of tissue loads, local wound care, management of bacterial colonization and infection, surgical intervention when indicated, and proper pain management (see Table 132-4). [5] Assessment of the patient should include proper evaluation of the ulcer, a thorough history and physical examination, identification and treatment of comorbid conditions, a nutritional assessment, an evaluation of pain, a psychosocial evaluation, and an evaluation of the individual's risk for developing additional pressure ulcers.

Evaluation
Extent of wound
Identify and treat underlying infection
Identify and treat comorbidities that impair wound healing (diabetes, arterial disease, malnutrition, collagen vascular disease)
Address precipitants (e.g., unrelieved pressure, venous hypertension)
Biopsy (to rule out alternative diagnosis, to evaluate for development of squamous cell carcinoma, to identify bacterial pathogen)
Cleansing
Use cleanser, such as normal saline, that is physiologic and nontoxic to epithelial cells and fibroblasts.
A 35-mL syringe with 19-gauge angiocatheter is necessary to provide adequate pressure (e.g., 4 to 15 psi) to remove bacteria and necrotic debris without harming healthy tissue
Dressing
Use moisture dressing that promotes moisture of wound bed without macerating surrounding normal skin
Debridement
Remove fibrinous debris, devitalized tissue, eschar
Sharp debridement
Often indicated when there is extensive devitalized tissue or infection
Mechanical debridement (wet-to-dry dressings, hydrotherapy, wound irrigation)
Enzymatic debridement
Autolytic debridement (avoid in infected wounds)
Antibiotics
Use systemic antibiotics for infectious complications of wounds (e.g., cellulitis, osteomyelitis, sepsis)
Topical antibiotics for wounds not responding to treatment or for foul smelling wounds
Pain management
For chronic pain associated with a chronic wound
For acute pain associated with infection, debridement, dressing changes, transferring

TABLE 132-4 **Wound Care**

Assessment of the pressure ulcer itself includes identifying stage, location, undermining, tunneling, exudate, necrotic tissue, and the presence or absence of granulation tissue and reepithelization. Proper assessment of the ulcer is important because pressure ulcers may appear shallow on initial inspection despite deep involvement. The ulcer should be reevaluated weekly for complications or more often if dictated by a change in patient status. It should be anticipated that assessing response to treatment may take several weeks to months of observation. Peripheral vascular disease, diabetes mellitus, immune deficiencies, collagen vascular diseases, malignancies, mental health disorders, immobility, and incontinence should be evaluated and treated because they may impede wound healing. Possible complications of pressure ulcers, such as maggot infestation, sinus tract or abscess formation, osteomyelitis, cellulitis, bacteremia, sepsis, septic arthritis, meningitis, and endocarditis, should be treated. Additional complications of chronic pressure ulcers include amyloidosis, heterotopic bone formation, perineal-urethral fistula, pseudoaneurysm, and development of squamous cell carcinoma in the wound. [5] Side effects of treatment including contact dermatitis and systemic effects of local treatment (e.g., iodine toxicity) should also be monitored. Nutritional assessment is also essential to the care of patients with pressure ulcers. The stage of ulcer may correlate with degree of malnutrition, particularly protein deficiency and hypoalbuminemia. [42] Markers of malnutrition include albumin less than 3.5 mg/dL, total lymphocyte count less than 1800/mm [3], and patient body weight less than 80 percent of ideal. [43] Inability to take food by mouth and a history of involuntary weight loss are important risk factors for malnutrition. Nutrition should be reassessed every 3 months in patients at risk while treating a patient with a pressure ulcer. Vitamins and minerals important to wound healing, such as vitamin C and zinc, should be supplemented in individual patients with deficiencies. However, supplementation with vitamin C or zinc in patients without deficiency has not been shown to be helpful in clinical trials, and zinc may be harmful to wound healing when given at high doses. [44], [45] Alimentation of 30 to 35 calories/kg/day and 1.25 to 1.50 g of protein/kg/day is recommended to maintain a positive nitrogen balance in order to improve healing. [46] Enteral tube feeding to supplement protein and calories in an effort to improve wound healing has not been effective in all studies, however. Management of tissue loads is a critical component of treating pressure ulcers. The distribution of pressure on the tissues, as well as the frictional and shear forces, must be managed. Positioning and repositioning techniques are necessary to offload pressure forces away from bony prominences (e.g., trochanters) and pressure ulcers. Pillows and foam wedges may be useful positioning devices. Donut-type devices are to be avoided as they result in venous congestion and may be deleterious. [47] To minimize shearing forces on the sacral area, the head of the bed should be maintained at the lowest degree of elevation tolerable by the patient's medical condition. A variety of support devices are available for patients with pressure ulcers. They can be rated based on cost and performance characteristics. These characteristics include level of support, low moisture retention, reduced heat accumulation, shear reduction, pressure reduction, and dynamic changes in forces exerted. Examples include (in order from highest cost and best performance characteristics to lowest cost and performance): air-fluidized, low-air loss, alternating air, static flotation (air or water), foam, and standard mattresses. There is no compelling evidence that one support surface consistently performs better than all others in all circumstances. [4], [5] Static support surfaces are recommended for patients who can assume multiple positions without bearing weight on a pressure ulcer and without bottoming out (e.g., fully compressing the static support surface by having less than 1 inch of support material underneath areas of pressure). [48] Dynamic support surfaces, such as air-fluidized, low-air-loss, or alternating air, are recommended for patients who cannot assume a variety of positions without bearing weight on an ulcer. They should also be used if the patient bottoms out, or if the ulcer does not show evidence of healing. [5] For patients with large stage III or IV pressure ulcers on multiple turning surfaces, a low–air-loss or air-fluidized bed may be indicated. Air-fluidized beds may benefit patients in the acute care setting with large ulcers; however, these beds are limited by their cumbersome size and weight, the difficulties they cause for nurses in transferring patients, and their excessive cost. Low-air-loss beds are generally cheaper than air-fluidized beds and are better equipped for transferring patients. A review of four randomized controlled trials totaling 259 patients showed improvement in wound healing rates for low-air-loss beds from 64 to 80 percent as compared to 47 to 68 percent of controls. [5] The comparative efficacy of air-fluidized and low–air-loss beds has not been studied in head-to-head trials; air-fluidized beds, however, have the theoretical advantage of improved shear reduction. Air-fluidized and low-air-loss beds may also be indicated for patients in whom moisture is leading to maceration and skin breakdown. For patients who are able to sit in a chair, techniques are necessary to prevent pressure ulcer development and to minimize exacerbation of existing ulcers. Individuals who are able should reposition themselves every 15 min. [5] If the patient cannot self-reposition then they should be repositioned at least every hour or be returned to bed. Proper care and dressing of the wound is an important aspect of treating pressure ulcers. Proper care includes debriding, cleansing, and dressing. Ulcers with devitalized, necrotic tissue should be debrided by using sharp, mechanical, enzymatic, or autolytic methods. An exception to this recommendation is heel ulcers that do not exhibit edema, erythema, fluctuance, or drainage. [5] The sharp method involves use of a scalpel or other sharp instruments and may require use of an operating room for larger ulcers. When stage IV ulcers are debrided in the operating room, a bone biopsy for culture should be considered to evaluate the presence of osteomyelitis. Sharp debridement is generally indicated when there is frank evidence of infection, sepsis in which the wound is the source, or cellulitis. Mechanical debridement involves techniques such as wet-to-dry dressings, hydrotherapy (e.g., whirlpool), or wound irrigation. Wet-to-dry dressings should be changed every 4 to 6 h and additional pain control may be necessary during dressing changes. The main disadvantage of wet-to-dry dressings is that they are nonselective and may remove healthy granulation tissue. Wound irrigation can remove dead tissue and bacteria when using a 35-mL syringe and 19-gauge angiocatheter to provide adequate force (e.g., 4 to 15 psi). [49] Enzymatic debridement can be accomplished using topical debriding agents such as collagenase, papain/urea, or papain/urea-chlorophyll. Enzymatic treatments poorly penetrate thick eschars, however, and the benefit of enzymatic debridement on wound healing rate is unclear. Autolytic debridement can be performed by the use of occlusive dressings

that allow the wound's own exudate to break down devitalized tissue. The autolytic method should be avoided in infected wounds. Wound cleansing should occur with dressing changes. Cleansing should be performed gently to minimize trauma to healing tissues. Skin cleansers and antiseptics such as povidone-iodine, iodophor, sodium hypochlorite solution, hydrogen peroxide, acetic acid should be avoided because they are toxic to wound tissue. [50] Normal saline is preferred as it is most physiologic and will not harm healing tissue. Wound dressings should maintain moisture of the wound bed at all times to maximize wound healing [51] (see Chap. 272). It has been demonstrated experimentally that dressings that promote moisture of the wound bed heal 40 percent faster then air-exposed wounds. [52] Occlusive dressings, such as polymer films, polymer foams, hydrogels, hydrocolloids, alginates, and biomembranes, are appropriate. The type of dressing that promotes moisture is not clearly significant as long as wound bed moisture is maintained. Choice should be based on the individual wound with the goal of promoting a moist wound environment without causing maceration of the wound edges. Management of bacterial colonization and wound infection is important in the healing process. It has been demonstrated experimentally that pressure ulcers are more susceptible to bacterial colonization than wounds not subjected to pressure. [52] Healing is impaired when bacterial counts exceed 10^5 per gram of tissue. Proper wound debridement, cleansing, and bandaging help to minimize bacterial colonization and risk of infection. Because bacterial colonization (particularly *Pseudomonas aeruginosa* and *Providencia* species) is associated with delayed wound healing, a trial of topical antibiotic active against gram-positive, gram-negative, and anaerobic bacteria (silver sulfadiazine, triple antibiotic) should be considered for nonhealing or exudative wounds. [4], [5] Clinical trials of topical antibiotics in decubiti have demonstrated improvement in the appearance of these wounds and therefore may be helpful in wound healing. [4] Topical metronidazole may be helpful for wounds colonized by anaerobic bacteria, clinically recognized as foul-smelling wounds. Systemic antibiotics should be reserved for clinical infections such as cellulitis, bacteremia, sepsis, and osteomyelitis. *Staphylococcus aureus,* gram-negative rods, and *Bacteroides fragilis* are frequent causes of sepsis in these patients. Because it should be anticipated that all chronic wounds will be colonized by bacteria, swab cultures of wound beds should not be used to diagnose infection. [53] Only samples obtained by tissue biopsy are reliable for determining the pathogen of a clinically infected wound. It should be emphasized that quantitative tissue cultures alone are insufficient to determine infection in a chronic wound, and therefore clinical signs such as pain, erythema, fever, and exudate are necessary to diagnose infection. Beyond medical therapies, a variety of surgical techniques are also available to repair pressure ulcers. These techniques include direct closure, skin grafts, skin flaps, and myocutaneous flaps. Patients must be carefully selected for surgical intervention and the patient's therapeutic goals and ability to tolerate surgery should be considered. Surgical repairs of pressure ulcers are limited by high cost and high postoperative recurrence rate. [4] Thus, the efficacy of surgical repair of pressure ulcers has been questioned even in young patients.

Venous Leg Ulcers

PROGNOSIS Venous leg ulcers take a prolonged time period to heal and many patients will never achieve complete wound healing. Within 24 weeks of therapy the best success rates vary from 30 to 60 percent, and within a year the best success rates vary from 70 to 85 percent. [54], [55] Several risk factors are associated with failure of venous leg ulcers to heal, including wound area; wound duration; history of venous ligation or stripping; history of hip or knee replacement surgery; ankle brachial index of less then 0.80; deep vein involvement on noninvasive testing; fixed limb joints; and general immobility. [55], [56] Venous leg ulcers are also frequently complicated by contact dermatitis, particularly to topical steroids, and can be a frequent source of infection, such as cellulitis. [57]
TREATMENT Treatments for venous leg ulcer are aimed at reducing ambulatory venous hypertension. Elevation of the legs above heart level for 30 min, three to four times per day, allows for improvement in leg swelling. Leg elevation at night can be accomplished by raising the foot end of the bed by 15 to 20 cm. Walking and exercise further improve venous circulation through calf muscle pump action. [9], [11] The standard of care for venous leg ulcers centers on the use of compression therapy. [58], [59] Since 1966, MEDLINE has listed more than 1200 studies concerning the treatment of venous leg ulcers. These papers describe alleviating venous hypertension; removing lower limb edema; wound debridement; wound cleansing; wound bandaging and dressing; the use of systemic and topical compounds to augment healing; the use of mechanical devices to augment healing; and the use of surgery to improve venous hemodynamics. Unfortunately, none of these studies have been able to demonstrate a consistent and reproducible advantage over lower-limb compression; [60] consequently, compression therapy remains the cornerstone of treatment. Compression therapy increases transcutaneous oxygen pressure, [61] improves lymph transport, enhances fibrinolysis, improves reflux in the deep venous system, [62] improves deep venous valve function, and reduces the release of macromolecules into the extravascular space. [63] The most popular compression bandage for venous leg ulcers was introduced by P.G. Unna in 1885, and has not been substantially improved upon since. [59] This form of lower-limb compression is gauze impregnated with zinc and fitted to the patient's leg. Although not appreciated by Unna, the essential component of this technique is the compression of the lower limb afforded by this bandage and not the zinc. [64] The consensus is that 35 to 40 mmHg at the ankle is required for therapeutic efficacy. [11] Compression therapy can be applied via a rigid inelastic dressing, such as the Unna boot, or by elastic or multilayered bandages. [65] Rigid dressings provide high pressure with muscle contraction but little pressure at rest, and do not accommodate for changes in volume of the leg associated with changes in edema. Rigid dressings may be particularly useful for reducing edema in the acute management of venous leg ulcers. Rigid dressings cannot absorb exudate from wounds efficiently and therefore can create irritant dermatitis, as well as foul odors. Less-rigid alternatives to the Unna boot dressing include short-stretch dressing such as Unna-Flex and Comprilan. Long-stretch elastic compression bandages may allow for more frequent dressing changes, which may be appropriate for exudative wounds. Long-stretch bandages provide higher resting pressures and therefore may be more useful after the initial edema has been resolved with rigid dressings. Elastic compression bandages need to be applied with 50 percent overlap as they progress up the leg in order to produce sustained pressure and require skill in their application. [66] Multilayered bandages such as three-layered systems (Dynaflex) and four-layered systems (Profore) may provide for faster healing rates when compared to rigid Unna boot dressings. [67] Multilayered dressings can be used for legs of various sizes and can provide sustained pressures of 40 to 45 mmHg at the ankle; however, their use is limited by their cost. After a leg ulcer is healed, compression therapy should be continued empirically to prevent recurrence. This recommendation is based on clinical experience and has not been rigorously validated by clinical trials. [32] Elastic compression stockings are suitable for this indication. Compression class I (20 to 30 mmHg), class II (30 to 40 mmHg),

class III (40 to 50 mmHg), and class IV (> 60 mmHg) are available. Elastic compression stockings should be replaced every 6 months to maintain adequate function. Custom fitting may be indicated for some individuals. Aids have been developed to assist patients in the donning and removal of compression stockings and are available at medical supply stores. Dressing of the wound is important in providing pain relief, improving wound healing by promoting a moist wound environment, and for absorption of wound exudate. Hydrogels, alginates, hydrocolloids, foams, and films do not necessarily improve healing relative to simple nonadherent dressings, but may have relative advantages for individual patients and practitioners. [68] As with pressure ulcers, the goal is to maintain moisture of the wound bed while minimizing maceration of the wound edges. Removal of necrotic debris and or fibrinous exudates can be accomplished with sharp debridement, enzymatic debridement (such as collagenase), or by mechanical debridement (e.g., wet-to-dry dressing, whirlpool therapy). Few systemic treatments for venous leg ulcers have been rigorously investigated. Pentoxifylline has shown mixed results in a number of randomized controlled trials. A grouped analysis of these studies demonstrated the benefit of pentoxifylline as an adjuvant to compression therapy. [69] Recent studies suggest that higher doses of pentoxifylline (800 mg po tid) may be necessary for efficacy. [70] Surgical treatment of venous leg ulcers is generally reserved for patients who are not responding to treatment or for patients with large ulcers. Split-thickness skin grafts have been reported as beneficial, but their success rate is variable. [71] Possible risk factors for failure to heal with a split-thickness skin graft include comorbidities, living alone, stasis dermatitis, and prolonged duration of wound. Superficial vein ligation or sclerosis may decrease recurrence of venous leg ulcers if the deep veins are competent. [72] Tissue-engineered skin equivalents such as Apligraf were approved for use by the Food and Drug Administration and have demonstrated clinical efficacy in one randomized controlled trial. [73]

Other Therapies for Chronic Wounds

Numerous therapies for chronic wounds have been and continue to be investigated. Laser, ultrasound, ultraviolet, infrared, electrotherapy, electromagnetic therapy, hyperbaric oxygen, topical application of growth factors, and topical application of phenytoin have shown promise in some reports, however, all await more rigorous investigation to validate their efficacy. [5], [74], [75] and [76] Studies of therapies for chronic wounds often report wound healing rate and clinical appearance of the wound as outcomes, however, complete wound healing is the gold standard outcome for assessing efficacy of a wound healing agent.

Pain Control

Adequate assessment and treatment of pain is a critical component in caring for patients with chronic wounds. Both venous leg ulcers and pressure ulcers may be associated with severe pain. Appropriate treatment of chronic pain with additional medication for breakthrough episodes (e.g., dressing changes or debridement during turning or transferring) is indicated. Systemic analgesics including acetaminophen, nonsteroidal anti-inflammatories, and opiates may be necessary.

REFERENCES

1. Stromber K et al: Regulatory concerns in the development of topical recombinant ophthalmic and cutaneous wound healing biologics. *Wound Repair Regen* **2**:155, 1994

2. Rowling JT: Pathological changes in mummies. *Proc R Soc Med* **54**:409, 1961

3. Scholz A: Historical aspects, in *Leg Ulcers: Diagnosis and Treatment,* edited by W Westerhof. Elsevier, Elsevier Science Publishers, 1993

4. Thomas DR: Issues and dilemmas in the prevention and treatment of pressure ulcers: A review. *J Gerontol* **56A**:M328, 2001

5. Bergstrom N et al: *Treatment of Pressure Ulcers. Clinical Practice Guideline, No. 15.* Rockville, MD, US Department of Health and Human Services, 1994

6. Cuddigan J et al: *Pressure Ulcer in America: Prevalence, Incidence, and Implications for the Future*. Reston, VA, National Pressure Ulcer Advisory Panel, 2001

7. Berquist S et al: Pressure ulcers in community-based older adults receiving home health care. Prevalence, incidence, and associated risk factors. *Adv Wound Care* **12**:339, 1999

8. Garber SL et al: Pressure ulcer risk in spinal chord injury: Predictors of ulcer status over three years. *Arch Phys Med Rehab* **81**:465, 2000

9. Margolis et al: The incidence and prevalence of pressure ulcers among elderly patients in general medical practice. *Ann Epidemiol* **12**:321, 2002

10. Lee TA et al: Prevalence of lower limb ulceration in an urban health district. *Br J Surg* **79**:1032, 1992

11. Valencia IC et al: Chronic venous insufficiency and venous leg ulceration. *J Am Acad Dermatol* **44**:401, 2001

12. Dale JJ et al: Chronic ulcers of the leg: A prevalence study in a Scottish Community. *Health Bull* **41**:310, 1983

13. Callam MJ et al: Chronic ulceration of the leg: Extent of the problem and provision of care. *Br Med J* **290**:1855, 1985

14. Cornwall JV et al: Leg ulcers: Epidemiology and aetiology. *Br J Surg* **73**:893, 1986

15. Nelzén O et al: Long-term prognosis for patients with chronic leg ulcers: A prospective cohort study. *Eur J Vasc Endovasc Surg* **13**:500, 1997

16. Heit JA et al: Trends in the incidence of venous stasis syndrome and venous ulcer: A 25-year population-based study. *J Vasc Surg* **33**:1022, 2001

17. Maklebust J et al: Pressure ulcers: Guidelines for prevention and nursing management. Springhouse, PA, Springhouse, 1996

18. Bennett L et al: Shear vs. pressure as causative factors in skin blood flow occlusion. *Arch Phys Med Rehabil* **60**:309, 1979

19. Dinsdale SM: Decubitus ulcers: Role of pressure and friction in causation. *Arch Phys Med Rehabil* **55**:147, 1974

20. Baker SR et al: Aetiology of chronic leg ulcers. *Eur J Vasc Surg* **6**:245,1992

21. Alguire PC et al: Chronic venous insufficiency and venous ulceration. *J Gen Intern Med* **12**:374, 1997

22. Falanga V et al: The trap hypothesis of venous ulceration. *Nature* **341**:1006, 1993

23. Gaber Y et al: Resistance to activated protein C due to factor V Leiden mutation: High prevalence in patients with post-thrombotic leg ulcers. *Br J Dermatol* **144**:546, 2001

24. Hafner J et al: Factor V Leiden mutation in postthrombotic and non-postthrombotic venous ulcer. *Arch Dermatol* **137**:599, 2001

25. Berlowitz DR et al: Are we improving the quality of nursing home care: The case of pressure ulcers. *J Am Geriatr Soc* **48**:59, 2000

26. Hopkins B et al: Reducing nosocomial pressure ulcers in an acute care facility. *J Nurs Care Qual* **14**:28, 2000

27. Norton D et al: *An Investigation of Geriatric Nursing Problems in Hospitals*. Edinburgh, Churchill-Livingstone, 1975

28. Waterlow J: Pressure scores: A risk assessment card. *Nurse Times* **8**:49, 1985

29. Bergstrom N et al: The Braden scale for predicting pressure sore risk. *Nurse Res* **36**:205, 1987

30. Franks PJ et al: Factors associated with healing leg ulceration with high compression. *Age Aging* **24**:407, 1995

31. Margolis DJ. The treatment of lower extremity venous ulceration. *Hosp Pract* **27**:32, 1992

32. Nelson EA et al: Compression for preventing recurrence of venous ulcers. *Cochrane Database Syst Rev* **4**:CD002303, 2000

33. Barwell JR et al: Surgical correction of isolated superficial venous reflux reduces long-term recurrence rate in chronic venous leg ulcers. *Eur J Vasc Endovasc Surg* **4**:363, 2000

34. London NJM et al: ABC of arterial and venous disease. Ulcerated lower limb. *BMJ* **320**:1589, 2000

35. Feied C. Venous insufficiency, in *Emedicine Dermatology Online Textbook,* edited by James, WD and Elston, DM. Available at http://www.emedicine.com/

36. Witkowski JA et al: Histopathology of the decubitus ulcer. *J Am Acad Dermatol* **6**:1014, 1982

37. Petersen NC et al: The epidemiology of pressure ulcers. *Scand J Plast Reconstr Surg* **5**:62, 1971

38. Bryan CS et al: Bacteremia associated with decubitus ulcers. *Arch Intern Med* **143**:2093, 1983

39. Sugarman B et al: Osteomyelitis beneath pressure sores. *Arch Intern Med* **143**:683, 1983.

40. Bergstrom N et al: A prospective study of pressure sore risk among institutionalized elderly. *J Am Geriatr Soc* **40**:747, 1992

41. Thomas DR et al: Pressure ulcers and risk of death. *J Am Geriatr Soc.* **44**:1435, 1996

42. Pinchcofsky-Devin GD et al: Correlation of pressure sores and nutritional status. *J Am Geriatr Soc* **34**:435, 1986

43. Greer et al: Nutrition Screening Manual for Professionals Caring for Older Americans: Nutrition Screening Initiative. Washington, DC, The Nutrition Screening Initiative, 1991

44. Ter Riet G et al: Randomized controlled trial of ascorbic acid in the treatment of pressure ulcers. *J Clin Epidemiol* **48**:1453, 1995

45. Thomas DR. The role of nutrition in prevention and healing of pressure ulcers. *Clin Geriatr Med* **13**:497, 1997

46. Breslow RA et al: The importance of dietary protein in healing pressure ulcers. *J Am Geriatr Soc* **41**:357, 1993

47. Crewe RA. Problems of rubber ring nursing cushions and a clinical survey of alternative cushions for ill patients. *Care Sci Pract* **5**:9, 1987

48. Ferrell BA et al: A randomized trial of low air loss beds for treatment of pressure ulcers. *JAMA* **269**:494, 1993

49. Stevenson TR et al: Cleansing the traumatic wound by high pressure syringe irrigation. *JACEP* **5**:17, 1976

50. Johnson AR et al: Comparison of common topical agents for wound treatment: Cytotoxicity for human fibroblasts in culture. *Wounds* **1**:186, 1989

51. Gorse GJ et al: Improved pressure sore healing with hydrocolloid dressings. *Arch Dermatol* **123**:766, 1987

52. Krizek T et al: Biology of surgical infection. *Surg Clin North Am* **55**:1261, 1975

53. Garner JS et al: CDC guidelines for the prevention and control of nosocomial infections. *Am J Infect Control* **16**:177, 1988

54. Marston WA et al: Healing rates and cost efficacy of outpatient compression treatment for leg ulcers associated with venous insufficiency. *J Vasc Surg* **30**:491, 1999

55. Margolis DJ et al: Risk factors associated with the failure of a venous leg ulcer to heal. *Arch Dermatol* **135**:920, 1999

56. Franks PJ et al: Factors associated with healing leg ulceration with high compression. *Age Aging* **24**:407, 1995

57. Wilkinson SM. Hypersensitivity to topical corticosteroids. *Clin Exp Dermatol* **19**:1, 1994

58. Abu-Own A et al: Effect of leg elevation on the skin microcirculation in chronic venous insufficiency. *J Vasc Surg* **20**:705, 1994

59. Margolis DJ. Management of chronic venous ulcers: a literature guided approach. *Clin Dermatol* **12**:19, 1994

60. Fletcher A et al: A systematic review of compression treatment for venous leg ulcers. *BMJ* **315**:576, 1997

61. Kolari PJ et al: Effects of intermittent compression treatment on skin perfusion and oxygenation in lower legs with venous ulcers. *Vasa* **16**:312, 1987

62. Christopoulos D et al: Venous reflux: Quantification and correlation with the clinical severity of chronic venous disease. *Br J Surg* **75**:352, 1988

63. Van de Scheur M et al: Pericapillary fibrin cuffs in venous disease. *J Dermatol Surg Oncol* **23**:955, 1997

64. Agren MS. Studies on zinc in wound healing. *Acta Derm Venereol Suppl (Stockh)* **154**:1, 1990

65. Partsch H. Compression therapy of the legs: A review. *J Dermatol Surg Oncol* **17**:575, 1991

66. Simon DA et al: Approaches to venous leg ulcer within the community: Compression, pinch skin grafts, and simple venous surgery. *Ostomy Wound Manag* **42**:34, 1996

67. Phillips TJ et al: Successful methods of treating leg ulcers: The tried and the true, plus the novel and new. *Postgrad Med* **105**:159, 1999

68. Freak L et al: Comparative study of three primary dressings in the healing of chronic venous ulcers. *Br J Surg* **79**:1235, 1992

69. Jull AB et al: Oral pentoxifylline for the treatment of venous leg ulcers. *Cochrane Database Syst Rev.* **2**:CD00173, 2000

70. Falanga F et al: Systemic treatment of venous leg ulcer with high doses of pentoxifylline: Efficacy in a randomized, placebo-controlled trial. *Wound Repair Regen* **7**:208, 1999

71. Kirsner RS et al: Split-thickness skin grafting of leg ulcers. *J Dermatol Surg* **21**:701, 1995

72. Barwell et al: Surgical correction of isolated superficial venous reflux reduces long-term recurrence rate in chronic venous ulcer. *Eur J Vasc Endovasc Surg* **4**:363, 2000

73. Falanga V et al: Rapid healing of venous leg ulcers and lack of clinical rejection with an allogeneic cultured human skin equivalent. *Arch Dermatol* **134**:293, 1998

74. Cullum N et al: Systematic reviews of wound care management: (5) beds; (6) compression; (7) laser therapy, therapeutic ultrasound, electrotherapy and electromagnetic therapy. *Health Technol Assesss (Rockv)* **5**:1, 2001

75. Payne WG et al: Long-term outcome study of growth factor-treated pressure ulcers. *Am J Surg* **181**:81, 2001

76. Rhodes RS et al: Topical phenytoin treatment of stage II decubitus ulcers in the elderly. *Ann Pharmacother* **35**:675, 2001

T>

Chapter 133

Irene Kochevar Charles Taylor

Photophysics, Photochemistry, and Photobiology

ELECTROMAGNETIC RADIATION
EM Radiation Considered as Waves
EM Radiation Considered as a Particle
FROM EM RADIATION TO DERMATOLOGY
Absorption of EM Radiation
Excited States of Molecules
Formation of Photoproducts
From Photoproducts to Skin Responses
Action Spectrum
OPTICAL PROPERTIES OF SKIN
SOURCES OF EM RADIATION
Solar Radiation
Artificial Sources of Radiation
ULTRAVIOLET RADIATION DOSIMETRY
REFERENCES

Why should a clinical dermatologist be interested in reading a chapter on photophysics, photochemistry, and photobiology? Simply put, knowledge of the interaction of sunlight with the skin is fundamental to understanding the pathogenesis, diagnosis, and treatment of more than 100 cutaneous disorders. The material in this chapter provides the foundation for all photodermatology: phototesting, photopatch testing, photosensitivity, the porphyrias, photodermatoses, phototherapy, photochemotherapy, photodynamic therapy, photopheresis, photoprotection, laser surgery and photocarcinogenesis. Whenever ultraviolet (UV) radiation is used to treat a skin condition, important principles of photophysics involving absorption and emission of light underlie the success of the therapy. When a patient suffers from increased sun sensitivity, critical photochemistry has occurred. Sunscreen recommendations rely on an understanding of solar UV radiation and the ways in which the causative wavelengths can be minimized. Skin cancer is an epidemic clinical problem, and its pathophysiology necessitates comprehension of the photophysical, photochemical, and photobiological events described in this chapter.

Almost every ancient civilization worshipped a god of the sun whose healing powers were believed to be broad reaching. Even today, sun exposure is widely felt to induce a sense of well being. In addition, sunlight is important for the synthesis of vitamin D_3 and the setting of internal clocks. On the negative side, sunlight causes deleterious acute and chronic effects such as sunburn, skin cancer, and photoaging, and can elicit adverse reactions to certain drugs (Fig. 133-1). Abnormal responses to sunlight occur in polymorphic light eruption, solar urticaria, certain porphyrias, and many other conditions (Chap. 135, Chap. 136, Chap. 149). While the sun is a major source of UV and visible radiation that interacts with human skin, UV and/or visible radiation are also emitted from common sources such as fluorescent lights, incandescent bulbs, photocopy machines, and phototherapy lamps. Tanning salons are another familiar example. Dentists use UV for hardening of acrylates, as do nail salon estheticians. Thus, UV and visible radiation are a constant part of the human environment and play a role in health, disease, and therapy. Photomedicine is the study of this interaction between human tissue and UV or visible radiation, usually from the sun, but from artificial sources as well. To understand the responses of skin to UV and visible radiation, it is essential to be acquainted with the properties of electromagnetic (EM) radiation and with the principles governing the interaction of EM radiation with biomolecules.



FIGURE 133-1 Deleterious effects of UV and visible radiation in human skin and eye. DT, delayed tanning; IPD, immediate pigment darkening; LC, Langerhans cells.

ELECTROMAGNETIC RADIATION

Electromagnetic radiation is a form of energy. UV and visible radiation are part of the continuous EM spectrum. The wavelengths of EM radiation vary from fractions of nanometers to thousands of meters along a continuous spectrum. Specific wavelengths are classified into wave-bands and given the names shown in Table 133-1 and Fig. 133-2.

Waveband	Wavelength Range (nm)
X-ray	0.1–10
Vacuum UV	10–200
Ultraviolet C (UVC)	200–290
Ultraviolet B (UVB)	290–320
Ultraviolet A (UVA)	320–400
UVAI	340–400
UVAII	320–340
Visible	400–760
Violet	400
Blue	470
Green	530
Yellow	600
Red	700
Near infrared	760–1000
Far infrared	1000–100,000
Microwaves and radiowaves	> 10^5

TABLE 133-1 **Electromagnetic Radiation According to Wavelength**

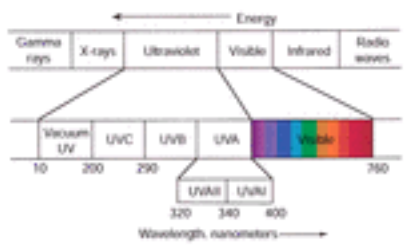

FIGURE 133-2 Electromagnetic spectrum divided into major wavelength regions. The lower band emphasizes the UV and visible bands that are important for photobiological responses in human skin.

Short wavelengths and high energy are properties of x-rays and gamma rays. Such wavelengths are useful for destroying tumors because they generally ionize molecules (remove electrons) indiscriminately. Consequently, they are known as ionizing radiations, the subject of radiobiology (Chap. 128). Longer wavelengths and lower energy are associated with infrared radiation. Infrared wavelengths may be felt as heat, and they can trigger a variety of disorders such as cholinergic urticaria.

The UV and visible radiation region lies between the x-ray/gamma ray portion and infrared radiation. This part of the EM spectrum is of special interest because dozens of skin disorders are aggravated by wavelengths in these regions. Moreover, many popular therapies, such as UVB phototherapy, photochemotherapy (PUVA), blue-light aminolevulinic acid (ALA)-photodynamic therapy, and several routine lasers (e.g., pulsed dye laser, Q-switched ruby) all function using wavelengths in this region.

For medical photobiology, the UV range is broken into certain convenient subdivisions (Table 133-1; Fig. 133-2). A division was made at 290 nm because wavelengths from the sun shorter than 290 nm do not reach the earth's surface at sea level. The energy is absorbed by the ozone layer in the stratosphere. Such wavelengths in the range of 200 to 290 nm are referred to as UVC. When produced by artificial sources, these wavelengths are absorbed by DNA, RNA, and proteins of cells, as well as by the stratum corneum, and they can be lethal to viable cells of the epidermis. Because germicidal lamps emit 254-nm radiation within this waveband, the UVC region of the spectrum is often called *germicidal radiation*.

Another division is made at 320 nm, the upper limit of the most erythemogenic wavelengths reaching the earth's surface. Also, ordinary window glass filters out wavelengths shorter than about 320 nm. The range 290 to 320 nm is known as UVB and is often referred to as *mid-UV* or *sunburn spectrum*. Most sunscreens work very efficiently at minimizing the effects of this waveband. In fact, the sun protection factor (SPF) is actually based on testing against this waveband. Properly used, a sunscreen with a SPF rating of 15 effectively means that 15 times more incident UVB is needed to give the same degree of erythema.

Long-wave UV or UVA (320 to 400 nm) is sometimes referred to as *black light* because it is not visible to the human eye and causes certain substances to emit visible fluorescence. Recently, UVA has been divided into UVA-I (340 to 400 nm) and UVA-II (320 to 340 nm) because the latter band is more damaging to unsensitized skin than the longer wavelengths. It is important to remember that there may be great variation in the biologic effects of different wavelengths within these subdivisions. For example, 297-nm radiation is nearly 100 times more erythemogenic than 313-nm radiation, although both are in the UVB region.

Certain principles are better illustrated by conceptualizing EM radiation as a *wave,* whereas others are better understood by thinking of it as packets of energy called *photons*. These two descriptions are entirely complementary. The concepts of " *light as waves*" and " *light as photons*" are discussed below.

EM Radiation Considered as Waves

Waves consist of periodic motion or oscillations that travel through a medium or space. When the motion is perpendicular to the direction of propagation, such as waves traveling down a length of rope, the waves are called *transverse waves*. EM radiation travels as a transverse wave. EM radiation consists of oscillating electric and magnetic fields at right angles to each other and to the direction of propagation.

EM radiation may be described either by its frequency (number of oscillations per second) or by its wavelength (distance traveled per oscillation). Since all EM radiation propagates at the same velocity through space, frequency and wavelength have an inverse relationship, which is expressed as:

$$\nu = \frac{c}{\lambda}$$

where ? = frequency of oscillations per second, c = velocity of radiation (the speed of light, 3×10^{8} m/s), and ? = wavelength in meters. When light is considered as a wave, specific colors of UV and visible radiation are associated with specific wavelengths of the EM spectrum. For example, red wavelengths occur around 700 nm, while blue ones occur around 470 nm (Table 133-1).

EM Radiation Considered as a Particle

In addition to its wave character, EM radiation may be described as a stream of discrete packets of energy known as *quanta* or *photons*. Photons have no mass; when the energy of a photon is absorbed by a molecule the photon ceases to exist. The amount of energy in a photon (quantum) is directly proportional to the frequency of the radiation and inversely proportional to the wavelength of radiation, as expressed by Planck's theory:

$$E = h\nu = \frac{hc}{\lambda}$$

where *E* = the energy of the photon in joules (J), h = Planck's constant (6.626×10^{-34} J × s), ? = frequency of oscillations per second, c = velocity of radiation (3×10^{8} m/s), and ? = wavelength in meters.

This relationship shows that the energy (*E*) of the photon increases when the wavelength is shorter and decreases when the wavelength is longer. Consequently, radiation of shorter wavelength has greater energy per photon. For example, a 300-nm photon has twice the energy of a 600-nm photon. Because of their lower energies, wavelengths longer than about 800 nm usually do not cause photochemical reactions. Primarily UV radiation is implicated in many normal and abnormal reactions in human skin. Skin responses to visible light usually require a higher than normal concentration of an endogenous chromophore (e.g., protoporphyrin) or the presence of an exogenous dye or drug to absorb the light.

FROM EM RADIATION TO DERMATOLOGY

Skin is affected by UV and visible radiation that is absorbed by molecules in skin. The pathway from light absorption to biological response can be broken into several steps (Fig. 133-3). In the first step, molecules in skin such as pyrimidine nucleotides, DNA (e.g., thymidine, cytosine), and urocanic acid absorb radiation. A light-absorbing molecule is referred to as a *chromophore*. In some cases, the chromophore is an exogenous agent such as an ingested photosensitizing drug, for example, tetracycline or 8-methoxypsoralen. After absorbing the energy of the radiation, the chromophore is in an *excited state*. Although this highly energetic species exists for only a fraction of a second, a chemical change may occur during this time to transform the molecule into a *photoproduct* such as an oxidized membrane lipid, [1], [2] pyrimidine dimer, [3] or psoralen-DNA adduct. [4] The presence of photoproducts in cells provokes biochemical responses, beginning with signal transduction processes that often involve adding and removing phosphate groups from proteins such as the growth factor receptors in the plasma membrane. [5], [6] These changes may activate transcription factors such as AP-1 [7], [8] and NF-kB [9], [10] and thereby initiate cellular synthesis of new proteins, for example, melanin, [11], [12] cytokines, [13], [14] and [15] cyclooxygenase, [16], [17] and matrix metalloproteinase-1. [18], [19] Other important processes, such as repair of UV-induced DNA damage, also occur in response to photoproducts. [20], [21] These biochemical responses culminate in cellular effects, such as proliferation, secretion of cytokines, and apoptosis that are observed as acute skin responses. For example, in the case of the patient who has taken tetracycline and overdone sun exposure, one might see exaggerated sunburn as a classic example of a phototoxic reaction. A similar series of steps is also responsible for responses to chronic exposure to UV radiation such as actinic keratoses and wrinkles (photoaging).

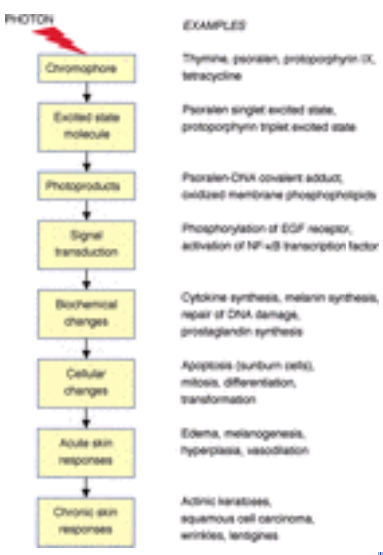

FIGURE 133-3 Generalized steps in the response of skin to UV or visible radiation.

Absorption of EM Radiation

Skin is composed mainly of water, organic molecules (proteins, lipids, nucleic acids), and inorganic ions such as sodium and chloride. The organic molecules may absorb in the UVA, UVB, and visible spectral regions. The specific wavelengths of UV or visible radiation absorbed by these molecules (called their absorption spectra) are determined by the electronic structure of the molecules. It is important to understand that only absorbed radiation can initiate biologic responses. In fact, the first law of photochemistry set forth by Grotthus and Draper, in 1818, is precisely the principle that only absorbed

light can cause a photochemical change.

The absorption spectrum of a compound is a plot of the probability of absorption (*y*-axis) against wavelength (*x*-axis). The wavelengths that have the highest probability of absorption are called absorption maxima, $?_{max}$, and are often used as identifying characteristics of a compound (e.g., DNA, $?_{max}$ = 260 nm; porphyrin, $?_{max}$ = 400 to 420 nm). Absorption maxima are important in the design of various therapies. Consider the recently introduced ALA-photodynamic therapy for the treatment of actinic keratoses. [22] Topically applied ALA is metabolized to protoporphyrin IX. Because the $?_{max}$ of the porphyrins lies in the range of 400 to 420 nm, a blue light source is chosen for the irradiation. [22]

Compounds that have absorption maxima in the UV spectrum include aromatic amino acids in proteins (280 to 300 nm), the purine and pyrimidine bases in DNA and RNA (~260 nm), urocanic acid (280 nm), NADH (340 nm), and 7-dehydrocholesterol (7-DHC) (~285 nm). Most photosensitizing drugs absorb some radiation in the UVA range although their absorption maxima are at shorter wavelengths. For example, the absorption maxima for psoralens are in the UVB, but for PUVA they are activated by UVA. Some photosensitizing drugs, such as sulfa antibiotics and the thiazide diuretics, also absorb in the UVB spectrum because of structural differences that allow for photon absorption in that range. Many endogenous cutaneous biomolecules absorb longer wavelengths of light (visible) because their structures include double bonds, heteroatoms (oxygen, nitrogen, sulfur) and charged groups. Examples include hemoglobin (410 nm), bilirubin (~450 nm), and beta-carotene (460 nm). Melanin absorbs throughout the UV and visible spectrum without a distinct absorption maximum wavelength.

Excited States of Molecules

For each molecule, a series of *electronic states* exists, each of which corresponds to a certain distribution of electrons in space around the nuclei. A specified energy is also associated with each electronic state. According to quantum mechanics, only certain energies are allowed; thus fixed energy gaps exist between electronic states. At room temperature almost all molecules are in the electronic state with the lowest energy, the so-called *ground state*. Molecules in states with higher energy are in *excited electronic states*. Energy absorbed by a molecule in the ground state promotes it to an excited electronic state.

The nuclei in molecules are in relatively fixed positions and are surrounded by negatively charged electrons in defined volumes known as orbitals. Each orbital holds a maximum of two electrons. In addition to their electronic charge, electrons have property called *spin*, an angular momentum that makes electrons act like tiny bar magnets. According to the Pauli exclusion principle, electrons in the same orbital must have opposite spins. Most ground-state molecules have two electrons in each orbital, and their spins are in opposite directions; these are called *singlet states*. Absorption of a photon does not change the electron spins. Some excited states have two electrons in different orbitals with the same spin and these are called *triplet states*. The chemical reactions that an excited-state molecule undergoes are modulated by the spin state (singlet or triplet) of the molecule. An excited-state molecule can discharge its energy by chemical reaction to form photoproducts, by emission of light, by decay to heat (internal conversion), by transfer of the energy to another molecule, and by changing from singlet to triplet or from triplet to ground state (intersystem crossing). Formation of photoproducts by reactions of the chromophore are of greatest interest to dermatologists and photobiologists since photoproducts initiate photobiologic responses. Excited singlet states usually exist for less than 100 ns (10^{-7} s) and triplets less than 10 μs (10^{-5} s) in tissue.

Emission of light is called *fluorescence* when it originates from a singlet excited state of a molecule and *phosphorescence* when it is from a triplet excited state of the molecule. A common example of fluorescence occurs every time a Wood's light is used. UVA emitted from this lamp causes autofluorescence of dermal collagen fibers. To the examining physician, this fluorescence is viewed through the overlying epidermis. Thus, any epidermal lesions such as lentigines tend to have their borders accentuated by contrast because the fluorescence is observed most brightly around the lesion.

The internal conversion pathway for loss of electronic excitation energy proceeds by conversion of the electronic energy into vibrational energy within the molecule. This energy is quickly transferred to neighboring molecules, especially water, in the tissue; if enough is transferred, heating may be detectable. The thermal destruction of tissue by visible laser irradiation is possible because many photons are absorbed in a small volume of tissue and the excited-state molecules decay by heat-producing internal conversion.

Formation of Photoproducts

During a photochemical reaction, the chromophore is transformed into a new molecule, the photoproduct. Often, the photoproduct is the result of bonding between the chromophore and a cell molecule. An important example is the formation of covalent adducts between psoralen, the chromophore, and DNA (Chap. 266). In other cases, the chromophore is not chemically changed; instead, it causes a chemical change in another molecule. The chromophore is then called a *photosensitizer* and the reaction is called a *photosensitized reaction*. Protoporphyrin IX, the porphyrin that accumulates to abnormally high levels in red blood cells of patients with erythropoietic protoporphyria (EPP, Chap. 149) is a photosensitizer that absorbs blue light (400 to 420 nm). The initially formed excited singlet state converts to an excited triplet state which then transfers that energy to oxygen molecules to form a highly reactive excited state of oxygen called singlet oxygen. [23] Singlet oxygen subsequently reacts with lipids, proteins, and DNA to form stable photoproducts. The term *photosensitizer* is often used also when the chromophore bonds to a cellular molecule. For example, psoralens are called photosensitizers because they alter DNA by binding to it.

The efficiency for photochemical reactions vary. Not all of the chromophore molecules that absorb a photon undergo a photochemical reaction because, as noted above, several pathways are available to molecules in excited states. In addition to forming photoproducts, the excited state molecule may emit fluorescence and phosphorescence, transfer energy to oxygen, and return to the ground state. The term *quantum yield* is used to define the likelihood that one of

these processes occurs. For example, the quantum yield for forming a certain photoproduct is:

$$\text{Quantum yield} = \frac{\text{Number of photoproduct molecules formed}}{\text{Number of photons absorbed}}$$

From Photoproducts to Skin Responses

Progress is being made in establishing how the photoproducts formed in skin lead to specific responses (see Fig. 133-3). Often the response involves multiple photoproducts and multiple responses may result from a single type of photoproduct. An example of beneficial photoproduct formation is production of previtamin D_3 in skin. 7-Dehydrocholesterol absorbs a photon of UVB radiation and is converted by a bond rearrangement into previtamin D_3. The previtamin D_3 thermally isomerizes to vitamin D_3 which binds to vitamin D-binding protein in the capillaries and is carried from the skin to the liver and then to the kidney. In skin, vitamin D_3 enhances keratinocyte differentiation and inhibits proliferation, which are believed to underlie the effectiveness of vitamin D_3 analogues in psoriasis therapy. [24], [25] The signal transduction and biochemical steps for these responses have been studied extensively for development of related therapeutic agents. [26]

Absorption of blue light by the high concentrations of protoporphyrin IX in the skin of patients with EPP results in the formation of singlet oxygen, a highly reactive oxidizing species, by energy transfer from excited state protoporphyrin molecules. The photoproducts are oxidized lipids and proteins, especially in the cell membranes where the majority of protoporphyrin molecules localize in cells. How these photoproducts lead to the erythema, wheals, and pain that EPP patients experience in sunlight is still being investigated. One possibility is that the membranes of mast cells are altered when the lipid and protein components in the membranes are oxidized by singlet oxygen. Release of histamine and synthesis of prostaglandin D_2 (PDG_2) by these stimulated mast cells would lead to the vasodilation and increased vasopermeability responsible for the erythema and wheal formation.

The photoproducts initiating a skin response may also be derived from exogenously administered (systemically or topically) photosensitizers (Chap. 135, Chap. 136). These responses are referred to as phototoxicity and photoallergy and the agent usually is a drug or plant material. Many phototoxic drugs and phytochemicals absorb in the UVA range and form singlet oxygen in the same manner as described above for protoporphyrin IX. This reactive form of oxygen then oxidizes nearby molecules in the cell. The differences in light-induced skin responses between those caused by phototoxic agents and that produced by protoporphyrin IX may be due to different tissue locations of the photosensitizer (e.g., epidermis, dermis, or vasculature). These photosensitizers may also be in different locations in the cells (i.e., nucleus, mitochondria, or cell membranes) which would influence the photoproducts formed. In some individuals, sunscreens (e.g., oxybenzone), may not induce an allergic rash until sun exposure occurs. The photoproducts that are possibly produced after oxybenzone absorbs UV radiation may be the cause. [27] Phototherapy of diseases such as psoriasis makes use of the phototoxicity of compounds such as 8-methoxypsoralen and its covalent photoaddition reaction with DNA (Chap. 266). In this case, light-induced cellular changes in DNA are apparently beneficial to the total organism.

Action Spectrum

The *action spectrum* for a photobiologic response indicates which wavelengths produce the response most effectively. Knowing the action spectrum of a patient's photosensitivity is helpful in determining the treatment plan. On the other hand, phototherapy will be most efficient when the emission of the lamp most closely matches the action spectrum for the beneficial response.

In an ideal case, the action spectrum corresponds to the absorption spectrum for the chromophore. Determination of an action spectrum is, therefore, a powerful tool for identification of the putative chromophore for a given photobiologic reaction. Peaks in the action spectrum correspond to the most effective wavelengths. An action spectrum is most accurately plotted as the reciprocal of the number of incident photons required to produce a given effect (*y*-axis) against wavelength (*x*-axis). Conventionally in dermatology, the reciprocal of the minimum fluence (dose) is plotted versus wavelength. Such a graph is shown in Fig. 133-4 for wheal formation in a patient with erythropoietic protoporphyria. [28] The maximum of the action spectrum at 400 nm is close to the maximum in the absorption spectrum for protoporphyrin supporting biochemical evidence for protoporphyrin as the chromophore for the photosensitivity.

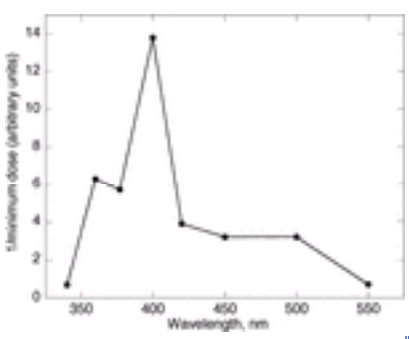

FIGURE 133-4 Action spectrum for wheal formation in erythropoietic protoporphyria patient. The *y*-axis is the reciprocal of the minimal dose required to produce a wheal. This dose of radiation (exposure time × irradiance) is expressed in arbitrary units. A monochromator with a quartz-xenon lamp was used to deliver selected narrow wavebands. (*From Magnus IA et al.,* [28] *with permission.*)

Lack of correspondence between an experimentally determined action spectrum and the absorption spectrum of the

actual chromophore may occur due to tissue optics. Light that impinges on a tissue is usually absorbed by other chromophores in the tissue; it is also reflected and scattered (Fig. 133-5). These effects decrease the amount of light transmitted to a specific depth in tissue and vary with wavelength. One familiar example is that of psoralen, which has absorption maxima around 295 and 330 nm with slight absorption extending into the longer UVA waveband in vitro (Chap. 266). However, determinations of the psoralen photosensitization action spectrum in vivo show that maximum responses occur with wavelengths >320 nm, possibly due to skin optical properties. [29], [30] Whenever possible, decisions about which wavelengths to use for a treatment should be based on action spectra rather than on the in vitro absorption spectrum of the photochemotherapeutic drug.

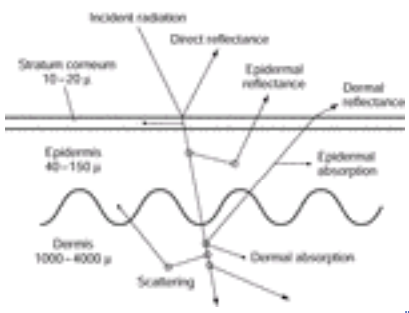

FIGURE 133-5 The interaction of UV and visible radiation with skin. The incident radiation is reflected from the surface, scattered (*circles*), and absorbed (*black dots*) as it travels through the skin.

OPTICAL PROPERTIES OF SKIN

When radiation strikes the skin, part is remitted (reflected and scattered), part is absorbed in various layers, and part is transmitted inward to successive layers of cells, until the energy of the incident beam has been dissipated [31], [32] (see Fig. 133-5). A very small fraction of the absorbed radiation is reemitted at longer wavelengths as fluorescence. The amounts of absorption and scattering of UV and visible radiation vary with wavelength.

UV wavelengths less than 320 nm are mostly absorbed by proteins and other components of epidermal cells, which, along with scattering, accounts for the low penetration of these wavelengths into skin (Fig. 133-6). For example, approximately 90 percent of 300 nm radiation is dissipated by about 14 nm into the epidermis, and only 10 percent of 350 nm radiation reaches the dermal–epidermal junction (˜140 nm). Between 5 and 10 percent of incident light is reflected by the outer surface of the stratum corneum. This surface or so-called specular reflectance is relatively constant for all visible wavelengths and accounts for the surface appearance of skin, which is especially glossy if the surface is smooth, wet, or oily. It is by this surface component of the total skin reflectance that we have learned to judge roughness of the skin. Moisturizers applied to the skin reduce this rough appearance by smoothing out the many air-surface interface irregularities, thus reducing specular reflectance and making the skin look shinier.

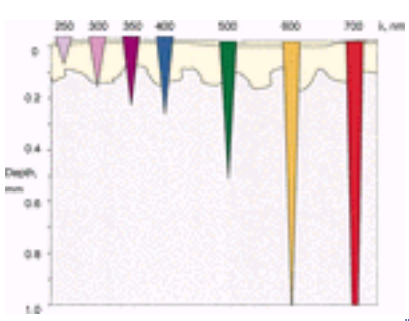

FIGURE 133-6 Representation of the variation in penetration of UV and visible radiation into skin.

In addition to the surface reflectance, white skin remits about 50 percent of the incident visible light by backward scattering from within the dermis. *Scattering* includes any process that deflects the path of optical radiation. For example, skin with scales, as in psoriasis, scatters more light than does normal skin. During phototherapy, application of emollients to the psoriatic plaques helps reduce the scattering of UVR and allows more of the effective wavelengths to penetrate into the viable tissue. In fair white skin, the bulk of the visible remittance is light that has penetrated the epidermis and has been scattered from various depths within the dermis back through the epidermis and skin surface.

Melanin, which absorbs relatively uniformly over the visible wavelengths and is normally present only in the epidermis, acts largely as a density (gray) filter to diminish dermal remittance. Melanosomes in darker-skinned individuals are larger and singly dispersed as compared to those of fairer-skinned individuals. By being larger, they absorb more. By being singly dispersed, they also create a darker color for the skin. Consider, for example, how the octopus changes color by shifting all its pigment. When widely dispersed, the octopus looks dark; when the pigment is gathered together in tight clusters it looks lighter.

Blood within the dermis absorbs the shorter (blue) visible wavelengths, diminishing these spectral regions of the dermal remittance component, and giving a reddish hue to our perception of the total remittance. Abnormal location and quantity of these or other pigments account for the appearance of the skin in pathologic conditions (e.g., melasma with extra pigment in the epidermis and/or dermis; vitiligo with an absence of epidermal melanin).

SOURCES OF EM RADIATION

Solar Radiation

The shortest wavelength of the solar spectrum reaching the earth's surface at sea level is approximately 290 nm; at higher altitudes, shorter wavelengths (up to 285) nm have been detected. [33] Although the sun emits shorter UV wavelengths, they are filtered out by the ozone layer and molecular oxygen of the stratosphere. Depending on the geographic location and the season, it has been estimated that sunlight produces between 2 and 6 mW/cm^2 of UV radiation between 290 and 400 nm. Filtering of wavelengths less than 290 nm by ozone is a very important process because the shorter UV wavelengths are highly damaging to animals and plants. Ozone is present in the stratosphere and is constantly being generated and degraded. Halocarbons from industrial and domestic uses rise to the stratosphere where photochemical reactions cause them to release the chlorine and bromine atoms that catalyze ozone destruction. Because the transmission of solar UVB through the atmosphere varies exponentially with ozone concentration, small changes in the ozone layer may result in hazardous increases in UV irradiance at the earth's surface. Calculations of the effects of ozone depletion on skin cancer incidence predict a doubling by 2100 even if the Montreal Protocol restrictions on ozone-depleting substances are followed. [34] Similarly, a decrease in the ozone layer was predicted to lead to greater UVB suppression of cellular immunity based on experimental studies. [35]

The recently introduced UV Index represents an attempt to quantify the risks attendant with solar radiation at a given time and place. Among other factors, the effects of altitude and clouds are considered. The scale goes up to 15 and any UV Index >10 is considered a high-risk day for possible overexposure on that day and in that locale.

Artificial Sources of Radiation

INCANDESCENT SOURCES The electric light bulb is an incandescent source. An electric current passed through a metal filament increases the filament temperature to that of incandescence. Most of the radiation emitted is in the visible and infrared spectrum. Only the occasional patient with solar urticaria, chronic actinic dermatitis or some porphyrias is bothered by the output of ordinary incandescent sources. Wavelengths shorter than 360 nm are usually not emitted because the hot filaments are encased in glass envelopes which transmit only UVA and visible radiation. Tungsten-halogen incandescent lamps, often used as floodlamps, emit UVA and visible radiation. Some quartz iodide incandescent lamps may produce significant UVA and some UVB emission.

ARC SOURCES In arc lamps, electrons are driven at high velocity by a potential difference between two electrodes. Gaseous molecules between the electrodes are ionized and electronically excited and subsequently release radiant energy. The spectral power distribution depends on the gas used, the arc temperature, the pressure within the lamp, the electrical input to the lamp, and the lamp wall material. Most of the radiation is emitted at wavelengths corresponding to the transition energies, between orbitals particular to the gas in the lamp. In addition to these spectral emission lines, a continuum of wavelengths is emitted by high-temperature arc lamps.

Xenon arc Xenon gas under 20 to 40 atm of pressure is heated to a high temperature in a rigid quartz envelope to produce intense visible and UV radiation. At these pressures the xenon spectrum becomes a continuum; that is, all wavelengths are emitted rather than just specific wavelengths. Xenon arc lamps are now the most common sources used in solar simulators. Photoprovocation testing for polymorphic eruption is often done with such sources. Filters are used to limit the wavelengths for phototesting with solar simulators. Xenon arcs are also used in some phototherapy and photobiologic research applications.

Mercury arc At low pressure, mercury vapor lamps emit 85 percent of the radiant energy at 254 nm and 5 percent at 185 nm. When the material used for the lamp envelope is quartz, nearly all the 254-nm radiation is transmitted. UVC is lethal to microorganisms and these are, therefore, called *germicidal lamps*. Because the operating temperature is low, they are also known as *cold quartz lamps*. With increasing pressure (1 atm), the primary 254-nm emission is absorbed by other mercury atoms within the lamp and reemitted at longer wavelengths (297, 302, 313, 334, and 365 nm, and visible wavelengths). With further pressure increases (2 to 100 atm), these spectral lines broaden and decrease relative to the intensity of the continuous spectral background. In medical practice, medium- and high-pressure mercury lamps (*hot quartz*) are used mainly as sources of UVB, although their spectral power distribution is mainly in the UVA and visible range.

FLUORESCENT LAMPS A fluorescent lamp is a glass tube containing low-pressure mercury with electrodes at both ends. Electric current passing through the tube ionizes the mercury atoms, which subsequently emit at 254 nm (germicidal radiation). When the inner surface of the glass envelope is coated with phosphor, the 254-nm radiation is absorbed and then reemitted at longer wavelengths. The composition of the phosphor determines which wavelengths are reemitted. In general, fluorescent lamps have a relatively wide, bell-shaped emission spectra, with spectral emission lines of mercury superimposed, and are referred to as *broadband light sources*.

UVB lamps Fluorescent sunlamps (type FS) emit mainly in the UVB range (Fig. 133-7). They are often referred to as UVB lamps, even though they emit a portion of UVA radiation, because the therapeutically significant radiation is in the UVB range (Table 133-2). A fluorescent lamp with a major emission peak at 311 nm (Philips TL01) was developed for use in phototherapy (Fig. 133-7). [36], [37] and [38] This lamp is an efficient source for psoriasis phototherapy since, compared to a conventional UVB lamp, the energy emitted almost entirely overlaps with the action spectrum for clearance of psoriasis. [39] Ironically, this lamp has been successfully employed for the treatment of vitiligo, atopic dermatitis, and polymorphic light eruption, all of whose action spectra are unknown and may well vary from that for psoriasis.



FIGURE 133-7 Emission spectra of some of the fluorescent lamps used in phototherapy. *A*. The broadband type FS fluorescent lamps and black light lamps are often referred to as UVB and UVA lamps, respectively. *B*. The TL01 lamp (*full line*) has its main emission at 311 nm and the TL12 (*dotted line*) is a broadband UVB lamp. (*From reference El-Ghorr AA, Norval M,* [38] *with permission.*)



TABLE 133-2 ***Approximate*** **Spectral Power Distribution of UVB and UVA Radiation Expressed as Percentage of Total Emission in the UV Waveband in Common Phototherapy Sources**

UVA lamps High-intensity, UVA-emitting fluorescent lamps are most often used in PUVA therapy of psoriasis, vitiligo, and other skin diseases. The most efficient UVA source for PUVA therapy would maximize the emission of 320- to 360-nm radiation for photoactivation of psoralen molecules, while minimizing the UVB emission. Table 133-2 shows the percentage of total emission that is in the 320- to 360-nm range from several UVA-emitting light sources that are used in phototherapy units.

Wood's lamps Current versions of Wood's lamps are small, low-pressure, UVA-emitting fluorescent lamps with a UVA-transmitting, visible-absorbing glass envelope. Wood's lamps are invaluable in clinical practice because the fluorescent emission from normal and abnormal components of skin, hair, and urine may be diagnostic (e.g., in porphyria, vitiligo, and fungal infection).

HALIDE LAMPS The metal halide lamp usually consists of a high-pressure mercury lamp with metal halides as additives. The continuous range of wavelengths emitted from halide lamps makes them preferable to medium-pressure mercury arc lamps that emit in narrow wavelength ranges. Approximately 20 percent of the power consumption can be UVA radiation. Because of the high-intensity continuum emission in the UVB and especially the UVA range, this lamp, with appropriate filters, is used increasingly as a UVB, as well as a UVA, source for phototherapy and photochemotherapy.

LASERS Laser is an acronym for Light Amplification by Stimulated Emission of Radiation. Lasers produce intense beams of monochromatic optical radiation. The laser operates by exciting molecules to a metastable excited state from which photon emission is stimulated by a subsequent photon incident upon the excited molecule. The emitted photon and the stimulating photon are then each capable of stimulating emission of yet other excited molecules, eventually producing an avalanche of photons of the same wavelength, phase, and direction of propagation. Lasers emit UV, visible, or infrared wavelengths and may operate as either continuous or pulsed sources. Applications of lasers in dermatology utilize their capacity to concentrate large amounts of energy in a small volume of tissue (Chap. 267).

ULTRAVIOLET RADIATION DOSIMETRY

The basic unit of energy is the joule (J). Power is the rate of energy flow or dissipation, given in watts (W), or joules per second (W = J/s). The rate at which radiant energy is delivered to a surface such as skin is expressed as the power delivered per unit area of surface [W/cm ^{2} = (J/s) per cm ^{2}]. This quantity is called *irradiance*. The total radiant energy delivered per unit area of skin surface, the *exposure dose*, or fluence, is the product of irradiance and time: Irradiance (W/cm ^{2}) × time(s) = exposure dose (J/cm ^{2}) For most photobiologic phenomena, it is the exposure dose at a particular wavelength that determines the magnitude of the response. The rate of energy delivery generally does not affect the response (Bunsen-Roscoe law of reciprocity). A common office example demonstrating the law of reciprocity occurs with PUVA boxes. A PUVA box with half as many bulbs in it would take twice as long to deliver a given dose as would one with twice as many bulbs of the same age, make and individual output.

The irradiance delivered by a source as a function of wavelength is called the *spectral irradiance*, expressed as units of irradiance per nanometer [(W/cm ^{2}) per nm]. The purpose of a *spectroradiometer* is to measure the spectral irradiance of a light source at the position of the skin. If one is interested only in measuring the irradiance provided by a source over a given spectral region, a detector might be used that measures only those wavelengths of interest (broadband radiometric measurements). For example, a broadband radiometric measurement of wavelengths less than 315 nm provides a rough indication of the erythemally effective wavelengths emitted by a source of UV radiation.

There is, however, no substitute for knowing the full spectral irradiance delivered by a source, as determined by a spectroradiometer. If spectral irradiance, exposure field size, angles of incidence, exposure duration, and environmental conditions such as humidity and temperature are recorded, the important conditions of the exposure are described with precision and may be repeated with some accuracy. These considerations are of practical importance in phototesting, phototherapy, and photochemotherapy. For example, in phototesting, only the wavelengths of interest should be

employed. To assess endogenous UVA sensitivity, the UVB portion of a source's emission, if present, must be filtered out so that the more erythemogenic UVB wavelengths do not lead to a falsely lowered erythema threshold in the UVA range. The spectroradiometer is critical in defining the full spectral output.

REFERENCES

1. Girotti AW: Lipid hydroperoxide generation, turnover, and effector action in biological systems. *J Lipid Res* **39**:1529, 1998

2. Geiger PG et al: Lipid peroxidation in photodynamically stressed mammalian cells: use of cholesterol hydroperoxides as mechanistic reporters. *Free Radic Biol Med* **23**:57, 1997

3. Cadet J et al: Effects of UV and visible radiations on cellular DNA. *Curr Probl Dermatol* **29**:62, 2001

4. Moor AC, Gasparro FP: Biochemical aspects of psoralen photochemotherapy. *Clin Dermatol* **14**:353, 1996

5. Katiyar SK: A single physiologic dose of ultraviolet light exposure to human skin in vivo induces phosphorylation of epidermal growth factor receptor. *Int J Oncol* **19**:459, 2001

6. Wan YS et al: Ultraviolet irradiation activates PI 3-kinase/AKT survival pathway via EGF receptors in human skin in vivo. *Int J Oncol* **18**:461, 2001

7. Djavaheri-Mergny M, Dubertret L: UV-A-induced AP-1 activation requires the Raf/ERK pathway in human NCTC 2544 keratinocytes. *Exp Dermatol* **10**:204, 2001

8. Fisher GJ, Voorhees JJ: Molecular mechanisms of photoaging and its prevention by retinoic acid: Ultraviolet irradiation induces MAP kinase signal transduction cascades that induce AP-1–regulated matrix metalloproteinases that degrade human skin in vivo. *J Invest Dermatol Symp Proc* **3**:61, 1998

9. Abeyama K et al: A role for NF-kappaB–dependent gene transactivation in sunburn. *J Clin Invest* **105**:1751, 2000

10. Legrand-Poels S et al: NF-kappa B: An important transcription factor in photobiology. *J Photochem Photobiol B* **45**:1, 1998

11. Gilchrest BA, Eller MS: DNA photodamage stimulates melanogenesis and other photoprotective responses. *J Invest Dermatol Symp Proc* **4**:35, 1999

12. Sturm RA: Human pigmentation genes and their response to solar UV radiation. *Mutat Res* **422**:69, 1998

13. Beissert S, Schwarz T: Mechanisms involved in ultraviolet light-induced immunosuppression. *J Invest Dermatol Symp Proc* **4**:61, 1999

14. Scholzen TE et al: Effect of ultraviolet light on the release of neuropeptides and neuroendocrine hormones in the skin: Mediators of photodermatitis and cutaneous inflammation. *J Invest Dermatol Symp Proc* **4**:55, 1999

15. Duthie MS, Kimber I and Norval M: The effects of ultraviolet radiation on the human immune system. *Br J Dermatol* **140**:995, 1999

16. Tang Q et al: Role of cyclic AMP responsive element in the UVB induction of cyclooxygenase-2 transcription in human keratinocytes. *Oncogene* **20**:5164, 2001

17. Isoherranen K et al: Ultraviolet irradiation induces cyclooxygenase-2 expression in keratinocytes. *Br J Dermatol* **140**:1017, 1999

18. Brenneisen P et al: Ultraviolet-B induction of interstitial collagenase and stromelyin-1 occurs in human dermal fibroblasts via an autocrine interleukin-6-dependent loop. *FEBS Lett* **449**:36, 1999

19. Fisher GJ et al: Pathophysiology of premature skin aging induced by ultraviolet light. *N Engl J Med* **337**:1419, 1997

20. Cleaver JE: Common pathways for ultraviolet skin carcinogenesis in the repair and replication defective groups of xeroderma pigmentosum. *J Dermatol Sci* **23**:1, 2000

21. McGregor WG: DNA repair, DNA replication, and UV mutagenesis. *J Invest Dermatol Symp Proc* **4**:1, 1999

22. Jeffes EW et al: Photodynamic therapy of actinic keratoses with topical aminolevulinic acid hydrochloride and fluorescent blue light. *J Am Acad Dermatol* **45**:96, 2001

23. Klotz LO et al: UVA and singlet oxygen as inducers of cutaneous signaling events. *Curr Probl Dermatol* **29**:95, 2001

24. Johansen C et al: 1Alpha, 25-dihydroxyvitamin D_3-induced differentiation of cultured human keratinocytes is accompanied by a PKC-independent regulation of AP-1 DNA binding activity. *J Invest Dermatol* **114**:1174, 2000

25. Griner RD et al: 1,25-Dihydroxyvitamin D_3 induces phospholipase D-1 expression in primary mouse epidermal keratinocytes. *J Biol Chem* **274**:4663, 1999

26. Kowalzick L: Clinical experience with topical calcitriol (1,25-dihydroxyvitamin D_3) in psoriasis. *Br J Dermatol* **144**:21, 2001

27. Tokura Y: Immune responses to photohaptens: Implications for the mechanisms of photosensitivity to exogenous agents. *J Dermatol Sci* **23**:S6, 2000

28. Magnus IA et al: Erythropoietic protoporphyria. A new porphyria syndrome with solar urticaria due to protoporphyrinemia. *Lancet* **ii**:448, 1961

29. Pathak MA: Mechanism of psoralen photosenstization and in vivo biological action spectrum of 8-methoxypsoralen. *J Invest Dermatol* **37**:397, 1961

30. Buck HW et al: The action spectrum of 8-methoxypsoralen for erythema in human skin. *Br J Dermatol* **72**:249, 1960

31. Anderson RR: Optics of the skin, in *Clinical Photomedicine*, edited by HW Lin, NA Soter. New York, Marcel Dekker, 1993, p 19

32. Anderson RR: Tissue optics and photoimmunology, in *Photoimmunology*, edited by JA Parrish, W Morison, M Kripke. New York, Plenum

Medical, 1983, p 73

33. Cadle RD, Allen ER: Atmospheric photochemistry. *Science* **167**:243, 1970

34. Slaper H et al: Estimates of ozone depletion and skin cancer incidence to examine the Vienna Convention achievements. *Nature* **384**:256, 1996

35. Garssen J et al: Estimation of the effect of increasing UVB exposure on the human immune system and related resistance to infectious diseases and tumours. *J Photochem Photobiol B* **42**:167, 1998

36. Green C et al: 311 nm UVB phototherapy—An effective treatment for psoriasis. *Br J Dermatol* **119**:691, 1988

37. van Weelden H et al: A new development in UVB phototherapy of psoriasis. *Br J Dermatol* **119**:11, 1988

38. El-Ghorr AA, Norval M: Biological effects of narrow-band (311 nm TL01) UVB irradiation: A review. *J Photochem Photobiol B* **38**:99, 1997

39. Parrish JA, Jaenicke KF: Action spectrum for phototherapy of psoriasis. *J Invest Dermatol* **76**:359, 1981

T>

Chapter 134

Susan Walker John Hawk Antony Young

Acute and Chronic Effects of Ultraviolet Radiation on the Skin

ULTRAVIOLET RADIATION
INTRODUCTION TO MOLECULAR AND CLINICAL EFFECTS OF UVR
MEASUREMENT OF HUMAN EXPOSURE TO UVR
ACUTE EFFECTS OF UVR
DNA Photodamage and Mutation
Sunburn Inflammation
Erythemal Effectiveness of Different UVR Wavelengths
Pharmacologic Mediators
Neuropeptides
Immunosuppression
Adaptive Responses of the Skin After UVR Exposure
Photosynthesis of Vitamin D
CHRONIC EFFECTS OF UVR
Skin Cancer: From DNA Photodamage to Tumors
Photoaging

REFERENCES

ULTRAVIOLET RADIATION

Extraterrestrial sunlight is electromagnetic radiation energy comprising mainly the ultraviolet (UV), visible, and infrared spectra, although both shorter (ionizing) and longer (microwave and radiofrequency) wavelengths are also present. They are modified significantly by their passage through the atmosphere, so that only about two-thirds of this energy reaches ground level.

UV radiation (UVR) comprises approximately 5 percent of terrestrial solar radiation and is defined as those wavelengths between 100 and 400 nm. By the official designation of the Commission Internationale de l'Eclairage (CIE), it is subdivided into UVA (315 to 400 nm), UVB (280 to 315 nm), and UVC (100 to 280 nm), but by popular convention the ranges are 320 to 400, 290 to 320, and 100 to 290 nm, respectively. Recently, UVA was divided into UVAI (340 to 400 nm) and UVAII (320 to 340 nm) because the biological effects of UVAII are mechanistically similar to those of UVB. Solar UVR at the earth's surface is approximately 95 to 98 percent UVA and 2 to 5 percent UVB, all the UVC having been completely absorbed by stratospheric ozone. The precise amount and composition of solar UVR depend on a number of factors, particularly the solar zenith angle, which varies with the time of day, season, and latitude; the stratospheric ozone concentration; and pollution, cloud cover, and altitude.

INTRODUCTION TO MOLECULAR AND CLINICAL EFFECTS OF UVR

The most obvious acute clinical effects of UVR on normal skin are sunburn inflammation (erythema) and tanning (melanogenesis). However, as will be discussed, UVR has a wide range of other acute effects, such as DNA photodamage, immunosuppression, and vitamin D synthesis. Chronic exposure to sunlight leads to photoaging and skin cancer (see Chap. 38). The acute effects of solar UVR are amenable to controlled laboratory investigation but logistics and ethics prevent the study of such effects over the decades necessary for the appearance of chronic effects. The determination of long-term effects requires an epidemiologic or clinicopathologic approach. By definition, chronic effects are the consequence of a series of acute effects or, less probably, the delayed outcome of a single acute event. In the understanding of long-term effects there is, therefore, a need to look at the interrelation between acute and long-term effects, as well as the mechanisms of acute effects. It has been useful to clinically assign sun-sensitivity according to skin phototype, as shown in Table 134-1, a classification that also shows a relationship between acute and chronic effects (see Chap. 88).



TABLE 134-1 **Classification of Human Skin Types with Respect to Relative Response to Acute and Long-term Solar Exposure**

It is widely assumed that sensitivity to UVR is directly and solely related to pigmentation or tanning ability, an assumption primarily based on epidemiologic evidence showing skin cancers are much less common in people who tan well (e.g., skin phototypes III and IV) or who have high levels of constitutive pigmentation (e.g., skin phototypes V and VI). Furthermore, studies comparing dark-skinned people with related albinos show the latter to have a higher incidence of photodamage and nonmelanoma skin cancer. However, comparisons based on pigmentation alone may fail to take into account other factors important in UVR sensitivity, such as DNA repair capacity and sensitivity to UVR-induced

immunosuppression (see Chap. 39), now also widely believed to be important in human skin cancer.

MEASUREMENT OF HUMAN EXPOSURE TO UVR

In photobiology, radiant exposure (fluence, dose) is denoted precisely in physical units of J/cm ^{2}. However, a biological dose unit, the minimal erythemal dose (MED), is more commonly used. An MED is the lowest UVR dose required to produce either a just perceptible erythema (MED $_{JP}$) on exposed skin of a given individual after 24 h or an erythema with sharp margins after 24 h. Clearly these end points refer to different physical doses, and it is therefore essential to define the measure on each occasion. In one study, the interobserver error in determining the MED $_{JP}$ was significantly less than that for sharp margins, [1] and this definition thus appears preferable. In general, individuals with higher skin types have higher MEDs. However, as shown in Fig. 134-1, there is considerable overlap of MED $_{JP}$ within skin types I to IV exposed to solar-simulated radiation (SSR). It was recently proposed that a new term, the standard erythema dose (SED), be used as a standardized measure of erythemogenic UVR. [2] The SED is equivalent to an erythemally weighted dose of 100 J/m ^{2}, and about 1.5 SED is equivalent to an MED in a skin type I person.

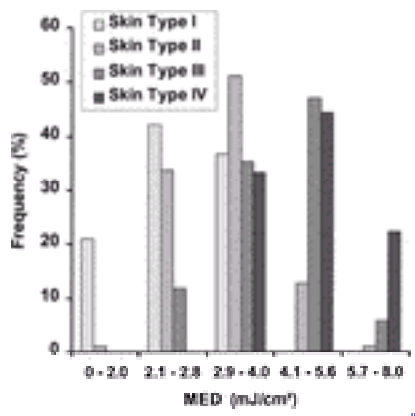

FIGURE 134-1 There is considerable overlap for SSR (just perceptible MED on previously unexposed buttock skin) in different white skin types. Mean MED for skins types I, II, III, and IV are 2.9 (SD ± 0.7), 3.5 (SD ± 1.0), 4.5 (SD ± 1.2), and 5.3 (SD ± 1.2) J/cm ^{2}, respectively.

Most human UVR exposure is to sunlight, although other sources include medical phototherapy lamps, sun beds, arc-welding apparatus, and unshielded fluorescent and tungsten-halogen lamps. Individual skin exposure to solar UVR depends on the ambient levels of UVR, fraction of ambient exposure received on different body sites, exposure behavior and time spent outdoors, as well as clothing, hat, and sunscreen use. Studies on indoor workers in Northern Europe have shown an annual exposure of about 200 SED, mainly from weekend and vacation activities, which represents about 5 percent of the total ambient available. [3] A study of children in the UK and Australia shows the importance of behavior. The median daily dose in Australia was 1.7 SED as compared to 0.9 SED in England, each being about 5 percent of the ambient UVR. However, on any given day 17 percent of the English children received more UVR than the Australian median exposure, and 26 percent of the Australian children had lower doses than the English median dose. [4]

ACUTE EFFECTS OF UVR

DNA Photodamage and Mutation

The photophysical and photochemical basis of photobiology is discussed in Chap. 133. The epidermis and the dermis contain UVR-absorbing chromophores including urocanic acid, aromatic amino acids (proteins), and melanin precursors. [5] However, there is increasing evidence that epidermal DNA is the most important chromophore for many of the acute and long-term effects of solar exposure. The absorption of UVR by DNA results in the formation of characteristic dipyrimidine lesions such as cyclobutane pyrimidine dimers (CPD) and pyrimidine (6-4) pyrimidone photoproducts in human epidermis (keratinocytes and melanocytes) in situ after suberythemal or erythemal exposures of SSR, UVB, and UVA. [6], [7] and [8] Figure 134-2 shows the action spectrum (the relative efficacies of different wavelengths) for the induction of thymine dimers (T=T), a specific type of CPD, in different epidermal layers, in human skin types I and II. It is clear that solar range UVB causes considerable DNA damage in the basal layer, but UVA can also induce epidermal CPD, albeit with much higher doses. Unless repaired, the molecular rearrangement of adjacent pyrimidine bases (cytosine or thymine) may give rise to highly characteristic UVR, so-called signature, mutations, namely C ? T or CC ? TT at dipyrimidine sites. [9]

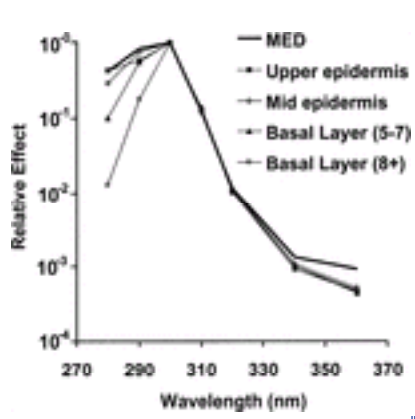

FIGURE 134-2 Comparison of action spectra for erythema and epidermal DNA photodamage (thymine dimers) in the same group of 40 skin-type I/II volunteers. From Young et al. [7]

Human studies have shown that, after a single exposure of SSR, global (i.e., whole genome) (6-4) photoproduct repair in situ is relatively rapid, while global CPD repair is much slower, many lesions persisting for at least 24 h. [6], [10] Such slow repair means that lesions may accumulate if skin is again exposed to UVR the following day, as is often the case in normal life. There is also evidence that cytosine-containing lesions (C=C, C=T) are repaired more rapidly than those with thymine only (T=T), [10] perhaps because photodamage to thymine is of less importance than to cytosine because of the "A rule," which dictates that adenine (the correct base match for thymine) be used in DNA repair in cases of uncertainty. There is also some evidence that epidermal DNA repair may be inducible by repeated SSR exposure in skin types that tan well (IV) but not in skin types that tan poorly (II). [11]

The tumor suppressor p53 protein is not detectable in normal human epidermis but is readily induced by a single exposure to UVR, as shown in Fig. 134-3A. This protein, which acts as a transcription factor, induces cell cycle (G1) arrest to allow time for the repair of DNA photolesions, thus minimizing the transfer of potentially carcinogenic mutations to daughter cells. [12]

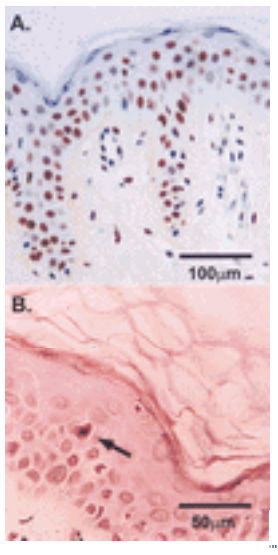

FIGURE 134-3 Epidermal responses in patients with skin type II at 24 h after 2 MED $_{JP}$ with solar-simulated radiation. *A*. Wild-type p53 (immunostained brown with DO-7 antibody) is expressed maximally. *B*. Sunburn cell counts are maximal. Note shrunken eosinophilic cytoplasm and condensed pyknotic nucleus after staining with hematoxylin and eosin. (*Photomicrographs courtesy of John Sheehan.*)

Sunburn Inflammation

Sunburn inflammation (erythema) is the most conspicuous and well-recognized acute cutaneous response to UVR, particularly in fair-skinned individuals, and is associated with the classic signs of inflammation, namely, redness, warmth, pain, and swelling. Generally, the degree of such erythema is determined by the total UVR energy administered, doubling of the irradiance and halving of the irradiation time thus leading to the same degree of sunburn, a relationship known as reciprocity. Such a relationship holds true over a very wide range of times and irradiances, except with very high irradiances and short times (e.g., with lasers), which often result in thermal rather than photochemical events, and very low irradiances and long times, which may enable repair processes to keep pace with damage or inflammatory mediators to diffuse away as they are formed. [13]

Erythema is UVR dose-dependent, solar range UVB (300 nm and 313 nm) and UVA (365 nm) erythemas having similar slopes, although the slopes for UVC (254 nm) and nonsolar UVB (280 nm) are much less steep. [14] Studies with 2 MED SSR in skin types I/II show the onset of erythema at about 6 h, a peak response at 18 to 24 h with marked erythema persisting for at least 1 week. [6] Repeated daily suberythemal SSR exposures result instead in a marked erythema after a few days, especially in sun-sensitive skin types. [11], [15]

Erythemal Effectiveness of Different UVR Wavelengths

Figure 134-2 shows one assessment of the action spectrum for erythema in skin types I and II. Erythemal effectiveness declines rapidly with increasing wavelength, with for example 360 nm (UVA) radiation requiring 1280 times more energy than 300 nm (UVB) radiation to produce the same effect. Therefore, the relatively small UVB component of solar UVR accounts for the majority of its erythemal effect, as shown in Fig. 134-4, which also shows the reference CIE action spectrum [16] for erythema, widely used for UVR hazard assessment. Fig. 134-2 also shows the action spectra for thymine dimers and for erythema in the same pool of volunteers are very similar, thereby providing strong indirect evidence that DNA is a major chromophore for erythema. Another erythema action spectrum determined with truly monochromatic irradiation from lasers shows results that are essentially similar to those of Fig. 134-2 and Fig. 134-4, but with a secondary peak at 362 nm, [17] strongly suggestive of a chromophore other than DNA in the UVA region, presumably acting through photosensitization reactions that are characteristically oxygen dependent. This observation supports earlier clinical studies showing that UVA-induced, but not UVB-induced, erythema is oxygen dependent. [18]

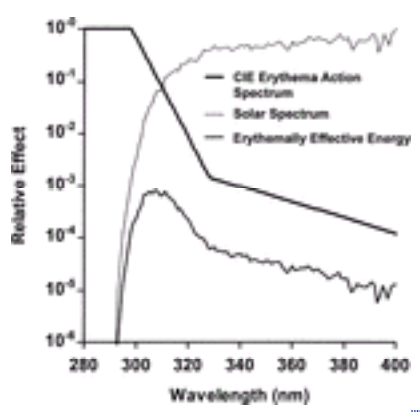

FIGURE 134-4 Standardized CIE erythema action spectrum, [16] noontime summer spectral irradiance in London, UK (51°N 29'), and resultant erythemal effectiveness spectrum. These data show that the 4.9 percent of the UVB (< 320 nm) in the solar spectrum contributes 80 percent of the erythemal effectiveness of the solar UVR spectrum.

Pharmacologic Mediators

UVR exposure induces the synthesis and release of an extensive array of mediators including histamine, by-products of arachidonic metabolism, proinflammatory and immunosuppressive cytokines, chemokines, adhesion molecules, growth factors, neurohormones and neurotransmitters, all of which may profoundly influence the biological function of the skin.

Epidermal keratinocytes are often reported to be the prime target for UVB-induced damage, in that in vitro models suggest that little UVB penetrates into the dermis. However, in situ studies in human skin demonstrate that 2 MED of UVB (300 nm) induces specific DNA lesions in both dermal cells and hair follicle keratinocytes, [7] suggesting that UVB does have a direct effect on most resident skin cells.

Mast cells present in the upper dermis are important in the development of the early phase of erythema as they contain preformed mediators, particularly histamine, serotonin, and tumor necrosis factor (TNF), which stimulate vasodilation and the synthesis of prostaglandins and leukotrienes in neighboring cells. [19], [20] and [21] Mast cell products can be detected within an hour of UVR exposure. The synthesis of prostaglandins and leukotrienes can also be initiated by UVR-induced oxidative damage to cell membranes by lipid peroxidation and their release parallels the development of erythema in humans in vivo. [22] The primary cytokine interleukin (IL)-1a is also stored preformed in keratinocytes and may be released as well at an early stage after UVR damage.

For the most part, however, mediators are not stored as preformed molecules but are synthesized following the activation of a variety of transcription factors. This leads to the upregulation of many genes central to the initiation of inflammation and recruitment of inflammatory cells to UVR-exposed skin. [23], [24] As a result, proinflammatory cytokines, [25], [26] chemokines, [26] complement components, [27] and adhesion molecules [26] are all readily detectable in human skin after in vivo UVR exposure.

An inflammatory infiltrate consisting largely of neutrophils and T lymphocytes appears in the upper dermis from as early as 3 h after UVB exposure and increases rapidly until 48 h. At 48 to 72 h, neutrophils and macrophages are also present in the epidermis. [28], [29] These infiltrating cells contribute to the inflammatory process through the release of cytokines, superoxide, chemotactic factors, and proteases that alter the microenvironment and guide the recruitment of further immune effector cells. [30] Macrophages peak at 72 h after exposure and these may play an important role in the resolution of erythema, having been reported as the major producers of the immunosuppressive cytokine IL-10, [31] shown to downregulate a broad spectrum of proinflammatory cytokines. [32] Keratinocytes and macrophages also release transforming growth factor (TGF)-ß, which may also play a role in the resolution of inflammation. [33], [34]

Neuropeptides

Afferent sensory nerves innervating the epidermis and dermis are also capable of releasing a variety of neuropeptides after UVR exposure. [35] These products, such as substance P and calcitonin gene-related peptide (CGRP), may act as mediators for pain and itch as well as for inflammation and immune modulation. In addition, a range of skin cells, including melanocytes, keratinocytes, and endothelial cells, upregulate the production of neurotrophins and hormones such as proopiomelanocortin (POMC) peptides and their receptors. These mediators can then stimulate vasodilation, mast cell degranulation, the augmentation of UVR-induced cytokine production, chemokine production, and cellular adhesion molecule expression, all required for the activation and trafficking of inflammatory cells into the skin. There is also evidence that the mediators a-melanocyte stimulating hormone (a-MSH) and CGRP play an important role in the resolution of UVR inflammation.

Immunosuppression (See also Chap. 39)

It is well established that UVR exposure suppresses cutaneous cell-mediated immunity in humans. The depletion of Langerhans cells, the principal antigen-presenting cells in the epidermis, recruitment of macrophages into the dermis and epidermis, and release of inflammatory mediators such as TNF-a, IL-10, TGF-ß, a-MSH, and CGRP, are all important events in the initiation of immunosuppression. [31], [33], [34], [35] and [36] These changes result in an alteration to the antigen presentation process leading to the generation of regulatory T cells that inhibit cell-mediated immune responses to newly encountered antigens. Such UVR-induced immunosuppression plays an important role in the emergence and growth of nonmelanoma skin cancers in mice and a similar role is suspected in humans, because transplant patients maintained on immunosuppressive therapy have an elevated risk of both nonmelanoma and melanoma skin cancer, especially if they also have a history of high sun exposure. [37] Exposure to UVR also increases the incidence and severity of infectious diseases in animal models and suppresses the elicitation of immunity to some infectious agents in humans, therefore

having theoretical implications for susceptibility to infectious diseases and vaccine effectiveness in humans.

Susceptibility to UVR-induced immunosuppression appears to be skin-type dependent. Thus, patients of skin phototypes I/II, who are at greater risk of skin cancer, are also more readily immunosuppressed than patients of skin phototypes III/IV. Figure 134-5 shows that a single suberythemal exposure of SSR, of either 0.25 MED or 0.5 MED, can suppress cutaneous cell-mediated immune responses by 50 and 80 percent, respectively, in normal volunteers of skin types I/II, whereas a full MED may only induce 40 percent suppression in those of skin type III/IV. [38] Such data suggest that skin-type–dependent sensitivity to immunosuppression may be a risk factor for skin cancer.

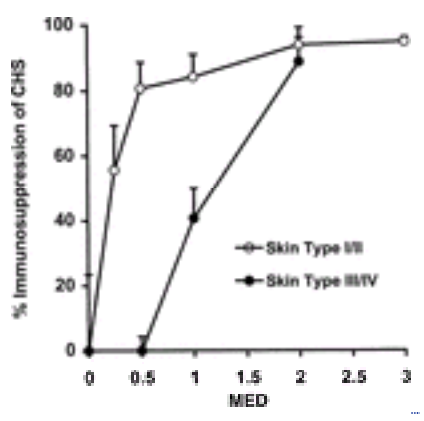

FIGURE 134-5 Erythema is a poor indicator of suppression of the induction phase of the contact hypersensitivity response. Patients with skin types I/II are suppressed with suberythemal exposure to solar simulated radiation, whereas erythemal exposures are necessary to suppress the CHS response in skin types III/IV. From Kelly et al. [38]

DNA seems to be an important chromophore for UVR-induced immunosuppression because the enhanced repair of CPD inhibits immunosuppression in animal models and the release of immunoregulatory cytokines such as TNF and IL-10 in vitro. [39] The photoisomerization of *trans*-urocanic acid (UCA), a component of stratum corneum, has also been implicated in such immunosuppression, perhaps by triggering the degranulation of mast cells. [36]

Adaptive Responses of the Skin After UVR Exposure

TANNING (See also Chap. 88) It is important to distinguish between true melanogenesis, also known as delayed tanning, and immediate pigment darkening (IPD). Thus, the latter is an immediate but transitory grayish color induced by UVA and visible radiation and is believed to result from the photo-oxidation of existing melanins and the redistribution of melanocytic melanosomes from a perinuclear position into the peripheral dendrites, to which cellular microfilament and microtubular activity may contribute. Persistent pigment darkening (PPD) may then be regarded as that portion of the IPD response that remains stable for up to 2 h post exposure. There is no evidence that IPD and PPD are photoprotective. Delayed tanning following UVR exposure is the result of increased epidermal melanin formation, the pigment becoming visible within days after UVB exposure. With exposure to the longer UVA wavelengths, tanning occurs earlier, sometimes blending with the IPD/PPD. Thus, with UVA, no apparent latency may be observed, while the tanning may also persist for prolonged periods. The action spectrum for tanning is broadly similar to that for erythema. However, for the UVB wavelengths, UVR effectiveness is greater for erythema than tanning in fair-skinned individuals, [40] while for UVA in darker-skinned subjects, it is greater for pigmentation. From these data, it is therefore likely that the mechanisms of melanin synthesis following UVB and UVA exposure are distinct. UVB delayed tanning is associated with an increase in the activity and numbers of melanocytes. In general, single exposures increase only activity, while repeated doses are required to increase numbers. Melanocyte tyrosinase activity also increases, melanocyte dendrites elongate and branch, and melanosomes increase in number and size. This may sometimes result in small freckles, particularly in fair-skinned individuals, while large single exposures, such as might occur in severe sunburn, may lead instead to large freckles or even to solar lentigines. UVA tanning has distinct effects that are wavelength dependent. Thus UVAI produces an increased melanin density localized to the basal cell layer, whereas UVAII increases the synthesis and transfer of melanized melanosomes to the epidermis, similar to the changes seen with UVB.

MECHANISMS OF UVR-INDUCED SKIN PIGMENTATION (See also Chap. 11) The rate-limiting enzyme in melanogenesis is tyrosinase, a copper-binding transmembrane glycoprotein localized to the melanosome. Thus, tyrosinase activity correlates closely with the melanin content of cultured pigment cells and increases during tanning. The mechanisms of melanogenesis have been reviewed by Gilchrest et al., [41] who advocated an important role for DNA photodamage and its repair. This is supported by the known enhancement of melanogenesis in vitro and in animal skin in vivo after the administration of a synthetic thymidine dinucleotide (pTpT) that mimics bases excised during the repair of UVR-induced DNA damage. Such damage may also upregulate cell surface receptors for a variety of keratinocyte-derived melanogenic factors, in particular MSH. In addition, there may be an increase in the production and release of factors such as basic fibroblast growth factor (bFGF), nerve growth factor (NGF), endothelin-1, and POMC-derived products such as MSH, adrenocorticotrophic hormone (ACTH), ß-lipotropic hormone (LPH), and ß-endorphin, all of which regulate the molecular and cellular aspects of melanogenesis. Gilchrest et al. [41] also proposed that melanogenesis is a so-called mammalian SOS (i.e., survival) response to UVR exposure, which would suggest a relationship between skin type and the effectiveness of DNA repair. In accordance with this hypothesis, Sheehan et al. [11] provided the first evidence for better epidermal DNA repair after repeated SSR exposure in patients with skin type IV, which tans well, as compared with skin type II, which tans poorly.

PHOTOPROTECTION FROM UVR-INDUCED TANNING Several in vivo and in vitro human studies suggest that the acute photoprotection afforded by constitutive (racial) and facultative (induced) pigmentation against DNA photodamage in keratinocytes and melanocytes and against sunburn is equivalent to the wearing of a sunscreen with a sun protection factor (SPF) of 2 to 4 [42] (see Chap. 247). Such comparable results for both DNA photodamage and erythema provide additional evidence that DNA is an important chromophore for erythema. Protection factors of 2 to 3 should clearly result in a 50 to 60 percent reduction of biologically effective dose and such a reduction, if maintained over long periods, would

theoretically be significant in terms of long-term risk of skin cancer. However, the maintenance of a facultative tan requires repeated exposures to UVR from the sun or artificial sources and it seems highly likely that this would be associated instead with the accumulation of epidermal DNA photodamage [11] sufficient to negate the benefits of the protection. There are, however, conflicting data about the role of a tan in affording protection against the development of malignant melanoma in women, with Weinstock et al. [43] suggesting that a tan may afford some protection and Holly et al. [44] reporting no benefit.

HYPERPLASIA Hyperplasia of the dermis, epidermis, and stratum corneum also follow UVR exposure, a period of initial growth and cellular arrest for 24 to 48 h followed by increased activity for days thereafter. For example, 2 weeks of daily suberythemal SSR results in a 20 to 40 percent increase in the number of cell layers in the stratum corneum in patients of skin types I, II, III, and IV. [45] A number of studies suggest that such UVR-induced hyperplasia, particularly of the stratum corneum, plays a major role in photoprotection particularly in the fair-skinned, whereas other studies suggest a much more limited effect. [15]

ANTIOXIDANT DEFENSES Various enzymatic and nonenzymatic antioxidants protect against oxidative damage in UVR-exposed skin, and are dramatically depleted after UVR exposure. Thus enzymes of this type that repair oxidative injury include superoxide dismutase, catalase, and thioredoxin reductase, while natural antioxidants such as vitamins A, C, and E, as well as glutathione, also act directly to prevent oxygen radical damage. Antioxidants inhibit the human sunburn response, [46] immunosuppression, and photocarcinogenesis in mice. [47], [48] Genetic variation at the glutathione S-transferase locus is also linked to variable susceptibility to sunburn [49] and to nonmelanoma and melanoma skin cancer risk in humans. [50], [51]

Photosynthesis of Vitamin D

The apparent single beneficial effect of UVR on skin is the photochemistry that leads to the production of vitamin D_3 (cholecalciferol). [52] For most people, this vitamin derives mostly from the action of solar UVB on the skin, with dietary sources providing only a minor component of the daily requirement. During exposure to sunlight, UVB is absorbed by 7-DHC (previtamin D_3) situated in the plasma membrane of epidermal and dermal cells, and the resulting photoproduct, known as previtamin D_3, is converted over a day or so into vitamin D_3 through a thermally dependent rearrangement of its double bonds. Once this product is synthesized, it enters the circulation, bound with high specificity to vitamin D_3-binding protein, and travels to the liver to be hydroxylated to 25-hydroxyvitamin D [25(OH)D]. This is the major circulating form of vitamin D_3, which is, in turn, hydroxylated in the kidney to its active form, 1,25-dihydroxyvitamin D_3[1,25$(OH)_2$D]. 1,25$(OH)_2$D then interacts with vitamin D_3 receptors (VDRs) in the small intestine to increase the efficacy of intestinal calcium and phosphorus absorption, as well as with VDRs on osteoblasts to promote the mineralization of bone. VDRs are also present on keratinocytes as targets mediating calcitriol-associated induction of keratinocyte differentiation and inhibition of cell proliferation. As a result of these properties, topical vitamin D derivatives are now being used with therapeutic success in psoriasis. Skin immune cells also express VDRs, and studies suggest a constitutive immunosuppressive role for 1,25-$(OH)_2$D. [53]

Vitamin D intoxication cannot result from excessive sunlight exposure because both previtamin D_3 and vitamin D_3 are photolabile and are converted to other biologically inactive photoproducts. Furthermore, during repeated UVB exposure, photoprotection from tanning and hyperplasia decrease cutaneous vitamin D synthesis, as does constitutive pigmentation, white individuals producing the highest levels, followed by Orientals and Asians, while production is extremely attenuated in black skin. Elderly individuals have lower serum 25(OH)D levels, when compared with their younger counterparts, as a result of the progressive decrease in epidermal 7-DHC, such that acute UVB exposure in aged subjects also results in reduced serum vitamin D responses.

CHRONIC EFFECTS OF UVR

Skin Cancer: From DNA Photodamage to Tumors (See also Chap. 38)

Basal cell carcinoma (BCC), squamous cell carcinoma (SCC), and malignant melanoma are reviewed in Chap. 81, Chap. 80, and Chap. 93, respectively. A relationship between solar exposure and all types of skin cancer has long been established by extensive epidemiologic studies, and animal studies show that UVR, especially UVB, is a causal factor. Molecular epidemiology has also provided a direct link between nonmelanoma skin cancer and UVR-induced damage to epidermal DNA. At least 50 percent of BCC contain UVR signature mutations (C ? T or CC ? TT) at p53 sites that appear to be UVR mutation hotspots. [12] Chronic sun exposure leads to actinic keratoses (AK), which may spontaneously regress, but in some circumstances may progress instead to SCC. Brash et al. [12] investigated the cutaneous p53 mutations induced by UVR and noted that those present in more than 90 percent of SCC were also found in AK. UVR signature mutations have also been found in the PTCH gene in BCC [9] and in p53 in malignant melanoma, [54] all of which supports the epidemiologic data suggesting a causal role for solar UVR in cutaneous carcinogenesis.

UVB irradiation induces early epidermal apoptosis in the form of highly characteristic sunburn cells (SBC) that are apparent within 30 min of exposure and maximal at 24 h. Histologically, when stained with hematoxylin and eosin, SBCs have pyknotic nuclei and shrunken glassy, eosinophilic cytoplasm, as shown in Fig. 134-3B. SBC formation is thought to be a way of eliminating keratinocytes with carcinogenic potential, namely cells that have failed to adequately repair DNA. Inactivating p53 in mouse skin reduces the appearance of SBC, leading Brash et al. [12] to propose a relationship between sunburn and p53 in the onset of skin cancer. Thus, these authors suggest that UVR-induced p53 mutations result in a reduced SBC apoptotic response, which gives rise to a sunburn-based selection for clonal expansion of a p53-mutated cell into an actinic keratosis with possible further progression to an SCC. UVR thus may have a role as both tumor initiator and promoter.

The frequent appearance of clonal patches of p53-mutated keratinocytes in normal human skin (especially in chronically exposed sites) [55] supports the hypothesis that these mutations arise from aberrant stem cell proliferation rather than as

random mutation events. This stem cell theory is further supported by the observation that these abnormal colonies are often arranged as conical clones, arguably arising from putative stem cells. Thus, protection from apoptosis results in a sunlight-induced selection pressure for clones of p53-mutated cells that are resistant to apoptosis and so able to accumulate further UVR-induced mutations that may lead to skin cancer. p53 clonal expansion is, however, a function of continuing UVR exposure rather than time, because these patches regress in mouse skin in the absence of continuing exposure. [56] p53-mutated keratinocyte clones are more frequent and larger in sun exposed skin. However, this does not necessarily mean all will become cancerous; rather, it means that larger colonies provide bigger targets with a greater chance for secondary mutations that can lead to cancer. Jonason et al. [55] suggested that p53 clonal expansion occurs by quantized colonization by the nonaggressive expansion of clones into compartments left empty by adjacent cells that have undergone UVR-induced apoptosis.

Our current understanding of nonmelanoma skin cancer is that DNA photodamage is the immediate acute effect that initiates a chain of molecular, mutational, cellular, and immunologic events that may lead to a skin tumor.

Photoaging (See also Chap. 144)

Photoaging is distinct from normal chronological aging. Clinically, photoaged skin is dry, deeply wrinkled, inelastic, leathery and telangiectatic, often with irregular pigmentation, freckling and lentigo formation (dermatoheliosis, Fig. 134-6). Histologically, such skin shows marked quantitative and qualitative abnormalities, particularly of the dermal connective tissue, including the accumulation of abnormal elastotic material, namely, elastosis, and proteoglycans. Furthermore, the degradation and disorganization of collagen fibrils, responsible for the strength and resilience of skin, have been observed.

FIGURE 134-6 Dermatoheliosis. Severe fine and deep wrinkling. The skin appears waxy with a yellowish hue due to actinic elastosis.

There are no comprehensive epidemiologic data on photoaging but sunlight is firmly implicated through comparison of adjacent sun-exposed and sun-protected skin, and animal studies provide conclusive evidence for a significant role for UVR, especially UVB. Recently, it was hypothesized that UVR-induced tissue-degrading matrix metalloproteinases (MMPs) may be involved in photoaging. [57] MMPs belong to a family of zinc-dependent endopeptidases that degrade structural proteins such as collagens and elastin in connective tissue. Their proteolytic activity is regulated by endogenous tissue inhibitors of metalloproteinases (TIMPs) that inhibit the active MMPs by the formation of tight noncovalent 1:1 complexes. Single exposures of UVB and environmentally relevant doses of SSR induce MMPs and TIMPs gene expression in human skin within 24 h, [57], [58] but the induction of MMP-1 is much greater than TIMP-1 at the mRNA level. MMP induction occurs through the activation of the AP-1 transcription factor. A current model of photoaging proposes that UVR-induced MMPs degrade the dermal matrix, which is followed by imperfect matrix repair. With repeated MMP induction over time, the faulty repair gives rise to a “solar scar” that manifests as skin wrinkling. [57] The chromophores for photoaging have not been investigated; these may well be molecules within cell surface receptors, [57] as well as DNA. [59]

REFERENCES

1. Quinn AG: Definition of minimal erythemal dose used for diagnostic phototesting. *Br J Dermatol* **131**:56, 1994

2. Diffey BL et al: The standard erythema dose: A new photobiological concept. *Photodermatol Photoimmunol Photomed* **13**:64, 1997

3. Diffey BL: Ultraviolet radiation and human health. *Clin Dermatol* **16**:83, 1998

4. Diffey BL, Gies HP: The confounding influence of sun exposure in melanoma. *Lancet* **351**:1101, 1998

5. Young AR: Chromophores in human skin. *Phys Med Biol* **42**:789, 1997

6. Young AR et al: The in situ repair kinetics of epidermal thymine dimers and 6-4 photoproducts in human skin types I and II. *J Invest Dermatol* **106**:1307, 1996

7. Young AR et al: The similarity of action spectra for thymine dimers in human epidermis and erythema suggests that DNA is the chromophore for erythema. *J Invest Dermatol* **111**:982, 1998

8. Young AR et al: Human melanocytes and keratinocytes exposed to UVB or UVA in vivo show comparable levels of thymine dimers. *J Invest*

Dermatol **111**:936, 1998

9. Wikonkal NM, Brash DE: Ultraviolet radiation induced signature mutations in photocarcinogenesis. *J Invest Dermatol Symp Proc* **4**:6, 1999

10. Xu G et al: Effect of age on the formation and repair of UV photoproducts in human skin in situ. *Mutat Res* **459**:195, 2000

11. Sheehan JM et al: Repeated ultraviolet exposure affords the same protection against DNA photodamage and erythema in human skin types II and IV but is associated with faster DNA repair in skin type IV. *J Invest Dermatol* **118**:825, 2002

12. Brash DE et al: Sunlight and sunburn in human skin cancer: p53, apoptosis, and tumor promotion. *J Invest Dermatol Symp Proc* **1**:136, 1996

13. Anderson RR et al: A survey of the acute effects of UV lasers on human and animal skin, in *Lasers in Photomedicine and Photobiology,* edited by R Pratesi, A Sacchi. Berlin, Springer-Verlag, 1980, p 109

14. Diffey BL, Farr PM: Quantitative aspects of ultraviolet erythema. *Clin Phys Physiol Meas* **12**:311, 1991

15. Sheehan JM et al: Tanning in human skin types II and III offers modest photoprotection against erythema. *Photochem Photobiol* **68**:588, 1998

16. McKinlay AF, Diffey BL: A reference action spectrum for ultraviolet induced erythema in human skin. *CIE J* **6**:17, 1987

17. Anders A et al: Action spectrum for erythema in humans investigated with dye lasers. *Photochem Photobiol* **61**:200, 1995

18. Auletta M et al: Effect of cutaneous hypoxia upon erythema and pigment responses to UVA, UVB and PUVA (8-MOP + UVA) in human skin. *J Invest Dermatol* **86**:649, 1986

19. Gilchrest BA et al: The human sunburn reaction: Histologic and biochemical studies. *J Am Acad Dermatol* **5**:411, 1981

20. Pentland AP et al: Enhanced prostaglandin synthesis after ultraviolet injury is mediated by endogenous histamine stimulation. A mechanism for irradiation erythema. *J Clin Invest* **86**:566, 1990

21. Walsh LJ: Ultraviolet B irradiation of skin induces mast cell degranulation and release of tumour necrosis factor-a. *Immunol Cell Biol* 7 **3**:226, 1995

22. Black AK et al: Time course changes in levels of arachidonic acid and prostaglandins D_2, E_2, F_2 alpha in human skin following ultraviolet B irradiation *Br J Clin Pharmacol* **10**:453, 1980

23. Bender K et al: UV-induced signal transduction. *J Photochem Photobiol B: Biol* **37**:1, 1997

24. Abeyama K et al: A role for NF-kappaB–dependent gene transactivation in sunburn. *J Clin Invest* **105**:1751, 2000

25. Barr RM et al: Suppressed alloantigen presentation, increased TNF-a, IL-1, IL-1Ra, IL-10 and modulation of TNF-R in UV-irradiated human skin. *J Invest Dermatol* **112**:692, 1999

26. Strickland I et al: TNF-a and IL-8 are upregulated in the epidermis of normal human skin after UVB exposure: Correlation with neutrophil accumulation and E-selectin expression. *J Invest Dermatol* **108**:763, 1997

27. Rauterberg A et al: Complement deposits in epidermal cells after ultraviolet B exposure. *Photodermatol Photoimmunol Photomed* **9**:135, 1993

28. Tadashi T et al: Occurrence of neutrophils and activated T_H1 cells in UVB-induced erythema. *Acta Derm Venereol* **81**:8, 2001

29. Meunier L et al: In human dermis, ultraviolet radiation induces expansion of a CD36+ CD11b+ CD1- macrophage subset by infiltration and proliferation; CD1+ Langerhans-like dendritic antigen-presenting cells are concomitantly depleted. *J Invest Dermatol* **105**:782, 1995

30. Savage JE et al: Activation of neutrophil membrane-associated oxidative metabolism by ultraviolet radiation. *J Invest Dermatol* **101**:532, 1993

31. Kang K et al: CD11b+ macrophages that infiltrate human epidermis after in vivo ultraviolet exposure potently produce IL-10 and represent the major secretory source of epidermal IL-10 protein. *J Immunol* **153**:5256, 1994

32. Moore KW et al: Interleukin-10 and the interleukin-10 receptor. *Ann Rev Immunol* **19**:683, 2001

33. Lee H-ST et al: Modulation of TGF-ß1 production from human keratinocytes by UVB. *Exp Dermatol* **6**:105, 1997

34. Stevens SR et al: Suppressor T cell-activating macrophages in ultraviolet-irradiated human skin induce a novel, TGF-ß–dependent form of T cell activation characterized by deficient IL-2ra expression. *J Immunol* **155**:5601, 1995

35. Scholzen TE et al: Effect of ultraviolet light on the release of neuropeptides and neuroendocrine hormones in the skin: mediators of photodermatitis and cutaneous inflammation. *J Invest Dermatol Symp Proc* **4**:55, 1999

36. Hart PH et al: Mast cells in UVB-induced immunosuppression. *J Photochem Photobiol B: Biol* **55**:81, 2000

37. Euvrard S et al: Skin cancers in organ transplant recipients. *Ann Transplant* **2**:28, 1997

38. Kelly DA et al: Sensitivity to sunburn is associated with susceptibility to UVR-induced suppression of cutaneous cell-mediated immunity. *J Exp Med* **191**:561, 2000

39. Vink AA, Rosa L: Biological consequences of cyclobutane pyrimidine dimers. *J Photochem Photobiol B: Biol* **65**:101, 2001

40. Parrish JA et al: Erythema and melanogenesis action spectra of normal human skin. *Photochem Photobiol* **36**:187, 1982

41. Gilchrest BA et al: Mechanisms of ultraviolet light-induced pigmentation. *Photochem Photobiol* **63**:1, 1996

42. Young AR, Sheehan JM: UV-induced pigmentation in human skin, in *Sun Protection in Man,* edited by PU Giacomoni. Elsevier Science BV, St Louis, MO, 2001, p 357

43. Weinstock MA et al: Melanoma and the sun: The effect of swimsuits and a “healthy” tan on the risk of nonfamilial malignant melanoma in women. *Am J Epidemiol* **134**:462, 1991

44. Holly EA et al: Cutaneous melanoma in women. I. Exposure to sunlight, ability to tan, and other risk factors related to ultraviolet light. *Am J Epidemiol* **141**:923, 1995

45. Young AR et al: Photoprotection and 5-MOP photochemoprotection from UVR-induced DNA damage in humans: The role of skin type. *J Invest Dermatol* **97**:942, 1991

46. Montenegro L et al: Protective effect evaluation of free radical scavengers on UVB-induced human cutaneous erythema by skin reflectance spectrophotometry. *Int J Cosmet Sci* **17**:91, 1995

47. Steenvoorden DP, Beijersbergen van Henegouwen G: Protection against UV-induced systemic immunosuppression in mice by a single topical application of the antioxidant vitamins C and E. *Int J Radiat Biol* **75**:747, 1999

48. Black, H: The defensive role of antioxidants in skin carcinogenesis, in *Oxidative Stress in Dermatology,* edited by J Fuchs, L Packer. New York, Marcel Dekker, 1993, p 243

49. Kerb R et al: Deficiency of glutathione S-transferases T1 and M1 as heritable factors of increased cutaneous UV sensitivity. *J Invest Dermatol* **108**:229, 1997

50. Heagerty AH et al: Glutathione S-transferase GSTM1 phenotypes and protection against cutaneous tumours. *Lancet* **343**:266, 1994

51. Lafuente A et al: Phenotype of glutathione S-transferase Mu (GSTM1) and susceptibility to malignant melanoma. Multidisciplinary Malignant Melanoma Group. *Br J Cancer* **72**:324, 1995

52. Holick MF: Environmental factors that influence the cutaneous production of vitamin D. *Am J Clin Nutr* **61**(suppl):638s, 1995

53. Muller K, Bendtzen K: 1,25-Dihydroxyvitamin D_3 as a natural regulator of human immune functions. *J Invest Dermatol Symp Proc* **1**:68, 1996

54. Zerp SF et al: p53 mutations in human cutaneous melanoma correlate with sun exposure but are not always involved in melanoma genesis . *Br J Cancer* **79**:921, 1999

55. Jonason AS et al: Frequent clones of p53-mutated keratinocytes in normal human skin. *Proc Natl Acad Sci U S A* **93**:14025, 1996

56. Berg RJ et al: Early p53 alterations in mouse skin carcinogenesis by UVB radiation: Immunohistochemical detection of mutant p53 protein in clusters of preneoplastic epidermal cells. *Proc Natl Acad Sci U S A* **93**:274, 1996

57. Fisher GJ, Voorhees JJ: Molecular mechanisms of photoaging and its prevention by retinoic acid: Ultraviolet irradiation induces MAP kinase signal transduction cascades that induce AP-1 regulated matrix metalloproteinases that degrade human skin in vivo . *J Invest Dermatol Symp Proc* **3**:61, 1998

58. Lahmann C et al: Induction of mRNA for matrix metalloproteinase-1 and tissue inhibitor of metalloproteinases-1 in human skin in vivo by solar simulated radiation. *Photochem Photobiol* **73**:657, 2001

59. Hawk J: Skin photoaging and the health benefits of cutaneous photoprotection, in *Photobiology for the 21st Century,* edited by TP Coohill, DP Valenzeno. Valdenmar Publishing, Overland Park, Kansas, 2001, p 31

T>

Chapter 135

John Hawk Paul Norris Herbert Hönigsmann

Abnormal Responses to Ultraviolet Radiation: Idiopathic, Probably Immunologic, and Photoexacerbated

POLYMORPHIC (POLYMORPHOUS) LIGHT ERUPTION
Epidemiology
Etiology and Pathogenesis
Clinical Features
Histology
Diagnosis
Treatment
ACTINIC PRURIGO
Pathogenesis
Clinical Features
Histology
Diagnosis
Treatment
HEREDITARY POLYMORPHIC LIGHT ERUPTION OF NATIVE AMERICANS
HYDROA VACCINIFORME
Pathogenesis
Incidence
Clinical Features
Histology
Diagnosis
Treatment
SOLAR URTICARIA
Pathogenesis
Clinical Features
Differential Diagnosis
Histology
Diagnosis
Treatment
CHRONIC ACTINIC DERMATITIS
Historical Aspects
Etiology and Pathology
Clinical Features
Histology
Diagnosis
Treatment
PHOTOEXACERBATED DERMATOSES
Acne
Darier's Disease
Disseminated Superficial Actinic Porokeratosis
Herpes Simplex
Lichen Planus Actinicus
Eczema
Lupus Erythematosus
Pellagra
Pemphigus
Bullous Pemphigoid
Psoriasis
APPROACH TO THE PATIENT WITH PHOTOSENSITIVITY
Clinical Features
Laboratory Studies
Phototesting
Photopatch Testing

REFERENCES

Abnormal responses to ultraviolet radiation (UVR) exposure can be broadly categorized into four groups (Table 135-1): acquired idiopathic, probably immunologic photodermatoses; DNA repair-defective photodermatoses; photosensitization by exogenous drugs or chemicals; and dermatoses exacerbated by UVR. The first group, the idiopathic, probably immunologic photodermatoses, and the last, the photoexacerbated dermatoses, as well as the approach to assessing a photosensitive patient, are all discussed in this chapter; the other groups are covered in Chap. 136, Chap. 149, and Chap. 155.

Acquired idiopathic, probably immunologic, photodermatoses	Polymorphic light eruption (PMLE) Actinic prurigo Hereditary PMLE of Native Americans Hydroa vacciniforme Solar urticaria Chronic actinic dermatitis
DNA repair-deficient disorders	Xeroderma pigmentosum Cockayne's syndrome Trichothiodystrophy Bloom's syndrome Rothmund-Thomson syndrome (probable)
Photosensitization by exogenous drugs or exogenous or endogenous chemicals	Porphyrias Acute inflammatory reactions (phototoxicity) Eczematous reactions (photoallergy)
Dermatoses exacerbated by ultraviolet irradiation	

TABLE 135-1 **Abnormal Reactions of Ultraviolet Irradiation**

POLYMORPHIC (POLYMORPHOUS) LIGHT ERUPTION

Polymorphic (or polymorphous) light eruption (PMLE) is a common acquired disorder characterized clinically by the abnormal occurrence, within hours to a day or so of UVR exposure, of itchy, nonscarring, erythematous papules, vesicles, or plaques of some or, less commonly, all light-exposed skin. The lesions are generally symmetric, and they resolve completely over days to a week or two. Histologically, there is a dense, dermal, predominantly perivascular, lymphocytic cellular infiltrate.

Epidemiology

PMLE is the most common photodermatosis: approximately 20 percent of Scandinavians [1] and 10 to 15 percent of those living in the northern United States [2] and the United Kingdom [3] appear to suffer from the condition. Conversely, only 5 percent of Australians [3] and virtually no equatorial Singaporeans [4] have the disease. The prevalence of the condition thus increases steadily with increasing distance from the equator.

The disorder [1], [2], [5] usually has onset in the first three decades of life and affects females two to three times more often than males. It may occur in all skin types and racial groups but appears more commonly to affect relatively fair-skinned individuals. A positive family history is present in about a sixth of the patients. [1]

Etiology and Pathogenesis

A delayed-type hypersensitivity response to a sunlight-induced, cutaneous neoantigen, first proposed in 1942 by Stephen Epstein because of the hours usually taken for the eruption to develop, and the lesional histologic appearances, has proved almost certainly to be the cause of PMLE, although the now fairly substantial evidence for this remains circumstantial. The underlying reason for the occurrence of the disorder in any given patient appears likely to be genetic, perhaps 70 percent of all subjects having a tendency to the condition, but its actual expression depends on the degree of gene penetrance. [6] Furthermore, the inherited defect may be a diminished capacity in patients for normal UV-induced cutaneous immunosuppression.

INDUCTION OF PMLE Difficulty in the reliable laboratory induction of clinical lesions has long frustrated investigations into the pathogenesis of PMLE. This frequent lack of response, often to adequate doses of artificially produced UVR, by patients who react readily to just suberythemogenic doses of natural sunlight, appears to relate to a number of variables. These include in particular the size of the UV irradiation site and its location and the irradiation of small, normally unaffected areas perhaps not eliciting sufficient immunologic stimulus to activate the response. It also may relate to the UV irradiation spectrum, irradiation dose, irradiation dose rate, and degree of cutaneous immunologic tolerance, which may be increased by any recent prior exposure. [7] The complex interrelationships between factors such as these have contributed significantly to the conflicting nature of reports concerning the most effective wavelengths for PMLE induction. In most series, UVA (315 to 400 nm) has been more reliably effective than UVB (280 to 315 nm). [7], [8] Thus, in one of these studies, [8] following exposures of buttock skin to UVA or UVB daily for 4 to 8 days, the action spectrum was in the UVA range in 56 percent, UVB in 17 percent, and both in 27 percent. However, Miyamoto [9] later confirmed earlier reports that induction with UVB can also be successful in a high proportion (57 percent) of selected patients. This apparent diversity in action spectrum for the induction of PMLE may very possibly be the result of different UV-evoked inducing antigens, as also appears likely in solar urticaria, [10] and perhaps also of different cutaneous levels for these antigens. Contradictory results regarding the action spectrum for PMLE induction could also conceivably be accounted for by the presence of inhibitory wavelengths in some patients. Pryzbilla et al. [11] reported patients in whom the condition could not be induced by broad-spectrum UVA; however, lesions developed at sites deprived of the shorter UVA wavelengths by filters, suggesting an inhibiting effect by this waveband. This phenomenon has not been confirmed by other investigators, however, and remains speculative, but theoretically could be due to interference with photoallergen induction or with subsequent reactions, as are also suggested to occur on occasion in solar urticaria. [12] Although chromophores for PMLE have not been identified, one study suggested that a form of heat shock protein may be responsible. [13] In addition, the induction of lesions by a UVA sunbed in the nontanning sacral pressure area [14] further suggests that the UV-chromophore interaction in some patients may be oxygen-independent. Variation in the proportions of UVA and UVB present in terrestrial sunlight may also explain certain clinical characteristics of PMLE. Thus, the greater proportion of UVA to UVB in temperate climates and during the spring and fall months might be expected to contribute to a higher incidence of PMLE in temperate rather than tropical regions, [3] with greater susceptibility to the condition in spring and occasionally fall, rather than summer, in most patients. Moreover, the higher proportion of UVB to UVA in summer sunlight probably inhibits PMLE development through a predominantly UVB-induced cutaneous immunosuppressive mechanism. Paradoxically, the use of sunscreens, which often predominantly remove UVB but are also generally advised for PMLE patients and are required for normal sun protection, might also have the same UVA- and PMLE-enhancing effect.

IMMUNOLOGIC ASPECTS Early immunohistochemical characterization of the inflammatory infiltrate in naturally occurring PMLE lesions of uncertain and varying age gave inconsistent results. However, a later study [15] of timed biopsies from such lesions induced by low-dose, solar-simulated radiation demonstrated the consistent appearance of a T cell-dominated perivascular infiltrate within 5 h, peaking by 72 h. CD4+ T cells were most numerous in the early lesions, whereas after 72 h CD8+ T cells were predominant, perhaps helping to limit the previous immunologically

mediated tissue damage. Increased numbers of dermal and epidermal Langerhans cells and dermal macrophages were also present. These findings are similar to those in allergic contact dermatitis and the tuberculin reaction, both known delayed-type hypersensitivity reactions, thus supporting a similar mechanism for PMLE. Intercellular adhesion molecule-1 (ICAM-1), which assists lymphocyte tissue trafficking, is absent from resting keratinocytes but strongly induced on them by interferon-?. Such expression has previously been demonstrated in the tuberculin reaction [16] and allergic contact dermatitis, [17] but not irritant contact dermatitis or following irradiation with two minimal erythema doses (MEDs) of UVB on normal skin. [16] ICAM-1 may therefore be a marker for immunologically specific responses, and its presence on keratinocytes overlying the perivascular infiltrate in PMLE [18] is probably secondary to interferon-? release by immunologically activated lymphocytes in the underlying dermis, further supporting an immunologic basis for PMLE. Finally, in a study of PMLE patients, high-dose UVB and UVA irradiation increased the stimulatory capability of epidermal cells in unidirectional culture with autologous peripheral blood mononuclear cells, [19] again consistent with immune sensitization against autologous UV-modified antigens. Beyond this, unpublished results by one of us (JH) indicate that patients with PMLE cutaneously immunosuppress significantly less easily than do normal subjects following solar simulated irradiation, such that they are more easily sensitized to dinitrochlorobenzene (DNCB) after UVR exposure than are normal subjects. This is very likely the genetically determined factor mentioned previously, [6] which leads to the putative immune recognition of photoinduced cutaneous antigen in PMLE but not normal subjects, although the antigen is presumably expressed in all individuals.

VARIATIONS IN ARACHIDONIC ACID METABOLISM In 13 of 23 patients with PMLE, the topical application of indomethacin for 2 h after irradiation inhibited UVB but not UVA erythema, as in normal subjects, whereas in the remaining 10 patients, it caused an abnormal augmentation of both UVB and UVA responses. [20] The 10 patients in the latter group had clinically more severe disease and more persistent lesions, and in general, they demonstrated abnormal erythemal responses to monochromatic UVA and sometimes to UVB irradiation. Such findings probably result from variations in disease severity rather than pathogenesis. However, polyunsaturated fatty acids compete with arachidonic acid as a substrate for prostaglandin A_2 resulting in the formation of less active prostanoids, and dietary supplementation with fish oil rich in omega-3 polyunsaturated fatty acids is reported to reduce both basal and UVB-generated prostaglandin levels in skin and to increase PMLE UVA-induced provocation thresholds, [21] leading to trials of their use in treatment.

Clinical Features

The eruption of PMLE [5] (Fig. 135-1) typically begins each spring, on sunny vacations, or after recreational sunbed use, often moderating with continuing exposure. Rarely, it occurs in winter after exposure to UVR reflected from snow; it may also occur only through window glass. Individual susceptibility varies considerably, the period of sun exposure needed to trigger the eruption usually being from 30 min to several hours, occasionally more or less, but often up to several days on vacations. Following exposure, new lesions appear after a latent interval of hours to days, but not less than about 30 min, although itching may develop sooner. In the absence of further exposure, all the lesions gradually subside completely without scarring over 1 to 7 days, occasionally 2 weeks, or, very rarely, longer in severe cases. In a given patient, the eruption tends always to affect the same skin sites, although its distribution may gradually spread or recede overall. Lesions also generally occur symmetrically and affect only some exposed sites, often those normally covered in winter such as the upper chest and arms. Associated systemic symptoms are rare, but chills, headache, fever, nausea, and a variety of other sensations are possible. Over 7 years, 64 of 114 patients (57 percent) reported steadily diminishing sun sensitivity, including 12 (11 percent) who totally cleared. [22] There is a higher chance than normal of prior PMLE in patients with lupus, but very few patients with PMLE ever develop that condition. [23]

FIGURE 135-1 Polymorphous light eruption. Lesions are on habitually exposed sites, which is unusual because they most often occur on areas normally covered in winter.

PMLE has many morphologic variants, while any combination of these is also possible. Thus, papular, papulovesicular (Fig. 135-2), plaque (Fig. 135-3), vesiculobullous, eczematous, insect bite-like, and erythema multiforme-like variants have been described, relating mostly to the clinical severity of the disorder and its site. Rarely, only pruritus may occur. [24] Such subdivisions do not apparently relate to differences in disease pathogenesis. The papular form, of either large or small separate or confluent lesions (generally tending to be in clusters), is the most common, followed by the papulovesicular and plaque variants; the others are rare. The eczematous form probably does not exist, representing instead chronic actinic dermatitis (see below), although PMLE may on occasion become secondarily lichenified or eczematized during resolution. Differing morphologies may also occur at different skin sites in the same patient; thus, diffuse facial erythema and swelling, for example, may accompany typical papular lesions at other sites. Complete sparing of small or large areas of exposed skin is an important characteristic distinguishing the disorder from other photodermatoses. Juvenile spring eruption, [25] which affects mainly boys, apparently represents an extreme example of this phenomenon. This condition is a self-limited eruption of pruritic grouped papules and vesicles confined to the light-exposed helices of the ears and characterized by a dense perivascular lymphocytic infiltration, although typical PMLE may sometimes coexist in the same patient. A final morphologic variant, a small papular form generally sparing the

face and occurring after several days' exposure, has been designated as benign summer light eruption in continental Europe.

FIGURE 135-2 Polymorphous light eruption. Rash composed of papulovesicular lesions on an arm.

FIGURE 135-3 Polymorphous light eruption. Variably sized plaques on cheek, simulating lupus erythematosus. However, they disappear in a few days.

Histology

The histologic features [26] of PMLE are characteristic but not pathognomonic and vary with the different clinical presentations. There is a moderate to intense, tight, perivascular infiltrate in the upper dermis and mid-dermis in all clinical types, the infiltrate consisting predominantly of T cells. Neutrophils are also present, while eosinophils are infrequent. Other common features are upper dermal and perivascular edema and endothelial cell swelling, and while epidermal changes may be absent or variable in severity, spongiosis, occasional dyskeratosis, exocytosis, and basal cell vacuolization are common.

Diagnosis

Diagnosis is made largely on clinical grounds, particularly based on the time course for lesion evolution and the morphology of the eruption, particularly because the responses to routine phototesting are often normal except in very photosensitive patients. Subacute cutaneous lupus erythematosus, not generally itchy as in PMLE, must be excluded by measurement of the circulating antinuclear, anti-SSA and anti-SSB antibody titers. Persistent plaque-type PMLE must also be differentiated from Jessner's lymphocytic infiltrate of the skin, while the photoexacerbation of dermatoses, such as atopic and seborrheic eczema, may occur in susceptible subjects with the same time course as for PMLE, but with differing and characteristic morphologies. Erythropoietic protoporphyria must also be distinguished from the pruritic variant of PMLE without eruption, as must any exaggerated sunburn of patients with xeroderma pigmentosum or very fair skin. Finally, solar urticaria may be readily differentiated on history, its lesions being wheals and typically appearing within just 5 to 10 min and resolving within only 1 to 2 h.

Treatment

The mild disease of many patients is satisfactorily controlled by the moderation of sun exposure at times of high UVR intensity and the regular application of broad-spectrum sunscreens with high protection factors, particularly against UVA. However, as stated earlier, sunscreens protecting against mostly UVB may be ineffective, perhaps delaying the onset of protective cutaneous immunosuppression while permitting longer UVA exposure before sunburning. More severely affected subjects suffering frequent attacks of their disease throughout the summer, may instead require courses of prophylactic low-dose photo(chemo)therapy (see Chap. 266). Thus, in a controlled trial in which UVR exposure was monitored by means of polysulfone film lapel badges, PUVA was more effective than UVB, satisfactorily controlling symptoms in 91 percent, as compared with 62 percent, of cases. [27] Furthermore, in another study [8] of 122 patients treated with PUVA, total protection was achieved in 64 percent and partial protection in 26 percent; only 10 percent did not respond. The use of narrow-band 312 nm UVB phototherapy is now also becoming popular, being simpler to administer, as safe as or safer than, and apparently of comparable efficacy to PUVA (see Chap. 265). [28] Prophylactic PUVA or UVB may sometimes trigger the eruption, particularly in severely affected subjects, necessitating concurrent systemic corticosteroid therapy on occasion; this approach is usually effective. [29]

Patients who only develop their disorder during infrequent vacations also generally respond well to oral corticosteroids prescribed for them in advance. [29] If their eruption should develop, the medication is taken at the first sign of pruritus and then each morning till clear, usually after at most several days. Rare adverse effects of nausea or depression only

occasionally necessitate stopping the drug. The treatment, if suitable and effective, may then be repeated every few months if required. Patients who are unsuitable for this approach or remain uncontrolled, however, may need phototherapy.

If none of the above therapies is effective or suitable, other potential therapies may be tried, but none are of certain efficacy. Such remedies include hydroxychloroquine, [30] which is occasionally helpful although not as much as tradition has long suggested; thalidomide, [31] which is helpful for some persistent forms; beta-carotene, [32] which is rarely useful; nicotinamide, which is probably not at all effective; and omega-3 polyunsaturated fatty acids, which are, perhaps, of moderate assistance in some patients. [21]

There then remains a small proportion of patients who are unsuitable for, unable to tolerate, or not helped by any of the above therapeutic measures. UVR avoidance may then be the only reasonable option. However, very few patients are so sensitive that they are continuously affected in spite of all reasonable UVR avoidance measures and, for them, intermittent immunosuppressive therapy with azathioprine or cyclosporine may be considered appropriate, their use having led to marked clinical improvement in a few patients. [33], [34]

ACTINIC PRURIGO

Actinic prurigo (AP) is a not infrequent, persistent, pruritic, excoriated, papular or nodular eruption of the sun-exposed and, to a lesser extent, non-exposed skin. It is worse in summer and frequently fails to clear completely in winter, while also usually arising in childhood and sometimes remitting at puberty. The condition appears likely to be a persistent variant of the sometimes coexistent PMLE but is clinically different. A similar condition is hereditary or familial PMLE, which predominantly affects North, Central, or South Americans of native or mixed race; this form of the disease is normally more severe and persists into adulthood.

Pathogenesis

UVR exposure appears to be the inducer of AP in that the disorder is more severe in spring and summer, and that abnormal skin responses to monochromatic irradiation are present in up to two-thirds of patients, more commonly with UVA than with UVB. [5] In addition, solar-simulated radiation may occasionally evoke a response resembling that of PMLE, while a dermal, perivascular mononuclear cell infiltrate, also similar to that of PMLE, may sometimes be seen in early lesions. This has not yet been investigated immunohistochemically. Finally, the reported augmentation of UVA erythema [35] by the topical application of indomethacin, as in some patients with PMLE, again suggests that AP may be immunologically mediated.

AP on balance may thus be a slowly evolving, excoriated form of PMLE, and thus also a delayed type hypersensitivity reaction. This is supported by the fact that more AP patients than expected have close relatives with PMLE; [6] that human leukocyte antigen (HLA) DR4, occurring in some 30 percent of normal subjects, is present in around 80 to 90 percent of those with AP; and that the DR4 subtype DRB1*0407, occurring in some 6 percent of normal subjects and not infrequently also in Native Americans, is present in approximately 60 percent of those with AP. [36], [37] This feature may be the genetic component responsible for converting PMLE into AP. In addition, some patients with the genetic characteristics of AP demonstrate clinical PMLE but have persistent lesions, while some with clinical AP may change to clinical PMLE and vice versa, [37] further suggesting a relationship between the two conditions. Inducing chromophores have not been studied, but may be the same as for PMLE.

Clinical Features

AP is more common in females and usually begins by the age of 10 years; [5] it then tends to improve and resolve by adolescence, but may on occasion persist into adult life. A positive family history occurs in some 15 to 50 percent of patients, [5] while atopy occurs in approximately 10 percent. [30] The AP eruption is often present throughout the year, but is generally worse in summer; very occasionally it occurs in winter instead, or else in both spring and fall, tolerance in these instances apparently developing during the summer. Furthermore, lesional exacerbations tend to occur in sunny weather rather than clearly following episodes of sun exposure, although PMLE-like outbreaks are possible. Lesions are typically pruritic, often excoriated, papules or nodules (Fig. 135-4), associated with eczematization, lichenification, or crusting, at least on some sites. All exposed areas are usually involved, the condition being most severe on consistently uncovered sites but fading gradually toward normally covered skin. The latter is often also mildly affected, particularly over the sacral area and buttocks. Cheilitis, particularly of the lower lip, is also possible, while facial lesions may sometimes heal with small, pitted or shallow, linear scars.

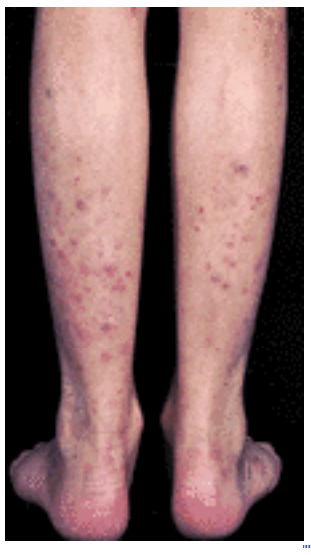

FIGURE 135-4 Actinic prurigo. Papules and nodules on legs of 15-year-old female.

Some patients clearly have PMLE or AP or both, but others may have a sufficiently mixed clinical picture to make precise diagnosis difficult. Thus, while AP almost always begins before age 10 years, PMLE may also begin in childhood. Furthermore, although individual AP lesions are generally more persistent than those of PMLE, lasting for weeks to months, those of PMLE may also be present on occasion for at least days to weeks. In addition, while AP is usually present all year round, patients with severe PMLE may also rarely be affected by winter sunshine. Finally, AP may be associated with a tendency to eczematization, but this might occasionally occur in PMLE, especially during its resolution phase. However, the often marked excoriation, the occasional mild scarring, and the usual fading of lesions toward and into covered skin sites in AP are very rare indeed in PMLE and their presence or absence tends usually to clarify the diagnosis.

Histology

Early papular lesions show changes similar to those of PMLE, namely mild acanthosis, exocytosis, and spongiosis in the epidermis and moderate lymphohistiocytic, dermal perivascular infiltration. In persistent, excoriated lesions, however, the epidermal features include also orthokeratosis, acanthosis, and sometimes hypergranulosis.

Diagnosis

Diagnosis is suspected on clinical grounds in the first instance, but there may be abnormal photosensitivity to monochromatic irradiation in up to two-thirds of patients, [5] which may involve the UVB, UVB and UVA, or, rarely, just UVA, wavelengths. In addition, lupus should be excluded by assessment of the circulating antinuclear factor and anti-SSA and anti-SSB antibody titers. Hepatic porphyria may occasionally need to be excluded by appropriate screening. Biopsy rarely aids diagnosis.

Treatment

The restriction of sun exposure and use of broad-spectrum, high-protection sunscreens may occasionally help milder cases, but these usually provide inadequate control. However, intermittent courses of low-dose thalidomide (50 to 200 mg at night) are very effective within a few weeks in the majority of patients, [38] although immediate, generally mild, side effects may include drowsiness, headache, constipation, and weight gain (see Chap. 264). To avoid peripheral neuropathy, the careful monitoring of nerve conduction every few months is also essential, while pregnancy must also be avoided because of the high risk of teratogenicity. If thalidomide is unavailable or unsuitable, PUVA therapy may occasionally be helpful. Thus, Farr and Diffey [39] successfully treated 5 patients twice weekly over 15 weeks, the skin shielded during treatment continuing to show abnormal UV sensitivity, however, suggesting a local mechanism of action. Nevertheless, this therapy seems to work more reliably as a prophylactic measure if the skin lesions are cleared first by thalidomide or by oral steroids. Chloroquine is not useful.

HEREDITARY POLYMORPHIC LIGHT ERUPTION OF NATIVE AMERICANS

This condition, which may affect North, Central, or South American patients of Native American or mixed race, appears indistinguishable from white AP except that it persists much more frequently into adulthood, [40] is clinically more severe, and regularly affects the lips and conjunctivae of patients. In addition, many patients have a positive family history and demonstrate the same HLA-DR4 and DRB1*0407 subtype positivity as their white counterparts. [41], [42] Onset is in childhood and affected females outnumber males by 2 to 1, while the clinical features are similar to those of white AP, namely a pruritic, excoriated, papular, eczematized eruption of the sun-exposed areas of the face and limbs with minimal scarring. As stated earlier, there is also a marked associated tendency to cheilitis and conjunctivitis.

HYDROA VACCINIFORME

Hydroa vacciniforme (HV) is a very rare photodermatosis of unknown etiology that principally starts in childhood. It is characterized by recurrent crops of papulovesicles or vesicles most commonly on the face and the dorsa of the hands but other sun-exposed areas of the skin may also be involved. The vesicles resolve with pocklike scarring. The disease was first described by Bazin in 1862, and it is possible that before the clear definition of erythropoietic protoporphyria by Magnus and associates (see Chap. 149), some of the cases that were classified as hydroa may have been protoporphyria.

Pathogenesis

The pathogenesis of hydroa vacciniforme is unknown. No chromophores have been identified as yet. The UVB MED reaction is normal in the majority of patients but reduced UVA MED values have been found in some patients. [43] Blood, urine, and stool porphyrins are negative and all other laboratory parameters, including immunologic tests, are within normal limits. The course, distribution of lesions and histopathology, with a perivascular lymphocytic infiltrate, are somewhat reminiscent of polymorphic light eruption. However, the clinical features are quite different. The action spectrum lies in the UVA region and repetitive irradiation with broad spectrum UVA has been shown to elicit typical skin lesions that are clinically and histologically identical to those produced by natural sunlight. [44], [45] Recent reports of an association with Epstein-Barr virus infection and lymphoma are interesting, but some of these cases are atypical, and may not represent the usual form of HV. [46], [47], [48] and [49]

Incidence

Although HV occurs in early childhood and may resolve spontaneously at puberty, some patients may suffer from life-long photosensitivity. There is a male predominance for the severe manifestations, whereas milder forms are more common in females. [43], [45] Familial incidence is exceptional. In a recent study, the estimated prevalence of HV was about 0.34 cases per 100,000 with an approximately equal sex ratio. Males had a later onset and longer duration of disease than did females. [45]

Clinical Features

Erythema with a burning or itching sensation, and sometimes with associated swelling, begins within hours of sufficient sun exposure in light-exposed skin areas, particularly on the face and the hands. This is followed by the appearance of symmetrically scattered tender papules within 24 h. These generally later become vesicular, umbilicated, and, on occasion, confluent and hemorrhagic (Fig. 135-5). Within a few weeks, crusting followed by detachment of the lesions leaves permanent, depressed, hypopigmented scars. Vesicles and bullae, as well as the scars, resemble the lesions of vaccinia. Occasional systemic features include headache, malaise, and fever. HV usually occurs only during the summer months, and sometimes, but not always, improves or resolves in adolescence. [43], [45]

FIGURE 135-5 Hydroa vacciniforme. Vesicular, bullous, and crusted lesions on the face that will result in vacciniform scars.

Histology

Distinctive histologic changes include initial intraepidermal vesicle formation with later focal epidermal keratinocyte necrosis and spongiosis in association with dermal perivascular neutrophile and lymphocyte infiltration. Vasculitic features have also been reported. [43] Immunofluorescence findings are nonspecific.

Diagnosis

The differential diagnosis includes several photosensitivity states. However, the typical history and the clinical features are characteristic. Of particular importance, however, is the exclusion of erythropoietic protoporphyria which may rarely have similar morphology. An evaluation of erythrocyte protoporphyrin levels, red cell photohemolysis, and stool analysis will exclude protoporphyria.

Treatment

The treatment of HV consists of restriction of sun exposure and use of broad-spectrum sunscreens. Occasionally, antimalarials have been helpful, but their true value remains to be established. Similar observations have been made with beta-carotene, which in our hands, was ineffective in three cases. As in polymorphic light eruption, prophylactic phototherapy with narrowband UVB or PUVA may be helpful, particularly the latter, although it should be administered with care to avoid exacerbations. [43], [44] and [45]

SOLAR URTICARIA

Solar urticaria (SU) is a rare but severely disabling, rarely even life-threatening, photosensitive disease in which UVR or

visible irradiation leads to whealing of some or all exposed skin.

Pathogenesis

SU is due to an immediate type I hypersensitivity response to a cutaneous or circulating photoallergen generated from a precursor after the absorption of light energy. Both a circulating photoallergen and reaginic antibodies have been demonstrated.

Two types of SU have been proposed. Type I is an IgE-mediated hypersensitivity to specific photoallergens generated only in SU patients. Type II is an IgE-mediated hypersensitivity to a nonspecific photoallergen that is generated in both SU patients and others. [50] Therefore, in type I SU, passive transfer tests may be positive or negative, while, in type II, passive transfer tests are always positive. The diversity of the action spectra reported in the literature can be attributed to differences in photoallergens. Patients with type I appear to have a photoallergen of molecular mass 25 to 34 kDa and an action spectrum in the visible region, while those with type II may have a photoallergen of molecular mass 25 to 1000 kDa and a variable action spectrum. [50]

Urticaria develops on exposure to specific, characteristic, and usually broad-spectrum UVB, UVA, visible light, or a combination of these. [51] Susceptibility to the condition can occasionally disappear spontaneously, while the range of eliciting wavelengths can also narrow or broaden over months to years. However, the determination of action spectra has not led to the identification of chromophores.

Exposure to longwave visible or UVA radiation before, during, or after the urticaria-inducing irradiation inhibits whealing in some patients, possibly by inactivation of the initial active photoproduct or the inhibition of subsequent reactions. Conversely, Horio and Fujigaki [52] reported a patient with SU induced by 320 to 420 nm light in whom preirradiation with 450 to 500 nm visible light augmented the whealing. Postirradiation with the same spectrum failed to increase the response, suggesting that the energy in those wavelengths was absorbed by a precursor of the photosensitizer, altering it to a state more readily reactive to the urticaria-eliciting radiation (for references see Ref. [51]).

Although mast cell degranulation and histamine release are implicated in SU, antihistamine therapy is only sometimes effective. This suggests the possible importance of other mediators, such as neutrophil and eosinophil chemotactic factors that accompany histamine in the venous blood draining irradiated skin. The initial mast cell degeneration is followed by the recruitment of circulating neutrophils and eosinophils, along with the tissue distribution of eosinophil major basic protein, which may, in turn, amplify the whealing response. [51]

True SU must not be confused with rare reactions due to photosensization by topical chemicals (e.g., tar, pitch, or dyes), protoporphyrin in erythropoietic protoporphyria, or some drugs (e.g., benoxaprofen) as these reactions are clinically different (see Chap. 136); only one patient with erythropoietic protoporphyria associated with SU has been reported. SU is not associated with an atopic background.

Clinical Features

SU is slightly more common in females, usually beginning between 10 and 50 years of age and persisting indefinitely, occasionally slowly worsening or gradually improving. Within 5 to 10 min of sun exposure, patients experience itching, erythema, and patchy or confluent whealing (Fig. 135-6), which resolves generally with sun avoidance within 1 to 2 h; very rarely, however, the onset of symptoms has been reported to be delayed by several hours. [53] SU may affect only normally covered skin, sparing the face and hands, because of a hardening phenomenon or usually all exposed sites, while sharp demarcation at lines of clothing is often seen in more severe cases; bruised skin appears particularly susceptible. [54] Attacks may be accompanied by headache, nausea, bronchospasm, faintness, and syncope, especially if extensive areas of the skin are affected.

FIGURE 135-6 Solar urticaria. These lesions appeared within 15 min of sun exposure, with wheals and marked pruritus. They were produced by irradiating the back of this patient through a template.

Differential Diagnosis

The primary diagnostic criteria are itching, burning, erythema, and whealing, which only appear after sun exposure and usually disappear within 1 to 2 h. The timing criterion is a guideline for the differential diagnosis from PMLE, which has the same localization, but PMLE lesions usually appear between hours to days after sun exposure and generally take 2 to 6 days to disappear after its avoidance. In addition, the lesions are not limited to wheals. Confirmation of the diagnosis of SU is given by phototesting, with transient itching or burning erythema and whealing occurring at the immediate reading. Primary SU should be differentiated by history from drug- or chemical-induced phototoxicity, which can also

cause a burning sensation within minutes of sun exposure.

Histology

There is dermal vasodilation and edema, while light-microscopic study of timed biopsies of induced lesions of SU has demonstrated a dose-dependent increase, predominantly perivascular, in upper dermal neutrophil and eosinophil numbers at 5 min and 2 h but not at 24 h. Endothelial cell swelling is also observed in early lesions, while late infiltration by mononuclear cells is seen only following high doses of radiation. In addition, staining by indirect immunofluorescence for eosinophil granule major basic protein shows extensive extracellular deposition in the dermis at 2 and 24 h, suggesting eosinophil degranulation. [55]

Diagnosis

Phototesting with an irradiation monochromator or broad-spectrum irradiation source generally allows confirmation of the diagnosis and definition of the action spectrum of SU. Several lamps can be used for phototesting, such as inexpensive fluorescent tubes or a more sophisticated solar simulator, while the most detailed phototesting procedure involves a xenon lamp combined with a monochromator; the urticarial reaction usually disappears in a few minutes. It is very important to realize that a negative phototest from a single light source does not exclude a diagnosis of solar urticaria, it being necessary to continue provocative testing with other light sources, such as polychromatic light sources, a slide projector, or even directly with sunlight.

Treatment

High-protection-factor sunscreens and appropriate clothing cover may be useful in UVB-sensitive subjects, but are much less effective in those sensitive to UVA and particularly visible light. However, nonsedating H_1 antihistamines may help significantly, increasing the minimum whealing dose tenfold or more. The addition of H_2 blockers rarely may offer a slight further advantage. In many patients chronically exposed skin, such as on the face and the hands, becomes tolerant. Based on this observation, therefore, patients with SU can be treated with repeated artificial UV exposures; this can be done with narrowband UVB, broadband UVB, UVA alone, a combination of UVB and UVA, and even visible light. The major disadvantage of phototherapy is that the tolerance obtained usually lasts only a few days, although a more lasting effect is obtained with PUVA, the protection provided lasting several weeks. Such regimens do not alter tissue histamine content or mast cell numbers, however, and they may act via nonspecific photoinduced stabilization of the mast cell activation mechanism or possibly through the persistent occupation of IgE-binding sites with photoallergen. [55] Multiple exposures with increasing doses within a day (“rush hardening”) also appear to be quite successful. [56] In addition, in patients with a detectable serum factor, removal of this by plasmapheresis has resulted in clinical remissions persisting several months. [57], [58]

CHRONIC ACTINIC DERMATITIS

Chronic actinic dermatitis is a persistent, generally eczematous, sometimes pseudolymphomatous eruption, worse in summer, with corresponding histologic features. It is induced and maintained by exposure to often very small amounts of UVB, often UVA, and sometimes also visible radiation; rarely, UVA alone appears responsible. It most commonly affects elderly men with outdoor interests, although many other subjects are also susceptible. The syndromes of persistent light reactivity, actinic reticuloid, photosensitive eczema, and photosensitivity dermatitis (Table 135-2), each independently named more than 30 or more years ago, are now all considered variants of the same condition. The disorder appears in all respects to have the features of allergic contact dermatitis, and thus may be an acquired, delayed-type hypersensitivity reaction to endogenous, photoinduced, epidermal antigen(s).



TABLE 135-2 **Original Published Criteria for Eczematous Photosensitivity Disorders**

Historical Aspects (See Table 135-2)

The possibility of persistent light reactivity appears to have been first mentioned in 1933 by Haxthausen, who described continuing photosensitivity in a patient intravenously injected with trypaflavine, following which Wilkinson, in 1961, reported an epidemic in older males of a prolonged photoallergy to tetrachlorosalicylanilide, an antibacterial agent present in soaps and hair toiletries. Jillson and Baughman then named this condition persistent light reaction. [60] Thus, following continuing cutaneous contact with photoallergens such as the halogenated salicylanilides, musk ambrette, or quinoxaline dioxide, occasional patients developed a photoallergic contact dermatitis to these substances, and a very few progressed to a persisting abnormal photosensitivity of not just exposed skin but often also covered sites, despite an apparent complete avoidance of exposure to the offending chemicals. Further, whereas the action spectrum for the initiating photocontact reaction generally encompassed just the UVA wavelengths, that of the persistent disorder generally included the UVB, and occasionally visible light.

In 1969, Ive et al. [61] introduced the term actinic reticuloid to describe a similar, but apparently more severe, dermatosis; in this case, however, there was no apparent prior photoallergen. Nevertheless, the condition again affected mostly elderly males, and it was characterized by infiltrated, erythematous plaques, on an eczematous background, predominantly

affecting exposed sites. The histopathologic features tended to resemble cutaneous T cell lymphoma, and there were abnormal cutaneous photobiologic responses to UVB, UVA, and, occasionally, visible radiation. Furthermore, although the authors noted a resemblance to persistent light reactivity, photopatch tests to all common photoallergens were negative in their patients. Similar, but purely eczematous variants of the condition, also without overt preceding photoallergy, were also described, with action spectra limited to the UVB (photosensitive eczema) [62] or UVB ± UVA (photosensitivity dermatitis). [63]

In 1979, Hawk and Magnus [64] proposed that actinic reticuloid, photosensitive eczema, and photosensitivity dermatitis be incorporated into the one syndrome of chronic actinic dermatitis (CAD), the validity of which was supported by reports of the transition of actinic reticuloid to photosensitive eczema, [65] and the occasional association of the clinicopathologic features of actinic reticuloid with just UVB photosensitivity, a variant with no specific name. Furthermore, in view of the close clinical, histological, and photobiological resemblances between persistent light reactivity and CAD, the end-stage persistent light reactivity syndrome and CAD also appear to be the same. Patients who do not demonstrate increased sensitivity to UVB irradiation on covered skin in the absence of an external photoallergen are excluded, however, thereby differentiating the persistent photosensitivity of CAD from the transient light reactivity of photoallergic contact dermatitis, which may nevertheless rarely eventually progress to CAD (see also Chap. 136).

Etiology and Pathology

The mechanism underlying the transition from photoallergy to CAD, in cases in which this disorder is in fact a precursor, remains unclear. Any explanation needs to account for the increased UVB, rather than just UVA, sensitivity of skin that has had no direct contact with any relevant chemical. However, it seems very possible [66] that during the initial localized photoallergic reaction, a normal skin constituent is altered to become antigenic, the induction of the local response apparently beginning with UVA-dependent covalent photochemical binding of hapten to endogenous protein, followed by an eczematous delayed-type hypersensitivity response. In the localized reaction, hapten must be present, but with the progression to CAD, UVB ± UVA irradiation alone may trigger the immune response at any site, very possibly by the continuing formation of antigenic photoproduct from the ubiquitous endogenous carrier protein alone. This outcome now also appears possible, and, in fact, usual, without any prior photoallergy. Kochevar and Harber, [67] using an in vitro model with the photosensitizer tetrachlorosalicylanilide, provided theoretical support for such a mechanism, demonstrating that the phototoxic oxidation of histidine with the modification of carrier protein into weak antigen was indeed possible. Although the chromophores for such putative antigen formation have not been identified, the action spectrum for CAD induction resembles that for sunburn inflammation, [68] at least in many instances, for which DNA is already considered the most likely main target. Thus, perhaps DNA, or a similar or related molecule, may also act as an antigen in CAD.

The histologic and immunohistochemical features of CAD, including adhesion molecule expression, are essentially the same as those of persistent allergic contact dermatitis, [69], [70] or, in more severe cases, cutaneous T cell lymphoma (CTCL). In particular, the dermal infiltrate consists predominantly of T lymphocytes with a significant trend toward lower CD4+/CD8+ ratios in patients with more florid histology, [69] features that may also all occur in persistent, pseudolymphomatous forms of allergic contact dermatitis. Thus, the occurrence of the actinic reticuloid variant of CAD may, in fact, reflect prolonged and marked endogenous antigenic stimulation.

Allergic contact dermatitis commonly coexists with CAD, often preceding the onset of any photosensitivity, [71] reactivity to one or more allergens occurring in 75 percent of patients. [72] Sesquiterpene lactone extracts from Compositae plants are implicated most commonly, but other allergens may include fragrance, colophony, rubber, and sunscreens. Such substances do not cause positive photopatch test reactions, although they may cause phototoxic reactions in vitro, [73], [74] including the ability to oxidize histidine, and might contribute additionally to altering endogenous protein to antigenic forms leading to CAD. As also proposed for persistent light reactivity, the avoidance of such substances may conceivably result in gradual resolution of the condition. [75] In addition, chronic cutaneous immunostimulation from constant patient exposure to airborne allergens during simultaneous ultraviolet exposure, as in gardening, may enhance cutaneous immune recognition of the putative, presumed weak, endogenous photoallergen.

Although photoallergy may progress to CAD and then to the actinic reticuloid variant [76] in a proportion of patients, there is often no evidence of preceding photoallergy. CAD is thus likely to represent an end state that may arise from a number of predisposing conditions, namely photoallergic contact dermatitis, allergic contact dermatitis to substances with possible phototoxic potential, endogenous eczema, [77] perhaps photosensitivity from oral medication, possibly polymorphic light eruption, and human immunodeficiency virus infection. [78] Finally, CAD also appears not uncommonly to arise de novo in normal subjects.

Significant exposure to sunlight, both photoaging the skin and activating putative endogenous photosensitizer, may lead to CAD in men such as gardeners, who are also regularly exposed to important airborne antigens such as Compositae oleoresins. Aged skin may also be more susceptible as a result of reduced barrier function and allergen removal. Finally, because only small doses of UVR are needed to evoke the eruption, the increased melanin of black skin does not apparently protect against the condition.

Clinical Features

Chronic actinic dermatitis usually affects the middle-aged or elderly throughout many areas of the world, [74], [78], [79] approximately 90 percent of patients being male. Occurrence under 50 years of age is unusual, unless patients have coexistent atopic eczema. [77] The eruption is usually worse in summer and after sun exposure, although patients may often fail to recognize this, particularly if affected year-round. Patchy or confluent eczematous changes are present on the exposed skin of the backs of the hands, face (Fig. 135-7 and Fig. 135-8), scalp, and upper chest, often with some degree of sparing of the skin of the finger webs, of the upper eyelids, behind the ears, and in the depths of skin creases. Severely affected patients also characteristically demonstrate shiny, erythematous, infiltrated papules or confluent

plaques on exposed sites, sometimes abruptly adjacent to patches of normal exposed skin. Irregular hyper- and hypopigmentation, sometimes marked, may also occur. In addition, there is the occasional progression to erythroderma, often, but not always, accentuated on exposed sites. Large numbers (up to 20 percent) of circulating CD8+ Sézary cells may be found in such patients without any suggestion of malignancy. [80] An association with lymphoma has, however, been reported but such reports are rare and any association may be coincidental, particularly because T cell receptor and immunoglobulin gene rearrangement studies fail to demonstrate any evidence of clonal lymphoid proliferation. [81]

FIGURE 135-7 Chronic actinic dermatitis. Infiltrated eczematous eruption on face.

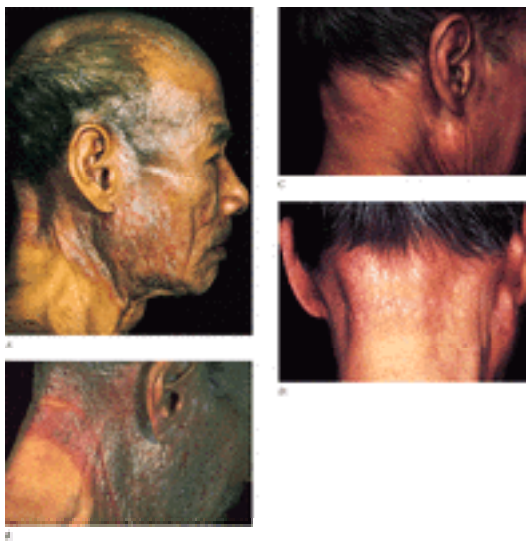

FIGURE 135-8 Chronic actinic dermatitis. *A, B.* Severe involvement of face and neck with marked eczematous dermatitis. *C, D.* In this instance, the disease resolved with a course of oral PUVA photochemotherapy over several weeks. Oral corticosteroids were necessary initially, however, to control the exacerbation induced by irradiation.

Histology

Histologic features [26] include epidermal spongiosis, acanthosis, and, sometimes, hyperplasia, along with a predominantly perivascular lymphocytic cellular infiltrate confined to the upper dermis, milder cases having the appearance of chronic eczema. Severe CAD, however, may mimic CTCL histologically, with epidermal Pautrier-like microabscesses and a deep, dense epidermotropic mononuclear cell infiltrate, sometimes with hyperchromatic convoluted nuclei and giant cells, but no marked increase in mitoses.

Diagnosis

Phototesting of the skin is essential to confirm the diagnosis of CAD, and is characterized by abnormally low erythemal thresholds with eczematous or pseudolymphomatous responses characteristic of the disorder itself following irradiation with UVB, and, in the majority of patients, also UVA. A minority of patients react also to the visible wavelengths, while a very small number may be sensitive to UVA alone, although drug or chemical photosensitivity must be carefully excluded in such instances. Such testing must be performed on uninvolved skin not exposed to systemic or topical corticosteroid administration over the preceding 3 to 4 days to avoid false-negative results. Broad-spectrum or monochromatic sources may both be effective at inducing abnormal responses, although the latter determine the action spectrum for the disease more precisely. Light-exacerbated endogenous eczemas must be distinguished by their differing clinical features and usually normal light tests, while CTCL may also rarely be photosensitive, more commonly to UVA than UVB. Such photosensitivity, however, is usually clinically mild.

Patch and photopatch tests are also essential in suspected CAD. Contact sensitivity to airborne or other ubiquitous allergens such as Compositae oleoresins, perfume, or colophony are able to mimic or coexist with CAD. In addition, secondary contact or photocontact sensitivity to sunscreens or topical applications may also occur. Finally, photopatch testing may also detect primary photoallergic contact dermatitis such as to the fragrance, musk ambrette.

Treatment

The treatment of CAD is usually difficult and often only partially effective. In the first instance, the rigorous avoidance of UVR and exacerbating allergen exposure and regular application of broad-spectrum topical sunscreens of low irritancy and allergenic potential (e.g., containing microfine titanium dioxide) are essential but rarely adequate as sole measures. Topical steroids and emollients and occasionally topical tacrolimus or pimecrolimus may help, but, in approximately two-thirds of resistant patients, azathioprine, 50 mg twice or three times daily, achieves remission within several months, [82] following which the drug dose may be reduced. However, recurrent therapeutic courses, generally each summer, are usually necessary. Cyclosporine too has been used and may give excellent results, [83] while mycophenolate mofetil can also be helpful. Finally, low-dose PUVA, and perhaps narrow-band UVB therapy, may be effective (see Chap. 266), although potent oral and topical steroid cover is generally necessary to avoid disease flares early on. As a result of these interventions, most CAD patients can now lead a reasonable life, until, in due course, many gradually recover from their disorder. [75]

PHOTOEXACERBATED DERMATOSES

Photoexacerbated (or photoaggravated) dermatoses represent a heterogeneous group of conditions that share one common feature: they can be precipitated or exacerbated by exposure to sunlight or to therapeutic or cosmetic UVR in at least a proportion of cases (Table 135-3). It is however important to recognize that these diseases are not true photodermatoses because they commonly develop without exposure to radiation. The precise underlying mechanisms of their exacerbations are generally undetermined, but UV irradiation apparently contributes specifically to pathogenesis in some disorders, such as lupus erythematosus, while in others, it may be just a nonspecific factor able to worsen the condition. Some of the disorders most frequently and importantly affected in this way are discussed below.

Acne
Atopic eczema
Carcinoid syndrome
Cutaneous T cell lymphoma
Dermatomyositis
Disseminated superficial actinic porokeratosis
Erythema multiforme
Familial benign chronic pemphigus (Hailey-Hailey disease)
Granuloma annulare
Keratosis follicularis (Darier's disease)
Lichen planus
Lupus erythematosus
Pellagra
Pemphigus foliaceus (erythematosus)
Pityriasis rubra pilaris
Psoriasis
Reticulate erythematous mucinosis syndrome
Rosacea
Seborrheic eczema
Transient acantholytic dermatosis (Grover's disease)
Viral infections

TABLE 135-3 **Diseases Exacerbated by Ultraviolet Irradiation**

Acne (See also Chap. 73)

Acne aestivalis, as first described by Hjorth et al., [84] was characterized by pruritic, 1- to 3-mm, pink or pale, dome-shaped papules occurring after sun exposure, usually on the face, neck, or trunk. Nieboer [85] then further reported two patients, describing the disorder as actinic superficial folliculitis with a predominantly follicular, pustular, nonpruritic rash occurring several hours after sun exposure, on the upper trunk and arms. Verbov [86] finally described patients with overlapping features of both acne aestivalis and actinic superficial folliculitis, suggesting the unifying term actinic folliculitis. The condition appears to be a form of UVR-exacerbated acne, for which high-protection-factor sunscreens, standard acne treatments, including topical retinoic acid, and topical and systemic antibiotics have not generally been helpful. Oral isotretinoin was however prophylactic and highly effective in two cases. [87]

Darier's Disease (See also Chap. 54)

There are not many reports of photosensitivity in Darier's disease. However, controlled tests with mainly UVB radiation have shown that lesions can be induced that exhibit the clinical and histopathologic criteria of the disease. The exacerbation of Darier' s disease after sun exposure is also well-documented, and one of the authors found exacerbation in two patients experimentally treated with psoralen photochemotherapy (PUVA).

Disseminated Superficial Actinic Porokeratosis (See also Chap. 56)

Disseminated superficial actinic porokeratosis (DSAP) may be induced or exacerbated by sun exposure, or by immunosuppression, [88] which suggests that the exacerbation by sunlight in part reflects the UVR-induced impairment of local cutaneous immunity.

Several authors have also reported the induction of new lesions or exacerbation of preexisting ones following exposure to artificial UVR radiation sources, in particular, during the long-term treatment of psoriasis, [89], [90] and the disorder has also been aggravated by suntan parlor exposure. Furthermore, in a study of potentially provocative wavelengths, UVB plus UVA was more effective in inducing new or exacerbating preexisting lesions than either wavelength alone. [91]

Herpes Simplex (See also Chap. 214)

It is common knowledge that many patients experience herpes simplex eruptions after sun exposure, particularly while sunbathing, mountain hiking, or skiing at higher altitudes. The mechanisms for viral activation by UVR are unknown but may be related to localized UVR immune suppression. However, several other nonspecific stimuli, such as fever, hormonal changes (menses), or heat, can trigger herpes lesions. Reports on sunlight-induced erythema multiforme may

actually reflect the fact that herpes may precipitate erythema multiforme. Finally, relapsing gluteal herpes simplex is not uncommon in patients treated with UVB or PUVA (see Chap. 266).

Lichen Planus Actinicus (See also Chap. 49)

In addition to being able to trigger lichen planus as a Koebner reaction to sunburn injury, UV irradiation in suberythemogenic doses can also induce a lichenoid reaction known as lichen planus actinicus. [92] The condition most commonly affects dark-skinned subjects, particularly from the Middle East, but patients have also been reported from India, Europe, and the United States. Several clinical patterns have been described. The most common consists of annular, hyperpigmented plaques predominantly on the face and dorsa of the hands. Others include pigmented melasma-like patches on the face and neck, or skin-colored, closely aggregated, pinhead papules particularly on the face and dorsa of the hands. [92], [93] The peak age of onset is the third decade, and the lesions are generally only mildly pruritic, developing mainly on exposed sites during spring and summer and improving or remitting in winter. Experimental reproduction of lesions was successful in one patient with UVB but not with UVA. [94] Histopathology is identical to classic lichen planus.

Eczema (See also Chap. 122 and Chap. 124)

Patients with atopic or seborrheic eczema occasionally report mild to oderate, nonspecific exacerbation of their condition following sun exposure. Normal responses are generally demonstrated on phototesting, thus allowing distinction from chronic actinic dermatitis. However, the majority of patients with atopic dermatitis actually benefit from both sunlight and artificial UV irradiation.

Lupus Erythematosus (See also Chap. 171)

Photosensitivity has been reported for several so-called collagen vascular diseases such as lupus erythematosus or dermatomyositis. However, only in lupus erythematosus (LE) is the correlation between sunlight exposure and the development of skin lesions well established. Therefore, photosensitivity that results in a specific skin rash has been added to the American Rheumatological Association (ARA) list of criteria to diagnose systemic lupus. The estimated prevalence of photosensitivity in this disease ranges from 30 to 70 percent in the white population. It is important to recognize that different subsets of lupus erythematosus show different degrees of photosensitivity. Chronic cutaneous LE with typical discoid lesions is usually not photoaggravated. However, discoid lesions occur primarily on sun-exposed areas such as the face, scalp, and ears, and some patients with discoid LE will progress to systemic LE. Whether such progression occurs in photosensitive patients only is unclear. In systemic LE, the typical butterfly rash may appear suddenly after sun exposure. Also widespread lesions may develop in other exposed skin areas associated with systemic exacerbation. The subset that exhibits photosensitivity most strikingly is subacute cutaneous LE. About 50 percent of these patients fulfill the ARA criteria for systemic LE but systemic manifestations tend to be milder than in patients with classical systemic LE. [95], [96] Patients with subacute cutaneous LE tend to have anti-Ro (SSA) antibodies that represent predictors of photosensitivity. Thus, several studies have supported the hypothesis that UVB irradiation may induce Ro antigens in the disease to translocate to the keratinocyte membrane by a glycosylation and microfilament-dependent process. At the membrane, they are bound by Ro autoantibodies, which leads to immunologic cell lysis, probably by antibody-dependent cellular cytotoxicity. [97], [98] and [99]

The action spectrum for the induction of LE skin lesions includes both UVB and UVA and there are reports about exacerbation during photochemotherapy for psoriasis. Lehmann et al. [100] investigated the reproduction of LE lesions with artificial UVR in 128 patients. They found the development of lesions on exposure to UVA and UVB in 53 percent, on exposure to UVA alone in 14 percent, and on exposure to UVB in 33 percent. Interestingly, lesions were induced in 64 percent of patients with subacute cutaneous LE, in 42 percent of patients with chronic discoid LE, and in only 25 percent of patients with systemic LE. [100] This strongly supports the idea that discoid LE is photoaggravatable. In view of this study and several previous investigations, photosensitivity to broadband UVR in LE is a well-documented phenomenon. [101] Because exacerbations can be provoked by UVA and UVB, appropriate broad-spectrum sun protection should be recommended for all forms of LE. [95]

Pellagra (See also Chap. 145)

Pellagra is characterized clinically by skin abnormalities, gastroenteritis, and encephalopathy, the cutaneous features often being sunlight-induced, appearing in the spring and summer and improving in winter. Pruritus and erythema occur initially on exposed areas, followed by vesicles, bullae, and essentially symmetric, chronic, scaly, hyperpigmented, thickened sclerotic papules and plaques. Dusky erythema and powdery scaling of the nose, a scaling collarette around the neck with sternal extension (Casal's necklace), glossitis, and mucous membrane ulcerations are also typical. The inducing wavelengths are unknown, as no lesions or other abnormalities have been demonstrated following artificial irradiation. It seems likely that decreased availability of NADP and NADPH resulting from niacin deficiency may prevent the oxidation/reduction reactions necessary for the normal repair of UVR-induced epidermal damage.

Pemphigus (See also Chap. 59)

Pemphigus vulgaris is not clinically associated with photosensitivity, although artificial UVR induction of lesions with typical acantholysis has been noted. Pemphigus foliaceus and erythematosus may however be aggravated or induced by sun exposure, characteristic lesions having also been produced in both variants with experimental UVR. [102], [103]

Bullous Pemphigoid (See also Chap. 61)

A few patients have been described who developed bullous pemphigoid lesions after UVB exposure. However, more

cases have been reported in which photochemotherapy (PUVA), given for unrelated diseases, was the triggering mechanism. [104]

Psoriasis (See also Chap. 42)

Some patients with psoriasis report exacerbation of their disease after sunbathing, particularly, after sunburn. Several groups have also attempted to estimate the prevalence of photosensitivity in psoriasis from surveys and questionnaires. Ros et al. sent questionnaires to 2000 patients with psoriasis in Stockholm, and after telephone interviews, considered the prevalence of photosensitivity to be 5.5 percent. In this study, in addition, the light-sensitive patients with psoriasis had a history of PMLE with a secondary exacerbation of their psoriasis in 43 percent of cases, and were more likely to have skin phototype I, psoriasis affecting their hands, a family history of psoriasis, and an advanced age. [105] Interestingly, despite photosensitivity, such patients can be successfully treated with PUVA. It is thus very likely that the phenomenon of photosensitive psoriasis represents a Koebner type of reaction to either PMLE or sunburn in fair-skinned subjects.

APPROACH TO THE PATIENT WITH PHOTOSENSITIVITY

Clinical Features

History taking is frequently the most important element in diagnosis of the photodermatoses, particularly of the intermittent conditions in which the eruption is often not present at the time of consultation. The following features of the eruption are of particular importance.

Exposure:
Latent interval between exposure and eruption
Seasonal variation
Minimum exposure duration to elicit eruption
Response to irradiation through window glass or clothing
Eruption:
Duration
Distribution
Morphology
Accompanying or premonitory symptoms (such as pruritus, dizziness, burning sensation, swelling)
Patient:
Age at onset
Sex
Occupation (outdoor or indoor, such as sailor, farmer, welder, roofer, gardener, phototherapist)
Topical applications or contacts (such as cosmetics, sunscreen, plants, chemicals, perfumes, sprays, aftershaves)
History of skin response to sun exposure (rash or susceptibility to sunburn)
History of effectiveness of sunscreens in prophylaxis
Systemic medications
Leisure activities such as gardening, outdoor pursuits
Family history

To establish the relationship between an eruption and UVR exposure, it is important in most patients to determine whether the exposed sites are affected predominantly, whether the condition is worse in summer, and whether the lesions develop only in association with UVR exposure. If photosensitivity is present, the eruption tends to occur on the forehead; bridge of nose; upper cheeks; chin; rims of ears; back and sides of the neck; upper chest; dorsa of the hands and feet; and extensor surfaces of the arms and lower legs. On the other hand, sparing characteristically occurs below the eyebrows; under the hair fringe; on the upper eyelids; below the nose, lower lip, and chin; behind the earlobes; in the webspaces of the fingers; and at the bottom of skin folds or creases. Involvement of the latter sites can sometimes occur, however, if allergic contact dermatitis to airborne allergens or extreme photosensitivity is present.

Central to the diagnosis of the acute intermittent photodermatoses is the time course of the eruption following sun exposure. Thus, onset within 5 to 10 min with resolution in an hour or so is typical of solar urticaria and photosensitivity due to certain drugs such as benoxaprofen (which has been withdrawn from the market) or amiodarone. A delay of 20 min to several hours with lesions lasting for several days is characteristic of PMLE, HV, erythropoietic protoporphyria, subacute cutaneous LE and other light-exacerbated dermatoses, and xeroderma pigmentosum, as well as drug photosensitivity to, for example, thiazide diuretics.

A description of the morphology of the eruption is also of great diagnostic importance. Patients with SU describe raised pruritic wheals, sometimes confluent, whereas those with erythropoietic protoporphyria or drug photosensitivity to amiodarone or previously benoxaprofen complain of an often severe, painful, burning sensation with initially no visible signs. Later they may develop diffuse swelling and erythema of the exposed sites with prolonged exposure. HV is differentiated from PMLE by its characteristic blistering response always leading to varioliform scarring. Helpful in distinguishing PMLE from subacute cutaneous LE are the usual lack of pruritus and the presence of discrete scaling plaques in the latter, although an eruption indistinguishable from PMLE has also been described in some subacute cutaneous LE patients.

Photoexacerbated dermatoses must be distinguished by their morphologies and distribution. Xeroderma pigmentosum and most drug-induced photosensitivity, on the other hand, can lead to an exaggerated sunburn-like response, which, in the case of xeroderma pigmentosum, may not reach its peak until 48 to 72 h after exposure.

In patients who report a more persistent, apparently photosensitive eruption, the morphology of lesions should be carefully considered. Persistent pruritic papules, occurring mostly on exposed sites but also involving the upper limbs and sometimes buttocks, are suggestive of AP. An eczematous eruption accentuated on or limited to the exposed sites

suggests CAD, particularly if there is a history of exposure to potential airborne contact allergens such as the Compositae oleoresins or colophony, but this must be differentiated from light-aggravated endogenous eczema and perhaps eczematous drug-induced photosensitivity (e.g., thiazide-induced) (see Chap. 136), although the latter seems rare. Fragility and blistering with scarring of the exposed skin, worse in the summer, suggests a hepatic porphyria or pseudoporphyria, particularly if drug or excessive alcohol ingestion, or frequent sunbed exposure, has occurred (see Chap. 149).

Other important general points in the history, often helpful in diagnosis, include the age at onset—young girls most often suffer from AP, children from HV, young women from PMLE, and elderly men from CAD. A family history of photosensitivity is sometimes present in AP, PMLE, and the porphyrias. Finally, a reaction to sun exposure through window glass may assist in diagnosis and treatment by suggesting the action spectrum of the eruption, as UVB radiation is absorbed by glass. Certain occupations or leisure activities may permit exposure to allergens or photocontact allergens, such as in outdoor workers or enthusiasts, in whom CAD is possible. Deterioration in the condition despite regular sunscreen application should suggest the possibility of allergic contact dermatitis to one of the sunscreen constituents.

Laboratory Studies

Unless the diagnosis is otherwise certain, important investigations in all cases of photosensitivity include measurement of the circulating antinuclear factor, anti-SSA (Ro) and anti-SSB (La) antibody titers, and of blood, urine, and stool porphyrin concentrations. Lesional skin histology, particularly in PMLE, HV, and CAD, may also be helpful, but rarely diagnostic. Direct immunofluorescence, however, can assist in the diagnosis of LE. On the other hand, phototesting of unaffected skin, usually of the back with narrow-waveband or monochromatic irradiation, may induce the eruption and thus define the action spectrum in certain disorders. This type of testing is however only moderately reliable overall, while solar simulating and broad-waveband irradiation are more effective eruption inducers but give less idea of the action spectrum. In eczematous photosensitivity, patch and photopatch testing are also important to identify any inducing or exacerbating allergens. Finally, special techniques, such as the measurement of DNA excision repair or the rate of recovery of RNA synthesis in cultured fibroblasts following UV irradiation, are also required to make the diagnosis in certain genophotodermatoses.

Phototesting

Phototesting of the unaffected skin, usually on the back, may assist in the diagnosis of photosensitivity and help to identify the responsible wavelengths by demonstrating reduced erythemal thresholds or reproducing the typical lesions. Table 135-4 lists the disorders in which such testing is likely to be helpful. Several suitable protocols have been described, either relatively simply with broad-spectrum light sources and filters if necessary, or, preferably, for precise definition of the action spectrum, with an irradiation monochromator. Sunlight with filters may also be used in some parts of the world but is generally too unpredictable for regular and reliable use (for references see Ref. [106] and Ref. [107]).

TABLE 135-4 **Phototest Responses in Photosensitivity Disorders**

Solar simulators produce imitation sunlight from xenon arc lamps; excitation of the highly compressed gas produces a continuous emission spectrum approximating fairly closely that of terrestrial sunlight after the unwanted wavelengths shorter than 285 nm and longer than 700 nm have been removed by appropriate filters. Such sources most reliably induce the typical eruption of the photodermatoses, enabling confirmation of the diagnosis, while further filters can also be used to enable some degree of action spectrum determination.

An irradiation monochromator (normally incorporating a xenon arc source, input slit, collimating mirror, and output slit) is required to establish precise action spectra, but the experience necessary for its correct use and the appropriate interpretation of results is such that this sophisticated and expensive equipment is not generally available. The apparatus emits any chosen narrow waveband with reliable purity, although usually relatively low irradiance, which may be accurately quantified with an appropriate radiometer such as a thermopile.

A number of other less expensive, more versatile, and more robust radiation sources have also been used to investigate patients with photosensitivity. For example, mercury vapor arc lamps emit throughout most of the solar spectrum but with superimposed isolated lines of relatively high output, rather than the smoothly continuous spectrum produced by the xenon arc. Thus, the Kromayer lamp has been a widely available, convenient, mobile, medium-pressure source emitting mostly in the UVB and UVC regions, but the difficulty in precise determination of the wavelengths and doses of light emitted have made it useful mainly for rapid nonquantitative studies or occasionally treatment. Fluorescent lamps on the other hand are low-pressure mercury arc glass tubes coated on their inner surfaces with fluorescent phosphors made of alkaline earth salts, which then convert the internally emitted 254-nm mercury line into a variety of external broadband outputs, for example, UVA or UVB. Such lamps can be used for phototesting in relatively inexpensive and easily constructed systems, if necessary with filters. However, they are even more useful for phototherapy and, in the case of UVA lamps, also for photopatch testing.

Phototesting is usually performed on the unaffected skin of the back, although the attempted induction, for example of PMLE, is best undertaken on previously involved skin. Systemic glucocorticoids in high doses should not have been administered nor test sites treated with topical glucocorticoids in the preceding few days in order to avoid false-negative

results. Furthermore, both patient and investigator must wear protective goggles.

Photopatch Testing (See also Chap. 136)

Photopatch testing is a well-established method to use for identifying phototoxic or photoallergic substances. It should be performed whenever a phototoxic reaction or photoallergic contact dermatitis is suspected. Diseases of the CAD spectrum are also indications for testing. In the latter, contact sensitivity may also be noted to airborne allergens such as plant oleoresins, which may have an inducing or exacerbating role in CAD. Other photodermatoses, such as PMLE, HV, SU (see above), or porphyrias, are diagnosed according to specific criteria of these entities and do not represent an indication for the photopatch test.

For patients who present with unclear photoreactions that cannot be associated with a genuine photodermatosis, photopatch testing should also be performed. This holds true in particular for patients with eczema in a photodistribution, or those with exacerbated sunburn reactions. Such lesions are suspicious for photoallergic or phototoxic reactions, respectively, and a careful history should evaluate all drugs and topical preparations. Among those, the photosensitizer should be identified in the photopatch test. Following such stringent criteria for photopatch testing, unnecessary test procedures are avoided and the positive test reactions obtained are likely to be highly relevant for the patients. Test materials are applied to the back in a duplicate set, one for irradiation, the other as a control. Patches to be irradiated are left on the skin for 24 h; control patches are applied for either 24 or 48 h. Nonirradiated patches are used as controls to exclude nonphotoinduced plain contact sensitivity. Test sites are evaluated before and immediately after irradiation as well as 24, 48, and 72 h later. Control sites are read shortly after removal of the patches as well as 24 and 48 h later.

Until the early 1980s, the photopatch test procedure was not standardized. Differences between the recommended test procedures included variations in the range of test substances, the irradiation doses, the precise irradiating wavelengths, the timing of the irradiation, the irradiance used, and the delay before reading the responses. The first attempt to devise a standard method was initiated by the Scandinavian Photodermatitis Research Group (SPRG). [108] Following this example, the German photopatch test working group was founded in 1984 in Germany, Austria, and Switzerland. This group also established a standardized protocol for photopatch testing. [109]

REFERENCES

1. Ros A, Wennersten G: Current aspects of polymorphous light eruption in Sweden. *Photodermatology* **3**:298, 1986

2. Morison WL, Stern RS: Polymorphous light eruption: A common reaction uncommonly recognized. *Acta Derm Venereol (Stockh)* **62**:237, 1982

3. Pao C et al: Polymorphic light eruption: Prevalence in Australia and England. *Br J Dermatol* **130**:62, 1994

4. Khoo SW et al: Photodermatoses in a Singapore skin referral center. *Clin Exp Dermatol* **21**:263, 1996

5. Norris PG, Hawk JLM: The idiopathic photodermatoses: polymorphic light eruption, actinic prurigo and hydroa vacciniforme, in *Photodermatology*, edited by JLM Hawk. London, Arnold, 1999, pp 178–190

6. McGregor JM et al: Genetic modeling of abnormal photosensitivity in families with polymorphic light eruption and actinic prurigo. *J Invest Dermatol* **115**:471, 2000

7. Hölzle E et al: Polymorphous light eruption: Experimental reproduction of skin lesions. *J Am Acad Dermatol* **7**:111, 1982

8. Ortel B et al: Polymorphous light eruption: Action spectrum and photoprotection. *J Am Acad Dermatol* **14**:748, 1986

9. Miyamoto C: Polymorphous light eruption: Successful reproduction of skin lesions, including papulovesicular light eruption, with ultraviolet B. *Photodermatology* **6**:69, 1989

10. Leenutaphong V et al: Pathogenesis and classification of solar urticaria: A new concept. *J Am Acad Dermatol* **21**:237, 1989

11. Pryzbilla B et al: Polymorphous light eruption: Eliciting and inhibiting wavelengths. *Acta Derm Venereol* **68**:173, 1988

12. Leenutaphong V et al: Solar urticaria induced by visible light and inhibited by UVA. *Photodermatology* **5**:170, 1988

13. McFadden JP et al: Heat shock protein 65 immunoreactivity in experimentally induced polymorphic light eruption. *Acta Derm Venereol (Stockh)* **74**:283, 1994.

14. Tegner E, Bradin AM: Polymorphous light eruption in hypopigmented pressure areas with a UVA sunbed. *Acta Derm Venereol (Stockh)* **66**:446, 1986

15. Norris PG et al: Polymorphic light eruption: An immunopathological study of evolving lesions. *Br J Dermatol* **120**:173, 1989

16. Norris PG et al: The expression of endothelial leukocyte adhesion molecule (ELAM-1), intercellular adhesion molecule-1 (ICAM-1), and vascular cell adhesion molecule-1 (VCAM-1) in experimental cutaneous inflammation: A comparison of ultraviolet B erythema and delayed hypersensitivity. *J Invest Dermatol* **96**:763, 1991

17. Vejlsgaard GL et al: Kinetics and characterization of intercellular adhesion molecule-1 (ICAM-1) expression on keratinocytes in various inflammatory skin lesions and malignant cutaneous lymphomas. *J Am Acad Dermatol* **20**:782, 1989

18. Norris PG et al: Adhesion molecule expression in polymorphic light eruption. *J Invest Dermatol* **99**:104, 1992

19. Gonzales-Amaro R et al: Immune sensitization against epidermal antigen in polymorphous light eruption. *J Am Acad Dermatol* **24**:70, 1991

20. Farr PM, Diffey BL: Effects of indomethacin on UVB- and UVA-induced erythema in polymorphic light eruption. *J Am Acad Dermatol* **21**:230, 1989

21. Rhodes L et al: Dietary fish oil reduces basal and ultraviolet B-generated PGE_2 levels in skin. *J Invest Dermatol* **105**:532, 1995

22. Jansen CT, Darvonen J: Polymorphous light eruption. A seven-year follow-up evaluation of 114 patients. *Arch Dermatol* **120**:862, 1984

23. Murphy GM, Hawk JLM: The prevalence of antinuclear antibodies in patients with apparent polymorphic light eruption. *Br J Dermatol* **125**:448, 1991

24. Dover JS, Hawk JLM: Polymorphic light eruption sine eruptione. *Br J Dermatol* **118**:73, 1988

25. Hawk J: Juvenile spring eruption is a variant of polymorphic light eruption. *N Z Med J* **109**:389, 1996

26. Hawk JLM et al: The photosensitivity disorders, in *Lever's Histopathology of the Skin* edited by DE Elder, R Elenitsas, C Jaworsky, B Johnson Jr. Philadelphia, Lippincott-Raven, 1997, pp 305–310

27. Murphy GM et al: Prophylactic PUVA and UVB therapy in polymorphic light eruption—a controlled trial. *Br J Dermatol* **116**:531, 1987

28. Bilsland D et al: A comparison of narrow band phototherapy (TL-01) and photochemotherapy (PUVA) in the management of polymorphic light eruption. *Br J Dermatol* **129**:708, 1993

29. Patel DC et al: Efficacy of short-course oral prednisolone in polymorphic light eruption: A randomized controlled trial. *Br J Dermatol* **143**:828, 2000

30. Murphy GM et al: Hydroxychloroquine in polymorphic light eruption: A controlled trial with drug and visual sensitivity monitoring. *Br J Dermatol* **116**:379, 1987

31. Saul A et al: Polymorphous light eruption: Treatment with thalidomide. *Australas J Dermatol* **17**:17, 1976

32. Corbett MF et al: Controlled therapeutic trials in polymorphous light eruption. *Br J Dermatol* **107**:571, 1982

33. Norris PG, Hawk JLM: Successful treatment of severe polymorphic light eruption with azathioprine. *Arch Dermatol* **125**:1377, 1989

34. Shipley DR, Hewitt JB: Polymorphic light eruption treated with cyclosporin. *Br J Dermatol* **144**:446, 2001

35. Farr PM, Diffey BL: Augmentation of ultraviolet erythema by indomethacin in actinic prurigo: Evidence of mechanism of photosensitivity. *Photochem Photobiol* **47**:413, 1988

36. Menagé H et al: HLA-DR4 may determine expression of actinic prurigo in British patients. *J Invest Dermatol* **106**:362, 1996

37. Grabczynska SA et al: Actinic prurigo and polymorphic light eruption: Common pathogenesis and the importance of HLA-DR4/DRB1*0407. *Br J Dermatol* **140**:232, 1999

38. Lovell CR et al: Thalidomide in actinic prurigo. *Br J Dermatol* **108**:467, 1983

39. Farr PM, Diffey BL: Treatment of actinic prurigo with PUVA: Mechanism of action. *Br J Dermatol* **120**:411, 1989

40. Birt AR, Davis RA: Hereditary polymorphous light eruption of American Indians. *Int J Dermatol* **14**:105, 1975

41. Bernal JE et al: Actinic prurigo among the Chimila Indians in Colombia: HLA studies. *J Am Acad Dermatol* **22**:1049, 1990

42. Sheridan DP et al: HLA typing in actinic prurigo. *J Am Acad Dermatol* **22**:1019, 1990

43. Sonnex TS, Hawk JLM: Hydroa vacciniforme: A review of ten cases. *Br J Dermatol* **118**:101, 1988

44. Jaschke E, Hönigsmann H: Hydroa vacciniforme—Aktionsspektrum, UV-Toleranz nach Photochemotherapie. *Hautarzt* **32**:350, 1981

45. Gupta G, Man I, Kemmett D: Hydroa vacciniforme: A clinical and follow-up study of 17 cases. *J Am Acad Dermatol* **42**:208, 2000

46. Murphy GM. Diseases associated with photosensitivity. *J Photochem Photobiol: B Biol* **64**:93, 2001

47. Steger GG et al: Permanent cure of hydroa vacciniforme after treatment of Hodgkin's disease with C-MOPP/AS VD regimen. *Br J Dermatol* **119**:684, 1988

48. Ohtsuka T et al: Hydroa vacciniforme with latent Epstein-Barr virus infection. *Br J Dermatol* **145**:509, 2001

49. Cho KH et al: Epstein-Barr virus-associated peripheral T-cell lymphoma in adults with hydroa vacciniforme-like lesions. *Clin Exp Dermatol* **26**:242, 2001

50. Leenutaphong V et al: Pathogenesis and classification of solar urticaria: A new concept. *J Am Acad Dermatol* **21**:237, 1989

51. Uetsu N et al: The clinical and photobiological characteristics of solar urticaria in 40 patients. *Br J Dermatol* **142**:32, 2000

52. Horio T, Fujigaki K: Augmentation spectrum in solar urticaria. *J Am Acad Dermatol* **18**:1189, 1988

53. Monfrecola G et al: Solar urticaria: A report on 57 cases. *Am J Contact Dermatol* **11**:89, 2000

54. Norris PG, Hawk JLM: Bruising and susceptibility to solar urticaria. *Br J Dermatol* **124**:393, 1991

55. Roelandts R, Ryckaert S: Solar urticaria: The annoying photodermatosis. *Int J Dermatol* **38**:411, 1999

56. Beissert S, Ständer H, Schwarz T: UVA rush hardening for the treatment of solar urticaria. *J Am Acad Dermatol* **42**:1030, 2000

57. Duschet P et al: Solar urticaria—Effective treatment by plasmapheresis. *Clin Exp Dermatol* **12**:185, 1987

58. Bissonnette R et al: Treatment of refractory solar urticaria with plasma exchange. *J Cutan Med Surg* **3**:236, 1999

59. Wilkinson DS: Photodermatitis due to tetrachlorosalicylanilide. *Br J Dermatol* **73**:213, 1961

60. Jillson OF, Baughman RD: Contact photodermatitis from bithionol. *Arch Dermatol* **88**:409, 1963 /P>

61. Ive FA et al: “Actinic reticuloid”: A chronic dermatosis associated with severe photosensitivity and the histological resemblance to lymphoma. *Br J Dermatol* **81**:469, 1969

62. Ramsay CA, Kobza-Black A: Photosensitive eczema. *Trans St John's Hosp Dermatol Soc* **59**:152, 1973

63. Frain-Bell W et al: The syndrome of chronic photosensitivity dermatitis and actinic reticuloid. *Br J Dermatol* **91**:617, 1974

64. Hawk JLM, Magnus IA: Chronic actinic dermatitis—An idiopathic photosensitivity syndrome including actinic reticuloid and photosensitive eczema. *Br J Dermatol* **101**(suppl 17):24, 1979

65. Hawk JLM, Magnus IA: Resolution of actinic reticuloid with transition to photosensitive eczema. *J R Soc Med* **71**:608, 1978

66. Norris PG, Hawk JLM: Chronic actinic dermatitis-a unifying concept. *Arch Dermatol* **126**:376, 1990

67. Kochevar IE, Harber LC: Photoreactions of 3,3',4',5-tetrachlorosalicylanilide with proteins. *J Invest Dermatol* **68**:151, 1977

68. Menagé H et al: The action spectrum for induction of chronic actinic dermatitis is similar to that for sunburn inflammation. *Photochem Photobiol* **62**:976, 1995

69. Norris PG et al: Chronic actinic dermatitis: An immunohistological and photobiological study. *J Am Acad Dermatol* **21**:966, 1989

70. Menagé H et al: A study of the kinetics and pattern of adhesion molecule expression in induced lesions of chronic actinic dermatitis. *Br J Dermatol* **134**:262, 1996

71. Murphy G et al: Allergic airborne dermatitis to Compositae with photosensitivity—Chronic actinic dermatitis in evolution. *Photodermatol Photoimmunol Photomed* **7**:38, 1990

72. Menagé H et al: Contact and photocontact sensitization in chronic actinic dermatitis: Sesquiterpene lactone mix is an important allergen. *Br J Dermatol* **132**:543, 1995

73. Addo HA et al: A study of Compositae plant reactions in photosensitivity dermatitis. *Photodermatology* **2**:68, 1995

74. Menagé HduP, Hawk JLM: The idiopathic photodermatoses: Chronic actinic dermatitis (photosensitivity dermatitis/actinic reticuloid syndrome), in *Photodermatology*, edited by JLM Hawk. London, Arnold, 1999, pp 127–142

75. Dawe RS et al: The natural history of chronic actinic dermatitis. *Arch Dermatol* **136**:1215, 2000

76. Wolf C, Hönigsmann H: Persistent light reaction-actinic reticuloid. *Hautarzt* **39**:635, 1988

77. Creamer D et al: Chronic actinic dermatitis occurring in young patients with atopic dermatitis. *Br J Dermatol* **139**:1112, 1998

78. Lim H et al: Chronic actinic dermatitis: An analysis of 51 patients evaluated in the United States and Japan. *Arch Dermatol Res* **130**:1284, 1994

79. Healy E, Rogers S: Photosensitivity dermatitis/actinic reticuloid syndrome in an Irish population: A review and some unusual features. *Acta Derm Venereol* **75**:72, 1995

80. Chu AC et al: Immunologic differentiation of the Sézary syndrome due to cutaneous T-cell lymphoma and chronic actinic dermatitis. *J Invest Dermatol* **86**:134, 1986

81. Menagé H et al: Analysis of T-cell receptor genes in chronic actinic dermatitis: No evidence of clonality. *J Invest Dermatol* **98**:546, 1992

82. Murphy GM et al: A double-blind controlled trial of azathioprine in chronic actinic dermatitis. *Br J Dermatol* **117**:16, 1987

83. Norris PG et al: Actinic reticuloid: Response to cyclosporin A. *J Am Acad Dermatol* **21**:307, 1989

84. Hjorth N et al: Acne aestivalis—Mallorca acne. *Acta Derm Venereol* **52**:61, 1972

85. Nieboer C: Actinic superficial folliculitis: A new entity? *Br J Dermatol* **112**:603, 1985

86. Verbov J: Actinic folliculitis. *Br J Dermatol* **112**:630, 1985

87. Norris PG, Hawk JLM: Actinic folliculitis—Response to isotretinoin. *Clin Exp Dermatol* **14**:69, 1989

88. Lederman JS et al: Immunosuppression: A cause of porokeratosis? *J Am Acad Dermatol* **13**:75, 1985

89. Hazen PG et al: Disseminated superficial actinic porokeratosis: Appearance associated with photochemotherapy for psoriasis. *J Am Acad Dermatol* **12**:1077, 1985

90. Allen AL, Glaser DA: Disseminated superficial actinic porokeratosis associated with topical PUVA. *J Am Acad Dermatol* **43**:720, 2000

91. Neumann RA et al: Disseminated superficial actinic porokeratosis: Experimental induction and exacerbation of skin lesions. *J Am Acad Dermatol* **21**:1182, 1989

92. Bedi TR: Summertime actinic lichenoid eruption. *Dermatologica* **157**:115, 1978

93. Verhagen AR, Koten JW: Lichenoid melanodermatitis. *Br J Dermatol* **101**:651, 1979

94. van der Schroeff JG et al: Induction of actinic lichen planus with artificial UV sources. *Arch Dermatol* **119**:498, 1983

95. Millard TP et al: Photosensitivity in lupus. *Lupus* **9**:3, 2000

96. Catherine H et al: The pathophysiology of photosensitivity in lupus erythematosus. *Photodermatol Photoimmunol Photomed* **17**:95, 2001

97. Furukawa F et al: Binding of antibodies to ENA SS-A/Ro and SS-B/La is induced in the surface of human keratinocytes by UVL: Implications for the pathogenesis of cutaneous lupus. *J Invest Dermatol* **94**:77, 1990

98. Furukawa F et al: Susceptibility to UVB light in cultured keratinocytes of cutaneous lupus erythematosus. *Dermatology* **189**:18, 1994

99. Wang B et al: SSA/Ro antigen expressed on membrane of UVB-induced apoptotic keratinocytes is pathogenic but not detectable in supernatant of cell culture. *Chin Med J (Engl)* **112**:512, 1999

100. Lehmann P et al: Experimental reproduction of skin lesions in lupus erythematosus by UVA and UVB radiation. *J Am Acad Dermatol* **22**:181, 1990

101. Kuhn A et al: Phototesting in lupus erythematosus: A 15–year experience. *J Am Acad Dermatol* **45**:86, 2001

102. Cram DL, Winkelmann RK: Ultraviolet-induced acantholysis in pemphigus. *Arch Dermatol* **92**:7, 1965

103. Dechamps P et al: Photoinduction of lesions in a patient with pemphigus erythematosus. *Photodermatology* **1**:38, 1984

104. Perl S et al: Bullous pemphigoid induced by PUVA therapy. *Dermatology* **193**:245, 1996

105. Ros AM: Photosensitive psoriasis. *Semin Dermatol* **11**:267, 1992

106. Roelandts R: The diagnosis of photosensitivity. *Arch Dermatol* **136**:1152, 2000

107. Neumann NJ, Lehmann P: Photodiagnostic modalities, in *Dermatological Phototherapy and Photodiagnostic Methods*, edited by J Krutmann, H Hönigsmann, CA Elmets, PR Bergstresser. Berlin, Springer, 2001, pp 329–337

108. Thune P, et al: The Scandinavian Multicenter Photopatch Test Study 1980–1985: Final report. *Photodermatology* **5**:261, 1988

109. Neumann NJ et al: Photopatch testing: The 12-year experience of the German, Austrian, and Swiss Photopatch Test Group. *J Am Acad Dermatol* **42**:183, 2000

T>

Chapter 136

Henry Lim

Abnormal Responses to Ultraviolet Radiation: Photosensitivity Induced by Exogenous Agents

INCIDENCE
HISTORICAL ASPECTS
PHOTOTOXICITY
Clinical Manifestations
Phototoxic Agents
Histopathology
Pathophysiology
Management
PHOTOALLERGY
Clinical Manifestations
Photoallergens
Histopathology
Pathophysiology
Management
EVALUATION OF PATIENTS WITH PHOTOTOXICITY AND PHOTOALLERGY
OTHER EXOGENOUS AGENT-INDUCED PHOTODERMATOSIS AND PHOTOEXACERBATED DERMATOSES
PORPHYRIA CUTANEA TARDA
LUPUS ERYTHEMATOSUS
PELLAGRA

REFERENCES

Photosensitivity induced by chemicals can be caused by exogenous or endogenous agents. Exogenous photosensitizers can be categorized into those administered systemically and agents applied topically. Well-characterized examples of photosensitivity induced by endogenous photosensitizers are the porphyrias, which are associated with enzymatic defects in heme biosynthetic pathways, resulting in elevated levels of porphyrins, known phototoxic agents (Chap. 149).

Photosensitivity induced by exogenous agents can be divided into phototoxicity and photoallergy. Phototoxicity is the result of a direct tissue injury caused by the phototoxic agent and radiation; it can occur in all individuals exposed to adequate doses of the agent and the appropriate radiation (Table 136-1). In contrast, photoallergy is a type IV delayed hypersensitivity response; it has a sensitization phase, occurs only in sensitized individuals, and requires only a minimal concentration of the photoallergen (see Table 136-1).



TABLE 136-1 **Characteristics of Phototoxicity and Photoallergy**

INCIDENCE

There are more than 300 medications in the United States that have been reported to cause photosensitivity, however, only a small number of them induce frequent reactions or have been well-studied. [1], [2] The estimated incidence of photosensitivity induced by exogenous agents ranges from 16 to 25 percent for chlorpromazine, 3 percent for doxycycline, and 0.025 to 15 percent for fluoroquinolones. [3], [4] The percentage of photopatch-tested patients who have clinically relevant reactions leading to a diagnosis of photoallergic contact dermatitis ranges from 4 to 20 percent. [5], [6]

HISTORICAL ASPECTS

The earliest documented clinical application of a photosensitizing agent was in 1400 B.C., when psoralens-containing seeds of the plant *Psoralia corylifolia* plus sunlight were used in India to treat vitiligo. [7] Around the twelfth century A.D., the Egyptians obtained psoralens from flowers of another plant, *Ammi majus;* the flowers were ground and rubbed on the leukodermic skin before sun exposure.

In 1913, Meyer-Betz reported one of the earliest experiments that conclusively demonstrated the photosensitizing effect of a systemically administered agent, hematoporphyrin. In 1916, Freund described mild erythema resolving with marked hyperpigmentation in patients using perfume containing 5-methoxypsoralen. Because the perfume was often applied to

the chest, the ensuing dermatitis was referred to as *berloque* (French for pendant) or necklace dermatitis. In the 1920s and 1930s, the synergistic effect of crude coal tar and light in the treatment of psoriasis was reported by Goeckermann at the Mayo Clinic.

The current understanding of phototoxicity and photoallergy was pioneered by the studies of Stephen Epstein. In 1939, he reported data obtained from volunteers injected intradermally with sulfanilamide and subsequently irradiated with a hot quartz mercury vapor lamp. He observed and defined the *phototoxic* response, which occurred in all individuals within 24 h, and the *photoallergic* response, which occurred in only a small number of individuals 10 days later.

Since 1974, 8-methoxypsoralen has been widely used in psoralen plus ultraviolet A (PUVA) photochemotherapy and, more recently in extracorporeal photopheresis (see Chap. 266). Porphyrin derivatives and other photosensitizers are currently used in the photodynamic therapy of tumors of the skin and internal organs. [8]

PHOTOTOXICITY

Clinical Manifestations

ACUTE PHOTOTOXICITY This occurs usually within hours of exposure to the phototoxic agent and light. The patient complains of a burning and stinging sensation on light-exposed areas, such as forehead, nose, V-area of the neck and dorsum of hands. These subjective complaints are especially pronounced after exposure to tar and pitch, and are referred to as “tar smarts.” Erythema and edema appear within hours of light exposure; in severe cases, vesicles and bullae may develop. Light-protected areas, such as nasolabial folds, postauricular and submental areas, and areas covered by clothing, are spared (Fig. 136-1). A notable exception to the above-described kinetics is psoralen-induced phototoxicity, where the acute response appears in 24 h, and peaks at 48 to 72 h. This is the rationale of administering PUVA photochemotherapy doses 48 h apart. The phototoxic response usually resolves with a varying degree of hyperpigmentation, which may last for months.

FIGURE 136-1 Phototoxicity associated with a heterocyclic antidepressant. Note erythema and edema on sun-exposed areas and sparing of sun-protected chest and shaded upper lip and neck. *(Courtesy of Dr. Adrian Tanew)*

PHOTO-ONYCHOLYSIS Separation of the distal nail from the nail bed is a manifestation of acute phototoxicity. It has been reported with *doxycycline* and other *tetracyclines, fluoroquinolones, psoralens, benoxaprofen, chlorazepate dipotassium,* and *quinine.* [9], [10]
SLATE-GRAY PIGMENTATION (See also Chap. 90) Blue-gray pigmentation on sun exposed areas has been associated with exposure to several agents. [11], [12] One to 10 percent of patients taking *amiodarone* develop this side-effect (Fig. 136-2). *Chlorpromazine* can induce a similar change. The tricyclic antidepressants *imipramine* and, less commonly, *desipramine* have also been reported to cause slate-gray pigmentation; a drug metabolite-melanin complex has been postulated to be the cause of this alteration. Chronic exposure to *diltiazem,* a benzothiazepine calcium channel blocker, has resulted in photodistributed, reticulated, slate-gray pigmentation (Fig. 136-3); pigmentary incontinence and melanosome complexes are the prominent histologic and electron microscopic findings. Slate-gray pigmentation seen in *argyria* involves lunulae of nails, mucous membranes, and sclerae. A photochemical reaction involving silver granules deposited in the dermis results in these pigmentary alterations.

FIGURE 136-2 Amiodarone-induced phototoxicity. Note the erythema and slate-gray pigmentation (nose, forehead) on the sun-exposed area.

FIGURE 136-3 Slate-gray, reticulated patches on sun-exposed areas in a patient taking diltiazem. Note the sparing of the postauricular area and skin folds on the neck.

LICHENOID ERUPTION This has been reported following exposure to *fenofibrate, quinine, quinidine, hydrochlorothiazide, demeclocycline, enalapril, pyrazinamide, chloroquine,* and *hydroxychloroquine*. [9], [13] Patients present with lichen planus-like lesions on sun-exposed areas; some consider this a variant of photoallergy.
PSEUDOPORPHYRIA The development of porphyria cutanea tarda-like cutaneous changes of skin fragility, vesicles, and subepidermal blisters is associated with several phototoxic agents (see Chap. 149). While histologic and immunofluorescence findings are similar to porphyria cutanea tarda, the porphyrin profile is normal in these patients. [14] *Naproxen* is the most commonly reported agent. Other drugs incriminated include *nabumetone, oxaprozin, ketoprofen, mefenamic acid, tiaprofenic acid, diflunisal, celecoxib, tetracyclines, nalidixic acid, amiodarone, furosemide,* and *etretinate.* [14], [15]
PHOTODISTRIBUTED TELANGIECTASIA Telangiectasia on sun-exposed areas has been reported with calcium channel blockers including *nifedipine* and *amlodipine,* and with the antibiotic *cefotaxime.* Provocation with UVA resulted in the development of telangiectasia. [16]
PERSISTENCE OF PHOTOSENSITIVITY AND EVOLUTION TO CHRONIC ACTINIC DERMATITIS While phototoxicity usually resolves following discontinuation of the exposure to the causative agent, there are reports of persistence of photosensitivity many years after the cessation of exposure, resulting in the development of chronic actinic dermatitis (see photoallergy below). This has been reported with *thiazides, quinidine,* and *quinine.* [17]
CHRONIC EFFECTS Cutaneous effects of chronic, repeated phototoxic tissue injury are best exemplified by patients who had received long-term PUVA photochemotherapy. These include premature aging of the skin, lentigines (Fig. 136-4), squamous cell and basal cell carcinomas, and melanoma. [18] These are discussed in greater detail in Chap. 266.

FIGURE 136-4 Lentigines on the forearm of a patient who had received high cumulative PUVA exposure.

Phototoxic Agents

TOPICAL AGENTS Table 136-2 lists the major topical phototoxic agents; therapeutic or occupational exposures to these agents are the common route of contact. The action spectrum is in the UVA range for most of them.

Agent	Exposure
Rose bengal	Ophthalmologic examination
Furocoumarins	Occur naturally in plants (especially Compositae species), fruits and vegetables (lime, lemon, celery, fig, parsley and parsnip); used in perfumes and cosmetics; used for topical photochemotherapy
Tar	Topical therapeutic agent; roofing materials

TABLE 136-2 **Topical Phototoxic Agents**

Furocoumarins Topical exposures to *furocoumarins* may occur in certain occupations (bartenders, salad chefs, gardeners), and in patients receiving topical photochemotherapy with *psoralens.* Such exposure could also occur among users of tanning preparations or perfumes containing *5-methoxypsoralen (bergapten),* although these preparations are not longer available in most countries. [19]
Tar Crude coal tar used in dermatologic therapy is the product of the destructive distillation of coal; it is a complex mixture of over 10,000 compounds including many phototoxic polyaromatic hydrocarbons. It may produce “tar smarts” upon exposure to UVA. In addition to phototoxicity, occupational exposure to tar is associated with increased risk of

nonmelanoma skin cancers; however, the carcinogenicity of coal tar used in dermatologic therapy remains controversial. [20]

SYSTEMIC AGENTS Table 136-3 lists the major systemic phototoxic agents; most are therapeutic or diagnostic agents. [1], [2] They produce an exaggerated sunburn reaction. However, some may also induce an eczematous photoallergic response, especially following topical exposure; phenothiazines, sulfonamides, quinine, and ketoprofen are examples of such agents. [21], [22], [23], [24] and [25] As a rule, the action spectra are in the UVA range; exceptions include sulfonamides and vinblastine, whose action spectra are in the UVB range, [9] and the porphyrins, fluorescein, and other dyes, whose action spectra are in the visible range. [8]

TABLE 136-3 **Systemic Phototoxic Agents**

The more commonly encountered systemic phototoxic agents are described below, following the sequence given in Table 136-3.

Antianxiety drugs Phototoxicity has been reported following systemic administration of *alprazolam* and *chlordiazepoxide.* [21]

Anticancer drugs *Dacarbazine, fluorouracil,* and *vinblastine* are well-documented phototoxic agents. [9] *Methotrexate* is known to be able to reactivate UVB-induced and PUVA-induced erythema. [26]

Antidepressants Phototoxicity induced by the tricyclics *amitriptyline* and *imipramine* is mediated by oxygen free radicals. [27] *Imipramine* and *desipramine* have been reported to induce slate-gray pigmentation in sun-exposed distribution, which is due to deposition of drug metabolite-melanin complexes. [11]

Antifungal *Griseofulvin* is a known phototoxic agent; it may also induce photoallergic reactions. [28]

Antimalarials The property of *chloroquine* as a phototoxic agent is unclear. Clinically, it is implicated as causing photosensitivity; however, a study involving 25 patients showed that chloroquine or hydroxychloroquine did not affect the response to UVA and UVB radiation. [29] *Quinine* is a phototoxic agent; in addition, it can induce a positive photopatch test, [24] lichenoid eruption, [23] and chronic actinic dermatitis. [30]

Antimicrobials All *quinolones* tested have been shown to be phototoxic, mediated by reactive oxygen species, and, in some, by photoproducts. [31], [32] Some of these are also photoallergens. [33] *Clinafloxacin, fleroxacin, lomefloxacin,* and *sparfloxacin,* all molecules with a halogen atom at position 8, have the highest potential for phototoxicity. *Ciprofloxacin, gemifloxacin, moxifloxacin, norfloxacin,* and *ofloxacin* produce only mild phototoxic reactions. *Enoxacin, lomefloxacin,* and *nalidixic acid* also elicit photoallergic responses. The quinolones were shown to have potential photocarcinogenic properties in an animal model, and are capable of inducing DNA breaks in vitro. [32] The *sulfonamides* are both phototoxic and photoallergic. [22] Among the *tetracyclines, demeclocycline* (used to treat diabetes insipidus) and *doxycycline* are the most potent phototoxic agents; the respective incidence is 1 to 2 percent, and 3 percent. [4], [34]

Antipsychotics The *phenothiazines* are phototoxic agents that can also induce photoallergic reactions, usually after an inadvertent topical exposure in a patient care environment. [23], [35] *Chlorpromazine* can also induce blue-gray pigmentation on light-exposed skin.

Cardiac medications *Amiodarone* induces an acute phototoxic response, occurring in up to 50 percent of patients; [36] it also results in a slate-gray pigmentation in sun-exposed areas (Fig. 136-2). *Quinidine* induces lichenoid photodermatitis [23] and an evolution to chronic actinic dermatitis; [17] although it has been considered to be a phototoxic agent, most studies now show that it is a systemic and topical photoallergen. [37]

Diuretics The *thiazides* are well known phototoxic agents (Fig. 136-1); [23] they can induce persistence of photosensitivity for many years. [17] *Furosemide* reportedly induces pseudoporphyria. [14]

Dyes *Fluorescein* and *methylene blue* reportedly induce phototoxicity. [38], [39]

Furocoumarins These are formed by the fusion of a furan with a coumarin. They occur naturally in many fruits, vegetables, and plants, including lime, lemon, fig, celery, parsley, and parsnip. The phototoxic properties of *5-methoxypsoralen, 8-methoxypsoralen,* and *4,5,8-trimethylpsoralen* are used therapeutically in the treatment of psoriasis, vitiligo, cutaneous T cell lymphoma, and other conditions (see Chap. 266).

Hypoglycemics Photosensitivity has been reported with the *sulfonylureas*; the mechanism involves reactive oxygen species. [40]

Nonsteroidal anti-inflammatory drugs (NSAIDs) *Piroxicam,* an enolic acid derivative, generates a metabolite that is phototoxic in mice and in tissue culture. Clinically, piroxicam-induced photosensitivity is associated with eczematous skin lesions and positive photopatch tests to piroxicam and its photoproducts, strongly indicating that this is a photoallergic response. [41] Generation of a photoproduct is responsible for the phototoxicity associated with *diclofenac*. *Ibuprofen,* a propionic acid derivative introduced in 1963, reportedly causes phototoxicity with a lowered minimal erythema dose (MED) to UVA; [9] however, ibuprofen-induced photosensitivity is a rare event. The phototoxicity of the other *propionic acid-derived NSAIDs* have been demonstrated in vitro, in an animal model, and in human volunteers; reactive oxygen species are partially responsible for the process. [25] Similar to the phenothiazines, topical exposure to this group of NSAIDs can result in photoallergic contact dermatitis. [25], [42] Pseudoporphyria has been reported with many NSAIDs, including *naproxen* (the most common precipitating agent) *, nabumetone* (whose chemical structure is very similar to naproxen), and the cyclooxygenase-2 inhibitor *celecoxib.* [15] *Benoxaprofen,* a highly phototoxic NSAID, was withdrawn from the market in 1982 because of its cholestatic hepatitis side effect.

Photodynamic therapy agents The phototoxic properties of these agents are used therapeutically in photodynamic

therapy [8] (see Chap. 266).
Retinoids Phototest results were normal in patients taking isotretinoin and suppressed in two of nine patients taking etretinate, with an action spectrum at 300 to 365 nm. [43] The decreased stratum corneum thickness may play a major role in this retinoid "photosensitivity."
Others Phototoxicity has also been reported to be induced by *flutamide,* a nonsteroidal antiandrogen, and *ranitidine,* an H_2 histamine receptor antagonist. [44], [45] *Hypericin,* an extract of St. John's wort, has antiretroviral activity in vitro but not in vivo, and is used in the management of depression. Up to 48 percent of patients developed phototoxicity at high doses, but not at the doses used for depression. [46] It is being investigated as an agent for photodynamic therapy. [47] Phototoxicity due to *pyridoxine (vitamin B_6)* is rare; it is caused by the generation of toxic photoproducts. [48]

Histopathology

Acute phototoxicity is characterized by necrotic keratinocytes, and in severe cases, epidermal necrosis. There may be epidermal spongiosis, dermal edema, and mild infiltrates consisting of neutrophils, lymphocytes, and macrophages. *Slate-gray pigmentation* is associated with increased dermal melanin, and dermal deposits of the drug or its metabolite. [11], [12] Histologic features of *lichenoid eruptions* are similar to those of idiopathic lichen planus; however, there may be a greater degree of spongiosis and dermal eosinophilic and plasma cell infiltrates, and a larger number of necrotic keratinocytes and cytoid bodies. Similar to porphyria cutanea tarda, there is dermal–epidermal separation at the lamina lucida in *pseudoporphyria,* and deposits of immunoglobulins at the dermal–epidermal junction and blood vessel walls. [14]

Pathophysiology

PHOTODYNAMIC PROCESSES Upon absorption of light energy by the photosensitizer (P) at its ground state, formation of an excited (usually triplet) state (^3P) molecule occurs. The excited state molecule may then participate in oxygen-dependent processes (i.e., photodynamic processes) in two major pathways: type I or type II reactions that both result in cytotoxic injury. [8] The *type I reaction* involves transfer of an electron or a hydrogen atom to the excited state photosensitizer (^3P), resulting in the formation of free radicals (Eq. 1). These may then participate in an oxidation-reduction reaction that results in peroxide formation and subsequent cell damage (*Eqs. 2* and *3*).

$$^3P + RH \rightarrow PH\cdot + R\cdot \qquad (1)$$

$$PH\cdot + PH\cdot \rightarrow P + PH_2 \qquad (2)$$

$$PH_2 + O_2 \rightarrow P + \underset{\text{hydrogen peroxide}}{H_2O_2} \qquad (3)$$

Interaction of ^3P with ground state oxygen could result in the formation of superoxide anion ($O_2^{-\bullet}$), which, in turn, can be converted into highly reactive and cytotoxic hydroxyl radicals (OH•). The *type II reaction* is also known as an energy transfer process. Transfer of energy to ground state oxygen results in the formation of singlet oxygen ($^1O_2$), which is highly reactive and has a lifetime of 50 nsec (*Eq. 4*).

$$^3P + O_2 \rightarrow P + {}^1O_2 \qquad (4)$$

Cytotoxic injury occurs upon singlet oxygen-induced oxidation of amino acids and unsaturated fatty acids; interaction with the latter results in the formation of hydroperoxides, which initiate lipid and protein oxidation. Phototoxicity induced by porphyrins, [8] quinolones, [32] and nonsteroidal anti-inflammatory agents [25], [49] are examples of photodynamic phototoxic reactions.
GENERATION OF PHOTOPRODUCTS With some photosensitizers, exposure to radiation may result in the generation of stable photoproducts, which are responsible for tissue injury. Phototoxic products have been demonstrated upon irradiation of chlorpromazine, tetracyclines, quinolones, and nonsteroidal anti-inflammatory agents. [32], [49]
BINDING TO SUBSTRATE Another mechanism of phototoxicity is radiation-mediated binding of the photosensitizer to its biologic substrate. A photoaddition reaction occurs when the excited state molecule covalently binds to a ground state molecule. An example is the covalent binding of 8-methoxypsoralen to pyrimidine bases of the DNA molecules, resulting in the formation of a cross-link of the DNA chains.
INFLAMMATORY MEDIATORS Mediators of inflammation and inflammatory cells participate in phototoxic tissue injury. Biologically active products of complement activation, mast cell-derived mediators, eicosanoids, proteases, and polymorphonuclear leukocytes contribute to the development of phototoxicity induced by porphyrins, demeclocycline, and chlorpromazine. [50], [51]

Management

Identification and avoidance of the causative phototoxic agent is the most important step in the management. Sun avoidance is central. Because the action spectrum for most agents is in the UVA spectrum, broad-spectrum sunscreens should be used. Acute phototoxicity could be managed with topical corticosteroids and compresses; systemic corticosteroids should be reserved only for the most severely affected patients. Management of patients with slate-gray pigmentation, a lichenoid eruption, pseudoporphyria, and photodistributed telangiectasia is symptomatic only, because it will take months after the discontinuation of the offending agent before the resolution of the eruption. Patients with NSAID-induced pseudoporphyria who require NSAIDs should be switched to a different class of agents, or to those that are less photosensitizing, such as indomethacin or sulindac. [14] Management of chronic actinic dermatitis evolving from exposure to exogenous agents is identical to that of chronic actinic dermatitis in general.

PHOTOALLERGY

Clinical Manifestations

The presence of photoallergen and the appropriate radiation is necessary for the clinical manifestation of photoallergy. In sensitized individuals, exposure to the photoallergen and sunlight results in the development of a pruritic, eczematous eruption within 24 to 48 hours after exposure (see Table 136-1, Fig. 136-5). This eruption is clinically indistinguishable from allergic contact dermatitis, is initially confined to light exposed areas, but, in contrast to phototoxic reactions, may spread beyond the exposed site. Lesions usually resolve with erythema; postinflammatory hyperpigmentation does not occur as commonly as in phototoxicity. The action spectrum is mostly in the UVA range.

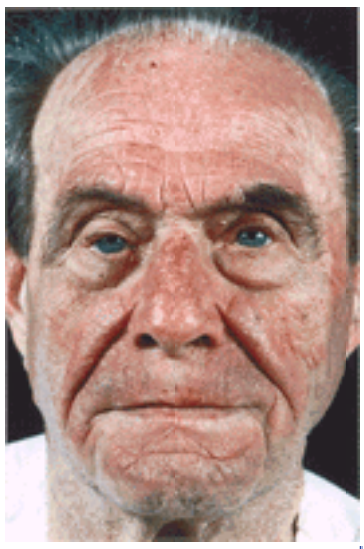

FIGURE 136-5 Photoallergic dermatitis. This eruption is clinically indistinguishable from allergic contact dermatitis, except it is distributed predominantly in sun-exposed areas.

The incidence of photoallergy in the United States peaked in the 1960s due to the widespread use of halogenated salicylanilide containing soaps and cleansers; [52] these have been now removed from personal care products in the United States. In the late 1970s and 1980s, fragrances in cosmetics and sunscreens, especially musk ambrette and 6-methylcoumarin, were common photoallergens. The removal of these agents has lessened their frequency. In the 1990s, sunscreen agents were the most common cause of photoallergy in the United States, United Kingdom, and France, which is a reflection of the current widespread use of sunscreens. [5], [53], [54] In Germany, Austria, and Switzerland, NSAIDs, antibacterials, and phenothiazines are the most common photoallergens. [6]

PERSISTENCE OF PHOTOSENSITIVITY AND EVOLUTION TO CHRONIC ACTINIC DERMATITIS (See also Chap. 135) Similar to phototoxicity, persistence of photosensitivity and evolution to chronic actinic dermatitis have been reported following exposure to photoallergens, including halogenated salicylanilides, musk ambrette, ketoprofen, dioxopromethazine, and quinidine. [17], [55], [56] The mechanism is not completely understood. One possible explanation is that UV radiation induces alteration of the carrier protein that originally binds the photoallergen; this results in the formation of a neoantigen that chronically stimulates the immune system. This is supported by the observation that the histidine moiety in albumin can undergo oxidation in the presence of salicylanilide that binds to albumin.

Photoallergens

Topical exposure to photosensitizers is the most common route of sensitization to photoallergens. Table 136-4 lists the common groups of photoallergens, which are discussed below.

TABLE 136-4 **Topical Photoallergens**

SUNSCREENS Photoallergy has been reported with practically all organic chemical sunscreen agents. Currently, the most commonly reported photoallergen is *benzophenone-3,* followed by *dibenzoylmethane.* [5], [52], [53], [57], [58] It should be noted that while sunscreen agents are a common cause of photoallergic contact dermatitis, the true prevalence of photosensitivity reaction to sunscreens is very low. Therefore, the potential for photoallergy should not deter one from using sunscreens. *Para-aminobenzoic acid (PABA)* and its esters, *octyl dimethyl PABA* and *amyl dimethyl PABA,* can

cause photoallergy. Amyl dimethyl PABA is no longer used in the United States or the European Union, although it is approved for use in Japan and Australia. [58] Individuals with a positive patch or photopatch test result to PABA or its esters may cross-react with other related chemicals such as *p-phenylenediamine* (hair dye), *procaine* and *benzocaine* (anesthetics), *procainamide* (antiarrhythmic agent), *sulfonamides* (antimicrobials) and *sulfonylureas* (hypoglycemic agents). [57]

FRAGRANCES Fragrances are the second most common cause of photoallergic reactions after sunscreens in the United States. [5], [53] *6-Methylcoumarin* is a known photoallergen that was used as a fragrance in suntanning lotions in the 1970s; it has been removed from the market. [57] *Musk ambrette* was commonly used in the 1970s in after-shave colognes; it was a common photosensitizer. It is much less commonly used now following the recommendation of the International Fragrance Association (IFA), in 1982, that it not be used in products intended for skin application; however, there are still products that contain this agent. *Sandalwood oil* infrequently causes photoallergic reactions.

ANTIBACTERIALS This is another group of common photosensitizers. [6], [59] *Halogenated salicylanilides* are well-characterized photoallergens. In the United States, they are no longer used in soaps and personal cleansers; however, they are used as surface disinfectants and mold inhibitors. They may also be present in personal care products sold in other countries. *Chlorhexidine, dimethylol-dimethyl hydantoin,* and *hexachlorophene* are used as skin cleansers. *Bithionol* is a potent photoallergen. It is no longer used in personal care products in the United States and Japan; however, it is used in industrial cleaners and in agricultural and veterinary products. It cross-reacts with hexachlorophene and halogenated salicylanilides. *Dichlorophene* and *triclosan* are present in personal care products; both have a low level of photoallergenicity. Triclosan is the most commonly used halogenated phenolic antibacterial agent worldwide.

ANTIFUNGALS *Fenticlor* (thiobisdichlorophenol) is an antifungal agent used in personal care products particularly in Canada, the United Kingdom, and Australia. [59] *Jadit* (butylchlorosalicylamide) and *multifungin* (bromochlorosalicylanilide) are antifungals used primarily in Australia and Europe; both are structurally related to halogenated salicylanilides.

OTHERS Exposure to the phenothiazines (*chlorpromazine* and *promethazine*) usually occurs in individuals handling medications. *Promethazine* is used as a topical antipruritic agent in some countries. [56] *Clioquinol* and *olaquindox* are antibiotics that are added to cattle feed; pig breeders are the most commonly exposed group. [60], [61] *Ketoprofen* is a NSAID used topically and systemically; it produces phototoxic and photoallergic reactions. It cross-reacts with fenofibrate (a triglyceride-lowering agent), tiaprofenic acid (a NSAID), and benzophenones (sunscreen agents). [25], [42], [55], [62] *Quinidine,* an antiarrhythmic agent, is a topical and systemic photoallergen. [37] *Thiourea (thiocarbamide)* is used in photocopy paper, photography, and rubber products. [57]

SYSTEMATIC PHOTOALLERGENS Photoallergy caused by systemic agents is much less frequent compared to that induced by topical agents. Table 136-5 lists the major photoallergens. All are also phototoxic agents and have been previously discussed in this chapter. *Pyridoxine*-induced photoallergy is rare but has been reported. [63], [64]

Property	Generic Name (US Trade Name)
Antifungal	Griseofulvin (Fulvicin-U/F)
Antimalarial	Quinine
Antimicrobials	Quinolone:
	Enoxacin (Penetrex)
	Sulfonamides
Cardiac medication	Quinidine (Quinaglute, Quinidex)
Nonsteroidal	Ketoprofen (Orudis, Oruvail)
	Piroxicam (Feldene)
Vitamin	Pyridoxine hydrochloride (vitamin B_6)

TABLE 136-5 **Systemic Photoallergens**

Histopathology

The histology of photoallergy is similar to that of allergic contact dermatitis. There is epidermal spongiosis associated with infiltrate of mononuclear cells in the dermis (see Table 136-1).

Pathophysiology

Photoallergy is a type IV delayed hypersensitivity response in which the concomitant presence of photoallergen and the appropriate radiation is necessary. [9] Following the absorption of light energy, a photoallergen may be converted to an excited state molecule, which subsequently reverts to ground state by releasing the energy. In this process, the molecule may conjugate with a carrier protein to form a complete antigen. This is thought to be the mechanism of photoallergy induced by halogenated salicylanilides, chlorpromazine, and *p*-aminobenzoic acid. Alternately, a photoallergen may form a stable photoproduct upon exposure to radiation, which, in turn, may conjugate with a carrier protein to form a complete antigen. Sulfanilamide and chlorpromazine have both been shown to participate in this reaction.

Once the complete antigen is formed, the mechanism of photoallergy is identical to that of contact allergy. The antigen is taken up and processed by epidermal Langerhans cells, which then migrate to regional lymph nodes to present the antigen to T lymphocytes. Cutaneous lesions develop when the activated T lymphocytes circulate to the exposed site to initiate an inflammatory response.

Management

This is identical to that of phototoxicity; namely, identification and avoidance of photoallergen, sun protective measures, and symptomatic therapy.

EVALUATION OF PATIENTS WITH PHOTOTOXICITY AND PHOTOALLERGY

The evaluation is similar to that of patients with other photosensitivity disorders and is described in greater detail in Chap. 135. Specifically, exposure to known photosensitizers needs to be obtained from the history. Development of lesions after the first exposure would suggest phototoxicity, while eruptions following a sensitization phase would suggest photoallergy. Furthermore, it is helpful to ascertain whether window glass-filtered sunlight can induce the cutaneous eruption, because UVB is filtered out by window glass. Distribution of the cutaneous eruption is a helpful clue to the type

of photosensitizer responsible. Widespread eruption would suggest systemic photosensitizers while topical photosensitizers would produce lesions only in areas that have been exposed to both sensitizers and radiation. Vesicular and bullous eruptions are most commonly associated with phototoxicity, while eczematous eruptions would suggest photoallergy; the former is associated with a burning sensation, the latter with pruritus. Skin biopsy may also be helpful in differentiating these two conditions: necrotic keratinocytes are commonly seen in phototoxicity, whereas spongiotic dermatitis is associated with photoallergy (see Table 136-1).

An integral part of the evaluation of photosensitivity are phototests and photopatch tests. Approximately 4 to 20 percent of patients who undergo photopatch tests have clinically relevant positive photopatch test results, eventuating in the diagnosis of photoallergic contact dermatitis. [5], [6]

The procedures for phototests and photopatch tests are as follows, although there are variations in testing methods. [65] On day 1, exposure to UVB, UVA, and visible light for MED determination is performed and duplicate sets of photoallergens are applied symmetrically to the back and covered by opaque tape. On day 2, the MEDs are quantitated. One set of patches is removed and exposed to 10 J/cm ^{2} of UVA, or 50 percent of the MED to UVA, whichever is lower. After irradiation, the test sites are covered again with opaque tape. On day 3, both irradiated and nonirradiated test sites are uncovered and the reactions are graded. On day 5 or day 8, the irradiated and nonirradiated sites are evaluated for delayed reactions. Table 136-6 outlines the interpretation of photopatch test reactions. Well-defined erythema that resolves promptly indicates an irritant dermatitis.

[illegible]	[illegible]	[illegible]
[illegible]	[illegible]	[illegible]
[illegible]	[illegible]	[illegible]
[illegible]	[illegible]	[illegible]

TABLE 136-6 **Interpretation of Photopatch Tests**

OTHER EXOGENOUS AGENT-INDUCED PHOTODERMATOSIS AND PHOTOEXACERBATED DERMATOSES

PORPHYRIA CUTANEA TARDA

Ingestion of wheat treated with *hexachlorobenzene* as a preservative resulted in an outbreak of a porphyria cutanea tarda-like syndrome in Turkey in the 1950s. [66] Inhibition of the enzyme uroporphyrinogen decarboxylase by hexachlorobenzene was responsible for the clinical manifestations (see Chap. 149).

LUPUS ERYTHEMATOSUS

Although a long list of medications are associated with drug-induced lupus erythematosus, it has been reported most frequently with *procainamide* and *hydralazine.* [67] Arthralgia and systemic symptoms are common; photosensitivity is a rare manifestation. Most patients have antibodies to histones. Individuals whose hepatic *N*-acetyltransferase system expresses a “slow acetylator” phenotype are most susceptible to develop this syndrome (see Chap. 171).

PELLAGRA (See Chap. 145)

Skin changes of pellagra (from the Italian *pelle agra,* “rough skin”) are associated with isoniazid, 6-mercaptopurine, 5-fluorouracil, chloramphenicol, sulfapyridine, anticonvulsants, and antidepressants. [68] The pathogenesis of drug-induced pellagra probably is related to the inhibition of conversion of niacin to NAD and NADP by the drug.

REFERENCES

1. Litt, JZ: *Drug Eruption Reference Manual 2001*. New York, Parthenon, 2001, pp 400–401

2. Drugs that cause photosensitivity. *Med Lett* **37**:35, 1995

3. González E, González S: Drug photosensitivity, idiopathic photodermatoses, and sunscreen. *J Am Acad Dermatol* **35**:871, 1996

4. Layton AM, Cunliffe WJ: Phototoxic eruptions due to doxycycline—A dose-related phenomenon. *Clin Exp Dermatol* **18**:425, 1993

5. Fotiades J et al: Results of evaluation of 203 patients for photosensitivity in a 7.3-year period. *J Am Acad Dermatol* **33**:597, 1995

6. Neumann NJ et al: Photopatch testing: The 12-year experience of the German, Austrian, and Swiss photopatch test group. *J Am Acad Dermatol* **42**:183, 2000

7. Harber LC, Bickers DR: *Photosensitivity Diseases. Principles of diagnosis and treatment,* 2nd ed. Toronto, BC Decker, 1989

8. Kalka K et al: Photodynamic therapy in dermatology. *J Am Acad Dermatol* **42**:389, 2000

9. Gould JW et al: Cutaneous photosensitivity diseases induced by exogenous agents. *J Am Acad Dermatol* **33**:551; 1995

10. Yong CK et al: An unusual presentation of doxycycline-induced photosensitivity. *Pediatrics* **106**:E13, 2000

11. Ming ME et al: Imipramine-induced hyperpigmentation: Four cases and a review of the literature. *J Am Acad Dermatol* **40**:159, 1999

12. Scherschun L et al: Diltiazem-associated photodistributed hyperpigmentation: A review of 4 cases. *Arch Dermatol* **137**:179, 2001

13. Choonhakarn C, Janma J: Pyrazinamide-induced lichenoid photodermatitis. *J Am Acad Dermatol* **40**:645, 1999

14. Green JJ, Manders SM: Pseudoporphyria. *J Am Acad Dermatol* **44**:100, 2001

15. Cummins R et al: Pseudoporphyria induced by celecoxib in a patient with juvenile rheumatoid arthritis. *J Rheumatol* **27**:2938, 2000

16. Borgia R et al: Photodistributed telangiectasia following use of cefotaxime. *Br J Dermatol* **143**:674, 2000

17. Lim HW et al: Chronic actinic dermatitis: Study of the spectrum of chronic photosensitivity in twelve patients. *Arch Dermatol* **126**:317, 1990

18. Morison WL et al: Consensus workshop on the toxic effects of long-term PUVA therapy. *Arch Dermatol* **134**:595, 1998

19. Moysan A et al: Evaluation of phototoxic and photogenotoxic risk associated with the use of photosensitizers in suntan preparations: Application to tanning preparations containing bergamot oil. *Skin Pharmacol* **6**:282, 1993

20. Pion IA et al: Is dermatologic usage of coal tar carcinogenic? A review of the literature. *J Dermatol Surg Oncol* **21**:227, 1995

21. Harth Y, Rapoport M: Photosensitivity associated with antipsychotics, antidepressants and anxiolytics. *Drug Saf* **14**:252, 1996

22. Epstein S: Photoallergy and primary photosensitivity to sulfanilamide. *J Invest Dermatol* **2**:43, 1939

23. Johnson BE, Ferguson J: Drug and chemical photosensitivity. *Semin Dermatol* **9**:39, 1990

24. Ljunggren B et al: Systemic quinine photosensitivity with photoepicutaneous cross-reactivity to quinidine. *Contact Dermatitis* **26**:1, 1992

25. Bagheri H et al: Photosensitivity to ketoprofen: Mechanisms and pharmacoepidemiological data. *Drug Saf* **22**:339, 2000

26. Okamoto H et al: Reactivation of phototoxicity test for psoralen plus ultraviolet A by low-dose methotrexate. *Photodermatol Photoimmunol Photomed* **10**:134, 1994

27. Viola G et al: In vitro studies of the phototoxic potential of the antidepressant drugs amitriptyline and imipramine. *Farmaco* **55**:211, 2000

28. Matsuo I et al: Possible involvement of oxidation of lipids in inducing griseofulvin photosensitivity. *Photodermatol Photoimmunol Photomed* **7**:213, 1990

29. Seidman P, Ros AM: Sensitivity to UV light during treatment with chloroquine in rheumatoid arthritis. *Scand J Rheumatol* **21**:245, 1992

30. Guzzo C, Kaidbey K: Persistent light reactivity from systemic quinine. *Photodermatol Photoimmunol Photomed* **7**:166, 1990

31. Stahlmann R, Lode H: Toxicity of quinolones. *Drugs* **58**(suppl 2):37, 1999

32. Man I et al: Recent development in fluoroquinolone phototoxicity. *Photodermatol Photoimmunol Photomed* **15**:32, 1999

33. Ohshima A et al: Formation of antigenic quinolone photoadducts on Langerhans cells initiates photoallergy to systemically administered quinolone in mice. *J Invest Dermatol* **114**:569, 2000

34. Kapusnik-Uner JE et al: Antimicrobial agents, in *Goodman & Gilman's The Pharmacological Basis of Therapeutics,* 9th edi, edited by JG Hardman, LE Limbird, PB Molinoff, RW Ruddon, A Goodman Gilman. New York, McGraw-Hill, 1996, p 1129

35. Eberlein-Konig B et al: Phototoxic properties of neuroleptic drugs. *Dermatology* **194**:131, 1997

36. Charlmers RTC et al: High incidence of amiodarone-induced photosensitivity in North-West England. *Br Med J* **285**:341, 1982

37. Schurer NY et al: Photosensitivity induced by quinidine sulfate: Experimental reproduction of skin lesions. *Photodermatol Photoimmunol Photomed* **9**:78, 1992

38. Danis RP et al: Phototoxicity from systemic sodium fluorescein. *Retina* **20**:370, 2000

39. Porat R et al: Methylene blue-induced phototoxicity: an unrecognized complication. *Pediatrics* **97**:717, 1996.

40. Vargas F et al: Studies on the in vitro phototoxicity of the antidiabetes drug glipizide. *In Vitr Mol Toxicol* **13**:17, 2000

41. Serrano G et al: Oxicam-induced photosensitivity. Patch and photopatch testing studies with tenoxicam and piroxicam photoproducts in normal subjects and in piroxicam-droxicam photosensitive patients. *J Am Acad Dermatol* **26**:545, 1992

42. Matsushita T, Kamide R: Five cases of photocontact dermatitis due to topical ketoprofen: Photopatch testing and cross-reaction study. *Photodermatol Photoimmunol Photomed* **17**:26, 2001

43. Ferguson J, Johnson BE: Photosensitivity due to retinoids: Clinical and laboratory studies. *Br J Dermatol* **115**:275, 1986

44. Yokote R et al: Photosensitive drug eruption induced by flutamide. *Eur J Dermatol* **8**:427, 1998

45. Todd P et al: Ranitidine-induced photosensitivity. *Clin Exp Dermatol* **20**:146, 1995

46. Schempp CM et al: Single-dose and steady-state administration of *Hypericum perforatum* extract (St. John's wort) does not influence skin sensitivity to UV radiation, visible light, and solar-simulated radiation. *Arch Dermatol* **137**:512, 2001

47. Vantieghem A et al: Different pathways mediate cytochrome *c* release after photodynamic therapy with hypericin. *Photochem Photobiol* **74**:133, 2001

48. Maeda T et al: Vitamin B_6 phototoxicity induced by UVA radiation. *Arch Dermatol Res* **292**:562, 2000

49. Encinas S et al: Phototoxicity associated with diclofenac: A photophysical, photochemical, and photobiological study on the drug and its photoproducts. *Chem Res Toxicol* **11**:946, 1998

50. Lim HW et al: Role of complement and polymorphonuclear cells in demethylchlortetracycline-induced phototoxicity. *J Clin Invest* **71**:1326,

1983

51. Torinuki W, Tagami H: Role of complement in chlorpromazine-induced phototoxicity. *J Invest Dermatol* **86**:142, 1986

52. Nehal KS, Lim HW: Phototoxicity and photoallergy. *Dermatol Nurs* **7**:227, 1995

53. DeLeo VA et al: Photoallergic contact dermatitis: Results of photopatch testing in New York, 1985 to 1990. *Arch Dermatol* **128**:1513, 1992

54. Darvey A et al: Photoallergic dermatitis is uncommon. *Br. J. Dermatol* **145**:597, 2001

55. Albes B et al: Prolonged photosensitivity following contact photoallergy to ketoprofen. *Dermatology* **201**:171, 2000

56. Schauder S: Dioxopromethazine-induced photoallergic contact dermatitis followed by persistent light reaction. *Am J Contact Dermat* **9**:182, 1998

57. Rietschel RL, Fowler JF Jr: *Fisher's Contact Dermatitis,* 5th ed. Philadelphia, Lippincott Williams & Wilkins, 2001

58. *IARC Handbook of Cancer Prevention. Vol. 5: Sunscreen*. Lyon, France, International Agency for Research on Cancer, 2001

59. Marks JG Jr, DeLeo VA: Photoallergens, in *Contact and Occupational Dermatology,* 2nd ed. St. Louis, Mosby, 1997, p 200

60. Rivara G et al: Photosensitivity in a patient with contact allergic dermatitis from clioquinol. *Photodermatol Photoimmunol Photomed* **8**:225, 1991

61. Schauder S et al: Olaquindox-induced airborne photoallergic contact dermatitis followed by transient or persistent light reaction in 15 pig breeders. *Contact Dermatitis* **35**:344, 1996

62. Le Coz CJ et al: Photocontact dermatitis from ketoprofen and tiaprofenic acid: Cross-reactivity study in 12 consecutive patients. *Contact Dermatitis* **38**:245, 1998

63. Tanaka M et al: Photoallergic drug eruption due to pyridoxine hydrochloride. *J Dermatol* **23**:708, 1996

64. Murata Y et al: Photosensitive dermatitis caused by pyridoxine hydrochloride. *J Am Acad Dermatol* **39**:314, 1998

65. Kim JJ, Lim HW: Evaluation of the photosensitive patient. *Semin Cutan Med Surg* **18**:253, 1999

66. Herrero C et al: Urinary porphyrin excretion in a human population highly exposed to hexachlorobenzene. *Arch Dermatol* **135**:400, 1999

67. Hahn BH: Systemic lupus erythematosus, in *Harrison's Principles of Internal Medicine,* 15th ed., edited by E Braunwald, AS Fauci, DL Kasper, S Hauser, DL Longo, JL Jameson. New York, McGraw-Hill, 2001, p 1922

68. Hendricks WM: Pellagra and pellagra-like dermatoses: Etiology, differential diagnosis, dermatopathology, and treatment. *Semin Dermatol* **10**:282, 1991

T>

Chapter 137

James Taylor Apra Sood

Occupational Skin Disease

HISTORICAL ASPECTS AND RESOURCES
EPIDEMIOLOGY
IRRITANT CONTACT DERMATITIS
Major Categories
Other Categories
Airborne Irritant Dermatitis
Diagnosis of Irritant Dermatitis
Common Occupational Irritants
Acids and Alkalis, Including Chemical Burns
ALLERGIC CONTACT DERMATITIS
CONTACT URTICARIA AND IMMEDIATE CONTACT REACTIONS
NICU
ICU
Uncertain Mechanism
Clinical Features/Other Terms
BIOLOGICAL CAUSES
Bacterial Infections
Viral Infections
Occupational Aspects of Bioterrorism
Fungal Infections
Parasitic Diseases
Arthropods
PHYSICAL CAUSES
Mechanical Trauma
HEAT
Thermal Burns
Electrical Burns
Erythema ab Igne
Miliaria
Intertrigo
Other Conditions
COLD
Frostbite, Chilblains, Immersion Foot
VIBRATION SYNDROME
OCCUPATIONAL CONNECTIVE TISSUE DISORDERS
OCCUPATIONAL AND ENVIRONMENTAL ACNE
Oil Acne
Coal Tar and Pitch Acne
Chloracne
OCCUPATIONAL SKIN CANCER
ULTRAVIOLET LIGHT
POLYCYCLIC AROMATIC HYDROCARBONS
ARSENIC
TRAUMA
IONIZING RADIATION
DIAGNOSIS OF OCCUPATIONAL SKIN DISEASE
DIAGNOSTIC TESTING FOR ALLERGY
Patch Testing
Tests for Immediate Hypersensitivity
Other Tests
TREATMENT
Fitness for Work and Workplace Accommodation
Prognosis and Persistence
Impairment and Disability Evaluation
Prevention
Health Risk Assessment

REFERENCES

Occupational dermatoses are any abnormal conditions of the skin caused or aggravated by substances or processes associated with the work environment. Disorders range from erythema, urticaria, and eczematous reactions to acneiform, pigmentary, ulcerative, granulomatous, and neoplastic conditions. Often overlooked is the importance of the skin as a major portal of entry for chemical exposure to systemic toxins.

HISTORICAL ASPECTS AND RESOURCES

Paracelsus (1498–1541), in his *Morbis Metallicus,* was the first to write about occupational diseases, including changes in the skin caused by salt compounds. At about the same time, Agricola described deep skin ulcers in his book about metal workers. And in 1700, Ramazzini, the father of modern occupational medicine, made many observations about occupational skin diseases in his classical work *De Morbis Artificium Diatriba*. Beginning in 1775, when Percival Pott described carcinoma of the scrotum among chimney sweeps, a number of other European authors described and studied occupational skin diseases and contact dermatitis. Earlier twentieth century texts include Prosser White's *The Dermatergoses or Occupational Afflictions of the Skin,* in 1915, and Schwartz, Tulipan, and Birmingham's *Occupational*

Diseases of the Skin in 1957. Selected current resources for more in depth information include Taylor JS (ed), *Dermatologic Clinics* (6:1–129, 1988 and 12:461–600, 1994); Marks and DeLeo's *Contact and Occupational Dermatology* (1997); Adams' *Occupational Skin Disease* (1999); Kanerva et al.'s *Handbook of Occupational Dermatology* (2000); *Fisher's Contact Dermatitis* (2001); and Rycroft et al.'s *Textbook of Contact Dermatitis* (2001).

EPIDEMIOLOGY

The US Department of Labor publishes annual incidence statistics on the safety and health of employees in private industry (http://www.osha.gov/). In 2000, 5.7 million nonfatal job-related injuries and illnesses were reported, a rate of 6.1 per 100 equivalent full-time workers. This is the lowest rate ever recorded. Illnesses accounted for 362,500 cases, the majority of which were repeated trauma disorders, such as carpal tunnel syndrome, followed by skin diseases or disorders, accounting for 41,800 cases. The number of skin disease cases has declined significantly since data collection began in the 1970s, and the drop has been more precipitous in the past 4 years. Reasons for this decline are not clear but include better prevention and a change in the ease with which workers' compensation cases are accepted, or a change in reporting patterns of employees or employers, or other factors. [1] Earlier studies showed significant underreporting of all classes of work-related disorders. Some cases are never reported but instead are filed with the employer's private health insurance. This decline in OSHA-reported occupational skin diseases has been widespread across industry sectors. Manufacturing and service industries account for about three-fourths of all skin disease cases, and contact dermatitis is the most frequent diagnosis (1994 data). One-third of workers with occupational skin disease missed more than 5 days of work [14.5 percent missed 6 to 10 days, 8.3 percent (11 to 20 days), 3.3 percent (21 to 30 days), and 5.8 percent (more than 31 days)]; two-thirds missed 1 to 5 days (1994 data). [2] Data from Germany and Denmark indicate that the incidence rate for skin disease among hairdressers and cooks is more than 10 to 20 times the average of all cases. [3] For years, skin disorders were considered an invariable accompaniment of work, but ideally, all occupational skin disease can and should be prevented.

IRRITANT CONTACT DERMATITIS

Irritant contact dermatitis (ICD), the most common occupational skin disease, is a nonimmunologic inflammatory reaction following exposure of the skin to an external chemical or physical agent. Irritation accounts for up to 80 percent of occupational skin disease cases and affects the most often exposed areas of skin, such as the hands and forearms. The clinical spectrum of irritation is very broad and in addition to the more common acute and chronic eczematous reactions also includes ulceration, folliculitis, acneiform eruptions, miliaria, pigmentary alterations, alopecia, contact urticaria and granulomatous reactions (Table 137-1). [4]

TABLE 137-1 **Clinical Features That May Suggest the Etiology of Irritant Dermatitis***

Major Categories

The two major types of irritant contact dermatitis are acute ICD, including chemical burns, and cumulative ICD.

ACUTE ICD, INCLUDING CHEMICAL BURNS Acute eczematous dermatitis after exposure to a potent irritant, often to a single chemical acid or alkali solution, may overlap with chemical burns. Highly irritating chemicals induce a reaction in any person's skin if the concentration and duration of action are sufficient; the intrinsic nature of the chemical is also important. Strong alkalis and acids, such as sodium and potassium hydroxides and hydrochloric and sulfuric acids are common irritants, among others. In national statistics for work-related injuries, acute ICD reactions are often classified as chemical burns (Fig. 137-1).

FIGURE 137-1 Vesiculobullous hand eruption in a 42-year-old man from prolonged wearing of solvent-soaked gloves.

CUMULATIVE ICD Cumulative ICD, the most common type of ICD, develops slowly after cumulative but additive subthreshold exposures to mild irritants (soap, water, detergents, industrial cleansers, solvents, etc.) under a variety of conditions. Dermatitis is usually localized to the finger webspaces, but later spreads to the sides and dorsal surface of the hands, and finally to the palmar surface. The volar aspect of the wrist is usually spared in contrast to allergic hand eczema. The hallmark is the absence of vesicles and the predominance of dryness and chapping. However, the diagnosis is complicated by hybrids, where there is a combination of ICD and allergic contact dermatitis, or of ICD and atopy, or even of all three. [5] High-risk occupations for cumulative ICD include bakers, canners, caterers, cleaners, cooks, health care workers such as dental assistants and technicians and nurses, hairdressers, mechanics, printers, and butchers. [6]

Other Categories

To more accurately define irritant dermatitis, other types have been described; some represent subcategories or overlap forms:

ACUTE DELAYED ICD Reaction is not seen until 8 to 24 h after exposure and may be misdiagnosed as allergic contact dermatitis. Examples include anthralin, bromine, [7] hexanediol diacrylate, podophyllin, ethylene oxide, and propylene glycol.
IRRITANT REACTION Irritant reaction is an early, almost subclinical dermatitis, or sentinel event, often seen on the hands of individuals exposed to wet work, such as hair dressers or metal workers, in their first several months of training. [5], [8] The eruption is monomorphous and is characterized by one or more of the following signs: dryness, erythema, vesicles, pustules, and erosions.
TRAUMATIC ICD See posttraumatic eczema in the section " Physical Causes."
NONERYTHEMATOUS ICD Another subclinical type characterized by changes in the stratum corneum barrier function without a clinical correlate.
SUBJECTIVE ICD Also called sensory ICD, this condition is characterized by lack of clinical signs but is accompanied by burning and stinging after contact with certain chemicals, such as lactic acid.
PREDISPOSING FACTORS IN ICD
Specific factors Occupational ICD, especially of the chronic, cumulative type, is a prime example of the concept of multifactorial causation of disease. Not only are the *properties of the irritating substance* important (pH, solubility, and detergent action), but also its *physical state* (gaseous, liquid, or solid). Important *host factors* include the presence or absence of occlusion, sweating, pigmentation, dryness, and sebaceous activity, and the simultaneous presence of another skin disease, especially one that is reactivated by contact with irritant(s). Important *environmental factors* include temperature, humidity, friction, pressure, occlusion, and coexisting lacerations. A *worker's age, gender, skin type,* and *genetic background* may also be important.
Other factors Atopy is one of the most important contributing factors to ICD. Individuals with a personal or past history of atopic eczema (see Chap. 122) have an increased susceptibility to skin irritation and account for a large percentage of workers compensation dermatitis claims. *Low relative humidity* in the workplace, especially in atopics is also an important factor in developing dermatitis, especially with the presence of other irritants. With relative humidity below 35 to 40 percent, the stratum corneum becomes drier and more brittle, with increasing permeability to marginal irritants. *Low humidity dermatitis* has been reported in closed, windowless offices, in manufacturing of soft contact lenses, and in the clean rooms of silicon-chip manufacturing plants. Symptoms, such as pruritus and burning may be the only complaints and are more distressing than physical signs, which may involve exposed or covered areas. Differential diagnosis includes airborne irritation, other dermatoses, and psychogenic causes. Treatment includes liberal use of emollients and increasing the indoor relative humidity to about 50 percent, if possible.

Airborne Irritant Dermatitis

Airborne irritants are an important cause of contact dermatitis. The pattern is fairly characteristic with distribution on the face, neck, anterior chest and arms. The most frequent causes are irritating dusts and volatile chemicals, such as solvents, ammonia, formaldehyde, epoxy resins and their hardeners, cement dust, fibrous glass, and sawdust- especially from irritating woods.

Diagnosis of Irritant Dermatitis

There are no reliable confirmatory tests for the diagnosis of ICD. Diagnosis is primarily based on a history of exposure to a known potential irritant that is consistent with the observed clinical appearance and anatomic distribution. Because of their close resemblance to allergic contact dermatitis, subacute and chronic irritant dermatitis are almost always

diagnoses of exclusion and it is necessary to patch test most affected patients. Rietschel [9] has proposed criteria for the clinical diagnosis of ICD (Table 137-2).

Subjective	
Major	**Minor**
1. Onset of symptoms within minutes to hours of exposure	1. Onset of dermatitis within 2 weeks of exposure
2. Pain, burning, stinging, or discomfort exceeding itching early in the clinical course	2. Many people in the environment affected similarly
Objective	
Major	**Minor**
1. Macular erythema, hyperkeratosis, or fissuring predominating over vesiculation	1. Sharp circumspection of the dermatitis
2. Glazed, parched, or scalded appearance of the epidermis	2. Evidence of gravitational influence, such as a dripping effect
3. Healing process begins promptly on withdrawal of exposure to the offending agent	3. Lack of tendency of the dermatitis to spread
4. Patch testing is negative	4. Morphologic changes suggesting small concentration differences or contact time produce large differences in skin damage

SOURCE: Rietschel et al.[9]

TABLE 137-2 **Diagnostic Criteria of Irritant Contact Dermatitis**

Common Occupational Irritants

Examples of common occupational irritants are described in the following sections.

SOAPS AND DETERGENTS Most toilet soaps do not irritate normal skin in normal usage. If the skin is already even slightly damaged from contact with other irritants, the use of industrial skin cleansers, designed to remove heavy industrial soil from the skin, can be very irritating, especially to atopic skin. Industrial skin cleansers are available commercially as cakes, liquids, powders, or creams. The choice of cleanser varies with the job for which it is intended. Machinists and auto-mechanics need a cleanser with a high detergent and abrasive action. Borax has been used for years for this purpose, and has the advantage of dissolving as it cleans. Somewhat more irritating are abrasives of vegetable origin. Sand and pumice have been used in some hand cleansers but are highly irritating and should generally be avoided or used sparingly, mainly on the palms and only for removal of the most tenacious soils.
WATERLESS HAND CLEANSERS Waterless hand cleansers are formulated to remove difficult oil and grease stains and are widely used at worksites where there is no convenient source of water. These products should not be used for skin cleaning when ordinary hand soaps would suffice, and they may provoke dermatitis from unnecessary overuse. They should be used sparingly during the workday, because they contain a higher percentage of petroleum-derived solvent. Rags are often used to remove these cleansers, and by the end of a shift they can be saturated with a variety of irritants. After use, the potentially irritating residual film should be washed off with mild soap and water. Disposable towels or presaturated wipes from dispensers are better choices and are useful in many situations, especially in the clean rooms of the semiconductor industry. They usually contain antibacterial agents as preservatives, which also may be contact allergens. Instant hand sanitizers, often containing high concentrations of alcohol, are now available. Some of these can be drying to skin. Many chemicals are capable of causing skin damage, making chemical burns an important cause of occupational injury. [10] Copious washing is the primary measure required in treating all chemical burns. However, certain types of burns require specific antidotes and therapies (Table 137-3). [11]

Chemical	Treatment
Burning metal fragments of sodium, potassium, and lithium	Extinguish with sand, cover with mineral oil, and irrigate with water before mechanically extracting particles
Hydrofluoric acid	Running water, then calcium gluconate gel (2.5%) followed by intralesional injection, if needed
Phosphorus	Remove particles mechanically; soap and water, then copper (II) sulfate in water for several minutes; remove black copper phosphide and wash with water
Phenolic compounds	Initial soap and water washing followed by polyethylene glycol 300 or 400 or ethanol (10%) in water
Bromine or iodine	Wash frequently with soap and water followed by treatment with 5% sodium thiosulfate

SOURCE: Bhuyan M et al.[11]

TABLE 137-3 **Selected Burns That Require Unique Therapies**

Acids and Alkalis, Including Chemical Burns

Inorganic acids are used in enormous quantities in industry, especially sulfuric, hydrochloric, chromic, hydrofluoric, nitric, and phosphoric acids. *Sulfuric acid* is one of the largest chemical commodities produced in the United States and is widely used in the manufacture of fertilizers, inorganic pigments, textile fibers, explosives, pulp and paper. *Hydrochloric acid* is used in the production of fertilizers, dyes, paints, and soaps. Sodium and potassium hydroxide, ammonium hydroxide, sodium and potassium carbonate and calcium oxide are widely used in the manufacture of bleaches, dyes, vitamins, plastics, pulp and paper, soaps and detergents. [12] Many of these acids and alkalis are common causes of chemical burns. Strong acids cause erythema, blistering and necrosis, and may discolor the skin. Strong alkalis saponify surface lipids and penetrate easily, leading to more severe and extensive tissue destruction, including deep ulcerations that heal very slowly.

Organic acids, such as acetic, acrylic, formic, glycolic, benzoic and salicylic acids, tend to be less irritating than inorganic acids, but especially after prolonged exposure, even in weak concentrations, they can cause chronic irritant dermatitis. *Formic acid* is used in the textile industry in dyeing and finishing, as a delimer and neutralizer in leather manufacture, and as a coagulant in the production of natural latex, among other uses. It has greater corrosive potential than most other

organic acids. *Acrylic acid,* used chiefly as a monomer for acrylic plastics, is irritating and corrosive to the skin. Fatty acids, such as palmitic, oleic, and stearic acids tend to be less irritating. [12]

HYDROFLUORIC ACID Hydrofluoric acid (HF) is a strong acid with many uses including etching and frosting of glass, rust removal, and “spot cleaning” in dry cleaning. HF is extremely irritating to skin, even in concentrations of 15 to 20 percent. Fluoride ions penetrate deep into the tissues and bind to the calcium and magnesium ions, causing severe tissue damage including bone destruction, especially of the terminal digits of the hand. [11] Following exposure to lower concentrations of HF, the onset of symptoms may be delayed until release of fluoride ions occurs in deep tissues. Exposure to HF is a medical emergency requiring topical or subcutaneous calcium gluconate after lavage to bind the fluoride ions (Table 137-3).

CEMENT Exposure to wet cement may cause severe alkaline and thermal burns due to the exothermic reaction of calcium oxide with water forming calcium hydroxide. [13] Kneeling in wet cement for prolonged periods leads to deep burns of the knees (cement knees) and shins; [14] lesions may become deep enough to require excision and grafting. Burns may also result from the trapping of wet cement in gloves and boots.

CHROMIC ACID Chromic acid is highly irritating to the skin, causing ulcerations of the skin (“chrome holes”) and perforation of the nasal septum. Exposures occur in chrome plating, copper stripping, and aluminum anodizing operations. Chromic acid may be absorbed and lead to renal failure. [15]

PHOSPHORUS Phosphorus is used in the manufacture of insecticides and fertilizers, and can cause deep, destructive burns. It ignites spontaneously on exposure to air so that the affected area should be kept moist until the chemical is completely removed. Severe metabolic derangements have been reported following phosphorus burns and patients should be closely monitored for multiorgan failure. [16]

ETHYLENE OXIDE Ethylene oxide is used commercially and in hospital central supply units for sterilization of surgical and medical instruments and devices as well as textiles and plastic material. Burns may result from contact with porous materials and devices that have been sterilized with ethylene oxide but not properly aerated. [17]

PHENOL Phenol is rapidly absorbed through intact skin and can cause local necrosis and nerve damage.

METAL SALTS Arsenic compounds such as arsenic trioxide, the dust of which can be contacted during the smelting of copper, gold, lead, and other metals, can cause a persistent folliculitis in addition to systemic poisoning. In the semiconductor industry, exposure to arsenic can occur during maintenance activities and especially during the handling of raw materials. Allergic contact dermatitis has been reported from sodium arsenate. *Beryllium compounds* are employed in the aerospace and other industries for the production of hard, corrosion-resistant alloys, among other uses. They may cause an irritant dermatitis, but especially characteristic are ulcerating granulomas from implantation of beryllium salts. [12] Allergic contact dermatitis and allergic granulomas are also reported. *Calcium oxide* (quicklime), used as a refractory, as a flux in the manufacture of steel (among many other uses) is a strong skin irritant that releases heat on contact with water, causing painful skin ulcerations. *Copper salts* are skin irritants and occasionally contact allergens. Inorganic arsenic may contaminate coppers ores. Metal fume fever, a flulike illness of brief duration, may result from inhalation of the fine particle of oxides of copper, as well as from magnesium and zinc. Today, it is usually associated with welding operations performed with inadequate ventilation. [18] *Cobalt salts,* used in alloys, ceramics, electroplating, electronics, magnets, paints and varnishes, cosmetics, and the like, may be irritants and also cause allergic contact dermatitis. When used in hard metal alloys, the dust may also cause pulmonary sensitization. [19] Inorganic mercury exposure sometimes causes a bluish linear pigmentation on the gums and tongue, which should be considered a marker for systemic poisoning. *Compounds of mercury* have been widely used as bactericides, dental amalgams, catalysts, and the like. Alkyl mercury compounds cause severe burns and corrosion of the skin. Exposure to *selenium compounds* can cause a conjunctivitis termed *rose eye,* as well as a reddish discoloration of the skin and hair. Selenium dioxide and selenium oxychloride are strong skin vesicants.

SOLVENTS Millions of workers are exposed to solvents daily. Until recently, most solvents were used to dissolve other substances or as diluents for adhesives or surface coatings. Today the chief uses are in the manufacture of other chemicals; as carriers for chemical reactions; as pressure transmitters for hydraulic systems; and in coatings, industrial cleaners, printing inks, and pharmaceuticals. After water, the most common solvents are aliphatic and aromatic hydrocarbons, esters, ethers, ketones, amines, and nitrated and chlorinated hydrocarbons (Table 137-4). [20] Volatile solvents, especially, act by dissolving the intercellular lipid of the epidermis, causing “whitening” of the skin and a feeling of dryness. By dissolving the skin's lipid barrier layer, percutaneous absorption of the solvent, and any chemical it contains is increased. The more lipophilic the solvent, the greater the absorption. Prolonged skin contact with solvent-soaked clothing can result in systemic symptoms, as well as severe burns, and sometimes even death. There is an inverse correlation between the boiling point of a solvent and its primary irritant effect. [21]

Solvent Class/Solvent	Comments
Coal tar solvents: Benzene, toluene, xylene, ethyl, benzene, cumene	Industrial use reduced by environmental regulation; benzene associated with aplastic anemia/leukemia
Petroleum solvents: Gasoline, kerosene, Stoddard solvent, hexane	Stoddard solvent widely used; gasoline vapors may induce narcosis; *N*-hexane may cause sensory/motor neuropathy
Chlorinated hydrocarbon solvents: Carbon tetrachloride, trichloroethane, tetrachloroethane, trichloroethylene (TCE), methylene chloride, ethylene dichloride	Many are degreasers with systemic (especially liver, renal, and CNS) toxicity; alcohol ingestion after TCE exposure causes degreaser's flush
Alcohol solvents: Methyl-, ethyl-, and isopropyl alcohols	Methyl alcohol ingestion and inhalation causes blindness
Ethylene glycol ether solvents: Glycidyl ethers; ethyl-amyl-, and butyl acetates	Solvents for paints and dyes; lower molecular weight glycidyl ethers are contact allergens
Others: Turpentine, ethyl ether, acetone, methyl ethyl ketone, carbon disulfide, DMSO, dioxane, styrene	Acetone widely used; turpentine is a contact allergen

SOURCE: Wahlberg JE et al.[20]

TABLE 137-4 **Selected Industrial Solvents That Are Skin Irritants**

Workers are rarely exposed to a single solvent. More often they are exposed to mixtures of several solvents, but clinically, it is often difficult to demonstrate the relative importance of an individual ingredient of a mixture. Mineral spirits, kerosene, gasoline, and various thinners are widely used as mixtures.

FIBROUS GLASS Glass fibers, also called man-made vitreous fibers (MMVF), causes a characteristic highly pruritic contact dermatitis, that may resemble scabies. Fibers larger than 3.5 µm are generally responsible, causing pruritus and furious scratching and excoriations. Symptoms usually subside in a week or two and workers can usually return to the same work without recurrence. Patients with atopic eczema or dermographism may have to change jobs. Pathogenesis is via direct, indirect (through clothing), or airborne irritant dermatitis. Symptoms may occur through simple mechanical irritation by sting, penetration of fibers into the skin and a secondary allergic contact dermatitis from the associated finishing resins, for example, epoxy.

FABRICS Wool and rough synthetic clothing are well known to cause itching dermatitis, especially in atopic individuals. Fire-retardant fabrics, “NCR” paper, and paper face masks, as used in the semiconductor and other industries, also frequently induce irritation in such persons.

PLANTS Irritant dermatitis is the most frequent type of plant-related dermatitis and can appear as erythema, hyperkeratosis of the hands and fingers, papules, vesicles, necrosis, abrasions, or granulomas. Plant families most commonly associated with irritation are the *Euphorbiaceae* (various spurges, crotons, poinsettias, manchineel tree); *Ranunculaceae* (buttercup) and *Cruciferae,* also termed *Brassicaceae* (black mustard); *Urticaceae* (nettles); *Solanaceae* (pepper, capsaicin); and *Opuntia vulgaris* (prickly pear). [22] Many plants cause only simple irritation, as from spines, thorns, sharp-edged weeds, and trichromes and barbs (glochids) of certain cacti. [23] Sabra dermatitis, for example, is a term used for dermatitis caused by contact with tiny glochids on the surface of the Indian fig (*Opuntia ficus-indica*), which penetrate the skin and cause a dermatitis resembling scabies. Sometimes foreign-body granulomas are formed. The chemicals present in various sections of plants are responsible for much of the irritation from plants. These include oxalic, formic and acetic acids; various glycosides; proteolytic enzymes; phorbol esters; isothiocyanates; and crystals of calcium oxalate. [24] Phototoxic eruptions from plants (phytophotodermatitis) are fairly common among farm workers, nursery personnel, florists, and gardeners, and occur more frequently than photoallergic reactions. Plants containing furocoumarins, such as 5-methoxypsoralen (bergapten, 5-MOP), are the most common causes of phototoxic reactions, which result from contact with the plant followed by exposure to ultraviolet light (UVA) at wavelengths of 320 to 400 nm in sunlight. Large bullae appear on exposed skin, which are almost always nonpruritic. After resolving in a week or so, characteristic linear, hyperpigmented streaks remain, which may last for months. Outdoor workers exposed to moist plants, either from fog or irrigation, and sunlight may develop these characteristic lesions, which usually appear a few hours after exposure but sometimes not until 36 to 48 h later. Plant families responsible for most of these eruptions are the *Umbelliferae* (parsley, celery, parsnip, giant hogweed, and others), *Rutaceae* (rue, burning bush or gas plant, bergamot), and *Moraceae* (fig tree). A widespread phytophotodermatitis may result from contact with weeds, such as cow parsley (*Anthrisis sylvestris*) and hogweed (*Heracleum sphondylium*). The term *strimmer dermatitis* (or “weed-whacker dermatitis”) is applied to a photodermatitis caused by contact with newly mowed, moist plant fragments on sunny days. The eczematous eruption is often bullous, leaving characteristic hyperpigmented streaks. Celery harvesters and grocery clerks handling celery may develop a phytophotodermatitis, as well as bartenders squeezing limes, especially out-of-doors on sunny days. By testing celery pickers with serial dilutions of 8-methoxypsoralen, 5-methoxypsoralen, and trimethylpsoralen, Ljunggren was able to differentiate allergy from phototoxicity. [25]

ALLERGIC CONTACT DERMATITIS (See also Chap. 120)

Allergic contact dermatitis (ACD) in the working environment is reported less frequently to workers' compensation authorities than irritant dermatitis, in part because most workers with contact dermatitis are never patch tested to determine the presence of contact allergy; thus many cases are not diagnosed and reported. In a recent multicenter study from the North American Contact Dermatitis Group, of 839 occupational dermatitis cases (29 percent of 2889 patients referred for evaluation of contact dermatitis), 54 percent were primarily allergic, 32 percent irritant, and 14 percent were diagnoses other than contact dermatitis, aggravated by work. [26] In this series, nursing was the occupation most commonly found to have allergic contact dermatitis. Other occupations were assemblers, nurse's aides and orderlies, machinists, students, machine operators, auto mechanics, compressing and compacting jobs, and cooks. Allergens strongly associated with occupational exposure were rubber (thiuram and carbamate accelerators), epoxy resin, and ethylenediamine. The hands are the most commonly affected site in occupational allergic contact dermatitis. The dorsal hands are typically involved along with the finger webspaces and the forearms. Nail dystrophy may occur if there is involvement of the periungual areas.

Table 137-5 [27] lists the principal occupational contact allergens and Table 137-6 [28] lists blind spots in the diagnosis of allergic contact dermatitis. Also see “ Patch Testing” later in this chapter.

Biocides: isothiazolinones, formaldehyde releasers
Chromate
Cobalt
Colophony
Dyes
Epoxy resin systems (may need to test with worker's own resin)
Formaldehyde
Formaldehyde resins
Fragrances and essences
Nickel—primarily, usually nonoccupational
Plants and woods
Rubber processing chemicals

TABLE 137-5 **Major Occupational Contact Allergens**

Blind Spot	Example
ACD may be identical to another disease	Infectious dermatitis like ACD caused by bad tattoo Tinea pedis misdiagnosed as occupational ACD; positive KOH prep made the diagnosis Facial dermatitis of the hand diagnosed as occupational ACD; cured with Lyme/hand eczema thinning ACD caused by synthetic organic pigment benzophenone 1 in a utility literature; misdiagnosed as epithelioma
Failure to make a second diagnosis	ACD was incorrectly misdiagnosed as fear of allergic eczema Chronic active dermatitis of the face with ACD from topical corticosteroids in a reader
Circuit exposure to an allergen	Belt in pants pocket caused ACD of the lateral thigh in a nickel plater allergic to nickel ACD caused by preservative methylchloroisomethiazolinone in a sunscreen with a label that listed only active ingredients Chronic hand eczema and contact allergy to Fragrance mix in a rubber washer caused by recurrent beverage holder
Inadequate or deceptive history—patient does not recall exposure to specific allergens	Patient with chronic hand eczema treated for dermatitis cream and vasodilator only; those in pharmacy prescription bin Patient allergic to neomycin with persistent perianal eczema caused by sulfonamide containing ointment, not recognized as a cross-reacting allergen
Failure of patch testing	Occupational contact dermatitis of the hands attributed to an latex protein; irritant patch test reaction to a cleanser Occupational contact dermatitis of the hands with a false-negative patch test reaction to latex; usage of gloves; further patch testing unilateral an allergy to Rosacea, present as accentuated in the gloves

TABLE 137-6 **Blind Spots in the Diagnosis of Allergic Contact Dermatitis (ACD)**

The mechanism of ACD is discussed in Chap. 120. It is important to remember, however, that the induction of allergic sensitization to a specific allergen in a nonsensitive individual requires 4 or 5 days or more. Following subsequent contact with the allergens, the sensitive person will develop a clearly defined reaction, appearing as early as 24 to 48 h later. This information is important in determining when and where sensitization took place. If ACD develops in a worker after only 2 or 3 days following initial contact with an allergen, the induction of sensitivity must have occurred previously, perhaps during an earlier occupation.

CONTACT URTICARIA AND IMMEDIATE CONTACT REACTIONS

There are three varieties of contact urticaria (CU): (1) nonimmunologic (NICU); (2) Immunologic (ICU), a type I IgE-mediated reaction; and (3) CU of uncertain mechanism (see also Chap. 116).

NICU

In NICU, nearly all exposed individuals will develop reactions without previous sensitization, depending on the nature of the substance, its concentration, the area of skin exposed, and mode of exposure. The reaction usually remains localized, and systemic symptoms of wheezing, rhinorrhea and syncope usually do not occur. Among the most potent ubiquitous urticants causing this type of CU are benzoic acid, sorbic acid, cinnamic acid, cinnamic aldehyde, and nicotinic acid esters. [29] Gardeners (nettles, various plants, caterpillar hairs, moths, and other insects), cooks (fish, mustard, cayenne pepper, and thyme), and medical and related personnel (alcohol, balsam of Peru, benzocaine, methyl salicylate, tar extracts, tincture of benzoin, witch hazel, and DMSO) are some of the occupational groups that may be affected.

ICU

ICU, an IgE-mediated, immediate allergic reaction, occurs in persons previously sensitized to a specific agent. Individuals with a history of atopy, especially atopic dermatitis, are more susceptible. The paradigm for occupational ICU is natural rubber latex (NRL) allergy, which results from a reaction to one or more of the 240 proteins present in NRL. The highest prevalence of NRL allergy is in spina bifida patients. Also affected are health care workers, kitchen workers, cleaners, rubber band, surgical glove, and latex doll manufacturing workers, and others who wear NRL gloves. Greatest risk is from exposure to dipped NRL devices (gloves, especially if powdered; balloons; condoms; catheters; and dental dams) in contrast to dry-molded rubber products (syringes, plungers, vial stoppers, etc.), which contain lower residual or extractable protein levels. [30] See Chap. 120 and the section “Prevention” in this chapter for more information on NRL allergy. Besides latex, the next most common cause of ICU is foodstuffs, occurring in cooks, grocery workers, and handlers of meat, fish, and other foodstuffs. Raw potato, meat (especially liver), and raw fish are common causes, as are antibiotics and other medications, preservatives, disinfectants, fragrances, epoxy resin hardeners, several woods, birch pollen, formaldehyde in clothing, and many others.

Uncertain Mechanism

Of uncertain mechanism are reactions to ammonium persulfate, used as a “booster” in bleaching hair to obtain a platinum blonde effect. The dermatitis, occurring mostly in clients, is sudden in onset and characterized by erythema, edema, severe itching, urticaria, and, occasionally, syncope, with wheezing and dyspnea. Hairdressers should be made aware of the seriousness of this problem.

Clinical Features/Other Terms

The term *contact urticaria* typically refers to a wheal-and-flare reaction elicited, usually at the site of contact, within 20 to 30 min of exposure; delayed onset CU (up to 4 to 6 h) has been described, as has delayed onset (24 h) and prolonged (1 week) CU. The concept of CU has been expanded and the precise usage of related terms varies considerably in the literature and includes (1) immediate contact reaction, the broadest concept, referring to both immunologic and nonimmunologic urticarial or nonurticarial reactions, but says nothing about the appearance of the reaction; (2) protein contact dermatitis with allergic or nonallergic eczematous immediate reactions, often dyshidrosis caused by proteins—initially described in food handlers; (3) contact urticaria syndrome with local reactions in the skin, and systemic reactions (angioedema, asthma, and anaphylaxis) in other organs; usually immunologic; (4) atopic contact dermatitis, a historical term referring to an immediate urticarial or eczematous IgE-mediated contact reaction in an atopic person; and

(5) immediate-type irritancy with nonallergic urticarial or nonurticarial reactions.

Other than for NRL, there is little statistical data on CU. Data from Finland lists farmers with the most cases and bakers as having the highest rate. [31] Cow dander was the number one cause of CU and was also the most frequent cause of occupational rhinitis and asthma in Finland. This is in contrast to other reports of respiratory and food allergy that have only occasionally been associated with contact urticaria. This association is assumed to be uncommon, because it is thought that the responsible large protein molecules do not ordinarily penetrate intact skin, but require inflamed skin. The Finnish data also identified several low molecular weight chemicals as a cause of contact urticaria: methyltetrahydrophthalic anhydrides, diglycidyl ether of bisphenol, an epoxy resin, polyfunctional aziridines nickel, and reactive dyes. Diagnosis of ICU typically involves skin testing with the suspected substance and serologic assays for specific IgE. Where a chemical hapten is suspect, it is necessary to centrifuge it with a protein, usually human serum albumin, a nonstandard procedure.

Contact urticaria occurs from direct contact with skin (most examples) or mucosa (latex and chlorhexidine; the latter may be associated with systemic toxicity), or by airborne contact (cinchona, mulberry, xylene). Exposure may be accidental or due to equipment failure (xylene). Ingredients (Tinofix) or trace contaminants or impurities (an anhydride present in sorbitan sesquioleate) may be responsible. Contact urticaria may be associated with other urticaria, such as delayed pressure urticaria. [32] Occasionally, only erythema, burning, and itching occur, but at least some people should develop urticaria at the application site to be regarded as contact urticaria. Combined CU and delayed allergic eczematous reactions may occur. [32]

BIOLOGICAL CAUSES

Potential exposure to infectious agents is significant in many occupations. Service workers in the health, food, cleaning, and personal service jobs develop most of the cases, but many are never reported, especially those among agricultural workers.

Establishing a definite relationship between the work and a specific infection is not always simple. Laboratory isolation of the infective organism and a supporting medical history and examination are helpful, but often the evidence is based on conjecture. However, the circumstantial evidence is sometimes so strong that a definite connection can be made, as, for example, herpes simplex on the ungloved finger of a dental assistant or tinea pedis in a sewage worker with frequently wet feet.

Bacterial Infections

STAPHYLOCOCCAL AND STREPTOCOCCAL INFECTIONS (See also Chap. 194) Secondary bacterial skin infections due to *Staphylococcus* and *Streptococcus* are common complications of abrasions, lacerations, burns and puncture wounds. Butchers and meat handlers are likely to develop infected cuts and scratches; paronychia, abscesses, and lymphangitis. Folliculitis and boils are common in farm workers and construction workers. Workers in hot, humid, and dirty environments (Fig. 137-2) or those working in close contact with infected persons, such as nurses, hairdressers and manicurists are at risk. Staphylococcal colonization of individuals with active atopic dermatitis limits their work in food service and health care jobs. The increase in multidrug-resistant bacterial strains and widespread cross-resistance to antibiotics may present a therapeutic challenge in some cases. [33]

FIGURE 137-2 Infectious eczematoid dermatitis frequently follows contact dermatitis that is untreated and in an area where there is constant rubbing. In this case, the patient was a logger working in an area with poor access to medical attention.

ANTHRAX (See also Chap. 199) Anthrax, caused by *Bacillus anthracis,* is primarily an animal disease seen in cattle, sheep, horses, goats, and wild herbivores. Agricultural workers, stockbreeders, butchers, and meat-processors can become infected by contact with diseased animals. Contaminated hides, goat hair, wool, and bones can infect longshoremen, freight handlers, warehouse workers, and employees of processing plants where these products are treated for use. Tanners, carpet makers, and upholsterers are also at risk. The cutaneous form is more common and begins as a papule at the site of inoculation. This progresses to a characteristic, usually painless necrotic eschar surrounded by brawny edema. Regional lymphadenopathy is common, and constitutional symptoms and a generalized maculopapular eruption may be seen. A vaccine is available for those in high-risk occupations. Anthrax spores are highly infectious, making it a desirable agent of germ warfare, especially for the development of the often-fatal pulmonary anthrax. However, of the 22 cases of anthrax recently reported in the United States as a result of bioterrorism, 12 were the cutaneous form. Immunohistochemistry (IHC) was crucial to the diagnosis. All demonstrated *Bacillus anthracis* cell wall antigen by IHC, including the New York City index case, which had a negative culture and Gram's stain. A cutaneous anthrax management algorithm has been published and is available online at http://www.aad.org/.

CUTANEOUS TUBERCULOSIS

Typical mycobacterial infections (See also Chap. 200) The classic example of work-acquired tuberculosis of the skin is tuberculosis cutis verrucosa, a slow-growing warty growth acquired by the inoculation of *Mycobacterium tuberculosis hominis* or *M. bovis*. It is usually seen in pathologists and morgue attendants (prosectors or necrogenic wart). Surgeons, veterinarians, farmers, and butchers are also at risk.

Atypical mycobacterial infections *Mycobacterium marinum* causes swimming pool or fish-tank granuloma, a solitary or disseminated granulomatous infection in fishermen, fish-tank cleaners (Fig 137-3), and workers cleaning contaminated swimming pools; surgeons are also at risk. *M. ulcerans, M. fortuitum, M. avium, M. intracellulare, M. kansasii,* or *M. chelonae* may also cause infection, especially in persons with suppressed immunity. [12]

FIGURE 137-3 Sporotrichoid atypical mycobacterial infection with *M. marinum* in a woman who worked in a shop selling tropical fish.

BRUCELLOSIS (See also Chap. 199) Brucellosis is a zoonosis transmitted to humans from contact with infected animals or ingestion of untreated milk or milk products. The organism is a nonmotile, gram-negative rod, with any of the four species capable of causing infection: *Brucella melitensis* from goats, sheep and camels; *B. abortus* from cattle *; B. suis* from pigs; and *B. canis* from dogs. Skin manifestations are nonspecific and include maculopapular eruptions, purpura and petechiae, chronic ulcerations, abscesses, discharging sinuses, and superficial thrombophlebitis. Farmers, livestock-breeders, meatpackers, veterinarians, and laboratory workers are at risk. An epidemic caused by sniffing bacterial cultures has been reported. [34] When cases go undiagnosed and unreported, they constitute a major health hazard. As a result, chronic forms occur, which may present as endocarditis, meningitis, and other organ infections. Although the disease is rarely fatal, it is a potential agent of bioterrorism.

TULAREMIA (See also Chap. 199) Tularemia is caused by *Francisella tularensis,* a gram-negative, pleomorphic, non–spore-forming bacillus, transmitted by ticks, fleas, and deer flies. Animal reservoirs include wild rabbits, squirrels, birds, sheep, beavers, muskrats, and domestic dogs, and cats. In nature, the most common form is ulceroglandular tularemia, presenting as an ulcerative lesion with eschar formation at the site of inoculation, with regional lymphadenopathy and lymphadenitis. A generalized maculopapular eruption and constitutional symptoms resembling typhoid may be seen in other forms of the disease, which may also be weaponized in germ warfare. Tularemia is ordinarily seen in hunters, trappers, game wardens, butchers, fur handlers, and laboratory workers. This highly infectious organism readily penetrates unbroken skin, and great care should be exercised in handling infected tissues and excreta.

ERYSIPELOID (See also Chap. 199) Erysipeloid is almost always an occupational disease caused by *Erysipelothrix rhusiopathiae,* a slender, gram-negative rod that infests freshwater and saltwater fish, ducks, emus, turkeys, chicken, and other farmed animals such as sheep. [35] Butchers, fishermen, and retailers of fish and poultry are commonly affected. Infection usually follows puncture wounds and lacerations and presents as a painful, purplish-red, nonvesicular papule or plaque with burning or itching, which gradually disappears in 3 to 4 weeks.

Viral Infections

HERPES SIMPLEX (See also Chap. 214) The most common viral infection of occupational origin is herpes simplex virus (HSV) type 1. HSV type 1, or, occasionally, HSV type 2, are seen in occupations where there is exposure to infected secretions from the mouth or the respiratory tract. Dentists, dental assistants, nurses, and respiratory technicians are particularly vulnerable. When localized to the fingers, it is termed herpetic whitlow and is characterized by erythema and edema resembling a bacterial infection. Herpes gladiatorum refers to HSV infection on the body surfaces of wrestlers and rugby players, and is temporarily disqualifying for infected athletes. The rapid appearance of grouped vesicles usually clarifies the diagnosis, which is confirmed by culture of the vesicle fluid. The use of protective gloves, safety glasses, and masks is the best preventive measure, and has greatly reduced the incidence of the infection.

VIRAL WARTS (See also Chap. 223) Handlers of meat, poultry, and fish have a high prevalence of viral warts. Minor cuts and abrasions acquired during work by butchers and slaughterhouse workers are predisposing factors. Human papilloma virus-7 has been isolated more frequently in this group of patients. [36]

MOLLUSCUM CONTAGIOSUM (See also Chap. 221) This infection may be seen in professional wrestlers and boxers, as well as in runners and swimmers.

ORF (ECTHYMA CONTAGIOSUM) (See also Chap. 220) Orf, caused by a parapox virus, is endemic in sheep and goats, and is easily transmitted to humans through direct contact. Veterinarians, farmers, and shepherds are at risk. Usually one or two rather large (1 to 2 cm) painful nodules appear on the hands and may be accompanied by fever, lymphangitis, and regional lymphadenopathy. Lesions are self-healing in 3 to 6 weeks, occasionally with secondary infection, and second attacks are common.

MILKER'S NODULES (See also Chap. 222) The paravaccinia virus, infecting the udders of cows and producing ulcers in the mouths of calves, can be transmitted to dairy farmers and veterinarians causing milker's nodules (or pseudocowpox). The lesions are commonly seen on the hands as relatively painless erythematous nodules (Fig. 137-4). There is regional lymphadenopathy, but the disease is benign, disappearing after 4 to 6 weeks and confers permanent immunity.

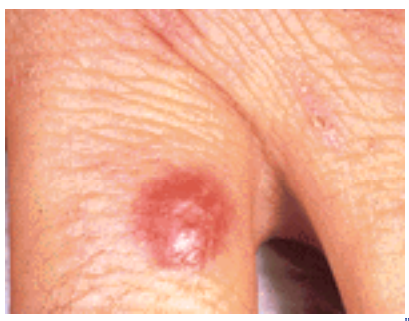

FIGURE 137-4 Milker's nodule is a self-limited condition on the fingers.

Occupational Aspects of Bioterrorism

Twelve agents are of highest concern for germ warfare: anthrax, plague, small pox, botulism, tularemia, two filoviruses (Ebola and Marburg), and five arenaviruses (Lassa and four South American viruses: Guanarito, Junin, Machupo, and Sabia). All have cutaneous manifestations with the exception of botulism and Lassa fever. [37] Risk of human-to-human transmission is high for pneumonic plague, for small pox, and for the viral hemorrhagic fevers, putting health care workers at risk. In Uganda, a number of hospital employees have succumbed to Ebola hemorrhagic fever despite strict isolation measures. [38] Anthrax, tularemia, and botulism are not contagious. Personal protection, decontamination, vaccination, and/or quarantine are important measures for preventing occupational spread of these diseases. [37]

Fungal Infections (See also Chap. 205)

DERMATOPHYTE SKIN INFECTIONS Dermatophyte skin infections are frequent in certain occupations, especially in farmers and those tending cattle who may develop infections with *Trichophyton verrucosum,* a zoophilic dermatophyte. Infections with *T. rubrum* and *T. mentagrophytes,* which are seen in the general population, may occur in work situations involving increased perspiration and occlusion. *Microsporum gypseum* and *T. mentagrophytes* are geophilic fungi, which cause infection in agricultural and other outdoor workers (Fig. 137-5). *M. canis* infects small animals as well as veterinarians and laboratory workers.

FIGURE 137-5 Fungal infection of the fingernails in a greengrocer. Trauma from repeatedly opening boxes of produce, in addition to the almost constant wetness, contributed to its development.

CANDIDIASIS (See also Chap. 206) Infection with *Candida albicans* is common in occupations that expose the skin to moisture and occlusion, such as wearing gloves for long periods of time. Food handlers, nurses, dental assistants, dishwashers, and laundry workers are at risk.
SPOROTRICHOSIS (See also Chap. 207) Sporotrichosis, caused by the saprophytic fungus *Sporothrix schenckii,* is acquired by inoculation through puncture wounds with thorns, sticks, or splinters. It is seen in farmers, nursery and forestry workers, and in other outdoor occupations. Gardeners working with sphagnum moss used for packing plant roots may also be at risk.
MYCETOMA (MADURA FOOT) (See also Chap. 207) Mycetoma, caused by various species of fungi and actinomycetes, is seen mainly in farmers and outdoor workers, who walk barefoot in tropical and subtropical countries. The organisms become implanted after trauma and lesions present as chronic, localized granulomatous infections of the feet or hands, with multiple draining sinuses.
CHROMOBLASTOMYCOSIS (See also Chap. 207) Chromoblastomycosis, a deep mycosis, often follows a puncture wound or other trauma, during which soil inhabiting fungi of *Phialophora, Hormodendrum,* and *Fonsecaea* species are injected deep into the tissues. Agricultural and other outdoor workers are at risk.
BLASTOMYCOSIS (See also Chap. 207) Blastomycosis, caused by a dimorphic fungus, *Blastomyces dermatitidis,* is found in the southeastern United States and northern Mexico. It is primarily an infection of the lungs, but dissemination occurs frequently with skin involvement. Those at risk include agricultural, forest, and construction workers, farmers, and persons working with heavy earth-moving equipment.
COCCIDIOIDOMYCOSIS (See also Chap. 207) Coccidioidomycosis is seen in the southwestern United States and Central and South America. Infection is acquired by inhalation of dust containing the spores of *Coccidioides immitis*. The clinical picture is usually of a self-limiting upper respiratory tract infection, often followed by the development of erythema nodosum, and, in rare instances, dissemination. Occasionally, a primary cutaneous infection follows a traumatic puncture wound. Farmers, construction workers, bulldozer and heavy equipment operators, professional baseball players and laboratory workers are susceptible.

Parasitic Diseases (See also Chap. 235)

Leishmaniasis, caused by *Leishmania tropica* (oriental sore) and by *L. brasiliensis* (American leishmaniasis) is endemic in the Middle East and Central and South America, respectively. Cutaneous ulcers and mucocutaneous lesions are common and workers in rural areas are infected, the vector is a tiny sandfly.

The larvae of *Ancylostoma braziliense* and *Necator americanus* cause creeping eruption (larva migrans) in agricultural workers, fishermen, sewer workers, and lifeguards. Feces of dogs, cats, and cattle contain the larvae, and humans are the final host. Skin divers, lifeguards, dockworkers, and caretakers who maintain lakes and ponds are prone to develop swimmer's itch caused by the cercariae of a schistosome. The cercariae penetrate human skin inadvertently, causing itching within minutes of leaving the water; uncovered areas of skin are involved. A secondary stage follows in 10 to 15 h

with an intensely pruritic, urticarial, and occasionally vesicular eruption. In contrast, sea-bather's eruption, caused by different larvae or other marine toxins, occurs on covered body areas. Dogger bank itch is an allergic eczematous eruption of fishermen and dockworkers in the North Sea, who are exposed to the marine bryozoan, *Alcyonidium gelatinosum*.

Arthropods (See also Chap. 239)

The bites of bees, wasps, hornets, ants, ticks, mites, centipedes, and millipedes frequently cause work-related skin disease. Outdoor workers, food handlers, chicken farmers (chicken mites), workers in food processing plants, restaurant workers, and dockworkers may be affected. Epidemics of *scabies* have occurred in nursing homes, hospitals, and other residential facilities for the aged. An infected employee is often the source.

Lyme disease (Fig. 137-6) (see also Chap. 203) is transmitted through a tick bite and can affect outdoor workers, loggers, ranchers and construction workers in wilderness areas.

FIGURE 137-6 Erythema surrounding a tick bite that is several weeks old. Erythema chronicum migrans is common following such bites and may last for months. Lyme disease, transmitted by ticks of the genus *Ixodes,* frequently follows such reactions.

PHYSICAL CAUSES

Mechanical Trauma

Mechanical trauma, an accompaniment of many different occupations, is a primary factor in many cases of occupational skin disease, and accounts for a number of skin manifestations. The skin may be subjected to friction, pressure, cuts, lacerations, and abrasions. Repeated mechanical trauma such as low-intensity pressure or friction, the most common mechanical trauma, leads to hyperpigmentation and lichenification, whereas heavier and persistent friction leads to hyperkeratosis and callus formation (Fig. 137-7). Sudden shearing forces may lead to the formation of friction blisters, erosions, or ulcers. [39] Prolonged and excessive pressure may produce erythema, vesicobullae, and later necrosis, but usually only hyperpigmentation and thickening, which are so characteristic as the stigmata of various occupations [40] (Fig. 137-8). In athletes, repetitive trauma from running may lead to black heel or “talon noir,” which represents punctate petechiae on the heels as a result of ruptured dermal papillary capillaries. Corns may also develop due to extreme pressure associated with bony deformities, poor foot mechanics, or improper footwear. [41]

FIGURE 137-7 In spite of growing automation of many jobs, the hands are still useful tools. Here a bodyshop worker is sanding a fender in preparation for painting.

FIGURE 137-8 Nail dystrophy in a slaughterhouse worker. Holding a knife in his right hand to cut off the hide, he pulled and tugged on the hide with his left. Note the calluses over the distal interphalangeal joints on the left.

Underlying skin conditions such as psoriasis and lichen planus are aggravated by the occupational trauma as a result of the isomorphic response of Koebner. Patients with psoriasis may develop lesions at the sites of repeated friction or pressure and should be advised to avoid occupations that may subject them to mechanical injury.

Workers, often of middle age, engaged in manual work and nearing retirement, may present with a chronic

hyperkeratotic, scaly, fissured dermatitis involving the palms (Fig. 137-9). Chronic callus formation after years of repeated trauma may result in permanent disability, contributing to early retirement. This is termed *hyperkeratotic hand eczema* and is a relatively severe and recalcitrant condition. Repeated friction and pressure is thought to play a role. Although it may be a manifestation of psoriasis, a review concluded that it was an independent entity, unrelated to psoriasis and mechanical irritation. [42]

FIGURE 137-9 Chronic hypertrophic dermatosis of the palms in a 59-year-old machinist. He was transferred to work in a storeroom, where he continually handled tools, and was forced to retire because of persistence of the dermatosis with its fissuring and bleeding.

A dry, scaly, fissuring, painful dermatitis may be seen on the fingertips, especially in women engaged in domestic work. This is a form of frictional dermatitis known as *pulpitis.* It may sometimes affect only the thumb and first two fingers of the dominant hand, indicating an occupational basis, such as that seen in persons handling newspapers repeatedly. [43] Kanerva et al. have reported a similar condition, in which paresthesia on the fingertips are prominent symptoms, in dental personnel allergic to acrylates. [44]

Before the onset of automation of industry, the location and nature of calluses were considered representative of a person's occupation. [40] Besides calluses and corns, occupational marks include discolorations, telangiectases, tattoos, odors, deformities, and other changes caused by specific work activities. Occupational marks are less common today because of greater automation and better protective clothing, especially a wider selection of gloves.

Mathias reported a series of patients with *posttraumatic eczema,* which is defined as the occurrence of dermatitis at the site of cutaneous trauma. The trauma is insufficient to cause obvious tissue damage accompanied by inflammation or tissue regeneration. The eczema usually develops within a few weeks of the acute injury and may persist or recur for long periods of time. [45] The damaged, functionally altered skin is thought to play a role in precipitating the eczema. It has to be distinguished from posttraumatic psoriasis and secondary allergic contact dermatitis from topical medicaments applied to the injured skin. Table 137-7 lists the types of posttraumatic eczema. [45]

Idiopathic reaction (endogenous eczema absent)
Isomorphic reaction
Primary (precedes endogenous eczema)
Secondary (follows endogenous eczema)

TABLE 137-7 **Clinical Classification of Posttraumatic Eczema**

Occupational skin granulomas may form due to the penetration of the skin by foreign material. Substances such as beryllium, zirconium, chromium, and tattoo pigments may induce an allergic reaction in the skin, leading to the formation of immunogenic granulomas. [46] Granulomas formed as a reaction to oils, starch, suture material, silk, wool, liquid paraffin, thorns, cactus spikes, and wood splinters are nonallergic or foreign-body granulomas. The penetration of human hair into the interdigital spaces of barbers, and of cow and sheep hair into the hands of animal tenders, can also produce foreign-body granulomas.

Preexisting dermatitis caused by friction and pressure may predispose to the development of allergic sensitization. It is well known that allergic contact dermatitis and contact urticaria to natural rubber latex gloves develops when these are worn over dermatitic skin. Hard metal workers are predisposed to develop cobalt allergy due to the trauma sustained during work. The microtrauma facilitates the entry of allergens and irritants into the skin and contributes to irritant and allergic contact dermatitis. Even minor lacerations and abrasions, which may not be serious, can increase the likelihood of contact sensitization to allergens present in the immediate environment.

HEAT

Thermal Burns

Workers are at risk for thermal burns as a result of scalding, contact with liquid metal, hot equipment and tar, and flame burns following explosions. Kitchen workers and adolescents working in fast food restaurants may develop scalds from hot grease. [47] Roofers frequently experience hot tar burns, whereas explosives and use of flammable liquids cause most industrial burns. Persons working in foundries and smelting plants are at risk for molten metal burns.

In evaluating impairment (see section " Impairment and Disability Evaluation ") of patients scarred or otherwise disfigured from burns, the degree of scarring, pigmentary changes and cosmetic disfigurement are the chief considerations. Superficial partial thickness burns heal without scarring but may become hyperpigmented, especially in those with darker skin types. Deeper burns are associated with scarring, and some persons heal with hypertrophic scars, limiting movement. Leukoderma may also occur with deep burns; when there is total pigment loss, actinic damage and skin

malignancy can result, especially in outdoor workers. Pigmentary changes alone may be cosmetically disfiguring. While hyperpigmentation often disappears in a year or two, in some cases permanent pigmentary changes may be severe enough to limit occupational possibilities.

Electrical Burns

In industrial settings electrical burns are usually high voltage injuries, which may result in serious tissue destruction, as well as potentially fatal cardiac arrhythmias. Extensive muscle injury carries a risk of renal failure. Low voltage injuries appear mild, but deceptively extend away from the edges of the visible wound, penetrating deep into tissue along nerves and blood vessels. Lightening burns, an ever present hazard of outdoor workers, may show characteristic bizarre feather- and/or fern-like patterns.

Erythema ab Igne

Erythema ab igne is a reticular, telangiectatic, and pigmented dermatosis resulting from prolonged or repeated exposure to infrared radiation (heat) insufficient to produce a burn. Persons working over a heat source, including stokers, blacksmiths, glassblowers, and bakers, may develop this condition, which may progress to skin cancer after a number of years.

Miliaria (See also Chap. 76)

Miliaria is a common work-related condition, caused by sweat retention resulting from pore closure. The clinical picture, depending upon the degree and duration of heat exposure, ranges from mild erythema (miliaria crystallina), patches of erythema studded with tiny vesicles (miliaria rubra), and deep-seated vesicles and papules (miliaria profunda) associated with symptoms of heat exhaustion if left untreated. Miliaria rubra, or prickly heat, is commonly misdiagnosed as contact dermatitis.

Intertrigo

Intertrigo is a macerated, superficial erythematous eruption seen in the body folds, caused by excessive sweating and sweat retention, especially in obese persons. It is commonly seen in the interdigital spaces of workers whose hands are continuously wet, such as from wearing rubber gloves for prolonged periods. Secondary infection with *Candida albicans* is common.

Other Conditions

Acne vulgaris and *rosacea* may be aggravated by the heat of open furnaces, heat torches, ovens, and stoves. *Herpes simplex* may also be triggered by heat exposure. *Heat-induced urticaria* may result from excessive physical exercise.

COLD (See also Chap. 126)

Frostbite, Chilblains, Immersion Foot

Frostbite, chilblains, immersion foot, and *cold urticaria* are common in workers employed in cold environments. Military personnel stationed in cold climates are most commonly affected with these conditions, but firefighters, icemakers, liquefied-gas makers, refrigeration workers, persons engaged in winter sports, and others who work outdoors in the cold may be affected. Cold urticaria is described in Chap. 116.

FROSTBITE Frostbite is due to the freezing of the skin and subcutaneous tissue resulting in formation of ice crystals, causing tissue injury. The extent of skin damage is dependent on temperature, duration of insult, and rate of cooling. If the rate of rewarming is slow then tissue damage is greater.
CHILBLAINS Chilblains (perniosis) represent the mildest form of cold injury, with reddish blue, swollen and boggy lesions with bullae and ulceration. Gangrene and loss of tissue rarely occur. Exposed fingers, toes, nose, ears, and lower legs are especially affected. Treatment is symptomatic and calcium channel blockers such as nifedipine have been recommended.
IMMERSION FOOT Immersion foot results from exposure to temperatures a few degrees above freezing for several days, in the presence of moisture and constrictive clothing, such as ill-fitting boots. It is not as severe as frostbite, and gangrene does not occur. However, there may be prolonged vasomotor instability, hyperhidrosis, and persistent sensitivity to cold. Treatment is the same as for frostbite.

VIBRATION SYNDROME

The vibration of handheld tools may induce a type of vascular spasm in the fingers and hands, known as “white fingers,” “dead fingers,” and “vibration-induced white finger disease.” [48] This syndrome is one of a growing list of cumulative trauma disorders that primarily affect the musculo-tendinous-osseous-nervous system. Operators of vibrating impact and power tools such as jackhammers, pounding machines, riveting hammers, chain saws, and hand grinders may develop this condition, especially in cold climates. The vasospastic symptoms may be associated with neuromuscular and arthritic symptoms, and even with bone degeneration. [49] Symptoms commonly appear after a few years, but may be seen as early as 3 months. Earlier symptoms are mild and consist of numbness and tingling, followed by blanching and stiffness of one or more fingers. Initial symptoms are often ignored by the worker; when they progress and workers develop paresthesias and weakening of grip, the condition can become disabling, sometimes causing workers to lose their jobs. Vibration frequencies between 30 and 300 Hz are most strongly associated with vibration syndrome; smoking is also considered a risk factor. Improvement in the design of chain saws and other vibrating tools has resulted in a decrease in the

prevalence of vibration-induced symptoms.

OCCUPATIONAL CONNECTIVE TISSUE DISORDERS

The occurrence of Raynaud's phenomenon and scleroderma-like skin lesions with osteolytic changes in the bones of the fingers is well described in vinyl chloride workers. [50] The syndrome has been called occupational acro-osteolysis; systemic abnormalities such as thrombocytopenia, portal and hepatic fibrosis, and hepatic angiosarcoma were associated. Only 3 percent of workers cleaning the reactor tanks containing the vinyl chloride monomers were affected. Today, the condition is rare because of better engineering controls. [50] Exposures to other organic solvents have also been reported to cause scleroderma-like disease. [50]

There are now a number of reports of systemic sclerosis and sclerodermatous skin changes associated with silica exposure and pulmonary silicosis, especially in underground miners (coal, gold, uranium, lead) or stone masons and related occupations. [50] The simultaneous operation of vibration tools during mining, a common activity in mining, contributes to the development of the disease. [50]

OCCUPATIONAL AND ENVIRONMENTAL ACNE

Oil Acne

Oil acne is a folliculitis consisting of follicular papules and pustules occurring on skin that contacts oils, especially heavy industrial oils or straight cutting oils in machinists. The skin areas where there is the greatest exposure to oil-soaked clothing, such as the arms and thighs, are most frequently involved. Topical and systemic treatment is the same as for acne vulgaris. With better engineering controls and greater emphasis on personal cleanliness, and protective clothing, its frequency has greatly diminished in the past several decades.

Coal Tar and Pitch Acne

Coal tar oils, creosote, and pitch can produce a comedonal type of acne, which often shows a predilection for exposed areas, particularly the malar regions. [51] Coal tar plant workers, roofers, road maintenance workers, and construction workers are among those at risk. Coal tar acne may be complicated by phototoxic reactions affecting both the skin and the eyes and resulting in hyperpigmentation known as coal tar melanosis. Late complications include the development of pitch and tar papillomas, keratoses, and acanthomas. [52]

Chloracne (See also Chap. 73)

Chloracne is one of the most sensitive biological indicators of occupational or environmental exposure to certain highly toxic halogenated aromatic hydrocarbons, which often occur as trace contaminants during synthesis of industrial chemicals. Chloracne appears regardless of whether chemical exposure has occurred via skin contact, the usual route, or by inhalation or ingestion. One of the most potent inducers of chloracne is 2,3,7,8- tetrachlorodibenzo- *p*-dioxin (TCDD). Table 137-8 lists other chloracnegenic chemicals that reportedly cause chloracne. [53] Chloronaphthalenes and polychlorinated biphenyls (PCBs) caused chloracne in the pre-World War II era. Since then, trace contaminants formed during the manufacture of PCBs and other polyhalogenated compounds, especially herbicides, have been the major causes. These include polyhalogenated dibenzofurans, polychlorinated dibenzo- *p*-dioxins, especially TCDD and chlorinated azo- (TCAOB) and azoxy- (TCAB) benzene compounds.

Polyhalogenated biphenyls
Polychlorinated biphenyls (PCBs)
Polybrominated biphenyls (PBBs)
Polychlorodibenzofurans
Contaminants of polychlorophenol compounds, especially herbicides
2,4,5-tetra and pentachlorophenol, and herbicide intermediates,
2,4,5-trichlorophenol and 2,3,7,8-tetrachlorodibenzo-*p*-dioxin (TCDD)
Hexachlorodibenzo-*p*-dioxin
Tetrachlorodibenzofuran
Contaminants of 3,4-dichloroaniline and related herbicides (e.g., Propanil, Methazole)
3,4,3′,4′-Tetrachloroazoxybenzene
3,4,3′,4′-Tetrachloroazobenzene
Others
1,2,3,4-Tetrachlorobenzene (experimental)
Dichlobenil (Casaron) herbicide
DDT (crude tichlorobenzene)

SOURCE: From Taylor.[17]

TABLE 137-8 **Chloracne-Producing Chemicals**

Most outbreaks have been occupationally related with more recent reports from the United States, Britain, and Mexico (chlorobenzenes), and China (dioxins and furans during pentachlorophenol production). Nonoccupational, environmental chloracne has resulted from some of the largest outbreaks, affecting hundreds of persons. These episodes have resulted from industrial accidents affecting the surrounding population (TCDD in Italy in 1976), contaminated industrial waste (Missouri horse arenas in the 1970s) and poisoned food products [PBBs in Michigan in the 1970's, PCBs in Japan (1968) and Taiwan (1979), and dioxins and furans in Spain in 1982]. [53], [54]

Clinical features of chloracne include multiple closed comedones and straw-colored cysts distributed primarily over the malar crescents and retroauricular folds, typically sparing the nose. This pattern of distribution is of significant diagnostic importance. As toxicity increases, the posterior neck, trunk, and extremities, buttocks, scrotum, and penis may become involved. Dermatologic findings associated with specific exposures include hyperpigmentation (PCBs, TCDD); mucous membrane and nail hyperpigmentation (PCBs); follicular hyperkeratosis (PCBs, TCDD); conjunctivitis and meibomian gland changes (PCBs); facial erythema and edema (trichlorophenol); hypertrichosis (TCDD); hyperhidrosis of palms and soles (TCDD, PCBs); and actinic elastosis (TCDD). PCBs and dibenzofurans are transplacental dermatotoxins producing

dystrophic finger and toe nails and hyperpigmented toe nails in exposed children whose mothers had accidentally ingested PCBs; dental abnormalities, growth deficit, and developmental delay also occur.

Diagnosis of chloracne requires documentation of exposure to known chloracnegen chemicals, compatible clinical findings, and absence of other causes of acneiform eruptions. Following initial chemical exposure there is a delay of 2 weeks to a month or more before the appearance of chloracne lesions. Based on clinical findings alone it may be difficult to differentiate chloracne from early acne vulgaris (Table 137-9) and senile (solar) comedones of the Favre-Racouchot syndrome. Dowling-Degos' disease also can be considered in the clinical differential diagnosis. Table 137-10 differentiates chloracne from other types of environmental acne such as oil folliculitis, pitch acne, and tropical acne. [54]

TABLE 137-9 **Clinical Features of Acne Vulgaris as Compared to Chloracne**

TABLE 137-10 **Differential Diagnosis of Various Forms of Occupational and Environmental Acne**

Threshold concentrations of dibenzodioxins and dibenzofurans in blood lipids associated with chloracne were determined in workers from a pentachlorophenol production facility in China. The blood levels were converted to toxicity equivalents and indicate that in addition to tetra isomers, the hepta and hexa congeners may cause chloracne. [55]

The mechanism for chloracne development is still unclear. TCDD is known to have an effect on in vitro keratinocyte differentiation, which may include changes of the epithelium of the pilosebaceous unit. Contrary to data from animal experiments, changes in epidermal retinol have not been observed in epidermal tissue from humans with chloracne. [55]

Systemic findings of liver disease, porphyria cutanea tarda, peripheral neuropathy, hyperlipidemia, plus involvement of other systems have been reported with chloracne, usually depending on the level of chemical exposure. Long-term follow-up of dioxin-exposed populations suggests an increased risk for soft tissue sarcoma, and non-Hodgkin's lymphoma. [54] Treatment, which is often unsatisfactory, consists in use of acne medications, including topical tretinoin, oral isotretinoin, and antibiotics. Acne surgery, light cautery, and dermabrasion have also been used. [55] Olestra, a nondigestible and nonabsorbable dietary fat substitute was recently reported to increase fecal excretion of TCDD in amounts sufficient to reduce the elimination half-life of TCDD from about 7 years to 1 to 2 years. [56]

OCCUPATIONAL SKIN CANCER

Nonmelanoma skin cancer (NMSC) is the most common cancer in whites. Approximately 1.2 million cases of nonmelanoma skin cancers occur each year in the United States, with approximately 300,000 being squamous cell carcinomas and 900,000 being basal cell carcinomas. How many of these cases are induced by the work environment is disputed; some studies suggest that in as many as 70 to 80 percent the work environment contributed to their development, [57] but other studies indicate a much lower percentage. [58] Although cancer registries are operative in most countries, an accurate count of skin cancer, even malignant melanoma, is impossible because many, if not most, skin cancers are entirely treated in physicians' offices and not reported. Furthermore, physicians treating these cancers rarely consider the role of the patient's occupation in its etiology. The proposition that sunlight exposure is the most important causative stimulus is supported by the observation that the majority of NMSCs occur on exposed areas of skin, such as the head and neck.

The skin is an ideal organ for the study of cancer. Indeed, it was the skin that occasioned the first report of an occupational cancer by the English physician Percival Pott in 1775; he described scrotal cancer in chimney sweeps, stating, “it seems to derive its origin from a lodgment of soot in the rugae of the scrotum….” Pott's astute and remarkably accurate observation initiated a study of chemical carcinogenesis that has continued unabated to the present. Even today, scrotal cancer is almost always considered occupational. Other malignancies found to have a definite occupational etiology are angiosarcoma of the liver in workers exposed to polyvinyl chloride, bladder cancer in workers exposed to certain dyes, and lung cancer in asbestos workers (with the added factor of cigarette smoking).

In the occupational environment, the most common causes of skin cancer are ultraviolet (UV) light, polycyclic aromatic hydrocarbons, arsenic trauma, and ionizing radiation.

ULTRAVIOLET LIGHT (See also Chap. 38)

Ultraviolet (UV) radiation from the sun is a carcinogen to which we all are exposed. UV light within the spectrum of UVB (290 to 320 nm) is a primary cause of skin cancer in humans. UVA (320 to 400 nm) augments UVB carcinogenesis and in large amounts can also induce skin cancers. UVC (100 to 290 nm) does not reach the earth but exposure to shorter wavelength rays can occur in industrial settings such as emissions from germicidal lamps and welding arcs.

Sunlight acts as a tumor initiator by inducing specific mutations in the p53 tumor suppressor gene (TP53). [59] In one study, these mutations were detected in more than 90 percent of squamous cell carcinomas and in more than 50 percent of basal cell carcinomas. [60] They are also found in actinic keratosis, implying an early role for potential conversion to squamous cell carcinoma. UV radiation also favors the clonal expansion of these mutated p53 cells, thus acting as a tumor promoter in addition to initiating the process of carcinogenesis. [59] The measurement of this unique pattern of mutations may be useful as a molecular marker of UV exposure and as a possible predictor of risk for skin cancer. It may also prove to be useful in cancer risk assessment in occupationally predisposed individuals.

The relationship between sunlight-induced skin cancer and outdoor exposure has been studied extensively. [61], [62] and [63] Most studies report a significant association between work-related sun exposure and skin cancer, [61] as well as the appearance of precancerous actinic keratoses [64] (Fig. 137-10). However, other studies have found no definite association between skin cancer and outdoor work, [63] or have found a very slight increase in the risk of such an association. [62] These latter findings may be a result of self-selection for indoor jobs in those with fair and medium skin types and a tendency to burn, as compared to those with less-susceptible skin types. [63]

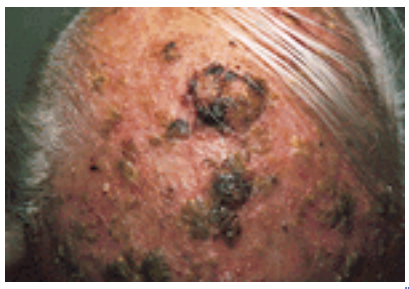

FIGURE 137-10 Severe actinic damage with actinic keratoses and squamous cell carcinomas in an elderly man who had worked outdoors as a fruit picker for most of his life.

UV exposure plays a critical role in the pathogenesis of malignant melanoma. [65] Prolonged occupational exposure to sunlight has been implicated in the development of melanomas of the head, face, and neck. However, some studies fail to show an increased risk of developing melanoma in outdoor workers as compared to indoor workers. [66] Occupational exposure to nonsolar radiation such as welding torches and fluorescent light is reportedly associated with an increased risk of melanoma.

Whereas exposure to intermittent high-dose UV exposure is implicated in the pathogenesis of malignant melanoma, chronic, repeated low-dose exposure is thought to be the likely cause of nonmelanoma skin cancers. [65] These findings may be the reason for a better correlation between nonmelanoma skin cancers and occupational UV exposure. [67] The association of squamous cell carcinoma with cumulative UV exposure is stronger, making outdoor occupations a significant risk factor. However, other occupational exposures, such as to chemical carcinogens, may also play a critical role, [68] and a cumulative effect cannot be excluded. A similar association between cumulative UV exposure and basal cell carcinoma is less clear, [69] although the occurrence of basal cell carcinoma on exposed areas has been shown to be related to UV exposure. In one case-control study artificial tanning devices were associated with an increase in the risk for basal and squamous cell skin cancers. [70]

Solitary keratoacanthomas may result from occupational exposures. The combination of sunlight, prolonged contact with tar and oil, mechanical trauma, and burns contribute to their development. These tumors grow rapidly, with a central keratin core surrounded by squamous cell growth.

Physicians are frequently asked to determine the role the workplace played in the development of actinic skin damage, including skin cancer. This information is important for medicolegal reasons, specifically for workers' compensation determination of permanent disability. Physicians who evaluate these patients must obtain a detailed occupational history, with job descriptions beginning with the first job after leaving school. Activities, especially sports, as a child and teenager are also important. Nonoccupational activities, hobbies and sports, and other recreational pursuits are important. After this information has been collected and evaluated, it should be possible to decide the significance of work-related actinic exposure on the current skin condition and even to assign a percentage of the work activity responsible for the actinic damage and resulting malignancy and/or premalignant lesions.

POLYCYCLIC AROMATIC HYDROCARBONS

Among the chemical carcinogens found at the work place, polycyclic aromatic hydrocarbons (PAHs) account for most of the reported occupational skin tumors. [71] PAHs are hydrophobic, nonpolar compounds that act both as initiators of carcinogenesis as well as complete carcinogens due to their ability to form DNA adducts. [72] Coal tar and petroleum products such as tar, pitch, coke, carbon black (soot), creosote, anthracene, crude paraffin, asphalt fuel and diesel oils, lubrication and coolant oils, untreated mineral oils, as well as oils, waxes, and tars from the distillation products of shale oil and lignite, contain PAHs and can play an important role in occupation related carcinogenesis. [73] High occupational exposure to PAHs occurs in several industries and occupations such as aluminum production, coal gasification, coke production, iron and steel foundries, tar distillation, shale oil extraction, and wood impregnation. Workers can be exposed to PAHs through inhalation or skin contact. High dermal exposure is a risk factor for skin cancer.

Clear epidemiologic evidence demonstrates that early formulations of mineral oil in metal machining and in cotton and jute spinning were carcinogenic to the skin. Mineral oils are a complex mixture of aliphatic hydrocarbons, naphthenics,

and aromatics.

The end products may contain PAHs (particularly benz[a]pyrene), nitrosamines, chlorinated paraffins, and long-chain aliphatics, the relative distribution of which depends on the source of the oil and the method of refinement. However, current formulations of mineral oils have lower concentrations of PAHs and nitrosamines. The potential presence of multiple carcinogens in the mixtures makes epidemiologic studies difficult and complicated. Although the risk for melanoma and internal cancers has been reported to be increased in oil refinery workers, it is unlikely that chemical carcinogens are a major cause of melanoma. [76]

Shale oil products have been found to be especially carcinogenic. In 1993, Cruickshank and Squire [77] noted the association with scrotal cancers and the use of cutting oils, probably related to the addition of shale oil. Coal tar pitch appears to be more carcinogenic than petroleum-derived tars. An additive action exists between polycyclic aromatic hydrocarbons and UVB, which has been used for years in the so-called Goeckerman regimen for the treatment of recalcitrant psoriasis. A parallel may be seen in the development of skin cancer in outdoor workers such as roofers, cable layers, timber treaters, and others who contact polycyclic aromatic hydrocarbons in their work. Creosote used in wood treatment has been suggested as a cause of skin and lip cancer when associated with sunlight exposure. [78] Roofers and road pavers are also at increased risk for skin cancers and internal cancers due to the potential carcinogenicity of bitumen, and PAHs from coal tar products. [79] Tar refinery workers are at increased risk of developing nonmelanoma skin cancers, mainly on the facial areas, forearms, and hands. [80] UV exposure is known to be a factor in the development of tar-induced skin cancers, although some authors believe that its role is now less important. Callahan et al. note that molecular epidemiology is a way to study cancer risk. They hypothesize that there are different p53 mutations for tar in contrast to UV-induced skin cancers. [76]

The clinical sequence of events leading to cancer includes repeated episodes of photosensitization dermatitis on exposed skin, accompanied by burning and pigment formation. After several years and many repeated episodes of burning, poikilodermatous changes appear, especially on the face, neck, and exposed parts of the arms and hands. Keratotic papillomas (tar warts) appear, sometimes as long as 20 years after onset of the first signs. Squamous cell carcinomas develop from many, but not necessarily all, of these verrucous keratoses. Basal cell carcinoma and keratoacanthomas also develop in the sun-damaged areas. Older skin appears to be more susceptible to these changes, with the appearance of malignancy after a shorter period of time. Heredity plays a very important role in skin carcinogenesis; persons of Celtic heritage are far more susceptible. The protective effect of melanin in the skin is considerable; deeply pigmented blacks rarely develop actinic skin cancers regardless of the amount of UV radiation they receive throughout their lives. The hereditary disease complex known as xeroderma pigmentosum, with several defective enzymes responsible for incomplete DNA repair following exposure to UV radiation, is marked by the presence, beginning even in young adulthood, of highly aggressive skin cancers, which often lead to premature death (see Chap. 35 and Chap. 38). Following organ transplantation and the use of drugs causing immunosuppression, an increase of cutaneous malignancy, mainly squamous cell carcinoma, has been reported. [81] Occupational sunlight exposure is also an important factor in the development of these lesions.

ARSENIC

Arsenic is widely distributed in nature in the form of metalloids or chemical compounds. Arsenic-containing drinking water is clearly associated with various skin and internal organ malignancies. [82] However, arsenic does not easily induce cancer in animal models. Recent advances in the knowledge of arsenic carcinogenesis indicate that the methylated, trivalent form of arsenic is more toxic than the pentavalent form. [83] Arsenic has been shown to induce chromosomal abnormalities both in experimental systems and in human tissues. It has been implicated in causing the expression of heme oxygenase; the oxidative stress protein and altering growth factors leading to cell proliferation. [83] Another mechanism may be indirect DNA damage by inhibiting DNA repair. [84] Further studies are required to understand the exact mechanism of arsenic genotoxicity and carcinogenicity.

Commercially, arsenic is used in industrial processes associated with glass production; copper, zinc, and lead smelters, and the manufacture of semiconductors. [82] Farmers exposed to arsenic pesticides are reported to be at risk for development of nonmelanoma skin cancers. [85] Although the commercial use and production of substances containing arsenic has decreased, it is still an important occupational hazard. [76]

Exposure to arsenic in the workplace may occur through ingestion of food or water, and to a lesser extent from inhalation of air-borne arsenic. Chronic arsenic exposure may lead to arsenical keratosis, squamous cell and basal cell carcinomas, and Bowen's disease. Merkel cell carcinoma has also been reported in a person with chronic arsenicalism. [86]

Arsenical keratoses are the characteristic feature of chronic arsenic exposure. These consist of multiple, yellow, punctate keratoses distributed symmetrically on the palms and soles. Mild erythema and hyperhidrosis may precede their appearance. From some of these keratoses, aggressive squamous cell carcinomas develop. More commonly associated with arsenicalism are Bowen's intraepidermal squamous cell carcinomas, which only rarely become aggressive. Callen [87] has reported that patients with Bowen's disease have an approximately 10 percent chance of developing internal malignancy, thus it is appropriate to recommend that patients with Bowen's disease have a regular physical examination with appropriate laboratory testing for their age group, but without extensive searches for internal malignancy, unless clearly indicated.

TRAUMA

Although trauma as a cause of skin cancer has been a controversial subject since Virchow first proposed a relationship in 1863, the concept has not gained universal acceptance. Proving that mechanical injury has lead to the development of a cutaneous neoplasm may be difficult. Not infrequently patients themselves report that a single injury preceded the

appearance of a skin cancer. Workers' compensation courts will often accept a relationship between trauma and cancer if testimony indicates a greater than 50 percent probability that a given cancer was caused by trauma. Ewing's original criteria for establishing a relationship between a single trauma and malignancy, [88] modified by Stoll and Crissey, [89] still probably hold true for medicolegal purposes:

1. The skin must previously have been normal.
2. Adequate and authenticated trauma must have occurred, preferably confirmed by a medical person.
3. A positive diagnosis of nonmetastatic carcinoma must be made, and the tumor must be histologically consistent with the tissues of that site.
4. The carcinoma must originate from the exact point of injury.
5. A reasonable time interval between the trauma and the first appearance of the carcinoma must be present.
6. There must be continuity of physical signs from the traumatic event to the appearance of carcinoma.

The fact that mechanical injuries may predispose to epidermal neoplasms has been demonstrated in mouse skin, using dimethylbenzanthracene as the initiator. The epidermal regeneration that follows abrasions results in epidermal hyperplasia that may function as a tumor promoter. However, surgically induced ulceration has not been shown to initiate carcinogenesis. [90] These experiments support the assertion that from a scientific viewpoint trauma most likely acts as a cocarcinogen or final trigger, rather than as a true carcinogen.

Marjolin ulcer is a term synonymous with malignant transformation of chronic ulcers, sinus tracts, and burn scars. The Kangri cancer of Kashmir [91] and the Kairo cancer of Japan are well recognized examples of burn scar neoplasms. It is easier to explain the appearance of malignancy in these settings of chronic irritation and scarring than those following single incidents of trauma.

Most malignancies are epithelial, although melanoma [92] and sarcoma [93] arising in burn scars have been described. Squamous cell carcinomas are more frequent than basal cell carcinomas by a ratio of 3:1. The growth usually arises from the margin and is solitary. The latent period may be long, posing difficulties for occupational physicians, insurance companies, and compensation boards. [94]

IONIZING RADIATION

Ionizing radiation as a cause of occupational skin cancer has been known since the early 1900s, only a few years after Roentgen's discovery of x-rays in 1895. Following high acute or cumulative exposures to ionizing radiation, in addition to radiodermatitis, several types of cancers may result, in skin, thyroid, liver, bone, and blood-forming tissues. Yamada et al., [95] in reporting a follow-up of atomic bomb survivors, found that the occurrence of basal cell and squamous cell carcinomas increased with the estimated ionizing radiation dose. In 1991, the International Commission on Radiological Protection indicated the probability of skin cancer following exposure to ionizing radiation to be 2×10^{-4}/Sv. [96] High-dose radiation exposure has also been found to shorten life, to contribute to premature aging, and to result in teratogenic and reproductive abnormalities. Even with relatively small doses of radiation, such as 500 to 1000 mGy (50 to 100 rad) received irregularly over many years, progressive dryness of the skin, loss or scantiness of hair, irregular areas of hyperpigmentation, and signs of premature aging develop. Squamous cell carcinomas of x-ray origin tend to be more invasive than those of actinic origin, with metastases occurring in 20 to 26 percent of patients, as opposed to only 3 percent of sunlight-induced squamous cell cancers [97] (Fig 137-11). Radiation carcinomas constitute approximately 1 percent of all occupational skin cancers. [94]

FIGURE 137-11 Radiodermatitis and squamous cell carcinoma in a woman who had worked as an x-ray technician for years, holding young patients still, but without protection, during x-ray examinations, including fluoroscopy.

DIAGNOSIS OF OCCUPATIONAL SKIN DISEASE

Medical determinations in putative occupational skin disorders and in workers compensation cases involve several dilemmas for the physician: (1) Patient assertions and demands concerning work relatedness of disease, job changes, and job modifications. (2) Social gate keeping concerning time off and date of return to work. (3) Lack of adequate workplace information: job description, list of work chemicals, and exposures including material safety data sheets. (4) Clinical judgment versus technology (determining whether hand eczema and negative patch tests in a machinist is work related). (5) Causation in the legal arena usually only requires probability (within reasonable certainty or greater than 50 percent medical certainty), rather than absolute certainty such as fulfilling Koch's postulates. [98]

Thus essentials in evaluating occupational skin disorders include:

1. *Accurate diagnosis,* which includes a detailed medical and occupational history, complete cutaneous examination and ancillary diagnostic tests as indicated. Information obtained should include the appearance of the lesions, site of the eruption, course of the disease and predisposing or contributing factors. Diagnostic tests may include patch testing and other allergy tests, KOH exams and fungal, bacterial and viral smears and cultures, and skin biopsies.

Sufficient time is necessary to make a detailed diagnosis and determine the role of the work environment, which may be difficult or impossible initially. Because the initial diagnosis becomes the basis for future evaluations, and is often the one accepted by insurance companies, legal and rehabilitation personnel, and even other physicians, it becomes difficult to change a diagnosis that has been previously made.

2. *Causation.* Mathias [99] has proposed that a "yes" answer to four of the following seven questions would generally be adequate to establish occupational causation and aggravation in contact dermatitis cases and establish probable cause:
   a. Is the clinical appearance compatible with contact dermatitis?
   b. Are there workplace exposures to potential irritants or allergens?
   c. Is the anatomic distribution of the eruption compatible with job exposure?
   d. Is the temporal relationship between exposure and onset consistent with contact dermatitis?
   e. Have nonoccupational exposures been excluded as causes?
   f. Does the dermatitis improve away from work exposure to the suspected irritant or allergen?
   g. Do patch or provocation tests identify a probable cause?
3. *Recommendations* for treatment, prevention, disability (if any), job placement, rehabilitation, and use of other resources (industrial hygiene consultation and other medical specialists, such as allergy, pulmonary, or occupational medicine consultations).

DIAGNOSTIC TESTING FOR ALLERGY

Patch Testing

Because of the importance of allergic contact dermatitis in the etiology of occupational skin disease, patch testing should be performed in almost all cases of contact dermatitis, even in those patients who initially are thought to have only irritant dermatitis. Testing should be done with commercially prepared allergens. Further testing is sometimes indicated with the worker's environmental substances, including topical medications, protective equipment such as gloves, sensitizing ingredients in cleansers or other products, and, occasionally, the products themselves (cutting oils, etc.). Testing with irritants, such as most solvents, soaps, cement, and the like, should not be done, and patch testing with other environmental chemicals should only be performed by individuals knowledgeable in the procedure, in order to avoid false-positive irritant reactions. Standard texts can be consulted for patch test concentrations.

Tests for Immediate Hypersensitivity

The diagnosis of immediate contact reactions is often overlooked. If the dermatosis is thought to be due to type I immediate hypersensitivity (contact urticaria) then testing suspected agents in nonirritating concentrations can be carried out in the following manner and sequence:

- Application to normal skin
- If negative, application to previously affected, yet normal appearing, skin.
- If negative, test on eczematous skin on an area showing only slight erythema, so that an urticarial response can be observed.
- If all of the above tests are negative then perform occluded patch tests on normal or previously affected skin and read at 10 and 45 min.
- If still negative, perform prick testing. Intradermal tests are more likely to be associated with anaphylaxis and are rarely reported to document contact urticaria.
- If available, a commercial radioallergosorbent assay test (RAST) can be performed for diagnosis of specific causes of contact urticaria such as latex. The RAST is generally considered to be less sensitive than a prick test. [100]

Other Tests

Photopatch testing is important in the evaluation of patients with photosensitivity (see Chap. 136). Other procedures include the repeat open application use test, in which a small amount of the suspected allergen is rubbed into the skin twice daily, usually near the antecubital fossae. If dermatitis appears within 1 week, the test is considered positive. Chemical analysis may be helpful in situations where it is difficult to determine whether the patient has actually been exposed to the suspected substance. The dimethylgloxime test for nickel is readily available. More complicated tests are available for other chemicals such as formaldehyde and chromate. [101]

TREATMENT

Initial therapy of occupational skin disease depends upon the etiology and is essentially the same as diseases of nonoccupational origin. However it is important that patients are told the specific cause(s) of their disease and methods to avoid recurrences, and given information on appropriate use of skin cleansers, topical therapy, and protective clothing along with other preventive measures.

Fitness for Work and Workplace Accommodation

The Americans with Disabilities Act of 1990 brought to the fore issues of job placement and accommodation. Few instances of skin disease exclude a person from performing a given job, although a specific skin disorder may be considered a basis for exclusion in certain circumstances. Table 137-11 discusses fitness to work with skin disease and lists selected conditions, which may disqualify an individual for work. [101] Most individuals with chronic skin conditions can perform normal work activities, but in some instances require accommodation in the workplace. Table 137-12 lists some work-aggravated skin disorders that may require accommodation by employers. [101]

Diseases	Exclusion for
1. Herpes simplex virus whitlow of a finger recurrent and not controllable	Health care worker with direct patient contact
2. Dermatophyte infection of the palms recurrent and not controllable	Massage therapy
3. Recurrent impetigo in chronic pyogenic staphylococcus aureus infection	Health care workers
4. Dermatoses of the feet	Police and fire work
5. Thermoregulatory skin disorders: urticaria; acrodermal dysplasia	Extreme heat with potential for prolonged heat stress
6. Thermoregulatory skin disorders: patients with chronic erythrodermia	Extremely cold indoor or outdoor jobs
7. Physical agent intolerance: lupus erythematosus	Extensive outdoor work
8. Physical agent intolerance: Raynaud's disease	Prolonged cold exposure
9. Physical agent intolerance: cold urticaria	Prolonged cold exposure; ocean or lake lifeguard
10. Hand dermatitis	May limit grip strength

Source: Stone MA.[77]

TABLE 137-11 **Selected Dermatologic Conditions That, Under Some Circumstances, May Exclude an Individual from Work**

Disease	Circumstances
1. Dermatophyte infection of the palms	Glove liner over a large bandaid is required to prevent the infection
2. Psoriasis and other plaques	Frequent exposure that induces Koebner phenomenon, e.g., scrubs
3. Vitiligo	Distinguishing contrast alone, but does not impair work unless in many multiple
4. Collagenosis or acute dermatitis	Avoid sun, work as much as possible. Obtain allergen and have physical work hardening (PK condition)
5. Contact dermatitis	Avoidance, allergen substitution, protective equipment
6. Hyperhidrosis	Contact with water in handling paper documents and work with cotton and other materials
7. Basal cell carcinoma in a setting of possibilities xeroderma	Prolonged standing may aggravate the condition
8. Type I—but complicated patients discuss contracts and alternatives	Prolonged outdoor work in sunlight may be a hazard work with sunscreens and clothing
9. Hidradenitis or acquired bullous disorders	Physical work involving friction and pressure

Source: Stone MA.[77]

TABLE 137-12 **Selected Dermatologic Conditions That May Require Accommodation**

Prognosis and Persistence

The prognosis for acute irritant and allergic contact dermatitis is quite good in most cases, especially in a well-motivated worker with a cooperative plant management. Recurrence is likely with repeated, chronic exposures to low levels of irritants and allergens. Certain diagnoses, such as chromium sensitivity, have a poor prognosis and are notoriously long lasting. Negative influences in prognosis also include atopic eczema, especially in occupations where there is heavy contact with water, soaps, and detergents, food products, and the like. A number of studies confirm the guarded prognosis of chronic occupational contact dermatitis. Factors determining return to work for dermatologic disorders include severity of the condition, site and extent of involvement, effect of therapy and comorbid conditions, frequency of recurrences, age, effect of job availability and of alternative work, and recommendations of health care providers, including results of diagnostic tests. [98], [102]

Of the several causes of persistence of occupational skin disease, the most important is an incomplete or incorrect diagnosis. Other factors include failure to eliminate the cause(s), improper job placement, improper therapy, the presence of secondary diagnoses (e.g., allergy to topical medications or multiple contact allergies), exposure to cross-reacting substances in home or vocational activities, and improper cleansing of the skin. Prolonged rubbing and scratching may lead to lichen simplex chronicus, which is often self-perpetuating. Rarely, self-inflicted lesions are used surreptitiously to maintain disease activity and an attractive compensation status. [98]

Impairment and Disability Evaluation

Detailed evaluation of patients with disabling skin disorders is discussed in more detail in other sources. However, dermatologists should be familiar with the existence of the *Guides to the Evaluation of Permanent Impairment,* published by the American Medical Association. The *Guides*' chapter on skin disease has been used for more than 30 years to evaluate patients with permanently impairing skin disorders (diseases that have reached maximum medical improvement—often after 6 to 12 months duration) of occupational and nonoccupational origin. The *Guides* are used by a number of state workers' compensation authorities and provide examples of five classes of impairment ranging from 0 percent to 95 percent.

Prevention

Most occupational skin disorders are preventable and multidimensional control measures are required, involving environmental, personal, and medical methods. [103]

ENVIRONMENTAL METHODS Environmental methods are the preferred, but most expensive, control measures and use industrial hygiene and environmental engineering interventions such as (1) hazard identification; (2) substitution of less irritating and allergenic chemicals, such as rubber gloves without thiurams and carbamates, an alternative resin (phenolic or polyester) for epoxy resins, and an alternative metal working fluid without a sensitizing additive; (3) isolation and enclosure of the process; (4) local exhaust ventilation and chemical dispensers; and (5) good housekeeping.
WORKPLACE VISITS Workplace visits are an important, but often overlooked part of the evaluation of workers with occupational skin disease. Hazard identification and assessment of methods of exposure can be evaluated by direct observation and may be requisite for problem solving, especially when more than one worker is affected.
PERSONAL METHODS
Barrier creams Barrier creams have been called invisible gloves, but in fact they are rarely an adequate substitute for protective clothing. Nevertheless, they are often used in situations in which glove, sleeves, and face masks cannot be conveniently or safely used. Because they are washed out before coffee breaks and at mealtimes, they encourage cleanliness and at the same time remove industrial dirt from the skin. Several types are available: ordinary emollient creams, water repellant creams, oil- and solvent-resistant creams, and miscellaneous products for use against poison ivy and oak. Over the years, their effectiveness has been greatly overrated. The most effective products are sunscreens and blocks, which ideally should be worn by all outdoor workers. Problems associated with the use of barrier creams are a false sense of security, improper selection and use, allergy to an ingredient (often a preservative or fragrance), potential for increased absorption of occupational chemicals, and inadequate or infrequent application.
SKIN CLEANSERS (See “ Common Occupational Irritants” earlier in this chapter.)
PROTECTIVE CLOTHING Many types of protective clothing are available ranging from gloves, aprons, hoods, boots, and work shoes to full body clothing. Fabrics that resist heat, cold, acids, alkalis, solvents, and UV radiation are available. Certain types are mildew and fire resistant. Federal Occupational and Safety Administration (OSHA) requirements for personal protective equipment (PPE), as amended in 1994, are described in the US Government Code

of Federal Regulations (29 CFR Part 1910). Other privately promulgated national and international standards also exist. Manufacturers of PPE provide catalogues with guidelines for selection of clothing for various exposures. A handy reference guide is also very useful: Forsberg K, Mansdorf SZ. *Quick Selection Guide to Chemical Protective Clothing,* 3rd ed. New York, Wiley, 1997. Table 137-13 lists major glove materials and general guidance for their suitability for use with certain chemicals. Several important factors to consider in glove selection are that (1) completely impermeable PPE does not exist, and no single item of clothing can provide a barrier to all chemicals; (2) chemicals ultimately penetrate gloves and can do so without evidence of damage to the glove; (3) gloves should not be worn if torn or damaged; and (4) frequent donning and doffing of gloves may allow contamination of their interior surfaces with work chemicals.



TABLE 137-13 **General Recommendations for Use of Glove Materials with Certain Chemicals***

MEDICAL METHODS Physicians often overlook certain medical aspects of prevention. Basic considerations include the following: (1) Initial and subsequent employment physical examinations should include appraisals of the skin and evaluation of fitness for work (Table 137-11). (2) Workers with skin disease may require accommodation in the workplace (see Table 137-12). (3) Avoid potentially sensitizing topical preparations (neomycin, bacitracin, Furacin, benzocaine, etc.) when treating occupational dermatoses. (4) Medical and vocational rehabilitation of well-motivated workers with occupational skin disease is important and is often covered by many workers compensation plans. It is important that the personnel of rehabilitation agencies understand the nature of skin disease and especially the chemicals found in specific jobs.

Health Risk Assessment

The current scientific approach to risk reduction in occupational health is based upon risk assessment, which is separated into four basic elements: [1], [106]

1. *Hazard identification* involves determining whether exposure to an agent can cause disease or injury. Material Safety Data Sheets (MSDSs) are often used as the basis for this determination. All employers are required to provide MSDSs to their employees. The sheets provide basic chemical and health and safety information only about substances that are considered hazardous; those present in concentrations under 1 percent are not routinely required to be listed. Accordingly, many chemicals are not listed, but this information can be obtained by telephone from a number present on the first page of the MSDS. A physician can then decide whether any ingredient is a known allergen and patch test accordingly.
2. *Dermal exposure assessment* is the term used to describe the nature and size of various populations exposed to a chemical agent via the skin, as well as the magnitude and duration of the exposure. Dermal toxicity depends upon a number of factors including the degree, duration and route of exposure, the bioavailability of the chemical and the presence of dermatitis. Published data for workplace exposures (Threshold Limit Values or TLV's) to a number of chemicals by the American Conference of Governmental Industrial Hygienists is based upon measurement of airborne exposures. Skin notations for a number of substances indicate only the potential significant contribution to overall exposure by the cutaneous route and convey no quantitative information. Some of the best data exists for pesticides, where percutaneous absorption can result in significant systemic toxicity. Practical considerations for exposure include the method of exposure: spills, contaminated tools or rags, aerosols or sprays, or permeation of protective clothing. Thus, work activity (task duration and frequency; amount of chemical used), work substance (molecular weight, particle size, solubility, volatility, etc.), and worker (surface area exposed, personal hygiene, presence of dermatitis) are three major considerations. Methods for measuring dermal exposure to chemicals include wipe samples, hand or skin rinses, dermal dosimeter patches and fluorescent tracers; there is no gold standard. Studies on bioavailability of nickel show that plasma is more effective than heat or water in dissolving nickel from earrings, which is also dependent on the metallurgy and composition of various nickel-containing alloys.
3. *Dose response assessment* describes the quantitative relationship between the dose at the target and the toxicologic effect. Studies in allergic contact dermatitis have shown a wide range in the maximum and minimum concentrations of nickel and other chemicals, which will elicit contact allergy. Thus very small quantities of some allergens may provoke a reaction in some sensitized individuals. Persons with atopic dermatitis have increased transepidermal water loss and enhanced reactivity to irritants.
4. *Risk characterization* involves the integration of the data from the other three steps to determine safe exposure by comparing exposure levels with no observed adverse effect levels (NOAEL), while allowing for a safe margin of error. With the possible exception of nickel and chrome, few skin exposures have been characterized in this way and it may be difficult to do so. Additionally in determining risk assessment for cutaneous exposure to chemicals, at least as much attention needs to be given to percutaneous absorption as to dermal exposure.

REFERENCES

1. Emmett EA: Occupational contact dermatitis II. Risk assessment and prognosis. *Am J Contact Dermat*. In press.

2. Burnett CA et al: Occupational dermatitis causing days away from work in U.S. private industry, 1993. *Am J Ind Med* **34**:568, 1998

3. Coenraads JP et al: Epidemiology, in *Textbook of Contact Dermatitis* 3rd ed, edited by RJG Rycroft, T Menne, P Frosch, JP Lepoittevin. Berlin, Springer, 2001, p 200

4. Lammintausta K, Maibach HI: Contact dermatitis due to irritation, in *Occupational Skin Disease,* 2nd ed, edited by RM Adams. Philadelphia, Saunders, 1990, p 11

5. Frosch PJ: Clinical aspects of irritant contact dermatitis, in *Textbook of Contact Dermatitis* 3rd ed, edited by RJG Rycroft, T Menne, P

Frosch, JP Lepoittevin. Berlin, Springer, 2001, p 313

6. Bruze H, Emmett EM: Occupational exposure to irritants, in *Irritant Contact Dermatitis,* edited by EM Jackson, R Goldner. New York, Marcel Dekker, 1990, p 81

7. Kim IH, Seo SH: Occupational chemical burns caused by bromine. *Contact Dermatitis* **41**:43, 1999

8. Schwanitz HJ, Uter W: Interdigital dermatitis: sentinel skin damage in hairdressers. *Br J Dermatol* **142**:1011, 2000

9. Rieschel RL: Diagnosing irritant contact dermatitis, in *Irritant Contact Dermatitis,* edited by EM Jackson, R Goldner. New York, Marcel Dekker, 1990, p 167

10. Singer A et al: Chemical burns: Our 10-year experience. *Burns* **18**:250, 1992

11. Bruze M, Fregert S: Chemical skin burns, in *Handbook of Occupational Dermatology,* edited by L Kanerva, P Elsner, JE Wahlberg, HI Maibach. Springer, Berlin, 2000, p 325

12. Adams RM: Occupational skin disease, in *Dermatology in General Medicine,* 5th ed, edited by IM Freedberg, AZ Eisen, K Wolff, KE Austen, LA Goldsmith, SI Katz, TB Fitzpatrick, New York, McGraw-Hill, 1999, p 1609

13. Spoo J, Elsner P: Cement burns: A review 1960–2000. *Contact Dermatitis* **45**:68, 2001

14. Fisher AA: Cement injuries: Part II. Cement burns resulting in necrotic ulcers due to kneeling on wet cement. *Cutis* **61**:121, 1998

15. Terrill PJ, Gowar JP: Chromic acid burns; beware, be aggressive, be watchful. *Br J Plast Surg* **43**:699, 1990

16. Eldad A et al: Phosphorus burns: Evaluation of various modalities for primary treatment. *J Burn Care Rehabil* **16**:49, 1995

17. Karacalar A, Karacalar SA: Chemical burns due to blood pressure cuff sterilized with ethylene oxide. *Burns* **26**:760, 2000

18. Lewis R: Metals, in *Occupational Medicine,* edited by J LaDou. Stamford, CT, Appleton & Lange, 1997, p 434

19. Schwartz I et al: Allergic dermatitis due to metallic cobalt. *J Allergy* **16**:51, 1945

20. Wahlberg JE, Adams RM: Solvents, in *Occupational Skin Disease,* 3rd ed, edited by RM Adams. Philadelphia, Saunders, 1999, p 484

21. Klauder JV, Brill FA: Correlation of boiling ranges of some petroleum solvents with irritant action on skin. *Arch Dermatol* **56**:197, 1947

22. Zug K, Marks JG Jr: Plants and woods, in *Occupational Skin Disease,* 3rd ed, edited by RM Adams. Philadelphia, Saunders, 1999, p 567

23. Lovell CR: *Plants and the Skin*. Oxford, Blackwell Scientific, 1993

24. Epstein WL: House and garden plants, in *Irritant Contact Dermatitis,* edited by EM Jackson, R Goldner. New York, Marcel Decker, 1990, p 127

25. Ljunggren B: Psoralen photoallergy caused by plant contact. *Contact Dermatitis* **3**:85, 1977

26. Rietschel RL et al: A preliminary report of the occupation of patients evaluated in patch test clinics. *Am J Contact Dermat* **12**:72, 2001

27. Rycroft RJG: Occupational contact dermatitis, in *Textbook of Contact Dermatitis,* 3rd ed, edited by RJG Rycroft, T Menne, P Frosch, JP Lepoittevin. Berlin, Springer, 2001, p 555

28. Shelley WB, Shelley ED: *Contact Dermatitis, Advanced Dermatologic Diagnosis*. Philadelphia, WB Saunders, 1992

29. Lahti A: Immediate contact reactions, in *Textbook of Contact Dermatitis,* edited by RJG Rycroft, T Menne, PJ Frosch, JP Lepoittevin. Berlin, Springer-Verlag, 1995, p 69

30. Taylor JS et al: Latex allergy, in *1999 Yearbook of Dermatology and Dermatological Surgery,* edited by Thiers BH, Lang PG. St. Louis, Mosby, 1999, p 1

31. Kanerva L et al: Statistical data on occupational contact urticaria. *Contact Dermatitis* **35**:229, 1996

32. Taylor JS et al: Contact urticaria, in *Occupational Skin Disease* 3rd ed, edited by RM Adams. Philadelphia, Saunders, 1999, p 111

33. Nichols RL: Optimal treatment of complicated skin and skin structure infections. *J Antimicrob Chemother* **44**:19, 1999

34. Grammont-Cupillard M et al: Brucellosis from sniffing bacteriological cultures. *Lancet* **348**:1733, 1996

35. Brooke CJ, Riley TV: Erysipelothrix rhusiopathiae: Bacteriology, epidemiology and clinical manifestations of an occupational pathogen. *J Med Microbiol* **48**:789, 1999

36. Keefe M et al: Cutaneous warts in butchers. *Br J Dermatol* **132**:166, 1995

37. McGovern T: Can derm warfare fight germ warfare? *Medscape Dermatol* 2001. Available at: http://www.medscape.com/medscape/Dermatology/journal/2001/vo2.no6/md1115.01.mcgov . Accessed November 15, 2001

38. Ebola hemorrhagic fever (Uganda). *MMWR Morb Mortal Wkly Rep* **50**:73, 2001

39. Freeman S, Rosen RH: Irritant contact dermatitis resulting from repeated low-grade frictional trauma, in *The Irritant Contact Dermatitis Syndrome,* edited by P van der Valk, HI Maibach. Boca Raton, FL, CRC Press, 1996 p 205

40. Ronchese F: *Occupational Marks and Other Physical Signs. A Guide to Personal Identification.* New York, Grune & Stratton, 1948

41. Rogachefsky AS, Taylor JS: Professional sports: Skin disorders in athletes, in *Handbook of Occupational Dermatology,* edited by L Kanerva, P Elsner, JE Wahlberg, HI Maibach. Berlin, Springer, 2000, p 1072

42. Menne T: Hyperkeratotic dermatitis of the palms, in *Hand Eczema,* edited by T Menne, HI Maibach. Boca Raton, FL, CRC Press, 1994, p

43. Wilkinson DS: Introduction, definition and classification, in *Hand Eczema,* edited by T Menne, HI Maibach. Boca Raton, FL, CRC Press, 1994, p 1

44. Kanerva L et al: Allergic contact dermatitis from dental composite resins due to aromatic epoxy acrylates and aliphatic acrylates. *Contact Dermatitis* **20**:201, 1989

45. Mathias CGT: Post-traumatic eczema. *Dermatol Clin* **6**:35, 1988

46. Rietschel RL, Fowler JF: Noneczematous contact dermatitis, in *Fisher's Contact Dermatitis,* 5th ed, edited by RL Rietschel, JF Fowler. Philadelphia, Lippincot Williams & Wilkins, 2001, p 71

47. Riina LH et al: Burn injury in kitchen workers: A cause for prevention. *J Burn Care Rehabil* **21**:563, 2000

48. Taylor JS: Vibration syndrome in industry: Dermatological viewpoint. *Am J Ind Med* **8**:415, 1985

49. Kanerva L: Physical causes and radiation effects, in *Occupational Skin Disease,* 3rd ed, edited by RM Adams. Philadelphia, Saunders, 1999, p 35

50. Haustein UF, Haupt B: Occupational connective tissue disorders, in *Handbook of Occupational Dermatology,* edited by L Kanerva, P Elsner, JE Wahlberg, HI Maibach. Berlin, Springer, 2000, p 295

51. Adams BB et al: Periorbital comedones and their relationship to pitch tar: A cross-sectional analysis and a review of the literature. *J Am Acad Dermatol* **42**:624, 2000

52. Taylor JS: The pilosebaceous unit, in *Occupational and Industrial Dermatology,* 2nd ed, edited by HI Maibach. Chicago, Year Book Medical, 1987, p 105

53. Taylor JS: Environmental chloracne: Update and overview. *Ann N Y Acad Sci* **320**:295, 1979

54. McDonnell K, Taylor JS: Occupational and environmental acne, in *Handbook of Occupational Dermatology,* edited by L Kanerva, P Elsner, JE Wahlberg, HI Maibach. Berlin, Springer, 2000, p 225

55. Coenraads PJ et al: Blood lipid concentrations of dioxins and dibenzofurans causing chloracne. *Br J Dermatol* **141**:694, 1999

56. Geusau A et al: Olestra increases faecal excretion of 2,3,7,8-tetrachlorodibenzo- *p*-dioxin. *Lancet* **354**:1266, 1999

57. Schottenfield P, Haas F: Carcinogens in the workplace. *CA Cancer J Clin* **29**:144, 1979

58. Doll R: Relevance of epidemiology to policies for the prevention of cancer. *J Occup Med* **23**:601, 1981

59. Wikonkal NM, Brash DE: Ultraviolet radiation induced signature mutations in photocarcinogenesis. *J Investig Dermatol Symp Proc* **4**:6, 1999

60. Brash DE et al: Sunlight and sunburn in human skin cancer: p53, apoptosis, and tumor promotion. *J Investig Dermatol Symp Proc* **1**:136, 1996

61. Lear JT et al: A comparison of risk factors for malignant melanoma, squamous cell carcinoma and basal cell carcinoma in the UK. *Int J Clin Pract* **52**:145, 1998

62. Freedman DM et al: Residential and occupational exposure to sunlight and mortality from non-Hodgkin's lymphoma: Composite (threefold) case-control study. *BMJ* **314**:1451, 1997

63. Green A et al: Skin cancer in a subtropical Australian population: Incidence and lack of association with occupation. The Nambour Study Group. *Am J Epidemiol* **144**:1034, 1996

64. Suzuki T et al: Incidence of actinic keratosis of Japanese in Kasai City, Hyogo. *J Dermatol Sci* **16**:74, 1997

65. Gilchrest BA et al: The pathogenesis of melanoma induced by ultraviolet radiation. *N Engl J Med* **340**:1341, 1999

66. Pion IA et al: Occupation and the risk of malignant melanoma. *Cancer* **75**:637, 1995

67. Gallagher RP et al: Sunlight exposure, pigmentation factors, and risk of nonmelanocytic skin cancer. II. Squamous cell carcinoma. *Arch Dermatol* **131**:164, 1995

68. Gallagher RP et al: Chemical exposures, medical history, and risk of squamous and basal cell carcinoma of the skin. *Cancer Epidemiol Biomarkers Prev* **5**:419, 1996

69. Gallagher RP et al: Sunlight exposure, pigmentary factors, and risk of nonmelanocytic skin cancer. I. Basal cell carcinoma. *Arch Dermatol* **131**:157, 1995

70. Kavages MR et al: Use of tanning devices and risk of basal cell and squamous cell cancers. *J Natl Cancer Inst* **94**:224, 2002

71. Emmett EA: Occupational skin cancer—A review. *J Occup Med* **17**:44, 1975

72. Ingram AJ et al: DNA adducts produced by oils, oil fractions and polycyclic aromatic hydrocarbons in relation to repair processes and skin carcinogenesis. *J Appl Toxicol* **20**:165, 2000

73. Porru S et al: [The toxicology and prevention of the risks of occupational exposure to aromatic polycyclic hydrocarbons. III. The effects: epidemiological evidence, early effects. Individual hypersusceptibility. Health surveillance]. *G Ital Med Lav Ergon* **19**:152, 1997

74. Boffetta P et al: Cancer risk from occupational and environmental exposure to polycyclic aromatic hydrocarbons. *Cancer Causes Control* **8**:444, 1997

75. Tolbert PE: Oils and cancer. *Cancer Causes Control* **8**:386, 1997

76. Callahan CP, Merk HF: Occupational skin cancer and tumors, in *Handbook of Occupational Dermatology,* edited by L Kanerva, P Elsner, JE

Wahlberg, HI Maibach. Berlin Springer, 2000, p 248

77. Cruickshank CN, Squire JR: Skin cancer in the engineering industry from the use of mineral oil. 1949. *Br J Indust Med* **50**:289, 1993

78. Karlehagen S et al: Cancer incidence among creosote-exposed workers. *Scand J Work Environ Health* **18**:26, 1992

79. Partanen T, Boffetta P: Cancer risk in asphalt workers and roofers: Review and meta-analysis of epidemiologic studies. *Am J Ind Med* **26**:721, 1994

80. Letzel S, Drexler H: Occupationally related tumors in tar refinery workers. *J Am Acad Dermatol* **39**:712, 1998

81. Ramsay HM et al: Clinical risk factors associated with nonmelanoma skin cancer in renal transplant recipients. *Am J Kidney Dis* **36**:167, 2000

82. Basu A et al: Genetic toxicology of a paradoxical human carcinogen, arsenic: A review. *Mutat Res* **488**:171, 2001

83. Kitchin KT: Recent advances in arsenic carcinogenesis: modes of action, animal model systems, and methylated arsenic metabolites. *Toxicol Appl Pharmacol* **172**:249, 2001

84. Hartwig A et al: Interaction of arsenic (III) with nucleotide excision repair in UV-irradiated human fibroblasts. *Carcinogenesis* **18**:399, 1997

85. Spiewak R: Pesticides as a cause of occupational skin diseases in farmers. *Ann Agric Environ Med* **8**:1, 2001

86. Tsuruta D et al: Merkel cell carcinoma, Bowen's disease and chronic occupational arsenic poisoning. *Br J Dermatology* **139**:291, 1998

87. Callen JP: Bowen's disease and internal malignant disease. *Arch Dermatol* **124**:675, 1988

88. Ewing J: Relation of trauma to malignant tumors. *Am J Surg* **40**:30, 1926

89. Stoll HI, Crissey JT: Epithelioma from single trauma, in *Cancer Dermatology,* edited by F Helm. Philadelphia, Lea & Febiger, 1979, p 25

90. Hasegawa R et al: Evaluation of epidermal cell kinetics following freezing or wounding of mouse skin and their potential as initiators of carcinogenesis. *J Invest Dermatol* **88**:652, 1987

91. Aziz SA et al: Profile of Kangri cancer: A prospective study. *Burns* **24**:763, 1998

92. Jerbi G et al: Melanoma arising in burn scars: Report of 3 observations and a literature review. *Arch Dermatol* **135**:1551, 1999

93. Can Z et al: Sarcoma developing in a burn scar: Case report and review of the literature. *Burns* **24**:68, 1998

94. Epstein JH et al: Occupational skin cancer, in *Occupational Skin Disease,* 3rd ed, edited by RM Adams. Philadelphia, Saunders, 1998, p 142

95. Yamada M et al: Prevalence of skin neoplasms among the atomic bomb survivors. *Radiat Res* **146**:223, 1996

96. ICRP (International Commission on Radiological Protection): *Recommendations of the ICRP. Annals of the ICRP 21:(1–3). ICRP Publication 60.* Oxford, Pergamon Press, 1991

97. Schwartz RA, Stoll HL Jr: Squamous cell carcinoma, in *Dermatology in General Medicine,* 5th ed, edited by IM Freedberg, AZ Eisen, K Wolff, KE Austen, LA Goldsmith, SI Katz, TB Fitzpatrick. New York, McGraw-Hill, 1999, p 840

98. Taylor JS: Dermatology, in *Disability Evaluation,* edited by SL Demeter, GBJ Andersson, GM Smith. St. Louis, Mosby, 1996, p 415

99. Mathais CGT: Contact dermatitis and workers' compensation: Criteria for establishing occupational causation and aggravation. *J Am Acad Dermatol* **20**:842, 1989

100. Warner MR et al: Agents causing contact urticaria. *Clin Dermatol* **15**:623, 1997

101. Veien NK: Diagnostic procedures for eczema patients: Exogenous dermatoses, in *Environmental Dermatitis,* edited by T Menne, MI Maibach, Boca Raton, FL, CRC Press, 1991

102. Nethercott JR: Fitness to work with skin disease and the Americans with Disability Act of 1990 . *Occup Med* **9**:11, 1994

103. Taylor JS: The skin and occupational dermatoses, in *Fundamentals of Industrial Hygiene,* edited by B Plog, PJ Quinlan. Itasca, IL, National Safety Council, 2002

104. Estlander T, Jolanki R: How to protect the hands. *Dermatol Clin* **6**:105, 1988

105. Berardinelli SP: Prevention of occupational skin disease through use of chemical protective glove. *Dermatol Clin* **6**:115, 1988

106. Paustenbach D et al: Health risk assessment, in *Occupational Skin Disease,* 3rd ed, edited by RM Adams. Philadelphia, Saunders, 1998, p 291

T>

Chapter 138

Neil Shear Sandra Knowles John Sullivan Lori Shapiro

Cutaneous Reactions to Drugs

PATHOGENESIS OF DRUG ERUPTIONS
MORPHOLOGIC APPROACH TO DRUG ERUPTIONS
Exanthematous Eruptions
Urticarial Eruptions
Pustular Eruptions
Bullous Eruptions
Fixed Drug Eruptions
Coumarin-Induced Skin Necrosis
Drug-Induced Lichenoid Eruptions
Drug-Induced Cutaneous Pseudolymphoma
Drug-Induced Vasculitis
Drug-Induced Lupus
DIAGNOSIS AND MANAGEMENT
PREVENTION
REFERENCES

Complications from drug therapy are a major cause of patient morbidity and account for a significant number of patient deaths. [1] Approximately 14 percent of adverse drug reactions in hospital patients are cutaneous or allergic in nature. [2] Drug eruptions range from common nuisance eruptions to rare or life-threatening drug-induced diseases. Drug reactions can be solely limited to the skin, or they may be part of a systemic reaction, such as the drug hypersensitivity syndrome or toxic epidermal necrolysis (TEN).

Drug eruptions are distinct disease entities and must be approached as any other cutaneous disease. A precise diagnosis of the reaction pattern can help narrow possible causes, as different drugs are more commonly associated with different types of reactions.

PATHOGENESIS OF DRUG ERUPTIONS

Constitutional factors influencing the risk of cutaneous eruption include pharmacogenetic variation in drug-metabolizing enzymes and human leukocyte antigen (HLA) associations. Acetylator phenotype alters the risk of developing drug-induced lupus due to hydralazine, procainamide, and isoniazid. Acetylator phenotype is also important in many other drug eruptions. Fast acetylator status appears to partially protect against the risk of developing TEN and the drug hypersensitivity syndrome due to sulfonamide antibiotics. [3] HLA-DR4 is significantly more common in individuals with hydralazine-related drug-induced lupus than in those with idiopathic systemic lupus erythematosus. [4] HLA factors may also influence the risk of bullous drug reactions. [5]

Many drugs associated with severe idiosyncratic drug reactions are metabolized by the body to form reactive, or toxic, drug products. [6] These reactive products comprise only a small proportion of a drug's metabolites and are usually rapidly detoxified. However, patients with the drug hypersensitivity syndrome, TEN, and Stevens-Johnson syndrome (SJS), resulting from treatment with sulfonamide antibiotics and the aromatic anticonvulsants (e.g., carbamazepine, phenytoin, and phenobarbital), show increased sensitivity in in vitro assessments to the oxidative, reactive drug metabolites of these drugs as compared to control subjects. [7], [8]

Acquired factors also alter an individual's risk of drug eruption. Active viral infection and concurrent medications have been shown to alter frequency of drug-associated eruptions. Drug–drug interactions may also alter risk of cutaneous eruption. Valproic acid increases the risk of severe cutaneous adverse reactions to lamotrigine, another anticonvulsant. [9] The basis of these interactions and reactions is unknown but may represent a mixture of factors including alteration in drug metabolism, drug detoxification, antioxidant defenses, and immune reactivity.

The course and outcome of drug-induced disease are also influenced by host factors. Older age may delay the onset of drug eruptions and has been associated with a higher mortality rate in some severe reactions; a higher mortality rate is also observed in patients with severe reactions with underlying malignancy. [10] Reactivation of latent viral infection with human herpesvirus (HHV)-6 also appears common in the drug hypersensitivity syndrome and may be partially responsible for some of the clinical features and/or course of the disease. [11]

The pathogenesis of most drug eruptions is not understood, although the clinical features of most drug eruptions are consistent with immune-mediated disease. The immune system may target the native drug, its metabolic products, altered self, or a combination of these factors.

MORPHOLOGIC APPROACH TO DRUG ERUPTIONS

Exanthematous Eruptions

Exanthematous eruptions, known also as morbilliform or maculopapular, are the most common form of drug eruptions,

accounting for approximately 95 percent of skin reactions. [12] Simple exanthems are erythematous changes in the skin without evidence of blistering or pustulation. The eruption typically starts on the trunk and spreads peripherally in a symmetric fashion. Pruritus is almost always present. These eruptions usually occur within 1 week of starting therapy and resolve within 7 to 14 days. Resolution occurs with a change in color from bright red to a brownish-red, which may be followed by scaling or desquamation. The differential diagnosis in these patients includes a viral exanthem, collagen vascular disease, and bacterial and rickettsial infections.

Exanthematous eruptions can be caused by many drugs including the penicillins, sulfonamides, nonnucleoside reverse transcriptase inhibitors (e.g., nevirapine), and antiepileptic medications. [12] Clinical experience and laboratory data have indicated that T cells are involved in these reactions because they are able to recognize the drug directly, without covalent hapten modification of proteins or peptides. [13] In patients who have concomitant infectious mononucleosis, the risk of developing an exanthematous eruption while being treated with an aminopenicillin (e.g., ampicillin) increases to 60 to 100 percent. [14] Patients are able to tolerate all beta-lactam antibiotics, including the aminopenicillins, after the infectious process has resolved. A similar drug–viral interaction has been observed in 50 percent of HIV-infected patients who are exposed to sulfonamide antibiotics. [15]

An exanthematous eruption in conjunction with fever and internal organ involvement (e.g., liver, kidney, central nervous system) signifies a more serious reaction, known as the *hypersensitivity syndrome reaction* (HSR). HSR occurs most frequently on first exposure to the drug, with initial symptoms starting 1 to 6 weeks after exposure. Fever and malaise are often the presenting symptoms. Atypical lymphocytosis with a subsequent eosinophilia may occur during the initial phases of the reaction in some patients. Even though most patients resent with an exanthematous eruption, more serious cutaneous manifestations may be evident (Fig. 138-1). Internal organ involvement can be asymptomatic. Some patients may become hypothyroid approximately 2 months after the first symptoms appear. [16]

FIGURE 138-1 Hypersensitivity syndrome reaction, characterized by fever, a pustular eruption, and hepatitis, in a 23-year-old man after 18 days of treatment with minocycline.

The formation of toxic metabolites by the aromatic anticonvulsants, namely phenytoin, carbamazepine, and phenobarbital, may play a pivotal role in the development of the HSR. [7] Approximately 70 to 75 percent of patients who develop anticonvulsant HSR in response to one aromatic anticonvulsant show cross-reactivity to the other aromatic anticonvulsants. In addition, in vitro testing shows that there is a familial occurrence of HSR due to anticonvulsants. [7] Thus, counseling of family members and disclosure of risk is essential.

Sulfonamide antibiotics are also metabolized to toxic metabolites, namely hydroxylamines and nitroso compounds. Because siblings and other first-degree relatives are at an increased risk (perhaps as high as 1 in 4) of developing a similar adverse reaction, counseling of family members is essential.

Urticarial Eruptions

Urticaria is characterized by pruritic red wheals of various sizes. Individual lesions generally last for less than 24 h, although new lesions can continually develop. When deep dermal and subcutaneous tissues are also swollen, the reaction is known as *angioedema*. Angioedema is frequently unilateral and nonpruritic and lasts for 1 to 2 h, although it may persist for 2 to 5 days.

Urticaria and angioedema, when associated with drug use, are usually indicative of an IgE-mediated immediate hypersensitivity reaction; this mechanism is typified by immediate reactions to penicillin and other antibiotics. Nonimmunologic activation of inflammatory mediators may also result in urticarial reactions. For example, narcotic analgesics may directly cause release of histamine from mast cells independent of IgE [17] (see Chap. 116).

Angiotensin-converting enzyme (ACE) inhibitors are frequent causes of angioedema. [18] The onset is usually within hours of starting ACE-inhibitor therapy but can occur as late as 1 week to several months into therapy. Angioedema usually resolves within 48 h with treatment. Angioedema has also been reported to occur with angiotensin II antagonists; in many of these patients, a prior history of angioedema related to an ACE-inhibitor was documented. [19]

Serum sickness-like reactions are defined by the presence of fever, rash (usually urticarial), and arthralgias 1 to 3 weeks after initiation of drug. Lymphadenopathy and eosinophilia may also be present; however, in contrast to true serum sickness, immune complexes, hypocomplementemia, vasculitis, and renal lesions are absent.

Cefaclor is associated with an increased relative risk of serum sickness-like reactions. In genetically susceptible hosts, a reactive metabolite is generated during the metabolism of cefaclor that may bind with tissue proteins and elicit an inflammatory response manifesting as a serum sickness–like reaction. [20]

Pustular Eruptions

Acneiform eruptions are associated with iodides, bromides, adrenocorticotropic hormone (ACTH), glucocorticoids, isoniazid, androgens, lithium, actinomycin D, and phenytoin. Drug-induced acne may appear in atypical areas, such as on the arms and legs, and is most often monomorphous. Comedones are usually absent. The fact that acneiform eruptions do not affect prepubertal children indicates that previous hormonal priming is a necessary prerequisite. In cases where the offending agent cannot be discontinued, topical tretinoin may be useful. [21]

Acute generalized exanthematous pustulosis (AGEP) is an acute febrile eruption that is often associated with leukocytosis [22] (Fig. 138-2). After drug administration, it may take 1 to 3 weeks before skin lesions appear; however, in previously sensitized patients, the skin symptoms may occur within 2 to 3 days. The lesions often start on the face or main skin creases. Generalized desquamation occurs approximately 2 weeks later. The estimated incidence rate of AGEP is approximately 1 to 5 cases per million per year. [23] Differential diagnosis includes pustular psoriasis, the hypersensitivity syndrome reaction with pustulation, subcorneal pustular dermatosis (Sneddon-Wilkinson disease), pustular vasculitis, or TEN, especially in severe cases of AGEP. The typical histopathologic analysis of AGEP lesions shows spongiform subcorneal and/or intraepidermal pustules, an often marked edema of the papillary dermis, and perivascular infiltrates with neutrophils and exocytosis of some eosinophils. [23]

FIGURE 138-2 Acute generalized exanthematous pustulosis (AGEP) in a 48-year-old man who developed nonfollicular pustules and fever after 7 days of treatment with diltiazem.

Bullous Eruptions

Pseudoporphyria is a cutaneous phototoxic disorder that can resemble either porphyria cutanea tarda (PCT) in adults or erythropoietic protoporphyria (EPP) in children (see Chap. 149). Pseudoporphyria of the PCT variety is characterized by skin fragility, blister formation, and scarring in photodistribution; it occurs in the presence of normal porphyrin levels. The other clinical pattern mimics EPP and manifests as cutaneous burning, erythema, vesiculation, angular chicken pox-like scars, and waxy thickening of the skin. The eruption may begin within 1 day of initiation of therapy or may be delayed for as long as 1 year. The course is prolonged in some patients, but most reports describe symptoms that disappear several weeks to several months after the offending agent is withdrawn. Because of the risk of permanent facial scarring, the implicated drug should be discontinued if skin fragility, blistering, or scarring occurs. [24] In addition, broad-spectrum sunscreen and protective clothing should be recommended.

Both idiopathic and *drug-induced linear IgA* disease are heterogeneous in clinical presentation. Cases of the drug-induced type have morphologies resembling erythema multiforme, bullous pemphigoid, and dermatitis herpetiformis. The drug-induced disease may differ from the idiopathic entity in that mucosal or conjunctival lesions are less common, spontaneous remission occurs once the offending agent is withdrawn, and immune deposits disappear from the skin once the lesions resolves.

Biopsy specimens are necessary for diagnosis. Histologically, the two entities are similar. A study suggests that, as in the idiopathic variety, the target antigen is not unique in the drug-induced disease. While 13 to 30 percent of patients with sporadic linear IgA have circulating basement membrane zone antibodies, these antibodies have not been reported in drug-induced cases. [25] In patients with linear IgA bullous disease proven by direct immunofluorescence, the index of suspicion of drug induction should be higher in cases with only IgA and no IgG in the basement membrane zone.

Pemphigus may be considered as drug-induced or drug-triggered (i.e., a latent disease that is unmasked by the drug exposure). Drug-induced pemphigus caused by penicillamine and other thiol drugs tends to remit spontaneously in 35 to 50 percent of cases, presents as pemphigus foliaceus, has an average interval to onset of 1 year, and is associated with the presence of antinuclear antibodies in 25 percent of patients.

Most patients with nonthiol drug-induced pemphigus manifest clinical, histologic, immunologic, and evolutionary aspects similar to those of idiopathic pemphigus vulgaris with mucosal involvement with a 15 percent rate of spontaneous recovery after drug withdrawal. Treatment of drug-induced pemphigus begins with drug withdrawal. Systemic glucocorticoids are often required until all symptoms of active disease disappear. Vigilant follow-up is required after remission to monitor the patient and the serum for autoantibodies to detect an early relapse. [26]

Drug-induced bullous pemphigoid (see Chap. 61) can encompass a wide variety of presentations, ranging from the classic features of large, tense bullae arising from an erythematous, urticarial base, with moderate involvement of the oral cavity, through mild forms with few bullous lesions, or scarring plaques and nodules with bullae. [26] In contrast to the idiopathic form, patients with drug-induced bullous pemphigoid are generally younger; as well, the histopathologic findings are of a perivascular infiltration of lymphocytes with few eosinophils and neutrophils, intraepidermal vesicles with foci of necrotic keratinocytes, thrombi in dermal vessels, and a possible lack of tissue-bound and circulating antibasal membrane zone IgG.

In the acute, self-limited condition, resolution occurs after the withdrawal of the culprit agent, with or without glucocorticoid therapy. However, in some patients, the drug may actually trigger the idiopathic form of the disease.

Erythema multiforme-major (EM-major), SJS, and *TEN* (see Chap. 58), which may represent variants of the same disease process, encompass a spectrum of serious dermatologic eruptions (Fig. 138-3). The more severe the reaction, the more likely it is that it has been drug-induced. A large percentage of cases of EM/SJS are not drug related and may develop after a variety of other predisposing factors including infections (e.g., herpes simplex, *Mycoplasma pneumoniae*), neoplasia, and autoimmune diseases. The risk of TEN has been estimated to be 1 per million per year and 1 to 6 per million per year for SJS. [27]

FIGURE 138-3 Toxic epidermal necrolysis in a child after 18 days of treatment with phenobarbital for febrile seizures.

The pathogenesis of severe cutaneous adverse drug reactions is unknown, although a metabolic basis has been hypothesized. [7]

Treatment of EM, SJS, and TEN includes discontinuation of the suspected drug and supportive measures, such as careful wound care, hydration, and nutritional support. The use of glucocorticoids to treat SJS and TEN is controversial. [28], [29] Intravenous immunoglobulin (IVIG, 0.2 to 0.75 g/kg for 4 consecutive days) has rapidly reversed disease progression within 48 hours. [30] A limited number of patients have been treated with cyclophosphamide [31] and cyclosporine. [32] Patients who have developed a severe cutaneous adverse reaction (i.e., EM/SJS/TEN) should not be rechallenged with the drug or undergo desensitization with the medication.

Fixed Drug Eruptions

Fixed drug eruptions (FDE) usually appear as solitary, erythematous, bright red or dusky red macules that may evolve into an edematous plaque; bullous-type lesions may be present. FDE are most commonly found on the genitalia and in the perianal area, although they can occur anywhere on the skin surface. Some patients may complain of burning or stinging, and others may have fever, malaise, and abdominal symptoms. FDE can develop 30 min to 8 to 16 h after ingestion of the medication. After the initial acute phase lasting days to weeks, residual grayish or slate-colored hyperpigmentation develops. Upon rechallenge, not only do the lesions recur in the same location, but also new lesions often appear.

More than 100 drugs have been implicated in FDE, including ibuprofen, sulfonamides, and tetracyclines. A haplotype linkage in the setting of trimethoprim-sulfamethoxazole–induced FDE was recently documented. [33]

Histologically, FDE resembles erythema multiforme, with an interface dermatitis with lymphocytes at the dermal–epidermal junction and degenerative changes of epithelium with dyskeratosis. However, there is also evidence of chronic injury in FDE, which is manifested by acanthosis, hyperkeratosis, and hypergranulosis. Eosinophils and neutrophils are also present. The numbers of helper and suppressor T lymphocytes are increased in lesional skin. The T cells may persist in lesional skin and are believed to contribute to immunologic “memory.” [34]

A challenge or provocation test with the suspected drug may be useful in establishing the diagnosis. Patch testing at the site of a previous lesion yields a positive response in up to 43 percent of patients. In some patients, prick and intradermal skin tests may be positive in 24 and 67 percent of patients, respectively. [35]

Coumarin-Induced Skin Necrosis

Coumarin-induced skin necrosis (Fig. 138-4) begins 3 to 5 days after initiation of treatment. Early, red, painful plaques develop in adipose-rich sites such as breasts, buttocks, and hips. These plaques may blister, ulcerate, or develop into necrotic areas. It is estimated that 1 in 10,000 persons who receive the drug is at risk of this adverse event. [36] The incidence is four times higher in women, especially in obese women, with a peak incidence in the sixth and seventh decades of life. Afflicted patients often have been given a large initial loading dose of coumarin in the absence of concomitant heparin therapy. An accompanying infection such as pneumonia, viral infection, or erysipelas may be seen in up to 25 percent of patients. An association with protein C and protein S deficiencies exists, but pretreatment

screening is not warranted. An association with a heterozygote for the factor V Leiden mutation has been reported recently. [37]

FIGURE 138-4 Skin necrosis in a patient after 4 days of warfarin therapy.

Treatment involves the discontinuation of coumarin, administration of vitamin K, and infusion of heparin at therapeutic doses. Fresh-frozen plasma and purified protein C concentrates have been used. [38] Supportive measures for the skin are a mainstay of therapy. The morbidity rate is high; 60 percent of affected individuals require plastic surgery for remediation of full thickness skin necrosis by skin grafting. These patients may be treated with coumarin in the future, but small doses (2 to 5 mg daily) are recommended with initial treatment under heparin coverage.

The pathogenesis of this adverse event is the paradoxical development of occlusive thrombi in cutaneous and subcutaneous venules due to a transient hypercoagulable state. This results from the suppression of the natural anticoagulant protein C at a greater rate than the suppression of natural procoagulant factors.

Drug-Induced Lichenoid Eruptions

Drug-induced lichen planus produces lesions that are clinically and histologically indistinguishable from idiopathic lichen planus; however, lichenoid drug eruptions often appear initially as eczematous with a purple hue and involve large areas of the trunk. Usually the mucous membranes and nails are not involved. Histologically, focal parakeratosis, focal interruption of the granular layer, cytoid bodies in the cornified and granular layers, the presence of eosinophils and plasma cells in the inflammatory infiltrate, and an infiltrate around the deep vessels favor a lichenoid drug eruption. [39] Many drugs, including beta blockers, penicillamine, and ACE-inhibitors, especially captopril, reportedly produce this reaction. The mean latent period is between 2 months and 3 years for penicillamine, approximately 1 year for ß-adrenergic blocking agents, and 3 to 6 months for ACE inhibitors. The latent period may be shortened if the patient has been previously exposed to the drug. [39] Resolution usually occurs with 2 to 4 months. Rechallenge with the culprit drug has been attempted in a few patients, with reactivation of symptoms within 4 to 15 days. [40]

Drug-Induced Cutaneous Pseudolymphoma

Pseudolymphoma is a process that simulates lymphoma but has a benign behavior and does not meet the criteria for malignant lymphoma. Drugs are a well-known cause of cutaneous pseudolymphomas, but the condition may also be provided by foreign agents such as insect bites, infections (e.g., HIV), and idiopathic causes. [41]

Anticonvulsant-induced pseudolymphoma generally occurs after 1 week to 2 years of exposure to the drug. Within 7 to 14 days of drug discontinuation, the symptoms generally resolve. The eruption often manifests as single lesions but can also be widespread erythematous papules, plaques, or nodules. Most patients also have fever, marked lymphadenopathy and hepatosplenomegaly, and eosinophilia. [42] Mycosis fungoides-like lesions are also associated with these drugs. [43]

Drug-Induced Vasculitis

Drug-induced vasculitis represents approximately 10 percent of the acute cutaneous vasculitides and usually involves small vessels. [44] Drugs that are associated with vasculitis include allopurinol, penicillins, and thiazide diuretics. The average interval from initiation of drug therapy to onset of drug-induced vasculitis is 7 to 21 days. [45]

The clinical hallmark of cutaneous vasculitis is palpable purpura, classically found on the lower extremities. Urticaria can be a manifestation of small vessel vasculitis, with individual lesions remaining fixed in the same location for more than 1 day. Other features include hemorrhagic bullae, urticaria, ulcers, nodules, Raynaud's disease, and digital necrosis. [46] The same vasculitic process may also affect internal organs such as the liver, kidney, gut, and central nervous system and can be potentially life-threatening.

Drug-induced vasculitis can be difficult to diagnose and is often a diagnosis of exclusion. In some cases, serology has revealed the presence of perinuclear-staining antineutrophil cytoplasmic autoantibodies (p-ANCA) against myeloperoxidase. [47] Alternative etiologies for cutaneous vasculitis such as infection or autoimmune disease must be eliminated. Treatment consists of drug withdrawal. Systemic glucocorticoids may be of benefit.

Drug-Induced Lupus (See Chap. 171)

Drug-induced lupus is characterized by frequent musculoskeletal complaints, fever, weight loss, pleuropulmonary involvement in more than half of patients, and, rarely, renal, neurologic, or vasculitic involvement. [48] Most patients have no cutaneous findings of lupus erythematosus. The most common serologic abnormalities are positivity for antinuclear

antibodies with a homogeneous pattern, as well as the presence of antihistone antibody. The recent identification of minocycline as a cause of drug-induced lupus makes it important for dermatologists to recognize this syndrome. Minocycline-induced lupus typically occurs after 2 years of therapy. The patient presents with a symmetric polyarthritis. Hepatitis is often detected on laboratory evaluation. [49] Cutaneous findings include livedo reticularis, painful nodules on the legs, and nondescript eruptions. Antihistone antibody is seldom present. A study of HLA class II alleles revealed the presence of HLA-DR-4 or HLA-DR-2 in many of the patients. [50]

In contrast, *drug-induced subacute cutaneous lupus erythematosus* (SCLE) is characterized by a papulosquamous or annular cutaneous lesion, which is often photosensitive, and absent or mild systemic involvement; circulating anti-Ro (SSA) antibodies have also been identified in many patients. The most commonly reported causative agents are thiazide diuretics, calcium channel blockers, and ACE inhibitors. The number of patients who develop SCLE during treatment with these medications is very small, and these drugs are thought to have low risk for causing or exacerbating cutaneous lupus. [51]

DIAGNOSIS AND MANAGEMENT

These iatrogenic disorders are distinct disease entities, although they may closely mimic many infective or idiopathic diseases. A drug cause should be considered in the differential diagnosis of a wide spectrum of dermatologic diseases, particularly when the presentation or course is atypical.

The diagnosis of a cutaneous drug eruption involves the precise characterization of reaction type (Table 138-1 and Table 138-2). A wide variety of cutaneous drug-associated eruptions may also warn of associated internal toxicity (Table 138-3). Even the most minor cutaneous eruption should trigger a clinical review of systems, as the severity of systemic involvement does not necessarily mirror that of the skin. [52] Hepatic, renal, joint, respiratory, hematologic, and neurologic changes should be sought, and any systemic symptoms or signs investigated. Fever, malaise, pharyngitis, and other systemic symptoms or signs should be investigated. A usual screen would include a full blood count, liver and renal function tests, and a urine analysis.

TABLE 138-1 **Drug Eruptions**



TABLE 138-2 **Clinical Features of Cutaneous Reactions to Drugs**



Systemic
- Fever and/or other symptoms of internal organ involvement such as pharyngitis, malaise, arthralgia, cough, and meningism
- Lymphadenopathy

Cutaneous
- Evolution to erythroderma
- Prominent facial involvement +/– edema or swelling
- Mucous membrane involvement (particularly if erosive or involving conjunctiva)
- Skin tenderness, blistering, or shedding
- Purpura

TABLE 138-3 **Clinical Features That Warn of a Potentially Severe Drug Reaction**

Skin biopsy should be considered for all patients with potentially severe reactions, such as those with systemic symptoms, erythroderma, blistering, skin tenderness, purpura, and pustulation, or in those cases where diagnosis is uncertain. Some cutaneous reactions, such as FDE, are virtually always due to drug therapy, and nearly 90 percent of TEN cases are also drug related. [27] Other more common eruptions, including exanthematous or urticarial eruptions, have many nondrug causes.

There is no gold standard investigation for confirmation of a drug cause. Instead, diagnosis and assessment of cause involve analysis of a constellation of features such as timing of drug exposure and reaction onset, course of reaction with drug withdrawal or continuation, timing and nature of a recurrent eruption on rechallenge, a history of a similar reaction to a cross-reacting medication, and previous reports of similar reactions to the same medication. Investigations to exclude nondrug causes are similarly helpful.

Several in vitro investigations can help to confirm causation in individual cases, but their exact sensitivity and specificity remain unclear. Investigations include the lymphocyte toxicity and lymphocyte transformation assays. [7], [9] Penicillin skin testing with major and minor determinants is useful for confirmation of an IgE-mediated immediate hypersensitivity reaction to penicillin. [53] Patch testing has been used in patients with ampicillin-induced exanthematous eruptions [54] and in the ancillary diagnosis of fixed drug eruptions. Patch testing has greater sensitivity if performed over a previously

involved area of skin. [55]

Cutaneous drug eruptions do not usually vary in severity with dose. Less-severe reactions may abate with continued drug therapy (e.g., transient exanthematous eruptions associated with commencement of a new HIV antiretroviral regimen). However, a reaction suggestive of a potentially life-threatening situation should prompt immediate discontinuation of the drug, along with discontinuation of any interacting drugs that may slow the elimination of the suspected causative agent(s). Resolution of the reaction over a reasonable time frame after the drug is discontinued is consistent with drug cause but also occurs for many infective and other causes of transient cutaneous eruptions. Patients should not be rechallenged if they have suffered a potentially serious reaction.

PREVENTION

Cutaneous reactions to drugs are largely idiosyncratic and unexpected; serious reactions are rare. Once a reaction has occurred, however, it is important to prevent future similar reactions in the patient with the same drug or a cross-reacting medication. For patients with hypersensitivity and severe reactions, wearing a bracelet (e.g., MedicAlert) detailing the nature of the allergy is advisable, and patient records should be appropriately labeled.

Host factors appear important in many reactions. Some of these can be inherited, placing first-degree relatives at increased risk over the general population of a similar reaction to the same or a metabolically cross-reacting drug. This finding appears to be important in SJS, TEN, and drug hypersensitivity syndrome. [7], [56]

Reporting reactions to the manufacturer or regulatory authorities is important. Postmarketing voluntary reports of rare, severe, or unusual reactions remain crucial to enhance the safe use of pharmaceutical agents.

REFERENCES

1. Lazarou J et al: Incidence of adverse drug reactions in hospitalized patients: A meta-analysis of prospective studies. *JAMA* **279**:1200, 1998

2. Leape LL et al: The nature of adverse events in hospitalized patients. Results of the Harvard Medical Practice Study II. *N Engl J Med* **324**:377, 1991

3. Wolkenstein P et al: A slow acetylator genotype is a risk factor for sulphonamide-induced toxic epidermal necrolysis and Stevens-Johnson syndrome. *Pharmacogenetics* **5**:255, 1995

4. Batchelor JR et al: Hydralazine-induced systemic lupus erythematosus: Influence of HLA-DR and sex on susceptibility. *Lancet* **1**:1107, 1980

5. Roujeau JC et al: HLA phenotypes and bullous cutaneous reactions to drugs. *Tissue Antigens* **28**:251, 1986

6. Uetrecht J: Is it possible to more accurately predict which drug candidates will cause idiosyncratic drug reactions? *Curr Drug Metab* **1**:133, 2000

7. Shear N, Spielberg S: Anticonvulsant hypersensitivity syndrome, in vitro assessment of risk. *J Clin Invest* **82**:1826, 1988

8. Shear N et al: Differences in metabolism of sulfonamides predisposing to idiosyncratic toxicity. *Ann Intern Med* **105**:179, 1986

9. Sullivan JR, Shear NH: What are some of the lessons learnt from in vitro studies of severe unpredictable drug reactions? *Br J Dermatol* **142**:205, 2000

10. Bastuji-Garin S et al: SCORTEN: A severity-of-illness score for toxic epidermal necrolysis. *J Invest Dermatol* **115**:149, 2000

11. Hashimoto K, Tohyama M: HHV-6–associated drug eruptions. *Allergologie* **24**:219, 2001

12. Bigby M et al: Drug-induced cutaneous reactions: A report from the Boston Collaborative Drug Surveillance Program on 15,438 consecutive inpatients, 1975 to 1982. *JAMA* **256**:3358, 1986

13. Pichler W, Yawalkar N: Allergic reactions to drugs: Involvement of T cells. *Thorax* **55**(suppl 2):S61, 2000

14. Kerns D et al: Ampicillin rash in children. *Am J Dis Child* **125**:187, 1973

15. Coopman S et al: Cutaneous disease and drug reactions in HIV infection. *N Engl J Med* **328**:1670, 1993

16. Gupta A et al: Drug-induced hypothyroidism: The thyroid as a target organ in hypersensitivity reactions to anticonvulsants and sulfonamides. *Clin Pharmacol Ther* **51**:56, 1992

17. Fisher M et al: Anaphylactoid reactions to narcotic analgesics. *Clin Rev Allergy* **9**:309, 1991

18. Pracy J et al: Angioedema secondary to angiotensin-converting enzyme inhibitors. *J Laryngol Otol* **108**:696, 1994

19. Warner K et al: Angiotensin II receptor blockers in patients with ACE inhibitor-induced angioedema. *Ann Pharmacother* **34**:526, 2000

20. Kearns G et al: Serum sickness-like reactions to cefaclor: role of hepatic metabolism and individual susceptibility. *J Pediatr* **125**:805, 1994

21. Remmer H, Falk W: Successful treatment of lithium-induced acne. *J Clin Psychiatry* **47**:48, 1986

22. Beylot C et al: Acute generalized exanthematous pustulosis. *Semin Cutan Med Surg* **15**:244, 1996

23. Sidoroff A et al: Acute generalized exanthematous pustulosis (AGEP): A clinical reaction pattern. *J Cutan Pathol* **28**:113, 2001

24. Lang B, Finlayson L: Naproxen-induced pseudoporphyria in patients with juvenile rheumatoid arthritis. *J Pediatr* **124**:639, 1994

25. Primka E et al: Amiodarone-induced linear IgA disease. *J Am Acad Dermatol* **31**:809, 1994

26. Ruocco V, Sacerdoti G: Pemphigus and bullous pemphigoid due to drugs. *Int J Dermatol* **30**:307, 1991

27. Roujeau J et al: Medication use and the risk of Stevens-Johnson syndrome or toxic epidermal necrolysis. *N Engl J Med* **333**:1600, 1995

28. Patterson R et al: Effectiveness of early therapy with corticosteroids in Stevens-Johnson syndrome: Experience with 41 cases and a hypothesis regarding pathogenesis. *Ann Allergy* **73**:27, 1994

29. Barone C et al: Treatment of toxic epidermal necrolysis and Stevens-Johnson syndrome in children. *J Oral Maxillofac Surg* **51**:264, 1993

30. Viard I et al: Inhibition of toxic epidermal necrolysis by blockade of CD95 with human intravenous immunoglobulin. *Science* **282**:490, 1998

31. Heng M, Allen S: Efficacy of cyclophosphamide in toxic epidermal necrolysis. *J Am Acad Dermatol* **25**:778, 1991

32. Sullivan J, Watson A: Lamotrigine-induced toxic epidermal necrolysis treated with intravenous cyclosporin: A discussion of pathogenesis and immunosuppressive management. *Australas J Dermatol* **37**:208, 1996

33. Ozkaya-Bayazit E, Akar U: Fixed drug eruption induced by trimethoprim-sulfamethoxazole: Evidence for a link to HLA-A30 B13 Cw6 haplotype. *J Am Acad Dermatol* **45**:712, 2001

34. Crowson A, Magro C: Recent advances in the pathology of cutaneous drug eruptions. *Dermatol Clin* **17**:537, 1999

35. Barbaud A et al: The use of skin testing in the investigation of cutaneous adverse drug reactions. *Br J Dermatol* **49**:139, 1998

36. Bauer K: Coumarin-induced skin necrosis. *Arch Dermatol* **129**:766, 1993

37. Freeman B et al: Factor V Leiden mutation in a patient with warfarin-associated skin necrosis. *Surgery* **127**:595, 2000

38. Schramm W et al: Treatment of coumarin-induced skin necrosis with a monoclonal antibody purified protein C concentrate. *Arch Dermatol* **19**:753, 1993

39. Halevy S, Shai A: Lichenoid drug eruptions. *J Am Acad Dermatol* **29**:249, 1993

40. Thompson D, Skaehill P: Drug-induced lichen planus. *Pharmacotherapy* **14**:561, 1994

41. Rijlaarsdam J, Willemze R: Cutaneous pseudolymphoma: Classification and differential diagnosis. *Semin Dermatol* **13**:187, 1994

42. Souteyrand P, d'Incan M: Drug-induced mycosis-fungoides-like lesions. *Curr Probl Dermatol* **19**:176, 1990

43. Rijlaarsdam J et al: Cutaneous pseudo-T-cell lymphomas. *Cancer* **69**:717, 1992

44. Sanchez N et al: Clinical and histopathologic spectrum of necrotizing vasculitis: Reports of findings in 101 cases. *Arch Dermatol* **121**:220, 1985

45. Dubost J et al: Drug-induced vasculitides. *Ballieres Clin Rheumatol* **5**:119, 1991

46. Roujeau JC, Stern R: Severe adverse cutaneous reactions to drugs. *N Engl J Med* **331**:1272, 1994

47. Colakovski H, DL: Propylthiouracil-induced perinuclear-staining antineutrophil cytoplasmic autoantibody-positive vasculitis in conjunction with pericarditis. *Endocr Pract* **7**:37, 2001

48. Price E, Venables P: Drug-induced lupus. *Drug Saf* **12**:283, 1995

49. Gough A et al: Minocycline-induced autoimmune hepatitis and systemic lupus erythematosus-like syndrome. *BMJ* **312**:169, 1996

50. Dunphy J et al: Antineutrophil cytoplasmic antibodies and HLA class II alleles in minocycline-induced lupus-like syndrome. *Br J Dermatol* **142**:461, 2000

51. Callen J: Drug-induced cutaneous lupus erythematosus, a distinct syndrome that is frequently unrecognized. *J Am Acad Dermatol* **45**:315, 2001

52. Sullivan JR, Shear NH: The drug hypersensitivity syndrome: What is the pathogenesis? *Arch Dermatol* **137**:357, 2001

53. Sogn D et al: Results of the National Institute of Allergy and Infectious Diseases Collaborative Clinical Trial to test the predictive value of skin testing with major and minor penicillin derivatives in hospitalized adults. *Arch Intern Med* **152**:1025, 1992

54. Romano A et al: Aminopenicillin allergy. *Arch Dis Child* **76**:513, 1997

55. Philips K et al: The importance of patch testing on previously affected skin in the diagnosis of type IV drug allergy. *Allergologie* **24**:224, 2001

56. Shear NH, Bhimji S: Pharmacogenetics and cutaneous drug reactions. *Semin Dermatol* **8**:219, 1989

T>

Chapter 139

James Fitzpatrick

Mucocutaneous Complications of Antineoplastic Therapy

PHARMACOLOGY
Alkylating Agents
Antibiotics
Antimetabolites
Enzymes
Hormonal Agonists/Antagonists
Mitotic Inhibitors
Miscellaneous Cytotoxic Agents
MUCOCUTANEOUS COMPLICATIONS
Hair Follicle Complications
Nail Complications
Sweat Gland Complications
Epidermal Complications
Dermal Complications
Mucosal Complications
Reactions to Immune Modifiers

REFERENCES

The last decade has seen an explosion of new treatment modalities for neoplastic diseases. Prolonged survival and even cures of many cancers can now be attributed to advances in chemotherapy, radiation therapy, surgery, and, more recently, drugs that augment the immune response or target specific receptors or antigenic targets on tumor cells. Some chemotherapeutic agents have also found a role in the treatment of immunologically mediated systemic and skin disease, making it even more important that dermatologists are cognizant of the side effects that may be encountered from these drugs.

More than 70 drugs now are classified as antineoplastic agents, and several excellent reviews have been published summarizing the clinical [1], [2] and histopathologic [3], [4] findings associated with them. Because there is an unavoidable delay from the time that new drugs are introduced until many of the cutaneous reactions are described in the literature, dermatologists are frequently faced with evaluating patients who are taking new chemotherapeutic agents for which all of the side effects are not yet known. This chapter is organized by clinical presentation rather than by a discussion of specific drugs and their side effects because the clinical presentation is more relevant for patient evaluation. Because related chemotherapeutic agents often have similar side effects, it is also useful to understand the mechanism of action of drugs and how they are related. Table 139-1 lists the drugs by class with a brief discussion of the mechanisms of action.

TABLE 139-1 **Classification of Antineoplastic Agents**

This chapter focuses on mucocutaneous reactions that are unique to (e.g., acral erythema), specific for (e.g., bleomycin-induced flagellate hyperpigmentation), or commonly associated with (e.g., asparaginase-induced urticaria) chemotherapeutic agents. It does not discuss drug reactions that can be associated with any drug class (e.g., erythema multiforme, spongiotic drug eruptions, fixed drug eruptions, pruritus).

PHARMACOLOGY

Alkylating Agents

Alkylating agents can be subdivided into mustard gas derivatives (e.g., chlorambucil, cyclophosphamide,

mechlorethamine hydrochloride) and heavy metal alkylating agents (e.g., cisplatin). The nonplatinum alkylating drugs work by producing intrastrand and interstrand crosslinks of DNA strands, which, in turn, block the synthesis of DNA, RNA, and, ultimately, protein. The heavy metal alkylating agents primarily work by producing interstrand DNA crosslinks. The effect for all drugs in this class is cell-cycle phase-nonspecific. Some authorities prefer to place carboplatin and cisplatin in a separate category because they are heavy metal complex alkylating agents with a platinum atom surrounded by two ammonia molecules. Chlorambucil is the slowest-acting and least toxic of the drugs in this class.

Antibiotics

Most of the cytotoxic antibiotics work by intercalating with the DNA molecule and inhibiting DNA synthesis. This action blocks DNA-dependent RNA synthesis and, ultimately, protein synthesis. Mitomycin, although classified as an antibiotic, works like an alkylating agent; it exerts its cytotoxic activity by forming cross-links between strands of DNA and inhibiting DNA, RNA, and protein synthesis. All of the antibiotics are cell-cycle phase-nonspecific. Bleomycin is inactivated by a hydrolase enzyme that is found in all tissues except lung and skin. This fact may account for the high incidence of bleomycin-related side effects in these tissues.

Antimetabolites

The antimetabolites constitute a diverse group of antineoplastic agents. The folic acid analogues (i.e., methotrexate, trimetrexate) block folic acid participation in nucleic acid synthesis by binding competitively and irreversibly to dihydrofolate reductase with a stronger affinity than folic acid. The pyrimidine analogues (capecitabine, floxuridine, and fluorouracil) compete for thymidine synthetase, the enzyme required for synthesis of thymidine and ultimately DNA. These drug are cell-cycle phase-specific and affect the S phase. Cytarabine is a pyrimidine analogue that is believed to interfere with DNA synthesis by blocking conversion of cytidine to deoxycytidine. It may also be incorporated into the RNA molecule. It is specific for the S phase during DNA synthesis, but under some conditions it may also prevent cells from going from G_1 to S phase. The purine analogues (mercaptopurine, thioguanine) compete with hypoxanthine and guanine for hypoxanthine guanine phosphoribosyltransferase and ultimately interfere with purine synthesis by multiple mechanisms. Hydroxyurea is a synthetic analogue of urea that blocks the incorporation of thymidine into DNA and may also damage DNA directly.

Enzymes

Asparaginase is a polypeptide enzyme that catalyzes the hydrolysis of asparagine to aspartic acid and ammonia, which depletes the extracellular asparagine necessary for synthesis of DNA. Because normal cells are able to synthesize asparagine and some malignant cells cannot, asparaginase is selectively cytotoxic for these malignant cells. The drug is cell-cycle phase-nonspecific and is primarily used in the treatment of acute leukemias.

Hormonal Agonists/Antagonists

A discussion of the mechanisms of the hormonal agonists and antagonists is beyond the scope of this chapter. In general, glucocorticoids are used for their lympholytic effects and ability to suppress lymphocyte mitotic activity. Thus, they are often included in many lymphocytic leukemia and lymphoma regimens. Another category of hormonal antagonist includes adrenocortical suppressant drugs (e.g., aminoglutethimide, mitotane) that are used primarily to treat adrenal carcinomas. Androgens (e.g., testolactone) and estrogens are used for their effect in breast carcinoma but have been largely supplanted by the antiestrogens (e.g., tamoxifen). Progestins are second-line hormonal drugs useful in the treatment of breast and endometrial carcinomas that have hormonal receptors on tumor cells. Gonadotropin-releasing analogues (i.e., goserelin, leuprolide) are used to treat prostatic carcinoma and breast cancer because they inhibit the secretion of luteinizing hormone (LH) and follicle stimulating hormone (FSH) and ultimately produce profound depression in the levels of testosterone and estrogen. Bicalutamide and flutamide are nonsteroidal antiandrogens that uniquely work by inhibiting the translocation of the androgen receptor from the nucleus to the cytoplasm in the prostate and hypothalamus. Because they inhibit the binding of androgen to its intracellular receptor, these drugs are useful to treat prostatic carcinoma.

Mitotic Inhibitors

The mitotic inhibitors include the vinca alkaloids, epipodophyllotoxins, and taxanes. The vinca alkaloids are cell-cycle phase-specific drugs that bind to tubulin and block the assembly into microtubules, thus arresting cells in metaphase. The taxanes bind directly to the microtubules that are needed for the interphase phase of cell mitosis. This action stabilizes the microtubule network and results in inhibition of cells that are mitotically active. The epipodophyllotoxins, although semisynthetic derivatives of podophyllotoxin, do not arrest cells in mitosis; instead, they work by complexing with topoisomerase II and producing single and double-stranded DNA breaks. These drugs remain attached to the free end of the DNA and also inhibit resealing of the break by topoisomerase II. Cells in S and G_2 phases are susceptible to these drugs.

Miscellaneous Cytotoxic Agents

Procarbazine is a hydrazine derivative that is cell-cycle phase-specific for cells in S phase. Its precise mechanism is unknown. It is metabolized to multiple cytotoxic metabolites that methylate DNA and ultimately suppress mitotically active cells in interphase and also produce chromatid breaks and translocations. Irinotecan and topotecan are inhibitors of topoisomerase I, an enzyme required for the relaxation of supercoiled double-stranded DNA. By binding to this enzyme, these agents allow uncoiling but prevent recoiling, thereby causing a break between the two strands. Altretamine is a synthetic cytotoxic thiazine derivative that structurally resembles some alkylating agents but does not appear to work as an alkylating agent. It binds to DNA, but it is not known whether this action is relevant; the precise mechanism of action is unknown.

MUCOCUTANEOUS COMPLICATIONS

Hair Follicle Complications

ALOPECIA Chemotherapy-induced alopecia is the most common mucocutaneous side effect associated with cancer treatment, and it is often the most distressing to the patient's self-image. Chemotherapy-induced alopecia is primarily an anagen effluvium due to toxic effects on the rapidly dividing hair matrix cells. This effect is dependent on the chemotherapeutic agent, dose, schedule, and route of administration. Even at the same dose, intravenous infusion produces more severe alopecia than oral administration. Although numerous drugs produce alopecia (Table 139-2), doxorubicin, cyclophosphamide, and vincristine have the highest potential to do so. [5] Chemotherapy-induced alopecia typically occurs 7 to 10 days after induction of therapy and continues to progress over 1 to 2 months. In severe cases, more than 90 percent of the hair is lost; the remaining hairs are spared because they were in telogen at the time of therapy, but with prolonged treatment, even these will be shed. Although loss of scalp (Fig. 139-1) and eyebrow hair is clinically most noticeable, patients also shed eyelashes and body hair. To a lesser degree, telogen effluvium also participates in chemotherapy-induced alopecia secondary to weight loss, fevers, and other medications, and secondary to the effects of the cancer itself. The alopecia typically resolves after therapy is stopped, although hair may regrow with a different color or texture. Permanent alopecia was documented in 6 of 22 patients who received busulfan and cyclophosphamide. [6] Different methods have been used to prevent chemotherapy-induced alopecia, and a scalp cooling system has proved the most effective. The diagnosis is usually easily made clinically, but in those rare cases in which biopsies are performed for diagnosis, the hair follicles demonstrate a cell-poor alopecia with numerous necrotic follicular keratinocytes. [3]

TABLE 139-2 **Adverse Mucocutaneous Reactions to Antineoplastic Agents**

FIGURE 139-1 Alopecia after the administration of combined chemotherapy (cyclophosphamide, doxorubicin, vincristine).

FOLLICULITIS (ACNEIFORM ERUPTION) Folliculitis is most commonly associated with dactinomycin (actinomycin D) [7] and less commonly with methotrexate and cisplatin. Patients initially develop erythema of the face, followed over a 2- to 3-day period by the appearance of papules and pustules on the face and upper trunk. As the follicular erythema and pustules resolve over 10 days, comedones may persist. Biopsies of fully developed lesions are not specific and demonstrate an acute folliculitis with replacement of the pilosebaceous unit by neutrophils. Acne vulgaris may also be aggravated by androgens used as chemotherapeutic agents.

Nail Complications

BEAU'S LINES/ONYCHOLYSIS/ONYCHOMADESIS Nail toxicity is frequently associated with chemotherapeutic agents. Some antineoplastic agents (e.g., paclitaxel) produce nail changes in up to 40 percent of patients. Anthracyclines (e.g., daunorubicin, doxorubicin, idarubicin) and taxanes (e.g., paclitaxel, docetaxel) are the groups of drugs that most commonly produce severe nail toxicity. Mild toxic reactions produce Beau's lines, while severe toxic reactions produce onycholysis and even onychomadesis (Fig. 139-2). The first toe is the most common digit affected and may be the only digit affected in milder cases. In severe cases, all of the nails of the hands and feet may be involved. Less common findings include severe nail pain, nail thickening, nail thinning, splinter hemorrhages, and subungual hemorrhage. Nail

toxicity is dose dependent and is more common with high dosage regimens and prolonged therapy. These reactions are not life-threatening and rarely warrant changes in chemotherapy. The mechanism is probably due to direct toxicity to the nail plate, although inhibition of nail bed angiogenesis has been proposed. Clinical evidence suggests that for the taxanes sunlight exposure may either aggravate or actually be necessary for the development of onycholysis. [8]

FIGURE 139-2 Presence of a proximal indented Beau's line and distal band of leukonychia due to cyclophosphamide 3 months after bone marrow transplantation.

NAIL PIGMENT ABNORMALITIES Drugs from many different classes produce either hypopigmentation (leukonychia or transverse white banding) or hyperpigmentation of the nail. The mechanisms for the development of the various patterns of leukonychia are unknown but are presumed to be cytotoxic in nature (Fig. 139-2). Hyperpigmentation may appear as longitudinal hyperpigmentation, horizontal hyperpigmentation, pigmentation confined to the lunula, and diffuse hyperpigmentation. Chemotherapy-induced nail hyperpigmentation appears to be more common in black patients, presumably due to the increased numbers of melanocytes in the nail matrix. [9] Nail hyperpigmentation most commonly develops 10 days to 6 months after chemotherapy except for treatment with hydroxyurea when it develops after chronic therapy (1 to 3 years). [10] Chemotherapy-induced nail hyperpigmentation has not been critically studied by biopsies; but in those rare cases where it has been examined, there has been increased melanin in the ventral nail plate. The mechanism is not understood, but it has been hypothesized to be due to increased activity of the melanocytes. In the cases of daunorubicin and doxorubicin, it has been hypothesized that the increased melanocytic activity may be due to increased melanocyte-stimulating hormone (MSH) or corticotropin release, or secondary to a conjugate of the chemotherapeutic agent and MSH. [9]

Sweat Gland Complications

NEUTROPHILIC HIDRADENITIS Neutrophilic hidradenitis may occur in patients undergoing therapy with several different antineoplastic agents, most commonly cytarabine. Less commonly implicated antineoplastic agents include bleomycin and granulocyte colony-stimulating factor. [11], [12] This reaction is manifested as tender, erythematous macules, papules, and plaques of the trunk, neck, and extremities that develop days to months after induction. The lesions resolve spontaneously over a period of several days. Histologic changes are distinctive and include a neutrophilic infiltrate involving and surrounding the sweat gland coils. The eccrine coils are most commonly affected, but apocrine involvement may also occur. [13] The mechanism is most likely secondary to high concentrations of the cytotoxic drug being secreted in the sweat gland coils. This hypothesis is supported by the demonstration that bleomycin injected into normal human skin produces changes that resemble those seen with systemic administration of the drug. Because similar histologic findings have been reported in patients receiving drugs that are not chemotherapeutic agents (e.g., acetaminophen) and in other diseases (e.g., idiopathic palmoplantar eccrine hidradenitis of childhood), other pathogenic mechanisms can also produce this histologic pattern.

SYRINGOSQUAMOUS METAPLASIA (ECCRINE SQUAMOUS METAPLASIA) Chemotherapy-induced syringosquamous metaplasia is a clinicopathologic reaction that is closely related to neutrophilic hidradenitis. It has occurred with multiple different chemotherapeutic regimens. [14], [15] Like neutrophilic hidradenitis, it is thought to be secondary to direct toxic injury of sweat ducts by the antineoplastic agents. Clinically, these reactions have most commonly presented as erythematous papular eruptions that resemble miliaria. The papules resolve over a period of weeks after therapy is discontinued. The histologic findings are distinct and consist of marked squamous metaplasia of the upper sweat duct associated with necrotic ductal epithelial cells. There is usually a minimal host response, although scattered neutrophils and lymphocytes are often present. [4]

Epidermal Complications

CHEMOTHERAPY-INDUCED TOXIC ERYTHEMA Chemotherapy-induced toxic erythema is one of the most common adverse reactions to high-dose or multiple-drug regimens. In multiple-drug regimens, a single drug cannot usually be implicated because these regimens almost always include two or more drugs that are cytotoxic to the skin. Single drugs that commonly produce this reaction when administered in high-dose regimens are busulfan, [16] cytarabine, etoposide, [17] and methotrexate. The reaction typically begins with a prodrome of pain or tingling of the skin. Increasingly tender erythema and edema of the skin resembling toxic epidermal necrolysis rapidly follow the initial symptoms. The distribution varies with the drug regimen and may range from generalized to accentuated in acral areas, areas of pressure, intertriginous folds, or under tape. In some cases, the reaction may be localized to areas where the drug is infused in higher concentrations. Examples include intraarterial infusions of limbs, where the toxic reaction is confined to that limb, or intrathecal infusions, where the reaction is confined to the skin overlying the spine. In milder reactions, this is followed by desquamation, while in severe reactions, it is followed by bullae. Long-term hydroxyurea therapy produces a unique form of toxic erythema that clinically resembles dermatomyositis (drug-induced pseudodermatomyositis). In the largest study, 7 of 21 patients developed dermatomyositis-like changes on the hands, often in association with leg ulcers.

[18] Biopsies of early chemotherapy-induced lesions of toxic erythema demonstrate a cell-poor, interface tissue reaction manifesting as vacuolar alteration and necrotic keratinocytes. [3], [4] Older lesions may demonstrate varying degrees of epidermal dysmaturation with larger-than-normal keratinocytes and edematous-abundant eosinophilic cytoplasm. If the patients continue to receive chemotherapy, the epidermis may eventually become attenuated because it cannot be replenished with new cells. Etoposide and busulfan produce distinct histologic findings. Etoposide produces “starburst cells,” which are enlarged, pale-staining keratinocytes in mitotic arrest manifesting absence of the nuclear membrane associated with fragments of chromosomes haphazardly arranged in the cytoplasm. [17] Busulfan produces “busulfan cells,” which are abnormal keratinocytes with strikingly large nuclei (up to 22 µm in diameter) that have irregular contours and prominent nucleoli. Similar cells are seen in other epithelial-lined surfaces such as lung, gastrointestinal tract, and bladder. [16]

CHEMOTHERAPY-INDUCED ACRAL ERYTHEMA Since its description in 1982, [19] there have been numerous case reports and series documenting that many chemotherapeutic agents can produce a distinctive toxic reaction manifesting a painful acral erythema. The exact mechanism is unknown, but the concentration of drug in eccrine structures of the palms and soles has been postulated to play a role. This hypothesis is supported by the presence of syringosquamous metaplasia in conjunction with acral erythema. [20] Although numerous drugs have been implicated (see Table 139-2), this reaction is most common with high-dose cytarabine, with a reported incidence of 20 percent, [21] and doxorubicin, with an incidence of 29 percent. The reaction typically develops 4 to 23 days after chemotherapy is begun and manifests as painful, sharply demarcated erythema of the palmar and plantar surfaces (Fig. 139-3). In severe cases, the toxic reaction may progress to large bullae, may extend over the dorsum of the hands and feet, or may involve other cutaneous sites. The pain is sometimes so intense that patients cannot walk and they keep their hands immobile in a partially flexed position. Histologic changes can be difficult to distinguish from graft-versus-host reactions and demonstrate an interface tissue reaction with vacuolar alteration of the basal cell layer, necrotic keratinocytes, variable dysmaturation, and a minimal superficial perivascular lymphocytic infiltrate. The lesions resolve spontaneously with desquamation over a period of 2 to 3 weeks. Therapy is limited to analgesics and emollients.

FIGURE 139-3 Cytarabine-induced painful acral erythema with marked edema.

INFLAMMATION OF KERATOSES A number of different chemotherapeutic agents and chemotherapeutic combination protocols produce inflammation of actinic keratoses and seborrheic keratoses. Fluorouracil is the most common cause of toxic reactions in actinic keratoses, and this selective reaction is the basis for the use of this drug in the topical treatment of actinic keratoses. [22] The reaction usually develops within 1 week of initiating chemotherapy. The actinic keratoses may resolve or remain after therapy is discontinued. A similar reaction in seborrheic keratoses has been reported to occur with cytarabine.

HYPERPIGMENTATION Bleomycin commonly produces a unique form of flagellate (linear) hyperpigmentation with an incidence that has varied from 8 to 66 percent depending on the treatment protocol. [23] Typically this reaction starts within days after bleomycin therapy is initiated and manifests as severely pruritic, erythematous linear lesions that are slowly replaced by brown linear lesions (Fig. 139-4). The eruption resolves without treatment over a period of weeks to months. In one patient who developed flagellate hyperpigmentation, the subsequent use of a heating pad reproduced these areas of hyperpigmentation confined to the area of treatment. [24] The pathogenesis is unknown. Some authors have noted the development of these streaks in areas of excoriation. One group of investigators induced lesions in a patient by rubbing the skin during bleomycin administration. Other investigators have not been able to reproduce these lesions with trauma. The incidence of skin reactions secondary to bleomycin may be due to the absence of hydrolase, the enzyme that inactivates bleomycin, in the skin. The clinical findings of bleomycin-induced flagellate hyperpigmentation are so characteristic that biopsies are usually not required. Biopsies of early lesions demonstrate vacuolar alteration and necrotic keratinocytes with minimal inflammation, whereas biopsies of later lesions demonstrate hyperpigmentation of the basilar keratinocytes and melanin incontinence. [4] Bleomycin may also produce patchy pigmentation in areas of pressure, palmar creases, and striae distensae. [1]

FIGURE 139-4 Flagellate hyperpigmentation 2 weeks after administration of bleomycin.

Several chemotherapeutic agents, including fluorouracil [25] and vinorelbine, [26] also produce a unique form of hyperpigmentation manifesting as serpentine supravenous areas of hyperpigmentation. This reaction may follow the intravenous administration of fluorouracil and also occurs with several multiple-drug chemotherapeutic regimens. The reaction resolves spontaneously with time. Daunorubicin also produces a unique form of pigmentation manifesting as polycyclic bands of pigmentation of the scalp. [9] Numerous antineoplastic drugs produce other patterns of hyperpigmentation including patchy, acral, photoaccentuated, polycyclic, occlusion (e.g., tape) accentuated (Fig. 139-5), pressure accentuated, or generalized hyperpigmentation that may resemble Addison's disease (see Table 139-2). The causes of these patterns of chemotherapy-induced hyperpigmentation are unknown. Postulated mechanisms include a direct toxic effect on melanocytes, increased drug deposition due to increased blood flow, increased toxicity secondary to

secretion in the sweat, endocrinologic abnormalities (e.g., increased MSH), and drug-induced depletion of tyrosinase inhibitors. [1]

FIGURE 139-5 Hyperpigmentation at sites occluded during infusion of thiotepa.

PHOTOSENSITIVITY Most cases of chemotherapy-induced photosensitivity are phototoxic in terms of pathogenesis, although photoallergic reactions may also occur (see Table 139-2). Phototoxic reactions mimic sunburns and present as burning and erythema; vesiculobullous lesions appear in severe cases. As the erythema fades, varying degrees of desquamation develop. Biopsies demonstrate a cell-poor interface tissue reaction with necrotic keratinocytes. [27] Photoallergic reactions present as dermatitis reactions that often have a papulovesicular appearance. In contrast to phototoxic reactions, photoallergic reactions may not occur when the drug is started but may develop weeks or months later. Biopsies of photoallergic reactions demonstrate a spongiotic dermatitis that is primarily mediated by lymphocytes. [4]
SUNBURN RECALL REACTIONS Methotrexate produces a unique reactivation of sunburn when it is given 1 to 3 days after sun exposure; at least one case occurred as late as 8 days. [28] These reactions present as erythema confined to the area of previous sunburn with severe cases developing superficial blisters as in second-degree sunburns (Fig. 139-6). This reaction is not prevented by leucovorin rescue. The pathogenesis is not understood, but it has been postulated to be due to the fact that ultraviolet-damaged keratinocytes undergoing enhanced DNA, RNA, protein synthesis are further damaged by the methotrexate.

FIGURE 139-6 Reactivation of solar erythema 2 days after high-dose methotrexate administration to a young woman with choriocarcinoma. (*From Bronner and Hood: Cutaneous complications of chemotherapeutic agents. J Am Acad Dermatol 9:645,1983 with permission.*)

RADIATION ENHANCEMENT DERMATITIS Radiation enhancement is defined as a synergistic reaction between an antineoplastic drug and radiation. Radiation enhancement is often a desired effect on the tumor but is not desirable when it affects the skin. Radiation-enhanced skin reactions are most commonly associated with orthovoltage or megavoltage radiation, but they also can occur with electron beam therapy. [29] The mechanism for most drugs has not been established, but, for the vinca alkaloids, in vitro studies suggest that treated cells accumulate in G_2M-phase of the cell cycle and that cells in this state are more susceptible to radiation-induced apoptosis. In most cases, the drug and radiation are administered within 1 week of each other, but in occasional cases, the window for enhancement appears to be longer. Although a number of chemotherapeutic agents produce this reaction, doxorubicin and dactinomycin are most commonly implicated. The reaction presents initially as pain and erythema followed by desquamation and hyperpigmentation. Radiation-induced alopecia also appears to be enhanced by these drugs within the treatment port.
RADIATION RECALL DERMATITIS Radiation recall reactions are defined as cutaneous cytotoxicity that develops in a previously quiescent radiation field with the administration of an antineoplastic agent. [30] The mechanism for this reaction is unknown, but it has been hypothesized that the radiation depletes the cutaneous stem cells from the treatment field and that surviving cells are more susceptible to cytotoxic drugs. Another hypothesis is that the surviving stem cells within the radiation field are damaged by the initial treatment and thus more sensitive to the cytotoxic drugs. Radiation recall reactions may occur from days to as long as 15 years after radiation therapy. Recall usually occurs with induction chemotherapy and is sometimes absent or often milder with rechallenge. [31] Clinically, it resembles acute radiodermatitis with burning and erythema confined to the radiation field followed by desquamation and blisters in severe cases (Fig. 139-7). Treatment consists of discontinuing the offending drug and supportive local care. Although there are anecdotal reports of improvement with topical or systemic glucocorticoids, the value of this treatment is questionable given the pathogenesis and absence of prospective studies.

FIGURE 139-7 Radiation recall reaction appearing 2 weeks after the administration of methotrexate.

Dermal Complications

LOCAL INJURY The delivery of chemotherapeutic agents by intravenous or occasionally intraarterial routes (i.e., limb perfusion) is associated with a risk of extravasation estimated to be 0.1 to 6 percent in adults and even higher in children.

[1] Those agents having minimal toxicity produce only chemical cellulitis or phlebitis and are classified as being irritants. Those agents having severe toxicity produce tissue necrosis and are classified as vesicants. The degree of injury is related to the drug, rate of delivery, concentration, and amount extravasated. Chemical cellulitis manifests as erythema, induration, and pain at the injection site; sometimes it may follow the course of the vein. Chemical cellulitis is usually of relatively short duration and resolves without treatment. Chemotherapy-related phlebitis manifests as linear cords and may be associated with discomfort. Chemotherapy-induced tissue necrosis secondary to extravasation can be a devastating complication. Histologic studies of doxorubicin-associated extravasation suggest that the earliest findings are degenerative changes of blood vessels associated with extravasation of red blood cells. [32] This is followed by necrosis of the epidermis and collagen. The absence of significant numbers of inflammatory cells argues against the use of topical or intralesional glucocorticoids. Although a number of drugs have been implicated, doxorubicin is considered to be the most potent drug causing tissue necrosis. [33] Doxorubicin may produce ulcers that progress from 1 to 3 months and may eventually reach the level of tendons and bone (Fig. 139-8). Extravasation should be treated by immediate discontinuation of perfusion and the application of either hot or cold packs. Cold packs are used for all chemotherapeutic agents except vinca alkaloids to localize the drug and promote localized degradation. Vinca alkaloids are treated with hot packs because the application of cold promotes tissue necrosis. [1] Other treatments advocated but not proven include the application of potent topical glucocorticoids under occlusion, topical dimethylsulfoxide (DMSO), DMSO and a-tocopherol in conjunction, and locally injected hyaluronidase for vinca alkaloid and etoposide injections. [1] Severe ulcerations may require wide excision of the ulcer with grafting.

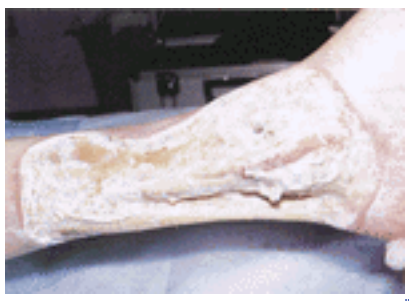

FIGURE 139-8 Severe tissue necrosis after extravasation of doxorubicin.

IMMEDIATE HYPERSENSITIVITY REACTIONS Dermatologists are rarely called on to treat immediate hypersensitivity reactions to chemotherapeutic agents, but these reactions are caused by a number of antineoplastic agents (e.g., cisplatin). [34] The most common causative agent is asparaginase, which produces urticaria, angioedema, or anaphylaxis in up to 65 percent of patients. [1] Because immediate hypersensitivity reactions to this agent are so common, it is recommended that intradermal testing be done before the initial dose is administered and repeated if the drug is used after an interval of 1 week or more.

SCLEROTIC DERMAL REACTIONS Bleomycin [35] and docetaxel [36] produce sclerotic tissue reactions that may be localized, regional, or diffuse. Localized tissue reactions may mimic morphea or progressive systemic sclerosis. Melphalan has been reported to produce a unique form of reticulate scleroderma after limb perfusion. [37] In some cases, these reactions have resolved after withdrawal of the offending drug. [35], [36] The mechanism has not been established, but in vitro bleomycin upregulates a $_1$(I) collagen, fibronectin, and decorin gene expression in both normal and scleroderma skin fibroblasts. [38] Biopsies demonstrate dermal sclerosis that is indistinguishable from morphea or progressive systemic sclerosis.

RAYNAUD'S PHENOMENON Raynaud's phenomenon, with or without digital ulcerations, is most often associated with bleomycin, [39] cisplatin, [40] or cisplatin in combination with gemcitabine. This reaction may occur either with systemic chemotherapy or after intralesional injection to treat verruca vulgaris. [41] The mechanism is unknown; but bleomycin is known to be toxic to endothelial cells, and in addition to Raynaud's phenomenon, it has produced acral leukocytoclastic vasculitis with acral ulcerations and digital gangrene. In a study of 90 patients receiving bleomycin for testicular cancer, 37 percent developed Raynaud's phenomenon, with 7 percent having transient disease. [39] Risk factors for the development of Raynaud's phenomenon include combination therapy with vinblastine and high cumulative doses of bleomycin.

Mucosal Complications

STOMATITIS Mucosal epithelium, because of its high mitotic activity, is extremely susceptible to several classes of chemotherapeutic agents including those that affect the synthesis of DNA or RNA and those that act as mitotic inhibitors. Oral complications occur in approximately 40 percent of patients receiving chemotherapy. Young patients, because of their higher mitotic index, and patients with preexisting oral disease are more susceptible to severe reactions. [1] Patients typically note burning and increased mucosal erythema within days after administration of the chemotherapy followed by erosions and ulcerations that are characteristically intensely painful (Fig. 139-9). The oral mucosa is most commonly affected, especially the buccal mucosa and tongue, but any mucosal surface, including ocular mucosa, may be involved. Eating and drinking may aggravate the pain; this problem sometimes necessitates altering the dosage regimen. [42] The mucositis is often accompanied by secondary bacterial and fungal infections. Meticulous, but not overly aggressive, oral hygiene may reduce the incidence of secondary infection, but antibiotics and antifungal agents are often needed to augment healing and reduce the incidence of septicemia. Oral hemorrhage secondary to chemotherapy-induced thrombocytopenia is also often present.

FIGURE 139-9 Stomatitis induced by cytarabine, doxorubicin, and methotrexate. (*Courtesy of Allan C. Harrington, MD.*)

MUCOSAL HYPERPIGMENTATION The mucosa may develop various patterns of hyperpigmentation including linear, patchy, and macular. Specific agents may affect certain anatomic areas such as the gingival margin (e.g., cyclophosphamide) or tongue (e.g., fluorouracil). The mechanism is not understood. The hyperpigmentation slowly resolves over a period of weeks to months except for the oral hyperpigmentation produced by cyclophosphamide, which may be permanent.

Reactions to Immune Modifiers

The immune modifiers are discussed separately because they work by modifying or intensifying the host immune response to the tumor. Their side effects are totally different from those of the classic chemotherapeutic agents.

INTERLEUKINS Interleukin-2 (IL-2) is a cytokine produced by antigen-activated T cells. It stimulates T cell proliferation, potentiates the apoptotic cell death of antigen-activated T cells, and stimulates the proliferation and effector functions of natural killer cells and B cells. It is used primarily for the treatment of malignant melanoma, but the mechanism of action in the treatment of tumors is unknown. Clinically, it is associated with a dose-related *capillary leak syndrome,* manifesting as peripheral and central edema. [43] It has also been reported to produce a persistent macular erythema with associated pruritus and burning, usually localized to the head and neck region. The eruptions desquamate and resolve after IL-2 administration is discontinued. Skin biopsies demonstrate papillary edema associated with a superficial mononuclear infiltrate. Other mucocutaneous complications of IL-2 administration include stomatitis, telogen effluvium, punctate superficial cutaneous ulcers, erosions in surgical scars, erythema nodosum, and exacerbation of psoriasis. Denileukin diftitox is a fusion protein consisting of diphtheria toxin and IL-2. Because some leukemias and lymphomas express the high affinity form of the IL-2 receptor, the fusion protein attaches to the receptor and produces cell death within hours. Cutaneous reactions include hypersensitivity reactions, dermatitis at the site of injection, generalized dermatitis, pruritus, and increased sweating. Premedication with steroids decreases the incidence and severity of skin reactions without compromising the clinical response. [44]

INTERFERONS Interferon-a2a and interferon-a2b are cytokines that have a variety of actions including inhibition of viral replication, increasing the lytic potential of natural killer cells, and stimulation of the development of T_H1 cells. Although flulike symptoms such as fever, chills, fatigue, and myalgias are the most frequent complications, cutaneous reactions are also common and include alopecia, pruritus, nonspecific dermatitis, and transient dermatitis. [45] Local reactions, such as erythema at the site of injection or inflammation of the nasal mucosa, have also been noted. Other cutaneous reactions include radiation enhancement, exacerbation of psoriasis, reactivation of oral herpes simplex, and increased growth of eyelashes. The eyelash growth is reversible. [46] In the largest study of ocular complications, increased eyelash growth occurred in 2 of 36 patients (6 percent). The mechanism for this unique reaction is not known. Paradoxically, alopecia is the most common generalized cutaneous manifestation of interferon-a therapy.

MONOCLONAL ANTIBODIES The development of monoclonal antibodies that target specific binding sites on tumors is one of the most exciting areas in oncology. Recently approved drugs include rituximab and trastuzumab. Rituximab is a genetically engineered chimeric/human monoclonal antibody directed against the CD20 antigen found in normal and malignant B cells. It is indicated for the treatment of low-grade or follicular, CD20-positive B cell lymphomas. Cutaneous reactions include toxic epidermal necrolysis, pemphigus, urticaria, and vasculitis. [47], [48] Trastuzumab is a monoclonal antibody that selectively binds to the human epidermal growth factor receptor 2 protein, HER2, which is overexpressed in 25 to 30 percent of breast cancers. Cutaneous reactions include anaphylactoid reactions, dermatitis, and possible activation of herpes zoster.

COLONY-STIMULATING FACTORS The hematopoietic colony-stimulating factors, granulocyte-macrophage colony-stimulating factor (GM-CSF) and granulocyte colony-stimulating factor (G-CSF), have increasingly been used in chemotherapeutic regimens to enhance leukemic cell proliferation before cell-cycle–specific antileukemic therapy or for chemotherapy-induced neutropenia. This class of drugs has been most commonly associated with macular or papular dermatitis that often demonstrates an accumulation of granulocytes, macrophages, and lymphocytes (GM-CSF) [49] or granulocytes (G-CSF). G-CSF is also associated with Sweet's syndrome. An X inactivation study performed in one case demonstrated clonality in the skin biopsy, suggesting that the Sweet's syndrome was due to induced differentiation of sequestered leukemic cells. [50]

REFERENCES

1. Susser WS et al: Mucocutaneous reactions to chemotherapy. *J Am Acad Dermatol* **40**:367, 1999

2. Koppel RA, Boh EE: Cutaneous reactions to chemotherapeutic agents. *Am J Med Sci* **321**:327, 2001

3. Fitzpatrick JE, Hood AF: Histopathologic reactions to chemotherapeutic agents. *Adv Dermatol* **3**:161, 1988

4. Fitzpatrick JE: The cutaneous histopathology of chemotherapeutic reactions. *J Cutan Pathol* **20**:1, 1993

5. Hussein AM: Chemotherapy-induced alopecia: New developments. *South Med J* **86**:489, 1993

6. Baker B et al: Busulphan/cyclophosphamide conditioning for bone marrow transplantation may lead to failure of hair regrowth. *Bone Marrow Transplant* **7**:43, 1991

7. Epstein EH, Lutzner MH: Folliculitis induced by actinomycin D. *N Engl J Med* **281**:1094, 1969

8. Hussain S et al: Onycholysis as a complication of systemic chemotherapy. Report of five cases associated with prolonged weekly paclitaxel therapy and review of the literature. *Cancer* **88**:2367, 2000

9. Anderson LL et al: Cutaneous pigmentation after daunorubicin chemotherapy. *J Am Acad Dermatol* **26**:255, 1992

10. Don PC, Sadjadi MM: Nail and skin pigmentation associated with hydroxyurea therapy for polycythemia vera. *Int J Dermatol* **32**:731, 1993

11. Fitzpatrick JE et al: Neutrophilic eccrine hidradenitis associated with induction chemotherapy. *J Cutan Pathol* **14**:272, 1987

12. Bachmeyer C et al: Neutrophilic eccrine hidradenitis induced by granulocyte colony-stimulating factor. *Br J Dermatol* **139**:354, 1998

13. Brehler R et al: Neutrophilic hidradenitis induced by chemotherapy involves eccrine and apocrine glands. *Am J Dermatopathol* **19**:73, 1997

14. Bhawan J, Malhotra R: Syringosquamous metaplasia: A distinctive eruption in patients receiving chemotherapy. *Am J Dermatopathol* **12**:1, 1990

15. Hurt MA et al: Eccrine squamous syringometaplasia: A cutaneous sweat gland reaction in the histologic spectrum of "chemotherapy-associated eccrine hidradenitis" and "neutrophilic eccrine hidradenitis." *Arch Dermatol* **126**:73, 1990

16. Hymes SR et al: Cutaneous busulfan effect in patients receiving bone-marrow transplantation. *J Cutan Pathol* **12**:125, 1985

17. Yokel BK et al: Cutaneous pathology following etoposide therapy. *J Cutan Pathol* **14**:326, 1987

18. Vassallo C et al: Muco-cutaneous changes during long-term therapy with hydroxyurea in chronic myeloid leukaemia. *Clin Exp Dermatol* **26**:141, 2001

19. Burgdorf WHC et al: Peculiar acral erythema secondary to high-dose chemotherapy for acute myelogenous leukemia. *Ann Intern Med* **97**:61, 1982

20. Rongioletti F et al: Necrotizing eccrine squamous syringometaplasia presenting as acral erythema. *J Cutan Pathol* **18**:453, 1991

21. Demircay Z et al: Chemotherapy-induced acral erythema in leukemic patients: A report of 15 cases. *Int J Dermatol* **36**:593, 1997

22. Omura EF, Torre D: Inflammation of actinic keratoses due to systemic fluorouracil therapy. *JAMA* **208**:150, 1969

23. Guillet G et al: Cutaneous pigmented stripes and bleomycin treatment. *Arch Dermatol* **122**:381, 1986

24. Kukla LJ, McGuire WP: Heat-induced recall of bleomycin skin changes. *Cancer* **50**:2283, 1982

25. Hrushesky WJ: Serpentine supravenous 5-fluorouracil hyperpigmentation. *Cancer Treat Rep* **60**:639, 1976

26. Cecchi R et al: Supravenous hyperpigmentation induced by vinorelbine. *Dermatology* **188**:244, 1994

27. Yung CW et al: Dacarbazine-induced photosensitivity reaction. *J Am Acad Dermatol* **4**:541, 1981

28. Westwick TJ et al: Delayed reactivation of sunburn by methotrexate: Sparing of chronically sun-exposed skin. *Cutis* **39**:49, 1987

29. Solberg LA Jr et al: Doxorubicin-enhanced skin reaction after whole-body electron-beam irradiation for leukemia cutis. *Mayo Clin Proc* **55**:711, 1980

30. Yeo W, Johnson PJ: Radiation-recall skin disorders associated with the use of antineoplastic drugs. Pathogenesis, prevalence, and management. *Am J Clin Dermatol* **1**:113, 2000

31. Camidge R, Price A: Characterizing the phenomenon of radiation recall dermatitis. *Radiother Oncol* **59**:237, 2001

32. Luedke DW et al: Histopathogenesis of skin and subcutaneous injury induced by Adriamycin. *Plast Reconstr Surg* **61**:86, 1978

33. Tsavaris NB et al: Conservative approach to the treatment of chemotherapy-induced extravasation. *J Dermatol Surg Oncol* **16**:519, 1990

34. Goldberg A et al: Anaphylaxis to cisplatin: Diagnosis and value of pretreatment in prevention of recurrent allergic reactions. *Ann Allergy* **73**:271, 1994

35. Cohen IS et al: Cutaneous toxicity of bleomycin treatment. *Arch Dermatol* **107**:553, 1973

36. Hassett G et al: Scleroderma in association with the use of docetaxel (Taxotere) for breast cancer. *Clin Exp Rheumatol* **19**:197, 2001

37. Landau M et al: Reticulate scleroderma after isolated limb perfusion with melphalan. *J Am Acad Dermatol* **39**:1011, 1998

38. Yamamoto T et al: Bleomycin increases steady-state levels of type I collagen, fibronectin, and decorin mRNAs in human skin fibroblasts. *Arch Dermatol Res* **292**:556, 2000

39. Berger CC et al: Secondary Raynaud's phenomenon and other late vascular complications following chemotherapy for testicular cancer. *Eur J Cancer* **31A**:2229, 1995

40. Lee TC et al: Severe exfoliative dermatitis associated with hand ischemia during cisplatin therapy. *Mayo Clin Proc* **69**:80, 1994

41. Vanhooteghem O et al: Raynaud's phenomenon after treatment of verruca vulgaris of the sole with intralesional injection of bleomycin. *Pediatr Dermatol* **18**:249, 2001

42. Bell KA et al: Mucositis as a treatment-limiting side effect in the use of capecitabine for the treatment of metastatic breast cancer. *J Am Acad Dermatol* **45**:790, 2001

43. Gaspari AA et al: Dermatologic changes associated with interleukin-2 administration. *JAMA* **258**:1624, 1987

44. Foss FM et al: Biologic correlates of acute hypersensitivity events with DAB389IL-2 (denileukin diftitox, ONTAK) in cutaneous T cell lymphoma: Decreased frequency and severity with steroid premedication. *Clin Lymphoma* **1**:298, 2001

45. Berglund EF et al: Hypertrichosis of the eyelashes associated with interferon-alpha therapy for chronic granulocytic leukemia. *South Med J* **83**:363, 1990

46. Stafford-Fox V, Guindon KM: Cutaneous reactions associated with alpha interferon therapy. *Clin J Oncol Nurs* **4**:164, 2000

47. Dillman RO: Infusion reactions associated with the therapeutic use of monoclonal antibodies in the treatment of malignancy. *Cancer*

Metastasis Rev **18**:465, 1999

48. Dereure O et al: Rituximab-induced vasculitis. *Dermatology* **203**:83, 2001

49. Horn TD et al: Intravenous administration of recombinant human granulocyte-macrophage colony-stimulating factor causes a cutaneous eruption. *Arch Dermatol* **127**:49, 1991

50. Magro CM et al: Sweet's syndrome in the setting of CD34-positive acute myelogenous leukemia treated with granulocyte colony stimulating factor: Evidence for a clonal neutrophilic dermatoses. *J Cutan Pathol* **28**:90, 2001

T>

Chapter 140

Maria Turner

Cutaneous Reactions to Cytokines and Growth Factors

INTERFERONS
Interferon-a (IFN-a)
Interferon-ß (IFN-ß)
Interferon-? (IFN-?)
INTERLEUKINS
Interleukin 2 (IL-2)
HEMATOPOIETIC GROWTH FACTORS
Granulocyte-Macrophage Colony-Stimulating Factor (GM-CSF)
Granulocyte Colony-Stimulating Factor (G-CSF)

REFERENCES

Discoveries and developments in molecular biology and recombinant gene technology have made possible the synthesis of large amounts of pure proteins such as cytokines and growth factors (see Chap. 26). The ready availability of these recombinant proteins has permitted their use in analysis of cellular signaling pathways as well as in therapeutic applications. As a result of the increase in the use of cytokines as therapeutic agents, adverse reactions associated with their use have been recognized. In this chapter we use a classification of cytokines based on their major function. [1] Those with antiviral properties are classified as *interferons;* cytokines produced by leukocytes with major effects on other white blood cells are called *interleukins;* and those that cause proliferation and differentiation of stem cells are classified as *colony-stimulating factors*. Just as the biologic effects of cytokines have a tendency to overlap or to be redundant, the same is true of their adverse effects. This is due to the tendency of cytokines with similar structures to bind to the same receptors and to the limited number of extracellular domains on the five “superfamilies” of cytokine receptors. [2] The discussion below focuses on the adverse cutaneous reactions to cytokines already approved for therapeutic use. Recognition of these reaction patterns facilitates differentiation of these complications from cutaneous reactions to other drugs or disease processes occurring in the complicated settings in which these cytokines are frequently used.

INTERFERONS

When originally discovered, interferons (IFNs) were thought to have only antiviral effects. However, they have since been shown to have potent immunoregulatory and antiproliferative actions as well. [3] Based on their sources, there are three groups of interferons: IFN-a (leukocyte IFN), which is produced by null lymphocytes and macrophages; IFN-ß (fibroblast IFN), which is produced by fibroblasts, macrophages, and epithelial cells; and IFN-? (immune IFN), which is produced by T lymphocytes, natural killer cells, and macrophages. IFN-a and IFN-ß share the same receptor and have some homology, properties that explain the similarity in their biologic and adverse effects. [3]

Interferon-a (IFN-a)

Recombinant IFN-a is approved for use as a single agent or as adjuvant therapy for hairy cell leukemia, AIDS-related Kaposi's sarcoma, melanoma, chronic myelogenous leukemia, genital human papillomavirus infection, and hepatitis B and C virus infections. IFN-a causes multiple adverse cutaneous reactions.

CUTANEOUS NECROSIS AND ULCERATIONS AT INJECTION SITES These are the most dramatic, although extremely rare, adverse cutaneous complications of subcutaneous injections of any of the various forms of IFN-a. These complications have been observed in patients with AIDS who are receiving IFN-a for Kaposi's sarcoma [4], [5] and in patients with chronic myelogenous leukemia, [6] multiple sclerosis, [7] and hepatitis C virus (HCV) infection. [8] The lesions start out as painful or pruritic red to purple indurated plaques at injection sites 2 months to 3 years after initiation of treatment. While some plaques clear spontaneously, others break down into necrotic ulcers (Fig. 140-1). Histopathologically, microthromboses of deep dermal and subcutaneous vessels are apparent. [7] Most ulcers heal after discontinuation of treatment; some heal after the dose is decreased; and some heal despite continuation of therapy. Some ulcers require debridement, with or without excision and closure. Ulcers can be prevented by rotating injection sites and avoiding erythematous and/or pruritic areas until they resolve.

FIGURE 140-1 Bilateral punched-out ulcers at IFN-a injection sites. Note absence of hair around perimeter of injection site ulcers.

DIGITAL NECROSIS This reaction is even more rare than ulcerations at injection sites. This complication is seen most often when IFN-a is given to patients who are also receiving cytotoxic agents for the treatment of malignancies. In two cases, histology revealed small-vessel thromboses without vasculitis. [9] In three patients with HCV infection and cryoglobulinemia-related ischemic disease, systemic manifestations improved with a combination of treatments including

IFN-a. In contrast, digital necrosis worsened and required amputation in two patients and resulted in enlargement of the ulcer in another. [10] A localized procoagulant effect of IFN-a may be the reason for this reaction.

PSORIASIS Psoriasis appears to be a relatively common complication of IFN-a therapy across the spectrum of patients treated with this cytokine. Wolfer et al. [11] chronicled 20 patients in whom psoriasis was exacerbated or induced by IFN-a therapy. Psoriasis has occurred at injection sites, and it waxes and wanes with IFN-a dosing. Severity appears to be dose-related. IFN-a–induced or -exacerbated psoriasis usually clears on discontinuation of therapy, and it responds to the usual antipsoriatic treatments. Since IFN-a upregulates both inflammatory and immune responses, [3] the pathogenesis of this side effect seems clear whether psoriasis is viewed as an autoimmune disease mediated by activated T cells [12] or as an epidermal hyperproliferative disorder mediated by inflammation.

HAIR ABNORMALITIES Hair loss is a frequent complaint with IFN-a therapy. Tosti et al. [13] described telogen effluvium in 5 of 10 patients who were followed with trichograms and the pull test. The authors did not feel that the onset and severity of hair loss were related to the dose of IFN-a or the duration of therapy. Ill-defined patches of hair loss around nonindurated injection sites and around an ulcerated injection site have been reported. [14] No “exclamation point” hairs were noted. Histology revealed perifollicular and intrafollicular lymphocytic infiltration. In all cases, hair regrew after injection sites were switched.

LICHEN PLANUS The literature is replete with case reports relating to the induction, aggravation, or improvement of lichen planus due to the use of IFN-a for the treatment of HCV infection. There are also some case reports calling attention to this association in patients with lymphoma and melanoma. In a group of 120 patients with chronic viral hepatitis who were treated with IFN-a, 3.3 percent developed mild lichen planus. [15] All had antinuclear antibodies before initiation of therapy. Because HCV infection itself is thought to be associated with an increased incidence of lichen planus, it is possible that the upregulation of immune function brought on by IFN-a further stimulates a system that is already primed for the development of lichen planus. Lichen planus associated with IFN-a therapy does not require discontinuation of therapy except in cases of recalcitrant erosive mucosal lichen planus.

SARCOIDOSIS There have been case reports of cutaneous and systemic sarcoidosis coincident with IFN-a treatment of HCV infection [16] and of chronic myelogenous leukemia. [17] It has been postulated that the upregulation of T_H1 responses by IFN-a may unmask an innate predilection of patients with these diseases to develop sarcoidosis. This theory is supported by the observation that systemic sarcoidosis tends to remit with dose reduction or discontinuation of IFN-a therapy. Although purely cutaneous lesions can be managed successfully with topical glucocorticoid therapy, systemic involvement often requires the addition of systemic glucocorticoids.

AUTOIMMUNE REACTIONS Cutaneous autoimmune reactions other than psoriasis and lichen planus have been reported in isolated cases. These include leukocytoclastic vasculitis, periarteritis nodosa, autoimmune bullous diseases, and systemic lupus erythematosus with cutaneous manifestations. [18] Vitiligo was noted at sites distant from lesions of metastatic melanoma in three patients who were being treated with IFN-a. The vitiligo was associated with a favorable response to treatment. [19]

MISCELLANEOUS REACTIONS These non-dose-limiting reactions include skin dryness, itching, erythemas, and urticaria. They have been reported in 10 percent of IFN-a recipients.

Interferon-ß (IFN-ß)

IFN-ß is also known as *fibroblast interferon*. Although natural IFN-ß is available, the recombinant forms (IFN-ß1a and IFN-ß1b) are more widely used for the treatment of multiple sclerosis, condylomata acuminata, malignant melanoma, and HCV infection. Cutaneous adverse reactions to the various forms are similar but seem to occur more frequently with IFN-ß1b.

INJECTION-SITE REACTIONS These reactions are the most common adverse event in patients receiving subcutaneous IFN-ß. Reactions consist of local pain, soreness, erythema, bruising, and rarely, sclerotic plaques. They have been reported in as many as 85 percent of patients. They generally appear within the first month of treatment and diminish over the next 6 months. Discontinuation of therapy is not often required and can be avoided by administering IFN-ß by deep intramuscular injections. [20] Single or multiple, painful, deep, necrotic ulcerations suggesting vascular compromise were found to develop in 5 percent of IFN-ß subcutaneous injection sites. [20] They were more likely to appear within the first few months of treatment. Deep biopsies revealed thrombosis of venules in the deep dermis and subcutaneous tissue with a mild superficial perivascular lymphocytic infiltrate. [21] It was hypothesized that thrombosis of the deep dermal vessels is related to a localized clotting abnormality caused by increased platelet aggregation. Necrotic ulcers could be prevented by regularly switching injection sites, by changing to intramuscular injections, by warming the injectable solution to room temperature, and by massaging the injection site to promote dispersion of the drug. [20] Conservative local therapy alone was frequently sufficient to promote healing. Surgical excision of the ulcer speeds the healing process. It also has been possible to continue IFN-ß therapy despite the ulcers. [20]

MISCELLANEOUS REACTIONS A flare of pustular psoriasis, [22] the appearance of psoriatic plaques at all injection sites (author's unpublished case) (Fig. 140-2), subacute cutaneous lupus, [23] and contact dermatitis with a positive patch test to the ophthalmic form of natural IFN-ß [18] have been observed.

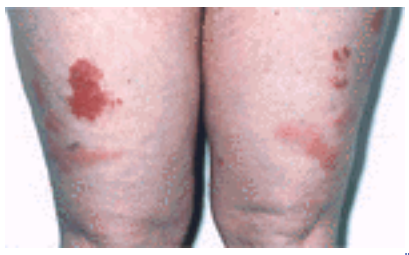

FIGURE 140-2 Psoriasis at IFN-ß injection sites. Note sharp-angled, erythematous, nonscaly plaques resulting from tape irritation. This eventually became psoriatic as well.

Interferon-? (IFN-?)

IFN-?, also known as *immune interferon,* is produced by activated T cells and natural killer (NK) cells. Recombinant IFN-? is approved for the treatment of chronic granulomatous disease, renal cancer, and congenital osteopetrosis. Unlike IFN-a and IFN-ß, there are only a few reports of cutaneous adverse reactions to IFN-?. Psoriasis at injection sites [18] and erythema nodosum leprosum (ENL) are two such reactions. ENL was induced in 60 percent of patients with lepromatous leprosy who received recombinant IFN-? over a period of 6 to 7 months in comparison with a 15 percent incidence in the group not treated with recombinant IFN-?. [24]

INTERLEUKINS

Interleukins are a heterogeneous group of cytokines produced by T cells, monocytes-macrophages, and at times, somatic cells. These agents have major effects on immune function and inflammation by virtue of their influence on the growth, differentiation, and activation of leukocytes.

Interleukin 2 (IL-2)

IL-2 is produced by activated T cells. By promoting the proliferation, growth, and activity of T, B, and NK cells, Il-2 not only upregulates immunity but also has marked proinflammatory effects. [2] The level of proinflammatory cytokines induced by the administered dose of IL-2 determines its toxicity. Recombinant IL-2 is approved for the treatment of metastatic renal cell carcinoma and metastatic melanoma in high-dose regimens. Low-dose regimens for HIV are currently in clinical trials. In the high-dose intravenous regimen used by Rosenberg et al., [25] the dose-limiting toxicity was “capillary leak syndrome,” characterized by massive weight gain, hypotension, tachycardia, and hypoxemia, symptoms also seen in septic shock syndrome. High fevers and chills were universal. For these reasons, patients are hospitalized for this form of therapy. The clinical and histologic descriptions of the cutaneous side effects that occur with the high-dose regimen are described by Gaspari et al. [26] and Wolkenstein et al. [27]

IL-2 DERMATITIS The markedly pruritic rash consists of various combinations of erythema, edema, blistering, and desquamation. At its worst, the initial presentation is that of an erythrodermic, somewhat edematous patient who has a very severe “sunburn” (Fig. 140-3). The eruption generally starts on the face within 48 to 72 hours of the initiation of infusions. This eruption may be accompanied by petechiae and tense bullae, especially of the lower extremities. The dermatitis clears on termination of therapy and results in scaling that varies from fine desquamation to sheetlike peeling, especially on the palms and soles. These reactions are not clearly dose-related. The findings on histologic examination and immunophenotyping of the infiltrate are consistent with “dermatitis.” In the author's experience, antihistamines are only minimally helpful in relieving the pruritus and only when taken to the point of sedation. In these patients, if the use of topical steroids is interdicted by protocol requirements, treatment can be with bland or mentholated lubricating lotions.

FIGURE 140-3 Sunburn-like erythema with desquamation and an erosion in a patient receiving high-dose IL-2 therapy.

MUCOSITIS AND GLOSSITIS Erosions of the tongue and oral mucous membranes occurred simultaneously with the skin changes. Glossitis was seen in 6 of 20 patients [27] and, together with the mucositis, cleared soon after discontinuation of IL-2.

AUTOIMMUNE DERMATOSES Gaspari [28] reviewed the cases of pemphigus, psoriasis, and vitiligo that had been reported in association with IL-2 therapy. The occurrence of vitiligo in patients being treated with IL-2 for metastatic melanoma was seen to be a predictor of a favorable response. High doses of IL-2 result in widespread immune activation. Thus the rarity of these autoimmune reactions suggests that the presence of risk factors such as preexisting mild disease or a family history may be necessary precursors of these side effects.

DRUG REACTIONS Patients who receive IL-2 at least 2 weeks before exposure to iodine-containing contrast media are reported to be 2 to 4 times more likely than those who are not treated with IL-2 to develop a reaction consisting of flushing, flulike symptoms, rash, pruritus, joint pains, wheezing, hypotension, edema, and oliguria. [29] These complications are likely to occur within 1 to 4 h of exposure to contrast media and can be avoided by premedication with systemic steroids. The use of noniodinated contrast media has been suggested to prevent this reaction. Multifocal fixed drug eruption in response to acetaminophen, tropisetron, and ondansetron has been reported. [30] The author has encountered a very similar case with IL-2 treatment.

MISCELLANEOUS ERUPTIONS There are isolated case reports of IL-2–induced grade II to III cutaneous graft-versus-host disease in autologous transplant patients, recall of subcutaneous injection-site reactions after intravenous dosing, telogen effluvium, urticaria, and erythema nodosum.

HEMATOPOIETIC GROWTH FACTORS

Hematopoietic growth factors (HGFs) are cytokines that trigger the proliferation, differentiation, and survival of

hematopoietic stem and progenitor cells. The availability of recombinant forms of HGFs has made possible dose intensification of chemotherapeutic regimens. The four approved, commercially available HGFs in the United States are erythropoietin (EPO), oprelvekin (IL-11), granulocyte-macrophage colony-stimulating factor (GM-CSF), and granulocyte colony-stimulating factor (G-CSF).

EPO stimulates the production and differentiation of red cells, whereas oprelvekin has similar effects on platelets. Neither is immunomodulatory, and they do not appear to have adverse cutaneous side effects except for mild injection-site reactions. [31], [32]

Granulocyte-Macrophage Colony-Stimulating Factor (GM-CSF)

There are two recombinant forms, one of which, filgrastim, is approved by the Food and Drug Administration (FDA) for the treatment of neutropenic states after chemotherapy and myeloablative treatment. GM-CSF is a panstimulator of all granulocytes and induces the production of inflammatory cytokines, an effect not shared with G-CSF. Vascular leak syndrome leading to massive edema, similar to that which occurs with IL-2, is the major dose-limiting toxic effect of GM-CSF. [33]

Injection-site reactions are common, severe, and exhibit “recall.” In a study with 5 mg/g per day given subcutaneously, all patients developed pruritic and burning erythemas that recurred after each injection so that treatment had to be discontinued. [34] In another protocol, generalized cutaneous reactions occurred in 21 of 26 patients who received GM-CSF by subcutaneous injection. [35] The eruption ranged from urticaria to exfoliative dermatitis, causing therapy to be discontinued in 13 patients and continued at a reduced dose in 3. Peripheral and tissue eosinophilia were noted in this cohort.

Granulocyte Colony-Stimulating Factor (G-CSF)

G-CSF stimulates the production, differentiation, and activity of neutrophils. A recombinant form is approved for the treatment of neutropenic states due to chemotherapy and myeloablative therapy. The same action accounts for its cutaneous side effects, which are uncommon and are mild enough not to cause discontinuation of therapy.

Neutrophilic dermatoses, consisting of eruptions such as Sweet's syndrome and bullous pyoderma gangrenosum (Fig. 140-4), are sometimes associated with malignancies, especially myeloproliferative ones. These eruptions have been reported as a complication of G-CSF therapy as single cases or in a small series. Typical is a report that G-CSF exacerbated a tendency of patients with myeloid leukemia to develop Sweet's syndrome. [36] These neutrophilic dermatoses also have been reported in association with nonhematologic malignancies treated with G-CSF. [37]

FIGURE 140-4 Bullous pyoderma gangrenosum–like lesion in a patient receiving G-CSF after chemotherapy for non-Hodgkin's lymphoma.

Leukocytoclastic vasculitis limited to the skin occurred in patients treated with G-CSF for malignant disease as well as for chronic benign neutropenias. [38] This complication was likely to occur when the absolute neutrophil count was above 800/mm [3]. Folliculitis involving the face and upper torso, recurring with each dose of G-CSF, has been reported in a patient with myelodysplasia as well as in a normal volunteer. [39] Histology revealed a mixed inflammatory infiltrate around hair follicles and eccrine glands.

The histopathology of a cutaneous reaction to G-CSF demonstrates numerous large, atypical histiocytes with mitotic figures. This is a G-CSF effect and should not be mistaken for a malignancy. [40]

This author has observed all the foregoing reactions to G-CSF in addition to injection-site reactions and exacerbation of preexisting dermatoses such as psoriasis and rosacea, and is of the opinion that allergic reactions to simultaneously administered drugs tend to be more florid and last longer. In general, G-CSF is safe and well-tolerated.

REFERENCES

1. Parkin J, Cohen B: An overview of the immune system. *Lancet* **357**:1777, 2001

2. Oppenheim JJ: Cytokines: Past, present, and future. *Int J Hematol* **74**:3, 2001

3. Pfeffer LLM et al: Biological properties of recombinant a-interferons: 40th anniversary of the discovery of interferons. *Cancer Res* **58**:2489, 1998

4. Orlow SJ, Friedman-Kein AE: Cutaneous ulcerations secondary to interferon-a therapy of Kaposi's sarcoma. *Arch Dermatol* **128**:566, 1992

5. Virgili A et al: Cutaneous lesions due to interferon seem not to be related to dosage. *J Eur Acad Dermatol Venereol* **13**:141, 1999

6. Krainick U et al: Local cutaneous necrotizing lesions associated with interferon injections. *J Interferon Cytokine Res* **18**:823, 1998

7. Sheremata WA et al: More on interferon-induced cutaneous necrosis. *N Engl J Med* **333**:1223, 1995

8. Sickler JB et al: Cutaneous necrosis associated with interferon-a2b. *Am J Gastroenterol* **93**:463, 1998

9. Bachmeyer C et al: Raynaud's phenomenon and digital necrosis induced by interferon-alpha. *Br J Dermatol* **135**:481, 1996

10. Cid MC et al: Interferon-alpha may exacerbate cryoglobulinemia-related ischemic manifestations: An adverse effect potentially related to its antiangiogenic activity. *Arthritis Rheum* **42**:1051, 1999

11. Wolfer LU et al: Interferon-alpha–induced psoriasis vulgaris. *Hautarzt* **47**:124, 1996

12. Griffiths CEM, Voorhees JJ: Psoriasis, T cells and autoimmunity. *J R Soc Med* **89**:315, 1996

13. Tosti A et al: Telogen effluvium due to recombinant interferon-a2b. *Dermatology* **184**:124, 1992

14. Lang A et al: Localized interferon alpha-2b–induced alopecia. *Arch Dermatol* **135**:1126, 1999

15. Dalekos GN et al: A prospective evaluation of dermatological side effects during alpha-interferon therapy for chronic viral hepatitis. *Eur J Gastroenterol Hepatol* **10**:933, 1998

16. Eberlein-Koenig B et al: Cutaneous sarcoid foreign body granulomas developing in sites of previous skin injury after systemic interferon-alpha treatment for chronic hepatitis C. *Br J Dermatol* **140**:358, 1999

17. Pietropaoli A et al: Interferon-a therapy associated with the development of sarcoidosis. *Chest* **116**:569, 1999

18. Vial T, Descotes J: Immune-mediated side effects of cytokines in humans. *Toxicology* **105**:31, 1995

19. LeGal F-A et al: More on cutaneous reactions to recombinant cytokine therapy. *J Am Acad Dermatol* **35**:650, 1996

20. Bayas A, Rieckmann P: Managing the adverse effects of interferon-beta therapy in multiple sclerosis. *Drug Saf* **22**:149, 2000

21. Elgart GW et al: Cutaneous reaction to recombinant human interferon beta-1b: The clinical and histologic spectrum. *J Am Acad Dermatol* **37**:553, 1997

22. Webster GF et al: Cutaneous ulcerations and pustular psoriasis flare caused by recombinant interferon beta injections in patients with multiple sclerosis. *J Am Acad Dermatol* **34**:365, 1996

23. Nousari HC et al: Subacute cutaneous lupus erythematosus associated with interferon beta-1b. *Lancet* **352**:1825, 1998

24. Sampaio EP et al: Prolonged treatment with recombinant interferon gamma induces erythema nodosum leprosum in lepromatous leprosy patients. *J Exp Med* **175**:1729, 1992

25. Rosenberg SA et al: A progress report on the treatment of 157 patients with advanced cancer using lymphokine-activated killer-cells and interleukin-2 or high-dose interleukin-2 alone. *N Engl J Med* **316**:889, 1987

26. Gaspari AA et al: Dermatologic changes associated with interleukin 2 administration. *JAMA* **258**:1624, 1987

27. Wolkenstein P et al: Cutaneous side effects associated with interleukin 2 administration for metastatic melanoma. *J Am Acad Dermatol* **28**:66, 1993

28. Gaspari AA: Autoimmunity as a complication of interleukin 2 immunotherapy: Many unanswered questions. *Arch Dermatol* **130**:894, 1994

29. Choyke P et al: Delayed reactions to contrast media after interleukin-2 immunotherapy. *Radiology* **183**:111, 1992

30. Bernard S et al: Multifocal fixed drug eruption to paracetamol, tropisetron and ondansetron induced by interleukin 2. *Dermatology* **201**:148, 2000

31. Markam A, Bryson HM: Epoietin alpha: A review of its pharmacodynamic and pharmacokinetic properties and therapeutic use in nonrenal applications. *Drugs* **49**:232, 1995

32. Moreland L et al: Results of a phase I–II randomized, masked, placebo-controlled trial of recombinant human interleukin 11 (rhIL-11) in the treatment of subjects with active rheumatoid arthritis. *Arthritis Res* **3**:247, 2001

33. Lieschke GJ, Burgess AW: Granulocyte colony-stimulating factor and granulocyte-macrophage colony-stimulating factor (part 1). *N Engl J Med* **327**:28, 1992

34. Locker GJ et al: Cutaneous side effects in breast cancer patients treated with cytostatic polychemotherapy with rhGM-CSF: Immune phenomena or drug toxicity. *Breast Cancer Res Treat* **34**:213, 1995

35. Mehregan DR et al: Cutaneous reactions to granulocyte-monocyte colony-stimulating factor. *Arch Dermatol* **128**:1055, 1992

36. Paydas S et al: Sweet's syndrome accompanying leukaemia: Seven cases and review of the literataure. *Leuk Res* **24**:83, 2001

37. Johnson ML, Grimwood RE: Leukocyte colony-stimulating factors: A review of associated neutrophilic dermatoses and vasculitides. *Arch Dermatol* **130**:88, 1994

38. Jain KK: Cutaneous vasculitis associated with granulocyte colony-stimulating factor. *J Am Acad Dermatol* **31**:213, 1994

39. Paul C et al: Cutaneous effects of granculocyte colony-stimulating factor in healthy volunteers. *Arch Dermatol* **134**:111, 1998

40. Farina MC et al: Histopathology of cutaneous reaction to granulocyte colony-stimulating factor: Another pseudomalignancy. *J Cutan Pathol* **25**:559, 1998

T>

Chapter 141

Miguel Sanchez

Cutaneous Manifestations of Drug Abuse

DEFINITIONS
COMMONLY ABUSED DRUGS
STATISTICS
PATHOGENESIS
CLINICAL MANIFESTATIONS
Fibrotic Changes and Ulcerations
Granulomas
Burns
Pigmentary Changes
Vascular Lesions
Vesiculobullous Lesions
Acne
Pruritus
Mucous Membrane Lesions
Pilosebaceous Effects
Bacterial Infection
FUNGAL INFECTION
DRUG-INDUCED REACTIONS
ASSOCIATED NONINFECTIOUS SKIN DISEASES

REFERENCES

Drug abuse can be suspected or diagnosed on the basis of skin findings. The parenteral administration of drugs causes skin lesions and eruptions predominantly through local or systemic, toxic or hypersensitivity-induced effects of the drug itself, adulterants, or infectious agents. Intravenous administration can produce a number of recognizable stigmata, which may identify an individual abusing drugs to anyone with experience in illicit drug use.

Behavior associated with drug abuse is an important factor in the spread of HIV infection. In the United States, 25 percent of all reported cases of AIDS in adults and adolescents resulted solely from sharing needles. In addition, 6.5 percent of cases occurred in men who have sex with men and inject drugs. Current or former drug users transmit most of the 11 percent of AIDS cases acquired through heterosexual contact. Parenteral drug users also have high risks for contracting hepatitis B and C and other blood-borne infections. About 60 percent of all new hepatitis C infections in the United States are attributed to syringe and needle sharing with an infected individual. In some user populations, hepatitis C is transmitted so rapidly that within 6 months of beginning drug use, one-third of users are infected, and within 2 years, 90 percent have contracted the infection. [1] Drug addicts also have higher incidences of sexually transmitted diseases, depression, accidental injuries, and trauma due to criminal violence or domestic abuse. Numerous sociologic problems, such as loss of work productivity and increases in crime, prison occupancy, and property damage, result from drug abuse and dependence. In 1992, the National Institute on Drug Abuse and the National Institute on Alcohol Abuse and Alcoholism estimated that the annual economic cost to society from drug abuse exceeded $97.7 billion.

DEFINITIONS

Drug abuse is a maladaptive pattern involving misuse or overuse of prescribed or recreational drugs, which results in related legal problems, social or interpersonal problems, failure to sustain major obligations at work, at school, or at home, or continued use despite potential physical harm. [2] In contrast, *drug dependence* is a pattern of recurrent or excessive drug use that has produced clinically significant physical, emotional, or social impairment or distress (especially with the induction of tolerance). It is characterized by recurrent and excessive use of drugs to avoid withdrawal symptoms associated with abstinence (Table 141-1). *Tolerance* is a physiologic state in which progressive increases in the dose of a drug are needed to achieve intoxication or the desired effects previously experienced at smaller doses. Drug dependence may be physical or psychological or both. Some drugs, particularly opiates, chiefly induce physical dependence, a neurobiologic state of physiologic adaptation to a drug that results in withdrawal symptoms during abstinence. Other drugs, such as marijuana, cocaine, amphetamines, and hallucinogens, cause predominantly *psychological dependence*, a biopsychosocial state characterized by a need to administer a drug repeatedly to produce desired psychological effects and prevent feelings of discontent.

The presence of three (or more) of the following, occurring at any time in the same 12-month period:
- Continued drug use despite awareness of the presence of a persistent or recurrent physical or psychological problem caused or exacerbated by the drug
- Sustained intent or unsuccessful efforts to abate drug use
- Tolerance
- Withdrawal symptoms
- Administration of drug in higher doses and longer duration than initially intended
- Significant time devoted to obtaining the drug or recovering from its effects
- Relinquishment or reduction of social, occupational, or recreational activities because of drug abuse

TABLE 141-1 **Criteria for Drug Dependence (DSM-IV)**

COMMONLY ABUSED DRUGS

Cannabis (marijuana, Mary Jane, pot, herb, weed, boom) is a mixture of dried shredded leaves and flowers of *Cannabis sativa* that contains the chemical delta-9-tetrahydrocannabinol (THC). Diacetylmorphine (heroin, junk, smack, horse, scag), the fastest-acting and most potent opiate, accounts for 90 percent of the opiate abuse in this country. A “rush” develops within 7 to 8 seconds if the opiate is injected intravenously or within 10 to 15 min if it is snorted or smoked. Persons addicted to opiates may alternate injections of heroin and cocaine (crisscrossing) or inject highly addictive “speedballs” of the two drugs together. Cocaine (coke, blow, toot, flake, and snow) is an alkaloid stimulant and topical anesthetic that is extracted from the leaves of the coca shrub. Crack (base, rock, hubba, gravel, girl), or crystallized, freebase cocaine, is far more addictive than heroin. Crystallized methamphetamine (ice, crystal, glass) may be inhaled or injected intravenously. The powder form may be ingestion or snorted. Because withdrawal symptoms are so intense, methamphetamine addiction is more difficult than any other addiction to treat. 3,4-Methylenedioxymethamphetamine, often abbreviated as MDMA (ecstasy, Adam, XTC, hug, beans, love drug) is a synthetic psychoactive drug with stimulant and mildly hallucinogenic properties. It is widely available at raves, clubs, and all-night parties. Lysergic acid diethylamide (LSD, acid) continues to be a popular hallucinogen.

STATISTICS

In 2000, an estimated 14.0 million persons in the United States (6.3 percent of the population over 12 years of age) used an illicit drug one or more times during the previous month. Of these, approximately 59 percent consumed only marijuana, 17 percent used marijuana and another illicit drug, and the remaining 24 percent used an illicit drug but not marijuana. Pain relievers (3.8 million persons) are the most commonly used illicit drugs, followed by cocaine (1.2 million persons), hallucinogens (1.0 million persons), tranquilizers (1.0 million persons), stimulants (0.8 million persons), sedatives (200,000 persons), and heroin (130,000 persons). The actual number of individuals who use heroin is difficult to determine because in the past decade there has been a growing tendency to sniff, snort (shabbang), or smoke (chase the dragon) rather than to inject heroin intravenously (shoot up) or subcutaneously (skin pop). In contrast to individuals who inject opiates intravenously, those who inhale opiates less often seek help for their addiction and are not detected by the usual cutaneous stigmata associated with injections. Offsetting the slow decline in use of the many addictive drugs has been a spiraling increase in the use of methamphetamine, especially by young people. More than 7 million persons have tried MDMA (ecstasy) at least once in their lifetime. The popularity of other so-called club drugs, such as benzodiazepin, flunitrazepam (Rohypnol, roofies), and the depressant gamma-hydroxybutyrate (GHB) waxes and wanes. However, GHB, known as the date rape drug, is being used increasingly by bodybuilders, who believe that it helps to metabolize fat and build muscle. In 2000, approximately 3.6 percent of male and 0.9 percent of female twelfth graders in the United States had used anabolic steroids. Although the number of adult users has not been determined, it is estimated to be in the hundreds of thousands.

PATHOGENESIS

Studies in concordant twins have shown a strong influence of genetic inheritance on the susceptibility to drug abuse. [3] The processes by which genes regulate physical reactions to addictive drugs have not been elucidated. Repeated exposure to cocaine causes a change at the level of gene expression that leads to altered levels of a specific brain protein called *cyclin-dependent kinase-5*. This protein regulates the action of dopamine, which potentiates the euphoric effects of cocaine and other drugs. [4] In mice, the absence of a gene for one of the receptors of serotonin predisposes to the use of cocaine. [5] However, environmental factors are clearly important.

The mechanisms leading to tolerance and dependence are complex, but drugs appear to cause these effects at least partly by stimulating the release of dopamine through activation of the mesolimbic system, especially the nucleus accumbens, augmenting the hedonic tone. Drugs also inhibit or excite neuronal activity in various areas of the nervous system. To compensate for these alterations, neuroadaptation develops with either formation of new neuroreceptor sites (upregulation) or diminished synthesis and sensitivity of neurotransmitters and neuroreceptor sites. Discontinuation of the drug reverses the neuroadaptation process and results in an exaggerated neural response that produces withdrawal symptoms.

CLINICAL MANIFESTATIONS

Fibrotic Changes and Ulcerations

The most specific sign of drug abuse by injection is the presence of *skin tracks* (Fig. 141-1). Initially, punctures, ecchymoses, and crusted lesions trail along the length of the vein (Fig. 141-2). With repeated injections of irritating drugs and adulterants, the veins become inflamed and scarred. [6] Due to their easy access, the veins of the arms and hands are injected initially by most novice addicts. However, to avoid the presence of incriminating tracks, some addicts prefer injections on the legs and feet. When these areas become scarred, drugs are injected into the vessels of the neck, abdomen, axillae, groin, sublingual area, genitals, hemorrhoids, or any visible or palpable vein or artery. When intact veins cannot be found, the skin may be cut superficially with razor blades or knifes and powdered drugs rubbed into the lacerations. Some young addicts actually prefer this technique. Subcutaneous and intradermal injections cause irregular, round, leukodermic, atrophic depressions known as *skin popping scars* (Fig. 141-3). In some cases, indurated, linear, hypertrophic, or keloidal scars form.

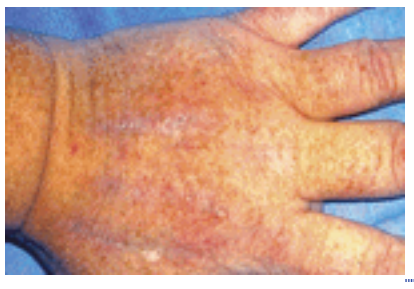

FIGURE 141-1 Skin tracks along the veins of the dorsal hand.

FIGURE 141-2 Purpuric puncture marks on several veins, suggesting intravenous drug use.

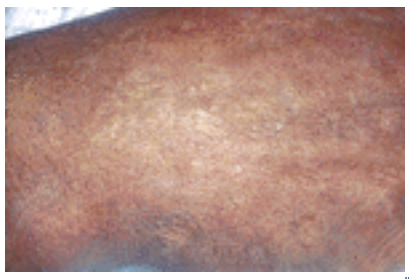

FIGURE 141-3 Depressed, circular scars (“pop scars”) due to subcutaneous heroin injection.

Intradermal injections or accidental extravasation of certain drugs and adulterants can cause tissue injury. Heroin and other powder drugs are frequently “cut” with fillers such as lactose, mannitol, dextrose, baking soda, and flour. [7] Injection of sclerosing adulterants and drugs can produce tender and inflammatory plaques or nodules that ulcerate and heal with epidermal pigmentary changes, woody induration of the dermis and subcutaneous tissue, and retracted cicatrices. Quinine, which is popular because of its bitter taste similar to heroin and its enhancement of the narcotic euphoria, is destructive to lymphatics, and repeated injections can lead to chronic, nonpitting hand or limb edema. [6] Drugs also can cause severe tissue damage. Injected propoxyphene produces thrombophlebitis and skin necrosis. [8], [9] Cocaine is a vasoconstrictor and can produce tissue ischemia, especially when extravasated. It does not regularly form tracks, but cutaneous fibrotic scars on the extremities resulting from intracutaneous injection have been reported. [10] Even inhalation of cocaine can cause skin and muscle infarction. [11] Extensive necrosis of the nose and upper lip accompanied by a necrotizing infection of the subcutaneous soft tissue of the cheeks, forehead, and temporal regions has been caused by forced intranasal impaction of crack cocaine. [12] Injection into soft tissue of barbiturates, which are highly alkaline, results in tender, erythematous, indurated plaques that break down into deep ulcers and frequently become infected. Trepalonamine (pyribenzamine), an antihistamine usually injected in combination with pentazocine or another opioid, also induces tissue necrosis and ulceration. Pentazocine injection alone can cause brawny, fibrotic skin and large, irregularly shaped, deeply penetrating ulcers that may extend to muscle. [13]

Granulomas

Pulmonary foreign body granulomas have been found in 30 percent of addicts on whom autopsies have been performed. Although cutaneous granulomas are not common, they can develop months and up to 50 years after the last intravenous or subcutaneous injection because granuloma formation requires conversion of silica to its colloidal form. [14] Most granulomas are caused by the injection of hydrous magnesium silicate (talc) and, less often, starch into the subcutaneous tissue, deep dermis, and walls of veins. The lesions are firm, movable cutaneous nodules (Fig. 141-4). Talc granulomas also may develop in the liver, lymph nodes, spleen, and bone marrow. In addition to being a popular adulterant for powder drugs, talc is the main ingredient in some narcotic tablets that are crushed, diluted in liquid, and injected. [14]

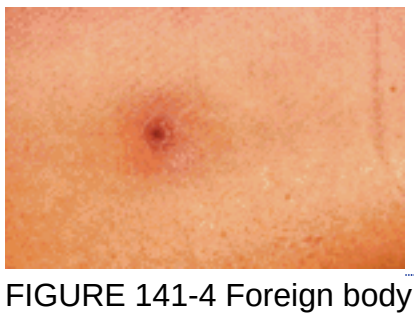

FIGURE 141-4 Foreign body granuloma from subcutaneous injection of adulterated heroin.

Burns

Burns from lit matches, cigarettes, paraphernalia, and contact with fire during cooking are common during the altered state of consciousness produced by drug intoxication. Cigarette burns, most commonly on the digits and sternum, occur from lit cigarettes that addicts were smoking before falling asleep. The *necklace sign* is produced by cigarette ashes that fall on the neck when the smoking addict dozes off. [6] Singeing of the eyelashes and eyebrows, resulting in madorosis, may be caused by rising hot vapors during smoking of crack cocaine. Individuals who use crack also may develop linear, circular, or oval blackened, hyperkeratotic lesions caused by the heat of the glass pipe. [15] The areas affected are the thenar eminences of the thumbs (*crack thumbs*) and the palm (*crack hands*) of the dominant hand. More severe thermal burns may be incurred on the hands while lighting a crack-cocaine pipe with a butane lighter directed downward onto the pipe.

Solvent inhalation has been gaining in popularity among adolescents. Minor, superficial burns have been reported as a result of flash fires caused by the ignition of lighter fluid composed of butane and isobutane in enclosed spaces while the fumes were being inhaled. Patients recovered with conservative medical care. However, extensive explosion burns can occur involving the face, neck, arms, and hands, as well as the trunk and/or lower extremities. [16] Severe burns also occur when other solvents, such as paint thinner or petrol, become ignited by a cigarette that the sniffer is simultaneously smoking.

Pigmentary Changes

Postinflammatory pigmentary changes are more common in persons with darkly pigmented skin. Circumferential pigmented bands due to pressure from tourniquets are common in dark-skin intravenous drug users. *Soot tattoos* are black macules produced by inadvertent injection of residual carbon that remains on the needle after flaming. Persons who abuse methamphetamine develop grayish, dry, leathery skin with a strange odor.

Vascular Lesions

The most common vascular lesions in addicts are ecchymosis and hematomas from extravasated blood along injected vessels. Petechiae may form distal to tourniquets. Addicts who inject drugs intraarterially are at risk of developing vascular compromise of the hands with discoloration, edema, and cold temperature. Arterial constriction or emboli can lead to gangrene and loss of digits or a limb. [17] Repeated vascular injury and infection of the digits may cause irreversible contractures (camptodactylia) that resemble Dupuytren's disease. It is important to evaluate any patient with contractures, inflammation, or edema of the hand for soft tissue infection, as well as for underlying musculoskeletal complications, such as fibrous myopathy, joint restriction, muscle contractures, inflexible ankylosis, and suppurative tenosynovitis. Distal thrombosis with extensive infarctive skin lesions and associated hepatitis and glomerulonephritis may follow intravenous injection of cocaine into an arm vein. [18] Painful discoloration with resulting ulceration of the palm also can result from injection of cocaine into the radial artery.

Necrotizing vasculitis from injected drugs usually develops on the neck or extremity as a warm, firm, tender mass that may be misdiagnosed as an abscess. Cocaine may produce superficial or deep venous thrombosis, which is treated with parenterally administered antibiotics, bed rest, elevation of the involved extremity, and anticoagulation, once a mycotic aneurysm, which can bleed, has been excluded. [8], [19] Mycotic aneurysms occur in 15 to 25 percent of patients with infective endocarditis, most frequently in the femoral artery, and require immediate surgery. Pseudoaneurysms result from infected injury to arteries during intraarterial injection of drugs (“hitting the pinkie”) and are most common in the extremities and groin. The typical lesion is a tender, diffusely indurated, pulsatile mass with an associated bruit (50 to 60 percent of cases) and decreased peripheral pulses (25 percent). Local suppuration, petechiae, and purpura are often present. Half resolve with antibiotics alone, but expanding lesions require proximal ligation of the vessel, resection of the pseudoaneurysm, and appropriate drainage.

An erythematous, tender cord is the hallmark sign of superficial septic thrombophlebitis. However, patients with deep vein thrombophlebitis present with a tender, swollen extremity, with or without erythema, that resembles cellulitis or an abscess. Indeed, infection may be simultaneously present, further complicating the diagnosis.

Cases of Henoch-Schonlein purpura, polyareritis nodosa, and necrotizing angiitis with renal and pulmonary disease have been reported.

Vesiculobullous Lesions

Traumatic vesicles or bullae at the site of injection are observed occasionally. Comatose patients who have overdosed with barbiturates or other sedative drugs often develop pressure erythema, bullae, and ulcers. [7] Unlike bedridden patients, who typically develop pressure-induced lesions on the sacral or ischial areas, elbows or heels, addicts may present with bullae in unusual body areas and configurations, depending on the body position in which they lost consciousness.

Acne

Anabolic steroid abuse can cause acne, cysts, oily hair and skin, male and female pattern alopecia, increased hair growth in women, gynecomastia in men, coarse skin, edema, testicular atrophy, and clitoral enlargement. There have been reports in habitual users of MDMA (ecstasy) of a papulopustular, facial, acneiform eruption that may indicate a higher risk of systemic adverse effects, such as hepatic damage. In some cases, the eruption responded to topical metronidazole. [20] Acne and other skin eruptions are anecdotally worsened by cannabis.

Pruritus

Chronic cocaine use coupled with marijuana inhalation may cause pruritus. Prolonged use of cocaine may lead to the development of formication, tactile hallucinations during which the individual senses that insects are crawling on or under the skin (*coke bugs*). Foraging behavior, involving compulsive searching for pieces of crack cocaine in locations where it was once used, has been reported by some long-term users. Repetitive, stereotypical skin picking leading to excoriations and skin ulcers on the face and extremities has been observed in individuals who abuse methamphetamine. The feeling of euphoria provided by heroin may be accompanied by skin flushing and itching, as well as dry mouth, watery eyes, and runny nose. Heroin addicts often have dry skin that becomes easily irritated and pruritic.

Generalized or focal, especially genital, itching after drug administration has been named *"high" pruritus*. Hypoesthesia is a manifestation of low-dose exposure to phencyclidine (PCP).

Mucous Membrane Lesions

The abuse of drugs via an intranasal route is an increasingly prevalent pattern of behavior. Snorting cocaine causes erythema and erosion of the nasal turbinates, nasopharynx, and soft palate. With continued use, the erosions progress to necrosis, atrophy, and eventual perforation of the nasal septum and even the palate [21] (Fig. 141-5). The pathogenesis is vasoconstriction with resulting ischemia and occasionally infection. Chronic rhinitis, epistaxis, osteolytic sinusitis, gingival retraction, and bruxism are other complications. Halitosis and frequent lip smacking are signs of cocaine abuse. Cuts from chipped glass pipes and thermal burns may be present on the lips of some crack users. Sniffing heroin less often causes these changes. However, invasive fungal rhinosinusitis appears to be a complication unique to intranasal narcotic abuse. [21] A case of pemphigus vegetans, Neumann type, restricted to the intranasal tissue was reported to have been induced by inhalation of heroin. The patient responded to systemic glucocorticoids. [22]

FIGURE 141-5 Cocaine-induced granuloma of the nasal septum.

Xerotic cheilitis is observed commonly in methamphetamine and heroin addicts. [7] Methamphetamine users also have red, dry noses. Transient eyelid edema has been described with opiate abuse. The typical red or "bloodshot" eye frequently occurs with marijuana and sometimes with cocaine or PCP use. Scleral hemorrhages in drug addicts are usually traumatic but may be caused by septic emboli due to endocarditis. There are reports of men applying cocaine powder to their glans penis to postpone ejaculation and of women rubbing cocaine on their genitals to enhance pleasure. These practices can lead to priapism, irritant dermatitis, and even ulcerations. Priapism can follow crack inhalation. [23] Penile ulcers have developed after injection of heroin into the shaft veins.

Marked dental decay and gingival disease are common in hard core users of opiates as a result of the effects of opiates and poor hygiene. Hallucinogen-induced xerostomia also predisposes to caries. Persons addicted to methamphetamine, especially snorters, have higher tooth wear caused by teeth clenching. Habitual chewing of betel palm seeds, which contain a narcotic stimulant—a practice in some areas of Southeast Asia—stains the teeth. A noted habit of children born to mothers who smoked marijuana during pregnancy is thumb sucking.

Pilosebaceous Effects

Hyperhidrosis is a common adverse effect of amphetamines. [20] Piloerection, paresthesias, and percutaneous flushings are manifestations of the somatic but not the perceptual phase of LSD intoxication. Together with constricted pupils and runny nose, gooseflesh skin is a sign of opiate intoxication.

Bacterial Infection

Skin and soft tissue infections are the most common disorders for which drug addicts seek health care or are hospitalized. [24], [25] and [26] In a study of 127 hospitalized intravenous drug users, the diagnoses were cellulitis (40.9 percent), abscess with cellulitis (32.3 percent), abscess alone (16.5 percent), infected skin ulcers (10.2 percent), necrotizing fasciitis (7.1 percent), and septic phlebitis with cellulitis (5.5 percent). [27] Cellulitis usually presents as one or more red, tender, warm, edematous, indurated plaques. However, only tenderness and edema may be apparent initially, and erythema may be difficult to assess in dark-skinned patients. Lymphangitis may accompany skin infection. In any addict with soft tissue infection, the possible presence of osteomyelitis or pyogenic arthritis should be considered. Since upper extremity vessels are used preferentially, cellulitis of the hand, arm, and forearm is very common and should be treated aggressively. In a 5-year review of 103 patients with upper extremity infection who required admission, 92 percent had cellulitis, which in one-third was associated with ulceration at the site of injection. Seven percent presented with gangrene. [17] The inclusion of vancomycin (for methacillin-resistant *Staphylococcus aureus*) and clindamycin (for anaerobes) in the antibiotic regimen has been recommended for hand infections [17] and, arguably, should be considered in any limb or life-threatening infection. About 10 percent of hand infections may require amputation of digits or of the

hand, even after appropriate antibiotic and surgical treatment. [17]

In parenteral drug users, *S. aureus* is the most frequently cultured bacteria from soft issue infections, followed by streptococcal species. [27], [28] An attempt to obtain a culture is prudent because skin infection by gram-negative bacteria, anaerobes, and unusual organisms is also common. [17] Notably, the flora spectrum of street heroin has no relationship to the bacteria causing infections in intravenous drug users. [17] However, tripelennamine and pentazocine may allow for the selective survival of *Pseudomonas aeruginosa*. The use of quinine to adulterate heroin appears to predispose to *Clostridium* infection. Wound botulism due to *Clostridium botulinum* type A occurs almost exclusively in drug addicts. [29] Several cases have been reported from California and other western states during the past decade. [30] It is associated with parenteral injection, especially skin popping of black tar heroin, a form that derives its color from impurities during its manufacture and from adulterants. This form of heroin is highly hygroscopic and has a high water content that supports the growth of organisms. The spores of *C. botulinum* are not destroyed by heating the contaminated heroin and are inoculated into the subcutaneous tissue, where they germinate and produce toxin. There is pain, tenderness, and swelling, but in the early stages a cellulitis or abscess may not be prominent. In cocaine snorters, the intranasal septum or paranasal sinuses may become infected. [31] Necrotizing cellulitis of the scrotum and penis has been reported in addicts who accidentally injected drugs into the femoral artery instead of the vein. [32]

Due to the popularity of skin popping, the incidence of abscesses has been increasing. Abscesses from such subcutaneous drug injection are often multilobulated and deep and have extensive necrosis that requires exploration and debridement. Superficial abscesses may rupture spontaneously, leaving punched-out ulcers. Abscesses may develop in any skin area of the body in which the addict injected drugs. In more than half of the abscesses, only one pathogen is cultured, but in 33 to 45 percent of abscesses, more than one organism is present. [27] Fever and leukocytosis are not absolutely reliable measures of severity and are absent in about half of cases. Any bacteria may be recovered from an abscess, but the more commonly cultured ones are *S. aureus* (20 to 60 percent), *Streptococcus* species (25 percent), and gram-negative rods (up to 25 percent). Anaerobic bacteria are also common, especially in polymicrobial infections. In one study, anaerobic bacteria were recovered from two-thirds of abscesses, and in one-third of these, they were the only cultured organism. [33] *Eikinella corrodens,* an oral flora bacterium, is cultured from some abscesses caused by injections of methylphenidate. Curiously, some abscesses develop months after a patient has ceased to use drugs.

Abscesses may be contiguous with bone when osteomyelitis of the long bones is present. Cervical abscesses usually occur in the anterior cervical triangle and may cause life-threatening complications such as mediastinitis, pneumomediastinum, airway obstruction, internal jugular vein thrombosis, and extension into the carotid sheath. Abscesses in the groin may present with only tenderness and edema. These abscesses can be deep and extensive, especially if they originate in the femoral triangle. The degree of pain usually exceeds that suspected from clinical findings. Computed tomographic (CT) scanning is needed to determine the extent of involvement of deep abscesses and abscesses in regions such as the neck and groin.

Necrotizing fasciitis with or without myositis often presents with lesions characterized by erythema (77 percent), fluctuance (20 percent), edema (20 percent), or induration (43 percent) that clinically resemble an abscess [34] but which require extensive subfascial debridement. In some cases, only swelling or inconspicuous cellulitis is apparent. However, severe pain, disproportionate to the clinical signs, is present in 94 percent of cases. [35] If the clinician disregards the patient's complaint merely as a request for narcotics, the outcome may be devastating. Fever and leukocytosis are common, but at the time of presentation, the classic cutaneous findings of bullae, tissue crepitance, and skin necrosis are only present in 3, 3, and 10 percent of cases, respectively. [34] For this reason, surgical exploration is mandatory in any addict with cellulitis and unexplainable severe pain. Multiple organisms are cultured in 59 to 85 percent of cases. The presence of gas is not pathognmonic for *Clostridium* infection. In most cases, the infection is polymicrobial, and multiple organisms are recovered. Anaerobes are present in 12 percent of cases. The infection will progress in 75 percent of patients treated with parenteral antibiotics without debridement. [36] A decrease in the mortality rate from 27 to 7 percent was reported with a protocol consisting of early diagnosis, intravenous wide-coverage antimicrobial therapy, supportive care, early subfascial debridement, and repeated wound debridement every 8 to 12 h until no necrotic tissue is formed. Between two and four debridements are needed. [34]

Sporadic cases of toxic shock syndrome related to intravenous heroin abuse have been reported. Nephrotic syndrome from amyloidosis has been reported in skin poppers and intravenous drug users with chronically draining skin lesions. [37]

Bacterial endocarditis is the most common systemic bacterial infection in intravenous drug users and accounts for 5 to 8 percent of hospitalizations. Although in some reports a third of hospitalized addicts with skin and soft tissue infection have positive blood cultures, bacteremia from skin infection is not common. [8] Several cutaneous signs (arterial emboli, conjunctival hemorrhages, splinter hemorrhages, Janeway lesions, Osler nodes) may be present.

FUNGAL INFECTION

Even in the absence of HIV infection, the incidence of dermatophytosis, including onychomycosis, tinea pedis, tinea cruris, and tinea corporis, is higher among intravenous drug addicts. [38] Injections of brown heroin have caused disseminated candidiasis due to yeast overgrowth in the lemon juice used to dissolve the heroin. The initial symptoms are high fever, rigors, headaches, myalgia, and occasionally jaundice, but at this stage, blood and urine cultures rarely grow organisms. After approximately 7 days, 88 percent of the patients develop pustular folliculitis and painful nodules on the scalp and other hairy areas. The folliculitis is often misdiagnosed as bacterial, but potassium hydroxide examination and biopsy demonstrates the presence of yeasts. Other complications include ocular disease (uveitis, endophthalmitis), monarthritis, osteochondritis, and pleuritis. [39] Unlike HIV infection, intravenous drug use is a predisposing factor to zygomycosis. The charcteristic cutaneous lesion is a cellulitic plaque or abscess that becomes necrotic.

DRUG-INDUCED REACTIONS

As expected, hypersensitivity reactions to drugs, especially exanthematous eruptions, urticaria, fixed drug reactions, leukocytoclastic vasculitis, erythema multiforme, and toxic epidermal necrolysis, occur more frequently in users of illicit drugs than in the general population. Dermatographism was found in 26 percent of patients comatose from heroin overdose. [40] Pigmented patches on the skin and mucous membranes may be extensive in addicts with fixed drug eruptions.

Narcotic abuse is a common cause of falsely reactive nontreponemal tests for syphilis (VDRL, RPR). In these cases, treponemal tests (MHATP, FTA-ABS) will be nonreactive. However, in addicts who have had syphilis, not only will both tests be positive but the titers of the treponemal test also may not decrease after treatment.

ASSOCIATED NONINFECTIOUS SKIN DISEASES

Seborrheic dermatitis may be more frequent in chronic cocaine users. Eczemas, especially contact dermatitis, have been reported to occur more frequently. Drug abuse may indirectly cause skin lesions through congenital malformations in the offspring, domestic violence, or systemic disease. Pseudoacanthosis nigricans has been observed in heroin addicts.

REFERENCES

1. Garfein RS et al: Viral infections in short-term injection drug users: The prevalence of the hepatitis C, hepatitis B, human immunodeficiency, and human T-lymphotropic viruses. *Am J Public Health* **86**:655, 1996

2. American Psychiatric Association: *Diagnostic and Statistical Manual of Mental Disorders IV-TR,* 4th ed. Washington, DC, American Psychiatric Press, 2000

3. Tsuang MT et al: The Harvard twin study of substance abuse: What we have learned. *Harvard Rev Psych* **9**:267, 2001

4. Bibb JA et al: Effects of chronic exposure to cocaine are regulated by the neuronal protein Cdk5. *Nature* **410**:376, 2001

5. Castanon N et al: Modulation of the effects of cocaine by 5-HT1B receptors: A comparison of knockouts and antagonists. *Pharmacol Biochem Behav* **67**:559, 2000

6. Young AW: Cutaneous stigmas of heroin addiction. *Arch Dermatol* **104**:80, 1971

7. Burnett JW: Drug abuse. *Cutis* **49**:307, 1992

8. Levine DP: Skin and soft tissue infections in intravenous drug abusers, in *Infections in Intravenous Drug Abusers,* edited by DP Levine, JD Sobel. New York, Oxford University Press, 1991, p 183

9. Tennant FS: Complications of propoxyphene abuse. *Arch Intern Med* **132**:191, 1973

10. Kircik LH et al: Scars on the legs: Cutaneous fibrosis resulting from intracutaneous injection of cocaine. *Arch Dermatol* **128**:1644, 1992

11. Zamora-Quezada JC et al: Muscle and skin infarction after free-basing cocaine (crack). *Ann Intern Med* **108**:564, 1988

12. Tierney BP, Stadelmann WK: Necrotizing infection of the face secondary to intranasal impaction of “crack” cocaine. *Ann Plast Surg* **43**:640, 1999

13. Furner BB: Parenteral pentazocine: Cutaneous complications. *J Am Acad Dermnatol* **22**:694, 1990

14. Posner DI, Guill A: Cutaneous foreign body granulomas associated with intravenous drug abuse. *J Am Acad Dermatol* **13**:869, 1985

15. Feeney CM, Briggs S: Crack hands: A dermatologic effect of smoking crack cocaine. *Cutis* **50**:193, 1992

16. Ho WS et al: Burn injuries during paint thinner sniffing. *Burns* **24**:757, 1998

17. Smith DJ et al: Drug injection injuries of the upper extremity. *Ann Plast Surg* **22**:19, 1989

18. Heng M, Haberfeld G: Thrombotic phenomena associated with intravenous cocaine. *J Am Acad Dermatol* **16**:462, 1987

19. Lisse JR et al: Cocaine abuse and deep venous thrombosis. *Ann Intern Med* **110**:571, 1989

20. Wollina U et al: Ecstasy pimples: A new facial dermatosis. *Dermatology* **197**:171, 1998

21. Yewell J et al: Complications of intranasal prescription narcotic abuse. *Ann Otol Rhinol Laryngol* **111**:174, 2002

22. Downie JB et al: Pemphigus vegetans, Neumann variant associated with intranasal heroin abuse. *J Am Acad Dermatol* **39**:872, 1998

23. Altman AL et al: Cocaine associated priapism. *J Urol* **161**:817, 1999

24. Organ CH: Surgical procedures upon the drug addict. *Surg Gynecol Obstet* **134**:947, 1972

25. Orangio GR et al: Soft tissue infections in parenteral drug abusers. *Ann Surg* **199**:97, 1984

26. White AG: Medical disorders in drug addicts: 200 consecutive admissions. *JAMA* **223**:1469, 1973

27. Hasan SB et al: Infectious complications in IV drug abusers. *Infect Surg* **7**:218, 1988

28. Tuazon CU, Sheagren JN: Staphylococcal endocarditis in parenteral drug abusers: Source of the organism. *Ann Intern Med* **82**:788, 1975

29. MacDonald KL et al: The changing epidemiology of adult botulism in the United States. *Am J Epidemiol* **124**:794, 1986;

30. CDC: Wound botulism—California, 1995. *Morbid Mortal Weekly Rep* **44**:889, 1995

31. Kudrow DB et al: Botulism associated with *Clostridium botulinum* sinusitis after intranasal cocaine abuse. *Ann Intern Med* **109**:984, 1988

32. Alguire PC: Necrotizing cellulitis of the scrotum: A new complication of heroin addiction. *Cutis* **34**:93, 1984

33. Webb D, Thadepalli H: Skin and soft tissue polymicrobial infections from intravenous abuse of drugs. *West J Med* **130**:200, 1979

34. Callahan TE et al: Necrotiizng soft tissue infection masquerading as cutaneous abscess following illicit drug injection *Arch Surg* **133**:813, 1998

35. Sudarsky LA et al: Improved results from a standardized approach in treating patients with necrotizing fasciitis. *Ann Surg* **206**:661, 1987

36. Clark DD: Surgical management of infections and other complications resulting from drug abuse. *Arch Surg* **101**:619, 1970

37. Neugarten J et al: Amyloidosis in subcutaneous heroin abusers (“skin poppers' amyloidosis”). *Am J Med* **81**:635, 1986

38. Gaeta GB et al: Mucocutaneous diseases in drug addicts with or without HIV infection: A case-controlled study. *Infection* **22**:77, 1994

39. Dupont B, Drouhet E: Cutaneous, ocular, and osteoarticular candidiasis in heroin addicts: New clinical and therapeutic aspects in 38 patients. *J Infect Dis* **152**:577, 1985

40. Cotliar RW et al: Dermatographism, erythema and flare: Clinical signs of drug overdose in the comatose patient. *South Med J* **66**:1277, 1973

T>

Chapter 142

Thomas Lawley Kim Yancey

Skin Changes and Diseases in Pregnancy

HORMONAL CHANGES
CUTANEOUS CHANGES COMMONLY ASSOCIATED WITH PREGNANCY
Pigmentation
Hair
Connective Tissue
Vascular
WELL-DEFINED DERMATOSES ASSOCIATED WITH PREGNANCY
Pemphigoid (Herpes) Gestationis
Pruritic Urticarial Papules and Plaques of Pregnancy
Recurrent Cholestasis of Pregnancy (Prurigo Gravidarum)
Impetigo Herpetiformis
INCOMPLETELY DEFINED ERUPTIONS ASSOCIATED WITH PREGNANCY
Prurigo Gestationis (Besnier)
Pruritic Folliculitis of Pregnancy
Miscellaneous Disorders
REFERENCES

Cutaneous changes and eruptions during pregnancy are exceedingly common and in some cases a cause for substantial anxiety on the part of the prospective mother. These alterations may range from normal cutaneous changes that occur with almost all pregnancies, to common skin diseases that are not associated with pregnancy, to eruptions that appear to be specifically associated with pregnancy. Likewise, the concerns of the patient may range from cosmetic appearance, to the chance of recurrence of the particular problem during a subsequent pregnancy, to its potential effects on the fetus in terms of morbidity and mortality. This chapter reviews the cutaneous changes that are specifically associated with pregnancy.

HORMONAL CHANGES

Pregnancy is a time of significant and complex physiologic changes. Some of these changes are due to the de novo production of a variety of protein and steroid hormones by the fetoplacental unit as well as to the increased activity of the maternal pituitary, thyroid, and adrenal glands. The currently recognized hormones produced by the placenta include the protein hormones human chorionic gonadotropin (HCG), human placental lactogen (HPL) or human somatomammotropin, human chorionic thyrotropin, and human chorionic corticotropin, as well as the steroid hormones progesterone and estrogen. [1], [2] A description of the chemistry, function, and metabolism of these hormones is beyond the scope of this chapter, but it should be kept in mind that the production and the serum levels of these hormones are dynamic. For instance, HCG levels peak between the tenth and twelfth weeks of gestation, although they remain elevated throughout pregnancy. The levels of progesterone and estrogen rise throughout the first and second trimesters of pregnancy and plateau during the third trimester. The levels of these hormones are of diagnostic significance in certain obstetric conditions and complications, but their exact impact on cutaneous physiology, as well as their influence on the immunology of the skin and the inflammatory response, is essentially unknown.

CUTANEOUS CHANGES COMMONLY ASSOCIATED WITH PREGNANCY

Although the influences that the individual hormones have on the skin are incompletely understood, it is thought that they are responsible, either primarily or secondarily, for many of the cutaneous changes that normally occur during pregnancy.

Pigmentation

The nipples, areolae, and external genitalia become hyperpigmented during pregnancy. The linea alba becomes the linea nigra. Occasionally, hyperpigmentation is noted in the axillae and the proximal medial portions of the thighs. The most noticeable pigmentary change during pregnancy is the development of a masklike hyperpigmentation of the face, known as *chloasma* or *melasma,* in more than 50 percent of women [3] (Fig. 142-1). This tendency is exacerbated by sun exposure in susceptible individuals and also may be exacerbated by birth control pills in nonpregnant women. Additionally, preexisting nevi or ephelides frequently darken during pregnancy. The degree of hyperpigmentation tends to be related to the skin type of the individual, with lightly complected individuals developing less intense pigmentation. In all these instances, partial or, at times, complete regression of the hyperpigmentation usually occurs gradually after termination of pregnancy. The physiology of the hyperpigmentation appears to be related to the increased production of estrogens and perhaps to increased levels of progesterone or melanocyte-stimulating hormone.

FIGURE 142-1 Melasma.

Hair

Mild to moderate hirsutism is seen frequently during pregnancy. The hirsutism tends to resolve shortly after delivery or in some instances in the third trimester. After delivery, the resulting telogen effluvium may be severe, resulting in significant hair loss from 1 to 5 months postpartum. In these instances, regrowth, usually within 1 year, is the rule.

Connective Tissue

The most common change in connective tissue is the development of striae distensae over the abdomen, hips, buttocks, and sometimes the breasts (Fig. 142-2). Striae distensae occur in up to 90 percent of pregnant women. The exact cause of striae is unknown, although a combination of hormonal factors (e.g., adrenocortical hormones, estrogen, relaxin) associated with increased lateral stress on the connective tissue due to increased size of the various portions of the body is thought to be important. Striae distensae initially appear as pink to purple atrophic bands (see Fig. 142-2) sometimes associated with mild pruritus. After delivery, they become pale and less apparent. Skin tags, also known as *molluscum fibrosum gravidarum,* often appear on the lateral portions of the neck and axillae during pregnancy and may persist after delivery.

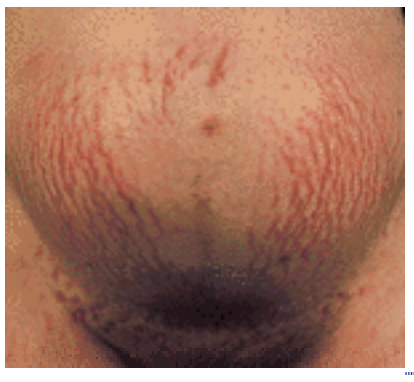

FIGURE 142-2 Striae distensae.

Vascular

Hyperemia is physiologic during pregnancy. This, combined with a tendency toward vascular proliferation, results in a number of common cutaneous changes during pregnancy. Up to two-thirds of women develop palmar erythema and/or spider angiomas during pregnancy. [4] Vascular distention resulting in part from increased intraabdominal pressure is thought to be responsible for the edema and venous varicosities that commonly occur on the legs and feet. Hemorrhoids also occur for the same reasons. Vascular tumors such as glomus tumors or hemangiomas may appear or enlarge during pregnancy. The pregnancy tumor of the gingiva (i.e., the granuloma gravidarum or pregnancy epulis) is a pyogenic granuloma that may appear in the second or third trimester and resolves shortly after delivery.

WELL-DEFINED DERMATOSES ASSOCIATED WITH PREGNANCY

A number of cutaneous diseases have been reported to be associated with pregnancy (Table 142-1). Some of these are well characterized clinically, although there is some dispute about their nomenclature. This section describes the best-known and most common of these dermatoses.

Well-defined eruptions
Pemphigoid (herpes) gestationis
Pruritic urticarial papules and plaques of pregnancy (PUPPP)
Recurrent cholestasis of pregnancy
Impetigo herpetiformis
Incompletely defined eruptions
Prurigo gestationis (Besnier)
Pruritic folliculitis of pregnancy

TABLE 142-1 **Dermatoses of Pregnancy**

Pemphigoid (Herpes) Gestationis

Pemphigoid (herpes) gestationis is an extremely pruritic, recurrent, bullous dermatosis of pregnancy and the immediate postpartum period. Herpes gestationis is a misnomer because the disorder is not related to any active or prior viral infection. *Pemphigoid gestationis* has been suggested as an alternative name for this disease and will be used

throughout this chapter. Pemphigoid gestationis is immunologically mediated. This disease is discussed in Chap. 64.

Pruritic Urticarial Papules and Plaques of Pregnancy

Pruritic urticarial papules and plaques of pregnancy (PUPPP) is a very common, intensely pruritic dermatosis that usually occurs late in the third trimester. It typically affects primigravidas. Its incidence has been estimated at 0.33 to 0.76 percent of pregnancies.

HISTORY The eruption was first described in detail and named by Lawley et al. [5] in 1979. Previously, Nurse [6] and Bourne [7] reported similar eruptions that may have represented PUPPP. Nurse termed these eruptions *prurigo of pregnancy late type,* and Bourne used the term *toxemic rash of pregnancy.* Subsequently, Holmes et al. [8] used the name *polymorphous eruption of pregnancy* to describe a somewhat similar group of patients.

CLINICAL FEATURES PUPPP is characterized by the onset of tiny (1- to 2-mm) erythematous papules on the abdomen, most often in the latter part of the third trimester. [5], [9], [10], [11], [12], [13] and [14] The papules frequently begin in striae distensae (Fig. 142-3A) but soon coalesce to form large, erythematous plaques centered around the umbilicus. The lesions are extraordinarily itchy, and patients frequently are unable to sleep at night. Curiously, despite the intense pruritus, excoriations are extremely unusual. The urticarial papules and plaques spread over the course of a few days to involve the buttocks and thighs (see Fig. 142-3B). The morphology of the lesions, as well as their anatomic progression, is rather uniform from patient to patient. In some instances, lesions also occur on the arms, forearms, and legs. Lesions on or above the breasts are rare, and lack of involvement of the face is a characteristic feature. Close observation of the primary erythematous papules often reveals a surrounding narrow pale halo. Occasionally, some papules are so edematous as to appear as papulovesicles.

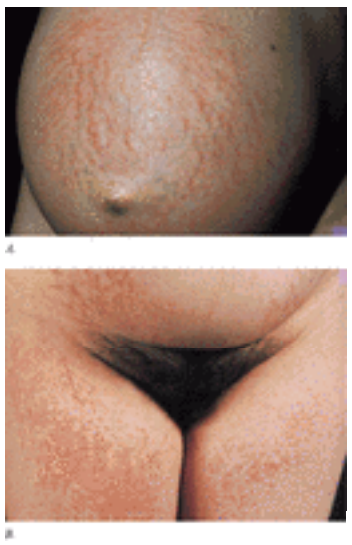

FIGURE 142-3 Pruritic urticarial papules and plaques of pregnancy. *A.* The earliest lesions are tiny erythematous papules frequently localized to the striae distensae. *B.* The papules coalesce to form erythematous plaques and spread to involve buttocks and thighs.

Almost all reported cases have begun in the third trimester and most after the thirty-fifth week. The onset of PUPPP in the immediate postpartum period is rare. Although this eruption can occur in any pregnancy, it appears most frequently in primigravidas. In the experience at the National Institutes of Health with 25 patients, 19 (76 percent) were primigravidas. [9] All these patients had their onset of disease in the third trimester except one, who developed lesions in the immediate postpartum period. The average time of onset was the thirty-sixth week of gestation, and the most frequent week of onset was the thirty-ninth. In all 25 patients, lesions began on the abdomen, and nearly one-half specifically indicated onset in their periumbilical striae distensae. One study found an increased maternal weight gain, increased neonatal birth weight, and an increased incidence of twinning in 30 patients with PUPPP. [15] These findings, as well as subsequent studies showing an increased incidence of PUPPP in twin and triplet pregnancies, suggest that abdominal distention or a reaction to it may play a role in the development of this disorder. [16], [17] In contrast, these features were not documented in 22 patients studied by Roger et al. [18] The etiology of PUPPP remains unknown.

HISTOPATHOLOGY AND IMMUNOFLUORESCENCE The histopathologic findings in PUPPP are not specific. Biopsy of skin reveals a superficial and often mid-dermal perivascular lymphohistiocytic infiltrate associated, in some cases, with a variable number of eosinophils and edema of the papillary dermis. Epidermal changes may include mild focal spongiosis and parakeratosis. Direct immunofluorescence microscopy of lesional or perilesional skin shows no specific immunoreactants. [9]

COURSE The natural history of PUPPP appears to be spontaneous resolution of most cases within a few days after delivery. Unlike pemphigoid gestationis, postpartum onset or exacerbation of PUPPP is exceptional. It tends not to recur in subsequent pregnancies, although a few cases have been reported. PUPPP is not associated with an increased incidence of fetal morbidity or mortality. [9], [19] There is one report of an infant being born with lesions. [10] In our series of patients with PUPPP, eight patients had subsequent pregnancies, and none was complicated by PUPPP. [9]

DIFFERENTIAL DIAGNOSIS In most instances, the diagnosis of PUPPP is not difficult. The classic presentation is a primigravida late in the third trimester with an extraordinarily pruritic eruption of papules and plaques that began in periumbilical striae distensae and then spread to involve the buttocks and thighs yet spared the upper chest and face. Pemphigoid gestationis must be considered as a diagnostic possibility in some instances, although usually prominent vesicular and/or bullous lesions are found in these patients. Direct immunofluorescence microscopy of perilesional skin should be performed if pemphigoid gestationis is considered. It must be kept in mind that all the eruptions that occur in nonpregnant individuals also may occur in pregnancy and should not be confused with those dermatoses which are apparently pregnancy-specific. Thus erythema multiforme, drug eruptions, contact dermatitis, urticaria, and insect bites at times can be confused with PUPPP (or other pregnancy-related dermatoses).

TREATMENT Intense (three or four times per day) therapy with potent topical glucocorticoids provides symptomatic relief in almost all cases. New lesions usually stop appearing within 2 to 3 days, and most patients can then begin to taper the frequency of applications. In many instances, patients are able to stop all therapy before delivery. Brief tapering courses

of systemic glucocorticoids also provide relief. H_1 antihistamines are not as effective as potent topical glucocorticoids.

Recurrent Cholestasis of Pregnancy (Prurigo Gravidarum)

Recurrent cholestasis of pregnancy, also known as *prurigo gravidarum* or *benign recurrent intrahepatic cholestasis,* is a hepatic condition usually occurring late in pregnancy. It is first manifested by severe generalized pruritus that often is followed by the appearance of clinical jaundice. It is thought to be hormonally induced in susceptible individuals. Its incidence has been estimated at 0.02 to 2.4 percent of pregnancies. [20]

HISTORY Recurrent cholestasis of pregnancy was first separated from other causes of jaundice in pregnancy by Svanborg and Ohlsson. [21]
CLINICAL FEATURES Recurrent cholestasis of pregnancy has no primary cutaneous lesions, although secondary excoriations may occur. The first symptom of recurrent cholestasis of pregnancy is pruritus. The severity may vary from moderate to severe, and in the early stages the pruritus may manifest itself only at night. Although often localized at first, the pruritus tends to become generalized. [22] The pruritus may precede the onset of clinical jaundice by up to 4 weeks, although, rarely, the interval can be much longer. Patients may complain of fatigue and anorexia and, in some instances, may develop nausea and vomiting. Most cases occur during the third trimester, although the onset has been reported as early as the first trimester. In fully developed cases, numerous excoriations may be seen in conjunction with icterus. Patients may complain of right quadrant fullness or tenderness as well as dark urine and light-colored stools. Although the diagnosis of this disorder is largely clinical, laboratory studies may reveal elevations in hepatic transaminases and total serum bile salts (predominantly cholic acid). Postprandial determinations of the latter are probably one of the most sensitive indicators of this disorder. [13], [23]
COURSE The pruritus associated with recurrent cholestasis of pregnancy usually remits within a few days after delivery. The disorder tends to recur in subsequent pregnancies, and there have been reports of several members of families being affected, suggesting a genetic predisposition in some instances. [24] There also have been documented instances where patients who had developed recurrent cholestasis of pregnancy developed cholestatic jaundice while taking synthetic estrogens and progestational agents for contraception. [24] It is not clear whether estrogen or progesterone is the primary inciting agent; they may work synergistically. The precise pathophysiology of the cholestasis is unknown. There have been patients who have been diagnosed with recurrent cholestasis of pregnancy who did not develop clinical jaundice. The incidences of prematurity, fetal distress, and fetal death seem to be increased in the offspring of patients with recurrent cholestasis of pregnancy. [25] Postpartum hemorrhage is also more likely in these women. The incidence of untoward events seems to be highest in patients with both jaundice and pruritus. [26]
TREATMENT Attempts should be made to control pruritus with bland emollients and topical antipruritic regimens. In many instances these provide adequate relief. Antihistamines and ultraviolet B (UVB) phototherapy are at times of some benefit. Cholestyramine occasionally may be effective. [27] The use of ursodeoxycholic acid (15 mg/kg per day) has gained favor recently. [28] Some clinicians have advocated the administration of vitamin K before delivery to diminish the risk of postpartum hemorrhage (and offset deficiency of this fat-soluble vitamin).

Impetigo Herpetiformis

Impetigo herpetiformis is a form of pustular psoriasis that occurs during pregnancy and may be life-threatening (see Chap. 42). It is exceedingly rare, and only approximately 100 cases have been reported. [29]

HISTORY This disorder was first reported in 1872 by von Hebra in five pregnant women, four of whom died. [30]
CLINICAL FEATURES Impetigo herpetiformis tends to occur in the third trimester of pregnancy, although cases have been reported as early as the first trimester. Many of the affected women have had no personal or family history of psoriasis. Recurrences in subsequent pregnancies have been reported. The earliest lesions are erythematous patches occurring in the groin, axillae, and anterior as well as posterior neck. [31] At their margins these erythematous patches are studded with tiny superficial pustules (Fig. 142-4). The lesions expand by peripheral extension, with new pustules occurring at the leading edges and the old pustules at the interior of the expanding lesions breaking down, resulting in crusting or in some cases impetiginization. Pruritus is unusual in impetigo herpetiformis. Large areas of the body may be affected eventually, and in flexural areas the lesions may become vegetative. In some cases mucous membranes may be affected, and subungual pustules can cause onycholysis.

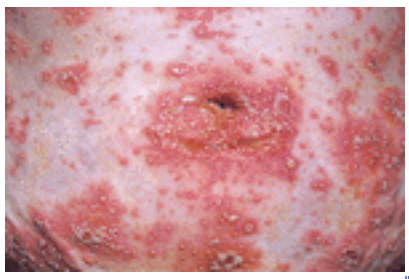
FIGURE 142-4 Impetigo herpetiformis. This is pustular psoriasis occurring in pregnancy. Erythematous patches are studded with tiny superficial sterile pustules.

Most patients also have constitutional signs and symptoms, the most common being fever and chills accompanied at times by nausea, vomiting, and diarrhea. In the past, delirium, convulsions, and tetany secondary to hypocalcemia were reported often, but these complications, as well as bacterial sepsis, are seen infrequently in the modern era.
HISTOPATHOLOGY The histopathology of impetigo herpetiformis is the same as that of pustular psoriasis. The characteristic finding in an early lesion is the presence of collections of polymorphonuclear neutrophils in spongiotic foci in the epidermis, known as *spongiform pustules of Kogoj.* In mature lesions, the spongiform pustules become quite large and may assume a subcorneal location. Parakeratosis and elongation of rete ridges are found often.
LABORATORY RESULTS Elevated white blood cell counts and sedimentation rates are quite common in impetigo herpetiformis. When these occur in the presence of fever, infection must be ruled out. The unopened pustules are sterile, but the skin may become secondarily infected. Serum calcium and serum albumin levels are sometimes decreased.

COURSE The disease tends to remit promptly after delivery but may recur in subsequent pregnancies. [32] There may be an increased risk of fetal morbidity and mortality associated with placental insufficiency.
TREATMENT Systemic glucocorticoids are the treatment of choice in impetigo herpetiformis, with prednisone in doses of 30 to 60 mg/day being necessary at times to control the eruption. [32], [33], [34] and [35] Once the disease is under control, the prednisone can be tapered judiciously, but there is a risk of sudden exacerbation of disease if it is tapered too rapidly. Patients should be monitored for systemic and cutaneous infections and treated with appropriate antibiotics when indicated. Serum calcium and albumin levels also should be followed, and replacement therapy should be undertaken if levels become too low.

INCOMPLETELY DEFINED ERUPTIONS ASSOCIATED WITH PREGNANCY

Prurigo Gestationis (Besnier)

Prurigo gestationis is a pruritic dermatosis that may occur any time in the fourth to ninth months of gestation with a peak incidence between the twentieth and thirty-fourth weeks of pregnancy. It is characterized by the occurrence of small papules, most of which are excoriated, on the proximal limbs and upper trunk. In some instances the limb lesions are distributed on extensor surfaces. Although Costello [36] estimated a 2 percent incidence of prurigo gestationis during otherwise normal pregnancies, this is clearly a large overestimation. Nurse [6] suggested an incidence of 0.5 percent, but this also is probably much too high. Moreover, as much as 25 percent of Nurse's series of patients probably had PUPPP.

The eruption tends to resolve quickly after delivery, although postinflammatory hyperpigmentation may persist for some time. Therapy with topical glucocorticoids is helpful. It is uncommon for prurigo gestationis to recur in subsequent pregnancies, and there is no known increased incidence of fetal morbidity or mortality associated with it.

Pruritic Folliculitis of Pregnancy

Six patients with an eruption termed *pruritic folliculitis of pregnancy* were described by Zoberman and Farmer. [37] The onset of their eruptions ranged from the fourth to the ninth month of gestation, and their lesions consisted of 3- to 5-mm excoriated, erythematous papules. The lesions were generalized in five patients and confined to the extremities and abdomen in one. The striking feature of the histopathology of five of these patients was the presence of folliculitis, with the hair follicles showing intraluminal pustule formation. The skin biopsy of one patient did not reveal folliculitis but only a mild perivascular infiltrate in the upper dermis and parakeratosis at the edges of the acrotrichium. Direct immunofluorescence microscopy was negative in all four patients tested. Two patients reported similar eruptions in previous pregnancies. All the offspring born of these pregnancies were healthy. Of the five patients available for follow-up, the eruption resolved in two at delivery, in two 1 month after delivery, and in one spontaneously within a week of onset. Since the original rticle, there have been other reports. [19] It has been suggested that many cases have been misdiagnosed previously as bacterial folliculitis.

Miscellaneous Disorders

Other eruptions thought to be associated with pregnancy have been described. Examples include Spangler's papular dermatitis, autoimmune progesterone dermatitis of pregnancy, and linear IgM dermatosis of pregnancy. These entities have neither been substantiated nor elucidated. Accordingly, their existence is in doubt.

REFERENCES

1. Jaffe RB: Endocrine physiology of normal pregnancy, in *Obstetrics and Gynecology,* edited by DN Danforth. Philadelphia, Harper & Row, 1982, p 342

2. Osathanondoh R, Tulchinsky D: Placental polypeptide hormones, in *Maternal-Fetal Endocrinology,* edited by D Tulchinsky, KJ Ryan. Philadelphia, Saunders, 1980, p 17

3. Winton GB, Lewis CV: Dermatoses of pregnancy. *J Am Acad Dermatol* **6**:977, 1982

4. Demis DJ: Skin conditions during pregnancy, in *Clinical Dermatology,* edited by DJ Demis et al. Hagerstown, MD, Harper & Row, 1980, p 1

5. Lawley TJ et al: Pruritic urticarial papules and plaques of pregnancy. *JAMA* **241**:1696, 1979

6. Nurse DS: Prurigo of pregnancy. *Australas J Dermatol* **9**:258, 1968

7. Bourne G: Toxemic rash of pregnancy. *Proc R Soc Med* **55**:462, 1962

8. Holmes RC et al: A comparative study of toxic erythema of pregnancy and herpes gestationis. *Br J Dermatol* **106**:499, 1982

9. Yancey KB et al: Pruritic urticarial papules and plaques of pregnancy: Clinical experience in 25 patients. *J Am Acad Dermatol* **10**:473, 1984

10. Ulhin SR: Pruritic urticarial papules and plaques of pregnancy. *Arch Dermatol* **117**:238, 1981

11. Ahmed AR, Kaplan R: Pruritic urticarial papules and plaques of pregnancy. *J Am Acad Dermatol* **4**:679, 1981

12. Callen JP, Hanno R: Pruritic urticarial papules and plaques of pregnancy: A clinicopathologic study. *J Am Acad Dermatol* **5**:401, 1981

13. Roger D et al: Specific pruritic diseases of pregnancy: A prospective study of 3192 pregnant women. *Arch Dermatol* **130**:734, 1994

14. Aronson IK et al: Immunopathology of pruritic urticarial papules and plaques of pregnancy. *J Invest Dermatol* **94**:504, 1990

15. Cohen LM et al: Pruritic urticarial papules and plaques of pregnancy and its relationship to maternal-fetal weight gain and twin pregnancy.

Arch Dermatol **125**:1534, 1989

16. Bunker CB et al: Severe polymorphic eruption of pregnancy occurring in twin pregnancies. *Clin Exp Dermatol* **15**:228, 1990

17. Elling SV et al: Pruritic urticarial papules and plaques of pregnancy in twin and triplet pregnancies. *J Eur Acad Dermatol Venereol* **14**:378, 2000

18. Roger D et al: Pruritic urticarial papules and plaques of pregnancy are not related to maternal or fetal weight gain. *Arch Dermatol* **126**:1517, 1990

19. Kroumpouzos G, Cohen LM: Dermatoses of pregnancy. *J Am Acad Dermatol* **45**:1, 2001

20. Sasseville D et al: Dermatoses of pregnancy. *Int J Dermatol* **20**:223, 1981

21. Svanborg A, Ohlsson S: Recurrent jaundice of pregnancy. *Am J Med* **27**:40, 1939

22. Holzbach RT: Jaundice in pregnancy. *Am J Med* **61**:367, 1976

23. Laatikainen TJ, Tulenheimo A: Maternal serum bile acid levels and fetal distress in cholestasis of pregnancy. *Int J Gynaecol Obstet* **22**:91, 1984

24. DePagter AGF et al: Familial benign recurrent intrahepatic cholestasis. *Gastroenterology* **71**:202, 1976

25. Fisk NM, Storey GNB: Fetal outcome in obstetric cholestasis. *Br J Obstet Gynaecol* **95**:1137, 1988

26. Johnston WG, Baskett TF: Obstetric cholestasis: A 14-year review. *Am J Obstet Gynecol* **133**:299, 1979

27. Laatikainen T: Effect of cholestyramine and phenobarbital on pruritus and serum bile levels in cholestasis of pregnancy. *Am J Obstet Gynecol* **132**:501, 1978

28. Shornick JK: Dermatoses of pregnancy. *Semin Cutan Med Surg* **17**:172, 1998

29. Braverman IM: Pregnancy and the menstrual cycle, in *Skin Signs of Systemic Disease.* Philadelphia, Saunders, 1981, p 761

30. von Hebra F: On some affections of the skin occurring in pregnant and puerperal women. *Wien Med Wochenschr* **48**:1197, 1872; abstracted in *Lancet* **1**:399, 1872

31. Baker H, Ryan TJ: Generalized pustular psoriasis: A clinical and epidemiological study of 104 cases. *Br J Dermatol* **80**:771, 1968

32. Beveridge GW et al: Impetigo herpetiformis in two successive pregnancies. *Br J Dermatol* **78**:106, 1966

33. Sauer G: Impetigo herpetiformis. *Arch Dermatol* **83**:119, 1961

34. Oosterling RJ et al: Impetigo herpetiformis. *Arch Dermatol* **114**:1527, 1978

35. Oumeish OY et al: Some aspects of impetigo herpetiformis. *Arch Dermatol* **118**:103, 1982

36. Costello MJ: Eruptions of pregnancy. *NY State J Med* **41**:849, 1941

37. Zoberman E, Farmer E: Pruritic folliculitis of pregnancy. *Arch Dermatol* **112**:1534, 1976

T>

Chapter 143

Mary Chang Seth Orlow

Neonatal, Pediatric, and Adolescent Dermatology

NEONATES AND INFANTS
Neonatal Skin Care
Examination Techniques
Diseases of Neonates and Infants
Infections of the Neonate
Congenital Malformations of the Skin
INFANCY AND CHILDHOOD
Evaluation Techniques
Performing Procedures on the Young Child
Diseases of Infancy and Childhood
ADOLESCENT DERMATOLOGY
Evaluation Techniques
Acne and the Adolescent
SPECIAL TOPICS IN PEDIATRIC DERMATOLOGY
Drug Labeling for Pediatric Patients
Topical Medications
Systemic Medications
Child Abuse

REFERENCES

Many, if not all, dermatologic diseases exhibit different manifestations in infants and children, and it is not possible to discuss the pediatric manifestations of all cutaneous diseases in one chapter. Instead, we will focus on certain methods, diseases, and issues pertinent to the practice of pediatric dermatology. Within this chapter, pediatric dermatology will be discussed in three age divisions (neonates and infants, children, and adolescents). Topics of special importance to pediatric dermatology, such as pediatric medication use, biopsy pitfalls, and child abuse, are discussed, and a selected drug formulary is provided.

NEONATES AND INFANTS

The neonatal period is defined as the first 30 days of life. Neonatal skin diseases evolve much more rapidly than adult skin diseases, and some conditions that initially appear to be serious turn out to be trivial, whereas in others the opposite is true. Infancy is defined as beginning after the first 30 days of life.

Neonatal Skin Care

Although sweating may be inefficient, the full-term infant's skin is otherwise functionally mature at birth. The barrier portion of the epidermis, the stratum corneum, is intact and effectively protects the full-term infant. However, the infant is at increased risk for systemic toxicity from topically applied compounds. This is related to five factors, the most important being that the infant has a large surface-area-to-body-mass ratio. In addition, the infant's metabolism, excretion, distribution, and protein binding of substances can be quite different from those of an adult. [1]

The skin of the postmature infant (>40 weeks' gestation) often appears dry and cracked shortly after birth (Fig. 143-1). Topical care should include moisturizing lotions or creams to retain the soft, flexible texture of the infant's skin and to prevent bacterial superinfection. For infants in a dry environment, moisturizers may need to be used indefinitely; infants in a more humid environment may need their use only intermittently.

FIGURE 143-1 The feet of a postdates newborn. The dry, hyperlinear, and scaly skin is typical of a postdates baby. There are also pustules of transient neonatal pustular melanosis.

The premature infant (born before 37 weeks' gestation) is at much greater risk for skin problems than the mature newborn. The premature infant has markedly decreased epidermal barrier function and an even greater surface-area-to-volume ratio. In addition, the immature organs of the premature infant may affect the metabolism, excretion, distribution, and protein binding of chemical agents. Local or systemic toxicity can occur in the premature infant from soaps, lotions, or other cleansing solutions. [1], [2]

Increased skin fragility is also a hallmark of prematurity. Epidermal and dermal injury may lead to significant cutaneous pain accentuated by routine handling and nursing care. The premature infant is at risk for developing sepsis from skin-associated organisms entering through breaks in the thin and fragile skin. Sweating in the premature infant is functionally reduced and contributes to poor thermal regulation. Heat regulation also is dysfunctional because of lack of a subcutaneous fat layer for insulation and poor autonomic control of cutaneous vessels. Maintaining a humid environment will decrease the infant's transepidermal water loss and optimize skin hydration. This is usually done by placing the infant in a humidity-controlled isolette or by placing thin plastic tents over infants under infrared warmers in the nursery.

Dry, flaking, fissured skin of premature infants should be treated with moisturizing creams or ointments. Petrolatum- or lanolin-based ointments with few or no preservatives appear to offer the greatest benefit and lowest risk. [2], [3] Ointments placed on an infant's skin under an infrared warmer usually will not cause cutaneous burns, although infants who suffer asphyxia may be more susceptible to burns. [3] Semipermeable wound dressings may offer additional cutaneous pain relief and protection, but further studies must be done to analyze the potential for bacterial growth under such dressings. Removing wound dressings may tear fragile premature infant skin; therefore, selecting nonstick dressings and minimizing tape use are critical.

Once at home, bathing once or twice a week in plain water is sufficient for most infants; if bathing is more frequent, moisturization with unscented, simple moisturizers is recommended. The face, hands, and diaper area may be cleansed daily using a small amount of a mild, unscented soap. Well-meaning parents may bathe their infants too frequently and use a multitude of products on the infant's skin, leading to irritation and asteatosis. It has been estimated that the average newborn is exposed to approximately 10 skin care products in the first month of life, leading to exposure to over 50 different chemicals ranging from mildly toxic to toxic. [4] Parents should be taught that “less is best.” [5]

Examination Techniques

A complete history includes gestational and birth history as well a family history. Exposures during pregnancy, including medications, illicit drugs, and infectious diseases such as varicella and sexually transmitted diseases, should be reviewed. Obstetrical data including placental cultures can be invaluable.

The most important element in the examination of an infant is thoroughness. Whether the infant is examined in the lap of the parent or on the examination table, all surfaces, including the creases and valleys of body folds and the diaper region (including the genitalia), deserve close examination. A vascular stain or erosion can be the presenting sign of a hemangioma. [6] A seemingly benign stray hair may later strangulate an appendage and should be removed. Infants with digital tourniquet (pseudoainhum) and clitoral tourniquet have been described. [7], [8] Congenital lesions of all classifications (e.g., pigmented, vascular, aplasias) warrant closer inspection to rule out associated findings. Midline lesions on the face, scalp, or spine may have central nervous system (CNS) connections and should not be biopsed without proper evaluation. The diaper area has its own unique set of problems and deserves examination at every visit.

Medical and surgical decision making for the infant is based primarily on function rather than cosmesis. For example, extraction of a natal tooth is indicated if breast-feeding is impaired, whether or not the tooth is a sign of a genetic syndrome. There are times when the parents' desire for treatment may not be in the best interest of the patient.

Diseases of Neonates and Infants

TRANSIENT DERMATOSES OF THE NEONATE Skin conditions encountered in newborns that tend to resolve by 30 days of age are considered to be transient. They are very common and almost expected in newborns.

Caput succedaneum and cephalohematoma Caput succedaneum is subcutaneous edema over the presenting part of the head and is a common occurrence in newborns. Cephalohematoma is a subperiosteal collection of blood and is less common. Both lesions are due to shearing forces on the scalp skin and skull during labor. Caput succedaneum is soft to palpation, and borders are ill-defined. Cephalohematoma is bounded by the suture lines of the skull and often feels fluctuant. If purpura is extensive, it can lead to hyperbilirubinemia. Congenital lymphedema or lymphatic malformations (such as in Turner's sundrome) can mimic caput succedaneum. Both conditions resolve spontaneously, with caput succedaneum fading in 7 to 10 days and cephalohematoma clearing slowly over several weeks.

Milia Milia are multiple pinpoint to 1-mm papules representing benign superficial keratin cysts. They are seen most commonly on the nose of infants (Fig. 143-2) and may be present in the oral cavity as well, where they are called *Epstein's pearls.* They are expected findings in the newborn and resolve spontaneously within a few weeks of life.

FIGURE 143-2 Milia on the nose of a 1-day-old infant.

Sebaceous gland hyperplasia At least 50 percent of normal newborns have sebaceous gland hyperplasia. Tiny (<1-mm) yellow macules or papules are seen at the opening of each pilosebaceous follicle over the nose and cheeks of term newborns. It is a benign condition that clears spontaneously by 4 to 6 months of age.

Erythema toxicum neonatorum Erythema toxicum neonatorum (ETN) is an idiopathic, common condition seen in up to 75 percent of term newborns. It is rarely seen in premature infants. Blotchy erythematous macules 1 to 3 cm in diameter with a 1- to 4-mm central vesicle or pustule are seen (Fig. 143-3) in ETN. They usually begin at 24 to 48 h of age, but delayed eruption as late as 10 days of age has been documented. [9] Lesions can be located anywhere but tend to spare the palms and soles. A smear of the central vesicle or pustule contents will reveal numerous eosinophils on Wright-stained preparations. A peripheral blood eosinophilia of up to 20 percent may be associated, particularly in infants with numerous lesions. Transient neonatal pustular melanosis (TNPM) mimics ETN, except that neutrophils rather than eosinophils are found within the pinpoint vesicles, and individual lesions heal with residual pigmentation, which is not seen in erythema toxicum. Bacterial infections, *Pityrosporum* folliculitis, and congenital candidiasis also may mimic erythema toxicum. Bacterial and fungal culture of lesions and Gram staining will help differentiate among these entities. ETN is benign and clears spontaneously by 2 to 3 weeks of age without residua. [9]

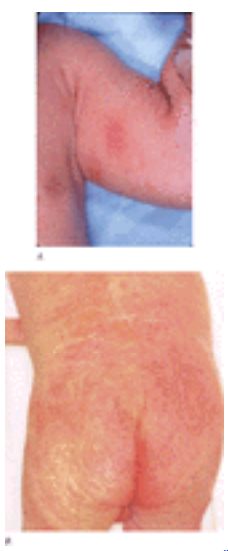

FIGURE 143-3 *A.* Erythema toxicum neonatorum. Erythematous macules, some with a tiny central papulopustule, on the arm of a 1-day-old newborn. *B.* A more extensive eruption with a more prominent pustular component.

Transient neonatal pustular melanosis TNPM is an idiopathic pustular eruption of the newborn that heals with residual brown pigmentation (Fig. 143-4). It is less common than erythema toxicum and is more prevalent among newborns with darkly pigmented skin. Lesions are present at birth as superficial vesicles and pustules, with ruptured lesions evident as collarettes of scale. Pigmented macules are also often present at birth or develop at the sites of resolving pustules or vesicles within hours or during the first day of life. Lesions can occur anywhere but are common on the forehead and mandibular area. The palms and soles may be involved. Smear of the vesicle or pustule contents will reveal a predominance of neutrophils with occasional eosinophils on Wright-stained preparations. [10]

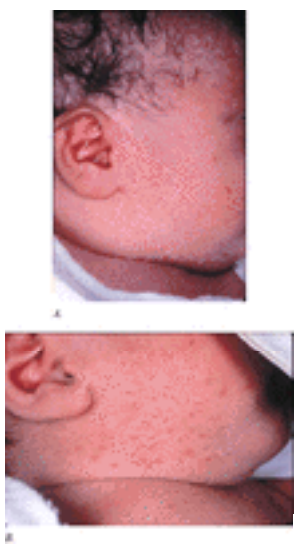

FIGURE 143-4 Transient neonatal pustular melanosis. *A.* A newborn with congenital thin-walled pustules that rupture easily. *B.* Hyperpigmented macules appeared by 10 h of age.

Miliaria rubra is frequently confused with erythema toxicum and TNPM. The erythema around miliaria rubra is small in

area (1–2 mm versus 20–30 mm in erythema toxicum). The central pustule of TNPM may mimic congenital candidiasis, *Pityrosporum* folliculitis, or bacterial folliculitis lesions. Herpes simplex should be considered if lesions are vesicular. A Gram-stained slide of the pustules of erythema toxicum or TNPM will not show organisms. A Wright-stained slide usually will show a predominance of neutrophils. TNPM is a harmless condition that requires no treatment. The pustules usually disappear by 5 days of age, leaving residual pigmented macules that resolve over 3 weeks to 3 months.

Mottling Mottling is a blotchy or lacelike pattern of dusky erythema over the extremities and trunk of neonates that occurs with exposure to a decrease in temperature. Virtually all babies demonstrate mottling at some time during the newborn period due to immaturity of the autonomic control of the skin vascular plexus. This physiologic mottling disappears on rewarming, differentiating it from cutis marmorata telangiectatica congenita and livedo reticularis. Normal mottling resolves spontaneously by 6 months of age.

Harlequin color change Harlequin color change is an unusual vascular phenomenon occurring in low-birth-weight infants. When the infant is placed on one side, an erythematous flush with a sharp demarcation at the midline develops on the dependent side, and the upper half of the body becomes pale. The color change usually subsides within a few seconds of placing the baby in the supine position but may persist for as long as 20 min. The exact mechanism of this unusual phenomenon is not known, but it may be due to immaturity of autonomic vasomotor control. Harlequin color change is seldom seen after 10 days of age.

Sucking blisters Sucking blisters are blisters apparent at birth as the result of intrauterine sucking; they are uncommon. Sucking blisters are usually solitary, intact oval blisters or erosions on noninflamed skin on the dorsal aspect of forearms, wrists, or fingers or on the upper lip. They resolve within a few days. Herpesvirus infection is often considered when sucking blisters are encountered, but lesions of herpes simplex are grouped vesicles occurring on an erythematous base or “punched out,” hemorrhagic erosions.

Acne neonatorum Acneiform facial lesions that develop within the first 30 days of life are called *neonatal acne* (Fig. 143-5). It is estimated that 50 percent of newborns may experience neonatal acne. Neonatal acne may be hormonally mediated because there is evidence that newborns with acne experience transient increases in circulating androgens. [11] However, recent studies suggest that many cases may be triggered by infection or colonization with *Malassezia* spp., and the term *neonatal cephalic pustulosis* has been proposed as a more accurate name for this condition. [12] Most cases resolve spontaneously, but severe cases can be treated topically with benzoyl peroxide, erythromycin, or ketoconazole.

FIGURE 143-5 Neonatal acne (benign cephalic pustulosis). Tiny papulopustules on the cheeks of a 3-week-old infant.

BIRTHMARKS Birthmarks represent an excess of one or more of the normal components of skin per unit area: blood vessels, lymph vessels, pigment cells, hair follicles, sebaceous glands, epidermis, smooth muscle, collagen, or elastin. While most birthmarks are of little medical or psychosocial consequence, the social and cultural impact of a disfiguring birthmark should not be underestimated, from both the patient's and the parents' perspectives. [13] The age-old theory of maternal imprinting is still widely accepted in many countries, including the United States, and the mother may be subtly or actively blamed for congenital conditions in the newborn. With selective photothermolysis offered by some lasers and advances in surgical and topical therapies, therapeutic options are increasing for some birthmarks. The two most common birthmarks are nevus flammeus (salmon patch) and Mongolian spots. Nevus flammeus occurs most commonly on the glabella and nuchal area and is observed with high frequency in infants regardless of race, occurring in 70 percent of white infants and 59 percent of black infants. Mongolian spots, which represent collections of dermal melanocytes, are seen in 80 to 90 percent of infants of color but in only 5 percent of white infants. [14], [15] Other common birthmarks are listed in Table 143-1.

Mongolian spots
Nevus flammeus (salmon patch, "stork bite," "angel's kiss")
Port-wine stain (see Chap. 103)
Hemangioma (see Chap. 103)
Epidermal nevus, including nevus sebaceus (see Chaps. 84 and 188)
Congenital nevocellular nevi (see Chap. 91)
Congenital melanocytic nevi (see Chap. 91)
Nevus depigmentosus (see Chap. 90)
Café-au-lait spots (see Chap. 90)

TABLE 143-1 **Common Birthmarks in the Newborn**

HEMANGIOMAS Hemangiomas are the most common tumors of infancy. They are discussed in detail in Chap. 103.

LYMPHANGIOMAS Both types of lymphatic malformations, microcystic (lymphangiomas) and macrocystic (cystic hygromas), are discussed in Chap. 103.

UNCOMMON DERMATOSES OF THE NEONATE Selected dermatoses of the neonate are discussed below. Table

143-2 lists differential diagnoses for selected cutaneous conditions encountered in neonates and infants.

Pustules in the neonate
Erythema toxicum neonatorum
Transient neonatal pustular melanosis
Congenital candidiasis
Letterer-Siwe disease (Langerhans' cell histiocytosis) (see Chap. 161)
Neonatal cephalic pustulosis
Bacterial sepsis
Herpes simplex infection (see Chap. 214)
Benign cephalic pustulosis
Blistering in the neonate
Sucking blisters
Herpes simplex virus (see Chap. 214)
Aplasia cutis congenita
Cutaneous mastocytosis (see Chap. 163)
Epidermolysis bullosa
Neonatal pemphigus
Varicella (see Chap. 215)
Impetigo
Incontinentia pigmenti
Epidermolytic hyperkeratosis (see Chap. 51)
The red scaly baby
Physiologic scaling and redness (postdates infant)
Psoriasis
Atopic dermatitis
Scabies
Seborrheic dermatitis
Netherton's syndrome (see Chap. 51)
Acrodermatitis enteropathica (see Chap. 146)
The collodion baby (see Chap. 51)
Lamellar ichthyosis (see Chap. 51)
Gaucher's syndrome
X-linked ichthyosis (see Chap. 51)
Epidermolytic hyperkeratosis (see Chap. 51)
The "blueberry muffin" baby
TORCH infections
Cutaneous neuroblastoma
Congenital self-healing reticulohistiocytosis (see Chap. 160, 161)
Blue rubber bleb nevus syndrome

TABLE 143-2 **Selected Differential Diagnoses of Neonates and Infants**

Cutis marmorata telangiectatica congenita (CMTC) CMTC is characterized by persistent cutis marmorata, telangeiectasia, and sometimes associated cutaneous atrophy (Fig. 143-6). Its incidence is sporadic, and its etiology is obscure. Theories of vascular malformation are currently favored. Diagnosis is often evident on clinical examination. Usually a lower extremity is involved; location on the trunk or upper extremity is not uncommon. A multitude of associated anomalies can occur, including limb asymmetry, hemangiomas and other vascular birthmarks, pigmented nevi, and aplasia cutis congenita. However, the majority of patients have a good prognosis, with half demonstrating improvement of the mottled appearance over several years. [16]

FIGURE 143-6 Cutis marmorata telangiectatica congenita. Note the atrophic, dusky, stellate patches with overlying telangiectasias.

Subcutaneous fat necrosis (SCFN) Firm, circumscribed, reddish or purple subcutaneous nodules or plaques appear over the back, cheeks, buttocks, arms, and thighs (Fig. 143-7). The lesions usually begin within the first 2 weeks of life and resolve spontaneously over several weeks. Occasionally, the lesions heal with atrophy, leaving a skin depression. Histologically, granulomatous inflammation surrounding ruptured fat cells with necrotic amorphous debris is seen. Sometimes fat crystals are found within lipocytes.

FIGURE 143-7 Subcutaneous fat necrosis of the newborn. This infant developed an erythematous firm mass on the back by 2 weeks of age. She later developed hypercalcemia.

Fetal distress, birth asphyxia, and meconium aspiration are strongly associated with SCFN. Other suggested etiologies include such fetal factors as a primary defect in subcutaneous fat, hypothermia, and local trauma and such maternal factors as gestational diabetes, preeclampsia, or exposure to cocaine or calcium antagonists. [17] Hypercalcemia can be a life-threatening complication and was noted in 4 of 11 infants in one series. [17] Serum calcium evaluations should be repeated every 1 to 2 weeks until the lesions have resolved totally for a month or more. Residual local skin atrophy usually resolves fully by 1 year of age.

Sclerema Sclerema is diffuse hardening of the skin in a sick premature newborn and is becoming rare as neonatal care improves worldwide. The onset is characteristically after 24 h of age. The skin feels hard and immobile and looks yellow and shiny. The trunk is always involved. Severely ill premature newborns that have suffered sepsis, hypoglycemia, metabolic acidosis, or other severe metabolic abnormalities are at risk. Histologically, edema of fibrous septa surrounding fat lobules is found. There is no necrosis of fat, differentiating it from SCFN. The etiology of this rare condition is unclear, and infant mortality is high.

Aplasia cutis congenita (ACC) ACC represents a developmental failure of the skin usually occurring on the scalp, but any location on the body surface can be affected (Fig. 143-8). It is often an isolated finding, but a multitude of associated conditions have been described. ACC has no single underlying cause. [18] Some cases may represent a form fruste of a neural tube defect. [19]

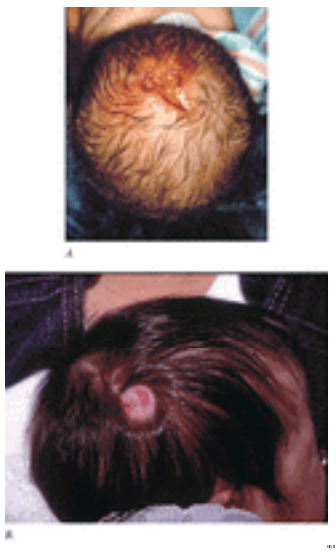

FIGURE 143-8 Two infants with aplasia cutis congenita. *A.* Scalp erosions grouped at the vertex scalp. Scraping or biopsy is contraindicated. *(Courtesy of 1991 Yale Resident Photograph Collection.) B.* An atrophic, well-circumscribed round patch with visible capillaries on the scalp of an infant.

In the most common form of ACC, oval, sharply marginated atrophic macules are seen on the midline of the posterior scalp. They are solitary or multiple, hairless, and may appear vesicular or ulcerated or covered by a thin epithelial membrane. Epidermis, dermis, and fat all may be missing, or single layers may be absent. Lesions may range from a few millimeters to many centimeters in diameter. Epidermolysis bullosa (discussed in Chap. 65) may present as aplasia cutis congenita, especially on one or both legs. Scalp ulcers at birth may be mistaken for obstetric trauma. Other forms of congenital circumscribed hair loss should be considered. Midline blisters or erosions should not be biopsied, scraped for herpes cultures, or otherwise traumatized. After a careful examination to rule out associated malformations, ACC is treated by protecting the lesions and allowing protective scar formation. Surgical revision of the scar later in childhood or adolescence can improve cosmesis in some patients.

Infections of the Neonate

Since infants under the age of 2 months are unable to localize infection due to immature immunologic function, life-threatening sepsis can develop insidiously. Subtle clues such as a decrease in body temperature, poor feeding, or other nonspecific signs must be taken seriously by the pediatrician, and a “rule out sepsis” admission including blood, cerebrospinal fluid (CSF), and urine cultures and intravenous antibiotics is implemented when suspicions are high. All bacterial and viral infections should be treated aggressively in infants. Cutaneous infections of the neonate are listed in Table 143-3. Bacterial infections such as staphylococcal scalded skin syndrome and viral infections such as varicella are discussed in Chap. 195 and Chap. 215, respectively.

Staphylococcal infections (see Chap. 194)
Impetigo
Staphylococcal scalded skin syndrome (see Chap. 195)
Omphalitis
Breast abscess (usually due to *Staphylococcus aureus* and gram-negative organisms)
Viral infections (see Chap. 208)
Varicella (see Chap. 215)
Herpes simplex virus (see Chap. 214)
Fungal/candidal infections (see Chaps. 205 and 206)
Scabies (see Chap. 238)

TABLE 143-3 **Selected Cutaneous Infections in the Neonate**

NEONATAL HERPES SIMPLEX VIRUS (HSV) INFECTION It is estimated that untreated neonatal herpes has a 50 percent mortality rate, with three-quarter of survivors suffering neurologic sequelae. [20] The greatest risk of neonatal herpes occurs when the delivery is vaginal and the mother has primary genital herpes (as opposed to recurrent herpes, in which the mother has antibodies protective to the neonate), the herpes infection involves the cervix, and the infant is premature and delivered with instrumentation (e.g., scalp electrodes). The vast majority of cases are due to HSV type 2. The typical lesions of herpes are present in the skin, eye, or mouth in a large majority of infected neonates, but some patients with CNS or disseminated disease never have skin lesions [20], [21] (Fig. 143-9). Vesicles present during the first 24 h of life suggest in utero acquisition of HSV, but onset during the first week of life is more common, representing infection during birth. [21]

FIGURE 143-9 Herpes simplex infection. Grouped vesicles on an erythematous base. Pustules and erosions are also present. *(Courtesy of Alvin H. Jacobs, M.D.)*

A high index of suspicion should be maintained even in the absence of maternal infection or history of genital herpes. Specimens for Tzanck smear, direct fluorescent antibody assays, and/or viral cultures for HSV should be obtained. Cultures require 12 to 120 h to grow, and in all infected or suspected neonates, cultures of skin lesions, urine, nasopharynx, eyes, and CSF are indicated. If available, a polymerase chain reaction (PCR) test can be helpful in rapid diagnosis. Intravenous acyclovir should be instituted as soon as possible after specimens are collected to minimize the chance of replication of virus in the CNS and systemic dissemination of HSV. Prompt recognition and early therapeutic intervention lead to an improved outcome in the HSV-infected infant. [21]

Congenital Malformations of the Skin

Congenital malformations are developmental defects and are frequently observed in newborns. Single minor anomalies occur in approximately 15 percent of all newborns. These include the supernumerary nipple and the accessory tragus and are by definition of no functional significance. The occurrence of two is less common, however, and the presence of three or more is unusual, occurring in just 1 percent of all newborns. Between 20 and 90 percent of infants with three or more minor malformations have an associated major malformation (e.g., cardiac, renal, or vertebral defects). [22], [23] Forty-two percent of patients with idiopathic mental retardation have three or more malformations, 80 percent of which are minor. [23]

CUTANEOUS MARKERS OF DYSRAPHISM The skin and the nervous system are both derived from the ectoderm. The neural ectoderm separates from the epithelial ectoderm during the third to fifth weeks of gestation, occuring simultaneously with the formation and closure of the neural tube. Hence errors in neural tube development, i.e., dysraphism (incomplete fusion), can be associated with cutaneous lesions. Midline facial lesions such as dermoid cysts, nasal gliomas, and ACC can be markers of cranial dysraphism, whereas cutaneous lesions seen on the lumbosacral midline can signify underlying spinal dysraphism. Imaging studies should be considered for midline nasal lesions prior to biopsy to rule out intracranial connections and of the lumbosacral spine to rule out tethered cord or occult spina bifida. [24] Table 143-4 lists lumbosacral lesions that warrant careful management.

High Index of Suspicion	Low Index of Suspicion
Hypertrichosis	Telangiectasia
Dimples (especially deep)	Capillary malformation
Acrochordons/pseudotails/true tails	Hyperpigmentation
Lipomas	Melanocytic nevi
Hemangiomas	Teratomas
Aplasia cutis or scar	
Dermoid cysts or sinus	

Source: Adapted from Drolet.[24]

TABLE 143-4 **Cutaneous Signs of Spinal Dysraphism (Usually Seen on the Midline Lumbosacral Region)**

INFANCY AND CHILDHOOD

Evaluation Techniques

When entering the room, prolonged or intense eye contact with the young child should be avoided because this can be threatening to the child. Observing the play of a child allows for a quick assessment of his or her neurologic development. If a language barrier exists between the parent and physician, it is best not to have the bilingual patient serve as an interpreter for the parents because this can add an additional burden of responsibility and increase anxiety in the child.

Examination of the perineum and genitalia is best accomplished with the child in the knee-chest position on the examination table (Fig. 143-10) or the parent's lap. Alternatively, the child may sit on the parent's lap with legs held apart by the parent. Figure 143-11 illustrates anatomic terminology of the young female genitalia for accurate documentation. Caution must be used in interpreting the genital examination in the young female so as not to underdiagnose or overdiagnose disease or abuse. For example, the presence of labia minora adhesions is not diagnostic of trauma or abuse because they occur in as many as one-third of girls who are not abused. [25] The diastasis ani is a normal structure that can be mistaken for perianal scarring. [26] The infantile perianal pyramidal protrusion may be mistaken for condyloma acuminata but is a harmless normal finding. [27] Child abuse is discussed in more detail later in this chapter.

FIGURE 143-10 The knee-chest position allows visualization of the perineum and genitalia. *(From Finkel MA, DeJong AR: Medical findings in child abuse, in Child Abuse: Medical Diagnosis and Management, edited by RM Reece. Philadelphia, Lea & Febiger, 1994,* Chap. 9 *, pp 185–247. Used with permission.)*

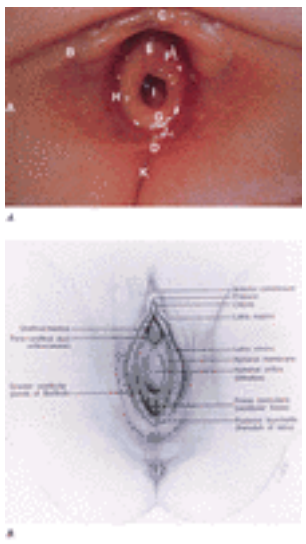

FIGURE 143-11 *A.* Magnified view of a normal female child's genital anatomy. The following structures are labeled: A, labia majora; B, labia minora; C, clitoris; D, posterior fourchette; E, urethra; F, periurethral tissue; G, hymen; H, perihymenal sulcus; I, vagina; J, posterior navicular fossa (fossa navicularis); K, perineum. *(From Siegfried and Frasier* [26] *with permission.) B.* Genital anatomy of an older female child. *(From Finkel MA, DeJong AR: Medical findings in child sexual abuse, in Child Abuse: Medical Diagnosis and Management, edited by RM Reece. Philadelphia, Lea & Febiger, 1994,* Chap. 9 *, pp 185–247. Used with permission.)*

Performing Procedures on the Young Child

Historically, there has been a widespread reluctance to biopsy skin lesions in children. With proper preparation of the parent and child, skin biopsies and other outpatient procedures are easily performed. There are certain situations in which a biopsy can be detrimental; examples of these “biopsy pitfalls” are outlined in Table 143-5.



TABLE 143-5 **Biopsy Pitfalls in Pediatric Dermatology**

Children are fearful because of their experience with immunizations and an age-appropriate fear of bodily mutilation. Eutectic mixtures of lidocaine and prilocaine (EMLA or ElaMax cream) are useful in minimizing the pain of intralesional injections or local anesthetic injections for biopsies. The application of ice or cryospray is another option to numb the skin prior to injections. Alkalinizing local anesthetics to a pH of 7.0 (0.1 meq/mL sodium bicarbonate or a 1:10 bicarbonate-to-anesthetic ratio by volume) minimizes the pain of cutaneous infiltration without limiting anesthetic effects. [28] Alkalinization decreases the solution's shelf life to approximately 1 week [29] due to more rapid oxidation of epinephrine. Warming lidocaine also lessens the pain of injection. [28]

Instruments and blood-stained gauze should be kept out of view of the patient and parent, and all equipment and materials should be prepared ahead of time to ensure rapid performance of the procedure.

Diseases of Infancy and Childhood

DIAPER DERMATITIS *Diaper dermatitis,* like hand dermatitis, denotes a group of region-specific dermatoses. Diaper dermatitis is one of the most common dermatologic conditions in infants and children, noted in approximately 1 million pediatric outpatient visits each year. [30] With the advent of superabsorbant disposable diapers in the last decade, severe forms of diaper dermatititis have diminished in incidence. Irritant and candidal diaper dermatitis comprise the vast majority of diaper dermatitides in diaper-wearing individuals of all ages. The etiology of diaper dermatitis is multifactorial. The initiating factor is prolonged and increased wetness to the skin. This leads to increased frictional damage, decreased barrier function, and increased reactivity to irritants. Other interrelated etiologic factors include contact with urine and feces, fecal proteolytic and lipolytic digestive enzymes, increased skin pH, and superinfection with *Candida* and, less

commonly, bacteria. [31]

Irritant diaper dermatitis By far the most common type of diaper dermatitis is irritant diaper dermatitis or generic diaper dermatitis. This dermatitis occurs in any person who wears diapers, regardless of age. Irritant diaper dermatitis appears as erythematous, moist, and sometimes scaly patches on the convexities of the genitalia and buttocks, beginning in areas in closest contact with the diaper. Shallow erosions are sometimes present on the convex surfaces. It can be asymptomatic or tender.

Candida diaper dermatitis *Candida* diaper dermatitis is the second most common type of diaper dermatitis and presents with bright red erythematous, moist papules, patches, and plaques that tend to involve body folds as well as convex surfaces. Satellite lesions are very characteristic. Oral thrush can be associated. *Candida* from intestinal flora frequently contaminates any type of diaper dermatitis present for greater than 3 days, and *Candida* levels increase with the clinical severity of the dermatitis. [32]

Miliaria rubra Miliaria rubra tends to occur at sites where plastic components of the diaper cause occlusion of eccrine ducts of the skin.

Pseudoverrucous papules and nodules Pseudoverrucous papules and nodules occur in the diaper and perianal areas in patients of any age who have a predisposition to prolonged wetness. Children who wear diapers due to chronic urinary incontinence are prone to this type of dermatitis.

Jacquet erosive dermatitis This is an uncommon, severe diaper dermatitis that can occur at any age. It is characterized by well-demarcated, punched-out ulcers or erosions with elevated borders. Prolonged contact with urine and feces under occlusion leads to this condition. [33] It is seen less commonly since the advent of superabsorbent diapers.

Granuloma gluteale infantum This uncommon condition is characterized by reddish purplish nodules of different sizes (0.5–3 cm) occurring on the convexities of the diaper area in 2- to 9-month-old infants. It arises within preexisting diaper dermatitis. Biopsy shows dense dermal infiltrates of lymphocytes, plasma cells, neutrophils, and eosinophils but no true granulomas. It appears to be an unusual reaction to the usual irritant factors, candidal infection, and in some cases, topical steroid use in the diaper region. [33] Treatment consists of avoidance of irritants, use of barrier pastes, and avoidance of topical steroids. Resolution occurs over several months.

Dermatoses not etiologically related to diaper-wearing Seborrheic dermatitis, atopic dermatitis, psoriasis (Fig. 143-12), bullous impetigo, acrodermatitis enteropathica, scabies, hand-foot-and-mouth disease, herpes simplex infections, and Langerhans' cell histiocytosis (Letterer-Siwe disease) are conditions that occur in the diaper region but are not primarily due to the wearing of diapers and should be considered in the differential diagnosis. Skin biopsy is indicated to rule out Langerhans' cell histiocytosis (see Chap. 160) if nonhealing erosions or petechiae are seen in the diaper area (Fig. 143-13).

FIGURE 143-12 *A, B.* Infantile psoriasis with involvement in the diaper region.

FIGURE 143-13 *A, B.* Langerhans cell histiocytosis. Note erosions and petechiae.

Treatment of diaper dermatitis The treatment of diaper dermatitis is outlined in Table 143-6. Education of parents and primary care physicians should include instructions regarding the use of topical steroids in the diaper area. Because of greatly increased percutaneous absorption of steroids from moisture and occlusion from diapers, topical steroid use should be limited to a short course (3–7 days) of hydrocortisone 1% or 2.5% ointment. It is effective in nearly all cases when a topical steroid is needed. Similarly, prolonged use of the combination products containing nystatin and triamcinolone (Mycolog) and clotrimazole and betamethasone diproprionate (Lotrisone) should be avoided due to increased risks of steroid atrophy and hypothalamic-pituitary axis (HPA) suppression when these middle- and high-potency topical steroids are used in the diaper area. Lastly, parents will be reassured by the fact that even the most problematic diaper dermatitis will resolve when toilet training is achieved and diapers are no longer worn.

A = Air. The diaper should be left open as much as possible when the infant sleeps to allow drying of the skin.
B = Barrier ointments. Zinc oxide pastes, petrolatum, and other bland, unmedicated barrier preparations are mainstays of therapy. A continuous layer of barrier paste or ointment should be maintained, reapplying with every diaper change if necessary. Baby powder on the diaper area offers no antimicrobial benefit to the infant and adds a risk of aspiration.
C = Cleansing and anticandidal treatment. Gentle cleansing with plain water, mineral oil, or unscented gentle cleanser is recommended. Avoidance of friction or rubbing is important. A topical anticandidal agent should be added for any signs of candidiasis. Oral nystatin is indicated if oral thrush is present.
D = Diapers. Diapers should be changed as frequently and as soon after soiling as possible, especially if cloth diapers are used.
E = Education of parents and caregivers.
(ABCE: Modified from Bulter.[37])

TABLE 143-6 **ABCs in the Treatment of Diaper Dermatitis**

TINEA CAPITIS In children, collection of specimens for fungal culture for tinea capitis may be accomplished by the use of a toothbrush, ring curette, or moistened cotton swab, which are effective and less expensive than using a scalpel. [34] Alternatively, a media plate with nonslanted agar may be applied directly to the infected areas of the scalp to collect material. Superficial fungal infections are reviewed in Chap. 205.

ADOLESCENT DERMATOLOGY

Dermatologic diagnoses of adolescents overlap with those of general adult dermatology; however, caring effectively for the adolescent patient requires different interviewing skills and different strategies to enhance compliance.

Evaluation Techniques

Greeting the adolescent first and the parents second and interviewing the adolescent patient alone at the beginning of the visit help to earn the patient's trust. [35] Confidentiality issues should be addressed with the family. The confidentiality laws of each state should be considered and the patient's right to privacy respected. [35] Many states protect the adolescent's right to confidential medical care for problems such as drug abuse, sexually transmitted diseases, contraception, pregnancy, and abortion.

The open-ended questioning style used for adults frequently fails with adolescents. Phrasings using the third person and giving choices when asking questions are more effective techniques to obtain information. For example, “Many women on oral contraceptives forget to take their pill once in a while. How often do you forget to take your birth control pills: often, sometimes, or almost never?” will yield a more accurate reply than, “Do you take your birth control pills every day?”

Adolescents lack a well-developed sense of future time. Goals should be concrete, short term, and relevant to the present because long-term consequences are less valued. Rather than using goals related to more distant benefits, such as the reduction of potentially serious disease complications (e.g., smoking causes increased risk of lung cancer), emphasis should be placed on immediate and concrete effects (e.g., smoking causes your clothes, hair, and breath to smell bad and your teeth to turn yellow). Body image is a more powerful motivator (e.g., tanning salons cause premature wrinkles and ugly skin) than future health concerns (e.g., tanning salons increase your risk of skin cancer). Any treatment that is disfiguring or has visible side effects will meet with resistance. [35]

Physical development and psychosocial development may not be congruent. An adolescent should not be expected to shoulder all medical responsibilities for himself or herself or for younger siblings. The physician's role is not to befriend, nor is it to parent the adolescent patient, but rather it is to be a trusted, valuable authority.

Acne and the Adolescent

Acne vulgaris is an extremely common and variable disorder that can have far-reaching detrimental effects on self-image and self-esteem. Increased unemployment has been documented among patients with a history of severe acne. [36] For adolescents, a single- or two-drug regimen will optimize compliance and cost-effectiveness.

The Food and Drug Administration (FDA) has received reports of depression, suicidal ideation, suicide attempts, and suicide in patients treated with isotretinoin. Additional studies are needed to determine whether isotretinoin causes depression and to identify susceptible persons. In the meantime, physicians are advised to inform patients prescribed isotretinoin (and parents, if appropriate) of the possibility of development or worsening of depression. [37], [38] A discussion of acne is found in Chap. 73.

SPECIAL TOPICS IN PEDIATRIC DERMATOLOGY

Drug Labeling for Pediatric Patients

The lack of FDA approval for pediatric use does not imply that a drug is contraindicated or disapproved; it simply means that insufficient data are available to grant approval status. The thalidomide tragedy led to more stringent regulation of drugs in the early 1960s, and manufacturers began omitting drug studies in infants and children. In the 1970s, pediatric dosage information in package inserts tended to exclude children from therapeutic benefit. Performing research in healthy children is problematic because of ethical and logistical questions, medicolegal risk, and cost. According to the American Academy of Pediatrics, only a small fraction of all drugs marketed in the United States today have had clinical trials performed in pediatric patients, and a majority of marketed drugs are not labeled or are insufficiently labeled for use in pediatric patients. [39] Safety and effectiveness information for drug use in children under 2 years of age is particularly lacking. The absence of pediatric testing and labeling poses significant safety risks for children. Additionally, children may be denied the benefits from therapeutic advances because physicians choose to prescribe existing, less effective medications in the face of insufficient pediatric information about a new medication. In 1997, as part of the FDA Modernization Act, Congress enacted a new law known as the Pediatric Exclusivity Provision that provides marketing incentives (i.e., extension of patent protection) to manufacturers who conduct studies of drugs in children. This law has been highly effective in generating pediatric studies on many drugs. Hopefully, in the near future physicians caring for children will no longer need to prescribe drugs “off label,” and children will no longer be “therapeutic orphans.” Recent legal opinions have raised questions about the future of this program of pharmaceutical studies in children.

Topical Medications

Because of increased surface-area-to-body-weight ratio and alterations in metabolism of drugs, children are at increased risk for toxicity from topically applied agents. Examples are listed in Table 143-7.

Topical Medication	Complication	Reference
Benzocaine 3% (Lanacaine)	Methemoglobinemia in a 2-year-old child	58
Iodoquinol, clioquinol (Vioform)	Neurotoxicity when used as treatment for diaper dermatitis	59, 60
Lindane	Neurologic toxicity in children with disrupted epidermal barrier and/or excessive topical application or ingestion	61, 62
N, N-diethyl-m-toluamide (DEET)	Slurred speech, tremors, seizures, and death in children after repeated and extensive application of high concentrations of DEET	63
Povidone-iodine (Betadine)	Hypothyroidism in infants with spina bifida	64
Povidone-iodine (Betadine)	Decreased free thyroxine and elevated iodine levels in infants treated with diluted povidone-iodine during S. aureus epidemic	65
Salicylic acid	In a 7-year-old boy treated for ichthyosis vulgaris, life-threatening salicylism occurred with neurologic sequelae lasting 6 months	66
Saline, sodium chloride	Fatalities in infants and children following ancient Turkish custom of "salting"	67
Viscous lidocaine, 2%	Lidocaine overdose following frequent application to oral lesions	68

TABLE 143-7 **Topical Medications Reported to Cause Systemic Toxicity in Children**

Systemic Medications

DRUG DOSAGES Pediatric doses are calculated according to body weight (mg/kg) or body surface area to account for size variations between patients of the same age and to account for weight gain due to growth. Prescriptions for syrups or suspensions must indicate concentration (e.g., milligrams per teaspoon) to avoid serious error. A selected pediatric dermatology formulary of systemic drugs is presented in Table 143-8.

Download image

in PDF format

TABLE 143-8 **Pediatric Dermatology Formulary of Selected Systemic Drugs**

SYSTEMIC GLUCOCORTICOIDS HPA suppression, osteonecrosis, and other adverse effects of systemic glucocorticoid therapy affect patients of all ages and are reviewed in Chap. 253. The potential risk of growth suppression is unique to childhood. Exogenous glucocorticoids disrupt the secretion of growth hormone (GH), causing abnormal spontaneous GH secretion with reduced pulse amplitude of GH release and reduced response to provocative stimuli. [40], [41] There is also decreased local production of insulin-like growth factor 1. These and other effects of glucocorticoids act to cause delayed growth at the bony epiphyses, with the most noticeable reduction in growth velocity occurring during early childhood and adolescent growth spurts. There is a linear relation between the daily dose and growth suppression. Alternate-day dosing, with single morning doses, decreases the risk of glucocorticoid growth suppression. Most children will have adequate catch-up growth eventually with reduction of doses, alternate-day therapy, or cessation of therapy. [42] For the pediatric patient on long-term systemic steroid therapy, charting height and weight on a standardized growth curve is the best method to screen for decreasing growth velocity. Children taking immunosuppressive doses of systemic glucocorticoids should not be vaccinated with live-virus vaccines (e.g., measles, oral polio, varicella). A dosage

equivalent to 2 mg/kg per day or greater of prednisone or a total of 20 mg/day or greater for children weighing more than 10 kg, when given for more than 14 days, is sufficient to warrant withholding immunization with live-virus vaccines. [43] Systemic steroids should not be given to a healthy child if he or she has had recent varicella exposure and is not varicella-immune because varicella infection can be fatal in this situation. In addition, children with ocular herpes simplex and untreated tuberculosis should not be given systemic steroids, and patients with underlying diabetes, hypertension, peptic ulcer disease, renal insufficiency, or psychosis should be treated with great caution or with an alternative agent. [43]

ANTIMICROBIALS Tetracycline use is contraindicated in children younger than 8 years of age because it causes brown discoloration of developing teeth and decreased bone growth. [44] Ciprofloxacin and quinolone use in children younger than 18 years of age is restricted because the fluoroquinolones have been shown to cause cartilage damage in every juvenile animal model tested at therapeutic doses. [44] The mechanism is unknown. To date, ciprofloxacin is the fluoroquinolone that has been used most extensively in children. It appears to be well tolerated, does not appear to cause arthropathy, and is an effective oral agent for a number of diseases that otherwise would require parenteral therapy. It is recommended that its use be restricted to relatively serious infections for which no other oral agent is available or intravenous antibiotics would be impractical and for certain pathogenic infections or situations such as multidrug resistance. [44] Griseofulvin doses of 20 mg/kg per day of the liquid and 15 mg/kg per day of the ultramicrosized tablets for 6 to 8 weeks remains first-line therapy for tinea capitis, and this drug remains the only FDA-approved drug for tinea capitis in children at this time. Itraconazole, fluconazole, and terbinafine hold promise, but data in children are still limited.

Child Abuse

Approximately 10 American children die each day from child abuse. Ninety percent of all abused children are said to have suggestive or confirmative dermatologic findings. [45], [46] The laws of all 50 states require that clinicians report any suspicions to child protective services. While each case must be considered individually, Table 143-9 lists factors that may raise the possibility of child abuse. Children with a history of prematurity or chronic illnesses are at higher risk for abuse (Fig. 143-14). Munchausen's syndrome by proxy is a specific form of child abuse in which the caretaker (who is usually but not always female) secretly inflicts physical injury on the child in order to obtain psychological secondary gain from the medical establishment. [47], [48] A high index of suspicion is needed in many situations to arrive at the correct diagnosis.

TABLE 143-9 **Criteria for Suspecting Child Abuse**

FIGURE 143-14 *A.* A young boy with hypohidrotic ectodermal dysplasia who was abused by his parents. *B.* Sole of foot with thermal burn.

When abuse or neglect is suspected, the child's immediate safety should be the foremost priority. Hospitalization of the child may be appropriate. Examinations and interviews should be age-appropriate and carefully documented. The history of sexual abuse as disclosed by a child can be the single most important piece of evidence in a court of law. [49] More criminal convictions of sexual abuse have occurred in cases without physical evidence when the child's history was well documented than in cases that included physical evidence of abuse. [26], [50] Fewer than 20 percent of girls and 10 percent

of boys referred with a history of sexual abuse have abnormal examinations, particularly if examination occurs later than 72 h after the assault. [26] Thus abuse cannot be excluded based on a normal physical examination alone. The subject of child abuse is large and complex, and expert consultation for performing interviews and examinations always should be considered.

ANOGENITAL WARTS AND CHILD ABUSE The incidence of anogenital warts among children is rising, yet the relationship to child abuse remains controversial. [51], [52] and [53] While many cases of anogenital warts in children probably represent autoinoculation, vertical transmission, or nonsexual transmission, anogenital warts can be the only manifestation of child sexual abuse. Anogenital warts may not be equated with sexual abuse; however, the possibility must be considered in every case. [52] Unfortunately, there is no reliable test to distinguish benign from abusive situations. Human papillomavirus (HPV) typing does not provide definitive evidence for or against sexual abuse. [53] The potentially long incubation period of the HPV virus also confounds the picture. Vertical transmission may be common in newborns to 3-year-olds. [51], [52] Some investigators believe that the appearance of warts before the age of 2 years is suggestive of perinatal transmission, and appearance either at birth or within the first week of life is diagnostic of perinatal transmission. [51] Long-term follow-up is recommended in view of the oncogenic nature of some HPV types. Human papillomavirus infections are detailed in Chap. 223.

REFERENCES

1. Rutter N: The immature skin. *Eur J Pediatr* **155**(suppl 2):S18, 1996

2. Lane AT: Development and care of the premature infant's skin. *Pediatr Dermatol* **4**:1, 1987

3. Nopper AJ et al: Topical ointment therapy benefits premature infants. *J Pediatr* **128**:660, 1996

4. Cetta F et al: Newborn chemical exposure from over-the-counter skin care products. *Clin Pediatr* **30**:286, 1991

5. Malloy-McDonald MB, Lambert GH: Neonatal skin care. *Compr Ther* **19**:286, 1993

6. Liang MG, Frieden IJ: Perineal and lip ulcerations as the presenting manifestation of hemangioma of infancy. *Pediatrics* **99**:256, 1997

7. Poole SR: The infant with acute, unexplained, excessive crying. *Pediatrics* **88**:450, 1991

8. Press S et al: Clitoris tourniquet syndrome. *Pediatrics* **66**:781, 1980

9. Chang MW et al: Atypical erythema toxicum neonatorum of delayed onset in a term infant. *Pediatr Dermatol* **16**:137, 1999

10. Van Praag MC et al: Diagnosis and treatment of pustular disorders in the neonate. *Pediatr Dermatol* **14**:131, 1997

11. Lucky AW: A review of infantile and pediatric acne. *Dermatology* **196**:95, 1998

12. Niamba P et al: Is common neonatal cephalic pustulosis (neonatal acne) triggered by *Malassezia sympodialis*? *Arch Dermatol* **134**:995, 1998

13. Shaw WC: Folklore surrounding facial deformity and the origins of facial prejudice. *Br J Plast Surg* **34**:237, 1981

14. Jacobs AH, Walton RG: The incidence of birthmarks in the neonate. *Pediatrics* **58**:218, 1976

15. Alper JC, Holmes LB: The incidence and significance of birthmarks in a cohort of 4,641 newborns. *Pediatr Dermatol* **1**:58, 1983

16. Amitai DB et al: Cutis marmorata telangiectatica congenita: Clinical findings in 85 patients. *Pediatr Dermatol* **17**:100, 2000

17. Burden AD, Krafchik BR: Subcutaneous fat necrosis of the newborn: A review of 11 cases. *Pediatr Dermatol* **16**:384, 1999

18. Frieden IJ: Aplasia cutis congenita: A clinical review and proposal for classification. *J Am Acad Dermatol* **14**:646, 1986

19. Drolet B et al: “Membranous aplasia cutis” with hair collars: Congenital absence of skin or neuroectodermal defect? *Arch Dermatol* **131**:1427, 1995

20. Overall JC Jr: Herpes simplex virus infection of the fetus and newborn. *Pediatr Ann* **23**:131, 1994

21. Kimberlin DW et al: Natural history of neonatal herpes simplex virus infections in the acyclovir era. *Pediatrics* **108**:223, 2001

22. Leppig KA et al: Predictive value of minor anomalies: I. Association with major malformations. *J Pediatr* **110**:531, 1987

23. Marden P: Congenital anomalies in the newborn infant, including minor variations. *J Pediatr* **64**:357, 1964

24. Drolet B: Birthmarks to worry about: Cutaneous markers of dysraphism. *Dermatol Clin* **16**:447-53, 1998

25. McCann J et al: Genital findings in prepubertal girls selected for nonabuse: A descriptive study. *Pediatrics* **86**:428, 1990

26. Siegfried E: The spectrum of anogenital diseases in children. *Curr Probl Dermatol* **9**:33, 1997

27. Kayashima K et al: Infantile perianal pyramidal protrusion. *Arch Dermatol* **132**:1481, 1996

28. Mader TJ et al: Reducing the pain of local anesthetic infiltration: Warming and buffering have a synergistic effect. *Ann Emerg Med* **23**:550, 1994

29. Proudfoot J: Analgesia, anesthesia, and conscious sedation. *Emerg Med Clin North Am* **13**:357, 1995

30. Ward DB et al: Characterization of diaper dermatitis in the United States. *Arch Pediatr Adolesc Med* **154**:943, 2000

31. Wolf R et al: Diaper dermatitis. *Clin Dermatol* **18**:657, 2000

32. Weston WL et al: Diaper dermatitis: current concepts. *Pediatrics* **66**:532, 1980

33. De Zeeuw R et al: Granuloma gluteale infantum: A case report. *Pediatr Dermatol* **17**:141, 2000

34. Elewski BE: Tinea capitis: A current perspective. *J Am Acad Dermatol* **42**:1, 2000

35. Blair S, Bowes G: Compliance issues in adolescence: Practical strategies. *Aust Fam Phys* **24**:2037, 1995

36. Cunliffe WJ: Acne and unemployment. *Br J Dermatol* **115**:386, 1986

37. Wysowski DK et al: Depression and suicide in patients treated with isotretinoin. *N Engl J Med* **344**:460, 2001

38. Wysowski DK et al: An analysis of reports of depression and suicide in patients treated with isotretinoin. *J Am Acad Dermatol* **45**:515, 2001

39. Guidelines for the ethical conduct of studies to evaluate drugs in pediatric populations. Committee on Drugs, American Academy of Pediatrics. *Pediatrics* **95**:286, 1995

40. Brook CG et al: Growth and growth hormone secretion. *J Endocrinol* **119**:179, 1988

41. Fine RN: Corticosteroids and growth. *Kidney Int Suppl* **43**:S59, 1993

42. Lucky AW: Principles of the use of glucocorticosteroids in the growing child. *Pediatr Dermatol* **1**:226, 1984

43. American Academy of Pediatrics: Immunization in special clinical circumstances, in *2000 Red Book: Report of the Committee on Infectious Diseases,* 25th ed, edited by L Pickering. Elk Grove Village, IL, American Academy of Pediatrics, 2000, p 54

44. American Academy of Pediatrics: Antimicrobial agents and related therapy, in *2000 Red Book: Report of the Committee on Infectious Diseases,* 25th ed, edited by L Pickering. Elk Grove Village, IL, American Academy of Pediatrics, 2000, p 645

45. Duarte AM et al: Life-threatening dermatoses in pediatric dermatology. *Adv Dermatol* **10**:329, 1995

46. Raimer BG et al: Cutaneous signs of child abuse. *J Am Acad Dermatol* **5**:203, 1981

47. Bryk M, Siegel PT: My mother caused my illness: The story of a survivor of Munchausen by proxy syndrome. *Pediatrics* **100**:1, 1997

48. Meadow R: Munchausen syndrome by proxy abuse perpetrated by men. *Arch Dis Child* **78**:210, 1998

49. Myers JE: Role of physician in preserving verbal evidence of child abuse. *J Pediatr* **109**:409, 1986

50. De Jong AR, Rose M: Frequency and significance of physical evidence in legally proven cases of child sexual abuse. *Pediatrics* **84**:1022, 1989

51. Handley J et al: Common association of HPV 2 with anogenital warts in prepubertal children. *Pediatr Dermatol* **14**:339, 1997

52. Bingham E: Significance of anogenital warts in children. *Br J Hosp Med* **52**:469, 1994

53. Gutman LT et al: Transmission of human genital papillomavirus disease: Comparison of data from adults and children. *Pediatrics* **91**:31, 1993

54. Frieden IJ et al: Suture ligation of supernumerary digits and “tags”: An outmoded practice? *Arch Pediatr Adolesc Med* **149**:1284, 1995

55. Paller AS et al: Nasal midline masses in infants and children: Dermoids, encephaloceles, and gliomas. *Arch Dermatol* **127**:362, 1991

56. Wagner A: Lumps and bumps in childhood. *Curr Probl Dermatol* **8**:137, 1996

57. Boiko S: Making rash decisions in the diaper area. *Pediatr Ann* **29**:50, 2000

58. Eldadah M, Fitzgerald M: Methemoglobinemia due to skin application of benzocaine. *Clin Pediatr* **32**:687, 1993

59. Singalavanija S, Frieden IJ: Diaper dermatitis. *Pediatr Rev* **16**:142, 1995

60. Clioquinol (iodochlorhydroxyquin, vioform) and iodoquinol (diiodohydroxyquin): Blindness and neuropathy. American Academy of Pediatrics Committee on Drugs. *Pediatrics* **86**:797, 1990

61. Davies JE et al: Lindane poisonings. *Arch Dermatol* **119**:142, 1983

62. Friedman SJ: Lindane neurotoxic reaction in nonbullous congenital ichthyosiform erythroderma. *Arch Dermatol* **123**:1056, 1987

63. Brown M, Hebert AA: Insect repellents: An overview. *J Am Acad Dermatol* **36**:243, 1997

64. Barakat M et al: Hypothyroidism secondary to topical iodine treatment in infants with spina bifida. *Acta Paediatr* **83**:741, 1994

65. Aihara M et al: Prevention and control of nosocomial infection caused by methicillin-resistant *Staphylococcus aureus* in a premature infant ward: Preventive effect of a povidone-iodine wipe of neonatal skin. *Postgrad Med J* **69**:S117, 1993

66. Germann R et al: Lebensbedrohliche salicylatintoxikation durch perkutane resorption bei einer schweren ichthyosis vulgaris. *Hautartzt* **47**:624, 1996

67. Yercen N et al: Fatal hypernatremia in an infant due to salting of the skin. *Am J Dis Child* **147**:716, 1993

68. Gonzalez del Rey J et al: Lidocaine overdose: Another preventable case? *Pediatr Emerg Care* **10**:344, 1994

69. American Academy of Pediatrics: *2000 Red Book: Report of the Committee on Infectious Diseases,* 25th ed. Elk Grove Village, IL,

American Academy of Pediatrics, 2000

70. Solomon BA et al: Fluconazole for the treatment of tinea capitis in children. *J Am Acad Dermatol* **37**:274, 1997

71. Bennett ML et al: Oral griseofulvin remains the treatment of choice for tinea capitis in children. *Pediatr Dermatol* **17**:304, 2000

T>

Chapter 144

Mina Yaar Barbara Gilchrest

Aging of Skin

THEORIES OF AGING
The Programmatic Theory
The Stochastic Theory
AGING AND THE IMMUNE SYSTEM12
SKIN AGING
Clinical and Histologic Skin Changes
Hair Changes
Nerves and Cutaneous Glands
Photoaging
Smoking and Skin Aging
Relevance to Skin Disease in the Elderly
TREATMENT
Photoprotection
All-trans-Retinoic Acid
Alpha-Hydroxy Acids
Antioxidants114
Hormone Therapy115

REFERENCES

In both developed and developing nations, the number and proportion of older people are increasing. Thirty-one percent of the U.S. population is expected to be 55 years or older by the year 2040, [1] and in the United States, depending on the population assumptions used, the number of elderly persons will double or triple during the first quarter of the twenty-first century. This demographic shift compels health care providers and government officials to confront the pathophysiology of aging and associated health issues.

THEORIES OF AGING

There are two basic theories of aging. [2] The programmatic theory states that aging, like development, is a preordained process due to an inherent genetic program that is played out at a rate characteristic of each species. The stochastic theory states that random cumulative environmental damage to genes and proteins ultimately produces aging and homeostatic failure. Available data suggest that aging is in fact the interactive result of both a genetic program and cumulative wear and tear during the life span.

The Programmatic Theory

TELOMERE SHORTENING [3] Telomeres, the terminal portions of eukaryotic chromosomes, consist of up to many hundreds of tandem short sequence repeats (TTAGGG). During mitosis of somatic cells, DNA polymerase cannot replicate the final base pairs of each chromosome, resulting in progressive shortening with each round of cell division. A special reverse transcriptase, telomerase, can replicate these chromosomal ends but with few exceptions the enzyme is expressed normally only in germ-line cells. Human telomere length shortens more than 30 percent during adulthood even in relatively quiescent skin fibroblasts, and telomeres of patients with premature aging syndromes such as Werner's syndrome and progeria are shorter than those of age-matched controls. Critically short telomeres signal in some way for cell cycle arrest or apoptosis, depending on cell type, and appear to compromise DNA stability and transcription of subtelomeric genes, [4] presumably contributing to the aged phenotype.

CELLULAR SENESCENCE The limited capacity of cells to undergo cell division is termed *cellular senescence* and is regarded by some as having evolved in multicellular organisms as a cancer-prevention mechanism. [5] Senescent cells display critically short telomeres, irreversible growth arrest, resistance to apoptosis, and altered differentiation. Fusion studies in which young (early passage) cells are fused with senescent cells indicate that senescence is dominant, the effect of genes residing on human chromosomes 1, 4, and 7. [6] The majority of genes overexpressed during in vitro cellular senescence contribute to blocking the cells in the G_1 phase of the cell cycle. Some encode DNA-binding proteins that act as gene regulators. Others, including statin [7] and the cyclin-dependent kinase inhibitors p21 (SDI-1) [8] and p16, [9] encode inhibitors of cell cycle regulatory nuclear proteins. In addition, senescent cells fail to induce some of the genes that are required for progression through the G_1 phase of the cell cycle, including *c-fos* [10] and certain helix-loop-helix transcription factors (Id1H and Id2H). [10] Other overexpressed senescence-associated genes encode products including proteins such as fibronectin and proteases involved in modulation of extracellular matrix, such as collagenase and stromelysin. In addition, the level of certain tissue inhibitors of matrix metalloproteinases (TIMPs) is decreased. [11] These findings raise the possibility that signals from extracellular matrix proteins may regulate cellular proliferation and perhaps the aging processes themselves.

The Stochastic Theory

OXIDATIVE STRESS AND THE RATE OF LIVING [12] It has long been speculated that oxygen use is related to aging. Oxygen, which is required for survival of aerobic organisms, readily accepts single-electron transfers, generating O^{-2}, H

$_2O_2$ and OH, which further generate an array of reactive oxygen species (ROS) that damage biologic molecules. Such damage includes peroxidation of membrane fatty acids, DNA base alterations, single-strand DNA breaks, sister chromatin exchange, DNA-protein cross-links, carbonyl modifications, and loss of sulfhydryl groups in proteins leading to inactivation of enzymes and increased proteolysis. Since the antioxidative defense systems of the organism are not fully efficient, throughout life, cells accumulate molecular oxidative damage, sometimes leading to apoptotic cell death. [13] Several studies show that there is an age-associated increase in both ROS generation [14] and the level of oxidatively damaged proteins and DNA. [13] Caloric restriction, which decreases the metabolic rate of the organism, reduces oxidative stress and extends life span in all species examined, including fish, spiders, rats, mice, and primates. [15] In addition to life span extension, lifelong caloric restriction is associated with delays in age-associated pathologies, manifested as improvement in learning ability, immune responses, gene expression, enzyme activities, hormonal action, glucose utilization, DNA repair capacity, and rate of protein synthesis in old animals.

AGING AND DNA DAMAGE[16] In humans, the only genes implicated in the rate of aging are those in which mutations are responsible for premature aging syndromes. For example, Cockayne syndrome patients display mutations in the DNA helicases encoded by the *ERCC6* or *ERCC3* genes, and ataxia telangiectasia is caused by a mutation in the *ATM* gene, encoding a kinase that senses DNA damage. Werner's syndrome, caused by a mutation in an apparent DNA helicase, [17] features elevated rates of DNA nonhomologous recombination, rapid telomere shortening, and decreased repair of telomeres. These studies suggest that decreased DNA repair capacity is associated with accelerated aging and that cumulative DNA damage plays a major role in the aging process. Still, the role of these genes in normal aging is not established, since patients with so-called premature aging syndromes display some manifestations of aging at an accelerated rate but lack other features of normal aging and have characteristic findings that differ greatly from those of normal aging. In other species, however, so-called longevity genes have been identified whose mutation or overexpression increases life span. Interestingly, all characterized longevity genes encode proteins that assist in control of environmental stress. The *ras*-2 gene in yeast, whose overexpression delays senescence, acts as an environmental sensor for response to a variety of stresses including starvation, ultraviolet (UV) irradiation, oxidative damage, and heat shock. In the nematode *Caenorhabditis elegans,* approximately 10 longevity genes have been identified to date, and all confer greater resistance to environmental stresses such as elevated temperature and UV irradiation. Mutations in one or more of these genes doubles or triples maximal life span. In long-lived *Drosophila,* expression of higher levels of antioxidative enzymes or overexpression of genes associated with resistance to starvation, desiccation, or heat have been identified. Finally, mice with extended life spans show high expression of a small number of gene loci that control immune responses, a critical mammalian defense against environmental insults. In the aggregate, these studies strongly support a role of cellular damage, particularly DNA damage, in the aging process. A recent hypothesis links telomere shortening and DNA damage to a common cellular signaling pathway [18] that, depending on both the cell type and signal intensity, mediates adaptive differentiation, apoptosis, or senescence. [18] It is suggested that during both telomere shortening and repair of telomere damage, the normal loop structure at the end of telomeres is disrupted, exposing the 3' single-stranded G-rich segment that under baseline conditions is “buried” in the loop structure. Exposure of the TTAGGG tandem repeat sequence then appears to activate p53 and results in p53-dependent responses, known to include proliferative senescence. [19]

AMINO ACID RACEMIZATION[12] Racemization, a process that substitutes D-amino acids for L-amino acids within proteins, occurs during aging and may affect protein function. Furthermore, racemization affects the deamidation of the amino acids aspargine and glutamine, a process that decreases the rate of protein degradation. Thus racemization may lead to accumulation of dysfunctional proteins in aged tissues.

NONENZYMATIC GLYCOSYLATION [12] Nonenzymatic glycosylation of proteins occurs when reducing sugar aldehydes condense with protein amino groups, resulting in brown discoloration, loss of function, and altered degradation. Glycosylation of extracellular matrix proteins such as dermal collagen leads to cross-linking, with trapping and sequestration of other, unaffected proteins (see below).

AGING AND THE IMMUNE SYSTEM [12]

The immune system has two major roles: defense against external insults and internal immunologic surveillance. Age-associated decrements in the function of B and T lymphocytes and a variety of accessory cells are postulated to contribute to the increased incidence of infections and malignancies in the elderly.

SKIN AGING

Cutaneous aging includes two distinct phenomena: Intrinsic aging is a universal, presumably inevitable change attributable to the passage of time alone; photoaging is the superimposition on intrinsic aging of changes attributable to chronic sun exposure, which are neither universal nor inevitable. The former is manifested primarily by physiologic alterations with subtle but undoubtedly important consequences for both healthy and diseased skin. The latter has major morphologic as well as physiologic manifestations and corresponds more closely to the popular notion of old skin.

Clinical and Histologic Skin Changes

The skin changes that occur with aging (Table 144-1) lead to a gradual physiologic decline (Table 144-2). [20] Major age-related changes in the skin's appearance include dryness (roughness), wrinkling, laxity, and a variety of benign neoplasms. Aged skin is less pliant and recovers more slowly following trauma.



TABLE 144-1 **Histologic Features of Aging Human Skin**

Cell replacement	Immune responsiveness
Barrier function	Thermoregulation
Chemical clearance	Sweat production
Sensory perception	Sebum production
Mechanical protection	Vitamin D production
Wound healing	DNA repair

TABLE 144-2 **Functions of Human Skin That Decline with Age**

THE EPIDERMIS The most striking and consistent histologic change is flattening of the dermal-epidermal junction with effacement of both the dermal papillae and epidermal rete pegs. [21] This is accompanied by a more than 50 percent reduction in the number of these interdigitations per unit skin surface length between the third and ninth decades. This results in a considerably smaller surface between the epidermis and dermis and presumably less communication and nutrient transfer. Dermal-epidermal separation has been demonstrated to occur more readily in old skin, undoubtedly explaining the propensity of the elderly to torn skin and superficial abrasions following minor trauma such as bandage removal and to bulla formation in edematous sites. In females a sharp decline in the number of interdigitations occurs between 40 and 60 years of age, whereas in males the rate of decline is more constant throughout adulthood. [22] Average interrete epidermal thickness probably remains constant with advancing age, but variability in epidermal thickness and in individual keratinocyte size increases. At the electron microscopic level, sun-protected old skin is characterized by some widening of interkeratinocyte spaces, by reduplication of the lamina densa and anchoring fibril complex in the basement membrane zone, and by loss of the numerous microvillous projections of basal cell cytoplasm into the dermis. Average thickness and degree of compaction of the stratum corneum appear constant with increasing age, although individual corneocytes become larger. The skin surface pattern, a patchwork of fine lines possibly determined by papillary dermal architecture, reveals slight age-associated loss of regularity. Age effects on percutaneous absorption depend in part on drug structure, with hydrophilic substances such as hydrocortisone and benzoic acid being less well absorbed through the skin of old versus young individuals but with hydrophobic substances such as testosterone and estradiol being equally well absorbed. [23] Of perhaps greater clinical importance, aging markedly delays the recovery of barrier function in damaged stratum corneum, apparently because of slow replacement of neutral lipids leading to decreased amount of lipids in the newly formed lamellar bodies. [24] Subtle changes in overall stratum corneum lipid profile with aging also may affect barrier function. [22], [25] In the elderly, the skin often appears dry and flaky, especially over the lower extremities, an area in which a remarkable age-associated decrease in the content of epidermal filaggrin has been reported. [26] Filaggrin, required for binding of keratin filaments into macrofibrils, is also decreased in the skin of patients with ichthyosis vulgaris, and its lack has been postulated to cause the increased scaliness in both conditions. [26] Barrier function also may be affected by this structural change. Epidermal turnover rate and thymidine-labeling index decrease approximately 30 to 50 percent between the third and eighth decades, with a corresponding prolongation in stratum corneum replacement rate. Linear growth rates also decrease for hair and nails. Epidermal repair rate after wounding likewise declines with age. With increasing donor age, cultured keratinocytes and fibroblasts also show progressive decline in the response to growth factors, [27] associated with decrements in growth factor signal transduction. [28] A decrease in the number of enzymatically active melanocytes per unit surface area of the skin, approximately 10 to 20 percent of the remaining cell population each decade, has been documented repeatedly, presumably reducing the body's protective barrier against UV radiation. The number of melanocytic nevi also decreases progressively with age, from a peak of 15 to 40 in the third and fourth decades to an average of four per person after age 50; such nevi are rarely observed in persons beyond age 80. Between early and late adulthood there is a 20 to 50 percent reduction in the number of morphologically identifiable epidermal Langerhans cells, the skin's immune effector cells responsible for antigen presentation. The remaining cells display morphologic abnormalities, including shorter dendrites. These changes, compounded by decreases in production of interleukin and perhaps other cytokines by keratinocytes, presumably contribute to the observed age-associated decrease in cutaneous immune responsiveness. An endocrine function of human epidermis that declines with age is vitamin D production. [29] Some elderly individuals also have reduced serum levels of vitamin D and/or osteomalacia, [30] the decreased mineralization of bone classically associated with vitamin D deficiency. Although avoidance of dairy products (the principal dietary source of vitamin D), insufficient sun exposure, and sunscreen use undoubtedly contribute to vitamin D deficiency in the elderly, the level of epidermal 7-dehydrocholesterol per unit skin surface area also appears to decrease linearly by approximately 75 percent between early and late adulthood, [29] suggesting that lack of its immediate biosynthetic precursor also may limit vitamin D production. Indeed, in one study, older adult volunteers subjected to total-body UV irradiation produced far less vitamin D_3 than did complexion-matched younger adult volunteers exposed to the same UV dose. [31] With regard to susceptibility to oxidative damage, there is no consensus about age-associated changes in the activities of antioxidative enzymes, including catalase, superoxide dismutase, glutathione peroxidase, or glutathione reductase. [32], [33]

THE DERMIS Loss of dermal thickness approaches 20 percent in elderly individuals, although in sun-protected sites significant thinning occurs only after the eighth decade. [34] Old skin is relatively acellular and avascular. Precise histologic concomitants of wrinkling, if any, are unknown, although the age-related loss of normal elastic fibers may be contributory, and increases in papillary dermal collagen are observed in photoaged skin after medical or surgical treatment that improves wrinkling. [35], [36] Deep expression lines seem to result from contractions of connective tissue septa within the subcutaneous fat. [37] In one study, an approximately 50 percent reduction in mast cells and a 30 percent reduction in venular cross sections were noted in the papillary dermis of buttock skin from elderly adults compared with that from young adult controls, associated with a corresponding reduction in histamine release and other manifestations of the inflammatory response following UV radiation exposure. The dermal microvasculature in middle-aged or elderly subjects also may show mild vascular wall thickening; vascular wall thinning to less than half the normal young adult measurement, associated with absent or reduced perivascular veil cells, has been reported in skin of very elderly subjects and probably contributes to vascular fragility. Electron microscopic studies show sporadic degeneration of the elastic component of dermal arterioles. The striking age-associated loss of vascular bed, especially of the vertical capillary loops that occupy the dermal papillae in young skin, is felt to underlie many of the physiologic alterations in old skin, including palor, decreased skin temperature, and the approximately 60 percent reductions in basal and peak induced cutaneous blood flow. [38] Furthermore, reduction in the vascular network surrounding hair bulbs and eccrine, apocrine, and sebaceous glands may contribute to their gradual atrophy and fibrosis with age. Age-associated decreases in wheal resorption and dermal clearance of transepidermally absorbed materials have been reported, [39] probably due to alterations in both the vascular bed and the extracellular matrix. Conversely, the time required for development of a tense

blister after topical ammonium hydroxide application is nearly twice as long in older individuals, suggesting a decreased transudation rate with age in injured skin. Impaired transfer of cells as well as solutes between the extravascular and intravascular dermal compartments is suggested by several studies; multiple factors undoubtedly contribute. Decreased vascular responsiveness in the skin of older individuals has been documented by clinically assessing vasodilation and transudation after UV exposure and application of standardized irritants, histamine, or the mast cell degranulating agent 48/80. [39] However, factors such as age-associated changes in percutaneous absorption or cytokine release also may contribute to the response. [39] Compromised thermoregulation, which predisposes the elderly to sometimes fatal heat stroke or hypothermia, may be due in part to reduced vasoactivity of dermal arterioles and, in the latter instance, to loss of subcutaneous fat as well. Compared with young adult controls, healthy older subjects are less able to manifest skin sensitivity to dinitrochlorobenzene or standard recall antigens, undoubtedly reflecting the well-documented decrease in total number of circulating thymus-derived lymphocytes and in their responsiveness to standard mitogens, [40] as well as the above-mentioned local cutaneous changes. Biochemical changes in collagen, elastin, and dermal ground substance during fetal and early postnatal development are far greater than those described with advancing age, but collagen content per unit area of skin surface decreases approximately 1 percent per year throughout adult life, [41] and the remaining collagen fibrils appear disorganized, more compact, and granular. [42] In rats, a gradual decline in collagen synthesis rate with advancing age was determined, and the rate at 24 months was only 10 percent that at 1 month of age. [41] In addition, approximately 50 percent of the newly synthesized collagen in old rats was degraded versus only 6 percent in immature animals. Similarly, dermal fibroblasts derived from human donors of different ages have an age-associated increase in basal and induced levels of interstitial collagenase mRNA due to increased transcriptional activity of the collagenase promoter, as well as age-associated decreases in concentrations of procollagen type I and type III, a measure of collagen synthesis rate, in suction blister fluid. In women, both bone mass (due primarily to collagen I) and skin collagen decline rapidly in the immediate postmenopausal years, [43] suggesting an additional influence of estrogen on collagen synthesis and degradation. Such changes almost certainly contribute to impaired wound healing in the elderly. [44] Finally, a number of biochemical analyses indicate increased cross-linkage of the collagen molecule with advancing age. [44], [45] Beginning in early adulthood, elastic fibers decrease in number and diameter; by old age, they often appear fragmented with small cysts and lacunae, especially in the dermal-epidermal junction. [46] Similar changes can be produced experimentally by incubation of dermal slices with elastase or chymotrypsin in vitro, suggesting that enzymatic degradation of elastin may be a mechanism for normal dermal aging. Elastic fibers also show progressive cross-linkage and calcification with age in adult skin. The few reports concerning the possible postmaturational changes in mucopolysaccharides (glycosaminoglycans and proteoglycans) or other molecules of the ground substance in which collagen and elastic fibers are embedded suggest decreases relative to dry weight or collagen content of the skin, especially for hyaluronic acid, [47] or in hyaluronic acid extractability [48]. Electron-dense hyaluronic acid granules also decrease with age and in one study were not detected in those over age 60. [47] These changes may adversely influence skin turgor because proteoglycans bind to 1000 times their own weight in water. Changes with age in the mechanical properties of the skin during adulthood include progressive loss of elastic recovery, consistent with gradual destruction of the dermal elastic network, and marked prolongation of the time required for excised skin to return to its original thickness after compression. In vivo studies of ventral forearm skin of 133 volunteers in each decade of life revealed linear declines during adulthood of approximately 25 percent in both men and women for elasticity and extensibility. [49] Loss of elasticity began in childhood and continued through the ninth decade, whereas extensibility was constant through the sixth decade and then declined more rapidly thereafter. [49] Overall, a picture emerges of aging dermis as an increasingly rigid, inelastic, and unresponsive tissue that is less capable of undergoing modifications in response to stress.

Hair Changes

By the end of the fifth decade, approximately half the population has at least 50 percent gray (white) scalp hair, and virtually everyone has some degree of graying, due to progressive and eventually total loss of melanocytes from the hair bulb. [50] Loss of melanocytes is believed to occur more rapidly in hair than in skin because the cells proliferate and manufacture melanin at maximal rates during the anagen phase of the hair cycle, whereas epidermal melanocytes are comparatively inactive throughout their life span. Scalp hair may gray more rapidly than other body hair because its anagen-to-telogen ratio is considerably greater than that of other body hair. Advancing age is also accompanied by a modest decrease in number of hair follicles, due in part to atrophy and fibrosis. In addition, with aging there is an increase in the proportion of telogen hair follicles. Remaining hairs may be smaller in diameter and grow more slowly.

The process termed *balding* results primarily from the androgen-dependent conversion of the relatively dark, thick terminal scalp hairs to lightly pigmented short, fine vellous hairs similar to those on the ventral forearm. Bitemporal hairline recession begins during late adolescence in most women and virtually all men. The rate at which hair loss proceeds and its ultimate extent are highly variable, with a strong hereditary predisposition for which the exact determinants are unknown. [51] Assessment of baldness is hampered by lack of a precise definition, but by certain criteria, advanced bitemporal and occipital hair loss in men increases in prevalence from 20 and 3 percent, respectively, at the end of the third decade to more than 60 and 25 percent by the seventh decade. Women are affected less often and far less severely. However, estrogens prolong the growth phase (anagen) of the hair cycle. [51] In postmenopausal women, hair loss may be the result of decreased estrogen levels, as well as a decrease in the estrogen-androgen ratio. It is estimated that by age 50, more than 50 percent of women would have some degree of alopecia, [51] often diffuse rather than predominantly temporal and occipital as observed in men. Whether this age-associated hair loss represents androgenetic alopecia or so-called senescent alopecia, [51] the association with decreased estrogen levels is impressive. Besides hair loss, almost 50 percent of women over age 60 display facial hirsutism, presumably attributable to the same hormonal changes as hair loss. In susceptible women, testosterone and/or progestin derivatives that are present in some hormone-replacement regimens may exacerbate hair loss and induce hirsutism.

Nerves and Cutaneous Glands

Eccrine glands decrease by approximately 15 percent in average number during adulthood in most body sites.

Spontaneous sweating in response to dry heat is further reduced, more than 70 percent in healthy older subjects as compared with younger controls, attributable primarily to a decreased output per gland. Maximal sweat production has not been quantified in the elderly but is almost certainly reduced and probably predisposes to heat stroke in this age group. Apocrine gland size and function also decrease with aging. Lipofuscin ("age pigment") gradually accumulates with age in the secretory cells of both eccrine and apocrine glands.

Sebaceous gland size and number appear not to change with age. The exponential decrease in sebum production of approximately 23 percent per decade beginning in the second decade in both men and women (approximately 60 percent over the adult life span) is attributed to the concomitant decrease in production of gonadal or adrenal androgens to which sebaceous glands are exquisitely sensitive. [52] The clinical effects of decreased sebum production, if any, are unknown. There is no direct relationship to xerosis or seborrheic dermatitis.

Pacinian and Meissner's corpuscles, the cutaneous end organs responsible for pressure perception and light touch, progressively decrease to approximately one-third their initial average density between the second and ninth decades of life, as determined histochemically in two body sites, and display greater size variation and structural irregularities. There are very few histologically demonstrable aging changes in Merkel's disks or in free nerve endings.

Decreased sensory perception in old skin encompasses optimal stimulus for light touch, vibratory sensation, and corneal sensation; ability to discriminate two points; and spatial acuity. [53], [54] Cutaneous pain threshold increases up to 20 percent with advancing adult age. The available data do not permit differentiation among an age-associated increase in the prevalence of peripheral neuropathy, a true aging change in healthy subjects, increased rate of heat dispersion in old skin due to age-associated dermal alterations, an increased peripheral nerve threshold to painful stimuli, and an increased central threshold to pain perception. The many psychological and social factors influencing an individual's reaction to pain also may be presumed to vary with age. In any case, either decreased awareness of or reaction to noxious stimuli facilitates wounding and irritation of old skin.

Photoaging

Initially due to ignorance of its true pathophysiology and subsequently due to lack of an appropriate word, chronic sun damage has been widely mislabeled in both the lay and medical literature as *aging, premature aging,* or *accelerated aging.* Clinical features of actinically damaged skin are listed in Table 144-3 and histologically contrasted with those of intrinsic aging in Fig. 144-1.

TABLE 144-3 **Features of Actinically Damaged Skin***

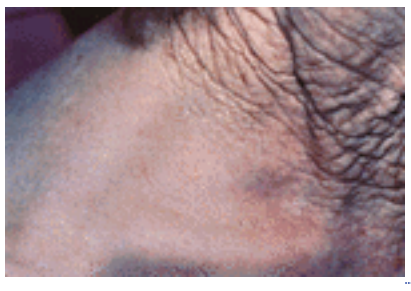

FIGURE 144-1 Photoaged versus intrinsically aged skin of an elderly man. Habitually sun-exposed skin above the collar line is prominently wrinkled and lax, in contrast with the equally chronologically aged sun-protected skin of the shoulder. Despite the striking difference in appearance, both areas manifest age-associated functional decrements.

A prominent feature of photoaged skin is elastosis, a process characterized histologically by tangled masses of degraded elastic fibers that further deteriorate to form an amorphous mass (Fig. 144-2). In addition, the amount of ground substance, largely composed of glycosaminoglycans and proteoglycans, increases in photodamaged skin, whereas the amount of collagen decreases, in part because of increased metaloproteinase activity and enhanced cytokine release. In contrast with aged sun-protected skin that demonstrates hypocellularity, photodamaged skin frequently displays inflammatory cells, including mast cells, histiocytes, and other mononuclear cells, giving rise to the term *heliodermatitis* (literally, "cutaneous inflammation due to sun") (Fig. 144-3). Fibroblasts are also more numerous than in sun-protected skin.

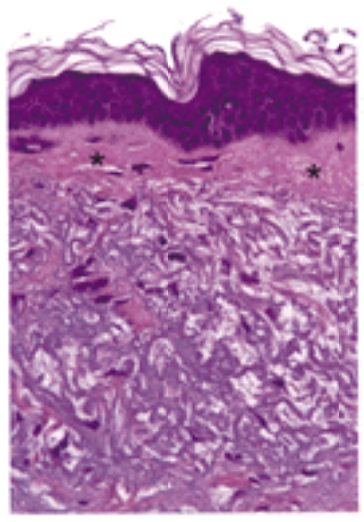

FIGURE 144-2 Photodamaged facial skin. Large masses of deranged elastic fibers characterize solar elastosis. A thin subepidermal Grenz zone (*asterisks*) is present, and the epidermis is acanthotic. (*Courtesy of Lorraine H. Kligman.*)

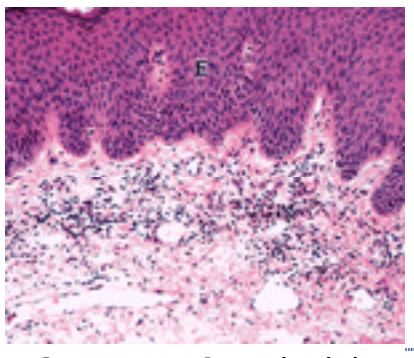

FIGURE 144-3 Marked dermal inflammatory infiltrate associated with the heliodermatitis (dermatoheliosis) that is characteristic of ongoing and chronic actinic exposure. E = epidermis. (*Courtesy of Lorraine H. Kligman.*)

In contrast with chronologically aged skin, photodamaged epidermis is frequently acanthotic, although severe atrophy also can be seen, displaying, in addition, loss of polarity and cellular atypia. Also, there is a decrease in the number and function of Langerhans cells. Additional changes are described in Table 144-3.

The relative severity of sun-induced cutaneous changes varies considerably among individuals, undoubtedly reflecting inherent differences in vulnerability and repair capacity for the solar insult. Photoaging occurs not only in fair-skinned individuals (skin types I and II) but also in individuals with darker skin types III and IV with a history of ample past sun exposure. It usually involves the face, neck, or extensor surfaces of the upper extremities most severely. Interestingly, the gross appearance of photodamaged skin of individuals with skin types I and II differs from that of individuals with skin types III and IV, the former generally showing atrophic and dysplastic skin changes with actinic keratoses and epidermal malignancies rather than hypertrophic responses such as wrinkling, lentigines, and coarseness. One study has noted that patients presenting with basal cell carcinoma are less wrinkled than peers of similar complexion and degree of photodamage, [55] suggesting that different factors determine these two responses to chronic UV exposure.

Wrinkling of photodamaged skin is exacerbated by cigarette smoking [56] and possibly other environmental factors. The apparent influence of sex on the prevalence of certain photoaging features undoubtedly reflects different hair styles, patterns of dress, and nature of sun exposure (occupational versus recreational) between men and women over the past several generations. Other sex differences, such as epidermal thickness and sebaceous gland activity, and as yet unrecognized effects of circulating sex hormones also may influence their development. The characteristic distribution of different lesions is a complex function of relative sun exposure for different body sites, anatomic distribution of the participating cutaneous structures (e.g., melanocytes and sebaceous glands), and other poorly understood factors.

The action spectrum for human photoaging has never been determined, and hence the relative contribution of the various spectral bands within sunlight is unknown. There is no truly appropriate animal model. In rodent skin, an elastosis-like condition can be produced by prolonged intense irradiation with either a predominantly UVB or UVA source, but attempts to determine the action spectrum for murine elastosis have yielded conflicting results. [57], [58] UVB photons are on average 1000 times more energetic than UVA photons and are overwhelmingly responsible for sunburn, suntanning, and photocarcinogenesis following sun exposure, [59] although UVA also contributes to these end points. [60], [61] UVA is suspected of playing a proportionately larger role in photoaging because of its minimally 10-fold greater abundance in terrestrial sunlight, far greater year-round and day-long average irradiance, and greater average depth of penetration into the dermis compared with UVB. Moreover, human skin exposed daily for only 1 month to suberythemogenic doses of UVA alone demonstrates epidermal hyperplasia, stratum corneum thickening, Langerhans cell depletion, and dermal inflammatory infiltrates with deposition of lysozyme on the elastic fibers. [62] These latter changes have been interpreted to suggest that frequent casual exposure to sunlight containing principally UVA, e.g., while wearing a UVB-absorbing sunscreen, eventually may result in damage to dermal collagen and elastin in ways expected to produce photoaging.

Although the clinical manifestations of aging and chronic sun damage differ, in many instances these differences are subtle. Initially, histologic changes in elderly sun-exposed skin were described by experienced investigators as differing only in degree from those in elderly sun-protected skin at both the light microscopic and electron microscopic levels. Many of the age-associated physiologic decrements, such as slowed wound healing and loss of immunoresponsiveness, also appear to be accelerated in sun-exposed skin. Furthermore, cells cultured from chronically sun-exposed skin sites differ from cells cultured from sun-protected sites of the same donors in having shortened culture life spans, slower

growth rates, lower saturation densities, and altered responsiveness to retinoic acid, [63] all changes also observed as a function of advanced chronologic donor age. Only in recent decades have qualitative differences in the dermal fibrous proteins and microvasculature of paired sun-exposed and sun-protected sites been documented. On a theoretical level, several of the mechanisms known to be involved in UV-mediated cellular damage are also postulated to underlie chronologic aging. [32], [64] These include DNA injury and/or decreased DNA repair, oxidative damage, lysosomal disruption, and altered collagen structure.

Molecular mechanisms for some of the degenerative changes observed in photoaged skin, particularly the enzymatic breakdown of collagen, [65] have been tentatively identified, consistent with the overall clinical appearance of photodamaged skin. It was shown that modest physiologic doses of UVB activate the transcription factors AP-1 and NF-?B in human skin. [65] In intact human skin, even a suberythemogenic dose of UVB transcriptionally upregulates and activates extracellular matrix-degrading metalloproteinases that are regulated by AP-1, including collagenase, stromelysin, and the 92K gelatinase, in both keratinocytes and fibroblasts. [66] There is also a concomitant upregulation of TIMPs that limits further matrix degradation, although TIMPs presumably are not completely effective in blocking cumulative damage to dermal collagen.

Degradation of matrix proteins is aggravated by NF-?B–mediated induction of interleukin (IL)-1 and tumor necrosis factor (TNF), two proinflammatory cytokines, leading to recruitment of neutrophils and secretion of neutrophil collagenase. [66] UV irradiation also downregulates procollagen transcription through an as yet unknown mechanism, leading to decreased levels of both type I and type III procollagen. [66] Presumably, over many years, these events in combination reduce the collagen content of skin and promote wrinkling.

Other studies using UVA irradiation and the hairless mouse model showed decreased activity of the enzyme prolyl-hydroxylase that participates in posttranslational modification of collagen. [67] In contrast with UVB, which renders collagen more susceptible to enzymatic degradation, irradiation with UVA rendered dermal collagen more resistant to degradation, in part as a result of increased cross-linking of the fibers.

Smoking and Skin Aging

Cigarette smoking exacerbates photoaging, particularly in women, with a irect correlation between the number of pack-years smoked and the severity of wrinkling and grayish discoloration. [56], [68] Histologic analysis of “smoker's skin” reveals elastic fiber thickening and fragmentation, similar to that found in sun-damaged skin. [69] However, while solar elastosis is restricted in the papillary dermis, elastic fiber changes in smoker's skin also occur in the reticular dermis. This dermal elastosis has been suggested to result from increased elastase activity in neutrophils, [70] chronic dermal ischemia, the prooxidant effects of cigarette smoke compounded by decreased levels of vitamin A, which reduce the capacity to quench free oxygen radicals, and increase DNA damage. [56], [68] Smoking also has been associated with decreased stratum corneum water content [56], [68] and accelerated hydroxylation of estradiol, leading to decreased estrogens in the skin that may in turn contribute to dryness and atrophy. [56] Smokers have an increased incidence of skin cancers as well as increased severity of photoaging-like changes compared with nonsmokers with otherwise similar risk factors, [71] consistent with the possibility that mutagens present in cigarette smoke directly affect cells in the dermis and epidermis.

Relevance to Skin Disease in the Elderly

Virtually by definition, aging is associated with increased vulnerability to disease and injury. Disorders of the skin are known to be common and bothersome in the elderly, and some occur predominantly in this age group. [1] Such disorders often appear to be the consequence of age-associated intrinsic losses of cutaneous cellular function. However, many dermatoses observed more commonly in the elderly reflect the higher prevalence of systemic diseases such as diabetes, vascular insufficiency, and various neurologic syndromes that compound physiologic changes in the skin itself. The increased prevalence of some disorders also may reflect reduced local skin care due to immobility or neurologic impairment rather than changes in the skin itself. Alternatively, subtle age-associated changes in immune status may be responsible, in analogy to the increased prevalence and severity of skin disease in patients with acquired immunodeficiency syndrome.

Reduced tolerance to systemically administered drugs is well documented in the elderly, [72] due to decrements in lean body mass and metabolism and renal excretion of the active ingredients. Comparable data for topically applied medications do not exist, but it is tempting to postulate that retarded dermal clearance of absorbed material, reduced dermal mass and cellularity, and possibly altered metabolic capacity may render old skin more susceptible to both beneficial and adverse effects of topical medications or may at least alter the optimal therapeutic schedule. In the case of glucocorticoid preparations, relative vascular unresponsiveness may render blanching of erythema an unreliable indicator of other effects in old skin.

Selected common cutaneous disorders in the elderly are discussed briefly below, with special emphasis on their pathogenesis and clinical presentation in this segment of the population (Table 144-4). Most of these entities are covered more comprehensively in other chapters.

Disorder	Pathophysiology
Benign neoplasia	
Seborrheic keratosis	Focal epidermal homeostatic loss leading to increased endothelin-1
Malignant neoplasia	
Squamous cell carcinoma and actinic keratosis	UV-induced DNA damage Decreased DNA damage repair capacity
Basal cell carcinoma	
Malignant melanoma	
Merkel cell carcinoma	
Angiosarcoma	Cumulative age-associated DNA damage Decreased DNA damage repair capacity
Papulosquamous disorders	
Psoriasis	Changes in patient's environment leading to koebnerization Systemic medications
Xerosis/asteatotic dermatitis	Disturbance of epidermal maturation (decreased filaggrin production and/or altered lipid profile) Decreased water content in outer layers of stratum corneum Slower corneocyte transit
Pruritus	Penetration of irritants through damaged stratum corneum (↑) Altered sensory threshold (neuropathy) (↑) Metabolic disorder Endocrine disorder Malignant neoplasm Adverse drug reaction Parasitic infestation
Infections	Compromised local cutaneous health predisposing to growth of infective organism Age-associated decreased immune function Underlying systemic disorder associated with decreased immune function
Ulcers	Impaired wound healing capacity (decreased levels of growth factors, decreased cellular proliferative capacity, increased perivascular fibrin deposition) Underlying systemic disorder Compromised local cutaneous health (venous stasis, arteriosclerosis, hypertension)
Bullous pemphigoid	Flattening of the dermal-epidermal junction Increased circulating autoantibodies Basement membrane changes (↑)
Photosensitivity reactions	Medications with unsaturated ring structures

TABLE 144-4 **Presumptive Pathophysiologic Causes for Common Cutaneous Disorders in the Elderly**

TUMORS

Benign neoplasia Benign proliferative growths are especially characteristic of aging skin. Acrochordons, cherry angiomas, seborrheic keratoses, and lentigines begin to appear in middle age and are numerous in nearly every adult beyond age 65 years.

Seborrheic keratoses These benign papules or plaques are highly variable in size and color. Because their number increases with aging, independent of sun exposure, they are considered by some as a biomarker of intrinsic aging. [73] Seborrheic keratoses represent clonal proliferations of both keratinocytes and melanocytes, [74] presumably the result of focal epidermal homeostatic loss. They have no malignant potential. Although the pathogenesis of these keratoses is not completely understood, it has been shown recently that lesional keratinocytes express high levels of endothelin-1 and that lesional melanocytes have increased tyrosinase expression, [75] leading to the hypothesis that endothelin-1, an inducer of melanogenesis, dendricity, and proliferation in melanocytes, [76], [77] plays an etiologic role in seborrheic keratoses.

Skin cancer The age-specific incidence of skin cancer, including melanoma, increases exponentially with age, [78] presumably due in part to cumulative exposure to carcinogens over the lifetime followed by cell division, with the attendant risk of incorporating mutations. There are also well-documented age-associated decreases in DNA repair capacity [79], [80] and immunosurveillance, [81] as well as subtle loss of proliferative homeostasis. The major etiologic factor for skin cancer is UV irradiation. Habitual sun exposure of fair-skinned individuals induces squamous cell carcinoma (SCC) as well as actinic keratoses, a premalignant lesion that may evolve into SCC, in a direct dose-response relationship. [82] In contrast, the risk of basal cell carcinomas (BCC) and particularly malignant melanoma is related not only to total sun exposure but also to intense intermittent sun exposure. [83] The mechanism of these different epidemiologic patterns is unknown, although relative resistance of the responsible cell types to apoptosis may contribute. [84] The elderly, particularly men, present with melanomas that are thicker than those of young adults, presumably in part because of difficulties in properly examining their skin, poor vision, and other medical problems, and their melanomas arise on a background of multiple benign cutaneous lesions. Presumably because of delays in diagnosis, men over age 50 have an increased mortality risk from melanoma compared with women or younger men. Although all types of melanoma have increased age-specific incidences, [78] lentigo maligna melanoma overwhelmingly develops in the sixties or later in habitually sun-exposed skin. [85] Merkel cell carcinoma (trabecular carcinoma) is a rare cutaneous tumor thought to arise from a pleuripotential cell that displays neuroendocrine differentiation. [86] It is seen most often in sun-exposed areas of the head, neck, or extremities and presents as a rapidly growing nodule. More than 90 percent of patients diagnosed with this tumor are older than age 50, with the mean age of onset being 68 years. There is a high rate of local recurrence of the tumor (26–44 percent), and metastases to lymph nodes are frequent (53 percent regional and 75 percent distant). The 5-year survival is between 30 and 64 percent. The most common form of angiosarcoma occurs overwhelmingly in the head and neck of the elderly. The tumor first presents as a bluish macule and is frequently misdiagnosed as a bruise, cellulitis, or erysipelas. In most patients the tumor is multicentric, and its rapid growth, associated with early metastasis, usually results in death within 2 years of diagnosis. [87] Traditional treatment includes surgical excision and radiotherapy, as well as chemotherapy for more extensive disease. Combination therapy with interferon-a2a and 13- *cis*-retinoic acid may be effective for recurrent disease. [88]

PAPULOSQUAMOUS DISORDERS

Psoriasis [89] ***(See also Chap. 42)*** Although psoriasis occurs most commonly in young adults, a milder form of the disease with weaker genetic association is known to begin in later life. Flexural psoriasis appears to be more prevalent in the elderly than in young adults, and like other inflammatory conditions, psoriasis in the elderly often displays atypical features. Characterized by the Koebner phenomenon and exacerbation or precipitation by numerous agents, psoriasis is highly influenced by the patient's environment, a feature that likely accounts for many cases in the elderly. For example, intertrigo as a result of change in body habitus may account for the higher frequency of flexural disease. Also, the elderly frequently take medications that aggravate psoriasis, such as ß-blockers, nonsteroidal anti-inflammatory drugs, and ACE inhibitors. Among the other triggering factors, urinary incontinence or the use of hearing aids, corsets, or braces may lead to koebnerization. Perhaps because of altered proliferative homeostasis, psoriasis in the elderly is often exquisitely sensitive to antiproliferative drugs such as methotrexate. Minute doses may lead to resolution of plaques, and conversely, standard doses may cause extensive erosions.

Xerosis/asteatotic dermatitis Xerosis is a dry, rough quality of skin that is almost universal in the elderly and may be attributed to a subtle disturbance of epidermal maturation, such as inadequate filaggrin production [26] or altered lipid profile. [24], [25] Histologic studies reveal little alteration of either the viable epidermis or the stratum corneum with age. Available data fail to demonstrate an overall decrease in stratum corneum lipids [24], [90] or altered amino acid composition as etiologic factors. [91] Water content of the viable epidermis is normal, but there is some reduction in the outermost layers of the stratum corneum. [90] The surface irregularity may be attributed simply to slower transit of corneocytes through the stratum corneum, allowing accumulation of damage in situ. There is no explanation for the pruritus that often accompanies xerosis. [92] Speculations include frequent penetration of irritants through an abnormal stratum corneum and

an altered sensory threshold due to subtle neuropathy. Asteatotic eczema, a condition frequently found in the elderly during the wintertime, is a dermatitis superimposed on xerosis. It is often caused by low humidity in a heated environment. It manifests by dry, fissured skin with fine scale and is usually located to the pretibial region. This condition, which may be extremely pruritic, responds to application of medium-potency topical steroid ointments and/or liberal application of emollients.

Pruritus [92] ***(See also Chap. 41)*** Pruritus is perhaps that most common skin-related complaint of the elderly. In a majority of cases, pruritus is attributable only to xerosis, often exacerbated by low humidity, frequent bathing, or application of irritants to the skin. However, in up to 10 to 50 percent of patients in some series, pruritus may have other etiologies. These include metabolic or endocrine disorders such as diabetes mellitus, renal failure, thyroid disease, or hepatic disease, in particular the obstructive type. Pruritus can be a manifestation of a malignant neoplasm, in particular lymphoma or leukemia, or the result of a hematologic disease such as polycythemia vera. Adverse drug reactions can manifest predominantly or exclusively as pruritus and always should be considered in this segment of the population. Finally, infestations such as scabies lead to intense pruritus, and associated primary skin lesions may be overlooked. Although in the majority of cases pruritus can be managed by frequent use of moisturizers, if there is inadequate symptomatic relief, other causes should be pursued through appropriate laboratory evaluation.

INFECTIOUS PROCESSES

Bacterial [93] ***(See also Chap. 193)*** Impetigo and folliculitis in the elderly are caused by staphylococci, in contrast to impetigo in the pediatric population, which usually is caused by streptococci. Hence, in the older age group, impetigo should be treated with penicillinase-resistant semisynthetic penicillin or erythromycin until culture confirms the identity of the organism. Cellulitis is an infectious inflammatory process that involves the subcutaneous tissue and is caused most frequently by streptococci or staphylococci. Like other inflammatory conditions, cellulitis in the elderly may present with only subtle rubor, tumor, calor, and dolor. Predisposing factors with increased prevalence in the elderly include chronic edema, compromised circulation, diabetes mellitus, surgical sites, and asteatotic eczema. Distinct forms of cellulitis preferentially affect older individuals. These include orbital cellulitis that is caused by *Streptococcus viridans* alone or in combination with gram-negative bacteria. Another form of cellulitis that is relatively rare in the younger population is *Pseudomonas* cellulitis of the ear, an infectious process that affects elderly diabetic individuals. Erysipelas, a ß-hemolytic streptococcal infection of the skin, is more common in the elderly and tends to spread more readily in this age group, creating a life-threatening situation. Necrotizing fasciitis, caused by a strain of *Streptococcus,* is a rare cutaneous infection, but it is seen more frequently in the elderly and is associated with increased morbidity and mortality in this age group.

Parasitic [93] Scabies infestation can occur in any age group, but nursing homes provide a fertile ground for rapid spread of the infestation. In the elderly, in part because of their decreased immunity, lesions may be atypical and display less inflammation and pruritus. In addition, frequently the elderly have xerosis, and their pruritus at times may be attributed to this etiology. Treatment of scabies in the elderly is often difficult, in part because of reinfestations in nursing home environments and in part because the elderly may have difficulty in compliance. Permethrin (5%) treatment of scabies in nursing homes is safe and has the advantage of remaining on the skin surface for days, protecting the patient from reinfestation. Ivermectin, a systemic treatment that has been recommended frequently for scabies infestations of nursing homes because of its efficacy and ease of administration, has been associated with mortality in the elderly and therefore should be prescribed with caution.

Dermatophytes and yeasts [94] ***(See also Chap. 205 and Chap. 206)*** Onychomycosis is present in approximately 40 percent of patients after age 60, and tinea pedis is present in approximately 80 percent of this patient population. Although usually present for decades, tinea pedis may exacerbate with age. Indeed, in elderly diabetic patients, interdigital tinea pedis may ulcerate and predispose to bacterial cellulitis, a presentation that is relatively rare in the young adult immunocompetent patient. For tinea pedis without toenail involvement, topical antifungal preparations are effective. Clotrimazole, econazole, or terbinafine cream should give substantial improvement within a few weeks. However, indefinite use of a moisture-absorbing antifungal powder is required to prevent reinfection. When onychomycosis is present, oral therapy is required. Agents including terbinafine, fluconazole, or itraconazole are effective if used throughout the period required for the nail(s) to grow out (often 9 to 12 months in the elderly) but may cause hepatotoxicity or cross-react with other medications. Such concerns and frequent lack of third-party coverage for these expensive drugs have curtailed their use in the elderly. Cutaneous infections due to *Candida albicans* are common in the elderly. When recurrent or difficult to control, candidiasis may be a sign of poorly controlled diabetes, an endocrinopathy, malnutrition, or malignancy. Oral candidiasis or thrush presents as white plaques on the buccal mucosa, palate and/or tongue that reveal an eroded base when scraped off. Predisposing factors include the use of broad-spectrum oral antibiotics, corticosteroids, or dentures. Systemic conditions associated with the development of thrush include diabetes, malignancies, and AIDS. Topical antimycotic agents such as nystatin and clotrimazole that are formulated for oral use usually are effective. Systemic agents that can be used to treat oral candidiasis include fluconazole, itraconazole, and ketoconazole. Angular cheilitis or perleche presents as painful, erythematous, crusted fissures at the corners of the mouth. Predisposing factors include occlusive skin folds and drooling. The condition can be treated successfully with topical antifungal preparations, but to prevent recurrence, it is important to keep the oral commissures dry. Candidal intertrigo presents as painful erosions with peripheral scale and satellite pustules in body folds, where the moist, warm environment is ideal for candidal growth. In addition to antifungal creams, moisture-absorbing antifungal powders are excellent treatment options. Only rarely is systemic anticandidal treatment required.

Viral (varicella-zoster virus) [93] ***(See also Chap. 215)*** Varicella infection (chicken pox) occurs in almost all children. The virus then remains dormant in spinal ganglia indefinitely but may reactivate at times of stress, trauma, or impaired cellular immunity to cause herpes zoster. Virus transmitted along affected nerves to skin produces grouped vesicles in a dermatomal distribution. The eruption may be preceded, accompanied, and followed by significant pain. Both the incidence and severity of herpes zoster increase dramatically during adulthood, presumably because of subtle age-associated decreases in cellular immunity, as well as the increased incidence with age of predisposing factors such as injury, surgery, and malignancy. The incidence of herpes zoster peaks at approximately 1500 cases per 100,000 persons annually at age 75. Postherpetic neuralgia, uncommon in patients less than 40 years old, occurs in more than 40 percent of patients aged 60 to 69 years and 50 percent of patients 70 years of age or older. [95] A number of patients older than 60 years also experience paresthesias and muscle weakness. Decreased cellular immunity and impaired wound healing in the elderly may account for slower resolution of the acute eruption, but the pathogenesis of their postherpetic neuralgia is unclear. Age-associated muting of the inflammatory response indeed may be expected to reduce the risk of neuralgia, since prophylactic use of anti-inflammatory glucocorticoids is reported to reduce its severity. The antiviral

agents famciclovir (500 mg tid) and valacyclovir (1 g tid), if started within the first 3 days of the eruption, significantly decrease the risk of postherpetic neuralgia and shorten duration of the lesions even in immunocompetent elders and are strongly recommended for those with known immunosuppression. The National Institutes of Health (NIH) is urrently investigating whether vaccination of individuals in their forties and fifties can prevent herpes zoster later in life by boosting their immunity.

Ulcers [96] ***(See also Chap. 132)*** Chronic ulcers of all etiologies are more common in the elderly than in younger individuals, presumably due to a combination of impaired wound healing and higher prevalence of underlying diseases. The most common are leg ulcers, usually in the setting of chronic venous insufficiency leading to venous hypertension. Exudation of macromolecules such as fibrinogen into the dermis may block the passage of oxygen and nutrients and sequester cytokines and growth factors required for tissue homeostasis, maintenance, and repair. The sclerotic indurated quality of affected skin, termed *lipodermatosclerosis,* is postulated to further impair healing. In addition, diseases such as diabetes mellitus and atherosclerotic peripheral vascular disease may contribute to ulcer evolution. Venous ulcers can be managed by medical or surgical interventions or by a combination of both. Ulcer prevention, of course, is preferable to treatment for established ulcers. Because the source of the problem lies in increased venous pressure, compression therapy is recommended when surgical correction is impossible or ill-advised. Either compression bandages or stockings can provide graduated compression along the leg sufficient to prevent edema and to reach a pressure of 30 to 40 mmHg. Newer therapies for this prevalent disorder of the elderly include pentoxifylline, intended to reduce perivascular fibrin deposition, and topical application of cultured allografts or growth factors, such as epidermal growth factor, to the wound bed.

Bullous Pemphigoid (See also Chap. 61) Bullous pemphigoid is an autoimmune disease characterized by subepidermal blister formation with fixation of complement and immunoglobulins along the basement membrane. It is far more common after age 60 than in younger persons, a predilection that may be explained in part by the age-associated increases in circulating autoantibodies and ease of dermal-epidermal separation, [97] although many other autoimmune and blistering dermatoses are not more common in old age. Bullous pemphigoid antibodies recognize one of two antigens, a 230-kDa protein that is a component of the hemidesmosome and a 180-kDa protein that spans the basal cell plasma membrane, the hemidesmosome, and the lamina lucida. [98] Possibly, age-associated changes in the basement membrane itself render it specifically vulnerable to this disease process. Bullous pemphigoid is a self-limited condition that frequently resolves within 6 to 12 months, but elderly patients may experience increased morbidity and mortality because of debilitated general health or as a side effect of treatment, which usually includes oral corticosteroids or other immunosuppressive therapy.

PHOTOSENSITIVITY DISORDERS (See also Chap. 135 and Chap. 136) Chronic actinic dermatitis is a rare photodermatosis believed to be induced by photoallergens in the skin. Photosensitive eczema and actinic reticuloid are considered subgroups. [99] Approximately 80 percent of patients are elderly men that display, primarily in sun-exposed areas, intensely pruritic, lichenified, scaly plaques. Histologically, there is a deep dermal lymphohistiocytic infiltrate, and in the more infiltrated plaques, there may be epidermotropism. Lesions may result from exposure to UVB, UVA, and even visible light. In the elderly, photosensitivity reactions to therapeutic drugs are relatively common. Causative agents classically have unsaturated ring structures capable of absorbing UVA. Phototoxic responses (exaggerated sunburn response) are most common, and a subset of affected patients also develop photoallergic eruptions (a drug rash restricted to sun-exposed areas). Thiazides, certain antibiotics, and psychotropic drugs are frequent offenders. Other medications, including nalidixic acid, furosemide, and naproxen, can induce porphyria cutanea tarda–like reactions with increased skin fragility and blister formation after minor trauma. Other drugs may produce dermal pigmentation (e.g., amiodarone) or lichen planus–like changes (e.g., gold) in sun-exposed areas. Discontinuation of the responsible agent allows for gradual resolution.

DRUG ERUPTIONS Adverse drug reactions of all kinds increase with age, in part because the elderly consume more medications than younger age groups and in part because of altered drug metabolism as a result of medical conditions including impaired renal, cardiac, or hepatic function that compromise drug metabolism or excretion. The most frequently observed adverse cutaneous drug reactions are pruritus, exanthems, and urticaria, but drug-induced autoimmune reactions including pemphigus, bullous pemphigoid, and lupus erythematosus also occur in the elderly. A careful history to elicit all prescription medications as well as over-the-counter preparations is critical to diagnosis and optimal patient care.

TREATMENT

Photoprotection

Until the 1990s, the only proven way to treat photoaging was photoprotection. Work in the rhino mouse model of photoaging first demonstrated that discontinuation of daily irradiation allowed deposition of new papillary dermal matrix, with downward compression of UV-induced elastosis; similar repair occurred despite continued irradiation if a highly protective sunscreen was applied to the mice. [100] Subsequently, in large multicenter studies investigating topical tretinoin as a treatment for photoaging (see below), patients in the control groups were found to have statistically significant improvement in fine wrinkling, roughness, dyspigmentation, and overall appearance after 6 months of daily sunscreen and moisturizer use compared with their own baseline status, [35] changes presumably due principally to cessation of their ongoing photodamage.

In mice it was shown that repair is continuously taking place in photodamaged skin in the subepidermal Grenz zone where new procollagen I is being synthesized and laid down. On discontinuation of sun exposure, this zone widens, and the area where active repair of photodamage injury takes place is enlarged (Fig. 144-4). Avoidance of sun exposure and use of sun protection also allows regression of actinic keratoses. [101] These data suggest an intrinsic repair capacity for photoaging and a central role for photoprotection in any treatment regimen.

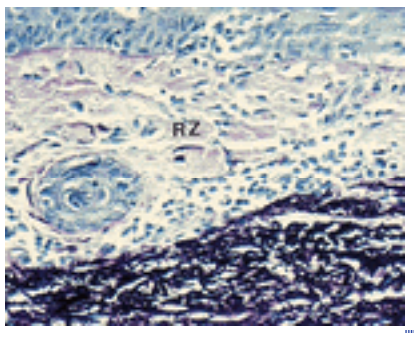

FIGURE 144-4 Repair in human skin. Biopsy from the bald scalp of a retired outdoor worker after 10 years of indoor residence in a home for the aged. As in the hairless mouse, a reconstructive zone (RZ) of new connective tissue has been laid down subepidermally, above the darkly stained elastosis. (*Courtesy of Lorraine H. Kligman.*)

All- *trans*-Retinoic Acid (See also Chap. 244)

The ability of topical retinoic acid, also termed *tretinoin,* to improve photoaging changes in skin was suggested by studies in the rhino mouse model [102] and later definitively demonstrated in patients. [103] Clinically modest but highly statistically significant improvements in global appearance, surface roughness, fine and coarse wrinkling, mottled pigmentation, and sallowness were shown subsequently in several double-blind, vehicle-controlled trials involving more than 700 subjects. [35] The beneficial effects are dose-dependent and increase with duration of therapy for at least 10 to 12 months. Accompanying epidermal acanthosis and hypergranulosis, as well as stratum corneum compaction, prominent in the first months of therapy, [35], [104] regress within 12 months of continuous therapy despite continued clinical improvement, [105] suggesting that they are not relevant to tretinoin's mechanism of action. In contrast, reduction and redistribution of epidermal melanin parallel improvement in mottled hyperpigmentation and lentigines. [35], [105] Improvements in wrinkling are best correlated with increased papillary dermal collagen deposition in tretinoin-treated skin, [106] although increased anchoring fibrils [107] and improved ultrastructural characteristics of the epidermis and superficial dermis [35] also may contribute. Increased vascularity of the papillary dermis, well documented in tretinoin-treated mouse skin [108] and also reported in human skin, [109] presumably reduces sallowness and renders the skin more responsive to environmental stimuli.

At a more fundamental level, tretinoin effects on photoaged skin, like all tretinoin effects, are presumed to be mediated through binding to the nuclear retinoic acid receptors (RARs) with subsequent binding of retinoic acid–RAR complexes to specific response elements in regulated genes. [110] In addition to reversing photoaging changes, it has been shown that tretinoin therapy blocks dermal matrix degradation following sun exposure. [106] Pretreatment of human skin with tretinoin inhibited induction of the AP-1 transcription factor and AP-1–regulated matrix-degrading metalloproteinases that otherwise followed even suberythemogenic UV exposures. [65] Tretinoin did not interfere with UV-induced upregulation of TIMP, the tissue inhibitor of metalloproteinases, thus favoring collagen preservation.

Tretinoin treatment also appears to reverse histologic changes associated with intrinsic aging both in vivo [111] and in vitro. [109] Whether the retinoid effect on photoaged skin constitutes a true reversal of aging or of age-associated environmental damage only cannot be determined without a better understanding of these processes at the cellular and molecular levels.

Alpha-Hydroxy Acids

Alpha-hydroxy acids (AHAs) are compounds derived from dairy products (lactic acid), fruit (malic acid, citric acid), or sugar cane (glycolic acid). Topical treatment of photodamaged skin with AHAs has been reported to result in subtle clinical improvements in wrinkling, roughness, and dyspigmentation within months of daily application. [112], [113] Histologically, improvement is also reported after 6 months of daily applications of products containing 25% glycolic, lactic, or citric acid. [113]

Antioxidants [114]

Naturally occurring antioxidants include vitamins A (retinol), C (ascorbic acid), and E (tocopherols), beta-carotene, and bioflavinoids. Although their role as endogenous protectors against oxidative stress is well documented, the ability of topically applied antioxidants to modify acute or chronic damage mediated by free radicals in skin is controversial. Controlled human studies of possible beneficial effects of antioxidants on photoaging are lacking.

Hormone Therapy [115]

Both systemic hormone-replacement therapy (HRT) and topical estrogen therapy mitigate certain of the age-associated skin changes in postmenopausal women. Results depend on the type of estrogen provided, the dose, and whether estrogen is given alone or in combination with other steroidal hormones.

Systemic treatment of postmenopausal women with conjugated estrogens or a combination of estrogen-glucocorticoids (mestranol-paramethasone) significantly increases total skin and dermal thickness, dermal collagen content, and mitotic activity of keratinocytes. These changes are said to be accompanied by decreased slackness or improved elasticity of the skin, and a large epidemiologic study also strongly suggests that estrogen use by postmenopausal women mitigates against skin dryness and wrinkling. Increased sebaceous gland activity, decreased roughness, and increased hydration of skin and stratum corneum are also reported.

Several studies examining the effect of topically applied estrogen cream or gel showed a significant increase in collagen

content, improvement of the morphologic appearance of elastic fibers, increased skin thickness, and reduced fine wrinkling.

Estrogen therapy may improve cutaneous function as well as appearance in older women. A significant acceleration of the rate of epithelialization of acute wounds in women receiving HRT was reported, and the rate of wound healing was comparable with that of young women. In addition, HRT increased the levels of transforming growth factor ß (TGF-ß) in the wound bed, leading to increased collagen deposition.

In addition to HRT for postmenopausal women, growth hormone treatment of older men (> 60) significantly increased skin thickness, suggesting that age-associated decrease of growth hormone levels may contribute to cutaneous aging. 116

REFERENCES

1. Smith ES et al: Demographics of aging and skin disease, in *Geriatric Dermatology*, Part I, edited by BA Gilchrest. Philadelphia, WB Saunders, 2001, p 631

2. Masoro EJ: Aging: Current concepts, in *Aging,* edited by EJ Masoro. Oxford, England, Oxford University Press, 1995, p 3

3. Ahmed A, Tollefsbol T: Telomeres and telomerase: Basic science implications for aging. *J Am Geriatr Soc* **49**:1105, 2001

4. Vaziri H, Benchimol S: From telomere loss to p53 induction and activation of a DNA-damage pathway at senescence: The telomere loss/DNA damage model of cell aging. *Exp Gerontol* **31**: 295, 1996

5. Campisi J: Replicative senescence: An old lives' tale? *Cell* **84**:497, 1996

6. Golletz TJ et al: Molecular genetic approaches to the study of cellular senescence. *Cold Spring Harbor Symp Quant Biol* **59**:59, 1994

7. Stein GH, Dulic V: Origins of G_1 arrest in senescent human fibroblasts. *Bioessays* **17**:537, 1995

8. Noda A et al: Cloning of senescent cell-derived inhibitors of DNA synthesis using an expression screen. *Exp Cell Res* **211**:90, 1994

9. Alcorta DA et al: Involvement of the cyclin-dependent kinase inhibitor p16 (INK4a) in replicative senescence of normal human fibroblasts. *Proc Natl Acad Sci U S A* **93**:13742, 1996

10. Stein GH, Dulic V: Molecular mechanisms for the senescent cell cycle arrest. *J Invest Dermatol Symp Proc* **3**:14, 1998

11. Khorramizadeh MR et al: Aging differentially modulates the expression of collagen and collagenase in dermal fibroblasts. *Mol Cell Biochem* **194**:99, 1999

12. Balin AK, Allen RG: Molecular bases of biologic aging, in *Clinics in Geriatric Medicine,* vol 5/1: *Geriatric Dermatology,* edited by BA Gilchrest. Philadelphia, WB Saunders, 1989, p 1

13. Ames BN et al: Oxidants, antioxidants, and the degenerative diseases of aging. *Proc Natl Acad Sci USA* **90**:7915, 1993

14. Sohal RS, Brunk UT: Mitochondrial production of pro-oxidants and cellular senescence. *Mutat Res* **275**:295, 1992

15. Sohal RS, Weindruch R: Oxidative stress, caloric restriction, and aging. *Science* **273**:59, 1996

16. Jazwinski SM: Longevity, genes, and aging. *Science* **273**:54, 1996

17. Yu CE et al: Positional cloning of the Werner's syndrome gene. *Science* **272**:258, 1996

18. Eller MS et al: The single-stranded telomeric DNA induces DNA damage responses. *J Invest Dermatol* **37**:756, 2001

19. Itahana K et al: Regulation of cellular senescence by p53. *Eur J Biochem* **268**:2784, 2001

20. Yaar M, Gilchrest BA: Skin aging: Postulated mechanisms and consequent changes in structure and function. *Clin Geriatr Med* **17**:617, 2001

21. Kurban RS, Bhawan J: Histologic changes in skin associated with aging. *J Dermatol Surg Oncol* **16**:908, 1990

22. Moragas A et al: Mathematical morphologic analysis of aging-related epidermal changes. *Anal Quant Cytol Histol* **15**:75, 1993

23. Roskos KV et al: The effect of aging on percutaneous absorption in man. *J Pharmacokinet Biopharm* **6**:617, 1989

24. Ghadially R et al: The aged epidermal permeability barrier: Structural, functional, and lipid biochemical abnormalities in humans and a senescent murine model. *J Clin Invest* **95**:2281, 1995

25. Denda M et al: Age- and sex-dependent change in stratum corneum sphingolipids. *Arch Dermatol Res* **285**:415, 1993

26. Tezuka T et al: Terminal differentiation of facial epidermis of the aged: Immunohistochemical studies. *Dermatology* **188**:21, 1994

27. Stanulis-Praeger BM, Gilchrest BA: Growth factor responsiveness declines during adulthood for human skin-derived cells. *Mech Ageing Dev* **35**:185, 1986

28. Reenstra WR et al: Aging affects epidermal growth factor receptor phosphorylation and traffic kinetics. *Exp Cell Res* **227**:252, 1996

29. MacLaughlin J, Holick MF: Aging decreases the capacity of human skin to produce vitamin D3. *J Clin Invest* **76**:1536, 1985

30. Gloth FM III et al: Vitamin D deficiency in homebound elderly persons. *JAMA* **274**:1683, 1995

31. Holick MF et al: Age, vitamin D, and solar ultraviolet. *Lancet* **2**:1104, 1989

32. Lopez-Torres M et al: Effect of age on antioxidants and molecular markers of oxidative damage in murine epidermis and dermis. *J Invest*

Dermatol **102**:476, 1994

33. Shindo Y et al: Changes in enzyme activities in skin fibroblasts derived from persons of various ages. *Exp Gerontol* **26**:29, 1991

34. de Rigal J et al: Assessment of aging of the human skin by in vivo ultrasonic imaging. *J Invest Dermatol* **93**:621, 1989

35. Gilchrest BA: A review of skin ageing and its medical therapy. *Br J Dermatol* **135**:867, 1996

36. Nelson BR et al: A comparison of wire brush and diamond fraise superficial dermabrasion for photoaged skin: A clinical, immunohistologic, and biochemical study. *J Am Acad Dermatol* **34**:235, 1996

37. Pierard GE, Lapiere CM: The microanatomical basis of facial frown lines. *Arch Dermatol* **125**:1090, 1989

38. Tsuchida Y: The effect of aging and arteriosclerosis on human skin blood flow. *J Dermatol Sci* **5**:175, 1993

39. Roskos KV et al: Pharmacodynamic measurements of methyl nicotinate percutaneous absorption: The effect of aging on microcirculation. *Br J Dermatol* **122**:165, 1990

40. *Report of the Task Force on Immunology and Aging.* Washington, US Department of Health and Human Services, National Institutes of Health, March, 1996

41. Shuster S et al: The influence of age and sex on skin thickness, skin collagen, and density. *Br J Dermatol* **93**:639, 1975

42. Bernstein EF et al: Long-term sun exposure alters the collagen of the papillary dermis: Comparison of sun-protected and photoaged skin by northern analysis, immunohistochemical staining, and confocal laser scanning microscopy. *J Am Acad Dermatol* **34**:209, 1996

43. Castelo-Branco C et al: Relationship between skin collagen and bone changes during aging. *Maturitas* **18**:199, 1994

44. Gerstein AD et al: Wound healing and aging. *Dermatol Clin* **11**:749, 1993

45. Sell DR et al: Longevity and the genetic determination of collagen glycooxidation kinetics in mammalian senescence. *Proc Natl Acad Sci USA* **93**:485, 1996

46. Rongioletti F, Rebora A: Fibroelastolytic patterns of intrinsic skin aging: Pseudoxanthoma-elasticum-like papillary dermal elastolysis and white fibrous papulosis of the neck. *Dermatology* **191**:19, 1995

47. Ghersetich I et al: Hyaluronic acid in cutaneous intrinsic aging. *Int J Dermatol* **33**:119, 1994

48. Meyer LJ, Stern R: Age-dependent changes of hyaluronan in human skin. *J Invest Dermatol* **102**:385, 1994

49. Escoffier C et al: Age-related mechanical properties of human skin: An in vivo study. *J Invest Dermatol* **93**:353, 1989

50. Tobin DJ, Paus R: Graying: gerontobiology of the hair follicle pigmentary unit. *Exp Gerontol* **36**:29, 2001

51. Hordinsky M et al: Hair loss and hirsutism in the elderly, in *Geriatric Dermatology,* Part II, edited by BA Gilchrest. Philadelphia, WB Saunders, 2002, p 121

52. Jacobsen E et al: Age-related changes in sebaceous wax ester secretion rates in men and women. *J Invest Dermatol* **85**:483, 1985

53. Shimokata H, Kuzuya F: Two-point discrimination test of the skin as an index of sensory aging. *Gerontology* **41**:267, 1995

54. Stevens JC, Patterson MQ: Dimensions of spatial acuity in the touch sense: Changes over the life span. *Somatosens Mot Res* **12**:29, 1995

55. Brooke RC et al: Discordance between facial wrinkling and the presence of basal cell carcinoma. *Arch Dermatol* **137**:751, 2001

56. Smith JB, Fenske NA: Cutaneous manifestations and consequences of smoking. *J Am Acad Dermatol* **34**:717, 1996

57. Kligman LH, Sayre RM: An action spectrum for ultraviolet induced elastosis in hairless mice: Quantification of elastosis by image analysis. *Photochem Photobiol* **53**:237, 1991

58. Wulf HC et al: Narrow-band UV radiation and induction of dermal elastosis and skin cancer. *Photodermatology* **6**:44, 1989

59. Kochevar IE: Molecular and cellular effects of UV radiation relevant to chronic photodamage, in *Photodamage,* edited by BA Gilchrest. Cambridge, MA, Blackwell Science, 1995, p 51

60. Ying CY et al: Additive erythemogenic effects of middle- (280–320 nm) and long- (320–400 nm) wave ultraviolet light. *J Invest Dermatol* **63**:273, 1974

61. Kligman LH: UVA enhances low dose UVB tumorigenesis. *Photochem Photobiol* **47**:8s, 1988

62. Lavker RM et al: Cumulative effects from repeated exposures to suberythemal doses of UVB and UVA in human skin. *J Am Acad Dermatol* **32**:53, 1995

63. Gilchrest BA: In vitro studies of aging human epidermis. 1990, in *Review of Biological Research in Aging,* vol 41, edited by M Rothstein. New York, Alan R Liss, 1990, p 281

64. Gilchrest BA, Bohr VA: Aging processes, DNA damage, and repair. *FASEB J* **11**:322, 1997

65. Fisher GJ et al: Molecular basis of sun-induced premature skin aging and retinoid antagonism. *Nature* **379**:335, 1996

66. Kang S et al: Photoaging: Pathogenesis, prevention, and treatment, in *Geriatric Dermatology,* edited by BA Gilchrest. Philadelphia, WB Saunders, 2001, p 643

67. Johnston KJ et al.: Ultraviolet radiation-induced connective tissue changes in the skin of hairless mice. *J Invest Dermatol* **82**:587, 1984

68. Joffe I: Cigarette smoking and facial wrinkling. *Ann Intern Med* **115**:659, 1991

69. Frances C et al: Changes in the elastic tissue of the non-sun-exposed skin of cigarette smokers. *Br J Dermatol* **125**:43, 1991

70. Weitz JI et al: Increased neutrophil elastase activity in cigarette smokers. *Ann Intern Med* **107**:680, 1987

71. Davis BE, Koh HK: Faces going up in smoke: A dermatologic opportunity for cancer prevention. *Arch Dermatol* **128**:1106, 1992

72. Vestal RE, Cusack BJ: Pharmacology and aging, in *Handbook of the Biology of Aging,* 3d ed, edited by EL Schneider, JW Rowe. San Diego, Academic, 1990, p 349

73. Yaar M, Gilchrest BA: Aging and photoaging of keratinocytes and melanocytes. *Clin Exp Dermatol* **26**:583, 2001

74. Nakamura H et al: Clonal nature of seborrheic keratosis demonstrated by using the polymorphism of the human androgen receptor locus as a marker. *J Invest Dermatol* **116**:506, 2001

75. Teraki E et al: Role of endothelin-1 in hyperpigmentation in seborrhoeic keratosis. *Br J Dermatol* **135**:918, 1996

76. Imokawa G et al: Endothelin-1 as a new melanogen: Coordinated expression of its gene and the tyrosinase gene in UVB-exposed human epidermis. *J Invest Dermatol* **105**:32, 1995

77. Hara M et al: Endothelin-1 of keratinocyte origin is a mediator of melanocyte dendricity. *J Invest Dermatol* **105**:744, 1995

78. Sachs DL et al: Skin cancer in the elderly, in *Geriatric Dermatology,* edited by BA Gilchrest. Philadelphia, WB Saunders, 2001, p 715

79. Moriwaki S et al: The effect of donor age on the processing of UV-damaged DNA by cultured human cells: Reduced DNA repair capacity and increased DNA mutability. *Mutat Res* **364**:117, 1996

80. Goukassian D et al: Mechanisms and implications of the age-associated decrease in DNA repair capacity. *FASEB J* **14**:1325, 2000

81. Kessler II: Epidemiological considerations in the role of dendritic/Langerhans cells in human cancer. *In Vivo* **7**:305, 1993

82. Armstrong BK, Kricker A: Epidemiology of sun exposure and skin cancer. *Cancer Surv* **26**:133, 1996

83. Kricker A et al: Does intermittent sun exposure cause basal cell carcinoma? A case-control study in western Australia. *Int J Cancer* **60**:489, 1995

84. Gilchrest BA et al.: The pathogenesis of melanoma induced by ultraviolet radiation. *N Engl J Med* **340**:1341, 1999

85. Morris BT, Sober AJ: Cutaneous malignant melanoma in the older patient, in *Clinics in Geriatric Medicine*, vol 5, edited by BA Gilchrest. Philadelphia, WB Saunders, 1989, p 171

86. Moll I et al: Establishment and characterization of two Merkel cell tumor cultures. *J Invest Dermatol* **102**:346, 1994

87. Fedok FG et al: Angiosarcoma: current review. *Am J Otolaryngol* **20**:223, 1999

88. Spieth K et al: Therapeutic efficacy of interferon-a2a and 13- *cis*-retinoic acid in recurrent angiosarcoma of the head. *Arch Dermatol* **135**:1035, 1999

89. van Voorhees A et al: Papulosquamous disorders of the elderly, in *Geriatric Dermatology,* edited by BA Gilchrest. Philadelphia, WB Saunders, 2001, p 739

90. Elias PM, Ghadially R: The aged epidermal permeability barrier, in *Geriatric Dermatology,* Part II, edited by BA Gilchrest. Philadelphia, WB Saunders, 2002, p 103

91. Jacobson TM et al: Effects of aging and xerosis on the amino acid composition of human skin. *J Invest Dermatol* **95**:296, 1990

92. Gilchrest BA: Pruritus in the elderly. *Semin Dermatol* **14**:317, 1995

93. Elgart ML: Skin infections and infestations in geriatric patients, in *Geriatric Dermatology,* Part II, edited by BA Gilchrest. Philadelphia, WB Saunders, 2002, p 89

94. Martin ES, Elewski BE: Cutaneous fungal infections in the elderly, in *Geriatric Dermatology,* Part II. edited by BA Gilchrest. Philadelphia, WB Saunders, 2002, p 59

95. Helgason S et al: Prevalence of postherpetic neuralgia after a first episode of herpes zoster: prospective study with long term follow up. *Br Med J* **321**:794, 2000

96. Paquette D, Falanga V: Leg ulcers, in *Geriatric Dermatology,* Part II, edited by BA Gilchrest. Philadelphia, WB Saunders, 2002, p 77

97. Yaar M, Gilchrest BA: Bullous pemphigoid: Disease of the aging immune system, in *Clinics in Dermatology,* vol 5, edited by AR Ahmed. Philadelphia, Lippincott, 1987, p 135

98. Uitto J, Pulkkinen L: Molecular complexity of the cutaneous basement membrane zone. *Mol Biol Rep* **23**:35, 1996

99. Hawk JL, Magnus IA: Chronic actinic dermatitis: An idiopathic photosensitivity syndrome including actinic reticuloid and photosensitive eczema. *Br J Dermatol* **101**(suppl 17):24, 1979

100. Kligman LH et al: Prevention of ultraviolet damage to the dermis of hairless mice by sunscreens. *J Invest Dermatol* **78**:181, 1982

101. Thompson SC et al: Reduction of solar keratoses by regular sunscreen use. *N Engl J Med* **329**:1147, 1993

102. Kligman LH et al: Topical retinoic acid enhances the repair of ultraviolet damaged dermal connective tissue. *Connect Tissue Res* **12**:139, 1984

103. Olsen EA et al: Tretinoin emollient cream for photodamaged skin: Results of 48-week, multicenter, double-blind studies. *J Am Acad Dermatol* **37**: 217, 1997

104. Bhawan J et al: Effects of tretinoin on photodamaged skin: A histologic study. *Arch Dermatol* **127**:666, 1991

105. Bhawan J et al: Histologic evaluation of the long-term effects of tretinoin on photodamaged skin. *J Dermatol Sci* **11**:177, 1996

106. Griffiths CE et al: Restoration of collagen formation in photodamaged human skin by tretinoin (retinoic acid). *N Engl J Med* **329**:2038, 1993

107. Woodley DT et al: Treatment of photoaged skin with topical tretinoin increases epidermal-dermal anchoring fibrils: A preliminary report. *JAMA* **263**:3057, 1990

108. Kligman LH: Effects of all- *trans*-retinoic acid on the dermis of hairless mice. *J Am Acad Dermatol* **15**:779, 884, 1986

109. Varani J et al: All- *trans*-retinoic acid (RA) stimulates events in organ-cultured human skin that underlie repair: Adult skin from sun-protected and sun-exposed sites responds in an identical manner to RA while neonatal foreskin responds differently. *J Clin Invest* **94**:1747, 1994

110. Chambon P: A decade of molecular biology of retinoic acid receptors. *FASEB J* **10**:940, 1996

111. Kligman AM et al: Effects of topical tretinoin on non-sun-exposed protected skin of the elderly. *J Am Acad Dermatol* **29**:25, 1993

112. Stiller MJ et al: Topical 8% glycolic acid and 8% lactic acid creams for the treatment of photodamaged skin: A double-blind vehicle-controlled clinical trial. *Arch Dermatol* **132**:631, 1996

113. Ditre CM et al: Effects of alpha-hydroxy acids on photoaged skin: A pilot clinical, histologic, and ultrastructural study. *J Am Acad Dermatol* **34**:187, 1996

114. Werninghaus KI: Role of antioxidants on reducing photodamage, in *Photodamage,* edited by BA Gilchrest. Cambridge, MA, Blackwell Science, 1995, p 249

115. Phillips TJ et al: Hormonal effects on skin aging, in *Geriatric Dermatology,* edited by BA Gilchrest. Philadelphia, WB Saunders, 2001, p 661

116. Rudman D et al: Effects of human growth hormone in men over 60 years old. *N Engl J Med* **323**:1, 1990

T>

Chapter 145

David Nieves Lowell Goldsmith

Cutaneous Changes in Nutritional Disease

ENERGY AND PROTEIN
Protein-Energy Malnutrition in Adults
Protein-Energy Malnutrition in Children
Cancrum Oris (Noma, Necrotizing Ulcerative Gingivitis)
Tropical Ulcer (Tropical Sloughing Phagedena)
Obesity
VITAMINS
Vitamin A (Retinol)
Vitamins of the B Complex
Vitamin C (Ascorbic Acid)
Vitamin K
Vitamin D
ESSENTIAL FATTY ACIDS
ESSENTIAL ELEMENTS
Iron
Zinc
Copper
Selenium
Manganese
ACKNOWLEDGMENT

REFERENCES

Nutrition is the process by which a living organism assimilates food or other substances (i.e., nutrients) and uses them for life, growth, and the maintenance of health. Clinical disease can be caused by nutrient deficiency or, less commonly, by nutrient excess. Nutrient deficiency can be due to inadequate intake, abnormal absorption, or improper utilization. Persons at greatest risk for inadequate nutrient intake include infants and the elderly, the impoverished and neglected, those in and from third-world countries, those with chronic alcoholism, vegetarians, persons on parenteral nutrition, and those with eating disorders or unusual dietary habits. In hypercatabolic states, such as severe chronic illness (cancer, AIDS, etc.), intake may be normal but insufficient to meet the body's increased metabolic needs. Abnormal absorption can be seen in patients with gastrointestinal diseases such as sprue, following gastrointestinal surgery, or after prolonged antibiotic therapy. Improper utilization can be due to hepatic disease or drug-nutrient interactions. Genetic metabolic defects or enzyme deficiencies also can lead to nutrient deficiency, usually presenting early in life. Nutrient excess is usually due to excess dietary or therapeutic intake.

Although the focus of this chapter is the cutaneous manifestations of nutritional disease, it is important to remember that nutritional disorders affect biochemical pathways in multiple organs, producing systemic consequences. Cutaneous findings in nutritional diseases can be very specific, such as the changes seen in scurvy or pellagra. However, the skin findings are often nondiagnostic. Although certain physical findings are associated with inadequate amounts of specific nutrients, it is important to remember that inadequate dietary intake often leads to multiple deficiencies with overlapping clinical signs. The skin and its appendages can be very useful in the diagnosis of nutritional disease, and cutaneous changes are often the patient's chief complaint. The clinician must be careful to suspect and screen for nutritional disease, given the appropriate constellation of skin, hair, nail, mucous membrane, and systemic findings. Laboratory analysis of blood and urine nutrient levels can be helpful but should be interpreted cautiously because there is often poor correlation with tissue concentrations. Clinical improvement following replacement therapy may be the only way to confirm the clinical diagnosis. Table 145-1 summarizes some of the skin findings in nutritional disorders. Several excellent reviews have discussed nutrition and the skin. [1], [2], [3], [4] and [5]

Hair findings	Hypopigmentation
Alopecia	Biotin deficiency
Adult starvation	Copper deficiency
Anemia	Kwashiorkor
Biotin deficiency	Hyperpigmentation
Bulimia	Carotenemia
Essential fatty acid deficiency	Iron overload
Iron deficiency	Kwashiorkor
Marasmus	Lycopenemia
Selenium intoxication	Vitamin B_{12} deficiency
Vitamin A intoxication	Dermatitis
Vitamin D–resistant rickets, type II	Seborrheic dermatitis
Hair shaft changes	Pyridoxine deficiency
Copper deficiency	Riboflavin deficiency
Vitamin C deficiency	Periorificial dermatitis
Hair color	Biotin deficiency
Kwashiorkor	Essential fatty acid deficiency
Manganese deficiency	Zinc deficiency
Selenium deficiency	Acral dermatitis
Selenium intoxication	Zinc deficiency
Vitamin B_{12} deficiency	Photodistributed dermatitis
Follicular hyperkeratosis	Niacin deficiency
Essential fatty acid deficiency	Other dermatitis
Starvation	Folate deficiency
Vitamin A deficiency	Manganese deficiency
Vitamin B-complex deficiency	Purpura
Vitamin C deficiency	Vitamin C deficiency
Vitamin E deficiency	Vitamin K deficiency
Nail findings	Oral and perioral findings
Anemia	Bulimia nervosa
Kwashiorkor	Kwashiorkor
Selenium deficiency	Riboflavin deficiency
Selenium intoxication	Selenium intoxication
Vitamin A intoxication	Thiamine deficiency
Skin findings	Vitamin A intoxication
Biotin deficiency	Vitamin B_{12} deficiency
Kwashiorkor	Vitamin C deficiency
Marasmus	Zinc deficiency
Vitamin A deficiency	Ocular findings
Vitamin A intoxication	Biotin deficiency
Xerosis	Vitamin A deficiency
	Vitamin C deficiency

TABLE 145-1 **Physical Signs of Nutritional Disease**

ENERGY AND PROTEIN

Protein-Energy Malnutrition in Adults

In times of famine and war, many abnormal changes develop in the skin, hair, and nails. The most obvious change is the loss of subcutaneous fat from prominent deposits. The skin becomes dry and rough and loses its elasticity. Follicles appear more prominent. Follicular hyperkeratosis develops, giving the skin a “nutmeg grater” texture. Brown pigmentation develops around the mouth, eyes, and malar prominences. Acne disappears, yet it resumes when nutrition is restored. Hair grows slowly, falls out prematurely, and turns gray. Nail growth is retarded. Furunculosis, scabies, impetigo, skin ulcers, and sores abound. The development of these conditions undoubtedly is exacerbated by the breakdown of sanitary facilities.

The most thorough study of the effects of inanition on the skin of human volunteers was made as part of the monumental Minnesota experiment. The skin of 31 subjects was assessed after 23 weeks on a diet providing only 1570 kcal. In 15 subjects the skin became dry and scaly. It also became cool, and cyanosis developed in the lips and nail beds. Patchy pigmentation appeared in 19 subjects, usually around the mouth, under the eyes, and over the malar eminences. Follicular hyperkeratosis developed in 24 subjects, chiefly on the extensor surfaces of the arms and legs. Of note, the serum vitamin A levels measured at this time were essentially unchanged from the prestarvation baseline values, and no other stigmata of vitamin A deficiency were seen; this suggested an etiology for the follicular hyperkeratosis independent of vitamin A deficiency. In all the volunteers, vesicles filled with sweat were observed frequently during exertion, most likely due to occlusion of sweat ducts. Scalp hair was described as dry and lusterless and fell out easily. [6]

Cutaneous signs of starvation also can be seen in patients with underlying eating disorders such as anorexia nervosa and bulimia nervosa. [7] Eating disorders should be on the differential diagnosis of starvation-related findings, particularly in industrialized nations. Additional findings include features of self-induced vomiting, such as abrasions and scars on the knuckle pads (Russell's sign), dental enamel erosions, and gingivitis. Nails may be brittle. Other psychiatric signs are often present, and management by an appropriate psychiatric professional is critical (see Chap. 40). [7]

Protein-Energy Malnutrition in Children

MARASMUS Total inanition in the child, with intake of all nutrients greatly reduced but especially protein and energy, soon leads to the state of marasmus (Greek, “wasting”). Marasmus is widely prevalent throughout the developing regions of the world and to a large extent contributes to the high mortality in infancy and early childhood. The disturbed nutrition is usually secondary to weaning problems resulting from disease, poor hygiene, poverty, and cultural factors. Infants with repeated bouts of gastroenteritis are particularly at risk. In marasmus, the skin is dry, wrinkled, and loose due to marked loss of subcutaneous fat. The “monkey facies” with loss of the buccal fat pads is characteristic (Fig. 145-1). Emaciation may be extreme (Fig. 145-2). There is some evidence to suggest that pitting edema is seen only if the subcutaneous fat is largely preserved, as in kwashiorkor. Hair is thin, grows slowly, and falls out easily. Broken hairs are common. Nails may be fissured, and nail growth is retarded. In contrast to kwashiorkor, there is classically no clinical edema or dermatosis in marasmus. [8] The presence of HIV infection exacerbates the severity of the protein-energy malnutrition and leads to an extremely poor prognosis. [9]

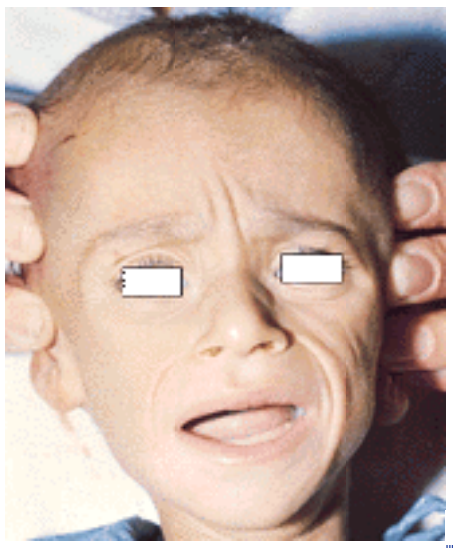

FIGURE 145-1 Marasmus. “Monkey facies” in an Arab infant with wrinkled skin and loss of subcutaneous fat.

FIGURE 145-2 Marasmus. General appearance with advanced disease.

KWASHIORKOR Kwashiorkor is a form of protein-energy malnutrition characterized by edema and variable physical findings that include dermatosis, depigmentation of the hair, irritability, apathy, fatty liver changes, glossitis, and impairment of growth to between 60 and 80 percent of expected body weight. [10] The term *kwashiorkor,* taken from the Ga language of Ghana, refers to the changes "the first child gets when the second is on the way" and the first child is weaned onto a starchy diet. [8] While kwashiorkor originally was believed to be due to severe protein deficiency and relative excess of carbohydrates, other evidence implicates alternative causes, such as free oxygen radicals, leukotrienes, zinc deficiency, essencial fatty acid deficiency, and aflatoxins. [11] Aflatoxins are produced by the fungus *Aspergillus flavus* and may contaminate several of the dietary staples of tropical countries (especially in Africa): maize, casava, and groundnuts. [12] In kwashiorkor, depigmentation develops around the mouth, on the legs, and along wounds, ulcerations, and other injuries (Fig 145-3). In fair-skinned children, the dermatosis begins with blanchable erythema followed by small, dusky purple patches that do not blanch. In dark-skinned children, depigmentation is marked, and disease progression leads to waxy "enamel paint" spots on the trunk, diaper area, trochanters, knees, and ankles. These lesions have a sharp edge and are raised above the skin.

FIGURE 145-3 Kwashiorkor. "Flaky paint" dermatosis.

In mild cases, patients show only a superficial desquamation. In fair-skinned children, this leads to cracking along skin lines termed *mosaic skin* or *cracked skin.* The shins, outer sides of the thighs, and back of the trunk are among the other areas commonly affected. In fair-skinned Arab children, the changes lead to hyperpigmentation of the forehead (Fig. 145-4).

FIGURE 145-4 Kwashiorkor. Scaly hyperpigmented dermatosis of the forehead in an Arab child.

Severe cases display large areas of erosion known as the "flaky paint" or "crazy paving" dermatosis. Advanced cases also may show linear fissuring in the flexures around the pinna, on the backs of the knees, in front of the elbow, in the axilla, between the toes, at the edge of the foreskin, and in the center of the lips. All these lesions appear to be precipitated by intermittent tension, and those occurring at the corners of the mouth should be distinguished from the angular stomatitis of riboflavin deficiency, in which there is a heaped-up, sodden appearance; (Fig. 145-5; see also Fig. 145-13). In severe kwashiorkor, the skin is damaged easily; care must be taken not only to avoid acute trauma but also to avoid chronic pressure injuries in bedridden children. The skin changes of kwashiorkor bear a remarkable resemblance to those of acrodermatitis enteropathica (see Chap. 146). True pellagrous skin changes (see below) can occur in children with evidence of kwashiorkor. This is especially apt to arise when children are weaned onto a diet containing much maize flour, as in south and central Africa.

FIGURE 145-5 Kwashiorkor. Fissuring of lips in a child (compare with riboflavin in Fig. 145-13).

FIGURE 145-13 Riboflavin deficiency. Angular stomatitis with maceration in an Arab child. Riboflavin excretion in the urine was diminished.

Changes in hair also occur in kwashiorkor. Hair that is normally black becomes brown or reddish, and brown hair turns blond. Especially striking is the flag sign (*signe de la bandera*), which refers to the appearance of alternating dark and pale bands in hair that is normally dark; the bands record alternating periods of adequate and inadequate nutrition (Fig. 145-6). The number of anagen hair bulbs is significantly decreased, and the number of telogen bulbs, conversely, is increased. Hairs are severely atrophic and fall out easily. The nails are often thin and soft. [10] The histopathologic findings in the skin include parakeratosis, pallor of keratinocytes in a band across the upper part of the epidermis, and a superficial perivascular lymphocytic infiltrate.

FIGURE 145-6 Kwashiorkor. *A.* Flag sign in a Salvadoran child. *B.* Hypomelanization of the hair and skin.

Although kwashiorkor in children is primarily a disorder seen in developing nations, on occasion it may be seen in the United States. Although early cases in the United States were associated with extreme poverty, most recent cases occur in the setting of avoidance of actual or perceived food allergens, nutritional ignorance, or faddish, unorthodox diets (Rice Dream milk, vegan brown rice emulsion, and goat's milk diet). Because of the early age of onset, the flag sign is generally absent. [11] Kwashiorkor also may be seen in adult hospital patients, although the incidence of this likely has been reduced with improved methods of enteral and parenteral feeding. [8] Treatment of kwashiorkor involves standard food with adequate protein and caloric intake, mineral and vitamin supplements, and antibiotics. Restoring electrolyte balance, particularly of potassium, is also very important. Mortality in kwashiorkor tends to decrease with increased age of onset. However, the severity of growth failure and degree of hypoproteinemia, hypoalbuminemia, and electrolyte imbalance predicts poorer prognosis. Coexisting HIV disease is associated with a very poor prognosis. [13] During treatment, patients may experience involuntary parkinsonian-like tremors known as *kwashi shakes.* The tremors are generalized, gradual in onset, and most pronounced during the third through sixth days of treatment. They usually resolve after 2 weeks. The tremors may be accompanied by cogwheel rigidity, myoclonic jerks, pill-rolling finger tremors, insomnia, and abnormal posturing. The etiology for these findings is unknown. [14]

Cancrum Oris (Noma, Necrotizing Ulcerative Gingivitis)

Cancrum oris (Fig. 145-7) is a gangrenous disease of the tissues of the mouth, face, and surrounding areas. Most cases occur in Africa, although noma occasionally occurs in Asia and Latin America. The disease primarily affects malnourished children, and up to several hundred thousand children under age 6 contract noma each year. The key risk factors are poverty, malnutrition, poor oral hygiene, poor environmental sanitation, close residential proximity to livestock, and recent bacterial or viral infection, particularly measles. [15] Noma is an infectious disease that destroys the orofacial structures and surrounding structures. The infection is polymicrobial and consists mainly of *Fusobacterium necrophorum* and *Prevotella intermedia*. Most cases probably start as an area of ulcerative gingivitis with a tender, firm swelling of the upper gum and underlying bone and some swelling of the overlying part of the face. Very soon the teeth loosen, and inflammation spreads into the underlying bone, with osteitis and a sequestrum. The cheek usually ulcerates, producing a cavity leading directly into the mouth. A strong putrid odor is usually present. Some case reports describe involvement of the scalp, neck, shoulders, perineum, and vulva.

FIGURE 145-7 Cancrum oris (noma). Massive destruction of the face in a Tanzanian child.

Without treatment, there is rapid progress of the disease, leading to death in 70 to 90 percent of patients. [15] Antibiotics can halt the progression of the disease. Treatment consists of penicillin plus either streptomycin or metronidazole. Clindamycin has been used successfully in Japan. Despite treatment, however, massive residual defects continue to present extremely difficult reconstructive surgery problems, particularly in relation to the relatively primitive medical facilities available where the disease occurs. A full diet is of great value, especially one rich in protein, high in energy value, and providing all vitamins and essential elements. Feeding difficulties can be overcome if total parenteral nutrition is available. [16] Although largely a disease of developing nations, noma has been reported rarely in the West. Several cases developed in Nazi concentration camps. It also has been noted in immunodeficiency states resulting from medications, HIV/AIDS, and severe combined immunodeficiency syndrome. This would indicate that multiple local and systemic factors are implicated in the pathogenesis of noma, with the common denominator being a depressed immune system. [15]

Tropical Ulcer (Tropical Sloughing Phagedena)

This chronic condition, chiefly affecting the lower limbs above the malleoli, shares with cancrum oris the frequent background of general malnutrition of the patient and the occurrence of Vincent's organisms in the lesions. A survey [17] of 170 patients in Zambia, Gambia, South India, and Papua New Guinea found that children and teenagers were affected most commonly. In this particular study there was no correlation between the development of an ulcer and nutritional status. Nevertheless, a good diet, rest, and antibiotics give good results, and healing is usually complete within 6 months. Surgical debridement of dead tissue may be very helpful. [18] The disease starts with the formation of a larger or smaller blister with serosanguineous contents. When the bulla ruptures, an ash-gray moist slough is exposed. The sloughing process extends rapidly until the skin and subcutaneous fascia over quite a large area may be converted into a yellowish, moist, foul-smelling ulcer. In extensive cases, muscles, tendons, nerves, vessels, and even the periosteum may share in the gangrenous process. Even after healing, deformity may ensue from ankylosis, and a contracting cicatrix may strangulate a vital part, necessitating amputation. Smaller healed tropical ulcers leave behind tissue paper–like scars with pigmented edges. These are prone to break down.

Obesity

Skin disorders tend to be common in the obese. Excessive fat folds lead to intertrigo from friction between skin surfaces and to maceration of the skin from accumulated moisture in the folds. Infection frequently supervenes, particularly with staphylococci, dermatophytes, and yeast. The obese become overheated easily and sweat more profusely because of the thick layers of subcutaneous fat; areas of inflammation and skin rashes are thus exaggerated. Striae are seen more frequently, with common sites including the thighs, arms, abdomen, back, and buttocks. Obesity-associated acanthosis nigricans manifests as symmetric, velvety, papillomatous, hyperpigmented plaques in the axilla, groin, and sides of the neck. However, other sites can be involved. Skin tags are seen often in obesity, with or without associated acanthosis nigricans. Hirsutism is more common in the obese, and many obese patients have either a diabetic tendency or frank diabetes, with all the accompanying dermatoses. It is important in all these circumstances that due attention be paid during treatment to measures aimed at correction of the underlying obesity; otherwise, local treatment of the skin lesions will remain purely palliative. [19]

VITAMINS

Vitamin A (Retinol)

Vitamin A plays an important role in development, epithelial proliferation, keratinization, and the transduction of visual images by the retina. Vitamin A is a fat-soluble vitamin found only in the animal kingdom. It is obtained in the diet through consumption of liver, fish, and other animal products. After absorption, it is transported via chylomicrons to the liver. It may be stored there as retinyl esters or transported to peripheral sites by retinol-binding protein. Vitamin A also may be obtained in the diet through metabolism of carotenoids found in fruits and vegetables. Vitamin A is measured in international units, where 1 IU = 0.3 µg retinol. [20]

VITAMIN A DEFICIENCY The principal causes of vitamin A deficiency are inadequate diet (chiefly in the third world or in cases of anorexia), fat malabsorption, and liver disease. [5] The clinical manifestations primarily involve the visual system, the immune system, and the skin. Vitamin A deficiency has been associated with increased childhood mortality. Ocular manifestations of vitamin A deficiency include night blindness and disease of the conjunctiva (xerosis conjunctivae), sclera (Bitot spots, which are white patches representing shed corneal epithelium), and cornea (xerosis corneae and karatomalacia). Vitamin A deficiency is a leading cause of blindness, especially in children, throughout the developing world. [4] Vitamin A deficiency also has been shown to reduce immunity in a number of ways. Production of antibodies to bacterial polysaccharides becomes impaired. Natural killer cell number and function are decreased. Activity against viral infections (such as measles and HIV) and parasites is also diminished. [21] Severely malnourished persons with vitamin A

deficiency exhibit skin changes termed *dermomalacia*. The skin over large areas of the body is dry, wrinkled, and covered with fine scales. Deep, excavated lesions also may be present. Marked changes of this type are extremely uncommon, even in children with bilateral keratomalacia (Fig. 145-8 and Fig. 145-9).

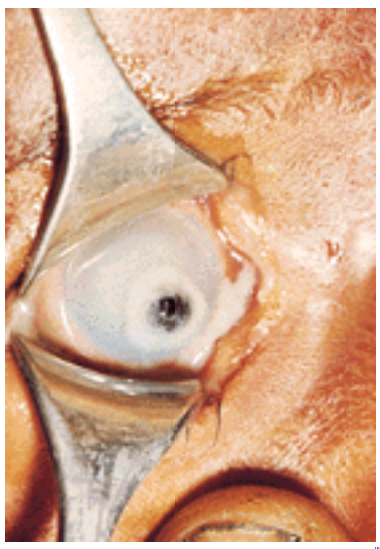

FIGURE 145-8 Vitamin A deficiency, advanced keratomalacia, in a 5-month-old Arab child. Note hyperkeratosis of facial skin. Serum vitamin A level was 2 µg/dL (normal 20–50 µg/dL).

FIGURE 145-9 Vitamin A deficiency. General appearance in the same patient as in Fig. 145-8.

Histologically, skin lesions that can confidently be attributed to vitamin A deficiency represent primary hyperkeratinization and hyperplasia of the epidermis, including the lining of the hair follicles and sebaceous glands. In infants and very young children, before the pilosebaceous follicle has matured fully, simple xerosis, or xeroderma, is usually the characteristic feature. [22] In adults, especially with advanced ocular changes, the stratum corneum forms a broad network of horny plates, with abundant desquamation of fine scales. The basal layers have increased melanin deposition. Sebaceous glands are reduced in number. Sweat ducts are occluded by keratinous material; although normal in appearance, they are probably hypofunctional. Other epithelial surfaces of the body may develop keratinizing metaplasia. The dermis is otherwise normal except for a perifollicular infiltrate. [5] Another cutaneous response to vitamin A deficiency is a type of follicular hyperkeratosis called *phrynoderma* or “toad skin.” This eruption (Fig. 145-10 and Fig. 145-11) has been associated with deficiencies of vitamins A, B complex, C, and E, calories, and essential fatty acids. The morphology of these lesions is variable and may range from filiform papules to small conical papules to large papules with large horny centers. They may be the same color as the surrounding skin or may be slightly hyperpigmented. In a review of 105 patients with phrynoderma, 82 cases were limited to the areas around the elbows and knees. In the remaining 23 patients, the initial lesions appeared at these sites but spread rapidly along the anterolateral aspects of the thighs, the posterolateral aspects of the superior forearms, the extensor surfaces of the upper and lower extremities, and the shoulders, abdomen, back, and buttocks. The background skin in affected areas appeared wrinkled. Of note, in this series, serum vitamin A level was found to be abnormal in only 4 of 76 patients in whom it was measured. [23] Alternative diagnoses that can cause hyperfollicular keratosis include keratosis pilaris and Darier's disease.

FIGURE 145-10 Vitamin A deficiency. Typical perifollicular hyperkeratosis of the chest in a Tanzanian adult male.

FIGURE 145-11 Vitamin A deficiency. Marked perifollicular hyperkeratosis on the arm in an undernourished Iranian child.

Vitamin A deficiency is assessed by measurement of the serum retinol level. Treatment of vitamin A deficiency with administration of 100,000 to 300,000 IU/day of retinol rapidly corrects some visual disturbances, although corneal ulcers are permanent. Skin changes respond over a period of weeks to months. [5] General dietary supplementation of vitamin A reduces childhood mortality in developing countries. [21]

VITAMIN A TOXICITY (HYPERVITAMINOSIS A) The skin is frequently involved in both acute and chronic forms of vitamin A toxicity. Birth defects have been associated with maternal intake of 25,000 IU/day. [20] Acute toxicity may occur after ingestion of 500,000 IU or greater by adults or proportional amounts by children (over 100 times the recommended daily allowance). [24] Acute vitamin A intoxication causes skin desquamation, abdominal pain, nausea, vomiting, and muscle weakness. Chronic poisoning results from injudicious therapeutic use of the vitamin or its derivatives. Chronic intoxication typically occurs after consuming 50,000 IU/day for several months, although lower doses may be toxic in individuals with liver disease or malnutrition or in individuals taking certain drugs. Children are especially vulnerable and may suffer toxicity with daily intakes as low as 1500 IU/kg. The cutaneous symptoms include desquamation, pruritus, facial dermatitis, dryness of the mucous membranes, erythema, brittle nails, cheilitis, and alopecia. Systemic sequelae include bone pain, elevated CSF pressure, headache, fatigue, irritability, splenomegaly, pseudotumor cerebri, and hepatoxicity. [20] Symptoms of acute and chronic vitamin A intoxication are reversible on cessation of overdosing. [24]

CAROTENEMIA Carotenemia is a clinical condition that may lead to yellow discoloration of the skin. Carotenemia is caused by elevated serum concentrations of carotenoids, pigments of plant origin that are dietary precursors to vitamin A in humans. Among the carotenoids that have been characterized, carotene is the chief dietary source of vitamin A in humans. Carotene exists in three forms: a, ß, and ?. Of these, ß-carotene has the greatest physiologic activity and yields two molecules of vitamin A when metabolized. Carotenemia may develop in several ways. The main cause by far is excessive consumption of carotene-rich foods. In general, the deeper green or yellow color of a vegetable or fruit correlates with increased carotene content. [25] During World War II, dietary carotenemia was observed commonly in Great Britain, where the public was exhorted to consume carrots in place of meat. In parts of West Africa, dietary carotenemia often results from use of red palm oil in cooking. [26] Dietary carotenemia also may be seen in food fadists, patients attempting to lose weight by eating low-calorie foods such as carrots, infants consuming the breast milk of carotenemic mothers, and children consuming homogenized diets (especially baby food). Anorexia nervosa is well known to cause carotenemia, although the etiology is unclear. Lycopene, an inert isomer of ß-carotene, is found chiefly in tomatoes, beets, and rose hips. [25] Excess ingestion of this compound results in orange-yellow skin pigmentation termed *lycopenemia.* Endocrine dysfunction can lead to carotenemia. Hypothyroidism markedly reduces conversion of carotene to vitamin A, leading to accumulation of excess carotene. Moreover, the hyperlipidemia that results from hypothyroidism results in increased amounts of ß-lipoproteins, which are the major carriers of carotene in the blood. In persons with diabetes, the conversion of vitamin carotene into vitamin A is also deficient and may lead to carotenemia. Hypothalamic amennorhea has been described in association with carotenemia as well. Chronic glomerulonephritis and the nephrotic syndrome lead to carotenemia, although in nephrosis the skin changes may be absent. Malaria has been described as a cause of carotenemia. Finally, inborn errors of metabolism also may cause carotenemia, although the biochemistry of these has not yet been characterized. Clinically, carotenemia is characterized by yellow pigmentation of the skin. Carotene is excreted by eccrine and sebaceous glands, and the distribution of pigmentation favors the palms, soles, and nasolabial folds. The discoloration is most pronounced in artificial light. The palate may be involved occasionally. Overall, carotenemia is harmless. It can resemble jaundice clinically but may be distinguished by the distribution of pigment, the absence of scleral icterus, and normal bilirubin levels. Treatment of carotenemia is directed at the underlying etiology. Correction of dietary excess reduces serum carotene levels sharply within 1 week. The yellow discoloration fades within several weeks to months.

Vitamins of the B Complex

NIACIN (PELLAGRA) Niacin (vitamin B_3) is obtained in the diet or may be synthesized endogenously from tryptophan. Two amide derivatives of niacin, nicotinamide-adenine dinucleotide (NAD) and nicotinamide-adenine dinucleotide phosphate (NADP), play important roles in carbohydrate and fatty acid metabolism. Deficiency of niacin may occur in several states. Historically, the most important cause has been inadequate dietary intake, chiefly in impoverished populations subsisting on corn-based diets. Other populations at risk include alcoholics, elderly persons, homeless persons, and the mentally ill. Classically, it occurs in impoverished populations subsisting on monotonous corn-based diets. This was described by Casal in 1735 and was studied in depth during the early twentieth century by Goldberger. [5] In a series of classic clinical trials, Goldberger demonstrated that the clinical features of pellagra could be both prevented and corrected by a varied diet rich in animal protein. It is worth noting that corn does in fact contain sufficient quantities of niacin to meet human dietary needs; however, much of this exists in a bound form that is not absorbed easily. Bound niacin may be released by soaking corn in alkali prior to cooking, a traditional practice among native peoples of Mexico and Central America that was protective against pellagra. In the early twentieth century, a pellagra epidemic that occurred in the southern United States was likely caused by the introduction of degermination, which reduced the niacin content of corn products by 25 to 40 percent. [27], [28] Gastrointestinal malabsorption may cause pellagra. Malabsorption of niacin may occur in persons with jejunoileitis, Crohn's disease, gastroenterostomy, or subtotal gastrectomy. Drugs also can cause pellagra. Isoniazid impairs the activity of pyridoxine, a cofactor in endogenous niacin biosynthesis. 6-Mercaptopurine has been associated with pellagra, possibly due to interference with NAD phosphorylase. 5-Fluorouracil may cause pellagra and has been demonstrated to inhibit conversion of tryptophan to niacin. [5] Other medications that have been implicated include sulfonamides, anticonvulsants, and antidepressants. [1] Some systemic illnesses induce the deficiency. Carcinoid tumors produce large quantities of serotonin, depleting the supply of tryptophan available for niacin synthesis. Hartnup's disease, a rare autosomal recessive disorder of amino acid transport,

causes malabsorption of dietary tryptophan and several other amino acids and may lead to pellagra, cerebellar ataxia, psychosis, and aminoaciduria. Pellagra is characterized by the three D's—dermatitis, diarrhea, and dementia—although many cases do not present with the classic triad. The dermatosis is usually preceded by prodromal symptoms, especially of the digestive system. The skin changes are characteristic and pathognomonic, and their distribution is determined especially by exposure to the sun and by localized pressure. The dermatosis begins as erythema on the dorsa of the hands with pruritus and burning. It is characteristically symmetric with slight edema of the skin. In some patients, several days after the onset of the erythema, blisters appear; these run together to form bullae and then break. In others, dry brown scales form. On the face, the scales are thicker, larger, and frequently become pustular. In the second stage, the dermatosis becomes hard, rough, cracked, blackish, and brittle. The epidermis of the fingers thickens, and the articular folds disappear. Painful fissures develop in the palms and on the digits. When the deficiency state is far advanced, the skin becomes covered with scales and blackish crusts that are due to hemorrhages. The usual sites are the face and neck and dorsal surfaces of the hands, arms, and feet. On the dorsa of the hands, the lesions may extend up the arms to form the “glove” or “gauntlet” of pellagra (Fig. 145-12A). The symmetry and clear line of demarcation from normal skin are especially striking. On the feet, the lesions usually do not rise proximally to the malleoli, which are included; the heels remain free. Distally, the eruption ends at the toes or on the backs of the great toes. The front and back of the leg may be involved to form a “boot.” On the face, the symmetry of the lesions is striking. They tend to spread from the sides to the rest of the nose, the forehead, cheeks, chin, lips, and more rarely, eyelids and ears. The “butterfly” appearance, similar to lupus erythematosus, is frequent. On the forehead, there is always a narrow border of normal skin between the erythema and the hair. The face is often only slightly affected. The facial lesions never appear independently of lesions on the hands and elsewhere.

FIGURE 145-12 Pellagra. Acute dermatosis: *A.* “Glove” or “gauntlet” exudative and crusted lesions on the hands. *B.* “Casal's necklace” on the neck with facial involvement.

Casal's necklace extends as a fairly broad band, or collar, entirely around the neck (see Fig. 145-12B). If the band is incomplete, the lesions are striking in their symmetry. The upper border reaches from somewhat below the hairline to the larynx anteriorly. The lower border begins under the vertebral prominences and extends to the edge of the manubrium. In many instances the necklace has an anterior continuation or broad “cravat” extending from the manubrium over the sternum to the level of the nipples, ending in a point or square. The necklace is always accompanied by the characteristic dermatosis elsewhere. Other sites occasionally affected are the shoulders, elbows, forearms, and knees. [5] In the past, niacin deficiency was believed to lead to angular cheilitis and nasolabial seborrhea, and their presence without the remainder of the rash described earlier was known as *pellagra sine pellagra*. In later years, these findings, as well as the so-called pellagrous vulvitis, vaginitis, and lesions of the perianal region and scrotum, were found to be caused by deficiency of riboflavin rather than niacin. [29] Healing of the skin lesions usually takes place centrifugally, with the line of demarcation remaining actively inflamed after the center of the lesion has desquamated. Histologically, pellagra skin lesions show hyperkeratosis, parakeratosis, acanthosis, and increased numbers of melanin granules throughout the epidermis. The spinous layer may show vacuolar changes—a finding also seen in acrodermatitis enteropathica and necrolytic migratory erythema. Sebaceous glands may be atrophic. A mild to moderate mononuclear infiltrate may be present. In later lesions, only psoriasiform rete ridge elongation remains. [5] The photobiology of pellagra is poorly understood. [30] Although pellagra is primarily a clinical diagnosis, it may be confirmed by fluorometric assay of urinary metabolites (2-pyridone/ *N′*-methyl niacinamide ratio less than 2.0). [31] Specific therapy consists of the oral administration of 100 to 300 mg of niacinamide daily in divided doses. The amide is preferable because it does not precipitate the vasomotor disturbances resulting from administration of niacin in large doses. Therapy may be given subcutaneously when diarrhea or a noncooperative patient makes oral administration ineffective or difficult. Multivitamins (especially other vitamins of the B complex) and a high-quality protein diet should be given.

RIBOFLAVIN (ORO-OCULOGENITAL SYNDROME) Riboflavin (vitamin B_2) is metabolized to flavin mononucleotide (FMN) and flavin-adenine dinucleotide (FAD), which are cofactors for enzymes involved in oxidation-phosphorylation, neutrophil superoxide formation, purine metabolism, and vitamin B_6 metabolism. It is found in milk, meat, fish, and eggs. [5] Deficiency of riboflavin occurs in several clinical settings, with the predominant one being a diet of unenriched cereals. Clinical deficiency usually occurs 3 to 5 months after an inadequate diet. In rural areas of India, China, and Iran, riboflavin deficiency is endemic and develops in infants who are not fed milk after being weaned from breast-feeding. Biochemical evidence of riboflavin deficiency also has been reported in association with hypothyroidism, Plummer-Vinson's syndrome, chlorpromazine use, acute borate poisoning, [32] and phototherapy for neonatal hyperbilirubinemia. [33] The clinical manifestations of riboflavin deficiency in humans are mainly cutaneous. It may affect the mouth, eyes, and genital area and is known as the oro-oculogenital syndrome. In the mouth, glossitis denudes the papillae and causes the tongue to appear magenta-colored. Angular stomatitis, also called *perlèche* (French, *perlècher*, “to lick thoroughly with the tongue”) develops; this refers to soggy, white, angular perioral lesions often associated with moniliasis (Fig 145-13). These lesions may bleed. Vertical fissures of the lip, termed *cheilosis,* develop. A dermatitis similar to seborrheic dermatitis develops along the nasalolabial folds, cheeks, forehead, and postauricular regions. Ocular findings associated with riboflavin deficiency are conjunctivitis and photophobia. Dermatitis of the genital area may develop, followed by lichenification in chronic cases. In men, dermatitis begins on the scrotum and spares the

median commisure. It may extend up the penis or onto the inner aspects of the thighs. In women, the vulva is affected. Infants and children with concurrent kwashiorkor develop epidermal necrosis, leading to the so-called peeling-paint dermatosis. Extracutaneous findings also may develop in persons deficient in riboflavin. A normochromic, normocytic anemia may occur. In children, retarded intellectual development and electroencephalographic changes have been noted. [4], [5] Photophobia develops in severe cases. [32] When solitary, riboflavin deficiency usually responds promptly and dramatically to riboflavin supplementation. Therapy is with 1 to 3 mg/day in infants and 10 to 20 mg/day in adults. [5]

PYRIDOXINE (VITAMIN B_6) Vitamin B_6 occurs in three interchangeable forms: pyridoxine, pyridoxamine, and pyridoxal. The active form in most enzyme systems is pyridoxal-5-phosphate. Vitamin B_6 acts mainly as a coenzyme in the decarboxylation and transamination of a number of amino acids. It also plays a role in the conversion of linoleic to arachidonic acid and in adrenocortical function. The primary dietary sources of pyridoxine are meat, whole-grain cereals, green leafy vegetables, and potatoes. [34] The daily physiologic requirement of pyridoxine is 1 mg. Clinical deficiency of pyridoxine may occur due to inadequate dietary intake, usually in conjunction with other vitamin deficiencies. Alcoholism can lead to pyridoxine deficiency. Pyridoxine deficiency may be induced by drugs that increase excretion or decrease activity of the coenzyme, chiefly isoniazid, hydralazine, phenelzine, cycloserine, and penicillimine. Oral contraceptives may alter pyridoxine metabolism but rarely cause clinical symptoms of deficiency. Patients taking isoniazid or birth control pills require 30 mg/day, and patients taking penicillamine require 100 mg/day. In addition, symptoms of pyridoxine deficiency can occur after prolonged administration of an antimetabolite, desoxypyridoxine. In one study, 50 participants were administered variable doses of desoxypyridoxine daily for periods ranging between 3 and 52 weeks and were followed prospectively for sequelae. Cutaneous findings observed included seborrhea-like changes of the face, scalp, neck, shoulders, buttocks, and perineum. Other findings included angular stomatitis, cheilosis, glossitis, conjunctivitis, and intertrigo. Participants developed constitutional symptoms of anorexia, nausea, and vomiting. Many subjects developed neurologic disturbances that included hyperesthesia, ascending paresthesia, altered vibration and position sense, and hypoactive deep tendon reflexes. Normochromic, normocytic anemia, lymphopenia, and eosinophilia also were seen. [35] The diagnosis of pyridoxine deficiency may be established by detection of decreased serum levels of pyridoxal phosphate. [4] Alternatively, a tryptophan loading test can be performed. Tryptophan is endogenously converted into thiamine via a pathway that includes the pyridoxine-dependent enzyme kynurenase. When pyridoxine is deficient, 3-OH kynurenine accumulates and ultimately is broken down to xanthurenic acid, leading to urinary xanthurenic acid excretion. Replacement of pyridoxine leads to rapid improvement of oral and cutaneous lesions over days. Treatment is with 10 to 25 mg pyridoxine per day. [4] Pyridoxine deficiency should not be confused with pyridoxine dependency. The latter refers to inborn errors of metabolism in which the binding of pyridoxine to its apoenzyme is impaired (due to, for example, a mutation at the binding site) but can be overcome when pyridoxine is administered in large doses. Some disorders that lead to pyridoxine dependency are pyridoxine-dependent epilepsy, [36] pyridoxine-responsive homocysteinuria, [37] and xanthurenic aciduria. [38]

VITAMIN B_{12} (CYANOCOBALAMIN) This vitamin is a cofactor for two reactions in animals: the conversion of methylmalonyl coenzyme A (CoA) to succinyl CoA by methylmalonyl CoA mutase and synthesis of methionine from homocysteine by homocytsteine methyltransferase (which also results in conversion of *N* [5]-methyl-tetrahydrofolate into tetrahydrofolate). Tetrahydrofolate from the latter reaction is a substrate for DNA synthesis. Vitamin B_{12} is produced by the natural bacterial flora of animals and is obtained in the diet only from consumption of animal products. [39] Deficiency of vitamin B_{12} occurs in several settings. Insufficient dietary intake occurs among vegetarians and alcoholics. Malabsorption occurs when gastric synthesis of intrinsic factor is impaired, such as in autoimmune pernicious anemia or following gastrectomy. Ileal absorption of vitamin B_{12} may be decreased by tropical sprue, Crohn's disease, postileectomy states, Zollinger-Ellison's syndrome, and Whipple's disease. Alterations of gut flora, especially those caused by infection with *Diphyllobothrium latum,* reduce vitamin B_{12} absorption. [5] Congenital lack of transcobalmin II, a B_{12} transport protein, has been reported. [4] Because body stores of vitamin B_{12} are large (4 mg) relative to the minimum daily requirement (2.5 µg), a deficiency state must persist for 3 to 6 years before symptoms develop. The predominant cutaneous manifestation of vitamin B_{12} deficiency is the development of generalized hyperpigmented macules and patches. These favor the skin of flexural areas, palmar creases, soles, knuckles, and oral mucosa. Nail plates develop longitudinal, hyperpigmented streaks. The hair may turn gray. Vitamin B_{12} deficiency caused by pernicious anemia is associated with vitiligo and alopecia areata. The tongue may be beefy red and may burn. The hyperpigmentation of vitamin B_{12} deficiency must be distinguished from the hyperpigmentation of Addison's disease. Descriptions of the histology of the hyperpigmented lesions of vitamin B_{12} deficiency vary. One report described an increased number of melanocytes in the basal layer with numerous melanophages in the papillary dermis. Pigmentary incontinence has been reported with and without increased epidermal melanin. Hypotheses to describe these latter findings include (1) levels of the reduced form of glutathione are decreased, thus permitting unopposed synthesis of melanin by tyrosinase, (2) defective transfer of melanin between melanocytes and keratinocytes, and (3) corresponding increases in biopterin, which is involved in hydroxylation of phenylalanine and may stimulate melanin production. Systemic findings in vitamin B_{12} deficiency include macrocytic anemia and occasional cardiac symptoms. Synthesis of myelin is impaired, causing paresthesias, numbness of the extremities, ataxia, altered reflexes, and changes in mental status. If the deficiency is not corrected, serious degeneration may occur in the dorsal columns of the spinal cord. Treatment with parenteral cyanocobalamin (1 mg per week for a month and then 1 mg per month thereafter) reduces fatigue in several days, corrects anemia in weeks, and reverses cutaneous changes in 1 year. Neurologic symptoms may resolve or persist. [5], [40]

VITAMIN B_1 (THIAMINE) Thiamine pyrophosphate is an enzyme involved in carbohydrate metabolism by decarboxylating a-keto acids. It is also a coenzyme in the pentose monophosphate pathway for glucose. Thiamine is obtained in the diet through consumption of pork, poultry, milk, eggs, dry beans, peas, and enriched bread products. Although it occurs naturally in brown rice and cereal grains, the “polishing” of rice and milling of grain cause it to be lost. Thiamine deficiency causes two clinical disorders. In Asia, persons subsisting on polished-rice diets develop beri-beri, a disorder characterized by fatigue, peripheral neuropathy, polyneuritis, heart failure, edema, angular stomatitis, and glossitis. In the United States, thiamine deficiency mainly results from poor dietary intake in association with alcoholism. This presents as the Wernicke-Korsakoff syndrome, characterized by apathy, loss of memory, and confabulations. [34] Thiamine replacement is critical. Thiamine deficiency is often seen associated with other B-complex vitamin deficiencies as well as folate deficiency, and broad nutritional support is usually required.

FOLIC ACID Folic acid acts as a coenzyme in purine and pyrimidine nucleotide biosynthesis. Folic acid deficiency

produces a megaloblastic anemia. Dermatologic findings are rare but were described in one case report. Findings included scaly papules and plaques on the face, trunk, and extremities, particularly on extensor surfaces. Stomatitis and glossitis were also present. The histology of folic acid deficiency shows changes of chronic dermatitis with marked epidermal abnormalities. The keratinized layers are separated by blood and proteinaceous material. The granular layer is absent at some sites. Keratinocyte nuclei show significant variations in size, and many large, irregular forms are present. The basal layer shows some areas of hyperpigmentation and spongiosis. In the dermis, there is a heavy inflammatory cell infiltrate. [41] Serum levels of folic acid are low. Prior to treatment with folate, it is important to rule out a coexisting vitamin B_{12} deficiency. Otherwise, the folate supplementation will alleviate the megaloblastic anemia, but the neurologic damage (from vitamin B_{12} deficiency) will continue to progress.

BIOTIN Biotin is a coenzyme in carboxylation reactions involved in fatty acid synthesis, gluconeogenesis, and amino acid catabolism. It is found throughout the diet, particularly in egg yolks, legumes, and nuts. It is also synthesized by bacteria in the human gut. Biotin deficiency may be acquired or may be due to inborn deficiency of either holocarboxylase synthetase or biotinidase. Acquired biotin deficiency usually results from excess intake of egg whites. Egg whites contain avidin, which blocks absorption of biotin. Malabsorption also has been described in an infant with short gut syndrome receiving broad-spectrum antibiotics. Deficiency also has occurred in patients receiving total parenteral nutrition without added biotin. The clinical features are fine desquamation on the extremities, periorificial eczema, alopecia, pallor, and atrophy of the tongue. Treatment with biotin 150 µg/day corrects symptoms within 1 week. [5] Holocarboxylase synthetase links free biotin to apocarboxylase enzymes that use it as a cofactor. Deficiency of holocarboxylase synthetase causes multiple carboxylase deficiency, an autosomal recessive disorder that presents with overwhelming, often fatal illness in the neonatal period. Massive ketosis and metabolic acidemia (especially lactic acidemia) develop, and 3-hydroxyisovaleric acid and 3-methylcrotonylglycine are excreted in the urine. Seizures often occur. An erythematous, scaly rash resembling ichthyosis or seborrheic dermatitis develops over the entire body. Alopecia is present over the scalp, eyelashes, and eyebrows. Lanugo hair is also absent. T cell responses to *Candida* antigen are diminished. Treatment with biotin (10–40 mg daily) corrects the acidemia, skin lesions, and most neurologic symptoms, although urinary 3-hydroxyisovaleric acid remains high. Biotinidase deficiency reduces biotin absorption and reduces the recycling of free biotin. The estimated frequency of profound biotinidase deficiency is approximately 1 in every 140,000 live births. The most frequent symptoms, which usually present after several months of age, are feeding problems, irritability, respiratory problems, seizures, delayed mental development, and hypotonia, especially delayed head control. Irreversible abnormalities of the optic and auditory nerves have been reported. Affected children have a nonspecific scaly, erythematous rash in periorificial areas similar to that seen in acrodermatitis enteropathica and essential fatty acid deficiency. Hair is sparse on the head, and the eyebrows and eyelashes may be involved. Occasionally, alopecia totalis occurs. Corneal ulcers and keratoconjunctivitis may develop. Life-threatening episodes of acidemia can occur, and chronic acidosis has been reported. The organic acidura described earlier is present in this disorder as well. T cell responses to *Candida* antigen are diminished. Inborn errors of biotin metabolism may be diagnosed by elevated levels of urinary 3-hydroxyisovaleric acid. Subsequent measurement of serum biotinidase levels distinguishes between the two. In 1984, biotinidase deficiency became part of many routine neonatal screening programs. [5], [42], [43]

PANTOTHENIC ACID (VITAMIN B_5) This is a component of coenzyme A and is involved in the process of acetylation. No cutaneous changes occur in humans deficient in this vitamin.

Vitamin C (Ascorbic Acid)

Vitamin C plays an important role in the formation of collagen. It is a necessary cofactor for prolyl hydroxylase, which catalyzes the hydroxylation of proline and lysine residues in procollagen. Nonhydroxylated collagen is weaker, less stable, and does not adopt the usual triple-helical structure. Vitamin C also aids iron absorption, increases bioavailability of selenium, and may increase the conversion of cholesterol to bile acid.

Vitamin C deficiency (scurvy) usually is seen in individuals with inadequate intake of fresh fruits or vegetables, such as the elderly or those who abuse alcohol. In addition, the human vitamin C requirement is increased by smoking, aspirin, sulfinpyrozone, indomethacin, phenylbutazone, tetracycline, oral contraceptives, corticosteroids, and chlorcyclizine. [1]

Clinical manifestations often remain latent for several months following onset of severe vitamin C deficiency. Symptoms begin with myalgias, malaise, and weakness. Cutaneous manifestations begin with follicular hyperkeratosis; the associated hair is often coiled or looped (corkscrew hairs). Hairs may be bent at multiple sites, leading to a swan-neck deformity. The main sites affected are the upper arms, back, buttocks, thighs, calves, and shins. Perifollicular purpura follows, particularly on the legs (Fig. 145-14). Electron microscopy reveals discontinuity of the vascular endothelium, ballooned endothelial cells, and a decrease in the dermal collagen that provides vascular support. The perifollicular location of the hemorrhages may be the result of mechanical irritation caused by the movement of hair. Generalized ecchymoses can occur. Old scars break down, and new wounds heal poorly. Lower-extremity edema also has been noted, and in the mouth, the gums become red, swollen, and may bleed. Gingival necrosis may occur ultimately. Gingival abnormalities occur only in the presence of teeth.

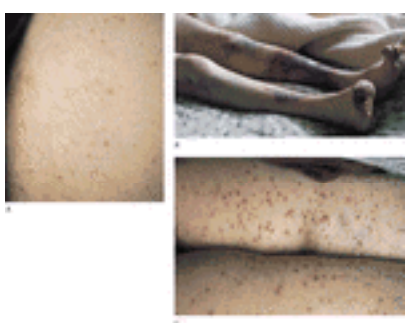

FIGURE 145-14 Vitamin C deficiency (scurvy) in a 61-year-old male in Edinburgh, Scotland. *A.* Swan-neck deformity of the hairs. *B.* Ecchymoses over the legs, especially around a varicose ulcer on the left. *C.* Numerous perifollicular hemorrhages.

Patients with scurvy experience musculoskeletal pain that can be incapacitating. This may be caused by hemarthroses and subperiosteal hemorrhage. Hemorrhages also occur in various compartments of the eyes. [44] One uncommon finding is the development of a Sjögren-like syndrome consisting of keratoconjunctivitis sicca, xerostomia, and enlargement of salivary glands. The etiology of this is unknown. [45] Hypotension, dyspnea, and chest pain occur in scurvy, although the mechanism is unclear. [5]

Diagnosis is usually based on history, characteristic findings on physical examination, and determination of L-ascorbic acid levels.

Biopsy is usually not necessary but can help to exclude cutaneous vasculitis. Patients respond quickly to the administration of oral vitamin C (100 mg three times daily). A daily intake of vitamin C in the form of fresh fruits or supplements should be ensured. [44]

Vitamin K

Vitamin K, or phytonadione, is a cofactor in the carboxylation of glutamate residues for coagulation factors II (prothrombin), VII, IX, and X and proteins C and S. Consumption of green leafy vegetables, meats, and dairy products provides 50 percent of the body's vitamin K requirement. Gastrointestinal flora synthesize the other 50 percent. Vitamin K deficiency impairs coagulation and leads to hemorrhage. Bleeding may occur anywhere in the body and in some cases can be massive. In the skin, the hemorrhage manifests as purpura. Neonatal vitamin K deficiency is called *hemorrhagic disease of the newborn.* Areas of predilection include the umbilicus, skin, nose, mouth, intestines, and subgaleal and intracranial regions. Neonatal vitamin K deficiency is caused by poor placental transfer of the vitamin, inadequate dietary intake, and absent vitamin K synthesis by the uncolonized neonatal gut. Premature infants are especially at risk for vitamin K deficiency. As prophylaxis, newborns are routinely given 1 mg of vitamin K intramuscularly at birth.

Several other factors may precipitate vitamin K deficiency both during and after the neonatal period. These include states of fat malabsorption (steatorrhea due to regional ileitis, sprue, cystic fibrosis, and biliary obstruction), anorexia nervosa, and prolonged antibiotic therapy. Some drugs interfere with the physiologic role of vitamin K. Coumarin anticoagulants inhibit vitamin K-2,3-epoxide reductase. High doses of salicylates inhibit vitamin K reductase. Cephalosporins with the *N*-methylthiotetrazole moiety (e.g., cefotetan, moxalactam, cefoperazone, cefamandole) inhibit vitamin K–dependent carboxylase. Newborns of mothers who take phenytoin are at increased risk for the development of hemorrhagic disease.

The diagnosis can be confirmed by a prothrombin time measurement. Intramuscular phytonadione (vitamin K_1) is the treatment. Dosage is 5 to 10 mg in adults, 2 mg in young children, and 1 mg in newborns, who usually receive it routinely. Because coagulation factor synthesis requires several days, acute bleeding should be managed with fresh-frozen plasma. [5]

Skin reactions occurring after vitamin K_1 injection occur rarely. These include an acute eczematous reaction (a type IV response) and, more rarely, a late-onset localized sclerosis and atrophy resembling morphea. [46]

Vitamin D

Vitamin D is a fat-soluble vitamin whose synthesis begins in the skin. In vitamin D deficiency, calcium and phosphorus metabolism is deranged, and patients develop osteomalacia and muscle weakness without cutaneous findings. The main causes for acquired vitamin D deficiency include inadequate diet, malabsorption, and decreased exposure to solar ultraviolet B (UVB) radiation. Elderly and debilitated patients are particularly predisposed to the latter. Although rigorous use of sunscreens can lead to vitamin D deficiency, a randomized, controlled clinical trial showed no change in vitamin D levels with regular use. [47] The symptoms of vitamin D deficiency also may develop due to inborn errors of metabolism. In vitamin D–dependent rickets type I, renal vitamin D-1a -hydroxylase is decreased. [48] In vitamin D–dependent rickets type II, mutations in the nuclear vitamin D receptor cause resistance to physiologic levels of 1,25-dihydroxyvitamin D. This causes not only musculoskeletal and endocrinologic disturbances but also alopecia. Massive doses of vitamin D and calcium treat all the findings except the alopecia. Research in gene knockout mice suggests that a ligand-independent function of the vitamin D receptor in keratinocytes is necessary for proper anagen initiation. [49]

ESSENTIAL FATTY ACIDS

Essential fatty acids are polyunsaturated fatty acids that the body cannot synthesize and therefore must be obtained from the diet. Essential fatty acids are divided into three groups. The O-3 series is based on linolenic acid and is found in fish oil. The O-6 series is based on linoleic acid and is found in vegetable oils. The O-9 series is based on oleic acid. Among these, linoleic acid is of greatest physiologic importance. Linoleic acid is the parent molecule of arachidonic acid, a precursor of the prostaglandins, leukotrienes, and thromboxanes. In the skin, essential fatty acids contribute to the formation of lamellar granules of the stratum corneum. [4], [5], [34]

Essential fatty acid deficiency has been associated with long-term parenteral nutrition, although this rarely occurs now due to the use of fat emulsion formulations. Deficiency also may be caused by disorders that impair fat absorption. A diet of skimmed milk has been reported to cause essential fatty acid deficiency. [5] Linoleic acid deficiency is associated with growth failure and a dry, scaly skin eruption, frequently on the legs. Alopecia can occur. Weeping intertriginous erosions sometimes develop. Skin changes favor periorificial areas and may resemble those seen in zinc deficiency. Essential fatty acid deficiency has been associated with impaired inflammatory reactions, particularly delayed skin hypersensitivity. [50] Additional systemic manifestations of essential fatty acid deficiency include fatty liver changes, thrombocytopenia,

anemia, impaired wound healing, and increased vulnerability to infections.

Essential fatty acid deficiency is characterized by low plasma levels of linoleic and arachidonic acid. There are also increased levels of eicosatrienoic acid (upper limit of normal for ratio of eicosatrienoic acid to arachidonic acid is 0.4). [5] Treatment is with essential fatty acid replacement. Approximately 5 g of linoleic acid per day (2–3 percent of total calories) is required to prevent deficiency. [34]

ESSENTIAL ELEMENTS

Iron

Chronic iron deficiency is associated with anemia, glossitis, cheilosis, and koilonychia (spoon-shaped deformity of fingernails and toenails). In advanced cases, dysphagia associated with a postcricoid esophageal web is seen (Plummer-Vinson's syndrome). Iron deficiency may cause damage to hair, including hair loss. Iron replacement can be provided by ferrous sulfate or ferrous gluconate. However, a search for the cause of the iron deficiency is perhaps the most important aspect of management.

Chronic iron overload (hemosiderosis), when associated with tissue injury, is known as *hemochromatosis.* Typical findings include cirrhosis of the liver, a bronze pigmentation of the skin, diabetes mellitus, and cardiomyopathy. Iron overload is also a factor in the development of porphyria cutanea tarda. Phlebotomy is the treatment of choice. Early diagnosis and management often can prevent the end-organ damage. [51]

Zinc

Zinc deficiency causes a clinical syndrome whose hallmark features are dermatitis, diarrhea, and alopecia. This syndrome, acrodermatitis enteropathica, is discussed in Chap. 146.

Copper

Copper deficiency can result from long-term total parenteral nutrition, dietary insufficiency (particularly a diet consisting exclusively of milk), and chronic malabsorption. [1] A major cause of copper malabsorption is Menkes' disease (also called *Menkes' kinky hair disease*), an X-linked recessive disorder caused by a defect in the Menkes gene (*ATP7A*) at Xq13.3, which encodes an ATP-dependent copper transport protein. [52] The clinical presentations of copper deficiency are similar regardless of the underlying etiology. [1]

In Menkes' disease, the clinical findings manifest early in life. The most serious is neurologic deterioration, which causes seizures, hypotonia, and developmental delay. Hair abnormalities include pili torti (multiple 180-degree twists about their long axis), trichorrhexis nodosa, monilethrix, and hypopigmentation. Hypothermia may develop. Cerebral vessels are tortuous, and intracerebral infarcts may occur. Skeletal changes resemble scorbutic bone disease. A characteristic facies is sometimes seen, consisting of pallor, pudgy cheeks, and an expressionless lateral gaze. [53]

The clinical symptoms of Menkes' disease result from dysfunction of copper-dependent enzymes. Impairment of ascorbate oxidase results in skeletal defects. [5] Defective lysyl oxidase results in abnormal cross-linking of keratin hair fibers and abnormal formation of the internal elastic lamina of arteries. Tyrosinase is also impaired, causing hypopigmentation of the skin and hair. Aberrations in cytochrome C oxidase, superoxide dismutase, and dopamine ß-hydroxylase lead to hypothermia and neurologic symptoms. [54] The diagnosis is suggested by low serum levels of copper and ceruloplasm and can be confirmed by genetic testing. Genetic testing can be used for prenatal diagnosis during the first trimester of pregnancy. Treatment is with parenteral copper, preferably copper histidine (200–1000 µg/day, 2–7 times per week). If started before 2 months of age, parenteral copper may prevent neurologic degeneration. [53] Infants on an exclusively milk diet or prolonged parenteral nutrition can develop a similar syndrome that is copper-responsive. [55]

Selenium

Selenium is a trace element found in soil and is an essential component of the antioxidant enzyme glutathione peroxidase. Deficiency occurs in areas with low concentrations of selenium in soil, such as Keshan, China. It also has been described in patients receiving parenteral nutrition and in low-birth-weight infants. The principal clinical findings are cardiomyopathy and muscle pain and weakness. Nail changes similar to Terry's nails in hepatic cirrhosis have been described. Other findings include dyschromotrichia and macrocytosis; these were corrected with selenium supplementation. A dose of 3.0 µg/kg per day has been recommended to correct deficiency states. [4] Acute poisoning with selenium is often fatal, and skin changes include alopecia, paronychia, possible nail loss, and red pigmentation of nails, hair, and teeth. [56]

Manganese

Manganese activates enzymes in the formation of glycoproteins and is present in melanocytes in high concentration. It is necessary for arginase activity in the epidermis. [1] A report exists of a single case of manganese deficiency occurring in a volunteer who inadvertently received a deficient diet and developed transient dermatitis, changes in hair color, and slow growth of hair. [57]

ACKNOWLEDGMENT

The authors recognize the contributions of authors of this chapter in previous editions of this text.

REFERENCES

1. Ryan AS, Goldsmith LA: Nutrition and the skin. *Clin Dermatol* **14**:389, 1996
2. Brooke P: Diseases of nutrition and metabolism. *Adv Dermatol* **8**:155, 1993
3. Goskowicz M, Eichenfield LF: Cutaneous findings of nutritional deficiencies in children. *Curr Opin Pediatr* **5**:441, 1993
4. Prendiville JS, Manfredi LN: Skin signs of nutritional disorders: *Semin Dermatol* **11**:88, 1992
5. Miller SJ: Nutritional deficiency and the skin. *J Am Acad Dermatol* **21**:1, 1989
6. Keys A et al: The Biology of Human Starvation. Minneapolis, Univ of Minnesota Press, 1950
7. Gupta MA et al: Dermatologic signs in anorexia nervosa and bulimina nervosa. *Arch Dermatol* **123**:1386, 1987
8. McLaren DS: Skin in protein calorie malnutrition. *Arch Dermatol* **123**:1674, 1987
9. Prazuck T et al: HIV infection and severe malnutrition: A clinical and epidemiological study in Burkina Faso. *AIDS* **7**:103, 1993
10. Albers SE et al: A case of kwashiorkor. *Cutis* **51**:445, 1993
11. Liu T et al: Kwasiorkor in the United States: Fad diets, perceived and true milk allergy, and nutritional ignorance. *Arch Dermatol* **137**:630, 2001
12. Hendrickse RG: Kwashiorkor: The hypothesis that incriminates aflatoxins. *Pediatrics* **88**:376, 1991
13. Manary MJ, Brewster DR: Potassium supplementation in kwashiorkor. *J Pediatr Gastroenterol Nutr* **24**:194, 1997
14. Thame M et al: Parkinsonian-like tremors in the recovery phase of kwashiorkor. *W Ind Med J* **43**:102, 1994
15. Enwonwu CO et al: Noma (cancrum oris): Questions and answers. *Oral Diseases.* **5**:144, 1999
16. Adolph HP et al: Noma: A review. *Ann Plast Surg* **37**:657, 1996
17. Robinson DC et al: The clinical and epidemiologic features of tropical ulcer (tropical phagedenic ulcer). *Int J Dermatol* **27**:49, 1988
18. Jackson R, Bell M: Phagedena: Gangrenous and necrotic ulcerations of skin and subcutaneous tissue. *Can Med Assoc J* **126**:363, 1982
19. Bray GA: Health hazards of obesity. *Endocrinol Metabol Clin North Am* **25**:907, 1996
20. Hathcock JN et al: Evaluation of vitamin A toxicity. *Am J Clin Nutr* **52**:183, 1990
21. Bates CJ. Vitamin A. *Lancet* **345**:31, 1995
22. Christiansen EN et al: Serum lipids in children with xeroderma from an inland district of Sri Lanka. *Ann Nutr Metab* **39:**9, 1995
23. Nakjang Y, Yuttanavivat T: Phrynoderma: A review of 105 cases. *J Dermatol* **15**:531, 1988
24. Bendich A, Langseth L: Safety of vitamin A. *Am J Clin Nutr* **49**:358, 1989.
25. Leung AKC: Carotenemia. *Adv Pediatr* **34**:223, 1987
26. Monk B: Carotenemia. *Int J Dermatol* **22**:326, 1983
27. Rajakumar K: Pellagra in the United States: A historical perspective. *South Med J* **93**:272, 2000
28. Carpenter KJ: Effects of different methods of processing maize on its pellagragenic activity. *Fed Proc* **40**:335, 1953
29. Sebrell WH: Identification of riboflavin deficiency in human subjects. *Fed Proc* **38**:2694, 1979
30. Darvay A et al: Isoniazed induced pellagra despite pyridoxine supplementation. *Clin Exp Dermatol* **24**:167, 1998
31. Isaac S: The “gauntlet” of pellagra. *Int J Dermatol* 37:599, 1998
32. Roe DA: Riboflavin deficiency: Mucocutaneous signs of acute and chronic deficiency. *Semin Dermatol* **10**:293, 1992
33. Gromisch DS et al: Light (phototherapy)-induced riboflavin deficiency in the neonate. *J Pediatr* **90**:118, 1977
34. Morrison G, Hark L: *Medical Nutrition and Disease*. Cambridge, Blackwell Science, 1996
35. Vilter RW et al: The effect of vitamin B_6 deficiency induced by desoxypyridoxine in human beings. *J Lab Clin* Med **42**:335, 1953
36. Cormier-Daire V et al: A gene for pyridoxine-dependent epilepsy maps to chromosome 5q31. *Am J Hum Genet* **67**:99, 2000
37. Mudd SH et al: Disorders of transsulfuration, in *Metabolic and Molecular Bases of Inherited Disease*, 8th ed, edited by Scriver CR et al. New York, McGraw-Hill, 2001, p 2007
38. Tada K: Vitamin B_6-dependent xanthurenic aciduria, *Tohoku J Exp Med* **93**:115, 1967
39. Harvey RA, Champe PC: *Lippincott's Illustrated Reviews: Pharmacology*, 2d ed. Philadelphia, Lippincott-Raven, 1997

40. Mori K et al: Generalized hyperpigmentation of the skin due to vitamin B_{12} deficiency. *J Dermatol* **28**:282, 2001

41. Nagaraju M et al: Skin manifestations of folic acid deficiency. *Br J Derm* **84**:32, 1971

42. Navarro et al: Cutaneous and neurologic manifestations of biotinidase deficiency. *Int J Dermatol* **39**:363, 2000

43. Nyhan WL: Inborn errors of biotin metabolism. *Arch Dermatol* **123**:1696, 1987

44. Hirschmann JV, Raugi GJ: Adult scurvy. *J Am Acad Dermatol* **41**:895, 1999

45. Hood J et al: Sjögren's syndrome in scurvy. *N Engl J Med* **282**:1120, 1970

46. Moreau-Cabarrot A et al: Cutaneous hypersensitivity at the site of injection of vitamin K_1. *Ann Dermatol Venereol* **123**:177, 1996

47. Marks R et al: The effect of regular sunscreen use on vitamin D levels in an Australian population. Results of a randomized controlled trial. *Arch Dermatol* **131**:415, 1995

48. Wang JT et al: Genetics of vitamin D_1 alpha-hydroxylase deficiency in 17 families. *Am J Hum Genet* **63**:1694, 1998

49. Sakai Y et al: Metabolic and cellular analysis of alopecia in vitamin D receptor knockout mice. *J Clin Invest* **107**:961, 2001

50. Cederholm TE et al: Low levels of essential fatty acids are related to impaired delayed skin hypersensitivity in malnourished chronically ill elderly people. *Eur J Clin Invest* **24**:615, 1994

51. Phatak PD, Caoppucio JD: Management of hereditary hemochromatosis. *Blood Rev* **8**:193, 1994

52. Kodama H, Murata Y: Molecular genetics and pathophysiology of Menkes disease. *Pediatr Int* **41**:430, 1999

53. Kodama H, Murata Y: Clinical manifestations and treatment of Menkes disease and its variants. *Pediatr Int* **41**:423, 1999

54. Oyler RM: Fragile hair and seizures in a child. *Arch Dermatol* **136:**417, 2000

55. Bennani-Smiers C et al: Infantile nutritional copper deficiency. *Am J Dis Child* **134**:1155, 1980

56. Ruta DA, Haider S: Attempted murder by selenium poisoning. *Br Med J* **299**:316, 1989

57. Doisy EA: Human managenes deficiency, in *Trace Substances in Environmental Health,* VI, edited by DD Hemphill. Minneapolis, Univ of Minnesota Press, 1972, p 193

T>

Chapter 146

Kenneth Neldner

Acrodermatitis Enteropathica and Other Zinc-Deficiency Disorders

HEREDITARY ZINC DEFICIENCY: ACRODERMATITIS ENTEROPATHICA
Historic Aspects
Epidemiology
Pathogenesis
Clinical Manifestations and Diagnosis
NONHEREDITARY (ACQUIRED) ZINC DEFICIENCY
ZINC AND IMMUNITY
WOUND HEALING AND OTHER DERMATOLOGIC DISORDERS
ZINC AND GENETICS
BIOCHEMISTRY OF ZINC METABOLISM
LABORATORY DIAGNOSIS OF ZINC DEFICIENCY
TREATMENT OF ZINC DEFICIENCY
ZINC TOXICITY

REFERENCES

Zinc is an essential trace element required for immune function, growth, reproduction, and antioxidant activities. There are over 300 zinc metalloenzymes involved in many stages of carbohydrate, protein, and fat metabolism. Zinc deficiency may be broadly divided into hereditary and nonhereditary types. Both forms have similar, if not identical, clinical manifestations that vary in direct proportion to the severity of the deficiency. Low-grade, marginal, nonhereditary zinc deficiency is far more common than the hereditary form. It is also the most difficult to diagnose because the clinical manifestations are minimal and often overlooked or misdiagnosed. A general review of the current status of zinc metabolism has been published recently. [1]

HEREDITARY ZINC DEFICIENCY: ACRODERMATITIS ENTEROPATHICA

Acrodermatitis enteropathica (AE) is a rare inherited disorder transmitted as an autosomal recessive trait. Prior to the discovery that the disorder was caused by an inability to absorb sufficient zinc from the diet, the disease often was fatal in infancy or early childhood. It is now cured rapidly and dramatically with simple dietary supplements of zinc salts.

The clinical syndrome is characterized by a triad of acral dermatitis, alopecia, and diarrhea. The acral distribution of the rash (i.e., face, hands, feet, anogenital area) has become recognized as a virtually pathognomonic cutaneous marker for zinc deficiency, whether secondary to hereditary AE or to any of the numerous nonhereditary causes for zinc deficiency.

Historic Aspects

AE was described originally as a hereditary disorder by Danbolt and Closs [2] in 1943. In 1953, Dillaha et al. [3] reported modest therapeutic success with oral diiodohydroxyquin. While studying a patient with lactose intolerance and unrecognized AE in 1973, Moynahan and Barnes [4] observed that alterations in zinc concentrations affected the well-being of the patient, leading to the discovery that AE was a disease of zinc deficiency. The first case of AE in the United States treated successfully with zinc was reported by Neldner and Hambidge in 1975. [5] Historically, the term *acrodermatitis enteropathica* defined only the hereditary form; however, the term has been used recently to describe both hereditary and nonhereditary forms, often leading to confusion. A diagnosis of AE probably should be limited to the hereditary form.

Epidemiology

Hereditary AE has worldwide distribution with no apparent predilection for race or gender. Because of the early interest in the disease throughout Europe, particularly northern Europe, there are seemingly larger numbers of cases reported from those geographic areas. A Dutch study [6] reported 226 patients with hereditary AE and 374 with nonhereditary zinc deficiency. There are reports of cases from Saudi Arabia and throughout the Mideast. [7]

Pathogenesis

After AE was discovered to be a disorder of zinc deficiency, the mechanism of zinc absorption was studied extensively. Zinc absorption is not totally absent in hereditary AE because the patients can absorb a small amount of zinc from an average diet, and dietary zinc supplementation will raise plasma levels to normal rapidly and cure the disease. The fact that zinc in human milk is significantly more bioavailable to infants with AE than zinc from bovine milk, with an essentially equal zinc concentration, is still unexplained. Zinc in human milk is preferentially bound to low-molecular-weight ligands (~10,000), and in bovine milk zinc is bound to higher-molecular-weight ligands. [8], [9] Casey et al. [10] found a similarly sized low-molecular-weight zinc ligand in human duodenal-pancreatic secretions of patients with AE, suggesting that the size of the zinc-binding ligand (ZBL) was critical. Cousins and Smith [11] postulated that the difference in total protein of human milk (5.3 mg/mL) compared with bovine milk (29 mg/mL) influenced the bioavailability of zinc in some unknown way. Individuals with protein-deficient malnutrition are commonly deficient in zinc.

Menard and Cousins [12] found that intestinal zinc was complexed with citrate (MW 600–650), which they proposed to be a major intestinal ZBL. However, Oestreicher and Cousins [13] have since reported that the addition of citrate to milk does not enhance absorption of zinc in the rat.

To further complicate the picture, other ZBLs have been reported. Song [14] proposed that prostaglandin E_2 has a role in zinc absorption from the gut. Evans and Johnson [15] found that picolinic acid, present in milk and duodenal contents, has a high affinity for zinc. However, Rebello et al. [16] found the intestinal concentration of picolinic acid to be normally so low that a significant role in zinc absorption was questioned.

Progress has been made recently regarding cellular zinc transport at a molecular genetic level. [17] Biologically active zinc is a highly charged species that cannot cross cell membranes by passive diffusion. Recent studies therefore have focused on a search for mechanisms for zinc to both enter and exit a cell. Some elemental zinc probably can cross cell membranes, but the process is greatly enhanced when zinc is complexed with ZBLs. Furthermore, zinc efflux from cells is believed to be a different process from that involved in zinc influx. [18], [19] and [20]

In brief, a group of mammalian zinc transporter genes have been identified and cloned that are designated *zinc transporters 1* (ZnT-1) to *4* (ZnT-4). ZnT-1 is located in the plasma membrane of all cells and functions primarily as an exporter mechanism for zinc efflux. ZnT-2 appears to function in cytoplasmic vesicular zinc uptake and efflux. ZnT-3 is associated with vesicular zinc uptake in neurons and in the testes. ZnT-4 is thus far found to be concentrated in the plasma membrane of cells in the mammary gland and the brain. A fifth metal transporter, called *divalent cation transporter* (DCT-1), is associated with the transport of several cations (i.e., Fe^{2+}, Cu^{2+}, Cd^{2+}, and Mn^{2+}) in addition to zinc. It is concentrated in the intestinal crypts and lower villi. The DCT-1 gene has a high homology to a family of mammalian genes called the *macrophage Nramp group* involved in host defense mechanisms.

Grider and Mouat [21] have shown that human fibroblasts from AE patients have an impaired uptake of zinc in vitro, suggesting that the genetic defect in AE may not be limited to malabsorption from the gut. However, a specific biochemical defect has not been found. Two novel proteins (49.6 and 49.9 kDa) were identified as possible factors.

Other factors, such as the overall state of total-body zinc nutriture of the host, will influence zinc absorption; i.e., zinc-depleted individuals will absorb zinc much more avidly than those in a zinc-adequate or -excess state. Poorly understood interactions with other trace elements, particularly copper, lead, iron, cadmium, and chelating drugs, alter absorption. [22] Once zinc is absorbed across the intestinal villous brush border, another complex series of homeostatic events involving metallothioneines regulates the transport of zinc into the circulation and then to the liver and kidneys, where a final homeostatic surveillance system operates to regulate how much zinc will be preserved in the poorly understood zinc storage sites and how much will be excreted. These mechanisms appear to function normally in AE. The defect in AE, therefore, is postulated to be somewhere in the early stages of zinc absorption, where the bioavailability of the chemical form and the structure in which dietary zinc is presented to the intestinal mucosal brush border in some way cause malabsorption. Recent reviews of zinc absorption and excretion were presented by Lonnerdal [23] and Krebs. [24]

Clinical Manifestations and Diagnosis

Classic hereditary AE usually begins within days to a few weeks after birth in infants bottle-fed with bovine milk or soon after weaning from the breast in older infants. Acral dermatitis begins slowly with dry, scaly, eczematous plaques on the face, scalp, and anogenital areas (Fig. 146-1). Perlèche (Fig 146-2A) is a common early sign and also has been called a sign heralding relapse. All lesions become progressively worse as vesicobullous, pustular, and erosive lesions develop (Fig. 146-3A). Superficial oral aphthous-like lesions may appear. The hands (see Fig. 146-2B and Fig. 146-3B) and feet are soon involved, commonly with paronychia and a brightly erythematous dermatitis of the palmar and finger creases, including annular lesions with collarette scaling. As the dermatitis worsens, secondary infections with bacteria and *Candida albicans* are common aggravating factors. Alopecia worsens gradually with time. Diarrhea is the most variable manifestation and may be only intermittent or totally absent. If diarrhea is severe and persistent, the clinical course will be further complicated by the loss of fluids, electrolytes, and other nutrients.

FIGURE 146-1 Acrodermatitis enteropathica. Erosive, eczematous, and secondarily infected lesions in genital area.

FIGURE 146-2 Acrodermatitis enteropathica in older individuals showing typical lesions. *A.* Facial. *B.* Palmar.

FIGURE 146-3 Zinc deficiency. *A.* There are plaques of dry, scaly, eczematous skin around the buttocks. The lesions often become secondarily infected with *Candida albicans. B.* Hands. The fingers are enlarged, and there are paronychia and bright erythema on the terminal phalanges.

Within a few weeks, growth failure becomes measurable and more apparent as the child approaches adolescence, when hypogonadism in males also becomes obvious. Emotional and mental disturbances are common manifestations of zinc deficiency, although they are difficult to evaluate. They are often best appreciated when zinc supplementation is instituted, which results in a rapid improvement in mood, disposition, and overall mental status within 24 to 48 h.

Photophobia develops gradually and is believed to be due to malfunction of zinc-dependent retinol-binding protein. Other manifestations include anorexia, hypogeusia, hyposmia, and anemia. A “zebra-striped” light and dark banding of hair may be seen with polarized light microscopy.

Prior to the use of zinc in AE, fertility was low in the children of mothers with AE who reached reproductive age. Congenital malformations were common, particularly neural tube defects, and the disease often was fatal during infancy. In those with milder cases who survived and those who received larger amounts of dietary zinc for unrelated reasons, the manifestations were less severe but usually resulted in growth retardation and dwarfism, delayed puberty, hypogonadism in male adolescents, continuing skin problems (dry skin and/or acral dermatitis of varying degrees), frequent infections, delayed wound healing, and mental disturbances. [5] Rare reports of spontaneous remission occurring in adolescence may have been examples of the nonhereditary form of zinc deficiency, as described below.

In recent years, a number of infants with presumed hereditary AE have been reported who had all the typical findings of AE as outlined earlier but who were found subsequently to have hypozincemia as a result of a very low concentration of zinc in their mother's milk. [25], [26] Unlike those with hereditary AE, as soon as these infants were weaned, they no longer required supplemental zinc, confirming that they suffered from simple acute dietary zinc deficiency and did not possess the hereditary defect in zinc absorption. No specific genetic reasons were found for the low maternal milk zinc levels. The mothers most likely became marginally zinc-deficient due to the increased demands for zinc during pregnancy and lactation. Such reports suggest that any breast-fed infant (especially premature infants) who develops an acral dermatitis of even mild degree should be checked for zinc status, and the maternal milk also should be analyzed.

NONHEREDITARY (ACQUIRED) ZINC DEFICIENCY

Based on the knowledge gained from hereditary AE, similar signs and symptoms can be diagnosed in patients with zinc deficiency from many other causes. The acral distribution of dermatitis is now recognized as the hallmark of zinc deficiency, whether on a hereditary or nonhereditary basis. As a general rule, zinc deficiency should be suspected in anyone with a chronic wasting disease, particularly if the gastrointestinal tract is involved along with a dermatitis in an acral distribution. Any catabolic chronic disorder is likely to induce zinc deficiency. Alcoholics are particularly prone. [27] Other general causes include chronic infection, nutritional deficiencies, and many others, as listed in Table 146-1. Patients falling into any of these categories should be checked for serum (or plasma) zinc status.

Disorder	Etiology
Gastrointestinal	
Mucosal diseases	Diarrhea
Malabsorption syndromes	Diarrhea
Pancreatic disorders	Reduced zinc ligands
Cirrhosis	Increased urinary loss
Postgastrectomy syndrome	Diarrhea
Blind-loop syndromes	Diarrhea
Dietary factors	
High dietary phytate	Chelation, ethnic diets
Alcoholism	Increased urinary loss
Total parenteral nutrition	Lack of zinc supplementation
Faddish weight reduction	Inadequate dietary zinc
Bulimia	Inadequate dietary zinc
Anorexia nervosa	Inadequate dietary zinc
Trauma	
Burns	Exudation, catabolism
Postsurgical procedure	Catabolism, anorexia
Malignancy	
All types	Catabolism, anorexia
Renal disorders	
Renal tubular disease	Failure to absorb zinc
Nephrotic syndrome	Proteinuria
Dialysis	Loss of zinc in dialyzate
Infection	
Parasitic	Chronic blood loss
Bacterial, viral	Redistribution, urinary loss
Miscellaneous	
Antimetabolite drug therapy	Catabolism
Chelation drug therapy	Chelation-urinary loss
Diabetes mellitus	Urinary loss
Hemolytic anemias	Urinary loss of erythrocyte zinc
Collagen-vascular diseases	Catabolism
Pregnancy/lactation	Increased fetal requirements

TABLE 146-1 **Conditions and Disorders That May Cause Zinc Deficiency**

In contrast to the hereditary type, where profound deficiency usually develops rapidly during infancy or childhood, marginal deficiency of the acquired type may go undetected for long periods of time. There is a growing body of evidence to suggest that such individuals are at significant long-term risk for a number of systemic and cutaneous disorders, as listed in Table 146-2. Globally, the two most common causes for marginal zinc deficiency probably are chronic alcoholism and diets high in phytates where such diets are common for ethnic or geographic reasons. [28] Phytates are present in most cereal grains and are potent chelators of zinc, inhibiting zinc absorption from the gastrointestinal tract. Several long-term consequences of zinc deficiency are listed in Table 146-3.

Rough dry skin
Progressively severe, patterned acral dermatitis (the diagnostic hallmark)
Perléche (angular stomatitis)
Seborrheic dermatitis–like eruption
Alopecia
Diarrhea (variable)
Hypogeusia
Anorexia
Mental disturbances
Delayed wound healing
Growth retardation (children and adolescents)
Delayed puberty
Hypogonadism in developing males
Defective embryogenesis (neural tube defects)

TABLE 146-2 **Clinical Manifestations of Moderate to Severe Zinc Deficiency Observed in Nonhereditary Acquired Conditions**

Abnormal lymphocyte function
Increased susceptibility to infection
Delayed wound healing
Aggravation of other dermatologic disorders
Impaired free radical scavenging

TABLE 146-3 **Potential Long-Term Effects of Low-Grade, Marginal Zinc Deficiency**

ZINC AND IMMUNITY

Numerous human and animal studies have demonstrated T cell and immune dysfunction at all levels of zinc deprivation, including marginal levels, particularly if extended over long periods of time. [29] As immune function declines, there is an increased susceptibility to infection. This is well demonstrated in the more severe forms of animal and human zinc deficiency. Marginal zinc deficiency in infants and children has been shown to cause failure to thrive and affect a broad range of anthropometric parameters. [30]

In both AE and an animal model of AE (Danish black pied Friesian breed of cattle), thymic atrophy is one consequence. [31] As a result, thymocytes and cellular immune functions, particularly T cell functions, are depressed. Neutrophils, peripheral blood monocytes, tissue macrophages, and mast cells require optimal concentrations of zinc for normal function. [32] Zinc also plays an important, although not completely understood, role in essential fatty acid metabolism. [33]

Human studies involving experimental zinc deficiency have shown a dichotomy between the effects on T_H1 and T_H2 function. [34] Production of interferon-? and interleukin (IL)-2, T_H1 cell products, was decreased, but the production of IL-4, IL-6, and IL-10, products of T_H2 cells, was not affected by zinc deprivation. Natural killer (NK) cell lytic activity and precursor cytolytic cells were decreased in zinc deficiency. In a T_H0 cell line, zinc deficiency decreased gene expression of thymidine kinase and caused delayed cell cycles and decreased cell growth. Gene expression of IL-2 and IL-2 receptors and binding of NF-?B to DNA were decreased in zinc deficiency. Human immunodeficiency virus (HIV) infection has been shown to progress more rapidly if there is associated zinc deficiency. [35] An excellent review of recent studies involving all aspects of zinc metabolism and immune defects was covered in a supplement to the *Journal of Nutrition* [130(suppl), 2000].

WOUND HEALING AND OTHER DERMATOLOGIC DISORDERS

Wound healing requires many nutrients, one of which is zinc. However, most likely, there is no additional clinical benefit from oral zinc supplementation if zinc status is otherwise normal; indeed, prolonged high doses can be toxic (see "Zinc Toxicity" below). A determination of the plasma zinc level therefore is indicated in patients with leg ulcers or slow-healing

wounds or infections prior to the institution of supplemental zinc therapy. A role for zinc in the treatment of several other dermatologic disorders has been controversial.

Topical zinc conpounds (e.g., calamine, zinc oxide) are some of the oldest dermatologic medications known, being recorded in the 2000 B.C. Ebers papyrus. Claims for efficacy of zinc in acne have been made and disputed. [36] One study found epidermal zinc to be low in dermatitis herpetiformis, acne, psoriasis, and Darier's disease, but plasma levels were low only in dermatitis herpetiformis. [37] Bruske and Salfeld [38] found low serum zinc levels in patients with vitiligo. Others found low serum and epidermal zinc levels in atopic eczema, but dietary zinc supplementation had no readily apparent efficacy, indicating that if zinc does play a role, it is probably not primary, but one that conceivably could facilitate healing once the primary damage has been addressed.

ZINC AND GENETICS

The genetic locus for AE on chromosome 8q24.3 was described recently by Wang et al. [39] and this now paves the way for discovery of the gene and then its specific role in the pathogenesis of the disorder. AE has not been studied adequately for a possible mutation in any of the zinc transporter genes. *SLC39A4* has been identified as the hZIP4 transporter responsible for intestinal zinc absorption. [40], [41]

Nuclei are rich in zinc, where it is critically involved in maintaining genetic stability and gene expression. DNA transcription factors are at least partially controlled by so-called zinc fingers that bind to DNA and along with other transcription factors control cell proliferation, cell differentiation, and cell death. [42] Muga and Grider [43] showed the AE mutation to affect protein expression in human fibroblasts by differential display. Zinc is therefore an essential element for cell division and growth.

BIOCHEMISTRY OF ZINC METABOLISM

Even though zinc has been known to be required for normal growth and development in the rat since 1934, it was not established as an essential human nutrient by the National Research Council until 1974, when a recommended dietary allowance (RDA) was set at 15 mg of elemental zinc per day. The adult body contains 2 to 3 g of zinc, which is about half the iron content and 10 to 20 times more than other essential trace elements such as copper, magnesium, and nickel. The zinc cation exists almost totally in the Zn^{2+} oxidation state and does not readily undergo further oxidation or reduction, providing a stability that is believed to be significant in zinc biochemistry, such as hydrolysis and transfer or addition to double bonds.

The average diet in the United States provides approximately 12 to 15 mg of elemental zinc per day. Body stores and homeostatic mechanisms combine to ensure adequate supplies during times of reduced intake; however, during periods of dietary deprivation, the body will soon fall into a negative metabolic balance. In the mouse, a negative balance develops within a few days after it has been fed a zinc-deficient diet, causing a rapid reduction in DNA synthesis. [44] Normally, about 30 percent of the daily intake is absorbed, although this figure is variable. The intravascular transport of zinc is primarily as a loosely bound complex with albumin (60–70 percent), and lesser amounts are more tightly bound to a $_2$-macroglobulin (10–20 percent), transferrin (1–5 percent), amino acid chelates (5–10 percent), and IgG (1 percent).

All body tissues contain zinc. Muscle, bone, and the prostate gland have the richest stores. In the skin, zinc is concentrated in the epidermis, which contains up to five or six times greater concentration than the dermis. Zinc also concentrates in hair, but changes in host zinc intake will be reflected in hair zinc concentration only after prolonged periods of deprivation (or excess), so its quantitation is unreliable for assessment of short-term or recent events.

The principal biochemical function of zinc results from its incorporation into a wide range of enzymes. Since zinc was discovered in 1940 to be present in carbonic anhydrase, the list of zinc metalloenzymes has grown to over 300, if those from nonhuman species are included. [45] There are two basic types of zinc-activated enzymes. One is a metal-enzyme complex that readily dissociates but requires the presence of zinc for continued activity. The other is one in which zinc is firmly bound to the active site so that it will not dissociate during isolation of the enzyme.

A possible role for biotin in AE has been proposed, particularly in premature infants with zinc deficiency, who responded better to a combination of zinc and biotin than to zinc alone. [46] However, no evidence has been found for a biotinidase deficiency in these infants.

Superoxide dismutase is an important free-radical scavenger and a zinc-copper-manganese metalloenzyme. Low concentrations of superoxide dismutase have been reported in the skin in severe zinc deficiency but have not been studied in marginally deficient humans or animals. Free-radical scavengers as a group (vitamins A, C, and E, the carotenoids, catalases, zinc, selenium, and copper) protect against oxidative damage to all cell membranes, DNA macromolecules, and other vital cellular components. Free radicals are also potent carcinogens. The important role of zinc and other trace elements and vitamins in disease prevention has been reviewed by Christian et al., [47] who showed that zinc status influences vitamin A metabolism, including absorption, transport, and use.

Zinc has been shown recently to be required for normal neuronal transmission. [48] A possible role in Alzheimer's disease is also being studied. Preliminary observations have linked zinc, copper, insulin, and lipids in Alzheimer's disease e4 apolipoprotein E allele carriers. [49]

LABORATORY DIAGNOSIS OF ZINC DEFICIENCY

The laboratory verification of zinc deficiency is the same for hereditary deficiency (AE) or the acquired forms. Plasma or

serum zinc levels are currently the easiest, most accurate, and most commonly used method for assessing zinc status. Erythrocyte and leukocyte zinc also can be measured, but these tests are more difficult and expensive, in addition to being more subject to error. Blood levels fluctuate rapidly following infection, injury, burns, or any sudden stressful stimuli, resulting in redistribution of zinc from the blood to other body compartments, and do not correctly reflect total zinc nutriture. Normal plasma levels are 70 to 110 µg/dL. Serum levels are 80 to 120 µg/dL (for conversions to micromoles per liter, multiply by 0.153). Urinary zinc excretion is highly variable under normal circumstances and decreases gradually as zinc deficiency progresses. The normal urinary excretion ranges from 200 to 500 µg per 24 h. Hair zinc concentration is commonly measured but, again, reflects only the long-term zinc status. Its use and interpretation therefore will depend on the clinical situation and type of information desired. Serum alkaline phosphatase is a zinc-dependent enzyme, and its activity is a moderately sensitive indicator of zinc status, although not a particularly accurate marker for early or marginal deficiency. Leukocyte and erythrocyte zinc levels have been shown to be quite sensitive to early minor changes in total-body zinc nutriture, but their measurement has the disadvantage of being difficult and expensive.

Specimen collections and laboratory technique are important. Contamination with environmental zinc in collecting tubes or containers, plus laboratory contamination in the handling and transfer of specimens and in the preparation of laboratory chemicals and solutions, is common. Spurious laboratory results therefore almost always will be on the side of higher than actual values, which may lead to a missed diagnosis of marginal zinc deficiency. The time between collection of blood and separation of serum or plasma also affects zinc concentration, with increases in the plasma concentration of up to 6 percent during the first 4 h if the plasma is not separated from the cells. [50] It is therefore recommended that zinc-free vacuum tubes and stainless steel needles be used and that contact with rubber stoppers (they contain zinc) be avoided. To avoid hemolysis, plasma or serum must be separated from cells within 45 min, and anticoagulants should be used that are low in zinc or are zinc-free. There is also a normal diurnal rhythm in plasma zinc concentration; morning fasting specimens are recommended for the most accurate results. Several methods have been proposed for the assessment of low-grade marginal zinc deficiency, but none has proven to be satisfactory. [51]

TREATMENT OF ZINC DEFICIENCY

The treatment of zinc deficiency of any etiology is dietary or intravenous supplementation with zinc salts. In most instances, dietary supplementation with two to three times the RDA (15 mg) in doses of 30 to 50 mg of elemental Zn^{2+} daily will be adequate to restore a normal zinc status within days to a few weeks, depending on the degree of depletion. In all circumstances, a rapid clinical response will occur with dramatic reversal of many manifestations within a few days. [5] Severely infected and erosive skin lesions will heal within 1 to 2 weeks without additional topical therapy. Diarrhea, if present, usually stops within 24 h. Rapid improvement in mental disturbances is often detectable within 24 to 48 h. In children, a surge of total-body and hair growth can be detected within 3 to 4 weeks after commencing zinc therapy.

Any of the zinc compounds available appear to work well (e.g., zinc sulfate, zinc acetate, zinc gluconate, zinc chloride, or amino acid chelates). However, $ZnSO_4$ has been recommended more for oral supplementation and $ZnCl_2$ for intravenous use. Dosage prescribed must be based on the amount of elemental zinc present in the preparation, which varies from one compound to another. For example, a standard capsule of 220 mg $ZnSO_4 \cdot 7H_2O$ contains approximately 55 mg elemental zinc, which is an adequate daily dose for most deficient individuals.

High pharmacologic doses of oral zinc have been recommended by some investigators for the therapy of sickle cell anemia, acne, delayed wound healing, and leg ulcers. All these conditions will improve with zinc therapy if a preceding zinc deficiency exists. However, in general, proof is lacking for a pharmacologic effect over and above that of restoration of a normal zinc nutritional status. Furthermore, the threat of zinc toxicity must be guarded against if prolonged high doses are ingested.

ZINC TOXICITY

Most heavy metals, including zinc, become toxic if taken excessively. Moderate overdose is eliminated through homeostatic mechanisms involving decreased absorption and/or increased urinary and biliary excretions. However, plasma levels of 150 to 300 µg/dL (22.9–45.9 µmol/L) are easily achieved by persons ingesting zinc supplements of 50 to 100 mg Zn^{2+} daily. Such doses usually produce no immediately apparent adverse effects, although the long-term safety of such a dose is unknown.

$ZnSO_4$ is listed in the *U.S. Pharmacopoeia* as an emetic. Not surprisingly, its most common adverse effect is gastric irritation with nausea, vomiting, and mild gastric hemorrhage. Acute and fatal zinc toxicity has been reported following large accidental oral and intravenous overdoses. [52] Chronic toxicity among zinc smelter workers is known as *metal fume fever* and causes fevers, chills, gastroenteritis, and pulmonary symptoms. [53] Rats and mice fed moderate overdoses for long periods have shown reduced growth rates, anemia, declining rates of reproduction, and hypertrophy of the adrenal cortex and pancreatic islets.

A reciprocal interaction with copper is well recognized. [54] Patients receiving prolonged oral zinc supplementation are prone to develop hypocupremia as a consequence of long-standing hyperzincemia. One adverse effect of hypocupremia is a refractory microcytic anemia that will not respond to iron therapy until the serum zinc and copper levels are normalized. Neutropenia, immune dysfunction, and hypoceruloplasminemia also occur with hypocupremia. [55]

It is recommended that patients on long-term zinc therapy should be monitored periodically with the following tests: plasma zinc concentration taken as a fasting morning specimen to regulate dosage, complete hemogram with erythrocyte indices, leukocyte differential count, serum copper level, and a stool examination for occult blood.

REFERENCES

1. Hambidge KM: Human zinc deficiency. *J Nutr* **130**(suppl 5):1344S, 2000

2. Danbolt N, Closs K: Acrodermatitis enteropathica. *Acta Derm Venereol (Stockh)* **23**:172, 1943

3. Dillaha CJ et al: Acrodermatitis enteropathica: Review of the literature and a report of a case successfully treated with Diodiquin. *JAMA* **152**:509, 1953

4. Moynahan EJ, Barnes PM: Zinc deficiency and a synthetic diet for lactose intolerance. *Lancet* **1**:676, 1973

5. Neldner KH, Hambridge KM: Zinc therapy of acrodermatitis enteropathica. *N Engl J Med* **292**:879, 1975

6. Van Wouwe JP: Clinical and laboratory assessment of zinc deficiency in Dutch children: A review. *Biol Trace Elem Res* **49**:211, 1995

7. Mostafa WZ, Al-Zayer AA: Acrodermatitis enteropathica in Saudi Arabia. *Int J Dermatol* **29**:134, 1990

8. Eckert CD et al: Zinc binding: A difference between human and bovine milk. *Science* **195**:789, 1977

9. Hurley LS et al: Zinc binding ligands in milk and intestine: A role in neonatal nutrition. *Proc Natl Acad Sci U S A* **74**:3547, 1977

10. Casey CE et al: Zinc binding in human duodenal secretions. *J Pediatr* **95**:1008, 1979

11. Cousins RJ, Smith KT: Zinc-binding properties of bovine and human milk in vitro: Influence of changes in zinc content. *Am J Clin Nutr* **33**:1083, 1980

12. Menard MD, Cousins RJ: Effect of citrate, glutathione and picolinate on zinc transport by brush border membrane vesicles from rat intestine. *J Nutr* **113**:1653, 1983

13. Oestreicher P, Cousins RJ: Influence of intraluminal constituents on zinc absorption by isolated, vascularly profused rat intestine. *J Nutr* **112**:1978, 1982

14. Song MK: Evidence for an important role of prostaglandin E_2 and F_2 in the regulation of zinc transport in the rat. *J Nutr* **109**:2152, 1979

15. Evans GW, Johnson PE: Characterization and quantitation of a zinc binding ligand from human milk. *Pediatr Res* **14**:870, 1980

16. Rebello T et al: Picolinic acid in milk, pancreatic juice and intestine: Inadequate for role in zinc absorption. *Am J Clin Nutr* **35**:1, 1982

17. McMahon RJ, Cousins RJ: Mammalian zinc transporters. *J Nutr* **128**:667, 1998

18. McMahon RJ, Cousins RJ: Regulation of the zinc transporter ZnT-1 by dietary zinc. *Proc Natl Acad Sci USA* **95**:4841, 1998

19. Huang L, Gitscher J: A novel gene involved in zinc transport is deficient in the lethal milk mouse. *Nature Genet* **17**:292, 1997

20. Gunshin H et al: Cloning and characterization of a mammalian proton-coupled metal-ion transporter. *Nature* **388**:482, 1997

21. Grider A, Mouat MF: The AE mutation affects protein expression in human fibroblasts: Analysis by two-dimensional gel electrophoresis. *J Nutr* **128**:1311,1998

22. Solomons NW: Competitive mineral-mineral interaction in the intestine: Implications for zinc absorption in humans, in *Nutritional Bioavailability of Zinc,* edited by GE Inglett. Washington, ACS Symposium Series, 1983, p 247

23. Lönnerdal B: Dietary factors influencing zinc absorption. *J Nutr* **130**(suppl 5):1378S, 2000

24. Krebs NF: Overview of zinc absorption and excretion in the human gastrointestinal tract. *J Nutr* **130**(suppl 5):374S, 2000

25. Heinen F et al: Zinc deficiency in an exclusively breast-fed preterm infant. *Eur J Pediatr* **154**:71, 1995

26. Lee MG et al: Transient symptomatic zinc deficiency in a full-term breast-fed infant. *J Am Acad Dermatol* **23**:375, 1990

27. Taniguchi S et al: Acquired zinc deficiency associated with alcoholic liver cirrhosis. *Int J Dermatol* **34**:651, 1995

28. Ferguson EL et al: The zinc nutriture of preschool children living in two African countries. *J Nutr* **123**:1487, 1993

29. Fraker PJ et al: The dynamic link between the integrity of the immune system and zinc status. *J Nutr* **130**(suppl 5):1399, 2000

30. Walravens PA et al: Zinc supplementation in infants with a nutritional pattern of failure to thrive: A double-blind controlled study. *Pediatrics* **83**:532, 1989

31. Machen M et al: Bovine hereditary zinc deficiency: Lethal trait A46. *J Vet Diagn Invest* **8**:219, 1996

32. Beisel WR: The role of zinc in neutrophil function, in *Clinical, Biochemical, and Nutritional Aspects of Trace Elements,* edited by AS Prasad. New York, Alan R Liss, 1982, p 203

33. Neldner KH et al: Acrodermatitis enteropathica. *Arch Dermatol* **110**:711, 1974

34. Prasad AS: Zinc and immunity. *Mol Cell Biochem* **188**:63, 1998

35. Wellinghausen N et al: Zinc serum level in human immunodeficiency virus-infected patients in relation to immunological status. *Biol Trace Elem Res* **73**:139, 2000

36. Orris L et al: Oral zinc therapy of acne. *Arch Dermatol* **114**:1018, 1977

37. Michaëlsson G, Ljunghall K: Patients with acne, psoriasis, dermatitis herpetiformis, and Darier's disease have low epidermal zinc concentrations. *Acta Derm Venereol (Stockh)* **70**:304, 1990

38. Bruske K, Salfeld K: Zinc and its status in some dermatologic diseases: A statistical assessment. *Z Hautkr* **62**(suppl):125, 1987

39. Wang K et al: Homozygosity mapping places the acrodermatitis enteropathica gene on chromosomal region 8q24.3. *Am J Hum Genet* **68**:1055, 2001

40. Wang K et al: A novel member of a zinc transporter family is defective in acrodermatitis enteropathical. *Am J Hum Gent* **71**:66, 2002

41. Küry S et al: Identification of *SLC39A4*, a gene inrolved acrodermatitis enteropathica. *Nature Genet* **31**:239, 2002

42. Dreosti IE: Zinc and the gene. *Mutat Res* **415**:161, 2001

43. Muga SJ, Grider A: Partial characterization of a human zinc deficiency syndrome by differential display. *Biol Trace Elem Res* **68**:1, 1999

44. Aughey E et al: The effect of oral zinc supplementation in the mouse. *J Comp Pathol* **87**:1, 1977

45. McCall KA et al: Function and mechanism of zinc metalloenzymes. *J Nutr* **130**(suppl 5):1437S, 2000

46. Lagier P et al: Zinc and biotin deficiency during prolonged parenteral nutrition in the infant. *Presse Med* **31**:1795, 1987

47. Christian P, West KP Jr: Interactions between zinc and vitamin A: An update. *Am J Clin Nutr* **68**(suppl 2):435S, 1998

48. Colvin RA et al: Zinc transport in the brain: Routes of zinc influx and efflux in neurons. *J Nutr* **130**(suppl 5) 1484S, 2000

49. Gonzalez C et al: Serum zinc, copper, insulin and lipids in Alzheimer's disease epsilon 4 apolipoprotein E allele carriers. *Eur J Clin Invest* **29**:569, 1999

50. English JL, Hambidge KM: Plasma and serum zinc concentration: Effect of time between collection and separation. *Clin Chim Acta* **175**:211, 1988

51. Wood RJ: Assessment of marginal zinc deficiency in humans. *J Nutr* **130**(suppl 5):1350S, 2000

52. Brocks A et al: Acute intravenous zinc poisoning. *Br Med J* **28**:1390, 1977

53. Papp JP: Metal fume fever. *Postgrad Med* **43**:160, 1968

54. Prasad AS et al: Hypocupremia induced by zinc therapy in adults. *JAMA* **240**:2166, 1978

55. Sandstrom B et al: Acrodermatitis enteropathica, zinc status, copper status and immune function. *Arch Pediatr Adolesc Med* **148**:980, 1997

T>

Chapter 147

Lowell Goldsmith

Cutaneous Changes in Errors of Amino Acid Metabolism: Tyrosinemia II, Phenylketonuria, Argininosuccinic Aciduria, and Alkaptonuria

TYROSINEMIA TYPE II
General Features
Laboratory Findings
Treatment
Differential Diagnosis
PHENYLKETONURIA
Clinical Features
Diagnosis
Treatment
ARGININOSUCCINIC ACIDURIA
Definition and Clinical Features
Hair Defects
Other Disorders of the Urea Cycle30
Diagnosis
Microargininosuccinic Aciduria
ALKAPTONURIA36
Historical Aspects
Epidemiology
Etiology and Pathogenesis36
Clinical Manifestations36,45
Laboratory Findings
Pathology
Diagnosis and Differential Diagnosis
Treatment
Course and Prognosis
OTHER ABNORMALITIES OF AMINO ACID METABOLISM

REFERENCES

Three disorders with prominent cutaneous findings are discussed in depth in this chapter, and other disorders of intermediate metabolism with cutaneous findings are summarized at the end of the chapter. Detailed historical information, clinical information on tissues other than the skin, and genetic data on all these diseases have been summarized recently and comprehensively. [1]

TYROSINEMIA TYPE II

Tyrosinemia type II (Richner-Hanhart's syndrome) is a distinctive clinical syndrome involving the eyes, skin, and central nervous system. Tyrosine levels are elevated because of a deficiency of hepatic tyrosine aminotransferase. [2]

General Features

Fewer than 100 patients with this clinical syndrome have been reported. All had tyrosinemia, phenolicaciduria, and inflammatory skin and eye lesions. [3] The sexes are affected equally, and the disease is worldwide in distribution. Half the patients are of Italian descent. There is often consanguinity, which is strongly suggestive of autosomal recessive inheritance.

DERMATOLOGIC FEATURES Patients have hyperkeratotic skin lesions limited to the palms and soles. [4], [5] Lesions usually begin during the first year of life; in one patient, the first lesions appeared at age 6. The skin lesions are painful, nonpruritic, and frequently associated with hyperhidrosis (Fig. 147-1). The pain can be intense enough to cause patients to crawl rather than apply pressure to the lesions. Bullous lesions may occur and progress rapidly to erosions; these then become crusted and hyperkeratotic. Lesions are often linear. The fingertips and hypothenar eminences are commonly involved. Rare patients have hyperpigmentation and/or hyperkeratotic subungual lesions.

FIGURE 147-1 Hyperkeratotic and erosive lesions in a patient with tyrosinemia II.

OPHTHALMOLOGIC FEATURES Eye lesions occur weeks to months before the skin lesions. Eye symptoms start as early as 2 weeks of age and as late as 8 years. Tearing, redness, pain, and photophobia are early signs; late signs include corneal clouding and central or paracentral opacities, which are initially intraepithelial and can progress to superficial or deep dendritic ulcers (Fig. 147-2). Neovascularization is prominent. The eye disease may lead to scarring, nystagmus, and exodeviation. One patient had a persistent conjunctival plaque. [5] Topical therapy is ineffective, and herpes simplex virus and bacterial cultures are consistently negative.

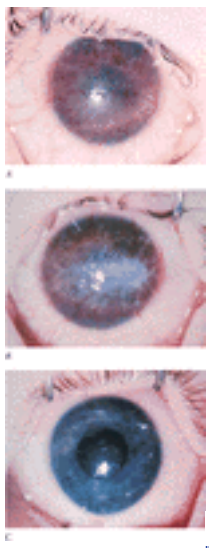

FIGURE 147-2 Corneal changes in tyrosinemia II. *A.* Cornea before treatment (left eye); corneal opacity and neovascularization are prominent. *B.* The right eye has even more extensive involvement. *C.* After 6 weeks of therapy, there is marked clearing of the lesions.

NEUROLOGIC FEATURES Mental retardation of varying degrees is reported, as is normal mental development. Untreated tyrosinemia II during pregnancy may be associated with mental retardation or seizures in the children resulting from that pregnancy. [2]

OTHER ORGAN SYSTEM INVOLVEMENT Renal and liver function tests are uniformly normal. One patient had multiple congenital anomalies, including microcephaly, cleft lip and palate, inguinal hernias, talipes equinovarus, and the absence of one kidney associated with a chromosomal deletion.

Laboratory Findings

AMINO ACID ABNORMALITIES The blood and urine tyrosine levels of affected patients are markedly elevated. Other amino acids are not increased. Urinary tyrosine metabolites are elevated; these include *p*-hydroxyphenylpyruvic acid, *p*-hydroxyphenyllactic acid, *p*-hydroxyphenylacetic acid, tyrosine, and *N*-acetyltyrosine (Fig. 147-3). All these metabolic effects are consequences of the deficiency of hepatic tyrosine aminotransferase.

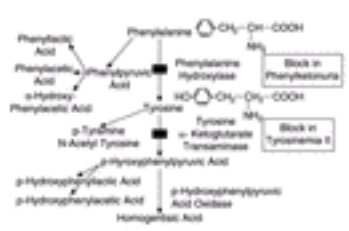

FIGURE 147-3 Metabolic pathway of phenylalanine, tyrosine, and their derivatives.

Tyrosine aminotransferase (TAT) is a pyridoxal phosphate-dependent cytoplasmic enzyme that transaminates tyrosine, forming *p*-hydroxyphenylpyruvate (PHPPA). The human *TAT* gene contains 12 exons and transcribes a 2.75-kb mRNA that codes for a 454–amino acid protein. [2] The liver is the richest source of TAT; this specific TAT is not present in skin. In tyrosinemia II, the liver biopsy shows little or no soluble TAT, although there is normal or slightly increased mitochondrial tyrosine (aspartate) transaminase activity. [6], [7] Mitochondrial aspartate aminotransferase using tyrosine as a substrate produces increased amounts of PHPPA from the increased amounts of tyrosine available in tyrosinemia II. Since mitochondria do not have PHPPA oxidase activity, PHPPA and its metabolic products increase and appear in the urine, creating the unusual situation in which metabolites are increased both proximally and distally to the defective enzyme.

HISTOPATHOLOGY Routine histopathology is not diagnostic; it shows hyperkeratosis, parakeratosis, and acanthosis. In one patient, the palmar papules showed parakeratosis with homogeneous, refractile, eosinophilic inclusions 2 to 3 μm in diameter in the stratum corneum and stratum spinosum. [5] Electron microscopy in one case suggested that the 2- to 3-μm inclusions were lipid-like granules. Discrete 10-nm filaments and myelin-like figures were intermixed with lipid-like droplets. These results were interpreted as showing possibly lysosomal activation. In some cases, electron microscopy studies have shown increases in tonofibrils and keratohyalin, very tightly packed microtubular and microfibrillar masses, and minute tyrosine crystals in keratinocytes and Merkel cells. [8], [9] The conjunctival plaques of one patient showed eosinophilic inclusions in the superficial epithelial cells and a plasma cell infiltrate.

GENETICS *TAT* maps to the q22–q24 region of chromosome 16. [2] Detailed studies of one patient showed her to be a double heterozygote with a contiguous deletion syndrome. [10] On her maternal 16q she had a deletion of at least 11 of 12 *TAT* exons and a small de novo deletion in q22.1::q22.3. Her other somatic defects, which have not been part of the tyrosinemia syndrome, may be related to the deletions. Multiple point mutations scattered throughout the *TAT* gene have been associated with tyrosinemia type II. [2]

PATHOPHYSIOLOGY OF THE SKIN AND EYE LESIONS IN TYROSINEMIA II Rats fed a 12 percent protein diet with 0.5 to 2.0 percent tyrosine developed a syndrome resembling tyrosinemia II, with weight loss, a shortened life span, keratitis, conjunctivitis, alopecia, cheilitis, and inflammatory toe changes. [11] The high-tyrosine syndrome in rats was ameliorated by increasing the protein content of the diet or by adding threonine or thiouracil or TAT inducers. The affected animals had photophobia, corneal erosions, exudate, and panblepharitis. Microscopically, the initial lesion was

epithelial edema associated with disorganization of the basal cells and polymorphonuclear leukocyte (PMNL) infiltration.[12] PMNLs invaded the epithelium, the stroma, and the anterior chamber; the cornea became opaque, thickened, vascularized, and by 2 to 3 weeks ulcerated. The eyes contained birefringent crystals limited to the areas of corneal damage. The crystals were long (10–25 µm), slender (0.5–1.1 µm), and appeared to be membrane-bound; the crystals passed from cell to cell and penetrated nuclei. Multinucleate cells, vacuoles, autophagic vacuoles, and multivesicular bodies were present, which suggested lysosomal activation by the tyrosine crystals. There are ranch minks and dogs with the clinical metabolic features of tyrosinemia.[13], [14] In vitro studies showed that tyrosine crystals can cause release of lysosomal enzymes and as yet uncharacterized heat-labile chemotactic factors.[15], [16] Crystal-induced inflammation has been studied in model systems using calcium pyrophosphate dihydrate and monosodium urate monhydrate. Phosphatidylinositol 3-kinase activation and tyrosine phosphorylation of several proteins occurred early in the activation process.[16]

Treatment

With a low-tyrosine, low-phenylalanine diet (Mead Johnson), there is a rapid decrease in tyrosine to normal levels (30–90 µ *M*) (Fig. 147-4). Skin and eye lesions resolved within days in all individuals treated with the diet.[4] Normal growth and development took place in a patient kept on the diet for 30 months starting at the age of 14 months. In this patient, 6 weeks after diet therapy was begun, the corneas were much clearer and less injected (see Fig. 147-2C), and the patient had sufficient vision to follow colored objects during play. At age 6 years, examination showed only remnants of vessels, and vision was normal except for myopia. Other patients have had slower resolution of symptoms. A 55-year-old man with tyrosinemia II had diffuse plantar hyperkeratosis (Fig. 147-5) that responded to a low-tyrosine, low-phenylalanine diet.[6]



FIGURE 147-4 The response of elevated plasma tyrosine to a low-tyrosine, low-phenylalanine diet and failure of response to various cofactors in a child with tyrosinemia II.

FIGURE 147-5 *A.* Diffuse plantar hyperkeratosis in an adult with tyrosinemia. *B.* The hyperkeratosis cleared on a low-tyrosine, low-phenylalanine diet without topical treatment.

Two adults have responded objectively to an aromatic retinoid (Ro 10-9359) (1.0 mg/kg per day). There was resolution without decrease in plasma tyrosine.[17] In none of the patients studied has there been a response to cortisone acetate, ascorbic acid, pyridoxine, or folic acid, which are cofactors or known inducers of TAT and PHPPA oxidase.

Since the consequences of tyrosinemia II are serious and a safe treatment is available, a patient presenting with any atypical bullous or hyperkeratotic disease on the palms and soles in the first months of life should be screened for tyrosine and its metabolites; screening tests (nitrosonaphthol in the presence of nitric acid and sodium nitrite) are available in most hospital laboratories. Amino acid analysis is necessary to confirm the diagnosis and follow the response to diet therapy.

Differential Diagnosis

CLINICAL DISORDERS OF TYROSINE METABOLISM[2] The disorders of tyrosine metabolism have a bewildering set of names. Tyrosinemia II (Richner-Hanhart's syndrome) is distinct from the others; none of the others have any skin manifestations. These diseases are reviewed more completely elsewhere and include neonatal tyrosinemia and hereditary tyrosinemia.

CLASSIC RICHNER-HANHART'S SYNDROME Richner-Hanhart's syndrome classically (before amino acid analysis) consisted of keratosis palmoplantaris, persistent dendritic lesions of the cornea with unaffected corneal sensitivity, photophobia, tearing, profound mental retardation, and autosomal recessive inheritance. In a review of the classic syndrome, 14 cases from 10 families were discussed.[18] All had corneal disease, 12 had keratosis palmoplantaris, and 8 were retarded. Consanguinity was common. Although none of the 14 patients had the extensive eye lesions of the patient in Fig. 147-2, it is suspected that most of these patients had tyrosinemia II. An autosomal dominant syndrome of volar keratosis and keratitis that is clinically similar to tyrosinemia was described in one family by Zmegac and Sarajlic.[19] The lesions were more extensive than those in the classic Richner-Hanhart's syndrome but were similar to those seen in patients with tyrosinemia II. The keratitis of the Spanglang-Tappeiner's syndrome, which is associated with palmar and plantar keratosis, appears to be related to lipid infiltration of the cornea.

PHENYLKETONURIA

Phenylketonuria (PKU) is an autosomal recessive disease caused by a deficiency of hepatic phenylalanine hydroxylase or cofactors for phenylalanine hydroxylase, and its genetics and physiology have been exhaustively reviewed recently. [20] The increased levels of phenylalanine are associated with mental retardation; seizures; decreased pigmentation of the skin, hair, and eyes; and eczematous dermatitis.

Clinical Features

This common metabolic defect occurs in 1 of 10,000 births and can be detected by screening procedures in neonatal life. One percent of institutionalized retarded patients have PKU. Mental retardation, athetosis, restlessness, increased tendon reflexes and muscle tone, hyperkinesis, tremors, and seizures accompany the untreated disease. The general features of the disease, its detailed genetics, biochemistry, heterozygote detection, prenatal diagnosis, and treatment are reviewed elsewhere. [20] Although there is a detailed understanding of the genetic abnormalities at the PKU focus and other related loci, there has been little research into the skin manifestations associated with PKU.

Patients with PKU have an increased incidence of eczematous dermatitis, pigment dilution of hair and skin color, and occasionally sclerodermatous skin changes. Other changes reported included a decreased number of pigmented nevi and an increased incidence of keratosis pilaris. Phenylalanine levels are higher in PKU skin than in normal skin. [21]

Braun-Falco and Geissler [22] and Fleisher and Zeligman [23] found an increased incidence of atopic dermatitis in PKU. In the former study, atopic dermatitis was present in 3 of 23 patients; in the latter, it was present in 15 of 25 patients. A potential mechanism suggested for the increased incidence of atopic disease is an increased tendency to vasoconstriction in PKU. Dramatic clearing of eczema and seborrheic dermatitis with a low-phenylalanine diet has been reported in some patients, and the potential role of altered biotin recycling is suggested. [24] It is possible that an inborn tendency to an eczematous dermatitis has been nonspecifically triggered in these patients, [24] although normal patients with eczema have no abnormality of phenylalanine metabolism detectable after a phenylalanine load. Patients with PKU often have a lighter hair and eye color than their siblings. [25] The color changes may be especially striking in the rare black or Japanese patient with PKU, whose eye or hair color may be very different from that of other members of the ethnic group. With a low-phenylalanine diet or with aging alone, hair color darkens. When tyrosine is added to the diet of patients with PKU, hair darkens; if tyrosine is removed, the hair will lighten, and banded hair is produced. The increased levels of phenylalanine and its oxidation products (phenylpyruvic acid, *o*-hydroxyphenylacetic acid, phenylacetic acid) inhibit the enzyme tyrosinase and therefore reduce melanization. [25]

The sclerodermatous changes in PKU are very striking and have been reviewed by Jablonska and Stachow. [26] Patients with PKU have had the onset of indurated areas of skin during the first year of life, most prominently on the thighs and associated with contractures. Acral areas of the body are least affected, in contradistinction to systemic sclerosis. Biopsy shows increased fibroblasts and histiocytes and atrophy of skin appendages. The elastic fibers are scanty and fragmented and are thus different from those found in true scleroderma. With dietary control, the sclerodermatous lesions clear. The lesions may be due to alterations in tryptophan metabolism, which occur in patients with PKU; tryptophan absorption is decreased in the presence of high blood levels of phenylalanine. [27] In two siblings with PKU, one had atrophoderma of Pasini and Pierini and the other localized scleroderma. [28] Pronounced skin lesions with skin dimpling are well documented and reviewed.

Diagnosis

Phenylalanine can be quantitated by chromatography. Increased levels of its metabolites in the urine are detected by a screening test in which $FeCl_3$ forms a bluish green (olive-green) color in the presence of phenylpyruvic acid.

Treatment

A low-phenylalanine diet results in increased pigmentation and, often, clearing of the eczema. Overly rigorous control of diet can lead to protein deficiency and an eczematous dermatitis. Treating phenylketonuric mice with adenovirus containing phenylalanine hydroxylase lead to restoration of dark skin color and stimulated hair growth in *Pah* [*enu2*] mice. [29]

ARGININOSUCCINIC ACIDURIA

Definition and Clinical Features

Argininosuccinic aciduria (ASA) is characterized by hepatomegaly, mental retardation, seizures, episodic lethargy and ataxia, autosomal recessive inheritance, and friable, brittle hair with the morphology of trichorrhexis nodosa. The deficiency of an essential cytosolic enzyme in the urea cycle, argininosuccinase (argininosuccinate lyase), causes citrullinemia and an increase in blood ammonia. Argininosuccinate is increased in the blood and spinal fluid and is excreted in large amounts (2–9 g/day) in the urine.

The detailed clinical and biochemical features of the disease and the principles of therapy are reviewed elsewhere. [30] The disease presents in the neonatal period as failure to thrive and ammonia intoxication or, in the second year of age, with psychomotor retardation, seizures, and ataxia. The hair abnormality is more characteristic of the late-onset disease. Weaning and a change to a diet with higher protein content can be precipitating factors in clinical disease. Essential to

current therapeutic regimens are diets providing adequate energy, protein, and arginine.

The molecular pathology of the nucleic acids in this disease has been clarified, but the detailed pathophysiology of the hair defect remains to be studied. [30] Argininosuccinase cDNA has been cloned, sequenced, and mapped to chromosome 7 and is about 60 percent homologous to the d-crystallins of the lens. Although there are at least 12 different mutant alleles, they all belong to one complementation group. Defining the molecular pathology allows prenatal diagnosis so that therapy can be instituted expeditiously.

Hair Defects

CLINICAL AND MORPHOLOGIC [31] About half the reported patients have had abnormally friable hair with visible trichorrhexis nodosa; the other half have grossly normal hair. Brushing and combing accentuate breaking (i.e., brittle hair). No definite correlation can be made between liver ASase level, argininosuccinic acid levels, arginine levels, and the degree of hair abnormalities; some patients with severe ASA have had seemingly normal hair. Some patients' hair has improved with diet or without specific therapy. One patient had trichorrhexis nodosa at birth and improvement in her hair with the addition of increased amounts of arginine to the diet. [32] Eyelashes, eyebrows, and general body hair, as well as the nails, may be involved. There is variation in diameter within the same hair and torsion, grooving, and irregular contours of the intrafollicular portions of growing hairs. With polarizing microscopy, there is no correlation of the lesion with polarized or nonpolarized regions. Stains of the hair with acridine orange and subsequent fluorescent microscopy show red fluorescence instead of the green fluorescence seen in ordinary, mechanically induced trichorrhexis nodosa. [31]
MOLECULAR NATURE OF HAIR DEFECTS During stress-strain testing in air, ASA hair broke prematurely. In two patients there was no argininosuccinic acid in the hair, and the only abnormality in amino acid content was a decreased serine level. In another patient the amino acid content was normal except for a cystine value one-half that of normal. The basic nature of the hair defects is not known. Are the brittle hair and the trichorrhexis nodosa a consequence of the deficiency of a product from the urea cycle (e.g., arginine), or is the hair defect related to an excess of one of the products that are increased due to argininosuccinate lyase deficiency? The administration of argininosuccinic acid to adult rats did not cause any specific effects, although there are no data on whether the argininosuccinic acid was absorbed from the gut. Increasing arginine in the diet aids hair growth and structure in this disease, suggesting that the decrease in arginine may be related to the defective hair. Since the urea cycle is depressed in ASA, the arginine required for protein synthesis would come predominantly from dietary sources. Hair protein is rich in arginine (up to 10 percent of the amino acid residues are arginine), and furthermore, the citrulline present in certain specialized proteins in the medulla and internal root sheath is derived from arginine. [33] Increased ammonia levels also might inhibit e-(?-glutamyl) lysine bond formation, which is important for stabilization of the internal root sheath and medulla.

Other Disorders of the Urea Cycle [30]

In citrullinemia, a rare recessive disease due to the absence of argininosuccinic acid synthetase, there is somatic and mental retardation and increased levels of blood, urine, and cerebral spinal fluid citrulline; low to normal values of plasma arginine; and increased blood ammonia. Hair from a patient with citrullinemia was lightly pigmented, grew only to a length of 6 cm, and showed irregular areas of dystrophy and interruption of the cuticle. The hair of an adult with the syndrome was said to be normal.

Deficiency of the cytosolic enzyme argininosuccinic acid synthetase is associated with trichorrhexis nodosa. Its overall clinical presentation is almost identical to that of ASA, although the plasma citrulline levels are usually higher (>1 m *M*) in the former disease. Enzymatic and genetic analyses confirm the diagnosis.

Mice with deficiency in the X-linked urea cycle enzyme ornithine carbamyl transferase have sparse hair, but hair defects are not described in humans with that mutation.

Diagnosis

Retardation, ammonia intolerance, and abnormal hair will suggest these syndromes. The diagnosis is confirmed by high-voltage electrophoresis or ion-exchange chromatography of the urine, blood, or spinal fluid. Only a tiny percentage of the cases of trichorrhexis nodosa and brittle hair are due to ASA.

Microargininosuccinic Aciduria

In true ASA, urinary ASA ranges between 2 and 9 g/day. In contradistinction, there have been instances of normal individuals excreting a few milligrams of argininosuccinic acid a day, and some of these patients have had monilethrix, trichorrhexis nodosa, or pili torti. [34] In some of these individuals, ASA was not correctly identified, or there may have been dietary sources. [35] In any case, it is difficult to make a cause-and-effect relationship between these trivial levels of argininosuccinic acid and the associated hair defects.

ALKAPTONURIA [36]

Alkaptonuria is a rare autosomal recessive disorder caused by deficiency of homogentisic acid oxidase (HGO), the sole catabolic enzyme for homogentisic acid (HGA). Excessive HGA is excreted in the urine, which often turns dark, and HGA accumulates in connective tissues, including the dermis.

Historical Aspects

In 1859, Boedeker originally used the term *alcapton* to denote a urinary substance with great avidity for oxygen at an alkaline pH; later, he spelled the word *alkapton.* In 1866, Virchow saw the diffuse, bluish black pigmentation of

connective tissue in a presumably alkaptonuric individual and called the condition *ochronosis* because of the ochre (yellow) hue seen microscopically. The prediction of Garrod, set forth in 1908, that alkaptonuria was caused by a specific enzyme deficiency was fully confirmed 50 years later when La Du and associates demonstrated the absence of hepatic HGA oxidase in an alkaptonuric patient.

Epidemiology

Alkaptonuria is inherited as an autosomal recessive trait. Pedigrees suggestive of a dominant mode of transmission contain a high degree of consanguinity and, when subjected to careful scrutiny, are actually pseudodominants. In populations, alkaptonuria is rare (1 in 250,000), but clusters of high incidence are found in certain groups with inbreeding, e.g., in Slovakia and Santo Domingo. In Slovakian newborns the incidence is 1 in 19,000. Disease distribution is worldwide, and there is an approximately equal incidence in the sexes.

Etiology and Pathogenesis [36]

The *HGO* gene maps to the q21–q23.60 region of chromosome 3. Multiple mutations have been found. [37], [38] and [39] The mutations change residues, which are conserved evolutionarily between *Aspergillus* HGO and human HGO, suggesting that they are fundamental to the activity of HGO. Both compound heterozygotes and homozygotes have been detected. [40] A mouse (*aku*) with the autosomal recessive metabolic syndrome has been described, but no skin lesions exist.

The biochemical pathway by which phenylalanine and tyrosine normally undergo oxidative degradation to acetoacetic acid is shown in Fig. 147-6. HGA (2,5-dihydroxyphenylacetic acid), the last molecule in the sequence to contain an intact aromatic ring, is cleaved to maleylacetoacetic acid. The enzyme catalyzing ring cleavage, HGA oxidase, is normally present in the soluble fraction of liver and kidney cells but not in other cells. It is highly specific for HGA. HGO mRNA is found in liver, kidney, and prostate. [40] Atmospheric oxygen, ferrous ion, and sulfhydryl groups are required for enzymatic function. Quinones inhibit the enzyme. HGA oxidase activity is totally absent in both liver and kidney tissue from alkaptonuric subjects. In patients with alkaptonuria, HGA undergoes renal excretion or is transformed to ochronotic pigment within connective tissue. HGA may not be present in the first days of life due to the absence of enzymatic activity of other enzymes in the pathway of tyrosine catabolism.

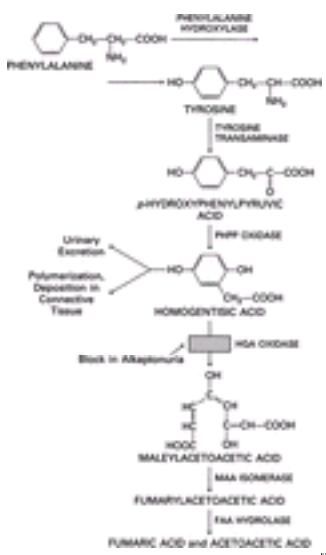

FIGURE 147-6 Metabolic pathway of phenylalanine and tyrosine degradation with homogentisic acid metabolites.

The renal clearance of HGA is extremely high (up to 400–500 mL/min) in both normal and alkaptonuric subjects, indicating active tubular secretion of HGA. [36] This explains how with relatively low fasting plasma concentrations of HGA (in the range of 3 mg/dL), excretion may be up to 4 to 8 g/day in alkaptonuria. Compounds inhibiting this secretion may be an important factor in ochronosis. Once excreted, HGA (which is itself colorless in solution) gradually oxidizes to dark products. Oxidation occurs by degrees when the urine is exposed to air, but it can be hastened markedly by alkalinization. Urinary pH is the major variable causing the darkening of the urine, and some patients with acidic urine may never have spontaneously black urine. A diet high in protein or tyrosine increases the amount of HGA excreted in disease.

The precise manner by which HGA accumulation in tissues leads to ochronosis is only partially understood. A presumed HGA polymer has never been characterized. When HGA is injected into guinea pigs, it has a high predilection to localize in skin and cartilage; benzoquinoneacetic acid (BQA), the highly reactive quinone of HGA, binds irreversibly to connective tissue. Homogentisic acid polyphenol oxidase, a copper-containing enzyme in human, guinea pig, and rabbit skin and cartilage, catalyzes the oxidation of HGA into ochronotic pigment. In the presence of increased HGA, this enzyme may form BQA, which can then be polymerized by the same polyphenol oxidase. [41]

Alkaptonuric mice (*aku*) do not have black urine or deposition of pigment possibly related to the mouse's ability to synthesize ascorbic acid. [42] (Humans and guinea pigs are the only common mammals that are auxotrophs, i.e., unable to synthesize ascorbic acid.)

Experimental ochronosis induced by prolonged feeding of high-tyrosine diets to rats may delineate the precise interaction between HGA and its products and connective tissue. [43] Joint capsules, sternum, and trachea were affected, and there were increased nonsulfated acid mucopolysaccharides and decreased sulfated mucopolysaccharides. HGA and BQA were in the subcutaneous tissue. Alkaptonuria also has been produced in experimental animals by L-phenylalanine

feeding and diets deficient in sulfur amino acids or tryptophan and the iron chelator a,a'-dipyridyl.

HGA inhibits an enzyme crucial for collagen cross-linking, lysyl hydroxylase, in chick embryo calvaria, suggesting that a reduction in the structural integrity of collagen consequent to deficient hydroxylysine-derived cross-linkages may be responsible for cartilaginous degeneration in alkaptonuria. [44] The plasma level of HGA, approximately 0.1 m *M*, would cause 30 percent inhibition of lysyl hydroxylase.

Clinical Manifestations [36], [45]

Dark urine is not always the initial manifestation of alkaptonuria. The urine is most apt to discolor rapidly at a pH above 7.0 and when reducing substances such as ascorbic acid, which normally protect HGA from oxidation, are not present in sufficient quantity. An early diagnosis of alkaptonuria is made frequently when (1) it is specifically sought because of family history, (2) discoloration of diapers occurs after cleansing in (alkaline) soap, (3) the urinary pH favors the polymerization of HGA, or (4) testing for urinary glucose with Benedict's solution yields an orange precipitate (indicating a reducing substance) accompanied by a dark supernatant. A positive Benedict's reaction and a negative glucose analysis with a glucose oxidase test reagent strongly suggest the diagnosis.

Although the diagnosis of alkaptonuria may be made during childhood, rare individuals are not detected until they develop pathologically significant changes in connective tissue in their third or fourth decade. If coincidental renal disease prevents effective HGA excretion, the development of ochronosis may be accelerated, and diffuse hyperpigmentation may result. [46]

Dark brown or black cerumen may be present in the first decade, even in those younger than 5 years of age. Axillary skin pigmentation (greenish blue, blue, greenish yellow, or brown) in the pattern of glandular orifices may be present late in the first decade; this may be accompanied by staining of underwear (“sweat that stains”).

A grayish blue tinge overlying ear cartilage occurs relatively early in the course of ochronosis. Later in the disease, structural changes result in loss of transillumination, stiffening, irregular contours, and eventually, in the third decade, calcification of the pinnae. The tympanic membrane may be blue. Tinnitus and variable degrees of deafness have been ascribed to ochronotic degeneration of the tympanic membrane and underlying ossicles. Laryngeal and tracheal cartilage becomes heavily pigmented but is asymptomatic.

The visible changes that occur with the passage of time are due primarily to the formation of ochronotic pigment granules in the dermis and sweat follicles and, most important, to the transmission of ochronotic discoloration through thin areas of skin overlying pigmented cartilage and tendon. The latter pigmentation, which is fairly uniform in ochronosis, is most apparent at the nose tip, ear (Fig. 147-7), costochondral junctions, and extensor tendons of the hands. Pigmentation of the skin is less prominent but may occur in a butterfly pattern on the nose and cheeks and even the palms. [47] Rarely, bluish gray fingernails and intensely dark nevi have been reported.

FIGURE 147-7 Ochronotic discoloration seen through the thin area of skin overlying the pigmented cartilage of the ear.

Ochronotic pigment sometimes accumulates in the outer ocular tissues: sclerae (Fig. 147-8), corneas, conjunctivae, and tarsal plates. Scleral discoloration generally is restricted to that portion of the globe exposed by the palpebral fissure. The scleral pigmentation is usually triangular in shape, with the base of the triangle facing the cornea at the site of recti muscle insertion. [36] Tiny “oil droplets” of ochronotic pigment appear at the inner and outer poles of the corneas in advanced ochronosis.

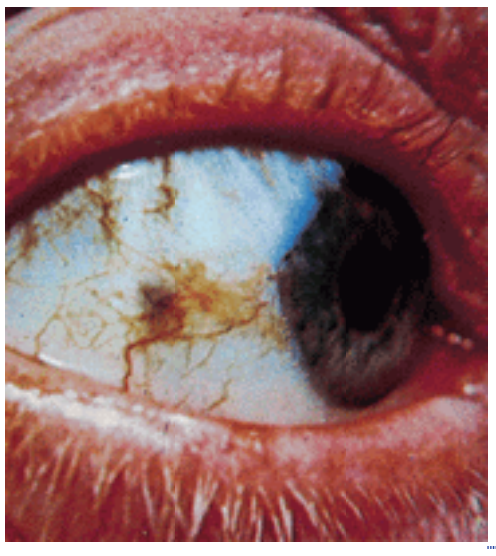

FIGURE 147-8 Ochronosis (alkaptonuria) has pathognomonic ocular signs. The first to appear is grayish black scleral pigmentation anterior to the tendon insertions of the horizontal recti muscles. At times, pigmentation of the elastic tissue in pinguecula may stain a dark brown or black, and it usually has the configuration of small, dark rings. In advanced cases of ochronosis, Bowman's membrane, adjacent to the limbus, may have areas of black pigmentation.

Insidious progression of ochronotic arthropathy, which generally begins in the third and fourth decades in males and about 10 years later in females, is the most disabling manifestation of alkaptonuria. The disease is more severe in males. Bouts of acute inflammation may occur. Hip, knee, and shoulder limitation is an early sign. Lumbar pain, lordosis, kyphosis, and sciatica are common. X-rays show a characteristic appearance of early calcification of the intervertebral disk and later narrowing of the intervertebral spaces, with eventual disk collapse and progressive loss of height (Fig. 147-9). In addition to the spine, ochronotic arthropathy typically involves larger joints, such as the shoulders, knees, and hips. The hands and feet generally are spared. Pseudogout may coexist with ochronosis.

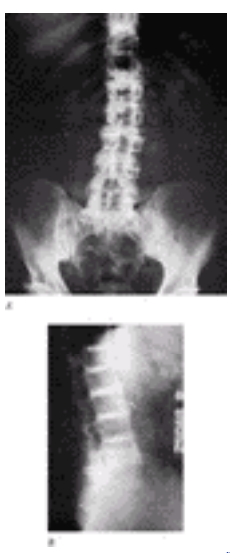

FIGURE 147-9 Roentgenographic findings in ochronosis. Marked intervertebral disk calcification is present.

There is some suggestion of an increased incidence of cardiovascular disease in ochronosis, but accelerated arteriosclerosis has not been clearly documented. At postmortem examination, pigmentation is commonly observed in the heart valves and annuli and in arteriosclerotic plaques. A case of aortic valve stenosis has been attributed to the deposition of ochronotic pigment.

Prostatic symptoms in older males frequently are due to the formation of soft pigmented calculi in the alkaline secretions of the ducts and sinuses of that gland. Porous black renal stones containing calcium, phosphate, and oxalate also have been reported. Prostate has high levels of HGO mRNA, which may explain the black prostate calculi that are occasionally present in the disease. [40]

Laboratory Findings

Aside from the excretion of HGA, alkaptonuric patients show no abnormalities on routine clinical laboratory tests. Normal individuals do not excrete HGA; therefore, darkening of the urine on addition of sodium hydroxide is presumptive evidence of alkaptonuria.

Other tests based on the reducing properties of HGA include the black reaction after treatment with $FeCl_3$ and blackening of photographic emulsion paper on application of a drop of alkaptonuric urine followed by a drop of sodium hydroxide. Specific identification and quantitation of urinary (as well as blood) HGA can be achieved by the use of a direct spectrophotometric method employing HGA oxidase or with HPLC or stable isotopes. [36], [40]

With the development of ochronotic arthropathy, x-rays of the spine show characteristic disk calcification, which occurs rarely in other forms of spondylitis. Periostitis, ligament calcification, and sacroiliac sclerosis are not features of ochronotic spondylitis.

Pathology

Yellow to light-brown (ochre) pigment granules, which gave the original designation of ochronosis, are present as free bodies and in dermal macrophages. [48] Irregular masses may be over 100 µm in diameter. The pigment is not bleached by 10% H_2O_2 after 72 h. [48] Routine special stains for melanin react with the ochronotic pigment.

Electron microscopic studies show smaller-sized homogeneous bodies fusing to form larger non-membrane-bound structures. [48] Although the original pigment is brown, Tyndall scattering of light makes involved skin appear blue.

The tendency of connective tissue, cartilage in particular, to darken gradually over the years constitutes the cardinal pathologic finding in alkaptonuria. Intervertebral disks are pigmented (jet black) and darken when examined. Articular cartilage, when heavily pigmented, displays the degenerative changes of fibrillation, fissuring, fragmentation, and erosion to bare bone. Phagocytosis of collagen fibrils is found in synovial macrophages. [49]

Diagnosis and Differential Diagnosis

The diagnosis of alkaptonuria may be made on the basis of typical urinary discoloration or may await the onset of ochronosis in adulthood. Inasmuch as the disease behaves in a quite stereotypical manner with few confusing variants in its mode of presentation, it has been concluded that the diagnosis need only be thought of to be made. Other causes of dark urine—melaninuria, porphyria, myoglobinuria, bilirubinuria, hematuria, etc.—ought not to be confused with alkaptonuria. An ochronotic-like pigmentation of skin and cartilage has been produced iatrogenically by quinacrine administration over a period of months and at the site of quinine injections. [50] Pigmentation due to antimalarial treatment is usually much more pronounced on mucosal surfaces and will fluoresce with a Wood's lamp.

Ochronotic pigmentation also has resulted from chronic application of carbolic acid to cutaneous ulcers, a form of therapy used rarely today. In a patient described by Osler and Garrod, the blue color was present on the sclera, the conchar concavity of the anthelix, and the extensor tendons of the hands. The pigmentation on the eyes and ears regressed during hospitalization and on discontinuation of carbolic acid. The light-related distribution of pigmentation was noted by the authors.

It is possible that the reversible ochronotic pigmentation caused by prolonged carbolic acid treatment is due to HGA polyphenol oxidase polymerizing the carbolic acid to an HGA polymer–like substance that differs from the polymer found in the genetic disease by its reversibility.

Exogenous ochronosis and pigmented colloid milia have been reported in a number of South Africans who used hydroquinone bleaching creams, stronger than 2%, for a prolonged period. [51], [52] Forty-two percent of women and 15 percent of men who used hydroquinones had exogenous ochronosis. [52] A similar condition has been seen in American blacks. [53] The dermal material was autofluorescent, electron dense, and phagocytosed, although another study emphasized the elastotic nature of the dermal fibers in the abnormal skin. [54] The precise etiology of the pigmentation remains to be determined. An occupationally induced blue-black dermal pigmentation resembling ochronosis has been described in a tiler who handled glues, varnishes, dyes, diluents, and stain removers. [55] Ochronotic arthropathy does not occur in these exogenous forms of hyperpigmentation.

Treatment

It is disappointing that despite advances in our biochemical understanding of alkaptonuria and the disposition of accumulated HGA to form ochronotic pigment in connective tissue, this information has yet to be translated into a successful therapeutic program for managing the disease. The treatment of ochronotic arthropathy centers around the proper balance of rest, physiotherapy, and analgesia. Prosthetic joint replacement is likely to be of considerable benefit for patients with advanced degenerative joint changes. Exogenous cutaneous ochronosis induced by hydroquinone has been treated with the carbon dioxide laser. [56]

Course and Prognosis

The ultimate course in adults with alkaptonuria is that of increasing pigmentation and skeletal incapacity. Little can be done to interrupt this progression; however, the disease is not incompatible with a normal life span, and the oldest patient on record lived to 99 years of age.

OTHER ABNORMALITIES OF AMINO ACID METABOLISM

Table 147-1 lists some of the abnormalities of amino and organic acid metabolism and their associated skin manifestations. Prolidase deficency in two sisters responded to intermittant pulse corticosteroid therapy followed by oral prednisone. [57] In lysinuric protein intolerance, which is due to defective transport, the skin may be hyperelastic, joints hypermobile, and the hair sparse and brittle. The skin may appear loose and too large for the body. One-half of the patients have been from Finland.

Disease	Skin Manifestations	Enzyme Defect/Pathophysiologic Effect or Treatment?
Alkaptonuria	Ochronosis Black urination, sclerosis and spontaneous ossicles	Homogentisic acid oxidase (AR)
Argininosuccinic aciduria	Trichorrhexis nodosa	Argininosuccinase (AR)
Aspartylglucosaminuria	Rough skin Thick skin Coarsening of facies Sagging skin folds Increased acne Photosensitivity	Aspartylglucosaminidase (AR)
Biotinidase deficiency	Periorbital and perioral dermatitis Conjunctivitis Alopecia Oral candidiasis Seborrheic dermatitis Cheilitis	Biotinidase (AR)
Citrullinemia	Light, short hair with interrupted cuticle	Argininosuccinate synthetase (AR)
Cystinosis, nephropathic type II	Odor of sweaty feet	Defect in lysosomal membrane cystine carrier
Dihydrofolate synthetase deficiency	Seborrheic dermatitis Alopecia	Dihydrofolate synthetase (AR)
Homocystinuria	Fine, sparse friable hair Thin skin Livedo reticularis Malar flush Vascular occlusions Thromboembolic phenomena	Cystathionine β-synthetase (AR)
Hydroxykynureninuria	Chronic dermatitis Ulcerated gums, gingivitis Photosensitivity	Kynureninase (AR)
Iminoglycinuria (proline deficiency)	Chronic skin ulcers especially on hands and feet Alopecia Pellagra	Prolidase (AR)
Isovaleric aciduria	Odor of sweaty feet, alopecia	Isovaleryl-CoA dehydrogenase (I)
Methionine malabsorption syndrome	White hair Dried colors or coefficient color Dilation	Defective methionine transport (I)
Phenylketonuria	Hypopigmentation Atopic dermatitis Eczematoid	Phenylalanine hydroxylase (AR) Dihydropteridine reductase Defective dihydrobiopterin synthesis
Tyrosinemia II	Painful, acral erosions Hyperkeratosis Corneal/conjunctival disease and erosions	Tyrosine aminotransferase (AR)
Tryptophanuria with deafness	Photosensitivity	Clue patient (I)
Xanthurenic aciduria	Urticaria Dermatitis	Kynureninase (AD)

AR, autosomal recessive; AD, autosomal dominant; I, inherited in another manner.

TABLE 147-1 **Inherited Disorders of Amino Acid and Organic Acid Metabolism with Skin Manifestations**

REFERENCES

1. Scriver CR et al: *The Metabolic and Molecular Bases of Inherited Disease,* 8th ed. New York, McGraw-Hill, 2001

2. Mitchell G et al: Hypertyrosinemia, in *The Metabolic and Molecular Bases of Inherited Disease,* 8th ed, edited by CR Scriver, A Beaudet, W Sly, and D. Valle. New York, McGraw-Hill, 2001, p 1777

3. Goldsmith LA, Laberge C: Tyrosinemia and related disorders, in *The Metabolic Basis of Inherited Disease,* 6th ed, edited by CR Scriver, A Beaudet, W Sly, and D. Valle. New York, McGraw-Hill, 1989, p 547

4. Goldsmith LA, Reed J: Tyrosine-induced eye and skin lesions: A treatable genetic disease. *JAMA* **236**:382, 1976

5. Goldsmith LA et al: Tyrosinemia with plantar and palmar keratosis and keratitis. *J Pediatr* **83**:798, 1973

6. Goldsmith LA et al: Hepatic enzymes of tyrosine metabolism in tyrosinemia II. *J Invest Dermatol* **73**:530, 1979

7. Burns RP: Soluble tyrosine aminotransferase deficiency: An unusual cause of corneal ulcers. *Am J Ophthalmol* **73**:400, 1972

8. Bohnert A, Anton-Lamprecht I: Richner-Hanhart's syndrome: Ultrastructural abnormalities of epidermal keratinization indicating a causal relationship to high intracellular tyrosine levels. *J Invest Dermatol* **79**:68, 1982

9. el Shoura SM, Tallab TM: Richner-Hanhart's syndrome: New ultrastructural observations on skin lesions of two cases. *Ultrastruct Pathol* **21**:51, 1997

10. Natt E et al: Inherited and de novo deletion of the tyrosine aminotransferase gene locus at 16q22.1–q22.3 in a patient with tyrosinemia type II. *Hum Genet* **77**:352, 1987

11. Schweizer W: Studies on the effect of l-tyrosine on the white rat. *J Physiol (Lond)* **106**:167, 1947

12. Beard ME et al: Histopathology of keratopathy in the tyrosine-fed rat. *Invest Ophthalmol* **13**:1037, 1974

13. Goldsmith LA et al: Tyrosine aminotransferase deficiency in mink (*Mustela vision* [*sic*]): A model for human tyrosinemia II. *Biochem Genet* **19**:687, 1981

14. Jezyk PF et al: Screening for inborn errors of metabolism in dogs and cats. *Prog Clin Biol Res* **94**:93, 1982

15. Goldsmith LA: Hemolysis and lysosomal activation by solid state tyrosine. *Biochem Biophys Res Commun* **64**:558, 1975

16. Jackson JK et al: The involvement of phosphatidylinositol 3-kinase in crystal induced human neutrophil activation. *J Rheumatol* **24**:341, 1997

17. Hunziker NEA: Richner-Hanhart syndrome (RHS)–tyrosinemia type II and oral aromatic retinoid (Ro 10-9359): Report of two cases, in *Retinoids: Advances in Basic Research and Therapy,* edited by CE Orfanos, O Braun-Falco, EM Farber, Ch. Grupper, MK Polano, R. Schuppli. New York, Springer, 1981, p 453

18. Franceschetti AT et al: The cornea in Richner-Hanhart's syndrome (in German). *Ber Zusammenkunft Dtsch Ophthalmol Ges* **71**:109, 1972

19. Zmegac ZJ, Sarajlic MV: A rare form of an inheritable palmar and plantar keratosis. *Dermatologica* **130**:40, 1964

20. Scriver CR, Kaufman S: Hyperphenylalaninemia phenylalanine hydroxylase deficiency, in *The Metabolic and Molecular Bases of Inherited Disease,* 8th ed, edited by CR Scriver, A Beaudet, W Sly, and D. Valle. New York, McGraw-Hill, 2001, p 1667

21. Fisch RO: Studies of phenylketonuria with dermatitis. *J Am Acad Dermatol* **4**:284, 1981

22. Braun-Falco O, Geissler H: Hautersheinungen bei Phenylketonuria. *Med Welt* **37**:1941, 1964

23. Fleisher TL, Zeligman I: Cutaneous findings in phenylketonuria. *Arch Dermatol* **81**:898, 1960

24. Schulpis KH et al: Biotin recycling impairment in phenylketonuric children with seborrheic dermatitis. *Int J Dermatol* **37**:918, 1998

25. Miyamoto M, Fitzpatrick TB: The competitive inhibition of mammalian tyrosinase by phenylalanine and in relationship to hair pigmentation in phenylketonuria. *Nature* **179**:199, 1957

26. Jablonska S, Stachow A: Scleroderma-like lesions in phenylketonuria (PKU), in *Scleroderma and Pseudoscleroderma,* 2d ed, edited by S Jablonska. Warsaw, Polish Medical Publishers, 1975, p 489

27. Yarbro MT, Anderson JA: L-Tryptophan metabolism in phenylketonuria. *J Pediatr* **68**:895, 1966

28. Lasser AE et al: Phenylketonuria and scleroderma. *Arch Dermatol* **114**:1215, 1978

29. Nagasaki Y et al: Reversal of hypopigmentation in phenylketonuria mice by adenovirus-mediated gene transfer. *Pediatr Res* **45**:465, 1999

30. Brusilow SW, Horwich AL: Urea cycle enzymes, in *The Metabolic Basis of Inherited Disease,* 6th ed, edited by CR Scriver, A Beaudet, W Sly, D. Valle. New York, McGraw-Hill, 1989, p 629

31. Levin B: Argininosuccinic aciduria: An inborn error of amino acid metabolism. *Arch Dis Child* **36**:622, 1961

32. Hartlage PL et.al: Argininosuccinic aciduria: Perinatal diagnosis and early dietary management. *J Pediatr* **85**:86, 1974

33. Rogers GE, Harding HWJ: Molecular mechanisms in the formation of hair, in *Biology and Disease of the Hair,* edited by T Kobofi, W Montagna. Baltimore, University Park Press, 1976, p 411

34. Winther A, Bundgaard L: Argininosuccinic aciduria in hereditary hair diseases. *Acta Derm Venereol (Stockh)* **48**:567, 1968

35. Efron ML, Hoefnagel D: Argininosuccinic acid in monilethrix. *Lancet* **1**:321, 1966

36. La Du BN: Alkaptonuria, in *The Metabolic and Molecular Bases of Inherited Disease,* 7th ed, edited by CR Scriver, A Beaudet, W Sly, D. Valle. New York, McGraw-Hill, 2001, p 1371

37. Beltran-Valero D et al: Mutational analysis of the *HGO* gene in Finnish alkaptonuria patients. *J Med Genet* **36**:922, 1999

38. Zatkova A et al: High frequency of alkaptonuria in Slovakia: Evidence for the appearance of multiple mutations in *HGO* involving different mutational hot spots. *Am J Hum Genet* **67**:1333, 2000

39. Zatkova A et al: Novel mutations in the homogentisate-1,2-dioxygenase gene identified in Slovak patients with alkaptonuria. *J Med Genet* **37**:539, 2000

40. Fernandez-Canon JM et al: The molecular basis of alkaptonuria. *Nature Genet* **14**:19, 1996

41. Zannoni VG et al: Oxidation of homogentisic acid to ochronotic pigment in connective tissue. *Biochim Biophys Acta* **177**:94, 1969

42. Kress W et.al: The genetic defect of the alkaptonuric mouse (*aku*). *Mamm Genome* **10**:68, 1999

43. Blivaiss BB et al: Experimental ochronosis: Induction in rats by long-term feeding with L-tyrosine. *Arch Pathol Lab Med* **82**:45, 1966

44. Murray JC et al: In vitro inhibition of chick embryo lysyl hydroxylase by homogentisic acid: A proposed connective tissue defect in alkaptonuria. *J Clin Invest* **59**:1071, 1977

45. Phornphutkul, C et al: Natural history of alkaptonuria. *N Engl J Med* **349**:2111, 2002

46. Abreo K et al: A fifty-year-old man with skin pigmentation, arthritis, chronic renal failure and methemoglobinemia. *Am J Med Genet* **14**:97, 1983

47. Vijaikumar M et al: Alkaptonuric ochronosis presenting as palmoplantar pigmentation. *Clin Exp Dermatol* **25**:305, 2000

48. Attwood HD et al: A histological, histochemical and ultrastructural study of dermal ochronosis. *Pathology (Phila)* **3**:115, 1971

49. Gaines JJ et al: An ultrastructural and light microscopic study of the synovium in ochronotic arthropathy. *Hum Pathol* **18**:1160, 1987

50. Bruce S et al: Exogenous ochronosis resulting from quinine injections. *J Am Acad Dermatol* **15**:357, 1986

51. Findlay GH et al: Exogenous ochronosis and pigmented colloid milium from hydroquinone bleaching creams. *Br J Dermatol* **93**:613, 1975

52. Hardwick N et al: Exogenous ochronosis: An epidemiological study. *Br J Dermatol* **120**:229, 1989

53. Hoshaw RA et al: Ochronosislike pigmentation from hydroquinone bleaching creams in American blacks. *Arch Dermatol* **121**:105, 1985

54. Tidman MJ et al: Hydroquinone-induced ochronosis: Light and electronmicroscopic features. *Clin Exp Dermatol* **11**:224, 1986

55. Dupre A et al: Idiopathic pigmentation of the hands: Professional exogenous ochronosis? A new entity? *Arch Dermatol Res* **266**:1, 1979

56. Diven DG et al: Hydroquinone-induced localized exogenous ochronosis treated with dermabrasion and CO_2 laser. *J Dermatol Surg Oncol* **16**:1018, 1990

57. Yasuda K et al: Corticosteroid treatment of prolidase deficiency skin lesions by inhibiting iminodipeptide-primed neutrophil superoxide generation. *Br J Dermatol* **141**:846, 1999

T>

Chapter 148

Stephen Breathnach

Amyloidosis of the Skin

DEFINITION AND CLASSIFICATION OF AMYLOIDOSIS
ETIOLOGY AND PATHOGENESIS
Systemic Amyloidosis
Localized Cutaneous Amyloidosis
Nonfibrillar Amyloid Proteins
CLINICAL MANIFESTATIONS
Primary and Myeloma-Associated Systemic Amyloidosis
Heredofamilial Amyloidosis
Localized Cutaneous Amyloidosis
LABORATORY AND SPECIAL EXAMINATION
Primary and Myeloma-Associated Systemic Amyloidosis1,5,13,25,26,27 and 28
HISTOPATHOLOGY
Systemic Amyloidosis
Localized Cutaneous Amyloidosis18
DIAGNOSIS
OTHER DIAGNOSTIC PROCEDURES IN SYSTEMIC AMYLOIDOSIS1,25
DISTINCTION BETWEEN PRIMARY AND MYELOMA-ASSOCIATED AMYLOIDOSIS
TREATMENT
Systemic Amyloidosis1,25,27
Localized Cutaneous Amyloidosis
PROGNOSIS

REFERENCES

DEFINITION AND CLASSIFICATION OF AMYLOIDOSIS

The generic term *amyloidosis* signifies the abnormal extracellular tissue deposition of one of a family of biochemically unrelated proteins that share certain characteristic staining properties, including apple-green birefringence of Congo red–stained preparations viewed under polarized light, and a fibrillar ultrastructure. [1], [2], [3] and [4] Paired 7.5- to 10-nm, rigid, linear, nonbranching, aggregated, hollow fibrils of indefinite length constitute the bulk of amyloid deposits, regardless of clinicopathologic type or the tissue involved, and are arranged in a loose meshwork. Amyloid fibrils have been shown by x-ray diffraction crystallography and infrared spectroscopy to have, at least in part, a beta-pleated sheet configuration, which probably accounts for their ability to bind Congo red.

Amyloid deposition may occur throughout many organs of the body (systemic amyloidosis) or may be restricted to a single tissue site (organ-limited or localized amyloidosis) (Table 148-1) and usually is associated with considerable tissue dysfunction. Interest in amyloidosis has increased tremendously with the realization that it is involved in the pathology of aging and of neurodegenerative diseases, including Alzheimer's disease and stroke. [3], [4] Systemic types of amyloidosis include those associated with plasma cell dyscrasia, either overt as in multiple myeloma or occult as in “primary” systemic amyloidosis, [5] and amyloidosis secondary to a variety of chronic diseases. [6], [7] The latter include acute recurrent and chronic infections, rheumatoid arthritis, juvenile chronic arthritis, ankylosing spondylitis, Reiter's syndrome, Behçet's syndrome, Sjögren's syndrome, systemic lupus erythematosus (very rarely), inflammatory bowel disease, Hodgkin's disease, and some solid nonlymphoid tumors, as well as Castleman's disease. Secondary systemic amyloidosis also may arise as a complication of a number of dermatoses, [8] such as venous ulceration, [9] generalized psoriasis and psoriatic arthritis, [10] lepromatous leprosy, hidradenitis suppurativa, chronically infected burns, chronic skin infection in drug addicts, nodular nonsuppurative panniculitis, giant ulcerated or metastatic basal cell carcinoma, [11] acne conglobata, epidermolysis bullosa of dystrophic [12] and aquisita types, and X-linked anhidrotic ectodermal dysplasia.

TABLE 148-1 **Classification of Amyloid and Biochemical Nature of Fibril Proteins**

Clinically evident involvement of the skin is frequent in primary systemic and myeloma-associated systemic amyloidosis but occurs only rarely, if at all, in secondary systemic amyloidosis. Although there is a degree of overlap, primary and myeloma-associated systemic amyloidosis typically involve the tongue, heart, gastrointestinal tract, skeletal and smooth muscle, carpal ligaments, nerves, and skin, whereas secondary systemic amyloidosis affects the liver, spleen, kidneys, and adrenals. [13] Skin manifestations are associated with a number of systemic heredofamilial syndromes of amyloid deposition, including familial Mediterranean fever, [14] the Muckle-Wells syndrome, [15] and heredofamilial amyloid polyneuropathy. [16] Localized cutaneous amyloidosis may be of primary (nodular and macular amyloid and lichenoid amyloidosis) or secondary type [17], [18] (see Table 148-1).

ETIOLOGY AND PATHOGENESIS

Amyloid may accumulate as a result of a variety of different pathogenic mechanisms, and the biochemical composition of amyloid fibrils varies according to the clinicopathologic type of amyloidosis. [1], [2], [3] and [4] The various known amyloid fibril proteins are listed in Table 148-1. Only those relevant to cutaneous disease will be discussed further.

Systemic Amyloidosis

Amyloid deposition in primary and myeloma-associated systemic amyloidosis occurs as a result of plasma cell dyscrasia, and the fibrils are composed of immunoglobulin light chain material (protein AL), [1], [2] either intact light chains, light chain fragments (particularly the variable aminoterminal region), or both. Abnormal light chain material is almost always present in the serum or urine, even in so-called primary systemic amyloidosis, and can be demonstrated on tissue culture of bone marrow cells from affected patients. Proteolytic digestion of only a proportion of Bence Jones proteins results in amyloid fibril formation, which may account for the fact that amyloidosis develops in only about 15 percent of patients with myelomatosis.

In secondary systemic amyloidosis and familial Mediterranean fever, the fibrils are composed of a non-immunoglobulin protein designated protein AA. [1], [4], [6] A precursor of protein AA, known as serum amyloid A protein (protein SAA), is present in the serum of normal individuals as an apolipoprotein of high-density lipoprotein and behaves as an acute-phase reactant. A number of types of familial amyloidosis, which may manifest initially with progressive neuropathy, cardiomyopathy, or renal involvement, are related to a variant of transthyretin (prealbumin) inherited as a dominant trait and produced by a point mutation in the transthyretin gene leading to an amino acid substitution in the transthyretin protein. This may destabilize the transthyretin tetramer in favor of a monomeric amyloidogenic intermediate under lysosomal (acidic) conditions. [1], [2] and [3] However, in senile systemic amyloidosis, the amino acid primary structure of the transerythritin of which the fibrils are composed is normal, so factors other than the primary structure must be involved in amyloid deposition. In patients undergoing long-term hemodialysis, the amyloid fibrils are composed of $ß_2$-microglobulin. [19]

Localized Cutaneous Amyloidosis

SECONDARY LOCALIZED CUTANEOUS AMYLOIDOSIS Deposition of insignificant microscopic amounts of amyloid in relation to a variety of cutaneous lesions is the most common type of localized cutaneous amyloidosis. Reported predisposing conditions include intradermal nevi, sweat gland tumors, pilomatrixoma, dermatofibroma, seborrheic keratosis, solar elastosis, photosensitive annular elastolytic giant cell granuloma, actinic keratosis, porokeratosis of Mibelli, Bowen's disease, and basal cell carcinoma, [18] as well as following PUVA therapy.
PRIMARY LOCALIZED CUTANEOUS AMYLOIDOSIS (PLCA) This comprises macular, papular (lichen amyloidosus), and the rare nodular (tumefactive) forms. [17], [18] Nodular PLCA may be regarded as akin to extramedullary plasmacytoma, since the fibrils are of immunoglobulin AL type and are thought to arise as a result of local aberrant light chain material production by clonally expanded plasma cells. [20] Fibrils in lichenoid amyloidosus and macular amyloidosis do not bind antibodies to protein AA or prealbumin and although immunoglobulins, kappa and lambda light chains, and complement are observed frequently in deposits of macular and papular PLCA, they are not thought to be integral constituents of the fibrils because they are readily eluted. Instead, the concept has arisen of focal epidermal damage and filamentous degeneration of keratinocytes, followed by apoptosis and conversion of filamentous masses (colloid bodies) into amyloid material in the papillary dermis, perhaps with a contribution from the dermal-epidermal junction. [21] In support of this theory is the fact that dermal amyloid deposits in these forms of PLCA cross-react immunohistochemically with keratin. [22] It has been proposed that in lichenoid amyloidosus specific immunologic tolerance to the presence of colloid bodies in the papillary dermis favors their transformation into amyloid by macrophages or fibroblasts, whereas in lichen planus a brisk inflammatory response ensures their removal.

Nonfibrillar Amyloid Proteins

In addition to the fibrillar component, amyloid deposits invariably contain up to 14 percent by dry weight of a protein termed *amyloid P* (*plasma*) *component* (AP), [1], [23] which is derived from and identical to serum amyloid P component (SAP), a protein present in the blood of all normal individuals. AP component is also constantly associated with the microfibrillar sheath of elastic fibers throughout the body in normal adults. [24] SAP component prevents proteolysis of the amyloid fibrils of Alzheimer's disease, of AA amyloidosis, and of AL amyloidosis and thus may contribute to their persistence in vivo. [23] In this regard, it is of interest that AP compenent is absent from nonamyloidotic monoclonal immunoglobulin deposits. AP component shows calcium-dependent binding to isolated amyloid fibrils in vitro, which may account for the frequent observation of amyloid deposition in the vicinity of elastic fibers. Amyloid deposits also contain extracellular matrix components, including glycosaminoglycans and proteoglycans, that may be involved in the pathogenesis.

CLINICAL MANIFESTATIONS

Primary and Myeloma-Associated Systemic Amyloidosis

The field has been reviewed extensively. [1], [5], [13], [17], [25], [26], [27], [28] and [29] These conditions are very rare before age 40, the mean age of onset being about 65 years; there is a slight male preponderance. Diagnosis is often delayed because of nonspecific presenting symptoms; these include fatigue, weight loss, paresthesias, hoarseness, edema, dyspnea, and syncope secondary to orthostatic hypotension. The classic presentation with symptoms of carpal tunnel syndrome, macroglossia (which occurs in about 10 percent of patients and may result in painful dysphagia), specific mucocutaneous lesions, hepatomegaly, and edema always should alert the clinician to the presence of an underlying plasma cell dyscrasia.

MUCOCUTANEOUS FINDINGS Clinically evident mucocutaneous involvement occurs in up to 40 percent of patients [5], [13], [25], [26] (Table 148-2). The surface of the tongue may be smooth and dry or studded with waxy papules, nodules, plaques, or bullae; there may be fissuring, ulceration, and hemorrhage, as well as tooth indentations on the lateral border.

Common	Less Common
Petechiae, purpura, ecchymoses	Pigmentary changes
Waxy, translucent or purpuric papules	Scleroderma-like infiltration
Nodules	Bullous lesions
Plaques	Alopecia
Tumefactive lesions	Cordlike blood vessel thickening
	Nail dystrophy
	Amyloid elastosis
	Cutis laxa

TABLE 148-2 **Cutaneous Lesions in Primary and Myeloma-Associated Systemic Amyloidosis**

The most common skin signs consist of petechiae, purpura, and ecchymoses occurring spontaneously or after minor trauma and are the result of amyloid infiltration of blood vessel walls. Purpuric lesions are especially found in flexural regions, such as the eyelids (Fig. 148-1), nasolabial folds, neck, axillae, umbilicus and anogenital area, as well as in the mouth. Eyelid purpura following pinching (pinch purpura) and periorbital purpura following coughing, vomiting, the Valsalva maneuver, forced expiration during spirometric testing, or proctoscopy (postproctoscopic palpebral purpura) are very characteristic. Pigmentary changes include jaundice due to hepatic disease, cardiac failure or severe hemorrhage, pallor due to anemia, and hyperpigmentation due to hemorrhage.

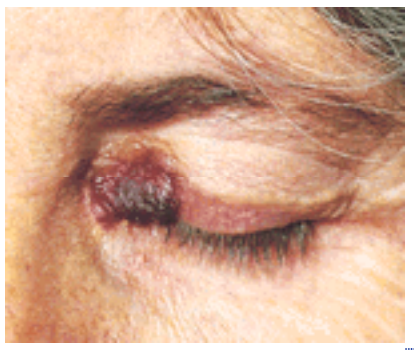

FIGURE 148-1 Amyloidosis of the eyelid with purpura.

Waxy, smooth, shiny papules (Fig. 148-2), nodules, and plaques that may be skin or amber colored with a hemorrhagic appearance are the most characteristic skin lesions. Translucent lesions may resemble vesicles. Flexural areas are sites of predilection, including the eyelids, retroauricular region, neck, axillae, umbilicus, and inguinal and anogenital regions. Lesions also may be found on the central face, lips, tongue, and buccal mucosa. Nodules, which occur at any site, may resemble condylomata lata on perianal and vulval skin [30] and, when widespread, may appear like xanthomata. Plaques may be isolated or coalesce to produce large tumefactive lesions. Diffuse amyloid infiltration may produce a sclerodermatous appearance of the face, hands, and feet. [31] Alternatively, a myxedema-like appearance may develop; scalp lesions may resemble cutis verticis gyrata or lead to patchy or universal alopecia.

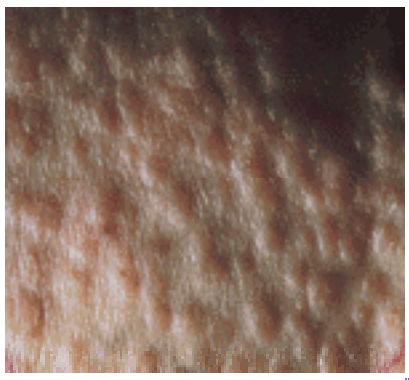

FIGURE 148-2 Papular lesions of cutaneous amyloidosis.

Signs that occur rarely include bullae of the skin or mucous membranes as a result of shearing within dermal amyloid deposits. [32] Dystrophic nail changes, including brittleness, crumbling, subungual striations, and partial or complete anonychia, may be a presenting sign. [33] Amyloid elastosis is an unusual, recently recognized syndrome in which papulonodular cutaneous lesions are associated with widespread amyloid infiltration of visceral and cutaneous blood vessels, particularly in relation to elastic fibers. [34]

SYSTEMIC FINDINGS Hepatomegaly occurs in about 50 percent of patients at presentation, but splenomegaly is seen in less than 10 percent. Pitting edema is common and may be the result of the nephrotic syndrome or of congestive heart failure, both of which occur in about 30 percent of patients; rarely, it may be a complication of protein-losing enteropathy from amyloid involvement of the small bowel. Ascites may develop. Angina, infarction, arrhythmias, or orthostatic

hypotension may develop as a consequence of cardiac infiltration. [35] Congestive heart failure or arrhythmias account for death in about 40 percent of patients with AL-type systemic amyloidosis. Pulmonary involvement is common but usually asymptomatic. Amyloid infiltration of blood vessels may lead to claudication of the legs or jaw, and gastrointestinal tract involvement may simulate inflammatory bowel disease with hemorrhage; malabsorption is found in 5 percent of patients. The carpal tunnel syndrome has been reported in up to 25 percent of patients with primary systemic amyloidosis. Peripheral neuropathy, [36] initially of the lower extremities, tends to pursue a chronic course and may be accompanied by superimposed autonomic neuropathy leading to orthostatic hypotension, diarrhea, loss of bladder control, or impotence. Muscle weakness may be caused by neuropathy or by direct infiltration of muscle or its vascular supply, and infiltration between muscle fibers leading to pseudohypertrophy is recognized. Lymphadenopathy, which occurs in about 10 percent of patients, Sjögren's syndrome, or sicca syndrome may be presenting features occasionally. Amyloid deposition in joints may mimic rheumatoid arthritis, and deposition around the shoulders may cause extensive soft tissue enlargement (the shoulder-pad sign). Giant cell arteritis and polymyalgia rheumatica have been reported. Among the hematologic complications of systemic amyloidosis are isolated factor X deficiency, disseminated intravascular coagulation, and fibrinolysis with severe bleeding.

Heredofamilial Amyloidosis

Familial Mediterranean fever, inherited as an autosomal recessive, has erysipelas-like lesions on the lower legs, urticaria, Henoch-Schönlein purpura, and vasculitic nodules. [14] Associated features are intermittent fevers and a tendency to peritonitis, pleurisy, synovitis, and renal amyloidosis. The Muckle-Wells syndrome, inherited as an autosomal dominant trait, is characterized by periodic attacks of urticaria, fever, and limb pains associated with progressive perceptive nerve deafness and renal amyloidosis. [15] Trophic skin changes may develop in heredofamilial amyloid polyneuropathy. [16]

Localized Cutaneous Amyloidosis

Nodular localized cutaneous amyloidosis [17], [18], [37], [38] presents clinically with single or, more commonly, multiple lesions on the limbs (Fig. 148-3), face, trunk, or genitalia. These appear indistinguishable from those associated with plasma cell dyscrasia–related systemic amyloidosis and vary in size from a few millimeters to several centimeters. The condition may follow a prolonged benign course over many years [37]; however, some patients later develop paraproteinemia and overt systemic amyloidosis. [18]

FIGURE 148-3 Nodular primary localized amyloidosis of the leg.

MACULAR AMYLOIDOSIS AND LICHENOID AMYLOIDOSUS (PLCA)[17], [18], [25] Macular amyloidosis, which tends to persist unchanged for many years, is a pruritic eruption of small brownish macules distributed typically in a rippled, symmetrical fashion on the upper back (Fig. 148-4), limbs, and occasionally chest and buttocks; itching is not always present. Lichenoid amyloidosus is a persistent pruritic eruption of multiple discrete hyperkeratotic papules that may coalesce to form plaques that are distributed principally on the shins. There may be spread to the calves, ankles, dorsa of the feet, and thighs, and the extensor aspects of the arms and abdominal or chest wall also may be involved. [39] Because macular amyloid and lichenoid amyloidosus may coexist in an affected individual (biphasic amyloidosis), they are regarded as variants of a single pathologic process.

FIGURE 148-4 Macular amyloidosis of the upper back.

Lichenoid amyloidosus is more common among the Chinese, [39] and macular amyloidosis is more common among Central and South Americans, Middle Easterners, and non-Chinese Asians. This apparent racial incidence in the case of the Japanese may be contributed to in part by a habit of rubbing the skin vigorously with a nylon towel or brush (friction amyloidosis). [40] The importance of genetic factors in the development of PLCA is emphasized by the occurrence of

familial cases. [41] PLCA occasionally has been reported to be associated with connective tissue diseases (including systemic sclerosis, primary biliary cirrhosis, and systemic lupus erythematosus) and in a few kindreds with pachyonychia congenita or multiple endocrine neoplasia type 2a [42]; in the latter, involvement is restricted to the interscapular area. Unusual variants of PLCA include macular forms with diffuse hyperpigmentation, simulating nevoid hyperpigmentation and a poikiloderma-like form.

ANOSACRAL CUTANEOUS AMYLOIDOSIS This is a rare syndrome described in Japanese and Chinese males in which pigmented macules and glossy hyperkeratotic lesions radiate out from the anus. [43]

LABORATORY AND SPECIAL EXAMINATION

Primary and Myeloma-Associated Systemic Amyloidosis [1], [5], [13], [25], [26], [27] and [28]

Anemia is not a prominent feature, the leukocyte and differential counts are usually within normal limits, and the erythrocyte sedimentation rate (ESR) is usually less than 50 mm/h (Westergren). Thrombocytosis of greater than 500,000/mm ^{2} occurs in up to 10 percent of patients. Hepatic function abnormalities are usually minor apart from hypoalbuminemia, but the serum creatinine is elevated in 50 percent of patients, and proteinuria is present in about 80 percent; hypercalcemia occurs in a third of myeloma patients but is rare in primary cases.

Immunoglobulin estimation reveals reduced IgG levels in half the primary and two-thirds of the myeloma-associated cases. Serum protein electrophoresis shows a spike pattern in slightly less than half the primary and two-thirds of the myeloma patients. However, the spike is usually of modest size and may be missed; monoclonal light chains rarely produce a recognizable band. Immunoelectrophoresis of serum reveals a monoclonal protein in two-thirds of patients with AL amyloidosis; only 45 percent have a monoclonal heavy chain, whereas 20 percent have free monoclonal light chains (Bence Jones proteinemia).

The heat test for Bence Jones protein is usually negative. Immunoelectrophoresis of concentrated urine reveals a monoclonal light chain in about two-thirds of patients (lambda-kappa ratio 2:1). When screening of both serum and urine is performed, the frequency of patients with an identifiable monoclonal protein rises to about 86 percent. Nevertheless, in some patients with the clinical features of AL amyloidosis it is not possible to demonstrate a paraprotein.

HISTOPATHOLOGY

Systemic Amyloidosis

In primary and myeloma-associated systemic amyloidosis, [17], [25], [44] papular lesions contain amorphous, often fissured, faintly eosinophilic masses in the papillary dermis, and there is associated thinning or obliteration of the rete ridges. There may be diffuse amyloid deposition in the reticular dermis and subcutis in nodular lesions and plaques. There is usually little in the way of any associated inflammatory infiltrate. Amyloid infiltration of blood vessel walls, pilosebaceous units, arrector pili muscles, the lamina propria of sweat glands and ducts, and around individual fat cells in the subcutis as amyloid rings is characteristic. Amyloid deposition in the nail fold and bed of dystrophic nails has been reported.

In secondary systemic amyloidosis, amyloid deposits may be found deep in the dermis in small blood vessels and around adnexal structures, as well as surrounding individual cells in the subcuticular fat. [45]

Localized Cutaneous Amyloidosis [18]

NODULAR PLCA The histopathology resembles that of primary systemic amyloidosis with the single exception that in nodular PLCA there is usually a marked infiltrate of plasma.

LICHENOID AMYLOIDOSUS AND MACULAR PLCA Amyloid deposits usually are confined to the papillary dermis and do not involve blood vessels or adnexal structures. Early lesions contain small, multifaceted, amorphous globules within the papillae, and these are missed easily without the use of special stains. Later lesions show globules that coalesce, expand the papillae, and displace the rete ridges laterally. In lichenoid amyloidosus the deposits are slightly larger and are accompanied by irregular acanthosis and hyperkeratosis of the overlying epidermis.

USE OF SPECIAL STAINS [17], [25], [46] The special stains for amyloid include the triphenyl-methane dyes methyl and cresyl violet for the demonstration of metachromasia, the periodic acid–Schiff method, the substantive cotton dyes Congo red and Sirius red with or without fluorescence [47] or polarized light microscopy, and fluorescence with thiazole dyes such as thioflavine T. Alternative cotton dyes including Pagoda red, RIT scarlet no. 5, and RIT cardinal red no. 9 may be used, and fluorescence methods using an optical brightener for cellulose (Phorwhite BBU) and immunohistochemical staining with anti-SAP component also have been advocated. Unfortunately, methyl violet and Congo red staining may be equivocal and inadequate for detecting small deposits of amyloid; false-positive results occur in colloid milium and lipoid proteinosis. False-positive staining with thioflavine T is seen with stromal hyaline deposits, collagen fibers, and colloid bodies in lichen planus; anti-SAP component also stains colloid bodies and elastotic elastic fibers. Thus none of the existing stains is absolutely reliable, and ultrastructural examination sometimes may be necessary. AL-type amyloid, unlike AA-type amyloid, retains its affinity for Congo red and its typical polarization characteristics after exposure to potassium permanganate. [48] Immunohistochemical staining with specific antisera [49], [50] or amino acid sequencing or mass spectroscopy of material extracted from fibrillar deposits using sections of formalin-fixed, paraffin-embedded biopsy specimens [51] is used to differentiate between the various types of fibril protein in amyloid deposits.

DIAGNOSIS

The diagnosis of cutaneous amyloidosis depends on the histochemical, immunohistochemical, or ultrastructural demonstration of amyloid in a skin biopsy specimen. Biopsy of even clinically normal forearm skin has been reported to

be positive in up to 50 percent of patients with primary and myeloma-associated disease.

OTHER DIAGNOSTIC PROCEDURES IN SYSTEMIC AMYLOIDOSIS[1], [25]

Fine-needle biopsy of subcutaneous fat of clinically normal abdominal skin has become established as a simple, minimally invasive diagnostic test with a high-positive yield in AL-type and AA-type systemic amyloidosis, as well as in heredofamilial amyloidosis. [52] In AL- and AA-type amyloidosis, rectal biopsy is positive in up to 80 percent of patients, but the specimen must contain submucosal tissue; jejunal biopsy is positive in about two-thirds of patients, but gingival biopsy is positive in only 19 percent. Gastric biopsy may produce a higher yield than rectal biopsy in AL-type amyloidosis. Ninety-six percent of hepatic and 90 percent of renal and splenic percutaneous needle biopsies are positive. Bone marrow aspiration may be positive in up to 45 percent of patients. Electrocardiography, echocardiography, angiocardiography, technetium scanning, and endomyocardial biopsy are useful in the diagnosis of amyloid heart disease. [53] Computed tomography, ultrasound examination, and Doppler analysis of blood flow may be useful in renal amyloidosis. Sural nerve biopsy in patients with peripheral neuropathy, synovial fluid analysis in patients with arthropathy, and examination of tissue removed at carpal tunnel decompression may be helpful. Scanning with ^{123}I-labeled serum AP component enables specific localization and imaging of amyloid deposits in vivo. [1]

DISTINCTION BETWEEN PRIMARY AND MYELOMA-ASSOCIATED AMYLOIDOSIS

Differentiation between the two ends of the spectrum of AL-type amyloidosis is of prognostic significance but is by no means clear-cut. Most myeloma patients and no primary systemic amyloidosis patients have more than 15 percent plasma cells in the marrow. Similarly, 50 percent of myeloma patients show radiologic evidence of bone involvement compared with only 6 percent of primary patients. In general, myeloma is not present if a patient has no lytic bone lesions, hypercalcemia, or anemia; has only a small serum or urine monoclonal component; and has less than 25 percent bone marrow plasma cells.

TREATMENT

Systemic Amyloidosis [1], [25], [27]

Assessment of response to therapy is hindered by the lack of reliable methods for the quantification of the extent of amyloid in individual patients and by the fact that apparent spontaneous clinical remissions of amyloid nephropathy may occur despite histologic evidence of progressive amyloid infiltration. Liver transplantation in familial amyloid polyneuropathy caused by transthyretin gene mutations leads to the disappearance of variant transthyretin from the plasma and halts progression of neurologic disease.

REACTIVE AA-TYPE (SECONDARY) AMYLOIDOSIS Resolution or remission has followed therapy of underlying disease, including nephrectomy for hypernephroma, antibiotic treatment of chronic infection, and etretinate and PUVA therapy for psoriasis. [1], [25] Colchicine prevents the development of amyloidosis and deterioration of renal function in patients with familial Mediterranean fever [54] and psoriatic arthropathy. [55] Cytotoxic therapy has prolonged survival in patients with underlying rheumatic diseases. [56] Dimethyl sulfoxide (DMSO) may improve renal function and is relatively nontoxic, but its use is limited because of the associated offensive breath odor.

AL-TYPE AMYLOIDOSIS Despite the relatively high risk of development of leukemia or a dysmyelopoietic syndrome, it is reasonable for patients to receive a trial of chemotherapy, with or without autologous bone marrow transplantation. [25], [57], [58] Melphalan, prednisone, and/or colchicine are most usually administered. Diuretics are the mainstay of therapy for congestive heart failure because digoxin may result in arrhythmias and calcium channel-blocking agents are contraindicated. Cardiac transplantation has been used for intractable cases. [59] Renal failure may be treated with regular dialysis; hemodialysis membranes are nearly impermeable to the immunoglobulin light chain precursors of protein AL, so peritoneal dialysis may be preferable. Renal amyloidosis is not an absolute contraindication to transplantation, although amyloid may reaccumulate in the transplanted kidney.

Localized Cutaneous Amyloidosis

Deposits of nodular PLCA may be excised surgically or treated with curettage and cautery, [60] cryotherapy, dermabrasion, [61] or the carbon dioxide or pulsed-dye laser, [38], [62] but they tend to recur. Macular and papular (lichenoid amyloidosis) forms of PLCA unfortunately respond relatively poorly to topical steroids combined with systemic antihistamines to alleviate pruritus, calcipotriol, and phototherapy. [63], [64] Dermabrasion has been advocated for lichenoid amyloidosus. [65] There have been reports of response to topical DMSO therapy in some [66] but not all cases. Etretinate or acitretin therapy has been beneficial in a proportion of but not all patients. [67]

PROGNOSIS

The prognosis of systemic amyloidosis, especially of the primary and myeloma-associated variants, remains poor because there is no very effective therapy; cardiac and renal failure are the major causes of death. [25] The median survival of patients with myeloma-associated amyloidosis is only 5 months. The median survival of 859 patients with primary systemic amyloidosis seen at the Mayo Clinic from 1982 to 1992 was 2.1 years [68]; actuarial survival for 810 patients seen from 1966 to 1987 was 51 percent at 1 year, 16 percent at 5 years, and 4.7 percent at 10 years. [69] Prognosis depends on response to therapy and the extent of disease; the median survival of patients with primary amyloidosis with a positive response to chemotherapy was 18 to 29 months compared with 8.5 months in those receiving colchicine alone. [57] Cardiac involvement indicates a very poor prognosis, with a median survival of 1.08 years from diagnosis and 9 months from onset of heart failure; cardiac transplantation improves survival to 60 percent at 2 years and 30 percent at 5 years. [59] Occasional patients surviving longer than 10 years have been recorded. [69], [70] Patients

presenting with amyloid neuropathy without associated cardiac, renal, or hepatic involvement have a significantly better prognosis (median survival 40–50 months; 5-year survival 31.6 percent). [36]

REFERENCES

1. Hawkins PN: The diagnosis, natural history and treatment of amyloidosis. *J R Coll Phys Lond* **31**:552, 1997

2. Stevens FJ, Kisilevsky R: Immunoglobulin light chains, glycosaminoglycans, and amyloid. *Cell Mol Life Sci* **57**:441, 2000

3. Buxbaum JN, Tagoe CE: The genetics of the amyloidoses. *Annu Rev Med* **51**:543, 2000

4. Picken MM: The changing concepts of amyloid. *Arch Pathol Lab Med* **125**:38, 2001

5. Kyle RA et al: Primary systemic amyloidosis: Clinical and laboratory features in 474 cases. *Semin Hematol* **32**:45, 1995

6. Gertz MA: Secondary amyloidosis (AA). *J Int Med* **232**:517, 1992

7. Brownstein MH, Helwig EB: Secondary systemic amyloidosis: Analysis of underlying disorders. *South Med J* **64**:491, 1971

8. Brownstein MH, Helwig EB. Systemic amyloidosis complicating dermatoses. *Arch Dermatol* **102**:1, 1970

9. Landau M et al: Systemic amyloidosis secondary to chronic leg ulcers. *Cutis* **50**:47, 1992

10. Tsuda S et al: Secondary amyloidosis complicating arthropathic psoriasis. *Clin Exp Dermatol* **21**:141, 1996

11. Yamamoto S et al: Giant basal cell carcinoma associated with systemic amyloidosis. *J Dermatol* **23**:329, 1996

12. Gunduz K et al: Recessive dystrophic epidermolysis bullosa complicated with nephrotic syndrome due to secondary amyloidosis. *Int J Dermatol* **39**:151, 2000

13. Isobe T et al: Patterns of amyloidosis and their association with plasma cell dyscrasia, monoclonal immunoglobulins and Bence Jones proteins. *N Engl J Med* **290**:473, 1974

14. Sohar E et al: Familial Mediterranean fever: A survey of 470 cases and a review of the literature. *Am J Med* **43**:227, 1967

15. Lieberman A et al: Muckle-Wells syndrome: Case report and review of cutaneous pathology. *J Am Acad Dermatol* **39**:290, 1998

16. Rubinow A et al: Skin involvement in familial amyloidotic polyneuropathy. *Neurology* **31**:1341, 1981

17. Wong C-K, Breathnach SM (eds): Cutaneous amyloidosis. *Clin Dermatol* **8**(2): 1990. Enfire issue on amyloidosis.

18. Brownstein MH et al: The cutaneous amyloidoses: I. Localized forms. *Arch Dermatol* **102**:8, 1970

19. Sato KC et al: Lichenoid skin lesions as a sign of beta $_2$-microglobulin-induced amyloidosis in a long-term haemodialysis patient. *Br J Dermatol* **128**:686, 1993

20. Grünewald K et al: Gene rearrangement studies in the diagnosis of “primary” systemic amyloidosis and nodular localized cutaneous amyloidosis. *J Invest Dermatol* **97**:693, 1991

21. Chang YT et al: Apoptosis in primary cutaneous amyloidosis. *Br J Dermatol* **140**:210, 1999

22. Huilgol SC et al: Cytokeratins in primary cutaneous amyloidosis. *Australas J Dermatol* **39**:81, 1998

23. Tennent GA et al: Serum amyloid P component prevents proteolysis of the amyloid fibrils of Alzheimer disease and systemic amyloidosis. *Proc Natl Acad Sci USA* **92**:4299, 1995

24. Breathnach SM et al: Amyloid P component is located on elastic fibre microfibrils in normal human tissue. *Nature* **293**:652, 1981

25. Breathnach SM: Amyloid and amyloidosis. *J Am Acad Dermatol* **18**:1, 1988

26. Wong CK et al: Systemic amyloidosis: A report of 19 cases. *Dermatology* **189**:47, 1994

27. Gertz MA et al: Amyloidosis: Recognition, confirmation, prognosis, and therapy. *Mayo Clin Proc* **74**:490, 1999

28. Kyle RA: Clinical aspects of multiple myeloma and related disorders including amyloidosis. *Pathol Biol (Paris)* **47**:148, 1999

29. Daoud MS et al: Monoclonal gammopathies and associated skin disorders. *J Am Acad Dermatol* **40**:507, 1999

30. Konig A et al: Vulvar amyloidosis mimicking giant condylomata acuminata in a patient with multiple myeloma. *Eur J Dermatol* **9**:29, 1999

31. Gerster JC et al: Scleroderma-like changes of the hands in primary amyloidosis. *J Rheumatol* **27**:2275, 2000

32. Robert C et al: Bullous amyloidosis: Report of 3 cases and review of the literature. *Medicine* **72**:38, 1993

33. Mancuso G et al: Nail changes as the only skin abnormality in myeloma-associated systemic amyloidosis. *Br J Dermatol* **137**:471, 1997

34. Winkelmann RK et al: Amyloid elastosis: A new cutaneous and systemic pattern of amyloidosis. *Arch Dermatol* **121**:498, 1985

35. Dubrey SW et al: The clinical features of immunoglobulin light-chain (AL) amyloidosis with heart involvement. *Q J Med* **91**:141, 1998

36. Duston MA et al: Peripheral neuropathy as an early marker of AL amyloidosis. *Arch Intern Med* **149**:358, 1989

37. Woollons A, Black MM: Nodular localized primary cutaneous amyloidosis: A long-term follow-up study. *Br J Dermatol* **145**:105, 2001

38. Kakani RS et al: Nodular amyloidosis: Case report and literature review. *J Cutan Med Surg* **5**:101, 2001

39. Wong C-K: Lichen amyloidosus: A relatively common skin disorder in Taiwan. *Arch Dermatol* **110**:438, 1974

40. Venkataram MN et al: Frictional amyloidosis: A study of 10 cases. *Australas J Dermatol* **42**:176, 2001

41. Hartshorne ST: Familial primary cutaneous amyloidosis in a South African family. *Clin Exp Dermatol* **24**:438, 1999

42. Hofstra RM et al: RET mutation screening in familial cutaneous lichen amyloidosis and in skin amyloidosis associated with multiple endocrine neoplasia. *J Invest Dermatol* **107**:215, 1996

43. Wang WJ et al: Anosacral cutaneous amyloidosis: A study of 10 Chinese cases. *Br J Dermatol* **143**:1266, 2000

44. Elder D et al (eds): *Lever's Histopathology of the Skin*, 8th ed. Philadelphia, Lippincott, 1997

45. Westermark P: Occurrence of amyloid deposits in the skin in secondary systemic amyloidosis. *Acta Path Microbiol Scand [A]* **80**:718, 1972

46. Elghetany MT et al: Methods for staining amyloid in tissues: A review. *Stain Technol* **63**:201, 1988

47. Linke RP: Highly sensitive diagnosis of amyloid and various amyloid syndromes using Congo red fluorescence. *Virchows Arch* **436**:439, 2000

48. Wright JR et al: Potassium permanganate reaction in amyloidosis: A histologic method to assist in differentiating forms of this disease. *Lab Invest* **36**:274, 1977

49. Fujihara S et al: Identification and classification of amyloid in formalin-fixed, paraffin-embedded tissue sections by the unlabeled immunoperoxidase method. *Lab Invest* **43**:358, 1980

50. Linke RP et al: High-sensitivity diagnosis of AA amyloidosis using Congo red and immunohistochemistry detects missed amyloid deposits. *J Histochem Cytochem* **43**:863, 1995

51. Murphy CL et al: Chemical typing of amyloid protein contained in formalin-fixed paraffin-embedded biopsy specimens. *Am J Clin Pathol* **116**:135, 2001

52. Guy CD, Jones CK: Abdominal fat pad aspiration biopsy for tissue confirmation of systemic amyloidosis: Specificity, positive predictive value, and diagnostic pitfalls. *Diag Cytopathol* **24**:181, 2001

53. Dubrey SW et al: Electrocardiography and Doppler echocardiography in secondary (AA) amyloidosis. *Am J Cardiol* **77**:313, 1996

54. Simsek B et al: Regression of nephrotic syndrome due to amyloidosis secondary to familial Mediterranean fever following colchicine treatment. *Nephrol Dial Transplant* **15**:281, 2000

55. Kagan A et al: Reversal of nephrotic syndrome due to AA amyloidosis in psoriatic patients on long-term colchicine treatment: Case report and review of the literature. *Nephron* **82**:348, 1999

56. Chevrel G et al: Renal type AA amyloidosis associated with rheumatoid arthritis: A cohort study showing improved survival on treatment with pulse cyclophosphamide. *Rheumatology (Oxford)* **40**:821, 2001

57. Gertz MA et al: Prospective randomized trial of melphalan and prednisone versus vincristine, carmustine, melphalan, cyclophosphamide, and prednisone in the treatment of primary systemic amyloidosis. *J Clin Oncol* **17**:262, 1999

58. Dember LM et al: Effect of dose-intensive intravenous melphalan and autologous blood stem-cell transplantation on AL amyloidosis-associated renal disease. *Ann Intern Med* **134**:746, 2001

59. Dubrey SW et al: Long term results of heart transplantation in patients with amyloid heart disease. *Heart* **85**:202, 2001

60. Vestey JP et al: Primary nodular cutaneous amyloidosis: Long-term follow-up and treatment. *Clin Exp Dermatol* **19**:159, 1994

61. Lien MH et al: The efficacy of dermabrasion in the treatment of nodular amyloidosis. *J Am Acad Dermatol* **36**:315, 1997

62. Alster TS, Manaloto RM: Nodular amyloidosis treated with a pulsed dye laser. *Dermatol Surg* **25**:133, 1999

63. Khoo BP et al: Calcipotriol ointment versus betamethasone 17-valerate ointment in the treatment of lichen amyloidosis. *Int J Dermatol* **38**:539, 1999

64. Jin AG et al: Comparative study of phototherapy (UVB) versus photochemotherapy (PUVA) versus topical steroids in the treatment of primary cutaneous lichen amyloidosis . *Photodermatol Photoimmunol Photomed* **17**:42, 2001

65. Wong CK et al: Dermabrasion for lichen amyloidosus: Report of a long-term study. *Arch Dermatol* **118**:302, 1982

66. Ozkaya-Bayazit E et al: Intermittent use of topical dimethyl sulfoxide in macular and papular amyloidosis. *Int J Dermatol* **37**:949, 1998

67. Hernandez-Nunez A et al: Widespread biphasic amyloidosis: Response to acitretin. *Clin Exp Dermatol* **26**:256, 2001

68. Gertz MA et al: Amyloidosis: Prognosis and treatment. *Semin Arthritis Rheum* **24**:124, 1994

69. Kyle RA et al: Long-term survival (10 years or more) in 30 patients with primary amyloidosis. *Blood* **93**:1062, 1999

70. Goldsmith DJ et al: Twenty-one years survival with systemic AL-amyloidosis. *Am J Kidney Dis* **28**:278, 1996

T>

Chapter 149

David Bickers Jorge Frank

The Porphyrias

PORPHYRIN–HEME BIOSYNTHESIS
d-Aminolevulinic Acid Synthase
d-Aminolevulinic Acid Dehydratase
Porphobilinogen Deaminase
Uroporphyrinogen III Synthase
Uroporphyrinogen Decarboxylase
Coproporphyrinogen Oxidase
Protoporphyrinogen Oxidase
Ferrochelatase
PATHOPHYSIOLOGY OF CUTANEOUS LESIONS IN THE PORPHYRIAS
Reactive Oxygen Species
Erythrocytes
Mast Cells
Polymorphonuclear Cells
Fibroblasts
The Complement System
Factor XII–Dependent Pathways of Coagulation
The Eicosanoids
Matrix Metalloproteinases
CLASSIFICATION OF THE PORPHYRIAS
ACUTE AND NONACUTE PORPHYRIAS
ACUTE INTERMITTENT PORPHYRIA (AIP) (Table 149-6)
Etiology
Epidemiology
Clinical Manifestations
Laboratory Findings
Histopathology
Differential Diagnosis
Treatment
VARIEGATE PORPHYRIA (VP)
Etiology
Epidemiology
Clinical Manifestations
Laboratory Findings
Histopathology
Differential Diagnosis
Treatment
HEREDITARY COPROPORPHYRIA
Etiology
Epidemiology
Clinical Manifestations
Laboratory Findings
Histopathology
Differential Diagnosis
Treatment
ALA DEHYDRATASE DEFICIENCY PORPHYRIA
TREATMENT OF THE ACUTE ATTACKS IN THE ACUTE PORPHYRIAS
PREVENTION OF THE ACUTE ATTACKS IN THE ACUTE PORPHYRIAS
PORPHYRIA CUTANEA TARDA (PCT)
Etiology
Epidemiology
Clinical Manifestations
PSEUDOPORPHYRIA (BULLOUS PHOTOSENSITIVITY)
Laboratory Findings
Histopathology
Differential Diagnosis
Treatment
ERYTHROPOIETIC PROTOPORPHYRIA (EPP)
Etiology
Epidemiology
Clinical Manifestations
Laboratory Findings
Histopathology
Differential Diagnosis
Treatment
CONGENITAL ERYTHROPOIETIC PORPHYRIA (Table 149-7)
Etiology
Epidemiology
Clinical Manifestations
Laboratory Findings
Histopathology

Differential Diagnosis
Treatment
HEPATOERYTHROPOIETIC PORPHYRIA (HEP) (Table 149-7)
Etiology
Epidemiology
Clinical Manifestations
Laboratory Findings
Histopathology
Differential Diagnosis
Treatment
ABNORMAL PORPHYRIN PROFILE AND SIDEROBLASTIC ANEMIA
MOLECULAR GENETIC RESEARCH STRATEGIES FOR THE PORPHYRIAS
ANIMAL MODELS AND FUTURE OPTIONS FOR GENE THERAPY
FUTURE PROSPECTS

REFERENCES

The porphyrias are among the most intriguing diseases of humans. Widely variable, almost bizarre in their clinical manifestations, these disorders of porphyrin or porphyrin-precursor metabolism result from aberrations in the control of the heme biosynthetic pathway. Heme is essential for oxygen binding and transport (as hemoglobin and myoglobin), for electron transport (as cytochromes), and for mixed-function oxidases such as cytochrome P450. Chlorophyll, a magnesium-chelated porphyrin, is another important tetrapyrrole and is critical for photosynthesis, the specialized energy-storing system found in plants, in which the conversion of light energy into stabilized chemical energy is achieved with a sequence of oxidation-reduction reactions. The corrin ring, a cobalt-chelated tetrapyrrole, is a major constituent of vitamin B_{12}, the lack of which results in pernicious anemia. Porphyrins are ubiquitous and essential biochemical constituents of living beings. The biologic importance of the porphyrins and their iron complexes in metabolism lies in their capacity to act as mediators of oxidation reactions, either as oxidative components in the metabolism of steroids, drugs, and environmental chemicals, or as a means of exchanging gases, such as oxygen and carbon dioxide, between the environment and the tissues of the body.

Daily synthesis of porphyrins and heme in humans occurs in amounts sufficient to provide for the body's metabolic requirements. The control of heme synthesis is so precise that, under normal circumstances, microgram quantities or less of pathway intermediates are present in plasma, red blood cells (RBCs), urine, and feces (see Table 149-1).



TABLE 149-1 **Normal Values of Porphyrins and Porphyrin Precursors in Humans**

Porphyria results from either inherited or acquired abnormalities in enzymes crucial for heme synthesis. There are eight enzymes in the heme pathway that control its synthesis. The human porphyrias are characterized by deficient activity of specific enzymes (Table 149-2); each of these enzymes will be discussed separately. The different porphyrias arising from such derangements of normal heme synthesis manifest patterns of accumulation and excretion of specific porphyrins and/or their precursors. [1], [2] In general, the major porphyrins excreted in a specific type of porphyria are the irreversibly oxidized substrate(s) for the deficient or defective enzyme. The different porphyrias arising from such derangements of normal heme synthesis are also characterized by accumulation and excretion of specific intermediate porphyrins and/or their precursors (Table 149-3). These intermediates, when present in excess amounts, exert toxic effects that are likely responsible for the neurologic and cutaneous features of clinical porphyria. The porphyrias are of particular dermatologic interest because several of them have distinct cutaneous manifestations that may permit diagnosis from clinical signs alone.



TABLE 149-2 **Enzyme Activities in Various Porphyrias**



TABLE 149-3 **Biochemical Features of the Porphyrias**

PORPHYRIN–HEME BIOSYNTHESIS

The major sites of heme synthesis in the body are the bone marrow and the liver. Heme is the prosthetic group for a number of proteins, including, among others, hemoglobin, myoglobin, mitochondrial cytochromes, microsomal cytochromes (including cytochrome P450), catalase, peroxidase, tryptophan pyrrolase, prostaglandin endoperoxide synthase, and the soluble form of guanylate cyclase. Approximately 85 percent of heme synthesis occurs in bone marrow, where it is used for the production of hemoglobin; the majority of the rest occurs in the liver for making cytochrome P450, catalase, and various mitochondrial cytochromes. Heme is a critical cellular constituent essential for a variety of metabolic processes, primarily because of its unique ability to take up and release oxygen and to facilitate electron transport. Heme synthesis is regulated by the interplay of a number of factors and is directly dependent upon its concentration within cells and upon the requirements of the cell for production of the various hemoproteins described above. Many of these have rapid turnover times (minutes to hours), thereby necessitating continuously high rates of hepatic heme synthesis (e.g., cytochrome P450, an important membrane-bound enzyme in the liver involved in the detoxification and metabolism of drugs, has a half-life of 90 to 180 min). This regulation (and indeed the ability to synthesize heme at all) is dependent upon a series of eight intracellular enzymes. The first (ALA synthase) and the last three enzymes involved (COPROGEN oxidase, PROTOGEN oxidase, and ferrochelatase) are localized in mitochondria, and the remaining intermediate enzymes (ALA dehydratase, PBG deaminase, UROGEN III synthase, and UROGEN decarboxylase) are localized in the cytosol. Heme cleavage is catalyzed by the microsomal enzymes NADPH-cytochrome C reductase, heme oxygenase, and biliverdin reductase that convert the cyclic tetrapyrrole to linear bile pigments. cDNAs for the eight enzymes in the heme synthesis pathway and the enzymes in the heme catabolic pathway have been cloned in mammalian cells. Abnormal control of heme synthesis may result from partial defects in enzymes of the pathway, and this may occur as the result of inherited and/or environmental factors leading to the accumulation in the body of one or more heme pathway intermediates, such as the porphyrins or their precursors. Although a diagnosis of porphyria can often be made from a careful history and physical examination, the definitive diagnosis rests upon measurements of porphyrin and/or porphyrin excretion or the activity of one or another of the enzymes in the heme pathway or in the identification of mutations in the genes encoding the enzymes (Table 149-3). The techniques of molecular biology have helped to clarify the mechanistic basis of the porphyrias. [1], [3] Figure 149-1, Figure 149-2, Figure 149-3 and Figure 149-4 summarize the steps involved in the biosynthesis of porphyrins and heme synthesis and its regulation.

FIGURE 149-1 The porphyrin-heme biosynthetic pathway (see also legend for Fig. 149-2).

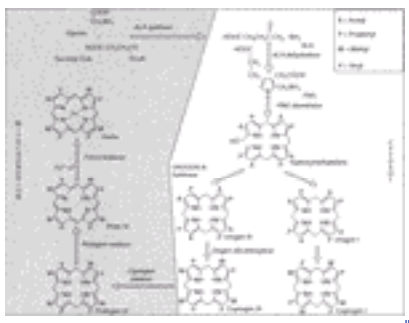

FIGURE 149-2 Major steps in the porphyrin-heme biosynthetic pathway: (*1*) Delta-aminolevulinic acid (ALA) synthase can be formed from glycine and succinyl CoA, which is the primary source in mammalian systems and is catalyzed by the mitochondrial enzyme d-aminolevulinic acid synthase (ALAS). Two molecules of aminolevulinic acid form the monopyrrole porphobilinogen (PBG). (*2*) Four molecules of PBG are converted by PBG deaminase to a linear tetrapyrrole, hydroxymethylbilane, which can cyclize spontaneously to form uroporphyrinogen (UROGEN) I. (*3*) The four acetyl groups of UROGEN I are sequentially decarboxylated by UROGEN decarboxylase to form coproporphyrinogen (COPROGEN) I. (*4*) Hydroxymethylbilane can also be converted to UROGEN III by the enzyme UROGEN III synthase. In this reaction one of the monopyrrole rings is “flipped over,” thereby altering the sequence of the side chains. (*5*) The acetyl groups of UROGEN III are sequentially decarboxylated by UROGEN decarboxylase to form coproporphyrinogen III. (*6*) Coproporphyrinogen III is converted to protoporphyrinogen (PROTOGEN) IX by the enzyme COPROGEN oxidase, which oxidatively decarboxylates each of the propionyl groups. (*7*) PROTOGEN IX is converted to protoporphyrin (PROTO) IX by PROTOGEN oxidase. PROTO IX is converted to heme by ferrochelatase, which catalyzes the insertion of ferrous iron into the molecule.

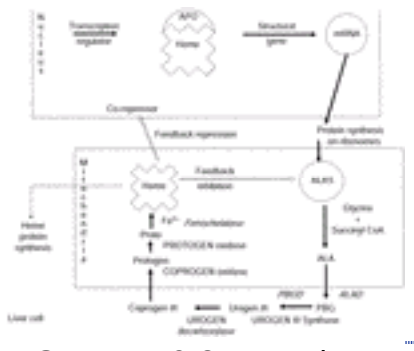

FIGURE 149-3 Heme is capable of regulating its synthesis by either directly inhibiting or repressing the synthesis of its rate-limiting enzyme, ALA synthase. The repression may result from the binding of heme, as a corepressor, to an aporepressor protein (APO) which, when combined with heme, becomes a functional unit that blocks transcription of ALA synthase mRNA. Heme may also block transport of the holoenzyme into the mitochondrion.

FIGURE 149-4 A regulatory pool of “free” heme unbound to apoproteins may be the critical determinant for regulation of synthesis of ALA synthase activity.

d-Aminolevulinic Acid Synthase

Heme synthesis begins in the mitochondrion of the cell where succinate and glycine (single molecules of glycine and succinyl CoA) are conjugated to form a five-carbon aminoketone d-aminolevulinic acid (ALA). The reaction requires pyridoxal 5'-phosphate as a cofactor. ALA synthase is the mitochondrial enzyme that catalyzes the formation of ALA and is a homodimer of two identical catalytically active subunits of molecular mass 55 kDa, linked to catalytically inactive substrates of higher molecular mass. [1], [4]

The major significance of this enzyme is its regulatory role in controlling the rate of heme synthesis in the liver. Heme acts at multiple sites to regulate ALA synthase levels in the liver. It is thought that two pools—one cytosolic and one nuclear—regulate the isozymes. Heme represses transcription of the ALA synthase-1 gene and inhibits movement of its precursor into the mitochondria where it is proteolytically processed to produce the mature form. Heme also can reduce the stability of ALA synthase-1 mRNA. ALA synthase activity is increased in the liver of patients with those hepatic porphyrias in which acute attacks characterized by a neurologic–visceral symptom complex occur. This increase in ALA synthase is a major marker for acute intermittent porphyria (AIP), variegate porphyria (VP), and hereditary coproporphyria (HCP). It is also an inducible enzyme in the liver, and factors that lead to further increases in activity of ALA synthase are accompanied by exacerbation of the clinical manifestations of these types of porphyria. Conversely, factors that reduce ALA synthase activity are often useful therapeutically in those porphyrias characterized by elevated activity of the enzyme. The importance of ALA synthase for the regulation of heme synthesis is discussed later in the chapter. ALA synthase-2 in the erythroid compartment behaves in a rather different manner in that it is not inducible by xenobiotics that augment the synthesis of ALA synthase-1. Immunochemical differences exist between the hepatic and erythroid enzyme in various animal species. Two genes encode ALA synthase mRNAs found in these tissues and the erythroid gene product is expressed exclusively in erythroid cells, whereas the hepatic form is expressed ubiquitously. The human housekeeping gene is located on chromosome 3p21 and the erythroid gene has been assigned to a distal subregion of chromosome Xp21-Xq21. The erythroid preprotein is more than 75 percent homologous to the hepatic protein.

d-Aminolevulinic Acid Dehydratase

In the next reaction, two molecules of ALA are combined in the presence of an enzyme known as ALA dehydratase to form the monopyrrole porphobilinogen (PBG) (Fig. 149-1 and Fig. 149-2). ALA dehydratase is present in the cytoplasm of the cell. Its activity is 50- to 100-fold greater than ALA synthase so that virtually all of the ALA synthesized is converted to PBG. [5] The human enzyme is located on chromosome 9q34 and is a homo-octamer containing subunits of 36-kDa. The enzyme requires an intact sulfhydryl group and one zinc atom per subunit for maximal catalytic activity. ALA dehydratase is identical to the 240-kDa proteasome inhibitor (CF-2), which may be an example of “gene-sharing.” [5] ALA dehydratase from human liver is encoded by an open reading frame of 990 bp, possessing a high degree of homology with the enzyme in rats. Genetic variation in the level of ALA dehydratase may be a result of differences in copy number of the gene that has separate housekeeping- and erythroid-specific promoters. [6] mRNA isoforms for each arise by employing the specific promoters and alternative splicing. The isozymes are structurally identical.

ALA dehydratase porphyria is an autosomal recessive disorder due to homozygous ALA dehydratase deficiency that causes acute attacks associated with increased excretion of ALA but not PBG. Compound heterozygotes exist. [7]

Porphobilinogen Deaminase

The third enzyme in the pathway combines four molecules of the monopyrrole PBG to form the linear tetrapyrrole, hydroxymethylbilane (Fig. 149-2), which cyclizes spontaneously to form the initial porphyrinogen, or tetrapyrrole, known as uroporphyrinogen I (UROGEN I) (Fig. 149-2). Depending on the manner in which the PBG molecules are arranged,

several different isomers of the tetrapyrroles are possible. The sole difference between type I and type III porphyrinogens is that one of the four pyrrole rings is “flipped over.” Only two of them (labeled I and III) are known to occur in the mammalian heme synthetic pathway. PBG deaminase was purified from human RBC and shown to have a molecular mass of approximately 37 kDa and a pH optimum of 8.2. [8]

The PBG deaminase gene has been cloned and characterized. Two isoforms, one ubiquitous, and one erythroid-specific, are encoded by a single gene localized to chromosome 11q23?11qter. [1] It comprises 15 exons spread over 10 kb of DNA. The two isoforms of the enzyme are encoded by two distinct mRNAs that arise from two overlapping transcription units, the first of which (upstream) is active in all tissues and its promoter has some features of a housekeeping promoter, whereas the second, located 3 kb downstream, is active only in erythroid cells and displays structural homology with beta-globin gene promoters. Differential splicing gives rise to two isozymes of slightly different molecular weight. [4]

PBG deaminase is present in the second lowest concentration of any enzyme in the heme pathway; ALA synthase is the lowest. This suggests that factors (genetic or acquired) that influence PBG deaminase activity may have important regulatory influences on the rate of heme synthesis. Consequently, if excessive PBG is formed because of increased ALA synthase activity, as is often seen in the acute hepatic porphyrias, there may be only partial conversion of this monopyrrole to UROGEN I. These factors account for the elevated urinary PBG characteristic of attacks of the acute hepatic porphyrias. PBG deaminase activity is known to be reduced by about 50 percent in the tissues of patients with AIP and is currently thought to be the primary enzymatic abnormality in this autosomal dominant disorder. There is a variant form of AIP (perhaps 10 percent of cases) in which the PBG deaminase defect is restricted to nonerythropoietic tissues because of mutations in exon 1 that are absent from erythroid mRNA. To date, more than 100 mutations have been reported at the PBG deaminase locus, including deletions, insertions, missense, nonsense, and splicing mutations. ALA and PBG, the two aliphatic nonporphyrin precursors of heme, are excreted primarily in the urine; normally this amounts to less than 4000 and 1500 ng of each, respectively, per 24 h (Table 149-1). However, in certain acute hepatic porphyrias (AIP and VP), there may be a 10- to 100-fold increase in urinary excretion of ALA and PBG, which can be detected by using relatively simple diagnostic tests. For example, PBG reacts with Ehrlich's reagent, which contains *p*-dimethylaminobenzaldehyde in hydrochloric acid, to give a positive red-color reaction (Watson-Schwartz test) during attacks of AIP and VP. The cherry-red chromogen is not extracted into chloroform or butanol and remains in the aqueous phase when PBG is elevated. The Hoesch test is a modification of the Watson-Schwartz test that enhances its sensitivity. [9]

Uroporphyrinogen III Synthase

The fourth enzyme in the heme pathway is UROGEN III synthase, which catalyzes the formation of uroporphyrinogen III from hydroxymethylbilane or from PBG, if PBG deaminase is also present. The only difference between the I and III porphyrinogen isomers is the reversal of the side chains on the D ring of this tetrapyrrole. By simple inversion of one PBG molecule during synthesis of UROGEN I, the III isomer is formed (Fig. 149-2). This apparently minor structural alteration is of considerable biologic importance as only the III isomer can proceed to the formation of heme. Heme is a type III porphyrin, and no type I heme has been identified in nature. The formation of UROGEN III is catalyzed by the cytoplasmic enzyme UROGEN III synthase, closely linked to PBG deaminase. This enzyme has been purified from human erythrocytes, is monomeric, and has a molecular mass of approximately 29.5 kDa; it is thermolabile and exhibits maximum catalytic activity at pH 7.4, The human gene for UROGEN III synthase has also been cloned and sequenced and encodes a protein of 265 amino acids. [10] There are 10 exons and the gene is located on chromosome 10q25.3?10q26.3. In most tissues, UROGEN III synthase is present in considerable excess as compared to PBG deaminase, thus assuring efficient conversion to the III isomer. The hepatic and erythroid forms of the enzyme are identical. This enzyme is deficient in patients with congenital erythropoietic porphyria. To date approximately 30 mutations in the UROGEN III synthase gene have been identified, including several in the erythroid-specific promoter. [11]

Uroporphyrinogen Decarboxylase

UROGEN I and III each contain eight carboxyl groups as side chains, four of which are acetate ($–CH_2COOH$) and four of which are propionate, ($–CH_2–CH_2–COOH$) moieties (Fig. 149-2). The soluble cytosolic enzyme UROGEN decarboxylase catalyzes the sequential decarboxylation of the four carboxyl groups of the acetate side chains to methyl groups to form COPROGEN (Fig. 149-2). Decarboxylation first occurs on ring D, after which the enzyme turns around to decarboxylate rings A, B, and C in a clockwise fashion. This converts the original 8-carboxyl porphyrinogen (UROGEN I or III) first to 7-carboxyl, then to 6-carboxyl, and then to 5-carboxyl porphyrinogen. The 5-carboxyl porphyrinogen can then undergo decarboxylation of its last acetyl group to form the 4-carboxyl porphyrinogen that is known as coproporphyrinogen (COPROGEN I or III) (Fig. 149-2). These intermediates are also referred to as hepta-, hexa-, penta-, and tetracarboxylate porphyrinogens. As discussed above, COPROGEN I cannot be further metabolized to heme. The human enzyme purified from erythrocytes has a molecular mass of about 42 kDa. The human cDNA for UROGEN decarboxylase has been isolated, and the deduced sequence is equivalent to 367 amino acids, consistent with the molecular mass and the amino acid composition of the purified protein. Human UROGEN decarboxylase is encoded by a single gene on 1p34 that contains 10 exons spread over 3 kb. [12]

UROGEN decarboxylase activity is reduced in the liver of patients with porphyria cutanea tarda (PCT) and hepatoerythropoietic porphyria (HEP). Approximately 20 percent of patients with PCT have a 50 percent decrease in UROGEN decarboxylase concentration in all tissues; this form of PCT is inherited as an autosomal dominant trait with low penetrance (type II PCT). Multiple mutations of UROGEN decarboxylase (at least 30) have been identified that either decrease the stability of the enzyme or produce defective pre-mRNA splicing. [1], [12], [13], [14] and [15] In type I PCT, also known as the sporadic form, the enzyme deficiency is limited to the liver. Type II PCT is a disease in which the enzyme is deficient in all tissues, although penetrance is low and relatively few patients have a family history of skin symptoms. [14] There is also a rare type III PCT in which the activity and concentration of the erythrocyte enzyme is normal suggesting that an autosomal gene, not necessarily at the UROGEN decarboxylase locus, could influence the expression of this form of PCT. [16] Normal amounts of mRNA for the enzyme are present in type II PCT, and a splice-site mutation has been

found in at least one pedigree with type II PCT that causes a deletion of exon 6 from the mRNA. [17] The resulting protein is shorter than the normal protein, missing the amino acids encoded by exon 6, and this aberrant protein lacks catalytic activity and is rapidly degraded.

In HEP, UROGEN decarboxylase activity is usually 5 to 10 percent of normal, and patients are either homozygotes or compound heterozygotes for mutations of the UROGEN decarboxylase gene. One mutation occurring in HEP homozygotes is also associated with overt PCT in heterozygotes. [18] A mutation that has been identified in some, but not all, families with HEP is a 281 (Gly-Glu) shift. [13], [14], [19]

Coproporphyrinogen Oxidase

This is a mitochondrial enzyme located in the intermembrane space.

COPROGEN III has four carboxyl groups, each of which is part of a propionate side chain. COPROGEN oxidase, a mitochondrial enzyme of molecular mass 74 kDa, catalyzes the sequential oxidative removal of the carboxyl group from two of the propionate groups, forming first 3-carboxyl porphyrinogen, or harderoporphyrinogen (HARDEROGEN), and then 2-carboxylporphyrinogen, or protoporphyrinogen IX (PROTOGEN) (Fig. 149-2). Southern analysis of human restriction fragments suggests the presence of a single gene located on chromosome 3q12. [20] The COPROGEN oxidase gene spans 14 kb and consists of seven exons and six introns. Multiple mutations have been found in patients with heterozygous and homozygous HCP. These include point mutations resulting in base substitutions or exon skipping.

A unique modification of normal heme synthesis can occur in PCT. No additional enzymes or enzymatic reactions are involved, but there is a reversal in the sequence of action of the enzymes UROGEN decarboxylase and COPROGEN oxidase. UROGEN decarboxylase normally acts on 5-carboxylporphyrinogen to decarboxylate the final remaining acetate group, forming a tetracarboxyl porphyrinogen known as COPROGEN III (Fig. 149-1). This is subsequently converted to PROTOGEN by COPROGEN oxidase (Fig. 149-1 and Fig. 149-2). However, in PCT where UROGEN decarboxylase is deficient, COPROGEN oxidase may first oxidatively decarboxylate a propionate group on 5-carboxylporphyrinogen to form dehydroisocoproporphyrinogen (Fig. 149-1). The acetyl group on dehydroisocoproporphyrinogen can be decarboxylated by UROGEN decarboxylase to form HARDEROGEN, resulting in diversion back into the normal heme synthesis pathway (Fig. 149-1). Alternatively, dehydroisocoproporphyrinogen can undergo hydration to isocoproporphyrinogen (Fig. 149-1). These steps rarely, if ever, occur during the normal process of heme synthesis, but become important in certain of the porphyrias such as PCT, where they provide one explanation for the increased isocoproporphyrin (ISOCOPRO) characteristically found in the feces of patients with this disease.

Protoporphyrinogen Oxidase

The oxidation of PROTOGEN IX to PROTO is catalyzed by the enzyme PROTOGEN oxidase, an integral protein of the inner mitochondrial membrane (Fig. 149-1 and Fig. 149-2). This reaction can also occur nonenzymatically, but the enzyme appears to be necessary for heme synthesis to proceed at a normal rate. This reaction leads to the removal of six hydrogens from PROTOGEN IX. PROTOGEN oxidase activity is reduced in patients with VP. Multiple mutations have been identified, one of which (R59W) is the founder gene underlying the high incidence of the disorder in South Africa. PROTOGEN oxidase isolated from rat liver mitochondria has a molecular mass of 51 kDa and requires molecular oxygen to catalyze the oxidation of PROTOGEN to PROTO. The human PROTOGEN oxidase gene has been mapped to chromosome 1q22–23 and consists of 13 exons spanning 8 kb. [21] Northern blot analyses from a variety of tissues indicate that there is a single transcript of 1.8 kb encoding a protein of 477 bp.

Ferrochelatase

The final step in the formation of heme, the incorporation of ferrous iron (Fe^{2+} into PROTO, is catalyzed by the enzyme ferrochelatase located at the matrix face of the inner mitochondrial membrane (Fig. 149-1 and Fig. 149-2). This enzyme is also referred to as heme synthase or proto-heme-ferro-lyase. Unlike other enzymes in the heme biosynthesis pathway, that require reduced forms of the porphyrins (porphyrinogens) as substrates, ferrochelatase uses oxidized PROTOGEN. This lysine-rich enzyme has a molecular mass of 63 kDa and a pH optimum of 7.8. Ferrochelatase activity is decreased in various tissues of patients with EPP.

The cDNA for human ferrochelatase has also been cloned, sequenced, and shown to have 88 percent identity to the mouse enzyme. Human ferrochelatase mRNA is encoded by a single nuclear gene that spans about 45 kb of chromosomal DNA. The gene is located on chromosome 18q and consists of 11 exons and 10 introns. Molecular genetic studies conducted in patients with EPP reveal approximately 30 mutations of various types of which exon deletions are the most common, resulting in encoding of truncated proteins that would be expected to have little or no catalytic activity. It is of interest that expression of these mutations in bacteria identified a common loss of the iron–sulfur metal center essential for catalytic activity. A C?T transition at position -23 in intron 1 is detectable in all EPP patients, as well as in some normals, suggesting that individuals with EPP are heterozygous for mutations of the enzyme. Recent studies show that the penetrance of EPP is modulated by expression of wild-type ferrochelatase that contains an intronic single nucleotide polymorphism that results in aberrantly spliced mRNA that is degraded by a nonsense-mediated decay mechanism. [22] Slight variations in expression of the normal allele may be decisive in determining clinical expression of EPP. The end product of the pathway, ferrous-PROTO (FePROTO) or heme, diffuses out of the mitochondrion into the cytoplasm, where it is available to function as a prosthetic group by combining with appropriate apoproteins (Fig. 149-3 and Fig. 149-4). Heme thus controls its own synthesis based upon the needs of the cell.

It is important to emphasize that porphyrinogens (reduced porphyrins) are the true intermediates in heme synthesis. The irreversibly oxidized porphyrins, with the exception of PROTO, do not function as substrates for the enzymes of the pathway. These porphyrins exhibit an absorption spectrum with a major peak in the 400 nm region, the so-called Soret band, and smaller absorption peaks between 580 and 650 nm. These oxidized porphyrins induce photodynamic effects in

skin tissue and subcellular components when exposed to ultraviolet and short visible light (360 to 420 nm) or red wavelengths (640 to 700 nm). Thus, porphyrins are actually heme pathway by-products, which are of special interest to dermatologists because of their unique photosensitizing properties.

PATHOPHYSIOLOGY OF CUTANEOUS LESIONS IN THE PORPHYRIAS

A common cutaneous manifestation of the porphyrias is photosensitivity; it is observed in patients with several of these disorders (EP, EPP, PCT, VP, HCP, and HEP) in whom plasma and tissue porphyrins are increased. Patients with AIP, in whom only nonphotosensitizing porphyrin precursors (ALA, PBG) are formed in substantially increased amounts, do not have photosensitivity nor do any of the four patients reported with ALA dehydratase-deficiency porphyria.

Patients with the erythropoietic types of porphyria frequently complain of an intense burning sensation and pruritus following exposure to sunlight. A priming effect of sun exposure on cutaneous photosensitivity in EPP has been described in which a threshold exposure on one day that evokes virtually no reaction seems to augment the response to subsequent sun exposure on the following day. [23] The cause of this is unknown, but the phenomenon suggests that repair of damage to skin by photosensitized porphyrins may be prolonged. These subjective symptoms are notably absent in patients with the chronic hepatic porphyrias such as PCT and VP. Although there is some information about the pathophysiology of photosensitivity and sclerodermoid skin changes in the chronic hepatic porphyrias, the causes of the pigmentary alterations and hypertrichosis seen in these patients remain to be elucidated.

Porphyrins have certain unique photobiologic and spectroscopic properties. The metal-chelated porphyrins (e.g., heme or FePROTO) show no fluorescence. Porphyrins that are chelated to other paramagnetic metals, such as Mn^{2+}, Co^{2+}, or Zn^{2+} (e.g., chlorophyll, ZnPROTO), also do not fluoresce. This is the reason that patients with lead intoxication, in which ZnPROTO is elevated, do not have photosensitivity. However, metal-free porphyrins (e.g., URO, COPRO, PROTO) in acidic solutions show a major absorption peak in the 400- to 410-nm region (Soret band); they also exhibit four additional absorption bands with decreasing intensity between 500 and 700 nm. Exposure of porphyrins to the Soret band spectra results in two major fluorescence emission peaks at the 600- to 610-nm and 640- to 660-nm regions (Table 149-4).

Porphyrin	Excitation (nm)	Emission (nm)	Fluorescent Porphyrins
Erythropoietic porphyria (EP)	398	619	URO I, COPRO I
Erythropoietic protoporphyria (EPP)	409	634	PROTO
Porphyria cutanea tarda (PCT)	398	619	URO I, III, COPRO III
Variegate porphyria (VP)	405	626	COPRO III, PROTO
Acute intermittent porphyria (AIP)	398	619	URO III
Hereditary coproporphyria (HCP)	398	619	COPRO III
Hepatoerythropoietic porphyria (HEP)	398	619	URO I

Source: Modified from Kim Kaspperk.[17]

TABLE 149-4 **Fluorescence Characteristics of Porphyrin-Containing Plasma Diluted with 1:10 Phosphate Buffered Solution**

Although there is no single, clearly defined pathway that can currently explain the photosensitization evoked by porphyrins and light, there are a number of potential cellular and soluble factors that could be responsible. Among them, reactive oxygen species (ROS), certain cells (erythrocytes, mast cells, polymorphonuclear cells, and fibroblasts), and soluble mediators (the complement system, factor XII–dependent pathways, and the eicosanoids), as well as matrix metalloproteinases will be discussed (Table 149-5). It is likely that interactions among these factors will prove to be responsible for the pathogenesis of the cutaneous lesions in the porphyrias.

Sunlight, especially blue and red light (380–760 nm)
Reactive oxygen species ($^1O_2$, $O_2^{\cdot-}$, H_2O_2, $\cdot OH$)
Cells
Erythrocytes
Mast cells
Polymorphonuclear leukocytes
Fibroblasts
Soluble mediators
The complement system
Factor XII–dependent pathways
The eicosanoids
Matrix metalloproteinases

TABLE 149-5 **Factors Contributing to the Development of Cutaneous Lesions in Porphyrias**

Reactive Oxygen Species

Porphyrins such as URO, COPRO, and PROTO absorb light intensely around 400 nm and in the longer visible range between 580 and 650 nm. Absorption results in the generation of “excited” state porphyrin molecules (Fig. 149-5). The initial excited state porphyrin generated has an extremely short half-life of less than 0.01 µs. Singlet excited-state porphyrins may spontaneously convert to a triplet, another excited state that has a lower energy level but a longer half-life (in the order of microseconds to milliseconds). Because of their long half-life, triplet-state porphyrins are more likely to react with biologic substrates and are likely candidates to mediate most porphyrin-associated photobiologic reactions. Excited-state porphyrin molecules ultimately must return to their normal ground states by releasing their absorbed energy in the form of light (fluorescence is emitted by singlet-state molecules and phosphorescence by triplet states), heat, or by transferring energy to cell constituents (cell membranes, organelles, proteins, DNA) (Fig. 149-6 and Fig. 149-7).



FIGURE 149-5 Photoexcited porphyrins release energy in a variety of ways when returning to their ground state, and these may contribute to damaging reactions in biologic systems.

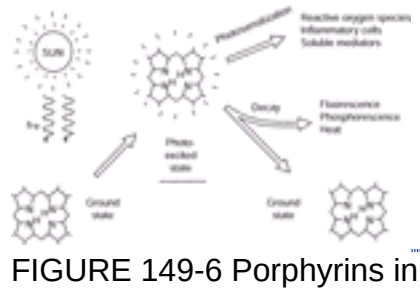

FIGURE 149-6 Porphyrins in ground state upon absorption of radiant energy (h *v*) undergo transition to photoexcited states. The photoexcited porphyrins generate reactive oxygen species, damaging cells by release of proinflammatory mediators; in turn, these may contribute to damaging reactions in biologic systems such as skin.

FIGURE 149-7 Photoexcited porphyrins in their triplet state transfer the absorbed energy to exygen (O_2) molecules, thereby producing reactive oxygen species ($^1O_2$, $\cdot O_2^{\cdot-}$, ·OH, and lipid peroxides). These reactive oxygen species interact with cell membranes to cause tissue damage.

Excited porphyrins in their singlet and triplet states can also transfer their absorbed energy to oxygen molecules thereby creating reactive “excited” oxygen states. Cellular and tissue damage induced by photoactivated porphyrins is believed to occur primarily as a result of the formation of reactive singlet oxygen ($^1O_2$), as illustrated in Fig. 149-5 and Fig. 149-7. [24] Various forms of ROS capable of causing tissue damage are known to exist, including singlet oxygen ($^1O_2$) and superoxide anion ($O_2^{\cdot-}$). In some cases, the sensitized porphyrin may react with oxygen to yield hydrogen peroxide (H_2O_2) or with water to form hydroxyl radicals ($^{\cdot}OH$). Those processes in which activated oxygen species play a role in photosensitization are referred to as photodynamic reactions. Most of the porphyrin-mediated cutaneous photosensitization reactions are essentially photodynamic and can be minimized or prevented if reactive oxygen is eliminated from the reaction system through inactivation processes known as quenching or scavenging.

Although these concepts regarding excited porphyrins and ROS are valid in simple systems, their applicability to complex tissues such as the skin remains to be established. Several hypotheses have been advanced regarding the mechanism of porphyrin-induced photosensitivity. One hypothesis involves the transfer of energy from excited species of oxygen to water or to lipids, creating hydrogen and/or lipid peroxides. These peroxides, in turn, can evoke damage in lipid-rich cellular membranes (Fig. 149-7). Evidence for this type of reaction has come from the demonstration of porphyrin-UV–induced cross-linkage of proteins within RBC membranes and destruction of fibroblast membrane sulfhydryl groups. If such damage occurs in plasma membranes in cells in or adjacent to the skin, it could result in tissue destruction and possibly explain the photosensitivity seen in the cutaneous porphyrias. It has been shown that photoexcitation of PROTO-enriched RBC results in the formation of hydrogen peroxide and lipid peroxides, each of which would be highly destructive to lipid-rich membranous structures. There is evidence in RBC of peroxidation of cholesterol groups in the cell membrane resulting in hemolysis following exposure to UV radiation and PROTO.

Several other studies have also supported the participation of ROS in porphyrin-induced phototoxicity. The release of inflammatory mediators from mast cells induced by photoexcited PROTO can be suppressed by catalase, which inactivates hydrogen peroxide by converting it to water and oxygen. [25] Singlet oxygen mediates porphyrin-induced photodamage to hepatic and epidermal microsomal cytochrome P450. [26] Porphyrin and radiation-induced damage of lysosomal and mitochondrial membranes also occur. DNA exposed to visible light and hematoporphyrin manifests selective degradation of the guanine moiety. In vivo, beta-carotene, a scavenger of singlet oxygen, is effective in diminishing the severity of cutaneous photosensitivity in patients with EPP. [27] In a murine model, it was demonstrated that xanthine oxidase–generated $O_2^{\cdot-}$ also plays a significant role in the development of the phototoxicity induced by HPD. [28]

Erythrocytes

Photoexcited PROTO elicits peroxidation of cholesterol groups in erythrocyte membranes, whereas URO or COPRO have no such effect. This difference, which is also true of mast cells, polymorphonuclear leukocytes, and fibroblasts, most likely relates to variations in lipid-water partitioning of the different porphyrins, which may relate to their polarity. The lipophilic PROTO, a 2-carboxyl porphyrin, is more damaging to lipid-rich membranes as compared to the more water-soluble COPRO and URO.

Mast Cells

Mast cell degranulation occurs in the exposed skin of patients with EPP. [29] Irradiation of PROTO-treated mast cells in vitro induces release of mast cell–derived mediators, although exposure to lower doses of PROTO and radiation results in inhibition of secretagogue-induced histamine release from these cells. [30] In contrast, no mediator release is detectable when cells are radiated in the presence of URO. These findings may help to explain the differences in the clinical presentation of patients with EPP and PCT. The elevated PROTO in patients with EPP may induce the release of mast cell mediators in vivo following sun exposure, resulting in painful, pruritic erythema and edema. The absence of these changes in patients with PCT may be explained by the apparent inability of photoexcited URO to damage cutaneous mast cells.

Phototoxicity is associated with elevated serum histamine levels and dermal mast cell degranulation, [31] and the phototoxic response can be suppressed by pretreatment with antihistamines (H_1 blockers) or by intradermal injection of a mast cell secretagogue (compound 48/80). [32]

Polymorphonuclear Cells

Exposure of human polymorphonuclear leukocytes (PMNs) to PROTO and radiation in vitro results in membrane damage, whereas photoexcited URO induces no such alterations. These results are strikingly similar to those obtained in studies with mast cells (see above). In an animal model, the porphyrin-induced phototoxic response was associated with a dermal PMN infiltrate, [31] and the phototoxicity was markedly suppressed in leukopenic animals. [32] These results appear to suggest that PMNs may be necessary but not sufficient for porphyrin-induced phototoxicity.

Fibroblasts

Differential phototoxic effects of various porphyrins have also been verified in studies using dermal fibroblasts. An increase in collagen biosynthesis is observed following incubation of fibroblasts with URO. [33] This effect is independent of irradiation and may partly explain the sclerodermoid changes observed in patients with PCT, which can occur in sun-exposed and in sun-protected areas. In contrast, PROTO induces photolysis of fibroblasts in vitro. [34]

The Complement System

The participation of the complement system in porphyrin-induced phototoxicity was initially suggested by immunofluorescent studies identifying selected complement components localized near vessel walls at the dermal–epidermal junction in patients with cutaneous porphyria. In addition to endothelial cell damage, histologic changes consistent with those mediated by complement activation products, that is, mast cell degranulation and infiltration of PMNs, are observed during the acute phase of photosensitivity in the skin of patients with EPP. [29] In vitro irradiation of sera obtained from patients with EPP and PCT results in complement activation. [35] In animal models, porphyrin-induced phototoxicity is associated with complement activation and is suppressed in complement-depleted animals, as well as in animals congenitally deficient in the fifth component of complement. [36] Generation of complement-derived chemotactic activity is also seen following exposure of the skin of patients with EPP and PCT to Soret band radiation. [37]

Factor XII–Dependent Pathways of Coagulation

Activation of Hageman factor–dependent pathways in the presence of PROTO has been demonstrated in vitro. [38], [39] In contrast, neither URO nor COPRO induces such activation. Whether this activation, which is independent of irradiation, contributes to the pathogenesis of porphyrin-induced phototoxicity remains to be determined.

The Eicosanoids

Porphyrins and radiation affect eicosanoid metabolism. Incubation of mouse peritoneal macrophages or radiation-induced fibrosarcoma tumor cells in vitro with hematoporphyrin-derivative PHOTOFRIN II, followed by 630-nm radiation, results in dose-dependent generation of prostaglandin E_2 (PGE_2). [39]

Matrix Metalloproteinases

Photoexcited URO coordinately induces interstitial collagenase [matrix metalloproteinase (MMP)-1], 72-kDa type IV collagenase (MMP-2), and stromelysin-1 (MMP-3) in human dermal fibroblasts in vitro. [40] The induction of the MMPs by porphyrin photosensitization suggests that blistering could be due to activation/release of these enzymes.

Cutaneous phototoxicity in porphyrias is directly related to the interaction of porphyrins with light of the Soret and other bands, resulting in the generation of ROS; in turn, this can induce lipid peroxidation and cell membrane alterations. Release of mediators and enzymes from cells such as mast cells and PMNs contributes to the inflammatory response; the reaction relates to the effects of porphyrins on the complement system, factor XII–dependent pathways, and the

eicosanoids. Variations in solubility influenced by the lipid-water partitioning of porphyrins may account for the striking patterns of the skin findings observed in various types of porphyria.

CLASSIFICATION OF THE PORPHYRIAS

Most classifications of the porphyrias are based on the primary site of expression of the specific enzymatic defect, thereby distinguishing erythropoietic and hepatic forms. However, an alternative approach is to classify the porphyrias as acute and nonacute, thereby categorizing patients with or without acute neurologic attacks. It should be pointed out that VP and HCP also should be considered as neurocutaneous porphyrias because they can manifest neurologic signs and cutaneous manifestations (Table 149-6).



TABLE 149-6 **Overview and Summary of the Features of the Acute Porphyrias**

An acute porphyric attack can present a constellation of symptoms and signs, among them, intense abdominal pain; vomiting; electrolyte dysregulation (hyponatremia); constipation; tachycardia; hypertension; muscle pain and weakness; seizures; paresis of the upper and lower extremities; paralysis; and a variety of other neurologic and psychiatric symptoms. These myriad clinical manifestations inevitably mimic other diseases, thereby challenging the diagnostic acumen of even experienced physicians, particularly because the porphyrias are rare disorders. It is known that acute porphyric attacks can be precipitated by a variety of external factors, in particular porphyrinogenic drugs, alcohol, hormonal fluctuations, and diminished caloric intake from dieting or fasting. [41] Yet in practice, it is often impossible to identify the causative agent of an acute crisis in an individual patient. Timely diagnosis of an acute porphyric attack can be lifesaving because several complications may have fatal consequences if not recognized and treated. As an example, in a patient with episodic abdominal pain, treatment with analgesics may prolong or aggravate the attack. Diffuse abdominal pain can mimic acute appendicitis, diverticulitis, or other painful gastroenterologic disorders that may necessitate surgical intervention. After administration of certain drugs (e.g., barbiturates), or during general anesthesia, acute attacks can be exacerbated. [2] The acute porphyric attack is associated with several complications that are potentially life-threatening. Of these, muscle paralysis is particularly problematic. This can range from mild paralysis of small muscle groups to flaccid paralysis of multiple muscle groups that may result in paraplegia and respiratory compromise. These findings may be accompanied by severe sensory loss and amyotrophy. In some cases, paralysis may progress rapidly and can affect cranial nerves or develop into a pseudo–Guillain-Barré syndrome.

ACUTE AND NONACUTE PORPHYRIAS

The acute porphyrias include AIP, VP, HCP, and ALA dehydratase deficiency porphyria or plumboporphyria (Table 149-6). [3] Although AIP is the most prevalent form of acute porphyria worldwide, in some countries, other acute forms may predominate, as is the case for VP in Chile. In addition to neurovisceral symptoms, individuals suffering from VP or HCP can also present with cutaneous findings, including increased photosensitivity, abnormal skin fragility, bullous skin eruptions on sun-exposed areas, erosions, chronic scarring, and postinflammatory pigmentary change. Thus, VP and HCP are also referred to as neurocutaneous porphyrias, to distinguish them from AIP and ALA dehydratase deficiency porphyria that have no cutaneous abnormalities. [3]

The nonacute porphyrias consist of PCT, the most prevalent type of porphyria overall, EPP, CEP, and HEP, the recessively inherited variant of PCT (Table 149-7). [3] The nonacute porphyrias can present with different types of cutaneous findings, including mild to severe photosensitivity, increased skin fragility, vesicles and bullae, burning and stinging, edema, pruritus, hypertrichosis, scarring, hyperpigmentation, and mild to severe scarring changes. [3] It is of interest that alcohol and estrogens, which can trigger acute porphyric attacks in AIP, VP and HCP, can also exacerbate PCT although acute attacks do not occur in this disease.



TABLE 149-7 **Overview and Summary of the Features of the Nonacute Porphyrias**

ACUTE INTERMITTENT PORPHYRIA (AIP) (Table 149-6)

Etiology

Several excellent reviews summarize the clinical and biochemical features of AIP. [1], [42], [43] The disease may affect the peripheral, autonomic, or central nervous systems with neuropathic symptoms and dysfunction. Increased hepatic ALA synthase is a characteristic finding in AIP, as it is in the acute hepatic porphyrias. [44] It is now clear that the enzyme PBG

deaminase, which converts PBG to UROGEN I, is deficient in various tissues of affected individuals and latent carriers of the disease. This helps to explain the excessive ALA and PBG excretion of AIP. PBG deaminase activity in AIP is approximately 50 percent of that in unaffected normal individuals, consistent with an autosomal dominant mode of inheritance. Diminished PBG deaminase partially blocks heme synthesis, which, in turn, decreases the regulatory heme pool and leads to derepression of ALA synthase mRNA synthesis. Fewer than 10 percent of latent carriers of the PBG deaminase defect ever express the clinical phenotype. The gene defect alone seems to be inconsequential unless the individual is exposed to additional triggering factors, of which certain drugs that induce hepatic cytochrome P-450s (CYPs), are particularly important (see Table 149-8).

Amidopyrine	Hydralazine
Aminoglutethimide	Isopropylmeprobamate
Aminopyrine	Mephenytoin
Amphetamines	Meprobamate
Antipyrine	Methyldopa
Barbiturates	Methylprylon
Bemegride	N-butylscopolammonium bromide
Carbamazepine	Nalidixic acid
Carbromal	Nikethamide
Chloromethazone	Nitrazepam
Chloropropamide	Nortriptyline
Chloroquine	Novobiocin
Danazol	Pargyline
Dapsone	Pentazocine
Diclophenac	Pentylenetetrazole
Diethylpropione	Phenoxybenzamine
Diphenylhydantoin	Phenylbutazone
Dramamine	Primadone
Enflurane	Pyrazinamide
Ergot preparation	Rifampin
Erythromycin	Sedormid
Ethchlorvynol	Succinimides
Ethinamate	Sulfonamides
Ethosuximide	Sulfonethylmethane
Ethyl alcohol	Sulfonylureas
Fentanyl	Synthetic estrogens, progestins
Furosemide	Theophylline
Furpwne	Tolazamide
Glutethimide	Tolbutamide
Griseofulvin	Trimethadione
Halothane	Valproic acid
Heavy metals	

TABLE 149-8 **Examples of Drugs Potentially Hazardous in Patients with the Acute Hepatic Porphyrias**

Epidemiology

AIP is an autosomal dominant disease that rarely, if ever, manifests before puberty. Most published series emphasize the female predominance of affected patients, ranging from ratios of 1.5 to 2.0:1 The incidence in the human population is approximately 1.5:100,000 in most areas of the world. However, in Scandinavia, particularly Lapland, the incidence is much higher (1:1000).

Clinical Manifestations (See Table 149-6)

The clinical signs and symptoms of AIP may be related to the effects of porphyrin precursors or heme depletion in the autonomic nervous system. The acute attack is characterized by abdominal pain and neurologic and psychiatric symptoms that can mimic various disorders. Attacks are often precipitated by ingestion of drugs such as those listed in (Table 149-8). Acute attacks of AIP are accompanied by seizures, especially in patients with hyponatremia resulting from vomiting and inappropriate fluid therapy.

There are no cutaneous lesions related to photosensitivity in AIP. This is logical as the abnormal excretion pattern of the disease consists mostly of the porphyrin precursors ALA and PBG, which are not photosensitizers.

These patients usually have abdominal pain (80 to 90 percent) during an acute attack (between attacks patients are often completely symptom free). The pain may be diffuse or localized and is often intermittent and spastic. Vomiting and constipation are frequently associated. Mild fever and leukocytosis may occur, making differential diagnosis extremely difficult. This is one reason many patients with AIP undergo repeated exploratory laparotomies before the diagnosis is finally established.

Peripheral neuropathy is a major part of the clinical syndrome in many patients varying from sensory (localized pain) to motor (weakness progressing to generalized flaccid paralysis). Patients may succumb to the disease, usually as a result of respiratory failure, or may improve slowly, although residual muscle weakness frequently persists for extended periods.

Laboratory Findings

The primary gene defect in AIP results in PBG deaminase deficiency, which causes excessive urinary excretion of ALA and PBG. Urinary porphyrins may also be elevated (Table 149-3). Urinary excretion of ALA and PBG as high as 100 mg/24 h may occur during an acute attack. During clinical remission of the disease, urinary excretion of ALA and PBG decreases, but usually remains above normal values. This is in contrast to patients with VP who often exhibit normal urinary excretion of ALA and PBG between acute attacks.

Two rapid screening tests are available to test freshly voided urine for increased PBG. The first is simply to expose the urine to bright sunlight for several hours. Darkening to a deep red color suggests that PBG is present but does not prove it. (Porphobilin, another dark pigment, can also be photocatalytically formed in urine.) The second rapid screening test, known as the Hoesch test, is also a simple procedure for detecting excessive urinary PBG. To 2 mL of Ehrlich's reagent (3 g of *p*-dimethylaminobenzaldehyde dissolved in 125 mL of acetic acid and 24 mL of perchloric acid) 2 drops of fresh urine are added. A uniform cherry-red color of the sample indicates a positive reaction. This test is based upon the formation of a chromogen by PBG and Ehrlich's aldehyde reagent that produces a red pigment with strong absorbance at 552 nm. The well-known Watson-Schwartz test is based on this same principle, but it is often not helpful. In patients with suspected AIP, quantitative 24-h measurement of urinary ALA and PBG using ion-exchange chromatography or

high-performance liquid chromatography is essential. [44]

Histopathology

Histopathologic findings of skin are unremarkable.

Differential Diagnosis

The clinical manifestations of AIP are so variable and resemble so many different diseases that Waldenström has used the term *little imitator* to describe it. Excellent reviews have summarized the differential clinical features of AIP. [1], [43]

Treatment

Although there is still no specific treatment for AIP, several therapeutic modalities have been used, including glucose loading (2 L of 20% glucose over 24 h in divided doses of 500 mL through a central venous line). [43], [45] Administration of a gonadotropin-releasing hormone analogue has also been recommended. [46] Infusion of hematin in the form of heme arginate (Normosang, Orphan Europe, Paris, or Panhematin, Abbott Laboratories, N. Chicago, IL) is effective in shortening attacks. [43] Precipitating factors such as drugs (Table 149-8), sex steroid hormones, and starvation should be avoided. AIP patients should wear medical warning bracelets and be given lists of drugs to avoid. Table 149-9 lists drugs thought to be safe for AIP patients.

Acetaminophen	Insulin
Adrenaline	Labetalol
Amitryptyline	Lithium
Aspirin	Mandelate
Atropine	Methenamide
Bromide	Naproxen
Cephalosporins	Narcotic analgesics
Chloralhydrates	Neostigmine
Chloramphenicol	Nitrofurantoin
Chlordiazepoxide	Nitrous oxide
Colchicine	Oxazepam
Digoxin	Penicillin and derivatives
Diphenhydramine	Phenothiazines
EDTA	Propranolol
Ether	Prostigmine
Glucocorticoids	Rauwolfia alkaloids
Guanethidine	Streptomycin
Heparin	Succinylcholine
Hyocine	Tetracycline
Hypocine	Thiouracil
Ibuprofin	Thyroxine
Indomethacin	

EDTA, Ethylenediaminetetraacetic acid

TABLE 149-9 **Drugs Considered to Be Safe (or Probably Safe) in Patients with the Acute Hepatic Porphyrias**

VARIEGATE PORPHYRIA (VP) (See Table 149-6)

Etiology

The disease is most prevalent in South Africa, but occurs worldwide.

ALA synthase is elevated in the liver of patients with VP, just as it is in those patients with AIP. This is a nonspecific finding because it occurs in each of the acute hepatic porphyrias. A 50 percent decrease in PROTOGEN oxidase activity is now recognized as the primary enzyme defect in VP. [47], [48] The enzyme acts specifically on PROTOGEN IX, the penultimate step in heme synthesis, and cannot catalyze the oxidation of COPROGEN I or III or UROGEN I.

Epidemiology

This form of porphyria is quite common among the white and so-called Cape-Coloured South Africans because of the "founder" effect described above. A high proportion of the present white population is descended from a pair of early Dutch settlers who immigrated to South Africa from Holland in 1688. The disease is inherited as an autosomal dominant trait, and the incidence in South Africa is the highest in the world, approximately 1:300 individuals in the white population.

The cutaneous manifestations of PCT and VP are for the most part indistinguishable. Among the native black population of South Africa, typical PCT without associated acute attacks also occurs. There is apparently no family history, and porphyrin excretion patterns are as for PCT, not VP. In South Africa, excessive intake of home-brewed spirits (Kaffir beer) and dietary iron overload from cooking vessels are considered important factors in the development of this disease. Thus, VP occurring in the descendants of the Dutch immigrants of South Africa is quite distinct from the PCT seen in the native black population. Finally, Dean pointed out that the group he designated as Cape-Coloured who are descendants of white European and Indian immigrants who intermarried with black natives, may have VP and PCT in the same family. [49] Factors that precipitate or lead to activation of AIP also appear to induce VP (various drugs, starvation, etc.). All patients with suspected PCT should be screened for VP because VP has a life-threatening potential, and death can follow the ingestion of these drugs.

Clinical Manifestations

The clinical manifestations of VP include those of AIP and PCT, either or both of which may occur in the same individual. In general, females have more frequent acute attacks typical of AIP and males are more likely to have the cutaneous lesions of PCT. Two major differences between VP and PCT are (1) the skin reactions which usually develop at an earlier age (second and third decades) as compared to PCT (fourth and fifth decades) and (2) the neurovisceral symptomatology. The clinical features of VP are (1) positive personal or family history of chronic skin involvement with or without attacks of abdominal pain, constipation, vomiting, muscle weakness, and neuropsychiatric manifestations of

stupor and coma; and (2) photocutaneous lesions associated with minor mechanical trauma. The skin lesions of VP are indistinguishable from those of PCT. These include bullae, erosions, or ulcers following minor trauma of light-exposed skin (Fig. 149-8). Hyperpigmentation, milia, hypertrichosis, and increased skin fragility are also seen. They appear to be more common in the hot climate of South Africa and are less frequently seen in cold climates. Blisters are often blood-tinged, heal slowly, and form milia with some scarring. Occasionally, the patient gives a history of acute sun sensitivity occurring during or soon after a period of exposure; this may include burning, erythema, and edema. In the chronic state, the skin changes may include thickening and scarring (Fig. 149-9A). Some authors believe that melanin pigmentation may reduce the severity of the photocutaneous findings (Fig. 149-9B). The skin manifestations do not correlate with the acute attacks in most patients. These clinical and biochemical features are usually seen after puberty, except in the homozygous patients who may develop signs and symptoms at or shortly after birth These patients frequently manifest short stature and small hands with shortening of the digits. [50]

FIGURE 149-8 A case of variegate porphyria. *A*. Blisters, crusted erosions, and pigmentary changes over the dorsa of the hands and fingers. *B*. Close-up view of index finger shows an intact blister with milia and pigmentary changes. *C*. Healing phase shows milia (*arrows*) and pigmentary changes. *D.* Large bullae of dorsum of foot and toes. *Note:* Patients with porphyria cutanea tarda have indistinguishable cutaneous findings.

FIGURE 149-9 Variegate porphyria. *A*. A peculiar leathery thickening of skin of the face of a patient chronically exposed to strong sunlight. A similar appearance has been noted in South African patients with erythropoietic protoporphyria. (*Courtesy of GH Findlay, MD, FP Scott, MD, and DJ Cripps, MD: Br J Dermatol 78:69, 1966.*) *B*. A South African pigmented patient showing less severe photodamage; the melanin appears to be photoprotective.

Laboratory Findings

Urinary ALA and PBG are elevated during acute attacks of VP (when the Watson-Schwartz test may be positive) but characteristically fall to normal levels between attacks (see Table 149-3), whereas in AIP patients, the urinary ALA and PBG are elevated, both during and between attacks. Another distinguishing feature of the two disorders is stool porphyrin excretion. Asymptomatic patients with VP usually, but not always, have marked elevations of stool PROTO and COPRO between attacks. These may fluctuate somewhat during acute attacks. PROTO typically exceeds COPRO. In AIP, fecal porphyrins are not elevated between attacks and usually increase only slightly during attacks. It is said that certain patterns of fecal and urinary porphyrin excretion may help in distinguishing VP from PCT. URO in the urine is only moderately elevated in VP whereas urinary COPRO is often higher. This is in marked contrast to active PCT where the reverse is seen, that is, urinary URO is much higher than COPRO. Again in VP, fecal porphyrins exceed 500 µg/g dry weight in >90 percent of patients, whereas in PCT this amount of stool porphyrin is excreted by only 1 percent of patients. Furthermore, the ratio of stool PROTO to COPRO in VP usually exceeds 1.5:1, whereas in PCT the ratio is almost always <1:1 because of the increased ISOCOPRO content characteristic of this disease. Stool porphyrin excretion patterns consistent with both VP and PCT have been found in different members of single families. [51] These types of findings led to the suggestion that measurement of bile porphyrins may be decisive in confirming a diagnosis of VP when excretory porphyrin patterns are ambiguous. Saline-diluted plasma specimens from patients with VP have characteristic fluorescence emission spectra (626-nm emission peak) that can be used to differentiate this disease from other forms of acute porphyria, PCT, EPP, and lead poisoning (Table 149-4). [52]

Histopathology

The skin lesions of VP are indistinguishable from those of PCT (see PCT below).

Differential Diagnosis

The differential diagnosis of VP should be considered from two perspectives. Acute attacks of abdominal pain and neurologic signs and symptoms are identical to those described for AIP. Fecal and biliary PROTO and COPRO determinations and plasma fluorescence spectra are decisive in making the diagnosis. The skin lesions of VP are identical to those of PCT, and, as such, the differential diagnosis includes the bullous diseases as well as other photosensitivity disorders. In HCP there may be identical acute attacks, but markedly elevated fecal COPRO III is diagnostic for this disease. HEP must also be considered, but this usually begins in childhood and is characterized by markedly deficient erythrocyte UROGEN decarboxylase and elevated erythrocyte PROTO, as well as increased stool ISOCOPRO. The presence of skin lesions rules out AIP. The determination of urinary ALA and PBG concentrations may help to rule out PCT and HEP. Screening of family members by measuring fecal porphyrins may also be helpful in differentiating VP and PCT.

Treatment

Preventive treatment of VP is identical to that described in AIP: avoidance of inducing drugs (see Table 149-8). Glucose loading and hematin infusions have also been used with ill-defined success. Phlebotomy and the antimalarials are not effective.

HEREDITARY COPROPORPHYRIA (See Table 149-6)

Etiology

HCP is an autosomal dominant disorder caused by mutations in the gene encoding COPROGEN oxidase. [53] This results in increased excretion of COPRO in the urine and stool.

Epidemiology

The disease appears to occur worldwide and, like AIP, to have a female preponderance and probably also an autosomal dominant inheritance. Fewer than 50 cases have been reported. A patient with HCP who developed AIDS has been reported. [54] As mentioned above, an extremely rare form of porphyria, known as harderoporphyria, appears to be a variant of HCP in which COPROGEN oxidase activity is very low (10 percent of control values). [55] This disease has been identified in three siblings.

Clinical Manifestations

The acute attacks are similar to those of AIP, and neurovisceral symptomatology predominates in HCP. This includes abdominal pain, vomiting, constipation, neuropathies, and psychiatric symptoms. The oral hypoglycemic agent glipizide has been reported to exacerbate a coproporphyria-like syndrome that was reversible following discontinuation of the drug. Cutaneous photosensitivity occurs in 20 percent of cases and resembles that seen in PCT and VP. [44] In general, it appears that this disorder is not associated with acute attacks as severe as those of AIP or VP.

Laboratory Findings

HCP is characterized by increased excretion of COPRO III in urine and feces. Markedly elevated (usually 10- to 100-fold) fecal COPRO, more than 90 percent of which is the III isomer, is present at all times in these patients. In addition, the feces may also contain increased amounts of hepta-, hexa-, and pentacarboxylic porphyrins. Urinary COPRO III is also raised, as are ALA and PBG, during attacks. The latter may be normal between attacks.

Histopathology

No histology has been reported.

Differential Diagnosis

Acute attacks are similar to those of AIP. The differential diagnosis rests on stool porphyrin determinations and measurement of COPROGEN oxidase in fibroblasts or leukocytes testing for mutations in the COPROGEN oxidase gene can also be performed. The skin lesions resemble those seen in PCT and VP. Fecal predominance of COPRO III is more suggestive of HCP than VP, in which PROTO and COPRO are usually increased.

Treatment

Avoidance of inducing drugs, glucose loading, and hematin infusions may be helpful.

ALA DEHYDRATASE DEFICIENCY PORPHYRIA (See Table 149-6)

This is a rare type of acute hepatic porphyria, and only a few patients have been reported. [5], [7] Clinically, these patients

have symptoms similar to AIP, and no skin lesions have been noted. Stress and ethanol ingestion reportedly precipitate attacks. The patients have erythrocyte ALA dehydratase activity that is <5 percent of normal. Although it has been suggested that ALA dehydratase deficiency porphyria may represent a homozygous ALA dehydratase defect, cloning of a mutant ALA dehydratase cDNA in a patient showed that the patient was doubly heterozygous for two independent mutant alleles of ALA dehydratase. [7]

In the few patients studied, the urinary porphyrin profile revealed elevated ALA, COPRO, and, to a lesser extent, URO. Fecal porphyrins revealed mildly elevated COPRO and PROTO in one patient, elevated COPRO in another, and a normal profile in two others. Erythrocyte PROTO was elevated in all patients. Increases of plasma ALA, COPRO, and PROTO have been reported. The porphyrin excretion pattern in these patients is unexplained.

TREATMENT OF THE ACUTE ATTACKS IN THE ACUTE PORPHYRIAS

Until recently, therapeutic interventions in the acute porphyrias were only partially effective and often limited to preventive measures and supportive care. Nowadays, most patients experiencing an acute attack can be treated successfully and life-threatening complications like paralysis, respiratory failure, and coma can be avoided if a timely diagnosis is made and appropriate aggressive treatment is implemented immediately. The importance of rapid intervention is illustrated by the fact that untreated or inappropriately treated patients suffering an acute porphyric crisis may have a 10 to 15 percent risk of mortality. Today, with mechanism-based therapeutic intervention the mortality rate of the acute attack has decreased to approximately 2 percent. Once the diagnosis of an acute porphyric attack has been confirmed, treatment should be initiated quickly and one approach involves four steps:

First, all potentially porphyrinogenic drugs should be stopped immediately and the patient should be monitored carefully and admitted to an intensive care unit if necessary. Virtually all drugs should be considered as posing a risk of exacerbating or prolonging an acute attack and several guidelines have been developed in an effort to categorize drugs as relatively “safe” or “unsafe” in patients with acute porphyria. [41] In addition to guidelines published in medical journals, extensive information about drugs and their safety in porphyria patients can also be obtained on the World Wide Web, for example, at www.uct.ac.za/depts/liver/index%20porphyria.htm, www.uq.edu.au/porphyria or http://www.knowdeep.org/porphyria/

Second, symptomatic treatment of neurovisceral manifestations like abdominal pain, vomiting, tachycardia, and seizures should be initiated promptly. Here we provide some recommendations for the symptomatic treatment of patients suffering from acute porphyric attacks. These are based on personal experience as well as on recommendations from different sources and include:

Symptom/Sign	Treatment
Abdominal pain	Acetylsalicylic acid; morphine
Vomiting	Chlorpromazine; promethazine
Hypertension and tachycardia	Propranolol
Hyponatremia	Electrolyte balance; saline infusions
Convulsions	Gabapentin
Constipation	Neostigmine

Third, the management of an acute attack can be initiated with the intravenous infusion of high doses of carbohydrates, preferably 400 to 500 g of glucose/24 h. This can be achieved by administration of 2 L of a 20% glucose solution or 1 L of a 40% solution. Simultaneously, diuresis should be induced by administration of furosemide with careful monitoring of serum electrolytes. Patients experiencing an acute attack are often unable to eat or drink because of severe nausea and recurrent vomiting. The rationale for high-dose glucose is based on experimental evidence showing that carbohydrates suppress the induction of ALA synthase, the first and rate-limiting enzyme of the heme biosynthetic pathway. Unfortunately, in many patients this regimen is only partially helpful.

Fourth, intravenous administration of heme arginate (Normosang), currently not FDA approved, is the most efficient method to suppress heme synthesis. The rationale for this approach is based on administering high doses of the end-product heme, which helps to repress the synthesis of ALA synthase. The early hematin preparations had the disadvantage of being very unstable. Furthermore, intravenous administration of these compounds was associated with a high risk of thrombophlebitis. A newer derivative, heme arginate, consists of human hemin and L-arginine as an additive to increase the solubility and stability of the product. In contrast to the older hematin preparations, heme arginate does not induce any significant changes in coagulation and fibrinolysis, and the frequency of thrombophlebitis, as well as the overall rate of side effects is markedly reduced. [56] Heme arginate exerts its specific action by correcting the underlying heme deficiency and restoring the negative feedback control of heme on ALA synthase, thereby decreasing the excessive hepatic production of porphyrins and porphyrin precursors. Heme arginate should be administered intravenously as a short infusion in a dosage of 3 mg/kg body weight/day over a period of 4 days. Cautious continued administration can be continued if the attack is not aborted; however, use of use heme arginate for more than 7 days is not recommended.

PREVENTION OF THE ACUTE ATTACKS IN THE ACUTE PORPHYRIAS

An important goal in porphyria therapy is the prevention of acute attacks. Therefore, all putative risk factors should be strictly eliminated. Patients should be advised to avoid fasting or dieting, to be abstinent of alcohol and to avoid the

intake of porphyrinogenic drugs, such as barbiturates, sulfonamides, and estrogens, to name several. [41], [44] By using appropriate screening procedures, asymptomatic carriers of an enzyme deficiency should be identified in the family of a patient suffering from an acute porphyria. In this context, it is important to define the inheritance patterns, as well as to identify mutations in the genes encoding for heme pathway enzymes that characterize these disorders.

The identification of mutations in the respective genes has greatly enhanced our understanding of the porphyrias. Once a mutation has been identified in a patient suffering from porphyria, the detection of asymptomatic gene carriers within the patient's family is easily accomplished by using standard molecular biologic techniques. In the acute porphyrias, the identification of these “silent” carriers is the first and most important step in the prevention of life-threatening acute attacks. Genetic analysis provides an effective way to make an early diagnosis thereby enhancing the likelihood of providing patients and asymptomatic gene carriers in their family with advice regarding the avoidance of precipitating factors.

PORPHYRIA CUTANEA TARDA (PCT) (See Table 149-7)

Etiology

PCT is caused by either an inherited or acquired deficiency of UROGEN decarboxylase, the fifth enzyme in the heme pathway. [12] UROGEN decarboxylase is present as a single copy per haploid genome and encodes a polypeptide of 42 kDa containing 10 exons within approximately 3 kb of DNA. The gene has been mapped to chromosome 1p34. The enzyme is cytosolic and catalyzes the sequential oxidative decarboxylation of the four acetic acid side chains of UROGEN to yield the tetracarboxylic COPROGEN. The UROGEN III isomer is most efficiently decarboxylated by the enzyme.

Most classifications of PCT separate the disorder into at least two broad categories, both associated with decreased UROGEN decarboxylase activity: (1) PCT-symptomatic, or sporadic (also referred to as acquired or type I); and (2) PCT-hereditary, or type II. In symptomatic (sporadic) PCT, the enzyme is deficient only in the liver, which could be explained either by a different gene defect restricted to the liver or by exposure to chemicals that selectively inhibit the hepatic but not the RBC enzyme (Table 149-10). Some of these substances (e.g., alcohol and estrogen) may provoke porphyria only in selected individuals, and others (e.g., hexachlorobenzene) in practically all exposed individuals.

Ethyl alcohol	2,3,7,8-Tetrachlorodibenzo-*p*-dioxin (TCDD)
Estrogenic hormones	Polychlorinated biphenyls (PCB)
Hexachlorobenzene (HCB)	Herbicides 2,4-dichloro- and trichlorophenoxyacetic acid
Chlorinated phenols	
Iron	

TABLE 149-10 **Drugs and Chemicals Associated with the Clinical Expression of Porphyria Cutanea Tarda**

In hereditary (type II) PCT, UROGEN decarboxylase is decreased approximately 50 percent in all tissues, including RBC and cultured skin fibroblasts. [14], [16] The defect is inherited in an autosomal dominant manner. Decreased enzyme concentration appears to follow a bimodal distribution, suggesting two overlapping groups of patients: a large group (>80 percent) with normal UROGEN decarboxylase concentration, and a small group (<20 percent) in whom the amount of detectable enzyme is about half normal. Some patients with type II PCT were found to have UROGEN decarboxylase activity at the lower end of the normal range. Penetrance of type II PCT is relatively low (approximately 20 percent), so that the majority of individuals with the inherited enzyme defect do not manifest the disease, suggesting that additional genetic or nongenetic factors are needed for disease expression.

On the other hand, it is important to emphasize that not every patient with a positive family history of PCT will have type II disease. Several patients have been described who had one or more relatives with type I PCT but with normal RBC UROGEN decarboxylase concentrations. [57] These patients could either have inherited some form of UROGEN decarboxylase that is immunochemically indistinguishable from the normal enzyme but which is uniquely susceptible to inhibition in the liver, or they may have a second inherited enzyme deficiency unrelated to UROGEN decarboxylase. These possibilities require further investigation. Some investigators designate this latter category of PCT as type III. [16]

It is likely that patients who were initially reported as having hereditary PCT actually had VP, an autosomal dominant disorder. PCT and VP may occur in different members of the same family, so-called dual porphyria. [51] Another form of dual porphyria in which PCT and AIP coexist has been described. [58]

The most frequently incriminated agents that contribute to the development of PCT (type I, acquired, or sporadic) are alcohol, estrogens, iron, viral infections (hepatitis C and HIV), polychlorinated hydrocarbons, particularly hexachlorobenzene (HCB) and 2,3,7,8-tetrachlorodibenzo- *p*-dioxin (TCDD), and hemodialysis in patients with renal failure. Each of these precipitating factors is discussed briefly below.

ALCOHOL Heavy alcohol intake is known to exacerbate PCT. Ethanol induces hepatic ALA synthase in patients with PCT. Erythrocyte UROGEN decarboxylase activity is diminished in healthy subjects following acute ethanol ingestion and in chronic alcoholics. Ethanol can also inhibit the activity of other enzymes in the heme pathway, including ferrochelatase and ALA dehydratase. Chronic alcoholism leads to suppression of erythropoiesis and increased absorption of dietary iron, perhaps linked to inherited mutations associated with hemochromatosis (see below). The fact that ALA synthase is increased in patients with hepatic cirrhosis without porphyria raises questions concerning the relevance of alcohol effects on ALA synthase in the clinical expression of PCT. [59]
ESTROGENS The widespread use of estrogens as contraceptive agents or as hormone supplements for postmenopausal replacement therapy in females and as adjunctive hormonal therapy in males with prostatic carcinoma is associated with PCT. The mechanism of the estrogen effect on the expression of PCT is not established.

Diethylstilbestrol, an estrogen, induces hepatic ALA synthase, but this would not explain the distinctive porphyrin excretion pattern found in PCT. The vast majority of patients receiving estrogens do not manifest the biochemical abnormalities associated with PCT.

HEXACHLOROBENZENE This fungicide caused an “epidemic” of a PCT-like syndrome in southeastern Turkey in the 1950s. [60] It was added as a preservative to wheat intended for planting, but, because of a famine, several thousand individuals of diverse ethnic origin, mostly children, ingested the seed wheat and subsequently developed typical PCT. More than 4000 cases of this syndrome were reported from 1956 to 1961. The porphyrin excretion pattern and the cutaneous findings in these patients were similar to those seen in PCT evoked by ethanol or estrogens. The outbreak of PCT in Turkey caused by ingestion of hexachlorobenzene (HCB) indicated that the disease could occur in nongenetically predisposed individuals. Twenty-five years after onset, the most common clinical findings in these HCB-poisoned individuals were those of chronic porphyria, including sclerodermoid scarring (84 percent), hyperpigmentation (78 percent), hirsutism (49 percent), thyromegaly, and increased skin fragility (38 percent). [61] A painless arthritis was seen in two of three affected individuals, and a variety of neurologic signs and symptoms were seen in the majority. Stool and urine porphyrins remained elevated in many patients. Studies show that the chronic administration of HCB to experimental animals produces excessive porphyrin accumulation in the liver in a pattern quite similar to that seen in PCT in humans. These data are consistent with the hypothesis that chlorinated hydrocarbons, such as HCB, or their metabolites inhibit hepatic UROGEN decarboxylase, leading to excessive hepatic storage of URO and other acetate substituted porphyrins. Experimental studies also show that HCB can inactivate UROGEN decarboxylase by abolishing catalytic activity without changing the amount of immunoreactive enzyme protein. [62] Chemical porphyria, similar to PCT, is caused by other chlorinated hydrocarbons such as the polychlorinated biphenyls (PCBs) and TCDD, a by-product in the synthesis of the herbicide 2,4,5-trichlorophenoxyacetic acid. Additional studies on the porphyrinogenic effects of HCB, dioxin, and PCBs suggest that metabolic activation of the compounds mediated by cytochrome P450 1A2 and involving iron-mediated ROS is associated with an attack on the catalytic site of UROGEN decarboxylase. [14], [63]

2,3,7,8-TETRACHLORODIBENZO- *p*-DIOXIN TCDD is a toxic environmental pollutant chemical. Among its numerous effects are chloracne, liver damage, and hepatic porphyria in experimental animals, and perhaps also in humans. The hepatic porphyrinogenic effect of TCDD can be abolished in mice by first depleting them of iron. Furthermore, it is known that highly inbred mouse strains vary in their susceptibility to induction of hepatic porphyria by TCDD, indicating that the porphyrogenic effect of this hydrocarbon is modulated by as yet undefined genetic factors.

IRON Serum iron and ferritin concentrations are elevated or in the upper range of normal in PCT, confirming the important role of iron in the pathogenesis of the disease. [64] Hepatic iron overload accompanies clinical PCT in practically all cases, and elevation of plasma iron is found in one-third to one-half of patients. In PCT, the quantity of iron that can be mobilized by phlebotomy indicates that total iron stores are approximately twice normal. Ferrokinetic studies in patients with PCT are said to be normal. The long remissions that follow repeated phlebotomy and the apparent ineffectiveness of this treatment if supplemental iron is administered concomitantly suggest that iron plays a role in the excessive hepatic porphyrin production of PCT. PCT is particularly common where alcoholism and iron overload occur together. The role of iron in the pathogenesis of PCT is complex, and several hypotheses have been proposed to explain it. Iron may directly inhibit UROGEN decarboxylase. However, studies with purified UROGEN decarboxylase prepared from human erythrocytes show that the purified enzyme is not inhibited by Fe^{2+} or Fe^{3+}. [65] Chronic iron overload can produce peroxidative damage to lipid-rich mitochondrial and microsomal membranes in the liver of experimental animals, but the relationship of this toxic effect to changes in hepatic heme synthesis has not been clearly defined. An increased frequency of the hemochromatosis C282Y mutation in a gene encoding for the HLA class I–like protein HFE has been found in British patients with sporadic PCT. [66] This mutation is responsible for much of the iron overload in populations of European descent. A second mutation in the HFE gene *H63D* may also be associated with PCT in some populations. [67] PCT is rare in heterozygotes for each of these mutations, but 20 percent of British patients with PCT are *C282Y* homozygotes. *C282Y* homozygosity is an important susceptibility factor for both type I and type II PCT. [13] Iron may have a permissive effect on the inhibition by halogenated hydrocarbons of UROGEN decarboxylase, and it can also enhance the induction response of hepatic ALA synthase to drugs. Although such an iron-augmented increase in ALA synthase activity could lead to enhanced porphyrinogenesis, this alone would not explain the porphyrin excretion pattern seen in PCT. Addition of ferrous iron to liver in vitro causes a marked increase in porphyrin synthesis and inhibits UROGEN III synthase activity providing an explanation for the URO isomer I excess characteristic of PCT. More recently, a mouse model of type II PCT was developed in which one allele of UROGEN decarboxylase is disrupted and these animals are then bred to mice homozygous for HFE disruption. [68] These animals develop a PCT-like phenotype.

VIRAL INFECTIONS There is an association between PCT and hepatitis C virus (HCV) infections and combined HCV and HIV infections. [69] The role of these viral infections in the pathogenesis of PCT is unclear, although some connection with the hemochromatosis mutation *H63D* has been suggested. [14] It is possible that the connection is fortuitous and secondary to nonspecific hepatotoxic effects of these viruses. From these known effects of alcohol, estrogens, chlorinated hydrocarbons, iron, and viral infections on the heme pathway, it is clear that each of these could contribute to the excessive hepatic porphyrinogenesis characteristic of PCT. There is growing evidence that hepatic siderosis is the critical pathologic event in PCT and that the other agents somehow intensify the ability of iron to attack the catalytic site of UROGEN decarboxylase. The clinical expression of PCT is therefore dependent upon the interaction of a number of factors, both genetic and environmental. However, it is important to note that the ingestion of drugs associated with inducing attacks of the acute hepatic porphyrias (see Table 149-8) has not been reported to exacerbate PCT.

Epidemiology

PCT occurs throughout the world, and it is the most common of all the porphyrias. The disease most often begins in middle-aged individuals but can develop earlier. Prior to the widespread use of oral contraceptives, PCT developed predominantly in males and most now believe that the sex incidence is approximately equal. The rising incidence of PCT in females is probably a result of the widespread ingestion of estrogens in oral contraceptives or in hormone supplements. It should be noted that males treated with estrogens, for example, as adjunctive therapy for carcinoma of the prostate, have also developed PCT.

Clinical Manifestations

Vesicles and bullae followed by erosions and crusting occur predominantly in areas subject to repeated trauma (see Fig. 149-8). There is increased skin fragility, usually on the dorsa of the hands, but occasionally on the feet as well (Fig. 149-8D). The traumatized skin becomes crusted and, as the lesions resolve, areas of scarring may ensue. Numerous small milia can develop, particularly on the fingers and hands. These are pearly white to yellow, spherical subepidermal inclusions 1 to 5 mm in diameter and, characteristically, they are present in each of the hepatic porphyrias with cutaneous photosensitivity (PCT and VP) (Fig. 149-8C, Fig. 149-10, and Fig. 149-11). Although the cutaneous lesions are primarily seen on the light-exposed areas, patients are often unaware that sunlight plays a role in producing their lesions because the acute photosensitivity, so characteristic of the erythropoietic porphyrias, is rare in PCT. However, most patients do recognize that their skin condition worsens in the spring and summer and seems to improve in the fall and winter. Porphyrin excretion in PCT appears to increase in summer months and decrease in winter months.

FIGURE 149-10 A case of porphyria cutanea tarda showing bullae filled with clear fluid. Elsewhere are remnants of blisters, and on the second metacarpophalangeal joint are small milia.

FIGURE 149-11 Periorbital and malar violaceous coloration, hyperpigmentation, and hypertrichosis. Bullae, crusts, and scars are seen on the dorsa of the hands.

Other skin changes seen in PCT include hyperpigmentation and hypopigmentation that may be mottled, resembling chloasma. There may be an associated purplish red (“heliotrope”) suffusion of the central part of the face, particularly involving the periorbital areas, which may bear a striking resemblance to the plethora seen in polycythemia rubra vera (Fig. 149-12). This is not seen in the porphyrias of bone marrow origin.

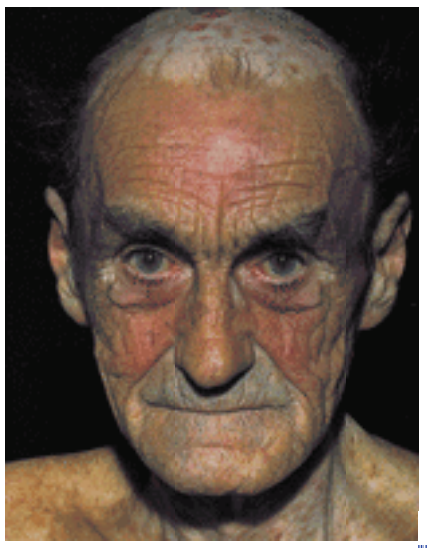

FIGURE 149-12 Porphyria cutanea tarda. Purple-red suffusion (“heliotrope”) of central facial skin is most pronounced in the periorbital and frontal areas.

Hypertrichosis (nonvirilizing) is a useful diagnostic sign that often brings the female patient to the dermatologist (Fig. 149-13). Facial hypertrichosis develops gradually and is more apparent in females. The hair may vary in texture between fine and coarse, and in color between light and dark. These hairs are particularly prominent along the temples and the cheeks but may occasionally involve the trunk and extremities in severe cases. Such hair may continue to grow, darken, and thicken, particularly on the cheeks, the forehead between the eyes, and at the hairline of the scalp. Males may complain that shaving is more difficult and that the growth pattern of their beard has changed. Hypertrichosis may be the presenting symptom in women, and a particularly severe form of hypertrichosis may occur in some children with PCT. In the reports of HCB poisoning in Turkey, some of the children were described as “monkey-like” because of marked hypertrichosis. [70] The mechanism of this phenomenon is unknown; androgen levels are reported to be normal. It is possible that surface receptors or growth factors for hair bulb keratinocytes are activated by the dual action of light and

porphyrins. The hypertrichosis of PCT usually improves slowly following appropriate treatment.

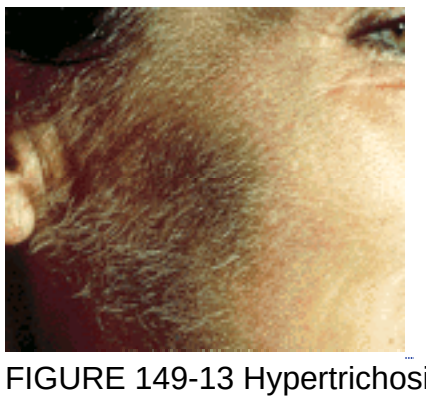

FIGURE 149-13 Hypertrichosis in a female with PCT; mostly pronounced on the zygomatic and malar skin.

Sclerodermoid plaques can occur in PCT and in HEP. These typically develop on both light-exposed and light-protected body areas (Fig. 149-14 and Fig. 149-15). These are usually scattered, waxy yellow to white, indurated plaques that closely resemble, both clinically and histopathologically, morphea or scleroderma. There is some evidence to indicate that PCT may occur concomitantly with true scleroderma, but this seems to be quite rare. As discussed earlier, URO I stimulates collagen synthesis in human skin fibroblasts. [33] In some patients, calcification has developed in these sclerodermoid plaques, necessitating excision and grafting.

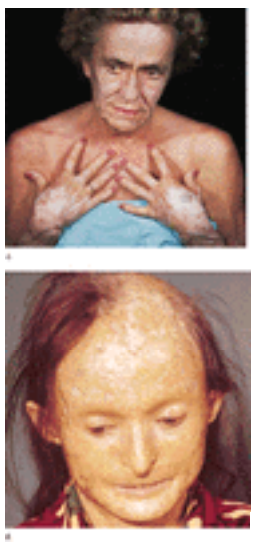

FIGURE 149-14 *A*. Porphyria cutanea tarda. The patient exhibits marked photoaging changes on the face and depigmented scars on the dorsa of the hands. *B*. Sclerodermoid thickening, shrinkage of facial and scalp skin with ulcerations and scars in a patient with hepatoerythropoietic porphyria where these sclerodermoid changes are particularly pronounced.

FIGURE 149-15 Porphyria cutanea tarda. Shiny sclerodermoid plaques on the chest.

PCT–like syndromes are occasionally seen in association with hepatic tumors and lupus erythematosus. Subepidermal bullous dermatoses mimicking PCT clinically and histologically have been described (see “ Pseudoporphyria” below). A number of cases of true PCT have occurred in patients with renal failure undergoing hemodialysis. Confirmation of the diagnosis rests on detection of markedly elevated plasma porphyrins (usually 5- to 100-fold) and increased ISOCOPRO in the feces.

PSEUDOPORPHYRIA (BULLOUS PHOTOSENSITIVITY)

Pseudoporphyria describes patients who clinically exhibit cutaneous manifestations of PCT without the characteristic abnormal porphyrin profile. This disorder may develop in association with ingestion of certain drugs such as furosemide, nalidixic acid, tetracycline, naproxen, pyridoxine, and isotretinoin. In the drug-induced type of pseudoporphyria, the

blistering process is subepidermal with little or no dermal inflammation. Staining with periodic acid–Schiff (PAS) reveals little or no deposition around upper dermal blood vessels and capillary walls. Indirect immunofluorescence studies conducted on split skin reveal no dermal deposition of fluorescent material in pseudoporphyria. Direct immunofluorescence studies have shown patchy granular deposition of IgG and C3 at the basement membrane zone in pseudoporphyria, PCT, and in epidermolysis bullosa acquisita (EBA).

A bullous dermatosis that is morphologically and histologically indistinguishable from PCT has also been observed in patients with chronic renal failure receiving maintenance hemodialysis. Such patients have moderately elevated plasma porphyrins (two- to fourfold) secondary to impaired renal clearance as well as diminished clearance through dialysis filters.

Laboratory Findings

Virtually all patients with PCT have excessive total body iron stores manifested as increased serum iron, ferritin, and/or hepatocellular iron. Occasionally, there is mild erythrocytosis. An abnormal glucose tolerance test occurs in a minority of patients.

Patients with PCT excrete increased amounts of porphyrins in the urine, which rarely may exhibit characteristic pink-red fluorescence when examined with a Wood's lamp. The porphyrin excretion pattern of PCT has three main features: (1) increased urinary excretion of URO and of other acetate-substituted porphyrins; (2) a distinctive pattern of excretion of isomer series I and III porphyrins; and (3) increased excretion of fecal ISOCOPRO. [14] PCT patients excrete greatly increased amounts of urinary 8-carboxyl URO as well as porphyrins with 7-, 6-, and 5-carboxyl groups; 4-carboxyl porphyrin (COPRO) is also increased but to a lesser extent than URO, and rarely surpasses 600 µg/24 h (see Table 149-3). In PCT, the hepatic UROGEN decarboxylase deficiency results in the accumulation of 5-carboxylporphyrinogen III (Fig. 149-1 and Fig. 149-2). This can be used as a substrate by the enzyme COPROGEN oxidase and it forms dehydroisocoproporphyrinogen, which, in turn, is oxidized to ISOCOPRO, resulting in the characteristic elevation of this compound in the feces of these patients.

The 8-carboxyl URO and 7-carboxyl porphyrins are the predominant urinary porphyrins in PCT (>90 percent of total porphyrins). The urinary porphyrin excretion pattern is a mixture of type I and type III isomers. URO is approximately 60 percent type I isomer and 40 percent type III; the 7- and 6-carboxyl porphyrins are >90 percent type III and <10 percent type I isomer; the 5- and 4-carboxyl porphyrins are approximately 50 percent each isomer. This distinctive isomer pattern is found consistently in patients with PCT.

In general, only trace amounts of URO are present in the stools of normal individuals. The porphyrin content of stool is increased in PCT and consists primarily of ISOCOPRO (type III), 7-carboxyl porphyrin, and lesser amounts of URO and COPRO. The total daily 24-h fecal porphyrin excretion may exceed total urinary porphyrin excretion.

The ratio of URO to COPRO in the urine is often helpful in differentiating PCT and VP. Thus, in PCT, the URO/COPRO ratio is usually >3:˜1, whereas in VP the ratio is usually <1:˜1. Occasionally, 24-h urine porphyrins will be normal or only slightly increased in a patient with the cutaneous findings of PCT. This should alert the physician to evaluate stool porphyrins as these are elevated in patients with VP (see “ Variegate Porphyria” above).

The constellation of clinical and laboratory findings often suffices to make the tentative diagnosis of PCT. Suspected PCT can frequently be confirmed by acidifying a random urine sample with a few drops of 10% hydrochloric acid or acetic acid and looking for orange-red fluorescence.

It should be emphasized that patients with clinical signs of PCT may have a negative urine fluorescent screening test for porphyrins. In such patients, it is absolutely essential to obtain plasma porphyrin levels and perform quantitative 24-h urine URO and COPRO determinations and stool PROTO and COPRO determinations, preferably by using high-performance liquid chromatography, which often permit differentiation of PCT from VP. However, some patients with VP will have normal fecal porphyrin excretion, and bile porphyrin measurements may be helpful in evaluating such patients.

Biochemical tests for liver function may be performed to identify liver disease. Elevated serum transaminases and ?-glutamyltranspeptidase levels may occur. Serum iron and ferritin concentrations may be elevated. The measurement of erythrocyte UROGEN decarboxylase is useful for detection of patients with type II PCT. Mutational analysis is an essential part of evaluating these patients (see below).

Histopathology

The characteristic histopathologic finding in PCT is a subepidermal blister (Fig. 149-16). Bullae characteristically show a corrugated, undulating base that has been termed festooned. [71] There is little or no inflammatory infiltrate. Periodic acid–Schiff stain reveals a mild degree of thickening of the papillary vessel wall, not nearly so marked as that seen in patients with EPP. Reticulin staining demonstrates slight proliferation of fibers along the basement membrane. Direct immunofluorescence studies reveal deposition of C3 and IgG in a granular pattern at the dermal–epidermal junction and in and around vessel walls in affected individuals. These changes are most apparent in sun-exposed areas of patients with active disease and high urinary porphyrin excretion, and they decrease substantially in patients after appropriate treatment. It is also possible that the deposition of immunoglobulins and complement is a nonspecific result of injury to the cutaneous tissue. The locus of damage to the upper dermal vessels and the dermal–epidermal junction suggests that damage to these areas evoked by porphyrin photosensitivity may be responsible for the unique skin fragility seen in PCT. Increased porphyrin concentrations are found in the skin of patients with PCT. With rare exception, blisters have not been induced by phototesting; however, erythema and delayed edema have been induced in the skin of patients with

PCT. [72]

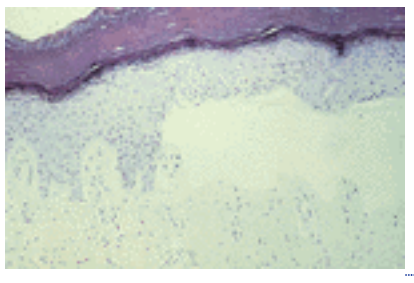

FIGURE 149-16 Porphyria cutanea tarda: subepidermal blistering in a late lesion. There is virtually no inflammatory response, but the form of the dermal papillae is partially preserved.

Differential Diagnosis

Other dermatoses that can be confused with PCT include VP, HEP, HCP, pseudoporphyria, scleroderma, and epidermolysis bullosa acquisita. Each of these can be differentiated on histopathologic grounds, by immunofluorescence tests, or by appropriate porphyrin studies. Careful evaluation of urine, stool, plasma, or bile porphyrins will almost always permit confirmation of the diagnosis of PCT. It should be emphasized that patients with PCT are not prone to the acute life-threatening attacks characteristic of the acute hepatic porphyrias. A very limited number of drugs and chemicals, particularly alcohol, estrogens, and selected halogenated hydrocarbons, seem capable of eliciting the disease in susceptible individuals (Table 149-10). Drugs such as barbiturates, which are contraindicated in AIP, have been administered to PCT patients without untoward effect. Nonsteroidal anti-inflammatory drugs such as naproxen, antibiotics such as the tetracyclines and nalidixic acid, and a variety of other agents may rarely produce clinical signs of a bullous photosensitivity closely resembling PCT (see " Pseudoporphyria" above). VP has skin lesions identical to PCT. However, in VP, stool PROTO and COPRO excretion is usually increased (PROTO>COPRO), and urinary porphyrin levels are only moderately increased (COPRO>URO). In PCT, stool ISOCOPRO is elevated, and total urinary porphyrin (URO>COPRO) is much higher than that observed in VP.

Treatment

Initially, a careful history should be taken in an effort to identify an environmental toxin (e.g., alcohol, estrogen, or chlorinated hydrocarbon) that may have triggered the disease. If HCV or HIV infection is present, these should be managed appropriately. Elimination of toxin exposure alone may result in gradual improvement. However, in most patients with PCT, more aggressive treatment is usually appropriate to accelerate therapeutic benefit and this currently consists of either repeated phlebotomy [14] or orally administered antimalarials, either chloroquine or hydroxychloroquine, or a combination of both. Other forms of treatment that have been described include administration of iron chelators [73] and the oral administration of cholestyramine. [74]

PHLEBOTOMY Phlebotomy is the treatment of choice for PCT. Numerous reports emphasize the safety and efficacy of this form of therapy, [75] which was introduced by Ippen in 1961. Phlebotomy is effective because it depletes the excessive hepatic iron stores characteristic of PCT. Biochemical remission of PCT has occurred in patients treated with phlebotomy who had iron overload, as well as in patients with quantitatively normal iron stores. Replenishment of iron following phlebotomy-induced remission of PCT has resulted in biochemical and clinical exacerbation of the disease. Abstinence from the porphyrinogenic agent alone, especially alcohol, may induce a clinical and biochemical remission, although this may take months to years. [75] The efficacy of phlebotomy may relate to several effects:

1. Iron effect on ALA synthase. Iron can enhance the induction response of ALA synthase to drugs and the hepatic porphyrinogenic response to HCB in experimental animals, and its depletion could render ALA synthase less inducible and thereby diminish hepatic porphyrinogenesis.
2. Iron depletion effects on other heme pathway enzymes. Ferrous iron inhibits UROGEN decarboxylase and increases the rate of hepatic porphyrin synthesis from ALA or PBG, suggesting that removal of iron can allow UROGEN decarboxylase activity to return to normal and/or reduce excessive porphyrinogenesis. This concept has been verified by the creation of genetically engineered mice in which iron overload inhibits the enzyme.
3. Iron effects on hepatic lipid peroxidation secondary to ROS. Iron depletion could reverse this response of the liver to iron overload.
4. Iron effects on oxidation of URO. Removal of iron could result in a diminished capacity of the ferrous metal to irreversibly oxidize the UROGEN substrate to nonmetabolizable porphyrins.

Phlebotomy is carried out as an ambulatory procedure. The total amount of blood removed varies widely, usually ranging from 1500 to 12,000 mL. It is most convenient to use plastic blood-drawing bags available in any blood bank. Approximately 500 mL of blood is removed at weekly or biweekly intervals until the hemoglobin decreases to approximately 10 g/dL or until the serum iron drops to 50 to 60 µg/dL. Some authors believe that phlebotomies should be continued until serum ferritin falls to the lower range of normal. Patients are strongly encouraged to discontinue or decrease exposure to porphyrinogenic agents because this usually hastens clinical and biochemical remission. It is particularly important to reassure the patient that clinical improvement may not become apparent for variable intervals after beginning the phlebotomies. Porphyrin excretion continues to fall long after phlebotomies are discontinued. It has been shown that in more than 90 percent of patients treated with regular phlebotomy, urinary URO excretion reaches normal levels (<100 µg/24 h) after 5 to 12 months. [75] Blistering is the first sign to disappear, followed by improvement in skin fragility and in hypertrichosis over a period of 3 to 18 months. Even sclerodermoid changes can resolve slowly, although this may take several years. There is little or no published information on long-term follow-up of treatment, but most relapsed patients have again responded to repeated courses of phlebotomies. The length of remission induced by

phlebotomy varies widely and ranges from 6 months to more than 10 years. At least 10 to 20 percent of patients will relapse within 1 year. Phlebotomy is a safe, effective, and relatively simple form of therapy with minimum associated morbidity. A few patients may complain of mild to moderate fatigue and weakness during the treatment period, but this usually resolves as the hemoglobin returns to normal. Phlebotomy remains the treatment of choice for uncomplicated PCT.

ANTIMALARIALS In some patients, phlebotomy is not recommended or is contraindicated owing to the presence of anemia or cardiopulmonary disorders or HIV infection. In such cases low-dose antimalarial therapy may be useful. The antimalarial aminoquinolines chloroquine (Aralen) and hydroxychloroquine (Plaquenil) have been recommended for treating PCT. In 1957, it was first suggested that chloroquine was useful in treating PCT. [76] The cutaneous signs of the disease cleared within 1 year in one patient who received 500 mg daily for several months. However, such doses will trigger severe hepatotoxicity in many PCT patients and this is no longer an acceptable approach. Experience with low doses shows that this is an effective approach. The clinical and biochemical remission of PCT obtained with chloroquine appears to be identical in all respects to that evoked by phlebotomy. However, it has been reported that rapid relapse occurred in several patients treated with hydroxychloroquine. There is a marked increase in urinary URO excretion in patients receiving higher doses of the antimalarial. The effect of chloroquine may relate to formation of water-soluble drug-porphyrin complexes that are then excreted from the liver. It is possible that chloroquine chelates iron in the hepatocyte and that the bound iron is then eliminated. [77] Use of low-dose (125 mg twice weekly) chloroquine therapy in PCT obviates the drug's hepatotoxic effect. [78] Remission of the disease was obtained in a single patient who received 50 mg of chloroquine twice weekly for 7 months. Additional studies confirmed good results in seven of eight PCT patients treated with chloroquine sulfate (330 mg base) twice weekly for several months. [77] Low-dose chloroquine (125 mg twice weekly for 8 to 18 months) was employed successfully in more than 100 patients with PCT. [79] Liver function tests and urinary porphyrins are monitored quarterly, and the medication continued until urinary URO is <100 µg/24 h. This usually requires 6 to 12 months of treatment. Studies comparing the therapeutic efficacy of phlebotomy with that of low-dose chloroquine suggest that they are equally efficacious. The combination of phlebotomy and chloroquine treatment may reduce the severity of the hepatotoxic response to chloroquine and also accelerate remission of the disease. Patients are treated with a series of one to four phlebotomies prior to starting chloroquine (250 mg daily for 7 days). The procedure is repeated when signs of biochemical or clinical relapse develop, which may occur in 1 to 2 years. It should be emphasized that despite the tendency of the antimalarials to evoke hepatotoxic responses in patients with PCT, there is no evidence to suggest that the changes in hepatocellular pathology characteristic of PCT worsen as a result of treatment with these drugs. The antimalarials may cause retinopathy, and the low-dose regimen helps to minimize the risk of this complication. Pretreatment and semiannual ophthalmologic examinations should be obtained on patients treated with these drugs. In patients with PCT and chronic renal failure, standard phlebotomy and antimalarial therapy are not feasible. The combination of high-dose recombinant erythropoietin and small-volume phlebotomy has been successful in selected patients. [80]

ERYTHROPOIETIC PROTOPORPHYRIA (EPP) (See Table 149-7)

Etiology

The specific defective enzyme in EPP is ferrochelatase, which is decreased in RBCs, mitogen-stimulated lymphocytes, and cultured skin fibroblasts of patients and unaffected carriers. [81] Because the activity of ferrochelatase in cultured skin fibroblasts of EPP patients is only 10 to 25 percent of normal, questions have been raised about the dominant inheritance of the disease. In one study several families with EPP were examined with respect to the mode of inheritance and on the basis of erythrocyte ferrochelatase activity this was said to be either autosomal dominant or recessive. [81]

Epidemiology

Although the exact incidence of EPP is unknown, it has been reported with increasing frequency since 1961, indicating that it is likely the most common cutaneous porphyria except for PCT. Studies from one laboratory performing diagnostic tests for RBC porphyrins in patients with suspected cutaneous photosensitivity indicated that 8 percent of such samples demonstrate elevated RBC PROTO levels diagnostic of EPP. The disease has been reported from many countries around the world, and it is likely that no ethnic group is spared.

Clinical Manifestations

The disease begins early in life and is characterized by cutaneous photosensitivity and by elevated PROTO in RBC, feces, and plasma; there is no excess porphyrin excretion in the urine except in the setting of hepatic failure. The acute episodes of cutaneous photosensitivity include burning, stinging (smarting), and pruritus in light-exposed skin, particularly of the nose, cheeks, and dorsal aspects of the hands. These are followed by erythema, edema (Fig. 149-17), urticarial lesions, and, less commonly, purpura. Photosensitivity may occur within minutes of sun exposure; it is often seasonal, starting early in the spring, continuing through the summer, and diminishing in the winter. The skin lesions often resolve slowly, leaving small, atrophic, waxy or pitted scars (Fig. 149-18). There may be some pursing of perioral skin (pseudorhagades). The skin of the knuckles and fingers, particularly over the metacarpophalangeal and interphalangeal joints, often appears thickened, wrinkled, and waxy, suggesting a premature aging (so-called old knuckles in a child). This subtle change is pathognomonic, particularly in children. Superficial scarring on the bridge of the nose and small circular shallow scars may be seen on the face. Vesicular or bullous lesions rarely occur in EPP in temperate climates, although they have occurred in patients exposed to tropical sunlight. The porphyrin abnormality persists throughout life, although some patients seem to be less symptomatic as they get older.

FIGURE 149-17 A case of erythropoietic protoporphyria showing swelling and purpura on dorsa of hands resulting from exposure to solar radiation.

FIGURE 149-18 *A*. One hour after exposure to sunlight, the face of this 35-year-old female is edematous, erythematous, and there is purpura on the forehead, cheeks, and nose. The patient experiences severe burning sensations. *B*. *A* 15-year-old patient with erythropoietic protoporphyria with severe sensitivity to sunlight. The nose, lower lip, and chin show erythematous, in part erosive, and crusted lesions. Nose and cheeks show erythematous lesions, a few small slightly depressed scars, and peculiar waxy thickening of skin. Linear scars are seen between the nose and mouth.

Controversy exists concerning the tissue origin of the excessive PROTO. Some authors have shown that RBC PROTO levels alone are sufficient to explain the increased levels of PROTO, [82] whereas others have suggested that hepatic PROTO production contributes to the excessively high levels of circulating PROTO. [83]

Associated findings are few in most patients with EPP. There is no erythrodontia, hypertrichosis, milia, sclerodermoid change, or hyperpigmentation. Hemolytic anemia is decidedly uncommon, although approximately 11 percent of patients with EPP have a mild anemia of unknown cause.

Gallstones have been reported in some patients with EPP at a relatively early age; in one series, 12 percent of patients had cholelithiasis, of whom three underwent cholecystectomy. [84]

Light microscopy of liver biopsies has revealed slight portal and periportal fibrosis and deposition of brown pigment, which may occlude bile canaliculi and ducts; it is also present in hepatocytes, in Kupffer cells, and in periportal macrophages. The pigment is birefringent on polarization microscopy. Hepatocytes may also contain cytoplasmic or mitochondrial inclusions, which at the ultrastructural level appear as needle-like crystals (Maltese crosses), probably caused by precipitated PROTO (Fig. 149-19). Biliary excretion of PROTO is coupled to secretion of phospholipid, translocated from the inner to outer canalicular membrane leaflet by the mdr2P glycoprotein. PROTO excretion from the liver requires bile acids and excessive amounts of the porphyrin inhibit its transport out of the hepatocyte.

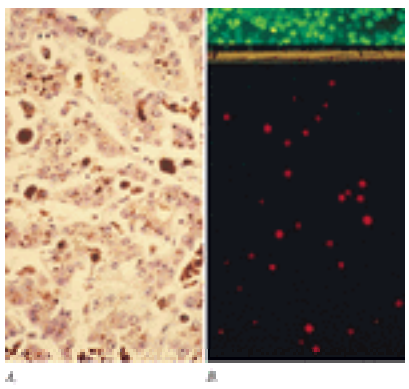

FIGURE 149-19 *A*. Brown pigment deposits in the liver tissue found in bile canaliculi, hepatocytes, and Kupffer cells. *B*. Bright-red fluorescence in red blood cells of a fresh smear of an EPP patient. Where all red blood cells contained in this smear are revealed by green fluorescence only (*top*), a few RBC contain increased amounts of protoporphyrins and thus fluorescence in red (*bottom*).

The huge increase in hepatic throughput of PROTO overwhelms the liver's excretory capacity in a small percentage of patients with EPP. This may be aggravated by hemolysis of PROTO-laden RBCs creating a vicious cycle of increased erythropoiesis and increased PROTO loading of the liver. Terminal hepatic failure has been reported in approximately 5 percent of patients. [85] All these individuals were jaundiced, had hepatic cirrhosis, and died in hepatic coma or as a consequence of portal hypertension. Some patients with end-stage liver disease may develop axonal neuropathy resembling that in the acute hepatic porphyrias despite normal serum ALA and PBG. Risk factors for EPP-associated hepatic failure remain unknown, but it is likely that the deposits of crystalline PROTO lead to hepatocyte injury. Experimental studies show that perfusion of rat liver with PROTO induces a dose-dependent cholestasis that could contribute to the hepatotoxic effect of PROTO. Liver failure has also occurred in two siblings who inherited EPP in an autosomal recessive pattern as compound heterozygotes, suggesting that this genotype may augment the risk of this complication. [86] However, this has been disputed because there are cases in which compound heterozygotes have had

normal liver function and cases in which heterozygotes developed liver failure. [87]

Laboratory Findings

The diagnosis of EPP is based on the detection of elevated free PROTO in the RBCs and/or feces (see Table 149-3 and Table 149-7). In addition, there may be increased plasma PROTO, increased fecal COPRO, and, occasionally, slightly increased RBC COPRO. In patients with deteriorating hepatic function, the fecal excretion of PROTO may decrease as plasma levels and cutaneous photosensitivity increase. Examination of a blood smear under a fluorescent microscope reveals red-fluorescing RBCs (5 to 30 percent). This fluorescence is often transient and quite light sensitive, thus the procedure should be carried out in subdued light or preferably in the dark. A rapid quantitative microfluorometric assay for free erythrocyte and plasma PROTO has been developed that is useful as a screening test for suspected EPP. Finger-prick samples of blood collected on filter paper are used for this test. In one series of 32 patients with EPP, the RBC PROTO levels ranged from 131 to 1617 µg/dL of RBC (normal <90 µg/dL of RBC). [88]

The photosensitizing activity of porphyrins is most probably related to the light absorption and emission characteristics of these tetrapyrroles that results in the generation of reactive oxygen species (see Fig. 149-5 and Fig. 149-7). Irradiation of PROTO-enriched RBCs enhances egress of the porphyrin suggesting that sun exposure may augment skin concentrations of PROTO in these patients. Unchelated (metal-free) PROTO is the photosensitizer in EPP, as evidenced by data from studies designed to explain the perplexing observation that in lead poisoning and in iron-deficiency anemia, RBC PROTO levels are similar to those found in EPP, but cutaneous photosensitivity does not occur. In these nonphotosensitizing disorders, the excessive PROTO is probably chelated with zinc and bound to globin chains in the RBC, which renders it incapable of diffusing into the plasma and then into cutaneous tissue, explaining why plasma PROTO is not elevated in these nonphotosensitizing disorders. In EPP, however, the majority of the excessive PROTO is probably unchelated or free. Free PROTO can diffuse out of the RBCs and is detectable in the plasma of patients with EPP who manifest cutaneous photosensitivity. In one study, a patient with sideroblastic anemia had marked increases in free PROTO, both in the RBCs and in the plasma, but had no cutaneous photosensitivity. [89] Because ferrochelatase activity was normal in this patient, it is possible that the excessive free PROTO was either chelated with zinc or readily converted to heme in the skin, thereby precluding cutaneous accumulation of PROTO and associated photosensitivity. It has also been suggested that the infrequency of hemolytic anemia in EPP is due to the unique capacity of PROTO to move out of the RBCs and to bind to albumin in the plasma. The porphyrin does not remain within the lipid-rich red cell membrane sufficiently long for light exposure to cause damage, and serum albumin has a potent inhibitory effect on photohemolysis in EPP.

Histopathology

Immediately following irradiation, endothelial cell damage, mast cell degranulation, and PMN cells are seen in the dermis. [29] In sun-exposed areas, there is often marked eosinophilic homogenization and thickening of vessels in the papillary dermis as a result of the accumulation of an amorphous, homogeneous, slightly basophilic (hyaline-like) substance in and around the vessel walls. The perivascular deposits of concentric eosinophilic layers of hyaline-like material stain strongly positive with PAS and are diastase positive (see Fig. 149-20). Histochemical studies suggest that this material may be a neutral glycoprotein with smaller amounts of acid mucopolysaccharide and lipids. The histologic findings are similar to those of lipoid proteinosis (hyalinosis cutis et mucosae). Electron microscopic studies in EPP show that the amorphous material consists of a multilayered partially fragmented basement membrane and finely fibrillar material of moderate density that permeates and surrounds the vessel walls. Other studies show that type IV collagen and laminin, as well as amyloid P and fibronectin, are deposited in the walls of dermal blood vessels. [90]

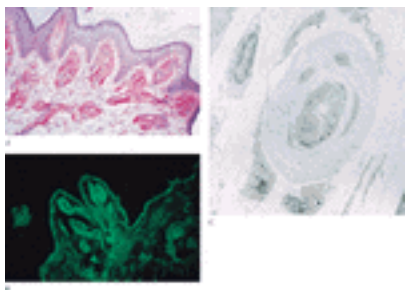

FIGURE 149-20 *A*. A biopsy of light-exposed skin from a patient with erythropoietic protoporphyria. There is marked thickening of the blood vessel walls of the upper dermis, which are surrounded by a hyaline-like material that stains brightly red with the PAS stain. *B*. Direct immunofluorescence reveals that the PAS-positive stain around papillary vessels contains immunoglobulins of classes. Immunoglobulins are also deposited along the dermal-epidermal junction. *C*. Electron micrograph of biopsy of chronically exposed skin from a patient with erythropoietic protoporphyria. Multiple concentric basal laminae surrounding dermal blood vessels and finely fibrillar material admixed with amorphous masses within perivascular tissue are shown.

Differential Diagnosis

EPP must be differentiated from other causes of photosensitivity, primarily hydroa aestivale, polymorphous light eruption (PMLE), idiopathic solar urticaria, and other types of porphyria. Contact dermatitis and angioedema should also be considered. In PMLE, the lesions are characteristically papules, plaques, and papulovesicles. A family history of photosensitivity is less common. Burning and smarting of the skin during or soon after sun exposure is unusual in PMLE, whereas it is a common occurrence in EPP. Porphyrin profile and skin biopsy with PAS staining may also be helpful in differentiating between PMLE and EPP. Idiopathic solar urticaria can be easily differentiated from EPP; it is not associated with elevated RBC or fecal PROTO. Contact dermatitis may involve non–light-exposed areas such as the skin folds and the submental areas. Patch testing with suspected allergens and negative porphyrin values help to differentiate

this condition. The lesions of angioedema may occur anywhere on the body, including the mucous membranes. Because discomfort is often disproportionate to visible lesions, EPP has been confused with psychoneurosis and malingering. This problem in differential diagnosis is readily solved by porphyrin determinations. Erythrocyte coproporphyrin (ECP), an extremely rare condition, should also be considered in the differential diagnosis. Clinically, it resembles EPP and could only be diagnosed by chromatographic study of RBC porphyrins.

Treatment

The treatment of photosensitivity in EPP has been aided by the use of the orally administered antioxidant beta-carotene. Topical sunscreens, particularly products containing titanium or zinc oxides, as well as dihydroxyacetone, that deposits in the stratum corneum forming a brown-tan pigment that absorbs in the UVA-Soret border, antimalarial drugs, cholestyramine, and vitamins E and C have all been suggested but are of unproven benefit. Beta-carotene (60 to 180 mg per day by mouth) has been found helpful in preventing or minimizing the symptoms of skin photosensitivity reactions of EPP. [27], [91] One hundred twelve of 133 patients (84 percent) claimed to triple their tolerance to sunlight after an adequate course of beta-carotene exceeding 2 months. The therapeutic effectiveness of the drug has been confirmed by several groups of investigators. These results are, however, based on limited controlled laboratory testing and on uncontrolled clinical impressions; the one controlled clinical trial failed to confirm the therapeutic effectiveness of beta-carotene although the adequacy of the dosage has been questioned. [92] To achieve optimal photoprotection, serum carotene levels should be maintained at a minimum of 600 µg/dL. In adult patients, this can usually be achieved by oral administration of two to six capsules of 30 mg each per day, which will produce serum carotene levels of 600 to 800 µg/dL after 4 to 6 weeks of therapy. Children younger than 12 years of age may receive 30 to 90 mg daily. Because maximum effectiveness may not occur until 1 to 2 months after initiating therapy, patients should receive therapy in early spring through the fall season (February to October in the northern hemisphere). The drug is remarkably well tolerated at these doses, and there are no known toxic systemic effects of beta-carotene. Occasionally, diarrhea occurs in a small number of patients. Orange or rusty discoloration of stools is common and is not an indication for discontinuing treatment. The only other side effect of note is the visible yellowing of the skin that occurs as a result of carotenoderma and this is more noticeable on the palms and soles.

The mechanism of the photoprotective effect of beta-carotene is not precisely known. Beta-carotene does not function as a sunscreen; it is capable of quenching excited singlet oxygen and of trapping free radicals formed by the interaction of light with PROTO and molecular oxygen. Another antioxidant, the amino acid cysteine, improves photosensitivity. [93] Hematin infusions may decrease the production of heme temporarily and are associated with a decrease in fecal and plasma PROTO in some patients. [82] The use of RBC exchange with autologous washed cells has also been explored for its ability to induce clinical and biochemical remission of EPP. Such therapy resulted in a marked decrease in photosensitivity associated with a decline in free erythrocyte PROTO levels. Management of the hepatic failure is particularly challenging. Orally administered bile salts have been used in an effort to diminish the enterohepatic circulation of the excessive PROTO and to enhance the capacity of the liver to clear excess PROTO. Another approach was reported using large amounts of orally administered iron in a patient with EPP who manifested incipient hepatic failure as well as elevated erythrocyte and plasma PROTO levels and concomitant iron deficiency anemia. [94] Oral iron therapy exacerbated the disease in another patient. [95] Liver transplantation has also been used successfully. [96] Future therapy could include replacement of defective ferrochelatase. [97] The feasibility of obtaining detectable levels of the enzyme in fibroblasts from EPP patients by adding the cDNA for normal ferrochelatase employing a retroviral vector has been demonstrated. [98] Gene replacement has been achieved in a mouse model of EPP in which ex vivo preselection of hematopoietic stem cells transduced with a polycistronic retrovirus expressing human ferrochelatase resulted in complete correction of skin photosensitivity. [99]

CONGENITAL ERYTHROPOIETIC PORPHYRIA (Table 149-7)

Etiology

Congenital erythropoietic porphyria (CEP) is an autosomal recessive inborn error of metabolism that results from variably deficient activity of UROGEN III synthase, the fourth enzyme in the heme synthetic pathway. This results in accumulation of hydroxymethylbilane that converts spontaneously to UROGEN I.

Epidemiology

CEP has been observed to occur in countries around the world. Fewer than 200 cases had been reported until 1992. Nearly all begin in childhood and only a few in adults. CEP also occurs in a number of mammals, including swine, cattle, and cats, and studies in these animal models have greatly aided research in this disease.

Clinical Manifestations

The disease usually presents itself in the first few months of life with moderate to severe cutaneous photosensitivity associated with pinkish red urine. [100] CEP causes the most mutilating skin lesions of any of the porphyrias. The photosensitivity is a result of the excessive URO I and COPRO I in RBCs, plasma, and skin, which may result in photolysis of porphyrin-rich cells.

The skin manifestations include skin fragility and vesicles and bullae, which may contain pink fluorescent fluid. Secondary infection, delayed healing, and scar formation may occur. This may lead to loss of acral tissue, such as the tips of the ears, the nose, and fingers (Fig. 149-21A and Fig. 149-21B), and facial mutilation. Hirsutism, with long, dark, lanugo-like hair, may occur and is particularly evident in light-exposed areas such as the face, neck, and extremities. The scalp may develop a cicatrizing alopecia. Other chronic findings include eye changes (photophobia, keratoconjunctivitis, ectropion, symblepharon, and even loss of vision) and irregular hyper- and hypopigmentation of the skin. Erythrodontia (red-stained teeth) is a common finding in both deciduous and permanent teeth and is virtually pathognomonic of CEP.

The urine also fluoresces reddish pink (Fig 149-21C).

FIGURE 149-21 Two cases of congenital erythropoietic porphyria (Günther's diease). *A,B*. Severe scarring damage of the ear and nose cartilage, hair loss, and discolored teeth. *(Courtesy of A Wiskemann, MD, and J Kimmig, MD.) C*. Burgundy red urine of a patient with congenital porphyria.

In addition, splenomegaly, porphyrin-rich gallstones, and fluorescent bone marrow normoblasts are often observed. Hemolytic anemia associated with shortened erythrocyte lifespan and hypersplenism (36 versus 120 days) is seen. Whether the hemolytic anemia is a result of “photohemolysis” of circulating porphyrin-laden erythrocytes or to an associated intracorpuscular red cell defect is unresolved.

Laboratory Findings

The primary defect in CEP involves a decreased activity of UROGEN III synthase that results in accumulation and increased excretion of predominantly type I porphyrins in the tissues. The pink to burgundy red color of the urine from excess URO I is often visible on inspection Marrow normoblasts exhibit relatively stable fluorescence and contain markedly elevated URO I, COPRO I, and PROTO. Urinary excretion of ALA and PBG is normal. COPRO I may be present in large amounts in the feces. Table 149-3 summarizes typical biochemical findings of CEP.

Histopathology

The bullous lesions of CEP are subepidermal with minimal degrees of inflammation. Thickening of collagen bundles may be seen in areas of scarring. Perivascular deposits of porphyrin can be found when the unstained sections of skin or liver are viewed with a fluorescence microscope.

Differential Diagnosis

The diagnosis of CEP can usually be made from the early onset of severe cutaneous photosensitivity associated with red fluorescent urine and erythrodontia. Distinguishing CEP from other congenital types of photodermatoses is important. Cutaneous findings in patients with xeroderma pigmentosum, epidermolysis bullosa, hydroa vacciniforme, and bullous pemphigoid may mimic those in patients with CEP, but the porphyrin profiles of the former conditions are completely normal. Patients with chronic hepatic porphyrias such as PCT and VP can be differentiated from patients with CEP by the normal PROTO content of their erythrocytes. The cutaneous manifestations of HEP may be strikingly similar to those of CEP, and measurement of the enzymes UROGEN III cosynthase (decreased in CEP) and UROGEN decarboxylase (decreased in HEP) distinguishes one from the other. The dual occurrence of HCP and CEP in a single patient who inherited the HCP trait from her mother and the CEP trait from both of her parents has been reported. [101]

Treatment

The treatment of CEP is essentially preventive and symptomatic and includes avoidance of sun exposure, surveillance of the anemia, and treatment of recurrent skin infections. Protection from sunlight is absolutely essential and this alone may be of substantial benefit. Patients should be instructed to wear broad-brimmed hats and other photoprotective clothing. Topical sunscreens are relatively little used as the only ones effective at wavelengths greater than 400 nm are light opaque [sun protection factor (SPF) >30] and contain zinc oxide or titanium dioxide. Newer formulations with improved cosmetic properties may be helpful. The efficacy of oral administration of beta-carotene (120 to 180 mg daily) in CEP is not proven. Splenectomy because of intractable hemolytic anemia has occasionally resulted in marked improvement both in the anemia and in cutaneous photosensitivity. Suppression of erythropoiesis by transfusion of packed erythrocytes causes a marked decrease in porphyrin production and excretion; however, iron overload is a drawback. Oral treatment of a single patient with activated charcoal (60 g three times a day) for 9 months was found to lower the porphyrin levels in plasma and skin and there was complete remission of photosensitivity during the treatment period. [102] Charcoal is thought to interfere with the enterohepatic recirculation of the porphyrin and thereby enhance porphyrin clearance from the body. However, this beneficial effect has been disputed. [103] Allogeneic bone marrow transplantation has been curative for a small number of patients. [104]

HEPATOERYTHROPOIETIC PORPHYRIA (HEP) (Table 149-7)

Etiology

HEP is caused by homozygous deficiency of UROGEN decarboxylase; in some cases, this is the result of inheritance of a mutant allele from each parent (compound heterozygote), while in other cases, it is the result of being a homozygous form of type II PCT. The primary enzyme defect is a profound deficiency of UROGEN decarboxylase activity. [12] Measurement of the enzyme in hemolyzed whole blood or skin fibroblasts from three unrelated patients with the disease showed that it was 7 to 8 percent of normal levels. The father of one HEP patient was heterozygous for the same enzyme defect, suggesting that patients with HEP are homozygous for the gene that causes PCT. There is no evidence, as yet, that clinical expression of HEP is related to exposure to environmental drugs or chemicals, as is true for PCT. In one family clinical, biochemical, and enzymatic studies of three generations, in which a second-generation 31-year-old male

was shown to have HEP, revealed that both of the proband's parents and each of his three children had a moderate deficiency of UROGEN decarboxylase. [105]

Epidemiology

Patients with HEP have been reported in Europe and America.

Clinical Manifestations

This disease is usually manifest in early childhood, with dark urine being the most frequently observed sign. Severe cutaneous photosensitivity includes blistering and pruritus. The photosensitivity seems to diminish with age and is followed by hypertrichosis, hyperpigmentation, and scleroderma-like scarring similar to that seen in Günther's disease. Ocular manifestations include ectropion associated with cutaneous sclerosis and scleromalacia perforans. Splenomegaly has occurred in a small percentage of affected individuals, particularly after the age of 10 years, and hemolytic anemia has been documented as well. In some patients, liver function tests have been abnormal, but serum iron and iron binding are normal. In summary, the clinical manifestations of HEP resemble a combination of EP and PCT.

Laboratory Findings

Elevated urinary URO (I and III) and 7-carboxyl porphyrins (>90 percent III), elevated fecal COPRO and ISOCOPRO, and elevated RBC PROTO (zinc-chelated) have been observed in all patients. These findings suggest that there is abnormal porphyrin synthesis in both the liver and the bone marrow. In contrast to PCT patients, serum iron concentrations are usually normal in HEP.

Histopathology

Skin biopsies have shown subepidermal bullae resembling those occurring in PCT. PAS-positive material is seen in and around dermal capillaries.

Differential Diagnosis

The differential diagnosis is that of childhood porphyria and includes CEP, PCT, and EPP. CEP manifests erythrodontia and mutilating scarring, whereas EPP often presents with acute photosensitivity. Unlike CEP, in which increased RBC URO is a characteristic finding, in HEP there is elevated RBC PROTO of the zinc-chelated type. The urinary porphyrin pattern is similar to that found in PCT, with high URO (URO/COPRO ratio >5:˜1). The elevated PROTO in RBC helps to distinguish HEP from PCT. Urinary porphyrin analysis can differentiate HEP and EPP because urinary porphyrins are normal in EPP.

Treatment

There is no known treatment aside from careful photoprotection.

ABNORMAL PORPHYRIN PROFILE AND SIDEROBLASTIC ANEMIA

Some cases of sideroblastic anemia may be associated with an abnormal porphyrin profile. [106] These patients may have photosensitivity closely resembling that of EPP and they subsequently develop sideroblastic anemia; in some patients, the two conditions may develop within a few months of each other. All patients have elevated PROTO in RBC and/or plasma; many also have elevated stool PROTO levels. Urinary COPRO and URO are also elevated. The activities of ferrochelatase and, less frequently, of ALA synthase may be decreased. Chromosomal abnormalities, which include deletions in chromosomes 18 and 20, have been described.

MOLECULAR GENETIC RESEARCH STRATEGIES FOR THE PORPHYRIAS

In the various types of porphyrias, discrepancies between clinical findings and the results of biochemical tests or enzyme essays often lead to doubtful or incorrect diagnoses. In the case of the acute porphyrias, this can have fatal consequences for the patient if an accurate diagnosis is not established in a timely manner.

ANIMAL MODELS AND FUTURE OPTIONS FOR GENE THERAPY

Recently, animal models for EPP and PCT were described. [68], [99], [107] These models afford unique opportunities to explore the pathogenesis of these types of porphyria using in vivo models, and to study the feasibility of achieving phenotypic reversion by gene therapy. Retrovirus-mediated gene transfer of human ferrochelatase cDNA into deficient fibroblasts from an EPP patient has been achieved. [98] In transduced cells, ferrochelatase catalytic activity increased from 7 to 550 percent of the normal value, and partial metabolic correction of the phenotype was demonstrated. In CEP, correction of the underlying enzymatic defect in cultured cells was also accomplished by retrovirus-mediated gene transfer leading to partial normalization. [108] Excessive porphyrin levels in the transduced cells were reduced to normal These investigations demonstrate the potential utility of somatic stem cell gene therapy for the treatment of different types of porphyrias.

FUTURE PROSPECTS

The various human porphyrias often present with overlapping clinical and laboratory findings making precise diagnosis a challenging proposition, especially in the acute porphyrias. The clinical signs and symptoms are highly variable in

different patients and even in the same patient at different times. Biochemical analyses of urinary and/or fecal porphyrins/precursors often display overlapping values. These methods, as well as the measurement of enzymatic activities in fibroblasts or lymphocytes, are somewhat imprecise, and it is not uncommon to find values that do not distinguish between clinically unaffected gene carriers (so-called “silent” carriers), and normal controls. The identification of “silent” carriers within families suffering from the acute porphyrias is the first and foremost step toward the prevention of life-threatening acute attacks. Once a DNA-based diagnosis is made, patients and their families can be provided with genetic counseling and with advice regarding the avoidance of precipitating factors (Fig. 149-22). In case of a life-threatening acute attack, a prior genetic diagnosis permits the attending physician to begin appropriate treatment immediately. [44]

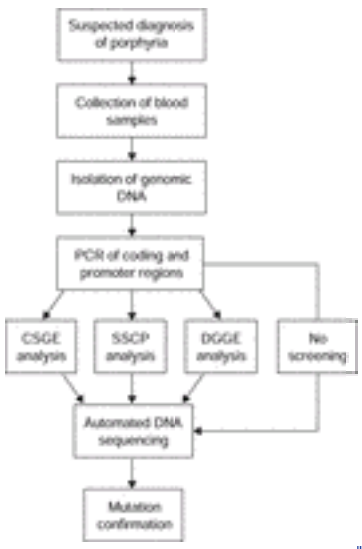

FIGURE 149-22 Algorithm for assessing the molecular genetics of human porphyria.

REFERENCES

1. Sassa S, Kappas A: Molecular aspects of the inherited porphyrias. *J Intern Med* **247**:169, 2000

2. James MF, Hift RJ: Porphyrias. *Br J Anaesth* **85**:143, 2000

3. Frank J, Christiano AM: The genetic bases of the porphyrias. *Skin Pharmacol Appl Skin Physiol* **11**:297, 1998

4. Thunell S: Porphyrins, porphyrin metabolism and porphyrias. I. Update. *Scand J Clin Lab Invest* **60**:509, 2000

5. Sassa S: ALAD porphyria. *Semin Liver Dis* **18**:95, 1998

6. Kaya AH et al: Human delta-aminolevulinate dehydratase (ALAD) gene: Structure and alternative splicing of the erythroid and housekeeping mRNAs. *Genomics* **19**:242, 1994

7. Gross U et al: 5-Aminolevulinic acid dehydratase deficiency porphyria: A twenty-year clinical and biochemical follow-up. *Clin Chem* **44**:1892, 1998

8. Anderson PM, Desnick RJ: Purification and properties of uroporphyrinogen I synthase from human erythrocytes. Identification of stable enzyme-substrate intermediates. *J Biol Chem* **255**:1993, 1980

9. Lamon J, With TK, Redeker AG: The Hoesch test: Bedside screening for urinary porphobilinogen in patients with suspected porphyria. *Clin Chem* **20**:1438, 1974

10. Tsai SF, Bishop DF, Desnick RJ: Human uroporphyrinogen III synthase: Molecular cloning, nucleotide sequence, and expression of a full-length cDNA. *Proc Natl Acad Sci U S A* **85**:7049, 1988

11. Solis C et al: Uroporphyrinogen III synthase erythroid promoter mutations in adjacent GATA1 and CP2 elements cause congenital erythropoietic porphyria. *J Clin Invest* **107**:753, 2001

12. Elder GH, Roberts AG: Uroporphyrinogen decarboxylase. *J Bioenerg Biomembr* **27**:207, 1995

13. Brady JJ et al: Co-inheritance of mutations in the uroporphyrinogen decarboxylase and hemochromatosis genes accelerates the onset of porphyria cutanea tarda. *J Invest Dermatol* **115**:868, 2000

14. Thunell S, Harper P: Porphyrins, porphyrin metabolism, porphyrias. III. Diagnosis, care and monitoring in porphyria cutanea tarda—Suggestions for a handling programme. *Scand J Clin Lab Invest* **60**:561, 2000

15. Phillips JD et al: Functional consequences of naturally occurring mutations in human uroporphyrinogen decarboxylase. *Blood* **98**:3179, 2001

16. Held JL et al: Erythrocyte uroporphyrinogen decarboxylase activity in porphyria cutanea tarda: A study of 40 consecutive patients. *J Invest Dermatol* **93**:332, 1989

17. Garey JR et al: Uroporphyrinogen decarboxylase: A splice site mutation causes the deletion of exon 6 in multiple families with porphyria cutanea tarda. *J Clin Invest* **86**:1416, 1990

18. Roberts AG et al: A mutation (G281E) of the human uroporphyrinogen decarboxylase gene causes both hepatoerythropoietic porphyria and overt familial porphyria cutanea tarda: Biochemical and genetic studies on Spanish patients. *J Invest Dermatol* **104**:500, 1995

19. de Verneuil H et al: Prevalence of the 281 (Gly—Glu) mutation in hepatoerythropoietic porphyria and porphyria cutanea tarda. *Hum Genet* **78**:101, 1988

20. Grandchamp B, Lamoril J, Puy H: Molecular abnormalities of coproporphyrinogen oxidase in patients with hereditary coproporphyria. *J*

Bioenerg Biomembr **27**:215, 1995

21. Taketani S et al: The human protoporphyrinogen oxidase gene (PPOX): Organization and location to chromosome 1. *Genomics* **29**:698, 1995

22. Gouya L et al: The penetrance of dominant erythropoietic protoporphyria is modulated by expression of wild-type FECH. *Nat Genet* **30**:27, 2002

23. Poh-Fitzpatrick MB: The “priming phenomenon” in the acute phototoxicity of erythropoietic protoporphyria. *J Am Acad Dermatol* **21**:311, 1989

24. Bickers DR, Dixit R, Mukhtar H: Hematoporphyrin photosensitization of epidermal microsomes results in destruction of cytochrome P-450 and in decreased monooxygenase activities and heme content. *Biochem Biophys Res Commun* **108**:1032, 1982

25. Lim HW, Gigli I, Wasserman SI: Differential effects of protoporphyrin and uroporphyrin on murine mast cells. *J Invest Dermatol* **88**:281, 1987

26. Dixit R, Mukhtar H, Bickers DR: Destruction of microsomal cytochrome P-450 by reactive oxygen species generated during photosensitization of hematoporphyrin derivative. *Photochem Photobiol* **37**:173, 1983

27. Mathews-Roth MM et al: Beta-carotene as an oral photoprotective agent in erythropoietic protoporphyria. *JAMA* **228**:1004, 1974

28. Athar M et al: A novel mechanism for the generation of superoxide anions in hematoporphyrin derivative-mediated cutaneous photosensitization. Activation of the xanthine oxidase pathway. *J Clin Invest* **83**:1137, 1989

29. Schnait FG, Wolff K, Konrad K: Erythropoietic protoprophyria—Submicroscopic events during the acute photosensitivity flare. *Br J Dermatol* **92**:545, 1975

30. Yen A, Gigli I, Barrett KE: Dual effects of protoporphyrin and long-wave ultraviolet light on histamine release from rat peritoneal and cutaneous mast cells. *J Immunol* **144**:4327, 1990

31. He D, Soter NA, Lim HW: The late phase of hematoporphyrin derivative-induced phototoxicity in mice: Release of histamine and histologic changes. *Photochem Photobiol* **50**:91, 1989

32. Lim HW et al: Delayed phase of hematoporphyrin-induced phototoxicity: Modulation by complement, leukocytes, and antihistamines. *J Invest Dermatol* **84**:114, 1985

33. Varigos G, Schiltz JR, Bickers DR: Uroporphyrin I stimulation of collagen biosynthesis in human skin fibroblasts. A unique dark effect of porphyrin. *J Clin Invest* **69**:129, 1982

34. Wakulchik SD, Schiltz JR, Bickers DR: Photolysis of protoporphyrin-treated human fibroblasts in vitro: Studies on the mechanism. *J Lab Clin Med* **96**:158, 1980

35. Lim HW et al: Generation of chemotactic activity in serum from patients with erythropoietic protoporphyria and porphyria cutanea tarda. *N Engl J Med* **304**:212, 1981

36. Lim HW, Gigli I: Role of complement in porphyrin-induced photosensitivity. *J Invest Dermatol* **76**:4, 1981

37. Lim HW, Poh-Fitzpatrick MB, Gigli I: Activation of the complement system in patients with porphyrias after irradiation in vivo. *J Clin Invest* **74**:1961, 1984

38. Becker CG et al: Activation of factor XII-dependent pathways in human plasma by hematin and protoporphyrin. *J Clin Invest* **76**:413, 1985

39. Henderson BW, Donovan JM: Release of prostaglandin E_2 from cells by photodynamic treatment in vitro. *Cancer Res* **49**:6896, 1989

40. Herrmann G et al: Photosensitization of uroporphyrin augments the ultraviolet A-induced synthesis of matrix metalloproteinases in human dermal fibroblasts. *J Invest Dermatol* **107**:398, 1996

41. Moore MR, Hift RJ: Drugs in the acute porphyrias—Toxicogenetic diseases. *Cell Mol Biol* (*Noisy-le-grand*) **43**:89, 1997

42. Deybach JC, Puy H: Porphobilinogen deaminase gene structure and molecular defects. *J Bioenerg Biomembr* **27**:197, 1995

43. Elder GH, Hift RJ: Treatment of acute porphyria. *Hosp Med* **62**:422, 2001

44. Thunell S et al: Porphyrins, porphyrin metabolism and porphyrias. II. Diagnosis and monitoring in the acute porphyrias. *Scand J Clin Lab Invest* **60**:541, 2000

45. Mustajoki P, Nordmann Y: Early administration of heme arginate for acute porphyric attacks. *Arch Intern Med* **153**:2004, 1993

46. Anderson KE et al: A gonadotropin releasing hormone analogue prevents cyclical attacks of porphyria. *Arch Intern Med* **150**:1469, 1990

47. Frank J et al: Homozygous variegate porphyria: Missense mutations on both alleles of the protoporphyrinogen oxidase gene in a severely affected proband. *J Invest Dermatol* **108**:647, 1997

48. Lam H et al: Molecular basis of variegate porphyria: A de novo insertion mutation in the protoporphyrinogen oxidase gene. *Hum Genet* **99**:126, 1997

49. Dean G: *The Porphyrias*. Philadelphia, Lippincott, 1963

50. Palmer RA et al: Homozygous variegate porphyria: A compound heterozygote with novel mutations in the protoporphyrinogen oxidase gene. *Br J Dermatol* **144**:866, 2001

51. Sieg I, Bhutani LK, Doss MO: Dual porphyria of coexisting variegata and cutanea tarda. *Eur J Clin Chem Clin Biochem* **33**:405, 1995

52. Poh-Fitzpatrick MB: A plasma porphyrin fluorescence marker for variegate porphyria. *Arch Dermatol* **116**:543, 1980

53. Sassa S et al: Molecular defects of the coproporphyrinogen oxidase gene in hereditary coproporphyria. *Cell Mol Biol (Noisy-le-grand)* **43**:59,

1997

54. Herrero C et al: Acquired immunodeficiency syndrome in a patient affected by hereditary coproporphyria: Safety of zidovudine treatment. *Arch Dermatol* **126**:122, 1990

55. Lamoril J et al: A molecular defect in coproporphyrinogen oxidase gene causing harderoporphyria, a variant form of hereditary coproporphyria. *Hum Mol Genet* **4**:275, 1995

56. Tenhunen R, Mustajoki P: Acute porphyria: Treatment with heme. *Semin Liver Dis* **18**:53, 1998

57. Roberts AG et al: Heterogeneity of familial porphyria cutanea tarda. *J Med Genet* **25**:669, 1988

58. Doss MO: New form of dual porphyria: Coexistent acute intermittent porphyria and porphyria cutanea tarda. *Eur J Clin Invest* **19**:20, 1989

59. Kodama T et al: Changes in aminolevulinate synthase and aminolevulinate dehydratase activity in cirrhotic liver. *Gastroenterology* **84**:236, 1983

60. Ochner RK, Schmid R: Acquired porphyria in man and rat due to hexachlorobenzene intoxication. *Nature* **189**:499, 1961

61. Cripps DJ, Gocmen A, Peters HA: Porphyria turcica. Twenty years after hexachlorobenzene intoxication. *Arch Dermatol* **116**:46, 1980

62. Elder GH, Sheppard DM: Immunoreactive uroporphyrinogen decarboxylase is unchanged in porphyria caused by TCDD and hexachlorobenzene. *Biochem Biophys Res Commun* **109**:113, 1982

63. Smith AG et al: Protection of the Cyp1a2(–/–) null mouse against uroporphyria and hepatic injury following exposure to 2,3,7,8-tetrachlorodibenzo- *p*-dioxin. *Toxicol Appl Pharmacol* **173**:89, 2001

64. Kushner JP, Steinmuller DP, Lee GR: The role of iron in the pathogenesis of porphyria cutanea tarda. II. Inhibition of uroporphyrinogen decarboxylase. *J Clin Invest* **56**:661, 1975

65. de Verneuil H, Sassa S, Kappas A: Purification and properties of uroporphyrinogen decarboxylase from human erythrocytes. A single enzyme catalyzing the four sequential decarboxylations of uroporphyrinogens I and III. *J Biol Chem* **258**:2454, 1983

66. Roberts AG et al: Increased frequency of the haemochromatosis Cys282Tyr mutation in sporadic porphyria cutanea tarda. *Lancet* **349**:321, 1997

67. Sampietro M et al: High prevalence of the His63Asp HFE mutation in Italian patients with porphyria cutanea tarda. *Hepatology* **27**:181, 1998

68. Phillips JD et al: A mouse model of familial porphyria cutanea tarda. *Proc Natl Acad Sci U S A* **98**:259, 2001

69. Chuang TY, Brashear R, Lewis C: Porphyria cutanea tarda and hepatitis C virus: A case-control study and meta-analysis of the literature. *J Am Acad Dermatol* **41**:31, 1999

70. Cam C, Nigogosyan G: Acquired toxic porphyria cutanea tarda due to hexachlorobenzene. *JAMA* **183**:88, 1963

71. Wolff K et al: Microscopic and fine structural aspects of porphyrias. *Acta Derm Venereol Suppl (Stockh)* **100**:17, 1982

72. Rimington C et al: Porphyria and photosensitivity. *Q J Med* **36**:29, 1967

73. Rocchi E et al: Iron removal therapy in porphyria cutanea tarda: Phlebotomy versus slow subcutaneous desferrioxamine infusion. *Br J Dermatol* **114**:621, 1986

74. Stathers GM: Porphyrin-binding effect of cholestyramine. Results of in vitro and in vivo studies. *Lancet* **2**:780, 1966

75. Ramsay CA et al: The treatment of porphyria cutanea tarda by venesection. *Q J Med* **43**:1, 1974

76. London ID: Porphyria cutanea tarda: Report of a case successfully treated with chloroquine. *Arch Dermatol* **75**:801, 1957

77. Taljaard JJ et al: Studies on low dose chloroquine therapy and the action of chloroquine in symptomatic porphyria. *Br J Dermatol* **87**:261, 1972

78. Saltzer EI, Redeker AG, Wilson JW: Porphyria cutanea tarda. Remission following chloroquine administration without adverse effects. *Arch Dermatol* **98**:496, 1968

79. Malina L, Chlumsky J: A comparative study of the results of phlebotomy therapy and low-dose chloroquine treatment in porphyria cutanea tarda. *Acta Derm Venereol* **61**:346, 1981

80. Shieh S, Cohen JL, Lim HW: Management of porphyria cutanea tarda in the setting of chronic renal failure: A case report and review. *J Am Acad Dermatol* **42**:645, 2000

81. Goerz G et al: Ferrochelatase activities in patients with erythropoietic protoporphyria and their families. *Br J Dermatol* **134**:880, 1996

82. Lamon JM, Poh-Fitzpatrick MB, Lamola AA: Hepatic protoporphyrin production in human protoporphyria. Effects of intravenous hematin and analysis of erythrocyte protoporphyrin distribution. *Gastroenterology* **79**:115, 1980

83. Scholnick P, Marver HS, Schmid R: Erythropoietic protoporphyria: Evidence for multiple sites of excess protoporphyrin formation. *J Clin Invest* **50**:203, 1971

84. Cripps DJ, Scheuer PJ: Hepatobiliary changes in erythropoietic protoporphyria. *Arch Pathol* **80**:500, 1965

85. Romslo I, Gadeholt HG, Hovding G: Erythropoietic protoporphyria terminating in liver failure. *Arch Dermatol* **118**:668, 1982

86. Sarkany RP, Alexander GJ, Cox TM: Recessive inheritance of erythropoietic protoporphyria with liver failure. *Lancet* **344**:958, 1994

87. Schneider-Yin X et al: Recessive inheritance of erythropoietic protoporphyria with liver failure. *Lancet* **344**:337, 1994

88. Poh-Fitzpatrick MB, Lamola AA: Direct spectrofluorometry of diluted erythrocytes and plasma: A rapid diagnostic method in primary and

secondary porphyrinemias. *J Lab Clin Med* **87**:362, 1976

89. Romslo I et al: Sideroblastic anemia with markedly increased free erythrocyte protoporphyrin without dermal photosensitivity. *Blood* **59**:628, 1982

90. Breathnach SM et al: Immunohistochemical studies of amyloid P component and fibronectin in erythropoietic protoporphyria. *Br J Dermatol* **108**:267, 1983

91. Mathews-Roth MM et al: Beta-carotene therapy for erythropoietic protoporphyria and other photosensitivity diseases. *Arch Dermatol* **113**:1229, 1977

92. Corbett MF et al: The long-term treatment with beta-carotene in erythropoietic protoporphyria: A controlled trial. *Br J Dermatol* **97**:655, 1977

93. Mathews-Roth MM et al: A double-blind study of cysteine photoprotection in erythropoietic protoporphyria. *Photodermatol Photoimmunol Photomed* **10**:244, 1994

94. Gordeuk VR et al: Iron therapy for hepatic dysfunction in erythropoietic protoporphyria. *Ann Intern Med* **105**:27, 1986

95. Milligan A et al: Erythropoietic protoporphyria exacerbated by oral iron therapy. *Br J Dermatol* **119**:63, 1988

96. Polson RJ et al: The effect of liver transplantation in a 13-year-old boy with erythropoietic protoporphyria. *Transplantation* **46**:386, 1988

97. Cox TM, Alexander GJ, Sarkany RP: Protoporphyria. *Semin Liver Dis* **18**:85, 1998

98. Mathews-Roth MM, Michel JL, Wise RJ: Amelioration of the metabolic defect in erythropoietic protoporphyria by expression of human ferrochelatase in cultured cells. *J Invest Dermatol* **104**:497, 1995

99. Pawliuk R et al: Long-term cure of the photosensitivity of murine erythropoietic protoporphyria by preselective gene therapy. *Nat Med* **5**:768, 1999

100. Fritsch C et al: Congenital erythropoietic porphyria. *J Am Acad Dermatol* **36**:594, 1997

101. Nordmann Y et al: Coexistent hereditary coproporphyria and congenital erythropoietic porphyria (Gunther disease). *J Inherit Metab Dis* **13**:687, 1990

102. Pimstone NR, Gandhi SN, Mukerji SK: Therapeutic efficacy of oral charcoal in congenital erythropoietic porphyria. *N Engl J Med* **316**:390, 1987

103. Minder EI, Schneider-Yin X, Moll F: Lack of effect of oral charcoal in congenital erythropoietic porphyria. *N Engl J Med* **330**:1092, 1994

104. Shaw PH et al: Treatment of congenital erythropoietic porphyria in children by allogeneic stem cell transplantation: A case report and review of the literature. *Bone Marrow Transplant* **27**:101, 2001

105. Toback AC et al: Hepatoerythropoietic porphyria: Clinical, biochemical, and enzymatic studies in a three-generation family lineage. *N Engl J Med* **316**:645, 1987

106. Lim HW et al: Photosensitivity, abnormal porphyrin profile, and sideroblastic anemia. *J Am Acad Dermatol* **27**:287, 1992

107. Fontanellas A et al: Successful therapeutic effect in a mouse model of erythropoietic protoporphyria by partial genetic correction and fluorescence-based selection of hematopoietic cells. *Gene Ther* **8**:618, 2001

108. de Verneuil H, Moreau-Gaudry F, Ged C: [A model of congenital erythropoietic porphyria for gene transfer in hematopoietic cells] [in French]. *Transfus Clin Biol* **4**:263, 1997

T>

Chapter 150

Lowell Goldsmith

Xanthomatoses and Lipoprotein Disorders

XANTHOMATA, HYPERLIPIDEMIA, AND DYSLIPOPROTEINEMIAS
Clinical Findings
LIPOPROTEINS AND THEIR METABOLISM
Chylomicrons (Fig. 150-1)
Very Low Density Lipoproteins
Low-Density Lipoproteins (LDL)
High-Density Lipoproteins
HYPERCHOLESTEROLEMIA
Familial Hypercholesterolemia
Familial Defective Apolipoprotein B-100
Moderate Hypercholesterolemia
CHYLOMICRONEMIA
Lipoprotein Lipase Deficiency
Apo C-II Deficiency
Chylomicronemia Combined with Endogenous Hypertriglyceridemia (Type 5 Hyperlipoproteinemia)
DEFECTIVE METABOLISM OF LIPOPROTEIN REMNANTS (DYSBETALIPOPROTEINEMIA)
DEFECTS IN HDL METABOLISM
Tangier Disease
HDL Deficiency with Plane Xanthomata
LCAT Deficiency Syndrome
DISORDERS OF STEROL METABOLISM
Cerebrotendinous Xanthomatosis
Sitosterolemia (Phytosterolemia)
DYSPROTEINEMIAS
BILIARY OBSTRUCTION
ACKNOWLEDGMENT

REFERENCES

XANTHOMATA, HYPERLIPIDEMIA, AND DYSLIPOPROTEINEMIAS

Lipoproteins are small spherical particles that transport lipids in the circulation. The major lipids carried in lipoproteins include cholesterol, triglycerides, and phospholipids. An elevation of serum lipid levels is called *hyperlipidemia,* or *hyperlipoproteinemia,* whereas *dyslipoproteinemia* signifies abnormalities in serum lipoproteins, whether or not serum lipid levels are elevated. Several disorders of lipoprotein metabolism promote coronary atherosclerosis, the precursor of coronary heart disease (CHD). The infiltration and deposition of lipoproteins into tissues, however, is not limited to the arterial tree. Lipoproteins can enter the skin, subcutaneous tissues, and tendons, and lipids can accumulate to produce xanthomata. Different species of lipoproteins typically produce different types of xanthomata, and the pattern of xanthomata provides important clues to the type of hyperlipoproteinemia (or dyslipoproteinemia) present.

Clinical Findings

Xanthomata, although caused by many individual metabolic and physiologic defects that are described in this chapter, present in four major forms: tendinous, planar, tuberous, and eruptive. There are characteristic clinical phenotypes associated with specific metabolic defects. The older clinical and pathologic literature has been thoughtfully reviewed by Parker. [1]

Tendinous xanthomata are firm subcutaneous nodules found in fascia, ligaments, the extensor tendons of the hands, knees, and elbows, and the Achilles tendons. Planar xanthomata are yellow macules, soft papules, or plaques. These lesions are found commonly on the upper eyelids (xanthelasma palpebrarum) and frequently on the palms. Tuberous xanthomata are yellow to reddish nodules that are frequently localized to the extensor surfaces of the elbows, knees, knuckles, and buttocks. Eruptive xanthomata are suddenly appearing, multiple, reddish yellow papules that are arranged in crops on the extensor surface of the extremities and the buttocks. Table 150-1 shows the association of different clinical xanthomata with disorders of lipoprotein metabolism.

TABLE 150-1 **Associations of Visible Xanthomata and Lipid Infiltrates with Lipoprotein Disorders**

LIPOPROTEINS AND THEIR METABOLISM

Chylomicrons (Fig. 150-1)

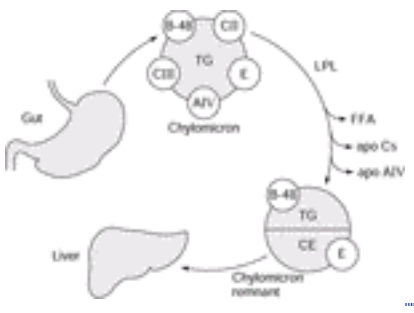

FIGURE 150-1 Metabolism of chylomicrons (see text for details).

Most dietary lipid is triacylglycerol (triglyceride). In the intestine, triglycerides are hydrolyzed by pancreatic lipase into fatty acids and monoglycerides, which are solubilized by the bile and taken up by the intestinal mucosa. In the enterocyte, fatty acids and monoglycerides are resynthesized into triglycerides and are incorporated into lipoproteins called *chylomicrons*. An enterocyte protein, microsomal lipid transfer protein, transfers the triglycerides into these chylomicron particles that have an inner core of triglycerides plus small amounts of cholesterol ester and a surface coat composed of unesterified cholesterol, phospholipids, and proteins (apolipoproteins). The major apolipoprotein of chylomicrons is apo B-48; other apolipoproteins are named apo C-II, apo C-III, apo E, apo A-I, and apo A-IV. All these apolipoproteins play special roles in the metabolism of chylomicrons.

Chylomicrons are secreted into the intestinal lymph and enter the systemic circulation through the thoracic duct, passing into the capillary bed of the peripheral circulation, where they come into contact with lipoprotein lipase (LPL). This enzyme, located on the endothelial surfaces of capillaries, hydrolyzes the triglycerides of chylomicrons into fatty acids. Several other surface components of chylomicrons are lost to the circulation during triglyceride lipolysis. When most triglycerides of chylomicrons have been hydrolyzed by LPL, a residual particle (chylomicron remnant) returns to the circulation. The core lipid of chylomicron remnants contains large amounts of cholesterol ester. These chylomicron remnants disappear quickly from the circulation in the liver, facilitated by the presence of apo Es.

Very Low Density Lipoproteins

Another class of triglyceride-rich lipoproteins is derived from the liver. This class includes the very low density lipoproteins (VLDLs). The VLDL particles contain less triglyceride than chylomicrons but relatively more cholesterol. Their synthesis in hepatocytes is analogous to chylomicron synthesis in enterocytes. In contrast to chylomicrons, however, VLDL particles contain apo B-100 as their major apolipoprotein; they also have apo Cs and apo Es. The total amount of triglyceride secreted daily associated with VLDL is only about one-fourth that entering through chylomicrons from the typical American diet. Newly secreted VLDL particles are named *nascent VLDLs*.

Like chylomicrons, circulating VLDLs pass into the peripheral circulation, where they interact with LPI, which hydrolyzes most of the VLDL triglycerides (Fig. 150-2). After much of the triglyceride is removed, a residual particle, called a *VLDL remnant,* returns to the circulation. Once VLDL remnants are formed, they have two fates. About half of VLDL remnants are removed directly by hepatic uptake facilitated by apo E. A portion of VLDL remnant uptake occurs via receptors for low-density lipoproteins (LDLs). These receptors are located on the surfaces of liver cells, where they bind both to apo E and apo B-100 but not to apo B-48. When VLDL remnants attach to liver cells, many are internalized and degraded; however, a portion of these particles interacts with hepatic triglyceride lipase, which removes residual triglycerides and converts them into LDL (Fig. 150-3). Newly formed LDL particles are released from hepatocytes and returned to the circulation.

FIGURE 150-2 Metabolism of very low density lipoproteins (VLDL) (see text for details).

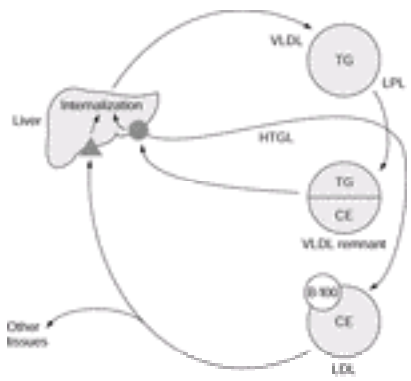

FIGURE 150-3 Metabolism of low-density lipoproteins (LDL) (see text for details).

Low-Density Lipoproteins (LDL)

LDL particles carry most of the cholesterol present in the fasting serum. LDLs are smaller than VLDLs and contain mostly cholesterol esters in their lipid cores. The only apolipoprotein associated with LDL is apo B-100. Removal rates of LDL from the circulation are slower than for VLDL; hence there is a tendency for LDL particles to accumulate in serum, which explains why serum LDL concentrations typically exceed those of VLDL. About three-fourths of circulating LDL is removed through LDL receptors on liver cells. Lesser amounts of LDL are cleared via nonreceptor pathways or by extrahepatic tissues. When LDL particles bind to LDL receptors, they are internalized and pass into lysosomes, where they are degraded.

High-Density Lipoproteins

High-density lipoproteins (HDLs) have unique properties and seem to perform a “cleanup” function. During lipid transport through triglyceride-rich lipoproteins (chylomicrons and VLDL), many component molecules are released to the circulation (Fig. 150-4). They are taken up by HDL particles and are either removed from the circulation or recycled to triglyceride-rich lipoproteins. Components of triglyceride-rich lipoproteins transferred to HDL during their catabolism include unesterified (free) cholesterol, phospholipids, apo Cs, apo Es, apo As, and small amounts of triglyceride. Some apo A-I and apo A-II molecules on HDL are derived by direct secretion from the liver. Excess unesterified (free) cholesterol in the membranes of peripheral tissue cells also may be taken up by HDL. This uptake is the first step of a process called *reverse cholesterol transport;* the process is so named because cholesterol synthesized in peripheral tissues is eventually returned to the liver for its disposal from the body. All these components may be removed from the circulation through direct tissue uptake of HDL; alternatively, apo Cs, apo Es, and cholesterol esters can be shuttled back to nascent triglyceride-rich lipoprotein for reutilization in their catabolism.

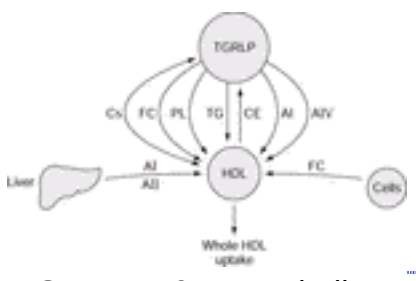

FIGURE 150-4 Metabolism of high-density lipoproteins (HDL) (see text for details).

HYPERCHOLESTEROLEMIA

The term *hypercholesterolemia* is usually taken to mean an increase in serum LDL-cholesterol concentrations. LDL has been identified as the major atherogenic lipoprotein by the National Cholesterol Education Program (NCEP). [2], [3] A large body of evidence—epidemiologic studies, animal models, clinical forms of hypercholesterolemia, tissue culture studies, and clinical trials—supports the concept that elevated serum LDL concentrations are atherogenic and a major cause of CHD. The NCEP has classified both total cholesterol and LDL-cholesterol levels in terms of risk for CHD. [2], [3] Approximate comparable values for total cholesterol and LDL-cholesterol are shown in Table 150-2. In the discussion to follow, severe forms of hypercholesterolemia will be considered first. These forms illustrate clearly the mechanisms of hypercholesterolemia, and they are commonly accompanied by xanthomata.

TABLE 150-2 **Classification of Total Cholesterol and Low-Density Lipoprotein (LDL) Cholesterol**

Familial Hypercholesterolemia

The primary defect in familial hypercholesterolemia (FH) is a genetic deficiency of LDL receptors. [4] Normally, two functional alleles encoding for LDL receptors are inherited—one from each parent. Both inherited LDL receptors function in removal of LDL from the circulation. The synthesis and expression of cell surface receptors are a multistep process. Defects occurring at any of these multiple steps can produce the clinical picture of FH. [5] In some cases, the functional activity of the receptor produced by a defective allele is zero; in other cases, mutations in the receptor gene or

associated genes produce defective receptor function.

In rare individuals, approximately 1 per 1 million persons in the general population, defective alleles for the LDL receptors are inherited from each parent. These doubly affected persons thus have homozygous FH. [5] They have either no LDL receptor activity or very low activity. Their serum LDL-cholesterol levels are markedly elevated, often in the range of 800 to 1000 mg/dL. They commonly develop CHD or other forms of atherosclerotic disease before their teenage years. Patients with homozygous FH usually have severe xanthomatosis.

Multiple types of xanthomata are found (Fig. 150-5). These include tuberous xanthomata (especially over the elbows), subperiosteal xanthomata (below the knees and over the olecranon process), tendon xanthomata (especially in the Achilles tendon and in the extensor tendon of the hand), and elevated xanthomatous plaques (over the extremities, buttocks, and hands). The rate of xanthoma deposition and growth is associated with the duration and severity of the LDL elevation.

FIGURE 150-5 Xanthomata typical of homozygous familial hypercholesterolemia.

Several forms of therapy have been proposed for homozygous FH. Since LDL receptor function is largely absent, drugs that act by enhancing LDL receptor activity produce little benefit. Such agents include bile acid sequestrants and lower doses of HMG-coenzyme A (HMG-CoA) reductase inhibitors (statins). High doses of statins, however, may cause moderate reductions in LDL-cholesterol levels in homozygous FH patients, probably by partial inhibition of VLDL secretion. A more radical approach to treatment of homozygous FH is liver transplantation. [6] This procedure supplies normal LDL receptors from the donor liver and markedly lowers LDL levels. A more practical approach is to remove LDL periodically from the circulation by plasmapheresis or LDL-apheresis. [7] The latter approach employs a variety of LDL-binding agents and is currently the preferred therapy.

As noted, the more common form of FH is heterozygous FH. This condition occurs from inheritance of a single abnormal allele for the LDL receptor. Serum LDL-cholesterol levels are approximately twice normal. The prevalence of heterozygous FH is about 1 in 500 people. Men with heterozygous FH commonly develop CHD in their thirties and forties; affected women typically manifest CHD in their fifties and sixties. In contrast to patients with homozygous FH, heterozygotes only rarely show tuberous xanthomata; tendon xanthomata, however, are common (Fig. 150-6). In fact, the majority of patients with tendon xanthomata will be found to have heterozygous FH. Less common causes of tendon xanthomata are discussed below.

FIGURE 150-6 Tendon xanthomata typical of heterozygous familial hypercholesterolemia. Similar xanthomata occur in patients with familial defective apolipoprotein B-100, cerebrontindinous xanthomatosis, and sitosterolemia.

Statins have proven to be effective drugs for treatment of heterozygous FH. [8] These agents inhibits HMG-CoA reductase, the rate-limiting enzyme in cholesterol synthesis. [9] A reduction in cellular cholesterol content sends a signal to the nucleus of the cell to stimulate the synthesis of LDL receptors. In patients with heterozygous FH, the one functional allele for the LDL receptor is “upregulated” by statin therapy; this supplies more LDL receptors and reduces serum LDL levels.

All statins have a similar mechanism of action, although the dose required to produce a given LDL-cholesterol lowering varies among the drugs. The frequency of side effects appears to correlate with LDL-lowering efficacy; i.e., higher doses cause more side effects. The major side effects of statins are myopathy and hepatotoxicity. These side effects are relatively rare but increase in frequency with increasing doses. The risk for myopathy is increased substantially when the statin is given with either a fibric acid (e.g., gemfibrozil) or cyclosporine. In patients with heterozygous FH, the lowering of LDL-cholesterol levels can be enhanced substantially by combining a statin with a bile acid sequestrant (e.g., cholestyramine or colestipol). In addition, statins prevent the synthesis of isoprenoid intermediates such as farnesylpyrophosphate and geranylpyrophosphate, which are posttranslational modifications of many cell signaling proteins. [10] There are several case reports of lichenoid drug eruptions associated with statins. [11]

Familial Defective Apolipoprotein B-100

Familial defective apolipoprotein B-100 (FDB) is another cause of moderately severe hypercholesterolemia. [12], [13] In this condition, the primary structure of apo B-100 is defective, and apo B binds poorly to LDL receptors. As a result, serum LDL levels are raised. Patients with FDB frequently resemble those with heterozygous FH except that they typically have somewhat lower LDL-cholesterol levels. Most patients with FDB are heterozygotes, and only half their LDL particles are defective in binding to LDL receptors. Rare patients are homozygous and have more severe hypercholesterolemia, although usually not to the degree seen in patients with homozygous FH. Some patients with heterozygous FDB develop tendon xanthomata that are identical in appearance to those associated with heterozygous FH. Patients with FDB are prone to premature CHD, [14] and their hypercholesterolemia usually responds well to statin therapy.

Moderate Hypercholesterolemia

Most patients with primary hypercholesterolemia have only moderate elevations of serum LDL-cholesterol levels (e.g., 160–219 mg/dL). Multiple mechanisms appear to underlie primary moderate hypercholesterolemia; these include reductions in LDL receptor activity, overproduction of lipoproteins containing apo B-100, and enrichment of LDL particles with cholesterol ester. [15], [16] Approximately 20 percent of American adults have moderate hypercholesterolemia. [2], [3] These persons are at increased risk for premature CHD, although less so than are those with severe forms of genetic hypercholesterolemia (i.e., FH and FDB). Patients with moderate hypercholesterolemia rarely have xanthomata, although one such patient with severe xanthomata in the Achilles tendons has been studied. [17] Presumably, tissue susceptibility in patients of this type combines with moderately high LDL levels to produce xanthomata.

CHYLOMICRONEMIA

Another severe form of hyperlipidemia is one in which triglyceride levels are markedly elevated. When triglyceride levels are below 500 mg/dL, most of the triglycerides are carried in VLDLs. At higher concentrations, chylomicrons begin to accumulate in the serum. Some patients manifest severe chylomicronemia begin to accumulate in the serum. Some patients manifest severe chylomicronemia with triglyceride levels ranging from 1000 to 10,000 mg/dL. These marked elevations result from either severe genetic defects in triglyceride metabolism or moderate genetic defects combined with aggravating acquired factors. Eruptive xanthomata are often associated with lipemia retinalis and pancreatitis.

Lipoprotein Lipase Deficiency

Rare (1 per million population) patients are homozygous for genetic defects in LPL function. [18] A large series of mutations in the *LPL* gene that prevent the normal function of LPL has been identified. Patients who are homozygous for LPL defects typically manifest severe chylomicronemia. Triglyceride levels can be severely elevated from birth. When serum triglyceride concentrations exceed 2000 mg/dL, patients are at high risk for developing acute pancreatitis. Triglyceride levels in this range are often associated with eruptive skin xanthomata (Fig. 150-7). These lesions are white to yellow papules on a slightly erythematous base. Sometimes they coalesce to form larger cutaneous plaques. Typical locations are over the buttocks, shoulders, and extensor surfaces of the extremities. Their rapid appearance usually signifies a striking rise of triglyceride concentrations. In this syndrome, only eruptive xanthomata occur. Patients with LPL deficiency generally are not at increased risk for CHD; the prevailing view has been that chylomicrons are too large to filter into the arterial wall to initiate atherogenesis. Although a few patients with LPL deficiency have manifested some atherosclerosis, premature CHD is rare. Patients who are heterozygous for LPL deficiency either have normal serum triglycerides or have mild hypertriglyceridemia.

FIGURE 150-7 Eruptive skin xanthomata characteristic of severe chylomicronemia.

There are no available drugs that can effectively treat the severe chylomicronemia of LPL deficiency. The most effective management is through dietary modification. The formation of chylomicrons can be curtailed by reducing the fat content of the diet. The intake of dietary fat should be reduced to less than 10 percent of total calories. Medium- chain triglycerides (MCTs) can be used as a substitute for dietary fat. The fatty acids of MCT are not incorporated into chylomicrons; thus 10 to 15 percent of total calories can be safely consumed as MCTs. The goal of therapy is to keep total triglyceride levels below 1500 mg/dL, which will greatly reduce the risk for pancreatitis.

Apo C-II Deficiency

Apo C-II is carried on triglyceride-rich lipoproteins and is required for activation of LPL. Rare patients have a congenital absense of apo C-II. These patients develop severe chylomicronemia resembling that developed with LPL deficiency. [19] They also manifest skin xanthomata identical to those of patients deficient in LPL. Treatment of chylomicronemia associated with apo C-II deficiency is the same as in patients with LPL deficiency.

Chylomicronemia Combined with Endogenous Hypertriglyceridemia (Type 5 Hyperlipoproteinemia)

This disorder is defined by combined elevations in levels of chylomicrons and VLDL. Most cases appear to result from a dual defect in triglyceride metabolism, namely, overproduction of VLDL and defective lipolysis of triglyceride-rich lipoproteins. [20] Both abnormalities can have multiple causes. Overproduction of VLDL is commonly due to obesity and may be accentuated by non-insulin-dependent diabetes mellitus. There is growing evidence that hepatic overproduction of VLDL is frequently the result of insulin resistance; the latter, in turn, can be due to either a primary metabolic abnormality or obesity. Defective lipolysis of triglyceride-rich lipoproteins can occur in the heterozygous state for LPL mutations or from functional reduction of LPL activity. [18] Recent evidence also suggests that high serum levels of apo C-III, an inhibitor of LPL activity, also can cause defective lipolysis. [21] Elevated serum apo C-III levels may be secondary to insulin resistance. [22] Thus insulin resistance appears to cause both overproduction of VLDL and defective lipolysis of triglycerides in VLDL and chylomicrons; both defects are characteristic of type 5 hyperlipoproteinemia. [20] Patients with type 5 hyperlipoproteinemia appear to be at increased risk for CHD, and they commonly manifest peripheral arterial disease. The risk for acute pancreatitis rises sharply when triglyceride levels exceed 2000 mg/dL. At this triglyceride level, eruptive skin xanthomata also commonly appear. Treatment of type 5 hyperlipoproteinemia consists of a very low fat diet (<10 percent of total calories as fat) and fibric acids (e.g., gemfibrozil). In addition, weight reduction in obese patients will reduce triglyceride levels, as will improved glucose control in diabetic patients.

DEFECTIVE METABOLISM OF LIPOPROTEIN REMNANTS (DYSBETALIPOPROTEINEMIA)

Dysbetalipoproteinemia (type 3 hyperlipoproteinemia) denotes a category of lipid disorders defined by accumulation in serum of remnant lipoproteins, i.e., chylomicron remnants and VLDL remnants. [23] The usual abnormality is the presence of an abnormal isoform of apo E, named apo E2. Normal isoforms are apo E3 and apo E4; these isoforms promote remnant uptake by the liver. When apo E2 is present, especially in the homozygous form of the disease, remnant uptake is impaired; as a result, remnant lipoproteins are removed slowly and accumulate in the serum. Isolated homozygous apo E2 typically produces mild remnant accumulation but not categorical hyperlipidemia.

However, hyperlipidemia of the dysbetalipoproteinemic type can develop when lipoprotein metabolism is otherwise disturbed, i.e., in patients with obesity, diabetes mellitus, or endogenous hypertriglyceridemia. Typically, in hyperlipidemic patients with dysbetalipoproteinemia, serum concentrations of cholesterol and triglycerides are about equally raised. The cholesterol-to-triglyceride ratio in the VLDL fraction usually exceeds 0.30. A definite diagnosis of dysbetalipoproteinemia is made by identifying the apo E2 isoform.

Hyperlipidemic patients with dysbetalipoproteinemia are at increased risk for CHD and often have peripheral arterial disease. About two-thirds of these patients have tuberoeruptive and tuberous xanthomata (Fig. 150-8). Also, they have a characteristic lipid deposition in the creases of the palms of the hands (xanthoma striata palmaris) (Fig. 150-8B and Fig. 150-9). Occasionally, patients manifest tendon xanthomata and xanthelasma. Some patients with dysbetalipoproteinemia exhibit tuberous xanthomata in the absence of raised serum levels of total cholesterol and triglyceride; in these patients, tissue susceptibility combined with increased remnant lipoproteins appears to be responsible for tuberous xanthomata. Tuberous xanthomata of the hands have been observed in two normolipidemic patients who were homozygous for apo E2. In one patient, xanthomata apparently developed in the fingers because of heavy manual labor [24]; the other tuberous xanthomata resulted from the presence of apo E2 combined with a form of histiocytosis. The hyperlipidemia in most patients with dysbetalipoproteinemia is responsive to fibric acids or nicotinic acid; however, if total cholesterol levels are markedly raised, statin therapy is more effective. Reducing serum lipids with drug therapy often causes xanthomata to regress.

FIGURE 150-8 Tuberoeruptive and tuberous xanthomata typical of familial dysbetalipoproteinemia. *A*. Knee *B.* Palm.

FIGURE 150-9 Xanthoma striata palmaris characteristic of familial dysbetalipoproteinemia.

DEFECTS IN HDL METABOLISM

Tangier Disease

This rare condition is characterized by profound deficiency of serum HDL. [25] The catabolism of HDL appears to be markedly increased in Tangier disease, which noticeably lowers serum HDL concentrations; the reasons for this excessive catabolism of HDL are unknown. Tangier homozygotes manifest accumulation of cholesterol esters in tonsils, spleen, lymph nodes, bone narrow, skin, thymus, and intestinal mucosa. These accumulations most commonly produce tonsillar hyperplasia, mild lymphadenopathy, and splenomegaly. Older patients with Tangier disease often develop CHD. Despite widespread tissue accumulation of cholesterol esters, skin xanthomata are not prominent.

HDL Deficiency with Plane Xanthomata

Mutations in apo A-I can reduce its synthesis and produce HDL deficiency. [26] In some cases, there is a concomitant defect in synthesis of apo C-III and apo A-IV. When the latter defects are present, complex abnormalities are present in lipoprotein metabolism, and affected patients are prone to premature CHD. Patients with defects limited to synthesis of apo A-I may manifest plane xanthomata. [27] It is uncertain whether these patients are prone to premature CHD; however, they do not appear to develop fulminant atherosclerosis, as do patients with homozygous FH.

LCAT Deficiency Syndrome

Lecithin-cholesterol acyl transferase (LCAT) is an enzyme responsible for esterification of cholesterol in plasma. Congenital defects in LCAT synthesis produce abnormalities in the metabolism of HDL and other lipoproteins. [28] Several such congenital defects have been discovered that produce related syndromes of varying degrees of clinical severity. The major clinical features include corneal infiltrates and opacity, anemia, and proteinemia. Xanthomatous deposits of the skin or tendons have not been reported with LCAT deficiency syndromes.

DISORDERS OF STEROL METABOLISM

Cerebrotendinous Xanthomatosis

Cerebrotendinous xanthomatosis (CTX) is a rare recessive disorder in which xanthomata occur in the tendons and brain. [29], [30] The genetic abnormality is a defect in the conversion of cholesterol into bile acids in the liver due to mutations in sterol 27-hydroxylase. A by-product of this defect is an increased synthesis of the sterol cholestanol.

Accumulation of this abnormal sterol in the serum apparently is responsible for xanthomata in the brain and tendons. Cerebroxanthomatosis causes several neurologic manifestations. Patients with CTX also appear to be at increased risk for CHD. Treatment consists of replacement of the bile acid pool with oral chenodeoxycholic acid. This therapy reduces cholestanol synthesis and has been reported to alleviate neurologic symptoms.

Sitosterolemia (Phytosterolemia)

This rare autosomal recessive disorder results from accumulation of plant sterols in the serum. [29] The major plant sterol in the serum is ß-sitosterol; other plant sterols are increased as well, but to a lesser extent. The molecular defect in sitosterolemia is unknown; however, the metabolic abnormality appears to be a defective transfer of sterols into bile for

excretion. [31] This defect causes retention of both cholesterol and plant sterols in the liver; in turn, serum cholesterol and plant sterol levels are raised. Early in life, serum cholesterol levels are extremely elevated, similar to those of homozygous FH. Hence sitosterolemia has been called *pseudohomozygous FH*. Later in life, cholesterol levels decline, but serum sitosterol levels remain elevated. Tendon xanthomata are common in sitosterolemia; they resemble those of patients with heterozygous FH. Seemingly, elevated serum sitosterol concentrations of a few milligrams per deciliter promote xanthoma formation, even without significant hypercholesterolemia. Treatment of sitosterolemia consists of a reduced intake of cholesterol and plant sterols. In addition, bile acid sequestrants promote conversion of cholesterol into bile acids and reduce serum levels of cholesterol.

DYSPROTEINEMIAS

A number of forms of dysglobulinemia or paraproteinemias are accompanied by diffuse plane xanthomata that typically are yellow-orange macules or slightly raised plaques over the eyelids, neck, and trunk. [32] Diffuse plane xanthomata have been reported in multiple myeloma, monoclonal gammopathy, cryoglobulinemia, leukemia, lymphoma, eosinophilic granulomatosis, and rheumatoid arthritis. The mechanism of production of xanthomata is typically the formation of a complex between a paraprotein and a particular lipoprotein species. Cellular uptake of these complexes by macrophages in the skin produces plane xanthomata.

BILIARY OBSTRUCTION

Prolonged obstruction of the biliary tree leads to accumulation of cholesterol in the serum. Causes include primary biliary cirrhosis and secondary biliary obstruction. Serum cholesterol is high in unesterified cholesterol, which leads to the formation of an abnormal lipoprotein called *lipoprotein X*. Besides having hypercholesterolemia, patients with prolonged biliary obstruction usually manifest jaundice, pruritus, and hyperpigmentation of the skin. Prolonged hypercholesterolemia leads to plane xanthomata (beige-orange plaques on hands, feet, and trunk), xanthelasma, and occasionally, tuberous xanthomata.

ACKNOWLEDGMENT

This is an adaptation of the chapter by Scott M. Grundy in the fifth edition of *Fitzpatrick's Dermatology in General Medicine*.

REFERENCES

1. Parker F: The hyperlipidemias, in *Pathogenesis of Skin Disease,* edited by BH Thiers, RL Dobson. New York, Churchill Livingstone, 1986, p 359

2. Expert Panel on Detection, Evaluation, and Treatment of High Blood Cholesterol in Adults: Summary of the second report of the National Cholesterol Education Program (NCEP) Expert Panel on Detection, Evaluation, and Treatment of High Blood Cholesterol in Adults (Adult Treatment Panel II). *JAMA* **269**:3015, 1993

3. Expert Panel on Detection, Evaluation, and Treatment of High Blood Cholesterol in Adults, National Cholesterol Education Program: Second report of the Expert Panel on Detection, Evaluation, and Treatment of High Blood Cholesterol (Adult Treatment Panel II). *Circulation* **89**:1329, 1994

4. Brown MS, Goldstein JL: A receptor-mediated pathway for cholesterol homeostasis. *Science* **232**:34, 1986

5. Goldstein JL et al: Familial hypercholesterolemia, in *The Metabolic and Molecular Bases of Inherited Diseases,* 8th ed, edited by CR Scriver, AL Beaudet, WS Sly, D Valle. New York, McGraw-Hill, 2001, p 2863

6. Bilheimer DW et al: Liver transplantation to provide low-density-lipoprotein receptors and lower plasma cholesterol in a child with homozygous familial hypercholesterolemia. *N Engl J Med* **311**:1658, 1984

7. Uauy R et al: Treatment of children with homozygous familial hypercholesterolemia: Safety and efficacy of low density lipoprotein apheresis. *J Pediatr* **120**:892, 1992

8. Grundy SM: HMG-CoA reductase inhibitors for treatment of hypercholesterolemia. *N Engl J Med* **319**:24, 1988

9. Endo A: The discovery and development of HMG-CoA reductase inhibitors. *J Lipid Res* **33**:1569, 1992

10. Liao JK: Isoprenoids as mediators of the biological effects of statins. *J Clin Invest* **110**:285, 2002

11. Keough GC et al: Prevastatin-induced lichenoid drug eruption. *Cutis* **61**:98, 1998

12. Vega GL, Grundy SM: In vivo evidence for reduced binding of low density lipoproteins to receptors as a cause of primary moderate hypercholesterolemia. *J Clin Invest* **78**:1410, 1986

13. Innerarity TL et al: Familial defective apolipoprotein B-100: A mutation of apolipoprotein B that causes hypercholesterolemia. *J Lipid Res* **31**:1337, 1990

14. Tybjaerg-Hansen A, Humphries SE: Familial defective apolipoprotein B-100: A single mutation that causes hypercholesterolemia and premature coronary artery disease. *Atherosclerosis* **96**:91, 1992

15. Vega GL et al: Metabolic basis of primary hypercholesterolemia. *Circulation* **84**:118, 1991

16. Grundy SM: Multifactorial etiology of hypercholesterolemia: Implications for prevention of coronary heart disease. *Arterioscler Thromb* **11**:1619, 1991

17. Vega GL et al: Normocholesterolemic tendon xanthomatosis with overproduction of apolipoprotein B. *Metabolism* **32**:118, 1983

18. Brunzell JD, Deeb SS: Familial lipoprotein lipase deficiency, Apo C-II deficiency, and hepatic lipase deficiency, in *The Metabolic and*

Molecular Bases of Inherited Disease, 8th ed, edited by CR Scriver, AL Beaudet, WS Sly, D Valle. New York, McGraw-Hill, 2001, p 2789

19. Breckenridge WC et al: Hypertriglyceridemia associated with deficiency of apolipoprotein C-II. *N Engl J Med* **298**:1265, 1978

20. Kesaniemi YA, Grundy SM: Dual defect in metabolism of very-low-density lipoprotein triglycerides: Patients with type 5 hyperlipoproteinemia. *JAMA* **251**:2542, 1984

21. Aalto-Setala K et al: Mechanism of hypertriglyceridemia in human apolipoprotein (apo) CIII transgenic mice: Diminished very low density lipoprotein fractional catabolic rate associated with increased apo CIII and reduced apo E on the particles. *J Clin Invest* **90**:1889, 1992

22. Dammerman M et al: An apolipoprotein CIII haplotype protective against hypertriglyceridemia is specified by promoter and 3' untranslated region polymorphisms. *Proc Natl Acad Sci USA* **90**:4562, 1993

23. Mahley RW, Rall SC Jr: Type III hyperlipoprotein (dysbetalipoproteinemia): The role of apolipoprotein E in normal and abnormal lipoprotein metabolism, in *The Metabolic and Molecular Bases of Inherited Diseases,* 8th ed, edited by CR Scriver, AL Beaudet, WS Sly, D Valle. New York, McGraw-Hill, 2001, p 2835

24. Abrams JJ et al: Normocholesterolemic dysbetalipoproteinemia with xanthomatosis. *Metabolism* **28**:113, 1979

25. Assmann G et al: Familial analphalipoproteinemia: Tangier disease, *The Metabolic and Molecular Bases of Inherited Diseases,* 8th ed, edited by CR Scriver, AL Beaudet, WS Sly, D Valle. New York, McGraw-Hill, 2001, 2937

26. Tall AR et al: Genetic disorders affecting plasma high-density lipoproteins, in *The Metabolic and Molecular Bases of Inherited Disease,* 8th ed, edited by CR Scriver, AL Beaudet, WS Sly, D Valle. New York, McGraw-Hill, 2001, p 2915

27. Lackner KJ et al: High density lipoprotein deficiency with xanthomata: A defect in reverse cholesterol transport caused by a point mutation in the apolipoprotein A-I gene. *J Clin Invest* **92**:2262, 1993

28. Santamarina-Fojo S et al: Lecithin cholesterol acyltransferase deficiency and fish eye disease, in *The Metabolic and Molecular Bases of Inherited Diseases,* 8th ed, edited by CR Scriver, AL Beaudet, WS Sly. New York, McGraw-Hill, 2001, p 2817

29. Bjökhem I, Boberg KM: Inborn errors in bile acid biosynthesis and storage of sterols other than cholesterol, in *The Metabolic and Molecular Bases of Inherited Diseases,* 8th ed, edited by CR Scriver, AL Beaudet, WS Sly. New York, McGraw-Hill, 2001, p 2961

30. Bel S et al: Cerebrotendinous xanthomatosis. *J Am Acad Dermatol* **45**:292, 2001

31. Bhattacharyya AK et al: Sluggish sitosterol turnover and hepatic failure to excrete sitosterol into bile cause expansion of body pools of sitosterol in patients with sitosterolemia and xanthomatosis. *Atheroscler Thromb* **11**:1287, 1991

32. Marcoval, J et al: Diffuse plane xanthoma: Clinicopathologic study of 8 cases. *J Am Acad Dermatol* **39**:439, 1998

T>

Chapter 151

Robert Desnick Maryam Banikazemi

Fabry Disease: a-Galactosidase A Deficiency (Angiokeratoma Corporis Diffusum Universale)

HISTORICAL ASPECTS
CLINICAL MANIFESTATIONS
Classically Affected Males
Cardiac Variants
Carrier Females
PATHOLOGY
Pathology of the Skin
Pathology of Other Systems
Histochemistry and Ultrastructure
BIOCHEMICAL GENETICS OF FABRY DISEASE
PATHOPHYSIOLOGY
Pathophysiology of the Vasculature
Pathophysiology of Other Systems
Abnormal Distribution in Tissues
MOLECULAR GENETICS OF a-GALACTOSIDASE A AND FABRY DISEASE
a-Galactosidase A Gene and Transcript
Molecular Pathology of Fabry Disease
GENETICS
Mode of Inheritance
Phenocopies
Genetic Counseling
DIAGNOSIS
Clinical Evaluation
Biochemical Confirmation
Molecular Diagnosis of Female Carriers
Prenatal Diagnosis
TREATMENT
Medical Management
Renal Transplantation
Enzyme Replacement Therapy

REFERENCES

Fabry disease, an inborn error of glycosphingolipid metabolism, results from the defective activity of the lysosomal enzyme, a-galactosidase A. The enzymatic defect, transmitted by an X-linked recessive gene, leads to the progressive deposition of neutral glycosphingolipids (predominantly globotriaosylceramide) with terminal a-galactosyl moieties in most visceral tissues and fluids of the body (Fig. 151-1). The birefringent glycosphingolipids are deposited in the lysosomes of the vascular endothelium; in perithelial and smooth muscle cells of the cardiovascular-renal system; in reticuloendothelial, myocardial, and connective tissue cells of the cornea, kidney, and other tissues; and in ganglion and perineural cells of the autonomic nervous system.

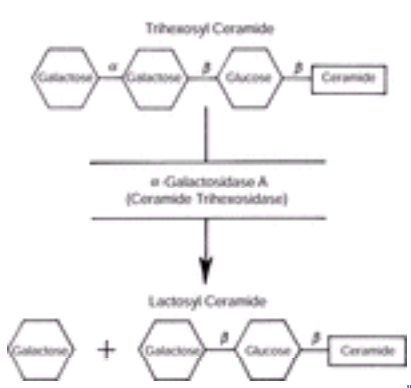

FIGURE 151-1 The metabolic defect in Fabry disease. Defective a-galactosidase A activity results in the accumulation of its major glycosphingolipid substrate, trihexosyl ceramide, which is also termed globotriaosylceramide.

Clinically, classically affected males, who have very little or undetectable a-galactosidase A activity, have a characteristic skin lesion of angiokeratoma corporis diffusum universale. They also have acroparesthesias, episodic crises of excruciating pain, corneal and lenticular opacities, hypohidrosis, and cardiac and renal dysfunction. Death usually occurs in adult life from renal, cardiac, or cerebral complications of their vascular disease.

In contrast, males with residual a-galactosidase A activity (1 to 5 percent of normal) have milder manifestations. These “cardiac variants” lack vascular endothelial glycolipid deposition and do not have angiokeratoma, acroparesthesias, hypohidrosis, or lenticular/corneal opacities. They present in mid- to late adulthood with left ventricular hypertrophy, cardiomegaly, mitral insufficiency, and/or conduction abnormalities. They may have proteinuria, but do not develop renal insufficiency.

Carrier females for the classic phenotype are asymptomatic or have only mild disease manifestations. Most carriers show the characteristic corneal opacities. Rarely, female carriers may develop disease manifestations as severe as those of affected males because of random X-chromosome inactivation.

HISTORICAL ASPECTS

In 1898, two dermatologists, Anderson [1] in England and Fabry [2] in Germany, independently described the first patients with angiokeratoma corporis diffusum. Fabry originally made the diagnosis of purpura nodularis in a 13-year-old male, whom he followed over the next 30 years (Fig. 151-2). He documented the presence of albuminemia; further described the cutaneous lesions, noting the presence of small vessel aneurysms; [3] and subsequently classified his case as one of angiokeratoma corporis diffusum, a designation that has persisted. Scriba definitively established the lipid nature of the storage material, [4] and Hornbostel and Scriba were the first to confirm the diagnosis histologically by demonstrating the refractile lipid deposits in the vessels of a skin biopsy specimen. [5] Opitz and colleagues documented the X-linked recessive inheritance of the disorder by pedigree analysis. [6]

FIGURE 151-2 Distribution of angiokeratoma in the 30-year-old classically affected male originally described by Fabry. [2]

In 1963, Sweeley and Klionsky isolated and characterized the two major accumulated neutral glycosphingolipids—globotriaosylceramide Gal-Gal-Glc-Cer (GL-3) and galabiosylceramide Gal-Gal-Cer (GL-2)—from an affected male's kidney obtained at autopsy, establishing Fabry disease as a sphingolipidosis. [7] Subsequent chemical analyses of various Fabry tissues and fluids have demonstrated the marked accumulation of GL-3 and, to a lesser extent, GL-2. [5], [6], [7] and [8] In addition, blood group B substances, glycosphingolipids with terminal a-galactosyl moieties, accumulate in affected individuals with B or AB blood types. [9]

In 1967, Brady and associates demonstrated that the enzymatic defect was the defective activity of ceramide trihexosidase, a lysosomal galactosyl hydrolase required for the catabolism of GL-3 and GL-2 [10] (see Fig. 151-1). Kint characterized the defective enzymatic activity as an a-galactosyl hydrolase (designated a-galactosidase A). [11] The accumulated glycosphingolipid substances, including blood group B substances, all had a-linked terminal galactosyl residues. The elucidation of the specific enzymatic defect permitted the enzymatic diagnosis of affected males, the identification of carrier females, [12] and the prenatal diagnosis of affected males. [13] The molecular cloning of the full-length cDNA and entire gene encoding human a-galactosidase A has resulted in the characterization of the various mutations that produce the classical and variant forms of the disease, and it has provided accurate carrier diagnosis. [14], [15] Recent Phase 1, 1/2, 2, and 3 clinical trials have demonstrated the safety and efficacy of recombinant a-galactosidase A replacement. [16], [17], [18] and [19]

In keeping with the terminology applied to other lipidoses and for the benefit of information retrieval, it would seem advisable to retain the commonly used eponym and to append the specific enzymatic defect. Thus, an appropriate designation is *Fabry disease: a-galactosidase A deficiency.* Other comprehensive reviews on the clinical, pathologic, biochemical, and genetic aspects of the disease are available. [20]

CLINICAL MANIFESTATIONS

Classically Affected Males

The major clinical manifestations of Fabry disease result from the progressive deposition of GL-3 in the vascular endothelium (Table 151-1). Onset of the disease usually occurs during childhood or adolescence with periodic crises of severe pain in the extremities (acroparesthesias), the appearance of vascular cutaneous lesions (angiokeratoma), hypohidrosis, and the characteristic corneal and lenticular opacities. With advancing age, the progressive accumulation leads to early demise because of renal, cardiac, or cerebrovascular involvement.

Manifestation	Classical Type	"Cardiac Variant"*
Clinical onset (yr)	4–8 yr	> 40 yr
Average age of death (yr)	41 yr	> 60 yr
Angiokeratoma	++	–
Acroparesthesia	++	–
Hypohidrosis/anhidrosis	++	–
Corneal/lenticular opacity	+	–
Heart	Ischemia/MI	LVH/cardiomyopathy
Brain	TIA/strokes	–
Kidney	Renal failure	Mild proteinuria
Residual α-Gal A activity	< 1%	1%–3%

*All in a hemizygote (male) patient. LVH = left ventricular hypertrophy. TIA = transient ischemic attack. + = present. – = absent.

TABLE 151-1 **Major Clinical Manifestations in Males Affected with the Classical and "Cardiac Variant" Phenotype of Fabry Disease**

PAIN The single most debilitating early symptom of Fabry disease is the pain, of which there are two types: (1) episodic "crises" consisting of agonizing, burning pain, initially in the palms and soles, and (2) a nagging, constant discomfort in the hands and feet, characterized by burning, tingling paresthesias. Exercise, fatigue, emotional stress, or rapid climatic changes in temperature and humidity usually trigger the painful crises. Attacks of abdominal or flank pain may simulate appendicitis or renal colic. With increasing age, the periodic crises usually decrease in frequency and severity; however, in some patients, they may occur more frequently, and the pain can be so excruciating that the patient may contemplate suicide. The common association of the pain with a low-grade fever and an elevated erythrocyte sedimentation rate has frequently led to the misdiagnosis of rheumatic fever, neurosis, or erythromyalgia. [21] In addition to these intermittent crises, most patients complain of a nagging, constant burning, tingling in their hands and feet. These acroparesthesias may occur daily, usually during late afternoon, and may represent an attenuated form of the excruciating episodic crises. However, 10 to 20 percent of older patients deny any history of Fabry crises or acroparesthesias.

SKIN LESIONS With age, there is a progressive increase in the number and size of the cutaneous vascular lesions of Fabry disease. Classically, the angiokeratomas develop slowly as clusters of individual, punctate, dark red to blue-black angiectases in the superficial layers of the skin (Fig. 151-3 and Fig. 151-4). The lesions may be flat or slightly raised, and they do not blanch with pressure; larger lesions may be hyperkeratotic. The clusters of lesions are most dense between the umbilicus and the knees and have a tendency toward bilateral symmetry. The hips, back, thighs, buttocks, penis, and scrotum are most commonly involved, but there is a wide variation in the pattern of distribution and density of the lesions. Involvement of the oral mucosa and conjunctiva is common, and involvement of other mucosal areas may also occur. There are some variants without the characteristic skin lesions. [22], [23], [24] and [25] Although it may not be easy to detect the angiectases in some patients, careful examination of the skin, especially the scrotum and umbilicus, may reveal the presence of isolated lesions. In addition to these vascular lesions, anhidrosis or, more commonly, hypohidrosis is an early and almost constant finding.

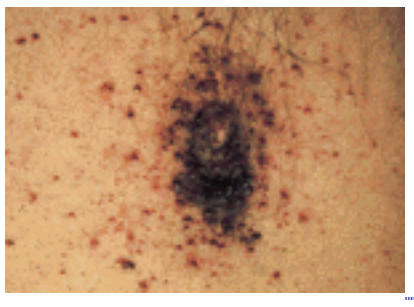

FIGURE 151-3 Clusters of dark red angiokeratomas in an affected male with Fabry disease.

FIGURE 151-4 Angiokeratomas in a 28-year-old affected male with Fabry disease. Note the "swimsuit" distribution.

CARDIAC, CEREBRAL, AND RENAL VASCULAR MANIFESTATIONS The infiltration of glycosphingolipid progresses in the vascular system with increasing age. Cardiac disease, including anginal chest pain, myocardial infiltration, ischemia and infarction, mitral valve prolapse, congestive heart failure, hypertension, mitral insufficiency, and cardiac enlargement, occurs in most affected males. [26], [27], [28], [29], [30], [31] and [32] Systemic hypertension related to vascular involvement of renal parenchymal vessels may accentuate these findings. Hypertrophic obstructive cardiomyopathy, and myocardial infarction secondary to occlusion of the coronary arteries by glycolipid deposition, have been reported. [33], [34] Resulting primarily from multifocal small vessel involvement, cerebrovascular manifestations may include thromboses, basilar artery ischemia and aneurysm, seizures, hemiplegia, hemianesthesia, aphasia, labyrinthine disorders, or frank cerebral hemorrhage. Personality changes and psychotic behavior may become manifest with increasing age. Severe neurologic signs may be present without evidence of major thrombosis and are presumably due to multifocal small vessel occlusive disease. [28], [29], [30], [31] and [32] Progressive glycosphingolipid deposition in the kidney results in proteinuria, with gradual deterioration of renal function and development of azotemia in middle age. During childhood and adolescence, protein, casts, red cells, and desquamated kidney and urinary tract cells may appear in the urine. Polarization microscopy reveals birefringent lipid globules with characteristic Maltese crosses free in the urine and within desquamated urinary sediment cells (Fig. 151-5). With age, renal impairment progresses to significant proteinuria, isosthenuria (specific gravities of 1.008 to 1.012), and alterations of other renal tubular functions. Gradual deterioration of renal function and the development of azotemia usually occur in the third to fourth decades of life, although renal failure has occurred in the second decade. [20] Death most often results from uremia, unless the patient undergoes chronic hemodialysis or renal transplantation. The mean age at death of a series of affected males who were not treated for uremia was 41 years, [35] but occasionally an affected individual has survived into his early 60s.

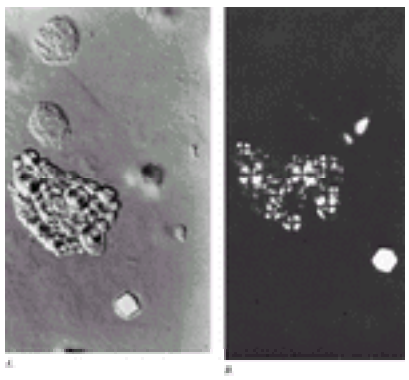

FIGURE 151-5 Photomicrographs of the urinary sediment from a male classically affected by Fabry disease, showing lipid accumulation by interference microscopy (*A*) and polarization light microscopy (*B*). Note that Maltese crosses are visible under polarization.

OCULAR FEATURES Ocular involvement is most prominent in the cornea, lens, conjunctiva, and retina. [36] A characteristic corneal opacity, observed only on slit-lamp microscopy, is evident in males with the disease and in most heterozygous females (Fig. 151-6). The earliest lesion is a diffuse haziness in the subepithelial layer. In more advanced cases, the opacities appear as whorled streaks that extend from a central vortex to the periphery of the cornea. Typically, the whorllike opacities are cream-colored; however, they range from white to golden brown. They are generally inferior and may be very faint. An indistinguishable, drug-induced phenocopy of the Fabry corneal dystrophy occurs in patients on long-term therapy with chloroquine or amiodarone (see " Genetics").

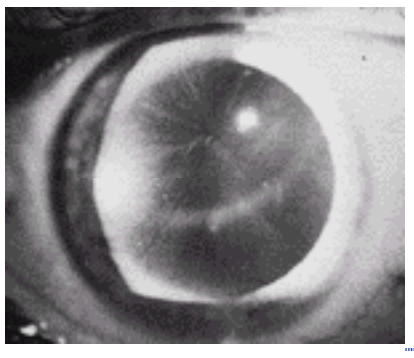

FIGURE 151-6 Corneal opacity observed on slit-lamp microscopy in a Fabry disease carrier female. The corneal involvement results from subepithelial glycosphingolipid deposition.

There are two specific types of lenticular changes. A granular anterior capsular or subcapsular deposit occurs in about one-third of affected males, but rarely in carrier females. Typically, these lenticular opacities are bilateral and inferior in position. They frequently appear in a propeller-like distribution, that is, wedge-shaped with their bases near the lenticular equator and aligned radially with the apices toward the center of the anterior capsule. A second, possibly unique to Fabry disease, lenticular opacity has occurred in both affected males and carrier females. [37] It may be the first ocular manifestation to appear. Posterior and linear, the opacity appears as a whitish, almost translucent, spokelike deposit of fine granular material on or near the posterior cortex. This unusual opacity has been termed the Fabry cataract [36] and is best seen by retroillumination. Conjunctival and retinal vascular lesions are common and represent part of the diffuse systemic vascular involvement. These vascular lesions occur early in life in normotensive individuals and are characterized by mild to marked tortuosity of the conjunctival and retinal vessels. There is an aneurysmal dilation of thin-walled venules as well as angulation and segmental, sausage-like dilatation of veins typically seen on the inferior bulbar conjunctiva. As the disease progresses, the development of hypertension and uremia may produce retinal changes. Neither the vascular lesions in the conjunctiva and retina nor the corneal dystrophy impair vision. However, acute visual loss has occurred in affected males as a result of unilateral total central retinal artery occlusion. [36]

OTHER CLINICAL FEATURES Because of the widespread visceral distribution of the glycosphingolipid deposits, signs and symptoms of this disorder arise in many other organs and systems. Patients have had chronic bronchitis, wheezing respiration, or dyspnea with alveolar capillary block. Older affected males may experience changes in pulmonary function, such as significant airflow obstruction, reduced diffusing capacity, and a reduction in the V_{max25} values. In affected males, airway obstruction occurs commonly, regardless of smoking history, and increases with age, most likely because of fixed narrowing of the airways by accumulated glycosphingolipid. [38] Lymphedema of the legs may be present in adulthood without hypoproteinemia, varices, or any clinically manifest vascular disease. Presumably, the lymphedema reflects the progressive glycosphingolipid deposition in the lymphatic vessels and lymph nodes. Many patients have varicose leg veins and hemorrhoids. Priapism has also been associated with Fabry disease. Episodic diarrhea and, to a lesser extent, nausea, vomiting, and flank pain, are the most common gastrointestinal complaints. These symptoms may be related to the deposition of glycosphingolipid in intestinal small vessels and in the autonomic ganglia of the bowel. Anemia is probably due to decreased red blood cell survival. Patients may have a decreased serum iron concentration, normal red blood cell fragility, and an elevated reticulocyte count. [20] Lipid-laden, foamy-appearing macrophages are present in the bone marrow. Many affected males appear to have retarded growth or delayed puberty and sparse, fine facial and body hair. In some kindreds, an acromegalic-like appearance has been described. Affected individuals may complain of fatigue and weakness and may be incapacitated for prolonged periods.

Cardiac Variants

Affected males with this variant phenotype of Fabry disease are essentially asymptomatic at ages when classically affected males would be severely affected or would have died of the disease [20] (see Table 151-1). In contrast to patients with the classic phenotype, who have very low or nondetectable a-galactosidase A activity, these variants have residual enzyme activity compatible with their milder phenotypes. Patients present with late-onset cardiac or cardiopulmonary disease including cardiomegaly, typically involving the left ventricular wall and interventricular septum, and electrocardiographic abnormalities consistent with a cardiomyopathy. [28], [39] Others have had hypertrophic cardiomyopathy or myocardial infarctions. Most had mild proteinuria. They had been essentially asymptomatic during most of their lives and did not experience the early classic manifestations, including acroparesthesia, angiokeratoma,

corneal and lenticular opacities, and hypohidrosis. In most of these cases, it was the onset of cardiac manifestations that led to the diagnosis.

Carrier Females

The clinical course of Fabry disease and the prognosis of affected males and carrier females differ significantly. [20] Many carrier females experience little difficulty in adult life at ages when affected males already have severe renal or cardiac involvement, although with increasing age some manifest minor symptoms of the disease. Approximately 30 percent of carrier females have a few isolated skin lesions; about 20 to 30 percent have acroparesthesias, particularly in adolescence; and about 70 to 80 percent have the whorllike corneal dystrophy.

Renal findings in carrier females include hyposthenuria (i.e., the occurrence of erythrocytes, leukocytes, and granular and hyaline casts in the urinary sediment), proteinuria, and other signs of renal impairment. In some carrier females, cardiac involvement will develop with advanced age. However, a few carrier females have disease as severe as that observed in classically affected males. In contrast, obligate carriers (daughters of affected males) may have no clinical manifestations with normal levels of leukocyte a-galactosidase A and urinary sediment glycosphingolipids. [40] Indeed, asymptomatic and symptomatic monozygotic female twins have been described. [41] Such markedly variable expression is expected in female carriers for X-linked diseases because of random X-chromosome inactivation (see " Genetics").

PATHOLOGY

Morphologically, Fabry disease is characterized by widespread tissue deposits of crystalline glycosphingolipids that show birefringence with typical Maltese crosses under polarization microscopy (see Fig. 151-5). Although deposits of glycosphingolipid may occur in all areas of the body, they occur predominantly in the lysosomes of endothelial, perithelial, and smooth muscle cells of blood vessels and, to a lesser degree, in the histiocytic and reticular cells of connective tissue. Lipid deposits are also prominent in the epithelial cells of the cornea, as well as in the glomeruli and tubules of the kidney, in the muscle fibers of the heart, and in the ganglion cells of the autonomic system.

Pathology of the Skin

The skin lesions are telangiectases or small superficial angiomas (Fig. 151-7). After a silent period, cumulative vascular damage leads eventually to clinically apparent and progressive angiectases. [42], [43] The early pathologic changes in the vascular endothelium and perithelium have been observed in the clinically normal skin from a 1-year-old affected male. [44]

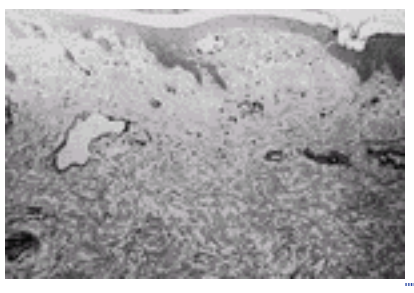

FIGURE 151-7 Telangiectatic vessels in the dermis that are typical of the changes in the skin seen with Fabry disease.

The capillaries, venules, and arterioles of those with classic Fabry disease contain pathologic lipid deposits in the endothelium, perithelium, and smooth muscle. There is marked dilatation of the capillaries of the dermal papillae. Deeper vessels show less dilatation and aneurysm formation. Lipid stores have been evident in arrectores pilorum muscles, gingival tissues, sweat gland epithelium, and perineural cells. [44], [45]

The fully developed classic lesions are usually located in the upper dermis, where they may produce the elevation, flattening, or hypertrophy of the epithelium. The larger lesions may have a slight to moderate keratosis, hence the term *angiokeratoma*.

Pathology of Other Systems

KIDNEY The earliest lesions in the kidney are due to the accumulation of glycosphingolipid in endothelial and epithelial cells of the glomerulus and of Bowman's space, and in the epithelium of the loops of Henle and of distal tubules. Lipid-laden distal tubular epithelial cells desquamate and may be detectable in the urinary sediment (see Fig. 151-5). Concurrently, the involvement of renal blood vessels progresses and often becomes extensive. An early finding is the presence of arterial fibrinoid deposits, which may result from the necrosis of severely involved muscular cells. Other histologic changes in the kidney are the sequelae of nonspecific, end-stage renal disease.

NERVOUS SYSTEM The vascular involvement of the nervous system, which is also prominent in Fabry disease, [46] presumably accounts for the observation of minor electroencephalographic and electromyographic abnormalities in these patients. In addition, vascular ischemia and lipid deposition in the perineurium may cause the peripheral nerve conduction abnormalities of slowed conduction velocities and distal latency, respectively. In both affected males and carrier females, glycosphingolipid deposition in nervous system tissue appears to be limited to the perineural sheath cells of peripheral nerves, neurons of the peripheral and central autonomic nervous system, and certain primary neurons of somatic afferent pathways. Qualitative and quantitative studies of peripheral sensory neurons in sural nerves and spinal ganglia have shown preferential loss of small myelinated and unmyelinated fibers, as well as small cell bodies of spinal ganglia. [47] Fabry disease may involve multiple brainstem centers. [47] Hemisphere involvement has been evident in the amygdaloid, hypothalamic, and hippocampal nuclei. Lipid storage in neuronal cells of the anterior and posterior lobes of

the pituitary has been observed. Detailed reviews of the neurologic findings are available. [48], [49]
EYE Histologically, there are abnormal glycosphingolipid deposits in endothelial, perivascular, and smooth muscle cells of all ocular and orbital vessels, in smooth muscle of the iris and ciliary body, in perineural cells, and in connective tissue of the lens and cornea. [50] Researchers have localized inclusions in the epithelium of the conjunctiva, cornea, and lens. Electron microscopy shows inclusions to be in the basal layer of conjunctival epithelial cells as well as in the surface epithelium. There may be hyperplasia and edema of corneal epithelial cells. Bowman's membrane appears normal, and no deposits appear in the stroma or endothelium. The whorllike corneal dystrophic pattern may result from the formation of a series of subepithelial ridges or from the reduplication of the basement membrane.
HEART The progressive deposition of glycosphingolipid in myocardial cells and valvular fibroblasts appears to be a primary cause of cardiac disease in affected males and some carrier females. [51], [52] Most commonly, the left atrium and ventricle are enlarged, and the ventricular walls and septum are markedly thickened; right atrial and ventricular dilatation and enlargement are variable findings. Within the myocardial cells, there is extensive glycosphingolipid deposition around the nucleus and between myofibrils.

Histochemistry and Ultrastructure

The accumulated glycosphingolipids can be stained in frozen sections with lipid-soluble dyes and may be removed from tissues by the process of dehydration and embedding in paraffin. If lipid-solubilizing procedures are used, empty vacuoles are observed on light microscopy. Most of the lipid crystals are retained through alcohol dehydration but are lost on exposure to xylene or pyridine. Improved fixation of the lipid deposits can be achieved with 1% calcium formol. A comparison of various fixation and embedding techniques to preserve the storage material has been reported. [53]

A modified periodic acid–Schiff (PAS) stain specific for neutral glycosphingolipids [54] and a positive test for sphingosine [55] have served to confirm the chemical identification of the accumulated glycosphingolipids. The levels of peroxidase- or fluorescence-labeled *Banderiaea simplicifolia* lectin, which is specific for a- *D*-galactosyl residues, and antiglobotriaosylceramide antibodies also have been used to stain the glycosphingolipid substrates selectively. [53], [56], [57]

At high resolution, a typical pattern of concentric or lamellar inclusions with alternating light- and dark-staining bands is evident (Fig. 151-8). The periodicity of these bands has been reported variably as 40 to 50 Å, 50 to 60 Å, 60 to 65 Å, or as great as 98 Å. The electron-dense component is 20 to 30 Å in thickness. These inclusions have coarser periods of 150 to 200 Å.

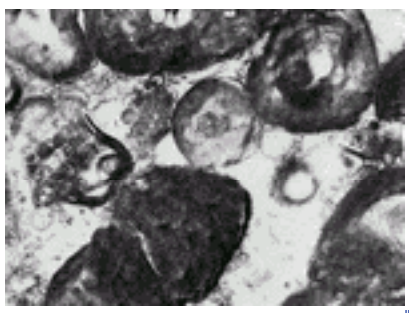

FIGURE 151-8 Electron photomicrograph of a section of the mitral valve from an affected male with Fabry disease, showing the concentric lamellar inclusions in lysosomes of fibrocytes. (*Courtesy of HL Sharp, MD.*)

BIOCHEMICAL GENETICS OF FABRY DISEASE

The deficient activity of the lysosomal enzyme a-galactosidase A results in the accumulation of glycosphingolipids with terminal a-galactosyl moieties in most visceral tissues and body fluids. The predominant glycosphingolipid accumulated is globotriaosylceramide or galactosyl-(a1 ? 4)-galactosyl-(ß1 ? 4)-glycosyl-(ß1 ? 1')-ceramide. A second neutral glycosphingolipid, galabiosylceramide [Gal(a1 ? 4)Gal(ß1 ? 1')Cer, also accumulates in Fabry disease–affected males to abnormally high concentrations. The deposition of galabiosylceramide, however, appears to be tissue-specific, because this substrate has been detected only in the kidney, pancreas, right heart, lung, and urinary sediment. In addition, the blood group B–specific substances, which have terminal a-galactosyl moieties [Gal(a1 ? 3)Gal(2 ? 1a-Fuc) (ß1 ? 3)GlcNAc(ß1 ? 3)Gal(ß1? 4)Glc(ß1 ? 1')Cer] and the blood group B1 glycosphingolipid [Gal(a1 ? 3)Gal(2 ? 1aFuc)(ß1 ? 4)GlcNAc(ß1 ? 3)Gal(ß1 ? 4)Glc(ß1 ?1')Cer], accumulate in patients who have the blood group B antigens. Thus, affected males and carrier females who have blood group B or AB accumulate four major glycosphingolipid substrates (and generally have a more rapid disease course), whereas patients with A or O blood groups accumulate globotriaosylceramide and galabiosylceramide.

Human a-galactosidase A is a homodimeric glycoprotein with native and subunit molecular masses of ˜101 and ˜46 kDa. The enzyme has a pH optimum of 4.6 and hydrolyzes the a-linked galactosyl moieties from glycolipids and glycopeptides. Isoelectric focusing studies of the enzyme from various sources reveal multiple forms with pI values ranging from 4.2 to 5.1, owing to glycoforms with varying sialylation and phosphorylation. [58] The a-galactosidase A subunit in cultured fibroblasts is normally synthesized as a precursor glycopeptide of ˜50 kDa. After cleavage of the signal peptide and carbohydrate modifications in the Golgi apparatus and lysosomes, the mature enzyme subunits of ˜46 kDa form the active, homodimeric enzyme, which contains complex, hybrid, and high-mannose type oligosaccharide moieties. The transport to the lysosome is dependent on mannose-6-phosphate receptors. Reviews of glycosphingolipid metabolism, the biochemistry of a-galactosidase A, and the metabolic defect in Fabry disease are available. [20]

As noted earlier, classically affected males with Fabry disease have no detectable a-galactosidase A activity. Studies of a-galactosidase biosynthesis have demonstrated several types of enzyme defects, suggesting allelic heterogeneity, including gene rearrangements and point mutations that affect a-galactosidase A synthesis, maturation, and stability. [20] In

contrast to classically affected males, those with atypical or cardiac variants of the disease have residual a-galactosidase A activity, consistent with the attenuation or absence of the characteristic clinical manifestations. [20]

Based on studies with synthetic substrates, two activities initially thought to represent a-galactosidase isozymes were detected and designated a-galactosidases A and B. [59] The two “isozymes” were separable by electrophoresis, isoelectric focusing, and ion exchange chromatography. Subsequently, the demonstration that polyclonal antibodies against a-galactosidase A or B did not cross-react with the other enzyme, [60] that only a-galactosidase A activity was deficient in affected males with Fabry disease, and that the genes for a-galactosidases A and B occurred on different chromosomes [20], [61] clearly established the genetic distinction between these enzymes. Thus, it was not surprising when a-galactosidase B was shown in 1977 to be an a- *N*-acetylgalactosaminidase, a homodimeric glycoprotein that hydrolyzed artificial and natural substrates with terminal a- *N*-acetylgalactosaminyl moieties. [60] The a-galactosidase B gene has been subsequently identified and characterized. [61], [62]

PATHOPHYSIOLOGY

The pattern of glycosphingolipid deposition in Fabry disease, particularly its predilection for vascular endothelial and smooth muscle cells, is different from that seen in other glycosphingolipidoses. [63] However, the origin of the accumulated glycosphingolipid substrates in Fabry disease has not been fully clarified. Certainly, there is a significant contribution from the endogenous synthesis and subsequent lysosomal accumulation of terminal a-galactosyl–containing glycosphingolipids after autophagy of cellular membranous material with these lipid substrates. Endogenous metabolism is likely to be the major source of substrate accumulation in avascular sites, such as the cornea, and in neural cells, which are presumably protected from the increased circulating levels of GL-3 by the blood-brain barrier. In addition, the turnover of GL-3 and particularly its precursor, globotriaosylceramide (globoside), which are present in higher concentrations in normal renal tissue than in any other tissue, is presumably responsible for the endogenous renal deposition of the Fabry substrate.

The unique cellular and tissue distribution of accumulated GL-3 suggests that a significant intracellular contribution may be derived by the endocytosis or diffusion of GL-3 from the circulation, where the concentration in affected males is three- to tenfold higher than that in healthy individuals. Circulating GL-3 is transported primarily in the low-density lipoprotein (LDL) and high-density lipoprotein (HDL) fractions. In plasma from affected males, the accumulated GL-3 is distributed in the LDL and HDL fractions in proportions similar to those in normal plasma, approximately 60 and 30 percent, respectively.

The finding that little, if any, substrate deposition occurs in Fabry hepatocytes (in contrast to the accumulation in Kupffer cells) supports the contention that GL-3 synthesized by the hepatocyte is associated with lipoprotein and secreted as a complex. In support of this concept is the fact that patients with hypercholesterolemia have proportional plasma elevations of both LDL and neutral glycosphingolipids, including GL-3. The circulating GL-3 then presumably gains access to vascular endothelial and smooth muscle cells throughout the body by the high-affinity lipoprotein receptor–mediated uptake pathway. Deposits in other tissues may also be derived to a lesser extent from receptor-independent diffusion or by nonabsorptive endocytosis of globoside- or GL-3–lipoprotein complexes from the plasma. Because the lysosomes in all cells are deficient in the a-galactosidase A activity needed to degrade the accumulated glycosphingolipids, they accumulate within extended multivesicular bodies or, in more advanced stages, as free intracytoplasmic masses, which may lead to cellular dysfunction or degeneration. In addition to hepatocyte biosynthesis, bone marrow synthesizes glycosphingolipids and incorporates them into the membranes of the formed blood elements.

It has been postulated that erythrocyte globoside (GalNAc-Gal-Gal-Glc-Cer), the predominant glycosphingolipid of erythrocytes and the catabolic precursor of GL-3, may be another major metabolic source of the circulating pathogenic lipid. Globoside is presumably released into the circulation from senescent erythrocytes and is subsequently catabolized (most likely in the spleen) to GL-3. In Fabry disease, the GL-3 cannot be metabolized and may be partly released into the circulation, where it can be incorporated into both HDL and LDL fractions and/or rapidly cleared by the liver, as intravenously administered neutral glycosphingolipids are known to be. Thus, the turnover of erythrocyte and other membrane glycosphingolipids may contribute significantly to the substrate load in Fabry disease. In addition, a minor amount of GL-3 may be “excreted” into the circulation from the secondary lysosomes of various cell types throughout the body. Because the glycosphingolipid cannot be catabolized in the circulation, it would slowly accumulate at a rate reflecting the turnover of various cells, the contribution from exocytosis, lipoprotein uptake, or diffusion.

The metabolism of at least two related compounds also is abnormal in Fabry disease, as demonstrated by the accumulation of galabiosylceramide, Gal-Gal-Cer, and the blood group B antigenic substances. Affected males and carrier females who are blood group type B or AB appear to be more severely affected, presumably because of the additional accumulation of B-specific glycosphingolipids. [20]

Thus, the total amount of glycosphingolipid stored in a given tissue depends on time, the rate of accumulation from intracellular and circulatory sources, the possibilities for excretion, the individual's ABO blood type, and the presence or absence of residual a-galactosidase A activity. The pattern of glycosphingolipid accumulation, predominantly in the cardiovascular-renal system, best correlates pathophysiologically with the major clinical manifestations of the disease.

Pathophysiology of the Vasculature

Narrowing, dilatation, motor unresponsiveness, and instability of blood vessels are major features of the altered physiology associated with Fabry disease. The swollen vascular endothelial cells, often accompanied by endothelial proliferation, encroach on the lumen, causing a focal increase of intraluminal pressure, dilatation, and angiectases, as well as peripheral ischemia or frank infarction. Such changes are frequently the precursors of thromboses and infarcts of

the brain and other tissues. Muscle and peripheral nerve ischemia may contribute to the pain or fatigue. [64]

There may be progressive aneurysmal dilatation of the weakened vascular walls. This process is apparent in the retinal and conjunctival vessels and in the transition from normality to telangiectasia and frank angiokeratoma in the skin.

Observed alterations of vasomotor control may reflect either the vascular lesions themselves or the extensive glycosphingolipid deposits in autonomic ganglia and perineural sheath cells. The blood vessels in both affected males and carrier females demonstrate an impaired ability to constrict, and those in the more severely affected males show, in addition, an inability to dilate. Such a combined vascular and neural lesion may also explain the clinically observed temperature intolerance. [65]

Pathophysiology of Other Systems

NERVOUS SYSTEM The involvement of peripheral and central autonomic nerve cells may be responsible for the paresthesias, pain, hypohidrosis, gastrointestinal symptoms (e.g., nausea and diarrhea), and a variety of vague neurologic signs and symptoms. Fukuhara and associates found marked degeneration of the secretory and myoepithelial cells of sweat glands by electron microscopy and proposed that the hypohidrosis was due to local lipid deposition rather than autonomic nervous system involvement. [64] The episodic fevers may be related to lesions of the hypothalamus. The observations of a selective decrease in the number of unmyelinated and small myelinated fibers in peripheral nerves [48], [66] suggest that the selective damage to these fibers may account for the pain and hypohidrosis in this disorder. Sympathetic and parasympathetic dysfunction, particularly in distal cutaneous responses, has been evident. Alternatively, it has been suggested that the lipid deposition in the vasa nervorum may lead to the acroparesthesias, rather than the involvement of the autonomic nervous system. [64]
KIDNEY The observed abnormalities in renal function associated with Fabry disease have their basis in lesions of the nephron and of the renal vasculature, and possibly of the posterior pituitary and hypothalamus as well. Early glycosphingolipid deposits antedate clinical signs and symptoms. Alteration of the glomerular epithelial cells and their foot processes or increased desquamation of lipid-laden tubular epithelial cells may explain the observed mild proteinuria. [56] Loss of renal concentrating ability with polyuria and polydipsia may occur well in advance of a significant decrease in glomerular filtration or evidence of renal failure. The defect in concentrating ability may be due to decreased water permeability of the distal tubules and collecting ducts secondary to lipid deposition. The later and more severe renal changes are the result of vascular lesions and of hypertension.
HEART The progressive deposition of glycosphingolipids in the myocardial cells, the valvular fibroblasts, and the coronary vessels is the primary cause of cardiac disease in males with Fabry disease and some carrier females. [34] The left ventricular myocardium and the mitral valve are the sites of the most marked lipid deposition in the heart. The marked deposition of GL-3 in the coronary arteries leads to myocardial ischemia and frank infarction. [34]
OTHER INVOLVEMENT Pulmonary symptoms of Fabry disease have been attributed to the involvement of lung vasculature or of bronchial and mucous gland epithelium. [38] The airflow obstruction may be due to the loss of elastic recoil secondary to lipid deposition in lung parenchyma. The lymphedema presumably results from lymphatic obstruction or venous insufficiency secondary to lipid-laden endothelial cells.

Abnormal Distribution in Tissues

Increased concentrations of globotriaosylceramide have occurred in all tissues except erythrocytes, [67], [68] which indicates that the catabolism of these glycosphingolipids involves most tissues. In one affected male, the level of glycosphingolipid accumulation was 30- to 300-fold higher than normal levels. [68] The greatest levels of accumulation were evident in the kidney, lymph nodes, vessels, prostate, and autonomic ganglia. A comparison of globotriaosylceramide accumulation in various tissues showed that affected males had markedly increased levels in the kidney, whereas a carrier female had the highest accumulation in the heart. [69] Accumulation of galabiosylceramide has been reported to occur only in the kidney, pancreas, heart, lungs, and urinary sediment. [7], [8], [51], [68]

MOLECULAR GENETICS OF a-GALACTOSIDASE A AND FABRY DISEASE

a-Galactosidase A Gene and Transcript

Human a-galactosidase A is encoded by a single housekeeping gene, which has been localized to the chromosomal region Xq22.1. [70] The 12-kb a-galactosidase A gene has been completely sequenced. [14], [15] It contains 7 exons, ranging from 92 to 291 bp, and 6 introns, ranging from 0.2 to 3.8 kb. The gene is remarkably rich in *Alu* repetitive sequences with nine intronic repeats and three repeats in the immediate 3' flanking region; these sequences represent ˜30 percent of the 12 kb gene, or ˜ 1 *Alu* /kb. The full-length 1437-bp a-galactosidase A cDNA encodes a precursor peptide of 429 amino acids, including a 31-residue signal peptide. The mature 398 amino acid subunit contains four *N*-glycosylation consensus sequences [14]

a-Galactosidase A is synthesized as a precursor peptide of 50 kDa that is processed to the mature lysosomal subunit of 46 kDa. The transport to the lysosome is dependent on mannose-6-phosphate receptors. The enzyme functions as a homodimer.

Molecular Pathology of Fabry Disease

The isolation of the gene encoding a-galactosidase A was a major advance that has provided (1) precise patient diagnosis, carrier identification, and prenatal diagnosis; (2) understanding of the nature of the mutations causing the classic and variant forms of the disease; and (3) the means to develop molecular-based therapies, including enzyme and gene replacement.

Studies of the a-galactosidase A mutations in unrelated Fabry families have identified a variety of lesions underlying the molecular genetic heterogeneity of the disease. To date, more than 300 a-galactosidase A mutations have been identified. [71] Classically affected males have a variety of mutations, including large and small gene rearrangements, splicing defects, and missense or nonsense mutations. [72], [73] and [74] In contrast, most of those with cardiac variants of Fabry disease have missense mutations that express residual a-galactosidase A activity, including I91T, R112H, F113L, N215S, M296I, R301Q, and G328R. [72] Of note, the N215S mutation occurred in several unrelated cardiac variants.

Most mutations occur only in a single pedigree (private mutation). However, mutations at CpG dinucleotides have been found in unrelated families of different ethnic or geographic backgrounds. Haplotype analysis of mutant alleles that occurred in two or more families revealed that those with rare novel alleles were probably related, whereas those with mutations involving CpG dinucleotide “hot spots” were not. [74]

The fact that most Fabry disease patients have private mutations limits efforts to establish genotype/phenotype correlations, as attempts to predict the phenotype require more extensive clinical information from unrelated patients with the same genotype. Of interest, three mutations (R112H, R301Q, and G328R) have been identified in patients with the classic disease and the cardiac variant phenotypes, suggesting that other modifying factors are involved in disease expression. [74]

GENETICS

Mode of Inheritance

Fabry disease is transmitted by an X-linked recessive gene, located at Xq22.1 (see “ Molecular Genetics of a-Galactosidase A and Fabry Disease ”) that normally encodes the gene product, a-galactosidase A. The prevalence of Fabry disease has not been determined; the disease is rare, and it is estimated that the incidence is about 1:40,000 to 60,000 males. [20], [75] Of the more than 400 described cases of affected males, most are white; however, cases have occurred in blacks, Latin Americans, Native Americans, Egyptians, and Asians. The Fabry gene is highly penetrant in males. Clinical onset is variable; the disease usually appears during childhood, but may not appear until the second or third decade. Both intrafamilial and interfamilial variations in the clinical expression have been reported, the intrafamilial being less than the interfamilial variation.

Expressivity in the carrier female is variable. Although proven carriers may be completely asymptomatic throughout a normal life span, several carrier females have experienced complete clinical and biochemical expression of the disease, as severe as in affected males. [20] The markedly variable expression of the Fabry gene in carrier females is anticipated for X-linked enzymatic deficiencies by the random X-chromosome inactivation hypothesis, which predicts that carrier females for X-linked enzymatic defects will leave two populations of cells, one with mutant and the other with normal enzymatic activity. Two such populations have been isolated from individual cultured skin fibroblasts from obligate carriers, one with normal and the other with defective a-galactosidase A activities. [76]

Phenocopies

A phenocopy is a mimic or simulation of a specific genetic trait that is usually the result of environmental factors and, thus, is not inherited. There are two such phenocopies for Fabry disease, one that mimics the characteristic corneal opacity and another that causes renal functional and ultrastructural changes resembling those in affected males. Because suspicion of the diagnosis of Fabry disease often arises from an eye examination or renal evaluation for proteinuria, these phenocopies have significant diagnostic import.

The whorllike keratopathy of Fabry disease is readily distinguishable from the corneal opacities of other lysosomal storage diseases, but is clinically and ultrastructurally identical to the corneal dystrophy associated with long-term chloroquine therapy. [77] Chloroquine has been shown to concentrate rapidly in lysosomes, increase the intralysosomal pH, decrease the activity of specific lysosomal hydrolases, alter the rate of proteolysis, and cause the formation of lysosomal inclusions. Based on these findings, it has been proposed that chloroquine-induced keratopathy results from the pH inactivation of lysosomal a-galactosidase A and the subsequent accumulation of GL-3. In support of this concept is the finding that corneal a-galactosidase A is more sensitive to increasing pH in vitro than other lysosomal hydrolases. More recently, amiodarone has also been shown to cause a phenocopy of Fabry disease keratopathy; although presumed to be similar to that of chloroquine, the mechanism underlying the amiodarone-induced pathology has not been elucidated. [78]

Another tissue-specific phenocopy of Fabry disease occurs in individuals who are environmentally exposed to silica dust. There are descriptions of the pulmonary complications of silicolipoproteinosis, but the renal manifestations of proteinuria and lipiduria have received little attention. Ultrastructural examination of renal tissue from these individuals has revealed the typical electron-dense lamellar inclusions in the lysosomes of glomerular epithelial and endothelial cells, and proximal and distal tubular cells as observed in Fabry disease. [79] The levels of a-galactosidase A and urinary sediment glycosphingolipids were normal in one such patient. [79] Although the mechanism responsible for the silica-induced phenocopy is unknown, the finding of such lesions in biopsied renal tissue warrants the inclusion of silicosis as well as Fabry disease in the differential diagnosis.

Genetic Counseling

All families that have a member with Fabry disease should have an opportunity to receive genetic counseling. Inheritance of the Fabry gene from both affected males and carrier females should be addressed, because both genotypes transmit the gene. All sons of affected males will be unaffected, but all daughters will be obligate carriers of the gene. Carrier

females have a 50 percent chance of transmitting the gene to sons who will have the disease and a 50 percent chance of transmitting the gene to daughters who will be carriers. On the average, therefore, half the sons of carrier females will have the disease, and half the daughters will be carriers. All possible carriers among close female relatives should undergo clinical examination, biochemical studies, and mutation analysis for carrier identification. Fabry disease has been detected antenatally from cultured fetal cells and amniotic fluid obtained by amniocentesis, as well as from chorionic villus samples (see " Prenatal Diagnosis").

DIAGNOSIS

Clinical Evaluation

The history and the observation of the characteristic skin lesions and/or corneal dystrophy generally lead to the clinical diagnosis of Fabry disease. The most common childhood symptom before the appearance of the cutaneous lesions is recurrent fever in association with pain in the hands and feet. The disorder has often been misdiagnosed as rheumatic fever, neurosis, erythromyalgia, or collagen vascular disease.

The differential diagnosis of the cutaneous lesions must exclude the angiokeratoma of Fordyce, angiokeratoma of Mibelli, and angiokeratoma circumscriptum, none of which have the typical histologic or ultrastructural pathology of the Fabry lesion (see Fig. 151-3 and Fig. 151-4). Angiokeratomas of Fordyce are similar in appearance to those of Fabry disease, but are limited to the scrotum and usually appear after age 30. Angiokeratomas of Mibelli are warty lesions on the exterior surfaces of extremities in young adults; they are associated with chilblains. Angiokeratoma circumscriptum or naeviformis, which can occur anywhere on the body, is clinically and histologically similar to those of Fordyce and is not associated with chilblains.

Angiokeratomas reportedly similar to or indistinguishable from the clinical appearance and distribution of the cutaneous lesions in Fabry disease have occurred in patients with other lysosomal storage diseases, including fucosidosis, sialidosis (a-neuraminidase deficiency with or without a-galactosidase deficiency), adult-type ß-galactosidase deficiency, aspartylglucosaminuria (a lysosomal disorder that presents with mental retardation and some features of the mucopolysaccharidoses), and an adult-onset variant of a- *N*-acetylgalactosaminidase deficiency. Ultrastructural examination of these lesions reveals lysosomal substrate deposition that differs in the fine structural appearance of the respective storage material. In addition, some patients with classically appearing angiokeratoma, but no other clinical symptoms or morphologic evidence of lysosomal storage, have normal levels of a-galactosidase A and other lysosomal hydrolase activities. Clinical and pathologic details of the differential diagnosis of the skin lesion are available in reviews. [31], [80], [81]

A presumptive diagnosis of Fabry disease in affected males can be made through the findings of a careful ophthalmologic examination, the demonstration of the birefringent inclusions in the urinary sediment, or the results of skin biopsy. The observation of the characteristic corneal dystrophy on slit-lamp examination should aid in the diagnosis. Biopsied skin will reveal the refractile lipid inclusions (Maltese crosses) in blood vessels. [44] Lipid-containing macrophages may also be evident in bone marrow aspirates. Women suspected of being heterozygous carriers of the Fabry gene should undergo a careful examination for evidence of the characteristic corneal opacity on slit-lamp microscopy and for isolated skin lesions, particularly on the breasts, back, trunk, and posterolateral thighs. The histologic finding of lipid-laden cells in biopsied skin, tissues, or in the urinary sediment may also be helpful in diagnosis.

Biochemical Confirmation

The diagnosis of Fabry disease should be confirmed biochemically by the demonstration of deficient a-galactosidase A activities in plasma or serum, leukocytes, biopsied tissues, or cultured cells. [12] Alternatively, multiprocedural glycosphingolipid analyses can demonstrate theincreased levels of GL-3 in urinary sediment, plasma, or cultured skin fibroblasts (Table 151-2). [8]



TABLE 151-2 **Mean Concentration of Globotriaosylceramide and Galabiosylceramide in Various Sources from Normal Individuals and Affected Males and Carrier Females with Fabry Disease** [8], [67], [80]

Although low or intermediate levels of a-galactosidase A activity in various tissues and their products identify many obligate carrier females, the biochemical identification of female carriers of the Fabry gene is problematic because of random X-chromosome inactivation. Thus, carriers can express levels of enzymatic activity ranging from essentially zero to normal, consistent with reports of obligate carrier females with normal a-galactosidase A activity and no keratopathy. [40] If carrier females have borderline or normal levels of enzymatic activity, then their recognition requires the identification of the specific molecular mutation present in affected males in the pedigree.

Molecular Diagnosis of Female Carriers

For families in which a specific a-galactosidase A gene lesion has been identified, carrier detection is specific. However, there are no common a-galactosidase A mutations that cause this disease, and almost every unrelated family in which a member has Fabry disease has a different mutation, [72], [74], [82], [83] necessitating a mutation study of the entire coding

region in each family. In informative families without an identified mutation, linkage analysis is possible by using intragenic single nucleotide polymorphisms and/or simple sequence repeat polymorphisms closely linked to the a-galactosidase A gene. [84]

Prenatal Diagnosis

An assay of a-galactosidase A activity in chorionic villi obtained at 9 to 10 weeks of pregnancy or a culture of amniotic cells obtained by amniocentesis at approximately 15 weeks of pregnancy permits the prenatal diagnosis of Fabry disease. [13], [85], [86] The minimum requirement for the diagnosis in a male fetus is the demonstration of deficient a-galactosidase A activity and an XY karyotype. Molecular studies by direct mutation testing or indirect studies by linkage analysis further confirm the diagnosis.

P>Biochemical and ultrastructural studies of tissues from fetuses with Fabry disease, consistent with the prenatal diagnosis, showed the a-galactosidase A activity to be defective in all tissues studied; [86] furthermore, there were increased concentrations of globotriaosylceramide in all tissues analyzed, with the exception of neural tissues. [87] Histologic and light microscopic examinations of various tissues were unremarkable, but ultrastructural examination revealed electron-dense concentric lamellar inclusions in the lysosomes of vascular endothelium, myocardial cells, renal tubules, and epithelial and endothelial cells of renal glomeruli. [86], [87]

TREATMENT

Medical Management

In Fabry disease, the chronicity of the clinical events causes severe debilitation and incapacity that extends over years. The single most debilitating and morbid aspect of Fabry disease is the excruciating pain. The pathophysiologic events that cause the incapacitating episodes of pain or the chronic burning acroparesthesias have not been clarified. With the exception of centrally acting narcotic analgesics, which have been only partially effective, conventional analgesic agents have not been successful in controlling the pain. However, the prophylactic administration of low maintenance dosages of diphenylhydantoin can provide relief from the periodic crises of excruciating pain and constant discomfort in affected males and symptomatic carriers. [21] Carbamazepine also provides pain relief. [88] The combination of diphenylhydantoin and carbamazepine can be used if either is not effective. Recently, gabapentin (Neurontin) has been used to prevent pain. [20]

Care of patients with regard to cardiac, pulmonary, and central nervous system manifestations remains nonspecific and symptomatic. Obstructive lung disease occurs in older affected males and carrier females, with more severe impairment in smokers; therefore, patients should be discouraged from smoking.

Renal Transplantation

Because renal insufficiency is the most frequent and serious late complication in patients classically affected by Fabry disease, chronic hemodialysis and/or renal transplantation have become lifesaving procedures. The first renal transplant in a patient with Fabry disease was performed in 1967. [89] Contrary to an unfavorable early report, [90] experience has supported the clear benefit of transplantation for patients with this disease. [91] In fact, recent reviews of the registries of the European Renal Association–European Dialysis and Transplantation Association and the United States Renal Data System suggest excellent outcomes for renal transplantation in Fabry disease. [91], [92] For example, when 93 patients who received transplants during the 10-year period from 1988 to 1998 were compared to a matched control group, transplant recipients with Fabry disease had equivalent, if not better, 5-year patient (82 versus 83 percent) and graft (67 versus 75 percent) survival results, respectively. Also, immune function in Fabry disease–affected males has been shown to be similar to that in other uremic patients, obviating any immunologic contraindication to transplantation in this disease. [93]

Successful transplantation corrects renal function, and the engrafted kidney will remain histologically free of glycosphingolipid deposition because the normal a-galactosidase A activity in the allograft will catabolize endogenous renal glycosphingolipid substrates. Rarely, electron microscopy of transplanted cadaveric kidneys has detected isolated glycosphingolipid deposits as small myelin figures in vascular endothelial cells. These endothelial cells were derived from the recipient and were deficient in a-galactosidase A. [53]

Transplantation of kidneys from Fabry carriers, which already may contain significant substrate deposition, should be avoided. In one reported case, transplantation of an allograft from a carrier to an affected male relative resulted in decreased renal function (serum creatinine, 3.0 mg/dL) 5 years later. [94] A kidney donated by a carrier female to her unaffected daughter showed glycolipid deposition in podocytes 7 years after transplantation. Although these deposits were not extensive, their persistence suggests that the uptake of the recipient's circulating normal enzyme by podocytes was minimal. [95] Therefore, it is essential to screen all potential related donors in order to exclude affected males and carrier females for the Fabry gene. Because enzyme analysis does not reliably detect carriers, it is necessary to demonstrate the absence of the specific a-galactosidase A mutation or disease haplotype in females who are potential donors.

In addition to its role in the treatment of the renal failure associated with Fabry disease, kidney transplantation has been undertaken to determine if the allograft could provide normal a-galactosidase A for substrate metabolism. [96] Hypothetically, the normal kidney might metabolize the accumulated substrate either by uptake and catabolism within the allograft or by the release of the active enzyme into the circulation for uptake and metabolism in other tissues, such as the vascular endothelium. Although biochemical and/or clinical improvement was initially reported, [96] no clear biochemical effect could be demonstrated. Several patients with successful engraftment who survived for 10 to 15 years have expired from complications of vascular disease [97] or other unrelated disorders. [98] Thus, the use of renal allografts to alter the rate

of progressive systemic substrate accumulation is not effective, and patients with allografts should consider enzyme replacement therapy to prevent the late cardiac and cerebrovascular complications of Fabry disease.

Enzyme Replacement Therapy

Early studies of enzyme replacement in Fabry disease indicated the feasibility of this therapeutic approach. [99], [100] and [101] However, the limiting obstacles were the inability to produce sufficient amounts of purified normal enzyme and the lack of an animal model in which to evaluate the pharmacokinetics and pharmacodynamics required for the design of clinical trials.

PRECLINICAL STUDIES IN FABRY MICE: PROOF OF CONCEPT The isolation of the human a-galactosidase A cDNA [14] and its high-level expression in CHO cells made it possible to overcome early obstacles to enzyme replacement therapy. [102] It provided a source of selectively secreted recombinant human enzyme that was highly sialylated and had mannose-6-phosphate residues for lysosomal targeting. In addition, the generation of an a-galactosidase A knockout mouse permitted the evaluation of enzyme replacement in an animal model of Fabry disease. [103], [104] With these advances, preclinical studies of four recombinant human a-galactosidase A glycoforms were performed in the enzyme-deficient mice. The pharmacokinetics and biodistributions were determined for the glycoforms, which differed in sialic acid and mannose-6-phosphate content. [103] Normal (or higher) enzymatic activity levels were reconstituted in the liver, spleen, heart, lung, and kidney following eight every other day doses of 10 mg/kg of the highly sialylated glycoform, a-galactosidase A-1. Four days later, a-galactosidase A-1 activity continued in the liver and spleen at 30 and 10 percent of that recovered at 1 h postinjection, respectively. Furthermore, GL-3 was cleared from the liver, heart, spleen, kidney, and plasma in a dose-dependent manner. These preclinical animal studies provided “proof of concept,” as well as the pharmacokinetic and pharmacodynamic data critical for the design of clinical trials of enzyme replacement.
PHASE 1 AND 1/2 CLINICAL TRIALS The preclinical studies served as the basis for Phase 1 and Phase 1/2 clinical trials. [18] A Phase 1/2 open-label, dose-escalation study involved 15 classically affected males who received five doses of recombinant human a-galactosidase A. [16] The enzyme was well tolerated, and rapid, marked reductions in plasma and tissue GL-3 were observed biochemically, histologically, and ultrastructurally. Mean GL-3 content was decreased 84 percent in the liver (n = 13), was markedly reduced in the kidney in 4 of 5 patients, and was modestly lowered in the endomyocardium of 4 of 7 patients. In addition, GL-3 deposits were cleared to near normal or were markedly reduced in the vascular endothelium of the liver, skin, heart, and kidney. These patients reported improvements in the level of pain, ability to sweat, and quality of life. Four patients experienced mild-to-moderate infusion reactions that were managed conservatively. Of the 15 patients, 8 (53 percent) developed IgG antibodies to a-galactosidase A; however, the antibodies were not neutralizing. These results provided dose-response data and explored possible primary efficacy endpoints for a Phase 3 pivotal trial.
PHASE 2 AND PHASE 3 CLINICAL TRIALS A single-center, double-blind, placebo-controlled Phase 2 trial of a-galactosidase A replacement involved 26 patients at a dosage of 0.2 mg/kg every 2 weeks for 6 months. [19] “Pain at its worst” in treated patients decreased significantly compared to no significant change in the placebo group. Mean creatinine clearance also was significantly improved; however, one placebo-treated patient went into renal failure. The Phase 3 trial was a multinational, double-blind, randomized, placebo-controlled trial involving 58 patients and eight centers in four countries. [17] Each patient received an infusion of 1 mg/kg of recombinant a-galactosidase A or placebo every 2 weeks for 20 weeks. The primary efficacy endpoint was the clearance of stored GL-3 in the vascular endothelium of the kidney, the organ of greatest morbidity in Fabry disease. Twenty of 29 (69 percent) patients treated with the enzyme achieved the primary endpoint (i.e., essentially normal renal vascular endothelial cells as determined by histologic examination; scored normal or near normal, on a 0-3 seventy scale), while 8 of the other 9 treated patients all had decreased renal vascular GL-3 deposits. The ninth patient's posttreatment biopsy was lost. In contrast, no patient receiving the placebo cleared the renal endothelial GL-3 deposits. These results were highly significant ($p < 0.001$). Compared to the levels found in the placebo group, the amount of GL-3 decreased significantly in the heart ($p < 0.001$) and the skin ($p < 0.001$) in response to the enzyme infusions. Clearance of plasma GL-3 was directly correlated with renal endothelial glycosphingolipid clearance; patients receiving the enzyme cleared the accumulated GL-3 in the circulation. The enzyme infusions were well tolerated, and the adverse event profiles of both groups were comparable, with the exception of transient mild-to-moderate infusion reactions in the enzyme-treated group, which were managed conservatively. Of the 29 enzyme-treated patients, 24 (83 percent) developed IgG antibodies, as might be expected for patients classically affected by Fabry disease who have essentially no native a-galactosidase A activity and are cross-reacting immunologic material (CRIM)–negative for the enzyme protein. However, seroconversion did not influence the efficacy of treatment. When the Phase 3 trial was completed, all 58 patients enrolled in an open-label extension study. All 29 enzyme-treated patients continued enzyme therapy, while all 29 patients originally randomized to the placebo group now received enzyme therapy. After 6 months of treatment, all 22 former placebo patients who underwent biopsies had cleared the GL-3 deposits from their renal vascular endothelial cells (as determined histologically). After 12 months of enzyme treatment, 22 of 23 patients who had optional renal biopsies retained their 0 scores for renal vascular endothelial GL-3 clearance. In total, 44 of 45 patients (98 percent) who received enzyme treatment for 6 or 12 months achieved 0 scores, indicating that the enzyme effectively cleared the renal vascular endothelial GL-3 deposits. Similar results (i.e., 0 scores) were found for GL-3 clearance in skin (96 percent) and heart (75 percent) in the extension study. Thus, the results of the extension study confirmed the results of the double-blind Phase 3 trial and demonstrated that the patients treated with enzyme for 12 months had continued GL-3 clearance from the vascular endothelium in the kidney, heart, and skin, the key sites of pathology in this disease. In addition, histologic examination of other renal, cardiac, and skin cell types revealed complete or partial clearance of accumulated GL-3. These findings further demonstrated the efficacy and safety of a-galactosidase A replacement in Fabry disease. On the basis of these findings, the European Agency for Evaluation of Medical Products has approved a-galactosidase A replacement therapy for Fabry disease, and approval by the Food and Drug Administration is pending. Because this disease is inborn, and because GL-3 accumulation begins in utero, treatment should begin in early childhood as soon as practical. In addition, transplanted or dialysis patients should receive enzyme therapy to treat or to prevent the morbidity and mortality associated with their progressive cardiac and cerebrovascular disease. After years of research, development, and evaluation, specific treatment for patients with Fabry disease may be available.

REFERENCES

1. Anderson W: A case of angiokeratoma. *Br J Dermatol* **10**:113, 1898

2. Fabry J: Ein Beitrag Zur Kenntnis der Purpura haemorrhagica nodularis (Purpura papulosa hemorrhagica Habrae). *Arch Dermatol Syphilol* **43**:187, 1898

3. Fabry J: Weiterer Beitrag zur klinik des Angiokeratoma naeviforme (Naevus angiokeratosus). *Dermatol Wochenschr* **90**:339, 1930

4. Scriba K: Zur Pathogenese des Angiokeratoma corporis diffusum Fabry mit kardiovasorenalem Symptomenkomplex. *Verh Dtsch Ges Pathol* **34**:221, 1950

5. Hornbostel H, Scriba K: Zur Diagnostik des Angiokeratoma Fabry mit kardiovasorenalem Symptomenkomplex als posphatidspeicherungs-krankheit durch Probeexcision der Haut. *Klin Wochenschr* **31**:68, 1953

6. Opitz JM et al: The genetics of angiokeratoma corporis diffusum (Fabry's disease), and its linkage with Xg(a) locus. *Am J Hum Genet* **17**:325, 1965

7. Sweeley CC, Klionsky B: Fabry's disease: Classification as a sphingolipidosis and partial characterization of a novel glycolipid. *J Biol Chem* **238**:3148, 1963

8. Desnick RJ et al: Diagnosis of glycosphingolipidoses by urinary-sediment analysis. *N Engl J Med* **284**:739, 1971

9. Wherrett JR, Hakomori SI: Characterization of a blood group B glycolipid, accumulating in the pancreas of a patient with Fabry's disease. *J Biol Chem* **248**:3046, 1973

10. Brady RO et al: Enzymatic defect in Fabry's disease: Ceramidetrihexosidase deficiency. *N Engl J Med* **276**:1163, 1967

11. Kint JA: The enzyme defect in Fabry's disease. *Nature* **227**:1173, 1970

12. Desnick RJ et al: Fabry's disease: Enzymatic diagnosis of hemizygotes and heterozygotes. a-Galactosidase activities in plasma, serum, urine, and leukocytes. *J Lab Clin Med* **81**:157, 1973

13. Brady RO et al: Fabry's disease: Antenatal detection. *Science* **172**:174, 1971

14. Bishop DF et al: Human a-galactosidase A: Nucleotide sequence of a cDNA clone encoding the mature enzyme. *Proc Natl Acad Sci U S A* **83**:4859, 1986

15. Kornreich R et al: Nucleotide sequence of the human a-galactosidase A gene. *Nucleic Acids Res* **17**:3301, 1989

16. Eng CM et al: A phase 1/2 clinical trial of enzyme replacement in Fabry disease: Pharmacokinetic, substrate clearance, and safety studies. *Am J Hum Genet* **68**:711, 2001

17. Eng CM et al: Safety and efficacy of recombinant human a-galactosidase A replacement therapy in Fabry's disease. *N Engl J Med* **345**:9, 2001

18. Schiffmann R et al: Infusion of a-galactosidase A reduces tissue globotriaosylceramide storage in patients with Fabry disease. *Proc Natl Acad Sci U S A* **97**:365, 2000

19. Schiffmann R et al: Enzyme replacement therapy in Fabry disease: A randomized controlled trial. *JAMA* **285**:2743, 2001

20. Desnick RJ et al: a-Galactosidase A deficiency: Fabry disease, in *The Metabolic and Molecular Bases of Inherited Disease*, 8th ed, edited by CR Scriver, AL Beaudet, WS Sly, D Valle. New York, McGraw-Hill, 2001, p 3733

21. Lockman LA et al: Relief of pain of Fabry's disease by diphenylhydantoin. *Neurology* **23**:871, 1973

22. Urbain G et al: Fabry's disease without skin lesions. *Lancet* **1**:1111, 1967

23. Clarke JT et al: Ceramide trihexosidosis (Fabry's disease) without skin lesions. *N Engl J Med* **284**:233, 1971

24. Ainsworth S, Smith R: A case study of Fabry's disease occurring in a black kindred without peripheral neuropathy or skin lesions. *Lab Invest* **38**:373, 1978

25. Wallace RD, Cooper WJ: Angiokeratoma corporis diffusum universale (Fabry). *Am J Med* **39**:656, 1965

26. Ferrans VJ et al: The heart in Fabry's disease: A histochemical and electron microscopic study. *Am J Cardiol* **24**:95, 1969

27. Becker AE et al: Cardiac manifestations of Fabry's disease: Report of a case with mitral insufficiency and electrocardiographic evidence of myocardial infarction. *Am J Cardiol* **36**:829, 1975

28. von Scheidt W et al: An atypical variant of Fabry's disease with manifestations confined to the myocardium. *N Engl J Med* **324**:395, 1991

29. Nakao S et al: An atypical variant of Fabry's disease in men with left ventricular hypertrophy. *N Engl J Med* **333**:288, 1995

30. Elleder M et al: Cardiocyte storage and hypertrophy as a sole manifestation of Fabry's disease: Report on a case simulating hypertrophic non-obstructive cardiomyopathy. *Virchows Arch A Pathol Anat Histopathol* **417**:449, 1990

31. Elleder M et al: Fabry's disease with isolated disease of the cardiac muscle, manifesting as hypertrophic cardiomyopathy. *Cas Lek Cesk* **129**:369, 1990

32. Linhart A et al: New insights in cardiac structural changes in patients with Fabry's disease. *Am Heart J* **139**:1101, 2000

33. Colucci WS et al: Hypertrophic obstructive cardiomyopathy due to Fabry's disease. *N Engl J Med* **307**:926, 1982

34. Fisher EA et al: Fabry disease: An unusual cause of severe coronary disease in a young man. *Ann Intern Med* **117**:221, 1992

35. Colombi A et al: Angiokeratoma corporis diffusum—Fabry's disease. *Helv Med Acta* **34**:67, 1967

36. Sher NA et al: The ocular manifestations in Fabry's disease. *Arch Ophthalmol* **97**:671, 1979

37. Spaeth GL, Frost P: Fabry's disease. Its ocular manifestations. *Arch Ophthalmol* **74**:760, 1965

38. Brown LK et al: Pulmonary involvement in Fabry disease. *Am J Respir Crit Care Med* **155**:1004, 1997

39. Nagao Y et al: Hypertrophic cardiomyopathy in late-onset variant of Fabry disease with high residual activity of a-galactosidase A. *Clin Genet* **39**:233, 1991

40. Avila JL et al: Fabry's disease: Normal a-galactosidase activity and urinary-sediment glycosphingolipid levels in two obligate heterozygotes. *Br J Dermatol* **89**:149, 1973

41. Levade T et al: Different phenotypic expression of Fabry disease in female monozygotic twins. *J Inherit Metab Dis* **14**:105, 1991

42. Sagebiel RW, Parker F: Cutaneous lesions of Fabry's disease: Glycolipid lipidosis; light and electron microscopic findings. *J Invest Dermatol* **50**:208, 1968

43. Tarnowski WM, Hashimoto K: New light microscopic skin findings in Fabry's disease; Study of four patients using plastic-embedded tissue. *Acta Derm Venereol* **49**:386, 1969

44. Breathnach SM et al: Anderson-Fabry disease: Characteristic ultrastructural features in cutaneous blood vessels in a 1-year-old boy. *Br J Dermatol* **103**:81, 1980

45. Hashimoto K et al: Angiokeratoma corporis diffusum (Fabry): Histochemical and electron microscopic studies of the skin. *J Invest Dermatol* **44**:119, 1965

46. Sung JH: Autonomic neurons affected by lipid storage in the spinal cord in Fabry's disease: Distribution of autonomic neurons in the sacral cord. *J Neuropathol Exp Neurol* **38**:87, 1979

47. Ohnishi A, Dyck P: Loss of small peripheral sensory neurons in Fabry disease: Histologic and morphometric evaluation of cutaneous nerves, spinal ganglia, and posterior columns. *Arch Neurol* **31**:120, 1974

48. de Veber GA et al: Fabry disease: Immunocytochemical characterization of neuronal involvement. *Ann Neurol* **31**:409, 1992

49. Mitsias P, Levine SR: Cerebrovascular complications of Fabry's disease. *Ann Neurol* **40**:8, 1996

50. Font RL, Fine BS: Ocular pathology in Fabry's disease. Histochemical and electron microscopic observations. *Am J Ophthalmol* **73**:419, 1972

51. Desnick RJ et al: Cardiac valvular anomalies in Fabry disease: Clinical, morphologic, and biochemical studies. *Circulation* **54**:818, 1976

52. Goldman ME et al: Echocardiographic abnormalities and disease severity in Fabry's disease. *J Am Coll Cardiol* **7**:1157, 1986

53. Faraggiana T et al: Light- and electron-microscopic histochemistry of Fabry's disease. *Am J Pathol* **103**:247, 1981

54. Lehner T, Adams CW: Lipid histochemistry of Fabry's disease. *J Pathol Bacteriol* **95**:411, 1968

55. van Mullem P, Ruiter M: Histochemical studies on lipid metabolism in so-called Fabry's disease (angiokeratoma corporis diffusum). *Arch Klin Exp Derm* **232**:148, 1968

56. Chatterjee S et al: Immunohistochemical localization of glycosphingolipid in urinary renal tubular cells in Fabry's disease. *Am J Clin Pathol* **82**:24, 1984

57. Robinson D, Khalfan H: Fabry's disease: Identification of carrier status by fluorescent/electron binding. *Biochem Soc Trans* **12**:1063, 1984

58. Bishop DF, Desnick RJ: Affinity purification of a-galactosidase A from human spleen, placenta, and plasma with elimination of pyrogen contamination: Properties of the purified splenic enzyme compared to other forms. *J Biol Chem* **256**:1307, 1981

59. Beutler E, Kuhl W: Purification and properties of human a-galactosidases. *J Biol Chem* **247**:7195, 1972

60. Schram AW et al: The identity of a-galactosidase B from human liver. *Biochim Biophys Acta* **482**:138, 1977

61. Desnick RJ, Schindler D: a- *N*-Acetylgalactosaminidase deficiency: Schindler disease. in *The Metabolic and Molecular Bases of Inherited Disease*, 8th ed, edited by CR Scriver, AL Beaudet, WS Sly, D Valle. New York, McGraw-Hill, 2001, p 3483

62. Wang AM, Desnick RJ: Structural organization and complete sequence of the human a- *N*-acetylgalactosaminidase gene: Homology with the a-galactosidase A gene proves evidence for evolution from a common ancestral gene. *Genomics* **10**:133, 1991

63. Johnson DL, Desnick RJ: Molecular pathology of Fabry's disease; Physical and kinetic properties of a-galactosidase A in cultured human endothelial cells. *Biochim Biophys Acta* **538**:195, 1978

64. Fukuhara N et al: Fabry's disease on the mechanism of the peripheral nerve involvement. *Acta Neuropathol (Berl)* **33**:9, 1975

65. Morgan SH et al: The neurological complications of Anderson-Fabry disease (a-galactosidase A deficiency)—Investigation of symptomatic and presymptomatic patients. *Q J Med* **75**:491, 1990

66. Pellissier JF et al: Morphological and biochemical changes in muscle and peripheral nerve in Fabry's disease. *Muscle Nerve* **4**:381, 1981

67. Vance DE et al: Concentrations of glycosyl ceramides in plasma and red cells in Fabry's disease, a glycolipid lipidosis. *J Lipid Res* **10**:188, 1969

68. Schibanoff JM et al: Tissue distribution of glycosphingolipids in a case of Fabry's disease. *J Lipid Res* **10**:515, 1969

69. Hozumi I et al: Biochemical and clinical analysis of accumulated glycolipids in symptomatic heterozygotes of angiokeratoma corporis diffusum (Fabry's disease) in comparison with hemizygotes. *J Lipid Res* **31**:335, 1990

70. Srivastava AK et al: Integrated STS/YAC physical, genetic, and transcript map of human Xq21.3 to q23/q24 (DXS1203-DXS1059). *Genomics* **58**:188, 1999

71. Human Gene Mutation Database, http://archive.uwcmac.uk/uwcm/mg/hgmd0.html .

72. Bernstein HS et al: Fabry disease: Six gene rearrangements and an exonic point mutation in the a-galactosidase gene. *J Clin Invest* **83**:1390, 1989

73. Eng CM et al: Fabry disease: Thirty-five mutations in the a-galactosidase A gene in patients with classic and variant phenotypes. *Mol Med* **3**:174, 1997

74. Ashton-Prolla P et al: 22 novel mutations in the a-galactosidase A gene and genotype/phenotype correlations including mild hemizygotes and severely affected heterozygotes. *J Invest Med* **48**:227, 2000

75. Meikle PJ et al: Prevalence of lysosomal storage disorders. *JAMA* **281**:249, 1999

76. Romeo G, Migeon BR: Genetic inactivation of the a-galactosidase locus in carriers of Fabry's disease. *Science* **170**:180, 1970

77. Desnick R et al: Fabry keratopathy: Molecular pathology of the chloroquine-induced phenocopy. *Am J Hum Genet* **26**:A26, 1974

78. Whitley CB et al: Amiodarone phenocopy of Fabry's keratopathy [letter]. *JAMA* **249**:2177, 1983

79. Banks DE et al: Silicon nephropathy mimicking Fabry's disease. *Am J Nephrol* **3**:279, 1983

80. Frost P et al: Fabry's disease—Glycolipid lipidosis. Histochemical and electron microscopic studies of two cases. *Am J Med* **40**:618, 1966

81. Imperial R, Heliwig E: Angiokeratoma: A clinicopathological study. *Arch Dermatol* **95**:166, 1967

82. Kornreich R et al: a-Galactosidase A gene rearrangements causing Fabry disease: Identification of short direct repeats at breakpoints in an Alu-rich gene. *J Biol Chem* **265**:9319, 1990

83. Ashley GA et al: Fabry disease: Twenty novel a-galactosidase A mutations causing the classical phenotype. *J Hum Genet* **46**:192, 2001

84. Caggana M et al: Fabry disease: Molecular carrier detection and prenatal diagnosis by analysis of closely linked polymorphisms at Xq22.1. *Am J Med Genet* **71**:329, 1997

85. Desnick R et al: Prenatal diagnosis of glycosphingolipidoses: Sandhoff's (SD) and Fabry's diseases (FD). *J Pediatr* **83**:149, 1973

86. Kleijer WJ et al: Prenatal diagnosis of Fabry's disease by direct analysis of chorionic villi. *Prenat Diagn* **7**:283, 1987

87. Malouf M et al: Ultrastructural changes in antenatal Fabry's disease. *Am J Pathol* **82**:132, 1976

88. Filling-Katz MR et al: Carbamazepine in Fabry's disease: Effective analgesia with dose-dependent exacerbation of autonomic dysfunction. *Neurology* **39**:598, 1989

89. Buhler FR et al: Kidney transplantation in Fabry's disease. *Br Med J* **3**:28, 1973

90. Maizel SE et al: Ten-year experience in renal transplantation for Fabry's disease. *Transplant Proc* **13**:57, 1981

91. Ojo A et al: Excellent outcome of renal transplantation in patients with Fabry's disease. *Transplantation* **69**:2337, 2000

92. Tsakiris D et al: Report on management of renal failure in Europe, XXVI, 1995. Rare diseases in renal replacement therapy in the ERA-EDTA Registry. *Nephrol Dial Transplant* **11**:4, 1996

93. Donati D et al: Immune function and renal transplantation in Fabry's disease. *Proc Eur Dial Transplant Assoc* **21**:686, 1984

94. Popli S et al: Involvement of renal allograft by Fabry's disease. *Am J Nephrol* **7**:316, 1987

95. Grunfeld JP et al: Renal transplantation in patients suffering from Fabry's disease: Kidney transplantation from an heterozygote subject to a subject without Fabry's disease. *Nouv Presse Med* **4**:2081, 1975

96. Desnick RJ et al: Correction of enzymatic deficiencies by renal transplantation: Fabry's disease. *Surgery* **72**:203, 1972

97. Kramer W et al: Progressive cardiac involvement by Fabry's disease despite successful renal allotransplantation. *Int J Cardiol* **7**:72, 1985

98. Mosnier JF et al: Recurrence of Fabry's disease in a renal allograft eleven years after successful renal transplantation. *Transplantation* **51**:759, 1991

99. Brady RO et al: Replacement therapy for inherited enzyme deficiency: Use of purified ceramidetrihexosidase in Fabry's disease. *N Engl J Med* **289**:9, 1973

100. Desnick RJ et al: Enzyme therapy in Fabry disease: Differential in vivo plasma clearance and metabolic effectiveness of plasma and splenic a-galactosidase A isozymes. *Proc Natl Acad Sci U S A* **76**:5326, 1979

101. Mapes CA et al: Enzyme replacement in Fabry's disease, an inborn error of metabolism. *Science* **169**:987, 1970

102. Ioannou YA et al: Overexpression of human a-galactosidase A results in its intracellular aggregation, crystallization in lysosomes and selective secretion. *J Cell Biol* **119**:1137, 1992

103. Ioannou YA et al: Fabry disease: Preclinical studies demonstrate the effectiveness of a-galactosidase A replacement in enzyme-deficient

mice. *Am J Hum Genet* **68**:14, 2001

104. Wang AM et al: Generation of a mouse model with a-galactosidase A deficiency. *Am J Hum Genet* **59**:A208, 1996

T>

Chapter 152

Ch. Lapière

Lipoid Proteinosis

HISTORICAL ASPECTS
INHERITANCE
CLINICAL PRESENTATION
Location of Lesions
Involvement of Other Organs
CLINICAL COURSE AND PROGNOSIS
LABORATORY FINDINGS
DIFFERENTIAL DIAGNOSIS
MORPHOLOGIC, BIOCHEMICAL, AND GENETIC FINDINGS
THERAPY

REFERENCES

Lipoid proteinosis is an uncommon, recessive autosomal disorder linked to loss of function mutations in the extracellular matrix protein 1 gene. [1] It is characterized by noninflammatory persistent papules on the skin and mucous membranes. The accumulation of a basement membrane–like material in various connective tissues produces the papules. The detailed pathogenesis of the disease is not yet clear. Therapy is mainly symptomatic. [2]

HISTORICAL ASPECTS

In 1929, two Viennese, E. Urbach and C. Wiethe, a dermatologist and an otorhinolaryngologist, described an entity that they called lipoidosis cutis et mucosae on the basis of histologic investigations that demonstrated the deposition, in skin and mucous membranes, of a lipoid material associated with protein. [3] The initial name was later modified to lipoid proteinosis to avoid confusion with other lipoidoses. This syndrome is also called hyalinosis cutis et mucosae and may be referred to as Urbach-Wiethe disease eponymously.

INHERITANCE

Parental consanguinity, affected siblings, and equal numbers of male and female patients suggest autosomal recessive transmission of lipoid proteinosis. Most of the reported patients have a European background, and more than half of them belong to or are related to the Germanic linguistic group. Interesting studies performed in the Afrikaaner population of South Africa suggest that most of the reported cases in that country derive from descendants of a brother and a sister who immigrated to South Africa from Germany in the middle of the seventeenth century.

Using DNA from three affected siblings in a consanguineous Saudi Arabian family, the group of J. McGrath performed a genome-wide linkage analysis and mapped the disorder to 1q21. [1] The same linkage also appeared in five other families. Using the candidate gene approach, the group identified six different homozygous loss-of-function mutations in the extracellular matrix protein 1 gene (*ECM1*) and a reduction of ECM1 immunostaining in lipoid proteinosis skin. Knowing the defect did not solve the pathogenesis of the disorder, because the biologic function of ECM1 and its shorter splice variant are not yet known.

CLINICAL PRESENTATION

The first clinical sign of lipoid proteinosis is often hoarseness, caused by infiltration of the laryngeal mucosa that has developed by birth or in early childhood. Skin lesions usually appear shortly afterward or simultaneously. An intercurrent event as benign as, for example, vaccination may precipitate the clinical signs.

Location of Lesions

Patients with lipoid proteinosis may have papular, nodular, or diffuse yellow, waxy infiltrates on the face, the axillae, and the scrotum. Skin lesions resembling pitted acne scars may appear not only on the face, but also in nonacneogenic regions. Other lesions of the face resemble solar elastosis because the deposition of yellow material induces a marked thickening of the skin with deep wrinkles (Fig. 152-1). The classic and most easily recognizable sign, although not always present, is the beaded arrangement of waxy papules along the eyelids (see Fig. 152-1).

FIGURE 152-1 Lipoid proteinosis. Note the beaded arrangement of waxy papules along the margin of both eyelids and the pseudo solar elastosis of the cheeks and forehead. (*Courtesy of O. Braun-Falco, Munich.*)

Lesions on the scalp may occur and cause alopecia. Lesions on non–sun-exposed skin can be present, as well as alterations of the mucous membranes. The tongue is often firm, and its mobility may be limited (Fig. 152-2). The tonsils and other areas in the oral cavity may be infiltrated. A yellow discoloration of the lips is characteristic (see Fig. 152-2). Traumatized skin lesions may ooze and become hyperkeratotic.

FIGURE 152-2 Discoloration of the lips in lipoid proteinosis. Limitation of mobility of the tongue is related to infiltration of the frenulum. (*Courtesy of O. Braun-Falco, Munich.*)

The palm and dorsum of the hands (Fig. 152-3A and Fig. 152-3B), elbows, knees (Fig. 154-4), and buttocks may also show signs of hyperkeratosis, possibly related to frequent trauma in these locations.

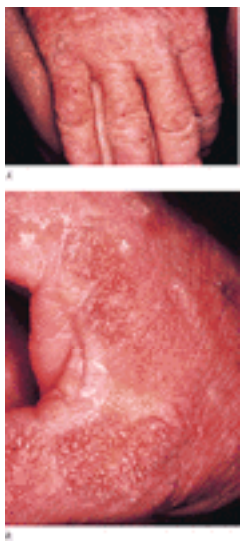

FIGURE 152-3 Hyperkeratotic papular lesions on dorsum of hands (*A*), interdigital web, and the sides of the fingers (*B*) in lipoid proteinosis.

FIGURE 152-4 Verrucous nodular lesions on the knee in lipoid proteinosis.

Involvement of Other Organs

Recurrent parotitis associated with lipoid proteinosis is related to occlusion of the salivary canal. The teeth are abnormal in almost 30 percent of patients; often, for example, patients lack permanent upper lateral incisors. Except for lesions in the oropharyngeal cavity, alterations of the digestive tract are uncommon and reported only as autopsy findings in a few patients. The respiratory tract may be involved by infiltration of the vocal cords and obstruction.

A bilateral, intracranial, bean-shaped suprasellar calcification appears in 50 percent of the patients, but not all of these patients present with epilepsy or any other signs of cerebral dysfunction. This calcification occurs in blood vessels of the hippocampal portions of the temporal lobes. Abnormalities of the peripheral nervous system are uncommon; four South African patients had peripheral nervous system lesions that may have been due to congenital analgesia.

Infiltration of the eyelids induces malpositioning of the eyelashes, causing corneal ulceration. Alopecia of the eyelashes

and eyebrows occurs. Focal degeneration of the macula has been evident in one-third of the examined patients.

Cardiac, endocrine, and urogenital disorders have been seen, but are not clearly a part of the spectrum of this disease.

Microscopic examination shows deposition of hyaline material around the blood vessels in internal organs. It indicates that the defect is a generalized disease. These changes appear to be asymptomatic.

CLINICAL COURSE AND PROGNOSIS

Except for the risk of respiratory obstruction that it carries for infants, lipoid proteinosis is compatible with a normal life span. Lesions of the upper respiratory tract may cause problems in patients with tracheotomy or disease of the trachea. The disfiguring lesions and the permanent hoarseness seriously impair the quality of life, however.

LABORATORY FINDINGS

No laboratory finding is typical of lipoid proteinosis. In some patients, glucose metabolism is abnormal. Porphyrins, liver function, protein electrophoresis, lipids, and lipoproteins are normal in the classic form of the disease. There may be signs of chronic or acute inflammation (increased alpha $_2$ or gamma globulins). Elevated serum calcium occurs rarely.

DIFFERENTIAL DIAGNOSIS

It is necessary to differentiate lipoid proteinosis from other diseases related to the deposition of amorphous material in the dermis. The differential diagnosis applies at both clinical and histopathologic levels.

Porphyria, especially erythropoietic protoporphyria, shows deposition of a PAS-positive material around the blood vessels, primarily in sun-exposed areas. Because light sensitivity is not a feature of lipoid proteinosis, the observation of lesions in non–sun-exposed sites aids the diagnosis. The pathologist should be aware of the site of the biopsy for differential diagnosis.

Lipid deposition in the various forms of xanthomatosis is rarely a problem of differential diagnosis. Furthermore, xanthoma cells never occur in lipoid proteinosis.

Amyloidosis may resemble lipoid proteinosis. Often, however, the development of amyloidosis is more progressive and may involve the kidneys, heart, and other tissues. Amyloid deposition may occur in the skin of lipoid proteinosis patients. The clinical presentation of diabetic microangiopathy is often different from that of lipoid proteinosis, but the pathologic picture may be confusing.

Acquired lipoid proteinosis in a patient with monoclonal immunoglobulinopathy has been reported. This form of the syndrome can be differentiated by immunoelectrophoresis of the plasma proteins.

MORPHOLOGIC, BIOCHEMICAL, AND GENETIC FINDINGS

The main manifestations of lipoid proteinosis are related to the deposition of an amorphous or laminated material in the connective tissues. The location and the immunohistochemical nature of the deposit support its relation to components of the basement membrane zone. It displays a PAS-positive reaction that resists digestion by enzymes and contains collagen type IV and laminin. The deposition of this material is progressive and often takes place next to cells that are known to synthesize a basement membrane.

Little is known about the initial stage of the disease. Most often, biopsy specimens collected from obvious lesions show deposition of the amorphous eosinophilic material initially around walls of the small and medium-sized blood vessels in the papillary dermis, with a pronounced “onion-skin” proliferation of the adventitia. [4] The hyaline material also appears around the smooth muscle cells of the arrectores pilorum and ultimately involves the surrounding dermis of the sweat glands. The development of these lesions may also involve the myoepithelial cells. The amount of amorphous material increases with time to progressively encase the adnexae, filling up the dermis and pushing aside most of the normal collagen bundles (Fig. 152-5).

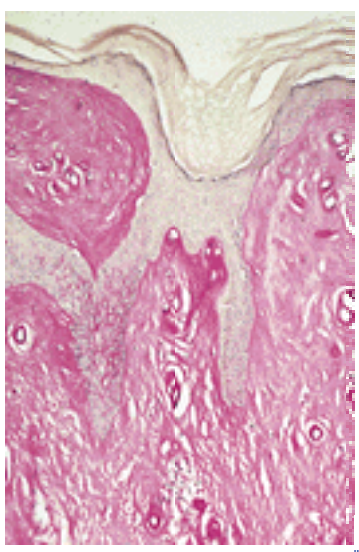

FIGURE 152-5 Extensive deposition of a PAS-positive material in the papillary dermis of a pitted acne scar lesion in

lipoid proteinosis.

By electron microscopy, the deposit seems to be composed of small granules and short filaments of low electron density, 3 to 5 nm in diameter. Electron-dense bodies (mineralized) appear around the sweat glands. Lysosomal inclusions, similar to those found in Farber disease, have been seen in the cutaneous lesions and normal skin of two unrelated patients. [5] A storage disease was considered as the mechanism for the disorder. [6]

The deposit in lipoid proteinosis is composed mainly of noncollagen protein, although the concentric layers of basement membrane–like material contain collagen types III and IV and laminin, as shown by immunodetection. A portion of this material, solubilized by reduction and injected to produce antibodies in rabbits, induced antibodies that recognize antigens also detectable in normal skin. This indicates that the disease may be related to the overproduction or the lack of degradation of a normal component of the human skin.

The lipid nature of the deposit remains controversial. Solubilization in various solvents gave nonreproducible results. The deposit stains with lipophilic agents, suggesting that unsaturated hydrophobic lipids may be present.

Exons 6 and 7 are the most common sites for mutations, and consanguinity has been present in most cases reported to date. [7]

THERAPY

There is presently no effective therapy. Topical glucocorticoids have been extensively used with beneficial effect.

Some patients have undergone plastic surgery and dermabrasion to remove lesions. The value of these therapies is questionable, because trauma has seemed to increase the deposition of the pathologic material. Some benefit has, however, been reported.

REFERENCES

1. Hamada T et al: Lipoid proteinosis maps to 1q21 and is caused by mutations in the extracellular matrix protein 1 gene. *Hum Mol Genet* **11**:833, 2002

2. Konstantinov K et al: Lipoid proteinosis: Review. *J Am Acad Dermatol* **27**:293, 1992

3. Urbach E, Wiethe C: Lipoidosis cutis et mucosae. *Virchows Arch Pathol Anat* **273**:285, 1929

4. Pierard GE et al: A clinicopathologic study of six cases of lipoid proteinosis. *Am J Dermatopathol* **10**:300, 1989

5. Navarro C et al: Lipoid proteinosis: A biochemical and ultrastructural investigation of two new cases. *Br J Dermatol* **141**:326, 1999

6. Bauer EA et al: Lipoid proteinosis: In vivo and in vitro evidence for a lysosomal storage disease. *J Invest Dermatol* **76**:119, 1981

7. Hamada T et al: Extracellular matrix protein 1 gene (*ECM1*) mutations in lipoid proteinosis and genotype-phenotype correlation. *J Invest Dermatol* **120**:345, 2003

T>

Chapter 153

John Walsh Janet Fairley

Cutaneous Mineralization and Ossification

CALCIUM
REGULATORY HORMONES
Parathyroid Hormone
Calcitonin
Vitamin D
ABERRANT CALCIFICATION AND OSSIFICATION
DYSTROPHIC CALCIFICATION
Connective Tissue Diseases
Panniculitis
Inherited Disorders
Porphyria Cutanea Tarda
Cutaneous Neoplasms
Infections
Trauma
METASTATIC CALCIFICATION
Chronic Renal Failure
Hypervitaminosis D
Milk-Alkali Syndrome
Other Disorders
IDIOPATHIC CALCIFICATION
IATROGENIC CALCIFICATION
PRIMARY OSSIFICATION

REFERENCES

CALCIUM

Calcium is involved in many physiologic processes. It is key to skeletal muscle and myocardial contraction, neurotransmission, and blood coagulation. In addition, it is the primary mineral in the bony skeleton. On the cellular level its diverse functions include transmission of information into and between cells, regulation of plasma membrane potential, and exocytosis. Only over the last 20 years has its effect on skin been fully appreciated. Calcium was first discovered to influence epidermal cell growth and differentiation in 1980, when it was shown that growth and differentiation of mouse epidermal cells in culture depended on extracellular calcium. [1] In cell culture, keratinocytes proliferate rapidly in low calcium conditions, but do not differentiate. With higher concentrations of extracellular calcium, keratinocytes begin to differentiate and express markers of terminal differentiation, such as transglutaminase activity and involucrin. Calcium also plays an integral role in modulating cell–cell adhesion. The function of the cadherin family of cell–cell adhesion molecules is calcium dependent, and mutations in plasma membrane calcium pumps were recently found to cause the acantholytic disorders Darier's disease and Hailey-Hailey disease. [2], [3]

REGULATORY HORMONES

Parathyroid Hormone

Parathyroid hormone (PTH) is an 84-amino acid, single-chain polypeptide that is synthesized in the parathyroid glands. Under normal conditions, a decrease in the serum concentration of ionized calcium results in an increase in PTH production, whereas an increase in the serum concentration of ionized calcium results in a decrease in PTH production. An increased PTH plasma concentration causes an increase in plasma calcium concentration by its direct effects on the kidney and bone and its indirect effects on the intestine. In the kidney, PTH increases renal tubular reabsorption of calcium and increases renal clearance of phosphate. PTH also acts directly on the bone to increase the plasma calcium concentration. It does this acutely by mobilizing calcium from bone into the extracellular fluid. Osteocytes and osteoblasts are the presumed target cells for this effect. PTH also stimulates osteoclastic bone resorption, possibly by stimulating osteoblasts to release factors that activate osteoclasts. PTH together with a decreased plasma phosphate concentration stimulates 1a-hydroxylase activity in the kidney, causing an increase in the plasma concentration of $1,25(OH)_2D_3$. $1,25(OH)_2D_3$ increases intestinal absorption of calcium.

Many malignant cells, particularly those derived from squamous epithelia, produce the PTH-like peptide that is responsible for the humoral hypercalcemia of malignancy. Cultured nonmalignant human keratinocytes also produce a similar protein called parathyroid hormone–related peptide (PTHrP). The existence of receptors that recognize PTH and PTH-like peptides on dermal fibroblasts suggests that PTH and keratinocyte-produced PTHrP may contribute to normal skin physiology.

The levels of PTH are elevated in some patients with keratinization disorders, [4] such as ichthyosis vulgaris, lamellar ichthyosis/nonbullous congenital ichthyosiform erythroderma, pityriasis rubra pilaris, ichthyosis linearis circumflexa, and Darier's disease. The cause and significance of this elevation are unknown.

Calcitonin

Calcitonin is a 32-amino acid polypeptide that is produced by parafollicular or C cells of the thyroid gland. Calcium is the primary stimulant for calcitonin secretion. Calcitonin lowers the serum calcium concentration, primarily through osteoclast inhibition, but whether it plays a major role in serum calcium metabolism in vivo is unclear.

Vitamin D

Vitamin D_3, or cholecalciferol, is a secosteroid formed by the opening of the beta ring of 7-dehydrocholesterol. In humans, this formation occurs in the basal layer of the epidermis. [5] First there is a UVB-mediated conversion of 7-dehydrocholesterol to previtamin D_3. Previtamin D_3 then undergoes thermal isomerization to form vitamin D_3.

Vitamin D_3 is inert. To become biologically active, it must first be hydroxylated at carbon position 25 in the liver and then at carbon position 1a by the enzyme 1a-hydroxylase in the kidney. 1a-Hydroxylase is tightly regulated. PTH and calcitonin increase its activity, whereas calcium, phosphate, and $1,25(OH)_2D_3$ inhibit it.

$1,25(OH)_2D_3$, like PTH, increases the concentration of plasma calcium. Its primary action is to stimulate the active transport of calcium across the intestine. $1,25(OH)_2D_3$ also increases the plasma calcium concentration by mobilizing calcium from bone. The simultaneous presence of PTH appears to be necessary for this effect.

$1,25(OH)_2D_3$ not only is important in calcium regulation but also plays a major role in the growth and differentiation of tissues, including skin. Receptors for $1,25(OH)_2D_3$ are present on epidermal keratinocytes, pilosebaceous structures, and in the dermis. In human keratinocyte cultures, $1,25(OH)_2D_3$ causes a dose-dependent decrease in proliferation, an increase in morphologic differentiation, and an increase in the terminal differentiation markers transglutaminase activity and involucrin. [6] Cultured human keratinocytes can convert $25(OH)D_3$ to $1,25(OH)_2D_3$, suggesting that the epidermis may regulate its own growth and differentiation by endogenously produced $1,25(OH)_2D_3$. [6] The mechanism by which $1,25(OH)_2D_3$ may induce differentiation of epidermal cells may be through calcium, because calcium is required for terminal differentiation of keratinocytes. $1,25(OH)_2D_3$ may facilitate calcium entry into cells and, through induction of calcium-binding proteins, facilitate the ability of calcium to regulate various cellular processes. [6] In addition, $1,25(OH)_2D_3$ may effect terminal differentiation hormonally.

ABERRANT CALCIFICATION AND OSSIFICATION

Despite the careful regulation of serum calcium, calcification and ossification of cutaneous and subcutaneous tissues may occur. Calcification is the deposition of insoluble calcium salts; when it occurs in cutaneous tissues it is known as *calcinosis cutis*. Ossification is the formation of true bony tissue by the deposition of calcium and phosphorus in a proteinaceous matrix as hydroxyapatite crystals. Cutaneous calcification may be divided into four major categories: dystrophic, metastatic, idiopathic, and iatrogenic (Table 153-1). Dystrophic calcification is the most common type of calcinosis cutis and occurs as a result of local tissue injury or abnormalities. Although calcium and phosphate metabolism and serum levels are normal, local tissue abnormalities, such as alterations in collagen, elastin, or subcutaneous fat may precipitate calcification. The internal organs usually remain unaffected. Metastatic calcification is the precipitation of calcium salts in normal tissue secondary to an underlying defect in calcium and/or phosphate metabolism. The calcification is usually widespread and affects predominantly blood vessels, kidneys, lungs, and gastric mucosa. Cutaneous and subcutaneous tissues also may be involved. All patients presenting with signs of metastatic calcification should receive a calcium and phosphate metabolic evaluation. Idiopathic calcification occurs without identifiable underlying tissue abnormalities or abnormal calcium and/or phosphate metabolism. Cutaneous calcification also may be iatrogenic. Cutaneous ossification most commonly occurs secondary to local tissue alteration or preexisting calcification. Any calcifying disorder of the skin may ossify secondarily. On rare occasions, primary cutaneous ossification may occur without underlying tissue abnormalities or preexisting calcification (Table 153-2).

Dystrophic
Connective tissue disease
Panniculitis
Pseudoxanthoma elasticum
Ehlers-Danlos syndrome
Werner's syndrome
Rothmund-Thompson syndrome
Porphyria cutanea tarda
Cutaneous neoplasms
Infections
Trauma
Metastatic
Chronic renal failure
Benign nodular calcification
Calciphylaxis
Hypervitaminosis D
Milk-alkali syndrome
Neoplasms
Sarcoidosis
Pseudoxanthoma elasticum
Idiopathic
Idiopathic calcification of the scrotum
Tumoral calcinosis
Subepidermal calcified nodule
Milia-like idiopathic calcinosis cutis in Down's syndrome
Iatrogenic
Intravenous calcium infusion
Calcium chloride electrode paste
Calcium alginate dressings
Liver transplantation

TABLE 153-1 **Causes of Cutaneous Calcification**

Miliary osteoma cutis of the face
Fibrodysplasia ossificans progressiva
Albright's hereditary osteodystrophy
Progressive osseous heteroplasia
Platelike osteoma cutis

TABLE 153-2 **Primary Ossification Disorders**

DYSTROPHIC CALCIFICATION

Connective Tissue Diseases

Dystrophic calcification frequently occurs in connective tissue diseases. Scleroderma and CREST syndrome (*c*alcinosis cutis, *R*aynaud's phenomenon, *e*sophageal dysfunction, *s*clerodactyly, *t*elangiectasia) are notable examples that are frequently associated with calcinosis cutis. In these disorders, nodules and plaques of calcium deposits may occur in the skin, subcutaneous tissue, muscle, or tendons, usually at least 10 years after disease onset. The calcium deposits most commonly occur on the upper extremities, especially on the fingers and wrists, but may occur in any area subject to trauma or motion. As the calcifications enlarge, they may ulcerate and exude a chalky material. Long-term diltiazem therapy has been used successfully in patients with calcinosis cutis associated with scleroderma or CREST syndrome. [7]

Dystrophic calcification also occurs in dermatomyositis. It is more commonly associated with juvenile rather than adult-onset dermatomyositis, occurring in 44 to 70 percent of children as opposed to 20 percent of adults. [8] The calcification tends to occur 2 to 3 years after disease onset. The subcutaneous calcified nodules most frequently appear on the elbows, knees, shoulders, and buttocks. The calcium deposits may be painful and can ulcerate. They also may exude a chalky material, form sinuses, and become chronically infected. Particularly in children, calcium salt deposition may become quite extensive, progressing along fascial planes of skin and muscle, forming an “exoskeleton,” and leading to significant morbidity and mortality. Calcinosis cutis in dermatomyositis is difficult to treat; however, if the patient survives long enough, the calcified nodules may improve spontaneously. A diet low in calcium and phosphate along with aluminum hydroxide may arrest or facilitate regression of the calcified nodules. [9] Disodium etidronate has also been used with some success, and intralesional glucocorticoids may have limited use. [10], [11] Diltiazem and colchicine have been reported to improve the calcinosis cutis in some patients. [12], [13] Because high levels of vitamin K–dependent ?-carboxyglutamic acid have been found in involved tissue of patients with calcinosis cutis, some investigators have treated patients with low-dose warfarin and found that it decreased the amount of extraskeletal ossification as measured by bone scan. [14] However, because none of the patients showed clinical improvement, this treatment has largely been abandoned. In advanced cases, glucocorticoid or immunosuppressant therapy may be attempted. Occasionally, calcium deposits must be removed surgically to clear sinus tracts, ulcers, or chronic infections.

Although uncommon, calcinosis cutis has been described in systemic lupus erythematosus, [15] subacute cutaneous lupus, [16] and discoid lupus erythematosus. [17]

Panniculitis

Pancreatic enzyme panniculitis is a type of lobular panniculitis that commonly demonstrates dystrophic calcification. Pancreatic enzyme panniculitis occurs in patients with pancreatitis or pancreatic adenocarcinoma and is presumably caused by the action of liberated pancreatic enzymes on subcutaneous fat. The fatty acids formed by lipolysis may combine with calcium and form calcium soap.

In subcutaneous fat necrosis of the newborn, erythematous, well-defined nodules and plaques occur during the first few weeks of life over the cheeks, back, buttocks, and extremities. The affected infants are generally otherwise healthy, and the nodules and plaques usually clear spontaneously. Occasionally, the lesions calcify, and in a small subset of patients symptomatic hypercalcemia may develop. [18]

Panniculitis may occur with connective tissue diseases and, like their cutaneous counterparts, may show dystrophic calcification. Lupus profundus and panniculitis associated with dermatomyositis may show calcification.

Inherited Disorders

Dystrophic calcification occurs in patients with pseudoxanthoma elasticum (PXE). PXE is a hereditary disorder of elastin tissue characterized by progressive calcification of elastin fibers, primarily within the skin, Bruch's membrane of the retina, and the cardiovascular system. The gene responsible for causing PXE was recently mapped to chromosome 16p13.1 and was identified as the ABC-C6 gene. [19] Although its exact function is unknown, this gene is thought to play a critical role in transmembrane transport. Most patients with PXE have normal calcium-phosphate metabolism, but a few have been identified who have abnormal calcium, phosphate, and/or vitamin D metabolism. Patients in this subset may develop metastatic calcification in the form of calcified or ossified tumors, calcification of the falx cerebri, and arterial calcification. [20], [21]

Ehlers-Danlos syndrome (EDS) is a group of inherited disorders of fibrillar collagen metabolism. Mutations in the *COL5A1, COL5A2,* and *COL5A3* genes encoding for collagen precursor proteins have been identified in some patients with classic forms of EDS. [22], [23] and [24] The skin characteristically shows hyperelasticity and fragility with formation of pseudotumors and large gaping scars. In addition, particularly in EDS type I, subcutaneous calcified spheroids may appear. Subcutaneous spheroids are thought to represent calcified ischemic fat lobules. Calcification of healing surgical incisions has also been reported in patients with Ehlers-Danlos syndrome. [25]

Werner's syndrome is an inherited disorder that leads to premature aging. The skin and subcutaneous tissues are often scleroderma-like in appearance and may show calcification. In one study, 12 of 24 patients with Werner's syndrome had soft tissue calcification. [26]

Calcinosis cutis presenting as numerous, small, yellow papules on the extremities has also been reported to occur in

association with Rothmund-Thomson syndrome. [27]

Porphyria Cutanea Tarda

Dystrophic calcification has been observed in patients with porphyria cutanea tarda (PCT). Sclerodermoid plaques with dystrophic calcification have occurred on the preauricular area, scalp, neck, and dorsa of the hands. [28] In one case report, a 78-year-old male with PCT developed extensive sclerodermoid changes with ulcerations on his torso, upper arms, and back. [29] The ulcerations contained transepidermally eliminated sheets of calcification.

Cutaneous Neoplasms

Dystrophic calcification occurs in association with a variety of benign and malignant cutaneous neoplasms. Often the neoplasms also show ossification in the surrounding stroma.

Pilomatricomas are the most common cutaneous neoplasms that manifest calcification and ossification. Recently, activating mutations in the adherens junction protein ß-catenin have been identified in a series of sporadic cases of pilomatricomas. [30] Approximately 75 percent of pilomatricomas show calcification and 15 to 20 percent show ossification. Some pilomatricomas perforate and exude a chalky material containing calcium. Ossification usually occurs within the connective tissue adjacent to the shadow cells, probably through metaplasia of fibroblasts into osteoblasts.

Other neoplasms reportedly are associated with calcification and ossification. Twenty-five percent of pilar cysts show foci of calcification, and approximately 20 percent of basal cell carcinomas show calcification. [31], [32] Intradermal nevi may infrequently show ossification, probably as a result of inflammation or folliculitis. [33] Mixed tumors (chondroid syringomas) may also show calcification and ossification. However, unlike other neoplasms, the ossification occurs within the tumor via ossification of the chondroid cells, much like endochondral bone formation occurring in the epiphyses of bones. Although rare, ossification has also been described in desmoplastic malignant melanomas and atypical fibroxanthomas. [34], [35] Other neoplasms rarely associated with ossification include pyogenic granulomas, hemangiomas, neurilemomas, trichoepitheliomas, and seborrheic keratoses.

Infections

Infectious agents may produce enough cutaneous damage to cause dystrophic calcification. Parasitic infections that may result in calcinosis cutis include onchocerciasis, [36] caused by the filaria *Onchocerca volvulus,* and cysticercosis, caused by the tapeworm *Taenia solium*. Calcinosis cutis has been reported as a complication of intrauterine herpes simplex infection. [37]

Trauma

Dystrophic calcification has been reported in a variety of settings where local tissue injury occurs, such as in scarring caused by burns, trauma, neonatal heel sticks, and surgery. One case report described calcification in abdominal keloids. [38]

METASTATIC CALCIFICATION

Chronic Renal Failure

Metastatic calcification most commonly occurs in chronic renal failure and takes the form of either benign nodular calcification or calciphylaxis. In chronic renal failure, decreased clearance of phosphate results in hyperphosphatemia. In addition, the impaired production of $1,25(OH)_2D_3$ results in a decrease in calcium absorption from the intestine and decreased serum calcium levels. The hypocalcemia results in increased PTH production and secondary hyperparathyroidism. Elevated levels of PTH cause bone resorption and mobilization of calcium and phosphate into the serum, leading to normalization of the serum calcium concentration but marked hyperphosphatemia. If the solubility product of calcium and phosphate is exceeded, metastatic calcification may occur. In benign nodular calcification, the calcifications typically occur at periarticular sites, and their size and number tend to correlate with the degree of hyperphosphatemia. The lesions disappear with normalization of calcium and phosphate levels.

Calciphylaxis is a life-threatening disorder characterized by progressive vascular calcification, soft tissue necrosis, and ischemic necrosis of the skin. Clinically it presents as firm, extremely painful, well-demarcated, violaceous plaques associated with soft tissue necrosis and ulceration (Fig. 153-1). The lesions may occur anywhere, but the lower extremities are most frequently involved. [39] The mortality rate is estimated to be approximately 80 percent. Histopathologically, there is medial calcification of small and medium-sized arteries with intimal hyperplasia, primarily in dermal and subcutaneous tissues. Calciphylaxis occurs almost exclusively in patients with a history of chronic renal failure and prolonged secondary hyperparathyroidism. However, there exist rare reports of the occurrence of calciphylaxis in the absence of renal failure. [40] Most of the patients reported are female, and there may be an association with obesity and poor nutritional status. [41], [42] Calciphylaxis is considered a type of metastatic calcification, although the calcium and phosphate solubility product is not elevated in all patients.

FIGURE 153-1 Calciphylaxis. The lesions develop as violaceous plaques that may progress to necrotic ulcers, as shown in this patient.

The pathogenesis of calciphylaxis is unknown. One theory is based on Selye's experimental animal studies in which calciphylaxis was induced in rats by exposing them to a sensitizing agent, such as PTH, dihydrotachysterol, or vitamin D, and then exposing them to a challenging agent, such as metallic salts, egg albumin, or glucocorticoids. [43] Whether or not Selye's studies are applicable to calciphylaxis in humans has been the subject of debate. In Selye's report, the clinical description of the treated rats differs from the clinical appearance of calciphylaxis in humans, and the histopathology was massive calcium deposition within connective tissue and not medial calcification of arteries.

Some patients with calciphylaxis have decreased protein C function. Protein C is a potent anticoagulant synthesized in the liver that inhibits clotting factors V and VIII. Quantitative or functional protein C deficiency leads to hypercoagulable states. Whether this plays a direct role in the pathogenesis of calciphylaxis or is a marker for a coagulation defect that predisposes a subset of these patients to calciphylaxis is unknown. Some investigators believe that patients with calciphylaxis have underlying small vessel disease, perhaps related to the etiology of their renal failure, and that this condition, in conjunction with high serum levels of PTH, predisposes them to medial calcification of small and medium arteries and to soft tissue necrosis. A recent report suggests that microorganisms may play a role in soft tissue calcification. [44]

Treatment of calciphylaxis is primarily supportive. Appropriate wound care with careful débridement of necrotic tissue and monitoring for infection are important. Oral phosphate binding therapy may be helpful in cases associated with hyperphosphatemia. Although it has not been studied in a controlled fashion, parathyroidectomy may help some patients. A total parathyroidectomy can be undertaken with autotransplantation of one gland in the forearm. The transplanted gland can be removed later if the patient's hyperparathyroidism persists. Hyperbaric oxygen therapy and systemic glucocorticoids followed by cimetidine have been anecdotally reported to be of some benefit. [45], [46] One case report demonstrated improvement with low-calcium dialysis. [47] Anticoagulant therapy does not appear to alter prognosis.

Hypervitaminosis D

Chronic ingestion of vitamin D in supraphysiologic doses (50,000 to 100,000 units per day) may produce hypervitaminosis D. The initial signs and symptoms of hypervitaminosis D are attributable to hypercalcemia and hypercalcuria and include weakness, lethargy, headache, nausea, and polyuria. Metastatic calcification may also occur.

Milk-Alkali Syndrome

Milk-alkali syndrome is characterized by excessive ingestion of calcium-containing foods or antacids, leading to hypercalcemia. Complications other than the acute manifestations of hypercalcemia include irreversible renal failure, nephrocalcinosis, and subcutaneous calcification, occurring predominantly in periarticular tissues.

Other Disorders

Other systemic disorders associated with hypercalcemia and/or hyperphosphatemia are reported to cause metastatic calcification. These disorders include the neoplasms associated with bony destruction, such as lymphoma, leukemia, multiple myeloma, and metastatic carcinoma. Sarcoidosis is also associated with metastatic calcification.

IDIOPATHIC CALCIFICATION

Calcified nodules characterize idiopathic calcification of the scrotum. The lesions usually appear in otherwise healthy males and tend to increase in size and number with time. Eventually, they may break down and exude a chalky material. Controversy exists over the etiology of this disorder. Many believe idiopathic calcification of the scrotum is truly idiopathic; others maintain that calcified scrotal nodules are inflamed or ruptured epidermoid cysts that undergo dystrophic calcification. Excision of the lesions is the treatment of choice, although patients may continue to develop nodules at other sites. Idiopathic calcification of the penis, vulva, and breast has also been reported.

Tumoral calcinosis is a disorder characterized by the deposition of calcific masses around major joints, such as hips, shoulders, elbows, and knees. It generally occurs in otherwise healthy adolescents. The masses are intramuscular or subcutaneous and may enlarge to sizes causing significant impairment of joint function. Usually the overlying skin is normal, but associated ulceration and calcinosis cutis may occur. Familial occurrences among siblings and associated hyperphosphatemia in a subset of patients have led some investigators to postulate that tumoral calcinosis is a form of metastatic calcification caused by an inborn error in phosphate metabolism. Others disagree because hyperphosphatemia is not a universal finding and the calcification occurs only in periarticular regions. Surgical excision is the treatment of choice, but phosphate deprivation has met with some success.

Subepidermal calcified nodules appear on the exposed areas of the head and the extremities. They may be congenital or acquired and typically appear as hard, 3- to 11-mm solitary lesions, although multiple lesions may occur. Some

investigators believe the lesions represent calcified sweat gland hamartomas.

Reports have described the appearance of milia-like idiopathic calcinosis cutis on the dorsa of hands and forearms of patients with Down's syndrome. [48] Some of the calcifications were associated with lesional or palpebral syringomas.

IATROGENIC CALCIFICATION

Cutaneous calcification may be iatrogenic. Calcinosis cutis is a complication of intravenous calcium chloride and calcium gluconate therapy. With extravasation of the calcium solution, calcified nodules may appear, probably as a result of an elevated tissue concentration of calcium and tissue damage at the site of the extravasated calcium solution. [49] Minor trauma and prolonged contact with calcium salts can lead to calcinosis cutis in a variety of settings. [50] It has occurred in patients undergoing electroencephalography who had prolonged contact with saturated calcium chloride electrode paste. Recently, a number of patients were reported as developing cutaneous calcification of skin graft donor sites after the application of calcium alginate dressings. [51] Transient deposits of calcium in the skin and other soft tissues have also been reported after liver transplantation. [52] It is hypothesized that these transient deposits are caused by the large amounts of calcium- and citrate-containing blood products used during surgery combined with metabolic abnormalities in the perioperative period.

PRIMARY OSSIFICATION

Primary ossification of cutaneous and subcutaneous tissues rarely occurs without any underlying tissue abnormality or preexisting calcification. In addition to miliary osteoma of the face, there are four well-described ossifying syndromes: fibrodysplasia ossificans progressiva, Albright's hereditary osteodystrophy, progressive osseous heteroplasia, and platelike osteoma cutis. Other primary ossification disorders reported in the literature, such as isolated osteoma or widespread osteoma, probably are variants of the above or represent a group of poorly described primary ossification disorders.

Miliary osteoma cutis of the face most commonly occurs as multiple small, firm nodules on the faces of young women with a history of acne vulgaris. There are, however, reports of multiple miliary osteoma cutis in older patients without acne vulgaris or other underlying skin disease. [53]

Fibrodysplasia ossificans progressiva (FOP) is an autosomal dominant syndrome characterized by the progressive ossification of deep connective tissues leading to significant morbidity and mortality. [54] Ossification is of the endochondral type, and involvement of the skin occurs as a result of direct extension from underlying tissues. Dysmorphic great toes are a characteristic feature of FOP. Other features include abnormal phalanges of the hands, deafness, baldness, and mental retardation. Although the genetic defect remains unknown, linkage analysis studies have identified potential loci at 17q21 and 4q27–31. Genes involved in the bone morphogenesis protein-signaling pathways are located in these regions. [55], [56]

Albright's hereditary osteodystrophy, progressive osseous heteroplasia, and platelike osteoma cutis are three closely related syndromes that are characterized by intramembranous bone formation in skin. Mutations in the gene encoding for the a subunit of the stimulatory G protein of adenyl cyclase have been identified in all three of these disorders. [57], [58] and [59] In addition, families have been described in which some members have platelike osteoma cutis while other members have progressive osseous heteroplasia. [60] How differing mutations in the same gene give rise to clinically distinct syndromes remains to be elucidated.

Albright's hereditary osteodystrophy is an X-linked or autosomal dominantly inherited syndrome characterized by the ossification of cutaneous and subcutaneous tissues in childhood. The ossification can occur anywhere on the body. Albright's hereditary osteodystrophy generally follows a limited course, and significant deformity and physical impairment are rare. Patients typically have brachydactyly, dimpling over the metacarpophalangeal joints (Albright's sign), obesity, round or moon facies, and mental retardation. Most patients have a deficient end-organ response to PTH or “pseudohypoparathyroidism” with hypocalcemia, hyperphosphatemia, and elevated levels of PTH. Other patients have “pseudo-pseudohypoparathyroidism” with normal serum levels of calcium and phosphorus.

Progressive osseous heteroplasia is characterized by progressive ossification of skin and deep tissues during infancy or childhood. [61] Most reported patients are female, although a small number of male patients have also been described. Ossification usually begins in the dermis and progresses to involve deeper tissues, such as muscle, as well as overlying skin. Skin involvement has been described as a papular eruption resembling “rice grains” and having a “gritty” consistency. Unlike Albright's hereditary osteodystrophy or fibrodysplasia ossificans progressiva, there are no associated dysmorphic features. Secondary orthopedic problems, such as limb-length discrepancy or ankylosis of the joint, arise if the cutaneous ossification is severe enough to limit motion.

Worret and Burgdorf first described platelike osteoma cutis in a 4-month-old infant who had a slowly spreading bony plate in the dermis on the lateral thigh and knee. [62] In addition, they described 12 other patients with similar findings. On the basis of these cases, they coined the term *platelike osteoma cutis* and proposed the following as diagnostic criteria: lesion present at birth or within first year of life; no evidence of abnormal calcium or phosphorus metabolism; no history of infection, trauma, or other predisposing events; and the presence of at least one bony plate with or without other cutaneous osteomas. After their report, many patients with various findings were described under the heading of platelike osteoma cutis. It is likely, however, that many of these patients actually had progressive osseous heteroplasia or another undefined ossification disorder. Platelike osteoma cutis is currently used to describe patients with a more limited, nonprogressive form of cutaneous ossification. Evidence is beginning to suggest that platelike osteoma cutis and progressive osseous heteroplasia may represent different ends of the spectrum of the same disorder.

REFERENCES

1. Hennings H et al: Calcium regulation on growth and differentiation of mouse epidermal cells in culture. *Cell* **19**:245, 1980

2. Hu Z et al: Mutations in ATP2C1, encoding a calcium pump, cause Hailey-Hailey disease. *Nat Genet* **24**:61, 2000

3. Sakuntabhai A et al: Spectrum of novel ATP2A2 mutations in patients with Darier's disease. *Hum Mol Gen* **8**:1611, 1999

4. Milstone LM et al: Serum parathyroid hormone level is elevated in some patients with disorders of keratinization. *Arch Dermatol* **128**:926, 1992

5. Holick MF et al: Photosynthesis of previtamin D_3 in human skin and the physiological consequences. *Science* **210**:203, 1980

6. Pillai S et al: Vitamin D and epidermal differentiation. Evidence for a role of endogenously produced vitamin D metabolites in keratinocyte differentiation. *Skin Pharmacol* **1**:149, 1988

7. Palmieri GM et al: Treatment of calcinosis with diltiazem. *Arthritis Rheum* **38**:1646, 1995

8. Cook DC et al: Dermatomyositis and focal scleroderma. *Pediatr Clin North Am* **10**:979, 1963

9. Wang WJ et al: Calcinosis cutis in juvenile dermatomyositis. Remarkable response to aluminum hydroxide therapy. *Arch Dermatol* **124**:1721, 1988

10. Rabens SF, Bethune JE: Disodium etidronate therapy for dystrophic cutaneous calcification. *Arch Dermatol* **11**:357, 1975

11. Lee SS et al: Calcinosis cutis circumscripta, treatment with an intralesional corticosteroid. *Arch Dermatol* **114**:1080, 1978

12. Dolan AL et al: Diltiazem induces remission of calcinosis in scleroderma. *Br J Rheumatol* **34**:576, 1995

13. Fuchs D et al: Colchicine suppression of local inflammation due to calcinosis in dermatomyositis and progressive systemic sclerosis. *Clin Rheum* **5**:527, 1986

14. Berger RG et al: Treatment of calcinosis universalis with low-dose warfarin. *Am J Med* **83**:72, 1987

15. Rothe MJ et al: Extensive calcinosis cutis with systemic lupus erythematosus. *Arch Dermatol* **126**:1060, 1990

16. Marzano AV et al: Dystrophic calcinosis cutis in subacute lupus. *Dermatology* **198**:90, 1999

17. Ueki H et al: Cutaneous calcinosis in localized discoid lupus erythematosus. *Arch Dermatol* **116**:196, 1980

18. Shackelford GD et al: Calcified subcutaneous fat necrosis in infancy. *J Can Assoc Radiol* **26**:203, 1975

19. Struk B et al: Mutations of the gene encoding the transmembrane transporter protein ABC-C6 cause pseudoxanthoma elasticum. *J Mol Med* **78**:282, 2000

20. Choi GS et al: Osteoma cutis coexisting with cutis laxa-like pseudoxanthoma elasticum. *J Am Acad Dermatol* **43**:337, 2000

21. Buka R et al: Pseudoxanthoma elasticum and calcinosis. *J Am Acad Dermatol* **43**:312, 2000

22. Giunta C, Steinmann B: Compound heterozygosity for a disease-causing G1489D and disease-modifying G530S substitution in COL5A1 of a patient with the classical type of Ehlers-Danlos syndrome: An explanation of intrafamilial variability? *Am J Med Genet* **90**:72, 2000

23. Richards AJ et al: A single base mutation in COL5A2 causes Ehlers-Danlos syndrome type II. *J Med Genet* **35**:846, 1998

24. Imamura Y et al: The pro-alpha3(V) collagen chain. Complete primary structure, expression domains in adult and developing tissues, and comparison to the structures and expression domains of the other types V and XI procollagen chains. *J Biol Chem* **275**:8749, 2000

25. Rees TD et al: The Ehlers-Danlos syndrome. *Plast Reconstr Surg* **32**:39, 1963

26. Murata K, Nakashima H: Werner's syndrome. Twenty-four cases and review of the Japanese medical literature. *J Am Geriatr Soc* **30**:303, 1982

27. Aydemir EH et al: Rothmund-Thomson syndrome with calcinosis universalis. *J Dermatol* **27**:591, 1988

28. Grossman ME et al: PCT: Clinical features and laboratory findings in 40 patients. *Am J Med* **67**:277, 1979

29. Wilson PR: Porphyria cutanea tarda with cutaneous “scleroderma” and calcification. *J Dermatol* **30**:39, 1985

30. Chan EF: Pilomatricomas contain activating mutations in beta-catenin. *J Am Acad Dermatol* **43**:701, 2000

31. Leppard BJ, Sanderson KB: The natural history of trichilemmal cysts. *Br J Dermatol* **116**:113, 1980

32. Walsh JS et al: Calcifying basal cell carcinomas. *Dermatol Surg* **25**:49, 1999

33. Roth SI et al: Cutaneous ossification. Report of 120 cases and review of the literature. *Arch Pathol* **76**:44, 1963

34. Moreno A et al: Osteoid and bone formation in desmoplastic malignant melanoma. *J Cutan Pathol* **13**:128, 1986

35. Chen KTK: Atypical fibroxanthoma of the skin with osteoid production. *Arch Dermatol* **116**:113, 1980

36. Harman R et al: in *Clinical Tropical Dermatology,* edited by O Canizares, R Harman. Boston, Blackwell Scientific, 1992, p 348

37. Beers BB et al: Dystrophic calcinosis cutis secondary to intrauterine herpes simplex. *Pediatr Dermatol* **3**:208, 1986

38. Redmond WJ, Baker SR: Keloidal calcification. *Arch Dermatol* **119**:270, 1983

39. Oh DH et al: Five cases of calciphylaxis and a review of the literature. *J Am Acad Dermatol* **40**:979, 1999

40. Fader DJ, Kang S: Calciphylaxis without renal failure. *Arch Dermatol* **132**:837, 1996

41. Walsh JS, Fairley JA: Calciphylaxis. *J Am Acad Dermatol* **35**:786, 1996

42. Bleyer AJ et al: A case control study of proximal calciphylaxis. *Am J Kidney Dis* **32**:376, 1998

43. Selye H: *Calciphylaxis*. Chicago, 1962, University of Chicago Press, p 1

44. Kajander EO, Ciftcioglu N: Nanobacteria: An alternative mechanism for pathogenic intra- and extracellular calcification and stone formation. *Proc Natl Acad Sci U S A* **95**:8274, 1998

45. Vassa N et al: Hyperbaric oxygen therapy in calciphylaxis-induced skin necrosis in a peritoneal dialysis patient. *Am J Kidney Dis* **23**:878, 1994

46. Elamin EM, McDonald AB: Calcifying panniculitis with renal failure: A new management approach. *Dermatology* **192**:156, 1996

47. Lipsker D et al: Low-calcium dialysis in calciphylaxis. *Arch Dermatol* **133**:798, 1997

48. Schepis C et al: Perforating milia-like idiopathic calcinosis cutis and periorbital syringomas in a girl with Down syndrome. *Pediatr Dermatol* **11**:258, 1994

49. Goldminz D et al: Calcinosis cutis following extravasation of calcium chloride. *Arch Dermatol* **124**:922, 1988

50. Wheeland RG, Roundtree JM: Calcinosis cutis resulting from percutaneous penetration and deposition of calcium. *J Am Acad Dermatol* **12**:172, 1985

51. Davey RB et al: Unusual donor site reactions to calcium alginate dressings. *Burns* **26**:393, 2000

52. Munoz SJ et al: Ectopic soft tissue calcium deposition following liver transplantation. *Hepatology* **8**:476, 1988

53. Levell NJ, Lawrence CM: Multiple papules on the face. *Arch Dermatol* **130**:373, 1994

54. Cohen RB et al: The natural history of heterotopic ossification in patients who have fibrodysplasia ossificans progressiva. *J Bone Joint Surg [Am]* **75A**:215, 1993

55. Feldman G et al: Fibrodysplasia ossificans progressiva, a heritable disorder of severe heterotopic ossification maps to human chromosome 4q27–31. *Am J Hum Genet* **66**:128, 2000

56. Lucotte G et al: Localization of the gene for fibrodysplasia ossificans progressiva (FOP) to chromosome 17q21–22. *Genet Couns* **11**:329, 2000

57. Eddy MC et al: Deficiency of the alpha-subunit of the stimulatory G protein and severe extraskeletal ossification. *J Bone Miner Res* **15**:2074, 2000

58. Yeh GL et al: GNAS1 mutation and Cbfa1 misexpression in a child with severe congenital platelike osteoma cutis. *J Bone Miner Res* **15**:2063, 2000

59. Bastepe M, Juppner H: Identification and characterization of two new, highly polymorphic loci adjacent to GNAS1 on chromosome 20q13.3. *Mol Cell Probes* **14**:261, 2000

60. Urtizberea JA et al: Progressive osseous heteroplasia. Report of a family. *J Bone Jt Surg [Br]* **80**:768, 1998

61. Miller ES et al: Progressive osseous heteroplasia: Report of two cases. *Arch Dermatol* **132**:787, 1996

62. Worret WI, Burgdorf W: Angeborenes plattenartiges Oseoma cutis bei einem Saugling. *Hautarzt* **29**:590, 1978

T>

Chapter 154

Richard Wenstrup Huiquan Zhao

Heritable Disorders of Connective Tissue with Skin Changes

THE EHLERS-DANLOS SYNDROMES
The Classical Type
The Hypermobile Type
The Vascular Type
The Kyphoscoliosis Type
The Arthrochalasia Type
The Dermatosparaxis Type
Tenascin Deficiency
Clinical Manifestations of EDS
MARFAN SYNDROME
Clinical Manifestations
Genetic Defect
HOMOCYSTINURIA
Clinical Manifestations
Metabolic Defect
Genetics
Treatment
PSEUDOXANTHOMA ELASTICUM
Clinical Manifestations
Molecular Defect
CUTIS LAXA (GENERALIZED ELASTOLYSIS)
Clinical Manifestations
Medical Management
Molecular Defect

REFERENCES

Heritable disorders of connective tissue are generalized defects caused by mutations in the genes for components of connective tissues or in enzymes modifying them. They involve many tissues, reflecting organ distribution of those components. Virtually all are inherited in a straightforward Mendelian pattern.

THE EHLERS-DANLOS SYNDROMES

The Ehlers-Danlos syndromes (EDS) are a genetically, biochemically, and clinically diverse group of disorders having joint laxity and dermal features in common. [1], [2] and [3] Prior classifications of EDS included up to 11 disorders. Recently a simplified classification was proposed that takes into account increasing clinical experience and recent advances in our understanding of the molecular pathogenesis of these disorders. Table 154-1 provides the new classification and its relationship to the most recent prior classification in 1988. [2], [4] For all forms of EDS, combined prevalence estimates of 1 in 5000 have been made. [5]



TABLE 154-1 **The Ehlers-Danlos Syndromes: Clinical Subtypes and Associated Defects**

The clinical features and molecular pathogenesis of each type of EDS will be discussed separately. All forms have generalized joint hypermobility as a feature (Fig. 154-1). Determination of hypermobility in adults and adolescents can be assessed using the scale derived by Beighton (Table 154-2). [6]

FIGURE 154-1 Ehlers-Danlos syndrome. Hyperextensibility of digits and Beighton's sign is demonstrated (see also Table 154-1).

Exam	Right	Left
Passive dorsiflexion of the fifth finger beyond 90 degrees	1	1
Passive apposition of the thumbs to the flexor aspect of the forearm (Beighton sign)	1	1
Hyperextension of the elbow beyond 10 degrees	1	1
Hyperextension of the knees beyond 10 degrees	1	1
Forward flexion of the trunk with knees fully extended so the palms of the hand rest flat on the floor	1	

A score of 5/9 or greater defines hypermobility.

TABLE 154-2 **Beighton Criteria for Joint Hypermobility**

The Classical Type

The *classical* form of Ehlers-Danlos syndrome is characterized by joint laxity, hyperextensibility of skin, and poor wound healing. The skin is soft and velvety and can be stretched easily (Fig. 154-2). The dermis is fragile and is easily bruised. Scars after trauma or surgical procedures are thin and atrophic and may stretch considerably after healing (Fig. 154-3). The more severely affected individuals have scars with a characteristic “cigarette paper” appearance. Molluscoid pseudotumors are present at the extensor surfaces of joints, in the foot, and on the shins (Fig. 154-4). Approximately half of affected individuals with Ehlers-Danlos syndrome I had been delivered up to 1 month prematurely because of premature rupture of fetal membranes. A significant number of individuals with EDS have cardiac abnormalities. Mitral valve prolapse is particularly common in the *vascular* form of EDS (type IV), [7] but can be seen in all types. Aortic root dilatation with occasional rupture has been reported in the classical and *hypermobile* form of EDS (types I to III). [8], [9] Musculoskeletal features seen in Ehlers-Danlos syndrome type I include joint hyperextensibility in all patients and a fairly high frequency of scoliosis and pes planus. The joint hypermobility can lead to the onset of osteoarthritis in the third or fourth decade.

FIGURE 154-2 Classical Ehlers-Danlos syndrome. Dermal elasticity is demonstrated. Unlike cutis laxa, the skin returns to original shape after stretching.

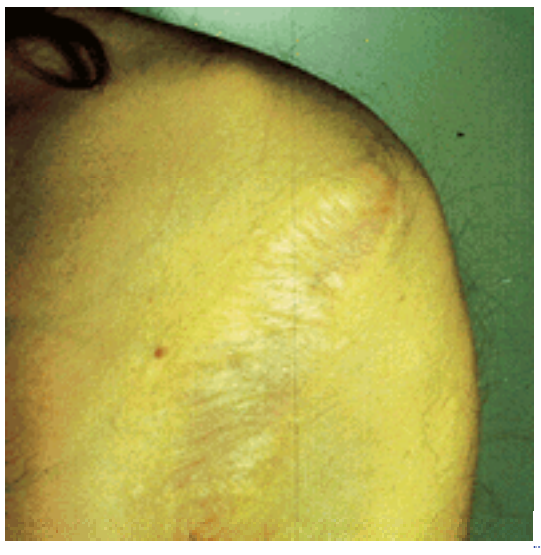

FIGURE 154-3 Classical Ehlers-Danlos syndrome. Widened, “cigarette-paper” scar is demonstrated. After a good primary repair of a injury after an automobile accident, the scar stretched out in the 6 months after the injury.

FIGURE 154-4 Classical Ehlers-Danlos syndrome. Chronic discolored scars and pseudotumors on knees and shins.

Ehlers-Danlos syndrome types I and II are autosomal dominant, single gene disorders. Ultrastructural findings show thickened collagen fibrils in skin; so-called cauliflower deformities of collagen fibrils have been reported as well. Mutations in the proa1(V) and proa2(V) chains of type V collagen are the most common cause of the classical type of Ehlers-Danlos syndrome, accounting for up to 50 percent of cases. [10], [11], [12], [13], [14], [15], [16] and [17] At least one other locus is involved, because several families are discordant for linkage to both COL5A1 and COL5A2. [14], [18]

The Hypermobile Type

This form of Ehlers-Danlos syndrome (EDS) was called type III in earlier classifications. It is characterized primarily by hyperextensibility of large and small joints, and soft velvety skin. Individuals with Ehlers-Danlos syndrome type III have near-normal scarring, but may have stretchy skin. Molluscoid pseudotumors are absent. As discussed above, a significant number of individuals with both the classical form and the hypermobile form have dilatation and/or rupture of the ascending aorta. Musculoskeletal features seen in the classical form of Ehlers-Danlos syndrome, such as scoliosis and pes planus, are also common. Musculoskeletal pain is a prominent feature of hypermobile EDS. The genetic basis of this form of EDS is unknown, and diagnosis is made on the basis of clinical criteria. [4]

The Vascular Type

This form represents a refined definition of Ehlers-Danlos syndrome type IV in that it is limited to those patients with dominant mutations in the gene for the proa1(III) chain of type III collagen. Patients with this condition often have a characteristic facies that is characterized by a thin nose, thin upper lip, and a hollowed out appearance under the eyes, which may also appear discolored (Fig. 154-5). The skin is thin, with easy bruisability; scar formation is usually normal. [19] In fair-skinned individuals, subcutaneous vasculature is easily visible beneath the skin (Fig. 154-6). Affected individuals are at high risk for life-threatening rupture of the large intestine and medium-sized arteries. [20] The most common sites of arterial rupture are the mesenchymal arteries in the abdomen, the splenic artery, renal arteries, and the descending aorta. There may also be an increased incidence of stroke. Another life-threatening complication is uterine rupture in the peripartum period. The vascular form of EDS is caused by abnormal synthesis, structure, or secretion of type III collagen. [3], [19], [21] Multiexon deletions, single-point mutations, and splicing defects have all been described, and no particular mutation type has been associated with more severe clinical effects. [20] Testing for this form of EDS can be reliably accomplished by analysis of type III procollagen and collagen chains harvested from cultured dermal fibroblasts.

FIGURE 154-5 Vascular Ehlers-Danlos syndrome. Characteristic facial features include thin nose, thin upper lip, and a hollowed out appearance under the eyes, which may also appear discolored.

FIGURE 154-6 Vascular Ehlers-Danlos syndrome. Venous pattern apparent in a fair-skinned individual.

The Kyphoscoliosis Type

The cardinal features of the *kyphoscoliosis* type of EDS, formerly called Ehlers-Danlos syndrome type VI, are neonatal onset of joint laxity, kyphoscoliosis, and hypotonia. [22] Ocular fragility, which was observed in the original reports, was found in only a minority of patients. Skin fragility, easy bruisability, and dermal hyperextensibility occurred to some extent in most patients, although they are much less prominent features than in patients with the classical form of EDS. Individuals with the kyphoscoliosis form of EDS, like those with the vascular form, are at risk of having a potentially

catastrophic arterial rupture. Most patients have radiologically detectable osteopenia, but pathologic fractures are rare.

This form of EDS is caused by a deficiency of lysyl hydroxylase (PLOD: procollagen lysyl 2-oxoglutarate 5 dioxygenase).[23] All patients with the kyphoscoliosis form of EDS have decreased hydroxylysine content in dermal tissues.[24] Many of the cross-links that normally occur between adjacent collagen monomers within a fibril begin as chemical modifications of hydroxylysyl residues. Therefore, although hydroxylysine-deficient collagen is efficiently secreted from cells, it is not capable of normal cross-linking. The deficiency is highly tissue- and collagen type-specific, apparently affecting only type I and III collagens.[25] Several patients have been reported who have defects at both PLOD alleles. Hautula and coworkers[26] reported homozygosity for an intragenic duplication of exons 9 to 15 in two patients, which appears to be the only common mutant allele, with an allele frequency of 19.1 percent in families with Ehlers-Danlos syndrome VI.[27] There appears to be a rare subtype that is clinically indistinguishable but has normal lysyl hydroxylase activity and normal hydroxylysyl content in skin.[28]

Although enzymatic testing for lysyl hydroxylase activity in cultured fibroblasts is available as a diagnostic test, measurement of the ratio of urinary excretion of pyridinium cross-links has become widely used as a screen for this disorder. Affected individuals demonstrate a narrow range of deoxypyridinoline: pyridinoline ratios that are at least one order of magnitude greater than age-matched controls.[29], [30] This method shows great promise in providing a rapid, inexpensive diagnostic test for this type of Ehlers-Danlos syndrome.

The Arthrochalasia Type

This rare form of Ehlers-Danlos syndrome, which corresponds to Ehlers-Danlos syndrome types VIIA and VIIIB in previous classifications, is characterized by extreme joint laxity, multiple joint dislocations, and congenital hip dislocations that are difficult to repair surgically. Dermal features include tissue fragility and widened scars; these dermal findings are less prominent than in the classical form of EDS.

The biochemical defect that results in this form of Ehlers-Danlos syndrome is the failure to accomplish the normal cleavage of the amino-terminal propeptide of type I collagen in all tissues. Electron micrographs of collagen fibrils from skin of a patient with this disorder show abnormal collagen fibrils that are irregular in outline and vary widely in diameter. Patients have autosomal dominant mutations that remove the exon containing the N-peptidase recognition sequence in proa1(I) (type A) or proa2(I) (type B) chains. This recognition sequence is contained in exon 6 of both COL1A1 and COL1A2, which are highly homologous and have well-conserved intron–exon boundaries. The molecular mechanism is almost always a mutation that disrupts the splice acceptor or splice donor sequences 5' or 3' to exon 6, causing removal of that exon during processing of mRNA.[1], [3], [31] Confirmation of the diagnosis is accomplished by electrophoretic demonstration of pNa1(I) or pNa2(I) chains extracted from dermal collagen or harvested from cultured skin fibroblasts. Direct demonstration of exon 6 skipping in cDNAs of COL1A1 or COL1A2 can be performed, followed by mutation analysis.

The Dermatosparaxis Type

This very rare form of Ehlers-Danlos syndrome, which corresponds to Ehlers-Danlos syndrome type VIIC in previous classifications, is characterized by striking dermal fragility. The skin is lax but not stretchy, and joint dislocation is usually not a feature of this disorder. Infants have been reported with premature rupture of membranes, and umbilical/inguinal hernias occur as well. The biochemical defect that results in this form of Ehlers-Danlos syndrome is the failure to cleave off the amino-terminal propeptide of type I collagen, due to deficiency of type I collagen N-peptidase.[32] In skin, procollagen metabolites that contain the N-propeptides are present, and cultured dermal fibroblasts secrete procollagens in which the N-propeptide, but not the C-propeptide, is retained.

Tenascin Deficiency

Deficiency of tenascin X results in a relatively rare variant of EDS that appears to be intermediate in severity between the classical and hypermobile forms, but with autosomal recessive inheritance.[33] Tenascin deficiency has been identified in approximately 3 percent of patients with classical EDS.[34]

Clinical Manifestations of EDS

SKIN In classical EDS, the dermal fragility associated with the severe classical form of Ehlers-Danlos syndrome presents special problems. When the skin splits from trauma, it is relatively painless and does not bleed excessively, but the wounds tend to gape. The wound margins tend to retract and heal slowly. Dehiscence is common, and complete wound breakdown may require repeated suturing. Alternatively, the skin may appear to hold the stitches well initially, but the wound may fall apart after sutures are removed. Wide, thin papyraceous scars develop, with eventual stretching of scars over several months. Thin, atrophic, darkly pigmented scars form as a consequence of intradermal or subdermal hematomatas, and occur mainly at pressure points (Fig. 154-4). Failure of dermal sutures prevents close apposition of wound edges. Healing is slow and wound dehiscence is common. An increased frequency of infection accompanies this slow healing. Scars may darken, and gradual stretching and widening may take place over a long period of time. During the initial healing, adhesive tapes and steri strips may help support the skin, but they will not be able to prevent spreading of scars, which occurs over many months. Retention sutures tied at a distance from the incision may help, and adhesive strips may be used to support the skin during scar formation. A significant number of patients will eventually present for scar revision; excision of hyperpigmented scars from elbows and knees is the most common cosmetic operation. In some cases, skin grafts may be necessary to repair extensive scarring on the shin. Early adolescence is probably the best time for this surgery, because additional traumatic events are less likely. Pseudotumors are easily removed from the elbows and knees, but those related to bursae over the heels are often diffusely involved with the underlying tissues and may be difficult to excise.
CARDIOVASCULAR There have been numerous reports of cardiac and aortic abnormalities in the Ehlers-Danlos

syndromes, including aortic and mitral valve prolapse or incompetence, aortic root dilatation (ARD), and aortic dissection/rupture. [22], [35], [36] A recent prevalence study of aortic root dilatation in a combined population of classical and hypermobile EDS patients indicated that 29 percent of EDS patients had ARD, and initial screening of all EDS patients by echocardiography was recommended. [9] The most commonly affected site was the sinus of Valsalva. ARD was more frequent in classical EDS than in hypermobile EDS. At present, there are no reliable data on rates of progression or frequency of serious complications. Aortic valve incompetence, aortic rupture and dissection do occur, but appear to do so far less commonly than in Marfan syndrome. Beta-blocker therapy with agents such as atenolol has been attempted in individual cases, but too few data exist to determine whether therapy is indicated or effective. Patients with the vascular form (Ehlers-Danlos syndrome IV) and the kyphoscoliotic form (type VI) of Ehlers-Danlos syndrome also have increased incidence of mitral valve prolapse and aortic abnormalities. The aortic disease in these forms may be more prevalent than that found in the other forms of Ehlers-Danlos syndrome; the disease is different in its location. Rupture and/or dissection of the aorta, when it occurs, is usually at or distal to the mid-aortic arch and extends distally. The major cause of mortality and severe complications in vascular EDS is rupture of medium-sized arteries, with the renal, splenic, and inferior mesenteric arteries being the most commonly affected. Arterial rupture generally occurs in the third, fourth, and fifth decades, and is the major cause of reduced life span in patients with this disorder. There is no good evidence that dissection and rupture of aorta or arteries is preceded by dilation, as is nearly always true for Marfan syndrome and probably true for the other forms of Ehlers-Danlos syndrome. [9], [35]

MUSCULOSKELETAL Joint dislocations are a relatively frequent complication of any form of Ehlers-Danlos syndrome. The joints most commonly affected are the shoulders, hip, patellae, temporomandibular joints, and digits. Congenital dislocation of the hip is a hallmark of the arthrochalasia form (Ehlers-Danlos syndrome VIIA and VIIB); however, it also occurs in the classical (Ehlers-Danlos syndrome I) and the vascular (Ehlers-Danlos syndrome IV) forms. Chronic pain is a major manifestation of the Ehlers-Danlos syndrome. Although it is seen in all forms, it is most common and most debilitating in the hypermobile form (Ehlers-Danlos syndrome III). The origin of this pain is not well understood. There is acute pain from dislocations and subluxations and from soft tissue injury. Many individuals with Ehlers-Danlos syndrome present with significant joint pain; many have been previously evaluated for inflammatory arthritis. However, the pain is not associated with erythema or point tenderness, and only rarely with swelling. For most patients, chronic pain began in at least one location during childhood. Chronic pain is frequently compounded by secondary depression. [37] With the exception of congenital dislocation of the hip, joint dislocations in Ehlers-Danlos syndrome either spontaneously resolve or can usually be corrected by closed reduction. Orthopedic procedures designed to reduce ligamentous laxity and therefore prevent recurrent dislocations have been generally unsatisfactory. Shoulder surgery has been particularly unsuccessful, [38] while procedures to reduce temporomandibular dislocation may be more successful. Surgery to prevent patellar dislocation is usually only temporarily successful. The most productive avenue of therapy involves a triad of anticipatory guidance, pain management, and physical therapy. Avoidance of standing or working on hardened floors for long periods and the wearing of supportive, cushioned shoes reduces foot, knee, hip, and back pain. Nonsteroidal anti-inflammatory drugs (NSAIDs) or COX-2 inhibitors may bring temporary relief; none are demonstrably superior. The relevant issue is the best-tolerated drug at the least cost. Other medications that may be used include fixed combination products (NSAID/opioid), or single-entity opioids, and tricyclic antidepressants. Hydrotherapy and behavioral and/or cognitive coping strategies may also be tried to improve pain. Physical therapy, particularly that directed at strengthening the shoulder girdle, has lowered the frequency of shoulder dislocations in individuals with chronic or recurrent dislocation. A regular exercise program may be helpful for strengthening muscles, helping to stabilize the joints and relieve stress. Some patients use orthopedic devices such as orthotics and braces.

OTHER CLINICAL MANIFESTATIONS Pregnant women with EDS should be referred to high-risk obstetric practices when possible, because of increased pregnancy risks. Women with the vascular form of EDS are at relatively high risk for catastrophic uterine rupture in the perinatal period. In addition, pregnancy is a period of increased risk of vascular rupture. Premature rupture of fetal membranes may occur because of abnormal membranes of a fetus with classical EDS, or because of premature cervical dilatation, typically occurring between 32 and 37 weeks gestation. Bowel rupture is a serious complication that is limited to the vascular form. [39] Diverticulosis with chronic inflammation can occur in all forms of EDS.

MARFAN SYNDROME

Marfan syndrome is an autosomal dominant generalized disorder of connective tissue that has primary manifestations in the skeletal, ocular, and cardiovascular systems. Premature death in Marfan syndrome is a result of its cardiovascular complications: proximal aortic dilatation associated with aortic valve incompetence, aortic rupture, or aortic dissection. The incidence of Marfan syndrome is approximately 1 in 10,000 live births. Approximately one-third of cases are new mutations without a clear family history. Patients with Marfan syndrome may have major abnormalities, primarily in three organ systems: in the eye—most characteristically dislocation of the lenses; in the skeletal system—excessive length of extremities, loose-jointedness, kyphoscoliosis, and anterior chest deformity; and in the cardiovascular system—most characteristically aortic aneurysm and mitral valve redundancy (reviewed by Godfrey [40]. Skin manifestations consist of striae distensae, a common finding, and elastosis perforans serpiginosa, a rare finding.

Clinical Manifestations

SKELETAL The skeletal features, particularly the long, narrow extremities, figured prominently in Marfan's initial description, in 1896, of the syndrome that now bears his name. Patients with Marfan syndrome are usually taller than their same-sex siblings. There is skeletal disproportion, with the most consistent and reliable measure being an abnormally low ratio of the upper segment to the lower segment (Fig. 154-7A and Fig. 154-7B). The segments are measured below and above the top of the pubic symphysis. In practice, two measurements are made with the patient standing: height and lower segment (top of the pubic symphysis to the floor). In adult whites, the mean ratio is about 0.92, and in adult blacks it is about 0.87. The excessive length of the extremities is responsible for the abnormally low upper-segment-to-lower-segment ratio (US:LS) in Marfan syndrome. Shortening of the trunk by kyphoscoliosis exaggerates the low US:LS. When kyphoscoliosis is more than minimal, the US:LS should not used. Another abnormal measurement includes the comparison of the arm span (fingertip to fingertip) with height; the arm span is usually longer by several centimeters. The ribs appear to undergo the same excessive longitudinal growth, as do the bones of the extremities. Depression of the sternum (pectus excavatum) or projection (pectus carinatum) or an asymmetric deformity

of the anterior chest results (Fig. 154-8).

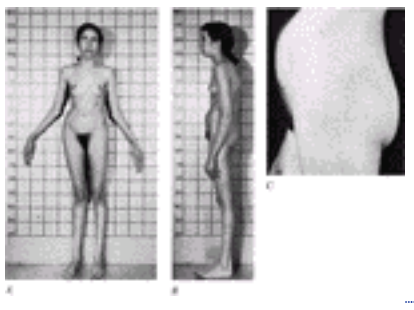

FIGURE 154-7 Marfan syndrome. Frontal (*A*) and lateral views (*B*) of a 15-year-old girl with Marfan syndrome. Note the tall stature, arachnodactyly, kyphoscoliosis, round shoulders, and strabismus. *C.* Striae distensae over the hips in the same patient.

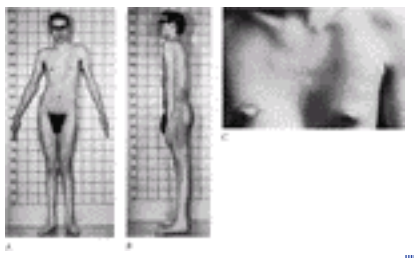

FIGURE 154-8 Marfan syndrome. Frontal (*A*) and lateral views (*B*) of a 20-year-old boy with Marfan syndrome. Note the tall stature, depressed sternum, scoliosis, and arachnodactyly. The father and a younger brother were also affected. This patient falls among the approximately 30 percent who do not have ectopia lentis. His brother, however, did have ectopia lentis. *C.* Striae distensae over the pectoral and deltoid areas.

Joint hyperextensibility is present in some, but not all, patients with Marfan syndrome. Flat-footedness, hyperextensibility at the knees (genu recurvatum) and elbows, and occasional dislocation of joints are manifestations of the loose-jointedness. Because of joint hyperextensibility and long, narrow extremities, the patient is often able to touch his or her umbilicus with the right hand passed around the back and approaching the umbilicus from the left. A relatively narrow palm of the hand with a long thumb and hyperextensibility is the basis of Steinberg's sign: the thumb propped across the palm extends well beyond the ulnar margin of the hand.

OCULAR Virtually all patients with Marfan syndrome have myopia as the result of an abnormally long anterior-posterior axis of the orbit and relatively flat corneas. In addition, approximately 70 percent of affected patients have ectopia lentis with the lens usually displaced upward. In an examination after the dilatation of the pupil, the margin of the lens is usually visible in the lower part of the pupil. Dislocation of the lens into the anterior chamber or trapping of the lens in the pupil sometimes occurs, and acute glaucoma may result. Detection of mild ectopia lentis requires full dilation of the pupils and slit lamp examination for redundancy of the suspensory ligament of the lens. Therefore, clinical exclusion of ectopia lentis in an individual suspected of having Marfan syndrome must include a slit lamp exam after dilation of the pupils. Detachment of the retina is also an ocular component of Marfan syndrome. Mild ectopia lentis can be treated by drugs that cause pupillary constriction. Contact lenses have been successful in treating patients with Marfan syndrome and high myopia. Others may require a combination of contact lenses and spectacles. More severe ectopic lentis requires lensectomy, in order to avoid glaucoma. Various procedures used to correct the flat cornea by reshaping should be avoided in patients with Marfan syndrome.

CARDIOVASCULAR The cardiovascular manifestations of Marfan syndrome are by far the most severe, and account for the overwhelming majority of morbidity associated with this disorder. The two major cardiovascular manifestations are mitral valve prolapse (MVP) and aortic root dilatation. MVP is a consequence of the redundancy of the valve leaflets, the stretching of the chordae tendineae, and dilation of the valve annulus. The prevalence of MVP in Marfan syndrome increases with age. Mitral valve prolapse can occasionally be associated with abnormal electrocardiograms, but these changes are no different than those found in individuals in the general population with MVP. Dilatation of the proximal aorta is progressive and, in some cases, may even occur in utero. Dilatation is first seen in the sinuses of Valsalva. Dilatation during life is often discontinuous and unpredictable. In general, dilatation of the aorta is more likely to occur in patients who have dilatation early in life or who have undergone rapid dilatation in the past. Patients with Marfan syndrome should be monitored on a yearly basis, as aortic complications of Marfan syndrome do not occur in aortas that are normal for age, or in adults in aortas less than 40 mm in diameter. The aortic pathology of Marfan syndrome is almost always in the proximal aorta; distal pathology is usually a result of forward progression of a dissecting lesion. Management of aortic disease in Marfan syndrome calls for lifestyle management, beta-blockers, and aortic repair. Patients with aortic dilatation are encouraged to avoid caffeine, stressful circumstances, and vigorous exercise. Beta-adrenergic blockade has been a mainstay of medical therapy for Marfan syndrome for many years, although it is based only on a single clinical trial. [41] Current recommendations are that all patients with Marfan syndrome be considered for beta-blocker therapy, except for those with significant asthma, Raynaud's phenomenon, and severe diabetes. Successful surgical repair of or replacement of an incompetent aortic valve and dilated proximal aorta has led to dramatic improvements in longevity in these patients. Current recommendations are that patients undergo aortic valve repair or replacement when the aortic sinuses dilate to 50 mm. Early use of either a valve-saving aortic repair or composite graft placement is now prudent because of significant improvements in the success of these procedures and the well-known difficulties in managing an acute aortic dissection in Marfan patients.

SKIN Most patients with Marfan syndrome have striae distensae, particularly in the pectoral and deltoid areas and over the buttocks, thighs, breasts and abdomen [42] (Fig. 154-7C), and thighs. In addition, incisional and inguinal hernias are common.

OTHER FEATURES A high-arched palate and crowding of the anterior teeth are common manifestations of the syndrome. Pulmonary manifestations include cystic changes, emphysema, and spontaneous pneumothorax. The skeletal musculature is often underdeveloped and hypotonic. Dural ectasia, due to stretching of the spinal dural meninges may cause radicular pain due to neural root compression.

Genetic Defect

Approximately 80 percent of patients with Marfan syndrome have a positive family history; in the rest, the syndrome results from de novo mutations in the sperm or ova of the parents. Thereafter, the syndrome is inherited as an autosomal dominant condition. Marfan syndrome is caused by heterozygous mutations in the gene for fibrillin (FBN1), a major constitutive element of extracellular matrix microfibrils throughout the body. Discovered in 1986, [43] fibrillin is abundant in tissues prominently affected with Marfan syndrome—the ascending aorta, suspensory ligament of the lens, periosteum, and skin. Prefibrillin is a 2871-residue protein with 5 distinct structural domains. The largest of these, comprising 75 percent of the protein, is a series of 46 EGF domains, which were originally observed in human epidermal growth factor. Most of the EGF domains are calcium-binding. [44] These EGF repeats are interrupted by eight cysteine motifs that resemble that found in latent TGF-ß–binding protein type 1 (LTBP-1). Initial studies showed that there was dramatically decreased binding of fluorescent antibodies to fibrillin in skin and dermal fibroblast matrix in patients with Marfan syndrome, [45] and the decreased antifibrillin staining cosegregated with the Marfan clinical phenotype in several Marfan families. Linkage studies by several investigators mapped Marfan syndrome to 15q21.1, which was also found to be the chromosomal locus of the fibrillin-1 (*FBN1*) gene. [46]

Over 80 mutations in the fibrillin-1 gene have been reported, nearly all of which occur only within a single family. [47], [48] Mutations have been reported over the entire coding region of the gene. Some, but not all, mutations result in the classical features of Marfan syndrome, and a few genotype-phenotype correlations are possible. Most missense mutations in the EGF domains result in the classic form of the disease. Patients with dramatic structural rearrangements such as exon skipping (approximately 10 percent of the total) have comparatively severe forms of the disease. Patients with mutations that lead to premature stop codons and reduced mRNA transcripts from the mutant allele have a surprisingly wide range of clinical severity, which is unlike the clear differences seen between osteogenesis imperfecta patients with dominant-negative mutations and loss-of-function mutations (null alleles).

It has also become apparent that genetic alterations in *FBN1* produce a spectrum of clinical abnormalities well beyond the classic Marfan phenotype, the so-called fibrillopathies. [49], [50], [51] and [52] The spectrum includes the severe neonatal Marfan phenotype at one end, extending to isolated aortic root dilatation or marfanoid skeletal features lacking cardiovascular involvement or ectopia lentis at the other.

HOMOCYSTINURIA

By definition, homocystinuria is a biochemical abnormality, not a specific disease entity. By far the most common cause of this condition is a deficiency of the enzyme *cystathionine-beta-synthase* (CBS) because of recessive mutations in its gene. Much less common causes of homocystinuria are defects in *5,10 methylenetetrahydrofolate reductase* activity, heritable vitamin B_{12} deficiency as a result of absorption abnormalities (Imerslund syndrome), and *transcobalamin II* deficiency, leading to defective cellular uptake of vitamin B_{12} (for review, see Mudd et al. [53].

The major clinical manifestations of CBS deficiency include dolichostenomelia, ectopia lentis, and chest and spinal deformities; the eye, spinal, and chest wall deformities make it superficially similar to Marfan syndrome, but generalized osteoporosis, arteriovenous thrombosis, and mental retardation are prominent features that allow relatively easy discrimination from Marfan syndrome. The cutaneous manifestations include malar flush, thin hair and skin, and cutis reticulata.

Clinical Manifestations

CARDIOVASCULAR The most serious and life-threatening complication of CBS deficiency is arterial and venous thrombosis. The cumulative risk of thrombosis in patients is approximately 25 percent. Acute occlusion of the coronary arteries can cause myocardial infarction; renal occlusion can cause severe hypertension; occlusion of carotid or cerebral arteries can cause stroke; and ophthalmic artery occlusion can cause blindness. Thrombotic complications in the venous system include renal or portal vein thrombosis and pulmonary embolism. These manifestations are usually seen in the homozygous state with the full-blown clinical syndrome. Although there have been suggestions in the literature that heterozygotes for a mutation at the cystathionine-beta-synthase locus may be at increased risk for myocardial infarction, the data are inconclusive. The vascular complications of homocystinuria are the cause of increased mortality in these patients. At least 20 percent of patients die prematurely from thrombotic complications.
OCULAR Most patients with homocystinuria have ectopia lentis in the first decade of life. Unlike Marfan syndrome, in which ectopia lentis is stable well before age 2 years, ectopia lentis is progressive in cystathionine-beta-synthase deficiency. Rupture of the sclera and retinal detachment has also been reported. Nearly all patients have significant myopia.
SKELETAL Patients with homocystinuria have the same asthenic habitus as those seen with Marfan syndrome and have a high incidence of scoliosis, thoracic asymmetry, and pectus excavatum. However, joint hyperextensibility is not a feature of this disorder; more characteristic is mild joint limitation. There is an increased incidence of pathologic fractures in patients with homocystinuria because of generalized osteopenia.
SKIN A prominent malar flush has been reported in many patients, which is most easily seen after vigorous exercise or after cold exposure. The dermis is usually fair and thin, and livedo reticularis is commonly seen on the extremities. In patients with deep venous thromboses, collateral venous channels are visible through the skin. Hair is often thinned and fair. Treatment may cause hair to darken.
OTHER FEATURES Mental retardation is a common but variable feature of CBS deficiency. About one-fifth of untreated patients have grand mal seizures. In addition, a survey reported that slightly more than 50 percent of the patients with documented CBS deficiency had psychiatric disorders such as depression, chronic behavioral disorders, obsessive-compulsive disorder, and other personality disorders. [54]

Metabolic Defect

CBS catalyzes the condensation of homocysteine and serine; in its absence, homocysteine is converted to homocystine, which is greatly increased in blood and appears in urine. Some homocysteine is converted back to methionine, which is also elevated in blood and urine. Cystine, which normally is supplied to the body by metabolism of methionine, becomes an essential amino acid in patients with CBS deficiency. There is considerable controversy over the mechanisms by which CBS and elevated homocysteine cause the clotting abnormality and the connective tissue findings characteristic of homocystinuria. With regard to the clotting abnormality, experimental work suggests that elevated homocysteine alters the aggregation of platelets, is toxic to endothelial surfaces, or alters the activity of soluble factors that regulate thrombosis, such as antithrombin III, but no widely accepted general explanation has taken hold.

The pathogenesis of the connective tissue abnormalities, including ectopia lentis, osteoporosis, and the vertebral and thoracic abnormalities, may be related to elevated homocystine levels, which inhibit cross-linking of collagen. Harris and Sjoerdsma [55] demonstrated a decrease of cross-linking of collagen in skin from two patients with homocystinuria. Specifically, they found an excess of monomeric collagen relative to the amount of dimerized collagen chains in reducing gels. The mechanism for decreased cross-linking in vivo is unknown. It might be in the earliest step in cross-linking, which is catalyzed by lysyl oxidase, or in later steps, which serve to mature the cross-links. The biologic basis for mental retardation and psychiatric disturbance in patients with homocystinuria is also unknown.

Genetics

The great majority of patients with homocystinuria have primary deficiency of CBS. A minority have an acquired (dietary) deficiency of cobalamin or heritable disorders that prevent conversion of dietary cobalamin to its biologically active forms; rarely, some have defects that cause decreased availability of 5-methyltetrahydrofolate, which is also required in the metabolism of methionine.

The clinical syndrome of homocystinuria caused by CBS deficiency is inherited as an autosomal recessive trait, based on segregation analysis of a number of families, on the increased incidence of homocystinuria in consanguineous matings, and on the finding of intermediate decreases of cystathionine-beta-synthase activity in liver biopsy specimens from parents of some patients. The gene for cystathionine-beta-synthase has been isolated and localized to the long arm of chromosome 21 (21q22.3). [56] Molecular analysis of the CBS locus has identified several mutant alleles in patients with homocystinuria. Substitution of serine for glycine at amino acid position 370 (G370S) is the most common mutation in northern European populations, but most patients are compound heterozygotes for rare mutant alleles. [57]

Treatment

It has been well documented that approximately one-half of patients with clinical CBS deficiency, respond to very high doses of pyridoxine (250 to 500 mg/day) with decreases of methionine in plasma and virtual elimination of homocysteine from urine. [53] Pyridoxine treatment, if initiated in infancy, significantly reduces the risk of thrombosis, grand mal seizures, and mental retardation. Increases in responsiveness are likely caused by increased production of pyridoxal-5'-phosphate, the active form of vitamin B_6 that is the cofactor for CBS. Sensitivity to pyridoxine is constant in affected sibs and only occurs in the presence of residual CBS activity. Specific CBS mutations predict pyridoxine responsiveness. [53]

PSEUDOXANTHOMA ELASTICUM

Pseudoxanthoma elasticum (PXE) is a heritable disorder characterized by progressive mineralization and fragmentation of elastic fibers in various tissues, involving skin (flexural sites), eye (angioid streaks and retinal defects) and cardiovascular system (hypertension, gastrointestinal bleeding, and vascular disease). The disease prevalence is estimated at 1 in 100,000 and it can be inherited as an autosomal dominant or autosomal recessive trait, with considerable morbidity and mortality. The pathogenesis of the disease was not known until recently, when the gene for PXE was mapped to chromosome 16p and its underlying molecular defect was elucidated.

Clinical Manifestations

PXE usually involves the skin, Bruch's membrane of the eye, and vascular tissues. Cases with involvement of other systems have been reported, including urinary tract and pulmonary tissues. The mortality and morbidity of PXE is dependent on the extent of extracutaneous involvement, especially the extent of vascular disease. PXE has been reported in all ethnic groups with average age of onset being 13.5 years. It is unclear whether the known female predominance (female-to-male ratio = 2:1) represents bias of ascertainment or whether there is a true gender-determined difference in disease penetrance.

SKIN Typically, yellowish papules giving a “plucked chicken” appearance in flexural skin begin in childhood. [58] However, their presence is usually not noted until adolescence or even later adulthood, because of their asymptomatic nature. Early diagnosis of this disease allows early recognition of ocular and cardiovascular manifestations reducing potential major complications. Skin involvement of PXE is of cosmetic concern. Commonly involved areas include antecubital, popliteal, inguinal, neck, axillae, and periumbilical areas, as well as oral, vaginal, and rectal mucosa (Fig. 154-9). Involvement may be progressive and the disease may ultimately involve the entire skin. In time, the skin may become soft, lax, wrinkled, and hang in folds, particularly in the neck, axillae, and groin. Patients usually present to their physicians with those lesions because of asymptomatic, cosmetic concern. Careful examination and differential diagnosis are warranted as is a skin biopsy.

FIGURE 154-9 Pseudoxanthoma elasticum. Papules on the neck. There is a distinct yellowish hue. Loose, thickened skin with a pebbled appearance on the neck.

The characteristic histology consists of fragmentation and calcification of elastic fibers in the middle and lower third of the dermis (Fig. 154-10). The normal elastic fibers may also be pathologically altered, staining blue because of their high calcium content. Skin defects of PXE usually remain unchanged throughout life. Elastosis perforans serpiginosa may coexist with PXE. Molecular studies can be done to confirm the clinical diagnosis and to help recognize asymptomatic patients with a positive family history.

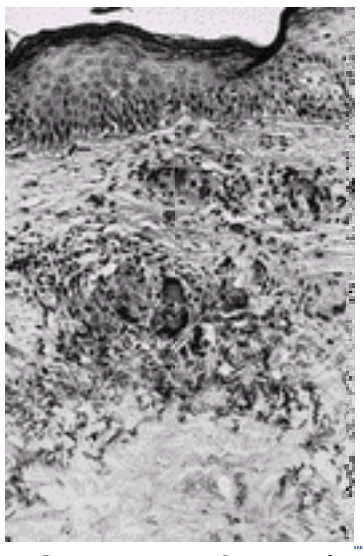

FIGURE 154-10 Pseudoxanthoma elasticum. The pathology affects the connective tissue of most of the reticular dermis. Even in routine hematoxylin and eosin preparations one may see the tightly, but irregularly coiled, basophilic elastic fibers. The collagen associated with the fibrils is also abnormal; the broad collagen bundles so characteristic of the reticular dermis are replaced by irregular and rather confluent collagen fibrils. (*Micrograph by Wallace H. Clark, Jr., MD.*)

OCULAR The characteristic ocular defects of PXE are angioid streaks of the retina, which are reddish-brown curvilinear bands radiating from the optic disk. Angioid streaks result from calcification of the elastic fibers in Bruch's membrane of the retina, with cracking and fissuring in its outer portion, the lamina elasticum. About 85 percent of the patients with PXE may have those lesions identified on routine ophthalmologic examination. The angioid streak is usually present bilaterally and is often first noted between the ages of 20 and 40 years, typically many years after the onset of cutaneous lesions. They may progress slowly or remain stationary for years. Angioid streaks are often mistaken for blood vessels, though they are irregular and generally wider. Early recognition of ocular defects is critically important because laser repair may be sight sparing. Fibrovascular ingrowth in the retina may lead to retinal hemorrhages, and may progress to the stage of retinal detachment and vision loss, worsening with each hemorrhage. Peripheral vision is often spared. Other ocular lesions may be present earlier than angioid streaks, such as the “leopard spotting” of the posterior pole of the retina, which may be concurrent with the onset of skin lesions and is characterized as yellowish speckled mottling. [59]
CARDIOVASCULAR Cardiovascular complications occur primarily in affected adults, but occasionally occur in children. Calcification of the elastic media of blood vessels with subsequent intimal proliferation leads to a variety of physical findings and to serious complications of PXE. Intermittent claudication is the most common cardiovascular manifestation and the one that presents the earliest. In adults, peripheral pulses are often severely diminished. Angina pectoris or abdominal angina may become incapacitating. Hypertension, caused by renal artery involvement, is three times more common in patients with PXE than in the general population. Severe coronary artery disease may cause early myocardial infarction. Mitral valve prolapse has a higher prevalence in PXE than the general population, [60] and cerebral artery involvement has also been reported. Seizures occur more frequently than in the general population because of the cerebral involvement. [61] Subarachnoid hemorrhage has been a major cause of death.
OTHER CLINICAL FEATURES Gastrointestinal hemorrhage, apparently caused by the fragility of calcified submucosal vessels, is the most significant vascular complication of PXE and it is usually gastric in origin. Hemorrhage may occur early in the disease progression and is often the presenting sign, presenting without warning in the second to fourth decade of life. Approximately 10 to 15 percent of patients with PXE have a gastrointestinal hemorrhage at some point in their lives. Depending on its severity, hospitalization, blood transfusion, and surgery may be necessary. Lung involvement has been seen, but rarely. Bleeding may occur in the urinary tract, and the patient presents with hematuria. Pregnancy is uncomplicated and thus not contraindicated in these patients, but there is an increased risk of miscarriage in the first trimester. [62]

Molecular Defect

At the pathologic level, PXE is known to be caused by progressive calcification and fragmentation of elastic fibers. The gene responsible for PXE has been localized to chromosome 16p13.1, and it encodes an ATP-binding cassette (ABC) subfamily C member 6 (ABCC6) transporter. [63], [64], [65] and [66] *ABCC6* consists of 31 exons spanning 75 kb and encodes a 165-kDa transmembrane protein.

Many mutations have been detected in *ABCC6* that are associated with both recessive and dominant forms of PXE. [63], [64], [65] and [66] PXE shows several distinct patterns of inheritance, including autosomal dominant forms and autosomal

recessive forms. Autosomal recessive inheritance occurs far more frequently, in approximately 90 percent of patients. Although most mutations appear to be unique variants, two disease-causing alleles occur frequently in apparently unrelated individuals. *R1141X* has been found predominantly in Europe at a frequency of 28.4 percent (overall, 18.8 percent). *ABCC6del23–29* occurred at an overall frequency of 12.9 percent and was most prevalent in patients from the United States (28.4 percent). These results suggested that *R1141X* and *ABCC6del23–29* might be derived regionally from founder alleles. [66] predominantly expressed in both the liver and kidney. [67] The precise function of the ABCC6 transported is unknown, and the genotype-phenotype relationship between *ABCC6* mutation and pathologic changes in PXE tissues remains to be elucidated.

CUTIS LAXA (GENERALIZED ELASTOLYSIS)

Cutis laxa describes a group of rare disorders that have in common loose, redundant skin and widespread manifestations in other organs. Autosomal dominant, autosomal recessive, and X-linked recessive forms of cutis laxa are recognized. [21], [68], [69] The dominant form of cutis laxa is primarily a cosmetic problem and the prognosis is good. Onset may be delayed and appear to be an acquired defect. One autosomal recessive form of cutis laxa is associated with severe cardiorespiratory complications and early death. Another less-severe form is characterized by growth retardation, developmental delay, and ligamentous laxity. [70] X-linked cutis laxa is characterized by mild joint laxity, bladder diverticula, hernias, and cranial occipital exostoses or horns. [69], [71] Acquired forms of cutis laxa have been reported, often following an ill-defined febrile illness. [72], [73] Other inherited disorders with cutis laxa as an associated feature include DeBarsy syndrome, Patterson syndrome, “wrinkly skin” syndrome, geroderma osteodysplastica, PXE, and SCARF (skeletal abnormalities, cutis laxa, craniostenosis, psychomotor) syndrome. Cutis laxa may also be associated with amyloidosis and plasma cell dyscrasias.

Clinical Manifestations

The clinical presentation of cutis laxa shows considerable heterogeneity. In both inherited and acquired forms, internal organs can be involved. As a rule, the autosomal dominant form of cutis laxa has primarily skin involvement. The autosomal recessive and X-linked forms are often associated with more severe multisystem complications that include emphysema, diaphragmatic hernia, and gastrointestinal and genitourinary diverticula. The most severe manifestation of cutis laxa is progressive emphysema, which may result in early death from cor pulmonale. Cutis laxa has been reported in all ethnic groups and, except for the X-linked recessive form, it affects men and women equally. Congenital onset is indicative of a heritable, autosomal recessive or X-linked form of cutis laxa; later onset is consistent with either a heritable or acquired form.

SKIN Skin lesions may occur in newborn infants. This is then called the “congenital” form of cutis laxa. Onset may be delayed, and thus the disease may appear to be an acquired defect. Many cases of acquired cutis laxa have developed after a febrile illness and/or inflammatory skin diseases such as lupus erythematous, urticaria, eczema, erythema multiforme, vesicular eruption, amyloidosis, and angioedema, as well as reactions to penicillin, or other drugs. Cutis laxa may affect any portion of body, but it often causes attention when it is present with loose appearance around the face, neck, shoulders, and thighs. In all forms of cutis laxa, the skin gives the appearance of being too large for the rest of the body. [74] At birth, the skin may be noticeably soft, loose, and hyperextensible. It tends to sag in the areas where the skin is normally loose, for example, around the face and eyes (Fig. 154-11). The skin may be excessively wrinkled and appears prematurely aged. Children with severe cutis laxa may have characteristic facial features known as the “bloodhound” look, an aged appearance with sagging jowls. At birth, the skin may be noticeably soft and loose; in contrast to the skin of EDS, it returns very slowly to its normal position after being stretched. Skin fragility, easy bruisability, joint hypermobility, and poor wound healing are not usually associated with cutis laxa. Cosmetic surgery can ordinarily be undertaken without complications. Histologically, elastic tissues are reduced in quantity and altered in morphology throughout dermis. The findings are highly variable and only imperfectly reflect clinical heterogeneity. [75]

FIGURE 154-11 Cutis laxa. The skin hangs in loose folds, giving the appearance of premature aging.

OTHER CLINICAL FEATURES The X-linked form of cutis laxa is known as the occipital horn syndrome because of occipital exostoses. [76] Characteristic facial features include inverted lower eyelids, a hooked nose, inverted nostrils, a short columella, and a long upper lip. The cry of an affected infant may be hoarse, and a low-pitched voice is often associated with redundancy of the vocal cords. Diagnostic skeletal features of this condition can be identified radiologically and include short flat clavicles, fused carpal bones, and occipital horns, which may not be present until a few years of age. This form is the only cutis laxa phenotype that has joint laxity as a feature. The autosomal recessive form of cutis laxa is often associated with severe internal complications, such as genitourinary and gastrointestinal diverticula. Chronic diarrhea is a widely reported complication and secondary kidney damage may be noted because of urinary tract obstruction as a consequence of diverticula. The most serious complications are diaphragmatic hernia and

emphysema, which may lead to cor pulmonale and death in first few years of life. Rare cardiovascular features include aortic dilatation with secondary cardiomegaly and congestive heart failure. Rectal prolapse, diaphragmatic atony, pneumothorax, peripheral pulmonary stenosis and aortic dilatation have also been reported. Facial features include down-slanting palpebral fissures, broad/flat nose, and large ears. [74] The autosomal dominant form of cutis laxa usually has a mild presentation and a benign clinical course. The phenotype is usually limited to skin involvement with few, if any, systemic complications. Cosmetic concerns are major issue for medical care.

Medical Management

There is no known medical treatment to prevent disease progression. Dapsone has been used with success in controlling acute swelling of the affected skin in acquired cutis laxa. [77] Surgical correction of redundant skin folds, rectal prolapse, or any hernias are temporarily beneficial and can be undertaken without major complication. [78] Regular evaluation of internal organ involvement is important in prevention and management of major complications.

Molecular Defect

Because of histologic abnormalities in elastin quantity or structure in virtually all forms of cutis laxa, investigations into the molecular pathogenesis have focused on genetic mutations that result in alterations in the structure, or processing of elastin in the extracellular matrix. The genetic heterogeneity of cutis laxa reflects the fact that several genes are required for normal elastin biosynthesis and function.

Elastin (see Chap. 15) is one of several matrix components responsible for the properties of reversible deformability in many tissues including the skin, lungs, and large blood vessels. The human elastin gene (*ELN*) is 45 kb in length and has been mapped to 7q11.2. [79], [80] Elastin initially is synthesized as individual tropoelastin molecules that are aligned on a network of elastic fibers. This alignment is stabilized by the formation of intermolecular cross-links that are mediated by the copper-dependent enzyme lysyl oxidase. Reduced lysyl oxidase activity [69] and a generalized abnormality in copper metabolism has long been described in patients with X-linked cutis laxa. [76] Recently, mutations were found in the gene encoding ATP7A, a member of the P-type ATPase family responsible for copper transport. [81], [82] and [83] ATP7A mediates copper transport from the gastrointestinal tract, efflux of excess copper from cells, and delivery of intracellular stores of copper to cuproenzymes. Lysyl oxidase deficiency has been also reported in the patients with autosomal recessive form of cutis laxa, [84] but its molecular basis remain unclear. More recently, elastin gene mutations that result in abnormal tropoelastin and abnormal elastic fibbers were reported in autosomal dominant cutis laxa. [80], [85]

REFERENCES

1. Beighton P: The Ehlers-Danlos syndromes, in *McKusick's Heritable Disorders of Connective Tissue,* 5th ed, edited by P Beighton. St. Louis, Mosby, 1992, p 189

2. Beighton P et al: International nosology of heritable disorders of connective tissue, Berlin, 1986. *Am J Med Genet* **29**:581, 1988

3. Steinmann B et al: The Ehlers-Danlos syndrome, in *Connective Tissue and its Heritable Disorders,* edited by PM Royce, B Steinmann. New York, Wiley-Liss, 1993, p 351

4. Beighton P et al: Ehlers-Danlos syndromes: Revised nosology, Villefranche, 1997. Ehlers-Danlos National Foundation (USA) and Ehlers-Danlos Support Group (UK). *Am J Med Genet* **77**:31, 1998

5. Barabas AP: Heterogeneity of the Ehlers-Danlos syndrome: Description of three clinical types and a hypothesis to explain the basic defect. *Br Med J* **2**:612, 1967

6. Beighton P et al: *Hypermobility of Joints.* London, Springer-Verlag, 1989

7. Jaffe AS et al: Mitral valve prolapse: A consistent manifestation of type IV Ehlers- Danlos syndrome. The pathogenetic role of the abnormal production of type III collagen. *Circulation* **64**:121, 1981

8. Tiller GE et al: Aortic root dilatation in Ehlers-Danlos syndrome types I, II and III. A report of five cases. *Clin Genet* **53**:460, 1998

9. Wenstrup RJ et al: Prevalence of aortic root dilatation in the Ehlers-Danlos syndrome. *Genet Med* **4**:112, 2002

10. Toriello, HV et al: A translocation interrupts the COL5A1 gene in a patient with Ehlers-Danlos syndrome and hypomelanosis of Ito. *Nat Genet* **13**:361, 1996

11. Wenstrup RJ et al: COL5A1 haploinsufficiency is a common molecular mechanism underlying the classical form of EDS. *Am J Hum Genet* **66**:1766, 2000

12. Schwarze U et al: Null alleles of the COL5A1 gene of type v collagen are a cause of the classical forms of Ehlers-Danlos syndrome (types I and II). *Am J Hum Genet* **66**:1757, 2000

13. Chessler SD et al: Mutations in the carboxyl-terminal propeptide of the pro alpha 1(i) chain of type I collagen result in defective chain association and produce lethal osteogenesis imperfecta. *J Biol Chem* **268**:18218, 1993

14. Wenstrup RJ et al: A splice-junction mutation in the region of proa1(V) chains results in the gravis form of the Ehlers-Danlos syndrome (type I). *Hum Mol Genet* **5**:1733, 1996

15. De Paepe A et al: Mutations in the COL5A1 gene are causal in the Ehlers-Danlos syndromes I and II. *Am J Hum Genet* **60**:547, 1997

16. Nicholls AC et al: An exon skipping mutation of a type V collagen gene (COL5A1) in Ehlers-Danlos syndrome. *J Med Genet* **33**:940, 1996

17. Burrows NP et al: The gene encoding collagen alpha1(V) (COL5A1) is linked to mixed Ehlers-Danlos syndrome type I/II. *J Invest Dermatol* **106**:1273, 1996

18. Greenspan DS et al: COL5A1: Fine genetic mapping and exclusion as candidate gene in families with nail-patella syndrome, tuberous sclerosis 1, hereditary hemorrhagic telangiectasia, and Ehlers-Danlos syndrome type II. *Genomics* **25**:737, 1995

19. De Paepe A: Ehlers-Danlos syndrome type IV. Clinical and molecular aspects and guidelines for diagnosis and management [review]. *Dermatology* **189**(Suppl 2):21, 1994

20. Pepin M et al: Clinical and genetic features of Ehlers-Danlos syndrome type IV, the vascular type. *N Engl J Med* **342**:673, 2000

21. Byers PH: Disorders of collagen biosynthesis and structure, in *The Metabolic Basis of Inherited Diseases,* 7th ed, edited by CR Schriver, AL Beaudet, WS Sly, D Valle, B Childs, KW Kinzler, B Vogelstein. New York, McGraw-Hill, 1995, p 4029

22. Wenstrup RJ et al: Ehlers-Danlos syndrome type VI: Clinical manifestations of collagen lysyl hydroxylase deficiency. *J Pediatr* **115**:405, 1989

23. Heikkinen J et al: Structure and expression of the human lysyl hydroxylase gene (PLOD): Introns 9 and 16 contain Alu sequences at the sites of recombination in Ehlers-Danlos syndrome type VI patients. *Genomics* **24**:464, 1994

24. Pinnell SR et al: A heritable disorder of connective tissue: Hydroxylysine-deficient collagen disease. *N Engl J Med* **286**:1013, 1972

25. Eyre DR et al: Reducible crosslinks in hydroxylysine-deficient collagens of a heritable disorder of connective tissue. *Proc Natl Acad Sci U S A* **69**:2594, 1972

26. Hautala T et al: A large duplication in the gene for lysyl hydroxylase accounts for the type VI variant of Ehlers-Danlos syndrome in two siblings. *Genomics* **15**:399, 1993

27. Heikkinen J et al: Duplication of seven exons in the lysyl hydroxylase gene is associated with longer forms of a repetitive sequence within the gene and is a common cause for the type VI variant of Ehlers-Danlos syndrome. *Am J Hum Genet* **60**:48, 1997

28. Ogur G et al: Clinical, ultrastructural and biochemical studies in two sibs with Ehlers-Danlos syndrome type VI-B-like features. *Clin Genet* **46**:417, 1994

29. Pasquali M et al: Urinary pyridinium cross-links: a noninvasive diagnostic test for Ehlers-Danlos syndrome type VI [letter]. *N Engl J Med* **331**:132, 1994

30. Steinmann B et al: Urinary pyridinoline cross-links in Ehlers-Danlos syndrome type VI [letter]. *Am J Hum Genet* **57**:1505, 1995

31. Byers PH: Disorders of collagen biosynthesis and structure, in *The Metabolic and Molecular Basis of Inherited Disease,* 8th ed, edited by CR Scriver, AL Beaudet, WS Sly, D Valle. New York, McGraw-Hill, 2001, p 5241

32. Colige A et al: Human Ehlers-Danlos syndrome type VII C and bovine dermatosparaxis are caused by mutations in the procollagen I N-proteinase gene. *Am J Hum Genet* **65**:308, 1999

33. Burch GH et al: Human tenascin-X deficiency causes an Ehlers-Danlos-like phenotype. *Am J Hum Genet* **59**:A16, 1997

34. Schalkwijk J et al: A recessive form of the Ehlers-Danlos syndrome caused by tenascin-X deficiency. *N Engl J Med* **345**:1167, 2001

35. Tiller GE et al: Aortic root dilatation in Ehlers-Danlos syndrome types I, II and III. A report of five cases. *Clin Genet* **53**:460, 1998

36. Leier CV et al: The spectrum of cardiac defects in the Ehlers-Danlos syndrome, types I and III. *Ann Intern Med* **92**:171, 1980

37. Lumley MA et al: Psychosocial functioning in the Ehlers-Danlos syndrome. *Am J Med Genet* **53**:149, 1994

38. Jerosch J et al: Shoulder instability in Ehlers-Danlos syndrome. An indication for surgical treatment? *Acta Orthop Belg* **56**:451, 1990

39. Pepin M et al: Clinical and genetic features of Ehlers-Danlos syndrome type IV, the vascular type [see comments]. *N Engl J Med* **342**:673, 2000

40. Godfrey M: The Marfan syndrome, in *McKusick's Heritable Disorders of Connective Tissue,* 5th ed, edited by P Beighton. St. Louis, Mosby, 1992, p 51

41. Shores J et al: Progression of aortic dilatation and the benefit of long-term beta-adrenergic blockade in Marfan's syndrome. *N Engl J Med* **330**:1335, 1994

42. Haber J: Miescher's elastoma (elastoma intrapapillare perforans verruciform). *Brit J Dermatol* **71**:85, 1959

43. Sakai LY et al: Fibrillin, a new 350-kD glycoprotein, is a component of extracellular microfibrils. *J Cell Biol* **103**:2499, 1986

44. Corson GM et al: Fibrillin binds calcium and is coded by cDNAs that reveal a multi-domain structure and alternatively spliced exons at the 5- prime end. *Genomics* **17**:476, 1993

45. Hollister DW et al: Immunohistologic abnormalities of the microfibrillar-fiber system in the Marfan syndrome. *N Engl J Med* **323**:152, 1990

46. Magenis RE et al: Localization of the fibrillin (FBN) gene to chromosome 15, band q21.1. *Genomics* **11**:346, 1991

47. Dietz HC et al: Mutations in the human gene for fibrillin-1 (FBN1) in the Marfan syndrome and related disorders. *Hum Mol Genet* **4**:1799, 1995

48. Robinson PN et al: The molecular genetics of Marfan syndrome and related microfibrillopathies. *J Med Genet* **37**:9, 2000

49. Aoyama T et al: Fibrillin abnormalities and prognosis in Marfan syndrome and related disorders. *Am J Med Genet* **58**:169, 1995

50. Francke U et al: A Gly1127Ser mutation in an EGF-like domain of the fibrillin-1 gene is a risk factor for ascending aortic aneurysm and dissection. *Am J Hum Genet* **56**:1287, 1995

51. Dietz HC et al: Clustering of fibrillin (FBN1) missense mutations in Marfan syndrome patients at cysteine residues in EGF-like domains. *Hum Mutat* **1**:366, 1992

52. Dietz HC et al: The phenotypic continuum associated with FBN1 mutations includes the Shprintzen-Goldberg syndrome. *Am J Hum Genet* **57**:A211, 1995

53. Mudd SLHKJ: Disorders of transsulfuration, in *The Metabolic and Molecular Basis of Inherited Disease,* 8th ed, edited by CR Scriver, AL Beaudet, WS Sly, D Valle. New York, McGraw-Hill, 2001, p 2007

54. Abbott MH et al: Psychiatric manifestations of homocystinuria due to cystathionine beta-synthase deficiency: Prevalence, natural history, and relationship to neurologic impairment and vitamin B_6 responsiveness. *Am J Med Genet* **26**:959, 1987

55. Harris ED Jr et al: Effect of penicillamine on human collagen and its possible application to treatment of scleroderma. *Lancet* **2**:996, 1966

56. Munke M et al: The gene for cystathionine beta-synthase (CBS) maps to the subtelomeric region on human chromosome 21q and to proximal mouse chromosome 17. *Am J Hum Genet* **42**:550, 1988

57. Kraus JP: Molecular basis of phenotype expression in homocystinuria. *J Inherit Metab Dis* **17**:383, 1994

58. Neldner KH: Pseudoxanthoma elasticum. *Int J Dermatol* **27**:98, 1988

59. McDonald HR et al: Reticular-like pigmentary patterns in pseudoxanthoma elasticum. *Ophthalmology* **95**:306, 1988

60. Lebwohl MG et al: Pseudoxanthoma elasticum and mitral-valve prolapse. *N Engl J Med* **307**:228, 1982

61. Iqbal A et al: Pseudoxanthoma elasticum: a review of neurological complications. *Ann Neurol* **4**:18, 1978

62. Viljoen DL et al: The obstetric and gynecological implications of pseudoxanthoma elasticum. *Br J Obstet Gynaecol* **94**:884, 1987

63. Bergen AA et al: Mutations in ABCC6 cause pseudoxanthoma elasticum. *Nat Genet* **25**:228, 2000

64. Ringpfeil F et al: Compound heterozygosity for a recurrent 16.5-kb Alu-mediated deletion mutation and single-base-pair substitutions in the ABCC6 gene results in pseudoxanthoma elasticum. *Am J Hum Genet* **68**:642, 2001

65. Struk B et al: Mutations of the gene encoding the transmembrane transporter protein ABC-C6 cause pseudoxanthoma elasticum. *J Mol Med* **78**:282, 2000

66. Le Saux O et al: Mutations in a gene encoding an ABC transporter cause pseudoxanthoma elasticum. *Nat Genet* **25**:223, 2000

67. Uitto J et al: Molecular genetics of pseudoxanthoma elasticum: a metabolic disorder at the environment-genome interface? *Trends Mol Med* **7**:13, 2001

68. Beighton P: The dominant and recessive forms of cutis laxa. *J Med Genet* **9**:216, 1972

69. Byers PH et al: X-linked cutis laxa: defective collagen crosslink formation due to decreased lysyl oxidase activity. *N Engl J Med* **303**:61, 1980

70. Ogur G et al: Syndrome of congenital cutis laxa with ligamentous laxity and delayed development: Report of a brother and sister from Turkey. *Am J Med Genet* **37**:6, 1990

71. Kuivaniemi H et al: Abnormal copper metabolism and deficient lysyl oxidase activity in a heritable connective tissue disorder. *J Clin Invest* **69**:730, 1982

72. Reed WB et al: Acquired cutis laxa. Primary generalized elastolysis. *Arch Dermatol* **103**:661, 1971

73. Koch SE et al: Acquired cutis laxa: Case report and review of disorders of elastolysis. *Pediatr Dermatol* **2**:282, 1985

74. Pope FM: Cutis laxa, in *McKusick's Heritable Disorders of Connective Tissue,* 5th ed, edited by P Beighton. St. Louis, Mosby, 1992, p 253

75. Boente MC et al: Wrinkly skin syndrome: Ultrastructural alterations of the elastic fibers. *Pediatr Dermatol* **16**:113, 1999

76. Kuivaniemi H et al: Abnormal copper metabolism and deficient lysyl oxidase activity in a heritable connective tissue disorder. *J Clin Invest* **69**:730, 1982

77. Fisher BK et al: Acral localized acquired cutis laxa. *J Am Acad Dermatol* **21**:33, 1989

78. Nahas FX et al: The role of plastic surgery in congenital cutis laxa: A 10-year follow-up. *Plast Reconstr Surg* **104**:1174, 1999

79. Indik Z et al: Alternative splicing of human elastin mRNA indicated by sequence analysis of cloned genomic and complementary DNA. *Proc Natl Acad Sci U S A* **84**:5680, 1987

80. Tassabehji M et al: An elastin gene mutation producing abnormal tropoelastin and abnormal elastic fibers in a patient with autosomal dominant cutis laxa. *Hum Mol Genet* **7**:1021, 1998

81. Ronce N et al: A C2055T transition in exon 8 of the ATP7A gene is associated with exon skipping in an occipital horn syndrome family [letter]. *Am J Hum Genet* **61**:233, 1997

82. Moller LB et al: Similar splice-site mutations of the ATP7A gene lead to different phenotypes: Classical Menkes disease or occipital horn syndrome. *Am J Hum Genet* **66**:1211, 2000

83. Dagenais SL et al: A novel frameshift mutation in exon 23 of ATP7A (MNK) results in occipital horn syndrome and not in Menkes disease. *Am J Hum Genet* **69**:420, 2001

84. Khakoo A et al: Congenital cutis laxa and lysyl oxidase deficiency. *Clin Genet* **51**:109, 1997

85. Zhang MC et al: Cutis laxa arising from frameshift mutations in exon 30 of the elastin gene (ELN). *J Biol Chem* **274**:981, 1999

T>

Chapter 155

Kenneth Kraemer

Heritable Diseases with Increased Sensitivity to Cellular Injury

XERODERMA PIGMENTOSUM
Frequency
Clinical Features
Laboratory Abnormalities
Treatment
Clinical-Laboratory Correlations
COCKAYNE SYNDROME
Clinical Features
Laboratory Abnormalities
Clinical-Laboratory Correlation
Patient Support Group
XERODERMA PIGMENTOSUM–COCKAYNE SYNDROME COMPLEX
TRICHOTHIODYSTROPHY
Laboratory Abnormalities
BLOOM SYNDROME
Clinical Features
Laboratory Studies
Clinical-Laboratory Correlation
FANCONI ANEMIA
Clinical Features
Laboratory Abnormalities
Clinical-Laboratory Correlation
Registry
DYSKERATOSIS CONGENITA
Clinical Features
Laboratory Studies
Clinical-Laboratory Correlation
CONCLUSION
REFERENCES

A group of heritable diseases with differing clinical features share the common characteristics of in vitro or in vivo cellular hypersensitivity to damage by certain physical or chemical agents (Table 155-1). Diseases with autosomal recessive, X-linked, and autosomal dominant inheritance fall in this group. These diseases include xeroderma pigmentosum, Cockayne syndrome, trichothiodystrophy, Bloom syndrome, Fanconi anemia, dyskeratosis congenita, basal cell nevus syndrome, ataxia-telangiectasia, and familial melanoma with dysplastic nevi. Clinical abnormalities involve the cutaneous, ocular, nervous, immune, hemopoietic, skeletal, and gastrointestinal systems. Some are associated with increased incidence of neoplasia.

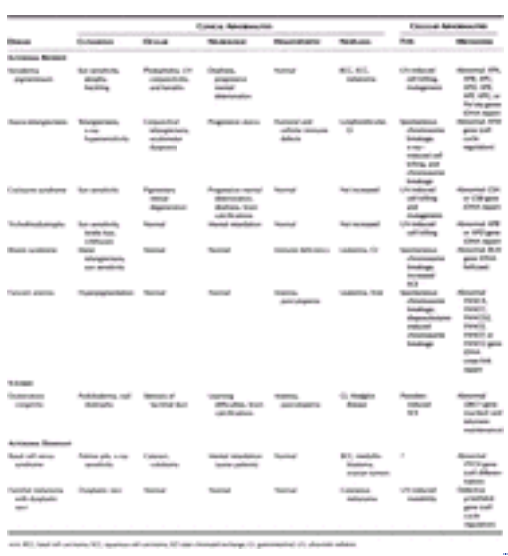

TABLE 155-1 **Heritable Diseases with Cellular Hypersensitivity**

Several have a major feature of progressive degeneration of previously normal bodily function.

The cellular hypersensitivity is often of diagnostic utility. Further, it may suggest pathogenic mechanisms and measures for therapeutic or prophylactic intervention. The molecular basis of the cellular hypersensitivity is currently being clarified in some of these disorders.

In this chapter the clinical features and laboratory abnormalities of the first six of the heritable diseases with cellular hypersensitivity listed above are presented. Basal cell nevus syndrome, ataxia-telangiectasia, and familial melanoma with dysplastic nevi are reviewed in Chap. 82, Chap. 92, and Chap. 191. The diseases are discussed in terms of the systems affected, the cellular hypersensitivity, and the relevance of the cellular abnormality to the clinical symptoms. The

major tests used to measure cellular hypersensitivity and to assess DNA repair are described in Chap. 35.

XERODERMA PIGMENTOSUM

Xeroderma pigmentosum (XP) serves as the prototype heritable disease with increased sensitivity to cellular injury. [1], [2] and [3] XP is an autosomal recessive disease with sun sensitivity, photophobia, early onset of freckling, and subsequent neoplastic changes on sun-exposed surfaces. There is cellular hypersensitivity to ultraviolet (UV) radiation and to certain chemicals in association with abnormal DNA repair. Some of the patients have progressive neurologic degeneration.

Frequency

Xeroderma pigmentosum occurs with an estimated frequency of 1 in 1 million persons in the United States. It is more common in Japan and the Middle East. Patients have been reported worldwide in all races, including whites, Asians, blacks, and Native Americans. [1] Consanguinity is common.

Clinical Features

SKIN Approximately half the patients with XP have a history of acute sunburn reaction on minimal UV exposure. The other patients apparently tan normally without excessive burning. In all patients, numerous freckle-like hyperpigmented macules appear (Fig. 155-1). The median age of onset of the cutaneous symptoms is between 1 and 2 years [1] (Fig. 155-2). These abnormalities are strikingly limited to sun-exposed areas (see Fig. 155-1E). Continued sun exposure causes the patient's skin to become dry and parchment-like, with increased pigmentation, hence the name *xeroderma pigmentosum* (“dry pigmented skin”) (see Fig. 155-1A). Premalignant actinic keratoses develop at an early age (see Fig. 155-1B). XP is an example of accelerated photoaging. The appearance of sun-exposed skin in children with XP is similar to that occurring in farmers and sailors after many years of extreme sun exposure.

FIGURE 155-1 Xeroderma pigmentosum. *A.* Pigmentary changes, atrophy, dryness, and cheilitis in a 16-year-old patient. *B.* Cheek of a 14-year-old patient with pigmented macules of varying size and intensity, actinic keratosis, basal cell carcinoma, and a surgical scar. *C.* Corneal clouding, prominent conjunctival blood vasculature, and loss of lashes. *D.* A 26-year-old patient with deafness and mental retardation. (Note hearing aid.) *E.* Myriads of pigmented macules of varying size and intensity and scattered achromic areas on the back, with marked sparing of sun-protected buttocks of a 14-year-old patient.

CANCER Patients with XP under 20 years of age have a greater than 1000-fold increased risk of cutaneous basal cell or squamous cell carcinoma or melanoma. [1], [4] The median age of onset of nonmelanoma skin cancer reported in patients with XP was 8 years. This 50-year reduction in comparison with the general population is an indication of the importance of DNA repair in protection from skin cancer in normal individuals (see Fig. 155-2). Multiple primary cutaneous neoplasms, including melanomas, occur commonly in XP patients.

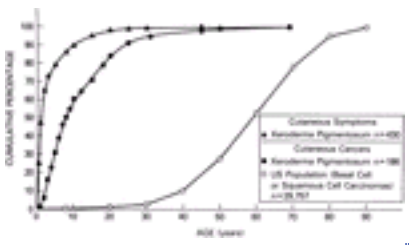

FIGURE 155-2 Xeroderma pigmentosum. Age at onset of clinical symptoms and skin cancers. Age at onset of cutaneous symptoms (generally sun sensitivity or pigmentation) was reported for 430 patients. Age at first skin cancer was reported for 186 patients and is compared with the age distribution for 29,757 patients with basal cell carcinoma or squamous cell carcinoma in the U.S. general population. There is a 50-year reduction in age of onset of skin cancer in the XP patients compared with the U.S. general population. (*From* Ref. [1].)

Review of the world literature has revealed a substantial number of cases of oral cavity neoplasms, particularly squamous cell carcinoma of the tip of the tongue—a presumed sun-exposed location. Brain (sarcoma and medulloblastoma), central nervous system (astrocytoma of the spinal cord), lung, uterine, breast, pancreatic, gastric, renal, and testicular tumors and leukemias have been reported in a few patients with XP. [1], [4], [5] Overall, these reports suggest an approximate 10- to 20-fold increase in internal neoplasms in XP.

EYES Ocular abnormalities are almost as common as the cutaneous abnormalities and are an important feature of XP [1], [4] (see Fig. 155-1C). The posterior portion of the eye (retina) is shielded from UV radiation by the anterior portion (lids, cornea, and conjunctiva). Clinical findings are strikingly limited to these anterior, UV-exposed structures. Photophobia is often present and may be associated with prominent conjunctival injection. Continued UV exposure of the eye may result

in severe keratitis leading to corneal opacification and vascularization. The lids develop increased pigmentation and loss of lashes. Atrophy of the skin of the lids results in ectropion, entropion, or in severe cases, complete loss of the lids. Benign conjunctival inflammatory masses or papillomas of the lids may be present. Epithelioma, squamous cell carcinoma, and melanoma of UV-exposed portions of the eye are common. The ocular manifestations may be more severe in black patients. [6]

NEUROLOGIC SYSTEM Neurologic abnormalities have been reported in approximately 30 percent of the patients. [1], [4], [7] The onset may be early in infancy or, in some patients, delayed until the second decade. The neurologic abnormalities may be mild (e.g., isolated hyporeflexia) or severe, with progressive mental retardation, sensorineural deafness (beginning with high-frequency hearing loss), spasticity, or seizures (see Fig. 155-1D). The most severe form, known as the *De Sanctis-Cacchione syndrome,* involves the cutaneous and ocular manifestations of classic XP plus additional neurologic and somatic abnormalities, including microcephaly, progressive mental deterioration, low intelligence, hyporeflexia or areflexia, choreoathetosis, ataxia, spasticity, Achilles tendon shortening leading to eventual quadraparesis, dwarfism, and immature sexual development. The complete De Sanctis-Cacchione syndrome has been recognized in very few patients; however, many patients with XP have one or more of its neurologic features. In clinical practice, deep tendon reflex testing and routine audiometry usually can serve as a screen for the presence of XP-associated neurologic abnormalities. The predominant neuropathologic abnormality found at autopsy in patients with neurologic symptoms was loss (or absence) of neurons, particularly in the cerebrum and cerebellum. There is evidence for a primary axonal degeneration in these patients. [7]

Laboratory Abnormalities

There have been no consistent routine clinical laboratory abnormalities in patients with XP. Tests of cellular hypersensitivity to UV damage, however, have shown uniformly abnormal results. [2], [3] One XP patient was reported with hypoglycinemia. [8]

CELLULAR HYPERSENSITIVITY Cultured cells from patients with XP generally grow normally when not exposed to damaging agents. The population growth rate or single-cell colony-forming ability is reduced to a greater extent than normal, however, following exposure to UV radiation. A range of post-UV colony-forming abilities has been found with fibroblasts from patients, some having extremely low post-UV colony-forming ability and others having nearly normal survival [2], [3] (see also Chap. 35). XP fibroblasts are deficient in their ability to repair some UV-damaged viruses or plasmids to a functionally active state. [2], [3] These host cell reactivation assays have detected an abnormality in every form of XP tested. UV-irradiated XP fibroblasts produce more mutations per survivor than normal fibroblasts. XP cells also introduce more mutations into UV-damaged plasmids than do normal cells. [9] This post-UV hypermutability is believed to be the basis of the increased frequency of sunlight-induced somatic mutations that lead to cancer in XP patients. [10]

CHROMOSOME ABNORMALITIES XP cells generally are found to have a normal karyotype without excessive chromosome breakage or increased sister chromatid exchanges. Following exposure to UV radiation, however, abnormally large increases in chromosome breakage and in sister chromatid exchanges have been observed. [11] The extent of this induced abnormality varies in different patients.

DNA REPAIR In 1968, hypersensitivity of cultured XP cells to UV damage was reported by Cleaver [12] to be the result of defective DNA repair. He found defective UV-induced repair replication, indicating a defect in the nucleotide excision repair system. Most XP cells have a normal response to treatment with x-rays, indicating the specificity of the DNA repair defect. The defective genes for the seven excision repair–defective forms of XP have been cloned, [3], [13] and their functions are being investigated (see Chap. 35).

COMPLEMENTATION GROUPS Genetic heterogeneity among the XP DNA repair defects was found by fusing cultured fibroblasts from different patients and defining complementation groups (see discussion in Chap. 35). Up to 2002, seven such DNA excision repair–deficient complementation groups have been identified (named *XP-A* to *XP-G*), and the corresponding genes have been identified [2], [3], [13] (Table 155-2). Additional patients with clinical XP but normal DNA excision repair have been called *XP variants*. Studies of cellular hypersensitivity revealed a slightly increased sensitivity to UV-induced inhibition of cell growth that was potentiated by caffeine. Cells from XP-variant patients were reported recently to have a defect in an error-prone DNA polymerase (pol ?) that bypasses unrepaired DNA damage. [14], [15]



TABLE 155-2 **Xeroderma Pigmentosum: Characteristics of DNA Repair Complementation Groups**

PRENATAL DIAGNOSIS This has been reported by measuring UV-induced unscheduled DNA synthesis in cultured amniotic fluid cells [16] and, more recently, by use of DNA diagnosis of trophoblast cells obtained early in pregnancy. [17]

DRUG AND CHEMICAL HYPERSENSITIVITY A number of DNA-damaging agents other than UV radiation have been found to yield hypersensitive responses with XP cells. These agents include drugs (psoralens, chlorpromazine), cancer chemotherapeutic agents (cisplatin, carmustine), and chemical carcinogens (benzo[*a*]pyrene derivatives). Presumably, these agents induce DNA damage whose repair involves portions of the DNA repair pathways that are defective in XP. [18]

Treatment

Management of patients with XP is based on early diagnosis, lifelong protection from UV radiation exposure, and early detection and treatment of neoplasms. Diagnosis rests on recognition of the characteristic clinical features and is confirmed by laboratory tests of cellular hypersensitivity.

SUN PROTECTION Patients should be educated to protect all body surfaces from UV radiation by wearing protective clothing and UV-absorbing glasses and long hair styles. They should adopt a lifestyle to minimize UV exposure and use

sunscreens with high sun protective factor (SPF) ratings (minimum SPF 15) daily. Cells from patients with XP are hypersensitive to killing by UVC, UVB, and UVA. Patients should be examined frequently by a family member who has been instructed in recognition of cutaneous neoplasms. A set of color photographs of the entire skin surface with close-ups of lesions (including a ruler) is often extremely useful to both the patient and the physician in detecting new lesions. A physician should examine patients at frequent intervals (about every 3 to 6 months depending on severity of skin disease). Premalignant lesions such as actinic keratoses may be treated by freezing with liquid nitrogen or with topical 5-fluorouracil. Larger areas have been treated with therapeutic dermatome shaving or dermabrasion to remove the more damaged superficial epidermal layers. [19], [20], [21] and [22] This procedure permits repopulation by relatively UV-shielded cells from the follicles and glands. Since cells from patients with XP are also hypersensitive to environmental mutagens such as benzo[*a*]pyrene found in cigarette smoke, prudence dictates that patients should be protected against these agents. One of our patients who smoked cigarettes for more than 10 years died of bronchogenic carcinoma of the lungs at age 35. [4]

CANCERS Cutaneous neoplasms are treated in the same manner as in patients who do not have XP. This involves electrodesiccation and curettage, surgical excision, or chemosurgery. Since multiple surgical procedures are often necessary, removal of undamaged skin should be minimized. Extremely severe cases have been treated by excision of large portions of the facial surface and grafting with uninvolved skin. [19], [20], [21] and [22] Most patients with XP are not abnormally sensitive to therapeutic x-rays, and XP patients have responded normally to full doses of therapeutic x-radiation for treatment of inoperable neoplasms. [5] However, cultured cells from a few XP-G patients were found to be hypersensitive to x-rays, [23] so when x-ray therapy is indicated, an initial small dose is advisable to test for clinical hypersensitivity. High-dose oral isotretinoin has been shown to be effective in preventing new neoplasms in patients with multiple skin cancers. [24] Because of its toxicity (hepatic, hyperlipidemic, teratogenic, calcification of ligaments and tendons, premature closure of the epiphyses), oral isotretinoin should be reserved for patients with XP who have had multiple skin cancers. A bacterial DNA repair enzyme, den V T4 endonuclease, in a topical liposome-containing preparation has been reported to reduce the frequency of new actinic keratoses and basal cell carcinomas in XP patients in one research study. [25] As of 2002, this treatment has not yet been approved by the U.S. Food and Drug Administration (FDA).

EYES The eyes should be protected by wearing UV-absorbing glasses with side shields. Methyl cellulose eye drops or soft contact lenses have been used to keep the cornea moist and to protect against mechanical trauma in patients with deformed eyelids. Corneal transplantation has restored vision in patients with severe keratitis with corneal opacity. Neoplasms of the lids, conjunctiva, and cornea are usually treated surgically. [26], [27] and [28]

Clinical-Laboratory Correlations

Patients with XP are hypersensitive to UV radiation, as are their cultured cells. Cutaneous and ocular abnormalities are strikingly limited to UV-exposed areas and usually spare such UV-shielded locations as the axillae, buttocks, and retina. The fact that black patients with XP have an increased frequency of skin cancer indicates that a normally functioning DNA repair system provides greater protection against skin cancer than does the natural pigmentation of black skin.

COMPLEMENTATION GROUPS At least eight different molecular defects are associated with the clinical abnormalities recognized as XP, as indicated by the existence of seven DNA excision repair–deficient complementation groups (A to G) and the variant form (see Table 155-2). A discussion of the cloned XP genes and their function can be found in Chap. 35. There is a complex relationship among the DNA repair genes and clinical disease (Fig. 155-3). These 11 genes are associated with at least 7 different clinical phenotypes. A clinical phenotype can be associated with defects in each of several genes. Conversely, mutations in one gene can be associated with several different clinical phenotypes. These complex relationships and the roles of DNA repair genes in regulation of transcription and in immune functions are under intense investigation.

FIGURE 155-3 Relationship of clinical disorders and molecular defects in DNA repair diseases. Seven clinical phenotypes of DNA repair diseases have been recognized (*red rectangles*). Defects in 11 DNA repair genes have been associated with these clinical phenotypes (*gray ovals*). Mutations in different DNA repair genes can be associated with the same clinical phenotype. Similarly, different mutations in one DNA repair gene can be associated with different clinical phenotypes. For example, mutations in the *XPD* gene have been associated with XP, with XP with neurologic abnormalities, with the XP-CS complex, with TTD, with XP-TTD, or with COFS (cerebro-oculo-facio-skeletal syndrome).

Complementation group A contains patients with the most severe neurologic and somatic abnormalities (the De Sanctis-Cacchione syndrome) as well as patients with minimal or no neurologic abnormalities [3] (see Table 155-2 and Fig. 155-3). This form is seen in the United States, Europe, and the Middle East. It is the most common form of XP in Japan. Approximately 90 percent of Japanese XP-A patients have the same single-base-substitution mutation in this gene. [29] This finding has served as the basis for development of a rapid diagnostic assay for Japanese XP-A patients (including prenatal diagnosis) using polymerase chain reaction analysis of a small sample of DNA. [17] Complementation group B (see Table 155-2; Fig. 155-3 and Fig. 155-4) is composed of three patients in two kindreds who had the cutaneous abnormalities characteristic of XP (including neoplasms) in conjunction with neurologic and ocular abnormalities typical of Cockayne syndrome (CS). [3] Surprisingly, a patient with trichothiodystrophy (TTD) also was found to have a defect in the *XPB* gene.

FIGURE 155-4 Xeroderma pigmentosum–Cockayne syndrome complex. (*A*) A 28-year-old patient (XP11BE) in XP complementation group B with cutaneous changes of xeroderma pigmentosum, including pigmentary changes and atrophy. She has the beaklike nose and loss of subcutaneous tissue typical of Cockayne syndrome. (*B*) The patient is of short stature (less than 4 ft tall). Her mother, an obligate heterozygote, is clinically normal.

Patients in complementation group C, with rare exceptions, have XP with skin and ocular involvement but without neurologic abnormalities [3], [30] (see Table 155-2 and Fig. 155-3). This is the most common group in the United States, Europe, and Egypt but has been found rarely in Japan. Patients in complementation group D have been described with six different clinical phenotypes (see Table 155-2 and Fig. 155-3). They may have cutaneous XP with late onset of neurologic abnormalities in their second decade of life or XP with no neurologic abnormalities. [3], [31] Two XP-D patients have been reported with clinical symptoms of both XP and CS. Cells from patients with a photosensitive form of TTD (without XP) also were assigned to XP complementation group D. Two patients were reported with combined symptoms of both TTD and XP (one patient had a skin cancer) and mutations in the *XPD* gene. [32] Finally, a patient with cerebro-oculo-facio-skeletal (COFS) syndrome had a mutation in the *XPD* gene. [33] Complementation group E was found in one kindred in Europe and several in Japan [3], [34] (see Table 155-2 and Fig. 155-3). These patients had relatively mild cutaneous abnormalities without neurologic involvement. Complementation group F patients have been found mainly in Japan [35], [36] (see Table 155-2 and Fig. 155-3). These patients have mild clinical symptoms without neurologic abnormalities or skin cancer. The residual rate of DNA repair, however, is very low (only 10–20 percent of normal). Thirteen patients in XP complementation group G have been identified in the United States, Europe, and Japan [37] (see Table 155-2; Fig. 155-3 and Fig. 155-5). There is a large variation in clinical features among these patients. Several patients with mutations in the *XPG* gene had clinical features of both XP and severe CS with cachexia and death in the first decade (see Fig. 155-5). Other patients with different mutations in the same gene had no neurologic abnormalities. Fibroblasts from one of the patients were found to be hypersensitive to killing by x-rays as well as by UV radiation. [23]

FIGURE 155-5 Severe and mild XP-G patients. (*Upper left*) Patient XP82DC at 3 years of age has deep set eyes characteristic of Cockayne syndrome and irregular lentiginous pigmentation on her face characteristic of XP indicating the XP-CS complex. (*Lower left*) Patient XP82DC at 3 years has characteristic XP pigmented lesions present on her forearms and dorsa of hands along with thin, translucent skin with readily visible veins. The small size of her hands is apparent in comparison with the hands of her mother. (*Middle column, top*) Patient XP65BE at age 6 months experienced severe sunburn of her face on minimal sun exposure. Erythema and swelling are seen on skin of forehead, cheeks, and periorbital area. (*Middle column, middle*) Patient XP65BE at age 9 months shows erythema and peeling of skin of malar area of face following sun exposure. (*Middle column, bottom*) Patient XP65BE at age 4.5 years shows pigmentary changes on her nose, malar area, and other portions of the face. (*Upper right*) Patient XP65BE at age 4.5 years shows blistering sunburn on upper thigh. Note spared area above knee where sunscreen was applied. (*Lower right*) Patient XP65BE at age 14 years shows minimal pigmentary changes on face and sparing of neck and hand. She used measures to protect her skin from sun exposure. (*From* Ref. 37.)

XP-variant cells have normal DNA nucleotide excision repair and thus do not fall into any of the complementation groups of cells with defective DNA excision repair [3] (see Table 155-2 and Fig. 155-3). There is, however, a defect in an error-prone DNA polymerase, pol ? [14], [15], [38] (see Chap. 35). XP-variant patients have been identified in the United States, Europe, and Japan. [3] Most XP-variant patients have clinical XP with no neurologic abnormalities. The cutaneous and ocular abnormalities have been severe in some patients and mild in others. A family with four affected individuals was described in Germany. The affected individuals had extensive sun exposure and late onset of cutaneous cancers. They originally had been thought to represent a separate disorder (pigmented xerodermoid). Subsequent laboratory studies showed the findings typical of XP variants.

ENVIRONMENTAL-GENETIC INTERACTION The cutaneous and ocular changes in patients with XP are consistent with the notion that repeated insults by environmental agents, particularly UV radiation, produce repeated bouts of DNA damage. Because of defective DNA repair, this damage results in cell death, diminished cell growth, or somatic cell mutations. Through mechanisms that are not completely understood, these cellular alterations lead to atrophy, hyper- and hypopigmentation, and telangiectasia, as well as to a 1000-fold increase in malignant neoplasms. Thus XP provides strong support for the somatic mutation theory of carcinogenesis. In addition, rigorous protection from UV radiation from early infancy in a few patients has been shown to prevent most of the serious cutaneous and ocular abnormalities. Some patients with XP demonstrate progressive neurologic degeneration (see Fig. 155-1 and Fig. 155-5). Severely affected patients lose their ability to walk and talk. Histologically, the picture is of a primary neuronal degeneration with loss (or absence) of neurons without evidence of vascular abnormality, deposition of abnormal material, or inflammatory reaction. It has been hypothesized, in analogy to the cutaneous degenerative changes, that the neurologic degeneration is a manifestation of unrepaired DNA damage. Since mature neurons do not divide, unrepaired DNA damage would lead to cell death without replacement by other neurons. This process would lead to progressive loss of neurologic function. The

specific cause of such damage, whether by exogenous or endogenous agents, and the explanation of why some neurons are more severely affected than others are not known. The severity of the neurologic symptoms in patients with XP with associated neurologic disease has been shown to correlate with the UV sensitivity of their skin fibroblasts. [7]

HETEROZYGOTES XP heterozygotes (parents and some other relatives) are carriers of the gene for XP but are clinically normal. There is limited epidemiologic evidence to indicate that such persons have an increased risk of developing skin cancer. [39] Most tests of cell function or DNA repair yield normal responses with cells from XP heterozygotes. A nonspecific test of hypersensitivity to x-ray–induced chromosome breakage has been reported to be abnormal with cells from obligate heterozygotes for XP. [40] Cloning of the defective genes in different XP complementation groups should provide a direct assay for detection of XP heterozygotes.

PATIENT SUPPORT GROUP The Xeroderma Pigmentosum Society is an educational, advocacy, and support organization for helping patients with XP and their families. The society's address is Xeroderma Pigmentosum Society, Inc., Box 4759, Poughkeepsie, NY 12602-4759 USA;Web site: http://www.xps.org/; e-mail: http://xps@xps.org/; telephone: toll-free (877) XPS-CURE (877-977-2873). The booklet “Understanding Xeroderma Pigmentosum,” prepared by the National Institutes of Health, is available on the Internet at http://www.cc.nih.gov/ccc/patient_education/pepubs/xeroderma.pdf. This booklet provides information about XP written in plain English. It may be useful for patients, their families, educators, students, health professionals, media inquiries, and others interested in learning more about XP. A Web site listing disease-causing mutations in XP and CS genes has been established: http://xpmutations.org/.

COCKAYNE SYNDROME

CS is a very rare autosomal recessive degenerative disease with cutaneous, ocular, neurologic, and somatic abnormalities [41], [42] (see Table 155-1). A review published in 1992 described 140 cases reported in the literature. [43]

Clinical Features

In 1936, Cockayne described a syndrome characterized by cachectic dwarfism, deafness, and pigmentary retinal degeneration with a characteristic “salt and pepper” appearance of the retina. The skin had photosensitivity without the excessive pigmentary abnormalities seen in XP. There was marked loss of subcutaneous fat, resulting in a “wizened” appearance with typical “bird-headed” facies and prominent “Mickey Mouse” ears. Other ocular findings included cataracts and optic atrophy. [44] Neurologic abnormalities, in addition to deafness, include peripheral neuropathy, normal pressure hydrocephalus, and microcephaly. Birth weight and early development are usually normal. The disease onset is usually in the second year of life with slowly progressive neurologic degeneration. Intellectual deterioration may be nonuniform, with some functions preserved better than others. A severe infantile form has been described, [45], [46] as well as a milder form with late onset. COFS syndrome [33], [47], [48] with microcephaly and severe mental retardation and CAMFAK syndrome of congenital cataracts, microcephaly, failure to thrive, and kyphoscoliosis [49] have some similar features. CS is not associated with an increased incidence of neoplasia.

Laboratory Abnormalities

Clinical laboratory testing often shows sensorineural deafness, neuropathic electromyogram, and slow motor nerve conduction velocity. [3], [7], [41], [43], [45], [50] The electroencephalogram may be abnormal, and x-ray examination may show thickened skull and microcephaly. Computed tomography (CT) may be diagnostically useful in the detection of normal-pressure hydrocephalus and showing calcification of the basal ganglia and other structures (Fig. 155-6). Magnetic resonance imaging (MRI) of the brain shows atrophy and dysmyelination of the cerebrum and cerebellum. Bone age is usually normal. Height and weight are usually well below the third percentile for the age.

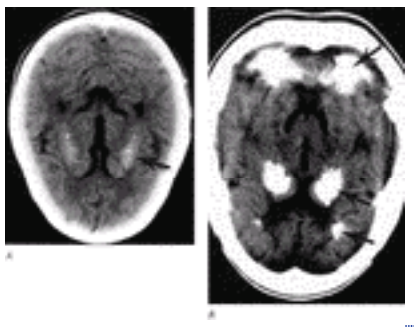

FIGURE 155-6 Cockayne syndrome. Calcification of brain visualized on CT scan. *A.* A 2-year-old patient with bilateral calcification of basal ganglia (*arrow*). *B.* A 15-year-old patient with extensive calcification involving basal ganglia, cerebellum, and cerebral hemispheres (*arrows*).

CELLULAR HYPERSENSITIVITY As with XP, cultured cells (fibroblasts or lymphocytes) from patients with CS are hypersensitive to UV-induced inhibition of growth and colony-forming ability. [3], [51] Host cell reactivation of UV-damaged adenovirus or plasmids is reduced, although generally to a lesser extent than in XP.

CHROMOSOME ABNORMALITIES Chromosome karyotype and sister chromatid exchange frequency are usually normal in untreated cells. UV treatment of CS cells results in a greater than normal increase in sister chromatid exchanges and a delayed recovery of chromosome damage after near-UV light exposure. In CS, the usual tests of DNA excision repair are normal. CS cells are defective in repair of actively transcribing genes. [3] There is also evidence that CS cells are unable to repair photoproducts of the cyclobutane dimer type but are able to repair nondimer photoproducts. [52] CS cells have a prolonged decrease in the rate of RNA synthesis following UV irradiation. There are two complementation groups (A and B) in CS (see Fig. 155-3), and their genes have been cloned. Patients with defects in *CSA* or *CSB* genes have similar clinical features. [51] A patient with COFS syndrome was reported with a defect in *CSB* [48] and another with a defect in *XPD*. [33]

PRENATAL DIAGNOSIS Prenatal diagnosis of CS has been performed [53] based on the delay in recovery of post-UV RNA synthesis and the increased cell killing by UV radiation.

Clinical-Laboratory Correlation

CS, like XP, is a disease of progressive neurologic degeneration. Pathologically, CS shows abnormal (dys)myelinization of neurons, whereas XP shows primary axonal degeneration. These findings are consistent with the theory that the myelin-producing cells in CS or neurons in XP are damaged repeatedly but do not recover fully and die. [7] Since mature neurons cannot divide, the dead neurons are not replaced, resulting in progressive loss of neurologic functioning. As in XP, the cause of this damage in CS and the reason for the precise anatomic location of the damage are not known.

Despite similar UV hypersensitivity to cell killing in CS as in XP, patients with CS do not have an increased frequency of cutaneous (or internal) neoplasia. The few patients with CS in the literature with multiple skin cancers also had XP (the XP-CS complex; see below). Thus cellular UV hypersensitivity does not necessarily result in increased neoplasia. The neoplastic process may be related more closely to the DNA excision repair defects present in XP (e.g., defective global genome repair) but absent in CS.

Patient Support Group

There is an educational, advocacy, and support organization for helping patients with CS and their families: The Share and Care Cockayne Syndrome Network, Inc., Box 570618, Dallas, TX 75357; Web site: http://www.cockayne-syndrome.org/.

XERODERMA PIGMENTOSUM–COCKAYNE SYNDROME COMPLEX

Twelve patients with CS have been found to have, in addition, clinical features of XP. [7], [37] These features include freckling on sun-exposed skin and cutaneous neoplasms (see Fig. 155-4). Cells from these XP-CS patients have reduced DNA excision repair characteristic of XP. Clinically, these patients may be distinguished from XP patients with neurologic abnormalities by the presence of the CS features of pigmentary retinal degeneration, calcification of the basal ganglia, normal-pressure hydrocephalus, and hyperreflexia. Cells from patients with this complex have been found to have mutations in three different XP genes: *XPB, XPD,* and *XPG,* [37], [51] demonstrating that several different genes are implicated in this disorder (see Table 155-2 and Fig. 155-3).

TRICHOTHIODYSTROPHY

Patients with trichothiodystrophy (TTD), [54] also called *Tay syndrome* or *IBIDS syndrome,* have ichthyosis, sulfur-deficient brittle hair, intellectual impairment, decreased fertility, and short stature. Some patients are also photosensitive (PIBIDS) (see Table 155-1 and Chap. 51 and Chap. 71). TTD is not associated with cancer. It is autosomal recessive, and affected families have been described in Italy [55] and elsewhere. TTD may be part of a group of similar rare disorders known variously as *Amish brittle hair syndrome, Sabinas brittle hair syndrome,* or *Pollitt syndrome;* they all have low cystine content of hair and in addition may have brittle nails, cataracts, hypogonadism, microcephaly, or ataxia. Patients may have abnormal brain myelin on MRI, a finding similar to that in CS. [56] A few patients have been described with both XP and TTD who have mutations in the *XPD* gene. One of these XP/TTD patients developed skin cancer at a early age. [32]

Laboratory Abnormalities

Diagnosis is based on microscopic observation of broken hair shafts with characteristic light and dark bands visible in polarized light (“tiger tail”), although this may not be present at birth. The sulfur content of the hairs is reduced due to low cystine content. It is not known whether other proteins also have low sulfur content. Fibroblasts from some TTD patients with photosensitivity (PIBIDS) (see Chap. 51 and Chap. 71) have been found to have similar abnormalities to fibroblasts from patients with XP in complementation group D [31], [51] or B, [57] whereas others form a unique TTD complementation group (see Fig. 155-3). The cells are hypersensitive to killing by UV radiation and have reduced unscheduled DNA synthesis. Fibroblasts from TTD patients without sun sensitivity have normal UV survival and normal unscheduled DNA synthesis.

BLOOM SYNDROME

Bloom syndrome (BS) is an autosomal recessive disease characterized by sun sensitivity, facial telangiectasia, short stature, and immunodeficiency [58] (see Table 155-1). Patients have an increased frequency of various internal neoplasms, including acute leukemia and carcinomas of skin, breast, and gastrointestinal tract. About 250 patients have been recognized. BS is most frequent among Ashkenazi Jews, in whom the carrier rate has been estimated as 1 in 100. [59]

Clinical Features

Facial erythema and telangiectasia superficially resembling lupus erythematosus are often present within the first few weeks after birth in the malar area, on the nose, and around the ears. [58] Sun exposure accentuates these abnormalities and may induce bullae, bleeding, and crusting of the lips and eyelids. The telangiectatic lesions often involve the ears and dorsa of the hands but characteristically spare the trunk, buttocks, and lower extremities. The intensity of the facial lesions may vary from minimal telangiectasia around the lips to severe erythema of the malar area, cheeks, and nose (Fig. 155-7). Café-au-lait spots are common, at times accompanied by adjacent depigmented areas.

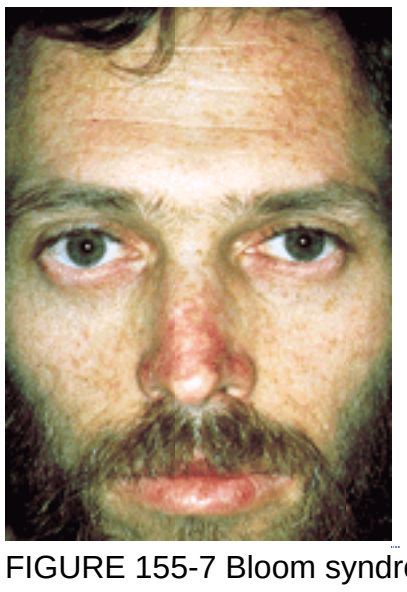

FIGURE 155-7 Bloom syndrome. Prominent telangiectasia in malar distribution.

Affected children generally are born at full term but are of low birth weight, averaging approximately 2000 g. Patients are well proportioned but small. Adult height is usually under 150 cm. Patients have a long, narrow head with a characteristic facies consisting of a narrow, prominent nose, relatively hypoplastic malar areas, and a receding chin. Major skeletal abnormalities are unusual, neurologic abnormalities are uncommon, and intelligence is generally normal.

Patients with BS are predisposed to multiple severe infections of the respiratory or gastrointestinal tracts. There is a tendency for the frequency of infections to decrease with advancing age. There is immune dysfunction. Diabetes mellitus is common. Sexual development generally appears to be normal, but male infertility due to defective sperm is the rule.

Approximately 20 percent of patients with BS develop neoplasms. [58] Half occur before age 20 years. Patients with BS have been estimated to have a 150- to 300-fold increased frequency of development of lymphatic and nonlymphatic leukemia, lymphosarcoma, lymphoma, and carcinoma of the oral cavity and digestive system.

Laboratory Studies

Laboratory studies of immunity have shown diminished immunoglobulin levels, reduced cellular proliferative response to mitogens, and decreased proliferation in the mixed leukocyte reaction.

CHROMOSOME ABNORMALITIES BS cells have a characteristic elevated frequency of chromosome abnormalities, accompanied by a markedly elevated rate of spontaneous sister chromatid exchanges (see Chap. 35) and spontaneous hypermutability of circulating blood cells. [11], [60], [61] The chromosome abnormalities include a high frequency of chromosomal breakage and rearrangements. The most characteristic of these aberrations, the quadriradial configuration, was found in 0.5 to 14.0 percent of all dividing phytohemagglutinin-stimulated lymphocytes from patients with BS. [61] Quadriradials are believed to be the result of a rearrangement before the onset of mitosis resulting from the exchange of chromatid segments of two homologous chromosomes. The quadriradial is almost never found in cells from normal individuals. Increased sister chromatid exchanges and the presence of quadriradials are considered essential for the diagnosis of BS. BS cells show an abnormally large increase in chromosome aberrations when treated with x-rays in the G_2 phase of the cell cycle. [62]

CELL KILLING AND MUTAGENESIS There are a few reports of cellular hypersensitivity to agents such as UVB, but this has not been a consistent finding. BS cells were reported to have an eight- to tenfold increase in the spontaneous mutation rate and a 50- to 100-fold increase in frequency of in vivo mutations at the *glycophorin A* (MN blood group) locus, hypermutability at a tandem-repeat locus, and a 100-fold increase in hypoxanthine-guanine phosphoribosyltransferase (*HGPRT*) mutations.

BLOOM SYNDROME GENE The defective gene in BS (*BLM*) [63], [64] was identified on chromosome 15q26.1 as a helicase that serves to unwind DNA. A founder deletion/insertion mutation in the *BLM* gene was identified in Ashkenazi Jews at a frequency of about 1 percent. [59], [65] This mutation may be used for DNA diagnosis of BS patients and carriers among Ashkenazi Jews.

Clinical-Laboratory Correlation

The clinical diagnosis of BS is confirmed by the findings of increased spontaneous sister chromatid exchanges and increased spontaneous chromosome breakage, including the presence of quadriradials. The high frequency of neoplasia in BS may be related to the chromosome breakage or the immune deficiency, as in ataxia-telangiectasia. The observation of an increased spontaneous mutation rate in cultured cells suggests that somatic mutations may play a role in the neoplasia. Homologous chromosome exchange (as in quadriradials) or genetic recombination may be a mechanism whereby heterozygous (recessive) traits become homozygous within somatic cells and thereby result in mutation or neoplasia.

The defective gene in BS is a helicase that functions to unwind DNA. DNA helicases also have been implicated in Werner syndrome, Rothmund Thompson syndrome, and XP complementation groups B and D. [64]

FANCONI ANEMIA

Fanconi anemia (FA) is an autosomal recessive disease with progressive loss of all the formed elements of the blood (pancytopenia) (see Table 155-1). Patients also may have malformations of the heart, kidney, or limbs, although about

one-third may not have congenital malformations. [66], [67] Internal neoplasms such as leukemia occur with greatly increased frequency. [68] Blood cells show increased spontaneous chromosome breakage. More than 700 patients have been reported to the International Fanconi Anemia Registry. [67]

Clinical Features

Cutaneous abnormalities are present in almost 80 percent of patients. [69] Hyperpigmentation is present from birth or early childhood and is diffuse and accentuated over the neck, joints, and trunk. Café-au-lait spots and achromic lesions are present. Following repeated blood transfusions, hyperpigmentation due to iron overloading may be present.

Hemopoietic manifestations usually have their onset before age 10 years. These consist of a hypocellular bone marrow with progressive decrease in the number of circulating platelets, granulocytes, and erythrocytes. Of 129 patients with FA, 66 percent had skeletal malformations. [66] These included aplasia or hypoplasia of the thumb, metacarpals, or radius; less frequently, hip dislocation or scoliosis were reported. [70] About 60 percent of the patients had short stature; most had low birth weight. Malformations of other organ systems also were observed: 28 percent of the patients had renal deformities, including renal aplasia and horseshoe kidney; 21 percent had ocular abnormalities, including strabismus and microphthalmia; and 20 percent had hypogonadism. CNS abnormalities (hyperreflexia and mild mental retardation) were observed in fewer than 20 percent of the patients, and deafness due to deformities of the ear anatomy was present in fewer than 10 percent. Heart defects (patent ductus arteriosus, aortic stenosis, auricular septum defect) were observed in eight patients.

Patients with FA have a high incidence of neoplasia, particularly nonlymphatic leukemia. [68] The frequency of acute myelogenous leukemia has been reported to be elevated 15,000-fold. [71] The course is often progressively downhill, with death from infection, hemorrhage, or neoplasia. Bone marrow transplantation has been attempted in more than 200 patients. [72], [73]

Laboratory Abnormalities

Clinical laboratory abnormalities reflect the bone marrow failure. There is a hypocellular marrow with thrombocytoplasia, leukopenia, and anemia.

CHROMOSOME ABNORMALITIES FA is associated with a high frequency of spontaneous chromosomal abnormalities, [60] including gaps, breaks, and translocations. With FA cells, the chromosomal abnormalities are increased to a greater extent than with normal cells following treatment with diepoxybutane, [74], [75] mitomycin C, psoralen plus UVA (PUVA), or isonicotinic acid hydrazide (INH), and chromosome abnormalities persist longer than normal after damage by x-irradiation in the G_2 phase of the cell cycle. [62]

CELL KILLING The colony-forming ability of cultured fibroblasts is hypersensitive to inhibition by treatment with agents that form cross-links in DNA. These include mitomycin C, busulfan, nitrogen mustard, PUVA, and cisplatin. [76] Colony-forming ability has a normal response to killing by UV radiation. The mechanism of the cellular hypersensitivity to DNA cross-linking agents is thought to involve defective DNA repair. A detailed understanding of this defect has not yet been attained.

FANCONI ANEMIA GENE Eight FA complementation groups have been described. [76], [77], [78] and [79] The genes for six of the FA complementation groups have been cloned. There is variability of the clinical phenotype and genotype. Mutations were detected in cloned genes in 169 patients. [80] FA-G patients had more severe cytopenia and a higher incidence of leukemia. Somatic abnormalities were less prevalent in FA-C. Founder mutations were described in Israel [65] and among Afrikaners in South Africa. [81]

HETEROZYGOTES Cells from heterozygous carriers of FA have an abnormal chromosomal response to damage with diepoxybutane or nitrogen mustard intermediate between the homozygotes and normal individuals. The carrier frequency of a particular base-substitution mutation in the *FAC* gene is greater than 1 percent among Ashkenazi Jews and thus may be used for carrier detection. [75]

PRENATAL DIAGNOSIS The chromosomal aberrations induced by diepoxybutane have been used successfully as a test for prenatal diagnosis of FA. [82] Many more chromosome aberrations are induced by diepoxybutane in cultured amniotic fluid cells from fetuses with FA than from normal fetuses.

Clinical-Laboratory Correlation

FA is a progressive degenerative disease with major involvement of the hematologic system. There is a high frequency of spontaneous chromosomal breakage in association with a high rate of neoplasia, particularly nonlymphatic leukemia. Immunodeficiency is not prominent. Cells are hypersensitive to killing and to induction of chromosome aberrations by DNA cross-linking agents. Six of the defective genes have been cloned recently.

At present, incorporating these diverse observations into a unitary theory involves considerable speculation: The progressive nature of the disease is similar to XP and ataxia-telangiectasia and suggests the presence of accumulated cellular damage. “Spontaneous” chromosomal breakage may be a manifestation of this damage. The neoplasia may be related to the chromosome breakage. When considering two diseases with spontaneous chromosome breakage (FA and ataxia-telangiectasia), lymphoid leukemia is absent in FA and predominant in ataxia-telangiectasia. In contrast, nonlymphoid leukemia predominates in FA and is absent in ataxia-telangiectasia. Thus other modifying factors, perhaps the immune defects in ataxia-telangiectasia, may be at work.

Registry

Patients may get information from several support groups. The Fanconi Anemia Research Fund, Inc., 1801 Willamette

St., Suite 200, Eugene, OR 97401; telephone: 1-541-687-4658 or 800-828-4891; fax: 1-541-687- 0548; e-mail: http://info@fanconi.org/ ; Web site: http://www.fanconi.org/. There also is an organization in Canada: Fanconi Canada, P.O. Box 38157, Toronto, Ontario M5N 3A9, Canada; phone: 416-489-6393; fax: 416-489-6393; e-mail: http://admin@fanconicanada.org/ ; Web site: http://www.fanconicanada.org/.

DYSKERATOSIS CONGENITA

Dyskeratosis congenita, the Zinsser-Engman-Cole syndrome, is an X-linked multisystem disease with cutaneous, mucosal, ocular, gastrointestinal, and hematologic abnormalities and an increased incidence of cancer (see Table 155-1). More than 100 cases are recorded in the literature, including some female cases. [83] A registry at Hammersmith Hospital in London recruited 46 families having 83 affected patients, including 76 males. [84] Patients have been reported from the United States, Europe, Japan, China, and India.

Clinical Features

The most common features are a triad of reticulated hyperpigmentation, dystrophic nails, and mucosal leukoplakia. [83], [84] and [85] During the first decade of life, patients develop reticulated poikiloderma of sun-exposed areas with hyperpigmentation and, occasionally, bullae. Nail dystrophy is present in virtually all patients, beginning at approximately age 2 to 5 years. The nails initially split easily and then develop longitudinal ridging with irregular free edges. Eventually, the nails become smaller, resulting in rudiments remaining. The fingernails are usually involved before the toenails. Other skin abnormalities include atrophic, wrinkled skin over the dorsum of hands and feet and hyperhidrosis and hyperkeratosis of palms and soles with disappearance of dermal ridges (absence of fingerprints).

Leukoplakia may be present in any mucosal site. The oral mucosa is the most frequent, but leukoplakia is also found in the urethra, glans penis, vagina, and rectum. Lingual hyperkeratosis may be present. Mucosal surfaces such as the esophagus, urethra, and lacrimal duct may become constricted and stenotic, resulting in dysphagia, dysuria, and epiphora. Multiple dental caries and early loss of teeth are common. Progressive pulmonary disease, including infections and fibrosis (and cirrhosis in some patients), was reported in 19 percent of affected males. [84] About 20 percent of patients had learning difficulties or mental retardation. [84]

There is an increased incidence of neoplasia, particularly squamous cell carcinoma of the mouth, rectum, cervix, vagina, esophagus, and skin. A large British kindred had Hodgkin's disease and adenocarcinoma of the pancreas. [86] Several patients had multiple primary neoplasms; most neoplasms occurred in the third or fourth decade. However, a gastric carcinoma was reported in an adolescent. Like FA, although hypoplasia is the main abnormality seen in bone marrow, there is a predisposition to both myelodysplasia and acute myeloid leukemia in patients with dyskeratosis congenita. [84]

The majority (93 percent) of patients developed bone marrow failure, which was the main cause (71 percent) of early death. [84] About half the patients (21 of 41) developed pancytopenia below the age of 10 years with a hematologic picture similar to FA. Patients have been treated with bone marrow transplantation. [87]

Laboratory Studies

Immune function has been studied in only a small number of patients. Defects in immunoglobulin levels and in cell-mediated immunity were found in some patients.

There have been several reports of intracranial calcifications, especially of the basal ganglia. [88], [89] These are also seen in CS.

Chromosomes are usually normal in untreated cells; however, chromosomal abnormalities have been found in fibroblasts and bone marrow cells from a few patients. [90], [91] The leukoplakia cells may show chromosomal changes presaging malignancy.

Clinical-Laboratory Correlation

A gene for dyskeratosis congenita (*DKC1*), which has been cloned, [92], [93] is located on the q28 region of the X chromosome. The protein, dyskerin, has a nucleolar function and a role in telomere maintenance and aging. [94], [95], [96], [97] and [98] Mutations in the *DKC1* gene have been detected in affected patients. [92], [99], [100] There is also evidence for an autosomal form with affected females. [84], [101], [102]

Dyskeratosis congenita, like FA, is associated with anemia and increased incidence of neoplasia. However, patients with dyskeratosis congenita do not have the developmental malformations or spontaneous chromosomal breakage seen in FA. In both disorders there is a suggestion of an abnormal chromosomal response to the DNA cross-linking induced by psoralens.

CONCLUSION

Increased sensitivity to some physical and chemical agents has been recognized in a number of heritable diseases in recent years (see Table 155-1). Clinical hypersensitivity to sunlight is manifested by a corresponding cellular hypersensitivity in XP, CS, and TTD. Ataxia-telangiectasia has a corresponding hypersensitivity to x-radiation. In patients with XP, CS, and the XP-CS complex and in some patients with TTD and COFS, the cellular hypersensitivity has been shown to be related to defective DNA repair.

Spontaneous chromosomal breakage is a feature of BS, FA, and ataxia-telangiectasia. There has been remarkable progress in identifying and cloning the genes responsible for ataxia-telangiectasia, XP, CS, TTD, BS, Werner syndrome, Rothmund-Thompson syndrome, dyskeratosis congenita, and FA. These genes may be useful for DNA diagnosis. Understanding their functioning should provide insights into the mechanism of disease and may provide opportunities for new therapeutic approaches.

Although these heritable diseases are rare, it can be calculated that carriers of the affected genes comprise several percent of the general population. These individuals are usually free of clinical symptoms. However, epidemiologic studies have suggested that they may have an increased risk of neoplasia. In particular, heterozygous carriers of ataxia-telangiectasia, who represent 1 to 2 percent of the general population, may have an increased risk of death from cancer. [103] There is a similar suggestion that persons heterozygous for XP have an increased risk of developing skin cancer. [39] Many of these individuals may be at an increased risk from exposure to environmental agents. As the defective genes are identified, molecular biologic techniques should permit carrier identification. Similarly, common polymorphisms in DNA repair genes may be associated with increased cancer risk. [104] Thus, there are implications for cancer control, preventive medicine, and occupational medicine.

REFERENCES

1. Kraemer KH et al: Xeroderma pigmentosum: Cutaneous, ocular, and neurologic abnormalities in 830 published cases. *Arch Dermatol* **123**:241, 1987

2. Van Steeg H, Kraemer KH: Xeroderma pigmentosum and the role of UV-induced DNA damage in skin cancer. *Mol Med Today* **5**:86, 1999

3. Bootsma D et al: Nucleotide excision repair syndromes: Xeroderma pigmentosum, Cockayne syndrome, and trichothiodystrophy, in *The Genetic Basis of Human Cancer,* 2d ed, edited by B Vogelstein, KW Kinzler. New York, McGraw-Hill, 2002, p 211

4. Kraemer KH et al: The role of sunlight and DNA repair in melanoma and nonmelanoma skin cancer: The xeroderma pigmentosum paradigm. *Arch Dermatol* **130**:1018, 1994

5. DiGiovanna JJ et al: Xeroderma pigmentosum: Spinal cord astrocytoma with 9-year survival after radiation and isotretinoin therapy. *J Cutan Med Surg* **2**:153, 1998

6. Bellows RA et al: Ocular manifestations of xeroderma pigmentosum in a black family. *Arch Ophthalmol* **92**:113, 1974

7. Rapin I et al: Cockayne syndrome and xeroderma pigmentosum. *Neurology* **55**:1442, 2000

8. Khan SG et al: Xeroderma pigmentosum group C splice mutation associated with autism and hypoglycinemia. *J Invest Dermatol* **111**:791, 1998

9. Gözükara EM et al: The human DNA repair gene, *ERCC2* (XPD), corrects ultraviolet hypersensitivity and ultraviolet hypermutability of a shuttle vector replicated in xeroderma pigmentosum group D cells. *Cancer Res* **54**:3837, 1994

10. Kraemer KH: Sunlight and skin cancer: Another link revealed. *Proc Natl Acad Sci U S A* **94**:11, 1997

11. Mamada A et al: Different sensitivities to ultraviolet light-induced cytotoxicity and sister chromatid exchanges in xeroderma pigmentosum and Bloom's syndrome fibroblasts. *Photodermatology* **6**:124, 1989

12. Cleaver JE: Defective repair replication of DNA in xeroderma pigmentosum. *Nature* **218**:652, 1968

13. Wood RD et al: Human DNA repair genes. *Science* **291**:1284, 2001

14. Johnson RE et al: *hRAD30* mutations in the variant form of xeroderma pigmentosum. *Science* **285**:263, 1999

15. Masutani C et al: The *XPV* (xeroderma pigmentosum variant) gene encodes human DNA polymerase eta. *Nature* **399**:700, 1999

16. Ramsay CA et al: Prenatal diagnosis of xeroderma pigmentosum: Report of the first successful case. *Lancet* **2**:1109, 1974

17. Kore-eda S et al: A case of xeroderma pigmentosum group A diagnosed with a polymerase chain reaction (PCR) technique: Usefulness of PCR in the detection of point mutation in a patient with a hereditary disease. *Arch Dermatol* **128**:971, 1992

18. Furuta T et al: Transcription coupled nucleotide excision repair as a determinant of cisplatin sensitivity of human cells. *Cancer Res* **62**:4899, 2002

19. Konig A et al: Dermabrasion for the treatment of xeroderma pigmentosum. *Arch Dermatol* **134**:241, 1998

20. Leal-Khouri S et al: Management of a young patient with xeroderma pigmentosum. *Pediatr Dermatol* **11**:72, 1994

21. Agrawal K et al: Xeroderma pigmentosum: Resurfacing versus dermabrasion. *Br J Plast Surg* **45**:311, 1992

22. Atabay K et al: Facial resurfacing in xeroderma pigmentosum with monoblock full-thickness skin graft. *Plast Reconstr Surg* **87**:1121, 1991

23. Arlett CF et al: Studies of a new case of xeroderma pigmentosum (XP3BR) from complementation group G with cellular sensitivity to ionizing radiation. *Carcinogenesis* **1**:745, 1980

24. Kraemer KH et al: Prevention of skin cancer in xeroderma pigmentosum with the use of oral isotretinoin. *N Engl J Med* **318**:1633, 1988

25. Yarosh D et al: Effect of topically applied T4 endonuclease V in liposomes on skin cancer in xeroderma pigmentosum: a randomised study: Xeroderma Pigmentosum Study Group. *Lancet* **357**:926, 2001

26. Jalali S et al: Penetrating keratoplasty in xeroderma pigmentosum: Case reports and review of the literature. *Cornea* **13**:527, 1994

27. Calonge M et al: Management of corneal complications in xeroderma pigmentosum. *Cornea* **11**:173, 1992

28. Gaasterland DE et al: Ocular involvement in xeroderma pigmentosum. *Ophthalmology* **89**:980, 1982

29. Nishigori C et al: Gene alterations and clinical characteristics of xeroderma pigmentosum group A patients in Japan. *Arch Dermatol* **130**:191, 1994

30. Chavanne F et al: Mutations in the *XPC* gene in families with xeroderma pigmentosum and consequences at the cell, protein, and transcript levels. *Cancer Res* **60**:1974, 2000

31. Lehmann AR: The xeroderma pigmentosum group D (*XPD*) gene: One gene, two functions, three diseases. *Genes Dev* **15**:15, 2001

32. Broughton BC et al: Two individuals with features of both xeroderma pigmentosum and trichothiodystrophy highlight the complexity of the clinical outcomes of mutations in the *XPD* gene. *Hum Mol Genet* **10**:2539, 2001

33. Graham JM Jr et al: Cerebrooculofacioskeletal syndrome with a nucleotide excision-repair defect and a mutated *XPD* gene, with prenatal diagnosis in a triplet pregnancy. *Am J Hum Genet* **69**:291, 2001

34. Itoh T et al: Reinvestigation of the classification of five cell strains of xeroderma pigmentosum group E with reclassification of three of them. *J Invest Dermatol* **114**:1022, 2000

35. Matsumura Y et al: Characterization of molecular defects in xeroderma pigmentosum group F in relation to its clinically mild symptoms. *Hum Mol Genet* **7**:969, 1998

36. Sijbers AM et al: Homozygous *R788W* point mutation in the *XPF* gene of a patient with xeroderma pigmentosum and late-onset neurologic disease. *J Invest Dermatol* **110**:832, 1998

37. Emmert S et al: Relationship of neurologic degeneration to genotype in three xeroderma pigmentosum group G patients. *J Invest Dermatol* **118**:972, 2002

38. Broughton BC et al: Molecular analysis of mutations in DNA polymerase eta in xeroderma pigmentosum–variant patients. *Proc Natl Acad Sci U S A* **99**:815, 2002

39. Swift M, Chase C: Cancer in families with xeroderma pigmentosum. *J Natl Cancer Inst* **62**:1415, 1979

40. Parshad R et al: Carrier detection in xeroderma pigmentosum. *J Clin Invest* **85**:135, 1990

41. Cantani A et al: Rare syndromes: I. Cockayne syndrome: A review of the 129 cases so far reported in the literature. *Riv Eur Sci Med Farmacol* **9**:9, 1987

42. Özdirim E et al: Cockayne syndrome: Review of 25 cases. *Pediatr Neurol* **15**:312, 1996

43. Nance MA, Berry SA: Cockayne syndrome: Review of 140 cases. *Am J Med Genet* **42**:68, 1992

44. Traboulsi EI et al: Ocular findings in Cockayne syndrome. *Am J Ophthalmol* **114**:579, 1992

45. Jaeken J et al: Clinical and biochemical studies in three patients with severe early infantile Cockayne syndrome. *Hum Genet* **83**:339, 1989

46. Patton MA et al: Early onset Cockayne's syndrome: Case reports with neuropathological and fibroblast studies. *J Med Genet* **26**:154, 1989

47. Del Bigio MR et al: Neuropathological findings in eight children with cerebrooculofacioskeletal (COFS) syndrome. *J Neuropathol Exp Neurol* **56**:1147, 1997

48. Meira LB et al: Manitoba aboriginal kindred with original cerebrooculofacioskeletal syndrome has a mutation in the Cockayne syndrome group B (*CSB*) gene. *Am J Hum Genet* **66**:1221, 2000

49. Talwar D, Smith SA: CAMFAK syndrome: A demyelinating inherited disease similar to Cockayne syndrome. *Am J Med Genet* **34**:194, 1989

50. Brumback RA et al: Normal-pressure hydrocephalus: Recognition and relationship to neurological abnormalities in Cockayne's syndrome. *Arch Neurol* **35**:337, 1978

51. Cleaver JE et al: A summary of mutations in the UV-sensitive disorders: Xeroderma pigmentosum, Cockayne syndrome, and trichothiodystrophy. *Hum Mutat* **14**:9, 1999

52. Parris CN, Kraemer KH: Ultraviolet-induced mutations in Cockayne syndrome cells are primarily caused by cyclobutane dimer photoproducts while repair of other photoproducts is normal. *Proc Natl Acad Sci U S A* **90**:7260, 1993

53. Lehmann AR et al: Prenatal diagnosis of Cockayne's syndrome. *Lancet* **1**:486, 1985

54. Itin PH et al: Trichothiodystrophy: Update on the sulfur-deficient brittle hair syndromes. *J Am Acad Dermatol* **44**:891, 2001

55. Mondello C et al: Molecular analysis of the *XPD* gene in Italian families with patients affected by trichothiodystrophy and xeroderma pigmentosum group D. *Mutat Res DNA Repair* **314**:159, 1994

56. Ostergaard JR, Christensen T: The central nervous system in Tay syndrome. *Neuropediatrics* **27**:326, 1996

57. Weeda G et al: A mutation in the *XPB/ERCC3* DNA repair transcription gene associated with trichothiodystrophy. *Am J Hum Genet* **60**:320, 1997

58. German J: Bloom's syndrome. XX. The first 100 cancers. *Cancer Genet Cytogenet* **93**:100, 1997

59. Shahrabani-Gargir L et al: High frequency of a common Bloom syndrome Ashkenazi mutation among Jews of Polish origin. *Genet Test* **2**:293, 1998

60. Sakamoto Hojo ET et al: Spontaneous chromosomal aberrations in Fanconi anaemia, ataxia telangiectasia fibroblast and Bloom's syndrome lymphoblastoid cell lines as detected by conventional ytogenetic analysis and fluorescence in situ hybridization (FISH) technique.

Mutat Res Environ Mutagen Related Subjects **334**:59, 1995

61. Chaganti RS et al: A manyfold increase in sister chromatid exchanges in Bloom's syndrome lymphocytes. *Proc Natl Acad Sci U S A* **71**:4508, 1974

62. Sanford KK et al: Factors affecting and significance of G_2 chromatin radiosensitivity in predisposition to cancer. *Int J Radiat Biol* **55**:963, 1989

63. Ellis NA et al: The Bloom's syndrome gene product is homologous to RecQ helicases. *Cell* **83**:655, 1995

64. van Brabant AJ et al: DNA helicases, genomic instability, and human genetic disease. *Annu Rev Genomics Hum Genet* **1**:409, 2000

65. Peleg L et al: Bloom syndrome and Fanconi's anemia: Rate and ethnic origin of mutation carriers in Israel. *Isr Med Assoc J* **4**:95, 2002

66. Gmyrek D, Syllm-Rapoport I: Fanconi's anemia: Analysis of 129 described cases. *Z Kinderheilkd* **91**:294, 1964

67. Giampietro PF et al: Diagnosis of Fanconi anemia in patients without congenital malformations: An international Fanconi anemia registry study. *Am J Med Genet* **68**:58, 1997

68. Alter BP: Fanconi's anemia and malignancies. *Am J Hematol* **53**:99, 1996

69. Auerbach AD: Fanconi anemia. *Dermatol Clin* **13**:41, 1995

70. De Kerviler E et al: The clinical and radiological features of Fanconi's anaemia. *Clin Radiol* **55**:340, 2000

71. Auerbach AD, Allen RG: Leukemia and preleukemia in Fanconi anemia patients: A review of the literature and report of the International Fanconi Anemia Registry. *Cancer Genet Cytogenet* **51**:1, 1991

72. Guardiola P et al: Outcome of 69 allogeneic stem cell transplantations for Fanconi anemia using HLA-matched unrelated donors: A study on behalf of the European Group for Blood and Marrow Transplantation. *Blood* **95**:422, 2000

73. Dufour C et al: Stem cell transplantation from HLA-matched related donor for Fanconi's anaemia: A retrospective review of the multicentric Italian experience on behalf of AIEOP-GITMO. *Br J Haematol* **112**:796, 2001

74. Auerbach AD et al: International Fanconi Anemia Registry: Relation of clinical symptoms to diepoxybutane sensitivity. *Blood* **73**:391, 1989

75. Seyschab H et al: Comparative evaluation of diepoxybutane sensitivity and cell cycle blockage in the diagnosis of Fanconi anemia. *Blood* **85**:2233, 1995

76. Grompe M, D'Andrea A: Fanconi anemia and DNA repair. *Hum Mol Genet* **10**:2253, 2001

77. Taniguchi T, Dandrea AD: Molecular pathogenesis of Fanconi anemia. *Int J Hematol* **75**:123, 2002

78. Joenje H, Patel KJ: The emerging genetic and molecular basis of Fanconi anaemia. *Nature Rev Genet* **2**:446, 2001

79. Faivre L et al: Association of complementation group and mutation type with clinical outcome in fanconi anemia: European Fanconi Anemia Research Group. *Blood* **96**:4064, 2000

80. Demuth I et al: Spectrum of mutations in the Fanconi anaemia group G gene, *FANCG/XRCC9*. *Eur J Hum Genet* **8**:861, 2000

81. Tipping AJ et al: Molecular and genealogical evidence for a founder effect in Fanconi anemia families of the Afrikaner population of South Africa. *Proc Natl Acad Sci U S A* **98**:5734, 2001

82. Auerbach AD et al: Fanconi anemia: Prenatal diagnosis in 30 fetuses at risk. *Pediatrics* **76**:794, 1985

83. Sirinavin C, Trowbridge AA: Dyskeratosis congenita: Clinical features and genetic aspects. Report of a family and review of the literature. *J Med Genet* **12**:339, 1975

84. Knight S et al: Dyskeratosis Congenita (DC) Registry: Identification of new features of DC. *Br J Haematol* **103**:990, 1998

85. Dokal I: Dyskeratosis congenita in all its forms. *Br J Haematol* **110**:768, 2000

86. Connor JM, Teague RH: Dyskeratosis congenita: Report of a large kindred. *Br J Dermatol* **105**:321, 1981

87. Ghavamzadeh A et al: Correction of bone marrow failure in dyskeratosis congenita by bone marrow transplantation. *Bone Marrow Transplant* **23**:299, 1999

88. Kelly TE, Stelling CB: Dyskeratosis congenita: Radiologic features. *Pediatr Radiol* **12**:31, 1982

89. Mills SE et al: Intracranial calcifications and dyskeratosis congenita. *Arch Dermatol* **115**:1437, 1979

90. Dokal I, Luzzatto L: Dyskeratosis congenita is a chromosomal instability disorder. *Leukemia Lymphoma* **15**:1, 1994

91. Coulthard S et al: Chromosomal breakage analysis in dyskeratosis congenita peripheral blood lymphocytes. *Br J Haematol* **102**:1162, 1998

92. Heiss NS et al: X-linked dyskeratosis congenita is caused by mutations in a highly conserved gene with putative nucleolar functions. *Nature Genet* **19**:32, 1998

93. Hassock S et al: Mapping and characterization of the X-linked dyskeratosis congenita (*DKC*) gene. *Genomics* **55**:21, 1999

94. Mitchell JR et al: A telomerase component is defective in the human disease dyskeratosis congenita. *Nature* **402**:551, 1999

95. Marciniak RA et al: Dyskeratosis congenita, telomeres and human ageing. *Trends Genet* **16**:193, 2000

96. Vulliamy TJ et al: Very short telomeres in the peripheral blood of patients with X-linked and autosomal dyskeratosis congenita. *Blood Cells Mol Dis* **27**:353, 2001

97. Dokal I: Dyskeratosis congenita: A disease of premature ageing. *Lancet* **358**(suppl):S27, 2001

98. Collins K, Mitchell JR: Telomerase in the human organism. *Oncogene* **21**:564, 2002

99. Knight SW et al: X-linked dyskeratosis congenita is predominantly caused by missense mutations in the *DKC1* gene. *Am J Hum Genet* **65**:50, 1999

100. Vulliamy TJ et al: Dyskeratosis congenita caused by a 3' deletion: Germline and somatic mosaicism in a female carrier. *Blood* **94**:1254, 1999

101. Elliott AM et al: Dyskeratosis congenita: An autosomal recessive variant. *Am J Med Genet* **83**:178, 1999

102. Vulliamy T et al: The RNA component of telomerase is mutated in autosomal dominant dyskeratosis congenita. *Nature* **413**:432, 2001

103. Su Y, Swift M: Mortality rates among carriers of ataxia-telangiectasia mutant alleles. *Ann Intern Med* **133**:770, 2000

104. Shen H et al: An intronic poly(AT)polymorphism of the DNA repair gene *XPC* and risk of squamous cell carcinoma of the head and neck: A case-control study. *Cancer Res* **61**:3321, 2001

105. Slor H et al: Clinical, cellular, and molecular features of an Israeli xeroderma pigmentosum family with a frameshift mutation in the *XPC* gene: Sun protection prolongs life. *J Invest Dermatol* **115**:974, 2000

T>

Chapter 156

Warren Piette

Hematologic Diseases

CUTANEOUS SIGNS AND SYMPTOMS ASSOCIATED WITH HEMATOLOGIC DISEASES
Pallor
Flushing and Erythroderma (Generalized Erythema)
Cyanosis
Jaundice
Infiltrative Lesions/Extramedullary Hematopoiesis
HEMOSTASIS AND THE DIFFERENTIAL DIAGNOSIS OF PURPURA
Hemostasis
Differential Diagnosis of Purpura

REFERENCES

Hematology includes the study of blood and blood-forming tissues. Given the large number and variety of hematologic disorders, it is not surprising that mucocutaneous manifestations of hematologic disorders are common. Many hematologic malignancies and malignancy-mimicking diseases can involve the skin through tumor infiltration (specific lesions), and some of these may present preferentially in the skin. These conditions, such as T and B cell cutaneous lymphomas, other leukemias and lymphomas, plasma cell dyscrasias, and Langerhans and non-Langerhans histiocytoses, are discussed in other chapters. Likewise, patients with serious or chronic hematologic diseases are often at risk for complications of therapy, especially chemotherapy, certain cytokine therapies, radiation therapy, or marrow transplantation. Any of these interventions may affect skin and mucous membranes; these associations are also discussed elsewhere.

The first major section of this chapter is directed toward nonspecific (non–tumor-containing) cutaneous findings that may be associated with hematologic disorders. Although the ready availability of laboratory testing has made early recognition of such conditions as anemia and polycythemia common and much less dependent on physical findings, cutaneous associations still may aid in the diagnosis of a hematologic condition or complicate its management. A comprehensive listing of these associations is presented in Table 156-1. Selected associations are covered in more detail in the text.

Download image in PDF format

TABLE 156-1 **Cutaneous Findings with Hematologic Associations** [32], [33], [34] and [35]

The second section of the chapter focuses on the differential diagnosis of purpura with an emphasis on those subsets of purpura with important underlying hematologic abnormalities.

CUTANEOUS SIGNS AND SYMPTOMS ASSOCIATED WITH HEMATOLOGIC DISEASES

Pallor

Cutaneous pallor results from a drop in the hemoglobin content of the cutaneous microvasculature. This decrease can occur either with a drop in the overall cutaneous blood flow as a result of emotion, epinephrine, cold exposure, or shock, or with physiologic adjustments to severe anemia.

Patients with acute severe anemia usually present with constitutional signs and symptoms such as dyspnea on exertion and occasionally at rest, faintness, dizziness, or hypotension and shock secondary to hypovolemia. Such acute severe anemia most commonly follows major bleeding or brisk hemolysis. Malaise and fatigue are also common, although with nutritional anemias these symptoms may be much more evident in retrospect after replacement therapy. Patients whose severe anemia develops more slowly often have surprisingly few complaints, presumably because of gradual physiologic adaptation.

A measurable increase in the resting cardiac output does not occur until the hemoglobin concentration is below 7 g/dL, and clinical signs of cardiac hyperactivity are not usually present until the hemoglobin concentration reaches even lower levels. [1] In human chronic anemia, oxygenation of oxygen-sensitive areas such as brain, heart, and muscle is maintained by a selective increase in blood flow, at the expense of perfusion to less oxygen-sensitive tissues, especially skin and kidneys. [1] Although vasoconstriction and oxygen deprivation in the subcutaneous tissue seem well tolerated, they are partly responsible for the anemic pallor. In the fully opened hand, the palmar creases appear pink until the hemoglobin level is less than 7 g/dL. [2]

Severe anemia due to marrow failure, fibrosis, or infiltration is typically accompanied by infections or bleeding secondary to associated neutropenia or thrombocytopenia. Development of a chronic anemia with the hemoglobin concentration below 7 g/dL and no other cytopenias is usually slow and caused by nutritional deficiencies or severe hypothyroidism, each of which may produce distinctive clinical syndromes. In any patient with anemia, examination of the peripheral blood smear can reveal important clues to the pathogenesis of the anemia. [3] Further testing (including Coombs' tests for antibody-mediated hemolysis; specific assays for vitamin B_{12}, folate, or iron; or a bone marrow aspirate or biopsy) generally leads to a correct diagnosis.

IRON DEFICIENCY Fatigue, irritability, and headaches are common complaints of individuals with iron-deficiency anemia. The severity of symptoms correlates poorly with the blood hemoglobin concentration. [4] The depletion of storage iron, and often of tissue iron, precedes the appearance of anemia. Some of the symptoms of iron deficiency may be a result of impaired function of iron-containing enzymes or proteins other than hemoglobin. For example, headache, paresthesia, and a burning sensation of the tongue are symptoms of iron deficiency that are likely caused by tissue cell iron depletion. Pica, the craving to eat substances such as dirt, clay, ice, laundry starch, salt, or cardboard, is a classic manifestation of iron deficiency and is usually cured promptly by iron therapy. [4] The physical findings of iron-deficiency anemia, in their approximate order of frequency, include pallor, glossitis (smooth, red tongue), stomatitis, and angular cheilitis. [4] Skin dryness and coarsening; brittle nails; and dry, fine, and brittle hair may also occur. Koilonychia (spooning of nails) is now rare. Retinal hemorrhages and exudates occur in patients with severe anemia (hemoglobin =5 g/dL), and proliferative retinopathy may accelerate in diabetic patients who are iron-deficient. The differential diagnosis of microcytic anemias includes the thalassemias and some other hemoglobinopathies, chronic inflammatory disorders, benign or malignant neoplasms, chemical blockade of heme synthesis (lead, pyrazinamide, isoniazid), and sideroblastic anemias. [4] Although serum levels of iron, iron-binding capacity (transferrin), and ferritin are useful in the diagnosis of iron deficiency, none of these is uniformly reliable when compared to stainable iron in marrow biopsies. For example, serum iron levels characteristically drop in patients after an acute myocardial infarction, with acute or chronic inflammatory disorders, or with malignancies, despite marrow evidence of sufficient iron. [4] Likewise, even in iron-deficient individuals, disorders such as hepatitis, chronic inflammatory diseases (e.g., rheumatoid arthritis, chronic infections), chronic renal disease, and malignancies can elevate serum ferritin into the normal range. Therefore, as with all laboratory values, the proper interpretation of serum indices of iron stores requires correlation with the clinical setting.

MEGALOBLASTIC ANEMIAS Megaloblastic anemias result from impaired DNA synthesis. [5] The most common causes of megaloblastic anemia are folate or cobalamin (vitamin B_{12}) deficiency. Acute megaloblastic anemia can result from nitrous oxide exposure or severe illness combined with extensive transfusion, dialysis, total parenteral nutrition, or exposure to weak folate antagonists (e.g., trimethoprim). Other causes of more chronic megaloblastosis include certain medications (especially antimetabolites, inhibitors of dihydrofolate reductase or deoxynucleotide synthesis, some anticonvulsants, oral contraceptives) and a variety of inborn metabolic errors. Megaloblastic anemias share certain clinical features. The slowly developing anemia produces few symptoms until the hematocrit is severely depressed. Symptoms of weakness, palpitation, fatigue, light-headedness, and shortness of breath are a result of anemia. Hyperbilirubinemia secondary to ineffective erythropoiesis with hemolysis can lead to mild jaundice. Severe anemic pallor and slight jaundice combine to produce a lemon-yellow skin color. Hyperpigmentation is common, particularly in dark-skinned individuals, in both folate- and vitamin B_{12}-deficient patients. [6] In the latter, the hyperpigmentation frequently localizes to the face, hands, and feet, but occasionally only to the fingers. [7] Poikilodermatous pigmentary change has also been described in vitamin B_{12} deficiency; replacement typically reverses the hyperpigmentation. When pernicious anemia is the etiology, there is an increased incidence of vitiligo and of premature graying. [8] Cheilosis and atrophy of filiform papillae of the tongue may develop with folate or cobalamin deficiency. Leukopenia and thrombocytopenia may occur but are seldom severe enough to be symptomatic. Characteristic findings on peripheral blood smear are red cell oval macrocytosis and neutrophil hypersegmentation. Folate deficiency typically results from poor nutrition (common in elderly, poor, or alcoholic individuals), from decreased absorption (such as with sprue), or from increased metabolic requirements because of pregnancy or increased cell turnover (chronic hemolytic anemia, exfoliative dermatoses). [5], [9] Cobalamin deficiency results from impaired absorption or decreased intake of vitamin B_{12}. Dietary deficiency is uncommon but is most likely to develop in vegetarians who avoid dairy products, eggs, and B_{12} supplements (vegans). Impaired absorption is usually the cause of cobalamin deficiency and may be a result of gastric causes (pernicious anemia, gastrectomy, Zollinger-Ellison syndrome), intestinal causes (ileal resection or disease, blind loop syndrome, fish tapeworm), or pancreatic insufficiency. The most common disorder of impaired vitamin B_{12} absorption is pernicious anemia, an autoimmune disease of insidious onset producing gastric atrophy and impaired intrinsic factor production. Absorption of cobalamin is severely impaired by the absence of intrinsic factor. In addition to anti-(gastric) parietal cell antibodies, many patients with pernicious anemia also develop antibodies to intrinsic factor or the intrinsic factor–cobalamin complex. Antiparietal cell antibodies occur in 90 percent of patients with pernicious anemia, but also in 60 percent of patients with other forms of atrophic gastritis, and in 5 percent of a random 30- to 60-year-old population. Although anti-intrinsic factor antibodies are found in only approximately 70 percent of patients with pernicious anemia, they are highly specific for this condition. Other autoimmune diseases occurring more often than expected in patients with pernicious anemia include thyroid disease, type I diabetes, hypoparathyroidism, Addison's disease, postpartum hypophysitis, ulcerative colitis, vitiligo, acquired agammaglobulinemia, and certain forms of infertility. [5], [8] The hematologic manifestations of vitamin B_{12} or folate deficiency are indistinguishable, but it is critical to determine the deficient nutrient because of the often serious neurologic complications of severe vitamin B_{12} deficiency. With folate deficiency, physiologic replacement of folate (200 µg daily) should result in a full hematologic response, while a pharmacologic dose of folate (5 mg daily) corrects the hematologic abnormalities of cobalamin deficiency. [8] However, this replacement should not be used as a diagnostic test to distinguish the two, because any folate replacement may accelerate the neurologic damage of cobalamin deficiency. [8] Neurologic complications include paresthesia in the feet and fingers; changes in vibratory sense and proprioception; and progression to spastic ataxia, somnolence, altered taste, smell, and vision, dementia, psychotic depression, or paranoid schizophrenia. [5] In some patients, the neurologic findings may appear in the absence of megaloblastic changes. Because numbness and dysesthesia are perceived by some patients as skin problems, it is possible that a patient might present with these findings to a dermatologist.

ANEMIA OF ENDOCRINE DISORDERS Pituitary deficiency, adrenal dysfunction, gonadal dysfunction, and thyroid

dysfunction are the endocrine disorders in which hormonal deficiency is most likely to lead to anemia. The absence of androgen in men is followed by a drop in hemoglobin levels to those of women. The lowest hemoglobin levels are associated with myxedema, which may present with dry, coarse, and scaly skin and anemia. Hemoglobin levels in hypothyroidism are seldom below 8 to 9 g/dL. [10] Uncomplicated thyroid hormone deficiency produces a normochromic, normocytic anemia. However, for reasons only partly understood, iron deficiency frequently accompanies severe hypothyroidism, producing a hypochromic and microcytic anemia. To further complicate matters, pernicious anemia, with vitamin B_{12} deficiency and a megaloblastic anemia, is also associated with autoimmune thyroid disease at a rate higher than chance alone.

Flushing and Erythroderma (Generalized Erythema)

Just as emotional factors or cold may trigger cutaneous vasoconstriction and pallor, so may emotion or heat stimulate vasodilatation and flushing. Rosacea or actinic damage can cause facial redness. Rarely, the POEMS syndrome (polyneuropathy, organomegaly, endocrinopathy, M protein, and skin changes) with idiopathic flushing may mimic carcinoid syndrome. [11] Patients with cutaneous mastocytosis may also develop flushing episodes lasting =30 min, unlike the typical carcinoid flush of =10 min. [12] Widespread erythroderma occurs in cutaneous T cell lymphoma, in some cases of chronic lymphocytic leukemia, in lymphocytic lymphoma, and, rarely, in angioimmunoblastic lymphadenopathy or hypereosinophilic syndrome. [13], [14] and [15] The skin is often involved, sometimes severely enough to produce erythroderma, in both acute and chronic graft-versus-host disease.

A sustained increase in red cell production leads to an increase in both hematocrit and blood volume, directly raising blood viscosity and vascular volume. In turn, these are responsible for many of the signs and symptoms of polycythemia. [1] A ruddy cyanosis or acrocyanosis is seen in conditions associated with abnormally high levels of hemoglobin and sluggish flow of deoxygenated blood through dilated cutaneous vessels. An increased red cell mass may be compensatory, as in chronic hypoxic states, or primary, as in polycythemia vera.

POLYCYTHEMIA VERA Ruddy cyanosis or plethora is probably the best known cutaneous finding in polycythemia vera (PV), but patients with this myeloproliferative disease may present to the dermatologist with a variety of cutaneous findings. This disorder involves all hematopoietic stem cell lines, even though erythroid proliferation is usually dominant. It occurs most commonly after age 50 years. [16] Bleeding and thrombosis are frequent and often serious complications of this disease, including stroke and Budd-Chiari syndrome (hepatic vein occlusion). A cerebral event may precede the diagnosis of PV in up to 35 percent of patients. Signs and symptoms involving the peripheral vasculature are frequent (34 to 62 percent), including peripheral vascular disease (6 to 22 percent), erythromelalgia (18 percent), peripheral gangrene (16 percent), deep venous thrombosis (7 to 13 percent), digital artery occlusion (7.5 percent), Raynaud's phenomenon (1 to 3 percent), and leg ulcers (2 percent). Erythromelalgia, a syndrome of burning erythema in the feet or hands triggered by warmth, may precede the diagnosis of PV by several years (Table 156-1). PV-associated erythromelalgia is probably caused by the platelet abnormalities that occur in PV, may result in cutaneous necrosis, and should respond well to treatment with aspirin. Other possible cutaneous findings include paresthesia (29 percent) and pruritus (14 to 50 percent). [16], [17] Aquagenic pruritus is distinct from various forms of water-related urticaria, is characterized by intense itching after water exposure without visible skin changes, and is usually of unknown origin. Recognized associations include PV and rarely myelodysplastic syndromes or juvenile xanthogranuloma. [18], [19] and [20] The pruritus is often sudden in onset after a warm bath or shower and must be distinguished from transient pruritus after bathing or aquagenic pruritus of the elderly. True aquagenic pruritus is characterized by intense, constant, disabling, and often progressive symptoms. [19] There is no clear relationship between the degree of pruritus and the severity of the disease, with roughly 20 percent of patients continuing to itch despite adequate control of their PV. [17] Although the pathogenesis of pruritus has been tied to elevated blood and urine histamine levels, H_1 antagonists are generally of little value. Occasional patients may respond to aspirin, cholestyramine, H_2 receptor antagonists, oral iron, or PUVA. [17] Recombinant interferon-a may be an effective therapy in PV, and in one study provided greater than 50 percent improvement in pruritus control in 77 percent of patients. [17] Suberythemal UVB and PUVA may also induce at least temporary remissions. [19] The diagnosis of PV depends on an increased red cell mass (=36 mL/kg in males or =32 mL/kg in females) and arterial O_2 saturation (=92 percent). In addition, patients must have either splenomegaly or any two numerically defined minor criteria, which include thrombocytosis, leukocytosis, an elevated leukocyte alkaline phosphatase level, and a greatly elevated serum vitamin B_{12}-binding capacity. [16] Phlebotomy is the treatment of choice for relief of symptoms of hypervolemia and hyperviscosity, but it does not relieve pruritus or thrombocytosis. Beyond phlebotomy, there is no single best treatment for PV. Myelosuppressive therapy or radioactive phosphorus (^{32}P) is indicated to reduce the incidence of thrombosis, but may be complicated by the development of acute leukemia or other secondary malignancies.

Cyanosis

In patients with normal hemoglobin levels, peripheral cyanosis indicates at least 5 g/dL of reduced hemoglobin in capillary blood. Peripheral cyanosis has multiple etiologies, including vasoconstriction with resulting slow acral flow. Only central cyanosis (tongue and sublingual region) reliably indicates significant arterial deoxygenation or altered hemoglobin. Cyanosis is best observed in fluorescent lighting. Thin skin areas are the best places to look for cyanosis; in adults, these areas include the lips, earlobes, nail beds, and oral mucous membranes; in newborns, these areas include the highly vascular palms and heels. However, multiracial studies suggest that the tongue is the most sensitive site for detection of central cyanosis.

Lingual cyanosis as the earliest manifestation of central cyanosis is reliably detectable at a level of 3.4 g/dL of reduced arterial hemoglobin, resulting in a level of 5 g/dL of reduced capillary hemoglobin. The total concentration of hemoglobin determines the level of arterial deoxygenation that this lower limit of detectable cyanosis represents. For example, in a patient with a hemoglobin of 15 g/dL, 3.4 g/dL corresponds to an SaO_2 of 77 percent and a PaO_2 of 43 mmHg. This same level of reduced hemoglobin in a patient with 12 g/dL hemoglobin corresponds to a PaO_2 of 39 mmHg. A severely

anemic patient with a hemoglobin of =7 g/dL may never manifest cyanosis despite fatal hypoxia. In contrast, a polycythemic patient with 18 g/dL hemoglobin and 3.4 g/dL of reduced hemoglobin will develop central cyanosis with an SaO_2 of 84 percent and a PaO_2 of 49 mmHg. Because cyanosis depends on the absolute amount of reduced hemoglobin, patients with PV can easily manifest peripheral cyanosis despite normal arterial saturation, which explains their ruddy cyanosis.

Central cyanosis in an individual with normal hemoglobin levels and an acceptable PaO_2 implies an abnormal hemoglobin level or a related problem. These include inherited methemoglobinemia (hemoglobin M), toxic methemoglobinemia, inherited NADH-diaphorase (cytochrome b5 reductase) deficiency, cytochrome b5 deficiency, acquired sulfhemoglobinemia, and low oxygen-affinity hemoglobins. [21]

Methemoglobin occurs naturally as 1 percent of total hemoglobin. At a 1.5-g/dL concentration (roughly 10 percent in men), cyanosis is easily detectable. At 20 percent, a chocolate cyanosis is seen, turning the tongue and sublingual area brown. Levels >60 percent methemoglobin are a medical emergency and should be treated with IV methylene blue or exchange transfusion. Many medications may cause elevated levels of methemoglobin, including dapsone, phenazopyridine (Pyridium), sulfamethoxazole, nitroglycerin, nitrites, and the local anesthetics benzocaine and prilocaine. [21] Nitrates in drinking water and aniline dyes in diapers are important and easily overlooked causes of this condition in infants. [21] NADH-diaphorase deficiency and the very rare cytochrome b5 deficiency impair the ability of the red cells to reduce iron to the divalent form, thereby increasing the formation of methemoglobin.

Sulfhemoglobin produces cyanosis at levels of only 0.5 g/dL capillary blood and cannot be reversed. Medications (especially sulfonamides, phenacetin, acetanilid, and phenazopyridine) are the usual cause of sulfhemoglobinemia, but this condition has occurred independent of drug use in association with chronic constipation and with purging.

Hemoglobins with altered oxygen affinity produce cyanosis through different mechanisms, but the predominant abnormalities are either lowered oxygen affinity with higher levels of reduced hemoglobin, or increased formation of methemoglobin. Cyanosis of the ears or fingertips is observed after exposure to cold in some individuals with cryoglobulins or cold agglutinins. Raynaud's phenomenon and acrocyanosis are nonhematologic causes of peripheral cyanosis with characteristic clinical presentations.

Jaundice

Jaundice is caused by staining of the skin by bile pigment. Bilirubin glucuronide (direct-reacting or conjugated bilirubin) stains the skin more readily than does the unconjugated form. [2] Jaundice of the skin may not be visible if the bilirubin level is below 2 to 3 mg/dL. Unconjugated hyperbilirubinemia suggests hemolytic anemia or inefficient hematopoiesis, as in megaloblastosis. Usually, total bilirubin is only modestly increased (<5 mg/dL), with unconjugated bilirubin comprising at least 85 percent of the total amount. [22] Urinary urobilinogen is increased regularly, but bile is not detected in the urine unless serum conjugated bilirubin is increased. Usually, serum-haptoglobin levels are low, and lactate dehydrogenase (LDH) levels are elevated. Hemoglobinuria is encountered in rare patients with hyperacute hemolysis who develop significant hemoglobinemia.

Infiltrative Lesions/Extramedullary Hematopoiesis

Specific (tumor-containing) lesions occur in many leukemias, lymphomas, and related disorders and are detailed elsewhere. Some of these same conditions induce non–tumor-containing extramedullary hematopoiesis, with the skin being an occasional and sometimes presenting site. Lesions of extramedullary hematopoiesis may present as red, pink, or violaceous papules or plaques, hemangioma-like nodules, bullae, or leg ulcerations; they may occasionally be surrounded by a hemorrhagic border. [23] Such extramedullary hematopoiesis usually occurs in idiopathic myelofibrosis, but rarely has been seen in other myeloproliferative diseases. Neonatal cases are associated with congenital infections, erythroblastosis fetalis, and, even more rarely, conditions such as twin transfusion syndrome. [23]

HEMOSTASIS AND THE DIFFERENTIAL DIAGNOSIS OF PURPURA

Hemostasis

Hemostasis is divided into two components: primary and secondary. Primary hemostasis depends both on vasoconstriction of the injured vessel and on the development of a platelet plug at the site of injury. Primary hemostasis is a critical homeostatic mechanism for repair of small defects and is a sufficient mechanism for most focal injury in the microcirculation. Because it is richly endowed with microcirculatory vessels, presumably in part to support its heat exchange function, the skin is a sensitive early warning site for problems in primary hemostasis, especially with problems in platelet function or numbers. Defects larger than those that can be sealed by a platelet plug alone and defects in larger vessels require secondary hemostasis. Secondary hemostasis involves the cascade pathway of coagulation factors and results in fibrin clot reinforcement for the platelet plug. Whereas platelet problems are an important cause of purpuric skin lesions, defects or deficiency of a single procoagulant clotting factor are an uncommon cause of cutaneous hemorrhage, usually leading instead to soft tissue hemorrhage, particularly into joints.

Differential Diagnosis of Purpura

The differential diagnosis of purpura can be confusing, and etiologies encompass hematologic, rheumatologic, dermatologic, infectious, and traumatic entities. Although it is the pathogenesis or etiology of the purpura that we usually most want to know, many approaches to the differential diagnosis of purpura begin with classifications by etiology. To circumvent this requirement, we must understand what the morphology of purpura can reveal about its likely pathogenesis. At the most basic level, purpura in the skin can be caused by simple hemorrhage, inflammatory hemorrhage, or microvascular occlusion with ischemic hemorrhage. Careful inspection of purpuric lesions is essential for

the sorting of lesions clinically into one of these fundamental categories as well as for providing an initial focus for history taking, further clinical examination, and laboratory assessment.

Morphologic differentiation can be extremely helpful in sorting through the differential diagnosis, but this approach requires a definition of terms not always used in a standard fashion and the addition of terms to categorize important morphologic subsets not previously distinguished. In this chapter, *purpura* refers to visible hemorrhage in skin or mucous membranes. Morphologic subsets of purpura include petechia (pl. petechiae), ecchymosis (pl. ecchymoses), contusions (bruises), classic palpable purpura, target lesions, inflammatory retiform purpura, and noninflammatory retiform purpura. [24]

The morphologic diagnosis of purpura begins with three P's: Is the lesion *purpuric,* is it *primary,* and is it *palpable*? For a lesion to qualify as purpuric, it must have a color that is compatible with hemorrhage—usually some shade of red, blue, or purple, but sometimes yellow-brown, green, or black—and at least some of this color must persist on compression of the skin. If the vessels are compressible, and if the color is caused by red cells that are free to move, then the color should completely blanch on compression. False-positive results occur if the lesion contains tortuous vessels that kink or constrict each other on compression, or if the lesion is difficult to compress sufficiently because of lesional firmness or because it is located in an area of dermis overlying a particularly soft subcutis, such as on the abdomen.

Red cells that have extravasated or are trapped within thrombi or vascular plugs are not free to move, and therefore some of the color persists on compression. In addition to defining purpura, compression of a lesion can be used to determine the ratio of erythema to hemorrhage. A lesion due solely to the erythema of inflammation or flushing should blanch completely. A lesion consisting of some inflammation and some hemorrhage, such as vasculitis, should blanch partially. A lesion of simple hemorrhage or extravasation of red cells, or one related to ischemic or thrombotic hemorrhage, usually has no blanchable component. Lesions caused by microvascular occlusion alone appear to induce visible purpura through ischemic extravasation of red cells around the vessel, inasmuch as thrombosis within the dermal microvasculature itself is too small to be seen directly.

The color of lesions provides additional clues. Red implies saturated hemoglobin, whereas blue implies desaturated hemoglobin. Usually, color because of blood flow is red, whereas color because of hemorrhage is blue. However, hemorrhage may remain bright red even without an inflammatory component, most often when small and superficial—for example, petechial hemorrhage. Presumably, it is possible for the hemoglobin in the extravasated cells to remain saturated through simple diffusion of oxygen from the dermis or through the epidermis. Likewise, slow flow in the skin commonly produces the bluish-purple discoloration of livedo reticularis. The term *livedo reticularis* should be limited to a completely blanchable, netlike discoloration of the skin; defined in this way, livedo reticularis is a sign of slowed or restricted cutaneous blood flow. Cyanosis, discussed previously, is another nonpurpuric cause of bluish discoloration.

Next, one must decide whether purpura is primary, that is, caused by the same process that induces the lesion. With simple extravasation, the entire visible lesion is solely a result of red cells in the dermis, resulting in macular, nonerythematous (nonblanching) purpura. In contrast, a mosquito bite is not a clinically evident hemorrhagic event for most people, but sufficient scratching can induce purpura in such a lesion. This purpura is secondary and not primary. Vasculitis as a vessel-directed injury can induce both a papule and hemorrhage as part of the same vessel injury, producing a primary purpura lesion.

Palpability must be evaluated. Red cells alone do not determine palpability, because simple hemorrhage in the dermis is usually not palpable. Extravasation of blood into or beneath the panniculus can produce a palpable hematoma, which may or may not be purpuric (the overlying dermis may or may not show visible hemorrhage). Edema confers palpability to purpuric lesions, usually secondary to inflammation but sometimes to occlusion with preceding microvascular ischemia.

Finally, a very important morphologic feature is the presence of retiform or branching features. Retiform (branching, stellate) purpura without inflammation suggests microvascular occlusion as the etiology of the lesion, whereas prominent erythema in early retiform lesions suggests vasculitis caused by either IgA or mixed–vessel-size inflammatory syndromes. [24], [25] It is presumed that the reticulate, livedoid, or stellate patterning of such lesions is caused by the same microvascular anatomy of the skin responsible for the localization of the livedo reticularis pattern in slow-flow states. Figure 156-1 summarizes this bedside approach to purpura.

FIGURE 156-1 Algorithm for assessing purpura.

NONPALPABLE PURPURA Petechial, nonpalpable hemorrhage in the skin and mucous membranes raises concerns about two general categories of hematologic syndromes: hemostatically relevant thrombocytopenia, usually less than

50,000 platelets per microliter, and abnormal platelet function (Table 156-2). There are also nonhematologic causes of nonpalpable petechial hemorrhage. The most common include spiking elevations of intravascular pressure (e.g., straining during childbirth, repetitive vomiting, and paroxysmal coughing), which usually result in petechial hemorrhage above the clavicles, chronic elevation of venular pressure (e.g. stasis), increased transmural pressure gradients (e.g., high altitudes), and the syndromes of chronic pigmented purpura. The clinical features of the chronic pigmented purpuras typically include clustered petechiae within patches of orange-brown discoloration. This color results from a mix of mild erythema with hyperpigmentation from hemosiderin and melanin in dermis. The subsets of chronic pigmented purpuras or pigmented purpuric dermatoses are discussed in Chap. 176. Occasionally, viral syndromes may present with widespread petechiae, which in some patients are not palpable. Enteroviral syndromes seem most likely to produce this outcome. Rarely, benign hypergammaglobulinemic purpura of Waldenström can present as nonpalpable petechiae.



TABLE 156-2 **Partial Diffferential Diagnosis of Nonpalpable, Nonretiform Purpura by Size of Lesion**

Macular hemorrhage >4 mm and <1 cm in diameter (intermediate or indeterminate hemorrhage) can be a result of most of the causes of either petechial or ecchymotic hemorrhage. Laboratory studies are therefore less directed, and physicians must screen for both platelet and procoagulant problems. Patients who are immunocompromised may have little or no inflammatory response to organisms, and therefore septic lesions may not be palpable in these patients. Another disorder that often presents with similar-sized macular lesions is benign hypergammaglobulinemic purpura of Waldenström. [26] This syndrome is seen most characteristically as an idiopathic syndrome in young women, with recurring crops of macular hemorrhage, most often on the legs, frequently after exercise or prolonged standing. In women middle-aged and older, it may be associated with Sjögren's or sicca syndrome, lupus, rheumatoid arthritis, or, rarely, a lymphoproliferative syndrome or monoclonal gammopathy. [26] A polyclonal gammopathy is the typical finding, but the most distinctive finding is an IgG or IgA rheumatoid factor that may be monoclonal and that acts to form 12- to 15-s immune complexes on analytic ultracentrifugation. Standard tests for rheumatoid factor detect only IgM rheumatoid factor and are of no help in diagnosing this syndrome. Ecchymoses have multiple etiologies and are probably the most common form of hemorrhage (Table 156-2). They are almost always localized by minor trauma and therefore typically develop in areas prone to trauma (dorsum of hand, pretibial area, extensor forearm, lateral or anterior thighs) and in a geometric pattern, usually linear or rectangular (Fig. 156-2 and Fig. 156-3). Petechial hemorrhage arranged linearly, often with skip areas, may have the same significance as ecchymoses, especially when the petechiae are themselves asymmetric or linear rather than symmetric and round. Easy bruising is a common complaint, most often because of the dermal effects of chronic sun injury, glucocorticoids, or (in some geographic areas) scurvy. In some individuals, usually women, no abnormalities may be found after detailed study, leaving the etiology uncertain. Less commonly, ecchymoses may result from a mild hereditary bleeding disorder.

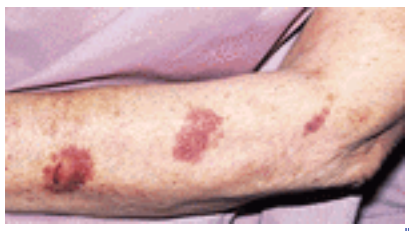

FIGURE 156-2 Nonpalpable ecchymoses in a patient on chronic oral glucocorticoid therapy. Note the rectangular and linear lesions that suggest the minor trauma component. (*From Piette,* [37] *with permission.*)

FIGURE 156-3 Close-up of one of the ecchymotic areas shown in Fig. 156-2, showing a linear traumatic injury with surrounding ecchymosis. (*From Piette,* [37] *with permission.*)

Contusions and hematomas are usually a result of trauma significant enough to be remembered. Such lesions are often swollen and therefore palpable and tender; they may also show erythema or abrasions, depending on the degree of trauma. Determining the age of ecchymoses and contusions can be a critical aspect of forensic medicine and in suspected abuse, but recent studies have suggested that dating hemorrhage is far less precise than reported earlier. [27], [28] A bruise may become more prominent with the passage of hours or days as a result of continued bleeding from the ruptured vessels or of a delay in reaching the surface because of deflection by fascial planes and other anatomic

structures. Additionally, bruises may move under gravity, such as those related to a laceration on the upper forehead. The subcutaneous hemorrhage can slide downward over the eyebrow ridge and appear in the orbit, to give a “black eye.” Similarly, a bruise of the upper arm or thigh may surface lower around the elbow or knee. Another factor in the delayed prominence of hemorrhage is hemolysis of the extravasated cells, inasmuch as free hemoglobin stains tissues more diffusely than intact red blood cells. Chemical degradation of hemoglobin into hemosiderin, biliverdin, and bilirubin causes a sequence of color changes from purple or bluish brown, to greenish brown or green, and finally to yellow before completely fading. Variables affecting color changes in bruising include the size of the extravasation (a larger bruise may contain more color changes due to delay in resolution from the margin inward), the age and constitution of the individual (severely sun-damaged skin resolves purpura much more slowly), and individual idiosyncrasies such as persistent coagulation defects. Hemosiderin does not usually appear within the first 2 or 3 days. Hematoidin, another breakdown product of blood pigment, can appear in old bruises and in hematomas after the first week. The capillaries of the subcutaneous tissues make the greatest contribution to bruising. Data are sparse regarding the reliability of wound dating by appearance. In experiments with cattle, the sequence of color development is red from 15 min to 2 days (due to red cells and free hemoglobin), green on days 3 and 4, and yellow and orange from days 4 to 6 (due to bilirubin). In humans, a long-standing consensus has been that red, blue, and purple are early colors; greens show after 4 to 7 days; and yellow color is delayed until after the seventh day. Recent studies challenge this consensus with the demonstration that red, blue, purple, or black coloration can develop from within 1 h of bruising up to 21 days. [27], [28] A bruise with yellow color is at least 18 h old in any individual, although the development of a yellow color occurs significantly faster in persons younger than 65 years of age. [27]

PALPABLE OR RETIFORM PURPURA The differential diagnosis of inflammatory hemorrhage, including vasculitis, is extensive. Summarized in Table 156-3, such syndromes are discussed elsewhere in this text. Figure 156-4, Figure 156-5, and Figure 156-6 provide examples of classic palpable purpura, target lesions, and inflammatory retiform purpura.



TABLE 156-3 **Partial Differential Diagnosis of Palpable or Retiform Purpura with Prominent Early Erythema by Lesion, Shape, and Degree of Erythema**

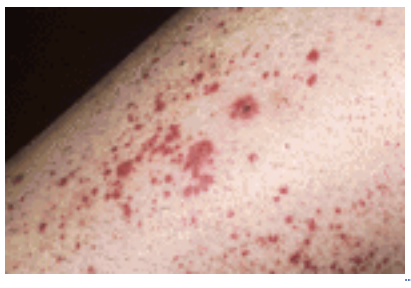

FIGURE 156-4 Classic palpable purpura on the leg of a patient with IgA vasculitis. Partial blanching of an early lesion on compression supports the clinical impression of inflammatory hemorrhage.

FIGURE 156-5 Target lesions with central hemorrhage in a patient with erythema multiforme (EM). Unfortunately, many patients with EM do not develop target lesions, and some may develop lesions clinically identical to those in Fig. 156-4.

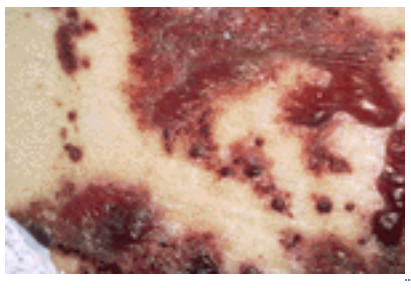

FIGURE 156-6 Inflammatory retiform palpable purpura in a patient with IgA vasculitis. The initial erythematous phase is still present but fading in these lesions.

It is critical to distinguish vascular injury in which inflammation predominates from processes in which microvascular thrombosis or occlusion is the primary mechanism. Table 156-4 summarizes the major differential possibilities for microvascular occlusion, characterized clinically by noninflammatory retiform (branching, stellate) purpura or by large

areas of purpura/necrosis with minimal early erythema (Fig. 156-7) and histologically by bland (noninflammatory) occlusion of dermal vessels. An important, but nonpurpuric presentation of cutaneous microvascular occlusion includes the development of painful atrophie blanche (livedoid vasculitis)-like ulcers or porcelain white scars, especially on the legs. Such lesions may develop secondary to occlusion in patients with primary atrophie blanche, in some patients with antiphospholipid antibody syndrome, either primary or secondary to lupus, or with severe anemia with high reticulocyte counts (especially sickle cell disease or thalassemias). Syndromes important in cutaneous microvascular occlusion have been reviewed. [29]

TABLE 156-4 **Differential Diagnosis of Palpable or Retiform Purpura with Minimal Early Erythema by Lesion, Shape, and Degree of Erythema**

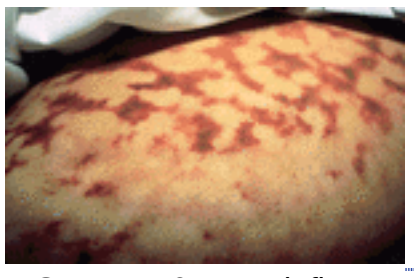

FIGURE 156-7 Noninflammatory retiform palpable purpura on the thigh in a patient with disseminated intravascular coagulation secondary to sepsis. None of the lesional color faded on compression. The biopsy showed multiple dermal vessels occluded by clot without inflammation.

Medicine has seen important advances in understanding hypercoagulable states in recent years, especially in the areas of the protein C–thrombomodulin pathway, factor V Leiden, antiphospholipid antibody syndrome, and homocystinuria. [30], [31] It is important to recognize that the causes of microvascular thrombosis or occlusion overlap with, but are not identical to, the causes of thrombotic disorders of larger vessels. For example, antithrombin III deficiency is an important risk factor for large-vein thrombosis but is rarely responsible for occlusion of the dermal microvasculature. Likewise, cryoglobulins can cause dermal vessel occlusion in acral areas but do not occlude major veins. Therefore, expertise in this area of cutaneous disease can be critical not only in interpreting the cutaneous changes but also in suggesting likely individual syndromes responsible for occlusion. The proper interpretation of morphologic findings of purpura can be an important aid in the timely and accurate evaluation of causes of cutaneous hemorrhage.

REFERENCES

1. Erslev A: Clinical manifestations and classification of erythrocyte disorders, in *Williams Hematology,* 6th ed, edited by E Beutler, M Lichtman, B Coller, T Kipps, U Seligsohn. New York, McGraw-Hill, 2001, p 369

2. Beutler E et al: Approach to the patient, in *Williams Hematology,* 6th ed, edited by E Beutler, M Lichtman, B Coller, T Kipps, U Seligsohn. New York, McGraw-Hill, 2001, p 3

3. Bull B: Morphology of the erythron, in *Williams Hematology,* 6th ed, edited by E Beutler, M Lichtman, B Coller, T Kipps, U Seligsohn. New York, McGraw-Hill, 1995, p 271

4. Fairbanks V, Beutler E: Iron deficiency, in *Williams Hematology,* 6th ed, edited by E Beutler, M Lichtman, B Coller, T Kipps, U Seligsohn. New York, McGraw-Hill, 2001, p 447

5. Babior B: The megaloblastic anemias, in *Williams Hematology,* 6th ed, edited by E Beutler, M Lichtman, B Coller, T Kipps, U Seligsohn. New York, McGraw-Hill, 2001, p 425

6. Downham T et al: Hyperpigmentation and folate deficiency. *Arch Dermatol* **112**:562, 1976

7. Ridley C: Pigmentation of fingertips and nails in vitamin B_{12} deficiency. *Br J Dermatol* **97**:105, 1977

8. Howitz J, Schwartz M: Vitiligo, achlorhydria, and pernicious anemia. *Lancet* **1**:1331, 1971

9. Hild D: Folate losses from the skin in exfoliative dermatitis. *Arch Intern Med* **123**:51, 1969

10. Erslev A: Anemia of endocrine disorders, in *Williams Hematology,* 6th ed, edited by E Beutler, M Lichtman, B Coller, T Kipps, U Seligsohn. New York, McGraw-Hill, 2001, p 407

11. Myers B et al: POEMS syndrome with idiopathic flushing mimicking carcinoid syndrome. *Am J Med* **90**:646, 1991

12. Longley J et al: The mast cell and mast cell disease. *J Am Acad Dermatol* **32**:545, 1995

13. Kurzrock R, Cohen P: Mucocutaneous paraneoplastic manifestations of hematologic malignancies. *Am J Med* **99**:207, 1995

14. Weller PF: The idiopathic hypereosinophilic syndrome. *Blood* **83**:2759, 1994

15. Schmuth M et al: Cutaneous involvement in prelymphomatous angioimmunoblastic lymphadenopathy. *J Am Acad Dermatol* **36**:290, 1997

16. Bilgrami S, Greenberg B: Polycythemia rubra vera. *Semin Oncol* **22**:307, 1995

17. Taylor P et al: Efficacy of recombinant interferon-alpha (rIFN-a) in polycythaemia vera: A study of 17 patients and an analysis of published data. *Br J Haematol* **92**:55, 1996

18. Kligman A et al: Water-induced itching without cutaneous signs. Aquagenic pruritus. *Arch Dermatol* **122**:183, 1986

19. de Peloux Menagé H, Greaves M: Aquagenic pruritus. *Semin Dermatol* **14**:313, 1995

20. Handfield-Jones S et al: Aquagenic pruritus associated with juvenile xanthogranuloma. *Clin Exp Dermatol* **18**:253, 1993

21. Beutler E: Methemoglobinemia and other causes of cyanosis, in *Williams Hematology,* 6th ed, edited by E Beutler, M Lichtman, B Coller, T Kipps, U Seligsohn. New York, McGraw-Hill, 2001, p 611

22. Packman C, Leddy J: Acquired hemolytic anemia due to warm-reacting autoantibodies, in *Williams Hematology,* 6th ed, edited by E Beutler, M Lichtman, B Coller, T Kipps, U Seligsohn. New York, McGraw-Hill, 2001, p 639

23. Patel B et al: Cutaneous extramedullary hematopoiesis. *J Am Acad Dermatol* **32**:805, 1995

24. Piette WW: The differential diagnosis of purpura from a morphologic perspective. *Adv Dermatol* **9**:3, 1994

25. Piette WW, Stone MS: A cutaneous sign of IgA-associated small dermal vessel leukocytoclastic vasculitis in adults (Henoch-Schönlein purpura). *Arch Dermatol* **125**:53, 1989

26. Habib G et al: Hypergammaglobulinemic purpura of Waldenström associated with systemic lupus erythematosus: Report of a case and review of the literature. *Lupus* **4**:19, 1995

27. Langlois N, Gresham G: The ageing of bruises: A review and study of the colour changes with time. *Forensic Sci Int* **50**:227, 1991

28. Stephenson T, Bialas Y: Estimation of the age of bruising. *Arch Dis Child* **74**:53, 1996

29. Robson JK, Piette WW: The presentation and differential diagnosis of cutaneous vascular occlusion syndromes. *Adv Dermatol* **15**:153, 1999.

30. Nahass GT: Antiphospholipid antibodies and the antiphospholipid syndrome. *J Am Acad Dermatol* **36**:149, 1997

31. Mandel H et al: Coexistence of hereditary homocystinuria and factor V Leiden—Effect on thrombosis. *N Engl J Med* **334**:763, 1996

32. Kurzrock R et al: Clinical manifestations of vasculitis in patients with solid tumors: A case report and review of the literature. *Arch Intern Med* **154**:334, 1994

33. Piette W: An approach to cutaneous changes caused by hematologic malignancies. *Dermatol Clin* **7**:467, 1989

34. Piette W: Leukemia and lymphoma, in *Dermatological Signs of Internal Disease,* 3rd ed, edited by J Callen et al. Philadelphia, Saunders, 2003

35. Cohen P: Paraneoplastic dermatopathology: Cutaneous paraneoplastic syndromes. *Adv Dermatol* **11**:215, 1996

36. Dominey A, Tschen J: Cutaneous manifestations of dysproteinemias. *Dermatol Clin* **7**:449, 1989

37. Piette W: Myeloma, paraproteinemias, and the skin. *Med Clin North Am* **70**:155, 1986

38. Farell G: Fanconi's familial hypoplastic anaemia with some unusual features. *Med J Aust* **1**:116, 1976

39. Fanconi G: Familial constitutional panmyelocytopathy, Fanconi's anemia (FA) 1. Clinical aspects. *Semin Hematol* **4**:233, 1967

40. Tchou P, Kohn T: Dyskeratosis congenita: An autosomal dominant disorder. *J Am Acad Dermatol* **6**:1034, 1982

41. Bolognia J, Pawelek J: Biology of hypopigmentation. *J Am Acad Dermatol* **19**:217, 1988

42. Goldblatt J, Beighton P: Cutaneous manifestations of Gaucher disease. *Br J Dermatol* **111**:331, 1984

43. Mardini M et al: Niemann-Pick disease: Report of a case with skin involvement. *Am J Dis Child* **136**:650, 1982

44. Joliffe D, Sarkany I: Niemann-Pick type III and Crohn's disease. *J R Soc Med* **76**:307, 1983

45. Etzioni A: Adhesion molecules—Their role in health and disease. *Pediatr Res* **39**:191, 1996

46. Wahl S et al: Regulation of leukocyte adhesion and signaling in inflammation and disease. *J Leuk Biol* **59**:789, 1996

47. Blume R, Wolff S: The Chédiak-Higashi syndrome: Studies in four patients and a review of the literature. *Medicine* **51**:247, 1977

48. Griscelli C et al: A syndrome associating partial albinism and immunodeficiency. *Am J Med* **65**:691, 1978

49. Howard T et al: The 47-kD protein increased in neutrophil actin dysfunction with 47- and 89-kD protein abnormalities is lymphocyte-specific protein. *Blood* **83**:231, 1994

50. Ormerod A: The Wiscott-Aldrich syndrome. *Int J Dermatol* **24**:77, 1985

51. Rosenstein Y et al: CD43, a molecule defective in Wiskott-Aldrich syndrome, binds ICAM-1. *Nature* **354**:233, 1991

52. Bayle P et al: Neutrophilic dermatosis: A case of overlapping syndrome with monoclonal antineutrophil cytoplasmic autoantibody activity. *Dermatology* **189**:69, 1994

53. Younus J, Ahmed A: The relationship of pemphigus to neoplasia. *J Am Acad Dermatol* **23**:498, 1990

54. Anhalt G: Paraneoplastic pemphigus. *Adv Dermatol* **12**:77, 1997

55. Whitworth S et al: Acquired immunobullous disease: A cutaneous manifestation of IgM macroglobulinaemia. *Br J Dermatol* **135**:283, 1996

56. McEvoy M, Connolly S: Linear IgA dermatosis: Association with malignancy. *J Am Acad Dermatol* **22**:59, 1990

57. Levi F et al: Non-Hodgkin's lymphomas, chronic lymphocytic leukemias and skin cancers. *Br J Cancer* **74**:1847, 1996

58. Sanchez-Guerrero J et al: Vasculitis as a paraneoplastic syndrome. Report of 11 cases and review of the literature. *J Rheumatol* **17**:1458, 1990

59. Milone G et al: Cutaneous vasculitis in non–Hodgkin's lymphoma. *Haematologica* **80**:529, 1995

60. Pavlidis N et al: Cutaneous lymphocytic vasculopathy in lymphoproliferative disorders—a paraneoplastic lymphocytic vasculitis of the skin. *Leuk Lymphoma* **16**:477, 1995

61. Ruiz-Maldonado R et al: Edematous, scarring vasculitic panniculitis: A new multisystem disease with malignant potential. *J Am Acad Dermatol* **32**:37, 1995

62. Davis MDP et al: Natural history of erythromelalgia: Presentation and outcome in 168 patients. *Arch Dermatol* **136**:330, 2000

63. Mørk C: Erythromelalgia—a mysterious condition? *Arch Dermatol* **136**:406, 2000

64. Cohen JS: Erythromelalgia: New theories and new therapies. *J Am Acad Dermatol* **43**:841, 2000

65. Fleischer AB Jr, Resnick SD: Livedo reticularis. *Dermatol Clin* **8**:347, 1990

66. Picascia DD, Pellegrini JR: Livedo reticularis. *Cutis* **39**:429, 1987

67. Pereira A et al: Anti-Sa cold agglutinin of IgA class requiring plasma-exchange therapy as early manifestation of multiple myeloma. *Ann Hematol* **66**:315, 1993

68. Maroon M: Polycythemia rubra vera presenting as livedo reticularis. *J Am Acad Dermatol* **26**:264, 1992

69. Eng A: Cutaneous expressions of antiphospholipid syndromes. *Semin Thromb Hemost* **20**:71, 1994

70. Weir N et al: Livedo reticularis associated with hereditary protein C deficiency and recurrent thromboembolism. *Br J Dermatol* **132**:283, 1995

71. Donnet A et al: Cerebral infarction, livedo reticularis, and familial deficiency in antithrombin-III [letter]. *Stroke* **23**:611, 1992

72. Gross A et al: Heparin-associated thrombocytopenia and thrombosis (HATT) presenting with livedo reticularis. *Int J Dermatol* **32**:276, 1993

73. Frankel D et al: Acral lividosis—a sign of myeloproliferative diseases. Hyperleukocytosis syndrome in chronic myelogenous leukemia. *Arch Dermatol* **123**:921, 1987

74. Speight E, Lawrence C: Reticulate purpura, cryoglobuliaemia, and livedo reticularis. *Br J Dermatol* **129**:319, 1993

75. Hasegawa H et al: Multiple myeloma-associated systemic vasculopathy due to crystal globulin or polyarteritis nodosa. *Arthritis Rheum* **39**:330, 1996

76. Ball N et al: Crystal globulinemia syndrome. A manifestation of multiple myeloma. *Cancer* **71**:1231, 1993

77. Furie R et al: Syndrome of acquired factor X deficiency and systemic amyloidosis. *N Engl J Med* **297**:81, 1977

78. Carroll C et al: Atrophic outpouchings of abdominal skin. *Arch Dermatol* **132**:223, 1996

79. Lipsker D et al: Examination of cutaneous macroglobulinosis by immunoelectron microscopy. *Br J Dermatol* **135**:287, 1996

80. Jenkins R et al: Cutaneous crystalline deposits in myeloma. *Arch Dermatol* **130**:484, 1994

81. Requena L et al: Follicular spicules of the nose: A peculiar cutaneous manifestation of multiple myeloma with cryoglobulinemia. *J Am Acad Dermatol* **32**:834, 1995

82. Dineen A, Dicken C: Scleromyxedema. *J Am Acad Dermatol* **33**:37, 1995

83. Crocker A, Farber S: Niemann-Pick disease: A review of 18 patients. *Medicine* **37**:1, 1958

84. Griffiths W, Daneshbod K: Pseudoxanthomatous mastocytosis. *Br J Dermatol* **93**:91, 1975

85. Jubert C et al: Anetoderma may reveal cutaneous plasmacytoma and benign cutaneous lymphoid hyperplasia. *Arch Dermatol* **131**:365, 1995

86. Kahn L et al: Florid sarcoid reaction associated with lymphoma of the skin. *Cancer* **33**:1117, 1974

87. Rapini R: Multicentric reticulohistiocytosis. *Clin Dermatol* **11**:107, 1993

88. Van Dijk E: Ichthyosiform atrophy of the skin with internal malignant diseases. *Dermatologica* **127**:413, 1963

89. Ellis D, Yates R: Sign of Leser-Trélat. *Clin Dermatol* **11**:141, 1993

90. Bull R et al: Eosinophilic folliculitis: A self-limiting illness in patients being treated for haematological malignancy. *Br J Dermatol* **129**:178, 1993

91. Gross A et al: Fever, maculopapular eruption, and lymphadenopathy. Angioimmunoblastic lymphadenopathy (AILD). *Arch Dermatol* **130**:1551, 1994

92. Piette W: Hematologic associations of leg ulcers. *Clin Dermatol* **3/4**:66, 1990

93. Aractingi S et al: Specific mucosal erosions in hypereosinophilic syndrome. Evidence for eosinophil protein deposition. *Arch Dermatol* **132**:535, 1996

94. Rutherford CJ, Frenkel EP: Thrombocytopenia: Issues in diagnosis and therapy. *Med Clin North Am* **78**:555, 1994

95. Najean Y, Lecompte T: Hereditary thrombocytopenias in childhood. *Semin Thromb Hemost* **21**:294, 1995

96. Kottke-Marchant K: Laboratory diagnosis of hemorrhagic and thrombotic disorders. *Hematol Oncol Clin North Am* **8**:809, 1994

97. Sham R, Francis C: Evaluation of mild bleeding disorders and easy bruising. *Blood Rev* **8**:98, 1994

98. Champion RH, Rook A: Idiopathic thrombocythemia—Cutaneous manifestations. *Arch Dermatol* **87**:302, 1963

99. Piette WW: Purpura, in *Dermatological Signs of Internal Disease,* 2nd ed, edited by JP Callen, JL Jorizzo, KE Greer, NS Penneys, WW Piette, JJ Zone. Philadelphia, Saunders, 1995, p 87

100. Sams W Jr: Macular purpuras, in *Principles and Practice of Dermatology,* 2nd ed, edited by W Sams Jr, P Lynch. New York, Churchill Livingstone, 1996, p 559

101. Piette WW: Primary systemic vasculitis, in *Cutaneous Manifestations of Rheumatic Diseases,* edited by RD Sontheimer, TT Provost. Baltimore, Williams & Wilkins, 1996, p 177

102. Jennette CJ et al: Vasculitis affecting the skin: A review. *Arch Dermatol* **130**:899, 1994

103. Tancrede-Bohin E et al: Schönlein-Henoch in adult patients: Predictive factors for IgA glomerulonephritis in a retrospective study of 57 cases. *Arch Dermatol* **133**:438, 1997

104. Piette WW: What is Schönlein-Henoch purpura, and why should we care? *Arch Dermatol* **133**:515, 1997

105. Warkentin T: Heparin-induced skin lesions. *Br J Haematol* **92**:494, 1996

106. Moake J, Byrnes J: Thrombotic microangiopathies associated with drugs and bone marrow transplantation. *Hematol Oncol Clin North Am* **10**:485, 1996

107. Sams W Jr: Diseases presenting with a livedo or stellate pattern, in *Principles and Practice of Dermatology,* 2nd ed, edited by W Sams Jr, P Lynch. New York, Churchill Livingstone, 1996, p 565

108. Cohen SJ et al: Cutaneous manifestations of cryoglobulinemia: Clinical and histopathologic study of seventy-two patients. *J Am Acad Dermatol* **25**:21, 1991

109. Smith S, Arkin C: Cryofibrinogenemia: Incidence, clinical correlations, and a review of the literature. *Am J Clin Pathol* **58**:524, 1972

110. McKee P, Kalbfleisch J: Incidence and significance of cryofibrinogenemia. *J Lab Clin Med* **61**:203, 1963

111. Stone MS et al: Cutaneous necrosis at sites of transfusion: Cold agglutinin disease [letter]. *J Am Acad Dermatol* **19**:356, 1988

112. Greene S et al: Ecthyma gangrenosum: Report of clinical, histopathologic, and bacteriologic aspects of eight cases. *J Am Acad Dermatol* **11**:781, 1984

113. Ronan S et al: Disseminated strongyloidiasis presenting as purpura. *J Am Acad Dermatol* **21**:1123, 1989

114. Robboy S et al: The skin in disseminated intravascular coagulation: Prospective analysis of thirty-six cases. *Br J Dermatol* **88**:221, 1973

115. Marlar RA, Neumann A: Neonatal purpura fulminans due to homozygous protein C or protein S deficiencies. *Semin Thromb Hemost* **16**:333, 1990

116. Dreyfus M et al: Treatment of homozygous protein C deficiency and neonatal purpura fulminans with a purified protein C concentrate. *N Engl J Med* **325**:1565, 1991

117. Frances RB Jr: Acquired purpura fulminans. *Semin Thromb Hemost* **16**:310, 1990

118. Manco-Johnson MJ et al: Lupus anticoagulant and protein S deficiency in children with postvaricella purpura fulminans or thrombosis. *J Pediatr* **128**:319, 1996

119. Schramm W et al: Treatment of coumarin-induced skin necrosis with a monoclonal antibody purified protein C concentrate. *Arch Dermatol* **129**:753, 1993

120. Gladson C et al: Coumarin necrosis, neonatal purpura fulminans, and protein C deficiency. *Arch Dermatol* **123**:1701a, 1987

121. Rietschel R et al: Skin lesions in nocturnal paroxysmal hemoglobinuria. *Arch Dermatol* **114**:560, 1978

122. Draelos Z, Hansen R: Hemorrhagic ullae in an anemic woman. *Arch Dermatol* **122**:1325, 1986

123. Bard J, Winkelman R: Livedo vasculitis: Segmental hyalinizing vasculitis of the dermis. *Arch Dermatol* **96**:489, 1967

124. Shornick J et al: Idiopathic atrophie blanche. *J Am Acad Dermatol* **8**:792, 1983

125. Falanga V et al: The cutaneous manifestations of cholesterol crystal embolization. *Arch Dermatol* **122**:1194, 1986

126. Greer KE et al: Primary oxalosis with livedo reticularis. *Arch Dermatol* **116**:213, 1980

127. Ivker R et al: Calciphylaxis in three patients with end stage renal disease. *Arch Dermatol* **131**:63, 1995

128. Hafner J et al: Uremic small-artery disease with medial calcification and intimal hyperplasia (so-called calciphylaxis): A complication of chronic renal failure and benefit from parathyroidectomy. *J Am Acad Dermatol* **33**:954, 1995

129. Rostaing L et al: Calciphylaxis in a chronic hemodialysis patient with protein S deficiency. *Am J Nephrol* **15**:524, 1995

T>

Chapter 157

Jo-Ann Latkowski Peter Heald

Cutaneous T Cell Lymphomas

HISTORICAL ASPECTS
EPIDEMIOLOGY
ETIOLOGY
PATHOPHYSIOLOGY
CLINICAL MANIFESTATIONS
Clinical Features
Mycosis Fungoides and Variants
CTCL TUMORS
Dual Lymphoid Neoplasia of the Skin
PATIENT ASSESSMENT (LABORATORY FINDINGS)
Skin Evaluation
Lymph Nodes
Peripheral Blood
Staging
Disease in Other Tissues
PATHOLOGY
DIAGNOSIS AND DIFFERENTIAL DIAGNOSIS
TREATMENT
Uni/Oligo Lesional CTCL: Skin-Directed Therapy
Disseminated Patch/Plaque Disease
Erythroderma
Refractory Patch-Plaque or Erythroderma
Tumors

REFERENCES

HISTORICAL ASPECTS

The earliest descriptions of cutaneous T cell lymphomas (CTCL) appeared during the era of descriptive dermatology when the great French clinicians recognized the distinctive features of this disease. Alibert observed the unique features in the early 1800s and coined the term *mycosis fungoides* (MF). Later in the nineteenth century there were descriptions of the patch, plaque, and tumor stages of MF. By using sheep red blood cell rosetting these disorders could be unified as being malignancies of T lymphocytes. Sheep red cell rosetting was the first marker for T cells and is now known to be related to expression of CD2. As research tools were applied, it was discovered that there were cutaneous B cell lymphomas, ?d cutaneous lymphomas and NK lymphomas. Cutaneous homing lymphocytes include T cells, B cells, and subsets thereof. Cutaneous T cells are a dynamic population with distinct cell surface markers. Subsequent work clearly shows that the malignant cells of CTCL are cutaneous T cells, providing the unifying concept for lymphomas of cutaneous T cells. Thus, the concept of the old clinical entity MF has been expanded to the spectrum of CTCL including non-MF cutaneous T cell lymphomas. Whereas all forms of MF are CTCL, not all CTCLs are MF. [1] Table 157-1 lists the distinct variants of CTCL.

I. Mycosis fungoides variants
  A. Classic mycosis fungoides
  B. Clincopathologic syndromes
    1. Hypopigmented
    2. Granulomatous slack skin
    3. Pagetoid reticulosis
    4. Pigmented purpuria
    5. Alopecia mucinosa
    6. Follicular
    7. Adnexotropic
  C. Immunophenotypic syndromes
    1. CD8+
    2. Gamma-delta+
    3. NK T cell
  D. Erythrodermas
    1. Sézary syndrome
    2. Erythrodermic MF
    3. Erythrodermic CTCL
  E. Tumors of mycosis fungoides
II. Nonmycosis fungoides CTCL
  A. CD30+ and CD30−
  B. Large vs. small vs. mixed cell type
  C. Angiocentric
  D. Lipotropic (subcutaneous)

CTCL = cutaneous T cell lymphoma; MF = mycosis fungoides; NK = natural killer

TABLE 157-1 **Distinct Variants of CTCL**

EPIDEMIOLOGY

The difficulty in determining the changing epidemiology of CTCL relates to the restriction of study patient groups to tertiary centers that accrue patients in a nonrandom manner. Although early epidemiologic studies reported a substantial increase in the incidence of MF before the early 1980s, [2] a more recent study that used a substantially larger database with a longer interval of time showed that the incidence rate has stabilized, at an average rate of 0.3 per 10^5 person-years. [3] The data were derived from cancer registries that participated in the Surveillance, Epidemiology, and End Results (SEER) program data of the National Cancer Institute from 1973 through 1992. Among racial groups, the

incidence rate of MF is highest among blacks and lowest among Asians. Males are twice as likely to get MF than are females, and this is consistent among racial groups. Underregistration was identified as a potential problem in their data because most MF patients are treated as outpatients. The often indolent nature of the disease further hinders diagnosis, as patients die of other causes before CTCL progresses to an advanced stage.

The mortality rate of MF has declined. [4] Data were obtained from death certificates reported to the National Center for Health Statistics for the United States during the period 1979 to 1991. The mortality rate was found to be 0.064 per 10 [5] person-years and the rate ratio for men versus women was 1.8 overall. Identical to the incidence rate, the mortality rate was highest among blacks and lowest among Asians. But the overall mortality rate declined approximately 22 percent during the period studied. A Swedish study also showed a decrease in mortality rates between 1961 and 1980. [5] Those declines in mortality rates can be attributed to improved diagnostic techniques, early diagnosis, and rapid treatment of MF.

The same SEER data were used for the period between 1973 to 1992 to evaluate the trend in survival among MF patients. [4] This study identified important prognostic factors as age, and race and a larger group of patients (1633) were followed for a substantially longer period of time (greater than 10,000 person-years). It was found that advanced age and black race were associated with poorer prognosis and there was improvement in survival rates over the 20-year period studied. The data showed that when patients survived 11 years after diagnosis of their disease, it was unlikely they were going to die because of MF.

In a study of long-term outcome of patients with generalized patches and/or plaques of MF (T2, see below), 24 percent of patients had disease progression and 20 percent eventually died of advanced disease. [6] Younger patients had a better disease-specific prognosis than older patients and presence of lymphadenopathy at the time of diagnosis did not indicate poorer long-term outcome. Lack of complete response to initial therapy and lymphadenopathy at diagnosis were predictive of disease progression.

Patients with limited, early stage disease (T1) have no significant difference between observed and expected survival. [7] As expected, the relative survival of patients with CTCL decreases with increasing disease stage. In this study, the 10-year relative survival rates were calculated for 489 patients: T2 = 67.4 percent, T3 = 39.2 percent, and T4 = 41 percent. Lymphadenopathy at time of diagnosis had an unfavorable impact on prognosis, conflicting with other studies where it was shown not to impact long-term outcome.

Uniform standards for diagnosing and staging CTCL patients are necessary in order to determine the true epidemiologic statistics and significance of this disease. Dermatologists must take an example from oncologists in regards to staging a patient with CTCL. The stage at initial presentation must be maintained for each patient whether their disease improves or progresses so that data collection accurately represents the CTCL patient population. It is important to adhere to the oncologic principle that the patient's stage will not change, although their disease status may. In addition, consistent reporting to local cancer registries will lead to more complete data for CTCL. These changes will result in more reliable statistics including incidence, prognosis and mortality rates.

ETIOLOGY

For many years, CTCL was thought of as a disease of chronic antigen stimulation in which an initial inflammatory response in the epidermis leads to T cell proliferation and, finally, to the emergence of a malignant clone. Despite much effort to identify a unifying antigen in this disease, the etiology remains unknown.

A viral etiology for CTCL was an attractive hypothesis given the cutaneous similarities with adult T cell lymphoma/leukemia(ATL), associated with human T cell lymphotrophic virus type I (HTLV-1) infection. The results of studies to determine an association between CTCL and HTLV-1 are contradictory. An early study reported a partially deleted HTLV-1 provirus in a cell line established from a patient with MF detected by polymerase chain reaction (PCR) analysis. However, studies have been done in American and European populations that find no association of MF with HTLV-1 infection. PCR, Southern blot, and reverse transcriptase assays have been used, but no HTLV-1 has been demonstrated. These data suggest that HTLV-1 does not play an important role in the etiology of CTCL and that the only reason for screening patients for antibodies is when one suspects the diagnosis of ATL, not MF. Epstein-Barr virus (EBV) has also been proposed as a pathogen. Given its association with other lymphoproliferative disorders and lymphomas, such as Burkitt's lymphoma, its connection seemed logical. The possibility that EBV infection can lead to the proliferation and activation of T cells in the epidermis has been suggested, but this has not yet been definitively proven.

Bacterial infections have also been implicated in CTCL. One group suggested an association of *Staphylococcus aureus*. [8] Of the CTCL patients studied, 75 percent had a positive staphylococcus culture from the blood or skin with half of these cultures positive for *S. aureus* carrying enterotoxin genes, such as toxic shock toxin-1. The patients with positive blood cultures had Sézary syndrome or progressive plaque and tumor MF but only four had monoclonal expansion of a specific Vß gene. This study suggested that *S. aureus* superantigen enterotoxins could provide or potentiate lymphocytic infiltration and chronic antigenic stimulation leading to T cell clonal expansion in CTCL.

It has been suggested that occupational risk factors also play a causative role in CTCL, because an indolent dermatitis often precedes the diagnosis. Exposure to carcinogens in the work environment can provide the chronic antigenic stimulation needed to initiate clonal expansion. An occupational exposure to chemicals considered hazardous was recorded in 30 percent of patients in the Mycosis Fungoides Study Group [7]. However, a case control study in California and Washington State demonstrated no correlation between MF and occupation or chemical exposure. [9]

Even though the hypothesis that CTCL is a disease due to chronic antigenic stimulation with ultimate emergence of a malignant T cell clone remains well established, the etiology of CTCL, including the discovery of some possible initiating

events, has yet to be determined.

PATHOPHYSIOLOGY (See also Chap. 23 and Chap. 28)

The clinical entities encompassed by the term *cutaneous T cell lymphoma* share several components, including a T cell clonal population, a modulated antitumor response, and an epidermal microenvironment.

CTCL is a malignancy of skin-homing T cells thta are best delineated from other T cells by a unique cell surface receptor called *cutaneous lymphocyte-associated antigen* (CLA). CLA is expressed on memory T cells that have the ability to home to the skin by binding to E-selectin, which is expressed on vascular endothelial cells and superinduced during cutaneous inflammation. As these T cells circulate through high endothelial venules, they respond to yet unknown signals from the epidermis by tethering and rolling on P-selectin and E-selectin and, finally, extravasating into inflamed skin.

CLA is a cell surface glycoprotein that is defined by its reactivity with a monoclonal antibody, HECA-452. It was recently discovered that CLA is actually an inducible carbohydrate modification of a ubiquitously expressed T cell surface protein, P-selectin glycoprotein ligand-1 (PSGL-1). CLA is produced by a posttranslational modification of PSGL-1 by a(1,3)-fucosyltransferase (FucT VII) that is found in lymphocytes that bind E-selectin.

CLA is also expressed on cells of myeloid lineage, including monocytes, neutrophils and dendritic cells. Less than 20 percent of peripheral T cells express CLA, suggesting that these cells can be readily recruited to the skin. More than 85 percent of T cells participating in a cutaneous inflammatory response express CLA. However, CLA-expressing lymphocytes are not found in inflammatory infiltrates in the kidney, synovium, or other tissues. In vitro studies show that CLA can be induced in all peripheral blood T cells populations, implying that all T cells have the capacity to home to the skin, depending on yet undetermined regulatory signals. [10]

The second similarity unifying CTCLs is the presence of a modulated antitumor response. Lesions of CTCL often have a CD8+ T cell component. Once thought to be innocent bystanders in the epidermis, we now have data defining the responsibility of CD8+ T cells in the antitumor response. The first insight into defects in the integrity of normal T cell function in advanced CTCL patients came from observations in patients who had been treated with extracorporeal photochemotherapy (see Chap. 266). Responding patients had significantly lower CD4/CD8 T cell ratios and higher absolute numbers of CD8+ T cells in their peripheral blood at the outset of treatment than did nonresponders. [11] In general, skin biopsies of MF lesions in early stages (T1 and T2) harbor a higher proportion of CD8+ cells as compared to lesions in advanced stages. Improved long-term prognosis was correlated with the presence of these CD8+ tumor-infiltrating lymphocytes (TIL) in MF. [12] It is now believed that these CD8+ cytotoxic T cells play an important part in the pathogenesis of CTCL, mainly in mediating an antitumor response.

One possible mechanism for this antitumor response may be mediated through the Fas/FasL pathway, which can also provide neoplasms with immune privilege and protection. Fas receptor and Fas ligand (FasL) are transmembrane proteins of the tumor necrosis factor (TNF) family and are expressed on cells of lymphoid and myeloid lineage. Upon binding of the ligand to the receptor, a cascade of events occurs leading to apoptosis. In melanoma, loss of Fas expression by tumor cells has been correlated with tumor progression suggesting that absence of this apoptotic initiator mediator leads to immunosurveillance escape. In other tumor models, the converse has been demonstrated. Expression of FasL on tumor cells can trigger apoptosis in cytotoxic T cells that express Fas, thereby providing a counterattack to the immune response and evading destruction itself.

Aberrations of the Fas/FasL pathway have been studied in CTCL. Immunohistochemical studies of Fas and FasL expression in frozen and paraffin-embedded skin biopsies of CTCL patients demonstrated loss of Fas expression in advanced MF and aggressive forms of CTCL and strong expression in early stages of MF. The Fas/FasL pathway may contribute to the immunosuppression seen in MF patients and provide immune advantage/privilege to tumor cells, rendering them immunologically tolerant.

The third unifying concept in the pathophysiology of CTCL is the participation of the epidermis as a microenvironment for malignant cells (see Chap. 23). Within the skin, cytokines have an important role in maintaining the milieu and initiating immune responses (see also Chap. 26). It is well established that patients with CTCL have variable production and response to T_H1 and T_H2 cytokines. Early studies that measured the mRNA levels of T_H1 and T_H2 cytokines showed that, at any stage of disease, IL-5 and IL-4 mRNA, T_H2 cytokines, could be found with the persistence of T_H2 cytokine mRNA in skin more frequent in tumor stage. The decline in interferon (IFN)-? and predominance in T_H2 cytokines might be responsible for loss of immunosurveillance, allowing CTCL to progress.

Other cytokines are also likely to play a role in the pathogenesis of CTCL. Culture studies and immunohistochemical studies on skin biopsies demonstrate the presence of interleukin (IL)-15 and IL-7 in CTCL patients. IL-7 is a cytokine, produced by keratinocytes, which has been identified as a T cell growth factor. IL-15, also produced in the skin by keratinocytes, has functional properties similar to IL-2, a growth-stimulating cytokine for both B and T cells and a potent T cell chemoattractant.

To better define the microenvironment and cellular components of the epidermis, a new technique of micromanipulation to obtain single immunolabeled T cells in tissue sections followed by single-cell PCR was developed. [13] By using this technique, the exact localization and immunophenotype of clonal and nonclonal (likely reactive) T cells in the different skin compartments can be determined. Once the single cells were obtained, their genetic material could be precisely analyzed by PCR without reactive T cell component contamination. This allowed insight into the microanatomic preferences of the tumor cells. In addition, these techniques are simply done on skin punch biopsies of patients at any stage of disease. Initial experiments with single-cell micromanipulation found that clonal CD4+ T cells, especially in early stages of CTCL, were localized to the epidermis and that nonclonal CD4+ T cells had a preference for the dermis rather than the epidermis. This suggests that the polyclonal CD4+ T cells in the subepidermal infiltrate establish a barrier of

lymphocyte-mediated antitumor response. Further investigations using this novel technique will bring us closer to an understanding of the unique epidermal sanctuary that harbors, preserves, and perpetuates CTCL.

For many years, the role of oncogenes and tumor-suppressor genes in the pathogenesis of CTCL have been investigated, but the data are inconsistent and nonconclusive. A recent allelotyping study was performed to identify the chromosomal regions of allelic loss and sites of tumor-suppressor genes in MF. [14] Loss of heterozygosity (LOH) was present in 45 percent of MF patients and in 67 percent of Sézary syndrome patients with no significant difference in age at diagnosis or number of treatment received by the patients with LOH and those without. In all stages of disease, LOH on 1p and 9p was found, implicating tumor-suppressor genes such as p73, TAL1, p15, and p16 in early stages of MF. LOH on 17p and 10q were restricted to patients with advanced disease, suggesting that Fas, PTEN, and p53 could be important in disease progression.

CLINICAL MANIFESTATIONS

The clinical syndromes of CTCL, as listed in Table 157-1, are as varied as the functions of cutaneous T cells. The major components of the disease (discussed above) interplay to varying degrees of intensity to produce lesions and the clinical entities can be categorized by their clinical, pathologic, and/or immunopathologic features. The most commonly encountered type of CTCL is the mycosis fungoides spectrum. The other syndromes are often referred to as the nonmycosis fungoides types of CTCL. The nonmalignant conditions often confused with CTCL are discussed in the chapters on parapsoriasis (Chap. 47) and cutaneous pseudolymphomas (Chap. 159). Other systemic lymphomas with skin infiltrations are discussed in Chap. 158.

Clinical Features

Malignant skin-homing T cells growing primarily in the skin give rise to several clinical patterns. In general, the process begins with flat lesions (macules and patches). These erythematous patches, as shown in Fig. 157-1, are often associated with inflammation and pruritus. The diagnosis is elusive as the lymphomatous cells are mature helper T cells and the lesions have an admixture of cell types that suggests an inflammatory etiology. These nondiagnostic patches can persist for years or resolve spontaneously. The lymphoma's affinity for the skin persists throughout all but the final stages of the disease. Invasion of the epidermis is typically associated with the clinical changes of scaling and pruritus. As the cells proliferate, lesions become firmer and more varied in their surface and contour (plaques). The clinical progression of the disease then proceeds at variable rates with the development of cutaneous nodules and tumors or erythroderma.

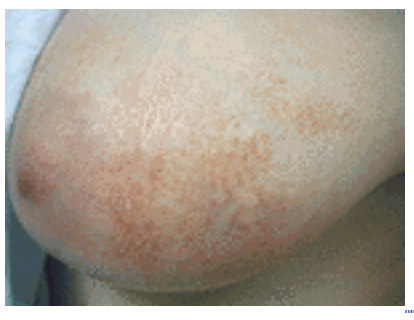

FIGURE 157-1 Patch lesion of cutaneous T cell lymphoma with poikiloderma and scale in a typical location on the breast.

Mycosis Fungoides and Variants

PATCH AND PLAQUE STAGE MYCOSIS FUNGOIDES In early patch stage MF, there are single or multiple, erythematous, scaly macules and patches that vary in size and are usually well defined. The color of the lesions may vary from orange to a dusky violet-red. The distribution classically favors non–sun-exposed sites with the “bathing trunk” and intertriginous areas predominant early in the course of the disease. The eruption may be intensely pruritic or asymptomatic and occasionally may be transitory, disappearing spontaneously without scarring. Diagnosis at this stage may be difficult. Often a patient will recall a preceding “chronic dermatitis” for 10 to 20 years that may have been considered to be therapeutically resistant contact dermatitis, atopic dermatitis, psoriasis, or eczema. Of 211 patients studied by the Mycosis Fungoides Cooperative Study Group, 77 percent were reported to have had antecedent, noninfectious skin conditions, 32 percent of which were diagnosed as dermatitis, not otherwise specified. [15] In any patient with a dermatosis that is refractory to the usual modalities of treatment, multiple biopsies should be taken to pursue a diagnosis. Patches may last for months or years before progressing to the plaque stage, or plaques may arise de novo. Plaques arise as sharply demarcated, scaly, elevated lesions that are dusky red to violaceous in color and variably indurated (Fig. 157-2, Fig. 157-3, Fig. 157-4, and Fig. 157-5). Lesions in this stage may regress spontaneously or may coalesce to form large plaques with annular, arcuate, or serpiginous borders, and may clear centrally with disease activity remaining at the periphery of the lesion. There may be hyper- or hypopigmentation and poikiloderma (see Fig. 157-1).

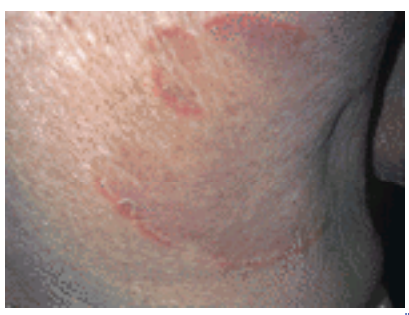

FIGURE 157-2 Large plaque/patch of cutaneous T cell lymphoma on the right flank. Annular and arcuate configurations on the border with more atrophy centrally.

FIGURE 157-3 Patches and plaques of cutaneous T cell lymphoma on the back and arm.

FIGURE 157-4 Confluent plaques with scaling and developing nodules.

FIGURE 157-5 Polymorphic nature of mycosis fungoides type of cutaneous T cell lymphoma. On the right buttock is a large violaceous plaque while further down the thigh is a pink psoriasiform annular lesion. Smaller atrophic lesions can also be noted in the surrounding skin.

Hypopigmented mycosis fungoides Patients with dark skin develop hypopigmented mycosis fungoides, a variant of patch MF. In darker-skinned individuals, this may be the most common presentation the disease. Patients respond to therapy by repigmenting, and a relapse often presents as hypopigmentation. [16]

Pigmented purpura Close examination of the skin in patients with a diagnosis of CTCL often reveals lesions of capillaritis. Some patients may present with pigmented purpura, and CTCL is found on biopsy. These lesions respond to skin-directed therapy (SDT) for CTCL. The distinction between CTCL pigmented purpura and Schamberg's disease can be made by using the diagnostic guidelines noted below. Thus, pigmented purpuric lesions, as shown in Fig. 157-6, occurring in a distribution typical of mycosis fungoides with patches >4 cm in size, should be biopsied. [17]

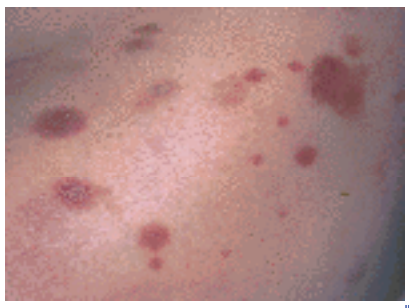

FIGURE 157-6 In the pigmented purpuric variant of mycosis fungoides, the lesions are the typical size of mycosis fungoides lesions, but are distributed in areas that are not usually affected by pigmented purpura, as shown here in the periaxillary skin. (*Photo courtesy of Kathy Zug, MD.*)

Granulomatous CTCL and slack skin This is a constellation of unique clinical and histologic findings. [18] It is not infrequent that granulomatous changes are encountered in the histology of CTCL. At the extreme end of this spectrum, however, is a distinctive syndrome called granulomatous slack skin, which is discussed in Chap. 158.

Pagetoid reticulosis (Woringer-Kolopp disease) Pagetoid reticulosis is another cutaneous presentation of CTCL (see

Fig. 157-7) that typically presents as a chronic solitary plaque. [19] The eponym Woringer-Kolopp is typically applied to patients with uni- or oligolesional disease (see Chap. 158). The long duration, slow growth, and benign nature of the disease are not typical of a lymphoma. There is a disseminated form that is much more aggressive. [20]

FIGURE 157-7 A solitary papulosquamous lesion on an extremity, as shown here, on the hand, is the most common presentation of the Woringer-Kolopp variant of pagetoid reticulosis.

Alopecia mucinosa The clinical picture that is produced by the T cell infiltrative disease known as follicular mucinosis is referred to as *alopecia mucinosa*. It was first described as grouped follicular papules or red, raised, boggy, occasionally nodular plaques. In hair-bearing areas, alopecia may be the presenting sign (Fig. 157-8). Lesions may be isolated or multiple. The eruption presents as indurated papules or plaques with follicular accentuation. [21] An attempt to assess the malignant potential of follicular mucinosis reveals the enigmatic nature of this condition which is discussed further in Chap. 158.

FIGURE 157-8 Alopecia mucinosa. Note the follicular localization and the resulting hair loss.

Adnexotropic CTCL The cutaneous infiltrates of CTCL may display an affinity for the adnexal structures of the skin. As noted above, follicular infiltration with CTCL cells may be accompanied by mucin production within the follicular epithelium. However, follicular infiltration has been recognized as occurring without the signs or findings of follicular mucinosis and this variant is called the follicular mycosis fungoides type of CTCL (Fig. 157-9). The clinical features include follicular-based, erythematous papules and alopecia. Pruritus may also accompany lesions. Plaquelike lesions may result from the accumulation of follicular papules. Additionally, CTCL infiltrates can be centered on the eccrine structures producing multiple small papules, as shown in Fig. 157-10. Anhidrosis and compromise of the eccrine system in lesional skin may often be subtle to detect. [22]

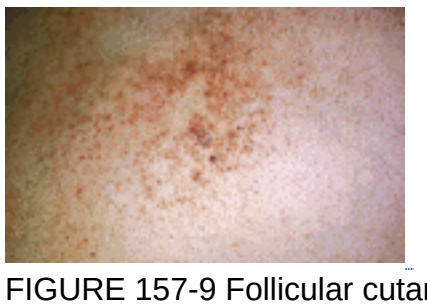

FIGURE 157-9 Follicular cutaneous T cell lymphoma (CTCL) begins as perifollicular papules that group to create lesions typical (>4 cm) in size for CTCL. Alopecia in affected areas is common.

FIGURE 157-10 Adnexotropic cutaneous T cell lymphoma is clinically similar to the follicular disease shown in Fig. 157-9; the lesions are groups of periadnexal infiltrates that are ˜2-mm papules. Individual papules may coalesce to form plaques.

IMMUNOPHENOTYPIC SYNDROMES

Suppressor T cell lymphoma (CD8+ lymphoma) There are at least two variants of this suppressor T cell lymphoma, one of which differs from patch/plaque disease only by the immunophenotypic difference. There is a distinctive clinical subtype that is rapidly progressive with formation of nodules that ulcerate (Fig. 157-11). The distribution is diffuse with involvement of palmar/plantar surfaces. The two subtypes of CD8+ lymphoma differ by other immunophenotypic markers. The aggressive subtype has a low expression of CD2 and a high expression of CD7, whereas the more chronic variant has the exact opposite pattern (see also Chap. 158). [23]

FIGURE 157-11 Multiple papulonodular lesions of aggressive suppressor T cell lymphomas.

Gamma-delta T cell lymphoma The malignant cell in the vast majority of CTCL patients expresses the surface proteins CD3+ and CD4+, with only rare CD3+ CD8+ cases reported. Even more rare are “double-negative” (CD3+, CD4–, CD8–) CTCL cases. These malignant cells express the ?d T cell receptor instead of the aß receptor. ?d T cells have been demonstrated in normal murine epidermis, but have not been found in human skin The immunologic repertoire of such double-negative cells includes the ability to lyse target cells. There often is pronounced epidermal necrosis in conjunction with the ?d tumor cell epidermotropic infiltrates suggesting that the malignant cells participate in keratinocyte lysis. Marked epidermal necrosis in such a patient progressed to ulcerations following an attempt to initiate interferon therapy. [24] There is another variant of this disease that has deep dermal and subcutaneous infiltrates (see “ CTCL Tumors” below). Subcutaneous, lipotropic infiltrates of ?d lymphoma are invariably accompanied by excessive ?-interferon production and the hemophagocytic syndrome. [25]

Cutaneous natural killer cell lymphomas Natural killer (NK) cell activity is traditionally associated with the cell surface expression of the CD56 marker. Expression of CD56 in cutaneous lymphomas occurs with T cell–derived lymphomas and lymphomas that do not have a T cell origin. The NK-expressing T cell lymphomas are clinically indistinguishable from the NK lymphomas that do not express other T cell markers. Morphologically, the T cell–derived NK lymphomas tend to have large granular lymphocytes. The lesions vary from erythematous papules to tumors with ulceration, as shown in Fig. 157-12. In general, these lymphomas are aggressive with median survival after diagnosis rarely exceeding 15 months. The presence of extracutaneous disease is quite common. [26]

FIGURE 157-12 In natural killer (NK) T cell lymphoma there is minimal epidermotropism to produce scaling and patchlike lesions. As a result, papules, nodules, and ulcers (as shown here) are the more typical clinical findings.

ERYTHRODERMIC VARIANTS Erythroderma may start de novo or follow mycosis fungoides. Some patients with the erythrodermic form of CTCL develop tumors. The skin is diffusely bright red with readily apparent scaling, but there may be characteristic symmetric islands of uninvolved skin (Fig. 157-13). There may be sparing of the areas of skin that are frequently folded, such as the abdomen, antecubital, axillary areas. This sparing produces a finding often called the “deck chair” or “folded luggage” sign, as shown in Fig. 157-14. Differential diagnosis includes pityriasis rubra pilaris, as well as erythroderma secondary to psoriasis, atopic dermatitis, seborrheic dermatitis, and drug eruption. Involvement of the face may lead to leonine facies with marked accentuation of facial folds (Fig. 157-15). The differential diagnosis of this presentation includes lepromatous leprosy, sarcoidosis, and leishmaniasis. The patient may complain of fever, chills, weight loss, malaise, insomnia secondary to the overwhelming pruritus, and poor body temperature homeostasis. There may be hyperkeratosis, scaling and fissuring of palms and soles, alopecia, ectropion, nail dystrophy, and ankle edema with the integument being shiny and hidebound. These changes result in pain on walking and extreme difficulty with manual dexterity. Such patients become cutaneous cripples, being severely debilitated by the skin manifestations of this fatal disease. Pruritus is often intense, resulting in excoriation, exudation and secondary changes that may dominate the clinical picture.

FIGURE 157-13 Cutaneous T cell lymphoma erythroderma (Sézary syndrome). Note coppery redness, infiltration of skin

as reflected by increased skin folds and scaling.

FIGURE 157-14 In patients with cutaneous T cell lymphoma and erythroderma, there may be sparing of areas where the skin folds, as shown here. This finding is often called the “deck chair” or “folded luggage” sign.

FIGURE 157-15 Leonine facies characterized by infiltrated plaques of cutaneous T cell lymphoma.

The nomenclature for erythrodermic phases of CTCL varies. One workshop has proposed that erythroderma should be defined by 80 percent body surface area involvement with ill-defined borders (Fig. 157-13) and patients with a preexisting history of mycosis fungoides should be separated out as the syndrome of “erythrodermic mycosis fungoides.” For the diagnosis of Sézary syndrome, [27] the patient should be erythrodermic, with a biopsy consistent with CTCL, evidence of >5 per 100 lymphocytes having cerebriform nuclei (“Sézary cells”) on peripheral blood smear review, and corroborating evidence of CTCL in the peripheral blood (either a positive gene rearrangement study or elevated CD4/CD8 ratio). Patients lacking the atypia on the peripheral blood smear or the corroborating evidence are considered as having erythrodermic CTCL. The hematologic evaluation of patients has improved from the era of Sézary when the syndrome he described was characterized by the peripheral blood appearance of “monster cells.” As the disease progresses, the normal lymphocytes are destroyed before the leukocytosis appears. By the time the Sézary syndrome appears, there is very little normal immunity left. Indeed, Sézary's patients died from infectious complications, not from progressive disease.

CTCL TUMORS

T cell lymphomas of the skin can give rise to nodular lesions that are deep, protuberant, or ulcerating, as shown in Fig. 157-16, Fig. 157-17, and Fig. 157-18. The classification of a patient presenting with tumors of CTCL is partly guided by history and mostly guided by the dermatopathologic interpretation.

FIGURE 157-16 Tumor stage cutaneous T cell lymphoma. Large tumor on the cheek.

FIGURE 157-17 Cutaneous T cell lymphoma. Ulcerated, infected tumor on the digit.

FIGURE 157-18 A mixture of plaque and tumor stage lesions on the face of a cutaneous T cell lymphoma patient. *A.* Patch and plaque on the cheek and infected centrofacial ulcer. *B.* Ulcerated nodules on the trunk and (*C*) annular and crusted tumors/ulcers on the legs.

MYCOSIS FUNGOIDES TUMORS The tumor stage may occur anywhere, but tumors have a predilection for the face and body folds: axillae, groin, antecubital fossae, and, in women, the inframammary area. These may occur in preexisting plaques or patches of CTCL, which suggests the development of a vertical growth phase (Fig. 157-18). At this point, the neoplastic cells behave in a more biologically malignant manner, with vertical spread that leads to the clinical appearance of an expanding dermal nodule (Fig. 157-16). De novo occurrence suggests metastatic spread by cells of a malignant T cell clone. The nodules are reddish brown or purplish red and smooth-surfaced, but they often ulcerate and may become secondarily infected (see Fig. 157-17). Growth rate is variable, and ulceration may occur. Spontaneous resolution of tumors is occasionally observed. Patients with tumors tend to have a more aggressive form of the disease than patients with patch and plaque disease. In this respect, it is of interest that one study used the depth of the infiltrate as a prognostic guide similar to the Breslow depth of melanomas. The differential diagnosis of CTCL includes those processes that produce violaceous nodules that may or may not ulcerate. This extensive differential diagnosis includes tumors of other cell lines (B cell lymphoma or leukemia), carcinoma cutis, sarcoidosis, and infectious etiologies such as deep fungi, atypical mycobacteria, or leprosy.

NONMYCOSIS FUNGOIDES CTCL TUMORS The categorization of tumor stage CTCL is made on clinical and histologic features. If the patient had a previous diagnosis of mycosis fungoides or if there is concomitant epidermotropism typical of this subset, then the best assignation is mycosis fungoides tumor. If tumor mycosis fungoides is the initial presentation of the disease, the patient is often referred to as having the “tumeur d'emblee” variant. Tumors in patients without a previous history or without accompanying histologic features of mycosis fungoides are best termed *nonmycosis fungoides CTCL tumors*. The rest of the categorization depends on histologic features. Cellular morphology is important, and these tumor patients can be subdivided into large, small, and pleomorphic categories based on the cytomorphology. If angiotropism or lipotropism is present, then this is added as a descriptor. CD30 expression is also recorded in the characterization of a non-mycosis fungoides CTCL.

CD30+ (Ki-1) lymphoma versus CD30- lymphoma The typical clinical appearance is that of a tumor stage lesion with central ulceration. The CD30+ lymphomas have been traditionally thought of as having a better prognosis than CD30- lymphomas. A perplexing feature of CD30+ lymphomas is a tendency to spontaneous resolution, although there is also a tendency to progress to an aggressive malignant lymphoma. The unpredictable course of this condition has led to uncertainty in its therapy. Aggressive radiotherapy with or without follow-up chemotherapy is recommended. Follow-up studies suggest that systemic polychemotherapy as initial treatment does not result in higher cure rates or less relapses when compared to local ablative therapy. [28]

SMALL CELL VERSUS LARGE CELL VERSUS PLEOMORPHIC T CELL CUTANEOUS LYMPHOMA These entities are histologically separable from other cutaneous T cell lymphomas. The histologic differentiation of large and small cells is discussed in the section on histology. However, the reproducibility of cutaneous lymphoma staging by the small cell–large cell dichotomy is variable, and as yet there has not been a clear definition of the prognosis based on these classification criteria. Nonetheless, the degree of cellular atypia should be recorded at the time of diagnosis and relapse. [29]

ANGIOCENTRIC CUTANEOUS T CELL LYMPHOMA This syndrome was first labeled as malignant angioendotheliomatosis. It was recognized as a progressive, fatal condition that begins typically with reddish-brown patches of plaques. Frequently, these appear on the head, and there may be progression to aggressive central nervous system involvement. The histology demonstrates atypical cells inside blood vessels. [29]

SUBCUTANEOUS (LIPOTROPIC, PANNICULOTROPIC) CTCL This variant typically has the deepest infiltrates of atypical cells with involvement of the septa and lobules of the subcutaneous fat. Not surprisingly, it is the most aggressive disease variant with the worst prognosis. This disease typically presents de novo, without any preceding patch or plaque mycosis fungoides. The initial lesions appear as inflammatory nodules and there is often considerable difficulty distinguishing this from inflammatory panniculitides. Ulceration of the lesions is not uncommon. There are two features that are distinct for subcutaneous CTCL. One is that the malignant cell frequently expresses the ?d T cell receptor. The other is that these cells often induce variable degrees of the hemophagocytic syndrome. [25] In this condition, cytokines that are presumably produced by the malignant cells induce macrophages to engulf and destroy normal

hematologic components including platelets, erythrocytes, and neutrophils. As a result, subcutaneous CTCL is frequently accompanied by anemia, thrombocytopenia, and granulocytopenia. These complications often result in the terminal events of patients suffering from this rare variant. It is important to emphasize that, as the immunopathogenesis of the hemophagocytic syndrome is further understood, specific cytokine therapy to reverse this complication may be just as important as debulking the tumor burden.

Dual Lymphoid Neoplasia of the Skin

This represents a collection of syndromes characterized by combined B cell and T cell lymphoproliferative disorders with skin lesions. [30] One hypothesis is that there is an increased risk of second malignancies in CTCL patients. Another hypothesis is chronic B cell stimulation from malignant T_H2 cells selecting out a clonal proliferation of B cells, which become malignant. Possibly, there is a mutation in a lymphoma-suppressor gene that allows both B- and T-derived cells to proliferate beyond normal regulatory controls. In support of this concept is the aforementioned study showing an increase in hematologic malignancies in relatives of CTCL patients. One must also consider the mutagenic properties of therapy used to treat the initial lymphoproliferative condition as a potential cause of the second malignancy. In patients with this dual lymphoid neoplasia, biopsies for immunophenotyping provide the only reliable way to distinguish between the entities present on the skin.

PATIENT ASSESSMENT (LABORATORY FINDINGS)

The evaluation of the CTCL patient (Table 157-2 and Table 157-3) focuses on the three major features of CTCL that affect outcome: tumor burden, the degree of atypia in the malignant cells, and the immunocompetence of the patient. Of these three components, tumor-burden assessments also play a role in the follow-up of patients on therapy. The realm of the cutaneous T cell includes the skin, lymph nodes, and peripheral blood. Samples of these can be evaluated for tumor burden, the degree of histologic atypia, and for determining where the patient's immune system is on the spectrum from immunocompetent to immunosenescent. Tumor burden can be reliably assessed in the skin, blood, and lymph nodes. Increasing involvement of each of these sites by lymphoma correlates with decreasing survival. Another evaluable feature of CTCL is the degree of transformation of the malignant cells. This “anaplastic nature” of the lymphoma cells also correlates with poor prognosis. Finally, the immunologic competence of the patient must be taken into account. Some of the immunologic responses crucial to the survival of CTCL patients are an intact antitumor response and effective antimicrobial defenses.

	Tissue Biopsies	Stains	Immune Status
Skin	Skin scan Biopsy depth Cytotyping	H&E Stripes Phenotyping	Phenotyping
Blood	CBC Phenotyping Cytotyping	Smear	Phenotyping
Lymph node	CT scan Cytotyping H&E Stripes	H&E Stripes	Architecture phenotyping

*The three rows are the three tissues available for assessing the parameters listed in columns. The assessment of atypia and immune status are dates as the rows of presentation for prognostic information. The measures of tumor burden are charted specially only to assess the impact of therapy.
CBC = complete blood cell count; H&E = hematoxylin and eosin.

TABLE 157-2 **Tests Used in the Evaluation of CTCL***

Skin
Body surface area assessment
Routine histology
Immunophenotyping
Polymerase chain reaction for T cell receptor rearrangement
Blood
Complete blood count with smear exam
Immunophenotyping
Lymph Node
Palpate all nodes
Measure enlarged nodes by CT scan
Biopsy enlarged nodes

TABLE 157-3 **Patient Evaluation**

Skin Evaluation

IDENTITY OF THE MALIGNANT CELL POPULATION After a diagnosis of CTCL is made, skin biopsies are used to provide an immunophenotypic and immunogenotypic description of the malignant cells. Immunogenotyping on skin biopsies is best done with the PCR technique. The majority of the mycosis fungoides variants can be adequately studied with a shave biopsy. In a study of epidermal samples versus dermal samples in mycosis fungoides, the malignant clone could be more readily detected in the epidermal samples. [31] This reflects the preference of the malignant cells for the epidermis and the dilution of the malignant clone in a reactive infiltrate in the dermis. Another value of performing the PCR test at the time of diagnosis is that if this technique is to be used on any other tissues, it is best to know whether or not the patient is one of the 15 percent false negatives by PCR testing. [32] If the clone is not detectable in involved skin, there is no value in studying other tissues or skin at other times unless new primers for the PCR technique become available.
TUMOR BURDEN A parameter of CTCL that has significant prognostic value is the extent and type of skin involvement evident on the physical examination. For this reason, the Mycosis Fungoides Cooperative Study Group, in 1975, adopted a modified TNM classification system. [15] This was further modified by the Cutaneous T Cell Lymphoma Workshop and is shown in Table 157-4 and Table 157-5. Staging of the disease using this classification is done at the time of diagnosis and, as discussed earlier, the stage of a patient does not change. As the skin lesions on an individual may change over time, it is common to use the T system as a way to denote this, recognizing that the stage (I to IV) of an individual never changes. This classification grades lesions as patch/plaque(T1 and T2), tumor (T3), and erythroderma (T4), To assist in the day-to-day management of CTCL patients, there are standard target lesion and body surface area assessments available. Whole-body photography is a useful adjunct in skin tumor-burden assessments.

Classification	Description
T: Skin	
T_0	Lesions clinically and/or histopathologically suggestive of CTCL
T_1	Limited plaques, papules, or eczematous patches covering <10% of the skin surface
T_2	Generalized plaques, papules, or erythematous patches covering ≥10% of the skin surface
T_3	Tumors(≥1)
T_4	Generalized erythroderma
N: Lymph nodes	
N_0	No palpable adenopathy, lymph node pathology negative for CTCL
N_1	Palpable adenopathy, lymph node pathology negative for CTCL
N_2	No palpable adenopathy, lymph node pathology positive for CTCL
N_3	Palpable adenopathy, lymph node pathology positive for CTCL
B: Peripheral blood	
B_0	Atypical circulating cells not present (<5%)
B_1	Atypical circulating cells present (>5%); record total white blood cell count, total lymphocyte count, and number of atypical cells/100 lymphocytes
M: Visceral organs	
M_0	No visceral organ involvement
M_1	Visceral involvement (must have pathology confirmation and organ involved should be specified)

TABLE 157-4 **Staging of Cutaneous T Cell Lymphoma: TNM Classification**

Stage	Classification		
	T	N	M
IA	1	0	0
IB	2	0	0
IIA	1,2	1	0
IIB	3	0,1	0
III	4	0,1	0
IVA	1–4	2,3	0
IVB	1–4	0–3	1

TABLE 157-5 **Staging Classification of CTCL**

The skin biopsy can also be used in tumor-burden assessment. Tumors should be confirmed and defined by biopsy. The use of the skin biopsy in staging patients has been explored. One study measured the thickness of cutaneous infiltration from the granular layer to the lower limit of the infiltrate. The depth of infiltrate correlated with morbidity. [33]
ATYPIA OF THE CTCL CELLS Skin biopsies can also assess the degree of transformation in the cellular infiltrate. Atypical cells with enlarged pale nuclei, prominent nucleoli, or loss of T cell markers portend a worse prognosis and a tendency to be refractory to therapy. Routine histology and immunophenotyping are necessary studies to evaluate the degree of atypia in the skin. In a study of immunophenotypic anomalies associated with transformation, there were more abnormalities by immunoperoxidase in patients with aggressive transformed lymphoma. [34]
IMMUNOCOMPETENCE OF THE PATIENT Immunophenotyping is routinely performed on skin biopsies in the workup of CTCL patients. As mentioned earlier, several studies have noted correlations between immunophenotyping and stage of disease. [12] As the disease progresses, there are fewer CD8 cells in the tissue and the CD4/CD8 ratio in tissue increases. Other clinical clues to impairment of cutaneous immunity are the presence of yeast, tinea, and herpetic infections along with a tendency to develop cutaneous malignancies.

Lymph Nodes

In early disease, the lymph node has the appearance of dermatopathic lymphadenopathy, which is a histologic picture seen also in chronic dermatoses. This reactive hyperplasia is characterized by increase in size of the germinal follicles, with proliferation of histiocytes containing lipids, melanin, or hemosiderin. Because CTCL is usually present in the skin for some time prior to lymph node biopsy, dermatopathic lymphadenopathy is nearly always present. With progression of the disease, atypical lymphoid cells with deeply indented (cerebriform) nuclei and relatively scant cytoplasm accumulate focally in the T cell areas of the lymph node, that is the paracortical area, superimposed on the dermatopathic changes. With time, these atypical cells proliferate and expand throughout the node and eventually efface the architecture. Lymph node biopsies are performed primarily to confirm the presence of disease (and to rule out other etiologies), to look for large cell transformation, and to evaluate the architecture. PCR testing is not that valuable because most lymph nodes should have CTCL cells trafficking through them in the normal recirculation of lymphocytes.

TUMOR BURDEN The incidence of lymphadenopathy by physical examination increases with the stage of cutaneous involvement. Lymphadenopathy, whether histologically dermatopathic lymphadenopathy (N1) or infiltration by CTCL (N2, N3), is a sign of poor prognosis. In practice, enlarged nodes are biopsied at initial staging or if adenopathy develops in progressive disease. Just the presence of a clinically enlarged node has prognostic importance, [35] with these patients having lower survival rates than those patients without adenopathy. The best measure of lymph node tumor burden is a CT scan of affected node groups. [36] Enlarged nodes can be measured to an accuracy of 0.1 cm, and periodic reassessments can provide evidence as to the efficacy of therapy.
ATYPIA The impact of the anaplastic histology on survival was demonstrated in a review of lymph node biopsies. In that series, 195 lymph node biopsies were graded into three categories. Patients with lymph nodes containing malignant lymphocytes that were small cells with hyperchromatic nuclei had a median survival of 40 months. Those patients with lymph nodes containing CTCL cells that were larger with pale nuclei had a median survival of 9 months. A third category of patients with lymph nodes containing a mixture of these cell types had median survival between these two extremes (26 months). [37]
IMMUNOCOMPETENCE The only reflection of immunocompetence is a normal lymph node architecture in the face of regional disease. This is intuitively associated with a better outcome than if the node were effaced by malignant cells. [37]

Peripheral Blood

In CTCL patients with limited patch/plaque disease, it has long been suspected that malignant T cells have hematogenously spread to different sites despite the fact that conventional techniques were unable to detect a circulating component of the disease. The lymphocyte recirculation pathway model would predict that malignant cells are continuously moving from the skin to lymph nodes, and from there to the vascular system. Even the earliest phases of the

disease should be characterized by malignant cells in both the peripheral vasculature and lymph nodes. Utilizing PCR with primers for T cell receptor (TCR) rearrangements, it is possible to detect clonal T cell populations in patients with limited cutaneous disease. [38] In no way, however, does this finding change the stage of a patient. To assign clinical importance to this observation, a quantitative method to assess the numbers of circulating malignant T cells must be developed so that survival can be correlated with increments of circulating cells.

TUMOR BURDEN A routine complete blood count may reveal a markedly elevated lymphocyte count and provide a readily measurable parameter of tumor burden in the peripheral blood. Circulating CTCL cells are often indistinguishable from circulating mature T cells. A variety of tests are available to assess tumor burden, and these have been compared to determine sensitivity. To assess the magnitude of peripheral blood involvement, a panel of antibodies has been developed that recognizes different segments of the variable sections of the beta chain of the TCR. Normally, none of the variable region antibodies react with more than 5 percent of circulating peripheral blood lymphocytes. A clonal expansion in the peripheral blood compartment can readily be detected if one of the existing framework antibodies reacts with that clone. Results with these antibodies in leukemic patients have provided a point of reference for comparing readily available tests. [39] An elevated CD4/CD8 ratio is indicative of disease expansion into this compartment. Thus, flow cytometry for CD4 and CD8 should be a component of the staging of all patients with >T1 CTCL. The rapidity and ease of applying this technology also makes it applicable for following patients. The “memory cell” marker CD45RO is expressed on the majority of leukemic CTCL cells. An elevated level of CD45RO-expressing lymphocytes in the peripheral blood may indicate the magnitude of peripheral blood involvement by CTCL. Another widely used combination of markers is to assess the percentage of circulating T cells that express CD4 yet lack expression of CD7. Circulating CTCL cells in overtly leukemic patients are frequently CD4+ CD7–, although some patients will have malignant cells that express CD7. [40] A practical approach for the use of these varied tests begins with the complete blood count for total lymphocyte count, eosinophil count, and for overt lymphocyte nuclear abnormalities. A flow cytometry panel should initially include CD3, CD4, CD8, and CD45RO. Any elevation of the CD4/CD8 ratio or elevation of the percentage of CD45RO would select patients in whom gene rearrangement studies could confirm leukemic disease if the malignant clone can be detected using PCR primers on the skin infiltrate.
ATYPIA “CELLULES MONSTREUSES” OF SÉZARY Previously, the presence of more than 5 percent circulating cells with hyperconvoluted nuclei was used to define blood involvement because it was associated with a poor prognosis. Sézary cell analysis in the peripheral blood has been documented to change during the course of the day and to vary dramatically between observers. As a result, there is tremendous subjective input in assessing the blood smear. Sézary described circulating atypical lymphocytes in patients with erythroderma. The estimation of Sézary cell percentage was the only technology available for blood testing in the decades preceding the more reproducible antibody and gene testing. The nuclei of these cells are hyperchromatic and hyperconvoluted when compared to their nonmalignant counterparts. Sézary cells, which represent activated T cells, can be seen in inflammatory dermatoses, and Sézary cells appear in large numbers in the Dilantin hypersensitivity syndrome (see Chap. 159). At least 100 lymphocytes are counted to determine the percentage of cells showing the Sézary phenomenon. Although the enumeration of Sézary cells has variability, there is prognostic information in the determination of whether there are large, low, or no numbers of circulating Sézary cells.
IMMUNOCOMPETENCE The immunocompetence of the CTCL patient, especially with regards to the antitumor response, has recently become the focus of many studies. The poor prognosis traditionally associated with hyperleukocytic CTCL cannot simply be a consequence of the presence of circulating CTCL cells, since these cells are now detectable in patients at all stages of disease. [38] In fact, it is compromise of the immune system that is the most common cause of mortality in CTCL patients, including the original patients described by Sézary, who died of infection. Thus, an assessment of a patient's immunologic competence should yield important information regarding prognosis. As mentioned previously, this is now possible through the use of antibodies to various TCR variable regions, which can be clone-specific. These antibodies can enumerate malignant T cells in the peripheral blood of selected patients. This allows the numbers of nonmalignant T cells to be determined by subtraction of the malignant T cell number from the total T cell pool. By using this methodology in six patients with advanced CTCL, it was observed that the nonmalignant T cell population was decreased in some patients to the same level as that seen with advanced HIV disease. [39] Even though antibodies that recognize all CTCL clones are not available, the normal T cell population can also be estimated by measurement of the CD8+ population. Increases in the CD4/CD8 ratio and decreases in the numbers of CD8+ T cells are readily assessed by flow cytometry as measures of the immunocompetence of the patient. Assessing normal immunity by flow cytometry is a rapid and reproducible staging technique. Knowledge of a patient's immunocompetence affects the management of a CTCL patient. For instance, because of the increased risk of second malignancies, [41] symptoms or physical findings should be pursued with this predisposition to malignancy in mind. Antibiotic prophylaxis should also be considered in patients with advanced stage disease.

Staging

The heterogeneity in lymphomas of cutaneous T cells is reflected in the varied clinical outcomes that occur: cure, persistent disease, death by complication, death. Attempts to predict outcome have been complicated by our incomplete understanding of the disease components. Many of these components have been identified and can be incorporated into the patient's evaluation (Table 157-3).

What are those features that can predict outcome at the time of presentation? Tumor burden plays a role, and unilesional CTCL has the best outcome. [42] As the degree of cellular atypia increases, prognosis decreases. Immunocompetence affects outcome and confers responsiveness to some therapies. [11] Understanding CTCL can refine patient evaluation and prediction of outcome. What needs to be done with the parameters of CTCL is to determine their relative weight of importance and their degree of independence from other variables. Predicting the outcome of an individual patient with CTCL utilizes all of the information available from the staging workup. There are many rough guidelines on what to expect with CTCL. In general, the worse the skin, the worse the prognosis as discussed above.

In the modified TNM system, T0 represents skin lesions that are clinically and/or histopathologically suggestive of CTCL but the biopsy is not clearly diagnostic. Repeat skin biopsies are recommended at intervals for these patients. T1 to T4 represent skin lesions whose biopsies are diagnostic of CTCL. Whole-body mapping is performed with the palmar

surface of the hand representing about 1 percent of the skin surface. When more than one type of lesion exists, the most advanced is used for staging, although both are recorded. For example, a patient with generalized plaques and a tumor would be T3, whereas a patient with generalized erythroderma and a tumor would be T4. In addition to body surface area assessment, it is useful to select several “target lesions” at baseline and to query the patient with a CTCL related questionnaire to help assess objective and subjective responses to therapies. The methodology for these assessments is available utilizing methods found in clinical trials for CTCL. [43]

Table 157-4 and Table 157-5 show the staging classification used at diagnosis. Stage I patients are those whose lesions are confined to the skin without clinical adenopathy stage IIA patients are those with plaques and adenopathy and stage IIB patients are those with skin tumors with or without clinical adenopathy but, by definition, lymph node biopsies are negative. Stage III patients have generalized erythroderma with or without adenopathy, but node biopsy is nondiagnostic by definition. Stage IV patients have biopsy-proved CTCL of lymph nodes (IVA) or visceral organs (IVB) with a skin stage (T1 to T4) and any node stage (N0 to N3).

Disease in Other Tissues

Further evaluation of specific organ systems is indicated when involvement is suggested by history, examination, or routine tests. However, further routine invasive staging procedures are not indicated. Once the disease process becomes extracutaneous, any organ may be involved (Table 157-6). Widespread CTCL is commonly found at autopsy, but clinically apparent extracutaneous disease is detected much less often. Considering the varied sites of dissemination, it is not surprising that symptomatic disease has been identified in vivo in virtually every organ system. Survival is directly related, therefore, to the type of skin involvement and the presence or absence of extracutaneous disease.

Organ System	Manifestation
Pulmonary	Parenchymal nodules
	Pulmonary infiltrates
	Pleural effusion
	Mediastinal and/or hilar adenopathy
Ocular	Intraocular disease—optic nerve, retina, choroid
	Extraocular disease—lid, conjunctiva cornea
Skeletal	Solitary or numerous osteolytic lesions
	Diffuse osteoporosis
	Arthritis
Oral	Infiltrated lesions, Manifested as raised or eroded areas on lips, buccal mucosa, tonge, larynx
Nervous	Intracerebral tumor mass
	Leptomeningeal disease
	Peripheral neuropathy
	Cerebral hemorrhage
	Progressive multifocal leukoencephalopathy
Gastrointestinal	Diarrhea
	Ascites
	Hemorrhage
	Perforation
Cardiovascular	Congestive cardiac failure
	Cardiac arrhythmias
Renal	Progressive renal failure
Hematologic	Eosinophilia
	Monocytosis
	Monoclonal paraproteinemia
	Cryoglobulinemia

TABLE 157-6 **Extracutaneous Manifestation of CTCL**

Bone marrow involvement by CTCL is uncommon but increases with the stage of disease. Thus, the absence of involvement of marrow in the presence of increased circulating lymphocytes and skin lesions suggests a diagnosis of CTCL.

Pulmonary involvement is present in 40 to 60 percent of CTCL patients at autopsy, but antemortem recognition occurs uncommonly; it may or may not be symptomatic. On chest x-ray, pulmonary disease may be manifest as parenchymal nodules, pleural effusions, mediastinal and/or hilar adenopathy, diffuse parenchymal infiltrates, or patchy areas of consolidation. Parenchymal nodules are the most often observed abnormality and are variable in size, poorly marginated, and usually bilateral. Pulmonary infiltrates are also usually bilateral and are symmetric, interstitial, and involve the lower portions of the lungs. Pleural effusion with atypical T cells has also been reported. Differential diagnosis of such radiographic findings includes infections, drug-related infiltrates, and other primary or metastatic neoplasms. Most patients have extensive and progressive extracutaneous disease by the time pulmonary disease becomes apparent. [44]

Bone involvement is seen in 30 to 40 percent of patients at autopsy but is generally not apparent antemortem. Radiographic evidence of bone involvement includes osteolytic lesions and pathologic fractures. [45] Infiltration of the synovium may produce an inflammatory polyarthritis. [46]

Other sites of clinical involvement by CTCL are the oral cavity and the upper respiratory tract, gastrointestinal tract, heart, kidney (rarely), eye and the brain, leptomeninges, and the peripheral nervous system. [47], [48], [49] and [50] Magnetic resonance imaging and spinal fluid analysis for Sézary cells are often useful in confirming central nervous system involvement.

PATHOLOGY

The role of histopathology in CTCL patient management is in making the diagnosis, confirming a change in T status (e.g., from patch to tumor), and in the evaluation of relapse. In performing the biopsies, it is often best to have the patient abstain from any topical or systemic therapy for at least 4 weeks prior to biopsy. There are many components that can contribute to the pathologic diagnosis of mycosis fungoides and the CTCL variants. [51], [52] and [53] Rarely are all of these components present in the same location as the biopsy. The classic findings are characterized by finding lymphocytes with hyperchromatic and hyperconvoluted nuclei that cluster in the epidermis in microabscesses (Pautrier type) as shown in Fig. 157-19. The classical dermal infiltrate underneath this would be mostly mononuclear cells with deeply indented nuclei along with a mixed inflammatory response of lymphocytes, plasma cells, and eosinophils (Fig. 157-20).

Frequently, the epidermal lymphocytes appear larger than the dermal lymphocytes. In the absence of these findings the diagnosis of mycosis fungoides can be suggested by a constellation of findings. The epidermotropic lymphocytes in patch and plaque MF biopsies (Fig. 157-21) are often accompanied by minimal spongiosis. These solitary epidermotropic cells often have a lacunae that develops while processing the biopsy and the cells appear to have a halo around them (halo cells). Lymphocytes can often appear to be lined up along the dermal–epidermal junction awaiting entry to the epidermis. In the dermis, as shown in Fig. 157-22 there can be a lichenoid or perivascular infiltrate with mononuclear cells that may or may not be atypical, that is, with pleomorphic, hyperchromatic, convoluted nuclei. Also, there is often is a lamellar ibroplasia in the papillary dermis. As the patches become more plaquelike clinically, there is an increasing lichenoid quality of the infiltrate. The epidermis itself may be histologically normal, atrophic, or psoriasiform. A classic biopsy of plaque MF contains a lichenoid and perivascular infiltrate with epidermotropic cells. In America and Europe, studies with panels of pathologists have demonstrated that there is a significant disagreement between pathologic opinions on any particular slide. [54], [55]

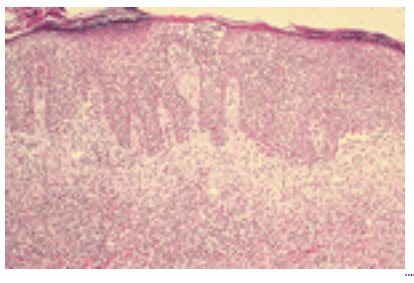

FIGURE 157-19 Dense mononuclear cell infiltrate extending from the papillary dermis into the epidermis. The epidermis is completely permeated be these cells, which form a Pautrier's abscess.

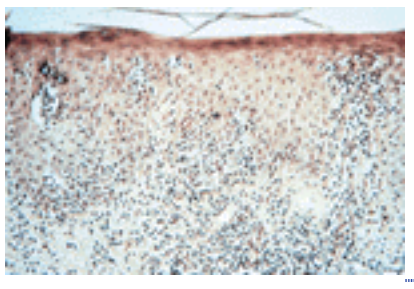

FIGURE 157-20 There is epidermotropism with a dermal infiltrate that contains many cell types.

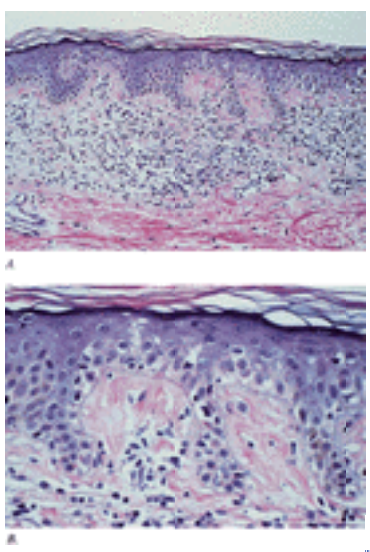

FIGURE 157-21 Patch stage of CTCL. *A*. Single atypical mononuclear cells in epidermis with sparse superficial perivascular infiltrate in papillary dermis. H&E stained section. *B.* High-power view of atypical cells in epidermis of same section.

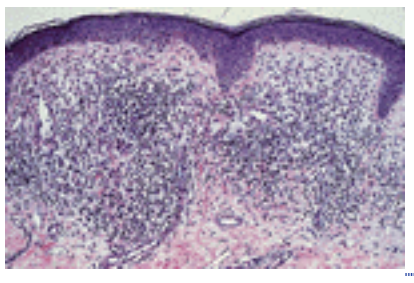

FIGURE 157-22 Plaque of CTCL. There are scattered cells in the epidermis and a dense bandlike infiltrate of lymphocytes in the dermis.

Many of the CTCL variants are defined by their histologic features. In pagetoid reticulosis, the lymphomatous cells show a pronounced epidermotropism. The histology of the disease is diagnostic but should not be confused with Paget's disease or pagetoid melanoma. In follicular mucinosis, the epithelial cells of the sebaceous glands and outer root sheaths are disrupted with formation of cystic spaces and mucin deposition (Fig. 157-23). [21] For diagnosing follicular CTCL, the pathologist will often orient the epithelial lining horizontally because the findings are similar to the features

above except that the invasion of the epidermis is limited to the follicular epithelium.

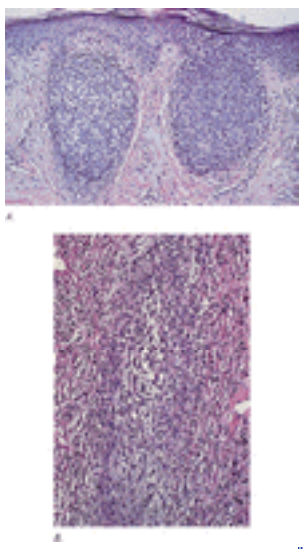

FIGURE 157-23 Follicular mucinosis (alopecia mucinosa). *A*. Outer root sheath of hair follicle is disrupted with formation of cystic spaces and mucin deposition. H&E stained section. *B*. High-power view of disrupted outer root sheath at base of hair follicle.

The histology of the erythrodermic stage is extremely variable. The development of erythroderma is characterized by perivascular accumulation of lymphocytes. Multiple biopsies are needed to make the diagnosis because of the marked variability in epidermotropism and infiltrate density. Secondary changes such as psoriasiform hyperplasia from chronic scratching can also dominate the histology.

In tumors (Fig. 157-24), two histologic appearances may be observed. In some patients, a polymorphous infiltrate is present, similar to that seen in the plaque stage, but the infiltrate is denser and extends into subcutaneous fat. In areas where tumors originated in plaques, the epidermis may show typical epidermotropism, but in other areas may show no involvement, even with the presence of a grenz zone in the upper dermis (an area of sparing between infiltrating lymphocytes and the basement membrane of the epidermis). In other patients, the infiltrate is monomorphous, composed almost exclusively of tumor cells. Epidermotropism is not a prominent feature in these tumors. There may be varying degrees of transformation. Tumors are frequently accompanied by transformation where cells and their nuclei are larger with hyperchromatic nuclei, prominent nucleoli, and frequent mitotic figures. As discussed above, histologic features important for diagnosis and classification of the tumor include concomitant findings of epidermotropism, cytomorphology (large cell, small cell, or pleiotropic), angiotropism, lipotropism, and CD30 expression.

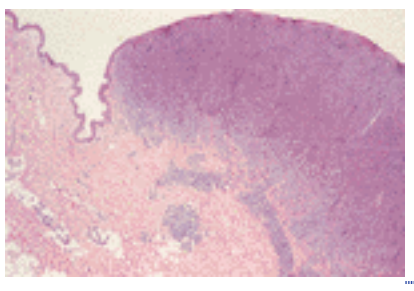

FIGURE 157-24 Low-power view of a CTCL tumor. The dense infiltrate extends deep into the dermis.

DIAGNOSIS AND DIFFERENTIAL DIAGNOSIS

The diagnosis of CTCL still rests on having compatible clinical and histopathologic features. Although T cell clonal infiltrates can be demonstrated in the skin by using the PCR techniques previously described, clonality can also occur in the nonmalignant eruption of Mucha-Habermann disease (PLEVA) (see also Chap. 159). It should not, therefore, be equated with malignancy. The diagnosis of CTCL rests on the combination of the appropriate clinical lesion and histology. For the most common type of CTCL, mycosis fungoides, it is possible to weigh the strength of diagnosis with a scoring system that equally rates lesion morphology, distribution, and histology (as discussed above).

The diagnosis of cutaneous T cell lymphoma is often made in evaluating cutaneous lesions initially thought to represent some banal dermatosis. The index of clinical suspicion for CTCL is heightened if a particular skin eruption is refractory to therapy. Chronic inflammatory eruptions on the skin may be mimicked by lymphoma. Epidermotropic infiltrates can produce findings similar to eczema, psoriasis, erythroderma, pityriasis rubra pilaris, lichen planus, drug eruptions, photosensitivity, pompholyx, vitiligo, annular erythemas, seborrheic dermatitis, intertrigo, tinea, and alopecia. Dermal infiltrates may mimic urticaria, vasculitis, annular erythemas, purpura, insect bites. Subcutaneous lymphoma may present like erythema nodosum, leg ulcers, or pyoderma gangrenosum.

As discussed earlier, there have been no standard guidelines for the diagnosis of CTCL, lending variability to the patient populations reported from different centers. Working groups have developed a practical format to assist in standardizing the diagnosis of mycosis fungoides, by far the most common variant of CTCL.

The diagnostic format uses input derived from the physical exam (lesion morphology and distribution) and integrates this with the biopsy and ancillary studies as shown in Table 157-7. The lesion morphology can be considered as meeting major criteria (arcuate lesions with scale, poikilodermatous patches, and plaques with atrophy), and minor criteria

(erythema, papulosquamous plaques, alopecia, hypopigmentation). Lesions atypical for mycosis fungoides are those with the finger-like lesions of digitate dermatosis. The distribution of lesions can also be used to assess the strength of diagnosis of mycosis fungoides. Again, there are major and minor criteria. Major criteria for distribution are lesions on the buttocks, breasts, and intertriginous regions. Minor criteria are lesions on the trunk or extremities. The biopsy is frequently signed out by the dermatopathologist as typical of mycosis fungoides or as consistent with the diagnosis of mycosis fungoides. The former is regarded as a major criterion and the latter as a minor criterion.



TABLE 157-7 **Guidelines for Diagnosing Patients with T1, T2 Mycosis Fungoides Type of CTCL**

How can these assessments be integrated into the practice of dermatology? For those patients with two major criteria, the diagnosis is firm. For those with anything weaker than three minor criteria the diagnosis of mycosis fungoides should not be made. The role for new technology in making the diagnosis of mycosis fungoides is limited to those cases with three minor criteria. PLEVA and digitate disease may have clonal populations but these would not be assessed as lesions appearing consistent with, in a distribution consistent with, or with a biopsy that meets major criteria for mycosis fungoides. In those borderline cases where the PCR is negative and a diagnosis cannot be made, subsequent followup and repeat biopsies may eventually document an evolving case of mycosis fungoides.

TREATMENT

Every successful strategy in managing CTCL begins with goals, tumor-burden assessments, questionnaires, and a timetable. The primary goals of therapy are to improve the quality of life, to prolong life and to cure. With a chronic disease like CTCL surrogate markers are a necessity and tumor burden is still the best surrogate marker for survival. Tumor-burden measurements and measures of palliation are the markers most commonly utilized. Skin score systems and health-assessment questionnaires that assess both discrete and global manifestations of the disease have also provided disease activity measurements. [43] The first staging of CTCL was done on the basis of skin involvement in a multicenter project by the Mycosis Fungoides Cooperative Group. [15] The T staging provided the only underpinning for linking tumor burden with survival in that from limited patch to 100 percent involvement, the more the skin was involved, the worse the prognosis. In addition to skin staging, there are other factors, previously discussed, that contribute to the heterogeneity of CTCL. This heterogeneity has undermined the utility of the TNM staging system. Markers such as CD8 expression in biopsies have yet to be adopted as staging tools. Currently, skin scores provide measures of objective responses to therapy and questionnaires guide the assessment of subjective responses to therapy. It has not been shown that the reduction of a patient from a T3 to a T1 is accompanied by any benefit in survival, yet it is also recognized that cure is unattainable unless the patient is first in remission with a skin score of 0 by whatever skin scoring system is used. Thus, remission is the first step toward achieving a cure.

There are a few principles that help guide therapy strategies. Excellent long-term results have been reported with the localized therapy of localized disease. [7], [42] More widespread disease requires total skin or systemic therapy. However, it is not known at what percentage of skin surface involvement it becomes imperative to treat the entire skin. Onced a remission is achieved, maintenance therapy has a role in preventing relapse. Because many patients will have therapies that span decades, it is also important to minimize exposure to therapies that have cumulative toxicities on keratinocytes (i.e., mutagens) or the bone marrow.

With the above mentioned principles, one can approach the therapy of a given patient based on the patient's clinical presentation. The therapies discussed later are presented roughly in the same order as summarized in Table 157-8. The clinical presentation of the patient can be matched up with a successful therapy modality for both the remittive phase of therapy and the maintenance therapy. For patients with several types of lesions, priority is given to those further down the column on the left in the table. For example, a patient with patches and tumors would be approached as tumors until those lesions are cleared. The therapies utilized to help a patient with CTCL can be best categorized into skin directed therapies, biological response modifiers, cytotoxic therapies, and combination therapies. Within each category, the individual modalities have unique properties that are discussed in the context of how these modalities are used.



TABLE 157-8 **Matching Treatment Modalities with Clinical Scenarios***

Uni/Oligo Lesional CTCL: Skin-Directed Therapy

The modalities considered for inducing a remission of uni/oligo lesional disease are spot x-ray therapy (XRT), topical chemotherapy with carmustine (BCNU), and topical retinoid therapy with bexarotene. Topical glucocorticoid therapy is discussed below. Spot radiotherapy [42] is the most reliable and rapid method of inducing a remission of localized CTCL.

There is widespread availability of radiotherapy and most lesions, no matter where they occur on the body (e.g., eyelid, buttock crease, ear) can be treated with this modality. There are no compliance problems, with each session performed by professional radiotherapists. The toxicity is minimal acutely, but the chronic toxicity of radiation dermatitis and cutaneous malignancy encourages the conservative use of this modality.

The limitations of topical BCNU therapy are the systemic toxicity from absorption of this chemotherapeutic agent and the local irritant response. As a result, topical carmustine is primarily used for limited body surface area. The initial protocols for using BCNU involved an alcohol-based solution kept in the refrigerator. However, ointment based protocols are now more common. BCNU can be easily made up in 20 mg%, 30 mg%, or 40 mg% ointments in petrolatum. Patients typically apply BCNU ointment at night and wash it off in the morning. Locally, there may be a dose-responsive irritation and/or hyperpigmentation that appear over the 8 to 20 weeks needed to clear lesions. Monitoring includes complete blood counts every 2 weeks looking for marrow suppression. The cumulative toxicity of BCNU is primarily structural damage with skin thinning and telangiectasias. Reliable and compliant patients are needed for this therapy to succeed. [56]

Similarly, the limitations of topical bexarotene gel are primarily due to the dose-responsive irritant response. Hence, bexarotene gel is typically used for <15 percent body surface area, as was the case in most of the patients in the pivotal trial that led to its approval. The gel is commercially available in a 1% formulation so that dose intensity is varied by the frequency of application. Patients typically initiate therapy with nightly lesional applications of bexarotene gel. After a week, the frequency is increased to twice daily and the patient cautioned about an irritant dermatitis at the site of the lesions. Complete clearance of lesions will usually occur after 12 to 16 weeks of therapy. Irritant responses can be managed by decreasing the frequency of application. [57] Successful topical bexarotene therapy also requires a compliant patient willing to put up with the irritating properties of this vitamin A derivative.

Disseminated Patch/Plaque Disease

Cutaneous T-cells recirculate through the vascular system, capable of patrolling the entire skin. When CTCL lesions are scattered about the skin, the most successful treatment strategies are those that treat the entire skin so as to extend the antilymphoma effect to the entire realm of the cutaneous T cell. Because recirculating CTCL cells are detectable even in limited disease, there are recirculating cells capable of recapitulating the disease. These cells provide some of the basis for using maintenance therapy following a complete response in the management of a patient with disseminated patch/plaque disease. The total skin treatment modalities most commonly used as first-line therapy against disseminated patch/plaque disease are phototherapies, topical chemotherapy, and total skin electron-beam radiotherapy.

PHOTOTHERAPIES (See also Chap. 266) Administration of oral 8-methoxypsoralen and UVA radiation can produce a definite clinical response and complete remissions of long duration in patients with patch/plaque CTCL. [58] PUVA therapy requires regular treatments, initially three to four times a week for up to 3 months or until remission occurs. The follow up of a patient on PUVA for CTCL includes an assessment to be sure there is some mild degree of phototoxicity. Otherwise, there may be insufficient dosing of either the psoralen or the UVA light. Risks of the treatment include possible induction of cutaneous epithelial neoplasms and cataract formation. Therefore, all patients should be observed closely and checked regularly for development of skin cancer. In addition, patients are advised to protect their eyes for 24 h following PUVA therapy and to have annual ophthalmologic examinations. These precautions should be enforced early because PUVA is a therapy that may continue for years as a maintenance treatment. Even after poor responses with conventional therapy, patients have had complete clearing of the skin with PUVA. [58], [59] However, maintenance therapy may be needed, as shown by the prolongation of clinical remission with continued PUVA. [60] For this reason, a gradual taper of therapy from thrice weekly to one session every 2 to 4 weeks after the patient has a stable remission is typical. UVB and narrow band ultraviolet B (NBUVB) are both effective for CTCL. [61] These phototherapies are more convenient for patients although their efficacy, especially for plaque disease, may not be as great as PUVA. Patch CTCL can often be completely cleared with UVB or NBUVB. A complete response can typically be induced with three to five treatment sessions per week. After a complete response has occurred, phototherapy can be continued on a maintenance schedule initially at once per week. The acute toxicities are primarily due to phototoxicity and the chronic toxicity is the increased risk for cutaneous malignancy.
TOTAL-SKIN TOPICAL CHEMOTHERAPY This consists of nitrogen mustard (mechlorethamine hydrochloride) that is applied as either an ointment base or as a freshly prepared aqueous solution. [62] As an initial dose, 10 mg of the drug is dissolved in approximately 50 mL of tap water. The entire volume is then applied to the whole body surface by the patient. The patient should wear protective plastic gloves while applying the solution. A delayed hypersensitivity reaction may complicate treatment and it is possible to desensitize patients, although their confidence in the therapy may be compromised. Ointment-based mechlorethamine, typically 10 mg% in ointment, may be less sensitizing and is stable on the shelf over a long period of time. Other side effects from mechlorethamine hydrochloride therapy, besides hypersensitivity reactions and primary irritant reactions, include the development of second cutaneous malignancies [63] and hypo- and hyperpigmentation (Fig, 157-25). This method is relatively easy for the patient to use at home, but daily whole-body application is required with maintenance therapy once remission is induced.

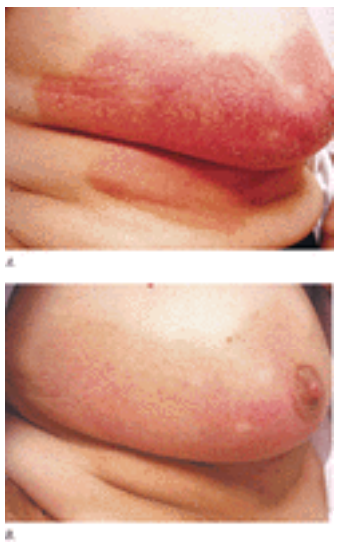

FIGURE 157-25 Typical lesions of mycosis fungoides on the breast before (*A*) daily total skin topical nitrogen mustard therapy. (*B*) After 3 months of therapy the lesions are starting to clear with residual hyperpigmentation.

TOTAL-SKIN RADIATION THERAPY The radiosensitivity of cutaneous lymphomas has been therapeutically exploited by total-skin electron-beam (TSEB) radiation. [64] Because electrons penetrate only to the upper dermis, electron-beam therapy may be used without systemic effect. The limited penetration of the electrons is advantageous in that it spares the mucous membranes, bone marrow, gastrointestinal tract, and other vital internal organs. Only those portions of the skin that are directly exposed to the beam are radiated. Therefore, palms, soles, scalp, axillae, and perineum may need separate exposure to ensure total-body treatment. The eyelids are routinely covered with lead eye shields to protect the cornea and lens from the effects of radiation. If the eyelids are involved, 5-mm–thick contact lenses are worn between the lid and cornea within the conjunctival sac. Nail shields may also be used to prevent anonychia. Whole-body electron-beam irradiation brings about complete remission in 80 to 95 percent of patients. The relapse rate is highest in the later stages of CTCL, that is, in those patients with tumors, lymphadenopathy, and visceral involvement. Patients with limited plaque disease had the best relapse-free rate (42 percent at 10 years). Most relapses occurred within the first year after completion of therapy and were very rare after 3 years. The median disease-free interval was greater than 3 years in the limited plaque group, approximately 1 year for patients with generalized plaque or erythrodermic disease, and less than 6 months for patients with cutaneous tumors. The total dose of irradiation is important, and a dose of 30 cGy (3000 rad) or more gives better complete remission rates and disease-free survival than do lower ones. The major disadvantages are that this type of therapy requires a specialized center, and takes up to 3 months for complete treatment. Local side effects include alopecia, atrophy of sweat glands and skin generally, radiodermatitis, and edema. When the total dose is highly fractionated, these complications are minimized and often avoided. The question is what is the maximum radiation tolerance of the skin? With the highly fractionated approach, patients can receive a second course of electron beam therapy of 36 cGy (3600 rad) to reinduce a remission. As the total radiation dose increases, so does the risk of squamous cell carcinoma and radiodermatitis. Small-field or spot orthovoltage radiotherapy using soft x-rays (60 to 100 kV with half-value layers of 1 to 1.5 mm Al) fractionated to doses of 0.75 to 5 cGy (75 to 500 rad) and total doses of 8 to 15 cGy (800 to 1500 rad) will adequately eliminate most lesions. In many patients, a second or even third complete course of total-skin electron-beam radiation can be safely administered. [65] The strategy of using electron beam for repeat courses requires the use of a highly fractionated dose of 1 Gy per dose.

MAINTENANCE THERAPY AND TOPICAL STEROID THERAPY The concept of treating normal skin evolved from the clinical experiences with skin directed therapies. There are two components to this: treatment of normal skin during remittive SDT and the treatment of normal skin during the remission maintenance phase. Topical chemotherapy, PUVA, and TSEB all involve the exposure of normal skin as an integral component of their success in achieving remission. [66] This success reflects the ability of the therapy to interrupt the critical skin based phase of the life cycle of a recirculating CTCL cell. Once a remission has been achieved, normal skin can be maintained with lower doses and frequencies of the therapies used to clear it. Maintenance therapies have been described with PUVA, [58] total-skin nitrogen mustard, [67] extracorporeal photochemotherapy, [68] and interferon. [69] The most commonly used maintenance therapy is PUVA (see Chap. 266) or UVB. As a maintenance therapy, PUVA is initially administered at once-weekly frequencies until 1 year has passed. At this point, the schedule is changed every other week for another year, every third week for a year and finally every fourth week for 2 years. At this point, the patient should have been in remission for 5 years. Consideration should be given to stopping therapy at this point. Cures are defined as 8 years disease free off all therapy. This definition arose from experience with nitrogen mustard and with total-skin electron-beam radiotherapy showing that after a patient achieves a remission off therapy of 5 to 8 years, late relapse is extremely rare. This would imply that malignant cutaneous T cells recirculate without lesions for up to 5 years. With 5 years of intermittent PUVA, it is less likely that one of these cells will survive, but it is still possible. After a patient is off therapy, they should not be considered a cure unless they stay clear for 8 years after stopping therapy. The management of suspected relapse often includes topical glucocorticoids and reflects the critical role this modality can play in the management of suspicious lesions. Early in the course of CTCL and in the recapitulation of the disease in a patient in remission, the T cell activation process can be blunted by the aggressive use of topical glucocorticoids. Indeed, most patients have a history of using these agents before a firm diagnosis is made. A regimen for treating early lesions of mycosis fungoides involves twice daily applications of a class I topical glucocorticoids for 8 weeks. [70] This regimen is one of the first-line modalities for suspected relapse and it can help identify which patients need to undergo a 4-week “wash-out” before repeat biopsies are performed.

Erythroderma

The erythrodermas of CTCL represent florid immune dysfunctions that result in total-skin redness, scaling, and discomfort. It is not surprising that immune-based therapies take the forefront in the management of these disorders. The three major biologic response modifiers (BRMs) used in the treatment of CTCL are oral retinoids, intravenous extracorporeal photochemotherapy (ECP), and subcutaneous injections of interferon-a. In the clinical trials of these agents, patients have undergone monotherapy of what has usually been heavily pretreated refractory disease. In practice, these are often used first line as monotherapy in erythroderma and combination therapies are incorporated if

there is an incomplete response. With these agents, partial responses are more common than complete responses. Thus, if the goal is remission, a combination therapy is more common than monotherapy. If the goal is palliation, monotherapies with BRMs are often sufficient. The BRMs differ in terms of their administration, side effects, interactions with other therapy modalities, and their availability.

RETINOID THERAPY (See Chap. 257) The first-generation retinoids such as isotretinoin have an impact on CTCL. The more CTCL-specific retinoid, bexarotene, selectively binds the retinoid X receptor, whereas the other available retinoids have less-specific binding patterns. In the monotherapy trials, bexarotene was dosed at 300 mg/m ^{2} (average dose, 450 to 675 mg per day, taken as capsules with the evening meal). Responses were seen at all phases of the disease: plaques, erythroderma, and tumors. Responses paralleled the secondary endpoints: decreases in overall body surface area involvement, overall tumor aggregate area, and improvement in pruritus. Erythrodermic patients may experience increased desquamation during the first few weeks of oral bexarotene therapy. Improvement typically occurs by week 12 of therapy. [71] Although there appeared to be a dose-response relationship with respect to efficacy, the higher doses were also associated with a higher rate of adverse events and dose-limited toxicities. The most common were hyperlipidemia/hypercholesterolemia and neutropenia. Elevations in the lipids occurred rapidly, within 2 to 4 weeks, and were associated with serious, but reversible, pancreatitis. Institution of monitoring lipids and use of lipid-lowering drugs were helpful in controlling the lipid levels. Dose reductions of bexarotene capsules were also required in some patients. Drug interactions of oral bexarotene with gemfibrozil and warfarin have been observed. Patients started on bexarotene develop central hypothyroidism with low thyroid-stimulating hormone (TSH) and free thyroxine levels within weeks of starting the medication. Symptoms of hypothyroidism may be subtle because they include symptoms of fatigue and feeling cold that may be attributed to CTCL. Supplementation with levothyroxine while patients were on bexarotene alleviates the symptoms and improves tolerance to treatment. The condition was reversible within weeks of stopping therapy. There is no immunosuppression with bexarotene therapy. Patients on bexarotene typically have monthly monitoring visits to follow lipid, liver, and thyroid parameters.

EXTRACORPOREAL PHOTOCHEMOTHERAPY (See Chap. 266) ECP therapy involves the photoinactivation of a portion of a patient's lymphocyte compartment with 8-methoxypsoralen (8-MOP) in the presence of ultraviolet A light, followed by reinfusion of these cells. The treatment is performed via an intravenous line feeding into a photoinactivation device that typically requires the patient to be recumbent for 3 h. Treatments are conducted on two consecutive days every 4 weeks. Erythrodermic CTCL is manageable with ECP monotherapy, [11] but other stages have not been rigorously studied with monotherapy. In a multicenter study of erythrodermic CTCL patients, approximately one-fourth had a complete response, one-fourth had no response, and the remainder had partial responses. However, it is clear that even a partial response can improve the quality of life of these patients. Improvement may begin as early as 6 weeks into therapy, and yet some patients do not completely clear until 12 months after starting therapy. There were occasional temporary responses immediately following a 2-day cycle of therapy. On average, after 4 to 6 months there was typically a gradual and permanent decrease in erythema, scaling, and pruritus. Patients often notice more subtle changes such as the return of body hair, loss of rigors, and a return of the ability to sweat. Partial responses may also decrease the morbidity these patients suffer in terms of infectious complications. More heavily involved and inflamed skin is more readily colonized, providing both a reservoir and access point for microbes to invade the host. Thus, cutaneous improvement can also minimize complications of CTCL. The clinical experiences with ECP for CTCL suggest that the therapeutic response may well be based in the immune system. One feature is that when less than 5 percent of the malignant lymphocyte pool is photoinactivated with 8-MOP/UVA, there can be clinical responses, with more than 95 percent of the malignant lymphocytes disappearing over time. It also appears that most immunocompetent patients respond. Patients heavily pretreated, with longer disease durations, had less of a response. Also, patients with more normal CD8+ lymphocyte levels were responsive to ECP. [11] In one study, total-skin electron beam was combined with ECP in T3 and T4 patients. By comparing the SDT+BRM group to historic controls who underwent electron-beam radiotherapy at the same institution, the impact of ECP was demonstrable in the significantly longer survival of patients in the SDT+BRM group. [68]

a-INTERFERON The most studied interferon has been a, but clinical trials have also been done with ß- and ?-interferon in the treatment of CTCL. The initial studies with a-interferon showed complete responses varying from 10 to 27 percent with durations less than 6 months as a monotherapy. Again, the heterogeneity of the disease and the pretreatments patients undergo affect outcomes to make comparisons with other modalities impossible. a-Interferon is typically started at 3 million units (MU) three times a week and can be increased to a maximally tolerated dose, typically in the range of 12 MU per day. Like the other BRMs, the response to interferon is gradual, with 3 to 6 months being needed to determine the maximal response. [72] After patients achieve a maximal response, interferon can be lowered to a maintenance dose of 1 MU daily. All interferons have similar toxicities. The initial week of interferon is complicated by a flulike illness that may be accompanied by fever, myalgia, fatigue, and listlessness. As this wears off, patients are often left with a slight feeling of chronic fatigue. The long-term toxicity that causes most concern is neurologic: depression, neuropathy, dementia, and myelopathy. There are autoimmune phenomena that may occur such as proteinuria, thrombocytopenia, and anemia. Monitoring of interferon therapy includes blood counts and urinalysis along with questionnaires assessing the impact on the quality of life. The combined modality therapies that use interferon in the management of erythrodermas include ECP and retinoids. If monotherapy of erythroderma produces a partial response, the addition of either of these agents can induce the desired goals of either complete response or increased palliation.

Refractory Patch-Plaque or Erythroderma

COMBINATION THERAPY As mentioned above, the BRMs induce complete remissions as a monotherapy in only a minority of cases. As also noted, the SDTs are occasionally ineffective at completely clearing the disease. Thus, a practical combination of these two treatment strategies was inevitable. The role of interferon in CTCL has been primarily as a BRM that enhances PUVA therapy. Patients with extensive plaque stage CTCL that does not clear with PUVA have been shown to go into remission when interferon injections were started. The interferon could be tapered and PUVA used as a maintenance therapy. [73] Similar to psoriasis, the combination of retinoids with PUVA therapy can be synergistic in the therapy of patch/plaque disease. The successful strategy of combining a BRM with a debulking treatment is understandable in the context of the previous discussion of the pathogenesis of CTCL. The malignant cells are the source of some, if not all, of the immunosuppressive features of progressive CTCL. By reducing the number of cells, contributions to the immunosuppression would decrease and the immune-enhancing therapies would have a greater

chance of success.

CYTOTOXIC THERAPY Cytotoxic agents are often beneficial in the management of a patient with CTCL. The major problem with cytotoxic therapy has been that the malignant T cells of CTCL are virtually identical to other mature T cells in their sensitivity to these agents. Thus, traditional cytotoxic therapy is often complicated by side effects that are more frequent in CTCL patients treated with traditional chemotherapy. [74] To exploit the benefits of cytotoxic therapy, several successful strategies have been developed. Targeting cytotoxic therapy can be accomplished with the fusion toxins. These recombinant proteins have portions that preferentially bind actively growing T cells and portions that deliver cytotoxicity to these cells. Another strategy is to utilize chronic low dose oral chemotherapy. These well-tolerated agents can be administered for months to years if necessary to help control symptoms and, at times, to induce a complete response.

LOW-DOSE ORAL CHEMOTHERAPY Chlorambucil and methotrexate have been the most frequently used agents in daily low-dose chemotherapy of CTCL. [75] Typically, chlorambucil is combined with prednisone (40 mg prednisone and 4 mg chlorambucil per day). If no hematologic toxicity is noted, the chlorambucil can be increased in 2 mg increments. Once the maximum response is achieved, the prednisone is tapered to a long-term tolerable dose of 20 mg every other day. Once-weekly methotrexate has also been used in doses from 20 to 60 mg per week. [76] Patients with refractory plaque and erythroderma have benefited from weekly methotrexate, palliative responses are reliable but complete responses are rare.

DENILEUKIN DIFTITOX Denileukin diftitox (DD) is a fusion protein, a unique cytotoxic therapeutic agent that targets specific receptors on CTCL cells while minimizing damage to normal cells not expressing the receptor. DD uses both the cytotoxic action of diphtheria toxin and the cell-targeting ability of interleukin (IL)-2 to selectively damage CTCL cells. DD is approved in the United States for the treatment of patients with persistent or recurrent CTCL. There is some controversy as to whether it is necessary to have the high-affinity IL-2 receptor present at the levels of detection by immunoperoxidase in order for this therapy to work, because many immunoperoxidase CD25- patients have responded. DD is administered at doses of either 9 or 18 µg/kg per day IV over 20 min daily for 5 consecutive days every 3 weeks. Patients may experience infusion-related fever and chills requiring subsequent prolongation of infusion time and the addition of premedications. The safety and efficacy of DD in patients with CTCL whose malignant cells express the CD25 component of the IL-2 receptor was examined in a phase III trial of 71 patients who had failed a median of 5 prior therapies. DD was administered at two doses: 9 µg/kg per day or 18 µg/kg per day for 5 consecutive days. The overall response rate was 30 percent, with a 10 percent complete remission rate. Patients with more advanced disease (stage IIB or higher) had a greater likelihood of response at the higher dose. The median time to response was 6 weeks. A common toxicity is a reversible elevation of liver enzymes that reaches a peak during the week following an infusion. This will usually return to normal by the start of the second infusion and any subsequent elevations are of a lower magnitude. Thus, patients with cachexia, hypoalbuminemia, and hepatic abnormalities are at increased risk for toxicity from DD. The most frequent grade IV (most severe) toxicity of DD was edema from the vascular leak syndrome. No premedication was available for this during the clinical trial because it could have potentially interfered with the disease activity assessments. One of the most valuable parameters for measuring the vascular leak syndrome was to have the patient do daily weights during DD therapy. A sudden weight gain is good evidence of capillary leak. Patients receiving DD are currently dosed with the same regimens of intravenous corticosteroids that are used with other intravenous biologic therapies, typically for all 5 days of the infusion. The time to response with DD is relatively quick and after three cycles of therapy, responders will be evident. In responders, the next step is to maximize that response with continued therapy cycles. [77]

GEMCITABINE Gemcitabine is a pyrimidine antimetabolite with a low-toxicity profile. This is typically administered at a dose of 1.2 g/m ^{2} intravenously over 30 min for three doses over a 1-month period. These monthly treatment cycles can be repeated if efficacy is observed. Approximately half of the patients treated with this regimen show a palliative response and treatment is well tolerated with mild hematologic toxicity and no nausea or vomiting. [78]

MULTIAGENT CHEMOTHERAPY Chemotherapy is mostly palliative in the management of CTCL. Palliation has been obtained with a variety of multiagent regimens. Combination chemotherapy produces high objective response rates (up to 85 percent overall) but the duration of remission varies widely. Consequently, it should be emphasized that various combinations of agents may induce significant clinical responses and apparent remission in some cases, but no regimen has been shown to be curative for advanced disease. Systemic high-dose chemotherapy is most often used as a palliative agent in advanced disease. Most patients in advanced stages will exhibit some degree of steroid sensitivity, which makes the glucocorticoids a usual component of therapy. The combination regimen of cyclophosphamide, doxorubicin, vincristine, and prednisone (CHOP) is one of the safer, better-tolerated regimens for advanced CTCL. [79]

Tumors

Tumors of CTCL are a heterogenous group as discussed above. The initial therapy of tumors is usually with radiotherapy given the high response rates. For patients with disseminated tumors, total-skin electron-beam radiotherapy (as discussed earlier) is needed. Given the aggressive nature of tumor disease, patients cleared with radiotherapy typically undergo maintenance therapy (see above) once remission is achieved. Given the finite tolerance of the skin for radiotherapy, relapsing tumors are frequently treated with the previously discussed chemotherapy or combination therapy regimens discussed in the section on refractory patch/plaque disease. Cytotoxic therapy typically begins with denileukin diftitox infusions to get debulking of the lymphoma without compromise of bone marrow or immune status. If there is no response, CHOP or gemcitabine infusions are useful but often require hematologic support for bone marrow suppression and close monitoring for infections. The propensity for infection is increased in patients with indwelling catheters that are often used for chemotherapy infusions. These are easily seeded from the low-level bacteremias that result from the compromised skin of patients with CTCL, especially those with erosions and ulcers. Following the induction of a complete response with any of these modalities it is worthwhile pursuing a course of maintenance therapy although only the use of nitrogen mustard, ECP, interferon, or PUVA (as discussed previously in the section on maintenance therapy) have been reported as useful following total-skin electron-beam radiotherapy.

REFERENCES

1. Heald P et al: Skin selective lymphocyte homing mechanisms in the pathogenesis of leukemic cutaneous T-cell lymphoma. *J Invest*

Dermatol **101**:222, 1993

2. Weinstock MA, Horm JW: Mycosis fungoides in the United States. *JAMA* **60**:42, 1988

3. Weinstock MA, Gardstein B: Twenty-year trends in the reported incidence of mycosis fungoides and associated mortality. *Am J Pub Health* **89**:1240, 1999

4. Weinstock MA, Reynes JF: The changing survival of patients with mycosis fungoides. *Cancer* **85**:208, 1999

5. Swanbeck G et al: Indications of a considerable decrease in the death rate in mycosis fungoides by PUVA treatment. *Acta Derm Venereol* **74**:465, 1994

6. Kim YH et al: Clinical characteristics and long-term outcome of patients with generalized patch and/or plaque (T2) mycosis fungoides. *Arch Dermatol* **135**:26, 1999

7. Kim YH et al: Clinical stage IA (limited patch and plaque mycosis fungoides. *Arch Dermatol* **132**:1309, 1996

8. Jachow CM et al: Association of erythrodermic cutaneous T-cell lymphoma, superantigen-positive *Staphylococcus aureus,* and oligoclonal T-cell receptor Vb gene expression. *Blood* **89**:32, 1997

9. Whittemore AS et al: Mycosis fungoides in relation to environmental exposures and immune response: A case-control study. *J Natl Cancer Inst* **81**:1560, 1989

10. Kieffer JD et al: Neutrophils, monocytes, and dendritic cells express the same specialized form of PSGL-1 as do skin-homing memory T cells: Cutaneous lymphocyte antigen. *Biochem Biophys Res Commun* **285**:577, 2001

11. Heald PW et al: Treatment of erythrodermic cutaneous T-cell lymphoma patients with photopheresis. *J Am Acad Dermatol* **17**:427, 1992

12. Hoppe RT et al: CD8-positive tumor infiltrating lymphocytes influence the long-term survival of patients with mycosis fungoides. *J Am Acad Dermatol* **32**:448, 1995

13. Gellrich S et al: Microanatomical compartments of clonal and reactive T cells in mycosis fungoides: molecular demonstration by single cell polymerase chain reaction of T cell receptor gene rearrangements. *J Invest Dermatol* **115**:620, 2000

14. Scarisbrick JJ et al: Allelotyping in mycosis fungoides and Sézary syndrome: Common regions of allelic loss identified on 9p, 10q and 17p. *J Invest Dermatol* **117**:663, 2001

15. Lamberg SI, Bunn PA: Proceeding of the workshop on cutaneous Tcell lymphomas (mycosis fungoides and Sézary syndrome). *Cancer Treat Rep* **63**:561, 1979

16. Akaraphanth R et al: Hypopigmented mycosis fungoides: Treatment and a 6.5-year follow-up of 9 patients. *J Am Acad Dermatol* **42**:33, 2000

17. Barnhill RL, Braverman IM: Progression of pigmented purpura-like eruptions to mycosis fungoides: Report of three cases. *J Am Acad Dermatol* **19**:25, 1988

18. LeBoit P et al: Granulomatous slack skin: Clonal rearrangement of the T-cell receptor beta gene is evidence for the lymphoproliferative nature of a cutaneous elastolytic disorder. *J Invest Dermatol* **89**:183, 1987

19. Burns MK et al: Woringer-Kolopp disease (localized pagetoid reticulosis) of unilesional mycosis fungoides? An analysis of eight cases with benign disease. *Arch Dermatol* **131**:325, 1995

20. Berti E et al: Primary cutaneous gamma-delta lymphoma presenting as disseminated pagetoid reticulosis. *J Invest Dermatol* **96**:718, 1991

21. Gibson LE et al: Follicular mucinosis: Clinical and histopathologic study. *J Am Acad Dermatol* **20**:441, 1989

22. Dubin DB et al. Adnexotropic T-cell lymphoma presenting with generalized anhidrosis, progressive alopecia, pruritus, and Sjögren's syndrome. *J Am Acad Dermatol* **38**:493, 1998

23. Agnarsson BA et al: Cutaneous T cell lymphoma with suppressor/cytotoxic (CD8) phenotype: Identification of rapidly progressive and chronic subtypes. *J Am Acad Dermatol* **22**:569, 1990

24. Heald P et al: Unique clinical and immunophenotypic correlations of cutaneous gamma-delta T-cell lymphoma. *J Am Acad Dermatol* **26**:865, 1992

25. Burg G et al: A subcutaneous delta positive T-cell lymphoma that produces interferon gamma. *N Engl J Med* **325**:1078, 1991

26. Mraz-Gernhard S et al: Natural killer/natural killer-like T-cell lymphoma, CD56+, presenting in the skin: An increasingly recognized entity with an aggressive course. *J Clin Oncol* **19**:2179, 2001

27. Sézary A, Bouvrain Y: Erythrodermie avec presence de cellules monstreuses dans le derme et le sang circulant. *Bull Soc Fr Dermatol Syphil* **45**:254, 1938

28. Krishnan J et al: Primary cutaneous CD30 positive anaplastic large cell lymphoma: Report of 27 cases. *J Cutan Pathol* **20**:1931, 1993

29. Kerl H et al: The morphologic spectrum of T-cell lymphomas of the skin. A proposal for a new classification. *Semin Diagn Pathol* **8**:55, 1991

30. Florent G et al: Coexistent cutaneous T-cell lymphoma and B-cell malignancy. *J Am Acad Dermatol* **31**:724, 1994

31. Fivensen DP et al: Localization of clonal T cells to the epidermis in cutaneous T-cell lymphoma. *J Am Acad Dermatol* **31**:717, 1994

32. Wood GS et al: Detection of early cutaneous T cell lymphoma. *J Invest Dermatol* **103**:34, 1994

33. Marti RM et al: Prognostic clinicopathologic factors in cutaneous T-cell lymphoma. *Arch Dermatol* **127**:1511, 1991

34. Cerroni L et al: Clinicopathologic and immunologic features associated with transformation of mycosis fungoides to large cell lymphoma.

Am J Surg Pathol **16**:543, 1992

35. Lamberg SI et al: Status report of 376 mycosis fungoides patients at 4 years: Mycosis Fungoides Cooperative Group. *Cancer Treat Rep* **63**:701, 1979

36. Bass JC et al: Cutaneous T-cell lymphoma: CT in evaluation and staging. *Radiology* **186**:273, 1993

37. Vonderheid EC et al: Lymph node classification systems in cutaneous T-cell lymphoma. Evidence for the utility of the Working Formulation of Non-Hodgkin's Lymphomas for Clinical Usage. *Cancer* **73**:207, 1994

38. Veelken H et al. Molecular staging of cutaneous T-cell lymphoma: evidence for systemic involvement in early disease. *J Invest Dermatol* **104**:889, 1995

39. Heald P et al: Profound deficiency in normal circulating T-cells in erythrodermic cutaneous T-cell lymphoma. *Arch Dermatol* **130**:198, 1994

40. Vonderheid EC et al: Variable CD7 expression on T cells in the leukemic phase of cutaneous T cell lymphoma (Sézary syndrome). *J Invest Dermatol* **117**:654, 2001

41. Kantor AF et al: Risk of second malignancy after cutaneous T-cell lymphoma. *Cancer* **63**:1612, 1989

42. Heald P, Glusac E: Unilesional cutaneous T-cell lymphoma: Clinical features, therapy, and follow-up of ten patients with a treatment responsive mycosis fungoides variant. *J Am Acad Dermatol* **42**:283, 2000

43. Heald P: Clinical trials and efficacy assessment in the therapy of cutaneous T-cell lymphoma. *Ann N Y Acad Sci* **941**:155, 2001

44. Stokar LM et al: Clinical manifestations of intrathoracic cutaneous T cell lymphoma. *Cancer* **56**:2694, 1985

45. Brigham BA et al: Skeletal manifestations in cutaneous T cell lymphoma. *Arch Dermatol* **118**:461, 1982

46. Van't Veen AJ et al: Mycosis fungoides and polyarthritis. *Br J Dermatol* **131**:721, 1994

47. Sirois D et al: Oral manifestations of cutaneous T-cell lymphoma. A report of eight cases. *Oral Surg Oral Med Oral Pathol* **75**:700, 1993

48. Gordon LJ et al: Mycosis fungoides of the larynx. *Otolaryngol Head Neck Surg* **107**:120, 1992

49. Tien RD et al: CNS mycosis fungoides: CT and MR findings. *J Comput Assist Tomogr* **16**:529, 1992

50. Kaufman DK et al: Neurological complications of peripheral and cutaneous T-cell lymphomas. *Ann Neurol* **36**:625, 1994

51. Guitart J et al: Histologic criteria for the diagnosis of mycosis fungoides: Proposal for a grading system to standardize pathology reporting. *J Cutan Pathol* **28**:174, 2001

52. Burg G et al: Pathology of cutaneous T-cell lymphoma. *Hematol Oncol Clin* **9**:961, 1995

53. Glusac EJ et al: Cutaneous T-cell lymphoma. Refinement in the application of controversial histologic criteria. *Dermatol Clin* **17**:601, 1999

54. Olerud JE et al: Cutaneous T-cell lymphoma: Evaluation of pretreatment skin biopsy specimens by a panel of pathologists. *Arch Dermatol* **128**:501, 1992

55. Santucci M et al: Accuracy, concordance, and reproducibility of histologic diagnosis in cutaneous T-cell lymphoma: An EORTC Cutaneous Lymphoma Project Group Study. *Arch Dermatol* **136**:497, 2000

56. Zackheim HS: Topical carmustine (BCNU) for patch/plaque mycosis fungoides. *Semin Dermatol* **13**:202, 1994

57. Cohen MH et al: Drug approval summaries: arsenic trioxide, tamoxifen citrate, anastrazole, paclitaxel, bexarotene. *Oncologist* **6**:4, 2001

58. Hoenigsmann H et al: Photochemotherapy for cutaneous T cell lymphoma: A follow-up study. *J Am Acad Dermatol* **40**:238, 1984

59. Gilchrest BA: Methoxsalen photochemotherapy for mycosis fungoides. *Cancer Treat Rep* **63**:663, 1979

60. Rosenbaum MM et al: Photochemotherapy in cutaneous T cell lymphoma and parapsoriasis en plaques. *J Am Acad Dermatol* **13**:613, 1985

61. Ramsay DL et al: Ultraviolet-B phototherapy for early-stage cutaneous T-cell lymphoma. *Arch Dermatol* **128**:931, 1992

62. Vonderheid EC et al: Long-term efficacy, curative potential, and carcinogenicity of topical mechlorethamine chemotherapy and cutaneous T-cell lymphoma. *J Am Acad Dermatol* **20**:416, 1989

63. Lee LA et al: Second cutaneous malignancies in patients with mycosis fungoides treated with topical nitrogen mustard. *J Am Acad Dermatol* **7**:590, 1982

64. Jones GW et al: Electron beam treatment for cutaneous T-cell lymphoma. *Hematol Oncol Clin* **9**:1057, 1995

65. Wilson LD et al: Additional courses of total skin electron beam therapy in the treatment of patients with recurrent cutaneous T-cell lymphoma. *J Am Acad Dermatol* **35**:69, 1996

66. Quiros PA et al: Total skin electron beam therapy followed by adjuvant psoralen/ultraviolet-A light in the management of patients with T1 and T2 cutaneous T-cell lymphoma (mycosis fungoides) *Int J Radiat Oncol Biol Phys* **38**:1027, 1997

67. Chinn DM et al: Total skin electron beam therapy with or without adjuvant topical nitrogen mustard or nitrogen mustard alone as initial treatment of T2 and T3 mycosis fungoides *Int J Radiat Oncol Biol Phys* **43**:951, 1999

68. Wilson LD et al: Systemic chemotherapy and extracorporeal photochemotherapy for T3 and T4 cutaneous T-cell lymphoma patients who have achieved a complete response to total skin electron beam therapy. *Int J Radiat Oncol Biol Phys* **32**:987, 1995

69. Jumbou O et al: Long-term follow-up in 51 patients with mycosis fungoides and Sézary syndrome treated by interferon-alfa. *Br J Dermatol* **140**:427, 1999

70. Zackheim HS et al: Topical corticosteroids for mycosis fungoides. Experience in 79 patients. *Arch Dermatol* **134**:949, 1998

71. Duvic M et al: Phase 2 and 3 clinical trial of oral bexarotene for the treatment of refractory or persistent early-stage cutaneous T-cell lymphoma. *Arch Dermatol* **137**:581, 2001

72. Olsen EA, Bunn PA: Interferon in the treatment of cutaneous T-cell lymphoma. *Hematol Oncol Clin* **9**:1089, 1995

73. Mostow EN et al: Complete remissions in psoralen and UV-A (PUVA)-refractory mycosis fungoides-type cutaneous T-cell lymphoma with combined interferon alfa and PUVA. *Arch Dermatol* **129**:747, 1993

74. Kaye FJ et al: A randomized trial comparing combination electron-beam radiation and chemotherapy with topical therapy in the initial treatment of mycosis fungoides. *N Engl J Med* **321**:1784, 1989

75. Winkelmann RK et al: The treatment of Sézary syndrome. *J Am Acad Dermatol* **10**:1000, 1984

76. Zackheim HS, Epstein EH: Low-dose methotrexate for Sézary syndrome. *J Am Acad Dermatol* **21**:757, 1989

77. Olsen E et al: Pivotal phase III trial of two dose levels of denileukin diftitox for the treatment of cutaneous T-cell lymphoma. *J Clin Oncol* **19**:376, 2001

78. Zinzani PL et al: Gemcitabine treatment in pretreated cutaneous T-cell lymphoma: Experience in 44 patients. *J Clin Oncol* **18**:2603, 2000

79. Rosen ST, Foss FM: Chemotherapy for mycosis fungoides and the Sézary syndrome. *Hematol Oncol Clin* **9**:1109, 1995

T>

Chapter 158

Wolfram Sterry J. Muche

Other Systemic Lymphomas with Skin Infiltration

PRIMARY CUTANEOUS T CELL LYMPHOMAS
Mycosis Fungoides and Associated Indolent T Cell Lymphoma of the Skin
Primary Cutaneous CD30+ Lymphoproliferative Disorders
Aggressive Primary Cutaneous T Cell Lymphomas
Provisional Entities of Primary Cutaneous T Cell Lymphomas
PRIMARY CUTANEOUS B CELL LYMPHOMAS
Indolent Variants
Primary Cutaneous B Cell Lymphomas with Intermediate Course
Provisional Entities of Primary Cutaneous B Cell Lymphomas
SECONDARY SKIN INVOLVEMENT IN LYMPHOID NEOPLASIAS

REFERENCES

Systemic lymphomas represent a heterogeneous group of neoplastic diseases of the lymphoid tissue. Definition and classification of these entities are rapidly changing as knowledge grows. Currently, lymphoid neoplasias are best classified by the World Health Organization (WHO) Classification of Neoplastic Diseases of the Hematopoietic and Lymphoid Tissues [1] (Table 158-1), which primarily categorizes the entities according to lineage and, subsequently, according to a combination of morphology, immunophenotype, genetic features, and clinical syndromes.

TABLE 158-1 **WHO Classification of Neoplastic Diseases of the Hematopoietic and Lymphoid Tissues**

Infiltration of the skin may represent the first manifestation of the lymphoma (primary cutaneous lymphoma) or may occur as skin involvement of a primary extracutaneous lymphoma (secondary cutaneous lymphoma). Primary cutaneous lymphomas are defined as clonal proliferations of skin-infiltrating B/T lymphocytes primarily (at least during the first 6 months) presenting in the cutaneous compartment (see Chap. 157). [2], [3] They show a considerable variation in clinical presentation, histology, immunophenotype, and prognosis. Following the group of primary gastrointestinal lymphomas, they form the second most common group of extranodal lymphomas. [4] The annual incidence is estimated to be between 0.5 and 1 per 100,000. [5] Secondary cutaneous lymphomas are rarely seen and show a clinically uniform picture despite their different histopathologic and morphologic features.

Differentiation of primary and secondary skin involvement has prognostic relevance. [6] Differences in the expression of oncogenes, viral sequences, and adhesion molecules, as well as the presence of specific translocations, further support the view that primary cutaneous lymphomas represent a clinically and biologically distinct lymphoma group. This fact is taken into account by the proposal of the Cutaneous Lymphoma Study Group of the European Organization for Research and Treatment of Cancer (EORTC). Based on clinical presentation, histology, immunophenotype, and prognosis, primary cutaneous T cell lymphomas and primary cutaneous B cell lymphomas are classified into distinct disease entities with an indolent, intermediate, or aggressive clinical course (Table 158-2).

TABLE 158-2 **EORTC Classification for Cutaneous Lymphomas**

The unifying concept that considers all T cell lymphomas of the skin to be variations of a single pathogenetic process called cutaneous T cell lymphoma (CTCL) [7] has attracted considerable interest in disorders whose historically developed names were known mainly to the dermatologic community. However, the group of cutaneous T cell lymphoma is too heterogeneous to be pooled into a single pathogenetic concept. The major entities covered by the term CTCL are described in Chap. 157, and for reasons of completeness, some overlap with this chapter is unavoidable.

The EORTC classification provides the basis for this chapter. No consideration is given here to the etiology and pathogenesis of cutaneous malignant lymphomas, because only limited data exist despite very active research.

PRIMARY CUTANEOUS T CELL LYMPHOMAS

Mycosis Fungoides and Associated Indolent T Cell Lymphoma of the Skin

MYCOSIS FUNGOIDES Mycosis fungoides is defined as an epidermotropic cutaneous T cell lymphoma, which is extensively discussed in Chap. 157. The cases forming primary tumors, previously described as mycosis fungoides *d'emblée,* are classified according to their cytologic and immunophenotypic characteristics. [8]

MYCOSIS FUNGOIDES-ASSOCIATED FOLLICULAR MUCINOSIS Mycosis fungoides-associated follicular mucinosis represents a distinct variant of mycosis fungoides with preferential involvement of head and neck by folliculotropic T cell infiltrates, and mucinous degeneration of the hair follicles. This is also discussed in Chap. 157. Follicular papules, indurated plaques, and tumors, which usually involve the head and neck region, constitute the typical clinical appearance. The occurrence of alopecia, pruritus, and secondary bacterial infections is common. The folliculotropism of the infiltrating lymphocytes is histologically prominent. Medium-sized to large hyperchromatic cells with cerebriform nuclei form dermal infiltrates and invade the follicular epithelium, which is accompanied by a mucinous degeneration of the adnexal structures. A considerable number of eosinophils and plasma cells can be observed within the infiltrates. The neoplastic T cells express a phenotype identical to that of mycosis fungoides. Because epidermotropism can be absent in some cases, mycosis fungoides-associated follicular mucinosis may be incorrectly classified as pleomorphic T cell lymphoma of the skin. Recognition of the typical folliculotropism ensures the diagnosis.

PAGETOID RETICULOSIS (See also Chap. 157)

Definition Pagetoid reticulosis is regarded as a distinct type of cutaneous T cell lymphoma that is characterized by the presence of localized patches or plaques with an intraepidermal proliferation of neoplastic cells. Two types of the disease are described: [9], [10] The localized Woringer-Kolopp type [11] presents almost exclusively in males and is associated with an excellent prognosis (disease-related 5-year survival of 100 percent). The disseminated Ketron-Goodman type [12] mostly affects elderly people. Because the disseminated type behaves like classical mycosis fungoides, only the localized variant should be referred to as pagetoid reticulosis.

Clinical manifestations Patients develop slowly enlarging hyperkeratotic or psoriasiform plaques, most often localized on the distal extremities (Fig. 158-1). Extracutaneous dissemination has not been observed.

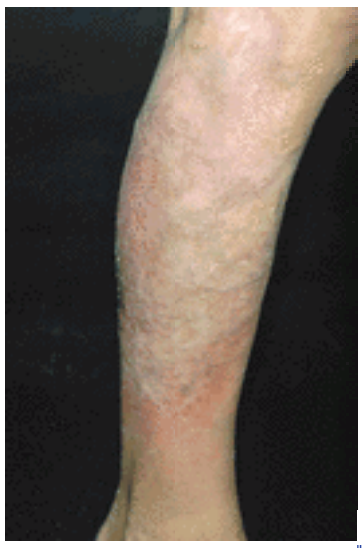

FIGURE 158-1 Pagetoid reticulosis. Hyperkeratotic plaque localized on the lower leg of a male patient.

Pathology The histologic picture resembles the pattern of Paget's disease. Acanthosis and spongelike disaggregation of the epidermis are caused by a dense, strongly epidermotropic infiltrate of large atypical mononuclear cells. These cells show medium-sized to large, sometimes hyperchromatic, nuclei and a clear cytoplasm. Immunophenotyping reveals the tumor cells to be CD3+, CD4+, CD8- or CD3+, CD4-, CD8+; whereas CD30 positivity is inconsistently observed. [13], [14] The strong expression of cutaneous lymphocyte antigen and a ^{E} ß $_{7}$, an adhesion molecule interacting with E-cadherin on epithelial cells, might be the basis of the prominent epidermotropism of the neoplastic cells. [15] A characteristic feature of pagetoid reticulosis is the variable loss of the CD2, CD5, and CD45 surface antigens.

Diagnosis and differential diagnosis The localized variant must be distinguished from hypertrophic lichen planus or Bowen's disease.

Treatment and prognosis Localized pagetoid reticulosis is best treated with x-rays or excision. Widespread generalized pagetoid reticulosis will respond to PUVA treatment combined with retinoids or interferon-a. The localized Woringer-Kolopp type presents with an excellent prognosis of a disease-related 5-year survival of 100 percent.

Primary Cutaneous CD30+ Lymphoproliferative Disorders

CD30+ CUTANEOUS LARGE CELL LYMPHOMA

Definition This is a cutaneous lymphoma consisting of large tumor cells that in majority express the CD30 antigen, with no evidence or history of lymphomatoid papulosis, mycosis fungoides or another type of primary cutaneous T cell lymphoma. Irrespective of the morphology of the tumor cells (anaplastic, immunoblastic or pleomorphic large cells) the clinical presentation and behavior are identical.

Clinical manifestations CD30+ cutaneous large cell lymphomas occur in adults, rarely in children and adolescents, with a male-to-female ratio of 1.5:1. The clinical picture is characterized by the solitary or locoregional occurrence of reddish to brownish nodules and tumors, which frequently tend to ulcerate (Fig. 158-2A). Although observed in roughly 25 percent of the patients, secondary involvement of the regional lymph nodes is not necessarily associated with an unfavorable prognosis. [16]

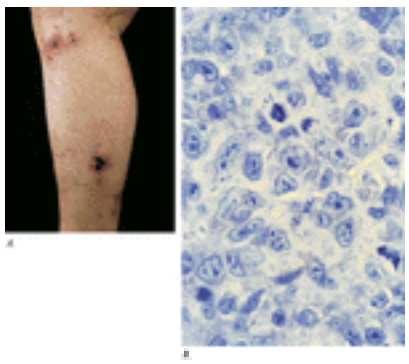

FIGURE 158-2 CD30+ cutaneous large cell lymphoma. *A.* Localized nodules, partially with ulcerations. *B.* Pleomorphic large cell lymphoma T cell infiltrate.

Pathology A nodular or diffuse nonepidermotropic infiltrate of large cells is seen in the dermis (Fig. 158-2B). In the majority of cases, the neoplastic cells show an anaplastic morphology with oval or irregularly shaped nuclei, prominent nucleoli, and an abundant cytoplasm. Less commonly, a pleomorphic or immunoblastic appearance is observed. Atypical mitotic figures are frequent. In the periphery of the lesions, inflammatory cells (T cells, eosinophils, and neutrophils) are present, sometimes imitating the histologic picture seen in lymphomatoid papulosis. By definition, at least 75 percent of the large cells are CD30+. Additionally, they express a CD4+ phenotype with variable loss of pan-T cell antigens such as CD2, CD3, and CD5. Cases with CD8+ neoplastic cells occur rarely. Unlike nodal CD30+ lymphomas, CD30+ large cell lymphomas of the skin are negative for CD15 and epithelial membrane antigen (EMA).
Diagnosis and differential diagnosis Clinicopathologic correlation is crucial. The histologic picture may suggest lymphomatoid papulosis (see Chap. 159), but lesions of CD30+ cutaneous large cell lymphoma are clinically larger and localized and they do not tend to disappear spontaneously. CD30 positivity of at least 75 percent of the large cells excludes a CD30- T cell lymphoma.
Treatment and prognosis In cases of solitary or localized skin lesions, radiotherapy is the preferred mode of treatment. Successful treatment with PUVA in combination with interferon-a has been reported. In cases of more generalized skin lesions or in cases of extracutaneous dissemination, multiagent chemotherapy should be considered. [17] In contrast to extracutaneous large cell lymphomas, CD30+ cutaneous large cell lymphomas of the skin have a favorable prognosis with a disease-related 5-year survival rate of 90 percent.

LYMPHOMATOID PAPULOSIS

Definition Lymphomatoid papulosis is a chronic recurrent, self-healing papulonodular skin eruption with histologic features that suggest cutaneous T cell lymphoma. Because this entity is not unanimously regarded as a lymphoid neoplasia, it is discussed in Chap. 159.

Aggressive Primary Cutaneous T Cell Lymphomas

SÉZARY SYNDROME

Definition Sézary syndrome is defined by the triad of erythroderma, generalized lymphadenopathy, and the presence of neoplastic T cells (Sézary cells) in skin, lymph nodes, and peripheral blood. The disease is discussed in Chap. 157.

CD30- CUTANEOUS LARGE CELL LYMPHOMA

Definition CD30- cutaneous large cell lymphoma is characterized by the occurrence of skin lesions consisting of CD30- large neoplastic T cells without prior or concurrent mycosis fungoides. Although the histologic appearance may be identical to that of classical mycosis fungoides undergoing transformation into large cell lymphoma, the absence of prior or concurrent patches or plaques represents the decisive criterion.
Clinical manifestations Patients present with solitary, localized or generalized plaques, nodules, or tumors of a reddish to brownish color (Fig. 158-3). Generalization of the lesions is more common than in CD30+ cutaneous large T cell lymphoma, and sometimes occurs at the onset of the disease.

FIGURE 158-3 CD30- cutaneous large cell lymphoma. Localized tumors of a reddish to brownish color on the face of a male patient.

Pathology Variable numbers of medium-sized to large pleomorphic T cells infiltrate the dermis and/or subcutis in a nodular or diffuse pattern. In rare cases, the neoplastic cells may show an immunoblastic morphology. By definition, large cells represent at least 30 percent of the total infiltrate. Epidermotropism, as well as angiocentricity, may occur in some cases. Immunophenotyping reveals CD30 expression to be negative or restricted to a few scattered cells. Neoplastic

cells show an aberrant CD4+ phenotype with variable loss of pan-T cell antigens.
Diagnosis and differential diagnosis Absence of prior or concurrent patches or plaques excludes transformed mycosis fungoides.
Treatment and prognosis Multiagent chemotherapy is the treatment of choice. Radiotherapy may be considered as initial treatment only in patients with solitary or localized disease. CD30- cutaneous large cell lymphomas show an aggressive clinical behavior with a disease-related 5-year survival of 15 percent.

Provisional Entities of Primary Cutaneous T Cell Lymphomas

In addition to the above-mentioned diseases, a number of provisional entities was included in the EORTC classification system. These primary cutaneous T cell lymphomas display characteristic histologic features, but no distinct clinical presentation and/or outcome has been defined so far.

PLEOMORPHIC SMALL/MEDIUM-SIZED CUTANEOUS T CELL LYMPHOMA
Definition A neoplastic proliferation of pleomorphic small- or medium-sized T cells in the skin without any clinical signs of classical mycosis fungoides defines the pleomorphic small/medium-sized cutaneous T cell lymphoma.
Clinical manifestations Patients present with one or several red-purplish papules or nodules at any location. Because histologic differentiation from mycosis fungoides and from mycosis fungoides-associated follicular mucinosis can raise problems, the absence of patches and plaques in pleomorphic small/medium-sized cutaneous T cell lymphoma is the decisive criterion.
Pathology Histologically, a dense, diffuse or nodular infiltrate containing small- to medium-sized pleomorphic cells is observed within the dermis and sometimes the subcutis. Epidermotropism may be present. The neoplastic cells express a helper T cell phenotype with frequent loss of pan-T cell markers. In some cases that show a more aggressive clinical course, expression of CD8+ is observed.
Diagnosis and differential diagnosis Demonstration of an aberrant phenotype and of T cell clonality, as well as predominance of pleomorphic T cells in the infiltrate, serve as useful criteria for the exclusion of pseudolymphomas, which often show an identical histologic pattern. Mycosis fungoides is excluded by the absence of a dominant cerebriform tumor cell population.
Therapy and prognosis In the case of solitary or localized lesions, radiotherapy is the preferred mode of action. PUVA treatment, possibly in combination with interferon-a, is useful in cases with disseminated lesions. A 5-year survival rate between 60 and 90 percent is reported for this type of lymphoma. [18], [19]
GRANULOMATOUS SLACK SKIN (See Chap. 157)
Definition Granulomatous slack skin represents a rare primary cutaneous T cell lymphoma characterized by the slow development of folded lax skin and granulomatous infiltrates with clonal T cells. Currently, only limited data concerning the clinical behavior of granulomatous slack skin are available, but in our opinion, this entity is better categorized as a variant of mycosis fungoides.
Clinical manifestations Patients develop large poikilodermatous and infiltrated areas, predominantly involving the axillary region and the groins. The lesions subsequently become atrophic and develop skin folds, caused by an elastolysis within the entire dermis (Fig. 158-4). Males are predominantly affected, and in about 30 percent of the cases, an association with Hodgkin's disease is observed. [20]

FIGURE 158-4 Granulomatous slack skin. Note skin folds due to secondary elastolysis.

Histopathology Light microscopy reveals a dense granulomatous infiltrate in the dermis. Apart from small atypical cells with cerebriform nuclei, macrophages, as well as numerous multinucleated giant T cells, occur [21] and palisade around necrobiotic areas where, destruction of the elastic tissue is observed. The neoplastic cells express a CD3+ CD4+ CD8- phenotype.
Therapy and prognosis Radiotherapy may be effective, but experience is still limited. Rapid recurrences after surgical excision have been reported. [22] Most patients have an indolent clinical course similar to that of mycosis fungoides, but the association with Hodgkin's disease has to be considered.
CYTOTOXIC LYMPHOMAS OF THE SKIN
Definition Cytotoxic lymphomas of the skin are peripheral natural killer (NK)/T cell lymphomas, which express cytotoxic proteins, that is, T cell–induced antigen (TIA), granzyme A/B, and perforin and are frequently associated with an aggressive clinical course. Although subcutaneous panniculitis-like T cell lymphoma, nasal-type NK/T cell lymphoma, CD8+ cutaneous T cell lymphoma, and nonhepatosplenic ?d-positive T cell lymphoma have been described, subentities still have to be defined. Because the EORTC classification includes subcutaneous panniculitis-like T cell lymphoma as primary cutaneous lymphoma, we describe the four entities mentioned in this context. Subcutaneous panniculitis-like T cell lymphoma is characterized by subcutaneous nodules and plaques, which usually involve legs and, less commonly, the trunk. [23] Patients often present B cell symptoms, that is, weight loss, fever, and fatigue, which are due to a frequently associated hemophagocytic syndrome. The histologic picture presents with subcutaneous infiltrates simulating a panniculitis. Infiltrates contain a mixture of neoplastic pleomorphic cells of various sizes and macrophages. Usually,

tumor cell necrosis, karyorrhexis, and erythrophagocytosis are found. By means of immunophenotyping, the neoplastic cells express CD3, CD43, CD45RO, TIA-1, perforin, granzyme B, and either T cell receptor aß (75 percent) or ?d (25 percent). Despite aggressive chemotherapy, the disease shows a rapidly progressive course and the prognosis is generally poor, although dissemination into extracutaneous sites rarely occurs. A small number of patients with aß expression may show an indolent clinical course with spontaneous regression. [24] Nasal-type NK/T cell lymphoma represents the prototype of cytotoxic lymphomas. It either affects the naso-oropharynx, which leads to destruction of the nasal region (former description: lethal midline granuloma), or manifests in skin, subcutis, lungs, viscera, and testes. Skin lesions enclose subcutaneous tumors, erythematous plaques, ulcers or an exanthema with macules and papules. The clinical course is often aggravated by a hemophagocytic syndrome with pancytopenia. [25] The histologic picture resembles that of subcutaneous panniculitis-like T cell lymphoma, but neoplastic cells strongly express CD56 and are characteristically positive for Epstein-Barr virus. Despite aggressive chemotherapy, the disease is often lethal within months. CD8+ cutaneous T cell lymphoma is clinically characterized by patches, plaques, papulonodules, and tumors mimicking disseminated pagetoid reticulosis and by a metastatic spread to unusual sites, that is, lung, testis, central nervous system, and oral cavity, but not to the lymph nodes. Histologically, bandlike infiltrates consisting of pleomorphic lymphocytes or immunoblasts are observed, displaying a diffuse infiltration of an acanthotic epidermis with variable degrees of spongiosis, intraepidermal blistering, and necrosis. The neoplastic cells express the Ki-67 antigen at a high frequency and are positive for CD3, CD8, CD7, CD45RA, and TIA, whereas CD2 and CD5 are frequently lost. Expression of TIA identifies these lymphomas derived from a cytotoxic T cell subset. [26] Despite multiagent chemotherapy, the disease shows an aggressive course with a median survival of 32 months. Nonhepatosplenic ?d-positive T cell lymphoma encompasses the peripheral T cell lymphomas with a T cell receptor ?d phenotype. The definition overlaps with subcutaneous panniculitis-like T cell lymphoma, nasal-type NK/T cell lymphoma and pagetoid reticulosis.
Staging Staging of cutaneous T cell lymphoma includes examination of the entire skin, chest x-ray, and ultrasonography of abdominal organs and peripheral lymph nodes (cervical, axillary, and inguinal). Blood investigations comprise complete blood cell count, lactate dehydrogenase level, sedimentation rate, and T cell clonality. A biopsy has to be taken from representative skin lesions and from enlarged lymph nodes. Staging may be completed by CT scan and/or histologic investigation of suspicious lymph nodes and/or visceral organs. Staging examination should be repeated at relapse and every 12 months (chest x-ray every 2 to 3 years). The aforementioned investigations allow for the assignment to the TNM system (Table 158-3). Although prognostic value and applicability of TNM staging in different cutaneous T cell lymphomas is controversial, the TNM scheme [27] directs the decision-making process toward an appropriate therapeutic regimen in most cutaneous T cell lymphomas.



TABLE 158-3 **TNM Staging of Cutaneous Lymphomas**

Treatment Multiple strategies have been proposed to treat the different types of cutaneous T cell lymphomas. These strategies include skin-targeted therapies such as photo(chemo)therapy (e.g., psoralen plus UVA [PUVA]), [28] combination of photochemotherapy and IFN-a [29] or retinoids, topical application of nitrogen mustard [30] or chlormustine (BCNU), [31] and radiochemotherapy including total skin electron-beam irradiation. [32] Surgical excision is preferred for solitary or localized skin lesions. Oral chemotherapy is effective in cases of lymphomatoid papulosis (methotrexate [33]), Sézary syndrome (methotrexate, [34], [35] chlorambucil, and prednisone [36]) or pleomorphic small/medium-sized cutaneous T cell lymphoma (cyclophosphamide). PUVA and extracorporeal photopheresis (ECP) are effective in Sézary syndrome and in extensive skin disease in mycosis fungoides. [37] In case of unequivocal lymph node or secondary visceral involvement, as well as in the case of CD30- cutaneous large cell lymphoma or widespread cutaneous involvement, multiagent chemotherapy is indicated. However, none of these regimens have shown a curative effect. Therefore, therapy of cutaneous T cell lymphoma should be adapted to the stage of the disease. [38]

PRIMARY CUTANEOUS B CELL LYMPHOMAS

Indolent Variants

FOLLICLE CENTER CELL LYMPHOMA

Definition Primary cutaneous follicle center lymphoma can be defined as a neoplasm of clonal centrocytes (small and large cleaved follicle center cells) and centroblasts (large follicle center cells with prominent nucleoli) with or without formation of follicular centers. [39], [40]
Clinical manifestations Patients present symptoms such as nonscaling, solitary or grouped papules, and thick plaques or tumors, and, occasionally, an annular erythema can be observed in the surrounding area (Fig. 158-5). A typical symptom is the occurrence of lesions in a circumscribed area of the head and neck region.

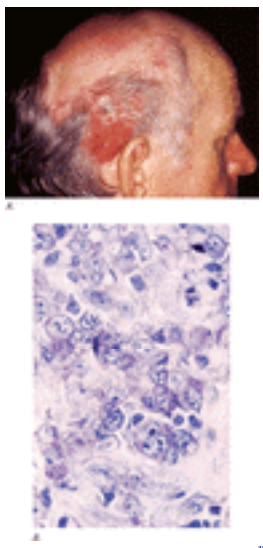

FIGURE 158-5 Cutaneous follicle center cell lymphoma. *A.* Tumor in the head area surrounded by erythema. *B.* The

cellular infiltrate consists of a mixture of centrocytes, a number of centroblasts, and reactive T cells.

Pathology The histologic picture is characterized by a nodular or diffuse infiltrate, composed of centrocytes, a small number of centroblasts, and large numbers of reactive T lymphocytes. The infiltrate spares the epidermis and remnants of reactive follicle centers can be observed in some cases. At the more advanced stage of lesions, the number of centroblasts increases and a monotonous infiltrate of large follicle center cells is evident. The typical phenotype of the neoplastic cells is CD19+ CD20+ CD22+ CD79A+. By molecular genetic analysis, clonal immunoglobulin rearrangements can be detected. However, unlike nodular follicular lymphomas, the t(14;18) translocation is not present and bcl-2 protein is expressed only in a minority of cases.
Therapy and prognosis Radiotherapy is the preferred mode of treatment. Chemotherapy should be considered only in rare cases with more generalized skin lesions. Single lesions can be excised. [41] Immune therapies such as IFN-a and interleukin-2 or monoclonal antibodies against CD20 may be beneficial in cases with disseminated lesions. With an estimated 5-year survival of 97 percent, the follicle center cell lymphoma is classified as an indolent entity of primary cutaneous B cell lymphomas. In untreated patients, the skin lesions increase in size over the years, but extracutaneous dissemination is uncommon.

IMMUNOCYTOMA/MARGINAL ZONE LYMPHOMA

Definition The cutaneous immunocytoma/marginal zone lymphoma is defined as a neoplastic proliferation of small lymphocytes, lymphoplasmacytoid cells and plasma cells, which are initially localized in the marginal zone of a follicular center. [42], [43] It is still controversial whether or not marginal zone lymphoma of the skin represents a defined entity or should be grouped together with immunocytoma of the skin. [44]
Clinical manifestations Patients present with solitary or multiple papules and nodules, which occur with preferential location on the trunk and extremities.
Pathology Diffuse or nodular infiltrates of small lymphocytes, lymphoplasmacytoid cells and plasma cells are observed in the dermis and typically spare the epidermis. The neoplastic cells express monotypic immunoglobulin and CD79, but are CD5-. A clonal rearrangement of the immunoglobulin genes can be detected in most cases. However, specific translocations have not yet been demonstrated.
Therapy and prognosis Radiotherapy is the treatment of choice. Immune therapies such as IFN-a and interleukin-2 or monoclonal antibodies against CD20 may be administered in cases with disseminated lesions. This entity is classified as an indolent form of cutaneous B cell lymphoma, with an estimated 5-year survival of close to 100 percent.

Primary Cutaneous B Cell Lymphomas with Intermediate Course

LARGE B CELL LYMPHOMA OF THE LEG

Definition This entity shows an intermediate clinical course and is defined by tumors composed of large T cells, which present exclusively on the legs (Fig. 158-6). [45]

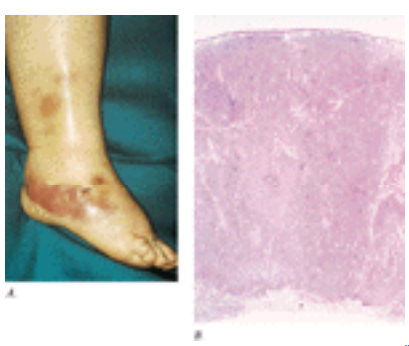

FIGURE 158-6 Large B-cell lymphoma of the leg. *A.* Nodules and tumors on the right leg 3 months after disease onset. The patient died 5 months later. *B.* The same patient. Diffuse infiltrate of large B cells with centroblasts, large centrocytes, and numerous immunoblasts.

Clinical manifestations The tumors show a red to bluish color and affect one or both lower legs of, preferentially, female patients over 70 years of age.
Pathology The histologic picture is characterized by diffuse infiltrates of large B cells in the dermis without any epidermotropism; small cells and admixed reactive cells only rarely occur. The immunophenotype of the tumor cells is CD19+, CD20+, CD22+, CD79A+. Strong expression of the BCL2 protein is found, and a clonal immunoglobulin rearrangement is detected in most cases.
Therapy and prognosis In cases of solitary or localized skin lesions, radiotherapy may be undertaken; in all other cases and when progression is observed, multiagent chemotherapy should be administered. The prognosis is less favorable with a 5-year survival of 46 to 58 percent.

Provisional Entities of Primary Cutaneous B Cell Lymphomas

In addition to the clearly defined primary cutaneous B cell lymphomas mentioned above, provisional entities have been included in the EORTC classification.

The intravascular cutaneous B cell lymphoma (CBCL) is defined by clusters of large neoplastic T cells within dermal and subcutaneous blood vessels. [46] Occasionally, slight extravascular infiltrates of atypical cells are observed. Clinically, red to bluish, indurated plaques can be observed on the legs or trunk; sometimes a panniculitis-like pattern can be seen. Multiagent chemotherapy is the preferred mode of treatment.

Cutaneous plasmacytoma is defined as a rare type of CBCL with a clonal proliferation of plasma cells, primarily developing in the skin. [47] Clinically, solitary or multiple red to bluish nodules occur without any predilection of the skin. The histologic picture is characterized by dermal infiltrates of major plasma cells, expressing monotypic immunoglobulin and CD38 but lacking expression of CD20 and LCA. Radiotherapy or surgical excision is recommended.

STAGING Staging of cutaneous B cell lymphoma includes examination of the entire integument, chest x-ray,

ultrasonography of abdominal organs and lymph nodes (cervical, axillary, and inguinal), and bone marrow biopsy. A complete blood cell count, lactate dehydrogenase level, sedimentation rate, serum and immune electrophoresis, *Borrelia* serology, and B cell clonality are ordered for most patients. In the case of pathologic findings, staging is completed by CT scan and/or histologic investigation of suspect lymph nodes and/or visceral organs. Staging examination should be repeated at relapse and every 12 months (chest x-ray every 2 to 3 years, bone marrow biopsy at relapse only).
TREATMENT SUMMARY Treatment of primary cutaneous B cell lymphomas should be adapted to the favorable prognosis of these entities, in particular the follicle center cell lymphoma and immunocytoma. Because no curative regimen has been defined so far, therapy depends on entity and the dissemination of the cutaneous lesions. [48] In the case of solitary lesions, complete excision of the tumor is the treatment of choice, and, in addition, local irradiation (single dosage: 3 to 4 Gy; total dosage: 20 to 40 Gy), by x-ray or electron beam can be considered. By using this regimen, long-lasting remissions can be observed. [49] As local treatment, intralesional application of cisplatin has also been found to induce long-lasting, complete remissions, in the case of solitary lesions. [50] In the case of indolent cutaneous B cell lymphomas with disseminated lesions, immunotherapeutic regimens, including the combined application of IFN-a and interleukin-2 [51] or the application of anti-CD20 antibodies, are evaluated for their efficacy. Systemic treatment regimens are recommended in the case of large B cell lymphomas of the leg, the occurrence of multiple lesions in other cutaneous B cell lymphomas, as well as in the presence of secondary extracutaneous manifestations. Polychemotherapy (6 cycles of CHOP [cyclophosphamide, hydroxydaunomycin, Oncovin (vincristine), and prednisone], COP [cyclophosphamide, Oncovin (vincristine), and prednisone] or MACOP [methotrexate-leucovorin, Adriamycin, cyclophosphamide, Oncovin (vincristine), prednisone]) is administered. [52] After complete remission, maintenance therapy with IFN-a may be applied for a period of 1 year. Alternatively, administration of a COP polychemotherapy with longer cycle intervals of 4 to 12 weeks is possible. For stage IV disease, combined myeloablative chemotherapy and irradiation with subsequent autologous bone marrow transplantation can be taken into consideration, although only a small number of cases have been treated by this regimen so far.

SECONDARY SKIN INVOLVEMENT IN LYMPHOID NEOPLASIAS

Secondary skin involvement in lymphoid neoplasias is rarely observed and defines advanced stages with a poor prognosis. In such cases, skin lesions are caused by specific infiltrations of neoplastic cells or by nonspecific inflammatory processes.

Specific infiltrates appear as nodules, tumors, plaques, or diffuse infiltrations. Diffuse nonepidermotropic infiltrates predominated by the neoplastic cell type characterize the pathologic picture. Definition of the lymphoma subtype depends upon immunophenotyping of the neoplastic cells.

Nonspecific skin lesions are more frequently observed and develop in about 30 percent of all patients. Signs include pruritus, purpura, mouth ulcers, and erythroderma. In addition, Sweet's syndrome (see Chap. 94 and Chap. 184), pyoderma gangrenosum, and drug reactions have been described.

Table 158-4 summarizes lymphoid neoplasias, in which secondary skin involvement has been described.



TABLE 158-4 **Lymphoid Neoplasias with Secondary Skin Involvement**

REFERENCES

1. Harris NL et al: The World Health Organization classification of neoplastic diseases of the hematopoietic and lymphoid tissues. *Ann Oncol* **10**:1419, 1999

2. Willemze R et al: EORTC classification for primary cutaneous lymphomas: A proposal from the cutaneous lymphoma study group of the European Organization for Research and Treatment of Cancer. *Blood* **90**:354 1997

3. Grange F et al: Prognostic factors in primary cutaneous lymphomas other than mycosis fungoides and the Sézary syndrome. The French Study Group on Cutaneous Lymphomas. *Blood* **93**:3637, 1999

4. Isaacson PG, Norton AJ: Cutaneous lymphoma, in *Extranodal Lymphoma*. London, Churchill Livingstone, 1994, p 172

5. Weinstock MA, Horn JW: Mycosis fungoides in the United States: Increasing incidence and descriptive epidemiology. *JAMA* **260**:42, 1988

6. Beljaards RC et al: Primary cutaneous CD30-positive large cell lymphoma: Definition of a new type of cutaneous lymphoma with a favorable prognosis. A European multicenter study on 47 cases. *Cancer* **71**:2097, 1993

7. Schein PS et al: Cutaneous T cell lymphoma. *Cancer* **38**:1859, 1976

8. Sterry W, Merk H. *Checkliste Dermatologie und Venerologie*. New York, Thieme, 1992, p 449

9. Mielke V, Wolff HH, Winzer M et al: Localized and disseminated pagetoid reticuloses. *Arch Dermatol* **125**:402, 1989

10. Burg G, Braun-Falco O: *Cutaneous lymphomas, pseudolymphomas and related disorders*. Berlin, Springer-Verlag, 1983

11. Woringer F, Kolopp P: Lésion érythémato-squameuse polycyclique de l'avant-bras évoluant depuis 6 ans chez un garconnet de 13 ans.

Histologiquement infiltrat intra-épidermique d'apparance tumorale. *Ann Dermatol Syphil* **10**:945, 1939/40

12. Ketron LW, Goodman MH: Multiple lesions of the skin apparently of epithelial origin resembling clinically mycosis fungoides. *Arch Dermatol* **24**:758, 1931

13. Deneau DG, Wood GS, Beckstead J: Woringer-Kolopp disease (pagetoid reticulosis). Four cases with histopathologic, ultrastructural, and immunohistologic observations. *Arch Dermatol* **120**:1045, 1984

14. Burns MK, Chan LS, Cooper KD: Woringer-Kolopp disease (localized pagetoid reticulosis) or unilesional mycosis fungoides? *Arch Dermatol* **131**:325, 1995

15. Drillenburg P, Bronkhorst CM, van der Wal AC: Expression of adhesion molecules in pagetoid reticulosis (Woringer-Kolopp disease). *Br J Dermatol* **136**:613, 1997

16. Willemze R, Beljaards RC: Spectrum of primary cutaneous CD30 (Ki-1)-positive lymphoproliferative disorders. *J Am Acad Dermatol* **28**:973, 1993

17. Duvic M et al: Combined modality therapy for cutaneous T-cell lymphoma. *J Am Acad Dermatol* **34**:1022, 1996

18. Sterry W, Siebel A, Mielke V: HTLV1-negative pleomorphic T cell lymphoma of the skin. The clinicopathologic correlations and natural history of 15 patients. *Br J Dermatol* **126**:456, 1992

19. Friedmann D et al: Primary cutaneous pleomorphic small T cell lymphoma. *Arch Dermatol* **131**:1009, 1995

20. LeBoit PE et al: Granulomatous slack skin: clonal rearrangement of the T cell receptor ß gene is evidence for the lymphoproliferative nature of a cutaneous elastolytic disorder. *J Invest Dermatol* **89**:183, 1987

21. LeBoit PE et al: Granulomatous variants of cutaneous T cell lymphoma. *Am J Surg Pathol* **12**:83, 1987

22. LeBoit PE: Granulomatous slack skin. *Dermatol Clin* **12**:375, 1994

23. Gonzalez CL et al: T cell lymphoma involving the subcutaneous tissue. *Am J Surg Pathol* **15**:17, 1991

24. Pernicario C et al: Subcutaneous T cell lymphoma: report of two additional cases and further observations. *Arch Dermatol* **129**:1171, 1993

25. Jaffe ES: Nasal and nasal-type T/NK cell lymphomas: A unique form of lymphoma associated with the Epstein Barr virus. *Histopathology* **27**:581, 1995

26. Berti E et al: Primary cutaneous CD8-positive epidermotropic cytotoxic T cell lymphomas. A distinct clinicopathological entity with an aggressive clinical behavior. *Am J Pathol* **155**:483, 1999

27. Proceedings of the International Consensus Conference on CTCL Treatment Recommendations, Boston, 1994. *J Am Acad Dermatol* **36**:460, 1997

28. Herrmann JJ, Roenigk HH, Hurria A et al: Treatment of mycosis fungoides with photochemotherapy (PUVA): Long-term follow up. *J Am Acad Dermatol* **33**:234, 1995

29. Ross C, Tingsgaard P, Joergensen H et al: Interferon treatment of cutaneous T cell lymphoma. *Eur J Haematol* **51**:63, 1993

30. Vonderheid EC, Tan E, Kantor AF et al: Long-term efficacy, curative potential and carcinogenicity of topical mechlorethamine chemotherapy in cutaneous T cell lymphoma. *J Am Acad Dermatol* **20**:416, 1989

31. Zackheim HS et al: Topical carmustine (BCNU) for cutaneous T cell lymphoma: A 15-year experience in 143 patients. *J Am Acad Dermatol* **22**:802, 1990

32. Hoppe RT, Cox TS, Fuks Z et al: Electron-beam therapy for mycosis fungoides: The Stanford experience. *Cancer Treat Rep* **63**:691, 1979

33. Vonderheid EC et al: Methotrexate is effective therapy for lymphomatoid papulosis and other primary cutaneous CD30-positive lymphoproliferative disorders. *J Am Acad Dermatol* **34**:470, 1996

34. Zackheim HS et al: Low-dose methotrexate to treat erythrodermic cutaneous T cell lymphoma: Results in twenty-nine patients . *J Am Acad Dermatol* **34**:626, 1996

35. Zackheim HS, Epstein EH Jr: Low-dose methotrexate for the Sézary syndrome. *J Am Acad Dermatol* **21**:757, 1989

36. Winkelmann RK et al: The treatment of Sézary syndrome. *J Am Acad Dermatol* **10**:1000, 1989

37. Heald P et al: Treatment of erythrodermic cutaneous T cell lymphoma with extracorporeal photochemotherapy. *J Am Acad Dermatol* **27**:427, 1996

38. Muche JM et al: Treatment of cutaneous T cell lymphomas. *Semin Cutan Med Surg* **19**:142, 2000

39. Willemze R et al: Primary cutaneous large cell lymphomas of follicular center cell origin. *J Am Acad Dermatol* **16**:518, 1987

40. Kerl H, Cerroni L: The morphologic spectrum of cutaneous B cell lymphomas. *Arch Dermatol* **132**:1376, 1996

41. Rijaarsdam JU et al: Treatment of primary cutaneous B cell lymphoma of follicle center cell origin: A clinic follow-up study of 55 patients treated with radiotherapy or polychemotherapy. *J Clin Oncol* **14**:549, 1996

42. Cerroni L et al: Primary cutaneous marginal B cell lymphoma: A recently described entity of low-grade malignant cutaneous B cell lymphoma. *Am J Surg Pathol* **21**:307, 1997

43. Rijaarsdam JU et al: Cutaneous immunocytomas: A clinicopathologic study of 26 cases. *Histopathology* **23**:117, 1993

44. Willemze R et al: Are most primary cutaneous B cell lymphomas marginal cell lymphomas? *Br J Dermatol* **133**:950, 1995

45. Vermeer MH et al: Primary cutaneous large B cell lymphomas of the legs. A distinct type of cutaneous B cell lymphoma with an

intermediate prognosis. *Arch Dermatol* **132**:1304, 1996

46. Wick MR et al: Reassessment of malignant “angioendotheliomatosis.” Evidence in favor of its reclassification as “intravascular lymphomatosis.” *Am J Surg Pathol* **10**:112, 1986

47. Torne F, Su WPD, Winkelmann FK et al: Clinicopathologic study of cutaneous plasmacytoma. *Int J Dermatol* **29**:562, 1990

48. Watsy KL et al: Primary cutaneous B cell lymphoma. Diagnosis, treatment and prognosis. *J Dermatol Surg Oncol* **18**:951, 1992

49. Piccinno R et al: Radiotherapy of cutaneous B cell lymphomas. Our experience in 31 cases. *Int J Radiat Oncol Biol Phys* **27**:385, 1993

50. Kemp W et al: Intralesional cisplatin for the treatment of cutaneous B cell lymphoma. *Arch Dermatol* **134**:1343, 1998

51. Zenone G et al: Complete remission of a primary cutaneous B cell lymphoma treated with intralesional recombinant interferon-alpha 2a. *Eur J Cancer* **30A**:246, 1994

52. Nagatani T et al: A case of cutaneous B cell lymphoma treated successfully with MACOP-8. *J Dermatol* **20**:40, 1993

T>

Chapter 159

Gary Wood

Inflammatory Diseases That Simulate Lymphomas: Cutaneous Pseudolymphomas

THE ASSOCIATION BETWEEN PSEUDOLYMPHOMAS AND LYMPHOMAS
EVALUATION OF PATIENTS WITH PSEUDOLYMPHOMA
CUTANEOUS LYMPHOID HYPERPLASIA
KIMURA'S DISEASE
CASTLEMAN'S DISEASE
PSEUDO-MYCOSIS FUNGOIDES
FOLLICULAR MUCINOSIS
LYMPHOMATOID CONTACT DERMATITIS
ACTINIC RETICULOID
LYMPHOMATOID PAPULOSIS
ANGIOIMMUNOBLASTIC LYMPHADENOPATHY WITH DYSPROTEINEMIA
LYMPHOMATOID GRANULOMATOSIS
LYMPHOCYTIC INFILTRATION OF THE SKIN

REFERENCES

Cutaneous pseudolymphoma is a term used to describe skin lesions that bear a clinical and/or histopathologic resemblance to lymphoma. Over the years, a wide variety of designations have been included in this category. Some of these represent outdated synonyms, some refer to variants of the same entity, and some are misnomers for diseases now recognized to be true lymphomas. The pseudolymphomas that are discussed in this chapter can be organized into several distinct entities based on their lymphoid subset composition, pattern of cutaneous infiltration, and associated clinical findings (see Table 159-1).

TABLE 159-1 **Classification of Cutaneous Pseudolymphomas**

THE ASSOCIATION BETWEEN PSEUDOLYMPHOMAS AND LYMPHOMAS

One of the most challenging issues concerning cutaneous pseudolymphomas has been the nature of their relationship to true lymphomas. Many patients with cutaneous B cell lymphoma (CBCL) present with a history of prior biopsies diagnosed as cutaneous lymphoid hyperplasia (CLH) or *atypical CLH*. Patients with disorders such as lymphomatoid papulosis, lymphomatoid granulomatosis, and angioimmunoblastic lymphadenopathy with dysproteinemia (AILD) have an increased risk of developing various forms of overt lymphoma. [1], [2], [3] and [4] The advent of molecular biologic methods for determining B cell or T cell clonality by analyzing immunoglobulin or T cell receptor gene rearrangements, respectively, has provided important insights into the relationship between pseudolymphomas and lymphomas. [2], [3] and [4] It appears that many forms of cutaneous pseudolymphoma represent the benign end of a lymphoproliferative continuum eventuating in true lymphoma at its malignant extreme (see Table 159-2). In between lies a spectrum of intermediate disorders that are often difficult to classify unless one is cognizant of this spectral paradigm. In some cases, such as the CLH-CBCL spectrum, lesions range from polyclonal CLH at the benign extreme, through an intermediate form known as clonal CLH, to overt CBCL at the malignant extreme. In other instances, such as the lymphomatoid papulosis–CD30+ lymphoma spectrum, dominant clonality is already present in most cases at the clinically benign end of the spectrum. The most compelling evidence for the validity of this spectral concept is that case studies verify that the same dominant lymphoid clone is involved in the clonal pseudolymphomatous precursor and the subsequent overt lymphoma when they arise in the same individual. This relationship between overt neoplasia and clonal precursor lesions is not unique to cutaneous pseudolymphomas. It is also seen in the connection between other forms of extranodal lymphoid hyperplasia and overt lymphoma, and in the relationship between monoclonal gammopathy of uncertain significance (formerly termed *benign monoclonal gammopathy*) and subsequent B cell malignancies.



TABLE 159-2 **Pseudolymphoma—Lymphoma Disease Spectra**

The spectral paradigm for cutaneous pseudolymphomas and associated lymphomas has several important implications for their diagnosis, management, and pathogenesis. First, because some cases will exhibit lesions at an intermediate point along their lymphoproliferative continuum, they may be difficult to classify neatly into a specific disease entity. It is probably more important to recognize that they belong to a particular disease spectrum because it is the spectrum that is often the most relevant factor for determining optimal therapy, as well as the magnitude and nature of the subsequent lymphoma risk. Second, because many patients with cutaneous pseudolymphomas are at increased risk for a clonally

related lymphoma, they should maintain regular clinical follow-up, and all reasonable attempts should be made to eradicate or suppress their disease. Third, patients with pseudolymphomas probably have underlying abnormalities in the regulation of lymphoid proliferation and/or clearance (e.g., via apoptosis). Clonal evolution and concomitant clinical disease progression are likely to occur through a sequence of somatic mutations that act through these mechanisms to confer progressively increasing autonomy to the dominant lymphoid clone. Elucidating these pathogenetic mechanisms will be important not only for developing novel therapies for cutaneous pseudolymphomas, but also for improving the treatment of analogous lymphoproliferative disorders occurring in other organ systems.

EVALUATION OF PATIENTS WITH PSEUDOLYMPHOMA

Although the details of the workup of individual patients will vary with the specific type of pseudolymphoma being considered, certain data are generally important for establishing the correct diagnosis, identifying potential causative factors, and ruling out an underlying lymphoma. The clinical history should include duration and symptomatology of lesions; nature and pace of clinical progression; past treatment; local or systemic exposure to foreign antigens, including medications; personal or family history of other lymphoproliferative disorders; and a review of systems focusing on so-called lymphoma B symptoms, such as fever of unknown origin, unexplained weight loss, night sweats, fatigue, and malaise. A general physical examination is important, with special attention to the type and distribution of skin lesions and to the status of peripheral lymph nodes, liver, and spleen. A complete blood count with differential review, general chemistry panel, and a chest radiograph are screening tests that help to exclude extracutaneous involvement. Lesional skin biopsy is an essential part of the diagnostic evaluation. Topical and systemic glucocorticoids should be discontinued if possible about 4 weeks prior to biopsy because these agents can attenuate lymphoid infiltrates and thereby confound their interpretation. Skin specimens should be large enough and deep enough to ensure representative sampling and to provide adequate tissue for routine histopathology, immunohistology, and molecular biologic studies. As with squamoproliferative skin lesions, the most diagnostic areas within cutaneous lymphoid infiltrates are often their deepest portions (Fig. 159-1 and Fig. 159-2). To be cost-effective, it is often possible to perform these biopsy studies in a sequential fashion, proceeding to the next test only if a firm diagnosis cannot be made based on the results of preceding analyses. However, rigorous characterization of a pseudolymphomatous infiltrate requires the full complement of these assays. If there is only a solitary lesion, it is generally best to obtain all biopsy material simultaneously because inflammatory changes induced by the initial biopsy may interfere with the interpretation of subsequent specimens from the same locale.

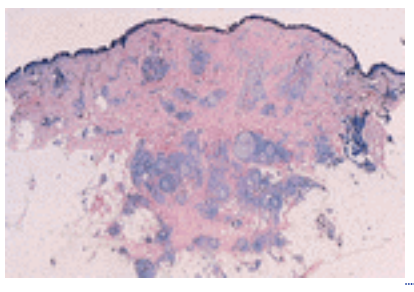

FIGURE 159-1 Cutaneous lymphoid hyperplasia. Infiltrate is wedge-shaped and tapers out in its deeper portions. Note reactive lymphoid follicles containing pale germinal centers (see Fig. 159-8).

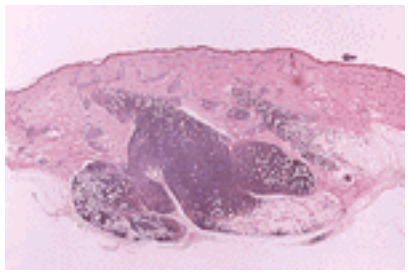

FIGURE 159-2 Cutaneous lymphoma. Infiltrate is dense and does not taper out in its deeper portions.

In the event that there is still uncertainty as to whether the lymphoid infiltrate represents a pseudolymphoma or a lymphoma, additional workup can be helpful. This includes computed tomographic (CT) scans of the chest, abdomen, and pelvis, as well as bone marrow aspiration and biopsy. Abnormally enlarged lymph nodes identified by physical examination or radiography can be biopsied and evaluated as described above for skin lesions. The author has seen patients with atypical cutaneous B cell infiltrates, presenting as only one or a few skin lesions, whose workup was otherwise unremarkable until radiographic scans of deep lymph nodes or bone marrow sampling demonstrated that they actually had advanced stage B cell lymphoma with minor skin involvement.

CUTANEOUS LYMPHOID HYPERPLASIA

CLH is characterized by a relatively dense lymphoid infiltrate, centered in the reticular dermis, that is usually B cell rich and may resemble lymphoma clinically and/or histopathologically. Many terms refer to this type of pseudolymphoma, including *Spiegler-Fendt sarcoid, lymphocytoma cutis, lymphadenosis benigna cutis,* and *cutaneous lymphoplasia*. CLH is the preferred term because it accurately describes the underlying pathophysiology of the lesion and is unlikely to be confused with terms used to describe various forms of cutaneous lymphoma. [2], [4], [5], [6] and [7]

CLH presents most commonly as a solitary nodule but it can also appear as a localized array of nodules, plaques, or papules. Generalized forms occur rarely. Adults and children may be affected, females more commonly than males. The head, neck, extremities, breasts, and genitalia are common sites (Fig. 159-3, Fig. 159-4, Fig. 159-5, and Fig. 159-6). Lesions have a doughy to firm consistency and range from red-brown to violaceous in color. Lesions secondary to

arthropod bites can be pruritic, ulcerated, or crusted. Occasionally, reactive lymphadenopathy may be present in the area of regional lymphatic drainage. The clinical differential diagnosis includes granuloma faciale, angiolymphoid hyperplasia with eosinophilia (ALHE, see below), nodular secondary syphilis, lymphoma, leukemia, Merkel cell tumor, and metastatic carcinoma. The *hydantoin-associated pseudolymphoma syndrome* is caused by anticonvulsant drugs such as phenytoin. This syndrome involves fever, lymphadenopathy, hepatosplenomegaly, arthralgia, eosinophilia, and generalized cutaneous macules and papules or, rarely, nodules. [4], [5] Nodules may contain aggregates of large lymphoid cells worrisome for lymphoma; however, both B and T cells are polyclonal. Subcutaneous lymph nodes may exhibit reactive follicular hyperplasia or atypical features suggestive of lymphoma. The macular and papular lesions of this syndrome share histopathologic features with hypersensitivity reactions to other drugs. *Acral pseudolymphomatous angiokeratoma of children (APACHE)* presents as a unilateral eruption of angiomatous papules on the extremities. [8] There is a dense lymphoid infiltrate associated with histiocytes, plasma cells, and prominent, thickened capillaries. This disorder is probably a variant of CLH secondary to arthropod bites. *Large cell lymphocytoma,* originally reported as a cutaneous pseudolymphoma, most likely represents a mixed cell or large cell form of primary CBCL. [2]

FIGURE 159-3 Cutaneous lymphoid hyperplasia. Solitary infiltrated nodule with a smooth surface in a classic location. (Lymphocytoma cutis in Lyme borreliosis.)

FIGURE 159-4 Cutaneous lymphoid hyperplasia. Involvement of the breast in a patient with elevated titers of antibodies against *Borrelia burgdorferi* spirochetes.

FIGURE 159-5 Cutaneous lymphoid hyperplasia. Multiple lesions of nodular scabies involving the genitalia.

FIGURE 159-6 Cutaneous lymphoid hyperplasia. Lymphomatoid drug reaction manifest as a generalized papulonodular eruption in a patient who was taking various neuroleptics.

In most cases, CLH is idiopathic; however, some lesions are associated with exposure to foreign antigens from arthropods (bites, stings, infestations), infections (herpes zoster, *Borrelia burgdorferi*), tattoos, acupuncture, trauma, gold jewelry, vaccinations, hyposensitization injections, or medications (Fig. 159-4, Fig. 159-5, and Fig. 159-6). [2], [4], [5], [6] and [7] Medications include phenytoin, carbamazepine, phenobarbital, beta blockers, calcium channel blockers, angiotensin-converting enzyme inhibitors, allopurinol, D-penicillamine, penicillin, mexiletine chloride, cyclosporine, and agents that inhibit binding of histamine to H_1, H_2, or H_{1c} receptors. These drugs include conventional H_1 and H_2 antagonists, as well as tricyclic and nontricyclic antidepressants and phenothiazines. Rather than being the target of an immune response themselves, it has been proposed that these latter agents may alter lymphocyte reactivity in a way that promotes a CLH response to other antigens in occasional individuals. [9]

Histopathologic examination of CLH lesions reveals a dense, nodular or diffuse lymphoid infiltrate that is concentrated in the reticular dermis (Fig. 159-1). It tends to be top-heavy and to taper out in the lower dermis, although more widespread dermal infiltration with extension into the subcutis can sometimes be seen. In most cases, the epidermis is normal and separated from the underlying infiltrate by a narrow Grenz zone of uninvolved papillary dermis. Occasionally, the

epidermis may exhibit variable degrees of hyperkeratosis, parakeratosis, acanthosis, dyskeratosis, spongiosis, and basal vacuolar degeneration. Arthropod reactions may show prominent epidermal hyperplasia or ulceration. Rarely, retained mouth parts may be seen associated with foreign-body granulomatous reactions. The dermal infiltrate is composed primarily of small mature lymphocytes, with a minor component of large lymphoid cells containing large, pale vesicular nuclei with small nucleoli (Fig. 159-7). Fewer than half of cases exhibit well-defined reactive lymphoid follicles discernible in routinely stained sections (Fig. 159-2 and Fig. 159-8). These B cell follicles may be either primary or secondary. The former are composed of homogeneous small lymphocytes, whereas the latter are compartmentalized into a peripheral mantle zone of small lymphocytes surrounding a germinal center composed of a heterogeneous mixture of small and large lymphoid cells, with cleaved and noncleaved nuclei, known as centrocytes and centroblasts. Also present in germinal centers are tingible-body macrophages, so named because they contain phagocytized debris from apoptotic lymphoid cells. Mitotic figures may be numerous within germinal centers but are usually uncommon elsewhere in the infiltrate. Various types of histiocytes, including macrophages, dermal dendritic cells, and Langerhans cells, are scattered throughout the infiltrate in variable proportions. Capillary hyperplasia and endothelial swelling are often present. Other cells are sometimes admixed, including plasma cells, eosinophils, mast cells, neutrophils, and histiocytic giant cells. The first two are particularly common in arthropod reactions such as nodular scabies (Fig. 159-9).

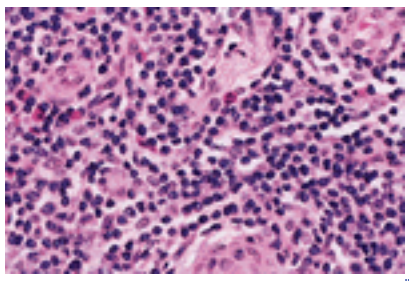

FIGURE 159-7 Cutaneous lymphoid hyperplasia. Infiltrate consists predominantly of small lymphocytes with an admixture of large lymphoid cells, histiocytes, and eosinophils.

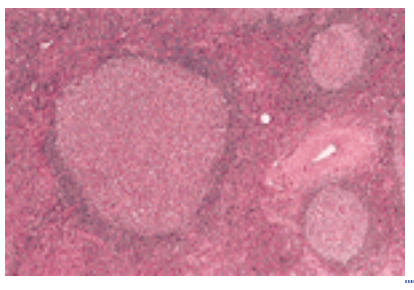

FIGURE 159-8 Cutaneous lymphoid hyperplasia. Lymphoid follicles in the dermis contain pale germinal centers surrounded by darker mantle zones.

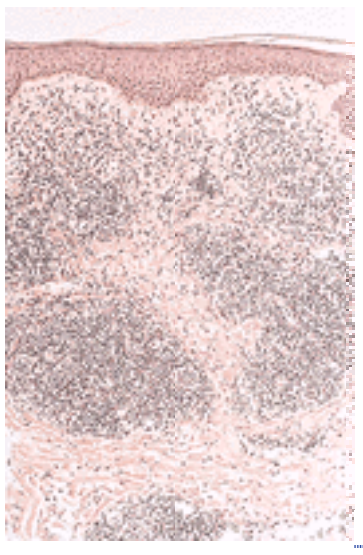

FIGURE 159-9 Cutaneous lymphoid hyperplasia. Nodular scabies. Patchy dense infiltrate composed of small lymphocytes, histiocytes, eosinophils, and plasma cells.

CLH is just one special case of extranodal lymphoid hyperplasia that may occur in a variety of organ systems. In their most well developed form, these extranodal reactions recreate the immunoarchitectural features of reactive follicular lymphoid hyperplasia occurring in lymphoid tissues. CLH is generally a B cell–predominant or mixed B cell/T cell disorder. B cells may be organized into primary or secondary lymphoid follicles, simple clusters devoid of the follicular dendritic cell network seen in B cell follicles, or may be randomly scattered throughout the infiltrate (Fig. 159-10). [7] A defining immunophenotypic feature of CLH is that the small, nongerminal center B cells and plasma cells are polytypic, that is instead of restriction to only one type of immunoglobulin light chain, there is a mixture of ?-positive and ?-positive cells. The follicular dendritic cell networks in lymphoid follicles coexpress both immunoglobulin light chains because of the polytypic nature of the immunoglobulins bound to these networks (Fig. 159-11). The larger germinal center B cells are also polytypic but generally have very low levels of immunoglobulin expression, which is obscured by the more intense staining of the follicular dendritic cell networks in which they are enmeshed. Consistent with their role as a site of antigen selection and apoptosis, reactive germinal centers are negative for the bcl-2 oncoprotein. [2]

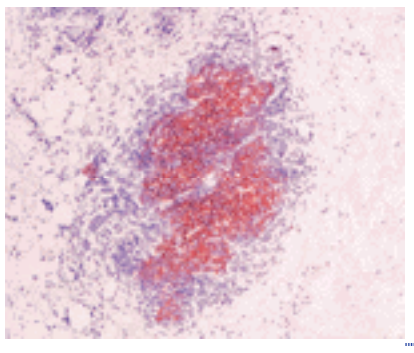

FIGURE 159-10 Cutaneous lymphoid hyperplasia. Reactive lymphoid follicle contains B cells (blue) enmeshed in a network of follicular dendritic cells (red). Frozen section immunoperoxidase-stained using the anti-DRC (dendritic reticulum cell) monoclonal antibody.

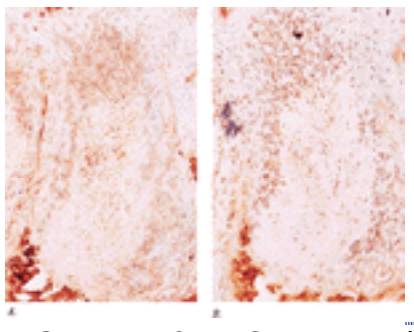

FIGURE 159-11 Cutaneous lymphoid hyperplasia. Reactive lymphoid follicle contains a germinal center surrounded by a mantle zone composed of a mixture of B cells that express either (*A*) ?-immunoglobulin light chain or (*B*) ?-immunoglobulin light chain. Note that the central follicular dendritic cell network stains positive for both light chains because polytypic immunoglobulins are bound to its surface.

Some observers classify CLH into follicular and diffuse variants based on the identification of lymphoid follicles in routinely stained sections. This distinction is probably not relevant biologically because most of the apparently diffuse cases also exhibit B cell follicles when examined immunohistologically. T cells are also present in all cases of CLH. They are found in small numbers within lymphoid follicles but are concentrated mainly between follicles, constituting an interfollicular T cell domain. This imparts an overall compartmentalization of B and T cells in CLH lesions. The CD4+ T cell subset predominates over the CD8+ subset. There is a normal pattern of T cell–antigen expression except that CD7 may be moderately deficient sometimes, being expressed by only 20 to 40 percent of T cells. Germinal center B cells, mantle zone B cells, interfollicular B cells, and plasma cells also express the same complement of cell surface differentiation antigens expressed by their counterparts in reactive lymphoid tissues.

In contrast to most nodal follicular B cell lymphomas (see Chap. 158), the t(14;18) translocation, which results in inappropriate expression of the bcl-2 oncoprotein, is absent in CLH. [2], [3], [10] Molecular biologic studies show that 5 to 33 percent of CLH cases defined by clinicopathologic and immunohistologic criteria contain occult dominant immunoglobulin gene rearrangements, indicating the presence of a dominant B cell clone. [2], [11], [12], [13], [14] and [15] These cases, known as clonal CLH, have progressed in some cases to overt B cell lymphoma exhibiting the same dominant B cell clone. These findings support the view that CLH, clonal CLH, and primary cutaneous B cell lymphoma exist as points along a continuum of cutaneous B cell lymphoproliferative disorders (Table 159-2). Progression across this spectrum of diseases clearly occurs in some cases, most likely as the result of serial mutations within the dominant B cell clone. This implies that patients with persistent CLH require regular monitoring for the development of lymphoma. Clonal T cell receptor gene rearrangements have also been detected in up to one-third of CLH cases. [15] This may represent an expanded reactive T cell clone within the CLH infiltrate. Evidence for this has been observed in HIV-related CLH. [16] Other less likely possibilities include an abortive T cell lymphoma or an evolving B cell lymphoma bearing T cell receptor gene rearrangements.

A principal challenge in the differential diagnosis of CLH is its distinction from CBCL of either diffuse or follicular types (see Chap. 158). [2], [3], [4] and [5], [17] The most common variant of CBCL is the diffuse large cell lymphoma, which is readily distinguished from follicular CLH on the basis of its diffuse architecture and monomorphous large cell composition. Differentiating follicular CLH from follicular CBCL can be difficult (Fig. 159-12). Follicular CBCL tends to be more bottom heavy with adnexal infiltration and lymphoid follicles lacking the cellular heterogeneity, zonation, and macrophages typical of reactive follicles. Immunophenotyping shows the neoplastic B cell follicles are either monotypic or immunoglobulin-negative. Cases involving cutaneous lymphoid infiltrates that are hard to classify, or that contain a dominant lymphoid clone, often benefit from a staging workup as described above. In those instances representing lymphoma, workup will sometimes reveal extracutaneous involvement, biopsies of which may be easier to diagnose as lymphoma. Staging also provides useful prognostic data and is essential for appropriate management of patients with overt lymphoma.

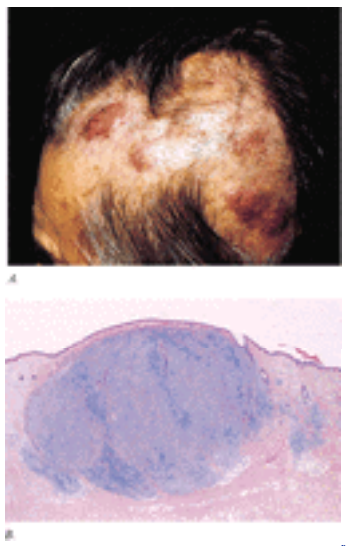

FIGURE 159-12 Cutaneous follicular B cell lymphoma. *A.* Red-brown nodules on the scalp. *B.* Dense expansile lymphoid infiltrate containing poorly circumscribed neoplastic lymphoid follicles with confluence.

CLH must also be distinguished from lymphocytic infiltrates such as chronic lymphocytic leukemia, deep figurate erythemas, polymorphous light eruption, discoid lupus erythematosus, and Jessner's lymphocytic infiltration of the skin (LIS). All of these disorders tend to produce perivascular, and sometimes periadnexal, infiltrates whose density is far less than that of the nodular or diffuse infiltrates typical of CLH. With the exception of chronic lymphocytic leukemia, these are all T cell disorders. Chronic lymphocytic leukemia is a B cell disorder that exhibits monotypic immunoglobulin and CD5 expression and involves the blood and bone marrow. CLH lesions rich in plasma cells must be distinguished from those of secondary syphilis, plasmacytoma, myeloma, and immunocytoma. The infiltrate in secondary syphilis is generally richer in plasma cells or histiocytes than small lymphocytes and is associated with epidermal hyperplasia, an interface inflammatory component, and positive serology. The plasma cells in plasmacytoma and myeloma are monotypic and tend to exhibit mitotic figures, atypia, immaturity, and multinucleated forms. Monotypic immunoglobulin is also present in the tumor cells of primary cutaneous immunocytoma. This B cell neoplasm is also known as marginal zone lymphoma, mucosa-associated lymphoid tissue (MALT)-type lymphoma, and low-grade SALT B cell lymphoma. [1], [2] and [3] It is composed of varying proportions of small lymphocytes, plasmacytoid lymphocytes, plasma cells, and marginal zone-like B cells. The latter have monocytoid features with a halo of cytoplasm visible around their nuclei. These cells often surround clusters of small lymphocytes, imparting a “reverse reactive follicle” appearance with smaller cells centrally and the larger monocytoid cells peripherally.

It should be noted that typical reactive lymphoid follicles with germinal centers are not specific for CLH. They can be seen in some lymphomas (e.g., marginal zone lymphoma), Kimura's disease, ALHE (see below), Castleman's disease, inflammatory pseudotumor of the skin, and morphea and as part of the host response to tumors such as basal cell carcinoma. The broad histopathologic differential diagnosis of CLH also includes histiocytoses, especially Rosai-Dorfman disease (sinus histiocytosis with massive lymphadenopathy; see Chap. 161), as well as so-called small round cell tumors such as Merkel cell carcinoma (see Chap. 86), oat cell carcinoma, neuroblastoma, and Ewing's sarcoma.

In the less common T cell CLH, there are only rare B cells. [2], [4], [5], [18], [19] and [20] Lesions may be idiopathic or secondary to drugs or arthropods. Sparse to moderate epidermotropism by atypical lymphoid cells may be seen. The dermal infiltrate has a nodular or diffuse pattern and may contain cerebriform cells, immunoblasts, and histiocytes mixed with a preponderance of small mature lymphocytes. The histiocytes are sometimes numerous enough to impart a vaguely granulomatous appearance. [20] The author has seen one such case presenting as multiple nodules on the trunk and extremities that was associated with rheumatoid arthritis and eventuated in T cell lymphoma. Differentiation between T cell CLH and T cell lymphomas relies on the fact that most cases of mycosis fungoides exhibit marked epidermotropism, and most nonmycosis fungoides cutaneous T cell lymphomas are either diffuse large cell or mixed cell types, although a pleomorphic small cell type occurs rarely. Many T cell lymphomas show loss of one or more T cell antigens, and most have monoclonal T cell receptor gene rearrangements. Progression to T cell lymphoma has been reported in occasional patients with T cell CLH. [18], [19]

CLH lesions may resolve spontaneously or persist indefinitely. Nodular scabies (Fig. 159-5 and Fig. 159-9) is a well-recognized form of persistent CLH. Solitary lesions sometimes regress after biopsy or may be eradicated by excision. Those lesions secondary to drugs usually regress when the offending agent is withdrawn. CLH related to *B. burgdorferi* (lymphocytoma cutis; see Chap. 203) responds to antibiotic therapy, as do some cases of idiopathic CLH. Glucocorticoids (topical, intralesional, systemic), cryotherapy, antimalarials, minocycline, and radiation therapy have all been used with variable success. The latter is particularly effective but is usually regarded as a last resort. Local or distant recurrence can occur following any of these treatments. Cases of atypical CLH that cannot be distinguished from lymphoma are usually treated as localized lymphoma after staging rules out extracutaneous disease. Treatment typically involves local radiation therapy that may be preceded by excision of the lesion.

KIMURA'S DISEASE

Kimura's disease presents as a solitary or multiple nodules up to 10 cm in diameter centered in the subcutis, most commonly involving the head of a young to middle-aged adult. [21], [22] and [23] Peripheral eosinophilia and regional lymphadenopathy are characteristic. Histopathologically, the dermis and/or subcutis exhibit hyperplasia of small blood vessels lined by plump endothelial cells similar to those present in the high endothelial venules of lymphoid tissues. These venules are a major point of lymphocyte trafficking between the blood and the paracortical T cell domain of lymph nodes. Surrounding these hyperplastic vessels is a dense infiltrate composed of small lymphocytes, plasma cells, histiocytes, and eosinophils. The latter are typically prominent but may be absent in some cases. There are usually multiple secondary lymphoid follicles with prominent germinal centers, particularly in the subcutaneous lesions. It is

possible that Kimura's disease represents a florid, deep-seated form of the same basic pathogenetic process that gives rise to classic CLH.

There is controversy regarding whether Kimura's disease and ALHE are variants of the same disorder or separate clinicopathologic entities. [21], [22] and [23] The terms *epithelioid hemangioma* and *pseudopyogenic granuloma* have been used as synonyms for ALHE (Fig. 159-13). Some regard ALHE essentially as a malformation of blood vessels caused by an underlying arteriovenous shunt. They consider the CLH-like aspects of the lesional infiltrate to be a secondary feature. Proponents of ALHE as a separate disorder argue that, relative to Kimura's disease, ALHE lesions tend to be smaller (Fig. 159-13A) and exhibit a more prominent vascular hyperplasia, characterized by small blood vessels lined by plump endothelial cells with abundant cytoplasm and sometimes atypical nuclei (Fig. 159-13B). In addition, there is often evidence of arteriovenous anastomoses, the lymphoid infiltrate is less extensive, secondary lymphoid follicles are present only in a minority of cases, and lymphadenopathy is absent.

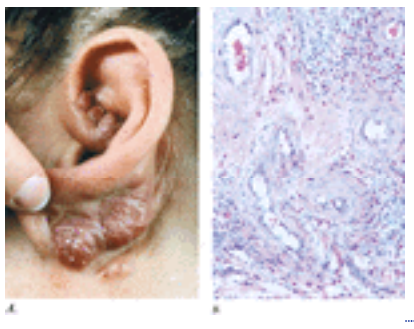

FIGURE 159-13 Angiolymphoid hyperplasia with eosinophilia. *A.* Clinically there are soft, confluent papular lesions typically located in the auricular region. *B.* Histologically blood vessels are lined by plump endothelial cells protruding into the lumen; there is vascular hyperplasia with thickened vascular walls, lymphocytic infiltrates, and prominent eosinophilia.

CASTLEMAN'S DISEASE

Castleman's disease is also known *as angiofollicular lymphoid hyperplasia* or *giant lymph node hyperplasia*. [24], [25], [26] and [27] It is a lymphoproliferative disorder that most often presents as an isolated mediastinal mass, although a multicentric form of the disease also exists. Rarely, it may present as a solitary subcutaneous or cutaneous tumor in various locations. Surgical excision is effective therapy, and the clinical course is usually favorable. Castleman's disease may be associated with *p*olyneuropathy, *o*rganomegaly, *e*ndocrinopathy, *M* protein, and *s*kin changes, the POEMS syndrome. [28] Studies of multicentric Castleman's disease demonstrate increased levels of lesional and circulating interleukins 1ß and 6, suggesting that cytokine abnormalities may mediate the systemic manifestations of POEMS syndrome. [28], [29] Castleman's disease occurring in the setting of HIV infection is associated with human herpesvirus type-8, [30] which has also been detected in Kaposi's sarcoma (see Chap. 104), and primary effusion lymphomas.

Two histopathologic variants of Castleman's disease exist. The more common hyaline vascular variant exhibits small, concentrically whorled, lymphoid follicles surrounded by small lymphocytes arranged in a concentric, onion-skin pattern. An extensive proliferation of capillaries is present between follicles. The rarer plasma cell variant exhibits large, hyperplastic secondary lymphoid follicles associated with a highly vascular interfollicular zone rich in plasma cells. The differential diagnosis of subcutaneous Castleman's disease includes eosinophil-poor ALHE, Kimura's disease, plasmacytoma, myeloma, CLH, and follicular types of CBCL. All of these diseases lack the characteristic features of the lymphoid follicles seen in the two histopathologic variants of Castleman's disease. These disorders also lack prominent vascular hyperplasia, except for ALHE and Kimura's disease whose characteristic endothelial cells aid their recognition. Plasmacytoma and myeloma contain dense sheets of atypical plasma cells and differ in their associated clinical findings. CLH is usually centered in the dermis rather than the subcutis. Most cutaneous lymphomas have a diffuse, monomorphous appearance. The rare follicular types of CBCL have distinctive features, as summarized in the CLH section.

PSEUDO-MYCOSIS FUNGOIDES (See also Chap. 157)

Pseudo-T cell lymphomas with a bandlike or mycosis fungoides–like histopathologic pattern may arise spontaneously; as a T cell infiltrate coexisting with B cell chronic lymphocytic leukemia; as a rare variant of the eruption of lymphocyte recovery (which occurs in the setting of leukocyte reconstitution after iatrogenic marrow aplasia); or in association with ingestion of various drugs including hydantoins, carbamazepine, propylvalerate, dexchlorpheniramine maleate (Polaramine), and other antihistamines. [2], [4], [5], [9], [20] The lesions present clinically as one or a few plaques on the trunk or extremities. Occasionally, several plaques or a Sézary-like syndrome develop. Histopathologically, there is a papillary dermal, bandlike infiltrate containing mostly small- and medium-sized atypical lymphocytes with clefted and cerebriform nuclei. Moderate numbers of histiocytes are admixed, but eosinophils and plasma cells are rare. The dermal–epidermal junction is obscured, and there is no Grenz zone. The overlying epidermis may be hyperplastic and/or may contain a sparse to moderate atypical lymphoid infiltrate; however, relative to mycosis fungoides, epidermotropism is typically far less prominent and Pautrier's microabcess-like cell aggregates are rare. The differentiation of these pseudolymphomas from mycosis fungoides is aided by their tendency toward minimal epidermotropism in many cases, the small number of lesions, and resolution following drug discontinuation and/or local therapy with excision or topical glucocorticoids.

Lichenoid drug eruptions, caused by agents such as gold, thiazides, and antimalarials, may also bear a histopathologic resemblance to atrophic forms of large plaque parapsoriasis and overt mycosis fungoides when they result in a bandlike, dermal lymphoid infiltrate that involves an atrophic epidermis. As in mycosis fungoides, eosinophils and plasma cells may also be present. However, these lesions lack lymphoid atypia, exhibit the clinical features of typical lichenoid drug

rashes, and regress eventually following discontinuation of the causative agent. Poikilodermatous skin lesions of collagen vascular diseases and genodermatoses are distinguished from mycosis fungoides by their associated clinical and laboratory findings; sparser infiltrates lacking atypia; and, for collagen vascular diseases, dermal mucin, thickened epidermal basement membranes, and characteristic epidermal alterations. Chronic radiodermatitis may resemble poikilodermatous mycosis fungoides clinically but is distinguished by clinical history, sparse infiltrate, keratinocyte atypia, dermal fibrosis, and loss of adnexa. Some cases of secondary syphilis may also mimic mycosis fungoides by virtue of showing a dense, bandlike, upper dermal infiltrate that obscures the dermal–epidermal junction and invades a nonspongiotic epidermis. However, the infiltrate contains more plasma cells and fewer lymphocytes than expected in mycosis fungoides; there is no lymphoid atypia; there may be neutrophils in the epidermis; and there is a deep perivascular extension of the infiltrate that is unusual in mycosis fungoides except in the tumor phase. Furthermore, the patient's history, clinical appearance of lesions, serology, and response to antibiotic therapy will facilitate the correct diagnosis.

Three other disorders that may mimic mycosis fungoides/Sézary syndrome clinically and/or pathologically include follicular mucinosis, lymphomatoid contact dermatitis, and actinic reticuloid. Because of their distinctive features, each is discussed separately below.

FOLLICULAR MUCINOSIS (See also Chap. 157 and Chap. 158)

Follicular mucinosis, also referred to as alopecia mucinosa, presents as variably pruritic, pink to yellow-white follicular papules or red boggy plaques that result in alopecia when they involve hairy areas such as the scalp. [2], [3], [4], [5], [31] Three clinical variants exist: (1) one or a few lesions that usually present on the head or neck of a child and resolve spontaneously within a few years; (2) generalized lesions in older individuals that may persist or recur indefinitely; and (3) follicular mucinosis secondary to other disorders, usually mycosis fungoides but occasionally Sézary syndrome, other skin lymphomas, discoid lupus, or ALHE. It has been proposed that follicular mucinosis secondary to mycosis fungoides should be termed *follicular mycosis fungoides* because the degree of mucinosis can vary among cases and even in the same case over time. [32] Follicular mucinosis may occur as an isolated disease but has also arisen in patients with chronic lymphocytic leukemia, Hodgkin's disease, and Kaposi's sarcoma. Histopathologic examination reveals a variably dense, dermal lymphoid infiltrate that surrounds hair follicles and infiltrates their epithelia. Histiocytes and sometimes eosinophils are admixed. The hair follicles contain pools of acid mucopolysaccharides associated with follicular disruption. In cases of mycosis fungoides with secondary follicular mucinosis, characteristic tumor cells are present in the follicular epithelium, epidermis, and/or dermis. Atypical lymphocytes are unusual in primary alopecia mucinosa and reportedly do not form Pautrier's microabscesses; however, some observers have found it difficult to differentiate these two disorders, especially when the primary form presents as generalized plaques. Eosinophils have been reported in both primary and secondary types. [33] Dominant T cell clones have been detected in some cases of primary follicular mucinosis as well as in mycosis fungoides–related follicular mucinosis, indicating that the primary form is a lymphoproliferative disorder that cannot be distinguished from mycosis fungoides merely on the basis of monoclonality. [2], [3], [32] Treatment options include topical and systemic PUVA, topical and intralesional glucocorticoids, retinoids, topical nitrogen mustard, and radiation therapy.

LYMPHOMATOID CONTACT DERMATITIS

This condition was described originally in four patients with persistent allergic contact dermatitis proven by patch tests. [34] The clinical and histopathologic changes in the lesions are said to resemble those of mycosis fungoides.

Clinically, lymphomatoid contact dermatitis is characterized by generalized, pruritic, red, scaly papules and plaques that may become confluent (Fig. 159-14) with resultant exfoliative erythroderma. Patch tests for a variety of common allergens, such as ethylenediamine dihydrochloride, may be positive.

FIGURE 159-14 Lymphomatoid contact dermatitis. Erythematous papules and plaques on the forehead. Patch test with local anesthetics was positive.

Histopathologically, lymphomatoid contact dermatitis contains foci of spongiosis, simulating the appearance of cutaneous T cell lymphomas. It must be differentiated from mycosis fungoides (Fig. 159-15), usually on the basis of changes within the epidermis; specifically, in mycosis fungoides more atypical lymphocytes have a tendency to form Pautrier's microabscesses in the epidermis. Frequently there is edema in the papillary dermis of lymphomatoid contact dermatitis, a finding that is absent from mycosis fungoides. Immunohistopathologic investigations indicate that lymphomatoid contact dermatitis represents a T cell pseudolymphoma. Examination of the cells in the infiltrate by electron microscopy reveals many atypical lymphocytes with cerebriform nuclei like those of mycosis fungoides.

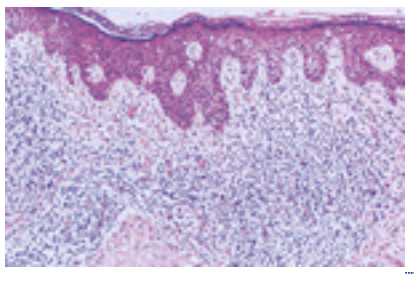

FIGURE 159-15 Lymphomatoid contact dermatitis. Dense bandlike infiltrate in the upper part of the dermis and spongiotic foci in the epidermis (“spongiotic simulator” of mycosis fungoides).

Although lymphomatoid contact dermatitis has been reported, albeit rarely, to evolve into lymphoma, it is more likely that those patients had lymphoma from the outset.

A thorough search for the offending antigen by way of patch tests is necessary if the process of lymphomatoid contact dermatitis is to be interrupted. Avoidance of the responsible allergens leads to eventual resolution of the condition, aided by topical application of glucocorticoids.

ACTINIC RETICULOID (See also Chap. 135 and Chap. 136)

Actinic reticuloid, a chronic inflammatory condition that tends to affect older men, is a consequence of persistent photoallergic sensitivity. [35], [36] and [37] It may be regarded as the most severe expression of chronic actinic dermatitis. The clinical and histopathologic aspects of actinic retinoid have been described as resembling those of T cell lymphoma.

Clinical examination reveals red-purple, sometimes scaly, lichenoid papules and plaques situated almost entirely on sites exposed to sunlight. In some patients, there are nodules, and generalized erythroderma may develop. The facies may be leonine with deep furrows in markedly thickened skin (Fig. 159-16), strikingly similar to the facies of patients with lymphomas and leukemias. Alopecia may be diffuse as a consequence of prolonged, vigorous rubbing. Pruritus is generally severe and intractable. Generalized lymphadenopathy is common. Differentiation of actinic reticuloid from T cell lymphoma may be difficult clinically, especially because circulating Sézary-like cells are found in the peripheral blood in approximately 10 percent of cases of actinic retinoid.

FIGURE 159-16 Actinic reticuloid. Markedly thickened and erythematous skin with deep furrows and lichenoid papules on the face.

Patients with actinic reticuloid are sensitive to both short- and long-wave ultraviolet radiation, and occasionally to visible light. Fluorescent light is said to sometimes lead to exacerbation of the disease. The minimal erythema dose is lower than normal in patients with actinic reticuloid. Some evidence suggests that photosensitivity in actinic reticuloid is related to allergic contact dermatitis (compositae plants, rubber components, potassium dichromate, and fragrance material). In rare instances, exposure to halogenated salicylanilides has been demonstrated in patients with actinic reticuloid.

Histopathologically, actinic reticuloid consists of moderately dense, superficial and deep, perivascular, mixed-cell infiltrates of lymphocytes, histiocytes, plasma cells, mast cells, and eosinophils. Atypical mononuclear cells with hyperchromatic, lobulated nuclei have been reported by some observers. The infiltrate is patchy and may be bandlike in the upper part of the dermis. The papillary dermis is thickened by coarse bundles of collagen in vertical streaks perpendicular to the skin surface and parallel to the rete ridges. Often plump, stellate, multinucleated fibroblasts are present in the thickened papillary dermis. The epidermis often shows psoriasiform hyperplasia. The constellation of changes in the papillary dermis and epidermis just enumerated are indubitable evidence of prolonged rubbing of skin, that is lichen simplex chronicus. Solitary lymphocytes may be found within a spongiotic epidermis.

The presence of IgE+ cells with a dendritic morphology (Langerhans cells) associated with elevated serum IgE levels are notable features. [38] Electron microscopy reveals cells that resemble Lutzner cells and Langerhans cells. In contrast to mycosis fungoides, which is almost always a tumor of CD4+ T cells, there is a predominance of CD8+ T cells in the lesional skin and blood of most patients with actinic reticuloid. [39] This difference and the photosensitivity help to distinguish actinic reticuloid from mycosis fungoides. Furthermore, the histopathologic changes of actinic reticuloid can be differentiated from those of mycosis fungoides because the former has features of lichen simplex chronicus

superimposed on a persistent photoallergic dermatitis. The latter is an epidermotropic form of lymphoma.

The development of lymphoma in the course of actinic reticuloid has been reported. [36] T cell receptor gene rearrangement analysis has not shown evidence of dominant clonality. [38], [40] Frequently a chronic course is observed in actinic reticuloid. The condition does not usually respond to conventional therapy such as systemic glucocorticoids, chloroquine, or beta-carotene. Total avoidance of light can lead to improvement, but that is a long-term endeavor and not a solution. Treatment modalities include PUVA and UVB phototherapy, azathioprine, cyclosporine, and danazol. [36] Prescription of sun-protective agents and avoidance of contact allergens are crucial.

LYMPHOMATOID PAPULOSIS (See also Chap. 48)

Lymphomatoid papulosis often bears a close clinical resemblance to pityriasis lichenoides et varioliformis acuta (PLEVA). [2], [41] It usually presents as generalized crops of red to red-brown papules and/or nodules that develop scales, vesicles, pustules, crusts, or ulcers prior to their spontaneous resolution within several weeks of onset (Fig. 159-17). Lesions in different stages of clinical evolution are present concurrently (Fig. 159-17A). Burned-out lesions may exhibit varioliform scarring or postinflammatory hyper- or hypopigmentation. Sometimes lesions arise and regress without appreciable epidermal changes. Occasionally, the lesions are regionalized or few in number and may sometimes appear as plaques. In addition to the acute and chronic forms of pityriasis lichenoides, the clinical differential diagnosis includes arthropod bites, cutaneous lymphomas, and histiocytoses. Both sexes are affected, with a wide age range and a peak incidence in middle age. Patients with lymphomatoid papulosis have about a 20 percent risk of developing mycosis fungoides, large cell lymphoma, and/or Hodgkin's disease. In some instances, these diseases precede the onset of lymphomatoid papulosis.

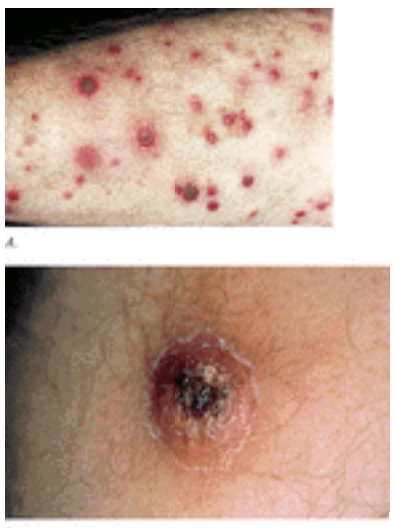

FIGURE 159-17 Lymphomatoid papulosis. *A*. Papular papulonecrotic and modular skin lesions. Note various stages of development are present at the same time (*courtesy of W. Sterry, MD*). *B*. Lymphomatoid papulosis. Crusted erythematous papulonodule.

Histopathologic examination reveals a wedge-shaped, top-heavy, atypical lymphoid infiltrate associated with epidermal destruction. [2], [3], [4] and [5], [42], [43] Epidermal changes depend on the stage of lesional evolution. Initially, they are minimal, but subsequently lymphoid infiltration, spongiosis, necrosis, and formation of vesicles, pustules, crusts, or ulcers supervene. The atypical lymphoid cells are large and mixed with banal lymphocytes and sometimes neutrophils and eosinophils. The large atypical cells vary from a small minority to a great majority of the total lymphoid infiltrate. They are classified into two cytologic types that may exist concurrently or serially in various lesions in individual cases (Fig. 159-18). [3] Type A cells resemble Reed-Sternberg cells and their mononuclear variants as seen in Hodgkin's disease. Type B cells resemble the larger tumor cells in mycosis fungoides and exhibit hyperchromatic, irregular nuclei. These cells are found in type A and B lesions, respectively. When type A cells form diffuse sheets without many admixed inflammatory cells, the lesions are referred to as type C. Mitotic figures may be numerous and abnormal. Extravasation of erythrocytes is a frequent finding. A minority of cases exhibit lymphocytic vasculitis, but true fibrinoid necrosis is rare.

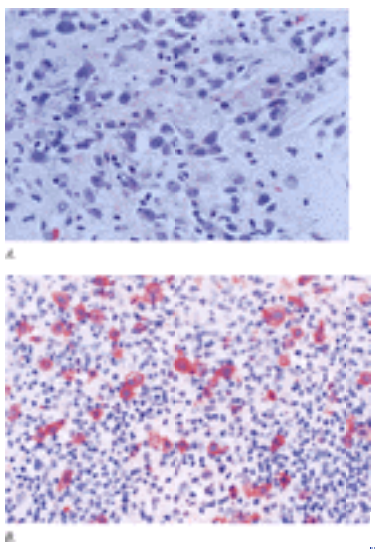

FIGURE 159-18 A. Lymphomatoid papulosis. Dermal infiltrate contains several large lymphoid cells with nuclei containing evenly dispersed chromatin and variably prominent nucleoli (so-called type A cells). B. Type A with large

CD30+ T cells (red) among admixed inflammatory cells (*B courtesy of Wolfram Sterry MD*).

Immunohistologic studies reveal a predominantly T cell infiltrate, with the CD4+ subset outnumbering the CD8+ subset. [2], [3], [4] and [5], [42], [43] As with most cutaneous lymphoid infiltrates, macrophages and histiocytic dendritic cells are admixed. Lymphomatoid papulosis lesions have two distinctive immunophenotypic features: (1) the type A large atypical cells are CD25+, CD30+, and sometimes CD15+, analogous to the Reed-Sternberg cells of Hodgkin's disease; and (2) there is often deficiency of one or more T cell antigens, analogous to the phenotypic abnormalities seen in many T cell lymphomas. Type A lymphomatoid papulosis and cutaneous CD30+ large cell lymphomas generally express a T_H2 cytokine pattern (interleukins 4, 5, and 10). [44] Molecular biologic studies of T cell receptor gene rearrangements show that most cases of lymphomatoid papulosis are dominant clonal T cell disorders. [2], [3], [4] and [5], [43] /SUP>, [44], [45] and [46] Furthermore, studies of patients with lymphomatoid papulosis and one or more of the lymphomas with which it is associated have generally shown the same dominant clonal T cell receptor gene rearrangement in each disease in individual cases. [2], [47], [48] This indicates that these clinicopathologically distinct diseases all arise as subclones of a common precursor T cell clone. The exact mechanism by which these subclones develop is currently under investigation. Existing evidence suggests somatic mutations in genes that confer a proliferation or survival advantage, such as the transforming growth factor ß type II receptor or p53. [49], [50] Lymph node–based CD30+ large cell lymphomas often contain a t(2;5)(p23;q35) translocation that results in inappropriate expression of the anaplastic lymphoma kinase gene, which is believed to be involved in their pathogenesis. This translocation has been seen in some pediatric cases with primary skin involvement. [51] In contrast, CD30+ primary skin diseases in adults rarely exhibit this translocation, suggesting that usually they arise by a different mechanism. [52]

The characteristic clinicopathologic and immunophenotypic features of lymphomatoid papulosis allow its differentiation from classic cases of mycosis fungoides. The latter presents as persistent patches or plaques containing a superficial, bandlike, atypical lymphoid infiltrate with Pautrier's microabscesses and few or no CD30+ cells. As noted earlier in this chapter, lymphomatoid papulosis exists on a continuum with CD30+ large cell lymphoma. As a consequence, there are causes that are difficult to classify because they have the clinical features of lymphomatoid papulosis and the histopathologic features of large cell lymphoma, or vice versa. The exact designation given to such cases is less important than the recognition that they belong to this disease spectrum. There is also debate as to whether lymphomatoid papulosis is part of the pityriasis lichenoides disease spectrum. [2], [41] Some observers allow a few atypical lymphoid cells in lesions that they diagnose as PLEVA. Others regard such cases as lymphomatoid papulosis. In favor of a connection between these diseases are the following: (1) individuals have been reported who exhibited lesions of PLEVA and lymphomatoid papulosis either concurrently or serially; (2) dominant T cell clonality has been documented in many cases of PLEVA and pityriasis lichenoides chronica, as well as lymphomatoid papulosis; and (3) some cases of both PLEVA and pityriasis lichenoides chronica have been associated with mycosis fungoides. [41], [45], [46], [53], [54], [55] and [56]

There are certain other uncommon cutaneous lymphoproliferative disorders with the capacity for spontaneous resolution that might be regarded as part of the lymphomatoid papulosis–lymphoma spectrum. These include *primary cutaneous Hodgkin's disease* and *regressing atypical histiocytosis*. Patients with the very rare primary cutaneous Hodgkin's disease disorder develop one or a few slowly evolving cutaneous nodules that may ulcerate or self-heal and bear a close histopathologic and immunophenotypic resemblance to Hodgkin's disease. [57] However, in contrast to the rarely occurring secondary cutaneous involvement by classic Hodgkin's disease, systemic workup is negative. [58] Cutaneous recurrence or progression to nodal involvement is possible, even years after radiation or chemotherapy. Regressing atypical histiocytosis presents with skin nodules that may spontaneously regress and exhibit an extensive dermal infiltrate of large atypical CD30+ lymphoid cells with pleomorphic nuclei, prominent nucleoli, and abundant cytoplasm. [59] These cases are now recognized to be CD30+ anaplastic large cell lymphomas, and the old terminology should be dropped.

Lymphomatoid panniculitis is a diagnosis that has been given to rare patients who develop tender, spontaneously regressing nodules, centered in the subcutis, with a septal panniculitis containing large atypical lymphoid cells morphologically similar to those in classic lymphomatoid papulosis. Lymphocytic vasculitis may also be present. At least one case has been associated with systemic lupus erythematosus. Although disease may be persistent, progression to systemic lymphoma has not been observed within a few years, and lesions can be suppressed with small doses of prednisone. The differential diagnosis includes lupus panniculitis, subcutaneous panniculitic T cell lymphoma, anaplastic large cell lymphoma, and angiocentric T cell lymphoma. Some of these lymphomas have been preceded for several years by spontaneously resolving subcutaneous nodules, suggesting that a condition analogous to cutaneous lymphomatoid papulosis exists in the subcutis. Recognizing that not all variants of the lymphomatoid papulosis spectrum exhibit the same clinicopathologic features, Macaulay, who first described the condition, proposed that the term *rhythmic paradoxical eruptions* be used as an umbrella designation for the whole array of idiopathic, spontaneously regressing atypical cutaneous lymphoid infiltrates. [60]

Even when unusual variants are excluded, the clinical course of classic lymphomatoid papulosis is highly variable. Some cases resolve without treatment in a few months. Others may persist for decades, sometimes marked by periods of complete remission lasting for years. Evolution to more aggressive lymphoproliferative disorders, such as CD30+ large cell lymphoma, is heralded by the development of larger lesions that are more persistent and contain sheets of large atypical cells. As noted earlier, mycosis fungoides and Hodgkin's disease may also develop. Because an association has rarely been observed between PLEVA and oral contraceptives, a trial discontinuation of such drugs may be warranted. Initial treatment with tetracycline or erythromycin is sometimes effective, presumably related to their anti-inflammatory properties. An effective treatment for this spectrum of diseases is low-dose oral methotrexate. [61] The vast majority of cases respond to weekly doses of about 10 to 25 mg within 1 month, including those classified as primary cutaneous CD30+ large cell lymphoma. This can spare such patients treatment with multiagent chemotherapy, although the latter may be required for those failing less intensive treatments. Other therapies for lymphomatoid papulosis have included PUVA, sulfones, retinoids, topical carmustine, topical and systemic glucocorticoids, and intralesional and systemic interferon-a2b. [43] Localized lesions may be managed effectively with radiation therapy.

ANGIOIMMUNOBLASTIC LYMPHADENOPATHY WITH DYSPROTEINEMIA

AILD, also known as *immunoblastic lymphadenopathy,* is a lymphoproliferative disorder that typically presents in the elderly as lymphadenopathy, hepatosplenomegaly, hypergammaglobulinemia, and anemia. [1], [2] and [3], [62], [63] Skin lesions arise in nearly half of the cases and often precede other clinical manifestations. They generally appear as a diffuse macular and papular eruption, although some of these are suspected drug reactions. Less often, petechiae, plaques, or nodules may develop. The clinical course may be chronic and marked by remissions, or patients may die acutely, often secondary to sepsis. AILD is considered to be a lymphoma in its own right by some. [1], [2] Progression to high-grade lymphoma occurs, usually diffuse large cell immunoblastic, of T cell or, less often, B cell type. [1], [2] AILD and AILD-like peripheral T cell lymphomas constitute the two ends of a lymphoproliferative disease continuum. Serial molecular biologic and karyotypic studies are consistent with the view that progression along the AILD-lymphoma spectrum involves the emergence of a dominant lymphoid clone from a polyclonal or oligoclonal background. [64], [65] Dominant clonal T cell receptor gene rearrangements are present in many cases of AILD and in all cases of AILD-like peripheral T cell lymphoma. [64], [65] The presence of clonal Epstein-Barr virus (EBV) genomes in many AILD-associated lymphomas suggests that this virus may play a role in the development of AILD-related lymphomas analogous to its role in other immunocompromised states. [66] Some AILD-associated lymphomas have shown increased levels of cytokines such as tumor necrosis factor a, lymphotoxin, and interleukins 1ß and 6. [67] These factors may contribute to the immune dysfunction seen in the AILD disease spectrum and may facilitate the proliferation of EBV-infected cells. Minimal levels of recombinase-activating genes 1 and 2 in most cases suggest that AILD is a disorder of genotypically mature lymphoid cells, that is, ones that have already completed antigen receptor gene rearrangement. [68]

The histopathologic features of cutaneous AILD lesions are generally nondiagnostic but may be suggestive in the appropriate clinical setting. The macular and papular lesions contain a perivascular and periadnexal dermal lymphocytic infiltrate mixed with plasma cells and occasional large immunoblasts. Vascular proliferation, lymphocytic vasculitis, and erythrocyte extravasation may be present. Occasionally, the infiltrate is composed primarily of plasma cells, plasmacytoid cells, and immunoblasts. Plaques and nodules may exhibit features ranging from nonnecrotizing lymphohistiocytic inflammation to dense, diffuse atypical lymphoid infiltrates, including those diagnostic of immunoblastic large cell lymphoma. Differential diagnosis may be challenging because of the nonspecific nature of many AILD lesions. Drug eruptions need to be excluded. AILD is differentiated from mycosis fungoides by its systemic manifestations and the absence of cerebriform T cells exhibiting epidermotropism. Fully evolved AILD-associated lymphomas involving the skin are uncommon but, when present, resemble other skin lymphomas of similar histopathologic type.

LYMPHOMATOID GRANULOMATOSIS

Lymphomatoid granulomatosis is a pulmonary lymphoproliferative disorder with systemic manifestations including cutaneous involvement. [1], [2], [69], [70] and [71] Skin lesions appear first in more than 10 percent of patients. Another 33 to 50 percent of patients develop skin involvement following the onset of pulmonary disease. The skin lesions are localized or generalized, sometimes symmetric, red to purple maculopapules, dermal nodules, or subcutaneous nodules. They may be pruritic or tender and resolve spontaneously, persist unchanged, or ulcerate. Skin involvement heralds a more aggressive clinical course, with a median survival time of only about 1 year.

Many patients with lymphomatoid granulomatosis die with overt systemic lymphoma because, in at least some cases, this disease appears to be the clinically benign end of a spectrum of angiocentric lymphoproliferative disorders that has angiocentric lymphoma as its malignant extreme. Some observers refer to this continuum as *angiocentric immunoproliferative lesions*. [1], [2], [72] Other observers suspect that past reports of lymphomatoid granulomatosis included a heterogeneous collection of pulmonary T cell lymphomas, B cell lymphomas, Hodgkin's disease, AILD, and the like. [73] Some overt angiocentric lymphomas arising in the setting of lymphomatoid granulomatosis have exhibited T cell differentiation and clonal T cell receptor gene rearrangements. [1], [2], [72] Other cases of lymphomatoid granulomatosis have shown evidence of dominant B cell clonality and EBV in atypical B cells within a T cell–predominant background. [74] This suggests that at least some cases of lymphomatoid granulomatosis may be analogous to so-called T cell–rich B cell lymphomas, and that the T cells may mount an angiodestructive response to EBV-infected clonal B cells. Angiocentric immunoproliferative lesions involving the midface, nasal cavity, paranasal sinuses, and/or upper aerodigestive tract have been referred to in the past as *lethal midline granuloma* or *polymorphic reticulosis*. [1], [2], [72]

Cutaneous lesions of lymphomatoid granulomatosis typically exhibit an angiocentric, polymorphous infiltrate of small lymphocytes, plasma cells, histiocytes, immunoblasts, and small and large atypical lymphoid cells. Sometimes eosinophils are admixed. T cells predominate. The blood vessels are surrounded and their walls are invaded by the infiltrate, which is often heaviest in the deep dermis or subcutis. There is usually sparing of the epidermis and adnexa, and Pautrier's microabscesses are absent. These features distinguish lymphomatoid granulomatosis from mycosis fungoides, which generally contains an epidermotropic infiltrate concentrated in the upper dermis. Lymphomatoid papulosis also exhibits a top-heavy, cutaneous lymphoid infiltrate with a distinct clinical presentation, including the absence of extracutaneous disease. Lymphomatoid granulomatosis is differentiated from Wegener's granulomatosis and allergic granulomatosis (Churg-Strauss disease) by the presence of leukocytoclastic vasculitis and well-formed granulomas in the latter two conditions, as well as by associated clinical findings. Cases of lymphomatoid granulomatosis that have evolved to overt angiocentric lymphoma show angiocentricity, angioinvasion, and necrosis combined with the features of diffuse mixed cell or large cell lymphoma.

LYMPHOCYTIC INFILTRATION OF THE SKIN

LIS, which was first described by Jessner and Kanof, [75] presents as one or more erythematous plaques or nodules, generally localized to only one or a few sites on the face, neck, upper trunk, or arms. [76], [77] Pustules, pruritus, and epidermal alterations are absent. Photoexacerbation may occur in a minority of patients according to some observers. The vast majority of cases occur in adults with a roughly equal gender ratio. LIS may respond favorably to topical or intralesional glucocorticoids, antimalarials, or thalidomide; however, a persistent, indurated variant has been described that may require systemic glucocorticoid therapy to achieve remission. The etiology of LIS is unknown. Some regard it as a distinct disease, whereas others consider it to be a variant of lupus erythematosus or, less commonly, polymorphous light eruption, CLH, or lymphocytic lymphoma. The course is chronic and may show periods of spontaneous remission and eventual resolution. Immunologic investigations have

shown decreased natural killer cell function as well as elevated circulating immune complexes, the level of which were reported to parallel disease activity. [78] Skin lesions known as *arcuate dermal erythema* may arise in female carriers of chronic granulomatous disease. These lesions resemble LIS clinically and microscopically.

Histopathologic examination reveals a superficial and deep, perivascular and variably periadnexal infiltrate of small mature lymphocytes, often with a minor admixture of histiocytes, plasmacytoid monocytes, and plasma cells. Lymphoid follicles and eosinophils are absent. The epidermis is unremarkable. Direct immunofluorescence is negative or nonspecific. Immunohistologic studies have demonstrated a predominantly HLA-DR–Leu-8+ T cell infiltrate with some B cells and histiocytes admixed. In contrast, most of the T cells in discoid lupus are HLA-DR+ Leu-8–. [79], [80] Initial studies indicate that the infiltrate is polyclonal. [2]

The differential diagnosis of LIS includes discoid lupus erythematosus, polymorphous light eruption, CLH, lymphocytic lymphoma and leukemia, deep figurate erythemas such as erythema chronicum migrans, and reticular erythematous mucinosis. Discoid lupus generally exhibits epidermal changes, an interface inflammatory component, and a lupus band on direct immunofluorescence. The tumid variant of discoid lupus is typified by abundant dermal mucin and subtle alterations at the dermal–epidermal interface. These changes are not seen in LIS. Antinuclear antibody panel and erythrocyte sedimentation rate are also normal. Polymorphous light eruption exhibits papillary dermal edema, which is absent in LIS. CLH contains nodular or diffuse, dermal lymphoid infiltrates that are much denser than the predominantly perivascular infiltrate of LIS. Furthermore, LIS lacks reactive B cell follicles. Well-differentiated or small lymphocytic lymphoma/leukemia is usually a monoclonal B cell process, and there is a peripheral lymphocytosis in the leukemic form of the disease. These findings are absent in LIS. Erythema chronicum migrans and some cases of CLH exhibit serologic evidence of active infection with *B. burgdorferi,* whereas this is rarely seen in LIS. Reticulated erythematous mucinosis has a reticulated clinical appearance, favors the trunk rather than the head and neck, and shows bipolar fibroblasts. These are not features of LIS.

The author gratefully acknowledges Drs. Helmut Kerl and A. Bernard Ackerman who allowed selected material to be retained from the fourth edition of this textbook.

REFERENCES

1. Harris NL et al: A revised European-American classification of lymphoid neoplasms: A proposal from the International Lymphoma Study G *Blood* **84**:1361, 1994

2. Wood GS: The benign and malignant cutaneous lymphoproliferative disorders including mycosis fungoides *Neoplastic Hematopathology* 2nd ed, edited by DM Knowles. Baltimore, Williams & Wilkins, 2001, p 1183

3. Willemze R et al: EORTC classification for primary cutaneous lymphomas: A proposal from the Cutaneous Lymphoma Study Group of the European Organization for Research and Treatment of Cancer. *Blood* **90**:354, 1997

4. Gilliam AC, Wood GS: Cutaneous lymphoid hyperplasia *Semin Cutan Med Surg* **19**:133, 2000

5. Ploysangam T et al: Cutaneous pseudolymphoma *J Am Acad Dermato* **38**:877, 1998

6. Caro WA, Helwig EB: Cutaneous lymphoid hyperplasi *Cancer* **24**:487, 1969

7. Medeiros LJ et al: Cutaneous lymphoid hyperplasia: Immunologic characteristics and assessment of criteria recently proposed as diagnostic of malignant lympl *J Am Acad Dermato* **21**:929, 1989

8. Ramsay B et al: Acral pseudolymphomatous angiokeratoma of childr *Arch Dermato* **126**:1524, 1990

9. Magro CM, Crowson AN: Drugs with antihistaminic properties as a cause of atypical cutaneous lymphoid hyperpla *J Am Acad Dermato* **32**:419, 1995

10. Cerroni L et al: bcl-2 Protein expression and correlation with the interchromosomal 14;18 translocation in cutaneous lymphomas and pseudolymph *J Invest Dermato* **102**:231, 1994

11. Rijlaarsdam U et al: Demonstration of clonal immunoglobulin gene rearrangements in cutaneous B-cell lymphomas and pseudo-B-cell lymphomas: Differential diagnostic and pathogenetic aspects. *J Invest Dermato* **99**:749, 1992

12. Wood GS et al: Clonal rearrangements of immunoglobulin genes and progression to B-cell lymphoma in cutaneous lymphoid hyperp *Am J Patho* **135**:13, 1989

13. Hammer E et al: Immunophenotypic and genotypic analysis in cutaneous lymphoid hyperpla *J Am Acad Dermato* **28**:426, 1993

14. Thomine E et al: Polymerase chain reaction analysis of immunoglobulin gene rearrangement in cutaneous lymphoid hyperplasias. French Study Group for Cutaneous Lymp *Arch* s. *Dermato* **135**:168, 1999

15. Nihal M et al: Cutaneous lymphoid hyperplasia (CLH): A lymphoproliferative continuum with malignant pote *J Invest Dermato* **114**:817, 2000

16. Bachelez H et al: Oligoclonal expansion of HIV-specific CD8 T lymphocytes in the skin of HIV-1–infected patients with cutaneous pseudolymph *J Clin Inves* **101**:2506, 1998

17. Garcia CF et al: Cutaneous follicular lymphom *Am J Surg Patho* **10**:454, 1986

18. Griesser H et al: T-cell receptor and immunoglobulin gene rearrangements in cutaneous T-cell–rich pseudolympho *J Invest Dermato* **95**:292, 1990

19. Bendelac A et al: Cutaneous pleomorphic T-cell lymphom *J Am Acad Dermato* **15**:657, 1986

20. Rijlaarsdam JU et al: Cutaneous pseudo-T-cell lymphomas: A clinicopathologic study of 20 patie *Cancer* **69**:717, 1992

21. Chun S, Ji HG: Kimura's disease and angiolymphoid hyperplasia with eosinophilia: Clinical and histopathologic differen *J Am Acad Dermato* **27**:954, 1992

22. Urabe A et al: Epithelioid hemangioma versus Kimura's diseas *Am J Surg Patho* **11**:758, 1987

23. Googe PB et al: Kimura's disease and angiolymphoid hyperplasia with eosinophilia: Two distinct histopathological ent *J Cutan Patho* **14**:263, 1987

24. Keller AR et al: Hyaline-vascular and plasma cell types of giant lymph node hyperplasia of the mediastinum and other local *Cancer* **29**:670, 1972

25. Grossin M et al: Subcutaneous forms of the Castleman's benign lymphom *Ann Dermatol Venerec* **112**:497, 1985

26. Kubota Y et al: Skin involvement in giant lymph node hyperplasia (Castleman's disea *J Am Acad Dermato* **29**:778, 1993

27. Skelton HG et al: Castleman's disease in the skin; a rare lymphoid hyperplasia not previously reported in the *J Cutan Patho* **24**:125, 1997

28. Gherardi RK et al: Elevated levels of interleukin-1 beta (IL-1 beta) and IL-6 in serum and increased production of IL-1 beta mRNA in lymph nodes of patients with polyneuropathy, organomegaly, endocrinopathy, M protein, and skin changes (POEMS) syndron *Blooc* **83**:2587, 1994

29. Ishiyama T et al: Immunodeficiency and IL-6 production by peripheral blood monocytes in multicentric Castleman's dise *Br J Haemato* **86**:483, 1994

30. Cesarman E et al: Kaposi's sarcoma-associated herpesvirus-like DNA sequences in AIDS-related body-cavity–based lympho *N Engl J Mec* **332**:1186, 1995

31. Pinkus H: Alopecia mucinosa *Arch Dermato* **76**:419, 1957

32. Flaig MJ et al: Follicular mycosis fungoides. A histopathologic analysis of nine cas *J Cutan Patho* **28**:525, 2001

33. Mehregan DA et al: Follicular mucinosis: Histopathologic review of 33 cas *Mayo Clin Proc* **66**:387, 1991

34. Gómez Orbaneja J et al: Lymphomatoid contact dermatiti *Contact Dermatitis* **2**:139, 1976

35. Ive FA et al: “Actinic reticuloid”: A chronic dermatosis associated with severe photosensitivity and the histologic resemblance to lymph *Br J Dermato* **81**:469, 1969

36. González E, González S: Drug photosensitivity, idiopathic photodermatoses, and sunscree *J Am Acad Dermato* **35**:871, 1996

37. Lim HW et al: Chronic actinic dermatitis *Arch Dermato* **126**:317, 1990

38. Toonstra J et al: Actinic reticuloid: Immunohistochemical analysis of the cutaneous infiltrate in 13 patie *Br J Dermato* **120**:779, 1989

39. Ashinoff R et al: Lymphoma in a black patient with actinic reticuloid treated with PUVA: Possible etiologic considerati *J Am Acad Dermato* **21**:1134, 1989

40. Bakels V et al: Differentiation between actinic reticuloid and cutaneous T cell lymphoma by T cell receptor gamma gene rearrangement analysis and immunopheno *J Clin Patho* **51**:154, 1998

41. Wood GS et al: The immunohistology of pityriasis lichenoides et varioliformis acuta and pityriasis lichenoides chronica: Evidence for their interrelationship with lymphomatoid papulosis. *J Am Acad Dermato* **16**:559, 1987

42. Wood GS et al: Lymphomatoid papulosis expresses immunophenotypes associated with T cell lymphoma but not inflamma *J Am Acad Dermato* **15**:444, 1986

43. Karp DL, Horn TD: Lymphoid papulosis *J Am Acad Dermato* **30**:379, 1994

44. Yagi H et al: Th2 cytokine mRNA expression in primary cutaneous CD30-positive lymphoproliferative disorders: Successful treatment with recombinant interferon-ga *J Invest Dermato* **107**:827, 1996

45. Weiss LM et al: Clonal T cell populations in lymphomatoid papulosis: Evidence for a lymphoproliferative etiology in a clinically benign dis *N Engl J Mec* **315**:475, 1986

46. Kadin ME et al: Clonal composition of T-cells in lymphomatoid papulos *Am J Patho* **126**:13, 1987

47. Wood GS et al: Lymphomatoid papulosis and associated cutaneous lymphoproliferative disorders exhibit a common clonal o *J Invest Dermato* **105**:51, 1995

48. Chott A et al: The same dominant T cell clone is present in multiple regressing skin lesions and associated T cell lymphomas of patients with lymphomatoid papu *J Invest Dermatol* **106**:696, 1996

49. Kadin ME et al: Progression of lymphomatoid papulosis to systemic lymphoma is associated with escape from growth inhibition by transforming growth factor-beta and CD30 l *Ann* d. *N Y Acad Sc* **941**:59, 2001.

50. McGregor JM et al: p53 gene mutations in cutaneous T-cell lymphom *J Invest Dermato* **106**:855, 1996

51. Trowers A et al: Three pediatric cases of CD30+ cutaneous anaplastic large cell lymphomas (ALCLs) bearing the t(2;5)(p21;q35) transloca *J Invest Dermato* **117**:490, 2001

52. Wood GS et al: Lack of the t(2;5) or other mutations resulting in expression of anaplastic lymphoma kinase (ALK) catalytic domain in CD30+ primary cutaneous lymphoproliferative disorders and Hodgkin's disease *Blood* **88**:1765, 1996

53. Black MM: Lymphomatoid papulosis and pityriasis lichenoides: Are they relate *Br J Dermato* **106**:717, 1982

54. Fortson JS et al: Cutaneous T-cell lymphoma (parapsoriasis en plaque): An association with pityriasis lichenoides et varioliformis acuta in young chi *Arch Dermato* **126**:1449, 1990

55. Dereure O et al: T-cell clonality in pityriasis lichenoides et varioliformis acuta: A heteroduplex analysis of 20 ca *Arch Dermato* **136**:1483, 2000

56. Shieh S et al: Differentiation and clonality of lesional lymphocytes in pityriasis lichenoides chron *Arch Dermato* **137**:305, 2001

57. Sioutis N et al: Primary cutaneous Hodgkin's diseas *Am J Dermatopatho* **16**:2, 1994

58. Cerroni L et al: Cutaneous Hodgkin's disease: An immunohistochemical analys *J Cutan Patho* **22**:229, 1995

59. Headington JT et al: T-cell receptor gene rearrangement in regressing atypical histiocyto *Arch Dermato* **123**:1183, 1987

60. Macauley WL: Lymphomatoid papulosis *Int J Dermato* **17**:204, 1978

61. Vonderheid EC et al: Methotrexate is effective therapy for lymphomatoid papulosis and other primary cutaneous CD30-positive lymphoproliferative disc *J Am Acad Dermato* **34**:470, 1996

62. Frizzera G et al: Angioimmunoblastic lymphadenopathy: Diagnosis and clinical cour *Am J Mec* **59**:803, 1975

63. Lukes RJ, Tindle BH: Immunoblastic lymphadenopath *N Engl J Mec* **292**:1, 1975

64. Ohshima K et al: Genetic changes in atypical hyperplasia and lymphoma with angioimmunoblastic lymphadenopathy and dysproteinaemia in the same p *Virchows Archiv* **425**:25, 1994

65. Schlegelberger B et al: Detection of aberrant clones in nearly all cases of angioimmunoblastic lymphadenopathy with dysproteinemia-type T-cell lymphoma by combined interphase and metaphase cytogenetics *Blood* **84**:2640, 1994

66. Weiss L et al: Detection and localization of Epstein-Barr viral genomes in angioimmunoblastic lymphadenopathy and angioimmunoblastic lymphadenopathy-like lymp *Blood* **79**:1789, 1992

67. Foss HD et al: Patterns of cytokine gene expression in peripheral T-cell lymphoma of angioimmunoblastic lymphadenopathy *Blood* **85**:2862, 1995

68. Knecht H et al: Expression of human recombination activating genes (RAG-1 and RAG-2) in angioimmunoblastic lymphadenopathy and anaplastic large cell lymphoma of T *Br J* e. *Haemato* **83**:655, 1993

69. Liebow AA et al: Lymphomatoid granulomatosi *Hum Patho* **3**:457, 1972

70. Kessler S et al: Cutaneous lesions of lymphomatoid granulomatosis: Comparison with lymphomatoid papul *Am J Dermatopatho* **3**:115, 1981

71. James WD et al: Cutaneous manifestations of lymphomatoid granulomatos *Arch Dermato* **117**:196, 1981

72. Jaffe ES et al: Lymphomatoid granulomatosis and angiocentric lymphoma: A spectrum of post-thymic T-cell proliferati *Semin Resp Mec* **10**:167, 1989

73. Colby TV: Central nervous system lymphomatoid granulomatosis in AID *Hum Patho* **20**:301, 1989

74. Madison JF et al: Lymphomatoid granulomatosis of the skin and lung: An angiocentric T-cell rich B-cell lymphoproliferative diso *Arch Dermato* **132**:1464, 1996

75. Jessner M, Kanof NB: Lymphocytic infiltration of the ski *Arch Dermatol Syph* **68**:447, 1953

76. Toonstra J et al: Jessner's lymphocytic infiltration of the skin: A clinical study of 100 patier *Arch Dermato* **125**:1525, 1989

77. Guillaume JC et al: Crossover study of thalidomide vs placebo in Jessner's lymphocytic infiltration of the s *Arch Dermato* **131**:1032, 1995

78. Braddock SW et al: Clinical and immunologic studies in reticular erythematous mucinosis and Jessner's lymphocytic infiltrate of s *J Am Acad Dermato* **28**:691, 1993

79. Willemze R et al: Immunohistochemical studies in lymphocytic infiltration of the skin (Jessner) and discoid lupus erythemato *J Am Acad Dermato* **1**:832, 1984

80. Ashworth J et al: A comparison of the dermal lymphoid infiltrates in discoid lupus erythematosus and Jessner's lymphocytic infiltrate of the skin using the monoclonal antibody *J* eu 8. *Cutan Patho* **14**:198, 1987

T>

Chapter 160

Ruggero Caputo

Langerhans Cell Histiocytosis

CLINICAL FINDINGS
Letterer-Siwe Disease
Hand-Schüller-Christian Disease
Eosinophilic Granuloma
Hashimoto-Pritzker Disease
INCIDENCE
COURSE AND PROGNOSIS
LABORATORY FINDINGS
HISTOPATHOLOGIC, IMMUNOHISTOCHEMICAL, AND ULTRASTRUCTURAL FINDINGS
ETIOPATHOGENESIS
DIFFERENTIAL DIAGNOSIS47
MANAGEMENT

REFERENCES

Langerhans cell histiocytosis (LCH), previously called histiocytosis X, is a disease of unknown cause characterized by the proliferation of a distinct cell type that is S-100 and CD1a positive and contains cytoplasmic Langerhans granules (LG). [1] LCH includes four main clinical forms: Letterer-Siwe disease (LSD), Hand-Schüller-Christian disease (HSCD), eosinophilic granuloma, and Hashimoto-Pritzker disease (HPD). [1], [2] and [3]

In 1953, Lichtenstein [4] integrated the three previously described clinical conditions LSD, HSCD, and eosinophilic granuloma into a single nosologic entity called histiocytosis X (HX); in 1978 Hashimoto and Pritzker [5] described self-healing reticulohistiocytosis, a condition characterized by nodular, self-healing lesions restricted to the skin. Basset and Nezelof [6] demonstrated that the proliferating cells present in the lesions of these conditions share the ultrastructural characteristics of Langerhans cells. Thus, these conditions are now designated as Langerhans cell histiocytosis. [7]

CLINICAL FINDINGS

Letterer-Siwe Disease

LSD is the acute, disseminated multisystemic form of LCH. LSD begins within the first 6 months of life in one-third of cases and before 2 years of age in most of the others. [1], [3] More than 20 congenital cases [3] and approximately 30 adult cases have been documented. [3], [8]

Cutaneous manifestations are very common in LSD. The cutaneous lesions are characteristic and may represent the earliest sign of the disease. The typical lesion is a small translucent papule, 1 to 2 mm in diameter, slightly raised, rose-yellow in color (Fig. 160-1A and Fig. 160-1B), and usually located on the trunk (Fig. 160-1A and Fig. 160-1C) and scalp (Fig. 160-1B). The lesions frequently show scaling (Fig. 160-1A) and may become crusted and ulcerate (Fig. 160-1C and Fig. 160-1D). Vesicles and pustules may occur, simulating eczema, miliaria, scabies, and varicella. Purpura represents a poor prognostic sign. [1], [3]

FIGURE 160-1 Langerhans cell histiocytosis, Letterer-Siwe disease. *A.* Abdominal area of infant with multiple yellowish erythematous papules covered by scale or crust. *B.* Seborrheic papules on the scalp mimicking seborrheic dermatitis. *C.* Infant with multiple ulcerated skin lesions on the trunk. *D.* Severe Letterer-Siwe disease with confluent erosive and crusted lesions forming ulcers; distension of abdomen reflects hepatosplenomegaly.

Cutaneous lesions appear in successive crops. The lesions tend to merge on the scalp, leading to a seborrheic dermatitis-like appearance, and on the folds (retroauricular, axillary, and genital), mimicking intertrigo. [1], [3], [9] In LSD, mucous membrane involvement, consisting of erosions and ulcerations, is rare. Nail changes including paronychia, nail

fold destruction, onycholysis, subungual hyperkeratosis, and purpuric striae of the nail bed (Fig. 160-2) are considered an unfavorable prognostic sign. Cutaneous manifestations in elderly patients (Fig. 160-3) are similar to those seen in LSD of early childhood. [3], [8]

FIGURE 160-2 Letterer-Siwe disease. All nails, save one, show purpuric striae of the nail bed. Nail changes are considered an unfavorable prognostic sign.

FIGURE 160-3 Letterer-Siwe disease in an 81-year-old woman. The diffuse papuloscaling and papulocrusted lesions on the trunk are similar to those seen in early childhood. Systemic involvement consists of hepatosplenomegaly and pulmonary lesions. (*From Caputo et al.,* [8] *with permission.*)

Systemic manifestations of LSD are variable. Pulmonary involvement can be detected in more than half of affected children. [1], [3] Functional symptoms consist of dyspnea, cyanosis, and pneumothorax. The lungs may show a classic "honeycomb" appearance (Fig. 160-4). Pulmonary lesions can be asymptomatic, but can also cause death. [10], [11] Hepatosplenomegaly is never the initial sign of the disease but is a frequent complication and is a prognostically unfavorable sign, particularly when accompanied by jaundice. [1], [3], [10], [11] Lymphadenopathy is rarely prominent but has been noted in 25 to 75 percent of fatal cases. [10], [11] In the later stages of the disease, bone lesions occur in about 60 percent of patients; [1], [2], [11] in addition, flat bones, vertebral bones, and cranial bones are more frequently involved. Osteolytic lesions, either asymptomatic or accompanied by pain and functional impairment, are generally multiple and appear gradually. Their presence is more frequent in cases with a favorable course. Teeth may be lost prematurely. Chronic otitis media is frequent. [3] Hemopoietic involvement is rare. [1], [2] and [3] When thrombocytopenia and severe anemia occur, death is almost certain. [2] Bone marrow involvement is characterized by the presence of numerous histiocytic cells. Fever is frequently present.

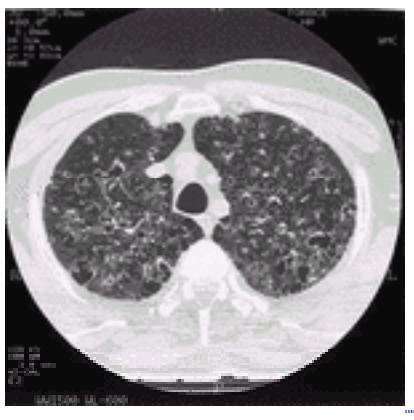

FIGURE 160-4 Letterer-Siwe disease. Bilateral involvement of lungs characterized by multiple cystic cavities (honeycomb appearance). (*Courtesy of E. De Juli, MD.*)

Hand-Schüller-Christian Disease

HSCD is the chronic, progressive, multifocal form of LCH. HSCD begins between the second and sixth year of life in 70 percent of cases and before the age of 30 years in 91 percent of cases. [1] The disorder is characterized by the four findings: bone lesions, diabetes insipidus, exophthalmos, and mucocutaneous lesions. [1], [2] and [3], [10], [11] Rarely are all four manifestations seen together in the same patient. [1]

Although the initial manifestations of HSCD most frequently are diabetes insipidus, otitis media, or skin lesions, [10] bone lesions are the most frequent manifestations of HSCD (80 percent of cases). They preferentially involve the calvaria, especially in the temporoparietal region, where the infiltrates lead to limited osteolytic foci that merge to typical “map” lesions (Fig. 160-5). Because osteolysis of the lower maxillary bones is also frequent, on x-ray, the teeth appear to be floating in the mouth. [3], [11] Bone lesions of the mastoidal region, which are usually painful but not tender, [2] may cause otitis media.

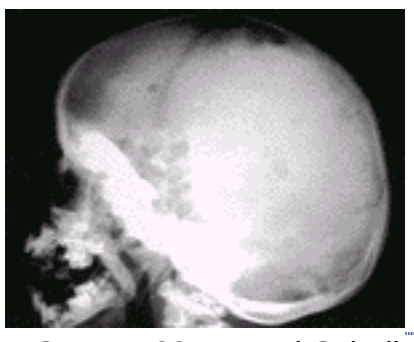

FIGURE 160-5 Hand-Schüller-Christian disease. X-ray of the skull shows well-circumscribed osteolytic areas with a typical “map” appearance.

Diabetes insipidus is present in more than 50 percent of cases and is easily controlled by vasopressin. It occurs more often in children and in patients with involvement of the skull and the orbits. [1], [3] Diabetes insipidus is considered a prognostically favorable symptom. Exophthalmos [1], [2] and [3] usually appears later; it is present in 10 to 30 percent of cases and may be unilateral or bilateral. Because it is infrequent, it has little diagnostic significance.

Mucocutaneous lesions occur in about one-third of the cases. In the early stage, cutaneous lesions are papular with the same morphologic characteristics as those observed in LSD. In the later phases, skin lesions are frequently grouped on the medial aspect of the chest (Fig. 160-6), back, and temporoparietal regions, [1], [10], [11] and they may become xanthomatous. [8] Occasionally, the lesions merge into plaques. The involvement of the large body folds may mimic intertrigo, while on the scalp the lesions may look like seborrheic dermatitis (Fig. 160-6) or folliculitis. Mucous membrane lesions are commonly noduloulcerative [3], [10], [11] and mainly involve the gingiva (Fig. 160-7) and the vulva.

FIGURE 160-6 Hand-Schüller-Christian disease. The papuloscaling and papulocrusted lesions show a typical distribution on the trunk and the scalp. The involvement of the face in the patient is unusual.

FIGURE 160-7 Hand-Schüller-Christian disease. Infiltrating lesions of the gingival tissue, frequently leading to loss of teeth.

Pulmonary infiltrates can be found in fewer than 20 percent of HSCD cases, and hepatomegaly and lymphadenopathy are rare. [1], [2], [3], [11]

Eosinophilic Granuloma

Eosinophilic granuloma is the localized, benign form of LCH. It occurs between the ages of 5 and 30 years and is more

common in males. [1], [3] The granulomatous lesions affect the bones in the following decreasing order of frequency: [12], [13] cranial vault, ribs, vertebral column, pelvis, scapulae, and long bones (Fig. 160-8). The onset is insidious. The osseous lesion is frequently single and may go undetected until spontaneous fracture and/or otitis media occur. When the lesions become symptomatic, there is localized pain, tenderness, and soft-tissue swelling.

FIGURE 160-8 Eosinophilic granuloma. The bones of the elbow reveal well-defined osteolytic lesions. These lesions manifest by swelling of soft tissue and localized pain.

Noduloulcerative mucocutaneous lesions [1], [3], [14], [15] are rare and preferentially involve the mucous membranes and the perigenital, perioral, or perianal regions (Fig. 160-9).

FIGURE 160-9 Eosinophilic granuloma. Noduloulcerative lesions in the vulva and on the perianal area. These lesions, although rare, are as unique as the bone lesions.

Hashimoto-Pritzker Disease

HPD, or congenital self-healing reticulohistiocytosis, [18] is the benign self-healing variant of LCH. HPD is usually present at birth or may appear during the first few days of life. [16], [17], [18], [19], [20] and [21] Typically, the disease is characterized by the eruption of multiple disseminated, elevated, firm, red-brown nodules (Fig. 160-10). [17] These lesions can grow in size and number in the first few weeks of life, and some may become quite large; they then form brown crusts, which are shed and occasionally leave whitish atrophic scars. In a few cases, solitary lesions have been reported (Fig. 160-11). [19], [22] The absence of mucous membrane lesions is a key feature of HPD. Systemic signs are usually absent except for occasional hepatomegaly. [18] No significant hematologic abnormalities have been observed. Physical and mental development is normal. The salient features of HPD are multiple or solitary papulonodular lesions, sparing of mucous membranes, absence of systemic involvement, and rapid spontaneous regression.

FIGURE 160-10 Hashimoto-Pritzker disease. Multiple, disseminated, elevated, firm red-brown or dark red nodules (multiple form) present at birth. *(From Bonifazi et al.,* [17] *with permission.)*

FIGURE 160-11 Hashimoto-Pritzker disease. Solitary nodule on the temple. The central crust is an expression of rapid spontaneous regression.

INCIDENCE

The annual incidence of LCH is estimated at 0.5 per 100,000 children in the United States [2], [8] and at 1 per 2 million children worldwide. [8] The male to female ratio is 1.8:1. [1]

COURSE AND PROGNOSIS

LCH presents a very wide clinical spectrum and runs a variable course; manifestations range from isolated self-healing lesions to generalized and fatal destructive disease. Classically, the course of LSD is rapid and fatal; for HSCD, it is protracted but progressive (and fatal in about 50 percent of untreated patients); for eosinophilic granuloma, it is chronic and benign; and for HPD, it is self-healing. [1] The most frequent causes of death are pulmonary and bone marrow involvement and intercurrent infections. [1], [9], [10], [11]

Single-system disease is usually associated with a good prognosis, whereas multisystem disease may be fatal. [9], [23], [24] and [25] However, some patients with LSD have been reported to recover spontaneously. [2]

The appearance of xanthomatous lesions in the course of LCH in children [9] and adults [3] is considered by some authors to be an expression of a shift from a disseminated subacute form (LSD) into a progressive chronic form (HSCD); [3] others believe that these lesions may represent a distinct clinical entity independent of the primary disease. [1]

The synchronous occurrence of HX with leukemias [26], [27], [28] and [29] may be interpreted as additional clinical evidence in favor of a common origin of monocytes and Langerhans cells.

Intercurrent infections (mainly candidiasis) are frequently observed in LSD. [1], [3], [9] Several staging systems have been proposed on the basis of prognostic factors derived from retrospective case studies. The age of patients at diagnosis, [23], [30] the number of organs involved, [24] and organ dysfunction [25] are the three main parameters on which the evaluation of prognosis is based. [2]

It is impossible to attribute prognostic significance to any single symptom, but jaundice, thrombocytopenia, anemia, hepatic failure, and nail involvement are considered unfavorable prognostic signs. [1], [24] A favorable prognosis can be ascribed to a small number of lesions, nodular lesions (as in HPD), their prompt resolution, and the involvement of only one organ system (skin or bones). [1], [24] Multisystem LCH in adults carries a better prognosis than in children. [3]

LABORATORY FINDINGS

The laboratory evaluation of a patient with LCH should include complete blood count, platelet count, prothrombin time, partial thromboplastin time, liver function tests, urinalysis, serum protein electrophoresis, T and B cell counts, T cell subset analysis for immunologic evaluation, chest x-ray, complete skeletal radiographic survey, and biopsy of the most accessible lesion. [2] In some cases, these examinations are also required: abdominal sonography, computed tomography of the head, pulmonary function tests, and bone marrow aspirate.

Lahey's concept of organ dysfunction [30], [31] may be evaluated as follows. Liver dysfunction is considered present if there is hypoproteinemia (<5.5 mg/dL total protein and/or <2.5 g/dL of albumin), or edema, or ascites, and/or hyperbilirubinemia (total serum bilirubin >1.5 mg/dL). Lung dysfunction is considered present if there is tachypnea and/or dyspnea, cyanosis, pneumothorax, or pleural effusion attributable to the disease rather than to infection. The presence of radiographic densities alone is not interpreted as evidence of dysfunction. Hemopoietic dysfunction is considered present if there is anemia (<10 g/dL hemoglobin not due to iron deficiency or superimposed infection), leukopenia (white blood count <4000/µL), or thrombocytopenia (<100,000 platelets/µL). The presence of excessive numbers of histiocytes in the marrow aspirate per se is not considered as evidence of dysfunction.

HISTOPATHOLOGIC, IMMUNOHISTOCHEMICAL, AND ULTRASTRUCTURAL FINDINGS

The unifying aspect of the entire spectrum of LCH lies in its pathologic features. The linking histologic element of the different lesions is the typical “LCH cell,” a cell easily identified and differentiated from the nonspecific elements of the infiltrate by its size and configuration. This cell is approximately four to five times larger than small lymphocytes; has an irregular and vesiculated nucleus; is often reniform (kidney shaped); and has abundant, slightly eosinophilic cytoplasm (Fig 160-12). [1], [2]

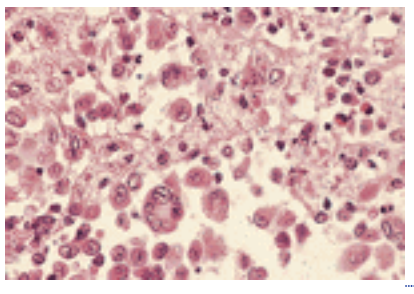

FIGURE 160-12 Langerhans cell histiocytosis. Proliferative reaction. A pure LCH cell infiltrate invades and destroys the epidermis.

The histologic patterns observed in LCH are of three types: [1], [3] proliferative, granulomatous, and xanthomatous. A proliferative reaction is seen in early papules. It consists of an extensive LCH cell infiltration in the upper dermis close to the epidermis, which soon becomes compressed, thinned, invaded, and even destroyed (Fig. 160-12). In the upper dermis, LCH cells are typically separated by edema, whereas in the lower dermis their cell membranes coalesce. In the deep dermis, the infiltrate is often localized around vessels and may invade the hypodermis. A few mitotic figures are occasionally found. [3] Cytologic examination of LCH cells is easily performed by scraping early papules. [1] The granulomatous reaction (Fig. 160-13) consists of an aggregation of LCH cells with some multinucleated histiocytes and a varying number of eosinophils, generally in clusters. Neutrophils, lymphocytes, and plasma cells may also be present in the infiltrate. This type of reaction is seen in the chronic stages of the disease. The xanthomatous reaction is encountered mainly in HSCD and consists of numerous foam cells intermingled with LCH cells and eosinophils (Fig. 160-14). Multinucleated giant cells are frequently seen. They are mainly of the foreign-body type but occasionally may have the appearance of Touton giant cells. Lipid accumulation is considered to be a late secondary phenomenon. [1], [3]

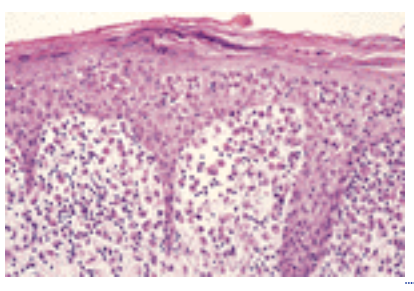

FIGURE 160-13 Langerhans cell histiocytosis. The granulomatous reaction consists of an aggregation of LCH cells with some multinucleated histiocytes, as well as with varying numbers of eosinophils, neutrophils, lymphocytes, and plasma cells. This type of reaction is seen in the chronic stage of the disease.

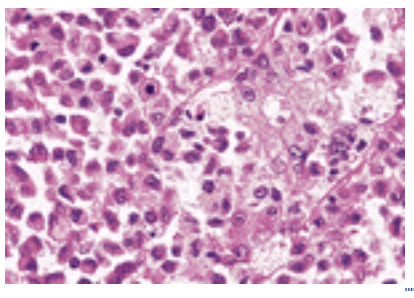

FIGURE 160-14 Langerhans cell histiocytosis. The xanthomatous reaction consists of numerous foam cells intermingled with LCH cells and is encountered mainly in Hand-Schüller-Christian disease. Mitotic figures are occasionally seen.

These different types of histologic reactions may be found simultaneously in the same patient, [1] and the visceral lesions present in LCH show the same three types of reactions observed in the skin. [2], [3]

In HPD, [16], [17], [18], [19], [20], [21] and [22] the infiltrate appears to consist mostly of large multinucleated giant cells intermingled with typical LCH cells. The cytoplasm of the giant cells is either acidophilic or has a “ground glass” appearance. It is usually localized in the mid- and deep dermis; occasionally, the epidermis may be infiltrated and ulcerated.

The LCH cells show the immunophenotype of normal Langerhans cells, expressing high levels of major histocompatibility complex (MHC) class II molecules, CD1a complex, CD4 molecules and S-100 protein; however, in contrast to Langerhans cells, LCH cells also express several macrophage-associated markers including CD11c, CDW32, and CD1, [3], [32], [33] and [34] Moreover, heterogeneity with respect to the expression of various cell markers has been reported. [33], [34] There are few reliable markers capable of distinguishing LCH cells from Langerhans cells of normal skin. Three markers, placental alkaline phosphatase (PLAP), peanut agglutinin (PNA), and interferon-gamma receptor (IFN-(R), are especially valuable in differentiating normal Langerhans cells from LCH cells. [35]

Electron microscopic studies show that approximately 50 percent of the histiocytes of LCH contain LG (Fig. 160-15). [36], [37]

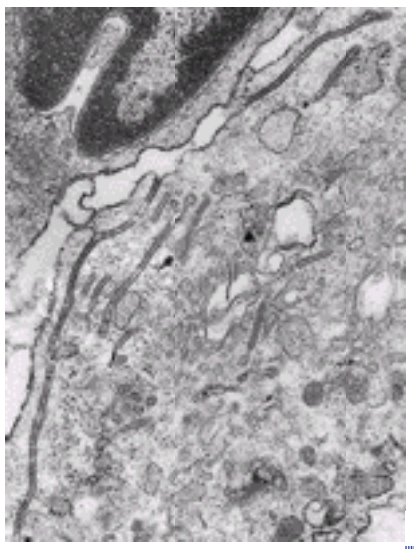

FIGURE 160-15 Langerhans cell histiocytosis. Electron microscopy. A LCH cell containing a large number of very long Langerhans granules.

In HPD, LCH cells are less numerous (10 to 25 percent of tumor cells) and may contain dense and regularly laminated bodies. [3]

ETIOPATHOGENESIS

The etiopathogenesis of LCH remains a mystery despite numerous investigative efforts. A reactive or neoplastic nature of LCH cells is debated. These features substantiate the reactive hypothesis: (1) LCH cells are highly differentiated; (2) histologically the granulomatous lesions resemble those seen in infections or foreign-body reactions, and (3) the possibility of spontaneous regression.

Favara [38] suggested these pathogenic steps: (1) viruses induce activation of histiocytes; (2) immunologic mechanisms produce the pathologic LC phenotype; and (3) a cytokine-mediated storm results in HX lesions.

Many viruses (human herpesvirus-6, cytomegalovirus, adenovirus, parvovirus) were suspected to play an etiologic role, but none have been proved to be responsible for the disease. [39]

The following observations substantiate the clonal neoplastic origin of LHC: [40], [41], [42] and [43] (1) bone marrow derivation and clonality of LCH cells, [42], [43] finding of familial cases of LCH, [44] chromosomal instability with an abnormality on chromosome 7, [45] and of p53 protein in LCH; [46] and (2) concurrence of LCH and a myelodysplastic marrow. [27], [28] and [29]

Two possible explanations have been proposed for the association of LCH and myelodysplasia. [43] The first is that the marrow dysplastic features are secondary to the infiltration of the marrow by LCH cells induced by cytokines and do not represent elements of a “true” myelodysplastic syndrome. A second possibility is that the abnormal marrow cells are related to the clonal LCH cells and are part of the disease process; that is, myelodysplastic cells could be arising from the same clonal cell (an anomalous pluripotent dendritic [Stein] cell line). This possibility raised the issue of whether LCH could be considered a “myeloid dendritic Stein cell disorder.” These findings suggest a genetic predisposition in LCH and stimulate the search for potential candidate genes in LCH.

DIFFERENTIAL DIAGNOSIS [47] (See also Chap. 161)

Skin lesions of disseminated LCH are similar to those of seborrheic dermatitis, moniliasis, and miliaria, but the presence of purpura suggests the diagnosis of LCH. When a condition thought to be banal, such as seborrheic dermatitis, does not respond to proper therapy, LCH should be suspected. The diagnosis can be confirmed promptly by a cytologic examination of the scrapings of an early papule.

In Darier-White disease (see Chap. 54), the lesions appear between ages 8 and 15 years, and the papules are hyperkeratotic and may involve the extremities. Lichen nitidus (see Chap. 50) is differentiated from LCH by the presence of shiny, skin-colored, nonscaling papules and the Koebner phenomenon, which does not occur in LCH. Chronic and persistent xanthomatous lesions of LCH must be differentiated from urticaria pigmentosa (see Chap. 163) and non-Langerhans cell histiocytosis (see Chap. 161). In urticaria pigmentosa, the lesions are macular, papular, or nodular, and wheal immediately after they have been rubbed.

Benign cephalic histiocytosis is characterized by flat dome-shaped nonscaling papules that preferentially involve the head. Here, the scalp, trunk, mucous membranes, and viscera are spared.

Histopathologic examination is necessary to differentiate some lesions of juvenile xanthogranuloma and xanthoma disseminatum from the xanthomatous lesions of LCH; in juvenile xanthogranuloma, bone lesions are not present, and in xanthoma disseminatum, cutaneous xanthomas are distributed symmetrically and tend to coalesce.

In sinus histiocytosis with massive lymphadenopathy, cervical lymphadenopathy is a prominent feature and is usually accompanied by fever, leukocytosis with neutrophilia, and polyclonal hypergammaglobulinemia. Papules of generalized eruptive histiocytosis are differentiated from those of LCH by absence of scales and crusts, a red-brown or red-blue color, and symmetric distribution.

The presence of violaceous plaques or nodules with patulous follicular ostia on the face distinguishes granuloma faciale

from eosinophilic granuloma. HPD must mainly be differentiated from nodular forms of LCH such as eosinophilic granuloma, juvenile xanthogranuloma, generalized eruptive histiocytosis, and urticaria pigmentosa. The distinction of HPD from nodular lesions present in the disseminated form of LCH may be difficult because of the histologic, ultrastructural, and immunologic similarities. HPD is distinctive in that the skin alone is involved and the lesions are rapidly self-healing. Nodular lesions of juvenile xanthogranuloma may be present at birth. However, they rapidly become yellow, do not tend to ulcerate, and heal spontaneously within several years but never in a few months. Histologically, the lesions are composed of foamy cells and multinuclear giant cells; S-100– and CD1a-positive cells are absent, and LG are not detected by electron microscopy.

Generalized eruptive histiocytosis consists of numerous, discrete papules appearing in successive crops and involving mainly the trunk and proximal limbs. The disease is rare in children and has never been seen at birth. Histologically, the infiltrate is monomorphous and the histiocytes are S-100 and CD1a negative and do not contain LG (see also Chap. 161). The absence of urtication and, histologically, of mast cells, rules out urticaria pigmentosa.

MANAGEMENT

Treatment strategies of LCH are chosen on the basis of the age of patients, extent of disease, and location of lesions (Table 160-1). [2], [19]



TABLE 160-1 **Treatment of Langerhans Cell Histiocytosis**

In “single-system disease” involving skin or bone, management is nonaggressive. In children with skin involvement only, observation is the best option; [9] if the lesions are persistent, topical nitrogen mustard may be an effective treatment. [48], [49] Therapy consists of application of nitrogen mustard diluted in water to a concentration of 20 mg/dL and applied daily for 5 days. Systemic glucocorticoids or antimitotic drugs are indicated in resistant cases. [9] In adults with skin involvement only, topical treatment with nitrogen mustard may be an effective treatment strategy. Significant improvement has been obtained with conventional PUVA treatment in a considerable number of cases. [50], [51] CO_2 laser therapy has been suggested in periorificial eosinophilic granuloma. [52] The use of thalidomide, at a dose of 100 mg per day for 1 month and then 50 mg per day for 1 or 2 months (see Chap. 264), may induce a remission of skin lesions. [53], [54] and [55] Usually the disease recurs after stopping treatment. The effect of thalidomide seems to be a result of its immunomodulatory and anti-inflammatory properties. In one case, a complete remission of skin lesions was obtained after oral isotretinoin therapy. The patient was treated with 1.5 mg/kg daily for a period of 8 months and remained free of recurrence and visceral involvement for 5 years. [56]

For patients with bone involvement only, surgery (excision or curettage) is the treatment of choice if the lesions are accessible. [2], [9], [57] In children, glucocorticoid injections into selected sites may avoid surgical trauma to developing teeth or the growth plate of long bones. [9] In adults, radiotherapy is indicated for involvement of vertebrae, the sella turcica, and weight-bearing bones with risk of spontaneous fracture. [2], [10] In children, radiotherapy must be reserved for cases that fail to respond to other measures in order to avoid the risk of long-term effects. [9] In the case of multiple bone lesions, monochemotherapy is suggested as with multiorgan involvement.

The management of patients with multisystem disease is controversial. [58] Currently, monochemotherapy with vinblastine or etoposide with or without glucocorticoids is probably the most suitable treatment. [59], [60] Vinblastine is given intravenously at doses of 0.1 to 0.2 mg/kg once weekly (6.5 mg/m ^{2}) for 1 to 3 months. Readministration of the alkaloid should be instituted only when new lesions appear. [1], [3], [59] Etoposide [60], [61] and [62] is administered at a dose of 200 mg/m ^{2} orally or intravenously for 3 consecutive days every 3 to 4 weeks for at least three to four courses. Etoposide gave approximately a 90 percent response rate in one study. [60] Both vinblastine and etoposide are well tolerated and cause only a few toxic effects. In case of relapses, retreatment with the same type of monochemotherapy may result in complete clearing in 60 percent of cases. [2] Finally, methylprednisolone (30 mg/kg intravenously on 3 consecutive days) may be the initial therapeutic approach.

Only nonresponders to monochemotherapy should be given multiagent regimens including vincristine, cyclophosphamide, doxorubicin, and chlorambucil. [2], [59], [63] In refractory and advanced cases of LCH, cyclosporine [64], [65] and interferon-a $_2$, [66] and 2-chlorodioxyadenosine (2CdA) [67] have been used. Allogenic bone marrow transplantation was successful in one child with a very poor prognosis. [68]

REFERENCES

1. Gianotti F, Caputo R: Histiocytic syndromes: A review. *J Am Acad Dermatol* **13**:383, 1985

2. Lahey MA et al: Langerhans' cell histiocytosis. *Curr Probl Dermatol* **6**:1, 1994

3. Caputo R. *Text Atlas of Histiocytic Syndromes*. London, Martin Dunitz, 1988

4. Lichtenstein L: Histiocytosis X: Integration of eosinophilic granuloma of bone. Letterer-Siwe disease and Hand-Schüller-Christian disease as

related manifestations of a single nosologic entity. *Arch Pathol* **56**:84, 1953

5. Hashimoto K, Pritzker MS: Electron microscopic study of reticulohistiocytoma. An unusual case of congenital self-healing reticulohistiocytosis. *Arch Dermatol* **107**:263, 1978

6. Basset F, Nezelof C: Les histiocytoses. *Presse Med* **12**:2809, 1983

7. Chu T et al: Histiocytosis syndromes in children. *Lancet* **1**:208, 1978

8. Caputo R et al: Mucocutaneous expressions of Langerhans cell histiocytosis in adults. *Eur J Dermatol* **4**:528, 1994

9. Esterly NB et al: Histiocytosis X: A seven-year experience at a children's hospital. *J Am Acad Dermatol* **13**:481, 1985

10. De Lacharriere O, Ougier E: Histiocytose Langerhansienne de l'adulte à expression cutanée. Revue genérale. *Ann Dermatol Venereol* **117**:303, 1990

11. Howarth DM et al: Langerhans cell histiocytosis. *Cancer* **85**:2278, 1999

12. McGavian MH, Spady HA: Eosinophilic granuloma of bone: A study of 28 cases. *J Bone Joint Surg* (*Am*) **42**:979, 1960

13. Sparbaro JL, Francis KC: Eosinophilic granuloma of bone. *JAMA* **178**:706, 1961

14. Cavender PA, Bennett RG: Perianal eosinophilic granuloma resembling condyloma latum. *Pediatr Dermatol* **5**:50, 1988

15. Otis CN et al: Histiocytosis X of the vulva. A case report and a review of the literature. *Obstet Gynecol* **75**:555, 1990

16. Hashimoto K, Pritzker MS: Electron microscopic study of reticulohistiocytoma: An unusual case of congenital self-healing reticulohistiocytosis. *Arch Dermatol* **107**:263, 1978

17. Bonifazi L et al: Congenital self-healing histiocytosis. *Arch Dermatol* **118**:267, 1982

18. Hashimoto K et al: Self-healing reticulohistiocytosis. *Cancer* **49**:331, 1982

19. Berger TG et al: A solitary variant of congenital self-healing reticulohistiocytosis: Solitary Hashimoto-Pritzker disease. *Pediatr Dermatol* **3**:230, 1986

20. Cambazard F et al: Hashimoto-Pritzker congenital self-healing histiocytosis. *Pediatrics* **148**:29, 1988

21. Enjolras O et al: Congenital cutaneous Langerhans histiocytosis. A propos of 7 cases. *Ann Dermatol Venereol* **119**:111, 1992

22. Taieb A et al: Solitary Langerhans cell histiocytoma. *Arch Dermatol* **122**:1033, 1986

23. Komp DM et al: A staging system for histiocytosis X: A Southwest Oncology Group study. *Cancer* **47**:798, 1981

24. Nezelof C et al: Disseminated histiocytosis X: Analysis of prognostic factors based on retrospective study of 50 cases. *Cancer* **44**:1824, 1979

25. Oberman HA: Idiopathic histiocytosis: A clinicopathologic study of 40 cases and review of literature on eosinophilic granuloma of bone, Hand-Schüller-Christian disease and Letterer-Siwe disease. *Pediatrics* **58**:307, 1961

26. Egeler RM et al: Association of Langerhans cell histiocytosis with malignant neoplasm. *Cancer* **71**:865,1993

27. Egeler RM et al: Acute leukemia in association with Langerhans cell histiocytosis. *Med Pediatr Oncol* **23**:81, 1994

28. Baikian B et al: Histiocytose langerhansienne et leucémie de la lignée myelomonocytaire: une association non fortuite. *Ann Dermatol Venereol* **126**:409, 1999

29. Surico G et al: Concurrent Langerhans cell histiocytosis and myelodysplasia in children. *Med Pediatr Oncol* **35**:421, 2000

30. Lahey ME: Histiocytosis X: An analysis of prognostic factors. *J Pediatr* **87**:184, 1975

31. Lahey ME: Prognostic factors in histiocytosis X. *Am J Pediatr Hematol Oncol* **3**:57, 1981

32. Cambazard F et al: Identification immunohistologique des cellules de l'histiocytosis X. Intérnet diagnostique. *Ann Dermatol Venereol* **110**:33, 1983

33. Bos JD et al: Acute disseminated histiocytosis X: In situ immunophenotyping with monoclonal antibodies. *J Cutan Pathol* **11**:59, 1984

34. Groh V et al: The phenotypic spectrum of histiocytosis X cells. *J Invest Dermatol* **90**:441, 1988

35. Chu T, Jaffe R: The normal Langerhans cell and the LCH cell. *Br J Cancer* **70**:4, 1994

36. Tarnowski W, Hashimoto H: Langerhans' cell granules in histiocytosis X. *Arch Dermatol* **96**:298, 1976

37. Caputo R, Gianotti F: Cytoplasmic markers and unusual ultrastructural features in histiocytic proliferations of the skin. *G Ital Dermatol Venereol* **115**:107, 1980

38. Favara BE: Langerhans cells histiocytosis pathobiology and pathogenesis. *Semin Oncol* **18**:3, 1991

39. McClain K et al: Langerhans cell histiocytosis: Lack of a viral etiology. *Am J Hematol* **47**:16, 1994

40. Jenney MEM: Langerhans cell histiocytosis: Where do we go from here? *Lancet* **344**:1717, 1994

41. Yu RC et al: Clonal proliferation of Langerhans cell in Langerhans cell histiocytosis. Lancet **1**:767, 1994

42. William CI et al: Langerhans cell histiocytosis (histiocytosis X): A clonal proliferative disease. *N Engl J Med* **331**:154, 1994

43. Egeler RM, Willman CL: Is Langerhans cell histiocytosis a myeloid dendritic Stein cell related to myelodysplastic disorders? *Med Pediatr Oncol* **35**:426,2000

44. Aricò M et al: Familial clustering of Langerhans cell histiocytosis. *Br J Haematol* **107**:883, 1999

45. Betto DR et al: Cytogenetic abnormalities in Langerhans cell histiocytosis. *Br J Cancer* **77**:552, 1998

46. Weintraub M et al: p53 expression in Langerhans cell histiocytosis. *J Pediatr Hematol Oncol* **20**:12, 1998

47. Caputo R et al: Histiocytosis X, in *Pediatric Dermatology and Dermatopathology,* vol II edited by R Caputo, AB Ackerman, and ES Torre. Philadelphia, Lea and Febiger, 1993, p 471

48. Atherton DJ et al: Topical use of mustine hydrochloride in cutaneous histiocytosis X. *Med Pediatr Oncol* **14**:112, 1986

49. Sheehan MP et al: Topical nitrogen mustard: An effective treatment for cutaneous Langerhans' cell histiocytosis. *J Pediatr* **119**:317, 1991

50. Kaudewitz P et al: Cutaneous lesions in histiocytosis X: Successful treatment with PUVA. *J Invest Dermatol* **86**:324, 1986

51. Sakai H et al: Satisfactory remission achieved by PUVA therapy in Langerhans cell histiocytosis in an elderly patient. *J Dermatol* **23**:42, 1996

52. Truong TT et al: Granulome éosinophile: Essai de traitement avec le laser au CO_2. *Nouv Dermatol* **9**:850, 1990

53. Bensaid P et al: Histiocytose Langerhansienne de l'adulte: Localisation parotidienne régressive après traitement par thalidomide. *Ann Dermatol Venereol* **119**:281, 1992

54. Misery L et al: Remission of Langerhans cell histiocytosis with thalidomide treatment. *Clin Exp Dermatol* **18**:487, 1993

55. Thomas L et al: Successful treatment of adults Langerhans cell histiocytosis with thalidomide. *Arch Dermatol* **129**:1261, 1993

56. Tsambaos D et al: Langerhans' cell histiocytosis: Complete remission after oral isotretinoin therapy. *Acta Dermatol Venereol* **75**:62, 1995

57. McLelland J et al: Langerhans' cell histiocytosis: The case for conservative treatment. *Arch Dis Child* **65**:301, 1990

58. Broadbent V, Pritchard J: Histiocytosis X—current controversies. *Arch Dis Child* **60**:605, 1985

59. Lahey ME: Histiocytosis X—comparison of three treatment regimens. *Pediatrics* **87**:179, 1975

60. Ceci A et al: Etoposide in recurrent childhood Langerhans' cell histiocytosis: An Italian cooperative study. *Cancer* **82**:2528, 1988

61. Broadbent V et al: Etoposide (VP16) in the treatment of multisystem Langerhans' cell histiocytosis (histiocytosis X). *Med Pediatr Oncol* **17**:97, 1989

62. Shaehan MP, Chu AC: Oral, skin and bone multisystem Langerhans' cell histiocytosis and its response to etoposide—a case report. *Clin Exp Dermatol* **16**:463, 1991

63. Komp DM et al: Combination therapy in histiocytosis X. *Med Pediatr Oncol* **3**:267, 1977

64. Mahmoud HH et al: Cyclosporine therapy for advanced Langerhans' cell histiocytosis. *Blood* **77**:721, 1991

65. Arico M: Cyclosporine therapy for refractory Langerhans' cell histiocytosis. *Blood* **78**:3107, 1991

66. Bellmunt J et al: Interferon and disseminated Langerhans' cell histiocytosis. *Med Pediatr Oncol* **20**:336, 1992

67. Weitzman S et al: Nucleoside analogues in the therapy of Langerhans cell histiocytosis: A survey of members of the histiocyte society and review of the literature. *Med Pediatr Oncol* **33**:476, 1999

68. Stoll M et al: Allergic bone marrow transplantation for Langerhans' cell histiocytosis. *Cancer* **66**:284, 1990

T>

Chapter 161

Ruggero Caputo

Cutaneous Nonhistiocytoses X

JUVENILE XANTHOGRANULOMA
Definition and Historic Aspects
Incidence
Age of Onset
Clinical Findings
Associations
Histopathologic Findings
Differential Diagnosis
Course and Prognosis
GENERALIZED ERUPTIVE HISTIOCYTOSIS
Definition and Historic Aspects
Incidence
Age of Onset
Clinical Findings
Histopathologic Findings
Differential Diagnosis
Course and Prognosis
BENIGN CEPHALIC HISTIOCYTOSIS
Definition and Historic Aspects
Incidence
Age of Onset
Clinical Findings
Histopathologic Findings
Differential Diagnosis
Course and Prognosis
SINUS HISTIOCYTOSIS WITH MASSIVE LYMPHADENOPATHY
Definition and Historic Aspects
Incidence
Age of Onset
Clinical Findings
Associations
Histopathologic Findings
Etiology
Differential Diagnosis
Treatment
Course and Prognosis
XANTHOMA DISSEMINATUM
Definition and Historic Aspects
Incidence
Age of Onset
Clinical Findings
Associations
Histopathologic Findings
Differential Diagnosis
Treatment
Course and Prognosis
PAPULAR XANTHOMA
Definition and Historic Aspects
Incidence
Age of Onset
Clinical Findings
Histopathologic Findings
Differential Diagnosis
Course and Prognosis
NECROBIOTIC XANTHOGRANULOMA
Definition
Incidence
Age of Onset
Clinical Findings
Associations
Complications
Laboratory Findings
Histopathologic Findings
Etiopathogenesis
Differential Diagnosis
Treatment
Course and Prognosis
PROGRESSIVE NODULAR HISTIOCYTOSIS
Definition and Historic Aspects

Incidence
Clinical Findings
Associations
Histopathologic Findings
Differential Diagnosis
Course and Prognosis
Etiopathogenesis
Treatment
HEREDITARY PROGRESSIVE MUCINOUS HISTIOCYTOSIS
Definition and Historic Aspects
Incidence
Clinical Findings
Histopathologic Findings
Differential Diagnosis
Course
Etiopathogenesis
Treatment

REFERENCES

Nonhistiocytoses X, [1] or non-Langerhans cell histiocytoses, are characterized by the proliferation of histiocytes that always lack Langerhans granules (LG) and are usually S-100 and CD1a negative. Nonhistiocytoses X include a series of nonaggressive, frequently self-healing diseases, affecting both children and adults. [2], [3]

JUVENILE XANTHOGRANULOMA

Definition and Historic Aspects

Juvenile xanthogranuloma (JXG) is a benign, self-healing disorder of infants, children, and, occasionally, adults, that is characterized by yellowish papulonodular lesions located in the skin and other organs in the absence of metabolic disorders and consisting of an infiltrate of histiocytes with a progressively greater degree of lipidation.

Nevoxanthoendothelioma [4] was the name first used, in 1912, to describe this disease. Because there was no evidence for a relationship to nevi or endothelial cells, in 1954, Helwig and Macknay [5] proposed the term *juvenile xanthogranuloma*. Laurb and Lain [6] reported the first case of JXG with visceral involvement in 1937; in 1949, Blank et al. [7] first described ocular involvement.

Incidence

JXG is the most common form of nonhistiocytosis X. [8] The author has observed 117 cases in the past 30 years. [3] There is no sexual or racial predilection.

Age of Onset

JXG appears within the first year of life in about 80 percent of cases; [2], [3] in 20 to 30 percent of cases, it is present at birth. [3] Approximately 25 adult cases are reported in the literature. [1], [3]

Clinical Findings

Two main clinical forms can be distinguished: a papular form and a nodular form. [2], [3] The papular form (Fig. 161-1) is characterized by numerous (up to 100), firm, hemispheric lesions, 2 to 5 mm in diameter, that are initially red-brown but quickly turn yellowish. These lesions are irregularly scattered throughout the skin but are located mainly on the upper part of the body. Mucous membrane involvement is rare. The nodular form (Fig. 161-2) is less frequent and occurs as one or a few lesions. Such nodules are generally round, 10 to 20 mm in diameter, translucent, red, tan or yellowish, and might show telangiectases on their surface. The term *giant JXH* indicates lesions larger than 2 cm. [3], [9] Mucous membrane lesions are more commonly seen in the nodular form than in the papular form. Both types of lesions are generally asymptomatic. Unusual clinical variants have been recently reported. [9] The mixed form is characterized by the simultaneous presence of both small and large nodules. The term *JXG en plaque* defines a group of JXG lesions with a tendency to coalesce into a plaque as the only expression of the disease. The subcutaneous form [3] consists of a solitary, deep-seated congenital or perinatal lesions, 1 to 2 cm in diameter, usually located on the head.

FIGURE 161-1 Juvenile xanthogranuloma. Papular form.

FIGURE 161-2 Juvenile xanthogranuloma. Nodular form.

Associations

Café au lait macules are noted in approximately 20 percent of patients with the papular form of JXG. [10] In this form, ocular involvement [11] is the most typical extracutaneous manifestation; it may precede or follow the cutaneous lesions. Such lesions are usually unilateral and may lead to hemorrhage and glaucoma. An extremely rare extracutaneous manifestation of the papular variant is central nervous system involvement. [12]

The nodular form of JXG may occasionally be related to systemic lesions of lungs, bones, kidneys, pericardium, colon, ovaries, and testes. [2], [3] Juvenile chronic myeloid leukemia has been observed in association with this variant of JXG. [3]

Histopathologic Findings

Early lesions are characterized by a monomorphous, non–lipid-containing histiocytic infiltrate [1], [2] and [3], [8] that occupies at least the upper half, and sometimes the entire thickness, of the dermis. Mature lesions (Fig. 161-3) contain foamy cells, foreign-body giant cells, and Touton giant cells, mainly distributed in the superficial dermis and on the border of the infiltrate. Lymphocytes, eosinophils, and neutrophils are variably associated. Older lesions may show fibrosis. In mature lesions, fat stains are positive. The histiocytes forming the infiltrate are CD15, CD36, CD116, and CD4 positive and S-100 negative.

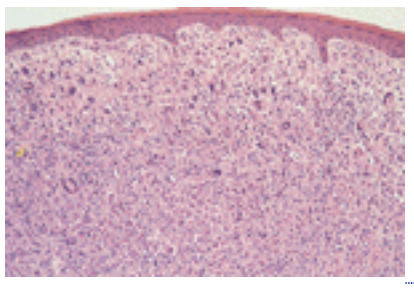

FIGURE 161-3 Juvenile xanthogranuloma. Histopathologic findings. A mature lesion containing foamy cells, foreign-body giant cells, and Touton giant cells.

Under the electron microscope, [2], [3] the histiocytes that characterize the early stage of the disease exhibit pleomorphic nuclei, are rich in pseudopods, and contain many elongated and irregular dense bodies.

Clusters of “comma-shaped bodies,” but no Langerhans cell granules (LG), can occasionally be observed electronmicroscopically. In older lesions, there is a predominance of foamy cells, the cytoplasm of which is completely filled with lipid vacuoles, cholesterol clefts, and myeloid bodies. The cells corresponding to Touton giant cells are extremely large and sometimes contain more than 10 nuclei. At their periphery, such cells are rich in lipid material, whereas in their center, mitochondria and lysosomes predominate.

Differential Diagnosis

JXG can be differentiated from nodular urticaria pigmentosa, in which lesions become urticarial immediately after rubbing and histologically have many mast cells. Benign cephalic histiocytosis (BCH) differs from JXG because its papular lesions are located only on the head and neck. Its infiltrate lacks foamy cells and multinucleated giant cells. Generalized eruptive histiocytoma (GEH) is not granulomatous, and lipidation of the cells never occurs; histiocytes are monomorphous and are rich in dense and regularly laminated bodies on electron microscopic examination. In self-healing reticulohistiocytoma, the cutaneous lesions persist for only the first few months of life and 10 to 25 percent of the cells are S-100 protein-positive and show LG. Tuberous xanthoma appears only in hyperlipidemic states. Papular xanthoma (PX) is distinguishable from JXG and xanthoma disseminatum (XD), from a histologic point of view, only because the primitive pure histiocytic phase is lacking. The nodular forms of histiocytosis X can be differentiated because of the different histologic, immunocytochemical, and ultrastructural characteristics (i.e., the presence of histiocytosis X cells, which are S-100 positive and contain LG). Single JXG may be clinically difficult to distinguish from a Spitz nevus, which is characterized by the presence of spindle and epithelial nevus cells. Histologically, however, they are distinct.

Course and Prognosis

The cutaneous lesions tend to flatten with time. Each lesion evolves separately; thus, lesions at different stages of evolution may be seen in the same patient. [1], [2] and [3] Both cutaneous and visceral lesions disappear spontaneously within 3 to 6 years. The patient's general health is not impaired, and physical and mental development is normal. Metabolic disturbances have not been identified. In the absence of associated conditions, prognosis is good.

GENERALIZED ERUPTIVE HISTIOCYTOSIS

Definition and Historic Aspects

GEH [13] is a papular, nonlipidic, self-healing histiocytosis affecting mainly adults. The first adult case of this disease was described, in 1963, by Winkelmann and Muller [13]; in 1987, Caputo et al. [14] reported a series of pediatric cases.

Incidence

GEH is an extremely rare disease. Approximately 30 cases have been described, of which 7 were in children. [3], [14]

Age of Onset

GEH may start at any age, with reports of starting ages ranging from 3 months to 58 years.

Clinical Findings

The skin lesions consist of an asymptomatic eruption of round or oval papules that are firm, dark red or dark blue, and range in size from 3 to 10 mm (Fig. 161-4). These lesions appear in successive crops and are usually numerous (hundreds). In adults, the lesions are symmetrically distributed and may involve mucous membranes, whereas in children, the lesions are irregularly scattered over the entire body and mucous membranes are spared. [14] No visceral lesions have been observed in either children or adults.

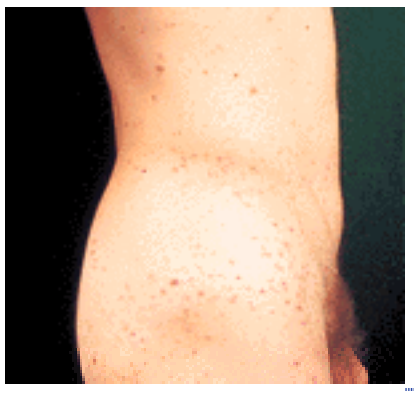

FIGURE 161-4 Generalized eruptive histiocytosis in an adult.

Histopathologic Findings

The lesions (Fig. 161-5) consist of a dense, monomorphous, histiocytic infiltrate in the papillary and midportion of the dermis, with a few lymphocytes. [14], [15] The histiocytes contain a nucleus with scanty chromatin and an abundant, light, poorly limited cytoplasm. These cells are often arranged in nests around vessels. Older lesions in children may contain foamy cells. [14]

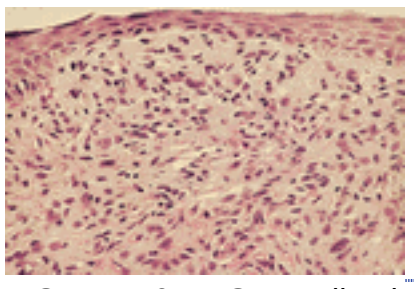

FIGURE 161-5 Generalized eruptive histiocytosis. Histopathologic findings. Dense monomorphous histiocytic infiltrate in the papillary and mid–dermis, intermingled with a few lymphocytes.

In all the cases studied by using immunologic techniques, [14] the histiocytes of the infiltrate were negative for S-100 protein and CD1a and positive for CD11b and CD4, except for the case described by Sigal-Nahum et al. [16] in which many cells of the infiltrate were S-100 negative and CD1a positive. Electron microscopy shows the tumor cells to contain a large number of dense and regularly laminated bodies, often clustered together. Occasionally, wormlike bodies are found, but LG are always absent. [2], [3], [14], [15]

Differential Diagnosis

JXG and PX can be excluded in view of the color of the lesions and the presence of both foamy cells and Touton giant cells. Multicentric reticulohistiocytosis can be ruled out because of the absence of arthritis and the lack of multinucleated giant cells. BCH has lesions localized on the face and affects only children; nevertheless, this disease may represent a problem in differential diagnosis because it is histologically closely related to GEH.

Histiocytosis X is easily excluded based on its clinical features and because of its typical histologic, immunocytochemical, and ultrastructural features.

Course and Prognosis

New crops of lesions may continue for years. Slowly the disease subsides spontaneously without a trace or leaving anetoderma-like macules. General health is always normal. Winkelmann [1] suggests that this syndrome could represent the primitive form of other, more developed, nonhistiocytoses X (JXG, PX, BCH, multicentric reticulohistiocytosis). The appearance of xanthomatous lesions in children with the disease [14] might support this hypothesis.

BENIGN CEPHALIC HISTIOCYTOSIS

Definition and Historic Aspects

BCH is self-healing, cutaneous, nonhistiocytosis X, characteristically occurring on the head, especially the face.

First described in 1971 by Gianotti et al., [17] it was named “histiocytosis with intracytoplasmic wormlike bodies” because of the presence of such structures in the cytoplasm. Ultrastructural examination of specimens from many different histiocytopathies has shown comma-shaped bodies. Therefore, the name benign cephalic histiocytosis was suggested, [2] focusing on its most typical clinical feature. The first two cases observed in the United States were reported in the mid-1980s. [18], [19]

Incidence

The condition is very rare. Over the past 3 decades, approximately 30 cases have been described. [3], [20], [21], [22] and [23] The incidence in boys and girls is about the same.

Age of Onset

The age of onset is 5 to 34 months (mean, 13.5 months).

Clinical Findings

The eruption consists of asymptomatic, slightly raised, round or oval, pinkish and brownish-yellow papules, 2 to 8 mm in diameter, localized first on the upper part of the face, mainly around the eyelids, forehead, and cheeks (Fig. 161-6). Other lesions subsequently appear over the entire head, the auricles (particularly on the posterior side), the occipital region, and the neck; a few other lesions may appear on the shoulders and arms. Mucous membranes and viscera are always spared. The number of lesions at the beginning of the disease varies considerably, from 2 to more than 100. New lesions continue to appear for many months.

FIGURE 161-6 Benign cephalic histiocytosis.

Histopathologic Findings

By conventional microscopy, [23] early lesions show a well-circumscribed infiltrate, closely attached to the lower surface of the epidermis, which is thin and flattened. Most of the cells in the infiltrate are histiocytes with pleomorphic nuclei, sparse chromatin, and barely recognizable, sometimes glassy, cytoplasm. Scattered or grouped lymphocytes and a few eosinophils are found among the histiocytes. Old lesions have few multinucleated giant cells with peripheral nuclei. The histiocytes are S-100 and CD1a negative and CD11b and CD4 positive. By electron microscopy, [2], [3], [17], [18], [20] many coated vesicles with a diameter ranging from 500 to 1500 nm are seen in all the histiocytes. Clusters of “comma-shaped bodies” are present in nearly one-fourth of the histiocytes. The comma-shaped bodies are formed by two electron-dense membranes of approximately 6 nm, separated by a light space of about 8 nm. Where the infiltrate is more dense, desmosome-like junctions may be observed among the histiocytes. These cells always lack LG.

Differential Diagnosis

BCH can be differentiated from JXG (particularly the small nodular type), in which the nodules are pleomorphic and not limited to the head and neck. Histologically, the latter nodules appear to be composed of many multinucleated giant cells and foamy cells. Electron microscopy demonstrates lipid droplets without limiting membranes in the cytoplasm of the macrophages. The nodular type of urticaria pigmentosa is distinguishable because of the wheal that follows rubbing;

mast cells are an obvious histopathologic marker. The lichenoid form of sarcoidosis can be diagnosed by its islands of epithelioid cells permeated and surrounded by reticulum fibers. GEH is distinguishable because of the age of onset (mainly adults) and the sites involved. Electron microscopy demonstrates many dense and regularly laminated bodies clustered together in the macrophages. PX can be differentiated because the lesions are widespread and show foamy cells and Touton giant cells, even in the early stage. Histiocytosis X, especially the chronic disseminated form (Hand-Schüller-Christian disease), is distinguishable because its papular lesions spread to the scalp and the trunk. Histopathology, S-100 protein staining, and electron microscopy confirm the diagnosis.

Course and Prognosis

Spontaneous regression of lesions occurs months to years after the onset of the eruption. Regression of lesions starts characteristically where papules first appeared. The papules begin to flatten and then, after a short period of hyperpigmentation, the lesions disappear without leaving scars. Both the mental and the physical development of the patients are normal.

SINUS HISTIOCYTOSIS WITH MASSIVE LYMPHADENOPATHY

Definition and Historic Aspects

Sinus histiocytosis with massive lymphadenopathy (SHML) [24], [25] is a benign, generally self-limited disease confined mainly to cervical lymph nodes. It is usually accompanied by fever, elevated erythrocyte sedimentation rate, leukocytosis with neutrophilia, and polyclonal hypergammaglobulinemia. Cutaneous manifestations are observed in approximately 10 percent of patients. [26], [27] and [28]

SHML was first described in 1969 by Rosai and Dorfman [24] (Rosai-Dorfman syndrome). Thawerani et al. [26] emphasized the cutaneous manifestations in 1978.

Incidence

SHML is a relatively rare disease; approximately 365 cases have been studied and followed. [29] The disease has a worldwide distribution with a predilection for blacks from Africa and the West Indies. There is no sexual predilection.

Age of Onset

Any age group may be affected, but 80 percent of cases occur in the first or second decades of life. [28], [29]

Clinical Findings

Cutaneous lesions are polymorphic (Fig. 161-7). [27], [28] They may occur as yellowish macules and patches, reddish-brown papules, plaques, and nodules that may become eroded or ulcerated. In one patient, [26] firm purple nodules and tumors as large as 10 cm in diameter were noted, but in most instances, the lesions are much smaller, multiple, widespread, and asymptomatic. A special presentation of SHML on the skin can be misinterpreted when periocular involvement results in a lobulated induration of the eyelids. [3] Cutaneous manifestations may be the initial presentation and sole presenting feature of the disease. [30] Massive, bilateral cervical lymphadenopathy, usually painless, is the hallmark of the condition. Less commonly, axillary, mediastinal, inguinal, and preauricular lymph nodes may be affected.

FIGURE 161-7 Sinus histiocytosis with massive lymphadenopathy.

Associations

Extranodal disease occurs in approximately 25 percent of patients [28] and may be the initial manifestation of the disorder. The extranodal noncutaneous sites most commonly affected are the eye, [3] upper respiratory tract, [30] liver, spleen, testes, skeleton, [31] and nervous system. [32] Fever, an elevated erythrocyte sedimentation rate, leukocytosis with neutrophilia, and polyclonal hypergammaglobulinemia are common (90 percent of tested patients). [29] Less-frequent findings include moderate anemia (60 percent), lymphopenia, elevated titers of Epstein-Barr virus, [29] and, in one case, elevated Klebsiella antibody titers. [28]

Histopathologic Findings

Histopathologically, [26], [28] the skin lesions are characterized by a dermal infiltrate composed predominantly of histiocytes with large vesicular nuclei and abundant pale cytoplasm. Some histiocytes are foamy, multinucleated, or both. Lymphophagocytosis has been described. Histiocytes are sometimes aggregated in clusters resembling lymph node sinuses. Lymphocytes, plasma cells, and polymorphonuclear leukocytes may be intermixed in the infiltrate. Recent reports [29] show that most of the histiocytes of SHML lesions are S-100 positive and CD1a negative. Electron microscopy [3] shows that most histiocytes forming the infiltrate are rich in phagosomes and may contain clusters of “comma-shaped bodies.” LG are absent.

Etiology

The cause of SHML remains obscure. Two main hypotheses have been proposed: a disturbance of cell-mediated immunity or a primary infection (Epstein-Barr virus, Klebsiella). [28], [29]

Differential Diagnosis

There is a broad differential diagnosis with many diseases, both proliferative and inflammatory, mainly based on histopathologic and immunologic findings. The histopathologic combination of histiocytes with abundant pale cytoplasm, a mixed-cell infiltrate, and karyophagocytosis is an important criterion of differentiation. The observation that histiocytes forming the infiltrate of SHML are mainly S-100 positive and CD1a negative, if confirmed, could be another distinctive feature of this disease.

Treatment

As a rule, because the vast majority of lesions of SHML heal spontaneously, no treatment is necessary. In rare instances, a space-occupying lesion will interfere with the function of an organ and then treatment with systemic glucocorticoids or with various chemotherapeutic regimens might be useful. [28]

Course and Prognosis

In most patients, SHML has a benign course [28] with spontaneous regression over a period of months to years. Usually the extranodal lesions regress first, whereas adenopathy may persist for years. [25] A worse prognosis results mainly from associated immunologic abnormalities. [33]

XANTHOMA DISSEMINATUM

Definition and Historic Aspects

XD, or Montgomery's syndrome, is a rare, benign, normolipemic form of histiocytoxanthomatosis affecting the skin and mucous membranes, and frequently associated with diabetes insipidus.

Montgomery and Osterberg, [34] in 1938, first recognized this distinct type of cutaneous xanthomatosis. Altman and Winkelmann [35] reviewed the literature and confirmed this syndrome.

Incidence

The condition is rare (about 100 published cases), [36], [37] affecting males more frequently than females. [34] The random nature of the disorder does not permit an exact evaluation of either familial involvement or morbidity.

Age of Onset

In approximately 60 percent of patients, onset is before age 25 years. [35]

Clinical Findings

The cutaneous manifestations consist of hundreds of papules that are red-brown at first and then become yellowish. They symmetrically involve the trunk, face, and proximal extremities and, in flexures and folds, tend quickly to merge, forming verrucous plaques (Fig. 161-8). [35], [37] In approximately 50 percent of the cases, [35], [36] xanthomatous lesions may also be observed on the mucous membranes of the mouth, pharynx, and larynx, and on the conjunctiva and cornea. Symptoms of dyspnea and dysphagia are not uncommon. Vasopressin-sensitive transitory diabetes insipidus may be present, [35], [36] but polyuria and polydipsia are generally mild. A normal lipid profile is present in this disease but, slightly elevated values of serum cholesterol or triglycerides have been found in a few cases. [36]

FIGURE 161-8 Xanthoma disseminatum.

Associations

Osteolytic lesions have been reported in only a few patients. [3] XD may be associated with multiple myeloma, Waldenström's macroglobulinemia, and monoclonal gammopathy. [3]

Histopathologic Findings

In the early stage, there is a mixture of histiocytes, foamy cells, and inflammatory cells; later, foamy cells predominate and Touton giant cells are frequently present. [36] (Fig. 161-9) Siderosis is often observed. The proliferating cells are S-100 and CD1a negative and, ultrastructurally, they are similar to those present in JXG and in PX, but the plasma membranes of foamy cells show many microvilli. [37] LG are absent.

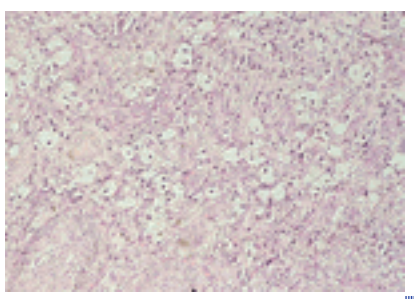

FIGURE 161-9 Xanthoma disseminatum. Histopathologic findings. The lesions are characterized by a mixture of histiocytes, inflammatory cells, and foamy cells. Touton giant cells are present.

Differential Diagnosis

In hyperlipemic xanthomatoses, lesions are more yellowish and their distribution is different. XD differs from PX in that lesions merge into plaques, there is mucous membrane involvement and associated diabetes insipidus. JXG mainly affects children, and the lesions do not merge into plaques; there may be visceral involvement, but diabetes insipidus is absent. Multicentric reticulohistiocytosis (see Chap. 162) occurs mainly in adults, is associated with destructive joint lesions, and is not self-limited. The lesions of GEH never contain lipids. In the chronic disseminated form of histiocytosis X (Hand-Schüller-Christian disease), papular lesions spread to the scalp and trunk and bone lesions are the most frequent manifestation. Histiocytosis X cells are S-100 and CD1a positive and contain LG.

Treatment

Treatment is usually not helpful. [35], [36] Systemic glucocorticoids and antimitotic agents have been used for the more disfiguring forms. Vasopressin is necessary for the associated diabetes insipidus.

Course and Prognosis

Based on the evolution and prognosis of reported cases, Caputo et al. [37] have distinguished three clinical variants of XD: a self-healing form, a persistent form, and a progressive form. The persistent form is the most frequent one. XD could represent the evolution of other, less-developed nonhistiocytoses such as generalized eruptive histiocytoses. [35], [38] Prognosis is usually good, but respiratory tract involvement may lead to dyspnea and dysphagia. Tracheotomy has been required in a few cases. [35]

PAPULAR XANTHOMA (See also Chap. 150)

Definition and Historic Aspects

PX is a normolipidemic papular xanthomatosis, histologically different from other normolipidemic xanthomatoses such as JXG and XD. This disease was first described by Winkelmann [1] in 1981 in adults. The first pediatric cases were reported

by Caputo et al. in 1990. [39]

Incidence

PX is a rare disorder; fewer than 20 cases have been described. [1], [39]

Age of Onset

The onset of PX in children is usually during the first year of life. [39] The disease seems to be more frequent in males.

Clinical Findings

PX is characterized by the eruption of 2- to 12-mm, rounded, yellowish, asymptomatic, papulonodular lesions in a generalized distribution with no tendency to merge into plaques (Fig. 161-10). Occasionally mucous membranes may be involved. No visceral involvement can be found; the lipid profile is normal; diabetes insipidus is absent.

FIGURE 161-10 Papular xanthoma in a child.

Histopathologic Findings

The lesions are composed almost entirely of foamy cells and Touton giant cells. There is no evidence of a primitive histiocytic phase and inflammatory cells are absent [1], [39]. The foamy cells are S-100 and CD1a negative. [39], [40] and [41] Ultrastructurally, [39], [40] the cytoplasm is completely filled with lipid vacuoles without a limiting membrane, myeloid bodies, and lysosomal inclusions. Neither LG nor “comma-shaped bodies” are found in these histiocytes.

Differential Diagnosis

PX differs from XD in that the lesions do not tend to merge into plaques and do not turn red-brown, the skin folds are spared, and there is no diabetes insipidus. Histologically, inflammatory cells are absent. JXG can be recognized by its pure primitive histiocytic phase and, in mature lesions, by the presence of inflammatory cells. Benign cephalic histiocytosis differs in localization and never shows lipidation. GEH does not have lipid-containing cells. PX is clinically and histologically difficult to differentiate from the xanthomatous lesions that may appear in histiocytosis X, but the history and the absence of lesions typical of histiocytosis X, the absence of S-100 positivity, and the absence of LG are discriminating findings. Although it is clinically and histologically indistinguishable from disseminated papular xanthomas with hyperlipoproteinemia, in this case, serum lipids provide the correct diagnosis.

Course and Prognosis

In most of the cases involving children, the lesions regressed within 1 to 5 years; [39] thus PX seems to be, at least in children, a self-healing xanthomatosis, but a progressive course has also been described in several cases. [40]

NECROBIOTIC XANTHOGRANULOMA

Definition

Kossard and Winkelmann, in 1980, were the first to recognize necrobiotic xanthogranuloma (NXG) as a distinct entity. [42] It is an inflammatory histiocytoxanthomatosis involving the dermis and subcutaneous tissue, primarily of the face and, less frequently, of the trunk and extremities. Clinically, the disorder is characterized by indurated yellow-red nodules or plaques, often ulcerated and histologically by xanthogranulomatous features with various amounts of necrobiosis or hyalin necrosis and the presence of lymphoid nodules. There is frequently paraproteinemia, and, occasionally, there are elevated erythrocyte sedimentation rate, cryoglobulinemia, anemia, and leukopenia. [3], [42], [43], [44], [45], [46], [47], [48] and [49]

Incidence

Approximately 60 cases are described in the literature. [48]

Age of Onset

The age of onset of NXG ranges from 17 to 85 years, and the disease has no sex predilection. [46]

Clinical Findings

Early cutaneous lesions consist of firm papulonodules varying in color from red-orange to violaceous or yellow. [42], [44], [46] These lesions slowly enlarge into plaques with well-demarcated edges, ranging in diameter size from a few centimeters to 25 cm. There is central atrophy with telangiectasias or areas of ulceration (Fig. 161-11). Most cases are asymptomatic, but pain or a burning sensation may be noted. [46] The lesions are usually multiple and involve, in order of frequency, the face, trunk, and extremities. The periorbital area is the site of predilection (85 percent of cases). [46] The oral mucosa is occasionally involved. [47] Hepato- and splenomegaly have been observed in approximately 20 percent of patients. [46]

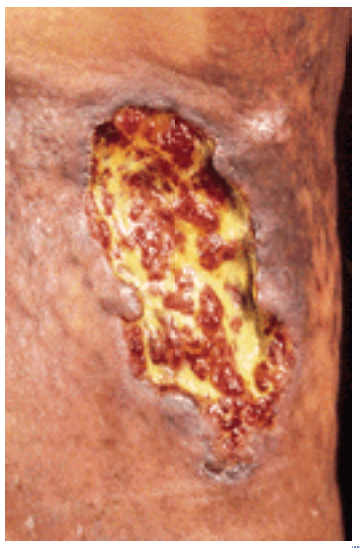

FIGURE 161-11 Necrobiotic xanthogranuloma on the calf. Note “granulomatous” periphery of the lesion, with central ulceration and necrotic material at the base.

Associations

NXG may be associated with myeloma, [43], [45], [49] arthropathy, [46] hypertension, [46] neuropathy, [46] neoplastic syndrome, [45] primary biliary cirrhosis, [44] and Graves' disease. [46]

Complications

The periorbital involvement may lead to important ocular complications such as lagophthalmos, conjunctivitis, keratitis, scleritis, uveitis, and corneal ulceration, and even to loss of ocular function. [45], [46]

Laboratory Findings

Ninety percent of patients have paraproteinemia (IgG ? or ?), while cryoglobulinemia has been found in about 40 percent of cases. [44], [45], [46] and [47] Other abnormal laboratory tests include an elevated sedimentation rate (57 percent), neutropenia (30 percent), leukopenia (35 percent), and decreased CH50 (47 percent).

Histopathologic Findings

The histopathologic picture of NXG is characteristic and consists of a granulomatous infiltrate involving the whole dermis and the subcutis and composed of a mixture of lymphocytes, epithelioid cells, foamy cells, and Touton giant cells. [43], [44], [45] and [46], [49] Areas of severe, clearly defined necrobiosis are sharply marginated from the surrounding granuloma. Cholesterol crystals may be located within the necrobiotic areas. Numerous, atypical, very large, bizarrely angulated, multinucleated giant cells may be seen adjacent to the areas of necrobiosis. Dense, well-defined lymphoid nodules, occasionally containing a germinal center, may be present in the dermis or subcutis. A Touton cell panniculitis may involve the entire fat lobules. Occasionally, a granulomatous infiltrate may surround some vessels.

Immunohistochemically, the cells constituting the infiltrate are CD15 and CD4 positive and CD1a and S-100 negative. [46], [49] Ultrastructurally, cells are rich in lipid droplets, cholesterol clefts, and myeloid bodies [49] and are similar to those observed in JXG.

Etiopathogenesis

Both the pathogenesis of NXG and its link to paraproteinemia are unclear.

Differential Diagnosis

The differential diagnosis of NXG includes necrobiosis lipoidica diabeticorum, granuloma annulare, XD, and multicentric reticulohistiocytosis. In necrobiosis lipoidica diabeticorum, facial and scalp lesions are exceptional and are not associated with any serum protein abnormalities but are associated with diabetes. Histologically, the necrobiotic changes and the granulomatous infiltrate are less prominent, lymphoid nodules are absent, and cholesterol clefts are rare. The subcutaneous form of granuloma annulare occurs mainly in children and does not tend to ulcerate. Giant cells are rare,

and lymphoid nodules and cholesterol clefts are absent. In XD, the large body folds are the main sites of predilection and the periorbicular lesions are less firm and infiltrated and do not tend to ulcerate.

In multicentric reticulohistiocytosis, the lesions do not tend to ulcerate and do not merge into plaques; they are frequently associated with severe arthropathy and histologically feature large histiocytes with a typical “ground glass” cytoplasm and no necrobiosis.

Treatment

Intermittent glucocorticoid treatment can induce partial response without complete disappearance of the lesions. [44] Low-dose alkylating agents, such as chlorambucil or melphalan, produced remission of the paraproteinemia and skin lesions in several cases [44], [45] and [46] but did not prevent the evolution to multiple myeloma. [45] Temporary remissions of skin lesions have been obtained with radiation therapy and with plasmapheresis. [50]

Course and Prognosis

NXG has a chronic, often progressive course that is characterized by the appearance of new lesions and ulcerations. [45], [46] The prognosis of patients is difficult to predict and depends on extracutaneous involvement, multiple myeloma, or visceral tumors.

PROGRESSIVE NODULAR HISTIOCYTOSIS

Definition and Historic Aspects

Progressive nodular histiocytosis (PNH) [51] is a histiocytic disorder of skin and mucous membranes with a progressively deforming course.

Incidence

P>The condition is extremely rare and effects both children and adults. [51], [52]

Clinical Findings

This disorder consists of the eruption of hundreds of lesions of two different types: superficial papules and deep nodules. [51], [52] and [53] The most common lesions are yellow to orange papules, 2 to 10 mm in diameter, that are randomly scattered on the body without localization in the flexural areas. These lesions may be present in the oral, laryngeal, and conjunctival mucosae. The deep lesions are dermal nodules ranging from 1 to 5 cm, with overlying telangiectasia, mainly located on the trunk. Café au lait spots, arthritis and diabetes insipidus are absent.

Associations

In one case, an association with hepatosplenomegaly, hypocholesterolemia, and chronic myeloid leukemia was observed. [54]

Histopathologic Findings

The pathologic features are that of a xanthogranuloma with a predominance of storiform, spindle-shaped histiocytes that are positive for macrophage/dendritic cell line markers (CD 68, HAM 56, and factor XIIIa) and are S-100 and CD1 negative. [53], [54] Electron microscopic examination revealed histiocytes with a large indented nucleus, and no LG were observed. [53]

Differential Diagnosis

Xanthoma disseminatum is easily ruled out if the flexural areas are spared and diabetes insipidus is absent.

Course and Prognosis

New lesions continue to develop during successive years with no sign of spontaneous involution. Despite the progressive nature of the lesions, patients remain in good health. [51], [52] and [53]

Etiopathogenesis

PNH is a progressive disease with no tendency to spontaneous involution as a consequence of a proliferation of mature spindle-shaped cells. It may represent an evolution of other non LC histiocytoses. [2]

Treatment

This disease is resistant to all forms of therapy. [54]

HEREDITARY PROGRESSIVE MUCINOUS HISTIOCYTOSIS

Definition and Historic Aspects

Hereditary progressive mucinous histiocytosis (HPMH) is a familial, benign, but progressive, non–LC-histiocytosis that affects women exclusively. [55], [56]

Incidence

The disease has been reported in 11 female patients from 4 different families and it is inherited most likely as an autosomal-dominant trait. [56], [57], [58], [59] and [60]

Clinical Findings

The cutaneous lesions consist of the eruption of numerous asymptomatic skin colored or red nodules, 2 to 15 mm in diameter, scattered over the entire body. [56], [57], [58], [59] and [60]

The number of the nodules increase gradually during life (several hundreds), and the lesions do not resolve spontaneously nor do they ulcerate or merge into plaques. The mucous membranes are always spared. The patients remain in good general health, and no visceral lesions have been reported. All laboratory investigations are normal.

Histopathologic Findings

Histopathologic examination reveals a well circumscribed dermal tumor consisting almost exclusively of oval or spindle-shaped histiocytes with large nuclei and abundant cytoplasm. [57], [58], [60] Staining with toluidine blue reveals marked metachromasia of histiocytes. An outstanding finding is the marked production of mucinous material, predominantly in long-standing tumors. [57], [58], [60] Immunohistochemical findings show positive labeling for vimentin, a $_1$-antitrypsin, a $_1$-antichymotrypsin, and lysozyme, while S-100, CD1a, and factor XIIIa are negative. [57], [58] and [59] Under the electron microscope, the cytoplasm of the histiocytes is filled with myeloid bodies and zebra-like bodies, and LG are absent. [57], [58], [59] and [60]

Differential Diagnosis

Clinically and histologically, HPMH is very similar to progressive nodular histiocytosis but differs by inheritance, female involvement, and the presence of mucinous material.

Course

The course is progressive but lesions remain confined to the skin.

Etiopathogenesis

It is not clear whether this disease is a proliferation, or an accumulation of macrophages caused by an unknown and persistent stimulus, or if it could be an inherited storage disease.

Treatment

No treatment is known.

REFERENCES

1. Winkelmann RK: Cutaneous syndromes of non–X histiocytosis. A review of the macrophage-histiocyte diseases of the skin. *Arch Dermatol* **117**:667, 1981

2. Gianotti F, Caputo R: Histiocytic syndromes: A review. *J Am Acad Dermatol* **13**:383, 1985

3. Caputo R: *Text Atlas of Histiocytic Syndromes*. London, Martin-Dunitz, 1988

4. McDonough JFR: A contribution to our knowledge of naevo xanthoendothelioma. *Br J Dermatol Syphilol* **24**:85, 1912

5. Helwig EB, Macknay VC: Juvenile xanthogranuloma. *Am J Pathol* **30**:625, 1954

6. Laurb HM, Lain ES: Nevoxanthoendothelioma: Its relationship to juvenile xanthomas. *S Afr Med J* **30**:585, 1937

7. Blank M et al: Nevoxanthoendothelioma with ocular involvement. *Pediatrics* **4**:349, 1949

8. Cohen BA, Hood A: Xanthogranuloma: Report on clinical and histologic findings in 64 patients. *Pediatr Dermatol* **6**:262, 1989

9. Caputo R et al: Unusual aspects of juvenile xanthogranuloma. *J Am Acad Dermatol* **29**:868, 1993

10. Newell GB et al: Juvenile xanthogranuloma and neurofibromatosis. *Arch Dermatol* **107**:262, 1973

11. Zimmerman E: Ocular lesions of juvenile xanthogranuloma. *Am J Ophthalmol* **60**:1011, 1965

12. Flach DB, Winkelmann RK: Juvenile xanthogranuloma with central nervous system lesions. *J Am Acad Dermatol* **14**:405, 1986

13. Winkelmann RK, Muller SA: Generalized eruptive histiocytoma: A benign papular histiocytic reticulosis. *Arch Dermatol* **88**:586, 1963

14. Caputo R et al: Generalized eruptive histiocytoma in children. *J Am Acad Dermatol* **17**:449, 1987

15. Caputo R et al: Generalized eruptive histiocytoma. A clinical, histological, ultrastructural study. *Arch Dermatol* **117**:216, 1981

16. Sigal-Nahum M et al: Histiocytose non X (histiocytome éruptive généralisé?) marquée par l'OKT6, à filaments de vimentine. *Ann Dermatol Venereol* **114**:211, 1987

17. Gianotti F et al: Singulière histiocytose infantile à cellules avec perticules vermiformes intracytoplasmiques. *Bull Soc Fr Dermatol Syphilol* **72**:232, 1971

18. Barsky BL et al: Benign cephalic histiocytosis. *Arch Dermatol* **120**:650, 1984

19. Eisemberg EL et al: Benign cephalic histiocytosis. *J Am Acad Dermatol* **12**:328, 1985

20. Gianotti F et al: Benign cephalic histiocytosis. *Arch Dermatol* **122**:1038, 1986

21. Larralde de Luna M et al: Benign cephalic histiocytosis: Report of four cases. *Pediatr Dermatol* **6**:198, 1989

22. Godfrey KM, James MP: Benign cephalic histiocytosis: A case report. *Br J Dermatol* **123**:245, 1990

23. Pena-Penabad C et al: Benign cephalic histiocytosis: Case report and literature review. *Pediatr Dermatol* **11**:164, 1994

24. Rosai J, Dorfman RF: Sinus histiocytosis with massive lymphadenopathy: A newly recognized benign clinicopathological entity. *Arch Pathol* **87**:63, 1969

25. Rosai J, Dorfman RF: Sinus histiocytosis with massive lymphadenopathy: A pseudolymphomatous benign disorder. Analysis of 34 cases. *Cancer* **30**:1174, 1972

26. Thawerani H et al: The cutaneous manifestations of sinus histiocytosis with massive lymphadenopathy. *Arch Dermatol* **114**: 191, 1978

27. Lorette G et al: Histiocytose sinusale avec manifestations cutanées. *Ann Dermatol Venereol* **114**:1430, 1987

28. Olsen EA et al: Sinus histiocytosis with massive lymphadenopathy. *J Am Acad Dermatol* **18**:1322, 1988

29. Foucar E et al: Sinus histiocytosis with massive lymphadenopathy. Current status and future directions. *Arch Dermatol* **124**:1211, 1988

30. Foucar E et al: Sinus histiocytosis with massive lymphadenopathy. Ear, nose and throat manifestations. *Arch Otolaryngol* **104**:687, 1978

31. Walker PD et al: The osseous manifestations of sinus histiocytosis with massive lymphadenopathy. *Am J Clin Pathol* **75**:131, 1981

32. Foucar E et al: The neurologic manifestations of sinus histiocytosis with massive lymphadenopathy. *Neurology* **32**:365, 1982

33. Foucar E et al: Sinus histiocytosis with massive lymphadenopathy. An analysis of 14 deaths occurring in a patient registry. *Cancer* **54**:1834, 1984

34. Montgomery H, Osterberg AE: Xanthomatosis. Correlation of clinical, histopathologic and chemical studies of cutaneous xanthoma. *Arch Dermatol Syphilol* 208:373, 1938

35. Altman J, Winkelmann RK: Xanthoma disseminatum. *Arch Dermatol* 85:582, 1962

36. Beury J et al: Xanthoma disseminatum (sindrome de Montgomery). *Ann Dermatol Venereol* **106**:353, 1979

37. Caputo R et al: The various clinical patterns of xanthoma disseminatum. *Dermatology* **190**:19, 1995

38. Coldiron BM et al: Benign non-X histiocytosis: A unique case bridging several non-X histiocytic syndromes. *J Am Acad Dermatol* **18**:1282, 1988

39. Caputo R et al: Papular xanthoma in children. *J Am Acad Dermatol* **22**:1052, 1990

40. Sanchez RL et al: Papular xanthoma. *Arch Dermatol* **121**:626, 1985

41. Bundino S et al: Papular xanthoma. Clinical, histological and ultrastructural study. *Dermatologica* **177**:382, 1988

42. Kossard S, Winkelmann RK: Necrobiotic xanthogranuloma. *Australas J Dermatol* **21**:85, 1980

43. Finan MC, Winkelmann RK: Necrobiotic xanthogranuloma with paraproteinemia: A review of 22 cases. *Medicine (Baltimore)* **65**:376, 1986

44. Holden CA et al: Necrobiotic xanthogranuloma: A report of four cases. *Br J Dermatol* **114**:241, 1986

45. Venencie PY et al: Necrobiotic xanthogranuloma with myeloma: A case report. *Cancer* **59**:588, 1987

46. Mehregan DA, Winkelmann RK: Necrobiotic xanthogranuloma. *Arch Dermatol* **123**:94, 1992

47. Forstson JS, Schroeter AL: Necrobiotic xanthogranuloma with IgA paraproteinemia and extracutaneous involvement. *Am J Dermatopathol* **12**:579, 1990

48. Umbert I, Winkelmann RK: Necrobiotic xanthogranuloma with cardiac involvement. *Br J Dermatol* **133**:438, 1995

49. Plotnick H et al: Periorbital necrobiotic xanthogranuloma and stage I multiple myeloma. *J Am Acad Dermatol* **25**:373, 1991

50. Finelli LG, Ratz JL: Plasmapheresis: A treatment modality for necrobiotic xanthogranuloma. *J Am Acad Dermatol* **17**:351, 1987

51. Taunton OD et al: Progressive nodular histiocytoma. *Arch Dermatol* **114**:1505, 1978

52. Burgdorf WHC et al: Progressive nodular histiocytoma. *Arch Dermatol* **117**:644, 1981

53. Gibbs NF, O'Grady TC: Progressive nodular histiocytomas. *J Am Acad Dermatol* **35**:323,1996

54. Gonzalez Ruiz A et al: Progressive nodular histiocytosis accompanied by systemic disorders. *Br J Dermatol* **143**:628, 2000

55. Bork K, Hoede N: Hereditary progressive mucinous histiocytosis in women. *Arch Dermatol* **124**:1225, 1988

56. Bork K: Hereditary progressive mucinous histiocytosis. *Arch Dermatol* **130**:1300, 1994

57. Schroder K et al: Hereditary progressive mucinous histiocytosis. *J Am Acad Dermatol* **35**:298, 1996

58. Wong D et al: Hereditary progressive mucinous histiocytosis. *Br J Dermatol* **141**:1101, 1999

59. Sass U et al: A sporadic case of progressive mucinous histiocytosis. *Br J Dermatol* **142**:133, 2000

60. Antoni-Bach N et al: Histiocytose mucineuse héréditaire progressive. *Ann Dermatol Venereol* **127**:400, 2000

T>

Chapter 162

Karl Holubar

Multicentric Reticulohistiocytosis

HISTORICAL ASPECTS
EPIDEMIOLOGY
ETIOLOGY AND PATHOGENESIS
CLINICAL MANIFESTATIONS
Skin Changes
Articular Changes
Mucosal Changes
Other Clinical Manifestations
LABORATORY FINDINGS
PATHOLOGY
Skin and Mucous Membranes
Lesions in Other Tissues
ASSOCIATED CONDITIONS
TREATMENT
COURSE AND PROGNOSIS

REFERENCES

Multicentric reticulohistiocytosis is a rare disorder. Over the last 30-odd years only two comprehensive reviews have appeared, and they could not offer any clues as to the nature of this peculiar disease. [1], [2] No revealing details have been unraveled since that time. Unfortunately, there have been no new insights into the basis of the pathologic process.

Multicentric reticulohistiocytosis is a systemic granulomatous disease of unknown cause characterized by a distinct histopathology. Skin, mucosa, synovia, bone, and internal organs may be involved. Cutaneous nodules and destructive arthritis are the most prominent clinical features. Multicentric reticulohistiocytosis is a paraneoplastic process in a portion of the patients afflicted. Twenty-eight percent of patients with multicentric reticulohistiocytosis develop cancer. In 75 percent of these patients, multicentric reticulohistiocytosis preceded the diagnosis of cancer. [3]

HISTORICAL ASPECTS

In 1952, Caro and Senear [4] first studied histopathologic skin sections of a patient with the features of multicentric reticulohistiocytosis; they called the syndrome reticulohistiocytic granuloma. [4] Goltz and Laymon in 1954 created the term *multicentric reticulohistiocytosis,* which most authors now use, because of the multifocal origin and the systemic nature of the process. [5] At least a dozen synonyms appear in the literature, including lipoid dermatoarthritis, giant cell (reticulo)histiocytosis, (giant cell) reticulohistiocytoma, and nondiabetic cutaneous xanthomatosis. By the early 1950s, the entity of multicentric reticulohistiocytosis was established. [1]

EPIDEMIOLOGY

Fewer than 200 cases of multicentric reticulohistiocytosis have been reported, but many others may have gone undiagnosed. [6] There appears to be no geographic area of prevalence. White patients predominate, but this finding may merely reflect the higher number of reports from North America, Australia, and Europe. Patients of African, South American, Japanese, and American-Indian ancestry have also been identified. In one study, the disease affected a greater number of women than men [1]; in another, the distribution between the sexes was equal. [2] The mean age of onset is 43 years. After an average of 8 years, the disease becomes inactive. Children and adolescents may develop the disease, [7], [8], [9] and [10] and there has been one report of multicentric reticulohistiocytosis during pregnancy. [11]

During the past four decades, most investigators considered multicentric reticulohistiocytosis to be of histiocytic rather than lymphocytic origin. In 1996 Zelger and associates proposed a new concept of non–Langerhans cell histiocytoses, called it indeterminate cell histiocytosis, and included multicentric reticulohistiocytosis as an oncocytic type among more than a dozen types of these histiocytoses. [12], [13] These investigators claim that each of the mononuclear and multinucleate histiocytic types reveals characteristic, but as yet not diagnostic, immunophenotypic features. They consider the KiM1p marker (CD68 family) to be the most reliable marker of the non–Langerhans cell histiocytoses.

ETIOLOGY AND PATHOGENESIS

The etiology of multicentric reticulohistiocytosis remains obscure, and its pathogenesis can be only a matter of speculation. [1], [2] The hallmark of the disease is a granulomatous, proliferative process of histiocytes, some of which are multinucleated and laden with lipids. The stimulus is not known, and no specific metabolic defect has been found. There is no evidence of an infectious agent, and there are no convincing data on a compromise of the immune status of the host. Little, if any, evidence exists to permit the categorization of multicentric reticulohistiocytosis with disorders of deranged lipid metabolism.

CLINICAL MANIFESTATIONS

Skin and joint symptoms dominate the clinical picture. Almost two-thirds of patients note arthritis first; one-fifth note skin

nodules first; and in another fifth, skin and joint changes appear simultaneously. About half of the patients develop mucous membrane manifestations. [1]

Skin Changes

The face (particularly the nose and paranasal areas), hands (particularly the nail folds; Fig. 162-1), ears, forearms, scalp (especially behind the ears), neck, eyelids, [14] the limbus and the cornea, [15] and the trunk are involved in decreasing order of frequency. The hemispherical, nontender nodular lesions have a reddish-brown hue; they vary in size from a few millimeters to conglomerate nodules measuring several centimeters. Ulceration is uncommon. Erythema may precede the formation of nodules. Pruritus may be a prominent symptom.

FIGURE 162-1 Hands of a patient with active skin lesions of multicentric reticulohistiocytosis. Note the periungual array of some of the nodules. (*From Barrow and Holubar,* [1] *with permission of Hautarzt.*)

Articular Changes

There is symmetric involvement of the interphalangeal joints, knees, shoulders, wrists, hips, ankles, feet, elbows, and vertebral and temporomandibular joints, in decreasing order of frequency. The arthritis is destructive (arthritis mutilans); as a result of the damage to bone and cartilage, severe deformation ensues. The disease progresses rapidly in the beginning, tapers, and finally burns out. There is a marked discrepancy between the severity of the radiographic findings and the underlying bone destruction, and the relative mildness of the clinical symptoms. In far advanced cases, the fingers are considerably shortened, but can be pulled out to their full length, leading to such designations as *la main en lorgnette,* opera-glass hand, telescope fingers, and concertina hand. There is no periosteal reaction or osteoporosis. Spontaneous fracture of the femoral neck has been observed. [16]

Mucosal Changes

Roughly half the patients have mucosal lesions; these lesions may involve the lips, buccal mucosa, tongue, gingiva, nasal septum, larynx, and trachea. Physically, the nodules mimic those in the skin (Fig. 162-2).

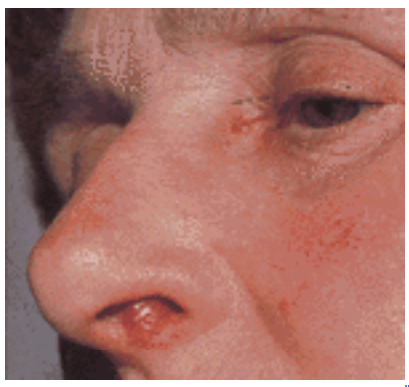

FIGURE 162-2 Mucocutaneous nodular infiltrate on the nasal mucosa and adjoining skin in a patient with multicentric reticulohistiocytosis.

Other Clinical Manifestations

Patients with multicentric reticulohistiocytosis may also exhibit xanthelasma, lesions along tendon sheaths, lesions in the myocardium and the lungs, adenopathy, pathologic fractures, hypertension, and hyperextensible joints. Kamel and associates reported a nodule in the muscles of the thoracic wall in 1996. [17] In some cases, it is impossible to substantiate a definitive diagnosis of multicentric reticulohistiocytosis, and the association of unusual findings may be fortuitous, as in patients with carpal tunnel syndrome, Dupuytren's contracture, and pleural effusion; cardiopulmonary complications; splenomegaly and pancytopenia; abnormal level of gamma heavy-chain paraprotein; and involvement of the salivary glands and pericardial effusion. Chevrant-Breton in her review cited reports of neurologic and (terminal) hematologic changes. [2]

LABORATORY FINDINGS

One report cites an association of multicentric reticulohistiocytosis with type IV hyperlipidemia [18]; another considers multicentric reticulohistiocytosis a lipid disorder with normolipidemic xanthomatosis. [19] These are chance findings. Otherwise, only nonspecific laboratory findings are present in individual cases: anemia, elevated sedimentation rate, leukocytosis, eosinophilia, hypo- and hypercholesterolemia, hypergammaglobulinemia, and the presence of cold

agglutinins and cryoglobulins.

Articular destruction due to oversecretion of cytokines, especially interleukin (IL)-1ß, IL-6, and tumor necrosis factor–a, has been reported. [16]

PATHOLOGY

Skin and Mucous Membranes

The histopathology of skin lesions is fairly uniform. [1], [2] Nonencapsulated and moderately well circumscribed, the nodules occupy the entire dermis or parts of it. Frequently, there is a narrow zone of noninfiltrated connective tissue between the infiltrates and the slightly atrophic epidermis.

Lesions consist of histiocytic cells that are irregular in size and shape (Fig. 162-3A). Many have transformed into multinucleated giant cells, generally not more than 250 nm in diameter, but occasionally larger (Fig. 162-3B). They may contain 20 or more aggregated nuclei with a distinct nuclear membrane and prominent nucleoli. The cytoplasm is slightly eosinophilic, has a granular appearance (“ground glass cytoplasm”), and may be foamy or show tiny vacuoles. There are no Touton giant cells.

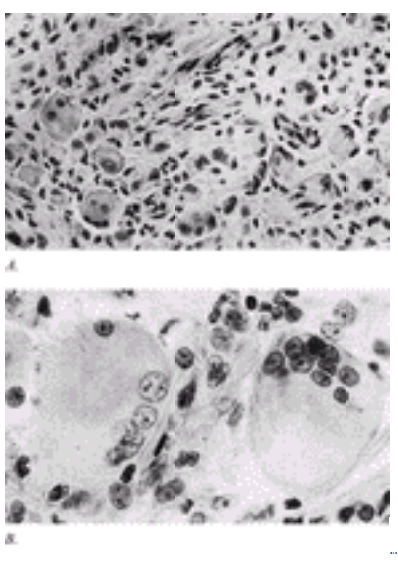

FIGURE 162-3 Microphotographs of a lesion from the patient shown in Fig. 162-1. Note histiocytic infiltrate (*A*) and multinucleated giant cells with aggregated nuclei and ground glass cytoplasm (*B*). (*From Holubar K, Mach K: Histiocytosis giganto-cellularis. Hautarzt 17:440, 1966, with permission of Hautarzt*.)

Multicentric reticulohistiocytosis nodules contain lymphocytes, which are more numerous in early lesions, and plasma cells, eosinophils, mast cells, and, occasionally, extravasated erythrocytes. As the age of the lesions increases, lymphocytes and giant cells decrease in number, fibroblasts appear, and fibrosis ensues. Lesions are well vascularized, and capillaries show endothelial hypertrophy. In places, histiocytes and giant cells have a perivascular arrangement. Elastic fibers are fragmented, clumped, and thickened, particularly in early lesions.

HISTOCHEMICAL INVESTIGATIONS The cytoplasm of histiocytes and giant cells is PAS-positive and hyaluronidase- and diastase-resistant, suggesting the presence of glycoproteins. It contains phospholipids, neutral fats, and iron. Biochemical studies have not revealed an isolated enzyme defect responsible for lipid accumulation.
ELECTRON MICROSCOPY There are no Langerhans cell granules in the histiocytic cells of multicentric reticulohistiocytosis. Both histiocytes and giant cells have lobulated nuclei with indented contours and margination of nuclear chromatin, an enlarged Golgi apparatus, and hyperplastic endoplasmic reticulum with dilated cysternae. Lipid-laden vacuoles are present, and numerous small, electron-dense, ovoid or rod-shaped cytoplasmic granules, up to 250 nm in size, may appear. These granules are positive for acid phosphatase, as are autophagic vacuoles. A characteristic feature is the complex interdigitation of the membranes of adjacent histiocytic cells. In addition, collagen phagocytosis has been observed, and intra- and extracellular fragments of collagen VI in histiocytes have been documented. [20] The histiocytes of multicentric reticulohistiocytosis have been characterized by their iron uptake, positivity of acid phosphatase, presence of unspecific esterase, and presence of lysozyme. The histopathology of synovial lesions is identical to that of skin lesions.

Lesions in Other Tissues

The morphology and localization of cutaneous nodules, the typical articular symptoms, and the radiographic findings (i.e., symmetric involvement of distal interphalangeal joints) are highly suggestive of multicentric reticulohistiocytosis, but histopathologic examination of a nodule permits the diagnosis. It is necessary to differentiate several disorders from multicentric reticulohistiocytosis: rheumatoid arthritis, the various types of xanthomas, Farber's disseminated lipogranulomatosis, lepromatous leprosy, lipoid proteinosis, sarcoidosis, histiocytosis X, juvenile and adult xanthogranuloma, solitary reticulohistiocytoma, generalized eruptive histiocytoma of Hashimoto and Pritzker, and Zayid and Farraj's familial histiocytic dermatoarthritis. Multicentric reticulohistiocytosis is not familial or congenital. The proposed grouping, still under discussion, into Langerhans and non-Langerhans types of histiocytic and lymphocytic proliferations may make many of these previously detailed diagnoses obsolete. [12], [13]

ASSOCIATED CONDITIONS

Possible concomitant diseases include thyroid disorders; tuberculosis; diabetes; hemoblastoses; systemic sclerosis and Sjögren's syndrome; cancer of the colon, breast, bronchus, cervix, ovary, and stomach; mesothelioma; and melanoma. [21], [22] An association with sarcoma and lymphomas has also been reported. The tumors may progress, and multicentric reticulohistiocytosis may remit; in contrast, multicentric reticulohistiocytosis may progress despite removal of the tumor. Although many investigators therefore remain skeptical about the alleged paraneoplastic nature of multicentric reticulohistiocytosis, there are enough questions to warrant a careful tumor search in all patients with the disease.

TREATMENT

Gianotti and Caputo stated that “treatment is usually not helpful.” [23] Glucocorticoids (administered also as pulse therapy); ACTH; antimalarials; salicylates; indomethacin; pyrazolone; clofibrate; penicillamine; and, increasingly, various antimitotic compounds, such as azathioprine, methotrexate, cyclophosphamide, cyclosporine, and nitrogen mustard (administered systemically and topically) have been used; but no controlled studies have been performed. Antimitotic agents appear to be a rational choice for therapy. However, because multicentric reticulohistiocytosis is a potentially paraneoplastic condition, antimetabolites and cytostatics may be harmful when malignancies are associated. Surgical measures have also been used.

COURSE AND PROGNOSIS

The skin nodules and arthritis associated with multicentric reticulohistiocytosis do not necessarily run in a parallel course. Articular changes may wax and wane, finally evolving into mutilating arthritis, whereas skin nodules may not appear at all or may erupt in successive crops with new infiltrates superimposed on older, regressing ones. The course of multicentric reticulohistiocytosis is capricious and unpredictable; about half of the patients will eventually suffer from prominent destructive arthritis. Most commonly, the disease burns out after 5 to 8 years, leaving the patient with severe articular deformations and disfigurement of the hands, face, and scalp.

REFERENCES

1. Barrow MV, Holubar K: Multicentric reticulohistiocytosis. *Medicine (Baltimore)* **48**:287, 1969

2. Chevrant-Breton J: La réticulo-histiocytose multicentrique: Revue de la litterature récente (depuis 1969). *Ann Dermatol Venereol* **104**:745, 1977

3. Kurzrock R, Cohen PR: Cutaneous paraneoplastic syndromes in solid tumors. *Am J Med* **99**:662, 1995

4. Caro MR, Senear FE: Reticulohistiocytoma of the skin. *Arch Dermatol* **65**:701, 1952

5. Goltz RW, Laymon CW: Multicentric reticulohistiocytosis. *Arch Dermatol* **69**:717, 1954

6. Liang GC, Granstone AS: Complete remission of multicentric reticulohistiocytosis with combination therapy of steroid, cyclophosphamide, and low dose pulse methotrexate. *Arthritis Rheum* **39**:171, 1996

7. Omdal M et al: Multicentric reticulohistiocytosis in a 9-year-old boy. *Arthritis Rheum* **31**:1588, 1988

8. Kuramoto Y et al: Multicentric reticulohistiocytosis in a child. *J Am Acad Dermatol* **20**:329, 1989

9. Raphael SA et al: Multicentric reticulohistiocytosis in a child . *J Pediatr* **114**:266, 1989

10. Kuramoto Y et al: Development of a Ki-1 lymphoma in a child suffering from multicentric reticulohistiocytosis. *Acta Derm Venereol* **71**:448, 1991

11. Conaghan P et al: A unique presentation of multicentric reticulohistiocytosis in pregnancy. *Arthritis Rheum* **36**:269, 1993

12. Zelger BWH et al: Non–Langerhans cell histiocytoses: A new unifying concept. *Am J Dermatopathol* **18**:490, 1996

13. Sidoroff A et al: Indeterminate cell histiocytosis—A clinicopathological entity with features of both X- and non-X histiocytosis. *Br J Dermatol* **134**:525, 1996

14. Eagle RC Jr et al: Eyelid involvement in multicentric reticulohistiocytosis. *Ophthalmology* **102**:426, 1995

15. Allaire GS et al: Reticulohistiocytoma of the limbus and cornea: A clinicopathologic study of two cases. *Ophthalmology* **97**:1018, 1990

16. Nakamura H et al: A case of spontaneous femoral neck fracture associated with multicentric reticulohistiocytosis. *Arthritis Rheum* **40**:2266, 1997

17. Kamel H et al: Case report: The CT demonstration of soft tissue involvement in multicentric reticulohistiocytosis. *Clin Radiol* **51**:440, 1996

18. Gharpuray MB et al: Multicentric reticulohistiocytosis. *Int J Dermatol Venerol Leprol* **55**:253, 1989

19. Kesäniemi YA et al: Multicentric reticulohistiocytosis, another lipid disorder with normolipidemic xanthomatosis? *Atherosclerosis* **68**:179, 1987

20. Fortier-Beaulieu M et al: New electron microscopic findings in a case of multicentric reticulohistiocytosis: Long spacing collagen inclusions. *Am J Dermatopathol* **15**:587, 1993

21. Gibson G et al: Multicentric reticulohistiocytosis associated with recurrence of malignant melanoma. *J Am Acad Dermatol* **32**:134, 1995

22. Takahashi M et al: A case of multicentric reticulohistiocytosis, systemic sclerosis and Sjögren syndrome. *J Dermatol* **24**:530, 1997

23. Gianotti F, Caputo R: Histiocytic syndromes: A review. *J Am Acad Dermatol* **13**:383, 1985

T>

Chapter 163

Dean Metcalfe

The Mastocytosis Syndrome

ETIOLOGY AND PATHOGENESIS
CLINICAL FEATURES
DIAGNOSIS
TREATMENT
PROGNOSIS

REFERENCES

Mastocytosis is a condition characterized by mast cell hyperplasia in the bone marrow, liver, spleen, lymph nodes, gastrointestinal tract, and skin. Clinically, the disease is often accompanied by evidence of mast cell activation, which includes pruritus, flushing, urtication, abdominal pain, nausea, vomiting, diarrhea, bone pain, vascular instability, headache, and neuropsychiatric difficulties. Mastocytosis can occur at any age and demonstrates a slight male-to-female predominance (1.5:1.0). The prevalence of the disease is unknown, and familial occurrence appears unusual.

Mastocytosis is divided into clinicopathologic variants on the basis of clinical presentation, pathologic findings, and prognosis. Table 163-1 shows a consensus-based classification for mastocytosis. [1] Patients with cutaneous mastocytosis (CM) or indolent systemic mastocytosis (ISM) have a good prognosis, whereas patients with other variants have a less favorable outcome. Most children diagnosed with mastocytosis have CM with good prognosis. Mastocytosis is diagnosed on the basis of characteristic bone marrow findings plus at least one of the following minor criteria: (1) detection of a point mutation in *c-kit* at codon 816, (2) bone marrow mast cells that express CD2 and/or CD25, (3) a total serum tryptase of greater than 20 ng/mL, or (4) a tissue biopsy specimen in which more than 25 percent of mast cells have an atypical morphology. Mastocytosis may also be diagnosed when three of the four minor criteria are present. ISM is diagnosed when the criteria for mastocytosis are met and there is no evidence of an associated clonal hematologic disorder or of severe liver disease, hypersplenism, or significant lymphadenopathy. In most cases, patients with ISM are managed successfully with medications that provide symptomatic relief.

Cutaneous mastocytosis (CM)
Urticaria pigmentosa (UP)/maculopapular cutaneous mastocytosis (MPCM)
Typical UP
Plaque form
Nodular form
Telangiectasia macularis eruption perstans (TMEP)
Diffuse cutaneous mastocytosis (DCM)
Solitary mastocytoma of skin
Indolent systemic mastocytosis (ISM)
Systemic mastocytosis with an associated clonal hematologic non-mast cell lineage disease (SM-AHNMD)
Aggressive systemic mastocytosis (ASM)
Mast cell leukemia (MCL)
Mast cell sarcoma (MCS)
Extracutaneous mastocytoma

TABLE 163-1 **WHO Classification of Mastocytosis**

The second most common form of mastocytosis is systemic mastocytosis with an associated clonal hematologic non-mast cell lineage disease (SM-AHNMD). It is not often observed in children. In this group, examination of the bone marrow and peripheral blood reveals the hematologic abnormality. The prognosis for these patients is determined by the course of the associated hematologic disorder.

Patients with aggressive systemic mastocytosis (ASM) are usually adults. These patients have poor prognostic features, including impaired liver function, hypersplenism, and malabsorption, but they do not have a distinctive hematologic disorder or mast cell leukemia. There exists a subset of patients with ASM who have a distinct syndrome termed *lymphadenopathic mastocytosis with eosinophilia* because of the pronounced eosinophilia, hepatosplenomegaly, and lymphadenopathy. Patients with ASM have rapidly increasing mast cell numbers and are difficult to manage medically. Their prognosis is less favorable than that of patients with ISM.

Patients with mast cell leukemia (MCL) have numerous atypical immature mast cells in the bone marrow, and mast cells account for 10 percent or more of peripheral blood white cells. Mast cell sarcomas (MCS) are rare; they have localized destructive growth, and distant spread is possible. Mast cells in these tumors are highly atypical and immature. Extracutaneous mastocytomas are very rare, usually localized to the lung, and consist of mature mast cells.

ETIOLOGY AND PATHOGENESIS

Human mast cells originate from pluripotent CD34+, CD13+, CD117+ bone marrow cells [2] and circulate through the bloodstream [3] to specific sites in the body where they mature into fully granulated cells. The targeting of mast cells to defined locations appears to be determined by the sequential expression of cell surface adhesion molecules, predominantly members of the integrin family. [4]

The regulation of mast cell number and mast cell differentiation is under the control of factors produced both in the bone marrow and by cells in the tissues in which mast cells finally reside. For example, human mast cell differentiation depends on Kit ligand, also known as stem cell factor (SCF). Differentiation is inhibited by factors such as interferon gamma. [5] Final maturation and granule composition depend on factors produced in the tissue microenvironment, [6]

including SCF produced by fibroblasts and stromal cells. Inhibition of local production of SCF leads to mast cell apoptosis. [7]

The receptor for SCF is Kit. Mutations have now been identified in *c-kit* in peripheral blood cells and tissues from patients with mastocytosis. [8] These mutations are associated with enhanced receptor function and may contribute to the increase in mast cell number and disordered cell migration [8], [9] that is characteristic of mastocytosis. The first and most common mutation identified in patients with mastocytosis consists of an A to T substitution at codon 816 of *c-kit* mRNA that causes an aspartic acid to valine substitution. [8] The fact that this mutation can be found in multiple cell lineages suggests it takes place in a pluripotential stem cell, [10] and it appears to be a somatic mutation. This substitution, as well as others at codon 816, are observed in most adult patients with mastocytosis associated with a hematologic disorder and in patients with ISM. [11] Other mutations have now been described, including an inactivating mutation at codon 839 in some children with CM, which is of uncertain significance. Other genetic polymorphisms such as the Q576R polymorphism in the interleukin-4 receptor alpha chain may mitigate disease expression. [12] The relationship of these mutations to chromosomal abnormalities is unknown. However, fluorescent in situ hybridization has been used to identify trisomy 8 in five patients and trisomy 9 in one patient with unspecified patterns of mastocytosis. [13]

The systemic effects of mastocytosis are in large part the result of the increased production of mast cell mediators, which have effects both at the site of their production and remote from their origin, irrespective of the etiology of the increased burden of mast cells or the category of disease. Mast cell products are of three categories; all may circulate through the bloodstream and lymphatics to produce biologic effects in patients with mastocytosis (Table 163-2).

Mediators	Effects
Granule-associated	
Histamine	Pruritus, urticaria, increased vasopermeability, gastric hypersecretion, bronchoconstriction
Heparin	Local anticoagulation, osteoporosis
Lipid-derived	
Prostaglandin D_2	Vasodilation, bronchoconstriction
Cytokines	
TNF-α	Cachexia
Stem cell factor	Survival and proliferation of mast cells and mast cell progenitors
IL-6	Mast cell survival

Key: IL, interleukin; TNF, tumor necrosis factor.

TABLE 163-2 **Mast Cell Products Implicated in the Pathogenesis of Mastocytosis**

CLINICAL FEATURES

All categories of mastocytosis share clinical features that are caused by the excess production of mast cell-dependent mediators, although some aspects of disease may predominate in a specific category. The skin, gastrointestinal tract, lymph nodes, liver, spleen, bone marrow, and skeletal system contribute the most significant management problems. The respiratory tract and endocrine systems are seldom if ever involved. Also, patients with mastocytosis do not suffer from recurrent bacterial, fungal, or viral infections even though mast cells release mediators such as histamine that inhibit immune responses in vitro.

Urticaria pigmentosa (UP) is the most common skin manifestation of cutaneous disease in both children (Fig. 163-1) and adults (Fig. 163-2). It is seen in more than 90 percent of patients with ISM and in fewer than 50 percent of patients with SM-AHNMD or with ASM. The lesions of UP appear as small, yellow-tan to reddish-brown macules or slightly raised papules scattered over the body. The palms, soles, face, and scalp may be free of lesions. Mild trauma, including scratching or rubbing of the lesions, usually causes urtication and erythema around the macules; this is known as Darier's sign. UP is associated with a variable amount of pruritus, which may be exacerbated by changes in climatic temperature, skin friction, ingestion of hot beverages or spicy foods, ethanol, and certain drugs. The diagnosis is confirmed by characteristic skin histopathology. [14]

FIGURE 163-1 Urticaria pigmentosa in a child with cutaneous disease only.

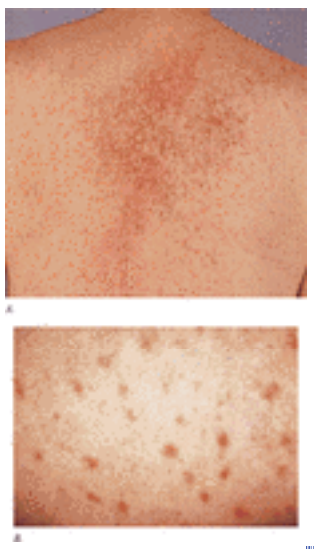

FIGURE 163-2 Urticaria pigmentosa in an adult with indolent systemic mastocytosis. *A*. Hundreds of lentigo-like macules are seen on the back of this adult. If vigorously rubbed, these lesions will show urtication and become erythematous, raised, and pruritic. *B*. Close-up.

Diffuse cutaneous mastocytosis (DCM) consists of a diffuse mast cell infiltration of the skin without discrete lesions. It usually occurs before the age of 3 years. The entire cutaneous integument is involved. The skin is normal to yellow-brown in color and is diffusely thickened. [14]

Solitary mastocytomas of the skin (Fig. 163-3) do occur but are rare. Their onset is generally before 6 months of age. In most cases, such lesions involute spontaneously.

FIGURE 163-3 Solitary mastocytoma. *A*. A tan macule is seen on the buttocks of an 18-month-old child. *B*. After the child's diaper was changed, the lesion became an urticarial plaque.

Young children with UP or DCM may have bullous eruptions with hemorrhage (Fig. 163-4). Blisters may erupt spontaneously or in association with infection or immunization. Blisters may occur at birth and thus are in the differential diagnosis of neonatal disorders with blisters.

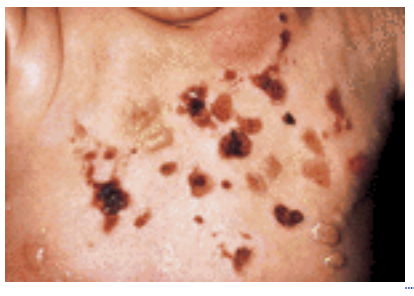

FIGURE 163-4 Bullous eruption on the back of a child with diffuse cutaneous mastocytosis and indolent mastocytosis.

Telangiectasia macularis eruptiva perstans (TMEP) is observed in fewer than 1 percent of patients with mastocytosis. It appears as tan to brown macules and patchy erythema. Telangiectasias are observed. This form of cutaneous disease in mastocytosis is observed exclusively in adults.

Both children and adults with mastocytosis may develop gastrointestinal disease. Gastric hypersecretion caused by elevated plasma histamine with resultant gastritis and peptic ulcer disease is the most common problem. [15] Diarrhea and abdominal pain are also common and are followed by the onset of malabsorption in a subset of patients with advanced disease. Roentgenographic abnormalities fall into three major categories: peptic ulcers; abnormal mucosal patterns such as mucosal edema, multiple nodular lesions, coarsened mucosal folds, or multiple polyps; and motility disturbances. Histologic sections of jejunal biopsies show moderate blunting of the villi; however, significant mast cell hyperplasia is uncommon.

Significant hepatic disease in adults with ISM is relatively infrequent, although liver function tests are somewhat above normal in about half of all patients with extracutaneous disease. [16] The most common chemical abnormality is an elevated level of alkaline phosphatase, which must be distinguished from bone-derived alkaline phosphatase (which may also be elevated). Serious manifestations of hepatic and splenic involvement, including portal hypertension and ascites associated with liver fibrosis, [16] are more common in patients who have SM-AHNMD or ASM.

Splenic involvement is also present in about half of patients with mastocytosis with evidence of systemic disease. [17] A peritrabecular distribution of mast cell infiltrates and fibrosis is most common. Eosinophilic infiltrates are also noted, as are areas of extramedullary hematopoiesis. Markedly increased splenic weights (greater than 700 g) generally occur in patients who fit into unfavorable categories of mastocytosis, that is, ASM or SM-AHNMD.

Bone marrow lesions usually consist of multifocal clusters or aggregates of tryptase-positive mast cells, often mixed with eosinophils, and T and B lymphocytes (Fig. 163-5). [1], [18] These lesions are rarely seen in children. [19] Alternatively, the diagnosis of mastocytosis may be made if more than 25 percent of mast cells are spindle-shaped, or have atypical morphology, and other criteria of mastocytosis (*c-kit* mutation at codon 816; CD2+ CD25+ mast cells; total serum tryptase >20 ng/mL) are met. Anemia, leukopenia, thrombocytopenia, and eosinophilia may occur in association with systemic disease and suggest SM-AHNMD, ASM, or MCL.

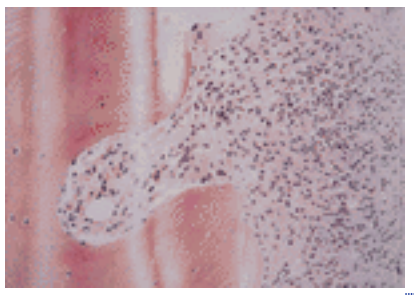

FIGURE 163-5 Bone marrow biopsy shows a characteristic lesion of systemic mastocytosis with peritrabecular infiltrates of mast cells and bony erosion. Mast cells are spindle-shaped, resembling fibroblasts or histiocytes.

Bone marrow infiltration with mast cells may induce bone changes that cause radiographically detectable lesions. The proximal long bones are most often affected, followed by the pelvis, ribs, and skull. Skeletal scintigraphy (bone scan) is more sensitive than a radiographic survey in detecting and locating active lesions. [20] Musculoskeletal pain affects 19 to 28 percent of patients. In patients with severe or advanced disease, pathologic fractures may occur.

Patients in every category of mastocytosis sometimes experience flushing or vascular collapse. In occasional patients, such reactions may be provoked by alcohol, aspirin, narcotics, iodinated contrast media, insect stings, exercise, or infections.

Neuropsychiatric abnormalities have been reported. [21], [22] Problems include decreased attention span, memory impairment, and irritability. Depression as a consequence of chronic disease or possibly mediated by mast cell products is a possibility.

DIAGNOSIS

The diagnosis of mastocytosis is suspected on clinical grounds and is confirmed by histology. Supporting evidence is derived from biochemical data (Table 163-3). [1] Mast cells may be overlooked on histologic sections, depending on the fixation and/or stain employed. The most useful stain for mast cells is tryptase, although metachromatic stains, such as toluidine blue and Giemsa; enzymatic stains, such as chloroacetate esterase and aminocaproate esterase; and avidin, which binds to heparin, also may be employed. [1], [23] These procedures highlight the granules in the cytoplasm of the mast cell, thereby facilitating identification. In trephine core bone marrow biopsies, decalcification interferes with subsequent attempts to visualize mast cell granules with metachromatic stains, thereby making tryptase the stain of choice.

Routine studies
Skin examination—gross and microscopic
Plasma tryptase
Bone marrow biopsy and aspiration
24-h urine for mediators
Additional studies as required by initial findings
Bone scan/skeletal survey
GI workup—upper GI series, small bowel x-ray, CT scan, endoscopy
EEG, neuropsychiatric workup

TABLE 163-3 **Consensus Diagnostic Workup for Mastocytosis Suspected on Clinical Grounds**

Most patients with mastocytosis have either UP or DCM, which can be recognized on physical examination. [14] These diagnoses should be confirmed by skin biopsy. Blind skin biopsies must be interpreted with caution because other skin conditions, including eczema and chronic urticaria, are associated with a two- to fourfold increase in dermal mast cells. [24]

In patients with UP, mast cells are found in increased numbers in the dermal papillae, particularly near blood vessels. [24] Mast cells may distribute in a bandlike infiltrate of the papillary dermis (Fig. 163-6) or appear as nodular infiltrates from the papillary dermis to subcutaneous tissues. Analysis of the relationship between mast cells and blood vessels has suggested that mast cells in patients with mastocytosis first increase in number around blood vessels and later appear in

tissues distant from vessels. [24] Mast cells may also be found in increased numbers in skin between lesions of UP. The greatest increases in mast cell number occur beneath UP macules and papules. On average, there is a 15- to 20-fold increase in mast cells beneath those lesions, but in occasional patients, only a two- to fourfold increase in mast cells is found. Two- to fourfold increases in mast cell number have also been documented in patients with recurrent episodes of anaphylaxis [24] at skin sites involved in scleroderma, [25] chronic urticaria, [26] and prolonged antigenic contact. [27] These observations document the need to correlate the gross skin examination with skin mast cell numbers and to avoid the diagnosis of UP solely on the basis of small increases in dermal mast cells. Cutaneous responses to intradermal histamine are unchanged in patients with UP. [28]

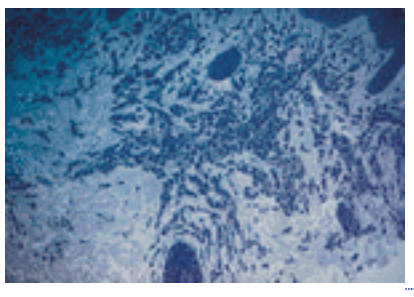

FIGURE 163-6 Mast cell hyperplasia in the dermis of a patient with systemic mastocytosis.

In patients with DCM, prominent bandlike infiltrates are present, which may be indistinguishable from some lesions of UP or from tissue obtained from mastocytomas. Cutaneous mast cell hyperplasia in patients with TMEP is present around the capillary venules of the superficial plexus.

Mastocytosis should be suspected in patients without skin lesions if they have one or more of the following: unexplained ulcer disease or malabsorption, radiographic or ^{99m}Tc bone scan abnormalities, hepatomegaly, splenomegaly, lymphadenopathy, peripheral blood abnormalities, or unexplained flushing or hypotension. Elevated levels of plasma [29], [30] or urinary histamine or histamine metabolites, [31] prostaglandin D_2 metabolites in the urine, [32] or plasma mast cell tryptase [33] are not diagnostic but do raise the index of suspicion of mastocytosis. Other surrogate markers of disease are serum interleukin (IL)-6 levels, [34] and soluble SCF receptor (CD117) and IL-2 receptor (CD25) levels. The levels of the latter receptors are highly correlated with the severity of bone marrow pathology. [35]

In the absence of skin lesions, patients suspected of having mastocytosis should have a bone marrow biopsy and aspirate for diagnosis and categorization of the type of mastocytosis. Adult patients with UP should also have this procedure, particularly if they have peripheral blood abnormalities, hepatomegaly, splenomegaly, or lymphadenopathy, to determine if they have mastocytosis with an associated hematologic disorder. Other tissue specimens, such as lymph nodes, spleen, liver, and gastrointestinal mucosa, define the extent of mast cell involvement, but are usually obtained only as dictated by necessity. For example, gastrointestinal biopsies are obtained only if a gastrointestinal workup is indicated, and lymph nodes are biopsied only if lymphoma is considered.

Patients suspected of having mastocytosis should have 24-h urine 5-hydroxyindoleacetic acid (5-HIAA) and urinary metanephrines measured to help eliminate the possibility of a carcinoid tumor or pheochromocytoma. The fact that patients with mastocytosis do not excrete increased amounts of 5-HIAA suggests that serotonin, present in the mast cells of some species, is not synthesized by human mast cells. Idiopathic anaphylaxis and flushing must also be ruled out. Patients with these disorders do not have histologic evidence of significant mast cell proliferation and should have normal plasma tryptase levels between episodes of anaphylaxis. [33]

TREATMENT

The primary objective of treatment in all categories of mastocytosis is to control mast cell mediator-induced signs and symptoms such as vascular collapse, gastric hypersecretion, gastrointestinal cramping, and pruritus. H_1 receptor antagonists such as hydroxyzine, loratadine, and fexofenadine are helpful in reducing pruritus, flushing, and tachycardia. If insufficient relief occurs, the addition of an H_2 antagonist such as ranitidine or cimetidine may be beneficial. However, many patients continue to complain of musculoskeletal pain, headaches, and flushing, resulting in part from the inability to block the effects of high levels of histamine with histamine antagonists and the presence of other mast cell mediators.

Disodium cromoglycate (cromolyn sodium) inhibits the degranulation of mast cells and may have some efficacy in the treatment of mastocytosis, particularly in relieving gastrointestinal complaints. [36] Cromolyn sodium does not lower plasma or urinary histamine levels in patients with mastocytosis. Both ketotifen and azelastine, antihistamines with mast cell-stabilizing properties, help by relieving the pruritus and whealing associated with mastocytosis. However, neither drug appears to offer an advantage over a standard antihistamine such as hydroxyzine. [37], [38]

Epinephrine is used to treat episodes of vascular collapse. Patients with such episodes should be prepared to self-administer this drug and have a plan for emergency management. If subcutaneous epinephrine is insufficient, intensive therapy for vascular collapse should be instituted. Patients with recurrent episodes of vascular collapse may be placed on H_1 and H_2 antihistamines to lessen the severity of attacks. Episodes of vascular collapse may be spontaneous but have also occurred after stings from insects or after administration of iodinated contrast media. In the latter case, premedication is recommended before such procedures.

Methoxsalen with long-wave ultraviolet radiation (PUVA) relieves pruritus and whealing after 1 to 2 months of treatment. [39], [40] Improvement is associated with a temporary decrease in dermal mast cells. Pruritus recurs within 3 to 6 months

after treatment is stopped. Photochemotherapy should be used only in instances of extensive cutaneous disease that do not respond to other forms of therapy. Some patients report a diminution in the number or intensity of cutaneous lesions after exposure to natural sunlight.

Topical glucocorticoids, such as 0.05 percent betamethasone dipropionate ointment, under plastic-film occlusion for 8 h per day over 8 to 12 weeks can be used to treat extensive cutaneous disease. Mast cell numbers decrease as the lesions clear. These lesions eventually recur after discontinuation of therapy, [41] although the treatment may lead to improvement in the cutaneous lesions for up to 1 year.

Treatment of gastrointestinal disease is directed to controlling peptic symptoms, diarrhea, and malabsorption. [15] Gastric acid hypersecretion leading to peptic symptoms and ulcerations is controlled with H_2 antagonists and proton pump inhibitors. Diarrhea is difficult to manage, and H_2 antagonists are generally not effective. Anticholinergics may give partial relief. In patients with severe malabsorption, systemic glucocorticoids have been effective. Ascites is difficult to control. Portal hypertension in one patient was successfully managed with a portacaval shunt. [42] Another patient with an exudative ascites was treated successfully with systemic glucocorticoid therapy. [43] Osteoporosis in patients with mastocytosis may be underrecognized. Recommended approaches to treatment include calcium supplementation, estrogen replacement in postmenopausal women, and the use of biphosphonates. [44]

Patients with SM-AHNMD are managed as dictated by the specific hematologic abnormality. Interferon-alpha 2b has been used to treat patients with SM-AHNMD or ASM with mixed results. [44] Some patients responded, but others did not. Various chemotherapeutic regimens for the treatment of aggressive forms of mastocytosis (ASM, MCL, some forms of SM-AHNMD) have been tried with limited success (reviewed in Ref. 44). One recent case report of the use of cladribine [45] suggests continued evolution in attempts to treat this disease. Tyrosine kinase inhibitors are under investigation, but some may not inhibit cells bearing the 816 mutation. [46] Chemotherapy has no place in the treatment of CM or ISM. Splenectomy may improve survival in patients with forms of mastocytosis that have a poor prognosis. [47] Radiotherapy has been used to treat refractory bone pain in advanced disease. [48] Bone marrow transplantation may be considered for gravely ill patients, although little is known about long-term prognosis after transplant.

PROGNOSIS

Prognosis must be addressed separately for each category of mastocytosis. A number of variables are associated with poor survival: constitutional symptoms, anemia, thrombocytopenia, abnormal liver function tests, a lobated mast cell nucleus, a low percentage of fat cells in the bone marrow biopsy, and an associated hematologic disorder. Other poor prognostic variables include absence of UP, male sex, absence of skin and bone symptoms, hepatomegaly, splenomegaly, and normal bone x-ray findings.

As a group, patients with CM or ISM have the best prognosis. Among children with isolated UP, at least 50 percent of cases reportedly resolve by adulthood. [49], [50] Furthermore, children born of mothers with ISM reportedly are free of disease. [51] Adults with UP usually progress gradually to systemic disease and rarely develop hematologic disease. [51] DCM is usually associated with ISM. Older patients with UP who experience fading of their lesions continue to exhibit bone marrow lesions typical of their diagnosis, whether ISM or SM-AHNMD. [52] Patients with SM-AHNMD have a variable course dependent on the prognosis of their hematologic disorder. With MCL, mean survival is generally less than 6 months. With ASM, mean survival is 2 to 4 years without therapy. The prognosis appears to improve with aggressive symptomatic management.

REFERENCES

1. Valent P et al: Mastocytosis, in *World Health Organization Classification of Tumours: Pathology and Genetics in Tumours of Haematopoietic and Lymphoid Tissues,* edited by ES Jaffee, NL Harris, H Stein, JW Varderman. Lyon, IARC Press, 2001, p 291

2. Kirshenbaum AS et al: Demonstration that human mast cells arise from a bipotential progenitor cell population that is CD34+, *c-kit*+, and expresses aminopeptidase N (CD13). *Blood* **94**:2333, 1999

3. Castells MC et al: The presence of membrane-bound stem cell factor in highly immature nonmetachromatic mast cells in the peripheral blood of a patient with aggressive systemic mastocytosis. *J Allergy Clin Immunol* **98**:831, 1996

4. Gurish MF et al: Intestinal mast cell progenitors require CD49dß7 (a4ß7 integrin) for tissue-specific homing. *J Exp Med* **194**:1243, 2001

5. Kirshenbaum AS et al: Inhibition of human mast cell growth and differentiation by interferon gamma-1. *Exp Hematol* **26**:245, 1998

6. Gurish MF et al: Tissue-regulated differentiation and maturation of a v-abl-immortalized mast cell-committed progenitor. *Immunity* **3**:175, 1995

7. Finotto S et al: Glucocorticoids decrease tissue mast cell number by reducing production of the *c-kit* ligand, stem cell factor, by resident cells: In vitro and in vivo evidence in murine systems. *J Clin Invest* **99**:1721, 1997

8. Nagata H et al: Identification of a point mutation in the catalytic domain of the proto-oncogene *c-kit* in the peripheral blood mononuclear cells of patients with mastocytosis. *Proc Natl Acad Sci U S A* **92**:10560, 1995

9. Taylor ML et al: The kit-activating mutation D816V enhances stem cell factor-dependent chemotaxis. *Blood* **98**:1195, 2001

10. Akin C et al: Analysis of the surface expression of *c-kit* and occurrence of the *c-kit* Asp816Val activating mutation in T cells, B cells, and myelomonocytic cells in patients with mastocytosis. *Exp Hematol* **28**:140, 2000

11. Longley BJ Jr et al: Activating and dominant inactivating *c-kit* catalytic domain mutations in distinct clinical forms of human mastocytosis. *Proc Natl Acad Sci USA* **96**:1609, 1999

12. Daly T et al: Association of the Q576R polymorphism in the interleukin-4 receptor a chain with indolent mastocytosis limited to the skin. *Blood* **98**:880, 2001

13. Lishner M et al: Trisomies 9 and 8 detected by fluorescence in situ hybridization in patients with systemic mastocytosis. *J Allergy Clin Immunol* **98**:199, 1996

14. Soter NA: Mastocytosis and the skin. *Hematol Oncol Clin North Am* **14**:537, 2000

15. Jensen RT: Gastrointestinal abnormalities and involvement in systemic mastocytosis. *Hematol Oncol Clin North Am* **14**:579, 2000

16. Mican JM et al: Hepatic involvement in mastocytosis: Clinicopathologic correlations in 41 cases. *Hepatology* **22**:1163, 1995

17. Travis WD, Li C-Y: Pathology of the lymph node and spleen in systemic mast cell disease. *Mod Pathol* **1**:4, 1988

18. Parker RI: Hematologic aspects of systemic mastocytosis. *Hematol Oncol Clin North Am* **14**:557, 2000

19. Kettelhut BV et al: Hematopathology of the bone marrow in pediatric cutaneous mastocytosis: A study of seventeen patients. *Am J Clin Pathol* **91**:558, 1989

20. Chen CC et al: A retrospective analysis of bone scan abnormalities in mastocytosis: Correlation with disease category and prognosis. *J Nucl Med* **35**:1471, 1994

21. Rogers MO et al: Mixed organic brain syndrome as a manifestation of systemic mastocytosis. *Psychosom Med* **48**:437, 1986

22. McFarlin KE et al: A preliminary assessment of behavioral problems in children with mastocytosis. *Intl J Psych Med* **21**:281, 1991

23. Kasper CS, Tharp MD: Quantification of cutaneous mast cells using morphometric counting and a conjugated avidin stain. *J Am Acad Dermatol* **16**:326, 1987

24. Garriga MM et al: A survey of the number and distribution of mast cells in the skin of patients with mast cell disorders. *J Allergy Clin Immunol* **82**:425, 1988

25. Nishioka K et al: Mast cell numbers in scleroderma. *Arch Dermatol* **123**:205, 1987

26. Elias J et al: Studies of the cellular infiltrate of chronic idiopathic urticaria: Prominence of T-lymphocytes, monocytes, and mast cells. *J Allergy Clin Immunol* **78**:914, 1986

27. Mitchell EB et al: Increase in skin mast cells following chronic house dust mite exposure. *Br J Dermatol* **114**:65, 1986

28. Keffer JM et al: Analysis of the wheal and flare reactions that follow the intradermal injection of histamine and morphine in adults with recurrent unexplained anaphylaxis and systemic mastocytosis. *J Allergy Clin Immunol* **83**:595, 1989

29. Kettelhut BV, Metcalfe DD: Plasma histamine in the evaluation of pediatric mastocytosis. *J Pediatr* **111**:419, 1987

30. Friedman BS et al: Analysis of plasma histamine levels in patients with mast cell disorders. *Am J Med* **87**:649, 1989

31. Van Gysel D et al: Value of urinary N-methylhistamine measurements in childhood mastocytosis. *J Am Acad Dermatol* **35**:556, 1996

32. Morrow JD et al: Improved diagnosis of mastocytosis by measurement of the major urinary metabolite of prostaglandin D_2. *J Invest Dermatol* **104**:937, 1995

33. Schwartz LB et al: The alpha form of human tryptase is the predominant type present in blood at baseline in normal subjects, and is elevated in those with systemic mastocytosis. *J Clin Invest* **96**:2702, 1995

34. Brockow K et al: Levels of mast cell growth factors in plasma and in suction skin blister fluid in adults with mastocytosis: Correlation with dermal mast cell numbers and mast cell tryptase. *J Allergy Clin Immunol* **109**:82, 2002

35. Akin C et al: Soluble stem cell factor receptor (CD117) and IL-2 receptor (CD25) levels in the serum of patients with mastocytosis: Relationships to disease severity and bone marrow pathology. *Blood* **96**:1267, 2000

36. Horan RF et al: Cromolyn sodium in the management of systemic mastocytosis. *J Allergy Clin Immunol* **85**:852, 1990

37. Kettelhut BV et al: A double-blind placebo-controlled trial of ketotifen versus hydroxyzine in the treatment of pediatric mastocytosis. *J Allergy Clin Immunol* **83**:866, 1989

38. Friedman BS et al: Comparison of azelastine and chlorpheniramine in the treatment of mastocytosis. *J Allergy Clin Immunol* **92**:520, 1993

39. Vella-Briffa D et al: Photochemotherapy (PUVA) in the treatment of urticaria pigmentosa. *Br J Dermatol* **109**:67, 1983

40. Czarnetski PM et al: Phototherapy of urticaria pigmentosa: Clinical response and changes of cutaneous reactivity, histamine, and chemotactic leukotrienes. *Arch Dermatol Res* **277**:105, 1985

41. Barton J et al: Treatment of urticaria pigmentosa with corticosteroids. *Arch Dermatol* **121**:1516, 1985

42. Bonnet P et al: Intractable ascites in systemic mastocytosis treated by portal diversion. *Dig Dis Sci* **32**:209, 1987

43. Reisberg IR, Oyakawa S: Mastocytosis and malabsorption, myelofibrosis and massive ascites. *Am J Gastroenterol* **82**:54, 1987

44. Worobec AS: Treatment of systemic mast cell disorders. *Hematol Oncol Clin North Am* **14**:659, 2000

45. Tefferi A et al: Treatment of systemic mast cell disease with cladribine. *N Engl J Med* **344**:307, 2001

46. Ma Y et al: The *c-kit* mutation causing human mastocytosis is resistant to STI571 and other KIT kinase inhibitors; kinases with enigmatic site mutations show different sensitivity profiles than wild-type kinases and those with regulatory type mutations. *Blood* **99**:1741, 2002

47. Friedman B et al: Splenectomy in the management of systemic mast cell disease. *Surgery* **107**:94 1990

48. Johnstone PA et al: Radiotherapy of refractory bone pain due to systemic mast cell disease. *Am J Clin Oncol* **17**:328, 1994

49. Sondergaard J, Asbo-Hansen E: Mastocytosis in childhood, in *Pediatric Dermatology,* edited by R Happle. Berlin, Springer-Verlag, 1987, p 148

50. Kettelhut BV, Metcalfe DD: Pediatric mastocytosis. *J Invest Dermatol* **96**:15S, 1991

51. Worobec AS et al: Mastocytosis complicating pregnancy. *Obstet Gynecol* **95**:391, 2000

52. Brockow K et al: Regression of urticaria pigmentosa in adult patients with systemic mastocytosis: Correlation with clinical patterns of disease. *Arch Dermatol* **138**:785, 2002

T>

Chapter 164

Graham Johnston Robin
Graham-Brown

The Skin and Disorders of the Alimentary Tract and the Hepatobiliary System

THE SKIN AND THE ALIMENTARY TRACT
Dysphagia
Gastrointestinal Bleeding
Abdominal Pain
Diarrhea and Malabsorption
SKIN LESIONS DUE TO HEPATOBILIARY DISEASE
Jaundice
Melanosis and Other Pigmentary Changes
Vascular Changes
Hormone-Induced Changes of the Skin
Cutaneous Manifestations of Primary Biliary Cirrhosis
Miscellaneous Changes of the Skin
Nail Changes in Liver Disease
Itching
Hepatitis and the Skin
Disorders That May Involve Both Skin and Liver
EFFECTS OF SKIN DISEASE ON THE LIVER
Extensive Loss of Skin
Erythroderma
Psoriasis
Dermatitis Herpetiformis
Cancers of the Skin
HEPATOTOXIC EFFECTS OF DRUGS USED IN THE TREATMENT OF SKIN DISEASE

REFERENCES

Diseases of the skin and the alimentary tract or the skin and the hepatobiliary system frequently occur together. Just as a full physical examination should be part of a full dermatologic assessment, it is important to examine the skin in someone presenting with a gastrointestinal or liver problem.

Disorders of the pharynx, esophagus, stomach, pancreas, and intestines that may lead to skin changes include dysphagia, gastrointestinal bleeding, abdominal pain, and diarrhea and malabsorption. Skin changes may also occur in conjunction with liver disease. In some cases, pathologic processes affect both the skin and the liver. In some cases, skin disease is a cause of liver abnormalities; furthermore, drugs used to treat skin disease sometimes have an impact on the liver.

THE SKIN AND THE ALIMENTARY TRACT

Dysphagia

When dermatologic diseases extend into the pharynx and esophagus, as well as when the oro-oculogenital syndromes, esophageal cancer, and collagen vascular disease develop (Table 164-1), dysphagia may occur.

Rashes that may extend to the esophagus	Carcinoma of the esophagus
Infections	Iron deficiency
Blistering diseases, congenital and acquired	Dermatitis herpetiformis
Lichen planus	Tylosis
Darier's disease	Inorganic arsenic ingestion
Acanthosis nigricans	Collagen vascular diseases
Oro-oculo-genito-cutaneous syndromes	Systemic sclerosis
Stevens-Johnson syndrome	Dermatomyositis
Behçet's syndrome	

TABLE 164-1 **Skin Abnormalities That Occur with Dysphagia**

RASHES THAT EXTEND TO THE PHARYNX AND ESOPHAGUS
Infections Cutaneous and oral infections are discussed elsewhere (see Section 28, Section 29, and Section 30). Symptoms resulting from infections of the esophagus occur in patients who are taking oral and inhaled glucocorticoids or in those who have an immunodeficiency (e.g., AIDS; see Chap. 225). *Candida albicans* is the most frequent pathogen, although opportunistic viruses can also be responsible for infection.
Blistering diseases Extensive esophageal involvement with blisters, erosions, and strictures can occur in hereditary epidermolysis bullosa (see Chap. 65), particularly in the recessive dystrophic and junctional forms. Management of strictures includes esophageal dilatation, colonic interposition, and gastrostomy insertion to maintain adequate nutrition. [1] Acquired immunobullous disorders, such as pemphigus, bullous pemphigoid, acquired epidermolysis bullosa, and dermatitis herpetiformis, can affect mucosae (Fig. 164-1). Dysphagia is most troublesome in cicatricial pemphigoid (see Chap. 62). Half of the patients will have pharyngeal involvement and up to 13 percent esophageal involvement, usually of the upper esophagus, [2] with a risk of stricture formation requiring surgical dilatation.

FIGURE 164-1 Ulceration of the mouth in a patient with mucous membrane pemphigoid.

Other conditions Esophageal lichen planus has been reported only in women, typically middle-aged women, with oral involvement. Half have had strictures of the upper esophagus, but therapeutic dilatation can lead to a Koebner-like exacerbation of the stricture. [3] Esophageal involvement also occurs in Darier's disease, sometimes in association with esophageal carcinoma, [4] and in acanthosis nigricans.

ORO-OCULO-GENITO-CUTANEOUS SYNDROMES The mucosae may be extensively involved in Stevens-Johnson syndrome, toxic epidermal necrolysis (see Chap. 58), and Behçet's syndrome [5] (see Chap. 192). Isolated mucosal ulcers can occur at any point along the gastrointestinal tract. A typical site is the ileocecal region. Oral ulceration, occurring at least three times in a 12-month period, is usually evident on the nonkeratinized epithelium and can be difficult to distinguish from the mouth ulceration associated with Crohn's disease.

CARCINOMA OF THE ESOPHAGUS In the Plummer-Vinson (Paterson-Kelly) syndrome, a postcricoid web is associated with koilonychia, angular stomatitis, a sore tongue, and, usually, iron deficiency. Between 5 and 10 percent of patients with a postcricoid web develop carcinoma at the site. Tylosis is exceedingly rare, but 95 percent of those with tylosis eventually develop esophageal cancer. In two families, both tylosis and carcinoma of the esophagus were inherited as dominant traits. [6] Finally, inorganic arsenic is associated with malignancy. Non-melanoma skin cancers and palmoplantar keratoses are useful dermatologic markers.

COLLAGEN VASCULAR DISEASES Dysphagia occurs, particularly in systemic sclerosis and dermatomyositis (see Chap. 173 and Chap. 172). Up to 90 percent of patients with systemic sclerosis have gastrointestinal involvement, but this is subclinical in one-third. Dyspepsia due to gastroparesis is common; decreased peristalsis, esophageal dilation, and stricture formation occur and may require prokinetic agents or endoscopic dilatation, respectively. Gastric antral vascular ectasia is a rare manifestation that may cause significant bleeding. [7] In dermatomyositis and polymyositis, decreased esophageal motility and difficulty swallowing are indications for urgent treatment with the systemic administration of glucocorticoids and immunosuppressive drugs (see Chap. 172). Vasculitic ulcers in the mouth and pharynx infrequently occur in systemic lupus erythematosus (see Chap. 171).

Gastrointestinal Bleeding

Hematemesis, melena, or passing of fresh blood in the stools are signs of gastrointestinal bleeding. The skin may give diagnostic clues in a number of causes (Table 164-2), some of which may cause a change in bowel habit or abdominal pain (see " Abdominal Pain," below).

Congenital malformations of blood vessels	Kaposi's sarcoma
Hereditary hemorrhagic telangiectasia	Vasculitis
Blue rubber bleb nevi	Polyposis
Inherited defects of connective tissue	Ulcerative colitis and Crohn's disease
Ehlers-Danlos syndrome	Gastrointestinal tumors
Pseudoxanthoma elasticum	Drugs used to treat skin disease

TABLE 164-2 **Skin Abnormalities in Patients with Gastrointestinal Bleeding**

VASCULAR ABNORMALITIES The characteristic picture of hereditary hemorrhagic telangiectasia is of a familial pattern of epistaxis with telangiectases on mucosal surfaces (see Fig. 166-6) and arteriovenous malformations in multiple organs [8] (see Chap. 166). Hemorrhage from gastrointestinal lesions occurs in 10 to 40 percent of patients, usually from the stomach or duodenum, and at an average age of 55 years. Treatment includes low-dose estrogen/progestogen to reduce hemorrhage. Bipolar coagulation, argon, or neodymium:YAG laser ablation can be helpful in the treatment of local lesions. The benefits of embolization remain to be proven. Most cases of blue rubber bleb nevus syndrome are sporadic (see Chap. 103), but there are families with autosomal dominant inheritance. The venous malformations look and feel as their name suggests and project into the gut lumen, particularly that of the small intestine. In contrast to cutaneous lesions, they bleed easily, causing chronic anemia and, less commonly, acute hemorrhage. [9]

INHERITED DEFECTS OF CONNECTIVE TISSUE In the autosomal dominant vascular type of the Ehlers-Danlos syndrome, type IV, rupture of the bowel, often involving the sigmoid colon, accounts for one-quarter of all complications and 8 percent of all deaths. [10] Diverticula, and hiatus and inguinal hernias, may also occur (see Chap. 154). Thirteen percent of patients with pseudoxanthoma elasticum experience gastrointestinal bleeding, usually from the stomach. This bleeding is often the first clinical manifestation of the disease. Although treatment is conservative, surgery is effective when necessary. [11]

KAPOSI'S SARCOMA The gut, particularly the small intestine, is a common site for Kaposi's sarcoma (see Chap. 104). Involvement is commonly asymptomatic, but severe bleeding may occur.

DRUGS USED IN DERMATOLOGY Gastrointestinal bleeding in a patient with a dermatologic disease may be due to drug therapy. The systemic administration of glucocorticoids commonly causes dyspepsia; less commonly, it causes gastric erosions, ulceration, and hemorrhage. Methotrexate may cause enteritis, gastrointestinal ulceration, and hemorrhage.

Abdominal Pain

Skin signs may occasionally help in the diagnosis of abdominal pain (Table 164-3). Vasculitis, polyposis, inflammatory

bowel disease, and cancers have several possible dermatologic presentations.

Herpes zoster
Angioedema
Porphyria
Anderson-Fabry disease
Vasculitis
Henoch-Schönlein disease
Collagen vascular diseases
Malignant atrophic papulosis
Polyposis
Gardner's syndrome
Peutz-Jeghers syndrome
Canada-Cronkhite syndrome
Neurofibromatosis
Ulcerative colitis
Inflammatory bowel disease: ulcerative colitis and Crohn's disease
Pancreatitis
Gastrointestinal tumors
Metastases
Dermatomyositis
Acanthosis nigricans
Hypertrichosis lanuginosa

TABLE 164-3 **Skin Abnormalities in Patients with Abdominal Pain**

HERPES ZOSTER Involvement of the sensory roots of the vertebrae T6-L1 in herpes zoster may produce abdominal pain even before skin lesions appear. Occasionally, herpes zoster in the distribution of S2, S3, and S4 is associated with perineal pain and disturbances of urination and defecation (see Chap. 215).

ANGIOEDEMA Acute attacks of urticaria and angioedema may present as abdominal pain. Edema of the bowel wall and mucosal thickening, often in association with free peritoneal fluid, is evident ultrasonographically, which makes it possible to avoid unnecessary surgery in acute cases. [12] This is especially true in the autosomal dominant disorder hereditary angioedema where angioedema, usually without urticaria, may cause colicky abdominal pain and life-threatening laryngeal edema. Treatment of acute episodes is with injection of purified C1 inhibitor concentrate [13] (see Chap. 117).

VARIEGATE PORPHYRIA It is only in the rare variegate porphyria that skin involvement and attacks of abdominal pain coexist. The skin shows changes identical to those in porphyria cutanea tarda (see Chap. 149). Pregnancy or drugs such as estrogen and griseofulvin may precipitate acute attacks. Although the detection of urinary uroporphyrin and fecal protoporphyrin indicates the diagnosis, plasma fluorescence with emission maxima at 626 nm is more sensitive; it reveals the condition even in patients who are in remission. [14]

ANDERSON-FABRY DISEASE (ANGIOKERATOMA CORPORIS DIFFUSUM) A rare disease, Anderson-Fabry disease is an X-linked recessive multisystem lysosomal storage disorder caused by a deficiency of a-galactosidase A (see Chap. 151). Clinical signs and symptoms include severe, painful neuropathy; progressive renal, cardiovascular, and cerebrovascular dysfunction; and early death. Gastrointestinal symptoms include abdominal pain, postprandial cramps with delayed gastric emptying, and diarrhea. The diagnosis may be missed without the skin signs. Angiokeratomas may not appear until adolescence and, even then, can be subtle. Assay of a-galactosidase A is possible not only in established cases, but also before birth, and female carriers often identifiable. Treatment with intravenous infusions of a-galactosidase A is safe and efficacious. [15]

VASCULITIS (See Chap. 174 and Chap. 175.) Henoch-Schönlein purpura is palpable, especially on the legs and buttocks, and may occur in conjunction with joint swelling. Up to 76 percent of patients have gastrointestinal involvement, ranging from colicky abdominal pain, nausea, and vomiting to bloody diarrhea, intussusception, and pancreatitis. Renal involvement is common, especially in patients with bloody stools. [16] Upper gastrointestinal endoscopy reveals multiple raised erythematous lesions or ulceration that resolves after systemic treatment with glucocorticoids. [17] Acute involvement of vessels in the small and large intestine also occurs in collagen vascular diseases and may be fatal. Chronic obliteration of small intestinal vessels can result in malabsorption, and impairment of motility can cause abdominal pain. [7] Malignant atrophic papulosis is an idiopathic systemic obliterative vasculopathy (see Chap. 101). Recurrent crops of porcelain-white atrophic papules with an elevated erythematous border are the characteristic skin lesions. Gut vessels are involved in half of the cases, [18] and this involvement manifests itself clinically as bleeding, abdominal pain, diarrhea, malabsorption, and bowel perforation with peritonitis. Patients usually die of cerebrovascular bleeding or sepsis following perforation of the gut, but skin lesions may have been present for years with no other apparent disease.

POLYPOSIS True polyps are rare except in the colon and rectum. Polyp-like lesions that are hamartomatous or inflammatory occur in all parts of the gut. The term *hamartoma* implies a non-neoplastic tumor composed of tissue elements normally present in that organ. The hamartomatous polyposis syndromes (e.g., Peutz-Jeghers, Cronkhite-Canada) should be distinguished from the adenomatous polyposis syndromes (e.g., Gardner's). All may have dermatologic associations. In many of these syndromes, hamartomatous polyps of the gastrointestinal tract coexist with adenomas, and adenomas may develop within hamartomatous polyps. Either situation may contribute to the frequent occurrence of adenocarcinoma in most of these syndromes. [19]

Gardner's syndrome An autosomal dominant disorder, Gardner's syndrome is characterized by cutaneous cysts and premalignant adenomatous polyps, particularly in the colorectum. Duodenal and hepatic carcinoma has also occurred in conjunction with the disorder. The cutaneous lesions frequently predate the gastrointestinal lesions and include solitary or multiple epidermoid cysts, fibromas, lipomas, pilomatricomas, facial osteomas, and distinctive ocular lesions. [20] Regular colonoscopy is mandatory for patients at risk.

Peutz-Jeghers syndrome Like Gardner's syndrome, Peutz-Jeghers syndrome is an autosomal dominant condition. In the latter syndrome, small darkly pigmented macules occur around the mouth, on the lips and buccal mucosa, and on the digits (see Chap. 90). A histologically unique type of hamartomatous polyp occurs, mainly in the small intestine, which predisposes to recurrent intussusception in the majority of cases. Bleeding is relatively rare, but up to 2 percent of patients develop adenocarcinoma of the stomach, duodenum, and colon. [19] There is also an increased risk of malignancy in general.

Cronkhite-Canada syndrome In Cronkhite-Canada syndrome, a rare, nonfamilial disease, there is patchy alopecia and characteristic, but not diagnostic, nail changes or nail loss. Inflammatory polyps are present in the stomach and bowel, and abdominal pains with a severe protein-losing enteropathy are common. The hair and nail changes may precede the gastrointestinal symptoms. [19]

Neurofibromatosis type 1 Neurofibromas can involve any portion of the gastrointestinal tract (see Chap. 190). Leiomyomas and other tumors (both benign and malignant) also occur.

Ulcerative colitis Inflammatory polyposis occurs in ulcerative colitis. P> **INFLAMMATORY BOWEL DISEASE:**

ULCERATIVE COLITIS AND CROHN'S DISEASE Both ulcerative colitis and Crohn's disease can present with abdominal pain, gastrointestinal bleeding, or diarrhea. Ulcerative colitis predisposes to carcinoma of the colon. The skin complications of the two diseases are similar, although some occur with different frequencies; in particular, granulomas are much more common in Crohn's disease (Table 164-4).

Pyoderma gangrenosum
Erythema nodosum
Aphthous ulcers
Malnutrition
Rashes at ileostomy and colostomy sites
Metastatic cutaneous Crohn's disease

TABLE 164-4 **Skin Lesions in Ulcerative Colitis and Crohn's Disease**

Pyoderma gangrenosum (See Chap. 98.) Up to one-half of patients with pyoderma gangrenosum may have inflammatory bowel disease, although only 12 percent of patients with ulcerative colitis and 2 percent of patients with Crohn's disease will develop the condition. [21] The severity and extent of ulceration in pyoderma gangrenosum may be linked to the activity of the underlying disease, and pyoderma gangrenosum can heal with effective treatment of the underlying bowel disease.
Granulomas Oral granulomatous nodules are common in Crohn's disease, where they may coalesce to give a “cobblestone” appearance. Crohn's disease is one cause of granulomatous cheilitis (see Chap. 112), which may predate bowel disease by several years. Granulomas may also occur in the perineum, at colostomy and ileostomy sites (see Chap. 129), and in association with scars, sinuses, and fistulas. Very rarely, granulomas occur at sites not contiguous with the bowel, such as the trunk and limbs: the so-called “metastatic” cutaneous Crohn's disease. [22]
Erythema nodosum Ulcerative colitis and Crohn's disease are an uncommon cause of erythema nodosum.
Aphthous ulcers In inflammatory bowel disease or celiac disease, aphthous ulcers may be the presenting feature. Patients with both dermatitis herpetiformis and celiac disease are more likely to be affected than those with dermatitis herpetiformis alone. [23]
Malnutrition Signs of nutritional deficiencies can arise from inflammatory bowel disease or its treatment with elemental diets (see below).
Skin disorders in colostomy and ileostomy sites (See Chap. 129.)
PANCREATITIS Bruising of the skin around the umbilicus (Cullen's sign) or in the flanks (Grey Turner's sign) are well-known features of acute pancreatitis, but occur in less than 3 percent of cases. [24] Subcutaneous fat necrosis is even rarer. Chronic pancreatitis may cause tender, subcutaneous nodular areas of fat necrosis that may ulcerate (see Chap. 109).
GASTROINTESTINAL CANCER AND OTHER MALIGNANCIES Many skin changes occur in association with gastrointestinal malignancies. Dry skin (acquired ichthyosis) with cracking and eczematization (“eczema craquelé”) and hyperpigmentation may occur in malignancy, as well as in malabsorption syndromes (see below).
Metastases Any tumor may metastasize to the skin. The scalp is a common site. Metastases at the umbilicus (Sister Joseph nodules) occur, particularly with carcinoma of the stomach, colon, or ovary (Fig. 164-2).

FIGURE 164-2 Umbilical metastasis (Sister Joseph nodule) from intraabdominal adenocarcinoma.

Dermatomyositis (See Chap. 172.) Adult onset dermatomyositis is associated with underlying malignant disease in 32 percent of cases. [25] Pancreatic, gastric, and colorectal cancers are the third most common after bronchogenic and ovarian cancers in Europe and North America. In China, nasopharyngeal carcinoma is a common tumor and also frequently occurs in association with dermatomyositis. The rash and myopathy can regress after removal of the tumor, and, because 60 percent of patients develop cancer after the appearance of dermatomyositis, its recognition is potentially life-saving.
Acanthosis nigricans (See Chap. 185.) In two-thirds of patients with acanthosis nigricans and cancer, the tumor is gastric. The changes may regress if the tumor, usually an adenocarcinoma of the stomach or bowel, is removed.
Hypertrichosis lanuginosa Excessive growth of lanugo hair is a rare complication of gastrointestinal cancer (see Chap. 184).
Other skin changes Diverse cutaneous paraneoplastic syndromes may arise from underlying tumors. [26] They may precede, coincide with, or follow the diagnosis of cancer and often indicate a poor prognosis. They include reactive erythemas, such as erythema gyratum repens and necrolytic migratory erythema; the vascular dermatoses (Trousseau's syndrome); and papulosquamous disorders, including tripe palms (Fig 164-3), palmar hyperkeratosis, acquired ichthyosis, pityriasis rotunda, Bazex's syndrome, florid cutaneous papillomatosis, the sign of Leser-Trelat, and extramammary Paget's disease.

FIGURE 164-3 Patient with “tripe hands” due to adenocarcinoma of the jejunum.

Some gastrointestinal tumors have specific dermatologic signs. (See Carcinoma of the Esophagus, above.) For example, carcinoma of the stomach may result from atrophic gastritis and may lead to pernicious anemia. Patients with pernicious

anemia may develop vitiligo and alopecia areata. Small bowel tumors (see Chap. 170) produce a variety of hormones and vasoactive amines of which the best characterized is serotonin. The most common tumors are in the appendix, rectum, and ileum, where they are usually multiple. Episodic flushing (Fig. 164-4), wheezing, or diarrhea does not occur until the vasoactive amines reach the systemic circulation. Therefore, flushing usually indicates metastasis to the lymph nodes or liver or a primary tumor at a different site (e.g., lung or ovary). [27]

FIGURE 164-4 Facial rash in a patient with liver metastases from a carcinoid tumor of the small bowel.

One-third of patients with systemic mastocytosis have gastrointestinal involvement. Symptoms include nausea, vomiting, abdominal pain, malabsorption, diarrhea, esophagitis, esophageal strictures, peptic ulceration, and gastrointestinal bleeding (see Chap. 163). Patients with more aggressive disease may develop hepatosplenomegaly with ascites and lymphadenopathy. [28] Skin signs occur with the potentially malignant forms of adenomatous and hamartomatous polyposis and in ulcerative colitis. Paget's disease (see Chap. 87) in the perianal skin is often associated with an underlying carcinoma. The tumor is not always in adjacent tissue, but most commonly arises from rectal mucosa. Migratory superficial thrombophlebitis occurs in association with neoplasia, particularly carcinoma of the pancreas. Glucagonoma (see Chap. 184) is one of the amine precursor uptake and decarboxylation (APUD) cell tumors. Those that produce glucagon usually arise in the islet cells of the pancreas, are often malignant, and generally occur in association with a distinctive necrolytic migratory erythema.

Diarrhea and Malabsorption

Some of the skin associations of gastrointestinal disease that produce diarrhea have already been mentioned. If steatorrhea is present, the clinician should consider additional possibilities. Many skin changes occur in association with malabsorption—some as a result of it, some because of a disease process that affects the bowel as well as the skin. In addition, skin disease may be the cause of malabsorption.

SKIN CHANGES THAT RESULT FROM MALABSORPTION The various malabsorption syndromes have an impact on the skin and vice versa (Table 164-5). Skin changes due to malabsorption can be either nonspecific (e.g., those that occur as a result of wasting illnesses) or well defined (e.g., the rash of zinc deficiency) (see Chap. 146).

Skin changes due to malabsorption
Nonspecific
Acquired ichthyosis and pruritus
Hair and nail changes
Hyperpigmentation
Skin texture and elasticity
Eczematous and psoriatic rashes
Jejunoileal and jejunocolic anastomoses
Specific nutrients
Zinc
Essential fatty acids
Vitamins
Malabsorption due to skin disease
Dermatogenic enteropathy
Collagen vascular disease
Dermatitis herpetiformis and celiac disease

TABLE 164-5 **Malabsorption and Skin Disease**

Nonspecific cutaneous signs

Acquired Ichthyosis and Pruritus Ill health is often associated with pallid, dry, rough, scaly skin that is usually itchy. Eczema (asteatotic eczema, or eczema craquelé) may develop. The presence of this sign in patients with malabsorption, cancer, chronic renal disease, or chronic hepatic disease is nonspecific. Some patients itch without any visible abnormality of their skin.

HAIR (See Chap. 71.) Malnutrition or starvation causes hair to grow more slowly, fall out more easily, and become grey. The hair root diameter and the proportion of anagen hairs decrease. Lanugo hair may develop. Kwashiorkor, a form of protein-energy malnutrition, causes hair to become hypopigmented, varying from red-yellow to white, and curly. There may be alternating bands of pale and dark hair. [29] Total parenteral nutrition has been associated with hair loss and pigmentation of remaining hair. Type 2 vitamin D–dependent rickets is associated with alopecia totalis.

NAILS (See Chap. 72.) In conditions associated with malabsorption or starvation, nails grow more slowly, become brittle, and may develop fissures. [29], [30] Multiple pigmented bands may appear. Koilonychia in malnourished patients usually indicates iron deficiency, even without anemia (see below). White nails, thought to be due to selenium deficiency, have occurred with total parenteral nutrition.

SKIN COLOR Malabsorption or starvation can lead to hyperpigmentation, which is most pronounced on the face. Vitamin B_{12} deficiency causes pigmentation of the distal extremities in a glove and stocking distribution. The facial and limb eruption of pellagra can be deeply pigmented. Diffuse hyperpigmentation occurs in folate deficiency. Kwashiorkor produces generalized depigmentation.

SKIN TEXTURE AND ELASTICITY In the course of wasting diseases, the skin becomes thinner, dry, and less elastic. Vasoconstriction leads to a cold, cyanotic appearance.

JEJUNOILEAL AND JEJUNOCOLIC ANASTOMOSES Patients with gross obesity occasionally undergo treatment by gastric bypass or reduction. Dryness of the skin, hair loss, and inflammatory and vasculitic skin lesions have occurred,

together with recurrent fever and arthralgia. “Bowel bypass syndrome without bowel bypass” is recognized as the same constellation of symptoms, but with other gastrointestinal disorders. [31]

Cutaneous effects of malabsorption of specific nutrients (See Chap. 145.) Deficiencies in various nutrients can have cutaneous effects. [29] For example, vitamin deficiency can follow intestinal surgery, pancreatic disease, malabsorption syndromes, and malnutrition, including that associated with alcoholism. The effects of such deficiencies vary:

1. Vitamin A deficiency causes xerotic wrinkled skin covered with fine scales, occasionally accompanied by deep erosions (dermomalacia).
2. Deficiency of vitamin B_3 causes pellagra with its triad of diarrhea, dermatitis, and dementia. The cutaneous changes may overlap with essential fatty acid deficiency (see below).
3. Vitamin B_{12} (cyanocobalamin) deficiency is common in ileal malabsorption syndromes such as pancreatic disease and occurs rarely in dermatitis herpetiformis with a gluten-sensitive enteropathy. There is a symmetric “glove and stocking” hyperpigmentation, but a lemon yellow pallor to the skin elsewhere.
4. The follicular keratoses, hemorrhage, and corkscrew hairs associated with a vitamin C deficiency are described in Chapter 145.
5. Malabsorption of vitamin K occurs in obstructive jaundice and leads to impaired coagulation, resulting in cutaneous hemorrhage with ecchymoses and purpura.

Theoretically, drugs used for dermatologic diseases such as methotrexate, a folate antagonist, can exacerbate folic acid deficiency. A diffuse hyperpigmentation, cheilitis, and perineal ulceration or dermatitis can occur in deficiency states. Iron deficiency presents with angular stomatitis, smooth painful tongue, and fragile/brittle nails, which have longitudinal ridging and lamellation. In marked iron deficiency anemia koilonychia, a spoonlike convexity of the nails, develops. Hair changes include diffuse scalp alopecia with brittle, split hairs. All take a long time to resolve on replacement therapy. The association of pruritus with iron deficiency has not been conclusively demonstrated. Zinc deficiency can result from acrodermatitis enteropathica, malabsorption, or a lack of zinc in long-term parenteral nutrition (see Chap. 146). Acrodermatitis enteropathica usually presents at weaning or in very early infancy with dermatitic or vesicobullous lesions of the hands, on the feet, and around the mouth and anus, together with progressive alopecia and “failure to thrive.” Linoleic acid is metabolized to arachidonic acid, which is then converted to prostaglandins and leukotrienes. In linoleic acid deficiency, oleic acid is used as the substrate. Deficiency occurs due to malabsorption, malnutrition, bypass surgery for obesity, biliary disease, and, most important, parenteral nutrition. The epidermis becomes hyperkeratotic, resulting in diffuse xerosis, scale, and erythema with brittle nails and capillary fragility. Clinically, the topical application of linoleic acid, such as that found in sunflower seed oil, may improve the skin. There is diffuse hair loss with hyperpigmentation of remaining hair.

MALABSORPTION DUE TO SKIN DISEASE

Malabsorption in collagen vascular diseases Malabsorption can result from poor intestinal peristalsis in systemic sclerosis or chronic obliteration of mesenteric vessels in polyarteritis and other forms of vasculitis. Of patients with diffuse scleroderma and systemic sclerosis, 8 percent will develop malabsorption or recurrent intestinal pseudo-obstruction, usually within 3 years of disease onset. [32] Vasculopathy interferes with peristalsis and leads to malabsorption by allowing bacterial colonization higher up the bowel than is usual. In malabsorption syndromes that do not respond to antibiotic therapy, a small bowel biopsy may be appropriate. Resection or bypass surgery of affected segments or placement of enterostomy tubes for feeding or decompression may be necessary. [7]

Dermatitis herpetiformis The gastrointestinal associations of dermatitis herpetiformis, including celiac disease, malabsorption, and gastrointestinal lymphoma, are discussed in Chapter 67.

SKIN LESIONS DUE TO HEPATOBILIARY DISEASE

When skin lesions occur in association with liver disease, they are usually not specific to a particular hepatic pathology. The most florid cutaneous lesions generally appear in patients with chronic active hepatitis or alcoholic liver disease, but the changes seen in the skin, nails, and hair of patients with hepatobiliary disease may also occur in the absence of such disease or in association with physiologic states (Fig. 164-5). For example, spider nevi may occur in healthy children and in pregnant women. It is also possible for there to be no visible skin changes in patients with severe or advanced liver disease, and dramatic cutaneous manifestations may develop in those with minimal hepatic dysfunction. Severe itching may antedate other features of biliary cirrhosis by months or years.

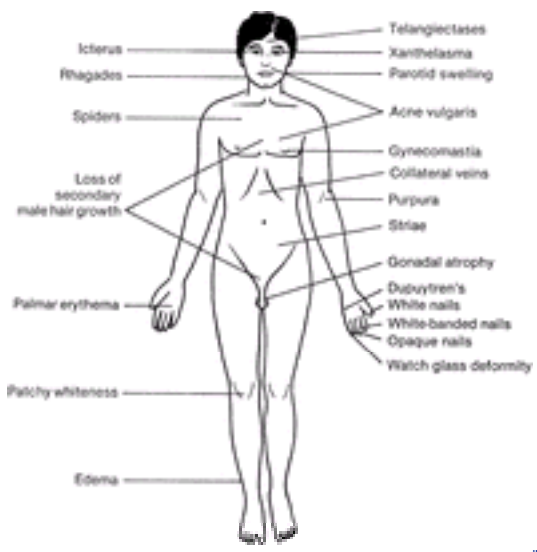

FIGURE 164-5 The main skin changes in liver disease.

Jaundice

In patients with jaundice, or icterus, the raised plasma level of bilirubin produces a generalized yellow or ocher coloration of the skin, mucous membranes, and other body tissues. Both jaundice and pigmentation are most prominent in disease states that produce extrahepatic biliary obstruction and in primary biliary cirrhosis. Involvement of the sclerae differentiates jaundice from other causes of skin pigmentation, including olive or sallow complexions, carotenemia, the yellow skin pigmentation produced by quinacrine and busulfan, and lycopenemia due to the ingestion of tomato juice.

PATHOGENESIS A functional classification of jaundice appears in Table 164-6. Jaundiced skin, varying in hue from faint golden to dark green-yellow, results from increased local cellular or connective tissue binding of bilirubin or its metabolites. Bilirubin has an affinity for elastin, but circulates almost exclusively as a tightly bound complex with albumin. Eighty-five percent of bilirubin comes from the degradation of heme, the remainder from other heme-containing proteins, such as myoglobin and cytochromes. Jaundice results from an imbalance between the tissue production and hepatic clearance of bilirubin.



TABLE 164-6 **Functional Classification of Jaundice**

Tissue-serum equilibration is slow, and the intensity of clinical jaundice often fails to reflect the concurrent serum bilirubin level. Hyperbilirubinemia may, therefore, antedate the onset of detectable jaundice, and jaundice may persist despite falling or normal serum bilirubin levels. The correlation between skin color and serum pigment levels is especially poor in newborns. A further discrepancy between tissue and serum pigment levels in infants may result from the administration of drugs that uncouple protein-bound bilirubin and favor its passage into body tissues. [33] Clinically detectable jaundice appears when a sufficient amount of bilirubin has become tissue-bound, generally when total serum levels have exceeded 3.0 mg/dL in adults or 8.0 mg/dL in infants.

CLINICAL FEATURES Careful inspection of the sclerae or the mucous membrane of the soft palate in natural or bluish light are the best clinical methods for detecting jaundice. Prolonged and deep jaundice produces a greenish-tan quality. Degradation of bilirubin occurs with exposure to ultraviolet radiation, which is the rationale for phototherapy to prevent kernicterus in severe neonatal jaundice. The intensity of jaundice and levels of serum bilirubin in patients with biliary atresia, acquired bile duct obstruction, or defective bilirubin conjugation tend to stabilize despite continued pigment production. The urine becomes dark yellow and then brown as conjugated serum bilirubin rises. Hyperbilirubinemia is not a feature of unconjugated hyperbilirubinemic states. Because most of the brown color of normal feces is produced by urobilins derived from degradation of bilirubin in the intestine, the jaundice of impaired bilirubin excretion or bile obstruction is associated with “clay-colored” stools.

DIAGNOSIS The diagnosis of jaundice requires a methodical consideration of four important questions (see Table 164-6):

1. Is the jaundice due to biliary tree obstruction?
2. Is there evidence of chronic liver disease?
3. Are alcohol or drugs responsible?
4. Is there evidence of hemolysis?

A careful history and clinical examination should indicate the cause in 60 to 70 percent of cases; review of standard laboratory tests should afford a diagnosis in another 10 to 15 percent. [33] Additional investigations may include a liver ultrasound examination (especially if the clinician suspects an obstruction), abdominal computed tomography (which is not as accurate as ultrasonography in detecting cholelithiasis), and endoscopic investigation of the biliary tree and pancreatic ducts. In the absence of obstruction, serologic tests such as those for hepatitis or autoantibodies may be necessary

TREATMENT AND COURSE The jaundice of biliary obstruction resolves after the obstruction is relieved. Jaundice in patients with acute hepatitis resolves spontaneously. The jaundice of chronic liver disease may improve after transplantation. Jaundice in chronic active hepatitis and, occasionally, in acute alcoholic hepatitis, can decrease after glucocorticoid therapy. Neonatal jaundice may respond to phototherapy. Infants with the Crigler-Najjar syndrome, in which benign unconjugated hyperbilirubinemia occurs in association with otherwise normal liver function, have received treatment with a combination of phototherapy and microsomal enzyme inducers, such as phenobarbital. This treatment decreases hyperbilirubinemia. [34]

Melanosis and Other Pigmentary Changes

In addition to jaundice, both diffuse and circumscribed pigmentary changes may occur in chronic liver disease. A diffuse muddy gray color in patients with long-standing cirrhosis is due to basal cell melanin.

Melanosis is common in primary biliary cirrhosis and may be an early presenting sign. It initially involves exposed areas, but it gradually becomes generalized. Blotchy, circumscribed areas of dirty brown pigmentation are also occasionally evident. Accentuation of normal freckling and areolar pigmentation can occur. Localized linear pigmentation may appear in the creases of the fingers and palms. Pigmentation resembling chloasma may localize to the perioral and periorbital areas. Guttate hypomelanosis, a condition in which small white macules, sometimes with a central spider, appear on the skin of the buttocks, back, thighs, and forearms, may occur in cirrhosis and, rarely, in primary biliary cirrhosis. [35]

The generalized metallic gray or bronze-brown color of the skin in hemochromatosis is so striking that its alternative name is bronzed diabetes. There is accentuation over sun-exposed and traumatized skin, and occasionally there is buccal mucosal and conjunctival pigmentation. Clinical features alone may not distinguish alcoholic cirrhosis without iron overload from that of constitutional hemochromatosis. [36]

The yellow and orange lesions of dermal, subcutaneous, and tendon xanthomas and also xanthelasma are common in primary biliary cirrhosis and can be extensive (see Chap. 150).

With pellagra, lichenified, hyperpigmented skin in sun-exposed sites may develop in patients with alcoholic liver disease (see Chap. 145).

The etiology and pathogenesis of hyperpigmentation in chronic liver disease remains obscure. The cutaneous pigmentation in primary biliary cirrhosis is due predominantly to the presence of excess melanin with no stainable iron. In hemochromatosis, cutaneous pigmentation results not only from the presence of hemosiderin in the skin, but also from excess melanin. After phlebotomy, histologic siderosis and clinical skin pigmentation decrease, even though melanosis remains histologically.

The differential diagnosis of pigmentation includes primary adrenal insufficiency (Addison's disease) and some pituitary tumors that produce pigmentary changes of the skin and mucous membranes. Chronic diseases, such as lymphoma, tuberculosis, and malabsorption syndromes (see above), may produce both pigmentation and hepatic dysfunction.

Vascular Changes

Patients with chronic liver disease often have telangiectatic changes, mainly on light-exposed skin. Numerous tiny telangiectases sometimes give the impression of a diffuse, almost exanthematic redness. They are known as “dollar paper markings” after the small threads visible in paper money held up against the light. They fade on pressure with a glass slide and rarely pulsate.

SPIDER NEVUS Although it may also appear in alcoholics without liver involvement, the spider nevus, or spider angioma, is the most representative and classic vascular lesion of chronic liver disease. Clinically, it has a central arteriole represented by a red point, often slightly elevated, from which numerous small, twisted vessels radiate (Fig. 164-6). Spider nevi range in size from a pinhead to 2 cm. When sufficiently large, they can be seen or felt to pulsate, especially when pressed with a glass slide. Pressure over the central arteriole causes blanching of the whole lesion. Spider nevi are characterized by the abnormal permanent dilatation of end vessels. These are mainly end venules, although capillaries and arterioles of the subpapillary plexus can be involved. Histologically, spider nevi consist of a central ascending arteriole ending in a thin-walled ampulla beneath the epidermis from which small arterial branches radiate outward into the papillary dermis. [37]

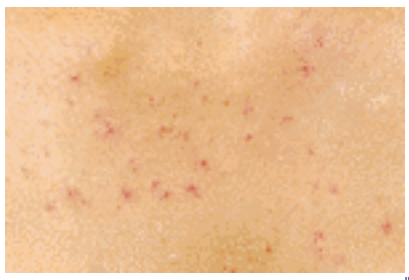

FIGURE 164-6 Spider nevi in a patient with cirrhosis.

Spider nevi are most common on the face, neck, forearms, hands, and upper part of the chest (i.e., over the region drained by the superior vena cava; see Fig. 164-6). Only rarely are they found in the mucous membranes of the nose, mouth, and pharynx. They may be seen in 10 to 15 percent of healthy adults and not infrequently in children, where they tend to affect the hands and fingers. They may appear in large numbers during pregnancy, but usually disappear after parturition. They may also be seen in patients who have thyrotoxicosis and in women who take oral contraceptives. In patients with liver disease, spider nevi may regress with improvement of the underlying condition, although they are more likely to persist. Spider nevi are more common in patients with alcoholic cirrhosis than in those with viral or idiopathic cirrhosis. In alcoholic cirrhosis, they are associated with the presence of esophageal varicosities, and their presence may be a useful predictive marker for the future risk of esophageal bleeds. [38] Traditionally, vascular spider nevi and palmar erythema (see below) have been attributed to estrogen excess, particularly because they also occur during pregnancy and because estrogens have an enlarging, dilating effect on the spiral arterioles of the endometrium. This would also explain the cutaneous spider nevi seen in men receiving estrogen therapy for prostatic cancer, although such nevi are very rare. Patients with nonalcoholic cirrhosis have been shown to have higher plasma estradiol:testosterone ratios and substance P levels than healthy controls do, and the substance P levels may have an etiopathogenic role. [39] In alcoholic cirrhosis patients, the presence of alcoholism and impaired liver function (elevated serum bilirubin) are both important predictors of the presence of spider nevi. [40]

PALMAR ERYTHEMA There are two clinical forms of palmar erythema or “liver palm.” In the first (Fig. 164-7), there is an exaggeration of normal mottling; the hands are warm and bright red, especially on the palm, the dorsae of the hands, the fingers, and the nail bases. In the second, there is well-demarcated redness of the hypothenar eminence that

gradually spreads to the fingertips and then to other areas of the palm. The soles of the feet may show similar changes.

FIGURE 164-7 Palmar erythema showing the characteristic blotchy redness.

The mottling blanches on pressure and, when a glass slide is pressed on the palm, it flushes synchronously with the pulse rate. Patients may complain of throbbing or tingling. “Liver palms” occur not only in liver disease, but also in pregnancy and thyrotoxicosis. An accompanying change in those with cirrhosis is atrophy of the muscles of the thenar and hypothenar eminence. This is of myogenic rather than neurogenic origin and not considered to be related to hormonal factors. [41]

OTHER VASCULAR CHANGES Corkscrew scleral vessels (tortuous small arteries that traverse the margins of the ocular sclerae) have developed in patients with chronic liver disease. Cardiac output frequently increases in patients with cirrhosis, and total peripheral resistance may decrease. Arteriovenous shunting may occur within the lungs (the hepatopulmonary syndrome [42], liver, and extremities. These arteriovenous malformations, including spider nevi, may regress after transplantation. [43] Portal-systemic collateral vessels may develop and may be an important clue to the existence of portal hypertension. Often, the umbilical vein is dilated and visible in the epigastrium, an occurrence more common than the well-recognized, but rare, caput medusae. Purpuric lesions, ranging from pinpoint-sized spots to large ecchymoses, occur mainly on the lower limbs. They are secondary both to acquired clotting defects such as thrombocytopenia and to vascular fragility. They may be transient and recurrent, and they are sometimes accompanied by follicular hyperkeratosis. [37] Bruising is common at venipuncture sites.

Hormone-Induced Changes of the Skin (See Chap. 169.)

With liver disease, loss of forearm, axillary, and pubic hair may occur in both sexes. Men may experience a decrease in the rate of growth of facial hair, pectoral alopecia, and female pubic hair distribution, as well as loss of libido, testicular atrophy, and oligospermia. Striae distensae occur in both men and women in association with chronic liver disease (Fig. 164-8). Gynecomastia, together with Dupuytren's contracture and swelling of the parotid gland, is also associated with cirrhosis. Many of these changes occur more commonly in those with alcoholic cirrhosis. Patients with chronic alcoholism also develop a “pseudo-Cushing's syndrome,” even in the absence of liver disease; signs include facial mooning, truncal obesity, and proximal muscle wasting. [37] These changes may regress if the patient discontinues the use of alcohol.

FIGURE 164-8 Widespread striae in a 16-year-old boy with chronic active hepatitis.

Cutaneous Manifestations of Primary Biliary Cirrhosis

The basis for a diagnosis of primary biliary cirrhosis is a typical clinical picture of a middle-aged female with jaundice and pruritus, liver function test results that suggest cholestasis, the presence of antimitochondrial antibodies, and histologic changes in the liver associated with inflammatory duct destruction with fibrosis and cirrhosis. Several cutaneous changes may be evident in addition to the skin changes usually associated with liver disease.

The combination of the CREST syndrome (i.e., *c*alcinosis cutis, *R*aynaud's phenomenon, *e*sophageal dysfunction, *s*clerodactyly, and *t*elangiectasia) and primary biliary cirrhosis occurs more often than would be expected by chance and has been termed Reynold's syndrome (see Chap. 173). Patients with this combination have a higher incidence of anticentromere antibodies (especially the antiprotein C isotype) and Sjögren's syndrome, as well as, to a lesser extent, calcinosis cutis and telangiectasia. [44]

Lichen planus has a well-recognized association with primary biliary cirrhosis and may occur in either the presence or the absence of penicillamine treatment for primary biliary cirrhosis (see Chap. 49). It can resolve following liver

transplantation. [45]

Cutaneous xanthomas also occur with primary biliary cirrhosis. Rarely, both lichenoid and xanthomatous changes appear in the same lesion [46] (see Chap. 150).

Miscellaneous Changes of the Skin

Porphyria cutanea tarda and erythropoietic protoporphyria are considered in Chapter 149. Liver disease is frequently associated with the former, and the latter may rarely seriously damage the liver.

Nail Changes in Liver Disease (See Chap. 72.)

The nails of many patients with liver disease are normal, and nail abnormalities are a less constant physical sign than spider nevi or liver palms. In patients with cirrhosis, however, a number of changes may occur: clubbing, curved nails, thickened nails, longitudinally ridged nails, white nails, watch-glass deformity, flattened nails, white bands, striations, and brittleness. [30]

Clubbing of the fingers is quite common in all forms of cirrhosis, especially primary biliary cirrhosis and chronic active hepatitis. Anatomically, there is an increased thickness of the nail bed. This is due to edematous infiltration of the soft parts of the terminal segment followed by hyperplasia of the dermal fibrovascular tissue with increased vascularity. [30]

White nails may occasionally be seen in healthy individuals or in association with systemic disease, including congestive heart failure, diabetes, cryoglobulinemia, Raynaud's syndrome, and systemic sclerosis. However, intensely white nails are characteristic of cirrhosis (Fig. 164-9 and Fig. 164-10), although their presence does not correlate with the severity of cirrhosis. Terry (after whom the sign is named) reported white nails in 82 of 100 patients with cirrhosis. [47] The reason for the whiteness, which does not alter with nail growth or with compression of digital vessels, is likely to be the opacity of the nail plate itself. In severe cases, the condition may affect all fingernails; almost the entire nail bed may show a ground glass–like opacity (see Fig. 164-10), although there may be a pink zone at the distal edge of the nail. Thumbs and forefingers are often most affected. The so-called watch-glass deformity may accompany white nails (see Fig. 164-9).

FIGURE 164-9 Flat white nails with slight convex watch-glass deformity, showing a distal pink band in a patient with liver disease.

FIGURE 164-10 Terry's white nails in a patient with cirrhosis.

Azure lunulae, a bluish color of the lunular portion of nails, occur in hepatolenticular degeneration (Wilson's disease). Azure lunulae and corneal changes resembling Kayser-Fleischer rings may also be evident in patients with argyria or following treatment with busulfan or antimalarials. [30]

The characteristic nail changes of lichen planus, including longitudinal ridging, pterygium formation, and permanent nail loss, occur both with and without skin changes in primary biliary cirrhosis (see Chap. 72).

Splinter hemorrhages and hypertrophic osteopathy also occur in cirrhosis. Flat or spoon nails are less common in patients with liver disease. The nails are flat or concave, pale in color, and frequently show longitudinal ridging. In hemochromatosis, koilonychia is probably the most common of the nail abnormalities, but it is not related to anemia. [30]

Itching

One of the most common and most distressing symptoms of hepatobiliary disease is pruritus. It may be mild and transient or so severe and prolonged that it dominates the clinical picture of the disease. Pruritus often complicates those conditions causing cholestasis, but less commonly occurs in diseases such as chronic hepatitis C infection in which cholestasis is not as clinically prominent. In viral hepatitis, itching is frequently missed as an early sign of the disease, but it occurs in the later, icteric phase. Some drugs, especially erythromycin, oral contraceptives, phenothiazines,

chlorpropamide, para-aminosalicylic acid, and nitrofurantoin, may also induce cholestasis accompanied by pruritus. Pruritus is the presenting symptom in more than 50 percent of cases of primary biliary cirrhosis and may precede jaundice by months or even years.

Itching in hepatobiliary disease may be transient or continuous and may occur without jaundice. Although usually most marked on the extremities, severe pruritus may affect the trunk; however, it only rarely involves the neck and face, and hardly ever involves the genitalia. Pruritus may be debilitating in patients with primary biliary cirrhosis, mechanical biliary obstruction, or intrahepatic obstruction. There is little correlation between the severity of cholestasis and the severity of perceived pruritus, and a spontaneous decrease in the intensity of pruritus may signal the development of hepatocellular failure rather than improvement. Scratching does not relieve the pruritus of cholestasis, and there may be no visible skin change except scratch marks and excoriations. In chronic pruritus of cholestasis, lichenified plaques or nodular prurigo occur. Histologically, the changes are nonspecific.

PATHOGENESIS OF PRURITUS (See Chap. 41.) The physiologic basis of the pruritus of cholestasis is still not completely understood. Although retained cutaneous bile acids have long been implicated, the poor correlation between the plasma level of bilirubin and the severity of pruritus, and the lack of convincing evidence that bile acids can induce the pathophysiologic changes of pruritus suggest that they do not have a direct role. However, the partial relief of itching by bile salt chelating resins and the disappearance of pruritus when liver cells fail suggest that the liver manufactures at least one of the agents contributing to pruritus. It is well recognized that opiate agonists such as morphine induce pruritus. Animal studies show that the intracerebral presence of morphine induces pruritus that is reversed by the opiate antagonist nalaxone, [48] confirming that opiate agonists induce scratching of central origin. In addition, the administration of the opioid antagonist nalmefene to patients with primary biliary cirrhosis produces a reaction similar to that of opiate withdrawal, and the injection of plasma from patients with primary biliary cirrhosis into monkeys produces pruritus. Taken together, these studies suggest that opioidergic tone increases in cholestasis. [48] These studies do not indicate which endogenous opioid receptor ligands may contribute to the pruritus of cholestasis or whether the agents responsible for increased opioidergic tone originate peripherally (e.g., in the liver) or centrally. They do, however, suggest less empirical therapies for the treatment of the pruritus of cholestasis.
MANAGEMENT Pruritus rapidly decreases when cholestasis secondary to mechanical bile duct obstruction is relieved. Drugs to relieve cholestasis such as ursodeoxycholic acid do not consistently relieve pruritus, nor do the anion exchange resins cholestyramine and cholestipol, which are thought to bind intestinal pruritogens and prevent them making their way to the skin. Hepatic enzyme inducers, including phenobarbital and rifampicin, may induce the metabolism of pruritogens: the latter has been shown to be relatively efficacious in randomized controlled trials. [49] Antihistamines or glucocorticoids given topically, although frequently prescribed, have not been proven to be efficacious. Trials of plasmapheresis and charcoal hemoperfusion are inconclusive. Sedatives, including phenobarbital, benzodiazepines, and sedating antihistamines, may help in patients prepared to tolerate the sedation. Neurotransmitter receptor antagonists such as oral nalmefene may be useful in the long-term control of the pruritus of cholestasis, [50] and naloxone administered IV has been shown to be efficacious for short-term use in a randomized controlled trial. [51] Naltrexone is an orally administered alternative, [52] but has been associated with hepatotoxicity. Miscellaneous therapies, including androgens, lidocaine, and ultraviolet light, are often tried in clinical practice.

Hepatitis and the Skin

Cutaneous striae may appear in patients with chronic hepatitis, whatever the underlying cause and even before glucocorticoid therapy (see Fig. 164-8). Pyoderma gangrenosum, urticaria, vasculitis, acne, scleroderma, and splinter nail hemorrhages occur, depending on the underlying cause of the hepatitis.

The clinical features of infection with the different hepatotrophic viruses that cause acute viral hepatitis are often so similar as to be indistinguishable. Specific diagnosis requires serologic testing. In the pre-icteric phase, nonspecific malaise, lethargy, nausea, and abdominal pain occur. In the early phase, a discrete, transient, maculopapular, urticarial, or petechial rash may develop, together with arthritis or arthralgia. These symptoms may worsen with the appearance of jaundice, dark urine, and pale stools. Malaise and fatigue may persist for some time after resolution of the disease.

Hepatitis A The transmission of the hepatitis A virus takes place via the fecal-oral route. In countries where sanitation conditions have improved, the mean age of exposure has increased, and the total infection rate has decreased. Clinical disease with jaundice in infants and young children is uncommon. Although relapses may occur, hepatitis A does not progress to chronic hepatitis.
HEPATITIS B The hepatitis B virus (HBV) is transmitted by percutaneous and permucosal routes. It is endemic in many countries, and even where it appears only sporadically, health care professionals are at risk. A recombinant DNA vaccine is available, but has been associated with cutaneous side effects. [53], [54] Five percent of HBV-infected subjects become carriers, and 90 percent of infants born of infected mothers develop chronic infection. There are four main cutaneous associations of hepatitis B: (1) a serum sickness–like syndrome, (2) cryoglobulinemia, (3) polyarteritis nodosa, and (4) papular acrodermatitis of childhood. The serum sickness–like syndrome occurs in approximately 5 to 15 percent of patients in the pre-icteric phase of acute hepatitis B infection. Urticaria may be the predominant or sole feature, but is usually accompanied by a low-grade fever, arthralgia of the peripheral joints, proteinuria, and hematuria. There may be vasculitis (see also Chap. 175). There are three types of cryoglobulinemia, identified according to the class of immunoglobulin that forms the cryoprecipitate (see Chap. 177). Both HBV and hepatitis C virus (HCV) infection are associated with cryoglobulinemia although HCV infection is more common. Mixed cryoglobulinemia in HCV infection is usually of type III, [55] and the cryoglobulinemia may indicate the presence of active viral replication. [56] Patients develop recurrent purpura, acrocyanosis, arthralgia, lymphadenopathy, peripheral neuropathy, and hepatosplenomegaly. Renal involvement is common. Histopathologically, there is a necrotizing vasculitis. Polyarteritis nodosa can occur in the acute phase of HBV infection, or it may not present for several years. Circulating immune complexes containing hepatitis B surface antigen (HBsAg) and immunoglobulin occur. Leukocytoclastic vasculitis may develop (see Chap. 174). Papular acrodermatitis (Gianotti-Crosti syndrome; see Chap. 143) usually affects children. The appearance of monomorphic, flat-topped, erythematous papules on the face and limbs is characteristic. This eruption is self-limited and asymptomatic in most, but may be accompanied by lymphadenopathy and anicteric acute HBV infection. [57] Other infectious agents and

immunizations have been implicated in papular acrodermatitis as well. [58] Sweet's syndrome (see Chap. 94) has recently been reported with both acute [61] and chronic HBV infection.

HEPATITIS C The majority of cases of posttransfusion hepatitis have been due to HCV infection, but screening has reduced the number of new cases dramatically. Cutaneous manifestations of acute and chronic HCV infection include leukocytoclastic vasculitis, usually due to cryoglobulinemia (see above); cutaneous necrosis; [56] pruritus; [60] acquired angioedema; [61] porphyria cutanea tarda; erythema nodosum; urticaria; erythema multiforme; and polyarteritis nodosa. [62] Lichen planus occurs more commonly in patients infected with HCV, although studies disagree on the incidence. [63] There is an increased frequency of the HLA-DR6 allele in Italian patients with HCV-associated oral lichen planus, [64] suggesting that host factors may play a part in this association.

Disorders That May Involve Both Skin and Liver

Many systemic diseases involve both the skin and the liver, but the changes may not be dependent on one another, do not always occur together, or may be separated by an interval of months or years. Table 164-7 contains a list of some of the more important ones.

Argininosuccinic aciduria	Porphyrias
Dermatomyositis	Porphyria cutanea tarda
Drug reactions	Variegate porphyria
Eruptive neonatal angiomatosis	Erythropoietic (erythrohepatic) porphyria
Graft-versus-host disease	Hereditary coproporphyria
Hereditary hemorrhagic telangiectasia (Osler-Weber-Rendu disease)	Sarcoidosis
Histiocytoses	Syphilis
Immunodeficiency states	Systemic lupus erythematosus
Mastocytosis	Tuberous sclerosis
Mucocutaneous lymph node syndrome (Kawasaki disease)	Vinyl chloride disease

TABLE 164-7 **Disorders Involving Both Skin and Liver**

Argininosuccinic aciduria (see Chap. 147) is a rare autosomal recessive disorder characterized by ataxia, seizures, severe mental retardation, hepatomegaly with liver dysfunction, and brittle hair. Dermatomyositis (see Chap. 172) may be the presenting sign of an underlying cancer with primary [65] or secondary hepatic malignancy. In eruptive neonatal angiomatosis, multiple angiomas may occur anywhere on the skin surface; in addition, vascular lesions may occur in internal organs, including the liver. Both acute and chronic phases of graft-versus-host reactions may have prominent effects on both skin and liver, most commonly in patients receiving bone marrow transplants. In hereditary hemorrhagic telangiectasia, arteriovenous fistulas can cause shunting, and “cirrhosis” (i.e., multiple small telangiectatic hepatic vessels) occurs. [8] Several of the histiocytoses, including Langerhans cell histiocytosis (see Chap. 160) and malignant histiocytosis, may involve both skin and liver. Cytophagic histiocytic panniculitis has been associated with interferon-a therapy for chronic HCV infection [66] (see Chap. 109). Immunodeficiency states may result in multiple infections of skin and liver, some with specific cutaneous signs. Examples include congenital disorders (e.g., ataxia telangiectasia, Chediak-Higashi syndrome, chronic granulomatous disease) and acquired disorders (e.g., AIDS).

Hepatomegaly occurs in systemic mastocytosis [28] (see Chap. 163). In Kawasaki disease (see Chap. 204), children may develop upper abdominal pain associated with hepatobiliary changes, nonspecific elevation of liver enzyme levels due to vasculitic changes, or bile duct inflammation. [67] (See Chap. 149 for a detailed discussion of the porphyrias.)

Sarcoidal infiltration of the liver may accompany the cutaneous signs of sarcoidosis (see Chap. 183). Hepatic granulomas may also occur in tuberculosis, glandular fever, and syphilis, or as a side effect of drugs such as phenylbutazone, allopurinol, and the sulfonamides. True syphilitic hepatitis is rare and presents with pruritus and cholestatic jaundice.

Patients with systemic lupus erythematosus have a 25 to 50 percent chance of abnormal liver test results in their lifetime. [68] The most common cause is drug-induced hepatitis. Thrombotic conditions, including Budd-Chiari syndrome and veno-occlusive disease, occur with or without lupus anticoagulant. Rare abnormalities include nodular regenerative hyperplasia, perihepatitis, and hepatic or splenic rupture. Autoimmune hepatitis, primary biliary cirrhosis, [69] granulomatous hepatitis, cryptococcal infection, porphyria, or idiopathic portal hypertension [70] may also occur.

Cholestatic hepatitis occurs as a rare complication of Stevens-Johnson syndrome and may precede the skin signs. [71]

Angiomyolipomas are frequently seen on ultrasound examination of the livers of patients with tuberous sclerosis but are usually asymptomatic (see Chap. 189). Liver function abnormalities are common in patients with vinyl chloride disease and may be associated with hepatosplenomegaly, cirrhosis, and, rarely, angiosarcoma.

EFFECTS OF SKIN DISEASE ON THE LIVER

Several systemic complications occur as a consequence of skin disease, and some of them reflect abnormalities of hepatic function.

Extensive Loss of Skin

Patients may lose large areas of skin because of thermal burns, severe pemphigus, staphylococcal scalded skin syndrome, or toxic epidermal necrolysis. In experimental animal models, extensive thermal injury results in a halving of the hepatic arterial blood flow. [72] Postburn sepsis amplifies this injury and induces portal hypertension. This may in turn account for a gut barrier dysfunction (the so-called “dermatogenic enteropathy”), but research has not convincingly

demonstrated this relationship in humans with extensive skin disease.

Erythroderma

The systemic effects of erythroderma are considerable (see Chap. 44). Patients can develop hypothermia, hypoalbuminemia, hypovolemia, secondary sepsis, the initial stages of renal failure, and high-output cardiac failure with secondary effects on hepatic function. Death from sepsis, cardiac failure, adult respiratory distress syndrome, and capillary leak syndrome occur. [73]

Psoriasis (See Chap. 42.)

The high incidence of abnormalities of the liver architecture in patients with psoriasis has been attributed to alcohol misuse. Psoriasis is more common than expected in alcoholic cirrhosis than in cirrhosis due to other causes. [36], [74] Those who misuse alcohol are said to have a unique, acral, distribution of psoriasis. [36] Alcohol appears not only to trigger psoriasis, especially in men, but also to influence the course of the disease, as heavy drinkers have more severe, extensive, inflamed disease. Patients who decrease alcohol consumption may decrease the extent of their disease and increase their response to treatment. [74]

Dermatitis Herpetiformis

Results of liver function tests are sometimes abnormal in patients with dermatitis herpetiformis [75] and can also occur secondary to treatment or as a result of associated conditions [76] (see Chap. 67).

Cancers of the Skin

Primary cutaneous neoplasms, including melanoma, squamous cell carcinoma, Merkel cell tumor, and Kaposi's sarcoma, occasionally metastasize to the liver.

HEPATOTOXIC EFFECTS OF DRUGS USED IN THE TREATMENT OF SKIN DISEASE

Several drugs used in managing patients with skin disease are hepatotoxic (Table 164-8). Many others, such as antimalarials or terbinafine, warrant caution in patients with hepatic impairment.

Drug	Interaction	Side Effects
Azathioprine	Bullous disorders, dermatomyositis	Raised liver enzymes
Ciclosporin	Psoriasis, dermatitis	Raised liver enzymes
Cyproterone acetate	Hirsutism and virilization	May worsen preexisting dysfunction
Danazol	Hereditary angioedema	May worsen preexisting dysfunction and porphyria
Dapsone	Dermatitis herpetiformis, erythema elevatum diutinum, granuloma faciale, and others (Chap. 224)	May cause dapsone syndrome (rash, eosinophilia liver hepatitis). Avoid in porphyria
Griseofulvin	Fungal infections	May worsen preexisting liver disease
Ketoconazole	Fungal infections	Raised liver enzymes and hepatitis
Methotrexate	Psoriasis, sarcoidosis	Cirrhosis
Minocycline	Acne	Hepatitis
Retinoids	Acne, psoriasis, disorders of keratinization	Elevated liver enzymes, increases hepatotoxicity of methotrexate
Stanozolol	Hereditary angioedema	May worsen preexisting dysfunction and porphyria
Terbinafine	Fungal infections	Hepatitis

TABLE 164-8 **Hepatotoxic Drugs Used in the Treatment of Skin Disease**

Patients who have psoriasis and who are undergoing long-term treatment with methotrexate have a high frequency of liver fibrosis and cirrhosis, especially if their total doses exceed 1.5 g. Those with a history of alcohol misuse, impaired renal function, diabetes, and obesity are at higher risk. Diagnosis of fibrosis is histologic and requires liver biopsy. The morbidity of liver biopsy can be as high as 10 percent, and the mortality up to 0.1 percent. [77] In hepatic fibrosis, the synthesis of predominantly type III collagen is increased, and the amino-terminal propeptide of type III procollagen (PIIINP) is cleaved off and released into the circulation. Because it is now possible to measure serum PIIINP levels accurately, this test has become a valuable noninvasive marker of active hepatic fibrogenesis during methotrexate treatment of psoriasis. Thus, the number of liver biopsies taken in patients with normal serial serum PIIINP levels can be reduced to a minimum. [77]

REFERENCES

1. Marinkovich MP: Update on inherited bullous dermatoses. *Dermatol Clin* **17**:473, 1999

2. Lekas MD, Thayer WR: Dysphagia from benign mucous membrane pemphigoid. *Ear, Nose Throat J* **67**:113, 1988

3. Abraham SC et al: Esophageal lichen planus: Case report and review of the literature. *Am J Surg Pathol* **24**:1678, 2000

4. Shimizu H: Darier's disease with esophageal carcinoma. *Eur J Dermatol* **10**:470, 2000

5. Pickering MC, Haskard DO: Behçet's syndrome. *J R Coll Physicians Lond* **34**:169, 2000

6. Howel-Evans W et al: Carcinoma of the oesophagus with keratosis palmaris et plantaris (tylosis). *Q J Med* **27**:413, 1958

7. Sjögren RW. Gastrointestinal features of scleroderma. *Curr Opin Rheumatol* **8**:569, 1996

8. Haitjema T et al: Hereditary hemorrhagic telangiectasia (Osler-Weber-Rendu disease): New insights in pathogenesis, complications, and treatment. *Arch Intern Med* **156**:714, 1996

9. Oksuzoglu BC et al: Blue rubber bleb nevus syndrome. *Am J Gastroenterol* **91**:780, 1996

10. Pepin M et al: Clinical and genetic features of Ehlers-Danlos syndrome type IV, the vascular type. *N Engl J Med* **342**:673, 2000

11. Costopanagiotou E et al: An unusual cause of massive gastric bleeding in a young patient. *Am J Gastroenterol* **95**:2400, 2000

12. Dinkel H-P et al: Sonographic appearances of the abdominal manifestations of hereditary angioedema. *Pediatr Radiol* **31**:296, 2001

13. Bork K, Barnstedt SE: Treatment of 193 episodes of laryngeal edema with C1 inhibitor concentrate in patients with hereditary angioedema. *Arch Intern Med* **161**:714, 2001

14. von und zu Fraunberg M, Kauppinen R: Diagnosis of variegate porphyria—Hard to get? *Scand J Clin Lab Invest* **60**:605, 2000

15. Brady RO, Schiffmann R: Clinical features of and recent advances in therapy for Fabry disease. *JAMA* **284**:2771, 2000

16. Tizard EJ: Henoch-Schönlein purpura. *Arch Dis Child* **80**:380, 1999

17. Gunasekaran TS: Henoch-Schönlein purpura: What does the “rash” look like in the intestinal mucosa? *Pediatr Dermatol* **14**:437, 1997

18. Lankisch MR et al: Acute abdominal pain as a leading symptom for Degos' disease (malignant atrophic papulosis). *Am J Gastroenterol* **94**:1098, 1999

19. Harned RK et al: The hamartomatous polyposis syndromes: clinical and radiologic features. *Am J Roentgenol* **164**:565, 1995

20. Tsao H: Update on familial cancer syndromes and the skin. *J Am Acad Dermatol* **42**:939, 2000

21. Friedman S et al: Intravenous cyclosporine in refractory pyoderma gangrenosum complicating inflammatory bowel disease. *Inflamm Bowel Dis* **7**:1, 2001

22. Miller AM et al: Rapid response of severe refractory metastatic Crohn's disease to infliximab. *J Gastroenterol Hepatol* **16**:940, 2001

23. Lahteenoja H et al: Oral mucosa is frequently affected in patients with dermatitis herpetiformis. *Arch Dermatol* **134**:756, 1998

24. Bem J, Bradley EL: Subcutaneous manifestations of severe acute pancreatitis. *Pancreas* **16**:551, 1998

25. Hill CL et al: Frequency of specific cancer types in dermatomyositis and polymyositis: A population-based study. *Lancet* **357**:96, 2001

26. Kurzrock R, Cohen PR: Cutaneous paraneoplastic syndromes in solid tumors. *Am J Med* **99**:662, 1995

27. Kulke MH, Mayer RJ: Carcinoid tumors. *N Engl J Med* **340**:858, 1999

28. Hartmann K, Henz BM: Mastocytosis: Recent advances in defining the disease. *Br J Dermatol* **144**:682, 2001

29. Ryan AS, Goldsmith LA: Nutrition and the skin. *Clin Dermatol* **14**:389, 1996

30. Tosti A et al: The nail in systemic disease, in *Diseases of the Nails and Their Management*, 2d ed, edited by R Baran, RPR Dawber. Oxford, Blackwell Scientific Publications, 1994, p 191

31. Geary RJ et al: Bowel bypass syndrome without bowel bypass. *Cutis* **63**:17, 1999

32. Steen VD, Medseger TA: Severe organ involvement in systemic sclerosis with diffuse scleroderma. *Arthritis Rheum* **43**:2437, 2000

33. Burroughs A, Dagher L: Acute jaundice. *Clin Med* **1**:285, 2001

34. Ito T et al: Phenobarbital following phototherapy for Crigler-Najjar syndrome type II with good fetal outcome: A case report. *J Obstet Gynaecol Res* **27**:33, 2001

35. Viraben R et al: Disseminated reticulate hypomelanosis developing during primary biliary cirrhosis. *Dermatology* **195**:382, 1997

36. Smith KE, Fenske NA: Cutaneous manifestations of alcohol abuse. *J Am Acad Dermatol* 43:1, 2000

37. Requena L, Sangueza OP: Cutaneous vascular anomalies: Part 1. Hamartomas, malformations and dilatation of existing vessels. *J Am Acad Dermatol* **37**:523, 1997

38. Foutch PG et al: Cutaneous vascular spiders in cirrhotic patients: Correlation with hemorrhage from esophageal varices. *Am J Gastroenterol* **83**:723,1988

39. Li CP et al: Role of substance P in the pathogenesis of spider angiomas in patients with nonalcoholic liver cirrhosis. *Am J Gastroenterol* **94**:502, 1999

40. Li CP et al: Spider angiomas in patients with liver cirrhosis: Role of alcoholism and impaired liver function. *Scand J Gastroenterol* **34:** 520, 1999

41. Nambu M et al: Biochemical and clinical study of muscle atrophy at thenar and hypothenar eminences in patients with cirrhosis. *Liver* **16:** 19, 1996

42. Fried M et al: Cyanosis and cirrhosis of liver: Hepatopulmonary syndrome. *Ned Tijdschr Geneeska* **144**:1790, 2000

43. Alcolado R et al: Systemic arteriovenous malformations: A feature of advanced liver disease. *Gut* **35**:1145, 1994

44. Akimoto S et al: Clinical and immunological characterization of patients with systemic sclerosis overlapping primary biliary cirrhosis: A comparison with patients with systemic sclerosis alone. *J Dermatol* **26**:18, 1999

45. Oleaga JM et al: Generalized lichen planus associated with primary biliary cirrhosis which resolved after liver transplantation. *Acta Derm Venereol* **75**:87, 1995

46. Chu CY et al: Lichen planus with xanthomatous change in a patient with primary biliary cirrhosis. *Br J Dermatol* **142**:377, 2000

47. Terry RB: White nails in hepatic cirrhosis. *Lancet* **1**:757, 1954

48. Jones EA, Bergasa NV: Evolving concepts of the pathogenesis and treatment of the pruritus of cholestasis. *Can J Gastroenterol* **14**:33, 2000

49. Ghent CN, Carruthers SG: Treatment of pruritus in primary biliary cirrhosis with rifampicin. *Gastroenterology* **94**:488, 1988

50. Bergasa NV et al: Oral nalmefene therapy reduces scratching activity due to the pruritus of cholestasis: A controlled study. *J Am Acad Dermatol* **41**:431, 1999

51. Bergasa NV et al: Effects of naloxone infusions in patients with pruritus of cholestasis: A double blind randomized controlled trial. *Ann Intern Med* **123**:161, 1995

52. Wolfhagen FHJ et al: Oral naltrexone for cholestatic pruritus—A double blind, placebo-controlled study. *Gastroenterology* **113**:1264, 1997

53. Usman A et al: Lichenoid eruption following hepatitis B vaccination: First North American case report. *Pediatr Dermatol* **18**:123, 2001

54. Wolf F et al: Generalized granuloma annulare and hepatitis B vaccination. *Eur J Dermatol* **8:** 435, 1998

55. Breitschwerdt B et al: Hepatitis virus-related and ethanol-induced chronic liver disease with or without cryoglobulins—Is there a difference concerning clinical or laboratory manifestation? *Infection* **27**:248, 1999

56. Nan DN et al: Atypical skin lesions associated with mixed cryoglobulinemia and hepatitis C infection in a cocaine consuming patient. *Br J Dermatol* **143**:1330, 2001

57. Baleviciene G et al: Papular acrodermatitis of childhood: The Gianotti-Crosti syndrome. *Cutis* **67**:291, 2001

58. Tay YK. Gianotti-Crosti syndrome following immunization. *Pediatr Dermatol* **18**:262, 2001

59. Tan E et al: Bullous Sweet's syndrome associated with acute hepatitis B infection: A new association. *Br J Dermatol* **143**:914, 2000

60. Chia SC et al: Pruritus as a presenting symptom of chronic hepatitis C. *Dig Dis Sci* **43**:2177, 1998

61. Farkas H et al: Acquired angioedema associated with chronic hepatitis C. *J Allergy Clin Immunol* **103**:711, 1999

62. Hadziyannis SJ: Skin diseases associated with hepatitis C virus infection. *J Eur Acad Dermatol Venereol* **10**:12, 1998

63. Beaird LM et al: Incidence of hepatitis C in lichen planus. *J Am Acad Dermatol* **44**:311, 2001

64. Carozzo M et al: Increased frequency of the HLA-DR6 allele in Italian patients with hepatitis C virus associated oral lichen planus. *Br J Dermatol* **144**:803, 2001

65. Inuzuka M et al: Acquired icthyosis associated with dermatomyositis in a patient with hepatocellular carcinoma. *Br J Dermatol* **144**:416, 2001

66. Kuno M et al: Histiocytic cytophagic panniculitis which developed during interferon-alpha therapy. *Intern Med* **35**:115, 1996

67. Nasr I et al: Kawasaki disease: An update. *Clin Exp Dermatol* **26**:6, 2001

68. van Hoek B: The spectrum of liver disease in systemic lupus erythematosus. *Neth J Med* **48**:244, 1996

69. Islam S et al: Case report: A rare association of primary biliary cirrhosis and systemic lupus erythematosus and review of the literature. *J Gastroenterol Hepatol* **14**:431, 1999

70. Inagaki H et al: Idiopathic portal hypertension associated with systemic lupus erythematosus. *J Gastroenterol* **35**:235, 2000

71. Morelli MS, O'Brien FX: Stevens-Johnson syndrome and cholestatic hepatitis. *Dig Dis Sci* **46**:2385, 2001

72. Tadros T et al: Hepatic blood flow and oxygen consumption after burn and sepsis. *J Trauma* **49**:101, 2000

73. Rothe MJ et al: Erythroderma. *Dermatol Clin* **18**:405, 2000

74. Higgins EM: Alcohol, smoking and psoriasis. *Clin Exp Dermatol* **25**:107, 2000

75. Bode S, Gudmand-Hoyer E: Symptoms and hematologic features in consecutive adult celiac patients. *Scand J Gastroenterol* **31**:54, 1996

76. Kirby B et al: Abnormal liver function tests induced by dapsone in a patient with dermatitis herpetiformis and primary sclerosing cholangitis. *Br J Dermatol* **141**:172, 1999

77. Zachariae H: Liver biopsies and methotrexate: A time for reconsideration? *J Am Acad Dermatol* 42:531, 2000

T>

Chapter 165

Susan Sweeney Thomas Cropley

Cutaneous Changes in Renal Disorders

CUTANEOUS MANIFESTATIONS OF CHRONIC RENAL FAILURE
General Skin Changes
Pruritus
Calcification
Bullous Disease of Hemodialysis
Acquired Perforating Dermatoses
NEPHROGENIC FIBROSING DERMOPATHY

REFERENCES

The protean cutaneous manifestations of renal disease are primarily encountered in patients with chronic renal failure (CRF). In contrast, although acute renal failure (ARF) causes uremia, hypertension, congestive heart failure, and other serious conditions, only two skin changes—edema and uremic frost—occur in the acute setting. Edema is a particular feature of ARF with nephrotic syndrome. Uremic frost results from eccrine deposition of urea crystals on the skin surface of individuals with severe uremia, and it is now rarely encountered because of the wide availability of acute hemodialysis.

CUTANEOUS MANIFESTATIONS OF CHRONIC RENAL FAILURE

General Skin Changes

The skin of patients with CRF is typically dry, often with ichthyosis-like scaling. This condition may result in part from altered vitamin A metabolism in CRF, [1] along with fluid volume shifts from dialysis. Skin color is also altered in CRF. The skin is pale (from anemia) and often exhibits a distinctive gray-yellow hue, because of the accumulation of carotenoid and nitrogenous pigments (urochromes) in the dermis. The nails also exhibit color changes. Lindsey's, or half-and-half, nails are normal in their distal 50 percent and white in the proximal 50 percent. The term *Terry's nails* has been applied to nails in which only the distal 20 percent is normal. These nail changes are fairly specific to CRF but may be encountered in patients with chronic liver disease and in healthy individuals.

Pruritus

Pruritus is frequently reported by patients with chronic end-stage renal disease. The incidence of renal pruritus is reported to approach 50 to 90 percent of patients undergoing hemodialysis. [2], [3], [4] and [5] Some patients complain of pruritus only during or soon after dialysis, whereas others report symptomatic exacerbation during this same period. [4] Although the etiology is poorly understood, localized and generalized forms of renal pruritus are likely caused by a combination of several mechanisms: increased serum levels of histamine, vitamin A, and parathyroid hormone (PTH); mast cell hyperplasia; peripheral polyneuropathy; and xerosis. [3], [5], [6] Clinically, the skin may appear normal or demonstrate a varied pattern of lichenified or hyperkeratotic lesions.

Treatment of renal pruritus is often empirical. Topical moisturizers alleviate pruritus associated with xerotic skin. Topical glucocorticoids and ultraviolet phototherapy are often used to suppress inflammation in treated areas. Topical capsaicin depletes substance P from nerve endings, thereby suppressing itch sensation. [6] Improving the efficacy of dialysis and/or changing the dialysate concentration may help to alleviate pruritus. [6], [7] Some patients have responded to treatments with intravenous lidocaine, heparin, and cholestyramine. [6] Surgical options include subtotal parathyroidectomy, electric needle stimulation, and renal transplantation. [2], [3], [6] De Marchi et al. [5] found erythropoietin to be effective in lowering plasma histamine concentrations with subsequent improvement in pruritus. Preliminary studies indicate that oral evening primrose oil and topical tacrolimus ointment may each have some therapeutic effect. [8], [9]

Calcification

Metastatic calcification of the skin in CRF results from secondary or tertiary hyperparathyroidism. Abnormally elevated levels of PTH may trigger deposition of crystalline calcium pyrophosphate in the dermis, subcutaneous fat, or arterial walls. [10] Vascular calcification is, in fact, very common in patients with long-term CRF, and is seldom symptomatic. Occasionally however, calcified vessels may thrombose acutely, resulting in a syndrome that has been called *calciphylaxis* (a term originally coined by the physiologist Selye, who experimentally induced abrupt calcification of tissues in animals). This is probably not the mechanism in the CRF-associated disorder. This acute thrombosis produces symmetrical livedo reticularis. Livedoid areas are excruciatingly painful due to ischemia, and they quickly become hemorrhagic and ulcerate (Fig. 165-1). Calciphylaxis is associated with a high mortality rate, particularly when the skin of the trunk is involved (as opposed to a somewhat better prognosis if skin infarction is limited to the extremities). [10] Laboratory evaluation usually demonstrates marked elevation of intact PTH. The serum calcium and phosphate levels, and the calcium-phosphate product (Ca mg/dL × PO_4 mg/dL) are frequently only minimally elevated and may be normal.

FIGURE 165-1 Calciphylaxis. (*Courtesy of Suzanne N. Granados, MD.*)

In addition to vascular calcification and calciphylaxis, nodular calcification may occur in the skin and fat of patients with CRF. These calcium deposits are identical to calcinosis cutis in other disorders, such as tumoral calcinosis or CREST (calcinosis cutis, Raynaud's phenomenon, esophageal dysfunction, sclerodactyly, and telangiectasia) syndrome. The involved skin may ulcerate, but this process occurs in subacute fashion, without livedo or ischemic pain. The prognosis for patients with this nonvascular form of calcification is excellent.

Treatment of calciphylaxis is extraordinarily difficult. Pain management, careful débridement of gangrenous tissue, and, especially, parathyroidectomy have been successful. [10], [11] However, no prospective trial of parathyroidectomy has been conducted, and convincing evidence of improved prognosis for patients with calciphylaxis after this procedure is lacking. Studies to evaluate the role of anticoagulation or thrombolytic therapy in calciphylaxis have yet to be conducted. The nonvascular form of CRF-associated calcinosis may be managed with surgical excision of calcific nodules and treatment of ulcers with hydrocolloid dressings and the like.

Bullous Disease of Hemodialysis

Porphyria cutanea tarda (PCT) has been described in patients with CRF undergoing hemodialysis. Although the etiology of this phenomenon is still unclear, inadequate clearance of plasma-bound porphyria precursors by urine excretion or hemodialysis may lead to porphyrin deposition in the skin manifested clinically as photosensitivity and subepidermal bullae. [12], [13] and [14] Patients undergoing hemodialysis may also produce or be exposed to compounds that alter normal heme synthesis. PCT has been reported both in a patient undergoing peritoneal dialysis [12] and in a patient undergoing hemodialysis after reactivation of hepatitis C virus infection. [15]

Bullous dermatosis of dialysis or pseudoporphyria may occur in 8 to 18 percent of patients undergoing hemodialysis. [12], [14], [16] This condition is often clinically indistinguishable from PCT with marked skin fragility and blister formation on sun-exposed skin. However, hypertrichosis is less common, and plasma porphyrin levels are typically normal. [12], [16] Pseudoporphyria may also occur in some patients taking tetracycline, nabumetone, nalidixic acid, furosemide, and phenytoin. [12]

Treatment of PCT or pseudoporphyria in most patients with CRF may be difficult. Phlebotomy can reduce iron levels in the liver, allowing new hepatic uroporphyrinogen decarboxylase to be formed. [17] However, patients with end-stage renal disease often have significant anemia and cannot tolerate phlebotomy. Intravenous erythropoietin may both lower total body iron stores and support phlebotomy as needed. [13], [17] Chloroquine effectively clears porphyrins from the liver. In patients with CRF, however, porphyrins may not be effectively cleared by hemodialysis or excreted in the urine. [14], [17] Deferoxamine may lower serum porphyrin levels in some patients. [13] Others may require renal transplantation to obtain complete resolution of symptoms. [13]

Acquired Perforating Dermatoses

Acquired perforating dermatosis can occur in association with CRF and diabetes mellitus. [18], [19] This condition, which occurs in up to 10 percent of patients undergoing hemodialysis, may be more common in blacks [18], [20], [21] and appears to be distinct from the four primary perforating disorders (elastosis perforans serpiginosa, Kyrle's disease, perforating folliculitis, and reactive perforating collagenosis). [19], [21] Clinically, patients develop hyperkeratotic papules with a central crust-filled crater on the trunk and extensor surfaces, often in a linear distribution. [21] Simultaneous transepidermal elimination of both collagen and elastic fibers has been detected. [20] The etiology of this process is unclear. Proposed mechanisms include diabetes microangiopathy, microtrauma caused by chronic pruritus, dysregulation of vitamin A or vitamin D metabolism, abnormality of collagen or elastic fibers, or local inflammation and connective tissue degradation caused by dermal microdeposition of substances such as uric acid and calcium pyrophosphate. [20], [22] However, we regard this entity as a secondary response to scratching associated with renal pruritus. Successful treatment depends on addressing the underlying etiology of pruritus. Topical and intralesional glucocorticoids, topical and systemic retinoids, cryotherapy, and ultraviolet light also may be helpful. [20], [21]

NEPHROGENIC FIBROSING DERMOPATHY

Nephrogenic fibrosing dermopathy (NFD), a recently described disorder, resembles scleromyxedema (see Chap. 187) in some of its aspects. [23], [24] To date, NFD has been found only in patients with renal disease. Most affected individuals have been on hemodialysis, and many have restarted dialysis after failure of a renal transplant. NFD also has been described in a few patients with ARF. Clinically, patients progressively develop erythematous, sclerotic dermal plaques on the arms and legs, with sparing of the head and neck. Pruritus is a common feature. The histopathology of NFD similarly resembles that of scleromyxedema, with proliferation of fibroblasts in the dermis and subcutaneous septae, accompanied by increased dermal and septal collagen and mucin. [24]

The etiology of NFD is unknown. The disorder has been described in clusters of patients from widely scattered dialysis centers in Europe and North America, prompting epidemiologic investigations that currently are ongoing. All patients described have had persistent disease (even though renal failure resolved in some cases). [23] There is no effective treatment.

REFERENCES

1. Vahlquist A et al: Skin content and plasma transport of vitamin A and beta-carotene in chronic renal failure. *Eur J Clin Invest* **12**:63, 1982

2. Szepietowski JC, Schwartz RA: Uremic pruritus. *Int J Dermatol* **37**:247, 1998

3. Ståhle-Bäckdahl M: Uremic pruritus. *Semin Dermatol* **14**:297, 1995

4. Gilchrest BA et al: Clinical features of pruritus among patients undergoing maintenance hemodialysis. *Arch Dermatol* **118**:154, 1982

5. De Marchi S et al: Relief of pruritus and decreases in plasma histamine concentrations during erythropoietin therapy in patients with uremia. *N Engl J Med* **326**:969, 1992

6. Schwartz IF, Iaina A: Management of uremic pruritus. *Semin Dial* **13**:177, 2000

7. Kyriazis J, Glotsos J: Dialysate calcium concentration of =1.25 mmol/L: Is it effective in suppressing uremic pruritus [letter]? *Nephron* **84**:85, 2000

8. Yoshimoto-Furuie K et al: Effects of oral supplementation with evening primrose oil for six weeks on plasma essential fatty acids and uremic skin symptoms in hemodialysis patients. *Nephron* **81**:151, 1999

9. Pauli-Magnus C et al: Short-term efficacy of tacrolimus ointment in severe uremic pruritus [letter]. *Perit Dial Int* **20**:802, 2000

10. Worth RL. Calciphylaxis: Pathogenesis and therapy. *J Cutan Med Surg* **2**:245, 1998

11. Hafner J et al: Uremic small-artery disease with medial calcification and intimal hyperplasia (so-called calciphylaxis): A complication of chronic renal failure and benefit from parathyroidectomy. *J Am Acad Dermatol* **33**:954, 1995

12. Kelly MA, O'Rourke KD: Treatment of porphyria cutanea tarda with phlebotomy in a patient on peritoneal dialysis. *J Am Acad Dermatol* **44**:336, 2001

13. Stevens BR et al: Porphyria cutanea tarda in the setting of renal failure. *Arch Dermatol* **129**:337, 1993

14. Sarkell B, Patterson JW: Treatment of porphyria cutanea tarda of end-stage renal disease with erythropoietin. *J Am Acad Dermatol* **29**:499, 1993

15. Albalate M et al: Development of porphyria cutanea tarda in a hemodialysis patient after reactivation of hepatitis C virus infection. *Nephron* **88**:170, 2001

16. Poh-Fitzpatrick MB et al: Porphyria cutanea tarda associated with chronic renal disease and hemodialysis. *Arch Dermatol* **116**:191, 1980

17. Anderson KE et al: Erythropoietin for the treatment of porphyria cutanea tarda in a patient on long-term hemodialysis. *N Engl J Med* **322**:315, 1990

18. Patterson JW: The perforating disorders. *J Am Acad Dermatol* **10**:561, 1984

19. Rapini RP et al: Acquired perforating dermatosis. *Arch Dermatol* **125**:1074, 1989

20. Morton CA et al: Acquired perforating dermatosis in a British dialysis population. *Br J Dermatol* **135**:671, 1996

21. Farrell AM: Acquired perforating dermatosis in renal and diabetic patients. *Lancet* **349**:895, 1997

22. Haftek M et al: Acquired perforating dermatosis of diabetes mellitus and renal failure: Further ultrastructural clues to its pathogenesis. *J Cutan Pathol* **20**:350, 1993

23. Cowper SE et al: Scleromyxedema-like cutaneous diseases in renal-dialysis patients. *Lancet* **356**:1000, 2000

24. Cowper SE et al: Nephrogenic fibrosing dermopathy. *Am J Dermatopathol* **23**:383, 2001

T>

Chapter 166

Andrew Franks Victoria Werth

Cutaneous Aspects of Cardiopulmonary Disease

ALTERATIONS IN SKIN QUALITY
CHANGES IN SKIN COLOR
Cyanosis
Redness/Flushing
ALTERATIONS IN SWEATING
ALTERATIONS OF NAILS, HANDS, AND ARMS
Nail Clubbing
Quincke Pulse
Hypertrophic Osteoarthropathy
REFLEX SYMPATHETIC DYSTROPHY
THE HEART AND THE SKIN
Coronary Heart Disease
Cardiomyopathy
Myxoma
LEOPARD Syndrome
Subacute Bacterial Endocarditis
THE LUNGS AND THE SKIN
Yellow Nail Syndrome
Pulmonary Arteriovenous Fistulas
Chronic Pulmonary Diseases
Cystic Fibrosis
Larva Migrans and Pulmonary Involvement
Fat Embolism Syndrome
SELECTED DISEASES AFFECTING THE CARDIOPULMONARY SYSTEM
Lipoid Proteinosis (Hyalinosis Cutis et Mucosae)
Multicentric Reticulohistiocytosis
Sarcoidosis
Amyloidosis
Lymphomatoid Granulomatosis
COLLAGEN VASCULAR DISEASES
Rheumatoid Arthritis
Systemic Lupus Erythematosus
Dermatomyositis
Systemic Sclerosis
Relapsing Polychondritis

REFERENCES

Descriptions of abnormalities of the skin in association with diseases of the heart and lungs are among those first recorded in medical antiquity. While many of these abnormalities are familiar and easily recognizable by the physician, others are unique and may remain a diagnostic challenge (Table 166-1). This chapter presents the cutaneous manifestations of selected cardiopulmonary diseases; in addition, interesting associations between the skin, heart, and lung are included.

Joint and connective tissue diseases	Watson syndrome
Rheumatoid arthritis	Neurofibromatosis
Systemic lupus erythematosus	Tuberous sclerosis
Reiter's syndrome	LEOPARD syndrome
Behçet's syndrome	LAMB syndrome
Systemic scleroderma	NAME syndrome
Dermatomyositis	Danoff syndrome
Rheumatic fever	Infectious diseases
Ehlers-Danlos syndrome	Varicella
Cutis laxa	Gonococcemia
Marfan's syndrome	Subacute and acute bacterial endocarditis
Periarteritis nodosa	Chagas' disease
Multicentric reticulohistiocytosis	Diphtheria
Metabolic diseases	Miscellaneous (protozoal, viral, rickettsial, and bacterial infections)
Hemochromatosis	Diseases of uncertain etiology
Amyloidosis	Sarcoidosis
Fabry's disease	Whipple's disease
Carcinoid tumors	Kawasaki disease
Myxedema	Degos' disease
Hyperlipidemias	
Hyperthyroidism	
Nevoid or genetic disorders	
Progressive lentigines (Moynahan syndrome)	

NOTE: See Table 166-4 for definitions of LEOPARD, LAMB, and NAME syndromes.
SOURCE: Modified and reprinted with permission from *Dermatologic Capsule & Comment*, edited by TB Fitzpatrick, September 1987, p 9.

TABLE 166-1 **Diseases with Heart and Skin Involvement**

A number of situations in which the skin and the cardiopulmonary system are both involved are described elsewhere in this volume. These conditions include pruritus associated with cardiac failure or pulmonary insufficiency, pigmentary changes associated with hemochromatosis, or endocrine abnormalities (see Chap. 164, Chap. 169, respectively), the hyperlipidemias (see Chap. 150), mucocutaneous lymph node syndrome (see Chap. 204), lipoid proteinosis (see Chap. 152), and amyloidosis (see Chap. 148).

ALTERATIONS IN SKIN QUALITY

The skin may be warm in patients with erythroderma or exfoliative dermatitis as a result of shunting or increased metabolism with or without high-output congestive failure (see Chap. 44). Hyperthyroidism with increased cardiac output and vasodilation may also lead to increased skin temperature. Conversely, the temperature may be reduced in patients with hypothyroidism and low-output congestive failure secondary to atherosclerotic disease or myocardial infarction. Systemic amyloidosis may cause waxy induration of the skin, and when stroked the skin may become hemorrhagic ("pinch purpura") (see Chap. 148). Cardiac conduction disturbances, myocardial disease, and orthostatic hypotension are common.

Hyperelastic velvety skin that rebounds to the original position after being stretched, "cigarette-paper" scars, and hyperextensible joints are characteristic of the Ehlers-Danlos syndrome (see Chap. 154). Mitral and tricuspid prolapse, dilatation of the aorta and pulmonary artery, arterial rupture, a variety of congenital heart diseases, acute myocardial infarction, and panacinar emphysema may accompany this syndrome. [1] A progressive looseness of the skin with pendulous folds and droopy eyelids can be a clue to cutis laxa (see Chap. 154). This condition may be associated with generalized hyperelastosis that may cause aortic dilatation and rupture, congestive heart failure, or cor pulmonale with pulmonary artery stenosis and progressive emphysema. The skin of patients with pseudoxanthoma elasticum (see Chap. 154) is thick, lax, and yellowish, especially over the axillae, antecubital area, and neck. The skin around the mouth may sag. Yellow patches may occur on mucous membranes, especially the labia. The arteries may be calcified, and the aortic and mitral valves thickened. Angina pectoris and claudication are frequent symptoms. [2]

In Werner's syndrome (progeria), the skin appears atrophic and tight: there s marked loss of subcutaneous tissue, with ulcerations of the legs and severe coronary atherosclerosis; death by myocardial infarction is frequent at an early age.

CHANGES IN SKIN COLOR

Changes in skin color are caused by a number of variables including hemoglobin, melanin, carotene, vasoactivity, metals, and miscellaneous other phenomena.

Cyanosis

An increase in the absolute amount of desaturated (reduced) hemoglobin results in a purplish or bluish discoloration of the skin. By definition, cyanosis is divided into "central" and "peripheral" types, the latter being the more common. Conceptually, the terms refer to the level of arterial oxygen saturation and not to the anatomic source of the cyanosis. Thus, central cyanosis occurs in states that produce low arterial oxygen saturation, such as congenital heart disease with intracardiac or intrapulmonary right-to-left shunting, as well as most severe pulmonary diseases. Peripheral cyanosis occurs in states that have normal arterial oxygen saturation but reduced blood flow, such as low-output cardiac failure of any etiology, and local vasospastic phenomena. Pulmonary embolism may result in a combination of central cyanosis caused by intrapulmonary shunting and peripheral cyanosis caused by low cardiac output.

Central cyanosis is usually present on the warm areas of the skin such as the tongue, oral mucosae, and conjunctivae. Peripheral cyanosis is usually seen on the cool areas such as the nose, lips, earlobes, and fingertips. However, this distinction is not absolute because both central and peripheral cyanosis may affect any of the aforementioned areas of the body. Detection of cyanosis may be difficult, even to the experienced observer. Although the tongue is probably the area where it is most easily detected, a number of false-positive evaluations may occur. Therefore examination of the fingertips and conjunctivae, although less sensitive, may reflect the underlying condition more clearly. In the anemic patient, detection of cyanosis may be impossible because the absolute amount of reduced hemoglobin is not increased. To avoid confusion with staining of the skin, either topically or from systemic deposits of heavy metals or other chemicals, it is important to note that cyanosis fades when pressure is applied because the color is within the blood vessels. Cyanosis that is more intense in the fingers than in the toes suggests complete transposition of the great vessels, with either a preductal coarctation or complete interruption of the aortic arch, pulmonary hypertension, and a reversed shunt through a patent ductus arteriosus. If the cyanosis is slightly more on the right hand, coarctation of the aorta is more likely. Equal cyanosis of both hands suggests complete aortic interruption. Cyanosis and clubbing of the toes associated with cyanosis in the left hand and a normal right hand suggest pulmonary hypertension with a reversed shunt through a patent ductus arteriosus bringing saturated blood to the left arm and both legs.

Redness/Flushing

Redness of the skin may be caused by an increase in the amount of saturated hemoglobin, an increase in the diameter or actual number of skin capillaries, or a combination of these factors. Erythroderma or exfoliative dermatitis with intense redness may be associated with so much capillary dilatation that high-output cardiac failure occurs, especially in compromised patients (see Chap. 44). Polycythemia may produce the characteristic "ruddy" complexion, but may also cause a peculiar ruddy cyanosis. The tongue, lips, nose, earlobes, conjunctivae, and fingertips especially demonstrate this coloration, which results when increased amounts of saturated hemoglobin produce the redness and when increased amounts of desaturated hemoglobin produce cyanosis because of the inability of the body to oxygenate fully the increased absolute amounts of hemoglobin. The absence of nail clubbing may help differentiate patients with polycythemia vera from those patients with cardiopulmonary disease who develop secondary polycythemia. In addition, the hypervolemic state of polycythemia vera is associated with increased stroke volume and may lead to high-output cardiac failure, while pulmonary infarction may result from venous thrombosis and embolization caused by hyperviscosity.

Paroxysmal intense flushing of the face, neck, chest, and abdomen, often with telangiectases of the face and neck, may occur in patients with carcinoid tumors (see Chap. 170), systemic mastocytosis (see Chap. 163), pheochromocytoma, and Sipple's syndrome. Edema of the face, arms, and hands associated with redness and/or cyanosis may indicate

obstruction of the superior vena cava due to mediastinal disease.

ERYTHROMELALGIA (LABILE HYPERTHERMIA) (See also Chap. 167) Erythromelalgia is a clinical syndrome that is characterized by recurrent attacks of burning pain in the hands and/or feet together with redness, warmth, and sometimes swelling that may extend to the elbows and knees. The pulse is either normal or slightly increased. Erythromelalgia may be primary (it was recently associated with a chromosomal marker) or secondary to a wide variety of disorders such as atherosclerosis, hypertension, and polycythemia. [3] Recently, human immunodeficiency/AIDS patients were identified with the syndrome. Symptoms are hypothesized to be caused by dysfunctional vascular dynamics including arteriovenous shunting and reduced capillary perfusion with corresponding tissue hypoxemia. [4]
PALMAR ERYTHEMA Palmar erythema may occur in many healthy women, but recent onset or increased intensity of this condition raise the possibility of liver involvement (see Chap. 164). Palmar erythema may be associated with high-output cardiac failure. The erythema primarily involves the hypothenar eminence but may also affect the thenar eminence and the fingertips. Other factors, including pregnancy and hyperthyroidism, may cause this condition.
JAUNDICE (See also Chap. 164) Hyperbilirubinemia and jaundice may occur in patients in heart failure as a result of raised intrahepatic pressure due to passive congestion. Hemorrhagic pulmonary infarction with destruction of red cells and hemoglobin may also produce jaundice, especially in patients with passive congestion of the liver. Constrictive pericarditis and tricuspid valvular disease may produce jaundice secondary to cardiac cirrhosis. Under fluorescent light, jaundice may be difficult to assess.

ALTERATIONS IN SWEATING

Sweating may be prominent in a number of cardiopulmonary states such as acute myocardial infarction, cardiogenic shock, left ventricular failure, massive pulmonary emboli, and pulmonary edema. Pallor and clamminess or coldness of the extremities and exposed surfaces are also often found. When associated with hypertension, excessive sweating may suggest pheochromocytoma. There may also be additional features such as flushing, which is most prominent in those patients with Sipple's syndrome in whom prostaglandin and serotonin production by the tumor may simulate a carcinoid. Myocardial infarction may occur or cardiac failure may develop as a consequence of a metabolic cardiomyopathy. Neurofibromatosis and café au lait macules have been found in as many as 10 percent of patients, especially those with bilateral pheochromocytoma. The sodium and chloride content of sweat is increased in patients with cystic fibrosis and may lead to an increase in skin wrinkling after immersion, as when bathing. [5]

ALTERATIONS OF NAILS, HANDS, AND ARMS

Nail Clubbing

Nail clubbing and osteoarthropathy are distinct entities that may be associated with significant cardiopulmonary abnormalities (Fig. 166-1). Clinically, nail clubbing has various manifestations. Beaking or distal curvature of the nail may occur. There may be loss of the normal 15° angle between the nail and cuticle. Sponginess or “floating” of the nail when pressure is applied is also characteristic. Finally, the size of the terminal tuft may increase. This change may be quantified by measuring the depth of the finger at the base of the nail and dividing by the depth of the finger at the distal interphalangeal (DIP) joints. The ratio should normally be less than 1.0. Clubbing most commonly occurs in patients with bronchogenic carcinoma, suppurative lung disease, endocarditis, and congenital heart disease, but it may be idiopathic or familial.

FIGURE 166-1 Clubbing of fingernails.

Quincke Pulse

Flushing of the nail beds that is synchronous with the heartbeat is one sign of the aortic regurgitation called *Quincke pulsation*. In addition, the fingernail beds may be used to evaluate the microcirculation. Capillary “fill” is estimated by pressing down on the nail bed until blanching occurs. Following release, there should be immediate filling and a pink appearance. However, perfusion of the skin may not reflect perfusion of internal organs.

Hypertrophic Osteoarthropathy

Hypertrophic osteoarthropathy often has clubbing as a feature, but in addition there is associated arthralgia and/or arthritis of the fingers, wrists, knees, and ankles, as well as painful periostitis revealed as subperiosteal new bone formation on x-ray. Suffusion of the digits may be prominent, with pitting edema. Shiny skin with increased sweating and paronychial thickening are sometimes noted. Although hypertrophic osteoarthropathy is most often associated with malignant tumors of the chest, there are numerous other disorders that produce this syndrome. In addition, some cases are primary or idiopathic. Pachydermoperiostosis, a primary form, is frequently familial. Its onset is around puberty, and it has a number of cutaneous manifestations. Distinctive thickening and furrowing of the skin of the scalp, forehead, and cheeks may create leonine facies. Other features include excessive sweating, especially of the hands and feet, severe seborrhea of the scalp and face, and dermatitis of the hands and feet. Familial clubbing alone may also be found and

may represent a partial expression of this syndrome. Thyroid acropachy (Chap. 169) may mimic osteoarthropathy but is most often painless.

REFLEX SYMPATHETIC DYSTROPHY

The shoulder-hand syndrome is a painful periarthritis or adhesive capsulitis of the shoulder ("frozen shoulder"), usually on the left side, associated with erythema, sweating, shiny induration, edema, tenderness, pain, and immobility of the ipsilateral hand. Neurotrophic ulcerations of the fingers and thickening of the palmar aponeurosis with nodules and/or Dupuytren's contracture may be late sequelae. This syndrome was observed in up to 15 percent of patients with myocardial infarction in the past when bed rest was prolonged, but it is now uncommon. Other predisposing conditions include arterial embolization, cerebrovascular accidents, and protective disuse of the arms for any reason. [6]

THE HEART AND THE SKIN

Coronary Heart Disease

FAMILIAL HYPERLIPIDEMIA The risk of coronary artery disease (CAD) may increase with elevation of plasma cholesterol and triglyceride concentrations. Familial hyperlipidemias comprise a group of metabolic disorders with elevated plasma cholesterol and/or triglycerides, and some may be associated with a high incidence of CAD. Xanthomatosis may be present in patients with these disorders, and they have been associated for many years with a high incidence of CAD (see Chap. 150).

EARLOBE CREASE A number of reports relate CAD to the presence of a diagonally positioned skin crease along the earlobe. These creases may be unilateral or bilateral. It is not known whether such creases are congenital or acquired, nor is the mechanism of their formation understood. Their presence suggests an increased risk for CAD in men younger than age 60 years, based on clinical, angiographic, and postmortem studies. [7]

MALE BALDING Male pattern baldness was 40 percent more prevalent in a case-control hospital-based study of 842 men admitted with nonfatal myocardial infarction. After allowing for age and other established coronary risk factors, the relative risk of myocardial infarction for frontoparietal male pattern baldness compared with no hair loss was 1.77 (95% CI 1.27 to 2.45). [7] Another large study of 22,081 male physicians over an 11-year time frame also reached similar conclusions, and also suggested that vertex hair loss was more strongly associated with cardiovascular risk factors, such as hypertension and hypercholesterolemia. [8]

CHOLESTEROL EMBOLI (See also Chap. 167) In patients with advanced atherosclerosis of the abdominal aorta, cholesterol crystals may microembolize to the lower extremities, particularly after invasive vascular procedures or surgery. The pulses may remain normal. In addition to complaints of pain in the legs, buttocks, and low back, as well as myalgia, restless legs, or abdominal symptoms, both renal insufficiency and various skin lesions frequently develop. Livedo reticularis may affect the lower abdomen and back, buttocks, and legs, and ulcerations on the legs and feet, surrounded by an erythematous or violaceous halo and a small scab, may be present. Digital cyanosis ("blue toe") and gangrene may simulate necrotizing vasculitis (Fig. 166-2). Indurated plaques and nodules and their association with livedo reticularis and ulceration may mimic polyarteritis nodosa (see Chap. 174). These plaques and nodules are firm, violaceous, painful, and necrotic in the center. Deep skin biopsy of areas of livedo reticularis or adjacent to nodules or ulceration reveal occlusions of arterioles by multinucleated foreign-body giant cells and fibrosis surrounding biconvex, needle-shaped clefts corresponding to the cholesterol crystal microemboli. [9]

FIGURE 166-2 Cholesterol emboli: Blue toe and infarctions.

POSTBYPASS SKIN CHANGES Coronary artery bypass surgery is commonly performed using the superficial veins of the legs as donor-graft sites. A dermatitis has been reported to occur along the saphenous vein graft scars on the medial aspect of the legs. Patients have no history of venous stasis, thrombophlebitis, ankle edema, or skin disease. Examination generally reveals a reddish-brown, slightly scaling, and fissured dermatitis along the distal part of a well-healed saphenous vein graft scar. Dermatitis develops 2 to 6 months after surgery and the patient's return to full activity. The cause is unclear but may be related to the high incidence of postoperative thrombophlebitis and resultant stasis dermatitis. The dermatitis responds to topical glucocorticoids. Recurrence is usual and most patients require continued treatment. Recurrent cellulitis may develop in the healed vein graft many months after surgery. These patients present with fever and chills; erythema may extend along the entire vein graft site, accompanied by pain and tenderness. Swelling may be significant, and often the patients are initially considered to have thrombophlebitis. Although cultures are not always positive, beta-hemolytic streptococcus has been isolated in a number of cases. The presence of tinea pedis in patients with this complication has been reported and it is recommended that all patients considered for vein graft surgery be examined carefully for evidence of tinea infections of the feet. If found, patients should be treated vigorously with antifungal medication prior to surgery.

Cardiomyopathy

Cutaneous abnormalities may aid in the diagnosis, classification, and subsequent treatment of some kinds of cardiomyopathy. These disorders of the myocardium affect ventricular function and may produce cardiac failure. A useful classification divides cardiomyopathies into dilated, nondilated, and hypertrophic types. [10] It was recently stressed that each type of cardiomyopathy has a distinct differential diagnosis and that little etiologic overlap occurs. [11], [12] Thus, a specific cutaneous finding, in conjunction with the appropriate studies to determine the type of cardiomyopathy, may be

very important in making the correct diagnosis. For instance, *Naxos disease* is an autosomal recessive mutation in desmoplakin, the most abundant protein in desmosomes that are important for cell adhesion in many tissues, including skin and heart. [13] Individuals affected by this disorder have generalized striate keratoderma particularly on the palmoplantar epidermis, woolly hair and dilated left ventricular cardiomyopathy, which leads to arrhythmia, heart failure, and early sudden death. Either radionuclide ventriculography or two-dimensional echocardiography estimates ventricular volume and left ventricular ejection fraction. These measurements are used to distinguish among the three types of cardiomyopathy. Table 166-2 and Table 166-3 list the causes of cardiomyopathy according to type.

Dilated	Neoplastic*
Coronary artery disease	Melanoma*
with multiple infarcts*	Ventricular thrombosis
Alcoholic*	Polycythemia vera*
Peripartum	Mitral valve prosthesis
Valvular*	Idiopathic
Infectious acute inflammatory	Hypertrophic
myocarditis*	Genetic form (↑ autosomal
Chagas' disease*	dominant)
Sarcoid*	Acquired or secondary forms
Doxorubicin toxicity	Neurofibromatosis*
Uremia*	Lentiginosis*
Hemochromatosis*	Hyperthyroidism*
Pheochromocytoma*	Hypothyroidism*
Hypocalcemia	Noonan's syndrome
Diabetes mellitus*	Hypertension
Nutritional (↑ selenium)	Valvular or subvalvular
Idiopathic	obstruction of left ventricular
Nondilated	outlet tract
Amyloid heart disease*	Pompe's disease
Endomyocardial diseases	Friedreich's ataxia
Löffler's disease*	In infants of diabetic mothers
Pseudoxanthoma elasticum*	
Endomyocardial fibrosis	
(Davies' disease)	

*May have significant cutaneous features.
SOURCE: Modified from Johnson and Palacios.[10]

TABLE 166-2 **Causes of Cardiomyopathy by Type**

Coxsackie virus B	Cytomegalovirus
Coxsackie virus A	Mumps
Echo virus	Psittacosis
Poliovirus	*Cryptococcus neoformans*
Arbovirus (dengue, chikungunya fever)	*Candida albicans*
Toxoplasma gondii	*Trichinella spiralis*
Trypanosoma cruzi	*Schistosoma mansoni*
Mycoplasma pneumoniae	*Corynebacterium diphtheriae*
Varicella	*Neisseria meningitidis*
Variola	*Leptospira*
Influenza	Polymicrobial bacterial
Rabies	myocarditis

*Most have cutaneous features.
SOURCE: Modified from Johnson and Palacios.[10]

TABLE 166-3 **Infectious Causes of Acute Dilated Cardiomyopathy**

Myxoma

Atrial myxomas, the most common primary tumors of the heart, are benign hamartomatous intracardiac tumors that may produce a wide variety of clinical symptoms and signs and may simulate a number of disease states. The cardiopulmonary findings include, in order of frequency, congestive heart failure, mitral murmur, chest pain, pulmonary edema, and embolic phenomena. Additionally, valvular insufficiency, constrictive pericarditis, conduction blocks, arrhythmias, and intracardiac shunts may occur. Variable murmurs may be an important clue. Pulmonary emboli and pulmonary hypertension may also occur in addition to other systemic findings, including fever, cachexia and malaise, arthralgias, arthritis, clubbing, hypergammaglobulinemia, anemia or polycythemia, thrombocytosis or thrombocytopenia, and leukocytosis.

The cutaneous manifestations of atrial myxomas may be dramatic. In addition to biphasic digital color changes on cold exposure, various cutaneous lesions have been described that simulate collagen vascular disease or vasculitis: tender, violaceous, nonblanching, annular, and serpiginous lesions of the digital pads, as well as splinter hemorrhages presenting as a systemic vasculitis or infective endocarditis. Characteristic pruritic, erythematous papules as well as cyanosis and ecchymosis of the extremities may also occur. The diagnosis may be made by biopsy of the skin and subcutaneous tissue in an area of embolic infarct. Myxomatous emboli with large pale-staining cytoplasms and stellate nuclei may be found among occluded blood vessels.

Before the introduction of the echocardiogram in 1960, more than 80 percent of patients were undiagnosed postmortem. The diagnosis may now be made earlier and more frequently during routine echocardiography, allowing successful surgical intervention. [14] Various associations of atrial myxoma with mucocutaneous pigmented lesions, including lentigines (Fig. 166-3), nevomelanocytic nevi, and blue nevi, as well as dermal myxomatous nodules, have been described (Table 166-4). [15]

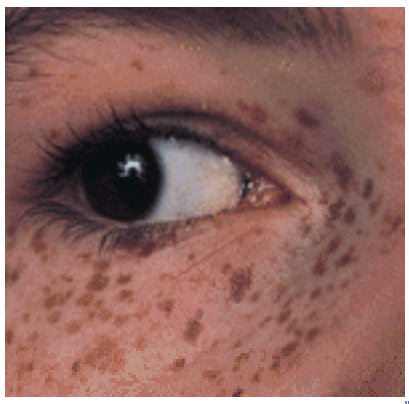

FIGURE 166-3 Lentiginous lesions in the atrial myxoma syndrome complex. This child has the LAMB syndrome (see Table 166-4).

LEOPARD syndrome	NAME syndrome
Lentiginosis	Nevi
Electrocardiographic abnormalities	Atrial myxoma
Ocular hypertelorism	Myxoid neurofibroma
Pulmonic stenosis	Ephelides
Abnormal genitalia	Danoff syndrome
Retardation	Adrenocortical micronodular dysplasia
Deafness	Lentigines
LAMB syndrome	Atrial myxoma
Lentigines	Spindle-cell tumors
Atrial myxoma	
Mucocutaneous myxomas	
Blue nevi	

TABLE 166-4 **Clinical Findings Associated with Lentigines**

LEOPARD Syndrome

Multiple lentigines syndrome, an autosomal dominant disorder, is associated with numerous abnormalities of variable clinical expression including disturbances of the heart. Each letter of the mnemonic represents a feature of the syndrome (see Table 166-4): *l*entigines, multiple; *e*lectrocardiogram conduction defects; *o*cular hypertelorism; *p*ulmonary stenosis; *a*bnormalities of genitalia; *r*etardation of growth; *d*eafness, sensorineural (see also Chap. 90). The types of cardiac involvement include electrocardiographic conduction disturbances and anatomic malformations. Axis deviation, prolonged P-R intervals, left anterior hemiblock, bundle branch block, and complete heart block have been reported.

Hypertrophic cardiomyopathy appears to be the most common anatomic abnormality. Subaortic stenosis is the most common valvular lesion. Although earlier reports suggested that pulmonary stenosis was frequent, some of the clinical and physiologic features of hypertrophic cardiomyopathy mimic pulmonary stenosis and were clarified only after catheterization or echocardiography. Because the clinical expression of the conduction disturbances and the anatomic malformation vary in onset and severity, frequent cardiac evaluation should be performed.

Subacute Bacterial Endocarditis

The cutaneous manifestations of bacterial endocarditis are important clues to the diagnosis, although less frequently than in the preantibiotic era. They include Osler's nodes, Janeway lesions, subungual splinter hemorrhages, cutaneous purpura and petechiae, and conjunctival petechiae (Roth's spots) (see also Chap. 194). Petechiae are the most common mucocutaneous manifestation of bacterial endocarditis, their incidence varying from 20 to 40 percent of patients with both acute and subacute bacterial endocarditis. Small, red or violaceous macules that do not blanch subsequently become brownish and fade. Purpuric lesions, both flat and elevated, are also associated with subacute endocarditis without evidence of platelet dysfunction and may represent a leukocytoclastic vasculitis. The petechiae may be observed on the skin, especially on the heels, shoulders, and legs, but the conjunctiva and oral mucosa must also be evaluated.

Osler's nodes and Janeway lesions may both present as erythematous or hemorrhagic macules, papules, or nodules (Fig. 166-4). However, while Osler's nodes are exquisitely painful, tender, and located distally on the digital tufts, Janeway lesions are nontender and located proximally on the palms and soles. Osler's original description, in 1885, did not specify the tenderness of these lesions, but his later report did emphasize the findings noted above. Histologically, Osler's nodes are a perivasculitis or necrotizing vasculitis without microabscess formation or other evidence of infection or emboli. Cultures have generally been negative, although more recent reports have reemphasized the possibility of septic microemboli with microabscess formation. Janeway lesions have also been described histologically as a vasculitis with microabscess formation. The cutaneous and conjunctival petechiae are histologically similar.

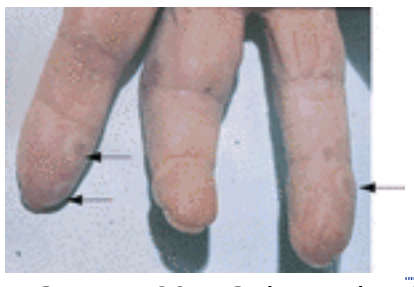

FIGURE 166-4 Osler nodes (*arrows*).

Current theories regard the pathogenesis of both Osler's nodes and Janeway lesions as immunologic or allergic due to immune complex deposition. Some reports dispute this concept, suggesting that the initial event is a septic microembolism that subsequently causes the endothelial swelling and perivasculitis seen in older lesions. Thus, organisms may be occasionally cultured initially, but later the lesions become sterile. That infected arterial catheters may precipitate clinical lesions comparable to Osler's nodes, Janeway lesions, and splinter hemorrhages, supports the concept that these lesions are infectious in etiology. Osler's nodes and Janeway lesions have been found in patients with other conditions, particularly systemic lupus erythematosus (SLE), gonococcemia, hemolytic anemia, and typhoid fever.

THE LUNGS AND THE SKIN

Yellow Nail Syndrome

Yellow nails with primary lymphedema were described in 1964. Separately, primary lymphedema and pleural effusion

were reported. The triad of yellow nails, primary lymphedema, and pleural effusion was then recognized, followed by a number of reports with partial or complete features. The characteristics of the nails include thickening, transverse ridging, diminished growth, increased curvature with a “hump,” and onycholysis. The lunulae and cuticles may be absent. The color may vary from pale yellow to green (Fig. 166-5). The nail changes are secondary to congenitally hypoplastic lymphatics, [16] leading to lymphedema, which is characteristically slowly progressive and somewhat asymmetric, with induration and hyperkeratosis extending to the thighs. Periodic lymphangitis is frequent and may contribute to the swelling.

FIGURE 166-5 Yellow nail syndrome. There is thickening, increased curvature, and yellowish discoloration of all fingernails. This patient had lymphedema of the extremities and bronchiectasis with multiple recurrent respiratory infections.

Respiratory findings include sinusitis, bronchiectasis, and pleural effusions. Symptoms vary from mild to severe, and some patients require repeated thoracentesis, treatment for pneumonia secondary to bronchiectasis, and drainage of the sinuses. Patients may have a productive or nonproductive cough, dyspnea, frequent upper respiratory infections, and pneumonia. Chest x-rays may be normal, but generally reveal evidence of fibrosis and/or effusion at the bases.

Pulmonary features and lymphedema may not occur until late in the course; therefore follow-up of patients who present with this type of nail dystrophy is recommended. Finally, a number of patients have developed lymphomas or sarcomas with metastases.

Pulmonary Arteriovenous Fistulas

Pulmonary arteriovenous fistulas are congenital abnormalities of capillary development that may not become clinically apparent until late adolescence. *Osler-Rendu-Weber* disease (hereditary hemorrhagic telangiectasia), an autosomal dominant trait, may be present in one-third to one-half of such patients. It is characterized clinically by punctate, linear, or spider-like telangiectasias of the skin, especially the upper body, oral and nasal mucous membranes, and nail beds (Fig. 166-6). The radiating arms about an elevated punctum are the most characteristic feature, especially on the lips and tongue. They are distinguished from true spider telangiectasis in that they do not pulsate.

FIGURE 166-6 Osler-Rendu-Weber disease. Note the punctate and splinter-like telangiectasia on the lips and tongue.

Recurrent epistaxis is the most frequent presenting symptom and may begin in early childhood or adolescence. Other organ systems besides the lungs may be involved, including the liver, gastrointestinal and genitourinary tracts, and central nervous system, and recurrent hemorrhage may result. Bleeding may be enhanced by an associated von Willebrand's disease.

The pulmonary findings in those patients with an arteriovenous fistula of the lungs include dyspnea, hemoptysis, cyanosis, clubbing, polycythemia, and pulmonary bruits accentuated by inspiration. Chest x-rays reveal nodular “coinlike” lesions, sometimes initially considered to be metastatic disease.

Chronic Pulmonary Diseases

Chronic obstructive pulmonary disease (COPD) is actually a group of disorders that includes chronic bronchitis, bronchiectasis, emphysema, and asthma. The incidence and mortality of COPD have increased recently and approach

that of heart disease in the United States. Smoking habits, as well as increased longevity of the population, may be partly responsible for this increase. Genetic, infectious, occupational, and environmental factors also contribute.

There are two basic types of COPD: type A, or emphysematous, and type B, or bronchial. Clinically, both may present with dyspnea, cough, wheezing, and recurrent respiratory infections. Type A patients have been termed “pink puffers” because they usually hyperventilate and maintain arterial oxygen tension. Type B patients have been termed “blue bloaters” because they frequently are hypoxic with cyanosis and associated right congestive heart failure. These patients, especially if young, should be evaluated for the possibility of cystic fibrosis.

Cystic Fibrosis

Cystic fibrosis is an autosomal recessive disorder of the exocrine glands that subsequently involves the tracheobronchial tree, pancreas, and gastrointestinal tract. The basic alteration of mucus is unknown, but viscid mucous plugs may cause fecal impaction, intussusception, and rectal prolapse in infancy. Pancreatic insufficiency may subsequently predominate, but it is the pulmonary disease that is the most significant feature. Progressive lung disease with chronic bronchitis, emphysema, and cor pulmonale from cystic fibrosis is a leading cause of death among patients with genetic disorders in the United States. The cutaneous features of this disorder result from increased amounts of electrolyte in the sweat, which leads to excessive skin wrinkling when the palms and soles are immersed in water. Although this feature is not always present, it may be a valuable clue to the disease. Parents are often aware of, but not disturbed by, the wrinkling. [5]

Larva Migrans and Pulmonary Involvement (See also Chap. 236)

Cutaneous larva migrans, or creeping eruption, may occasionally cause minimal respiratory symptoms and be associated with transient pulmonary infiltrates and a peripheral eosinophilia (Löffler's syndrome). Visceral larva migrans, or toxocariasis, may lead to granulomatous involvement of the liver, lungs, heart, muscle, brain, and eyes. Marked eosinophilia, hyperglobulinemia, pneumonitis with wheezing, recurrent bronchitis, fever, and tender hepatomegaly frequently occur. Skin lesions may present as patchy urticaria or erythematous papular eruptions.

Fat Embolism Syndrome

Petechiae, respiratory insufficiency, and cerebral dysfunction after long bone fracture are termed the *fat embolism syndrome*. Petechiae alone after fractures should suggest this syndrome. Histologically, fat globules are present within the dermal and pulmonary vessels. Additional factors such as hyperglycemia, diabetes, or elevated ß-lipoproteins may play a contributing role. The petechiae are most commonly on the neck, axillae, shoulders, chest, and conjunctivae, and they often appear before other manifestations. They begin about the second or third day after injury, appear in crops, and are almost never found on the face or posterior aspects of the body. When widespread, they tend to herald more significant cerebral and pulmonary dysfunction. In addition, cyanosis may be prominent.

The respiratory involvement may begin with dyspnea, tachypnea, or hemoptysis. Tachycardia, fever, and pulmonary edema may occur. X-rays may show patchy densities or linear streaks progressing to the bilateral opacities characteristic of the adult respiratory distress syndrome. Cerebral dysfunction includes restlessness, irritability, delirium, and coma. Additional features include jaundice, renal involvement, anemia, thrombocytopenia, and elevated sedimentation rate. [17]

SELECTED DISEASES AFFECTING THE CARDIOPULMONARY SYSTEM

Lipoid Proteinosis (Hyalinosis Cutis et Mucosae) (See also Chap. 152)

Skin changes include confluent, waxy papules, acne-like scarring, and plaques, particularly on the face. Oropharyngeal and laryngeal mucous membranes are usually affected early in the course of the disease, during infancy or childhood. The tongue enlarges and acquires a firm consistency and a smooth, glistening surface. Hoarseness due to laryngeal infiltration is often the initial finding and may be present at birth. Laryngeal and tracheal infiltration may progress to obstruction and cause respiratory insufficiency requiring tracheostomy. The trachea and main stem bronchus may be thickened and studded with wartlike hyaline projections. An increased risk of aspiration pneumonia has been reported, as has repeated upper respiratory infections. Cardiovascular involvement is rare, but conduction defects and arrhythmias have been reported.

Multicentric Reticulohistiocytosis (See also Chap. 162)

Multicentric reticulohistiocytosis is an uncommon disorder presenting with characteristic mucocutaneous lesions consisting of deeply set, firm, small papules, and a deforming arthritis in association with systemic symptoms such as fever, malaise, weight loss, and myopathy. Neurofibroma-like, soft, sessile, larger lesions have been reported. The cardiopulmonary complications include pulmonary infiltrates, pleural effusions, pericarditis, cardiomegaly, congestive heart failure, angina pectoris, myocardial infarction, and pulmonary infarction. An association of multicentric reticulohistiocytosis with malignancy has been recorded in a few reports, suggesting the need for complete evaluation of these patients. [18]

Sarcoidosis (See also Chap. 183)

Sarcoidosis is a multisystem granulomatous disease with unknown cause and widespread manifestations. Cardiac involvement consisting of myocardial or conduction system granulomata may be occult, but it may be clinically evident in about 20 percent of the patients. Ventricular arrhythmias and conduction disturbances are responsible for the palpitations, presyncope, and syncope reported. Congestive heart failure and chest pain occur less frequently and may be due to cardiomyopathy or cor pulmonale. Additionally, prolapsed mitral valves, papillary muscle dysfunction, and aneurysm formation are rarely found. The prognosis for patients with cardiac involvement is unfavorable. Sarcoidosis

affecting the pulmonary system may be suggested by lupus pernio (see Chap. 183) with involvement of the hilar nodes, bronchi, and/or alveoli resulting in obstructive and/or restrictive dysfunction. Respiratory failure is often the most difficult clinical problem, characterized by shortness of breath and hypoxemia. [19]

While there are at least two forms of sarcoidosis—acute (transient) and chronic (persistent)—no definite correlation between skin and internal involvement has been made. However, those patients who present abruptly with hilar adenopathy and nonspecific skin involvement, such as erythema nodosum (Löfgren's syndrome), appear to respond to glucocorticoid therapy and have fewer recurrences and a more favorable prognosis.

Amyloidosis (See also Chap. 148)

Cutaneous involvement occurs most often in the primary and myeloma-associated types, and therefore serves as a marker for cardiopulmonary involvement. A skin biopsy of clinically normal skin in a patient suspected of having amyloidosis might demonstrate deposition within the vessels in as much as 50 percent of patients.

Involvement of the heart may be associated with all three systemic forms of amyloidosis but appears to be clinically predominant in the primary myeloma-associated types. Senile amyloidosis may also affect the heart but is often asymptomatic. Clinical findings include dizziness, palpitations, syncope, orthostatic hypotension, and congestive heart failure. Chest x-ray may reveal cardiomegaly. Electrocardiograms may show low-voltage, abnormal Q waves, conduction defects, and arrhythmias. Echocardiography may reveal a restrictive cardiomyopathy with enlargement of the left ventricular wall and obstruction of the outflow tract. Pathologically, infiltration of the endocardium, myocardium, pericardium, valves, and coronary vessels may occur. [20] Upper and lower respiratory tract involvement also occurs in all systemic forms of amyloidosis but is clinically predominant in primary and myeloma-associated types. Macroglossia may impede respiration, especially when complicated by bleeding. The larynx and trachea may become infiltrated, causing hoarseness, cough, and respiratory stridor. Bronchial and lung parenchymal involvement may cause asthma-like symptoms, hemoptysis, and severe pulmonary disease. Chest x-rays may reveal interstitial type involvement and occasionally amyloid nodules may mimic a malignant tumor. Pulmonary function studies may reveal obstructive or restrictive dysfunction depending on the location of the amyloid deposition.

Lymphomatoid Granulomatosis (See also Chap. 158)

Lymphomatoid granulomatosis (LYG) is a rare angiocentric and angiodestructive, Epstein-Barr virus-associated B cell lymphoproliferative disorder, varying widely from an indolent process to an aggressive large cell lymphoma. The skin is the extrapulmonary organ most commonly involved. The disease also affects the lungs, heart, central nervous system, kidneys, and other organs. Pulmonary involvement may begin with transient alveolar or interstitial infiltrates and effusions on chest x-ray, which subsequently may progress to nodular, masslike densities. These lesions may cavitate and be responsible for profuse hemoptysis. Although many patients remain asymptomatic, cough, dyspnea, and chest pain may occur. Cardiac involvement is uncommon but, when present, may involve the coronary vessels with subsequent myocardial ischemia.

COLLAGEN VASCULAR DISEASES

The cardiopulmonary complications of the various collagen vascular diseases may sometimes be associated with a specific cutaneous sign or constellation of features.

Rheumatoid Arthritis (See also Chap. 179)

Extraarticular manifestations of rheumatoid arthritis, especially in the pulmonary system, appear to correlate with subcutaneous nodules and vasculitic skin lesions. In addition, laboratory evidence of high-titer rheumatoid factor, hypocomplementemia, cryoimmunoglobulinemia, and hypereosinophilia may be associated with the extraarticular manifestations including cardiopulmonary disease. These manifestations occur more commonly in men with long-standing disease, but may not necessarily correlate with arthritis activity at the time. The pulmonary disease consists of pleural effusions, localized or diffuse parenchymal infiltrates, or, rarely, lung nodules. Complaints include dyspnea, cough, pleuritic chest pain, and hemoptysis. Cardiac involvement may not be clinically apparent, although autopsy studies have revealed a high incidence of cardiac lesions related to granuloma or vasculitis.

Systemic Lupus Erythematosus (See also Chap. 171)

Cutaneous manifestations of SLE appear in more than 75 percent of patients during the course of their disease. While the extent of the cutaneous features in SLE may not correlate with the severity of visceral disease, the trend toward serologic and clinical subsets has suggested certain associations.

PLEUROPULMONARY DISEASE IN SLE Pleuritis may be present during the course of the disease in about half of patients with SLE. Chest pain may become subacute or chronic because of adhesions and may be confused with costochondritis. Pleural effusions with or without a friction rub may also occur. Parenchymal lung involvement in SLE is usually a result of secondary factors such as infections or pulmonary emboli. Primary lung involvement in SLE may be classified as (1) diffuse interstitial pneumonitis, (2) acute pneumonitis, (3) intrapulmonary hemorrhage, (4) diaphragm dysfunction with decreased lung volume (shrinking lung syndrome), (5) pulmonary hypertension with cor pulmonale, and (6) fibrosing alveolitis. [21] Respiratory difficulty may also be due to acute epiglottitis, necrotic and ulcerative laryngitis, and tracheobronchitis.
CARDIAC DISEASE IN SLE Cardiac involvement in patients with SLE is frequently subclinical. Pericarditis may be more common in patients with drug-induced syndromes or in those patients with photosensitive discoid lesions. Chest pain may be present, especially when associated with effusion. A friction rub may be heard. The ECG changes primarily are T-wave abnormalities. Myocarditis is often undiagnosed and may be associated with prolonged P-R intervals, heart

block, and arrhythmias. Since the introduction of glucocorticoid therapy, an increased incidence of atherosclerotic-related myocardial infarction has been reported. Valvular heart disease in patients with SLE, most often of the Libman-Sacks type, is frequently associated with antiphospholipid antibodies, and manifested by systolic murmurs, which may occur in almost 50 percent of all patients. These murmurs are rarely clinically significant. [22] Although diastolic murmurs may occur because of noninfectious mitral stenosis or aortic insufficiency, the onset of a new diastolic murmur should provoke a search for subacute bacterial endocarditis. The cutaneous clues of this disease, such as splinter hemorrhages, Osler's nodes, Janeway lesions, and Roth's spots, should be sought, although they may occur in SLE without infection. It appears that SLE, as well as other cutaneous vascular diseases, may be associated with complete heart block in newborn infants. In SLE, this may be because of placental transfer of maternal antibodies, especially the anti-Ro antibody. [23] The newborn infants of patients with SLE or of clinically normal but Ro-antibody–positive mothers may also have distinctive evanescent cutaneous eruptions, including prominent telangiectasia and periorbital erythema (neonatal lupus erythematosus). [24]

Dermatomyositis (See also Chap. 172)

Interstitial lung disease occurs as part of the disease process itself, and occurs in 5 to 30 percent of patients with inflammatory muscle disease. [25] The course of the lung disease is variable; other pulmonary manifestations seen in dermatomyositis include bronchiolitis obliterans, vasculitis, pneumomediastinum, subcutaneous emphysema, and spontaneous pneumothorax. Upper pharyngeal weakness can lead to chronic aspiration and resulting parenchymal changes. In addition, exertional dyspnea can occur because of weakness of the respiratory muscles. Anti-Jo-1 antibodies are associated with increased lung disease, as well as “mechanics hands.”

Symptomatic cardiac involvement is rare. Patients can have rhythm disturbances, conduction defects, left ventricular diastolic dysfunction, congestive heart failure, and, rarely, pericarditis and pulmonary hypertension. Mitral valve prolapse has been described. Myocardial fibrosis, necrosis, or carditis can be seen.

Systemic Sclerosis (See also Chap. 173)

Microvascular abnormalities are among the earliest pathologic changes seen in patients with systemic sclerosis, a finding supporting the concept of a primary vascular defect in the disease. Typically, the vascular lesions are characterized by intimal proliferation with loose connective tissue at the internal elastic membrane, medial thinning, and adventitial fibrosis. Many of the cutaneous features of this disorder are directly attributable to vascular abnormalities and occur early in the disease. They include vasospastic episodes (Raynaud's), telangiectases, and nail fold capillary changes appearing as dilated and distorted capillary loops alternating with avascular areas on wide-field capillary microscopy.

PULMONARY ABNORMALITIES Dyspnea on exertion, occurring in approximately 50 percent of patients, is usually the most common symptom. Chronic, nonproductive cough and pleuritic chest pain may also occur. Examination may reveal dry rales, especially at the bases, as well as diminished breath sounds and pleural rubs. Chest x-ray may show a diffuse reticulonodular interstitial pattern, cystic changes, calcification, pleural effusion, or scarring. Pulmonary function tests reveal diminished diffusing capacity, decreased volume, and decreased compliance characteristic of restrictive disease. [26] Abnormalities of the respiratory system may be due to processes other than parenchymal lung disease. For example, pulmonary hypertension with cor pulmonale and congestive heart failure may develop independently of parenchymal disease, and is seen fairly early in the course of limited cutaneous scleroderma [calcinosis cutis, Raynaud's phenomenon, esophageal dysfunction, sclerodactyly, and telangiectasia (CREST)]. Biopsies of the lung show the typical changes described earlier around the small pulmonary arteries and arterioles. Esophageal dysmotility may cause aspiration pneumonia and acute respiratory insufficiency, and is associated with a higher incidence of interstitial lung disease. [23] Finally, abrupt changes in respiratory function suggest the possibility of a bronchoalveolar carcinoma in association with long-standing pulmonary fibrosis.
CARDIOVASCULAR DISEASE Acute or chronic pericarditis is an important feature of the disease and, when associated with congestive heart failure, may be a marker for incipient renal failure. Pericardial effusions may be occult, and constrictive pericarditis and tamponade may occur. Transient vasospasm may involve the coronary vessels and cause myocardial ischemia with angina. Additionally, small-vessel involvement of the myocardium may lead to fibrosis (scleroderma heart). Fibrosis of the conduction system may cause arrhythmias and sudden death. Right ventricular hypertrophy because of cor pulmonale with congestive heart failure and pulmonary hypertension is observed. The presence of the CREST variant may be associated with biliary cirrhosis and may not imply diminished cardiopulmonary or renal involvement in all cases as originally described. Increased tortuosity of capillaries and areas of avascularity suggest an increased probability of cardiopulmonary and renal disease.

Relapsing Polychondritis (See also Chap. 178)

Relapsing polychondritis is characterized by inflammation and destruction of cartilage and connective tissues, including those of the cardiopulmonary system. The pathogenesis is unknown, although it appears to be an autoimmune process frequently associated with other immunologic disorders such as SLE and rheumatoid arthritis. Auricular chondritis with pain, swelling, and redness of the pinna but complete sparing of the lobes is characteristic. Respiratory tract involvement may begin with hoarseness or tenderness of the anterior trachea. Degeneration of the laryngeal, tracheal, and/or bronchial rings may lead to progressive insufficiency or to sudden collapse requiring emergency tracheostomy. Adequate ventilatory support may not be possible if advanced scarring and deformity are present. Cardiac involvement includes degeneration of the aortic ring with valvular insufficiency and aneurysmal dilatation. “Floppy” mitral valve syndrome also occurs. Pericardial and myocardial abnormalities have been reported.

REFERENCES

1. Pepin M et al: Clinical and genetic features of Ehlers-Danlos syndrome type IV, the vascular type. *N Engl J Med* **342**:673, 2000

2. Nolte KB: Sudden cardiac death owing to pseudoxanthoma elasticum: A case report. *Hum Pathol* **31**:1002, 2000

3. Davis MD et al: Natural history of erythromelalgia: Presentation and outcome in 168 patients. *Arch Dermatol* **136**:330, 2000

4. Cohen JS: Erythromelalgia: New theories and new therapies. *J Am Acad Dermatol* **43**:841, 2000

5. Johns MK: Skin wrinkling in cystic fibrosis. *Med Biol Illustr* **25**:205, 1975

6. Zyluk A: The sequelae of reflex sympathetic dystrophy. *J Hand Surg [Br]* **26**:151, 2001

7. Miric D et al: Dermatological indicators of coronary risk: A case-control study. *Int J Cardiol* **67**:251, 1998

8. Lotufo PA et al: Male pattern baldness and coronary heart disease: The Physicians' Health Study. *Arch Intern Med* **160**:165, 2000

9. Chaudhary K et al: Livedo reticularis: An underutilized diagnostic clue in cholesterol embolization syndrome. *Am J Med Sci* **321**:348, 2001

10. Johnson RA, Palacios I: Dilated cardiomyopathies of the adult. *N Engl J Med* **307**:1051, 1982

11. Schonberger J, Seidman CE: Many roads lead to a broken heart: The genetics of dilated cardiomyopathy. *Am J Hum Genet* **69**:249, 2001

12. Elliott P: Cardiomyopathy. Diagnosis and management of dilated cardiomyopathy. *Heart* [Br] **84**:106, 2000

13. Norgett EE et al: Recessive mutation in desmoplakin disrupts desmoplakin-intermediate filament interactions and causes dilated cardiomyopathy, woolly hair, and keratoderma. *Hum Mol Genet* **9**:2761, 2000

14. Ha JW et al: Echocardiographic and morphologic characteristics of left atrial myxoma and their relation to systemic embolism. *Am J Cardiol* **83**:1579, 1999

15. Rhodes AR et al: Mucocutaneous lentigines, cardiomucocutaneous myxomas, and multiple blue nevi: The “LAMB” syndrome. *J Am Acad Dermatol* **10**:72, 1984

16. Bull RH et al: Lymphatic function in the yellow nail syndrome. *Br J Dermatol* **134**:307, 1996

17. Mellor A, Soni N: Fat embolism. *Anaesthesia* **56**:145, 2001

18. Valencia IC et al: Multicentric reticulohistiocytosis associated with recurrent breast carcinoma. *J Am Acad Dermatol* **39**:864, 1998

19. Baydur A et al: Respiratory muscle strength, lung function, and dyspnea in patients with sarcoidosis. *Chest* **120**:102, 2001

20. McCarthy RE, Kasper EK: A review of the amyloidoses that infiltrate the heart. *Clin Cardiol* **21**:547, 1998

21. Keane MP, Lynch JP 3rd: Pleuropulmonary manifestations of systemic lupus erythematosus. *Thorax* **55**:159, 2001

22. Moder KG et al: Cardiac involvement in systemic lupus erythematosus. *Mayo Clin Proc* **74**:275, 1999

23. Marie I, Dominique S, Levesque H, et al: Esophageal involvement and pulmonary manifestations in systemic sclerosis. *Arthritis Rheum* **45**:346, 2001

24. Krafchik BR: Neonatal lupus erythematosus. *Adv Exp Med Biol* **455**:23, 1999

25. Spiera R, Kagen L: Extramuscular manifestations in idiopathic inflammatory myopathies. *Curr Opin Rheumatol* **10**:556, 1998

26. Veeraraghavan S, Sharma OP: Progressive systemic sclerosis and the lung. *Curr Opin Pulm Med* **4**:305, 1998

T>

Chapter 167

Jay Coffman Robert Eberhardt

Cutaneous Changes in Peripheral Vascular Disease

ARTERIOSCLEROSIS OBLITERANS
- Epidemiology
- Etiology and Pathogenesis
- Prevention
- Clinical Manifestations
- Bedside and Special Examinations
- Pathology
- Diagnosis and Differential Diagnosis
- Treatment and Prognosis

ATHEROMATOUS EMBOLISM
- Epidemiology
- Etiology and Pathogenesis
- Prevention
- Clinical Manifestations
- Laboratory and Specific Examinations
- Pathology
- Diagnosis and Differential Diagnosis
- Treatment and Prognosis

THROMBOANGIITIS OBLITERANS
- Epidemiology
- Etiology and Pathogenesis
- Prevention
- Clinical Manifestations
- Laboratory and Special Examinations
- Pathology
- Diagnosis and Differential Diagnosis
- Treatment and Prognosis

ERYTHROMELALGIA (ERYTHERMALGIA)
- Epidemiology
- Etiology and Pathogenesis
- Genetics
- Clinical Manifestations
- Pathology
- Laboratory and Special Examinations
- Diagnosis and Differential Diagnosis
- Treatment and Prognosis

VASOSPASTIC DISEASES AND DISEASE DUE TO COLD EXPOSURE
- Raynaud's Phenomenon
- Epidemiology
- Etiology and Pathogenesis
- Prevention
- Clinical Manifestations
- Laboratory and Special Examinations
- Pathology
- Diagnosis and Differential Diagnosis
- Treatment and Prognosis

LIVEDO RETICULARIS
- Epidemiology
- Etiology and Pathogenesis
- Clinical Manifestations
- Laboratory and Special Examinations
- Pathology
- Diagnosis and Differential Diagnosis
- Treatment and Prognosis

DISEASES OF THE VEINS
- Thrombophlebitis
- Varicose Veins (see also Chap. 273
- Postphlebitic Syndrome

LYMPHEDEMA
- Epidemiology
- Etiology and Pathogenesis
- Prevention
- Genetics
- Clinical Manifestations
- Laboratory and Special Examinations
- Pathology
- Diagnosis and Differential Diagnosis
- Treatment and Prognosis
- Differential Diagnosis of Ulcers

REFERENCES

ARTERIOSCLEROSIS OBLITERANS

Arteriosclerosis obliterans is characterized by muscle pain or fatigue with exercise or by rest pain, ulcers, or gangrene of the distal lower extremities as a result of stenosis or obstruction of large arteries by atheroma and thrombosis.

Epidemiology

Intermittent claudication because of arteriosclerosis obliterans affects about 1 percent of the population older than 35 years of age. It occurs predominantly in males. Most patients have superficial femoral artery disease and develop symptoms in the seventh decade, but symptoms from aortoiliac disease usually occur a decade earlier. [1]

Etiology and Pathogenesis

Arteriosclerosis is similar to vascular disease that occurs in other areas of the body. Arteriosclerosis obliterans develops at twice the frequency in patients who smoke than in nonsmokers. Approximately 50 percent of patients have hyperlipidemia. It is more common in patients with hypertension. Patients with diabetes mellitus develop the disease at an earlier age than do nondiabetics and have more severe and progressive disease. The distribution of the disease is different in diabetics than in nondiabetics in that diabetics have less aortoiliac disease and more disease of the vessels between the knees and the ankles than do nondiabetics; however, superficial femoral artery disease is similar in both populations. [1]

The cause of atheromas is unknown, but progressive buildup of cholesterol plaques narrows the vessel lumen, and, finally, occlusion may occur by thrombosis. Because the disease progresses slowly, collateral blood vessels develop to supply the extremity distal to the stenosis or obstruction. Therefore, the blood supply to the limb is usually adequate at rest, but the blood pressure distal to the lesions is decreased because of the high resistance of the collateral vessels. [1] When skin lesions develop, the blood supply to the limb is severely compromised.

Prevention

Preventive measures that may help avoid arteriosclerosis obliterans are targeted at the risk factors. [2] Tobacco smoking is contraindicated. Hypertension and diabetes mellitus should be controlled, and hyperlipoproteinemias should be treated. Evidence is accumulating that control of hypercholesterolemia will prevent progression of atherosclerotic complications. In patients with diabetic neuropathy, trauma to the limbs must be avoided and special shoes may be needed.

Clinical Manifestations

The patient complains of pain, fatigue, or a tiredness in the muscles distal to the diseased segment on walking (intermittent claudication). The distance covered before symptoms appear is quite constant for each patient, except that shorter distances can be covered when walking up inclines or carrying heavy bundles. The symptoms are usually relieved within 5 min by rest, even while standing. Patients with inadequate collateral circulation will complain of coldness, hyperesthesias, rest pain, discolored toes, or skin breakdown. Rest pain may be so severe that patients cannot sleep or sleep with the leg in a dependent position; they then may develop edema of the lower parts of the extremity.

The limbs in patients with only intermittent claudication may appear normal, although there may be hair loss, coldness, and thickened or malformed toe nails. In aortoiliac disease, there may be global atrophy of the lower limbs. Pulses will be decreased or absent distal to the diseased arterial segment, and there may be bruits over the distal vessels. In patients with severe ischemia, the skin is apt to be atrophic, dry, and shiny. In patients with rest pain, the foot is usually bright red and cold in dependency. Rest pain occurs in the foot; the muscles rarely have rest symptoms. Ulcerations most often start at the tips of the toes and are extremely painful except when a diabetic neuropathy is present. Ulcers occasionally start on the lower calves (Fig. 167-1). The ulcers have a sloughing gray or black base. The heels may show cracks in the skin. When gangrene occurs, usually one or more toes become black, dry, and mummified.

FIGURE 167-1 An ischemic ulcer in a patient with arteriosclerosis obliterans. The location on the lateral aspect of the ankle is typical. The base of the ulcer shows fibrous tissue with scant granulation tissue and the outline of tendons. The distal foot and toes are cyanotic from ischemia.

Bedside and Special Examinations

The collateral circulation to limbs affected by arteriosclerosis obliterans can be evaluated by simple tests. [1] With the patient supine, elevation of the limb at a 45-degree angle for 2 min should not produce pallor. The collateral circulation is not adequate if the toes and feet become pale. If the patient then assumes a sitting position with the legs dependent, the

times for filling of the foot veins and flushing of the feet can be measured. The veins should fill within 20 s and the feet flush immediately in a warm environment. When these times exceed 30 s, the collateral circulation is inadequate and the patient must be observed frequently for the development of rest pain, ulcers, or gangrene. Venous filling times are not of value in the presence of varicose veins. An objective test to document the disease is the measurement of ankle systolic blood pressure. The ankle systolic pressure in the supine position should be equal to or greater than the brachial artery systolic pressure. An ankle-to-arm systolic pressure index is usually calculated; values greater than 0.95 are considered normal, while those less than 0.4 are indicative of severe disease. Arteriography or magnetic resonance angiography can be used to demonstrate the location and extent of disease in the arteries but supply no hemodynamic information. They are usually used only before vascular surgery and not as a diagnostic test.

Pathology

There is a focal accumulation of lipids, mucopolysaccharides, blood and blood products, fibrous tissue, and calcium deposits in the intima of arteries. Localized areas of thickening of the intima by fibroblastic proliferation and phagocytes laden with lipid material are seen. The media is atrophic with thin strands of smooth muscle, disrupted elastic lamella, collagen tissue, and calcium deposits. Enlarging plaques encroach on the lumen despite dilation of the artery, and the plaques may ulcerate. Hemorrhages occur in the arterial wall. Thrombi may form and occlude the narrowed arterial lumen.

Diagnosis and Differential Diagnosis

The diagnosis of arteriosclerosis obliterans can usually be made by the typical history of intermittent claudication and palpation for diminished or absent pulses in the limbs. In questionable cases, ankle systolic blood pressures should be measured at rest and, if needed, after exercise. In patients with diabetes mellitus, ulcers may develop on the heel, toes, or anterior calf in the presence of normal pulses. These painless ulcers are due to repetitive trauma not noticed by the patient because of peripheral neuropathy (Fig. 167-2; see also Chap. 168). Other causes of neuropathy also lead to neurotropic ulcers. Surrounding callus formation is typical of these ulcers.

FIGURE 167-2 Two neurotropic ulcers over the metatarsal head and on the heel in a patient with diabetes mellitus and neuropathy. The ulcers are painless and deep, and surrounded by callus.

Thromboangiitis obliterans also causes intermittent claudication, ulcers, and gangrene. It occurs in a younger age group (onset of symptoms before age 45) and is often associated with superficial thrombophlebitis and vasospasm. It affects medium and smaller arteries and the upper extremities more commonly than does arteriosclerosis obliterans. Neurogenic claudication is often a difficult differential diagnosis and is due to compression or intermittent ischemia of the lower spinal cord or corda equina with exercise. Etiologic factors are prolapsed intervertebral discs, congenital stenosis, or hypertrophic bony ridging of the spinal canal. In contrast to arteriosclerosis obliterans, leg pain may occur in the erect position without exercise, neurologic signs may be present before or after exercise, and peripheral pulses are normal. Magnetic resonance imaging (MRI) or computed tomographic (CT) scan will confirm the diagnosis.

Treatment and Prognosis

For patients with intermittent claudication and an adequate collateral circulation, an exercise regime is the treatment of choice. [2] Patients are instructed to exercise to tolerable pain, rest, and then exercise again for 30 to 60 min a day in excess of their normal activity. The exercise period must be performed in one session, and any type of exercise is beneficial as long as it is in the upright position. In several studies, approximately 80 percent of patients have increased their walking distance. Patients must also quit smoking, for smokers have a greater amputation and vascular graft occlusion rate than nonsmokers. Patients should also be instructed to keep their feet warm, clean, and dry; extremes of temperature should be avoided, as ischemic tissue is more susceptible to burning and to frostbite than normal tissue. Cuts or severe bruises of the limbs or feet should be treated immediately. Vasodilators have no value in treatment. Cilostazol, a phosphodiesterase inhibitor, and propionyl-L-carnitine increase treadmill walking distance and quality of life; the latter is not available in the United States and the former has formidable side effects. [3] In some studies, pentoxifylline, an agent that has hemorheologic effects, has improved walking distance.

Surgery or endovascular intervention is usually reserved for patients with intermittent claudication that interferes with employment, ischemic symptoms at rest, or ulcers and gangrene. Sympathectomy is not of value for intermittent claudication but may allow small ulcers or areas of gangrene to heal. In patients with rest pain, ulcers, or gangrene who cannot undergo revascularization procedures, treatment is difficult. A period of rest with legs dependent may help some patients, but amputation is a frequent outcome. Parenterally administered prostacyclin or prostaglandin E_1 has had favorable reports but has not yet been adequately evaluated.

Dry gangrene of the digits or lower limbs should be allowed to demarcate by itself. Soaking or ointments are unnecessary. The edges of the gangrenous areas should be kept open if possible and observed frequently for infection. Pain medication is usually necessary for 2 to 3 months with digital gangrene. Conservatism and patience will save many

digits and extremities. Infected (wet) gangrenous areas must be débrided and appropriate antibiotics administered. Amputations may be necessary.

In most studies, 60 to 90 percent of patients with intermittent claudication as a consequence of arteriosclerosis obliterans remained stable over a period of 5 to 9 years. Patients with diabetes mellitus, however, have progressive disease, and their amputation rate is fourfold greater than for patients without diabetes.

ATHEROMATOUS EMBOLISM

Atheromatous embolism is the embolization of small pieces of atheromatous debris from arteries to the extremities or body organs. This disease has also been called “blue toe syndrome” and “trash foot syndrome.”

Epidemiology

In 100 consecutive autopsies of patients predominantly older than 50 years of age, 4 percent revealed atherosclerotic emboli. [4] In another autopsy series, only 0.79 percent of 2126 patients over 60 years of age had such emboli, but many cases may have been missed. Usually patients are males older than age 50 years.

Etiology and Pathogenesis

Instigating causes are often absent, but coughing or straining has been postulated as a factor in breaking loose the emboli. Catheterization of blood vessels is one of the most common causes of embolization. [4] Coumarin derivatives have also been blamed, but it is more likely that they aggravate the lesions and prevent healing. The emboli usually originate from the aorta or proximal blood vessels that are severely involved with atherosclerotic lesions. An aneurysm can also be the source. The vessel lining of the atherosclerotic vessels is usually irregularly ulcerated and shaggy. The clinical picture is caused by ischemia of the skin and muscle due to the emboli, although all organs of the body may be involved.

Prevention

One way of prevention is to avoid catheterization of severely atherosclerotic blood vessels.

Clinical Manifestations

Patients will present with unilateral or bilateral discolored or ulcerated painful toes. They may complain of painful and tender calf muscles and a rash on the lower calf or foot. If the entire aorta is involved, transient ischemic attacks or strokes, renal failure, hemorrhagic pancreatitis, and gastrointestinal ulcerations and bleeding may occur. In these patients, almost all organs except the lung have been shown to contain cholesterol crystals. [4]

Physical examination reveals tender, blue toes, and there may be ecchymoses of the sole and lateral aspects of the feet. In some patients, the entire extremities and trunk may show ecchymotic lesions and petechiae. Livedo reticularis and petechiae may be present on the calf and feet. Ulcers or gangrene may be present (Fig. 167-3A, Fig. 167-3B), although surrounding the ischemic areas is normally perfused tissue. The calf muscles are often tender. Occasionally there are elevated plaques of skin. The upper extremities are involved in patients with disease of the entire aorta (Fig. 167-4). Pedal and proximal pulses are usually normal, but there may be systolic bruits over the aorta or common femoral arteries. Fever may be present.

FIGURE 167-3 Multiple atheromatous emboli to the lower body and limbs in a patient with extensive atheromatous disease of the aorta. *A*. Livedoid vascular pattern with early infarcts. *B*. Within several days the initial infarction and necrosis is much more extensive.

FIGURE 167-4 Atheromatous emboli to the fingers in an 80-year-old patient with extensive atheromatous disease of the aorta. There is gangrene of the third and fourth distal fingers and ecchymotic discrete areas proximally. Radial and ulnar pulses were normal.

Laboratory and Specific Examinations

Eosinophilia is common and has been described in up to 80 percent of patients with renal atheromatous emboli. [5] Thrombocytopenia, hypocomplementemia, and anemia may occur. The sedimentation rate is often elevated. In patients with multisystem involvement, there may be elevated renal function tests, increased amylase levels, blood in the urine or stool, and anemia. Angiography demonstrates diffuse atherosclerotic involvement of the vessels proximal to the lesions.

Pathology

Skin or muscle biopsies may reveal the characteristic elongated, needle-shaped clefts of cholesterol crystals in small arterial vessels. There may be inflammatory infiltrates, intimal thickening, and perivascular fibrosis. Giant cells may also be present.

Diagnosis and Differential Diagnosis

The diagnosis of atheromatous emboli is suggested by the blue or ulcerated painful digits, livedo reticularis, petechiae, tender calf muscles, and elevated skin plaques in the presence of normal pulses. A definite diagnosis can be made by skin, muscle, or renal biopsies. Occasionally, cholesterol emboli may be visualized in the retinal arterioles. In the differential diagnosis of the blue toe syndrome, several other entities must be considered (Table 167-1). Biopsy of skin or muscle showing cholesterol crystals usually rules out other causes.

Atheromatous emboli	Vasculitis
Emboli from the heart	Polyarteritis
Connective tissue diseases	Malignancy with or without cryoglobulins or macroglobulins
Primary Raynaud's disease	Antiphospholipid and anticardiolipin antibodies
Thrombocytosis	
Polycythemia	

TABLE 167-1 **Differential Diagnosis of the Blue Toe Syndrome**

Treatment and Prognosis

Atheromatous emboli can usually be stopped by surgical bypasses or endarterectomy to remove or exclude the source, although many of these patients have contraindications to major surgery. In these cases, antithrombotic therapy such as subcutaneous heparin or low molecular weight heparin, or antiplatelet agents such as or aspirin and dipyridamole, can be tried and, if successful, therapy should be continued for at least 1 year. [4] Warfarin is usually avoided, especially if toe ulcers are present. Many patients will not respond to any therapy except surgery. The syndrome usually subsides and lesions heal following successful surgical or medical treatment. Sometimes the emboli cease spontaneously. When surgery cannot be performed and emboli continue, amputations may result. In the malignant multisystem disease, patients usually die within a year if treatment is unsuccessful.

THROMBOANGIITIS OBLITERANS

Thromboangiitis obliterans (also known as Buerger's disease) is an inflammatory occlusive disease affecting medium and small arteries and veins.

Epidemiology

The prevalence of the disease is greatest in eastern Europe, the Mediterranean area, and Asia. Males are afflicted in much greater number than females, although an increased incidence in females has occurred in recent years. Patients are usually between the ages of 20 and 40 years. For some reason, there has been a marked decline in the prevalence of the disease in the United States.

Etiology and Pathogenesis

The etiology of thromboangiitis obliterans remains unknown. [6] Almost all patients who develop this disease are smokers, and the syndrome sometimes abates with the cessation of tobacco smoking. An increased cellular sensitivity to types I and III collagen has been reported as compared to the sensitivity of normal men and patients with arteriosclerosis obliterans. During active disease serum antiendothelial cell antibody titers are very high, and impaired

endothelial-dependent vasodilation to acetylcholine has been found, even in nondiseased limbs. The pathogenesis involves the production of tissue ischemia and all its manifestations by an inflammatory reaction of medium and small arteries of the extremities and obstruction by thrombi. Veins may also be involved. Occasionally, cardiac, intestinal, and cerebral vessels are involved.

Prevention

The only preventive measure is never to smoke.

Clinical Manifestations

The most common initial complaints are claudication of the foot or lower calf, digital cyanosis or gangrene, or rest pain. Patients may present with ulcers of the toes or fingers, for although the lower extremities are affected most often, more than a third of patients have upper extremity involvement. Ulcerations or gangrenous areas are characteristically extremely painful. Vasospasm or migratory superficial thrombophlebitis may occur in 40 percent of patients. Physical examination may reveal cyanotic, ulcerated, or gangrenous, very painful digits. The dorsalis pedis, posterior tibial, and ulnar pulses are often absent. During episodes of thrombophlebitis, small indurated red, tender nodules will be found, which follow the course of superficial veins and are common on the thigh or calf. Typical changes of Raynaud's phenomenon, with well-demarcated pallor or cyanosis of the digits, may be seen on exposure to cold; one or more extremities may be involved.

Laboratory and Special Examinations

There are no specific blood studies. Arteriography is sometimes typical, showing segmental occlusions of medium and small blood vessels with normal vessel walls between diseased areas, no arteriosclerosis of proximal vessels, and corkscrew configuration of collateral vessels originating from occluded vessels.

Pathology

In the acute stage, there is a panvasculitis of arteries and veins; the diagnostic finding is arterial thrombi with foci of microabscesses and giant cells. In contrast to systemic vasculitis (see Chap. 174) and arteriosclerosis obliterans, the vessel wall and internal elastic lamina are not disrupted. [6] In the chronic stage, only fibrotic obliteration of the arteries is seen, and the diagnosis can only be surmised because arteriosclerosis is absent.

Diagnosis and Differential Diagnosis

The diagnosis should be considered in young male smokers presenting with symptoms and signs of distal extremity ischemia, migratory thrombophlebitis, and Raynaud's phenomenon. Arteriography may suggest the diagnosis, but only a biopsy of an artery or vein during the active phase of the disease that shows the characteristic pathologic picture is diagnostic. Arteriosclerosis obliterans occurs in an older age group, usually over 45 years of age, larger vessels are involved, Raynaud's phenomenon is infrequent, and the upper extremities are rarely involved. In diabetes mellitus, the arteriosclerosis may affect medium-sized vessels, but the blood sugar is normal in thromboangiitis obliterans. Raynaud's phenomenon associated with scleroderma may present with a similar picture, but systemic symptoms, proximal skin changes, and antinuclear antibodies will help in the diagnosis.

Treatment and Prognosis

There is no specific treatment. Patients must give up smoking; in some, the disease will abate. Daily infusions of iloprost, a prostaglandin analogue, relieve rest pain, heal ulcers, and prevent amputation more frequently than does aspirin. Bypass surgery is rarely possible because of the small size of the vessels affected. Vascular endothelial growth factor gene therapy may prove of value. Sympathectomy may help patients with a prominent vasospastic component. The course of the disease is marked by exacerbations and remissions, but the disease usually becomes quiescent after many years. Cessation of tobacco smoking sometimes hastens the disappearance of the disease. Amputations of digits or even extremities may be necessary, especially in patients who continue to smoke. Patients have a normal life expectancy.

ERYTHROMELALGIA (ERYTHERMALGIA)

Erythromelalgia is characterized by intense, burning pain with marked erythema of the affected region.

Epidemiology

This is a rare disorder with limited epidemiologic data available. In Norway, the incidence is estimated to be 0.25 for 100,000 population with a prevalence of 2 per 100,000. [7] Primary erythromelalgia occurs, although at all ages more in males than females. In contrast, secondary erythromelalgia has an equal sex distribution and occurs mostly after the third decade.

Etiology and Pathogenesis

The etiology of the primary disease is unknown. [7] It is postulated that the precapillary sphincters may be constricted while the arteriovenous shunts are open leading to an increased total perfusion but a deficient nutritive blood flow. The substances produced by the local hypoxia cause increased local blood flow, warmth, redness, and pain. Secondary erythromelalgia occurs in polycythemia, thrombocythemia, autoimmune disease, hypertension, and neuropathies. The blood dyscrasia syndromes are believed to be caused by platelet breakdown products because they respond to aspirin

therapy.

Genetics

The primary erythromelalgia gene has been localized to chromosome 2q. Families have been described with an autosomal dominant mode of inheritance of erythromelalgia.

Clinical Manifestations

The disorder is characterized by intense burning pain, redness, swelling, and increased skin temperature. It occurs primarily in the feet but may also involve the hands, face, and ears. It may spread to the limbs and is usually bilateral although it can be unilateral in secondary cases. The onset may be gradual or abrupt. Symptoms may be continuous or occur in flares late in the day or night. Exposure to heat, dependency of the extremity, or exercise may trigger flares while cold water immersion relieves them. Examination during attacks reveal warm, red, extremely sensitive extremities with normal pulses. Between flares, the extremities may appear normal. The constant use of ice water leads to maceration of the skin, secondary infection, nonhealing ulcers, and necrosis.

A few patients have been described who have both erythromelalgia and Raynaud's phenomenon. During the hyperemic phase of Raynaud's phenomenon, patients often complain of erythromelalgic-like symptoms. It is postulated that both syndromes have a common basis in a dysfunction of the regulation of vasomotor tone.

Pathology

The pathology of the primary disease is unknown. In the secondary syndrome caused by thrombocythemia or polycythemia, fibromuscular dysplasia, internal elastic membrane splitting, and thrombotic occlusions of arterioles are present.

Laboratory and Special Examinations

There are no confirmatory tests. Warm water immersion at 32° to 36°C (89.6° to 96.8°F) may induce attacks.

Diagnosis and Differential Diagnosis

The diagnosis must be made from the history and clinical manifestations. Skin injury is sometimes present from the constant cold-water immersion. Secondary disease must be ruled out by complete blood cell counts and platelet counts; antinuclear antibodies will help to distinguish autoimmune diseases. The main differential diagnosis is reflex sympathetic dystrophy during the early warm phase, but this is usually unilateral and there is a history of trauma. Nerve conduction studies may be necessary to rule out neuropathies.

Treatment and Prognosis

No therapy has proved beneficial in all patients. [7] Serotonin reuptake inhibitors or tricyclic agents may help. Biofeedback, hypnosis, propranolol, lorazepam, cycloheptadine, methysergide, piroxicam, pizotifen, and calcium channel antagonists are not usually beneficial. Gabapentin or capsaicin cream may reduce the pain. Intravenous prostaglandins have also been used, as has surgical or medical sympathectomies. Aspirin is often of great benefit, but only in secondary cases. The symptoms may be mild for several years or totally disabling within weeks. Many patients become unable to work or carry on daily activities. Constant immersion in ice water may lead to trophic changes of the skin and even the necessity of amputation from ulcers and infections.

VASOSPASTIC DISEASES AND DISEASE DUE TO COLD EXPOSURE (See alsoChap. 126)

Raynaud's Phenomenon

Raynaud's phenomenon is the occurrence of episodic attacks of well-demarcated blanching or cyanosis of one or more digits on exposure to cold.

Epidemiology

Primary Raynaud's phenomenon usually occurs in patients 15 to 40 years of age but may occur in children younger than 15 years of age, and in patients older than 50 years of age. [8] There is a strong 4:1 female to male predominance. Primary Raynaud's phenomenon occurs in 4.6 to 30 percent of randomized questioned populations. [9]

Etiology and Pathogenesis

The pathogenesis of primary Raynaud's phenomenon or episodic vasospastic attacks is unknown. A local fault at the digital artery level in which the blood vessels are abnormally sensitive to cold and an overactivity of the sympathetic nervous system are the two proposed theories. The local fault theory has the most scientific backing. The local fault may be at the a $_2$-adrenoceptor level, because there are increased levels of a $_2$-adrenoceptors in platelets of patients with primary Raynaud's phenomenon and they show an increased digital vasoconstrictor response to an intraarterial a $_2$-adrenoceptor but not to an a $_1$-adrenoceptor agonist. [10] Vasospastic attacks are probably due to a combination of factors, including (1) normal vasoconstriction as a result of reflex sympathetic activity and local cold; (2) low systemic and intravascular blood pressure; (3) external pressure on the digit; (4) increased sensitivity of certain receptors (a

$_2$-adrenoceptors, S $_2$-serotonergic receptors); and (5) release of vasoactive agents from platelets.

The connective tissue diseases are the most common cause of secondary Raynaud's phenomenon (Table 167-2). [8] Between 80 and 90 percent of patients with scleroderma manifest Raynaud's phenomenon and/or persistent vasospasm. It is the presenting symptom in about one-third of patients, and may be the only manifestation of the disease for years. Raynaud's phenomenon occurs in 10 to 35 percent of patients with systemic lupus erythematosus and in about 30 percent with dermatomyositis. Arteriograms in patients with connective tissue diseases show digital and sometimes ulnar or radial artery obstructions.

Connective tissue disease	Trauma
Sclerodema	Vibratory tools
Systemic lupus erythematous	Hypothenar hammer syndrome
Dermatomyositis and polymyositis	Pianists, typists
Mixed connective tissue disease	Meat cutters
Rheumatoid arthritis	Hematologic causes
Sjögren's syndrome	Cryoproteins
Obstructive arterial disease	Cold agglutinins
Arteriosclerosis obliterans	Macroglobulins
Thromboangiitis obliterans	Polycythemia
Arterial embolism	Miscellaneous
Neurogenic disorders	Hypothyroidism
Thoracic outlet syndrome	Vinyl chloride disease
Carpal tunnel syndrome	Neoplasms
Reflex sympathetic dystrophy	Vasculitis and hepatitis B antigenemia
Hemiplegia	Intraarterial injections
Poliomyelitis	
Multiple sclerosis	
Syringomyelia	
Drug	
β-Adrenergic blockers	
Ergot preparations	
Methysergide	
Bleomycin and vinblastine	
Clonidine	
Bromocriptine	
Cyclosporine	

TABLE 167-2 **Causes of Raynaud's Phenomenon**

Raynaud's phenomenon may be occupational in origin and is especially common in people who use vibratory tools to cut stones or wood. Arteriograms have shown digital, radial, ulnar, or palmar arch thromboses. Any neurologic condition that produces permanent disuse of a limb can produce a sympathetic nervous system disturbance to that limb. This is usually manifested by persistent vasospasm with coldness, paleness, or cyanosis, and even ulcerations, but Raynaud's phenomenon may occur. Nerve root pressure or nerve entrapment may produce Raynaud's phenomenon. It is often present in the carpal tunnel syndrome and may occur secondary to neurovascular compression at the thoracic outlet.

Several drugs are implicated as causing Raynaud's phenomenon. Both selective and nonselective ß-adrenoceptor blocking drugs are common causes. Ergot preparations and methysergide used in the treatment of migraine headaches also cause the phenomenon. Ergotamine is a powerful a-adrenoceptor vasoconstrictor agonist that can produce gangrene of the fingers. Methysergide, a serotonin antagonist and agonist, produces peripheral vascular symptoms or signs in about 7 percent of patients. Industrial exposure to the vinyl chloride polymerization process may produce acroosteolysis of the distal phalanges of the fingers in a small percentage of workers, and Raynaud's phenomenon may also occur. Arteriograms in these patients show digital artery obstructions. The chemotherapeutic agents bleomycin and vinblastine may also cause the phenomenon.

Patients with cryoglobulins, macroglobulins, and polycythemia can exhibit Raynaud's phenomenon, probably secondary to rheologic disturbances or actual occlusion of small vessels. Cold agglutinins may occasionally cause the syndrome due to blockage of the vessels by agglutinated erythrocytes. The most common hormonal disturbance causing Raynaud's phenomenon is hypothyroidism, and the condition usually remits with thyroid replacement.

Prevention

Moving to a warmer climate alleviates symptoms in about 50 percent of patients. Some of the secondary causes can be prevented. Measures have been instituted to decrease the vibration of tools and to shorten hours for workers to prevent traumatic vasospastic disease. Vasoconstrictor drugs must be used with care to prevent overdoses. Mechanics and meat cutters should be warned not to use the hand as a hammer.

Clinical Manifestations

Patients complain of episodic attacks of well-demarcated, white or blue digits on exposure to cold; these are also sometimes induced by emotional stimuli (Fig. 167-5). During the attacks, one or more fingers or toes may become numb and be described as “dead.” The thumbs are often spared. On rewarming, the digits may become bright red and throbbing pain may occur. When pain is a prominent symptom in the ischemic phase, a secondary cause should be suspected. Attacks may last minutes to hours. Patients may experience one or more attacks per cold season or multiple attacks throughout the year. The fingers are most commonly involved, but vasospastic attacks may occur in the toes in 40 percent of patients.

FIGURE 167-5 A vasospastic attack in a young woman with Raynaud's phenomenon. Well-demarcated blanching of the fingers on exposure to cold is present. Ulnar and radial pulses were normal. The hand is not involved. The attacks were episodic.

Examination is usually normal in patients with primary Raynaud's phenomenon, and vasospastic attacks are difficult to induce in the office. If an attack is witnessed, there is well-demarcated blanching or cyanosis of the digits extending from the tips to varying levels of the digits. The digits distal to the line of ischemia are cold, while the proximal skin is pink and warmer. The hands and feet are not involved except in some secondary etiologies. On rewarming, blanched digits may become cyanotic due to the slow blood flow and then bright red due to reactive hyperemia. The digits appear normal between attacks but may be cool and moist with excess perspiration. The radial and ulnar pulses are normal. Patients may show the nail change known as pterygium, which refers to a cuticle widened to several millimeters with a proximal thin skin fold that merges with the cuticle (see also Chap. 72). Trophic changes with tense and atrophic skin, deformity of nails, and shortening and contracture of digits (sclerodactyly) may also be present.

Gangrene is rare and only affects the tips of fingers. Patients with secondary Raynaud's phenomenon may show other manifestations of their underlying disease; persistent ischemic discoloration of digits suggests a secondary cause.

Laboratory and Special Examinations

Blood and urine studies are normal in patients with primary Raynaud's phenomenon. The effect of local cooling with an ischemic stimulus has been used as a diagnostic test for Raynaud's phenomenon. When compared to normal individuals, patients with Raynaud's phenomenon have a greater reduction in finger systolic pressure with cooling and many show a loss of pressure or digital artery closure. Nail-fold capillary microscopy might be valuable for diagnosing secondary causes of Raynaud's phenomenon, but is normal in the primary disease. In scleroderma, mixed connective tissue disease, and dermatomyositis, there may be enlarged, deformed capillary loops surrounded by avascular areas. [11] Abnormal capillary loops and a prominent subpapillary venous plexus occur in lupus erythematosus, whereas bushy capillary formations are most prominent in mixed connective tissue disease.

Pathology

Histologic examination of digital arteries has been performed in a few patients with mild primary Raynaud's phenomenon and has been normal. In patients with more severe disease, intimal hyperplasia, narrowing or total occlusion of arteries, or thrombi are present.

Diagnosis and Differential Diagnosis

The diagnosis is usually made from the history of typical episodic attacks of well-demarcated white or blue discoloration of the digits on cold exposure. Patients with sufficient symptoms to seek a physician's advice should have a complete workup to exclude secondary causes. The history will elicit symptoms of connective tissue disease, a drug etiology, symptoms of obstructive arterial diseases, and exposure to vibratory tools or continuous finger trauma. During the physical examination, the physician should pay attention to all pulses, blood pressure in both the arms, and signs of secondary causes. The thoracic outlet maneuvers should be performed, and Tinel's sign (distal tingling or pain on percussion of the median nerve at the wrist) sought. Blood analyses for anemia, polycythemia, leukopenia, sedimentation rate, serum protein electrophoresis, antinuclear antibodies, rheumatoid factor, cryoglobulins, and cold agglutinins are necessary. Proteinuria and red blood cell casts should be specifically looked for in the urinalysis. A chest film will rule out the presence of cervical ribs. The history, physical examination, and laboratory tests should all be normal before a patient is reassured that the benign, idiopathic disease is probably the diagnosis. The main differential diagnoses are patients complaining of cold digits and acrocyanosis. Many patients complain of cold, sometimes painful digits but color changes are absent. This may be one extreme of the spectrum of normal sympathetic nerve activity. In acrocyanosis, the hands and feet are involved, whereas in Raynaud's phenomenon only the digits are involved, the color change is persistent and not episodic, a pallor phase is absent, and there is no sex predilection.

Treatment and Prognosis

Most patients with primary Raynaud's phenomenon respond to reassurance that they have a benign disease, to instructions to wear loose-fitting warm clothes covering as much of the body as possible to prevent reflex sympathetic vasoconstriction, and to avoid cold especially with pressure on the digits. [8] Tobacco smoking should be discouraged because nicotine induces cutaneous vasoconstriction; smokers are more numerous among patients with primary Raynaud's phenomenon and with traumatic vasospastic disease. The underlying cause must be treated in patients with secondary Raynaud's phenomenon.

Drug therapy can be used in the more severe cases of the phenomenon but is only successful in about two-thirds of patients. [8] Several studies show that nifedipine decreases the frequency, duration, and severity of attacks in about two-thirds of patients with primary or secondary Raynaud's phenomenon. The long-acting preparations have fewer side effects and are just as beneficial. [12] Diltiazem, felodipine, and isradipine, but not verapamil, may also be beneficial. Prazosin, an a_1-adrenoceptor antagonist, produces moderate benefit. Nitrates or their ointments have their proponents,

but are usually used in combination with other agents. Parenteral prostacyclin is reportedly beneficial, but oral preparations are not available. Either biofeedback or pavlovian conditioning may provide some benefit to patients, but they require a time commitment by the patient. Upper extremity sympathectomy is not of value in primary or secondary Raynaud's phenomenon; its benefit only lasts from 6 months to 2 years. Lumbar sympathectomy does produce lasting relief for lower-extremity Raynaud's phenomenon.

In patients with primary Raynaud's phenomenon, approximately 38 percent have no change in symptoms over time, 36 percent improve, 16 percent develop more severe attacks, and in 10 percent, the syndrome disappears. Although trophic changes of the fingers may develop in many patients, the prognosis is fairly good. Unfortunately, scleroderma is difficult to diagnose, and some patients will develop manifestations of this disease many years after the onset of Raynaud's phenomenon.

LIVEDO RETICULARIS

Livedo reticularis is characterized by a reddish-blue mottling of the skin in a “fishnet” reticular pattern.

Epidemiology

All types of livedo reticularis occur most commonly in women younger than 40 years of age.

Etiology and Pathogenesis

Livedo reticularis has been called by many names including idiopathic livedo reticularis, cutis marmorata, livedo annularis, livedo racemosa, sympathetic livedo reticularis, and asphyxia reticularis. Livedo reticularis with ulceration is also known as livedo or livedoid vasculitis and atrophie blanche. A variety of names usually reflects an unknown etiology. Secondary livedo reticularis is most commonly seen accompanying vasospastic conditions such as primary and secondary Raynaud's phenomenon, acrocyanosis, and vasculitis. It is often a manifestation of an underlying disease and may be a clue to its diagnosis. It has been reported in association with connective tissue diseases, especially lupus erythematosus, obstructive arterial disease, endocrine disorders, neurogenic diseases, drug reactions, hyperviscosity states, hypertension, and lymphomas. It is an important diagnostic manifestation in atheromatous embolization. It is induced by amantadine, a drug used for Parkinson's disease and influenza. Livedo reticularis with cerebrovascular lesions has been described (Sneddon's syndrome); [13] this may be part of a syndrome with arterial and venous thromboses, spontaneous abortions, and anticardiolipin or antiphospholipid antibodies (Fig. 167-6). [14]

FIGURE 167-6 Livedo reticularis of the buttocks and thighs in a woman who had a cerebrovascular thrombosis. This is an example of Sneddon's syndrome.

Livedo reticularis with ulceration (livedoid vasculitis) may be secondary to a localized vasculitis. [15] Immunofluorescence studies have shown IgM deposits. Complement factors, fibrin, and sometimes IgA have also been found in the vessel walls, which suggests an immune complex pathogenesis. Other investigators consider that this disease may be caused by blood or tissue abnormalities that induce thromboses of arterioles. A defect in the fibrinolytic system may be present. Abnormalities of platelet aggregation or increased platelet adhesiveness have also been reported. Amantadine causes livedo reticularis and is known to release norepinephrine from central and peripheral nerves in addition to enhancing the action of norepinephrine and dopamine on several peripheral tissues. These actions with amantadine's ability to inhibit uptake of dopamine and norepinephrine in neurons could lead to arteriolar constriction.

Vasospasm or obstruction of the small perpendicular arterioles in the dermis is the probable cause of the fishnet appearance of the skin. The red to blue periphery of each web of the net is a result of deoxygenated blood in surrounding horizontally arranged venous plexuses. Elevation of the extremity therefore decreases the intensity of the color changes by emptying the veins. The reversibility of the color pattern with warming, the frequent association with vasospastic diseases of the digits, and the beneficial response to sympathetic blocking agents suggest an increased sympathetic nerve activity as the cause of benign livedo reticularis.

Clinical Manifestations

Patients with benign livedo reticularis have no complaints except for the cosmetic appearance of the cutaneous fishnet. Numbness and pain are rare, but a subjective feeling of coldness is common. Patients with secondary livedo reticularis may complain of symptoms of their underlying disease. Persistence of the fishnet pattern during warming and purpuric macular lesions or skin nodules that ulcerate are the complaints in patients with livedo reticularis with ulceration. Most patients have the painful ulcers only in winter, although a few also have them in summer. In the benign form, a fishnet pattern affects mainly the extremities and the webs are rose, violet, red, or blue. Between the webs, the skin appears pale. The colors are aggravated by exposure to cold and may disappear on warming. The examination is normal except for the skin. In livedo reticularis with ulceration (livedoid vasculitis), purpuric lesions, cutaneous papules, or ulcers may be found (Fig. 167-7A). The ulcers are usually covered with eschars and surrounded by red inflammation; they are very

tender. Approximately 50 percent of patients have edema of the legs, which often occurs before the ulcerations. Healed ulcers have a smooth ivory-white plaque of atrophic skin surrounded by hyperpigmented borders and telangiectatic blood vessels (atrophie blanche) (Fig. 167-7B). Most ulcers are found on the lower part of the legs, ankles, and dorsa of the feet. In patients with secondary livedo reticularis, other manifestations of their underlying disease may be present.

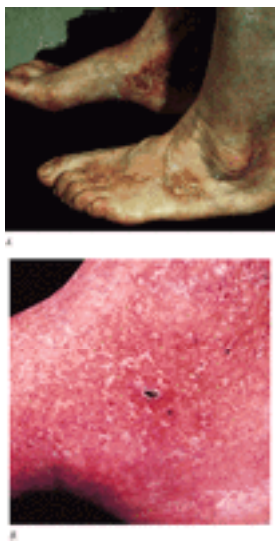

FIGURE 167-7 *A*. Recurrent irregular, extremely painful ulcers of the feet and lower legs in a 32-year-old woman with livedo reticularis with ulceration. Pigmented areas of healed ulcers are present. Ulcerations had been recurrent since age 16 years with no relation to seasons. Pedal pulses were normal. *B*. Close up of atrophie blanche with irregular porcelain-white atrophic scars, ulcerations, and crusting in a similar patient.

Laboratory and Special Examinations

In livedo reticularis with or without ulceration, no specific blood or urine tests are abnormal. [15]

Pathology

In benign livedo reticularis and that due to drug therapy, biopsies have shown nonspecific changes or increased numbers of dilated capillaries. A segmental hyalinizing vasculitis of the middle dermal vessels has been described in the ulcerative disease. [15] In Sneddon's syndrome, there is also a noninflammatory hyalinization and thickening of vessel walls and vascular occlusions, which are seen only in biopsies obtained from the center of the mesh of the fishnet pattern.

Diagnosis and Differential Diagnosis

The diagnosis is made easily from the typical fishnet pattern on the skin in the benign form. In patients with ulcers, other causes of lower extremity ulcers must be ruled out. Secondary causes must be sought before the diagnosis is considered to be benign livedo reticularis or with ulceration. It is therefore a diagnosis by exclusion of underlying diseases.

Treatment and Prognosis

The benign type of livedo reticularis needs no treatment. The skin discoloration can be covered with cosmetics or, as a last resort, sympatholytic agents can be tried for patients bothered by the social stigma.

In secondary causes, the underlying disease should be treated. Patients with anticardiolipin antibodies and thromboses should be treated with anticoagulants. In livedo reticularis with ulceration, treatment has been unsuccessful. Saline soaks and analgesic ointments are helpful. Antiplatelet agents and agents that induce fibrinolysis [16] are the most recently recommended therapies. A large variety of other therapies have all been reported to benefit some patients. Because the disease is rare, there are no large controlled studies of treatment modalities. The benign condition has an excellent prognosis. In livedo reticularis with ulceration, the painful ulcers are often recurrent and may be disabling. The lower limbs and feet become scarred; amputations have been necessary for deep ulcers and severe pain.

DISEASES OF THE VEINS

Thrombophlebitis

Thrombophlebitis or deep venous thrombosis is due to thrombotic obstruction of veins with or without an inflammatory response to the thrombus.

ETIOLOGY AND PATHOGENESIS The mechanisms of thrombosis described by Virchow includes the triad of vessel wall injury, stasis, and hypercoagulability. In the lower extremity, low venous flow and hypercoagulability are the key elements, whereas in the upper extremity, vascular damage and hemodynamic factors, such as after strenuous exercise, probably play the major role. Table 167-3 lists the most common causes. Some malignancies, such as those of the lung, pancreas, and stomach, are associated with thrombophlebitis, which may be of the migratory variety. Oral contraceptives disturb the hemostatic balance with an increase in procoagulant effects, a decrease in anticoagulant effects, and equivocal effects on fibrinolysis yielding a net prothrombotic effect. The past decade has seen discovery of genetic mutations or inherited thrombophlebitis that predispose to thrombosis. These include the common mutation in the factor V gene (factor V Leiden), providing resistance to activated protein C, and the mutation in the prothrombin gene (factor II), as well as the rarer antithrombin, protein C, and protein S deficiencies. [17] Elevated levels of several coagulation factors,

including factor VIII, factor IX, factor XI, and dysfibrinogenemia, are associated with thrombosis. Arterial and venous thrombosis may occur in patients with hyperhomocystinuria caused by genetic disorders affecting the transsulfuration or remethylation pathways of homocysteine metabolism or with antiphospholipid antibodies.

Common Factors	
Major surgery	Oral contraceptives
Fractures	Malignancies
Congestive heart failure	Venous varicosities
Acute myocardial infarction	Previous history of venous thrombosis
Stroke	Leiden factor 5 mutation
Pregnancy and postpartum	Prothrombin gene mutation (G 20210A)
Spinal cord injuries	Severe pulmonary insufficiency
Shock	Prolonged immobilization
Less-Common Factors	
Sickle cell anemia	Antithrombin III deficiency
Homocystinuria	Antiphospholipid antibodies
Protein C or S deficiency	Ulcerative colitis

TABLE 167-3 **Predisposing Factors in Deep Venous Thrombosis**

Superficial thrombophlebitis is usually a result of infections of or trauma to superficial veins from needles or catheters. A migratory variety is seen in thromboangiitis obliterans and malignancies. Mondor's disease is an inflamed subcutaneous vein from the breast to the axillary region, which has no association with underlying disease. [18] An occlusion of a vein by thrombus imposes a block to venous return, which leads to increased venous pressure and causes pain and tenderness. Prominent collateral veins appear early to bypass the obstruction and relieve the edema; recanalization may occur in several weeks. If the venous pressure is too high, arterial inflow may rarely be compromised and ischemia of the distal limb occurs. The thrombus within the vein often has a free-floating tail, which may break off to produce a pulmonary embolus. The free-floating tail is bound down to the vein wall in about 10 days. Organization of the thrombus in the vein destroys the venous valves which leads to the postphlebitic syndrome.

PREVENTION Agents evaluated to prevent the development of deep vein thrombosis include unfractionated heparin, low molecular weight heparin, and warfarin. Early ambulation has been advocated for the low risk surgical patient. Adjunctive therapy includes elastic compression stockings and intermittent pneumatic compression in selected patient populations. Unfractionated heparin (dosed at 5000 U subcutaneously every 8 to 12 h) is effective in general surgical and selected medical patients, but not in orthopedic patients. The use of low molecular weight heparin is preferred with major orthopedic surgeries, trauma, and acute spinal cord injuries.

CLINICAL MANIFESTATIONS The presenting history may be quite varied depending upon the clinical setting. Symptomatic patients may complain of pain or aching in the involved limb or have notable limb swelling. Some patients present with symptoms of pulmonary emboli without extremity symptoms. Other patients may be entirely asymptomatic at the time of diagnosis but were at high risk because of concurrent medical conditions. The clinical assessment alone is unreliable to establish or exclude the diagnosis. The clinical picture may vary from subtle signs of swelling to a tensely swollen, warm, tender limb with prominent, distended collateral veins. Swelling may first be detected by an increased turgor of the muscles or careful measurement of limb circumference and comparing it to the opposite limb. Pitting edema may occur but is not always present. A tender cord may be felt where the vein is thrombosed. With iliofemoral thrombophlebitis, the limb is swollen from the foot to the inguinal region (Fig. 167-8), tenderness is not present in the limb because the thrombus is proximal, and collateral veins may form from the thigh to the abdominal wall. The limb may be very pale (*phlegmasia alba dolens*) or may be cyanotic with cold digits if the arterial inflow is compromised (*phlegmasia coerulea dolens*). In thrombosis of calf veins, the calf and foot are swollen and warm; there is deep tenderness with or without a palpable cord. Increased resistance to dorsiflexion of the foot may be present (Homans' sign). Thrombophlebitis of a superficial vein or varicosity is evidenced by painful induration of the vein with redness and increased heat. Migratory cases have successive areas of superficial veins involved over a variable period of time. Mondor's disease is manifested by a tender cord from the breast to the axillary region; during healing, the venous cord shortens and puckers the skin. [18]

FIGURE 167-8 Acute iliofemoral deep venous thrombosis in a woman postpartum. The thigh and calf are very swollen, when compared to the opposite limb, and have a blotchy cyanotic discoloration.

LABORATORY AND SPECIAL EXAMINATIONS Contrast venography remains the gold standard for the diagnosis of venous thrombosis but has numerous clinical limitations including its invasive nature. Noninvasive modalities, most commonly venous ultrasonography and impedance plethysmography, have nearly replaced venography. Venous ultrasonography using B-mode imaging with venous compression, with or without Doppler flow assessment, is the optimum noninvasive test for the diagnosis of deep vein thrombosis. [19] Incomplete compressibility of the lower extremity veins is the principal diagnostic feature but direct visualization of the thrombus and abnormalities in Doppler flow, such as loss of spontaneous respiratory variation, may be seen. This test is most accurate for the first symptomatic proximal deep vein thrombosis and is much less reliable for asymptomatic, recurrent, or isolated calf (distal) deep vein thrombosis. Complementary tests, particularly the D-dimer assay, may be used to clarify the results of other testing. Serial examinations, particularly with venous ultrasonography, have been employed with a negative proximal evaluation to monitor for progression of distal deep vein thrombosis over 1 to 2 weeks if treatment with anticoagulation is not being employed.

PATHOLOGY The thrombus is composed of fibrin, red blood cells, and platelets. The thrombus propagates proximally and then consists predominantly of fibrin interspersed with red cells. The underlying vein wall may show minimal to marked inflammatory changes with infiltration of white blood cells and loss of endothelium. The thrombus may also undergo the same process and thereby become adherent to the vein wall. Some thrombi recanalize. The venous valves within the area of the thrombus are permanently damaged as the thrombus becomes adherent to the vein wall.

DIAGNOSIS AND DIFFERENTIAL DIAGNOSIS Thrombophlebitis is difficult to diagnose clinically. The symptoms and signs are nonspecific: studies show that the clinical diagnosis is incorrect in about 50 percent of patients. [20] A definitive test by impedance plethysmography, or, preferably, by venous ultrasound, is necessary to make a diagnosis. A venogram is only necessary when these tests give indeterminate results. Although the cause of a painful or swollen extremity is

often not found, these patients have a benign prognosis if noninvasive tests are negative for deep venous thrombosis. Superficial thrombophlebitis can be diagnosed by the characteristic clinical picture, although lymphangitis and cellulitis must be considered; the former usually has red streaking up the limb and tender lymph nodes proximally, while the latter presents a more diffuse involvement of the extremity. The most common differential diagnosis of thrombophlebitis includes rupture of the plantar muscle, which produces an ecchymotic area in the dependent ankle area and sometimes a tender knot over the muscle. Ruptured synovial membrane of the knee joint can imitate thrombophlebitis; knee joint fluid, inflammation or arthritis are clues to the diagnosis, but an arthrogram may be needed.

TREATMENT AND PROGNOSIS Anticoagulation is the mainstay in the treatment of deep vein thrombosis—preventing embolism and preventing clot propagation. [21] Heparin has been given by using weight-based protocols to achieve a therapeutic level, corresponding to an activated partial thromboplastin time of 1.5 to 2.5 times control. Low molecular weight heparins are replacing unfractionated heparin because of equal or greater efficacy with a more predictable anticoagulant response and no need for monitoring. These agents are shifting the care of the routine deep vein thrombosis to the outpatient setting, which may significantly decrease cost but has raised some safety concerns. Warfarin is used as a long-term oral anticoagulant to prevent recurrence. Warfarin is dose adjusted to prolong the international normalized ratio (INR) to 2.0 to 3.0 times normal. Because of transient prothrombotic effects, heparin should be overlapped with warfarin for 5 days. The duration of therapy with warfarin is under some debate but should continue for at least 3 months. Prolonged therapy has been suggested for idiopathic deep vein thrombosis and prolonged, or even indefinite, therapy for inherited thrombophlebitis. [17] Thrombolytic agents enhance lysis of thrombi but do not reduce subsequent pulmonary embolus mortality. Early thrombolytic use may help to alleviate symptoms, and perhaps reduce late complications, and should be considered for massive iliofemoral or subclavian venous thrombosis. Ambulation is allowed when symptoms and signs subside, and elastic compressive stockings (with a tension of 30 mmHg or greater) should be worn for several months. The therapy of choice for patients who have a contraindication, hemorrhage during anticoagulation, or pulmonary emboli while adequately anticoagulated, is insertion of an inferior vena cava filter. When gangrene of the toes is impending in ileofemoral venous thrombosis, surgical removal of the thrombus often alleviates the condition, even though there is rethrombosis of the vein. Septic thrombophlebitis is treated by removal of catheters and appropriate antibiotic therapy. However, resistant cases may require removal of the affected area of the vein. Treatment of upper extremity deep venous thrombosis is controversial. Early reports of a low risk of developing a pulmonary embolus with an upper extremity deep venous thrombus have been refuted and anticoagulation is the therapy of choice if there are no contraindications. The treatment of superficial thrombophlebitis has been conservative with warm compress and limb elevation. Most cases of thrombophlebitis subside within 10 days, but many patients have persistent limb swelling, especially with iliofemoral and subclavian venous thrombosis. The postphlebitic syndrome may develop in some patients within 2 years, whereas it may not occur for 20 years in others.

Varicose Veins (see also Chap. 273

Varicose veins are dilated, distended, tortuous veins with incompetent valves.

EPIDEMIOLOGY Varicose veins are more common in women than in men and usually appear in women during the child-bearing years. They are more common in countries where the population eats a low-fiber diet than in African countries where the diet is high in fiber. [22]

ETIOLOGY AND PATHOGENESIS A hereditary influence in some patients with varicose veins is suggested by the presence of the disorder in several members of the same family and the appearance of varices during adolescence. Because varicosities, hemorrhoids, and diverticula of the colon are infrequent in countries subsisting on a high-fiber diet, constipation with its associated increased intraabdominal pressure has been incriminated for all three entities. [22] Pregnancy is a prime cause of varicose veins due to vein relaxation by the increased hormones, expansion of blood volume, and increased venous pressure, especially in the limb whose iliac vein is compressed by the enlarged uterus. Thrombophlebitis leads to the formation of varicosities by the destruction of venous valves. Arteriovenous communications also cause varices. The first abnormality inducing varicosities is a weakening of the commissures of the valves with dilation. The dilation leads to incompetence of the valves and increased venous pressure distally. The increased venous pressure creates a vicious cycle because it causes further dilation of the vein and valves. The increased venous pressure is transmitted to the capillaries, which results in leakage of fluid into the subcutaneous tissues and muscles.

PREVENTION Many varicose veins would be prevented if women wore elastic support hose during pregnancy. Chronic constipation should be avoided.

CLINICAL MANIFESTATIONS Most patients have no symptoms but seek medical advice because of the cosmetic appearance. Some patients do complain of fatigue or aching in the calves or swelling of the ankles at the end of the day. The swelling disappears with bed rest overnight. Rarely, patients with very large varicosities will complain of lightheadedness or blurry vision on standing due to venous pooling. Varicose veins can be seen as dilated, tortuous, sacculated superficial veins (Fig. 167-9). They are often thick walled. The greater saphenous vein is most commonly involved, but varicosities may be found anywhere on the legs and feet without involvement of the saphenous veins. There may be pitting edema at the ankle area or increased turgor of the calf muscles. In patients with very large varicosities, systemic blood pressure may fall on standing. Many patients have prominent, multiple, fine cutaneous veins on the thigh which are not varicose veins; they usually appear after age 20 years in females and increase in number with aging (superficial phlebectasia or spider veins).

FIGURE 167-9 Extensive superficial varicose veins of the thigh and calf.

LABORATORY AND SPECIAL EXAMINATIONS The incompetent valves of varicose veins can be demonstrated by applying a tourniquet on the elevated extremity so that the superficial veins are empty (Fig. 167-10). On patient's assuming the erect posture, release of the tourniquet will allow rapid filling of a varicose vein if the valves are incompetent. Venography is seldom necessary but will show the dilated, tortuous veins and incompetent valves. Air plethysmography can document the degree of venous insufficiency. Duplex scanning with Doppler flow assessment can show reversal of venous flow during distal muscle compression and estimate the severity of reflux. Involvement of the superficial and deep venous system in the lower extremity can be determined using venous duplex imaging.

FIGURE 167-10 Varicose veins. Demonstration of venous reflux by the Trendelenburg test. *A*. Elevation of the leg empties the varices and a tourniquet is applied. *B*. While the patient is standing, varices remain empty until the tourniquet is removed, showing reflux from the saphenous vein. *C*. Reflux takes place via communicating veins before removal of the tourniquet, with additional reflux from the saphenous vein when the tourniquet is removed.

PATHOLOGY The pathology is variable, with some varicose veins appearing normal but dilated so that the venous valves no longer are in opposition. Others show damage, deformed valves, and fibrotic vein walls.
DIAGNOSIS The diagnosis of varicose veins rests primarily on seeing and palpating the varices. The above tourniquet test will delineate the incompetent valves.
TREATMENT AND PROGNOSIS (See also Chap. 273) Symptoms from varicose veins respond to heavy-gauge elastic stockings (30 mmHg or greater). Such stockings will prevent further enlargement of veins and edema but will not reverse the size of varicosities. Panty girdles or garters should never be worn. Ligation and stripping of veins are usually reserved for patients with very large and symptomatic varicosities. Small to medium-sized varicosities can be injected with a sclerosing solution 0.5 to 1 mL of sodium tetradecyl sulfate (Sotradecol) or concentrated saline solutions. These solutions cause an inflammation and then fibrosis of the vein. Stab avulsion has been used successfully to remove clusters of varicose veins and to interrupt perforating veins in the leg; this method usually involves small incisions. Laser therapy has been used to treat superficial and spider veins. Without adequate external support, varicose veins continue to enlarge in most, but not all, patients. New varicose veins usually appear in a 10-year period after stripping or sclerosing injections. Some patients will develop a postphlebitic syndrome.

Postphlebitic Syndrome

The postphlebitic syndrome is characterized by edema, stasis pigmentation, and ulcers of the lower extremities as a result of venous stasis.

EPIDEMIOLOGY Studies are lacking on the epidemiology, but it is more common in females than in males. Whites and blacks appear equally affected.
ETIOLOGY AND PATHOGENESIS The postphlebitic syndrome may occur soon after an episode of deep venous thrombosis or up to 20 years later. [23], [24] It is a common belief that most patients have had thrombophlebitis, although many do not give a history of the disease. It can occur in patients with superficial varicosities or incompetent deep veins; the perforating veins may also have defective valves. Valve destruction occurs with thrombophlebitis and is the main factor in causing increased venous pressure in the leg. The edema is caused by leakage of fluid from the capillaries. Stasis pigmentation is the result of red blood cells escaping into the tissues, which results in an inflammatory reaction to the deposited hemoglobin. The exact mechanism of spontaneous ulcer formation is unknown. A reasonable explanation is that there is ischemia in the area in the erect state from the high venous pressure preventing capillary blood flow. Venous blood drawn from the ulcer area is often “black” from desaturation. Marked fibrosis in the subcutaneous tissue may develop, and channels can be palpated where veins course in the fibrotic tissue.
PREVENTION Elastic stockings with suitable venous compression will prevent progression of venous insufficiency to the postphlebitic syndrome. Similarly, elastic compression may prevent recurrence of venous ulcers late in the disease.
CLINICAL MANIFESTATIONS Patients complain of swelling of the limb, discoloration of the calf and ankle area, and breakdown of skin or ulcers. Because the ulcers are often painless, patients may not see a physician for several weeks to months after the beginning of an ulcer. A history of thrombophlebitis may or may not be obtained. Some patients present with fever, chills, and redness of the involved extremity because of cellulitis. Pitting edema of the extremity is usually present, but varicose veins are not always apparent. There is brownish to dark pigmentation and often extensive scaling of the skin, especially on the medial side of the ankle and lower calf. Although cellulitis may occur, the leg may also be red, warm, and tender from an inflammatory reaction to the pigment in the dermis. Small erosions to very large, but

usually not deep, ulcers may develop (Fig. 167-11). The ulcers usually have a red base of granulation tissue. They also occur on the medial ankle or lower calf in the majority of cases. Sometimes a fluctuant area denoting an incompetent perforating vein can be palpated at the base or near an ulcer, or a varicosity can be traced draining the ulcer area. The subcutaneous tissue may be indurated, and retraction of the subcutaneous tissue of the lower third of the leg may occur with pitting edema above it. One or both legs may be involved with signs of the postphlebitic syndrome.

FIGURE 167-11 A large venous ulcer in a patient with the postphlebitic syndrome. This painless ulcer is shallow with good granulation tissue. Surrounding tissue shows typical stasis pigmentation, varicose veins, and subcutaneous tissue fibrosis and contraction.

LABORATORY AND SPECIAL EXAMINATIONS Incompetence of the superficial or deep venous system can be determined by tourniquet tests as described in the preceding section on varicose veins. Incompetent perforators can be detected by applying two tourniquets at various levels of an extremity with the veins empty (see Fig. 167-10). When the patient assumes the standing position, the segment of the superficial vein between the two tourniquets will fill when the underlying perforator has an incompetent valve. Before surgery, air plethysmography or high-resolution real-time ultrasonic imaging combined with Doppler pulsed-wave ultrasound should be performed.

PATHOLOGY In the area of postphlebitic changes there may be edema, inflammation, fibrosis, hemosiderin deposits, and tissue breakdown of the skin and subcutaneous tissues. In late cases, venous walls are thickened, and endothelial proliferation and fragmentation of the walls of venules and arterioles of the skin may be seen.

DIAGNOSIS AND DIFFERENTIAL DIAGNOSIS The characteristic picture of edema, stasis pigmentation, and ulcers is diagnostic of the postphlebitic syndrome. The differential diagnosis includes lymphedema, which does not have stasis pigmentation or ulcers. Other causes of ulcers discussed below are usually painful, while venous ulcers are painless or only tender. Demonstration of superficial or deep venous valvular incompetence by plethysmography, Doppler, duplex scanning, or venography may be needed when varicosities are absent.

TREATMENT AND PROGNOSIS (See also Chap. 272) The treatment of the postphlebitic syndrome is elastic compression to prevent venous stasis. Ace bandages or elastic stockings (30 mmHg or greater) must be worn throughout the day whenever the patient is sitting or standing. It also helps to sleep with the foot of the bed elevated 18 cm so that the patient starts the day with as little tissue fluid as possible. Itching or inflammation of stasis dermatitis usually yields to the application of glucocorticoids in cream or ointment. Unna boots are a very successful treatment method for venous ulcers. Without treatment, stasis dermatitis will usually progress to venous ulceration. The course is then recurrent ulcers and episodes of cellulitis. With adequate elastic compression and sometimes surgical procedures to decrease venous pressure in the area, the course will stabilize. However, the prognosis depends on great effort and cooperation by the patient.

LYMPHEDEMA

Lymphedema is the occurrence of chronically swollen extremities as a consequence of an inadequate drainage of interstitial tissue fluid by the lymphatic vessels.

Epidemiology

The prevalence of primary lymphedema is less than 1 in 6000 [25] and it has a 1:3 male to female predominance. Secondary lymphedema is more common in countries with warm climates because of their higher prevalence of filariasis.

Etiology and Pathogenesis

Primary lymphedema is most often seen in women and appears between the ages 10 and 25 years. [26] It may be congenital, appear at puberty (praecox), or occur after age 35 years (tardum) (Table 167-4). Milroy's disease is both familial and congenital. Other lymphatic defects causing yellow finger and toe nails (yellow nail syndrome), chylous pleural effusions or ascites, malabsorption, or intrahepatic cholestasis rarely might accompany primary lymphedema. Secondary lymphedema is caused by obstruction of lymphatic flow following surgical removal or radiation fibrosis of lymph nodes, infiltration by malignancies of lymph vessels or nodes, or destruction of lymphatics by recurrent infections or filariasis. The pathogenesis is the accumulation of tissue fluid as a consequence of failure of lymphatic drainage.

Primary
Congenital
Familial (Milroy's disease)
Idiopathic
Praecox
Tardum
Variant with yellow nails and pleural effusions
Secondary
Infection
Bacterial
Filariasis
Bartonella (cat-scratch fever)
Radical lymph node excision or surgical scarring
Malignant infiltration
Fibrosis
Radiation therapy
Stasis
Localized myxedema
Panniculitis
Idiopathic or pharmacologic retroperitoneal fibrosis

TABLE 167-4 **Classification of Lymphedema**

Prevention

In some patients, recurrent episodes of cellulitis and lymphangitis occur in the involved limb. Each attack destroys more lymphatic vessels and aggravates the lymphedema. These patients should be treated with antibiotic prophylaxis, usually penicillin. The acute attacks produce a red, warm extremity with increased swelling; red streaks may be seen on the proximal extremity extending from the inflamed area, and regional lymph nodes may be enlarged and tender. Fever and leukocytosis may accompany the infection. The common offending organisms are the coagulase-positive staphylococcus and the hemolytic streptococcus. Even when organisms cannot be cultured, therapy should be directed toward these bacteria.

Genetics

A genetic abnormality (FOX C2) causing distichiasis and lymphedema affects males more than females. [27]

Clinical Manifestations

The patient often does not notice the swelling of the limb as the onset is very gradual and the edema is painless. The swelling may also disappear overnight, which leads to delay in seeking medical advice. The abdomen may swell with ascites. Intestinal lymphangiectasis may produce pale-colored stools and diarrhea. Secondary lymphedema will have symptoms of the underlying disease. There is soft, pitting edema of the distal extremity in the beginning. In the later stages, the swelling becomes indurated and nonpitting. The skin may thicken and resist wrinkling; hair follicles are prominent. A pebbled surface may develop and may lead to pseudopapillary growths and hyperkeratosis (Fig. 167-12A). This process is known as elephantiasis nostras verrucosa. Some patients proceed to develop disfigured extremities with thick folds of skin (Fig. 167-12B). Patients may present with cellulitis of the involved extremity because lymphedematous limbs are susceptible to infection.

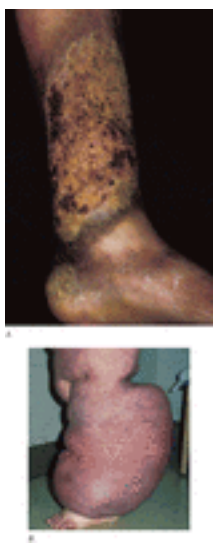

FIGURE 167-12 *A.* Lymphedema with hyperkeratosis (elephantiasis nostra verrucosa). Edema has been replaced by fibrosis, pseudopapillomatosis, hyperkeratosis, and hyperpigmentation. *B*. Lymphedema of the left leg in a 47-year-old fireman. The extreme swelling began at birth and was painless. Note the lack of stasis pigmentation or ulceration. The patient functioned normally at work and wanted no treatment.

In primary lymphedema, the lower extremities are involved most often and bilateral swelling occurs in about 50 percent of patients. In secondary lymphedema, usually only one extremity is involved. Discoloration of nails, distichiasis (a double row of eyelashes), jaundice, and signs of pleural effusion or ascites may occur rarely in patients with primary lymphedema.

Laboratory and Special Examinations

Invasive diagnostic tests are usually unnecessary. Blood and urine studies are normal in primary and most cases of secondary lymphedema. Lymphoscintigraphy with radioisotope preparations is useful in differentiating lymphedema from other causes of extremity edema. [28] Lymphangiography is usually avoided because it is painful and involves an incision with the chance of infection.

Pathology

The pathologic picture as determined by lymphangiography varies from aplasia or hypoplasia to varicosities of the lymphatic channels. [26] Primary lymphedema with distichiasis is associated with bilateral hyperplasia of the lymphatic vessels. In secondary cases, there may be neoplastic involvement of lymph nodes or fibrosis of lymph nodes and lymph vessels.

Diagnosis and Differential Diagnosis

The diagnosis of lymphedema can usually be made by physical examination; the patient has a swollen, painless limb without varicosities, stasis pigmentation, or collateral veins (Table 167-5). Invasive tests are unnecessary in most

patients. Noninvasive studies of the venous system or venography may be indicated to rule out venous disease. Lymphoscintigraphy and, rarely, lymphangiography are used to distinguish the lipomatous nodular masses of lipodystrophy. Secondary lymphedema should be considered in most patients before a diagnosis of primary lymphedema is made. A history of radiation or radium treatment, surgery of lymph nodes, or symptoms of malignancy should be ascertained. Patients from endemic areas may need blood tests or biopsies for filariasis. Males should be carefully examined for prostate cancer, which often presents with a unilateral swollen limb due to lymph node invasion. An ultrasound examination of the abdomen is usually performed, especially in females, to rule out tumors or enlarged lymph nodes. A venogram may be necessary to rule out the May-Thurner syndrome, which results in impaired venous return because of compression of the left common iliac vein by the right common iliac artery. [28] Occasionally, women present complaining of swollen legs, but no edema or other pathology can be found in the large legs. This configuration of the legs is usually familial. Clues to the absence of pathology are symmetric measurements of the ankles, calves, and thighs; small ankles in comparison to the calves and thighs; and lack of edema.

Postphlebitic syndrome	Idiopathic or cyclic edema
Edema of inactivity (old age)	Arthritis and synovitis
Hereditary "piano" legs	Panniculitis
Edema of constitutional disease	Localized myxoedema
Lipodystrophy	

TABLE 167-5 **Differential Diagnosis of Lymphedema**

Treatment and Prognosis

It is important to minimize extremity edema to prevent subcutaneous fibrosis, skin thickening, and recurrent episodes of cellulitis. Elastic garments with at least 30 mmHg pressure, but sometimes as high as 60 mmHg, must be worn from morning to bedtime. The elastic garments should have graded pressure from the distal to the proximal portion of the extremity. The patient should also sleep with the foot of the bed elevated 18 cm to promote drainage of tissue fluid overnight. A low-sodium diet and occasional, but not continuous, use of diuretics may be helpful. Administration of 5,6-benzo-alpha-pyrone (coumarin) decreases the size of the arms and legs slowly and improves symptoms in patients with primary and secondary lymphedema. [29] In patients with edema resistant to conservative measures, a sequential pneumatic compression device may be used. However, these machines must be used for at least 4 h on the extremity each night, are uncomfortable, and only move the fluid more proximally in some patients. Decongestive physical therapy may also help. In very large incapacitating limbs or for the development of lymphangiosarcoma, various surgical procedures have been performed, including removal of the subcutaneous tissue [26] or lymphovenous anastomoses. Removal of the subcutaneous tissue leaves a very scarred but more usable limb. Lymphovenous anastomosis is less successful in primary than in secondary lymphedema. Lymphatic grafts are also being used with some benefit.

Primary lymphedema usually progresses to a chronically swollen limb. Some patients with primary, and many patients with secondary, lymphedema remain stable and do not progress. Malignant degeneration of the lymphatic vessels, called lymphangiosarcoma, develops in 1 percent of cases and is more common in secondary lymphedema as a consequence of mastectomies (Stewart-Treves syndrome). In lymphedema associated with Turner's syndrome, the edema has abated in some patients.

Differential Diagnosis of Ulcers

Table 167-6 lists the common and some of the uncommon etiologies and characteristics of extremity ulcers. The most common ulcer is caused by venous stasis. Arterial ulcers due to large vessel disease are next in frequency; then the neurotropic ulcers of diabetic neuropathy. Normal pulses are usually present in the limbs except in ulcers due to large vessel arterial disease. Pain is characteristically absent to mild in venous, neurotropic, and neoplastic ulcers. An ulcer with a red granulating base is usually venous. Excess callus formation around a painless ulcer on pressure points suggests a neuropathic ulcer (see Fig. 167-2). Very painful, often serpiginous ulcers occur on the feet and legs in vasculitis, connective tissue diseases, and livedo reticularis with ulceration (see Fig. 167-7). Most secondary causes of Raynaud's phenomenon may lead to digital ulcers. Ulcers may also occur in scleroderma over subcutaneous calcification and will not usually heal until the calcium is extruded. These ulcerations usually occur on the digits, wrists, elbows, knees, or ankles.

[illegible]	[illegible]	[illegible]	[illegible]	[illegible]
[illegible]	[illegible]	[illegible]	[illegible]	[illegible]
[illegible]	[illegible]	[illegible]	[illegible]	[illegible]
[illegible]	[illegible]	[illegible]	[illegible]	[illegible]
[illegible]	[illegible]	[illegible]	[illegible]	[illegible]
[illegible]	[illegible]	[illegible]	[illegible]	[illegible]
[illegible]	[illegible]	[illegible]	[illegible]	[illegible]
[illegible]	[illegible]	[illegible]	[illegible]	[illegible]
[illegible]	[illegible]	[illegible]	[illegible]	[illegible]

TABLE 167-6 **Differential Diagnosis of Ulcers**

A painful ulceration may occur on the posterolateral aspect of the calf in hypertensive patients (hypertensive ulcer). [30] These lesions may start as purplish blebs and then ulcerate with a black eschar that is surrounded by purpura (Fig. 167-13). The etiology is unknown, but biopsy of surrounding tissue shows thrombosis and hyalinization of arterioles. A variety of infections may cause ulcerations, and diagnosis is usually difficult without a culture or biopsy. Ulceration of the nonischemic lesion of necrobiosis lipoidica in diabetes mellitus is uncommon. Malignancies of the skin must always be considered in indolent, nonhealing ulcers.

FIGURE 167-13 A hypertensive ulcer in a 56-year-old woman. The usual location is the lateral aspect of the calf. The base has a black eschar with surrounding ecchymotic tissue. Pain was extreme. All pulses in the extremity were normal.

REFERENCES

1. Coffman JD: Intermittent claudication and rest pain: Physiological concepts and therapeutic approaches. *Prog Cardiovasc Dis* **22**:53, 1979

2. Coffman JD: Principles of conservative treatment of occlusive arterial disease, in *Clinical Vascular Disease,* edited by JA Spittel Jr. Philadelphia, FA Davis, 1983, p 13

3. Hiatt WR: Medical treatment of peripheral arterial disease and claudication. *N Engl J Med* **344**:1608, 2001

4. Coffman JD: Atheromatous embolism. *J Vasc Med Biol* **1**:267, 1996

5. Kasinath BS et al: Eosinophilia in the diagnosis of atheroembolic renal disease. *Am J Nephrol* **7**:173, 1987

6. Olin JW. Thromboangiitis obliterans (Buerger's disease). *N Engl J Med* **343**:864, 2000

7. Cohen JS: Erythromelalgia: New theories and new therapies. *J Am Acad Dermatol* **43**:841, 2000

8. Coffman JD: *Raynaud's Phenomenon*. New York, Oxford University Press, 1989

9. Maricq HR et al: Geographic variation in the prevalence of Raynaud's phenomenon; Charleston, S.C., U.S.A. vs Tarentaise, Savoie, France. *J Rheumatol* **20**:70, 1993

10. Coffman JD, Cohen RA: a $_2$-Adrenergic and 5HT $_2$-receptor hypersensitivity in Raynaud's phenomenon. *J Vasc Med Biol* **2**:100, 1990

11. Maricq HR et al: Diagnostic potential of in vivo capillary microscopy in scleroderma and related disorders. *Arthritis Rheum* **23**:183, 1980

12. Raynaud's Treatment Study Investigators: Comparison of sustained-release nifedipine and temperature biofeedback for treatment of primary Raynaud phenomenon: Results from a randomized clinical trial with 1-year follow-up. *Arch Intern Med* **160**:1101, 2000

13. Sneddon IB: Cerebrovascular lesions and livedo reticularis. *Br J Dermatol* **77**:180, 1965

14. Weinstein C et al: Livedo reticularis associated with increased titers of anticardiolipin antibodies in systemic lupus erythematosus. *Arch Dermatol* **123**:596, 1987

15. Winkelmann RK et al: Clinical studies of livedoid vasculitis (segmental hyalinizing vasculitis). *Mayo Clin Proc* **49**:746, 1974

16. Milstone LM et al: Classification and therapy of atrophie blanche. *Arch Dermatol* **119**:963, 1983

17. Seligsohn U, Lubetsky A: Genetic susceptibility to venous thrombosis. *N Engl J Med* **344**:122, 2001

18. Abramson DJ: Mondor's disease and string phlebitis. *JAMA* **196**:1087, 1966

19. Kearon C et al: The McMaster Diagnostic Imaging Practice Guidelines Initiative: Noninvasive diagnosis of deep vein thrombosis. *Ann Intern Med* **128**:663, 1998

20. Barnes RW et al: The fallibility of the clinical diagnosis of venous thrombosis. *JAMA* **234**:605, 1975

21. Myers TM et al: Antithrombotic therapy for venous thromboembolic disease. *Chest* **119**:176S, 2001

22. Burkitt DP: Varicose veins: Facts and fantasy. *Arch Surg* **111**:1327, 1976

23. Jacobs P: Pathogenesis of the postphlebitic syndrome. *Ann Rev Med* **34**:91, 1983

24. McEnroe CS et al: Correlation of clinical findings with venous hemodynamics in 386 patients with chronic venous insufficiency. *Am J Surg* **156**:148, 1988

25. Dale RF: The inheritance of primary lymphoedema. *J Med Genet* **22**:274, 1985

26. Kinmonth JB: *The Lymphatics: Diseases, Lymphography, and Surgery*. Baltimore, Williams & Wilkins, 1972

27. Fang JM et al. Mutations in FOXC2 (MFH-1), a forkhead family transcription factor, are responsible for the hereditary lymphedema distichiasis syndrome. *Am J Hum Genet* **67**:1382, 2000

28. Heniford BT: May-Thurner syndrome: Management by endovascular surgical techniques. *Ann Vasc Surg* **12**:482, 1998

29. Casley-Smith JR et al: Treatment of lymphedema of the arms and legs with 5,6-benzo-alpha-pyrone. *N Engl J Med* **329**:1158, 1993

30. Schnier BR et al: Hypertensive ischemic ulcer: A review of 40 cases. *Am J Cardiol* **17**:560, 1966

T>

Chapter 168

Jennifer Bub John Olerud

Diabetes Mellitus

CUTANEOUS DISORDERS OF DIABETES MELLITUS ASSOCIATED WITH METABOLIC, VASCULAR, NEUROLOGIC, OR IMMUNOLOGIC ABNORMALITIES
Acanthosis Nigricans
Diabetic Thick Skin
Eruptive Xanthomas
Cutaneous Infections
Diabetic Ulcers
DISORDERS ASSOCIATED WITH DIABETES MELLITUS BUT OF UNKNOWN PATHOGENESIS
Necrobiosis Lipoidica
Granuloma Annulare
Diabetic Dermopathy
Acquired Perforating Disorders
Bullosis Diabeticorum
GLUCAGONOMA SYNDROME

REFERENCES

Diabetes mellitus (DM) is a major cause of morbidity and mortality in the United States. More than 15 million Americans have the disease, and approximately 13 percent of all health care expenditures in the United States are for DM. [1], [2] The risk of overall mortality is almost four times greater for women with DM than for those without DM. [3] Of great importance, major studies show that tight glycemic control decreases retinopathy, neuropathy, nephropathy, and coronary artery disease, which remain the major contributors to morbidity and mortality. [4], [5] Likewise, tight glycemic control may have a beneficial effect on a subset of skin-related, DM-associated disorders.

DM is characterized by a state of relative or complete insulin deficiency leading to gross defects in glucose, fat, and protein metabolism. In type 1 DM [insulin-dependent DM (IDDM)], an insufficiency of insulin occurs through a gradual, antibody-driven destruction of beta islet cells in the pancreas. In type 2 diabetes [non-insulin-dependent DM (NIDDM)], chronic hyperglycemia occurs mainly through end-organ insulin resistance followed by a progressive decrease in pancreatic insulin release associated with aging. A genetic predisposition and a strong association with obesity exist in type 2 DM. In both types of DM, abnormalities of insulin and elevated blood glucose levels lead to metabolic, vascular, neuropathic, and immunologic abnormalities. Affected organs include the cardiovascular, renal, and nervous systems, the eyes, and the skin.

Nearly all patients with DM have cutaneous manifestations. Although the mechanisms for many DM-associated skin conditions remain unknown, the pathogenesis of others is linked to hyperglycemia and insulin dysfunction, either directly, or through damage to the vascular, neurologic, or immune systems.

Hyperglycemia leads to nonenzymatic glycosylation (NEG) of various structural and regulatory proteins, including collagen. Although NEG occurs normally with aging, the process is greatly accelerated in DM. [6], [7] NEG leads to formation of nondegradable advanced glycosylation end products (AGEs) that are responsible for decreases in both acid solubility and enzymatic digestion of cutaneous collagen. Disorders such as diabetic thick skin and limited joint mobility (LJM) are thought to result directly from accumulation of AGEs. [8] Studies show that the degree of cutaneous AGEs correlates strongly with retinopathy, nephropathy, and other microvascular complications of DM. [9]

Macro- and microangiopathy contribute significantly to the cutaneous complications of DM. Microvascular abnormalities include increased “leakiness” or vessel wall permeability, decreased response of vessels to sympathetic innervation, and less ability to respond to thermal and hypoxemic stress. [10] In combination with arteriosclerosis of large vessels, these microvascular abnormalities contribute to the formation of diabetic ulcers.

In addition, a loss of cutaneous sensory innervation occurs with DM, predisposing patients to infection and injury. The loss of neuroinflammatory cell signaling plays a causal role in nonhealing lower extremity ulcers. [11] Patients with DM who lack lower extremity vibratory perception have a 15.5-fold increased probability of leg amputation. [12]

Derangements of immunoregulatory mechanisms also occur in DM. Hyperglycemia and ketoacidosis diminish chemotaxis, phagocytosis, and bactericidal ability of white blood cells. [10] Despite immune dysfunction at the cellular level, studies fail to document an increased prevalence of cutaneous infection in patients with well-controlled DM. [13], [14] Certain infections, however, such as streptococcal pyoderma, candidiasis, and the more devastating diseases of mucormycosis and necrotizing fasciitis, do appear to be associated with poorly controlled diabetes [15] (see below).

Dysregulation of lipid metabolism occurs with DM-associated insulin deficiency. The activity of lipoprotein lipase (LPL) is directly dependent on insulin, [16] making insulin central to the processing of triglyceride-rich chylomicrons and very-low-density lipoproteins (VLDLs). In insulin-deficient diabetic patients, defective lipid processing may lead to massive hypertriglyceridemia, manifesting in the skin as eruptive xanthomas. Naturally, disorders of lipid processing also play an integral role in the vasculopathies of DM.

Finally, cutaneous manifestations result from hyperinsulinemia, which occurs in early insulin-resistant type 2 DM. In this

case, the excess insulin is thought to bind and activate insulin-like growth factor-1 (IGF-1) receptors that may mediate the abnormal epidermal proliferation and resulting phenotype of acanthosis nigricans. [17]

This chapter reviews the cutaneous disorders associated with DM. They are characterized by disorders with evidence for metabolic, vascular, neurologic, or immunologic pathogenesis (induced by glucose and insulin abnormalities) and disorders associated with DM, but without a clear pathogenesis (Table 168-1 and Table 168-2). The glucagonoma syndrome is described briefly, with emphasis on cutaneous manifestations.



TABLE 168-1 **Cutaneous Disorder of DM with Known or Postulated Pathogenesis**



TABLE 168-2 **Cutaneous Disorders of DM without a Clear Pathogenesis**

CUTANEOUS DISORDERS OF DIABETES MELLITUS ASSOCIATED WITH METABOLIC, VASCULAR, NEUROLOGIC, OR IMMUNOLOGIC ABNORMALITIES

Acanthosis Nigricans (See Chap. 185)

Clinically, acanthosis nigricans (AN) presents as brown to gray-black papillomatous cutaneous thickening in the flexural areas including the posterolateral neck, axillae, groin, and abdominal folds. The affected skin has a dirty, velvety texture. In some cases, oral, esophageal, pharyngeal, laryngeal, conjunctival, and anogenital mucosal surfaces may be involved. In general, however, the back of the neck is the most consistently and severely affected area. [18]

Although some reports on AN suggest an association with malignancy, [19] other studies show that AN is common in the general population and most cases are associated with obesity, insulin resistance, and hyperinsulinemia. [19], [20] AN may be considered as a prognostic indicator for development of type 2 DM. [18] In a large, population-based study from Galveston, Texas, AN was present in 7.1 percent of 1412 school-age children. [20] AN occurred in 66 percent of children who weighed 200 percent of ideal body weight (IBW), and in 27 percent of children at 120 percent IBW. In this study, fasting insulin levels correlated with the presence and severity of AN.

The rate of AN varies among different ethnic groups. In the Galveston study, despite similar obesity rates, the prevalence was 0.5 percent in white, 5 percent in Hispanic, and 13 percent in African American children. [20] This finding suggests a possible genetic predisposition or increased sensitivity of the skin to hyperinsulinemia among certain populations. [18]

Advances are taking place in understanding the pathogenesis of AN. It is postulated that excess growth factor stimulation in the skin causes aberrant proliferation of keratinocytes and fibroblasts resulting in the phenotype of AN. [19] In states of insulin resistance and hyperinsulinemia, AN may result from excess insulin binding to IGF-1 receptors on keratinocytes and fibroblasts. [17], [21] Studies show, for example, that high concentrations of insulin stimulate in vitro fibroblast DNA synthesis and proliferation through IGF-1 receptors. [22] In AN associated with malignancy, evidence suggests that transforming growth factor -a released from the tumor cells may stimulate keratinocyte proliferation via epidermal growth factor (EGF) receptors. [23], [24] Support for the role of different growth factors in the pathogenesis of AN continues to accrue.

In addition to hyperinsulinemia, other associations with AN include hyperandrogenic states in females [25] and certain medications. Systemic glucocorticoids, nicotinic acid, and estrogens such as diethylstilbestrol have all been implicated. [19]

Treatment of AN is generally ineffective. Resolution may occur with weight loss (to IBW) in obese patients. [17], [19] Removal of offending medications generally results in skin clearance. [26] Although historical data have emphasized the relation between AN and malignancy, a true association is rare and does not warrant an extensive work up in the face of a negative history and physical examination. Of 12,000 patients with cancer in a 10-year study, only 2 developed AN. [27] The most important aspect of recognizing AN is that hyperinsulinemia is a known risk factor for type 2 DM, [28] and possibly coronary heart disease. [29]

Diabetic Thick Skin

Several specific syndromes are associated with localized thickening of the skin in DM. The common underlying

pathogenesis involves biochemical alterations in dermal collagen and mucopolysaccharides. Increased deposition and improper degradation of these constituents (through the formation AGEs) results in the clinical syndromes.

LIMITED JOINT MOBILITY AND SCLERODERMA-LIKE SYNDROME Diabetic LJM, or cheiroarthropathy, presents as tightness and thickening of the skin and periarticular connective tissue of the fingers, resulting in a painless loss of joint mobility. Initial involvement of the distal interphalangeal joints of the fifth digit usually progresses proximally to involve all fingers. Larger joints of the elbow, knee, and foot may be affected. The actual joint space, however, remains uninvolved, so that LJM is not a true arthropathy. This disorder is characterized by the "prayer sign" [30] (Fig. 168-1), which is an inability to approximate the palmar surfaces and interphalangeal joint spaces with the hands pressed together and fingers separated.

FIGURE 168-1 LJM in a 31-year-old male with type 1 DM. Patient is unable to approximate the palmar surfaces of the proximal and distal interphalangeal joints with palms pressed together (known as the "prayer sign"). *A.* Ulnar view: only fingertips are able to be approximated. *B.* Radial view: straining to press palms together.

Thirty to 50 percent of adult patients with type 1 DM have LJM; some authors believe this to be the earliest clinically apparent complication of diabetes in childhood and adolescence. [31] It also is common in type 2 DM. LJM is associated with increased duration of diabetes and poor glucose control. [31], [32] One longitudinal prospective study showed a 2.5-fold increase in the risk of LJM for every unit increase in the glycosylated hemoglobin (HbA1c). [32] Most importantly, LJM is directly correlated with microvascular disease. [30], [31], [33] Evidence indicates that intensive insulin therapy is important in prevention, and possibly treatment of LJM and scleroderma-like syndrome (SLS). Monnier et al. [9] showed that long-term tight glycemic control leads to decreased skin AGEs, and tight glycemic control is associated with delayed onset and severity of LJM. [32] On the basis of improvements in DM management, Infante et al. [34] reported a fourfold reduction in the frequency of LJM over the last 20 years. Treatment for LJM is difficult and should focus on tight control of blood sugar as well as physical therapy to preserve active range of motion. SLS is discussed together with LJM in patients with DM. It appears clinically as thickened waxy skin over the dorsal hands and feet, perhaps involving the forearms and thighs. The thickened skin may have a "pebbly" quality. [35] Although SLS can occur independently, most patients also have LJM. SLS is not associated with systemic sclerosis but does correlate with the duration of DM, the severity of joint contractures, and retinopathy. [33] It seems likely that the historical description of "diabetic hand syndrome" represents the same syndrome as SLS and LJM.

SCLEREDEMA DIABETICORUM (See Chap. 186) Recognized in 1970 as a syndrome, [36], [37] scleredema of diabetes [scleredema diabeticorum (SD)] presents with the insidious onset of painless, symmetric induration and thickening of the skin on the upper back and neck. Spread to the face, shoulders, and anterior torso may occur. The skin retains a nonpitting, woody, "peau d'orange" quality. Identical changes occur with postinfectious scleredema (see Chap. 186), usually associated with streptococcal pharyngitis. In scleredema associated with infection, however, the onset is often sudden, and the symptoms usually remit over time. Reported in 2.5 to 14 percent of patients with DM, SD is not uncommon. [38], [39] SD is a disease of long-standing diabetes, associated with obesity. Most patients have type 2 DM. This disorder has not been reported in children. The pathogenesis of SD is postulated to be unregulated production of extracellular matrix molecules by fibroblasts leading to thickened collagen bundles and increased deposition of glycosaminoglycans (mainly hyaluronic acid). Studies using in vitro fibroblast analysis from involved skin have variably demonstrated increased synthesis of glycosaminoglycans (GAGs) and type I collagen. [40] However, most of these reports involved nondiabetic patients with paraproteinemia and were based on small numbers of cases. Patients with SD may experience decreased sensation to pain and light touch over the affected areas and difficulties with upper extremity and neck range of motion. Extreme cases may result in full loss of range of motion. Unlike LJM and SLS, the presence of scleredema does not correlate with retinopathy, nephropathy, neuropathy, or principal vascular disease. [38] However, no large-scale prospective studies have been done. Most patients with SD become insulin dependent, are difficult to treat, and have multiple complications of DM. [40] Treatment for SD is usually unsuccessful. Case reports describe treatment with radiotherapy, low-dose methotrexate, and prostaglandin E_1. [41], [42]

Eruptive Xanthomas (See Chap. 150)

Eruptive xanthomas present clinically as 1- to 4-mm reddish-yellow papules on the buttocks and extensor surfaces of the extremities. The lesions occur in crops, and may coalesce into plaques over time (Fig. 168-2). Although eruptive xanthomas are generally asymptomatic, correct diagnosis is crucial because these lesions are often the first harbingers of untreated DM and severe hypertriglyceridemia. Histologic and biochemical studies show that lipoproteins (mainly chylomicrons) in the blood permeate cutaneous vessel walls and accumulate in macrophages in the dermis. [43] Because the triglycerides in eruptive xanthomas are mobilized more easily than the cholesterol, the initially triglyceride-rich lesions contain progressively more cholesterol as they resolve. [43] Whether this mechanism plays a role in the atherosclerosis of large arteries is unknown.

FIGURE 168-2 Eruptive xanthomas. Yellow-orange papules and plaques on the buttocks of a male patient with type 2 DM. (*Courtesy of G. Raugi, MD.*)

Most patients with hypertriglyceridemia do not have onset until adulthood. The prevailing thought is that these patients have a mild to moderate genetic defect in LPL and subsequently develop an additional acquired disorder of lipid metabolism. [44] The main acquired forms of hypertriglyceridemia result from medications (estrogens, retinoids), alcohol, and, importantly, untreated DM. In fact, DM is the most common cause of massive hypertriglyceridemia in genetically susceptible individuals. [45]

In uncontrolled DM, LPL activity decreases. [16] The degree of enzymatic dysfunction is proportionate to the amount of insulin deficiency and hyperglycemia. [16] Clearance of plasma lipoproteins depends on adequate insulin. [46] The inability to metabolize and clear triglyceride-rich chylomicrons and VLDLs can lead to plasma triglyceride levels in the thousands.

In addition to eruptive xanthomas, triglyceride levels above 4000 may cause lipemia retinalis. On funduscopic examination, lipemia retinalis appears as pale pink to white retinal arterioles and venules. The fundus may have a milky hue. Untreated, severe hypertriglyceridemia may also lead to abdominal pain, hepatosplenomegaly, pancreatitis, or dyspnea from decreased pulmonary diffusing capacity and abnormal hemoglobin oxygen affinity. [45] Treatment of hypertriglyceridemia involves strict dietary fat restrictions and control of the underlying DM. LPL activity returns to normal after treatment with long-term insulin or oral glucose-lowering agents. [16] The eruptive xanthomas respond rapidly and usually resolve completely in 6 to 8 weeks. [47]

Cutaneous Infections

Although the association between DM and cutaneous infections is not well supported, [12], [14] several infections are discussed below that occur more commonly, with greater severity, or with a greater risk for complications in patients with DM. Because dermatologists are often the only physicians to routinely examine the skin (a critical barrier to infection), they should be aware of these infections in patients with DM. Joshi et al. recently reviewed this subject. [15]

Much research has been undertaken on the pathogenesis of immune dysfunction in DM. Although some studies could not detect defects at the cellular level, [48] other studies show that leukocyte chemotaxis, adherence, and phagocytosis are impaired in patients with DM, especially during hyperglycemia and diabetic acidosis. [10], [49] Further studies show that cutaneous T cell function and response to antigen challenge are also decreased in DM. [15]

BACTERIAL INFECTIONS Patients with DM are at a higher risk for contracting certain bacterial infections, including Group A and Group B streptococcal infections, necrotizing fasciitis, and malignant otitis media. The relation between diabetes and staphylococcal infections is controversial.

Group B streptococcal infections (See Chap. 194) Group B streptococcus (*Streptococcus agalactiae*), a major cause of morbidity in neonates and pregnant women, is also a significant source of invasive bacterial infection in nonpregnant adults. Both retrospective and prospective population-based studies show DM to be a risk factor in these infections. [50], [51] In a study of 424 nonpregnant adults with invasive group B streptococcal infection, 30 percent of cases occurred in patients with DM. The most common sites of infection were skin, soft tissue, and bone (cellulitis, foot ulcers, and decubitus ulcers). [51] In young adults, the presence of DM increases the risk of group B streptococcal infection 30-fold. [51] Despite therapy, approximately 20 percent of these cases are fatal. [50], [51] In pregnancy, maternal DM (but perhaps not gestational DM alone) [52] increases the risk even more. [53]

Group A streptococcal infections In a prospective population-based surveillance of invasive group A streptococcal disease, the risk of infection was 3.7-fold greater in patients with DM. Soft tissue infections were the most common clinical presentation for all patients. [54]

Staphylococcal infections (See Chap. 194) Historically, *Staphylococcus aureus* skin infections were associated with DM. Past recommendations even suggested testing patients with recurrent furunculosis or folliculitis for DM. [55] In a review, however, Breen and Karchmer [56] concluded that current data do not permit estimation of proportional risk of staphylococcal infections in patients with DM. With respect to staphylococcal carriage rates in patients with DM, they concluded that, although study comparisons were difficult, it is likely that certain subsets of patients with DM have increased carriage rates. [56]

Malignant external otitis Invasive “malignant” otitis externa is an uncommon, life-threatening infection of the external auditory canal with potential cranial bone and intracranial involvement. *Pseudomonas aeruginosa* is usually implicated, and preceding aural irrigation with tap water may play an etiologic role. [57] This painful infection, which occurs in older patients with DM, is characterized by purulent discharge, unilateral facial swelling, hearing loss, and granulation tissue in the ear canal. [15], [58] Approximately 70 to 94 percent of patients with malignant external otitis have underlying diabetes. [10] Diagnosis is often delayed, and mortality rates are as high as 20 to 40 percent despite appropriate antibiotic therapy. [15], [58]

Necrotizing fasciitis (See Chap. 196) Ten to 60 percent of all cases of necrotizing fasciitis occurs in patients with DM. [59] Necrotizing fasciitis is a life-threatening bacterial infection of the soft tissues with spread along fascial planes. The perineum, trunk, abdomen, and upper extremities are most commonly involved. [10] Clinical presentation includes erythema, swelling, induration, necrosis, and possible bullae formation. The degree of pain and toxicity are often out of

proportion to the severity of the findings. Although most cases result from polymicrobial facultative gram-negative bacilli such as *Escherichia coli* and anaerobes such as *Bacteroides*, *Peptostreptococcus,* and clostridium species, approximately 10 percent of cases are monomicrobial, often due to streptococcal species. [15], [60] Treatment includes urgent surgical debridement and appropriate antibiotics. Mortality rates of 40 percent have been reported. [15]

FUNGAL AND YEAST INFECTIONS

Candidal infections (See Chap. 206) Most authors believe that mucocutaneous *Candida* infections occur more frequently among patients with DM, especially those with poorly controlled disease. [13], [61] Intertrigo (axillary, inguinal, web space), vulvovaginitis, balanitis, paronychia, onychomycosis, glossitis, and angular cheilitis are most common. In one study, the clinical diagnosis of candidal paronychia was made in 9.6 percent of 250 diabetic women, compared to only 3.4 percent of nondiabetic women. [62] In addition to symptomatic vaginal yeast infections, asymptomatic carriage rates are also elevated in patients with DM. [61] Postmenopausal females with recurrent vulvovaginal candidiasis should undergo screening for diabetes. Treatment for candidal infections includes topical and oral antifungals. Patients with candidal paronychia should avoid wetting of the nails and use drying agents (e.g., 15% sulfacetamide in 50% ethanol, three to four drops, four times per day, and after each time hands get wet). [10]

Dermatophyte infections (See Chap. 205) Although two studies failed to show an overall increased prevalence of dermatophyte infections in patients with DM compared to control subjects, [14], [63] Gupta et al. [64] demonstrated that the rate of toenail onychomycosis was 2.77 times greater for patients with DM as compared to controls. In addition, they found peripheral vascular disease to be a significant predictor. Probably the most important aspect of dermatophyte infection in patients with DM is aggressive diagnosis and treatment of tinea foot infections because of the potential portal of entry for subsequent bacterial infections.

Rhinocerebral mucormycosis (See Chap. 207) Rhinocerebral mucormycosis (RCM) is caused by Zygomycetes (*Mucor* and *Rhizopus* species). It often presents with headache, fever, and lethargy, in addition to nasal congestion and facial–ocular pain and swelling. Subsequent findings include unilateral proptosis, ophthalmoplegia, and palate or nasocutaneous necrosis. Seventy-five to 80 percent of all cases occur in patients with DM, [65] with diabetic ketoacidosis as the most important risk factor. [15] Ketoacidosis reportedly blunts the normal inhibitory activity of serum against *Rhizopus*. [66] Amphotericin B and surgical debridement are the treatments of choice. Mortality rates for RCM range from 15 to 34 percent. [66] In addition to RCM, *Mucor* species have also been observed complicating skin ulcers on the legs and hands of patients with DM. [10], [61]

Diabetic Ulcers

Chronic, nonhealing foot ulcers are a significant problem for patients with DM, accounting for a quarter of all days spent in the hospital by this population. [67] Lower-extremity ulcers were the proximal cause of amputation in 67 of 80 patients (84 percent) in a 1990 study by Pecoraro et al. [68] It has been estimated that 15 percent of individuals with DM will develop lower-extremity ulcers [69] and that 14 to 24 percent of patients with DM who have foot ulcers will eventually undergo amputation. [70]

The pathogenesis of diabetic ulcers is affected by many of the factors previously described in this chapter. For example, LJM and SLS (related to NEG) result in a less flexible foot with uneven distribution of pressure while walking. NEG of regulatory molecules that participate in the wound healing cascade may also contribute to the slow healing observed in patients with DM. Neuropathy (associated with uncontrolled hyperglycemia) is one of the major predictors of diabetic ulcers. [12] The loss of cutaneous sensory nerves also diminishes neuroinflammatory signaling via neuropeptides to keratinocytes, fibroblasts, endothelial cells, and inflammatory cells. [11] Blood lipid abnormalities (associated with insulin deficiency or resistance) are associated with vasculopathy, a major contributing factor in the formation of lower-extremity ulcers leading to amputation. [12] Factors affecting the immune response to infection become important when the skin barrier is breached and the healing response is adversely affected by the poor response of patients with DM to wound infection.

Ulcer prevention is the most important intervention physicians and other health care professionals can provide for diabetic patients with neuropathy. These interventions [10] are summarized as follows:

- Implement formal education, including recommendation of daily foot inspection.
- Advise careful selection of footwear that is not rigid or constricting in design and does not require a break-in period. Ill-fitting shoes and socks were the most common reasons for foot ulcers in a study of 314 diabetic patients with ulcers. [71] Issuing sports shoes to a group of patients with DM as an experimental variable resulted in a measurable reduction of calluses. [72] Calluses are a sign of excess friction and often precede foot ulcers (see Chap. 130).
- Advise patients to inspect shoes for foreign bodies before putting them on and to avoid walking barefooted, even indoors.
- Urge patients to seek early health care attention for calluses, blisters, “ingrown” toenails, dermatitis, or “athlete's foot.”
- Personally inspect the feet of patients with DM at each visit.
- Advise patients with a history of ulceration that they are at high risk for reulceration (34 percent at 1 year, 61 percent at 3 years, and 70 percent at 5 years). [73] Redouble education and prevention efforts in this group. Lifelong surveillance is required.

Treatment of diabetic ulcers requires modification of factors that have contributed to the ulceration, for example, stasis dermatitis, leg edema, and skin infection. Standard therapy for neuropathic diabetic ulcers includes debridement, pressure relief (often non–weight bearing), wet compresses, and protective dressings.

Data on treatment for diabetic ulcers were recently reviewed at an international Consensus Development Conference on Diabetic Foot Wound Care in Boston, MA. [70] The following assessment was published in *Diabetes Care*: “New technologies include growth factors, living skin equivalents, electrical stimulation, cold laser, and heat. Becaplermin

(recombinant platelet-derived growth factor) for the topical treatment of diabetic foot ulcers shows a modest benefit if used with adequate off-loading, debridement, and control of infection." For patients with significant ischemia it was concluded: "Once infection is controlled, arteriography, including visualization of the foot vessels, and subsequent vascular reconstruction can be undertaken in suitable patients with vascular insufficiency." A large multicenter, clinical trial of a bilayered living skin equivalent (Graftskin) [74] showed 56 percent healing at 12 weeks as compared with 38 percent healing for standard care. The most favorable published results for a monolayered living skin equivalent (Dermagraft) and platelet-derived growth factor (Becaplermin) show roughly comparable improvement in healing to that reported for Graftskin when each is compared to standard care or placebo. [75] These newer technologies await definitive analysis of cost effectiveness compared to standard older approaches.

Specialized ulcer care teams have published impressive results on the prevention and healing of ulcers. [76] This multidisciplinary team approach is likely to become important in the treatment of diabetic ulcers in large population centers.

DISORDERS ASSOCIATED WITH DIABETES MELLITUS BUT OF UNKNOWN PATHOGENESIS

Necrobiosis Lipoidica

Coined by Urbach in 1932 as necrobiosis lipoidica diabeticorum, this disorder was named after characteristic histologic findings and was first described in patients with DM. Because not all patients have concurrent DM, the shortened term, necrobiosis lipoidica (NL), is preferred. [77]

The classic clinical picture of NL is one to several sharply demarcated yellow-brown plaques on the anterior pretibial region (Fig. 168-3). The lesions have a violaceous, irregular border that may be raised and indurated. Initially, NL often presents as red-brown papules and nodules that may mimic sarcoid or granuloma annulare (GA). Over time, the lesions flatten, and the central yellow area becomes atrophic and develops telangiectasias, taking on the characteristic "glazed-porcelain" sheen. Aside from the shins, other sites of predilection include ankles, calves, thighs, and feet. Fifteen percent of patients develop lesions on the upper extremities and trunk that tend to be more papulonodular. Although pain and pruritus have been reported, most lesions are asymptomatic. Anesthesia of the plaques does occur. [78] Epidemiologic data show that the mean age of onset is around 30 years and that NL occurs three times more often in women than in men. [79]

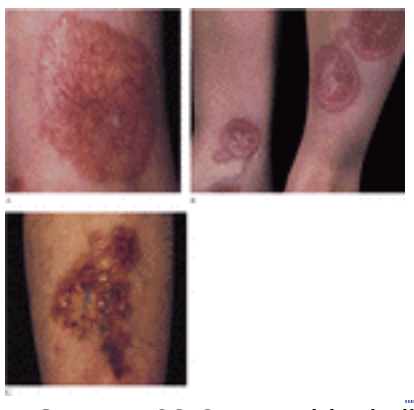

FIGURE 168-3 Necrobiosis lipoidica (NL) *A.* A single orange plaque with atrophy of the overlying epidermis and arborizing telangiectasis is seen on the lower leg of a juvenile with DM; the crust marks an area of early ulceration. *B.* Older lesions with striking central atrophy involving both the epidermis and dermis. *C.* NL of long-standing duration with sharply demarcated atrophic areas and sites of healed ulcerations.

The course of NL is often indolent, with spontaneous remission in less than 20 percent of cases. [10] Over time, the plaques of NL tend to stabilize, and formation of new lesions tapers off. However, the possibility of ulceration, a poor spontaneous remission rate, and cosmetic concerns lead patients to seek treatment. Ulceration, the most serious complication, occurs in approximately 13 to 35 percent of cases on the legs. [77], [79], [80] A few cases of squamous cell carcinoma arising in chronic ulcerative NL have been reported. [81] Multiple reports document the association of NL with GA and sarcoidosis. [82]

The most often quoted statistics concerning the association of NL with DM are from a 1966 retrospective study at the Mayo Clinic. Of 171 patients with NL, two-thirds had DM at diagnosis, and another 5 to 10 percent had glucose tolerance abnormalities. [79] In a 1999 study of 65 patients with NL, only 11 percent had DM after 15 years of follow-up. [83] Conversely, the prevalence of NL has been found to be only 0.3 to 3 percent in patients with DM. [79], [84] Although lacking full concordance, NL definitely has a strong association with DM and remains a valid marker of disease.

The pathogenesis of NL is unclear. Many etiologic mechanisms have been proposed and reviewed. [77] Evidence suggests that the degree of hyperglycemia and diabetic control does not correlate with the presence of NL. [85]

Treatment for NL is disappointing. At this time, only case reports and small, uncontrolled trials provide the basis for treatment decisions (summarized in Lowitt et al. [77]. Early application of potent topical glucocorticoids might slow progression. [77] Although some authors [79] report improvement with intralesional injection of glucocorticoids to the active border, the risk of ulceration with this treatment modality should be considered. A few case reports [80] and one series of six patients [86] showed benefit with short-term systemic glucocorticoids. Aspirin and dipyridamole have produced variable

results. [77]

Given the generally benign nature of the lesions, physicians should consider the adage “do no harm.” Focus should be on prevention of ulcers. When ulceration occurs in patients with NL, the same wound care principles apply as for all diabetic ulcers. Recently, cyclosporine resulted in ulcer closure and sustained response in two patients. [87] Surgical excision down to fascia and split-thickness skin grafting remain as the last resort for very recalcitrant NL ulcers. [88]

Granuloma Annulare (See Chap. 100)

Clinically, GA presents as erythematous to violaceous domed-shaped papules arranged in an annular configuration. They may form indurated, circular or semicircular plaques with central clearing. Localized GA, the most common form, occurs more frequently in children and young adults. Eighty-five percent of patients have fewer than 10 lesions, and sites of predilection include the dorsum of the hands, ankles, and feet. GA is a benign, self-limited disorder. Forty to 50 percent of patients report clearing within 2 years. [89] Women are affected two to three times more often than men. [89], [90] Atypical forms of GA include generalized, subcutaneous, and perforating types. Seven to 10 percent of patients have generalized GA, [90] which presents as hundreds to thousands of 1- to 2-mm flesh-colored papules that may form small annular plaques. The lesions are symmetric, and appear more commonly on the abdomen, chest, thighs, and extensor elbows. [90] Generalized GA occurs more frequently in older adults (mean age of onset is 52) [90] and has a more chronic and relapsing course. [89] Only 8 percent clear spontaneously. [90]

The association of GA with DM is widely discussed and appears to be less strong than that of NL. Although most patients with GA are in good health, without underlying systemic illness, an association with DM is supported in the literature. Dabski and Winklemann [90] reported DM in 10 percent of 1353 patients with localized GA and 21 percent of 100 patients with systemic GA. [90] An additional small retrospective case-control study showed an increased prevalence of DM among patients with GA (11 of 61, 18 percent) as compared with the prevalence in age-matched controls (10 of 120, 7.9 percent). [91]

Although controversial, many authors agree that DM is found more frequently in patients with adult onset GA, and in those with generalized or perforating GA, and that these patients tend to experience a more chronic, relapsing course of GA. [89] However, most studies to date suffer from referral bias or are small and retrospective, thus making interpretation of data difficult. To adequately address the association between GA and DM, a large, longitudinal population-based study is needed.

The pathogenesis of GA is unclear. Proposed mechanisms are discussed in Chap. 100. The mainstay of treatment remains potent topical or intralesional glucocorticoids. Because generalized GA may be pruritic and also cosmetically crippling, systemic treatments have been tried including systemic glucocorticoids, niacinamide, chloroquine, aspirin, and potassium iodide. [92] There is no clear drug of choice. Clofazimine has shown promise, [93] and treatment with PUVA resulted in complete clearance in one case [94] and in a series of five patients. [92] Taking a careful history and performing a physical examination to discern possible DM are recommended. In addition, most experts advocate checking a fasting glucose level in patients with chronic relapsing, perforated, or generalized GA. [10], [89]

Diabetic Dermopathy

Atrophic skin lesions of the lower extremity, or shin spots, were first characterized and presented as a cutaneous marker for DM by Melin in 1964. [95] Shortly after, Binkley coined the term diabetic “dermopathy” to correlate the pathologic changes with those of retinopathy, nephropathy, and neuropathy. [96] Since that time, controversy has existed as to the disorder's etiology, specificity for DM, and association with other microangiopathic complications of DM.

Diabetic dermopathy presents as small (<11 mm), atrophic, brown, scarlike macules on the pretibial areas (Fig. 168-4). The lesions are asymptomatic and clear within 1 to 2 years with light residual atrophy or hypopigmentation. [95] New lesions usually arise, giving the sense that the pigmentation and atrophy are persistent.

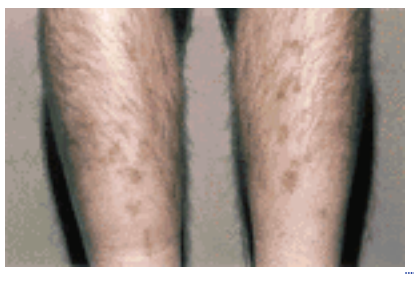

FIGURE 168-4 Diabetic dermopathy. Hyperpigmented macules are seen on the anterior lower legs.

The prevalence of shin spots in ambulatory patients with DM varies. In a recent population-based study from Sweden, diabetic dermopathy was found in 33 percent of patients with type 1 DM, and in 39 percent of patients with type 2 DM. Of the healthy control group, only 2 percent had similar lesions on their shins. [97] In other studies, the prevalence rate for individuals without DM ranges from 1.5 percent for healthy medical students, to 20 percent for a group of nondiabetic endocrine patients. [98] Diabetic dermopathy occurs more often in patients with an increased duration of DM and is more frequent in men. [98]

An association does seem to exist between diabetic dermopathy and the more serious complications of DM. In a study of

173 patients with DM, the incidence of shin spots was significantly increased in patients with retinopathy, nephropathy, and neuropathy. [99] Diabetic dermopathy does not, however, correlate with obesity or hypertension in patients with DM. [98]

It is likely that the lesions are related to antecedent trauma. Lithner [100] induced diabetic dermopathy on the legs of diabetic patients with heat and cold injury, whereas nondiabetic control subjects healed without residual change. [100] When questioned, most patients feel that the changes are caused by injury but they are often unable to detail preceding trauma, and they note that the lesions tend to be painless. No treatment is necessary for the individual atrophic tibial lesions. They are asymptomatic and are not directly associated with an increase in morbidity.

Acquired Perforating Disorders (See Chap. 57)

Acquired perforating disorders (APDs) comprise an overlapping group of disorders characterized by transepidermal elimination or “spitting” of altered dermal constituents. Clinically, lesions grouped under the heading of APDs appear as pruritic, keratotic papules mainly on the extensor surfaces of the extremities. Papules and nodules with a perforating component may also occur on the trunk and face. Many are follicular and contain a prominent central keratotic plug. The papules may be grouped, or coalesce to form verrucous plaques.

The APDs include Kyrle's disease, reactive perforating collagenosis, perforating folliculitis, and elastosis perforans serpiginosa. [101] Historical attempts have been made to delineate the disorders in this group based on differing pathogenesis, associated diseases, and hereditary versus acquired forms of APD. [101] Unlike the inherited forms of perforating collagenosis, APDs occur in adulthood and lack a predilection for sex or race. [102] Several studies in the literature suggest a causal relationship of APDs with chronic renal failure and DM with or without hemodialysis. [102] The prevalence among patients on hemodialysis is reported at 4.5 to 10 percent. [103]

The pathogenesis of the APDs is unknown. One possible factor may be deposition of “uremic substances,” such as uric acid or hydroxyapatite, that incite an inflammatory response and foreign body reaction resulting in transepidermal elimination of dermal constituents. [102] Local trauma and chronic rubbing secondary to pruritus appear to play a role. Microangiopathy and dysregulation of vitamins A or D have also been proposed. [102]

Treatment for APDs is usually unsuccessful. Retinoic acid, topical glucocorticoids, and PUVA have been found to be partially successful. [102]

Bullosis Diabeticorum

Bullosis diabeticorum (BD) is characterized by abrupt onset of bullae on the lower extremities, usually the toes, feet, and shins. Occasionally, the distal upper extremities are involved. The blisters are usually painless and not pruritic. Healing occurs within 2 to 5 weeks and rarely leaves scarring. The condition may recur as successive crops of bullae over many years. Studies of affected individuals excluded other blistering skin disorders, and revealed no abnormalities of porphyrin metabolism. [104] As of 1985, 43 cases of BD had been reported. [105]

The pathogenesis of diabetic bullae is unknown. Patients with BD do not have a history of antecedent trauma or infection. Histopathologic examination of the bullae shows an inconsistent level of separation varying from intraepidermal to subepidermal. [105] No immunopathologic features are consistently observed. One study found a decreased threshold to suction-induced blister formation in patients with DM. [106] Reduced suction blister time is also observed with increasing age in nondiabetic subjects. [105] Although a history of antecedent trauma is not elicited, this finding suggests a role of increased skin fragility in diabetic bullae. Perhaps the formation of AGEs leads to increased fragility.

The differential diagnosis of diabetic bullae includes bullous impetigo, bullous pemphigoid, pemphigus vulgaris, epidermolysis bullosa acquisita, porphyria cutanea tarda, bullous erythema multiforme (e.g., to drugs), and insect bite reaction. Biopsy should be performed and the tissue examined histologically as well as by immunofluorescence. In addition, cultures and blood work to screen for porphyrins should be considered.

BD runs a benign course, without involvement of large body surface areas. The only serious complication is that of secondary infection, which should be managed with culture and appropriate antibiotics if suspected. Otherwise, therapy is supportive. The real importance of this disorder is that of correct diagnosis because several of the blistering skin diseases have a high rate of morbidity and require potentially toxic systemic treatments. A negative workup should be documented, and the patient should be educated and reassured.

GLUCAGONOMA SYNDROME (See Chap. 164 and Chap. 184)

Glucagonoma syndrome is a rare paraneoplastic syndrome consisting of DM, an erosive rash [necrolytic migratory erythema (NME)], glossitis, weight loss, diarrhea, anemia, and hypoalbuminemia (Table 168-3). It is caused by a glucagon-secreting pancreatic tumor of the alpha islet cells. Age of onset is typically 50 to 60 years, and no gender predilection has been observed. [107] More than 15 percent of patients may not have DM. [108] Malignancy as defined by presence of metastases is reported to be 60 to 70 percent, [10] but the true malignancy rate may be as high as 100 percent. Metastases occur with most frequency in the liver, and then adjacent lymph nodes, bone, adrenals, kidney, and lung. [109]

Sign/Symptom	Frequency (or Review)
Diabetes mellitus	56–94%[107,108,110]
Cutaneous findings	
Necrolytic migratory erythema	~70–80%[108,110] most common presenting symptom
Cheilitis, angular cheilitis	~30%[107,108]
Weight loss, cachexia	56–97%[107,108,110] marker of metastasis
Gastrointestinal abnormalities	
Diarrhea	20–30%[108,109]
Constipation	5%
Neuropsychiatric disorder	16–20%[108]
Depression	
Paranoid delusions	
Insomnia	
Apnea	
Visual difficulties	
Thromboembolic disease	~23% overall[108]
Pulmonary emboli	
Deep venous thrombosis	11%[108]
Cerebrovascular artery thrombosis	
Laboratory abnormalities	
Elevated glucagon levels[a]	~100%,[110] rarely, initial level is normal
Elevated sedimentation rate	
Anemia, normocytic	55–80%[107,110]
Hypoalbuminemia	
Hypoaminoacidemia	100%[107]
Other neuroendocrine syndromes	
Zollinger-Ellison syndrome	11%[108]
MEN1[b]	5–17%[107,108]
Insulinoma	

Source: Reference numbers correlate with those of the chapter.
[a]Secondary causes of elevated serum glucagon levels: Other skin cell tumors, cirrhosis, chronic renal failure, pancreatic disease, microcellular carcinoma, prolonged fasting, diabetic ketoacidosis, familial hyperglucagonemia, infection, trauma, medications.
[b]Other potentials: elevated hormones in glucagonoma: insulin, gastrin, 1-hydroxycorticosteroids and 11-OHCS, human parathyroid hormone, calcitonin, vasoactive intestinal peptide, calcitriol, adrenocorticotropic hormone, melanocyte-stimulating hormone, somatostatin.
[c]Multiple endocrine neoplasia type 1.

TABLE 168-3 **Signs and Symptoms of Glucagonoma Syndrome**

All patients with untreated glucagonoma eventually develop NME. [107] Sites of involvement include groin, thighs, buttock, central face, frictional areas, and distal extremities. [109], [110] Initial clinical presentation is usually erythematous macules and papules, often in the groin. [107], [109] The lesions evolve into blistering plaques resulting in a scalded appearance with erosion and crusting. Perilesional pustules may occur, and pain and intense pruritus are common. [109] The rash has a cyclical nature with concurrent lesions at different levels of healing. In addition to NME, approximately 30 percent of patients develop glossitis and angular chelitis. [108], [110]

Although there may be histologic variation in skin lesions of NME, [111] typical lesions show epidermal necrosis, edema, and separation in the upper spinous layer. Infiltrates are mainly neutrophilic. [111] The differential diagnosis of NME includes bullous and papulosquamous disorders, as well as certain nutritional deficiencies in which clinical and histologic skin findings closely resemble those of NME.

Normally, glucagon maintains glucose levels during states of metabolic stress such as fasting, exercise, and childbirth by increasing liver gluconeogenesis and glycogenolysis and inhibiting glycogen synthesis. In glucagonoma syndrome, excessive levels of glucagon promote amino acid catabolism, leading to a deficiency of the proteins needed for cellular growth and division. This chronic state of amino acid deficiency is thought to be responsible for the cellular necrosis of the epidermis in NME. Supporting data include improvement of NME with correction of hypoaminoacidemia [112] and the cutaneous resemblance to other states of nutritional deficiency.

The rarity of glucagonoma syndrome often results in delayed diagnosis, and many patients have metastatic disease at the time of workup. In the correct clinical setting, an elevated serum glucagon level is usually diagnostic. Levels generally range from 1000 to 5000 pg/mL [110] (normal, 50 to 150 pg/mL). Contrast-enhanced computed tomography is recommended for visualization of the tumor. The gold standard, however, remains selective celiac axis arteriography for localization of tumor as well as liver metastases. [109], [113] A high level of suspicion is necessary to diagnose glucagonoma syndrome, and several authors recommend obtaining glucagon levels in any patient with DM and a chronic dermatosis. [10], [107] In addition, given the association between glucagonomas and other neuroendocrine tumors, evaluation for abnormal levels of other gastrointestinal hormones should be undertaken. [107]

The mainstay of treatment is surgical resection of the primary tumor. [10], [107], [108] Most patients show significant clinical improvement even with incomplete resection of metastases. [107] Octreotide and other new longer acting somatostatin analogs have been shown to significantly reduce serum glucagon levels and improve symptoms. [107], [110] In advanced metastatic and nonresectable disease, chemotherapeutic agents such as streptozotocin, 5-fluorouracil (5-FU), and dimethyltriazenoimidazolecarboxamide (DTIC) have been used. Although good prognostic data still are lacking, the overall 5-year survival rate appears to be greater than 50 percent, and those with localized tumors have complete cure with total resection. [108], [110]

REFERENCES

1. Harris MI et al: Prevalence of diabetes, impaired fasting glucose and impaired glucose tolerance in US adults. The third National Health and Nutrition Examination Survey, 1988–1994. *Diabetes Care* **21**:518, 1998

2. Javitt JC, Chiang YP: Economic impact of diabetes, in *Diabetes in America*, 2nd ed, edited by MI Harris, CC Cowie, MP Stern, EJ Boyko, GE Reiber, PH Bennett. (NIH publ. No. 95–1468) Washington, DC, US Government Printing Office, 1995, p 601

3. Hu FB et al: The impact of diabetes mellitus on mortality from all causes and coronary heart disease in women. Twenty years of follow up. *Arch Intern Med* **161**:1717, 2001

4. The Diabetes Control and Complications Trial (DCCT): The effect of intensive treatment of diabetes on the development and progression of long-term complications in insulin-dependent diabetes mellitus. *N Engl J Med* **329**:977, 1993

5. Andersson DK, Svärdsujd K: Long-term glycemic control relates to mortality in type 2 diabetes. *Diabetes Care* **18**:1534, 1995

6. Beisswenger PJ et al: Relationship between glycemic control and collagen-linked advanced glycosylation end products in type I diabetes. *Diabetes Care* **16**:689, 1993

7. Dyer DG et al: Accumulation of Maillard reaction products in skin collagen in diabetes and aging. *J Clin Invest* **91**:2463, 1993

8. Buckingham BA et al: Scleroderma-like changes in insulin-dependent diabetes mellitus: Clinical and biochemical studies. *Diabetes Care* **7**:163, 1984

9. Monnier VM et al: Skin collagen glycation, glycoxidation, and cross-linking are lower in subjects with long-term intensive versus conventional therapy of type 1 diabetes. *Diabetes* **48**:870, 1999

10. Olerud JE: Diabetes and the skin, in *Ellenberg & Rifkin's Diabetes Mellitus,* 6th ed, edited by D Porte Jr, RS Sherwin, A Baron. New York, McGraw-Hill, 2003, p 895

11. Ansel JC et al: Interactions of the skin and nervous system. *J Invest Dermatol Symp Proc* **2**:23, 1997

12. Reiber GE et al: Risk factors for amputation in patients with diabetes mellitus, a case-control study. *Ann Intern Med* **117**:97, 1992

13. Gilgor RS: Cutaneous infections in diabetes mellitus, in *The Skin in Diabetes*, 1st ed, edited by JE Jelink. Philadelphia, Lea & Febiger, 1986, p 111

14. Lugo-Somolinos A, Sanchez JL: Prevalence of dermatophytosis in patients with diabetes. *J Am Acad Dermatol* **26**:408, 1992

15. Joshi N et al: Infections in patients with diabetes mellitus. *N Engl J Med* **341**:1906, 1999

16. Brunzell JF et al: Abnormal lipoprotein-lipase-mediated plasma triglyceride removal in untreated diabetes mellitus associated with hypertriglyceridemia. *Metabolism* **28**:901, 1979

17. Cruz PD, Hud JA: Excess insulin binding to insulin-like growth factor receptors: Proposed mechanism for acanthosis nigricans. *J Invest Dermatol* **98**:82S, 1992

18. Stuart CA et al: Acanthosis nigricans. *J Basic Clin Physiol Pharmacol* **9**:407, 1998

19. Schwartz RA: Acanthosis nigricans. *J Am Acad Dermatol* **31**:1, 1994

20. Stuart CA et al: Prevalence of acanthosis nigricans in an unselected population. *Am J Med* **87**:269, 1989

21. Geffner ME, Golde DW: Selective insulin action on skin, ovary, and heart in insulin-resistant states. *Diabetes Care* **11**:500, 1988

22. Flier JS et al: Monoclonal antibody to the type I insulin-like growth factor (IGF-I) receptor blocks IGF-I receptor-mediated DNA syntheses: Clarification of the mitogenic mechanisms of IGF-I and insulin in human skin fibroblasts. *Proc Natl Acad Sci U S A* **83**:664, 1986

23. Ellis DL et al: Melanoma, growth factors, acanthosis nigricans, the sign of Leser Trélat, and multiple acrochordons. *N Engl J Med* **317**:1582, 1987

24. Koyama S et al: Transforming growth factor-alpha (TGF-a)-producing gastric carcinoma with acanthosis nigricans: An endocrine effect of TGF-a in the pathogenesis of cutaneous paraneoplastic syndrome and epithelial hyperplasia of the esophagus. *J Gastroenterol* **32**:71, 1997

25. Flier JS et al: Acanthosis nigricans in obese women with hyperandrogenism. *Diabetes* **34**:101, 1985

26. Coates P et al: Resolution of nicotinic acid-induced acanthosis nigricans by substitution of an analogue (acipimox) in a patient with type V hyperlipidaemia. *Br J Dermatol* **126**:412, 1992

27. Andreev VC: Malignant acanthosis nigricans. *Semin Dermatol* **3**:265, 1984

28. Kekäläinen P et al: Hyperinsulinemia cluster predicts the development of type 2 diabetes independently of family history of diabetes. *Diabetes Care* **22**:86, 1999

29. Després J-P et al: Hyperinsulinemia as an independent risk factor for ischemic heart disease. *N Engl J Med* **334**:952, 1996

30. Rosenbloom AL et al: Limited joint mobility in childhood diabetes mellitus indicates increased risk for microvascular disease. *N Engl J Med* **305**:191, 1981

31. Frost D, Beischer W: Limited joint mobility in type I diabetic patients. *Diabetes Care* **24**:95, 2001

32. Silverstein JH et al: Long-term glycemic control influences the onset of limited joint mobility in type I diabetes. *J Pediatr* **132**:944, 1998

33. Buckingham B et al: Skin, joint, and pulmonary changes in type 1 diabetes mellitus. *Am J Dis Child* **140**:420, 1986

34. Infante JR et al: Changes in frequency and severity of limited joint mobility in children with type I diabetes mellitus between 1976–78 and 1998. *J Pediatr* **138**:33, 2001

35. Hollister DS, Brodell RT: Finger “pebbles”: A dermatologic sign of diabetes mellitus. *Postgrad Med* **107**:209, 2000

36. Fleischmajer R et al: Scleredema and diabetes mellitus. *Arch Dermatol* **101**:21, 1970

37. Cohn BA et al: Scleredema adultorum of Buschke and diabetes mellitus. *Arch Dermatol* **101**:27, 1970

38. Cole GW et al: Scleredema diabeticorum: A common and distinct cutaneous manifestation of diabetes mellitus. *Diabetes Care* **6**:189, 1983

39. Sattar MA et al: Scleroedema diabeticorum: A minor but often unrecognized complication of diabetes mellitus. *Diabet Med* **5**:465, 1988

40. Varga J et al: Scleredema adultorum: Case report and demonstration of abnormal expression of extracellular matrix genes in skin fibroblasts in vivo and in vitro. *Br J Dermatol* **132**:992, 1995

41. Seyger MMB et al: A patient with a severe scleroedema diabeticorum, partially responding to low-dose methotrexate. *Dermatology* **198**:177, 1999

42. Lee MW et al: Electron beam therapy in patients with scleredema. *Acta Derm Venereol* **80**:307, 2000

43. Parker F et al: Evidence for the chylomicron origin of lipids accumulating in diabetic eruptive xanthomas: A correlative lipid biochemical histochemical, and electron microscopic study. *J Clin Invest* **49**:2172, 1970

44. Brunzell JD, Bierman EI: Chylomicronemia syndrome: Interaction of genetic acquired hypertriglyceridemia. *Med Clin North Am* **66**:455, 1982

45. Chait A et al: Chylomicronemia syndrome in diabetes mellitus. *Diabetes Care* **4**:343, 1981

46. Bagdade JD et al: Diabetic lipemia: A form of acquired fat-induced lipemia. *N Engl J Med* **276**:427, 1967

47. Parker F: Xanthomas and hyperlipidemias. *J Am Acad Dermatol* **13**:1, 1985

48. Valerius NH et al: Neutrophil and lymphocyte function in patients with diabetes mellitus. *Acta Med Scand* **211**:463, 1982

49. Gallacher SJ et al: Neutrophil bactericidal function in diabetes mellitus: Evidence for association with blood glucose control. *Diabet Med* **12**:916, 1995

50. Jackson LA et al: Risk factors for Group B streptococcal disease in adults. *Ann Intern Med* **123**:415, 1995

51. Farley MM et al: A population-based assessment of invasive disease due to Group B streptococcus in nonpregnant adults. *N Engl J Med* **328**:1807, 1993

52. Piper JM et al: Group B streptococcus infection rate unchanged by gestational diabetes. *Obstet Gynecol* **93**:292, 1999

53. Ramos E et al: Group B streptococcus colonization in pregnant diabetic women. *Obstet Gynecol* **89**:257, 1997

54. Davies HD et al: Invasive Group A streptococcal infections in Ontario, Canada. Ontario Group A streptococcal study group. *N Engl J Med* **335**:590, 1996

55. Smith JA et al: Nasal carriage of *Staphylococcus aureus* in diabetes mellitus. *Lancet* **2**:776, 1966

56. Breen JD, Karchmer AW: *Staphylococcus aureus* infections in diabetic patients. *Infect Dis Clin North Am* **9**:11, 1995

57. Rubin J et al: Aural irrigation with water: a potential pathogenic mechanism for inducing malignant external otitis? *Ann Otol Rhinol Laryngol* **99**:117, 1990

58. Yu LH et al: Malignant otitis externa. *Chung Hua I Hsueh Tsa Chih (Taipei)* **62**:362, 1999

59. Eke N: Fournier's gangrene: A review of 1726 cases. *Br J Surg* **87**:718, 2000

60. Sentochnik DE: Deep soft-tissue infections in diabetic patients. *Infect Dis Clin North Am* **9**:53, 1995

61. Vazquez JA, Sobel JD: Fungal infections in diabetes. *Infect Dis Clin North Am* **9**:97, 1995

62. Stone OJ, Mullins JF: Incidence of chronic paronychia. *JAMA* **186**:71, 1963

63. Romano C et al: Prevalence of dermatophytic skin and nail infections in diabetic patients. *Mycoses* **44**:83, 2001

64. Gupta AK et al: Prevalence and epidemiology of toenail onychomycosis in diabetic subjects: A multicentre survey. *Br J Dermatol* **139**:665, 1998

65. Batra VK et al: Mucormycosis in a diabetic. *Postgrad Med J* **58**:781, 1982

66. Lehrer RI et al: Mucormycosis. *Ann Intern Med* **93**:93, 1980

67. Bild DE et al: Lower extremity amputation in people with diabetes. Epidemiology and prevention. *Diabetes Care* **12**:24, 1989

68. Pecoraro R et al: Pathways to diabetic limb amputation: Basis for prevention. *Diabetes Care* **13**:513, 1990

69. Reiber GE: The epidemiology of diabetic foot problems. *Diabet Med* **13**:S6, 1996

70. American Diabetes Association: Consensus development conference on diabetic foot wound care. April 7–8, 1999, Boston, MA. *Diabetes Care* **22**:1354, 1999

71. Apelqvist J et al: The influence of external precipitation factors and peripheral neuropathy on the development and outcome of diabetic foot ulcer. *J Diabetes Complications* **4**:21, 1990

72. Soulier SM: The use of running shoes in the prevention of plantar diabetic ulcers. *J Am Podiatr Med Assoc* **76**:395, 1986

73. Apelqvist J et al: Long-term prognosis for diabetic patients with foot ulcers. *J Intern Med* **233**:485, 1993

74. Veves A et al: Graftskin, a human skin equivalent, is effective in the management of noninfected neuropathic diabetic foot ulcers. *Diabetes Care* **24**:290, 2001

75. Edmonds M et al: New treatments in ulcer healing and wound infection. *Diabetes Metab Res Rev* **16**(Suppl 1):S51, 2000

76. Van Gils CC et al: Amputation prevention by vascular surgery and podiatry collaboration in high-risk and nondiabetic patients. *Diabetes Care* **22**:678, 1999

77. Lowitt MH, Dover JS: Necrobiosis lipoidica. *J Am Acad Dermatol* **25**:735, 1991

78. Mann RJ, Harman RRM: Cutaneous anaesthesia in necrobiosis lipoidica. *Br J Dermatol* **110**:323, 1984

79. Muller SA, Winkelmann RK: Necrobiosis lipoidica diabeticorum. *Arch Dermatol* **93**:272, 1966

80. Dwyer CM, Dick D: Ulceration in necrobiosis lipoidica—A case report and study. *Clin Exp Dermatol* **18**:366, 1993

81. Imtiaz KE, Khaleeli AA: Squamous cell carcinoma developing in necrobiosis lipoidica. *Diabet Med* **18**:325, 2001

82. Crosby DL et al: Concomitant granuloma annulare and necrobiosis lipoidica. *Dermatologica* **183**:225, 1991

83. O'Toole EA et al: Necrobiosis lipoidica: Only a minority of patients have diabetes mellitus. *Br J Dermatol* **140**:283, 1999

84. Borssén B et al: The epidemiology of foot lesions in diabetic patients aged 15–50 years. *Diabet Med* **7**:438, 1990

85. Dandona P et al: Glycosylated haemoglobin in patients with necrobiosis lipoidica and granuloma annulare. *Clin Exp Dermatol* **6**:299, 1981

86. Petzelbauer P et al: Necrobiosis lipoidica: Treatment with systemic corticosteroids. *Br J Dermatol* **126**:542, 1992

87. Darvay A et al: Persistent ulcerated necrobiosis lipoidica responding to treatment with cyclosporin. *Br J Dermatol* **14**:725, 1999

88. Dubin BJ, Kaplan EN: The surgical treatment of necrobiosis lipoidica diabeticorum. *Plast Reconstr Surg* **60**:421, 1977

89. Studer EM et al: Precipitating factors and associated diseases in 84 patients with granuloma annulare: A retrospective study. *Dermatology* **193**:364, 1996

90. Dabski K, Winkelmann RK: Generalized granuloma annulare: Clinical and laboratory findings in 100 patients. *J Am Acad Dermatol* **20**:39, 1989

91. Veraldi S et al: Laboratory abnormalities in granuloma annulare: A case-control study. *Br J Dermatol* **136**:652, 1997

92. Kerker BJ et al: Photochemotherapy of generalized granuloma annulare. *Arch Dermatol* **126**:359, 1990

93. Mensing H: Clofazimine—Therapeutic alternative in necrobiosis lipoidica and granuloma anulare. *Hautarzt* **40**:99, 1989

94. Setterfield J et al: Generalised granuloma annulare successfully treated with PUVA. *Clin Exp Dermatol* **24**:458, 1999

95. Melin H: An atrophic circumscribed skin lesion in the lower extremities of diabetics. *Acta Med Scand* **423**(Suppl):1, 1964

96. Binkley GW: Dermopathy in diabetes mellitus. *Arch Dermatol* **92**:106, 1965

97. Borssen B et al: The epidemiology of foot lesions in diabetic patients aged 15–50 years. *Diabet Med* **7**:438, 1990

98. Danowski TS et al: Shin spots and diabetes mellitus. *Am J Med Sci* **251**:570, 1966

99. Shemer A et al: Diabetic dermopathy and internal complications in diabetes mellitus. *Int J Dermatol* **37**:113, 1998

100. Lithner F: Cutaneous reactions of the extremities of diabetics to local thermal trauma. *Acta Med Scand* **198**:319, 1975

101. Rapini RP et al: Acquired perforating dermatosis. Evidence for combined transepidermal elimination of both collagen and elastic fibers. *Arch Dermatol* **125**:1074, 1989

102. Faver IR et al: Acquired reactive perforating collagenosis. Report of six cases and review of the literature. *J Am Acad Dermatol* **30**:575, 1994

103. Picö MR et al: Cutaneous alterations in patients with chronic renal failure. *Int J Dermatol* **31**:860, 1992

104. Bernstein JE et al: Bullous eruption of diabetes mellitus. *Arch Dermatol* **115**:324, 1979

105. Toonstra J: Bullosis diabeticorum. Report of a case with a review of the literature. *J Am Acad Dermatol* **13**:799, 1985

106. Bernstein JE et al: Reduced threshold to suction-induced blister formation in insulin-dependent diabetics. *J Am Acad Dermatol* **8**:790, 1983

107. Chastain MA: The glucagonoma syndrome: A review of its features and discussion of new perspectives. *Am J Med Sci* **321**:306, 2001

108. Frankton S, Bloom SR: Glucagonomas. *Baillieres Clin Gastroenterol* **10**:697, 1996

109. Prinz RA et al: Clinical aspects of glucagon-producing islet cell tumors. *Am J Gastroenterol* **76**:125, 1981

110. Wermers RA et al: The glucagonoma syndrome: Clinical and pathologic features in 21 patients. *Medicine* **75**:53, 1996

111. Kheir SM et at: Histologic variation in the skin lesions of the glucagonoma syndrome. *Am J Surg Pathol* **10**:445, 1986

112. Boden G: Insulinoma and glucagonoma. *Semin Oncol* **14**:253, 1987

113. Reyes-Govea JR et al: Response of glucagonomas to surgical excision and chemotherapy: Report of two cases and review of the literature. *Am Surg* **55**:523, 1989

T>

Chapter 169

Janie Leonhardt Warren Heymann

Cutaneous Manifestations of Other Endocrine Diseases

THYROID HORMONE
Physiology of Thyroid Hormone and the Skin
Cutaneous Manifestations of Hyperthyroidism
Cutaneous Manifestations of Hypothyroidism
PARATHYROID HORMONE
Physiology of Parathyroid Hormone and the Skin
Cutaneous Manifestations of Hyperparathyroidism
Cutaneous Manifestations of Hypoparathyroidism
GLUCOCORTICOIDS
Physiology of Glucocorticoids and the Skin
Cushing's Syndrome
Addison's Disease
GONADAL HORMONES
Physiology of Sex Hormones and the Skin
Cutaneous Manifestations of Androgen Excess
Cutaneous Manifestations of Androgen Deficiency
Cutaneous Manifestations of Estrogen Excess
Cutaneous Manifestations of Estrogen Deficiency
OTHER PITUITARY HORMONES
Physiology of Growth Hormone
Cutaneous Manifestations of Growth Hormone Excess
Cutaneous Manifestations of Growth Hormone Deficiency and Panhypopituitarism

REFERENCES

A hormone is a substance produced by a cell that interacts with another cell to cause a specific biologic change or activity. Hormones are major effectors of homeostasis, and the effect of abnormalities in their balance can be widespread. Many hormones have direct effects on the skin, and disruptions in a hormonal axis can alter normal skin physiology in various ways. For instance, a disruption may not affect mature skin in the same way it affects developing skin, either in the fetus or prior to puberty. The effect may also be appropriate in one sex and undesired in the other. Hormonal axis disruption may cause distant effects that secondarily affect the skin, as is the case with hyperthyroid-induced hyperhidrosis or flushing related to vasodilatory effects of thyroid hormone. Cutaneous effects may also occur as a byproduct of immunologically related endocrine disease, an example being pretibial myxedema in Graves' disease. It must be emphasized that the skin not only is a target for hormone activity but also is a synthesizer and secretor of hormones (for example, the peripheral conversion of testosterone to dihydroxytestosterone). [1]

Hormones are regulated by feedback mechanisms specific to each hormonal axis. Their effect on the skin is contingent upon their binding to a specific receptor expressed by the target cell. The number of these receptors is the determinant of the magnitude of the response. There are two principal types of hormone receptors: cytosolic-nuclear receptors that bind steroid and steroid-like molecules, and plasma membrane-associated receptors that bind peptide hormones and other ligands. [2]

Steroids (glucocorticoids, mineralocorticoids, androgens, estrogens, and progestins) and thyroid hormone share a “steroid” mechanism of action. In general, these hormones promote keratinocyte growth and differentiation, glycosaminoglycan synthesis, and growth factor production and secretion. Steroid and steroid-like hormones penetrate the cell membrane by either passive diffusion or carrier protein-enhanced transport. Inside the cell, they bind to a hormone-binding protein that is maintained in an inactive multiprotein-bound complex of multiple heat shock proteins (hsps). Once the hormone is bound, the heat shock proteins are released and the hormone-protein complex enters the nucleus and attaches to a chromatin acceptor site. The sequence of protein production occurs with initiation of mRNA transcription with protein translation. Peptide hormones (growth hormone, thyroid-stimulating hormone, and parathyroid hormone) are bound onto cell surface receptors. This attachment initiates a conformational change in the cell membrane or hormone receptor and/or internalization of the hormone-receptor complex. To facilitate a biologic response, the receptor is coupled to an enzyme or an intermediate acceptor protein (G protein) juxtaposed between the hormone complex and the enzyme. The G protein is then coupled to adenylate cyclase or phospholipase C, which, upon binding of the hormone, become activated to initiate the intracellular response. [2]

THYROID HORMONE

Physiology of Thyroid Hormone and the Skin

Thyroid homeostasis and the regulation of appropriate concentrations of thyroid hormone are regulated by the hypothalamic-pituitary-thyroid axis. Neural stimulation by the hypothalamus produces thyrotropin-releasing hormone (TRH), which traverses the hypophyseal-hypothalamic portal system to the anterior pituitary where thyrotropin (TSH) and prolactin synthesis and secretion are initiated. TSH is released from the anterior pituitary in a circadian rhythm, with the highest levels occurring at night. After TSH binds to the thyroid follicular cells in the thyroid gland, a cyclic adenosine monophosphate second messenger system is activated, leading to the production of thyroid hormone. Approximately 90 percent of the thyroid secretion is thyroxine [3,5,3',5'-tetraiodothyronine (T4)] and 10 percent is triiodothyronine

[3,5,3'-triiodothyronine (T3)]. T4 is more prevalent, but T3 is four times as potent. [3] Most T4 is eventually converted to T3 by deiodination in peripheral tissues, primarily the liver and kidneys, although cutaneous fibroblasts and keratinocytes both harbor the conversion enzyme. [4] Both T4 and T3 are highly bound to serum proteins, including thyroxine-binding globulin (TBG), thyroxine-binding prealbumin, and albumin. [3] Negative feedback of thyroid hormone synthesis appears to be through T4 and T3 downregulation of TRH mRNA expression (and TRH secretion), direct inhibition of TSH synthesis and release, and downregulation in the thyroid follicular cell of the TRH receptor gene. [4]

The skin is a target for thyroid hormone, in particular skin fibroblasts and keratinocytes, although the mechanism of action on cutaneous receptors is unknown. Thyroid hormone stimulates proteoglycan synthesis by skin fibroblasts, regulates epidermal differentiation, and appears to be essential for hair formation and sebum production. [3] It has been suggested that T3 induces expression of epidermal turnover genes and promotes keratinocyte differentiation by activating the plasminogen activator gene. [2] Epidermal maturation is also linked to thyroid hormone by its effects on epidermal growth factor (EGF). Thyroid hormones elevate the levels of EGF in the skin and affect the binding of EGF to skin receptors to promote maturation. [2] Skin perfusion depends, in part, on the regulation of the cardiovascular system by thyroid hormones. In hyperthyroid states, there is increased cardiac output, decreased peripheral resistance, and increased venous constriction, which increases cutaneous circulation. In hypothyroid states, the converse is true, leading to pale, cool skin. [5] In almost all tissues, thyroid hormone accelerates oxygen consumption and increases the metabolic rate either through direct action or by sensitizing tissues to catecholamine stimulation. [3]

Cutaneous Manifestations of Hyperthyroidism

Hyperthyroidism may occur secondary to a stimulatory disruption in any part of the hypothalamic-pituitary-thyroid-target cell axis. A patient may have a TSH-secreting pituitary adenoma, a single toxic nodule of the thyroid gland, a toxic multinodular goiter, Graves' disease, early non-Graves' thyroiditis, excessive thyroxine intake, or, less commonly, a molar pregnancy, struma ovarii, or metastatic follicular carcinoma. The skin is warm, moist, and smooth, resembling infantile skin. The increased cutaneous circulation leads to facial flushing and palmar erythema. Generalized hyperhidrosis may occur, often more pronounced on the palms and soles. The epidermis may be thin but is not atrophic. The scalp hair may be fine, soft, or friable, and diffuse nonscarring alopecia may be present. Approximately 5 percent of patients exhibit nail changes consisting of soft, rapidly growing nails and/or Plummer's nails with concave contours and distal onycholysis. [3] Approximately 2 percent of patients have hyperpigmentation, which may resemble addisonian hyperpigmentation (palmar creases, soles, gingivae, and buccal mucosa) or may occur diffusely with a prominence on the shins and feet while sparing the mucous membranes, nipples, and genital skin (in contrast to addisonian hyperpigmentation). [6] Pruritus may occur in both hyper- and hypothyroidism, and urticaria and angioedema have been described as uncommon manifestations of hyperthyroidism. [7]

GRAVES' DISEASE Graves' disease is an autoimmune infiltration of the thyroid gland by specific T cells that stimulate B cells to produce antibodies. The antibodies stimulate TSH receptors to initiate thyroid hormone production and hyperthyroidism. [4] Classic clinical findings include those of hyperthyroidism as well as pretibial myxedema (dermopathy), ophthalmopathy, and acropachy (Fig. 169-1).

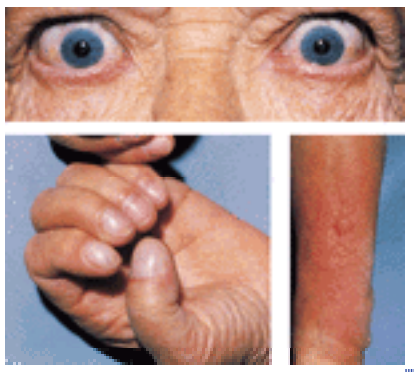

FIGURE 169-1 Graves' disease. This composite illustrates the proptosis, acropachy, and pink or skin-colored papules, plaques, and nodules of pretibial myxedema.

Pretibial myxedema is a misnomer because lesions may appear on the arms, shoulders, head, neck, or at sites of trauma or scars. It may present in 0.4 percent to 4 percent of patients with Graves' disease in the setting of a hyperthyroid, hypothyroid, or euthyroid state. It has also been reported in patients with Hashimoto's thyroiditis. The usual presentation is that of bilateral, asymmetric, raised, firm plaques or nodules of a pink to purple-brown hue (Fig. 169-2). The depth and degree of cutaneous glycosaminoglycan infiltration result in appearances ranging from a “peau d'orange” over the shins and feet to elephantiasis nostras verrucosa. Hyperhidrosis and hypertrichosis may overlie the affected areas in rare cases. Ophthalmopathy usually accompanies cutaneous findings, but even the most extreme forms of dermopathy (elephantiasic) have been reported to occur in the absence of periocular findings. [8]

FIGURE 169-2 Hyperthyroidism with pretibial myxedema. Note infiltrated plaques that also extend to the calf and are partially hyperkeratotic. There is also an isolated nodule on the dorsum of the right foot.

Thyroid acropachy is a triad consisting of digital clubbing, soft tissue swelling of the hands and feet, and periosteal new bone formation. It is the least frequent manifestation of hyperthyroidism, and fewer than 100 cases have been reported, with 95 percent of those affected developing the condition after the diagnosis and treatment of thyrotoxicosis. It can also occur in the setting of Hashimoto's thyroiditis and H¨rthle cell adenocarcinoma. Graves' disease is associated with other autoimmune disorders, including bullous diseases (pemphigus vulgaris, pemphigus foliaceus, bullous pemphigoid, and herpes gestationis), Sweet's syndrome, and vitiligo. Chronic urticaria and angioedema are linked to thyroid autoimmunity. [7] The pathogenesis of myxedematous dermopathy is unclear. Histologically, dermopathy presents as an accumulation of hyaluronic acid in the dermis and sometimes the subcutis. Marked hyperkeratosis may be present in verrucous lesions. It is postulated that a target cell in the skin, most likely the fibroblast, is stimulated to produce abnormally high amounts of glycosaminoglycans by autoantibodies directed against thyroid antigen(s). Another possibility is that T cells that react with the TSH receptor are targeted to the skin and, in the presence of antigen, secrete cytokines to stimulate production of hyaluronic acid. [9] A third theory is that Graves' dermopathy and ophthalmopathy are the product of local factors such as edema and trauma in the setting of a connective tissue inflammation, leading to a decrease in the return of lymphatic fluid and a prolonged half-life of fibroblast-stimulating cytokines, which, in turn, cause an increased deposition of glycosaminoglycans in affected tissues. [10] However, fibroblasts have not been confirmed to be the source of deposited glycosaminoglycans; other possible sources are adipocytes, keratinocytes, and endothelial cells. [3] The management of dermopathy remains problematic, as lesions do not resolve with resolution of the thyroid hormone abnormality. Surgery should be avoided. Topical and intralesional glucocorticoids have demonstrated value, and case reports exist of improvement after intravenous glucocorticoids followed by oral glucocorticoids. Newer therapies include the use of octreotide, a somatostatin analogue that appears to work by suppressing insulin-like growth factor-I activity. Intravenous immunoglobulin (IVIG) has also been used effectively and is believed to function either as an immunomodulatory agent that decreases autoantibody production or by stabilizing immune complexes. Pentoxifylline decreases production of glycosaminoglycans by fibroblasts in vitro. Adjunctive compression therapy is often valuable.

Cutaneous Manifestations of Hypothyroidism

Hypothyroidism is the result of inadequate circulating thyroid hormone, or, rarely, of peripheral resistance to hormone stimulation. Primary hypothyroidism is the most common form of hypothyroidism; it is caused by glandular failure that results from autoimmune destruction, previous therapy with ^{131}I, thyroid surgery, administration of antithyroid drugs, or infiltrative disease. Secondary hypothyroidism and tertiary hypothyroidism are caused by pituitary and hypothalamic dysfunction, respectively. Secondary hypothyroidism results from a defect in TSH release due to tumor, infarction, trauma, radiation, or surgical treatment of the pituitary gland. Secondary hypothyroidism is usually accompanied by other endocrinopathies. Tertiary hypothyroidism is caused by similar etiologies; however, primary idiopathic hypothalamic hypothyroidism has been reported and is presumably secondary to a TRH deficiency, with pituitary function being normal.

The skin is cold, dry, and pale, particularly over extensor surfaces. Hypothermia and a reduced core body temperature result from a hypometabolic state and reflex cutaneous vasoconstriction. Pallor of the skin is a result of both peripheral vasoconstriction and increased amounts of water and mucopolysaccharides in the dermis, which alter the refraction of incident light. Despite pallor elsewhere, a malar flush may occur in up to 50 percent of patients. [11] Xerosis may be the result of a multitude of factors, including diminished epidermal sterol biosynthesis, diminished sebaceous gland secretion, and hypohidrosis secondary to eccrine apparatus changes. The dryness can become so severe that it resembles an acquired ichthyosis. The palms and soles can present as an acquired keratoderma. A yellowish hue, predominantly on the palms, soles, and nasolabial folds, may be present and is due to carotenemia because of a reduced capacity of the liver to synthesize vitamin A. Hair of the scalp and body is classically dry, coarse, and brittle, and tends to fall out, resulting in a diffuse or partial alopecia. Loss of the lateral third of the eyebrows is a characteristic finding. The rate of hair and nail growth is slowed, and nails tend to be thick and brittle with longitudinal and transverse striations.

The most classic cutaneous manifestation of hypothyroidism is generalized myxedema. In contrast to the dermopathy associated with Graves' disease, myxedema of hypothyroidism will disappear in time with correction of the level of thyroid hormone. The skin typically appears doughy, swollen, dry, pale, and waxy to the touch; however, despite the edematous appearance, it is nonpitting. The face manifests a characteristic appearance with a broad nose, swollen lips, macroglossia, puffy eyelids, and a flat affect (Fig. 169-3). The eyelids may droop as the result of decreased sympathetic stimulation of the superior palpebral muscle. Wound healing is impaired, and purpura may be a consequence of diminished clotting factors and/or the loss of vascular support secondary to the dermal mucin. [3]

FIGURE 169-3 Hypothyroidism. This patient has many of the typical features of hypothyroidism: a cold, dry, pale skin; absence of hair in the lateral third of the eyebrow; and a puffiness of the face and lips due to the accumulation of water and mucopolysaccharides in the dermis. The hair is dry, coarse, and brittle. The nose is broadened; the tongue is large, smooth, red, and clumsy; and there is drooping of the eyelids. The face lacks expression and is the most pathognomonic of any of the features.

The pathogenesis of myxedema may be explained by the deposition of dermal acid mucopolysaccharides, especially hyaluronic acid and chondroitin sulfate, which are hygroscopic and accumulate water. This is presumably secondary to increased production by skin fibroblasts that in vitro accumulate hyaluronate in the absence of T3. [12] Extravascular accumulation of albumin and inadequate lymphatic drainage may also contribute to the edematous state.

There are several associations of other disorders with autoimmune-related hypothyroid states. Alopecia areata, pernicious anemia, dermatomyositis, polymyositis, myasthenia gravis, pemphigoid, dermatitis herpetiformis, and Norwegian scabies are all associated with Hashimoto's thyroiditis. There has also been reported a relationship between primary hypothyroidism and chronic mucocutaneous candidosis, which appears to be manifest as an autosomal dominant syndrome with no identifiable autoantibodies. [13]

PARATHYROID HORMONE

Physiology of Parathyroid Hormone and the Skin

Parathyroid hormone (PTH) maintains homeostasis of calcium levels in the body through various mechanisms, including the stimulation of vitamin D production, which, in turn, promotes gastrointestinal absorption of calcium, increases renal reabsorption of calcium, decreases renal reabsorption of phosphate, and mobilizes calcium from bone. The release of PTH is regulated by circulating levels of ionized calcium. Cutaneous manifestations of PTH abnormalities are primarily the result of the dysregulation of calcium.

The effects of PTH on the skin have not been fully elucidated. PTH-like protein is present in keratinocytes and is implicated in keratinocyte growth and dermal fibroblast function. PTH-like protein has also been linked to skin wound healing, squamous neoplasms, and control of the hair growth cycle. [14], [15]

Cutaneous Manifestations of Hyperparathyroidism

Skin manifestations in hyperparathyroidism are uncommon. When associated with a calcium phosphate product (serum calcium × serum phosphate) of greater than 65 to 70 mg/dL, subcutaneous calcifications can be seen, usually overlying large joints as linearly arranged firm white papules, or as infiltrating plaques. Histologically, large subcutaneous deposits of von Kossa–positive material, with a foreign-body reaction consisting of histiocytes, giant cells, and fibrosis, appear. Lesions do not contain true cutaneous ossification in contrast to the lesions of pseudohypoparathyroidism and Albright's syndrome, in which cutaneous osteocytes, true bony spicules, and haversian canals can be seen. Subcutaneous calcification can be associated with severe pruritus that improves with normalization of mineral levels or ultraviolet light. [1] Chronic urticaria has been reported with primary hyperparathyroidism, with resolution of symptoms after parathyroidectomy. [16]

An important association is that of hyperparathyroidism and potentially life-threatening calciphylaxis. Although calciphylaxis is more commonly reported in chronic renal failure with secondary hyperparathyroidism, there have been reports of occurrence with primary hyperparathyroidism in the absence of renal abnormalities. Calciphylaxis typically presents as violaceous, mottled to reticulated patches and plaques with occasional bullae. Lesions evolve into painful necrotic, indurated plaques, nodules, and ulcers with a thick, dark eschar. They are most common on the lower extremities but can also appear on the trunk. Acral gangrene that necessitates amputation may occur. Histologically, calcium deposits are present in the walls of small- to medium-sized vessels in the dermis and subcutaneous fat. Fibroblast proliferation and giant cell formation may lead to fibrosis, intimal hyperplasia, and, occasionally, thrombosis of the vessel, which, in turn, result in ischemia and necrosis of the skin. [17] The cause of calciphylaxis is not clear, although hypercoagulable states and microorganisms capable of inducing calcium salt deposition have been implicated in the pathogenesis. The prognosis is poor, with the mortality rate as high as 80 percent; death usually ensues secondary to overwhelming infection. Total or subtotal parathyroidectomy is the treatment most frequently reported to have the best results. [17]

Hyperparathyroidism in the setting of multiple endocrine neoplasia type 1 (MEN1) is associated with multiple angiofibromas (particularly on the face), collagenomas, and lipomas, which are presumably related to allelic deletion of

the *MEN1* gene. [18]

Cutaneous Manifestations of Hypoparathyroidism

Hypoparathyroidism results from a disruption in the parathyroid hormonal axis. There may be a PTH deficiency secondary to a congenital absence of the parathyroid gland (as in DiGeorge's syndrome), destruction of the parathyroid gland as a result of thyroid surgery (the most common cause), infiltration (hemochromatosis) and invasion (metastatic cancer), or resistance of target cells to normal or elevated levels of PTH. Idiopathic hypoparathyroidism also exists, often related to a multiple endocrine deficiency syndrome.

Hypoparathyroidism presents with scaly, hyperkeratotic, and puffy skin. Hair may demonstrate patchy alopecia or generalized thinning with coarse texture. Nails can become opaque and brittle with transverse ridges. [1] Impetigo herpetiformis, eczematous dermatitis, and psoriatic flares have also been reported in association with hypoparathyroidism. Normalization of the calcium level is usually accompanied by resolution of the skin abnormalities, and thus calcium is implicated in the pathogenesis of skin changes, as opposed to a deficiency of PTH directly.

Idiopathic hypoparathyroidism may present with prominent ectodermal malformations including skin abnormalities, dental changes, and chronic mucocutaneous candidiasis. Ectodermal defects, which occur in 50 percent of patients with idiopathic hypoparathyroidism, manifest as dry, scaly skin, dental abnormalities (anodontia, hypoplasia, alveolar bone changes, abnormally spaced dentition, stumpy roots, and a thickened lamina dura), and nail changes. Nails tend to be thin and brittle, may split or crumble at the free edge, and have characteristic transverse grooves. Chronic mucocutaneous candidiasis occurs in 15 percent of patients with idiopathic hypoparathyroidism and can present with nail, paronychial, vaginal, oral, and rarely laryngeal and pulmonary involvement. It can precede the diagnosis of hypoparathyroidism by years. The pathogenesis of chronic mucocutaneous candidiasis is unclear, although a deficiency in cell-mediated immunity has been implicated. Treatment of the underlying hypoparathyroidism with calcium and vitamin D does not lessen the susceptibility to chronic candidal infections. [19]

GLUCOCORTICOIDS

Physiology of Glucocorticoids and the Skin

Glucocorticoids are regulated by the hypothalamic-pituitary-adrenal axis. Corticotropin-releasing hormone (CRH), the most potent regulator of corticotropin secretion, is released from the hypothalamus, traverses the hypophyseal portal system to the pituitary, and stimulates secretion of adrenocorticotropic hormone (ACTH). ACTH is derived from a precursor molecule, pro-opiomelanocortin, which gives rise to other molecules besides ACTH, including ß-lipoprotein, ß-endorphin, and alpha-melanocyte–stimulating hormone (a-MSH). ACTH enters the systemic circulation to stimulate the adrenal cortex to secrete cortisol, which exerts negative feedback on pituitary ACTH secretion.

Glucocorticoids regulate tissue metabolism through binding to cytosolic receptors and traversing nuclear membranes to interact with DNA in the cell nucleus. In the skin, glucocorticoids cause profound effects through regulation of cell cytokine production and the inflammatory response, collagen synthesis, keratinocyte growth and differentiation, wound healing, glycosaminoglycan synthesis, and hair growth.

Glucocorticoids inhibit the inflammatory reaction in the epidermis through a variety of mechanisms. Glucocorticoids regulate cytokines involved in the inflammatory process such as interleukin (IL)-1, IL-1a, tumor necrosis factor-a (TNF-a), interferon-?, IL-2, and migration inhibitory factor. [20] The numbers of resident Langerhans cells in the epidermis are decreased with the use of topical glucocorticoids. [20] The mechanisms of these cutaneous actions remain unknown.

Glucocorticoids affect keratinocyte growth, differentiation, and wound healing. Histologic examination of skin exposed to cortisol demonstrates a noncornified epidermis, flattening of the epidermal granular layer, and a reduced size and number of keratohyalin granules. [2] It has been proposed that one reason for these changes is a glucocorticoid effect on keratinocyte growth factor (KGF). Glucocorticoids inhibit KGF mRNA production in dermal fibroblasts by reducing the rate of KGF gene transcription and by causing destabilization of KGF mRNA. [21] Glucocorticoids may also have a deleterious effect on wound healing through inhibition of the production of collagen VII, an important component of anchoring fibrils in the basement membrane zone, which is expressed in both epidermal keratinocytes and dermal fibroblasts. [22]

Glucocorticoids induce significant skin atrophy, possibly by affecting glycosaminoglycan regulation. Glucocorticoids reduce the tissue content of glycosaminoglycan, particularly hyaluronic acid, through inhibition of hyaluronan synthase in dermal fibroblasts. [23] Additionally, glucocorticoids dramatically reduce the synthesis of collagen types I and III, which constitute 70 to 80 percent and 15 percent of the total skin collagen, respectively. [24]

Glucocorticoids inhibit hair formation by blocking expression of hair-forming genes at the point of anagen initiation. [25] Despite this finding, hirsutism is a common complaint in syndromes of hypercortisolism, most commonly manifested by vellus hypertrichosis of the forehead or upper cheeks. Signs of virilization, with terminal hair growth on the face and body in women, and development of pattern thinning of scalp hair, is usually secondary to associated adrenal-derived androgen excess.

Glucocorticoids do not directly affect skin pigmentation; however, regulatory elements of the hypothalamus-pituitary-adrenal axis (ACTH, a-MSH, and beta-lipoprotein) do induce pigmentary changes. Both ACTH and a-MSH stimulate melanogenesis in the skin.

Cushing's Syndrome

Cushing's syndrome of chronic glucocorticoid excess may be induced by ACTH-dependent and independent mechanisms. In 60 to 80 percent of cases, hypercortisolism is caused by Cushing's disease, which is defined as pituitary-dependent Cushing's syndrome, and is most commonly caused by ACTH overproduction from a pituitary microadenoma. [26] Other causes include iatrogenic Cushing's syndrome (secondary to glucocorticoid therapy), ectopic ACTH production (secondary to small cell lung cancer and other malignancies), ectopic CRH, adrenal adenoma, adrenal carcinoma, and adrenal hyperplasia.

Cutaneous manifestations of Cushing's syndrome mirror the previously described biologic effect of excess glucocorticoids. The skin is atrophic, smooth, and transparent, often described as paper-thin, with decreased collagen, elastic fibers, ground substance, and epidermal thinning. Mild trauma may cause tearing, ulceration, purpura, and ecchymoses, and wound healing is poor. Underlying vasculature may be more easily visualized and may be accompanied by broad purple striae, particularly on the abdomen, arms, and thighs. [27] The striae have significant depth, breadth, and intensity of color, which differentiate them from striae common in pregnancy, obesity, and adolescence. Striae continue to be present even after the hypercortisolism is corrected. Petechiae and a purplish mottling (cutis marmorata) are common on the lower extremities, secondary to decreased vascular tone. The face may have a plethoric appearance with telangiectasias related to vascular proliferation, polycythemia, and erythrocytosis.

Glucocorticoids cause a profound redistribution of subcutaneous fat, resulting in moon facies (full, round facies); a buffalo hump; increased fat in the supraclavicular fossae, over the dorsal cervical vertebrae, and around the pelvic girdle; and a relative lack of fat deposition over the extremities (Fig. 169-4). [27] Compression fractures of the spine may result in pronounced kyphosis and decreased height. Suppression of growth hormone in children may lead to compromised adult height. [28]

FIGURE 169-4 Cushing's syndrome. Plethoric moon facies.

Suppression of immune function is evidenced by a variety of infections. Patients are particularly susceptible to cutaneous fungal infections by *Malassezia furfur* and *Trichophyton rubrum,* resulting in tinea versicolor and chronic nail, toe web, inguinal, trunk, and buttock infections. These infections may resolve with treatment of the underlying excess glucocorticoid state.

Steroid acne may occur, and is composed of monomorphic, small pustules and erythematous papules in the absence of open comedones, with a predilection for the trunk, shoulders, and arms, with the face less often affected. Acne vulgaris may become aggravated in the setting of concomitant androgen excess.

When the etiology of Cushing's syndrome is Cushing's disease or ectopic ACTH production, generalized hyperpigmentation, identical to that seen in Addison's disease, may also be present. Sex hormone disruption may also occur in Cushing's syndrome when the adrenal glands are involved in the pathogenesis. This may manifest as hirsutism, and/or male pattern baldness in females and prepubertal children, feminization in males, or acanthosis nigricans. [27]

Addison's Disease

Addison's disease is defined as primary adrenocortical insufficiency, which leads to inadequate amounts of both glucocorticoids and mineralocorticoids. In 60 to 70 percent of cases, the cause is autoimmune adrenalitis in which complement-fixing adrenocortical autoantibodies destroy adrenocortical tissue. The steroid-producing enzyme 21-hydroxylase is a target antigen. Other possible etiologies for adrenal destruction include infectious causes (tuberculosis and systemic fungal infections, including coccidioidomycosis, histoplasmosis, and cryptococcus), infiltrative causes (metastatic cancer, sarcoidosis, or amyloidosis), adrenoleukodystrophy, hemorrhage, and Waterhouse-Friderichsen syndrome. [29] Primary adrenal insufficiency may also occur as congenital adrenal hypoplasia.

The most classic clinical manifestation of Addison's disease is hyperpigmentation. Sun-exposed areas may be affected (face, neck, and arms) leading patients to attribute the appearance to a persisting suntan. Hyperpigmentation commonly occurs in flexural areas, or sites of frequent pressure, such as intertriginous folds, axillae, perineum, nipples, knuckles, knees, and elbows. Scars and preexisting nevi may be accentuated, and new nevi may appear. In patients with lighter skin types, hyperpigmentation of the palmar creases is highly indicative of Addison's disease (although it may also be seen in pernicious anemia), whereas in darker skin types, it is a normal variant (Fig. 169-5). Mucous membranes are frequently affected, and hyperpigmentation may be seen in the mouth (buccal mucosa, gums, and tongue), vagina, and

anus. Although this appearance may also exist as a normal variant in darker skin types, when it is present in multiple sites, or extensive in nature, it suggests the diagnosis of Addison's disease. The nails may be affected and manifest longitudinal pigmented bands. [27] Generalized xerosis is common and is thought to arise from excess salt on the stratum corneum and/or disrupted keratinocyte differentiation. [27] Congenital adrenal atrophy or hypoplasia occurs in 1 of 12,500 births and may manifest with hyperpigmentation ranging from generalized coal-black at birth (rarely) to gradually increasing pigmentation over the first months to years of life. [30]

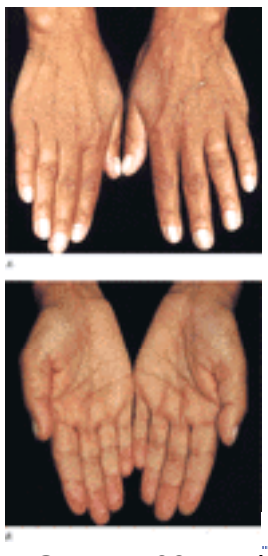

FIGURE 169-5 Addison's disease. Hyperpigmentation of the hands: (*A*) dorsa; (*B*) palmar creases.

Symptoms of adrenocortical insufficiency may not appear until 90 percent of the adrenocortical tissue is lost. In addition to hyperpigmentation, patients may present with weakness, fatigue, depression, salt craving, diarrhea, weight loss, anorexia, nausea, vomiting, hypotension, syncope, and addisonian crisis. The latter is a rapidly deteriorating clinical setting of hypotension, shock, hypoglycemia, and hyperkalemia. [29]

Hyperpigmentation in primary adrenal insufficiency results from a disruption in the negative feedback pathway of glucocorticoids and ACTH. As previously detailed, glucocorticoids suppress ACTH production in the pituitary gland. In the absence of glucocorticoids, excess proopiomelanocortin is produced, leading to increased levels of ACTH and MSH peptides. ACTH and a-MSH then stimulate melanogenesis to cause hyperpigmentation. Correction of glucocorticoid levels suppresses ACTH and MSH levels and results in a gradual disappearance of increased pigment.

In addition to loss of glucocorticoids, androgen production by the adrenal glands is disrupted in primary adrenal insufficiency. Ambisexual hair (axillary and lower pubic triangle) is lost in postpubertal females and fails to grow in prepubertal females. Glucocorticoid replacement can partially reverse this occurrence. Postpubertal males do not manifest similar findings because production of testosterone by the testes overshadows the loss of adrenally derived androgens.

Other cutaneous findings in Addison's disease include fibrosis and calcification of ear cartilage with long-standing adrenal insufficiency, vitiligo, and mucocutaneous candidiasis in association with polyendocrine autoimmune failure syndrome type I. [27] Other autoimmune disorders may occur in conjunction with Addison's disease. When present with autoimmune thyroid disease (Graves' disease for example) and/or insulin-dependent diabetes mellitus, the association is referred to as polyglandular autoimmune syndrome type II.

GONADAL HORMONES

Physiology of Sex Hormones and the Skin

Gonadal hormones in general exert a trophic effect on cutaneous cells with a predilection for hair follicles, sebaceous glands, and sexual zones. The response of gonadal hormones is regulated by cutaneous receptors, which have varying density and expression levels depending on anatomic site and gender. Gonadal hormones exert their effect similarly to glucocorticoids in that they bind to cytosolic receptors, traverse nuclear membranes, and act directly to stimulate mRNA transcription. [31] Gonadal hormone receptors are not entirely specific, and cross-reactivity may occur. For example, progesterone is able to bind to androgen receptors and exert either androgenic or antiandrogenic effects, depending on the site of action, and may downregulate estrogen receptor expression at other receptor sites. [2] Both androgens and estrogens are implicated in the regulation of hair growth, sebaceous gland function, proliferation and differentiation of epithelial cells of the epidermis and adnexa, functional activity of dermal fibroblasts and fibrocytes, wound healing, and skin immune cell activity. [31] Androgens and estrogens stimulate collagen synthesis, maturation, and turnover in the dermis; however, their effect on dermal ground substance may differ. [2] Melanocytic proliferation and melanogenesis are regulated by both androgens and estrogens, but the mechanism is unclear.

Androgens promote hair growth in the beard, axillary, and pubic regions while playing a primary role in the development of androgenetic alopecia in susceptible individuals. Androgens also promote sebaceous gland function (with increased sebum production and secretion), epithelial cell differentiation via androgen receptors in epithelial cells of hair follicle and sebaceous gland structures, and in specialized dermal papilla fibroblasts that regulate hair morphogenesis. Androgen receptors have been found in epidermal keratinocytes, melanocytes, dermal fibroblasts, and resident and circulating immune-related cells. [31] Both keratinocytes and hair follicle cells harbor 5a-reductase, the enzyme that converts circulating testosterone to the potent androgen dihydrotestosterone (DHT). DHT is primarily responsible for end-organ

effects of androgen receptor binding, including androgenetic alopecia, hirsutism, and acne. It is necessary for development of male beard growth, whereas testosterone alone may stimulate axillary and pubic hair growth. [32]

Estrogen receptors are expressed in epithelial cells of the epidermis, hair follicle, sebaceous glands, eccrine, and apocrine glands; in melanocytes; and in dermal fibroblasts. [31] Estrogens tend to inhibit hair growth and decrease sebaceous gland function. Cutaneous estrogen receptors have been found in greater number in women than in men, especially in the face and lower extremities. Estrogens may have a role in cutaneous vascularization, prevention of epidermal atrophy, dermal ground substance and collagen composition, and stratum corneum barrier function. [33]

Cutaneous Manifestations of Androgen Excess

Androgen excess may occur in various settings. Adrenal and ovarian tumors may produce androgens or androgen precursors; and congenital adrenal hyperplasia due to a deficiency in 11-hydroxylase, 21-hydroxylase, or 3ß-hydroxylase steroid dehydrogenase can result in increased androgen precursors. Polycystic ovarian syndrome in women is a major cause of virilization with increased plasma androgen levels as well as increased levels of luteinizing hormone. Exogenous glucocorticoid, testosterone, and oral contraceptives may all act at androgen receptors to provoke hirsutism or virilization. Relative androgen excess may result from altered cutaneous metabolism of circulating hormones. For example, the enzyme 5a-reductase is increased in pubic and labial skin of hirsute women, and urinary concentrations of DHT metabolites have been found in hirsute women, raising the possibility that cutaneous metabolism of androgens may be an independent risk factor in the development of virilization and hirsutism in women. [27]

The primary clinical manifestations of androgen excess are acne, hirsutism, and virilization in women, and precocious puberty in prepubertal children. Body hair growth is accelerated with coarse, heavy, thick, pigmented hair on the chest, abdomen, extremities, and bearded areas. Women may develop menstrual irregularities, clitoromegaly, increased muscle mass and loss of typical female-distributed fat over the thighs and shoulders, and androgenetic alopecia (vertex thinning with temporal hair recession). Men may manifest increased muscle mass as well as hypertrophy of the penis, with accentuation of scrotal folds. Sebaceous glands are stimulated, resulting in enlargement of facial pores, oily residue, and exacerbation or production of acne vulgaris. Hyperpigmentation may occur both in erogenous skin (genitalia, areolae, and nipples) and elsewhere. Children may develop pubic and axillary hair prematurely. Accelerated bone growth and premature epiphyseal closure with resultant relatively short stature may occur. [27]

Cutaneous Manifestations of Androgen Deficiency

Androgen deficiency may result from either inadequate production (gonadal failure, destruction, or lack of stimulation) or end-organ unresponsiveness. In the setting of inadequate testosterone production by the testes in males, with retained adrenal androgen production, ambisexual hair in the pubic region and axillae develops, but remains sparse.

In prepubertal males, a eunuchoid appearance occurs with maintenance of childhood-like fine, thin skin with small pores, the absence of sebaceous and apocrine maturation, and lack of acne vulgaris. Secondary sexual characteristics of facial, chest, and abdominal hair do not develop. The penis remains small, and the scrotum is smooth. Body habitus remains child-like, with poor muscular development and delayed closure of the epiphyses, resulting in disproportionate increased height because of the length of extremities.

Males in the postpubertal stage are less dependent on large amounts of androgens to maintain secondary sexual characteristics and, depending on the etiology and degree of androgen loss, may show little change. Although coarse hair is present on the extremities, trunk, and face, growth may be noticeably slowed. Sebaceous glands, requiring constant androgen stimulation, cease to be active, leading to decreased sebum deposition and resolution of acne vulgaris. Pallor of both genital and nongenital skin is due to both decreased pigment and reduced cutaneous blood flow. Flushing may occur in the setting of acute testicular failure and may manifest as sweating and flush of the face and neck. The administration of exogenous androgens reverses all skin changes associated with deficiency. [27]

Cutaneous Manifestations of Estrogen Excess

Estrogen excess can result from excess secretion by ovarian, testicular, or hypothalamic tumors, or more commonly, from oral contraceptive and hormonal replacement therapy in women, and pregnancy. In men, estrogen excess is manifest as gynecomastia, which may exist alone or in combination with testicular atrophy and manifestations of androgen deficiency. In prepubertal females, precocious puberty may occur with development of secondary sexual characteristics. Genitalia display maturation of the vaginal epithelium, breasts develop, axillary and pubic hair arise, and there is premature epiphyseal closure with resultant relative shortening in height. The menstrual cycle may also begin. In cases of adrenal or ovarian pathology, excess secretion of androgens may occur simultaneously, with concomitant manifestations of androgen excess (acne, hirsutism, and clitoromegaly). [27]

Exogenous estrogens from oral contraceptives or hormonal replacement can have both beneficial and undesired effects. In postmenopausal women, estrogen therapy appears to reverse epidermal atrophy and to prevent or restore cutaneous collagen with a beneficial effect on cutaneous extensibility. Estrogen therapy also increases the water-holding capacity of the stratum corneum with potential improvement in the epidermal barrier. [33] Estrogen therapy inhibits sebum production, and acne may improve with the use of estrogen dominant oral contraceptives. In pregnancy, however, acne may become exacerbated due to relative androgen excess with elevated progesterones. [27]

Undesired effects of estrogens include telangiectasias, palmar erythema, and spider angiomas, which appear with increased frequency in pregnant women and those taking synthetic estrogens. Pigmentary changes are frequent. For example, melasma may present with mottled or hyperpigmented irregularly shaped macules and patches over the forehead, cheeks, upper lip, nose, chin, and neck. Hyperpigmentation of the nipples, linea nigra, and genitalia may occur, acanthosis nigricans may develop, and preexisting nevi may darken. Because exposure to ultraviolet light may

accentuate the pigmentation, the use of broad-spectrum sunscreen is recommended. Melasma may fade completely with delivery, although it frequently recurs with subsequent pregnancies. Conversely, in patients in whom oral contraceptive use results in melasma, cessation of the drug therapy rarely results in complete disappearance of pigmentary changes. Hirsutism over the face, breasts, and extremities may develop in pregnancy and with oral contraceptive use, secondary to estrogen stimulation of hair growth. Telogen effluvium may develop after delivery or cessation of oral contraceptive medication, with a diffuse loss of scalp and body hair. [27]

Estrogens have been implicated in the enhancement of autoimmune processes. Specifically, hormone replacement therapy has been linked to increased risk of systemic lupus erythematosus, herpes gestationis, and erythema nodosum. Estrogen dermatitis has been described and is marked by cyclic perimenstrual flares with clinical manifestations that include pruritus (either localized or generalized), urticaria, vesicles, papules, and eczematous eruptions. Familial porphyria cutanea tarda (type II) may be induced by estrogen therapy in those patients with the underlying enzymatic deficiency. The mechanism is not well defined. [33]

Cutaneous Manifestations of Estrogen Deficiency

Estrogen deficiency most commonly arises as a component of menopause in women aged 49 to 51 years. Estrogen deficiency may also arise from either pituitary or gonadal failure. Vasomotor instability (hot flashes), atrophy of urogenital epithelium, and decreased breast size are the most common manifestations of estrogen deficiency. [27] Estrogen therapy reverses these changes in most women, although the benefits and risks of hormone replacement therapy must be weighed on an individual basis.

OTHER PITUITARY HORMONES

Physiology of Growth Hormone

Growth hormone (GH) secretion from the adenohypophysis of the pituitary gland is regulated by GH-releasing hormone (GHRH) and somatostatin, which exerts an inhibitory effect on GH secretion. GH is secreted in a pulsatile manner; consequently, single measurements are not reliable diagnostic indicators for abnormalities in GH levels. Once released into the systemic circulation, GH stimulates the synthesis and release of insulin growth factor-1 (IGF-1; somatomedin C) from the liver, as well as other sites.

GH receptors have been detected in human epidermis, hair follicles, eccrine glands, dermal fibroblasts, adipocytes, Schwann cells, and myocytes. [31] This finding suggests a direct effect of GH on the skin; however, IGF-1 is implicated in many of the manifestations of GH dysregulation. Specifically, IGF-1 is implicated in the dermal proliferation in acromegaly manifested by connective tissue proliferation, accumulation of intercellular matrix, and the deposition of hyaluronic acid with subsequent interstitial edema. [1]

Cutaneous Manifestations of Growth Hormone Excess

Acromegaly, the clinical state of GH hypersecretion, is the result of a GH-secreting pituitary adenoma in greater than 98 percent of cases. [34] Acromegaly may also result from disordered hypothalamic function (excess GHRH or deficient somatostatin secretion or action), GH-secreting pituitary carcinoma, ectopic GH secretion (pancreas, adrenal, breast, and ovary), or lymphocytic hypophysitis.

The most striking clinical manifestation of GH excess is coarsening of the facial features because of dermal thickening (Fig. 169-6). This dermal thickening results in accentuation of facial, neck, and scalp creases, leading to deep folds and furrows, and imparting a corrugated appearance to the surface of the scalp and neck (cutis verticis gyrata). [1] Although obvious in retrospect, the changes occur slowly, and only infrequently do patients consult their physician for this condition. [35] The hands and feet may become swollen, doughy, and blunted, with increased ring, glove, and shoe size. Heel pad thickness increases, and measurements with x-ray or ultrasound are used to follow response to therapy. [1] The lips may become large and protruding, the eyelids may thicken, macroglossia may occur, and the nose may widen with a characteristic triangular shape. The nails may thicken; the skin may darken moderately, with acanthosis nigricans being a common presenting feature; and the numbers of small fibromas and fibroepithelial polyps may increase. Patients with increased numbers of fibroepithelial polyps may also have increased numbers of adenomatous polyps of the colon and a potential for increased malignancy of the gastrointestinal tract. [35]

FIGURE 169-6 Acromegaly. Coarse facies with enlargement of the nose, chin, hands, and fingers.

GH affects sebaceous and eccrine structures, resulting in increased size and function of sebaceous glands and sweat glands in acromegaly. This condition may be accompanied by an offensive odor and oily residue in areas of sebaceous secretion with the potential for exacerbation of acne vulgaris. [1] Body hair may be coarse. Other characteristics of

acromegaly include osteoarthritis, headaches, fatigue, visual abnormalities, peripheral neuropathies, and sleep apnea. Associated gonadal hormone disruption may lead to ovulatory dysregulation, amenorrhea, and galactorrhea in women and hypogonadism with decreased libido in men. [34] Diagnosis is difficult because the clinical presentation may be confounded by plurihormonal tumors that secrete both GH and one or more anterior pituitary hormones such as prolactin. With successful treatment of the underlying abnormality and normalization of GH levels, the signs of dermal proliferation can regress within days to weeks.

Cutaneous Manifestations of Growth Hormone Deficiency and Panhypopituitarism

The destruction of the pituitary gland through any means, including postpartum hemorrhage (Sheehan's syndrome), mass effect (pituitary adenoma or craniopharyngioma), infiltration (sarcoidosis, neoplasm), and infection (tuberculosis), may create a deficiency in the hormones that the gland secretes and regulates. The simultaneous loss of multiple hormones may lead to cutaneous effects that differ from those produced by the loss of any single hormone. For instance, hypothyroidism secondary to pituitary failure results in less myxedema than elicited by primary hypothyroidism, as the other hormones required for expression of myxedema are also absent. Moreover, most endocrine glands controlled by the pituitary retain a basal level of hormonal secretion, even after pituitary destruction, resulting in less severe deficiency than that observed in primary end-organ failure. [1]

In solitary GH deficiency, skin thickness and total skin collagen are reduced and sweat secretion rates are lowered, all of which may have implications in the reduced exercise capacity of GH-deficient patients. [36] In panhypopituitarism, the skin is typically xerotic, with fine wrinkling around the eyes and mouth, imparting an aged appearance. The nails may be thin, brittle, slow growing, and opaque. Pallor may be evident as a result of anemia and decreased cutaneous blood flow. Carotenemia may be present. Melanin content is decreased resulting in increased sensitivity to sunlight.
Hypopigmentation may be generalized. Hypotrichosis may present with generalized hair thinning of the scalp, beard, and pubic regions with loss of axillary hair. Eccrine and sebaceous gland secretion may be diminished.

REFERENCES

1. Feingold KR, Elias PM: Endocrine-skin interactions. *J Am Acad Dermatol* **17**:921, 1987

2. Grando SA: Physiology of endocrine skin interrelations. *J Am Acad Dermatol* **28**:981, 1993

3. Heymann WR: Cutaneous manifestations of thyroid disease. *J Am Acad Dermatol* **26**:885, 1992

4. Leonard J, Koehrle J: Intracellular pathways of iodothyronine metabolism, in *Werner and Ingbar's The Thyroid: A Fundamental and Clinical Text*, edited by LE Braverman, RD Utiger. Philadelphia, Lippincott Williams & Wilkins, 2000, p 162

5. Pazos-Moura CC et al: Nail fold capillaroscopy in hypothyroidism and hyperthyroidism: blood flow velocity during rest and postocclusive reactive hyperemia. *Angiology* **49**:471, 1998

6. Banba K et al: Hyperpigmentation caused by hyperthyroidism: differences from the pigmentation of Addison's disease. *Clin Exp Dermatol* **24**:196, 1999

7. Heymann WR: Chronic urticaria and angioedema associated with thyroid autoimmunity: Review and therapeutic implications. *J Am Acad Dermatol* **40**:229, 1999

8. Cho S et al: Graves' disease presenting as elephantiasic pretibial myxedema and nodules of the hands. *Int J Dermatol* **40**:276, 2001

9. Heymann WR: Advances in the cutaneous manifestations of thyroid disease. *Int J Dermatol* **36**:641, 1997

10. Rapaport B et al: Elephantiasic pretibial myxedema: insight into and a hypothesis regarding the pathogenesis of the extrathyroidal manifestations of Graves' disease. *Thyroid* **10**:685, 2000

11. Jabbour SA, Miller JL: Endocrinopathies and the skin. *Int J Dermatol* **39**:88, 2000

12. Hierholzer K, Finke R: Myxedema. *Kidney Int* **51**:S82, 1997

13. Coleman R, Hay RJ: Chronic mucocutaneous candidosis associated with hypothyroidism: a distinct syndrome? *Br J Dermatol* **136**:24, 1997

14. Blomme EA et al: Parathyroid hormone-related protein is a positive regulator of keratinocyte growth factor expression by normal dermal fibroblasts. *Mol Cell Endocrinol* **152**:189, 1999

15. Schilli MB et al: Control of hair growth with parathyroid hormone (7–34). *J Invest Dermatol* **108**:928, 1997

16. Leichty RD, Firminger HI: Hyperparathyroidism and urticaria. *JAMA* **250**:789, 1983

17. Oh DH et al: Five cases of calciphylaxis and a review of the literature. *J Am Acad Dermatol* **40**:979, 1999

18. Pack S et al: Cutaneous tumors in patients with multiple endocrine neoplasia type 1 show allelic deletion of the MEN 1 gene. *J Invest Dermatol* **110**:438, 1998

19. Kalb RE, Grossman ME: Ectodermal defects and chronic mucocutaneous candidiasis in idiopathic hypoparathyroidism. *J Am Acad Dermatol* **15**:353, 1986

20. Miyazaki Y et al: Glucocorticoids augment the chemically induced production and gene expression of interleukin-1a through NF-? B and AP-1 activation in murine epidermal cells. *J Invest Dermatol* **115**:746, 2000

21. Chedid M et al: Glucocorticoids inhibit keratinocyte growth factor production in primary dermal fibroblasts. *Endocrinology* **137**:2232, 1995

22. Gras MP et al: Downregulation of human type VII collagen (COL7A1) promoter activity by dexamethasone. Identification of a glucocorticoid receptor binding region. *Exp Dermatol* **10**:28, 2001

23. Zhang W et al: Glucocorticoids induce a near-total suppression of hyaluronan synthase mRNA in dermal fibroblasts and in osteoblasts: a molecular mechanism contributing to organ atrophy. *Biochem J* **349**:91, 2000

24. Autio P et al: Systemic glucocorticoids decrease the synthesis of type I and type III collagen in human skin in vivo, whereas isotretinoin treatment has little effect. *Br J Dermatol* **131**:660, 1994

25. Stenn KS et al: Glucocorticoid effect on hair growth initiation: A reconsideration. *Skin Pharmacol* **6**:125, 1993

26. Boscaro M et al: Cushing's syndrome. *Lancet* **357**:783, 2001

27. Feingold K, Elias P: Endocrine-skin interactions. *J Am Acad Dermatol* **19**:1, 1988

28. Stratakis C et al: Skin manifestations of Cushing disease in children and adolescents before and after resolution of hypercortisolemia. *Pediatr Dermatol* **15**:253, 1998

29. Erickson QL et al: Addison's disease: The potentially life-threatening tan. *Cutis* **66**:72, 2000

30. Jones D et al: Coal-black hyperpigmentation at birth in a child with congenital adrenal hypoplasia. *J Am Acad Dermatol* **33**:323, 1995

31. Slominski A, Wortsman J: Neuroendocrinology of the skin. *Endocrinol Rev* **21**:457, 2000

32. Fritsch M et al: Sebocytes are the key regulators of androgen homeostasis in human skin. *J Invest Dermatol* **116**:793, 2001

33. Mor Z, Caspi E: Cutaneous complications of hormonal replacement therapy. *Clin Dermatol* **15**:147, 1997

34. Melmed S et al: Recent advances in pathogenesis, diagnosis, and management of acromegaly. *J Clin Endocrinol Metab* **80**:3395, 1995

35. Ezzat S: Acromegaly. *Endocrinol Metab Clin North Am* **26**:703, 1997

36. Carrol P et al: Growth hormone deficiency in adulthood and the effects of growth hormone replacement: A review. *J Clin Endocrinol Metab* **83**:382, 1998

T>

Chapter 170

Eva Hurst Michael Heffernan

Cutaneous Changes in the Flushing Disorders and the Carcinoid Syndrome

FLUSHING
Clinical Evaluation
Flushing Syndromes
CARCINOID SYNDROME
Historical Aspects
Epidemiology
Etiology and Pathogenesis
Genetics
Clinical Manifestations
Pathology
Diagnosis
Treatment and Prognosis

REFERENCES

FLUSHING

Flushing is defined as episodes of erythema on the face, ears, and neck, and sometimes the upper chest and epigastric areas. [1] It is caused by a transient increase in cutaneous blood flow. The limited distribution of flushing can be accounted for by both greater capacitance of facial vasculature and greater visibility of blood vessels near the surface with less tissue to obscure them. [2], [3]

The mechanisms of flushing are classified according to the Burnstock-Iwayama model, which emphasizes dual control of vascular smooth muscle by nerves and circulating vasoactive agents. [4] Vasomotor innervation of cutaneous blood vessels consists of both vasodilatory and vasoconstrictor control, although active vasodilation, not release of vasoconstriction, is the mechanism that predominates in the scalp, forehead, cheek, chin, neck, and upper chest. [5] Because autonomic nerves also control eccrine sweat glands, sweating often accompanies flushing caused by autonomic vasodilation. Thus, it has been proposed that perspiration at the time of erythema, or “wet flushing,” can be distinguished from “dry flushing” caused by the direct action of vasoactive agents, in which there is no activation of eccrine sweating. [1]

Repeated episodes of flushing eventually lead to rosacea with fixed erythema, telangiectasias, and inflammatory changes. [6] The term *flushing* is sometimes misused to describe other conditions that can cause a red face, such as photosensitivity reactions, drug eruptions, lupus erythematosus, and seborrheic dermatitis. [2] However, flushing is transient, whereas these other disorders cause long-term reddening of the face. Because the differential diagnosis of flushing is broad (Table 170-1), the clinician must be aware of the possible causes of flushing and know when to investigate for internal disease.



TABLE 170-1 **Differential Diagnosis of Flushing Reactions**

Clinical Evaluation

Evaluation of the patient with flushing begins with a focused medical history that should consist of four key elements: provocative and palliative factors, morphology, associated findings, and temporal characteristics. [1] Key provocative factors to consider are alcohol, foods, drugs, emotional stimuli, and exposures. When flushing is associated with a systemic disease, it is common for a variety of nonspecific agents to trigger flushing, such as exercise, hot foods, and

stress.

Different causes of flushing often result in unique clinical presentations. For example, the presence of perspiration and its temporal relationship to the flush can help determine whether the flush is neurologically based. [1] The color of the flush, which may range from bright pink to cyanotic, is a clue, as is the presence of pallor or cyanosis preceding or following the flush. The physician must ask about the specific location of the flush, whether it is patchy or confluent, and if it occurs in a single phase or in discrete phases and stages.

Associated findings include abdominal cramping, diarrhea, headache, urticaria, pruritus, hypotension, tachycardia, and bronchospasm. Associated urticaria and pruritus should focus consideration on mast cell disorders, whereas cramping, diarrhea, and bronchospasm suggest the carcinoid syndrome. The patient should be questioned about psychologic symptoms such as anxiety, depression, or a vague sense of malaise or lethargy, as psychiatric disorders are occasionally the source of flushing. The age of onset, frequency (both original and current), and temporal patterns (e.g., only on the weekends) can also provide useful information. For example, flushing present since childhood could suggest Rovsing's syndrome; this condition occurs in patients with a horseshoe kidney and is characterized by flushing, abdominal pain, and nausea, which are relieved by an anteflexed posture. [7]

As patients often are not prepared to answer detailed historical questions at the first office visit, a 2-week diary can be helpful. [1] Patients are asked to record detailed qualitative and quantitative aspects of each flushing episode. All possible precipitating agents, including foods, drugs, alcohol, activities, exposures, and emotions, should be recorded. The 2-week diary often reveals the cause(s) of flushing, which can then be appropriately eliminated.

When the 2-week diary is inconclusive, it is advisable to place the patient on a diet that eliminates foods and additives high in histamines (see Table 170-1), alcohol, and hot foods and beverages that are commonly associated with flushing. Menopausal flushing should be treated with hormone replacement therapy or low-dose clonidine. The elimination of foods and additives that affect urinary excretion of 5-hydroxyindoleacetic acid (5-HIAA) (Table 170-2) also prepares the patient for diagnostic urine collection. If the exclusion diet eliminates flushing, then each item can be restored individually until the cause is discovered. [1] If flushing continues unabated despite the exclusion diet, systemic causes must be sought.

Foods and beverages
Hot (thermal) food/beverages
Spicy food
Chocolate
Cheeses
Tomatoes
Avocados
Red plums
Walnuts
Eggplant
Ingestion of any food
Alcohol
Emotional stress
Valsalva maneuver
Straining during defecation
Vigorous coughing
Sudden, direct pressure on a large carcinoid tumor
Physical examination
Intraoperative manipulation
Spontaneous

SOURCE: Wilkin JK: Skin changes in the flushing disorders and the carcinoid syndrome, in Dermatology in General Medicine, Vol 1, 3rd Ed., edited by IM Freedberg, AZ Eisen, K Wolff, KF Austen, LA Goldsmith, SI Katz, TB Fitzpatrick, New York, McGraw-Hill, 1993, p. 1990.

TABLE 170-2 **Factors That Precipitate Flushing in the Carcinoid Syndrome**

Flushing Syndromes

BLUSHING Blushing, or emotional flushing, is very common, although it infrequently causes patients to seek medical attention. If severe, this type of flushing is often accompanied by sweating, indicative of its neurologic origin. Sometimes, anxiety may be the cause of blushing, and these patients respond to anxiolytics. More often, blushing is just an exaggerated physiologic response to emotion, often in predisposed individuals with fair skin and readily visible vasculature. Emotional blushing can often be effectively reduced with nadolol, a long-acting nonselective beta blocker, at a dose of 40 to 80 mg every morning. [8]

THERMAL FLUSHING Overheating, due either to endogenous causes such as exercise or to exogenous ones such as sitting in a sauna, can also cause physiologic flushing or lower the flushing threshold for other causes such as the carcinoid syndrome. The anterior hypothalamus, which is the site of the body's thermostat, reacts to an increase in blood temperature by heat-dissipating mechanisms such as flushing and eccrine sweating. [1] Simple measures, such as sucking on ice chips or applying a cold wet towel to the face and neck, often alleviates thermal flushing. Flushing from the ingestion of hot liquids occurs primarily via a countercurrent heat exchange mechanism. The increased heat of the oral cavity is transferred to the internal jugular vein. The heat then gets exchanged with blood in the contiguously running internal carotid, and from there is transmitted to the anterior hypothalamus, where it sets off the heatregulating mechanisms leading to flushing and sweating. [1]

MENOPAUSAL/CLIMACTERIC FLUSHING The most common type of physiologic flushing is menopausal, otherwise known as a “hot flash.” Approximately 75 percent of women experience flushing during the time surrounding the transition to menopause (the climacteric) or after oophorectomy. [7] Various drugs, including 4-hydroxyandrostenedione, danazol, tamoxifen, clomiphene citrate, decapeptyl, and leuprolide, can induce a “pharmacologic menopause.” Flushing episodes also can occur in women in their thirties, just before or during their menstrual periods, when estrogen levels are lowest. [1] The most common feature described is a sudden, intense sensation of uncomfortable heat. The flush typically lasts for 3 to 5 min and is often accompanied by drenching perspiration. Other associated symptoms are palpitations, throbbing sensations, headaches, and nausea. [9] Hot flashes often are provoked by hot drinks, meals, alcohol, emotional upset, or exogenous heat; but they can occur at any time, often resulting in sleep disturbances. Climacteric flushing is thought to be caused by a sudden lowering of the setting of the central thermostat. The flushing is not directly related to plasma estrogen because blood estrogen levels do not correlate with symptoms. [7] Pulsatile release of luteinizing hormone follows the flush in most women, but flushing still can occur after hypophysectomy. [9] Naloxone, a specific opiate antagonist, is an

effective treatment for menopausal flushing and suggests that opiate-mediated central mechanisms may be involved. [10] Although hormone replacement therapy is the mainstay of treatment for menopausal flushing, clonidine, starting at a dose of 0.05 mg twice daily, is an effective nonhormonal regimen. [11] Although uncommon, “hot flashes” can occur in men, most often in association with either surgery (orchiectomy or bilateral hernia repairs with subsequent vascular compromise to the testes) or drug therapy with luteinizing hormone-releasing hormone (LHRH) analogues such as leuprolide acetate (Lupron). Antiandrogens, once thought to precipitate hot flashes in men, apparently have no effect on the incidence of male flushing. The most effective treatment for male hot flashes is sex steroid replacement. However, this is not always possible, as in the case of men with prostate cancer. In one study, megestrol acetate, 20 mg bid, completely eliminated hot flashes in a majority of affected men being treated for prostate cancer. [12]

ALCOHOL FLUSHING Alcohol is a well-established cause of flushing. Sensitivity to alcohol alone is usually due to aldehyde or alcohol dehydrogenase deficiency, which is most prevalent in Asians but has also been reported in Native Americans and Eskimos (Inuits). The flush usually occurs within 20 min after drinking and is the result of elevated acetaldehyde levels. The flushing may also be associated with tachycardia, tachypnea, and decreased blood pressure. [2] Fermented alcoholic beverages, such as beer and sherry, can cause flushing independent of ethnicity because they contain vasoactive chemicals such as tyramine and histamine. [7] Alcohol-related flushing, along with dizziness, can occur in workers exposed to organic solvents such as trichloroethylene, carbon disulfide, and others (see Table 170-1). Several drugs, including disulfiram, cephalosporins, metronidazole, and chlorpropamide, are associated with flushing when combined with alcohol. Flushing within minutes of drinking alcohol is associated with carcinoid tumors, mastocytosis, medullary carcinoma of the thyroid, and lymphoid tumors. [7]

DRUG-INDUCED FLUSHING Drugs, alone or in combination with alcohol, are common causes of flushing (see Table 170-1). If severe, these reactions may require discontinuation of the offending agent. Notably, aspirin or indomethacin can be used to inhibit flushing from nicotinic acid. [13]

FOOD-ASSOCIATED FLUSHING Spicy foods are a well-known cause of flushing, and foods containing nitrites or sulfites can also cause flushing, along with headaches and wheezing in some individuals. Sour foods can cause unilateral flushing. Monosodium glutamate (MSG), which was once regarded as the cause of “Chinese restaurant syndrome,” has since been shown to be an uncommon cause of flushing. [14] Flushing associated with spoiled scombroid fish is a result of histamine intoxication and is usually accompanied by sweating, vomiting, and diarrhea. [15]

SYSTEMIC DISEASES ASSOCIATED WITH FLUSHING Several systemic diseases can cause flushing and are often included in the differential diagnosis of carcinoid syndrome. Mastocytosis is discussed in Chap. 163. Flushing is uncommon in pheochromocytoma and usually occurs only after an attack, whereas pallor is found during the attack. [2] Medullary carcinoma and various pancreatic tumors (e.g., VIPoma, insulinoma) can cause flushing. A patient was reported to have carcinoid-like flushing associated with POEMS syndrome (polyneuropathy, organomegaly, endocrinopathy, monoclonal proteinemia, and skin changes), which was accompanied by hypotension and bronchospasm. The flushing improved with steroid therapy. [16]

CARCINOID SYNDROME

Carcinoid tumors arise from neuroendocrine cells and can appear in a variety of locations such as the lungs, bronchi, stomach, small intestine, appendix, and large bowel. [17] Carcinoid tumors secrete a variety of hormones and biogenic substances and are best-known for serotonin secretion. In some patients with carcinoid tumors, the secretion of serotonin and other vasoactive substances leads to the carcinoid syndrome. The characteristic manifestations of the carcinoid syndrome are bronchoconstriction, gastric hypermotility and diarrhea, right-sided cardiac valvular disease, and flushing. [18] Up to 5 percent of new onset flushing may be due to the carcinoid syndrome. [19] Carcinoid-associated flushing episodes are often precipitated by foods, alcohol, stress, and exercise (see Table 170-2). When severe and untreated, carcinoid flushing can lead to constant facial erythema, telangiectasias, and other rosacea-like symptoms. [2]

Historical Aspects

Oberndorger first used the term *karzinoide* in 1907, and the carcinoid syndrome was first described by Thorson et al. in 1954. [18] It was initially thought that elevated levels of serotonin were its cause, but a variety of chemical mediators have been implicated. [20]

Epidemiology

Recent reports estimate the overall incidence of carcinoid tumors to be anywhere from 1 to 8.4 cases per 100,000 people. Many carcinoid tumors are indolent and may be discovered only at autopsy. Analyses of cases from 1950 through 1971 reported the appendix as the most common site for carcinoid tumors, followed by the rectum, ileum, lungs, bronchi, and stomach. [17] However, more recent data from 1973 to 1991 report pulmonary sites to be most common (32.7 percent), followed by the ileum (17.6 percent), rectum (10.1 percent), and appendix (7.6 percent). [21] Differences are likely a result of increased detection and reporting of carcinoid tumors.

Carcinoid syndrome occurs in about 5 percent of patients with carcinoid tumors. [19] When carcinoid tumors are present in the abdomen, the liver effectively detoxifies most vasoactive substances secreted by the tumor. Symptoms of the carcinoid syndrome often suggest liver metastases, a bulky abdominal tumor producing large amounts of neuroendocrine products, or extra-abdominal disease. An estimated 40 to 50 percent of patients with small bowel or proximal colonic tumors have some symptoms, likely related to the propensity for these sites to metastasize. [6] The carcinoid syndrome occurs in less than 5 percent of patients with carcinoid tumors of the lung, rectum, or appendix. [17]

Etiology and Pathogenesis

Although serotonin (5-hydroxytryptamine, 5-HT) is the likely cause of the diarrhea, it is not solely responsible for the carcinoid flush because intravenous 5-HT does not produce a true carcinoid flush and arterial concentrations do not rise

during a flush. Bradykinin has been investigated as a cause of flushing. [20] The systemic infusion of substance P reportedly causes flushing, tachycardia, and hypotension in humans, and some authors suggest that substance P may be responsible for the fibrosis that often surrounds intestinal carcinoid tumors. [6] However, the fact that there is no reported relationship between plasma levels of substance P and the degree of flushing argues against substance P as the primary mediator. [20]

Histamine is implicated in the flushing due to gastric carcinoid tumors. [22] Other substances that may be involved in the carcinoid syndrome are prostaglandins, tachykinins, neuropeptide K, and neurokinin A. Carcinoid tumors may stimulate the release of endothelium-derived relaxing factor (EDRF), thereby causing indirect vasodilation. Because various foods can precipitate attacks, it may be that intestinal hormones or food derivatives trigger carcinoid tumor secretion. [6], [20]

Genetics

The only type of carcinoid tumors with a reported genetic basis are gastric carcinoids associated with the Zollinger-Ellison syndrome, which occur almost exclusively in patients with multiple endocrine neoplasia type 1 (MEN1). This is an autosomal dominant disorder associated with the loss of *MEN1*, a possible tumor-suppressor gene, located on chromosome 11q13. This type of carcinoid is uncommon, accounting for only 5 to 10 percent of all gastric carcinoid tumors, and is very rarely associated with the carcinoid syndrome. [17]

Clinical Manifestations

DERMATOLOGIC MANIFESTATIONS Severe flushing episodes occur in approximately 75 percent of patients affected by the carcinoid syndrome. Some reports indicate that up to 90 percent of patients with carcinoid syndrome complain of flushing. [19] The location of the secreting tumor helps to determine the character of the flushing along with associated symptoms. Gastric carcinoid tumors produce histamine, causing a vivid, bright, pinkish-red and patchy (a geographic pattern) flush, with bright white patches most evident at the base of the neck. This pattern is often associated with a sensation of burning along with lacrimation, sweating, and wheezing. Bronchial carcinoid tumors often cause intensely red, occasionally purple flushing that may last several hours to days. Flushing of other body areas may occur, along with profuse lacrimation. Repeated episodes can cause facial swelling and accentuation of skin folds. The “classic” carcinoid flush, which is associated with mid-gut (small intestine to mid-colon) carcinoid tumors, is usually characterized by areas of pallor and erythema superimposed on a cyanotic background. These flushes are often of shorter duration, sometimes only a few minutes. Diarrhea, hypotension, and bronchoconstriction are common accompanying symptoms. [20], [23] A common skin finding is pellagra, which is a result of niacin deficiency. Tryptophan is a precursor for both serotonin and niacin. Consequently, when tryptophan stores are shunted toward excessive serotonin production, there is little left for generation of niacin. Pellagra includes hyperkeratosis, xerosis, diffuse scaling, gray-black pigmentation, angular cheilitis, and glossitis. The repeated severe episodes of flushing can lead to rosacea, including ocular rosacea, telangiectasias, cyanosis, and connective tissue hypertrophy leading to phymas. [2] Other skin changes reported in association with the carcinoid syndrome include yellow-brown or brown-gray patches on the forehead, back, and wrists; pruritus; pruritus with pressure-induced “orange blotches” [24]; scleroderma-like changes [25], [26]; acropachyderma and pachyperiostitis [27]; cutaneous metastatic nodules [27]; erythematous, telangiectatic, atrophic patches with central ulceration [28]; pyoderma gangrenosum [29]; erythema annulare centrifugum and white banding of the toenails [30]; blisters that heal leaving white sclerotic papules and macules surrounded by an erythematous halo [31]; and reddish, cyanotic, hyperkeratotic papules. [32]
SYSTEMIC MANIFESTATIONS Seventy to 85 percent of patients experience watery diarrhea with the carcinoid syndrome. Common respiratory manifestations include bronchospasm, wheezing, stridor, dyspnea, and cough. [33] Systemic symptoms include arthritis, psychiatric symptoms, osteoblastic bone lesions from metastases, acromegaly due to ectopic growth hormone secretion, and Cushing's syndrome from corticotropin secretion. Two-thirds of patients with the carcinoid syndrome experience carcinoid heart disease. Heart disease is the result of fibrosis, which characteristically affects the right side of the heart, especially the tricuspid and pulmonary valves. Left-sided heart disease affects less than 10 percent of patients with the carcinoid syndrome and is associated with pulmonary carcinoid tumors. Fibrosis appears in other areas as well and may lead to intestinal obstruction when it occurs around intestinal tumors. Both serotonin and substance P have been postulated to cause the fibrosis. [6], [34]

Pathology

Because carcinoid tumors are derived from neuroendocrine cells, they are characterized on pathologic examination by reactions to silver stains and to markers of neuroendocrine tissue, including neuron-specific enolase, synaptophysin, and chromogranin. Electron microscopy reveals numerous membrane-bound neurosecretory granules. [17]

Diagnosis

A search for the carcinoid syndrome should be made when flushing episodes are accompanied by systemic symptoms such as abdominal cramping, diarrhea, bronchoconstriction, tachycardia, and hypotension. A carcinoid tumor should be considered when an exclusion diet and the removal of other possible provocative factors (see “ Clinical Manifestations” above) does not yield an etiology for flushing. Furthermore, because most patients with the carcinoid syndrome have liver metastases, an enlarged liver in a patient with flushing should always warrant testing for carcinoid syndrome. A history of systemic complaints, such as weight loss and vague abdominal pain, should raise the suspicion for carcinoid syndrome in a patient with flushing.

The carcinoid syndrome is characterized by 5-HT overproduction. The diagnosis is made by testing for elevated urinary excretion of 5-HIAA, the major metabolite of serotonin (Table 170-3). Urinary excretion fluctuates, so collections should be repeated if initial findings are negative but the clinical picture is highly suggestive of carcinoid syndrome. Because many foods and drugs affect urinary excretion of 5-HIAA (Table 170-4), it is important for the patient to be on an exclusion diet at least 3 days before urine collection. The reference range of 5-HIAA excretion is usually 8 to 47 µmol/24

h, and a level of 80 µmol/24 h has a specificity of 100 percent when dietary intake is controlled. [19]

1. Perform qualitative "spot-test" for urine 5-HIAA.
2. If negative, place patient on 3-day exclusion diet (see Table 170-4).
3. Perform quantitative 24-h urine 5-HIAA measurement.
   a. Reference range: 8–47 µmol/24 h.
   b. Level of 80 µmol/24 h is 100 percent specific for carcinoid syndrome.
4. If quantitative test negative, but clinical suspicion high, repeat test.
5. If repeat test is negative, consider radiolabeled octreotide scintigraphy.

TABLE 170-3 **Carcinoid Syndrome Diagnosis**

Foods	
Avocados	Red plums
Bananas	Tomatoes
Eggplant	Walnuts
Pineapples	
Drugs	
ACTH	Mephenesin
Acetaminophen	Methamphetamine
Acetanilid	Methenamine
Bromocriptine	Methocarbamol
Caffeine	Methyldopa
Chlorpromazine	Methysergide
Fluorouracil	Monoamine oxidase inhibitors
Guaifenesin	Phenacetin
Glyceryl guaiacolate	Phenmetrazine
Heparin	Phenothiazines
Imipramine	Promethazine
Isoniazid	Reserpine
Lugol's solution	Somatostatin analogues (e.g., octreotide)
Melphalan	

TABLE 170-4 **Foods and Drugs That Affect Urinary Excretion of 5-Hydroxyindoleacetic Acid**

If liver metastases are suspected, abdominal CT with and without contrast can often be useful to identify tumors. Primary abdominal tumors are often very small and difficult to visualize before surgery. Scintigraphy with radiolabeled octreotide has been successful in localizing both primary and metastatic carcinoid tumors and is also useful in predicting response to octreotide therapy. [17] One study reported that somatostatin scintigraphy had a sensitivity of 89 percent for detecting carcinoid tumors. [35] With newer methods for detecting carcinoid tumors such as octreotide scanning, the potentially dangerous provocative method of injecting intravenous adrenaline to provoke flushing is now considered outdated and should be used only as a last resort in the appropriate clinical setting. [6]

Treatment and Prognosis

The prognosis for patients with carcinoid tumors correlates closely with the stage of the tumor at presentation. [17] Because the carcinoid syndrome usually indicates the presence of either bulky abdominal tumor or liver metastases, it usually carries a worse prognosis. Typical mean survival periods are in the range of 8 years, with long survival times ranging up to 20 years. [36]

Patients with the carcinoid syndrome should avoid alcohol, foods, and activities that are known to exacerbate their symptoms (see Table 170-2). Niacin supplementation is often needed to prevent pellagra. Clonidine is sometimes used in treatment because catecholamines are known to precipitate carcinoid attacks. [37] The combination of both H_1 and H_2 antihistamines is often effective in blocking the flush caused by gastric carcinoids. [22]

Somatostatin analogues are the gold standard in the treatment of the carcinoid syndrome, relieving both flushing and diarrhea. [38] Somatostatin binds to its receptors, found on more than 80 percent of carcinoid tumors, and inhibits the secretion of a broad range of hormones. Octreotide is a long-acting somatostatin analogue that is given as a subcutaneous injection one to three times a day. Doses necessary to relieve symptoms vary, but 450 µg per day relieves the symptoms in up to 90 percent of patients. While some authors suggest that octreotide is also effective in shrinking tumors, recent reports suggest that the role of the somatostatin analogues is in controlling symptoms, not in curing disease. There is no convincing evidence that octreotide alters survival in patients with carcinoid tumors. Octreotide is also essential in reducing operative complications of cardiovascular and respiratory instability ("carcinoid crisis") in patients with the carcinoid syndrome. [17], [38]

Surgical resection has been the only treatment shown to prolong life in patients with carcinoid tumors. [38] However, by the time of presentation, tumor burden is often bulky and surgical cure is often impossible. Hepatic artery occlusion and embolization have been tried, although the duration of response is often short. Other studies suggest that chemoembolization, or the combination of tumor ischemia and chemotherapy, may elicit a better and longer-lasting response. [39] Liver transplantation has historically played little role in the treatment of carcinoid tumors, but a recent report is encouraging. Although only performed in a small number of highly selected patients, a French study reported a 5-year survival rate of 69 percent. [40]

Other than with somatostatin analogues, medical management of carcinoid disease has been lacking. Interferon-a monotherapy decreases urinary 5-HIAA in 42 percent of patients and causes tumor regression in 15 percent. It has been used in combination with octreotide for patients who are resistant to octreotide alone. [41] The use of interferon-a is often limited by its side effects, which include fever, fatigue, anorexia, and weight loss. Chemotherapeutic regimens have been tried for intractable carcinoid disease with only moderate success. [17] Although radiation therapy has not been extensively studied, recent small studies suggest that radiolabeled somatostatin analogues may have a role in tumor shrinkage and symptomatic improvement for metastatic carcinoid tumors. [42], [43]

REFERENCES

1. Wilkin JK: The red face: Flushing disorders. *Clin Dermatol* **11**:211, 1993

2. Wilkin JK: Flushing reactions: Consequences and mechanisms. *Ann Intern Med* **95**:468, 1981

3. Wilkin JK: Why is flushing limited to a mostly facial cutaneous distribution? *J Am Acad Dermatol* **19**:309, 1988

4. Burnstock G, Iwayama T: Fine-structural identification of autonomic nerves and their relation to smooth muscle. *Prog Brain Res* **34**:389, 1971

5. Freeman R, Waldorf HA, Dover JS: Autonomic neurodermatology (part II): Disorders of sweating and flushing. *Semin Neurol* **12**:394, 1992

6. Ray D, Williams G: Pathophysiological causes and clinical significance of flushing. *Br J Hosp Med* **50**:594, 1993

7. Mooney E: The flushing patient. *Int J Dermatol* **24**:549, 1985

8. Wilkin JK: Effect of nadolol on flushing reactions in rosacea. *J Am Acad Dermatol* **20**:202, 1989

9. Graham-Brown R: Dermatologic problems of the menopause. *Clin Dermatol* **15**:143, 1997

10. Katsambas AD, Nicolaidou E: Acne, perioral dermatitis, flushing, and rosacea: Unapproved treatments or indications. *Clin Dermatol* **18**:171, 2000

11. Edington RF, Chagnon JP, Steinberg WM: Clonidine (Dixarit) for menopausal flushing. *Can Med Assoc J* **123**:23, 1980

12. Smith JA: Management of hot flushes due to endocrine therapy for prostate carcinoma. *Oncology* **10**:1319, 1996

13. Phillips WS, Lightman SL: Is cutaneous flushing prostaglandin mediated? *Lancet* **1**:754, 1981

14. Wilkin JK, Fortner G: Does monosodium glutamate cause flushing? *J Am Acad Dermatol* **15**:225, 1986

15. Morrow JD et al: Evidence that histamine is the causative toxin of scombroid fish poisoning. *N Engl J Med* **324**:716, 1991

16. Myers BM et al: POEMS syndrome with idiopathic flushing mimicking carcinoid syndrome. *Am J Med* **90**:646, 1991

17. Kulke MH, Mayer RJ: Carcinoid tumors. *N Engl JMed* **340**:858, 1999

18. Thorson A et al: Malignant carcinoid of the small intestine with metastases to the liver, valvular disease of the right side of the heart (pulmonary stenosis and tricuspid regurgitation without septal defects), peripheral vasomotor symptoms, bronchoconstriction, and an unusual type of cyanosis: A clinical and pathological syndrome. *Am Heart J* **47**:795, 1954

19. Tormey WP, Fitzgerald RJ: The clinical and laboratory correlates of an increased urinary 5-hydroxyindoleacetic acid. *Postgrad Med J* **71**:542, 1995

20. Grahame-Smith DG: What is the cause of the carcinoid flush? *Gut* **28**:1413, 1987

21. Modlin IM, Sandor A: An analysis of 8305 cases of carcinoid tumors. *Cancer* **79**:813, 1997

22. Roberts LJ III, Marney SR Jr, Oates JA: Blockade of the flush associated with metastatic gastric carcinoid by combined histamine H_1 and H_2 receptor antagonists: Evidence for an important role of H_2 receptors in human vasculature. *N Engl J Med* **300**:236, 1979

23. Williams ED, Sandler M: The classification of carcinoid tumors. *Lancet* **1**:238, 1963

24. Mengel C: Cutaneous manifestations of malignant carcinoid syndrome. *Ann Intern Med* **58**:989, 1963

25. Zarafonetis C, Lorber S: Association of functioning carcinoid syndrome and scleroderma. *Am J Med Sci* **236**:1, 1958

26. Fries JF, Lindgren JA, Bull JM: Scleroderma-like lesions and the carcinoid syndrome. *Arch Intern Med* **131**:550, 1973

27. Walker J: Metastasizing argentaffinomas from dermatologist's point of view. *S Afr Med J* **31**:1271, 1957

28. Bean SF, Fusaro RM: An unusual manifestation of the carcinoid syndrome. *Arch Dermatol* **98**:268, 1968

29. Lee SS, Biro L, Price E: Pyoderma gangrenosum with carcinoid tumor. *Cutis* **18**:791, 1976

30. Everall JD, Dowd PM, Ardalan B: Unusual cutaneous associations of a malignant carcinoid tumour of the bronchus: Erythema annulare centrifugum and white banding of the toe nails. *Br J Dermatol* **93**:341, 1975

31. Smith AS, Greaves MW: Blood prostaglandin activity associated with noradrenaline-produced flush in the carcinoid syndrome. *Br J Dermatol* **90**:547, 1974

32. Lachapelle JM et al: Syndrome carcinoide: Manifestations cutanées chroniques florides [Carcinoid syndrome: Chronic florid skin manifestations]. *Ann Dermatol Venereol* **104**:66, 1977

33. Beaton H et al: Gastrointestinal carcinoids, and the malignant carcinoid syndrome. *Surg Gynecol Obstet* **152**:268, 1981

34. Robiolio PA et al: Carcinoid heart disease: Correlation of high serotonin levels with valvular abnormalities detected by cardiac catheterization and echocardiography. *Circulation* **92**:790, 1995

35. Krenning EP et al: Somatostatin-receptor scintigraphy in gastroenteropancreatic tumors: An overview of European results. *Ann N Y Acad Sci* **733**:416, 1994

36. Norheim I et al: Malignant carcinoid tumours. An analysis of 103 patients in relation to tumour localization, hormone production and survival. *Ann Surg* **206**:115, 1987

37. Wilkin JK, Rowntree CB: Blockade of carcinoid flush with cimetidine and clonidine. *Arch Dermatol* **118**:109, 1982

38. Bax NDS et al: Octreotide therapy in carcinoid disease. *Anticancer Drugs* **7**:17, 1996

39. Moertel CG et al: The management of patients with advanced carcinoid tumors and islet cell carcinomas. *Ann Intern Med* **120**:302, 1994

40. Le Treut YP et al: Results of liver transplantation in the treatment of metastatic neuroendocrine tumors: A 31-case French multicentric report. *Ann Surg* **225**:355, 1997

41. Janson EM et al: Octreotide and interferon alfa: A new combination for the treatment of malignant carcinoid tumors. *Eur J Cancer* **28A**:1647, 1992

42. McCarthy KE et al: In situ radiotherapy with ^{111}In-pentetreotide: Initial observations and future directions. *Cancer J Sci Am* **4**:94, 1998

43. Otte A et al: Yttrium-90-labelled somatostatin-analogue for cancer treatment. *Lancet* **351**:417, 1998

T>

Chapter 171

Melissa Costner Richard Sontheimer

Lupus Erythematosus

HISTORICAL ASPECTS
EPIDEMIOLOGY
Demographics
ETIOLOGY AND PATHOGENESIS
Role of Genetics in LE-specific Skin Disease
Role of UV Light in LE-specific Skin Disease
Role of Tobacco Exposure
Role of Drugs
Role of Viruses
CLINICAL MANIFESTATIONS
ACLE
SCLE
CCLE
Vesiculobullous Skin Change in LE
LABORATORY FINDINGS
HISTOPATHOLOGY
ACLE
SCLE
CCLE
IMMUNOHISTOLOGY
ACLE
SCLE
CCLE
DIAGNOSIS AND DIFFERENTIAL DIAGNOSIS
ACLE
SCLE
CCLE
TREATMENT
Local Therapy
Systemic Therapy
Surgical and Cosmetic Therapy
PROGNOSIS
ACLE
SCLE
CCLE
LE-NONSPECIFIC SKIN LESIONS

REFERENCES

Lupus erythematosus (LE) is the root designation for a diverse array of illnesses that are linked together by distinctive clinical findings and characteristic patterns of polyclonal B cell autoimmunity. Some patients present with life-threatening manifestations of systemic lupus erythematosus (SLE); whereas others, who are affected with what likely represents the same basic underlying disease process, express little more than discoid lupus erythematosus (DLE) skin lesions throughout their illness. Many physicians find it convenient to conceptualize LE as a clinical spectrum ranging from mildly affected patients with only localized DLE skin lesions to those at risk of dying from the systemic manifestations of LE such as nephritis, central nervous system disease, or vasculitis. The pattern of skin involvement expressed by an individual patient with LE can provide insight about the position on the spectrum where the patient's illness might best be placed.

The nomenclature and classification system originally devised by James N. Gilliam divides the cutaneous manifestations of LE into those lesions that show characteristic histologic changes of LE (LE-specific skin disease) and those that are not histopathologically distinct for LE and/or may be seen as a feature of another disease process (LE-nonspecific skin disease). The rationale behind this system of nosology and classification was recently discussed in depth. [1] The term cutaneous LE is often used synonymously with LE-specific skin disease as an umbrella designation for the three major categories of LE-specific skin disease: acute cutaneous lupus erythematosus (ACLE), subacute cutaneous lupus erythematosus (SCLE), and chronic cutaneous lupus erythematosus (CCLE). This will be the framework used in our discussion of the extraordinarily diverse set of cutaneous lesions that occur in patients with LE (Table 171-1).



TABLE 171-1 **The Gilliam Classification of Skin Lesions Associated with LE**

The essence of LE is in its heterogeneity, and the challenge for those who treat it is to recognize clinically useful patterns within the mosaic of features that constitute this protean illness. The focus of this presentation is on the cutaneous features of this disorder, especially the LE-specific skin lesions. (The LE-nonspecific skin lesions are summarized in the last section of this chapter, “LE-nonspecific Skin Lesions.”) The systemic manifestations of LE and their management are covered in current monographs. [2] An overview of the systemic manifestations of LE can be surmised from the American College of Rheumatology's classification criteria for SLE, [3] which are presented in Table 171-2, and from the outline of the systemic manifestations of SLE presented in Table 171-3. In addition, the cutaneous manifestations of LE with comprehensive citations have been reviewed elsewhere. [2], [3], [4] and [5]

TABLE 171-2 **The 1982 Revised Criteria for Classification of Systemic Lupus Erythematosus***



TABLE 171-3 **Overview of the Extracutaneous Manifestations of SLE**

HISTORICAL ASPECTS

Cazenave is credited for first using the term *lupus érythèmateaux,* in 1851, to refer to Biett's earlier description of DLE skin lesions. The use of this term helped to distinguish cutaneous LE from cutaneous tuberculosis (lupus vulgaris) with which it had been earlier confused. In 1875, Kaposi expanded Hebra's description of what is now recognized as SLE. Kaposi employed the “butterfly” simile, which had first been used by Hebra to describe the facial skin lesions associated with SLE. Jonathan Hutchinson, in 1880, and William Osler, at the turn of the century, emphasized the multisystem nature of LE. Until 1936, it was thought to be unusual for the systemic features of LE to be present in the absence of skin lesions. Comprehensive historic perspectives on the cutaneous manifestations of LE have been written. [2]

EPIDEMIOLOGY

The epidemiology and socioeconomic impact of LE in general, [6] and cutaneous LE specifically, [2], [7] have been reviewed. Skin disease is the second most frequent clinical manifestation of LE after joint inflammation. As many as 45 percent of patients with cutaneous LE experience some degree of vocational handicap.

Demographics

Malar, or butterfly rash (localized ACLE), has been reported in 20 to 60 percent of large cohorts of patients with LE. Limited data suggest that the maculopapular or SLE rash of generalized ACLE is present in about 35 to 60 percent of patients with SLE. ACLE, like SLE in general, is much more common in women than men (8:1). All races are affected; however, the early clinical manifestations of ACLE can be overlooked in a dark-skinned individual.

Patients presenting with SCLE lesions constitute 7 to 27 percent of LE patient populations. SCLE is primarily a disease of white females, with the mean age of onset in the fifth decade.

The most common form of CCLE, a classic DLE skin lesion, is present in 15 to 30 percent of SLE populations selected in various ways. Approximately 5 percent of patients presenting with isolated localized DLE subsequently develop SLE. It has been suggested that SLE is sevenfold more common than DLE. Although DLE can occur in infants and the elderly, it is most common in individuals between 20 and 40 years of age. DLE has a female:male ratio of 3:2 to 3:1, which is much lower than that of SLE. All races are affected, but investigations suggest that DLE might be more prevalent in blacks.

ETIOLOGY AND PATHOGENESIS

The cause(s) of and pathogenetic mechanisms responsible for LE-specific skin disease are not fully understood. The pathogenesis of LE-specific skin disease is inextricably intertwined with SLE pathogenesis. An attractive contemporary model of SLE pathogenesis describes four theoretical temporally sequential phases that are prerequisite for the clinical expression of this disease. These phases are the inheritance of susceptibility genes, induction of autoimmunity, expansion of autoimmune processes, and immunologic injury (Figure 171-1).

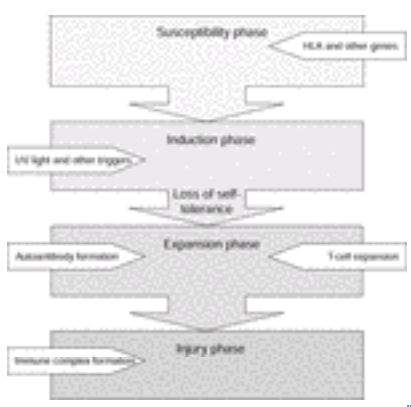

FIGURE 171-1 Model of SLE pathogenesis.

The first phase can be thought of as a susceptibility phase involving the inheritance of genes that confer predisposition to SLE. There is a ten-fold difference in heritability of SLE between dizygotic and monozygotic twins, suggesting the presence of at least four genes. The genetic association between LE-specific skin disease and serologically determined major histocompatibility (MHC) class II DR specificities is well known, and is described in detail below. Additionally, other genes have been implicated in the pathogenesis of SLE, including genes encoding complement proteins and tumor necrosis factor, genes mediating apoptosis, genes involved in cell-cell signaling processes, and genes for the clearance of immune complexes. [8]

The second phase of SLE pathogenesis or the induction phase involves the initiation of autoimmunity characterized by the appearance of autoreactive T cells that exhibit the loss of self-tolerance. Potential mechanisms include the presentation of cryptic peptides during apoptosis, aberrant expression of human leukocyte antigen (HLA)-DR molecules, failure of central thymic or peripheral tolerance mechanisms, and molecular mimicry induced by infection. UV exposure and other environmental factors play a large role in this stage (see below).

Once an autoimmune clone is established, mechanisms to perpetuate and expand this aberrant clone come into play. This third or expansion phase seems to involve progressive augmentation of the autoimmune response and has features of an antigen-driven response. Elucidation of cell-cell signaling mechanisms involving costimulatory molecules such as CD40 and CD40 L have shed valuable light on this process and also serve as potential novel therapeutic targets. [9] During the expansion phase, serologically detectable autoantibodies are produced by the population of clonally expanded B cells. Despite their abundance, autoantibodies in SLE are directed against a limited number of nuclear and cytoplasmic antigens. Three major targets are the nucleosome (anti-DNA and antihistone antibodies), the spliceosome (anti-Sm and anti-RNP antibodies) and the Ro and La molecules (anti-Ro and anti-LA).These autoantibodies often arise in grouped sets, probably because these targets are available to the immune system as intact rather than as individual particles. The aggregation of these autoantibodies and the source of the triggering autoantigens were a mystery until it was realized that most of the lupus target autoantigens are clustered in distinct structures at the surface of apoptotic cells. Once immune tolerance to the intact particles is broken down, the autoantibody response diversifies to the individual components via recognition of new epitopes within the intact complex. This phenomenon has been referred to as *epitope spreading*. [10]

The last and perhaps clinically most relevant stage that heralds the onset of clinical disease is that of immunologic injury. Much of this phase can be attributed to the action of autoantibodies and the immune complexes they form, which may cause tissue damage by means that include direct cell death, cellular activation, opsonization, and the blocking of target molecule function.

Role of Genetics in LE-specific Skin Disease

Initial associations of SLE were detected with genes of the MHC, specifically HLA alleles. While there is a strong theoretical basis that MHC alleles can act as disease susceptibility genes by shaping the T cell repertoire, it is also increasingly recognized that HLA class II alleles are more closely associated with specific autoantibody and clinical phenotypes of disease. ACLE is usually encountered in patients having overt SLE, and SLE is known to be associated with HLA-DR2 and -DR3. Several other genes outside the MHC region have been identified in the pathogenesis of SLE and LE-specific skin disease.

SCLE was initially associated with the HLA-B8, DR3 haplotype. Advances in DNA typing of HLA molecules revealed that patients with SCLE and overlapping features of Sjögren's syndrome are more likely to have the HLA-DR3, DQA1*0501, DQB1*0502 haplotype, which is more closely associated with anti-Ro antibodies. This autoantibody occurs in high frequencies in patients with SCLE. [11] Genetic deficiencies of complement components, including C2, C3, C4, and C5, as well as the C1 esterase inhibitor, are associated with both SCLE and DLE.

Significant increases of HLA-B7, -B8, -DR2, -DR3, and -DQA0102 and a significant decrease in HLA-A2 have been reported for patients with DLE. The combination of HLA- DR3, HLA-DQA0102, and HLA-B7 conferred the maximum relative risk (7.4) for DLE. DLE also occurs with increased frequency in female carriers of X-linked chronic granulomatous disease.

Interleukin (IL)-1 receptor antagonist and tumor necrosis factor-a (TNF-a) gene polymorphisms have been implicated as genetic factors in cutaneous LE. Werth and colleagues found a substantial increase in the prevalence of a promoter polymorphism of TNF-a (-308A) in patients with SCLE. Additionally, they found that there was a striking synergy between UVB and added IL-1a (a photoinduced cytokine) in the induction of transcription of the TNF-a 308A promoter. [12] This finding suggests that this polymorphism may directly contribute to the photosensitivity of patients with SCLE. An alternate explanation is that TNF-a may be a marker allele for the extended HLA-A01,B08, DRB1*0301 haplotype that is associated with a number of autoimmune conditions, including SCLE. [13]

Role of UV Light in LE-specific Skin Disease

Ultraviolet light is probably the most important environmental factor in the induction phase of LE-specific skin disease. Early studies demonstrated that cutaneous LE lesions could be provoked in the clinically normal skin of patients with both SLE and cutaneous LE by repeated delivery of high doses of UVB radiation to the same test site. More recent studies argue that UVA radiation can also induce cutaneous LE lesions.

UV light could uncover an already established autoimmune state by triggering autoantigen release from an injured keratinocyte. Conceivably, UV light could also affect localization of preexisting autoantibody-containing immune complexes by altering endothelial permeability. UV light may additionally have an early critical role in the induction phase by altering cellular DNA. Aberrant expression of HLA-DR molecules may result in the recognition of self peptides that may have escaped thymic tolerance. UVB radiation can displace autoantigens such as Ro/SS-A and related autoantigens, La/SS-B and calreticulin, from their normal locations inside epidermal keratinocytes to the cell surface. Evidence suggests that UV-induced keratinocyte apoptosis is a major mechanism responsible for this aberrant pattern of cell surface autoantigen expression. [10], [14] Cell surface expression would allow Ro/SS-A, La/SS-B, and calreticulin autoantibodies in the circulation to bind to these autoantigens that are normally sequestered from the humoral immune response inside cells. Autoantibody binding to the exposed antigens could result in tissue injury through complement-mediated lysis or antibody-dependent cell-mediated cytotoxicity. It is possible that humoral factors other than anti-Ro/SS-A might be involved in the pathogenesis of LE photosensitivity.

UV light may cause an exaggerated release of immune mediators such as IL-1, TNF-a, prostaglandin E, proteases, oxygen free radicals, and histamine in genetically predisposed individuals with LE. The aberrant expression of adhesion molecules such as intercellular adhesion molecule (ICAM)-1 could play a role in the pathogenesis of LE photosensitivity. UV light may directly affect immunoregulatory cells such as cutaneous T cells, which normally help suppress “abnormal” patterns of cutaneous inflammation. [14], [15] and [16]

Role of Tobacco Exposure

A recent large case-control study reported that smokers are at a greater risk of developing SLE than are nonsmokers and former smokers. Investigators suggest that this fact may be related to lupogenic aromatic amines, which are contained in tobacco smoke. Two abstracts from the Baltimore Lupus Cohort suggest an increased frequency of DLE in smokers, and several authors have shown that patients with LE-specific skin disease who smoke are less responsive to antimalarial treatment. [17], [18] and [19]

Role of Drugs

Numerous drugs have been implicated in inducing various features of SLE [e.g., procainamide, hydralazine, isoniazid, chlorpromazine, phenytoin (Dilantin), and, most recently, minocycline, as well as COL-3, an anticancer tetracycline derivative]. [20], [21] Classic drug-induced SLE is associated with antihistone antibodies and manifests similarly to SLE, but without cutaneous involvement. A mechanism for drug-induced LE by which the provocative agent induces T cell DNA hypomethylation inducing altered repair of DNA has been proposed. A decrease in the amount of methylation of DNA correlates with increased biological autoreactivity of lymphocytes. [22]

The skin is often spared in classic drug-induced SLE states in contrast to drug-induced SCLE, which has been convincingly associated with exposure to hydrochlorothiazide, calcium channel blockers, angiotensin-converting enzyme

inhibitors, and cinnarizine. Recently, there have been accounts of patients with terbinafine-induced SCLE, including one report documenting Ro (SS-A), La (SS-B), and antihistone antibody positivity in these patients. Other drugs reported to precipitate SCLE include piroxicam, d-penicillamine, sulfonylureas, oxprenolol, parenteral gold therapy, griseofulvin, naproxen, spironolactone (Aldactone), interferon-ß, and ranitidine. [20], [23]

Role of Viruses

There has been much speculation about the role of infectious agents, particularly viruses, in the induction of SLE and cutaneous LE. Infections of all types have long been known to exacerbate SLE. Infection by alphaviruses such as Sindbis, rubella, and cytomegalovirus appears able to induce cell surface expression of Ro/SS-A and related autoantigens in cells undergoing virus-induced apoptosis. Seroconversion to Epstein-Barr virus among patients with SLE is nearly universal. Epstein-Barr virus infection is associated with overexpression of bcl-2 and the inability of lupus T cells to suppress growth of infected/activated B cells. [24]

CLINICAL MANIFESTATIONS

Table 171-4 compares the key clinical, histopathologic, and laboratory features of patients presenting with ACLE, SCLE, and CCLE (classic DLE) skin lesions. It is important to distinguish among the subtypes of LE-specific skin disease, because the type of skin involvement in LE can reflect the underlying pattern of SLE activity. In fact, the designations acute, subacute, and chronic, in regard to cutaneous LE, refer to the pace and severity of any associated SLE and are not necessarily related to how long individual lesions have been present. For example, ACLE almost always occurs in the setting of acutely flaring SLE, whereas CCLE often occurs in the absence of SLE or in the presence of mild smoldering SLE. SCLE occupies an intermediate position in this clinical spectrum. Subclassification, although important for assigning risk, is sometimes difficult, as it is not uncommon to see more than one subtype of LE-specific skin disease in the same patient, especially in patients with SLE.

Disease Features	ACLE	SCLE	Classic DLE
Clinical features of skin lesions			
Induration	0*	0	+++
Dermal atrophy	0	0	+++
Pigment changes	+	++	+++
Follicular plugging	0	0	+++
Hyperkeratosis	+	++	+++
Histopathology			
Thickened basement membrane	0	+	+++
Lichenoid infiltrate	+	++	+++
Periappendageal inflammation	0	+	+++
Lupus band			
Lesional	++	++	+++
Nonlesional	++	+	0
Antinuclear antibodies	+++	++	+
Ro/SS-A antibodies			
By immunodiffusion	+	+++	0
By ELISA	++	+++	+
Anti–double-stranded DNA antibodies	+++	+	0
Hypocomplementemia	+++	+	+
Risk for developing SLE	+++	++	+

* +++, Strong association; ++, moderate association; +, weak association; 0, negative, no association.
ELISA = Enzyme-linked immunosorbent assay.
SOURCE: Reprinted from Sontheimer and Provost,[7] with permission from Williams & Wilkins Publishers.

TABLE 171-4 **Comparison of the Major Types of LE-Specific Skin Disease**

ACLE

Although ACLE localized to the face is the usual pattern of presentation, ACLE can assume a generalized distribution. Localized ACLE has commonly been referred to as the classic butterfly rash or malar rash of SLE (Fig. 171-2). In localized ACLE, confluent symmetric erythema and edema is centered over the malar eminences and bridges over the nose (unilateral involvement with ACLE has been described). The nasolabial folds are characteristically spared. The forehead, chin, and V area of the neck can be involved, and severe facial swelling may occur. Occasionally, ACLE begins as small macules and/or papules on the face that later may become confluent and hyperkeratotic. Generalized ACLE presents as a widespread morbilliform or exanthematous eruption often focused over the extensor aspects of the arms and hands and characteristically sparing the knuckles (Fig. 171-3A). Although perivascular nail fold erythema and telangiectasia can occur (Fig. 171-3B), they are considerably more common and occur in more exaggerated forms in dermatomyositis (see Fig. 172-3). Generalized ACLE has been indiscriminately referred to as the maculopapular rash of SLE, photosensitive lupus dermatitis, and SLE rash. An extremely acute form of ACLE is rarely seen that can simulate toxic epidermal necrolysis. This form of bullous LE results from dissolution of the epidermal basal cell layer due to very intense lichenoid inflammation.

FIGURE 171-2 Localized acute cutaneous LE (ACLE). Erythematous, slightly edematous, sharply demarcated erythema is seen on the malar areas in a “butterfly” distribution.

FIGURE 171-3 Generalized ACLE. *A.* Well-demarcated patches of erythema with fine overlying scale on the dorsal aspect of the hands, fingers, and periungual areas. Note the characteristic sparing of the knuckles, which are preferentially involved in dermatomyositis. *B.* Closeup view of periungual erythema and grossly visible telangiectasia. Although these lesions can be seen in LE, they are more typical of dermatomyositis.

ACLE is typically precipitated or exacerbated by exposure to UV light. This form of cutaneous LE can be quite ephemeral, lasting only hours, days, or weeks; however, some patients experience more prolonged periods of activity. Postinflammatory pigmentary change is most prominent in patients with heavily pigmented skin. Scarring does not occur in ACLE unless the process is complicated by secondary bacterial infection. ACLE occasionally occurs in conjunction with SCLE; however, the simultaneous occurrence of ACLE and active DLE is unusual. [6] Both localized and generalized ACLE wax and wane in parallel with underlying SLE disease activity, including LE nephritis.

SCLE

A number of names have been used to describe SCLE skin lesions: symmetric erythema centrifugum; disseminated DLE; autoimmune annular erythema; subacute disseminated LE; superficial disseminated LE; psoriasiform LE; pityriasiform LE; maculopapular photosensitive LE; and lupus erythematosus gyratum repens. A disease presentation dominated by SCLE lesions marks the presence of a distinct subset of LE having characteristic clinical, serologic, and genetic features. Although a finding of circulating autoantibodies to the Ro/SS-A ribonucleoprotein particle strongly supports a diagnosis of SCLE, the presence of this autoantibody specificity is not required to make a diagnosis of SCLE.

SCLE initially presents as erythematous macules and/or papules that evolve into hyperkeratotic papulosquamous or annular/polycyclic plaques (Fig. 171-4). Whereas most patients have either annular or papulosquamous SCLE, a few develop elements of both morphologic varieties. SCLE lesions are characteristically photosensitive and occur in predominantly sun-exposed areas (i.e., upper back, shoulders, extensor aspects of the arms, V area of the neck, and, less commonly, the face). SCLE lesions typically heal without scarring but can resolve with long-lasting if not permanent vitiligo-like leukoderma and telangiectasias.

FIGURE 171-4 Subcute cutaneous LE (SCLE). *A.* Annular SCLE on the upper back of a 38-year-old woman. Note the central areas of hypopigmentation in which no dermal atrophy is present. *B.* Papulosquamous SCLE over the extensor aspect of the forearm of a 26-year-old woman.

Several variants of SCLE have been described. On occasion, SCLE lesions present initially with an appearance of erythema multiforme, and such cases can simulate the appearance of Rowell's syndrome (erythema multiforme-like lesions occurring in patients with SLE in the presence of La/SS-B autoantibodies). As a result of intense injury to epidermal basal cells, the active edge of an annular SCLE lesion occasionally undergoes a vesiculobullous change that can subsequently produce a strikingly crusted appearance. Such lesions mimic toxic epidermal necrolysis. Rarely, SCLE presents with exfoliative erythroderma or displays a curious acral distribution of annular lesions. Pityriasiform and exanthematous variants of SCLE have been reported. In one case, annular SCLE lesions were observed to evolve over time to plaques of morphea. The skin lesions of neonatal LE (transient, photosensitive, nonscarring LE-specific skin lesions in neonates who have received IgG anti-Ro/SS-A, and, occasionally, other autoantibody specificities

transplacentally) share many features with SCLE. [25]

Between 15 and 20 percent of patients with SCLE lesions may also develop ACLE or classic DLE at some point. ACLE skin lesions tend to be more transient than SCLE lesions and heal with less pigmentary change. They are also more edematous and less hyperkeratotic than SCLE lesions. ACLE more commonly affects the malar areas of the face, whereas SCLE focuses more on the neck, shoulders, upper extremities, and trunk. DLE lesions occurring in the context of SCLE are generally associated with a greater degree of hyper- and hypopigmentation, atrophic dermal scarring, follicular plugging, and adherent scale. A consistent clinical difference is that DLE lesions are characteristically indurated, whereas SCLE lesions are not; this difference reflects the greater depth of inflammation seen histopathologically in DLE lesions.

Approximately half of patients with SCLE meet the American College of Rheumatology's revised criteria for the classification of SLE. However, manifestations of severe SLE such as nephritis, central nervous system disease, and systemic vasculitis develop in only 10 to 15 percent of patients with SCLE. It has been suggested that the papulosquamous type of SCLE, leukopenia, high titer of antinuclear antibody (ANA) (>1:640), and anti–double-stranded DNA antibodies are risk factors for the development of SLE in a patient presenting with SCLE lesions.

SCLE can overlap with other autoimmune diseases including Sjögren's syndrome, rheumatoid arthritis, and Hashimoto's thyroiditis. Other disorders that have been anecdotally related to SCLE are Sweet's syndrome, porphyria cutanea tarda, gluten-sensitive enteropathy, and Crohn's disease. There has also been the suggestion that SCLE can be associated with internal malignancy (carcinoma of the breast, lung, gastrointestinal tract, uterus; Hodgkin's disease).

CCLE

Classic DLE lesions, the most common form of CCLE, begin as red-purple macules, papules, or small plaques and rapidly develop a hyperkeratotic surface. Early classic DLE lesions typically evolve into sharply demarcated, coin-shaped (i.e., discoid) erythematous plaques covered by a prominent, adherent scale that extends into the orifices of dilated hair follicles (Fig. 171-5).

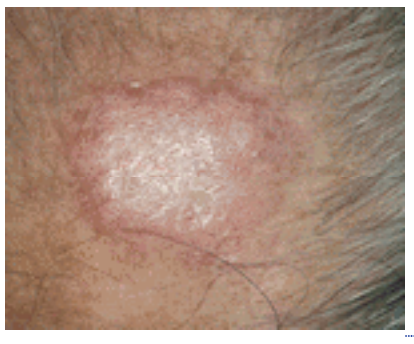

FIGURE 171-5 Classic discoid LE (DLE). Typical early erythematous plaque on the forehead demonstrating hyperkeratosis and accentuation of follicle orifices in a 60-year-old male with a 25-year history of cutaneous LE. The lesion had been present for 3 months; no dermal atrophy was present at this stage.

Early DLE lesions typically expand with erythema and hyperpigmentation at the periphery, leaving atrophic central scarring, telangiectasia, and hypopigmentation (Fig. 171-6). DLE lesions at this stage can merge to form large, confluent, disfiguring plaques. DLE in persons of certain ethnic backgrounds, such as Asian Indians, can present clinically as isolated areas of macular hyperpigmentation. Follicular involvement is a prominent feature. Keratotic plugs accumulate in dilated follicles that soon become devoid of hair. When the adherent scale is lifted from more advanced lesions, keratotic spikes similar in appearance to carpet tacks can be seen to project from the undersurface of the scale (i.e., the “carpet tack” sign).

FIGURE 171-6 Classic DLE. Sharply demarcated, round-to-ovoid, slightly indurated, erythematous plaques on the neck and face. Most plaques show a mild degree of hyperkeratosis and some show dermal atrophy. Noninflamed areas of hypopigmentation and scarring mark the sites of prior lesions that have resolved.

DLE lesions are most frequently encountered on the face, scalp, ears, V area of the neck, and extensor aspects of the

arms. Any area of the face including the eyebrows, eyelids, nose, and lips can be affected. A symmetric, hyperkeratotic, butterfly-shaped DLE plaque is occasionally found over the malar areas of the face and bridge of the nose. Such lesions should not be confused with the more transient, edematous, minimally scaling ACLE erythema reactions that occur in the same areas. DLE, like ACLE and SCLE, usually spares the nasolabial folds. When DLE lesions occur periorally, they resolve with a striking acneiform pattern of pitted scarring. DLE characteristically affects the external ear including the outer portion of the external auditory canal (Fig. 171-7A). Such lesions often present initially as dilated, hyperpigmented follicles. The scalp is involved in 60 percent of patients with DLE; irreversible, scarring alopecia resulting from such involvement has been reported in one-third of patients (Fig. 171-7B). The irreversible, scarring alopecia resulting from DLE differs from the reversible, nonscarring alopecia that patients with SLE often develop during periods of systemic disease activity. This type of hair loss, so-called “lupus hair,” may be telogen effluvium occurring as the result of flaring systemic disease.

FIGURE 171-7 Classic DLE and mucosal DLE in a 45-year-old African-American female with a 20-year history of untreated cutaneous LE. *A.* Characteristic involvement of the ear shows lesions with atrophy and postinflammatory hyperpigmentation as well as inflammatory red plaques on the scalp with postinflammatory hypopigmentation. *B.* Confluent lesions on the scalp have resulted in extensive scarring alopecia. *C.* Plaques of DLE on the palatal mucosa showing morphologic features similar to those of cutaneous lesions.

Localized DLE lesions occur only on the head or neck, whereas generalized DLE lesions occur both above and below the neck. DLE lesions below the neck most commonly occur on the extensor aspects of the arms, forearms, and hands, although they can occur at virtually any site on the body. The palms and soles can be the sites of painful, and at times disabling, erosive DLE lesions. On occasion, small DLE lesions occurring only around follicular orifices appear at the elbow and elsewhere (follicular DLE). DLE activity can localize to the nail unit. The nail can be impacted by other forms of cutaneous LE as well as SLE, producing nail fold erythema and telangiectasia, red lunulae, clubbing, paronychia, pitting, leukonychia striata, and onycholysis.

DLE lesions can be potentiated by sunlight exposure but to a lesser extent than ACLE and SCLE lesions. DLE, as well as other forms of LE skin disease activity, can be precipitated by any form of cutaneous trauma (i.e., the Koebner or isomorphic response).

The relationship between classic DLE and SLE has been the subject of much debate. [2], [5] The following summary points can be made: (1) 5 percent of patients presenting with classic DLE lesions subsequently develop unequivocal evidence of SLE; and (2) patients with generalized DLE (i.e., lesions both above and below the neck) have somewhat higher rates of immunologic abnormalities, a higher risk for progressing to SLE, and a higher risk for developing more severe manifestations of SLE than patients with localized DLE.

The following have been suggested as risk factors for the development of SLE in patients with DLE: diffuse nonscarring alopecia; generalized lymphadenopathy; periungual nail fold telangiectasia; Raynaud's phenomenon; SCLE/ACLE skin lesions; LE-nonspecific skin lesions such as vasculitis; unexplained anemia; marked leukopenia; false-positive tests for syphilis; persistently positive high-titer ANA assay; anti–single-stranded DNA antibody; hypergammaglobulinemia; an elevated erythrocyte sedimentation rate (especially >50 mm/h); positive, sun-protected, nonlesional lupus band test; and elevated levels of soluble IL-2 receptor.

Roughly one-fourth of patients with SLE develop DLE lesions at some point in the course of their disease, and such patients tend to have less severe forms of SLE. Figure 171-8 illustrates the relative risks for systemic disease activity that are associated with the clinical varieties of LE-specific skin disease.

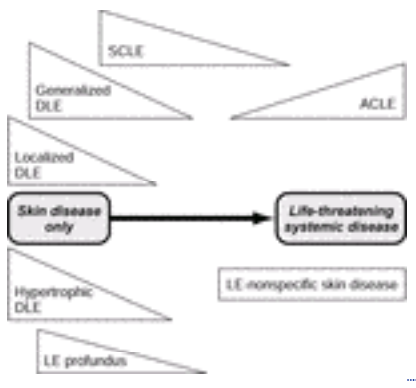

FIGURE 171-8 Relative risk for coexistence of or progression to SLE in patients presenting with various forms of LE-specific skin disease. The spectrum of LE is depicted as a disease continuum ranging from skin disease alone to life-threatening systemic disease.

Hypertrophic DLE, also referred to as hyperkeratotic or verrucous DLE, is a rare variant of CCLE in which the hyperkeratosis normally found in classic DLE lesions is greatly exaggerated. The extensor aspects of the arms, the upper back, and the face are the areas most frequently affected. Overlapping features of hypertrophic LE and lichen planus have been described under the rubric lupus planus. The entity lupus erythematosus hypertrophicus et profundus appears to represent a rare form of hypertrophic DLE affecting the face with the additional features of violaceous/dull red, indurated, rolled borders and striking central, crateriform atrophy. The name for this clinical entity is ambiguous because LE panniculitis is not characteristic of its histopathology. Patients with hypertrophic DLE probably do not have a greater risk for developing SLE than do patients with classic DLE lesions.

Patients with DLE in a linear configuration following the lines of Blaschko have been described. This rare subtype of DLE appears most frequently in children and seems to be associated with a low incidence of associated SLE. [26]

Mucosal DLE occurs in approximately 25 percent of patients with CCLE. The oral mucosa is most frequently affected; however, nasal, conjunctival, and genital mucosal surfaces can be targeted. In the mouth, the buccal mucosal surfaces are most commonly involved, with the palate (Fig. 171-7C), alveolar processes, and tongue being sites of less frequent involvement. Lesions begin as painless, erythematous patches that evolve to chronic plaques that can be confused with lichen planus. Chronic buccal mucosal plaques are sharply marginated and have irregularly scalloped, white borders with radiating white striae and telangiectasia. The surfaces of these plaques overlying the palatal mucosa often have a honeycomb appearance. Central depression often occurs in older lesions, and painful ulceration can develop. Oral mucosal DLE lesions can degenerate into squamous cell carcinoma, similar to long-standing cutaneous DLE lesions. Any degree of nodular asymmetry within a mucosal DLE lesion should be evaluated for the possibility of malignant degeneration. Chronic DLE plaques also appear on the vermilion border of the lips. At times, DLE involvement of the lips can present as a diffuse cheilitis, especially on the more sun-exposed lower lip.

The nasal, conjunctival, and anogenital mucosa can be sites of DLE lesions. Perforation of the nasal septum is more often associated with SLE than DLE. Conjunctival DLE lesions affect the lower lid more often than the upper lid. Lesions begin as focal areas of nondescript inflammation most commonly affecting the palpebral conjunctivae or the lid margin. Scarring becomes evident as lesions mature, and the permanent loss of eyelashes and ectropion can develop, producing considerable disability.

The risk for systemic disease activity in patients with LE and mucosal involvement is a function of the type of mucosal lesion present. Chronic mucosal DLE plaques are seen most commonly in patients with LE who do not have life-threatening manifestations of SLE. However, transient superficial oral or nasal mucosal ulcerations with a relatively nonspecific histopathology occur in patients with active SLE. Mucosal lesions of this type represent 1 of the 11 revised classification criteria for SLE of the American College of Rheumatology.

LESS COMMON SUBTYPES OF LE-SPECIFIC SKIN DISEASE LE profundus/LE panniculitis (Kaposi-Irgang disease) is a rare form of CCLE typified by inflammatory lesions in the lower dermis and subcutaneous tissue. Approximately 70 percent of patients with this type of CCLE also have typical DLE lesions, often overlying the panniculitis lesions. The term *LE profundus* is used to designate those patients who have both LE panniculitis and DLE lesions, whereas *LE panniculitis* refers to those having only subcutaneous involvement. Typical subcutaneous lesions present as firm nodules, 1 to 3 cm in diameter. The overlying skin often becomes attached to the subcutaneous nodules and is drawn inward to produce deep, saucerized depressions (Fig. 171-9). The head, proximal upper arms, chest, back, breasts, buttocks, and thighs are the sites frequently affected. LE panniculitis in the absence of overlying DLE may produce breast nodules that can mimic carcinoma clinically and radiologically (lupus mastitis). Confluent facial involvement can simulate the appearance of lipoatrophy. Dystrophic calcification frequently occurs in older lesions of LE profundus/LE panniculitis, and pain associated with such calcification can at times be the dominant clinical problem. Roughly 50 percent of patients with LE profundus/panniculitis have evidence of SLE. The systemic features of patients with LE panniculitis/profundus tend to be less severe, similar to those of patients with SLE who have DLE skin lesions.

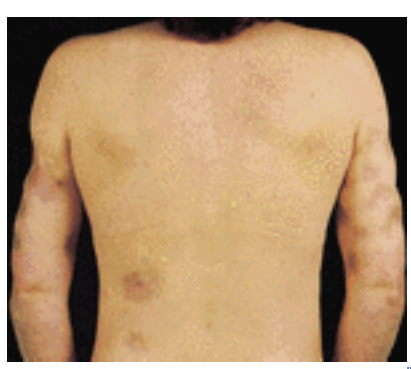

FIGURE 171-9 LE panniculitis. Lupus panniculitis has resulted in large, sunken areas of overlying skin; erythema and

atrophy of the skin are present.

Chilblain LE/perniotic LE lesions initially develop as purple-red patches, papules, and plaques on the toes, fingers, and face that are precipitated by cold, damp climates and are clinically and histologically similar to idiopathic chilblains (pernio). As they evolve, these lesions usually assume the appearance of scarred atrophic plaques with associated telangiectases. They may resemble old lesions of DLE or may mimic acral lesions of small vessel vasculitis. Histologic findings include a superficial and deep lymphocytic vascular reaction in addition to fibrin deposition in reticular dermal-based blood vessels. Patients with chilblain LE often have typical DLE lesions on the face and head. Chilblain LE appears to be associated with anti-Ro/SSA antibodies. [27] A recent study suggests that persistence of lesions beyond the cold months, a positive ANA, or presence of one of the other American College of Rheumatology criteria for SLE at the time of diagnosis of chilblain lesions helps to distinguish chilblain LE from idiopathic chilblains. [28] Approximately 20 percent of patients presenting with chilblain LE later develop SLE. Lupus erythematosus tumidus (LET; tumid LE) is a rare variant of CCLE in which the dermal findings of DLE, namely excessive mucin deposition and superficial perivascular and periadnexal inflammation, are found on histologic evaluation. The characteristic epidermal histologic changes of LE-specific skin disease are only minimally expressed, if at all. This results in succulent, edematous, urticaria-appearing plaques with little surface change (Fig. 171-10). The paucity of epidermal change often produces confusion concerning the diagnosis of LET as a form of cutaneous LE. Recently, there have been several reports of patients with this clinicopathologic presentation that have helped to alleviate some of this confusion. Ruiz and Sanchez [29] reported four patients who had firm diagnoses of classic DLE and/or SLE in addition to red-violet plaques on the upper body; histologic examination showed the dermal changes that occur in LE-specific skin disease. Kuhn et al. [30] reported a cohort of 40 patients with similar clinical and histologic features who were markedly photosensitive and who had a very high response rate to antimalarial therapy. [30] This cohort had a very low incidence of SLE, further suggesting that LET is a subset of CCLE. The authors noted that unlike classic DLE, however, LET lesions tend to resolve completely without either scarring or atrophy. [30], [31]

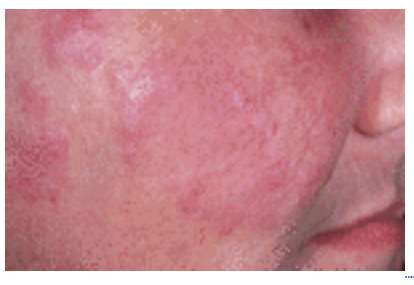

FIGURE 171-10 LE tumidus. Note succulent, indurated plaques.

Vesiculobullous Skin Change in LE

Vesiculobullous skin change in LE is a very confusing subject. [5] As with nonbullous LE skin disease, vesiculobullous skin lesions in patients with LE can be divided on the basis of histopathology into those that are LE-specific and those that are LE-nonspecific (Table 171-5). Bullae may develop in ACLE and SCLE as a manifestation of particularly aggressive liquefactive degeneration of the epidermal basal layer, resulting in basal cell dissolution and simulating the clinical and histopathologic appearance of toxic epidermal necrolysis. Vesiculobullous changes can develop at the active edge of annular SCLE lesions, and subepidermal bullous changes occasionally develop in DLE lesions.

LE-Specific Vesiculobullous LE
Acute cutaneous LE
Toxic epidermal necrolysis-like ACLE
Subacute cutaneous LE
Toxic epidermal necrolysis-like SCLE
Vesiculobullous annular SCLE
Chronic cutaneous LE
Bullous DLE
LE-Nonspecific Vesiculobullous LE
"Bullous SLE" (proposed alternative terms: dermatitis herpetiformis (DH)-like LE-nonspecific skin disease, epidermolysis bullosa acquisita (EBA)-like LE-nonspecific skin disease; LE-nonspecific vesiculobullous eruption of SLE)
Vesiculobullous skin disorders anecdotally reported to occur in LE patients but whose relationship to LE has not yet been firmly established
Bullous pemphigoid
Dermatitis herpetiformis
Pemphigus erythematosus
Porphyria cutanea tarda

SOURCE: Reprinted from Sontheimer,[1] with permission from Stockton Journals, Macmillan Press, Ltd.

TABLE 171-5 **Proposed Classification Scheme for Vesiculobullous Skin Disorders Encountered in Patients with LE**

The cutaneous entity described as bullous SLE is an example of LE-nonspecific bullous skin change. Patients who typically have or subsequently develop active SLE including nephritis occasionally develop a severe vesiculobullous eruption. Histopathologically, marked neutrophilic infiltration with papillary microabscess formation is present similar to that of dermatitis herpetiformis (DH) and the inflammatory variant of epidermolysis bullosa acquisita (EBA). However, the direct immunofluorescence findings are more typical of those of LE. Type VII collagen autoantibodies are present in some patients. Although the vague term *bullous SLE* is most often used to describe such lesions, more descriptive terms such as *DH-like cutaneous LE* or *EBA-like cutaneous LE* seem more appropriate inasmuch as other forms of bullous skin lesions can occur in patients with SLE, as noted above.

Other bullous skin diseases that have been linked anecdotally to LE include bullous pemphigoid, pemphigus erythematosus (the Senear- Usher syndrome), DH, and porphyria cutanea tarda. It is not clear whether there is a primary association between these bullous skin disorders and LE, or whether their coexistence is the result of chance alone.

LABORATORY FINDINGS

Table 171-4 summarizes the major laboratory findings associated with the varieties of LE-specific skin disease, and Table 171-6 presents the autoantibody associations of SLE. Because of the strong association between ACLE and SLE, the laboratory features of ACLE are those associated with SLE (high-titer ANA, anti–double-stranded DNA, anti-Sm, hypocomplementemia).



TABLE 171-6 **Autoantibodies Associated with Unselected SLE**

The laboratory markers for SCLE are the presence of anti-Ro/SS-A (70 to 90 percent) and, less commonly, anti-La/SS-B (30 to 50 percent) autoantibodies. ANA are present in 60 to 80 percent of patients with SCLE, and rheumatoid factor is present in approximately one-third. Other autoantibodies in patients with SCLE include false-positive serologic tests for syphilis [Venereal Disease Research Laboratory (VDRL) rapid plasma reagin] (7 to 33 percent), anticardiolipin (10 to 16 percent), antithyroid (18 to 44 percent), anti-Sm (10 percent), anti–double-stranded DNA (10 percent), and anti-U1 ribonucleoprotein (RNP) (10 percent). Patients with SCLE, particularly those with systemic involvement, may have a number of laboratory abnormalities including anemia, leukopenia, thrombocytopenia, elevated erythrocyte sedimentation rate, hypergammaglobulinemia, proteinuria, hematuria, urine casts, elevated serum creatine and blood urea nitrogen (BUN), and depressed complement levels (resulting from genetic deficiency or increased complement consumption).

ANA are present in low titer in 30 to 40 percent of patients with DLE; however, fewer than 5 percent have the higher ANA levels that are characteristic of patients with overt SLE (>1:320). Antibodies to single-stranded DNA are not uncommon in DLE, but antibodies to double-stranded DNA are distinctly uncommon. Precipitating antibodies to U1RNP are sometimes found in patients whose disease course is dominated by DLE lesions; however, such patients usually have only mild manifestations of SLE or overlapping connective tissue disorders such as mixed connective tissue disease. Precipitating Ro/SS-A and La/SS-B autoantibodies are rare in patients with DLE; low levels of anti-Ro/SS-A antibody detected by enzyme-linked immunoassay are more common. A small percentage of patients with DLE have low-grade anemia, biologic false-positive serologic tests for syphilis [VDRL, rapid plasma reagent (RPR)], positive rheumatoid factor tests, slight depressions in serum complement levels, modest elevations in gamma globulin, and modest leukopenia. It has been suggested that such findings are risk factors for the development of SLE. ANA are present in 70 to 75 percent of patients with LE profundus/panniculitis, but anti–double-stranded DNA antibodies are rare.

The laboratory findings associated with SLE, as well as with cutaneous LE, in both adults and newborns, have been reviewed. [5], [25], [32]

HISTOPATHOLOGY

The LE-specific skin disease histopathology is a distinctive constellation of hyperkeratosis, epidermal atrophy, vacuolar basal cell degeneration, dermal–epidermal junction basement membrane thickening, dermal edema, dermal mucin deposition, and mononuclear cell infiltration of the dermal–epidermal junction and dermis, focused in a perivascular and periappendageal distribution (Fig. 171-11). Variable degrees of these features are encountered in the different forms of LE-specific skin disease. Differences of opinion exist as to whether ACLE, SCLE, and DLE lesions can be distinguished reliably on the basis of their histopathologic appearances alone. [5], [8], [33]

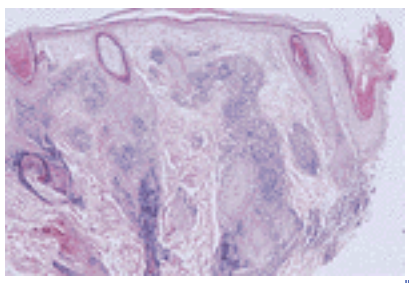

FIGURE 171-11 Histopathology of LE-specific skin disease. Histology of a DLE lesion demonstrating marked basal cell layer damage with vacuolization and irregularity of basal cell size. Mild hyperkeratosis is present.

ACLE

P>The histopathologic changes in ACLE lesions are generally less impressive than those in SCLE and DLE lesions, and are mainly those of a cell-poor interface dermatitis. The lymphohistiocytic cellular infiltrate is relatively sparse. Some authors have noted an increase in the number of neutrophils in the infiltrate. A mild degree of focal vacuolar alteration of basal keratinocytes can be seen, in addition to telangiectases and extravasation of erythrocytes. One may see individually necrotic keratinocytes, and in its most severe form, ACLE can display extensive epidermal necrosis similar to toxic epidermal necrolysis. The upper dermis usually shows pronounced mucinosis, and may be very helpful in

distinguishing ACLE from other causes of a cell-poor interface dermatitis. It is uncommon to see basement membrane zone thickening, follicular plugging, or alteration of epidermal thickness in ACLE, although epidermal atrophy is sometimes present. [33]

SCLE

SCLE also frequently presents as an interface dermatitis, with foci of vacuolar alteration of basal keratinocytes alternating with areas of lichenoid dermatitis. Pronounced epidermal atrophy is often present. SCLE is in the differential diagnosis of atrophic lichenoid dermatitis, along with atrophic lichen planus and lichenoid drug eruptions. Dermal changes include edema, prominent mucin deposition, and sparse mononuclear cell infiltration usually limited to areas around blood vessels and periadnexal structures in the upper third of the dermis. Lesser degrees of hyperkeratosis, follicular plugging, mononuclear cell infiltration of adnexal structures, and dermal melanophages might help distinguish SCLE lesions from DLE lesions. It has not been possible to differentiate papulosquamous from annular SCLE by histopathologic criteria alone. [8]

CCLE

In classic DLE lesions, epidermal changes include hyperkeratosis, variable atrophy, and interface changes similar to those described for SCLE. The epidermal basement membrane is markedly thickened. Dermal changes include a dense mononuclear cell infiltrate composed primarily of CD4 T lymphocytes and macrophages predominantly in the periappendageal and perivascular areas, melanophages, and dermal mucin deposition. The infiltrate is often quite dense and typically extends well into the deeper reticular dermis and/or subcutis, which may help to distinguish it from ACLE or SCLE. In chronic scarring DLE lesions, the dense inflammatory cell infiltrate subsides and is replaced by dermal fibroplasia. A folliculotropic variant of DLE, in which the inflammatory infiltrate is predominantly around hair follicles, has been described, as have lymphomatoid variants, in which there are extremely dense infiltrates that may contain atypical lymphoid cells. [33]

LESS COMMON SUBTYPES OF LE-SPECIFIC SKIN DISEASE The histopathology of hypertrophic DLE lesions is similar to that of classic DLE lesions except for a much greater degree of epidermal acanthosis and hyperkeratosis. At times, prominent acanthosis may simulate keratinocytic neoplastic processes such as squamous cell carcinoma. In LE panniculitis, the absence of the characteristic epidermal and dermal changes of LE can make the histologic diagnosis difficult. In LE panniculitis, subcutaneous tissue displays a lobular lymphocytic panniculitis with perivascular infiltration with lymphocytes, plasma cells, and histiocytes in the deep dermis and subcutaneous fat (including lymphoid nodule formation); vessel wall thickening and invasion by mononuclear cells (lymphocytic vasculitis); absence of polymorphonuclear leukocytes; hyaline fat necrosis; prominent fibrinoid degeneration of collagen; and mucinous degeneration and calcification in old, established lesions. Except for the differences related to the absence of hair follicles and stratum corneum in mucous membranes, the microscopic changes of mucosal DLE are highly reminiscent of those in cutaneous DLE lesions. Chilblain LE shows an interface dermatitis, with superficial and deep perivascular lymphocytic infiltration much like classic DLE. However, a lymphocytic vasculitis and fibrin within the lumina of dermal blood vessels are present in addition. [8], [33] In tumid LE, the dermal changes of DLE are present, namely a variable perivascular mononuclear infiltrate with prominent mucin between collagen bundles; but the classic epidermal changes that occur in other forms of LE-specific skin disease are not present. [29], [31] Histopathologic changes in vesiculobullous lesions of LE are noted above.

IMMUNOHISTOLOGY

Immunohistology is often helpful in confirming a diagnosis of LE-specific skin disease and has been shown to boost the sensitivity and specificity of diagnosis. [33] Because it is not uncommon to see negative immunofluorescence studies in patients with acute, subacute, and chronic LE, and false-positive studies in healthy individuals, immunohistology must be interpreted in the context of clinical and histologic findings in a given patient.

Immunoglobulins (IgG, IgA, IgM) and complement components (C3, C4, Clq, properdin, factor B, and the membrane attack complex C5b-C9) deposited in a continuous granular or linear bandlike array at the dermal–epidermal junction have been observed in the lesional and nonlesional skin of patients with LE since the early 1960s (Fig. 171-12). However, debate about terminology in this area continues to cloud the field. [5] Some restrict the use of the term lupus band test (LBT) to refer to the examination of nonlesional skin biopsies for the presence of this bandlike array of immunoreactants at the dermal–epidermal junction. Others qualify the LBT as being either “lesional” or “nonlesional.” Less confusion might exist if the terms lesional LBT or lesional lupus band and nonlesional LBT or nonlesional lupus band were uniformly adopted.

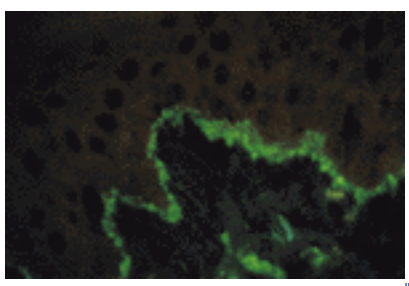

FIGURE 171-12 Immunopathology of LE-specific skin disease. Direct immunofluorescence examination of a DLE lesional skin biopsy showing a continuous band of granular fluorescence at the dermal-epidermal junction as a result of staining with fluorescein isothiocyanate-conjugated goat anti-IgG.

ACLE

The sparse data that exist suggest that 60 to 100 percent of ACLE lesions display a lesional lupus band. However, the realization that sun-damaged skin from otherwise healthy individuals can display similar immunopathology has diluted the clinical value of this finding.

SCLE

Initial studies indicated that approximately 60 percent of patients with SCLE had lesional lupus bands. A “dustlike particle” pattern of IgG deposition focused around epidermal basal keratinocytes has been suggested to be more specific for SCLE by reflecting the presence of in vivo-bound Ro/SS-A autoantibody.

CCLE

Early reports suggested that more than 90 percent of classic DLE lesions had lesional immunoreactants at the dermal–epidermal junction, often extending along the basement membrane of the hair follicle, but subsequent studies report somewhat lower rates. Lesions on the head, neck, and arms are positive more frequently (80 percent) than those on the trunk (20 percent). The lesional lupus band also appears to be a function of the age of the lesion being examined, with older lesions (>3 months) being positive more often than younger ones. Ultrastructural localization of immunoglobulin at the dermal–epidermal junction confirms that these proteins are deposited on the upper dermal collagen fibers and along the lamina densa of the epidermal basement membrane zone.

In LE profundus, immunoglobulin and complement deposits are usually found in blood vessel walls of the deep dermis and subcutis. Immunoglobulin deposits at the dermal–epidermal junction may or may not be present depending on the site biopsied, the presence or absence of accompanying SLE, and the presence or absence of overlying changes of DLE at the dermal–epidermal junction.

Nonlesional Lupus Band Test There has been much debate over the past three decades regarding the diagnostic and prognostic significance of an immunoglobulin/complement band at the dermal–epidermal junction of nonlesional skin taken from patients with LE. [5], [8] When totally sun-protected nonlesional skin (e.g., buttocks) is sampled, the diagnostic specificity for SLE appears to be very high when three or more immunoreactants are present at the dermal–epidermal junction. Prospectively ascertained follow-up data also suggest that the presence of a nonlesional LBT correlates positively with risk for developing LE nephritis. However, the nonlesional LBT has fallen out of favor as a clinical tool largely because the information gained from this invasive procedure has not been proven to be of significantly greater value than the results of more readily available serologic assays such as antibody to double-stranded DNA.

DIAGNOSIS AND DIFFERENTIAL DIAGNOSIS

ACLE

A number of unrelated dermatoses that can produce a red face, such as acne rosacea, dermatomyositis, seborrheic dermatitis, polymorphous light eruption, and photoallergic contact dermatitis, can be confused with localized ACLE. Routine histopathologic examination of a lesional skin biopsy is the most definitive way to make this distinction, since each of these red face look-alikes except for dermatomyositis has a pathology quite different from that of LE-specific skin disease (dermatomyositis can be distinguished from cutaneous LE by its nonfacial clinical features). Generalized ACLE can be confused with other causes of widespread exanthematous reactions such as drug hypersensitivity and viral infections.

SCLE

Papulosquamous SCLE can be simulated by the photosensitive variant of psoriasis. Annular SCLE lesions can be confused with erythema multiforme and other figurate erythemas such as erythema annulare centrifugum, erythema gyratum repens, and granuloma annulare. The photodistribution of SCLE lesions and the LE-specific histopathology are often crucial in helping the clinician differentiate SCLE from these other conditions. Seborrheic dermatitis, polymorphous light eruption, dermatophyte infections, nummular eczema, contact dermatitis, dermatomyositis, pityriasis rubra pilaris, disseminated superficial actinic porokeratosis, and cutaneous T cell lymphoma/mycosis fungoides have also been confused with SCLE. The presence of circulating Ro/SS-A autoantibodies further supports a diagnosis of SCLE.

CCLE

Although fully evolved classic DLE lesions are unlikely to be confused with other dermatoses, DLE lesions lacking all of the classic clinical findings might be confused with other disorders that produce persistent red plaques on the face such as plaque-type polymorphous light eruption; granuloma faciale; sarcoidosis; Jessner's benign lymphocytic infiltration of the skin; pseudolymphoma of Spiegler-Fendt (synonymous with Spiegler-Fendt sarcoid); lymphocytoma cutis; lymphoma cutis; angiolymphoid hyperplasia with eosinophilia; lupus vulgaris; and tertiary syphilis. The histopathologies of these conditions are quite distinct from that of DLE and would be expected to be negative for immunoglobulin and complement components at the dermal–epidermal junction on direct immunofluorescence microscopic examination. Hypertrophic DLE can be mistaken for keratoacanthoma, squamous cell carcinoma, prurigo nodularis, or hypertrophic lichen planus. The differential diagnosis of patients with lupus panniculitis includes Weber-Christian panniculitis; factitial panniculitis; meperidine (Talwin)-induced panniculitis; pancreatic panniculitis; traumatic panniculitis; morphea profundus; eosinophilic fasciitis; sarcoidosis; subcutaneous granuloma annulare; and rheumatoid nodules. Deep excisional biopsy may be required to distinguish LE panniculitis from these other disorders, particularly when classic DLE lesions are not present. With respect to the differential diagnosis, oral lichen planus presents the closest clinical appearance to that of oral

mucosal DLE.

TREATMENT

The initial management of patients with any form of cutaneous LE should include an evaluation to rule out underlying SLE disease activity at the time of diagnosis. All patients with cutaneous LE should receive instruction about protection from sunlight and artificial sources of UV radiation and should be advised to avoid the use of potentially photosensitizing drugs such as hydrochlorothiazide, tetracycline, griseofulvin, and piroxicam. With regard to specific medical therapy, local measures should be maximized and systemic agents used if significant local disease activity persists or systemic activity is superimposed.

ACLE lesions usually respond to the systemic immunosuppressive measures required to treat the underlying SLE disease activity that so frequently accompanies this form of cutaneous LE (e.g., systemic glucocorticoids, azathioprine, cyclophosphamide). Increasing evidence suggests that aminoquinoline antimalarial agents such as hydroxychloroquine can have a steroid-sparing effect on SLE, and these drugs can be of value in ACLE. The local measures discussed below can also be of value in treating ACLE. Because the lesions of SCLE and CCLE are often found in patients who have little or no evidence of underlying systemic disease activity, unlike the lesions of ACLE, nonimmunosuppressive treatment modalities are preferred for SCLE and CCLE (Table 171-7). For the most part, SCLE and CCLE lesions respond equally to such agents.

First line
Hydroxychloroquine (Plaquenil, Quineprox)
Hydroxychloroquine + quinacrine (Atabrine)
Chloroquine (Aralen) + quinacrine
Second line
Dapsone, retinoids (isotretinoin (Accutane), etretinate (Tegison), acitretin (Soriatane)), thalidomide
Third line
Clofazimine, gold
Fourth line
Systemic glucocorticoids
Oral prednisone
Pulse intravenous methylprednisolone
Azathioprine (Imuran)
Methotrexate
Cyclophosphamide (Cytoxan)
Evolving/experimental
Sulfasalazine, phenytoin (Dilantin), danazol, dehydroepiandrosterone, cytosine arabinoside (Cytarabine), cyclosporine, immunotherapy (high dose IV gamma globulin, CD4 T cell–depleting monoclonal antibody), phototherapy (UVA-I phototherapy, photopheresis)

TABLE 171-7 **Options for Systemic Therapy in Cutaneous LE**

Local Therapy

SUN PROTECTION Advise patients to avoid direct sun exposure, wear tightly woven clothing and broad-brimmed hats, and regularly use broad-spectrum, water-resistant sunscreens [SPF =15 with an efficient UVA blocking agent such as Parsol 1789 (avobenzone) or micronized titanium dioxide]. UV-blocking films should be applied to home and automobile windows, and acrylic diffusion shields should be placed over fluorescent lighting. Corrective camouflage cosmetics such as Dermablend and Covermark offer the dual benefit of being highly effective physical sunscreens as well as aesthetically pleasing cosmetic masking agents.
LOCAL GLUCOCORTICOIDS Although some prefer intermediate-strength preparations such as triamcinolone acetonide 0.1% for sensitive areas such as the face, superpotent topical class I agents, such as clobetasol propionate 0.05% or betamethasone dipropionate 0.05%, produce the greatest benefit in cutaneous LE. Twice-daily application of the superpotent preparations to lesional skin for 2 weeks followed by a 2-week rest period can minimize the risk of local complications such as steroid atrophy and telangiectasia. Ointments are more effective than creams for more hyperkeratotic lesions such as hypertrophic DLE. Occlusive therapy with glucocorticoid-impregnated tape (e.g., flurandrenolide) or glucocorticoids with plastic food wrap (e.g., Saran) can potentiate the beneficial effects of topical glucocorticoids but also carries a higher risk of local side effects. Class I or class II topical glucocorticoid solutions and gels are best for treating the scalp. Unfortunately, even the most aggressive regimen of topical glucocorticoids by itself does not provide adequate improvement for most patients with SCLE and CCLE.
INTRALESIONAL GLUCOCORTICOIDS Intralesional glucocorticoids (e.g., triamcinolone acetonide suspension, 2.5 to 5 mg/mL for the face with higher concentrations allowable in less sensitive sites) are more useful in the management of DLE than SCLE. Intralesional glucocorticoids themselves can produce cutaneous and subcutaneous atrophy (deep injections into the subcutaneous tissue enhances this risk). A 30-gauge needle is preferred because it produces only mild discomfort on penetration, especially when injected perpendicularly to the skin. The active borders of lesions should be thoroughly infiltrated. Intralesional therapy is indicated for particularly hyperkeratotic lesions or lesions that are unresponsive to topical glucocorticoids, but most patients with cutaneous LE have too many lesions to be managed exclusively by intralesional glucocorticoid injections.

Systemic Therapy

ANTIMALARIALS One or a combination of the aminoquinoline antimalarials can be effective for approximately 75 percent of patients with cutaneous LE who have failed to benefit adequately from the local measures described above. [34] The risks of retinal toxicity should be discussed with the patient, and a pretreatment ophthalmologic examination should be performed. However, the risk of antimalarial retinopathy is extremely rare if recommended daily dose maximum levels of these agents are not exceeded (hydroxychloroquine, 6.5 mg/kg per day; chloroquine, 4 mg/kg per day). Patients should have follow-up ophthalmologic evaluations every 6 to 12 months while on therapy. Hydroxychloroquine sulfate (Plaquenil), 400 mg/day by mouth, should be given for the first 6 to 8 weeks of treatment to reach equilibrium blood levels. Once an adequate clinical response has been achieved, the daily dose should be decreased to a maintenance dose of 200 mg/day for at least a year to minimize chances of recurrence (some authorities recommend even longer periods of inductive treatment). If no response is seen after 8 to 12 weeks, quinacrine hydrochloride, 100 mg/day (currently available in the United States only through compounding pharmacies), can be added to the hydroxychloroquine without enhancing the risk of retinopathy (quinacrine does not cause retinopathy). If after 4 to 6 weeks adequate clinical

control has not been achieved, consideration should be given to replacing the hydroxychloroquine with chloroquine diphosphate (Aralen), 250 mg/day. In Europe, chloroquine is generally felt to be more efficacious than hydroxychloroquine in treating cutaneous LE, perhaps due to the earlier therapeutic responses that might occur as a result of the shorter time period required to reach equilibrium blood levels with chloroquine as compared to hydroxychloroquine. Hydroxychloroquine and chloroquine should not be used simultaneously because of enhanced risk for retinal toxicity. Multiple side effects other than retinal toxicity are associated with the use of antimalarials. Quinacrine is associated with a higher incidence of side effects, such as headache, gastrointestinal intolerance, hematologic toxicity, pruritus, lichenoid drug eruptions, and mucosal or cutaneous pigmentary disturbance, than is either hydroxychloroquine or chloroquine. Quinacrine commonly produces a yellow discoloration of the entire skin in fair-skinned individuals, which is completely reversible when the drug is discontinued. Quinacrine can produce significant hemolysis in patients with glucose-6-phosphate dehydrogenase (G6PD) deficiency (this adverse effect has also been reported to occur rarely with hydroxychloroquine and chloroquine). Each of the aminoquinoline antimalarials can produce bone marrow suppression including aplastic anemia, although this effect is exceedingly rare with the current dosage regimens. Toxic psychosis, grand mal seizures, neuromyopathy, and cardiac arrhythmias occurred with the use of high doses of these drugs in the past; these reactions are uncommon with the lower daily dose regimens used today. Before therapy with hydroxychloroquine and chloroquine is begun, complete blood counts, as well as liver and renal function tests, should be performed; these tests should be repeated 4 to 6 weeks after therapy has been initiated, and every 4 to 6 months thereafter. A screen for hematologic toxicity when quinacrine is used is recommended more often. To reduce the risk of acute hemolysis, some authorities advocate confirming that patients are not deficient in G6PD activity before beginning treatment with antimalarials, especially quinacrine. Patients with overt or subclinical porphyria cutanea tarda are at particularly high risk for developing acute hepatotoxicity, which often simulates an acute surgical abdomen, when treated with therapeutic doses of antimalarials for cutaneous LE. It is also recommended to check urine levels of beta-human chorionic gonadotropin initially in women with childbearing potential, although recent evidence indicates that the risk to pregnant women of currently recommended dose regimens of antimalarials is minimal.

NONIMMUNOSUPPRESSIVE OPTIONS FOR ANTIMALARIAL-REFRACTORY DISEASE Some patients with refractory cutaneous LE (SCLE more than DLE) respond to diaminodiphenylsulfone (Dapsone). [35] An initial dose of 25 mg by mouth twice daily can be increased up to 200 to 300 mg/day if necessary. Significant dose-related hemolysis and/or methemoglobinemia can result from the use of diaminodiphenylsulfone, especially in individuals deficient in G6PD activity, and therefore complete blood counts and liver function tests should be performed regularly. Isotretinoin (Accutane), 0.5 to 2 mg/kg per day, and acitretin (Soriatane), 10 to 50 mg/day, have also been used in this setting, but their efficacy is limited by their side effects (teratogenicity, mucocutaneous dryness, hyperlipidemia). In addition, breakthrough of cutaneous LE activity has been a problem with the long-term use of retinoids. Thalidomide (Thalomid) (50 to 300 mg/day) is strikingly effective for cutaneous LE that is refractory to other medications. Several studies have cited response rates between 85 percent and 100 percent, with many patients experiencing complete remission. [36] However, strict prescribing regulations, put in place in the United States, in 1998, because of severe teratogenicity, make thalidomide challenging to dispense to women of childbearing potential. Sensory neuropathy is another toxicity associated with thalidomide, and approximately 25 percent of patients with cutaneous LE develop peripheral neuropathy while taking the drug. Most cases are reversible when therapy is stopped. Excess somnolence as well as constipation and other minor side effects sometimes limit its use, although these effects usually abate with lower daily doses. Relapses after the drug is stopped are common. Other drugs reported to be of value in the treatment of refractory cutaneous LE are gold (Auranofin, Myochrysine) and clofazimine (Lamprene); however, the benefit varies from case to case and both of these agents are associated with the risk of significant side effects. Vitamin E, phenytoin (Dilantin), sulfasalazine, danazol, dehydroepiandrosterone (DHEA), and phototherapy (UVA-I phototherapy, photopheresis) have also been reported in uncontrolled trials to be of value in cutaneous LE.

SYSTEMIC GLUCOCORTICOIDS Every effort should be made to avoid the use of systemic glucocorticoids in patients with LE limited to the skin. However, in occasional patients who have especially severe and symptomatic skin disease, intravenous pulse methylprednisolone has been used. In less acute cases, moderate daily doses of oral glucocorticoids (prednisone, 20 to 40 mg/day, given as a single morning dose) can be used as supplemental therapy during the loading phase of therapy with an antimalarial agent. The dose should be reduced at the earliest possible time because of the complications of long-term glucocorticoid therapy, especially avascular (aseptic) bone necrosis, a side effect to which patients with LE are particularly susceptible. Because steroid-induced bone loss occurs most rapidly in the first 6 months of use, all patients who do not have contraindications should begin agents to prevent osteoporosis with the initiation of steroid therapy. An excellent review describing current recommendations for prevention of bone loss and other side effects of systemic glucocorticoids has been published. [37] When the disease activity is controlled, the daily dosage should be reduced by 5- to 10-mg decrements until activity flares again or until a daily dosage of 20 mg/day is achieved. The daily dose should then be lowered by 2.5-mg decrements (some physicians prefer to use 1-mg dose decrements below 10 mg/day). Alternate-day glucocorticoid therapy has not been successful in suppressing disease activity in most patients with cutaneous LE or SLE. Prednisolone rather than prednisone should be used in patients who have significant underlying liver disease, because prednisone requires hydroxylation in the liver to become biologically active. Any amount of prednisone given as a single oral dose in the morning has less adrenal-suppressing activity than the same amount given in divided doses throughout the day. However, any given amount of this drug, taken in divided doses, has a greater LE-suppressing activity than does the same amount of drug given as a single morning dose.

OTHER IMMUNOSUPPRESSIVES Azathioprine (Imuran) (1.5 to 2.0 mg/kg per day orally) can play a glucocorticoid-sparing role in the severely affected patient with cutaneous LE. Mycophenolate mofetil (CellCept) (25 to 45 mg/kg per day orally) is a purine analogue similar to azathioprine, but with more specific inhibition of the de novo pathway in lymphocytes. This characteristic may allow for more efficacy and less toxicity in treating severe, recalcitrant cutaneous LE, including refractory erosive DLE of the palms and soles. [38] Methotrexate (7.5 to 25 mg orally 1 day per week) is effective for severe refractory cutaneous LE. A double-blind, randomized, placebo-controlled trial in patients with SLE showed that moderate doses of methotrexate (15 to 20 mg weekly) effectively controlled cutaneous and articular activity and permitted a reduction in prednisone dose. [39] Several biologic therapies are being studied at present, including a monoclonal antibody to CD40 ligand and another to IL-10. [9] T cell-depleting anti-CD4 monoclonal antibody therapy has been reported to be of value in refractory cutaneous LE. Other immunosuppressives that have been used anecdotally include cytosine arabinoside (Cytarabine) and cyclosporine. Immunotherapy with high-dose IV gamma globulin has also been used.

Surgical and Cosmetic Therapy

DLE lesions can produce permanent scarring alopecia, cosmetically disturbing dermal atrophy, and pigmentary changes. Patients so affected often ask about the possibility of cosmetic correction of these changes. Surgical interventions such as hair transplantation and dermabrasion carry finite risks because cutaneous LE is characterized by a tendency for nonspecific mechanical trauma, including surgical incision or laser ablation, to exacerbate disease activity (i.e., Koebner's phenomenon/isomorphic phenomenon). Some patients tolerate scar revision techniques, including dermabrasion, if they are on maintenance systemic therapy (e.g., antimalarials). Anecdotal reports of the successful management of active cutaneous LE with argon and pulsed dye laser therapy have appeared. Resurfacing of atrophic scars with the Erbium:YAG or carbon dioxide resurfacing laser has been reported to be beneficial. [40], [41] The injection of atrophic lesions with collagen or other similar materials should be avoided.

PROGNOSIS

ACLE

Both localized and generalized forms of ACLE lesions flare and abate in parallel with underlying SLE disease activity. Therefore, the prognosis for any given patient with ACLE is dictated by the pattern of the underlying SLE. Both 5-year (80 to 95 percent) and 10-year (70 to 90 percent) survival rates for SLE have progressively improved over the past four decades as a result of earlier diagnosis made possible by more sensitive laboratory testing and improved immunosuppressive treatment regimens. Ominous prognostic signs in SLE are hypertension, nephritis, systemic vasculitis, and central nervous system disease.

SCLE

Because SCLE has been recognized as a separate disease entity for only two decades, the long-term outcome associated with SCLE lesions has yet to be determined. It is the authors' experience that most patients with SCLE have intermittent recurrences of skin disease activity over long periods of time without significant progression of systemic involvement (we are aware of only one death directly attributable to SLE in approximately 150 patients with SCLE). Other patients enjoy long-term if not permanent remissions of their skin disease activity. A few patients have experienced unremitting cutaneous disease activity.

It has also been the authors' experience that approximately 15 percent of the patients with SCLE develop active SLE, including lupus nephritis. This subgroup of patients is marked by the presence of papulosquamous SCLE, localized ACLE, high-titer ANA, leukopenia, and/or antibodies to double-stranded DNA. Long-term follow-up studies of SCLE are required to determine the true risk of severe systemic disease progression in patients presenting with SCLE skin lesions. CCLE lesions, typically classic DLE, have also arisen in patients initially presenting with SCLE.

Evidence suggests that overlap occurs between SCLE and Sjögren's syndrome. Patients with SCLE who develop Sjögren's syndrome are at risk for developing the extraglandular systemic complications associated with Sjögren's syndrome, including vasculitis, peripheral neuropathy, autoimmune thyroiditis, renal tubular acidosis, myositis, chronic hepatitis, primary biliary cirrhosis, psychosis, lymphadenopathy, splenomegaly, and B cell lymphoma.

CCLE

Most patients with untreated classic DLE lesions suffer indolent progression to large areas of cutaneous dystrophy and scarring alopecia that can be psychosocially devastating and occupationally disabling. However, with treatment, skin disease can be largely controlled. Spontaneous remission occurs occasionally, and the disease activity can recrudesce at the sites of older, inactive lesions. Rebound after discontinuation of treatment is typical, and slower taper of medications during periods of inactivity is recommended. Squamous cell carcinoma occasionally develops in chronic smoldering DLE lesions.

Death from SLE is distinctly uncommon in patients who present initially with localized DLE. As previously discussed, patients presenting with localized DLE have only a 5 percent chance of subsequently developing clinically significant SLE disease activity. Generalized DLE and persistent, low-grade laboratory abnormalities appear to be risk factors for such disease progression.

LE-NONSPECIFIC SKIN LESIONS

LE-nonspecific skin lesions are lesions that occur in clinical settings other than LE. For the most part, LE-nonspecific skin lesions are seen in the setting of SLE. A comprehensive discussion of the numerous LE-nonspecific skin lesions can be found elsewhere. [5] From 20 to 70 percent of patients with SLE develop vasculitic lesions that range from palpable purpura to urticaria-like lesions to large ulcers. Most frequently, such lesions are the result of cutaneous small vessel leukocytoclastic vasculitis. Urticarial vasculitis (and chronic urticaria) is occasionally the presenting manifestation of SLE. However, some vessel-based skin lesions in patients with LE result from thrombotic vasculopathies rather than vasculitis. Skin lesions resulting from thrombotic occlusion of cutaneous vessels (livedo reticularis with or without ulceration, acral cyanosis, cutaneous infarction, Degos'-like lesions, atrophie blanche- or “livedo vasculitis”-like lesions) often occur in the setting of antiphospholipid antibody (i.e., anticardiolipin antibodies and/or lupus anticoagulant). Approximately 10 to 15 percent of patients with SLE have nail fold erythema and/or telangiectasia; however, this finding is more frequent in patients with dermatomyositis. The incidence of Raynaud's phenomenon in patients with SLE ranges between 18 and 46 percent and often occurs in patients with LE who have features of an overlapping connective tissue disease associated with anti-U1RNP antibodies, such as mixed connective tissue disease. Erythromelalgia (erythermalgia) has been found

on rare occasion to be associated with SLE.

Several forms of nonscarring alopecia occur in patients with SLE. Patients may have a transient, diffuse, nonscarring hair loss associated with exacerbations of their systemic disease that appears to be a form of telogen effluvium. Another form of nonscarring alopecia in patients with SLE, especially at the periphery of the scalp, has been termed lupus hair or wooly hair. Alopecia areata has occasionally been detected.

Other LE-nonspecific skin lesions include sclerodactyly, rheumatoid nodules, erythema multiforme-like lesions in the context of Rowell's syndrome, cutaneous mucinosis, anetoderma, cutis laxa, lichen planus, acanthosis nigricans, and cytophagic histiocytic panniculitis.

Nail changes, including pitting, horizontal and longitudinal ridging, leukonychia, onycholysis, dyschromia, nail bed atrophy, and telangiectasia of the cuticle nail fold, have been observed in patients with SLE. Red lunulae are thought to be a marker of SLE, although they have been seen in association with other disorders as well. [42] The pathogenesis is unknown, but both vascular dilatation and nail matrix/plate composition have been implicated. Most commonly, all 10 fingernails are involved. [42]

It is important to recognize LE-nonspecific skin lesions because they may be a marker of underlying systemic disease activity. In a recent study of 66 patients with SLE, those with LE-nonspecific lesions had significantly increased disease activity when compared to those with only LE-specific lesions and to those with both kinds of lesions. [43] Additionally, patients with more than one type of either LE-nonspecific or LE-specific skin lesions had a significant increase in systemic disease symptoms. This study adds to our understanding of LE skin lesions as markers of underlying systemic disease by documenting that both the type and the number of cutaneous diagnoses are important in assigning risk and in following activity of SLE.

REFERENCES

1. Sontheimer RD. The lexicon of cutaneous lupus erythematosus—A review and personal perspective on the nomenclature and classification of the cutaneous manifestations of lupus erythematosus. *Lupus* **6**:84, 1997

2. Wallace DJ, Hahn BH. *Dubois' Lupus Erythematosus,* 6th ed. Baltimore, Lippincott Williams & Wilkins, 2001

3. Tan EM et al: The 1982 revised criteria for the classification of systemic lupus erythematosus. *Arthritis Rheum* **25**:1271, 1982

4. McCauliffe DP, Sontheimer RD: Cutaneous lupus erythematosus, in *The Clinical Management of Systemic Lupus Erythematosus,* 2nd ed., edited by PH Schur. Philadelphia, Lippincott-Raven, 1996, p 67

5. Sontheimer RD, Provost TT: Lupus erythematosus, in *Cutaneous Manifestations of Rheumatic Diseases,* edited by RD Sontheimer, TT Provost. Baltimore, Williams & Wilkins, 1996, p 1

6. Watanabe T, Tsuchida T: Classification of lupus erythematosus based upon cutaneous manifestations. Dermatological, systemic and laboratory findings in 191 patients. *Dermatology* **190**:277, 1995

7. Tebbe B, Orfanos CE: Epidemiology and socioeconomic impact of skin disease in lupus erythematosus. *Lupus* B>6:96, 1997

8. David-Bajar KM, Davis BM: Pathology, immunopathology, and immunohistochemistry in cutaneous lupus erythematosus. *Lupus* **6**:145, 1997

9. Strand V: Monoclonal antibodies and other biologic therapies. *Lupus* **10**:216, 2002

10. Casciola-Rosen LA, Anhalt G, Rosen A: Autoantigens targeted in systemic lupus erythematosus are clustered in two populations of surface structures on apoptotic keratinocytes. *J Exp Med* **179**:1317, 1994

11. Reveille JD et al: Specific amino acid residues in the second hypervariable region of HLA-DQA1 and DQB1 chain genes promote the Ro (SS-A)/La (SS-B) autoantibody responses. *J Immunol* **146**:3871, 1991

12. Werth VP et al: Association of a promoter polymorphism of tumor necrosis factor-alpha with subacute cutaneous lupus erythematosus and distinct photoregulation of transcription. *J Invest Dermatol* **115**:726, 2000

13. Millard TP et al: A candidate gene analysis of three related photosensitivity disorders: cutaneous lupus erythematosus, polymorphic light eruption and actinic prurigo. *Br J Dermatol* **145**:229, 2001

14. Furukawa F et al: Selective expansions of T cells expressing V beta 8 and V beta 13 in skin lesions of patients with chronic cutaneous lupus erythematosus. *J Dermatol* **23**:670, 1996

15. Casciola-Rosen L, Rosen A: Ultraviolet light-induced keratinocyte apoptosis: A potential mechanism for the induction of skin lesions and autoantibody production in LE. *Lupus* **6**:175, 1997

16. Bennion SD, Norris DA: Ultraviolet light modulation of autoantigens, epidermal cytokines and adhesion molecules as contributing factors of the pathogenesis of cutaneous LE. *Lupus* **6**:181, 1997

17. Rahman P, Gladman DD, Urowitz MB: Smoking interferes with efficacy of antimalarial therapy in cutaneous lupus. *J Rheumatol* **25**:1716, 1998

18. Hardy CJ et al: Smoking history, alcohol consumption, and systemic lupus erythematosus: A case-control study. *Ann Rheum Dis* **57**:451, 1998

19. Jewell ML, McCauliffe DP: Patients with cutaneous lupus erythematosus who smoke are less responsive to antimalarial treatment. *J Am Acad Dermatol* **42**:983, 2000

20. Callen JP: Drug-induced cutaneous lupus erythematosus, a distinct syndrome that is frequently unrecognized. *J Am Acad Dermatol* **45**:315, 2001

21. Ghate JV et al: Drug-induced lupus associated with COL-3: report of 3 cases. *Arch Dermatol* **137**:471, 2001

22. Yung RL et al: Mechanism of drug-induced lupus. I. Cloned Th2 cells modified with DNA methylation inhibitors in vitro cause autoimmunity in vivo. *J Immunol* **154**:3025, 1995

23. Bonsmann G et al: Terbinafine-induced subacute cutaneous lupus erythematosus. *J Am Acad Dermatol* **44**:925, 2001

24. Wallace DJ, Linker-Israeli M: It's not the same old lupus or Sjögren's anymore: One hundred new insights, approaches, and options since 1990. *Curr Opin Rheumatol* **11**:321, 1999

25. Lee LA, Weston WL: Cutaneous lupus erythematosus during the neonatal and childhood periods. *Lupus* **6**:132, 1997

26. Abe M, Ishikawa O, Miyachi Y: Linear cutaneous lupus erythematosus following the lines of Blaschko. *Br J Dermatol* **139**:307, 1998

27. Franceschini F et al: Chilblain lupus erythematosus is associated with antibodies to SSA/Ro. *Lupus* **8**:215, 1999

28. Viguier M et al: Clinical and histopathologic features and immunologic variables in patients with severe chilblains. A study of the relationship to lupus erythematosus. *Medicine (Baltimore)* **80**:180, 2001

29. Ruiz H, Sanchez JL: Tumid lupus erythematosus. *Am J Dermatopathol* **21**:356, 1999

30. Kuhn A et al: Phototesting in lupus erythematosus tumidus—Review of 60 patients. *Photochem Photobiol* **73**:532, 2001

31. Dekle CL et al: Lupus tumidus. *J Am Acad Dermatol* **41**:250, 1999

32. von Muhlen CA, Tan EM: Autoantibodies in the diagnosis of systemic rheumatic diseases. *Semin Arthritis Rheum* **24**:323, 1995

33. Crowson AN, Magro C: The cutaneous pathology of lupus erythematosus: A review. *J Cutan Pathol* **28**:1, 2001

34. Costner M, Sontheimer RD: Antimalarial therapy in photosensitive dermatoses. *Dermatol Ther* **4**:86, 1997

35. Neri R et al: A case of SLE with acute, subacute and chronic cutaneous lesions successfully treated with Dapsone. *Lupus* **8**:240, 1999

36. Karim MY et al: Update on therapy—Thalidomide in the treatment of lupus. *Lupus* **10**:188, 1902

37. Vittorio CC, Werth VP: Preventive techniques to limit glucocorticoid-induced side effects. *Adv Dermatol* **16**:273, 2000

38. Goyal S, Nousari HC: Treatment of resistant discoid lupus erythematosus of the palms and soles with mycophenolate mofetil. *J Am Acad Dermatol* **45**:142, 2001

39. Carneiro JR, Sato EI: Double-blind, randomized, placebo-controlled clinical trial of methotrexate in systemic lupus erythematosus. *J Rheumatol* **26**:1275, 1999

40. Tremblay JF, Carey W. Atrophic facial scars secondary to discoid lupus erythematous: treatment using the Erbium:YAG laser. *Dermatol Surg* **27**:675, 2001

41. Walker SL, Harland CC: Carbon dioxide laser resurfacing of facial scarring secondary to chronic discoid lupus erythematosus. *Br J Dermatol* **143**:1101, 2000

42. Wollina U et al: Lupus erythematosus-associated red lunula. *J Am Acad Dermatol* **41**:419, 1999

43. Zecevic RD et al: Skin lesions—An indicator of disease activity in systemic lupus erythematosus? *Lupus* **10**:364, 2002

T>

Chapter 172

Richard Sontheimer Melissa Costner

Dermatomyositis

EPIDEMIOLOGY
Classic DM
Clinically Amyopathic DM
ETIOLOGY AND PATHOGENESIS
CLINICAL MANIFESTATIONS
Cutaneous Features
Systemic Features
Relationship Between Cutaneous and Systemic Manifestations
LABORATORY FINDINGS
Classic DM
Clinically Amyopathic DM
HISTOPATHOLOGY
Skin
Muscle
IMMUNOHISTOLOGY
Skin
Muscle
DIAGNOSIS AND DIFFERENTIAL DIAGNOSIS
TREATMENT
Local
Systemic
PROGNOSIS
Classic DM
Clinically Amyopathic DM

REFERENCES

Classic dermatomyositis (DM) is one of the idiopathic inflammatory myopathies (IIM). The IIM are a heterogeneous group of genetically determined autoimmune disorders that predominately target the skin and/or skeletal musculature, resulting in widespread, highly symptomatic, inflammatory cutaneous disease and/or skeletal muscle weakness. Of particular interest to the dermatologist is the subgroup of patients who express the hallmark cutaneous manifestations of DM for prolonged periods without clinical evidence of muscle weakness [clinically amyopathic DM (C-ADM; syn. DM siné myositis)] (see Table 172-1 for definitions of terminology used in this chapter). In a minority of patients with IIM, other organ systems such as the lungs (e.g., interstitial lung disease), joints (arthritis), and heart (e.g., cardiomyopathy, conduction defects) can also be the target of inflammatory injury. Differences exist between adult-onset and juvenile-onset DM. For example, juvenile DM displays higher rates of the hallmark skin lesions of DM and vasculopathy/vasculitis with the resulting complication of dystrophic calcification. Thus, the IIM can be conceptualized as a spectrum of illness with subgroups of patients who share common clinical and immunologic features at distinct positions along this spectrum (Fig. 172-1).

TABLE 172-1 **Dermatomyositis-Related Terminology Used in This Chapter***



FIGURE 172-1 Graphic representation of the relationships between the cutaneous and muscular manifestations of the idiopathic inflammatory dermatomyopathies, including the nosologic entities within this spectrum of illness.

The diagnostic criteria for DM under the current consensus IIM classification system have not allowed for the inclusion of cutaneous-only or cutaneous-predominantly subsets of DM such as amyopathic DM and hypomyopathic DM (i.e., C-ADM) (Table 172-2). A more inclusive disease category designation, “idiopathic inflammatory dermatomyopathies” (IIDM), has been proposed as an alternative to the “IIM” designation since it allows for the inclusion of these cutaneous subsets of DM [1] (Table 172-3). For further discussion, the reader is referred to multiple comprehensive reviews of all aspects of DM, [1], [2], [3], [4], [5], [6], [7], [8], [9], [10], [11], [12], [13] and [14] including a historical perspective emphasizing the cutaneous

manifestations of DM. [2]

Clinical subgroups
1. Polymyositis
2. Dermatomyositis
3. Polymyositis or dermatomyositis associated with malignancy
4. Childhood dermatomyositis
5. Polymyositis or dermatomyositis with an associated connective tissue disorder
Diagnostic criteria
1. Typical skin rash
2. Symmetric proximal muscle weakness with or without dysphagia or respiratory muscle involvement
3. Abnormal muscle biopsy specimen
4. Elevation of skeletal muscle-derived enzymes
5. Abnormal electromyogram
Confidence limits for diagnosis of dermatomyositis
1. Definite dermatomyositis—rash and three of the four other diagnostic criteria
2. Probable dermatomyositis—rash and two of the four other diagnostic criteria
3. Possible dermatomyositis—rash and one of the four other diagnostic criteria

SOURCE: Bohan et al: Computer-assisted analysis of 153 patients with polymyositis and dermatomyositis. Medicine (Baltimore) 56:255, 1977.

TABLE 172-2 **The Bohan Classification of Polymyositis/Dermatomyositis**

Dermatomyositis (DM)
Adult onset
Classic DM
Classic DM alone
Classic DM with malignancy
Classic DM as part of an overlap connective tissue disorder
Clinically amyopathic DM
Amyopathic DM
Hypomyopathic DM
Juvenile onset
Classic DM
Clinically amyopathic DM
Amyopathic DM
Hypomyopathic DM
Polymyositis (PM)
PM alone
PM as part of an overlap connective tissue disorder
PM associated with internal malignancy*
Inclusion Body Myositis
Other Clinical-Pathologic Subgroups of Myositis
Focal myositis
Proliferative myositis
Orbital myositis
Eosinophilic myositis
Granulomatous myositis

*While recent population-based European studies have clearly confirmed that adult-onset classic DM is associated with a significant risk for internal malignancy, if such a relationship exists for PM, it is much weaker.

TABLE 172-3 **Comprehensive Classification of Idiopathic Inflammatory Dermatomyopathies**

EPIDEMIOLOGY

Classic DM

Cutaneous involvement occurs in 30 to 40 percent of adults and in 95 percent of children with DM and polymyositis (PM). By definition, skin disease is absent in patients with PM and present in 100 percent of patients with classic DM and C-ADM. Skin disease commonly precedes muscle disease in classic DM by weeks to months.

The incidence of classic DM/PM between 1963 and 1982 was estimated to be 5.5 cases per million. The incidence probably is higher, inasmuch as this study was based on hospital-based diagnoses only and did not include cases of ADM. Black women during their childbearing years were affected most frequently, and DM might be underdiagnosed in blacks because of the more subtle coloration of inflammatory changes in their skin. Recent reports from Singapore, Hong-Kong, and Taiwan indicate that individuals of those ethnic backgrounds with DM are more likely to be male than female (females are affected twice as often as males in white populations). DM-associated interstitial lung disease appears to occur more commonly in Japanese patients than in other ethnic groups.

Classic DM can occur from infancy to adult life, most frequently presenting in the fifth and sixth decades (PM is extremely rare in children). Cutaneous ulceration occurring as a result of infarctive vasculopathy and calcification is more common in the childhood form of the disease. Familial concordance occurs rarely, and concordant disease expression has been reported in identical twins.

Environmental factors have been implicated as disease triggers. Seasonality, suggesting the possibility of an infectious etiology, has been noted in both childhood-onset and adult-onset DM/PM. DM- and PM-like syndromes have been reported in patients with Coxsackie virus, parvovirus B19, Epstein-Barr virus (EBV), AIDS, and human T cell leukemia virus type I infection. Other environmental factors that have been implicated include silicone breast implants and bovine collagen implants (however, the links to silicone implants and bovine collagen implants have not been established). In addition, drugs such as hydroxyurea, penicillamine, statin-type cholesterol-lowering agents, niflumic acid/diclofenac, phenytoin, tryptophan, and practolol can induce skin changes that mimic both classic DM and C-ADM. [1], [15]

Clinically Amyopathic DM

The incidence/prevalence of C-ADM in the United States is unknown, but it is assumed to be extremely low. However, most incidence data relating to classic DM have been collected from hospitalized patient populations fulfilling the Bohan and Peter diagnostic criteria, thereby excluding patients with C-ADM. Information related to the incidence of C-ADM in the United States derives predominately from the outpatient practices of academic dermatologists; in these settings, C-ADM is estimated to occur with approximately 10 percent the incidence of classic DM. In Europe, a similar incidence has been observed, [16] whereas in Asia, C-ADM appears to be relatively more common. A retrospective analysis of 28 patients with DM at the National Skin Center in Singapore between 1996 and 1998 revealed that 13 (46 percent) had C-ADM. [17] In another cohort of 143 Taiwanese patients with DM/PM treated in a veterans hospital system, C-ADM was

the second most commonly encountered subgroup (14 percent) after classic adult-onset DM (64 percent). C-ADM was somewhat more common than juvenile DM/PM (13 percent) and PM (10 percent) in this study. [18] Very little information currently exists about the incidence of juvenile C-ADM. In a retrospective analysis of all children with DM seen at an academic medical center in Pennsylvania between 1968 and 1998, 2 of 16 (12 percent) were categorized as having C-ADM. [19]

C-ADM appears to have an even stronger female preponderance than classic DM in the United States. In Asian patients, C-ADM appears to be more common in males. [18] One of the authors (RDS) has observed a familial constellation of ADM in a father and his only children—two adult daughters. Indirect evidence suggests that C-ADM has human leukocyte antigen (HLA) associations similar to those found in patients with classic DM (i.e., HLA-DQA1). [20]

Certain drugs can induce the cutaneous and/or systemic manifestations of DM/PM. [1], [15] Chronic hydroxyurea therapy for chronic myelogenous leukemia can produce a DM-like cutaneous eruption that is clinically and histopathologically similar to idiopathic DM-specific skin disease. [21] However, muscle weakness and other systemic symptoms are absent. Painful leg ulcers are often seen in association, as are xerosis and cutaneous atrophy. This symptom complex usually occurs only after the patient has been treated with hydroxyurea for long periods (2 to 10 years).

ETIOLOGY AND PATHOGENESIS

The inflammatory nature of the muscle and skin manifestations coupled with the characteristic humoral autoimmune abnormalities have led to the hypothesis that DM/PM results from a genetically determined, aberrant autoimmune response to environmental agents. Figure 172-2 presents a summary overview of current thought in this area. Like other systemic autoimmune diseases involving autoantibody production such as systemic lupus erythematosus (SLE), DM is thought to evolve through multiple sequential phases: the susceptibility phase, the induction phase, the expansion phase, and the injury phase.

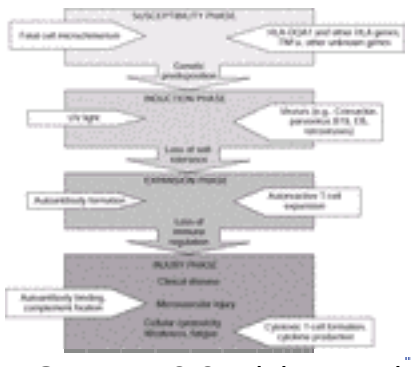

FIGURE 172-2 Etiology and pathogenesis of DM: current concepts. See text for discussion.

The susceptibility phase of DM is thought to result largely from a genetic predisposition. DM is one of the human autoimmune diseases that is linked to the 8.1 ancestral haplotype (HLA-A1, -C7, -B8, -C4AQ0, -C4B1, -DR3, -DQ2). [22] PM and DM have been specifically associated with HLA-B8, -DR3, and -DRw52, especially in white patients. This association is likely a result of linkage disequilibrium with HLA-DQA1*0501. The production of antisynthetase antibodies such as Jo-1 is strongly linked to HLA-DR3, and even more strongly linked to its supertypic specificity HLA-DRw52. A single nucleotide polymorphism in the tumor necrosis factor (TNF)-a promoter (TNF-a308A), which is also a component of the 8.1 ancestral haplotype, has been associated with disease chronicity, calcinosis, and high levels of TNF-a in a cohort of white patients with juvenile-onset classic DM. [23] In addition, there was a single case report of adult-onset DM in a young Japanese woman who was shown to be genetically deficient in the fifth component of complement. [24]

The cutaneous manifestations of DM are precipitated or exacerbated by natural and artificial sources of ultraviolet light. Approximately 50 percent of patients with DM experience photosensitivity. The action spectrum appears to include both ultraviolet B (UVB) and ultraviolet A (UVA). TNF-a308A promoter polymorphism has been linked to the photosensitive lupus erythematosus (LE)-specific skin disease subset, subacute cutaneous LE. [25] In these studies, epidermal keratinocytes containing this TNF-a allele produced exaggerated levels of TNF-a in the presence of interleukin (IL)-1a after exposure to ultraviolet B radiation. These observations raise the possibility that TNF-a–inhibiting therapy such as thalidomide or monoclonal antibodies (infliximab, etanercept) might be of value in selected patients with photosensitive DM as well as subacute cutaneous LE.

Environmental stimuli, including infection and ultraviolet irradiation, could represent inductive factors in DM leading to loss of self tolerance. Various types of infections have been circumstantially implicated as causative factors in DM. These include RNA viruses such as coxsackievirus, echovirus, and human retroviruses [i.e., human T cell leukemia/lymphoma virus type I (HTLV-1) and HIV]. Nonviral pathogens such as *Toxoplasma gondii* have also been implicated. However, repeated attempts to confirm persistent myotropic infection by viruses or other pathogens have not been successful.

The expansion phase of DM is marked by autoantibody production signaling loss of normal immune regulation. DM is associated with the production of a number of different autoantibody specificities (Table 172-4). Whether these autoantibodies are truly pathogenetic or represent only a by-product of muscle injury is unknown. It was recently suggested that C-ADM might be associated with a specific autoantibody profile (antibodies to 155 kDa and Se antigens). [26] It is assumed that autoantibodies and autoreactive T cells play a major role in the tissue-injury phase of DM. Cell-mediated immunity against muscle autoantigens is thought to be predominately responsible for the muscle injury that occurs in PM, whereas humoral autoimmune mechanisms have been implicated in the pathogenesis of muscle and skin injury in DM. Further evidence was presented recently supporting the concept that cell-mediated myocytotoxicity plays a

role in the pathogenesis of myositis. Both myocytotoxic CD3+ T cell clones and non–HLA-restricted myocytotoxic cells of other lineages have been identified in the peripheral blood of patients with inflammatory myopathies. [27] Little has been done experimentally to date to probe for cytotoxic epidermal or dermal cell injury in patients having DM skin disease activity.



TABLE 172-4 **Autoantibodies in the Idiopathic Inflammatory Dermatomyopathies**

There is not always good agreement between the degree of muscle weakness or fatigue experienced by patients with classic DM and the degree of inflammation noted on muscle biopsy and elevation of serum muscle enzymes. This observation has led to the idea that inflammatory cytokines might be capable of mediating metabolic disturbances within muscle that can exacerbate muscle weakness and fatigue. [28] As with other rheumatic diseases such as systemic sclerosis, maternal microchimerism has been observed in children with juvenile classic DM. [29] The pathogenetic significance of the presence of alloreactive maternal lymphoid cells in the circulation, muscle, and skin of patients with juvenile DM is unknown. The overproduction of primary cytokines such as TNF-a after exposure to environmental stimuli such as UV irradiation could play a role in the induction of DM cutaneous inflammation.

The pathogenesis of cutaneous inflammation in C-ADM and classic DM requires study. The preliminary observation that patients with C-ADM might preferentially produce a pair of autoantibodies (155 kDa, Se) [26] could yield a new experimental approach to addressing this issue. It is not yet known whether these two autoantigens might be aberrantly expressed in the skin of patients with C-ADM endogenously or as a result of environmental stimuli (e.g., ultraviolet light), thereby targeting cutaneous tissue for autoantibody-mediated inflammatory injury.

The immunopathology of cutaneous DM includes a variable degree of immunoglobulin and complement deposition at the dermal–epidermal junction and within the dermal microvasculature. The predominate infiltrating cell types in cutaneous DM are activated macrophages and CD4 T cells, arguing for a cell-mediated pattern of immune injury.

The dermal microvasculature is more prominently altered in cutaneous DM than in cutaneous LE. It has been suggested that humoral factors could produce microvascular injury by triggering local activation of complement with deposition of C5–9, perhaps through endothelial-specific autoantibodies. Class II histocompatibility antigen expression by dermal endothelial cells is decreased in DM skin lesions, and this cell type appears to display an activation phenotype with respect to adhesion molecule expression [intercellular adhesion molecule-1 (ICAM-1), vascular cell adhesion molecule-1 (VCAM-1), and E-selectin].

Dermal mucin is a prominent finding in biopsies of DM skin lesions. It has been suggested that this might be caused by the increased production of glycosaminoglycans by dermal fibroblasts as a result of immunologic stimulation. Evidence suggesting that mononuclear cells from patients with DM can be cytotoxic for cultured dermal fibroblasts exists. Serum factors in patients with LE can stimulate the production of glycosaminoglycans by dermal fibroblasts. Recent work indicates that factor XIIIa+ dermal perivascular dendritic cells may be the source of abnormal mucin production in conditions such as the reticular erythematous mucinosis syndrome. [30] It is tempting to extrapolate these observations to autoimmune conditions that involve abnormal dermal mucin accumulation such as cutaneous LE and DM.

CLINICAL MANIFESTATIONS

Cutaneous Features

HALLMARK SKIN LESIONS Table 172-5 presents the hallmark cutaneous manifestations of DM and amyopathic DM (to date, no recognizable differences in the cutaneous manifestations of classic DM and amyopathic DM have been reported). Some of these lesions, such as Gottron's sign of DM (Fig. 172-3) and Gottron's papules (Fig. 172-3 and Fig. 172-4), are pathognomic of this disease, whereas others are highly characteristic, such as periorbital, confluent, macular, violaceous (heliotrope) erythema/edema, and grossly visible periungual telangiectasia/dystrophic cuticles. The primary skin change of DM is a highly characteristic, often pruritic, symmetric, confluent, macular violaceous erythema variably affecting the skin overlying the extensor aspect of the fingers, hands, forearms, arms, deltoid areas, posterior shoulders, and neck (the shawl sign), the V area of the anterior neck and upper chest, the central aspect of the face, periorbital areas, the forehead, and the scalp (Fig. 172-5 and Fig. 172-6). The lateral aspects of the hips and thighs (holster sign) are also frequently involved. [31] Lesions such as poikiloderma atrophicans vasculare (poikilodermatomyositis) (Fig. 172-7) and calcinosis cutis are often present in patients with DM but may also appear in patients with cutaneous T cell lymphoma (poikiloderma atrophicans vasculare) and scleroderma (calcinosis cutis).

Pathognomonic

1. Gottron's papules
   Papules having a violaceous hue overlying the dorsal-lateral aspect of interphalangeal and/or metacarpophalangeal joints. When fully formed, these papules become slightly depressed at the center, which can assume a white, atrophic appearance. Associated telangiectasia can be present.
2. Gottron's sign of DM
   Symmetric confluent macular violaceous erythema with or without edema overlying the dorsal aspect of the interphalangeal/metacarpophalangeal joints, olecranon processes, patellae, and medial malleoli.

Characteristic

1. Periorbital confluent macular violaceous (heliotrope) erythema with or without associated edema of the eyelids and periorbital tissue.
2. Grossly visible periungual telangiectasia with or without dystrophic cuticles and cuticular hemorrhage.
3. Symmetric confluent macular violaceous erythema overlying the dorsal aspect of the hands and fingers (where it can track along the extensor tendons), extensor aspects of the arms and forearms, deltoids, posterior shoulders and neck (shawl sign), V area of anterior neck and upper chest (V sign), central aspect of the face and forehead, and scalp.
4. Mechanic's hand lesion—bilaterally symmetric confluent hyperkeratosis having the appearance of that produced by manual labor distributed along the ulnar aspect of the thumb and radial aspect of the fingers; also prominent on the index and middle fingers with occasional extension to the palmar surfaces.

Compatible with dermatomyositis

1. Poikilodermatomyositis
   Circumscribed violaceous erythema with associated telangiectasia, hypopigmentation, hyperpigmentation, and superficial atrophy most commonly found over the posterior shoulders, back, buttocks, and V area of the anterior neck and chest. Often asymmetric.
2. Calcinosis cutis

SOURCE: Adapted from Sunzel and Sontheimer[7] and from Gunter M, Sontheimer RD: Dermatologic aspects of myositis. Curr Clin Rheumatol 9:63, 1994, with permission from the publishers, Current Science and Williams & Wilkins.

TABLE 172-5 **Classic Cutaneous Manifestations of Dermatomyositis**

FIGURE 172-3 Hand of a 30-year-old female with a 15-year history of amyopathic DM. Note the confluent macular violaceous erythema, most pronounced over the metacarpophalangeal/interphalangeal joints, extending in a linear array over the extensor tendons overlying the hand and fingers. These changes, referred to as Gottron's sign, are a hallmark cutaneous feature of DM. Early Gottron's papules, an extension of Gottron's sign, can be seen over the distal interphalangeal joints along with periungual erythema and dystrophic cuticles. In DM, the violaceous erythema is centered over the metacarpophalangeal/interphalangeal joints, whereas in LE, these areas are relatively spared.

FIGURE 172-4 Fingers of an elderly female with classic DM. Note the fully formed Gottron's papules over the distal interphalangeal joints, a hallmark cutaneous feature of DM. Prominent, grossly visible nail fold telangiectasias are also present, along with dystrophic cuticles. The combination of Gottron's papules and nail fold changes such as these is pathognomic for DM. Such changes are seen to an equal degree in classic DM and amyopathic DM.

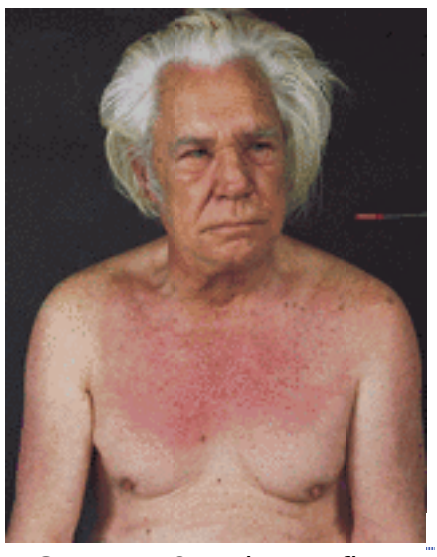

FIGURE 172-5 The confluent, macular, violaceous erythema of the V area of the upper chest and neck (V sign), when persistent over time, can evolve to poikilodermatous skin changes. Less evident in this photograph are periorbital edema and confluent, macular, violaceous (heliotrope) erythema of the upper eyelids. Note the absence of involvement of the malar areas, which are often involved in LE.

FIGURE 172-6 Periorbital confluent, macular, violaceous (heliotrope) erythema most prominent on the upper eyelids.

Like Gottron's papules and Gottron's sign, this is a hallmark cutaneous feature of DM.

FIGURE 172-7 An asymmetric plaque of poikiloderma atrophicans vasculare on the flank of a 55-year-old male with classic DM.

Several other types of skin lesions have been suggested to be characteristic of DM/PM; however, there is not yet enough published experience to determine their true disease specificity or prevalence. The mechanic's hand lesion consists of a nonpruritic, hyperkeratotic eruption accompanied by scaling, fissuring, and hyperpigmentation, giving the false appearance of the callused hands of a laborer. These changes are bilaterally symmetric and distributed along the ulnar aspect of the thumb and radial aspect of the fingers; they are prominent on the index and middle fingers with occasional extension to the palmar surfaces. It was originally suggested that there was a strong association between this skin lesion and the presence of active myositis and antisynthetase antibodies such as Jo-1. However, subsequent observations suggest that this skin change occurs in classic DM without elements of the antisynthetase syndrome, as well as in C-ADM. Table 172-6 presents the characteristic anatomic distribution of the hallmark cutaneous manifestations of DM. There is very little published information on the prevalence of involvement in these different anatomic locations. In some series reported by dermatologists, Gottron's papules have been more commonly seen than periorbital heliotrope erythema, which, by many outside of dermatology, is felt to be the hallmark cutaneous manifestation of DM.

Anatomic Location	Lesions
Scalp	Confluent, macular, violaceous erythema (CMVE) nonscarring diffuse alopecia
Face	
Periorbital region	CMVE (usually most intense on the upper eyelids), edema
Malar eminences	CMVE sparing the nasolabial fold
Forehead, chin	CMVE
Neck and shoulders	
Anterior	CMVE evolving to poikiloderma
Posterior	CMVE (shawl sign)
Upper extremities	
Arms, forearms	CMVE on the extensor aspects
Elbows	CMVE usually most intense in this location (Gottron's sign of CDM)
Hands, fingers	
Dorsal aspect	CMVE usually most intense over the extensor tendons and metacarpophalangeal/interphalangeal joints (Gottron's sign), Gottron's papules overlying the dorsal lateral aspect of the metacarpophalangeal/interphalangeal joints, relative sparing of the dorsal aspects of the phalanges, periungual nailfold telangiectasia (often greatly visible), cuticular microvascular hemorrhage, dystrophic/haggard cuticles
Palmar aspect	Mechanic's hand lesion, mucinous plaques centered over the flexural creases
Trunk	CMVE evolving to large areas of poikiloderma (poikiloderma atrophicans vasculare) commonly seen over the flanks and lower back
Lower extremities	
Thighs	CMVE (holster sign)
Knees	CMVE (Gottron's sign)
Lower legs, feet	CMVE often focal centered over the medial malleoli, Gottron's sign overlying the medial malleoli

TABLE 172-6 **Anatomic Distribution of Hallmark Cutaneous Manifestations of Dermatomyositis**

The violaceous hue of the cutaneous inflammation is a striking clinical finding that usually is evident from the outset of disease activity. This hue helps to distinguish cutaneous DM from cutaneous LE, in which it is a late finding when present. It has been suggested that edema associated with the DM skin disease indirectly produces the violaceous hue by displacing the hyperemic cutaneous vasculature more deeply into the dermis. It could also result from the deoxygenation of blood flow through an abnormal dermal microvascular bed. A striking clinical feature that helps to distinguish cutaneous DM from cutaneous LE is pruritus, which can be so severe in DM as to be disabling, even in the absence of systemic involvement. A number of other skin changes can be encountered in patients with DM. Hyperkeratosis may follow the onset of the confluent, macular, violaceous erythema; however, the scale in DM skin lesions is usually less prominent than that in subacute cutaneous LE and discoid LE. Secondary skin changes in DM skin lesions include excoriation with secondary infection and ulceration. Subepidermal vesicles and/or bullae occasionally occur in areas of particularly intense cutaneous inflammation. Postinflammatory pigmentary changes, both hyperpigmentation and hypopigmentation, occur. Older lesions may have white lacy markings somewhat similar to those of Wickham's striae in lichen planus. Other similarities between cutaneous DM and lichen planus include the characteristic violaceous hue. Mucinous infiltration, a common histologic finding in the dermis of DM skin lesions, can be clinically prominent, producing an infiltrated, glistening appearance. Superficial erosions and ulcers can subsequently develop over the face and eyelids, as well as in other areas affected by intense and protracted inflammation. Deep, irregular retiform ulcers can also develop in areas of poikiloderma in both adults and children. Clinical experience suggests that the activity of DM/PM can be precipitated or exacerbated by emotional and physical stress, although there is scant published evidence. Strenuous physical exertion can be detrimental to patients suffering from active myositis. Cutaneous calcification is more common in children than in adults with DM. The higher rate of vasculopathy/vasculitis that occurs in juvenile DM is thought to be a forerunner of dystrophic calcification. Approximately 25 percent of children with juvenile-onset classic DM have dystrophic calcification at the time of diagnosis, and 40 to 50 percent develop calcinosis sometime during the course of their illness. Some patients die from septic complications of ulcerating dystrophic calcification long after complete resolution of their myositis disease activity. In adults, calcification often presents as firm dermal and/or subcutaneous papules or nodules that are often most prominent around the elbows and hands. Large subcutaneous tumoral deposits can also occur over the trunk; such lesions can be filled with a liquid suspension of calcium crystals (i.e., “milk of calcium”). Four types of calcification have been described in children with DM: (1) a superficial pattern consisting of small, firm nodules and plaques in the skin; (2) periarticular subcutaneous nodules (calcinosis circumscripta); (3) deposition along fascial planes in muscles (calcinosis universalis) (Fig. 172-8); and (4) a severe “exoskeleton” pattern of deposition in the subcutaneous tissue. Calcinosis cutis or calcium deposition in muscles and tendons is more common in the late phases of the disease in children. The TNF-a308A promoter polymorphism might represent a risk factor for developing calcinosis. [23]

FIGURE 172-8 Calcinosis universalis. Calcification of subcutaneous tissue and pectoralis fascia in a child with DM.

Magnetic resonance imaging (MRI) may identify edema/ inflammation in skin, subcutaneous tissue, and fascia resulting from vasculopathy/vasculitis in patients with classic juvenile DM. [32] In approximately 80 percent of the 26 children studied, MRI abnormalities indicating skin, subcutaneous, and/or fascial edema were observed. Clinical skin disease activity scores correlated positively with MRI skin edema scores. Five children developed soft tissue calcification in areas previously found to be edematous by MRI after 4- to 9-month follow-up intervals. These observations suggest that the assessment of soft tissue by MRI could be of value in predicting risk for developing calcification and in monitoring treatment to prevent or minimize it. Dystrophic calcification appears to be quite uncommon in both adult- and juvenile-onset C-ADM. Little relationship was found between MRI indices of edema/inflammation in the superficial (skin and subcutaneous tissue) and deep (fascial and muscle) tissue compartments of patients with juvenile-onset classic DM. [32] DM can develop as a component of an overlap connective tissue disorder. Most common are overlaps with SLE and systemic sclerosis. Raynaud's phenomenon, sclerodactyly, sclerosis of the skin, and the characteristic hyperpigmentation can all be present in the latter setting. The term *sclerodermatomyositis* describes patients who present with DM and who develop striking features of scleroderma 6 months to 3 years later. In addition, myositis occurs in approximately 5 percent of anti-Ro/SS-A autoantibody-positive patients (most of whom have Sjögren's syndrome). The cutaneous manifestations of DM are usually not found in this setting. The highly pruritic scaling scalp involvement in patients with adult-onset classic DM and C-ADM that can be associated with nonscarring alopecia was also recently demonstrated to occur in approximately 25 percent of patients with juvenile-onset DM. [19]

UNCOMMON CUTANEOUS ASSOCIATIONS A number of rare cutaneous associations have been reported in patients with DM, including acquired ichthyosis; erythroderma; facial swelling without erythema; follicular hyperkeratosis; hypertrichosis; lichen planus; linear IgA bullous dermatosis; malakoplakia; malignant erythema (suffusion); mucous membrane lesions; nasal septal perforation; panniculitis; cutaneous mucinosis; glucocorticoid-induced acanthosis nigricans; urticaria/urticarial vasculitis; cutaneous vasculitis; vulvar and scrotal involvement; zebra-like stripes (i.e., centripetal flagellate erythema); malignant atrophic papulosis; and anasarca (reviewed in Ref. [5]). Recently, attention has been refocused on another unusual cutaneous finding of DM: pityriasis rubra pilaris (PRP)-like lesions (i.e., type Wong DM). [33] This variant usually presents as perifollicular keratosis over the extensor aspects of the upper extremities in adult-onset classic DM. [34] It can simulate the appearance of florid keratosis pilaris, and some such patients have had atopic dermatitis as well as DM. However, more widespread patterns of involvement that better simulate PRP have been described, although such patients have not had other classic features of PRP such as desquamative palmar plantar hyperkeratosis. Acquired lipodystrophy has been increasingly recognized in patients with juvenile classic DM. One report of 20 patients indicated that 25 percent had evidence of lipodystrophy, while 50 percent demonstrated hypertriglyceridemia and insulin resistance. [35] In another preliminary report, lipodystrophy was associated with calcinosis. [36] Gingival telangiectasia is an oral mucosal manifestation of juvenile-onset classic DM. [37] However, these mucosal changes are not specific for DM, occurring also in patients with LE and systemic sclerosis. Mucinous plaques centered over the flexural creases of the palms and fingers have also been seen in the context of DM/PM. [5], [38]

Systemic Features

Table 172-7 outlines the systemic manifestations and associations of classic DM/PM. Most of the extramuscular systemic features associated with classic DM have not been reported in amyopathic DM except for interstitial pneumonitis.

Musculoskeletal
Myositis with proximal weakness
Muscle atrophy and contracture*
Muscular calcification*
Cardiac
Cardiomyopathy
Conduction defects
Respiratory
Dysphonia
Diffuse interstitial pneumonitis/fibrosis
Aspiration pneumonia
Respiratory failure from muscle weakness
Gastrointestinal
Proximal dysphagia
Large bowel infarction/perforation secondary to vasculopathy*
Ophthalmologic
Retinopathy*
Internal malignancy†

*Usually limited to juvenile dermatomyositis.
†Not significantly increased in juvenile dermatomyositis.

TABLE 172-7 **Systemic Manifestations/Associations of Dermatomyositis/Polymyositis**

MUSCLE DISEASE Muscle involvement typically presents as symmetric weakness of the proximal muscles of the extremities. Lower extremity weakness manifesting as difficulty with routine activities of daily living, such as rising from a chair or bathtub and climbing stairs, is often the initial clinical finding. Weakness of the upper extremities soon follows, often manifest by difficulty in raising the arms above the head to perform routine activities such as combing the hair. Pain or tenderness in the affected muscle groups commonly occurs. Some patients experience a fulminant course, resulting in disabling weakness within a few weeks. Confirmation that proximal muscle weakness is caused by the inflammatory myositis of DM/PM can be difficult because so many other clinical disorders produce proximal muscle weakness (Table 172-8). The diagnosis can be supported by demonstration of characteristic serum muscle enzyme elevations, as well as identification of diagnostic electromyographic (EMG), muscle imaging, and muscle biopsy changes. It is possible that some patients with amyopathic DM suffer from low-grade, subclinical muscle disease (hypomyopathic DM). However, no

symptoms of muscular weakness develop in some patients who express the hallmark cutaneous manifestations of DM for 10 to 20 years.

Infectious myopathies
HIV-1, HTLV-I, coxsackievirus, echovirus, influenza, adenovirus, hepatitis B, Epstein-Barr virus
Other myopathies
Inclusion-body myositis, rheumatic disease vasculitis, muscular dystrophies, metabolic myopathies
Neurologic disorders
Myasthenia gravis, amyotrophic lateral sclerosis, Guillain-Barré syndrome
Endocrine disorders
Hypothyroidism and hyperthyroidism, Cushing's syndrome, diabetic neuropathy, hypokalemia
Drug-induced myopathies
Alcohol, antimalarials (vacuolar myopathy), colchicine, glucocorticoids, cyclosporine, street drugs (cocaine, heroin), lipid-lowering agents (lovastatin, simvastatin, gemfibrozil, clofibrate, niacin), D-penicillamine, zidovudine, isotretinoin/etretinate

SOURCE: Adapted from Evans and Sontheimer,[7] with permission of the publisher, Williams & Wilkins.

TABLE 172-8 **Conditions That Can Simulate the Proximal Muscle Weakness of Dermatomyositis/Polymyositis**

Inclusion-body myositis is a pathologically distinctive type of steroid-resistant myositis that more commonly affects the distal muscle groups of men in an asymmetric pattern. Cutaneous involvement is not seen with this disorder or with classic PM. Myositic inflammation can be highly focal. A number of noninvasive techniques are currently being examined for their ability to localize affected muscle groups. MRI is the method of choice for diagnostic imaging of muscle abnormalities in patients with myositis. [39] The possibility that MRI-guided needle biopsy could obviate the need for the more costly and invasive open muscle biopsy is being explored. In addition, MRI and ^{31}P magnetic resonance spectroscopy (MRS) are also useful in assessing the status of muscle disease activity during treatment with systemic glucocorticoids and other immunosuppressive drugs. These procedures are expensive and cannot be used in some individuals with metallic implants. Less costly approaches to monitoring muscle disease activity, such as power Doppler and gray-scale ultrasonography, are being examined. [40] Functional metabolic changes in muscles identified by MRS have been especially evident on exercise in some patients with amyopathic DM (such patients would better be classified as having “hypomyopathic DM”). Artificial neural networks have been proposed as an effective way to analyze the multichannel functional data that result from ^{31}P MRS examination. [41] A central issue in this area is whether the subtle muscular abnormalities that can be identified with these sensitive imaging systems have clear prognostic value. A retrospective analysis of all patients with DM seen at the Mayo Clinic between 1976 and 1994 revealed that 32 (4 percent) of 746 patients conformed to the definition of C-ADM [42]; 27 had amyopathic DM and 5 had hypomyopathic DM. Follow-up information was available on 16 of the patients with amyopathic DM. Ten had no muscle weakness after 2 to 10 years, 4 had no weakness at 1 year, and 2 developed weakness within 5 years after diagnosis. None of the three patients with hypomyopathic DM who were followed showed evidence of muscle weakness 8 to 17 years after diagnosis. Thus, of these 19 patients with C-ADM, only 2 developed clinical evidence of myositis after prolonged periods of time. The presence of subclinical muscle abnormalities at the time of diagnosis of amyopathic DM does not necessarily portend the subsequent development of clinically significant muscle disease. While fatigue and/or myalgia without objective evidence of muscle inflammation have been described in a number of C-ADM case descriptions, a single case report of documented fibromyalgia occurring in amyopathic DM has now appeared. [43] The symptoms of fatigue, muscle pain, and muscle tenderness associated with fibromyalgia could falsely imply the development of myositis in a patient with C-ADM. There continues to be debate concerning the risk for patients with juvenile-onset C-ADM of ultimately developing clinically significant myositis. Some groups see a relatively low risk, [44] while others see a relatively high risk. [45] To fulfill the definition of C-ADM, clinical evidence of muscle weakness should not be present. Muscle strength testing is graded on a scale of 1 to 5: 0 = no muscle action; 1 = trace contraction; 2 = visible contraction but unable to overcome gravity; 3 = fair contraction but can overcome gravity; 4 = contraction able to offer some resistance; 5 = evaluator cannot overcome contracted muscle. The examination should focus on the proximal muscle groups that control the neck, shoulders, and hips. Manual muscle testing is reproducible; variables such as pain, contractures, voluntary effort, and motivation may influence the ability of an individual to exert maximal muscle effort.

PULMONARY DISEASE Among the most feared nonmuscular systemic manifestations (Table 172-7) is pulmonary disease. Lung function can be compromised in a number of ways in patients with classic DM: a restrictive lung defect because of respiratory muscle weakness; aspiration pneumonia secondary to gastrointestinal reflux and impaired esophageal muscle function; opportunistic infections; or a pattern of interstitial pneumonitis related to the underlying autoimmune disease process. In addition, systemic drugs used to treat DM such as methotrexate can produce pulmonary complications (i.e., hypersensitivity pneumonitis). Interstitial pneumonitis resulting from both classic DM and C-ADM was recently reviewed. [46], [47] Between 5 and 40 percent of patients with classic DM develop interstitial lung disease (chest CT scan can identify earlier lung involvement than routine chest x-ray). This complication presents clinically with symptoms of nonproductive cough and exertional dyspnea that are accompanied by bibasilar fine crackling rales. Pulmonary function tests show a restrictive pattern with reduced diffusion capacity. Several clinical patterns of interstitial lung disease have been described: bronchiolitis obliterans organizing pneumonia; diffuse alveolar damage; desquamative interstitial pneumonia; nonspecific interstitial pneumonia; and respiratory bronchiolitis interstitial lung disease. Interstitial lung disease can present clinically as an acute/subacute type or a chronic type. In the acute or subacute type, patients present with severe, rapidly progressive dyspnea and progressive hypoxemia within a month from onset of lung involvement. Such a patient is often treatment-resistant and at risk for death. In the chronic type, patients present with a much slower pace of progressive dyspnea. Interstitial lung disease can also be identified by chest x-ray and/or pulmonary function tests in the complete absence of symptoms. It has been suggested that interstitial lung disease associated with the myositis-specific autoantibodies (antisynthetases) can occasionally occur in the absence of skin and muscle disease. [48] In some individuals, interstitial lung disease presents before the clinical appearance of myositis. Patients with classic DM who have the antisynthetase syndrome (Jo-1, PL-7, PL-12 or other synthetase autoantibodies; arthritis; Raynaud's phenomenon) have increased risk of developing interstitial lung disease. The antisynthetase syndrome and interstitial pneumonitis occur also in children with classic DM. Interstitial pneumonitis and air leakage were recently observed in one child with classic juvenile DM. [49] Interstitial pneumonitis and pulmonary fibrosis can complicate both C-ADM and classic DM. [50] In many cases, interstitial pneumonitis has occurred in patients with C-ADM in the absence of antisynthetase autoantibodies such as Jo-1, which are considered to be markers for interstitial lung disease risk in patients with classic DM. The prevalence of interstitial pneumonitis in C-ADM may approach 5 to 10 percent. A disproportionately high percentage of patients with C-ADM and interstitial lung disease has been reported from Japan, perhaps related to the fact that interstitial pneumonitis appears to be an especially common complication of classic DM in the Japanese. In addition, the acute/subacute pattern of disease presentation with rapidly progressive dyspnea,

progressive hypoxemia, treatment-resistance, and fatal outcome has been observed in a disturbingly high percentage of patients with C-ADM who develop pulmonary disease.

ARTHRITIS Arthritis occurs in 20 to 65 percent of patients with juvenile-onset classic DM. [51] Typically, this is a nonerosive arthritis involving knees, wrists, elbows, and fingers. It is seen early in the course of the disease. For some patients, arthritis can be a major symptomatic problem. Arthritis also occurs in some patients with juvenile-onset C-ADM. In one recent study, 3 of 5 patients with juvenile C-ADM (60 percent) followed over an average period of 4.9 years were reported to have arthritis, whereas 49 of 80 children with classic DM had arthritis. [51]

INTERNAL MALIGNANCY Population-based studies document that patients with DM have a higher than expected risk for malignancy. [52], [53], [54], [55] and [56] Relative risks for malignancy range from 2.4 in males with DM to 3.4 in females with DM. The risk for malignancies was negligible in patients with PM. During the 5-year period after the diagnosis of DM, the risk of a woman developing ovarian cancer in these studies was 16.7-fold higher than the risk for women without DM. In a more recent study, the standardized incidence ratio for malignancy in patients with DM was 6.5. In the first year following diagnosis, the relative risk for malignancy in patients with DM was 26.0. Females with DM in this study had a 32-fold higher risk of developing ovarian carcinoma. This study also found that PM was not associated with an increased risk of cancer and that the treatment of DM with cytotoxic drugs did not increase the risk of malignancy. Because of the risk of ovarian cancer in females with DM, it has been suggested that all women with DM (classic DM and amyopathic DM) undergo an initial and repeat comprehensive gynecologic examination at 6- to 12-month intervals at least for the first 2 years after the diagnosis. Cancer antigen-125 (CA-125) serum level determinations and transvaginal ultrasonography are also recommended for females with DM and intact ovaries. Tumors other than ovarian carcinoma have been reported with DM, including melanoma, mycosis fungoides, and Kaposi's sarcoma. Carcinomas are more frequent than sarcomas, and lymphoproliferative malignancies are uncommon. Except for ovarian cancer in women, no preponderance of specific types of cancer are seen in whites with DM/PM. Oriental males most frequently develop nasopharyngeal carcinoma. [52], [53] The diagnosis of cancer is most often made by history, review of systems, physical examination, and routine laboratory/radiologic testing. Debate exists about the routine use of surveillance imaging techniques, such as chest or abdominal computed tomography and/or MRI, in this setting. Age appears to be a factor in malignancy risk; there is not a significant risk of occult malignancy in children with juvenile-onset DM, whereas individuals 50 years of age or older at the time of onset of DM appear to have an increased risk of malignancy. The leading cause of death in patients with DM/PM who have malignancy is metastatic spread of the malignancy rather than complications directly related to the myositis. In patients with malignancy, the myositis and cutaneous manifestations are less responsive to systemic glucocorticoid therapy. In a few well-documented cases, definitive therapy for the malignancy resulted in resolution of the DM, and a recurrence of the cancer was associated with the reappearance of the DM. Increasing age, skin disease extent and severity (i.e., blistering, ulceration), and creatine kinase levels appear to enhance the risk of malignancy in patients with classic DM. It has been suggested that other systemic manifestations of DM, such as interstitial lung disease, are negatively correlated with risk for internal malignancy. [18] All routine age- and sex-directed malignancy surveillance guidelines should be followed. Repeat malignancy surveillance measures need to be carried out regularly (every 6 to 12 months) for the first 2 years after the diagnosis of DM. After 2 years, the risk of malignancy appears to fall back to that of the age- and sex-matched population in general. However, many physicians carefully observe such patients for the first 5 years after diagnosis. There is a broad consensus that serum tumor markers (e.g., CEA, CA-125, CA 15–3, MUC-1, TPS) are not sufficiently sensitive or specific enough for malignancy screening purposes in the general population. However, in a patient population (i.e., classic DM) having a higher incidence of a disease (i.e., malignancy), Bayes' theorem would argue that the usefulness of tumor markers should increase. [57] Thus, tumor markers such as those indicated above might be of greater value in monitoring for malignancy in patients with classic DM, especially if a trend of changing values is noted in multiple assays obtained sequentially over time in the same patient. [57] There have been no reports examining the role that screening for mutations in familial and sporadic cancer-associated genes such as BRCA-1/2 might have in stratifying the risk of malignancy in women with classic DM. There are no population-based data concerning the risk of internal malignancy in patients with C-ADM. In a recent systematic review of the world literature, approximately 300 published cases of C-ADM were identified, [58] and only 10 percent of these cases were associated with internal malignancy. Population-based studies will be required to resolve the apparent risk of malignancy in C-ADM. Until then it is recommended that the same approach to occult malignancy surveillance be used with patients with C-ADM as is used with patients with classic DM.

Relationship Between Cutaneous and Systemic Manifestations

There is little correlation between skin and muscle disease activity in DM. Patients who have skin and muscle disease at the outset of their illness and have all evidence of their disease activity suppressed by systemic immunosuppressive therapy can have DM skin disease activity return unaccompanied by muscle disease activity once their treatment has been discontinued.

Attempts have been made to correlate the periungual microvascular changes in patients with adult and juvenile DM by nail fold capillaroscopy (i.e., dilatation, tortuosity, budding or arborization, and avascularity) with the systemic manifestations of this disease process, including myositis. In our experience the periungual nail fold capillary changes in patients with C-ADM are qualitatively similar and as prominent as those in patients with classic DM. Similar changes can be seen in patients with systemic sclerosis and, to a lesser degree, in those with systemic LE and mixed connective tissue disease.

LABORATORY FINDINGS

Classic DM

MUSCLE ENZYMES An elevation in the level of serum creatine kinase (CK) is the most sensitive and specific laboratory indicator of muscle disease activity in DM/PM. Ninety percent of patients with classic DM/PM have elevated levels of CK at some point. The elevated CK activity is predominately caused by the CK-MM isoenzyme; however, elevations caused by the CK-MB isoenzyme are also seen. Elevated levels of CK can be associated with some of the disorders listed in Table 172-8 (e.g., other myopathies, hypothyroidism, and drug ingestions), as well as with strenuous physical exertion

and needle trauma (intramuscular injection, EMG needle insertion). Enzymatic detection of CK activity can at times be inhibited by serum factors. Levels of CK may become elevated before the development of weakness and can normalize several weeks before the return of normal strength during treatment. Patients with DM/PM who present with normal CK levels may have a worse prognosis with respect to pulmonary disease and associated malignancy. Levels of CK are usually normal in patients suffering from glucocorticoid-induced myopathy. Serum aldolase is a somewhat less sensitive indicator than CK for active myositis in DM/PM. However, aldolase levels are occasionally elevated in the presence of a normal CK level, especially in juvenile DM. Levels of transaminases (AST, ALT) and lactic dehydrogenase can also be elevated in active myositis, but these values are less useful clinically because of their low degree of specificity. Elevations of transaminase levels during treatment with methotrexate may reflect the activity of myositis, as well as drug-induced hepatotoxicity. Urinary creatine excretion can also be used to monitor the status of myositis. However, the specificity is low in that urinary creatine excretion can also be elevated in steroid myopathy. Serum myoglobin levels can also be elevated in DM/PM.

AUTOANTIBODIES Elevated antinuclear antibody (ANA) levels with human tumor cell substrates are found in 60 to 80 percent of patients with classic DM. Autoantibodies of known molecular specificity in DM are now categorized into two groups: myositis-specific autoantibodies and myositis-associated autoantibodies. [59], [60] Myositis-specific autoantibodies include the antisynthetases (Jo-1, PL-7, PL-12, OJ), Mi-2, and SRP. PM/Scl, Ro/SS-A (Ro52, Ro60), and U1RNP represent the major myositis-associated autoantibodies. Table 172-4 lists the molecular specificities and clinical correlations of these autoantibodies. The fact that none of the myositis-specific autoantibodies occurs with a prevalence greater than 1 in 5 of patients with DM makes routine clinical testing for these autoantibodies of little clinical use. Among the most frequently encountered myositis-specific autoantibodies are those that target the various aminoacyl transfer RNA synthetases. Of these “antisynthetase” autoantibodies, autoantibodies to Jo-1 (histidyl transfer RNA synthetase) are the most common, being found in 20 percent of patients with classic DM/PM overall and 30 to 40 percent of adult patients with PM. Fever, interstitial lung disease, polyarthritis, Raynaud's phenomenon, and incomplete response to therapy occur more often in patients who produce these antibodies (the “antisynthetase syndrome”), as does the mechanic's hand skin lesion. Patients who produce Jo-1 antibodies less frequently display the classic cutaneous manifestations of DM. Signal-recognition particle (SRP) antibodies occur in 5 percent of patients with PM and are more common in those who exhibit acute-onset, severe, treatment-resistant forms of classic DM/PM with cardiac involvement. Such patients rarely have any type of skin involvement. Autoantibodies to Mi-2, a nuclear protein complex, are seen almost exclusively in patients with classic DM. Mi-2 antibody is found in 5 to 10 percent of patients with classic DM/PM overall, and in 15 to 20 percent of patients with classic DM. This autoantibody is associated with more treatment-responsive forms of classic DM, as well as with the shawl sign and prominent cuticular changes. The clinical correlations of the myositis-specific autoantibodies found in adults also occur in children with classic DM/PM. DM/PM autoantibodies that currently have less clinical significance are also listed in Table 172-4.

OTHER LABORATORY ABNORMALITIES The erythrocyte sedimentation rate is elevated in about half of patients with classic DM/PM, but it does not closely correlate with disease activity. Rheumatoid factor is elevated in 20 percent of cases, more often in patients with overlap disease. Other serum factors such as neopterin and factor VIII-related antigen (von Willebrand factor) and CD19+ B cells [23] have been reported to correlate with disease activity in children with classic DM. Elevated levels of other markers of vascular activation including soluble forms of VCAM-1 and E-selectin have also been reported to occur in the circulation of patients with classic DM. KL-6 is a human MUC-1 class mucin that is preferentially expressed on type II pneumocytes. KL-6 has been proposed to be a sensitive serum marker for the presence of interstitial pneumonia in the setting of classic DM (reviewed in Ref. [61]).

ELECTROMYOGRAPHY The EMG changes of myositis include a myopathic pattern of the motor unit action potential, a myopathic recruitment pattern, increased insertional activity, and increased spontaneous activity. EMG changes of myositis can be erratically distributed. The paraspinous muscles can be abnormal by EMG when the limb girdle musculature is normal. As many as 10 percent of patients with biopsy-documented myositis have a normal EMG.

Clinically Amyopathic DM

By definition, the levels of CK and other muscle enzymes are normal in amyopathic DM. Most of the reported patients with C-ADM are ANA-positive. However, such patients do not appear to produce myositis-specific or myositis-associated antibodies. Preliminary studies have indicated that a unique pair of new autoantibody specificities (155 kDa and Se) might serve as serologic markers for this subset of patients with DM. [26], [62] When the results of immunoblot and immunoprecipitation studies employing HeLa cell extracts were combined, 16 of 18 (89 percent) white adult patients with C-ADM showed autoantibodies to the 155-kDa autoantigen and/or the Se autoantigen. The molecular identities of these autoantigens have not yet been revealed, but neither appears to be associated with RNA. If these preliminary results can be confirmed, they could provide a useful clinical tool for confirming a diagnosis of C-ADM. As in classic DM, serum levels of KL-6 are also suggested to be correlated with the activity of interstitial pneumonia in patients with C-ADM. [63]

HISTOPATHOLOGY

Skin

The earliest histologic appearance of cutaneous DM is similar to normal skin except for PAS-positive thickening of the basement membrane, a smudgy, homogeneous appearance of the papillary dermis, and increased dermal mucin and edema. No lymphocytic infiltrate is seen at this stage, and vacuolar alteration of basal keratinocytes, pigment incontinence, and colloid body formation are variably present. Biopsy specimens from more advanced lupus-like skin lesions (i.e., scaling violaceous erythema) have changes similar to or indistinguishable from those of LE. These changes include hyperkeratosis, epidermal atrophy, and effacement of the rete ridges. An interface dermatitis with vacuolar degeneration of the basal keratinocytes and a sparse, superficial, patchy, or bandlike perivascular lymphocytic infiltration can also be seen, along with thickening of the basement membrane and pigment incontinence. The dermis is often pale as a result of the accumulation of edema and mucin. In poikiloderma, these same features are encountered except that ectatic dermal vessels are present. Hyperkeratosis, acanthosis, undulating papillomatosis, vacuolar alteration of basal keratinocytes, thickened basement membrane, variable lymphocytic exocytosis, and increased mucin deposition in the epidermis are seen in Gottron's papules. The cutaneous histologic changes of amyopathic DM are reportedly indistinguishable from those of classic cutaneous DM. Lipomembranous (membranocystic) changes previously thought to

be specific for panniculitis have been noted in the histopathology of punched-out ulcers of DM. No differences in the histopathology or immunopathology of the cutaneous manifestations of classic and amyopathic DM have been observed.

Muscle

Muscle fiber degeneration/regeneration, perifascicular atrophy, and capillary injury are frequently present in the muscle biopsies of patients with DM/PM. A perivascular infiltrate of T lymphocytes and histiocytes and occasionally B lymphocytes, plasma cells, and eosinophils is also seen. Biopsies from patients with DM often show CD4 T cells and B cells in the perivascular areas, whereas CD8 T cells preferentially associate with damaged muscle fibers in patients with PM. The capillary density in muscle specimens from patients with DM is decreased. Inflammation may be absent in up to 25 percent of biopsy specimens from patients with otherwise typical muscle disease by clinical, electromyographic, or biochemical criteria.

An occlusive vasculopathy is a striking aspect of the pathology of childhood DM/PM. Phlebitis and arteritis leading to intimal hyperplasia, fibrinous occlusion of vessels, and infarction of the involved tissues can be seen. The muscles, gastrointestinal tract, and nerves are particularly affected. This vasculopathy in muscles is noninflammatory and occurs predominately in the capillaries. There is a spectrum of endothelial changes from swelling to obliteration to necrosis.

IMMUNOHISTOLOGY

Skin

Bandlike granular deposits of immunoglobulin and complement along the dermal–epidermal junction, subepidermal cytoid bodies, dermal connective tissue staining, and epidermal cytoplasmic staining have been described in DM skin lesions. Lesional dermal–epidermal junction immunoglobulin and complement bands reportedly occur in 5 to 86 percent of patients, depending on the site of biopsy, with the nail fold being a high-prevalence area. However, similar findings can be observed in actinically exposed skin of otherwise normal individuals. It has been suggested that components of the complement membrane attack complex (C5–9) are more often present in the dermal microvessels than at the dermal–epidermal junction in cutaneous DM lesions, whereas the opposite occurs in cutaneous LE lesions. However, there is no general agreement in this area.

The dermal infiltrate of cutaneous DM lesions contains predominately macrophages and CD4 T lymphocytes, some of which demonstrate an activation phenotype. Focal HLA-DR antigen expression has been noted on lesional keratinocytes while being reduced on dermal endothelial cells.

Muscle

Immunoglobulin and complement deposition occur in affected muscle tissue, albeit inconsistently and unrelated to disease activity. The presence of the complement membrane attack complex in muscle capillaries suggests that local activation of complement with resulting endothelial cell toxicity could be related to the microvascular abnormalities of this disorder.

DIAGNOSIS AND DIFFERENTIAL DIAGNOSIS

In the earlier stages, cutaneous DM might be confused with contact dermatitis, seborrheic dermatitis, lichen planus, psoriasis, polymorphic light eruption, and atopic dermatitis. In the later stages, when the more typical cutaneous manifestations of DM have evolved, the greatest challenge can be to distinguish the skin involvement of DM from that of LE (Table 172-9). Periorbital heliotrope erythema and edema can occasionally be seen in SLE, but Gottron's papules are never seen as a cutaneous manifestation of LE. The pattern of involvement over the hands also differs; in LE the skin over the dorsal interphalangeal and metacarpophalangeal joints is spared, and the skin between these joints is preferentially involved. The exact opposite is true for DM; the skin overlying the dorsal interphalangeal and metacarpophalangeal joints is usually affected first (Fig. 172-3). However, when extensive, the linear streaking of violaceous erythema along the track of the extensor tendons of the hands and fingers can sometimes obscure this point of differential diagnosis.

	Dermatomyositis	Lupus Erythematosus
Distribution		
Face		
Malar eminences	+	++
Eyelids, periorbital areas	++	+
Scalp	++	++
Oral mucosa	+	++
Extensor arms, forearms	++	++
Hands		
Dorsal aspect	++	++
Palmar aspect	+	+
Dorsal fingers	+	++
Knuckles	++	+
Periungual telangiectasia	++	+
Color of skin lesions		
Violaceous	++	+
Red, pink	+	++
Alopecia	+	++
Hyperkeratosis	+	++
Gottron's papules	++	0
Pruritus	++	+
Pathology		
Dermal mucinosis	++	++
Intense mononuclear cell infiltrate	+	++
Immunopathology		
Dermal-epidermal junction Ig, complement band	+	++
Dermal microvessel C5–9 deposits	++	+
Laboratory findings		
ANA	++	++
Anti-Ro/SS-A	+	++
Antinative DNA	0	++
Anti-Sm	0	++
Elevated ESR	+	++
Malignancy association	++	0

Abbr: ++ = frequently seen; + = occasionally seen; 0 = absent.
Source: Lupus and Scleroderma.[7] Reprinted with permission of the publisher, Williams & Wilkins.

TABLE 172-9 **Comparative Features of Skin Involvement in Dermatomyositis and Lupus Erythematosus**

As previously noted, certain drugs can produce an eruption with clinical similarities to cutaneous DM. Multicentric reticulohistiocytosis has been reported to masquerade as DM. However, the “string of pearls” papules that occur in the periungual areas in multicentric reticulohistiocytosis can be clearly distinguished from the periungual inflammatory changes of DM by clinical and pathologic examination. Many conditions other than DM/PM can be associated with proximal muscle weakness. [64] Table 172-8 outlines these disorders.

TREATMENT

While systematically ascertained information exists about the treatment of the muscle manifestations of DM, virtually no such information exists that is related specifically to treatment of the cutaneous manifestations of this disease.

Local

Patients with either classic or amyopathic DM should avoid excessive sun exposure and use substantive broad-spectrum sunscreens. An in-depth discussion of practical and theoretical photoprotection and local therapy for autoimmune connective tissue skin disease such as DM was recently presented elsewhere. [65] Topical glucocorticoids (classes I and II) can dampen cutaneous inflammation and pruritus, and such agents can be used safely for prolonged periods of time when administered cyclically (2 weeks of daily treatment followed by 2 weeks off treatment). However, these agents alone usually cannot fully suppress DM skin disease activity. Daily use of a medicated shampoo followed by application of a topical glucocorticoid solution, gel, spray, or foam to the affected areas can provide relief for the scalp pruritus. Xerosis is often present, especially in the elderly, and effective moisturization regimens can be of value in managing the pruritus often experienced by patients with DM. Topical antipruritic agents such as combinations of menthol/phenol/camphor, pramoxine, and doxepin can provide short-term relief.

Systemic

When possible, nonsteroidal systemic therapy should be maximized. Doxepin, a tricyclic antidepressant, is a potent H_1- and H_2-blocking antihistamine. When given at bedtime in doses of 10 to 50 mg, it can ameliorate pruritus and excoriation. Conventional or nonsedating antihistamines can be used during the day. Hydroxychloroquine sulfate (6 mg/kg per day given as two divided doses) has been used to treat DM skin disease. Some patients respond better to a combination of hydroxychloroquine and quinacrine, 100 mg/day, or to chloroquine (4 mg/kg per day) and quinacrine (100 mg/day). However, the authors' experience has been that even with combination therapy, only a minority of DM patients respond fully. Precautions should be taken to minimize the risk of retinal toxicity with hydroxychloroquine or chloroquine and hematologic toxicity with quinacrine. If extrapolation from the experience gained from patients with cutaneous LE is valid, patients with DM who smoke cigarettes might be less responsive to antimalarial therapy than those patients who do not smoke. It should be remembered that on rare occasion antimalarials can contribute to muscular weakness by causing a vacuolar myopathy. Dapsone has recently been suggested to be of value for the cutaneous manifestations of DM.

Systemic glucocorticoids remain the traditional first-line therapy for classic DM. Early intervention with systemic glucocorticoids is associated with a better overall prognosis. In adults, prednisone (prednisolone for those with decreased liver function) is given orally in divided doses of 1 to 1.5 mg/kg per day, while children are given 1 to 2 mg/kg per day. Significant improvement of muscle strength, normalization of muscle enzyme levels, and improvement in cutaneous inflammation are the end points of therapy. Most patients require 1 to 3 months of full-dose treatment with prednisone. With improvement, the dose can be consolidated from a divided dose to a single daily dose given in the morning to reduce the risk of adrenal suppression and other glucocorticoid side effects. The glucocorticoid dose can then be progressively decreased. Treatment should be continued for 12 to 24 consecutive months to minimize the chance for recurrence. Attention should be paid to managing the side effects of long-term systemic glucocorticoids. In acutely ill patients, intravenous pulse therapy with methylprednisolone can be used; this approach has become increasingly popular in the management of juvenile DM. Alternate-day glucocorticoids usually do not provide adequate relief during active phases of the disease. The cutaneous lesions of DM can be refractory to high-dose, long-term glucocorticoids in some patients. Other patients have recrudescent disease activity only in their skin after complete suppression of their muscle disease with systemic glucocorticoid therapy.

Systemic glucocorticoids have also been used for the disabling skin disease activity in patients with amyopathic DM. However, it remains to be determined whether early aggressive immunosuppressive treatment of C-ADM might prevent the development of clinically significant myositis later.

Approximately 25 percent of patients with classic DM/PM do not respond adequately to systemic glucocorticoids within the first 2 months of treatment. Azathioprine (1 to 2 mg/kg per day), cyclophosphamide (1 to 2 mg/kg per day), methotrexate (10 to 50 mg/week), chlorambucil (2 to 6 mg/day), cyclosporine (3 to 5 mg/kg per day), and mycophenolate (1 to 1.5 g/day) have been used in this setting for patients who cannot tolerate the side effects of high-dose glucocorticoids. Extracorporeal photochemotherapy has been explored as an adjunctive therapy.

Oral methotrexate (10 to 25 mg) given once weekly has also been successful in the treatment of patients with classic DM and some patients primarily affected by the cutaneous manifestations of DM. Higher doses can be given subcutaneously or intravenously; the intramuscular route may spuriously elevate muscle enzyme levels. Cyclosporine and cyclophosphamide have each been reported to be of benefit in severe complications of interstitial lung disease in patients with C-ADM, especially when started before frank respiratory failure has developed. [66], [67] In children, oral cyclophosphamide (2 to 4 mg/kg per day) has traditionally been used in cases that could not be satisfactorily managed by systemic glucocorticoids. High-dose intravenous gamma globulin therapy has been used in both children and adults in this setting, with the advantage of low toxicity. A controlled clinical trial has indicated that plasmapheresis and leukapheresis have little additional value in the management of DM/PM.

Based on experimental evidence indicating a role for TNF-a in the pathogenesis of the classic DM muscle inflammation, anti–TNF-a therapy was recently used on an anecdotal basis for both the muscular and cutaneous manifestations of DM. A small number of cases of severe, treatment-resistant DM have been successfully treated with etanercept (Enbrel) or infliximab (Remicade), and thalidomide has been used in several centers. More systematic study is needed to define the value of such treatment. Such therapy would have to be used with caution concerning the possibility of its uncovering other patterns of systemic autoimmunity (e.g., SLE).

Because enzymatic indicators of muscle inflammation tend to normalize quite quickly after systemic therapy is begun, other surrogate markers of DM systemic disease activity are used by some to guide therapy. Such markers include the vWF:Ag, CD19+ B cells, and neopterin (reviewed in Ref. [23]). Serum levels of KL-6 have also been suggested to reflect DM interstitial lung disease activity.

Treatment of dystrophic calcification in DM is challenging. Aluminum hydroxide antacids and diltiazem are currently used for this problem with less-than-ideal results. Other agents that can be tried include probenecid (250 mg/day), potassium para-amino benzoic acid (15 to 25 g/day), warfarin (1 mg/day), EDTA, and colchicine (1.2 to 1.8 mg/day). The bisphosphonates, such as alendronate, might be of value. [68] The surgical removal of symptomatic cutaneous or subcutaneous calcium deposits can be considered as a last resort.

Passive range-of-motion exercise should be provided early in the disease course to prevent disabling joint contractures, especially in children. After disease activity is suppressed medically, an active exercise program can facilitate the return of normal strength.

Surveillance for the detection of occult malignancy was discussed earlier. In addition, changes in the clinical status of the respiratory, cardiovascular, and gastrointestinal systems should be evaluated carefully for the possibility of systemic disease activity in these target organs.

Current approaches to the treatment of adults and children with C-ADM are based on anecdotal observations of individual cases or a relatively small case series.

One approach has been to treat patients with C-ADM aggressively from the outset with systemic glucocorticoids in the hope that progression to systemic involvement might be delayed or prevented. [69] This approach is supported by studies of patients with both juvenile- and adult-onset classic DM that indicate that early systemic immunosuppressive treatment can lessen long-term disability from muscle dysfunction and complications such as calcification. However, in the large majority of published reports, a more conservative treatment approach has been taken. This approach is validated by reports of patients with C-ADM going 10 to 20 years and longer without any sign of disease activity other than in the skin. [1], [42], [43], [70]

Until it is confirmed that adult patients with C-ADM do not have an increased risk of internal malignancy, they should be evaluated for this potential complication in a manner similar to patients with classic DM. Because internal malignancy has not been reported in juvenile C-ADM, it can be assumed that, as in children with classic DM, routine evaluation for internal malignancy is not indicated.

PROGNOSIS

Classic DM

Reports of mortality rates vary from 25 to 80 percent, depending on the case mix and the medical era in which the cases were collected. In the past two decades, the mortality rate has decreased considerably because of the more aggressive use of glucocorticoids and other immunosuppressives and better supportive medical care. The 5- and 8-year survival rates for 76 patients with DM/PM studied in the 1980s were 80 and 73 percent, respectively. A more recent examination of prognosis in 77 consecutive patients with DM/PM having a minimum of 18 months follow-up revealed a 22 percent mortality rate resulting predominately from malignancy and lung disease. [71] As was previously observed, a better prognosis was seen in individuals who received early systemic treatment for their disease. The early and aggressive use of glucocorticoids has reduced the mortality rate in children to less than 10 percent. The most common causes of death in DM/PM are malignancy, infection, and cardiac and pulmonary disease.

Antisynthetase antibodies and TNF-a308A allele may represent risk factors for disease chronicity and severity in juvenile-onset classic DM. [23] African American children with DM tend to have more aggressive disease than do white or Hispanic children. Calcinosis remains a primary cause of both disease morbidity and mortality in patients with juvenile classic DM.

Some adults with classic DM respond quickly to treatment with systemic glucocorticoids and enjoy treatment-free intervals of various durations after these drugs have been tapered. Most such patients eventually experience a recurrence of disease activity. Others do not respond fully to systemic glucocorticoids or to other immunosuppressive agents and have a long-term, unremitting course. Some patients have a fulminant course with early death. Factors suggested to be associated with a poor prognosis include older age at onset, fulminant disease onset, dysphagia, interstitial lung disease, cardiac involvement, associated malignancy, glucocorticoid resistance, and delay in treatment.

Certain types of skin lesions have also been said to correlate with a poor outcome. Ulcers arising over violaceous indurated plaques on the trunk with or without indurated papules were reported to be more frequent in adults with DM who developed a malignancy. Necrotic/ulcerative skin disease has been noted to be a bad prognostic feature. The mechanic's hand lesion has been suggested to be associated with an increased risk for interstitial lung disease.

Prognosis in both adults and children with classic DM/PM is associated with the types of autoantibodies produced. Antisynthetase autoantibodies (Jo-1, PL-7, PL-12) have been correlated with incomplete response to therapy and interstitial lung disease. Signal-recognition particle antibodies have been found in patients with more acute onset, severe, and treatment-resistant forms of disease with frequent cardiac involvement. Autoantibodies to Mi-2 are associated with more treatment-responsive forms of DM.

Clinically Amyopathic DM

There are insufficient long-term follow-up data available to assess prognosis in adults or children with amyopathic DM. All six patients in one cohort, who initially presented with only skin disease and who were treated conservatively, ultimately developed muscle disease. [72] In another cohort, none of the five adults with amyopathic DM treated aggressively with high-dose systemic glucocorticoids developed clinical evidence of myositis. [69] While fatal malignancies have been reported to occur in patients with amyopathic DM, the statistical significance of such an association has not yet been determined. Based on the reports to date, there appears to be a low frequency of systemic organ involvement in patients with amyopathic DM. However, the potentially fatal complication of interstitial lung disease has been reported in approximately 40 patients presenting with C-ADM. [50]

One study has suggested that patients with juvenile DM who have only cutaneous manifestations are usually not treated aggressively and may frequently develop pathologic calcifications. [45] This report is contrary to other studies of C-ADM, in both children [44] and adults, [16], [42] that have indicated that this mode of presentation is usually not associated with a high rate of subsequent dystrophic calcification. One study indicating that both rheumatologists and dermatologists tend to be conservative in treating patients with C-ADM [44] also reports that a high percentage of patients with juvenile-onset C-ADM enjoy spontaneous remission without systemic immunosuppressive treatment.

REFERENCES

1. Sontheimer RD: Cutaneous features of classical dermatomyositis and amyopathic dermatomyositis. *Curr Opin Rheumatol* **11**:475, 1999

2. Sontheimer RD: Would a new name hasten the acceptance of clinically-amyopathic dermatomyositis (dermatomyositis sine myositis) as a distinctive subset within the idiopathic inflammatory dermatomyopathies spectrum of clinical illness? *J Am Acad Dermatol* **46**:626, 2002

3. Sontheimer RD: Lupus erythematosus and dermatomyositis. *Curr Prob Dermatol* **12**:5, 2000

4. Sontheimer RD: Dermatomyositis, in *Fitzpatrick's Dermatology in General Medicine,* 5th ed, edited by IM Freedberg, AZ Eisen, K Wolff, KF Austen, LA Goldsmith, SI Katz, TB Fitzpatrick. New York, McGraw Hill, 1999, p 2009

5. Euwer RL, Sontheimer RD: Dermatomyositis, in *Cutaneous Manifestations of Rheumatic Diseases,* edited by RD Sontheimer, TT Provost. Baltimore, Williams and Wilkins, 1996, p 73

6. Caro I: Dermatomyositis. *Semin Cutan Med Surg* **20**:38, 2001

7. Rendt K: Inflammatory myopathies: Narrowing the differential diagnosis. *Cleve Clin J Med* **68**:505, 509, 2001

8. Koler RA, Montemarano A: Dermatomyositis. *Am Fam Physician* **64**:1565, 2001

9. Reed AM: Myositis in children. *Curr Opin Rheumatol* **13**:428, 2001

10. Callen JP: Dermatomyositis. *Lancet* **355**:53, 2000

11. Rider LG, Miller FW: Idiopathic inflammatory muscle disease: Clinical aspects. *Baillieres Best Pract Res Clin Rheumatol* **14**:37, 2000

12. Rider LG et al: Clinical, serologic, and immunogenetic features of familial idiopathic inflammatory myopathy. *Arthritis Rheum* **41**:710, 1998

13. Kovacs SO, Kovacs SC: Dermatomyositis. *J Am Acad Dermatol* **39**:899, 1998

14. Olsen NJ, Park JH: Inflammatory myopathies: Issues in diagnosis and management. *Arthritis Care Res* **10**:200, 1997

15. Dourmishev AL, Dourmishev LA: Dermatomyositis and drugs. *Adv Exp Med Biol* **455**:187, 1999

16. Caproni M et al: Amyopathic dermatomyositis. A review by the Italian Group of Immunodermatology. *Arch Dermatol* **138**:23, 2002

17. Ang P et al: Classical and amyopathic dermatomyositis seen at the National Skin Centre of Singapore: A 3-year retrospective review of their clinical characteristics and association with malignancy. *Ann Acad Med Singapore* **29**:219, 2000

18. Chen YJ et al: Predicting factors of malignancy in dermatomyositis and polymyositis: A case-control study. *Br J Dermatol* **144**:825, 2001

19. Peloro TM et al: Juvenile dermatomyositis: A retrospective review of a 30-year experience. *J Am Acad Dermatol* **45**:28, 2001

20. Arnett FC et al: Interrelationship of major histocompatibility complex class II alleles and autoantibodies in four ethnic groups with various forms of myositis. *Arthritis Rheum* **39**:1507, 1996

21. Marie I et al: Pseudo-dermatomyositis as a complication of hydroxyurea therapy. *Clin Exp Rheumatol* **18**:536, 2000

22. Price P et al: The genetic basis for the association of the 8.1 ancestral haplotype (A1, B8, DR3) with multiple immunopathological diseases. *Immunol Rev* **167**:257, 1999

23. Pachman LM et al: TNFalpha-308A allele in juvenile dermatomyositis: Association with increased production of tumor necrosis factor alpha, disease duration, and pathologic calcifications. *Arthritis Rheum* **43**:2368, 2000

24. Ichikawa E et al: Hereditary complement (C9) deficiency associated with dermatomyositis. *Br J Dermatol* **144**:1080, 2001

25. Werth VP et al: Association of a promoter polymorphism of tumor necrosis factor-alpha with subacute cutaneous lupus erythematosus and distinct photoregulation of transcription. *J Invest Dermatol* **115**:726, 2000

26. Targoff IN et al: Autoantibodies to 155 KD and Se antigens in patients with clinically-amyopathic dermatomyositis. *Arthritis Rheum* **43**:S194, 2000

27. Bank I et al: Mechanisms of cell-mediated myocytotoxicity in the peripheral blood of patients with inflammatory myopathies. *J Clin Immunol* **21**:328, 2001

28. Lundberg IE: Idiopathic inflammatory myopathies: Why do the muscles become weak? *Curr Opin Rheumatol* **13**:457, 2001

29. Reed AM et al: Chimerism in children with juvenile dermatomyositis. *Lancet* **356**:2156, 2000

30. Tominaga A et al: Reticular erythematous mucinosis syndrome with an infiltration of factor XIIIa+ and hyaluronan synthase 2+ dermal dendrocytes. *Br J Dermatol* **145**:141, 2001

31. Sontheimer RD: Dermatomyositis. An overview of recent progress with emphasis on dermatological aspects. *Clin Dermatol* **20**:387, 2002

32. Kimball AB et al: Magnetic resonance imaging detection of occult skin and subcutaneous abnormalities in juvenile dermatomyositis. Implications for diagnosis and therapy. *Arthritis Rheum* **43**:1866, 2000

33. Lupton JR et al: An unusual presentation of dermatomyositis: The type Wong variant revisited. *J Am Acad Dermatol* **43**:908, 2000

34. Wong KO: Dermatomyositis: A clinical investigation of 23 cases in Hong Kong. *Br J Dermatol* **81**:544, 1969

35. Huemer C et al: Lipodystrophy in patients with juvenile dermatomyositis—Evaluation of clinical and metabolic abnormalities. *J Rheumatol* **28**:610, 2001

36. Rider L et al: Lipodystrophy in juvenile dermatomyositis is associated with calcinosis, but not with hepatocyte differentiation factor DLK levels. *Arthritis Rheum* **44**:S264, 2001

37. Ghali FE et al: Gingival telangiectases: An underappreciated physical sign of juvenile dermatomyositis. *Arch Dermatol* **135**:1370, 1999

38. Del Pozo J et al: Dermatomyositis and mucinosis. *Int J Dermatol* **40**:120, 2001

39. Park JH, Olsen NJ: Utility of magnetic resonance imaging in the evaluation of patients with inflammatory myopathies. *Curr Rheumatol Rep* **3**:334, 2001

40. Meng C et al: Combined use of power Doppler and gray-scale sonography: A new technique for the assessment of inflammatory myopathy. *Rheumatology* **28**:1271, 2001

41. Park JH et al: Analysis of ^{31}P MR spectroscopy data using artificial neural networks for longitudinal evaluation of muscle diseases: Dermatomyositis. *NMR Biomed* **11**:245, 1998

42. el-Azhary R, Pakzad SY: Amyopathic dermatomyositis: Retrospective review of 37 cases. *J Am Acad Dermatol* **46**:560, 2002

43. Thune P: The coexistence of amyopathic dermatomyositis and fibromyalgia. *Acta Derm Venereol* **80**:453, 2000

44. Plamondon S, Dent PB: Juvenile amyopathic dermatomyositis: Results of a case-finding descriptive survey. *J Rheumatol* **27**:2031, 2000

45. Eisenstein DM et al: Juvenile dermatomyositis presenting with rash alone. *Pediatrics* **100**:391, 1997

46. Hirakata M, Nagai S: Interstitial lung disease in polymyositis and dermatomyositis [review]. *Curr Opin Rheumatol* **12**:501, 2000

47. Douglas WW et al: Polymyositis-dermatomyositis-associated interstitial lung disease. *Am J Resp Crit Care Med* **164**:1182, 2001

48. Friedman AW et al: Interstitial lung disease with autoantibodies against aminoacyl-tRNA synthetases in the absence of clinically apparent myositis. *Semin Arthritis Rheum* **26**:459, 1996

49. al-Mayouf SM et al: Cyclosporine in the treatment of an unusual case of juvenile systemic sclerosis. *J Rheumatol* **25**:791, 1998

50. Sontheimer RD, Miyagawa S: Potentially-fatal interstitial lung disease presenting in the context of amyopathic dermatomyositis [letter]. 2002 (submitted for publication)

51. Tse S et al: The arthritis of inflammatory childhood myositis syndromes. *J Rheumatol* **28**:192, 2001

52. Sigurgeirsson B: Skin disease and malignancy. An epidemiological study. *Acta Derm Venereol Suppl (Stockh)* **178**:1, 1992

53. Airio A, Pukkala EIsomäki H: Elevated cancer incidence in patients with dermatomyositis: A population based study. *J Rheumatol* **22**:1300, 1995

54. Leow YH, Goh CL: Malignancy in adult dermatomyositis. *Int J Dermatol* **36**:904, 1997

55. Yazici Y, Kagen LJ: The association of malignancy with myositis. *Curr Opin Rheumatol* **12**:498, 2000

56. Stockton D et al: Risk of cancer in patients with dermatomyositis or polymyositis, and follow-up implications: A Scottish population-based cohort study. *Br J Cancer* **85**:41, 2001

57. O'Gradaigh D, Merry P: Tumour markers in dermatomyositis: useful or useless [letter]? *Br J Rheumatol* **37**:914, 1998

58. Lewis JM, Sontheimer RD: A systematic review of clinically-amyopathic dermatomyositis (dermatomyositis siné myositis). 2002 (submitted for publication)

59. Targoff IN: Update on myositis-specific and myositis-associated autoantibodies. *Curr Opin Rheumatol* **12**:475, 2000

60. Brouwer R et al: Autoantibody profiles in the sera of European patients with myositis. *Ann Rheum Dis* **60**:116, 2001

61. Hirakata M, Nagai S: Interstitial lung disease in polymyositis and dermatomyositis. *Curr Opin Rheumatol* **12**:501, 2000

62. Sontheimer RD et al: Autoantibodies to 155 KD and Se antigens in patients with clinically amyopathic dermatomyositis. *J Invest Dermatol* **117**:466, 2001

63. Kubo M et al: Serum KL-6 in adult patients with polymyositis and dermatomyositis. *Rheumatology (Oxford)* **39**:632, 2000

64. Rendt K: Inflammatory myopathies: Narrowing the differential diagnosis. *Clev Clin J Med* **68**:505, 2001

65. Ting WW, Sontheimer RD: Local therapy for cutaneous and systemic lupus erythematosus: Practical and theoretical considerations. *Lupus* **10**:171, 2001

66. Ozawa Y et al: Therapeutic efficacy of cyclosporin A in four cases of amyopathic dermatomyositis with rapidly progressive interstitial pneumonia. *Ryumachi* **40**:798, 2000

67. Takashi S et al: Amyopathic dermatomyositis with interstitial pneumonia: effective treatment with cyclophosphamide pulse therapy. *Nihon Kokyuki Gakkai Zasshi* **37**:647, 1999

68. Mukamel M et al: New insight into calcinosis of juvenile dermatomyositis: A study of composition and treatment. *J Pediatr* **138**:763, 2001

69. Euwer RL, Sontheimer RD: Amyopathic dermatomyositis (dermatomyositis sine myositis). Presentation of six new cases and review of the literature. *J Am Acad Dermatol* **24**:959, 1991

70. Schmid MH, Trueb RM: Juvenile amyopathic dermatomyositis. *Br J Dermatol* **136**:431, 1997

71. Marie I et al: Polymyositis and dermatomyositis: Short-term and long-term outcome, and predictive factors of prognosis. *J Rheumatol* **28**:2230, 2001

72. Krain L: Dermatomyositis in six patients without initial muscle involvement. *Arch Dermatol* **111**:241, 1975

73. Euwer RL, Sontheimer RD: Amyopathic dermatomyositis: A review. *J Invest Dermatol* **10**:124S, 1993

T>

Chapter 173

Benjamin Yu Arthur Eisen

Scleroderma

CLASSIFICATION
EPIDEMIOLOGY
Scleroderma-like Disorders
CLINICAL MANIFESTATIONS
Localized Scleroderma
Systemic Sclerosis
CREST SYNDROME
MIXED CONNECTIVE TISSUE DISEASE
EOSINOPHILIC FASCIITIS AND EOSINOPHILIA-MYALGIA SYNDROME
TOXIC OIL SYNDROME
CUTANEOUS HISTOPATHOLOGY
PATHOGENESIS
COURSE
MANAGEMENT

REFERENCES

Scleroderma is a chronic disease of unknown etiology that affects the microvasculature and loose connective tissue. It is characterized clinically by fibrous deposition and obliteration of vessels in the skin, lungs, gastrointestinal tract, kidneys, and heart. [1] Scleroderma literally means “hard skin” and was first reported by William and Robert Watson in 1754. The diffuse thickening and induration of the skin in the systemic form of scleroderma, systemic sclerosis (systemic scleroderma, SSc) is accompanied by fibrosis and vascular obliteration of internal organs. Its course is often progressive and fatal. The localized form has a more restricted pattern of involvement and does not affect internal organs.

CLASSIFICATION

Several clinical forms of localized scleroderma are now recognized, including morphea, generalized morphea, guttate morphea (which may be a variant of lichen sclerosus et atrophicus, LSA), nodular (keloidal) morphea, subcutaneous morphea (morphea profunda), and linear scleroderma. Localized scleroderma is not a life-threatening disease but can cause disfigurement. The most common type is morphea, in which the lesions are usually single or few in number. In the generalized form of morphea, symmetric and bilateral lesions occur. The absence of Raynaud's phenomenon, acrosclerosis, and organ involvement differentiates generalized morphea from SSc. In linear scleroderma the lesions are arranged in a bandlike linear distribution and may involve the deeper layers of the skin and underlying structures. Deformities, such as hemiatrophy, may be associated with linear scleroderma.

Systemic scleroderma is divided into two distinct subsets: limited SSc (lSSc) and diffuse SSc (dSSc). [2] Several other minor scleroderma subtypes are also recognized (Table 173-1). Sixty percent of patients with SSc are in the lSSc group, which includes individuals with the CREST syndrome, so-called for its features of *c*alcinosis cutis, *R*aynaud's phenomenon, *e*sophageal dysfunction, *s*clerodactyly, and *t*elangiectasia. Patients with lSSc typically are women who are older than patients with dSSc and have a long history (10 to 15 years) of Raynaud's phenomenon; skin involvement limited to the digits or hands, face, feet, and forearms; nail fold capillary dilatation; and early onset of facial and digital telangiectasias. Anticentromere antibodies (ACA) have been identified in 50 to 96 percent of patients with CREST syndrome, but in only 12 to 25 percent of patients with dSSc. Scl-70 autoantibodies are more frequently associated with dSSc (approximately 30 percent). Systemic involvement (notably pulmonary hypertension) may not appear for years (often decades), and many patients outlive their disease and die of other causes. Miners, users of vibrating machines, and those exposed to chemicals or plastics may develop a seronegative form of lSSc.

“Presclerodermа”
Raynaud's phenomenon plus nail fold capillary changes
Disease-specific circulating antinuclear autoantibodies (antitopoisomerase-I, anticentromere (ACA), or nucleolar)
Digital ischemic changes
Diffuse cutaneous SSc (dSSc)
Onset of skin changes (puffy or hidebound) within 1 year of onset of Raynaud's phenomenon
Truncal and acral skin involvement
Tendon friction rubs
Early and significant interstitial lung disease, oliguric renal failure
Diffuse gastrointestinal disease
Myocardial involvement
Nail fold capillary dilatation and drop out
Antitopoisomerase-I (Scl-70) antibodies (30% of patients)
Limited cutaneous SSc (lSSc)
Raynaud's phenomenon for years (occasionally decades)
Skin involvement limited to hands, face, feet, and forearms (acral)
A significant (10–15%) late incidence of pulmonary hypertension, with or without interstitial lung disease, skin calcification, telangiectasia, and gastrointestinal involvement
High prevalence of ACA (70–80%)
Dilated nail fold capillary loops, usually without capillary dropout
Scleroderma sine scleroderma
Raynaud's phenomenon
No skin involvement
Presentation with pulmonary fibrosis, scleroderma, renal crisis, cardiac or gastrointestinal disease
Antibodies may be present (Scl-70, ACA, nucleolar)

TABLE 173-1 **Classification of Systemic Scleroderma Subsets**

The typical patient with dSSc is well until the abrupt onset of swelling (nonpitting) of the hands and feet associated with Raynaud's phenomenon and hidebound changes in the skin, often sparing only the back and buttocks. Polyarticular symmetric synovitis, tenosynovitis, and tendon friction rubs are often present. Nail fold capillary dilatation and destruction

are common, and there is early onset of internal organ involvement. In some patients, skin involvement progresses rapidly initially and then subsides slowly over years. [1] Some patients with dSSc do not develop extensive or severe internal organ involvement. These patients form a subset whose disease is termed *chronic dSSc*. The subsets of SSc are classified in detail in Table 173-1.

EPIDEMIOLOGY

Localized scleroderma is relatively uncommon. Women are affected 2.6 times more often than men. The disease appears more commonly in whites than in blacks, and 75 percent of patients with morphea present between the ages of 20 and 50. In linear scleroderma, the age of onset is earlier, with a significant number occurring in the first two decades of life.

SSc is four times more common in women than in men. Results from two large US studies spanning the period between 1950 and 1979 indicate incidence rates from 10 to 12 per million and prevalence rates between 105 and 138 per million. [3] Certain populations are more likely to develop scleroderma. Black women have higher prevalence rates of scleroderma than do black men and whites. A 50-fold higher prevalence of scleroderma has been reported in Choctaw Native Americans residing in Oklahoma than in the general population. [4] Diffuse disease occurs more commonly in the black than in the white population, and the age of onset is younger than the age of onset of limited disease. SSc may occur at any age, but the age of onset generally lies between 30 and 50 years.

The classification of SSc into the lSSc and dSSc subsets is important prognostically. It is estimated that the survival rates for 1, 6, and 12 years for patients with dSSc are 80 percent, 30 percent, and 15 percent, respectively, whereas for those patients with lSSc, the corresponding survival rates are 98 percent, 80 percent, and 50 percent, respectively. [2] Older patients have a significantly decreased survival rate. Women have a significantly better survival rate than men, and the mortality from scleroderma for black women is significantly greater, because of their predilection for diffuse disease, than for white women. In a study of 177 patients, [5] the 10-year survival rate was 71 percent in patients with sclerodactyly alone, 58 percent in patients with skin stiffness proximal to the metacarpophalangeal joint but sparing the trunk, and only 21 percent in those with diffuse skin stiffness including the trunk.

Familial transmission of scleroderma is rare. In an Australian study of 710 patients with scleroderma and their families, the frequency of familial scleroderma was 1.4%. [6] The relative risk of developing scleroderma in patients with a positive family history is high, approximately 11-fold. [5] Also noted in this study is the increased prevalence of lupus and other collagen vascular diseases in those same families. The modifiers that favor scleroderma over other diseases are unknown. Human leukocyte antigen (HLA) types correlate more with the expression of specific autoantibody subsets than with scleroderma itself and may play a role in modifying disease.

Scleroderma-like Disorders

Scleroderma-like disorders have been reported in association with numerous environmental toxins and drugs. These agents include solvents (vinyl chloride, benzene, toluene, epoxy resins), drugs (bleomycin, carbidopa, pentazocine, cocaine, docetaxel, metaphenylenediamine), and miscellaneous substances (silica, rapeseed oil, L-tryptophan).

SSc was reported to occur in underground coal and gold miners. In male patients with silicosis who are older than 40 years of age, the likelihood of developing SSc is approximately 190 times greater than in males not exposed to silica, and 50 times greater than in males without silicosis but exposed to silica dust. [7] Most epidemiologic studies have failed to show a significant association between silicone gel implants and other silicone products and the development of scleroderma. [8]

An unusual form of scleroderma characterized by Raynaud's phenomenon, morphea-like skin changes, capillary abnormalities of the nail fold (similar to those in SSc), osteolysis of the distal phalanges, and hepatic and pulmonary fibrosis may occur in workers exposed to polyvinyl chloride. Bleomycin also produces pulmonary fibrosis, Raynaud's phenomenon, and cutaneous changes indistinguishable from those of SSc. [9] The development of these changes appears to be dose dependent and is reversible upon discontinuation of the drug.

Collectively, chemical exposures account for a small fraction of scleroderma cases. Large epidemiologic studies have not yet revealed a significant role for toxins and drugs in scleroderma.

Scleroderma-like skin changes may also be associated with scleromyxedema, porphyria cutanea tarda, and graft-versus-host disease (GVHD). Similar skin changes, primarily in the legs, have been described in the carcinoid syndrome, but these entities, although related, are clearly separable from scleroderma per se.

CLINICAL MANIFESTATIONS

Localized Scleroderma

Localized morphea is characterized by circumscribed sclerotic plaques with ivory-colored centers and, if the disease is in an active state, violaceous borders (Fig. 173-1). The lesion often begins as a reddened or lilac-colored area that may show some nonpitting edema. The center gradually becomes white or yellowed. There may be a diminished sweat response and an absence of hair in the lesion. The plaques, whether slightly elevated or depressed, are indurated but not bound to the deeper structures. Most commonly, the lesions are single or few in number, but they may be multiple, ranging in size from 1 to 30 cm. Uncommonly, localized morphea may occur after radiation therapy at the site of treatment. Its development is not related to dosage or to the severity of the acute reaction. Whether it results from the well-recognized fibroblastic response to irradiation is unknown.

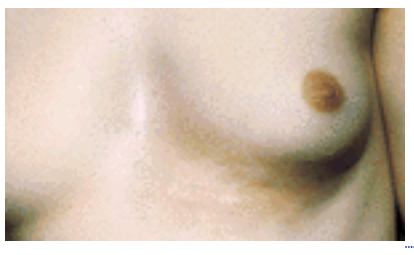

FIGURE 173-1 Morphea. There is an indurated, poorly defined plaque under the left breast. The lesion is multicolored with a central, yellow, “carnauba-wax” area surrounded by a lilac border.

Generalized morphea is a severe form of the local disease. Involvement of the skin is widespread, with multiple indurated plaques and hyperpigmentation. The plaques may be larger than the lesions of localized morphea, but in early stages they are often indistinguishable. They involve the upper trunk, abdomen, buttocks, and legs. Generalized morphea is not associated with systemic disease.

Guttate morphea may be a variant of localized morphea or of LSA. The coexistence of these two disorders in patients has been reported, with the same lesion frequently showing histologic evidence of both diseases. [10] Guttate morphea is characterized by multiple small chalk-white lesions that lack the firm character of morphea, involving primarily the neck and upper trunk.

Nodular (keloidal) morphea is a rare variant characterized by the presence of nodular lesions resembling keloids. The coexistence of typical lesions of localized morphea may aid in the diagnosis.

Subcutaneous morphea (morphea profunda) is characterized by deep, bound-down, sclerotic plaques. Because inflammation is in the subcutaneous fat and fascia, the typical color changes that occur in the skin of localized morphea are absent.

A morphea-like reaction to phytonadione injections has also been described, which involves the proximal limbs and buttocks, a pattern akin to a “gunbelt-and-holster.” [9]

Atrophoderma of Pierini and Pasini is an uncommon superficial form of localized morphea in which several oval, hyperpigmented, atrophic plaques develop on the trunk. The unusual feature is the absence of sclerosis. The well-defined lesions have a slightly depressed center; the defined border has been described as having a cliff-drop appearance. Whether this disorder is an end stage of morphea is unclear.

Linear scleroderma is a form of the disease that occurs as a linear band, usually with a single unilateral lesion. The lower extremities are most often involved, followed in frequency of occurrence by the upper extremities, frontal areas of the head, and anterior thorax. If the upper and lower extremities are involved, the lesions are on the same side. Calcinosis within a linear lesion occurs rarely. Frontal or frontoparietal linear scleroderma, called *coup de sabre,* is characterized by atrophy and a furrow in the skin (Fig. 173-2). The depression may be extensive, causing facial hemiatrophy, sometimes with atrophy of the tongue on the same side. Linear frontal lesions and active morphea plaques may coexist on the same side of the face. An important distinction between linear scleroderma and morphea is that linear scleroderma involves not only superficial but also deeper layers of the skin, with fixation to underlying structures. Because linear scleroderma occurs most often during the first two decades of life, it may cause severe deformities, such as hemiatrophy of an extremity or a side of the face, or contractures. Linear scleroderma may also be associated with anomalies of the vertebral column, the most common being spina bifida occulta.

FIGURE 173-2 *Coup de sabre.* Linear, atrophic depression involving the forehead.

Melorheostosis is an unusual linear, dense, cortical hyperostosis that occurs rarely. It usually affects an involved limb but occasionally is widespread.

The *tick-borne spirochete Borrelia burgdorferi,* the etiologic agent of Lyme disease, is thought to play a role in morphea and LSA. [11] Polymerase chain reaction (PCR) has been used to show the presence of *B. burgdorferi* in some cases of morphea reported from Europe and Japan. However, no cases have been linked to *Borrelia* infection in the United States. Furthermore, *Borrelia* infection responds readily to treatment with penicillin or ceftriaxone, whereas morphea is chronic and refractory to treatment. [9] Thus, cases related to *Borrelia* infection may represent a variant of morphea.

The *Parry-Romberg syndrome* (facial hemiatrophy) is characterized by unilateral hyperpigmentation, usually along trigeminal nerve distributions, followed by atrophy of the dermis, subcutaneous fat, and muscle, and sometimes the underlying bone. [9] The skin is less bound down than that seen in *coup de sabre,* but the atrophy is usually deeper. A scleroderma-like hemiatrophy of the face that spreads to the homolateral or contralateral side of the body may be a

variant of the Parry-Romberg syndrome. A patient with progressive facial hemiatrophy and serum positive antinuclear antibodies (ANA), rheumatoid factor, and elevated gamma globulin levels has been reported. [12]

ANA, elevated immunoglobulin levels, and rheumatoid factor have been reported in all forms of localized scleroderma particularly in linear scleroderma. Eosinophilia may occur in localized scleroderma. In one such study, [13] eosinophilia (> 400 cells/µL) was most common in generalized morphea and linear scleroderma and correlated with active disease. The prognosis is good; the disease often becomes inactive in 3 to 5 years. Slight atrophy, often with hyperpigmentation, may be the only persisting sequela of either form of morphea. However, disability from muscle atrophy may be a sequela of severe morphea.

Systemic Sclerosis

The clinical manifestations of SSc depend on the sites involved. The initial complaints are usually related either to Raynaud's phenomenon or to chronic, usually nonpitting, edema of the hands and fingers. As many as one-third of patients first have pain and stiffness of the fingers and knees. In some patients, the first manifestation is active, often migratory, polyarthritis. In others, severe erosive digital osteoarthritis (related to the CREST syndrome, particularly in females) occurs first. Flexion contractures and sclerodactyly are present; on x-ray, digital tuft resorption, subcutaneous calcification, joint space narrowing, and focal erosions of the periarticular bone are seen. Usually, skin changes precede visceral involvement by several years, but occasionally this order is reversed.

The disease then extends to involve the upper extremities (Fig. 173-3), trunk, face, and, finally, the lower extremities, which may sometimes be spared. In the early stages, the painless, slightly pitting edema often lasts several months before tightening of the skin occurs. Isolated periorbital edema may occur in the early edematous phase in patients with few other manifestations of SSc. Often the skin feels indurated and stiff; as it progresses to the atrophic state, it becomes tense, smooth, hardened, and, eventually, firmly bound to the underlying structures (Fig. 173-4). The skin of the face becomes masklike and expressionless, with loss of the normal facial lines and then thinning of the lips and constriction of the opening of the mouth (microstomia). Radial furrowing around the mouth is seen (Fig. 173-5). Uncommonly, the mucous membranes are involved, with painful induration of the gums and tongue. A prominent feature is tightening of the skin over the nose, giving it a small, sharp appearance. The neck sign, ridging and tightening of the skin of the neck on extending the head, is common. Matlike telangiectases may develop (Fig. 173-5), especially about the face and upper trunk. There may be thinning or complete loss of hair and anhidrosis in the affected areas. Generalized hyperpigmentation, similar to that of Addison's disease but with no evidence of adrenal insufficiency or elevated plasma levels of melanocyte-stimulating hormone ß, can occur and may antedate the sclerosis. Focal hyper- or hypopigmentation may represent a postinflammatory response in the areas of sclerosis.

FIGURE 173-3 Scleroderma. The connective tissue changes in the face result in loss of the normal facial lines producing a masklike appearence, a thinning of the lips, and a perioral furrowing (rhagades). The hands exhibit a sclerodactylia with tapering of the fingers and a waxy, shiny, atrophic skin. There are flexion contractures and ulceration of the skin overlying the bony prominences on the right hand.

FIGURE 173-4 Scleroderma. Skin is atrophic, appears tense and smooth, and has become firmly bound to the underlying structures.

FIGURE 173-5 Radial furrowing around the mouth and matlike telangiectases are prominent on the cheeks in a patient with scleroderma.

Sclerodactyly causes the fingers to become tapered, with marked skin atrophy. As in systemic lupus erythematous and dermatomyositis, periungual telangiectasia occurs. In as much as 75 percent of patients with SSc, enlarged, dilated nail fold capillaries forming “giant” or sausage-shaped loops can be seen by capillary microscopy of nail folds (done with an ophthalmoscope), and this examination can be useful in confirming the diagnosis. [14] The pattern in scleroderma can be distinguished from the changes in systemic lupus erythematosus but not from those in dermatomyositis. Capillary microscopy may be of prognostic value in Raynaud's disease, because, if nail fold capillary changes are present, the patient is more likely to develop SSc later. Another common problem is recurrent painful ulceration of the fingertips (Fig. 173-6). Slow-healing ulcers over the knuckles may also occur. These may heal with stellate scarring, become chronic, or, rarely, become gangrenous. Flexion contractures of the stiff fingers trouble many patients. Resorption of bone may cause dissolution of terminal phalanges, and cutaneous calcification develops in some cases, especially around fingertips and bony prominences but also in any area involved with scleroderma. These calcifications may ulcerate, extrude calcified material, and reepithelialize very slowly.

FIGURE 173-6 Ulceration of the fingertips in a patient with Raynaud's phenomenon and scleroderma.

Dental x-rays of patient with SSc often show widening of the periodontal membrane and loss of the lamina dura. Bone absorption at the angle of the mandible may occur, perhaps secondary to tightness of facial skin and atrophy of the underlying muscles.

Systemic involvement manifests itself in many ways. Esophageal dysfunction is the most common internal manifestation, occurring in more than 90 percent of patients. Dysphagia is a result of diminished peristalsis, especially in the distal two-thirds of the esophagus, and is easily seen on radiologic or manometric study. Heartburn from reflex esophagitis because of a loss of tone in the lower esophageal sphincter occurs commonly, but hemorrhage is rare. Dysphagia may occur long before skin involvement, thereby giving rise to the idea of systemic sclerosis sine scleroderma. Abnormal esophageal motility has also been reported in Raynaud's phenomenon, dermatomyositis, and lupus erythematosus. In SSc, the small intestine may be involved, producing symptoms of constipation, diarrhea, bloating, and sometimes malabsorption. Common findings on x-ray include delayed transit with prolonged retention of barium and distension of the small bowel, all secondary to atonia.

Another important feature of SSc is pulmonary involvement with fibrosis. Patients complain of exertional dyspnea, and small airway disease is an early sensitive indicator of pulmonary involvement that often precedes measurable impairment of gas diffusion. Alveolitis, which can be detected by bronchoalveolar lavage, occurs frequently in SSc and results in progressive reduction in pulmonary function over time. Early treatment with prednisone and cyclophosphamide may produce significant clinical improvement. Early pulmonary involvement, functionally characterized by a lowered diffusing capacity of the alveolocapillary membrane, correlates with morphologic changes of the nail fold capillaries. [15] Cardiac involvement in SSc may cause conduction defects, heart failure, or pericarditis; the latter is often associated with pericardial effusion and sometimes with tamponade. The overall prevalence of myocardial fibrosis in SSc is approximately 50 to 70 percent. Myocardial fibrosis is associated with microvascular coronary vasospasm, which is linked to a myocardial Raynaud's phenomenon.

Renal involvement occurs in about 45 percent of patients with SSc. Some patients have slowly progressive uremia, but for most, the renal failure is abrupt and associated with a malignant form of hypertension. Although there has been some suggestion that the acute renal failure and hypertension were induced by glucocorticoids, these findings have occurred in patients who had never received glucocorticoids.

CREST SYNDROME

A clinical variant of scleroderma is the CREST syndrome. The telangiectasias are most evident on the skin of the face (see Fig. 173-5), upper trunk, and hands, but also occur on the lips and oral mucosa and throughout the entire gastrointestinal tract. Gastrointestinal bleeding from the lesions is uncommon. The CREST syndrome is a more slowly progressive form of scleroderma; it develops later in life than dSSc and so has a more favorable prognosis. It is not entirely a benign syndrome, because the esophageal dysfunction is identical to that of the more severe forms of the disease, and occasionally pulmonary hypertension and biliary cirrhosis occur.

MIXED CONNECTIVE TISSUE DISEASE

Patients with combined features of scleroderma, lupus erythematosus, and myositis have been grouped under the heading of mixed connective tissue disease. The patients have high titers of antibody to a ribonucleoprotein, the extractable nuclear antigen. Patients with SSc do not have this antibody.

EOSINOPHILIC FASCIITIS AND EOSINOPHILIA-MYALGIA SYNDROME

Other syndromes that cause scleroderma-like skin changes, such as eosinophilic fasciitis (Shulman's syndrome) and the eosinophilia-myalgia syndrome, are discussed in Chap. 96.

TOXIC OIL SYNDROME

The toxic oil syndrome occurred in epidemic form in Spain in 1981, and affected approximately 25,000 people. [7], [16] It resulted from the consumption of denatured rapeseed oil sold as olive oil for cooking. Ingestion of the denatured rapeseed oil caused approximately 600 deaths and left 300 individuals disabled by a chronic multisystem disease. This syndrome has the features of a toxic allergic reaction, with an acute phase associated with a morbilliform-type eruption, pruritus, fever, interstitial pneumonitis, myalgia, and liver function abnormalities. Serum IgE levels were elevated in 37 to 50 percent of the cases. Approximately 5 percent of those affected presented with seizures and encephalopathy. Several months after onset, a chronic phase began that was characterized by severe neuromuscular abnormalities, generalized edema, scleroderma-like skin lesions, joint contractures, Sjögren-like syndrome, and pulmonary hypertension. The histopathology of the skin lesions is similar to that described in the eosinophilia-myalgia syndrome (see Chap. 96). In both processes, the primary injury is vascular, with evidence of perivascular inflammation, intimal proliferation, reduplication of the basal lamina, endothelial damage, and luminal obliteration. Immunofluorescence with antiprocollagen and antifibronectin antibodies and electron microscopy confirmed the vascular damage.

The exact cause of the syndrome remains obscure, but it appears that the ingestion of aniline-degraded, reprocessed rapeseed oil led to a chronic autoimmune disease. An oil of comparable chemical composition to case-related oils has been produced, and an in vitro toxicologic assay with mouse neuroblastoma and rat liver epithelial cells has been developed. [17] Extracts from aniline-treated rapeseed oil and several high-performance liquid chromatography fractions were toxic to these cells when compared to appropriate controls. It appears that at least some of the puzzling aspects of this syndrome may be solved.

CUTANEOUS HISTOPATHOLOGY

The features of morphea or SSc in histologic sections of a skin biopsy depend on the stage of the disease and the biopsy site (Fig. 173-7 and Fig. 173-8). In morphea, specimens from the peripheral violaceous border show many inflammatory cells among collagen bundles of the lower two-thirds of the reticular dermis, the fibrous trabeculae of the subcutaneous tissue. Usually lymphocytes and histocytes predominate, but there may be large numbers of plasma cells, and occasionally there are mast cells. Formation of typical lymphoid follicles with germinal centers may be seen. Mononuclear cell infiltrates are much less common in SSc than in localized scleroderma, and are often less prominent.

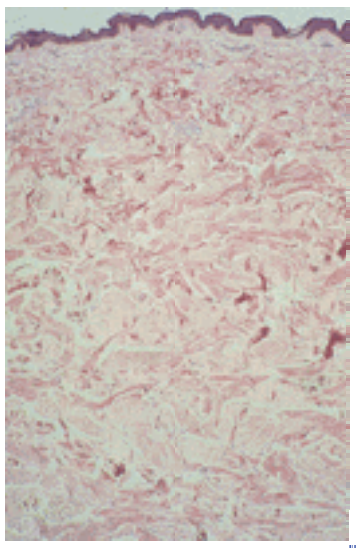

FIGURE 173-7 Scleroderma. The changes of generalized scleroderma and localized scleroderma (morphea) overlap; the former, however, is dominated by dense, acellular sclerosis, and the latter shows varying degrees of inflammation with some extension into the subcutis. Fig. 173-7 shows the pathologic changes of scleroderma, and Fig. 173-8 shows the pathologic changes of morphea. In this photomicrograph one sees broad collagen bundles that tend to parallel each other, diminished interbundle spaces, and few cells of any kind.

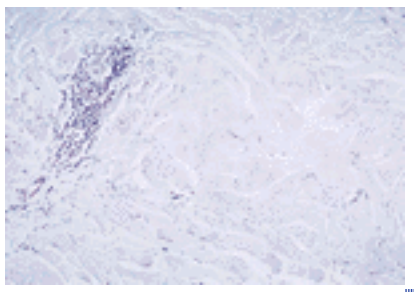

FIGURE 173-8 Morphea. The connective tissue changes in morphea seem to extend from the lower reticular dermis outward and are usually indistinguishable from the changes of generalized scleroderma. Biopsies taken from the margins of morphea lesions, however, frequently show extensive inflammation; such inflammation may be patchy, as one sees here, or it may involve the reticular dermis rather diffusely, presenting some difficulty in histologic diagnosis.

Associated with the inflammatory infiltrate are collagen changes that first occur in the lower third of the dermis and in the fibrous trabeculae of the subcutaneous tissues. Later in the disease, the changes extend to the upper portion of the dermis and consist of a markedly increased eosinophilia of collagen, broadening of collagen bundles, and decreased space between collagen bundles. Biopsies from the central region of well-developed lesions of morphea may show only collagen changes and no inflammation. In these later stages of morphea the pathology is similar to that of SSc. The collagen bundle pattern is altered so that most bundles appear to parallel the dermal-epidermal junction. The inflammatory stage is followed by the replacement of the subcutaneous tissue by hyalinized connective tissue. On electron microscopy, the fibrous trabeculae of the subcutaneous tissue are increased in thickness by deposition of immature collagen fibrils smaller in diameter than normal, suggesting increased collagen synthesis.

In morphea profunda, the lesions are associated with a subcutaneous, dense, mononuclear cell infiltrate with abundant plasma cells. There is extensive sclerosis and hyalinization of the connective tissue and occasional involvement of the underlying fascia. Lymphoid aggregates with germinal center formation have been described in some of the solitary lesions.

The pathology of SSc is similar to that of morphea. The lower two-thirds of the dermis and the subcutaneous fibrous trabeculae are sclerosed. Panniculitis may also be a prominent feature in the early stages. Subcutaneous fat is replaced by hyalinized connective tissue, and this process is particularly evident around eccrine sweat glands. The collagen bundles appear pale, homogeneous, and swollen, but the collagen bundle swelling, increased numbers of eosinophils, and inflammation are not as prominent as in morphea. In the late stages of SSc, secondary changes, such as absence of pilosebaceous units, eccrine ducts, and glands, and effacement of the rete ridges of the epidermis may be evident. Electron microscopy has revealed randomly arranged “immature” collagen fibrils, from 10 to 40 nm in diameter, in contrast to mature collagen fibrils, from 70 to 80 nm in diameter. Whether the immature fibrils represent newly synthesized collagen remains speculative.

Vessels of all sizes may be involved in SSc, and vascular involvement is an important, although inconsistent, feature. In the early stages, there may be only dilatation of capillaries and lymphatics. Then intimal proliferation and complete occlusion of the vessel can occur. These changes also appear in muscle capillaries.

Occlusive vascular changes are not found in morphea, but the precise implications of the difference are unclear; possibly they are related to the spontaneous involution of morphea. In morphea, skeletal muscle fibers underlying affected skin may be structurally damaged in the absence of histologic changes in muscle capillaries.

PATHOGENESIS

The primary defect in scleroderma is still unknown. Exposures to environmental toxins and perhaps infections such as *Borrelia* account for only a small subset of scleroderma patients. The majority of patients have no identifiable trigger. [1]

Three pathologies have been identified in scleroderma: endothelial damage, immunologic and inflammatory activation, and dysregulated extracellular matrix production. The basic pathogenic mechanisms are believed to be similar in localized and systemic disease.

A number of experimental models, including UCD-200 and UCD-206 avian models, [18] suggest that endothelial damage is an early event in the pathogenesis of scleroderma. The first identifiable histologic changes in scleroderma include endothelial cell swelling and contraction of intercellular junctions, which correlate clinically with the early edematous lesions seen in this disorder. [19] Biochemical changes in the endothelium are found in both early lesional and nonlesional scleroderma skin, and include decreased stores of von Willebrand factor, factor VIII, and Weibel-Palade bodies. These changes are accompanied by decreased adenosine uptake and membrane blebbing, which collectively indicate endothelial damage and activation. Endothelial damage leads to the release of proinflammatory cytokines such as tumor necrosis factor alpha (TNF-a), interleukin-1 (IL-1a, -1ß), IL-6, IL-8, and others that shift the endothelium from an anticoagulant, vasodilatory resting state to a proinflammatory, procoagulant, vasoconstrictive-activated phenotype. [4], [20], [21] Release of prostaglandins, nitric oxide, and endothelin-1 affect vascular beds, both locally and systemically, perhaps contributing to the micro- and macrovascular dysfunction in scleroderma. Platelet aggregation and activation occur as a result of endothelial activation and lead to the release of platelet-derived growth factor (PDGF), a potent mitogen for fibroblasts and smooth muscle cells. These signals are also thought to contribute to intimal thickening of vessel walls.

The mechanism of endothelial damage is unclear. Cytotoxic autoantibodies have been implicated as one mechanism. [22] Pooled IgG immunoglobulin from scleroderma patients recognizes a common cytomegaloviral (CMV) protein and cross-reacts with an endothelial adhesion molecule. These antibodies are present in 93 percent of patients with scleroderma, as compared to 0 percent of age/sex-matched controls, 5 percent of patients with rheumatoid arthritis, and 12 percent of patients with systemic lupus erythematosus. Importantly, these antibodies in vitro can trigger endothelial

apoptosis. The molecular mimicry in these studies between a CMV antigen and an endothelial cell surface protein is intriguing, but it is as of yet unknown whether inhibition of these autoantibodies can affect progression or inhibit scleroderma. Furthermore, the role of autoantibodies (Table 173-2) against topoisomerase I (IgG1), centromeres (IgG1, IgG3), RNA polymerase I/III, and U3 ribonucleoprotein in the pathogenesis of scleroderma is also unknown. [23] These antibodies do not cause apoptosis, and immunofluorescence studies on lesional skin do not show antibody deposition.

TABLE 173-2 **Autoantibodies in Scleroderma**

The role of the immune response in the initiation of scleroderma is unclear as many of the early changes are not specific to scleroderma. The late response involves CD4-positive T helper cells, plasma cells, and histiocytes, and is believed to lead to tissue fibrosis. The T helper 2 (T_H2) subset, which is important in chronic graft-versus-host disease (cGVHD), may contribute during fibrotic stages of scleroderma. Sera from patients with SSc show elevated levels of IL-4, IL-10, and IL-13, indicative of a T_H2 response. [24] Interferon (IFN)-?, a cytokine produced by T_H1 cells, has been reported to be unchanged in patients with SSc, despite other reports demonstrating elevated IL-12 levels. Whether T_H1 and T_H2 subsets predominate at different stages of the disease and how they might participate have not been clarified. The production of a number of other cytokines has been reported in patients with scleroderma, including IL-2, soluble IL-2 receptors, TNF, PDGF, and ß-thromboglobulin. [25], [26] IL-2, which is critical for T cell activation and proliferation, is found in abundance in patients with scleroderma. IL-2 also plays a role in natural killer cell activation, which may also contribute to endothelial damage. Intimately linked to tissue remodeling and the chronic immune response are mast cells, which produce many cytokines, vasoactive peptides, and lipid mediators (prostaglandins, platelet-activating factors, and leukotrienes). Mast cells are a rich source of histamine and heparin, the latter of which is important in fibroblast growth factor (FGF) signaling. [27] Several investigators have shown that histamine levels are elevated in patients with SSc and, in experimental models, can play a role in sclerosis. Fibrosis is also seen in cGVHD, porphyria cutanea tarda, and a number of experimental models of scleroderma, [28] but often differs clinically in terms of organ involvement or tissue-specific patterns. These patterns may reflect vascular bed-specific differences or chemokine dysregulation.

IL-4 and transforming growth factor-ß (TGF-ß) [29] are two important mediators of tissue fibrosis, and both are elevated in scleroderma. The role of TGF-ß is complex because of its leiomorphic effects on immune regulation and tissue remodeling. Production of TGF-ß $_2$ by perivascular lymphocytes, monocytes, and endothelial cells directly activates transcription of collagen in adjacent fibroblasts. [6], [30] TGF-ß can be secreted in a latent form that is bound by latent TGF-ß binding proteins; this latent form cannot bind to TGF-ß receptors until it is activated by proteases, glycosidases, and other posttranslational modifications. TGF-ß leads to the activation of SMAD transcription factors, which may serve as novel targets for the pharmacologic intervention of tissue fibrosis. [31]

IL-4 plays a role in collagen upregulation and is countered by the activities of IFN-?. [29] In an autosomal dominant murine model of scleroderma known as the tight-skin mouse (tsk), in which many features of SSc, including pronounced dermal fibrosis, overproduction of collagen I, II, VI, and production of antitopoisomerase I antibodies are present, IL-4R or STAT6 deficiency rescues the sclerotic phenotype. [5] In addition, mice deficient in IFN-? develop vascular intimal thickening and increased collagen production. [32] The mutations in the tsk mouse lead to genomic duplications and rearrangements in the fibrillin gene. Overexpression of this mutant fibrillin gene leads to localized and diffuse sclerosis. [33] Fibrillin dysfunction has also been proposed in populations with genetic susceptibility to scleroderma. Linkage analysis of the Choctaw Native American population has mapped the susceptibility locus within a 2 cM interval on chromosome 15q, proximal to the fibrillin gene. Polymorphisms in the fibrillin gene have also been identified in this population. These mutations have been hypothesized to alter TGF-ß and latent TGF-ß–binding protein (LTBP) stability, processing, or extracellular matrix signaling properties. [34] In the tsk mice, however, an inflammatory infiltrate is often absent, and lymphocyte deficiency does not abrogate the sclerotic phenotype. [35] These mice do not develop the exact pattern of internal organ involvement present in human scleroderma. The tsk mouse model suggests that fibrosis and vascular disease can exist as distinct pathologies and that the key features of scleroderma, fibrosis, and Scl-70 autoantibody production are tightly linked events. The exact role of fibrillin dysfunction in scleroderma, however, still remains unclear.

cGVHD frequently has been compared to SSc (although renal involvement is rare in cGVHD). [36] The sclerodermatous cGVHD displays progressive skin and internal organ fibrosis as well as production of autoantibodies such as the Scl-70 antibody. A noniatrogenic form of GVHD, termed fetal microchimerism, was recently described. Fetal microchimerism refers to the seeding of maternal tissue by fetal cells during pregnancy. Surprisingly, allogeneic cells, which are presumably of fetal origin, can be found in the blood and skin of women as many as 27 years postpartum, as detected by the presence of male-specific Y chromosome markers. Microchimerism is a common finding in scleroderma. With the polymerase chain reaction, male DNA was detected in the skin of 11 of 19 women with scleroderma, but not in 68 unaffected women. [37] Also, allogeneic DNA has been detected in women with no previous history of pregnancy, and in men, presumably due to maternal intrauterine mixing. It is also possible that HLA associations allow syngenic fetal tissue to persist and to interact with the maternal T cells. Additional studies are required to demonstrate a functional relationship between fetal microchimerism and the pathology of scleroderma. However, it is tempting to speculate that microchimerism could provide an explanation for the female predominance and the onset of scleroderma around the childbearing age.

COURSE

In patients with morphea or linear scleroderma, the disease may last from a few months to many years. In the 50 percent of patients in whom lesions disappear or soften, areas of hypo- or depigmentation are left. *Coup de sabre* lesions may remain unchanged or become more extensive.

Limited SSc rarely progresses to dSSc. In dSSc, visceral involvement develops in most patients if they are followed for sufficient duration. The overall 5-year mortality rate in dSSc is 40 to 50 percent. The main causes of death are pulmonary fibrosis and renal hypertensive crisis in dSSc and isolated pulmonary hypertension in lSSc. [38] Clinical parameters associated with poor prognosis include proximal sclerosis, trunk skin involvement, presence of anti–Scl-70 autoantibody, pulmonary and/or heart involvement, and advanced age at time of diagnosis (45 or older). [39], [40] ACA are predictive for lSSc including CREST (sensitivity 60 percent, specificity 98 percent); Scl-70 are predictive for dSSc (sensitivity 38 percent, specificity 100 percent). Findings of ACA and Scl-70 are positively associated with the development of telangiectasias and tight skin, respectively. [41] Scl-70 and HLA-DR3/DR52a are associated with increased risk of pulmonary fibrosis, a major cause of morbidity and mortality in SSc. [42] Antibodies to RNA-polymerases seem to correlate with severe renal and lung disease. [43] Laboratory methods to track disease activity include measurement of soluble IL-2 receptor levels and von Willebrand factor (vWF) levels, which correlate with clinical disease activity and vascular damage, respectively.

MANAGEMENT

The treatment of localized scleroderma (morphea) remains unsatisfactory, but because the disease is generally self-limited, most cases require little or no treatment. When treatment is attempted, it usually involves application of high- to ultrahigh-potency topical glucocorticoids to the lesions, which may be augmented by intralesional injections of glucocorticoids. Antimalarials, phenytoin, colchicine, and systemic glucocorticoids are used in generalized morphea, but provide little proven benefit. In one study of 11 patients with severe localized scleroderma treated with D-penicillamine, 6 improved after 3 to 6 months of therapy, with skin softening, resumption of growth in affected limbs, and absence of new lesions. The mean length of treatment was 21 months (range, 15 to 53) at a daily dose of 2.0 to 5.0 mg/kg. Careful monitoring for renal and hematologic toxicity is essential. [44] The use of high dose UVA 1 (340 to 450 nm) produced marked clinical improvement of treated lesions in patients with morphea. [45] Relapse did not occur once therapy was discontinued, but a longer period of observation will be required to determine whether the results of treatment are long lasting.

Organ-specific aspects of SSc, particularly renal, lung, and gastrointestinal involvement should be treated to ameliorate morbidity and potential mortality. Prior to the introduction of angiotensin-converting enzyme (ACE) inhibitors by Lopez-Ovejero and colleagues, renal crisis was the leading cause of mortality in patients with scleroderma. [46]

Blood pressure monitoring should be routinely performed, particularly in light of reports of normotensive renal crisis. Captopril markedly improves survival and, in some patients, may permit discontinuation of dialysis. Inflammatory lung disease, which has a “ground glass” appearance on high-resolution CT scan, responds to cyclophosphamide and prednisolone. [47], [48] Continuous epoprostenol therapy may be helpful in the treatment of pulmonary hypertension associated with scleroderma. [49]

The peripheral vasospasm in lSSc occasionally improves with oral vasodilators such as diltiazem. [50] Angiotensin receptor blockers have also been introduced as possible remedies in Raynaud's phenomenon, although their role in the treatment of renal crisis is still unclear. [51] Intravenous prostacyclin infusion or radical microarteriolysis is advocated for critically ischemic digits. [52] In patients with calcinosis in both CREST and dSSc, there is some suggestion that calcium channel blockers may alleviate the calcinosis. [53] Reflux esophagitis with spasm responds to omeprazole and cisapride. Bacterial overgrowth, identifiable by a positive hydrogen breath test, can be treated with courses of broad-spectrum antibiotics. Octreotide (30 to 100 µg/day subcutaneously) stimulates intestinal motility in patients with dSSc and reduces abdominal symptoms, small-bowel dysfunction, intestinal pseudoobstruction, and bacterial overgrowth. [54]

Physical therapy is paramount in minimizing the loss of function in sclerotic digits and limbs. The cessation of smoking provides a significant decrease in morbidity in those patients with documented Raynaud's phenomenon.

Of the many agents tried in the therapy of SSc, most have been found wanting. Global immunosuppression with such agents as azathioprine, chlorambucil, methotrexate, cyclophosphamide, and minocycline has had variable success. Plasmapheresis [55] and extracorporeal photopheresis [56] have demonstrated equivocal results.

Cyclophosphamide improves survival and may be useful in the treatment of SSc lung fibrosis, [57] but long-standing fibrosis does not appear to be affected significantly by global immunosuppression. Systemic glucocorticoids may be of some benefit early in the disease, or for specific inflammatory lesions (e.g., myositis, alveolitis, myocarditis), but do not alter the overall disease course. Chlorambucil, 5-fluorouracil, and ketotifen (a mast cell stabilizer) are ineffective. In some studies, cyclosporine has resulted in a 40 percent decrease in mean skin thickness scores over 1 year. Pulmonary diffusing capacity remains unchanged. However, the use of cyclosporine is limited at higher doses by hypertension and renal insufficiency, which may be attributable to either the drug or SSc and may confound clinical assessment of efficacy. [58]

D-Penicillamine, which interferes with intermolecular cross-linking of collagen, has been used with some success in the treatment of early aggressive dSSc, decreasing body surface area involvement from 65 to 16 percent. [59] It is administered orally at a dosage of 250 mg/day on an empty stomach, and the dosage is increased every 2 to 3 months to a maximum of 750 to 1500 mg/day. In patients with a disease duration of less than 3 years, significant reductions in skin thickness and joint contractures are apparent after 18 to 30 months of therapy. Patients have improved survival, due in part to a lower incidence of renal disease. However, long-term use is limited by side effects that include hematologic abnormalities as well as autoimmune syndromes such as pemphigus, nephrotic syndrome, lupus/polymyositis-like syndrome,

Goodpasture syndrome, and myasthenia gravis. Relaxin, a hormone produced during pregnancy, has antifibrotic activities and is under investigation for the treatment of scleroderma. [60]

One early trial series of 18 patients with rapidly progressive SSc, treated with an 18-week course of IFN-?, showed a decrease in the mean skin thickness score from a baseline of 25.9 to 19.1, and a decrease of the mean area scores from 33.1 to 19.6. Ten patients had more than a 25 percent decrease in the area score, five patients had more than a 70 percent decrease in the area score, and three had not experienced disease recurrence 6 to 17 months after cessation of IFN-?. [61] Other novel immunomodulatory agents are currently being evaluated, including anti-TNF blockade, intravenous immunoglobulins, [62] immune tolerance induction to type I collagen, [63] and autologous bone marrow transplantation. [64], [65]

REFERENCES

1. Hawk A, English JC: Localized and systemic scleroderma. *Semin Cutan Med Surg* **20**:27, 2001

2. LeRoy EC et al: Scleroderma (systemic sclerosis): Classification, subsets and pathogenesis. *J Rheumatol* **15**:202, 1988

3. Englert H et al: Systemic sclerosis prevalence and mortality in Sydney 1974–88. *Aust N Z J Med* **29**:42, 1999

4. Herrick AL: Vascular function in systemic sclerosis. *Curr Opin Rheumatol* **12**:527, 2000

5. Tan FK, Arnett FC: Genetic factors in the etiology of systemic sclerosis and Raynaud phenomenon. *Curr Opin Rheumatol* **12**:511, 2000

6. Englert H et al: Familial risk estimation in systemic sclerosis. *Aust N Z J Med* **29**:36, 1999

7. Nietert PJ, Silver RM: Systemic sclerosis: environmental and occupational risk factors. *Curr Opin Rheumatol* **12**:520, 2000

8. Mayes MD: Epidemiologic studies of environmental agents and systemic autoimmune diseases. *Environ Health Perspect* **107**(suppl 5):743, 1999

9. Jablonska S, Blaszczyk M: Scleroderma-like disorders. *Semin Cutan Med Surg* **17**:65, 1998

10. Uitto J et al: Morphea and lichen sclerosus et atrophicus. Clinical and histopathologic studies in patients with combined features. *J Am Acad Dermatol* **3**:271, 1980

11. Fujiwara H et al: Detection of *Borrelia burgdorferi* DNA (B garinii or B afzelii) in morphea and lichen sclerosus et atrophicus tissues of German and Japanese but not of US patients. *Arch Dermatol* **133**:41, 1997

12. Hickman JW, Shiels WS: Progressive facial hemiatrophy. *Arch Intern Med* **113**:716, 1964

13. Falanga V, Medsger TA Jr: Frequency, levels, and significance of blood eosinophilia in systemic sclerosis, localized scleroderma, and eosinophilic fasciitis. *J Am Acad Dermatol* **17**:648, 1987

14. Maricq HR et al: Predictive value of capillary microscopy in patients with Raynaud's phenomenon. *Arthritis Rheum* **23**:716, 1980

15. Groen H et al: Pulmonary diffusing capacity disturbances are related to nailfold capillary changes in patients with Raynaud's phenomenon with and without an underlying connective tissue disease. *Am J Med* **89**:34, 1990

16. Phelps RG, Fleischmajer R: Clinical, pathologic, and immunopathologic manifestations of the toxic oil syndrome. Analysis of fourteen cases. *J Am Acad Dermatol* **18**:313, 1988

17. Slack PT: Toxic oil disaster. *Nature* **345**:583, 1990

18. Sgonc R: The vascular perspective of systemic sclerosis: of chickens, mice and men. *Int Arch Allergy Immunol* **120**:169, 1999

19. Prescott RJ et al: Sequential dermal microvascular and perivascular changes in the development of scleroderma. *J Pathol* **166**:255, 1992

20. Furst DE: The endothelium in the pathogenesis of systemic sclerosis: Is it primary or secondary? *J Mal Vasc* **24**:95, 1999

21. Cines DB et al: Endothelial cells in physiology and in the pathophysiology of vascular disorders. *Blood* **91**:3527, 1998

22. Lunardi C et al: Systemic sclerosis immunoglobulin G autoantibodies bind the human cytomegalovirus late protein UL94 and induce apoptosis in human endothelial cells. *Nat Med* **6**:1183, 2000

23. Weedon D: Disorders of collagen, in *Skin Pathology,* edited by G. Smith. Hong Kong, Churchill Livingston, 1998, p 288

24. Hasegawa M et al: Elevated serum levels of interleukin 4 (IL-4), IL-10, and IL-13 in patients with systemic sclerosis. *J Rheumatol* **24**:328, 1997

25. Needleman BW: Immunologic aspects of scleroderma. *Curr Opin Rheumatol* **4**:862, 1992

26. Ihn H et al: Demonstration of interleukin-2, interleukin-4 and interleukin-6 in sera from patients with localized scleroderma. *Arch Dermatol Res* **287**:193, 1995

27. Sueki H et al: Novel interactions between dermal dendrocytes and mast cells in human skin. Implications for hemostasis and matrix repair. *Lab Invest* **69**:160, 1993

28. Chosidow O et al: Sclerodermatous chronic graft-versus-host disease. Analysis of seven cases. *J Am Acad Dermatol* **26**:49, 1992

29. Libby P, Pober JS: Chronic rejection. *Immunity* **14**:387, 2001

30. Widom RL: Regulation of matrix biosynthesis and degradation in systemic sclerosis. *Curr Opin Rheumatol* **12**:534, 2000

31. Nakao A et al: Transient gene transfer and expression of Smad7 prevents bleomycin-induced lung fibrosis in mice. *J Clin Invest* **104**:5, 1999

32. Le Hir M et al: A syndrome resembling human systemic sclerosis (scleroderma) in MRL/lpr mice lacking interferon-gamma (IFN-?) receptor

(MRL/lpr?R–/–). *Clin Exp Immunol* **115**:281, 1999

33. Saito S et al: Induction of skin fibrosis in mice expressing a mutated fibrillin-1 gene. *Mol Med* **6**:825, 2000

34. Saito S et al: Characterization of mutated protein encoded by partially duplicated fibrillin-1 gene in tight skin (tsk) mice. *Mol Immunol* **36**:169, 1999

35. Bona C, Rothfield N: Autoantibodies in scleroderma and tight skin mice. *Curr Opin Immunol* **6**:931, 1994

36. Nelson JL: Microchimerism and the pathogenesis of systemic sclerosis. *Curr Opin Rheumatol* **10**:564, 1998

37. Artlett CM et al: Identification of fetal DNA and cells in skin lesions from women with systemic sclerosis. *N Engl J Med* **338**:1186, 1998

38. Arroliga AC et al: Pulmonary manifestations of scleroderma. *J Thorac Imaging* **7**:30, 1992

39. Vayssairat M et al: Long-term follow-up study of 164 patients with definite systemic sclerosis: Classification considerations. *Clin Rheumatol* **11**:356, 1992

40. Silman AJ: Scleroderma and survival. *Ann Rheum Dis* **50**:267, 1991

41. Weiner ES et al: Prognostic significance of anticentromere antibodies and anti-topoisomerase I antibodies in Raynaud's disease. A prospective study. *Arthritis Rheum* **34**:68, 1991

42. Briggs D et al: Genetic factors in scleroderma. *Rheum Dis Clin North Am* **16**:31, 1990

43. Hirakata M et al: Identification of autoantibodies to RNA polymerase II. Occurrence in systemic sclerosis and association with autoantibodies to RNA polymerases I and III. *J Clin Invest* **91**:2665, 1993

44. Falanga V, Medsger TA Jr: D-Penicillamine in the treatment of localized scleroderma. *Arch Dermatol* **126**:609, 1990

45. Stege H et al: High-dose UVA1 radiation therapy for localized scleroderma. *J Am Acad Dermatol* **36**:938, 1997

46. Steen VD: Scleroderma renal crisis. *Rheum Dis Clin North Am* **22**:861, 1996

47. Wells AU et al: High-resolution computed tomography as a predictor of lung histology in systemic sclerosis. *Thorax* **47**:738, 1992

48. Silver RM et al: Cyclophosphamide and low-dose prednisone therapy in patients with systemic sclerosis (scleroderma) with interstitial lung disease. *J Rheumatol* **20**:838, 1993

49. Badesch DB et al: Continuous intravenous epoprostenol for pulmonary hypertension due to the scleroderma spectrum of disease. A randomized, controlled trial. *Ann Intern Med* **132**:425, 2000

50. Sturgill MG, Seibold JR: Rational use of calcium-channel antagonists in Raynaud's phenomenon. *Curr Opin Rheumatol* **10**:584, 1998

51. Dziadzio M et al: Losartan therapy for Raynaud's phenomenon and scleroderma: clinical and biochemical findings in a fifteen-week, randomized, parallel-group, controlled trial. *Arthritis Rheum* **42**:2646, 1999

52. O'Brien BM et al: Radical microarteriolysis in the treatment of vasospastic disorders of the hand, especially scleroderma. *J Hand Surg [Br]* **17**:447, 1992

53. Dolan AL et al: Diltiazem induces remission of calcinosis in scleroderma. *Br J Rheumatol* **34**:576, 1995

54. Sjogren RW: Gastrointestinal motility disorders in scleroderma. *Arthritis Rheum* **37**:1265, 1994

55. Wach F et al: Treatment of severe localized scleroderma by plasmapheresis—Report of three cases. *Br J Dermatol* **133**:605, 1995

56. Rook AH et al: Treatment of systemic sclerosis with extracorporeal photochemotherapy. Results of a multicenter trial. *Arch Dermatol* **128**:337, 1992

57. White B et al: Cyclophosphamide is associated with pulmonary function and survival benefit in patients with scleroderma and alveolitis. *Ann Intern Med* **132**:947, 2000

58. Clements PJ et al: Cyclosporine in systemic sclerosis. Results of a forty-eight-week open safety study in ten patients. *Arthritis Rheum* **36**:75, 1993

59. Jimenez SA, Sigal SH: A 15-year prospective study of treatment of rapidly progressive systemic sclerosis with D-penicillamine [see comment]. *J Rheumatol* **18**:1496, 1991

60. Seibold JR et al: Recombinant human relaxin in the treatment of scleroderma. A randomized, double-blind, placebo-controlled trial. *Ann Intern Med* **132**:871, 2000

61. Freundlich B et al: Treatment of systemic sclerosis with recombinant interferon-?. A phase I/II clinical trial. *Arthritis Rheum* **35**:1134, 1992

62. Levy Y et al: Skin score decrease in systemic sclerosis patients treated with intravenous immunoglobulin–a preliminary report. *Clin Rheumatol* **19**:207, 2000

63. McKown KM et al: Induction of immune tolerance to human type I collagen in patients with systemic sclerosis by oral administration of bovine type I collagen. *Arthritis Rheum* **43**:1054, 2000

64. Marmont AM: New horizons in the treatment of autoimmune diseases: Immunoablation and stem cell transplantation. *Annu Rev Med* **51**:115, 2000

65. Binks M et al: Phase I/II trial of autologous stem cell transplantation in systemic sclerosis: Procedure related mortality and impact on skin disease. *Ann Rheum Dis* **60**:577, 2001

T>

Chapter 174

Brian Mandell Gary Hoffman

Systemic Necrotizing Arteritis

GENERAL PRINCIPLES OF DIAGNOSIS
SPECIFIC VASCULITIC SYNDROMES
Small Vessel Vasculitis
Wegener's Granulomatosis
Churg-Strauss Syndrome (Allergic Angiitis and Granulomatosis)
Polyarteritis Nodosa and Microscopic Polyangiitis
Kawasaki Disease
Large Vessel Arteritis (Takayasu's Arteritis and Temporal Arteritis)
GENERAL COMMENTS ON THE TREATMENT OF PATIENTS WITH SYSTEMIC ARTERITIS

REFERENCES

Blood vessels may be affected by a number of diverse processes, including Raynaud's vasospasm, coagulopathies, myointimal proliferation with occlusion (e.g., scleroderma), embolic occlusion, congenital or acquired dysplasias (e.g., Marfan's syndrome, fibromuscular dysplasia), and atherosclerosis. This chapter focuses on the primary inflammatory disorders that are grouped together as the systemic vasculitides. The small vessel vasculitides, Wegener's granulomatosis, Churg-Strauss syndrome, polyarteritis nodosa, microscopic polyangiitis, Kawasaki disease, Takayasu's arteritis, and giant cell arteritis of the elderly are presented in specific detail. Diseases characterized by primary isolated cutaneous vasculitis, the necrotizing capillaritis/venulitis syndromes, are discussed in greater detail in Chap. 175.

The inflammatory process per se is often associated with laboratory and clinical abnormalities; but these, however prominent, tend to be nonspecific (e.g., elevated erythrocyte sedimentation rate, anemia, fatigue, fevers) and do not substantially aid in distinguishing vasculitis from other inflammatory, infectious, or proliferative diseases. Blood vessels have limited ways of responding to injury: increased permeability may lead to edema and purpura, attenuation of the vessel wall may lead to aneurysm formation or hemorrhage, and intimal proliferation or thrombosis may cause stenosis or occlusion with tissue ischemia or infarction. The definitive diagnosis of a primary vasculitis remains dependent upon histopathologic documentation of vasculitis in conjunction with the appropriate clinical picture and the exclusion of diseases that can cause secondary vascular inflammation such as infection (e.g., meningococcemia, rickettsial diseases, and endocarditis). The principal clinical clue to diagnosis of a specific vasculitic disorder is the pattern of organ involvement. Identification of qualitative pathologic changes in affected organs (pattern of necrosis, presence of granulomas, eosinophilic infiltration) further delineates the differential diagnosis. The primary determinants of prognosis and selection of therapy include whether critical organs are involved, the severity of involvement, and the rate of disease progression. The toxic nature of the therapies for severe systemic vasculitis emphasizes the need for an accurate diagnosis. The nonspecific diagnosis of “vasculitis” should not be the final diagnosis; this concept should be avoided in favor of a more specific final diagnosis whenever possible.

Cutaneous involvement in systemic vasculitis may lead to consultation with a dermatologist. However, it is the symptomatic or asymptomatic involvement of other organ systems that is generally more ominous. Cutaneous involvement may precede visceral organ involvement. Conversely, not all cases of cutaneous vasculitis are part of a systemic process.

GENERAL PRINCIPLES OF DIAGNOSIS

The differential diagnosis of the systemic vasculitides often includes distinct or coexistent coagulopathy, occult malignancy, or infection; particularly deep-seated abscess, viral hepatitis, or bacterial endocarditis. Thus, an approach directed towards ruling in a specific form of vasculitis should be pursued, in addition to ruling out defined alternatives.

Cutaneous involvement can occur in any of the primary systemic vasculitic syndromes. However, the cutaneous features are virtually never sufficient to provide a complete diagnosis. Histopathology and immunofluorescent evaluation of skin biopsies may be invaluable in supporting the diagnosis of systemic inflammatory diseases such as Henoch-Schönlein purpura (HSP), sarcoidosis, Sweet's syndrome, or systemic lupus erythematosus (SLE); in diagnosing proliferative disorders (T cell lymphomas, leukemia cutis, Kaposi's sarcoma) and emboli from atherosclerosis or atrial myxomas; and, occasionally, in diagnosing specific infections (syphilis, cytomegalovirus, fungemia). Angiographic and selected serologic studies may provide support for certain diagnoses but are not by themselves pathognomonic for any specific form of vasculitis. In general, the diagnosis of a specific form of systemic arteritis will come from a careful documentation of the pattern of organ involvement and histopathology. Serologic tests, such as those for antineutrophil cytoplasmic autoantibodies (ANCA) or antinuclear antibodies (ANA), in the presence of clinically isolated cutaneous vasculitis, do not confirm the diagnosis of Wegener's granulomatosis or SLE.

Several classification schemes have been proposed in attempts to organize the systemic vasculitic disorders into a consistent paradigm. [1], [2] and [3] Such schemes are useful in providing a diagnostic framework to distinguish clinical disorders with distinct differences in prognosis and response to treatment. Although no scheme is perfect or universally accepted, classification systems such as the one shown in Fig. 174-1 provide useful constructs for communication.

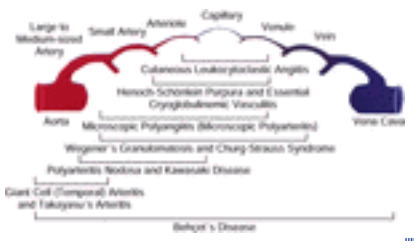

FIGURE 174-1 A classification scheme for the vasculitides. (*Adapted from Jennette et al.,* [2] *with permission.*)

The most widely used diagnostic classification systems are based on the caliber of affected blood vessels, the pattern of organ involvement, and the presence or absence of granulomas and/or eosinophilic infiltration. Some authors propose a prime diagnostic role for the presence or absence of specific serum ANCAs, particularly antibodies to PR3 and myeloperoxidase. We believe that the role of these tests at present is to support a rationally developed clinical diagnosis, not to define one. In patients who do not fit neatly into a well-defined diagnostic category, these serologic tests should not supplant an attempt to obtain a tissue diagnosis, if the latter is feasible. In patients who present with symptoms and findings shared by several diseases, such as cutaneous venulitis, targeted serologic testing for potential etiologies may be valuable. Examples include studies for hepatitis B or C infection, HIV, and cryoglobulinemia. The value of indiscriminate testing for ANAs, rheumatoid factor, and angiotensin-converting enzyme to look for the presence of possible systemic autoimmune disease is arguable, at best. These studies should be used primarily as aids in supporting a tenable clinical diagnosis.

The evaluation of the patient with a vasculitic syndrome begins with a detailed patient history and directed physical examination to seek or document specific organ involvement. Special attention should be paid to finding evidence of inflammation in the eyes, ears, nose, paranasal sinuses, mouth, trachea, joints, intestine, or peripheral nerves. The presence of adenopathy, periungual capillary abnormalities, cardiac abnormalities, asymmetric peripheral pulses, or abdominal and subclavian bruits provides other diagnostic clues. It is reasonable to include a few basic laboratory tests in the initial evaluation; more specialized studies should be obtained only after a focused differential diagnosis is generated. Initial studies should include a complete blood count with differential, measurement of serum creatinine and transaminase levels, and a dipstick and microscopic urinalysis. Ideally, the urinalysis should be performed immediately by a physician on a fresh sample; urine that has been allowed to sit for several hours before analysis will not permit identification of cellular casts that may rapidly degenerate ex vivo. Red blood cell casts are highly suggestive of the presence of glomerulonephritis. A clinical axiom is that the primary vasculitides are almost never associated with leukopenia or thrombocytopenia. The presence of these laboratory findings should suggest alternative diagnoses such as SLE, vasculitis associated with malignancy, disseminated intravascular coagulation, infection, or drug-induced cytopenias. Table 174-1 lists some of the disorders that may mimic or be associated with a vasculitis.

Infections	Carcinoma (disseminated: renal cell, colon, lung)*
Endocarditis*	Lymphoma*
Histoplasmosis	Hairy-cell leukemia*
Syphilis*	Myelogenous leukemia/myelofibroplasia*
Borrelia burgdorferi (Lyme disease)	Drug reactions, toxicities, and abuse
Viral	Phencyclidine
Hepatitis (A,B,C)*	Cocaine
HIV*	Amphetamines*
CMV*	Warfarin
Pneumonia (Legionella, Streptococcus pneumoniae)	Ergotamine
Mycobacteria	Others
Parasites	Amyloidosis
Trichinella	Cryoglobulinemia*
Toxoplasma	Sarcoidosis*
Plasmodium (malaria)	Anti-glomerular basement membrane disease
Strongyloides	Multiple sclerosis
Noninfectious processes	Familial Mediterranean fever
Sickle-cell anemia	Heavy metal poisoning
Disseminated intravascular coagulation	Hepatic porphyrias
Antiphospholipid antibody syndrome	Systemic lupus erythematosus*
Thromboangiitis obliterans	Hypereosinophilic syndrome
Protein C or S deficiency	Hypercoagulable syndrome
Warfarin-induced skin necrosis	Still's disease
Thrombotic thrombocytopenic purpura	Occult cirrhosis
Neoplastic diseases	Rheumatoid arthritis*
Atrial myxoma	Fabry's disease

TABLE 174-1 **Selected Conditions That May Mimic or Be Associated with* Systemic Arteritis**

SPECIFIC VASCULITIC SYNDROMES

Small Vessel Vasculitis

The most common form of vasculitis exclusively affects capillaries and venules, [4], [5] almost invariably involves the skin, and is extensively discussed in Chap. 175. It is frequently, although not always, associated with immune complex deposition. It can occur in these circumstances: (1) as an isolated primary cutaneous disorder; (2) secondary to drug allergy, bacterial endocarditis, viral infections (such as hepatitis B or C, [6] parvovirus B19, cytomegalovirus, or Epstein-Barr virus), or disseminated neisserial and rickettsial infection; (3) as part of defined systemic autoimmune disorders (e.g., Sjögren's syndrome, SLE, dermatomyositis, rheumatoid arthritis); or (4) in association with hematologic, [7], [8] lymphoid, [9], [10] and solid organ [11] malignancies. Primary small vessel vasculitis may be limited to the skin, [12] or may be associated with visceral involvement including pulmonary hemorrhage, [13] intestinal ischemia or hemorrhage, [14] and glomerulonephritis.

Visceral involvement may or may not be part of the syndrome of HSP, which occurs in adults as well as children and is usually associated with vascular and renal deposition of IgA-containing immune complexes. Common manifestations include purpura and/or urticaria, abdominal pain, gastrointestinal bleeding or intussusception, arthralgias, arthritis or periarthritis, and glomerulonephritis. Visceral symptoms may precede the skin lesions, leading to diagnostic confusion. Delayed skin involvement may be misinterpreted to be a drug reaction. Purpura tends to occur in crops of lesions of similar age. Small vessel vasculitis/purpura is generally more pronounced in gravity-dependent areas. One exception is vasculitis as a consequence of cryoglobulinemia, especially in association with lymphoma. Cutaneous vasculitis may be associated with such striking edema that nephrotic syndrome is suggested. A punch biopsy is useful in excluding infiltrative causes of nonvasculitic purpura. Immunofluorescent staining for IgA can support the diagnosis of HSP in the appropriate clinical setting.

In managing patients with cutaneous vasculitis, it must be established that the vasculitis is not caused by a process that may not benefit from, or that may be aggravated by, immunosuppressive therapy. Examples include infections such as disseminated gonorrhea, bacterial endocarditis, and viral-related vasculitides. Furthermore, the finding of small vessel vasculitis in the skin does not exclude concurrent medium or larger vessel arteritis. For example, purpura may occur in Wegener's granulomatosis (WG), [15] Churg-Strauss syndrome (CSS), polyarteritis, Behçet's disease, and Cogan's syndrome.

Therapy for isolated cutaneous vasculitis is directed at the underlying process, if one can be identified. Documented infections should be treated. Suspected offending antigens such as drugs should be withdrawn. If no precipitants are apparent, low-risk therapy can be attempted with nonsteroidal anti-inflammatory drugs, colchicine, pentoxifylline, dapsone, or short-term, low-dose glucocorticoids. However, if visceral involvement with organ dysfunction is present, a more aggressive approach is usually required. In the latter case, higher dose glucocorticoids are generally effective. In the setting of severe visceral involvement, methotrexate, azathioprine, cyclophosphamide, or other immunosuppressive agents may be required. When treating disease that is not organ- or life-threatening, close attention must be paid to the risk-versus-benefit ratio of selected therapies.

Urticarial vasculitis [16] represents a peculiar subset of small vessel vasculitis. The clinical presentation is that of typical wheals or serpentine papules, sometimes with surrounding or geographically separate angioedema. Individual lesions are slower to resolve than typical urticaria and often last for several days. There is frequently a burning, dysesthetic quality to the discomfort from the lesions. They often heal with skin discoloration, hyperpigmentation, or an ecchymotic area. Most cases are idiopathic, although they may be associated with an underlying autoimmune disorder such as SLE or Sjögren's syndrome, [17] IgM paraproteinemia (Schnitzler's syndrome [18], viral infections (hepatitis, acute Epstein-Barr), and HSP. Joint and, less commonly, abdominal pain may occur. There may be an association with ocular inflammatory disease and obstructive pulmonary disease. A form of urticarial vasculitis with neutrophil infiltration and destruction of the postcapillary venules has been described [19] in association with hypocomplementemia. The lesions are generally responsive to moderate doses of daily glucocorticoids. However, this approach is fraught with long-term toxicity. Anecdotal reports have noted improvement with colchicine, dapsone, nonsteroidal agents, and the antimalarials. [16]

Wegener's Granulomatosis

WG is a relatively uncommon, potentially lethal disease characterized by necrotizing granulomatous inflammation and vasculitis of small- and medium-sized vessels. Multiple organs are often involved, with a predilection for the upper and lower respiratory tracts, the eye, and the kidney. [20], [21] and [22] Males and females of all ages can be affected. Upper airway disease tends to be particularly striking but is often initially attributed for months or even years to “sinus disease” until other manifestations of WG are recognized. In addition to pansinusitis, WG can cause septal perforations and saddle nose deformities. Ear involvement is common, particularly otitis media. Auricular destruction, similar to that in polychondritis, has rarely been reported and may represent an overlap syndrome. [23] Occult involvement of the inner ear and nose must be sought. Sinus disease is often destructive and may be recalcitrant to therapy because of superinfection of the necrotic tissue by *Staphylococcus aureus*. [22] Laryngotracheal involvement may result in subglottic stenosis. [20] Orbital pseudotumors and nasolacrimal duct stenosis occur frequently in WG. Orbital pseudotumors may cause proptosis with intractable pain and loss of vision; these inflammatory and fibrous masses may be refractory to anti-inflammatory, immunosuppressive, and even radiation therapy. Isolated uveitis and retinal disease are less common.

Lower respiratory tract involvement is part of the WG diagnostic triad (upper and lower respiratory tract and glomerulonephritis). However, it may not be clinically evident at the outset of disease or even at the time of diagnosis. Pulmonary involvement may be dramatic with diffuse alveolar hemorrhage. More commonly, patients present with mild or no symptoms, and chest radiographs or computed tomography scans are necessary to demonstrate the infiltrates or nodules. Nodules may undergo necrosis, leading to cavity formation. Pleural involvement occurs, but bronchospasm is not characteristic of WG. It is frequently necessary to rule out infectious causes of the pulmonary infiltrates, and bronchoscopy is useful in this regard. However, tissue obtained from transbronchial biopsy is usually quantitatively insufficient to make the pathologic diagnosis of WG. Open-lung biopsy generally provides the optimal opportunity to demonstrate the typical pathologic findings of WG (Fig. 174-2 and Fig. 174-3) and to exclude malignancies and atypical infections. Biopsy of alternative tissues may not have the same likelihood of revealing the specific diagnosis. Nasal tissue, although readily available, has a far lower likelihood of yielding the correct diagnosis [24] than does lung tissue obtained by thoracoscopy-guided or open biopsy. Renal biopsy may reveal focal and segmental glomerulonephritis with variable proliferative changes, in the absence of significant immune-complex deposition. Although supportive of the diagnosis of WG, these are not specific histopathologic findings. Open-lung biopsies contain areas of necrosis (frequently in a “geographic” pattern), giant cell granulomas in the parenchymal tissue, and vasculitis. Not all histopathologic components may be present in the same section. Because these findings may also occur in chronic mycobacterial or fungal infections, special stains and cultures are essential.



FIGURE 174-2 Lung histopathology from a patient with Wegener's granulomatosis demonstrating necrosis, giant cells, and mixed cellular inflammation.

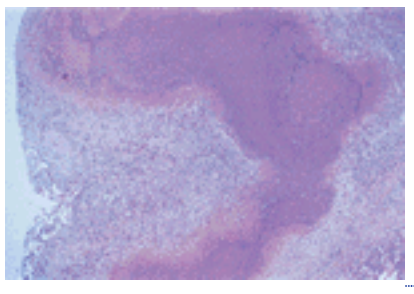

FIGURE 174-3 “Geographic necrosis” in a low-power view of an open lung biopsy specimen from a patient with Wegener's granulomatosis.

Glomerulonephritis is a common cause of morbidity and mortality in WG. Its presence or absence defines the generalized versus limited forms of the disease. When present, its expression may be relatively indolent or, more frequently, aggressive. It may be clinically and pathologically indistinguishable from idiopathic, rapidly progressive, crescentic glomerulonephritis. The evolution from subclinical to dialysis-dependent renal disease may take place over several weeks. [20], [25] Glomerulonephritis may be present at the outset or initial recognition of the disease or may develop only after the patient has been ill with an apparently limited form of the disease for long periods of time. [20], [21] and [22], [25] Frequent microscopic urinalyses in the initial and follow-up evaluation of patients with WG are important. Occasional 24-h urine collections to establish a more accurate estimate of the glomerular filtration rate than the serum creatinine measurement alone can provide may be valuable, especially in elderly or debilitated patients.

Musculoskeletal involvement occurs in more than half of patients with WG. Most note only arthralgias or myalgias, but some may experience true polyarthritis or migratory or fixed inflammatory mono- or oligoarthritis. [20], [26] Rheumatoid factor, which is frequently present in patients with WG, may cause some diagnostic confusion with rheumatoid arthritis when joint symptoms are significant. The joint disease of WG, however, only rarely produces bone erosions. [27] Neurologic signs and symptoms occur in fewer than 50 percent of patients, peripheral neuropathy in fewer than 20 percent, and involvement of the central nervous system in fewer than 10 percent. [20], [28] Oculomotor involvement may occur as a result of the presence of retroorbital mass impingement. Gastrointestinal ulcerations and ischemic syndromes can occur, [29] as can cardiac ischemia, conduction disease, and pericarditis. [20], [30]

Cutaneous involvement has been reported in up to 50 percent of patients with WG. [21] The author has seen several patients who experienced acute or indolent deep inflammatory skin masses as the initial manifestation of their disease. Reported manifestations include palpable purpura, [15], [31] pyoderma-like ulcerations, [31], [32] gingival hyperplasia, [33] inflammatory papules, small ulcers, panniculitis, and subcutaneous nodules. [21], [31], [33], [34] The activity of the skin disease generally parallels systemic disease activity. No skin histopathology is pathognomonic for WG. Leukocytoclastic angiitis is most apparent in the presence of purpura or inflammatory papules but is clearly not sufficient to make the diagnosis of WG. Granulomatous vasculitis [34] may be seen, occasionally in the presence of soft tissue necrosis or panniculitis, which may suggest the diagnosis of WG. Skin biopsies are not usually sufficient to confirm the diagnosis. Cutaneous granulomatous vasculitis, similar to that in patients with WG, has been described in patients with isolated skin involvement, Crohn's disease, sarcoidosis, or lymphoproliferative disorders. [5] Oral and nasal ulcerations are common. Several patients with orbital WG and a treatment-responsive yellow discoloration of the eyelids have been described. [35]

The diagnosis of WG should be considered in patients with otherwise unexplained inflammation of the upper or lower respiratory tract or eye or with glomerulonephritis. Suspicion of WG should be increased when multiple organ involvement is present, the upper airway disease is destructive, or pulmonary nodules (especially with cavities) are demonstrated by radiography. Any combination of organ involvement is conceivably possible, but most patients exhibit upper airway involvement at the time of diagnosis. [20] If the entire clinical picture is compatible with WG, and alternative diagnoses have been appropriately ruled out, the finding of a cytoplasmic pattern of antineutrophil cytoplasmic autoantibody (C-ANCA) with anti-PR3 specificity in the patient's serum is sufficient to make the diagnosis and initiate therapy. However, if there are any atypical features or special concerns about the initiation of immunosuppressive therapy, or if the patient does not respond appropriately to therapy, tissue documentation of the diagnosis is mandatory. Because WG generally requires glucocorticoid plus cytotoxic drug therapy, it should be distinguished from other inflammatory disorders, including other vasculitic syndromes, that may be effectively treated with a less toxic approach. ANCA positivity in the absence of a typical pattern of clinical WG is inadequate to make the diagnosis.

Treatment of systemic WG virtually always requires dual-drug immunosuppressive therapy. Glucocorticoids may induce symptomatic improvement in the upper airway, lungs, skin, and musculoskeletal system but only rarely produce remission. Glucocorticoids alone essentially never control aggressive renal disease. Even if improvement follows single-drug treatment with glucocorticoids, tapering usually results in a flare in the disease. Consequently, serious disease, particularly renal disease, is treated initially with glucocorticoids and daily cyclophosphamide, with subsequent tapering of the steroids. There are some strong relative contraindications to the use of cyclophosphamide, including bladder outlet obstruction and leukopenia. In patients with milder or limited WG, weekly methotrexate (0.20 to 0.30 mg/kg, adjusted for renal function) with folic acid or leucovorin may be substituted for the cyclophosphamide. [21], [36] Patients treated with either regimen must be continuously monitored for flares in disease or side effects of therapy. Side effects include cytopenias; hepatic or pulmonary toxicity from methotrexate; and pulmonary toxicity, cystitis, bladder cancer, or pancytopenia from cyclophosphamide. Some authors have suggested using trimethoprim-sulfamethoxazole as adjunctive therapy for treatment of the WG and/or for prevention of bacterial infections that may promote upper airway disease flares, but this approach remains controversial. [37] Three times weekly therapy with trimethoprim-sulfamethoxazole is of use, however, to protect patients against *Pneumocystis carinii* pneumonia (PCP) while they are receiving high doses of glucocorticoids or a cytotoxic agent. Patients who cannot tolerate sulfur antibiotics should receive prophylaxis against PCP with inhaled monthly pentamidine therapy. Local nasal and sinus care and

otolaryngoscopic evaluations are a routine part of the therapy of patients with WG and upper airway disease.

Churg-Strauss Syndrome (Allergic Angiitis and Granulomatosis)

CSS, like WG, affects small- to medium-sized arteries and veins. Clinically, CSS and WG have similar patterns of organ involvement and pathology, especially in regard to upper and lower airway disease and glomerulonephritis. CSS differs most strikingly from WG by its usual occurrence in patients with a history of atopy, asthma, or allergic rhinitis, which is often ongoing. In the prevasculitic atopy phase, as well as during the systemic phase of the illness, eosinophilia is characteristic and often of striking degree (>1000 eosinophils/µL). When eosinophilia is present in WG, it is usually more modest (500 eosinophils/µL). Systemic features of CSS include some combination of pulmonary infiltrates, cardiomyopathy, coronary arteritis, pericarditis, polyneuropathy (symmetric or mononeuritis multiplex), ischemic bowel disease, eosinophilic gastroenteritis, ocular inflammation, nasal perforations, glomerulonephritis, and cutaneous nodules and/or purpura.

The pulmonary infiltrates of CSS are usually transient and patchy, [38] and may be associated with alveolar hemorrhage. Pulmonary nodules are uncommon; when present, they rarely cavitate. [39] Pleural effusions are common and often contain abundant eosinophils. Clinical distinction of CSS from hypersensitivity pneumonitis, allergic aspergillosis, and pulmonary lymphoma is at times difficult. Cardiac disease can be severe and is a leading cause of death in these patients. It often does not manifest itself until late in the course of the illness. Valvular heart disease is not as striking or as common as in the hypereosinophilic syndrome. Neurologic involvement occurs in approximately 60 percent of patients, may be severe, and is generally attributable to arteritis of the vasa nervorum. Purpura is the most common cutaneous feature. Urticaria and polymorphous erythematous eruptions also occur. [40] Cutaneous nodules appear in approximately one-third of patients, primarily on the extensor surfaces of the arms and scalp. [41], [42] and [43] The nodules may be tender and occasionally may infarct. Gastrointestinal involvement is due to ischemic vasculitis and/or eosinophilic gastroenteritis, which can cause pain, cramping, and diarrhea.

Histopathologic examination of involved skin, nerve, lung, heart, and gastrointestinal tract typically reveals a vascular or extravascular granulomatous inflammation, with a prominent eosinophilic infiltrate and vasculitis. Vasculitis in a given tissue section may be granulomatous or nongranulomatous. Granulomas can be found in tissue at areas separate from the demonstrable vasculitis. Eosinophilic infiltrates are more striking than those in WG. Eosinophils, granulomas, and giant cells are not found in abundance in classic polyarteritis nodosa (PAN). It has been suggested that the initial small vessel vasculitis in the skin evolves into a pattern of inflammation with granulomas that coalesce into the palpable nodules. [44] However, the pathology of these nodules, by itself, is insufficient to make a diagnosis of CSS because similar pathology can be seen in lymphoma and sarcoidosis. [43], [45] Glomerulonephritis is not as common as in WG but, when present, is usually focal and segmental, occasionally with crescents. [46] The glomerulonephritis of CSS is often milder than that of WG or microscopic polyangiitis.

CSS generally responds to treatment with glucocorticoids. Some patients can be tapered from steroids. However, the presence of bronchial asthma and sinus disease may require ongoing therapy, even if the vasculitic component of the disease has remitted. Patients with severe or refractory visceral organ involvement are treated with additional agents, such as cyclophosphamide, [47], [48] methotrexate, or azathioprine.

Polyarteritis Nodosa and Microscopic Polyangiitis

Attempts to neatly separate these two forms of necrotizing small- and medium-sized vessel arteritis have not been universally accepted. [2], [48], [49] An international consensus conference proposed that the diagnosis of these disorders be based on the absence of granulomatous inflammation in both and the lack of involvement of arterioles, capillaries, venules, and glomerular capillaries in classic PAN. Microscopic polyangiitis (MPA) involves vessels ranging in size from capillaries and venules to medium-sized arteries (see Fig. 174-1). Glomerulonephritis, especially rapidly progressive glomerulonephritis, and alveolar hemorrhage are particularly common in MPA and absent in classic PAN. Antibody to myeloperoxidase, a type of perinuclear-staining antineutrophil cytoplasmic autoantibody (p-ANCA), is detected in sera from 60 percent of patients with MPA. It may well be that some cases of classic PAN do involve the smaller vessels, and until it can be demonstrated that the two syndromes have distinct pathophysiologies, attempts to clearly distinguish MPA from PAN will remain imperfect. Hepatitis B and C infections are associated with a classic PAN-like syndrome [48] as well as with MPA-like disease.

Given the diagnostic nuances and disagreements, it is not surprising that a clear-cut distinction between the two syndromes cannot be provided in terms of prognosis or response to therapy. Most importantly, because the distinction between these two syndromes is still being defined, it is difficult to interpret the clinical descriptions in the older studies of PAN, which included patients with both classic PAN and MPA. This accounts for some of the wide variation in the reported frequency of pulmonary [50] or glomerular involvement in PAN.

Constitutional symptoms, such as fever, asthenia, and myalgias, are often present in both PAN and MPA. Elevated acute-phase reactants, thrombocytosis, leukocytosis, and the anemia of inflammatory disease are common, although not uniformly present. MPA is typically manifest by crescentic necrotizing, segmental glomerulonephritis and/or alveolar hemorrhage in conjunction with small and medium-sized vessel vasculitis in other organ systems.

Antiglomerular basement membrane antibodies are generally absent. Alveolar hemorrhage may manifest as dyspnea, pulmonary infiltrates, and anemia. Hemoptysis may not be present. Peripheral neuropathy with symmetric mixed motor and sensory components, or mononeuritis multiplex pattern is common. Upper airway and ocular inflammation may occur [51] and may occasionally make the distinction from WG difficult. Purpura and/or splinter hemorrhages are commonly found in MPA. [51], [52]

Classic PAN may present with hypertension and/or renal insufficiency with a bland urine sediment or hematuria on microscopic analysis. Renal ischemia may result from inflammation, stenosis, or occlusion of preglomerular muscular arteries. Peripheral neuropathy, testicular pain, epididymitis, ischemic myalgias, and livedo reticularis occur. Both PAN and MPA may cause cardiac or gastrointestinal tract ischemia. PAN is associated with the development of microaneurysms, 1 to 5 mm in size, in the mesenteric, hepatic, or renal arteries in perhaps 40 percent of patients. Microaneurysms can also occur in patients with MPA, WG, CSS, Behçet's disease, SLE, and other disorders affecting medium-sized vessels (see Fig. 174-1), including endocarditis.

When PAN or MPA is recognized clinically, it is imperative to be certain that it is not associated with infection with hepatitis B or C. The presence of hepatitis B or C infection does not seem to alter the presentation of the PAN or MPA syndrome dramatically, although membranous glomerulonephritis, liver failure, and thrombocytopenia are more likely to occur with viral hepatitis infection. Infection with parvovirus B19 and HIV should also be excluded.

The diagnosis of these disorders should ideally be based on histopathology and clinical pattern of disease. In the patient with a urine sediment analysis suggestive of glomerulonephritis or with neuropathy, a renal biopsy or biopsy of a clinically involved nerve may provide the diagnosis of necrotizing medium vessel arteritis. The presence of serum p-ANCA with antimyeloperoxidase specificity further supports the clinical diagnosis but is not specific for this disease. p-ANCA positivity is also found in patients with drug-induced vasculitis. The renal biopsy tissue in MPA, as in WG, is negative for immune complexes by immunofluorescent staining and electron microscopy (so-called pauci-immune glomerulonephritis). Lung biopsy in the setting of pulmonary infiltrates or hemorrhage reveals capillaritis, but yields less specific pathology than in WG. Biopsy is useful to rule out alternative pulmonary diagnoses. The diagnosis of classic PAN is more difficult in the setting of dominant, but nonspecific, constitutional symptoms and the absence of easily accessible disease-affected tissue such as nerve. Biopsy of clinically uninvolved tissue (e.g., asymptomatic muscle or testes) is not usually fruitful. Several diagnostic algorithms have been proposed. [4], [53], [54] If biopsy is not indicated due to the absence of accessible involved tissue, complete abdominal angiography should be considered to evaluate the medium-sized vessels. The sensitivity and specificity of this procedure is not well defined, especially in the absence of abdominal complaints. Angiography is generally avoided, whenever possible, in the setting of progressive or significant renal insufficiency. Magnetic resonance angiography may not be sufficiently sensitive to detect microaneurysms.

Treatment of both PAN and MPA is somewhat empirical, although work by Guillevin et al. [55] has provided valuable information. Glucocorticoids in high doses remain the initial mainstay of therapy for both PAN and MPA. Glucocorticoids alone may be sufficient therapy for patients who do not have critical organ involvement, defined as renal insufficiency, gastrointestinal ischemia, cardiomyopathy, dense peripheral neuropathy, and central nervous system involvement. Those with critical organ involvement have increased risk of morbidity or mortality and are usually treated with glucocorticoids and an additional immunosuppressive agent such as cyclophosphamide. Although the use of initial combination therapy in this setting is the common practice, its efficacy has not been formally studied.

When active hepatitis B or C infection is present, a relatively short course of glucocorticoids should be considered, based on disease severity, in conjunction with antiviral therapy and perhaps apheresis. [55] Controlled studies have not been conducted to assess objectively the value of adding apheresis to the combination of antiviral and glucocorticoid therapy. In subsets of patients with cryoglobulinemia, particularly in the presence of nonhealing skin ulcers, apheresis may be of value.

Kawasaki Disease

Kawasaki disease (KD) was first described in 1967 as mucocutaneous lymph node syndrome. [56], [57] The presence of characteristic clinical features [58] has permitted the establishment of diagnostic criteria (Table 174-2). KD typically affects infants and young children with dominant cutaneous manifestations. The vascular component of the disease may involve vessels ranging in size from venules to the aorta. The inflammation is primarily in the larger coronary arteries, which results in aneurysm formation in approximately 25 percent of untreated patients. It has been postulated, but not proved, that there is an infectious trigger for KD. No specific diagnostic tests exist. However, the immediate and delayed life-threatening cardiac complications of the disease, coupled with its unique therapy (intravenous gamma globulin, IVIG), mandate prompt clinical diagnosis.

Persistent fever (>5 days)
Plus 4 of the following 5 conditions:
Bilateral conjunctivitis (nonpurulent)
Oral mucosal involvement (erythematous pharynx, red or fissured lips, strawberry tongue)
Soft tissue abnormalities of hands and feet (edema/erythema, desquamation)
Rash (polymorphous but nonvesicular)
Cervical adenopathy

TABLE 174-2 **Diagnostic Criteria for Kawasaki Disease**

Fever is usually high and spiking and may persist for 1 to 2 weeks if untreated, but rapid defervescence is usually achieved with the initiation of appropriate therapy. Conjunctivitis, usually nonexudative, often appears concurrent with the fever. Uveitis occurs less frequently. Aseptic (lymphocytic) meningitis may contribute to the photophobia as well as to headache and prominent irritability. Oral involvement includes erythema, dryness and fissuring of the lips, nonexudative pharyngitis, and tongue erythema with very prominent papillae (Fig. 174-4 and Fig. 174-5). Mucosal ulcerations do not characteristically occur.

FIGURE 174-4 Kawasaki disease: lip and facial involvement. (*Courtesy of B. Singsen, MD.*)

FIGURE 174-5 Kawasaki disease: strawberry tongue. (*Courtesy of B. Singsen, MD.*)

Distal limb swelling often begins several days after the fever. The hands and feet may have associated erythema and tenderness that is not limited to the joints. Desquamation (Fig. 174-6), often in sheets, may begin days to a few weeks after the onset of the fever. When desquamation occurs early in KD, it may appear concurrently with a truncal rash and with eye and lip changes and may mimic a drug reaction or Stevens-Johnson syndrome. The rash is usually diffuse and polymorphous (Fig. 174-7), with urticarial, morbilliform, annular, or plaque components; but it is not vesicular. It is generally less evanescent and more readily apparent than the rash of Still's disease (systemic pattern juvenile rheumatoid arthritis). However, it may not be present at the time of initial presentation or concurrent with the febrile component of the illness. Distal vasculitis has been described, and digital necrosis may occur. [59]

FIGURE 174-6 Kawasaki disease: distal extremity desquamation. (*Courtesy of B. Singsen, MD.*)

FIGURE 174-7 Kawasaki disease: rash on trunk. (*Courtesy of B. Singsen, MD.*)

Adenopathy, which is present in 75 percent of patients, is generally most apparent in the cervical region and ranges from mild to extensive. [60] Other, less common (noncardiac) aspects of the disease include abdominal cramping and diarrhea, hydrops of the gall bladder, synovitis of large and small joints, hepatitis, pulmonary infiltrates, otitis media, thrombocytopenia with evidence of disseminated intravascular coagulation, and urethritis.

The severe morbidity and mortality rates (3 percent) for KD are overwhelmingly associated with the development of inflammatory coronary artery aneurysms, most of which are asymptomatic at the time of formation. Many aneurysms can

be detected by echocardiography. Cardiac involvement occurs in at least 20 percent of unsuccessfully treated patients. Thrombosis occurs in some of the aneurysms, resulting in direct or embolic coronary occlusion syndromes, including sudden death. Clinical coronary events often do not occur until weeks or years after the onset of febrile illness. The focus of initial prompt therapy is on the prevention of aneurysm formation and coronary thrombosis. A baseline echocardiogram should be obtained at the time of the acute illness and repeated 2 and 6 weeks later. If abnormalities are identified, additional studies are warranted. [61] Early recognition of the disease and treatment with IVIG and aspirin have significantly decreased the frequency of aneurysm formation and thrombotic coronary events.

Histopathology of the conjunctiva or skin is not specific, revealing edema and vessel dilatation with a mixed mononuclear infiltrate of predominantly CD4-positive cells and macrophages. [62], [63] Lymph node pathology demonstrates variable necrosis and occasional areas of vasculitis.

Treatment should be initiated with IVIG (2 g/kg as a single dose) and aspirin (80 to 100 mg/kg per day, given every 6 h) as soon as the disease is suspected. [64] It has been suggested that the early administration of IVIG therapy is most effective at preventing aneurysm formation. Aspirin is more effective than glucocorticoids in preventing aneurysms, and glucocorticoid therapy is usually unnecessary. Fever, conjunctivitis, and rash tend to respond within several days to aspirin and IVIG. Patients who do not respond to aspirin and IVIG therapy may benefit from high-dose glucocorticoid therapy. [65]

Large Vessel Arteritis (Takayasu's Arteritis and Temporal Arteritis)

Takayasu's arteritis (TA) and temporal (giant cell) arteritis (GCA) are the most common inflammatory diseases of the aorta and its major branches. Similar vascular targeting may occur in Behçet's disease, Cogan's syndrome, and sarcoidosis. Their associated extravascular features readily distinguish these diseases. GCA generally affects individuals older than 50 years. It is associated in some patients with polymyalgia rheumatica, a syndrome characterized by proximal muscle pain that is more severe at night and in the early morning. There may be a subjective sense of weakness, without true weakness on examination or elevation of serum muscle enzyme levels. GCA is variably associated with fever, headache, masticatory muscle claudication, peripheral vascular disease, inflammatory aortic aneurysms, and retinal ischemic syndromes. Cutaneous manifestations include rare cases of scalp or tongue ischemia and necrosis and, in a minority of cases, cyanosis or pallor due to distal extremity ischemia arising from proximal large vessel occlusive disease. Symptoms and signs in the extremities may be clinically indistinguishable from those occurring in atherosclerotic obliterative disease.

GCA is generally diagnosed by biopsy of the superficial temporal artery. The pathology of GCA usually includes chronic mononuclear cell infiltrates and giant cells. There are isolated reports of GCA overlap syndromes also involving medium-sized vessels of the viscera, but generally this disease is not associated with small (capillary, venule) blood vessel inflammation. [4], [66]

Takayasu's arteritis (pulseless disease) is also a chronic inflammatory disease affecting the aorta and its major branches. Although it is usually recognized in younger (<40 years) predominantly female patients of reproductive age, it can also occur in children and older patients of either sex. TA is more commonly associated with aortic and aortic branch vessel stenoses and aneurysms than GCA. It is uncertain whether TA and GCA are distinct disorders or the same disorder, with modified expression in different age groups. TA is associated with erythema nodosum and, rarely, pyoderma-like lesions more frequently than is GCA. [67], [68] and [69] The presenting clinical syndrome may include prolonged flu-like illness, with a polymyalgia rheumatica pattern of muscle pain. Other patients present only with evidence of limb, cerebral, or cardiac ischemia. Renal ischemia can elicit high renin hypertension. The characteristic features of the disease reflect the ischemia produced by the inflammatory stenoses of the aorta and its major branches. Predominant sites of involvement are the aortic arch vessels, particularly the subclavian artery. Arm claudication is common. Bruits are frequently detectable. Superficial artery pain and tenderness (e.g., carotidynia) may be found on examination but are not diagnostic of TA. Severe central hypertension due to renal artery stenosis may not be recognized because of coexistent arm artery stenosis; thus, four extremity blood pressures must be evaluated initially and monitored on a frequent basis. Stroke is not uncommon and is often related to hypertension. It is extremely difficult to assess the activity of TA; the presence or absence of constitutional features or of elevated acute-phase reactants are poor measures of disease activity. This impression is supported by histopathologic studies of vessel tissue obtained at the time of reconstructive surgery. [67], [70], [71] More than 40 percent of specimens from patients thought to be in remission revealed active inflammation.

Diagnosis is usually made by arteriographic demonstration of stenotic and obstructive lesions. Aneurysms are less commonly observed. The entire arch as well as abdominal aorta and renal vessels should be evaluated; central arterial pressure should be obtained at the time of angiography and compared with simultaneously obtained arm and leg arterial pressures. The role for vascular magnetic resonance imaging in the evaluation and follow-up of these patients is under investigation. Pathologic documentation is more difficult to obtain in TA, but the histopathology is similar to that described above in GCA.

Sarcoidosis may involve the large arteries and occasionally may mimic the vascular disease of TA. [4] A full physical examination and chest radiograph are requisite components of the evaluation of any patient with suspected systemic vasculitic syndrome, and careful examination may reveal subtle findings, such as lacrimal enlargement, to suggest the diagnosis of sarcoidosis. Atherosclerotic disease often presents a more difficult diagnostic distinction in patients with obliterative arterial disease, and certainly can coexist with a primary form of large vessel arteritis. Livedo reticularis (Fig. 174-8) may be present in patients with peripheral vascular disease of various etiologies.

FIGURE 174-8 Livedo reticularis.

The initial therapy of both TA and GCA is with glucocorticoids. GCA is generally quite responsive, although the most appropriate initial dose remains controversial. Different authors have advocated different initial daily doses, ranging from a total of 20 mg to 1 mg/kg body weight, with tapering of the glucocorticoids over 8 to 12 months. The measurement of acute-phase reactants provides an imperfect index of disease activity and an imperfect guide to glucocorticoid tapering. If significant glucocorticoid-induced side effects occur, or if patients relapse during tapering, a second-line agent such as methotrexate is usually (empirically) added to the glucocorticoid regimen. TA appears to respond less consistently to initial glucocorticoid therapy than GCA, but this observation has not been carefully studied. Some authors have advocated the earlier use of methotrexate therapy in TA to reduce the toxicity risks of long-term glucocorticoid therapy. [72] Vascular reconstructive surgery or angioplasty is an adjunctive therapeutic option for some patients. [73]

GENERAL COMMENTS ON THE TREATMENT OF PATIENTS WITH SYSTEMIC ARTERITIS

The systemic vasculitides are potentially life-threatening and often require potent anti-inflammatory and immunosuppressive therapy. Diagnoses should be made with as much certainty as possible. However, questions regarding alternative diagnoses or coexistent diseases may linger. Hence, even after therapy is initiated, physicians need to maintain a high degree of vigilance to detect unrelated medical problems and/or complications of therapy. After the initiation of potent immunosuppressive therapy, there is increased susceptibility to opportunistic infection. The greatest risks occur in patients with marked neutropenia or lymphopenia. Physicians must be particularly wary about attributing new problems to a flare in the underlying disease without considering the possibility of a new or recrudescent infection. Varicella-zoster may present with fever and pain before the appearance of the tell-tale vesicles. Infections from *P. carinii* and cytomegalovirus, systemic fungal infections, and the reactivation of mycobacterial disease occur more frequently than in the normal host. Significant immunosuppression from glucocorticoids and the other medications is frequently associated with mucosal candidiasis, less commonly with molluscum contagiosum, and rarely with Kaposi's sarcoma. Methotrexate may cause a flulike illness after each dose. Methotrexate, azathioprine, and cyclophosphamide may cause leukopenia and, less often, other cytopenias. Glucocorticoids can cause a significant amount of facial and truncal acne, which, especially in younger patients, must be addressed to encourage compliance with therapy. Cutaneous complications, including allergic purpura, can also result from adjunctive medications for hypertension, epilepsy, or arthritis. Reactions to thrombolysis or angiographic studies may include urticaria as well as the cholesterol embolization syndrome in patients with atherosclerosis. Drug-induced pneumonitis has been reported with the use of immunosuppressive agents, especially methotrexate and cyclophosphamide. Azathioprine hypersensitivity reactions can include high spiking fevers, vasculitis, and polymorphous cutaneous eruptions.

REFERENCES

1. Fauci AS et al: The spectrum of vasculitis: Clinical, pathologic, immunologic and therapeutic considerations. *Ann Intern Med* **89**:660, 1978

2. Jennette C et al: Nomenclature of systemic vasculitides. Proposal of an international consensus conference. *Arthritis Rheum* **37**:187, 1994

3. Zeek PM: Periarteritis nodosa: A critical review. *Am J Clin Pathol* **22**:777, 1952

4. Mandell BF: General approach to the diagnosis of vasculitis, in *Inflammatory Diseases of Blood Vessels,* edited by GS Hoffman, CM Weyand. New York, Marcel Dekker, 2001, p 239

5. Gibson EL, Su WPD: Cutaneous vasculitis. *Rheum Dis Clin North Am* **21**:1097, 1995

6. Karlsberg PL et al: Cutaneous vasculitis and rheumatoid factor positivity as presenting signs of hepatitis C virus induced mixed cryoglobulinemia. *Arch Dermatol* **131**:1119, 1995

7. Blanco R et al: Cutaneous vasculitis in children and adults. Associated diseases and etiologic factors in 303 patients. *Medicine* (*Baltimore*) **77**:403, 1998

8. Stahl RL, Silver R: Vasculitic leg ulcers in chronic myelogenous leukemia. *Am J Med* **78**:869, 1985

9. Kesseler ME, Slater DN: Cutaneous vasculitis: A presenting feature in Hodgkin's disease. *J R Soc Med* **79**:485, 1986

10. Means RT et al: Leukocytoclastic vasculitis and multiple myeloma. *Ann Intern Med* **106**:329, 1987

11. Lacour JP et al: Cutaneous leukocytoclastic vasculitis and renal cancer: Two cases. *Am J Med* **94**:104, 1993

12. Cupps TR et al: Chronic recurrent small vessel cutaneous vasculitis. *JAMA* **247**:1994, 1982

13. Carbone L et al: Goodpasture's syndrome complicating Henoch-Schönlein purpura. *J Clin Rheum* **1**:350, 1995

14. Szer IS: Henoch-Schönlein purpura: When and how to treat. *J Rheumatol* **23**:1661, 1996

15. Mangold MC et al: Cutaneous leukocytoclastic vasculitis associated with active Wegener's granulomatosis. *J Am Acad Dermatol* **26**:579, 1992

16. O'Donnell B et al: Urticarial vasculitis. *Int Angiol* **14**:166, 1995

17. Asherson RA et al: Urticarial vasculitis in a connective tissue disease clinic: Patterns, presentations, and treatment. *Semin Arthritis Rheum* **20**:285, 1991

18. Morita A et al: A case of urticarial vasculitis associated with macroglobulinemia (Schnitzler's syndrome). *J Dermatol* **22**:32, 1995

19. Zeiss CR et al: A hypocomplementemic vasculitis urticarial syndrome. *Am J Med* **68**:867, 1980

20. Hoffman GS et al: Wegener's granulomatosis: An analysis of 158 patients. *Ann Intern Med* **116**:488, 1992

21. Duna G et al: Wegener's granulomatosis. *Rheum Dis Clin North Am* **21**:949, 1995

22. Fauci AS et al: Wegener's granulomatosis: Prospective clinical and therapeutic experience with 85 patients for 21 years. *Ann Intern Med* **98**:80, 1983

23. Diaz-Jouanen E et al: Chondritis of the ear in Wegener's granulomatosis. *Arthritis Rheum* **20**:1288, 1977

24. Devaney KO et al: Interpretation of head and neck biopsies in Wegener's granulomatosis. A pathologic study of 126 biopsies in 70 patients. *Am J Surg Pathol* **14**:555, 1990

25. Pinching AJ et al: Wegener's granulomatosis: Observations on 18 patients with severe renal disease. *Q J Med* **208**:435, 1988

26. Noritake DT et al: Rheumatic manifestations of Wegener's granulomatosis. *J Rheumatol* **14**:949, 1987

27. Jacobs RP et al: Wegener's granulomatosis presenting with erosive arthritis. *Arthritis Rheum* **30**:943, 1987

28. deGroot K et al: Standardized neurologic evaluations of 128 patients with Wegener's granulomatosis. *Arch Neurol* **58**:1215, 2001.

29. Hoffman GS et al: Gastrointestinal emergencies: Vasculitis and the gut, in *Current Topics in Gastroenterology and Hepatology,* edited by GNJ Tytgat, M Van Blankenstein. New York, Thieme, 1990, p 36

30. Forstot JZ et al: Cardiac complications of Wegener's granulomatosis: A case report of a complete heart block and review of the literature. *Semin Arthritis Rheum* **10**:148, 1980

31. Frances C et al: Wegener's granulomatosis. Dermatological manifestations in 75 cases with clinicopathologic correlations. *Arch Dermatol* **130**:861, 1994

32. Handfield-Jones SE et al: Wegener's granulomatosis presenting as pyoderma gangrenosum. *Clin Exp Dermatol* **17**:197, 1992

33. Patten SF et al: Wegener's granulomatosis: Cutaneous and oral mucosal disease. *J Am Acad Dermatol* **28**:710, 1993

34. Barksdale SK et al: Cutaneous pathology in Wegener's granulomatosis. A clinicopathologic study of 75 biopsies in 46 patients. *Am J Surg Pathol* **19**:161, 1995

35. Tullo AB et al: Florid xanthelasmata in orbital Wegener's granulomatosis. *Br J Ophthalmol* **79**:453, 1995

36. Langford CA et al: A staged approach to the treatment of Wegener's granulomatosis. *Arthritis Rheum* **42**:2666, 1999

37. Leavitt RY et al: The role of trimethoprim/sulfamethoxazole in the treatment of Wegener's granulomatosis. *Arthritis Rheum* **31**:1073, 1988

38. Chumbley LC et al: Allergic granulomatosis and angiitis. *Mayo Clinic Proc* **52**:477, 1977

39. Desgys GE et al: Allergic granulomatosis. Churg-Strauss syndrome. *Am J Radiol* **135**:1821, 1980

40. Abe-Matsuura Y et al: Allergic granulomatosis (Churg-Strauss) associated with cutaneous manifestations: Report of two cases. *J Dermatol* **22**:46, 1995

41. Crotty CP et al: Cutaneous clinicopathologic correlation of allergic granulomatosis. *J Am Acad Dermatol* **5**:571, 1981

42. Finan MC et al: The cutaneous extravascular necrotizing granuloma and systemic disease. A review of 27 cases. *Medicine (Baltimore)* **62**:142, 1983

43. Gibson LE et al: The spectrum of cutaneous granulomatous vasculitis: Histopathologic report of eight cases with clinical correlation. *J Cutan Pathol* **21**:437, 1994

44. Lanham JG et al: Churg-Strauss syndrome, in *Systemic Vasculitides,* edited by A Churg, J Churg. New York, Igaku-Shoin, 1991, p 101

45. Calonje JE et al: Cutaneous extravascular necrotizing granuloma (Churg-Strauss) as a paraneoplastic manifestation of non-Hodgkin's B-cell lymphoma. *J R Soc Med* **86**:549, 1993

46. Gaskin G et al: Renal disease in the Churg-Strauss syndrome. *Contrib Nephrol* **94**:58, 1991

47. Guillevin L et al: Systemic necrotizing angiitis with asthma: Causes and precipitating factors in 43 cases. *Lung* **65**:165, 1987

48. Lhote F et al: Polyarteritis nodosa, microscopic polyangiitis and Churg-Strauss syndrome. *Rheum Dis Clin North Am* **21**:911, 1995

49. Lie J: Nomenclature and classification of vasculitis: Plus a change, plus c'est la meme chose [editorial]. *Arthritis Rheum* **37**:181, 1994

50. Matsumoto T et al: The lung in polyarteritis nodosa: A pathologic study of 10 cases. *Hum Pathol* **24**:717, 1993

51. Lhote F et al: Microscopic polyangiitis: Clinical aspects and treatment. *Ann Med Interne (Paris)* **147**:165, 1996

52. Laque D et al. Microscopic polyangiitis with alveolar hemorrhage. A study of 29 cases and review of the literature. *Medicine (Baltimore)* **79**:222, 2000

53. Dahlberg PJ et al: Diagnostic studies for systemic necrotizing vasculitis. Sensitivity, specificity, and predictive value in patients with multisystem disease. *Arch Intern Med* **149**:161, 1989

54. Albert DA et al: The diagnosis of polyarteritis nodosa. II. Empirical verification of a decision analysis model. *Arthritis Rheum* **31**:1128, 1988

55. Guillevin L et al: Polyarteritis nodosa related to hepatitis B virus. A prospective study with long-term observation of 41 patients. *Medicine (Baltimore)* **74**:238, 1995

56. Kawasaki T: Acute febrile mucocutaneous syndrome with lymph node involvement with specific desquamation of the fingers and toes in children. *Arerugi* **16**:178, 1967

57. Kawasaki T et al: A new infantile acute febrile mucocutaneous lymph node syndrome. *Pediatrics* **54**:271, 1974

58. Wortman DW et al: Kawasaki syndrome. *Rheum Dis Clin North Am* **16**:363, 1990

59. Ames EL et al: Bilateral hand necrosis in Kawasaki syndrome. *J Hand Surg Am* **10**:391, 1985

60. Kim-Stamos J et al: Lymphadenitis as the dominant presentation of Kawasaki disease. *Pediatrics* **93**:525, 1994

61. Committee on Rheumatic Fever, Endocarditis and Kawasaki Disease, American Heart Association: Guidelines for long-term management of patients with Kawasaki disease. *Circulation* **89**:916, 1994

62. Burns JC et al: Conjunctival biopsy in patients with Kawasaki disease. *Pediatr Pathol Lab Med* **15**:547, 1995

63. Sato N et al: Immunopathology and cytokine detection in the skin lesions of patients with Kawasaki disease. *J Pediatr* **122**:198, 1993

64. Shulman ST et al: Kawasaki disease. *Pediatr Clin North Am* **21**:1013, 1995

65. Wright DA et al: Treatment of immune globulin resistant Kawasaki disease with pulsed doses of corticosteroids. *J Pediatr* **128**:146, 1996

66. Nordberg E et al: Giant cell arteritis. *Rheum Dis Clin North Am* **21**:1013, 1995

67. Kerr G et al: Takayasu's arteritis. *Ann Intern Med* **120**:919, 1994

68. Nikolic J et al: Takayasu's arteritis preceded by cardiac and cutaneous lesions. A case report. *Vasa* **22**:347, 1993

69. Frances C et al: Cutaneous manifestations of Takayasu's arteritis: A retrospective study of 80 cases. *Dermatologica* **181**:266, 1990

70. Hoffman GS: Treatment resistant Takayasu's arteritis. *Rheum Dis Clin North Am* **21**:73, 1995

71. Lagneau G et al: Surgical treatment of Takayasu's disease. *Ann Surg* **205**:157, 1987

72. Hoffman GS et al: Treatment of glucocorticosteroid resistant or relapsing Takayasu's arteritis with methotrexate. *Arthritis Rheum* **37**:578, 1994

73. Giordano JM: Takayasu's disease: Current status. *Eur J Vasc Endovasc Surg* **11**:1, 1996

T>

Chapter 175

Nicholas Soter

Cutaneous Necrotizing Venulitis

HISTORICAL ASPECTS
EPIDEMIOLOGY
ETIOLOGY AND PATHOGENESIS
CLINICAL MANIFESTATIONS
Associated Chronic Disorders
Precipitating Infections and Drugs
Idiopathic Disorders
LABORATORY FINDINGS
PATHOLOGY
DIAGNOSIS AND DIFFERENTIAL DIAGNOSIS
TREATMENT

REFERENCES

Necrotizing angiitis or *vasculitis* comprises a diverse group of disorders that combine segmental inflammation with necrosis of the blood vessels. The vascular damage may result from immunologic and/or inflammatory mechanisms. Clinical syndromes are based on criteria that include the gross appearance and the histologic alterations of the vascular lesions, the caliber of the affected blood vessels, the frequency of involvement of specific organs, and laboratory abnormalities. Necrotizing vasculitis may be a primary disease, may develop as a feature of a systemic disorder, or may be idiopathic.

Necrotizing vasculitis in the skin involves predominantly venules and is known as *cutaneous necrotizing venulitis* (CNV) and *leukocytoclastic vasculitis.* The occurrence of CNV in association with systemic involvement of the small blood vessels has been termed *hypersensitivity angiitis* or *vasculitis, systemic polyangiitis,* and *microscopic polyangiitis.* CNV may occur in association with an underlying chronic disease, may be precipitated by infections or drugs, or may develop for unknown reasons (Table 175-1). Although IgA-mediated small-vessel necrotizing vasculitis has been proposed as a nosologic entity, at the present time an immunopathobiologic classification of CNV is not possible. Systemic forms of necrotizing vasculitis that affect larger blood vessels are considered in Chap. 174.

Associated chronic disorders
Rheumatoid arthritis
Sjögren's syndrome
Systemic lupus erythematosus
Hypergammaglobulinemic purpura
Paraneoplastic vasculitis
Cryoglobulinemia
Ulcerative colitis
Cystic fibrosis
Antineutrophil cytoplasmic or antiphospholipid antibody syndromes
Precipitating events
Bacterial, viral, and mycobacterial infections
Therapeutic and diagnostic agents
Idiopathic disorders
Henoch-Schönlein syndrome
Acute hemorrhagic edema of childhood
Urticarial vasculitis and variants
Erythema elevatum diutinum
Nodular vasculitis
Livedoid vasculitis
Genetic complement deficiencies
Eosinophilic vasculitis
Idiopathic

TABLE 175-1 **Cutaneous Necrotizing Venulitis**

HISTORICAL ASPECTS

Various syndromes of necrotizing vasculitis were described in the nineteenth century, including necrotizing vasculitis of small blood vessels, which were described by Schönlein in 1837 and by Henoch in 1847. In 1952, Zeek differentiated systemic hypersensitivity angiitis that involved small blood vessels from polyarteritis nodosa. In various countries, different diagnostic terms were used to describe necrotizing vasculitis of the small blood vessels in the skin, which were perceived to be arterioles in the 1960s, but were shown to be venules in the 1970s by multiple investigators. CNV and leukocytoclastic vasculitis are the terms in current use.

EPIDEMIOLOGY

The age of patients has a limited influence on CNV. The associated chronic disorder usually determines the age of the affected individual. In children, CNV is most commonly described as the Henoch-Schönlein syndrome or acute hemorrhagic edema of childhood. Antineutrophil cytoplasmic antibody (ANCA)-associated vasculitides are most common in patients older than 50 years.

ETIOLOGY AND PATHOGENESIS

Experimental studies in animal models and observations in humans implicate immune complexes as a major pathobiologic mechanism in the production of CNV. Data obtained in animal models suggest that the localization in venules is related to vasoactive amines and subsequent vasopermeability alterations. Additional factors that are operative in the localization of immune complexes include endothelial-cell surface receptors and the defective clearance

of immune complexes by the reticuloendothelial system.

The most frequently postulated mechanisms in the production of CNV are the local deposition of circulating immune complexes formed during antigen excess or the formation of immune complexes in situ in the skin. Immune complexes may activate the complement system and lead to the generation of C5a anaphylatoxin, which attracts neutrophils. In turn, the neutrophils release lysosomal enzymes that damage tissue. The neutrophil superoxide-generating system may produce reactive oxygen products, which also cause tissue injury. The generation of the chemoattractant leukotriene (LT) B_4 from infiltrating neutrophils enhances the influx of neutrophils. An infiltrate composed predominantly of neutrophils in the lesional skin of patients with CNV is consistent with tissue damage induced by immune complexes that activate the complement system. In the Henoch-Schönlein syndrome, the fragmentation of neutrophils was attributed to apoptosis on the basis of the detection of inducible nitric oxide synthase and nitrotyrosine in the infiltrates and the detection of interleukin (IL)-8 on vascular endothelial cells. [1]

In patients with CNV, circulating immune complexes have been demonstrated in serum as mixed-type cryoglobulins and indirectly by assays that detect C1q precipitins, materials that bind to complement receptors on human lymphocytoid (Raji) cells, materials that bind to monoclonal rheumatoid factor, and substances that function in the antibody-dependent cellular cytotoxicity inhibition assay. The presence of immune complexes is inferred from the occurrence of serum hypocomplementemia with activation of the classic activating pathway and by the detection of increased plasma levels of C4a and C3a anaphylatoxins.

Immune complexes have been detected in lesional tissues by ultrastructural observation as electron-dense subendothelial deposits; and the membrane-attack complex, C5b-9, of the complement system has been detected on the surface of endothelial cells and infiltrating neutrophils. Decay-accelerating factor, a regulatory complement protein that prevents the assembly of the membrane-attack complex, is not present on the surface of endothelial cells of the upper dermal microvasculature. Tissue immune complexes also have been detected by direct immunofluorescence techniques as deposited immunoglobulins and complement proteins. In time-course studies of the evolution of cutaneous vascular lesions, immune reactants have been identified in lesions less than 24 h old. Antigens have been identified in only a few instances as bacterial, viral, mycobacterial, or rickettsial proteins by direct immunofluorescence techniques or by the polymerase chain reaction (PCR).

A role for lymphocytes, mononuclear cells, and Langerhans cells in the production of CNV is suggested by a perivenular infiltrate in skin lesions that is rich in lymphocytes with large and hyperchromatic nuclei, and by a prominence of mononuclear cells in the vascular skin lesions of patients with CNV and Sjögren's syndrome. The lymphocytes express CD3, CD4, CD1a, CD36, intercellular adhesion molecule (ICAM)-1, and lymphocyte function–associated antigen (LFA)-1. Lymphocytes may be activated by immune complexes, by cellular immune mechanisms, or by primary activation in autoimmune disease to produce lymphokines. Endothelial cells also can present antigens to and activate T lymphocytes. Activated macrophages secrete chemokines and lysosomal enzymes. Gamma/delta T cells have been detected in CNV with a neutrophil-rich pattern and with a documented infectious etiology. [2] In these specimens, a 72-kDa heat shock protein was expressed by endothelial cells and antigen-presenting cells.

The participation of mast cells in CNV is suggested by hypogranulated mast cells with shed extracellular granules, by a decreased number of mast cells in biopsy specimens of skin lesions, and by the development of vascular lesions after the intracutaneous injection of histamine in patients with active episodes of CNV. Mast cells can be activated directly by immune complexes through Fc?RIII or by complement fragments acting through their specific receptors. Through the production of histamine, prostaglandin (PG) D_2, and cysteinyl leukotrienes, the mast cell could alter venular permeability; interendothelial cell gaps have been noted in venules in patients with CNV. Eosinophils and neutrophils could be recruited by mast cell–derived chemotactic factors. The neutral proteases and acid hydrolases of mast cells may facilitate tissue damage, and the release of tumor necrosis factor (TNF)-a may increase expression of E-selectin on endothelial cells, thereby facilitating neutrophil recruitment.

Evidence for the role of the mast cell is provided by time-course analyses of the sequential histopathologic changes in individuals with physical urticaria. In a patient with circulating immune complexes and hypocomplementemia, in whom cold and trauma elicited CNV, initial mast cell degranulation was followed by the infiltration by neutrophils with an influx of eosinophils and basophils, the deposition of fibrin, and venular endothelial-cell necrosis. A postulated sequence of events would be the activation of the mast cell by physical stimuli, the release of vasoactive mediators, the deposition of circulating immune complexes with activation of the complement system, the influx of neutrophils, and the development of CNV. Another example of the time course of necrotizing vasculitis in human skin has been provided in an individual with exercise-induced vasculitis. [3] At 3 h, the number of mast cells decreased and the eosinophil was the next cell to appear around the venules with the deposition of eosinophil peroxidase. TNF-a levels were elevated, and E-selectin was expressed on endothelial cells. Subsequently, an influx of neutrophils appeared with the deposition of neutrophil elastase and the development of CNV.

Early in the course of necrotizing vasculitis, endothelial cells show increased expression of ICAM-1 and E-selectin without the expression of vascular cell adhesion molecule (VCAM)-1 in response to TNF-a. Because E-selectin is an adhesion molecule for neutrophils and for skin-homing, memory T lymphocytes, the increase in E-selectin is consistent with the appearance of an infiltrate of neutrophils that express CD11b within the first 24 h. [4]

In skin biopsy specimens from patients with idiopathic cutaneous vasculitis, hypersensitivity vasculitis, urticarial vasculitis, and Henoch-Schönlein syndrome, E-selectin was detected on endothelial cells of lesions less than 48 h old and was associated with an infiltrate of neutrophils expressing CD11b. The endothelial cells expressed human leukocyte antigen (HLA)-DR and very-late activating antigen (VLA)-1 but not P-selectin, and the perivascular cells demonstrated VCAM-1 and HLA-DR. Diminished cutaneous fibrinolytic activity with reduced release of plasminogen activator from venular endothelial cells occurs in patients with CNV; the subsequent reduction in fibrinolytic activity leads to fibrin deposition. Increased levels of plasma thrombomodulin, tissue-type plasminogen activator, and plasminogen activator

inhibitor-1 were detected in patients with Henoch-Schönlein syndrome. [5], [6]

Cutaneous nerve fibers can release neuropeptides, such as substance P, neurokinin A, and calcitonin gene-related peptide (CGRP), that cause vasodilation. Substance P activates mast cells and macrophages and increases fibrinolytic activity mediated by plasminogen activator. CGRP induces expression of E-selectin on endothelial cells and is chemotactic for T lymphocytes.

Eosinophils are minor infiltrating cells in CNV except in eosinophilic vasculitis. Eosinophils could produce LTC_4 and platelet-activating factor (PAF), which increase vascular permeability. Eosinophil granule proteins are toxic to endothelial cells and cause the release of chemical mediators from mast cells.

Associations have been recognized between small-vessel necrotizing vasculitis and ANCAs, which have specificity for proteins of the cytoplasmic granules of neutrophils and the lysosomes of monocytes. Two forms are recognized: cytoplasmic (C-ANCAs) and perinuclear (p-ANCAs). In patients with necrotizing vasculitis, most C-ANCAs are specific for proteinase 3 and most p-ANCAs are specific for myeloperoxidase. Antiendothelial cell antibodies have been detected in the sera of patients with systemic vasculitis, rheumatoid arthritis with vasculitis, microscopic polyangiitis, and Sneddon's syndrome.

An increased prevalence of the HLA haplotype HLA-A11, Bw35 in patients with CNV and associated connective tissue disorders suggests that genetic factors may be operative.

CLINICAL MANIFESTATIONS

The skin lesions of CNV are polymorphous; however, erythematous papules that do not blanch when the skin is pressed, which are known as *palpable purpura,* are the signature lesions (Fig. 175-1A). Macules, papules, urticaria/angioedema, pustules, vesicles, ulcers, necrosis, and livedo reticularis may be present. Occasionally, there is subcutaneous edema below the area of the dermal lesions.

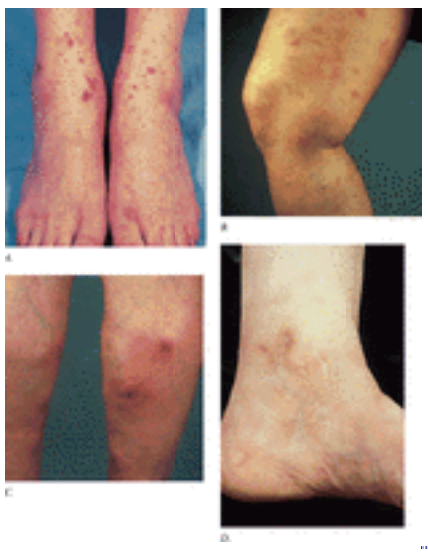

FIGURE 175-1 *A*. Palpable purpura over the feet and ankles of a patient with Henoch-Schönlein syndrome. *B*. Idiopathic urticarial vasculitis over the leg. *C*. Nodular vasculitis over the lower legs. Note ulcers. *D*. Atrophie blanche over the medial malleolus with atrophic areas, telangiectases, punctate ulcers, and hyperpigmentation.

The vascular eruption most often appears on the lower extremities or over dependent areas, such as the back and gluteal regions. The lesions may occur anywhere on the skin but are uncommon on the face, palms, soles, and mucous membranes. The clinical lesions are episodic and may recur over weeks to years. Palpable purpura persists for 1 to 4 weeks and resolves at times with transient hyperpigmentation and/or atrophic scars. Lesional symptoms include pruritus or burning and, less commonly, pain.

An episode of cutaneous vascular lesions may be attended by fever, malaise, arthralgias, or myalgias irrespective of a defined underlying or associated disease. Systemic involvement of the small blood vessels most commonly occurs in the synovia, gastrointestinal tract, voluntary muscles, peripheral nerves, and kidneys.

Associated Chronic Disorders

CNV is associated with connective-tissue diseases, notably rheumatoid arthritis, Sjögren's syndrome, systemic lupus erythematous (SLE), and hypergammaglobulinemic purpura. It rarely occurs in mixed connective-tissue disease, relapsing polychondritis, and scleroderma. In patients with rheumatoid arthritis and CNV, the development of vascular lesions is related to the severity of the disease, which is generally but not always seropositive. Subcutaneous nodules, as well as cutaneous ulcers, may be present. Patients with rheumatoid arthritis often have involvement of larger vessels with associated peripheral neuropathy, nail fold infarcts, and digital gangrene.

In patients with SLE, the vasculitis is associated with exacerbations of the underlying disease. Vasculitis, however, is rare in patients with subacute cutaneous lupus erythematosus. Approximately 5 percent of women with necrotizing vasculitis without connective-tissue disease have anti-Ro antibodies, and their infants may be born with neonatal lupus erythematosus. [7]

In patients with Sjögren's syndrome, the vascular lesions are located predominantly on the lower extremities and appear

after exercise. Both hyperpigmentation and cutaneous ulcers are common features. Hypergammaglobulinemic purpura occurs in older women and may be associated with Sjögren's syndrome, SLE, or a lymphoproliferative disorder. Dermatomyositis in children, but not in adults, may be associated with vasculitis of the gastrointestinal tract.

Paraneoplastic vasculitis is used to describe CNV with associated malignant conditions, including Hodgkin's disease, lymphosarcoma, adult T cell leukemia, mycosis fungoides, myelofibrosis, acute and chronic myelogenous forms of leukemia, IgA myeloma, diffuse large-cell leukemia, hairy-cell leukemia, squamous-cell bronchiogenic carcinoma, prostatic carcinoma, renal carcinoma, and colon carcinoma. However, the association between CNV and neoplasia is rare. It is not necessary to evaluate all patients with CNV for associated malignant conditions.

Cryoglobulins, especially mixed types II and III, may be found in patients with idiopathic CNV and in patients with CNV associated with connective-tissue diseases, lymphoproliferative disorders, and hepatitis A, B, and C virus infections, although hepatitis C virus is the most common infection. [8] CNV occurs in patients with cystic fibrosis, inflammatory bowel diseases of the colon, and Behçet's disease. [9]

Both ANCAs and antiphospholipid antibodies are associated with various forms of necrotizing vasculitis. ANCAs are present in patients with microscopic polyangiitis and cutaneous vasculitis with hepatitis C virus infection. The most common cutaneous feature in patients with ANCAs is palpable purpura. Microscopic polyangiitis is associated with small-vessel systemic vasculitis that involves the cutaneous venules and arterioles, kidneys with necrotizing and crescentic glomerulonephritis, and p-ANCAs. A male patient has experienced microscopic polyangiitis restricted to the skin and ANCAs for 20 years without progression to systemic vascular disease. [10]

Antiphospholipid antibodies, either anticardiolipin antibodies and/or lupus anticoagulant, occur in patients with autoimmune and connective-tissue diseases and as an idiopathic disorder. Livedo reticularis is the most frequently recognized cutaneous finding. [11] Antiphospholipid antibodies of the IgA class were detected in 6 of 10 patients with idiopathic cutaneous necrotizing vasculitis, and antiphospholipid antibodies have been detected in some individuals with livedoid vasculitis. [12] A female patient with antiphospholipid antibodies and cutaneous nodules that demonstrated vasculitis and thrombosis on biopsy has been reported.

Precipitating Infections and Drugs

Infections and drugs precipitate episodes of CNV. The most commonly recognized infectious agents are group A hemolytic streptococci, *Staphylococcus aureus, Mycobacterium leprae,* and hepatitis B and C viruses. Transient episodes of urticaria may occur early in the course of hepatitis B virus infection and represent immune complex–induced vasculitis; episodes of palpable purpura may occur in patients with chronic active hepatitis. Cutaneous vasculitis was identified in patients with hepatitis A and C infections. [13] Cutaneous vasculitis has been recognized in a limited number of individuals with HIV infection; the skin lesions consisted of palpable purpura, at times with a follicular localization, and cutaneous ulcers.

Erythema nodosum leprosum, which appears as cutaneous nodular lesions in lepromatous leprosy, is a form of necrotizing vasculitis involving capillaries, venules, arterioles, small-to- medium-sized arteries, and veins. The vascular lesions occur spontaneously or are precipitated by the administration of chemotherapeutic agents. They may be accompanied by fever, malaise, arthralgias, lymphadenopathy, and polyneuritis.

Necrotizing vasculitis caused by the direct invasion of the blood vessel wall occurs in *Neisseria meningitidis* bacteremia, in Rocky Mountain spotted fever, and in infections localized at the site of a catheter.

Palpable purpura is one of the less common forms of drug reactions. The most commonly incriminated therapeutic agents are penicillin, sulfonamides, thiazides, allopurinol, hydantoins, and nonsteroidal anti-inflammatory agents. Propylthiouracil [14] and hydralazine may cause vasculitis in association with ANCAs. Cutaneous vasculitis has occurred after the administration of streptokinase, radiocontrast media, monoclonal antibodies, granulocyte colony-stimulating factor, staphylococcal protein A column immunoadsorption therapy, drug additives, and etanercept. [15]

Idiopathic Disorders

HENOCH-SCHÖNLEIN SYNDROME The most widely recognized subgroup of idiopathic CNV is the *Henoch-Schönlein syndrome,* formerly known as anaphylactoid purpura. It occurs predominantly in children, with a peak incidence at 5 years of age, but it may occur in adults. [16] A history of a recent upper respiratory tract infection, especially streptococcal, is obtained in up to 75 percent of individuals; however, Henoch-Schönlein syndrome has been associated with other infections. Sites of involvement include the skin, synovia, gastrointestinal tract, and kidneys. Long-term morbidity from progressive renal disease occurs in 5 percent of patients. The spread of purpura to the upper parts of the trunk is a predictive factor for renal involvement. [16]

ACUTE HEMORRHAGIC EDEMA OF CHILDHOOD This uncommon disorder, which often goes unrecognized or has been confused with Henoch-Schönlein syndrome, affects infants and children younger than 2 years of age, but it has been reported in one adult. The lesions appear as painful, edematous petechiae and ecchymoses that affect the head and distal portions of the extremities. Facial edema may be the initial sign. The skin lesions may be associated with a target-like appearance and may develop bullae and necrosis. Infection, drugs, or immunization may be triggering factors. Acute hemorrhagic edema of childhood is distinguished from Henoch-Schönlein syndrome by its occurrence in children aged 4 months to 2 years, lack of systemic features, and resolution within 1 to 3 weeks without sequelae.

URTICARIAL VASCULITIS Episodes of recurrent and chronic urticaria and angioedema may be a clinical manifestation of CNV. [17], [18] Known as *urticarial vasculitis,* this edematous form of necrotizing venulitis occurs in patients with serum sickness, connective-tissue disorders, an IgM $_{K}$ M component, infections, and physical urticarias; after the administration of potassium iodide and nonsteroidal anti-inflammatory agents; and as an idiopathic disorder. Single case reports exist of

patients with urticarial vasculitis and colon carcinoma, IgA myeloma, polycythemia vera, [19] Muckle-Wells syndrome, and Cogan's syndrome. Infections include hepatitis B and C viruses and infectious mononucleosis. The term *hypocomplementemic urticarial vasculitis syndrome* has been used to describe patients with more severe systemic manifestations and an autoantibody to Clq. The skin lesions appear as erythematous, occasionally indurated, wheals that may contain foci of purpura (Fig. 175-1B). Other skin manifestations include angioedema, macular erythema, livedo reticularis, nodules, and bullae. Although the individual urticarial lesions may last for fewer than 24 h, they often persist for up to 3 to 5 days. The lesions are pruritic or possess a burning or painful quality; they usually resolve without residua, although some individuals may develop contusions or hyperpigmentation. The episodes of urticaria are chronic, range in duration from months to years, and vary in frequency. Approximately 70 percent of affected individuals are women. The prevalence of this disorder remains unknown. General features include fever, malaise, and myalgia; the lymph nodes, liver, and spleen may be enlarged (Table 175-2).

General features
Fever
Malaise
Myalgia
Specific organ involvement
Lymphadenopathy
Hepatosplenomegaly
Synovia (arthralgia, arthritis)
Kidneys (glomerulitis, glomerulonephritis)
Gastrointestinal tract (nausea, vomiting, pain, diarrhea)
Respiratory tract (laryngeal edema, shortness of breath, chronic obstructive pulmonary disease, and, less commonly, interstitial pulmonary disease)
Eyes (conjunctivitis, episcleritis, iridocyclitis, uveitis)
Central nervous system (headache, benign intracranial hypertension)

TABLE 175-2 **Extracutaneous Manifestations of Urticarial Vasculitis**

Episodic arthralgias are a major clinical manifestation and affect the elbows, wrists, fingers, knees, ankles, and toes. Arthritis with necrotizing venulitis apparent in biopsy specimens of the synovial tissue occasionally develops. Urticarial vasculitis is associated with Jaccoud's syndrome. [20] Renal involvement occurs as a diffuse glomerulitis or glomerulonephritis; however, progression to severe impairment of renal function is rare. Gastrointestinal tract manifestations include nausea, vomiting, diarrhea, and pain. Laryngeal edema may occur. Chronic obstructive pulmonary manifestations and less frequently interstitial lung disease may develop. Conjunctivitis, episcleritis, iridocyclitis, and uveitis develop in some individuals. Rarely, cardiac valvular involvement may occur. [21] There is one report of an individual becoming blind. Headaches and pseudotumor cerebri (benign intracranial hypertension) reflect central nervous system involvement. The natural history of urticarial vasculitis is unknown, although individuals have been described with historical episodes of cutaneous lesions for up to 25 years. In one series of patients followed for 1 year, 40 percent experienced complete resolution of skin lesions; in another series of individuals followed for as long as 14 years, resolution occurred in only one patient. Sjögren's syndrome and SLE have developed. Deaths have been reported from pulmonary disease, sepsis, and myocardial infarction. The prevalence of urticarial vasculitis in individuals with chronic idiopathic urticaria is unknown, although series have reported rates ranging from 1 percent to 50 percent. Most of these data have been reported from tertiary referral centers, and the prevalence is most likely less than 1 percent. Necrotizing vasculitis of cutaneous venules has been described in isolated instances of dermographism, cold urticaria, delayed pressure urticaria, solar urticaria, and exercise-induced urticaria. [3] However, the prevalence of necrotizing vasculitis in patients with physical urticaria is unknown, and the importance of this histologic finding for prognosis and therapy remains to be elucidated. Individuals with these physical urticarias have provided experimental models for time-course studies of the evolution of necrotizing vasculitis in human skin. *Schnitzler's syndrome* consists of episodes of urticarial vasculitis that occur in association with a monoclonal IgM $_K$ M component. Associated features include fever, lymphadenopathy, hepatosplenomegaly, bone pain with osteosclerosis, and a sensorimotor neuropathy. Evolution into a lymphoplasmacytic malignant condition has been reported in 15 percent of patients. [22]

ERYTHEMA ELEVATUM DIUTINUM *Erythema elevatum diutinum* (see Chap. 95) occurs as symmetric, persistent, red-purple or red-brown plaques that are predominantly disposed over the joints of extensor surfaces and over the gluteal area. Arthralgia of the associated joints may be a feature. Other systemic manifestations are lacking. A history of recurrent streptococcal infections is frequently obtained. This condition may be associated with IgA monoclonal gammopathy, multiple myeloma, B cell lymphoma, [23] myelodysplasia, celiac disease, relapsing polychondritis, and HIV infection. [24], [25]

NODULAR VASCULITIS *Nodular vasculitis* (Fig. 175-1C) appears as tender, red, subcutaneous nodules over the lower extremities, especially the calves, without systemic manifestations. At times, lesions may be develop on the thighs, buttocks, trunk, and arms, and ulcerated nodules are present. Recurrent episodes are common. It is more common in women and has a peak incidence in individuals between 30 and 40 years of age. *Erythema induratum* is a form of nodular vasculitis, that has been associated with *Mycobacterium tuberculosis* infection, as demonstrated by polymerase chain reaction (PCR) amplification for *M. tuberculosis* DNA in skin biopsy specimens. [26] Various sizes of blood vessels including venules are affected. [27]

LIVEDOID VASCULITIS *Livedoid vasculitis* (Fig. 175-1D), known also as livedoid vasculopathy, livedo vasculitis, segmental hyalinizing vasculitis, and atrophie blanche, occurs as recurrent, painful ulcers of the lower extremities in association with a persistent livedo reticularis (*livedo racemosa*) that often is deep purple in color. Healing results in sclerotic pale areas surrounded by telangiectases that are designated atrophie blanche. Many patients have arteriosclerosis or stasis of the lower extremities, and mononeuritis multiplex has been identified in a single patient. [28] Livedoid vasculitis is more common in women, may occur in patients with SLE who develop central nervous system features, and has been reported in two patients with protein C deficiency. [29] Atrophie blanche, however, probably represents the end stage of a variety of forms of vascular damage in the skin. Elevation of fibrinopeptide A levels may occur in blood. Pathogenesis has focused on a hypercoagulable state with fibrin thrombi in the lumens of the superficial blood vessels. Some consider this condition a thrombogenic vasculopathy rather than a small-vessel vasculitis. Antiphospholipid antibodies have been detected in a few individuals. [12] *Sneddon's syndrome* [30], [31] is a condition in which livedo reticularis and livedoid vasculitis are associated with ischemic cerebrovascular lesions, hypotension, and extracerebral arterial and venous thromboses. Antiendothelial cell antibodies were detected in the serum in 35 percent of individuals; antiphospholipid antibodies, anti–ß $_2$-glycoprotein antibodies, and antiprothrombin antibodies [32] were detected in some patients.

GENETIC COMPLEMENT DEFICIENCIES Genetic C2 deficiency has been recognized in association with CNV in three children, and a C4 deficiency was present in one child with CNV. Deficiencies of C4A and C4B isotypes were found in

some children and adults with Henoch-Schönlein syndrome. A partial C4B deficiency with C4 A1, A3, B1, and a null allele B*QO was reported in a 51-year-old woman with CNV. [33]

EOSINOPHILIC VASCULITIS Eosinophilic vasculitis has been described as an idiopathic syndrome in individuals with recurrent, pruritic, and purpuric papular skin lesions, urticarial plaques, and angioedema. Skin biopsy specimens showed an infiltrate composed of eosinophils expressing CD40 [34] and VCAM-1 on endothelial cells of involved vessels. Eosinophilic vasculitis also has been described in some individuals with a hypereosinophilic syndrome, [34] and in others with connective-tissue disorders. [35], [36]

IDIOPATHIC Individuals with CNV who do not meet the criteria for recognized syndromes are classified as idiopathic.

LABORATORY FINDINGS

The laboratory evaluation of patients with CNV depends on information obtained from the history and physical examination (Table 175-3). An elevated erythrocyte sedimentation rate is the most consistent abnormal laboratory finding. The platelet count is usually normal. Other abnormalities reflect either a coexistent chronic disorder or the involvement of additional organ systems. Occasionally, leukocytosis, anemia, thrombocytosis, an abnormal urine sediment, circulating immune complexes, rheumatoid factor, and antinuclear antibodies have been reported in idiopathic disease.

Erythrocyte sedimentation rate
White blood cell count with differential analysis
Platelet count
Urinalysis
24-Hour urine protein and creatinine clearance
Blood chemistry profile
Serum protein electrophoresis
Hepatitis B antigens and hepatitis A and C antibodies
Cryoglobulins
CH50
Antinuclear antibody
Rheumatoid factor
Antineutrophil cytoplasmic antibodies
Antiphospholipid antibodies
Circulating immune complexes
Skin biopsy

TABLE 175-3 **Laboratory Evaluation of Cutaneous Necrotizing Venulitis**

Serum complement levels are usually normal. Hypocomplementemia may develop in patients with concomitant connective tissue diseases or cryoglobulinemia and reflects the associated disease or the composition of the cryoglobulin. Hypocomplementemia also occurs in some individuals with idiopathic CNV and in 40 percent of individuals with urticarial vasculitis.

In some patients with the hypocomplementemic urticarial vasculitis syndrome, a low-molecular-weight 7s C1q precipitin, identified as an IgG autoantibody against the collagen-like region of C1q, was detected. The antigen-antibody interaction involves the $F(ab')_2$ fragment of IgG. Autoantibodies to vascular endothelial cells were detected in patients with the hypocomplementic urticarial vasculitis syndrome, in patients with SLE and urticarial vasculitis, and in patients with urticarial vasculitis alone. [37] In a single patient with Schnitzler's syndrome, autoantibodies against dermal microvascular endothelial cells, mast cells, and the FceRIa receptor were detected. [38] In Henoch-Schönlein syndrome, serum IgA_1 levels are elevated. In patients with CNV, various types of circulating immune complexes and IgA ANCAs [39] have been described. IgG autoantibodies against IgE also have been identified in four of eight patients with urticarial vasculitis.

PATHOLOGY

In skin biopsy specimens of palpable purpura and urticarial vasculitis stained with hematoxylin and eosin (H&E) (Fig. 175-2A), the histologic criteria requisite for the diagnosis of CNV include necrosis of the blood vessels with the deposition of fibrinoid material and dermal cellular infiltrates that consist of neutrophils with nuclear debris, mononuclear cells, and extravasated erythrocytes. The dermal inflammatory infiltrates vary in intensity and are usually perivenular in location but at times are dispersed widely. The fibrinoid material consists of fibrin, necrotic endothelial cells, and deposited immunoreactants.

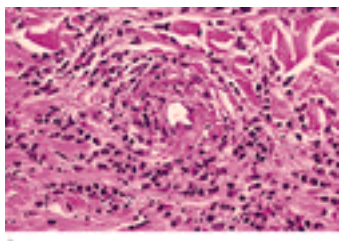

FIGURE 175-2 *A*. Perivenular infiltrate of neutrophils with fibrin deposition. H&E stain, ×50 in the original magnification. *B*. Endothelial cell necrosis of venule with perivenular fibrin and neutrophils. 1-µm section, Giemsa stain, ×1000 in the original magnification.

Studies with 1-µm-thick sections (Fig. 175-2B) show two distinct cellular patterns in CNV: one rich in neutrophils and the other in lymphocytes. Neither pattern appears to be the result of evolution of the tissue changes associated with the dynamic nature of the cellular infiltrate. Although the infiltrate of neutrophils regresses with the persistence of an infiltrate of mononuclear cells, repeat biopsy specimens in some patients consistently demonstrated an infiltrate of mononuclear cells. In a time-course study over 6 days of the evolution of experimentally induced CNV in a patient with physical urticarias, the number of infiltrating neutrophils decreased without a concomitant increase in lymphocytes, although the number of monocyte-macrophages was increased at 48 and 72 h. Other features in both cell patterns of CNV include hypogranulated mast cells, macrophages containing debris, and the perivenular and interstitial deposition of fibrin. Venular alterations in both cell patterns consist of endothelial cell swelling, activation of nuclei, wrinkling of nuclear membranes, necrosis (Fig. 175-2B), and basement membrane reduplication and thickening. The arterioles are not affected. Some patients with connective-tissue disorders and cutaneous vasculitis have an infiltrate of inflammatory cells composed of eosinophils with deposited major basic protein and decreased numbers of mast cells. [35]

By direct immunofluorescence techniques, fibrin deposition in venules is routinely identified in biopsy specimens, whereas the deposition of immunoglobulins and complement proteins varies widely. IgG is the most commonly deposited immunoglobulin, although IgM and IgA also have been detected. IgA is deposited about blood vessels in the skin, intestines, and kidneys in the Henoch-Schönlein syndrome and has become an immunopathologic marker of this condition. In the skin in Henoch-Schönlein syndrome, IgA_1 is the dominant subclass deposited. [40] C3 is the only complement protein that has been sought with frequency.

Biopsy specimens of the acute lesions of erythema elevation diutinum exhibit necrotizing venulitis with neutrophil infiltration, dermal expression of CR3 and LFA-1, and increased numbers of mast cells; [41] specimens of the chronic lesions exhibit fibrosis and an infiltrate containing macrophages. [42]

DIAGNOSIS AND DIFFERENTIAL DIAGNOSIS

Thrombocytopenia may result in purpura; however, these lesions are flat. Other causes of nonpalpable cutaneous purpura include local trauma to the skin of aged individuals with vascular fragility, chronic sun exposure, and endogenous or iatrogenic hypercorticism. Erythema elevatum diutinum may resemble Kaposi's sarcoma. Scurvy may appear as hemorrhagic, follicular papules over the lower extremities. Various infectious agents may be associated with hemorrhagic skin lesions that arise from disseminated intravascular coagulation or septic emboli. The cutaneous manifestations of disseminated intravascular coagulation, known as *purpura fulminans,* appear as extensive areas of purpura with a slate-gray color. These lesions occur in patients with acute meningococcemia; skin biopsy specimens show thrombosis but not necrotizing venulitis. Septic emboli occur as finite numbers of hemorrhagic pustules, papules, and vesicles distributed over acral areas. Rarely, echo and coxsackie virus infections may cause purpuric papules. Rocky Mountain spotted fever typically begins as purpuric papules over the ankles and wrists that spread to include the trunk. Cholesterol embolization includes purpura, livedo reticularis, ulcers, and nodules.

The progressive pigmentary purpuric dermatoses (purpura simplex) (see Chap. 176), which include a number of disorders, appear as macular, petechial, pigmented, or lichenoid lesions.

The differential diagnosis of cutaneous nodules includes erythema nodosum, panniculitis, superficial forms of thrombophlebitis, fat necrosis associated with pancreatic disease, and systemic vasculitides, such as polyarteritis nodosa, Wegener's granulomatosis, and Churg-Strauss syndrome.

TREATMENT

Therapeutic approaches may be divided into removal of the antigen, treatment of an underlying disease, and treatment of CNV. Treatment of necrotizing vasculitis consists of prevention of the deposition of immune complexes, suppression of the inflammatory response, modulation of underlying immunopathologic mechanisms, and local therapy. When the eruption is associated with a precipitating event, withdrawal of the medication or treatment of the infection results in resolution of the cutaneous lesions. If a coexistent chronic disease is present, treatment of the underlying disease may be associated with improvement in the cutaneous vascular lesions. In many cases, CNV is a self-limited condition, and double-blind, placebo-controlled, prospective trials of therapeutic agents are usually lacking.

The treatment of CNV can be divided into two phases (Table 175-4), each of which depends on an analysis of the cutaneous disability as well as the toxicity and side effects of the therapeutic agents. H_1 antihistamines are used in patients with palpable purpura to alleviate lesional symptoms and perhaps to reduce tissue deposition of circulating immune complexes. Nonsteroidal anti-inflammatory agents are combined with the H_1 antihistamine. Depending on the therapeutic response, colchicine or hydroxychloroquine sulfate can be added to or substituted for these agents. However, colchicine was shown to have no significant therapeutic effect in a prospective, randomized, controlled trial. If there is no benefit, dapsone can be used. If there still is no therapeutic response, a major decision must be made because the medications to be considered in the second phase (systemic glucocorticoids, azathioprine, methotrexate, cyclophosphamide, plasmapheresis, cyclosporine, [43] and intravenous immunoglobulin [44]) are associated with more serious side effects. Although all of these agents have been reported to benefit some patients, controlled clinical trials are not available. The administration of interferon-a is associated with clearing of cutaneous vasculitis in patients with hepatitis C virus infection.

Phase one
H_1 antihistamines
Nonsteroidal anti-inflammatory agents
Colchicine
Hydroxychloroquine sulfate
Dapsone
Phase two
Systemic glucocorticoids
Azathioprine
Cyclophosphamide
Intravenous gamma globulin
Cyclosporine
Plasmapheresis

TABLE 175-4 **Algorithm for Treatment of Cutaneous Necrotizing Venulitis**

The treatment of urticarial vasculitis is similar to that of palpable purpura. Additional case reports exist on the treatment of patients with intramuscular gold therapy, cyclophosphamide-dexamethasone pulse therapy, [45] mycophenolate mofetil, [46] and psoralen plus ultraviolet A (PUVA) photochemotherapy. [47]

In patients with erythema elevatum diutinum, dapsone is the drug of choice. Plasma exchange plus chlorambucil was a successful treatment for one individual with erythema elevatum diutinum and a monoclonal IgA paraprotein. [48] The treatment of nodular vasculitis consists of empiric trials of a variety of therapeutic agents that include a saturated solution of potassium iodide, nonsteroidal anti-inflammatory drugs, colchicine, and systemic glucocorticoids. Thalidomide is the treatment of choice for erythema nodosum leprosum.

In the treatment of livedoid vasculitis, support stockings are useful. Empiric trials of aspirin and dipyridamole, colchicine, dapsone, danazol, [49] low-dose heparin, systemic glucocorticoids, nicotinic acid, low-molecular-weight dextran, phenformin and ethylestrenol, nifedipine, and pentoxifylline are used. Infusions of prostacyclin, prostaglandin E_1, and intravenous immunoglobulin [50] have been used successfully in one patient each.

REFERENCES

1. Banno S et al: Apoptotic cell death of neutrophils in development of skin lesions of patients with anaphylactoid purpura. *J Dermatol* **24**:94, 1997

2. Campanile G et al: Gamma/delta T lymphocytes in cutaneous necrotizing vasculitis. *Int Angiol* **14**:119, 1995

3. Kano Y et al: Cellular and molecular dynamics in exercise-induced urticarial vasculitis lesions. *Arch Dermatol* **134**:62, 1998

4. Sais G et al: Adhesion molecule expression and endothelial cell activation in cutaneous leukocytoclastic vasculitis: An immunohistologic and clinical study of 42 patients. *Arch Dermatol* **133**:443, 1997

5. Besbas N et al: Thrombomodulin, tissue plasminogen activator, and plasminogen activator inhibitor-1 in Henoch-Schönlein purpura. *Clin Exp Rheumatol* **16**:95, 1998

6. Prandota J et al: Impaired activation of the fibrinolytic system in children with Henoch-Schönlein purpura: Beneficial effect of hydrocortisone plus Sigma-aminocaproic acid therapy on disappearance rate of cutaneous vasculitis and fibrinolysis. *Am J Ther* **8**:11, 2001

7. Borrego L et al: Neonatal lupus erythematosus related to maternal leukocytoclastic vasculitis. *Pediatr Dermatol* **14**:221, 1997

8. Trejo O et al: Cryoglobulinemia: Study of etiologic and clinical and immunologic features in 443 patients from a single center. *Medicine (Baltimore)* **80**:252, 2001

9. Chen K-R et al: Cutaneous vasculitis in Behçet's disease: A clinical and histopathologic study of 20 patients. *J Am Acad Dermatol* **36**:689, 1997

10. Irvine AD et al: Microscopic polyangiitis: Delineation of a cutaneous-limited variant associated with antimyeloperoxidase autoantibody. *Arch Dermatol* **133**:474, 1997

11. Nahass GT: Antiphospholipid antibodies and the antiphospholipid antibody syndrome. *J Am Acad Dermatol* **36**:149, 1997

12. Acland KM et al: Livedoid vasculitis: A manifestation of antiphospholipid syndrome? *Br J Dermatol* **140**:131, 1999

13. Abe Y et al: Leukocytoclastic vasculitis associated with mixed cryoglobulinaemia and hepatitis C infection. *Br J Dermatol* **136**:272, 1997

14. Chastain MA et al: Propylthiouracil hypersensitivity: Report of two patients with vasculitis and review of the literature. *J Am Acad Dermatol* **41**:757, 1999

15. Galaria NA et al: Leukocytoclastic vasculitis due to etanercept. *J Rheumatol* **27**:2041, 2000

16. Tancrede-Bohin E et al: Schönlein-Henoch purpura in adult patients: Predictive factors for IgA glomerulonephritis in a retrospective study of 57 cases. *Arch Dermatol* **133**:438, 1997

17. Soter NA: Urticarial venulitis. *Derm Ther* **13**:400, 2000

18. Davis MDP et al: Clinicopathologic correlation of hypocomplementemic and normocomplementemic urticarial vasculitis. *J Am Acad Dermatol* **38**:899, 1998

19. Farell AM et al: Urticarial vasculitis associated with polycythaemia rubra vera. *Clin Exp Dermatol* **21**:302, 1996

20. Ishikawa O et al: Hypocomplementaemic urticarial vasculitis associated with Jaccoud's syndrome. *Br J Dermatol* **137**:804, 1997

21. Hong L et al: Atypical fatal hypocomplementemic urticarial vasculitis with involvement of native and homograft aortic valves in an African American man. *J Allergy Clin Immunol* **106**:1196, 2000.

22. Lipsker D et al: The Schnitzler syndrome: Four new cases and review of the literature. *Medicine (Baltimore)* **80**:37, 2001

23. Futei Y, Konohana Z: A case of erythema elevatum diutinum associated with B-cell lymphoma: A rare distribution involving palms, soles

and nails. *Br J Dermatol* **142**:116, 2000

24. Dronda F et al: Erythema elevatum diutinum in human immunodeficiency virus-infected patients: Report of a case and review of the literature. *Clin Exp Dermatol* **21**:222, 1996

25. Muratori S et al: Erythema elevatum diutinum and HIV infection: A report of five cases. *Br J Dermatol* **141**:335, 1999

26. Baselga E et al: Detection of *Mycobacterium tuberculosis* DNA in lobular granulomatous panniculitis (erythema induratum-nodular vasculitis). *Arch Dermatol* **133**:457, 1997

27. Schneider JW, Jordaan HF: The histopathologic spectrum of erythema induratum of Bazin. *Am J Dermatopathol* **19**:323, 1997

28. Lee S-S, Yoon T-Y: Sensory perineuritis presented as a mononeuritis multiplex associated with livedo vasculitis. *Clin Neurol Neurosurg* **103**:56, 2001

29. Boyvat A et al: Livedoid vasculopathy associated with heterozygous protein C deficiency. *Br J Dermatol* **143**:840, 2000

30. Matsumura Y et al: Sneddon syndrome with multiple cerebral infarctions 12 years after the onset of livedo vasculitis: A possible involvement of platelet activation. *J Dermatol* **28**:508, 2001

31. Frances C et al: Sneddon syndrome with or without antiphospholipid antibodies: A comparative study in 46 patients. *Medicine (Baltimore)* **78**:209, 1999

32. Kalashnikova LA et al: Antibodies to prothrombin in patients with Sneddon's syndrome. *Neurology* **53**:223, 1999

33. Lilic D, Carmichael AJ: Cutaneous vasculitis with partial C4 deficiency responsive to dapsone. *Br J Dermatol* **137**:476, 1997

34. Jang K-A et al: Hypereosinophilic syndrome presenting as cutaneous necrotizing eosinophilic vasculitis and Raynaud's phenomenon complicated by digital gangrene. *Br J Dermatol* **143**:641, 2000

35. Chen K-R et al: Eosinophilic vasculitis in connective tissue disease. *J Am Acad Dermatol* **35**:173, 1996

36. Yomoda M et al: Cutaneous eosinophilic vasculitis associated with rheumatoid arthritis. *Br J Dermatol* **140**:745, 1999

37. D'Cruz DP et al: Autoantibodies in systemic lupus erythematosus and urticarial vasculitis. *J Rheumatol* **22**:1669, 1995

38. Sperr WR et al: Autoantibody reactivity in a case of Schnitzler's syndrome: Evidence for a Th1-like response and detection of 1gG2 anti-Fc epsilon RI alpha antibodies. *Int Arch Allergy Immunol* **122**:279, 2000

39. Rovel-Guitera P et al: IgA antineutrophil cytoplasmic antibodies in cutaneous vasculitis. *Br J Dermatol* **143**:99, 2000

40. Egan CA et al: IgA1 is the major IgA subclass in cutaneous blood vessels in Henoch-Schönlein purpura. *Br J Dermatol* **141**:859, 1999

41. Grabbe J et al: Erythema elevatum diutinum—Evidence for disease-dependent leukocyte alterations and response to dapsone. *Br J Dermatol* **143**:415, 2000

42. Sangüeza OP et al: Erythema elevatum diutinum: A clinicopathological study of eight cases. *Am J Dermatopathol* **19**:214, 1997

43. Tosca AD et al: Cyclosporin A in the treatment of cutaneous vasculitis: Clinical and cellular effects. *J Eur Acad Dermatol Venereol* **6**:135, 1996

44. Ong CS, Benson EM: Successful treatment of chronic leukocytoclastic vasculitis and persistent ulceration with intravenous immunoglobulin. *Br J Dermatol* **143**:445, 2000

45. Worm M et al: Hypocomplementaemic urticarial vasculitis: Successful treatment with cyclophosphamide-dexamethasone pulse therapy. *Br J Dermatol* **139**:704, 1998

46. Worm M et al: Mycophenolate mofetil is effective for maintenance therapy of hypocomplementaemic urticarial vasculitis. *Br J Dermatol* **143**:1324, 2000

47. Cianchini G et al: Efficiency of psoralen-UV-A therapy in 3 cases of Schnitzler syndrome. *Arch Dermatol* **137**:1536, 2001

48. Chow RKP et al: Erythema elevation diutinum associated with IgA paraproteinemia successfully controlled with intermittent plasma exchange. *Arch Dermatol* **132**:1360, 1996

49. Hsiao GH, Chiu HC: Livedoid vasculitis: Response to low-dose danazol. *Arch Dermatol* **132**:749, 1996

50. Amital H et al: Use of intravenous immunoglobulin in livedo vasculitis. *Clin Exp Rheumatol* **18**:404, 2000

T>

Chapter 176

Theresa Schroeder

Pigmented Purpuric Dermatoses

PROGRESSIVE PIGMENTARY DERMATOSIS (SCHAMBERG'S DISEASE)
PURPURA ANNULARIS TELANGIECTODES (MAJOCCHI'S PURPURA)
PIGMENTED PURPURIC LICHENOID DERMATOSIS (GOUGEROT AND BLUM)
ECZEMATID-LIKE PURPURA OF DOUCAS AND KAPETANAKIS
ITCHING PURPURA (DISSEMINATED PRURIGINOUS ANGIODERMATITIS)
LICHEN AUREUS (LICHEN PURPURICUS)
UNILATERAL LINEAR CAPILLARITIS
GRANULOMATOUS PIGMENTED PURPURA
HISTOPATHOLOGY
PATHOGENESIS
DIAGNOSTIC STUDIES
DIFFERENTIAL DIAGNOSIS
MANAGEMENT

REFERENCES

The pigmented purpuric eruptions are a group of dermatoses characterized by petechiae, pigmentation, and occasionally telangiectasia in the absence of associated venous insufficiency or hematologic disorders (see Table 176-1). Synonyms include *persistent pigmented purpuric dermatitis, purpura simplex,* and *purpura pigmentosa chronica*. They are found most commonly on the lower extremities; however, the lesions may involve the upper body and rarely become generalized. There are reports of palm, sole, and oral mucosal involvement. Although most common in men, they also occur in women and children. These benign, generally asymptomatic eruptions tend to be chronic with remissions and flares. They share common histopathologic features including perivascular lymphocytic inflammation, erythrocyte extravasation, and hemosiderin deposition.

TABLE 176-1 **Pigmented Purpuric Eruptions**

Despite the similarity in histopathology, the clinical variation among these processes led to the subclassification of pigmented dermatoses into eponymic groups. Although there is some clinical variation between the groups, there is also frequent overlap, which may make differentiation difficult. These subgroups are more of historical interest than clinical usefulness. It is especially important to distinguish the pigmented purpuric eruptions from the types of purpura associated with systemic disease.

PROGRESSIVE PIGMENTARY DERMATOSIS (SCHAMBERG'S DISEASE)

Schamberg first described a macular pigmented eruption on the legs of a 15-year-old boy in 1901. The patient had irregularly shaped reddish-brown patches with “pinhead sized reddish puncta, closely resembling grains of cayenne pepper.” [1]

Although the first case was described in a teenager, the average age of onset of Schamberg's disease is in the fifth decade. The lesions tend to develop insidiously on either or both lower legs. Lesions can involve the trunk or the upper extremities (Fig. 176-1 and Fig. 176-2). Schamberg's disease is generally asymptomatic and persistent. Remissions and flares can occur indefinitely.

FIGURE 176-1 Schamberg's disease.

FIGURE 176-2 “Cayenne pepper” appearance of Schamberg's disease. (*Courtesy of S. Mallory, MD.*)

PURPURA ANNULARIS TELANGIECTODES (MAJOCCHI'S PURPURA)

The original case described by Majocchi, in 1896, was a 21-year-old man with annular patches of follicular and punctate reddish-brown macules, with telangiectasias and purpura on the lower extremities. [2] The annular pattern is the distinctive characteristic of this subtype (Fig. 176-3). The individual lesions may have central hypopigmentation and slight atrophy, with peripheral telangiectasias. Linear and irregularly shaped patterns may also occur. The lesions most often present symmetrically on the lower extremities; however, the upper extremities and trunk may be involved. The lesions are asymptomatic and usually last several months with relapses and remissions. This subtype occurs more commonly in young adult females.

FIGURE 176-3 Purpura annularis telangiectodes (Majocchi's purpura).

PIGMENTED PURPURIC LICHENOID DERMATOSIS (GOUGEROT AND BLUM)

In 1925, Gougerot and Blum reported a pigmented eruption on the lower extremity of a 41-year-old male. [3] They described the lesions as orange-red, individual and grouped, papules. The distinguishing feature of this subtype is the primary lesion, a reddish-brown polygonal or round lichenoid papule, sometimes with telangiectasia (Fig. 176-4). Individual papules frequently coalesce into plaques with or without overlying scale. The term *lichenoid* describes the clinical appearance rather than a histologic feature. The color and morphology of the lesions can be mistaken clinically for Kaposi's sarcoma (Fig. 176-4). Like the other subtypes, this eruption is found on the lower extremities and occasionally the arms. It occurs in males more often than females, and has a chronic course.

FIGURE 176-4 Lichenoid dermatosis of Gougerot and Blum. (*Courtesy of S. Mallory, MD.*)

ECZEMATID-LIKE PURPURA OF DOUCAS AND KAPETANAKIS

Doucas and Kapetanakis reported a group of patients with an asymptomatic seasonal eruption occurring in the spring-summer. [4] Its distinguishing quality was the mild scale overlying the typical patches and pinpoint erythematous macules. These spread rapidly over a period of 15 to 30 days, involving the legs and, occasionally, the upper body. This eruption fades without treatment over several months to years.

ITCHING PURPURA (DISSEMINATED PRURIGINOUS ANGIODERMATITIS)

The acute onset and widespread involvement of orange-brown to purpuric macules with severe pruritus distinguishes this eruption (Fig. 176-5). It usually appears first on the lower extremities and may become generalized (Fig. 176-5). This disorder has a chronic course, but there can be spontaneous remissions. Middle-aged men are most commonly affected.

FIGURE 176-5 Disseminated pruriginous angiodermatitis (itching purpura). (*Courtesy of S. Mallory, MD.*)

LICHEN AUREUS (LICHEN PURPURICUS)

Marten first coined the term “lichen purpuricus” in 1958, [5] and Calnan later termed the same eruption “lichen aureus.” [6] In this condition, lichen refers to both the clinical and histopathologic descriptions. There is a bandlike dermal inflammatory infiltrate that accompanies the typical pathology of the pigmented purpuras. Clinically, there are circumscribed areas of confluent gold to copper-orange to purple macules or papules (Fig. 176-6). Although these lesions may be intensely pruritic they are typically asymptomatic. They are most commonly unilateral and localized on the lower extremities, but they can affect the forearms and trunk. This disorder has a predilection for young adults with a peak incidence in the second and third decades. The lesions tend to be chronic, remaining stable or progressing slowly. Spontaneous resolution rarely occurs in adults, but in children the eruption may be self-limited.

FIGURE 176-6 Lichen aureus. (*Courtesy of S. Mallory, MD.*)

UNILATERAL LINEAR CAPILLARITIS

Riordan et al. reported a linear and pseudodermatomal distribution of pigmented purpura in four young males (average age 22 years). [7] The four patients all had a macular, pigmented unilateral eruption involving the foot, leg, or buttock. Clinically, the lesions most closely represented lichen aureus; however, the pathology did not show a lichenoid infiltrate. Furthermore, all four cases resolved spontaneously in approximately 2 years, unlike the typically chronic course of lichen aureus. There are also reported cases of segmental or zosteriform lichen aureus. [8] A similar segmental pattern was described in a 48-year-old woman involving the right lower extremity and lower trunk. The clinical description of this case was that of “numerous punctate purpuric and ‘cayenne pepper’ spots most suggestive of Schamberg's disease.” [9]

GRANULOMATOUS PIGMENTED PURPURA

Saito and Matsuoka reported a granulomatous variant of pigmented purpuric dermatosis in 1996, [10] and Wong reported two additional cases. [11] The mean age of onset was 59 years; all patients were of Asian descent and all lesions occurred only on the dorsum of the feet. Histopathologic examination showed a dense mononuclear cell infiltrate with granulomas in the papillary dermis, thickened capillaries, and hemosiderin deposits. The duration of the lesions ranged from 2 months to 20 years.

HISTOPATHOLOGY

The pigmented purpuric dermatoses share similar histopathology. In early lesions, a lymphocytic perivascular infiltrate is found in the papillary dermis with extravasated erythrocytes (Fig. 176-7). The epidermis may show spongiosis or parakeratosis, especially in the pigmented purpuric lichenoid dermatitis of Gougerot-Blum and in the eczematid-like purpura of Doucas and Kapetanakis. In older lesions, there is less inflammation and extravasated red blood cells may no

longer be present. Hemosiderin is deposited primarily in macrophages. In lichen aureus, the mononuclear infiltrate in the upper dermis is distributed in a bandlike fashion with a Grenz zone.

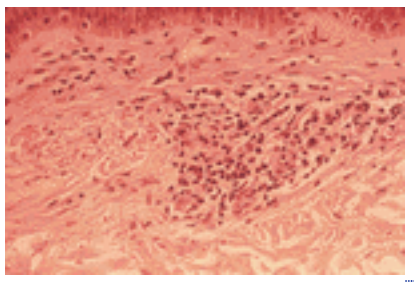

FIGURE 176-7 Pigmented purpuric dermatosis showing superficial perivascular lymphocytes and extravasated erythrocytes.

PATHOGENESIS

There are three different views to the pathogenesis of these processes. The first is a disturbance or weakness of the cutaneous blood vessels leading to capillary fragility and erythrocyte extravasation. However, this does not account for the inflammatory infiltrate common to these disorders. The second mechanism is humoral immunity. This suggested pathogenesis is supported by direct immunofluorescent studies showing vascular deposition of C3, C1q, IgM, or IgA. However, several cases have not shown these deposits. The third proposed mechanism is cellular immunity. The infiltrate in pigmented purpuric dermatoses consists of lymphocytes, macrophages, and Langerhans cells. This inflammatory infiltrate leads to vascular fragility and subsequent leakage of erythrocytes. Aiba and Tagami [12] used immunohistologic studies in eight cases of Schamberg's disease to demonstrate that the dermal infiltrate was predominantly composed of helper-inducer T cells and OKT6-reactive cells, whereas the epidermis showed intercellular staining with human leukocyte antigen (HLA)-DR antibody and OKT6 antibody. Based on this study, they concluded that a cellular immune reaction, specifically the Langerhans cell, likely plays an important role in the pathogenesis.

The mechanism behind drug-induced or other secondary causes may be immune-mediated, but this is unproven. Gravity and increased venous pressure may account for the lesions localizing to the lower extremities.

DIAGNOSTIC STUDIES

Diagnosis is generally made clinically and supported by histopathologic examination. No consistent laboratory abnormalities have been identified. The clinical measurement of capillary fragility by application of a sphygmomanometer (Hess test) does not appear to be reliable because some reports show an increased capillary fragility in pigmented purpuric eruptions, and others were negative. Because secondary causes may be reversible, review of the patient's medical history, medications, and potential contact allergens is advised. Skin biopsy to rule out vasculitis is especially helpful if the lesions are papular.

DIFFERENTIAL DIAGNOSIS

Table 176-2 shows the differential diagnosis.

Secondary Causes
Drug-induced[1–11]
Thiamine
Carbutamide
Carbromal
Meprobamate
Carbamazepine
Clipizide
Nitroglycerin
Chlordiazepoxide
Furosemide
Trichlomethiazide
Topical fluorouracil
Acetaminophen
Medroxyprogesterone acetate
Contact dermatitis[14–19]
Disperse dyes
Paraphenylenediamine
Black rubber
Cobalt
Benzoyl peroxide
Epoxy resin
Methylmethacrylate
EMLA
Venous stasis/hemangiodermatitis
Step aerobics
Rheumatoid arthritis
Diabetes mellitus
Benign hypergammaglobulinemic purpura (of Waldenstrom)/ dysproteinemic purpura
Hodgkin's disease
Polycythemia
Purpuric mycosis fungoides[1,17]
Vasculitis/Palpable purpura
Hypersensitivity vasculitis/necrotizing venulitis
Henoch-Schönlein purpura
Vascular Tumors
Angioma serpiginosum
Kaposi's sarcoma (especially versus Gougerot-Blum)

TABLE 176-2 **Differential Diagnosis of Pigmented Purpuric Dermatosis**

MANAGEMENT

Treatment is often ineffective. Discontinuation of the causative drug or contact allergen can lead to complete resolution; however, residual pigmentation may persist for years. Oral bioflavonoid (rutoside 50 mg bid) and ascorbic acid (500 mg bid) given to three patients with chronic pigmented purpura in an open trial led to clearance in all three patients within 4 weeks. [23] Corticosteroids have been reported to be effective, in particular triamcinolone spray or potent topical (fluorinated) steroids. Systemic corticosteroids may also be effective, but are not indicated due to the benign nature of the disorder. With both topical and systemic steroids, recurrence of the lesions is the rule if discontinued. Cyclosporin and griseofulvin are other systemic agents with reported success. [24], [25] PUVA has induced resolution of lesions in some

cases. The PUVA-induced immunosuppression of cell-mediated response is the proposed mechanism. [26]

REFERENCES

1. Schamberg JF: A peculiar progressive pigmentary disease of the skin. *Br J Dermatol* **13**:1, 1901

2. Majocchi D: Sopra una dermatosi telangiectode non ancora descritta “purpura annularis.” *G Ital Mal Ven* **31**:263, 1896

3. Gougerot H, Blum P: Purpura angiosclereux prurigineux avec elements lichenoides. *Bull Soc Franc Derm Syph* **32**:161, 1925

4. Doucas C, Kapetenakis J: Eczematid-like purpura. *Dermatologica* **106**:86, 1953

5. Marten RH: Case for diagnosis. *Trans St. John's Hosp Dermatol Soc* **40**:98, 1958

6. Calnan CD: Lichen aureus. *Br J Dermatol* **72**:373, 1960

7. Riordan CA et al: Unilateral linear capillaritis. *Clin Exp Dermatol* **17**:182, 1992

8. Ruiz-Esmenjaud JDM: Segmental lichen aureus: Onset associated with trauma and puberty. *Arch Dermatol* **124**:1572, 1988

9. Higgins EM, Cox NH: A case of quadrantic capillaropathy. *Dermatologica* **180**:93, 1990

10. Saito R, Matsuoka Y: Granulomatous pigmented purpuric dermatosis. *J Dermatol* **23**:551, 1996

11. Wong WR et al: Granulomatous variant of chronic pigmented purpuric dermatosis: Report of two cases. *Br J Dermatol* **145**:162, 2001

12. Aiba S, Tagami H: Immunohistologic studies in Schamberg's disease: Evidence for cellular immune reaction in lesional skin. *Arch Dermatol* **124**:1058, 1988

13. Nishioka K et al: Drug-induced chronic pigmented purpura. *J Dermatol* **16**:220, 1989

14. Adams BB, Gadenne AS: Glipizide-induced pigmented purpuric dermatosis. *J Am Acad Dermatol* **41**:827, 1999

15. Tsao H, Lerner LH: Pigmented purpuric eruption associated with injection medroxyprogesterone acetate. *J Am Acad Dermatol* **43**:308, 2000

16. Komericki P et al: Pigmented purpuric contact dermatitis from Disperse Blue 106 and 124 dyes. *J Am Acad Dermatol* **45**:456, 2001

17. Foti C et al: Purpuric clothing dermatitis due to Disperse Yellow 27. *Contact Dermatitis* **39**:273, 1998

18. Koch P et al: Purpuric patch test reaction and venulitis due to methyl methacrylate in a dental prosthesis. *Contact Dermatitis* **34**:213, 1996

19. De Waard-van der Spek FB, Oranje AP: Purpura caused by EMLA is of toxic origin. *Contact Dermatitis* **34**:213, 1996

20. Van Joost T et al: Purpuric contact dermatitis to benzoyl peroxide. *Contact Dermatitis* **22**:359, 1990

21. Martinez W et al: Cutaneous T-cell lymphoma presenting as disseminated, pigmented, purpura-like eruption. *Int J Dermatol* **40**:140, 2001

22. Toro JR et al: Persistent pigmented purpuric dermatitis and mycosis fungoides: Stimulant, precursor, or both? A study by light microscopy and molecular methods. *Am J Dermatopathol* **19**:108, 1997

23. Reinhold U et al: Treatment of progressive pigmented purpura with oral bioflavonoids and ascorbic acid: An open pilot study in 3 patients. *J Am Acad Dermatol* **41**:207, 1999

24. Okada K et al: Purpura pigmentosa chronica successfully treated with oral cyclosporin A. *Br J Dermatol* **134**:180, 1996

25. Tamaki K et al: Successful treatment of pigmented purpuric dermatosis with griseofulvin. *Br J Dermatol* **132**:159, 1995

26. Ling TC et al: PUVA therapy in lichen aureus. *J Am Acad Dermatol* **45**:145, 2001

T>

Chapter 177

Lynn Cornelius Thomas Lawley

Cryoglobulinemia and Cryofibrinogenemia

CRYOGLOBULINEMIA
Historical Aspects
Etiology and Pathogenesis
Isolation and Typing Techniques
Cryoglobulin Characteristics
Pathophysiology
Clinical Manifestations (Table 177-2)
Associated Diseases (Table 177-3)
Treatment
CRYOFIBRINOGENEMIA

REFERENCES

CRYOGLOBULINEMIA

Cryoglobulins are circulating immunoglobulins complexed with other immunoglobulins or proteins that reversibly precipitate in the cold. The symptoms of type I cryoglobulinemia are caused by vascular occlusion resulting from protein precipitation; mixed cryoglobulinemia (type II or III) is an immune complex disease. Cryoglobulins may be associated with a wide spectrum of infections, connective tissue diseases, and malignancies. “Essential” mixed cryoglobulinemia describes those cases in which no underlying disease association is found; before the recognition of the association of hepatitis C virus (HCV) infection with mixed cryoglobulinemia, this classification accounted for a large percentage of cryoglobulinemia cases.

Historical Aspects

The existence of cryoproteinemia as a clinical entity was first noted by Wintrobe and Buell in 1933. [1] The immunoglobulin composition of these cryoproteins was recognized by Waldenstrom in 1943. [2] The first large-scale examination of pathologic sera for cryoglobulins found them in 11 percent of the sera examined. [3] A recent series detected cryoglobulins in 6 percent of hospital patients screened in a single center in Spain. [4] Cryoglobulins have also been detected in the sera of less than 3 percent of “healthy” blood donors. [5]

Etiology and Pathogenesis

Cryoglobulinemia is classified in three distinct groups, types I, II, and III, initially described by Brouet et al. [6] based on immunoglobulin type (Table 177-1). Type I cryoglobulins consist of a single monoclonal immunoglobulin, typically an IgG or an IgM. Patients with type I cryoglobulinemia usually have an underlying hematologic malignancy, such as multiple myeloma or a B cell lymphoma. These patients may present with an occlusive vasculopathy, without any specific clinical manifestations. [7] Mixed, type II, and type III cryoglobulins consist of rheumatoid factors, usually IgM (the antibody) complexed with IgG (the antigen), and thus constitute immune complexes. Type II cryoglobulins are single monoclonal immunoglobulins, usually IgM, that coprecipitate with polyclonal IgG. Type III cryoglobulins are polyclonal immunoglobulins that form cryoprecipitates with polyclonal IgG or a nonimmunoglobulin serum component. Patients with mixed cryoglobulinemia may present with a vasculitis or an associated glomerulonephritis. [7]

Single (single-component) cryoglobulins (type I)
IgG
IgM
IgA
Immunoglobulin light chain
Complexed to other proteins
Mixed cryoglobulins
IgM rheumatoid factors
Monoclonal (type II)
Polyclonal (type III)

*The monoclonal components in types I and II cryoglobulinemias are most frequently light molecules, and it has been estimated that approximately 10% of all Waldenström's macroglobulins are cryoprecipitable. Immunoglobulin M type I cryoglobulins are approximately 1.5 times more prevalent than IgG type I cryoglobulins. Thus, significant skewing exists among type I cryoglobulins in the light isotype, especially given that, overall, IgM accounts for only about 15% of gammopathies. This proportion reflects closely the contribution of the light isotype to the total vascular body pool of immunoglobulins. This skewing toward IgM is even more striking among type II cryoglobulins, which are almost invariably IgMκ molecules using the 16/8 subgroup and selective V-region heavy- and light-chain genes.
SOURCE: Reproduced with permission from Kathemcakbal U, Gorevic PD: Evaluation of cryoglobulins. *Arch Pathol Lab Med* 123:119, 1999.

TABLE 177-1 **Types of Cryoglobulin***

Isolation and Typing Techniques

Gorevic described the isolation and characterization of cryoglobulins in detail. [8] In brief, cryoproteins are isolated from blood that is collected and kept at 37°C (98.6°F). Serum obtained by centrifugation of the blood at 37°C (98.6°F) is incubated at 4°C (39.2°F) for several days and observed for the presence of a cryoprecipitate. Initial screening includes the determination that the precipitate is capable of resolubilization when the serum is rewarmed. [7] Once formed, the cryoprecipitate is isolated and resuspended in saline at 37°C (98.6°F), and the protein components are characterized by immunofixation. [5] For types I and II disease, further analysis to identify a monoclonal gammopathy may be carried out

(see below). [7] Most type I cryoprecipitates are evident within 24 h, whereas mixed type III cryoglobulins may require several days of cold incubation for precipitation. Therefore, it is important to hold serum for approximately 1 week before final determination is made of the presence of a cryoprecipitate. Cryoglobulins may become associated with serum lipids and remain suspended during centrifugation, thereby obscuring the formation of a visible precipitate. [9] Conversely, in patients undergoing heparin therapy, an insoluble cryoprecipitate may form with other serum proteins, specifically fibronectin. [10]

Once a cryoprecipitate is identified in patients with type I and type II disease, additional serum studies may aid in their further assessment. [7] Although not always present, serum protein electrophoresis may reveal the presence of a monoclonal spike, suggesting a gammopathy consistent with type I or II cryoglobulins. The likelihood of detecting a cryoglobulin by this method can be increased by both collecting the sample and running the electrophoresis at 37°C (98.6°F) (37°C serum electrophoresis). An identified monoclonal spike can be characterized by serum immunofixation, which involves electrophoretic serum protein separation in an agarose gel, followed by incubation with antisera specific to immunoglobulin classes and light-chain types; this method is highly sensitive for immunotyping a monoclonal gammopathy. [11] Quantitative immunoglobulin determination may aid in further identification of cryoglobulin-associated diseases (i.e., lymphoproliferative diseases).

The concentration of cryoglobulins may be expressed as a percentage of the volume of the total collected serum (cryocrit), or, alternatively, as the concentration of protein in the dissolved cryoprecipitate (expressed in milligrams per milliliter). Type I cryoglobulins are typically present in concentrations greater than 5 mg/mL. In contrast, type III cryoglobulins are usually present in lesser amounts, that is, “cryocrits” <1 percent. Symptom severity does not necessarily reflect cryoprotein concentration in the serum or the temperature at which cryoprecipitation takes place. [12] Isolated cryoglobulin precipitates are typed by immunofixation, immunoblotting, two-dimensional gel electrophoresis, and capillary zone electrophoresis. [7] Immunofixation methods are the most sensitive and most widely used.

Cryoglobulin Characteristics

TYPE I MONOCLONAL CRYOGLOBULINS Type I cryoglobulins are monoclonal immunoglobulins, typically IgM or IgG, although IgA and Bence Jones proteins have been identified. In a review of 86 patients with cryoglobulinemia, Brouet et al. [6] reported that 25 percent of patients had only monoclonal cryoglobulins with a predominance of IgM immunoglobulin. In a larger cohort study, 34 percent of patients with cryoglobulins had type I disease; IgG? and IgM? were equally represented. [4] The large molecular size of IgM monoclonal cryoglobulins may predispose these immunoglobulins to precipitation; in fact, it has been postulated that, in some instances, cryoprecipitation may be an extension of normal immunoglobulin solubility. [13] In certain monoclonal IgG cryoprecipitates, earlier work suggested that the cryoprecipitate determinant resided in the variable region of the immunoglobulin, since the activity could be retained in the F(ab')2 fragment. [8] Some idiotypic relatedness may exist among monoclonal IgG cryoglobulins; the report of cross-reactivity among 5 of 15 IgG cryoglobulins suggested similar variable region structures and, possibly, antigenic specificities. [14] Preferential V-region gene expression has been documented in HCV-associated mixed cryoglobulinemia (see below). [15] Complement components are not routinely found as components of type I cryoprecipitates.
MIXED CRYOGLOBULINS Type II cryoglobulins consist of two immunoglobulin components, one of which is monoclonal. The most common composition is that of a monoclonal IgM rheumatoid factor complexed with a polyclonal IgG. Some evidence suggests that there is an increased prevalence of kappa light chains in the monoclonal IgM and that the monoclonal IgM has restricted specificity for IgG. Although the serum concentration of a type II cryoglobulin is often very high, a typical monoclonal spike is not always apparent on immunoelectrophoresis. IgG monoclonal rheumatoid factors are identified in a small percentage of patients with type II cryoglobulinemia, and IgA monoclonal rheumatoid factors are rare. “Essential” mixed cryoglobulinemia describes the presence of cryoglobulins and the concomitant manifestation of symptoms without an identifiable connective tissue, neoplastic, or infectious process. Levo et al. [16] recognized the high frequency of liver involvement in these patients and identified hepatitis B surface antigen, hepatitis B surface antibody, or Dane particles associated with their sera or cryoprecipitates. Later investigations demonstrated a significant association of essential mixed cryoglobulinemia with HCV infection. In chronic HCV infection, both types II and III cryoglobulins have been found. [17], [18] The prevalence of HCV antibody and/or RNA in serum samples of patients with the diagnosis of essential mixed cryoglobulinemia ranged from 44 to 96 percent of patients studied, as documented by recombinant immunoblot assay or polymerase chain reaction, respectively. [18] Type II cryoglobulins are the most commonly isolated precipitates, because of their frequent association with chronic HCV infection. [7] Recognition of HCV disease manifestations and improved detection methods have contributed to this increased incidence. Patients with type I cryoglobulinemia may be seropositive for HCV at a much lower incidence [14], [19]; by definition, however, the cryoprecipitate does not contain the virus/antibody. It is imperative that patients with mixed cryoglobulinemia, without previously identified associated disease, be evaluated for HCV infection. Type III cryoglobulins usually occur in low concentration and consist of polyclonal immunoglobulin complexes or polyclonal immunoglobulin-nonimmunoglobulin cryoprecipitates. These cryoglobulins are found in association with diseases that may involve the formation of immune complexes. IgM-IgG cryoglobulins are most frequent. [6] The finding of complement system components in these cryoprecipitates, in particular C1q, [20] provides evidence for the immune complex nature of this phenomenon. Indeed, these cryoglobulins may activate complement in vitro, and patients with type III cryoglobulinemia often have decreased serum complement levels. Both autologous and exogenous antigens have been found associated with polyclonal immunoglobulins in this disease.

Pathophysiology

Type I cryoglobulins demonstrate a self-association of monoclonal immunoglobulins at temperatures ranging from 0° to 30°C (32° to 86°F) or more. Monoclonal cryoglobulins are present in substantial amounts, often ranging from 1 to 30 mg/mL. [6] They may precipitate as a gel, a flocculent precipitate, or, in some instances, as crystals. The specific physical forces involved in causing precipitates of type I cryoglobulins appear to include temperature-induced conformational changes, deficient carbohydrate side chains, and nucleation reactions. [8] In some instances, type I cryoglobulins, even

when present in large amounts, may not result in signs or symptoms of disease. Clinical manifestations of type I disease usually consist of occlusive peripheral vascular phenomena such as Raynaud's phenomenon, cutaneous ulcers, or gangrene. Renal disease and peripheral neuropathy are much less common (see " Clinical Features " below).

Type II and III cryoglobulins are typically present in relatively small amounts. These monoclonal (type II) or polyclonal (type III) rheumatoid factor-IgG complexes usually occur with a concomitant disease process such as connective tissue disease, infection, hepatic disease, or lymphoproliferative disease. The exception is the occurrence of mixed cryoglobulins in "essential" mixed cryoglobulinemia, where an underlying disease process cannot be identified. Analysis of types II and III cryoglobulins often reveals the presence of complement in addition to immunoglobulins.

Early work on the complement system in cryoglobulinemia revealed decreased "functional complement activity" (CH50), C1, C4, and C2. [21] A number of clinical studies have since identified patients with mixed cryoglobulinemia with depressed levels of C3, along with decreased levels of CH50, C2, and C4. [22] In a large cohort study, [4] 71 percent of patients with cryoglobulinemia had low CH50 levels, 50 percent had low C4 levels, and 25 percent had low C3 levels. In this study, patients with HCV-associated cryoglobulins had a higher frequency of hypocomplementemia than did patients without HCV. Cold-dependent activation of complement may itself affect CH50 levels in HCV-positive patients. [23]

The immunoglobulins in the serum cryoprecipitate of patients with mixed cryoglobulinemia have been identified, along with complement, in involved renal vessels; the histologically normal vasculature may evidence immunoglobulin deposition without complement. Immunofluorescence studies of the skin of patients with cryoglobulinemia revealed immune reactants and complement in the small vessel walls of 50 percent of the patients studied, but not in the uninvolved skin. [22] Studies such as these have been cited as evidence for the pathogenic role of immune complex deposition in cryoglobulinemia. Investigations evaluating the localization of HCV antigen in small vessels of the skin of patients with HCV and mixed cryoglobulinemia found evidence of HCV antigen in 6 of 15 skin biopsy specimens studied by immunohistochemistry, with immunoglobulin deposition similar to the HCV antigen deposition. [24] HCV antigen deposition was detected in both lesional and, in some cases, nonlesional, apparently normal tissue.

Clinical Manifestations (Table 177-2)



TABLE 177-2 **Clinical and Laboratory Findings in Patients with Cryoglobulinemia**

The organ systems usually affected in cryoglobulinemia are the skin, kidneys, liver, and musculoskeletal and nervous systems. In general, type I cryoglobulins are typically associated with acrocyanosis, retinal hemorrhage, Raynaud's phenomenon, and arterial thrombosis. [8] Types II and III cryoglobulins are associated with arthritis or arthralgias and vascular purpura. [8] Renal and neurologic symptoms may be found in patients with types II and III cryoglobulins. [6] In an early series of 40 patients with mixed cryoglobulins, [20] 100 percent had recurrent palpable purpura, 73 percent had polyarthralgias, and 55 percent had renal disease. A later prospective study of 115 patients with mixed cryoglobulinemia found that 45 percent had underlying identifiable diseases, or "nonessential" cryoglobulinemia. Of the remaining patients ("essential" mixed cryoglobulinemia), approximately one-half had anti-HCV antibodies, associated with cutaneous and systemic signs and symptoms of greater severity than those patients who were HCV antibody negative. Cutaneous disease included Raynaud's phenomenon, purpura, livedo, distal ulcerations, and "gangrenous" changes (see below). This cohort also had higher serum alanine aminotransferase levels, higher cryoglobulin levels, and lower complement (CH50, C4) levels.

CUTANEOUS FEATURES Purpura is a cutaneous hallmark of cryoglobulinemia. It is usually located distally, most typically on the lower extremities. Showers of these lesions may occur spontaneously, may be provoked by cold exposure, and may be induced by long periods of standing or sitting. [6] Noninflammatory purpura, with histologic evidence of an amorphous eosinophilic precipitate within the vasculature, is characteristically seen in type I cryoglobulinemia. [25] Leukocytoclastic vasculitis, presenting clinically as palpable purpura, is the characteristic hallmark of the mixed cryoglobulinemias (Fig. 177-1). The lesions are intermittent in nature (typically lasting 3 to 10 days) and are usually nonpruritic. [22] In comparative studies, the incidence of palpable purpura was found to be higher in patients with mixed cryoglobulinemia who are HCV antibody positive. [26] In a large cohort of HCV-positive patients, cutaneous manifestations were found in 17 percent and included lower extremity purpura, Raynaud's phenomenon, cutaneous vasculitis, psoriasis, porphyria cutanea tarda, and lichen planus. [17] Ulcerations (type II), livedo reticularis (type I), acrocyanosis, and gangrene (type I) [4], [22] have been described. Before the classification system of cryoglobulinemia introduced by Brouet, urticaria, urticarial vasculitis, and cold urticaria were also described. [27], [28]

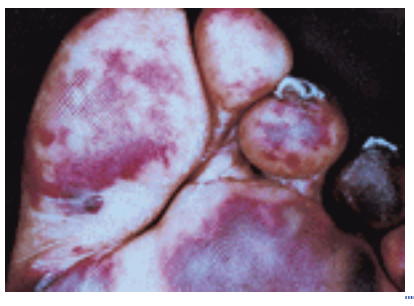

FIGURE 177-1 Leukocytoclastic vasculitis in a patient with mixed cryoglobulinemia manifested as palpable purpura. The patient also had tuberculosis, positive antinuclear antibodies, and hepatitis.

RENAL DISEASE Early reports indicated that 30 to 60 percent of patients with essential mixed cryoglobulinemia have, or will develop, renal disease. [8] Later studies demonstrate a slightly lower frequency. [29] Pathologic evaluation reveals predominantly a membranoproliferative glomerulonephritis. A specific membranoproliferative "cryoglobulinemic glomerulonephritis" has been recognized in association with HCV-induced type II cryoglobulinemia with characteristic renal findings. [30] The initial clinical presentation of membranoproliferative glomerulonephritis may include diastolic hypertension, edema, or frank renal failure. [4] Urinalysis may show proteinuria, hematuria, pyuria, and red cell casts. [22] Immunofluorescence analysis of renal tissue is characteristically positive and reflects the immunoglobulin and/or complement components identified in the isolated cryoglobulin.

OTHER Neurologic symptoms occur in a smaller percentage of patients and typically consist of a peripheral sensorimotor polyneuropathy, which may present as paresthesia or foot drop. [22] Central nervous system involvement is less common. [4] Articular manifestations, more common in types II and III cryoglobulinemias, rarely present as distinct arthritis, [9] but rather as arthralgias. [31] As serologic studies for hepatitis B and C may be positive, hepatic signs may include hepatomegaly and splenomegaly, and liver function test abnormalities. Other manifestations of vascular occlusive phenomena or immune complex disease may arise in the eye and gastrointestinal system.

Associated Diseases (Table 177-3)

Type I
Multiple myeloma
Waldenström's macroglobulinemia
Other lymphoproliferative diseases with monoclonal components
Type II
Chronic HCV infection
Sjögren's syndrome
Waldenström's macroglobulinemia
Chronic lymphocytic leukemia
Non-Hodgkin's lymphoma
Autoimmune diseases
Cold agglutinin disease
Type III*
Chronic infections
Viral (EBV, CMV, HIV, hepatitis viruses)
Bacterial (SBE, leprosy, spirochetal)
Fungal, parasitic
Autoimmune diseases
Systemic lupus erythematosus
Rheumatoid arthritis
Inflammatory bowel diseases
Biliary cirrhosis

*CMV = cytomegalovirus; EBV = Epstein-Barr virus; HIV = human immunodeficiency virus; SBE = subacute bacterial endocarditis.
SOURCE: Reproduced with permission from Kallemuccikkal U, Gorevic PD: Evaluation of cryoglobulins. *Arch Pathol Lab Med* 123:110, 1999.

TABLE 177-3 **Disease Associations**

Lymphoproliferative, autoimmune disorders, and infectious etiologies are the most frequently associated diseases. HIV infection may be present, usually coexistent with HCV. [4] Lymphoproliferative diseases such as macroglobulinemia and lymphomas are associated with types I and II cryoglobulins and autoimmune disorders, and hepatitis C is associated with types II and III (see above). Autoimmune disorders most typically include rheumatoid arthritis, systemic lupus erythematosus, and Sjögren's syndrome. In the large cohort study reported by Trejo et al., [4] autoimmune diseases were associated with 15 percent of patients with type I and with 26 percent of patients with mixed cryoglobulinemia.

Treatment

Treatment of cryoglobulinemia is based on the severity of disease presentation. Mild cutaneous symptoms may not require therapeutic intervention. Dermatologic and articular manifestations may be improved by nonsteroidal anti-inflammatory agents. More severe visceral involvement, particularly renal disease, may require glucocorticoid therapy in conjunction with cytotoxic agents. Melphalan, chlorambucil, or cyclophosphamide may benefit some patients. [8] Plasmapheresis has been used to treat patients with rapidly progressive disease refractory to conventional therapy, but a postpheresis rebound in disease activity may occur. Plasma exchange is usually instituted together with immunosuppressive or cytotoxic agents in an attempt at better disease control as well as avoidance of rebound. Patients with HCV-associated cryoglobulinemia have been treated successfully with interferon (IFN)-a. [32]

CRYOFIBRINOGENEMIA

Cryofibrinogens are cryoproteins in plasma that has been anticoagulated with oxalate, citrate, or EDTA which reversibly precipitate when the plasma is cooled to 4°C (39.2°F); cryoglobulins precipitate in both cooled serum and plasma. [6] This phenomenon was first described by Korst and Kratochvil in 1955, as referenced by Sankarasubbaiyan et al. [33] Cryoprecipitates are composed of fibrinogen, fibrin, fibrin split products with albumin, fibronectin (cold-insoluble globulin), factor VIII, immunoglobulins (rare in patients with isolated disease), and other plasma proteins. [5] Cryoprecipitates may, in fact, be composed of normal plasma proteins on freeze-thawing of plasma. [8] Heparin may produce false-positive

precipitates (heparin-precipitable fraction) through the formation of heparin-fibronectin cryoprecipitable complexes, the formation of which may be further enhanced by the presence of fibrinogen. [8]

Cryofibrinogenemias are classified as primary, without known etiology or disease association, or secondary. Many earlier investigators found evidence of cryofibrinogens in a small percentage of “normal” subjects. In fact, screening of normal “healthy” blood donors in one study revealed cryofibrinogens in 7 percent of these controls. [5] Secondary cryofibrinogenemia may occur in patients with connective tissue disease, infections, malignancies, and thromboembolic disorders, [33] and is more frequently found in patients with associated cryoglobulinemia. [5] Diabetes, hyperglycemia, chronic lung disease, hypothyroidism, and acute myocardial infarction have been described as disease associations, as has pregnancy and the use of oral contraceptive agents. [34], [35], [36] and [37] In one study of patients with associated cryoglobulinemia, [5] immunoglobulins were a predominant constituent of the cryofibrinogen precipitate, and, not surprisingly, of the same class as that characterizing the cryoglobulinemia. Similarly, fibronectin was found in the cryoglobulin cryoprecipitate.

Inhibition of fibrinolysis has been postulated in the pathogenesis of cryofibrinogenemia, a hypothesis that is based on the findings of increases in a $_1$-antitrypsin and a $_2$-macroglobulinemia in some patients. [35] These proteins are inhibitors of the major plasma fibrinolytic agent, plasmin. Plasma levels of cryofibrinogens may range from 0.05 g/L to >1 g/L. [5] In patients with isolated cryofibrinogenemia, and in those with coexisting cryoglobulinemia, plasma fibrinogen levels may be elevated. [5]

Similar to patients with cryoglobulinemia, patients with cryofibrinogenemia typically present with cutaneous disease. In primary disease, cold-induced, painful skin ulcerations may be present. [5] A thrombotic vasculopathy has been described, [38] as well as, histologically, eosinophilic thrombi of small intradermal vessels. [5] Cryofibrinogenemia may clinically simulate calciphylaxis and may similarly present in patients with end-stage renal disease. [33] Other findings in cryofibrinogenemia include purpura, ecchymosis, and arterial and venous thrombosis. [5], [35] In essential isolated cryofibrinogenemia associated with painful lower extremity ulcerations, the efficacy of fibrinolytic therapy, including stanozolol, has been described. [39] The treatment of secondary cryofibrinogenemia is that of the underlying disease or associated condition.

REFERENCES

1. Wintrobe NM, Buell M: Hyperproteinemia associated with multiple myeloma: With report of a case in which an extraordinary hyperproteinemia was associated with thrombosis of the retinal veins and symptoms suggesting Raynaud's disease. *Bull Johns Hopkins Hosp* **52**:156, 1993

2. Waldenstrom J: Klinska metoder for pavisande and hyperproteinam: Oc deras praktiska for diagnostiken. *Nord Med* **20**:2288, 1943

3. Lerner AB, Watson CJ: Studies of cryoglobulins II. The spontaneous precipitation of protein from serum at 5°C in various disease states. *Am J Med Sci* **214**:416, 1947

4. Trejo O et al: Cryoglobulinemia: Study of etiologic factors and clinical and immunologic features in 443 patients from a single center. *Medicine* **80**:252, 2001

5. Blain H et al: Cryofibrinogenemia: A study of 49 patients. *Clin Exp Immunol* **120**:253, 2000

6. Brouet JC et al: Biological and clinical significance of cryoglobulinemia: Report of 86 cases. *Am J Med Sci* **57**:775, 1974

7. Kallemuchikkal U, Gorevic PG: Evaluation of cryoglobulins. *Arch Pathol Lab Med* **123**:119, 1999

8. Gorevic PD: Cryopathies: Cryoglobulins and cryofibrinogenemia, in *Immunological Diseases,* 3rd ed, edited by M. Samter. Boston, Little, Brown, 1978, p 1687

9. Winfield JB: Cryoglobulinemia. *Hum Pathol* **14**:350, 1983

10. Fornasieri AS et al: High binding of immunoglobulin M kappa rheumatoid factor from type II cryoglobulins to cellular fibronetin: A mechanism for induction of in situ immune complex glomerulonephritis? *Am J Kidney Dis* **27**:476, 1996

11. Litwin CM et al: Comparison of capillary zone and immunosubtraction with agarose gel and immunofixation electrophoresis for detecting and identifying monoclonal gammopathies. *Am J Clin Pathol* **112**:411, 1999

12. Letendre L, Kyle RA: Monoclonal cryoglobulinemia with high thermal insolubility. *Mayo Clin Proc* **57**:629, 1982

13. Middaugh CR: Physicochemical characterization of six monoclonal cryoimmunoglobulins: Possible basis for cold dependent insolubility. *Proc Natl Acad Sci U S A* **75**:3440, 1978

14. Abraham GN: Idiopathic relatedness of human monoclonal IgG cryoglobulins. *Immunology* **48**:315, 1983

15. Ivanovski M et al: Somatic hypermutation, clonal diversity and preferential expression of the Vh 51p1/Vl kv325 immunoglobin gene combination in hepatitis C virus-associated immunocytomas. *Blood* **91**:2433, 1998

16. Levo YL et al: Association between hepatitis B virus and essential mixed cryoglobulinemia. *N Engl J Med* **296**:1501, 1977

17. Cacoub P et al: Extrahepatic manifestations associated with hepatitis C virus infection: A prospective multicenter study of 321 patients. *Medicine* **79**:47, 2000

18. Wong, VS et al: Incidence, character, and clinical relevance of mixed cryoglobulinemia in patients with chronic hepatitis C virus infection. *Clin Exp Immunol* **104**:25, 1996

19. Willems M et al: Hepatitis C virus and its genotypes in patients suffering from chronic hepatitis C with or without a cryoglobulinemia-related syndrome. *J Med Virol* **44**:226, 1994

20. Stastny P, Ziff M: Cold-insoluble complexes and complement levels in systemic lupus erythematosus. *N Engl J Med* **280**:1376, 1969

21. Linscott WD, Kane JP: The complement system in cryoglobulinaemia: Interaction with immunoglobulins and lipoproteins. *Clin Exp Immunol* **21**:510, 1975

22. Gorevic PD: Mixed cryoglobulinemia: Clinical aspects and long term follow-up of 40 patients. *Am J Med Sci* **69**:287, 1980

23. Ueda K et al: The association of complement activation at a low temperature with hepatitis C virus infection in comparison with cryoglobulin. *Clin Exp Immunol* **101**:284, 1995

24. Sansonno D et al: Localization of hepatitis C virus antigens in liver and skin tissues of chronic hepatitis C virus-infected patients with mixed cryoglobulinemia. *Hepatology* **21**:305, 1995

25. Lever WF, Schaumburg-Lever G: *Histopathology of the Skin,* 6th ed. Philadelphia, Lippincott, 1990, p 191

26. Dupin N et al: Essential mixed cryoglobulinemia: A comparative study of dermatologic manifestations in patients infected or noninfected with hepatitis C virus. *Arch Dermatol* **131**:1124, 1995

27. Costanzi JJ: Activation of complement by a monoclonal cryoglobulin associated with cold urticaria. *J Lab Clin Med* **74**:902, 1969

28. Rawnsley HM, Shelley WB: Cold urticaria with cryoglobulinemia. *Arch Dermatol* **98**:12, 1968

29. Monti G et al: Cryoglobulinemia. A multi-centre study of the early clinical and laboratory manifestations of primary and secondary disease. *Q J Med* **88**:115, 1995

30. D'Amico G, Fornasieri A: Cryoglobulinemic glomerulonephritis: A membranoproliferative glomerulonephritis induced by hepatitis C virus. *Am J Kidney Dis* **25**:361, 1995

31. Weinberger A: Articular manifestations of essential cryoglobulinemia. *Semin Arthritis Rheum* **10**:224, 1981

32. Abe K et al: Anti-liver/kidney microsome-1 positive chronic hepatitis C with type I cryoglobulinemia responding to interferon. *Intern Med* **34**:1114, 1995

33. Sankarasubbaiyan S et al: Cryofibrinogenemia: An addition to the differential diagnosis of calciphylaxis in end-stage renal disease. *Am J Kidney Dis* **32**:494, 1998

34. Rachmilewitz EA et al: Essential cryofibrinogenemia. Clinical, pathological and immunological studies. *Is J Med Sci* **6**:32, 1970

35. Smith SB, Arkin C: Cryofibrinogenemia. Incidence, clinical correlations, and a review of the literature. *Am J Clin Pathol* **58**:524, 1972

36. Zlotnick A et al: Studies in cryofibrinogenemia. *Acta Haematol* **42**:8, 1969

37. McKee PA et al: Incidence and significance of cryofibrinogenemia. *J Lab Clin Med* **61**:203, 1963

38. Beightler E et al: Thrombotic vasculopathy associated with cryofibrinogenemia. *J Am Acad Dermatol* **24**:342, 1991

39. Falanga V et al: Stanozolol in treatment of leg ulcers due to cryofibrinogenemia. *Lancet* **338**:347, 1991

T>

Chapter 178

Stephen Katz

Relapsing Polychondritis

HISTORICAL ASPECTS
ETIOLOGY AND PATHOGENESIS
CLINICAL MANIFESTATIONS
LABORATORY FINDINGS
PATHOLOGY
DIAGNOSIS
TREATMENT
COURSE AND PROGNOSIS

REFERENCES

Relapsing polychondritis is a rare disease manifested by recurring episodes of inflammation in cartilaginous tissues throughout the body.

HISTORICAL ASPECTS

The disease was first described by Jaksch-Wartenhorst in 1921, and given the name polychondropathia in 1923. [1] In 1960, Pearson et al. [2] suggested the name relapsing polychondritis to emphasize its episodic nature, which leads to degeneration and replacement of cartilaginous structures by fibrous tissue. In 1976, McAdam et al. reviewed 159 reported cases of relapsing polychondritis, including 23 patients whom they had seen over the 15-year period of 1960 to 1975. [3] They also empirically defined diagnostic criteria that included the most common clinical features. In 2001, Frances et al. reported a broad array of dermatologic manifestations in 200 patients with relapsing polychondritis followed at a single medical center. [4]

ETIOLOGY AND PATHOGENESIS

Considerable evidence suggests that relapsing polychondritis is an autoimmune disease mediated by immunity to type II collagen. In humans, type II collagen is restricted to cartilage and constitutes more than 50 percent of the proteins of cartilage. Foidart et al. [5] detected antibodies to type II collagen in the sera of 6 of 23 patients with relapsing polychondritis. All patients in whom antibodies were detected had active disease. Subsequently, Terato et al., [6] using an enzyme-linked immunosorbent assay (ELISA), found antibodies to type II collagen in the sera of 50 percent of patients with relapsing polychondritis, but in only 15 percent of patients with rheumatoid arthritis and 4 percent of normal individuals. More recently, Bradley et al. [7] showed that human leukocyte antigen (HLA)-DQ6/8 double-transgenic mice develop a relapsing polychondritis-like disease after immunization with type II collagen.

The demonstration of antibodies to type II collagen in sera of patients with relapsing polychondritis raises the question of whether these antibodies are functionally active in vivo or whether they simply represent an epiphenomenon secondary to injury to cartilage and consequent exposure to the relevant antigens. That the antibodies are directed mainly against native rather than denatured collagen would favor the former possibility. [5] Also, the epitope specificity of the antibodies is different in patients with rheumatoid arthritis and those with relapsing polychondritis. [6] The clinical manifestations may then be influenced by this specificity. Although relapsing polychondritis is not usually detected in neonates born of mothers with the disease, [8] the observation that relapsing polychondritis may be transferred from an afflicted mother to her newborn child and that the child may then recover completely from the disease [9] suggests an important role for antibodies in the pathogenesis of relapsing polychondritis. Finally, the finding in vivo of deposits of immunoglobulin and complement in inflamed cartilage in two patients with relapsing polychondritis [10] supports the likelihood that immunity to type II collagen plays a role in the pathogenesis of relapsing polychondritis. Further evidence that immunologic mechanisms play a role in the pathogenesis of relapsing polychondritis comes from immunogenetic studies demonstrating a significant association between relapsing polychondritis and HLA-DR4. [11]

Because relapsing polychondritis affects cartilage that primarily resides outside diarthrodial joints, usually the nose, outer ears, and trachea, Hansson et al. [12] developed an animal model that is induced by immunization with cartilage matrix protein (matrilin-1). Rats immunized with this noncollagenous protein, which is expressed mainly in tracheal cartilage, developed a disease very similar to relapsing polychondritis. A humoral and cellular response to matrilin-1 has been identified in an individual with relapsing polychondritis. [13]

CLINICAL MANIFESTATIONS

The most frequent presenting manifestations are auricular chondritis and arthritis. [3], [14] The chondritis is characterized by the sudden onset of redness, warmth, swelling, and tenderness limited to the cartilaginous portion of the external ears. Often only one ear is involved initially, and the ear lobe is typically uninvolved. The acute inflammation usually subsides spontaneously in 1 to 2 weeks. It is characterized by recurrences that appear after highly variable periods—from weeks to months. Eventually 85 to 90 percent of patients with relapsing polychondritis develop auricular chondritis. [3], [14] Nasal chondritis follows the same pattern as the auricular chondritis and eventually occurs in 54 to 70 percent of patients. The recurrent episodes of chondritis usually result in the destruction of normal cartilaginous structures and their fibrotic replacement. Clinically, this process results in floppy or cauliflower ears and nasal deformities (Fig. 178-1 and Fig.

178-2).

FIGURE 178-1 Relapsing polychondritis. Cartilaginous portion of ear is deformed and fibrotic.

FIGURE 178-2 Relapsing polychondritis. “Cauliflower” ear and nasal deformity.

Arthritis, which may involve only one or many small or large joints, is the second most frequent presenting sign and is eventually manifested in 52 to 80 percent of patients. At its onset, the arthritis is often migratory and is frequently associated with effusions, but it may be monoarticular and difficult to distinguish from gouty or infectious arthritis.

Other organ system involvement includes the eyes, where the inflammation may involve almost every part of the eye and adnexal structures, [3], [15] manifesting as conjunctivitis, episcleritis, keratitis, and iritis (Fig. 178-3); the respiratory tract, where symptoms may include hoarseness, aphonia, and dyspnea; the inner ear, where symptoms may include nausea, vomiting, tinnitus, and deafness as a result of audiovestibular damage; and, less frequently, the cardiovascular system, where the most frequent abnormalities are aortic regurgitation and aortic aneurysm. [16] Aortic valve replacement may become necessary. [17] A significant percent (30 to 71 percent) of patients have an associated rheumatic or autoimmune disease, and a significant percent of patients also have leukocytoclastic vasculitis. [3], [4], [14], [18], [19] Myelodysplastic syndromes are also associated with relapsing polychondritis. [4], [20], [21] and [22]

FIGURE 178-3 Relapsing polychondritis. Acute episcleritis.

LABORATORY FINDINGS

The only laboratory finding that is consistently abnormal is an elevated erythrocyte sedimentation rate. The white blood count is elevated and/or the hemoglobin or hematocrit is decreased in more than half of patients. [3] Indirect immunofluorescence and ELISA studies have detected circulating antibodies to type II collagen in one-third to one-half of patients. [5], [6]

PATHOLOGY

Relapsing polychondritis is characterized by a loss of the normal basophilia of cartilage with a perichondrial inflammatory infiltrate. The earliest of the inflammatory cells are thought by some to be neutrophils and by others to be mononuclear cells. The end stage of the disease is characterized by the fibrotic replacement of cartilage.

DIAGNOSIS

McAdam et al. [3] suggested that the diagnosis of relapsing polychondritis can be made when three of the following criteria are present along with histologic confirmation of the chondritis:

1. Bilateral auricular chondritis
2. Nonerosive seronegative inflammatory polyarthritis
3. Nasal chondritis
4. Ocular inflammation
5. Respiratory chondritis
6. Audiovestibular damage

Ordinarily, relapsing polychondritis presents little problem in diagnosis. However, there are patients who have only

auricular and nasal chondritis and none of the other manifestations of relapsing polychondritis. If the histology shows perichondrial inflammation and the loss of the normal cartilaginous basophilia, and if other conditions are excluded, a diagnosis of relapsing polychondritis should be made.

Concurrent rheumatologic diseases may, at times, obscure the diagnosis of relapsing polychondritis. Cellulitis of the ear or nose may be confused on rare occasion with relapsing polychondritis; however, sparing of the ear lobe favors the diagnosis of relapsing polychondritis.

TREATMENT

Because of the highly variable course of relapsing polychondritis, individualized therapy is the key to optimum management. Systemic glucocorticoids are helpful in controlling the acute inflammation. Seventy-five percent of the patients in McAdam's series required chronic glucocorticoid therapy; the average dose of prednisone was 25 mg/day. [3] Immunosuppressive therapy, including cyclosporine, may also be efficacious in severe progressive disease, [3], [23] and methotrexate has been helpful as a steroid-sparing agent. [24] Dapsone has also been reported to be an effective treatment [25]; however, my experience and that of others [14] with dapsone in relapsing polychondritis has been disappointing. Although dapsone may be effective in some patients with diffuse anterior scleritis, it does not control the destructive scleral inflammation. [26] The frequent spontaneous remissions that occur during the acute episodes have made evaluation of most treatments difficult. The more chronic manifestations of relapsing polychondritis can be managed with indomethacin in some patients.

COURSE AND PROGNOSIS

The course of relapsing polychondritis is unpredictable. The acute chondritis in most patients lasts for 1 to 4 weeks, but in a few patients, it may be more prolonged. Some patients have a relatively mild course with few episodes of chondritis. Other patients may have multiple episodes of chondritis. The degree of tissue destruction and fibrosis is difficult to predict early in the course of the disease. The presence of peripheral arthritis is said to be associated with widespread disease and a poorer prognosis. [27] About one-third of the patients die as a result of relapsing polychondritis. The most frequent causes of death are airway collapse or obstruction (for which self-expandable tracheobronchial stents should be considered), cardiovascular complications including systemic vasculitis and ruptured aneurysms, and infections (probably secondary to glucocorticoid-induced immunosuppression). [3], [14], [16], [28], [29]

REFERENCES

1. Jaksch-Wartenhorst R: Polychondropathia. *Wien Arch Inn Med* **6**:93, 1923

2. Pearson CM et al: Relapsing polychondritis. *N Engl J Med* **263**:51, 1960

3. McAdam LP et al: Relapsing polychondritis. Prospective study of 23 patients and a review of the literature. *Medicine (Baltimore)* **55**:193, 1976

4. Frances C et al: Dermatologic manifestations of relapsing polychondritis. *Medicine (Baltimore)* **80**:173, 2001

5. Foidart JM et al: Antibodies to type II collagen in relapsing polychondritis. *N Engl J Med* **299**:1203, 1978

6. Terato K et al: Specificity of antibodies to type II collagen in rheumatoid arthritis. *Arthritis Rheum* **33**:1493, 1990

7. Bradley et al: HLA-DQ6/8 double transgenic mice develop auricular chondritis following type II collagen immunization: A model for human relapsing polychondritis. *J Immunol* **161**:5046, 1998

8. Papo T et al: Pregnancy in relapsing polychondritis: Twenty-five pregnancies in eleven patients. *Arthritis Rheum* **40**:1245, 1997

9. Arundell FW, Haserick JR: Familial chronic atrophic polychondritis. *Arch Dermatol* **82**:439, 1960

10. Valenzuela R et al: Relapsing polychondritis: Value of immunomicroscopic examination of ear biopsy. *Hum Pathol* **11**:19, 1980

11. Zeuner M et al: Relapsing polychondritis: Clinical and immunogenetic analysis of 62 patients. *J Rheumatol* **24**:96, 1997

12. Hansson AS et al: A new animal model for relapsing polychondritis, induced by cartilage matrix protein (matrilin-1). *J Clin Invest* **104**:589, 1999

13. Buckner JH et al: Autoreactivity against matrilin-1 in a patient with relapsing polychondritis. *Arthritis Rheum* **43**:939, 2000

14. Michet CJ et al: Relapsing polychondritis—Survival and predictive role of early disease manifestations. *Ann Intern Med* **104**:74, 1986

15. Isaak BL et al: Ocular and systemic findings in relapsing polychondritis. *Ophthalmology* **93**:681, 1986

16. Del Rosso A et al: Cardiovascular involvement in relapsing polychondritis. *Semin Arthritis Rheum* **26**:840, 1997

17. Lang-Lazdunski L et al: Cardiac valve replacement in relapsing polychondritis: A review. *J Heart Valve Dis* **4**:227, 1995

18. Michet CJ: Vasculitis and relapsing polychondritis. *Rheum Dis Clin North Am* **16**:441, 1990

19. Gunaydin I et al: Articular involvement in patients with relapsing polychondritis. *Rheumatol Int* **18**:93, 1998

20. Hebbar M et al: Association of myelodysplastic syndrome and relapsing polychondritis. Further evidence. *Leukemia* **9**:731, 1995

21. Diebold L et al: Bone marrow pathology in relapsing polychondritis: High frequency of myelodysplastic syndromes. *Br J Haematol* **89**:820, 1995

22. Myers B et al: Relapsing polychondritis and myelodysplasia: A report of two cases and review of the current literature. *Clin Lab Haematol* **22**:45, 2000

23. Diercks K et al: Cyclosporin A therapy of chronic recurrent polychondritis. *Hautartz* **47**:376, 1996

24. Park J et al: Steroid-sparing effect of methotrexate in relapsing polychondritis. *J Rheumatol* **23**:937, 1996

25. Barranco VP et al: Treatment of relapsing polychondritis with dapsone. *Arch Dermatol* **112**:1286, 1976

26. Hoang-Xaun T et al: Scleritis in relapsing polychondritis. Response to therapy. *Ophthalmology* **97**:892, 1990

27. Balsa A et al: Joint symptoms in relapsing polychondritis. *Clin Exp Rheumatol* **13**:425, 1995

28. Eng J, Sabanathan S: Airway complications in relapsing polychondritis. *Ann Thorac Surg* **51**:686, 1991

29. Sorodia BD et al: Management of airway manifestations of relapsing polychondritis. *Chest* **116**:1669, 1999

T>

Chapter 179

Carlin Hollar Joseph Jorizzo

Rheumatoid Arthritis, Rheumatic Fever, and Gout

RHEUMATOID ARTHRITIS
Epidemiology
Etiology and Pathogenesis
Clinical Features
Laboratory Findings
Treatment
RHEUMATIC FEVER
Epidemiology
Pathogenesis
Clinical Features
Treatment
GOUT
Epidemiology
Pathogenesis
Clinical Manifestations
Laboratory Presentation/Pathology
Treatment

REFERENCES

This chapter discusses common rheumatologic diseases that ordinarily have prominent musculoskeletal presentations. All these conditions have extraskeletal manifestations that may be cutaneous in nature.

RHEUMATOID ARTHRITIS

Rheumatoid arthritis (RA) is a systemic inflammatory autoimmune disease that is characterized by a chronic, symmetric polyarthritis and significant extraarticular manifestations, which include rheumatoid nodules, vasculitis, and internal organ involvement. The disease process may be progressive and may destroy joint function, with a resultant decline in functional status and premature death. Permanent remission is extremely unusual.

Epidemiology

Approximately 1 percent of the adult population in most parts of the world is affected with RA. [1] Approximately 70 percent of patients follow a chronic disease course with exacerbations and remissions; 25 percent have intermittent disease with brief attacks of inflammation followed by remissions; and approximately 5 percent have an aggressive, malignant form with multiple extraarticular manifestations. [2] Onset of this disease is usually in the third to fifth decades. Incidence increases with increasing age until the seventh decade. RA is two to three times more common in females than in males. [1] This ratio is smaller in older populations.

Etiology and Pathogenesis

The exact cause of RA is unknown. The initial onset of joint symptoms may be induced by a variety of factors. The immunogenetic background of the patient may then determine whether the inflammation regresses or progresses. Monozygotic and dizygotic twins studies suggest both genetic and environmental factors. [3] An association between extraarticular disease and human leukocyte antigen (HLA)-DR1 and DR4 genes has been noted in some populations. [4] Some authors believe that HLA determines disease severity but not susceptibility.

Mechanical stress on joints (and at sites of subcutaneous nodules) may initiate an inflammatory response that lacks balance between a rapid response to trauma and the need to protect self from damage. Seropositive RA (positive rheumatoid factor) supports a major role of immune complexes in this disease process. Seronegative RA (negative rheumatoid factor) may still represent a disease process involving immune complexes, but also suggests other immune mechanisms. Immune complexes may interact with specific cell surface receptors on synovial macrophages, leading to the production of reactive oxygen species and other inflammatory cytokines, such as tumor necrosis factor-a (TNF-a). [3] Joints have unique anatomic and physiologic qualities that render them targets for immune and inflammatory attack. Cartilage is subject to repetitive mechanical stress, retains antigens and proinflammatory cytokines, and has a limited capacity for regeneration. Once proteolytic enzymes cause erosions, narrowing of the joint space, and mechanical instability, rheumatoid inflammation may become self-sustaining.

Clinical Features

RA often begins with general constitutional symptoms such as fatigue, anorexia, vague musculoskeletal complaints, and generalized weakness. It may be weeks or months before the characteristic synovitis presents. It is in these early stages that definite diagnosis is most difficult, despite a thorough patient evaluation. However, early diagnosis and treatment are important because most of joint damage is thought to occur in the first 2 years of the disease process. [5] The American College of Rheumatology has set guidelines for the diagnosis of RA (Table 179-1). [6] For a patient to be diagnosed with

definite RA, four of the seven criteria must be present. The first four criteria listed must be present for at least 6 weeks. Extraarticular manifestations may help to delineate the disease process early and may signify a more serious disease process requiring the initiation of aggressive therapy. [7]



TABLE 179-1 **1987 American College of Rheumatology Revised Criteria for the Classification of Rheumatoid Arthritis (Modified)**

ARTICULAR MANIFESTATIONS The articular manifestations of RA relate to an inflammatory synovitis that can affect the synovial lining of joints, tendons, and bursae. Synovial inflammation usually results in warmth but not erythema of the affected area. There is significant pain in association with stretching of the joint capsule. Hand and foot involvement forms the basis of the disease in most patients. Although the initial manifestations in the hand may be asymmetric, the clinical course subsequently takes on a very symmetric diffuse pattern. There is characteristic involvement of the proximal interphalangeal (PIP) and metacarpophalangeal (MCP) joints with sparing of the distal interphalangeal (DIP) joints. The developing pattern of joint involvement is very suggestive of the diagnosis. Chronic inflammation may result in irreversible structural damage of the joint, including cartilage destruction and bony erosion. Late structural deformities may result from soft tissue contractures or from bony ankylosis. Characteristic deformities include radial deviation of the hand with ulnar deviation of the digits, the “swan neck” deformity from hyperextension of the PIP joint and compensatory flexion of the DIP joint, and the boutonnière deformity from flexion contracture of the PIP joint and extension of the DIP joint. Similar structural deformities occur in the feet. All can be debilitating. Involvement of the thoracic and lumbar spine in RA is exceptional. Although the shoulder joint is often affected, it is soft tissue structures, which include the rotator cuff tendons and muscles and the subacromial bursa, that are usually involved in the patient's symptomatology.

DERMATOLOGIC MANIFESTATIONS Extraarticular manifestations occur in more aggressive or extensive forms of RA. [7] The commonly encountered dermatologic findings include rheumatoid nodules and rheumatoid vasculitis. The characteristic rheumatoid nodule occurs in a small percent of patients with RA (Fig. 179-1A). Rheumatoid factor is inevitably found within nodules that occur during active phases of the disease process and form subcutaneously, in bursae, and along tendon sheaths. The usual location is over pressure points such as the olecranons, the extensor surface of the forearms, and the Achilles tendons; but they have been described in almost every location, including viscera. The main findings histopathologically (Fig. 179-1B) are palisaded granulomas in the deep dermis or subcutaneous tissues with fibrinoid degeneration of collagen, a multitude of neutrophils and neutrophilic dust, with surrounding fibrosis and proliferation of vessels. [8] The main differential diagnoses histopathologically include subcutaneous granuloma annulare, necrobiosis lipoidica, foreign body or infectious granulomatous reaction, and epithelioid sarcoid. [8]

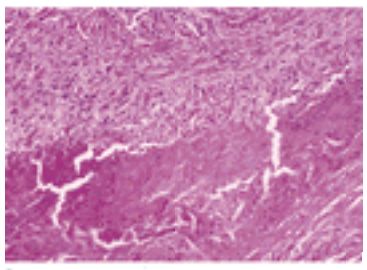

FIGURE 179-1 Rheumatoid nodules. *A.* Severely affected joints of a patient with rheumatoid arthritis with overlying rheumatoid nodules. *B.* Histopathologically, the nodule is a palisaded granuloma in the deep reticular dermis surrounding degenerated collagen.

Rheumatoid vasculitis typically affects small to medium-sized vessels with associated peripheral neuropathy (quite often motor), digital gangrene, nail fold infarcts, and palpable purpura. [9] Some patients may have nail fold telangiectasias, with minute digital ulcerations or petechiae and digital pulp papules (Bywaters' lesions) (Fig. 179-2). These papules are considered a manifestation of mild rheumatoid vasculitis because they typically occur without systemic signs of vasculitis. Histopathologic examination of skin biopsy specimens usually shows leukocytoclastic vasculitis with neutrophilic infiltration of the vessel wall, fibrinoid necrosis, and hemorrhage without palisaded granulomatous reaction. [8]

FIGURE 179-2 Bywaters' lesions. Note the purpuric papule on the finger.

Cutaneous small vessel vasculitis usually involves postcapillary venules of the skin, but the same fibrinoid process may occur in arterioles and in larger vessels of the viscera, heart, and central nervous system. The spectrum of clinical

lesions reported in rheumatoid vasculitis is wide and varies with the size and location of the vessels involved and with the extent of the disease. Fortunately, systemic vasculitis is an uncommon manifestation that usually occurs in patients with long-standing disease. Its presence, especially at the onset of the disease process, portends a poor outcome. [10] Patients with evidence of vasculitis affecting the skin should be followed closely for other organ involvement. Rheumatoid vasculitis can present as lower-extremity ulcers. However, pyoderma gangrenosum should be suspected if deep liquefying ulcers with a characteristic purple, undermined border occur in patients with RA. The ulcers may occur at any site but are most common on the abdomen and lower extremities. Leg ulcers may appear in patients with Felty's syndrome, a combination of chronic RA, hypersplenism, and leukopenia (Fig. 179-3).

FIGURE 179-3 Felty's syndrome. A refractory ulcer on the foot of a patient with rheumatoid arthritis and hypersplenism.

Rheumatoid neutrophilic dermatosis is a very rare cutaneous manifestation in patients with severe RA. First described by Ackerman in 1978, these lesions are usually chronic, erythematous, and urticaria-like plaques and papules that are sharply marginated (Fig. 179-4A). Histopathologically, these lesions have a dense infiltrate of neutrophils without leukocytoclasis, in the setting of a mixed infiltrate and often papillary edema (Fig 179-4B). [8] It may be difficult to differentiate rheumatoid neutrophilic dermatosis from acute febrile neutrophilic dermatosis (Sweet's syndrome).

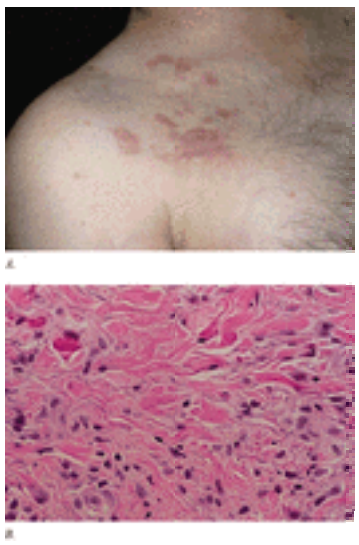

FIGURE 179-4 Rheumatoid neutrophilic dermatosis. *A.* Lesions present as erythematous urticaria-like papules and plaques in a patient with rheumatoid arthritis. *B.* Histopathologically, a mixed dermal infiltrate is predominated by neutrophils without leukocytoclasis. There is often papillary edema.

Lesions that resemble necrobiosis lipoidica diabeticorum have been called superficial ulcerating rheumatoid necrobiosis. These lesions are usually symmetric, on the lower extremities, and occur as multiple, yellow-red, well-circumscribed ulcers that do not become confluent. Telangiectasias as well as local atrophy may occur. The lesions are often confused with venostasis ulcers. Subclinical vasculitis is thought to initiate the palisading granuloma process when the RA is in an acute phase. A papular eruption with clinical and pathologic features of both granuloma annulare and leukocytoclastic vasculitis has been described. These lesions begin superficially and occur in crops, quite often during a flare of arthritis and, occasionally, in association with pyoderma gangrenosum. Other vasculitis syndromes such as erythema elevatum diutinum and livedo vasculitis (segmental hyalinizing vasculitis) have also been described in patients with RA. [7] Skin manifestations such as palmar erythema, erythromelalgia, autoimmune bullous diseases such as epidermolysis bullosa acquisita, yellow nail syndrome, erythema multiforme, erythema nodosum, and urticaria also have been reported in patients with RA and may be associated with the disease process. [7]

NONDERMATOLOGIC EXTRAARTICULAR MANIFESTATIONS In addition to systemic vasculitis, which can affect numerous organ systems, there are multiple nondermatologic extraarticular manifestations of RA. Table 179-2 lists the more common ones.

Type	Manifestations
Ocular	Keratoconjunctivitis sicca, scleritis, episcleritis, scleromalacia
Renal	Amyloidosis and vasculitis
Hematologic	Anemia, thrombocytosis, lymphadenopathy, Felty's syndrome
Neurologic	Entrapment neuropathy, cervical myelopathy, mononeuritis multiplex (vasculitis), peripheral neuropathy
Lung	Pleural effusions, pulmonary fibrosis, bronchiolitis obliterans, rheumatoid nodules, vasculitis
Cardiac	Pericarditis, premature atherosclerosis, vasculitis, nodules, aortic root dilatation

TABLE 179-2 **Nondermatologic Extraarticular Manifestations of Rheumatoid Arthritis**

Laboratory Findings

There is no specific histologic, radiographic, or laboratory test that conclusively permits the diagnosis of RA. Rheumatoid factor, an autoantibody that reacts with the Fc portion of IgG, is found in the serum of 85 percent of patients with RA. Rheumatoid factor should not be used as a definitive screening tool, because it can be found in other disease processes (sarcoidosis, liver diseases, pulmonary fibrotic processes, and cryoglobulinemia). It is also found in approximately 5 percent of the normal population. [9] A false-positive rheumatoid factor can be caused by many factors, including chronic

bacterial infections such as infective endocarditis, tuberculosis, and Lyme disease, as well as by viral diseases such as rubella and infectious mononucleosis.

Treatment

Because the exact cause of RA is unknown, treatment has been directed against various components of the chronic inflammatory process rather than at a specific cause. No single therapy is the treatment of choice. Many drugs, frequently in combination, are used to treat the disease. Because most of the joint damage occurs within the first 2 years, more rapid institution of drugs to attempt to modify the clinical course of disease activity is now suggested. [5] The decision about which drug to use and when to use it is somewhat individualized and determined by the clinical involvement, onset of loss of functional status, and concerns about the safety profile in a given patient.

Analgesics and anti-inflammatories such as salicylates and nonsteroidal anti-inflammatory drugs (NSAIDs) help symptomatically but do not alter the underlying disease course. Selective cyclooxygenase-2 (COX-2) inhibitor NSAIDs, such as celecoxib and rofecoxib, have a reduced incidence of nephrotoxicity and gastrointestinal side effects and are better tolerated. These NSAIDs block the COX-2 isoenzyme, which is upregulated during inflammation, but spare the COX-1 isoenzyme necessary for the regulation of normal cellular processes in the kidney collecting tubules, stomach, endothelial cells, smooth muscles, and platelets. These types of treatments have been considered “first line” in pyramidal treatment protocols in the past. They are still important treatments, often used first in these patients. However, more is now known about the importance of aggressive therapy to alter the disease course in the early years and to prevent permanent joint damage. Therefore, disease-modifying antirheumatic drugs (DMARDs), previously considered “second line,” are now used early in the disease process. Systemic glucocorticoids are potent anti-inflammatory agents but have a serious side effect profile when used over long periods of time. They are not a good option alone for chronic processes, such as RA, but can be used in a low dose with other DMARDs.

DMARDs decrease inflammation (confirmed by a reduction in acute phase reactants), reduce or prevent joint damage, and modify the disease process. [2] The use of DMARDs is recommended early in the disease course, when joint damage is thought to occur. Multiple medications fall into this category (Table 179-3). They may be used alone or in combination, but their use may be limited by loss of efficacy or drug toxicity. Like chemotherapy regimens, combinations of medicines at lower doses may afford a better side effect profile.

Methotrexate
Hydroxychloroquine
Gold salts
Sulfasalazine
Azathioprine
Cyclosporine
Cyclophosphamide
Leflunomide
D-Penicillamine

TABLE 179-3 **Disease-Modifying Antirheumatic Drugs (DMARDs)**

Many of the anti-inflammatory medications reviewed above work through modification of inflammatory cells or their cytokine mediators. Newer additions to the antirheumatic armamentarium are considered biologic response modifiers, and many act directly on those cytokines. The best known and now commercially available members of this category are the anti-TNF-a agents. TNF-a is a proinflammatory agent released by macrophages and T cells contributing to the synovitis and joint destruction.

There are multiple anti–TNF-a compounds, including two that have been approved by the Federal Drug Administration (FDA) in the United States for the treatment of RA: etanercept and infliximab. Etanercept (Enbrel) is a recombinant human TNF dimeric receptor fusion protein consisting of the ligand-binding portion of the human 75-kDa TNF receptor linked to the Fc portion of human IgG1. This treatment is given as a subcutaneous injection twice per week. Infliximab (Remicade) is a chimeric (mouse/human) IgG1 monoclonal antibody to TNF-a. It is given intravenously every 6 to 8 weeks. Both etanercept and infliximab block the interaction between TNF-a and its receptors, rendering it biologically inactive. Both significantly decrease the synovitis and retard the progression of cartilage destruction. [5] Other anti–TNF-a therapies are currently undergoing clinical trials.

Biologic response modifiers are very expensive treatment options. Some authors recommend that TNF-a blocking agents be reserved for patients who do not respond to an adequate trial of one or more DMARDs, including methotrexate. [5] Because TNF-a blocking agents modify the immune response, they may predispose patients to infections, such as tuberculosis, and possibly malignancies. Patients with current or recent serious infections or those predisposed to serious infections (patients with poorly controlled diabetes), as well as those with recent malignancies, may be poor candidates for this therapy. [5] Other biologic agents, such as anti-interleukin (IL)-6 and anti–IL-1 are being studied.

The dermatologist and rheumatologist must work together in the treatment of patients with cutaneous manifestations of RA, which present during phases of intense disease activity. Patients need their underlying rheumatic disease treated aggressively, but proven treatments for these associated dermatologic processes, such as pyoderma gangrenosum, cryoglobulins, vasculitis, and others, should not be forgotten. These specific treatment regimens are beyond the scope of this chapter.

RHEUMATIC FEVER

Rheumatic fever is a delayed sequel to group A ß-hemolytic streptococcal infection of the pharynx. It is an inflammatory disease that can affect the heart, joints, central nervous system, skin, and subcutaneous tissues. There is no specific diagnostic test; rather it is a clinical diagnosis. It is preventable by identification and treatment of streptococcal

tonsillopharyngitis.

Epidemiology

Acute rheumatic fever most commonly occurs in children ages 5 to 15 years after clinically severe tonsillopharyngeal infections. [11] However, it can occur in patients of all ages, even in those with asymptomatic streptococcal infections. Rheumatic fever remains a major health problem in developing countries, likely reflecting inadequate preventive medical care, crowded living conditions, and endemic strains of group A ß-hemolytic streptococcus. The incidence has declined significantly in industrialized nations over the last half century as a result of improved living conditions and the widespread use of penicillin to treat acute streptococcal infections. However, sporadic outbreaks still occur, commonly in crowded inner-city communities, but occasionally in more affluent areas. This disease should not be considered a problem of the past.

Pathogenesis

The exact mechanism by which rheumatic fever results from an infection with group A streptococcal bacteria is unclear. Theories for pathogenesis include direct infection of extrapharyngeal tissues by the bacteria, toxic effects of streptococcal products on host tissues, a serum sickness type reaction, and an autoimmune phenomenon caused by “antigenic mimicry” between antigens on certain bacterial strains and host proteins. [12] Not all strains of group A ß-hemolytic streptococci are rheumatogenic precursors. Specifically, those causing extrapharyngeal infections such as pyodermas and soft tissue infections do not result in rheumatic fever. There are more than 90 known streptococcal M-protein types, and only a limited number have a known association with rheumatic fever. [12] This finding may reflect a common antigenic domain on these M proteins that bears similarity to certain host proteins such as the glycoproteins of heart valves. There likely is a genetic predisposition, as some individuals exposed to endemic strains have not acquired rheumatic fever.

Clinical Features

Acute rheumatic fever can affect many different organ systems. The clinical picture depends upon the specific system involvement in an individual. The diagnostic criteria now known as the Jones Criteria, updated in 1992, [13] emphasize five characteristic clinical features as major manifestations: polyarthritis, carditis, chorea, subcutaneous nodules, and erythema marginatum. Additional nonspecific signs of systemic inflammation are considered minor criteria and include arthralgia, fever, elevated acute phase reactants, and a prolonged PR interval by echocardiogram. The presence of these manifestations in the setting of an antecedent group A streptococcal infection indicates a high probability of acute rheumatic fever.

Rheumatic carditis is the only manifestation that has the potential to cause long-term morbidity and mortality. It usually involves the endocardium, myocardium, and pericardium and almost always is associated with a murmur of valvulitis. [11] Carditis, if present, usually presents in the first 3 weeks of the illness. Diagnosis rests on the presence of new organic cardiac murmurs, cardiomegaly, pericarditis, and or congestive heart failure. [12]

Migratory polyarthritis, the most frequent manifestation, can affect any joint, but most often involves the large joints. It responds well to salicylate therapy, and therefore its presence may be masked by use of anti-inflammatory agents early in the disease course. [12] The diagnosis of chorea is based entirely on clinical signs, which include fleeting local muscular weakness, emotional lability, personality changes, and erratic, jerky, purposeless movements. Chorea does not occur in adult men.

DERMATOLOGIC MANIFESTATIONS The dermatologic manifestations are characteristic but rare. The subcutaneous nodules are small, painless, and localized over bony prominences and in tendon sheaths; they may be seen in the back of the scalp and over the vertebral spine. They last for a week or two and then disappear spontaneously. Erythema marginatum is most apparent in fair-skinned individuals. It begins as an erythematous macule or papule that extends outward while the skin in the center returns to normal. The eruption has a serpiginous pink border and is not usually indurated; it blanches on pressure and changes its shape to the clinician's observation. It is unusual on the face and on the lower extremities and is often hidden by the clothing. Patients are often unaware of its presence. Histopathologically, there is a superficial perivascular infiltrate of lymphocytes and sparse interstitial infiltrate of neutrophils. [8]

Treatment

The eradication of group A streptococcus from the throat of affected individuals is the primary method to prevent acute rheumatic fever. Penicillin is the antimicrobial of choice for treatment of group A streptococcus infection. It has proven efficacy, is inexpensive, and can be administered orally or intramuscularly. For individuals allergic to penicillin, oral cephalosporins or macrolide antibiotics can be substituted. Those affected with acute rheumatic fever should be treated for the primary infection but also are at increased risk of subsequent episodes. Therefore, antibiotic prophylaxis is recommended, especially in endemic areas. Sulfonamides are not effective in the treatment of acute infections but can be used as a preventive antibiotic in addition to those listed above. [14]

The acute inflammatory process, especially the carditis, should be treated with anti-inflammatory agents and rest. Salicylates are adequate for the treatment of mild carditis; more severe cases, however, may require more potent anti-inflammatory agents. Approximately 80 percent of patients who fulfill the criteria for this disorder recover spontaneously. Vaccination against rheumatic fever is not yet available.

GOUT

Gout is a clinical syndrome caused by a group of heterogeneous disorders characterized by deposition of monosodium urate crystals in synovial fluid and other tissues. Clinical manifestations include attacks of acute or chronic joint or periarticular inflammation (gouty arthritis); accumulation of tophi (tophaceous gout); renal impairment (gouty nephropathy); and uric acid calculi in the urogenital tract. The classic presentation is that of an acute lower extremity peripheral joint inflammatory synovitis. The most commonly affected sites are the first metatarsophalangeal joint and the ankle. Diagnosis can be made by demonstration under a polarized microscope of birefringent crystals in synovial fluid or other tissue.

Epidemiology

Gout is a disease that primarily affects middle-aged to elderly men. It rarely occurs in men before late adolescence or in women before menopause. Elderly patients are more likely to have a chronic indolent course. Affected women are more likely to have associated renal insufficiency and a history of diuretic use. [15] Gouty attacks in children are so uncommon that this diagnosis should prompt an evaluation for a malignant or genetic cause.

Pathogenesis

The relationship between hyperuricemia and gout is not well understood. Hyperuricemia is a risk factor for gout, but acute gouty arthritis can occur in patients with normal serum uric acid levels. Moreover, patients with elevated serum uric acid levels may never have gouty arthritis. The typical clinical presentation is in patients with elevated serum uric acid concentrations.

Uric acid is the end product of purine catabolism. Humans lack the enzyme uricase, which breaks down uric acid into a more water-soluble product. When the plasma monosodium urate level exceeds its limit of solubility, it is more likely to precipitate in tissues. Hyperuricemia results from either overproduction or underexcretion of uric acid. Most affected patients are underexcreters. Uric acid renal clearance sufficient to balance production is usually achieved with plasma concentrations below the limit of solubility of monosodium urate in plasma.

Table 179-4 presents a classification of hyperuricemia. Probably less than 10 percent of patients with hyperuricemia or gout excrete excessive quantities of uric acid in a 24-h urine collection. It is usually in this group that identifiable and inherited derangements in mechanisms regulating protein nucleotide synthesis, specifically a deficiency of hypoxanthine-guanine phosphoribosyltransferase (HGPRT), either partial or complete, can be found. In these instances, family history or early presentation may be a clue. The Lesch-Nyhan syndrome, well described but very infrequent, is an extremely severe form of HGPRT deficiency associated with mental retardation, gout, and self-mutilation.

Overproduction of uric acid
Primary hyperuricemia
Idiopathic
Hypoxanthine-guanine phosphoribosyltransferase deficiency
Phosphoribosylpyrophosphate synthetase superactivity
Secondary hyperuricemia
Excessive dietary purine intake
Increased nucleotide turnover (e.g., myeloproliferative and lymphoproliferative disorders, hemolytic diseases, psoriasis)
Diminished excretion of uric acid
Primary hyperuricemia
Idiopathic
Secondary hyperuricemia
Diminished renal function
Inhibition of tubular urate secretion by competitive anions (e.g., keto- and lactic acidosis)
Enhanced tubular urate reabsorption
Dehydration, diuretics
Miscellaneous
Hypertension
Hyperparathyroidism
Certain drugs (e.g., cyclosporine, pyrazinamide, ethambutol, low-dose salicylates)
Lead nephropathy

TABLE 179-4 **Classification of Hyperuricemia**

Uric acid underexcretion occurs in 90 percent of patients with primary yperuricemia. The kidney appears normal and no specific mechanism has been identified at the glomerulus, in the proximal tubule, or in the collecting ducts. Many pharmacologic agents affect tubular function including diuretics, cyclosporine at a low dose, and salicylates (which are frequently used for antiplatelet effect).

The presence of monosodium urate crystals in synovial fluid or other tissues incites an inflammatory response. The initial leukocytes involved may be mononuclear cells releasing IL-1. However, polymorphonuclear leukocytes later ingest the crystal and release multiple inflammatory mediators, initiating further inflammation and tissue damage.

Clinical Manifestations

Patients with gout often follow four clinical stages: asymptomatic hyperuricemia, acute gouty arthritis, intercritical gout (between gouty attacks), and tophaceous gout. [16] Often the patient has asymptomatic hyperuricemia for years. This condition does not necessitate any specific management unless there is a strong family history of gout, uric acid levels are exceedingly high, or there is a history of renal calculi.

Acute gouty arthritis usually occurs in the lower extremities. The most common site of initial involvement is the metatarsophalangeal joint (podagra). The first episode of acute gout usually has a dramatic presentation with a warm, red, tender joint. This may be confused with a sprain, a septic joint, or cellulitis, especially if cytokine-mediated constitutional symptoms such as fever are present. Other differential diagnoses include other forms of arthritis (psoriatic, Reiter's, osteoarthritis, or RA) and pseudogout (chondrocalcinosis). [16]

Intercritical gout describes the interval that occurs between attacks of gout. Initially, these periods are asymptomatic.

Repeat attacks often occur within 6 months to 2 years but become more frequent and severe if left untreated. Chronic tophaceous gout describes the presence of urate crystals in soft tissues. They are usually noted some time after the onset, often up to 10 years after the initial episode of gout. These tophi can occur anywhere, including extracutaneous sites such as cardiac valve leaflets, but the most common sites are overlying joints and tendons. They may also be found on the helix of the ear, overlying nasal cartilage, and on the eyelids and cornea (Fig. 179-5A). They may be confused with rheumatoid nodules, and aspiration or biopsy may prove useful. Subcutaneous tophi present as tender pink nodules or swellings. They may drain clear to white chalky fluid. If left untreated, they can ulcerate and erode into underlying structures. [16] Histopathologic examination shows granulomatous inflammation surrounding radially arranged needle-like spaces (Fig. 179-5B) Differential diagnoses should include rheumatoid nodules, xanthomas, and calcinosis cutis. [16]

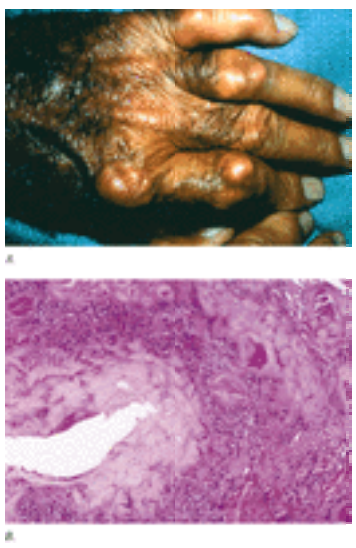

FIGURE 179-5 Gouty tophi. *A.* These tender nodules, often overlying joints and tendons, may drain chalky white material. *B.* On histopathologic examination after formalin fixation, there is granulomatous inflammation surrounding radially arranged needle-like spaces.

Laboratory Presentation/Pathology

Laboratory analysis may reveal elevated uric acid levels, but this finding is not necessary for the diagnosis. Leukocytosis and elevated sedimentation rate are often seen during acute arthritic attacks. The diagnosis depends on the demonstration by polarized microscopy of urate crystals, negatively birefringent needle-shaped crystals, in synovial fluid or tophi. Histopathologic examination of a gouty tophus reveals granulomatous inflammation surrounding yellow-brown urate crystals or needle-like spaces in a radial arrangement, representing crystals dissolved during processing (Fig. 179-5). [8]

Treatment

The goal of therapy in acute gouty attacks is analgesia and reduction in inflammation. The drugs of choice probably still are short-acting NSAIDs such as ibuprofen or indomethacin, which afford relief within hours. These drugs are often used for approximately 1 week and are discontinued when the episode has resolved. The newer COX-2 inhibitors celecoxib and rofecoxib are good alternatives. Because of the age and other characteristics of patients with gout, contraindications to the use of these agents often exist, namely, history of peptic ulceration, renal insufficiency, or a condition requiring anticoagulation. Colchicine remains an alternative to NSAIDs but has a high incidence of gastrointestinal toxicity. Systemic glucocorticoids tapered over 7 to 10 days, intralesional or intraarticular glucocorticoids, and adrenocorticotropic hormone (ACTH) are other options.

Conservative management may help to prevent future attacks and avoid the necessity for prophylaxis. Patients should avoid drugs that decrease the excretion of uric acid such as thiazide or loop diuretics, aspirin, pyrazinamide, or niacin. They should maintain adequate hydration, lose weight, control hypertension and hyperlipidemia, and make diet adjustments. Most people will not tolerate a strict purine-restricted diet. However, limiting cholesterol, fat, meat (especially organoid meat), and alcohol (especially beer) can make a difference. Conservative modification is occasionally adequate without drug therapy.

Lifelong therapy for a patient should be prescribed only when the diagnosis is absolutely established. The usual reasons for such therapy include the following: recurrent acute attacks (particularly if they occur within a short time interval); chronic tophaceous gout; renal calculi; extremely high values of serum uric acid; high serum uric acid levels in the setting of a known familial history of gout (for example, where there is a known deficiency of one of the relevant enzymes previously described); and prophylaxis for patients receiving acute courses of chemotherapy. The protracted use of small doses of colchicine, to a dose of 0.6 mg twice daily, is safe. This regimen is prophylactic against recurrent acute attacks without necessarily creating a need to address the issue of hyperuricemia.

The goal of urate-lowering drugs is to maintain the serum urate level consistently at less than 6 mg/dL. Because 90 percent of patients with gout and hyperuricemia are underexcreters of uric acid, which can be confirmed by a 24-h urine test, uricosurics are an ideal therapy. This treatment should be reserved for patients who are younger than 60 years of age, with normal renal function and, preferably documented, underexcretion of uric acid. Uricosurics include probenecid and sulfinpyrazone. The major risks associated with these medicines include hypersensitivity reactions and increased risk of uric acid nephrolithiasis (avoided by alkalinizing the urine).

The xanthine oxidase inhibitor allopurinol decreases production of uric acid. This drug is indicated for patients with nephrolithiasis, renal impairment, those who failed to respond to uricosuric agents, patients with myeloproliferative

disorders on chemotherapy, and many with hyperuricemia due to enzyme abnormalities. Dosages should be adjusted for the elderly and those with renal failure. Side effects of allopurinol include dyspepsia, headache, diarrhea, a pruritic papular eruption, thrombocytopenia, and hepatic function abnormalities. The syndrome of allopurinol hypersensitivity is well described and has a significant mortality rate. It usually occurs in elderly patients with some renal dysfunction, often with poorly defined gout. Characteristic clinical toxic features include fever, urticaria, leukocytosis, eosinophilia, interstitial nephritis, acute renal failure, granulomatous hepatitis, and toxic epidermal necrolysis.

REFERENCES

1. Lawrence RC et al: Estimates of the prevalence of arthritis and selected musculoskeletal disorders in the United States. *Arthritis Rheum* **41**:778, 1998

2. Seymour HE et al: Anti-TNF agents for rheumatoid arthritis. *Br J Clin Pharmacol* **51**:201, 2001

3. Maini RN, Zvaifler NJ: Rheumatoid arthritis and other synovial disorders, in *Rheumatology*, 2nd ed, edited by JH Klippel, PA Dieppe. Philadelphia, Mosby, 1998, p 5.1

4. Agrawal S et al: Compound heterozygosity of HLA-DR4 and DR1 antigens in Asian Indians increases the risk of extra-articular features in rheumatoid arthritis. *Br J Rheumatol* **34**:41, 1995

5. Kalden JR: How do the biologics fit into the current DMARD armamentarium? *J Rheumatol* **8**(suppl 62):27, 2001

6. Arnett FC et al: The American Rheumatism Association 1987 revised criteria for the classification of rheumatoid arthritis. *Arthritis Rheum* **31**:315, 1988

7. Jorizzo JL, Daniels E: Dermatologic conditions reported in patients with rheumatoid arthritis. *J Am Acad Dermatol* **8**:439, 1983

8. Ackerman AB et al: *Histological Diagnosis of Inflammatory Skin Disease,* 2d ed. Philadelphia, Williams and Wilkins, 1997

9. Craig SD et al: Cutaneous signs of rheumatic disease: Acral purpuric papules in a patient with rheumatoid arthritis. *Arthritis Rheum* **36**:957, 1994

10. Lakhanpal S et al: Clinical and prognostic significance of vasculitis as an early manifestation of connective tissue disease syndromes. *Ann Intern Med* **101**:743, 1984

11. Chakko S, Bisno AL: Acute rheumatic fever, in *Hurst's The Heart*, 10th ed, edited by V Fuster, RW Alexander, RA O'Rourke. New York, McGraw-Hill, 2001, p 1657

12. Dajani A et al: Treatment of acute streptococcal pharyngitis and prevention of rheumatic fever: A statement for health professionals. Committee on Rheumatic Fever, Endocarditis, and Kawasaki Disease of the Council on Cardiovascular Disease in the Young of the American Heart Association. *Pediatrics* **96**:758, 1995

13. Guidelines for the diagnosis of rheumatic fever. Jones Criteria, 1992 update. Special Writing Group of the Committee on Rheumatic Fever, Endocarditis, and Kawasaki Disease of the Council on Cardiovascular Disease in the Young of the American Heart Association. *JAMA* **268**:2069, 1992

14. Thatai D, Turi ZG: Current guidelines for the treatment of patients with rheumatic fever. *Drugs* **57**:545, 1999

15. Terkeltaub RA. Gout and mechanisms of crystal-induced inflammation. *Curr Opin Rheumatol* **5**:510, 1993

16. Touart DM, Sau P: Cutaneous deposition diseases. Pat II. *J Am Acad Dermatol* **39**:527, 1998

T>

Chapter 180

H. Nousari Thomas Provost

Sjögren's Syndrome

HISTORY
EPIDEMIOLOGY
IMMUNOGENETIC STUDIES
ANTIBODY STUDIES
VIRAL STUDIES
CLINICAL MANIFESTATIONS
Xerostomia
Xerophthalmia
Vaginal Dryness
Xeroderma
Inflammatory Dermatoses
Vasculitis
Nervous System Involvement
B Cell Lymphomas
RELATIONSHIP OF ANTI-RO-POSITIVE SS WITH SLE
TREATMENT
Oral Manifestations
Ocular Manifestations
Vaginal Manifestations
Cutaneous Manifestations
Systemic Manifestations

REFERENCES

Sjögren's syndrome (SS) is an autoimmune disease characterized by dryness of the mucous membranes of the eyes, nose, mouth, and vagina. Salivary, lacrimal, and sweat glands are infiltrated by T lymphocytes leading to xerostomia, keratoconjunctivitis sicca, and xerosis. SS may occur alone (primary SS) or in association with other connective tissue diseases and rheumatoid arthritis (secondary SS). Primary SS is a heterogeneous, insidious in onset, and progressive disease with a poorly understood pathogenesis. Some patients have only mucous membrane dryness. Others, especially those with anti-Ro (SS-A) and anti-La (SS-B) antibodies, frequently have extraglandular manifestations including vasculitis and arthritis (Table 180-1 and Table 180-2). The early recognition of SS patients with cutaneous vasculitis identifies individuals at risk for the development of a chronic relapsing disease, as well as peripheral and central nervous system involvement. In the authors' experience, the European Diagnostic criteria for SS (Table 180-3) are still the most reliable. [1]

Arthritis
Pulmonary disease
Interstitial
Necrotizing bronchoalveolitis
Chronic active hepatitis
Primary biliary cirrhosis
Renal disease
Interstitial disease
Glomerulonephritis
Myositis
Thyroiditis
Vasculitis (cutaneous)
Peripheral nervous system disease
Central nervous system disease
B cell lymphoma

TABLE 180-1 **Extraglandular Manifestations of Primary Sjögren's Syndrome**

	Patients with Anti-Ro(SS-A)		
Features	Positive (n = 33)	Negative (n = 42)	P Value
Clinical			
Vasculitis	24	4	0.0005
Lymphadenopathy	19	4	0.0005
Hematologic			
Anemia	19	6	0.0005
Leukopenia	14	3	0.001
Thrombocytopenia	7	1	0.025
Serologic			
Hypergammaglobulinemia	21	8	0.0005
Rheumatoid factor	29	17	0.0005
Cryoglobulinemia	7/13	0/22	0.001
Hypocomplementemia	11	2	0.005

SOURCE: Adapted from Alexander et al: Ro(SS-A) and La(SS-B) antibodies in the clinical spectrum of Sjögren's syndrome. J Rheumatol 9:219, 1982, with permission.

TABLE 180-2 **Association of Clinical and Laboratory Features in Anti-Ro(SS-A) Antibody-Positive Sjögren's Syndrome**

Criteria	Definition
1. Ocular symptoms: Positive response to any of these questions	Daily dry eyes for more than 3 months Recurrent sensations of sand or gravel in the eyes Tear substitutes employed ≥3 times per day
2. Oral symptoms: Positive response to any of these questions	Daily dry mouth for ≥3 months Recurrent or persistently swollen salivary glands in an adult Frequent drinking of liquids to swallow food
3. Ocular signs: Objective evidence of dryness in one of these tests	Schirmer's test ≤5 mm in 5 min Rose Bengal score ≥4 according to van Bijsterveld scoring system
4. Histopathology	A focus score ≥1 in a minor salivary gland (a focus defined as an aggregate of at least 50 mononuclear cells around an intralobular duct; the focus score is defined by the number of foci in 4 mm^2 of glandular tissue)
5. Salivary gland involvement: One of following test positive	Salivary scintigraphy Parotid sialography Unstimulated salivary flow (≤1.5 mL/15 min)
6. Autoantibodies: One of these antibodies present	Antibodies to La (SS-B) and/or Ro (SS-A) Antinuclear antibodies Rheumatoid factor

Sjögren's syndrome present if 4/6 criteria positive (93 percent sensitivity, 93 percent specificity).

SOURCE: Adapted from Vitali C et al: Preliminary criteria for the diagnosis of Sjögren's syndrome. Results of a prospective concerted action supported by the European Community. Arthritis Rheum 36:340, 1993, with permission.

TABLE 180-3 **European Community Criteria for Diagnosis of Sjögren's Syndrome**

HISTORY

Hadden first delineated SS in 1888. In 1892, Mikulicz described a patient with bilateral enlargement of the parotid glands. On biopsy, the glands demonstrated focal lymphocytic infiltrates. In 1933, Henrik Sjögren described the triad of keratoconjunctivitis sicca, xerostomia, and arthritis. In 1953, Castleman and Morgan reported that the pathologic features of Mikulicz disease and SS were identical.

In the early 1960s, Anderson et al. found two precipitin antibodies (detected by gel double-diffusion) in the sera of patients with SS. These were termed SjD and SjT antibodies. In 1963, Rowell et al. described erythema multiforme-like lesions in anti-SjT–positive patients with systemic lupus erythematosus (SLE) [this is the first description of subacute cutaneous lupus erythematosus (SCLE)-like lesions associated with anti-Ro (SS-A) and anti-La (SS-B) antibodies (see below)]. In 1969, Clark et al. described anti-Ro antibodies, and in 1974, Mattioli and Reichlin described anti-La antibodies in patients with SLE. In 1975, Alspaugh and Tan described two precipitin antibody systems (anti-SS-A and anti-SS-B) in patients with SS. Subsequently, an interlaboratory collaboration established the identity of anti-Ro with anti–SS-A and of anti-La with anti–SS-B.

EPIDEMIOLOGY

In North America, SS appears to occur with approximately the same frequency as rheumatoid arthritis. However, the true incidence of this disease remains largely unknown. [2] In Greece and the United Kingdom, a frequency of SS in elderly patients ranging from 3 to 5 percent has been reported. The disease most commonly occurs in women (9:1 female:male ratio). Males with SS generally have a more benign disease with fewer extraglandular manifestations and lower frequencies of anti-Ro and anti-La autoantibodies. Although SS usually occurs in the fourth and fifth decades of life, it has been described in children (albeit uncommonly). [3], [4] Elderly individuals have an increased frequency of both SS and anti-Ro antibodies. In one US study, approximately 12 percent of 103 patients >70 years of age had definite or probable SS; and of these patients with SS, 7 possessed anti-Ro antibodies.

IMMUNOGENETIC STUDIES

The pathogenesis of the syndrome remains largely unknown. In recent years, immunogenetic, autoantibody, and viral studies have provided important information possibly related to the pathogenesis of SS. Immunogenetic studies have described a variety of autoimmune diseases in relatives of SS patients, as well as various autoantibodies. Table 180-4 presents the autoimmune diseases found in 98 primary and secondary SS probands. [5] Furthermore, first-degree relatives of patients with SS demonstrate an increased frequency of antinuclear and anti-Ro antibodies.

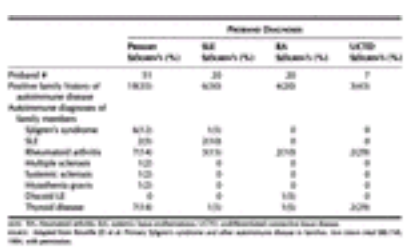

TABLE 180-4 **Autoimmune Diseases in Family Members of Probands with Primary or Secondary Sjögren's Syndrome**

Two antibody response patterns have been noted: (1) anti-Ro and anti-La and (2) anti-Ro without anti-La. The combination of anti-Ro and anti-La occurs more frequently in patients with primary SS than in patients with SLE. This coupled antibody response is associated with the serologically defined human leukocyte antigen (HLA)-B8, -DR3, -DQw2, -DRw52 haplotype (Table 180-5). The second antibody response, anti-Ro without anti-La antibodies, is detected primarily in patients with SLE and is associated with the HLA-DR2, DQwl haplotype. Heterozygosity (HLA-DQw1/DQw2) is associated with the highest anti-Ro antibody titers. Nucleotide sequence analysis of the DQA1 and DQB1 chain alleles reveals that 100 percent of anti-Ro antibody-positive patients with SS or SLE possess a glutamine residue at position 34 of the outermost domain of the DQA1 chain and/or a leucine at position 26 of the outermost domain of the DQB1 chain. Theoretically, these data indicate that the glutamine and leucine residues, located in the floor of the antigen-binding cleft of the HLA-DQA1/DQB1 heterodimer, may be important in binding the antigenic peptide(s) responsible for the anti-Ro and anti-La antibody responses. [6] A single-nucleotide polymorphism (SNP) in intron 3 was found to be strongly associated with the presence of anti-Ro 52-kDa autoantibodies in primary SS. [7] These studies also indicate that the HLA associations in SS are not disease specific; rather, they are associated with the anti-Ro antibody responses (see Table 180-5).

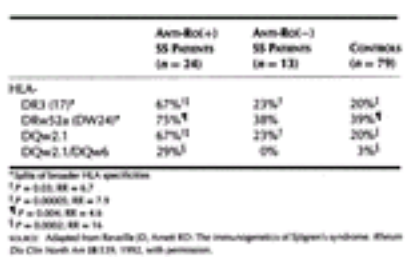

TABLE 180-5 **HLA-DR and DQ Specificities in Anti-Ro(+) and Anti-Ro(–) White Patients with Primary Sjögren's Syndrome**

ANTIBODY STUDIES

By gel double-diffusion, 40 to 45 percent of patients with primary SS possess anti-Ro antibodies, and approximately 20 percent demonstrate anti-La antibodies. However, more sensitive assays, such as hemagglutination and enzyme-linked immunosorbent assay (ELISA) techniques, show the presence of anti-Ro and anti-La antibodies in as many as 95 percent and 70 percent of these patients, respectively. [8] Anti-La antibodies are uncommonly found in the absence of anti-Ro antibodies. Thus, the frequency of anti-Ro and anti-La antibodies in patients with SS depends, at least in part, on the study techniques employed (see Table 180-2).

Immunoblotting studies have demonstrated that the anti-Ro antibody in patients with SS recognizes predominantly a 52-kDa protein. In contradistinction, the anti-Ro antibody in patients with SLE predominantly recognizes a 60-kDa protein. Mothers of infants with neonatal lupus possess anti-Ro antibodies that predominantly recognize the 52-kDa protein. [9] The 52-kDa and 60-kDa nuclear and cytoplasmic proteins are associated with small RNAs known as hY1, hY3, hY4, and hY5 RNAs. Molecular cloning studies of the Ro autoantigens have determined that the 52-kDa and the 60-kDa proteins are different, with little, if any, sequence homology. The 60-kDa protein has an RNA binding domain as well as a zinc finger motif. The RNA binding domain presumably binds with the hY RNAs, whereas the putative zinc finger motif of the 60-kDa protein may interact with the 52-kDa protein. The 52-kDa Ro protein contains a zinc finger as well as leucine zipper domains; consequently, it has been proposed that the 52-kDa Ro protein may be involved in the regulation of gene expression.

Anti-La antibodies are directed against an RNA binding protein that transiently binds all RNA polymerase III transcripts, as well as precursors of tRNA and 5sRNA.

Studies indicate that cells undergoing ultraviolet-induced apoptosis express a species of the Ro and La autoantigens on the cell surface membranes. Furthermore, keratinocytes cultured in the presence of 17ß-estradiol express these antigens on the keratinocyte cell surface. These studies suggest possible immune-mediated cellular injury mechanisms involving anti-Ro and anti-La autoantibodies. However, epitope mapping of the Ro and La peptides has thus far failed to establish a definite relationship of one or several epitopes with clinical disease expression (LE or SS).

Recently, a new subset of autoantibodies to proteins other than Ro and La was found in the sera of SS patients. Some of these antigens are proteins located in salivary and lacrimal ducts and acini, and include alpha fodrin, a membrane skeleton protein associated with ion channels and pumps, and muscarinic 3 receptor (M3R). There is a lack of definitive evidence for a primary pathogenic role of these recently described antibodies in SS. However, unique granzyme B and caspase 3 cleavage fragments of fodrin are also recognized by SS T cells, thus linking the humoral and cellular reactions in this disease. [10], [11], [12] and [13]

VIRAL STUDIES

A possible viral pathogenesis of SS is an area of active study. The salivary gland, the main site of mucous membrane involvement in SS, contains a number of viruses in their latent state. At present, all herpesviruses are possible candidates, but the strongest candidate is the Epstein-Barr virus (EBV). Biopsies of salivary glands from patients with SS contain increased Epstein-Barr viral DNA. This finding, however, is not specific for SS and has been detected n organ transplant patients receiving immune suppressive medication who have no evidence of SS.

Furthermore, experimental studies show that fodrin can be cleaved by EBV and these products induce a T cell-mediated reaction in SS. [14] Studies of the human acquired immunodeficiency syndrome (AIDS) have detected diffuse infiltrative lymphocytosis syndrome (DILS), a syndrome associated with HIV-1 infection (most commonly, AIDS) that may present with sicca features. [15] Clinically, most patients with DILS have bilateral parotid gland enlargement and xerostomia. Xerophthalmia and keratoconjunctivitis sicca occur less frequently. Although these clinical features are reminiscent of SS, there are many immunologic differences between SS and DILS. For example, in DILS, CD8 T cells predominate in the lymphocytic tissue infiltrate and peripheral lymphocytosis. In contradistinction, the inflammatory infiltrate in SS is predominantly CD4 positive. In addition, the frequency of autoantibody formation is much higher in SS, and the HLA associations in SS are markedly different from those found in DILS.

Recent studies show that several hepatitis C-infected patients have lymphohistiocytic infiltrates of the salivary and lacrimal glands. Although some of these patients complain of sicca syndrome, only a few will develop a full-blown clinical, histologic, or serologic syndrome. [16], [17]

CLINICAL MANIFESTATIONS

Mucous membrane dryness (eyes, mouth, vagina) is universally present in patients with SS. However, dryness of only one or two mucous membranes may predominate, and the disease may be heralded for several years by dryness involving only one mucous membrane.

Xerostomia

Xerostomia is caused by a chronic progressive destruction of the major and minor salivary glands by the lymphocytic inflammatory infiltrate. Dryness of the mouth is insidious in onset and progressively worsens. As a consequence, patients may have difficulty swallowing and may be unable to carry on a conversation without the frequent ingestion of fluids. Physical examination during the early phase of SS may fail to uncover dryness in the oral cavity. However, with

progression of the disease, an absence of the infralingual salivary pool becomes evident, and the patient may fail to produce any saliva or the saliva may be cloudy and stringy.

Several complications of xerostomia occur. Oral candidiasis is frequent, especially in those patients who wear dentures, and approximately one-third of patients with SS develop this complication. The oral candidiasis may manifest itself as perlèche or intraoral erythematous/whitish plaques. Patients with SS also have an increased frequency of dental caries, especially along the gingival margin. These caries are difficult to repair, making tooth restoration problematic. Consequently, many patients with SS have partial plates or are completely edentulous.

The major salivary glands are enlarged in approximately 20 percent of patients. Enlargement is generally transient and unilateral but on occasion is bilateral and, uncommonly, permanent. Both the parotid and submandibular glands are affected. Blockage of the salivary gland ducts by mucoid salivary secretion is responsible for the transient enlargement. Secondary infection is uncommon.

The diagnosis of the oral component of SS is difficult. Various drugs including sedatives, antipsychotics, antidepressants, antihistamines, anticholinergics, and diuretics may produce dryness. Also to be considered in the differential diagnosis are viral infections such as HIV. Radiation therapy to the neck, graft-versus-host disease, sarcoidosis, and amyloidosis may induce oral dryness. Furthermore, neoplasms, cirrhosis, and gonadal hypofunction may be associated with salivary gland enlargement.

PATHOLOGY OF SALIVARY GLANDS Although it is possible to investigate salivary gland function with sialometry and sialography, the most common technique is a lip biopsy to examine the minor salivary gland pathology. The lower lip is injected with a local anesthetic, and a 1-inch vertical incision is made (Fig. 180-1). The vermilion border is identified at all times and avoided. After the incision, five minor salivary glands are identified and excised with straight scissors. The incision is then closed with two or three absorbable sutures.

FIGURE 180-1 Lip biopsy technique exposing minor salivary glands (see text for description).

Both parenchymal and sialographic abnormalities detected by magnetic resonance imaging (MRI) and MR sialography are associated with the presence of Ro/SSA antibodies but not with age of the patient, disease duration, salivary flow rate, or the presence of hypergammaglobulinemia or extraglandular manifestations. [18] The classic pathology associated with SS is a patchy inflammatory infiltrate composed of mononuclear cells involving both the ductal and acinar tissue (Fig. 180-2). Most classifications are based on the detection of aggregates of 50 or more mononuclear cells. [19] Although the lip biopsy is proposed to be the “gold standard” for the diagnosis of SS, several caveats are important. Initially, the inflammatory infiltrate is patchy and may involve only one of several glands. In addition, large areas of an individual gland may be totally uninvolved; thus, sampling error is problematic. In addition, with long-standing SS, fatty metamorphosis and fibrosis of minor salivary glands occur, producing total destruction. No allowance for this end-stage SS is accommodated by the present minor salivary gland SS diagnostic criteria.

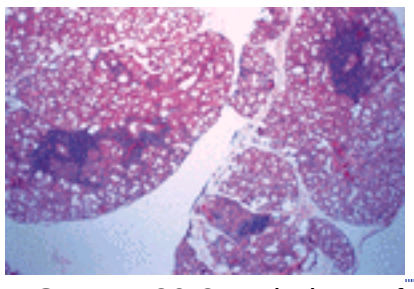

FIGURE 180-2 Pathology of SS in a minor salivary gland biopsy. Note patchy aggregates of lymphocytes involving glandular and ductal regions of the gland. Also note that large areas of gland are free of disease.

Polyclonal lymphohistiocytic infiltrates composed mostly of B cells and CD4-positive T lymphocytes are typical. B cell-attracting chemokines such as BCA1 (CXCL13) and SDF-1 (CXCL12) are abnormally and ectopically expressed in the germinal center-like structures in SS. [20] BAFF (BLyS, TALL-1, THANK, zTNF4) is a member of the tumor necrosis factor (TNF) superfamily that specifically regulates B lymphocyte proliferation and survival. In human and animal models with SS, upregulation of BAFF in blood and salivary gland occurs. [21] High levels of B7 costimulatory molecules and antiapoptotic molecules, such as Bcl-2 and Bcl-x, have a direct correlation with B cell oligoclonality and higher risk for the development of B cell lymphoma in SS. High levels of costimulatory molecules such as CD40 and CD40 ligand (CD154) and Fas-FasL (Fas ligand) may also be involved in apoptotic mechanisms in ductal acinar disease, as well as in the germinal-like structures and B cell lymphoma in SS. [22], [23], [24] and [25] Muscarinic 3 receptors are upregulated in the salivary and lacrimal acini of patients with primary SS. This phenomenon may explain the role of antimuscarinic drugs in the treatment of these patients. [26] The role of Aquaporin-5, an important protein involved in the water transport in salivary

and lacrimal glands, in the pathogenesis of SS still remains to be elucidated. [27], [28]

Xerophthalmia

The first symptoms of ocular dryness include a foreign-body sensation secondary to repeated blinking and rubbing of the eyes, which produces minor corneal abrasions. The minor corneal abrasions may produce photophobia. With severe dryness, a deep aching sensation may occur.

Ocular SS is commonly manifested by conjunctival injection. SS is one of the few conditions that may cause symmetric enlargement of the lacrimal or salivary glands (Table 180-6). However, rapid enlargement of the lacrimal or salivary glands, especially in an asymmetric fashion, should prompt studies to exclude a superimposed B cell lymphoma.

Sjögren's syndrome
Sarcoidosis
DILS
Lymphoma

NOTE: DILS, diffuse infiltrative lymphocytosis syndrome

TABLE 180-6 **Disorders Associated with Symmetric Enlargement of Lacrimal and/or Salivary Glands**

Filiform defects along the inferior portion of the cornea adjacent to the conjunctiva may occur and are detected by the rose bengal dye test. Patients with advanced SS may display a marked decrease in the aqueous component and an increased viscosity of their tears. Some can pull long strings of mucin from their eyes. Testing for ocular SS includes the Schirmer's test. The inferior eyelid is anesthetized, and a Whatman paper wick is folded over the lower eyelid. The migration of fluid along the wick is measured during a 5-min time period. Values of 5 mm or less are highly suggestive of SS.

In addition to these tests, lysosome, lactoferrin, and $ß_2$-macroglobulin assays have been used to evaluate ocular SS. These tests are more investigational and have not achieved widespread clinical acceptance.

Vaginal Dryness

Vaginal dryness in patients with SS is much more common than realized. It is not a symptom freely volunteered by the patient and generally must be elicited by direct questioning. Dyspareunia may be the initial manifestation of SS, antedating the development of other mucous membrane involvement by years. Yeast and bacterial vaginal infections are common.

Xeroderma

Table 180-7 lists the cutaneous manifestations of SS. Xerosis is a common complaint. Pruritus frequently accompanies the xerosis. [29] Patients with SS also complain of dryness of the hair and loss of luster as well as of severe dryness of the external ear canal with impaction of dried cerumen.

Xerosis
Palpable and nonpalpable purpura
Urticaria-like vasculitic lesions
Erythema multiforme-like, erythema perstans, erythema nodosum lesions
Cutaneous lymphoma
Nodular amyloidosis
Sweet's syndrome
Annular erythematous lesion (donut lesion) described in Japanese patients

TABLE 180-7 **Cutaneous Manifestations of Sjögren's Syndrome**

The pathogenesis of the xerosis is unknown. A lymphohistiocytic infiltrate of eccrine sweat glands has been reported. A decreased sweating response to pilocarpine has been observed in some patients with SS. It should be emphasized, however, that the major lubrication of the skin is provided by sebaceous glands. Whether or not the lymphohistiocytic infiltrate detected in the salivary glands and in other organs in SS also involves the sebaceous glands is not known.

Inflammatory Dermatoses

In addition to xerosis, approximately 20 percent of patients with SS have Raynaud's phenomenon. Furthermore, patients with SS uncommonly demonstrate erythematous nodules on the lower extremities. These lesions are not specific, and they may represent lesions of erythema nodosum, medium-sized vasculitis, or cutaneous extravascular necrotizing granulomas.

Neutrophilic dermatosis, such as Sweet's syndrome and pyoderma gangrenosum, has been detected in patients with SS. Cutaneous lymphomas and nodular amyloidosis have also been reported.

Japanese investigators report an erythematous, elevated, plaque-like lesion with central clearing resembling a “doughnut” in patients with SS. [30] Large quantities of mucin, a hydroscopic substance, are present in these erythematous, indurated, plaque-like lesions, which appear to fall into the clinicopathologic spectrum of lupus tumidus.

Vasculitis

The most important cutaneous feature associated with SS is vasculitis. Although medium-sized (polyarteritis nodosa-like) vessel vasculitis has been observed in patients with SS, the principal vasculitis is the one affecting small blood vessels. The most common morphologic lesions of this vasculitis are palpable and nonpalpable purpura and urticaria-like lesions (Fig. 180-3; Table 180-7 and Table 180-8). [31] The nonpalpable purpuric lesions usually mimic the presentation of Schamberg pigmented purpura disease (capillaritis). These lesions also are clinically, immunopathologically, and serologically indistinguishable from the lesions of Waldenström benign hypergammaglobulinemic purpura. Approximately 25 to 30 percent of patients with Waldenström benign hypergammaglobulinemic purpura have been reported to have clear evidence of SS. However, it is believed that most, if not all, of patients with Waldenström benign hypergammaglobulinemic purpura have SS, SLE, or overlap syndromes in the setting of anti-Ro antibodies and/or cryoglobulinemia type 2 or 3. Some of the SS patients who have both palpable and nonpalpable purpuric lesions may also have cryoglobulinemia type 2 or 3. The presence of the cryoglobulinemia syndrome in the setting of SS should prompt the exclusion of a superimposed B cell lymphoma.

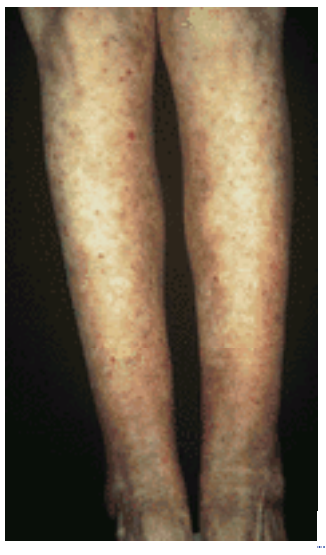

FIGURE 180-3 Palpable purpuric lesions of the lower extremities. Note, in addition to new lesions, the widespread deposition of hemosiderin (brownish patches), which is evidence of previous vasculitic lesions.

A. Small blood vessel vasculitis
1. Purpuric lesions
  a) Lymphocyte predominant vasculitis
    - Rare
    - Nonpalpable > palpable purpura
    - Clinically and histologically: mimic Schamberg's disease
    - DIF: negative
    - Associated with the so-called benign hypergammaglobulinemic purpura of Waldeström and cryoglobulinemia types 2 and 3
  b) Neutrophil predominant vasculitis
    - Common
    - Palpable > nonpalpable purpura
    - Associated with cryoglobulinemia types 2 and 3 and CTD, SS, hypersensitivity vasculitis
    - DIF very useful for cryoglobulinemia (strong IgM and C3) and to exclude IgA vasculitis
2. Urticaria-like lesions
  a) Hypocomplementemic urticarial vasculitis
    - Syndrome: arthritis, renal, ocular, etc.
    - Very-low complement levels
    - Abundant PMN and leukocytoclasia
    - Typical DIF finding: granular IgG along the BMZ and in vessels
  b) Normocomplementemic urticarial vasculitis
    - Bland histology
    - DIF inconsistent
    - Subset of hypersensitivity vasculitis (CLA)
B. Medium-sized vasculitis
    - Rare in SS
    - Occurs in severe cases of SS
    - PAN-like presentation (nodules, ulceration, livedo reticularis, digital infarcts)
    - Higher incidence of mononeuritis multiplex

NOTE: BMZ, basement membrane zone; CLA, cutaneous leukocytoclastic angiitis; CTD, connective-tissue disease; DIF, direct immunofluorescence; PAN, polyarteritis nodosa.

TABLE 180-8 **Cutaneous Vasculitis in Patients with Sjögren's Syndrome**

The second most common type of vasculitic lesion in patients with SS is hypocomplementemic urticarial vasculitis, although the normocomplementemic variant also occurs in these patients.

In both types of vasculitis—lymphocytic and neutrophilic—the architecture of the blood vessel is disrupted by the inflammatory cells.

Most of the nonpalpable purpura lesions, especially those that mimic pigment purpura belong to the lymphocytic vasculitis histology group. By contrast, most of the palpable purpura and all of the urticarial vasculitis fall into the leukocytoclastic vasculitis group. [32], [33]

Anti-La and/or anti-Ro antibodies, rheumatoid factor, antinuclear antibodies, cryoglobulins, hypocomplementemia, and hypergammaglobulinemia are significantly increased in patients with SS with neutrophilic inflammatory vascular disease (Table 180-2 and Table 180-9). The mononuclear inflammatory vascular process in patients with SS generally fails to demonstrate these serologic associations.

Pathology	ANA%	Glob%	RF%	Anti-Ro%	Anti-La%
Leukocytoclastic angiitis (%), n = 27	21(78)	14(52)	18(67)	20(74)	12(44)
Mononuclear vasculopathy (%), n = 18	7(39)	2(11)	3(17)	2(11)	2(11)
P-value	0.02	0.01	0.002	0.00006	0.036

NOTE: ANA, antinuclear antibody; Glob, hypergammaglobulinemia; RF, rheumatoid factor.
SOURCE: Adapted from Molina R et al: Two histopathologic prototypes of inflammatory vascular disease in Sjögren's syndrome: Differential association with seronegativity to rheumatoid factor and antibodies to Ro(SS-A) and with hypocomplementemia. Arthritis Rheum 28:1251, 1985, with permission.

TABLE 180-9 **Serologic Correlation with Histopathologic Type of Vascular Disease in Sjögren's Syndrome**

Nervous System Involvement

The inflammatory vascular disease in patients with SS recurs over time. In general, small blood vessels (postcapillary venules and arterioles) may be involved with peripheral and central nervous system (CNS) disease (Table 180-10). Spinal fluid studies, evoked sensory response testing, MRI, and autopsy studies have all documented the presence of peripheral and CNS disease in SS. The autopsy and MRI data suggest diffuse small cerebral vasculitis.

	Number (%) of SS Patients with Nervous System Disease		
Pathology (n)	Central Alone	Peripheral Alone	Both
Leukocytoclastic angiitis (17)	3(18)	6(35)	8(47)
Mononuclear vasculopathy (16)	2(12)	3(18)	11(70)
Total (33)	5(15)	9(28)	19(58)

SOURCE: Adapted from Molina R et al: Peripheral inflammatory vascular disease in Sjögren's syndrome: Association with nervous system complications. Arthritis Rheum 28:1241, 1985, with permission.

TABLE 180-10 **Central and Peripheral Nervous System Disease in Patients with Sjögren's Syndrome with Peripheral Vascular Disease**

Table 180-11 lists the peripheral and CNS manifestations that occur in patients with SS. Originally, the presence of CNS disease associated with SS was controversial. Spanish investigators have confirmed the presence of a multiple sclerosis-like CNS disease process in association with SS, and a Finnish group confirmed the presence of CNS disease in their SS population. [34] These latter investigators describe a higher frequency of CNS complications in patients with SS than that previously reported from the United States. An increased incidence of psychiatric disorders in patients with SS has been reported.

Brain
Cognitive dysfunction
Alzheimer-like disease
Multiple sclerosis-like disease
Aseptic meningitis
Focal neurologic disease
Intranuclear ophthalmoplegia
Spinal cord
Transverse myelopathy
Neurogenic bladder
Rectal incontinence
Peripheral nervous system
Trigeminal neuropathy
Sensory neuronopathy
Sensorineural hearing defect

TABLE 180-11 **Some of the Neurologic Features Associated with Sjögren's Syndrome**

B Cell Lymphomas

Patients with SS frequently have B cell proliferation characterized by hypergammaglobulinemia. Monoclonal light chains and heavy chains have been detected in patients with SS with very sensitive immunofixation techniques. Patients with SS are also at increased risk for developing B cell lymphomas. [35] In some cases, the lymphomas involve the salivary glands, especially the parotids; in other cases, they involve the skin. Anti-Ro antibody-positive patients with SS appear to be at greater risk to develop B cell proliferative responses (Table 180-2).

Eighty-five percent of SS patients with non-Hodgkin's follicular B cell lymphomas have a characteristic chromosome translocation involving the JH segment of the immunoglobulin heavy chain (14q32.3) and the antiapoptotic Bcl-2 gene (18q 21.3). Almost all of the lymphomas in SS are classified as marginal cell lymphomas.

It is thought that these patients are at a higher risk for developing extranodal B cell lymphomas and thus they should be followed closely. EBV and other viruses do not seem to be implicated in the development of lymphoma in patients with SS. In patients with primary SS, 1 in 5 deaths is attributable to lymphoma. The presence of palpable purpura and low C4 levels at the first visit adequately distinguishes high-risk patients (type I primary SS) from patients with an uncomplicated disease course [type II (low-risk) primary SS]. [36]

RELATIONSHIP OF ANTI-RO-POSITIVE SS WITH SLE

A close association exists between the phenotypic expression of SS and SLE, occurring in HLA-DR3, anti-Ro–positive female patients. Figure 180-4 depicts this interrelationship. A large number of these female patients with anti-Ro and SLE have an exquisite photosensitivity. Many of these patients relate experiencing sun burning through window glass. [37], [38]

FIGURE 180-4 Schematic representation of the interrelationship between the various clinical presentations of HLA-DR3, anti-Ro (SS-A) antibody-positive female patients (see text for discussion).

Asymptomatic anti-Ro antibody-positive patients may alternatively develop dryness of their mucous membranes and demonstrate a phenotypic expression of SS. With time, both the anti-Ro antibody-positive patients with SS and the anti-Ro antibody-positive patients with SLE may develop variable features of both SS and SLE. These patients with SS/SLE have a high frequency of cutaneous disease including subacute cutaneous lupus lesions and cutaneous vasculitis. [39] CNS manifestations and pulmonary interstitial disease are prominent features. Renal disease occurs less frequently.

The factors that determine the phenotypic expression of these anti-Ro antibody-positive, HLA-DR3–positive female patients are unknown. Certainly, ultraviolet light precipitates and exacerbates the cutaneous lupus disease process in anti-Ro antibody-positive patients with SLE. However, clinical experience indicates that those HLA-DR3–positive, anti-Ro antibody-positive female patients with the SS phenotype are not photosensitive.

Despite the phenotypic differences, all of these HLA-DR3, anti-Ro antibody-positive females with asymptomatic SS, SLE, or SS/SLE are at risk during their childbearing years to give birth to children with the neonatal LE syndrome. [40] These women may have a dynamic disease process associated with a great deal of morbidity and cutaneous features of vasculitis or SCLE lesions extending over a 30- to 40-year period.

TREATMENT

Oral Manifestations

The treatment of xerostomia is difficult. [41] Methylcellulose saliva substitutes are generally poor, with low patient acceptance. The frequent ingestion of water or other sugarless fluids is generally the most acceptable form of therapy. Chewing sugarless gum helps massage the minor and major salivary glands, resulting in increased fluid production.

Muscarinic M3 agonists, such as oral pilocarpine (Salagen) and its analogue cevimeline (Evoxac), increase tear and saliva flow. [42] These drugs may also effectively stimulate saliva production, and both have been approved by the FDA for the treatment of dry mouth of SS, as well as radiation-associated dry mouth. Prompt treatment of oral candidiasis, prophylactic fluoride treatment, and frequent routine dental examinations are recommended. Blockade of TNF-a with infliximab is safe and effective and improves the global assessment (e.g., sicca symptoms, as well as more objective measurements such as sedimentation rate, salivary flow rate, and the Schirmer's test in SS patients.) [43]

Ocular Manifestations

Ocular SS is treated successfully with artificial tears. Many preservative-free artificial tear preparations are now commercially available. Lubricant ointments, applied at night, are also of value. According to patients, the use of a humidifier in the bedroom to increase ambient humidity helps with both the ocular and the oral symptomatology. Patients also have indicated that using underwater goggles that contain water-soaked soft cotton at night is an effective means of relieving ocular dryness. Occlusion of the nasal lacrimal duct is a common therapeutic approach to preserve moisture in the eye. A temporary punctal occlusion is first tried; if successful, a permanent ductal occlusion after local anesthesia can be achieved with either an argon laser or electrocautery. Recent studies have shown the effectiveness of cyclosporine eyedrops in sicca syndrome. [44]

Vaginal Manifestations

Vaginal dryness is a problem. Vaginal moisturizers (e.g., Replens) are commercially available, but in the authors' experience, they are of limited value. The application of Vaseline after bathing has some benefit. The frequent use of vaginal suppositories at night is helpful in combating *Candida* infections.

Cutaneous Manifestations

Xeroderma can be treated with moisturizing topical preparations. After bathing, patients pat their skin dry, leaving a residue of moisture on the skin. A liberal amount of moisturizer is applied to predetermined areas of xerosis, trapping moisture between the moisturizer and the skin.

As a general measure to combat mucous membrane dryness and xeroderma, the ambient humidity should be increased in the patient's living area by placing a humidifier on the heating system or, as noted above, using a humidifier in the bedroom.

Systemic Manifestations

Patients with primary SS frequently complain of myalgias and arthralgias; hydroxychloroquine has been used with some success in the treatment of these symptoms. [45] A retrospective study with hydroxychloroquine for at least a 2-year period of time demonstrated an approximate 50 percent improvement in ocular symptoms of pain and dryness, as well as an

improvement in the rose bengal dye staining. The Schirmer's test improved by 2 mm or more for 5 min in approximately 50 percent of patients. The salivary flow rate increased in at least 82 percent of patients, and the physician global assessment indicated an improvement in more than 62 percent of the patients. Hydroxychloroquine at doses less than 6.5 mg/kg per day is extremely safe even during pregnancy. Smoking, through inhibition of cytochrome microsomal proteins, may reduce the effectiveness of hydroxychloroquine. [46]

The presence of cutaneous vasculitis should prompt a search for evidence of systemic involvement in which rheumatologists and/or neurologists participate. Cerebral involvement or peripheral nervous system involvement detected by MRI or positron emission tomography (PET) may warrant the need for long-term suppression of the vascular insult. The risk/benefit ratio of high-dose steroids, pulse glucocorticoids, and immunosuppressive agents such as azathioprine, mycophenolate mofetil, and cyclophosphamide should be considered in patients with severe disease.

REFERENCES

1. Vitali C et al: Preliminary criteria for the diagnosis of Sjögren's syndrome. Results of a prospective concerted action supported by the European community. *Arthritis Rheum* **36**:340, 1993

2. Pillemer SR et al: Incidence of physician-diagnosed primary Sjögren syndrome in residents of Olmsted County, Minnesota. *Mayo Clin Proc* **76**:593, 2001

3. Drosos AA et al: Subgroups of primary Sjögren's syndrome: Sjögren's syndrome in male and pediatric Greek patients. *Ann Rheum Dis* **56**:333, 1997

4. Tomiita M et al: The clinical features of Sjögren's syndrome in Japanese children. *Acta Paediatr Jpn* **39**:268, 1997

5. Reveille JD et al: Primary Sjögren's syndrome and other autoimmune diseases in families. Prevalence and immunogenetic studies in six kindreds. *Ann Intern Med* **101**:748, 1984

6. Bolstad AI et al: HLA markers and clinical characteristics in Caucasians with primary Sjögren's syndrome. *J Rheumatol* **28**:1554, 2001

7. Nakken B et al: Polymorphisms of the Ro52 gene associated with anti-Ro 52-kd autoantibodies in patients with primary Sjögren's syndrome. *Arthritis Rheum* **44**:638, 2001

8. Provost TT et al: The relationship between anti-Ro (SS-A) precipitin antibody positive Sjögren's syndrome and anti-Ro (SS-A) precipitin antibody positive lupus erythematosus. *Arch Dermatol* **124**:63, 1988

9. Boutjdir M et al: Arrhythmogenicity of IgG and anti-52 kD SSA/Ro affinity purified antibodies from mothers of children with congenital heart block. *Circ Res* **80**:354, 1997

10. Nagaraju K et al: Novel fragments of the Sjögren's syndrome autoantigens alpha-fodrin and type 3 muscarinic acetylcholine receptor generated during cytotoxic lymphocyte granule-induced cell death. *Arthritis Rheum* **44**:2376, 2001

11. Maeno N et al: Anti-alpha-fodrin antibodies in Sjögren's syndrome in children. *J Rheumatol* **28**:860, 2001

12. Kuwana M et al: Autoantibodies to the amino-terminal fragment of beta-fodrin expressed in glandular epithelial cells in patients with Sjögren's syndrome. *J Immunol* **167**:5449, 2001

13. Ishimaru N et al: Possible role of organ-specific autoantigen for Fas ligand-mediated activation-induced cell death in murine Sjögren's syndrome. *J Immunol* **167**:6031, 2001

14. Inoue H et al: Possible involvement of EBV-mediated alpha-fodrin cleavage for organ-specific autoantigen in Sjögren's syndrome. *J Immunol* **166**:5801, 2001

15. Itescu S, Winchester R: Diffuse infiltrative lymphocytosis syndrome: A disorder occurring in human immune deficiency virus-1 infection that may present as a sicca syndrome. *Rheum Dis Clin North Am* **18**:683, 1992

16. Manns MP, Rambusch EG: Autoimmunity and extrahepatic manifestations of hepatitis C virus infection. *J Hepatol* **31**(Suppl 1):39, 1999

17. Loustaud-Ratti V et al: Prevalence and characteristics of Sjögren's syndrome or sicca syndrome in chronic hepatitis C virus infection: A prospective study. *J Rheumatol* **28**:2245, 2001

18. Niemela RK et al: Magnetic resonance imaging and magnetic resonance sialography of parotid glands in primary Sjögren's syndrome. *Arthritis Rheum* **45**:512, 2001

19. Daniels TE, Fox PC: Salivary and oral components of Sjögren's syndrome. *Rheum Dis Clin North Am* **18**:571, 1992

20. Amft N et al: Ectopic expression of the B cell-attracting chemokine BCA-1 (CXCL13) on endothelial cells and within lymphoid follicles contributes to the establishment of germinal center-like structures in Sjögren's syndrome. *Arthritis Rheum* **44**:2633, 2001

21. Groom J et al: Association of BAFF/BLyS overexpression and altered B cell differentiation with Sjögren's syndrome. *J Clin Invest* **109**:59, 2002

22. Fleck M et al: Treatment of chronic sialadenitis in a murine model of Sjögren's syndrome by local FasL gene transfer. *Arthritis Rheum* **44**:964, 2001

23. Masago R et al: Elevated proapoptotic Bax and caspase 3 activation in the NOD.scid model of Sjögren's syndrome. *Arthritis Rheum* **44**:693, 2001

24. Abu-Helu RF et al: Induction of salivary gland epithelial cell injury in Sjögren's syndrome: In vitro assessment of T cell-derived cytokines and Fas protein expression. *J Autoimmun* **17**:141, 2001

25. Ohlsson M et al: Fas-induced apoptosis is a rare event in Sjögren's syndrome. *Lab Invest* **81**:95, 2001

26. Beroukas D et al: Upregulation of M3-muscarinic receptors in labial salivary gland acini in primary Sjögren's syndrome. *Lab Invest* **82**:203, 2002

27. Beroukas D et al: Subcellular distribution of Aquaporin-5 in salivary glands in primary Sjögren's syndrome. *Lancet* **358**:1875, 2001

28. Steinfeld S et al: Abnormal distribution of Aquaporin-5 water channel protein in salivary glands from Sjögren's syndrome patients. *Lab Invest* **81**:143, 2001

29. Markusse HM et al: Primary Sjögren's syndrome: Clinical spectrum and mode of presentation based on an analysis of 50 patients selected from a Department of Rheumatology. *Netherlands J Med* **40**:125, 1992

30. Nishikawa T, Provost TT: Differences in clinical, serologic, and immunogenetic features of White versus Oriental anti-SSA/Ro positive patients [editorial]. *J Am Acad Dermatol* **25**:6563, 1991

31. Tsokos M et al: Vasculitis in primary Sjögren's syndrome: Histologic classification and clinical presentation. *Am J Clin Pathol* **88**:26, 1987

32. Stone JH, Nousari HC: “Essential” cutaneous vasculitis: what every rheumatologist should know about vasculitis of the skin. *Curr Opin Rheumatol* **13**:23, 2001

33. Davis MD et al: Clinicopathologic correlation of hypocomplementemic and normocomplementemic urticarial vasculitis. *J Am Acad Dermatol* **38**:899, 1998

34. Heitaharju A et al: Nervous system manifestations in Sjögren's syndrome. *Acta Neurol Scand* **81**:144, 1990

35. Valesini G et al: Differential risk of non-Hodgkin's lymphoma in Italian patients with primary Sjögren's syndrome. *J Rheumatol* **24**:2376, 1997

36. Ioannidis JP et al: Long-term risk of mortality and lymphoproliferative disease and predictive classification of primary Sjögren's syndrome. *Arthritis Rheum* **46**:741, 2002

37. Simmons-O'Brien E et al: 100 anti-Ro(SS-A) antibody positive patients: A 10-year follow-up. *Medicine (Baltimore)* **74**:109, 1995

38. Provost TT et al: Significance of the anti-Ro(SS-A) antibody in the evaluation of patients with cutaneous manifestations of connective tissue diseases. *J Am Acad Dermatol* **35**:147, 1996

39. Provost TT: Anti-Ro(SS-A) antibody positive Sjögren's/lupus erythematosus overlap syndrome. *Lupus* **6**:105, 1997

40. Provost TT, Watson RM: Anti-Ro(SS-A), HLA-DR3–positive females: The interrelationship between some ANA-negative, SS, SCLE, NLE mothers and SS/LE overlap female patients. *J Invest Dermatol* **100**(Suppl):14S, 1993

41. Fox RI: Sjögren's syndrome: Current therapies remain inadequate for a common disease. *Expert Opin Investig Drugs* **9**:2007, 2000

42. Petrone D et al: A double-blind, randomized, placebo-controlled study of cevimeline in Sjögren's syndrome patients with xerostomia and keratoconjunctivitis sicca. *Arthritis Rheum* **46**:748, 2002

43. Steinfeld SD et al: Infliximab in patients with primary Sjögren's syndrome: A pilot study. *Arthritis Rheum* **44**:2371, 2001

44. Kunert KS et al: Analysis of topical cyclosporine treatment of patients with dry eye symptoms. *Arch Opthalmol* **118**:1489, 2000

45. Fox RI et al: Treatment of primary Sjögren's syndrome with hydroxychloroquine: A retrospective open label study. *Lupus* **5**(Suppl 1):S31, 1996

46. Jewell ML, McCauliffe DP: Patients with cutaneous lupus erythematosus who smoke are less responsive to antimalarial therapy. *J Am Acad Dermatol* **42**:983, 2000

T>

Chapter 181

John Klippel

Raynaud's Phenomenon

EPIDEMIOLOGY
PATHOPHYSIOLOGY
CLASSIFICATION
Primary Raynaud's Phenomenon
Secondary Raynaud's Phenomenon
DIFFERENTIAL DIAGNOSIS
HISTORY AND PHYSICAL EXAMINATION
LABORATORY AND SPECIAL INVESTIGATIONS
TREATMENT
General Measures
Drug Therapy
Digital Ulcers
Sympathectomy
Severe Vasospasm

REFERENCES

Raynaud's phenomenon is the occurrence of episodic attacks of digital ischemia provoked by exposure to cold or emotional stress. The condition was originally described by the French physician Maurice Raynaud in 1862 [1]; and the term *Raynaud's phenomenon* was suggested by Hutchinson, who recognized that digital vasospasm occurred with multiple different disorders. [2] The classic episode of Raynaud's phenomenon is characterized by a triphasic color change of pallor, cyanosis, and hyperemia of the fingers. Although patients are often totally asymptomatic throughout an attack, symptoms of numbness, tingling, or pain during the attack or with recovery are not infrequent. Raynaud's phenomenon is generally divided into primary (idiopathic) and secondary forms on the basis of whether an underlying cause or disease associated with peripheral vasospasm can be identified.

EPIDEMIOLOGY

Studies of the epidemiology of Raynaud's phenomenon are challenging because of underreporting (most patients with primary Raynaud's never seek medical attention) and biases of studies done by investigators interested in the secondary forms of the disorder. Surveys indicate that Raynaud's phenomenon affects up to 10 percent of the general population. [3], [4] Primary Raynaud's phenomenon is estimated to be approximately twice as common as secondary Raynaud's phenomenon. [5] Symptoms most often develop in the teenage years, although onset after the age of 40 is not infrequent. Most series show a female predominance of the disorder (female:male = 4:1). Increases in the frequency and severity of attacks during menses suggest that female sex hormones are most likely involved in the pathogenesis. [6] Differences in seasonal skin temperatures, marital status, alcohol use, age, and smoking between women and men have also been suggested to contribute to the sex differences. [7], [8] Familial aggregation has been identified in a number of studies and suggests the contribution of genetic factors. [9] Other associations reported in epidemiologic studies include living in a cold climate, occupation, cardiovascular disease, low body-mass index, and use of vibratory tools.

PATHOPHYSIOLOGY

The pathophysiology of the vasospasm is complex and only partially understood. Studies show significant reductions of peripheral blood flow throughout all phases of central body cooling and rewarming, suggesting impairments of central thermoregulatory control mechanisms. [10] The principal mechanisms thought to contribute to the development of Raynaud's phenomenon include a local defect of a digital blood vessel, causing abnormal vascular reactivity or reduced blood flow; an enhanced localized production of vasoconstrictors or reduced production of vasodilators; hyperreactivity of the sympathetic nervous system; and abnormal properties of the blood that compromise distal perfusion.

The results of gross histologic examinations of digital arteries in patients with primary Raynaud's phenomenon are normal. Structural abnormalities of the digital microvasculature are frequently seen in patients with secondary forms of Raynaud's phenomenon, particularly in the connective tissue diseases. Studies show a range of pathology including intimal hyperplasia, narrowing or total occlusion of arteries, or thrombi. In most patients with systemic sclerosis, there exists evidence of activation and damage of the endothelium, fibrinolysis, and platelet activation. [11] Microcirculatory flow studies with laser Doppler in patients with scleroderma have shown marked reductions in blood flow and hand temperature during an attack, with prominent abnormalities during rewarming—findings that suggest a failure of the arteriovenous anastomoses to open. [12]

Peripheral vascular resistance is primarily controlled by the interaction between a $_1$- and a $_2$-adrenergic receptors. In vivo studies indicate that a $_2$-adrenergic receptors are more important than a $_1$-adrenergic receptors during reflex sympathetic vasoconstriction, [13] and that a $_2$-adrenergic receptors predominantly affect arteriovenous anastomoses in the fingers. Skin blood flow is especially sensitive to a $_2$-adrenergic receptor antagonism. Studies of brachial artery infusions of a $_1$- and a $_2$-adrenergic receptor antagonists in patients with primary Raynaud's phenomenon show that activation of a $_1$-adrenergic receptors is necessary for the production of the vasospastic attacks. [14] Infusion studies with bradykinin and substance P demonstrate differences between unaffected individuals and patients with primary Raynaud's phenomenon;

these findings suggest a defect in distal signaling mechanisms. [15] The presence of increased levels of a $_2$-adrenergic receptors on platelets of patients with Raynaud's phenomenon raises the possibility of a generalized increased density or sensitivity of the receptor on vascular endothelium.

Neurotransmitters are important in the control of vascular tone, although the contribution of abnormalities in neurotransmitter functions in Raynaud's phenomenon is unclear. Increased levels of endothelin-1, a potent vasoconstrictor peptide present in the digital cutaneous microvasculature, appear not to be involved in pathogenesis. [16] The level of calcitonin-related peptide, a powerful vasodilator in digital cutaneous nerves, is reduced in patients with Raynaud's phenomenon. [17] A deficit of calcitonin-related peptide is hypothesized to result in a functional deficit of vasodilation by nitric oxide synthetase. Serotonin is also incriminated as an important mediator in the induction of ischemic attacks of Raynaud's phenomenon. Patients have an increased sensitivity to intraarterial infusions of serotonin, and an S2-serotonergic antagonist relieves, but does not prevent the induction of attacks.

The evidence of direct central sympathetic nervous system hyperactivity is strongest in vibration-induced injury, in which the use of a vibration tool in one hand produces vasospasm in the other hand. [18] Similarly, vasospasm can be inhibited by proximal nerve blockade in patients with vibration-induced injury. In general, most studies of the sympathetic nervous system in patients with primary or other secondary forms of Raynaud's phenomenon have failed to detect evidence of sympathetic hyperactivity. The results of microelectrode studies of skin sympathetic nervous activity during cold pressor tests are normal, and plasma levels of catecholamines are not increased in the venous drainage of the hands of patients with Raynaud's phenomenon.

Consistent abnormalities in plasma fibrinogen, cold agglutinins, platelets, or cryoglobulins have not been demonstrated in primary Raynaud's phenomenon, but are important in certain secondary cases, particularly scleroderma. Levels of von Willebrand factor and soluble thrombomodulin, thromboxane B $_2$ and ß-thromboglobulin, and tissue plasminogen activator inhibitor-1 are increased in patients with scleroderma, when compared to levels in patients with primary Raynaud's phenomenon. [11]

Genetic studies with microsatellite markers of extended families affected with primary Raynaud's phenomenon have identified several potential candidate genes. [19]

CLASSIFICATION

The classification of Raynaud's phenomenon involves the separation into primary (idiopathic) and secondary forms based on whether an underlying cause or disease association can be identified.

Primary Raynaud's Phenomenon

Primary Raynaud's phenomenon is a disorder in which known causes of attacks of peripheral vasospasm cannot be found. Criteria for the diagnosis of primary Raynaud's phenomenon have been developed by Allen and Brown [20] and LeRoy and Medsger [21] (Table 181-1). Patients with primary Raynaud's phenomenon are typically otherwise totally asymptomatic, with the possible exception of an increase in migraine headaches and variant angina pectoris.

1. Vasospastic attacks precipitated by exposure to cold or emotional stimuli
2. Bilateral involvement of extremities
3. Normal vascular examination with symmetric peripheral pulses and normal nail fold capillary microscopy
4. Absence of gangrene or, if present, limited to the skin of the fingertips
5. No evidence of an underlying disease, drug, or occupational exposure that could be reponsible for vasospastic attacks
6. Negative antinuclear antibody test
7. Normal erythrocyte sedimentation rate
8. History of symptoms for at least 2 years
Combined criteria of Allen and Brown[20] and Le Roy and Medsger.[21]

TABLE 181-1 **Criteria for Primary Raynaud's Phenomenon**

Several studies have examined the long-term outcome of patients with primary Raynaud's phenomenon. [5], [22] Progression to a secondary form of Raynaud's phenomenon, most commonly a connective tissue disease such as scleroderma, occurs in approximately 15 percent of patients during the first decade after onset. Variables predictive of a transition to a secondary form include nail fold capillary abnormalities, hand swelling, positive Allen's test, and antinuclear antibodies.

Secondary Raynaud's Phenomenon

CONNECTIVE TISSUE DISEASES The connective tissue diseases are the most common cause of secondary Raynaud's phenomenon (Table 181-2). Among patients with scleroderma, 80 to 90 percent manifest Raynaud's phenomenon and/or persistent vasospasm. It is the presenting symptom in about one-third of patients and may be the only manifestation of the disease for years. Raynaud's phenomenon occurs in about one-third of patients with systemic lupus erythematosus, idiopathic inflammatory myopathies, and systemic vasculitis. Although patients with rheumatoid arthritis often complain of cold hands with mottled red and white areas, true Raynaud's phenomenon appears to be no more common in persons with rheumatoid arthritis than in the general population. Arteriograms of patients with connective tissue diseases usually show digital and sometimes ulnar or radial artery obstructions.

Connective tissue disease	Clonidine
Scleroderma	Bromocriptine
Systemic lupus erythematosus	Cyclosporine
Dermatomyositis and polymyositis	Amphetamines
Undifferentiated connective tissue disease	Fluoxetine
Systemic vasculitis	Interferon-α
Sjögren's syndrome	Occupational/environmental exposure
Eosinophilic fasciitis	Vibration injury (turbojacks, pneumatic hammer operators)
Obstructive arterial disease	
Atherosclerosis	Posttraumatic injury (hypothenar hammer syndrome, crush pressure)
Thromboangiitis obliterans (Buerger's disease)	Vinyl chloride disease
Thromboembolism	Cold injury
Thoracic outlet syndrome	Hyperviscosity disorders
Neurologic disorders	Cryopathies
Carpal tunnel syndrome	Cold agglutinins
Reflex sympathetic dystrophy	Macroglobulins
Hemiplegia	Polycythemia
Poliomyelitis	Thrombocytosis
Multiple sclerosis	Miscellaneous
Syringomyelia	Hypothyroidism
Drugs and toxins	Infections (bacterial endocarditis, Lyme disease, viral hepatitis)
β-Adrenergic blockers	Hemoglobinopathies
Ergotamines	Primary pulmonary hypertension
Oral contraceptives	Arteriovenous fistula
Methysergide	Intraarterial injections
Bleomycin and vinblastine	

TABLE 181-2 **Secondary Raynaud's Phenomenon**

OCCUPATIONAL Raynaud's phenomenon may be occupational in origin. It is especially common in individuals who use vibratory tools (e.g., air hammers, chain saws, rivets) and in those whose occupation requires prolonged exposure of the extremities to cold temperatures (e.g., butchers, ice cream workers, fish packers). Prevalence rates correlate with the vibration level of the tool and the duration of exposure; they can be as high as 90 percent in high-risk occupations such as logging or mining. [23] Other working conditions associated with the development of Raynaud's phenomenon include occupations requiring the use of plastic gloves, continuous repetitive movements of an extremity, and work breaks in an unheated environment. Arteriograms in patients with occupation-induced Raynaud's phenomenon often reveal digital, radial, ulnar, or palmar arch thromboses.

NEUROLOGIC DISORDERS Any neurologic condition that produces permanent disuse of a limb can be associated with sympathetic nervous system disturbances to that limb. Patients often develop persistent vasospasm with coldness, paleness or cyanosis, and even ulcerations of the limb, and Raynaud's phenomenon may occur. Thermoregulatory abnormalities may be a prominent feature of reflex sympathetic dystrophy syndrome. [24] Nerve root pressure or nerve entrapment may produce Raynaud's phenomenon. It is often present in patients with carpal tunnel syndrome and typically involves the first, index, and middle fingers, digits innervated by the median nerve. Tapping the median nerve at the wrist (Tinel's sign) or wrist flexion for 60 s (Phalen's sign) may produce shooting pain in the distribution of the median nerve. Demonstration of a prolonged conduction time in the median nerve is the definitive diagnostic test. In addition, Raynaud's phenomenon may occur as a result of neurovascular compression at the thoracic outlet. The compression may be caused by cervical ribs; abnormalities of the scalenus anticus muscle; bony abnormalities of the cervical vertebrae, clavicle, or first rib; or shoulder compression syndromes (the costoclavicular or hyperabduction syndrome). To confirm the diagnosis, assumption of postures to exaggerate the abnormality—such as the Adson test, in which the patient holds a deep breath, extends the neck, and then turns toward the side being examined—must reproduce the symptoms or produce a pale hand from which the radial pulse disappears. Loss of the pulse is not diagnostic, nor are nerve conduction studies.

DRUGS AND TOXINS Drugs and toxins can produce Raynaud's phenomenon. Propranolol, one of the most widely used ß-adrenergic blockers for cardiovascular diseases and migraine headaches, is probably the most frequent offender. Ergot preparations and methysergide used to treat migraine headaches may also cause the phenomenon. Intraarterial use of many medications and recreational drugs can result in toxicity to endothelial cells with irreversible structural damage to the microvasculature of the extremities and be responsible for severe Raynaud's phenomenon. Industrial exposure to vinyl chloride polymerization processes may produce Raynaud's phenomenon, as well as acroosteolysis of the distal phalanges of the fingers; arteriograms show digital artery obstructions. [25] The chemotherapeutic agents bleomycin and vinblastine also may cause the phenomenon. [26]

HYPERVISCOSITY Patients with cold-precipitable plasma proteins, macroglobulins, cold agglutinins, and polycythemia can exhibit Raynaud's phenomenon as a result of flow disturbances or actual occlusion of small vessels. These episodes are usually associated with monoclonal gammopathies, particularly macroglobulinemia, or polyclonal gammopathies, as with rheumatoid arthritis. Cryoglobulins are most commonly present in patients with multiple myeloma, but they also occur in patients with rheumatic diseases, chronic infections, leukemia, and lymphoma, and as an idiopathic condition.

MISCELLANEOUS The most common endocrine disturbance associated with Raynaud's phenomenon is hypothyroidism; symptoms usually remit with thyroid hormone replacement. Raynaud's phenomenon may be a feature of various infectious disorders, including subacute bacterial endocarditis, Lyme disease, and viral hepatitis, presumably a reflection of systemic vasculitis. Peripheral vasospasm may also occur in association with malignant tumors, including pheochromocytoma, carcinoid, and ovarian carcinoma.

DIFFERENTIAL DIAGNOSIS

The main differential diagnoses are cold digits, chilblain (pernio), livedo reticularis, and acrocyanosis (see Chap. 126). Many patients complain of cold, sometimes painful digits without color changes. This condition likely represents one extreme of the spectrum of normal sympathetic nervous system activity. Chilblain is an inflammatory condition of the skin of the extremities induced by cold. Patients develop a bluish-red discoloration and edema, typically involving the lower limb and associated with warmth, erythema, and burning. In severe cases, hemorrhagic lesions, bullae, or ulcers may develop, and secondary infections may supervene. The lesions last from 7 to 10 days, often leaving a residual pigmentation of the skin. Livedo reticularis is a bluish discoloration of the skin of the extremities with a characteristic lacy, irregular appearance. The bluish discoloration becomes more intense on exposure to cold and may disappear in a warm environment. Most patients are entirely asymptomatic, although livedo reticularis may be a feature of the antiphospholipid syndrome, in which patients are at increased risk for venous and arterial thromboses, thrombocytopenia, and pregnancy losses. In acrocyanosis, the hands, and less commonly the feet, develop a persistent bluish discoloration. The blue color is intensified by exposure to cold and is converted into a purplish or red color by warming; a pallor phase is absent. The skin is cold, and the palms are often wet and clammy from sweat. Trophic changes or ulcerations are rarely observed.

HISTORY AND PHYSICAL EXAMINATION

The history is important to elicit a clear description of the attacks, which is necessary to establish the diagnosis of Raynaud's phenomenon and to screen for evidence of signs and symptoms suggestive of a secondary cause. Patients complain of episodic attacks of well-demarcated, white or blue digits induced by exposure to cold and sometimes by emotional stimuli (Fig. 181-1). Often only a portion of the digit is affected, and the thumbs are typically spared. A classic tricolor change (white to blue to red) described in most textbooks is rarely volunteered by patients; most describe only

blanching of the digits accompanied by numbness. During the attacks, one or more fingers or toes may be numb and be described as “dead.” On rewarming, the digits may become bright red, and throbbing pain may occur. When pain is a prominent symptom in the ischemic phase, a secondary cause should be suspected. Attacks last minutes to hours. The fingers and toes are most commonly involved; however, the attacks may involve the nose, earlobes, or nipples. A systemic form of Raynaud's phenomenon with vasospasm of major organ systems such as the heart, lungs, kidneys, esophagus, gastrointestinal tract, and cerebral circulation has been documented in patients with connective tissue disorders, and may be an important contributory factor to pathology. There is no evidence, however, to suggest that there is a systemic vasospastic component in patients with primary Raynaud's phenomenon.

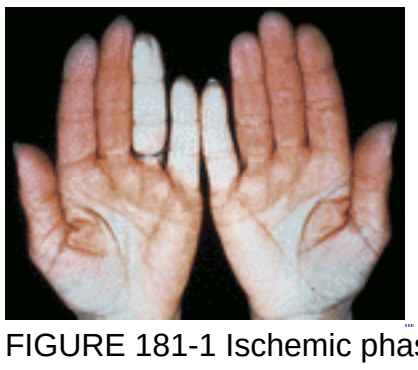

FIGURE 181-1 Ischemic phase of attack of Raynaud's phenomenon with marked pallor of the ring and little fingers of the left hand and little finger of the right hand.

A careful review of systems is important to screen for symptoms of connective tissue disease (arthralgias, arthritis, dysphagia, heartburn, rash, photosensitivity, skin changes, muscle weakness, shortness of breath, or sicca), a drug-related etiology, symptoms of obstructive arterial diseases (intermittent claudication), and exposure to vibratory tools or continuous finger trauma. In patients with primary Raynaud's phenomenon, a review of systems is entirely unrevealing with the exception of occasional complaints of migraine headaches or variant angina pectoris.

Attacks of Raynaud's phenomenon, presumably stress-induced, are commonly witnessed during the course of the history or physical examination. There is well-demarcated blanching or cyanosis of the digits extending from the tip to various levels of the digit. The digits distal to the line of ischemia are cold, while the proximal skin is pink and warmer. On rewarming, blanched digits may become cyanotic, because of the slow blood flow, and then bright red, because of reactive hyperemia. Persistent ischemic discoloration of digits suggests a secondary cause.

The digits should be carefully examined for trophic or ischemic changes, which are signs of prolonged or severe attacks of Raynaud's phenomenon. The skin may become atrophic, thin, and tight (sclerodactyly), with loss of hair over the dorsal surfaces. The nails may become brittle and deformed. Ulcerations, which can be extremely painful, particularly at night, may develop on the finger pads or around the nail bed. The ulcers heal slowly, leave characteristic small, pitted scars (Fig. 181-2), and may become infected. Gangrene of the distal aspects of the digit is rare.

FIGURE 181-2 Loss of pulp of the pad of the digit with pitting scars and ulcerations from chronic, severe Raynaud's phenomenon.

In general, the physical examination is unrevealing in patients with primary Raynaud's phenomenon. Patients with secondary Raynaud's phenomenon should have features of their underlying disease. The physical examination should pay attention to all pulses, and blood pressure should be obtained in both arms. Allen's test is useful to assess arterial and capillary function of the hands; abnormalities imply structural disease of the microcirculation and raise the suspicion of a secondary form of Raynaud's phenomenon. The radial and ulnar arteries are simultaneously compressed by the examiner's thumbs while the patient opens and closes the fist to induce blanching of the palm. Selective arterial filling is judged by the rate of color return as pressure is sequentially released from the radial and ulnar arteries. Vascular obstruction from the thoracic outlet syndrome should be assessed by the Adson maneuver, which tests for diminution in the radial pulse with exaggerated movements of the neck and shoulder. A careful neurologic examination should be performed to detect evidence of sympathetic hyperactivity, abnormal reflexes, muscular weakness or atrophy, or compression of the median nerve within the carpal tunnel. Skin changes, such as telangiectases, changes in skin texture, rashes, or purpura, provide valuable clues to the presence of a connective tissue or hyperviscosity disorder.

LABORATORY AND SPECIAL INVESTIGATIONS

Although differences in the vascular response to cooling have been reported between patients with primary and secondary Raynaud's phenomenon, [10] there is no need to attempt to induce an attack as by immersing the patient's hand in ice water. In all patients, a complete blood count, erythrocyte sedimentation rate, urinalysis, and antinuclear antibody test should be obtained. Additional laboratory studies should be directed by findings elicited by the history and physical examination. In patients with abnormal antinuclear antibody levels, tests for antibodies to specific nuclear antigens, such as topoisomerase or centromere antigens or the Smith (Sm) antigen, are helpful to detect early scleroderma or systemic

lupus erythematosus. A routine chest radiograph should be obtained to look for a cervical rib or evidence of interstitial lung disease.

Nail fold capillary microscopy is a useful procedure to distinguish primary from secondary Raynaud's phenomenon and should be done as part of the routine evaluation of all patients. [27] Although mild capillary abnormalities may be observed in patients with primary Raynaud's phenomenon, patients with connective tissue diseases may have enlarged, deformed capillary loops surrounded by avascular areas (Fig. 181-3). [28] Serial studies reveal progressive decreases in the total number of nail fold capillary loops in secondary, but not primary, forms of Raynaud's phenomenon. [29] The patency of small arteries can be assessed by Doppler techniques. Digital subtraction arteriography should be reserved for selected patients with prolonged, severe ischemia for whom arterial reconstruction is a consideration.

FIGURE 181-3 Nail fold capillary microscopy, in a patient with scleroderma, showing capillary drop out with enlarged, dilated, tortuous capillary loops.

TREATMENT

The management of Raynaud's phenomenon is guided by the frequency and severity of attacks and the complications from ischemia (Table 181-3). Secondary forms of Raynaud's phenomenon require treatment directed at the underlying medical disorder, discontinuation of drugs implicated in causing the vasospasm, or occupational modifications.

Infrequent or mild attacks	Preventive measures Cessation of smoking
Frequent or severe attacks	Calcium channel blockers (nifedipine, diltiazem) Antiadrenergic drugs (prazosin, reserpine) Topical nitroglycerin
Acute, severe ischemia	Intravenous prostaglandin E_1 or prostacyclin Digital sympathectomy Microvascular surgery
Digital ulcers	Antiseptic soaks, antibiotic ointments, occlusive dressing Calcium channel blockers (maximal doses) Intravenous prostaglandin E_1 or prostacyclin
Gangrenous, infected ulcers	Analgesics Antibiotics Surgical debridement Amputation

TABLE 181-3 **Management of Raynaud's Phenomenon**

General Measures

Mild Raynaud's phenomenon is generally easy to control with lifestyle changes to minimize exposure to the cold; dressing warmly with loose-fitting, layered clothing; and keeping the thermostat a few degrees higher than normal. Limiting time spent outdoors in winter, wearing insulated gloves, and using hand or foot warmers are usually helpful. Patients should be taught to recognize and terminate attacks promptly by returning to a warmer environment and applying local heat to the hands (e.g., by placing their hands in warm water or by using a hair dryer). Patients should be strongly encouraged to stop smoking and to avoid secondhand smoke, because nicotine induces cutaneous vasoconstriction. Stress modification and social support are valuable aspects of treatment to minimize vasoconstriction induced by hyperactivity of the sympathetic nervous system. Counseling, training in relaxation, or medications may be helpful. Some patients benefit from conditioning programs such as biofeedback training.

Dietary therapy with fish-oil supplements containing the omega-3 fatty acids (eicosapentaenoic acid and docosahexaenoic acid) has been studied in patients with Raynaud's phenomenon. [30] These fatty acids serve as alternate substrates for cyclooxygenase and 5-lipoxygenase pathways to produce vasodilation, inhibit platelet aggregation, and alter red cell deformability. The study showed that digital systolic pressures and digital artery flow improved in patients with primary but not secondary Raynaud's phenomenon.

Drug Therapy

Various drugs have been used to treat Raynaud's phenomenon, including vasodilators, platelet inhibitors, serotonin antagonists, and fibrinolytics. Drug therapy is usually reserved for patients with prolonged or frequent attacks that fail to respond to conservative measures. In general, improvements with drug therapy are more pronounced in patients with primary Raynaud's phenomenon, presumably as a consequence of fixed, structural damage in patients with secondary forms.

The calcium channel blockers are by far the most widely used and effective drugs for treating Raynaud's phenomenon. [31] Vasodilating properties vary among different agents. Nifedipine (10 to 20 mg tid or qid) reduces the severity and frequency of attacks; the long-acting preparation of nifedipine is better tolerated but may be less effective. Diltiazem (60 mg tid or qid) may be substituted if nifedipine is ineffective or not well tolerated. Side effects of calcium channel blockers

include fluid retention, light-headedness, and heartburn; these may limit therapy.

Both reserpine (0.1 to 0.5 mg daily) and guanethidine (10 to 40 mg daily) increase capillary blood flow during cold exposure and have the advantage of once-a-day administration. Painful ulcerations or gangrene respond to intraarterial reserpine (0.5 to 1.0 mg). Prazosin (1 to 5 mg tid), an a_1-adrenergic receptor agonist, produces a moderate benefit. Other sympatholytic drugs, including methyldopa, phenoxybenzamine, and tolazoline, have been recommended. The effect of ketanserin, a selective antagonist of the S2-serotonergic receptor, was not significantly different from that of placebo in primary Raynaud's phenomenon. [32] In a pilot study, the selective serotonin reuptake inhibitor fluoxetine reduced the frequency and severity of Raynaud's attacks. [33] Additional drug therapies reported to be beneficial in the treatment of Raynaud's phenomenon include low molecular weight heparin, [34] prazosin, [35] the angiotensin-II receptor antagonist losartan, [36] and stanozolol. [37]

Topical nitroglycerin paste (2%) and a sustained-release transdermal glyceryl patch are helpful in selected patients. [38] In a small study, topical minoxidil, a potent vasodilator, did not increase blood flow in patients with primary Raynaud's phenomenon. [39]

Prostaglandin E_1 (PGE_1) and prostacyclin (PGI_2), administered intravenously, have beneficial effects in patients with Raynaud's phenomenon [40]; however, the vasodilatory effects are not sustained and long-term therapy is required. [41] Oral prostaglandins are currently available only as investigational agents, although preliminary results from studies of a PGI_2 analogue (beraprost) and misoprostol, an analogue of PGE_1, have been disappointing.

Digital Ulcers

Digital ulcers from Raynaud's phenomenon can be extremely painful and typically take weeks or months to heal completely. Pain control is an important part of therapy, because pain can lead to additional vasospasm and more ischemia. On occasion, narcotic pain medications may be necessary to control symptoms. The finger should be soaked in a tepid antiseptic solution (e.g., half-strength hydrogen peroxide) twice daily to soften or loosen the crust or eschar. After drying, an antibiotic ointment is applied to the ulcer, and the digit is covered with an occlusive dressing. Maximum drug therapy with a calcium channel blocker should be used throughout treatment. Infection is a common complication of digital ulcers and is typically manifest by increasing pain, erythema, swelling, or purulent drainage. Cultures usually demonstrate *Staphylococcus* species, and treatment with dicloxacillin or cephalosporins is usually effective.

Sympathectomy

Sympathectomy may be a consideration for the management of patients with refractory, disabling attacks or with an acutely ischemic digit that is unresponsive to other measures. A positive vasodilator response to a stellate ganglion block or epidural infusion should be documented before a permanent procedure is done. Lumbar sympathectomy has an important role in the management of severe Raynaud's phenomenon of the feet, and selective digital sympathectomy may be used to relieve pain and heal digital ulcers in patients with ischemic digits. [42] The long-term effects of sympathectomy are poor, with up to two-thirds of patients reporting no benefit at the end of 1 year. Newer procedures for thoracic sympathectomy, including percutaneous radio frequency [43] and thoracoscopic procedures, [44] have been advocated as technically easier to perform, with fewer complications and more promising long-term results.

Severe Vasospasm

Severe vasospasm with prolonged ischemia (dead-white finger) poses a threat of gangrene and amputation; it is considered a medical emergency. The patient should be hospitalized and the affected extremity put to rest. Nifedipine (10 to 20 mg tid) should be started immediately, as well as PGE_1 (6 to 10 ng/kg per min) or prostacyclin (0.5 to 2 ng/kg), given by continuous intravenous infusion for several hours over 3 consecutive days. Intraarterial phentolamine or tolazoline may reverse acute vasospasm, but monitoring of vital signs is essential, and these drugs need to be used with great caution. A digital (or stellate ganglion) block with lidocaine hydrochloride or bupivacaine hydrochloride (without epinephrine) relieves pain and produces a chemical sympathectomy that may reverse vasoconstriction. Sympathectomy (thoracic, lumbar, or digital) should be considered in patients who have a positive response. Arterial reconstruction should be reserved for patients with angiographically documented occlusive vascular disease. [45]

REFERENCES

1. Raynaud M: *On Local Asphyxia and Symmetrical Gangrene of the Extremities,* 1862, and *New Research on the Nature and Treatment of Local Asphyxia of the Extremities,* 1877, translated by T. Barlow. In selected monographs, vol 121. London, New Syndenham Society, 1888

2. Hutchinson J: Raynaud's phenomenon. *Med Press Circ* **23**:403, 1901

3. Brand FN et al: The occurrence of Raynaud's phenomenon in a general population: The Framingham Study. *Vasc Med* **2**:296, 1997

4. Gelber AC et al: Symptoms of Raynaud's phenomenon in an inner-city African-American community: Prevalence and self-reported cardiovascular comorbidity. *J Clin Epidemiol* **52**:441, 1999

5. Hirschl M, Kundi M: Initial prevalence and incidence of secondary Raynaud's phenomenon in patients with Raynaud's symptomatology. *J Rheumatol* **23**:302, 1996

6. Greenstein D et al: The menstrual cycle and Raynaud's phenomenon. *Angiology* **47**:427, 1996

7. Gardner-Medwin JM et al: Seasonal differences in finger skin temperature and microvascular blood flow in healthy men and women are exaggerated in women with primary Raynaud's phenomenon. *Br J Clin Pharmacol* **52**:17, 2001

8. Fraenkel L et al: Different factors influencing the expression of Raynaud's phenomenon in men and women. *Arthritis Rheum* **42**:306, 1999

9. Freedman RR, Mayes MD: Familial aggregation of primary Raynaud's disease. *Arthritis Rheum* **39**:1189, 1996

10. Maricq HR et al: Digital vascular responses to cooling in subjects with cold sensitivity, primary Raynaud's phenomenon, or scleroderma spectrum disorders. *J Rheumatol* **23**:2068, 1996

11. Herrick AL et al: Von Willebrand factor, thrombomodulin, thromboxane, beta-thromboglobulin and markers of fibrinolysis in primary Raynaud's phenomenon and systemic sclerosis. *Ann Rheum Dis* **55**:122, 1996

12. Toms SL, Cooke ED: A comparison of the functioning of arteriovenous anastomoses in secondary Raynaud's phenomenon and control subjects in response to local hand warming. *Int Angiol* **14**:74, 1995

13. Chotani MA et al: Silent alpha (2C)-adrenergic receptors enable cold-induced vasoconstriction in cutaneous arteries. *Am J Physiol Heart Circ Physiol* **278**:H1075, 2000

14. Freedman RR et al: Blockade of vasospastic attacks by alpha 2-adrenergic but not alpha 1-adrenergic antagonists in idiopathic Raynaud's disease. *Circulation* **92**:1448, 1995

15. Freedman RR et al: Abnormal responses to endothelial agonists in Raynaud's phenomenon and scleroderma. *J Rheumatol* **28**:119, 2001

16. Smyth AE et al: Digital vascular responses and serum endothelial-1 concentrations in primary and secondary Raynaud's phenomenon. *Ann Rheum Dis* **59**:870, 2000

17. Bunker CB et al: Calcitonin gene-related peptide, endothelin-1, the cutaneous microvasculature and Raynaud's phenomenon. *Br J Dermatol* **134**:399, 1996

18. Chen GS et al: Responses of cutaneous microcirculation to cold exposure and neuropathy in vibration-induced white finger. *Microvasc Res* **47**:21, 1994

19. Susol E et al: A two-stage, genome-wide screen for susceptibility loci in primary Raynaud's phenomenon. *Arthritis Rheum* **43**:1641, 2000

20. Allen EV, Brown GE: Raynaud's disease: A critical review of minimal prerequisites for diagnosis. *Am J Med Sci* **183**:187, 1932

21. LeRoy EC, Medsger TA Jr: Raynaud's phenomenon: A proposal for classification. *Clin Exp Rheumatol* **10**:485, 1992

22. Spencer-Green G. Outcome in primary Raynaud phenomenon: A meta-analysis of the frequency, rates, and predictors of transition to secondary diseases. *Arch Intern Med* **158**:595, 1998

23. Palmer KT et al. Prevalence of Raynaud's phenomenon in Great Britain and its relation to hand transmitted vibration: A national postal survey. *Occup Environ Med* **57**:448, 2000

24. Herrick AL et al: Abnormal thermoregulatory responses in patients with reflex sympathetic dystrophy syndrome. *J Rheumatol* **21**:1319, 1994

25. Falappa P et al: Angiographic study of digital arteries in workers exposed to vinyl chloride. *Br J Ind Med* **39**:169, 1982

26. Doll DC, Yarbro JW: Vascular toxicity associated with chemotherapy and hormonotherapy. *Curr Opin Oncol* **6**:345, 1994

27. Anders HJ et al: Differentiation between primary and secondary Raynaud's phenomenon: A prospective study comparing nail fold capillaroscopy using an ophthalmoscope or stereomicroscope. *Ann Rheum Dis* **60**:407, 2001

28. Ohtsuka T: Quantitative analysis of nail fold capillary abnormalities in patients with connective tissue diseases. *Int J Dermatol* **38**:757, 1999

29. ter Borg EJ et al: Serial nail fold capillary microscopy in primary Raynaud's phenomenon and scleroderma. *Semin Arthritis Rheum* **24**:40, 1994

30. DiGiacomo RA et al: Fish-oil dietary supplementation in patients with Raynaud's phenomenon: A double-blind controlled prospective study. *Am J Med* **86**:158, 1989

31. Thompson AE et al: Calcium-channel blockers for Raynaud's phenomenon in systemic sclerosis. *Arthritis Rheum* **44**:1841, 2001

32. Pope J et al: Ketanserin for Raynaud's phenomenon in progressive systemic sclerosis. *Cochrane Database Syst Rev* CD000954, 2000

33. Coleiro B et al: Treatment of Raynaud's phenomenon with the selective serotonin reuptake inhibitor fluoxetine. *Rheumatology* **40**:1038, 2001

34. Denton CP et al: Long-term low molecular weight heparin therapy for severe Raynaud's phenomenon: A pilot study. *Clin Exp Rheumatol* **18**:499, 2000

35. Pope J et al: Prazosin for Raynaud's phenomenon in progressive systemic sclerosis. *Cochrane Database Syst Rev* CD000956, 2000

36. Dziadzio M et al: Losartan therapy for Raynaud's phenomenon and scleroderma: Clinical and biochemical findings in a fifteen-week, randomized, parallel-group, controlled trial. *Arthritis Rheum* **42**:2646, 1999

37. Helfman T, Falanga V: Stanozolol as a novel therapeutic agent in dermatology. *J Am Acad Dermatol* **33**:254, 1995

38. Teh LS et al: Sustained-release transdermal glyceryl trinitrate patches as a treatment for primary and secondary Raynaud's phenomenon. *Br J Rheumatol* **34**:636, 1995

39. Whitmore SE et al: Acute effect of topical minoxidil on digital blood flow in patients with Raynaud's phenomenon. *J Rheumatol* **22**:50, 1995

40. Pope J et al: Iloprost and cisaprost for Raynaud's phenomenon in progressive systemic sclerosis. *Cochrane Database Syst Rev* CD000953, 2000

41. Scorza R et al: Effects of long-term cyclic iloprost therapy in systemic sclerosis with Raynaud's phenomenon. A randomized, controlled study. *Clin Exp Rheumatol* **19**:503, 2001

42. McCall TE et al: The use of digital artery sympathectomy as a salvage procedure for severe ischemia of Raynaud's disease and phenomenon. *J Hand Surg* **24**:173, 1999

43. Wilkinson HA: Percutaneous radiofrequency upper thoracic sympathectomy. *Neurosurgery* **40**:216, 1997

44. Bonjer HJ et al: Advantages of limited thorascopic sympathectomy. *Surg Endosc* **10**:721, 1996

45. Tomaino MM et al: Surgery for ischemic pain and Raynaud's phenomenon in scleroderma: A description of treatment protocol and evaluation of results. *Microsurgery* **21**:75, 2001

T>

Chapter 182

Robert Winchester

Reiter's Syndrome

HISTORICAL ASPECTS
EPIDEMIOLOGY AND GENETIC FACTORS
ETIOLOGY AND PATHOGENESIS
Infectious Etiology
Genetic Factors
Immunologic Mechanisms
PATHOLOGY
Skin
Musculoskeletal System
Systemic
CLINICAL MANIFESTATIONS
Natural History
Skin Disease
Joint Disease
Nail Disease
Other Manifestations
LABORATORY FINDINGS
RADIOGRAPHIC FEATURES
DIAGNOSIS
TREATMENT
COURSE AND PROGNOSIS

REFERENCES

Reiter's syndrome and the closely related disorder of reactive arthritis are genetically determined and often protracted adaptive immune responses focused on the skin and joints, which usually develop several weeks after infection of the gut or urinary tract with certain microorganisms. Reiter's syndrome has been conceptualized as an autoimmune response, initiated by an infectious agent, that persists in a sterilized joint, but some new developments suggest that this could be an oversimplification. Fully developed Reiter's syndrome is recognized by a set of clinical manifestations that are usually highly distinctive: mouth ulcers; conjunctivitis; balanitis; keratoderma blennorrhagicum; onychodystrophy; acute oligoarthritis, primarily involving the knee and ankle; enthesopathy (inflammation of the tendon and ligament insertions), especially of the Achilles tendon; dactylitis; and urethritis or cervicitis. Because there is no specific diagnostic test, diagnosis is sometimes complicated by a *forme fruste* expression of the features of the illness or by a protracted evolution of the full illness. The term *reactive arthritis* is typically applied to situations where infection elicits only arthritis. In addition, some authors use the designation *complete reactive arthritis* as synonymous with Reiter's syndrome and *incomplete reactive arthritis* to refer to the syndrome when it is limited to the joints. This latter usage is not followed in this chapter.

Reiter's syndrome and reactive arthritis are members of a family of diseases termed the *seronegative spondyloarthritides* that have in common varying degrees of arthrocutaneous and sometimes ocular manifestations (Table 182-1). They exhibit familial clustering, susceptibility associated with the presence of certain major histocompatibility gene complex (MHC) class I alleles, such as human leukocyte antigen (HLA)-B27, and are frequently precipitated by infection with certain microorganisms. The presence of enthesopathy is a diagnostic hallmark in each of these entities. Nail involvement is often prominent. Psoriatic arthritis (see Chap. 43) is a member of the spondyloarthritis group and exhibits many parallels to Reiter's syndrome. The mechanism of disease in the spondyloarthritides appears to involve an as yet imprecisely characterized cellular immune response centered on the CD8 T cell. Behçet's syndrome and Whipple's disease are sometimes included among the spondyloarthritides. Reiter's syndrome is clearly distinguished from rheumatoid arthritis by the absence of rheumatoid factor, the presence of enthesopathy, and its occurrence with undiminished, and often enhanced, intensity in the setting of the frank immunosuppression of advanced HIV infection.

Disease	HLA Markers of Susceptibility	Mucocutaneous Involvement
Reiter's syndrome	HLA-B27, HLA-B7	Marked
Reactive arthritis	HLA-B27, HLA-B7	No
Psoriatic arthritis	HLA-Cw6, HLA-B13, HLA-B27, HLA-B57	Marked
Ankylosing spondylitis	HLA-B27	No
Enteric arthritis (ulcerative colitis, Crohn's disease)	HLA-B27 (axial disease)	Occasional
Behçet's syndrome?	HLA-B51	Marked

TABLE 182-1 **The Spondyloarthritides**

HISTORICAL ASPECTS

The earliest mentions of the characteristic triad of arthritis, conjunctivitis, and urethritis after enteric or venereal infections were in 1776, by Stoll, and in 1818, by Brodie. The differentiation of this triad from the similar findings in gonococcal infection was difficult. Indeed, the term *keratoderma blennorrhagicum* was introduced at the end of the nineteenth century to refer to a supposed complication of gonococcal infection. Reiter's syndrome was independently described by Reiter and by Feissinger and Leroy in the setting of epidemics of dysentery in the appalling sanitary conditions of the Balkan and Western fronts in World War I. During World War II, the distinctive epidemiology of Reiter's syndrome again was documented in a study of more than 150,000 Finns who developed shigellosis, of whom Reiter's syndrome was found in

344, and of 602 similarly infected sailors on the cruiser USS Little Rock, of whom Reiter's syndrome developed in 9. The understanding of the importance of ligament and tendon insertional inflammation, or enthesopathy, as a general manifestation of Reiter's syndrome was advanced by the work of Ball. [1]

The fundamental observation in 1973, by Brewerton et al., [2] that susceptibility to Reiter's syndrome was strongly associated with the MHC class I specificity HLA-B27, ushered in the intense period of current interest in this disease, and made Reiter's syndrome the first instance of a human immune response to a bacterial infection that was genetically regulated by allelic forms of MHC molecules. The role of HLA-B27 in Reiter's syndrome was confirmed by returning to the survivors of the two epidemiologic studies and identifying this HLA specificity in approximately 80 percent of those with Reiter's syndrome who were available for study, while the expected low frequency of HLA-B27 was found in the unaffected controls. The importance of CD8, and not CD4, T cells was provided by an experiment of nature in which it was recognized that Reiter's syndrome occurs with increased severity and prevalence in persons with advanced AIDS. This finding introduced the idea that Reiter's disease is a CD8 T cell-driven disease process. [3], [4]

EPIDEMIOLOGY AND GENETIC FACTORS

There are two epidemiologically distinct forms of Reiter's syndrome: the venereal or endemic form, which follows a sexually transmitted route and is initiated by nonspecific urethritis, and the epidemic or postdysenteric form, which follows enteric infection. The sex ratio is approximately equal in the postdysenteric form but is greatly male-biased in the clinically equivalent form that follows urethritis, perhaps because nonspecific urethritis is more common among men. Reiter's syndrome develops in from 1 to 3 percent of individuals with nonspecific urethritis. [5] Because epidemic enteric infections are relatively uncommon in the United States and Canada, Reiter's syndrome in North America is largely a disease of men (85 to 88 percent of cases).

As would be anticipated in a disorder with an infectious etiology, characteristic modes of transmission, a genetic susceptibility associated with an allele that has a complex distribution, and no specific diagnostic test to identify atypical clinical presentations, it is difficult to arrive at a reliable estimate of the prevalence or incidence of Reiter's syndrome. In the rural midwestern United States, the annual age-adjusted incidence [6] is reported to be 3.5 per 100,000. It is considered to be the most common cause of arthritis in young men. The most frequent age of onset is in the early twenties, but Reiter's syndrome has been recognized from childhood into the sixth decade. [7] Children are reported to develop reactive arthritis after enteric infection at a lower rate than adults; this finding suggests differences in immune responsiveness between children and adults. [8] In the pediatric age group, Reiter's syndrome typically develops after enteric infections, including cryptosporidial enteritis and *Salmonella enteritidis* infection. [9], [10]

The occurrence of Reiter's syndrome parallels the population frequency of HLA-B27, being found largely in circumpolar Asians and whites. Reactive arthritis is far more cosmopolitan in distribution. Indeed, it is one of the major rheumatic diseases to develop in Africans infected with HIV, emphasizing the global problem of this disease. [11] In addition to HLA-B27, other incompletely defined genes appear to be involved. In some families with HLA-B27, there is a strong familial aggregation of Reiter's syndrome without ankylosing spondylitis, whereas in other families the opposite is the case. [12], [13] Both disorders are found in approximately 10 percent of relatives of the proband. A similar divergence between Reiter's syndrome and ankylosing spondylitis is evident among certain groups of American Indians and Inupiat Eskimos in whom HLA-B27 is prevalent. For example, the Haida and Pima have a high frequency of ankylosing spondylitis, and the Navaho and Inupiat have a high frequency of Reiter's syndrome but not ankylosing spondylitis.

ETIOLOGY AND PATHOGENESIS

Infectious Etiology

The postdysenteric form of Reiter's syndrome is initiated by infections with a specific set of gram-negative enteric organisms that are designated as arthritogenic and largely share the property of persisting in macrophage endosomes. These include *Salmonella enteritidis, S. typhimurium,* and *S. heidelberg; Shigella flexneri* types 1b and 2a, and *S. dysenteriae* but not *S. sonnei; Yersinia enterocolitica* and *Y. pseudotuberculosis; Campylobacter fetus;* and *Clostridium difficile*. Among the *Salmonella* and *Shigella* infections that result in Reiter's syndrome there is a reported connection between the ability to induce Reiter's syndrome and the presence of a distinctive plasmid. [14] In contrast, the infectious etiology of the endemic or venereal form of Reiter's syndrome has been more difficult to define. *Chlamydia trachomatis* is implicated as a possible agent. This agent can be cultured from more than one-third of men with nonspecific urethritis, regardless of whether or not they develop Reiter's syndrome, and elementary bodies of the organism have been observed in the synovial membrane. [14] Identification of the chlamydial ribosomal RNA operon by polymerase chain reaction (PCR) analyses is proving to be a more efficient means of identification of infection by this organism. The identification is enhanced if synovial tissue obtained with needle biopsy is used, as opposed to only synovial fluid. [15]

Because the clinical response of Reiter's syndrome follows the apparent inciting infection by 1 to 4 weeks, the causative pathogen can only sometimes be identified with systematic application of current microbiologic diagnostic methods. In one report, [16] a pathogen was identified in only 56 percent of all patients by using enzyme immunoassay and Widal's agglutination test for detection of *Yersinia;* stool culture and enzyme immunoassay for the detection of *Salmonella* and *Campylobacter jejuni;* stool culture for infections with *Shigella* or *Yersinia;* and culture of the urogenital tract and microimmunofluorescence and immunoperoxidase assay for infections with *C. trachomatis*. One of the enteric bacteria was identified in 52 percent of the patients with enteric reactive arthritis. *C. trachomatis* was identified in 63 percent of those with antecedent urethritis. [16]

The frequency of antigen-specific T cells and their cytokine secretion pattern on stimulation with bacteria-derived recombinant proteins are being studied. The T cell proliferative response to microbial antigens by the lymphocytes of the joint fluid is much greater than that of blood lymphocytes among those who develop Reiter's syndrome. [17], [18] Application

of the tetramer technology showed that a B27/chlamydial peptide identified through the process described above specifically stained CD8+ T cells in patients with *Chlamydia*-induced arthritis. [19] The frequency of antigen-specific T cells to *Chlamydia*- and *Yersinia*-derived antigens in reactive arthritis joint fluid is between 1:200 and 1:50. Both the chlamydial heat shock protein 60 (hsp60) and major outer membrane protein (MOMP) are dominant T cell antigens in *Chlamydia*-induced reactive arthritis. [20]

There is increasing evidence by PCR for the presence of *Yersinia, Salmonella,* and, especially, *Chlamydia* in the tissue or, less efficiently, in the joint fluids of affected persons. [14], [15], [21], [22], [23], [24] and [25] However, many patients with arthritis have bacterial DNA in the joint, and in some cases, DNA from more than a single species is present, raising the question of the significance of the observation for the pathogenesis of Reiter's disease. [24]

Genetic Factors

Cross-sectional studies demonstrate a close association between HLA-B27 and Reiter's syndrome, usually in the range of 50 to 70 percent. HLA-B27 was found in 80 percent of 906 patients and in 9 percent of 13,477 ethnically matched controls [26] (relative risk = 37). In general, the intensity of the association between Reiter's syndrome and HLA-B27 is appreciably less than that between the same specificity and ankylosing spondylitis, where it approaches 95 percent. The 20 percent or more of HLA-B27–negative patients with Reiter's syndrome have one of a group of HLA class I specificities termed HLA-B27 cross-reacting antigens, [7], [27] including HLA-B7, HLA-Bw22, HLA-Bw40, and HLA-Bw42. They share structural similarities with HLA-B27. When Reiter's syndrome occurs in individuals infected with HIV, the same genetic predisposition is found that is primarily defined by the presence of HLA-B27. The relative risk of an HLA-B27–positive person in an epidemic setting developing Reiter's syndrome is calculated to be as high as 20, but in other epidemics, such as that among the Finns, the risk is as much as an order of magnitude lower. [28] The chromosomal region around the HLA-B and HLA-C loci contains several additional polymorphic genes including MICA, HLA-17, and BAT1, which could also be relevant. [29], [30]

Immunologic Mechanisms

The central immune recognition event in Reiter's syndrome appears to involve the response of a CD8 lineage T cell to a peptide presented by a class I molecule. This observation is based on three main lines of evidence: (1) Reiter's syndrome occurs with undiminished intensity in those with advanced AIDS and loss of CD4 T cell function; (2) the response does not involve classic autoantibodies that reflect the action of CD4 T cell help occurring in diseases such as systemic lupus erythematosus and rheumatoid arthritis; and (3) susceptibility is determined by the presence of certain class I alleles that act as immune response genes. The nature of the antigen and the specificity of the T cell receptor remain unknown. But it is this CD8 T cell response that initiates the inflammation and alteration of the pattern of gene expression in target tissues through the release of cytokines and other inflammatory mediators by the responding lymphocytes.

How HLA-B27 influences the CD8 T cell immune response remains unknown. Three quite dissimilar mechanisms are proposed. The first autoimmune mimicry model postulates that the HLA-B27 molecule binds one or more particular peptides encoded by the arthritogenic microorganisms. This initiates an immune response against the microorganism involving CD8 T cells. These activated T cells then encounter normal cells of the skin, joint, and entheses that express HLA-B27 molecules containing tissue-specific self peptides closely resembling the peptide encoded by the microorganism. The immune system now attacks the normal cells. This loss of tolerance most likely arises through an induced response to minor antigenic determinants on self molecules for which tolerance does not exist (clonal ignorance) and which are usually not seen as antigenic. The resulting pathogenic immune response against normal tissue-specific self peptides, occurring at the CD8 T cell level, is autoimmune in character, now driven by a self peptide available in unlimited quantities. Interestingly, *Y. enterocolitica* can infect dendritic cells in vitro, inducing rapid maturation reflected by upregulated CD83 and CD86, but greatly reduced MHC class II expression and loss of immunostimulatory capacity in a mixed leukocyte reaction. [31] This could inappropriately activate the T cell by deviation of the immune response towards cross presentation of peptides by a class I route.

A second model invokes CD8 T cell activation to self-reactivity through innate immune receptors that sense stereotyped injury, stress, and danger signals. This may occur in CD8 T cells that have differentiated to memory/effector status through prior clonal activation and thereby express additional receptors, such as activating NK receptors that recognize molecules expressed by stressed or injured cells. Engagement of these receptors then signals through pathways that intersect those induced by the T cell receptor, thus effectively lowering the threshold for CD8 T cell triggering by self-peptides.

A third, less likely possibility involves nonantigen-specific stimulation of T lymphocytes by superantigens contained in the infecting bacteria. [32] By binding to particular portions of the T cell receptor, the superantigen triggers the T cell to activation. Now it recognizes a self peptide presented by a HLA-B27 molecule in an extension of the events in the first model.

Three experimental models are particularly relevant to the pathogenesis of Reiter's syndrome. Adjuvant arthritis in rats, resulting from the administration of inactivated *Mycobacterium tuberculosis,* is a strain-specific response characterized by tendinitis, keratoderma blennorrhagicum, urethritis, and ophthalmitis that resembles Reiter's syndrome. [33] Similarly, the 57-kDa heat shock protein of *Chlamydia* induces experimental eye inflammation that mimics the inflammation in Reiter's syndrome. [34] The expression of the HLA-B27 molecule in mice at levels from five to ten times those of the mouse MHC molecules resulted in phenotypically normal animals that had enhanced susceptibility to *Yersinia* infection. [35] Taken together with the previous information, this finding reinforces the paradigm that Reiter's syndrome is a specific immunologic reaction to a microorganism antigen presented by MHC molecules to T cells.

Although clear differences exist between Reiter's syndrome and psoriasis/psoriatic arthritis at multiple levels, certain

elements in the pathogenesis of these two entities appear to be quite similar, if not identical. T cells of the CD8 lineage and immune recognition events involving class I MHC molecules appear centrally involved in both illnesses. A diagram of the role of the CD8 T cell applicable to the pathogenesis of Reiter's syndrome is found in Chap. 43.

PATHOLOGY

Skin

Histologically, the appearance of established keratoderma blennorrhagicum is indistinguishable from that of pustular psoriasis, and is characterized by hyperkeratosis and parakeratosis, elongation and hypertrophy of the rete pegs, general epidermal hyperplasia, and extensive neutrophilic infiltration with formation of microabscesses and spongiform pustules. The initial lesion is a vesicular, pustular, or erythematous macule. Balanitis in circumcised individuals has a similar histologic appearance, whereas the moist lesion in uncircumcised males is otherwise similar to the initial lesion but is not keratinized. Mouth ulcers are similarly unkeratinized.

P>Differentiation from psoriasis may be helped by the presence of a greatly thickened horny layer in Reiter's syndrome.

Musculoskeletal System

The characteristic lesions of the entheses have not been studied in detail; the lesions do, however, contain lymphocytes and proliferating fibroblasts. The appearance of the synovium is typical of any nonspecific chronic synovitis with an extensive T cell infiltrate, but with rather more marked vascular involvement and fibroblast proliferation. Edema, vascular congestion, increased surface fibrin, lining cell proliferation, and infiltration with neutrophils are found. Occlusion by platelet and fibrin thrombi, simulating that caused by endotoxins, is common. [14]

Systemic

Sixty-seven percent of patients with Reiter's syndrome are reported to have either acute ileocolitis or evidence of Crohn's disease on biopsy, with most having no gastrointestinal symptoms. Five percent of patients have granulomatous lesions at the aortic root and annulus that may cause abnormalities in conduction, including complete heart block and frank atonic regurgitation. Secondary amyloidosis with AA protein deposition is a rare complication that is usually found after a long course of illness.

CLINICAL MANIFESTATIONS

Natural History

The temporal evolution of Reiter's syndrome often provides the clue to diagnosis. The enteric or genitourinary infection that initiates Reiter's syndrome is followed by a latent period of 1 week to 1 month, during which the initial symptoms attributable to the infection subside. Then the features of Reiter's syndrome appear, heralded by urethritis and conjunctivitis; these manifestations are followed within several days by the often abrupt and diagnostically characteristic onset of severe arthritis. The mucocutaneous involvement occurs independently, sometimes coinciding with or preceding the phase of urethritis and conjunctivitis and sometimes developing after the onset of arthritis. During the acute phase of Reiter's syndrome, constitutional symptoms and signs are prominent, including fever, fatigue, and malaise, and sometimes profound weight loss.

Reiter's disease and reactive arthritis are generally considered to be self-limited. In most individuals, the illness responds to therapy, with one or two recrudescences occurring over a 2- to 6-month period. In a still incompletely defined subset of perhaps 20 percent of patients, the disease persists. In this setting, the process occasionally assumes more features of psoriatic arthritis and psoriasis. The chronic cutaneous and joint phase of this illness can be a particularly vexing problem.

Skin Disease

Circinate balanitis is the most common cutaneous finding, reported in approximately 36 percent of patients with Reiter's syndrome. [36] The lesion is initially vesicular with little or no surrounding erythema. Irregular moist superficial ulcers form in the uncircumcised male and may coalesce to give a circinate distribution (Fig. 182-1). These ulcers may occasionally become secondarily infected. In the circumcised male, the lesions evolve to form hard crusts and plaques. Painless mucosal ulcers of varying size on the tongue, palate, buccal mucosa, and lips are found in 17 percent of cases; they are usually transient and cause little or no morbidity.

FIGURE 182-1 Reiter's syndrome, balanitis circinata. Illustrated in this patient is circinate balanitis with moist, well-demarcated erosions with a slightly raised border.

The initial lesions of keratoderma blennorrhagicum are small vesicles or erythematous macules that may coalesce and are usually surrounded by an erythematous base. The vesicle wall becomes progressively thickened, forming a small papule, nodule, or even a horny excrescence. The appearance of the lesions varies from a scaling plaquelike process that resembles pustular psoriasis to combinations of crusting, exudation, and erosion associated with erythema. Lesions of keratoderma blennorrhagicum are found in approximately 15 percent of patients. Keratoderma blennorrhagicum is most commonly found on the soles, toes, and palms, where the lesions are often densely scattered. More isolated lesions occur on the glans penis, scrotum, trunk, limbs, and scalp. In severe cases, notably those associated with HIV infection, the keratoderma blennorrhagicum may be distributed over the entire body, with an intensification on the digits in a pattern that resembles the lesions of pustular psoriasis and in the groin in the pattern of inverse psoriasis or sebopsoriasis. The soles may exhibit unusually marked keratotic changes (Fig. 182-2). The keratoderma blennorrhagicum lesions may last for weeks to months, disappear, and then recur. [37] In patients with HIV infection, the initial Reiter's syndrome may gradually assume the chronic features of pustular psoriatic arthritis.

FIGURE 182-2 Severe keratoderma blennorrhagicum with marked dyskeratotic change in an HIV-positive person. The margins of the dyskeratotic process are intensely inflamed.

Joint Disease

The foot, ankle, and knee are the principal sites of musculoskeletal involvement. Joint disease includes both enthesopathy, mainly of the plantar fascia and Achilles tendon, and arthritis of the subtalar, ankle, and knee joints. The arthritis is generally abrupt in onset and may be florid, particularly in the knee joint where massive effusion may lead to rupture of a popliteal Baker's cyst and the syndrome of pseudothrombophlebitis. The joint inflammation occasionally subsides almost immediately; more commonly, it remains as a subacute, chronic, or recurrent problem. The small or large joints of the upper limbs may be involved, but usually only in association with predominant arthritis of the large joints of the legs. In the instances of Reiter's syndrome associated with HIV infection, the course of the joint disease is sometimes slowly cumulative, and ultimately results in an extensive polyarthritis with erosions and marked periarticular osteoporosis (Fig. 182-3) involving the small and large joints of the arms and legs in a pattern more similar to that of psoriatic arthritis.

FIGURE 182-3 Juxtaarticular osteoporosis in an HIV-positive person who presented with typical Reiter's syndrome, but who exhibited a cumulative pattern of joint involvement indistinguishable from that of psoriatic arthritis. The involvement

of the small joints in the hands is also more typical of psoriatic arthritis.

Inflammation at the sites of insertion of ligaments and tendons is a striking feature of Reiter's syndrome. In addition to the plantar fasciitis and Achilles and posterior tibial tendinitis, the enthesopathy results in chest wall and inflammatory lower back pain, tenderness over ischial tuberosities and iliac crests, and dactylitis, or sausage digits. While in most patients the inflammatory back pain is directly attributable to enthesopathy, where it characteristically includes stiffness and pain after periods of rest, such as in the early morning, and improves with exercise, approximately one-quarter of patients with chronic Reiter's syndrome develop chronic sacroiliitis or a characteristic asymmetric spondylosis that limits back mobility. [38]

Nail Disease

Involvement of the nail may begin as erythema of the nail fold or, more insidiously, as subungual hyperkeratosis, a diagnostic finding in psoriasis and Reiter's syndrome that distinguishes these entities from rheumatoid arthritis. The nail becomes thickened, yellowed, and brittle. Frank onycholysis with shedding of the nail often occurs. The acral portion of the digit may be hyperkeratotic with erythema and scaling, and may exhibit the appearance of pseudoparonychia. The tendency to extensive acral disease is pronounced in HIV-associated cases. In some cases of HIV-associated Reiter's syndrome, yellowing of the nails is the first manifestation of the syndrome. Pitting of the nails, characteristic of psoriasis, is not seen in Reiter's syndrome.

Other Manifestations

Urethritis and prostatitis are frequently associated. They may present only as sterile pyuria in the first voided specimen, or range up to moderately severe dysuria with frank mucopurulent discharge. The dominant ocular lesion in Reiter's syndrome is conjunctivitis of varying intensity that usually resolves quickly. A smaller proportion of patients also exhibits uveitis, initially manifest as acute anterior iritis, which may progress to chronic iridocyclitis and visual impairment. The uveitis resembles that of ankylosing spondylitis in that it is acute in onset, frequently unilateral, and spares the choroid and retina. [39] Uveitis is a potentially serious problem that must be carefully evaluated and treated.

The cardiac symptoms in Reiter's syndrome include palpitations, pericardial type chest pain, and, relatively rarely, symptoms of aortic valve incompetence. Findings in 5 percent of the patients include first-, second-, and third-degree heart block; ST-segment and T- and Q-wave changes on electrocardiography; pericardial rubs; and various degrees of aortic and, occasionally, mitral valve incompetence from granulomatous involvement at the aortic root. [40], [41] Atrioventricular conduction disturbances may appear early in the course. Relatively rare manifestations include peripheral neuropathy and other neurologic findings, pleuritic and pulmonary parenchymal inflammation, erythema nodosum, and amyloidosis.

LABORATORY FINDINGS

High levels of cytokines associated with the inflammation of Reiter's syndrome are reflected by the elevation in acute-phase reactants, a variably elevated erythrocyte sedimentation rate, hypochromic or normochromic anemia, and mild hypoalbuminemia. Elevated antibody titers to specific enteric pathogenic agents often help with differential diagnosis. Rheumatoid factor and classic autoantibodies are absent. Urine and stool cultures are helpful in perhaps as many as half of the cases, with the persistence of *Salmonella* carriage particularly important to determine. The demonstration of persistent components of microorganisms in tissue biopsies by molecular biologic methods is still an experimental technique, but one that holds considerable promise. [15], [42] Testing for HIV should be considered because HIV infection is also a sexually acquired disease.

Much has been written about whether or not to perform HLA typing for diagnostic reasons or to guide therapy. [43] In a classic but mild case, where Reiter's syndrome is an obvious clinical diagnosis, the test seems unnecessary. However, because HLA-B27 is associated with more severe and protracted disease (including the occurrence of uveitis, carditis, and sacroiliitis), [44], [45] testing may be useful in difficult cases for diagnostic or prognostic reasons.

The joint fluid cell count is elevated, occasionally to more than 50,000 neutrophils per µL, a level that, in conjunction with the intense inflammation, might otherwise suggest a septic joint and is designated pseudosepsis. Occasionally, “Reiter's cells” are observed, which are macrophages that have ingested a neutrophilic leukocyte. Total joint fluid protein levels are elevated in proportion to the degree of inflammation; and because there is little or no intraarticular consumption of complement, the joint fluid complement component levels are about two-thirds of their levels in serum when normalized on a per gram of serum protein basis. Glucose levels are normal, and standard bacteriologic cultures are uniformly negative; these two important points differentiate the intense inflammation of Reiter's syndrome from that of septic arthritis.

RADIOGRAPHIC FEATURES

Initially, only signs of an effusion are present. Periarticular osteoporosis can develop after several weeks of inflammation; in some instances, where the arthritis becomes chronic, erosions and loss of the cartilaginous joint space are seen. Enthesopathy is characterized by a combination of erosions about tendon and ligament insertions, bone lucency, and new bone formation, often in the form of spurs extending into the tendon or fascia. Widespread periosteal new bone formation can be found, especially on the bones of the pelvis and feet. Enthesopathy and periosteal new bone formation is not a feature of rheumatoid arthritis. Sacroiliitis is typical in appearance but may be only asymmetric, distinguishing it from the uniformly bilateral form in ankylosing spondylitis. Similarly, the frank spondyloarthritis, when present, is often asymmetric, without the uniformity in extension from the lower lumbar vertebrae that occurs in psoriatic arthritis. [38]

Indeed, neck involvement is common in Reiter's syndrome.

DIAGNOSIS

The diagnosis of Reiter's syndrome can be simple or exceedingly challenging. In the absence of the distinctive mucocutaneous findings, a careful differential diagnosis must be made among entities such as other spondyloarthritides (including especially ankylosing spondylitis and psoriatic arthritis), infectious arthritis (notably that caused by the gonococcus or Lyme disease), the crystal-induced arthritides (primarily gout), and other rheumatic diseases such as rheumatoid arthritis, Behçet's syndrome, and rheumatic fever. The history of a sexual contact or risk factors leading to the acquisition of HIV infections may be concealed, or an episode of dysentery may be disregarded unless the patient is specifically questioned. Similarly, many of the features of the illness may be mild so that mouth ulcers, if noticed at all, are passed off as cold sores and transient dysuria is dismissed.

Although gonococcal arthritis and Reiter's syndrome may superficially resemble one another in that urethritis, skin rash, oligoarthritis, and tenosynovitis occur in both, the character and natural history of the two illnesses are usually readily distinguishable. Gonococcal arthritis is more common in women, and upper limb joint involvement predominates. The arthritis is not florid and is usually preceded by insidiously developing migratory arthralgia. Enthesopathy, keratoderma blennorrhagicum, balanitis, and back pain are absent. Culture may be helpful but can be negative. Be aware that both entities can coexist.

In any florid arthritis, the fluid should be studied for the presence of microorganisms by culture and staining and examined for urate or phosphate crystals by polarized light microscopy. Rheumatic fever remains a rare but strong simulator of Reiter's syndrome. Behçet's syndrome is another rare entity in North America, but the combination of mucocutaneous lesions and arthritic disease in this syndrome can cause diagnostic difficulties. Neurologic findings and the pustulonecrotic pathergic lesions at injury sites, as well as extensive, painful genital and oral ulcers, suggest the diagnosis of Behçet's syndrome.

The complications of the effusive inflammatory arthritis include ruptured popliteal cysts and thrombophlebitis. The rupture of popliteal cysts with the syndrome of pseudothrombophlebitis should be differentiated from true thrombophlebitis, which can also be found in this setting because of pressure on the popliteal vein by the joint effusion and the contiguous inflammation.

The special problems of the radiologic diagnosis of juvenile-onset Reiter's syndrome with its disproportional degree of enthesitis and its distinction from the other spondyloarthritides and from forms of juvenile chronic arthritis have been reviewed. [46]

TREATMENT

Therapy of Reiter's syndrome varies from relatively straightforward in mild disease to difficult when the illness is sustained or severe. The uveitis, and the more uncommon visceral manifestations, especially those of the heart, while less overt to the patients than skin or joint disease, may require intensive drug therapy to prevent serious complications or disability.

Antibiotic therapy to eliminate persistent inciting microorganisms remains controversial. [23] The traditional view has been to not treat, although newer data about microbial persistence in the synovial tissues, especially that of *Chlamydia* described above, may support a role for antibiotics. There are conflicting double-blind studies. In a carefully performed 3-month trial with doxytetracycline, no beneficial effect was found on pain or functional status. [47] In contrast, ciprofloxacin used for 3 months to treat patients with *Yersinia*-triggered reactive arthritis resulted in faster remission, greater relief of arthritis, and much greater elimination of the microorganism from gut-associated lymphoid tissue. [48] Clearly, any suggestion that an individual had an impaired immune system with the question of enhanced microbial persistence, such as in HIV infection, would indicate antibiotic use where a specific inciting organism was documented. This is especially so because the inflammatory response of Reiter's syndrome may transactivate the virus, leading to an increase in viral load and a consequent increased viral cytopathogenic effect. For this reason, HIV-positive individuals with Reiter's syndrome should have a program of monitoring viral load and initiation of effective antiviral agents. Moreover, assiduous control of the HIV component of the disease is warranted, as emphasized by a case report describing striking improvement in Reiter's disease concomitant with introduction of highly active retroviral therapy. [49]

All patients with Reiter's syndrome must be informed about the sometimes difficult nature of the illness and its variable outcome. The management of the acute mucocutaneous lesions of uncomplicated Reiter's syndrome is usually limited to symptomatic or topical therapy. The severe, extensive, and chronic cutaneous reactions that are more common in the form of Reiter's syndrome associated with HIV infection present a much more difficult challenge. Moderate success has been obtained by treating these lesions in the same manner as pustular psoriasis. UVB irradiation, coal tar, and etretinate administration, combined with very judicious use of topical glucocorticoids, are the mainstay of therapy. When HIV infection is excluded, extremely severe skin lesions can be treated with immunosuppressive agents including methotrexate, PUVA therapy, or cyclosporine.

Whereas conjunctivitis is a common short-lived occurrence and can be adequately managed by nonspecific local therapy, the development, actual or suspected, of uveitis is a threatening complication. Eye pain, ciliary flush, and other symptoms of early iritis should prompt immediate referral to an ophthalmologist. Cardiac conduction disturbances and aortic or mitral valve involvement mandate immediate medical evaluation and systemic glucocorticoid therapy.

Arthritis and enthesopathy are the symptoms that necessitate treatment in most patients. In general, the anti-inflammatory agents have a high benefit-to-risk ratio, and the decision to use them is usually not complex. In contrast, the use of immunomodulatory/immunosuppressive agents is associated with considerably greater risks.

Nonsteroidal anti-inflammatory drug (NSAID) therapy is the first line of treatment. Sulfasalazine is reported to be effective but slow acting in the therapy of Reiter's syndrome that is unresponsive to NSAIDs, and side effects may occur. [50] Agents such as methotrexate or azathioprine remain choices for intractable, severe disease. Cyclosporine is also reported to be effective. [51] Methotrexate or other immunosuppressive agents should be used with particularly great caution, if at all, in those individuals with concurrent HIV infection. [3], [52]

COURSE AND PROGNOSIS

Reiter's syndrome does not always have a rapid, favorable outcome. Sixty-three percent of patients with Reiter's syndrome in a rural midwest setting had a prolonged or relapsing course, especially of the arthritis manifestations. [6] Less often, persistent dermal lesions, such as balanitis, can be extremely troublesome. A few patients with chronic disease progress into other forms of spondyloarthritis. The HIV-associated forms of Reiter's syndrome usually illustrate the worst features of this illness with a tendency to develop chronic arthritis and skin disease indistinguishable from pustular psoriasis.

REFERENCES

1. Ball J: Enthesopathy of rheumatoid and ankylosing spondylitis. *Ann Rheum Dis* **30**:213, 1971

2. Brewerton DA et al: Ankylosing spondylitis and HL-A 27. *Lancet* **1**:904, 1973

3. Winchester R et al: The co-occurrence of Reiter's syndrome and acquired immunodeficiency. *Ann Intern Med* **106**:19, 1987

4. Winchester R: Psoriatic arthritis. *Dermatol Clin* **13**:779, 1995

5. Keat AC et al: Role of *Chlamydia trachomatis* and HLA-B27 in sexually acquired reactive arthritis. *Br Med J* **1**:605, 1978

6. Michet CJ et al: Epidemiology of Reiter's syndrome in Rochester, Minnesota: 1950–1980. *Arthritis Rheum* **31**:428, 1988

7. Arnett FC: Incomplete Reiter's syndrome: clinical comparisons with classical triad. *Ann Rheum Dis* **38**(suppl 1):73, 1979

8. Rudwaleit M et al: Low incidence of reactive arthritis in children following a salmonella outbreak. *Ann Rheum Dis* **60**:1055, 2001

9. Kanakoudi-Tsakalidou F et al: Persistent or severe course of reactive arthritis following *Salmonella enteritidis* infection. A prospective study of 9 cases. *Scand J Rheumatol* **27**:431, 1998

10. Cron RQ, Sherry DD: Reiter's syndrome associated with cryptosporidial gastroenteritis. *J Rheumatol* **22**:1962, 1995

11. Njobvu P et al: Spondyloarthropathy and human immunodeficiency virus infection in Zambia. *J Rheumatol* **25**:1553, 1998

12. Hochberg MD: The application of genetic epidemiology to systemic lupus erythematosus [editorial]. *J Rheumatol* **14**:867, 1987

13. Calin A, Marks SH: The case against seronegative rheumatoid arthritis editorial. *Am J Med* **70**:992, 1981

14. Stieglitz et al: Identification of a 2-Md plasmid from *Shigella flexneri* associated with reactive arthritis. *Arthritis Rheum* **32**:937, 1989

15. Schumacher HRJ et al: Light and electron microscopic studies on the synovial membrane in Reiter's syndrome. Immunocytochemical identification of *Chlamydial* antigens in patients with early disease. *Arthritis Rheum* **31**:937, 1988

16. Fendler C et al: Frequency of triggering bacteria in patients with reactive arthritis and undifferentiated oligoarthritis and the relative importance of the tests used for diagnosis. *Ann Rheum Dis* **60**:337, 2001

17. van Bohemen CG et al: HLA-B27M1M2 and high immune responsiveness to *Shigella flexneri* in post-dysenteric arthritis. *Immunol Lett* **13**:71, 1986

18. Gaston JS et al: In vitro responses to a 65-kilodalton mycobacterial protein by synovial T cells from inflammatory arthritis patients. *J Immunol* **143**:2494, 1989

19. Kuon W et al: Identification of HLA-B27–restricted peptides from the *Chlamydia trachomatis* proteome with possible relevance to HLA-B27–associated diseases. *J Immunol* **167**:4738, 2001

20. Thiel A et al: Analysis of the antigen-specific T cell response in reactive arthritis by flow cytometry. *Arthritis Rheum* **43**:2834, 2000

21. Keat A et al: *Chlamydia trachomatis* and reactive arthritis: the missing link. *Lancet* **1**:72, 1987

22. Granfors K et al: Yersinia antigens in synovial fluid cells from patients with reactive arthritis. *N Engl J Med* **320**:216, 1989

23. Toivanen A: Bacteria-triggered reactive arthritis: Implications for antibacterial treatment. *Drugs* **61**:343, 2001

24. Gerard HC et al: Chromosomal DNA from a variety of bacterial species is present in synovial tissue from patients with various forms of arthritis. *Arthritis Rheum* **44**:1689, 2001

25. Gerard HC et al: Expression of *Chlamydia trachomatis* genes encoding products required for DNA synthesis and cell division during active versus persistent infection. *Mol Microbiol* **41**:731, 2001

26. Li F et al: Molecular detection of bacterial DNA in venereal-associated arthritis. *Arthritis Rheum* **39**:950, 1996

27. Tiwari JL, Terasaki PI: *HLA and Disease Associations*. New York, Springer Verlag, 1985, p 363

28. Paronen I: Reiter's disease: A study of 344 cases observed in Finland. *Acta Med Scand* **131**(suppl 212):1, 1948

29. Stein CM, Davis P: Arthritis associated with HIV infection in Zimbabwe. *J Rheumatol* **23**:506, 1996

30. Mizuki N et al: Nucleotide sequence analysis of the HLA class I region spanning the 237-kb segment around the HLA-B and -C genes. *Genomics* **42**:55, 1997

31. Schoppet M et al: Dendritic cell function is perturbed by *Yersinia enterocolitica* infection in vitro. *Clin Exp Immunol* **122**:316, 2000

32. Nickerson CL et al: Role of enterobacteria and HLA-B27 in spondyloarthropathies: studies with transgenic mice. *Ann Rheum Dis* **49**:426, 1990

33. Porcelli S: Molecular mimicry and the generation of autoimmune diseases. *Rheumatol Rev* **2**:41, 1993

34. Battisto JR et al: Susceptibility to adjuvant arthritis in DA and F344 rats: A dominant trait controlled by an autosomal gene locus linked to the MHC. *Arthritis Rheum* **25**:1194, 1982

35. Morrison RP et al: Chlamydial disease pathogenesis. The 57-kD chlamydial hypersensitivity antigen is a stress response protein. *J Exp Med* **170**: 1271, 1989

36. Cuvelier C et al: Histopathology of intestinal inflammation related to reactive arthritis. *Gut* **28**:394, 1987

37. Aho K et al: HLA B27 in reactive arthritis following infection. *Ann Rheum Dis* **34**(suppl 1):29, 1975

38. Hancock JAH: Surface manifestations of Reiter's disease in the male. *Br J Venereal Dis* **36**:36, 1960

39. Azouz EM, Duffy CM: Juvenile spondyloarthropathies: Clinical manifestations and medical imaging. *Skeletal Radiol* **24**:399, 1995

40. Csonka GW, Oates JK: Pericarditis and electrocardiographic changes in Reiter's syndrome. *BMJ* **1**:866, 1957

41. Belz J et al: Characterization of uveitis associated with spondyloarthritis. *J Am Acad Dermatol* **20**:898, 1989

42. Gerard HC et al: *Chlamydia pneumoniae* present in the human synovium are viable and metabolically active. *Microb Pathog* **29**:17, 2000

43. Tucker CR et al: Aortitis in ankylosing spondylitis: Early detection of aortic root abnormalities with two-dimensional echocardiography. *Am J Cardiol* **9**:680, 1982

44. Brewerton DA et al: HL-A 27 and arthropathies associated with ulcerative colitis and psoriasis. *Lancet* **1**:956, 1974

45. Calin A: HLA-B27 in 1982. Reappraisal of a clinical test. *Ann Intern Med* **96**:114, 1982

46. McEwen C et al: Ankylosing spondylitis and spondylitis accompanying ulcerative colitis, regional enteritis, psoriasis, and Reiter's disease. *Arthritis Rheum* **14**:291, 1971

47. Smieja M et al: Randomised, blinded, placebo controlled trial of doxycycline for chronic seronegative arthritis. *Ann Rheum Dis* **60**:1088, 2001

48. Hoogkamp-Korstanje JA et al: Ciprofloxacin v placebo for treatment of *Yersinia enterocolitica* triggered reactive arthritis. *Ann Rheum Dis* **59**:914, 2000

49. McGonagle D et al: Human immunodeficiency virus associated spondyloarthropathy: pathogenic insights based on imaging findings and response to highly active antiretroviral treatment. *Ann Rheum Dis* **60**:696, 2001

50. Leirisalo-Repo M et al: Follow-up study of Reiter's disease and reactive arthritis. Factors influencing the natural course and the prognosis. *Clin Rheumatol* **6**(2 suppl 19):73, 1987

51. Clegg DO et al: Comparison of sulfasalazine and placebo in the treatment of reactive arthritis (Reiter's syndrome). A Department of Veterans Affairs Cooperative Study. *Arthritis Rheum* **39**:2021, 1996

52. Romani J et al: Reiter's syndrome-like pattern in AIDS-associated psoriasiform dermatitis. *Int J Dermatol* **35**:484, 1996

T>

Chapter 183

Irwin Braverman

Sarcoidosis

HISTORICAL ASPECTS
EPIDEMIOLOGY
ETIOLOGY AND PATHOGENESIS
CLINICAL MANIFESTATIONS
Specific Lesions
Nonspecific Lesions
Systemic Associations
LABORATORY FINDINGS
PATHOLOGY
DIAGNOSIS AND DIFFERENTIAL DIAGNOSIS
COURSE AND PROGNOSIS
THERAPY

REFERENCES

Boeck's sarcoid is a systemic granulomatous disorder of unknown etiology with a predilection for involvement of lung, liver, lymph nodes, skin, and eyes. Other organs are less frequently affected.

HISTORICAL ASPECTS

In 1889, Besnier described a man with diffuse red swelling of the nose and fingers which he called lupus pernio, emphasizing that the disorder was an entity distinct from lupus erythematosus. In 1892, Tenneson reported another case in which a biopsy disclosed “excessive predominance of epithelioid cells and a great rarity of giant cells….” In 1898, Hutchinson reported another example of this disease in a 65-year-old woman who had dusky red plaques on the cheeks, arms, and nose. In 1899, Boeck observed a man with similar lesions on the scalp, face, and extremities, but accompanied by enlarged epitrochlear and femoral lymph nodes. He biopsied the lesions and found epithelioid granulomas with giant cells, which he interpreted as a “new growth” that developed in the perivascular lymph space. He coined the term “multiple benign sarkoid of the skin” to indicate that the lesions were of connective tissue origin. But by 1905, Boeck thought the disease was a bacillary infectious disease because he found acid-fast bacilli in the nasal mucosa in one patient. He preferred his new term “benign miliary lupoid,” but “sarkoid” had become entrenched. In 1904, Kriebrich correlated the cystic bone lesions of the fingers with lupus pernio. In 1906, Darier and Roussy described the subcutaneous form of the disease. In 1916, Boeck recognized that Besnier's lupus pernio was the same disorder he had described as “benign miliary lupoid.” Schaumann, in 1914, wrote a prize essay proposing that all the manifestations of sarcoidosis that had been reported represented the same disease. He did not publish this information until he had collected more data. In 1934, he published all his evidence and called the entity “lymphogranulomatosis benigna,” which he believed was related to tuberculosis. In 1946, Löfgren published his classic paper on the association between hilar adenopathy, erythema nodosum, and sarcoidosis. Boeck and Schaumann were the only clinicians to develop the concept of sarcoidosis as a systemic disease.

EPIDEMIOLOGY

Sarcoidosis occurs worldwide and is slightly more frequent in women than in men (ratios as high as 1.5). [1] Prevalence ranges from 10 to 40 per 100,000 in the United States and in Europe. It occurs most often between the ages of 20 and 40, but can occur in children and in the elderly. In two London clinics, sarcoidosis was 10 to 16 times more frequent, severe, and extensive in black West Indian, African, Indian, and Pakistani patients than in native whites. [2] In the United States, blacks are affected 3 to 4 times more often than whites. Sarcoidosis occurs 200 times more frequently in Irish women living in London and more frequently than expected in Puerto Rican female immigrants in New York City. The variation of prevalence in geographical locations and populations suggests that there are ethnic susceptibility factors as well as environmental factors underlying sarcoidosis.

ETIOLOGY AND PATHOGENESIS

The pathogenesis of sarcoidosis is beginning to be unraveled. In active sarcoidosis, T cells of the CD4+ helper/inducer phenotype (T_H1) are increased in affected lungs, and by implication in other affected organs as well, and show evidence of activation: expression of interleukin (IL)-2 receptors and secretion of IL-2. The alveolar macrophages are also activated: they spontaneously release IL-1, interferon ?, tumor necrosis factor (TNF)-a and IL-6, [3], [4] and demonstrate an enhanced capacity to present antigen. [4] In contrast, there is a peripheral T cell lymphopenia and absence of activated T cells in the circulation in active disease. [5] There is a sequestration of activated T cells and macrophages at sites of granulomatous inflammation. CD4+ T cells are diffusely distributed throughout the granuloma, while CD8+ suppressor cells form a mantle of sparse T cells around the granuloma. The increased numbers of CD4+ T cells within the granuloma are believed to have arisen in part through recruitment from the periphery, which explains the lymphopenia, and, in part, by proliferation in situ. In chronic berylliosis, the alveolitis is believed to be produced by a similar mechanism, except that the antigen, beryllium, is known. Berylliosis is a good model for sarcoid. [6]

Although anergy to tuberculin, mumps, *Candida,* and trichophytin antigens is present in two-thirds of patients, it can be overcome by strong antigenic challenge. The anergy is relative and not absolute as in Hodgkin's disease. In vitro, the peripheral T lymphocytes are defective in their cytotoxic and proliferative responses to antigens and mitogens. This

deficit can be partly explained by an abnormal suppression of these responses by prostaglandin-producing monocytes. Removal of the monocytes corrects the deficit in mitogen-stimulating proliferation and colony formation. [7] Despite the depression of T cell function, there is overactivity of B cells, as manifested by elevated serum levels of immunoglobulins, which can be found in up to 80 percent of patients with active sarcoidosis. However, there is no correlation of immunoglobulin elevation with the degree of disease activity or depression of delayed hypersensitivity.

Experimental data strongly support the concept that sarcoidosis is an antigen-driven disorder in which the helper/inducer T cell arm of the immune system reacts in an exaggerated fashion to as yet undetermined self- or exogenous antigen(s). The preferential use of the Vß8 regions suggests that a superantigen of microbial origin has to be specifically considered. [8]

For many years attention has focused on tuberculosis as the major cause of sarcoidosis because of the similar histopathology of the two entities and the increased incidence of tuberculosis in some patients with sarcoidosis. Scadding [9] described English patients in whom tuberculosis preceded the development of sarcoidosis. In one instance, sarcoidosis developed after the successful treatment of pulmonary tuberculosis, but disappeared when the tuberculosis became active again. He also described five cases of sarcoidosis that evolved into tuberculosis. [9] In three of the five patients, the typical cutaneous and pulmonary radiographic findings of sarcoidosis disappeared when the transition to active tuberculosis occurred.

James [10] pointed out that wherever tuberculosis is rampant, sarcoid is rarely seen, but as tuberculosis is brought under control, sarcoid becomes more frequent. This phenomenon has been observed among the Bantus in South Africa and the population in Uruguay. Some of the Bantu patients with sarcoid were found in leprosaria, just as many English patients had been discovered in sanitaria.

By using molecular biologic methods, contemporary investigators have demonstrated that DNA from *Mycobacterium tuberculosis* and unidentified nontuberculous mycobacterial DNA can be found in tissue sections of sarcoid lesions and bronchial washings from patients with sarcoid, strongly supporting the concept that tuberculosis may be a factor in some cases. [11] Mankiewicz et al. presented a role for atypical mycobacteria 35 years ago. [12]

CLINICAL MANIFESTATIONS

Skin lesions occur in 10 to 100 percent of cases, depending upon whether an internist or dermatologist is the observer. [13] Cutaneous lesions are found two to eight times more often in women than in men. In four representative series composed of adults, cutaneous lesions, histologically specific for sarcoid, occurred in 16 to 36 percent. [13] The prevalence of skin lesions in children is the same. In children, the disease occurs most commonly in the 8- to 15-year-old age group. Approximately 30 cases have been reported involving patients younger than 4 to 6 years old. The clinical features in the latter group are different from those seen in older children (Table 183-1).

Feature	Younger Than 4 Years (%)	Older Than 4 Years (%)
Rash	80	40
Eye disorders	60	45
Arthritis	55	5
Bone lesions	50	20
Adenopathy	40	45
Fever	35	24
Weight Loss	32	18
Lung involvement	22	70

*Adapted from Hetherington.[14]

TABLE 183-1 **Comparative Features of Sarcoidosis in Children***

The skin markers of sarcoid can be categorized as specific and nonspecific. The gross appearance of the specific eruption encompasses papules, nodules, plaques, subcutaneous tumors, and scaly erythematous and atrophic flat lesions. Although the lesions do not have a pathognomonic morphology, they do exhibit highly characteristic features that should strongly suggest the presence of the disease. Sarcoidosis can be diagnosed almost with certainty by histologic examination of specific lesions, thereby eliminating the need to biopsy lymph nodes, liver, muscle, or bronchial mucosa solely for diagnostic purposes.

Specific Lesions

The lesions of sarcoidosis are usually red or purple (Fig. 183-1), but they can also have a reddish-brown or yellowish-brown hue (Fig. 183-2). If the erythema is pressed out with a glass slide (diascopy), one can sometimes see tiny yellow-brown nodules produced by the granulomas; these nodules are similar to those seen in lupus vulgaris, the common form of cutaneous tuberculosis (see Chap. 200). Sarcoid lesions characteristically have a waxy translucent appearance and are almost never pruritic or painful.

FIGURE 183-1 Lesions of sarcoidosis are usually red or purple. Characteristically they are on the upper and lower lids, but they also occur in other regions of the face.

FIGURE 183-2 Lesions of sarcoidosis can also be reddish-brown or have a yellowish-brown hue. Often they occur in scars as shown here. A traumatic dermabrasion had occurred at the site 10 years before sarcoidosis developed.

Papules of sarcoidosis can arise anywhere on the body, affecting previously “normal” skin, but also occasionally occurring in surgical or posttraumatic scars and tattoos. Even scars many years old suddenly may become affected by the granulomatous reaction. Lesions are found most often around the eyes and in the nasolabial folds (see Fig. 183-1). These small elevated lesions are usually flat-topped, translucent, red or brown, and from 2 to 5 mm in diameter. Initially, papular lesions might be confused with flat warts or acne vulgaris, but on careful inspection, one can detect their characteristic translucence and color. The term *maculopapular* has been used to describe these small papules.

Papules can form a ring simulating granuloma annulare (see Chap. 100). However, the color and translucent quality of the lesions in sarcoid distinguish them from those of granuloma annulare; the borders of the latter are made up of opaque skin-colored papules. Annular lesions of sarcoid begin as papules that slowly expand peripherally and usually leave an atrophic and sometimes scaly center. In granuloma annulare, the center is neither scaly nor atrophic. Annular lesions also can be produced by plaques that undergo central atrophy. If the annular lesions have a yellow-brown color, it may be difficult to distinguish them clinically, but not histologically, from necrobiosis lipoidica (see Chap. 168). Annular lesions seem to be more common in American blacks than in other groups.

In one patient, the small papules of sarcoid mimicked lichen nitidus (see Chap. 50).

Nodules show a predilection for the extremities and trunk (Fig. 183-3), but they have also been observed on the vermillion border of the lips, on the finger pulps and palms, and on the lateral margins of the foot. Translucency is not characteristic of nodules, but the red and purple colors are. The nodules arise in the deep dermis and subcutaneous layer, with calcification a rare development. Although deep nodules of sarcoidosis are often called Darier-Roussy sarcoid, the eponym is not correct. Darier-Roussy sarcoid is a term used by dermatologists to describe several nonspecific inflammatory disorders that involve the subcutaneous fat. Uncommonly, the papules and nodules may have a verrucous surface.

FIGURE 183-3 Violaceous deep dermal and subcutaneous nodules of sarcoidosis. Nodular lesions often occur on the extremities.

Plaques of sarcoidosis are almost always violaceous and translucent and may be widespread (Fig. 183-4). Large telangiectatic vessels can be present on the surface, and some authors call these plaques *angiolupoid lesions*. However, when such extensive plaque formation arises on the ear lobes, nose, fingers, and toes, the term *lupus pernio* has been used (Fig. 183-5).

FIGURE 183-4 Reddish-violaceous plaques, some of which are annular, affecting the posterior trunk.

FIGURE 183-5 Red-purple plaque of sarcoidosis on the nose and cheek, which is called lupus pernio.

Sometimes, sarcoid mimics cutaneous T cell lymphoma (CTCL) (see Chap. 157)—the plaques become tumor-like, simulating an early leonine facies, or they can be multiple, with superficially eroded surfaces and exhibiting the "pasted-on" appearance typical of CTCL patches and plaques.

Lupus pernio of the fingers and toes produces bulbous and sausage-shaped digits and is almost always associated with lytic lesions in the underlying phalanges (Fig. 183-6). This is also a feature of sarcoidosis in infants and toddlers under 4 to 6 years of age. When the tip of the nose is involved by lupus pernio, the nasal bones may show osteoporosis and lytic lesions. The nasal mucosa may also be affected, producing purulent catarrh and obstructive symptoms. Bone involvement is present in 10 to 20 percent of patients. Although the bones most frequently involved are those of the hands and feet, occasionally the long bones, vertebrae, ribs, skull and facial bones, show identical lytic lesions. However, radiographic examination of the hands and feet of patients with sarcoid is worthwhile only if they have lupus pernio or chronic skin lesions elsewhere. Bone involvement may also portend a poorer prognosis in adults. The mortality rate of such patients was 21 percent in James' series, four times greater than the overall rate. [15] However, bony lesions, which are also a characteristic feature of sarcoid in children younger than 4 to 6 years of age, do not appear to be associated with a poor prognosis.

FIGURE 183-6 Erythema and swelling of digits associated with underlying osseous lesion (lupus pernio). (*From Braverman,* [13] *with permission.*)

Nail deformities can arise when lupus pernio develops close to the posterior nail fold (see Fig. 183-6). Often, the underlying bone will have lytic lesions. The nail plate may become thickened with an irregular surface. Sometimes there is distal crumbling of the nail plate.

Sarcoidal lesions can also take the form of red, violaceous, yellowish-brown, or reddish-brown scaly macules or patches (Fig. 183-7). The scale varies from thin and scant to heavy and thick. These types of lesions tend to develop cutaneous atrophy. When the scalp is affected, alopecia frequently results, mimicking lupus erythematosus and pseudopelade. When the face is affected, the “discoid” lesions of cutaneous lupus erythematosus are simulated (Fig. 183-8). On the trunk and extremities the picture of psoriasis or CTCL can be simulated, and on the palms, the appearance of secondary syphilis is mimicked. Psoriasiform lesions are considered to be characteristic of sarcoid in American blacks.

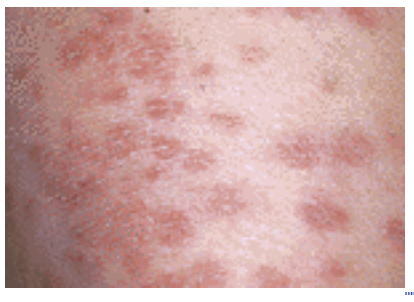

FIGURE 183-7 Violaceous minimally scaly macules characteristic of sarcoidosis.

FIGURE 183-8 A discoid lesion of sarcoidosis on the forehead and scalp with scaling, crusting, and atrophy simulating a discoid lesion of chronic cutaneous lupus erythematosus.

Well-demarcated, generalized, scaly, reddish-brown patches are rare manifestations that appear and remit intermittently over the course of years. In the acute phase, small superficial pustules arise within the patches. In the chronic phase, pustules are absent. The palms may be involved. When this reddish-brown scaling eruption covers extensive portions of the legs, buttocks, and trunk, the term “erythrodermic” sarcoidosis has been applied. In three persons, generalized skin involvement developed, simulating exfoliative dermatitis. Extensive involvement also may simulate poikiloderma vasculare atrophicans.

Ulceration may be a complication of lupus pernio on the nose and ears. Rarely, cutaneous plaques and deep cutaneous and subcutaneous nodules may ulcerate. Other uncommon manifestations include generalized perifollicular papules and pustules as the specific cutaneous markers of sarcoidosis. An ichthyosis-like picture has also been produced by the cutaneous granulomas. Only the ichthyotic areas show the histopathology of sarcoidosis.

Hypopigmentation is an uncommon manifestation. It may develop over papules and nodules or it may exist as patches that feel normal or slightly indurated. In the latter instance, papules and nodules usually arise later within or adjacent to the hypopigmented macules. Biopsies have shown sarcoid granulomas in the macules, papules, and nodules. All reported cases have been black patients. The hypopigmentation appears to be related to decreased melanization of the overlying epidermal cells. The melanocyte count is normal, and there is no evidence of postinflammatory hypopigmentation.

Occasionally, the oral mucosa and palpebral conjunctivae are involved with granulomas. Violaceous plaques can

develop on the hard palate and gingivae.

Nonspecific Lesions

Erythema nodosum (see Chap. 109) is a nonspecific sign of sarcoidosis that occurs most frequently in women 20 to 35 years old. Erythema nodosum with hilar adenopathy, arthralgia, fever, and chills is frequently the initial manifestation of sarcoidosis. When erythema nodosum occurs in sarcoid, the latter usually behaves as a benign self-limited disorder. As a general rule, progressive disease is associated with the presence of specific lesions, and not with erythema nodosum. However, exceptions do occur. The author has recorded five patients in whom sarcoidosis began with erythema nodosum and progressive sarcoidosis involving lung and liver developed a few months later. The prospective study of Veien et al. reported similar observations. [16] Several large series from different countries, compiled from 1960 to 1974, indicate that sarcoidosis is the cause of erythema nodosum in 37 percent of the cases (range, 11 to 74 percent). [17] The prevalence of erythema nodosum in sarcoidosis ranges from 4 to 35 percent (average, 17 percent). In the author's experience, sarcoid has accounted for 16 percent of the cases of erythema nodosum and erythema nodosum has occurred in 10 percent of patients with sarcoidosis.

Sarcoid in children 8 to 15 years of age is indistinguishable from that seen in adults. However, sarcoid in children younger than 4 to 6 years of age behaves differently. [14] Sarcoid can appear in infants as early as 4 months. These infants and toddlers have more joint involvement and rashes, less pulmonary disease, and eye problems only slightly more frequently than occurs in older children (see Table 183-1). The skin rashes have been described as eczematous and papular. Erythema nodosum may occur as multiple lesions and involve the soles, as well as more typical locations. The joints show a symmetric boggy synovitis without much pain or limitation of motion. Generally, the radiologic findings are negative. Although joint involvement usually does not lead to disability or contractures, sometimes they do occur. The fingers may be affected with a fusiform swelling, in which case one often finds lytic lesions and osteoporosis in the underlying bones, as in adults. In these children, multisystem involvement develops over periods of weeks to more than a year.

Eye involvement takes the form of phlyctenular keratoconjunctivitis, uveitis, miliary retinitis, and optic retinitis. Marked visual impairment has occurred in a few children.

Systemic Associations

In 20 to 40 percent of patients, sarcoidosis has an abrupt onset over weeks with fever, fatigue, weight loss, and anorexia. [18], [19] In 40 to 70 percent of patients, there may be an insidious development over months. The main organs affected are the lung (~90 percent), lymph nodes (~75 to 90 percent), and the eye (anterior and posterior uveitis, conjunctival nodules, lacrimal gland and duct involvement; ~25 percent). Less frequent associations are nasal mucosal involvement (~20 percent) and bone marrow lesions (~15 to 40 percent), usually without any functional consequences. Liver is often affected, but only in approximately 20 to 30 percent of patients are there any biochemical or functional sequelae, and renal involvement with hypercalcuria with or without hypercalcemia is uncommon. Hypercalcuria is caused by enhanced calcium absorption from the gut that is related to an abnormally high level of circulating 1,25-dihydroxyvitamin D produced by mononuclear phagocytes in the granulomas. The nervous system, musculoskeletal, heart, endocrine and reproductive systems, exocrine glands, and gastrointestinal tract are affected less often. Sarcoid also produces the Heerfordt-Waldenström syndrome, which is characterized by fever, parotid gland enlargement, anterior uveitis, and facial nerve palsy, and Mikulicz's syndrome in which the parotid, submandibular, sublingual, and lacrimal glands are affected.

LABORATORY FINDINGS

Common abnormalities often include lymphocytopenia, mild eosinophilia, increased erythrocyte sedimentation rate, hyperglobulinemia, and elevated serum levels of angiotensin-converting enzyme (ACE). Fifty to 60 percent of patients with active sarcoidosis have elevated serum levels of ACE, whose main source is the granulomas. [20] The serum level may reflect the magnitude of the body mass of granulomas. However, 10 percent of the elevated serum levels of ACE are false positives and serum levels do not reliably correlate with disease activity or progression. They are useful additional tests to support the diagnosis of sarcoidosis when other clinical features suggest that diagnosis.

The Kveim-Siltzbach test has been positive in 54 to 92 percent (average, 78 percent) of patients with sarcoid. [21] This skin test, in which an extract of splenic tissue from an affected patient is injected into the skin of a sarcoid suspect, is particularly useful when histologic confirmation of sarcoidosis is lacking or equivocal. It is also useful in the differential diagnosis of diffuse pulmonary mottling, uveitis, or erythema nodosum. The combination of the Kveim-Siltzbach test and determination of ACE levels should be especially helpful in such circumstances.

The chest x-ray in patients with sarcoidosis will almost always be abnormal with one of three patterns: bilateral hilar and mediastinal adenopathy with or without parenchymal involvement and diffuse parenchymal involvement without hilar adenopathy.

PATHOLOGY

The granulomatous reaction is composed of naked tubercles—collections of epithelioid cells with a thin rim of lymphocytes (Fig. 183-9). Giant cells are often present, necrosis is rare, and sometimes, the collar of lymphocytes is absent. The lungs, liver, lymph nodes, spleen, eyes, joints, muscles, exocrine glands, and nervous system are frequently affected by an identical granulomatous response.

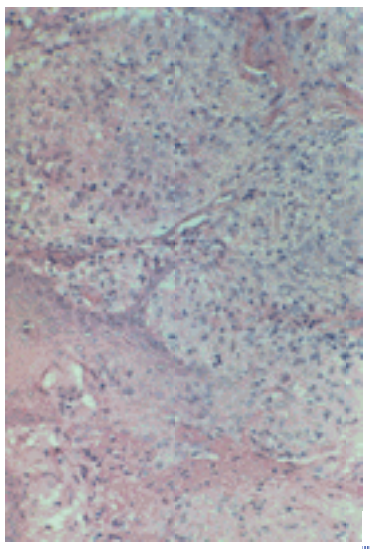

FIGURE 183-9 Histopathology of cutaneous sarcoidosis is characterized by naked tubercles, which are composed of epithelioid cells with a rim of lymphocytes, simulating tuberculosis. Although caseation necrosis is not observed, some foci of fibrinoid necrosis may be present in sarcoid infiltration, as shown here.

DIAGNOSIS AND DIFFERENTIAL DIAGNOSIS

Diagnosis cannot be made without demonstrating the noncaseating epithelioid granulomas in the affected tissue (see Fig. 183-9). This finding then has to be correlated with the history, physical examination, and laboratory findings to establish the diagnosis of sarcoidosis. The granulomas by themselves are insufficient to establish a diagnosis. It is worthwhile to perform a biopsy of any lesion, no matter how trivial, in a patient suspected of having sarcoidosis. The author has seen two patients in whom granulomas typical of sarcoid developed at sites of an earlier folliculitis. Clinically, the lesions looked like small scars. A biopsy of these banal marks established the diagnosis of sarcoidosis in these two patients, both of whom also had radiographic findings characteristic of pulmonary sarcoidosis.

The differential diagnosis of the specific papules and nodules found in sarcoid includes cutaneous amyloidosis, lichen planus, flat warts, syringoma, trichoepithelioma, lupus erythematosus, lymphocytoma cutis, CTCL, and xanthoma. The plaques resemble those seen in lupus erythematosus, lymphoma, CTCL, and photosensitivity reactions. In addition, the deep nodules could be confused with those of malignant lymphoma. However, all of these entities can be distinguished easily from one another and from sarcoidosis by histologic examination.

Granulomatous inflammation is a characteristic response to a number of mycotic and bacterial agents and minerals. The histology of granulomas ranges from the pure epithelioid cell granuloma without inflammation or necrosis to tubercles composed of multiple cell types accompanied by necrosis. The discovery of naked tubercles is presumptive evidence of sarcoidosis, but the diagnosis cannot be made unequivocally, nor should it be made unless correlated with the clinical findings. Sometimes tuberculosis, histoplasmosis, brucellosis, syphilis, leprosy, atypical mycobacterial infection, and toxoplasmosis produce similar granulomas, but usually these diseases are associated with inflammatory granulomas exhibiting necrosis. All granulomas should be examined with polarizing lenses to detect foreign bodies and, after selective staining, to uncover microorganisms.

The differential diagnosis of cutaneous sarcoidosis also includes granulomas produced by zirconium, beryllium, silica, and other foreign bodies. In some persons, deodorants and topical poison ivy remedies containing zirconium can produce a sarcoidal eruption by delayed hypersensitivity. Systemic involvement is not known to be a feature in these cases. Cutaneous zirconium granulomas are clinically and histologically indistinguishable from those of sarcoidosis.

COURSE AND PROGNOSIS

Whether or not cutaneous sarcoidosis indicates a poor prognosis is controversial; the limited data available through 1981 had suggested that involvement of the skin had no influence on the course of the disease. Since then, a prospective study of 188 Danish patients by Veien et al. [16] clearly established that skin involvement had no effect on the course of the disease and that the number of specific cutaneous lesions bore no relation to the extent of visceral involvement. In this study, 50 patients had only skin lesions. The spectrum of these lesions was identical to that seen in 88 patients with severe pulmonary disease. Other series have reached the same conclusions. [22], [23]

When systemic disease was associated with skin lesions, there was a correlation between acute disease (<2 years' duration) and the type of skin lesion. [16] Erythema nodosum and papular lesions (<10 mm) were usually present. With chronic disease (>2 years' duration), plaques, annular configurations, scar involvement, and unusual lesions were present.

There are good data concerning the outcome of the various types of skin lesions in sarcoidosis. [16] Erythema nodosum always disappears without scarring. James [23] observed that the associated hilar adenopathy cleared within 1 year, although others reported that in their patients erythema nodosum and hilar adenopathy cleared less quickly and less often. [13] Veien et al. [16] followed 79 patients until their skin lesions had clinically healed. They used diascopy, rather than biopsy, to determine whether granuloma formation was still present. An unspecified number of these patients also were receiving some form of therapy for their sarcoidosis. Of 79 patients, the skin lesions in 15 were healed in less than 2 years; in 5, the skin lesions healed in 2 to 5 years; in 49, the skin lesions healed in 6 to 9 years; and in 10, the skin lesions healed after more than 10 years. These data support the concept that skin involvement in sarcoid eventually burns itself out, as do most cases of sarcoidosis, and that the role of treatment in this disease is suppression of activity until spontaneous remissions develop. The papules and nodules of sarcoidosis disappeared without or with minimal scarring, but the plaques—angiolupoid and lupus pernio—which were usually persistent, especially in patients older than

30 years of age, formed unsightly telangiectatic scars when they did heal.

THERAPY

The therapy of choice for sarcoidosis with significant systemic involvement is corticosteroids, 1 mg/kg per day, in divided doses. This regimen almost always clears the skin of cutaneous lesions. The steroids are tapered slowly, using the degree of systemic activity as a guide for tapering and eventual discontinuation of the drug. Often, however, the skin lesions will return when the steroids have been discontinued or lowered. When there is no significant visceral involvement to justify systemic steroids, the options for therapy of the skin lesions are limited. There are anecdotal reports of success with chloroquine and hydroxychloroquine in small numbers of cases, but controlled studies need to be performed. Topical and intralesional corticosteroids are sometimes of benefit. Methotrexate, in low doses of 7.5 to 15.0 mg once weekly, shows promise of being successful in eradicating or minimizing the cutaneous, ocular, and pulmonary lesions. [24] Minocycline [25] and thalidomide [26] are two other promising agents for cutaneous sarcoidosis, but controlled studies are required for them as well.

REFERENCES

1. Scadding JG: *Sarcoidosis*. London, Eyre and Spottiswoode, 1967, p 45

2. Edmondstone WM, Wilson AG: Sarcoidosis in Caucasians, Blacks and Asians in London. *Br J Dis Chest* **79**:27, 1985

3. Steffen M et al: Increased secretion of tumor necrosis factor-alpha, interleukin-1-beta, and interleukin-6 by alveolar macrophages from patients with sarcoidosis. *J Allergy Clin Immunol* **91**:939, 1993

4. Robinson BW et al: Gamma interferon is spontaneously released by alveolar macrophages and lung T lymphocytes in patients with pulmonary sarcoidosis. *J Clin Invest* **75**:1488, 1985

5. Konishi K et al: Spontaneous expression of the interleukin 2 receptor gene and presence of functional interleukin 2 receptors on T lymphocytes in the blood of individuals with active pulmonary sarcoidosis. *J Clin Invest* **82**:775, 1988

6. Saltini C et al: Maintenance of alveolitis in patients with chronic beryllium disease by beryllium specific helper T cells. *N Engl J Med* **320**:1103, 1989

7. Muraguchi A et al: Depressed functions of T cells and the presence of suppressor macrophages in patients with sarcoidosis. *Clin Immunol Immunopathol* **23**:189, 1982

8. Schlievert PM: Role of superantigens in human disease. *J Infect Dis* **167**:997, 1993

9. Scadding JG: Mycobacterium tuberculosis in the etiology of sarcoidosis. *Br Med J* **2**:1617, 1960

10. James DG et al: Immunology of sarcoidosis. *Am J Med* **59**:388, 1975.

11. Fidler HM et al: Mycobacterium tuberculosis DNA in tissue affected by sarcoidosis. *BMJ* **306**:546, 1993

12. Mankiewicz E: The relationship of sarcoidosis to anonymous bacteria. *Acta Med Scand Suppl* **425**:68, 1964.

13. Braverman I: *Skin Signs of Systemic Disease,* 3rd ed. Philadelphia, WB Saunders, 1998, p 373

14. Hetherington S: Sarcoidosis in young children. *Am J Dis Child* **136**:13, 1982

15. James DG et al: Bone and joint sarcoidosis. *Semin Arthritis Rheum* **6**:53, 1976

16. Veien NK et al: Cutaneous sarcoidosis in Caucasians. *J Am Acad Dermatol* **16**:534, 1987

17. Scadding JG: *Sarcoidosis*. London, Eyre and Spottiswoode, 1967, p 55

18. Crystal RG: Sarcoidosis, in *Harrison's Principles of Internal Medicine,* 15th ed, edited by E Braunwald, AS Fauci, DL Kasper, SL Hauser, DL Longo, JL Jameson. New York, McGraw-Hill, 2001, p 1969

19. Johns CJ, Michele TM: The clinical management of sarcoidosis. A 50-year experience at the Johns Hopkins Hospital. *Medicine* **78**:65, 1999

20. Studdy P et al: Serum angiotensin-converting enzyme (SACE) in sarcoidosis and other granulomatous disorders. *Lancet* **2**:1331, 1978

21. James DG, Williams WJ: Kveim-Siltzbach test revisited. *Sarcoidosis* **8**:6, 1991

22. Olive KE, Kataria YP: Cutaneous manifestations of sarcoidosis. Relationships to other organ system involvement, abnormal laboratory measurements, and disease course. *Arch Intern Med* **145**:1811, 1985

23. James DG: Course and prognosis of sarcoidosis. London. *Am Rev Resp Dis* **84**:66, 1961

24. Lower EE, Baughman RP: Prolonged use of methotrexate for sarcoidosis. *Arch Intern Med* **155**:846, 1995

25. Bachelez H et al: The use of tetracyclines for the treatment of sarcoidosis. *Arch Dermatol* **137**:69, 2001

26. English JC III et al: Sarcoidosis. *J Am Acad Dermatol* **44**:725, 2001

T>

Chapter 184

David McLean Harley Haynes

Cutaneous Manifestations of Internal Malignant Disease: Cutaneous Paraneoplastic Syndromes

COLOR CHANGES SECONDARY TO THE DEPOSITION OF SUBSTANCES IN THE SKIN
- Icterus
- Melanosis
- Hemochromatosis
- Xanthomas
- Systemic Amyloidosis

VASCULAR AND BLOOD ABNORMALITIES
- Flushing
- Palmar Erythema
- Telangiectasia
- Purpura
- Vasculitis
- Cutaneous Ischemia
- Thrombophlebitis

BULLOUS DISORDERS
- Bullous Pemphigoid
- Cicatricial Pemphigoid
- Pemphigus
- Dermatitis Herpetiformis
- Herpes Gestationis
- Erythema Multiforme
- Epidermolysis Bullosa Acquisita
- Linear IgA Dermatosis

INFECTIONS AND INFESTATIONS
- Herpes Zoster
- Herpes Simplex
- Other Infections and Infestations

DISORDERS OF KERATINIZATION
- Acanthosis Nigricans
- Acquired Ichthyosis
- Palmar Hyperkeratosis
- Tripe Palm
- Erythroderma
- Paraneoplastic Acrokeratosis of Bazex

COLLAGEN-VASCULAR DISEASE
- Dermatomyositis
- Lupus Erythematosus
- Scleroderma

SKIN TUMORS AND INTERNAL MALIGNANT DISEASE
- Muir-Torre Syndrome
- Gardner Syndrome
- Cowden's Disease
- Mucosal Neuroma Syndrome
- Neurofibromatosis

HORMONE-RELATED CONDITIONS

OTHER DISORDERS ASSOCIATED WITH PRIMARY SKIN CANCERS
- Basal Cell Nevus Syndrome
- Arsenical Manifestations

OTHER DISORDERS ASSOCIATED WITH INTERNAL MALIGNANT DISEASE
- Pruritus
- Erythema Gyratum Repens
- Subcutaneous Fat Necrosis
- Sweet Syndrome
- Hypertrichosis Lanuginosa Acquisita
- Necrolytic Migratory Erythema
- Clubbing
- Peutz-Jeghers Syndrome
- Tuberous Sclerosis
- Multiple Eruptive Seborrheic Keratoses
- Porphyria Cutanea Tarda

DIRECT TUMOR INVOLVEMENT IN THE SKIN
- Solid Tumors
- Lymphoma-Leukemia
- Paget's Disease

REFERENCES

Changes in the skin can be a marker for an internal malignant neoplasm. The specific relationship of the cancer with the marker can be variable. For instance, hypertrichosis lanuginosa acquisita can be a marker for many different malignant neoplasms, whereas necrolytic migratory erythema is quite specific for a glucagon-producing tumor of the pancreas.

An attempt has been made to group these manifestations in a useful manner (Table 184-1). Where possible, these groupings have been made by the major clinical manifestation. Unfortunately, our lack of knowledge does not allow us to classify these diseases by a pathophysiologic approach in all cases. Indeed, there is a very large group in which the biochemical relationship to the neoplasia is not understood.

I. Lesions secondary to the deposition of substances in the skin	VI. Collagen-vascular disease
A. Icterus	A. Dermatomyositis
B. Melanosis	B. Lupus erythematosus
C. Hemochromatosis	C. Progressive systemic sclerosis
D. Xanthomas	VII. Skin tumors and internal malignant disease
E. Systemic amyloidosis	A. Muir-Torre syndrome
II. Vascular and blood abnormalities	B. Gardner's syndrome
A. Flushing	C. Cowden disease
B. Palmar erythema	D. Mucosal neuroma syndrome
C. Telangiectasia	E. Neurofibromatosis
D. Purpura	VIII. Hormone-related conditions
E. Vasculitis	IX. Disorders associated with primary skin cancer
F. Cutaneous ischemia	A. Nevoid basal cell carcinoma syndrome
G. Thrombophlebitis	B. Anogenital manifestations
III. Bullous disorders	X. Other disorders associated with internal malignant disease
A. Bullous pemphigoid	A. Pruritus
B. Pemphigus vulgaris	B. Erythema gyratum repens
C. Paraneoplastic pemphigus	C. Subcutaneous fat necrosis
D. Dermatitis herpetiformis	D. Sweet's syndrome
E. Herpes gestationis	E. Hypertrichosis lanuginosa acquisita
F. Erythema multiforme	F. Necrolytic migratory erythema
G. Epidermolysis bullosa acquisita	G. Clubbing
H. Linear IgA dermatosis	H. Peutz-Jeghers syndrome
IV. Infections and infestations	I. Tuberous sclerosis
A. Herpes zoster	J. Multiple eruptive seborrheic keratoses
B. Herpes simplex	K. Porphyria cutanea tarda
C. Bacterial infections	XI. Direct tumor involvement in the skin
D. Fungi and yeast infections	
E. Scabies	
V. Disorders of keratinization	
A. Acanthosis nigricans	
B. Acquired ichthyosis	
C. Palmar hyperkeratosis	
D. Tripe palm	
E. Erythroderma	
F. Paraneoplastic acrokeratosis of Bazex	

TABLE 184-1 **Cutaneous Manifestations of Internal Malignant Disease**

There must be a proven association of the cutaneous eruption with a tumor. This is not difficult when the supposed manifestation is very rare and the tumor is also very uncommon. It becomes a major problem, however, when the manifestation is very common, such as the seborrheic keratoses in the sign of Leser-Trélat, and the presumed association is with a wide spectrum of commonly occurring neoplasms. In this situation, the literature becomes replete with anecdotal reports, which may or may not be an indication of whether there is a true association with the malignant neoplasm.

Some cutaneous manifestations of cancer are paraneoplastic syndromes, i.e., dermatoses (often unique), secondary to the cancer. There is an evolving consensus of what constitutes a true paraneoplastic syndrome. [1] There are two essential criteria: (1) the dermatosis must develop only after the development of the malignant tumor, and (2) both the dermatosis and the malignant tumor follow a parallel course, in that complete removal of the cancer results in clearing of the dermatosis and recurrence of the cancer causes relapse of the dermatosis (certainly relapse of the dermatosis cannot occur in the absence of the cancer).

COLOR CHANGES SECONDARY TO THE DEPOSITION OF SUBSTANCES IN THE SKIN

Icterus (See Chap. 164)

Icterus as a manifestation of internal malignancy is generally a late sign and usually is secondary to obstruction of the bile duct or gross intrahepatic obstruction. Extrahepatic obstruction can be secondary to malignant disease of the gallbladder, pancreas, bile duct, or adjacent bowel.

Melanosis (See Chap. 90 and Chap. 93)

Melanosis is a condition caused by the abnormal deposition of melanin pigments in tissue. It is manifested externally by a diffuse gray-brown pigmentation of the skin (Fig. 184-1), but the pigment can be deposited in most of the organs of the body. A mild darkening of the skin may be seen with adrenal insufficiency, with ACTH-producing tumors such as primary tumors of the pituitary gland, or with other malignant tumors metastatic to the pituitary gland. [2]

FIGURE 184-1 Slate-gray dermal pigmentation with metastatic melanoma and melanogenuria. *A*. Diffuse blue argyria-like hypermelanosis. This patient died 1 month after this photograph was taken, illustrating that this striking argyria-like blue pigmentation is a terminal complication. *B*. Dark urine from a patient with melanogenuria compared with normal urine.

Diffuse melanosis also can be secondary to malignant melanoma (see also Chap. 93). Usually occurring late in the disease course, melanosis can, however, be the presenting sign. The pigment of the skin has been attributed to the

presence of melanin granules in both the circulation and tissue macrophage [3] or to the presence of single-cell metastases from the primary melanoma. [4] Diffuse micrometastases also can appear in the nail matrix, leading to pigment streaks in the nail plate. Circulating tumor cells also have been found in some patients with melanosis. [4] Melanuria is frequently associated with melanosis of the skin. Urine from patients who have melanuria is usually not black when voided but gradually darkens to a deep brown and later a black color when exposed to the air for several hours as the intermediary metabolites of tyrosine are oxidized spontaneously to melanin. (Fig. 184-1). Highly increased amounts of 5-S-cysteinyldopa have been reported in the urine of such patients. [5]

Hemochromatosis (See Chap. 164)

Hemochromatosis is an iron-storage disorder resulting predominantly from increased iron absorption from the gut. Patients develop a diffuse gray-brown pigmentation of the skin. There is deposition of iron in the form of hemosiderin in many tissues. A third of untreated patients with hemochromatosis will develop hepatocellular carcinoma.

Xanthomas (See Chap. 150)

The predominant type of xanthoma associated with internal malignant disease is the plane xanthoma. The most common association of diffuse plane xanthoma is with multiple myeloma. Xanthomas, as well as atypical eruptive histiocytosis with lipid deposition, also have been associated with myelocytic leukemia, myelomonocytic leukemia, leukemic lymphocytic reticuloendotheliosis, diffuse histiocytic lymphoma, and cutaneous T cell lymphoma. [6], [7] Juvenile xanthogranuloma can be associated with juvenile chronic myeloid leukemia. [8]

Patients with xanthomas associated with cancer may be normolipidemic, [9] or they may, more commonly, have a hyperlipoproteinemia. Type 2A hyperlipoproteinemia has been described in association with IgG L type myeloma, as has type 4 or type 5 hyperlipoproteinemia. Type 3 (broad beta) and prebeta hyperlipoproteinemia have been described in association with IgA myeloma.

Purpura may be a feature of diffuse plane xanthomas associated with malignant disease. Pinch purpura has been noted in a normolipidemic patient with myeloma. Hemorrhagic bullae have been associated with xanthoma disseminatum and IgG K type multiple myeloma. [10]

Systemic Amyloidosis (See Chap. 148)

Systemic amyloidosis of both the primary type and that associated with multiple myeloma commonly have skin lesions. It is important to differentiate skin lesions of systemic amyloidosis from the far more commonly seen purely cutaneous variants of amyloidosis. All patients with skin lesions of systemic amyloidosis should be investigated thoroughly for multiple myeloma.

Familial cutaneous lichenoid amyloidosis has been reported in a large kindred in association with multiple endocrine neoplasia (MEN) type 2A. [11]

VASCULAR AND BLOOD ABNORMALITIES

Flushing (See Chap. 170)

Acquired pronounced flushing, usually of the central face and upper trunk, often with wheezing and abdominal pain, may be a manifestation of carcinoid syndrome, caused by carcinoid tumors. [12] Palpitations, syncope, and hypotension are features of benign idiopathic flushing. [13] Diarrnea can occur in both.

Vasoactive substances also can be released in patients with extensive localized or systemic mastocytosis (see Chap. 163) and in patients with pheochromocytoma. Unilateral flushing and sweating (harlequin syndrome) have been associated with a contralateral lung cancer invading the spine in a patient with Pancoast's syndrome and with Horner's syndrome. [14]

Palmar Erythema (See Chap. 164)

Palmar erythema can be associated with advanced liver failure. Such liver failure may be secondary to either a primary or a metastatic tumor in the liver.

Telangiectasia

Localized, grouped telangiectatic vessels on the anterior chest wall may be a marker for breast cancer. There is often a clinically palpable, indurated, warm, subcutaneous plaque immediately beneath the telangiectatic area. Telangiectatic vessels also may be the first evidence of skin metastases of many cancers.

Generalized telangiectasia can be a presenting factor of malignant angioendotheliomatosis (see Chap. 157), and progressive telangiectases have been associated with carcinoid tumors (see Chap. 170).

Telangiectasia also may be a manifestation of a genodermatosis, such as ataxia-telangiectasia (see Chap. 191), Bloom's disease, and xeroderma pigmentosum and its variant, De Sanctis-Cacchione syndrome (see Chap. 155), which in turn can be associated with systemic malignant disease.

Telangiectasia also can be a marker for the collagen-vascular group of diseases, including progressive systemic sclerosis, which can be associated with an increased cancer risk (see Chap. 172 and Chap. 173).

Purpura

Lymphoma is the most common cause of idiopathic thrombocytopenic purpura (ITP) associated with malignant disease. Purpura related to cancer can occur from a wide variety of mechanisms: thrombocytopenia, consumption coagulopathy, hyper- or dysglobulinemia, vascular fragility, and vasculitis.

Disseminated intravascular coagulation (DIC) as a cause of purpura in malignant disease is associated most commonly with acute leukemia. Purpura also can be associated with the hyperglobulinemia seen in multiple myeloma or lymphoma. When purpura is secondary to the presence of cryoglobulins, lesions often are found in acral areas and may be associated with Raynaud's phenomenon.

It is important not to forget that vasculitis or a bacterial septicemia can present as a palpable purpuric eruption in patients with cancer.

Vasculitis (See Chap. 175)

Leukocytoclastic vasculitis, such as can be seen in Henoch-Schönlein purpura, very rarely can be associated with malignant neoplasms, such as squamous cell carcinoma of the bronchus, renal carcinoma, and leukemia and lymphoma. A periarteritis nodosa–like syndrome also has been reported in association with leukemia and multiple myeloma.

Cutaneous Ischemia

Peripheral ischemia has been associated with many malignant neoplasms, including carcinoma of the pancreas, stomach, small bowel, ovary, and kidney, as well as lymphoma and leukemia. [15] It is frequently manifested by evidence of digital ischemia, either as Raynaud's phenomenon or frank gangrene. There may be associated splinter hemorrhages of the nail bed, suggestive of an underlying vasculitic process. The etiology, though, is rarely apparent.

The peripheral cutaneous ischemia of polycythemia rubra vera appears to be secondary to the increased viscosity of the peripheral circulation associated with this disease. [16] Similarly, some patients with leukemia can develop leukostasis secondary to very high white blood cell concentrations.

The ischemia seen in cryoglobulinemia associated with multiple myeloma or with lymphoma appears also to be secondary to increased blood viscosity.

Thrombophlebitis (See Chap. 167)

Isolated vein thrombophlebitis is uncommonly associated with internal malignant disease. Multiple-lesion “migratory” superficial thrombophlebitis is seen much more often in association with cancer, and when this syndrome is present, the patient should be examined carefully for occult malignant disease. The association of peripheral thrombophlebitis (phlebothrombosis) with gastric carcinoma was noted by Trousseau in the nineteenth century. Migratory superficial thrombophlebitis as a marker for cancer has been confirmed, and the association has been extended to include tumors of the pancreas, prostate, lung, liver, bowel, gallbladder, and ovary, as well as lymphoma and leukemia. The migratory nature of the thrombophlebitis probably relates to a generalized hypercoagulable state.

Mondor's disease is thrombophlebitis of the anterior chest wall presenting as a tender or nontender cord. While usually benign and secondary to local trauma, it may be associated with primary or recurrent breast cancer.

Patients with deep venous thrombosis who are younger than 50 years of age appear to have a very significant risk of occult cancer (relative risk 19.0) [17] and thus should have an appropriately thorough examination and laboratory investigation. Those at greatest risk for cancer had a low hemoglobin and an eosinophilia.

BULLOUS DISORDERS

Bullous Pemphigoid (See Chap. 61)

There is probably no significantly increased risk of a malignant tumor in patients with bullous pemphigoid, other than that associated with the age of the patient. [18] However, a Japanese cohort of patients with bullous pemphigoid had a 5.8 percent prevalence of neoplasia versus 0.61 percent of controls. [19] Also, there have been anecdotal reports showing that some patients with bullous pemphigoid clear when the concomitant tumor is treated, indicating a possible causal relationship in some patients.

Cicatricial Pemphigoid (See Chap. 62)

Antiepiligrin cicatricial pemphigoid would appear to have an increased risk of solid tumors, estimated as a relative risk of 6.8 (3.3–12.5). [20]

Pemphigus (See Chap. 59 and Chap. 60)

Pemphigus vulgaris can be associated with Hodgkin's disease, in which case the two diseases can run a parallel course.

[21] The relationship of solid tumors to pemphigus vulgaris is less well defined, although in one series 5 percent of pemphigus vulgaris patients had cancer, a higher rate than in controls. [19] Pemphigus vulgaris has been reported in association with many solid tumors, but other than for lung cancer, [19] these associations have been in small series or isolated case reports. There is a well-defined association of pemphigus vulgaris with thymoma, with or without clinical myasthenia gravis. [22], [23] and [24])

Paraneoplastic pemphigus [25] is clinically, histopathologically, and immunopathologically a distinct form of pemphigus with features of erythema multiforme, pemphigus-like blisters, and intractable stomatitis [26] (see Chap. 60). Described in association with lymphoma, chronic lymphocytic leukemia, Castleman's disease, thymoma, sarcoma, and Waldenstrom's macroglobulinemia, it has a very poor prognosis.

Dermatitis Herpetiformis (See Chap. 67)

Dermatitis herpetiformis is occasionally associated with intestinal lymphoma. The relative risk of non-Hodgkin's lymphoma associated with dermatitis herpetiformis is 5.4 (2.2 to 11.1) in males, less in females. [27] The lymphoma, when it occurs, is usually a diffuse histiocytic lymphoma. [28] There is no indication that there are a greater than expected number of patients with dermatitis herpetiformis developing tumors other than intestinal lymphoma. [29]

Herpes Gestationis (See Chap. 64)

Herpes gestationis has been described in association with a hydatidiform mole [30] and germ cell tumor. [31]

Erythema Multiforme (See Chap. 58)

Erythema multiforme does not appear to be a specific marker for any internal neoplasm. It appears to occur more frequently in patients with acute leukemia, but whether this relates to the leukemia or to its treatment has not been well defined. It also can occur in cancer patients secondary to drug or radiation therapy, and it has been suggested to be particularly common in patients on phenytoin and receiving radiation therapy for intracranial tumors. [32]

Epidermolysis Bullosa Acquisita (See Chap. 66)

Epidermolysis bullosa acquisita is a very rare disorder that has been described rarely in association with carcinoma of the bronchus and with amyloidosis and multiple myeloma. [33] Most cases of epidermolysis bullosa acquisita are not associated with cancer.

Linear IgA Dermatosis (See Chap. 63)

Linear IgA dermatosis has been reported in association with lymphoma, chronic lymphocytic leukemia, myeloma, carcinoma of the bladder and esophagus, and hydatidiform mole. [34], [35]

INFECTIONS AND INFESTATIONS

Herpes Zoster (See Chap. 215)

Only a small percentage of patients with localized herpes zoster have concurrent malignant disease, and investigation for malignant disease in otherwise healthy patients is not indicated. Patients with leukemia or lymphoma do have an increased risk of herpes zoster, but the herpes zoster usually occurs late in the course of their disease. The incidence of herpes zoster in patients with lymphoma is approximately 10 percent, possibly even higher in patients with Hodgkin's disease. [36]

Localized herpes zoster also can occur in association with solid tumors such as breast cancer. In the case of breast cancer, the dermatomal distribution of the herpes zoster may indicate involvement of the nerve root area with metastatic tumor. The site of the primary tumor correlates with the site of herpes zoster in patients with breast cancer, cancer of the respiratory tract, and gynecologic cancer. Segmental herpes zoster also can occur after radiation therapy, presumably secondary to nerve damage with subsequent viral activation.

Disseminated herpes zoster is commonly associated with underlying malignant disease. Any patient with disseminated herpes zoster that is otherwise unexplained should be examined carefully for evidence of cancer. The most commonly associated malignant diseases are lymphoma and leukemia. [37]

The development of herpes zoster in a previously treated lymphoma patient can be evidence of the recurrence of a lymphoma. This sign is of particular value in patients who develop the herpes zoster more than 6 months after clinical remission. [36]

Herpes Simplex (See Chap. 214)

Typical localized herpes simplex is rarely a marker for cancer. Extensive, often chronic, local herpes simplex with massive ulceration and destruction of tissue (Fig. 184-2), generalized cutaneous herpes simplex, and disseminated systemic herpes simplex are indeed associated with malignant disease, which is often far advanced. Lymphoma and leukemia are most often the associated cancers, but any advanced malignant tumor can produce the compromised host immune response associated with these conditions.

FIGURE 184-2 Woman with advanced non-Hodgkin's lymphoma and chronic ulcerative herpes simplex involving lips, cheek, and nose.

Other Infections and Infestations

Other infections of the skin as a marker for the presence of internal malignancy are very uncommon, and when they are associated with malignancy, they are usually associated with very advanced disease. Bacterial, fungal, yeast, and severe scabetic conditions are most common in profoundly immune-compromised patients.

DISORDERS OF KERATINIZATION

Acanthosis Nigricans (See Chap. 185)

Malignant acanthosis nigricans is usually of sudden onset and is rapidly progressive, but it is otherwise clinically indistinguishable from benign acanthosis nigricans. Diffuse keratoderma involving the palms, soles, and flexor surfaces of the fingers and toes may be more common in malignant acanthosis nigricans than in the benign form.

Malignant acanthosis nigricans is usually secondary to an adenocarcinoma. The adenocarcinoma is usually intraabdominal (70 to 90 percent) and gastric (55 to 61 percent). [38]

Acquired Ichthyosis (See Chap. 51)

The sudden onset of ichthyosis in an adult may indicate an occult malignant tumor, most often lymphoma. The ichthyosis is a true hyperkeratosis and can be differentiated clinically and histologically from simple dry skin (xerosis). Erythema is often present in the ichthyotic fissures. Although the ichthyosis usually occurs as a late manifestation of a lymphoma, it may precede the diagnosis by several years.

Palmar Hyperkeratosis

There are two groups of patients with palmar hyperkeratosis and associated malignant tumors: those patients with diffuse palmar hyperkeratosis and those with punctate palmar hyperkeratosis. In 1958, diffuse hyperkeratosis, or tylosis, was reported by Howel-Evans [39] to be associated in two families with an almost certain development of esophageal carcinoma by age 65. The tylosis in these patients can be separated clinically from the benign form of tylosis, which occurs at an earlier age (early childhood), has sharply delimited edges, and is of uniform thickness. In addition to the Howel-Evans families, there would appear to be a greater than expected incidence of esophageal carcinoma in other families with a pedigree of tylosis. [40]

A large kindred has been described with palmoplantar keratoderma in association with breast or ovarian carcinoma or both. [41] The clinical lesions cover the entire surface of the palms and soles and show a yellowish uniform hyperkeratosis surrounded by a red border. Histologically, the lesions show features of epidermolytic hyperkeratosis. (see Chap. 52).

The second type of palmar hyperkeratosis that may be associated with neoplasia consists of discreet hyperkeratotic papules on the palms. These patients have been reported to have a greater than expected risk of cancer of the breast and uterus, among other tumors. [42] While some kindreds have been described, arsenic, known to be associated with punctate palmar hyperkeratosis and an increased risk of cancer, may be responsible for other cases. However, other authors question the existence of the relationship of punctate palmar hyperkeratosis and internal cancer. It appears that the association, if present, is not very strong.

Palmar hyperkeratosis is also seen in paraneoplastic acrokeratosis of Bazex (see below).

Tripe Palm

Tripe palm is a rugose thickening of the palms that is strongly associated with internal cancer. [43] The honeycombed and corrugated thickening of the palms may be associated with periungual tenderness. Normal dermatoglyphic ridges are accentuated. The most common cancers associated with tripe palms are carcinomas of the stomach and lung. [44] There may be an associated acanthosis nigricans (see Chap. 185).

Erythroderma

Erythroderma, a diffuse erythema of the skin surface usually associated with induration and scaling, is not uncommonly associated with malignancy, most commonly hematologic, in particular leukemia and lymphoma, especially cutaneous T cell lymphoma, where there is direct infiltration of the skin by the malignant cells (see Chap. 44 and Chap. 157). Among solid tumors, erythroderma has been associated with carcinoma of the lung, liver, prostate, thyroid, colon, pancreas, and

stomach. The erythroderma associated with solid tumors usually occurs at a relatively late stage of the disease, is of unknown etiology, and may resolve after resection of the tumor.

Paraneoplastic Acrokeratosis of Bazex

Paraneoplastic acrokeratosis of Bazex is a symmetric dermatosis that most commonly affects the hands, feet, ears, and nose with an erythematous psoriasiform eruption. The eruption is of a bluer hue than in psoriasis. [45] Later changes involve the malar skin, elbows, and knees, with still later changes often involving the central trunk, where bullae may be seen. Acanthosis nigricans may be an associated finding. In acrokeratosis of Bazex, the nails are involved early and severely. There is subungual hyperkeratosis, as well as a flaky white surface to the nail. The nails may be shed. The distal digits show an erythematous scaling eruption, often fissured and often with suppuration. [46] Biopsy of the skin lesions of one patient showed diffuse deposition of IgA, IgM, and IgG along the basement membrane. [47] Nails appeared to have an abnormal amino acid composition. [48]

Bazex syndrome is almost always associated with cancer and is seen overwhelmingly in males. [49] It is usually associated with neoplasia of the upper respiratory system, which includes the pharynx, esophagus, tongue, and lungs, although rarely other solid tumors have been reported in association. Lung tumors have included carcinoid. The eruption predates evidence of the cancer in 67 percent of patients, [49] with the cancer often not being diagnosed until the later stages of the syndrome. Bazex syndrome has been reported to respond to etretinate, even though the primary lesion was left untreated. This syndrome should not be confused with follicular atrophoderma associated with basal cell carcinoma, hypotrichosis, and localized or generalized hypohidrosis, also described by Bazex. [50]

COLLAGEN-VASCULAR DISEASE

Dermatomyositis (See Chap. 172)

Dermatomyositis can be a marker for internal neoplasia, and the development of the dermatomyositis can predate the diagnosis of the cancer. The most common cancers are ovarian, lung, pancreatic, stomach, colorectal, and lymphoma. [51] While dermatomyositis in an adult is strongly associated with concurrent cancer, polymyositis alone is much less strongly associated. [51], [52] The cancers are usually identifiable by history and physical examination. It would appear that adults with dermatomyositis should be examined thoroughly for evidence of an associated malignant tumor. In children, dermatomyositis is not statistically linked to malignancy.

The clinical manifestations of dermatomyositis appear to be the same with and without a malignant tumor, although Basset-Sequin et al. [53] noted that cutaneous necrosis and an elevated erythrocyte sedimentation rate appeared to be markers for those with cancer and a reduced survival.

Lupus Erythematosus (See Chap. 171)

Systemic lupus erythematosus (SLE) is only rarely associated with malignant neoplasia, most often with lymphoma or thymoma.

Scleroderma (See Chap. 173)

Systemic scleroderma is not commonly associated with internal malignancy. In 727 cases of systemic scleroderma, only 2.6 percent had an internal malignant lesion. [54] The only tumor that has been found to be consistently associated with scleroderma is carcinoma of the lung. [55] Almost all patients with associated lung tumors have very advanced systemic scleroderma. The association is most likely one of a lung tumor developing secondary to the chronic pulmonary fibrosis.

SKIN TUMORS AND INTERNAL MALIGNANT DISEASE

Muir-Torre Syndrome

First described by Muir and colleagues in 1967 and by Torre in 1968, the essential features of the Muir-Torre syndrome are sebaceous tumors of the skin (Fig. 184-3), with or without keratoacanthomas, in association with often more than one visceral neoplasm. [56], [57] The sebaceous tumors are usually on the face or trunk and are frequently multiple, and whereas most are sebaceous adenomas, they can include sebaceous hyperplasia, sebaceous epithelioma, and sebaceous carcinoma. Often the same patient will have the complete histologic spectrum of sebaceous tumors. Some skin lesions have histologic features of both keratoacanthoma and sebaceous proliferation. [58]

FIGURE 184-3 Muir-Torre syndrome showing typical sebaceous adenomas in association with colonic polyposis and carcinoma in situ. (*Courtesy of T. Christensen, MD, and R. Wilkinson, MD.*)

The visceral neoplasms are often multiple and include a wide variety of tissues. Colon cancers are particularly common and may be associated with colonic polyposis. [56], [57], [58], [59] and [60]) Other neoplasms include additional tumors of the gastrointestinal tract and tumors of the larynx, endometrium, and rarely, lymphoma. Patients with Muir-Torre syndrome appear to have a reasonably good survival, despite the profusion of neoplasms. It has been suggested that a solitary benign sebaceous gland tumor of the eyelid is a good marker for the Muir-Torre syndrome and that its presence warrants review for systemic cancer.

The Muir-Torre syndrome is inherited as an autosomal dominant trait. There is an association of the Muir-Torre syndrome with cancer family syndrome, [61] and markers have been identified in chromosome 2P, a site linked to Lynch II cancer family syndrome. [62]

Long-term treatment with isotretinoin appears to be useful in some patients, [63] and immunosuppression apparently exacerbates the cutaneous manifestations. [64]

Gardner Syndrome

The essential features of Gardner syndrome are intestinal polyposis (usually colonic), with a high rate of malignant transformation; epidermoid cysts, particularly of the face, scalp, and trunk; osteomatosis of the maxilla, mandible, and cranial bones; and fibromas, desmoids, and other fibrous tumors of the skin and subcutaneous tissue. [65] Histologically, the epidermoid cysts may show areas of pilomatrixoma or a hybrid cyst with epidermal keratinization and inner root sheath keratinization. The desmoids often occur in wounds and can be deeply invasive, requiring chemotherapy or radical surgery. At times, erroneously called sebaceous cysts, the epithelioid cysts of Gardner syndrome often precede the development of bowel cancer.

There is a virtual certainty of malignant transformation of the gastrointestinal tract polyps. Some of the polyps are almost always visible by proctoscope examination, but they can be found up to the stomach. [66] There is an association of hepatoblastoma, a rare neoplasm of infants and children, with Gardner syndrome, and there may be some overlap of the features of Gardner syndrome and nevoid basal cell carcinoma syndrome. Gardner syndrome is inherited as an autosomal dominant condition.

Cowden's Disease

Cowden's disease, or multiple hamartoma syndrome, was first described in 1963 by Lloyd and Dennis and was named after the propositus. [67] Inherited as an autosomal dominant trait, the distinctive cutaneous lesions are multiple tricholemmomas (Fig. 184-4A). These lesions are grouped around the mouth, nose, and ears and clinically resemble warts. Some patients also show closely set papules with a cobblestone pattern that have a fibromatous histology and also occur on the oral mucosa (see Fig. 184-4B). Small keratotic lesions resembling plane warts occur on the acral skin. Patients may have an adenoid facies and high arched palate. Other cutaneous lesions can include lipomas, hemangiomas, neuromas, vitiligo, café-au-lait lesions, and acromelanosis. Angioid streaks may be present in the retina.

FIGURE 184-4 *A.* Cowden disease with papular lesions on the forehead that histologically proved to be tricholemmomas. *B*. Oral mucosa of same patient with multiple fibropapillomas. (*Courtesy of Peter Fritsch, MD.*)

Patients with Cowden's disease have a greatly increased risk of breast and thyroid carcinoma and thyroid adenoma. The breast changes seen in women range from fibrocystic disease to adenocarcinoma and can occur at a young age. Prophylactic mastectomy may be indicated. Gastrointestinal tract polyposis is common. [69] There also may be an increased risk of gastrointestinal malignancy. Female reproductive tract hamartomas and benign tumors are common. Squamous carcinoma of the tongue and basal cell carcinoma of the perianal skin have been reported.

Mucosal Neuroma Syndrome

Mucosal neuroma syndrome is probably a variant of multiple endocrine neoplasia type 2 (MEN 2 or 2A, Sipple's syndrome). Also designated MEN 3 or MEN 2B, the typical features include oral, nasal, upper gastrointestinal tract, and conjunctival neuromas associated with medullary thyroid carcinoma (MTC) and pheochromocytoma. The neuromas are typically soft to firm intradermal nodules. Corneal nerves may be highly visible. [70] The appearance of the neuromas usually precedes the development of cancer, but MTC can appear in early childhood. The major cause of death in patients with MEN 3 is MTC, since metastases are common. The pheochromocytomas are often bilateral. Unlike MEN 2, parathyroid hyperplasia is rare.

In addition to the mucosal neuromas, other abnormalities can include “blubbery” lips, a marfanoid habitus, lax joints, kyphoscoliosis, lentigines, cafe-au-lait lesions, medullated corneal nerve fibers, diverticulosis, and megacolon. [71] Localized intense itching may be a feature in some patients.

Neurofibromatosis (See Chap. 190)

Von Recklinghausen neurofibromatosis has many associated malignant tumors. Malignant schwannoma is the most common, occurring in one series in 29 percent of patients. [72] These patients were usually over the age of 30. Other tumors include fibrosarcoma, rhabdomyosarcoma, nephroblastoma (Wilms' tumor), and acute and chronic myelogenous leukemia. There is an increased incidence of ocular melanoma, with anecdotal reports of cutaneous melanoma. Benign neural tumors, peripheral and intracranial, are common.

HORMONE-RELATED CONDITIONS (See Chap. 169)

Malignant tumors may release hormones into the circulation, and such hormones can produce skin manifestations. The manifestation of such hormone excess is not specific to the tumor and can occur secondarily from an excess of that hormone from any cause.

Hirsutism may be a manifestation of an increase in circulating androgens. When cancer-related, such androgen excess is seen most typically with testicular or ovarian tumors. Hypertrichosis lanuginosa acquisita, from nonandrogen causes, can occur secondary to internal malignant disease (see below).

Gynecomastia in the male can be produced by an excess of estrogens. Such estrogens may be produced by a tumor of the testis. Lung tumors also can produce gynecomastia.

Cushing syndrome is generally secondary to excessive ACTH production. Tumors from widely diverse sites can produce excessive ACTH, most commonly lung and pancreas.

OTHER DISORDERS ASSOCIATED WITH PRIMARY SKIN CANCERS

Basal Cell Nevus Syndrome (See Chap. 82)

Basal cell nevus syndrome, or Gorlin-Goltz syndrome, is a syndrome consisting of multiple basal cell carcinomas, jaw cysts, skin pitting, skeletal abnormalities, and a tendency to malignant disease. The most common malignant tumor is medulloblastoma. These tumors can occur in patients without any cutaneous basal cell carcinomas but with a family history of basal cell nevus syndrome. Other tumors include astrocytomas, meningiomas, and craniopharygiomas. Basal cell nevus syndrome is the result of a defective patched gene. [73]

Arsenical Manifestations

Chronic arsenic toxicity can be manifested by arsenical melanosis, plantar and palmar keratoses (Fig. 184-5), and Bowen disease. There also would appear to be an increased risk of internal neoplasia. Malignancies have included tumors of the urogenital region, mouth, esophagus, and lung. The increased cancer risk was estimated originally to be nine times the expected incidence, with approximately one-third of patients with Bowen disease developing an internal malignancy 6 to 10 years after their initial diagnosis. [74] There is now evidence that the risk may be very much lower in patients where Bowen disease alone was the marker of risk. [75] Arsenical keratoses on the palms (see Fig. 184-5) and soles, a more specific finding, do correlate with an apparent increase in internal malignancy.

FIGURE 184-5 Punctate palmar keratoderma in a patient with previous arsenic exposure.

OTHER DISORDERS ASSOCIATED WITH INTERNAL MALIGNANT DISEASE

Pruritus

Pruritus, often accompanied by excoriations, can be a nonspecific marker of internal malignant disease. Although often associated with xerosis, the pruritus of malignant disease can occur in apparently normal skin. It can be continuous or paroxysmal. It is usually generalized.

When it occurs with malignant diseases, pruritus is most commonly associated with lymphoma and leukemia. [76] The pruritus of Hodgkin's disease often will start on the legs, is usually continuous, and may be associated with a burning feeling. Pruritus is one of the most common cutaneous manifestations of leukemia, probably exceeded only by purpura. Although the pruritus of both leukemia and lymphoma can precede the diagnosis, it is usually a sign of late disease. Its severity tends to parallel the course of the disease, with severe pruritus heralding a poor prognosis.

Pruritus associated with bathing is a marker for polycythemia rubra vera and is present in one-half of patients. [77] This itch can be severe and paroxysmal. Patients with polycythemia rubra vera also can have chronic continuous pruritus unrelated to bathing.

Severe pruritus can be a feature of Fanconi's anemia and myeloma. Pruritus associated with solid neoplasms is most commonly associated with pancreatic and stomach tumors [78] but also may be associated with most other solid tumors. Renal and liver involvement with primary or metastatic cancer also can produce pruritus secondary to the accumulation in the skin of pruritogenic metabolites.

Erythema Gyratum Repens

Erythema gyratum repens is a cutaneous eruption consisting of concentric raised erythematous bands moving in waves over the body surface in a “wood grain” pattern. [79] The erythematous bands may be flat or raised. They are frequently surmounted by a fine marginal desquamation and may move at a speed of approximately 1 cm/day. Almost all cases of erythema gyratum repens, which is extremely rare, are associated with internal malignancy. Although first described with carcinoma of the breast, [74] erythema gyratum repens also has been found in association with tumors of the lung, [80] bladder, prostate, cervix, stomach, and esophagus and with multiple myeloma. Removal of the malignant tumor usually results in complete resolution of erythema gyratum repens within 6 weeks.

Subcutaneous Fat Necrosis (See Chap. 109)

Subcutaneous fat necrosis, sometimes associated with fever, eosinophilia, and arthralgia, is a cutaneous marker for acinar cell carcinoma of the pancreas. Identical lesions also can occur with pancreatitis [81] and pancreatic pseudocyst.

Sweet Syndrome (See Chap. 94)

Clinical lesions range from generalized crimson, aggminate papules, to large red to purple-red plaques, to lesions that are truly bullous in nature, and to lesions that are indistinguishable from pyoderma gangrenosum (Fig. 184-6.) There is often fever, and there may be blood neutrophilia. The skin lesions usually erupt suddenly. Malignancy-associated Sweet syndrome is seen most commonly with acute myelocytic leukemia but also may be associated with other leukemias, myelodysplastic syndrome, multiple myeloma, and lymphoma [82], [83] (see Table 94-3). Much less commonly it is seen with solid tumors such as embryonal carcinoma of the testes, ovarian carcinoma, gastric carcinoma, and adenocarcinoma of the breast, prostate, and rectum. [84]

FIGURE 184-6 Skin lesions of malignancy-associated Sweet syndrome present either (*A*) as classic “Sweet” lesions with pseudovesiculation (see Chap. 94) or (*B*) as truly bullous lesions or (*C*) as lesions resembling early pyoderma gangrenosum.

Hypertrichosis Lanuginosa Acquisita

Hypertrichosis lanuginosa acquisita (HLA) is an acquired excessive growth of lanugo (vellus) hairs. Soft downy hairs initially cover the face and ears, but eventually all hair-bearing skin may be involved (Fig. 184-7). Associated abnormalities include a glossitis that is often painful. The tongue is studded with red papules. [85] Fully expressed HLA is usually secondary to malignant tumors, but excessive lanugo hair growth also can be caused by drugs such as exogenous steroids, phenytoin, diazoxide, streptomycin, penicillamine, cyclosporine, and minoxidil or by conditions such as anorexia nervosa.

FIGURE 184-7 Hypertrichosis lanuginosa acquisita in a 19-year-old woman with pancreatic carcinoma.

HLA secondary to malignancy is usually abrupt in its onset and is rapidly progressive. Associated tumors reported include tumors of the colon (including carcinoid tumors), rectum, bladder, lung, pancreas, gallbladder, uterus, and breast and lymphoma. [85], [86]

Necrolytic Migratory Erythema

Necrolytic migratory erythema, also called glucagonoma syndrome, is a marker for an a $_2$-glucagon–producing islet cell tumor of the pancreas. [87] It is manifested by erythema, vesicles, pustules, bullae, and erosions, which typically involve the face, the intertriginous areas (in particular the groin), and the perigenital region (Fig. 184-8). Less commonly, it also involves the shins, ankles, feet and fingertips. The vesicles are often very superficial and tend to become confluent. Patients also can have brownish red papules scattered over much of the skin surface. Associated abnormalities include a glossitis, stomatitis, dystrophic nails, alopecia, weight loss, anemia, and diabetes. Resection of the tumor clears the eruption, sometimes within 48 h.

FIGURE 184-8 The glucagonoma syndrome, necrolytic migratory erythema. Flaccid and papulovesicular lesions (*A*) with erosions, crusting, and fissures around the orifices and (*B*) appearing as geographic, circinate “necrolytic migratory

erythema” in the groin.

The dermatosis also has occurred in patients, who have hepatitic cirrhosis and hyperglucagonemia, pancreatitis, celiac sprue, or zinc deficiency [88], [89] but no malignancy.

Clubbing

Clubbing describes soft tissue enlargement of the tips of the fingers and toes. More typically associated with chronic lung disease, it also can be associated with neoplasms of the chest, usually bronchogenic carcinoma. Five to ten percent of patients with bronchogenic carcinoma develop clubbing. [90] Mesothelioma also can produce similar changes. Clubbing also can be produced by other solid tumors metastatic to the thorax, and it has been reported in Hodgkin's disease of the lung. Clubbing also can be seen with diffuse intestinal lymphoma. Some patients with clubbing secondary to pulmonary disease can develop thickening and yellowing of the nails, the yellow nail syndrome (see Chap. 72).

Clubbing accompanied by subperiosteal new bone formation is called *hypertrophic osteoarthropathy,* and accompanied by acromegalic features, it is called *pachydermoperiostosis*. Patients with these latter two conditions can have diffusely painful bones. Pachydermoperiostosis is usually idiopathic but can be secondary to lung cancer.

Peutz-Jeghers Syndrome (See Chap. 90 and Chap. 164)

Hutchinson in 1900 first described the association of cutaneous and mucosal hyperpigmentation with gastrointestinal tract polyposis and carcinoma. [91] The pigmentary changes involve both the skin and mucous membrane. The cutaneous hyperpigmented macules are usually present at birth or in early infancy and frequently fade at puberty. They are typically grouped around the mouth, eyes, and nostrils, with macules less commonly located on the fingers, palms, toes, periumbilical skin, or diffusely over the skin surface. Muscosal pigmented lesions are similar but persist for life. Buccal mucosal pigmented papillomas also have been described.

The most common malignancy associated with the Peutz-Jeghers syndrome is duodenal carcinoma. These malignant tumors are frequently associated with hamartomatous polyps. A patient with Peutz-Jeghers syndrome carries an overall lifetime relative risk for developing an upper gastrointestinal tract malignancy of up to 18. [91] Granulosa theca cell tumors may be present in as many as 20 percent of females with the Peutz-Jeghers syndrome and may be associated with precocious puberty. Peutz-Jeghers syndrome is inherited as an autosomal dominant condition.

Tuberous Sclerosis (See Chap. 189)

Tuberous sclerosis can be associated with tumors within many organ systems. Most of these are hamartomatous, and some can become malignant. However, malignant transformation in tuberous sclerosis is uncommon, occurring in probably no more than 5 percent of patients.

Multiple Eruptive Seborrheic Keratoses

Multiple eruptive seborrheic keratoses (MESKs), also known as the *sign of Leser-Trélat*, have been mentioned in association with multiple internal malignancies. [92] MESKs also have been described in association with hyperkeratosis of the palms and soles associated with malignant disease and with acanthosis nigricans.

Although anecctotal reports abound, evidence to support the presumed relationship of seborrheic keratoses to malignant disease is meager. [92] Most of the associated cancers are common, and seborrheic keratoses are extremely common. Proving an uncommon causal relationship between a common cancer and a common skin sign is difficult. Anecctotal reports are many.

Porphyria Cutanea Tarda (See Chap. 149)

Porphyria cutanea tarda has been associated with the development of malignant tumors, predominantly of the liver. The relative risk of hepatocellular carcinoma in patients with porphyria has been estimated at 61, [93] a truly significant association. The porphyria cutanea tarda can predate or antedate the apparent development of the primary liver tumor.

H3>DIRECT TUMOR INVOLVEMENT IN THE SKIN

Solid Tumors

Direct involvement of the skin by metastatic spread from a distant primary tumor is perhaps the most unquestioned sign of internal malignancy. In a large review by Lookingbill et al., [94] skin involvement was the first sign of cancer in 0.8 percent of systemic cancer patients. Of this group, approximately equal numbers had direct extension to the skin, local metastases, or distant skin metastases. Direct extension was most common in patients with breast and oral cancer. Local metastases were most common in patients with breast cancer or pelvic cancer. Distant metastases were from many tumor types and sites.

Generally, such a metastatic lesion is rapidly growing erythematous cutaneous or subcutaneous mass. Most commonly breast cancer lesions metastasize to the anterior chest wall. They can show up as small nodules ranging from 1- to 2-mm lesions to large masses of tumor (Fig. 184-9C). The tiny nodules can be erythematous or frankly hemorrhagic. The hemorrhage can be present within the nodules or in the field surrounding the nodules. Metastatic breast cancer also can present as an erysipelas-like eruption known as *carcinoma erysipelatodes* (see Fig. 184-9A, *B*). Usually asymptomatic,

this type of breast cancer can be painful. Another clinical variant is the leather-like skin change of sclerosing metastatic breast cancer known as *carcinoma en cuirasse,* which may later present as nodules and ulceration (Fig. 184-10). Carcinoma en cuirasse can be progressive for many years, even decades, in the absence of any apparent systemic involvement.

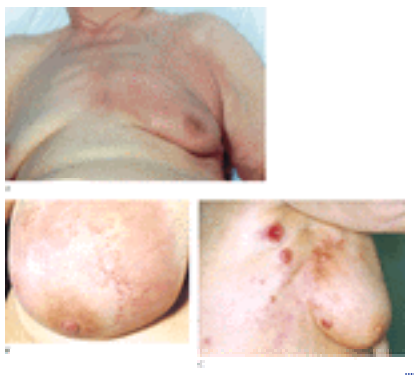

FIGURE 184-9 Involvement of skin by metastatic breast cancer. *A*. Carcinoma erysipelatodes. Intralymphatic spread of mammary carcinoma that manifests as erysipelas-like erythema. *B*. In this close-up of another patient, the erysipelas-like quality of the erythema is even more evident. In addition, there are small, bright-red lenticular metastases. *C*. Metastatic breast cancer also can present as nodules. These may ulcerate and can be very painful.

FIGURE 184-10 Carcinoma en cuirasse involving both breasts and thoracic wall.

Metastases from malignant melanoma are usually pigmented (see Chap. 93). Often there is a bluish tint to the lesion, even if it is deep in the skin. However, even if the primary tumor was pigmented, the metastases can be amelanotic. The reverse is also true.

Other tumors that commonly metastasize to skin include tumors of the lung, stomach, kidney, and ovary. The scalp is quite commonly involved by metastases from lung, kidney, and breast tumors. Alopecia may result.

The face and neck may be involved by metastases from oropharyngeal carcinomas.

Metastases to the skin can appear many years after extirpation of the primary tumor. Progression, as in the case of carcinoma en cuirasse, can be very slow and may indeed not appreciably shorten life expectancy. Generally, though, cutaneous metastases herald a poor prognosis because evidence of systemic spread to other sites is usually quickly apparent. Metastases from renal and thyroid carcinoma may be pulsatile and may have a bruit.

Lymphoma-Leukemia (See Chap. 157 and Chap. 158)

Involvement of the skin with lymphoma cells is quite common, particularly in the case of a T cell lymphoma. T cell leukemias frequently have skin involvement, and this involvement may manifest itself as a diffuse erythroderma, as is seen in Sézary syndrome.

B cell lymphomas also can involve the skin, with Hodgkin's disease being the most common. B cell lymphoma involvement of the skin is usually manifested by the development of one or more papules or nodules that may be ulcerated and form arcuate lesions (see Chap. 158). Alopecia also can be caused by lymphoma. Alopecia mucinosa is involvement of the hair follicles by lymphoma, with associated mucin deposition.

Aside from the erythroderma seen in T cell leukemia, other lymphocytic, myeloid, and myelomonocytic leukemias can have cutaneous manifestations. The most common of these are the infiltrations of the skin produced by monocytic or myelomonocytic leukemia, which can produce a leonine facies in addition to other infiltrative plaques. Involvement of the skin can be a presenting feature in myelomonocytic leukemia, although it generally occurs late in the course of the disease.

When assessing a solitary nodule that is histologically lymphoma but in the absence of any definable systemic disease, it is important to consider benign cutaneous lymphoid infiltrates in the differential diagnosis (see Chap. 159).

Paget's Disease (See Chap. 87)

Paget's disease of the nipple is an erythematous scaling eruption indicating ductal carcinoma of the underlying breast. Extramamamry Paget's disease, which can occur in the anogenital skin, similarly may be associated with an underlying adenocarcinoma. The underlying carcinoma may be of aporcine or eccrine sweat gland origin, or can be from the rectum

or urethra.

REFERENCES

1. McLean D: Cutaneous paraneoplastic syndromes. *Arch Dermatol* **122**:765, 1986

2. Nelson DH et al: ACTH-producing pituitary tumors following adrenalectomy for Cushing's syndrome. *Ann Intern Med* **52**:560, 1960

3. Silberberg I et al: Diffuse melanosis in malignant melanoma. *Arch Dermatol* **97**:671, 1968

4. Konrad K, Wolff K: Pathogenesis of diffuse melanosis secondary to malignant melanoma. *Br J Dermatol* **91**:635, 1974

5. Rorsman H et al: Trichochromuria in melanosis of melanoma. *Acta Derm Venereol (Stockh)* **66**:468, 1986

6. Lynch PJ, Winkelmann RK: Generalized plane xanthoma and systemic disease. *Arch Dermatol* **93**:693, 1966

7. McCadden ME et al: Mycosis fungoides associated with dystrophic xanthomatosis. *Arch Dermatol* **123**:91, 1987

8. Cooper PH et al: Association of juvenile xanthogranuloma with juvenile myeloid leukemia. *Arch Dermatol* **120**:371, 1984

9. Feingold KR et al: Cutaneous xanthoma in association with paraproteinemia in the absence of hyperlipidemia. *J Clin Invest* **83**:796, 1989

10. Maize JC et al: Xanthoma disseminatum and multiple myeloma. *Arch Dermatol* **110**:758, 1974

11. Gagel RF et al: Multiple endocrine neoplasia type 2A associated with cutaneous lichen amyloidosis. *Ann Intern Med* **111**:802, 1989

12. Kaplan LM: Endocrine tumors of the gastrointestinal tract and pancreas, in *Harrison's Principles of Internal Medicine,* 14th ed, edited by AS Fauci, E Braunwald, KJ Isselbacher, JD Wilson, JB Martin, DL Kasper, SL Hauser, DL Longo. New York, McGraw-Hill, 1998, p 584

13. Aldrich LB et al: Distinguishing features of idiopathic flushing and carcinoid syndrome. *Arch Intern Med* **148**:2614, 1988

14. Umeki S et al: Harlequin syndrome (unilateral flushing and sweating attack) due to spinal invasion of the left apical lung cancer (in Japanese). *Rinsho Shinkeigaku* **30**:94, 1990

15. Palmer HM: Digital vascular disease and malignant disease. *Br J Dermatol* **91**:476, 1974

16. Fagrell B, Mellstedt H: Polycythemia vera as a cause of ischemic digital necrosis. *Acta Chir Scand* **144**:129, 1978

17. Goldberg RJ et al: Occult malignant neoplasm in patients with deep venous thrombosis. *Arch Intern Med* **147**:251, 1987

18. Lindelöf B et al: Pemphigoid and cancer. *Arch Dermatol* **126**:66, 1990

19. Ogawa H et al: The incidence of internal malignancies in pemphigus and bullous pemphigoid in Japan. *J Dermatol Sci* **9**:136, 1995

20. Eqan CA et al: Antiepiligrin cicatricial pemphigoid and relative risk for cancer. *Lancet* **357**:1850, 2001

21. Sood VD, Pasricha JS: Pemphigus and Hodgkin's disease. *Br J Dermatol* **90**:575, 1974

22. Stillman MA, Baer RL: Pemphigus and thymoma. *Acta Derm Venereol (Stockh)* **52**:393, 1972

23. Safai B et al: Pemphigus vulgaris associated with a syndrome of immunodeficiency and thymoma: A case report. *Clin Exp Dermatol* **3**:129, 1978

24. Imamura S et al: Pemphigus foliaceus, myasthenia gravis, thymoma and red cell aplasia. *Clin Exp Dermatol* **3**:285, 1978

25. Anhalt GJ et al: Paraneoplastic pemphigus: An autoimmune mucocutaneous disease associated with neoplasia. *N Engl J Med* **323**:1729, 1990

26. Anhalt GJ et al: Paraneoplastic pemphigus: The role of tumours and drugs *Br J Dermatol* **114**:1102, 2001

27. Sigurgeirsson B et al: Risk of lymphoma in patients with dermatitis herpetiformis. *BMJ* **308**:13, 1994

28. Reunala T et al: Lymphoma in dermatitis herpetiformis: Report on four cases. *Acta Derm Venereol (Stockh)* **62**:343, 1982

29. Swerdlow AJ et al: Mortality and cancer incidence in patients with dermatitis herpetiformis: A cohort study. *Br J Dermatol* **129**:140, 1993

30. Dupont C: Herpes gestationis with hydatidiform mole. *Trans St Johns Hosp Dermatol Soc* **60**:103, 1974

31. Halkier-Sorensen L et al: Herpes gestationis in association with neoplasma malignum generalisatum. *Acta Derm Venereol (Stockh)* **120**(suppl):96, 1985

32. Delattre JY et al: Erythema multiforme and Stevens-Johnson syndrome in patients receiving cranial irradiation and phenytoin. *Neurology* **38**:194, 1988

33. Trump DL et al: Epidermolysis bullosa acquisita. *JAMA* **243**:1461, 1980

34. Green ST, Natarajan S: Linear IgA disease and oesophageal carcinoma. *J R Soc Med* **80**:48, 1987

35. McEvoy MT, Connolly SM: Linear IgA dermatosis: Association with malignancy. *J Am Acad Dermatol* **22**:59, 1990

36. Wilson JF et al: Herpes zoster in Hodgkin's disease. *Cancer* **29**:461, 1972

37. Rusthoven JJ et al: Varicella-zoster infection in adult cancer patients: A population study. *Arch Intern Med* **148**:1561, 1988

38. Rigel DS, Jacobs MI: Malignant acanthosis nigricans: A review. *J Dermatol Surg Oncol* **6**:923, 1980

39. Howel-Evans W et al: Carcinoma of the oesophagus with keratosis palmaris et plantaris (tylosis). *Q J Med* **27**:413, 1958

40. Harper PS et al: Carcinoma of the oesophagus with tylosis. *Q J Med* **30**:317, 1970

41. Blanchet-Bardon C et al: Hereditary epidermolytic palmoplantar keratoderma associated with breast and ovarian cancer in a large kindred. *Br J Dermatol* **117**:363, 1987

42. Mortimer P et al: Palmar keratoses and internal malignancy. *Br J Dermatol* **109**:21, 1983

43. Breathnach SM, Wells GC: Acanthosis palmaris: Tripe palms. A distinctive pattern of palmar keratoderma frequently associated with internal malignancy. *Clin Exp Derematol* **5**:181, 1980

44. Lo WL, Wong CK: Tripe palms: A significant cutaneous sign of internal malignancy. *Dermatology* **185**:151, 1992

45. Jacobsen F et al: Acrokeratosis paraneoplastica (Bazex syndrome). *Arch Dermatol* **120**:502, 1984

46. Bazex A, Griffiths A: Acrokeratosis paraneoplastica: A new cutaneous marker of malignancy. *Br J Dermatol* **102**:301, 1980

47. Pecora A et al: Acrokeratosis paraneoplastica (Bazex syndrome). *Arch Dermatol* **119**:820, 1983

48. Juhlin L, Baran R: Abnormal amino acid composition of nails in Bazex's paraneoplastic acrokeratosis. *Acta Derm Venereol (Stockh)* **64**:31, 1984

49. Bolognia JL: Bazex syndrome: Acrokeratosis paraneoplastica. *Semin Dermatol* **14**:84, 1995

50. Bazex A et al: Génodermatose complexe de type indéterminé associant une hypotrichose, un état atrophodermique généralisé et des dégéné rescence cutanées multiples (épithéliomas basocellulaires). *Bull Soc Fr Dermatol Syphiligr* **71**:206, 1964

51. Hill C et al: Frequency of specific cancer types in dermatomyositis and polymyositis: A population study. *Lancet* **357**:96, 2001

52. Zantos D et al: The overall and temporal association of cancer with polymyositis and dermatomyositis. *J Rheumatol* **21**:1855, 1994

53. Basset-Sequin N et al: Prognostic factors and predictive signs of malignancy in adult dermatomyositis. *Arch Dermatol* **126**:633, 1990

54. Tuffanelli DL, Winkelmann RK: Systemic scleroderma. *Arch Dermatol* **84**:359, 1961

55. Haggani MT, Holti G: Systemic sclerosis with pulmonary fibrosis and oat cell carcinoma. *Acta Derm Venereol (Stockh)* **53**:369, 1973

56. Muir EG et al: Multiple primary carcinomata of the colon, duodenum and larynx associated with kerato-acanthomata of the face. *Br J Surg* **54**:191, 1967

57. Torre D: Multiple sebaceous tumours. *Arch Dermatol* **98**:549, 1968

58. Burgdorf WH et al: Muir-Torre syndrome. Histologic spectrum of sebaceous proliferations. *Am J Dermatopathol* **8**:202, 1986

59. Housholder MS, Zeligman I: Sebaceous neoplasms associated with visceral carcinomas. *Arch Dermatol* **116**:61, 1980

60. Schwartz RA et al: The Torre syndrome with gastrointestinal polyposis. *Arch Dermatol* **116**:312, 1980

61. Fusaro RM et al: Torre's syndrome as phenotypic expression of cancer family syndrome. *Arch Dermatol* **116**:986, 1980

62. Hall NR et al: Genetic linkage in Muir-Torre syndrome to the same chromosomal regions as cancer family syndrome. *Eur J Cancer* **30A**:180, 1994

63. Spielvogel RL et al: Oral isotretinoin therapy for familial Muir-Torre syndrome. *J Am Acad Dermatol* **12**:475, 1985

64. Stone MD et al: Torre's syndrome: Exacerbation of cutaneous manifestations with immunosuppression. *J Am Acad Dermatol* **15**:1101, 1986

65. Gardner EJ: A genetic and clinical study of intestinal polyposis, a predisposing factor for carcinoma of the colon and rectum. *Am J Hum Genet* **3**:167, 1951

66. Golitz LE: Heritable cutaneous disorders which affect the gastrointestinal tract. *Med Clin North Am* **64**:829, 1980

67. Lloyd KM, Dennis M: Cowden's disease. *Ann Intern Med* **58**:136, 1963

68. Brownstein MH et al: Cowden's disease. *Cancer* **41**:2393, 1978

69. Taylor AJ et al: Alimentary tract lesions in Cowden's disease. *Br J Radiol* **62**:890, 1989

70. Aine E et al: Visible corneal nerve fibers and neuromas of the conjunctiva: A syndrome of type-3 multiple endocrine adenomatosis in two generations. *Graefes Arch Clin Exp Ophthalmol* **225**:213, 1987

71. Gorlin RJ et al: Multiple mucosal neuroma, pheochromocytoma and medullary carcinoma of the thyroid: A syndrome. *Cancer* **22**:293, 1968

72. Das Gupta TK, Brasfield RD: von Recklinghausen's disease. *Cancer* **21**:174, 1971

73. Johnson RL et al: Human homolog of *patched,* a candidate gene for the basal cell nevus syndrome. *Science* **272**:1668, 1996

74. Graham JH, Helwig EB: Bowen's disease and its relationship to systemic cancer. *Arch Dermatol* **80**:133, 1959

75. Andersen SLC et al: Relationship between Bowen's disease and internal malignant tumors. *Arch Dermatol* **108**:367, 1973

76. Rubinstein N et al: Generalized pruritus as a presenting symptom of phenytoin-induced Hodgkin's disease. *Int J Dermatol* **24**:54, 1985

77. Wasserman LR: The treatment of polycythemia vera. *Semin Hematol* **13**:57, 1976

78. Newbold PCH: Skin markers of malignancy. *Arch Dermatol* **102**:680, 1970

79. Gammel JA: Erythema gyratum repens. *Arch Dermatol Syphilol* **66**:494, 1952

80. Appell ML et al: Erythema gyratum repens. *Cancer* **62**:548, 1988

81. Hughes PSH et al: Subcutaneous fat necrosis associated with pancreatic disease. *Arch Dermatol* **111**:506, 1975

82. Cohen PR, Kurzrock R: Sweet's syndrome and cancer. *Clin Dermatol* **11**:14p, 1993

83. Cohen PRT et al: Malignancy-associated Sweet's syndrome: Review of the world literature. *J Clin Oncol* **6**:1887, 1988

84. Cohen PR et al: Sweet's syndrome in patients with solid tumors. *Cancer* **72**:2723, 1993

85. McLean DI, MacAulay JC: Hypertrichosis lanuginosa acquisita associated with pancreatic carcinoma. *Br J Dermatol* **96**:313, 1977

86. Jemec GBE: Hypertrichosis lanuginosa acquisita. *Arch Dermatol* **122**:805, 1986

87. Chastain MA: The glucagonoma syndrome: A review of its features and discussion. *Am J Med Sci* **321**:306, 2001

88. Rappersberger K et al: The glucagonoma syndrome [in German]. *Hautarzt* **38**:589, 1987

89. Sinclair SA, Reynolds NJ: Necrolytic migratory erythema and zinc deficiency. *Br J Dermatol* **136**:783, 1997

90. Minna JD: Neoplasms of the lung, in *Harrison's Principles of Internal Medicine,* 14th ed, edited by AS Fauci, E Braunwald, KJ Isselbacher, JD Wilson, JB Martin, DL Kasper, SL Hauser, DL Longo. New York, McGraw-Hill, 1998, p 552

91. Giardiello FM et al: Increased risk of cancer in the Peutz-Jeghers syndrome. *N Engl J Med* **316**:1511, 1987

92. Rampen HJ, Schwengle LE: The sign of Leser-Trélat: Does it exist? *J Am Acad Dermatol* **21**:50, 1989

93. Kauppinen R, Mustajoki P: Acute hepatic porphyria and hepatocellular carcinoma. *Br J Cancer* **57**:117, 1988

94. Lookingbill DP et al: Skin involvement as the presenting sign of internal carcinoma: A retrospective study of 7616 cancer patients. *J Am Acad Dermatol* **22**:19, 1990

T>

Chapter 185

Karen Houpt Ponciano Cruz

Acanthosis Nigricans

HISTORICAL ASPECTS
EPIDEMIOLOGY
ETIOLOGY AND PATHOGENESIS
CLINICAL MANIFESTATIONS
ASSOCIATED CONDITIONS
Insulin Resistance
Malignancy
Drugs
Idiopathic
Other
HISTOPATHOLOGY
DIFFERENTIAL DIAGNOSIS
LABORATORY TESTS
TREATMENT
REFERENCES

Acanthosis nigricans is a cutaneous marker, most commonly of insulin resistance and less frequently of malignancy. It is recognized clinically by hyperpigmented, hyperkeratotic, verrucous plaques that bestow a velvety texture on involved skin. Typically symmetric in distribution, it usually involves intertriginous areas [1] and occasionally mucocutaneous areas. [2]

HISTORICAL ASPECTS

The term *acanthosis nigricans* was originally proposed by Unna, although the first cases were described by Pollitzer and by Janovsky in 1891. Curth classified acanthosis nigricans into malignant, benign, syndromic acanthosis nigricans or pseudoacanthosis nigricans. [2] A key advance toward understanding pathogenesis was made in 1976 by Kahn et al., [3] who described two syndromes of insulin resistance. Type A syndrome, seen in women with acanthosis nigricans, masculinization, and hyperandrogenism, is characterized by defective insulin receptors, whereas type B syndrome, seen in women with acanthosis nigricans and autoimmune diseases, is associated with circulating anti-insulin receptor autoantibodies. The concept of acanthosis nigricans as a marker of malignancy is valid, but most cases are related to insulin resistance. [4], [5] and [6]

EPIDEMIOLOGY

The prevalence of acanthosis nigricans in selected subpopulations has been studied. Stuart et al. [5] identified it in 7 percent of public school children, a prevalence that rose to 28 percent among those judged to be obese based on ideal body weight. A higher frequency was noted in African Americans (13 percent) than in Hispanics (6 percent) and whites (0.5 percent). [5] In a separate study, an even higher prevalence was seen in Native American children (32 percent). [7] Hud et al. [6] observed acanthosis nigricans in 74 percent of adult patients treated for obesity, with African Americans having the highest frequency among ethnic groups. In a study of Mexican Americans with and without diabetes mellitus, the respective prevalences were 41 percent and 31 percent. [8]

Malignancy-associated acanthosis nigricans is rare. It was present in 1 of 35 patients with intrathoracic or intraabdominal malignancies, [9] and in 2 of 12,000 cancer patients. Although reported in all age groups, it is more common in individuals 40 years of age and older of either gender. [2], [9], [10]

ETIOLOGY AND PATHOGENESIS

Although the precise etiology of acanthosis nigricans remains unclear, there is evidence of a role for insulin. [11], [12] and [13]) At normal levels, insulin binds preferentially to classic receptors, transducing effects on glucose metabolism. In contrast, at higher levels, insulin binds with greater affinity to insulin-like growth factor (IGF) receptors, promoting effects on cell proliferation. [4], [14] Insulin can reach the skin and affect fibroblasts and keratinocytes, both shown to express classic insulin and IGF receptors. [15] Tissue resistance to insulin leads to hyperinsulinemia, which favors binding to IGF receptors that may stimulate proliferation of keratinocytes and dermal fibroblasts in a manner that may produce acanthosis nigricans. [14], [15]

Hyperinsulinemia may also trigger ovarian hyperandrogenism, which commonly coexists with acanthosis nigricans in women with severe insulin resistance (e.g., type A syndrome of insulin resistance and polycystic ovarian syndrome). [14] The prevalence of the skin eruption in hyperandrogenic women was reported to be 5 to 29 percent. [11], [12] An etiologic role for androgens was suggested by improvement of acanthosis nigricans in two hyperandrogenic women treated with antiandrogen medications. [16] On the other hand, antiandrogen treatments do reverse hirsutism, with no effect on the acanthosis nigricans or insulin resistance. [17], [18]

The pathogenesis of malignancy-associated acanthosis nigricans is even less clear. A humoral factor produced by the tumor is likely, given cases in which the skin disorder improved or resolved following treatment of the malignancy.

Elevated levels of transforming growth factor (TGF)-a in urine and of epidermal growth factor (EGF) receptors in lesional skin were noted in a patient with acanthosis nigricans, acrochordons, the sign of Leser-Trélat, and melanoma. The enhanced expression of this cytokine and its receptor normalized after removal of the melanoma, and the acanthosis nigricans, acrochordons, and seborrheic keratoses improved postoperatively. [19] A separate case, with gastric cancer was also shown to express TGF-a and EGF receptors. [20]

CLINICAL MANIFESTATIONS

The clinical hallmark of acanthosis nigricans is development of gray-brown, velvety plaques that may start as a dirty appearance. The hyperpigmentation is later accompanied by hypertrophy, increased skin markings, and papillomatosis. The most commonly involved locations are the axillae, neck (Fig. 185-1 and Fig. 185-2), external genitalia, groin, face, inner thighs, antecubital and popliteal fossae, umbilicus, and perianal area. [1] Acrochordons may develop, superimposed on the acanthosis nigricans (Fig. 185-1) or on other locations. Tylosis (palmoplantar hyperkeratosis) and acanthosis palmaris or pachydermatoglyphy (exaggeration of fingerprints) may also occur, especially in malignancy-associated acanthosis nigricans. Exuberant forms of the latter are called tripe palms because of similarity to the rugose appearance of bovine foregut (Fig. 185-3). Mucocutaneous surfaces may be affected and the eruption can be generalized, particularly in malignancy-associated cases. Mucosal involvement may consist of thickening and papillomatosis with minimal hyperpigmentation (Fig. 185-4). [2]

FIGURE 185-1 Acanthosis nigricans involving the axilla with numerous acrochordons.

FIGURE 185-2 Acanthosis nigricans involving the neck.

FIGURE 185-3 Acanthosis palmaris, pachydermatoglyphy, or tripe palms.

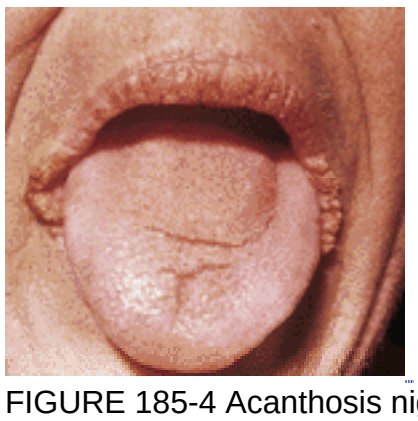

FIGURE 185-4 Acanthosis nigricans involving the lips, with minimal hyperpigmentation. *(All rights reserved. Reprinted*

with permission from the American Academy of Dermatology.)

ASSOCIATED CONDITIONS

Acanthosis nigricans is classified best based on the underlying problem or cause (Table 185-1).

Insulin resistance-related
Leprechaunism (Donohue syndrome)
Lipodystrophies
Obesity
Polycystic ovarian disease (Stein-Leventhal syndrome)
Pseudoacromegaly
Rabson-Mendenhall syndrome
Rud syndrome
Type A syndrome (HAIR-AN syndrome)
Type B syndrome
Type 2 diabetes mellitus
Malignancy-related (see Table 185-2)
Drug-induced
Idiopathic
Familial
Nonfamilial
Other
Syndromic (see Table 185-3)
Acral acanthotic anomaly
Nevoid form

HAIR-AN = hyperandrogenism, insulin resistance, and acanthosis nigricans

TABLE 185-1 **Classification of Acanthosis Nigricans Based on the Most Common Associations**

Insulin Resistance

Acanthosis nigricans is a common feature of several insulin-resistant states. Insulin resistance is defined as hyperinsulinemia inappropriate for the concurrent plasma glucose level. [2], [10], [21], [22] Obesity (previously categorized as pseudoacanthosis nigricans) is the most commonly associated condition. [23] There is a positive correlation between development of acanthosis nigricans and the severity of obesity. [5], [6] Not only do skin changes often parallel the development of obesity, but they typically regress following weight reduction. Obesity is intrinsically associated with hyperinsulinemia, insulin resistance, impaired glucose tolerance, and type 2 diabetes mellitus, as well as with dyslipidemia, hypertension, and hyperandrogenemia. [24] Genetic studies suggest that acanthosis nigricans, fasting plasma insulin level, and type 2 diabetes are under strong pleiotropic influences. [25] A study of African Americans showed fasting plasma insulin level to correlate with severity of acanthosis nigricans. [26]

Mutations of the insulin receptor gene or postreceptor defects have been implicated in other insulin-resistant states, such as leprechaunism, Lawrence-Seip syndrome (congenital lipodystrophy), pseudoacromegaly, Rabson-Mendenhall syndrome, and the type A syndrome. [4], [27], [28], [29] and [30]

Malignancy

Malignancy-associated acanthosis nigricans tends to be extensive and involves mucosal surfaces (Fig. 185-5). Other independent markers of malignancy, such as the sign of Leser-Trélat, tylosis, and florid cutaneous papillomatosis, may accompany acanthosis nigricans, suggesting common pathomechanisms. The overwhelming majority of associated malignancies are intraabdominal adenocarcinomas, most commonly gastric in origin (45 to 61 percent). Acanthosis nigricans may precede, occur simultaneously with, or develop after the clinical onset of the malignancy. [10], [31] Recent studies indicate that in many cases acanthosis nigricans was noted prior to detection of malignancy. Most tumors are inoperable or highly aggressive at the time of detection. Regression of acanthosis nigricans following tumor treatment and its redevelopment with tumor recurrence or metastasis have been reported. [2] Table 185-2 lists other associated malignancies. [2], [10], [32], [33] and [34]

Adenocarcinomas	Lung carcinomas
Gastric	Bronchoalveolar
Other	Squamous cell
Endocrinologic malignancies	Small cell
Carcinoid	Lymphomas (including cutaneous T cell lymphoma)
Pheochromocytoma	Other
Pinealoma	Wilms' tumor
Testicular	Cervical carcinoma
Thyroid	Urinary bladder carcinoma
Melanoma	
Sarcomas	

TABLE 185-2 **Malignancies Reported in Association with Acanthosis Nigricans**

FIGURE 185-5 *A.* Malignant acanthosis nigricans with pigmented, velvety, papillomatous lesions in both axillae and the neck and papillomatous, verrucous lesions on the vermilion border of the lips. *B.* Acanthosis nigricans in the groin and scrotal area. (*Courtesy of Fritz Gschnait, MD.*)

Drugs

Acanthosis nigricans is associated with systemic administration of somatotrophin, [35] testosterone, nicotinic acid, diethylstilbestrol, oral contraceptives, triazinate, and corticosteroids, and with topical application of fusidic acid. Acanthosis nigricans developing at sites of subcutaneous insulin injections has also been described. [2]

Idiopathic

True idiopathic acanthosis nigricans requires exclusion of an underlying cause (insulin resistance, obesity, endocrinopathy, malignancy, or drug). Familial cases of idiopathic acanthosis nigricans have been reported, with onset at birth or in early childhood. [10], [36] These cases appear to be inherited as an autosomal dominant trait with variable penetrance. [10], [36] Because obesity is commonly familial, it may be difficult to differentiate obesity-related familial acanthosis nigricans from the idiopathic familial form. Distinguishing features of the former are reversibility of the skin changes with weight reduction and onset at any age. [23]

Other

Numerous syndromes have been reported in association with acanthosis nigricans (Table 185-3). [2], [10], [21], [37], [38] Insulin resistance is a unifying component of many syndromes. Acral acanthotic anomaly is a variant that appears as velvety hyperkeratosis of the back of the hands and feet, often seen in dark-skinned individuals. [2] Finally, an idiopathic, unilateral (nevoid) form of acanthosis nigricans has been described. [2], [39]

Acromegaly	Laurence-Moon-Bardet-Biedl syndrome
Addison disease	Laurence-Seip syndrome (congenital lipodistrophy)*
Alström syndrome*	Lipoatrophic diabetes*
Ataxia-telangiectasia	Lipoid hepatitis
Baller syndrome	Lupus erythematosus
Beare-Stevenson syndrome	MORBAN syndrome (mental retardation, overgrowth, osteofaciale facies, and acanthosis nigricans)
Benign encephalopathy	Phenylketonuria
Bloom syndrome	Pituitary hypogonadism
Cappuccino syndrome	Pituitary tumors
Chondrodystrophy with dwarfism	Prader-Willi syndrome
Costello syndrome	Pseudoacromegaly*
Crouzon syndrome	Pyramidal tract degeneration
Cushing's syndrome	Rabson-Mendenhall syndrome*
Dermatomyositis	Ruvalcaba syndrome*
Diabetes insipidus	Schwachman
Donohue syndrome (leprechaunism)*	Stein-Leventhal syndrome (polycystic ovarian disease)*
Down syndrome	Small gonads
Edwards syndrome*	Type A syndrome of insulin resistance*
Gigantism	Type B syndrome of insulin resistance*
HAIR-AN syndrome (hyperandrogenism, insulin resistance, and acanthosis nigricans)*	Werner syndrome
Hashimoto thyroiditis	Wilson disease (hepatolenticular degeneration)
Hepatic cirrhosis	
Hirschsprung syndrome	

/A>

TABLE 185-3 **Syndromes Associated with Acanthosis Nigricans**

HISTOPATHOLOGY

The histology of acanthosis nigricans is consistent regardless of clinical associations. Characteristic features include hyperkeratosis and slight acanthosis undulating with dermal papillomatosis (Fig. 185-6). The clinical brown color is likely a result of hyperkeratosis (rather than of hypermelanosis, which is usually minimal to nil). Thus, the term acanthosis nigricans has little histologic justification. [10], [40], [41] Mucous membrane involvement may display focal parakeratosis, greater acanthosis, and epithelial papillary hyperplasia. [40]

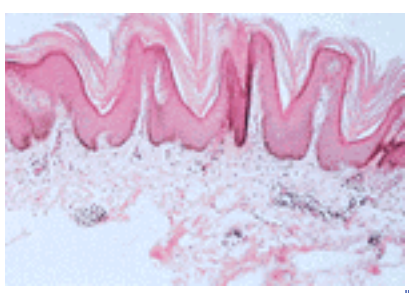

FIGURE 185-6 Histology of acanthosis nigricans demonstrating hyperkeratosis and slight acanthosis alternating with dermal papillomatosis.

DIFFERENTIAL DIAGNOSIS

The distinctive clinical appearance and distribution renders the diagnosis readily apparent. Occasionally, however, acanthosis nigricans may simulate a hyperpigmented nevus (Becker, epidermal, or melanocytic), reticulate pigmented flexural anomaly (Dowling-Degos disease), or confluent and reticulated papillomatosis (Gougerot and Carteaud). [2], [41] Mycosis fungoides can mimic acanthosis nigricans. [42] Oral acanthosis nigricans may be confused with Cowden disease, dyskeratosis congenita, hereditary benign intraepithelial dyskeratosis, lipoid proteinosis, pachyonychia congenita, pyostomatitis vegetans, and Wegener granulomatosis. [2]

LABORATORY TESTS

The underlying cause may be suggested by historical information and physical examination findings. A malignancy is important to exclude especially in nonobese patients with a history of sudden onset, severe involvement, or in cases in which there is no readily discernible cause. In these cases, diagnostic tests should be performed to screen for malignancy with particular attention paid to the possibility of an intraabdominal malignancy.

The presence of acanthosis nigricans should prompt consideration of insulin resistance. A simple screen is to test, in parallel, for fasting plasma levels of glucose and insulin. Although many insulin-resistant people may not demonstrate fasting hyperinsulinemia or have acanthosis nigricans, [43] an inappropriately elevated plasma level of insulin for the corresponding glucose level in a patient with acanthosis nigricans is evidence of insulin resistance as the cause. A fasting glucose/insulin ratio of <4.5 is used to screen for insulin resistance in adult women with polycystic ovary syndrome, [44] and <7 is considered abnormal in prepubertal girls with premature adrenarche. [45] Women with hyperandrogenism (irregular menses, acne, and hirsutism) should undergo endocrine evaluation. Patients with rheumatic diseases should be tested for the presence of anti-insulin receptor autoantibodies.

TREATMENT

Whenever possible, the underlying cause should be identified and treated. Obese patients can reverse the skin changes with weight loss. Patients with the type A syndrome have been treated with ovarian wedge resection with or without cyclical norethindrone and mestranol, [16], [46], [47] oral contraceptives, [16] /SUP>ketoconazole, [48] or cyproterone acetate. [49] Infusion of IGF in some type A patients improved the acanthosis nigricans and hyperinsulinemia, but aggravated the hyperandrogenism. [50], [51] The insulin-sensitizing agents, troglitazone (withdrawn by the Food and Drug Administration) and metformin, have been used to treat hyperandrogenemic, insulin-resistant women, but their effects on acanthosis nigricans have not been studied. [18] In a case of lipodystrophic diabetes mellitus, the acanthosis nigricans improved with dietary fish oil supplementation. [2] Management of the type B syndrome should focus on the underlying autoimmune disease.

Malignancy-associated acanthosis nigricans may regress following effective treatment of the underlying cancer. [31] In one case, treatment with cyproheptadine led to improvement of acanthosis nigricans despite progression of the metastatic disease. [52] Topical calcipotriol, salicylic acid, urea, podophyllin, systemic and topical retinoids have been used with varying success. [2], [53], [54] Continuous-wave carbon dioxide laser therapy was performed in one patient. [54]

REFERENCES

1. Pollitzer S: Acanthosis nigricans: A symptom of a disorder of the abdominal sympathe *JAMA* **53**:1369, 1909

2. Schwartz RA: Acanthosis nigricans *J Am Acad Dermato* **31**:1, 1994

3. Kahn CR et al: The syndromes of insulin resistance and acanthosis nigricans: Insulin-receptor disorders in m *N Engl J Mec* **294**:739, 1976

4. Flier JS: Lilly lecture: Syndromes of insulin resistance: From patient to gene and back ag *Diabetes* **41**:1207, 1992

5. Stuart CA et al: Prevalence of acanthosis nigricans in an unselected populati *Am J Med* **87**:269, 1989

6. Hud JA et al: Prevalence and significance of acanthosis nigricans in an adult obese populati *Arch Dermato* **128**:941, 1992

7. Stuart CA et al: Acanthosis nigricans among Native Americans: An indicator of high diabetes ri *Am J Pub Health* **84**:1839, 1994

8. Burke JP et al: A quantitative scale of acanthosis nigrican *Diabetes Care* **22**:1655, 1999

9. Kierland RH: Acanthosis nigricans: An analysis of data in twenty-two cases and a study of its frequency in necropsy mat *J Invest Dermato* **9**:299, 1947

10. Brown J, Winkelmann RK: Acanthosis nigricans: A study of 90 case *Medicine (Baltimore)* **47**:33, 1968

11. Flier JS et al: Acanthosis nigricans in obese women with hyperandrogenism: Characterization of an insulin-resistant state distinct from the type A and B syndr *Diabetes* **34**:101, 1985

12. Dunaif A et al: Characterization of groups of hyperandrogenic women with acanthosis nigricans, impaired glucose tolerance and/or hyperinsulin *J Clin Endocrinol Metal* **65**:499, 1987

13. Peters EJ et al: Acanthosis nigricans and obesity: Acquired and intrinsic effects in insulin acti *Metabolism* **35**:807, 1986

14. Flier JS: Metabolic importance of acanthosis nigrican *Arch Dermato* **121**:193, 1985

15. Cruz PDJr, Hud JA Jr: Excess insulin binding to insulin-like growth factor receptors: Proposed mechanism for acanthosis nigrica *J Invest Dermato* **98**:82s, 1992

16. Givens JR et al: Remission of acanthosis nigricans associated with polycystic ovarian disease and a stromal lutec *J Clin Endocrinol Metal* **38**:347, 1974

17. Corenblum B, Baglis BM: Medical therapy for the syndromes of familial virilization, insulin resistance and acanthosis nigric *Fertil Ster* **53**:421, 1990

18. Elkind-Hirsch KE, McWilliams RB: Pregnancy after treatment with the insulin-sensitizing agent troglitazone in an obese woman with the hyperandrogenic, insulin-resistant acanthosis nigricans syndrome. *Fertil Ster* **71**:943, 1999

19. Ellis DL et al: Melanoma, growth factors, acanthosis nigricans, the sign of Leser-Trélat, and multiple acrochordons: A possible role for alpha-transforming growth factor in cutaneous paraneoplastic syndromes *N Engl J Mec* **317**:1582, 1987

20. Wilgenbus K et al: Further evidence that acanthosis nigricans maligna is linked to enhanced secretion by the tumour of transforming growth factor a *Arch Dermatol Res* **284**:266, 1992

21. Ober KP: Acanthosis nigricans and insulin resistance associated with hypothyroidis *Arch Dermato* **121**:229, 1985

22. Panidis D et al: Association of acanthosis nigricans with insulin resistance in patients with polycystic ovary syndro *Br J Dermato* **132**:936, 1995

23. Curth HO, Aschner BM: Genetic studies on acanthosis nigricans *Arch Dermato* **79**:55, 1959

24. DiMartino-Nardi J: Pre- and postpuberal findings in premature adrenarch *J Pediatr Endocrinol Metal* **13**:1265, 2000

25. Burke JP et al: Genetic basis of acanthosis nigricans in Mexican Americans and its association with phenotypes related to type 2 diab *Hum Genet* **106**:467, 2000

26. Stuart CA et al: Acanthosis nigricans as a risk factor for non-insulin dependent diabetes mellit *Clin Pediat* **37**:73, 1998

27. Accili D et al: Mutations in the insulin receptor gene in patients with genetic syndromes of insulin resistance and acanthosis nigric *J Invest Dermato* **98**:77s, 1992

28. Taylor SI: Lilly lecture: Molecular mechanisms of insulin resistance. Lessons from patients with mutations in the insulin-receptor g *Diabetes* **41**:1473, 1992

29. Moller DE et al: Prevalence of mutations in the insulin receptor gene in subjects with features of the type A syndrome of insulin resista *Diabetes* **43**:247, 1994

30. Moller DE, Flier JS: Detection of an alteration in the insulin-receptor gene in a patient with insulin resistance, acanthosis nigricans, and the polycystic ovary syndrome (type A insulin resistance). *N Engl J Mec* **319**:1526, 1988

31. Curth HO: Cancer associated with acanthosis nigricans: Review of literature and report of a case of acanthosis nigricans with cancer of the br *Arch Surg* **47**:517, 1943

32. Gross G et al: Acanthosis nigricans maligna: Clinical and Virological investigatio *Dermatologica* **168**:265, 1984

33. Cottoni F et al: Follicular mucinosis plus mycosis fungoides and acanthosis nigricans plus alveolar bronchiolar carcino *Int J Dermato* **34**:867, 1995

34. Gohji K et al: Acanthosis nigricans associated with transitional cell carcinoma of the urinary blad *Int J Dermato* **33**:433, 1994

35. Downs AM, Kennedy CT: Somatotrophin-induced acanthosis nigrican *Br J Dermato* **141**:390, 1999

36. Tasjian D, Jarratt M: Familial acanthosis nigricans *Arch Dermato* **120**:1351, 1984

37. Seemanova E et al: MORFAN: A new syndrome characterized by mental retardation, pre- and postnatal overgrowth, remarkable face and acanthosis nigricans in 5-year-old boy [letter]. *Am J Med Gene* **45**:525, 1993

38. Edwards JA et al: A new familial syndrome characterized by pigmentary retinopathy, hypogonadism, mental retardation, nerve deafness and glucose intole *Am J Mec* **60**:23, 1976

39. Krishnaram AS: Unilateral nevoid acanthosis nigrican *Int J Dermato* **30**:452, 1991

40. Hall JM et al: Oral acanthosis nigricans: Report of a case and comparison or oral and cutaneous pathol *Am J Dermatopatho* **10**:68, 1988

41. Lever WF, Schaumburg-Lever G: Metabolic diseases, i *Histopathology of the Skin* edited by WF Lever, G Schaumburg-Lever. Philadelphia, JB Lippincott, 1990, p 478

42. Willemze R et al: Mycosis fungoides simulating acanthosis nigrican *Am J Dermatopatho* **7**:365, 1985

43. Barbieri RL: Induction of ovulation in infertile women with hyperandrogenism and insulin resistar *Am J Obstet Gyneco* **183**:1412, 2000

44. Legro RS et al: A fasting glucose to insulin ratio is a useful measure of insul *J Clin Endocrinol Metal* **83**:2694, 1999

45. DiMartino-Nardi J: Premature adrenarche: findings in prepubert *Acta Paediat* **88**:67, 1999

46. Barth JH et al: Acanthosis nigricans, insulin resistance and cutaneous virilis *Br J Dermato* **118**:613, 1988

47. Imperato-McGinley J et al: Primary amenorrhea associated with hirsutism, acanthosis nigricans, dermoid cysts of the ovaries, and a new type of insulin resist *Am J Mec* **65**:389, 1978

48. Tercedor J et al: Effect of ketoconazole in the hyperandrogenism, insulin resistance and acanthosis nigricans (HAIR-AN) syndro *J Am Acad Dermato* **27**:786, 1992

49. Tatnall FM et al: The syndrome of acanthosis nigricans, hyperandrogenism and insulin resistan *Clin Exp Dermato* **9**:526, 1984

50. Kuzuya H et al: Trial of insulinlike growth factor I therapy for patients with extreme insulin resistance syndron *Diabetes* **42**:696, 1993

51. Ishihama H et al: Long-term follow up in type A insulin-resistant syndrome treated by insulin-like growth fact *Arch Dis Chilc* **71**:144, 1994

52. Greenwood R, Tring FC: Treatment of malignant acanthosis nigricans with cyproheptadi *Br J Dermato* **106**:697, 1982

53. Bohm M et al: Treatment of mixed-type acanthosis nigricans with topical calcipotr *Br J Dermato* **139**:932, 1998

54. Bredlich RO et al: Continuous-wave carbon dioxide laser therapy in pseudoacanthosis nigrica *Br J Dermato* **139**:937, 1998

T>

Chapter 186

Raul Fleischmajer

Scleredema

PATHOGENESIS
CLINICAL MANIFESTATIONS
LABORATORY FINDINGS
PATHOLOGY
DIFFERENTIAL DIAGNOSIS
TREATMENT

REFERENCES

Scleredema is a connective tissue disease that was recognized as a distinct entity by Buschke in 1902. The disease affects all races and appears to be more prevalent among females. In a review of 209 cases by Greenberg et al., [1] 29 percent were children younger than 10 years of age, 22 percent were between 10 and 20 years old, and 49 percent were adults.

PATHOGENESIS

The cause of scleredema is unknown. Streptococcal hypersensitivity, injury of lymph channels, alterations of pituitary function, and peripheral nerve abnormalities have been proposed as causes, but none has been substantiated. The dermis is markedly increased in thickness, although it appears that this finding is due in part to the replacement of subcutaneous tissue by connective tissue (Fig. 186-1). Chemical analysis of the dermis reveals an increase in hydroxyproline and hexosamines proportional to the increase in skin thickness. [2]

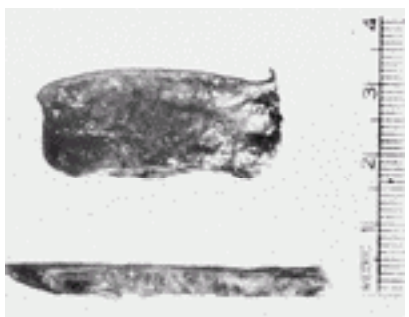

FIGURE 186-1 Scleredema skin from the back (*top*) and normal control. Note marked increase in thickness. (*From Fleischmajer et al.,* [2] *with permission.*)

Cultured fibroblasts reveal increased synthesis of total proteins and collagen and the elevation of procollagen I and III mRNA levels. [3] Fractionation of acid mucopolysaccharides shows a normal distribution of hyaluronic acid and dermatan sulfate. The water content of the skin is normal. [2] Electron microscopy reveals clumping of collagen fibrils, increase in ground substance, and collagen fibrils with reduced diameter. The urinary excretion of hydroxyproline and hydroxylysine appears normal. Scleredema has been found in association with a monoclonal gammopathy. Serum immunoglobulins are usually of the IgG type, although IgA and IgM have also been reported. The chains are either of the kappa or lambda type. [4] The association of multiple myeloma and scleredema has been documented. [5] There is some evidence that the serum of patients with scleredema may contain a factor that stimulates collagen synthesis.

CLINICAL MANIFESTATIONS

Skin involvement may be preceded by a prodrome of low-grade fever, malaise, myalgia, and arthralgia. A few days to 6 weeks before the onset, 65 percent of patients develop an infection, usually of streptococcal origin. [1] Influenza, scarlet fever, measles, mumps, tonsillitis, pharyngitis, otitis, furuncles, erysipelas, and impetigo have been observed.

The onset is frequently sudden and consists of marked, nonpitting, symmetric induration of the skin, usually affecting the posterior and lateral aspects of the neck and spreading to the face, shoulders, back, arms, and thorax (Fig. 186-2). The buttocks, legs, and abdomen are less frequently involved, and the hands and feet are affected in approximately 10 percent of the patients. The disease usually reaches maximal involvement in 1 to 2 weeks, although it may continue to spread for an additional 2 to 3 months.

FIGURE 186-2 Scleredema of 41-year duration affecting the neck and back.

The induration is of wooden-like consistency, waxy white or shiny in appearance, and rather diffuse, so that there is no sharp line of demarcation between involved and noninvolved areas. Folding of the skin is almost impossible, and the normal markings are lost. When the face is involved, there is lack of expression and, often, difficulty in opening the mouth. There is a transient, erythematous, macular or papular eruption during the early stage of the disease. Pain is absent, although paresthesia may occur. Heart abnormalities occur; in children, the most common are diastolic gallop without evidence of cardiac failure, a nonspecific S-T depression, and T-wave inversion, usually reverting to normal in 3 to 9 months. Carditis secondary to rheumatic fever has been noted. The disease may also affect the parotid gland, tongue, palate, pharynx, and upper esophagus (dysphagia). Ocular involvement may result in induration of the eyelids and conjunctiva, exophthalmos, and ophthalmoplegia. [6]

In 1970, a syndrome was recognized that consists of scleredema of long duration, obesity, maturity onset, latent or overt diabetes, and a high incidence of cardiovascular disease. [2] Diabetic retinopathy is common. [2] Most patients are quite resistant to antidiabetic therapy, including insulin and oral hypoglycemics. Antidiabetic therapy has no effect on the evolution of the scleredema.

LABORATORY FINDINGS

Most laboratory tests are usually normal except for an increase in antistreptolysin O titer in some patients. A glucose tolerance test should be performed to rule out diabetes mellitus. Hyperinsulinism may be present. [2]

PATHOLOGY

The epidermis and its appendages are normal. The dermis reveals collagen bundles separated by large interfascicular spaces (Fig. 186-3). The papillary layer is prominent and slightly edematous. In the upper dermis, there may be mild perivascular or scattered infiltrates consisting mostly of lymphocytes and histiocytic type cells. An increase in the numbers of mast cells has also been noted. The secretory coils of the eccrine sweat glands are found in the upper third or mid-dermis. The subcutaneous tissue is reduced, probably because of its replacement by connective tissue. [2] The ground substance reveals an increase in metachromatic material when stained with toluidine blue. This material also stains positive with Alcian blue at pH 2.5, but not with Alcian blue at pH 0.5, which stains sulfated acid mucopolysaccharides. Hyaluronidase digestion completely removes the Alcian blue–positive material, suggesting an increase in hyaluronic acid. However, this increase is only temporary and does not appear in all patients. Mucin deposition was also detected in extracutaneous sites including the bone marrow, nerves, liver, and salivary glands. [6]

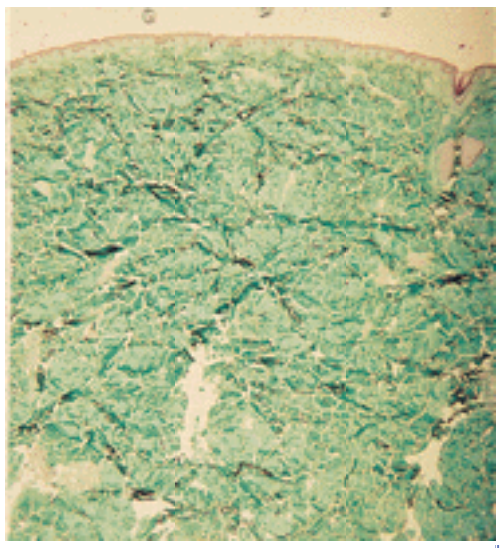

FIGURE 186-3 Scleredema. Edematous papillary layer, thick dermis, and large collagen bundles separated by interfascicular spaces.

DIFFERENTIAL DIAGNOSIS

Scleredema has to be differentiated from the early edematous stage of systemic scleroderma. In systemic scleroderma, Raynaud's phenomenon, a predilection for hands, abnormal pigmentation, telangiectasia, ischemia, and atrophic skin changes are usually present (Chap. 173); these findings are not present in scleredema. Scleredema should also be differentiated from trichinosis, dermatomyositis, scleromyxedema, myxedema, progeria, sclerema neonatorum, edema neonatorum, primary systemic amyloidosis, and edema from cardiac or renal origin.

TREATMENT

The treatment of scleredema remains difficult, although significant improvement has been reported with the use of electron-beam therapy, [7], [8] bath-PUVA, [9] and extracorporeal photopheresis. [10] Isolated reports claim some success with high-dose glucocorticoids, cyclosporine, and prostaglandin E_1.

Prognosis is usually good, and the disease undergoes spontaneous resolution in 6 months to 2 years. The disease persists indefinitely (from 2 to 41 years) [2] in those patients with associated diabetes mellitus.

REFERENCES

1. Greenberg LM et al: Scleredema adultorum in children. *Pediatrics* **32**:1044, 1963

2. Fleischmajer R et al: Scleredema and diabetes mellitus. *Arch Dermatol* **101**:21, 1970

3. Varga J et al: Scleredema adultorum: Case report and demonstration of abnormal expression of extracellular matrix genes in skin fibroblasts "in vivo" and "in vitro." *Br J Dermatol* **132**:992, 1995

4. Ulmer A et al: Scleredema adultorum Buschke. Fallbericht und literaturubersicht. *Hautarzt* **49**:48, 1998

5. Schmidt KT et al: Scleredema and smoldering myeloma. *J Am Acad Dermatol* **26**:319, 1992

6. Basarab T et al: Systemic involvement in scleredema of Buschke associated with IgG kappa paraproteinaemia. *Br J Dermatol* **136**:939, 1997

7. Besson CA et al: Electron-beam therapy in scleredema adultorum with associated monoclonal hypergammaglobulinemia. *Br J Dermatol* **130**:394, 1994

8. Tamburin LM et al: Scleredema of Buschke successfully treated with electron-beam therapy. *Arch Dermatol* **134**:49, 1998

9. Hager CM et al: Bath-PUVA therapy in three patients with scleredema adultorum. *J Am Acad Dermatol* **38**:240, 1998

10. Stables GI et al: Scleredema associated with paraproteinaemia treated by extracorporeal photopheresis. *Br J Dermatol* **142**:781, 2000

T>

Chapter 187

Raul Fleischmajer

Papular Mucinosis

PATHOGENESIS
CLINICAL MANIFESTATIONS
LABORATORY FINDINGS
PATHOLOGY
DIAGNOSIS AND DIFFERENTIAL DIAGNOSIS
TREATMENT
COURSE AND PROGNOSIS

REFERENCES

Papular mucinosis, or lichen myxedematosus, is a rare disease characterized by a papular-lichenoid eruption, mucin deposition, and paraproteinemia. A clinical variant of papular mucinosis is scleromyxedema, in which the disease is more generalized and is accompanied by erythema and sclerosis. [1]

PATHOGENESIS

The pathogenesis of papular mucinosis remains unknown. This disease is frequently associated with paraproteinemia that consists of a myeloma-like, homogeneous serum globulin of the IgG type with predominantly lambda light chains, although kappa light chains have also been noted. [2], [3] Less commonly, paraproteins of the IgM and IgA types have been identified. The paraprotein in papular mucinosis is a 7S, papain-sensitive globulin, which is strongly basic because of its high content of lysine. [3] Its molecular mass of approximately 100 kDa (normal IgG has a molecular mass of 160 kDa) suggests that this IgG globulin is incomplete, missing a significant antigenic portion of the Fc fragment. [4] The initial suggestion that papular mucinosis represents a plasma cell dyscrasia has never been substantiated. However, the presence of a paraproteinemia, occasional plasma cell dyscrasia in the bone marrow, and the demonstration of skin plasma cells monotypic for lambda light chains is suggestive of a plasma cell neoplasm. [5] The association of papular mucinosis with multiple myeloma is rare, if it occurs at all. Furthermore, the paraprotein in multiple myeloma is usually a monoclonal IgG with kappa light chains. Serum from patients with papular mucinosis can stimulate DNA synthesis and the proliferation of normal human fibroblasts in vitro. [6] The removal of the paraprotein from the culture medium does not decrease fibroblast mitosis, suggesting that another serum factor may be responsible for the proliferative effect.

CLINICAL MANIFESTATIONS

The disease affects adults from 30 to 70 years of age, has no sex predilection, and usually runs a chronic course. The primary lesion is a dome-shaped papule, skin color or erythematous, 2 to 4 mm in diameter; the lesions may be densely grouped in a lichenoid fashion or may show a linear arrangement. The areas most frequently affected are the dorsa of the hands and fingers, the axillary folds, and the external surfaces of the arms and legs. The coalescence of papules on the face, particularly in the glabella area, results in longitudinal folding, giving the appearance of leonine facies (Fig. 187-1). The lesions are usually asymptomatic, although mild pruritus may be present. In scleromyxedema, large parts of the body may be involved; the skin shows erythematous, scleroderma-like induration accompanied by reduced mobility of the lips, hands, arms, and legs (Fig. 187-2). Other skin lesions include urticaria, nodules, and cysts. Although the disease primarily affects the skin, systemic manifestations such as severe proximal myopathy, inflammatory polyarthritis, central nervous system symptoms resembling acute organic brain syndrome, esophageal aperistalsis, and hoarseness have been described. [7], [8] Ophthalmic findings consist of corneal opacities, lagophthalmos, ectropion, choroidal folds, and papilledema. [9] Recently, papular mucinosis was found in association with AIDS, but without a monoclonal gammopathy. [10]

FIGURE 187-1 Papular mucinosis. Note discrete papules on the forehead and longitudinal folding of the glabella. (*Courtesy of L. Shapiro, MD.*)

FIGURE 187-2 Scleromyxedema. Diffuse skin induration and erythema involving the chest, arms, and dorsum of hands.

LABORATORY FINDINGS

Paraproteinemia, usually an IgG with lambda light chains, is present in most patients, particularly in those with the clinical form of scleromyxedema. Immunofluorescence microscopy of the skin lesions occasionally shows deposits of IgG with or without IgM in the papillary and upper reticular dermis. Other inconsistent findings include an elevated sedimentation rate, leukocytosis with eosinophilia, albuminuria, and plasma cell aggregates in the bone marrow.

PATHOLOGY

The most striking changes are in the upper dermis, which shows a horizontal band of mucinous material between collagen bundles. This material is a glycosaminoglycan that stains with Alcian blue at pH 2.5 and is susceptible to hyaluronidase digestion (Fig. 187-3). The epidermis may appear thinner due to pressure from the mucinosis deposits. There is an increase in the number of fibroblasts, which appear plump and stellate, and dermal fibrosis. Cellular infiltrates may be present around the small blood vessels and appendages and consist mostly of lymphocytes with some histiocytic types and polymorphonuclear cells. An increase in the number of plasma cells has also been noted. Electron microscopy reveals fibroblasts with long cytoplasmic processes and dilated rough endoplasmic reticulum. In addition, there are numerous thin collagen fibrils, suggestive of young collagen. Muscle biopsies reveal an atypical necrotizing myopathy with fiber necrosis, severe type II fiber atrophy, and vacuolization. Mucin deposits have also been reported in the adventitia of blood vessels in kidney, heart, adrenal glands, pancreas, and kidney papillae. Papular mucinosis has to be differentiated histologically from follicular mucinosis, amyloidosis, hyalinosis cutis et mucosae, scleredema, scleroderma, cutaneous focal mucinosis, pretibial myxedema, and colloid degeneration.

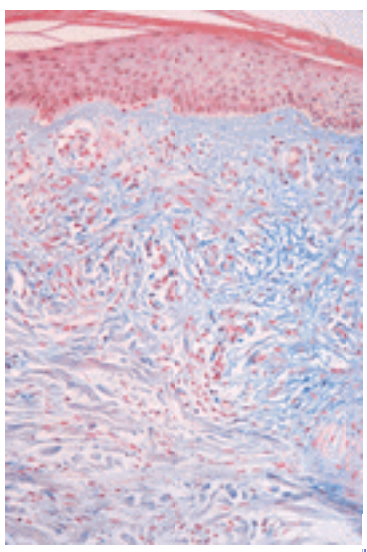

FIGURE 187-3 Scleromyxedema. Mucin and numerous plump fibroblasts in the upper dermis. Alcian blue, pH 2.5. (*Courtesy of L. Shapiro, MD.*)

DIAGNOSIS AND DIFFERENTIAL DIAGNOSIS

Diagnosis is based on the presence of papular lesions, the demonstration of mucin in the dermis, and the presence of paraproteinemia. Clinically, papular mucinosis should be differentiated from scleredema, scleroderma, amyloidosis, disseminated granuloma annulare, malignant lymphomas, and dermatomyositis. The more localized forms should be differentiated from colloid degeneration, lichen planus, and epithelioma adenoides cysticum.

TREATMENT

The treatment of papular mucinosis remains unsatisfactory. Topical therapy is of no help. Because the disease is rare, controlled therapeutic trials are not available. Complete clearance of lesions was reported with melphalan (1 to 10 mg/day). However, the long-term use of melphalan was associated with death from hematologic malignancy and sepsis. [11] Improvement was also noted with cyclophosphamide (200 mg/day) alone or in combination with prednisone. Glucocorticoids are particularly effective for the treatment of myopathy. Electron-beam therapy may improve skin involvement in scleromyxedema. [12] Beneficial effects were also noted with high-dose intravenous immunoglobulin (2g/kg per month). [13] More recently, cyclosporine (4 mg/kg per day) [14] and extracorporeal photopheresis [15] were found effective in scleromyxedema. Isolated reports claimed benefits from isotretinoin, plasmapheresis, chlorambucil, PUVA, interferon-a, and 2-chlorodeoxyadenosine.

COURSE AND PROGNOSIS

The disease runs a chronic course and usually has no tendency toward spontaneous resolution. The prognosis is poor, particularly in patients with diffuse disease with internal involvement. Reported causes of death appear to be unrelated to the disease and include tuberculosis, pneumonia, and vascular thrombosis.

REFERENCES

1. Gottron HA: Skleromyxodem (Eine eigenartige Erscheinungsform von Myxothesaurodermie). *Arch Dermatol Syphilol* **199**:71, 1954

2. Osserman EF, Takatsuki K: Role of an abnormal myeloma-type, serum gamma globulin in the pathogenesis of the skin lesions of papular mucinosis (lichen myxedematosus). *J Clin Invest* **42**:962, 1963

3. McCarthy JT et al: An abnormal serum globulin in lichen myxedematosus. *Arch Dermatol* **89**:446, 1964

4. Kitamura W et al: Immunochemical analysis of the monoclonal paraprotein in scleromyxedema. *J Invest Dermatol* **70**:305, 1978

5. Clark BJ et al: Papular mucinosis: Is the inflammatory cell infiltrate neoplastic? The presence of a monotypic plasma cell population demonstrated by in situ hybridization. *Br J Dermatol* **135**:467, 1996

6. Harper RA, Rispler J: Lichen myxedematosus serum stimulates human skin fibroblast proliferation. *Science* **188**:545, 1978

7. Taylor AL, Owen ET: Scleromyxoedema associated with synovitis and myopathy. *Br J Dermatol* **33**:872, 1994

8. Webster GF et al: The association of potentially lethal neurologic syndromes with scleromyxedema. *J Am Acad Dermatol* **28**:105, 1993

9. Davis MI et al: Ophthalmic findings in scleromyxedema. *Ophthalmology* **101**:252, 1994

10. Yen A et al: Papular mucinosis associated with AIDS: Response to isotretinoin. *J Am Acad Dermatol* **37**:127, 1997

11. Dinneen AM, Dicken CH: Scleromyxedema. *J Am Acad Dermatol* **33**:37, 1995

12. Koeppel MC et al: Electron-beam therapy in Arndt-Gottrom's scleromyxedema. *Br J Dermatol* **129**:733, 1993

13. Lister RK et al: Scleromyxedema: Response to high-dose intravenous immunoglobulin (hdIVIg). *J Am Acad Dermatol* **43**:403, 2000

14. Bata-Csorgo Z et al: Scleromyxedema. *J Am Acad Dermatol* **41**:343, 1999

15. Krasagakis K et al: Remission of scleromyxedema with extracorporeal photopheresis. *Br J Dermatol* **135**:463, 1996

T>

Chapter 188

Rudolf Happle

Neurocutaneous Diseases

GENERAL CONSIDERATIONS
AUTOSOMAL DOMINANT PHENOTYPES
NEVOID BASAL CELL CARCINOMA SYNDROME
LEOPARD SYNDROME
PIEBALD TRAIT WITH NEUROLOGIC DEFECTS
WAARDENBURG SYNDROME
NOONAN SYNDROME (CARDIOFACIOCUTANEOUS SYNDROME)
OSLER-WEBER-RENDU DISEASE (HEREDITARY HEMORRHAGIC TELANGIECTASIA)
VARIEGATE PORPHYRIA
KID SYNDROME
HID SYNDROME (HYSTRIX-LIKE ICHTHYOSIS WITH DEAFNESS)
VERBOV-SHARLAND SYNDROME (PALMOPLANTAR KERATODERMA WITH NEUROSENSORY DEAFNESS)
PREAXIAL ANONYCHIA WITH NEUROLOGIC DEFECTS
AUTOSOMAL RECESSIVE PHENOTYPES
MULTIPLE SULFATASE DEFICIENCY
STEIJLEN SYNDROME
BJØRNSTAD SYNDROME
SHAPIRA SYNDROME
ELEJALDE SYNDROME
CROSS SYNDROME
XERODERMA PIGMENTOSUM
COCKAYNE SYNDROME
ACRODERMATITIS ACIDEMICA
HARTNUP DISEASE
TANGIER DISEASE
CHIME SYNDROME
DE BARSY SYNDROME
X-LINKED MALE-LETHAL PHENOTYPES
FOCAL DERMAL HYPOPLASIA (GOLTZ SYNDROME)
INCONTINENTIA PIGMENTI
CHILD SYNDROME
MIDAS SYNDROME
OFD I SYNDROME (ORAL-FACIAL-DIGITAL SYNDROME)
X-LINKED NONLETHAL PHENOTYPES
PARTINGTON SYNDROME II
MENKES DISEASE
BULLOUS DYSTROPHY OF THE MENDES DA COSTA TYPE
ALBINISM-DEAFNESS SYNDROME
KALLMANN SYNDROME
LESCH-NYHAN SYNDROME
ADRENOLEUKODYSTROPHY
LETHAL AUTOSOMAL MUTATIONS SURVIVING BY MOSAICISM
STURGE-WEBER-KLIPPEL-TRENAUNAY SYNDROME
VAN LOHUIZEN SYNDROME (CUTIS MARMORATA TELANGIECTATICA CONGENITA)
ENCEPHALOCRANIOCUTANEOUS LIPOMATOSIS
DELLEMAN SYNDROME
SCHIMMELPENNING SYNDROME
SPECKLED LENTIGINOUS NEVUS SYNDROME
PHACOMATOSIS PIGMENTOKERATOTICA
NEVUS COMEDONICUS SYNDROME
PROTEUS SYNDROME
NEUROCUTANEOUS MELANOSIS
PIGMENTARY MOSAICISM OF THE ITO TYPE
PHYLLOID HYPOMELANOSIS
PALLISTER-KILLIAN SYNDROME
CHROMOSOMAL DISORDERS
ULLRICH-TURNER SYNDROME
KLINEFELTER SYNDROME
TRISOMY 21
PHENOTYPES STILL UNCLASSIFIABLE ACCORDING TO FORMAL GENETICS
BRACHMANN–DE LANGE SYNDROME
SATOYOSHI SYNDROME
NICOLAIDES-BARAITSER SYNDROME
JOHNSTON SYNDROME

REFERENCES

GENERAL CONSIDERATIONS

Neurocutaneous disease can be defined in various ways. A rather broad definition would include all diseases that may show both cutaneous and neurologic lesions. For the purpose of this chapter, however, a more strict definition will be applied. Neurocutaneous diseases in this context are genetically determined disorders showing both cutaneous and neurologic involvement. This definition includes both hereditary and nonhereditary phenotypes but excludes acquired disorders.

Progress in molecular genetics supports the view that neurocutaneous diseases can be reasonably classified according to formal genetics. [1] Either they follow the established Mendelian modes of inheritance, or they represent lethal mutations surviving by mosaicism, or they belong to the group of chromosomal disorders. Clinically similar disorders may follow different modes of Mendelian inheritance, but this does not constitute a major problem.

The group of neurocutaneous phenotypes that can be explained by a lethal mutation surviving in a mosaic state contains some disorders that have been classified in the past as autosomal dominant traits showing low penetrance or variable expressivity. Today, their sporadic occurrence can be explained reasonably. [2] Some of these disorders, however, may exceptionally affect several members of a family, and for this phenomenon, the concept of paradominant inheritance has been proposed (see below). [2] Chromosomal disorders showing both neurologic and cutaneous involvement are Turner syndrome and trisomy 21.

Some clinicians still use “phacomatosis” to categorize particular neurocutaneous diseases characterized by patchy lesions involving the skin and the nervous system. Unfortunately, this term has diminished rather than increased our understanding of these disorders because the group of phacomatoses has never been well defined. Today, this term should no longer be used for the classification of neurocutaneous diseases but may be applied, together with a specifying adjective, to some genetically determined diseases characterized by the presence of multiple nevi, such as phacomatosis pigmentovascularis.

AUTOSOMAL DOMINANT PHENOTYPES

A list of autosomal dominant neurocutaneous traits is presented in Table 188-1. Some of these phenotypes are presented in detail in separate chapters of this book, e.g., neurofibromatosis 1 and 2 in Chap. 190 and tuberous sclerosis in Chap. 189

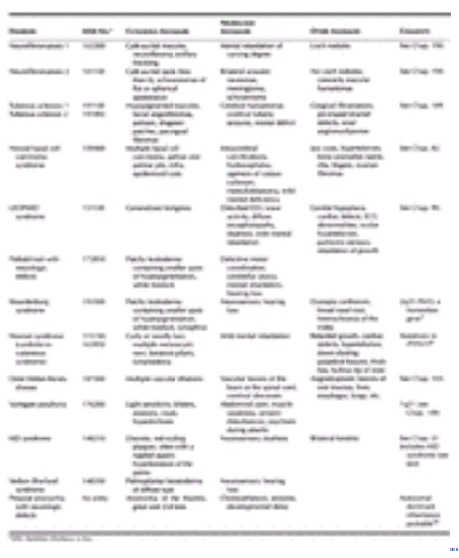

TABLE 188-1 **Neurocutaneous Syndromes: Autosomal Dominant Phenotypes**

NEVOID BASAL CELL CARCINOMA SYNDROME

This disorder is described in Chap. 82. The major CNS anomalies observed in this syndrome are presented in Table 188-1. In my experience, a remarkable neurologic feature observed in many patients with nevoid basal cell carcinoma syndrome is their good-natured, easy friendliness, or bonhomie. This good-naturedness should not be taken as a sign of mental deficiency. On the other hand, mental deficiency has been reported in about 3 percent of patients; it probably occurs more frequently in a mild form. [3]

LEOPARD SYNDROME

This syndrome also has been called *multiplel entigines syndrome* or *cardiomyopathic lentiginosis,* but the term *LEOPARD syndrome* has been firmly entrenched in the clinicians' language. The acronym was coined by Gorlin et al. [3] and stands for *l*entiginosis, *e*lectrocardiographic conduction abnormalities, *o*cular hypertelorism, *p*ulmonic stenosis, *a*bnormal genitalia, *r*etardation of growth, and sensorineural *d*eafness. Patients usually have a characteristic facial appearance with a triangular shape due to frontal bossing, hypertelorism, and low-set ears. The underlying autosomal dominant gene has a high penetrance, but the expression may vary to a large degree, often resulting in rather mild involvement or incomplete phenotypes. The typical lentigines usually develop in childhood, and their number increases with age (Fig. 188-1). In contrast to ordinary freckles, the number of melanocytes is definitely increased. Most patients tend to remain below average for height and weight. Encephalographic examination may show a disturbed wave activity. In some patients, mild mental retardation is present, but intellectual capacity may be completely normal in this syndrome.

FIGURE 188-1 Multiple lentigines as a feature of LEOPARD syndrome.

PIEBALD TRAIT WITH NEUROLOGIC DEFECTS

A piebald trait, consisting of unpigmented areas of skin showing smaller spots of hyperpigmentation in combination with a white forelock, has been described by Telfer et al. [4] in two families showing an autosomal dominant mode of transmission. Affected family members showed, in addition, defective motor coordination, cerebellar ataxia, and mental retardation of varying degree. Moreover, several affected family members suffered from hearing loss. Apparently, this association of anomalies is extremely rare, and this raises the question of whether these families were affected with a contiguous gene syndrome. In this way, the unusual co-occurrence of anomalies could be explained as a defect involving two neighboring genes.

WAARDENBURG SYNDROME

This phenotype has been mapped to 2q37.3. The mutation involves the *PAX3* gene, a homeobox gene that has been highly conserved during phylogenesis. [5] Various allelic mutations have been described.

NOONAN SYNDROME (CARDIOFACIOCUTANEOUS SYNDROME)

In the past, Noonan syndrome and cardiofaciocutaneous syndrome have been considered to represent different entities, but when the signs and symptoms of the two phenotypes are compared, it appears difficult to find any rhyme or reason to distinguish the disorders. [6], [7] Therefore, the two designations are considered synonyms. Noonan syndrome includes retarded growth and congenital cardiac defects and a peculiar facial appearance showing ptosis, hypertelorism, down-slanting palpebral fissures, thick lips, and low-set ears (Fig. 188-2). The nose shows a bullous tip. Characteristically, the scalp hair becomes more curly or woolly during childhood and adolescence. The skin may show many small melanocytic nevi, and keratosis pilaris is likewise noted frequently. Another cutaneous abnormality associated with this syndrome is lymphedema resulting from hypoplasia or aplasia of lymphatic vessels. The most common heart defects are pulmonic stenosis and atrial septal defect. Mild mental retardation is often noted, but the syndrome also may be associated with normal intelligence. The disorder is caused by mutations in *PTPN11.* [8]

FIGURE 188-2 Noonan syndrome: peculiar facies showing hypertelorism, low-set ears, thick lips, and curly hair.

OSLER-WEBER-RENDU DISEASE (HEREDITARY HEMORRHAGIC TELANGIECTASIA)

This disorder is described in Chap. 103.

VARIEGATE PORPHYRIA

For a detailed description of this disorder, the reader is referred to Chap. 149. Due to a founder effect, variegate porphyria is particularly frequent in South Africa. The high prevalence of variegate porphyria in Finland can be explained by a similar founder effect. Affected individuals may suffer from neuropathic features such as abdominal pain, muscle weakness, or sensory disturbances. During attacks, they may be disoriented or even frankly psychotic. These attacks are

often triggered by medication. Several patients homozygous for the underlying gene defect have been described. They tend to develop severe neurologic symptoms with seizures and mental deficiency.

KID SYNDROME

This phenotype is described in Chap. 51.

HID SYNDROME (HYSTRIX-LIKE ICHTHYOSIS WITH DEAFNESS)

In 1989, Traupe [9] proposed the term *HID syndrome* for a phenotype characterized by hystrix-like ichthyosis associated with bilateral neurosensory deafness (Fig. 188-3). Similar cases were published earlier under the designation “ichthyosis hystrix gravior, type Rheydt.” Today, however, molecular analysis has shown that HID and KID syndromes are associated with the same connexin 26 mutation. [10] Hence, the two disorders are identical.

FIGURE 188-3 “HID syndrome” (hystrix-like ichthyosis with deafness) has recently been found to be identical with KID syndrome. [10]

VERBOV-SHARLAND SYNDROME (PALMOPLANTAR KERATODERMA WITH NEUROSENSORY DEAFNESS)

Verbov [11] and Sharland et al. [12] described families with diffuse palmoplantar keratoderma and bilateral, progressive, high-frequency sensorineural hearing loss occurring in several consecutive generations. Molecular studies have so far not been performed in these families. [13]

PREAXIAL ANONYCHIA WITH NEUROLOGIC DEFECTS

Lynch et al. [14] described a syndrome of anonychia involving the thumbs as well as the first and the second toes combined with neurologic defects in a family showing vertical transmission of the trait.

AUTOSOMAL RECESSIVE PHENOTYPES

A list of autosomal recessive neurocutaneous traits is given in Table 188-2. For a more detailed description of the various ichthyoses associated with neurologic anomalies, such as neutral lipid storage disease, Refsum disease, Sjögren-Larsson syndrome (Fig. 188-4), as well as Tay syndrome and Amish brittle hair syndrome (IBIDS syndrome), the reader is referred to Chap. 51.

TABLE 188-2 **Neurocutaneous Syndromes: Autosomal Recessive Phenotypes**

FIGURE 188-4 Sjögren-Larsson syndrome: characteristic rippled appearance of hyperkeratotic skin. (*Courtesy of Peter*

M. Steijlen, MD, Maastricht, The Netherlands.)

MULTIPLE SULFATASE DEFICIENCY

Multiple sulfatase deficiency is a neurodegenerative disorder that usually leads to death in early childhood. The disorder is caused by a mutation that results in enhanced degradation of various sulfatases. [15] Despite some clinical similarities, the disease can be separated from metachromatic leukodystrophy on the basis of different metabolic features. Psychomotor retardation usually becomes manifest during the second year of life. A child that has already learned to walk begins to show an unsteady gait and needs help to stand upright; simultaneously, speech begins to deteriorate. In the final stage, the children are blind and unable to eat or drink. Microscopic examination of biopsies obtained from peripheral nerves shows metachromatic degeneration of myelin. Affected children usually die before their tenth year. The disease is associated with mild ichthyosis resulting from steroid sulfatase deficiency. It is usually less severe than observed in classic X-linked recessive ichthyosis. This difference may be explained by a residual activity of steroid sulfatases. [16]

STEIJLEN SYNDROME

A syndrome consisting of congenital atrichia (Fig. 188-5), transgredient palmar and plantar keratoderma (Fig. 188-6), early loss of teeth, and severe mental retardation was observed by Steijlen et al. [17] The disease occurred in four siblings. The mother had had five miscarriages. Autosomal recessive inheritance is most likely.

FIGURE 188-5 Microcephaly as a feature of Steijlen syndrome (atrichia, palmoplantar keratoderma, and mental retardation).

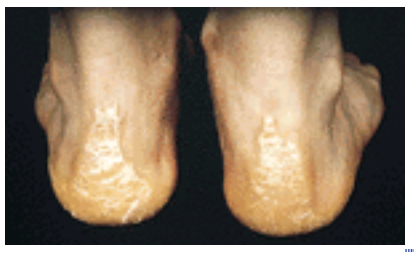

FIGURE 188-6 Steijlen syndrome: plantar keratoderma extending to the heels.

BJØRNSTAD SYNDROME

BjØrnstad syndrome is an autosomal recessive disorder characterized by pili torti and nerve deafness. [18]

SHAPIRA SYNDROME

Shapira et al. [19] described a syndrome consisting of sparse, brittle, and light-colored scalp hair; developmental delay; short stature; and mild to moderate neurologic abnormalities. Further clinical observations may show whether this combination of features represents a new entity.

ELEJALDE SYNDROME

Elejalde syndrome is a phenotype belonging to the group of silvery hair syndromes (Fig. 188-7). The disease should be distinguished from Chediak-Higashi syndrome and Griscelli syndrome. [20] Elejalde syndrome, which also has been called *neuroectodermal melanolysosomal disease,* is characterized by frequent occurrence of fatal neurologic alterations. Psychomotor impairment is a constant feature and may be observed in the newborn or during infancy. In contrast to Chediak-Higashi syndrome, microscopic examination of hair shafts shows an irregular distribution of abnormally small or large clumps of melanin (Fig. 188-8). Neuromuscular alterations consist of hypotonia, hemiplegia, quadriplegia, ataxia, and mental retardation that is usually of a severe degree.

FIGURE 188-7 Elejalde syndrome: bronzed skin and silvery hair.

FIGURE 188-8 Elejalde syndrome: hair shafts show irregular distribution of melanin clumps.

CROSS SYNDROME

This phenotype belongs likewise to the silvery hair syndromes. [20] It is characterized by generalized hypopigmentation, ocular anomalies, and neurologic defects such as mental and physical retardation, ataxia, and spasticity. [21]

XERODERMA PIGMENTOSUM

Several types of xeroderma pigmentosum are associated with neurologic abnormalities (see Chap. 155). In the past, the term *De Sanctis-Cacchione syndrome* has been used to designate this association, but this term should no longer be used because neurologic defects are not characteristic of a particular complementation group. [22] However, groups A and D appear to be especially prone to neurologic involvement. [23]

COCKAYNE SYNDROME

This disorder is described in Chap. 155.

ACRODERMATITIS ACIDEMICA

Some enzyme defects such as methylmalonic acidemia or propionic acidemia are characterized by lethargy, failure to thrive, vomiting, dehydration, dyspnea, and hypotonia. The affected infants often die in coma. These metabolic defects are often associated with cutaneous features reminiscent of acrodermatitis enteropathica, [24] and therefore, the term *acrodermatitis acidemica* has been proposed. [25] Sharply demarcated erythemas with desquamation are usually observed in a periorificial localization. [26] The scalp hair is sparse, brittle, and hypopigmented.

HARTNUP DISEASE

Hartnup disease is a metabolic disorder characterized by a transportation defect involving certain amino acids (see Chap. 147). Affected children show photosensitivity resulting in skin changes reminiscent of pellagra and progressive cerebellar ataxia.

TANGIER DISEASE

The disease is caused by *ABCA1* mutations involving cholesterol and apolipoprotein B metabolism that result in xanthomatosis of various tissues and recurrent neuropathy. [27] The disorder is named after Tangier Island in the Chesapeake Bay, where affected individuals are descendants from a small founder population. The skin may show xanthomatous papules resulting from abnormal deposition of cholesterol esters.

CHIME SYNDROME

The term *CHIME* is an acronym for colobomas of the eye, heart defects, ichthyosiform dermatosis, mental retardation, and ear defects. [28] The condition is characterized by a congenital, migratory, ichthyosiform dermatosis, hyperkeratotic palms and soles, and sparse, fine hair.

DE BARSY SYNDROME

This phenotype is characterized by growth retardation, progeroid facial appearance with pronounced nasolabial folds, and diminished subcutaneous tissue resulting in wrinkling, large dysplastic ears, corneal opacities, cataracts, hypermobility of joints, and mental retardation. [29] Microcephaly is often present.

X-LINKED MALE-LETHAL PHENOTYPES

Some X-linked neurocutaneous disorders occur almost exclusively in girls because the underlying genes exert a lethal effect on male embryos [31] (Table 188-3). In female embryos, the Lyon effect of X-inactivation accounts for survival. Exceptionally, however, male patients may be observed, and this can be explained either by a gonosome constitution XXY, by an early postzygotic mutation, or by a gametic half-chromatid mutation. [2]



TABLE 188-3 **Neurocutaneous Syndromes: X-linked Male-Lethal Phenotypes**

FOCAL DERMAL HYPOPLASIA (GOLTZ SYNDROME)

The main features include widespread lesions of dermal hypoplasia with herniation of adipose tissue, streaks of pigmentary disturbance following the lines of Blaschko, and severe absence deformities of bones. [32] Some patients may show mental retardation, which is usually mild, and others may suffer from hearing loss. The spectrum of ocular anomalies includes defects of the optic nerve.

INCONTINENTIA PIGMENTI

Incontinentia pigmenti is caused by *NEMO* mutations. [33] During the first months of life, linear lesions showing inflammation and blistering occur and apparently reflect a selection against the functionally defective cell clone. [34] The blisters are filled with eosinophils. Later on, these lesions are replaced by hyperkeratotic verrucous areas, whereas in the older child a linear or patchy pattern of hyperpigmentation is found (Fig. 188-9). In women, a fourth stage in the form of linear hypopigmentation involves the lower legs predominantly. The disorder is associated with ocular defects such as coloboma, retinal detachment, strabismus, cataracts, optic atrophy, and corneal opacities. Dental abnormalities include absence of deciduous or permanent teeth and crown deformities. Involvement of the CNS occurs rather frequently, but it appears impossible to present the incidence in terms of percentages because all case reports and reviews contain a considerable bias of ascertainment. Neurologic abnormalities comprise psychomotor etardation, microcephaly, seizures, spasticity, and cerebellar ataxia. The great variability of these phenotypic associations can be explained by the Lyon effect of random X-inactivation. [2] Morphologic evidence of functional X-chromosome mosaicism involving the brain has been provided. [35]

FIGURE 188-9 Incontinentia pigmenti: linear arrangement of hyperpigmented skin lesions.

CHILD SYNDROME

The term *CHILD* is an acronym for congenital hemidysplasia with ichthyosiform nevus and limb defects [36] (see Chap. 51). (The term *ichthyosiform erythroderma* is misleading and should no longer be used.) The disorder is caused by mutations of *NSDHL,* a gene involved in cholesterol metabolism. [37] The phenotype is characterized by a unique inflammatory nevus that has been called *CHILD nevus*. [38] Usually this nevus shows a striking lateralization with a sharp midline demarcation (Fig. 188-10). However, a streaky arrangement following the lines of Blaschko also may be present. Ipsilateral limb defects may vary from mild hypoplasia of one finger or toe to complete absence of an arm or leg. The nails are often replaced by keratotic, clawlike material. Ipsilateral CNS abnormalities include hypoplasia of a hemisphere or hypoplasia of cranial nerves or the spinal cord; there may be reduced sensation to touch and heat on the affected side. However, in most of these girls the mental development is completely normal. Apparently, the unaffected hemisphere can take over

all the necessary functions. In one case, mild intellectual impairment was reported. [39]

FIGURE 188-10 CHILD syndrome: CHILD nevus showing striking lateralization and ipsilateral limb defects.

MIDAS SYNDROME

The term *MIDAS* is an acronym that stands for microphthalmia, dermal aplasia, and sclerocornea. [40] All the associated defects reflect functional X-chromosome mosaicism. Microphthalmia is usually bilateral, but unilateral involvement also has been reported. Dermal aplasia typically involves the face (Fig. 188-11), the scalp, and the neck, but other body areas also may be affected. In contrast to focal dermal hypoplasia, these lesions never show herniation of the underlying fatty tissue. In some of the affected girls, neurologic defects such as focal dysplasia of the brain with absence of the septum pellucidum, microcephaly, or agenesis of the corpus callosum have been reported. However, the latter also may result from a deletion that involves a neighboring gene, producing a contiguous gene syndrome that includes Aicardi's syndrome in addition to the MIDAS syndrome. [41]

FIGURE 188-11 MIDAS syndrome: microphthalmia and dermal aplasia showing linear arrangement.

OFD I SYNDROME (ORAL-FACIAL-DIGITAL SYNDROME)

This syndrome is caused by *CXORF5* mutations at Xp22.3-p22.2. [42] It includes midfacial clefting defects, lobulation of the tongue, hypoplasia of the nose, syndactyly, brachydactyly, clinodactyly, and circumscribed hairlessness that visualizes the lines of Blaschko on the scalp. [31] The upper lip is short, and the nasal root is broad. During infancy, many milia may be present on the cheeks or the ears. Typical oral manifestations are large hyperplastic fibrous bands traversing the mucobuccal fold. Many of the affected girls show mild mental retardation. Neurologic examination of the brain may reveal porencephaly, partial agenesis of the corpus callosum, or hydrocephalus.

X-LINKED NONLETHAL PHENOTYPES

In this group of disorders, women are usually more mildly affected because of the Lyon effect of X-inactivation (Table 188-4). Remarkably, however, several X-linked genes located at different regions of the X chromosome escape inactivation, and one example may be the gene for bullous dystrophy of Mendes da Costa. [43]

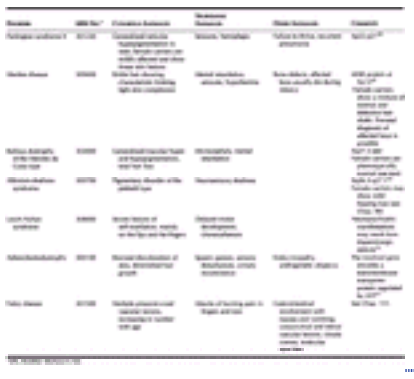

TABLE 188-4 **Neurocutaneous Syndromes: X-Linked Nonlethal Phenotypes**

PARTINGTON SYNDROME II

This syndrome is characterized by generalized reticulate hyperpigmentation, failure to thrive, recurrent pneumonia, seizures, and hemiplegia. [44] Female gene carriers are only mildly affected and show a patchy or linear pattern of hyperpigmentation.

MENKES DISEASE (See Chap. 71)

The disorder includes sparse, brittle hair showing characteristic kinking, mental retardation, seizures, hypothermia, and bone defects. The disease is caused by a defect of copper transport. [45] Affected boys usually die during infancy. Due to the Lyon effect of X-inactivation, female gene carriers show a mixture of normal and defective hair shafts and may be otherwise affected. [46], [47] There is a murine homologue of Menkes disease. [48]

BULLOUS DYSTROPHY OF THE MENDES DA COSTA TYPE

Affected boys show macular hyperpigmentation and depigmentation, total hair loss, microcephaly, and mental retardation. [49] Women heterozygous for this X-linked mutation are phenotypically normal. For this reason, it has been assumed that the underlying gene escapes X-inactivation. [43]

ALBINISM-DEAFNESS SYNDROME

This X-linked form of albinism represents a pigmentary disorder of the piebald type in combination with a profound deafness that results in deaf-mutism. [50] A less severe hearing impairment has been found in female carriers. [51]

KALLMANN SYNDROME

Kallmann syndrome is characterized by anosmia due to agenesis of the olfactory lobes and hypogonadotropic hypogonadism. [53] The underlying gene defect does not involve the skin. However, several patients affected with Kallmann syndrome display a contiguous gene syndrome that involves several neighboring gene loci, including that of steroid sulfatase. [54] Consequently, these patients are also affected with X-linked recessive ichthyosis.

LESCH-NYHAN SYNDROME

This phenotype is caused by a deficiency of hypoxanthine-guanine phosphoribosyl-transferase. [55] During the first months of life, neurologic anomalies such as delayed motor development and choreoathetosis become manifest. Affected boys usually show severe self-mutilation. The lips and fingers are involved most frequently. [56]

ADRENOLEUKODYSTROPHY

Adrenoleukodystrophy is a peroxisomal disorder characterized by progressive demyelination and adrenocortical insufficiency. [57] Affected male individuals show increased levels of long-chain fatty acids. Clinical symptoms include spastic paresis, sensory disturbances, urinary incontinence, and endocrinopathy. The cutaneous features consist of a bronzed discoloration of the skin and diminished hair growth. [58]

LETHAL AUTOSOMAL MUTATIONS SURVIVING BY MOSAICISM

Some autosomal mutations, when present in a zygote, cause early death of the embryo (Table 188-5). Cells carrying the mutation can survive only in a mosaic state, in close proximity with normal cells. [59] Such mosaics usually result from an early postzygotic mutation. The following neurocutaneous phenotypes can be best explained by this concept.

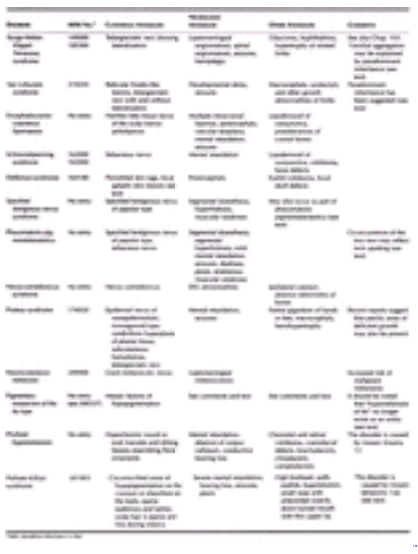

TABLE 188-5 **Neurocutaneous Syndromes: Lethal Autosomal Mutations Surviving by Mosaicism**

STURGE-WEBER-KLIPPEL-TRENAUNAY SYNDROME

According to conventional rules of classification, the Sturge-Weber syndrome and the Klippel-Trenaunay syndrome are separate entities, but from a genetic point of view, it is obvious that they are caused by the same gene defect. [59] For a detailed description of the Sturge-Weber phenotype, which is characterized by lateral telangiectatic nevi of the face (Fig. 188-12), see Chap. 103. Bilateral involvement occurs rather frequently. [60] Klippel-Trenaunay syndrome differs with regard to the location of the lesions and is characterized by lateral telangiectatic nevi associated with hypertrophy of related bones and soft tissues of one or several limbs. Again, bilateral involvement is observed frequently, and a combination of Sturge-Weber and Klippel-Trenaunay syndrome has sometimes been described.

FIGURE 188-12 Sturge-Weber-Klippel-Trenaunay syndrome. (*Courtesy of Jean Maleville, MD, Bordeaux, France*.)

Remarkably, this syndrome exceptionally may show a familial aggregation. [61], [62] To explain this phenomenon, paradominant inheritance has been proposed. [63] Heterozygous individuals would be phenotypically normal, and the trait would be expressed only when loss of heterozygosity occurs at an early stage of embryogenesis, giving rise to a mosaic population of cells that have become either homozygous or hemizygous for the underlying mutation. [64]

VAN LOHUIZEN SYNDROME (CUTIS MARMORATA TELANGIECTATICA CONGENITA)

The disease is characterized by reticular vascular lesions resulting in a bluish-red, livedo-like network that may involve large parts of the body. Extracutaneous symptoms comprise macrocephaly, seizures, and developmental delay, as well as growth anomalies of the limbs. [65] Vascular nevi similar to those observed in Sturge-Weber-Klippel-Trenaunay syndrome likewise may be present but, remarkably, do not always show lateralization. Most cases so far observed were sporadic, and for this reason they may originate from a lethal mutation surviving by mosaicism. Exceptional familial cases may be explained by paradominant inheritance. [65]

ENCEPHALOCRANIOCUTANEOUS LIPOMATOSIS

This syndrome includes an extensive fatty tissue nevus of the scalp, protuberances of the cranial bones, lipodermoid of the conjunctiva, multiple intracranial lipomas, and porencephaly. [66] It has been proposed that the associated fatty tissue nevus of the scalp should be distinguished from other connective tissue nevi such as the Hoffmann-Zurhelle nevus. [67] Involvement of the CNS may include vascular dysplasia, mental retardation, and epileptic seizures. All cases so far reported have been sporadic. [66]

DELLEMAN SYNDROME

This phenotype includes orbital cysts, porencephaly, skull defects, eyelid coloboma, and multiple skin tags that are usually arranged in the periorbital region; in addition, there are widespread aplastic skin lesions that never show herniation of the fatty tissue, as observed in focal dermal hypoplasia. [68] All these lesions suggest a mosaic arrangement, and all observations are sporadic. [59]

SCHIMMELPENNING SYNDROME

This syndrome is characterized by the presence of a systematized sebaceous nevus associated with various cerebral defects causing mental retardation and seizures, ocular anomalies including conjunctival lipodermoids or colobomas, and bone defects. [59], [69] The combination of these mosaic anomalies may vary to a large degree. There are two reports suggesting familial occurrence of this syndrome. If the clinical diagnosis was correct in these cases, they can be explained either by a coincidence or by paradominant inheritance. [64]

SPECKLED LENTIGINOUS NEVUS SYNDROME

This distinct neurocutaneous phenotype is characterized by a speckled lentiginous nevus that may be either unilateral or bilateral in association with hyperhidrosis, muscular weakness, dysesthesia, or other neurologic abnormalities. [70] The extracutaneous defects are usually ipsilateral. The disorder is most likely a paradominant trait.

PHACOMATOSIS PIGMENTOKERATOTICA

This disorder is defined by the co-occurrence of a speckled lentiginous nevus of a papular type and an epidermal nevus of a nonepidermolytic, organoid type, usually in the form of sebaceous nevus (Fig. 188-13). The coexistence of the two cutaneous lesions has been explained as a twin-spot phenomenon. [71] Associated neurologic defects include segmental dysesthesia, segmental hyperhidrosis, mild mental retardation, seizures, deafness, ptosis, strabismus, and muscular weakness of varying degrees. [72] Most likely this phenotype represents a combination of Schimmelpenning syndrome and speckled lentiginous nevus syndrome.

FIGURE 188-13 Systematized speckled lentiginous nevus in a woman who had, in addition, a large sebaceous nevus involving the scalp and the neck, in the form of phacomatosis pigmentokeratotica. Note asymmetric posture due to shortening of the left leg.

NEVUS COMEDONICUS SYNDROME

This syndrome is characterized by a nevus comedonicus in combination with ipsilateral cataract and skeletal defects. [69] In addition, electroencephalographic abnormalities and dysgenesis of the corpus callosum have been reported. [59], [73]

PROTEUS SYNDROME

This phenotype includes partial gigantism of hands or feet and other forms of hemihypertrophy, including macrocephaly; multiple subcutaneous hamartomas such as lymphangioma, hemangioma, lipoma, or fibroma; cerebriform hyperplasia of plantar connective tissue; and a linear epidermal nevus of the nonepidermolytic, nonorganoid type [74] (Fig. 188-14). Because of the marked variability of all these defects, the disorder was named after the Greek god Proteus, who was said to be able to change his outward appearance in many ways. Paradoxically, patchy areas of deficient growth have been observed in many cases. [75] Intelligence may be normal, but there is an increased incidence of mental retardation, seizures, or sensorineural hearing loss. [3], [76]

FIGURE 188-14 Proteus syndrome.

NEUROCUTANEOUS MELANOSIS

Neurocutaneous melanosis is characterized by giant melanocytic nevus in combination with leptomeningeal melanocytosis. The giant cutaneous lesion may be associated with widespread small congenital melanocytic nevi. The risk of malignant melanoma developing from either cutaneous or cerebral lesions is markedly increased. [77] Because all cases are sporadic, mosaicism of a lethal gene has been suggested. [59]

PIGMENTARY MOSAICISM OF THE ITO TYPE

Previously, such phenotypes visualizing the lines of Blaschko often were described under the designation *hypomelanosis of Ito,* but it is important to realize that this is an outdated term that does not refer to any specific neurocutaneous syndrome. [78] On the contrary, it simply describes a cutaneous symptom as observed in many different states of genetic mosaicism that may or may not involve, in addition, extracutaneous organs such as the brain or eyes. The associated neurologic anomalies vary to a large degree. Because virtually all cases are sporadic, they most likely represent mosaicism of a lethal mutation that may be a numerical chromosome aberration, a deletion, or a point mutation. Cytogenetic or molecular analysis to find one of the underlying defects is advisable.

PHYLLOID HYPOMELANOSIS

In contrast to hypomelanosis of Ito, phylloid hypomelanosis is a well-defined clinicogenetic entity that is usually caused by mosaic trisomy 13. [79] The hallmark is a pattern of hypopigmented, round or oval lesions reminiscent of the floral ornaments of art nouveau painting (Fig. 188-15). The term *phylloid* is derived from Greek *phyllon,* meaning “leaf.” The patients show CNS defects with mental retardation, absence of corpus callosum, and conductive hearing loss. In addition, choroidal and retinal coloboma, craniofacial defects, brachydactyly, clinodactyly, camptodactyly, and other osseous anomalies may be present.

FIGURE 188-15 Phylloid hypomelanosis in a 13-year-old girl with mosaic trisomy 13. (*Courtesy of Dr. Denise Horn, Berlin, Germany*.)

PALLISTER-KILLIAN SYNDROME

This disorder is caused by mosaic tetrasomy for the short arm of chromosome 12 (isochromosome 12p syndrome). [80], [81] From a heuristic point of view, the disease can be taken as a specific entity within the spectrum of so-called hypomelanosis of Ito. Clinical features are postnatal growth deficiency and severe mental retardation and a characteristic facial appearance with a high forehead, sparse eyebrows and lashes, puffy eyelids, ptosis, hypertelorism, hypoplastic nose with anteverted nostrils, and a down-turned mouth with a thin upper lip. During infancy, the hair is markedly sparse and fine, but later on, hair growth becomes normal. Circumscribed hypopigmented areas are often present on the cranium and sometimes elsewhere on the body. Apparently, these hypopigmented lesions do not follow the lines of Blaschko.

CHROMOSOMAL DISORDERS

Some phenotypes characterized by numerical chromosome aberrations are associated with characteristic cutaneous features (Table 188-6).

TABLE 188-6 **Neurocutaneous Syndromes: Disorders Caused by Numerical Chromosome Aberrations**

ULLRICH-TURNER SYNDROME

This syndrome was described in 1930 by Ullrich [82] and in 1938 by Turner. [83] The chromosome constitution 45,X results in a female phenotype with short stature, sexual infantilism, webbed neck, and various other anomalies. Remarkably, the intelligence deficit present in this syndrome does not refer to all brain functions. In general, affected women have a handicap in visual-spatial orientation and perceptual organization, whereas language skills are normal. Newborn girls may show marked lymphedema of the feet with hypoplastic toenails. Affected women show large numbers of melanocytic

nevi.

KLINEFELTER SYNDROME

The clinical features of Klinefelter syndrome result from the chromosome constitution 47,XXY. Affected men are relatively tall, and characteristically, the arm span exceeds the height. The testes are small, and gynecomastia is often present in adult individuals. Mental development is only mildly retarded. Typical cutaneous features are varicose veins and hypostatic leg ulcers. [84]

TRISOMY 21

Trisomy 21 is a well-known syndrome that will not be described in detail in this chapter. Rather, the cutaneous signs and symptoms observed in this phenotype will be mentioned. A more or less widespread ichthyosiform hyperkeratosis is often observed in adults. [85] Other typical features are elastosis perforans serpiginosa and milia-like calcinosis cutis. [86] Syringomas occur far more frequently than in the general population. [87] Moreover, individuals with trisomy show a markedly increased proneness to alopecia areata. [88]

PHENOTYPES STILL UNCLASSIFIABLE ACCORDING TO FORMAL GENETICS

Some neurocutaneous disorders are obviously genetically determined but so far cannot be categorized according to formal genetics (Table 188-7).



TABLE 188-7 **Neurocutaneous Syndromes: Disorders Still Unclassifiable According to Formal Genetics**

BRACHMANN–DE LANGE SYNDROME

This phenotype is characterized by low birth weight, delayed growth, and mental retardation. Affected children have a typical facial appearance with microcephaly, low frontal hair line, synophrys (meeting of the eyebrows across the midline), hypoplastic nose with anteverted nostrils, and protruding philtrum. [89] Absence deformities of hands or feet may be noted. As a characteristic cutaneous feature, pronounced hypertrichosis may be found in many areas of the body. Additional cutaneous anomalies include cutis marmorata, hypoplastic nipples, hypoplastic umbilicus, and simian crease of the palm. The genetic basis of this syndrome so far has not been fully elucidated. [90] Discordant monozygotic twins have been described. [91]

SATOYOSHI SYNDROME

Satoyoshi syndrome is of interest for the dermatologist because this genetically determined disorder is associated with early onset of alopecia areata [92] (see Table 188-7).

NICOLAIDES-BARAITSER SYNDROME

This syndrome includes mental retardation, sparse hair, prominent lower lip, and brachydactyly. [93] Further clinical research should show whether the concept of a new syndrome holds true.

JOHNSTON SYNDROME

Hyperkeratotic skin changes reminiscent of collodion baby were observed by Johnston et al. [94] in two brothers suffering from severe arthrogryposis. The two boys died shortly after birth. Autopsy performed on one of them showed severe hypoplasia of the posterior columns. The syndrome is most likely inherited as either a monogenic autosomal or an X-linked recessive trait.

REFERENCES

1. OMIM: Online Mendelian Inheritance in Man; available at http://www.ncbi.nlm.nih.gov/omim/ .

2. Happle R: Mosaicism in human skin: Understanding the patterns and mechanisms. *Arch Dermatol* **129**:1460, 1993

3. Gorlin RJ et al: *Syndromes of the Head and Neck,* 4th ed. New York, Oxford University Press, 2001

4. Telfer MA et al: Dominant piebald trait (white forelock and leukoderma) with neurological impairment. *Am J Hum Genet* **23**:383, 1971

5. Asher JH Jr et al: Effects of *Pax3* modifier genes on craniofacial morphology, pigmentation, and variability: A murine model of Waardenburg syndrome variation. *Genomics* **34**:285, 1996

6. Leichtman LG: Are cardiofaciocutaneous syndrome and Noonan syndrome distinct? A case of CFC offspring of a mother with Noonan syndrome. *Clin Dysmorphol* **5**:61, 1996

7. Wieczorek D et al: Cardiofaciocutaneous (CFC) syndrome: A distinct entity? Report of three patients demonstrating the diagnostic difficulties in delineation of CFC syndrome. *Clin Genet* **52**:37, 1997

8. Tartaglia M et al: Mutations in *PTPN11,* encoding the protein tyrosine phosphatase SHP-2, cause Noonan syndrome. *Nature Genet* **29**:465, 2001

9. Traupe H: *The Ichthyoses: A Guide to Clinical Diagnosis, Genetic Counseling, and Therapy.* Berlin, Springer, 1989

10. Van Geel M et al: HID and KID syndromes are associated with the same connexin 26 mutation. *Br J Dermatol* **146**:938, 2002

11. Verbov J: Palmoplantar keratoderma, deafness and atopy. *Br J Dermatol* **116**:881, 1987

12. Sharland M et al: Autosomal dominant palmoplantar hyperkeratosis and sensorineural deafness in three generations. *J Med Genet* **29**:50, 1992

13. Fitzgerald DA, Verbov J: Hereditary palmoplantar keratoderma with deafness. *Br J Dermatol* **134**:939, 1996

14. Lynch SA et al: Absent nails, kinesogenic choreoathetosis, epilepsy and developmental delay: A new autosomal dominant disorder? *Clin Dysmorphol* **6**:133, 1997

15. Schmidt B et al: A novel amino acid modification in sulfatases that is defective in multiple sulfatase deficiency. *Cell* **82**:271, 1995

16. Castaño–Suárez E et al: Ichthyosis: The skin manifestation of multiple sulfatase deficiency. *Pediatr Dermatol* **14**:369, 1997

17. Steijlen PM et al: Congenital atrichia, palmoplantar hyperkeratosis, mental retardation, and early loss of teeth in four siblings: A new syndrome? *J Am Acad Dermatol* **30**:893, 1994

18. Selvaag E: Pili torti and sensorineural hearing loss: A follow-up of Børnstad's original patients and a review of the literature. *Eur J Dermatol* **10**:91, 2000

19. Shapira SK et al: Unknown syndrome in sibs: Pili torti, growth delay, developmental delay, and mild neurological abnormalities. *J Med Genet* **29**:509, 1992

20. Duran-McKinster C et al: Elejalde syndrome: A melanolysosomal neurocutaneous syndrome. Clinical and morphological findings in 7 patients. *Arch Dermatol* **135**:182, 1999

21. Tezcan I et al: A new case of oculocerebral hypopigmentation syndrome (Cross syndrome) with additional findings. *Clin Genet* **51**:118, 1997

22. Greenhaw GA et al: Xeroderma pigmentosum and Cockayne syndrome: Overlapping clinical and biochemical phenotypes. *Am J Hum Genet* **50**:677, 1992

23. Kanda T et al: Peripheral neuropathy in xeroderma pigmentosum. *Brain* **113**:1025, 1990

24. Koopman RJJ, Happle R: Cutaneous manifestations of methylmalonic acidemia. *Arch Dermatol Res* **282**:272, 1990

25. Happle R: Neurocutaneous syndromes, in *Fitzpatrick's Dermatology in General Medicine,* edited by IM Freedberg, AZ Eisen, K Wolff, KF Austen, LA Goldsmith, SI Katz, TB Fitzpatrick, 5th ed. New York, McGraw-Hill, 1999, p 2131

26. Niiyama S et al: Acrodermatitis acidemica secondary to malnutrition in glutaric aciduria type I. *Eur J Dermatol* **11**:244; 2001

27. Schaefer EJ et al: Cholesterol and apolipoprotein B metabolism in Tangier disease. *Atherosclerosis* **159**:231; 2001

28. Shashi V et al: Neuroectodermal (CHIME) syndrome: An additional case with long-term follow-up of all reported cases. *J Med Genet* **32**:465, 1995

29. Karnes PS et al: De Barsy syndrome: Report of a case, literature review, and elastin gene expression studies of the skin. *Am J Med Genet* **42**:29, 1992

30. Winter RM: Dubowitz syndrome. *J Med Genet* **23**:11, 1986

31. Happle R: Lyonization and the lines of Blaschko. *Hum Genet* **70**:200, 1985

32. Bellosta M et al: Focal dermal hypoplasia: Report of a family with 7 affected women in 3 generations. *Eur J Dermatol* **6**:499, 1996

33. The International Incontinentia Pigmenti Consortium: Genomic rearrangement in *NEMO* impairs NF-kappa-B activation and is a cause of incontinentia pigmenti. *Nature* B>405:466; 2000

34. Parrish JE et al: Selection against mutant alleles in blood leukocytes is a consistent feature in incontinentia pigmenti type 2. *Hum Mol Genet* **5**:1777, 1996

35. Rott HD, Koniszewski G: L'analogie des lignes de Blaschko à l'oeil. *J Genet Hum* **35**:19, 1987

36. Happle R: Ptychotropism as a cutaneous feature of the CHILD syndrome. *J Am Acad Dermatol* **23**:763, 1990

37. König A et al: Mutations in the NSDHL gene, encoding a 3ß-hydroxysteroid dehydrogenase, cause CHILD syndrome. *Am J Med Genet* **90**:339;2000

38. Happle R et al: The CHILD nevus: A distinct skin disorder. *Dermatology* **191**:210, 1995

39. Baden HP, Rex IH: Linear ichthyosis associated with skeletal abnormalities. *Arch Dermatol* **102**:126, 1970

40. Happle R et al: MIDAS syndrome (microphthalmia, dermal aplasia and sclerocornea): An X-linked phenotype distinct from Goltz syndrome. *Am J Med Genet* **47**:710, 1993

41. Wapenaar MC et al: The genes for X-linked ocular albinism (*OA1*) and microphthalmia with linear skin defects (*MLS*): Cloning and

characterization of the critical regions. *Hum Mol Genet* **2**:947, 1993

42. Ferrante MI et al: Identification of the gene for oral-facial-digital type I syndrome. *Am J Hum Genet* **68**:569, 2001

43. Happle R: Cutaneous manifestation of X-linked genes escaping inactivation. *Clin Exp Dermatol* **17**:69, 1992

44. Gedeon AK et al: Localization of the gene for X-linked reticulate pigmentary disorder with systemic manifestations (PDR), previously known as X-linked cutaneous amyloidosis. *Am J Med Genet* **52**:75, 1994

45. Francis MJ et al: A Golgi localization signal identified in the Menkes recombinant protein. *Hum Mol Genet* **7**:1245;1998

46. Collie WR et al: Hair in Menkes disease: A comprehensive review, in *Hair, Trace Elements, and Human Illness,* edited by AC Brown, RG Crounse. New York, Praeger, 1980, p 197

47. Gerdes AM et al: Clinical expression of Menkes syndrome in females. *Clin Genet* **38**:452, 1990

48. Grimes A et al: Molecular basis of the brindled mouse mutant (Mo(br)): A murine model of Menkes disease. *Hum Mol Genet* **6**:1037, 1997

49. Lungarotti MS et al: X-linked mental retardation, microcephaly, and growth delay associated with hereditary bullous dystrophy, macular type: Report of a second family. *Am J Med Genet* **51**:598, 1994

50. Zlogotora J: X-linked albinism-deafness syndrome and Waardenburg syndrome type IIa: A hypothesis. *Am J Med Genet* **59**:386, 1995

51. Fried K et al: Hearing impairment in female carriers of the sex-linked syndrome of deafness with albinism. *J Med Genet* **6**:132, 1969

52. Shiloh Y et al: Genetic mapping of X-linked albinism-deafness syndrome (ADFN) to Xq26.3-q27.1. *Am J Hum Genet* **47**:20, 1990

53. Quinton R et al: The neuroradiology of Kallmann's syndrome: A genotypic and phenotypic analysis. *J Clin Endocrinol Metab* **81**:3010, 1996

54. Meindl A et al: Analysis of a terminal Xp22.3 deletion in a patient with six monogenic disorders: Implications for the mapping of X-linked ocular albinism. *J Med Genet* **30**:838, 1993

55. Nyhan WL: The recognition of Lesch-Nyhan syndrome as an inborn error of purine metabolism. *J Inherit Metab Dis* **20**:171, 1997

56. Ernst M et al: Presynaptic dopaminergic deficits in Lesch-Nyhan disease. *N Engl J Med* **334**:1568, 1996

57. Lachtermacher MB et al: Determination of 30 X-linked adrenoleukodystrophy mutations, including 15 not previously described. *Hum Mutat* **15**:348, 2000

58. König A et al: An X-linked gene involved in androgenetic alopecia: A lesson to be learned from adrenoleukodystrophy. *Dermatology* **200**:213, 2000

59. Happle R: Lethal genes surviving by mosaicism: A possible explanation for sporadic birth defects involving the skin. *J Am Acad Dermatol* **16**:899, 1987

60. Sujansky E et al: Outcome of Sturge-Weber syndrome in 52 adults. *Am J Med Genet* **57**:35, 1995

61. Aelvoet GE et al: Genetic aspects of Klippel-Trenaunay syndrome. *Br J Dermatol* **126**:603, 1992

62. Ceballos-Quintal JM et al: A new case of Klippel-Trenaunay-Weber (KTW) syndrome: Evidence of autosomal dominant inheritance. *Am J Med Genet* **63**:426, 1996

63. Happle R: Klippel-Trenaunay syndrome: Is it a paradominant trait? *Br J Dermatol* **128**:465, 1993

64. Happle R: Loss of heterozygosity in human skin. *J Am Acad Dermatol* **41**:143, 1999

65. Danarti R et al: Paradominant inheritance may explain familial occurrence of cuits marmorata telangiectatica congenita. *Dermatology* **203**:208, 2001

66. Happle R, Steijlen PM: Enzephalokraniokutane Lipomatose: Ein nichterblicher Mosaikphänotyp. *Hautarzt* **44**:19, 1993

67. Happle R, Küster W: Nevus psiloliparus: A distinct fatty tissue nevus. *Dermatology* **197**:6, 1998

68. Moog U et al: Oculocerebrocutaneous syndrome: A case report, a follow-up, and differential diagnostic considerations. *Genet Counsel* **7**:257, 1996

69. Happle R: Epidermal nevus syndromes. *Semin Dermatol* **14**:111, 1995

70. Happle R: Speckled lentiginous nevus syndrome: Delineation of a new distinct neurocutaneous phenotype. *Eur J Dermatol* **12**:133, 2002

71. Happle R: Phacomatosis pigmentokeratotica: A melanocytic-epidermal twin nevus syndrome. *Am J Med Genet* **65**:363, 1996

72. Tadini G et al: Phacomatosis pigmentokeratotica: Report of 3 cases and further delineation of the syndrome. *Arch Dermatol* **134**:333, 1998

73. Seo YJ et al: A case of nevus comedonicus syndrome associated with neurologic and skeletal abnormalities. *Int J Dermatol* **40**:648, 2001

74. Clark RD et al: Proteus syndrome: An expanded phenotype. *Am J Med Genet* **27**:99, 1987

75. Happle R: Elattoproteus syndrome: Delineation of an inverse form of Proteus syndrome. *Am J Med Genet* **84**:25, 1999

76. Turner JT et al: Natural history and complications in Proteus syndrome. *Am J Hum Genet* **69**:221, 2001

77. Demirci A et al: MR of parenchymal neurocutaneous melanosis. *Am J Neuroradiol* **16**:606, 1995

78. Küster W, König A: Hypomelanosis of Ito: No entity, but a cutaneous sign of mosaicism. *Am J Med Genet* **85**:346, 1999

79. Happle R: Phylloid hypomelanosis is closely related to mosaic trisomy 13. *Eur J Dermatol* **10**:511, 2000

80. Cormier-Daire V et al: Prezygotic origin of the isochromosome 12p in Pallister-Killian syndrome. *Am J Med Genet* **69**:166, 1997

81. Schubert R et al: Report of two new cases of Pallister-Killian syndrome confirmed by FISH: Tissue-specific mosaicism and loss of i(12p) by in vitro selection. *Am J Med Genet* **72**:106, 1997

82. Ullrich O: Über typische Kombinationsbilder multipler Abartungen. *Z Kinderheilk* **49**:271, 1930

83. Turner HH: A syndrome of infantilism, congenital webbed neck and cubitus valgus. *Endocrinology* **23**:566, 1938

84. Spier C et al: Recurrent leg ulcerations as the initial clinical manifestation of Klinefelter's syndrome. *Arch Dermatol* **131**:230, 1995

85. Wentscher U, Happle R: Ichthyosiform hyperkeratosis as a characteristic feature of trisomy 21. *Eur J Dermatol* **5**:417, 1995

86. Schepis C et al: Milia-like idiopathic calcinosis cutis: An unusual dermatosis associated with Down syndrome. *Br J Dermatol* **134**:143, 1996

87. Schepis C et al: Perforating milia-like idiopathic calcinosis cutis and periorbital syringomas in a girl with Down syndrome. *Pediatr Dermatol* **11**:258, 1994

88. Carter DM, Jegasothy BV: Alopecia areata and Down syndrome. *Arch Dermatol* **112**:1397, 1976

89. Jackson L et al: De Lange syndrome: A clinical review of 310 individuals. *Am J Med Genet* **47**:940, 1993

90. Krantz ID et al: Exclusion of linkage to the *CDL1* gene region on chromosome 3q26.3 in some familial cases of Cornelia de Lange syndrome. *Am J Med Genet* **101**:120, 2001

91. Carakushansky G et al: Identical twin discordance for the Brachmann–de Lange syndrome revisited. *Am J Med Genet* **63**:458, 1996

92. Wisuthsarewong W et al: Satoyoshi syndrome. *Pediatr Dermatol* **18**:406, 2001

93. Krajewska-Walasek M et al: Another patient with an unusual syndrome of mental retardation and sparse hair? *Clin Dysmorphol* **5**:183, 1996

94. Johnston K et al: Joint contractures, hyperkeratosis, and severe hypoplasia of the posterior columns: A new recessive syndrome. *Am J Med Genet* **47**:246, 1993

T>

Chapter 189

Amy Paller Lowell Goldsmith

Tuberous Sclerosis Complex

HISTORY
EPIDEMIOLOGY
ETIOLOGY AND PATHOGENESIS
CLINICAL MANIFESTATIONS
SKIN LESIONS
NONCUTANEOUS MANIFESTATIONS
SKIN PATHOLOGY
BRAIN AND EYE PATHOLOGY
DIAGNOSIS AND DIFFERENTIAL DIAGNOSIS
TREATMENT
COURSE AND PROGNOSIS24

REFERENCES

Tuberous sclerosis complex (TSC) is an autosomal dominant disease attributable to mutations in one of two different genes. Lesions occur predominantly in the skin, nervous system, heart, and kidney. The most commonly recognized clinical manifestations are ash-leaf hypopigmented macules, adenoma sebaceum, seizures, and mental retardation. [1], [2]

HISTORY

Although Virchow recognized scleromas of the cerebrum in the 1860s, and von Recklinghausen found a similar case with multiple myomata of the heart in 1862, Bourneville's articles, appearing between 1880 and 1900, presented the first systematic account of the disease and related the cerebral and skin lesions. Vogt, in 1908, delineated the classic triad of adenoma sebaceum, epilepsy, and mental retardation. [2]

EPIDEMIOLOGY

The prevalence of the disease is estimated to be approximately 3 to 10 per 100,000. [3], [4] There is no difference in frequency among whites, blacks, and Asians; both sexes are affected equally, although some symptoms are more predominant in women. Heredity is evident in approximately one-third of cases; the remaining cases are attributed to a de novo mutation. Prevalence data drawn from surveys of mental hospital populations probably magnified the overall incidence of mental retardation in this disorder. There is no increase in paternal age in patients with new mutations. There are several instances of mutations limited to the germ-line in parents with multiple affected children and no clinical evidence of parental disease. [5]

ETIOLOGY AND PATHOGENESIS

Mutations in two genes— *TSC1* and *TSC2*—each account for about half the cases of tuberous sclerosis. No third gene has been linked to the disease. *Tuberous sclerosis complex 1 (TSC1)* maps to 9q34, is a 8.6-kb gene and encodes hamartin, a 130-kDa protein, which is a tumor suppressor with a nuclear localization signal and a cdc2 kinase site. [6], [7]

The *TSC2* gene maps to 16p13.3 and codes for tuberin, a 1784-amino-acid protein, which has homology to a GTPase-accelerating protein (GAP) and has intrinsic GTPase activity. It colocalizes with Rap1 (a GTPase member of the Ras superfamily of GTP-binding proteins) in the Golgi apparatus. [8] Inhibition of *TSC2* expression upregulates cyclin; thus tuberin participates in regulating entrance into the S phase of the cell cycle from G1 or G0. *TSC2* mutations include deletions, insertions, missense duplications, and tandem repeats. There are no mutational hot spots in the GTPase-activating protein-related domain. [9]

Subependymal giant cell astrocytomas and angiomyolipomas associated with TSC show loss of heterozygosity in the 16p13 region, supporting a two-hit cancer-suppressor model for the pathogenesis of those tumors and for the role of *TSC2* as a tumor-suppressor gene. [10] Transgenic mice with a disrupted *TSC2* allele develop tumors in multiple sites.

CLINICAL MANIFESTATIONS

The disease may be present at birth, but not recognized. Careful examination often will reveal hypopigmented macules. Focal or generalized seizures with or without developmental delay is often the first sign of the disease. Adenoma sebaceum appears later in childhood, usually between the fourth and tenth years. [2]

SKIN LESIONS

In approximately 87 percent of the patients with tuberous sclerosis, congenital hypomelanotic macules are present (Fig. 189-1). Three hypopigmented macules are highly suspicious for the diagnosis TSC; 4.7 percent of the general population has at least one such lesion. These data and the relative incidence of tuberous sclerosis suggest that one macule per se should not prompt an extensive evaluation to rule out tuberous sclerosis. [11] Hypopigmented macules may be segmental or confetti-like on the extremities. [12] In some patients with multiple endocrine neoplasia type I, confetti-like

hypopigmented macules occur on the trunk.

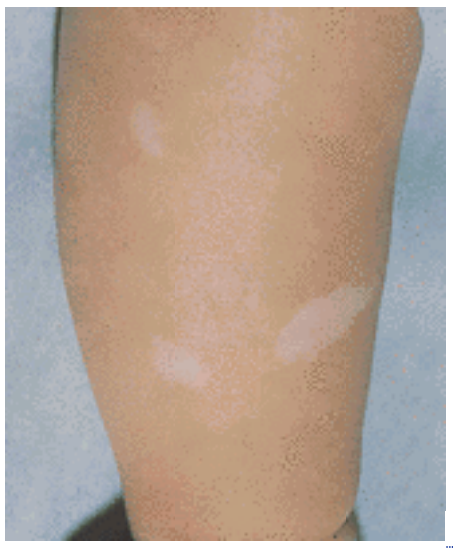

FIGURE 189-1 Hypomelanotic ash-leaf macules on the lower leg in a child with the tuberous sclerosis complex.

The contrast between normal skin and the hypopigmented macule(s) is accentuated by the Wood lamp, which may be essential when examining the skin of lightly pigmented subjects. [13] The average lesion is 1 to 3 cm in diameter with 89 percent greater than 1 cm. Individual lesions may range from 4 mm to 12 cm; large segmental lesions may occur. The lesions are often lance-ovate in shape and resemble the utline of the Eastern mountain ash leaf, hence “ash-leaf spots.” The margins are discrete and the color is not the pure white of vitiligo. Confetti lesions (2 to 3 mm), when they occur, are most commonly localized between the knees and the ankles and the wrists and the elbow. Lesions may fade with age, making use of the Wood lamp particularly helpful when trying to ascertain “asymptomatic” carriers.

Facial angiofibromas (often given the misnomer adenoma sebaceum), are diagnostic of tuberous sclerosis, and are present in 96 percent of patients. [14] The earliest manifestation of facial angiofibromatosis may be a mild erythema over cheeks and forehead, which is intensified by crying. Typically the angiofibromas are 0.1 to 0.3 mm red to pink papules with a smooth, glistening surface, localized to the nasolabial folds, cheeks, chin, and sometimes the forehead and scalp (Fig. 189-2). Segmental forms of the disease with unilateral distribution of the facial angiofibromas may occur. [15] The differential diagnosis for angiofibroma includes acne vulgaris, acne rosacea, agminated Spitz nevi, multiple trichoepitheliomas, and syringomas. Trichoepitheliomas have a similar centrofacial distribution of papules and nodules, but lack the pink vascular aspect of angiofibromas. Large connective-tissue nevi on the forehead (“fibrous forehead plaque”) represent another diagnostic feature, present in 25 percent of patients and often congenital. They are similar to facial angiofibromas, except for the absence of vascular elements.

FIGURE 189-2 Adenoma sebaceum, the classic facial lesions in the tuberous sclerosis complex. These angiofibromas are typically localized on the cheeks and the nasolabial folds; they are pink or red and have a smooth surface.

A characteristic truncal lesion is the shagreen patch, most often in the lumbosacral region (Fig. 189-3). It is a flat, slightly elevated, flesh-colored plaque with an “elephant hide” or “orange peel” appearance; the shagreen patch may vary in size from less than 1 cm to up to 10 cm in diameter.



FIGURE 189-3 Shagreen patch in tuberous sclerosis. This is a flat, elevated lesion with an orange peel appearance. It corresponds to circumscribed subepidermal fibrosis.

Periungual fibromas (Koenen tumors), most often appearing after puberty, are common (50 percent) in tuberous sclerosis. They may also be subungual (Fig. 189-4). Fibromas in the matrix or nail bed lead to thinning or even destruction of the nail plate. Excision is usually curative. Gingival fibromas also occur, as do fibromas on the palate or lips. Hyperplastic gingival lesions are common if diphenylhydantoin is administered for the associated seizures.

FIGURE 189-4 Koenen tumors in the tuberous sclerosis complex. These peri- and subungual fibromas are characteristic.

NONCUTANEOUS MANIFESTATIONS

Seizures, a reliable index of cerebral lesions, most commonly begin during the first year or two of life in the form of infantile spasms with the characteristic electroencephalographic (EEG) pattern of hypsarrhythmia. Other seizure types may develop with age. The occurrence of seizures and retardation does not parallel that of the skin abnormalities. Fewer than a third of patients have the complete Vogt triad. Although some patients with recurrent seizures retain relatively normal mental function, patients with mental retardation nearly all have seizures. When only a few skin lesions or a retinal phakoma are present, the diagnosis may require additional studies such as renal ultrasound and/or cranial neuroimaging [computed tomography (CT) or magnetic resonance imaging (MRI)]. [16]

Gray or yellow plaques (single or multiple) may be found in the retina (often in or near the optic disk) in about 50 percent of cases. It is from this lesion, called phakoma, that van der Hoeve derived the term *phakomatoses,* which is applied to all neurocutaneous diseases of this class. [2], [16] Benign rhabdomyomas of the heart are common and may be associated with Wolff-Parkinson-White syndrome. Eighty percent of all children presenting with rhabdomyomas have TSC. Most rhabdomyomas regress spontaneously and do not require surgical treatment. [17] Up to 60 percent of patients have renal angiomyolipomas, although symptomatic lesions predominate in women. The lesions present early and are often multiple and bilateral, in contrast to nontuberous sclerosis-associated angiomyolipoma that are seen in older women. Cystic renal disease is seen in association with tuberous sclerosis, more frequently in patients with mutations in *TSC2*. In some cases, this is related to a contiguous gene syndrome because mutations span both the *TSC2* gene and the adjacent polycystic kidney disease gene (*PKD*). [18] Benign tumors have been found in the liver, thyroid, testes, and gastrointestinal tract. Pulmonary lymphangiomyomatosis, a proliferation of smooth muscle cells, is a rare complication of TSC, found predominantly in women, that can occur without other findings of TSC; in these cases, it may represent a form of segmental TSC. [19] Cystic bone lesions in the phalanges are common. [20]

SKIN PATHOLOGY

The skin and nail lesions contain interlacing strands of fibroblasts and dense collagen with numerous ectatic blood vessels. The papillary dermis is absent. The upper dermis in angiofibroma and periungual fibromas contains plump stellate cells (“glial-like”), which are vimentin- and factor XIIIa–positive. Melanophages are often prominent. The shagreen plaque is composed of a relatively avascular, dense, sclerotic mass of bundles of collagen fibers. The hypopigmented macules have decreased numbers of melanocytes, decreased melanosome size, and decreased melanization with fewer stage III and IV melanosomes.

BRAIN AND EYE PATHOLOGY

The brain exhibits a number of diagnostic changes that include cortical tubers, areas of increased firmness on the cortical surface that on cut surface reveal loss of normal gray-white junction. The number and size of cortical tubers correlate with the occurrence of seizures and mental retardation in TSC. Subependymal nodules along the ventricular surface, particularly at the level of the caudate nuclei and close to the foramen of Monro, are the most typical neuropathologic finding in TSC. Subependymal nodules may enlarge and obstruct the outflow of the lateral ventricles with the development of obstructive hydrocephalus. Both cortical tubers and subependymal nodules can calcify over time and be evident on plain skull radiographs.

Retinal phakomas are generally asymptomatic and consists of neuronal and glial elements. Clinically, the translucent forms, in contrast to the calcified forms, need to be distinguished from retinoblastoma.

DIAGNOSIS AND DIFFERENTIAL DIAGNOSIS

When a patient has the triad of retardation, seizures, and the skin abnormalities, the diagnosis is clear. [16] Epilepsy (i.e., infantile spasms) and developmental delay, however, are by no means diagnostic of tuberous sclerosis. In these cases, especially when the family history is unrevealing, a thorough examination of the skin for hypomelanotic macules, adenoma sebaceum, collagenous patches, or subungual or gingival fibromas is rewarding. The hypopigmented macules, as the earliest manifestation of the disease, are most helpful. The history of seizures and/or mental retardation is supportive in the presence of other diagnostic features of tuberous sclerosis. The radiographic demonstration of cortical

tubers and subependymal nodules by either CT or MRI are more specifically diagnostic. [21]

Localized patches of hypopigmentation should lead to the consideration of alternative diagnosis, particularly of nevus depigmentosus, hypomelanosis of Ito, and nevus anemicus. Nevus depigmentosus is usually a single lesion, although it may be large and may assume a dermatomal distribution. Usually located on the trunk or proximal extremities, nevus depigmentosus may be congenital or may first “appear” during the first few years of life as normal pigmentation darkens. The condition is almost never associated with systemic consequences. Hypomelanosis of Ito describes a heterogeneous group of mosaic conditions characterized by hypopigmented to depigmented whorl-like patterns, which tend to follow lines of Blaschko. Systemic abnormalities, especially of bones, eyes, and the central nervous system, may be associated. [22] Careful Wood light exam is essential in these patients. Nevus anemicus results from localized vasoconstriction, and should not redden with rubbing.

TREATMENT

Prenatal counseling should be recommended for a couple when one is affected, given the 50 percent risk for each pregnancy, with the caveat that the clinical phenotype can be quite variable. If the affected individual on molecular testing has a detectable mutation in either *TSC1* or *TSC2,* molecular prenatal testing may be possible. The test, although informative if a fetus is affected, is not prognostic for the severity of possible symptoms. The presence of cardiac rhabdomyomas may be detected by prenatal echocardiography and the pregnancy monitored for fetal cardiac compromise. Complications of these cardiac lesions decrease with time and the lesions usually disappear by sequential echocardiography. Seizure management is important in the eventual intellectual outcome in children who present with early onset seizures. Neurosurgery for seizure control is a consideration in children with a demonstrable dominant electroconvulsive focus whose seizures are intractable to medical management. Shunting of the obstructive hydrocephalus, related to enlarged subependymal giant cell lesions obstructing the outflow of the lateral ventricles, is quite successful, with limited morbidity in centers with experience. The cosmetic appearance of patients can be helped by dermabrasion, electrodesiccation, or laser surgery (CO_2, copper vapor) of their facial lesions, with the knowledge that they will slowly regrow. [23]

COURSE AND PROGNOSIS [24]

The increased morbidity and mortality of patients with TSC relates to the extent of systemic involvement. The cause of mortality varies based on age, with cardiovascular involvement predominant during the first decade of life, followed by brain tumors in the second decade. Mortality related to complications of renal involvement include angiomyolipomas that can be symptomatic if large and the development of renovascular hypertension; decreased renal function, catastrophic hemorrhage and, in a smaller percentage of cases, malignant transformation have been described. Status epilepticus as a source of morbidity remains a significant source of mortality. Complications of pulmonary lymphangiomyomatosis also contribute to the mortality of patients in the fourth decades and beyond.

REFERENCES

1. Gomez M: Neurologic and psychiatric features, in *Tuberous Sclerosis,* 2nd ed, edited by M Gomez. New York, Raven Press, 1988, p 14

2. Butterworth T: Dermatologic aspects of tuberous sclerosis. *Arch Dermatol Syphilol* **43**:1, 1941

3. Sampson JR et al: Genetic aspects of tuberous sclerosis in the west of Scotland. *J Med Genet* **26**:28, 1989

4. Wiederholt WC et al: Incidence and prevalence of tuberous sclerosis in Rochester, Minnesota, 1950 through 1982. *Neurology* **35**:600, 1985

5. Rose VM et al: Germ-line mosaicism in tuberous sclerosis: How common? *Am J Hum Genet* **64**:986, 1999

6. Kwiatkowska J et al: Human XPMC2H: cDNA cloning, mapping to 9q34, genomic structure, and evaluation as TSC1. *Genomics* **44**:350, 1997

7. van Slegtenhorst M et al: Identification of the tuberous sclerosis gene TSC1 on chromosome 9q34. *Science* **277**:805, 1997

8. Soucek T et al: Role of the tuberous sclerosis gene-2 product in cell cycle control. Loss of the tuberous sclerosis gene-2 induces quiescent cells to enter S phase. *J Biol Chem* **272**:29301, 1997

9. Au KS et al: Germ-line mutational analysis of the TSC2 gene in 90 tuberous-sclerosis patients. *Am J Hum Genet* **62**:286, 1998

10. Henske EP et al: Loss of tuberin in both subependymal giant cell astrocytomas and angiomyolipomas supports a two-hit model for the pathogenesis of tuberous sclerosis tumors. *Am J Pathol* **151**:1639, 1997

11. Vanderhooft SL et al: Prevalence of hypopigmented macules in a healthy population. *J Pediatr* **129**:355, 1996

12. Fitzpatrick TB et al: White leaf-shaped macules. Earliest visible sign of tuberous sclerosis. *Arch Dermatol* **98**:1, 1968

13. Reed W: Internal manifestations of tuberous sclerosis. *Arch Dermatol* **87**:715, 1963

14. Gomez MR: Tuberous sclerosis, in *Neurocutaneous Diseases,* edited by MR Gomez. Boston, Butterworths, 1987, p 30

15. McGrae JDJ, Hashimoto K: Unilateral facial angiofibromas—A segmental form of tuberous sclerosis. *Br J Dermatol* **134**:727, 1996

16. Roach ES et al: Tuberous Sclerosis Consensus Conference: Recommendations for diagnostic evaluation. National Tuberous Sclerosis Association. *J Child Neurol* **14**:401, 1999

17. Webb DW et al: Cardiac rhabdomyomas and their association with tuberous sclerosis. *Arch Dis Child* **68**:367, 1993

18. Sampson JR et al: Renal cystic disease in tuberous sclerosis: Role of the polycystic kidney disease 1 gene. *Am J Hum Genet* **61**:843, 1997

19. Smolarek TA et al: Evidence that lymphangiomyomatosis is caused by TSC2 mutations: Chromosome 16p13 loss of heterozygosity in

angiomyolipomas and lymph nodes from women with lymphangiomyomatosis. *Am J Hum Genet* **62**:810, 1998

20. Bernauer T et al: Tuberous sclerosis. Part II. Musculoskeletal and visceral findings. *J Am Acad Dermatol* **45**:450, 2001

21. Caldemeyer K, Mirowski G: Tuberous sclerosis. Part I. Clinical and central nervous system findings. *J Am Acad Dermatol* **45**:448, 2001

22. Nehal KS et al: Analysis of 54 cases of hypopigmentation and hyperpigmentation along the lines of Blaschko. *Arch Dermatol* **132**:1167, 1996

23. Kaufman AJ et al: Treatment of adenoma sebaceum with the copper vapor laser. *J Am Acad Dermatol* **33**:770, 1995

24. Shepherd CW et al: Causes of death in patients with tuberous sclerosis. *Mayo Clin Proc* **66**:792, 1991

T>

Chapter 190

Eniko Pivnick Vincent Riccardi

Neurofibromatoses

NEUROFIBROMATOSIS TYPE 1
Clinical Features
Genetics of NF1
Diagnosis and Management
Related Conditions
NEUROFIBROMATOSIS TYPE 2

REFERENCES

The neurofibromatoses (NF) are a heterogenous set of genetic disorders having clinical manifestations that involve the skin, the nervous system, or both. On clinical grounds, at least two distinct autosomal dominant disorders (with somewhat overlapping features) have been definitively recognized. The most common type of NF is neurofibromatosis type 1 (NF1) (85 percent of patients), which should be distinguished from neurofibromatosis type 2 (NF2) (10 percent of patients). The other 5% have related conditions discussed below. Molecular biology confirms that NF1 and NF2 are genetically distinct: NF1 results from defects in the *NF1* gene on chromosome 17, and NF2 results from a defect in the *NF2* gene on chromosome 22. The nomenclature, definition, and diagnosis of NF1 and NF2 currently are based on the clinical criteria of the NIH Consensus Developmental Conference (Table 190-1). [1]

Neurofibromatosis Type 1
(The diagnostic criteria are met if two or more of the features listed are present)
Six or more café au lait macules over 5 mm in greatest diameter in prepubertal individuals and over 15 mm in greatest diameter in postpubertal individuals
Two or more neurofibromas of any type or one plexiform neurofibroma
Freckling in the axillary or inguinal regions
Optic glioma
Two or more Lisch nodules (iris hamartomas)
A distinctive osseus lesion such as sphenoid dysplasia or thinning of long bone cortex with or without pseudoarthrosis
A first-degree relative (parent, sibling, or offspring) with NF1 by the above criteria
Neurofibromatosis Type 2
(The criteria are met by an individual who satisfies condition 1 or 2)
1. Bilateral masses of the eighth cranial nerve seen with appropriate imaging techniques (e.g., computed tomography or MRI)
or
2. A first-degree relative with NF2 and either:
a. Unilateral mass of the eighth cranial nerve, or
b. Two of the following:
Neurofibroma
Meningioma
Glioma
Schwannoma
Juvenile posterior subcapsular lenticular opacity

SOURCE: From Stumf et al.[1]

TABLE 190-1 **Diagnostic Criteria for Neurofibromatosis Type 1 and Type 2**

NEUROFIBROMATOSIS TYPE 1

NF1 or von Recklinghausen neurofibromatosis is one of the most common autosomal dominant disorders in man, primarily affecting cells of neural crest origin and resulting in developmental, pigmentary, and neoplastic abnormalities. NF1, a distinctive inherited disease, has fascinated physicians and scholars for many centuries. The earliest known model of NF1 appears in the form of a statue, which has been dated to Hellenistic times. [2] Artistic illustrations of individuals presumed to have NF1 have been portrayed in medieval woodcarving, [3] Renaissance drawings, [4] and in the literature of the last century. [5] Tilesius was the first to record the disease in 1793. [6] Von Recklinghausen gave the first organized description of the classic syndrome in 1882. [7] Unfortunately, because of misdiagnosis, NF1 has erroneously earned the reputation of being identical with the “Elephant Man's Disease,” thereby causing enormous stress among the individuals affected with NF1. [8] A posthumous diagnosis of Joseph Merrick, the “Elephant Man,” revealed that he suffered from Proteus syndrome. [9]

NF1 is a dynamic pathologic process with physical manifestations often present at birth and becoming more apparent with age. Although the age at which NF1 is diagnosed is not predictive of the possible serious consequences of the disorder, the age of onset of serious problems means a higher lifetime burden. Early diagnosis of NF1 is important as it provides the opportunity for genetic counseling and education of the patient and family about neurofibromatosis, awareness of the serious consequences of this disorder, appropriate medical follow-up, and early intervention.

Clinical Features

The cardinal features of NF1 are multiple neurofibromas, café au lait spots (CLS), axillary and inguinal freckling, and pigmented iris hamartomas (Lisch nodules). [10] In addition, the disease can be confounded by a broad spectrum of complications, such as various kinds of osseous lesions, stenosis of the renal arteries, aqueduct stenosis, optic glioma, and learning disabilities. Malignant progression of tumors developing in NF1 patients is a major cause of morbidity and mortality. [11]

Skin involvement in NF1 has many more aspects than are often appreciated. Patches of cutaneous pigmentation and multiple cutaneous tumors create the most conspicuous findings. There are two basic types of NF1 hyperpigmentation abnormalities: focal and diffuse. The latter involves virtually all of the skin. [10]

CLS have long been known as part of the syndrome of neurofibromatosis. In fact, the first sign of this condition may be the presence of CLS (Fig. 190-1). In most of the cases, CLS are obvious at birth, although their number and definition tend to increase during the first year of life. Subsequent increases in pigmented macules largely relate to freckling. [10] In older patients with NF1, fading of the CLS may occur. [12] It is important to recognize that a few CLS do not establish the diagnosis of NF1, because approximately 10 percent of the normal population has one to five CLS. [13]

FIGURE 190-1 Multiple café au lait spots distributed over the trunk of an infant.

The CLS of NF1 may occur randomly distributed anywhere on the body except the eyebrows, scalp, palms, and soles. When CLS are limited to a single unilateral segment, other forms of NF should be taken into account, for example, segmental NF. [14]

The café au lait macules vary in size, shape, and hue, but are darker than the normal color of the surrounding skin (Fig. 190-1). The typical CLS are 10 to 30 mm in diameter, ovoid in shape, and of uniform color whose intensity is proportionate to the background skin coloration. The lesions have sharp, well-defined borders that are usually smooth. In some instances in NF1, a CLS alters the appearance of the “Mongolian spot” on which it may be superimposed. [15]

There are a number of disorders other than NF1 in which multiple CLS may occur. These mainly include NF2; Watson syndrome; McCune-Albright syndrome; multiple lentigines syndrome; multiple neuroma syndrome [multiple endocrine neoplasia 2B (MEN2B)]; Bannayan-Riley-Ruvalcaba syndrome; tuberous sclerosis; Maffucci syndrome; and familial multiple café au lait spots (FCLS). Most can be distinguished from NF1 by other clinical features, although this can be difficult in young children. Careful and thorough examination is essential. [16]

The other form of characteristic skin pigmentation in NF1 is axillary freckling. Freckling of the inguinal region and other areas limited to intertriginous zones or sites of skin-to-skin contact also appear to be features unique to NF1. Freckling is usually acquired later in childhood and adulthood. [10] Axillary freckling is found in 81 percent of children with NF1 who are younger than 6 years of age. [17] In some patients with NF1, there may be innumerable freckles over the entire body. [18] The time course and location of freckles suggests that freckling develops by a different mechanism than CLS. [19]

It has been reported that CLS of NF1 patients have more melanocytes than does the surrounding skin. There is also increased activity of the melanocytes, and giant pigment (melanin) granules can be found in the majority of cases. Patients with NF1, compared to normal individuals, also have a higher melanocyte count in their normally pigmented skin. [20] The higher melanin content of NF1 melanocytes is a result of aberrant regulation of melanogenesis. [21] It is unknown, however, how the altered function of neurofibromin (the NF1 gene product) leads to increased melanogenesis in the skin melanocytes of NF1 patients. [22] It should be noted that giant melanin granules are not unique to neurofibromatosis and can be found in conditions such as McCune-Albright syndrome and multiple lentigines syndrome. [18] Consequently, biopsy of the CLS has little or no utility in making the diagnosis of NF1.

In another type of hyperpigmentation in NF1, the edges of the hyperpigmented patch are concordant or extend the borders of an underlying plexiform neurofibroma. These patches are darker than typical CLS. Congenital localized *hypertrichosis* of varying degrees may be present simultaneously. [23] The recognition of an *aberrant hair whorl* pattern overlying a paraspinal neurofibroma or vertebral dysplasias may assist the clinician in early diagnosis of these potentially severe complications of NF1. Scalp *hypotrichosis* or *alopecia* may be seen occasionally in association with tumors of the scalp. [10]

Although *hypopigmentation* is not specific for NF1, it may occur as small punctate macules and local areas of skin hypoplasia, or as *pseudoatrophic macules*. Histopathologic examination of these macules suggests that these macules are variants of neurofibromas. [24]

Individuals with NF1 maintain a velvety quality of the skin even in adulthood. [25] Laxity of the skin often gives the face a prematurely aged appearance. Patients with NF1 often show secondary creases in their fingertip and palmar crease pattern. [26]

Juvenile xanthogranuloma (JXG) is a rare benign cutaneous abnormality that occurs in childhood in 1 percent of young children with NF1. The presence of this lesion should raise the clinician's concern because there may be an excess of juvenile chronic myelogenous leukemia (JCML) occurring in children with JXG and NF1. [27], [28]

Multiple *neurofibromas* are a distinctive feature in patients with NF1. The sometimes impressive number and size of these tumors resulted in the original term *neurofibromatosis*. Neurofibromas virtually always involve the skin. They may

become evident as skin tags or nodules located in cutaneous or subcutaneous tissues, or as subcutaneous masses involving deep tissues. Neurofibromas are benign tumors of nerve sheath origin. They consist of Schwann cells, nerve fibers, fibroblasts, vascular elements, mast cells, and myxoid matrix. [29] There is no histologic difference between the neurofibromas of neurofibromatosis and solitary neurofibromas in persons without the syndrome. Although the tumors are often seen in small numbers in childhood, they tend to appear more extensively around puberty in both sexes and during pregnancy. [17], [30] Areolar neurofibromas occur in 80 percent or more of postpubertal women. [10]

There are four distinct types of neurofibromas. *Cutaneous* neurofibromas move with the skin and are the most common tumors in NF1. These lesions may become apparent as early as 4 or 5 years of age, although their occurrence in the 8- to 12-year-old range is more typical. [31] They are soft, flesh-colored, and not painful tumors that range in size from several millimeters to many centimeters in diameter (Fig. 190-2). They can invaginate into an underlying dermal defect with light digital pressure (button-holing). [13] This feature is a useful sign in distinguishing the lesions of this disease from other surface tumors, for example, multiple lipomas. Their clinical consequences include cosmetically distressing appearance and, in approximately 10 percent of patients, varying degrees of pruritus.

FIGURE 190-2 A large number of neurofibromas (cutaneous, subcutaneous) are scattered over the entire torso of a patient.

Subcutaneous neurofibromas are firm, rubbery, often painful tumors that are deeply seated in the dermis. They may be small (a few millimeters in diameter) or as large as 8 cm (Fig. 190-2). Approximately 20 percent of patients with NF1 have at least one subcutaneous neurofibroma, and approximately 25 percent of these patients will have serious problems as a result.

Nodular plexiform neurofibromas are essentially a network clustering of large subcutaneous neurofibromas. They may be palpated as firm, usually tender, nodules along nerve plexuses or dorsal nerve roots (Fig. 190-3). As a serious consequence of neurofibromas extending through the vertebral foramina, disfigurement of the vertebra, scoliosis, vertebral collapse, and compression of the cord may occur, resulting in severe neurologic deficits. Involvement of the dorsal nerve roots and major nerves may be associated with severe pain and neurologic compromise. [10]

FIGURE 190-3 Right knee of NF1 patient showing a large, diffuse plexiform neurofibroma.

Approximately 5 percent of NF1 patients have *diffuse plexiform* neurofibromas, which are virtually always of congenital origin (though often not immediately visible) and are thought to be the hallmark of this condition (Fig. 190-4). Diffuse plexiform neurofibromas are highly vascular, and may involve all the layers of the skin, the immediately adjacent fascia, and deeper elements, at times even replacing whole sections of muscles, eroding bony structures, and infiltrating visceral elements. Small or modest-sized neurofibromas may actually be contiguous with extensive lesions in the mediastinum or retroperitoneum. [31] A common feature of plexiform neurofibroma is a localized or segmental hypertrophy of adjacent connective tissues including enlargement of the underlying bone. [18] Diffuse plexiform neurofibromas are often associated with overlying hyperpigmentation and hypertrichosis. When these skin changes overlap the neuroaxis, evaluation of spinal involvement is mandatory. [27] Visceral involvement with diffuse plexiform neurofibromas may lead to various complications such as constipation, bleeding, and obstruction. [10]

FIGURE 190-4 The left arm of NF1 patient demonstrates extensive nodular plexiform neurofibroma.

Plexiform neurofibromas tend to infiltrate diffusely the nerve and have an increased risk of progressing to neurofibrosarcoma, also termed *malignant peripheral nerve sheath tumor* (MPNST), in as many as 5 to 6 percent of affected individuals. These tumors are highly malignant and carry a poor prognosis. [11] Such malignant transformation in a known neurofibroma is often heralded by either physical or radiologic evidence of sudden growth or a rapid progression in clinical symptoms (pain and neurologic deficit).

Other tumors that commonly lead to confusion in the differential diagnosis of NF1 are schwannomas, lipomas, and angiolipomas. Multiple schwannomas require the consideration of NF2, regardless of the presence or absence of skin pigmentation abnormalities, although multiple schwannomatosis may be a strong alternative. [32], [33] Multiple lipomas, often associated with other tumors, including central nervous system tumors, are exemplified in Bannayan-Ruvalcaba-Myhre syndrome. This syndrome may be similarly confused with NF1. [34]

There are no specific treatments for neurofibromas. Surgery is palliative, not curative, and multiple procedures are expected due to the progressive nature of these tumors. Surgical removal of these tumors solely for cosmetic reasons is inappropriate and unnecessary. However, there are many reasons for removing neurofibromas, including excessive size, pain, and/or prominent cosmetic disfigurement. This is true for superficial as well as deep tumors, but in the latter case, a diagnostic biopsy may be another consideration because the tumor cannot be visualized or palpated for characterization. [10]

Some of the symptoms associated with these tumors are more bothersome than the tumors themselves. Generalized itching or itching localized to newly developing neurofibromas has been described in the literature. [10] There is a significant increase in mast cells in neurofibromas. Mast cells influence the growth of neurofibromas, because some of their mediators also act as growth factors. [35] One study showed that ketotifen, a mast cell stabilizer, decreased the rate of neurofibroma growth, pruritus, pain, and tenderness. [36] Another interesting observation is that trauma seems to be the initiating or aggravating event in the growth of neurofibromas. [10] It had been shown that in NF1, trauma results in an inadequate repair process during wound healing. Strategies to confound wound healing gone awry are likely to provide the earliest effective treatments of patients with NF1. [37], [38]

Certain ophthalmic manifestations (Lisch nodules, optic glioma, and sphenoid dysplasia) account for three of the six diagnostic criteria of NF1. *Lisch nodules* (Fig. 190-5) (multiple iris melanocytic hamartomas), presenting as small yellow-brown lesions on the surface of the iris, are the most common manifestation and have crucial diagnostic value. Lisch nodules are the only ocular findings that do not cause visual dysfunction. Lisch nodules are useful for confirming or discounting the diagnosis of NF1. They are present in 94 percent of patients who are 6 years of age or older. [39] Recently, it was pointed out that choroidal abnormalities are another commonly occurring ocular complication manifested by choroidal nodules seen under infrared light. [40]

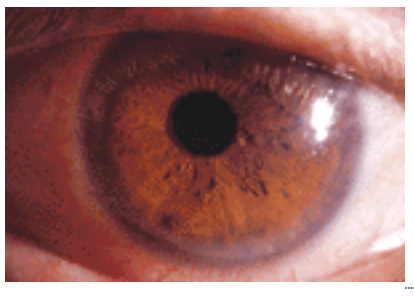

FIGURE 190-5 Lisch nodules in a patient with NF1.

Optic gliomas, a form of astrocytoma, are the most frequent central nervous system (CNS) complications in NF1 during early childhood, with an incidence of 10 to 15 percent. [41] These tumors may arise anywhere along the optic pathway. [42] The natural history of these tumors is not well understood. Two-thirds of these tumors are asymptomatic, and their mitotic activity is low and generally does not undergo malignant progression. A small subgroup of optic gliomas, however, appears with progressive vision loss, and/or proptosis associated with the expanding tumor. Mass lesions of the optic nerve and tract are neither biopsied nor treated unless clinical progression is documented. Optic gliomas are best demonstrated by magnetic resonance imaging (MRI). [43]

Characteristic congenital, and usually unilateral, bony defect in the posterior wall of the orbit is caused by *sphenoid dysplasia* and often results in pulsating exophthalmos. One may mistake this condition for an orbital tumor.

The skeletal system involvement in NF1 is also exemplified by the relative high frequency of macrocephaly and short stature. *Pseudoarthrosis* of long bones (usually the tibia or fibula) is an infrequent but distinctive congenital skeletal abnormality in NF1. [44] Appreciation of its significance should be helpful to the clinician who is faced with a patient who has subtle manifestations of this complex disease. The spectrum of this bony anomaly may range from mild bowing of the tibia to thinning of the cortex, which eventually predispose to pathologic fractures and false joint formation (Fig. 190-6). Early detection of this complication allows early treatment and prevents severe compromise of the affected limb.

FIGURE 190-6 Plain radiographs of the lower extremities of an NF1 patient. Note moderately severe tibial bowing.

Complications of NF1, other than pigmentary or tumor related, include endocrine disturbances and a variety of vasculopathies. Vascular pathology is an underestimated complication of NF1. Manifestations may include cardiovascular abnormalities, renovascular stenosis with associated hypertension, cerebrovascular occlusion, visceral ischemia, and aneurysms of smaller arteries. [45]

In NF1, the incidence of mental retardation (full-scale IQ <70) is estimated to be between 4 and 8 percent. NF1 involves a range of neurophysiologic deficits that are not limited to any one domain. Attention deficit and hyperactivity disorders are as common as impaired neuromotor skills. Cognitive difficulties include expressive and receptive language impairment, reading problems, spelling problems, deficient visual-spatial skills, and executive dysfunction. [46] These prevalent complications are estimated to occur in 30 to 50 percent of affected children. [47] The pathogenesis of learning disabilities in children with NF1 remains obscure. These special deficits may or may not be related to the severity of the clinical manifestations of NF1; therefore, mildly affected NF1 children should also be monitored for learning disabilities and behavioral problems. Care providers should attend to the psychoeducational needs of NF1 patients with the same rigor they impart to serving their physical needs.

A common neuroradiologic abnormality, high-signal abnormalities on T_2-weighted MRI, so-called UBSs (*u*nidentified *b*right *s*ignals), are found in the basal ganglia, cerebellum, and brainstem of more than 60 percent of patients with NF1. [48] These lesions are not visible with computed tomography (CT) scans. The impact of UBSs on measures of cognitive and academic performance is controversial. [49], [50]

There is an increased incidence of specific cancers in approximately 2 to 5 percent of affected NF1 individuals. These include MPNST and Triton tumor (a variant of MPNST), malignant gliomas, and extraneural malignancies such as pheochromocytoma, carcinoid tumors, rhabdomyosarcoma, and juvenile chronic myeloid leukemia. [51], [52] There is no increased incidence of malignant melanoma. Meningiomas, so characteristic of NF2, however, are not seen in NF1. [10]

Genetics of NF1

NF1 exemplifies many of the fundamental principles of classical genetics. It is inherited in an autosomal dominant manner; therefore affected individuals have a 50 percent risk of transmitting the disorder to their offspring. NF1 appears to affect all races, ethnic groups, and both sexes, and has an estimated incidence of 1 in 3000. NF1 has a rate of new mutations of approximately 1 in 10,000, one of the highest described for a human disorder. Approximately half of all index cases of NF1 have no family history of NF1 and are, therefore, thought to arise as a result of mutation in the sperm or egg of the parents. [13] Gene penetrance is virtually 100 percent by the age of 5 years. [53] The pleiotropic and protean manifestations of NF1 affect many different organ systems. Variable expression is observed in inter- and intrafamilial cases, which makes it difficult to predict clinical severity and complications of the disease in offspring of an affected parent. [54]

The *NF1* gene is located on chromosome 17 at band q11.2. [55] There is no locus heterogeneity in NF1. The gene, which is a tumor-suppressor gene, has been cloned and well characterized. Neurofibromin, the protein product of the nonmutated gene, shares sequence and functional homology with the group of Ras-GTPase-activating proteins (Ras-GAP family). Neurofibromin is capable of downregulation of the cellular p21-Ras protooncogene. [56] The loss of neurofibromin function produces increased mitogenic signaling, which may lead to uncontrolled cell growth or tumor formation. [57]

Numerous types of mutation in different parts of the *NF1* gene have been detected to date. There is no indication that the mutations are concentrated in any region of the gene (NF1 Genetic Analysis Consortium). The majority of the mutations within the *NF1* gene give rise to diminished function of neurofibromin in affected persons. No phenotype-genotype correlation has been established, except for cases in which deletion has removed the entire *NF1* gene, thereby resulting in facial dysmorphia, early onset of a large number of neurofibromas, and dull intelligence. [58]

Diagnosis and Management

A definite diagnosis of NF1 is commonly made on clinical grounds, based on NIH diagnostic criteria. Young children who present with six or more CLS, but without other physical findings or family history of NF1, may pose clinical dilemmas. Such children must be followed to look for the appearance of other manifestation of NF1. Most of these children turn out

to have NF1.

No single diagnostic test for *NF1* mutations is sufficient as a “stand-alone test,” and the identification of the majority of *NF1* mutations requires a combination of tests. Routine clinical application of DNA analysis in the diagnosis of NF1 is not yet a reality. Linkage studies using DNA markers in the molecular diagnosis of certain families with NF1 are not possible when there is only one affected individual in the family, as is often the case for NF1. [59] Recently, a new commercially available assay for *NF1* gene mutations has been developed that relies on a protein truncation test (PTT). Conformation of the *NF1* mutation in individuals with abnormal PTT fragments requires direct DNA sequencing. The use of PTT without DNA sequencing risks false-positive results. Also, the ability of the PTT to detect mosaic mutations remains untested. Unfortunately, NF1 exhibits much clinical variability within families, and these tests will tell only if an individual at risk is affected, but not how severely the individual will be affected. [60] Genetic counseling should be provided for anyone who is tested, so that the limitations of the assay are clearly understood. [61] Future research may facilitate improved DNA or biochemical diagnostic testing.

The effect of the complications in NF1 often leads to involvement of a multitude of subspecialists in the care of these patients. It is in the best interest of patients with NF1 to improve the coordination of their care by clinicians who have an expertise with the neurofibromatoses. Because there is no cure for NF1 at the present time, the main goal is the early detection of the various complications, intervention, and genetic counseling (Table 190-2). Routine follow-up is necessary, with the interval of these visits dependent on pertinent medical problems.

TABLE 190-2 **Clinical Features, Their Consequences, and Associated Complications in Neurofibromatosis Type 1 (NF1)**

Related Conditions

Segmental NF should be considered in individuals who have features of neurofibromatosis confined to a particular region of the body. [14] Segmental NF is postulated to arise from a somatic mutation in the NF1 gene early in embryo development. Segmental NF is less common than NF1, and is also more easily overlooked. Patients with segmental NF may have a child with classical NF1 because of germinal mosaicism. [62]

Watson syndrome is a variant of NF1 that features multiple CLS, only a small number of neurofibromas, short stature, pulmonary valvular stenosis, and dull intelligence. Molecular analysis in a few cases of Watson syndrome has shown a large deletion in the NF1 gene. [58]

Certain features *of Noonan syndrome* (characteristic face, pectus excavatum, short stature) have been observed in a subset of patients with NF1. Although it is likely that some features of these two common syndromes may overlap, a recent linkage study of several families showed that NF1 and Noonan syndrome are genetically distinct. [63]

NEUROFIBROMATOSIS TYPE 2

NF2, previously known as central neurofibromatosis or bilateral acoustic neuromas, is characterized by multiple slow-growing nervous system tumors, particularly schwannomas and meningiomas. The hallmark of NF2 is the development of bilateral vestibular schwannomas. NF2 is much less common than NF1, and has an estimated frequency of 1 in 50,000. [32] NF2 is an autosomal dominant disease with penetrance greater than 95 percent, so that for any offspring of an affected parent, the risk that these tumors will develop is approximately 50 percent. [64] In as many as 75 percent of NF2 cases there is no family history of the disease, and these may represent spontaneous mutations. [65] NF2 was once thought to be a form of NF1. [66] NIH Consensus Developmental Conferences (1987), however, provided clear guidelines on nomenclature, and recommended the use of the term neurofibromatosis type 2 (Table 190-1). This document also suggested substitution of the term “vestibular schwannoma” in the place of the term “acoustic neuroma,” so as to reflect the anatomic origin of these tumors. [1] Preliminary evidence suggests that there are two subtypes of NF2: a milder (Gardner) variant, and an intermediate or severe (Whishart) type. [67]

The skin manifestations in NF2 are less prominent than in NF1. Café au lait spots in NF2 tend to be fewer in number and show less distinct hyperpigmentation. Intertriginous freckling is not present. Other skin findings in NF2 include cutaneous and subcutaneous schwannomas. The most common of these is a superficial, discrete, slightly raised papule. The surface of the papule is rough, and is often pigmented and covered by excess hair. [32] Subcutaneous schwannomas are

often spherical tumors that occur on peripheral nerves. The thickened nerve can often be palpated at either end of the tumor. [65] The least-common cutaneous manifestations in NF2 are neurofibromas. Peculiarly, the palm of the hand and the lateral alae nasi are frequent sites of these tumors. Plexiform neurofibromas are distinctly unusual in NF2.

Dorsal nerve root paraspinal schwannomas are a relatively constant feature of NF2. They are the major source of morbidity from direct compromise of the involved nerves and by centripetal growth and compromise of the spinal cord. [68]

Schwannomas may occur on any of the cranial nerves except for the olfactory nerve. [65] Patients with NF2 tend to develop vestibular schwannomas, which are acoustic tumors arising from neural covering. Symptoms related to vestibular schwannomas are usually a result of pressure on the vestibulocochlear and facial nerve complex. In NF2, symptoms usually first begin in the second or third decade. However, occasionally patients may present as early as the first or as late as the seventh decade. [32] The first symptom is usually loss of hearing, which may be accompanied by intermittent tinnitus, unsteadiness, and facial weakness. Other tumors in NF2 include intracranial meningiomas, gliomas, and ependymomas. Spinal cord meningiomas and astrocytomas are common, in contrast to NF1. Meningiomas in NF2 tend to be bilateral and occur at a younger age than their sporadic counterparts. It is of interest that malignancies do not appear to be prevalent in NF2. [68] There is no evidence to suggest that mental function is impaired as a consequence of NF2.

The spectrum of ocular abnormalities of NF2 has only recently received attention. Presenile posterior cortical cataracts are highly specific for NF2. These lens opacities have little visual significance; however, their presence in an individual at risk may give a clue to the diagnosis of NF2. A host of other ocular manifestations, including retinal hamartomas, optic disk glioma, optic nerve meningioma, and eyelid ptosis, can impair the vision of patients with NF2. [69] Lisch nodules are extraordinarily rare in NF2.

The genetic defect that underlies NF2 has been localized to the long arm of chromosome 22, [70] and the gene responsible for NF2 has been cloned and characterized. The gene codes for a protein designated as “merlin” or “schwannomin,” which belongs to a superfamily of membrane organizing proteins. [71] Analysis of tumoral DNA from both NF2-associated and sporadic meningiomas and schwannomas demonstrates chromosome 22 deletions and inactivation of the merlin protein. This strengthens the argument that the *NF2* gene acts as a tumor suppressor. [72] However, the role of merlin in tumor suppression is still obscure. There is some evidence that genotype-phenotype correlation exists for certain *NF2* mutations. [73], [74]

As the course of NF2 is variable, once a patient is diagnosed as having NF2, a number of tests and procedures may be helpful to define the nature and progression of the disease in that individual. These include regular monitoring for CNS tumors (particularly, vestibular schwannoma, meningiomas, and spinal cord tumors) and for related functional impairments (hearing loss, focal neurological signs). MRI of the head and spine is the neurodiagnostic modality of choice in patients with known or suspected NF2. The natural history of NF2 is such that the onset of auditory and visual symptoms is often delayed, not infrequently until childbearing age. [75] Examination of high-risk patients may suggest the diagnosis before symptomatic CNS tumors arise, allowing genetic counseling and family planning.

Early detection of *NF2* gene mutation carriers has become possible by using linkage analysis in familial NF2. [76] For simplex cases, direct gene testing is becoming increasingly available. [77]

Treatment of vestibular schwannomas is aimed at preserving hearing. Presently the only treatments that are available for the tumors of NF2 are surgery and specialized radiation therapy. The timing of surgery is difficult to determine. However, early diagnosis allows for earlier surgical intervention and resection of subclinical vestibular schwannomas.

Multiple schwannomatosis is a disorder characterized by the development of multiple schwannomas in a variety of anatomical locations involving the skin, the spinal cord, or both, in the absence of CLS, neurofibromas, or other stigmata of NF1, and without evidence of vestibular tumor diagnostic of NF2. [78] In addition, various types of multiple schwannomatosis, including *multiple cutaneous plexiform schwannomas,* exist. These tumors have a growth pattern similar to that seen in plexiform neurofibroma, but do not have an association with progression to malignant peripheral nerve sheath tumor.

Recent molecular studies have shown that some forms of multiple schwannomatosis appear to be variant forms of NF2, but not all instances of multiple schwannomas are necessarily NF2. [79]

Familial meningiomas, without other features of NF2, represent yet another distinct entity, with its separate gene locus on the long arm of chromosome 22 (not too distant from the NF2 locus). [80]

REFERENCES

1. Stumf DA et al: NIH Consensus Development Conference: Neurofibromatosis conference statement. *Arch Neurol* **45**:575, 1988

2. Ragge NK, Munier FL: Ancient neurofibromatosis. *Nature* **368**:815, 1994

3. Madigan P, Masello MJ: Report of a neurofibromatosis-like case: Monstrorum Historica, 1642. *Neurofibromatosis* **2**;53, 1988

4. Madigan P, Shaw RV: Neurofibromatosis in thirteenth century Austria. *Neurofibromatosis* **1**:339, 1988

5. Solomon LM: Quasimodo's diagnosis. *JAMA* **204**:190, 1968

6. Tilesius WG cited by Worster-Drought C et al: Multiple meningeal and perineural tumours with analogous changes in the glia and ependyma (neurofibromatosis), with report of two cases. *Brain* **60**:85, 1937

7. von Recklinghausen FD: Ueber die multiplen fibrome der haut und ihre beziehung zu den multiplen neuromen. Festschrift fur Rudolf

Virchow. Berlin, Germany, August Hirschwald, 1882

8. Ablon J: “The Elephant Man” as “self” and “other”: The psycho-social costs of a misdiagnosis. *Soc Sci Med* **40**:1481, 1995

9. Cohen MM Jr: Understanding Proteus syndrome, unmasking the elephant man, and stemming elephant fever. *Neurofibromatosis* **1**:260, 1988

10. Riccardi VM: *Neurofibromatosis: Phenotype, Natural History, and Pathogenesis,* 2nd ed. Baltimore, The Johns Hopkins University Press, 1992

11. Kleihues P et al: *Histological Typing of Tumours of the Central Nervous System*. 2nd ed. Berlin, Springer-Verlag, 1993

12. Huson SM: Recent development in the diagnosis and management of neurofibromatosis. *Arch Dis Child* **64**:745, 1989

13. Crowe FW et al: *A Clinical, Pathological and Genetic Study of Multiple Neurofibromatosis*. Springfield, IL, Charles C. Thomas, 1956

14. Calzavara PG et al: Segmental neurofibromatosis: Case report and review of the literature. *Neurofibromatosis* **1**:318, 1988

15. Niimura M: Life cycle of Recklinghausen's disease. *J Pediatr Dermatol* **12**:146, 1983

16. Korf BR: Diagnostic outcome in children with multiple café au lait spots. *Pediatrics* **90**:924, 1992

17. Obringer AC et al: The diagnosis of neurofibromatosis in the child under the age of 6 years. *Am J Dis Child* **143**:717, 1989

18. Riccardi VM: Von Recklinghausen neurofibromatosis. *N Engl J Med* **305**:1617, 1981

19. Riccardi VM: Cutaneous manifestation of neurofibromatosis: Cellular interaction, pigmentation, and mast cells. *Birth Defects* **17**:129, 1981

20. Johnson BL, Charneco DR: Café au lait spot in neurofibromatosis and in normal individuals. *Arch Dermatol* **102**:442, 1970

21. Suzuki H et al: Activation of the tyrosinase gene promoter by neurofibromin. *Biochem Biophys Res Commun* **205**:1984, 1994

22. Kaufmann D et al: Increased melanogenesis in cultured epidermal melanocytes from patients with neurofibromatosis 1 (NF1). *Hum Genet* **87**:144, 1991

23. Riccardi VM: The pathophysiology of neurofibromatosis. IV. Dermatologic insights into heterogeneity and pathogenesis. *J Am Acad Dermatol* **3**:157, 1980

24. Pique et al: Pseudoatrophic macules: A variant of neurofibroma. *Cutis* **57**:100, 1996

25. Hall BD, Cadle RG: Extremely soft skin and hyperextensible joints in adult male with thousands of neurofibromas. Cause/effect relationship in possible connective tissue aberration. *Annual NNFF Clinical Care Symposium* 10, 1990

26. Vormittag W et al: Dermatoglyphics and creases in patients with neurofibromatosis von Recklinghausen. *Am J Med Genet* **25**:389, 1986

27. Riccardi VM: *Neurofibromatosis. Year Book of Pediatrics. Special Article*. St. Louis, Mosby-Year Book, 1992

28. Zvulunov A et al: Juvenile xanthogranuloma, neurofibromatosis, and juvenile chronic myelogenous leukemia; world statistical analysis. *Arch Dermatol* **131**:904, 1995

29. Harkin JC: Pathology of nerve sheath tumors. *Ann N Y Acad Sci* **486**:147, 1986

30. Jarvis GJ, Crompton AC: Neurofibromatosis and pregnancy. *Br J Obstet Gynaecol* **85**:844, 1978

31. Riccardi VM: Type 1 neurofibromatosis and the pediatric patient. *Curr Probl Pediatr* **22**:66, 1992

32. Martuza RL, Eldridge R: Neurofibromatosis 2 (bilateral acoustic neurofibromatosis). *N Engl J Med* **318**:684, 1988

33. Rongioletti F et al: Multiple cutaneous plexiform schwannomas with tumors of the central nervous system. *Arch Dermatol* **125**:431, 1989

34. Cohen MM Jr: Bannayan-Riley-Ruvalcaba syndrome: Renaming three formerly recognized syndromes as one etiologic entity. *Am J Med Genet* **35**:291, 1990

35. Nurnberger M, Moll I: Semiquantitative aspects of mast cells in normal skin and in neurofibromas of neurofibromatosis types 1 and 5. *Dermatology* **188**:296, 1994

36. Riccardi VM: A controlled multiphase trial of ketotifen to minimize neurofibroma-associated pain and itching. *Arch Dermatol* **129**:577, 1993

37. Atit R et al: The Nf1 tumor suppressor regulates mouse skin wound healing, fibroblast proliferation and collagen deposited by fibroblasts. *J Invest Dermatol* **112**:835, 1999

38. Riccardi VM: The vasculopathy of NF1 and histogenesis control genes. *Clin Genet* **58**:345, 2000

39. Lewis RA, Riccardi VM: Von Recklinghausen neurofibromatosis: Prevalence of iris hamartomas. *Ophthalmology* **88**:348, 1981

40. Yasunari T et al: Frequency of choroideal abnormalities in neurofibromatosis type 1. *Lancet* **356**:988, 2000

41. Lewis RA et al: von Recklinghausen neurofibromatosis. II: Incidence of optic gliomata. *Ophthalmology* **91**:929, 1984

42. Packer RJ et al: Intracranial visual pathway gliomas in children with neurofibromatosis. *Neurofibromatosis* **1**:212, 1988

43. NIH Consensus Conference. Magnetic resonance imaging. *JAMA* **259**:2132, 1988

44. Andersen KS: Congenital pseudoarthrosis of the tibia and neurofibromatosis. *Acta Orthop Scand* **47**:108, 1976

45. Hamilton SJ, Friedman JM: Insight into the pathogenesis of neurofibromatosis 1 vasculopathy. Mini review. *Clin Genet* **58**:341, 2000

46. Ozonoff S: Cognitive impairment in neurofibromatosis type 1. *Am J Med Genet* **89**:45, 1999

47. Riccardi VM: Neurofibromatosis update. *Neurofibromatosis* **2**:284, 1989

48. Duffner PK et al: The significance of MRI abnormalities in children with neurofibromatosis. *Neurology* **39**:373, 1989

49. Ferner RE et al: MRI in neurofibromatosis, the nature and evolution of increased intensity T_2-weighted lesions and their relationship to intellectual impairment. *J Neurol Neurosurg Psychiatry* **56**:492, 1993

50. North K et al: Specific learning disability in children with neurofibromatosis type 1: Significance of MRI abnormalities. *Neurology* **44**:878, 1994

51. Von Deimling A et al: Neurofibromatosis type 1: Pathology, clinical feature and molecular genetics. *Brain Pathol* **5**:153, 1995

52. Shannon KM et al: Loss of the normal NF1 allele from the bone marrow of children with type 1 neurofibromatosis and malignant myeloid disorders. *N Engl J Med* **330**:597, 1994

53. Riccardi VM, Lewis RA: Penetrance of von Recklinghausen neurofibromatosis; Distinction between predecessors and descendants. *Am J Hum Genet* **42**:284, 1988

54. Easton DF et al: An analysis of variation in expression of neurofibromatosis type 1 (NF1): evidence for modifying genes. *Am J Hum Genet* **53**:305, 1993

55. Barker D et al: Gene for von Recklinghausen neurofibromatosis is in the pericentric region of chromosome 17. *Science* **236**:1100, 1987

56. Xu G et al: The neurofibromatosis type 1 gene encodes a protein related to GAP. *Cell* **62**:599, 1990

57. Weiss B et al: Hyperactive Ras as a therapeutic target in neurofibromatosis type 1. *Am J Med Genet* **89**:14, 1999

58. Kayes LM et al: Deletions spanning the neurofibromatosis 1 gene: Identification and phenotype of five patients. *Am J Hum Genet* **54**:424, 1994

59. Ward K et al: Diagnosis of neurofibromatosis 1 by using tightly linked, flanking DNA markers. *Am J Hum Genet* **46**:943, 1989

60. Guttman DH et al: The diagnostic evaluation and multidisciplinary management of neurofibromatosis 1 and neurofibromatosis 2. *JAMA* **278**:51, 1997

61. Heim RA et al: Distribution of 13 truncating mutations in the neurofibromatosis 1 gene. *Hum Mol Genet* **4**:975, 1995

62. Rubinstein AE et al: Familial transmission of segmental neurofibromatosis. *Neurology* **33**(Suppl 2):76, 1983

63. Colley A et al: Neurofibromatosis/Noonan phenotype: A variable feature of type 1 neurofibromatosis. *Clin Genet* **49**:59, 1996

64. Eldridge R: Central neurofibromatosis with bilateral acoustic neuroma. *Adv Neurol* **29**:57, 1981

65. Evans DGR et al: A genetic study of type 2 neurofibromatosis in the United Kingdom: I. Prevalence, mutation rate, fitness, and confirmation of maternal transmission effect on severity. *J Med Genet* **29**:841, 1992

66. Wishart JH: Case of tumours in the skull, dura mater, and brain. *Edinburgh Med Surg J* **18**:393, 1822

67. Huson SM, Thrush DC: Central neurofibromatosis. *Q J Med* **55**:213, 1985

68. Riccardi VM: The neurofibromatoses. *Hematol Oncol Ann* **2**:119, 1994

69. Rettele GA et al: Blindness, deafness, quadriparesis, and a retinal malformation: The ravages of neurofibromatosis 2. *Surv Ophthalmol* **41**:135, 1996

70. Wolff R et al: Analysis of chromosomal deletions in neurofibromatosis type 2-related tumors. *Am J Hum Genet* **51**:478, 1992

71. Trofatter JA et al: A novel moezin-, ezrin-, radixin-like gene is a candidate for the neurofibromatosis 2 tumor suppressor. *Cell* **72**:791, 1993

72. Sanson M: Un nouveau gene supresseur de tumeur responsable de la neurofibromatose de type 2, est altere dans les neuromes et les meningiomes. *Rev Neurol (Paris)* **152**:1, 1996

73. Parry DM et al: Neurofibromatosis 2 (NF2): Clinical characteristics of 63 affected individuals and clinical evidence for heterogeneity. *Am J Med Genet* **52**:450, 1994

74. Parry DM et al: Germline mutations in the neurofibromatosis 2 gene: Correlation with disease severity and retinal abnormalities. *Am J Hum Genet* **59**:529, 1996

75. Mautner VF et al: Neurofibromatosis 2 in the pediatric age group. *Neurosurgery* **33**:92, 1993

76. Rouleau GA et al: Genetic linkage of bilateral acoustic neurofibromatosis to a DNA marker on chromosome 22. *Nature* **329**:246, 1987

77. MacCollin M et al: DNA diagnosis of neurofibromatosis 2. Altered coding sequence of the merlin tumor suppressor in an extended pedigree. *JAMA* **270**:2316, 1993

78. Shishiba T et al: Multiple cutaneous neurilemomas as a skin manifestation of neurilemomas. *J Am Acad Dermatol* **10**:744, 1984

79. Reith JD, Goldblum JR: Multiple cutaneous plexiform schwannomas. Report of a case and review of the literature with particular reference to the association with types 1 and 2 neurofibromatosis and schwannomatosis. *Arch Pathol Lab Med* **120**:399, 1996

80. Pulst SM et al: Familial meningioma is not allelic to neurofibromatosis 2. *Neurology* **43**:2096, 1993

T>

Chapter 191

Amy Paller

Ataxia-Telangiectasia

ETIOLOGY AND PATHOGENESIS
CLINICAL FEATURES
PATHOLOGY
DIFFERENTIAL DIAGNOSIS
LABORATORY FINDINGS
TREATMENT

REFERENCES

Ataxia-telangiectasia (AT) [MIM 208900], also called Louis-Bar syndrome, is an autosomal recessive disorder (incidence, 1:40,000) that is characterized by cerebellar ataxia, oculocutaneous telangiectases, recurrent sinopulmonary infections including bronchiectasis, immunodeficiency, and the development of lymphoreticular malignancies. [1]

ETIOLOGY AND PATHOGENESIS

In normal mammalian cells, exposure to ionizing radiation results in a delay in both progression from G1 to S phase and of G2 into M, and transient inhibition of DNA synthesis. AT cells in culture have abnormal radioresistant DNA synthesis and fail to activate either G1/S or G2/M checkpoints in response to ionizing irradiation. [2] As a result, AT cells demonstrate chromosomal instability and hypersensitivity to ionizing radiation and radiomimetic agents such as bleomycin. Responses to ultraviolet irradiation are normal.

The identification of the *ATM* gene and the functions of the protein that it encodes enables a more complete understanding of the molecular and clinical pathophysiology of the disease. [2], [3] The gene for the ataxia-telangiectasia phenotype maps to chromosome 11q22.3, a site involved in the chromosome translocations observed in the lymphoreticular malignant cells of patient with AT. Five AT complementation groups, all mapping to 11q22.3, have been identified.

The ATM protein is a 350-kDa phosphoprotein that resembles the phosphatidylinositol-3-kinases, and participates in checkpoint regulation. The gene has 66 exons and spans 150 kb of genomic DNA. More than 400 different *ATM* mutations have been identified in patients with AT.

The tumor-suppressor protein p53 has a major role in allowing passage through the G1/S checkpoint, which tests DNA integrity before initiation of new DNA synthesis and protects against strand breaks after immunoglobulin gene rearrangement. ATM phosphorylates p53 after induction by ionizing radiation, thus allowing cell cycling. The lack of induction of p53 may explain why intrachromosomal recombinant rates in AT cells are 30 to 200 times higher than in normal cells. [4] ATM is also associated with the synaptonemal complex of meiotic chromosomes, which may explain gonadal atrophy in AT. [5] The many other possible substrates for ATM and involvement in signaling complexes such as c-Abl and NF-?B signaling, may explain many other features of AT, such as cytoskeletal defects and insulin signaling abnormalities that are difficult to relate to DNA damage responses alone.

CLINICAL FEATURES

Characteristic oculocutaneous telangiectases begin near the ocular canthi and progress across the bulbar conjunctivae (Fig. 191-1). These telangiectases usually appear when patients are 3 to 6 years of age; rarely have they been described at earlier ages. Cutaneous telangiectases subsequently may develop on the malar prominences, ears, eyelids, anterior chest, popliteal and antecubital fossae, and the dorsa at the hands and feet (Fig. 191-2). The telangiectases may be subtle and resemble fine petechiae, especially in the flexural areas. The development of telangiectases may be related to sun exposure, because ocular, but not cutaneous, telangiectases develop in affected dark-skinned children, although the underlying mechanism for any ultraviolet light induced damage is unclear.

FIGURE 191-1 Bulbar conjunctival telangiectases in a patient with ataxia-telangiectasia. (*From Paller AS: Hereditary immunodeficiency disorders, in Genetic Disorders of the Skin, edited by JC Alper. Chicago, Mosby Year Book, 1991, p 105, with permission.*)

FIGURE 191-2 Ataxia-telangiectasia. Telangiectases inside and on the helix.

Progeric changes of the skin, including xerosis and gray hair, occur in 90 percent of patients. [6] During adolescence, the facial skin may become progressively more atrophic and sclerotic, causing a masklike appearance. Occasionally, the ears, arms, and hands also become sclerodermatous. The hair may be diffusely gray by adolescence, and subcutaneous fat is generally lost in childhood. Recurrent severe impetigo often develops in patients with AT. Seborrheic dermatitis occurs in many patients, and the associated blepharitis may lead to a diagnosis of blepharoconjunctivitis rather than ocular telangiectasia. Mottled hyper- and hypopigmentation frequently occur and, together with the telangiectases and atrophy, can resemble the poikiloderma of radiodermatitis, actinic damage, or scleroderma. Other pigmentary changes include café au lait spots that may be found in a dermatomal distribution, [7] multiple ephelides, and vitiligo. Hypertrichosis of the arms and legs, alopecia areata, multiple warts, atopic dermatitis, keratosis pilaris, nummular eczema, and acanthosis nigricans have also been described in association with AT. Among the most common cutaneous manifestations are noninfectious cutaneous granulomas (Fig. 191-3). [7] These persistent, atrophic, and often ulcerative lesions are often mistaken for other granulomatous processes, including sarcoidosis, necrobiosis lipoidica diabeticorum, granuloma annulare, and granulomatous dermatitis. Intralesional injections of triamcinolone have helped to promote healing of the painful associated ulcerations, although the lesions do not clear completely with treatment.

FIGURE 191-3 Noninfectious granulomatous dermatitis of a patient with ataxia-telangiectasia. These painful persistent lesions tend to ulcerate.

Usually, the progressive cerebellar ataxia first becomes apparent during infancy (median age, 1.2 years) with swaying of the head and trunk and apraxia of eye movements often years before skin or conjunctival abnormalities develop. In childhood, dysarthric speech, drooling, choreoathetosis, and myoclonic jerks become prominent. The gradual development of a persistent cerebellar ataxia, appearing in the first few years of life, should alert the clinician to ataxia-telangiectasia. Close inspection of the limbs shows none of the usual features of cerebellar ataxia, that is, dysmetria, lack of synergism of component muscle groups involved in skilled acts, hypotonia, or intention tremor. The diagnosis of AT is usually made at a median age of 7 years, after appearance of the mucocutaneous telangiectasia. Once fully developed, the neurologic features of AT include slow, dysarthric speech, impassive face, nystagmus, choreoathetosis, occasionally myoclonic jerks of the limbs, difficulty in initiating ocular deviation from the central position, and poor voluntary control of eye movements (apraxia of gaze). Tendon reflexes are diminished or absent; intelligence may deteriorate as the disease advances. Patients usually require a wheelchair by their teenage years.

Recurrent bacterial and viral sinopulmonary infections occur in up to 80 percent of patients; these are the most common cause of death, which is usually from bronchiectasis and respiratory failure. Approximately 75 percent of patients with AT may have growth retardation and endocrine disorders, especially ovarian agenesis or testicular hypoplasia and insulin-resistant diabetes. Malignant lymphoreticular neoplasms develop in 10 to 15 percent of patients, usually by adolescence, particularly the lymphomas of B cell origin and the T cell chronic lymphocytic leukemia. [8], [9]

Heterozygotes for the *ATM* gene (1 percent of the US population) are at increased risk for neoplasia, especially female breast cancer (up to fivefold relative risk). [10], [11] Heterozygotes show increased risk of chromosomal breaks after exposure to irradiation in vitro, suggesting that mammograms in known carriers of AT are contraindicated.

PATHOLOGY

Autopsy findings indicate that approximately 50 percent of the patients die from pulmonary disease and that most of the remainder die from lymphoreticular or other malignant tumors; the thymus is absent or hypoplastic, and the spleen may be reduced in size. The significant pathologic abnormalities in the central nervous system are severe degeneration in the

cerebellar cortex, loss of myelinated fibers in the posterior columns, and degenerative cell changes in the posterior root and sympathetic ganglia.

DIFFERENTIAL DIAGNOSIS

Ataxia-telangiectasia is one of a group of diseases characterized by defects in the repair process of DNA damage. The others are xeroderma pigmentosum, Bloom's syndrome, and Cockayne's syndrome (see Chap. 155). In fibroblast cultures from patients with ataxia-telangiectasia, several complementation groups have been found, suggesting clinical heterogeneity. Patients with the Nijmegen breakage syndrome show radiation sensitivity with radio-resistant DNA synthesis, chromosomal instability, and an increased risk of cancer, but have microcephaly rather than progressive ataxia as their neurologic abnormality. Nijmegen breakage syndrome results from mutations in the *NBS1* gene, which encodes a 95-kDa protein involved in repair of double-stranded breaks that is phosphorylated by ATM. [12]

LABORATORY FINDINGS

Patients with AT tend to have both humoral and cellular immunologic abnormalities. Serum IgA and IgE are absent or deficient in the majority of patients. Circulating anti-IgA antibodies are common in patients with IgA deficiency. Defective cell-mediated immunity is found in 70 percent of patients; T cells bearing gamma/delta receptors are increased in number. Virtually all patients have elevated levels of a-fetoprotein, and many have detectable carcinoembryonic antigen. Patients with AT often have elevated hepatic transaminases (40 to 50 percent), and glucose intolerance.

Spontaneous chromosomal abnormalities (fragments, breaks, gaps, and translocations) occur 2 to 18 times more frequently in patients with AT than in normal individuals and mainly involve chromosomes 2, 7, and 14. Rearrangements of chromosomes 7 and 14, and especially 14:14 translocations, seem to predict the development of lymphoreticular malignancy including leukemia.

TREATMENT

The therapy for AT is supportive and includes administration of antibiotics for infection, physiotherapy for pulmonary bronchiectasis, physical therapy to prevent contractures in patients with neurologic dysfunction, and sunscreens and sun avoidance to diminish actinic-like changes. Lymphoreticular malignancies, including lymphoid leukemia, are the second most common cause of death, leading to the deaths of 15 percent of patients with AT. Therapeutic radiation and radiomimetic chemotherapeutic agents, especially bleomycin, may lead to extensive tissue necrosis. The administration of small doses of other chemotherapeutic drugs and low-dose, fractionated radiation is the least harmful means of managing these malignancies. Death usually occurs by late childhood or early adolescence; the oldest surviving patient died at the age of 50 years.

Prenatal diagnosis has been achieved by measurement of amniotic a-fetoprotein levels, by increased spontaneous breakage of chromosomes of fetal amniocytes, by the presence of a clastogenic factor in the amniotic fluid, [13] and by detection of the DNA defect.

REFERENCES

1. Boder E: Ataxia-telangiectasia: An overview, in *Ataxia-Telangiectasia: Genetics, Neuropathology, and Immunology of a Degenerative Disease of Childhood,* edited by RA Gatti, M Smith. New York, Alan R Liss, 1985, p 1

2. Kastan MB, Lim D: The many substrates and functions of ATM. *Mol Cell Biol* **1**:179, 2000

3. Savistky K et al: A single ataxia telangiectasia gene with a product similar to PI-3 kinase. *Science* **268**:1749, 1995

4. Barlow C et al: ATM selectively regulates distinct p53-dependent cell-cycle checkpoint and apoptotic pathways. *Nat Genet* **17**:453, 1997

5. Plug AW et al: ATM and RPA in meiotic chromosome synapsis and recombination. *Nat Genet* **17**:457, 1997

6. Cohen LE et al: Common and uncommon cutaneous findings in patients with ataxia-telangiectasia. *J Am Acad Dermatol* **10**:431, 1984

7. Paller AS et al: Granulomatous lesions in patients with ataxia-telangiectasia. *J Pediatr* **119**:917, 1991

8. Morrell D et al: Mortality and cancer incidence in 263 patients with ataxia-telangiectasia. *J Natl Cancer Inst* **77**:89, 1986

9. Loeb DM et al: Lymphoid malignancy as a presenting sign of ataxia-telangiectasia. *J Pediatr Hematol Oncol* **22**:464, 2000

10. Swift M et al: Incidence of cancer in 161 families affected by ataxia-telangiectasia. *N Engl J Med* **325**:1831, 1991

11. Khanna KK: Cancer risk and the ATM gene: A continuing debate. *J Natl Cancer Inst* **92**:795, 2000

12. Lim DS et al: ATM phosphorylates p95/nbs1 in an S-phase checkpoint pathway. *Nature* **404**:613, 2000

13. Schwartz S et al: Tests appropriate for the prenatal diagnosis of ataxia-telangiectasia. *Prenat Diagn* **5**:9, 1985

T>

Chapter 192

Rachel Garton Joseph Jorizzo

Behçet's Disease

HISTORIC ASPECTS
EPIDEMIOLOGY
ETIOLOGY AND PATHOGENESIS
Genetics
Infectious Precipitants
Immunologic Aspects
CLINICAL MANIFESTATIONS
Mucocutaneous Lesions
Systemic Lesions
LABORATORY EVALUATION
HISTOPATHOLOGY
DIAGNOSIS
TREATMENT
COURSE AND PROGNOSIS

REFERENCES

Behçet's disease is a complex multisystem disease of unknown etiology characterized clinically by oral and genital aphthae, arthritis, cutaneous lesions, and ocular, gastrointestinal, and neurologic manifestations. The diagnosis is made by clinical criteria, as no pathognomonic laboratory tests exist. The absence of inflammatory bowel disease and collagen vascular diseases must be documented.

HISTORIC ASPECTS

Approximately 2,400 years ago Hippocrates used the designation *aphthai* to refer to common oral aphthae (canker sores), and he may have described the first patient with Behçet's disease. The disease is named after Hulusi Behçet, a Turkish dermatologist, who, in 1937, described patients with recurrent orogenital ulcerations and uveitis. [1] The first international multidisciplinary conference on Behçet's disease was organized by two dermatologists, Drs. Monacelli and Nazarro, in Rome, in 1964.

EPIDEMIOLOGY

The prevalence of Behçet's disease is highest in Japan, Southeast Asia, the Middle East, and southern Europe (along the so-called silk route from eastern Asia to the Mediterranean Basin). [2], [3] The disease is uncommon in northern Europe, the United States, and the United Kingdom. Behçet's disease most often affects patients in their twenties and thirties, but can occur at any age. [4] There seems to be a slight male predominance, but this finding varies from one country to another. [5] Behçet's disease occurs in children, albeit less frequently than in adults; girls and boys appear to be affected equally. [6]

ETIOLOGY AND PATHOGENESIS

Genetics

A significant association exists between Behçet's disease and human leukocyte antigen (HLA)-B51 in Japan, the Middle East, and the Mediterranean countries; however, this relationship is not as strong in Western countries. [5] The allele also seems to be associated with a more severe prognosis. Familial clustering of Behçet's disease is not common but is reported. [7]

Infectious Precipitants

Early theories of the pathogenesis of Behçet's disease proposed a viral or other infectious etiology. [1] Homology between the DNA of herpes simplex virus type 1 (HSV-1) and the RNA of peripheral blood lymphocytes from patients with Behçet's disease was reported. HSV-1 DNA was detected with polymerase chain reaction (PCR) in genital ulcers of patients with Behçet's disease. [4] Another study used PCR to detect HSV in saliva of patients with Behçet's disease and found no differences between those with and without oral ulceration. [8] Some evidence suggests a role of *Streptococcus* species in Behçet's disease. [9]

Immunologic Aspects

Early studies demonstrated autoantibodies reactive to oral mucosal antigens in patients with Behçet's disease. [10] The roles of immunologic mediators, including tumor necrosis factor (TNF), interleukin 1 (IL-1), IL-2 receptor, and soluble CD8 antigen, [11] ?d T cells, [12] and late expression of Fas antigen on CD4 and CD8 T cells [13] have been investigated. In addition to defective T cell immunity, B cell activation is impaired. [4]

Nazzaro [14] demonstrated that the earliest histology from aphthae, pustular vasculitic lesions, and erythema nodosum-like lesions is what we would now call a neutrophilic vascular reaction or even fully developed leukocytoclastic vasculitis, and

these findings have been confirmed. [15] Approximately 50 percent of patients with Behçet's disease have a significantly higher number of circulating immune complexes when compared to control subjects. [16] Light, immunofluorescence, and electron microscopic studies support a neutrophilic vascular reaction or even fully developed leukocytoclastic vasculitis as the earliest finding in mucocutaneous lesions. [14], [15] Pathergy lesions (cutaneous pustular vasculitis lesions induced by intradermal trauma) show a neutrophilic vascular reaction or leukocytoclastic vasculitis in a biopsy specimen obtained 24 h after histamine injection and on direct immunofluorescence usually show immunoreactants in biopsy specimens obtained 4 h after histamine injection. [15] Studies repeatedly suggest increased migration of neutrophils to chemoattractants in Boyden chamber or subagarose assays, and experiments in HLA-B51 transgenic mice show a similar phenomenon. [17], [18] Neutrophil adhesion to endothelial cells has been another important area of investigation. [19] The therapeutic benefit of colchicine, a drug that inhibits neutrophil migration and phagocytosis, may be a result of a blockade of the ability of neutrophils to hyperrespond to serum from patients with Behçet's disease.

CLINICAL MANIFESTATIONS

Mucocutaneous Lesions

Oral and genital aphthae, required for the diagnosis of Behçet's disease, are the most frequently observed mucosal manifestation and often are the presenting sign. [3], [5], [20] The typical lesion is painful, 1 to 3 cm in diameter, with a yellow fibrinous base. [11] The aphthae usually heal without scarring (Fig. 192-1A). Genital aphthae are similar in appearance to those that occur on the oral mucosa, but may not recur as often (Fig. 192-1B). [11] Herpes simplex should be excluded with appropriate Tzanck preparation, viral culture, or even skin biopsy.

FIGURE 192-1 Behçet's syndrome. *A.* On the labial mucosa there are painful aphthous-type ulcerations. *B.* Large, painful aphthous-type ulcer on the vulva.

Cutaneous lesions that should be accepted as diagnostically relevant in Behçet's disease should be confined to pustular vasculitis lesions (including pathergy lesions), erythema nodosum-like lesions, Sweet's-like lesions, pyoderma gangrenosum-like lesions, and palpable purpuric lesions of necrotizing venulitis (Fig. 192-2). All these lesions are characterized in their early stages by a neutrophilic vascular reaction. Acneiform lesions or follicle-based pustules should not be considered relevant. [21], [22]

FIGURE 192-2 Pustular vasculitic lesions on the hand of a patient with Behçet's disease.

Systemic Lesions

Ocular involvement is the major cause of morbidity in patients with Behçet's disease. The most diagnostically relevant lesion is posterior uveitis (called retinal vasculitis in Great Britain), which can lead to blindness. Other ocular lesions include anterior uveitis, hypopyon (pus in the anterior chamber of the eye, which is uncommon), and secondary complications such as cataracts, glaucoma, and neovascular lesions. [23]

The characteristic arthritis is a nonerosive, asymmetric oligoarthritis; however, symmetric polyarticular involvement is common. [3] Patients with HLA-B27–positive, erosive sacroiliitis have been included in some series of patients with Behçet's disease, but their condition is more appropriately considered as part of the Reiter's enteropathic arthritis spectrum of disease.

Significant neurologic manifestations occur in fewer than 25 percent of patients and may be delayed in onset. Meningoencephalitis, cerebral venous sinus thrombosis, benign intracranial hypertension, cranial nerve palsies, brainstem lesions, and pyramidal or extrapyramidal lesions have all been described. Poor prognosis is associated with a progressive course, relapse after treatment, repeated attacks, and cerebellar symptoms or parenchymal disease. [24], [25]

Systemic vascular involvement can be significant and includes aneurysms, arterial occlusions, venous occlusions, and varices that can be fatal. [26] Pulmonary artery aneurysms are the principal feature of pulmonary involvement in Behçet's

disease. [27] Cardiac involvement can include myocarditis, coronary arteritis, endocarditis, and valvular disease. [28] A wide spectrum of renal manifestations can occur, varying from minimal change disease to proliferative glomerulonephritis and rapidly progressive crescentic glomerulonephritis. [29] Immune complex deposition is thought to be responsible for the underlying pathogenesis in some cases of glomerulonephritis. [29] Aphthae may be present throughout the gastrointestinal tract and can result in perforation. Some patients with inflammatory bowel disease have been included in series of patients with Behçet's disease, but these cases are best excluded.

LABORATORY EVALUATION

There are no pathognomonic laboratory abnormalities in patients with Behçet's disease. Laboratory abnormalities may occur in association with dysfunction of various organ systems, depending on clinical disease manifestations.

HISTOPATHOLOGY

Characteristic histopathologic features of Behçet's disease are vasculitis and thrombosis. [11] Biopsies from early mucocutaneous lesions show a neutrophilic vascular reaction with endothelial swelling, extravasation of erythrocytes, and leukocytoclasia, or a fully developed leukocytoclastic vasculitis with fibrinoid necrosis of blood vessel walls. [14], [15], [21], [22] Although there are reports of lesions in patients with Behçet's disease that consist primarily of a lymphocytic perivasculitis, [30] most of these lesions are likely older. The neutrophilic vascular reaction should be considered the predominant histopathologic finding. [21]

DIAGNOSIS

Behçet's disease is a complex multisystem disease that must be diagnosed by clinical criteria in the absence of a pathognomonic laboratory test or histologic finding. Patients must have oral aphthae plus at least two of the following: genital aphthae, synovitis, posterior uveitis, cutaneous pustular vasculitis (see Fig. 192-2), or meningoencephalitis. The absence of inflammatory bowel disease, systemic lupus erythematosus, Reiter's disease, and herpetic infections must be confirmed.

Criteria were published in 1990 by the International Study Group and their usefulness has been validated. [31] These criteria require the presence of oral aphthae plus two of the following: recurrent genital aphthae, eye lesions, skin lesions, or a positive pathergy test. Table 192-1 explains these criteria. There are several problems with these criteria. The omission of synovitis and meningoencephalitis makes four of the five criteria variations of the same basic mucocutaneous lesion. We would require histologic confirmation that the cutaneous pustular lesions are indeed vessel-based and neutrophilic. Because 20 percent of normal young adults have oral aphthae and almost all adolescents have at least one acneiform lesion, they could practically meet the criteria if “acneiform skin lesions” are not excluded! Exclusion of inflammatory bowel disease should also be mandatory.

Criteria	Description
Oral	Minor aphthae, major aphthae, or herpetiform ulcers observed by physicians or reported reliably by patient. Recurrent at least three times in one 12-month period.
Genital	Recurrent genital aphthae or scarring, especially scrotal in males, observed by physician or reliably reported by patient.
Eye	Anterior uveitis, posterior uveitis, cells in vitreous on slit lamp examination, or retinal vasculitis, observed by qualified physician.
Skin	Erythema nodosum-like lesions observed by physicians or papulopustular lesions consistent with Behçet's disease, observed by a physician.
Pathergy	Positive pathergy test (neutrophilic vascular reaction or leukocytoclastic vasculitis) read by a physician at 24 or 48 h, performed with oblique insertion of a 20-gauge or smaller needle under sterile conditions.

*Findings are applicable if no other clinical explanation is present.

TABLE 192-1 **International Criteria for Behçet's Disease***

Several disorders need to be considered in the differential diagnosis and excluded before a definitive diagnosis of Behçet's disease can be made. Reiter's disease and the HLA-B27–positive spectrum of diseases are characterized by an axial erosive arthritis and by psoriasiform mucocutaneous lesions, but there are no aphthae and no pustular vasculitis in these patients. Patients with inflammatory bowel disease have an increased incidence of oral aphthae. These patients or those who have had bowel bypass or Billroth II surgery can have a dermatosis–arthritis syndrome that mimics Behçet's disease, including an indistinguishable pustular vasculitis. [17] However, eye disease is generally absent in these patients. Patients with complex aphthosis have recurrent oral and genital aphthae or almost ever-present, multiple (>3) oral aphthae, but no other features of Behçet's disease. [11] Patients with pustular vasculitis alone may have gonococcal or even chronic meningococcal sepsis, or the pustular vasculitis may occur as an idiopathic syndrome.

TREATMENT

The choice of treatment for patients with Behçet's disease depends on the site and severity of the clinical manifestations of the disease (Table 192-2). Aphthae are most often treated with palliative agents, such as counterirritant antipruritic agents, potent topical glucocorticoids, intralesional glucocorticoids, and local anesthetics. [11] Colchicine, 0.6 mg orally two to three times daily as tolerated by the gastrointestinal tract, can reduce the frequency and severity of mucocutaneous lesions. [15] Patients should be monitored for the infrequent neutropenia that can complicate therapy. In addition, dapsone therapy [32] has been used, as has pentoxifylline. [33] For more severe mucocutaneous lesions thalidomide has been shown to be beneficial. [17], [34] Low-dose methotrexate, interferon-a, and prednisone are also effective in treating more severe mucocutaneous disease. [11], [35], [36] Recently, a patient with a recalcitrant mucocutaneous ulceration was treated successfully with the anti–TNF-a antibody infliximab. [37] Severe ocular and systemic disease often requires

immunosuppressive treatment with agents such as prednisone, azathioprine, cyclophosphamide, chlorambucil, and cyclosporine. [11], [35] Recently, cases of gastrointestinal disease and uveitis have been treated with infliximab. [38], [39] Combination therapy with immunosuppressive agents is often used to treat the most severe disease.

Mucocutaneous disease
Topical, intralesional, or aerosolized glucocorticoids (3)
Topical tacrolimus (3)
Local anesthetics (3)
Pentoxifylline (2)
Colchicine (1)
Dapsone (3)
Combinations of the above (3)
Severe mucocutaneous disease
Thalidomide (1)
Low-dose weekly pulse methotrexate (3)
Prednisone with intermittent tapers (2)
Interferon-α (2)
Severe ocular and systemic disease
Prednisone (1)
Azathioprine (1)
Cyclophosphamide (3)
Chlorambucil (2)
Cyclosporine (1)
Infliximab (3)
Intravenous immunoglobulin (3)
Combinations of the above (3)

(1) Double-blind studies; (2) case series; (3) anecdotes.

TABLE 192-2 **Therapeutic Ladder for Behçet's Disease**

COURSE AND PROGNOSIS

The clinical course of Behçet's disease is variable. There can be a delay of up to several years before the diagnosis is made, which may influence the prognosis. Mucocutaneous and arthritic manifestations usually occur first. Ophthalmic involvement is the leading cause of morbidity. Skin lesions may be a predictive factor in vision loss, as is posterior as opposed to anterior uveitis. [40] Blindness can often be prevented with early aggressive therapy of posterior uveitis. Central nervous system, pulmonary, and large vessel involvement, as well as bowel perforation, are the major life-threatening complications. [6] Death may also result as a complication of immunosuppressive therapy. Markers of severe prognosis include HLA-B51 positivity, male gender, and early development of systemic features. Onset in childhood does not necessarily predict a poor prognosis. Spontaneous remissions of certain or all manifestations of Behçet's disease have been observed.

REFERENCES

1. Behçet H: Uber rezidivierende Aphthöse, durch ein Virus verusachte Geschwüre am Mund, am Auge und an den Genitale. *Dermatol Wochenschr* **105**:1152, 1937

2. Schirmer M et al: Ninth International Conference on Behçet's Disease, Seoul, Korea, May 27–29, 2000. *J Rheumatol* **28**:636, 2001

3. Sakane T et al: Behçet's disease. *N Engl J Med* **341**:1284, 1999

4. Hegab S, Samia A: Immunopathogenesis of Behçet's disease. *Clin Immunol* **96**:174, 2000

5. Saylan T et al: Behçet's disease in the Middle East. *Clin Dermatol* **17**:209, 1999

6. Koné-Paut I et al: Clinical features of Behçet's disease in children: An international collaborative study of 86 cases. *J Pediatr* **132**:721, 1998

7. Dundar SV et al: Familial cases of Behçet's disease. *Br J Dermatol* **113**:319, 1985

8. Lee S et al: Polymerase chain reaction reveals herpes simplex virus DNA in saliva of patients with Behçet's disease. *Arch Dermatol Res* **288**:179, 1996

9. Niwa Y, Mizushima Y: Neutrophil-potentiating factors released from stimulated lymphocytes: Special reference to the increase in neutrophil-potentiating factors from streptococcus-stimulated lymphocytes of patients with Behçet's disease. *Clin Exp Immunol* **79**:353, 1990

10. Rogers RS III et al: Lymphocytotoxicity for oral epithelial cells in recurrent aphthous stomatitis and Behçet's syndrome. *Arch Dermatol* **109**:361, 1974

11. Ghate J, Jorizzo J: Behçet's disease and complex aphthosis. *J Am Acad Dermatol* **40**:1, 1999

12. Hasan A et al: Role of gamma delta T cells in pathogenesis and diagnosis of Behçet's disease. *Lancet* **347**:789, 1996

13. Nakamura S et al: Insufficient expression of Fas antigen on helper T cells in Behçet's disease. *Br J Ophthalmol* **80**:174, 1996

14. Nazzaro P: Cutaneous manifestations of Behçet's disease, in *International Symposium on Behçet's Disease in Rome*, edited by M Monacelli, P Nazzaro. Basel, Karger, 1966, p 15

15. Jorizzo JL et al: Behçet's syndrome: Immunopathologic and histopathologic assessment of pathergy lesions is useful in diagnosis and follow up. *Arch Pathol Lab Med* **109**:747, 1985

16. Kwon OH et al: Relationship of circulating immune complex levels with clinical activity in Behçet's syndrome, in *Behçet's Disease: Basic and Clinical Concepts*, edited by JD O'Duffy, E Kokmen. New York, Marcel Dekker, 1991, p 355

17. Jorizzo JL et al: Thalidomide effects in Behçet's syndrome and pustular vasculitis. *Arch Intern Med* **146**:878, 1986

18. Takeno M et al: Excessive function of peripheral blood neutrophils from patients with Behçet's disease and from HLA-B51 transgenic mice. *Arthritis Rheum* **38**:426, 1995

19. Sahin S et al: Neutrophil adhesion to endothelial cells and factors affecting adhesion in patients with Behçet's disease. *Ann Rheum Dis* **55**:128, 1996

20. Balabanova M et al: A study of the cutaneous manifestations of Behçet's disease in patients from the United States. *J Am Acad Dermatol*

41:540, 1999

21. Jorizzo JL et al: Mucocutaneous criteria for the diagnosis of Behçet's disease: An analysis of clinicopathologic data from multiple international centers. *J Am Acad Dermatol* **32**:968, 1995

22. Mangelsdorf HC et al: Behçet's disease: Report of twenty-five patients from the United States with prominent mucocutaneous involvement. *J Am Acad Dermatol* **34**:745, 1996

23. Bhisitkuk RB, Foster CS: Diagnosis and ophthalmological features of Behçet's disease. *Int Ophthalmol Clin* **36**:127, 1996

24. Siva A et al: Behçet's disease: Diagnostic and prognostic aspects of neurological involvement. *J Neurol* **248**:95, 2001

25. Kidd D et al: Neurological complications in Behçet's syndrome. *Brain* **122**:2183, 1999

26. Sagdic K et al: Venous lesions in Behçet's disease. *Eur J Vasc Endovasc Surg* **11**:437, 1996

27. Erkan F: Pulmonary involvement in Behçet's disease. *Curr Opin Pulm Med* **5**:314, 1999

28. James DG, Thomson A: Recognition of the diverse cardiovascular manifestations of Behçet's disease. *Am Heart J* **30**:457, 1982

29. El Ramahi KM et al: Renal involvement in Behçet's disease: Review of 9 cases. *J Rheumatol* **25**:2254, 1998

30. Gul A et al: Immunohistology of skin pathergy reaction in Behçet's disease. *Br J Dermatol* **132**:901, 1995

31. Ferraz MB et al: Sensitivity and specificity of different diagnostic criteria for Behçet's disease according to the latent class approach. *Br J Rheumatol* **34**:932, 1995

32. Sharquie K: Suppression of Behçet's disease with dapsone. *Br J Dermatol* **110**:493, 1984

33. Yasui K et al: Successful treatment of Behçet disease with pentoxifylline. *Ann Intern Med* **124**:891, 1996

34. Hamuryudan V et al: Thalidomide in the treatment of the mucocutaneous lesions of Behçet's syndrome: A randomized double-blinded, placebo controlled trial. *Ann Intern Med* **128**:443, 1998

35. Kaklamani V, Kaklamanis P: Treatment of Behçet's disease—An update. *Semin Arthritis Rheum* **30**:299, 2001

36. O'Duffy JD et al: Interferon-alpha treatment of Behçet's disease. *J Rheumatol* **25**:1938, 1998

37. Goossens PH et al: Remission of Behçet's syndrome with tumour necrosis factor a blocking therapy. *Ann Rheum Dis* **60**:637, 2001

38. Sfikakis PP et al: Effect of infliximab in sight-threatening panuveitis in Behçet's disease. *Lancet* **358**:295, 2001

39. Hassard PV et al: Anti-tumor necrosis factor monoclonal antibody therapy for gastrointestinal Behçet's disease: A case report. *Gastroenterology* **120**:995, 2001

40. Sakamoto M et al: Prognostic factors of vision in patients with Behçet disease. *Ophthalmology* **102**:317, 1995

T>

Chapter 193

Morton Swartz Arnold Weinberg

General Considerations of Bacterial Diseases

NATURAL RESISTANCE OF THE SKIN
PATHOGENESIS OF BACTERIAL INFECTION OF THE SKIN
Pathogenicity of the Microorganism
Changing Patterns of Bacterial Infections of the Skin
Portal of Entry
Specific Features of Host Inflammatory Response to Cutaneous Infection
Interplay of Morphology and Specific Bacterial Properties
Influence of Hypersensitivity to Bacterial Antigens on Inflammatory Reaction in Skin
Vasculitis as a Cutaneous Response to Systemic Infection
CLASSIFICATION OF BACTERIAL INFECTIONS OF THE SKIN
DIAGNOSTIC STRATEGIES
Direct Examination of Aspirates and Biopsies
Methods of Culture of Skin Material
Other Diagnostic Procedures
ANTIBIOTIC THERAPY
Dosage: Methods of Administration—Excretion
Toxicity
Antibiotic Resistance Because of "R" Factors
Topical Antibacterial Agents

REFERENCES

The patient with a fever and cutaneous lesions presents a very challenging, yet frequently rewarding, problem in medicine. The question of a treatable etiology (bacterial, fungal, herpes group viruses) should always be raised initially. The physician must actively and thoughtfully consider these possibilities and seek confirmation by appropriate studies to ensure early optimal antimicrobial therapy.

Bacterial infection involving the skin may manifest itself in either of two major forms: (1) as a primarily cutaneous process, or (2) as a secondary manifestation in the skin of infection in some other organ. The cutaneous changes associated with infection are not always suppurative but may present as a vasculitis or a hypersensitivity response (e.g., lesions in subacute bacterial endocarditis or erythema nodosum).

The importance of the skin as a mirror of systemic infection cannot be overemphasized, especially when classic clinical findings are distorted as in immunocompromised patients. The timely recognition of the cutaneous clues of bacteremia may provide the early warning to consider life-threatening infections due to organisms such as *Pseudomonas aeruginosa, Vibrio vulnificus, Salmonella typhi, Staphylococcus aureus,* and *Neisseria meningitidis*.

NATURAL RESISTANCE OF THE SKIN

The normal skin of healthy individuals is highly resistant to invasion by the wide variety of bacteria to which it is constantly exposed. It is difficult to produce localized infections such as impetigo, furunculosis, or cellulitis in laboratory animals [1] or human volunteers [2] if the integument is intact. Pathogenic organisms such as *Streptococcus pyogenes* (group A streptococcus) and *S. aureus* produce characteristic lesions of cellulitis and furunculosis in the absence of any obvious impairment of host defenses via disruption of the intact integument, that is, by insect bites, an abrasion, or the introduction of a foreign body. For example, Elek [3] demonstrated that the presence of a silk suture reduces by a factor of 10,000, in the case of *S. aureus,* the number of organisms needed to produce an abscess in the human skin. Treatment with immunosuppressive agents can predispose patients to infections by the same organisms or by others of much lower intrinsic pathogenicity (e.g., *Corynebacterium jeikeium*). The basis for this enhanced susceptibility of the compromised host is not understood but undoubtedly involves specific and nonspecific factors such as immunocompetence, nutritional state, and integrity of the cutaneous barrier. [4]

Bacteria are unable to penetrate the keratinized layers of normal skin and, when applied to the surface, rapidly decrease in number. [2] The nature and the relative importance of the factors thought to be involved in this local resistance to bacterial multiplication and to infection are not clear. [5] The low pH (approximately 5.5) of the skin environment has been suggested as one of these properties, but it does not appear to have an important role. Many virulent bacteria are capable of growing at pHs below that of normal skin. The presence of natural antibacterial substances in the sebaceous secretions may be a factor in bacterial elimination from the skin. Streptococci appear to be particularly sensitive, in vitro, to the unsaturated long-chain fatty acids of the skin lipids, but in controlled studies in humans *S. pyogenes* (gpA streptococci) grow equally well in high- or low-lipid–containing regions. [2] Areas such as the palms and soles, lacking in sebaceous glands, remain relatively free of streptococci as well. On the other hand, reduction of skin surface lipids with topical solvent treatment has prolonged the survival time of *S. aureus* on the skin. [6] Several free fatty acids (linoleic and linolenic acids) among skin lipids are more inhibitory for *S. aureus* than for coagulase-negative staphylococci, a component of the normal skin flora. [7] The role of circulating immunoglobulins, cellular immunity, and delayed hypersensitivity in the defense of the skin against certain organisms is under intense investigation (see Chap. 23). IgM has not been found in normal sweat, and IgA, IgG, and IgD have been found only in minute amounts (0.01 percent of the level in serum). However, the greater frequency with which a specific cutaneous and mucous membrane mycotic

infection, candidiasis, occurs in patients with severe combined immunodeficiency suggests a relationship. Experimental and clinical observations, summarized by Kligman et al., [5] consistently support the importance of moisture content and the indigenous cutaneous microflora in limiting colonization of the skin by potential pathogens. The relative dryness of normal skin contributes to the marked limitation of growth of bacteria, especially gram-negative bacilli with their higher moisture requirements (*Escherichia coli, Pseudomonas, Proteus*). Whereas application of 10 [6] *P. aeruginosa* alone on normal skin produced no lesions, the presence of a similar inoculum under dressings that increased local skin hydration led to a superficial papular and pustular infection. [8] Bacterial interference (the suppressive effect of one bacterial strain or species on colonization by another) exerts a major influence on the overall composition of the skin flora. Although this effect is somewhat difficult to define, its relevance, at least in the case of colonization of the nose and skin by *S. aureus,* appears clear. [9] Profound changes in these bacterial interactions may be effected by the use of antibiotics.

All of these factors allow certain bacterial species to colonize the skin surface successfully, while rapidly excluding other species. The organisms that characteristically survive and multiply in various ecologic niches of the skin constitute the "normal cutaneous flora." As an example, the distribution of different species of coagulase-negative staphylococci varies among different anatomic areas, and their relative numbers can depend on age. In adults, *S. epidermidis* is the principal staphylococcal species isolated from the scalp, face, chest, and axilla. Gram-negative bacilli are relatively rare as components of the normal resident skin flora, with the exception of members of the *Acinetobacter calcoaceticus-baumannii* complex, found on approximately 25 percent of normal adults, primarily in axillae, groins, and toe webs. [10] An appreciation of the composition of this flora and the attributes of its major elements is important in understanding and treating many bacterial infections of the skin.

PATHOGENESIS OF BACTERIAL INFECTION OF THE SKIN

The host–bacteria relationship in infections of the skin, as in infectious disease in general, involves three major elements: (1) the pathogenic properties of the organism, (2) the portal of entry, and (3) the host defense and inflammatory response to microbial invasion of the anatomic region.

Pathogenicity of the Microorganism

The disease-producing capacity of bacteria is determined to a large measure by (1) the invasive potential (often based on antiphagocytic surface components), and (2) the toxigenic properties of the organism. A few species of bacteria (e.g., pneumococcus) appear to owe their pathogenicity solely to their ability to multiply extensively and invade tissues while resisting phagocytosis. No definable extracellular products or toxins that might contribute to their invasiveness have been discovered. Conversely, a few species have toxigenic properties that account for the local lesion (*C. diphtheriae, Bacillus anthracis*) or systemic manifestations (*Clostridium tetani*) of a local infection. In the case of *C. perfringens,* elaboration of a variety of extracellular toxins and enzymes (alpha-toxin or lecithinase, proteases, collagenases) appears to play an important role in the rapidly spreading skin lesions and the systemic manifestations of clostridial myonecrosis. Although it is useful to distinguish between these two major pathogenic mechanisms whenever possible, most bacterial infections result from the combination of the invasive and toxigenic properties of the organism. Local invasiveness (dependent to a considerable extent on the antiphagocytic M protein of the bacterial cell envelope) is an important element in streptococcal pharyngitis, but the clinical features of scarlet fever result from the elaboration of the erythrogenic toxin.
For most disease-producing bacteria, including *S. aureus,* the cause par excellence of suppurative lesions, a clear understanding of the basis for pathogenicity is lacking. Recently, evidence has accumulated indicating that the capsular polysaccharides of 2 (types 5 and 8) of the 11 known *S. aureus* capsular types are both virulence factors and protective antigens. [11] This evidence is both epidemiologic (80 percent of *S. aureus* bloodstream isolates in hospitalized patients belong to types 5 and 8) and derived from in vitro testing (types 5 and 8 resist opsonophagocytosis). *S. aureus* toxins have roles in the pathogenesis of a variety of entities such as the staphylococcal toxic shock syndrome (*S. aureus* toxic shock syndrome toxin, or TSST-1; see Chap. 194) and staphylococcal scalded skin syndrome (exfoliatin A and B; see Chap. 195). The increasing prevalence of serious infections in compromised hosts, caused by "traditionally" nonpathogenic bacteria that include the resident skin flora, supports the concept that pathogenicity is the result of microorganism and host interactions.

Gram-negative bacteria (*E. coli, S. typhi, N. meningitidis, N. gonorrhoeae, Brucella melitensis,* and others) contain endotoxin, complex phospholipid-polysaccharide macromolecules [lipopolysaccharides (LPS)] as an integral part of the bacterial cell envelope. Endotoxins, unlike exotoxins, are released only upon breakdown of the bacterial cell. Their toxicity appears to be linked principally to the lipid fraction, whereas their antigenic determinants reside with the polysaccharide component. [12] Although the biologic effects of LPS in experimental animals are numerous (shock, fever, gastrointestinal hemorrhages, leukopenia, abortion) and well studied, their role in invasiveness and the pathogenesis of localized bacterial diseases until recently remained ill defined. [13] During the past 20 years, this has changed considerably. Much is now known of the mechanisms by which LPS exerts its biologic effects, in systemic infections due to gram-negative bacteria or in major localized infections that may also be capable of producing the sepsis syndrome. [14] The effects are both toxic (lethality, shock, fever, anorexia and cachexia, somnolence, complement activation, disseminated intravascular coagulation, and capillary thrombosis) and immunologic (adjuvant function, polyclonal B cell stimulation, macrophage activation, cytokine production). The two cytokines most relevant to the toxic and proinflammatory effects of LPS are produced by LPS-activated macrophages: tumor necrosis factor (TNF) and interleukin (IL)-1, the latter formerly known as leukocytic pyrogen (see Chap. 26). [15], [16]

After it enters the circulation, TNF, among its many biologic effects, acts as an endogenous pyrogen on hypothalamic centers to induce fever. [17], [18] It also acts on mononuclear phagocytes to stimulate production of IL-1 (another endogenous pyrogen), IL-6 (an inducer of production of serum amyloid A and other proteins of the "acute phase response"), and IL-8 (an inflammatory cytokine stimulating leukocyte chemotaxis and activation) (see Chap. 26). Thus, TNF initiates a proinflammatory cytokine cascade. TNF itself acts on the liver to increase synthesis of acute phase reactants, including fibrinogen. It also activates the coagulation system through its effects on vascular endothelium and

decreases blood pressure and tissue perfusion by reducing myocardial contractility and by relaxing smooth muscle.

High circulating levels of TNF are demonstrable in patients with meningococcemia and other forms of severe sepsis. [19], [20] Its direct role as a mediator of circulatory collapse in gram-negative bacillary bacteremia is supported by the fact that pretreatment with antibody to TNF can prevent mortality (associated with hypotension and cardiac and renal failure) from experimental *E. coli bacteremia* in animals. [21] In addition, infusion of high concentrations of purified TNF alone can produce shock and death.

LPS can directly trigger release of IL-1 from activated macrophages as well as act indirectly through initial induction of TNF. Like TNF, IL-1 acts on endothelial cells as a procoagulant and as a stimulator of leukocyte adhesion. It can cause fever, stimulate production of acute phase proteins, and initiate (in combination with TNF) muscle wasting and cachexia. IL-1 also acts in an immunomodulatory role to enhance proliferation of CD4+ T cells and to stimulate B cell growth and differentiation.

The Shwartzman reaction is an intensified response in experimental animals to bacteria containing LPS or to purified LPS itself. LPS injected intravenously twice, 24 h apart, causes disseminated intravascular coagulation in rabbits (systemic Shwartzman reaction); LPS injected intradermally, followed by a second (intravenous) injection, produces hemorrhagic necrosis of the skin (localized Shwartzman reaction) at the site of intradermal introduction. The necrosis stems from poor tissue perfusion as a consequence of capillary blockage by neutrophils and platelets and by local fibrin formation. TNF is the major mediator of the Shwartzman reaction; unlike TNF, IL-1 cannot directly mediate this reaction. The ability of LPS, through TNF production, to induce leukocyte adherence to capillary endothelium and to induce fibrin deposition has been suggested as the basis for development of the hemorrhagic necrotic skin lesions (with or without direct bacterial invasion) that sometimes occur during the course of gram-negative bacillary bacteremias and particularly in meningococcemia. Purpura fulminans develops in 10 to 20 percent of cases of marked meningococcal sepsis, and severe cases may develop thrombosis of large vessels with infarction of digits (see Chap. 197). Evidence indicates that this disseminated intravascular coagulation in severe meningococcemia results from downregulation of the endothelial thrombomodulin-endothelial protein C receptor pathway with consequent impairment of protein C activation. [22] A large, randomized, multicenter trial of the use of human recombinant activated protein C [drotrecogin alfa (activated)] in patients with severe sepsis indicated a reduction of mortality but with an associated potential risk of bleeding. [23]

Changing Patterns of Bacterial Infections of the Skin

In addition to the usual pathogens, a variety of “nonpathogenic” members of the cutaneous, intestinal, or respiratory tract flora are capable of producing acute disease in debilitated patients and in individuals with altered humoral or cellular defenses and with a variety of skin defects. A patient receiving immunosuppressive therapy, for example, may have an atypical streptococcal or staphylococcal lesion because of impairment of the normal inflammatory response, or an unusual organism may be causal. Pain can be the most prominent feature, and etiologic considerations should include, in addition to streptococci and staphylococci, members of the Enterobacteriaceae (*E. coli, Klebsiella- Enterobacter-Serratia, Proteus* spp.); a variety of nonfermentative gram-negative bacilli (*Pseudomonas, Aeromonas, Acinetobacter* spp., etc.); halophilic vibrios (e.g., *V. vulnificus*); and the indigenous anaerobic flora (peptostreptococci, *Bacteroides* spp., *C. perfringens,* etc.). [4], [24], [25], [26] and [27]

Portal of Entry

In laboratory animal models the pathogenic potential of many microorganisms depends, to a considerable extent, on the route of administration. Similarly, the character of the cutaneous inflammatory response to certain bacteria will be influenced by how the organisms reached the involved area. Thus, the vascular wall is often the primary site of skin involvement during bacteremic infection; hemorrhage or thrombosis with infarction is the initial manifestation. This is followed somewhat later by the cellular reaction expected from direct inoculation of the bacteria into the skin. Local inflammation and suppuration commonly accompany direct bacterial invasion of the skin, and these may, in turn, give rise to systemic spread via the rich cutaneous vascular network. Certain bacteria can produce bacteremia or distant lesions without evoking an obvious inflammatory response at the portal of entry [e.g., *Yersinia pestis, Streptobacillus moniliformis* (rat-bite fever)] even in a nonimmunosuppressed host. Occasionally, a devastating *S. pyogenes septicemia* has followed closely upon an innocuous pinprick or abrasion that has not induced a significant local lesion. Table 193-1 lists those bacterial species most frequently involved in pyogenic infections of the skin.



TABLE 193-1 **Bacteria Involved in Cutaneous Infection***

Specific Features of Host Inflammatory Response to Cutaneous Infection

In view of the relatively few cell types present in the skin, it is surprising that such a variety of rather distinctive clinical responses to various bacterial infections have been catalogued. In most instances, it is the anatomic site of the infection and the attendant inflammatory response pattern, rather than the specific pathogen, that provide the characteristic

clinical picture. The following brief examples are expanded upon in Chap. 194 and Chap. 196.

IMPETIGO The very superficial location of the infection, with vesicopustule formation just beneath the stratum corneum, is the specific clinical feature.
FOLLICULITIS This represents a circumscribed infectious process that originates in the hair follicle and is defined by its anatomic features. It may be located superficially in the follicle or may extend more deeply to produce perifollicular inflammation.
FURUNCLE (BOIL) This infection either complicates an antecedent folliculitis or develops as a deep-seated nodule about a hair follicle. The distinctive pathologic change results from its relation to the hair follicle; thus, it does not occur in glabrous areas such as the palms. The deep location and its containment by the relatively thick dermis prevent spontaneous early drainage to the surface and contribute to the hard, nodular, painful character of the lesion.
CARBUNCLE This is a larger, more deep-seated extension of a furuncle, with infection spreading under and between fibrous tissue septa, forming a whole series of interconnected abscesses. Drainage occurs through a number of projecting necrotic points in the skin.
CELLULITIS This is an acute, inflammatory process in the skin, particularly in the deeper subcutaneous tissues. Because of the subcutaneous location, the borders of the lesion are usually indistinct, in contrast to the sharply defined margin of erysipelas (see below).

Interplay of Morphology and Specific Bacterial Properties

ERYSIPELAS This is a superficial inflammatory process of the skin and subjacent lymphatics, characterized by marked edema of the dermis and extensive invasion of connective tissue usually, but not exclusively, caused by *S. pyogenes* (gpA streptococci). The rapid progression of the process and the prominence of edema of the affected skin relate to the biologic properties of the microorganisms and to the involvement of superficial lymphatics.

Influence of Hypersensitivity to Bacterial Antigens on Inflammatory Reaction in Skin

Although the introduction of certain bacteria in large numbers into the skin will elicit a local inflammatory reaction, the character and extent of this response may be modified by various host factors (e.g., leukopenia). In the case of skin infections caused by *S. aureus,* the tendency to recur is often quite striking. Initial lesions are usually suppurative and localized, whereas subsequent infections, when caused by the same antigenic strain, may have more prominent surrounding cellulitis. The immunologic response to *S. aureus* has been suggested as a factor in this altered inflammatory response. [28]

Vasculitis as a Cutaneous Response to Systemic Infection

Inflammatory changes in and about small blood vessels in the skin may occur in a variety of bacteremic infections in the absence of obvious localization of bacteria at these sites. The macular, papular, nodular, and petechial lesions of chronic meningococcemia (see Chap. 197) show such histologic changes. The lesions of erythema nodosum (see Chap. 109) have a prominent element of vasculitis, even though the initiating infection (e.g., streptococcal pharyngitis) is distant and has a suppurative character. The Osler nodes and petechiae of subacute bacterial endocarditis, caused by viridans streptococci, probably provide the best examples of this association of small-vessel vasculitis with bacteremia (see Chap. 166 and Chap. 194). Histologically, these lesions are more suggestive of vasculitis than of emboli. The occasional development of such lesions in profusion, localized to the lower extremities, supports the concept of cutaneous vascular inflammation rather than embolization.

CLASSIFICATION OF BACTERIAL INFECTIONS OF THE SKIN

The introduction of a variety of specific antibiotic and chemotherapeutic agents has effected rather striking changes in the management of bacterial infections. Indeed, with the availability of such drugs, attention has focused on the determination of the specific bacterial cause so that the proper choice of antibacterial agent can be made. This has rendered unnecessary, and even obsolete, descriptions of some of the dermatologic entities whose status depended on imprecise morphologic criteria rather than on etiologic considerations. Consequently, from the pragmatic (therapeutic) viewpoint, the approach has been to consider and classify these infections by bacterial causation, for example, infections caused by gram-positive organisms and infections caused by gram-negative organisms. Although the foregoing classification is helpful from the therapeutic point of view, there is still need for a system of categorizing bacterial infections of the skin so that the dermatologic picture will provide the basis for consideration of the most likely bacterial etiologies. To this end, the classification of skin infections as (1) primary infections (pyodermas), (2) secondary infections, and (3) cutaneous manifestations of systemic bacterial disease seems warranted. Primary bacterial infections are produced by the invasion of ostensibly normal skin by a single species of pathogenic bacteria. In such infections there is usually no doubt as to the primary etiologic role of the specific agent in the pathogenesis of the lesion. Treatment aimed at the bacterial pathogen almost universally results in cure of the lesion. Impetigo, erysipelas, and furunculosis are familiar examples of primary cutaneous infections; contrastingly, secondary infections develop in areas of already damaged skin. Although the bacteria present did not produce the underlying skin disorder, their proliferation and subsequent invasion of surrounding areas may aggravate and prolong the disease. Such secondary infection may occur when the integrity of the skin has been broken or bruised, primarily involved with mycotic or viral infections, or altered by sensitivity reactions or medications. In contrast to the primary infections, the secondary infections often show a mixture of organisms on culture, and not infrequently it is impossible to determine which plays the major role. Pathogenic organisms such as *S. aureus* and *S. pyogenes,* generally considered transients on the skin, can colonize such lesions and sometimes produce active secondary infection. The appearance of these lesions is not characteristic, in comparison to the primary pyodermas, but is largely dependent on the nature of the underlying skin condition. The result of antibacterial treatment is much less clear-cut, because it has no effect on the underlying process.

Table 193-2 presents an outline of infections involving the skin in a classification based upon the appearance of the lesions. In this outline, specific entities that are discussed elsewhere in detail are described only by the appropriate

chapter reference, and the more common bacterial etiologic agents are noted. This table refers exclusively to bacterial infections. Two of the categories identified in Table 193-2 present a broad differential diagnosis and warrant special consideration. These consist of infectious gangrene/gangrenous cellulitis (Table 193-3) and crepitant soft tissue wounds and cellulitis (Table 193-4). In addition, an uncommon group of infections present as chronic nodular, and sometimes ulcerative, granulomatous lymphangitis (with or without an evident initiating chancriform lesion) of a distinctive character. Because definition of the specific microbial etiology may be difficult without careful epidemiologic history, biopsy with culture, special stains of histologic sections, and an awareness of the broad variety of microorganisms (fungi, bacteria, mycobacteria, protozoa) that may be involved, a listing of the possible causes is presented separately (Table 193-5).

TABLE 193-2 **Bacterial Infections Involving the Skin***

TABLE 193-3 **Differential Diagnosis of Infectious Gangrene and Gangrenous Cellulitis**

TABLE 193-4 **Differential Diagnosis of Crepitant Soft Tissue Wounds***

Principal Considerations	Relative Frequency As Etiology
Fungi	
Sporothrix schenkii (causative agent of sporotrichosis (see Chap. 207)	Occasional
Mycobacteria	
Mycobacterium marinum (causative agent of "swimming pool granuloma" (see Chap. 200)	Occasional
M. Kansasii	
Bacteria	Rare
Nocardia brasiliensis	Rare
N. asteroides	Very rare
Francisella tularensis	Very rare
Staphylococcus aureus	Very rare
Botryomycosis (*S. aureus*)	Very rare
Protozoa	
Leishmania brasiliensis and *L. mexicana* (causative agents of new world cutaneous leishmaniasis (see Chap. 235)	Occasional

TABLE 193-5 **Causes of Chronic Nodular (Granulomatous) Sporotrichoid Lymphangitis**

DIAGNOSTIC STRATEGIES

Direct Examination of Aspirates and Biopsies

Identification of bacteria from skin lesions may provide important information as to the cause of cutaneous infections, whether primary or secondary to systemic processes. The presence of “normal skin flora” can confuse interpretation of these cultures. All too often, the finding of a potential pathogen such as *S. aureus* or *P. aeruginosa* is equated with the presence of disease. It is important to recall that damaged skin (operative incisions, exudative dermatoses, etc.) provides a medium for proliferation of certain bacteria. Only by correlating the clinical appearance of the lesion (local suppuration, cellulitis, etc.) with the bacteriologic data can one reach the proper decision concerning the presence of a bacterial disease. Examination of a Gram-stained smear of material from a suspected skin infection can guide decisions on early antibiotic therapy before a cultural diagnosis is made. For these reasons, bacteriologic investigation is an important part of the initial evaluation of patients with skin lesions and includes (1) appropriate sampling, (2) interpretation of

Gram-stained smears, and (3) use of selective growth media for culturing.

Gram staining provides a very rapid method for examining a sample for number and type of bacteria, as well as for the character of the inflammatory exudate. Skin contaminants are usually recognized by being present in low concentration, often clumped in characteristic microcolonies (growth in skin crypts) and usually not associated with polymorphonuclear leukocytes. Obtaining an appropriate specimen for microscopic study and culture requires care to avoid contamination. Results of needle aspiration of superficial erysipelas lesions have been generally unrewarding. Slightly better, but still limited, results have been obtained on aspiration culture of lesions of cellulitis. Aspirates from the advancing edge of cellulitis yielded positive cultures in only 10 percent of patients, and culture of skin punch biopsy specimens taken from the leading edge were positive in only 20 percent of patients in the study by Hook et al. [29] Positive cultures (beta-hemolytic streptococci and coagulase-positive *S. aureus*) were more likely in patients with apparent primary sites of infection associated with the cellulitis. In another study of needle aspiration cultures of the leading edge of erythema in patients with cellulitis, the yield of pathogenic bacteria was low (15 percent) as well. [30] Other studies have suggested a greater yield on needle aspiration of the leading edge of cellulitis when performed in patients with underlying conditions such as diabetes mellitus and neoplastic disease. [31] A higher yield (about 50 percent) for positive cultures has been reported in aspirates obtained from the point of maximal inflammation than that (5 percent) obtained from the leading edge of cellulitis in children. [32] The authors' personal experience is in accord with published results for sampling deeper cellulitic lesions and bullae associated with acute infections. Findings on needle aspiration, when positive, can provide an immediate useful guide to therapy. If sterile saline is injected into a lesion that initially yields no aspirate, bacteriostatic agent-free solutions should be employed. In circumstances where no data are available from needle aspiration, a surgical biopsy may yield information that is life-saving. In the recent bioterrorism-associated outbreak of anthrax infections in the United States, rapid specific diagnosis of cutaneous disease was accomplished by punch biopsy of an erythematous, indurated plaque and tissue Gram's stain demonstrating gram-positive rods, confirmed as *Bacillus anthracis* by immunohistochemical analysis. [33] Local lesions of the skin and subcutaneous tissues in immunocompromised patients should always be biopsied if aspiration fails to define a pathogen. [4] Encouraging results have been reported in a series of patients with suspected necrotizing fasciitis who had biopsies done to confirm the diagnosis early in the course of this devastating infection. [34]

Methods of Culture of Skin Material

All samples for culture should be planted routinely on blood agar and inoculated into a tube of thioglycollate (anaerobic) broth. Additional, more selective media should be used as indicated by clinical findings and evaluation of the Gram-stained smear and frozen sections if a biopsy is done. If cutaneous diphtheria is a consideration, Loeffler or tellurite agar should be inoculated. When gram-negative rod infection is suspected, an eosin-methylene blue (EMB) or MacConkey plate is used; a chocolate agar or modified Thayer-Martin plate incubated in a CO_2 atmosphere is indicated for suspected meningococcal or gonococcal lesions; a blood agar plate incubated in an oxygen-free atmosphere should be used if anaerobic streptococci, clostridia, or *Bacteroides* are suspected. When the skin lesions are thought to be part of a generalized infection, blood cultures should also be obtained prior to institution of antibiotic therapy.

Other Diagnostic Procedures

FLUORESCENT ANTIBODY The practical use of this procedure in bacterial diseases of the skin is currently of limited availability. Spirochetes can be demonstrated (by the direct or indirect techniques) in chancres, but dark-field examinations are easier to perform and more reliable (see Chap. 228). *N. gonorrhoeae, Actinomyces israelii, Legionella* spp., *Francisella tularensis,* and *Y. pestis* have been identified by this rapid direct fluorescent antibody staining method. This technique is still in the experimental development stage for identifying the etiologic agent in most common infections of the skin. [35] However, it can be extremely valuable in the specific diagnosis of uncommon but serious infections, as illustrated by the positive-immunostaining for *Bacillus anthracis* in an atypical erythematous indurated lesion on the arm of an infant infected during the recent outbreak of bioterrorism-related anthrax in the United States. [36]
OTHER IMMUNOLOGIC METHODS A variety of serologic tests may be helpful in the diagnosis of bacterial infections of the skin, particularly in those where the cutaneous manifestations are secondary to systemic disease (e.g., “rose spots” of typhoid fever). In general, these tests have value in confirming a diagnosis that has already been made by direct bacteriologic identification of the offending organism (e.g., *Salmonella* agglutination, *Brucella* agglutination, agglutination reaction for tularemia, leptospirosis complement fixation or agglutination tests). As in any serologic test, a fourfold or greater rise in titer during the course of the illness is considered significant.
POLYMERASE CHAIN REACTION Polymerase chain reaction (PCR) technology can be applied to diagnosis of material obtained on skin punch biopsy of lesional tissue or aspirates from a vesiculobullous lesion just as it has been used in diagnosis of infection in body fluids (cerebrospinal fluid, pleural fluid, blood). Appropriate precautions to exclude contamination during the acquisition of the specimen must be taken. The use of this procedure is most helpful when one particular bacterial species is being considered and appropriate primers are available. Such was the case in a patient with a cutaneous lesion during the bioterrorism-induced anthrax outbreak. [36]

ANTIBIOTIC THERAPY (See also Chap. 259)

The selection of the appropriate antibiotic should be made initially on the basis of the appearance of the skin lesion, the characteristics of any systemic illness, and a Gram-stained smear of material from a lesion if available to sample. Culture results and susceptibility testing of the isolated pathogen(s) are usually available within 48 h (Table 193-6).

TABLE 193-6 **Selection of Antibiotics**

Additional epidemiologic factors (current hospitalization or residence in a nursing home, recent antibiotic use, neutropenia, and immunocompromise) should be considered in the choice of initial antimicrobial therapy. Also, it is important to make the choice based on the latest data from the local area and from frequently updated sources (e.g., *Medical Letter*) in view of the rapidly changing patterns of antimicrobial resistance of various bacterial species, requiring alterations in the previous drugs of choice and the use of newer drugs or drug combinations.

Dosage: Methods of Administration—Excretion

Primary cutaneous infections of mild to moderate severity can be treated with local measures, topical drugs, oral antibiotics, or by a combination of these methods. In recent years, there has been a proliferation of oral cephalosporins with activity against group A streptococci and methicillin-susceptible *S. aureus,* which cause infections of the skin and soft tissues such as impetigo, cellulitis, subcutaneous abscesses, and wound infections (Table 193-7). Extensive infections of the skin, with or without systemic manifestations, should be vigorously treated with parenteral antibiotics in adequate dosages.

Drug	Adult Dosage
Cephalexin	250–500 mg q6h
Cefadroxil	500–1000 mg q12h
Cephradine	500 mg q6h
Cefaclor	250–500 mg q8h
Cefprozil	250–500 mg q12h
Cefuroxime	250–500 mg q12h
Cefpodoxime	200–400 mg q12h
Loracarbef	200–400 mg q12h

TABLE 193-7 **Oral Cephalosporins Used in Treating Skin Infections**

A number of factors must be considered in administering antibiotics: oral treatment may be limited by absorption and gastrointestinal disturbances; hypotension, severe thrombopenia, and extensive skin disease can prohibit the intramuscular route; and the proper drug selected may be suitable for administration only by a specific route. Caution must be exercised in administering intramuscular medications to avoid sterile or infected abscesses. When the intravenous route is used, a needle or “heparin-lock” is preferred. Percutaneous catheters should be changed frequently, and all line-skin sites kept clean with a topical antibiotic ointment and sterile dressing that is changed daily.

The excretory pattern of a given antibiotic should always be considered in order to avoid toxic accumulation in the face of specific organ malfunction (e.g., use of aminoglycosides or vancomycin in the presence of renal impairment).

Toxicity

The toxicity of antibiotics should be considered on an individual basis, but some problems are applicable to all antibiotics. Hypersensitivity reactions are relatively common and can include skin rashes, fever, or more severe manifestations such as acute anaphylaxis or exfoliative erythrodermas. The penicillins and sulfonamides are particularly likely to produce these problems. Questions regarding previous drug allergy should be asked whenever any antibiotic is to be administered. All antibiotics alter the relative kinds and absolute numbers of the indigenous flora, and superinfection may result from their use, especially with broad-spectrum agents such as the cephalosporins. Gastrointestinal disturbances and oral mucous membrane lesions are the major nonspecific types of problems encountered with alteration of the flora, although changes also occur on burn surfaces and other lesions. There are numerous other untoward reactions (renal, hematologic, hepatic, nervous system) to antibiotics that may represent acceptable risks if the reasons for use of these drugs are compelling (see footnotes, Table 193-6). The responsibility is the physician's, however, to be aware of the usual and unusual manifestations of toxicity to any of the antibiotics used and to be alert to possible novel effects in individual patients.

Antibiotic Resistance Because of “R” Factors

Transferable resistance to multiple antibiotics has emerged as a widespread problem. Extrachromosomal genetic elements (R plasmids) in bacteria are the basis for much of such resistance. [37], [38] Prolonged antibiotic therapy, especially in a closed environment such as a hospital, may select R-factor–carrying members of the indigenous flora (e.g., in the gastrointestinal tract), which may subsequently transfer this property to a recently acquired organism. In this way, antibiotic resistance to chloramphenicol, tetracycline, and kanamycin conferred by a plasmid in *E. coli* can be

transferred during mating to a *Klebsiella* or *Salmonella* strain. As a consequence, organisms with greater intrinsic pathogenicity can also become antibiotic-resistant. A number of studies have verified this phenomenon and its practical consequences. [39]

R plasmids (R factors) are found in most pathogenic gram-negative bacteria, including *E. coli, Klebsiella, Proteus, Pseudomonas, Salmonella,* and *Shigella*. They are also responsible for high-level resistance to the penicillins (penicillinase plasmids) and cephalosporins. R-factor–associated antibiotic resistance has been identified in *S. aureus* and *Enterococcus* spp., as well as in *Haemophilus influenzae* and *N. gonorrhoeae,* all important pathogens in skin and systemic infections.

Topical Antibacterial Agents

Topical antibacterial agents are frequently used to prevent, as well as to suppress, bacterial growth in burns and other open lesions (see Chap. 245). Their greatest usefulness is when employed along with strict aseptic techniques in preventing percutaneous line sepsis. These agents are capable of inhibiting the local flora, but, as is true of all antibiotics, they have a relatively limited spectrum of activity, which favors the emergence of bacterial resistance during treatment. In addition, topical drugs may precipitate contact dermatitis and can be absorbed to toxic levels. Furthermore, there has been very little evidence that they add a great deal therapeutically. [40] An exception to this is the result, in burn patients, of the use of Sulfamylon (mafenide) acetate cream or of 0.5% silver nitrate solution. However, even with these broad-spectrum agents, resistant species, such as *C. perfringens, Klebsiella,* and *Enterobacter,* may emerge as the dominant potential pathogen of the local flora.

Among the most useful topical antibacterial agents are acetic acid (1 to 5% for *Pseudomonas* nail and toe web infections and bacitracin (500 units per milliliter or gram) for selected superficial *S. aureus* and streptococcal lesions. Occasionally, topical bacitracin may be associated with a cutaneous hypersensitivity reaction. Neomycin (0.5% ointment) and gentamicin (0.17% cream) may be useful in selected patients when mixed gram-negative bacteria require local suppression. Mupirocin (2% ointment) has antibacterial activity against various streptococci and *S. aureus*. It is a safe and effective treatment of impetigo. [41] A number of broad-spectrum antiseptics are also available for topical use, combining antibacterial with nonirritating properties. Povidone-iodine (Betadine) is effective against most gram-positive and gram-negative bacteria but does not persist in the skin to provide a residual action. Chlorhexidine gluconate (4% solution) is an antiseptic that combines broad antibacterial properties with prolonged action due to local accumulation. An alcoholic preparation is especially effective, is not appreciably absorbed into the blood, and generally is not irritating to the skin. [42], [43] These broad-spectrum antiseptics can be used prophylactically or to treat local wounds and superficially infected dermatoses.

The topical therapy of burns is discussed in Chap. 127.

REFERENCES

1. Johnson JE II et al: Studies on the pathogenesis of staphylococcal infection. I. The effect of repeated skin infection. *J Exp Med* **113**:235, 1961

2. Leyden JJ et al: Experimental infections with group A streptococci in humans. *J Invest Dermatol* **75**:196, 1980

3. Elek SD: Experimental staphylococcal infections in the skin of man. *Ann N Y Acad Sci* **65**:85, 1956

4. Wolfson JS et al: Dermatologic manifestations of infection in the compromised host. *Annu Rev Med* **34**:205, 1983

5. Kligman AM et al: Bacteriology. *J Invest Dermatol* **67**:160, 1976

6. Miller SJ et al: In vitro and in vivo antistaphylococcal activity of human stratum corneum lipids. *Arch Dermatol* **124**:209, 1988

7. Lacey RW, Lord VL: Sensitivity of staphylococci to fatty acids: Novel inactivation of linolenic acid by serum. *J Med Microbiol* **14**:41, 1981

8. Leyden JJ et al: Experimental inoculation of *Pseudomonas aeruginosa* and *Pseudomonas cepacia* on human skin. *J Soc Cosmet Chem* **31**:19, 1980

9. Shinefield HR et al: Bacterial interference, in *Skin Bacteria and Their Role in Infection,* edited by HI Maibach, G Hildick-Smith. New York, McGraw-Hill, 1965

10. Swartz MN: Skin microbiology, in *Encyclopedia of Microbiology,* 2nd ed., vol 4, edited by J Lederberg, M Alexander, B Bloom, D Hopwood, R Hull, B Iglewski, A Laskin, S Oliver, M Schaechter, W Summers. New York Academic Press, 2000, p 271

11. Fattom A et al: Laboratory and clinical evaluation of conjugate vaccines composed of Staphylococcus aureus type 5 and type 8 capsular polysaccharides bound to *Pseudomonas aeruginosa* recombinant exoprotein A. *Infect Immun* **61**:1023, 1993

12. Elin RJ et al: Biology of endotoxin. *Annu Rev Med* **27**:127, 1976

13. Wolff SM: Biological effects of bacterial endotoxins in man. *J Infect Dis* **128**:S259, 1973

14. Young LS et al: University of California/Davis interdepartmental conferences on gram-negative septicemia. *Rev Infect Dis* **13**:666, 1991

15. Tracey KJ et al: Cachectin/tumor necrosis factor. *Lancet* **1**:1122, 1989

16. Dinarello CA et al: New concepts on the pathogenesis of fever. *Rev Infect Dis* **10**:168, 1988

17. Michie HR et al: Detection of circulating tumor necrosis factor after endotoxin administration. *N Engl J Med* **318**:1481, 1988

18. Cannon JG et al: Circulating interleukin-1 and tumor necrosis factor in septic shock and experimental endotoxin fever. *J Infect Dis* **161**:79,

1990

19. Waage A et al: Association between tumor necrosis factor in serum and fatal outcome in patients with meningococcal disease. *Lancet* **1**:355, 1987

20. Girardin E et al: Tumor necrosis factor and interleukin-1 in the serum of children with severe infectious purpura. *N Engl J Med* **319**:397, 1988

21. Tracey KJ et al: Anti-cachectin/TNF monoclonal antibodies prevent septic shock during lethal bacteraemia. *Nature* **330**:662, 1987

22. Faust SN et al: Dysfunction of endothelial protein C activation in severe meningococcal sepsis. *N Engl J Med* **345**:408, 2001

23. Bernard GR et al: Efficacy and safety of recombinant human activated protein C for severe sepsis. *N Engl J Med* **344**:699, 2001

24. Gold WL, Salit IE: *Aeromonas hydrophila* infections of skin and soft tissue: Report of 11 cases and review. *Clin Infect Dis* **16**:69, 1993

25. Fang FC, Madinger NE: Resistant nosocomial gram-negative bacillary pathogens: *Acinetobacter baumannii, Xanthomonas maltophilia,* and *Pseudomonas cepacia,* in *Current Clinical Topics in Infectious Diseases—16*, edited by JS Remington, MN Swartz. Cambridge, MA, Blackwell Science, 1996, p 52

26. Chuang Y-C et al: *Vibrio vulnificus* infection in Taiwan: Report of 28 cases and review of clinical manifestations and treatment. *Clin Infect Dis* **15**:271, 1992

27. Bornstein DL et al: Anaerobic infections-review of current experience. *Medicine (Baltimore)* **43**:207, 1964

28. Cluff LE: The inflammatory response of skin to bacterial invasion, in *Skin Bacteria and Their Role in Infection,* edited by HI Maibach, G Hildick-Smith. New York, McGraw-Hill, 1965, p 95

29. Hook EW III et al: Microbial evaluation of cutaneous cellulitis in adults. *Arch Intern Med* **146**:295, 1986

30. Sachs MK: The optimum use of needle aspiration in the bacteriologic diagnosis of cellulitis in adults. *Arch Intern Med* **150**:1907, 1990

31. Kielhofner MA et al: Influence of underlying disease process on the utility of cellulitis needle aspirates. *Arch Intern Med* **148**:2451, 1988

32. Howe PM et al: Etiologic diagnosis of cellulitis: Comparison of aspirates obtained from the leading edge and the point of maximal inflammation. *Pediatr Infect Dis J* **6**:685, 1987

33. Gallagher TC, Strober BE: Cutaneous *Bacillus anthracis* infection. *N Engl J Med* **345**:1646, 2001

34. Stamenkovic I et al: Early recognition of potentially fatal necrotizing fasciitis. The use of frozen-section biopsy. *N Engl J Med* **310**:1689, 1984

35. Bernard P et al: Streptococcal cause of erysipelas and cellulitis in adults. A microbiologic study using a direct immunofluorescence technique. *Arch Dermatol* **125**:779, 1989

36. Roche KJ et al: Cutaneous anthrax infection. *N Engl J Med* **345**:1611, 2001

37. Sanders CC et al: ß-Lactam resistance in gram-negative bacteria: Global trends and clinical impact. *Clin Infect Dis* **15**:824, 1992

38. Murray BE: New aspects of antimicrobial resistance and the resulting therapeutic dilemmas. *J Infect Dis* **163**:1185, 1991

39. Neu HC: The crisis in antibiotic resistance. *Science* **257**:1064, 1992

40. Topical antibiotics [editorial]. *BMJ* **1**:1494, 1977

41. Goldfarb J et al: Randomized clinical trial of topical mupirocin versus oral erythromycin for impetigo. *Antimicrob Agents Chemother* **32**:1780, 1988

42. Chlorhexidine and other antiseptics [editorial]. *Med Lett Drug Ther* **18**:85, 1976

43. Lilly HA et al: Detergents compared with each other and with antiseptics as skin “degerming” agents. *J Hyg (Lond)* **82**:89, 1979

T>

Chapter 194

Peter Lee Matthew Zipoli Arnold Weinberg Morton Swartz Richard Johnson

Pyodermas: Staphylococcus aureus, Streptococcus, and Other Gram-Positive Bacteria

STAPHYLOCOCCAL SKIN INFECTIONS
General Features
Superficial Staphylococcal Pyodermas
STAPHYLOCOCCAL BACTEREMIA AND ENDOCARDITIS
Syndromes Caused by Staphylococcal Exotoxins
STREPTOCOCCAL SKIN INFECTIONS
General Features
Specific Diseases Caused by Group A (and Other) Streptococci (Table 194-5)

REFERENCES

Normal human skin is colonized soon after birth by a large number of bacteria that live as commensals on the epidermis and epidermal appendages. Coagulase-negative staphylococci (*S. epidermidis*) are inoculated during vaginal passage; coryneform bacteria take up residence on neonatal skin shortly after birth; and within several weeks after birth, the flora of neonatal skin is similar to that of adults (for further reading see Chap. 193).

The majority of the primary and secondary pyodermas (cutaneous bacterial infections) are caused by either *S. aureus* or group A streptococcus. *S. aureus* pyodermas occur in individuals who are nasal carriers of the organism, which, when translocated onto the skin, is able to gain access via small breaks in the cutaneous integrity and cause superficial infections. Group A streptococcal pyodermas occur following colonization of the skin either from the skin of another individual colonized with group A streptococci or, less likely, from the patient's nasopharynx. *S. aureus* and group A streptococcus cause a broad clinical spectrum of infection, that is, superficial pyodermas and invasive soft-tissue infections (see Chap. 196), depending on the organism, on the anatomic location of infections, and on host factors.

STAPHYLOCOCCAL SKIN INFECTIONS

Staphylococci are classified into two major groups: the coagulase-negative staphylococci and coagulase-positive (*S. aureus*) staphylococci. Many different species of coagulase-negative staphylococci are found on the skin, the ratio varying according to the site. *S. epidermidis* is the most common. Individuals carry a combined minimum of 10 to 24 temporary and resident strains of *S. epidermidis*. The relatively high number of *S. epidermidis* strains is attributable in part to the wide habitat and niche range of this species; this number is usually maintained on the host even though the specific strain composition may change over time. *S. epidermidis* is a reluctant pathogen but is capable of causing superficial and invasive infections (particularly about implanted foreign bodies such as intravascular catheters).

S. aureus is a persistent member of the microbial flora in 10 to 20 percent of the population. Carriage is transient or intermittent in other individuals. Approximately 30 to 50 percent of healthy adults harbor *S. aureus* at some site at any given time. As many as 84 percent of healthy individuals have occasional carriage of *S. aureus* in their anterior nares. [1] Other sites of colonization include the axillae, perineum, pharynx, and hands. Conditions predisposing to *S. aureus* colonization include atopic dermatitis, diabetes mellitus (insulin-dependent), dialysis (hemo- and peritoneal), intravenous drug use, and HIV infection.

S. aureus is an aggressive pathogen and the most common cause of primary pyodermas and soft-tissue infections (STIs), as well as of secondary infections on disease-altered skin. *S. aureus* in pyodermas or STIs can invade the bloodstream, producing bacteremia, metastatic infection such as osteomyelitis, and acute infective endocarditis. Some strains of *S. aureus* also produce exotoxins, which cause constellations of systemic symptoms such as staphylococcal scalded-skin syndrome (SSSS), and staphylococcal toxic shock syndrome (TSS).

General Features

BACTERIOLOGY AND PATHOGENESIS Colonization by *S. aureus* may be transient or represent a prolonged carrier state. *S. aureus* produces many cellular components and extracellular products that may contribute to its pathogenicity. The role of these components in disease is not well understood, except for the variety of exotoxins that are made and secreted extracellularly. The production of coagulase, leukocidin, alpha toxin, and the like, may be the same in *S. aureus* strains isolated from staphylococcal cellulitis as in those from normal skin of the carrier. Thus, host factors such as immunosuppression, glucocorticoid therapy, and atopy may also play a major role in the pathogenesis of staphylococcal infections. Preexisting tissue injury or inflammation (surgical wound, burn, trauma, dermatitis, retained foreign body) are of major importance in the pathogenesis of staphylococcal disease. The production of coagulase, a factor capable of clotting plasma, has been employed in the past as the in vitro criterion of the potential pathogenicity of a staphylococcal strain. Coagulase may play a role in the development of the staphylococcal abscess by producing local fibrin thrombi that protect organisms and concentrate toxic factors elaborated by these pathogens. The surface of *S. aureus*, and particularly of coagulase-negative staphylococci, may be very mucoid, which facilitates adherence of the organism to surfaces of foreign bodies such as intravascular catheters or prostheses. Increased epithelial cell adherence is a factor in the increased incidence of *S. aureus* infections in individuals treated with oral retinoids. Exotoxins elaborated by *S. aureus* (Table 194-1) include enterotoxins and toxic shock syndrome toxin 1 (TSST-1), involved in TSS and related illnesses, and exfoliative toxins A and B, involved in SSSS (see Chap. 195) and bullous impetigo. These exotoxins, as

well as the similar toxins produced by group A streptococcus, are called *superantigens*. Superantigens act by binding directly to constitutively expressed human leukocyte antigen (HLA)-DR molecules [major histocompatibility complex (MHC) II] on professional antigen-presenting cells without antigen processing. While conventional antigens require recognition by all five elements of the T cell–receptor complex, superantigens require only the variable region of the ß chain (Vß). As a result, 5 to 30 percent of resting T cells may be activated where the "normal" antigenic response is only 0.0001 to 0.01 percent of T cells. [2] Nonspecific T cell activation leads to massive systemic release of cytokines, especially interleukin (IL)-2, interferon (IFN)-?, and tumor necrosis factor (TNF)-ß from T cells and IL-1 and TNF-a from macrophages. [3] Superantigen stimulation of T cells also results in activation and expansion of lymphocytes expressing specific T cell–receptor Vß region. They may activate B cells leading to high levels of IgE or autoantibodies. [4] Also, there is evidence that superantigens selectively induce cutaneous lymphocyte-associated antigen (CLA) on T cells, thereby "homing" them to the skin. [5]

Toxin	Clinical Syndrome
Enterotoxins B and C	TSS (nearly 50% of nonmenstrual cases)
TSS toxin 1 (TSST-1)	TSS (nearly all menstrual cases)
	Scarlatiniform eruption (staphylococcal scarlet fever)
Exfoliative toxins A and B	SSSS
	Bullous impetigo

TABLE 194-1 **Exotoxins (Superantigens) Produced by** *Staphylococcus aureus*

Drug resistance A major problem in dealing with staphylococcal infections has been the emergence of antibiotic-resistant strains, particularly those resistant to penicillin and the semisynthetic penicillinase-resistant penicillins. Undoubtedly, the initial introduction of the penicillinase-resistant penicillins has altered considerably the prognosis for serious staphylococcal infections. However, with ever-increasing use of such penicillins, methicillin-resistant *S. aureus* (MRSA) strains have become a major epidemiologic problem since the 1980s. Resistance to methicillin indicates pan-resistance to all beta-lactamX antibiotics. Recently, intermediate-level resistance of MRSA to vancomycin has emerged and constitutes a potential further problem in treatment. An alarming factor is that while in some countries *S. aureus* infection prevalence has not changed drastically over the years, the percentage of MRSA isolates of these infections has significantly increased. Those at higher risk for acquiring colonization or infection with MRSA are adults over 65 year of age, the chronically ill, those with prolonged hospitalizations (especially surgical), exposure to others with MRSA and prior antibiotic therapy. The main MRSA reservoirs are health care workers and hospitalized patients with subsequent transmission primarily through direct contact. [6] Attempts to eradicate MRSA have generally been unsuccessful. Treatment of anterior nares and wounds with mupirocin ointment has been shown to decrease *S. aureus* colonization but has failed to decrease the rate of transmission to a roommate in a long-term-care facility. [7] Although there are many other reports of topical mupirocin being used to reduce colonization of MRSA and methicillin-sensitive *S. aureus* (MSSA) strains, indiscriminate use of topical mupirocin must be avoided because significant mupirocin resistance has already emerged. [8]

Epidemiology At first glance, the high frequency of staphylococcal colonization of the respiratory tract and the frequency of staphylococci in our immediate environment suggest that their spread from person to person occurs principally via respiratory transmission or fomites. However, careful epidemiologic studies using phage-typing techniques suggest that transfer of organisms to patients occurs predominantly via the hands of personnel rather than through the air. This appears to be particularly true in newborn nurseries, where this route is important in the dissemination of the organisms from nasal carriers and also in the transfer of staphylococci between babies. Any individuals with open staphylococcal infections are particularly dangerous potential carriers and transmitters of infection. Nasal carriage of *S. aureus* appears to be a major risk factor for wound infection after cardiac surgery, resulting in higher mortality rates and longer postoperative stays. [9] The rate of *S. aureus* bacteremia is also higher in nasal carriers of *S. aureus*. [10] Good nursery technique, careful handling of patients, strict hand-washing procedures, and isolation of patients with open draining staphylococcal infections are important in the reduction of transmission of staphylococci. In older adults, *S. aureus* accounts for 9 percent of nosocomial infections and follows only *Escherichia coli, Pseudomonas aeruginosa*, and enterococci in prevalence. [11]

Immunity The high prevalence of staphylococci and staphylococcal infections is substantiated by the almost universal presence in adults of circulating antibody to one or more cell-wall antigens or extracellular toxins. The occurrence of staphylococcal infections in the presence of these antibodies suggests that they are not the primary determinants of resistance to such infections. Immunization of experimental animals with alpha toxin does not afford protection against staphylococcal disease following challenge. Hypersensitivity may play a role in recurrent staphylococcal skin infections in humans.

Superficial Staphylococcal Pyodermas

In industrialized nations, *S. aureus* is the most common cause of superficial pyodermas, having more of a "market share" than it did several decades ago. Group A streptococcus continues to be a common cause of pyoderma in developing countries. Pyoderma represents infections in the epidermis, just below the stratum corneum (impetigo) or in hair follicles (folliculitis) (Table 194-2). Untreated, superficial pyodermas can extend into the dermis, resulting in ecthyma and furuncle formation.

TABLE 194-2 **Infections and Toxin Syndromes Involving the Skin and Soft Tissues Caused by** *Staphylococcus aureus*

IMPETIGO Two clinical patterns of impetigo are recognized: bullous and nonbullous. Bullous impetigo is caused by *S. aureus*. Several decades ago, nonbullous impetigo was most commonly caused by group A streptococcus (see "Streptococcal Impetigo," below). Currently, in industrialized nations, nonbullous impetigo is most commonly caused by *S. aureus* and less often by group A streptococcus, or by both organisms. Group A streptococcus remains a common cause of nonbullous impetigo in developing nations.

Nonbullous impetigo This type accounts for >70 percent of cases of impetigo; it occurs in children of all ages as well as in adults. Intact skin is usually resistant to colonization or impetiginization, probably because of absence of fibronectin receptors for teichoic acid moieties on *S. aureus* and group A streptococcus. When both organisms are present, group A streptococcus appears to be the primary pathogen and *S. aureus* the secondary invader of the lesions (see "Streptococcal Impetigo," below). Production of bacteriocins, produced by certain *S. aureus* strains (phage group 71) and highly bactericidal to group A streptococcus, may be responsible for the isolation of only *S. aureus* from some lesions initially caused by streptococci. The sequence of spread of *S. aureus* is from nose to normal skin (about 11 days later) and to skin lesions (after another 11 days). Lesions commonly arise on the skin of the face (especially around the nares) or extremities after trauma. Pruritus may be present in some cases. Nasal carriers of *S. aureus* can present with a very localized type of impetigo confined to the anterior nares and the adjacent lip area (Fig. 194-1); soreness of the area is a common complaint (see Fig. 194-2). Conditions that disrupt the integrity of the epidermis, providing a portal of entry of impetiginization, include insect bites, epidermal dermatophytoses, herpes simplex, varicella, abrasions, lacerations, and thermal burns. The initial lesion is a transient vesicle or pustule (see Fig. 194-2) (usually not seen by the patient or the health care worker) that quickly evolves into a honey-colored crusted plaque that can enlarge to >2 cm in diameter (see Fig. 194-1). Surrounding erythema may be present. Constitutional symptoms are absent. Regional lymphadenopathy may be present in up to 90 percent of patients with prolonged untreated infection.

FIGURE 194-1 *S. aureus:* impetigo. Erythema and crusting on the nose and moustache area (*A*), which can spread to involve the entire centrofacial region (*B*).

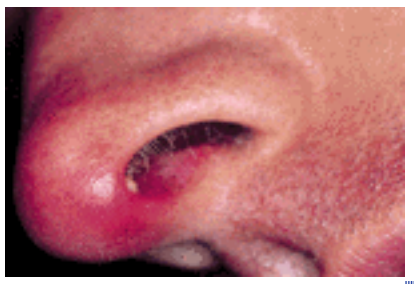

FIGURE 194-2 *S. aureus:* nasal carriage with impetigo. Erythema with a small pustule on the tip of the nose and nares in individual whose nares are colonized by *S. aureus*.

The differential diagnosis of nonbullous impetigo includes seborrheic dermatitis; atopic dermatitis; allergic contact dermatitis; epidermal dermatophyte infections; tinea capitis; herpes simplex; varicella; herpes zoster; scabies; and pediculosis capitis. Any of these disorders may occur primarily and become secondarily impetiginized with *S. aureus* or group A streptococcus. Untreated, the lesions may slowly enlarge and involve new sites over several weeks. In some individuals, lesions resolve spontaneously. In others, the lesions extend into the dermis forming an ulcer (ecthyma, see below).

Bullous impetigo Three types of skin lesions can be produced by phage group II *S. aureus*, particularly strains 77 and 55: (1) bullous impetigo, (2) exfoliative disease (staphylococcal scalded-skin syndrome), and (3) nonstreptococcal scarlatiniform eruption (staphylococcal scarlet fever). All three represent varying cutaneous responses to extracellular exfoliative toxins ("exfoliatin") types A and B produced by these staphylococci (for descriptions of the toxin and the clinical presentation see Chap. 195). Exfoliative toxin A acts as a serine protease of desmoglein 1, the desmosomal cadherin that is also the target of autoantibodies in pemphigus foliaceus. [12] In a study of bullous impetigo, 51 percent of patients had concurrent *S. aureus* cultured from the nose or throat; 79 percent of cultures grew the same strain from both sites. Bullous impetigo occurs more commonly in the newborn and in older infants, and is characterized by the rapid

progression of vesicles to flaccid bullae (Fig. 194-3). Several decades ago, extensive bullous impetigo (archaic term: pemphigus neonatorum or Ritter's disease) occurred in epidemics within neonatal nurseries.

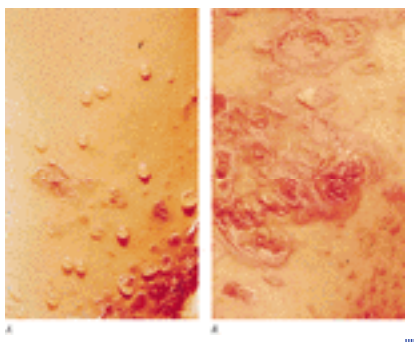

FIGURE 194-3 *S. aureus:* bullous impetigo. *A*. Multiple vesicles with clear and turbid contents that (*B*) rapidly coalesce to form flaccid bullae.

Bullae usually arise on areas of grossly normal skin. The Nikolsky sign (sheetlike removal of epidermis by shearing pressure) is not present. Bullae initially contain clear yellow fluid that subsequently becomes dark yellow and turbid (Fig. 194-3A), and their margins are sharply demarcated without an erythematous halo. The bullae are superficial, and within a day or two, they rupture and collapse, at times forming thin, light-brown to golden-yellow crusts (Fig. 195-3B). So-called bullous varicella represents superinfection by *S. aureus* (phage group II) of varicella lesions (bullous impetiginization). The differential diagnosis is that of blisters localized to one body region and includes allergic contact dermatitis (e.g., poison ivy or oak); pemphigus vulgaris; bullous pemphigoid; erythema multiforme; dermatitis herpetiformis; thermal burns; bullous fixed drug reaction; SSSS; bullous tinea pedis; and bullous insect bites. Gram stain of exudates from bullous impetigo reveals gram-positive cocci in clusters; *S. aureus* belonging to phage group II can be cultured from the contents of intact bullae. In comparison, Gram stain of exudates from lesions of SSSS do not show staphylococci, and *S. aureus* are not isolated on culture. Bulla formation in the latter condition is caused by distant production of toxin rather than local infection (see Chap. 195). Histologically, the lesions of bullous impetigo show vesicle formation in the subcorneal or granular region, occasional acantholytic cells within the blister, spongiosis, edema of the papillary dermis, and a mixed infiltrate of lymphocytes and neutrophils around blood vessels of the superficial plexus.

Course of staphylococcal impetigo Untreated, invasive infection can complicate *S. aureus* impetigo, including cellulitis, lymphangitis, and bacteremia, with resultant osteomyelitis, septic arthritis, pneumonitis, and septicemia. Exfoliatin production can lead to SSSS in infants, and in adults who are immunocompromised or have impaired renal function.

Management of staphylococcal impetigo Local treatment with mupirocin ointment or cream and removal of crusts and maintenance of cleanliness is sufficient to cure mild cases. [13] However, the results are further improved, particularly in extensive cases, by the administration of systemic antibiotics. The frequency of isolation of group A streptococcus makes such therapy a reasonable approach in most patients who have a significant degree of involvement. Staphylococcal impetigo responds quite promptly to appropriate treatment. In an adult with extensive or bullous lesions, dicloxacillin (or similar penicillinase-resistant semisynthetic penicillin) (250 to 500 mg PO qid), or erythromycin (in the penicillin-allergic patient) (250 to 500 mg PO qid) should be given. Treatment should be continued for 5 to 7 days (10 days if streptococci are isolated). Also, a single dose of oral azithromycin (in adults 500 mg on the first day, 250 mg daily on the next 4 days) has been shown to be equally as effective as dicloxacillin for skin infections in adults and children. For impetigo caused by erythromycin-resistant *S. aureus*, which is commonly isolated from impetigo lesions of children, amoxicillin plus clavulanic acid (Augmentin) (25 mg/kg per day given tid), cephalexin (40 to 50 mg/kg per day), cefaclor (20 mg/kg per day given tid), cefprozil (20 mg/kg once daily), or clindamycin (15 mg/kg per day tid or qid) given for 10 days are effective alternative therapies.

ECTHYMA Ecthyma is usually a consequence of neglected impetigo. *S. aureus* and/or group A streptococcus can be isolated on culture. Untreated staphylococcal or streptococcal impetigo can extend more deeply, penetrating the epidermis, producing a shallow crusted ulcer (Fig. 194-4). Ecthymatous lesions can evolve from a primary pyoderma or within a preexisting dermatosis or site of trauma (insect bites or excoriations). Ecthyma gangrenosum is a cutaneous ulcer caused by Pseudomonas aeruginosa and resembles staphylococcal or streptococcal ecthyma (see Chap. 197).

FIGURE 194-4 *S. aureus:* ecthyma. Multiple thickly crusted ulcers on the leg of a patient with diabetes and renal failure. Ecthymatous lesions were also present on the other leg, the arms, and the hands.

Ecthyma occurs most commonly on the lower extremities of children, or neglected elderly patients, or individuals with diabetes. Poor hygiene and neglect are key elements in pathogenesis. Multiple ecthymatous ulcers on the ankle and dorsum of the foot were the most common pyodermas seen during wartime in tropical climates. [14] The ulcer has a “punched out” appearance when the dirty grayish-yellow crust and purulent material are débrided. The margin of the ulcer is indurated, raised, and violaceous (see Fig. 194-4), and the granulating base extends deeply into the dermis. Untreated ecthymatous lesions enlarge over weeks to months to a diameter of 2 to 3 cm or more. The lesions are slow to heal, requiring several weeks of antibiotic treatment for resolution. Problems of spread by autoinoculation or by insect

vectors and of poststreptococcal sequela (glomerulonephritis) are the same as with impetigo.
Management of ecthyma Same as for staphylococcal impetigo (see above).
FOLLICULITIS This is a pyoderma that begins within the hair follicle, and is classified according to the depth of invasion, that is, superficial and deep, and by microbial etiology (Table 194-3).

Bacterial folliculitis
S. aureus folliculitis
Periporitis staphylogenes
Superficial (follicular or Bockhart's impetigo)
Deep (sycosis) (may progress to furuncle (boil) or carbuncle)
P. aeruginosa folliculitis ("hot tub" folliculitis)
Gram-negative folliculitis (occurs at site of acne vulgaris usually the face during long-term antibiotic therapy)
Syphilitic folliculitis (secondary) (acneform)
Fungal folliculitis
Dermatophytic folliculitis
Tinea capitis
Tinea barbae
Majocchi's granuloma
Pityrosporum folliculitis
Candida folliculitis
Viral folliculitis
Herpes simplex virus folliculitis
Follicular molluscum contagiosum
Infestation
Demodicidosis

TABLE 194-3 **Classification of Infectious Folliculitis**

Superficial folliculitis Superficial folliculitis has also been termed follicular or Bockhart's impetigo. A small fragile dome-shaped pustule occurs at the infundibulum (ostium or opening) of a hair follicle, often on the scalps of children and in the beard area (Fig. 194-5), axillae, extremities, and buttocks of adults. Isolated staphylococcal folliculitis is common on the buttock of adults. “Periporitis staphylogenes” refers to secondary infection of miliaria of the neonate by *S. aureus*. Staphylococcal blepharitis is an *S. aureus* infection of the eyelids, presenting with scaling (squamous type) or crusting (ulcerative type) of the eyelid margins, often with associated conjunctivitis; the differential diagnosis includes seborrheic dermatitis and rosacea of the eyelid.

FIGURE 194-5 *S. aureus:* superficial folliculitis. Multiple pustules confined to the beard area.

S. aureus folliculitis must be differentiated from other folliculocentric infections (see Table 194-3). Black men are subject to three noninfectious, inflammatory, follicular disorders: pseudofolliculitis barbae, which occurs on the lower beard area (Fig. 194-6); folliculitis keloidalis, on the nape of the neck; and perifolliculitis capitis, on the scalp. *S. aureus* can cause secondary infection in these inflammatory disorders. Exposure to mineral oils, tar products, and cutting oils can cause an irritant folliculitis. Acne vulgaris, drug-induced acneform eruptions, rosacea, hidradenitis suppurativa, acne necrotica of the scalp, and eosinophilic folliculitis of HIV disease must be distinguished from infectious folliculitis as well. Also, folliculitis caused by *P. aeruginosa* may be acquired from exposure in “hot tubs” (see Chap. 197).

FIGURE 194-6 Pseudofolliculitis barbae. Multiple papules in the lower beard area caused by ingrowing of the curved hair shaft in a black male who shaves. If pustules are present, secondary *S. aureus* infection must be ruled out.

Deep folliculitis Sycosis barbae is a deep folliculitis with perifollicular inflammation occurring in the bearded areas of the face and upper lip (Fig. 194-7). If untreated, the lesions may become more deeply seated and chronic. Local treatment with warm saline compresses and local antibiotics (mupirocin) may be sufficient to control infection. More extensive cases require systemic antibiotic therapy. Dermatophytic folliculitis must be differentiated from *S. aureus* folliculitis. In the latter fungal infection, the hairs are usually broken or loosened, and there are suppurative or granulomatous nodules rather than discrete pustules (see Chap. 205).

FIGURE 194-7 Sycosis barbae. Deep staphylococcal folliculitis of the mustache region.

Lupoid sycosis is a deep, chronic form of sycosis barbae associated with scarring, usually occurring as a circinate lesion. A central cicatrix surrounded by pustules and papules gives the appearance of lupus vulgaris (see Chap. 200).
FURUNCLES AND CARBUNCLES A furuncle or boil is a deep-seated inflammatory nodule that develops about a hair follicle, usually from a preceding, more superficial folliculitis and often evolving into an abscess. A carbuncle is a more extensive, deeper, communicating, infiltrated lesion that develops when suppuration occurs in thick inelastic skin. Furuncles arise in hair-bearing sites, particularly in regions subject to friction, occlusion, and perspiration, such as the

neck, face, axillae, and buttocks. They may complicate preexisting lesions such as atopic dermatitis, excoriations, abrasions, scabies, or pediculosis, but occur more often in the absence of any local predisposing causes. In addition, a variety of systemic host factors is associated with furunculosis: obesity, blood dyscrasias, defects in neutrophil function (defects in chemotaxis associated with eczema and high levels of IgE, defects in intracellular killing of organisms as in chronic granulomatous disease of childhood), treatment with glucocorticoids and cytotoxic agents, and immune globulin deficiency states. Whether diabetes mellitus predisposes to furunculosis is still controversial; once established, however, the process is often more extensive in patients with diabetes. The majority of patients with problems of furunculosis appear to be otherwise healthy. A furuncle starts as a hard, tender, red folliculocentric nodule in hair-bearing skin that enlarges and becomes painful and fluctuant after several days (i.e., undergoes abscess formation; Fig. 194-8A). Rupture occurs, with discharge of pus and often a core of necrotic material. The pain surrounding the lesion then subsides, and the redness and edema diminish over several days to several weeks. Furuncles may occur as solitary lesions or as multiple lesions in sites such as the buttocks (Fig. 194-8B).

FIGURE 194-8 *A*. Furuncle of the upper lip. The lesion is nodular and the central necrotic plug is covered by purulent crust. Several small pustules are seen lateral to the center of the lesion. *B*. Multiple furuncles. Multiple abscesses on the buttocks of long standing in a young man with inflammatory bowel disease. The lesions healed with scarring after a prolonged course of dicloxacillin.

A carbuncle is a larger, more serious inflammatory lesion with a deeper base, characteristically occurring as an extremely painful lesion at the nape of the neck, the back, or thighs (Fig. 194-9). Fever and malaise are often present, and the patient may appear quite ill. The involved area is red and indurated, and multiple pustules soon appear on the surface, draining externally around multiple hair follicles. The lesion soon develops a yellow-gray irregular crater at the center, which may then heal slowly by granulating, although the area may remain deeply violaceous for a prolonged period. The resulting permanent scar is often dense and readily evident.

FIGURE 194-9 Carbuncle. This lesion represents multiple confluent furuncles draining pus from multiple openings.

The differential diagnosis of furuncles and carbuncles includes “cystic acne,” kerion, a deep-seated dermatophytic infection with abscess formation of hair follicles (see Chap. 205), hidradenitis suppurativa (axillae and anogenital region), ruptured epidermal inclusion cyst, furuncular myiasis (e.g., *Dermatobia hominis*) apical (dental) abscess (face), and the external sites (on an extremity of a beginning fistulous track from an underlying osteomyelitis). Extensive furunculosis or a carbuncle may be associated with leukocytosis, particularly when there is a large amount of unliberated pus, surrounding cellulitis, or bacteremia. *S. aureus* is almost always the cause of furuncles and carbuncles. Histologic examination of a furuncle shows a dense polymorphonuclear inflammatory process in the dermis and subcutaneous fat. In carbuncles, multiple abscesses, separated by connective-tissue trabeculae, infiltrate the dermis and pass along the edges of the hair follicles, reaching the surface through openings in the undermined epidermis. The diagnosis is made on the basis of the clinical appearance. Gram stain of pus, clusters of gram-positive cocci, or isolation of *S. aureus* on culture confirms the diagnosis. The major problems with furunculosis and carbuncles are bacteremic spread of infection and recurrence. Lesions about the lips and nose raise the specter of spread via the facial and angular emissary veins to the cavernous sinus. Invasion of the bloodstream may occur from furuncles or carbuncles at any time, in an unpredictable fashion, resulting in metastatic infection such as osteomyelitis, acute endocarditis, or brain abscess. Manipulation of such lesions is particularly dangerous and may facilitate spread of infection via the bloodstream. Fortunately, these complications are not common. Recurrent furunculosis is a troublesome process that may continue for many years. Most often these lesions are limited to the area of the follicles, but sometimes they extend to produce surrounding cellulitis or bacteremia. Individuals who perspire excessively or who have poor skin hygiene appear more disposed to recurrent furunculosis.

Management of folliculitis, furuncles, and carbuncles Simple furunculosis may be treated by local application of moist heat, which relieves discomfort, aids in the localization of the infection, and promotes drainage. A carbuncle or a furuncle with surrounding cellulitis, or one with associated fever, should be treated with a systemic antibiotic. For severe infections or infections in a dangerous area, maximal antibiotic dosage should be employed by the parenteral route, the patient should be put to bed, and the involved area should be immobilized. If MRSA is implicated or suspected in serious infections, vancomycin (1.0 to 2.0 g IV daily in divided doses) is indicated. Antibiotic treatment should be continued for at least 1 week. When the lesions are large but localized, painful, and fluctuant, drainage (limited to the necrotic fluctuant area) is indicated. Antimicrobial therapy should be continued until all evidence of inflammation has regressed. After

adequate drainage (spontaneous or surgical) has occurred, moist dressings should not be applied because of the danger of local spread enhanced by tissue maceration. Application of a thin layer of 2% mupirocin ointment about the lesion protects the surrounding skin. Such draining lesions should be covered with a sterile dressing to prevent autoinoculation. Hands should be thoroughly washed after contact with the lesions. The treatment of patients with recurrent furunculosis presents a special and frequently exasperating problem (Table 194-4). There is no evidence that this disease is caused by any specific staphylococcal strains with special biologic properties. In addition to the treatment of acute lesions, as above, treatment involves steps in the prophylaxis of recurrent episodes.

TABLE 194-4 **Management of Recurrent Furunculosis**

ABSCESS As discussed above, abscesses caused by *S. aureus* commonly occur in folliculocentric infections—that is, folliculitis, furuncles, and carbuncles. Abscesses can also occur at sites of trauma, foreign bodies, burns, or sites of insertion of intravenous catheters. The initial lesion is an erythematous nodule. Often if untreated, the lesion enlarges with the formation of a pus-filled cavity (Fig. 194-10). In some cases, the portal of entry is apparent.

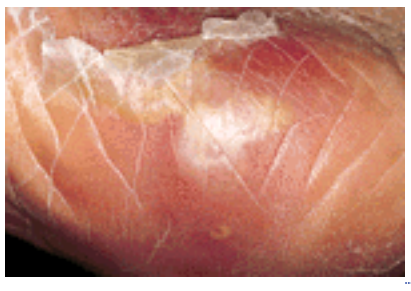

FIGURE 194-10 *S. aureus* abscess. A large painful abscess on the heel of a patient with diabetes improved clinically, however, the severe pain persisted. X-ray films of the heel revealed a broken-off sewing needle. The patient had sensory neuropathy and was unaware of stepping on this foreign body.

Management of abscess (See " Management of Folliculitis, Furuncles, and Carbuncles ," above) The initial treatment of an abscess is incision and drainage. If the abscess recurs at the same site, a foreign body should be ruled out by probing or imaging.

BOTRYOMYCOSIS (See also Chap. 201) This a very rare pyogenic disease, possibly related to a balance between numbers of organisms and host defenses. Predisposing factors include trauma, immunosuppression (HIV disease, hyperimmunoglobulin E syndrome), chronic alcoholism, and diabetes mellitus. The lesions (usually solitary) can occur in skin, bone, and liver. Cutaneous botryomycosis usually presents as a solitary or few lesions, often occurring in the genital area. The lesion has the gross appearance of a ruptured epidermal inclusion cyst (an erythematous circumscribed tender nodule), lichen simplex chronicus, or prurigo nodularis (Fig. 194-11). In the majority of reported cases, a foreign body (fish bone, broom straw, etc.) has played a role in initiating or perpetuating the lesion. For diagnosis and treatment see Chap. 201.

FIGURE 194-11 *S. aureus* botryomycosis. A plaque on the chest had been present for several months in this HIV-infected individual. The diagnosis was confirmed on lesional biopsy findings and culture.

STAPHYLOCOCCAL PARONYCHIA Individuals exposed to hand trauma or chronic moisture are predisposed to staphylococcal paronychia, as well as to other causes of paronychia (e.g., *Candida, Pseudomonas, Streptococcus,* dermatophytes). *S. aureus* is the major infectious cause of acute paronychia, usually around the fingernails, often originating from a break in the skin, such as a hangnail. Clinically, skin and soft tissue of the proximal and lateral nail fold are red, hot, and tender, and if not treated, can evolve to abscess formation (Fig. 194-12).

FIGURE 194-12 *S. aureus* paronychia. An abscess is seen in the dorsum of the finger, beginning in a small break in the cuticle. In contrast, *Candida* paronychia is a space infection, occurring in the space created by the separation of the proximal dorsal nail plate and the overlying proximal nail fold.

In contrast, chronic or recurrent paronychia caused by *Candida albicans* is an infection of the space created by separation of the proximal dorsal nail plate and the undersurface of the proximal nail fold. Candidal paronychia is most common in individuals who have their hands in water for a great deal of time; this is discussed in Chap. 206. Management of paronychia caused by *S. aureus* includes oral and topical antibiotics, and incision and drainage of abscesses.

STAPHYLOCOCCAL WHITLOW (FELON) A whitlow is a purulent infection or abscess involving the bulbous distal end of the finger. The most common causes are *S. aureus* and herpes simplex virus. The portal of entry of *S. aureus* is from a traumatic injury or possible extension of an acute paronychia. This infection is usually very painful. Clinically, an obvious portal of entry is often apparent. The finger bulb is red, hot, tender, and edematous, with possible abscess formation (Fig. 194-13). In contrast, individuals with herpetic whitlows usually have a history of prior lesions occurring in the same site, and present with grouped hemorrhagic vesicles, which may become confluent and form a single bulla (see Chap. 214). Management of a staphylococcal whitlow requires surgical drainage of loculated abscess(es) within the tissue and intravenous antibiotic therapy. X-ray examination of the involved finger is indicated to determine the presence of osteomyelitis.

FIGURE 194-13 *S. aureus* whitlow (felon). A pyogenic granuloma arose 1 week after trauma to the bulb of the thumb. A week later, the bulb became swollen, erythematous, and very tender. Abscess formation is seen with loculation of pus. X-ray films showed early osteomyelitis complicating the whitlow.

STAPHYLOCOCCAL BACTEREMIA AND ENDOCARDITIS (SeeChap. 166)

S. aureus from pyodermas and soft tissue infections can invade lymphatics and blood vessels, resulting in bacteremia and metastatic infection at distant sites, causing diverse processes such as acute bacterial endocarditis (ABE), septic arthritis, or acute osteomyelitis. *S. aureus* infection at internal sites or on the heart valves can result in dissemination to mucocutaneous sites.

Bacteremia with *S. aureus* is defined as seeding of the bloodstream in the presence (“secondary bacteremia”) or absence (“primary bacteremia”) of a defined peripheral focus of infection. The focus of infection is usually community-acquired (furuncle, carbuncle, wound infection) or nosocomial (intravascular catheter, urinary catheter, or chest tube). In the absence of localizing findings, the clinical presentation may be of a flulike syndrome and *S. aureus* may be isolated on multiple blood cultures. Presumably in this case, a small, unnoticed skin focus has been the initial source of bacteremia. Without an identifiable peripheral focus and in the presence of repeatedly positive blood cultures, endocarditis is assumed and the patient treated accordingly, even in the absence of a heart murmur, demonstrable vegetations, or embolic events.

The risk of endocarditis is probably less than 10 percent in patients with secondary bacteremia (from a defined peripheral site). Continued bacteremia increases the risk for endocarditis. In acute *S. aureus* infectious endocarditis, skin and/or mucous membrane lesions occur in 50 percent of patients, and can provide a clue to the diagnosis. These lesions include petechiae on the digits or extremities; a full spectrum of larger skin lesions with elements of infarction (Fig. 194-14), suppuration, and hemorrhage (pustules, subcutaneous abscesses, and purulent purpura); gangrenous symmetric involvement of the extremities; and purpura fulminans (see below) as a manifestation of disseminated intravascular coagulation. The purulent purpura consists of an area of purpura with a white purulent center. (Gram-stained smear of the aspirated contents from the center of the lesion shows gram-positive cocci in clusters and polymorphonuclear inflammatory cells.) Multiple tender subcutaneous nodules (2 to 4 cm) with erythema of the overlying skin may occur, with and without abscess formation. Culture of a lesional biopsy specimen often yields the causative *S. aureus*.

FIGURE 194-14 *S. aureus* endocarditis and bacteremia with cutaneous infarctions. Multiple cutaneous infections are seen on the plantar foot of the injected-drug user with acute infective endocarditis; lesions were also present on the other foot and the palms. (*Courtesy of David N. Silvers, MD.*)

Several types of lesions can be seen on the hands of individuals with acute infectious endocarditis. Janeway lesions are typically seen in *S. aureus* endocarditis and Osler's nodes are caused by microemboli leading to vascular occlusion with local vasculitis. Both Osler's nodes and Janeway lesions are escribed in more detail under subacute infectious endocarditis below. Subungual splinter hemorrhages associated with *S. aureus* acute infectious endocarditis occur in the middle third of the nail bed.

Embolization to the eye results in subconjunctival hemorrhage, petechial and flame-shaped hemorrhages in the retina, cotton–wool exudates in the fundus, Roth spots (oval or boat-shaped white areas in the retina surrounded by a zone of hemorrhage), and endophthalmitis (see Chap. 166).

Syndromes Caused by Staphylococcal Exotoxins

STAPHYLOCOCCAL SCALDED-SKIN SYNDROME This condition is described in detail in Chapter 195.
Staphylococcal scarlatiniform eruption This is identical to the generalized scarlatiniform rash with skin tenderness observed in the initial stage of SSSS (Chap. 195). Patients are febrile for the first few days. As in streptococcal scarlet fever (see below), the skin is diffusely erythematous, with a sandpaper roughness. Pastia's lines are present. Pharyngitis, strawberry tongue, and palatal enanthem, typical of streptococcal scarlet fever, are not seen. Bullae and exfoliation do not occur, although Nikolsky's sign may be present in an occasional patient. After 2 to 5 days of erythema, desquamation begins, initially on the face, and extends to involve most of the body. Healing of the skin occurs within 10 days. Staphylococci belonging to phage group II are recovered from sites of staphylococcal infection (conjunctivitis, abscesses, bacteremia, external otitis). These strains generally produce staphylococcal enterotoxins (SEs) similar to toxins responsible for TSS. Thus, staphylococcal scarlet fever may be a milder form of TSS.
STAPHYLOCOCCAL TOXIC-SHOCK SYNDROME TSS is a multiorgan systemic illness due to exotoxin-producing strains of *S. aureus*. It is characterized by a generalized erythematous eruption and a high fever. Additional elements making up the syndrome include (1) hypotension, (2) functional abnormalities in at least three organ systems, and (3) desquamation following the scarlatiniform eruption. More than 1600 cases occurred in a nationwide outbreak between 1979 and 1982, primarily, but not exclusively, in menstruating women. [15]
Bacteriology and pathogenesis Toxic shock syndrome has two forms: menstrual and nonmenstrual. *S. aureus* strains isolated from women with menstrual TSS are usually penicillin-resistant, and more than 93 percent of them produce TSS toxin 1 (TSST-1). In nonmenstrual TSS, 48 percent of isolates produce TSST-1 alone, 26 percent produce enterotoxin B, 7 percent produce enterotoxin C, and 19 percent produce both TSST-1 and enterotoxin C1 together. [16] Illness similar to TSS in humans can be produced in animals inoculated with either purified TSST-1 or with TSST-1–producing strains of *S. aureus*. The manifestations of this illness can be prevented by TSST-1 antiserum. TSST-1 stimulates release of TNF-a, and the induction of the shocklike state appears to be related to the synergistic action of TNF-a with interleukin-1. In 1980, approximately 85 to 90 percent of cases of TSS occurred in women at the time of menstruation; almost all had been tampon users (particularly of superabsorbent types). *S. aureus* has been isolated from vaginal cultures of more than 90 percent of menstruating women with TSS, but from only 10 percent of healthy menstruating women. Cervicovaginal ulcerations, possibly produced or aggravated by tampon use, may have provided the initiating infection and the portal for toxin absorption in menstruating women in whom TSS developed. Furthermore, superabsorbent tampons may allow increased oxygen tension, which results in higher amounts of toxin production. Recurrent menstrual TSS, which has been reported to occur in up to a third of TSS patients, requires two concurrent factors: persistent colonization with toxin producing *S. aureus* and persistent absence of toxin neutralizing antibodies. [17] Staphylococcal infections (skin, soft tissue, bone, lung) in children, men, and nonmenstruating women account for the remaining 10 to 15 percent of cases of TSS and clinical signs of local infection may be absent. Minor surgery, burns, trauma, and abrasions are some of the risk factors for nonmenstrual TSS. Other reported associations include sinusitis, tracheitis, IV drug abuse, HIV infection, influenza, allergic contact dermatitis, gynecologic infection, the postpartum period, and two cases of TSS in children with abrasive injuries beneath casts. [18] Between 1980 and 1990, the number of cases of menstrual TSS declined by more than 90 percent, but the number of nonmenstrual cases remained unchanged, leading to the current higher incidence of nonmenstrual TSS over menstrual TSS. The decrease in menstruation-associated TSS cases is directly related to the removal of superabsorbent tampons.
Clinical manifestations Fever, hypotension (or shock), and a rash (diffuse macular erythroderma) are the initial hallmarks of TSS (Fig. 194-15A). The cutaneous findings include a generalized scarlatiniform (resembling scarlet fever) erythema, most intense around an infected site. The rash may be indistinguishable from that of scarlet fever or may be less striking and suggest the flush associated with fever. Nonpitting edema may occur on the face and extremities. The bulbar conjunctivae show intense injection; the mucosa of the oropharynx, tongue (strawberry tongue), vagina, and tympanic membranes may show intense erythema. Less-common findings include petechiae, bullae, subconjunctival hemorrhages, and ulcerations of the mouth, vagina, esophagus, or bladder. Desquamation of palms and soles occurs 1 to 2 weeks later (Fig. 195-15 *B*). Evidence of multiple other organ dysfunctions seen in TSS include (1) muscular system—myalgias and rhabdomyolysis; (2) central nervous system—toxic encephalopathy; (3) kidney—azotemia; (4) liver—elevated levels of aspartate transaminase and serum bilirubin; and (5) blood—thrombocytopenia. Mortality is approximately 5 percent.

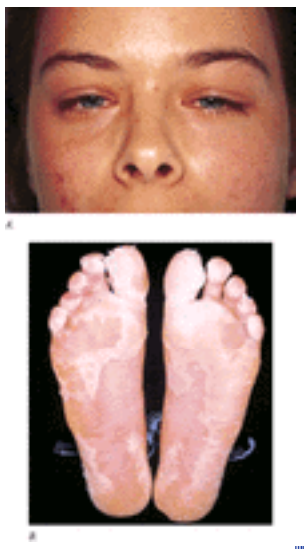

FIGURE 194-15 *S. aureus* toxic shock syndrome. *A*. Erythema and edema of the face with conjunctival injection during the acute presentation. *B*. Residual erythema and desquamation occurring 2 weeks after an episode of toxic shock syndrome; similar findings were also found on the palms. (*Courtesy of Stuart J. Salasche, MD.*)

Differential diagnosis The differential diagnosis include staphylococcal scarlatiniform eruption; SSSS (in which bullae and a positive Nikolsky sign are expected); scarlet fever (not usually associated with hypotension or shock); streptococcal toxic shock–like syndrome; a febrile drug reaction (not usually associated with hypotension); Kawasaki disease (usually in children, and features prominent lymphadenopathy; see Chap. 204); viral exanthem; systemic lupus erythematosus; acute graft-versus-host disease; and adverse cutaneous drug eruptions (confluent exanthematous, toxic epidermal necrolysis, erythema multiforme).

Laboratory findings Leukocytosis and thrombocytopenia are usually present. Microscopic hematuria may be present. Elevated blood urea nitrogen and creatinine levels occur in the majority of patients, and liver-function tests are frequently abnormal. Increased serum creatine kinase levels reflect muscle injury, and myoglobinuria occurs in some patients. Hypocalcemia occurs in many patients but the basis is unclear.

Diagnosis Diagnosis is made on the basis of the clinical constellation of findings in a patient who has an *S. aureus* infection or in a menstruating woman, particularly in a tampon user.

Management Treatment of TSS involves (1) immediate institution of vigorous fluid replacement to combat the hypotension, (2) attention to focal staphylococcal infections (drainage of abscesses, removal of tampons), and (3) systemic antimicrobial therapy aimed at penicillinase-producing *S. aureus* (nafcillin 1.0 to 1.5 g intravenously in the adult every 4 h). Intravenous gamma globulin therapy and fresh-frozen plasma containing immunoglobulins have been successful, especially when administered early in the disease course.

Recalcitrant, erythematous, desquamating disorder This was described by Cone et al. in 1992 based on a series of AIDS patients with a TSS-like syndrome. [19] Clinical features include fever, hypotension, diffuse macular erythema, ocular and oral mucosal injection, strawberry tongue, and delayed desquamation. All have TSST-1, enterotoxin A or enterotoxin B producing *S. aureus* isolates from the blood, subcutaneous tissue or sinuses. Recalcitrant, erythematous, desquamating disorder (RED disorder) is a subacute illness of about 50 days mean duration with frequent recurrences. Despite the subacute nature, it has a higher reported mortality rate than TSS, likely a result of the effect of underlying immunosuppression. Treatment includes antibiotics (nafcillin, vancomycin or cephalosporin), IV fluids, and possibly IVIG.

KAWASAKI SYNDROME (See Chapter 204)

RECURRENT TOXIN-MEDIATED PERINEAL ERYTHEMA This was described by Manders et al. [20] in 1996 as a recurrent, toxin-mediated disease sharing some of the clinical characteristics of Kawasaki syndrome but occurring in young adults, rather than small children. Clinical features include macular erythema of the perineum within 24 to 48 h of a bacterial pharyngitis, strawberry tongue, and extremity changes including erythema, edema, and convalescent desquamation. No fever or hypotension is noted and recurrences are frequent. Culture of the pharynx during the acute pharyngitis identified a TSST-1 producing *S. aureus* or a pyrogenic exotoxin A and B producing group A streptococcus.

ATOPIC DERMATITIS (See Chap. 122) In individuals with atopic dermatitis (AD), *S. aureus* was found in the anterior nares and distal subungual spaces of their fingernails 5 and 10 times more frequently, respectively, than in normal subjects. [21] In children and adults with AD, 78 to 100 percent of eczematous lesions (more commonly in exudative lesions than chronic plaques) are colonized with *S. aureus*. Colonization of noneczematous skin is significantly less frequent. Topical glucocorticoid treatment of involved skin reduces the bacterial skin flora in patients with atopic dermatitis. Approximately 60 percent of isolates from AD patients secrete exotoxins, primarily enterotoxins A and B and TSST-1. These toxins may play a role in the frequent exacerbations seen in these patients since flares often temporally correlate with heavy staphylococcal colonization of the skin.

STREPTOCOCCAL SKIN INFECTIONS

General Features

BACTERIOLOGY AND PATHOGENESIS The Lancefield classification of streptococcal groups (A to T) is based on the C carbohydrate antigens of the cell wall. Although essentially all group A streptococcal strains are beta-hemolytic streptococci (BHS), not all streptococci producing beta-hemolysis belong to group A. Because serologic grouping of streptococci is not generally available, a reasonably accurate presumptive test for group A streptococci is necessary. Bacitracin disk (“Taxos S”) sensitivity has been widely used; group A streptococci are, almost without exception, susceptible to the low concentration of bacitracin contained in the disk, whereas streptococci of other groups are often resistant. Subtyping of group A streptococci can be performed according to their M protein antigenicity (see below). Certain M protein serotypes appear to correlate with greater virulence of the organism. The M protein inhibits phagocytosis, promotes adherence to host cells and allows bacterial growth in human blood. [22] Other virulence factors are cell surface molecules including the hyaluronic acid capsule, C5a peptidase, opacity factor and streptococcal inhibitor of complement (SIC). Secreted proteins playing a role in virulence include streptolysins O and S, cysteine proteinase, pyrogenic exotoxins, streptokinase, hyaluronidase, and other enzymes. The primary invasive streptococcal pyodermas are due almost exclusively to group A streptococcus. The invasive potential of group A streptococcus is

usually considerably greater than that of other streptococci. Nonsuppurative postinfectious complications have been limited mostly to those produced by group A streptococcus. Thus, group A streptococcal infections merit antibiotic treatment and eradication. The hallmarks of invasive group A streptococcal infection (erysipelas, see Chap. 196) are profuse edema, rapid spread through tissue planes, and the relatively thin character of the exudative response. Infection may spread via the lymphatic or hematogenous routes and result in a fulminant clinical course. The presence of streptococci of groups other than A in skin lesions may represent either surface colonization or actual secondary infection in preexisting dermatoses. Group C and group G streptococci have occasionally been implicated in impetiginous lesions, secondarily infected dermatitis, wound infections with lymphangitis, and even in erysipelas and cellulitis. Streptococci of groups B and D have been isolated from infections of skin lesions secondary to ischemia or venous stasis and have particularly involved the perineal area and operative wound sites. As with most secondary infections, those due to group B and group D streptococci are frequently mixed infections with enteric bacteria or *S. aureus*. Group B streptococci may cause cellulitis and otitis in neonates and sometimes in adults. Group L streptococci (often carried by pigs, cattle, and poultry) have been responsible for impetigo, secondarily infected wounds, and paronychias in meat handlers.

EPIDEMIOLOGY OF GROUP A STREPTOCOCCAL INFECTIONS Group A streptococci are usually spread by transfer of organisms from an infected person or carrier through close personal contact. The major source of such spread is from patients with infections in the upper respiratory tract. Approximately 10 percent of the normal population carry group A streptococcus asymptomatically—a higher percentage of adults than of children in the oropharynx and less commonly in the nares and anus. While the carriage rate of group A streptococcus on normal skin is less than 1 percent, a variety of skin lesions and puerperal sepsis may also be the source of intrahospital spread of infection. Group A streptococci introduced into the operating room in the form of a minor skin infection, or even through perianal carriage by a surgeon or anesthetist, may be responsible for an epidemic of streptococcal wound infections. Although viable streptococci are found on a variety of articles in the immediate surroundings of a carrier or infected individual, the major factor in spread is not the articles in the contaminated environment but rather proximity to an individual disseminating the organisms. Because many patients with group A streptococcal skin infections harbor the same organism in their pharynxes, they are, for both reasons, potential sources for spread of infection in a hospital. Particular care must be taken to prevent spread of infection, by isolating such patients until antibiotic therapy has rendered them noncontagious. Despite the salutary effects of penicillin on morbidity and mortality, the overall incidence of streptococcal disease has surged since the mid-1980s. [23] Reports of invasive group A streptococcal infections often associated with shock and multiorgan failure have increased globally. It is possible that more virulent serotypes of group A streptococcus are now distributed in the general population. Localized epidemics continue to appear and during such outbreaks, the carrier and infection rates in the community increase. Carriers may then enter the hospital environment. In this way, streptococci can be introduced into surgical incisions and lacerations and initiate infection. Streptococcal operative infections, because of the rapidity with which they progress, may be more severe and dramatic than those caused by staphylococci. After recovery (without antibiotic treatment) from streptococcal pharyngitis, some individuals may carry the organism for prolonged periods. The carrier state may also occur in the absence of overt antecedent infection. Fifteen to 20 percent of schoolchildren carry group A streptococci in the throat.

DELAYED NONSUPPURATIVE SEQUELAE The incidence of invasive complications (lymphangitis, suppurative lymphadenitis, bacteremia) of streptococcal infections of the skin has decreased in the antibiotic era. Besides these pyogenic complications, a variety of nonsuppurative complications (acute rheumatic fever, acute glomerulonephritis, erythema nodosum) may follow group A streptococcal infections. Distinct differences exist between acute rheumatic fever and acute glomerulonephritis in the site of the antecedent infection, the length of the latent period, and the streptococcal serotypes involved. Acute rheumatic fever may be a complication of group A streptococcal pharyngitis or tonsillitis, but it does not occur following streptococcal skin infections. In contrast, acute nephritis may follow infection of either the skin or the upper respiratory tract. The latent period between streptococcal pharyngitis and the onset of rheumatic fever is 2 to 3 weeks; whereas the latent period for pharyngitis-associated nephritis is about 10 days. A longer latent period, about 3 weeks, is characteristic of acute nephritis associated with streptococcal pyoderma. Group A streptococci are classified into over 80 subtypes, based on the antigenicity of their M proteins (fibrillar structures extending out from the cell surface). While there is as yet no strong evidence of an association between infection with any specific group A serotypes and the subsequent development of rheumatic fever, several serotypes (particularly mucoid strains of types 1, 3, and 18) have been implicated in a few outbreaks of streptococcal sore throat complicated by this sequela. [24] However, there is a clear relationship between infection with certain serotypes and the subsequent occurrence of nephritis—the so-called nephritogenic serotypes. Type 12 is the classic serotype responsible for pharyngitis-associated acute nephritis, but other serotypes, such as 1, 4, 25, and 49, have been implicated. The pyoderma-associated nephritogenic strains generally belong to different serotypes: types 2, 49, 42, 55, 56, 57, and 60. [25], [26] Unlike the pharyngitis strains, the pyoderma serotypes produce lipoproteinase or opacity factor, illustrating a fundamental difference between the two. [23] The skin rather than the pharynx is the principal site of antecedent streptococcal infection causing nephritis, and impetigo is now the most common form of such predisposing skin infections. Major epidemics of pyoderma-associated nephritis have been observed in communities, and multiple cases of overt and subclinical nephritis have occurred within families. The frequency of acute glomerulonephritis following infection with a known nephritogenic strain is 10 to 15 percent; the frequency of rheumatic fever following an unrecognized or inadequately treated pharyngeal infection by any serotype of group A streptococcus is 2 to 3 percent or less. The distinction between nephritogenic and other strains of streptococci that might be associated with rheumatic fever can be seen in studies from Trinidad, a hyperendemic area for pyoderma-associated nephritis. There the streptococcal serotypes causing outbreaks of nephritis differed from the serotypes associated with sporadically occurring cases of acute rheumatic fever in the same population. [24] It has been suggested that several biologic properties are associated with broad categories of group A streptococci. Most M proteins fall into one of two antigenic classes based on the presence (class I) or absence (class II) of a highly conserved antigenic domain. Almost all rheumatic fever outbreak–associated strains belong to serotypes of class I and require a precursor nasopharyngeal infection. However, because many class I serotypes are associated with impetigo as well, and because class II serotypes are responsible for both upper respiratory and skin infections, the class of M protein alone is not a determinant of tissue tropism. Current evidence indicates differences among class I organisms that may relate to their capacities to induce rheumatic fever: class I nasopharyngeal isolates appear to lack human IgG-binding activity, whereas nearly all impetigo isolates of the same class bear human IgG receptors. [27] As in *S. aureus*, there are several group A streptococcal superantigens that have been identified. These include streptococcal pyrogenic exotoxin (or erythrogenic exotoxin) A to C, F, and G to J, streptococcal superantigen, and streptococcal mitogenic exotoxin Z. These superantigens are associated with disease (see below). [28]

ANTIBODY RESPONSE AND IMMUNITY The immune response to group A streptococcal infection depends to a large measure on site of infection. Streptococcal infection is usually defined as a positive throat culture with a serologic response to group A streptococcus and the streptococcal carrier state by a positive throat culture and no serologic response. Following streptococcal pharyngitis, specific antibodies develop to many of the extracellular enzymes of the streptococci. Eighty-five percent of patients with acute rheumatic fever and a proven preceding streptococcal infection will have an elevated or increasing antistreptolysin O (ASO) titer. The serologic demonstration of an antecedent streptococcal infection in this situation can be increased to virtually 100 percent by the simultaneous testing for several other antibodies (antihyaluronidase, anti-DNase B). Antibodies to extracellular products, with the exception of antibody to the erythrogenic toxin of scarlet fever, appear to have no effect on the manifestations of illness. Streptococcal immunity is type specific (but not group specific), long-lasting, and depends on the production of bactericidal antibodies to the specific M proteins of the over 80 different serotypes of group A organisms. Although recurrent pharyngeal infections caused by the same serotype are most unusual, repeated clinical infections caused by different types are not uncommon. Early treatment of streptococcal upper respiratory tract disease with antibiotics may suppress the appearance of type-specific antibody (and immunity), as well as the development of antibody to the extracellular products of the organism. In contrast to pharyngeal infections, the ASO response with streptococcal skin infections or pyoderma-associated nephritis is weak. To define the latter serologically, anti-DNase B titers are much more reliable. Although pyoderma strains of streptococci produce M proteins, and although type-specific antibody may develop in patients with pyoderma-associated nephritis, the frequency of production of such antibodies and their role in protection against reinfection are unclear. While pharyngeal reinfection with the same streptococcal serotype is probably unusual, some evidence suggests that the same serotype can be associated with repeated episodes of pyoderma.

Specific Diseases Caused by Group A (and Other) Streptococci (Table 194-5)

Superficial pyodermas
Nonintertriginous skin
Impetigo
Ecthyma
Blistering distal dactylitis
Intertriginous skin
Perianal streptococcal cellulitis
Streptococcal vulvovaginitis
Streptococcal intertrigo
Invasive infections
Acute lymphangitis
Erysipelas
Cellulitis
Streptococcal gangrene
Bacteremia, septicemia
Toxin-associated syndrome
Scarlet fever
Streptococcal toxic-shock–like syndrome
Streptococcal gangrene
Nonsuppurative complications
Rheumatic fever
Glomerulonephritis
Other associated cutaneous reaction patterns
Erythema nodusum
Erythema multiforme
Guttate-pattern psoriasis
Vasculitis

TABLE 194-5 **Infections and Toxin Syndromes Caused by Group A Streptococci**

SUPERFICIAL PYODERMA Streptococcal pyodermas include all types of superficial streptococcal skin infections except erysipelas—that is, impetigo, ecthyma, and secondary infections of preexisting skin lesions (e.g., insect bites, abrasions, eczema). Streptococcal intertrigo such as streptococcal perianal "cellulitis" can occur primarily or secondarily in underlying conditions such as inverse psoriasis.

SUPERFICIAL PYODERMAS IN NONINTERTRIGINOUS SKIN

Impetigo Impetigo caused by group A streptococcus presents as a crusted superficial infection of the skin; an initial vesicular phase has been described but is rarely detected. Lesions are clinically indistinguishable from impetigo caused by *S. aureus*, with the exception of bullous impetigo (see " Staphylococcal Skin Infections," above).

EPIDEMIOLOGY AND BACTERIOLOGY Impetigo caused by group A streptococcus is a highly communicable infection and occurs predominantly in preschool-aged children (usually before the age of 2 years except in highly endemic areas). It is more common in warmer, more humid climates than in temperate zones. Its peak seasonal incidence is in the later summer and early fall. Several decades ago, group A streptococcus was the single most common isolate from impetigo in the United States. [29] Mixtures of streptococci and *S. aureus* were isolated from about half the patients with nonbullous impetigo. The relative roles for these two species in any analysis will probably vary, but the role of *S. aureus* has increased in recent years. Non-group A (groups B, C, and G) streptococci may be responsible for rare cases of impetigo; group B streptococci are associated with impetigo in the newborn. Whereas many different serotypes of group A streptococci may cause pharyngitis, a limited number of newly described types predominate in impetigo (types 49, 52, 53, 55, 56, 57, 59, and 61).

PATHOGENESIS AND PATHOLOGY Group A streptococci appear on normal skin of children about 10 days prior to the development of impetigo and they are not recovered from the nose and throat of the same patients until 14 to 20 days after skin acquisition of the organism. Streptococci are recovered from the respiratory tract of about 30 percent of children with skin lesions, but there is no clinical evidence of streptococcal pharyngitis. Thus, the sequence of spread in a given patient is from normal skin to lesions and eventually to the respiratory tract. [30] In contrast, the sequence of spread of *S. aureus* (in cases of impetigo in which it is the only organism isolated) is from nose to normal skin (about 11 days later) and to skin lesions (after another 11 days). Following acquisition of a streptococcal strain on normal skin from another family member or close contact (whose skin was already colonized or contained a pyoderma), minor traumas (insect bites, abrasions) or preexisting lesions such as scabies, varicella, or eczema. predispose to the appearance of infected lesions. Crowding, poor hygiene, and neglected minor skin trauma contribute to the spread of streptococcal impetigo in families. Minor outbreaks have also occurred among athletes involved in contact sports. Although the majority of cases occur in children, particularly of preschool age, young adults are also affected. The inflammatory process of impetigo is superficial, with a unilocular vesicopustule located between the stratum corneum above and the stratum granulosum below. This is usually situated near the opening of a hair follicle. Organisms, as well as leukocytes and epithelial cell debris, fill the vesicle.

CLINICAL MANIFESTATIONS Impetigo caused by *S. aureus* and group A streptococci cannot be differentiated on clinical findings. For clinical features see above (staphylococcal impetigo, Fig. 194-1 to Fig. 194-3). Pruritus and burning

may occur, but the lesions are usually painless. Systemic response is minimal unless complications occur.
LABORATORY FINDINGS A slight leukocytosis may occur. A gram-stained smear of early vesicle fluid reveals gram-positive cocci in chains. Culture of the weeping area or of the area beneath an unroofed crust reveals group A streptococci or a mixture of streptococci and *S. aureus* (particularly from older crusted lesions). The lesions of bullous impetigo are caused by *S. aureus* of phage group II.
DIAGNOSIS The diagnosis of impetigo usually presents no difficulties when the lesions are seen at the stage of crusting, but the specific bacteriologic diagnosis requires culture.
COURSE AND PROGNOSIS Untreated, the process may persist and new lesions may develop over the course of several weeks; thereafter, the infection tends to resolve spontaneously unless there is some underlying cutaneous disorder such as eczema. Untreated some lesions become chronic and deeper, such as, ecthyma (see above). Complicating erysipelas, cellulitis, or bacteremia are unusual. The major serious sequela is acute poststreptococcal glomerulonephritis.
MANAGEMENT Topical treatment (removal of dirt, crusts, and debris by soaking with soap and water) is a valuable adjunct. Mupirocin ointment appears to be as effective as parenteral or oral penicillin for treatment of impetigo. [31] However, prophylactic application of mupirocin ointment to insect bites and abrasions in children in an endemic area during the peak season for skin infections may be useful in preventing superficial streptococcal pyodermas. In superficial pyodermas known to be caused by group A streptococcus, penicillin is the drug of choice, administered either as a single injection of long-acting benzathine penicillin (300,000 to 600,000 units for children; 1.2 million units for adults) or orally (25,000 to 100,000 units/kg per day in divided doses q6h for 10 days). Although penicillin treatment will clear the lesions of group A streptococcal impetigo and prevent recurrence for a short time, streptococci can persist on or newly colonize normal skin in spite of this therapy. Erythromycin (30 to 50 mg/kg per day by mouth in divided doses q6h for children; 250 to 500 mg by mouth q6h for adults administered for 10 days) is a suitable alternative drug in patients allergic to penicillin. However, it should be noted that 20 percent or more of group A streptococcal strains became resistant to erythromycin in areas (Japan, Finland) where this antibiotic had been extensively used (or overused) for a variety of indications. [32] Whether administration of penicillin is effective in reducing the incidence of pyoderma-associated nephritis remains a moot point. Although the latent period following impetigo is longer than that following pharyngeal infection, the mildness of the illness delays or negates the seeking of medical attention. Practically, however, the majority of cases of nonbullous impetigo are caused by *S. aureus*, and systemic antimicrobial treatment should be directed at that pathogen (see above, Management of staphylococcal impetigo).
Ecthyma (See above, staphylococcal ecthyma)
STREPTOCOCCAL INFECTIONS IN INTERTRIGINOUS SKIN SITES Streptococcal pyodermas occur much less commonly in occluded sites such as the perineum/perianal region, vulva/vagina, axillae (Fig. 194-16), inframammary region, groin, preputial sac, and web spaces of the feet. Perianal (group A) streptococcal “cellulitis” occurs principally in children, presenting with intense perianal erythema (Fig. 194-17), pain on defecation, blood-streaked stools associated with anal fissures, and chronicity if untreated. [33] It is often confused with psoriasis, candidiasis, seborrheic dermatitis, inflammatory bowel disease, pinworm infection, or a behavioral problem. The infection can also involve the penis and vulva. Treatment options include oral antibiotics or topical mupirocin. Guttate psoriasis has also occurred in children, associated with perianal streptococcal infection. [34]

FIGURE 194-16 Group A streptococcus intertrigo. A sharply marginated erythematous and oozing plaque in the axilla, which was also present in the other axilla, inframammary area, and inguinal folds, was painful in this HIV-infected woman.

FIGURE 194-17 Group A streptococcus intertrigo—perianal streptococcal cellulitis. Well-demarcated erosive erythema in the perianal region and perineum in an 8-year-old boy who complained of soreness.

Blistering distal dactylitis Group A streptococcus is responsible for the majority of cases of this disease, usually occurring in children and adolescents. However, group B streptococcus can also cause this infection. A large, tense blister develops, filled with seropurulent fluid, over the volar skin pad of distal fingers or toes (Fig. 194-18). The blisters are often surrounded by an erythematous base. The lesion may be more proximally located on the finger or extend to involve the nail folds. Group A streptococcus may be cultured from the vesicle fluid. Blistering distal dactylitis may be treated with oral penicillins or erythromycin. Staphylococcal blistering distal dactylitis has been reported with an identical clinical picture as above. [35]

FIGURE 194-18 Group A streptococcus blistering dactylitis. A blister is seen on a toe adjacent to the nail fold; the patient also had group A streptococcal intertrigo of an abdominal skin fold.

Acute lymphangitis

DEFINITION Acute lymphangitis is an inflammatory process involving the subcutaneous lymphatic channels. It is most often caused by group A streptococci, but occasionally may be caused by *S. aureus*; rarely, soft-tissue infections with other organisms, such as *Pasteurella multocida* or herpes simplex virus may be associated with acute lymphangitis.

CLINICAL MANIFESTATIONS *History:* The portal of entry is commonly a wound on an extremity, an infected blister, or a paronychia. The systemic manifestations of infection may occur either before any evidence of infection is present at the site of inoculation or after the initial lesion has subsided. The patient may notice pain over an area of redness proximal to the original break in the skin. Systemic symptoms are often more prominent than one might expect from the degree of local pain and erythema. An unusual spread of streptococcal infection of the thumb (paronychia) or of the interdigital webs between the thumb and index finger may occur occasionally. Lymphatic drainage from this area can bypass the lymph nodes at the elbow and drain into the axillary nodes, which in turn communicate with the subpectoral nodes and the pleural lymphatics. As a consequence, subpectoral abscesses and pleural effusion develop. The subpectoral infection may dissect downward and appear over the lower chest and upper abdomen as an area of cellulitis. This is a very serious illness. The clinical clues to the development of this sequence of events are provided by the location of the original infection on the thumb or medial surface of the index finger and the early occurrence of axillary pain. *Cutaneous lesions:* Red linear streaks, which may be a few millimeters to several centimeters in width, extend from the local lesion toward the regional lymph nodes, which are usually enlarged and tender.

DIAGNOSIS AND DIFFERENTIAL DIAGNOSIS In the upper extremities, acute lymphangitis usually can be differentiated from subacute or chronic sporotrichoid syndrome caused by organisms such as *Sporothrix schenckii*. In the lower extremities, superficial thrombophlebitis may produce somewhat similar linear areas of tender erythema. The absence of a portal of entry and of tender regional adenopathy is helpful in distinguishing this process from lymphangitis.

LABORATORY FINDINGS The peripheral white blood cell count is elevated, with a marked increase in polymorphonuclear cells. The offending organism cannot be cultured from the skin, as the infection is restricted to the lymphatic channels. However, the primary portal of entry or a suppurative lymph node, if overt infection is present, may reveal the etiologic agent.

COURSE AND PROGNOSIS The frequent development of bacteremia with metastatic infection in various organs makes this a potentially serious disease. The infection responds readily to penicillin therapy if instituted promptly.

INVASIVE STREPTOCOCCAL INFECTIONS These are erysipelas cellulitis and streptococcal gangrene and are discussed in Chapter 196.

STREPTOCOCCAL TOXIN SYNDROMES

Scarlet fever Scarlet fever is a diffuse erythematous eruption resulting from the production and subsequent circulation of pyrogenic exotoxin (erythrogenic toxin) produced by group A streptococci usually located in a pharyngeal infection. The difference between streptococcal tonsillopharyngitis and scarlet fever is the greater toxicity and the cutaneous eruption in the latter.

BACTERIOLOGY AND PATHOGENESIS Pyrogenic exotoxin is produced by most, but not all, strains of group A streptococci, and its gene is encoded by a lysogenic bacteriophage in the streptococcus. This relationship is very similar to that involving bacteriophage infection and toxin production in *Corynebacterium diphtheriae*. There appear to be three immunologically distinct pyrogenic exotoxins (types A, B, and C) produced by approximately 90 percent of group A isolates, although several other exotoxins have been identified. A toxin-producing group A strain may contain the gene encoding for one or more of the exotoxins. In the first half of the twentieth century, when scarlet fever was more prevalent and often severe, most scarlet fever strains of group A streptococci produced type A toxin, but in the past three to four decades, strains producing either type B or combinations of type B and C toxins have predominated, perhaps related to the milder course of scarlet fever during this period. More recently, however, there has been a resurgence of severe forms of streptococcal illness resembling scarlet fever, now coined as streptococcal toxic shock syndrome or toxic shock–like syndrome (see below). [36] This increase in severity, once again, may be attributed to an increase in exotoxin type A producers. [37] The streptococcal pyrogenic exotoxins belong to a larger family of exotoxins produced by group A streptococcus and *S. aureus*. These exotoxins are involved in the pathogenesis of toxic shock–like syndromes and have been implicated in numerous autoimmune and skin disorders, including atopic dermatitis and psoriasis. They have been labeled as superantigens similar to the staphylococcal exotoxins (see above). [38] Type A toxin is a more potent stimulator of cytokine production (e.g., TNF-a) and T lymphocyte activation, which might explain its association with more severe

cases of scarlet fever. Group A streptococci can cause recurrent infections, but an individual usually has scarlet fever only once because of the development of protective antibody specific to the pyrogenic exotoxins. The few patients with documented recurrent attacks of scarlet fever may represent cases in which the episodes have been caused by either of the other two immunologically distinct toxins. The immune status of a patient will determine the response to exposure to a given pyrogenic exotoxin-producing strain of group A streptococcus; it consists of two parts: type-specific antibacterial immunity and antitoxic immunity. The responses fall into three patterns: (1) Patients with type-specific antibacterial immunity (with or without antitoxic immunity) to a given streptococcal type (e.g., type 12) will contract no clinical disease when exposed to that type. (2) Patients with no type-specific antibacterial immunity (but with antitoxic immunity) will contract streptococcal pharyngitis. (3) Patients with neither antibacterial nor antitoxic immunity will contract pharyngitis plus scarlet fever (unless treated early with appropriate antibiotics). The rash of scarlet fever requires both the presence of pyrogenic exotoxin and the existence of delayed-type skin reactivity to streptococcal products, the latter stemming from prior exposure to the organism. In support of this is the observation that although streptococcal infections are not uncommon in infants and very young children, scarlet fever is rarely seen in this age group, and these infants fail to react to intradermal injection of pyrogenic exotoxin (Dick test). This failure to react correlates with transfer of antibody from the mother. Similarly, infant guinea pigs are not susceptible to intradermal injection of pyrogenic exotoxin. Following immunization with the toxin in Freund's adjuvant, they become sensitized and the Dick test becomes positive.

CLINICAL MANIFESTATIONS *History:* The disease usually occurs in children (the maximal incidence being in the 2- to 10-year-old age group) and only rarely in adults. The clinical onset of the disease with the appearance of pharyngitis and fever is often abrupt after a 2- to 4-day incubation period. The temperature may be only slightly elevated in mild cases but it often rises rapidly to 38.9°C to 40°C (102°F to 104°F). Nausea and vomiting, headache, malaise, diffuse abdominal pain, and chilly sensations are prominent initial constitutional manifestations. The fever reaches its peak by the second day, and the temperature gradually returns to normal in 5 to 6 days in the average case. The rash appears 24 to 48 h after the onset of pharyngeal symptoms. Although the streptococcal focus of most patients with scarlet fever is in the pharynx, occasional patients have a form of the disease, surgical scarlet fever, as a consequence of operative or other wound (burn, etc.) infection. The acute manifestations of scarlet fever consist of those symptoms and signs related to the invasive streptococcal process at the portal of entry and those findings produced by pyrogenic exotoxin (malaise, nausea, vomiting, headache, fever, generalized lymphadenopathy, rash). Rabbits treated with exotoxin alone by either subcutaneous injection or slow-delivery subcutaneous mini-osmotic pump develop many classic signs of scarlet fever. [39]

Enanthem: The pharynx is beefy red in color, with edema involving the tonsillar area and extending anteriorly to include the soft palate and uvula. Manifesting the local group A streptococcal infection, the tonsils are enlarged, reddened, and often covered with discrete patches of white or yellow exudate filling the tonsillar crypts. Occasionally, the exudate becomes confluent. Bilateral tender submandibular lymphadenopathy is present, relating to the streptococcal pharyngitis. Pharyngitis and submandibular lymphadenopathy are not seen in individuals with group A streptococcal surgical wound scarlet fever or staphylococcal scarlet fever. During the first several days of the illness, the tongue is white and furred, but the edges and tip remain reddened. The papillae soon become reddened and hypertrophied and project through the white coating, producing what has been called the “white-strawberry” tongue. By the fourth or fifth day, the white coating has sloughed and the tongue assumes a bright red color punctuated with very prominent papillae, the so-called red-strawberry tongue (Fig. 194-19A). Punctate erythema and scattered petechiae are often present over the soft palate.

FIGURE 194-19 Group A streptococcus scarlet fever: Exanthem and enanthem. *A*. In this young woman with pharyngitis, the face is erythematous with perioral pallor and the tongue is a beefy or “strawberry” red. *B*. Close-up of scarlatina rash.

Exanthem: The rash usually appears first on the head and neck (Fig. 194-19A), and then rapidly encompasses the trunk, and finally spreads to the extremities. The involvement of the body is usually complete within 36 h, but the palms and soles are spared. The rash is a diffuse erythema, blanching on pressure, with numerous 1- to 2-mm punctate papular elevations, giving a rough sandpaper quality to the skin (Fig. 194-19B). There are usually no discrete lesions on the face, but only a marked flushing of the cheeks and forehead, contrasting quite sharply with the circumoral pallor. On the body the rash is most marked in the skin folds of the inguinal, axillary, antecubital, and abdominal areas and about sites of pressure such as the buttocks and sacrum. The eruption often exhibits a linear petechial character in the antecubital fossae and axillary folds (Pastia's lines). When the eruption is intense, pinhead vesicular lesions (miliary sudamina), seen in a variety of prolonged febrile illnesses, may appear on the abdomen and chest. When the rash is mild, the exanthem may be localized to the trunk and be seen as only a faint erythema. In black patients, the rash is often difficult to recognize but may be felt as punctate papular lesions resembling “gooseflesh” or sandpaper. At its peak the rash has a diffuse, bright scarlet appearance. Capillary fragility is increased in the severer cases, and the tourniquet test result is positive. Occasional frank purpura may develop, with or without thrombocytopenia. The exanthem usually persists for 4 or 5 days, but in mild cases may be very transient. One of the most characteristic features of the illness is the desquamation that begins as the rash starts to fade, commencing on the face, usually about the ears, and spreading to the trunk and extremities, involving the hands and feet last (between the second and third weeks of illness). The desquamation on the face and trunk has a brawny character, and frequently a punched-out appearance of the abdomen results from the peeling off of circular areas of skin. Skin on the hands and feet is frequently shed in large sheets. The desquamation is so prominent a feature that it may be helpful in making a retrospective diagnosis in a case in which the eruption was minimal (Fig. 194-20). Similar changes in the nail bed produce a transverse groove in the nails.

FIGURE 194-20 Group A streptococcus scarlet fever: desquamation. The patient had streptococcal pharyngitis 17 days previously that was successfully treated with ampicillin. The fingertips show the subtle desquamation that occurs in scarlet fever, related to epidermal damage and repair.

Other physical findings: Generalized lymphadenopathy is a common finding, and splenomegaly is present occasionally.
DIFFERENTIAL DIAGNOSIS Although the total clinical picture is highly suggestive of scarlet fever (caused by group A streptococci), scarlatiniform eruptions may occur in other conditions and cause confusion in diagnosis. Infection with toxin ("exfoliatin")-producing strains of *S. aureus* belonging to phage group II may produce a rash resembling that of scarlet fever (see above, " Staphylococcal Skin Infections"). Strains of *S. aureus* producing TSST-1 are responsible for TSS (see above). In infants and young children particularly, exanthem-subitum and rubella may be mistaken for scarlet fever, but the lack of a pharyngeal focus is important in distinguishing these conditions. Also, neither of these processes is followed by extensive desquamation. Patients with infectious mononucleosis (primary cytomegalovirus or Epstein-Barr virus infection) may have an erythematous eruption, and this, together with lymphadenopathy and membranous pharyngitis, may mimic scarlet fever. The typical blood picture and the heterophil agglutination test are helpful in distinguishing between these diseases. Diffuse erythroderma as part of a drug-sensitivity reaction (sulfonamides, streptomycin, penicillin) may be mistaken for scarlet fever, as may the fever and cutaneous blush associated with atropine toxicity. Sunburn in a child with pharyngitis may be a cause of confusion, but the distribution of the lesions is the crucial distinguishing point.
LABORATORY FINDINGS The hematologic findings in the early stages are of a polymorphonuclear leukocytosis, and later in the illness eosinophilia (5 to 10 percent). Throat culture reveals group A streptococci. If direct bacteriologic confirmation cannot be made during the early phases of the illness, determination of the ASO titer may provide, retrospectively, evidence of a recent streptococcal infection. Slight microscopic hematuria is found not infrequently during the peak of the exanthem and does not represent acute glomerulonephritis. It is usually transient and may be related to a generalized effect of the pyrogenic exotoxin on capillaries.
DERMATOPATHOLOGY There is an outpouring of polymorphonuclear leukocytes and scattered red blood cells into the skin about small blood vessels. The punctiform lesions are represented by dilated small blood vessels and a focal accumulation of exudate. The suppurative and nonsuppurative sequelae are the same as are seen with any group A streptococcal infection.
DIAGNOSIS The diagnosis is usually made on the basis of clinical features—fever, vomiting, exudative pharyngitis, and an erythematous punctiform eruption going on to desquamation. Confirmatory evidence is provided by isolation of group A streptococci from the pharynx.
COURSE AND PROGNOSIS The acute febrile course of the untreated, uncomplicated case lasts about 4 to 5 days; desquamation may continue for several weeks thereafter. Many cases seen currently are mild and last only a few days. The course of the illness is dramatically altered by the administration of penicillin, which produces a prompt subsidence of fever and of constitutional symptoms. Adequate, early penicillin treatment eradicates the streptococci from the pharyngeal or other foci, interferes with the development of ASO antibodies, and prevents the development of suppurative and nonsuppurative sequelae. The prognosis is excellent, and today deaths as a consequence of scarlet fever are extremely rare.
Group A streptococcus toxic shock–like syndrome ("toxic strep syndrome") Group A streptococci cause an acute multisystem syndrome coined toxic shock–like syndrome (TSLS) or streptococcal toxic shock syndrome resembling that caused by *S. aureus* (see section on " Staphylococcal Skin Infections," above). [40] The initiating streptococcal infection is commonly in soft tissues (cellulitis, necrotizing fasciitis, infection at site of liposuction); other infections include pharyngitis, suppurative phlebitis, peritonitis, osteomyelitis, endophthalmitis, and myometritis. The majority of cases occur in 20- to 50-year-old, otherwise healthy patients. Major differences between staphylococcal TSS and streptococcal TSLS are extensive soft-tissue infection and bacteremia. Staphylococcal TSS does not usually have an obvious cutaneous site of infection, nor is bacteremia common (15 percent). Streptococcal TSLS usually has an obvious soft-tissue site of infection (80 percent), and bacteremia occurs in over half of cases. A mortality rate near 50 percent has been reported for streptococcal TSLS, and it is five times more deadly than staphylococcal TSS. [41] Group A streptococcus producing pyrogenic exotoxin A is most closely linked to TSLS, although pyrogenic exotoxin B and C, streptococcal superantigen, and streptococcal mitogenic exotoxin Z have also been implicated. [2] Clinical features usually include many of the following: hypotension, chills, fever, tachycardia, myalgias, and mental changes, as well as manifestations of multiorgan dysfunction (gastrointestinal abnormalities, renal failure, adult respiratory distress syndrome). Localized erythema (usually about the face) is more commonly present than the generalized punctate erythema of scarlet fever. Injection of bulbar and palpebral conjunctivae may be present as well as a strawberry tongue; and skin desquamation may or may not be a later feature. Major risk factors for TSLS include wounds, chickenpox in children, nonsteroidal antiinflammatory drug (NSAID) use, pregnancy and multiple underlying illnesses. [3] Many patients will require extensive débridement of infected wounds. Therapy includes appropriate antibiotics, IV fluids and vasopressors. Intravenous immunoglobulin may improve survival for TSLS. [42] It is important to recognize as well that "septic scarlet fever" may be reemerging currently, after an absence during the postantibiotic era. Three cases of severe septic scarlet fever with the features of toxic shock in individuals with group A streptococcal cellulitis and bacteremia have been described. Although some clinical distinction could be made, TSLS may be a more severe form or variant of scarlet fever.
Cutaneous manifestations of subacute bacterial endocarditis A variety of skin lesions have been described in subacute bacterial endocarditis (usually caused by viridans streptococci). Although often ascribed to embolic phenomena, it appears that many of these lesions represent local areas of vasculitis.
PETECHIAE AND HEMORRHAGES (See Chap. 166) These are the most common of the skin and mucous membrane lesions in bacterial endocarditis and are found in approximately 50 percent of patients with this disease. These small, reddish-brown, flat lesions do not blanch on pressure. They occur particularly on the extremities and upper chest. Mucous membrane petechiae and/or hemorrhages on the conjunctivae (Fig. 194-21A) or palate is common. The petechiae frequently occur in small crops. Rarely, the lesions may be extremely numerous and involve primarily the lower extremities.

FIGURE 194-21 Enterococcal endocarditis with embolization. *A*. Subconjunctival hemorrhage. *B*. Subungual hemorrhages in the midportion of the nail bed. The patient had acute infective endocarditis following an enterococcal urinary tract infection with bacteremia.

SUBUNGUAL "SPLINTER HEMORRHAGES" These small, dark-red streaks resembling splinters in the midportion of the nail bed are suggestive of the diagnosis of subacute bacterial endocarditis (Fig. 194-21B; see Chap. 166). Similar lesions may, however, occur beneath the distal portion of the nail bed as a result of trauma (in dishwashers, carpenters, etc.) or poor hygiene. Splinter hemorrhages may also occur as part of the clinical picture in trichinosis and vasculitis. Subungual hemorrhages may occur in acute meningococcemia with extensive petechiae and purpura.
OSLER'S NODES These are split-pea–sized, erythematous, painful, nodular lesions. They appear to be in the skin and in some ways resemble an urticarial wheal, often with a whitish center. The most common location of these swellings is on the pads of the fingers and toes, on the thenar and hypothenar eminences, and over the arms. They are quite transient, lasting 12 to 24 h or perhaps several days. They are discussed in detail in Chap. 166.
JANEWAY LESIONS These lesions, consisting of minimally nodular hemorrhages, or occasionally erythematous macules, in the palms or soles, are seen in acute endocarditis (commonly caused by *S. aureus*) or, infrequently, in subacute bacterial endocarditis. They may be rather numerous and, unlike Osler's nodes, are painless. They are also discussed in Chap. 166.
POSTSTREPTOCOCCAL (GROUP A) NONSUPPURATIVE CUTANEOUS SEQUELAE
Erythema nodosum See Chap. 109.
Erythema marginatum (cutaneous lesions of acute rheumatic fever) See Chap. 179.
Purpura fulminans Purpura fulminans is an uncommon, acute, severe, usually fatal nonspecific hemorrhagic infarction and necrosis of the skin that occurs in the course of, or immediately following, a variety of infections, particularly those caused by group A streptococci. Marked depletion of multiple coagulation factors (disseminated intravascular coagulation) is responsible for this condition. Closely related, if not the identical process, is the symmetric peripheral gangrene that is sometimes seen (particularly in infants) during bacteremias.
EPIDEMIOLOGY Purpura fulminans occurs most often in children but has been seen at all ages. The antecedent or concomitant infections with which it has been associated include those due to bacteria (scarlet fever; group A streptococcal, staphylococcal, pneumococcal, and vibrio bacteremias; and meningococcemia) and, less commonly, those of a viral etiology (varicella). In patients with purpura fulminans after varicella, secondary streptococcal infection may have been an important etiologic factor.
ETIOLOGY AND PATHOGENESIS Purpura fulminans is one of several cutaneous syndromes whose common feature is a hemorrhagic tendency developing secondary to the acute intravascular activation of the clotting mechanism. The exact means of initiation of the consumption coagulopathy is not yet fully understood. However, there is evidence that endotoxin, via stimulation of IL-12, IFN-?, TNF-a, and IL-1, may lead to consumption of protein C and S and antithrombin III. [43] A host of coagulation abnormalities has been noted at one time or another. This variability probably reflects the rapid changes that occur during the evolution of the process and the effects of "secondary" fibrinolysis. The abnormalities more commonly recorded include thrombocytopenia; depression of prothrombin (factor II), fibrinogen (factor I), proaccelerin (factor V), and antihemophilic factor (factor VIII); and findings of secondary fibrinolysis (i.e., increased plasminogen levels or evidence of fibrinogen or fibrin breakdown products). The coagulopathy and microscopic pathology in purpura fulminans are very similar to those found in rabbits with generalized Shwartzman reaction (see Chap. 193).
CLINICAL MANIFESTATIONS *History:* The eruption develops during, or on convalescence from, one of the infections noted earlier. Chills and fever usually herald the onset of the hemorrhagic lesions, and the patient appears acutely ill. *Cutaneous lesions:* The lesions are localized, massive ecchymoses, often with sharp, irregular ("geographic") borders. They are usually symmetric and on the extremities, particularly in areas of pressure, but may involve the lips, ears, nose, and trunk. There may be a narrow surrounding zone of erythema. Hemorrhagic blebs may develop in the ecchymotic areas associated with edema of the areas (Fig. 194-22). The peripheral ecchymotic lesions, especially of the digits, may rapidly blacken and progress to gangrene.

FIGURE 194-22 Purpura fulminans. *A*. Hemorrhagic infarctions in a patient with diabetes with *S. aureus* septicemia and disseminated intravascular coagulation. The patient died within 24 h in spite of therapy. *B*. Purpura fulminans in disseminated intravascular coagulation following abdominal surgery. There are extensive geographic areas of cutaneous infarction involving the face, breasts, and extremities.

Other physical findings: The other findings are those of a systemically ill patient with high fever and tachycardia. The disease often rapidly progresses over 48 to 72 h, with peripheral vasoconstriction and shock supervening.
DIFFERENTIAL DIAGNOSIS All the causes of gross purpura must be considered in the differential diagnosis. The relationship of specific infections, the striking geographic nature of the lesions, and their location on the extremities are suggestive of the diagnosis. Rarely, morphologically similar lesions have been described as complications of coumarin therapy in individuals deficient in coagulation factor protein C.
LABORATORY FINDINGS There is usually a leukocytosis. The number of platelets is markedly reduced and coagulation factors V, VII, and VIII and prothrombin and fibrinogen are decreased. As a result, the prothrombin time and the partial thromboplastin time are prolonged. Split products of fibrinogen and fibrin may be present.
DERMATOPATHOLOGY The involved areas show occlusion of arterioles with fibrin thrombi. A dense polymorphonuclear reaction occurs in the dermis in the areas of infarction necrosis. Bacteria are not seen in the lesions.

Similar lesions may occur in the viscera, but they are often restricted to the skin.
COURSE AND PROGNOSIS The mortality rate is extremely high. In patients who survive, amputation of extremities or extensive skin grafting may be necessary to deal with the gangrenous areas.
MANAGEMENT Treatment includes vigorous antibiotic management of any associated infection. Only if bleeding is significant during the course of diffuse intravascular coagulation in the patient with purpura fulminans is replacement of platelets and coagulation factors undertaken and consideration given to the use of heparin (10 to 15 units/kg per h as a continuous intravenous infusion) to inhibit the intravascular clotting process. However, there is evidence mounting that early intervention with protein C concentrate may decrease morbidity and mortality associated with purpura fulminans. [44]
Other skin lesions accompanying or following group A streptococcal infections
ERYTHEMA MULTIFORME-LIKE LESIONS Round erythematous macules, up to 1.5 cm in diameter, some developing bright borders and subsequently showing clearing in the center, may occur during bacteremia caused by group A streptococci (or *S. aureus*) in infants and young children (see Chap. 58).
ACUTE GUTTATE PSORIASIS Rarely, erythematous, papulosquamous, guttate psoriasiform lesions may develop during or following group A streptococcal pharyngitis or skin infections. Children appear to be most commonly affected. Clearing of the lesions may occur within weeks of antimicrobial therapy of the streptococcal infection. Although the temporal relation of the two processes is striking, a direct causal connection has not been established, but the role of superantigens in guttate psoriasis is the subject of current research [45], [46] (see Chap. 42).
MANAGEMENT OF GROUP A STREPTOCOCCAL SKIN INFECTIONS
Antibiotic management
GENERAL PRINCIPLES Penicillin G is the drug of choice in the treatment of known group A streptococcal skin infections. When the etiology is not known immediately (e.g., in cellulitis) and when *S. aureus* is also a distinct consideration, a semisynthetic penicillin (nafcillin or oxacillin) should be employed initially. Penicillin treatment should be continued for at least 10 days to ensure eradication of the infection. Prophylactic penicillin therapy is indicated for close family contacts (particularly children) of patients with streptococcal pharyngitis.
ANTIMICROBIAL THERAPY Mild instances of infections such as impetigo, scarlet fever, or certain cases of erysipelas and cellulitis may be treated with oral penicillin V (250 to 500 mg four times daily). When staphylococcal infection is suspected, dicloxacillin (250 to 500 mg orally four times daily) should be substituted. In adults allergic to penicillin, erythromycin (250 to 500 mg orally four times daily) is a reasonable alternative. Other alternatives include azithromycin, clarithromycin, and clindamycin.
PREVENTION OF SPREAD Patients hospitalized with group A streptococcal infections should be isolated until the organisms have been eradicated by antibiotic treatment. Individuals with recurrent episodes of group A streptococcal infections can be treated with dicloxacillin or erythromycin 250 mg twice daily (penicillin-allergic individuals) as secondary prophylaxis. Where streptococcal infections are highly endemic, prophylactic antibiotics must be administered to all members of the population to reduce the incidence of group A streptococcal infections. [47]
SOFT-TISSUE STREPTOCOCCAL INFECTIONS See Chap. 196
CUTANEOUS INFECTIONS CAUSED BY MICROCOCCUS
Pitted keratolysis This bacterial infection involves the stratum corneum of the web spaces and plantar surface. Originally named keratoma plantare sulcatum by Castellani in 1910, this disease has become more commonly called by its current name after Taplin and Zaias coined it in 1967. The disease was first seen in those who went barefooted during the rainy season.
ETIOLOGY AND PATHOGENESIS The likely causative organism is *Micrococcus sedentarius*, which is a gram-positive staphylococcus-related bacterium that invades the stratum corneum softened by sweat and moisture. There is less convincing evidence that a *Corynebacterium* species or *Dermatophilus congolensis* may be involved. Pitted keratolysis tends to be much more severe in tropical climates than in temperate ones. Pitted keratolysis occurs in adults and children of both sexes, but adult males with sweaty feet are most susceptible (96 percent of cases). [48] Sliminess of the skin, often manifest by the foot sticking to the socks, is also a common complaint (70 percent of cases). The feet are typically very malodorous (89 percent) and may be mildly pruritic (8 percent). [49]
CLINICAL MANIFESTATIONS Pitted keratolysis presents a superficial erosion of the stratum corneum, composed of numerous small crateriform pits coalescing to form a large discrete defect with serpiginous borders on the plantar surface of the foot. The pits are usually >0.7 mm in diameter, but at times the pits are <0.5 mm in diameter. The pits have elongated configurations along the plantar furrows and are located predominantly on the pressure-bearing areas, such as the ventral aspect of the toe, ball of the foot, and the heel, but they are also seen on non–pressure-bearing areas. The web spaces between the toes are also commonly involved sites, and may be the only manifestation (Fig. 194-23).

FIGURE 194-23 Pitted keratolysis. The web spaces between the toes are sharply eroded. Interdigital tinea pedis and erythrasma may occur concurrently.

DIFFERENTIAL DIAGNOSIS Interdigital tinea pedis can present with erosive lesions in the web spaces. Erythrasma in the web spaces is usually hyperkeratotic but can be erosive.
LABORATORY FINDINGS Gram-staining of scraping may detect the microorganism more readily than potassium hydroxide examination. Histologically, the organisms are present in the walls and bases of the crateriform defects in the upper layer of the stratum corneum. The organisms appear as coccoid and filamentous forms with branches and septa, divided only transversely without longitudinal septation.
DIAGNOSIS The diagnosis is made on the unique clinical findings.
MANAGEMENT Prophylactic measures are aimed at keeping the feet as dry as possible. Inert antiseptic foot powders often help. A benzoyl peroxide wash and 5 percent gel are effective therapy in most cases. Other commonly used topical agents include clindamycin, erythromycin, clotrimazole, miconazole, and Whitfield's ointment.
INFECTIONS CAUSED BY CORYNEBACTERIUM

Erythrasma Erythrasma is a common superficial bacterial infection of the skin characterized by well-defined but irregular reddish brown patches, occurring in the intertriginous areas, or by fissuring and white maceration in the toe clefts.
ETIOLOGY AND EPIDEMIOLOGY *Corynebacterium minutissimum*, the etiologic agent of erythrasma, is a short, gram-positive rod with subterminal granules. The infection is more common in tropical than in temperate climates. In a study in a temperate climate, 20 percent of randomly selected subjects were found to have erythrasma by Wood lamp examination. The generalized disease is much more common in the tropics. Erythrasma is more common in men, and may occur in asymptomatic form in the genitocrural area.
CLINICAL MANIFESTATIONS Symptoms vary from a completely asymptomatic form, through a genitocrural form with considerable pruritus, to a generalized form with scaly lamellated plaques on the trunk, inguinal area, and web spaces of the feet. When pruritic, irritation of lesions may cause secondary changes of excoriations and lichenification. *Cutaneous lesions:* The most common site of involvement is the web spaces of the feet, where erythrasma presents as a hyperkeratotic white macerated plaque (Fig. 194-24), especially between the fourth and fifth toes. In the genitocrural, axillary, and inframammary regions, the lesions present as well-demarcated, reddish-brown, superficial, finely scaly, and finely wrinkled patches (Fig. 194-25). In these sites, the patches have a relatively uniform appearance as compared with tinea corporis or cruris, which often have central clearing.

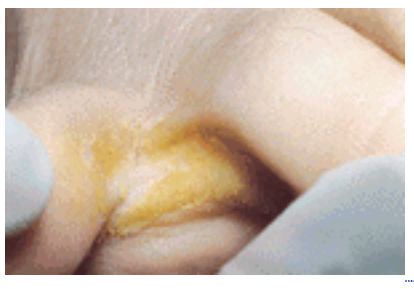

FIGURE 194-24 Erythrasma. Hyperkeratosis with a yellowish hue in the web space of the foot. The three lateral web spaces of both feet were involved. The potassium hydroxide preparation was negative; the Wood lamp examination showed a bright coral red fluorescence.

FIGURE 194-25 Erythrasma. Well-demarcated reddish-brown patches in the axilla (*A*) and groin (*B*). The potassium hydroxide preparations were negative; the Wood lamp examination showed a bright coral red fluorescence.

Wood lamp examination of erythrasma reveals a coral-red fluorescence caused by coproporphyrin III. The fluorescence may persist after eradication of the *Corynebacterium* as the pigment is within a thick stratum corneum. The red fluorescence distinguishes erythrasma from pityriasis (tinea) versicolor, where a yellow fluorescence can be seen on Wood lamp examination.
DIFFERENTIAL DIAGNOSIS Tinea versicolor is distinguished from erythrasma by the lesions on the trunk being most numerous at nonintertriginous sites. Tinea cruris tends to have an active scaling border with central clearing. Inverse pattern psoriasis usually presents as sharply demarcated plaques with a beefy shiny red color in the intergluteal cleft, inguinal folds, and axillae.
LABORATORY Culture of the specific *Corynebacterium* in abundance from the lesion corroborates the diagnosis. Gram-stained imprints of the horny layer of the skin show rod-like, gram-positive organisms in large numbers. Bacilli have been demonstrated within cells of the horny layer on examination by electron microscope.
DIAGNOSIS The diagnosis is strongly suggested by the location and superficial character of the process, but must be confirmed by demonstration of the characteristic “coral-red” fluorescence with Wood lamp illumination.
COURSE AND PROGNOSIS The disease may remain asymptomatic for years or may undergo periodic exacerbations. Relapses occasionally occur even after successful antibiotic treatment.
MANAGEMENT For localized erythrasma, especially of the web spaces of the feet, benzoyl peroxide wash and 5% gel are effective in most cases. Clindamycin (2% solution) or azole creams are several of the many effective topical agents. For widespread involvement, oral erythromycin is effective. A 1 g single dose of clarithromycin has been successfully used. [50] For secondary prophylaxis, use of an inexpensive antibacterial benzoyl peroxide bar when showering is effective and inexpensive.
Trichomycosis axillaris and pubis This bacterial infection of the hair shaft (not fungal as the name implies) is characterized by what appears to be nodular thickenings on the hair shaft, composed of colonies of aerobic *Corynebacterium*. The condition occurs both in the axillae and pubic areas, and not just in the axillae, as the name implies. The bacteria produce various pigments, giving the nodules a range of colors. In a study from the United Kingdom, axillary infection was noted in 27 percent of adult male students; in hospitalized mentally retarded patients, the finding was present in 42 percent of male patients and in 7 percent of female patients (many of the females had no axillary hair). [51] Trichomycosis is asymptomatic except for the patient's concern regarding the lesions themselves and because they are malodorous. The concretions on the hair shaft are usually a tan color but may be reddish, yellow, or black (Fig. 194-26). Lesions are most dense in and may be present only in the central portion of the axillary hair. The same lesions may occur in the pubic hair as well.

FIGURE 194-26 Trichomycosis axillaris. Tan-yellow concretions on the hair shafts of the axilla.

The diagnosis is usually made on the basis of the physical findings. The concretions can be visualized using a potassium hydroxide preparation. Pediculosis pubis infestation with multiple eggs on the hair shaft should be ruled out. The involved hair can be removed by shaving. Benzoyl peroxide wash and gel are effective as treatment and prevention against recurrence of trichomycosis.

REFERENCES

1. Eriksen NHR et al: Carriage of *Staphylococcus aureus* among 104 healthy persons during a 19-month period. *Epidemiol Infect* **115**:51, 1995

2. Manders SM: Toxin-mediated streptococcal and staphylococcal disease. *J Am Acad Dermatol* **39**:383, 1998

3. McCormick JK et al: Toxic shock syndrome and bacterial superantigens: An update. *Annu Rev Microbiol* **55**:77, 2001

4. Leung DYM et al: The role of superantigens in human diseases: Therapeutic implications for the treatment of skin diseases. *Br J Dermatol* **139**:17, 1998

5. Leung DYM et al: Bacterial superantigens induce T cell expression of the skin-selective homing receptor, the cutaneous lymphocyte-associated antigen, via stimulation of interleukin 12 production. *J Exp Med* **181**:747, 1995

6. Hryniewicz W: Epidemiology of MRSA. *Infection* **27**(Suppl 2):S13, 1999

7. Kauffman CA et al: Attempts to eradicate methicillin-resistant *Staphylococcus aureus* from a long-term-care facility with the use of mupirocin ointment. *Am J Med* **94**:371, 1993

8. Bradley SF: Effectiveness of mupirocin in the control of methicillin-resistant *Staphylococcus aureus. Infect Med* **10**:21, 1993

9. Kluytmans JAJW et al: Nasal carriage of *Staphylococcus aureus* as a major risk factor for wound infections after cardiac surgery. *J Infect Dis* **171**:216, 1995

10. Pujol M et al: Nosocomial *Staphylococcus aureus* bacteremia among nasal carriers of methicillin-resistant and methicillin-susceptible strains. *Am J Med* **100**:509, 1996

11. Bradley SF: *Staphylococcus aureus* infections and antibiotic resistance in older adults. *Clin Infect Dis* **34**:211, 2002

12. Amagai M et al: Toxin in bullous impetigo and staphylococcal scalded-skin syndrome targets desmoglein 1. *Nat Med* **6**:1275, 2000

13. Gisby J, Bryant J: Efficacy of a new cream formulation of mupirocin: Comparison with oral and topical agents in experimental skin infections. *Antimicrob Agents Chemother* **44**:255, 2000

14. Allen AM et al: Cutaneous streptococcal infections in Vietnam. *Arch Dermatol* **104**:271, 1971

15. Institute of Medicine, National Academy of Science: Conference on the toxic shock syndrome. *Ann Intern Med* **96**:835, 1982

16. Bohach GA et al: Staphylococcal and streptococcal pyrogenic toxins involved in toxic shock syndrome and related illnesses. *Crit Rev Microbiol* **17**:251, 1990

17. Andrews MM et al: Recurrent nonmenstrual toxic shock syndrome: Clinical manifestations, diagnosis and treatment. *Clin Infect Dis* **32**:1470, 2001

18. Spearman PW, Barson WJ: Toxic shock syndrome occurring in children with abrasive injuries beneath casts. *J Pediatr Orthop B* **12**:169, 1992

19. Cone LA et al: A recalcitrant, erythematous, desquamating disorder associated with toxin-producing staphylococci in patients with AIDS. *J Infect Dis* **165**:638, 1992

20. Manders SM et al: Recurrent toxin-mediated perineal erythema. *Arch Dermatol* **132**:57, 1996

21. Nishijima S et al: *Staphylococcal aureus* in the anterior nares and subungual spaces of the hands in atopic dermatitis. *J Int Med Res* **25**:155, 1997

22. Berkower C et al: Expression of different group A streptococcal M proteins in an isogenic background demonstrates diversity in adherence to and invasion of eukaryotic cells. *Mol Microbiol* **31**:1463, 1999

23. Cunningham MW: Pathogenesis of group A streptococcal infections. *Clin Microbiol Rev* **13**:470, 2000

24. Kaplan EL et al: Group A streptococcal serotypes isolated from patients and sibling contacts during the resurgence of rheumatic fever in the

United States in the mid-1980s. *J Infect Dis* **159**:101, 1989

25. Wannamaker LW: Differences between streptococcal infections of the throat and of the skin. *N Engl J Med* **282**:23, 78, 1970

26. Dillon HC Jr: Impetigo contagiosa: Suppurative and nonsuppurative complications. *Am J Dis Child* **115**:530, 1968

27. Bessen D, Fischetti VA: A human IgG receptor of Group A streptococci is associated with tissue site of infection and streptococcal class. *J Infect Dis* **161**:747, 1990

28. Schlievert PM: Use of intravenous immunoglobulin in the treatment of staphylococcal and streptococcal toxic shock syndromes and related illnesses. *J Allergy Clin Immunol* **108**:S107, 2001

29. Dajani AS et al: Natural history of impetigo. II. Etiologic agents and bacterial interactions. *J Clin Invest* **51**:2863, 1972

30. Ferrieri P et al: Natural history of impetigo. I. Site sequence of acquisition and familial patterns of spread of cutaneous streptococci. *J Clin Invest* **51**:2851, 1972

31. Britton JW et al: Comparison of mupirocin and erythromycin in the treatment of impetigo. *J Pediatr* **117**:827, 1990

32. Seppäla H et al: The effect of changes in the consumption of macrolide antibiotics on erythromycin resistance in group A streptococci in Finland. *N Engl J Med* **337**:441, 1997

33. Rehder PA et al: Perianal cellulitis. Cutaneous group A streptococcal disease. *Arch Dermatol* **124**:702, 1988

34. Honig PJ: Guttate psoriasis associated with perianal streptococcal disease. *J Pediatr* **113**:1037, 1988

35. Woroszylski A et al: Staphylococcal blistering dactylitis: report of two patients. *Pediatr Dermatol* **13**:292, 1996

36. Cone LA et al: Clinical and bacteriologic observations of a toxic shock–like syndrome due to *Streptococcus pyogenes*. *N Engl J Med* **317**:146, 1987

37. Lee PK, Schlievert PM: Quantification and toxicity of group A streptococcal pyrogenic exotoxins in an animal model of toxic shock syndrome–like illness. *J Clin Microbiol* **27**:1890, 1989

38. Leung DY, Travers JB, Norris DA: The role of superantigens in skin disease. *J Invest Dermatol* **105**:37S, 1995

39. Lee PK, Schlievert PM: Quantification and toxicity of group A streptococcal pyrogenic exotoxins in an animal model of toxic shock syndrome–like illness. *J Clin Microbiol* **27**:1890, 1989

40. Cone LA et al: Clinical and bacteriologic observations of a toxic shock–like syndrome due to *Streptococcus pyogenes*. *N Engl J Med* **317**:146, 1987

41. Eriksson BKG et al: Epidemiological and clinical aspects of invasive group A streptococcal infections and the streptococcal toxic shock syndrome. *Clin Infect Dis* **27**:1428, 1998

42. Kaul R et al: Intravenous immunoglobulin therapy for streptococcal toxic shock syndrome—A comparative observational study. *Clin Infect Dis* **28**:800, 1999

43. Darmstadt GL: Acute infectious purpura fulminans: Pathogenesis and medical management. *Pediatr Dermatol* **15**:169, 1998

44. Dhodapkar K et al: Purpura fulminans caused by group A ß-hemolytic streptococcus sepsis. *J Pediatr* **137**:562, 2000

45. Leung DYM et al: Evidence for a streptococcal superantigen-driven process in acute guttate psoriasis. *J Clin Invest* **96**:2106, 1995

46. Lewis HM et al: Restricted T-cell receptor Vß gene usage in the skin of patients with guttate and chronic plaque psoriasis. *Br J Dermatol* **129**:514, 1993

47. Gray GC et al: Hyperendemic *Streptococcus pyogenes* infection despite prophylaxis with penicillin G benzathine. *N Engl J Med* **352**:92, 1991

48. Takama H et al: Pitted keratolysis: Clinical manifestations in 53 cases. *Br J Dermatol* **137**:282, 1997

49. Nordstrom KM et al: The etiology of the malodor associated with pitted keratolysis. *J Invest Dermatol* **87**:159, 1986

50. Wharton JR et al: Erythrasma treated with single-dose clarithromycin. *Arch Dermatol* **134**:671, 1998

51. Savin JA et al: The bacterial flora of trichomycosis axillaris. *J Med Microbiol* **3**:252, 1970

T>

Chapter 195

Steven Resnick Peter Elias

Staphylococcal Scalded Skin Syndrome

HISTORY
ETIOLOGY AND PATHOGENESIS
CLINICAL FEATURES (Table 195-1)
Generalized Form (Ritter's Disease)
Localized Forms
Abortive Forms
LIGHT MICROSCOPIC AND ULTRASTRUCTURAL PATHOLOGY
DIAGNOSIS AND DIFFERENTIAL DIAGNOSIS
TREATMENT AND PROGNOSIS

REFERENCES

The staphylococcal scalded skin syndrome (SSSS) is a generalized exanthematous disorder with cutaneous tenderness, widespread blistering and superficial denudation/desquamation. SSSS represents the severe end of a spectrum of blistering skin disease that includes localized bullous impetigo. The disorders are caused by exfoliative (also known as epidermolytic) toxins A or B, produced by certain strains of *Staphylococcus aureus,* usually belonging to phage group 2.

HISTORY

In 1878, Ritter von Rittershain described 297 cases of “dermatitis exfoliativa neonatorum.” [1] Subsequently, a relationship of the disease to staphylococci was appreciated, and during the late 1940s and early 1950s the link between bullous impetigo and phage group 2 staphylococci became evident. The report of toxic epidermal necrolysis (TEN) by Lyell [2] drew attention to the similarity of the condition to the appearance of generalized scalding, but also led to a period of confusion between nonstaphylococcal TEN and the bacterial toxin–mediated scalded skin syndrome. [3] The situation was clarified with the development of a murine model of the staphylococcal disease. [4] SSSS is now clearly distinguished from other diseases of generalized epidermal necrolysis.

ETIOLOGY AND PATHOGENESIS

The staphylococcal exfoliative toxins A and B (ETA and ETB) are responsible for the characteristic blistering of SSSS. Although most toxigenic strains of *S. aureus* are identified by group 2 phage (types 71 and 55), toxin producers have also been identified among phage groups 1 and 3. ETA and ETB are trypsin-like serine proteases with 40 percent sequence homology. They produce blistering and denudation of skin by disruption of desmosomes in the epidermal granular cell layer, leading to intradesmosomal splitting. [5] For more than a decade it was suspected that the toxins bound directly to the desmosomal cadherin, desmoglein I (Dsg I). [6] Recently, it was demonstrated that ETA specifically cleaves Dsg I in both murine and human skin. [7] Dsg I is also the specific target of autoantibodies in pemphigus foliaceus, a disease with identical localization and histology of blistering as SSSS. Although epidermal cell separation is explained by exfoliative toxins (ETs), other clinical manifestations of SSSS are not explained by action of the toxin. Purified ETs do not cause erythema in either neonatal mice or humans, leading some to suggest that the delta-hemolysin toxin may play an important role in the full expression of the syndrome. [8] In addition, the ETs may act as lipases and activate other proteases, which, in turn, cause pathogenic effects. [9]

A controversy exists concerning whether the ETs possess superantigenic activity. The ETs display limited homology to the staphylococcal enterotoxins and toxic shock syndrome toxin-1. Recent work supports the notion of ET-induced T cell activation in a pattern consistent with other known bacterial superantigens. [10] Toxic shock–like presentations have not been described in patients with ET-producing staphylococcal infections, but it has been proposed that ETA may have properties unique from other superantigens. [10] Their unique properties could explain the discrepant clinical pattern of SSSS, when compared with the patterns of fulminant toxin syndromes such as staphylococcal toxic shock syndrome. In conflicting work, however, recombinant ET was shown to possess no T cell mitogenic or superantigenic activity, [11] which led to the proposal that reports of superantigenic activity of ET resulted from the use of preparations contaminated by minute quantities of other staphylococcal exotoxins. [12]

Children younger than 5 years of age, and particularly neonates, are most commonly affected by SSSS. This epidemiologic pattern is explained by the importance of mature renal function in the clearance of ETs. The combination of decreased ability to achieve renal clearance of toxin [13] and lack of specific immunity to the toxins make neonates the highest risk group.

There are two case reports of congenital SSSS in infants born to mothers with staphylococcal chorioamnionitis. [14], [15] Older children and adults may also develop the disease. In such cases, pathologic renal insufficiency or immunodeficiency appear to explain the susceptibility to the syndrome. Reports highlight the problem of SSSS in adults, including a case associated with HIV disease [16] and a review summarizing 32 adult cases. [17] Unlike most cases in young children, adults with SSSS are often found to have positive blood cultures for toxigenic *S. aureus* and mortality can be significant.

CLINICAL FEATURES (Table 195-1)



TABLE 195-1 **Differentiation of Toxic Epidermal Necrolysis (TEN) and Staphylococcal Scalded Skin Syndrome (SSSS)***

Generalized Form (Ritter's Disease)

Affected children initially have a faint, orange-red macular exanthem, typically associated with purulent conjunctivitis, otitis media, or occult nasopharyngeal infection (Fig. 195-1). Although the rash is not distinctive in appearance, cutaneous tenderness is often apparent at this stage. Tenderness may be so severe that infants stand in their beds whining because lying is too painful. Periorificial and flexural accentuation may be observed. Also, even prior to the appearance of clinical blisters, a positive Nikolsky's sign can often be elicited (Fig. 195-2). Within 24 to 48 h the rash progresses from a scarlatiniform to a blistering eruption. Characteristic tissue paper–like wrinkling of the epidermis is followed by the appearance of large, flaccid bullae in the axillae, groin, and around the body orifices. Subsequent generalized involvement occurs (Fig. 195-3A), sparing the mucous membranes. As sheets of epidermis are shed, a moist, erythematous base is revealed (Fig. 195-3B). Despite the worrisome appearance of the disease, which at this stage resembles generalized scalding, the entire process usually resolves with superficial desquamation (Fig. 195-4), and healing is usually complete within 5 to 7 days. Cultures obtained from intact bullae are usually sterile, consistent with the scenario of hematogenous dissemination of toxin produced at a distant focus of staphylococcal infection. The healing phase may be characterized by extensive desquamation with marked perioral crusting and fissuring.

FIGURE 195-1 Early stage of generalized staphylococcal scalded skin syndrome. Initial manifestation may be occult nasopharyngeal, conjunctival, or ear infection, followed by periorificial erythema and crusting.

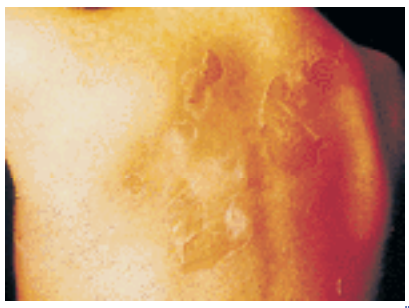

FIGURE 195-2 Generalized indistinct erythemas develop, accompanied by a positive Nikolsky's sign and superficial erosions.

FIGURE 195-3 Advanced stages show (*A*) flaccid bullae and (*B*) large denuded areas similar to scalding.

FIGURE 195-4 Late stage of generalized staphylococcal scalded skin syndrome: generalized desquamation with characteristic large sheets.

Localized Forms (See also Chap. 194)

Bullous impetigo is a localized manifestation of cutaneous staphylococcal infection by toxigenic strains, without hematogenous dissemination of toxin. Presumably, immunity to the toxin plays a crucial role in preventing dissemination, but other factors, including the total burden of toxin, and renal clearance of toxin play a role. As with generalized SSSS, bullous impetigo is predominantly a disease of children, although adult cases also occur. The early lesions are vesicles or bullae filled with cloudy fluid surrounded by an erythematous rim (Fig. 195-5), but more commonly superficial erosions with a silvery sheen and minimal crusting predominate. The lesions tend to be concentrated on exposed parts of the body and around body orifices. In contrast to generalized scalded skin syndrome, both Gram's stain and cultures of blisters reveal staphylococci, and cutaneous tenderness is absent. Rarely, localized bullous impetigo can progress to generalized scalded skin syndrome.

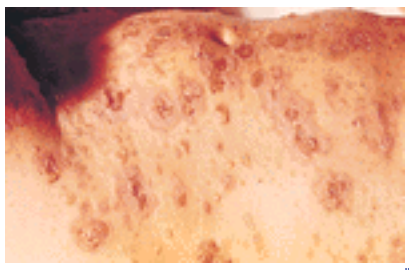

FIGURE 195-5 Bullous impetigo due to phage group 2 staphylococci. Blisters are initially filled with cloudy fluid and later rupture, leading to erosions and crusting.

Abortive Forms

Intermediate forms of SSSS may be seen that begin as localized bullous impetigo, which might evolve to produce regionally limited bullae and denuded areas that may or may not harbor staphylococci. An abortive form of SSSS known as the scarlatiniform variant is described, with features of the early erythrodermic and final desquamative stages but the bullous stage does not occur. [18] Such cases may be confused with other toxic exanthems, including toxic shock syndrome. A recent review suggests that most cases diagnosed as abortive SSSS (staphylococcal scarlet fever) actually represent mild presentations of toxic shock syndrome. [9]

LIGHT MICROSCOPIC AND ULTRASTRUCTURAL PATHOLOGY

All forms of the scalded skin syndrome are characterized by intraepidermal cleavage with splitting occurring beneath and within the stratum granulosum. [19] The cleavage space may contain free-floating or partially attached acantholytic cells (

Fig. 195-6A), but the remainder of the epidermis appears unremarkable and the dermis contains no inflammatory cells, except in cases of localized disease (bullous impetigo) (Fig. 195-6B). Cells bordering the cleavage space appear uninjured, and, ultrastructurally, separation seems to occur by simultaneous splitting of the desmosomes and interdesmosomal regions. [20]

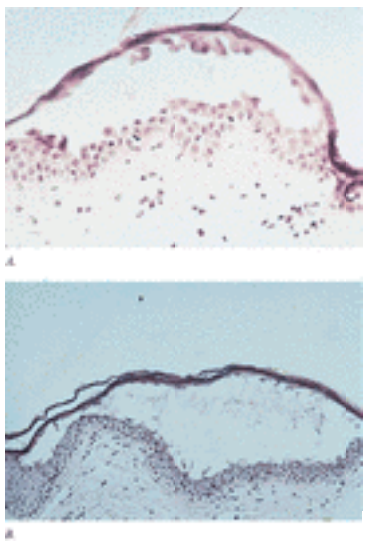

FIGURE 195-6 Generalized (*A*) and localized (*B*) staphylococcal scalded skin syndrome. In both conditions, intraepidermal cleavage occurs within or immediately beneath the stratum granulosum. However, although inflammatory cells are absent in the generalized disease, in the localized form (bullous impetigo) a leucocytic infiltrate impinges and extends from the dermis into the epidermis.

DIAGNOSIS AND DIFFERENTIAL DIAGNOSIS

The principal diagnostic problem is distinguishing SSSS from TEN (see Table 195-1; see also Chap. 58). Although TEN is rare in infancy and childhood, distinctions based solely on age are risky because TEN can occur in children and SSSS can occur in adults. [3], [4], [17] Although the use of exfoliative cytology * (Fig 195-7) and frozen sections for the rapid bedside differential diagnosis can be particularly useful in guiding initial therapy, [21] the definitive diagnosis depends on culture and permanent section biopsy results. In contrast to the subgranular epidermolysis of the scalded skin syndrome, TEN produces full-thickness epidermal necrosis and a dermal–epidermal separation.

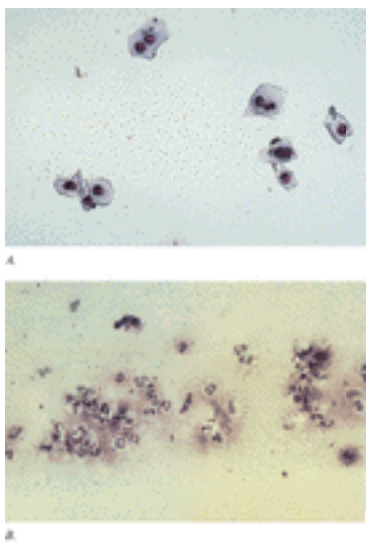

FIGURE 195-7 Giemsa-stained exfoliative cytology preparations from lesions of staphylococcal scalded skin syndrome and drug-induced toxic epidermal necrolysis. In the former (*A*), flattened, fried egg–like nucleated squamae predominate; in the latter (*B*), cellular debris, leukocytes, and occasional cuboidal keratinocytes appear.

TREATMENT AND PROGNOSIS

Therapy for SSSS should be directed toward eradication of staphylococci from the focus of infection, which generally requires intravenous penicillinase-resistant antistaphylococcal antibiotics. Usually, oral antibiotic therapy can be substituted within several days or sooner. Antibiotics, supportive skin care, and appropriate attention to fluid and electrolyte management in the presence of disrupted barrier function will usually ensure rapid recovery. The disease still carries a significant mortality (2 to 3 percent), and serious complications have been reported, including cellulitis, sepsis, pneumonia, and osteomyelitis. Adult patients with SSSS are more likely to be immunosuppressed and suffering from other medical problems. They are much more likely than children to have staphylococcal bacteremia, and they have a poorer prognosis. [17]

It is important to recognize the potential for epidemic scalded skin syndrome in neonatal care units. [22] Identification of health care workers colonized or infected with toxigenic *S. aureus* is an integral part of managing the problem. Control measures should be applied, including isolation of infected infants, barrier precautions, strict enforcement of chlorhexidine hand washing, oral antibiotic therapy for infected workers, and mupirocin ointment for eradication of persistent nasal carriage. [23]

*Smears are made from scrapings of Nikolsky-positive areas. After short fixation, the smears are stained with methylene blue or Giemsa stain. The test is considered positive when large “fried egg”–like cells are seen.

REFERENCES

1. Ritter von Rittershain G: Die exfolative Dermatitis jüngerer Sauglinge. *Zentralzeitung fur Kinderheilkunde* **2**:3, 1878

2. Lyell A: Toxic epidermal necrolysis: An eruption resembling scalding of the skin. *Br J Dermatol* **68**:355, 1956

3. Lyell A: Toxic epidermal necrolysis (the scalded skin syndrome): A reappraisal. *Br J Dermatol* **100**:69, 1979

4. Melish ME, Glasgow A: The staphylococcal scalded skin syndrome: Development of an experimental mouse model. *N Engl J Med* **282**:1114, 1970

5. Murono K et al: Microbiologic characteristics of exfoliative toxin-producing *Staphylococcus aureus. Pediatr Infect Dis J* **7**:313, 1988

6. Takagi Y et al: Action site of exfoliative toxin on keratinocytes. *J Invest Dermatol* **94**:52a, 1990

7. Amagai M et al: Toxin in bullous impetigo and staphylococcal scalded-skin syndrome targets desmoglein I. *Nat Med* **6**:1275, 2000

8. Gemmell CG: Staphylococcal scalded skin syndrome. *J Med Microbiol* **43**:318, 1995

9. Ladhani S et al: Clinical, microbial, and biochemical aspects of the exfoliative toxins causing staphylococcal scalded-skin syndrome. *Clin Microbiol Rev* **12**:224, 1999

10. Monday SR et al: Unique superantigen activity of staphylococcal exfoliative toxins. *J Immunol* **162**:4550, 1999

11. Plano LR et al: Recombinant *Staphylococcus aureus* exfoliative toxins are not bacterial superantigens. *Infect Immun* **68**:3048, 2000

12. Fleischer B, Bailey CJ: Recombinant epidermolytic toxin A of *Staphylococcus aureus* is not a superantigen. *Med Microbiol Immunol* **180**:273, 1992

13. Fritsch P et al: The fate of staphylococcal exfoliation in newborn and adult mice. *Br J Dermatol* **95**:275, 1976

14. Loughead JL: Congenital staphylococcal scalded skin syndrome. *Pediatr Infect Dis J* **11**:413, 1992

15. Lo WT et al: Intrauterine staphylococcal scalded skin syndrome: Report of a case. *Pediatr Infect Dis J* **19**:481, 2000

16. Farrell AM et al: Staphylococcal scalded skin syndrome in an HIV-1 seropositive man. *Br J Dermatol* **134**:962, 1996

17. Cribier B et al: Staphylococcal scalded skin syndrome in adults. A clinical review. *J Am Acad Dermatol* **30**:319, 1994

18. Melish ME, Glasgow LA: The staphylococcal scalded skin syndrome: The expanded clinical syndrome. *J Pediatr* **78**:958, 1971

19. Koblenzer PJ: Acute epidermal necrolysis (Ritter von Rittershain-Lyell): A clinicopathologic study. *Arch Dermatol* **95**:608, 1967

20. Lillibridge DB et al: Site of action of exfoliative toxin in the staphylococcal scalded skin syndrome. *Pediatrics* **50**:728, 1972

21. Amon RB, Diamond RL: Toxic epidermal necrolysis: Rapid differentiation between staphylococcal- and drug-induced disease. *Arch Dermatol* **111**:1433, 1975

22. Dancer SJ et al: Outbreak of staphylococcal scalded skin syndrome among neonates. *J Infect* **16**:87, 1988

23. Hoeger PH, Elsner P: Staphylococcal scalded skin syndrome: Transmission of exfoliatin-producing *S. aureus* by an asymptomatic carrier. *Pediatr Infect Dis J* **7**:340, 1988

T>

Chapter 196

Arnold Weinberg Morton Swartz Hensin Tsao
Richard Johnson

Soft-Tissue Infections: Erysipelas, Cellulitis, Gangrenous Cellulitis, and Myonecrosis

ETIOLOGY OF SOFT TISSUE INFECTIONS
PATHOGENESIS
CLINICAL SYMPTOMS OF SOFT-TISSUE INFECTIONS
OBJECTIVE CLINICAL FINDINGS IN SOFT-TISSUE INFECTIONS
Erysipelas
DIFFERENTIAL DIAGNOSIS
LABORATORY STUDIES
Smears of Pus, Exudate, and Aspirates
Imaging
Dermatopathology
SPECIFIC BACTERIAL SPECIES ASSOCIATED WITH STI
Person-to-Person Spread
Specific Bacterial Species Associated with Aqueous Environments
Specific Bacterial Species Associated with Soil Exposure
Specific Bacterial Species Associated with Animal Exposure
Miscellaneous Pathogens
COURSE AND PROGNOSIS
TREATMENT
Antibiotics
Local Measures
Surgical Intervention
Other Therapies

REFERENCES

Soft-tissue infections (STIs), are characterized by findings that include an acute, diffuse, tender, spreading, edematous, suppurative inflammation of the dermis, subcutaneous or muscular tissues, often associated with systemic symptoms of malaise, fever, chills, and local pain. Nonnecrotizing STIs are treated with antibiotics, drainage of abscesses, and supportive measures. Necrotizing STIs are often life-threatening and require, in addition, extensive surgical débridement.

In competent hosts these infections are usually caused by beta-hemolytic streptococci (primarily Group A), *Staphylococcus aureus,* and, in deep fascia and muscle, by mixed anaerobic and facultative gram-positive and gram-negative organisms, including histotoxic *Clostridia*. There is less predictability in compromised hosts. Organisms may include a range of traditional and rare pathogens, usual commensals, yeast, fungi, and parasites. Adding to the importance of determining an etiologic diagnosis is the observation that traditional patterns of symptoms and physical findings may be lacking or nonspecific in immunocompromised patients. [1] In both immunocompetent and compromised hosts bullae, necrosis, or gas-forming bacterial infections can lead to alarming physical findings, and signal urgency, as well as the location, in defining the cause (see Chap. 193, Table 193-3 and Table 193-4).

Erysipelas is a distinct type of superficial cutaneous cellulitis with marked dermal lymphatic vessel involvement caused by group A beta-hemolytic streptococcus (very uncommonly group C or G streptococcus) and rarely caused by *S. aureus*. In the newborn, Group B streptococci can cause erysipelas.

Cellulitis involves more of the soft tissues, extending deeper into the dermis and subcutaneous tissue. *S. aureus* and group A streptococci are by far the most common etiologic agents, but occasionally other bacteria are identified (e.g., group B streptococci in the newborn, pneumococci, gram-negative bacilli, and in immunocompromised individuals, a variety of other microorganisms, including yeasts and molds).

Gangrenous cellulitis, characterized by necrosis of the epidermis and deeper soft tissue structures including muscle, is classified as necrotizing fasciitis, clostridial STI, progressive bacterial synergistic gangrene and synergistic necrotizing cellulitis (see Chap. 193, Table 193-3 and Table 193-4).

Myonecrosis is an acute inflammatory and necrotizing infection usually caused by histotoxic *Clostridia* (including *C. perfringens, C. septicum*) as well as group A streptococci, peptostreptococci and, rarely, other microorganisms. Secondary soft tissue changes include edema, bulla formation, crepitus, skin discoloration, tenderness and pain.

ETIOLOGY OF SOFT TISSUE INFECTIONS

See Table 196-1.

TABLE 196-1 **Etiology of Soft Tissue Infections**

PATHOGENESIS

Normal intact skin plays a critical role in the defense against a wide range of pathogens. The details of the host–pathogen interaction are poorly understood, but appear to involve barrier function, bacterial factors, and host factors (Fig. 196-1). This issue is discussed in detail in Chap. 193.

FIGURE 196-1 Host–pathogen interaction.

CLINICAL SYMPTOMS OF SOFT-TISSUE INFECTIONS

In some cases, there is a history of an antecedent lesion (dermatitis, stasis ulcer, puncture wound, percutaneous catheter, or trauma). With onset of infection, patients often experience local pain and tenderness along with variable degrees of erythema and systemic symptoms (fever, chills, and malaise). Erythema, at first minimal at the site of infection, may rapidly intensify and spread. Local pain is often severe and in the absence of erythema should raise suspicions of early deeper seated infection. In some individuals, systemic symptoms may antedate localizing complaints and signs of STIs. In a study of 50 patients with cellulitis, only 26 percent had fever >38°C (>100.4°F). A potential portal of entry was identified in 66 percent of patients: 50 percent of those with upper extremity and 67 percent of those with lower extremity cellulitis. [2] Patients with early gangrenous cellulitis may experience severe pain out of proportion to the appearance of the local area.

OBJECTIVE CLINICAL FINDINGS IN SOFT-TISSUE INFECTIONS

Erysipelas

In the absence of underlying edema or other skin abnormalities, erysipelas usually begins on the face or on a lower extremity, heralded by pain, superficial erythema, and plaquelike edema with a sharply defined margin to normal tissue (Fig. 196-2 and Fig. 196-3). In the presence of antecedent edema or other anatomic abnormalities, the margin between normal and diseased soft tissue may be obscure, much like in primary cellulitis. There may not be an obvious portal of entry, and skipped areas may confuse the nature of the process. Facial erysipelas is less frequent than lower extremity disease, begins unilaterally but may spread by contiguity over the nasal prominence to involve the face symmetrically (Fig. 196-2). Inflammatory edema may extend to the eyelids but orbital complications are rare. Fever may precede local signs and occasionally patients complain of groin pain, caused by swelling of a femoral node, prior to distal extremity findings. Lymphangitis and abscess are very rare but the process may spread rapidly from the initial lesion, the pace of which can be evaluated by using a pen to define the borders. The most common pathogen identified is group A streptococcus, but cases caused by groups C, G, and B streptococci and more slowly evolving lesions secondary to *S. aureus* and other microorganisms are documented. [3], [4] Occasionally, in addition to rapid spread of the erythematous, edematous plaque, bullae may form in the involved area. [5] Recurrent erysipelas is associated with saphenous vein harvest (associated occasionally with tinea pedis) and the lymphedema complicating mastectomy with axillary node dissection.

FIGURE 196-2 Erysipelas. Painful, edematous erythema with sharp margination on both cheeks and the nose.

FIGURE 196-3 Erysipelas. Fiery-red, brawny, edematous erythema that is sharply and irregularly marginated. There is tenderness, and the patient has fever and chills. In the presence of underlying edema the margins of the cellulitis may be ill-defined and the process less confluent.

ACUTE CELLULITIS This has many of the features of erysipelas (erythema, tenderness, pain) but extends deeper into the subcutaneous tissues. Cellulitis can be differentiated from erysipelas by the lack of distinct margins between affected and normal skin, a deeper, firmer form of tender induration, fluctuance, and occasionally the presence of crepitus on palpation. In a study of 50 children with cellulitis, 16 percent of cases had facial infection with the remainder occurring on an extremity, the leg being affected three times as often as the arm. [6] In some cases of cellulitis, the overlying epidermis undergoes bulla formation or necrosis, resulting in extensive areas of epidermal sloughing and superficial erosion (Fig. 196-4A). Alternatively, with or without antibiotic therapy, infection may localize in the soft tissue, with dermal and subcutaneous abscess formation (Fig. 196-4B) or fasciitis (Fig. 196-5). Regional lymphadenopathy may be associated with cellulitis on an extremity. In older individuals, thrombophlebitis may complicate lower leg cellulitis. Most cases of spontaneous cellulitis or those secondary to skin lesions or trauma are due to *S. aureus*. Group A and other streptococci (especially groups B, C, and G), as well as *Escherichia coli* and other Enterobacteriaceae and anaerobes, are involved in cellulitis, especially in association with extremes of age, prolonged hospitalization, percutaneous intravascular lines, diabetes, immunocompromised states and glucocorticoids. [7]

FIGURE 196-4 *A*. Cellulitis following puncture trauma. The forearm is swollen, erythematous, and tender; there is abscess formation, blistering, and crusting. *B*. Cellulitis arising at the site of a surgical excision: *S. aureus*. Note discharge of pus.

FIGURE 196-5 *A*. Gangrenous cellulitis: necrotizing fasciitis. Note the black necrosis, resembling a third-degree burn, and an erythematous margin. There is severe systemic toxicity. *B*. 48 h later, there is progressive gangrene of the pubic, perigenital, and perianal tissue.

SURGICAL WOUND INFECTIONS These are classified as incisional (superficial) or deep. [8] Incisional wound infections involve the skin, subcutaneous tissue, and/or muscle. Deep infections involve structures adjacent to the surgical wound that were entered or exposed during the procedure, such as subfascial layers, viscera, and/or spaces within the peritoneum, thorax, or joints. Up to 80 percent of wound infections are incisional. A wound is considered to be infected if there is drainage of purulent material and evidence of inflammation. Incisional infections present with erythema, pain, tenderness, and local swelling (Fig. 196-4B), and often with low-grade fever. Purulent drainage reveals neutrophils and cultures most often grow *S. aureus.* Separation of the margins of the wound is usual and this allows appropriate drainage. Deep wound infections may be more subtle and delayed and often present as fever of uncertain cause. Progressive bacterial synergistic gangrene and other variants of gangrenous cellulitis can arise in surgical wounds or around sutures (see below). The complications of superficial and deep wound infections include poor healing, bacteremia, the local and systemic effects of prolonged hospitalization, poor nutrition, residual compromised tissue integrity, and the consequence of prolonged antibiotic therapy in a hospital setting. Additionally, wounds infected with toxin producing *S. aureus* or group A streptococci may result in systemic complications such as toxic shock syndrome or scarlet fever. Details of infections and intoxications secondary to pyogenic gram positive microorganisms are discussed in Chap. 194 and Chap. 195.

CELLULITIS COMPLICATING A PRESSURE ULCER Pressure ulcers, particularly those located in the sacrum in elderly, frail, malnourished individuals pose significant problems for the patient and the physician. In addition to reflecting poor skin nutrition, the location causes the site to be contaminated by a variety of facultative and anaerobic microorganisms from the skin and the bowel, including *S. aureus,* enterococci, *Pseudomonas aeruginosa,* and *Bacteroides fragilis*. In addition to pain and cellulitis, the ulcer can be undermined and may eventually be complicated by bacteremia, often polymicrobial, or the underlying bone can become infected. Like other open wounds, the identity of the active pathogen(s) may be difficult to determine.

CELLULITIS ARISING AT SITES OF ANIMAL BITES Domestic dog and cat bites are frequent and can give rise to painful and necrotizing cellulitis caused by *Pasteurella multocida, Capnocytophaga canimorsus* (especially in asplenic individuals) and a host of other aerobes and anaerobes from the animals' mouth or the skin of the infected individual. Dog bites are often accompanied by a crush injury that devitalizes tissues. The bite of cats can inject organisms (via sharp incisors) deep into tissues, including joint spaces, tendon sheaths, or below the periosteum of bone. Domestic and wild animal bite infections are discussed in detail in Chap. 199 and Chap. 237. Human bites have a higher incidence of infection than do animal bites because of the mix of oral bacteria (aerobes and anaerobes), as well as the crush injury imparted along with the bite. Organisms include various streptococci, *S. aureus,* and the anaerobic peptostreptococci and peptococci.

GANGRENOUS CELLULITIS, INFECTIOUS GANGRENE, AND CREPITANT SOFT-TISSUE WOUNDS (Table 196-2)

Necrotizing fasciitis
Streptococcal gangrene
Necrotizing fasciitis other than streptococcal gangrene
Synergistic necrotizing cellulitis (necrotizing cutaneous myositis, synergistic nonclostridial anaerobic myonecrosis)
Fournier's gangrene
Clostridial soft tissue infections
Anaerobic cellulitis
Anaerobic myonecrosis (gas gangrene)
Spontaneous, nontraumatic anaerobic myonecrosis
Progressive bacterial synergistic gangrene
Gangrenous cellulitis in the immunosuppressed individual
Localized areas of skin necrosis complicating conventional cellulitis

TABLE 196-2 **Classification of Gangrenous Cellulitis (Infectious Gangrene)**

These soft-tissue infections are characteristically rapidly developing, progressive, and accompanied by constitutional symptoms, severe pain, and tenderness, with changes in overlying skin that progress to bulla formation and frank necrosis. The process can be in the superficial or deep fascia with secondary changes in the overlying soft tissues. Palpation may reveal tenderness or gas in the area of involvement (see Chap. 193, Table 193-3 and Table 193-4; and Fig. 196-5A and Fig. 196-5B). This section focuses on the various types of necrotizing fasciitis and other necrotizing soft-tissue infections, with and without gas formation, excluding myonecrosis. During the past decade there has been increasing speculation, especially associated with necrotizing soft-tissue infections and toxic shock syndromes, that the use of nonsteroidal antiinflammatory drugs (NSAIDs) may be contraindicated. Citing examples of necrotizing fasciitis and streptococcal toxic shocklike syndrome, the arguments are interesting, but need study. [9] NSAIDs may interfere with leukocyte chemotaxis (inhibition of lipoxygenase), decrease the inflammatory response (through decreased leukotriene production), and blur cardinal symptoms of infection (fever and pain) by inhibition of prostaglandin action. [10] The above observations and speculations argue for more thoughtful and cautious use of NSAIDs in fragile patients.

Streptococcal angrene including type II necrotizing fasciitis The pathogen is almost always a group A streptococcus, although groups C and G isolates, as well as other microorganisms, are rarely identified. Occasionally, especially in newborns, but also in patients early postpartum, group B streptococci have been recovered. A recent description of seven cases (two new) of *Streptococcus pneumoniae* necrotizing fasciitis, behaving like group A streptococcal infections, is noteworthy, considering the infrequent cutaneous involvement of *S. pneumoniae,* the similarity of their inflammatory

characteristics, and the increasing problems of penicillin resistance. [10] Patients may be immunocompromised by age or illness, such as diabetes, alcoholism, or cirrhosis, but usually are healthy individuals. The location of the necrotizing lesion is most often an extremity, rarely the face. Pain, erythema, and edema with rapid formation of bullae, constitutional symptoms with high fever, and toxicity are characteristic of early progression. There is bacteremia in approximately two-thirds of patients and evolution of necrosis of the overlying skin can be rapid and dramatic with appearance of deeper structures including tendon sheaths and muscle. Streptococcal toxic shocklike syndrome often accompanies this infection, referred to in the lay press as a “flesh-eating” bacterial process. The terms *streptococcal gangrene* and *streptococcal necrotizing fasciitis* should be considered as a single disease continuum. With bulla formation, the diagnosis is apparent from a Gram stain of an aspirate. As the process evolves, necrosis and eschar formation precede sloughing of tissues. Early symptoms of local pain eventually evolve to anesthetic areas and progressive toxicity is often accompanied by mental depression. Treatment with penicillin and clindamycin as well as surgical débridement and supportive therapy can be life saving but the prognosis remains poor. [7], [11] Chapter 194 provides a detailed discussion of streptococcal toxic shocklike syndrome prognosis and therapy.

Type I necrotizing fasciitis This infection is caused by a mix of facultative and anaerobic microbes, often delivered into the subcutaneous tissues following surgery, bowel perforation secondary to neoplasm or diverticulitis, trauma, or parenteral drug abuse via skin-popping, and often occurs in patients compromised by diabetes or malnutrition. Organisms include nongroupable streptococci, enterococci, anaerobic streptococci and staphylococci, *Bacteroides* spp., and Enterobacteriaceae including *E. coli,* as well as various aquatic bacteria. Often three to five species contribute to the infection, which may have a slower pace than group A streptococci in evolving to a full-blown process with cutaneous manifestations. [12], [13] Type I necrotizing fasciitis most commonly occurs on an extremity, abdominal wall, perineum, or about operative wounds. Clinically, it is indistinguishable from streptococcal gangrene (Fig. 196-5). Although the initial pace of the illness may be slower, it is important to recognize that when this infection presents in the thigh (dissection along the psoas muscle) or abdominal wall, it may be secondary to an intestinal source (occult diverticulitis, rectosigmoid neoplasm). The involved area may be painful at first and then evolve with objective findings: swelling, erythema, warmth, and tenderness. The process is often more extensive than the overlying skin changes would suggest. Within several days, the skin color becomes purple, bullae develop, and frank cutaneous gangrene ensues (Fig. 196-5B). At this stage the involved area is no longer tender; it has become anesthetic as a result of occlusion of small blood vessels and destruction of superficial nerves in the subcutaneous tissues. Crepitus is often present, particularly in patients with diabetes mellitus or if gas-forming anaerobes, such as *Bacteroides* spp., are present. [7], [13]

Fournier's gangrene This is a localized variant of necrotizing fasciitis involving the scrotum and penis. [7], [14], [15] It is usually caused by the same mix of facultative and anaerobic organisms that are associated with type I necrotizing fasciitis. In rare cases, group A streptococci, as the single pathogen has been implicated, and this may be related to rectal ring carriage or to oral-genital sex. The average age at onset is 50 to 60 years. Most men have underlying diseases or procedures. These include diabetes mellitus, ischiorectal abscess, perineal fistula, bowel disease (rectal or colon carcinoma, diverticulitis), scrotal or penile trauma, prior hemorrhoidal or urogenital surgery, pressure ulcers of the scrotum and perineum (e.g., alcoholics sitting in a drunken stupor), and, rarely, obscure causes, such as dissection of pancreatic secretions through the retroperitoneum and into the scrotum in acute pancreatitis. The onset of Fournier's gangrene can be insidious, with a discrete area of edema, erythema, and necrosis on the scrotum, progressing to advancing skin necrosis rapidly over 1 to 2 days. Pain, swelling, and crepitus in the scrotum, perineum or suprapubic region may be marked. Foul-smelling drainage occurs, indicating a contribution from anaerobes. Purplish discoloration of the scrotum, an initial “red flag,” progresses to frank gangrene. The infection tends to be superficial, limited to skin and subcutaneous tissue and extending to the base of the scrotum, but it may spread to the penis, perineum, and abdominal wall along fascial planes. The testes, glans penis, and spermatic cord are usually spared as they have a separate blood supply. The infection may progress and invade the abdominal panniculus in obese patients, especially those with diabetes mellitus, leading to rapid and extensive destruction of tissue and requiring wide débridement and prolonged hospitalization.

Synergistic necrotizing cellulitis (necrotizing cutaneous myositis, synergistic nonclostridial anaerobic myonecrosis) This variant of necrotizing fasciitis is unique in that all soft-tissue structures, including muscle, can be involved in a painful, progressive, polymicrobial infection that is highly lethal. The poor prognosis relates to the demography of the usual patient: frail, elderly, diabetic, wasted or obese, and almost always with compromising cardiovascular and renal disease. The process may begin slowly, evolving over 7 to 10 days with mild symptoms, primarily pain. Individuals are often afebrile or have only low-grade fever, lacking systemic toxicity in the early stages. The initial skin lesion is a small area of necrosis or reddish-brown blister with extreme local tenderness; the superficial appearance belies the widespread destruction of the deeper tissues. Skin sinuses (with surrounding areas of blue-gray gangrene) form, draining a foul-smelling thin pale “dishwater” exudate containing fragments of necrotic fat. Gram stain of the drainage reveals both gram-positive and gram-negative organisms and rare or absent neutrophils. Extensive gangrene of the superficial tissues and fat can be visualized by direct inspection through skin open areas or with skin incisions. Gas can be palpated in the tissues in approximately a quarter of patients. Organisms frequently isolated included anaerobes (streptococci and/or bacteroides) and facultative bacteria, especially Enterobacteriaceae (*E. coli, Proteus, Klebsiella,* etc.). [16] The most common site of involvement in approximately half the cases is the perineum. The major predisposing causes are perirectal and ischiorectal abscesses. These localized infections track to the deeper structures of the pelvis, leading to a severe infection. A more superficial form involves the buttocks without extension to deeper muscles; 40 percent of individuals have involvement of the thigh and leg. Some infections arise in the adductor compartment of the thigh, often extending from an infected amputation stump or diabetic gangrene. The remaining 10 percent of cases are found on the lower abdomen, distal leg and rarely on the neck, often associated with severe vascular disease and diabetes. Even with rapid surgical and medical interventions, the mortality remains in the 40 to 50 percent range, in part because of accompanying diseases. Incision, drainage, extensive débridement, and amputation are the aggressive actions that must be taken, in concert with antibiotics (including one directed at bacteroides) guided initially by the Gram stain. [7]

PROGRESSIVE BACTERIAL SYNERGISTIC GANGRENE (MELENEY'S GANGRENE) This infection typically occurs in association with wire stay sutures in a drain site following an abdominal operation (ileostomy, colostomy), in an incision in the chest wall following abdominal or thoracic infection (empyema), at the exit site of a fistulous tract, or in a chronic ulcer. The infection usually is recognized as one or more shaggy, painful ulcers developing within a week or two of a procedure, especially in proximity to wires or other foreign bodies. [7] The name, synergistic gangrene, was coined by Meleney in the 1930s, based on studies done in vivo in rabbits. Clinical microbiology confirms that this rare infection usually is associated with a microaerophilic or anaerobic streptococcus at the advancing margin and *S. aureus* (or,

rarely, an enteric gram-negative bacillus) in the central, shaggy, ulcerated area. [17] The process usually starts with local redness, tenderness, and swelling that subsequently develops into a painful, superficial enlarging shaggy-based ulcer. Three zones of involvement become apparent: a central area of necrosis (ulceration); a surrounding zone of violaceous, tender edematous tissue with necrotic margins; and an outer zone of bright erythema and edema. Local pain and tenderness are nearly always present; fever and systemic toxicity, however, usually are minimal or absent. Untreated, the process progressively enlarges, ultimately resulting in enormous ulcerations (Fig. 196-6). Meleney's ulcer has the features of progressive bacterial synergistic gangrene (Meleney's gangrene), with associated burrowing necrotic tracts through tissue planes that emerge at distant skin sites. Treatment includes removal of foreign bodies and excision of the shaggy ulcer and necrotic margins, plus zinc sulfate topical cream and antibiotics, guided by Gram stains and cultures. [18]

FIGURE 196-6 Progressive bacterial synergistic gangrene. Necrosis and deep ulcerations of the genitalia and perineum in a toddler.

GANGRENOUS CELLULITIS IN THE IMMUNOCOMPROMISED INDIVIDUAL The microorganisms associated with necrotizing cutaneous infections in the normal host are joined by a variety of other traditionally pathogenic and nonpathogenic bacteria, as well as fungi in compromised patients. In the presence of thermal burns bacteremic *Pseudomonas aeruginosa* may colonize normal skin, producing ecthyma gangrenosum (see Chap. 197), or may home to burn areas, leading to extensive bacteremic *Pseudomonas* gangrenous cellulitis (see Chap. 193, Table 193-3). Mucormycotic gangrenous cellulitis can engraft onto thermal burns or complicate percutaneous catheter areas in immunosuppressed individuals. [19] In the immunocompromised host it becomes mandatory to biopsy any necrotic cellulitic lesions and to be alert to the possibility of a wide range of bacterial, viral, fungal and even parasitic pathogens.

NONCLOSTRIDIAL CREPITANT CELLULITIS The presence of a cellulitis with palpable gas raises the specter of a histotoxic *Clostridium* infection. The patient may have experienced a traumatic or surgical injury that was inadequately débrided or had an underlying local infection, a poorly performed needle stick or illicit drugs via skin popping. [20] Underlying diabetes, glucocorticoid or NSAID use and granulopenia may be present. The clinical presentation is often insidious, with low-grade fever, mild pain, and tenderness, but with early palpable gas and edema. Anaerobic isolates may include *Bacteroides* spp. or peptostreptococci, often with facultative gram-negative bacilli. In uncontrolled diabetes, the presence of gas may result from metabolism of glucose by *E. coli, Klebsiella, Aeromonas,* and other microorganisms (see Chap. 197).

CLOSTRIDIAL SOFT-TISSUE INFECTIONS The histotoxic clostridia are responsible for a variety of infections that involve the subcutaneous and muscular tissues, with changes in the overlying skin that can be abrupt and dramatic. Clostridial anaerobic cellulitis is an infection of the more superficial subcutaneous zone, usually in tissues that are already devitalized, and rarely involving the deep fascia or muscle. Clostridial myositis, or gas gangrene, is a process that is anatomically in the muscle layer but with significant changes in the skin and subcutaneous tissues via interference with vascular and lymphatic structures. The histotoxic clostridia primarily involved in these infections include the human gut commensal *Clostridium perfringens* and the environmentally resident *Clostridium septicum*. *C. perfringens* is present in approximately 90 percent of normal colons but *C. septicum* is rarely found, perhaps in 5 percent of asymptomatic individuals. Newer and traditional bacteriologic techniques allow for easy identification of these obligate anaerobes. [21]

ANAEROBIC CELLULITIS This is an infection of devitalized tissue, usually caused by *C. perfringens* with or without other bacteria, occurring in a dirty or inadequately débrided wound several days after injury or following a needle stick or surgery. The onset is more gradual than in anaerobic myonecrosis (gas gangrene). The clostridia are able to grow in the wound and extend rapidly through tissue planes, with attendant formation of large quantities of gas that is readily palpable. A thin, dark-gray to brown, foul, serous discharge is produced. Gram-stained smear of the drainage reveals short, plump, blunt-ended, gram-positive rods without spores, with a variable number of polymorphonuclear leukocytes and occasionally other bacterial forms. Unlike gas gangrene, there is relatively little local pain or edema, change in overlying skin, or toxemia. At surgery, the muscles appear normal, but gas may be readily evident throughout the exudate. Anaerobic cellulitis can be distinguished from anaerobic myonecrosis by inspection of muscle, to avoid needless mutilating surgery and amputations. Treatment consists of opening the wound, removing necrotic debris, and administering antibiotics (penicillin and either clindamycin or metronidazole). Occasionally, bacteremic *C. septicum* can spread to subcutaneous tissues. These patients are toxic, unstable and usually the suspicion of *C. septicum* is raised on finding subterminal spores in large gram-positive bacilli. [22]

ANAEROBIC MYONECROSIS (GAS GANGRENE) This is a rapidly progressing, toxemic, potentially lethal infection involving muscle but with secondary changes in the overlying skin. The infection may develop as a complication of muscle injury, a traumatic dirty wound with extensive muscle and soft-tissue damage, or following surgery on the bowel or gallbladder. *C. perfringens* is the most common pathogen and also part of the normal flora but rarely associated with spontaneous gas gangrene. The incubation period of anaerobic myonecrosis is often short (12 to 24 h) but may be delayed, rarely developing following anaerobic cellulitis. The first symptom is usually severe local pain, followed by fever, tachycardia, and hypotension. Gas formation is present, but not prominent, in subcutaneous tissues, and may be completely obscured by edema of the superficial tissues. The skin often takes on a dark yellow or bronze discoloration, with tense blebs or bullae containing dark brown fluid. A serosanguineous exudate can be expressed from the wound or aspirated from a bullous lesion. Gram stain of the exudate reveals plump gram-positive rods and rare or absent white blood cells even with a systemic leukocytosis. The overlying skin may develop patchy necrosis and desquamation. At surgery the process in the muscle is evident, with gray pallor, absence of bleeding, presence of gas and failure of muscle to respond to direct stimuli. Removal of devitalized tissue, antibiotics and supportive therapy must be quickly undertaken, and amputation can be life saving in limb involvement. Antitoxin is no longer available and hyperbaric oxygen is reserved for involvement of areas not amenable to débridement. [21]

SPONTANEOUS, NONTRAUMATIC ANAEROBIC MYONECROSIS In the absence of an external wound, septicemic gas gangrene may occur spontaneously, usually caused by *C. septicum* and often associated with hematologic malignancies or occult colon cancer, especially in the cecal area. Spontaneous *C. septicum* gas gangrene is a fulminant

disease, with a mortality approaching 100 percent and marked by a precipitous onset and progression, often with subcutaneous gas, myonecrosis, and high-grade septicemia. Overlying skin of an involved area becomes red-brown and the epidermis sloughs early in the illness. [22]

DIFFERENTIAL DIAGNOSIS

The differential diagnosis of erysipelas, cellulitis, necrotizing cellulitis, and myonecrosis includes other infections, as well as noninfectious inflammatory disorders that have features that may be confused with STI (Table 196-3 and Table 196-4).

Noninfectious Disorders
Dissecting cellulitis of the scalp (perifolliculitis capitis abscedens et suffodiens)
Acne conglobata
Hidradenitis suppurativa
Acute allergic contact dermatitis (e.g., to poison ivy or poison oak)
Erythema nodosum
Eosinophilic cellulitis
Giant urticaria and angioedema
Fixed drug eruption
Deep venous thrombosis and lipodermatosclerosis
Vasculitis such as polyarteritis nodosa
Familial Mediterranean fever
Inflammatory breast carcinoma (carcinoma erysipeloides)
Infectious Disorders
Osteomyelitis of the maxillary or frontal bones secondary to paranasal sinusitis
Extension of subperiosteal infection from long bone osteomyelitis
Erythema migrans
Erythema infectiosum (human parvovirus B19 infection with "slapped cheek")
Early primevsicular herpes zoster

TABLE 196-3 **Differential Diagnosis of Erysipelas and Acute Cellulitis**

Factitial ulcers
Pyoderma gangrenosum
Purpura fulminans (disseminated intravascular coagulation)
Calciphylaxis
Ischemic necrosis (atherosclerosis obliterans, thromboembolism)
Fixed drug eruption, warfarin necrosis, heparin necrosis
Pressure ulcer
Amebic (Entamoeba histolytica) skin gangrene following bowel surgery
Brown recluse spider bite

TABLE 196-4 **Differential Diagnosis of Necrotizing Soft-Tissue Infections**

LABORATORY STUDIES

Smears of Pus, Exudate, and Aspirates

Although classical morphologic descriptions of STI can provide insight into the likely etiologic diagnosis, one cannot assume that typical lesions equate to specific pathogens. This is particularly true when dealing with patients that are immunocompromised by diseases or their therapies. Typical appearance of an STI, coupled with epidemiologic and clinical data, may provide help when prescribing initial antibiotics, but cannot be totally relied on. Immediate and more substantial clues can come from aspiration of fluctuant lesions or bullae and from swabs of open lesions using the Gram stain, fungal stains, and other direct methods, including immunofluorescent methods (see Chap. 193).

Cellulitic plaques, characteristic of erysipelas, are rarely successfully cultured. Nonbacteriostatic saline can be injected into the advanced border, followed by aspiration of tissue fluid that is then subjected to staining. Successful identity of pathogens is uncommon, but cultures of the material along with blood cultures is a vital part of the search for the etiologic agent in all STIs. [23] Open lesions such as postsurgical, traumatic, and pressure ulcers, may contain multiple organisms, some of which may be significant although others are contaminants. The Gram stain may help initially to identify the most significant morphologic and staining bacteria but often a biopsy as well as the inflammatory cell type of the lesion, followed by cultures, special stains and pathologic investigation, will prove most helpful compared to study of surface material. Pathogens are more likely to be seen microscopically and cultured from abscesses, surgical wounds, bullae and deeper tissue exudates from necrotizing fasciitis and myonecrosis. Open lesions will attract a variety of microorganisms, among which a pathogen may be difficult to select. [24] Refer to Chap. 193 for a discussion of other methods, many noncultural, [25] being used or developed to identify a responsible pathogen—the gold standard in effective antimicrobial therapy of STI.

Imaging

Infections with anaerobic organisms, especially *Clostridia* and bacteroides, may lead to gas formation, which can then be visualized radiographically. Conventional x-ray of anaerobic cellulitis may reveal pockets of gas confined to superficial tissues and is usually readily palpable. True gas gangrene (clostridial myositis) can be distinguished from anaerobic cellulitis by the linear feathery appearance of gas infiltrating through groups of muscle fibers, although palpation may not reveal crepitus. [7], [21]

Magnetic resonance imaging (MRI) has gained favor as a technique in diagnosing STIs. In a recent study, 23 patients with acute STIs underwent MRI evaluation. T_2-weighted images best highlighted the cutaneous disease process. In patients with pyomyositis or subcutaneous abscesses, a spindle-shaped or round, well-defined area of high signal intensity was observed in the muscle or fat, respectively. Patients with necrotizing fasciitis had deep dermal, well-defined dome-shaped areas of increased signal. Patients with nonnecrotizing cellulitis had smaller, heterogeneous areas of increased signal. [26]

Dermatopathology

In addition to direct stains and cultures, pathologic investigation with special staining can be very useful. Lesional skin punch biopsy is often helpful in ruling out a cellulitis-simulating noninfectious inflammatory lesion such as erythema nodosum, vasculitis, or eosinophilic cellulitis. In ecthyma gangrenosum (caused by *P. aeruginosa*), a septic vasculitis is seen. Direct immunofluorescent techniques have been reported to identify streptococcal pathogens in 19 of 27 cases of erysipelas and in 10 of 15 cases of cellulitis. [27]

Histologically, erysipelas is characterized by intense edema, marked vascular dilatation of the superficial dermis and a profuse infiltration of tissue spaces and lymphatic channels with streptococci and neutrophils. The streptococci are not found in the blood vessels themselves, but their presence in the lymphatics produces an inflammatory reaction about these vessels. The dermis is markedly edematous, and there is infiltration with neutrophils and mononuclear cells. The epidermis is only secondarily involved, primarily with edema.

Deep incisional biopsy and histopathologic examination on frozen sections has been shown to improve diagnosis and decrease mortality in necrotizing fasciitis by rapidly establishing the diagnosis and thus defining the need for surgical débridement. [28] Indications for an open exploration and a biopsy include confusion, pain and tenderness, tachycardia, tachypnea, ketoacidosis/hyperglycemia, bullous or gangrenous skin changes, bronzing of the skin, spreading areas of anesthesia, thin reddish discharge with undermining of wound edges, crepitus, and an abscess with multiple tracts.

In streptococcal gangrene, the prominent angiitis and focal dermal necrosis with spread along fascial planes suggest that the disease is fundamentally gangrene of the subcutaneous tissues followed by necrosis of the overlying skin. Microscopically, fibrinoid necrosis is present in the media of many arteries and veins passing through the edematous and damaged fascia. [29] Fibrin thrombi are present. The epidermis, dermis, and skin appendages in the area of gangrene undergo coagulation necrosis. Numerous polymorphonuclear leukocytes and mononuclear cells infiltrate the lesion, and the upper layers of the dermis contain large numbers of gram-positive cocci.

SPECIFIC BACTERIAL SPECIES ASSOCIATED WITH STI

See Chap. 193, Table 193-1 and Table 193-2 and the preceding material in this chapter, including Table 196-1.

Person-to-Person Spread

***STAPHYLOCOCCUS AUREUS* AND GROUPS A, B, C, AND G BETA-HEMOLYTIC STREPTOCOCCI** (See Chap. 194)
ENTEROBACTERIACEAE, HAEMOPHILUS INFLUENZAE, NEISSERIA MENINGITIDIS, AND PSEUDOMONAS AERUGINOSA (See Chap. 197)
STREPTOCOCCUS PNEUMONIAE *S. pneumoniae* is a rare cause of cellulitis and necrotizing fasciitis, perhaps occurring more frequently in recent years and behaving like group A streptococcal STI. [30], [31] Predisposing or associated conditions include chronic alcoholism, drug abuse, HIV, connective-tissue disorders, glucocorticosteroids, and the use of NSAIDs. [10] Bacteremia is an underlying mechanism in about half of the cases described but relative or absolute penicillin resistance does not appear to be a factor.

Specific Bacterial Species Associated with Aqueous Environments

Aeromonas spp. and *Vibrio* spp. (see Chap. 199).

Specific Bacterial Species Associated with Soil Exposure

Clostridium species (primarily, excluding endogenous *C. perfringens,* the most frequently isolated pathogen) was discussed earlier in this chapter.

Specific Bacterial Species Associated with Animal Exposure (See Chap. 199)

Streptococcus iniae, Erysipelothrix rhusiopathiae, Bacillus anthracis, and *Pasteurella multocida* are associated with animal exposure.

Miscellaneous Pathogens

***MYCOBACTERIUM* SPECIES (See Chap. 200)** *M. fortuitum* complex species are rapid growers and include *M. fortuitum, M. chelonae,* and *M. abscessus*. These organisms are widely distributed in soil, dust, and water. Inoculation can occur via puncture wounds (injection or traumatic) or surgical procedures (augmentation mammoplasty, median sternotomy, percutaneous catheterization) (Fig. 196-7); rarely, primary cellulitis occurs without recognizable skin trauma. [32], [33] Contaminated gentian violet used for skin marking has been the source in some outbreaks. *M. fortuitum* complex STIs characteristically occur several weeks after the inciting injury and appear as indolent wound infections (nodules, ulcers, granulomatous papules, or verrucous plaques). In immunocompromised individuals, *M. fortuitum* can disseminate hematogenously to skin (multiple recurring abscesses on the extremities) and joints. Treatment regimens are complex, require careful susceptibility testing, and may include excisional biopsies.

FIGURE 196-7 Cellulitis: *Mycobacterium chelonae.* Cellulitis occurred at operative sites following venous harvest and coronary artery bypass in a 37-year-old male with diabetes mellitus. The infection combined with peripheral vascular disease necessitated amputation of both legs above the knees.

HELICOBACTER CINAEDI A syndrome characterized by fever, bacteremia, and recurrent *H. cinaedi* cellulitis has been described in immunocompromised patients. In a series of seven patients (six HIV-infected, one with a history of alcoholism) with *H. cinaedi* STIs, cellulitis with adjacent arthritis occurred in two patients. Ciprofloxacin was effective in treatment in five cases. [34] In a series of 23 febrile patients with *H. cinaedi* bacteremia, 11 were HIV-infected; 9 had cellulitis (some with a distinctive red brown or copper discoloration with minimal warmth); the others had underlying alcoholism, diabetes, or malignancy. [35]
CORYNEBACTERIUM JEIKEIUM Skin and soft tissue infections caused by *C. jeikeium* occur primarily in granulocytopenic patients and take either of two forms: (1) primary infections (cellulitis at bone marrow biopsy sites, infection at insertion sites of intravascular catheters), and (2) secondary infections (erythematous or hemorrhagic papular rash, soft tissue abscess, or necrotic lesions) following a bacteremia from primary infection sites. [7], [36] Vancomycin intravenously is the treatment of choice.

COURSE AND PROGNOSIS

Occasionally, group A streptococci or *S. aureus* will cause a persistent superficial infection in moist intertriginous sites, such as perianal cellulitis in children. The process can become chronic, marked by perianal erythema (Fig. 196-8) and pruritus, pain on defecation, blood-streaked stools, and spread to other perineal structures. Diagnosis can be made by culture of the erythematous area followed by treatment of the offending group A streptococcus or *S. aureus,* usually with prompt resolution of the persistent superficial cellulitis. [37]

FIGURE 196-8 Perianal streptococcal cellulitis. Erythema around the anus and on the perineum. (*Courtesy of Arthur R. Rhodes, MD.*)

Uncomplicated erysipelas remains confined primarily to the lymphatics and subcutaneous tissues, occasionally complicated by bleb formation and, rarely, by the presence of an abscess. Even in the days prior to antibiotic therapy, it was often a self-limited process, subsiding over 7 to 10 days. Occasionally, untreated erysipelas or cellulitis may be complicated by bacteremia with metastatic infection in various organs. Prompt treatment prevents both suppurative and nonsuppurative complications. However, in young infants and elderly debilitated patients and in individuals receiving glucocorticoids, the disease may progress with devastating rapidity to a fatal outcome. Erysipelas or cellulitis after saphenous vein harvest may be recurrent, especially in patients with underlying tinea pedis, presenting as edema, erythema, and tenderness along the course of the saphenous venectomy.

Erysipelas has a tendency to recur in the same area, probably a result of the predisposing effects of chronic lymphatic obstruction, persistent edema, and even elephantiasis-like swelling caused by earlier infections. Such recurrent infections may produce persistent swelling of the lips (macrocheilia), cheeks (particularly the lax tissues beneath the eyes), lower extremities, or even abdomen. Chronic lymphedema of the lower extremities secondary to recurrent erysipelas may result in elephantiasis nostras verrucosa (see Chap. 167). Areas of lymphatic obstruction are predisposed to recurrent infections; for example, following radical mastectomy some patients are liable to recurrent episodes of what appears to be erysipelas in the area of lymphedema. In summary, erysipelas, especially that caused by group A streptococci, causes local injury to lymphatics that further compromise tissue defenses resulting in edema, skin and scar changes, and potential for recurrent disease. Erysipelas leads to recurrent erysipelas such that early therapy and prolonged elevation of the affected area can help to preserve better tissue resistance to reinfection. Some patients with frequent recurrences in the same area benefit from prophylactic antibiotics, usually monthly benzathine penicillin injections. [38]

Acute cellulitis, with or without abscess formation, has a tendency to spread through the lymphatics and bloodstream,

and may be a serious disease if not treated early. In older patients, involvement of a lower extremity may be complicated by thrombophlebitis. In patients with chronic edema, the process may spread extremely rapidly and recovery may be slow, despite drainage and sterilization of the lesions by antibiotics.

The mortality rate for necrotizing fasciitis is high (reported to be approximately 40 percent greater when complicated by streptococcal toxic shock–like syndrome; see Chap. 194). Early diagnosis and aggressive treatment of necrotizing fasciitis is the most important factor in determining outcome. [39] Risk factors mentioned above can impact negatively on outcome and include older age, diabetes mellitus, malnutrition, hypertension, and intravenous drug abuse. Overall, clostridial infections have a mortality of 20 to 70 percent, depending upon the location of the process, with myonecrosis associated with the more lethal prognosis. Spontaneously occurring gas gangrene tends to have an even more ominous mortality, approaching 100 percent, because of its rapid onset, without an obvious predisposing traumatic or surgical wound and the association with an underlying malignancy. The mortality for synergistic necrotizing cellulitis is at least 50 percent, the patient usually succumbing to septic shock and circulatory collapse.

In assessing prognosis, the wide ranges described for these infections depends upon many variables. The underlying health and immune status of the patients clearly are factors predisposing to all of these entities. In like manner, early recognition and definition of etiologic agents guides appropriate antibiotic usage, as well as surgical decisions. Many of these infections are life-threatening and therefore urgent evaluation and therapy are capable of improving prognosis.

TREATMENT

Antibiotics

See Chap. 193, Table 193-6 for a complete outline of antimicrobial choices and Table 196-5 for therapeutic guidelines for necrotizing infections.



TABLE 196-5 **Antimicrobial Treatment of Necrotizing Infection of Skin, Fascia, and Muscle***

Mild cases of early erysipelas can be treated on an outpatient basis with either intramuscular procaine penicillin (600,000 units twice daily) or with oral penicillin V, 500 mg every 6 h. Erythromycin and clindamycin are also effective in penicillin-allergic individuals. [40]

Individuals with more extensive streptococcal infections and with underlying medical problems such as diabetes mellitus should be hospitalized and treated with intravenous aqueous penicillin G (1 to 2 million units every 4 to 6 h). In severe streptococcal skin infections (e.g., extensive erysipelas, cellulitis, or streptococcal gangrene), parenteral aqueous penicillin G should be administered in higher doses. In the ill patient in whom a staphylococcal etiology is identified, a penicillinase-resistant semisynthetic penicillin (e.g., nafcillin) should be employed and/or vancomycin substituted in the penicillin allergic individual. In the patient with a questionable penicillin allergy, cefazolin (1.0 g intravenously every 8 h) may be chosen. Vancomycin is the drug of choice in patients that have a methicillin-resistant organism or have a prior history of an immediate type reaction (IgE mediated) to a penicillin or a cephalosporin.

Treatment decisions for patients with crepitant or gangrenous STI, including necrotizing fasciitis, anaerobic cellulitis and myonecrosis must be based upon a rapid or presumptive identification of the etiologic agent(s) (see Table 196-5).

Local Measures

Care of the local lesions of erysipelas and cellulitis includes bed rest with immobilization and elevation of the involved area to reduce local edema. Cool, sterile saline dressings decrease the local pain and are particularly indicated in the presence of bullous lesions. The application of moist heat may aid in the localization of an abscess in association with cellulitis, but it should not be used in a patient with arterial insufficiency of the involved extremity.

Surgical Intervention

Treatment of necrotizing STIs requires early and complete surgical débridement of necrotic tissue in combination with appropriate drainage and high-dose antibiotics. Inspection of the deep fascia can confirm the presence of fat necrosis, preservation of the deep aponeurosis overlying muscle and provide material for bacterial and pathologic study. [28] Reexploration and débridement should be performed as necessary to ensure that all necrotic tissue has been removed and pockets of pus are drained.

When synergistic necrotizing cellulitis is considered a more likely diagnosis than an abscess, it becomes essential to explore the involved area including careful assessment of the area of necrosis in the deep subcutaneous tissues as well as inspection of the underlying muscle. A frozen-section soft-tissue biopsy early in the course of the illness may provide a definitive diagnosis and expedite appropriate débridement of the area of involvement until completely normal fascia is reached and muscle has been inspected. The wound is left open and if there is any question as to the adequacy of the initial débridement, a second-look procedure is indicated 24 to 48 h later. Prior to obtaining results from cultures, initial

antimicrobial therapy should be based on knowledge of the prominent role of anaerobic bacteria in this infection and on the specific findings of the gram-stained smear of the exudate.

Anaerobic clostridial cellulitis is treated with surgical débridement of all devitalized tissue. The use of hyperbaric oxygen drenching, particularly in patients with far-advanced disease involving the trunk in whom surgical excision would be mutilating, appears to have a place in current therapy. Although prospective studies are lacking, retrospective data indicate that adjunctive hyperbaric oxygen therapy may reduce morbidity and mortality in both clostridial and nonclostridial necrotizing infections. [41] Proposed mechanisms by which hyperbaric oxygen could improve outcome include enhancement of leukocyte production of bactericidal free radicals, direct inhibition of anaerobic bacterial growth, preservation of poorly perfused tissue, and promotion of wound healing.

The surgical approach to clostridial or streptococcal myonecrosis requires rapid evaluation, appropriate antibiotics with penicillin and metronidazole or clindamycin and exploration and débridement of affected muscle. Amputation of a limb can be rapidly accomplished and may be life saving in selected patients. Spontaneous myonecrosis and anaerobic cellulitis caused by *Clostridium septicum* or other histotoxic clostridia may benefit from exposure to hyperbaric oxygen because bacteremia is frequently present, toxin production may be halted and tissues still viable may be protected by an oxygen barrier. [42]

Other Therapies

Other adjunctive considerations in treatment of STI include the use of intravenous gamma globulin for type II necrotizing fasciitis caused by group A streptococci and recombinant human activated protein C in severe sepsis related to these soft-tissue infections. [43], [44] Patients with poor granulocyte production may be helped by granulocyte colony-stimulating factor. There is some evidence from the recent literature and from speculative observation that NSAIDs should be avoided in patients suspected of incubating or expressing early bacterial infections. Masking of fever and inhibition of granulocyte migration and function are arguments that deserve continued evaluation.

REFERENCES

1. Wolfson JS et al: Dermatologic manifestations of infection in the compromised host. *Annu Rev Med* **34**:205, 1983

2. Hook EWI et al: Microbiologic evaluation of cutaneous cellulitis in adults. *Arch Intern Med* **146**:295, 1986

3. Chartier C, Grosshans E: Erysipelas: An update. *Int J Dermatol* **35**:779, 1996

4. Jorup-Ronstrom C: Epidemiological, bacteriological, and complicating features of erysipelas. *Scand J Infect Dis* **18**:519, 1986

5. Guberman D et al: Bullous erysipelas: A retrospective study of 26 patients. *J Am Acad Dermatol* **41**;733, 1999

6. Fleisher G et al: Cellulitis: Bacterial etiology, clinical features, and laboratory findings. *J Pediatr* **97**:591, 1980

7. Swartz MN: Cellulitis and subcutaneous tissue infections, in *Principles and Practice of Infectious Diseases,* 5th ed, edited by GL Mandell, RE Douglas, R Dolin. New York, Churchill Livingstone, 2000, p 1037

8. Garner JS et al: CDC definitions for nosocomial infections, 1988. *Am J Infect Control* **16**:281, 1988

9. McCormick JK et al: Toxic shock syndrome and bacterial superantigens: An update. *Annu Rev Microbiol* **55**:77, 2001

10. Frick S, Cerny A: Necrotizing fasciitis due to *Streptococcus pneumoniae* after intramuscular injection of nonsteroidal anti-inflammatory drugs: Report of 2 cases and review of the literature. *Clin Infect Dis* **33**:740, 2001

11. Bisno AL, Stevens DL: Streptococcal infections of skin and soft tissues. *N Engl J Med* **334**:240, 1996

12. Giuliano A et al: Bacteriology of necrotizing fasciitis. *Am J Surg* **134**:52, 1977

13. Schecter W et al: Necrotizing fasciitis of the upper extremity *J Hand Surg* **7**:15, 1982

14. Laucks SS II: Fournier's gangrene. *Surg Clin North Am* **74**:1339, 1994

15. Green RJ et al: Necrotizing fasciitis. *Chest* **110**:219, 1996

16. Stone HH, Martin JJ Jr: Synergistic necrotizing cellulitis. *Ann Surg* **175**:702, 1972

17. Kingston D, Seal DV: Current hypotheses on synergistic gangrene. *Br J Surg* **77**:260, 1990

18. Bornstein DL et al: Anaerobic infections. Review of current experience. *Medicine (Baltimore)* **43**:207, 1964

19. Adam RD et al: Mucormycosis: Emerging prominence of cutaneous infections. *Clin Infect Dis* **19**:67, 1994

20. Henriksen BM et al: Soft tissue infections from drug abuse: A clinical and microbiological review of 145 cases. *Acta Orthop Scand* **65**:625, 1999

21. Swartz MN: Myositis, in *Principles and Practice of Infectious Diseases*, 5th ed., edited GL Mandell, RG Douglas, R Dolin. New York, Churchill Livingstone, 2000, p 1058

22. Stevens DL et al: Spontaneous, nontraumatic gangrene due to *Clostridium septicum*. *Rev Infect Dis* **12**:286, 1990

23. Sachs MK: The optimum use of needle aspiration in the bacteriologic diagnosis of cellulitis in adults. *Arch Intern Med* **150**:1907, 1990

24. Brook I, Frazier EH: Clinical features and aerobic and anaerobic microbiological characteristics of cellulitis. *Arch Surg* **130**:786, 1995

25. Shelley WB et al: Occult Streptococcus pyogenes in cellulitis: Demonstration by immunofluorescence. *Br J Dermatol* **132**:989, 1995

26. Saiag P et al: Magnetic resonance imaging in adults presenting with severe acute infectious cellulitis. *Arch Dermatol* **130**:1150, 1994

27. Bernard P et al: Streptococcal cause of erysipelas and cellulitis in adults. *Arch Dermatol* **125**:779, 1989

28. Stamenkovic I, Lew PD: Early recognition of potentially fatal necrotizing fasciitis: The use of frozen-section biopsy. *N Engl J Med* **310**:1689, 1984

29. Barker FG et al: Streptococcal necrotizing fasciitis: Comparisons between histological and clinical features. *J Clin Pathol* **40**:335, 1987

30. House NS et al: Acute onset of bilateral hemorrhagic leg lesions. Pneumococcal cellulitis. *Arch Dermatol* **132**:81, 1996

31. Choudhri SH et al: A case of necrotizing fasciitis due to *Streptococcus pneumoniae*. *Br J Dermatol* **128**:128, 1995

32. Torres JR et al: Infection site abscess due to *Mycobacterium fortuitum-chelonae* complex in the immunocompetent host. *Infect Dis Clin Pract* **7**:56, 1998

33. Lederman C et al: *Mycobacterium haemophilum* cellulitis in a heart transplant recipient. *J Am Acad Dermatol* **30**:804, 1994

34. Burman WJ et al: Multifocal cellulitis and monoarticular arthritis as manifestations of *Helicobacter cinaedi* bacteremia. *Clin Infect Dis* **20**:564, 1995

35. Kiehlbauch JA et al: *Helicobacter cinaedi*-associated bacteremia and cellulitis in immunocompromised patients. *Ann Intern Med* **121**:90, 1994

36. Dan M et al: Cutaneous manifestations of infection with *Corynebacterium* group JK. *Rev Infect Dis* **10**:1204, 1988

37. Spear RM et al: Perianal streptococcal cellulitis. *J Pediatr* **107**:557, 1985

38. Ericksson B et al: Erysipelas: Clinical and bacteriologic spectrum and serologic aspects. *Clin Infect Dis* **23**:1091, 1996

39. Voros D et al: Role of early and extensive surgery in the treatment of severe necrotizing soft tissue infection. *Br J Surg* **80**:1191, 1993

40. Gilbert DN et al: Outpatient parenteral antimicrobial drug therapy. *N Engl J Med* **337**:829, 1997

41. Mathur MN et al: Cellulitis owing to *Aeromonas hydrophilia*: Treatment with hyperbaric oxygen. *Aust N Z J Surg* **65**:367, 1995

42. Clark LA, Moon RE: Hyperbaric oxygen in the treatment of life-threatening soft tissue infections. *Respir Care Clin N Am* **5**:203, 1999

43. Schlievert PM: Use of intravenous immunoglobulin in the treatment of staphylococcal and streptococcal toxic shock syndromes and related illnesses. *J Allergy Clin Immunol* **108**:S107, 2001

44. Vincent JL et al: Clinical trials of immunomodulatory therapies in severe sepsis and septic shock. *Clin Infect Dis* **34**:1084, 2002

T>

Chapter 197

Arnold Weinberg Morton Swartz

Gram-Negative Coccal and Bacillary Infections

INFECTIONS DUE TO NEISSERIA MENINGITIDIS (MENINGOCOCCUS)
Bacteriology and Pathogenesis
Epidemiology
Acute Meningococcemia and Meningitis
Chronic Meningococcemia
Primary Meningococcal Conjunctivitis
Treatment and Prophylaxis
Immunization
INFECTIONS DUE TO PSEUDOMONAS AERUGINOSA
Bacteriology and Pathogenesis
Epidemiology
Local and Secondarily Infected Lesions
Septicemia and Cutaneous Involvement
Skin Infections Due to Other Pseudomonas Species
SKIN INFECTIONS DUE TO HAEMOPHILUS INFLUENZAE
Bacteriology and Pathogenesis
Epidemiology
Clinical Manifestations
Laboratory Findings
Pathology
Diagnosis and Differential Diagnosis
Course and Prognosis
Treatment and Prophylaxis
CUTANEOUS MANIFESTATIONS OF SALMONELLA INFECTION (ENTERIC FEVER)
Bacteriology and Pathogenesis
Epidemiology
Clinical Manifestations
Laboratory Findings
Pathology
Diagnosis and Differential Diagnosis
CUTANEOUS MANIFESTATIONS OF INFECTION WITH OTHER GRAM-NEGATIVE BACILLI
Bacteriology and Pathogenesis
Epidemiology
Clinical Manifestations
Laboratory Findings
Pathology
Diagnosis and Differential Diagnosis
Course and Prognosis
Treatment

REFERENCES

Many of the characteristic cutaneous manifestations of infection with gram-negative organisms are due to direct microbial invasion of the skin or subcutaneous tissues. In addition, responses of host cytokines, chemokines, receptor molecules, and other effector cells and factors may contribute to fever, hypotension, and a variety of cutaneous manifestations. [1]

The typical skin lesions in meningococcal or *Pseudomonas* septicemia, often among the earliest indications of generalized infection, can provide immediate and important clues to early diagnosis. [2] However, in the immunocompromised patient, unusual organisms and atypical presentations of typical pathogens occur.

INFECTIONS DUE TO *NEISSERIA MENINGITIDIS* (MENINGOCOCCUS)

Three clinical syndromes associated with cutaneous involvement occur in meningococcal disease: meningitis, acute meningococcemia, and chronic meningococcemia. Skin lesions are frequently the most dramatic manifestations and graphically add to the aura of fear attached to these infections. The presence of areas of purpura or gross hemorrhage correlates with greater numbers of bloodstream organisms and generally indicates a poorer prognosis than a local or generalized petechial eruption. Several reviews detailing the epidemiology, pathogenesis, and clinical presentations have recently been published. [1], [3], [4]

Bacteriology and Pathogenesis

The *Neisseria* are obligate, aerobic, encapsulated, gram-negative, kidney bean–shaped cocci that pair with their long axes in parallel. *Neisseria meningitidis* grows well on blood-enriched media (chocolate agar), supplemented by an atmosphere containing 5 to 10 percent CO_2 and approximately 50 percent humidity. In potentially mixed bacterial exudates, these organisms should be grown on a selective medium (e.g., modified Thayer-Martin); they can be distinguished from *Neisseria gonorrhoeae* by their fermentation of both glucose and maltose rather than of glucose alone. Meningococci are separable into at least 13 serologic groups on the basis of capsular antigens, of which A, B, C,

Y, and W-135 are the major pathogenic groups involved in human disease today. Antigenic variation resulting from the presence of outer membrane proteins that can identify serotypes, serosubtypes, and immunotypes, not only is helpful in epidemiologic studies, but also enables organisms to evade host defenses. [3] Recent studies, including an analysis of an epidemic of meningococcal disease, have identified a shift of capsular group, in this case from group B to group C organisms and vice versa, thus facilitating the evasion of host antibodies. [5]

The presence of a virulent strain colonizing the nasal mucous membranes precedes clinical disease in a nonimmune host. Pili that attach to specific receptors on nonciliated, columnar mucosal epithelial cells and production of an IgA protease that cleaves host secretory IgA may facilitate initial colonization. [3] Additionally, antigenic variation contributing to virulence may occur through changes in the semi- and hypervariable regions of pili of organisms attaching to epithelial, endothelial, and phagocytic cells. [6]

Encapsulated organisms resist phagocytosis. With the onset of a viral respiratory infection, they may multiply locally and invade the bloodstream or be aspirated into the lower respiratory tract. Meningitis, meningococcemia, or pneumonitis can result. Predisposition to sporadic and occasionally recurrent meningococcal disease occurs in patients with congenital or acquired complement deficiencies, particularly late-acting components C5–C9. [3], [7]

The skin lesions associated with meningococcemia and meningococcal meningitis result from damage to small dermal blood vessels. Light and electron microscopy reveal bacteria within endothelial and polymorphonuclear cells. [8] Organisms are sometimes apparent when needle aspirates or punch biopsies from involved areas of skin are Gram-stained. [9] Local endothelial damage, thrombosis, and necrosis of the vessel walls occur. Immunoglobulins and complement are present, even in early vascular lesions. [3], [8] Edema, infarction of overlying skin, and extravasation of red blood cells are responsible for the characteristic macular, papular, pustular, petechial, hemorrhagic, and bullous lesions. Similar vascular lesions occur in the meninges and in other tissues. In addition to direct involvement of skin vessels by meningococci, many of the cutaneous hemorrhagic lesions may be due directly to the effects of lipo-oligosaccharide (LOS) endotoxin or indirectly to the stimulation of host cytokines. [1] A contribution to the dermal inflammatory vascular injury, independent of immune complexes and cytokine activity, may come from the interaction between vascular endothelium (intercellular adhesion molecule-1) and an adhesion glycoprotein (CD18) on leukocytes, the so-called dermal Shwartzman reaction. [10] The profound effects on small blood vessels, directly related to bacterial invasion or indirectly due to LOS endotoxin host cytokine released or the dermal Shwartzman reaction may lead to diminished blood volume, lowered cardiac output, anoxia in vital organs, myocardial failure, hypotension, acidosis, and diffuse intravascular coagulation. [4]

Meningococci can be isolated from the blood in chronic meningococcemia, usually during periodic fevers, rash, and joint manifestations. The pathogenesis of this form of disease is not as well understood as that of the acute septicemia. This chronic form of meningococcal infection has been linked to the absence of terminal components of complement in several patients and to an isolated IgA deficiency in one patient, associations that may provide insights into pathogenic mechanisms in this unusual host-parasite interaction. [11], [12] The absence of bacteria, bacterial antigenic material, and granulocytic inflammation distinguishes the findings of chronic infection from those seen in acute infections. The histopathology of a skin biopsy specimen in an immunocompetent infant revealed leukocytoclastic vasculitis, an exception to the usual absence of vascular damage found in chronic meningococcemia. [12] The chronic course of the disease, lack of endotoxin-like manifestations (even with demonstrated bacteremia), and the potentiality for an eventual complication such as meningitis or endocarditis suggest that an unusual host-parasite relationship is central to this persistent, but rare, infection.

Epidemiology

Humans are the only known natural hosts of *N. meningitidis.* Nasopharyngeal carrier rates vary (5 to 15 percent overall) with age: 1 percent in children 3 to 48 months of age, 5 percent in those 14 to 17 years of age, and 20 to 40 percent in young adults. When conditions are crowded, such as in schools or military camps, or when a carrier of a new strain develops disease in a day-care or family setting, carrier rates can increase dramatically, independent of clinical disease. [13] The recent increase in cases among first-year college students living in dormatories illustrates the impact of crowding and stress, concentration of susceptible individuals, and variations in the antigenic makeup of microorganisms. [3], [14]

Globally, group A strains have been responsible for epidemics of meningitis, especially in sub-Saharan Africa. In Europe and the Americas, Groups B and C have predominated, and in the United States, a recent surge in group Y disease has been reported. These regional differences are not readily explained, but probably are influenced by host factors such as naturally acquired immunity and immunizations; circumstances such as travel or crowding, viral illness; and smoking—as well as microbial antigenic variation.

Adult family members probably introduce the organism into the household, but secondary cases are most frequently spread from ill children aged 1 through 14 years to other family members in the same age group, especially under crowded conditions. [15] Household spread is 500 to 800 times more frequent than secondary cases in the community at large. An exception to this is the increased incidence of secondary cases in day-care centers where large numbers of susceptible children congregate. [4], [16] Absence of the spleen has been associated with fulminant meningococcal disease, as has been reported for other encapsulated organisms. *Neisseria meningitidis* has been isolated from the genitourinary tract in individuals practicing orogenital sex and in homosexuals. [17]

Asymptomatic exposure to a variety of *N. meningitidis* strains, as well as nonpathogenic *Neisseria* and *Escherichia coli* K1 strains can stimulate protective bactericidal antibody. Consequently, immunity to meningococci increases with age, and protective bactericidal antibodies, both IgG and IgM, occur in 70 to 95 percent of young adults. Newborn infants are often resistant to meningococcal disease; this protection lasts until they are approximately 3 to 6 months of age, by which time

passively acquired maternal IgG antibody levels have markedly diminished. [18]

A number of conjugate vaccines have been in use outside the United States with favorable results, [3], [4] but the quadrivalent vaccine containing polysaccharides of groups A, C, Y, and W-135 is the only currently licensed vaccine in the United States against meningococcal disease. The poor immunogenicity and the inadequate protective efficacy of the quadrivalent vaccine in young children have led to the development of conjugate vaccines that appear to have the same protective efficacy for infants as the currently available *Haemophilus influenzae,* type b conjugate. The group B capsular polysaccharide, a polysialic acid polymer similar to human fetal neural tissue, does not induce protective immunity. With the use of outer membrane proteins of group B organisms, efforts continue to develop an effective vaccine for this frequently identified pathogenic group. [19]

Acute Meningococcemia and Meningitis

CLINICAL MANIFESTATIONS
History The disease often follows a mild upper respiratory infection associated with headache, grippelike complaints, nausea and vomiting, and muscle soreness. These symptoms can be so short-lived that fever, obtundation, and other manifestations of meningitis are the initial findings. In fulminant meningococcemia, vomiting, stupor, precipitous development of a hemorrhagic rash, and hypotension may be evident within a few hours of the onset of symptoms. Milder cases, developing at a slower pace, also occur.
Cutaneous lesions The skin findings associated with acute meningococcal infections are characteristically petechial, but transient urticarial, macular, or papular lesions (Fig. 197-1A), which can resemble those seen in viral exanthems, may be evident. [20] The petechiae are small and irregular with a “smudged” appearance, and they are often raised, with pale grayish vesicular centers. Although most commonly located on the extremities and trunk, lesions can also be found on the head (Fig. 197-1B), palms, soles, and mucous membranes (including the conjunctivae). Pustular or extensive bullous and hemorrhagic lesions with central necrosis (suggillations) can develop. Gangrenous hemorrhagic areas (indistinguishable from purpura fulminans; see Chap. 194) can appear in patients with severe meningococcemia, often complicated by disseminated intravascular coagulation (DIC; Fig. 197-1C). Skin lesions and bacteremia are rarely seen with meningococcal pneumonia, [21] but cellulitis has been noted in occasional patients, especially in children with meningococcal conjunctivitis (see below).

FIGURE 197-1 *Neisseria meningitidis:* Acute meningococcemia. *A.* Transient macular and papular lesions on the upper chest. *B.* Discrete, pink-to-purple macules and papules, as well as purpura, are seen on the face of this young child. These lesions represent early disseminated intravascular coagulation. *C.* Maplike gray-to-black areas of cutaneous infarction are seen in this child with disseminated intravascular coagulation.

Other physical findings Patients with meningitis display signs of meningeal irritation and altered consciousness. Occasionally, agitated or maniacal behavior predominates. Cranial nerve palsies, long-tract signs, seizures, and alterations in vital signs associated with changes in intracranial pressure may be present. Obtundation and hypotension without meningeal signs, associated with the syndrome of DIC, are characteristic features of acute fulminating meningococcemia. Rarely, meningococcemia may result in septic foci in other areas: (1) septic arthritis with a pyogenic effusion in one or several joints; (2) purulent pericarditis with precordial pain, enlarging cardiac silhouette, and findings of cardiac tamponade; and (3) bacterial endocarditis. More commonly, a delayed immune complex–mediated syndrome can result in a sterile arthritis, pericarditis, or episcleritis. [3] The acute arthritis-dermatitis syndrome, characterized by petechiae and nontraumatic arthritis, has traditionally been identified with disseminated *N. gonorrhoeae* (see Chap. 233), especially auxotype strains requiring arginine, hypoxanthine, and uracil for growth. In recent years, there has been a decline of gonococcal cases and an increase in this syndrome due to *N. meningitidis.* [22]
LABORATORY FINDINGS A polymorphonuclear leukocytosis is present in the peripheral blood and cerebrospinal fluid (CSF) in meningitis. The CSF protein level is increased, and the glucose value is commonly reduced. Characteristic organisms may be seen on Gram-stained smears of fluid, and meningococci are usually isolated from the CSF. *Neisseria meningitidis* may be isolated from the blood of approximately one-third of patients with meningitis and from almost 100 percent of patients with acute meningococcemia. The demonstration of organisms from cutaneous lesions has been variable, and the presence of gram-negative commensal organisms on the skin makes caution necessary. Published reports describe positive results in 50 to 80 percent of aspirates, skin films, or punch biopsies of petechial lesions. [9], [24] In our experience, aspirates of bullous and pustular lesions often demonstrate characteristic gram-negative diplococci. In patients already exposed to antimicrobial agents, the development of rapid, accurate, and inexpensive procedures for detection of soluble antigens in the CSF has been a major advance in laboratory methodology. The latex agglutination and the enzyme-linked immunosorbent assay (ELISA) methods are sensitive, and very specific, but their clinical usefulness in most situations has been questioned. [24] Rapid diagnosis using a modification of the polymerase chain reaction is available in Europe currently and should be commercially available in the United States shortly. [4]
DIFFERENTIAL DIAGNOSIS Meningococcal infection always warrants consideration in a patient with fever and a petechial or purpuric eruption, even in the absence of clinical meningitis. Unfortunately, acute meningococcemia may evolve after only a brief prodrome of nonspecific flulike symptoms and in the absence of any meningeal findings. Occasionally, the characteristic rash is absent, delaying a consideration of meningococcal disease. The differential diagnosis should include the following conditions:

- Acute bacteremias and endocarditis. Petechial eruptions may be present in acute bacteremias and endocarditis, with or without changes in platelet numbers. In endocarditis, mucous membrane and conjunctival lesions, as well as

subungual “splinter” hemorrhages, occur. Very infrequently, numerous petechial and purpuric lesions, almost indistinguishable from those of meningococcal bacteremia, occur in patients with acute *Staphylococcus aureus* endocarditis. These patients may also have meningismus and pleocytosis (usually without bacteria evident on a Gram-stained smear of CSF) secondary to cerebral embolization or staphylococcal meningitis, completing the mimicry of meningococcal disease. Usually, a few skin lesions in a patient with acute *S. aureus* endocarditis are purulent purpura; aspirate from the purulent center of the lesion usually shows gram-positive cocci in clusters (rather than gram-negative biscuit-shaped diplococci) on smear, and subsequently *S. aureus* can be isolated on culture. In acute gonococcemia, the skin lesions are usually nodular, hemorrhagic, few in number, and located on the distal parts of the extremities (see Chap. 233). Occasional patients with *H. influenzae* or *Streptococcus pneumoniae* septicemia develop petechial eruptions.

- Acute hypersensitivity vasculitis. The lesions associated with acute hypersensitivity vasculitis are usually palpable, present in greatest profusion on the lower extremities, and often symmetric. Renal involvement and hypertension may be present. Pathologically, the major focus of inflammation is in postcapillary venules (see Chap. 175).
- Enteroviral infections. Fever, petechial eruptions, and aseptic meningitis are characteristic features of enteroviral disease. Echo-(e.g., type 9) and coxsackieviruses are most often implicated.
- Rocky Mountain spotted fever. The history of exposure to ticks in an endemic area, absence of an antecedent respiratory infection, delay in appearance of the rash, and the location first on the distal parts of the extremities, including palms and soles, are helpful clues to Rocky Mountain spotted fever (see Chap. 227).
- Toxic shock syndrome (see Chap. 194).
- Purpura fulminans (see Chap. 194).
- Weil's disease (leptospirosis) (see Chap. 199).

COURSE AND PROGNOSIS Untreated, acute meningococcal disease usually ends fatally. The prognosis for treated meningitis is excellent, with recovery in approximately 90 percent of patients. In severe meningococcemia, especially with the rapid emergence of cutaneous hemorrhages, hypotension, and DIC, the entire course from onset to death can be measured in hours. These cases are often associated with massive adrenal hemorrhage (Waterhouse-Friderichsen syndrome). The mortality rate approaches 100 percent. Gradations in the severity of the illness make it difficult to assign an accurate prognosis in an individual case, although a bedside predictive model has been proposed and may prove useful. [4], [25]

Chronic Meningococcemia

CLINICAL MANIFESTATIONS

History Chronic meningococcemia is a rare disease, occurring much less frequently than the more acute dermatitis-arthritis syndrome of subacute gonococcemia that it resembles. [22] The manifestations of chronic meningococcemia are indefinite and vague at the onset, but tend to establish a pattern over a period of weeks or months. [11], [26] Initially, there may be an acute febrile illness, but it wanes and leaves the patient with vague, intermittent complaints of muscle aches and pains, joint soreness, mild headache, and anorexia with weight loss. The simultaneous emergence of a localized rash with several days of fever and joint soreness are characteristic symptoms. As the fever recedes, the rash usually fades as well, and the patient may be totally free of overt skin manifestations for days or weeks at a time. This pattern of recurring fever and rash may last for a period of a few weeks to as long as 6 to 8 months. The average duration of reported cases is 6 to 8 weeks. Untreated cases may eventually evolve into acute meningococcemia, meningitis, or endocarditis. Rare case reports relate this syndrome to the absence of a terminal component of complement, a finding also observed in some sporadic and recurrent acute meningococcal infections. [11]

Cutaneous lesions Variability is the hallmark of the eruption associated with chronic meningococcemia. Several different types of skin lesions may appear, usually distributed about one or more painful joints or on pressure areas in contrast to the acral distribution of skin lesions in gonococcemia. They may vary in appearance and in size (1 to 20 mm) from one crop of lesions to the next and include (1) pale to rose-colored macular and papular lesions (the most common type), occurring in about 30 percent of cases; (2) slightly indurated and tender erythema nodosum–like nodules, mainly on the lower extremities; (3) petechiae of variable size; (4) petechiae with vesicular or pustular centers; (5) hemorrhage (minute) with an areola of paler erythema (very characteristic when it occurs); (6) grossly hemorrhagic areas with pale blue-gray centers; or (7) hemorrhagic, tender nodules located deep in the dermis.

Other physical findings Aside from the rash, the physical findings of chronic meningococcemia are minimal except for occasional joint swelling and tenderness. If the disease progresses to an acute complication such as meningitis, the new findings will be those of the complicating process.

PATHOLOGY The skin lesions in chronic meningococcemia differ pathologically from those in acute meningococcemia. Bacteria are absent, and fluorescent antibody techniques do not detect meningococcal antigens. In addition to the absence of bacteria or their recognized products, thrombi do not occlude capillaries and venules, endothelial cell swelling is absent, and the perivascular infiltrate consists of mixed polymorphonuclear and mononuclear cells rather than predominantly polymorphonuclear leukocytes, as seen in acute infections. Pathologic findings may be reported as “leukocytoclastic angiitis.” An allergic basis for the skin lesions has been suggested in chronic meningococcemia, even though bacterial antigens are not identifiable. [11]

DIAGNOSIS AND DIFFERENTIAL DIAGNOSIS During the febrile periods, blood cultures frequently show the presence of meningococci and, thus, provide the specific means of diagnosis. Serologic tests have not proved helpful, and there are no available data for the use of antigen detection procedures in chronic meningococcemia. A number of diseases with periodic fever, skin lesions, and joint involvement resemble chronic meningococcemia:

- Subacute bacterial endocarditis. A prolonged febrile course with a pleomorphic petechial rash, joint symptoms, and no overt focus make subacute bacterial endocarditis an important consideration. A prominent heart murmur, evidence of renal impairment, and blood cultures that indicate bacterial infection help to establish the diagnosis.
- Acute rheumatic fever. When the fever is prolonged, joint findings are prominent, and macular and papular rashes appear (see Chap. 179), the diagnosis may be acute rheumatic fever.
- Henoch-Schönlein purpura. The petechial hemorrhagic rash in association with symptoms of arthritis and fever suggests an illness not unlike chronic meningococcemia; the eruption in Henoch-Schönlein purpura is more often symmetric, usually only on the lower extremities, and does not have the periodicity of the rash of chronic

meningococcemia (see Chap. 175).

- Rat-bite fever. Also referred to as Haverhill fever, rat-bite fever may be acute (mimicking acute meningococcemia) or chronic (resembling chronic meningococcemia). Intermittent fever, rash, and joint manifestations are hallmarks of an illness that follows a rodent bite or ingestion of contaminated milk (see Chap. 199).
- Erythema multiforme. The symmetric distribution of the eruption and the iris-type configuration of the lesions suggests erythema multiforme (see Chap. 58).
- Gonococcemia (chronic). The cutaneous and joint manifestations of chronic gonococcemia may continue for many days or even weeks (see Chap. 233.). The presence of tenosynovitis in gonococcemia, in contrast to its usual absence in chronic meningococcemia, can be an important clue.

COURSE AND PROGNOSIS Some patients with chronic meningococcemia recover spontaneously without specific therapy, whereas others develop serious systemic complications, such as endocarditis or meningitis. The prognosis for treated infection is excellent; almost 100 percent of patients are cured with antibiotic therapy.

Primary Meningococcal Conjunctivitis

The bacterial species most commonly involved in acute bacterial conjunctivitis are *Staphylococcus aureus, Streptococcus pneumoniae,* and *H. influenzae. Neisseria meningitidis* is the infecting microorganism in up to 2 percent of cases, and the source of infection is most likely either direct inoculation of airborne organisms from close contact with carriers or manual contact with secretions from the patient's own nasopharynx. [27] A Gram-stained smear of conjunctival exudate commonly reveals gram-negative, biscuit-shaped diplococci, and culture yields *N. meningitidis*. Several microorganisms that can be found in infected body fluids and blood may appear morphologically similar to *N. meningitidis* on Gram stain, including *N. gonorrhoeae.*

Clinical features of primary meningococcal conjunctivitis include low-grade fever, conjunctival hyperemia, purulent exudate, lid edema, chemosis, photophobia, and preauricular lymphadenopathy. The majority of cases occur in children. Meningococcal conjunctivitis progresses to systemic meningococcal disease in about 20 percent of patients within a few hours to 4 days after the initial ocular symptoms. In view of the risk of systemic spread of infection, treatment should include not only topical antimicrobial agents (e.g., sulfonamides), but also systemically administered penicillin. Cellulitis of the cheek or periorbital region can complicate meningococcal conjunctivitis in children; in adults with underlying diseases, cellulitis, appears most commonly on the face, neck, or upper limb. [28]

Treatment and Prophylaxis

CHEMOTHERAPY The widespread emergence of sulfonamide-resistant strains more than 30 years ago complicated the therapy for meningococcal infections. Initially, these strains belonged predominantly to serogroup B, but in recent years, they have been from serogroups A to C, essentially eliminating the sulfonamides as systemic agents for prevention or for treatment. These variations have resulted in penicillin G supplanting the sulfonamides as the treatment of choice for acute meningococcal infections. The usual adult dosage of penicillin G for meningococcal meningitis is 4 million units given IV every 4 h until approximately 7 days after the temperature has returned to normal. Treatment of chronic meningococcemia does not require “meningeal doses” of penicillin; 6 to 12 million units divided into four to six daily doses, given IV for 7 to 10 days, should be effective therapy. In the highly penicillin-allergic patient, the use of chloramphenicol (1 g given IV every 6 h) is preferable to risking cross-reactions with a third-generation cephalosporin. In many parts of the world, such as Spain and the United Kingdom, where meningococci that are relatively resistant to penicillin have been isolated, a third-generation cephalosporin (e.g., ceftriaxone, cefotaxime) should be considered for initial therapy. All meningococcal isolates from blood, CSF, or other normally sterile body cavities should be tested for penicillin susceptibility. [4]

SUPPORTIVE THERAPY Efforts to prevent acute brain swelling are critical in patients with meningitis. These include prevention of overhydration, reduction of body temperature, and employment of agents such as mannitol or dexamethasone (if evidence of rising intracranial pressure develops). Although it has been postulated that hypotension in acute meningococcemia may be due to adrenal failure associated with the Waterhouse-Friderichsen syndrome (adrenal hemorrhage), blood cortisol levels and corticosteroid secretion rates have been found elevated in this syndrome. The modern treatment of shock in sepsis begins with a number of well accepted measures, including antibiotic selection, drainage procedures for abscesses, appropriate use of volume expanders, ß-adrenergic–stimulating drugs such as dopamine or isoproterenol, correction of severe acidosis, and in selected patients, peripheral vasodilators. Therapies still considered experimental include those directed against cell envelope components of bacteria (e.g., LOS), those that neutralize host cell–mediated cytokines (e.g., interleukin 1, tumor necrosis factor), [1] and those capable of limiting tissue damage (e.g., protein C). [29] Although numerous studies have been completed and results have been variable, on balance glucocorticoids do not appear to be indicated for septic shock. Severe meningococcal infections can be complicated by the syndrome of DIC. The basis for the diagnosis is usually a composite of associated hematologic abnormalities, including thrombopenia and hypofibrinogenemia, prolongation of the prothrombin time and partial thromboplastin time, and presence of fibrin split products. If bleeding occurs, it may be necessary to administer fresh-frozen plasma. Treatment for each case must be individualized, because therapy may be harmful and produce more problems than the DIC syndrome, especially if acute respiratory distress syndrome is also present. Data on the use of heparin in treating DIC remain unconvincing and inconclusive, and because of potential adverse effects, most septic shock therapists no longer recommend it as routine therapy. Investigators are continuing to study antibodies to various cytokines that are elevated in meningococcal septicemia, the use of protein C replacement, [1], [29] and immunomodulatory therapies. [1], [29], [30]

PROPHYLAXIS There is a critical need for reliable chemoprophylaxis to rapidly protect day-care nursery exposures, crowded household contacts, or institutional groups because secondary cases can emerge rapidly, often within 24 to 48 h of an index case. [13], [31] Currently recommended prophylactic drug regimens for children and adults favor rifampin (age-adjusted for children), 600 mg orally twice daily for 2 days. [16] Rifampin resistance occurs, however, and recent reports document its failure with the development of invasive meningococcal disease. [28] Fortunately, the fluoroquinolones, ciprofloxacin and ofloxacin, are effective single-dose substitutes, and ceftriaxone is available for parenteral single-dose use in children as well as adults. [16] The effectiveness of these agents appears to be due to their

presence in adequate concentrations in upper respiratory and salivary secretions. [32]

Immunization

Polysaccharide vaccines have been developed from groups A, C, Y, and W-135 *N. meningitidis* and have proved to be safe and effective in preventing meningococcal disease in adults and in children over the age of 2 years. [16]

The currently available single and quadrivalent vaccines, especially as they apply to protection of susceptible young children, have limitations, however. Protein conjugated vaccines, successful in protecting young children from *H. influenzae,* type b (Hib) carriage and disease, have been developed and are in use, but are not yet available in the United States. [4], [30] A protective vaccine for group B infection that has been in development uses outer membrane proteins instead of the capsular sialic acid polymer, and clinical trials, outside of the United States, continue. [4] The elucidation of the complete genome of *N. meningitidis* has led to the identification of several conserved proteins that, in an experimental mouse model, have been protective for challenge with all pathogenic *N. meningitidis.* The future for vaccine development is hopeful.

INFECTIONS DUE TO *PSEUDOMONAS AERUGINOSA*

The ubiquitous gram-negative bacilli *Pseudomonas aeruginosa* can cause serious infections, usually in individuals who have altered defenses, who are receiving intense antibiotic therapy, or who are in hospital. Cutaneous manifestations of *Pseudomonas* infections are common and characteristic. They may represent the only overt findings in septicemias, or they may be the localizing focus in serious infections of the ear. In addition, these organisms can produce trivial cutaneous lesions involving nails, toe webs, skin, and the external auditory canal.

Bacteriology and Pathogenesis

Pseudomonas aeruginosa is a nonfermentative, obligately aerobic, robust, gram-negative bacillus that can even grow in distilled water. Some strains produce a blue pigment (pyocyanin) soluble in chloroform, a water-soluble yellow-green substance (fluorescein), or black pyomelinin. With Wood's ultraviolet lamp, it is possible to detect the presence of organisms in lesions of skin or nails and in the urine, if the infecting strain produces fluorescein. Either of the pigments or their combination will impart a characteristic greenish color to the surrounding growth media or the tissue substrate involved in clinical disease (e.g., “green nail” syndrome; Fig. 197-2). Pyomelinin strains can lead to confusion between pigment and/or necrotic changes. In addition, an odor of grapes, characteristic of trimethylamine, often accompanies the growth of these microorganisms.

FIGURE 197-2 *Pseudomonas aeruginosa:* “Green nails.” This 36-year-old bartender noted a greenish-yellow discoloration of 8 of 10 fingernails during the preceding year. Several of the fingers show chronic candidal paronychia as well.

Organisms gain entry through breakdown of the skin or mucous membrane barriers at sites of maceration, dermatophytic foci, trauma, or foreign bodies (e.g., indwelling venous or urinary catheters), or via aspiration or aerosolization into the respiratory tract. Infections in otherwise healthy individuals are unusual; when they occur, the involved regions are often areas with increased moisture (e.g., toe webs, the external auditory canal). Infection may begin in the base of the nail in persons who frequently have their hands or feet in water. This can progress to paronychia, followed by development of a green-blue discoloration of the nail due to local pigment production. The ability of this organism to infect healthy, but moistened, skin is evident in the numerous reports of a rash of disseminated papules and pustules on areas of skin of people immersed in public whirlpools, hot tubs (“hot tub folliculitis,” Fig. 197-3), wading and swimming pools. [33] These ubiquitous organisms can sometimes be aggressive secondary invaders in open wounds, in decubitus and other skin ulcerations, or in association with thermal burns. Rarely, a superficial pyoderma due solely to *Pseudomonas* is engrafted upon a generalized or localized dermatitis, such as tinea pedis or eczema, producing irregular pustular areas with macerated and eroded borders. [33]

FIGURE 197-3 *Pseudomonas aeruginosa:* “Hot tub folliculitis.” This 22-year-old female noted the appearance of erythematous, pruritic papules and pustules on the trunk, buttocks, and upper thighs several days after bathing in a hot tub. The eruption resolved without antibiotic therapy.

Serious invasive infections occur in debilitated patients; malnourished infants; individuals whose normal bacterial flora has been suppressed by antibiotics; patients with neoplastic diseases, granulocytopenias of various etiologies, or impaired circulating or cellular immunity, including that associated with AIDS; [34] and individuals requiring mechanical respiratory assistance. These ubiquitous organisms frequently colonize body surfaces and survive exposure to antibiotics. *Pseudomonas aeruginosa* can spread widely via the bloodstream, producing a disseminated infective vasculitis in which organisms can appear in the periadventitia, adventitia, and media of vessels without luminal clots. Occasionally, features of the generalized Shwartzman reaction are found, but less frequently than in infections due to *N. meningitidis* or Enterobacteriaceae.

Whole dead *Pseudomonas* cells injected into experimental animals produce little, if any, toxicity compared with the effects of live bacteria. This suggested to Liu that the pathogenicity of this organism may reside in an exotoxin rather than in the classic endotoxin of gram-negative bacteria. [35] Studies during the past 25 years have confirmed the relevance of a number of enzymatic and toxic substances to pathogenesis. Among these, collagenase and elastase may be important determinants for the development of hemorrhagic lesions. A phospholipase similar to the a-toxin of *Clostridium perfringens* may have a major role in the pathogenesis of respiratory infections through destruction of pulmonary surfactant. Studies have led to the identification and characterization of a potent protein, exotoxin A. The mechanism of action of this cytotoxin is identical to that of diphtheria cytotoxin, but it differs in its cellular specificities, molecular properties, and clinical expression. Among the critical effects of these cytotoxins, their influence on polymorphonuclear leukocyte migration and function is considered vital to pathogenicity. [36] The role of the various cellular and toxic components of *P. aeruginosa* that contribute to pathogenicity has been reviewed. [37] In addition, the potential for developing immunotherapies, including conjugate polysaccharide toxin A and outer membrane protein vaccines, for life-threatening infections in compromised patients has been discussed in a recent report. [38]

Epidemiology

Because *P. aeruginosa* is widely distributed in nature (in air, water, dust particles, and soil), it is not surprising that it may contaminate plants, vegetables, hot tubs, whirlpools, swimming and wading pools, and occasionally medicinal preparations such as procaine and fluorescein eye drops. In humans, the moist regions of skin folds and the external auditory canal are the most common sites of natural colonization (approximately 3 to 5 percent of individuals). *Pseudomonas aeruginosa* is found in small numbers in the feces of 10 to 20 percent of the population, but in as many as 35 to 50 percent of patients hospitalized for longer than 1 week.

Any activity that leads to excessive local moisture—laundry work, dishwashing, or hiking for long periods in wet terrain—will enhance the presence and growth of these organisms. Moist or weeping cutaneous lesions (e.g., thermal burns) encourage the growth of *Pseudomonas* as well as that of other gram-negative bacteria. Procedures that increase humidity in the environment are frequently associated with overgrowth of these organisms. Moisture-enhancing bath materials, like loofah or synthetic sponges, easily become contaminated with gram-negative bacteria and have served as vehicles of transmission of *Pseudomonas* to skin.

Systemic infection with these indigenous gram-negative bacteria depends primarily on altered susceptibility of the host rather than on spread from individual to individual or on increased pathogenicity. However, there may be exceptions to this in newborn nurseries, respiratory care units, and occasionally, urology wards, where dissemination from a primary source may occur. Hospitalized patients who are neutropenic or immunocompromised are more likely to become colonized and develop invasive disease.

Local and Secondarily Infected Lesions

Pseudomonas produces a number of characteristic lesions. In addition, these organisms contaminate and complicate other skin diseases and open wounds. [39]

CLINICAL MANIFESTATIONS

History Painful paronychial lesions, with or without characteristic green or blue discoloration of the nails occur most often in women with a history of continual immersion of the hands in water with soaps and detergents. People with toe web infection characteristically work or live in an atmosphere of high humidity and often have wet feet. Symptoms usually include slight persistent soreness and scaling of the web tissues. There are a large number of reports of therapeutic or

recreational whirlpool-, hot tub–, and swimming pool–associated skin rashes developing in healthy individuals within 1 to 5 days after use of public bathing facilities (see Fig. 197-3). In all instances, *P. aeruginosa* was isolated in large numbers from the pool water. The skin rash is usually self-limited, clearing without therapy within 1 week, but often accompanied by fatigue, malaise, low-grade fever, external otitis, and mastitis. [33] The hot-foot syndrome, a newly described disease caused by *P. aeruginosa* contamination of a wet surface, emphasizes the organism's opportunism in infecting the ventral surface of feet abraded by a roughened floor. [40]

Cutaneous lesions In addition to a tender paronychial lesion, patients with the “green nail” syndrome may have part or all of the associated nail colored green to blue. The color may be in horizontal bands, representing intermittent activity of the infection at the nail base (see Fig. 197-2). Individuals with toe web *Pseudomonas* infections have thick, macerated, scaling, slightly green, foul-smelling discolored areas between the toes. The hot-foot syndrome is characterized by tender, painful, red, plantar nodules independent of signs of folliculitis, developing within 1 to 2 days of exposure of individuals to an abrasive wet surface, such as a wading pool. [40] External otitis due to any type of bacteria presents a characteristically swollen, macerated appearance in the local area without any specific lesion involving the eardrum. Often referred to as “swimmer's ear,” the condition produces intense swelling and discoloration with excruciating pain on movement of the pinna. If the skin is traumatized naturally or during a surgical procedure, local infection can spread to the pinna, producing a perichondritis and chondritis with intense tender swelling of the ear. Cartilagenous necrosis may result from pressure effects or inflammatory damage unless immediate drainage with through-and-through incisions and appropriate antibiotics are instituted. Organisms other than *P. aeruginosa* may be causal, including *Staphylococcus aureus* and streptococci. [41] The most severe form of *Pseudomonas* infection, malignant external otitis, has a high mortality rate if therapy is delayed or inadequate. This serious infection usually occurs in elderly people who are diabetic with significant small-vessel disease, but may also occur in healthy elderly people, as a complication of surgical trauma, after minor trauma such as water irrigation of the external canal, and in patients with AIDS. [42] The onset and early progression of infection are insidious. Swelling, erythema, moderate discharge, and pain are present without fever or constitutional symptoms. As the surface breaks down, the *Pseudomonas* invade the soft tissues at the junction of cartilage and bone, and the process then advances to involve cartilage, mastoid, and temporal bone. Inflammation at the stylomastoid and jugular foramina can lead to 7th-nerve and 9th- to 11th-nerve palsies, the 7th-nerve palsy being the earliest objective neurologic defect seen. Diagnosis is made clinically and early if there is adequate visibility, and granulation tissue can be seen erupting at the cartilage-bone interface in the posterior inferior canal wall. The pinna is often swollen, and pain is intense. [43] Patients who develop folliculitis usually give a history of exposure to warm water in a theraputic whirlpool, a public bath such as a hot tub, a recreational spa for swimming, or a water slide. The rash can be localized if a limb has been immersed in a whirlpool or generalized in distribution in swimsuit and intertriginous areas. The rash begins as papules, evolves to papulopustules (see Fig. 197-3), and eventually heals with fine desquamation. Pruritus and pain may accompany the lesions along with localized areas of mastitis and external otitis. Serotype 0-11 of *P. aeruginosa* is most commonly involved. [44] A small outbreak of *P. aeruginosa* 0-11 folliculitis occurred in granulocytopenic patients in a cancer treatment center; but the lesions in these patients, in contrast to those in healthy individuals with swimming pool folliculitis, rapidly became widespread and progressed to bullae, which became necrotic (ecthyma gangrenosum–like) unless systemic antibiotic treatment began immediately. [45] Thus, the development of ecthyma gangrenosum can result from the progression of an initial folliculitis in a compromised patient rather than the incidental occurrence of superimposed bacteremic *P. aeruginosa* lesions. Sinks and faucets in the patients' rooms were sources of *P. aeruginosa* of identical serotype. In secondarily infected open skin areas, the presence of *Pseudomonas* is sometimes associated with a prominent greenish-blue color to the purulent exudate. Widespread, irregular, superficial pustular lesions may be superimposed on the underlying skin disease; the margins of these regions are usually sharply defined and irregular and may exhibit the characteristic grapelike odor and pigmented exudate. [44]

DIAGNOSIS AND DIFFERENTIAL DIAGNOSIS Nail and skin lesions resulting from *Pseudomonas* infection are recognized by the characteristic pigment and “fruity” odor of the exudate. The organisms can be identified as thin gram-negative rods, or a mixed infection (e.g., with *Candida*) may be observed. Fluorescence, demonstrated with a Wood's lamp, can help to support the diagnostic impression. Occasionally, *Aspergillus* infection of the nails produces a greenish color, there is usually no associated paronychia. A subungual hematoma may superficially resemble *Pseudomonas* nail infection.

COURSE AND PROGNOSIS Patients with minor *Pseudomonas* infections (e.g., onychia and paronychia, toe web inflammation, whirlpool-associated skin rash, and external otitis) usually improve rapidly with topical therapy and drying of the affected area. Malignant external otitis requires the systemic use of antibiotics directed against *Pseudomonas,* utilizing a fluoroquinolone (ciprofloxacin or ofloxacin) with or without imipenem or ceftazidime. High doses and prolonged therapy are combined with local surgical debridement to limit spread to bone, nervous system structures, and the meninges. [37], [46]

Septicemia and Cutaneous Involvement

CLINICAL MANIFESTATIONS

History In individuals ill with *Psedomonas* septicemia, the history is most frequently centered around the underlying problem and antecedent therapy. A premature infant may have required resuscitation and treatment of a nonspecific pneumonitis prior to developing high fever, obtundation, and macular or hemorrhagic vesicular skin lesions. Infants may present initially with omphalitis or severe diarrhea, followed by septicemia and skin lesions. Urinary tract infections complicating congenital lesions such as exstrophy of the bladder may predispose the infant to bacteremia. In adults, there is usually a history of antibiotic therapy, treatment with glucocorticoid hormones or antitumor agents, or the use of percutaneous catheters. Frequently, the patient is granulopenic, has already had a significant febrile illness, and may still be receiving antibiotics when one of the characteristic cutaneous manifestations develops. The local lesions are rarely painful, but the patient is usually too sick to focus on the local problem. Occasionally, hemorrhagic manifestations may develop secondary to the involvement of small vessels supplying the skin, to platelet reduction, or to DIC. *Pseudomonas* involvement of the gastrointestinal tract, particularly in the tropics, may produce the picture of an acute enteric infection, with headache, high fever, diarrhea, and cutaneous manifestations. If, rose spots are present, the syndrome is described as Shanghai fever and resembles typhoid fever. The same enteric syndrome with ecthyma gangrenosum has recently been observed in previously healthy infants. [47]

Cutaneous lesions The skin lesions, the most characteristic part of the physical findings in *Pseudomonas* septicemia, consist of four types [48]:

1. Vesicles and bullae. Singly or in clusters, these lesions spread in random fashion over the skin. They frequently become hemorrhagic as they evolve. Occasionally, in infants, they may be surrounded by large erythematous halos and may be mistaken for erythema multiforme.
2. Ecthyma gangrenosum. The lesion in this disorder starts with a gunmetal gray, infarcted lesion with surrounding erythema (Fig. 197-4) and evolves into a necrotic black or gray-black eschar and surrounding erythema (Fig. 197-4 and Fig. 197-5). This lesion often evolves from a necrotic vesicle. Frequently, but not exclusively, the lesion is in the anogenital or axillary region.

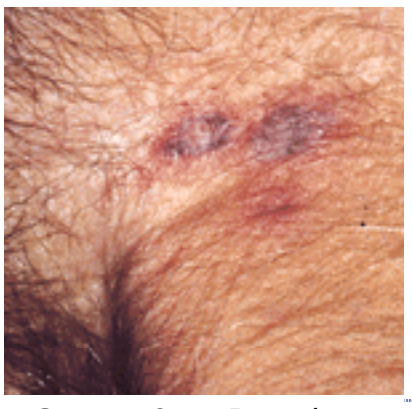

FIGURE 197-4 *Pseudomonas aeruginosa:* Ecthyma gangrenosum. Gunmetal gray, painless, infarcted lesions with surrounding erythema.

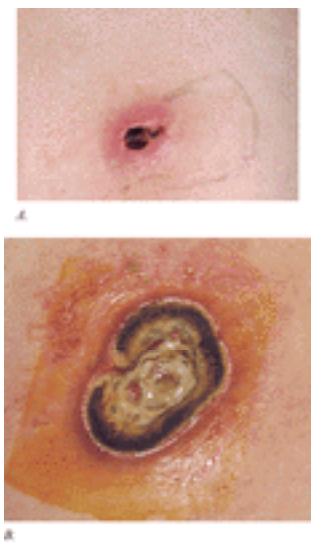

FIGURE 197-5 *Pseudomonas aeruginosa:* Ecthyma gangrenosum. This 32-year-old male with HIV disease noted the onset of a very tender plaque on the right buttock associated with fever and malaise. *A.* Five-day-old lesions with a central infarcted, necrotic area surrounded by erythema. *B.* At 5 weeks, the lesions had improved following ciprofloxacin treatment, which was discontinued owing to an adverse drug reaction. Without antibiotic treatment, the necrotic area enlarged and was associated with bacteremia. Eventually, the lesion reepithelialized, but the patient died of pseudomonal pneumonia.

3. Gangrenous cellulitis. Sometimes presenting as a sharply demarcated, superficial, painless, necrotic lesion, gangrenous cellulitis may resemble a decubitus ulcer. However, it is located in a nonpressure area and may complicate a prior area of injury, such as a thermal burn. Also, it may begin abruptly as an acute infection (with much clinical toxicity), producing local pain, swelling, and erythema, and involving deep subcutaneous tissue and fascia. Either local injury or bacteremia may introduce the infection.
4. Macular or papular nodular lesions. These are small, oval, and painless, located predominantly over the trunk. They resemble rose spots of typhoid fever.

Another cutaneous manifestation of *Pseudomonas* septicemia, usually occurring after days or weeks, is nodular cellulitis. The lesions are red, warm, sometimes fluctuant, but often situated deeply enough to feel solid. Surgical incision reveals suppuration, and *P. aeruginosa* can be cultured from the lesions. [48], [49] A variation of this process consists of numerous red, nonfluctuant, hot, nontender, subcutaneous nodules on the trunk and extremities that may be accompanied by other characteristic lesions, such as hemorrhagic bullae and ecthyma gangrenosum. Such lesions may be successfully treated by combination antipseudomonal antibiotic therapy. Other lesions that may appear in association with *Pseudomonas* infection include petechiae, ecchymoses, dermal Shwartzman-like reactions, and purpura fulminans. Occasionally, the cutaneous expression of *Pseudomonas* infection may take the form of a typical erythema multiforme reaction. Patients with extensive burns may develop lesions of the described types on areas of normal skin, as well as more florid diffuse growth secondarily infecting the burn surface with resultant necrosis.

Other physical findings Patients with *Pseudomonas* septicemia frequently exhibit physical findings associated with their underlying diseases: malnutrition, mucous membrane ulcerations, glossitis and stomatitis secondary to antibiotics and granulocytopenia, urinary tract infections, proctitis, adenopathy, hepatosplenomegaly, and hemorrhagic bronchopneumonia.

Laboratory findings Routine hematologic examination may reveal leukocytosis or leukopenia, with modifications based on underlying illnesses (e.g., aleukemic leukemia, leukemia). Platelets may be diminished, and fibrinogen and other clotting factors may be reduced in association with consumption coagulopathy, liver disease, or profound malnutrition. Characteristically, in *Pseudomonas* septicemia aspirated material from bullae, areas of cellulitis, and papular or nodular lesions reveals numerous organisms, but few leukocytes, even in patients with leukocytosis. Cultures of these lesions and of blood almost always show *Pseudomonas.*

PATHOLOGY The distinctive finding in *Pseudomonas* lesions is a necrotizing vasculitis in which a myriad of bacteria invade the walls of small arteries and veins. [50] The internal elastic lamellae may be destroyed by microbial elastase, but

the endothelial surface is rarely damaged and thrombosis is unusual. [47] Extravasation occurs around the vessels, edema and bland necrosis in the perivascular and adventitial regions are extensive, and blood flow to the region supplied by the affected vessel is decreased. This, in turn, leads to the formation of cutaneous lesions (bullae, hemorrhagic cellulitis, and gangrenous changes). Organisms tend to spread along the exterior surfaces of vessels and invade the skin. Similarly, bacteria may invade the blood vessel walls of the lungs, liver, kidneys, and brain, with the production of characteristic discrete nodular necrotic lesions.

DIAGNOSIS AND DIFFERENTIAL DIAGNOSIS The characteristic ecthyma gangrenosum skin lesions in an acutely ill patient suggest the diagnosis of *Pseudomonas* septicemia. The finding of abundant, thin, gram-negative rods with rare granulocytes in vesicle fluid or in association with gangrenous or hemorrhagic cellulitis constitutes further presumptive evidence. The differential diagnosis of *Pseudomonas* septicemia includes other infections that can produce ecthyma gangrenosum and other skin lesions through direct involvement of blood vessels (e.g., those caused by *N. meningitidis, Aeromonas hydrophila, E. coli, Klebsiella pneumoniae, Morganella,* spp. and fungi of the *Aspergillus* and *Rhyzopus* groups). In addition, other gram-negative bacteria and *Rickettsia* may produce petechial, ecchymotic, or gangrenous skin lesions suggestive of the dermal Shwartzman reaction.

COURSE AND PROGNOSIS *Pseudomonas* septicemia is frequently the terminal event in a complex illness involving a patient with malignant disease or altered cellular and humoral defense mechanisms. Therapy may be effective and recovery complete in some instances, especially when the septicemia occurs in patients with more favorable underlying problems such as thermal burns, in individuals with urinary tract foci of infection, or in association with the use of percutaneous venous catheters.

TREATMENT AND PROPHYLAXIS

Local infections Superficial skin and toe web infections and onychia usually respond to acetic acid, silver nitrate, or gentian violet compresses applied two to three times daily between long periods of absolute drying. Paronychia is best treated by surgical drainage, nail trimming, and 4 percent thymol in chloroform. Acetic acid, polymyxin (0.1 percent) in acetic acid, or glucocorticoids with neomycin are effective for otitis externa. When acetic acid is used topically on chronic ulcers or burns, a 2 to 5 percent solution is often effective. [51] In addition, topical silver nitrate (0.5 percent;) or silver sulfadiazine may eradicate these organisms in burn patients (see Chap. 127).

Systemic infections *Pseudomonas* septicemia requires early and vigorous systemic bactericidal antibiotic therapy. Effective therapeutic agents include the aminoglycosides gentamicin, tobramycin, and amikacin. One of these drugs is combined with an antipseudomonas penicillin or ceftazidime and given IV for patients who are acutely ill. In the presence of hypotension or of any renal impairment, the dosage of aminoglycoside antibiotics must be drastically reduced; in such circumstances, determinations of “peak” and “trough” serum levels of the aminoglycoside drug employed should guide therapy. In addition to the parenteral administration of antibiotics, surgical drainage is appropriate for nodular and fluctuant lesions. Acute *P. aeruginosa* gangrenous cellulitis/fasciitis requires debridement (often extensive), sometimes with a surgical “second look” 1 or 2 days later. Leukocyte transfusions have been effective in granulopenic infants, and investigations are ongoing into the experimental use of human immune globulins with activity against *P. aeruginosa* or specific *Pseudomonas* exotoxin A antibody preparations. [38] The markedly granulocytopenic patient with gangrenous cellulitis due to *P. aeruginosa* alone or in polymicrobial combination presents a particularly difficult problem. Because the progression of the process can be extremely rapid, such a patient needs very prompt surgical debridement in addition to therapy with antimicrobials and granulocyte colony–stimulating factor. Complicating thrombocytopenia and DIC may supervene and add to the urgency.

Prophylaxis Infections caused by *P. aeruginosa* are difficult to treat not only because they often occur in compromised hosts, but also because the organisms are highly resistant to many antibiotics. There is no place for prophylactic antibiotics against *P. aeruginosa* because of drug toxicity and emergence of resistant strains. This reality has led to attempts to develop protective vaccines against the limited number of serotypes of *P. aeruginosa* or immuno theraputic agents. [38]

Skin Infections Due to Other *Pseudomonas* Species

Pseudomonas putrefaciens, a psychrophilic bacterium, is a rare cause of cellulitis, particularly in the setting of chronic lower extremity infection in ulcers secondary to venous stasis. [52]

SKIN INFECTIONS DUE TO *HAEMOPHILUS INFLUENZAE*

The characteristic feature of the rare infection of the skin with *H. influenzae* is a cellulitis that usually involves the face, neck, or upper extremities. Most cases occur in young children (6 to 24 months old), but the infection can occur in adults. With the early administration of protective Hib conjugate vaccines, invasive manifestations of *H. influenzae* disease have nearly disappeared in the developed world, but they persist as major disease problems in developing countries.

Bacteriology and Pathogenesis

Haemophilus influenzae is a small coccobacillary, pleomorphic gram-negative organism. It is nonmotile and has fastidious growth requirements, including heme (X factor) and nicotinamide nucleoside (V factor). There are rough and encapsulated forms, the latter divided into six serologic types (a through f) based on capsular polysaccharide antigens.

Most infections with *H. influenzae,* including meningitis, epiglottitis, and cellulitis, are caused by encapsulated type b strains (Hib). The ribosyl-ribitol phosphate capsule inhibits phagocytosis in nonimmune individuals and allows a period of unchecked bacterial growth and invasiveness to occur. Rough, unencapsulated, nontypable, noninvasive species are not involved in cellulitis.

In the majority of Hib infections, there is an antecedent upper respiratory infection or acute otitis media. The characteristic localization of the cellulitis to the upper part of the body argues for the sequence of upper respiratory infection, fallout onto or invasion of the skin locally, and then bacteremia. This sequence is evident in adult, as well as in pediatric, cases. The association of otitis media with cellulitis has led to the hypothesis that the ear may serve as the primary focus of infection in cases involving the face. A primary bacteremic mechanism with secondary localization in the skin would be favored by a more random and widespread distribution of lesions than is seen. Localization of a subclinical

bacteremia could follow trauma and has been suggested as a possible antecedent predisposing event.

Epidemiology

Humans are the only known natural host for *H. influenzae.* These potentially pathogenic bacteria are carried in the oropharynx and nasopharynx, especially in children up to age 5 years, as part of the normal indigenous flora. However, early immunization using conjugate Hib vaccines has markedly decreased nasopharyngeal carrier rates and increased herd immunity, which has certainly contributed to the overall dramatic decline of invasive clinical disease. [53] Cellulitis as well as other forms of invasive disease, including meningitis, pneumonia, and epiglottitis, have all but disappeared in populations protected by Hib conjugate vaccine.

Susceptibility to Hib disease appears to be greatest among certain ethnic groups and in socioeconomically disadvantaged populations, a relatively small issue in the Western world, but a major continuing problem worldwide. [53], [54] Genetic factors, prompt antibiotic treatment of Hib disease (aborting an antibody response) congenital and acquired complement and antibody deficiency, and asplenia may also be responsible for increased susceptibility to disease and to recurrent episodes in nonimmunized traditional age groups, as well as in adults. Spread is via droplet aerosol or close contact, and susceptibility to *H. influenzae* infection appears to be greatest between the ages of 3 months and 3 years.

Although the mechanism of protection in the newborn period remains uncertain, it probably involves transplacental IgG transfer. There is general agreement that complement-dependent anticapsular and bactericidal antibodies increase with age and are protective. Paradoxically, Hib disease may occur in individuals endowed with adequate levels of bactericidal antibody.

Clinical Manifestations

HISTORY Typically, a nonimmunized young infant or child (under age 3) develops an area of swelling and discoloration on the face or arm following several days of coryza and abruptly rising temperature. Rarely, a similar process occurs in adults as a complication of respiratory tract infection involving the upper airway. [55]
CUTANEOUS LESIONS The typical lesion is a single, circumscribed, indurated area usually located on the face, neck, upper chest, or upper extremity. Although described in infants as characteristically blue-red to purple-red in color and surrounded by a zone of edema, the early lesion may be an area of pale edema or erythema (see Fig. 197-6). The margins are indistinct, in contrast to the sharply defined borders of erysipelas. Regional adenopathy is rarely present. Occasionally, in children with Hib buccal cellulitis, erythematous buccal mucosal lesions appear on the side of the affected cheek, suggesting direct bacterial spread from the oropharynx into buccal soft tissues. [56]

FIGURE 197-6 Cellulitis: Haemophilus influenzae. Erythema and edema of the face in a child. (*Courtesy of Sandy Urioste, MD.*)

When *H. influenzae* cellulitis occurs in adults, the infection follows a striking sequence: marked pharyngitis at first; high fever; then rapidly progressive anterior neck swelling, tenderness, erythema, and dysphagia. [55]
OTHER PHYSICAL FINDINGS Associated infections of the upper respiratory tract, including otitis media, sinusitis, or epiglottitis, and pneumonia occur. The patient may appear lethargic; occasionally, metastatic infections such as septic arthritis or meningitis may occur.

Laboratory Findings

The white blood cell count is invariably elevated, usually in the 20,000/mm ^{3} range. Results of blood cultures are positive in approximately 50 percent of cases. Aspiration and culture of the margin of the cellulitis has been positive in about half the patients encountered, and Gram-stained smears should be studied.

Pathology

No information is available about the histologic changes associated with this rare lesion, but the inflammatory response is doubtless an acute pyogenic reaction.

Diagnosis and Differential Diagnosis

Haemophilus influenzae cellulitis should be suspected when a child aged 3 to 24 months develops an acute facial (buccal) cellulitis with high fever. There may be concomitant upper airway inflammation. Immediate confirmation of the diagnosis may be possible from inspection of Gram-stained smears of an aspirate of the lesion. Although cellulitis caused by other microorganisms is more common in adults, Hib disease should be considered in patients with respiratory infections and upper body cellulitis, especially in adults or in young children not fully immunized. [54]

Streptococcal (group A, C, or G) or pneumococcal cellulitis may produce discoloration of the skin similar to Hib infection. Erysipelas, which rarely occurs in infants, is usually homogeneously erythematous, and the margins of the plaquelike swelling are distinct compared with the indefinite borders of *H. influenzae* cellulitis. The presence of pustules or boils is

helpful in identifying *S. aureus* as the etiologic agent.

Course and Prognosis

Most patients do well with antibiotic therapy, even though the disease is often associated with bacteremia. The abrupt onset of high fever and easily observed cellulitis indicates the urgency of the situation and mandates an early visit to a physician. Constant vigil must be maintained for suppurative complications in the upper airways, meninges, lungs, bones, joints, or other organs. Cellulitis is a rare complication of Hib disease.

Treatment and Prophylaxis

Third-generation cephalosporins (ceftriaxone or cefotaxime) are currently the drugs of choice in the treatment of Hib disease because of their activity against both ampicillin-susceptible and ß-lactamase–producing strains of *H. influenzae* and because of their efficacy in treating any complicating meningeal spread of infection. Infections caused by ß-lactamase–negative isolates can be treated with ampicillin given IV in four to six divided doses daily. However, with plasmid-mediated ampicillin resistance at levels of 30 to 45 percent among strains of Hib, therapy should begin with a third-generation cephalosporin. Chloramphenicol is not recommended, owing to its hematologic toxicity, especially in very young children.

As noted earlier, the introduction of Hib conjugate vaccine (capsular polysaccharide covalently linked to a protein moiety) in the past decade, has dramatically decreased the incidence of invasive Hib disease in the developed world. [53] These vaccines stimulate protective antibody when given to infants prior to 6 months of age, a period of great susceptibility to Hib invasive disease. As Hib immunization becomes a global reality it is fair to assume that cellulitis, meningitis, and other invasive manifestations of Hib disease will become infections of historical interest only.

CUTANEOUS MANIFESTATIONS OF *SALMONELLA* INFECTION (ENTERIC FEVER)

Salmonella organisms are widespread in nature. Carried by cold- and warm-blooded animals, they contaminate many foods derived from animals, are global in distribution, and therefore have an impact on human health as well as economic stability. *Salmonella* infections usually manifest as gastroenteritis, enteric fever (typhoid-like illness), or septicemia. Rose spots, the classic skin lesions of systemic *Salmonella* infection, have been variably reported (10 to 60 percent) during the natural (untreated) evolution of typhoid fever, but less frequently in enteric fevers caused by other *Salmonella* species.

Bacteriology and Pathogenesis

Salmonellae are not fastidious organisms, but their isolation from stool is made difficult by the fact that, when present, they represent only a small part of the abundant fecal flora. Extragastrointestinal isolates (i.e., from abscesses, blood, skin lesions) are easier to identify, as they are usually pure cultures of a given *Salmonella* species. The use of selective inhibiting media (e.g., MacConkey, SS agar) that inhibit the growth of gram-positive organisms, as well as many gram-negative species, facilitate the isolation of the organisms from stool specimens. Salmonellae are motile, gram-negative bacilli that do not ferment lactose. From a practical viewpoint, in stool bacteriology, initial selection of non–lactose-fermenting colonies is followed by biochemical and serologic (agglutination) procedures for identification and serotyping of the organism. There are approximately 2300 serovars determined by surface and flagellar antigens. Modern molecular biology has established a revised nomenclature, with *Salmonella choleraesuis* the single species, and all serovars serotypes of this single species. Because habits are difficult to change, organisms are usually still referred to as familiar species (e.g., *Salmonella typhi, Salmonella paratyphi, Salmonella enteritidis*) rather than serotypes of *S. choleraesuis.*

There is a latent period from 3 to as long as 50 days (usually 7 to 14) between the ingestion of bacteria and the dramatic onset of the clinical symptoms of enteric fever. Shorter latent periods often follow the ingestion of larger numbers of organisms. When resulting from the ingestion of salmonellae other than *S. typhi,* symptoms tend to begin earlier and are milder. During the latent period, organisms multiply in the distal small bowel and invade and multiply in lymphoid tissues in the area of Peyer's patches in the terminal ileum. A major factor facilitating dissemination may be the ability of these organisms to resist killing by macrophages, while simultaneously they are protected from circulating antibodies and antibiotics by their intracellular residence. [57] Invasion of the bloodstream from this focus heralds the onset of the clinical illness, with chills and fever and other constitutional effects of circulating endotoxin. Manifestations of infection occur in many organs, frequently in a predictable sequence: respiratory and central nervous system symptoms during the first week; skin manifestations during the second week; diarrhea, often following a period of constipation, during the second and third weeks. Bacterial invasion of the skin, liver, gallbladder, bones, and joints, as well as manifestations of endotoxemia, usually occur during the bacteremic phase of the illness (first 10 days). The reticuloendothelial system clears the organisms, leading to hyperplasia of these elements in the liver, spleen, and lymph nodes. Persistence of organisms in the gallbladder, biliary ducts, bone marrow, or the reticuloendothelial system may lead to a chronic asymptomatic carrier state.

Epidemiology

People acquire *Salmonella typhi* and other *Salmonella* species causing enteric fever by the ingestion of contaminated water or food. Travel in developing countries and other areas of marginal sanitation places people in the proximity of enteric pathogens. Rapid transportation can bring them home healthy during an incubation period that can be 5 to 6 weeks long. A history of recent travel and unusual or suspicious food or water encounters should be sought in a patient with appropriate clinical manifestations.

Humans are the only hosts for *S. typhi* and *S. paratyphi.* The chronic carrier state that may follow clinical typhoid fever is almost always asymptomatic, except for manifestations of gallbladder disease if cholelithiasis and active cholecystitis are

present. Other serotypes of *Salmonella* can produce an enteric fever syndrome similar to, but usually milder than, typhoid fever. Unlike *S. typhi,* these other *Salmonella* serotypes are ubiquitous in nature (occurring in animals, birds, reptiles, poultry products) and are difficult to control as sources of human infection.

A number of factors, exclusive of inoculum size, determine whether disease will occur after ingestion of *Salmonella.* Achlorhydria and previous gastric surgery allow organisms to escape destruction by the acid barrier of the stomach. Rapid transit of a smaller inoculum in a liquid vehicle may allow adequate numbers of viable bacteria to reach the distal small bowel. Suppression of competing bowel flora by antimicrobials and gastric acid reduction or neutralization by the variety of pharmacologic agents available are unproven, but likely, contributing factors to the emergence of disease. Underlying illnesses such as Hodgkin's disease, which alters cellular immunity, can interfere with the host defense mechanisms that normally eradicate these pathogens; hemoglobinopathies such as sickle cell disease appear to predispose to systemic *Salmonella* infections and osteomyelitis by saturating the protective reticuloendothelial system with red cell fragments and occluding small blood vessels, leading to local chronic foci; finally, tumor immunosuppression therapy may predispose patients to salmonellosis. Infants and young children, as well as the very elderly, appear to be especially susceptible to gastroenteritis and serious disease.

Clinical Manifestations

HISTORY Symptoms begin several days to several weeks after the ingestion of contaminated water or food. Headache, fever, generalized aching, abdominal discomfort, cough, and constipation are common. Delirium or mental torpor are not unusual, especially when there is a high fever. The pulse rate may be slower than expected for the magnitude of the fever. Symptoms increase in intensity, and the fever often reaches 39.5°C to 40.5°C (103.1°F to 104.9°F) by the end of the first week. During the second week, rose spots may appear on the trunk, and diffuse abdominal cramping becomes prominent, sometimes accompanied by diarrhea. In area endemic for typhoid fever, abdominal symptoms may be present from the onset, and diarrhea can also be an early manifestation.
CUTANEOUS LESIONS After approximately 7 to 10 days of high fever, the rose spots characteristic of *S. typhi* infection may appear. These lesions are 2- to 3-mm, slightly raised, pink papules that blanch on pressure and are usually nontender. Appearing in crops of approximately 10 to 20 lesions, they are often located between the nipple area and the umbilicus on the anterior trunk, rarely on the back or extremities. Without therapy, the crops of spots usually become brownish as they fade and disappear in 3 to 4 days. New lesions emerge over the ensuing 2 to 3 weeks in untreated patients. Their presence in 63 percent of a group of 62 patients should encourage careful observation for this subtle rash. [58] Antibiotic therapy instituted early in the course of the illness may be responsible for the decreasing incidence of rose spots. The rash is less frequently reported in people of color, but this may be because of difficulty in detecting the small, scarce lesions on dark skin. Rose spots occur infrequently in enteric fevers caused by other *Salmonella* species, but when they do appear, they may be present in greater numbers and in a more widespread distribution. A variety of other skin changes have appeared in enteric fever during the acute phase of illness. Erythema typhosum, an erythematous rash that is confluent and widely scattered, may occur during the first week of the disease. Erythema nodosum and urticarial lesions have been noted and ascribed to hypersensitivity phenomena. In several recent reports from the Indian subcontinent, subcutaneous and cutaneous abscesses and skin ulcers have been described. [59], [60] Transient loss of hair, changes in nails, and posttyphoid anhidrosis reflect the acute catabolic stress. It is distinctly uncommon to observe herpes labialis in enteric fever.
OTHER PHYSICAL FINDINGS During the acute phase of the disease, at the time the cutaneous lesions are appearing, the patient may be disoriented and have signs of pneumonia. The abdomen is often distended, tympanitic, and diffusely tender, with some localization to the right lower quadrant. The spleen is often enlarged, but may be difficult to palpate because of abdominal distension and guarding.

Laboratory Findings

Leukopenia or low normal leukocyte counts are often present, but values range from 3000 to 20,000/mm ^{3}. The percentage of mononuclear cells may be increased, and atypical lymphocytes can appear in small numbers, suggesting a viral illness. Thrombocytopenia and, rarely, hemolysis may occur. During the initial week of illness, blood cultures are usually positive for *Salmonella.* During the second week, or when diarrhea begins, stool cultures become positive for *Salmonella,* and the white blood cell count may increase.

In addition to blood and stool, the typical rose spots should be cultured, preferably using the technique of skin snips. [58] Bone marrow and skin lesion material may show *Salmonella* in approximately 65 to 95 percent of cases, even when routine blood cultures done simultaneously are negative for *Salmonella* or when the patient is receiving antibiotics. Standard serologic tests like the Widal agglutination procedure become positive only after several weeks to a month of illness. The accuracy of these tests is low, with many nonspecific elevations in a variety of other infectious diseases. A specific polymerase chain reaction assay is in development for identifying a number of pathogens and will add specificity and sensitivity to laboratory testing. [62]

Pathology

The rose spot associated with *Salmonella* infection characteristically blanches on pressure, and examination of the lesion histologically reveals gross dilatation of capillaries, described by some pathologists as “capillary atony.” Extravasation of blood is not observed, but there is considerable edema and an abundant pericapillary infiltration with macrophages; organisms may be present within these cells. [63] A cutaneous leukocytoclastic vasculitis has been described in a rose spot biopsy from a patient with *S. paratyphi* enteric fever.

Diagnosis and Differential Diagnosis

The diagnosis of *Salmonella* enteric fever may be difficult in a sporadic case, especially if the characteristic rash and gastrointestinal symptoms have not yet appeared and there is no history of travel in an endemic area. Headache, cough,

and high fever are not very specific findings. However, when these symptoms are associated with delirium, relative bradycardia, and leukopenia with increased numbers of circulating mononuclear cells, the diagnosis of enteric fever should be considered. The diagnosis is usually made by obtaining blood cultures, which are positive for *Salmonella* in approximately 80 percent of untreated cases during the first week to 10 days. The results of serologic tests (e.g., Widal) are usually negative during the early phase of the illness and may not be diagnostic later. Likewise, enteric fever due to other *Salmonella* species can usually be diagnosed through blood cultures. Other cultured material (e.g., bone marrow, rose spots) may be important, especially in patients who have had prior antibiotic therapy.

The differential diagnosis includes a wide range of diseases. Prominent cough and severe headache in the early phases may suggest a viral or atypical pneumonia (disease caused by *Legionella pneumophila, Chlamydia pneumoniae,* or *Mycoplasma pneumoniae;* psittacosis; or Q fever). Typhus and Rocky Mountain spotted fever can usually be excluded by geographic and epidemiologic considerations, serologic studies, the characteristic petechial component to the rash, and, in the case of Rocky Mountain spotted fever, the distribution of the rash on the distal parts of the extremities. Miliary tuberculosis may begin as an acute febrile illness with similar symptoms, leukopenia, and splenomegaly. The diagnosis may be delayed until a secondary complication such as meningitis occurs or until biopsy material (liver, lymph node) reveals granulomas, sometimes containing acid-fast rganisms. Among the viral diseases, the diagnosis of infectious mononucleosis is suggested by headache, cough, high fever, lymphadenopathy, splenomegaly, and a blood picture with leukopenia and some atypical mononuclear cells.

Malaria and toxoplasmosis are two parasitic illnesses that deserve consideration. Epidemiologic information plus intermittency of symptoms usually suggest the diagnosis of malaria. In generalized toxoplasmosis, the symptoms may be very similar to those of early enteric fever: prominent cough, high fever, a rash that is located on the trunk, and a mononucleosis-like blood picture. The rash tends to be more florid than the crops of 10 to 20 lesions seen in enteric fever, however, and is macular with a petechial component rather than papular. Diagnosis usually requires identification of *Toxoplasma gondii* in biopsy material or a rising antibody titer (19S fluorescent antibody or hemagglutination inhibition).

COURSE AND PROGNOSIS The response of patients with enteric fever to antibiotic therapy is usually gradual, with 3 to 6 days needed for the temperature to return to normal. With prolonged treatment, the incidence of relapse has declined, but the likelihood of relapse varies with the age, nutritional condition, and general health of the patient. The major complications in the preantibiotic days were bowel perforation and hemorrhage. Although rare, these complications still occur—even with prompt, effective antimicrobial therapy—and they are responsible for approximately 75 percent of the mortality in enteric fever. Deaths have been reduced from approximately 10 percent to 1 to 2 percent with antibiotic therapy, although the mortality rate is higher in immunocompromised patients. Following typhoid fever, approximately 1 to 2 percent of patients continue to harbor organisms in the gallbladder and excrete them in the stools for an indefinite period, becoming a major potential source for infecting other individuals.
TREATMENT OF PROPHYLAXIS The emergence of multidrug-resistant *Salmonella,* including endemic and imported *S. typhi,* in many areas of the world has essentially obviated the use of chloramphenicol, ampicillin, and trimethoprim-sulfamethoxazole as first-line antimicrobials to treat typhoid fever and other enteric fevers. [64] The fluoroquinolones (ciprofloxacin, ofloxacin) are active against drug-susceptible and multidrug-resistant *S. typhi* or other salmonellae causing enteric fever. Results of many clinical trials indicate that blood cultures become sterile promptly on treatment with ciprofloxacin and that this drug appears to be a safe and effective substitute for chloramphenicol; thus, ciprofloxacin has become the treatment of choice for typhoid fever. Ciprofloxacin is administered in 500- to 750-mg doses given orally every 12 h (or 400 mg given IV every 12 h) in adults for 14 to 21 days. Third-generation cephalosporins, especially ceftriaxone or cefotaxime, are acceptable alternatives for the treatment of typhoid fever if the previously noted antimicrobials cannot be used because of resistance of the infecting strain or because of drug hypersensitivity. Glucocorticoid therapy for a period of several days has been advocated in addition to antimicrobial treatment for severely ill and febrile patients, but its efficacy is unproved and prolonged use may increase the relapse rate. A report from Jakarta in 1984 found that high doses of dexamethasone reduced mortality significantly, and a subsequent review supported the use of glucocorticoids in severe typhoid fever. [65] Among the major complications, hemorrhage usually responds to conservative management, but perforation, often in the ileocecal region, requires immediate surgery. Identification and eradication of the biliary carrier *S. typhi* is an important preventive measure for controlling enteric fever. In the presence of stones, antibiotic therapy should be combined with cholecystectomy. In the absence of stones, a prolonged course of treatment with ampicillin or ciprofloxacin may eradicate the carrier site. Individuals traveling to areas of the world endemic for *S. typhi* or *S. paratyphi*. A should receive instruction in common-sense methods of eating and drinking to avoid potentially contaminated foods. Immunization with a live attenuated oral vaccine is available for *S. typhi* and is probably effective for all but massive exposure. A virulence (vi) capsular polysaccharide vaccine requiring a single dose is also available. Careful personal hygiene and avoidance of suspicious water or foods (e.g., leafy greens) will eliminate most encounters with *S. typhi* and other salmonellae capable of causing enteric fever and remains the cornerstone of prevention for all diseases transmitted fecally or orally.

CUTANEOUS MANIFESTATIONS OF INFECTION WITH OTHER GRAM-NEGATIVE BACILLI

An acute cellulitis, with or without production of gas, may be caused by *E. coli, Proteus* spp., *Klebsiella* spp., *Enterobacter* spp., *Serratia marcescens,* a variety of other facultative and nonfermenting bacilli, and members of the obligate anaerobic group of Bacteroides. These infections have occurred often, but not exclusively, in the very elderly; in patients with diabetes following trauma, surgery, bowel or perineal inflammation; and in immunocompromised individuals. The infectious process can be limited to the superficial soft tissues or found primarily in the deep fascia, but the extent of the cellulitis is often difficult to establish. Interference with vascular integrity can influence the findings. Location can be a factor in early diagnosis, as can the extent of spread along fascial planes (e.g., Fournier's necrotizing perineal fasciitis) and treatment decisions (antibiotics and surgery). (See Chap. 196.)

Drug addicts may develop mixed infections with these organisms when “skin popping” results in lesions such as necrotizing fasciitis. [66] Prior exposure to broad-spectrum antibiotics and altered host defenses can predispose an individual to this type of infection, which is often nosocomial in origin. The finding of gas in the tissues frequently leads to

an erroneous provisional diagnosis of clostridial cellulitis or gas gangrene.

Bacteriology and Pathogenesis

The family Enterobacteriaceae is composed of a number of bacilli that grow readily on blood agar and selective media. By means of a number of biochemical reactions and growth characteristics, seven tribes of Enterobacteriaceae have been recognized. *Escherichia coli* is closely related to *Shigella; Salmonella* spp., to *Citrobacter. Klebsiella-Enterobacter-Serratia* make up a third tribe, and *Proteus-Morganella-Providencia* comprise a fourth main division. There are a variety of facultative gram-negative bacilli that do not belong to this family, metabolize sugars variably, and are identifiable by means of other specialized biochemical tests. In addition, the obligate anaerobic *Bacteroides* spp. reside in the oral cavity, colon, and female vaginal region and are speciated by their anaerobic growth requirements and by a variety of metabolites that can be identified by gas-liquid chromatography and other methods.

Infection can result from endogenous (host flora) or exogenous (e.g., fresh- or saltwater) contamination of skin or subcutaneous tissues in an area of injury, surgery, or ischemia. Bacteria can also invade the subcutaneous tissues via the circulation from a distant source or by direct spread from contiguous structures such as the colon. By dissection along fascial planes, cellulitis can erupt in areas removed from the initial focus. The process is often necrotizing, containing a mixture of facultative and anaerobic bacteria and, especially in diabetic individuals, can be associated with gas formation (mainly hydrogen). Edema, bleb formation, ischemia, and gangrene result from thrombosis of nutrient blood vessels. [67] The underlying muscle is almost always spared. Polymorphonuclear leukocytes are abundant, compared to the relative scarcity of acute inflammatory cells in clostridial infections.

Epidemiology

Cellulitis usually follows contamination of adjacent tissues by bowel contents or a breakdown of skin. The conditions predisposing patients to this type of infection include (1) bowel perforation (e.g., appendicitis, neoplasm, diverticulitis, rectal mucosal tear), (2) colon surgery, (3) chronic edema, (4) vascular insufficiency, (5) injection of addictive drugs, (6) decubitus ulcers, (7) percutaneous lines, and (8) superficial perineal dermatitis, including diaper rash. Poorly controlled diabetes, alterations in host defense mechanisms (e.g., granulocytopenia), poor nutrition, or cirrhosis often further impair the health of these patients. Crepitant (gas-containing) cellulitis results from infection with gas-forming strains of bacteria (*E. coli, Klebsiella, Aeromonas hydrophila*), especially in patients who have poorly controlled diabetes or in the presence of *Bacteroides* spp. or anaerobic streptococci. [68], [69]

Water-related lacerations may cause soft tissue infection with a variety of nonenteric bacteria. Similarly, cellulitis, subcutaneous abscess, or myonecrosis due to *A. hydrophila* may follow penetrating trauma in either a fresh- or brackish-water environment, or it may be associated with fish or other aquatic animals. Halophilic vibrios, including *Vibrio vulnificus,* are responsible for acute infections of traumatized skin or septicemic spread to skin and soft tissues from seawater exposure or ingestion of raw shellfish. (See Chap. 199 for discussion of water-borne cellulitis.) Injuries on farms, particularly from corn-harvesting machinery, have been associated with gram-negative bacilli (*Enterobacter* spp. and *Stenotrophomonas* [formerly *Xanthomonas*] *maltophilia*). [70]

Gram-negative bacillary cellulitis (due to *E. coli, Proteus* spp., or *C. freundii*) may occur in immunocompromised patients, including individuals with AIDS or with the nephrotic syndrome. Grossly, the appearance of the lesions resembles those due to the more common gram-positive pathogens.

Clinical Manifestations

HISTORY Diabetes mellitus, malnutrition, chronic conditions (e.g., paraplegia with decubitus ulcers), or other conditions described under Epidemiology are usually present at the time of infection. The onset may be insidious, over 4 to 5 days, or abrupt. Pain, often severe, frequently precedes local skin changes, especially if the infection is at the level of the deep fascia. High fever, shaking chills, increasing pain, and falling blood pressure may follow. Symptoms of gastrointestinal inflammation, such as appendicitis or diverticulitis, may precede the soft tissue illness. Rectal or perineal pain can indicate a local process that may be especially devastating in a patient deficient in granulocytes.

CUTANEOUS LESIONS The areas of infection evolve to demonstrate the typical findings of cellulitis, with warmth and brawny edema. In the early stages, the skin is rarely discolored beyond a pink hue, and vesicles and blebs or bullae are almost never present. At this juncture, unless pain is present, the process may easily be overlooked, especially if the infection lies in a less obvious area or if the patient is obtunded. As the cellulitis progresses, edema and redness increase, and areas of gangrene may appear. Palpable tenderness and crepitus, if present, can help define the anatomic extent of the process. The cellulitis may remain localized to the superficial subcutaneous tissues and skin, but progression to the deep fascia with contiguous extension, necrosis of fat, and increasing pain and toxicity suggest a diagnosis of necrotizing fasciitis. [71] (See Chap. 196.)

SUPERFICIAL NASAL LESIONS Several subspecies of *K. pneumoniae* that infect the upper respiratory tract can produce unique superficial and invasive nasal lesions. Ozena is a chronic productive rhinitis caused by infection with *K. pneumoniae,* ssp. ozaenae. The process remains internal without any cutaneous manifestations except a profuse mucopurulent, foul-smelling discharge. [72] *Klebsiella pneumoniae,* ssp. rhinoscleromatis is the etiologic agent of a hypertrophic, granulomatous infection of the external nares known as rhinoscleroma. This disease often produces changes in the overlying nasal skin (Fig. 197-7) and the contiguous surfaces of the respiratory, sinus, and posterior pharyngeal regions. Most cases seen in the United States have been in patients who have emigrated from very specific areas of eastern and central Europe (where the disease is known as “Slavic leprosy”), from Africa, from the Near East, and from parts of Central and South America. [73]

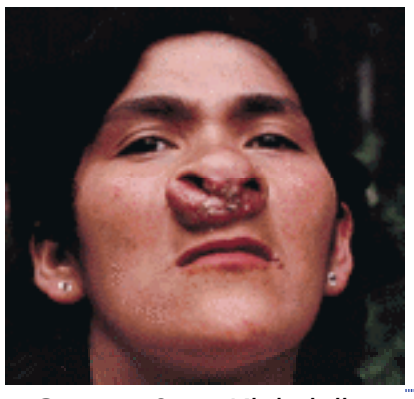

FIGURE 197-7 *Klebsiella pneumoniae rhinoscleromatis:* Rhinoscleroma. The nasal passages and nose are infected, resulting in obstructed respiration.

Dissemination of the organism is by prolonged close contact, often in family settings of crowding and poor sanitation. Infected individuals can shed organisms for years, resulting in recognized hyperendemic areas. The disease has been reported in patients with AIDs. [74] As seen in leprosy, the disease rarely becomes clinically apparent until early adulthood. Patients complain of fetid, purulent nasal discharge, epistaxis and obstructive symptoms, cutaneous nasal masses, and eventual scarring of nasal passages. Diagnosis depends upon biopsy identification of characteristic vacuolated Mikulicz cells and isolation of the organism on routine cultures, with biochemical and serologic confirmation. Both *K. pneumoniae,* ssp. ozaenae and *K. pneumoniae,* ssp. rhinoscleromatis are susceptible to ciprofloxacin, 250 to 500 mg two times daily for 1 to 3 months. A report from Mexico describes a successful outcome in all 28 patients taking ciprofloxacin (250 mg twice daily) for 1 month, compared to a group of 22 individuals treated with the more traditional combination of rifampin plus trimethoprim-sulfamethoxazole for six months. [75]

OTHER PHYSICAL FINDINGS The clinical course is often dominated by systemic manifestations of the underlying illness or decreased mental alertness, hypotension, and dehydration. Abdominal distension and other manifestations of localized or generalized peritonitis may be present. Extreme tenderness of the rectum, with or without a mass, can indicate the local source of a perineal process.

Laboratory Findings

The leukocyte count is usually elevated, in the range of 20,000 to 30,000/mm ^{3}, but may be markedly diminished in the presence of gram-negative septicemia. Elevated blood glucose values and findings of ketoacidosis are not unusual. In the presence of crepitant cellulitis, roentgenograms or magnetic resonance imaging (MRI) of the soft tissue may show the depth and extent of the gas-forming process. [76] In the absence of palpable gas, a soft tissue x-ray or MRI may indicate gas formation as part of the inflammatory process. Frozen-section biopsy materials in acute soft tissue infection can provide evidence of obliterative vasculitis, a finding suggestive of necrotizing fasciitis. [71]

Pathology

Edema, gangrene of overlying skin, fat necrosis, and a thin exudate containing visible fat droplets and polymorphonuclear leukocytes are usually present. Gas may be evident in the subcutaneous tissues. Blood vessels are often involved in a necrotic, obliterative, thrombotic inflammatory reaction. [71] The underlying muscle is usually not involved unless there is septicemia associated with major vascular thrombosis or there is myonecrosis with an organism such as *A. hydrophila.*

Diagnosis and Differential Diagnosis

A specific diagnosis can be made by needle aspiration of the cellulitis or an overlying bleb. Several morphologic forms of gram-positive as well as gram-negative organisms may be present. When gas is present, anaerobic cocci and *Clostridia* must also be considered. A foul, fetid odor may accompany the presence of anaerobes in the exudate. Radiologic and surgical evaluation can be helpful in determining a descriptive diagnosis such as crepitant cellulitis or necrotizing fasciitis.

Course and Prognosis

The process may be indolent and may respond quickly to effective antibiotic therapy. Unfortunately, especially in obese diabetic patients with perineal lesions, the progression of necrotizing fasciitis may be astonishingly rapid, even with vigorous antibiotic and surgical therapy. When the process is located centrally, in the perineal-gluteal area, the mortality rate is often as high as 50 percent. Infection of an extremity is often treated by antibiotics, drainage, and debridement, or by amputation, with more favorable results. The course is often prolonged and complex because of metabolic and nutritional complications. [69]

Treatment

Immediate antibiotic therapy and surgical drainage, guided by Gram-stained smears of the exudate and determinations of the extent of the process, are essential. Extensive debridement is usually unnecessary, and hyperbaric oxygen is not indicated in cellulitis or necrotizing fasciitis. Judgment and experience are vital in surgical decisions that include the question of amputation. The existence of a “feeding” source of contamination should be sought, especially with perineal or thigh involvement (e.g., from a ruptured appendix, diverticulum, or rectal tear). If a lower bowel leak is found, a diverting colostomy should be performed in addition to a local drainage procedure. Decubitus ulcers must be carefully evaluated for undermining necrosis, abscess formation, and cellulitis, because they may be the source of septicemias, including polymicrobial types.

Recent antibiotic usage, status of renal and hepatic function, and prior hospital exposure are factors that will help

determine the choice of antibiotics. Hospitalized patients already exposed to antibiotics and acutely ill should receive a combination of antimicrobials that includes an aminoglycoside if the presence of enteric gram-negative organisms is suspected. Crepitant cellulitis with foul exudate suggesting *B. fragilis* should be treated with metronidazole, clindamycin, or chloramphenicol. Selected second- or third-generation cephalosporins or fluoroquinolones can substitute for aminoglycosides in patients with severe renal impairment. If *P. aeruginosa, Klebsiella,* or *Serratia* is suspected in certain hospital-acquired infections, tobramycin or amikacin may be preferred to gentamicin and a broad-spectrum penicillin added if *Pseudomonas* is a major pathogen. The presence of gram-positive cocci on initial stained smears indicates the need for penicillin or ampicillin (for chaining streptococci) or nafcillin (for clusters of staphylococci). If resistant enterococci or methicillin-resistant staphylococci are suspected, then vancomycin is the drug of choice for either chaining or clustering gram-positive cocci.

REFERENCES

1. Hackett SJ et al: Cytokines, chemokines and other effector molecules involved in meningococcal disease. *J Med Microbiol* **50**:847, 2001

2. Kingston ME, Mackey D: Skin clues in the diagnosis of life-threatening infections. *Rev Infect Dis* **8**:1, 1986

3. Van Deuren M et al: Update on meningococcal disease with emphasis on pathogenesis and clinical management. *Clin Microbiol Rev* **13**:144, 2000

4. Rosenstein NE et al: Meningococcal disease. *N Engl J Med* **344**:1378, 2001

5. Swartley JS et al: Capsule switching of *Neisseria meningitidis. Proc Natl Acad Sci U S A* **94**:271, 1997

6. Deitsch K W et al: Shared themes of antigenic variation and virulence in bacterial, protozoal and fungal infections. *Microbiol Mol Biol Rev* **61**:281, 1997

7. Figueroa JF et al: Infectious diseases associated with complement deficiencies. *Clin Microbiol Rev* **4**:359, 1991

8. Sotto MN et al: Pathogenesis of cutaneous lesions in acute meningococcemia in humans: Light, immunofluorescent, and electron microscopic studies of skin biopsy specimens. *J Infect Dis* **133**:506, 1976

9. Van Deuran M et al: Rapid diagnosis of acute meningococcal infections by needle aspiration or biopsy of skin lesions. *BMJ* **306**:1229, 1993

10. Argenbright LW, Barton RW: Interactions of leukocyte integrins with intercellular adhesion molecule in the production of inflammatory vascular injury in vivo. *J Clin Invest* **89**:259, 1992

11. Ploysangam T, Sheth AP: Chronic meningococcemia in childhood: Case report and review of the literature. *Pediatr Dermatol* **13**:483, 1996

12. Farron F et al: A chronic meningococcemia and IgA deficiency in an adolescent. *Arch Pediatr* **3**:149, 1996

13. Zangwill KM et al: School-based clusters of meningococcal disease in the United States. *JAMA* **277**:389, 1997

14. Harrison LH et al: Risk of meningococcal infection in college students. *JAMA* **281**:1906, 1999

15. Munford RS et al: Spread of meningococcal infection within households. *Lancet* **2**:1275, 1974

16. CDC: Prevention and control of meningococcal disease and meningococcal disease in college students. *MMWR Morb Mortal Wkly Rep* **49**:RR-7, 2000

17. Salit IE et al: Seroepidemiologic aspects of *Neisseria meningitidis* in homosexual men. *Can Med Assoc J* **126**:38, 1982

18. Goldschneider I et al: Human immunity to the meningococcus: II. Development of natural immunity. *J Exp Med* **129**:1327, 1969

19. Wenger JD: Serogroup B meningococcal disease. *JAMA* **281**:1541, 1999

20. Feldman HA: Meningococcal infections. *Adv Intern Med* **18**:177, 1972

21. Koppes GM et al: Group Y meningococcal disease in United States Air Force recruits. *Am J Med* **62**:661, 1977

22. Rompalo AM et al: The acute arthritis-dermatitis syndrome. *Arch Intern Med* **147**:281, 1987

23. Periappuram M et al: Rapid detection of meningococci from petechiae in acute meningococcal infection. *J Infect* **31**:201, 1995

24. Perkins MD et al: Rapid bacterial antigen detection is not clinically useful. *J Clin Microbiol* **33**:1486, 1995

25. Barquet N et al: Prognostic factors in meningococcal disease. *JAMA* **278**:491, 1997

26. Benoit FL: Chronic meningococcemia. *Am J Med* **35**:103, 1963

27. Barquet N et al: Primary meningococcal conjunctivitis: Report of 21 patients and review. *Rev Infect Dis* **12**:838, 1990

28. Porras MC et al: Acute cellulitis: An unusual manifestation of meningococcal disease. *Scand J Infect Dis* **33**:56, 2001

29. Alberio L et al: Protein C replacement in severe meningococcemia: Rationale and clinical experience. *Clin Infect Dis* **32**:1338, 2001

30. Vincent J-L et al: Clinical trials of immunomodulatory therapies in severe sepsis and septic shock. *Clin Infect Dis* **34**:1084, 2002

31. Stephens DS: Uncloaking the meningococcus: Dynamics of carriage and disease. *Lancet* **353**:941, 1999

32. Darouiche R et al: Levels of rifampin and ciprofloxacin in nasal secretions: Correlation with MIC90 and eradication of nasopharyngeal carriage of bacteria. *J Infect Dis* **162**:1124, 1990

33. Agger WA, Mardan A: *Pseudomonas aeruginosa* infections of intact skin. *Clin Infect Dis* **20**:302, 1995

34. Berger TG et al: Cutaneous manifestations of *Pseudomonas* infections in AIDS. *J Am Acad Dermatol* **32**:279, 1995

35. Liu PV: Extracellular toxins of *Pseudomonas aeruginosa. J Infect Dis* **130** (suppl):S94, 1974

36. Bishop MB et al: The effect of *Pseudomonas aeruginosa* cytotoxin and toxin A on human polymorphonuclear leukocytes. *J Med Microbiol* **24**:315, 1987

37. Pollack M: *Pseudomonas aeruginosa,* in *Principles and Practice of Infectious Diseases,* 5th ed, edited by GL Mandell, JE Bennett, R. Dolin. New York, Wiley, 2000, p 2310

38. Holder IA: *Pseudomonas* vaccination and immunotherapy. *J Burn Care Rehabil* **22**:311, 2001

39. Noble WC: Gram-negative bacterial skin infections. *Semin Dermatol* **12**:336, 1993

40. Fiorillo L et al: The *Pseudomonas* hot-foot syndrome. *N Engl J Med* **345**:335, 2001

41. Bassiouny A: Perichondritis of the auricle. *Laryngoscope* **91**:422, 1981

42. Kielhofner M et al: Life-threatening *Pseudomonas aeruginosa* infections in patients with human immunodeficiency virus infection. *Clin Infect Dis* **14**:403, 1992

43. Ruskin J, Yu VL: Malignant external otitis: Insights into pathogenesis, clinical manifestations, diagnosis and therapy. *Am J Med* **85**:391, 1988

44. Silvestre JF, Betlloch MI: Cutaneous manifestations due to *Pseudomonas* infection. *Int J Dermatol* **38**:419, 1999

45. El Baez P et al: *Pseudomonas aeruginosa* 0-11 folliculitis: Development into ecthyma gangrenosum in immunosuppressed patients. *Arch Dermatol* **121**:873, 1985

46. Giamarellou H: Malignant otitis externa: The therapeutic evolution of a lethal infection. *J Antimicrob Chemother* **30**:745, 1992

47. Yeung CK, Lee KH: Community acquired fulminant *Pseudomonas* infection of the gastrointestinal tract in previously healthy infants. *J Paediatr Child Health* **34**:584, 1998

48. Bodey GP: Dermatologic manifestations of infections in neutropenic patients. *Infect Dis Clin North Am* **8**:655, 1994

49. Campo RE et al: Subcutaneous nodules as a dermatologic manifestation of bacteremia due to *Pseudomonas aeruginosa. South Med J* **87**:233, 1994

50. Teplitz C: Pathogenesis of *Pseudomonas* vasculitis and septic lesions. *Arch Pathol* **80**:297, 1965

51. Sloss JM et al: Acetic acid used for the elimination of *Pseudomonas aeruginosa* from burn and soft tissue wounds. *J Army Med Corps* **139**:49, 1993

52. Chen S et al: Cellulitis due to *Pseudomonas putrefaciens:* Possible production of exotoxins. *Rev Infect Dis* **13**:642, 1991

53. Peltola H: Worldwide *Haemophilus influenzae* type b disease at the beginning of the 21st century: Global analysis of the disease burden 25 years after the use of the polysaccharide vaccine and a decade after the advent of conjugates. *Clin Microbiol Rev* **13**:302, 2000

54. CDC: Progress toward elimination of *Haemophilus influenzae* type b invasive disease among infants and children—United States, 1998–2000. *MMWR* **51**:234, 2002

55. McDonnell WM et al: *Haemophilus influenzae* type B cellulitis in adults. *Am J Med* **81**:709, 1986

56. Chartrand S, Harrison C: Buccal cellulitis reevaluated. *Am J Dis Child* **140**:891, 1986

57. Miller SI, Peques DA: *Salmonella* species including *Salmonella typhi,* in *Principles and Practical Infectious Diseases,* 5th ed, edited by GL Mandell, JE Bennett, R. Dolin. New York, Wiley, 2000, p 2344.

58. Gilman RH et al: Relative efficacy of blood, urine, rectal swab, bone-marrow, and rose-spot cultures for recovery of *Salmonella typhi* in typhoid fever. *Lancet* **1**:1211, 1975

59. Lalitha MK, John R: Unusual manifestations of salmonellosis: A surgical problem. *QJM* **87**:301, 1994

60. Karthikeyan G, Mahadevan S: Cutaneous ulcers in typhoid fever. *J Trop Med Hyg* **97**:298, 1994

61. Guerera-Caceres JG et al: Diagnostic value of bone marrow culture in typhoid fever. *Trans R Soc Trop Med Hyg* **73**:680, 1979

62. Chaudhrey R et al: Standardization of polymerase chain reaction for the detection of *Salmonella* typhi in typhoid fever. *J Clin Pathol* **50**:437, 1997

63. Litwack KD et al: Rose spots in typhoid fever. *Arch Dermatol* **105**:252, 1972

64. Rowe B et al: Multidrug-resistant *Salmonella typhi:* A worldwide epidemic. *Clin Infect Dis* **24**:S106, 1997

65. McGowan JE Jr et al: Guidelines for the use of systemic glucocorticoids in the management of selected infections. *J Infect Dis* **165**:1, 1992

66. Henriksen BM et al: Soft tissue infections from drug use: A clinical and microbiological review of 145 cases. *Acta Orthop Scand* **65**:625, 1994

67. Rubenstein E et al: Severe necrotizing soft-tissue infections: Report of 22 cases. *Conn Med* **59**:67, 1995

68. Brook I, Frazier EH: Clinical features and aerobic and anaerobic microbiological characteristics of cellulitis. *Arch Surg* **130**:786, 1995

69. Heinzelmann M et al: Factors predisposing to bacterial invasion and infection. *Am J Surg* **183**:179, 2002

70. Agger WA et al: Wounds caused by corn-harvesting machines: An unusual source of infection due to gram-negative bacilli. *Rev Infect Dis* **8**:927, 1986

71. Nichols RL, Florman S: Clinical presentations of soft-tissue infections and surgical site infections *Clin Infect Dis* **33** (suppl 2): S84, 2001

72. Goldstein EJ et al: Infections caused by *Klebsiella ozaenae:* A changing disease spectrum. *J Clin Microbiol* **8**:413, 1978

73. Adraca R et al: Rhinoscleroma: A growing concern in the United States? Mayo Clinic Experience. *Mayo Clinic Proc* **68**:1151, 1993

74. Paul C et al: Infection due to *Klebsiella rhinoscleromatis* in two patients infected with human immunodeficiency virus. *Clin Infect Dis* **16**:441, 1993

75. Borgstein J et al: Ciprofloxacin for rhinoscleroma and ozena. *Lancet* **342**:122, 1993

76. Saiag P et al: Magnetic resonance imaging in adults presenting with severe acute infectious cellulitis. *Arch Dermatol* **130**:1150, 1994

T>

Chapter 198

Timothy Berger Francisco Bravo

Bartonellosis

MICROBIOLOGY
CAT-SCRATCH DISEASE
Epidemiology
Clinical Manifestations
Laboratory Findings
Pathology
Diagnosis/Differential Diagnosis
Treatment
TRENCH FEVER, URBAN TRENCH FEVER, AND BACTEREMIA/ENDOCARDITIS
Treatment
BARTONELLA INFECTION IN THE IMMUNOSUPPRESSED (BACILLARY ANGIOMATOSIS; PELIOSIS OF THE LIVER AND SPLEEN)
Epidemiology
Clinical Manifestations
Laboratory Findings
Pathology
Diagnosis/Differential Diagnosis
Treatment
OROYA FEVER AND VERRUGA PERUANA
Epidemiology
Clinical Manifestations
Laboratory Findings
Pathology
Diagnosis/Differential Diagnosis
Treatment

REFERENCES

Bartonella are aerobic, fastidious, gram-negative bacilli, with the remarkable capacity for intracellular persistence and the production of bacteremia. The number of identified *Bartonella* species has been rapidly expanding. The genus includes three important species: *B. henselae,* the cause of most cases of cat-scratch disease (CSD) as well as some cases of bacillary angiomatosis (BA) peliosis, and endocarditis; *B. quintana* the cause of trench fever, urban trench fever, BA, and endocarditis; and *B. bacilliformis,* the cause of Oroya fever and verruga peruana. Other potential human pathogens are *B. clarridgeiae,* a cause of CSD, *B. elizabethae* and *vinsonii,* which causes endocarditis, and *B. grahamii,* a cause of neuroretinitis (Table 198-1). Infections caused by most Bartonella are associated with arthropod vectors. Asymptomatic bacteremia rates in primary vertebrate (reservoir) hosts may exceed 50 percent. This suggests high prevalence of infection and prolonged and persistent bacteremia as characteristics of Bartonella infection.



TABLE 198-1 **Diseases Caused by** *Bartonella*

MICROBIOLOGY

The genus *Bartonella* contains organisms previously in the genuses *Rochalimaea* and *Grahamella*. *Bartonella* organisms are small aerobic, fastidious, pleomorphic, gram-negative bacteria; they are difficult to culture from clinical samples. This difficulty stems in part from their slow growth rate and complex nutritional requirements. Initial clinical isolates grow slowly and visible colonies may not be detected for weeks, but subsequent passages grow much more rapidly. [1] The organisms are short rods, ranging from 0.3 to 0.5 micrometers wide by 1.0 to 1.7 micrometers long. [1] The organisms stain poorly with Gram's stain, and are best visualized in tissue using modified silver stains (Warthin-Starry).

CAT-SCRATCH DISEASE

CSD is a relatively common, benign, self-limited disease caused by *B. henselae*. It is the most common cause of localized chronic lymphadenopathy in children and young adults. [2] The disease is usually transmitted by the bite or scratch of a cat or kitten, although it has rarely been associated with other pets. CSD was originally reported by Robert Debré in 1931. An infectious etiology was long suspected, but it was not until 1983 that Wear and his colleagues, by using Warthin-Starry staining, identified bacteria in 34 of 39 lymph nodes from patients with CSD. Bacilli were also identified in primary cutaneous and ocular lesions of CSD. Significant titers of antibodies against *B. henselae* are found in 90 to 95 percent of cases that meet the clinical definition of CSD. [3] By using polymerase chain reaction (PCR)

analyses, *B. henselae* DNA sequences can be identified in 30 percent of lymph node specimens from CSD patients and in CSD skin test antigens. [4], [5] and [6]) *B. henselae* causes the overwhelming majority (>95 percent) of cases of CSD. In the United States there appears to be only one infectious genotype of *B. henselae,* but in Europe there are two. This is analogous to the differences in *Borrelia* genotypes in the different continents, although, unlike *Borrelia,* no differences in the clinical manifestations have been identified in cases of CSD in the United States and Europe. *B. clarridgeiae* is also a potential cause of CSD, but the importance of this organism worldwide is unknown. [7] *B. quintana* has been isolated in Europe from two cases of chronic lymphadenopathy following cat exposure.

Epidemiology

Approximately 29.2 million (31 percent) households in the United States own a cat, averaging close to two cats per household, for a total household cat population of 57 million. [8] Given the large population of domestic cats, more than 22,000 cases of CSD are reported. [9] Significant health care dollars are spent in diagnostic work-up of these patients.

CSD affects persons of all ages, although 60 to 90 percent of cases are reported in children and young adults. CSD is seen worldwide and does not appear to have a racial prevalence. Most patients with CSD recall a history of cat contact, but this is not absolute (90.3 to 99.1 percent). The incidence of CSD is slightly higher in males and it occurs seasonally, mostly in the second half of the year.

CSD is associated with exposure to a cat, usually a flea-infested pet cat, and frequently a kitten 12 months old or younger. The method of spread from the cat is usually a scratch or bite. In California, 39.5 percent of cats are bacteremic for *B. henselae* with a single sampling, indicating a very high infection rate. Bacteremic cats were more likely to be stray cats, young (less than 1 year old), and flea-infested. [10] The seroprevalence of *B. henselae* among pet cats is highly variable throughout regions of North America (overall, 27.9 percent positive); a higher seroprevalence is associated with increasing climatic warmth and annual precipitation. [11] When the geographic seroprevalence of *B. henselae* is compared with predicted estimates of cat flea populations based on temperature and humidity, there is considerable overlap, supporting the role of the cat flea (*Ctenocephalides felis*) as the arthropod vector maintaining infection in cats. *B. henselae* can be transmitted from cat to cat via the cat flea; cat fleas contain *Bartonella* organisms after feeding on infected cats; cat flea feces contains viable *Bartonella;* and cats can be experimentally infected by the intradermal injection of infected cat flea feces. [12] The cat flea has not been demonstrated to spread *Bartonella* infection from cats to humans.

Clinical Manifestations

The clinical spectrum of CSD has expanded since serologic diagnosis became possible. Typical CSD exhibits two components, the primary inoculation papule and adenopathy proximal to the inoculation site. The papule appears at the site of inoculation within 3 to 10 days of exposure and progresses through an edematous (vesicular) and crusted stage. The primary inoculation papule lasts 1 to 3 weeks. The lymphadenopathy, seen in at least 90 percent of patients, develops on average 2 weeks following inoculation (range 3 to 50 days) (Fig. 198-1). [13] The inoculation papule is still present in 60 to 90 percent when the adenopathy develops, making it a valuable diagnostic finding. [14] The most commonly affected lymph nodes are axillary, cervical, and submandibular, with 98 percent of patients having involvement of only one anatomic region. The nodes are generally firm, tender and between 1 and 5 cm in diameter. The lymphadenopathy usually remits spontaneously after several months, although in 20 percent of cases, the adenopathy lasts longer than 6 months. Recurrences are uncommon.

FIGURE 198-1 Cat-scratch disease. Primary lesion adjacent to mouth with associated submandibular lymphadenopathy in a woman.

Suppuration of clinical significance occurs in less than 10 percent of cases, but when affected nodes are followed with ultrasonography, suppuration is found to be the natural course of resorption of affected nodes in nearly all cases. [14] Surgical drainage is seldom necessary.

With improved diagnosis, atypical cases of CSD have increased from fewer than 5 percent of cases to more than 30 percent of cases in some series. [15] In one pediatric series, atypical mononucleosis with pharyngitis and bilateral cervical adenopathy and thrombocytosis was a common presentation of *B. henselae* infection. [16] Fever of unknown origin with or without endocarditis, hepatic and splenic granulomatosis, and massive lymph node enlargement resembling lymphoma may also occur. [15] Involvement of the terminal ileum may mimic inflammatory bowel disease; and intraabdominal lymphadenopathy may obstruct the portal vein. [17], [18] *B. henselae* infection may also be the most common cause of neuroretinitis and focal retinochoroiditis. [19], [20] The most common neurologic complication of CSD is acute encephalopathy, presenting with seizures in 66 percent and status epilepticus in 10 percent of patients. [21], [22]

In one study, up to 20 percent of immunocompetent patients with serologically confirmed CSD had PCR positivity for *B. henselae* in peripheral blood, suggesting bacteremia may be common. [23] Not surprisingly, hematogenous dissemination of *B. henselae* complicating CSD in immunocompetent persons has been reported to affect bone (osteomyelitis), liver and spleen, lungs (pneumonia, pleural effusion, pulmonary nodules), and the optic nerve. [2], [24], [25], [26] and [27] These lesions may be markedly symptomatic, or, in one case of pulmonary involvement, completely asymptomatic. [24] *B. henselae,* which may cause endocarditis in persons with known valvular heart disease, usually affects the aortic valve, and 90 percent of patients require valvular surgery as a consequence of severe damage. [28] Erythema nodosum may be triggered by CSD. [15] One patient with CSD developed erythematous papules and plaques of the anterior chest, resembling Sweet's syndrome clinically, but a dermal infiltrate of lymphocytes, plasma cells, and eosinophils histologically. The eruption responded to systemic steroids without any adverse outcome. [29]

Laboratory Findings

Routine laboratory findings are nonspecific and usually not helpful except to exclude other diseases. Patients with CSD may have a slightly elevated white blood cell (WBC) count and elevated erythrocyte sedimentation rate during the acute phase. Blood cultures are rarely positive when using current testing techniques. PCR of affected lymph nodes may be positive in 30 percent of cases. Between 80 and 90 percent of cases of CSD will have positive serology for *B. henselae* at the time of presentation, and many of the seronegative cases will be positive 2 to 8 weeks later. Serologic testing has replaced the CSD skin test as the confirmatory test of choice in cases of CSD. Cases of CSD caused by *B. clarridgeiae* are often negative on serologic tests used to detect other *Bartonella* species. [7]

Pathology

Histopathologic examination of CSD lymph node lesions is not specific. Lymph nodes undergo three stages in the formation of a granuloma: (1) enlargement with hypertrophy of the germinal centers and thickening of the cortex; (2) formation of granulomas with invasion of lymphocytes and epithelioid cells; and (3) necrosis and infiltration with neutrophils—all of which may be simultaneously present within a single lymph node. [30] Abscess formation may occur. Organisms can be detected in lymph nodes and primary skin lesions, often in clumps or filaments, in or adjacent to areas of necrosis.

In primary skin lesions, microscopic examination reveals necrosis of the epidermis and upper dermis, and dermal inflammation ranging from neutrophil and macrophage infiltration to granuloma formation. Conjunctival lesions have similar histologic findings. In a few cases, conjunctival lesions produce proliferating blood vessels and a homogenous eosinophilic to basophilic granular appearance in the background—features similar to those of bacillary angiomatosis.

Diagnosis/Differential Diagnosis

The diagnosis of CSD is presumptive if there are characteristic clinical findings and history of a cat scratch or bite. A primary inoculation papule increases the likelihood of the diagnosis, and in typical cases may be adequate. The diagnosis is confirmed if acute or convalescent serology is positive for a *Bartonella* species known to cause CSD.

The differential diagnosis of typical CSD includes other causes of unilateral or regional lymphadenopathy: other pyogenic infections, tularemia, atypical mycobacteria, and lymphoma.

Treatment

Virtually all cases of CSD remit spontaneously without therapeutic intervention. In a retrospective study of 202 patients with CSD who were treated with antibiotics, [9] commonly prescribed antibiotics, including macrolides, tetracycline derivatives, and cephalosporins, were ineffective. [28] However, antibiotic susceptibility studies have shown that *B. henselae* is highly sensitive to macrolides, tetracycline derivatives, and second- and third-generation cephalosporins, and is variably sensitive to quinolones. The failure of antibiotics in classic CSD in the immunocompetent host may relate to the small infectious burden and the frequent initiation of therapy once the disease is already improving spontaneously (in its lymphatic phase). In a recent prospective randomized trial, azithromycin for 5 days was demonstrated to reduce the lymph node volume during the first 30 days of observation. Half of azithromycin-treated patients reached 20 percent of baseline lymph node volume by 1 month, as opposed to 7 percent of untreated patients. However, there was no difference in any other symptoms or findings, or in the long term outcome, and some treated patients had increases in lymph node size after treatment. [14]

TRENCH FEVER, URBAN TRENCH FEVER, AND BACTEREMIA/ENDOCARDITIS

B. quintana is the etiologic agent of trench fever, a disease that affected more than 1 million troops of the German and Allied armies during World War I. [31] This disease is characterized by a fever lasting about a week, followed by recurrent fevers every 4 to 8 days, most commonly every 5 days (quintana fever). Clinically, patients complain of severe headaches and neck, back, and shin pain (shin bone fever). [32] There are no specific cutaneous manifestations. Although significant morbidity is associated with the disease, fatalities are rare. Trench fever is caused by *B. quintana*. As opposed to most other *Bartonella* species, humans are the only known reservoir for this organism. The disease is transmitted from human to human by the human body louse (*Pediculus humanus corporis*). Close body contact and unsanitary conditions are associated with outbreaks. The incubation period ranges from 5 to 20 days. The organism can be isolated from patients with the disease and can be transmitted from person to person by direct inoculation or through lice. Recovered patients may be bacteremic for weeks. [31]

Recently, *B. quintana* caused bacteremia and endocarditis in the United States and France (urban trench fever). [28], [31], [33]

Virtually all of the patients are HIV-negative, homeless, alcoholic men. Moreover, in cities where urban trench fever has been described, from 15 to 50 percent of the indigent alcoholic inner-city male population has serologic evidence of infection with *B. quintana*. [34], [35] Patients present with fever, weight loss, and endocarditis. Classic "trench fever" shin pain is uncommon. Endocarditis occurs in patients without a known history of previous valvular disease, and surgery is required in more than 95 percent of patients. [28] The diagnosis is usually made by blood culture, which is >90 percent positive if done specifically to isolate *Bartonella,* and before any antibiotic therapy. After even a single dose of antibiotics, blood cultures are usually negative. [4] All patients are serologically negative at presentation but become positive after several weeks, making this a useful delayed confirmatory test, but of no value in the acute setting. [4]

Treatment

For uncomplicated bacteremia, 4 to 6 weeks of doxycycline 100 mg bid, erythromycin 500 mg qid, or azithromycin 500 mg qd is recommended. For endocarditis, 4 to 6 months of therapy is required, often in combination with valve replacement.

BARTONELLA INFECTION IN THE IMMUNOSUPPRESSED (BACILLARY ANGIOMATOSIS; PELIOSIS OF THE LIVER AND SPLEEN)

BA was originally reported in 1983 by Stoler, who described a patient with AIDS and multiple angioproliferative nodules that resolved with erythromycin. [36] Histologic examination by using Warthin-Starry staining revealed small bacillary forms that were confirmed by electron microscopy. In the following year, two groups reported similarities between the organisms seen in BA and CSD and proposed that they may be caused by the same bacteria. [37], [38] In 1990, Perkocha et al. described eight patients with AIDS with bacillary peliosis (BP) hepatitis, large, blood-filled cysts in the liver that contained clumps of bacteria identical to those seen in BA. [39] Some patients had skin and liver/spleen involvement simultaneously. Both *B. henselae* (the CSD bacillus) and *B. quintana* (the agent of trench fever) have been identified as causative agents of BA and BP. [40], [41], [42] and [43])

B. henselae causes both CSD and BA. At one end of the clinical spectrum, classic CSD is seen in young, immunocompetent hosts. At the other end, BA is seen in patients who are severely immunocompromised. Thus, it is the immunocompetence of the host and the bacterial load that dictates the clinical manifestations of the disease. Immunocompetent hosts are able to mount a significant immune response, kill the vast majority of the bacteria, and contain the infection (CSD). Immunocompromised hosts are unable to control the infection and a systemic disease occurs. Moreover, immunocompromised patients with BA develop an angioproliferative response (BA, BP), probably because of an angiogenic factor produced by the bacteria.

Epidemiology

Bacillary angiomatosis is most commonly seen in patients with advanced AIDS and a CD4 count less than 50 cells/mm ^{3}, with an incidence of 1.2 cases per 1000 at-risk patients. [44] Other immunosuppressed patients with BA, including patients with leukemia and recipients of organ transplants, have been reported. [45], [46] and [47]) Several patients with BA who were HIV-negative and nonimmunosuppressed have been reported. [48] In the cases of BA in immunocompetent persons, however, although the lesions were proliferative vascular papules, they were limited in number, had limited or no systemic involvement, and followed a benign course. There is no risk factor predisposition in terms of race, sex, or age. BA is not limited to adults. [45], [49] BA caused by *B. henselae* is acquired from infected cats and is a manifestation of CSD in the immunocompromised host. Peliosis hepatitis is exclusively associated with *B. henselae* infection. [50] In contrast, patients with BA caused by *B. quintana* develop subcutaneous masses and lytic bone lesions. [51], [52] *B. quintana* infection in the immunosuppressed patient is also associated with low income, homelessness, and exposure to body lice. [44]

Clinical Manifestations

The incubation period for BA is unknown. The clinical constellation of BA in AIDS patients include fever, a low CD4 lymphocyte count (usually less than 50 cells/mm ^{3}, cutaneous or subcutaneous vascular lesions, lymphadenopathy, and/or abdominal symptoms. [52] The most common cutaneous morphologies of BA are (1) pyogenic granuloma like lesions (Fig. 198-2), (2) subcutaneous nodules, and (3) hyperpigmented indurated plaques. The same patient may have several morphologies. Lesions resembling pyogenic granuloma can range in size from 1 mm to several centimeters and are dusky-red in color with a collarette of scale and peripheral satellite lesions (Fig. 198-2). The lesions are firm, bleed easily, and are often tender, occurring in skin and mucosa. Subcutaneous nodules can range from distinct nodules to diffuse swellings with or without induration and are also often tender. Hyperpigmented plaques are most commonly seen in African Americans with BA and are oval in shape; they are several centimeters in diameter with indistinct borders. Large, fungating masses rarely occur. [53] Patients with BA may have few to thousands of lesions with the number of lesions gradually increasing over time. Additional immunosuppression with chemotherapeutic agents may be followed by a shower of miliary skin lesions.

FIGURE 198-2 Bacillary angiomatosis. Multiple grouped dusky-red and violaceous papules and nodules that resemble pyogenic granulomas.

In addition to cutaneous lesions, other organ systems may be affected. Hepatic (BP) and splenic lesions can occur concomitantly with or independently of cutaneous lesions. [39] BP can be a cause of significant blood loss and anemia. *Bartonella* infection, especially that caused by *B. quintana,* can affect bone and soft tissues. [41], [54] Lesions of the central nervous system have been reported and can result in neurologic and psychiatric disorders. [55], [56] Bacteremia, chronic fevers, and pulmonary and gastrointestinal lesions have also been reported. [57], [58] Radiologic findings usually identify areas of systemic involvement. [59]

There are several reports of patients with other cutaneous diseases concomitant with BA, as well as the simultaneous existence of BA and another disease within the same lesion. Several patients have been reported with both BA and Kaposi sarcoma. [60] Cytomegalovirus, Epstein-Barr virus, *Cryptococcus neoformans,* and *Mycobacterium avium-intracellulare* have been found within lesions of BA. [61], [62], [63] and [64]) This emphasizes the importance of looking for multiple pathologic infectious processes in patients with advanced HIV disease.

Laboratory Findings

In patients with AIDS and BA, the CD4 T helper cell count is <200/m ^{3} and usually <50/mm ^{3}. Patients are anemic and may have elevated liver function tests [characteristically, lactic acid dehydrogenase (LDH) and alkaline phosphatase are more elevated than hepatocellular enzymes]. Blood cultures are positive for *Bartonella* species in about half of BA patients. [52]

Pathology

Lesions of BA have the general features of a lobular capillary hemangioma (=pyogenic granuloma) (Fig. 198-3A), but in contrast to a pyogenic granuloma, the endothelial cells are often larger and polygonal; they may have marked atypia. There is a prominent inflammatory infiltrate, with significant numbers of neutrophils as well as leukocytoclastic debris (Fig. 198-3B). Polymorphonuclear leukocytes (PMNs) are scattered throughout the lesion, as opposed to classical pyogenic granuloma lesions in which the PMNs are at or near the surface, even if the pyogenic granuloma is eroded and impetiginized. There is usually a finely granular, pink to purple material in areas of PMN infiltration adjacent to blood vessels (Fig. 198-3B). This represents large clumps of bacteria, best visualized with a modified Warthin-Starry stain (Fig. 198-3C). Standard tissue Gram's stain and the Warthin-Starry stain used for syphilis will not stain the organisms. If the diagnosis cannot be confirmed with special stains, electron microscopy may be used. The lack of spindle cells, atypically shaped vascular channels, and hyaline globules distinguish BA from Kaposi sarcoma. Lesions of BA in tissues other than liver show similar histologic features.

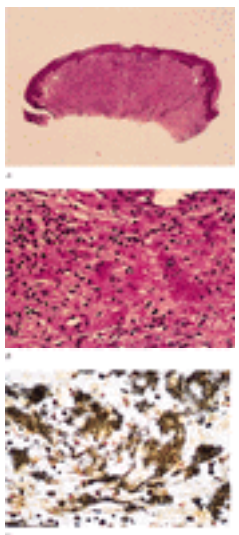

FIGURE 198-3 Histology of bacillary angiomatosis. *A*. Low-power magnification showing the architectural features of a lobular capillary hemangioma. *B*. High-power magnification showing new capillary formation and endothelial cells with cytological atypia, a prominent inflammatory infiltrate, and leukocytoclastic debris. *C*. Warthin-Starry stain showing numerous pleomorphic bacteria. (*Courtesy of P. LeBoit, MD.*)

Diagnosis/Differential Diagnosis

Because BA often resembles pyogenic granuloma, solitary lesions must be differentiated from nodular Kaposi sarcoma and pyogenic granuloma. Ulcerative BA lesions have a broad clinical differential diagnosis including pyoderma, atypical mycobacteria, *Acanthamoeba,* viral, and deep fungal infections. Clinically, widespread lesions may be indistinguishable from disseminated pyogenic granuloma or verruga peruana (see below), which can be excluded by travel history. Prior to the discovery of HIV, there were several cases of disseminated pyogenic granuloma associated with immunodeficiency; these cases may have been BA. [65], [66]

The diagnosis can usually be made histologically. *B. henselae* and *B. quintana* can be cultured from skin lesions and commonly from the blood of BA patients. The organisms grow slowly and may not be detected without prolonged culture (>1 month). PCR of affected tissue is virtually always positive if lesions are histologically characteristic and PCR is done

prior to antibiotic therapy.

Treatment

Erythromycin 500 mg four times a day or doxycycline 100 mg twice a day are the treatments of choice for BA. Other antibiotics thought to be effective are minocycline, tetracycline, chloramphenicol, azithromycin, and roxithromycin. [67] The treatment duration is unknown but should be at least 8 weeks for patients with skin lesions only and perhaps 6 months in patients with visceral infections (liver, spleen, bone). Some patients require lifelong suppressive therapy. Relapses have been reported, especially with shorter treatment courses. [50] A Jarisch-Herxheimer reaction not uncommonly occurs after initiation of therapy. Untreated BA is a fatal disease. Most patients respond rapidly to antibiotic therapy.

OROYA FEVER AND VERRUGA PERUANA

Oroya fever (also known as Carrión's disease) and verruga peruana are endemic diseases localized to Peru, Ecuador, and Colombia. The earliest recorded cases date back more than four centuries, and verruga peruana has been identified in a mummy from southern Peru. [68], [69] The disease was named after Daniel Carrión, who, as a Peruvian medical student in 1885, inoculated himself with a lesion of verruga peruana and died of the acute phase of Oroya fever, showing that both diseases are caused by the same agent. The causative organism of these diseases is *B. bacilliformis*. The arthropod vector is most commonly a sandfly, the main vector being *Lutzomyia verrucarum*.

Epidemiology

Oroya fever and verruga peruana are restricted to the South American Andes, from 2°5' latitude north to 13° south of the equator, including southern Colombia, parts of Ecuador, and Peru. [70], [71] and [72]) Seroprevalence may approach 75 percent in endemic areas, which suggests that many patients have milder disease that goes unrecognized. [72] Most cases have been reported in regions of altitude ranging from 500 to 3200 m above sea level. Recent epidemics have been reported in previously nonendemic areas of Peru, suggesting the endemic area is expanding to lower areas near the Amazon basin. Humans are the only known reservoir for *B. bacilliformis,* although verruga peruana lesions have been found in dogs, cows, mules, and chickens, and can be induced in rhesus monkeys.

Clinical Manifestations

After an incubation period between 10 and 210 days (average, 61 days), the acute stage develops, in which patients have severe fevers, headache, malaise, and a profound paleness. Other signs of hemolysis may also be present. Patients may develop signs of neurologic involvement, including coma. During the acute state, the patients are extremely susceptible to superinfection, either bacterial (*Salmonella*) or parasitic (*Toxoplasma*). Many patients will present with the eruptive lesions of verruga peruana having had no preceding acute phase. [72] The eruptive stage of verruga peruana is characterized by the appearance of red angiomatous lesions, identical to BA (Fig. 198-4). Three patterns of cutaneous lesions have been described: miliary, nodular, and mular. In the miliary form, lesions are about 3 mm in diameter (Fig. 198-4). Mular lesions are larger, fewer in number, and either sessile or pedunculated, with a superficial erosion. Nodular lesions are deeper dermal papules and nodules, and may not have overlying erythema. Mucosal lesions may be seen.

FIGURE 198-4 Bartonellosis (verruga peruana). Multiple small papules on the extremities. The lesions may ulcerate.

Laboratory Findings

During the acute hemolytic phase, a profound anemia may be present. Red blood cell (RBC) counts can reach levels below 106/mm ^{3} (two-thirds of patients have a hematocrit below 20). Oroya fever is one of the few bacterial diseases in which the agent can actually be seen on peripheral smears. Although initially the finding of bacteria within circulating RBCs was felt to be useful in confirming the diagnosis, in recent outbreaks, only one-third of patients had positive smears. It is the intracellular presence of bacteria that is thought to induce hemolysis by the liver and spleen.

Pathology

Lesions of verruga peruana are histologically identical to those of bacillary angiomatosis, showing the distinct angioproliferative pattern with areas of neutrophilic collection within the stroma. [71] The location of the proliferation varies

with the type of lesion; thus, in miliary lesions, it is in the papillary and superficial reticular dermis, and in nodular and mular lesions, it is in the deeper dermis. Old verrugas tend to lose the inflammatory component, retaining the vascular frame. At that point the lesion may look very similar to a pyogenic granuloma. In contrast to BA, the purple bodies of bacteria are hardly seen in verruga peruana lesions. However, the organisms can be seen in the tissue with modified silver-stain techniques that are similar to those used for BA.

Diagnosis/Differential Diagnosis

The differential diagnosis for verruga peruana is the same as that for BA, and includes BA, Kaposi sarcoma, pyogenic granuloma, and angiosarcoma.

Treatment

Untreated, Oroya fever may be a fatal disease. Because of the frequent concomitant infection with *Salmonella,* the treatment of choice for Oroya fever is chloramphenicol (50 mg/kg per day, maximum 3 g/day) for 10 days, although ciprofloxacin 500 mg bid also appears effective. Rifampin 10 mg/kg per day for 14 to 21 days is the treatment of choice for verruga peruana, although the macrolides and tetracyclines are also effective. Ciprofloxacin 500 mg bid for 7 to 10 days is an alternative. [71] Verruga peruana may also regress spontaneously.

REFERENCES

1. Maurin M, Raoult D: *Bartonella (Rochalimaea) quintana* infections. *Clin Microbiol Rev* **9**:273, 1996

2. Midani S et al: Cat-scratch disease. *Adv Pediatr* **43**:397, 1996

3. Dalton MJ et al: Use of *Bartonella* antigens for serologic diagnosis of cat-scratch disease at a national referral center. *Arch Intern Med* **155**:1670, 1995

4. La Scola S, Bernard S et al: Culture of *Bartonella quintana* and *Bartonella henselae* from human samples: a 5-year experience (1993–1998). *J Clin Microbiol* **37**:1899, 1999

5. Anderson B et al: Detection of *Rochalimaea henselae* DNA in specimens from cat scratch disease patients by PCR. *J Clin Microbiol* **32**:942, 1994

6. Bergmans AMC et al: Etiology of cat scratch disease: Comparison of polymerase chain reaction detection of *Bartonella* (formerly *Rochalimae*) and *Afipia felis* DNA with serology and skin tests. *J Infect Dis* **171**:916, 1995

7. Kordick DL et al: *Bartonella clarridgeiae,* a newly recognized zoonotic pathogen causing inoculation papules, fever, and lymphadenopathy (cat-scratch disease). *J Clin Microbiol* **35**:1813, 1997

8. Wise JK, Yang J-J: Veterinary service market for companion animals, 1992, part I: Companion animal ownership and demographics. *J Am Vet Med Assoc* **201**:990, 1992

9. Jackson L et al: Cat scratch disease in the United States: An analysis of three national databases. *Am J Public Health* **83**:1707, 1993

10. Chomel BB et al: *Bartonella henselae* prevalence in domestic cats in California: Risk factors and association between bacteremia and antibody titers. *J Clin Microbiol* **33**:2445, 1995

11. Jameson P et al: Prevalence of *Bartonella henselae* antibodies in pet cats throughout regions of North America. *J Infect Dis* **172**:1145, 1995

12. Breitschwerdt EB et al: *Bartonella* infection in animals: Carriership reservoir potential, pathogenicity, and zoonotic potential for human infection. *Clin Microbiol Rev* **12**:428, 2000

13. Spach DH et al: *Bartonella*-associated infections. *Emerg Infect Dis* **12**:137, 1998

14. Bass JW et al: Prospective randomized double-blind placebo-controlled evaluation of azithromycin for treatment of cat-scratch disease. *Pediatr Infect Dis J* **17**:447, 1998

15. Massei F et al: Widening the clinical spectrum of *Bartonella henselae* infection as recognized through serodiagnostics. *Eur J Pediatr* **159**:416, 2000

16. Massei F et al: Pseudoinfectious mononucleosis: A presentation of *Bartonella henselae* infection. *Arch Dis Child* **83**:443, 2000

17. Massei F et al: *Bartonella henselae* and inflammatory bowel disease. *Lancet* **356**:1245, 2000

18. Ruess M et al: Portal vein and bone involvement in disseminated cat-scratch disease: Report of 2 cases. *Clin Infect Dis* **31**:818, 2000

19. Suhler E et al: Prevalence of serologic evidence of cat scratch disease in patients with neuroretinitis. *Ophthalmology* **107**:871, 2000

20. Cunningham ET et al: Ocular bartonellosis. *Am J Opthamol* **130**:340, 2000

21. Armengol CE et al: Cat-scratch disease encephalopathy: A cause of status epilepticus in school-aged children. *J Pediatr* **134**:635, 1999

22. Noyola DE et al: Recurrent encephalopathy in cat-scratch disease. *Pediatr Infect Dis J* **18**:567, 1999

23. Tsukahara M et al: *Bartonella henselae* bacteraemia in patients with cat scratch disease. *Eur J Pediatr* **160**:316, 2001

24. Marseglia GL et al: Asymptomatic persistent pulmonary infiltrates in an immunocompetent boy with cat-scratch disease. *Eur J Pediatr* **160**:260, 2001

25. Margileth AM et al: Chest-wall abscess due to cat-scratch disease (CSD) in an adult with antibodies to *Bartonella clarridgeiae*: Case report and review of the thoracopulmonary manifestations of CSD. *Clin Infect Dis* **27**:353, 1998

26. Marie I et al: Atypical mass lesion associated with cat-scratch disease. *Clin Infect Dis* **29**:221, 1999

27. Krause R et al: Osteomyelitis of the hip joint associated with systemic cat-scratch disease in an adult. *Eur J Clin Microbiol Infect Dis* **19**:781, 2000

28. Fournier P et al: Epidemiologic and clinical characteristics of *Bartonella quintana* and *Bartonella henselae* endocarditis. *Medicine (Baltimore)* **80**:245, 2001

29. Landau M et al: Unusual eruption as a presenting symptom of cat scratch disease. *J Am Acad Dermatol* **41**:833, 1999

30. Carithers HA: Cat-scratch disease: An overview based on a study of 1200 patients. *Am J Dis Child* **139**:1124, 1985

31. Ohl ME et al: *Bartonella quintana* and urban trench fever. *Clin Infect Dis* **31**:131, 2000

32. Hurst A: Trench fever. *Br Med J* **2**:318, 1942

33. Spach DH et al: *Bartonella (Rochalimaea) quintana* bacteremia in inner-city patients with chronic alcoholism. *N Engl J Med* **332**:424, 1995

34. Jackson LA et al: Seroprevalence to *Bartonella quintana* among patients at a community clinic in downtown Seattle. *J Infect Dis* **173**:1023, 1996

35. Guibal F et al: High seroprevalence to *Bartonella quintana* in homeless patients with cutaneous parasitic infestations in downtown Paris. *J Am Acad Dermatol* **44**:219, 2001

36. Stoler MH et al: An atypical subcutaneous infection associated with acquired immune deficiency syndrome. *Am J Clin Pathol* **80**:714, 1983

37. LeBoit PE et al: Epithelioid haemangioma-like vascular proliferation in AIDS: Manifestation of cat scratch disease bacillus infection? *Lancet* **1**:960, 1988

38. Angritt P et al: Epithelioid angiomatosis in HIV infection: Neoplasm or cat-scratch disease? *Lancet* **1**:996, 1988

39. Perkocha LA et al: Clinical and pathological features of bacillary peliosis hepatitis in association with human immunodeficiency virus infection. *N Engl J Med* **323**:1581, 1990

40. Relman DA et al: The agent of bacillary angiomatosis: An approach to the identification of uncultured pathogens. *N Engl J Med* **323**:1573, 1990

41. Koehler JE et al: Isolation of *Rochalimaea* species from cutaneous and osseous lesions of bacillary angiomatosis. *N Engl J Med* **327**:1625, 1992

42. Welch DF et al: *Rochalimaea henselae* sp. nov., a cause of septicemia, bacillary angiomatosis, and parenchymal bacillary peliosis. *J Clin Microbiol* **30**:274, 1992

43. Tappero JW et al: The epidemiology of bacillary angiomatosis and bacillary peliosis. *JAMA* **269**:770, 1993

44. Plettenberg A et al: Bacillary angiomatosis in HIV-infected patients—An epidemiological and clinical study. *Dermatology* **201**:326, 2000

45. Myers SA et al: Bacillary angiomatosis in a child undergoing chemotherapy. *J Pediatr* **121**:574, 1992

46. Milde P et al: Cutaneous bacillary angiomatosis in a patient with chronic lymphocytic leukemia. *Arch Dermatol* **131**:933, 1995

47. Boyce S et al: An ulcerated nodule associated with lymphadenopathy. *Arch Dermatol* **135**:983, 1999

48. Tappero JW et al: Bacillary angiomatosis and bacillary splenitis in immunocompetent adults. *Ann Intern Med* **118**:363, 1993

49. Malane MS et al: An HIV-1-positive child with fever and a scalp nodule. *Lancet* **346**:1466, 1995

50. Koehler JE et al: Molecular epidemiology of *Bartonella* infections in patients with bacillary angiomatosis-peliosis. *N Engl J Med* **337**:1876, 1997

51. Santos R et al: Bacillary angiomatosis by *Bartonella quintana* in an HIV-infected patient. *J Am Acad Dermatol* **42**:299, 2000

52. Mohle-Boetani JC et al: Bacillary angiomatosis and bacillary peliosis in patients infected with human immunodeficiency virus: Clinical characteristics in a case-control study. *Clin Infect Dis* **22**:794, 1996

53. Fagan WA et al: Widespread cutaneous bacillary angiomatosis and a large fungating mass in an HIV-positive man. *J Am Acad Dermatol* **35**:286, 1996

54. Herts BR et al: Soft-tissue and osseous lesions caused by bacillary angiomatosis: Unusual manifestations of cat-scratch fever in patients with AIDS. *AJR Am J Roentgenol* **157**:1249, 1991

55. Baker J et al: Bacillary angiomatosis: A treatable cause of acute psychiatric symptoms in human immunodeficiency virus infection. *J Clin Psychiatry* **56**:161, 1995

56. Harris PJ: Intracerebral bacillary angiomatosis in HIV. *Ann Intern Med* **117**:795, 1992

57. Koehler JE, Cederberg L: Intra-abdominal mass associated with gastrointestinal hemorrhage: A new manifestation of bacillary angiomatosis. *Gastroenterology* **109**:2011, 1995

58. Slater LN, Min K-W: Polypoid endobronchial lesions: A manifestation of bacillary angiomatosis. *Chest* **102**:972, 1992

59. Moore EH et al: Bacillary angiomatosis in patients with AIDS: Multiorgan imaging findings. *Radiology* **197**:67, 1995

60. Berger TG et al: Bacillary (epithelioid) angiomatosis and concurrent Kaposi's sarcoma in acquired immunodeficiency syndrome. *Arch Dermatol* **125**:1543, 1989

61. Guarner J, Unger ER: Association of Epstein-Barr virus in epithelioid angiomatosis of AIDS patients. *Am J Surg Pathol* **14**:956, 1990

62. Lopez-Elzaurdia C et al: Bacillary angiomatosis associated with cytomegalovirus infection in a patient with AIDS. *Br J Dermatol* **125**:175, 1991

63. Sagerman PM et al: Localization of Mycobacterium avium-intracellulare within a skin lesion of bacillary angiomatosis in a patient with AIDS. *Diagn Mol Pathol* **1**:212, 1992

64. LeBoit PE: Bacillary angiomatosis. *Mod Pathol* **8**:218, 1995

65. Pembroke AC et al: Eruptive angiomata in malignant disease. *Clin Exp Dermatol* **3**:147, 1978

66. Zak FG et al: Viscero-cutaneous angiomatosis with dysproteinaemic phagocytosis: Its relation to Kaposi's sarcoma and lymphoproliferative disorders. *J Pathol Bacteriol* **92**:594, 1966

67. Cockerell CJ: Bacillary angiomatosis and related diseases caused by *Rochalimaea*. *J Am Acad Dermatol* **32**:783, 1995

68. Strong RP et al: Verruga peruviana, Oroya fever, and Uta: Preliminary report of the first expedition to South America from the Department of Tropical Medicine of Harvard University. *JAMA* **51**:1713, 1913

69. Allison MJ et al: A case of Carrión's disease associated with human sacrifice from the Huari culture of southern Peru. *Am J Phys Anthropol* **41**:295, 1974

70. Ellis B et al: An outbreak of acute bartonellosis (Oroya fever) in the Urubamba region of Peru, 1998. *Am J Trop Med Hyg* **61**:344, 1999

71. Maguina C et al: Bartonellosis new and old. *Infect Dis Clin North Am* **14**:1, 2000

72. Kosek M et al: Natural history of infection with *Bartonella bacilliformis* in a nonendemic population. *J Infect Dis* **182**:865, 2000

T>

Chapter 199

Morton Swartz Arnold Weinberg

Miscellaneous Bacterial Infections with Cutaneous Manifestations

DISEASES RELATED TO INTIMATE CONTACT WITH ANIMALS, FISH, FOWL, OR THEIR PRODUCTS
Anthrax
Brucellosis
Erysipeloid
Glanders
Streptobacillus moniliformis Infection (Rat-bite Fever)
Infections Caused by Streptococcus iniae
DISEASES ASSOCIATED PRIMARILY WITH A SPECIFIC GEOGRAPHIC DISTRIBUTION
Melioidosis
Plague
DISEASES ASSOCIATED WITH RANDOM ANIMAL CONTACT INDEPENDENT OF GEOGRAPHIC OR OCCUPATIONAL CONSIDERATIONS
Francisella tularensis Infections (Tularemia)
Leptospirosis
Pasteurella multocida Infections
UNCOMMON DISEASES IN WHICH ANIMAL OR WATER CONTACT OR CLIMATOLOGIC FACTORS MAY OCCASIONALLY BE RELEVANT
Listeria monocytogenes Infections (Listeriosis)
Diphtheria
Cutaneous Infections Caused by Vibrio Species
Aeromonas hydrophila Infections

REFERENCES

This chapter encompasses a group of “exotic” diseases rarely seen in urban practice in the United States. The thread of continuity that can be woven among this miscellaneous group involves epidemiologic considerations. The diagnosis can often be made expeditiously if the following are considered: (1) occupation and travel history; (2) the possibility of animal exposure; (3) the possibility of fresh, brackish, or saltwater immersion; and (4) the duration of the incubation periods. Many of the illnesses described in this chapter are systemic infections having a major cutaneous component that helps to suggest the proper diagnosis.

DISEASES RELATED TO INTIMATE CONTACT WITH ANIMALS, FISH, FOWL, OR THEIR PRODUCTS

Anthrax

The most common form of infection with *Bacillus anthracis* is an acute cutaneous lesion called “malignant pustule.” [1] Anthrax is primarily a disease of domestic and wild animals, but humans become accidentally involved through exposure to animals and their products. In addition, bioterrorism has been considered a potential source for decades. Unfortunately, this threat became a reality in October 2001 in the United States. [2]

BACTERIOLOGY AND PATHOGENIC ASPECTS

Bacteriology *B. anthracis* is a large, aerobic, encapsulated, gram-positive, square-ended rod that forms central spores in an unfavorable external environment and on culture, but not in tissues. Growth occurs readily on blood agar medium without a hemolytic reaction. This characteristic, plus pathogenicity for mice and lack of motility, helps to distinguish this organism from saprophytic *Bacillus* species.

Pathogenic aspects *B. anthracis* has two principal virulence factors. The first is a D-glutamyl polypeptide capsule, the synthesis of which depends on the presence of a specific plasmid. [3] The second is a pair of toxins, designated *edema toxin* and *lethal toxin*. Each of the toxins consists of a pair of noncovalently linked protein components: [4] edema toxin consists of edema factor (EF) plus protective antigen (PA); lethal toxin consists of lethal factor (LF) plus PA. PA binds to a surface receptor on most mammalian cells and is subsequently cleaved by furin-like proteases. The larger of the proteolytic products remains bound to its receptor, and these monomeric units of PA self-associate to form a heptameric prepore. The ligands EF and LF bind to the prepore, and this entire receptor-modified PA-ligand complex is then endocytosed and trafficked to an acidic intracellular compartment where the low PH converts the prepore to a pore. The latter allows translocation of EF and LF across the endosomal membrane into the cytosol where their toxic effects are elicited. EF is a calmodulin-dependent adenyl cyclase, which is responsible for the prominent edema at sites of infection and protects the bacilli from destruction by phagocytes [inhibiting neutrophil function and hindering production of tumor necrosis factor (TNF) and interleukin-6 by monocytes]. LF is a zinc metalloprotease that inactivates mitogen-activated protein kinase kinase, leading to inhibition of intracellular signaling. LF is capable of killing macrophages or, at lower concentrations, inducing them to overproduce cytokines (TNF-a, interleukin-1ß). [4] These actions are probably responsible for the sudden death from toxicity that occurs with high degrees of bacteremia (10^7 to 10^8 bacilli per milliliter of blood) and terminally high lethal toxin levels. Cutaneous infection usually follows introduction of spores at the site of an abrasion. Following germination, the encapsulated organisms resist phagocytosis and elaborate their toxins. Edema toxin is responsible for the characteristic gelatinous edema of the local lesion. [5] In 1881, Pasteur showed that *B. anthracis* grown at elevated temperatures were attenuated and capable of inducing immunity in animals upon subsequent challenge with virulent strains of the organism. Such vaccine strains, avirulent by virtue of their inability to produce toxins,

were shown, more than 100 years later, to have become attenuated by virtue of temperature-induced elimination of the plasmid-encoding toxin genes. However, the important protective immunogen is the anthrax toxin because vaccination with anthrax strains containing only the plasmid for capsule production, but lacking the one for toxin production, is not protective. Pasteur's vaccine was effective presumably because his attenuation procedure resulted in cultures with a relatively increased proportion of cells containing only the capsule plasmid and a relatively decreased proportion containing both plasmids. [6]

EPIDEMIOLOGY Natural infection occurs in many domestic and wild animals. Highly resistant spores persist for many years in cutaneous products of these animals and in pastures where they live. Vaccination, animal control programs, and industrial safety measures have essentially eliminated reservoirs of infection in the United States, but imported animal products from the Middle and Near East, Africa, India, and South America may still introduce spores into an unprotected industrial environment. Worldwide there are estimated to be from 20,000 to 100,000 cases of human anthrax annually. By contrast, in the United States, for two decades there has been less than 1 case annually, on average, until 2001, when over the course of a 6-week period 22 cases of anthrax (12 cutaneous, 10 inhalational with 4 deaths) were identified. [7] The cases resulted from bioterrorism acts in which “weaponized” anthrax (finely milled, nonclumping) spores that are optimal for dissemination and inhalation were sent through the mails, infecting postal workers and letter recipients and contaminating many offices. Outbreaks still occur in endemic areas. From 1979 to 1985, approximately 10,000 cases of anthrax (more than 90 percent involving the cutaneous form; the remainder representing, equally, pulmonary and gastrointestinal forms) occurred in Zimbabwe. [5] Direct cutaneous contact with carcasses of infected cattle was the major means of infection, but transmission by biting flies, which had earlier fed on carcasses of animals that had died of anthrax, may also have occurred. Infection in the United States, in the past, has been almost entirely limited to persons working in animal product–associated industries, particularly individuals handling raw materials in wool factories. However, transient exposure to infected animal products (e.g., hair) from abroad through ostensibly unrelated occupations (such as one-time air-conditioning duct repairs in a wool-sorting plant) has been incriminated in acquisition of anthrax. Shaving brushes, piano keys (ivory), hides, and raw wool have been implicated in sporadic infections in persons not related to the above industries. The use of protective vaccines, sophisticated ventilation systems, and steam sterilization of hides has drastically reduced cases from the animal product industry.

CLINICAL MANIFESTATIONS

History The patient is almost invariably employed in an animal-product industry, usually handling, for example, wool, goat, and other animal hair, hides, and bones. To this list must be added victims of bioterrorism attack, through the mail or by other means. The initial symptoms, following a 1- to 12-day incubation period, are usually low-grade fever and malaise. A painless papular lesion is usually noted on an exposed area. Itching or burning may accompany the early lesion; progressive edema, discoloration, and enlargement then occur, but the lesion and surrounding inflammatory edema remains painless (see below). The initial symptoms of inhalation anthrax are nonspecific, with fever, fatigue, and malaise, but chills, high fever, nonproductive cough, dyspnea, cyanosis, and collapse soon occur. Chest radiographs characteristically show symmetric mediastinal widening. In this form of the disease, as well as in septicemic anthrax (following cutaneous or ingestion anthrax), meningitis may develop and dominate the clinical picture. Gastrointestinal anthrax following ingestion of contaminated meat has never been reported in the United States. Although vegetative bacteria are killed by acid gastric juice, the anthrax spores are resistant. An uncommon but related form (oropharyngeal) of anthrax also results from ingestion of raw or undercooked meat from infected animals. Not surprisingly, there may be a cluster of cases in a family.

Cutaneous lesion The cutaneous lesion (“malignant pustule”) is the classic primary infection in anthrax, occurring in more than 95 percent of cases. It is most often located on an exposed area such as the hands (Fig. 199-1) or the head and neck, beginning as a papule. The painless lesion enlarges and develops into a vesicle or bulla with surrounding brawny, gelatinous, nonpitting edema. The vesicle becomes hemorrhagic and then necrotic and may be surrounded by small satellite papules and vesicles. The area of nonpitting edema increases, an eschar forms, and the red discoloration becomes more intense, but without pain. Rarely, the area of necrosis extends over most of the edematous region, or edema may be present without any detectable primary lesion or necrosis. The eschar dries and falls off in 1 to 2 weeks. Regional lymph nodes may be slightly enlarged and tender, but there is no lymphangitis unless secondary infection with streptococci or *Staphylococcus aureus* has developed.

FIGURE 199-1 Anthrax. The classic cutaneous lesion of a primary infection in anthrax is a painless papule that evolves into a hemorrhagic bulla with surrounding brawny nonpitting edema. Note the typical localization on the hand.

Other physical findings Systemic manifestations (fever, tachycardia, hypotension) may accompany either extensive cutaneous involvement or dissemination from a skin site. In woolsorter's disease, tachypnea, stridor, and cyanosis may be prominent. A thick, gelatinous, hemorrhagic nasal discharge may accompany acute sinusitis caused by *B. anthracis*.

LABORATORY FINDINGS The white blood cell count is usually elevated, with a preponderance of polymorphonuclear leukocytes. If meningitis is present, the cerebrospinal fluid is characteristically hemorrhagic and broad gram-positive bacilli may be seen. In inhalation anthrax, the chest x-ray shows significant mediastinal widening and hilar adenopathy because of edema and hemorrhagic necrosis of draining nodes. The pulmonary parenchyma is usually spared.

PATHOLOGY The prominent features of cutaneous anthrax are hemorrhagic edema, dilatation of lymphatics, and necrosis of the epidermis; gram-positive bacilli may be seen in the area of the eschar.

DIAGNOSIS AND DIFFERENTIAL DIAGNOSIS The diagnosis is usually suspected on the basis of the character of the lesion and the hobby exposure, occupational history, or likelihood of bioterrorism. Demonstration of large gram-positive rods in vesicle fluid on aspiration beneath the eschar, or on skin punch biopsy, also using a direct fluorescent antibody technique supports the diagnosis. Definitive diagnosis requires culture of the organism and demonstration of its susceptibility to specific bacteriophage lysis. Occasionally, the organism can be isolated from the blood during the acute cutaneous illness as well as in disseminated anthrax. Retrospective serodiagnosis is possible with the demonstration of a

titer rise in electrophoretic-immunotransblots of antibody to PA and enzyme-linked immunosorbent assay (ELISA) for detection of anticapsule antibodies. Acute staphylococcal cellulitis with a central pustular lesion or a carbuncle with necrotic eschar may be confused with early anthrax, but the former are usually very painful and tender, and the etiologic agent is usually present on Gram-stain examination. Differential diagnosis of cutaneous anthrax includes ecthyma (caused by *Streptococcus pyogenes* and usually without edema or systemic manifestations), ecthyma gangrenosum (usually in the setting of neutropenia and *Pseudomonas aeruginosa* bacteremia), orf (caused by a parapoxvirus through contact with sheep or goats; vesicopustular lesions without gelatinous edema), and a brown recluse spider bite (causes pain with incipient necrosis).

TREATMENT Parenteral crystalline penicillin G (2 million units every 6 h) was the treatment of choice prior to the 2001 bioterrorism outbreak. In one study, smears and cultures from vesicles or from the necrotic tissue beneath the eschar became negative within 6 h of initiation of penicillin therapy. [8] Similarly, for systemic infection (inhalation, gastrointestinal, meningeal), higher doses of penicillin (2 million units every 2 h for the adult) were the previously recommended therapies. Treatment of conventional cutaneous anthrax is continued until the local edema disappears or the lesion dries up, that is, for 7 to 14 days. After resolution of the edema, penicillin therapy may be switched to the oral route to complete the treatment course. Because a strain of *B. anthracis* had been produced overseas that was resistant to multiple antibiotics (penicillin, doxycycline, chloramphenicol, macrolides, and rifampin) ciprofloxacin was the drug of choice recommended for initial postexposure prophylactic therapy in the 2001 American episode. [9] Isolates from that outbreak were found susceptible to ciprofloxacin, doxycycline, imipenem, chloramphenicol, clindamycin and rifampin, but resistant to extended-spectrum cephalosporins. Although susceptible to penicillin in vitro, these isolates produced an inducible beta-lactamase resistant to beta-lactamase inhibitors. Thus, the most recent recommendations for treatment of inhalation anthrax involve the initial use of ciprofloxacin or doxycycline plus one or two additional antibiotics with known activity against *B. anthracis.* [5], [10] Current treatment of cutaneous anthrax in adults in the setting of bioterrorism involves the use of ciprofloxacin (500 mg po bid) or doxycycline (100 mg po bid) for 60 days because of the possibility of simultaneous exposure to inhalation anthrax. [10] Incision and débridement of the cutaneous lesion should be avoided because this increases the opportunity for bacteremia. The disease does not appear to impart permanent immunity. Two types of vaccine are available for immunization against anthrax. [6] The first vaccine is licensed for human use in the United States to protect workers in occupations that might expose them to *B. anthracis;* it has been given to members of the armed forces of the United States since 1998. The vaccine is a sterile culture filtrate (primarily PA) of an attenuated strain of *B. anthracis* adsorbed to an aluminum hydroxide adjuvant and administered in 6 doses over 18 months. The second vaccine is for immunization of livestock against anthrax and consists of viable spores of an attenuated, nonencapsulated, toxigenic strain.

COURSE AND PROGNOSIS Rapid defervescence and clinical improvement follow the institution of appropriate antibiotic therapy. In inhalational, intestinal, septicemic, and meningeal anthrax the prognosis has been exceedingly grave. Whereas the mortality rate from inhalational anthrax had been approximately 90 percent in the past, it was only 40 percent in the 2001 bioterrorism-associated outbreaks, probably reflecting early diagnosis and treatment. [5]

Brucellosis

Brucellosis is an acute or chronic infection (caused by any one of four species of the genus *Brucella*) transmitted to humans from contact with animals or animal products. Such infections may be acute with bacteremia, or chronic with a variety of symptoms and signs.

BACTERIOLOGY AND PATHOGENIC ASPECTS

Bacteriology The brucellae are nonmotile, coccobacillary gram-negative rods that require enriched media and an atmosphere containing 8 to 10 percent CO_2 for optimal growth.

Pathogenic aspects The common portal for these organisms is ingestion of contaminated unpasteurized milk or cheese. Also, contact with infected animals or contaminated excretions may allow organisms to enter through small skin abrasions. Inhalation of droplets occurred among abattoir workers. The organisms can multiply intracellularly in a variety of tissues and produce acute symptoms. They may persist within cells for prolonged periods, leading to chronic brucellosis.

EPIDEMIOLOGY Domestic animals are the reservoir of brucella; humans are infected primarily by direct contact with animal material or by ingestion of raw milk or unpasteurized cheese. In the past, most infections in the United States were due to *B. abortus* secondary to contact with infected cattle. More recently, 70 percent of blood culture isolates from meat-processing-plant employees with brucellosis have been *B. suis.* [11] Another important group of patients with brucella infection are travelers who were infected in endemic areas (countries of the Mediterranean littoral, the Middle East, Mexico) through ingestion of unpasteurized cow's or goat's milk or cheese. In recent years, *B. canis,* a *Brucella* species that produces abortion or prostatitis and epididymitis in dogs, has been recognized as a cause of infection in individuals (pet owners, veterinarians) in contact with infected canines.

CLINICAL MANIFESTATIONS

History In the majority of cases, contact with animals or their products is an essential feature of the history. The incubation period is usually 1 to 3 weeks, followed either by an acute febrile illness with headache (sometimes with involvement of liver, joints, or meninges) or an indolent disease with weakness, anorexia, and low-grade fever, which may persist for weeks or months. *Brucella* involvement of the spine is not infrequent. Rarer forms of infection include suppurative lymphadenitis and endocarditis. [11] Unlike adults, children frequently exhibit skin rashes, pharyngitis, and enlarged nodes. Relapses occur in approximately 15 percent of patients. They are often associated with less-effective antibiotics, positive blood cultures, and treatment begun too early to allow cell-mediated immunity to develop. [12]

Cutaneous lesions Characteristic cutaneous lesions have been described, especially in children, usually associated with bacteremic disease. The most frequently observed rash is a violet, erythematous, papulonodular eruption that is located primarily on the trunk and lower extremities. Other lesions have included erythema nodosum, purpura, and macular and papular eruptions, some extending into subcutaneous fat and producing a panniculitis. Histology may show dermal perivascular infiltration with histiocytes and lymphocytes arranged into pseudogranulomas. Skin cultures may be positive. [13] Rarely, subcutaneous abscesses or cutaneous sinus tracts may develop as a result of extension of suppuration from infected lymph nodes or sites of osteomyelitis, or following introduction of organisms through a skin abrasion. A severe hypersensitivity reaction to brucella antigen may occur among veterinarians and animal handlers, and may manifest as an acute febrile reaction and the appearance of discrete, elevated, red papules on the hands or arms

that may progress to ulceration.
Other physical findings Among the characteristic findings are lymphadenopathy, hepatosplenomegaly, suppurative arthritis, and evidence of osteomyelitis or spondylitis.
LABORATORY FINDINGS The white blood cell count is usually normal or depressed, and anemia is frequently present. Blood cultures may be positive during the acute illness. Histologically, lesions in the liver, spleen, and other organs consist of small, noncaseating granulomas. Rarely, larger areas with caseation necrosis and calcification occur in infections due to *B. suis*.
DIAGNOSIS AND DIFFERENTIAL DIAGNOSIS The diagnosis is usually based upon epidemiologic information (animal contact), cultures (blood, bone marrow, organ granulomas), and rising serum agglutination titer. A titer of greater than 1:160 should raise the possibility of this disease and warrant repetition of the test 7 to 14 days later. *B. canis* will not be detected by the routine agglutination test for *Brucella* spp. The antibody response to brucella infection is initially that of IgM followed by IgG antibodies. The IgM response may last for many months up to several years, but the IgG antibodies decrease rapidly following antimicrobial therapy. In patients with chronic symptomatology, the presence of IgG antibodies indicates continuing or recrudescent active infection. [11] Recently, use of IgM and IgG ELISA has suggested that they are very sensitive methods for detecting antibody to *Brucella* and that a secondary increase in IgG, but not IgM, ELISA occurs in patients undergoing clinical relapse. [14] Cross-reactions with *Francisella tularensis* occur uncommonly, and vaccination within the year for cholera may stimulate a brucella agglutinin titer. The differential diagnosis includes other acute bacterial infections such as salmonellosis, listeriosis, tuberculosis, and endocarditis. Hodgkin's disease may mimic many of the findings of brucellosis. Vertebral osteomyelitis may sometimes be the primary or sole manifestation of brucellosis.
TREATMENT Use of antimicrobials that penetrate into cells and treatment prolonged for 6 weeks constitute optimum therapy. The “gold standard” consists of a combination of doxycycline and either streptomycin or gentamicin. Equally effective results have been recorded with the combination of doxycycline and rifampin.
COURSE AND PROGNOSIS Early treatment results in rapid improvement. Brucellosis relapses in approximately 10 to 15 percent of patients who are treated suboptimally.

Erysipeloid

Erysipeloid is an acute infection of traumatized skin caused by *Erysipelothrix rhusiopathiae,* occurring most frequently in fishermen, butchers, and others, such as housewives, who handle raw fish, poultry, and meat products. [15]

BACTERIOLOGY *E. rhusiopathiae* is a thin, gram-positive, microaerophilic, nonmotile bacillus that is hardy enough to survive drying, putrefaction of tissue, and saltwater or freshwater exposure. [15] Growth occurs best on media fortified with serum at temperatures between 30°C and 37°C (86°F and 98.6°F) and in an atmosphere of 5 to 10 percent CO_2.
EPIDEMIOLOGY *E. rhusiopathiae* is the cause of a cutaneous and systemic infection of swine. It is present in rats and birds and in the slime of saltwater fish, on crabs and other shellfish, or associated with poultry, meats, hides, and bones. Occurrence of the disease is limited almost exclusively to persons handling contaminated products, primarily during summer months. Usually the organisms are inoculated through a break in the skin of the hands. Human infection takes one of four clinical forms: (1) localized cutaneous infection (erysipeloid); (2) diffuse cutaneous form, consisting of multiple serpiginous lesions with sharply defined borders; (3) subacute bacterial endocarditis; or (4) bacteremic form without endocarditis, usually in immunocompromised patients. [16] The disease does not seem to confer lasting immunity.
CLINICAL MANIFESTATIONS
History Usually the patient is employed in fishing or animal product industries. The incubation period is 2 to 7 days. Initially, there is burning pain at a site of injury. A violaceous, raised area appears and enlarges. Lymphangitis and regional lymphadenopathy occasionally occur. Constitutional symptoms include low-grade fever and malaise. Occasionally, an adjacent joint is involved. Rarely, bacteremia, and even endocarditis, may follow. [17]
Cutaneous lesion The distinctive “erysipeloid” lesion is usually on a finger or hand, is violet or purple-red in color, warm and tender, and has well-defined, raised margins (Fig. 199-2). As the lesion advances peripherally, the central region clears without desquamation or ulceration. [18] Rarely, dissemination occurs with multiple lesions distant from the original site of injury. Brownish discoloration develops as the lesion resolves.

FIGURE 199-2 Erysipeloid. Characteristically, the violaceous sharply marginated lesion is composed of macules and plaques and is localized on the hand.

Other physical findings Arthritis may be associated with the local lesion, and, rarely, distant joints are involved. Bronchitis may follow inhalation of organisms. Conjunctivitis also occurs. Typical peripheral stigmata, as well as cardiac findings of endocarditis or septicemia, have been reported, including prosthetic valve involvement. [15], [17]
LABORATORY FINDINGS There are no characteristic findings, and the organism is seldom seen on Gram-stained material from the surface of the lesion or from aspirated material. Culture of a biopsy from the advancing edge of the lesion may reveal the organism.
PATHOLOGY Dilatation of vessels in the papillary and subpapillary areas and perivascular cellular infiltrates deep in the

dermis are present. The depth of the process may explain why organisms are rarely seen or cultured from the lesion.
DIAGNOSIS AND DIFFERENTIAL DIAGNOSIS The character of the local lesion in a person handling fresh meat or fish products suggests the diagnosis. Other forms of bacterial cellulitis or erysipelas may be confused with erysipeloid. Erysipelas is very superficial with a raised border, there is only moderate pain, and the central area remains the most affected region compared to central clearing in erysipeloid. “Seal finger” may be mistaken for erysipeloid, but there is a history of a recent seal bite or contact. In addition to cultures, the diagnosis can be confirmed by using agar-gel diffusion precipitation or fluorescent antibody. [15]
TREATMENT Penicillin, in doses of 2 to 3 million units daily, orally or ntramuscularly, for 7 to 10 days, is the treatment for erysipeloid. In the penicillin-allergic patient who has not had anaphylaxis or angioedema, a third-generation cephalosporin, imipenem, or ciprofloxacin can be given. This recommendation is based primarily on in vitro studies, not clinical experience. [19] If arthritis, septicemia, or endocarditis is present, the dose of penicillin should be raised to 2 to 4 million units every 4 h, administered intravenously (for 4 weeks in the case of endocarditis). Vancomycin should not be used because most isolates are resistant.
COURSE AND PROGNOSIS In the untreated patient, the lesion usually lasts for 2 to 3 weeks but may persist, with cycles of improvement and worsening over several months. If penicillin is administered, the improvement is dramatic and recurrence is rare. In systemic infection, prognosis depends on early and appropriate treatment.

Glanders

Glanders is an equine disease caused by the bacterium *Burkholderia mallei* (formerly *Pseudomonas mallei*) and is rarely transmitted to humans. The clinical picture takes one of two forms: (1) an acute, febrile, disseminated, infectious process whose entire course may encompass only 10 to 30 days; or (2) an indolent, relapsing, chronic infection, with multiple cutaneous and subcutaneous abscesses and draining sinuses. “Farcy,” the name given to the disease in horses, refers to the nodular subcutaneous abscesses occurring along the course of lymphatics. Control measures have nearly eradicated this previously common equine infection and eliminated transmission to humans in the United States. Occasional cases still occur in Asia, Africa, and South America. Humans are infected by direct contact with horses. *B. mallei* has long been considered an ideal agent for biologic warfare because of the contagiousness and severity of glanders and has been studied in laboratories worldwide. The first case of human glanders in the United States in more than 50 years was reported in a microbiologist at an Army Research Laboratory who developed axillary lymphadenopathy and bacteremic infection with hepatic and splenic abscesses. [20]

In acute glanders, a nodule or cellulitis appears at the site of inoculation. Local swelling and suppuration occur, and the lesion ulcerates. The ulcer is painful and has irregular edges with a gray-yellow base. Nodular sores rapidly develop along lymphatics draining the lesion; they become necrotic and ulcerated, and sinuses form. Regional lymphadenopathy is present. Widespread dissemination quickly follows, with multiple nodular necrotic abscesses in subcutaneous tissues and muscle. Lesions frequently coalesce into gangrenous areas. During bacteremic spread, a characteristic eruption appears, which may be generalized or localized to the face and neck. Papules, bullae, and pustules appear in crops. Involvement of the nasal mucosa, either initially or by secondary spread, is prominent. Mucopurulent, bloody nasal discharge is commonly noted. Infection may spread to the paranasal sinuses, pharynx, and lung.

In chronic glanders, cutaneous and subcutaneous nodules appear on the extremities and occasionally on the face. The lesions ulcerate, and draining sinuses develop. Ulceration of the hard palate and perforation of the nasal septum can occur.

The pathologic picture is that of a suppurative, necrotic process, containing numerous intracellular and extracellular bacteria. In the chronic form of glanders, a granulomatous process is usually observed.

The diagnosis is made on the basis of the epidemiologic background, examination of Gram-stained smears of pus, and isolation of the organism from abscesses or blood. Acute glanders may resemble miliary tuberculosis or typhoid fever during the initial stages. The multiple subcutaneous abscesses suggest staphylococcal or mycotic infections or melioidosis. Lymphatic nodularity resembles the lesions of *Mycobacterium marinum, Sporothrix schenckii,* and *Francisella tularensis*.

There are almost no data on the antimicrobial treatment of glanders, because the disease largely had disappeared by the antibiotic era. In vitro data indicate susceptibility to ceftazidime, gentamicin, doxycycline, imipenem, and ciprofloxacin. [21] The most recent case of glanders responded well to a combination of imipenem and doxycycline. [20]

Streptobacillus moniliformis Infection (Rat-bite Fever)

Rat-bite fever is an acute infection that is usually acquired from rodents and is characterized by fever, polyarthralgias or arthritis, and a rash. [22]

BACTERIOLOGY *S. moniliformis* is a gram-negative, pleomorphic bacillus. Growth in culture occurs as chains of bacilli and filamentous forms, interspersed with swollen bodies that look like *Candida* (*Monilia*), hence the name *moniliformis*. In blood cultures these microaerophilic organisms typically grow as small “puff balls.” On occasion, growth may occur as an L form on initial culture.
EPIDEMIOLOGY *S. moniliformis* is found in the nasopharynx of wild and laboratory rats. In recent years, the latter have been an increasing source of infection. Infection may also occur following ingestion of contaminated food. One such milk-borne outbreak occurred in Haverhill, Massachusetts, 75 years ago, and this illness was designated “Haverhill fever” (erythema arthriticum epidemicum). [23]
CLINICAL MANIFESTATIONS
History The incubation period averages 1 to 5 days. The rat bite has often healed by the time the illness begins suddenly with fever, chills, headache, and myalgias.
Cutaneous lesions An erythematous macular or papular rash may develop within 2 to 3 days of the onset of symptoms.

It is most marked on the extremities (often involving palms and soles), particularly about joints, but may become generalized, resembling measles. Sometimes the lesions are petechial.
Other physical findings Within a week of onset arthritis can develop, involving larger joints such as the knee. This takes the form of either an asymmetric polyarthritis, resembling rheumatoid arthritis, [24] or a septic arthritis. Regional lymphadenopathy may be present.
LABORATORY FINDINGS Polymorphonuclear leukocytosis is common. *S. moniliformis* can usually be isolated from blood or joint fluid, or sometimes from an abscess developing at the bite site. Serologic diagnosis involves use of agglutination, fluorescent antibody, or complement fixation tests.
DIAGNOSIS AND DIFFERENTIAL DIAGNOSIS The diagnosis should be suspected in any febrile patient with a history of a recent rat bite. Blood cultures are the best way to establish the diagnosis. The other form of rat-bite fever (*Spirillum minus*) (sodoku) may cause a similar illness, but several features are helpful in distinguishing between the two conditions: [22] *S. moniliformis* infection has a shorter incubation period (usually less than 10 days); the bite site has usually healed by the time of onset of fever in *S. moniliformis* infection; and the incidence of arthritis is low in *S. minus* infection. The differential diagnosis should also include meningococcemia, gonococcemia, viral exanthems, and Rocky Mountain spotted fever.
TREATMENT Penicillin, 600,000 units intramuscularly every 6 h for 10 to 12 days, is the drug of choice. Doxycycline, erythromycin, or clindamycin are alternatives in the penicillin-allergic patient.
COURSE AND PROGNOSIS Untreated, the disease may last from a few days to several weeks. Rarely, it is complicated by endocarditis. Penicillin produces a prompt clinical response.

Infections Caused by *Streptococcus iniae*

S. iniae is a recently recognized fish pathogen that causes cellulitis and invasive infections in individuals handling fish from aquaculture farms. [25]

BACTERIOLOGY *S. iniae* is a beta-hemolytic, nongroupable, streptococcus capable of growth at 10°C (50°F) [but not at 45°C (113°F)]; most isolates do not grow in 6.5% sodium chloride.
EPIDEMIOLOGY *S. iniae* infection occurs in the setting of percutaneous injury while handling fresh aquacultured fish, particularly tilapia (Hawaiian sunfish). *S. iniae* colonizes the surface of aquacultured fish and can cause epizootic meningoencephalitis in cultured-fish ponds.
CLINICAL MANIFESTATIONS
History Cellulitis is initiated by a skin puncture wound while preparing fresh fish from aquaculture ponds. Most reported cases have been in individuals of Asian origin, perhaps related to the volume of tilapia consumed by this population.
Cutaneous lesions Characteristically, cellulitis involves the hand and develops within 16 to 24 h after injury. Neither skin necrosis nor bullae occur, but lymphangitis extending from the site of injury and fever are early features.
Other physical findings Bacteremia is frequent with *S. iniae* cellulitis. Metastatic infections may occur in the form of septic arthritis, meningitis, and endocarditis. [25]
LABORATORY FINDINGS Leukocytosis is usually present, with neutrophils predominating.
DIAGNOSIS AND DIFFERENTIAL DIAGNOSIS Diagnosis is made on the basis of the setting, clinical findings, and cultures of blood or wound exudate. The common causes of cellulitis (*S. pyogenes, Staphylococcus aureus*) as well as other freshwater and fish-borne pathogens (*Aeromonas hydrophila*) should be considered in the differential diagnosis.
TREATMENT *S. iniae* is susceptible to penicillin, cefazolin, ceftriaxone, erythromycin, clindamycin, and trimethoprim-sulfamethoxazole (TMP-SMX).
COURSE AND PROGNOSIS With prompt initiation of an appropriate antibiotic, the infection responds within 2 to 4 days. Treatment is continued for 10 days for the cellulitis/bacteremia, and longer if extracutaneous complications are present.

DISEASES ASSOCIATED PRIMARILY WITH A SPECIFIC GEOGRAPHIC DISTRIBUTION

Melioidosis

Melioidosis is an infectious disease of animals and humans, endemic in Southeast Asia but also occurring in Africa, the Caribbean, South America, and the Middle East, between 20° north and south latitudes, and caused by the gram-negative bacillus *Burkholderia pseudomallei* (formerly *Pseudomonas pseudomallei*). [26] Apart from rare laboratory-acquired infections, melioidosis has occurred in only those United States residents who have traveled abroad. During the war in Vietnam, extensive exposure to this organism resulted in cases of melioidosis among American servicemen. The clinical manifestations of the disease take one of two principal forms: (1) acute melioidosis with suppurative skin infection, pneumonia, or septicemia; or (2) chronic melioidosis, the most common form of the disease, which involves the lung (unresolved pneumonia or cavitary lesions), skin (subcutaneous abscesses and draining sinuses), bones, joints, liver, and spleen.

BACTERIOLOGY The etiologic agent is a small, pleomorphic, gram-negative bacillus with bipolar staining that can be grown aerobically on common laboratory media.
EPIDEMIOLOGY The etiologic agent of melioidosis can be isolated widely from soil, vegetables, and water in the rice-growing areas of Southeast Asia. Melioidosis appears to be transmitted by contamination of abraded skin with infected soil or water. [27] The prominence of pulmonary findings in many patients, and of diarrhea in some, suggests that it may be transmitted by inhalation or ingestion.
CLINICAL MANIFESTATIONS
History The incubation period is variable. It has been as short as 3 days, and the disease has also remained latent for years. The acute pneumonic form may begin with a short prodrome (malaise, anorexia, and diarrhea), but more commonly its onset is abrupt, with chills, fever, cough, dyspnea, and chest pain. The acute septicemic form may start with an ulceration at the site of inoculation, lymphangitis, and regional lymphadenitis. In northeastern Thailand, septicemic melioidosis occurs mainly in the rainy season, primarily in rice farmers. Predisposing factors are present in approximately 50 percent of patients and include diabetes mellitus and renal failure, as well as glucocorticoid therapy, leukemia, cirrhosis, and tuberculosis. In half the patients, no source for the bacteremia can be identified, but many have minor abrasions about the feet. [28] Chronic melioidosis may follow the acute disease. More often it develops as an indolent

pulmonary infection or as a low-grade febrile illness with multiple superficial abscesses. Recrudescence of a previous latent or clinical infection months or years after initial exposure to the organism may be precipitated by various subsequent illnesses (e.g., thermal burns, diabetic ketoacidosis) and may take the form of localized infections such as splenic abscess, osteomyelitis, subcutaneous abscesses, or lung abscess, as well as septicemia. It may also take the form of persistent, unexplained fever. [29]

Cutaneous lesions Cutaneous manifestations are not a specific or diagnostic feature of melioidosis. The acute septicemic form may complicate a superficial ulceration and cellulitis. Multiple superficial pustules may be present or, rarely, ecthyma gangrenosum. In chronic melioidosis, subcutaneous abscesses and draining sinuses are common.

Other physical findings In acute pulmonary melioidosis, the findings range from those of bronchitis to those of acute pneumonia or lung abscess. Septicemic spread of the disease leads to jaundice, hepatosplenomegaly, miliary pulmonary densities, myocarditis, and severe gastroenteritis. Chronic pulmonary melioidosis produces signs suggestive of fibrocavitary tuberculosis or lung abscess. The disseminated form of chronic disease may extend over many months with septic arthritis, osteomyelitis, suppurative lymphadenopathy, and visceral abscesses. In Thailand, acute suppurative parotitis is a common form of localized melioidosis in children.

LABORATORY FINDINGS The peripheral white blood cell count is usually normal or only moderately elevated. By histopathology, sharply circumscribed abscesses are found in many organs and in the subcutaneous tissues. There may be a surrounding granulomatous response.

DIAGNOSIS AND DIFFERENTIAL DIAGNOSIS The disease is a great imitator. Acute melioidosis may mimic typhoid fever, staphylococcal pneumonia, mycotic infections, or septicemia. In its chronic form, it must be differentiated from pulmonary tuberculosis, nocardiosis, fungal infections, and lung abscess. Chronic skin infections and draining sinuses in individuals from endemic areas should raise the possibility of melioidosis. The diagnosis is suspected on epidemiologic grounds and on the finding of bipolar-stained gram-negative bacilli in exudates or pus. Culture of the organism establishes the etiology. Hemagglutination, direct agglutination, and complement-fixation tests are helpful when a rise in titer is demonstrated. A positive serologic test, in the absence of a rising titer, may suggest the diagnosis but it is not definitive. The indirect hemagglutination assay (IHA) is the most commonly used test in Southeast Asia because it is simple to perform and cheap. An IHA titer of >1:80 is 80 to 90 percent sensitive and specific in the diagnosis of active melioidosis, but titers of 1:40 to 1:60 are frequently found in healthy individuals in endemic areas. [27]

TREATMENT Antibiotic susceptibility must be determined on each isolate. Most strains of *B. pseudomallei* are susceptible to some of the newer antibiotics in vitro: ceftazidime, piperacillin-tazobactam, imipenem, and amoxicillin-clavulanic acid. A recent multicenter clinical trial in Thailand, comparing ceftazidime with amoxicillin-clavulanate favored the former. [30] The combination of ceftazidime plus TMP-SMX is the initial therapy of choice. Surgical drainage of abscesses should be carried out, but only after initiation of appropriate antimicrobial therapy, in order to avoid a sudden septicemic episode. Antimicrobial treatment should be continued for from 6 to 20 weeks (the longer periods in the case of osteomyelitis or multiple suppurative foci). Following an initial period of intravenous therapy, amoxicillin-clavulanic acid is continued orally.

COURSE AND PROGNOSIS The mortality rate in melioidosis depends on the clinical form of illness: [30] (1) in disseminated septicemic melioidosis (with shock and evidence of dissemination to skin and viscera), it is approximately 50 percent; (2) in nondisseminated septicemic melioidosis it is 17 percent; and (3) in localized melioidosis (nonbacteremic slowly progressive focal infection), it is 9 percent.

Plague

Plague is a severe, acute, febrile infection in humans caused by *Yersinia pestis*. Transmission between the reservoir of this disease (wild and commensal rodents) and human beings is effected by fleas. Infection occurs in three forms: (1) bubonic plague; (2) bubonic-septicemic plague (a more acute and severe form of bubonic plague with bacteremia and delirium); and (3) pneumonic plague (fulminant form of infection resulting from respiratory spread of *Y. pestis*). [31]

BACTERIOLOGY *Y. pestis* is an aerobic gram-negative bacillus with “safety-pin” bipolar staining. It produces an intracellular toxin (plague toxin) that is plasmid-encoded and an important virulence factor. Two other plasmids encode other virulence factors. One mediates the “low calcium response,” which occurs when *Y. pestis* is transferred from the lower temperature of the flea to the 37°C (98.6°F) host whose intracellular (leukocytic) environment has a relatively low Ca^{2+} concentration, and which initiates synthesis of virulence factors. [32] The second plasmid encodes temperature-dependent coagulase and fibrinolysin activities, which also serve as virulence factors. Most strains produce an antiphagocytic capsule, and all have a potent cell envelope–associated lipopolysaccharide.

EPIDEMIOLOGY Endemic (sylvatic) plague is firmly established among wild rodents in the western United States. In this country, human plague is almost always flea borne and is usually of the bubonic type. Between 1956 and 1983, more than 200 cases of plague were reported in the United States. Most occurred during the warmer months and were transmitted by flea bites. “Off-season” (October to February) plague occurs during rabbit-hunting season in the western states and is associated with direct contact (skinning, dressing) with animal (rabbits, bobcats) carcasses. In recent years, epizootics have occurred among prairie dogs in the southwest, and sporadic human cases have been identified on several Indian reservations. Plague has also been transmitted by domestic cats via bites, scratches, or aerosol. Infected fleas can be carried significant distances and into households. Domestic dogs have become infected in endemic areas, but no human cases have resulted. The disease is also endemic in Vietnam and Africa. Rarely, plague pneumonia secondary to bacteremia complicating bubonic plague may initiate respiratory spread to other persons.

CLINICAL MANIFESTATIONS

History The incubation period is approximately 1 to 6 days, followed by the sudden onset of malaise, myalgias, backache, tachycardia, and high fever.

Cutaneous lesions In bubonic plague, the initial skin manifestation is related to the flea bite. Usually this cannot be seen, but occasionally, a small papule or vesicopustule persists. Painful, tender, enlarged lymph nodes are present in the area draining the bite site. The nodes become matted (buboes), and there is extensive surrounding subcutaneous gelatinous edema. Bacteremia may lead to overwhelming systemic illness. Petechiae and ecchymosis often occur because of the effects of plague toxin or because of the development of a disseminated intravascular coagulopathy. Eschars and ecthyma gangrenosum can complicate systemic disease or appear at the site of the flea bite. [31], [33]

Other physical findings Chills, fever, headache, and hypotension of septicemic plague are similar to those of gram-negative bacillemia. Abdominal pain is a feature of almost half the cases. [34] The onset of pneumonic plague is

abrupt, with high fever, tachycardia, and tachypnea. Signs of consolidation may appear, and within 24 h of onset, the patient is critically ill, raising bloody sputum loaded with *Y. pestis.* Meningitis may complicate all three forms of plague.
LABORATORY FINDINGS Leukocytosis occurs in all forms of the disease. In septicemic plague, bacilli can sometimes be seen on stained smears of venous blood (buffy coat). Histopathologically, in the bubonic form, acute inflammatory changes are seen in the involved nodes.
DIAGNOSIS AND DIFFERENTIAL DIAGNOSIS Bubonic plague should be distinguished from tularemia, lymphogranuloma venereum, cat-scratch disease, Eastern Hemisphere spotted fever, and suppurative lymphadenitis. Plague pneumonia must be differentiated from other acute bacterial pneumonias. Epidemiologic considerations and the tempo of the illness are major points in the differential diagnosis. The diagnosis is firmly established by examination of Gram-stained (or specific fluorescent antibody-stained) smears of infected material and by culture of the organism from blood, sputum, or aspirated buboes. Serologic methods can be used for retrospective diagnosis through demonstration of a fourfold or greater rise in titers. A convalescent passive hemagglutination titer of >1:16 is strongly suggestive of the diagnosis.
TREATMENT Streptomycin is the drug of choice, administered intramuscularly (2 g daily in divided doses in the adult) for 10 days. Chloramphenicol or tetracycline are alternatives, or may be added initially as strains resistant to streptomycin have been recovered. Preliminary results suggest that gentamicin may be effective. Strict isolation of pneumonia cases is essential to prevent spread via the respiratory route. Ordinarily, buboes should not be drained until the lesion is well localized and the patient has been treated with antibiotics.
COURSE AND PROGNOSIS Pneumonic and septicemic plague, if untreated, are almost invariably fatal. Untreated bubonic plague has a mortality rate of 30 to 70 percent. Early antibiotic therapy has reduced the mortality rate to 5 to 10 percent.

DISEASES ASSOCIATED WITH RANDOM ANIMAL CONTACT INDEPENDENT OF GEOGRAPHIC OR OCCUPATIONAL CONSIDERATIONS

Francisella tularensis Infections (Tularemia)

Tularemia is a disease of humans caused by *F. tularensis,* an organism that normally resides in a wide range of animal species and their immediate environments. In humans, most cases follow direct animal contact or transmission by insect vectors. The clinical manifestations fall into eight major patterns: glandular, ulceroglandular (most common form), chancriform, oculoglandular, typhoidal, pulmonary, oropharyngeal, and meningeal.

BACTERIOLOGY *F. tularensis* is a pleomorphic, gram-negative coccobacillus that grows best on cysteine blood agar or in thioglycollate heart infusion medium. Intracellular parasitism of the reticuloendothelial system of humans and experimental animals is characteristic.
EPIDEMIOLOGY Infection in humans, particularly among hunters, most commonly follows contact with infected rabbits but may follow exposure to foxes, squirrels, skunks, and pheasants. Aquatic animals (muskrats, beavers) and mud and water from streams may also be a source of infection. The organisms are commonly introduced through a minimal abrasion or puncture wound or by bites of infected deerflies or ticks that are responsible for maintaining the disease in animals. [35] Domestic cats may spread the organism via direct contact, bite, or aerosol. Rarely, ingestion of meat or conjunctival contamination leads to infection.
CLINICAL MANIFESTATIONS
History After an incubation period of 2 to 10 days, the onset of any of the forms of disease is characterized by headache, malaise, myalgias, and high fever. A primary lesion develops at the site of inoculation, accompanied by regional adenopathy. Tick-transmitted disease frequently occurs on the head or trunk or may be transmitted to the conjunctivae by careless handling of an engorged arthropod.
Cutaneous lesions In ulceroglandular tularemia, a reddish, tender, painful papule appears at a site of trauma or arthropod bite. Lesions are usually found on a finger or hand. A small vesicular pustule may develop, and the area rapidly enlarges and becomes necrotic. Nodular lymphangitis may complicate the initial lesion. The lesion then evolves to an ulcer with raised margins, often covered by a black eschar, which later is shed. It appears chancre-like (Fig. 199-3). Regional nodes are enlarged and tender. Systemic signs of toxicity may be marked and pneumonia may accompany dissemination of infection. A macular and papular or petechial exanthem, erythema nodosum, and erythema multiforme are occasional manifestations.

FIGURE 199-3 Tularemia. A chancre-like ulcer with raised margins on the dorsum of the fourth digit with accompanying axillary lymphadenopathy. The rash on the chest is unrelated and is pityriasis versicolor.

In oculoglandular tularemia, the organism is directly introduced via the conjunctivae. The findings are those of a purulent conjunctivitis with marked pain, edema, and congestion. Small yellow nodules may appear on the conjunctivae and ulcerate. Preauricular and submaxillary adenopathy are prominent.
Other physical findings Splenomegaly and generalized lymphadenopathy are relatively common, and hepatomegaly may occur. Ulcerative or exudative pharyngotonsillitis with cervical lymphadenopathy may follow ingestion of the organism, which may also be associated with the “typhoidal” form of the disease. Tularemic pneumonia may occur occasionally following inhalation of organisms but is more often secondary to bacteremia. Pleural effusion and mediastinal node enlargement are sometimes evident. Meningitis can occur.
LABORATORY FINDINGS The white blood cell count is normal or low, but a polymorphonuclear leukocytosis may be seen. Blood cultures are only rarely positive. [36]
PATHOLOGY The pathogen survives intracellularly in phagocytes, and small granulomatous lesions develop in lymph

nodes, liver, and spleen. Some of the lesions may caseate, progress to frank abscess formation, or become necrotic.
DIAGNOSIS AND DIFFERENTIAL DIAGNOSIS The primary lesion resembles a furuncle, paronychia, ecthyma, the initial lesion of anthrax, *Pasteurella multocida* infection, or sporotrichosis. The prominent regional adenopathy suggests cat-scratch disease, plague, melioidosis, or Eastern Hemisphere spotted fever. A febrile illness occurring after a tick bite might suggest Rocky Mountain spotted fever, but an exanthem is usually present in that condition, without a local chancriform lesion. A febrile illness with hepatomegaly and granulomas (on liver biopsy) resembles tuberculosis, brucellosis, or other causes of granulomatous hepatitis. Isolation of *F. tularensis* from tissues and blood requires special media and is difficult to accomplish. The diagnosis is usually made by serologic (agglutination or microagglutination) tests showing a fourfold or greater rise in titer. Cross-reactions occur in brucellosis.
TREATMENT Streptomycin (1.0 to 2.0 g intramuscularly per day in adults) is curative in all forms of tularemia if administered early in the course of the disease. Gentamicin appears to be an acceptable alternative. [37] Clinical improvement is evident within 24 to 48 h, but treatment should be continued for at least 7 to 10 afebrile days. Tetracycline and chloramphenicol are alternative drugs, but clinical relapses are more frequent, particularly if given for less than 14 days.
COURSE AND PROGNOSIS Untreated, the course may be weeks. Prior to the use of antibiotics, the mortality rate was about 5 percent in ulceroglandular disease and about 30 percent in typhoidal and pulmonary forms. Recovery provides immunity to systemic tularemia, but reinfection may produce a recurrent primary ulcer.

Leptospirosis

Leptospirosis is an acute febrile illness caused by any one of the serovarieties (serovars) of the species *Leptospira interrogans*. Although specific serovars have been reported with specific syndromes (canicola fever, Weil's disease, pretibial fever), any serovar may be responsible for a variety of clinical pictures, and a given clinical picture may be produced by many different serovars. [38], [39]

BACTERIOLOGY These organisms are spirochetes that can be cultured on special (Fletcher semisolid) media. More than 200 antigenically different serotypes have been described. They are now defined as serovarieties of the species *L. interrogans*. Thus, for example, a specific antigenic serotype would bear a designation such as *L. interrogans* serovar *canicola*. The most common serovars in the United States are *canicola, icterohaemorrhagiae, pomona, autumnalis,* and *grippotyphosa*.
EPIDEMIOLOGY The reservoir of leptospira is worldwide in the animal population: farm animals (cattle, swine); laboratory animals (mice); domestic animals (hamsters, dogs); wild animals (squirrels, rats); and reptiles. Infection in humans occurs as a result of direct contact with an animal (either a sick animal or an asymptomatic urinary “shedder”) or indirectly through contaminated water or soil. This is especially important considering travels to exotic places, and the risk of entering contaminated water to “cool off.” [40] Organisms usually enter the body through a break in the skin or, less often, through mucous membranes (including conjunctiva). The disease is most prevalent among children (from playing in contaminated puddles or ponds), farmers, hunters, or abattoir workers.
CLINICAL MANIFESTATIONS
History The incubation period is usually between 7 and 14 days, and the illness typically has a biphasic course. The onset is sudden, with headache, fever, chills, nausea, vomiting, abdominal pain, and myalgias. This initial nonspecific phase continues for about a week, when defervescence occurs. After several relatively asymptomatic days, the second phase of illness begins with low-grade fever. Meningeal symptoms may begin and persist for another 2 to 4 days or for several weeks. In the initial phase (leptospiremic), leptospiral organisms are present in the bloodstream, cerebrospinal fluid, and other tissues. The second (“immune”) phase coincides with the appearance of IgM antibodies. Clinically, this phase is characterized by the onset of meningitis, rash, uveitis, and, in more severe cases, by hepatic and renal involvement.
Cutaneous lesions Scleral conjunctival injection appears on the third or fourth day of illness. Skin lesions, usually on the trunk (consisting of macules, papules, urticaria, and petechiae), occur in fewer than 50 percent of cases. Peripheral desquamation and infarction of portions of the hands and feet have been observed in a few children with leptospirosis. [39] Weil's disease, often but not exclusively because of serovar *icterohaemorrhagiae,* is a form of infection with prominent hepatic (jaundice) and renal (hematuria, azotemia) involvement. Hemorrhagic manifestations occur in a variety of organs, including the skin. Pretibial (Fort Bragg) fever is a form of leptospirosis (serovar *autumnalis*) that has a rather distinctive rash occurring on the fourth or fifth day of illness and consisting of slightly raised, 1- to 5-cm, tender, erythematous lesions on the pretibial areas. [41] The rash subsides within 4 or 7 days. Erythema nodosum has occurred in association with infection caused by *L. interrogans*.
Other physical findings These depend on the particular syndrome that is presented: pyrexia of unknown origin with localizing signs lacking so that epidemiology is critical to diagnosis; aseptic meningitis—nuchal rigidity; Weil's disease—jaundice and hepatomegaly with interstitial nephritis; generalized hemorrhagic tendency with epistaxis, hematuria, and gastrointestinal bleeding; and pretibial fever with splenomegaly are common. In up to 20 percent of patients with leptospirosis, generalized lymphadenopathy may be observed. Pulmonary involvement with radiologically demonstrable infiltrates occurs rarely. In children, acalculous cholecystitis has been observed occasionally. Rarely, myocarditis occurs.
LABORATORY FINDINGS The white blood cell count varies from a leukopenia to a mild leukocytosis, and thrombocytopenia can occur. In Weil's disease, white blood cell count may reach levels of 40,000/mm^3. A cerebrospinal fluid pleocytosis, with up to several hundred mononuclear cells, may be present. Abnormalities of liver function are common. Azotemia and hematuria occur in patients with renal involvement, and jaundice is usually present.
DIAGNOSIS AND DIFFERENTIAL DIAGNOSIS Skin manifestations are not specific but may suggest leptospirosis in the context of jaundice and aseptic meningitis. Conjunctival suffusion with petechiae or hemorrhages may be helpful clues. The differential diagnosis includes viral hepatitis, all the causes of a lymphocytic aseptic meningitis, nephritis, and the causes of a fever of unknown origin. The diagnosis is established most commonly by serologic means: a fourfold or greater rise in microagglutination titer (to >1:100), an IHA, or an IgM-specific dot-ELISA. [40] It can also be confirmed by isolation of the organism from blood during the first 10 days of illness. In a series of cases of leptospirosis among military personnel in Panama, leptospires were isolated from blood cultures of 23 of 29 patients studied. [42]
TREATMENT In a controlled trial in anicteric leptospirosis, doxycycline, when administered early in the course of the disease, proved effective, and it has been used successfully by the military as a prophylactic measure for short-term

exposure in a hyperendemic area. [43] Penicillin has also been recommended, but no controlled studies of its efficacy are available. The Jarisch-Herxheimer reaction has been reported in several patients who were treated with penicillin. [44]
COURSE AND PROGNOSIS Recovery is the rule in anicteric cases. In the presence of jaundice, the mortality rate may be as high as 40 percent, although a recent report describes 100 percent survival in 32 patients, only 14 of whom received adequate therapy. [40]

Pasteurella multocida Infections

Infections produced by *P. multocida* follow one of several patterns: local skin infection with adenitis following animal bites (the most common form of infection); septic arthritis and osteomyelitis following an animal bite (usually of the hand); respiratory tract infections or colonization; systemic infections such as meningitis, bacteremia, or spontaneous bacterial peritonitis. [45]

BACTERIOLOGY *P. multocida* is a small, ovoid, gram-negative rod. It grows readily on nutrient blood agar, but not on MacConkey agar.
EPIDEMIOLOGY Although this organism is primarily a pathogen among birds and animals, it occasionally infects humans. *P. multocida* can be isolated from the upper respiratory tract of healthy cats, dogs, rats, and mice. Animal exposure has occurred in 70 to 80 percent of patients with *P. multocida* bacteremia. Predisposing conditions (alcoholic cirrhosis, neoplastic disease, chronic obstructive pulmonary disease) could be identified in the majority of patients. [46]
CLINICAL MANIFESTATIONS
History Local pain and swelling occur within a few days of a cat or dog bite. There is little if any fever.
Cutaneous lesions Redness, swelling, ulceration, and seropurulent drainage develop at the bite site. Cellulitis may progress rapidly and extensively, with associated lymphangitis. Local necrosis and abscess formation may follow, and necrotizing fasciitis has been reported, accompanied by septic shock.
Other physical findings Regional adenopathy may be present. Complicating osteomyelitis and septic arthritis may occur as a result of the introduction of organisms beneath the periosteum or into a joint space by the biting animal.
LABORATORY FINDINGS Mild leukocytosis is present. After several weeks, an x-ray of underlying bone may show osteomyelitis. Histopathologically, an acute pyogenic response is seen.
DIAGNOSIS AND DIFFERENTIAL DIAGNOSIS The diagnosis is suspected when a painful infection develops at the site of an animal bite. It must be distinguished from cat-scratch disease. Local ulceration and proximal lymphadenitis mimic ulceroglandular tularemia, but the lesion is characteristically a necrotizing cellulitis and not chancriform in appearance. The diagnosis is established by isolation of the organism.
TREATMENT Most strains of *P. multocida* are susceptible to penicillin, the drug of choice. In patients with simple cellulitis, oral penicillin (penicillin VK at 500 to 750 mg orally four times daily for adults), ampicillin, or amoxicillin-clavulanate may reasonably be used, but close follow-up is mandatory. If a prior animal bite is suspected to have penetrated deeply close to periosteum, parenteral penicillin should be administered until the local lesion is well healed. *P. multocida* is also susceptible to third-generation cephalosporins. For the penicillin-allergic patient, doxycycline is a suitable alternative. Chloramphenicol or TMP-SMX may be effective therapy for the rare patient unable to tolerate either penicillin or doxycycline. Ciprofloxacin has activity against *P. multocida* in vitro. Abscesses should be surgically drained.
COURSE AND PROGNOSIS The infection responds to local measures and antibiotic therapy.

UNCOMMON DISEASES IN WHICH ANIMAL OR WATER CONTACT OR CLIMATOLOGIC FACTORS MAY OCCASIONALLY BE RELEVANT

Listeria monocytogenes Infections (Listeriosis)

Infection with *L. monocytogenes* produces characteristic acute disease in infants (neonatal septicemia, meningitis, and septic granulomatosis) and in both healthy and immunosuppressed adults (septicemia, meningitis, vaginal infection, pneumonitis, and oculoglandular syndrome). [47]

BACTERIOLOGY *L. monocytogenes* is a small, thin, gram-positive rod that often appears coccoid in infected tissues and body fluids. The organism may resemble a chaining streptococcus, a diplococcus, or a diphtheroid. It is non–spore-forming, beta-hemolytic, and exhibits a characteristic tumbling motility when grown in broth at room temperature. This is the classic facultative intracellular bacterium against which host resistance is mediated by thymus-derived lymphocytes (and macrophages).
EPIDEMIOLOGY *L. monocytogenes* is found in the feces of many wild animals and birds, and in soil and vegetation. Approximately 5 percent of humans (this is probably a minimal figure as it is difficult to isolate the organism from stool) appear to be fecal carriers of the organism. Higher rates of carriage have been observed in family contacts of patients with listeriosis. Food-borne (unpasteurized or improperly pasteurized milk or cheese; coleslaw made from cabbage grown on a farm where sheep manure had been used as fertilizer) outbreaks have been described. [48] Sporadic cases of *Listeria* meningitis have occurred in immunocompromised individuals one or two days after gastroenteritis in which *L. monocytogenes* has been found in large numbers in the stool. The highest incidence of infections is in the perinatal period, suggesting that the fetus either becomes infected in utero or on passing through the birth canal. Many, but not all, adult cases occur on a background of altered cellular immunity (Hodgkin's disease, immunosuppression for organ transplantation, etc.) or cirrhosis. [49] Transfusional iron overload may also be a predisposing factor for listeriosis. *L. monocytogenes* produces a protein in culture supernatants that mobilizes iron from transferrin. [48]
CLINICAL MANIFESTATIONS
History and cutaneous lesions Neonatal listeriosis occurs in two clinical forms: early and late onset. Early onset neonatal listeriosis develops in infants infected in utero from mothers who were undergoing a bacteremic illness with nonspecific symptoms shortly before the onset of labor. Findings are evident at birth or become apparent within the first several days of life. Widespread granulomas (placenta, liver, spleen, lung, etc.) are characteristic of the syndrome known as *granulomatosis infantiseptica*. Neonatal infection would be suggested in an acutely ill, moribund infant who was meconium-stained at birth and who subsequently exhibited generalized pustular, papular, or petechial skin lesions. Late

onset neonatal listeriosis usually occurs several weeks after a normal birth, presumably resulting from postpartum acquisition. Meningitis rather than sepsis is the clinical picture. Listeriosis in the adult is not accompanied by skin lesions. Veterinarians may develop an acute febrile illness with headache, malaise, and tender, red papular lesions on the hands and arms, some of which evolve into pustules 2 to 3 days after handling infected bovine fetuses. Characteristic gram-positive rods can be demonstrated in these skin lesions. Tender axillary adenopathy is frequently present. In oculoglandular infection, there is acute conjunctivitis with preauricular adenitis.

Other physical findings In infants, meconium staining of the skin, hepatosplenomegaly, and lethargy are commonly present. Acute meningitis is accompanied by typical signs in infants and adults.

LABORATORY FINDINGS In adults with meningitis, the inflammatory reaction is usually a predominantly neutrophilic pleocytosis; in infants, the response in the cerebrospinal fluid may be mononuclear in approximately one-third of cases.

PATHOLOGY Skin lesions show focal necrosis and infiltration by polymorphonuclear leukocytes and monocytes about blood vessels. Abscesses are found in viscera, and granuloma formation may also be evident.

DIAGNOSIS AND DIFFERENTIAL DIAGNOSIS Listeriosis should be suspected in any newborn with meconium-stained skin who exhibits intrauterine growth retardation, fails to thrive, or develops a papular skin eruption. Gram's stain of meconium shows the characteristic gram-positive rods. The skin lesions, cerebrospinal fluid, or blood cultures reveal the etiologic agent. The differential diagnosis includes other forms of in utero neonatal infection such as toxoplasmosis, cytomegalovirus infection, rubella, disseminated herpes simplex infection, and a variety of disseminated bacterial infections. The latter include those caused by group B streptococci, *Escherichia coli, Salmonella,* and *Pseudomonas*.

TREATMENT Ampicillin (or penicillin) is the antibiotic of choice, administered by the intravenous route in neonates in two or three divided doses. Care must be exercised in adjusting the dosage of penicillin in the newborn period to 50,000 to 250,000 units/kg per day; ampicillin is administered in a dosage of 100 to 200 mg/kg per day. In adults with meningitis or bacteremia, the dosage of penicillin G should be 12 to 24 million units intravenously daily (in divided doses every 2 to 4 h) and that of ampicillin should be 12 g intravenously (in divided doses every 3 to 4 h).

COURSE AND PROGNOSIS In neonatal septicemia and meningitis, morbidity and mortality are high (up to 50 percent). In adult infections, treatment is effective and recovery is the rule, unless the underlying disease prevents this.

Diphtheria

Diphtheria is an acute febrile illness involving primarily the pharynx and mucous membranes of the upper respiratory tract. The major manifestations of this disease are a result of (1) local membranous obstruction of the airway and (2) the effects of a potent cytotoxin on the myocardium and peripheral nervous system. The hallmark of the local lesion is a gray, leathery membrane. Rarely, the primary lesion may be located on the skin, or the infection may complicate a preexisting wound. This is characteristically seen in tropical areas. The early 1990s saw an upsurge of cases of diphtheria, primarily in the newly independent states of the former Soviet Union, but also in other areas of the world, including the United States. An awareness of its epidemiologic features, including cutaneous disease, argues for its inclusion in this chapter. [50]

BACTERIOLOGY The causative organism (*Corynebacterium diphtheriae*) is a gram-positive club-shaped rod that exhibits metachromatic bipolar granules on staining with methylene blue. It grows well on ordinary media, but its presence may be obscured by other bacteria and for this reason, selective media, such as Loeffler's or tellurite agar, should be used.

EPIDEMIOLOGY Humans are the only natural host for *C. diphtheriae*. The organism is carried in the pharynx of asymptomatic individuals. Infection occurs when a nonimmune person is infected by a toxigenic strain of *C. diphtheriae*; epidemics occur when such a strain becomes widespread in a population of nonimmune individuals. Cutaneous diphtheria and wound diphtheria occur in tropical areas (“jungle sore”) and in association with poor hygiene. There has been an increase in skin diphtheria in the United States in the Pacific northwest and in the south. [51] The contagiousness of cutaneous diphtheria may be greater than that of respiratory infection among school children. [52] Diphtheria is primarily a disease of young children and the elderly. In the United States, most cases occur among poor, crowded, unimmunized individuals. Because of the widespread use and protective effect of toxoid immunization, the disease is rare in this country. It should be stressed, however, that this protection does not prevent the development of the carrier state and subsequent spread of organisms to susceptible individuals. In the past several decades, increasing numbers of cases have occurred in unimmunized migrant farm worker families, in older alcoholics living in “skid row” situations, and among Native Americans in the western United States and Canada. Three outbreaks, involving a total of 1100 infections (40 percent caused by toxigenic strains), occurred in indigent alcoholics in Seattle between 1972 and 1982; 86 percent of these infections were cutaneous. In underdeveloped and overcrowded parts of the world, diphtheria remains an important health problem. The majority of cases of cutaneous and wound diphtheria occur in this setting and are associated with poor hygiene and skin trauma.

CLINICAL MANIFESTATIONS

History Faucial diphtheria usually presents with pharyngitis and low-grade fever. Toxicity is disproportionate to the degree of fever and local findings. As the disease progresses, swelling and pain in the neck, symptoms of airway obstruction, or unilateral nasal discharge may develop. Cutaneous diphtheria occurs in the presence or absence of pharyngeal disease. However, 20 to 40 percent of patients with cutaneous diphtheria carry the identical strain of *C. diphtheriae* in their respiratory tract. Symptoms of cranial or peripheral neuritis or of myocarditis may complicate the course. The latter usually occurs 5 to 14 days after the onset of the illness, whereas the former may develop any time from 2 weeks to several months after the primary lesion. Myocarditis is extremely rare as a complication of cutaneous diphtheria. Neurologic symptoms such as blurred vision, diplopia, numbness of the tongue, palatal paralysis, long-tract sensory and motor findings, and the Guillain-Barré syndrome have occurred in 3 to 5 percent of patients with ulcerated diphtheritic skin lesions.

Cutaneous lesions There are basically two types of skin involvement. [53] The first is wound diphtheria, which is a secondary infection of a preexisting wound that occurs in temperate as well as tropical climates and may involve any part of the body. This type accounts for almost all cases of cutaneous diphtheria reported in the United States. Underlying (primary) skin lesions include those caused by abrasions, chronic dermatitis (eczema, scabies, etc.), and various pyodermas. A latent period of up to 3 weeks transpires between initiation of the primary lesion and evidences of superimposed diphtheritic infection (pain, erythema, tenderness, exudate). The lesion is usually partially covered with a membrane; a purulent exudate is present, and a zone of edema and erythema surrounds the area. In the Seattle outbreak, coinfection with *S. pyogenes* occurred in 73 percent of diphtheritic skin lesions. [54] The second type is primary

cutaneous diphtheria, which begins acutely as a tender, pustular lesion, and then breaks down and enlarges to form an oval punched-out ulcer with a gray membrane at the base. (A similar appearance may be the result of secondary infection by *C. diphtheriae* of a primary lesion of streptococcal ecthyma.) Later, the membrane becomes dark brown. This ulcer has edematous, rolled, bluish margins, is usually located on a lower extremity, and is most often seen in the tropics. Skin lesions with the appearance of impetigo, ecthyma, infected insect bites, etc., have been described as yielding *C. diphtheriae* on culture. [51] Whether these represent true infections with *C. diphtheriae* or are the cutaneous equivalent of the respiratory carrier state is unclear.

Other physical findings A membranous pharyngitis may accompany cutaneous diphtheria. Cranial or peripheral nerve palsies may be present.

LABORATORY FINDINGS The organism can be isolated on appropriate media from the skin ulcer or pharyngeal membrane. There is nothing characteristic about the histopathologic picture of the diphtheritic lesion. The membrane is composed of coagulation necrosis and inflammatory cells.

DIAGNOSIS AND DIFFERENTIAL DIAGNOSIS A presumptive diagnosis is usually based on the findings of membranous pharyngitis in faucial diphtheria and of a shallow membrane-covered ulcer in cutaneous involvement. In methylene blue–stained smears of material from the edge of the membrane, the characteristic beaded metachromatically stained rods can be seen, but proof of the diagnosis must await culture results and demonstration of toxin production. However, the presence of a pharyngeal membrane, should be presumptive evidence of infection with *C. diphtheriae,* and treatment should be started immediately. Membranous infectious mononucleosis can mimic the picture of faucial diphtheria or be complicated by diphtheria. Tropical ulcers may be confused with diphtheritic skin lesions, but they penetrate below the fascia, involving muscle and tendons. Bacterial infections in ulcerated wounds and following trauma are usually purulent and without membrane formation. Cutaneous mycotic infections are frequently more proliferative, and their margins are irregular, without surrounding reactive edema. Nonpathogenic (nontoxigenic) diphtheroids may be present in open skin lesions as superficial contaminants. Impetigo-like lesions and nondistinctive secondary pyodermas should be cultured in any contacts of a patient with diphtheria. An organism closely related to corynebacteria, *Rhodococcus equi* (formerly *C. equi*), has been identified as a cause of inhalation lung disease in AIDS patients. Rarely, this organism, which resembles *C. diphtheriae* on Gram's stain, can be responsible for skin and subcutaneous infections in healthy individuals, especially those exposed to horse manure or following an injury contaminated with soil. [55]

TREATMENT In faucial diphtheria, treatment consists of both specific equine antitoxin and penicillin. Treatment is initiated on the basis of clinical suspicion without awaiting cultural confirmation, as toxin elaborated in the intervening period could lead to irreversible myocardial damage. In ulcerative cutaneous diphtheria of the lower extremities, bed rest is essential for healing. Antitoxin in doses of 20,000 to 40,000 units is given intravenously after careful testing for horse serum hypersensitivity. Diphtheria antitoxin is no longer commercially available but may be obtained, in appropriate cases, through the Centers for Disease Control and Prevention. Injection of antitoxin into the subcutaneous area around the ulcer and surface application on the lesion have been suggested. Penicillin (2 to 4 million units intramuscularly daily) or erythromycin (2.0 g orally daily) is administered for 7 to 10 days. A few inducible erythromycin- and clindamycin-resistant strains of *C. diphtheriae* were recently isolated from the lesions of cutaneous diphtheria. The lesion should be débrided and kept clean after antitoxin and antibiotics have been administered. Close contacts of a case of cutaneous diphtheria should be examined for any skin lesions (which should be cultured for *C. diphtheriae*); the pharynx should be cultured regardless of the presence of pharyngitis or a membrane. Prophylactic treatment of contacts with erythromycin (or penicillin) should be initiated. In addition, if the immunization status of close contacts is unclear or incomplete, they should receive proper immunization against diphtheria. For children, 7 years of age and older, and adults, the adult formulation of the combined diphtheria-tetanus toxoid (Td) preparation should be used rather than the pediatric DPT vaccine.

COURSE AND PROGNOSIS If treatment is begun early, the prognosis is excellent. In untreated, unimmunized persons with cutaneous diphtheria, ulcers may persist for as long as 6 months. Neuritic symptoms and signs may occur as late as 5 months after the onset of illness and are almost always completely reversible.

Cutaneous Infections Caused by *Vibrio* Species

Infections caused by *Vibrio* species produce several different clinical syndromes: gastroenteritis (the most common primarily caused by *V. parahaemolyticus* and *V. cholerae* non-01); wound (and ear) infections; and septicemia (either “primary” or secondary to a wound infection). [56] There has been an upsurge of reports of the septicemia syndrome caused by many *Vibrio* species, including their distribution to areas of more temperate climate (e.g., Cape Cod, MA, and Denmark). This appears to be associated with ingestion of raw shellfish, cutaneous injuries before or during ocean water exposures, and the potential for systemic disease in individuals with cirrhosis and immunodeficiencies. [57]

BACTERIOLOGY AND PATHOGENIC ASPECTS

Bacteriology Nine *Vibrio* species in addition to *V. cholerae* are associated with human disease. Five species are capable of producing wound infections: *V. parahaemolyticus, V. vulnificus, V. alginolyticus, V. cholerae* non-01, and *V. damsela*. Of these, *V. vulnificus* is the most pathogenic, causing severe wound infections and a “primary septicemia” syndrome with a mortality rate approaching 50 percent. The *Vibrio* species grow in regular blood culture media and are hemolytic on sheep blood agar; they are curved gram-negative rods.

Pathogenic aspects Markers for pathogenicity have been described for some *Vibrio* species. Almost all *V. parahaemolyticus* strains associated with disease (diarrhea) in humans produce a hemolysin. *V. vulnificus* produces extracellular collagenolytic, proteolytic, and elastolytic activities that may be important in the invasiveness of this pathogen. A metalloprotease exotoxin may be an important factor causing gross edema and cellulitis. *V. cholerae* non-01 secretes a dermonecrotic factor that may be of pathogenic significance in the development of hemorrhagic bullous skin lesions. Among the *Vibrio* species, *V. vulnificus* exhibits a striking pathogenicity when introduced into animal models by either the gastrointestinal or parenteral routes.

EPIDEMIOLOGY *V. parahaemolyticus* and *V. vulnificus* are commonly found in saltwater and estuarine sediments and are adherent to fish and concentrated within shellfish. *V. parahaemolyticus* has been implicated in 24 percent of reported cases of food-borne gastroenteritis in Japan; it also has been involved in shellfish-associated outbreaks of gastroenteritis in the United States. [58] *V. vulnificus* is responsible for occasional wound infections incurred following lacerations from shellfish or in seawater as well as for septicemia with metastatic skin lesions after ingestion of raw clams. *V. vulnificus* (and other *Vibrio* species) are endemic along the Gulf of Mexico, to a lesser extent along the Atlantic and Pacific coasts, and in regions of northern Europe (Denmark), particularly in the summer when seawater temperatures exceed 20°C

(68°F). Primary septicemia caused by *V. vulnificus* is associated with the eating of raw oysters and clams and particularly in the setting of hepatic cirrhosis, hemochromatosis, diabetes, glucocorticoid use, or prior gastric surgery.

CLINICAL MANIFESTATIONS

History Gastroenteritis is most commonly associated with *V. parahaemolyticus*. *V. vulnificus* may occasionally cause a similar gastroenteritis. More typically it is responsible for a wound infection with occasional secondary bacteremia occurring several days after a laceration sustained in seawater or brackish inland lakes. Primary septicemia with *V. vulnificus* (or other *Vibrio* species) may follow 24 to 48 h after consumption of raw oysters. Fever, chills, nausea, vomiting, abdominal pain, and diarrhea are frequent symptoms in patients with primary septicemia, suggesting an initial gastrointestinal site of infection.

Cutaneous lesions Traumatic wound infections caused by *V. vulnificus* may consist of pustular lesions, lymphangitis and lymphadenitis, or cellulitis. These infections may be mild or develop into rapidly progressive, painful cellulitis with myositis, extensive skin necrosis, and gangrene requiring amputation. Secondary bacteremia may ensue, complicated by metastatic cutaneous lesions. Skin lesions, in the form of large hemorrhagic bullae on the extremities (Fig. 199-4) or trunk, develop commonly in the course of primary *V. vulnificus* septicemia and are seen with other vibrios, including *V. cholerae* non-01. [57], [59] These progress to necrotic ulcers and necrotizing fasciitis and can eventuate on the lower extremity in muscle necrosis in the anterior compartment.

FIGURE 199-4 *V. vulnificus* cellulitis with hemorrhagic plaque and bullae on the legs of an older diabetic with cirrhosis.

Other physical findings Systemic manifestations (high fever, tachycardia, hypotension) are common in *V. vulnificus* septicemia. One-third of patients are in shock on presentation or shortly thereafter.

LABORATORY FINDINGS Although *V. parahaemolyticus* usually produces a watery diarrhea, occasional patients will have a dysentery-like syndrome with leukocytes and blood present in the stool. In *V. vulnificus* primary septicemia, leukopenia is more frequent than leukocytosis. Thrombocytopenia is common and may progress rapidly to disseminated intravascular coagulation. *V. parahaemolyticus, V. vulnificus,* and other *Vibrio* species can be grown on blood agar media and isolated from routine blood cultures.

DIAGNOSIS AND DIFFERENTIAL DIAGNOSIS Infection with a pathogenic *Vibrio* species should be suspected when gastroenteritis occurs in the summer months associated with a history of recent ingestion of raw shellfish or exposure to seawater, especially, along the Gulf Coast. The development of unexplained fever, shock, and bullous skin lesions in a patient with cirrhosis who has recently eaten raw oysters should alert the physician to the possible diagnosis of limb- or life-threatening primary *Vibrio* septicemia. Wound infections sustained in freshwater would suggest *A. hydrophila* rather than *Vibrio* species. Bullous lesions occurring in a hypotensive febrile patient could be secondary to bacteremic *P. aeruginosa* infection or even clostridial myonecrosis. Clostridial myonecrosis would be suggested by the presence of crepitus in the involved area and finding typical gram-positive blunt-ended bacilli in the contents of the bullae. *Pseudomonas* bacteremia would be unlikely in a nonleukopenic, nonhospitalized patient without a prior history of infection and antibiotic usage.

TREATMENT *V. parahaemolyticus* gastroenteritis is usually a mild to moderately severe form of diarrheal disease that requires no treatment other than oral fluid replacement. Management of *V. vulnificus* (or other *Vibrio* species) septicemia involves the reversal of hypotension with fluid replacement and treatment of systemic infection with both doxycycline (or chloramphenicol) and ceftazidime. Débridement of necrotic lesions is indicated.

COURSE AND PROGNOSIS *V. parahaemolyticus* gastroenteritis is a self-limited disease. In contrast, the mortality rate for *V. vulnificus* primary septicemia is approximately 50 percent, about three times as high as the mortality for wound infections caused by the same organism. In view of this, patients with cirrhosis, diabetes, AIDS, and other immunocompromising illnesses or treatments should be advised against consuming raw shellfish or exposure of preexisting wounds to contact with warm seawater.

Aeromonas hydrophila Infections

Clinical infections with aeromonads are usually associated with exposure to contaminated fresh or brackish water. The most common form of disease is gastroenteritis but, during the past several decades, many reports have documented the importance of one species, *A. hydrophila,* in skin, soft-tissue, and muscle infections, as well as in septicemic disease. [60] Except for the freshwater habitat of the causative organism, the diseases and patient population infected resemble those caused by *Vibrio* species.

BACTERIOLOGY AND PATHOGENESIS

Bacteriology Aeromonads are widespread in nature. The major pathogen, *A. hydrophila,* is a facultative gram-negative bacillus that grows well on basic blood and MacConkey agar.

Pathogenesis In healthy individuals not exposed to trauma in a freshwater setting, acute gastroenteritis is the most common expression of *Aeromonas* infection. Virulence factors, combined with trauma and fresh- or brackish-water exposure, and cirrhosis, malignancy, or immunodeficiencies, can lead to severe soft-tissue and septicemic disease.

EPIDEMIOLOGY Aeromonads are found worldwide, especially in fresh and brackish water. They are the cause of disease in many aquatic inhabitants, including fish, amphibians, and reptiles. The upswing in use of leeches for medical purposes has resulted in a number of cases of soft-tissue disease. Fish tanks, swimming pools, and tap water have been contaminated with these organisms; common source infections and nosocomial spread and disease have occurred.

CLINICAL MANIFESTATIONS

History The epidemiology may direct the clinician to consider a water-related disease, especially if there has been a laceration or dermatitis. Gastroenteritis is the major clinical complaint associated with *Aeromonas,* but, compared to *V. vulnificus,* it is unusual to have bacteremia and metastatic skin and soft-tissue complications. Fever and hypotension, jaundice, and local disease, such as spontaneous peritonitis, occur in patients with underlying cirrhosis, cancer, and

immunocompromising diseases or therapies.

Cutaneous lesions The most common lesion is cellulitis associated with a laceration, often followed by evidence of an underlying abscess or spread to deeper subcutaneous tissues, with or without palpable gas; localized in healthy individuals but progressive with bacteremia in debilitated patients. [61] The exudate often has a foul or fishy odor. Myonecrosis or necrotizing fasciitis may develop rapidly and mimic clostridial gas gangrene in its rapid onset (24 to 48 h after the initiating wound) and swift progression with severe pain, marked swelling, serosanguineous bullae, crepitation, and systemic toxicity. Occasionally, macular, papular, and ecthymatous lesions occur, indistinguishable from those caused by *P. aeruginosa*.

Other physical findings Evidence of cirrhosis or other underlying disease may be present, and jaundice is often apparent. A distended and tender abdomen may indicate spontaneous peritonitis.

LABORATORY FINDINGS Gram's stains of material aspirated from abscesses or bullae may contain gram-negative bacilli. Cultures are polymicrobial in over half of the patients; blood cultures may be positive, but less frequently than in *V. vulnificus* infections. Liver function tests may be abnormal; peritoneal fluid shows polymorphonuclear leukocytes, elevated protein concentration, and organisms on Gram's stain or culture. The presence of gas in deeper soft tissues may be appreciated by MRI, CT, or overpenetrated standard radiographic techniques.

DIAGNOSIS AND DIFFERENTIAL DIAGNOSIS The diagnosis is usually suspected from the epidemiologic history of a traumatic or an existing wound exposed to fresh or brackish water, followed by local cellulitis (often with gas formation), increasing pain, and foul discharge. Culture results are confirmatory; bacteremia is rarely demonstrated. The differential diagnosis includes infections caused by *Vibrio* species, streptococcal cellulitis including that caused by *S. iniae,* and necrotizing fasciitis caused by mixed flora in patients with underlying conditions such as diabetes.

TREATMENT Prompt surgical exploration and débridement are essential, often guided by radiologic studies. Most isolates are susceptible to fluoroquinolones and TMP-SMX. The third-generation cephalosporins and aminoglycosides, other than streptomycin, are also effective. Consideration must be given to the polymicrobial nature of these infections, and Gram's stain and culture are essential for antimicrobial decisions.

COURSE AND PROGNOSIS With extensive surgical intervention and appropriate antimicrobial therapy, patients improve rapidly. Prognosis is excellent except when bacteremia is present, which often indicates severe underlying disease and metastatic complications such as peritonitis.

REFERENCES

1. LaForce FM: Anthrax. *Clin Infect Dis* **19**:1009, 1994

2. Bush LM et al: Index case of fatal inhalational anthrax due to bioterrorism in the United States. *N Engl J Med* **345**:1607, 2001

3. Dixon TC et al: Anthrax, *N Engl J Med* **341**:815, 1999

4. Miller CJ et al: Anthrax protective antigen: Prepore-to-pore conversion. *Biochemistry* **38**:10432, 1999

5. Swartz MN: Recognition and management of anthrax—an update. *N Engl J Med* **345**:1621, 2001

6. Ivins BE et al: Immunization studies with attenuated strains of *Bacillus anthracis*. *Infect Immun* **52**:454, 1986

7. Centers for Disease Control and Prevention: Update: Investigation of bioterrorism-related anthrax and adverse events from antimicrobial prophylaxis. *MMWR Morb Mortal Wkly Rep* **50**:973, 2001

8. Ronaghy HA et al: Penicillin therapy of human anthrax. *Curr Ther Res* **14**:721, 1972

9. Inglesby TV et al: Anthrax as a biological weapon: Medical and public health management. *JAMA* **281**:1735, 1999

10. Centers for Disease Control and Prevention: Update: Investigation of bioterrorism-related anthrax and interim guidelines for exposure management and antimicrobial therapy. *MMWR Morb Mortal Wkly Rep* **50**:909, 2001:

11. Young EJ: An overview of human brucellosis. *Clin Infect Dis* **21**:283, 1995

12. Ariza J et al: Characteristics of and risk factors for relapse of brucellosis in humans. *Clin Infect Dis* **20**:1241, 1995

13. Ariza J et al: Characteristic cutaneous lesions in patients with brucellosis. *Arch Dermatol* **125**:380, 1989

14. Aziza J et al: Specific antibody profile in human brucellosis. *Clin Infect Dis* **14**:131, 1992

15. Reboli AC, Farrar WE: *Erysipelothrix rhusiopathiae*: An occupational pathogen. *Clin Microbiol Rev* **2**:354, 1989

16. Garcia-Restoy E et al: Bacteremia due to *Erysipelothrix rhusiopathiae* in immunocompromised hosts without endocarditis. *Rev Infect Dis* **13**:1252, 1991

17. Gorby GL, Peacock JE Jr: *Erysipelothrix rhusiopathiae* endocarditis: Microbiologic, epidemiologic, and clinical features of an occupational disease. *Rev Infect Dis* **10**:317, 1988

18. Nelson E: Five hundred cases of erysipeloid. *Rocky Mountain Med J* **52**:40, 1955

19. Venditti M: Antimicrobial susceptibilities of *Erysipelothrix rhusiopathiae*. *Antimicrob Agents Chemother* **34**:2038, 1990

20. Srinivasan A et al: Glanders in a military research microbiologist. *N Engl J Med* **345**:256, 2001

21. Kenny DJ et al: In vitro susceptibilities of *Burkholderia mallei* in comparison to those of other pathogenic *Burkholderia* spp. *Antimicrob Agents Chemother* **43**:2773, 1999

22. Brown TMcP, Nunemaker JC: Rat-bite fever. A review of the American cases with re-evaluation of etiology. *Bull Johns Hopkins Hosp* **70**:201, 1942

23. Place EH, Sutton LE: Erythema arthriticum epidemicum (Haverhill fever). *Arch Intern Med* **54**:659, 1934

24. Holroyd KJ et al: *Streptobacillus moniliformis* polyarthritis mimicking rheumatoid arthritis: An urban case of rat bite fever. *Am J Med* **85**:711, 1988

25. Weinstein MR et al: Invasive infections due to *Streptococcus iniae,* a fish pathogen. *N Engl J Med* **337**:589, 1997

26. Dance DAB: Melioidosis: The tip of the iceberg. *Clin Microbiol Rev* **4**:52, 1991

27. Leelarasamee A, Bovornkitti S: Melioidosis: Review and update. *Rev Infect Dis* **11**:413, 1989

28. Lumbiganon P, Viengnondha S: Clinical manifestations of melioidosis in children. *Pediatr Infect Dis* **14**:136, 1995

29. Handa R et al: Melioidosis: A rare but not forgotten cause of fever of unknown origin. *Br J Clin Pract* **50**:116, 1996

30. Suputtamongkol A et al: Ceftazidime vs. amoxicillin clavulanate in the treatment of severe melioidosis. *Clin Infect Dis* **19**:846, 1994

31. Butler T: *Yersinia* infections: Centennial of the discovery of the plague bacillus. *Clin Infect Dis* **19**:655, 1994

32. Mehigh RJ et al: Expression of the low calcium response in *Yersinia pestis*. *Microbiol Pathogenesis* **6**:203, 1989

33. Centers for Disease Control and Prevention: Fatal human plague—Arizona and Colorado, 1996. *MMWR Morb Mortal Wkly Rep* **46**:617, 1997

34. Hull HF: Septicemic plague in New Mexico. *J Infect Dis* **155**:113, 1987

35. Markowitz LE et al: Tick-borne tularemia. An outbreak of lymphadenopathy in children. *JAMA* **254**:2922, 1985

36. Evans ME et al: Tularemia: A 30-year experience with 88 cases. *Medicine (Baltimore)* **64**:251, 1985

37. Enderlin G et al: Streptomycin and alternative agents for the treatment of tularemia. Review of the literature. *Clin Infect Dis* **19**:42, 1994

38. Heath CW Jr et al: Leptospirosis in the United States: Analysis of 483 cases in man, 1949–1961. *N Engl J Med* **273**:857, 1965

39. Wong ML et al: Leptospirosis: A childhood disease. *J Pediatr* **90**:532, 1977

40. van Crevel R et al: Leptospirosis in travelers. *Clin Infect Dis* **19**:132, 1994

41. Daniels WB, Grennan HA: Pretibial fever. *JAMA* **122**:361, 1943

42. McClain JBL et al: Doxycycline therapy for leptospirosis. *Ann Intern Med* **100**:696, 1984

43. Takafuji ET et al: An efficacy trial of doxycycline chemoprophylaxis against leptospirosis. *N Engl J Med* **310**:497, 1984

44. Emmanouilides CE et al: Leptospirosis complicated by a Jarisch-Herxheimer reaction and adult respiratory distress syndrome. Case report. *Clin Infect Dis* **18**:1004, 1994

45. Weber DJ et al: *Pasteurella multocida* infections. Report of 34 cases and review of the literature. *Medicine (Baltimore)* **63**:133, 1984

46. Raffi R et al: *Pasteurella multocida* bacteremia: Report of thirteen cases over twelve years and review of the literature. *Scand J Infect Dis* **19**:385, 1987

47. Lorber B: Listeriosis. *Clin Infect Dis* **24**:1, 1997

48. Farber JM, Peterkin PI: *Listeria monocytogenes,* a food-borne pathogen. *Microbiol Rev* **55**:476, 1991

49. Stamm AM et al: Listeriosis in renal transplant recipients: Report of an outbreak and review of 102 cases. *Rev Infect Dis* **4**:665, 1982

50. Centers for Disease Control and Prevention: Toxigenic *Corynebacterium diphtheriae*—Northern Plains Indian community, August–October 1996. *MMWR Morb Mortal Wkly Rep* **46**:506, 1997

51. Belsey MA et al: *Corynebacterium diphtheriae* skin infections in Alabama and Louisiana. A factor in the epidemiology of diphtheria. *N Engl Med* **280**:135, 1969

52. Koopman JS, Campbell J: The role of cutaneous diphtheria infections in a diphtheria epidemic. *J Infect Dis* **131**:239, 1975

53. Flor-Henry P: Cutaneous diphtheria: Brief historical review and discussion of recent literature, with presentation of two cases. *Med Serv J Canada* **17**:823, 1961

54. Harnish JP et al: Diphtheria among alcoholic urban adults. A decade of experience in Seattle. *Ann Intern Med* **111**:71, 1989

55. Adal KA et al: Primary subcutaneous abscess caused by *Rhodococcus equi*. *Ann Intern Med* **122**:317, 1995

56. Morris JG, Black RE: Medical progress. Cholera and other vibrioses in the United States. *N Engl J Med* **312**:343, 1985

57. Howard RJ, Bennett NT: Infections caused by halophilic marine *Vibrio* bacteria. *Ann Surg* **217**:525, 1993

58. Hally RJ et al: Fatal *Vibrio parahaemolyticus* septicemia in a patient with cirrhosis. A case report and review of the literature. *Dig Dis Sci* **40**:1257, 1995

59. Kontajiannis DP et al: Primary septicemia caused by *Vibrio cholerae* non-01 acquired on Cape Cod, Massachusetts. *Clin Infect Dis* **21**:1330, 1995

60. Gold WL, Salit IE: *Aeromonas hydrophilia* infections of skin and soft tissues: Report of 11 cases and review. *Clin Infect Dis* **16**:69, 1993

61. Ko WC, Chuang Y-C: *Aeromonas* bacteremia: Review of 59 episodes. *Clin Infect Dis* **20**:1298, 1995

Chapter 200

Gerhard Tappeiner Klaus Wolff

Tuberculosis and Other Mycobacterial Infections

CLASSIFICATION OF MYCOBACTERIA
MYCOBACTERIA AND THE AIDS PANDEMIC
TUBERCULOSIS OF THE SKIN
Definition and Classification
Epidemiology and Incidence
Etiology and Pathogenesis
Histopathology
Polymerase Chain Reaction
SKIN DISEASE CAUSED BY M. TUBERCULOSIS/BOVIS INFECTION
Primary Inoculation Tuberculosis (Tuberculous Chancre; Tuberculous Primary Complex)
Tuberculosis Verrucosa Cutis (Warty Tuberculosis)
Tuberculous Cellulitis
Lupus Vulgaris
Scrofuloderma (Tuberculosis Colliquativa Cutis)
Metastatic Tuberculous Abscess (Tuberculous Gumma)
Orificial Tuberculosis (Tuberculosis Ulcerosa Cutis et Mucosae)
Acute Miliary Tuberculosis of the Skin (Tuberculosis Cutis Miliaris Disseminata)
BCG Inoculation
THE TUBERCULIDS
Lichen Scrofulosorum
Papulonecrotic Tuberculid
Nodular Vasculitis (Erythema Induratum of Bazin) See Chap. 109)
Erythema Nodosum
"NONTUBERCULIDS"
Lupus Miliaris Disseminatus Faciei
Rosacea-Like Tuberculid
Lichenoid Tuberculid
THERAPY OF SKIN TUBERCULOSIS
Chemotherapy
Drug Combinations and Regimens
Cytokines and Thalidomide
Special Considerations in Treating Tuberculosis of the Skin
OTHER MYCOBACTERIAL DISEASES
Identification of Mycobacteria
Pathology and Pathogenesis
Skin Infections with Atypical Mycobacteria

REFERENCES

It has been estimated that the genus *Mycobacterium* causes more suffering for humans than all the other bacterial genera combined. Twenty years ago it was assumed that tuberculosis would become extinct in the developed countries, as its incidence decreased at an average rate of 6 percent in the United States and 10 percent in Europe between 1953 and 1985. However, by 1983 tuberculosis was declared a "global emergency" by the World Health Organization because of a sharp increase in incidence (e.g., doubling in sub-Saharan Africa) largely due to the HIV pandemic. One-third of the world's population is thought to be infected; in the United States, this figure is estimated at 15 million. Currently, tuberculosis accounts for an estimated 8 million new cases and 3 million deaths per year, 98 percent of them in developing countries. It also accounts for 1.5 million new cases and for 500,000 deaths per year among children. It is thought to be responsible for 25 to 30 percent of avoidable deaths and thus has the highest morbidity and mortality rates of all infectious diseases. With respect to mycobacterial skin disease, the so-called atypical mycobacteria may be the cause of skin disease more frequently than *M. tuberculosis*. [1]

There are obligate and facultative pathogenic mycobacteria. In contrast to the obligate pathogens, the environmental, facultative pathogenic mycobacteria do not cause disease by person-to-person spread. Infections caused by the latter depend primarily on their occurrence and on individual susceptibility for infection. The immune and tissue responses of the host play a decisive role in determining the type and extent of disease produced by mycobacterial infection.

CLASSIFICATION OF MYCOBACTERIA

Mycobacteria are acid-fast, weakly gram-positive, nonsporulating, nonmotile rods. The family Mycobacteriaceae consists of only one genus, *Mycobacteria,* which includes the obligate human pathogens *M. tuberculosis* and the closely related *M. bovis, M. africanum,* and *M. microti,* as well as *M. leprae* and a number of facultative pathogenic and nonpathogenic species, the atypical mycobacteria. Runyon, in the first and still often used classification of atypical mycobacteria, distinguished a slow-growing and a fast-growing group. The slow-growing group was subdivided according to pigment-forming properties in culture: group I—photochromogens, capable of pigment formation on exposure to light; group II—scotochromogens, capable of pigment production without light exposure; and group III—nonchromogens. Group IV includes the rapid growers.

Today, approximately 60 species are named, 41 of which were included in the Approved Lists of Bacterial Names in

1980. [2] New species continue to be identified. Species may be cultivable or not (e.g., *M. leprae, M. genavense*). The main distinction in the group of cultivable mycobacteria, that between the slow growers and the rapid growers, seems to have occurred early in the development of the genus.

For clinical purposes, the organisms may be further subdivided into obligate and facultative pathogens and nonpathogens; Table 200-1 presents a classification scheme of the genus. *M. leprae* and *M. genavense* are not included because they are not available for biochemical testing. The listing is neither exhaustive nor definitive.

	Runyon Group
Slow-growing mycobacteria	
Obligate human pathogens†	
M. tuberculosis-bovis group including bacillus Calmette-Guérin (BCG) and *M. africanum*	
Facultative human pathogens	
M. kansasii	I
M. marinum	I
M. simiae	I
M. scrofulaceum	II
M. szulgai	II
M. gordonae	II
M. avium-intracellulare complex	III
M. haemophilum	III
M. ulcerans	III
M. xenopi	III
Nonpathogens	
M. flavescens	II
M. terrae complex	III
M. triviale	III
M. gastri	III
Rapidly growing mycobacteria	
Facultative human pathogens	
M. fortuitum	IV
M. chelonae	IV
M. abscessus	IV
Nonpathogens	
M. smegmatis	IV
M. phlei	IV
M. vaccae	IV
Others	

M. leprae and *M. genavense* are not included in this table.
†Obligate human pathogens are not included in the Runyon classification.

TABLE 200-1 **Classification of Mycobacteria***

MYCOBACTERIA AND THE AIDS PANDEMIC

The pandemic of AIDS, with its profound and progressive suppression of cellular immune functions, has led to a resurgence of tuberculosis and the appearance or recognition of new mycobacterial pathogens. In the United States, the *M. avium-intracellulare* complex is the most common cause of disseminated bacterial infections in patients with AIDS, accounting for 20 to 40 percent of cases [3]; it is found much less frequently in European patients. *M. kansasii* is more common than *M. tuberculosis*. [4] The incidence of tuberculosis in patients with AIDS is almost 500 times that of the general population.

The sharp increase in pulmonary and bacteremic or disseminated mycobacterial infections has not been paralleled by an equal increase in mycobacterial skin disease. Cutaneous disease in these patients is caused most typically by *M. marinum, M. scrofulaceum, M. haemophilum, M. gordonae,* and the rapid growers.

TUBERCULOSIS OF THE SKIN

Definition and Classification

Tuberculosis of the skin is caused by *M. tuberculosis, M. bovis,* and, under certain conditions, the bacillus Calmette-Guérin (BCG), an attenuated strain of *M. bovis*. The clinical manifestations comprise a considerable number of skin changes, usually subclassified into more or less distinct disease forms. Classification is based on morphology and, more recently, the mode of infection or the immunologic state of the host, but none of them satisfies completely. The classification used in this chapter distinguishes between exogenous infection and endogenous spread of *M. tuberculosis/bovis*; conditions caused by vaccination with BCG; and a group of eruptions, the tuberculids, whose pathogenesis is poorly understood (Table 200-2). Some entities of a nontuberculous nature, which were once thought to be related to tuberculosis and were thus included with the tuberculids, are mentioned briefly at the end of this section.

Exogenous infection	Primary inoculation tuberculosis (infection of the nonimmune host)
	Tuberculosis verrucosa cutis (infection of the immune host)
Endogenous spread	Lupus vulgaris
	Scrofuloderma
	Metastatic tuberculous abscess (tuberculous gumma)
	Acute miliary tuberculosis
	Orificial tuberculosis
Tuberculids	Tuberculids
	Lichen scrofulosorum
	Papulonecrotic tuberculid
	Facultative tuberculids
	Nodular vasculitis
	Erythema nodosum
	Nontuberculids
	These conditions are not related to tuberculosis but for completeness are briefly discussed in the text
Tuberculosis caused by BCG vaccination	

TABLE 200-2 **Classification of Cutaneous Tuberculosis**

Epidemiology and Incidence

Even though diseases caused by mycobacteria are widespread and serious, the organisms are neither very virulent nor very infectious. Only approximately 5 to 10 percent of infections with *M. tuberculosis* lead to disease; the rate is similarly low for *M. leprae* and is very much lower for the facultative pathogens. Tuberculosis of the skin has a worldwide distribution; once more prevalent in regions with a cold and humid climate, it now occurs mostly in the tropics. In

European and North American countries, the incidence of skin tuberculosis has declined steadily over the past decades, paralleling the decreasing incidence of pulmonary tuberculosis. So far, there has been no increase of skin tuberculosis proportional to the resurgence of pulmonary tuberculosis.

The two most frequent forms of skin tuberculosis are lupus vulgaris and scrofuloderma. In the tropics, lupus vulgaris is rare, whereas scrofuloderma and verrucous lesions predominate. Lupus vulgaris is more than twice as common in women as in men, while tuberculosis verrucosa cutis is most often found in men. Generalized miliary tuberculosis is seen in infants (and adults with severe immunosuppression or AIDS), as is primary inoculation tuberculosis. Scrofuloderma usually occurs in adolescents and the elderly, while lupus vulgaris may affect all age groups.

Etiology and Pathogenesis

M. tuberculosis, M. bovis, and, under certain conditions, the attenuated BCG organism cause all forms of skin tuberculosis. Mycobacteria multiply intracellularly and are initially found in large numbers in the tissue. The mere presence of mycobacteria in the skin, however, does not necessarily lead to clinical disease, and colonization with *M. tuberculosis* is not synonymous with tuberculosis.

THE MYCOBACTERIUM Different mammalian species vary in their susceptibility to infection with different mycobacteria. In humans, *M. tuberculosis* and *M. bovis* cause identical skin manifestations. The incidence of skin tuberculosis elicited by these two organisms depends on the exposure to either organism. In more than 50 percent of cases of lupus vulgaris, the bacteria exhibit a virulence that may be as low as that of the attenuated BCG organism. In many forms of skin tuberculosis, the number of bacteria in the lesions is so small that it may be difficult to find them in histologic sections, whereas large numbers of bacteria can be demonstrated in the affected tissues of a primary chancre or of acute miliary tuberculosis. *M. tuberculosis* may become dormant in the host tissue. These dormant bacilli are resistant to antimycobacterial drugs and may be responsible for latency and reactivation of mycobacterial disease. [5]
THE HOST The human species is quite susceptible to tuberculous infections, but differences exist among populations and individuals. Populations whose contact with tuberculosis spans many generations are, in general, less susceptible than those who have come into contact with mycobacteria more recently; genetic factors also play a role. Age, state of health, and somatic type of the individual are of importance, as are environmental factors. In Africans, tuberculosis frequently takes an unfavorable course, but tuberculin sensitivity may be more pronounced than in whites. After mycobacteria have invaded the host, either they may multiply and lead to progressive disease or their multiplication is checked or completely arrested. The balance between bacterial multiplication and destruction is determined not only by the properties of the invading organisms but also by the ability of the host to control such an infection. Thus, with an increasing number of patients with a compromised immune system, caused either by infection or by therapy, the emergence of hitherto unusual clinical presentations of mycobacterial disease may be expected. The skin of an individual previously infected with tuberculosis shows an altered inflammatory response on a second exposure to the organism. An extract containing the specific protein of the mycobacteria (tuberculin) is able to elicit the same, so-called Koch phenomenon, or tuberculin reaction.
THE TUBERCULIN REACTION (KOCH PHENOMENON) The tuberculin reaction is a result of delayed-type hypersensitivity, mediated by sensitized T lymphocytes that, when injected into a nonsensitized individual, transfer the hypersensitivity. Sensitization is induced by mycobacteria during primary infection. The substance eliciting this reaction in sensitized individuals was designated tuberculin by Robert Koch. This “old tuberculin” (OT) was widely used for skin testing but has now been replaced by a purified derivative [purified protein derivative (PPD)], which is preferable to OT because its potency and composition are more consistent. More recently, purified species-specific antigens were developed. The tuberculin reaction of a sensitized individual may vary in expression, depending on the test dose used and the route of administration. Local intradermal injection (the method most widely used) leads to the local tuberculin reaction, which usually reaches its maximum intensity after 48 h. It consists of a sharply circumscribed area of erythema and induration and, in highly hypersensitive recipients or after large doses, may lead to a pallid central necrosis. In an attempt to make the tuberculin reaction quantifiable, a test system based on the measurement of specific antigen-driven interferon (IFN)-? synthesis by whole-blood cells has been developed, but its usefulness remains to be determined. [6] In approximately 95 percent of individuals, tuberculin sensitivity develops from 2 to 10 weeks after infection with *M. tuberculosis* and persists throughout life. Its intensity may be reduced by conditions that diminish delayed hypersensitivity reactions. The state of sensitivity of an individual infected with *M. tuberculosis* is of considerable significance in the pathogenesis of tuberculous skin lesions. A primary infection of the skin (tuberculous chancre) will result in clinical manifestations that are quite different from those occurring after inoculation of mycobacteria into the skin of a previously sensitized individual (tuberculosis verrucosa cutis). Similarly, the hematogenous spread of mycobacteria in individuals with low or greatly diminished sensitivity will evolve into a skin disease (miliary tuberculosis of the skin) unlike that occurring in persons in whom sensitivity is high (lupus vulgaris). In patients with clinical tuberculosis, an increase of skin sensitivity usually indicates a favorable prognosis; and in tuberculous skin disease with high levels of skin sensitivity, the number of bacteria within the lesions is small. However, tuberculin sensitivity is not necessary for immunity against *M. tuberculosis,* and sensitivity and immunity do not always parallel each other. There is now sufficient evidence that they are dissociable and that a high degree of tuberculin sensitivity may even be antagonistic to protection. Mycobacterial infection seems to elicit at least two distinct cell-mediated immune responses, very likely of the T_H1 and the T_H2 types; both produce positive tuberculin tests but vary in their protective efficacy and thus play a role in the course and severity of the ensuing disease.
ROUTE OF INFECTION The mode of introduction of mycobacteria into the skin and the properties of the tissue components affected are also essential pathogenic factors. The infection may be exogenous (i.e., from an outside source), may occur by autoinoculation, or may be endogenous. Exogenous infection will lead to the tuberculous chancre or to tuberculosis verrucosa cutis, depending on the immunologic state of the host. Lupus vulgaris at the site of BCG vaccination represents another example of exogenous infection, in this instance by attenuated mycobacteria (see below). Endogenous spread of mycobacteria may occur by continuous extension of a tuberculous process underlying the skin (scrofuloderma), by way of the lymphatics (lupus vulgaris), or by hematogenous dissemination (acute miliary tuberculosis of the skin or lupus vulgaris). Finally, the structure and vascular supply of the tissue invaded by mycobacteria must also be considered. Lesions developing in the upper dermis assume a clinical appearance and course different from those developing in the subcutaneous tissues. Impairment of local blood supply may have an important additive effect, and local injury may act as a localizing factor.

Histopathology

The hallmark of tuberculosis and infections with some of the slow-growing atypical mycobacteria is the tubercle. It consists of an accumulation of epithelioid histocytes with Langhans-type giant cells among them and a varying amount of caseation necrosis in the center. This formation is surrounded by a rim of lymphocytes and monocytes. Although this tuberculoid granuloma is highly characteristic of several forms of tuberculosis, it is not pathognomic. Deep fungal infections, syphilis, and leprosy, among other diseases, can produce a similar and, at times, identical lesion. As in leprosy, the histopathology of skin tuberculosis may be reflective of the host's immune status.

Polymerase Chain Reaction

Polymerase chain reaction (PCR) has been increasingly used in recent years to ascertain the mycobacterial etiology of mycobacterial DNA in skin specimens from patients with various tuberculous skin diseases (e.g., lupus vulgaris, papulonecrotic tuberculid, nodular vasculitis). [7], [8] While the detection of specific DNA in tissues has yielded valuable information and some surprising results, and will conceivably gain importance in the future, scrupulous interpretation of the results of these tests in individual patients has yet to be done. [9] In one recent study, samples from 16 of 20 patients with sarcoidosis contained mycobacterial DNA, both tuberculous and nontuberculous. [10] In another study of skin biopsies from 105 patients with confirmed or highly probable cutaneous tuberculosis or with erythema induratum, PCR was 100 percent sensitive and specific in multibacillary disease and 55 percent sensitive and specific in paucibacillary disease. Skin biopsy specimens from 54 percent of patients with erythema induratum also contained mycobacterial DNA, and this finding correlated with response to antituberculous therapy in 80 percent of patients. [8] Thus, although PCR currently is useful to distinguish multibacillary tuberculosis from infections with atypical mycobacteria, it cannot as yet be used as a tool to unequivocally prove or exclude a role of mycobacteria in the pathogenesis of a clinical entity. Mycobacterial culture remains the most reliable method to determine the presence of live mycobacteria and their sensitivity to antibiotics and to monitor response to therapy. [11]

SKIN DISEASE CAUSED BY *M. TUBERCULOSIS/BOVIS* INFECTION

Primary Inoculation Tuberculosis (Tuberculous Chancre; Tuberculous Primary Complex)

Primary inoculation tuberculosis results from the inoculation of mycobacteria into the skin of a host not previously infected with tuberculosis. The tuberculous chancre and the affected regional lymph nodes constitute the tuberculous primary complex of the skin.

INCIDENCE Primary inoculation tuberculosis is estimated to constitute a very small proportion of all primary tuberculous lesions; however, it may be not quite as rare as generally believed. In some regions, particularly in Asia where the incidence of tuberculosis is still high and where living conditions and hygiene are poor, primary inoculation tuberculosis of the skin is not unusual. Most affected individuals are children, but the lesions may also occur in adolescents and young adults. All parts of the body may be affected, but sites of predilection are the face, hands, and lower extremities, which are readily injured. One-third of the lesions are found on the mucous membranes of the conjunctiva and oral cavity.
PATHOGENESIS Because tubercle bacilli cannot actively penetrate intact skin, they are introduced into the tissue at the site of minor abrasions or wounds. Rarely, infection may occur in healthy individuals after sexual contact with patients suffering from genitourinary tuberculosis. Oral lesions may be due to bovine bacilli from nonpasteurized milk and occur after mucosal trauma or tooth extraction. The skin lesion appears 2 to 4 weeks after inoculation. Infection spreads to the regional lymph nodes, producing tuberculous lymphadenitis; with increasing acquired immunity, the process is localized to the particular region involved. Primary inoculation tuberculosis is initially a multibacillary type of skin tuberculosis that becomes paucibacillary as immunity develops.
CLINICAL MANIFESTATIONS The tuberculous chancre initially presents as a small papule, scab, or wound with little tendency to heal. A painless ulcer develops, which may be quite insignificant or may enlarge to a diameter >5 cm (Fig. 200-1). The lesion is shallow with a granular or hemorrhagic base studded with miliary abscesses or covered by necrotic tissue. The ragged edges are undermined and of a reddish-blue hue; as the lesions grow older, they become more indurated, with thick adherent crusts.

FIGURE 200-1 Primary inoculation tuberculosis. Note tuberculous chancre on the thigh and regional lymphadenopathy. A positive tuberculin test is noted on the arm.

Wounds inoculated with tubercle bacilli may heal temporarily but break down later, giving rise to granulating ulcers. Mucosal infections result in painless ulcers or fungating granulomas. Inoculation tuberculosis of the finger may present as a painless paronychia; inoculations of mycobacteria in puncture wounds have resulted in subcutaneous abscesses. Slowly progressing, regional lymphadenopathy develops 3 to 8 weeks after the infection (see Fig. 200-1) and may rarely be the only clinical symptom. After weeks or months, cold abscesses may develop that perforate to the surface of the skin and form sinuses; the lymph nodes draining the primary glands may also be involved. Body temperature may be slightly elevated; occasionally, lymph node enlargement, abscess formation, and perforation may take a more acute course. Fever, pain, and inflammatory swelling of the surrounding tissues simulating a pyogenic infection are present in half the cases.

HISTOPATHOLOGY In the early phase, there is an acute nonspecific inflammatory reaction in both skin and lymph nodes, and mycobacteria are easily detected. After 3 to 6 weeks, the infiltrate and the regional lymph nodes acquire a tuberculoid appearance and caseation may occur.
DIAGNOSIS AND DIFFERENTIAL DIAGNOSIS Lack of awareness of the condition is probably the most common reason for diagnostic error. Any ulcer with little or no tendency to heal and unilateral regional lymphadenopathy in a child should always arouse suspicion. Acid-fast organisms can be demonstrated in histologic sections or in smears obtained from the primary ulcer and draining nodes in the initial stages of the disease, but may be difficult to find in older lesions. The diagnosis is verified by bacterial culture. The reaction to intradermal PPD is negative initially and later converts to positive (see Fig. 200-1). A previous tuberculous infection should be excluded. The differential diagnosis includes the primary complexes of syphilis, tularemia, cat-scratch fever, sporotrichosis, and ulcerative lesions of other mycobacterioses as well as other forms of skin tuberculosis.
COURSE Without treatment, the condition may last up to 12 months. Lesions heal by scarring, but in rare cases, lupus vulgaris develops at the site of a healed tuberculous chancre; in more than 50 percent of patients the regional lymph nodes calcify. Usually, the primary tuberculous complex yields satisfactory immunity, but reactivation of the disease may occur. Hematogenous spread may give rise to tuberculosis of other organs, particularly of the bones and joints. Depending on the size of the inoculum and the age and resistance of the host, primary inoculation tuberculosis may progress to acute miliary disease with fatal outcome. Erythema nodosum is a feature in approximately 10 percent of the cases.

Tuberculosis Verrucosa Cutis (Warty Tuberculosis)

This disorder is verrucous skin tuberculosis caused by exogenous reinfection in previously sensitized individuals.

INCIDENCE In Western countries, tuberculosis verrucosa cutis is rare. It is the most frequent form of tuberculous skin disease in Hong Kong, accounting for more than 40 percent of cases.
PATHOGENESIS Tuberculosis verrucosa cutis is inoculation tuberculosis occurring in persons who have acquired a certain degree of immunity; thus, skin tests are highly positive and it is a paucibacillary type of skin tuberculosis. Inoculation occurs at sites of minor wounds or abrasions or, rarely, from the patient's own sputum. In the past, certain professional groups, particularly physicians, pathologists, medical students, and laboratory attendants, were most liable to acquire warty tuberculosis from tuberculous patients or from autopsy material ("verruca necrogenica," "anatomist's wart," "postmortem wart"). Farmers, butchers, and knackers contracted the disease from tuberculous cattle, and in these cases, *M. bovis* was responsible. Children can become infected by playing on contaminated ground, a frequent occurrence in underdeveloped countries.
CLINICAL MANIFESTATIONS Tuberculosis verrucosa cutis usually occurs on the hands. In children, the sites of predilection are the lower extremities. The lesions are asymptomatic and start as a small papule or papulopustule with a purple inflammatory halo; they become hyperkeratotic and are often mistaken for a common wart. Slow growth and peripheral expansion lead to the development of a verrucous plaque with an irregular outline and a papillomatous horny surface (Fig. 200-2). Clefts and fissures discharging pus extend into the underlying brownish-red to purplish infiltrated base. The lesion usually is solitary, but multiple lesions may occur. The regional lymph nodes are rarely affected but may become enlarged from secondary bacterial infection.

FIGURE 200-2 Tuberculosis verrucosa cutis on the back of the hand.

HISTOPATHOLOGY The most prominent histopathologic features (Fig. 200-3) are pseudoepitheliomatous hyperplasia with marked hyperkeratosis, a dense inflammatory infiltrate, and abscesses in the superficial dermis or within the pseudoepitheliomatous rete pegs. Epithelioid cells and giant cells are found in the upper and middle dermis; typical tubercles are uncommon. Mycobacteria can occasionally be seen. At times, the dermal infiltrate may be nonspecific.

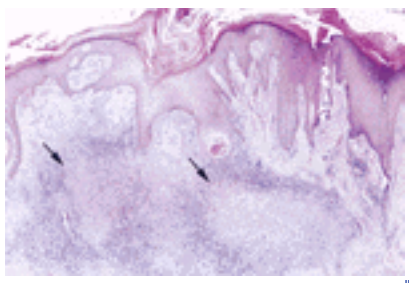
FIGURE 200-3 Tuberculosis verrucosa cutis. There is pronounced epidermal hyperplasia. Below the epithelium there is tuberculoid granulation tissue surrounded by lymphocytes (*arrows*).

DIAGNOSIS AND DIFFERENTIAL DIAGNOSIS Early lesions resemble warts or keratoses. Hyperkeratotic lupus vulgaris exhibits "apple-jelly" nodules at the periphery and occurs in sites where tuberculosis verrucosa cutis is rare (see below). Blastomycosis, chromomycosis, and bromoderma may be similar clinically and histopathologically but can be excluded by

special stains and by culture. Negative fungal cultures and small tuberculoid foci are diagnostic aids. Chronic vegetating pyoderma and hyperkeratotic lesions due to other mycobacteria may be difficult to exclude. Hypertrophic lichen planus is pruritic and more disseminated, and usually other cutaneous and mucosal lesions are found. Tertiary syphilis is not quite as verrucous and is accompanied by diagnostic serology.
COURSE The lesions progress slowly, and, if untreated, persist for many years. Secondary pyogenic infection may temporarily lead to more acute inflammatory changes, with lymphangitis and regional lymphadenitis. Spontaneous involution does occur and results in sunken atrophic scars. Occasionally, ulcerative and sclerotic lesions or fungating granulomas are seen.

Tuberculous Cellulitis

Two cases of “cellulitis” caused by *M. tuberculosis* were recently described in patients on long-term systemic glucocorticoid therapy. [12] A mode of infection was not determined, although one of the patients had been treated previously for pulmonary tuberculosis. Histopathologically, multinucleated giant cells, granulomas, and acid-fast bacilli were present. Both patients responded to antituberculous antibiotics.

Lupus Vulgaris

Lupus vulgaris is an extremely chronic and progressive form of tuberculosis of the skin occurring in individuals with moderate immunity and a high degree of tuberculin sensitivity.

INCIDENCE Although the incidence of lupus vulgaris has steadily declined during the past decades, it was estimated in 1960 that some 50,000 new cases occur throughout the world every year. It has always been less common in the United States than in Europe. Females appear to be affected two to three times as often as males; all age groups are affected equally.
PATHOGENESIS Lupus vulgaris is a postprimary, paucibacillary form of skin tuberculosis arising in previously sensitized individuals with only moderate immunity. It originates by hematogenous, lymphatic, or contiguous spread from tuberculosis elsewhere in the body, most often from cervical adenitis or pulmonary tuberculosis, but sometimes from an old, apparently quiescent primary complex. Rarely, it follows primary inoculation tuberculosis or BCG vaccination [13] (see below). The lesions progress steadily. Spontaneous involution may occur and new lesions may arise within old scars. Complete healing occurs only rarely without therapy.
CLINICAL MANIFESTATIONS The lesions are usually solitary, but two or more sites may be involved simultaneously; in patients with active pulmonary tuberculosis, multiple foci may develop. In approximately 90 percent of patients, the head and neck are involved. Lupus vulgaris usually starts on the nose or cheek and slowly extends onto adjacent areas. The earlobes are often affected, and solitary patches may be encountered on the scalp. Only a small percentage of the lesions occur on the extremities, and, except for patients with disseminated lupus vulgaris, the trunk is rarely involved. In general, lupus vulgaris is asymptomatic. The initial lesion is a brownish-red, soft or friable lupus macule or papule with a smooth surface or covered by a scale. On diascopy the infiltrate exhibits a typical apple-jelly color. Progression is characterized by elevation, a deeper brownish color (Fig. 200-4), and formation of a plaque. Involution in one area and simultaneous expansion in another result in a gyrate outline.

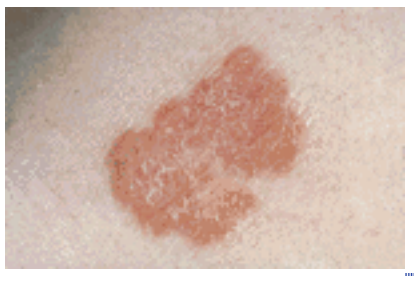
FIGURE 200-4 Slightly raised, brownish plaque of lupus vulgaris.

Lesions may become flat plaques with a serpiginous or polycyclic outline and a smooth surface (Fig. 200-4 and Fig. 200-5) or psoriasiform scaling; there may be erosions, ulceration, and scarring. Hypertrophic forms appear as a soft mass with a nodular (Fig. 200-6), hyperkeratotic surface (Fig. 200-7). Edema, lymphatic stasis, recurrent erysipelas, elephantiasic thickening, and vascular dilatation may lead to gross deformity. In ulcerative forms, the underlying tissue may be affected by progressive necrosis; involvement of the nasal or auricular cartilage results in extensive destruction and disfigurement (Fig. 200-8).

FIGURE 200-5 Lupus vulgaris. Large plaque of lupus vulgaris of 10 years' duration involving the cheek, jaw, and ear.

FIGURE 200-6 Hypertrophic form of lupus vulgaris involving the ear. There is a soft, brown, tumor-like thickening of the earlobe, which is partially eroded.

FIGURE 200-7 Hyperkeratotic lupus vulgaris on the thigh.

FIGURE 200-8 Lupus vulgaris of long duration, having led to the destruction of the nose. Ulcerating squamous cell carcinoma has developed on the upper lip.

Atrophic scarring, with or without prior ulceration, is a prominent feature of lupus vulgaris. Recurrence within a scar is characteristic. Sometimes, fibrosis is very pronounced and leads to deformations, mutilations, and contractures.

Lupus vulgaris of mucous membranes The mucosae may be primarily involved or become affected by the extension of skin lesions. They show small, soft, gray or pink papules, ulcers, or granulating masses that bleed easily. A dry rhinitis is often the only symptom of early nasal lupus, but progressive lesions destroy the cartilage of the nasal septum. Scarring of the soft palate and stenosis of the larynx may also result.

Lupus postexanthematicus After a transient impairment of immunity, particularly after measles (thus the term *lupus postexanthematicus*), multiple disseminated lesions may arise simultaneously in different regions of the body as a consequence of hematogenous spread from a latent tuberculous focus. During and after the eruption, a previously positive tuberculin test may become negative but will usually revert to positive as the general condition of the patient improves. Clinically and histopathologically, the lesions of postexanthematic lupus are typical for lupus vulgaris, and their appearance distinguishes the condition from acute miliary tuberculosis of the skin.

HISTOPATHOLOGY The most prominent histopathologic feature is the formation of typical tubercles (Fig. 200-9). Secondary changes may be superimposed: epidermal thinning and atrophy or acanthosis with excessive hyperkeratosis or pseudoepitheliomatous hyperplasia; acid-fast bacilli are usually not found. Nonspecific inflammatory reactions may partially conceal the tuberculous structures. Old lesions are composed chiefly of epithelioid cells and may be impossible to distinguish from sarcoidal infiltrates.

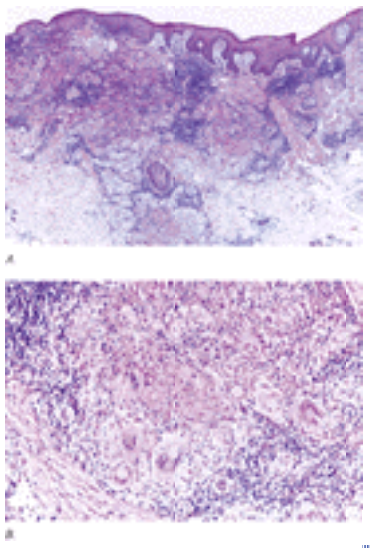

FIGURE 200-9 Lupus vulgaris. *A*. Epithelioid cell tubercles surrounded by dense lymphocytic infiltration but without caseation. There are some giant cells of the Langhans type. *B*. Higher magnification of a sarcoid-like epithelioid cell tubercle.

DIAGNOSIS AND DIFFERENTIAL DIAGNOSIS Typical lupus vulgaris plaques do not present diagnostic problems; they have to be distinguished from lesions of sarcoidosis, lymphocytoma, discoid lupus erythematosus, tertiary syphilis, leprosy, blastomycosis or other deep mycotic infections, lupoid leishmaniasis, and chronic vegetating pyodermas. Criteria helpful in the diagnosis are the softness of the lesions, the brownish-red color, and the slow evolution. The apple-jelly nodules revealed by diascopy are highly characteristic; finding them may be decisive, especially in ulcerated, crusted, or hyperkeratotic lesions. Histologic examination and a positive culture for *M. tuberculosis/bovis* confirm the diagnosis. The tuberculin test is strongly positive except for the early phases of postexanthematic lupus.

COURSE Lupus vulgaris is extremely chronic, and without therapy its course usually extends over many years or even decades. Thus, adults or older patients tend to have more extensive lesions than children. The disease is progressive and leads to considerable impairment of function and to disfiguration. Contractions result in a reduction of joint mobility, and ulceration and destruction of the cartilages of the face and scarring lead to disfigurement (see Fig. 200-8), to ectropion with its complications, to microstomia with impairment of speech and food intake, and to other severe mutilations. The most serious complication of long-standing lupus vulgaris is the development of carcinoma (see Fig. 200-8). In the early 1900s, carcinoma was estimated to occur in almost 10 percent of patients. Squamous cell carcinomas outnumber basal cell carcinomas by far, and the incidence of metastases is surprisingly high.

RELATIONSHIP OF LUPUS VULGARIS TO TUBERCULOSIS OF OTHER ORGANS In 40 percent of patients there is associated tuberculous lymphadenitis, and 10 to 20 percent have pulmonary tuberculosis or tuberculosis of the bones and joints. The rate of occurrence of pulmonary tuberculosis is 4 to 10 times higher in patients with lupus vulgaris than in the general population. In some cases, lupus vulgaris may be regarded as a symptom of another tuberculous disease running a more serious course.

Scrofuloderma (Tuberculosis Colliquativa Cutis)

Scrofuloderma is a subcutaneous tuberculosis leading to cold abscess formation and a secondary breakdown of the overlying skin.

PATHOGENESIS Scrofuloderma results from contiguous involvement of the skin overlying another tuberculous process, most commonly tuberculous lymphadenitis, tuberculosis of bones and joints, or tuberculous epididymitis. It may affect all age groups, although there is a higher prevalence among children, adolescents, and the aged. It may be either a multibacillary or a paucibacillary form of skin tuberculosis.

CLINICAL MANIFESTATIONS Tuberculosis colliquativa most often occurs in the parotidal, submandibular, and supraclavicular regions, as well as on the lateral aspects of the neck; lesions may be bilateral. Lesions on the extremities or on the trunk accompany tuberculous disease of the phalangeal bones, the joints, the sternum, and the ribs. Skin lesions first present as firm, subcutaneous nodules or as a well-defined, freely movable asymptomatic infiltrate. As the infiltrate enlarges it softens, but it may take months before there is liquefaction with subsequent perforation (Fig. 200-10). Ulcers and sinuses develop and discharge watery and purulent or caseous material. The ulcers are linear or serpiginous with undermined, inverted, bluish edges and uneven, soft, and granulating floors. Sinusoidal tracts undermine the skin, and clefts and dissecting subcutaneous pockets alternate with soft nodules; scar tracts develop and bridge ulcerative areas or even stretches of normal skin. Tuberculin sensitivity is usually pronounced.

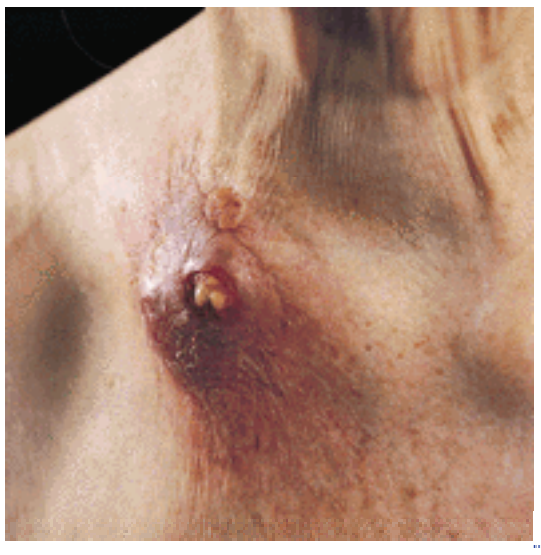

FIGURE 200-10 Scrofuloderma in the clavicular region. Note abscess formation, ulceration, and extrusion of purulent and caseous material.

HISTOPATHOLOGY Massive necrosis and abscess formation in the center of the lesion are nonspecific. However, the periphery of the abscesses or the margins of the sinuses contain tuberculoid granulomas and true tubercles, and *M. tuberculosis* can be found by acid-fast stains.
DIAGNOSIS AND DIFFERENTIAL DIAGNOSIS *M. avium-intracellulare* lymphadenitis and the more benign *M. scrofulaceum* infection have to be excluded by bacterial cultures. If there is an underlying tuberculous lymphadenitis or bone and joint disease, the diagnosis usually presents no difficulty. Syphilitic gummas, deep fungal infections, particularly sporotrichosis, actinomycosis, severe forms of acne conglobata, and hidradenitis suppurativa have to be excluded. The clinical diagnosis is confirmed by bacterial culture.
COURSE Spontaneous healing does occur, but the course is very protracted; it may take years before the inflammatory and ulcerative lesions have been completely replaced by scar tissue. The typical cribriform or criss-crossed scars permit a correct diagnosis, even after the process has become quiescent. Lupus vulgaris may develop at the site of scrofuloderma or in its vicinity.

Metastatic Tuberculous Abscess (Tuberculous Gumma)

DEFINITION AND PATHOGENESIS The metastatic tuberculous abscess is caused by hematogenous spread of mycobacteria from a primary focus during a period of lowered resistance, resulting in single or multiple cutaneous and subcutaneous lesions. It usually occurs in undernourished children or in immunodeficient or severely immunosuppressed patients. Occasionally, it may cause a carpal tunnel syndrome. It is a multibacillary type of skin tuberculosis.
CLINICAL MANIFESTATIONS Subcutaneous abscesses, which are generally nontender and fluctuant, arise either singly or as multiples on the trunk, extremities, or head (Fig. 200-11A); the lesions may invade the overlying skin and break down, forming fistulas and ulcers. Metastatic tuberculous abscesses may occur with progressive organ tuberculosis or in miliary tuberculosis but also without an underlying focus. Tuberculin sensitivity is usually lower than in other forms of skin tuberculosis and may be absent in severely ill patients.
HISTOPATHOLOGY As in scrofuloderma, massive necrosis and abscess formation are found. Acid-fast stains usually reveal copious amounts of mycobacteria (Fig. 200-11B).
DIAGNOSIS AND DIFFERENTIAL DIAGNOSIS All forms of panniculitis, deep fungal infections, syphilitic gumma, and hidradenitis suppurativa have to be excluded. The clinical diagnosis is confirmed by histopathology and bacterial culture.

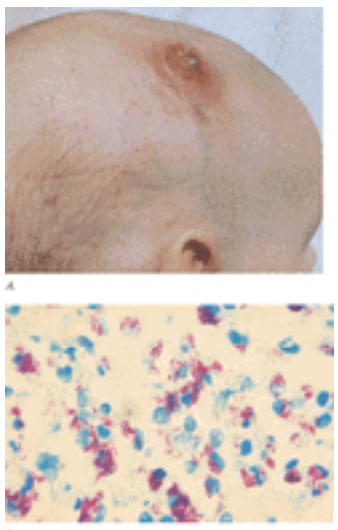

FIGURE 200-11 Metastatic tuberculous abscess on the scalp in an infant with combined immunodeficiency. *A*. Note abscess formation and discharge of purulent material but little inflammation. *B*. Histopathology of the lesion shown in (*A*) stained for acid-fast bacteria. There are hundreds of intracellular bacteria in this low-power field.

Orificial Tuberculosis (Tuberculosis Ulcerosa Cutis et Mucosae)

Orificial tuberculosis is a rare form of tuberculosis of the mucous membranes and the skin of the orifices due to autoinoculation of mycobacteria from progressive tuberculosis of internal organs.

PATHOGENESIS The underlying disease is far advanced pulmonary, intestinal, or, rarely, genitourinary tuberculosis. Mycobacteria shed from these foci in large numbers are inoculated into the mucous membranes, usually after trauma. Most patients show a positive intradermal tuberculin reaction, but in terminal stages anergy develops. Orificial tuberculosis is a multibacillary type of skin/mucous membrane tuberculosis.
CLINICAL MANIFESTATIONS In orificial tuberculosis of the mouth, the tongue is most frequently affected, particularly the tip and the lateral margins, but the soft and hard palates are also common sites. In advanced cases the lips are involved and the oral condition often represents an extension of ulcerative tuberculosis of the pharynx and larynx. In patients with intestinal tuberculosis, lesions develop around the anus, and in females with active genitourinary disease, the vulva is involved. A small yellowish or reddish nodule appears on the mucosa and breaks down to form a soft circular or irregular ulcer with a typical punched-out appearance, and undermined edges (Fig. 200-12). Its floor is covered by pseudomembranous material, and it often exhibits multiple yellowish tubercles and bleeds easily as a result of erosions of vessels. The surrounding mucosa is swollen, edematous, and inflamed. Lesions may be single or multiple and are extremely painful. The tenderness is often out of proportion to the size of the ulcers and results in dysphagia and inability to eat.

FIGURE 200-12 Orificial tuberculosis in advanced cavitary pulmonary tuberculosis.

HISTOPATHOLOGY There is a massive nonspecific inflammatory infiltrate and necrosis, but tubercles with caseation may be found deep in the dermis. Mycobacteria are easily demonstrated.
DIAGNOSIS AND DIFFERENTIAL DIAGNOSIS Painful ulcers of the mouth in patients with pulmonary tuberculosis should arouse suspicion. Large numbers of acid-fast organisms can be detected in smears, and bacterial culture confirms the diagnosis. Syphilitic lesions, aphthous ulcers, and carcinoma have to be excluded.
COURSE Orificial tuberculosis is a symptom of advanced internal disease with a most unfavorable prognosis. Affected individuals run a downhill course; and as the internal condition progresses, the orificial lesions enlarge and spread.

Acute Miliary Tuberculosis of the Skin (Tuberculosis Cutis Miliaris Disseminata)

DEFINITION AND PATHOGENESIS Miliary tuberculosis of the skin is an extremely rare skin manifestation of fulminating miliary tuberculosis caused by hematogenous dissemination of mycobacteria. [14] The initial focus of infection is either meningeal or pulmonary. The disease may follow immunosuppressive infections such as measles and HIV [15]; it most often occurs in babies and infants. Tuberculin sensitivity is usually absent. It is a multibacillary form of tuberculosis of the skin.
CLINICAL MANIFESTATIONS Disseminated lesions occur on all parts of the body, particularly on the trunk. They consist of minute erythematous macules or papules and purpuric lesions. Sometimes umbilicated vesicles or a central necrosis and crust develop.
HISTOPATHOLOGY Initially, necrosis, nonspecific inflammatory infiltrates, and small abscesses are prominent; occasionally signs of vasculitis may appear. Mycobacteria are present both in and around blood vessels. In later stages (if the patient develops immunity), lymphocytic cuffing of the vessels and even tubercles may occur.
DIAGNOSIS The eruption occurs in individuals already gravely ill, and because of the severity of the underlying process, it often goes unnoticed. A multitude of maculopapular and purpuric rashes must be excluded, but the diagnosis is usually suggested by the evidence of acute miliary disease of the internal organs.
COURSE The prognosis is poor, but a favorable outcome after treatment is possible.

BCG Inoculation

Vaccination with the attenuated bovine BCG appears to protect infants and young children from the more serious forms of tuberculosis, but its ability to prevent disease in adults remains uncertain. In the United States BCG immunization is recommended only in the following situations [16]:

1. For infants and children with negative tuberculin skin tests who (a) are at high risk of intimate and prolonged exposure to persistently untreated or ineffectively treated patients with infectious pulmonary tuberculosis, cannot be removed from the source of exposure, and cannot be placed on long-term preventive therapy; or (b) are continuously exposed to persons with tuberculosis who have bacilli resistant to both isoniazid and rifampin.
2. For tuberculin-negative infants and children in groups in which the rate of new infections exceeds 1 percent per year and for whom the usual surveillance and treatment programs have been attempted but are not operationally feasible. These groups include persons without regular access to health care, those for whom usual health care is culturally or socially unacceptable, or groups who have demonstrated an inability to effectively use existing accessible care. In view of the recent outbreaks of multidrug-resistant tuberculosis, these recommendations are currently under review.

Vaccination should be administered only by the route indicated in the package labeling and only in the suggested dose. If a newborn is vaccinated, one-half the usual dose should be used. Depressed host immunity (from illness such as HIV infection or therapy with immunosuppressive drugs) is a contraindication to BCG administration. However, untoward reactions are rare, even in HIV-infected persons. [17]

The normal course of BCG vaccination is as follows: After about 2 weeks, an infiltrated papule develops; after 6 to 12 weeks, the papule attains a size of about 10 mm, ulcerates, and then slowly heals, leaving a scar. Vaccination may provoke an accelerated reaction if given to a person who was previously infected but has a negative tuberculin test. The regional lymph nodes may enlarge but usually heal without breaking down. Tuberculin sensitivity appears 5 to 6 weeks after vaccination.

“Specific” complications caused by the BCG organism are lymphoglandular and skin reactions that mimic cutaneous responses to “natural” mycobacterial infection (Table 200-3). Their true incidence is difficult to ascertain, but it is extremely low in comparison to the great number of vaccinations performed in Europe in the past 50 years. Nonfatal generalized complications occurred in 1 or 2 persons per million; a perforating regional adenitis appeared in 2 percent of vaccinated children in Denmark, and the incidence of postvaccinal lupus vulgaris was estimated to be from 5 to 10 per million. Usually the BCG reactions run a milder course than “spontaneous” tuberculosis of the skin, and they occur more often after revaccination.

- Lupus vulgaris may develop at or in the vicinity of the vaccination site after a latency period of several months or after 1 to 3 years.[11,40]
- Individuals previously sensitive to tuberculin may exhibit a type of Koch phenomenon. Necrosis and ulceration occur as in normal nonsensitive individuals but with a shorter time course. Regional adenitis is common, and general symptoms may be present.
- Local subcutaneous abscesses may form if the vaccination material has been injected too deeply into the skin, and excessive ulceration may ensue.
- Severe regional adenitis is definitely the most common complication and occurs more often in the younger age groups. Scrofuloderma may develop, and suppuration may persist for 6 to 12 months.
- Generalized tuberculid-like eruptions are rarely observed.
- Generalized adenitis, osteitis, and tuberculous foci in distant organs (e.g., the joints) occur occasionally.

TABLE 200-3 **Specific Lesions after BCG Vaccination**

“Nonspecific” complications of BCG vaccination include keloid formation, epithelial cysts, granulomas, eczema, generalized hemorrhagic rashes, erythema nodosum, and other eruptions. After repeated vaccinations, fever, chills, arthralgia, and malaise may occur; anaphylactic shock may be fatal. Hepatic dysfunction and noncaseous granulomas containing the organisms have been observed.

Fatal disease caused by generalized BCG tuberculosis occurs in 1 in 10 million immunizations.

THE TUBERCULIDS

Originally considered to represent recurrent disseminated or systemic skin reactions to toxins of tubercle bacilli, with a tendency to spontaneous involution, the tuberculids were distinguished from “true” cutaneous tuberculosis. They included lichen scrofulosorum, erythema induratum, papulonecrotic tuberculids, lupus miliaris disseminatus faciei, and other eruptions with rather exotic designations.

During the first half of the twentieth century, tuberculids were eruptions quite familiar to dermatologists, but with the sharp decline and effective chemotherapy of tuberculosis in the developed countries, the tuberculids have also become rare. This does not appear to apply to areas where tuberculosis is still common, and with the recent resurgence of tuberculosis in some Western countries, some tuberculids have also been observed again.

Their pathogenesis and their relationship to tuberculosis are still poorly understood. While there is no doubt that such a relationship exists for some of them, there are good reasons to doubt it for others.

By using PCR, *M. tuberculosis* DNA was detected in skin lesions of erythema induratum (nodular vasculitis) and of papulonecrotic tuberculid. [18] In another series, however, 42 specimens from patients with erythema induratum, erythema nodosum, and papulonecrotic tuberculid were uniformly negative. [7] Thus, a positive PCR result still is rather weak proof for a pathogenic link to *M. tuberculosis*. [9]

Tuberculostatics have been found beneficial in some cases, and the involution of tuberculid lesions concomitant with the improvement of underlying tuberculosis has been described. However, some tuberculids tend to involute spontaneously, some cases do not respond to antituberculous treatment, and many react equally well to other antibiotics or even to plain rest and nonspecific measures.

The following discussion therefore employs a restrictive classification that acknowledges as tuberculids only those conditions for which a reasonable amount of evidence supporting a tuberculous etiopathogenesis exists (Table 200-4). Under this criterion, tuberculids comprise only lichen scrofulosorum and papulonecrotic tuberculid. Facultative tuberculids are conditions in which *M. tuberculosis* or its antigens can be considered as one of several possible causes; they comprise nodular vasculitis (erythema induratum) and erythema nodosum. Finally, nontuberculids are all those conditions that were formerly regarded as tuberculids but are, in fact, unrelated to tuberculosis.

Tuberculids (conditions in which M. tuberculosis/bovis appear to play a significant role)	1. Lichen scrofulosorum 2. Papulonecrotic tuberculid
Facultative tuberculids (conditions in which M. tuberculosis/bovis may be one of several etiopathogenic factors)	1. Nodular vasculitis (erythema induratum) 2. Erythema nodosum
Nontuberculids (conditions formerly designated tuberculids; there is no relationship to tuberculosis)	1. Lupus miliaris disseminatus faciei 2. Rosacea-like tuberculid 3. Lichenoid tuberculid

TABLE 200-4 **Tuberculids**

Lichen Scrofulosorum

Lichen scrofulosorum is a lichenoid eruption of minute papules occurring in children and adolescents with tuberculosis.

INCIDENCE AND PATHOGENESIS This uncommon disorder, first recognized by von Hebra, is ascribed to a hematogenous spread of mycobacteria in an individual strongly sensitive to *M. tuberculosis*. Lichen scrofulosorum is usually associated with chronic tuberculous disease of the lymph nodes and bones or with specific pleurisy, but is rare in phthisic patients; it has been observed after BCG vaccination and in association with *M. avium-intracellulare* infections. [19]

CLINICAL MANIFESTATIONS The eruption is asymptomatic and is usually confined to the trunk. The lesions consist of symptomless, small, firm, follicular or parafollicular papules of a yellowish or pink color; they have a flat top or bear a minute horny spine or fine scales on their surface. Lichenoid grouping is pronounced and results in the formation of rough, discoid plaques that tend to coalesce. The lesions persist for months, but spontaneous involution eventually ensues. Antituberculous therapy results in complete resolution within a matter of weeks.
HISTOPATHOLOGY Superficial tuberculoid granulomas develop around hair follicles but may also occur independent of the adnexa. Mycobacteria are not seen in the sections and cannot be cultured from biopsy material.
DIFFERENTIAL DIAGNOSIS Lichen planus, lichen nitidus, lichenoid secondary syphilis, and micropapular forms of sarcoidosis should be excluded.

Papulonecrotic Tuberculid

Papulonecrotic tuberculid is a symmetric eruption of necrotizing papules appearing in crops and healing with scar

formation.

INCIDENCE Reports on papulonecrotic tuberculids are rare. Today, the condition still appears to be not so uncommon in populations with a high prevalence of tuberculosis. It occurs preferentially in children or young adults.
PATHOGENESIS As a rule, bacteria cannot be demonstrated in lesions. In most cases, the tuberculin test is positive, and associated pulmonary or extrapulmonary tuberculosis is frequently found. [20] Lupus vulgaris was seen to evolve with papulonecrotic tuberculid. [21] This suggests that mycobacteria may have been present in the papulonecrotic lesions, but does not exclude the possibility that they may have lodged in these lesions secondarily. A prompt response to antituberculous therapy—irrespective of whether or not a tuberculous focus was known to exist—has been described. In several studies of skin lesions from patients with papulonecrotic tuberculid, [18], [22], [23] *M. tuberculosis* DNA was detected in approximately 50 percent of patients. It was also found in a patient with cutaneous *M. kansasii* infection. [24] Some forms of papulonecrotic tuberculid have been associated with discoid lupus erythematosus, arthritis, or erythema nodosum and may therefore be triggered by antigens other than those of *M. tuberculosis*.
CLINICAL MANIFESTATIONS Sites of predilection are the extensor aspects of the extremities, buttocks, and lower trunk (Fig. 200-13), but the eruption may become widespread. Distribution is symmetric and consists of disseminated crops of dusky red, symptomless, pea-sized papules with a central depression and an adherent crust over a crater-like ulcer. If the lesions are seated more deeply, they may enlarge to a diameter of 1 cm and acquire a more livid color. There is spontaneous involution, and pitted scars result. Usually there are no systemic symptoms.

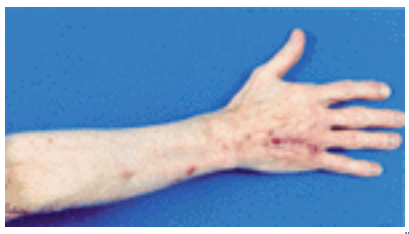

FIGURE 200-13 Papulonecrotic tuberculid on the forearm.

HISTOPATHOLOGY The most characteristic feature is a wedge-shaped necrosis of the upper dermis extending into the epidermis. The inflammatory infiltrate surrounding this necrotic area may be nonspecific but is usually tuberculoid. Involvement of the blood vessels is a cardinal feature and consists of an obliterative and sometimes granulomatous vasculitis leading to thrombosis and complete occlusion of the vascular channels. Recanalization of the vessels may be observed.
DIAGNOSIS AND DIFFERENTIAL DIAGNOSIS The diagnosis should be confirmed by histology. The exclusion of pityriasis lichenoides et varioliformis acuta may present difficulties as will eruptions caused by leukocytoclastic necrotizing vasculitis. The history, clinical appearance, and histology help to make the diagnosis. Lichen urticatus, prurigo, and secondary syphilis are easily excluded.

Nodular Vasculitis (Erythema Induratum of Bazin) See Chap. 109)

INCIDENCE Nodular vasculitis is quite common, particularly in Europe. The disease affects women in 90 to 95 percent of cases. The age of onset varies from the early teens to old age, but incidence peaks in adolescence and in menopause. There is a seasonal prevalence in winter and early spring.
PATHOGENESIS Active tuberculosis is found only rarely in these patients. Similarly, the tuberculin test is of no pathogenic significance; many patients exhibit high sensitivity, but up to 60 percent do not react to a 1:10,000 dilution of OT. PCR testing for mycobacterial DNA has so far not been helpful to clarify the issue. The introductory comments on the relationship of the tuberculids to tuberculosis are particularly relevant to the problem of “erythema induratum.” Nodular vasculitis now is considered to be a multifactorial syndrome of lobular panniculitis in which tuberculosis may or may not be one of a multitude of etiologic components. Today, most authors accept a subdivision of the erythema induratum-nodular vasculitis complex into two groups: one with and one without tuberculous etiology. At the same time, however, it is agreed that the term *erythema induratum* should be reserved for the first group, that is, for those cases in which the tuberculous origin can be proved. The demonstration of mycobacteria emerges as the only reliable criterion.
CLINICAL MANIFESTATIONS Most patients present with erythrocyanotic changes of the lower extremities and have heavy legs, with thick and firm but not edematous skin, and follicular perniosis. Cutis marmorata is common, and the histologic pattern reveals features of vasculitis. The vessels of the patients react abnormally to changes in ambient temperature. Thus, the eruptions are usually associated with exposure to cold. Clinical features are described in Chap. 109.

Erythema Nodosum (See Chap. 109)

Erythema nodosum is a septal panniculitis of the subcutis; it is associated with a variety of disease processes and results from inflammatory reactions that may be triggered by a multitude of antigenic stimuli including viral, bacterial, and mycobacterial antigens.

“NONTUBERCULIDS”

“Nontuberculids” are conditions with nontuberculous etiology that were previously considered to be tuberculids (Table 200-5).



TABLE 200-5 **Mycobacterial Infections**

The older dermatologic literature abounds with entities that were considered tuberculous in nature. Great significance was attached to nomenclature, and the resulting confusion is still reflected in the literature. In none of these conditions was the tuberculous etiology proved.

To avoid a perpetuation of the terminologic jumble, many of the older designations are not mentioned in this text. Most of them are synonymous.

Lupus Miliaris Disseminatus Faciei

Originally considered a variant of lupus vulgaris or a tuberculid, there is no evidence supporting a link to tuberculosis. Because the cause and pathogenesis of this condition are unknown, the designation lupus miliaris disseminatus is inappropriate. Some cases may represent a distinct entity, tentatively named "facial idiopathic granulomas with regressive evolution." [25] Others may be a micropapular forms of sarcoidosis. However, most represent a sarcoidal form of rosacea and respond to treatment with tetracyclines.

The eruption is uncommon and occurs in adults and adolescents of both sexes. It consists of multiple brownish-red, indolent papules with a smooth surface, 1 to 3 mm in diameter, symmetrically distributed in the centrofacial regions (Fig. 200-14); occasionally, more widespread dissemination occurs. The papules develop quite rapidly, may be follicular or nonfollicular, and are distributed at random. Diascopy reveals an infiltrate similar to the apple-jelly nodules of lupus vulgaris. Histopathology reveals well-defined globular masses of tuberculoid structures in the upper dermis. In the center, there may be frank necrosis, and thus the similarity to true tubercles may be striking. The condition runs a self-limited course. Individual papules regress, leaving pitted atrophic scars, and new crops of lesions arise. After a period of months or up to 2 years, the condition disappears spontaneously.

FIGURE 200-14 Condition formerly termed *lupus miliaris disseminatus faciei,* with the characteristic distribution of small follicular and nonfollicular papules. This disorder represents a sarcoidal form of rosacea.

Rosacea-Like Tuberculid

This condition was separated from ordinary rosacea on the basis of its tuberculoid histopathology. It is largely agreed that rosacea-like tuberculid is simply a micropapular form of rosacea with pronounced tuberculoid features (see Chap. 74).

Lichenoid Tuberculid

Lichenoid tuberculid is a sudden symmetric eruption, preferentially localized on the extremities but with a tendency toward generalization. [26] The lesions are brown to violaceous papules, with a diameter of 3 to 5 mm. They may be capped by an adherent scale, and telangiectases are present. Grouping and coalescence are prominent, and annular lesions may be formed. Involution results in brownish macules but no scarring. The condition probably also represents a sarcoidal reaction.

THERAPY OF SKIN TUBERCULOSIS

In many respects, the management of skin tuberculosis follows the same guidelines and has similar implications as that of tuberculosis of other organs. Chemotherapy is usually the treatment of choice, but ancillary measures may be required to provide the patient with optimal care. The type of cutaneous involvement, the stage of the disease, the level of immunity, and the general condition of the patient are important factors to be considered. Cutaneous tuberculosis associated with mycobacterial disease of internal organs requires a well-coordinated, multidisciplinary plan of therapy. The current guidelines for the treatment of tuberculosis are found in Ref. 27.

Chemotherapy

First-line drugs that are highly effective and which are used mainly in the initial treatment of susceptible organisms are isoniazid, rifampin, aminoglycosides, and ethambutol. Second-line drugs used mainly in the treatment of patients with

drug-resistant mycobacteria are pyrazinamide, ethionamide, viomycin, kanamycin, capreomycin, and cycloserine. The quinolones and particularly their fluorinated derivatives are active against *M. tuberculosis* and a number of other mycobacteria in vitro, and thus eventually may gain therapeutic importance.

Isoniazid remains the mainstay of antituberculous therapy. It is both tuberculostatic and tuberculocidal in vitro. It penetrates into all body fluids and cells and also into sclerotic tissue so that it is effective even in old fibrotic lesions. The common daily dose of the drug is 5 mg/kg, with a maximum of 300 mg. Side effects occur in 5.4 percent of patients treated and include fever (1.2 percent), skin eruptions (2.0 percent), peripheral neuritis (0.2 percent), hepatotoxicity, and hematologic complications (agranulocytosis, eosinophilia, anemia, and thrombocytopenia). Pyridoxine should be given concomitantly to prevent peripheral neuropathy, which may otherwise occur in as many as 20 percent of patients.

Pyrazinamide should be given in a dose of 15 to 30 mg/kg, with a maximum of 2 g daily.

Ethambutol, primarily a bacteriostatic drug given in doses of 15 to 25 mg/kg, is always used in combination with other drugs, usually rifampin and isoniazid. It accumulates in patients with impaired renal function and should not be given to children younger than 13 years of age. The incidence of side effects is low.

Rifampin is one of the most effective drugs for the treatment of tuberculosis. It should not be used alone because mycobacteria rapidly develop resistance in a one-step process. Although it produces a number of side effects, the incidence of these is low, seldom necessitating interruption of treatment. Rifampin is administered as a single oral dose of 600 mg/day, and patients should be warned that the drug may impart an orange stain to excretions, including saliva.

Streptomycin, a time-honored antibiotic in the treatment of tuberculosis, is bactericidal for *M. tuberculosis* in vitro, but in vivo its activity is essentially suppressive; it does not penetrate cell membranes (and thus cannot kill intracellular organisms). The toxicity of streptomycin prohibits continuous long-term therapy; nearly 75 percent of patients taking 2 g of streptomycin daily for 60 to 120 days develop vestibular disturbances and impairment of hearing. Other side effects include peripheral neuropathy, dysfunction of the optic nerve, rashes, fever, exfoliative dermatitis, and blood dyscrasias; but there is less nephrotoxicity than with other aminoglycoside antibiotics. Streptomycin is never used alone in the treatment of tuberculosis, and its use has been sharply reduced since other drugs have become available. It is given in doses of 1 to 2 g/day; it is usually combined with two other drugs to treat the more serious forms of tuberculosis.

Drug Combinations and Regimens

The aim of chemotherapy for tuberculosis is to cure the disease as rapidly as possible, to prevent the emergence of resistant strains, and to prevent relapses. The American Thoracic Society and the Centers for Disease Control and Prevention recommend the following regimen, [27] which comprises an initial, intensive phase and a continuation phase. Phase I is directed toward the rapid destruction of large populations of multiplying mycobacteria and therefore consists of initial, intensive chemotherapy: daily isoniazid, rifampin, pyrazinamide, and either ethambutol or streptomycin for 8 weeks; ethambutol or streptomycin may be discontinued if the mycobacteria prove susceptible to isoniazid and rifampin, or in areas where isoniazid resistance is less than 4 percent. Phase II aims at the elimination of remaining, “dormant” organisms: if they are susceptible to isoniazid and rifampin, these drugs are given either daily, three times weekly, or twice weekly for 16 weeks. If resistant mycobacteria are cultivated, the treatment regimen must be adapted accordingly.

Other treatment options on the basis of drug administration only two or three times weekly are also available but may be instituted only if “directly observed therapy” is possible.

Cytokines and Thalidomide

Although not yet established as a therapeutic option, cytokines [e.g., interleukin 2 (IL-2), interferon-?, IL-12, granulocyte/macrophage colony-stimulating factor] may help to control intracellular pathogens and thereby shorten the duration of therapy and overcome drug resistance. [28]

The immunomodulatory drug thalidomide (see Chap. 264) may prove to be useful to control the tumor necrosis factor a–related problems of the immune response in severe mycobacterial infection, [29] and could thus become an important adjunctive drug, as it is in leprosy.

Special Considerations in Treating Tuberculosis of the Skin

Essentially, the treatment of tuberculosis of the skin is that of tuberculosis in general. A full antituberculous regimen is administered, even in localized forms of skin tuberculosis where a primary focus or evidence of an underlying organ tuberculosis or tuberculosis of lymph nodes exists. Special considerations may apply to tuberculosis verrucosa cutis and localized forms of lupus vulgaris without evidence of associated internal tuberculosis, for which isoniazid has been given alone with a high cure rate. Prolonged treatment, extending up to 12 months, is necessary in these forms of lupus vulgaris, and total doses of 80 to 140 g may be required. Because viable mycobacteria have been cultured from clinically healed lesions, treatment should be continued for at least 2 months after complete involution of the lesions. If, however, there is concomitant internal tuberculosis, or if drug resistance emerges, then combination therapy is mandatory.

Careful observation and follow-up are essential. Surgical intervention is quite important in the treatment of scrofuloderma. It reduces morbidity and shortens the period necessary for chemotherapy. Small lesions of lupus vulgaris or of tuberculosis verrucosa cutis are also best excised, but tuberculostatics should be given concomitantly. Plastic surgery is important as a corrective measure in long-standing lupus vulgaris with mutilation.

OTHER MYCOBACTERIAL DISEASES

In addition to the overshadowing problem of infectious disease caused by *M. leprae* or *M. tuberculosis,* the pathogenic potential of other slow-growing mycobacterial species has been recognized only in the past five decades. The reasons are in part that these infections usually closely mimic infections with *M. tuberculosis* or, in rare instances, with other organisms, and in part that they have strict and often unusual requirements for culture.

M. ulcerans was identified as the cause of an ulcerating skin condition in Australia in 1948, and in the Buruli district of Uganda (hence the name Buruli ulcer) in 1958. *M. marinum,* which has been known since 1926, was isolated from patients with swimming-pool granuloma in 1954. Several other mycobacteria have since been identified as pathogens, producing a wide variety of clinical symptoms. [1], [30] Additional mycobacterial species may be found to cause disease in the future. The rapid growers have been known as human pathogens since 1938, when Da Costa isolated an organism, which he named *M. fortuitum,* from a postinjection skin abscess.

A current classification of these mycobacteria is found in Table 200-1, and is discussed at the beginning of this chapter.

Identification of Mycobacteria

As in other infectious diseases, the diagnosis of mycobacterial infection depends on the identification of the microorganism isolated from the host. Specimens should be sent to a special laboratory familiar with the culture requirements of mycobacteria, which vary somewhat from those of other microorganisms. Correct incubation temperatures, special media, and prolonged times in culture, as well as proper identification procedures, are needed.

Antigens for intradermal skin testing (PPDs) of many of the clinically relevant mycobacterial species have been prepared in analogy to PPD from *M. tuberculosis,* but are of very limited use.

As mentioned above, PCR testing for mycobacterial DNA is not yet reliable enough to play a role in the diagnosis of mycobacterial disease, but can be useful in the identification of the organism.

Pathology and Pathogenesis

These infections are thought to be the cause of mycobacterial skin disease more often than *M. tuberculosis* [1]; they tend to occur as sporadic cases, but certain types of exposure may lead to small community outbreaks. As in *M. tuberculosis* infection, any organ or organ system may be affected (see Table 200-5), but there seems to be much less tendency to dissemination.

Pulmonary infections, which most frequently occur in patients with a ventilatory defect (e.g., after long-term silica exposure), are pathologically indistinguishable from tuberculosis. Only two organisms, *M. ulcerans* and *M. marinum,* cause a disease with a distinct clinical picture. In contrast to *M. tuberculosis,* atypical mycobacteria are usually acquired from environmental sources (water, soil), and their occurrence reflects their natural distribution. These mycobacteria are widely distributed in different environments and are usually commensals or saprophytes rather than pathogens. An immunosuppressed state of the host or damage to a particular organ (e.g., in *M. kansasii* infection of the lung) facilitates these infections.

In recent years, a number of patients have developed infections with fast-growing mycobacteria after minor or major surgical procedures. Infections with atypical mycobacteria usually run a more benign and limited course than those with *M. tuberculosis*. As a rule, they are much less responsive to antituberculous drugs, but may be sensitive to other chemotherapeutic agents.

New mycobacterial pathogens are described from time to time, suggesting that we do not yet appreciate the full pathogenic potential of this genus. It seems desirable to develop a unifying concept of mycobacterial disease and its treatment, but at the present time, our knowledge in this area is not advanced enough to allow us to do so. Thus, mycobacterial skin infections are discussed here according to their causative organisms.

Bartralot et al. [31] discuss the general pattern of histopathologic features of these infections.

Skin Infections with Atypical Mycobacteria

M. MARINUM *M. marinum* occurs in fresh and salt water, including swimming pools (thus the older name *M. balnei*) and fish tanks.

Clinical manifestations [32] Risk factors for *M. marinum* infection are a history of trauma and water- or fish/seafood-related hobbies and occupations. The disease begins as a violaceous papule at the site of a trauma about 2 to 3 weeks after inoculation. Patients may present with a nodule or a psoriasiform or verrucous plaque at the site of inoculation, usually the hands, feet, elbows, or knees (Fig. 200-15); the lesions may ulcerate. Usually the lesions are solitary, but occasionally sporotrichoid spread occurs. Lesions frequently heal spontaneously within 1 to 2 years, with residual scarring. Sometimes penetration to underlying structures (bursae, joints) may occur. Regional lymph nodes are, as a rule, not involved. Occasionally the lesions are suppurative rather than granulomatous and may be multiple in normal or immunosuppressed hosts. Probably many of the cases described in the older literature and thought to represent “inoculation lupus vulgaris” as well as “swimmer's lupus,” have in fact been caused by *M. marinum* infection, as sea urchin granulomas possibly can be.

FIGURE 200-15 *A*. *M. marinum* infection on the back of the hand. Granulomatous nodular lesion with central ulceration at the site of inoculation. (*Courtesy of A. Kuhlwein, MD.*) *B*. Verrucous, violaceous plaque with central spontaneous clearing occurring at the site of an abrasion sustained in a fish tank. The lesion was caused by *M. marinum.*

Histopathology There is a tuberculoid inflammatory infiltrate in the dermis, sometimes with abscess formation.
Diagnosis and differential diagnosis As in all mycobacterial diseases, the diagnosis requires a high index of suspicion. An appropriate history (handling of fish, use of swimming pools) and the presence of a tuberculoid granuloma on histopathologic examination are suggestive. Skin testing with PPD is generally not helpful. Many other granulomatous infectious processes of the skin have to be considered in the differential diagnosis. Depending on the geographic area, other mycobacterial infections, blastomycosis, coccidioidomycosis, histoplasmosis, and sporotrichosis as well as nocardiosis, tertiary syphilis, and yaws have to be ruled out.
Treatment Like most atypical mycobacteria, *M. marinum* is poorly susceptible to antituberculous drugs, but spontaneous healing occurs frequently. Minocycline, 200 mg/day for 1 to 2 months, is the treatment of choice. In refractory cases the diagnosis should be reevaluated, and surgical therapy may be considered.
M. ULCERANS The natural habitat of *M. ulcerans* is still not known, and it has never been found outside the human body; but *M. ulcerans* infection occurs in wet, marshy, or swampy areas. *M. ulcerans* is the third most frequent mycobacterial pathogen in immunocompetent people.
Clinical manifestations [33] The disease is found most often in children and young adults; there is a female prevalence. After an incubation period of about 3 months, a painless subcutaneous swelling develops. The nodule gradually enlarges and eventually ulcerates; a blister may develop before ulceration. The ulcer is deeply undermined, and necrotic fat is exposed (Fig. 200-16). The nodule as well as the ulcer are painless, and the patient continues to feel well. The lesions may occur anywhere on the body but tend to be limited to the extremities in adults; they may be large, involving a whole limb. The ulceration may persist for months and years, and healing and progression of the ulceration may occur in the same patient. This process may lead to an appreciable and sometimes disabling amount of scarring and to lymphedema. Neither lymphadenopathy nor any constitutional signs appear at any time if the disease process is not complicated by bacterial superinfection.

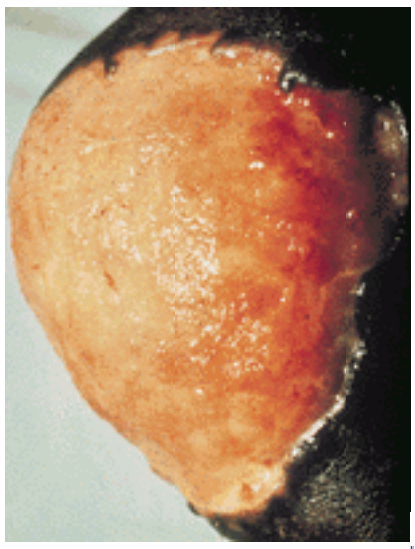

FIGURE 200-16 *M. ulcerans* infection in a child in Uganda. The knee bears an ulcer with an infiltrated undermined margin and a base of necrotic adipose and connective tissue. (*Courtesy of M. Dietrich, MD.*)

Histopathology Central necrosis, originating in the interlobular septa of the subcutaneous fat, is surrounded by granulation tissue with giant cells, but no typical caseation necrosis or tubercles. Acid-fast organisms can always be demonstrated in tissue sections.
Diagnosis and differential diagnosis Diagnosis is confirmed on the basis of histopathology and microbial culture from a subcutaneous node or an ulcer in an individual with an appropriate history. The differential diagnosis of *M. ulcerans* infection depends on the stage of the disease. The subcutaneous nodule must be distinguished from foreign body granuloma, phycomycosis, nodular fasciitis, panniculitis, nodular vasculitis, sebaceous cysts, or appendageal tumors. When the ulcerative stage is reached, necrotizing cellulitis, blastomycosis and other deep fungus infections, pyoderma gangrenosum, and suppurative panniculitis have to be considered.
Treatment The treatment of choice is simple excision of the early lesion; when ulceration has developed, wide excision and skin grafting are necessary. Local heat therapy, hyperbaric oxygen, and chemotherapy with rifampin and trimethoprim-sulfamethoxazole are of some value. BCG vaccination of exposed populations seems to provide about the same amount of protection as in tuberculosis and tuberculoid leprosy. Clofazimine is ineffective.
M. KANSASII *M. kansasii* is the atypical mycobacterium most closely related to *M. tuberculosis*. The organism is usually acquired from the environment; it has been found in tap water and in wild and domestic animals. In the United States, *M. kansasii* infection is endemic in Texas, Louisiana, the Chicago area, and California. It is also endemic in Japan. Skin disease caused by *M. kansasii* usually occurs in adults with or without an underlying condition such as Hodgkin's disease, immunosuppression for renal transplantation, or AIDS. The route of entry is usually through minor trauma such

as a puncture wound.
Clinical manifestations *M. kansasii* infection may present in several forms. Most frequently, there are papules in a sporotrichoid distribution; sometimes, subcutaneous nodules extend to deeper structures and may result in a carpal tunnel syndrome or joint disease; an ulcerated plaque may also develop as a metastatic lesion. Disseminated disease caused by *M. kansasii* infection occurs in immunosuppressed patients, and such patients have cellulitis and abscesses rather than granulomatous lesions. The most commonly affected organ is the lung, usually in patients with other pulmonary conditions (silicosis, emphysema). It may also cause cervical lymphadenopathy. As with *M. tuberculosis, M. kansasii* present in nasopharyngeal secretions can lead to periorificial cutaneous infection. These infections usually progress slowly, although a chronic persistent lesion or even spontaneous regression may occur. Consequently, drug therapy should be initiated as soon as the diagnosis is made.
Histopathology *M. kansasii* infection is histopathologically indistinguishable from tuberculosis.
Diagnosis and differential diagnosis The diagnosis can be confirmed only by the demonstration of *M. kansasii* in bacterial culture. The differential diagnosis includes sporotrichosis, tuberculosis, and other granulomatous infections of the skin (e.g., with *M. marinum* or *M. chelonae*).
Treatment *M. kansasii* is more susceptible than other atypical mycobacteria to antituberculous drugs, particularly to streptomycin, rifampin, and ethambutol. Multiple-drug regimens are of value, and the in vivo response does not always parallel in vitro sensitivities. As in *M. marinum* infection, treatment with minocycline hydrochloride, 200 mg daily, has resulted in complete resolution of sporotrichoid *M. kansasii* infection in one case, but more extensive studies of this regimen are not yet available. In localized skin disease, or in cervical lymphadenitis, surgical excision should be performed.
M. SCROFULACEUM This organism is widely distributed and has been isolated from tap water, soil, and other environmental sources. Infection probably occurs in children by accidental infestation or inhalation.
Clinical manifestations The usual manifestation of *M. scrofulaceum* infection is cervical lymphadenitis in young children, mainly between the ages of 1 to 3 years. Submandibular and submaxillary nodes are typically involved, rather than the tonsillar and anterior cervical nodes characteristic for *M. tuberculosis* infection. The disease is frequently unilateral. There are no constitutional symptoms except mild pain in the neck, but the involved lymph nodes enlarge slowly over several weeks, and eventually ulcerate and fistulate. There is no evidence of lung or other organ involvement. However, in older individuals with preexisting lung disease, pulmonary infection may rarely occur; and AIDS patients may have disseminated infection. [34] In most cases, the disease is benign and self-limited.
Histopathology *M. scrofulaceum* lymphadenitis is indistinguishable histopathologically from tuberculosis.
Diagnosis and differential diagnosis Unilateral cervical lymphadenitis in a young child with a normal chest roentgenogram should suggest this diagnosis. Skin testing with PPDs is usually negative. The diagnosis needs confirmation by bacterial culture of a biopsy specimen. Differential diagnoses include all causes of cervical lymphopathy, both infectious and neoplastic.
Treatment *M. scrofulaceum* is not very sensitive to antituberculous drugs; the treatment of choice for cutaneous lymph node disease is surgical excision. For more widespread disease, combinations of antituberculous drugs have to be tried until results from bacterial sensitivity testing are available.
M. AVIUM-INTRACELLULARE This species complex encompasses organisms with a wide variety of microbiologic and pathogenic properties. Well over 20 subtypes can be separated by immunologic techniques, although this is not necessary for clinical purposes. These organisms are usually grouped together with *M. scrofulaceum* in the so-called MAIS (*M. avium-intracellulare–scrofulaceum*) complex, but are separated here for clinical reasons. Whereas *M. scrofulaceum* produces only a benign, self-limited lymphadenopathy with no organ involvement, *M. avium-intracellulare* usually causes lung disease or, less frequently, osteomyelitis. It may also cause a cervical lymphadenitis with sinus formation that is clinically indistinguishable from tuberculous scrofuloderma.
Clinical manifestations Primary skin disease caused by *M. avium-intracellulare* has been reported in rare instances, presenting as single or multiple painless, scaling, yellowish plaques, sometimes resembling lupus vulgaris [35] or subcutaneous nodules, with a tendency to ulceration and a slowly progressing, chronic course. Sometimes, skin involvement occurs secondary to disseminated infection with *M. avium-intracellulare*. Skin lesions have included generalized cutaneous ulcerations, multiple cutaneous granulomas, infiltrated erythematous lesions on the extremities, pustular lesions, or soft tissue swelling. *M. avium-intracellulare* infections are an important cause of morbidity in patients with AIDS (see Chap. 225).
Histopathology Histopathologic examination of skin lesions shows noncaseating tuberculoid granulomas. Acid-fast bacilli can be found within giant cells and extracellularly.
Diagnosis and differential diagnosis Demonstration of *M. avium-intracellulare* in bacterial culture is necessary to establish the diagnosis. The differential diagnosis includes all chronic granulomatous conditions of the skin.
Treatment Where feasible, surgical treatment of *M. avium-intracellulare* infection is advisable as the organism seems to be poorly susceptible to chemotherapeutic agents. If dissemination of the disease does not allow curative surgery, combination therapy should be tried. Clarithromycin is the most effective antimicrobial agent against *M. avium-intracellulare* and should always be included in the therapeutic regimens. [36] Ethambutol, rifampin, amikacin, streptomycin, ciprofloxacin, clofazimine, azithromycin, and rifabutin are also highly active against *M. avium-intracellulare,* but isoniazid and pyrazinamide are not.
M. SZULGAI Cervical lymphadenitis as well as cellulitis or draining nodules and plaques are associated with *M. szulgai*. The organism causes bursitis and pneumonia; it is more susceptible to antituberculous drugs than most other atypical mycobacteria.
M. HAEMOPHILUM *M. haemophilum* was identified as the cause of a subcutaneous granulomatous eruption in several immunosuppressed and HIV-infected patients. Histopathologically, skin lesions show a mixed polymorphonuclear and granulomatous inflammation, the so-called dimorphic inflammatory response, with no caseation necrosis, similar to that seen in *M. fortuitum* complex infection (see below). The organism may be sensitive to *p*-aminosalicylic acid and rifampin.
M. GENAVENSE Little is known about the characteristics of *M. genavense*. It can cause disseminated disease similar to that caused by *M. avium-intracellulare* in patients infected with HIV. [37]
M. FORTUITUM, M. CHELONAE, M. ABSCESSUS These three species of rapid-growing, facultative pathogenic mycobacteria were usually grouped in the *M. fortuitum* complex. They now are recognized as distinct species. These organisms seem to be widely distributed and can commonly be found in soil and in water supplies. Contamination of various materials, including surgical supplies, occurs and does not always result in clinical disease.
Clinical manifestations These organisms cause similar clinical diseases. [38], [39] Infection usually follows a puncture wound or a surgical procedure. In one large series, it was found that cutaneous disease was present in 60 percent of

cases; of those, approximately one-half were a result of surgery and the other half were a result of accidental inoculation. The disease manifests itself as a painful red infiltrate at the site of inoculation; there are no signs of dissemination and no constitutional symptoms. This type of infection has followed augmentation mammoplasty, median sternotomy, and a variety of other procedures usually involving percutaneous catheterization. Cold postinjection abscesses, especially when occurring in the tropics, may also be caused by fast-growing mycobacteria. An outbreak of localized cutaneous postinjection abscesses or cellulitis in 350 patients was observed in Colombia. [39] It was suggested that the so-called fixation abscesses found in tuberculosis patients after intramuscular injections were often a consequence of inoculation with these organisms. Primary cutaneous inoculation occurs through skin injuries, in all age groups, without immunosuppression. The lesion presents as a dark red infiltrated node, often with abscess formation and clear fluid drainage. Disseminated disease involving the skin also occurs, usually in patients undergoing hemodialysis or those who are immunologically compromised. The skin lesions consist of multiple recurrent episodes of abscesses on the extremities or in a generalized macular and papular eruption. Other manifestations of infection with these organisms include pneumonitis or osteomyelitis, lymphadenitis, and postsurgical endocarditis.

Histopathology The lesions are characterized by the simultaneous occurrence of polymorphonuclear leukocyte microabscesses and granuloma formation with foreign body–type giant cells, the so-called dimorphic inflammatory response. There is usually necrosis but no caseation. Acid-fast bacilli may occasionally be found within microabscesses.

Diagnosis and treatment Organisms of the *M. fortuitum* complex may be identified by special laboratories. This is important for therapy because *M. fortuitum* is more susceptible to amikacin, cefoxitin, ciprofloxacin, and imipenem; *M. abscessus* is usually sensitive to amikacin, cefoxitin, and clarithromycin; *M. chelonae* is usually resistant to cefoxitin, and tobramycin is more effective than amikacin. Thus, a rational treatment has to await the identification of the organism and the results of in vitro susceptibility testing. In the Colombian series of 350 patients with postinjection abscesses caused by *M. abscessus,* a combination of surgical excision of the lesions and 3 to 6 months of clarithromycin resulted in a 95 percent cure rate, whereas either measure alone was successful in fewer than 30 percent of patients. [39]

REFERENCES

1. Dalovisio JR, Pankey GA: Dermatologic manifestations of nontuberculous mycobacterial diseases. *Infect Dis Clin North Am* **8**:677, 1994

2. Skerman VDB et al: Approved lists of bacterial names. *Int J Syst Bacteriol* **30**:225, 1980

3. French AL et al: Nontuberculous mycobacterial infections. *Med Clin North Am* **81**:361, 1997

4. Opravil M: Epidemiological and clinical aspects of mycobacterial infections. *Infection* **25**:56, 1997

5. Wayne LG: Dormancy of *Mycobacterium tuberculosis* and latency of disease. *Eur J Clin Microbiol Infect Dis* **13**:908, 1994

6. Mazurek GH et al: Comparison of a whole-blood interferon gamma assay with tuberculin skin testing for detecting latent *Mycobacterium tuberculosis* infection. *JAMA* **286**:1740, 2001

7. Tan SH et al: Detection of *Mycobacterium tuberculosis* DNA using polymerase chain reaction in cutaneous tuberculosis and tuberculids. *Int J Dermatol* **38**:122, 1999

8. Tan SH et al: Clinical utility of polymerase chain reaction in the detection of *Mycobacterium tuberculosis* in different types of cutaneous tuberculosis and tuberculids. *Ann Acad Med Singapore* **30**:3, 2001

9. Trinker M et al: False-positive diagnosis of tuberculosis with PCR. *Lancet* **348**:1388,1996

10. Li N et al: Identification of mycobacterial DNA in cutaneous lesions of sarcoidosis. *J Cutan Pathol* **26**:271, 1999

11. American Thoracic Society: Diagnostic standards and classification of tuberculosis in adults and children. *Am J Respir Crit Care Med* **161**:1376, 2000

12. Lee NH et al: Tuberculous cellulitis. *Clin Exp Dermatol* **25**:222, 2000

13. Stewart EJ, James MP: Lupus vulgaris-like reaction following BCG vaccination. *Clin Exp Dermatol* **21**:232, 1996

14. Rietbroek RC et al: Tuberculosis cutis miliaris disseminata as a manifestation of miliary tuberculosis: Literature review and report of a case of recurrent skin lesions. *Rev Infect Dis* **13**:265, 1991

15. Libraty DH, Byrd TF: Cutaneous miliary tuberculosis in the AIDS era: Case report and review. *Clin Infect Dis* **23**:706, 1996

16. Immunization Practices Advisory Committee and Advisory Committee for the Elimination of Tuberculosis: Use of BCG vaccines in the control of tuberculosis. *MMWR Morb Mortal Wkly Rep* **37**:663,1988

17. Felten MK, Leichsenring M: Use of BCG in high prevalence areas for HIV. *Trop Med Parasitol* **46**:69, 1995

18. Degitz K: Detection of mycobacterial DNA in the skin—Etiologic insights and diagnostic perspectives. *Arch Dermatol* **132**:71, 1996

19. Komatsu H et al: *Mycobacterium avium* infection of the skin associated with lichen scrofulosorum: Report of three cases. *Br J Dermatol* **141**:554, 1999

20. Jordaan HF et al: Papulonecrotic tuberculid in children. A report of eight patients. *Am J Dermatopathol* **18**:172, 1996

21. Senol M et al: Disseminated lupus vulgaris and papulonecrotic tuberculid: Case report. *Pediatr Dermatol* **17**:133, 2000

22. Victor T et al: Papulonecrotic tuberculid. Identification of *Mycobacterium tuberculosis* DNA by polymerase chain reaction. *Am J Dermatopathol* **14**:491, 1992

23. Baselga E et al: *Mycobacterium tuberculosis* DNA in papulonecrotic tuberculid. *Arch Dermatol* **132**:92, 1996

24. Callahan EF et al: Cutaneous *Mycobacterium kansasii* infection associated with a papulonecrotic tuberculid reaction. *J Am Acad Dermatol* **36**:497, 1997

25. Skowron F et al: F.I.GU.R.E: facial idiopathic granulomas with regressive evolution. Is “lupus miliaris disseminatus faciei” still an acceptable diagnosis in the third millennium? *Dermatology* **201**:287, 2000

26. Ockuly OE, Montgomery H: Lichenoid tuberculid. A clinical and histopathologic study. *J Invest Dermatol* **14**:415, 1950

27. American Thoracic Society: Treatment of tuberculosis and tuberculosis infection in adults and children. *Am J Respir Crit Care Med* **149**:1359, 1994

28. Holland SM: Cytokine therapy of mycobacterial infections. *Adv Intern Med* **45**:431, 2000

29. Tsenova L et al: Tumor necrosis factor alpha is a determinant of pathogenesis and disease progression in mycobacterial infection in the central nervous system. *Proc Natl Acad Sci U S A* **96**:5657, 1999

30. Weitzul S et al: Nontuberculous mycobacterial infections of the skin. *Dermatol Clin* **18**:xi, 359, 2000

31. Bartralot R et al: Cutaneous infections due to nontuberculous mycobacteria: Histopathological review of 28 cases. Comparative study between lesions observed in immunosuppressed patients and normal hosts. *J Cutan Pathol* **27**:124, 2000

32. Ang P et al: Retrospective study of *Mycobacterium marinum* skin infections. *Int J Dermatol* **39**:343, 2000

33. van der Werf TS et al: *Mycobacterium ulcerans* infection. *Lancet* **354**: 1013, 1999

34. Sanders JW et al: Disseminated *Mycobacterium scrofulaceum* infection: A potentially treatable complication of AIDS. *Clin Infect Dis* **20**:549, 1995

35. Kullavanijaya P et al: Primary cutaneous infection with *Mycobacterium avium intracellulare* complex resembling lupus vulgaris. *Br J Dermatol* **136**:264, 1997

36. Alvarez Elcoro S, Enzler MJ: The macrolides: Erythromycin, clarithromycin, and azithromycin. *Mayo Clin Proc* **74**:613, 1999

37. Pechère C et al: Clinical and epidemiologic features of infection with *Mycobacterium genavense. Arch Intern Med* **155**:400, 1995

38. Wallace RJ et al: Skin, soft tissue and bone infections due to *Mycobacterium chelonae*; importance of prior corticosteroid therapy, frequency of disseminated infections, and resistance to oral antimicrobials other than clarithromycin. *J Infect Dis* **166**:405, 1992

39. Villanueva A et al: Report on an outbreak of postinjection abscesses due to *Mycobacterium abscessus,* including management with surgery and clarithromycin therapy and comparison of strains by random amplified polymorphic DNA polymerase chain reaction. *Clin Infect Dis* **24**:1147, 1997

40. Vittori F, Groslafeige C: Tuberculosis lupus after BCG vaccination. A rare complication of the vaccination [in French]. *Arch Pediatr* **3**:457, 1996

T>

Chapter 201

Mauricio Goihman-Yahr Michael McNeil June Brown

Actinomycosis, Nocardiosis, and Actinomycetoma

ACTINOMYCOSIS
Epidemiology
Clinical Disease
Differential Diagnosis
Laboratory Diagnosis
Pathology
Serodiagnosis
Therapy
NOCARDIOSIS
Epidemiology
Nosocomial Infection
Clinical Disease
Differential Diagnosis
Pathophysiology
Laboratory Diagnosis
Diagnostic Immunology
Therapy
ACTINOMYCETOMA
Epidemiology
Clinical Disease
Histopathology
BOTRYOMYCOSIS
Diagnosis
Treatment

REFERENCES

Actinomycosis, nocardiosis, and actinomycetoma are chronic infections caused by human pathogenic species of filamentous bacteria. Actinomycosis is an infection caused by anaerobic *Actinomyces,* whereas aerobic actinomycete species cause nocardiosis and actinomycetoma. Actinomycosis is a chronic infection frequently of the cervicofacial area, thorax, or abdomen, usually caused by *Actinomyces israelii* and *A. gerencseriae,* but at least four other *Actinomyces* species (*A. naeslundii, A. viscosus, A. odontolyticus,* and *A. meyeri*), *Propionibacterium propionicum* (formerly *Arachnia propionica*), and *Bifidobacterium dentium* (formerly *Actinomyces eriksonii*) may also be responsible for similar or identical clinical symptoms. [1] Nocardiosis is primarily an infection of the lungs with a marked tendency to disseminate to multiple organs, particularly the brain. Members of the *Nocardia asteroides* complex (now separated into *N. abscessus, N. asteroides* sensu stricto type VI, *N. farcinica,* and *N. nova*) are the most common causes of nocardial disease in humans, but other species, including *N. brasiliensis, N. otitidiscaviarum,* and *N. transvalensis,* may also be etiologic agents. Actinomycetoma is a chronic infection of the subcutaneous tissues, skin, and bone. Actinomycosis, nocardiosis, and actinomycetoma may be occult at onset, progress in a chronic, indolent fashion, and be difficult to diagnose because of the similarity of their clinical features and, in cutaneous disease, their close resemblance to several other chronic dermatologic disorders.

In addition to the patient's clinical presentation, the demonstration of the microorganisms in smears of clinical material or in stained tissue sections may suggest the presumptive diagnosis; however, confirmation of the diagnosis depends upon the culture isolation and identification of the etiologic agents to the genus level (Table 201-1).



TABLE 201-1 **Presumptive Identification of the Major Medically Important Aerobic and Facultative Anaerobic Actiomycetes to the Genus Level**

The aerobic and facultative anaerobic actinomycetes belong to the order Actinomycetales. Phylogenetic investigations of 16S rRNA gene sequence clustering and the presence of unique signature nucleotides proposed by Stackebrandt et al. [2] generated a classification system for the genera described in this chapter: the genus *Actinomyces* and the related genus *Arcanobacterium* are classified in the family *Actinomycetaceae*; the genus *Propionibacterium* is classified in the family *Propionibacteriaceae*; the genus *Nocardia* in the family *Nocardiaceae*; and the genera *Streptomyces* and *Actinomadura* in the families *Streptomycetaceae* and *Thermomonosporaceae,* respectively. These taxa are in the lineage of the class *Actinobacteria,* order *Actinomycetales.* [2]

ACTINOMYCOSIS

Epidemiology

Actinomycosis is a rare infection that is worldwide in distribution. In the United States, it is more common in males. The disease's incidence is difficult to estimate because it is not a reportable disease and there is no skin test available for population surveys. The most common agents are *A. israelii* and *A. gerencseriae,* but at least four other *Actinomyces* species (*A. naeslundii, A. viscosus, A. odontolyticus,* and *A. meyeri)*, *Propionibacterium propionicum* (formerly *Arachnia propionica)*, and *Bifidobacterium dentium* (formerly *Actinomyces eriksonii*) may also be responsible for similar or identical clinical symptoms. Furthermore, eight new *Actinomyces* species (*A. europaeus, A. funkei, A. graevenitzii, A. neuii, A. radicidentis, A. radingae, A. turicensis,* and *A. urogenitalis*) [3] as well as the related taxon *Actinobaculum schaalii* [4] were recently isolated from patients with clinically less-specific inflammatory conditions, and two former *Actinomyces* species (*A. bernardiae* and *A. pyogenes*) were placed in the genus *Arcanobacterium.* [5] *Actinomyces bovis* causes granulomatous infections in cattle; however, this species is considered to be an unlikely human pathogen and earlier reports of human *A. bovis* infections might, in fact, have been caused by *A. israelii*. Of importance, characteristic actinomycotic lesions usually develop in the presence of concomitant flora that may consist of aerobic and/or anaerobic species. [6] Aerobic cultures chiefly yield coagulase-negative staphylococci, *Staphylococcus aureus,* alpha-hemolytic and beta-hemolytic streptococci as well as *Enterobacteriaceae* from abdominal and pelvic actinomycoses, whereas, anaerobic cultures chiefly yield *Actinobacillus* (*Haemophilus*) *actinomycetemcomitans* (25 percent of cases), so-called microaerophilic streptococci (mainly *S. milleri*), *Fusobacterium* spp., *Bacteroides, Prevotella* and *Porphyromonas* spp., *Leptotrichia buccalis, Eikenella corrodens,* and *Capnocytophaga* spp. [6]

The etiology of human actinomycoses is complex in two respects: the principal etiologic agents of the disease do not belong to a single species, but to a variety of different members of the genera *Actinomyces*, *Propionibacterium,* and *Bifidobacterium*. Furthermore, essentially all of the typical actinomycotic lesions contain between 1 and 10 bacterial species, in addition to the pathogenic actinomycetes. [1], [6] These concomitant bacteria apparently act as synergistic pathogens that strengthen the comparatively low invasive power of the pathogenic actinomycetes and are in particular responsible for the early symptoms of the disease and for treatment failures. [7] Because the etiologic term *actinomycosis* describes a polyetiologic inflammatory syndrome rather than a disease attributable to a single pathogen, it appears to be more appropriate to refer to this group of closely related conditions as “actinomycoses” in the plural.

Clinical Disease

Actinomycosis is a subacute to chronic bacterial disease that is characterized by slowly progressing, suppurative, fibrosing inflammation, development of draining sinus tracts that may discharge characteristic “sulfur granules,” and direct dissemination via contiguous tissues. It most commonly involves the cervicofacial area (Fig. 201-1), thorax (Fig. 201-2) or abdomen, including the pelvis, but rarely also the central nervous system (CNS), or bone.

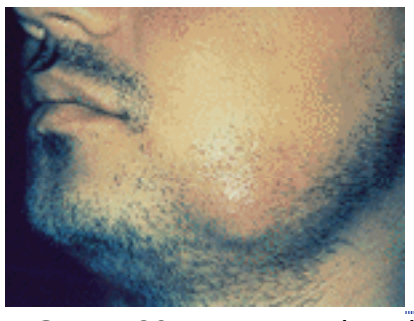

FIGURE 201-1 “Lumpy jaw” in a patient with cervicofacial actinomycosis. (*Courtesy of Maria Cecilia Albornoz, MD, Instituto de Biomedicina, Caracas.*)

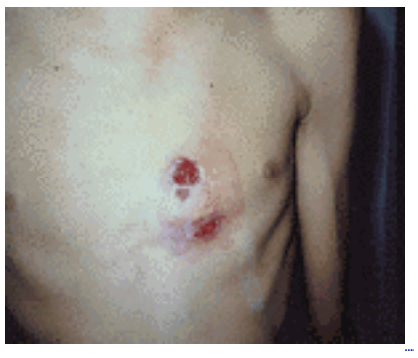

FIGURE 201-2 Ulcerated chest wall lesion from a patient who died from invasive actinomycosis. Note minimal drainage.

Cervicofacial actinomycosis is the most common form. Characteristic risk factors are poor oral hygiene resulting in periodontal abscesses or dental decay; orofacial trauma; foreign bodies penetrating the mucosal barrier such as bone splinters, fish bones, or spicules of grass or grain; and dental procedures. One to several weeks after dental extraction or mouth trauma, or spontaneously, the infection typically causes a painful, indurated cutaneous and soft tissue swelling (“woody” fibrosis) or presents as typical odontogenic abscess. The slowly enlarging inflammatory mass is most frequently located in tissue adjacent to the body of the mandible (54 percent), but may also involve cheek (16 percent), chin (13 percent), ramus and angle of the mandible (11 percent) (Fig. 201-1), upper jaw (6 percent), and mandibular joint (0.3 percent). [6], [8] Over ensuing weeks to months, the overlying skin may develop a bluish discoloration and become adherent, and the mass may become fluctuant and develop draining extra or intraoral sinuses that may extrude sulfur granules. Trismus may be prominent early in the patient's course; however, cervical lymphadenopathy is uncommon. Direct

extension may involve the tongue, sinuses, and meninges and, rarely, contribute to periostitis or osteomyelitis of the mandible. [6] Thoracic infection involving the lung and pleura is usually secondary to aspiration, but rarely may result from bloodstream dissemination. Pleuropulmonary infection may be complicated by mediastinal invasion with involvement of the pericardium and thoracic vertebrae. Actinomycosis of the gastrointestinal tract most commonly develops in the ileocecal region, but may also primarily involve the esophageal, gastric, or anorectal areas. Pelvic actinomycosis has been recognized with increasing frequency and predisposing factors have been identified to include intrauterine devices, contaminated pessaries, prolapse of the uterus, and septic abortion. [9], [10]

Differential Diagnosis

The most important conditions to consider in the differential diagnosis are other diseases that cause fistulae. These include granulomatous diseases such as Crohn's disease, foreign-body granulomas, tuberculosis, and certain pyogenic bacterial infections.

Actinomyces infections should be considered whenever there are chronic soft tissue orocervical lesions. However, the diagnosis of actinomycosis may be difficult when areas such as the pelvic, perigluteal, or perianal regions are affected. Steps in making the diagnosis include careful clinical examination, stained smear of exudate and culture isolation of the etiologic agent. In infected patients, the presence of an underlying immunodeficiency state should also considered, and evidence of polymicrobial infections should also be sought in histologic and microbiologic diagnostic tests.

Laboratory Diagnosis

A definitive diagnosis cannot be made solely on clinical grounds. The diagnosis of actinomycosis can be difficult and might depend on a heightened level of clinical suspicion and prior notification of the clinical laboratorian and pathologist. Detection of these microorganisms on Gram stain and culture from an appropriately obtained specimen is needed. Exudates and biopsy material are particularly suitable for laboratory examination. Bronchoscopy and bronchoalveolar lavage fluid smear examination and culture may be important in the diagnosis of thoracic actinomycosis. [8], [11], [12] After a sample is obtained, it should be examined by standard histologic methods and by immunofluorescence. In addition, a 2-week anaerobic culture should be performed.

CULTURE Culture is the least-reliable method of verifying infection (in Fiorino's series, only 35 percent of cultures were positive for *Actinomyces*) [10]; although an 86 percent success rate has been reported for samples cultured in the presence of metronidazole, which inhibits the growth of faster growing anaerobes. [13] Culture of abscess aspirates and vaginal and cervical swabs frequently grow multiple other species of microorganisms. Members of the genera *Actinomyces, Actinobaculum, Propionibacterium,* and *Bifidobacterium* are morphologically similar—anaerobic to less-stringently anaerobic bacteria. They are best isolated in prereduced anaerobic media such as thioglycollate with 0.5 mL sterile rabbit serum and may require 14 days of anaerobic incubation at 35°C (95°F). [14] Characteristically, they appear as gram-positive branched filaments (Fig. 201-3); however, fragmentation of these filaments readily occurs, producing bacillary or coccoid forms that are nonacid fast and nonmotile. Filamentous, microscopic colonies of *Actinomyces* species can be detected within 2 to 4 days of anaerobic incubation at 35°C (95°F). Mature colonies require 7 to 14 days to develop. Characteristics that differentiate these four genera from each other and from other anaerobically growing nonsporulating gram-positive bacteria are derived from cell wall or whole-cell analysis, acid end-product analysis, and certain physiologic tests that include fermentation of carbohydrates. These last tests are particularly necessary for differentiating between the various *Actinomyces* species, [14] but rapid and reliable identification to the species level may also be achieved by using direct or indirect immunofluorescence.

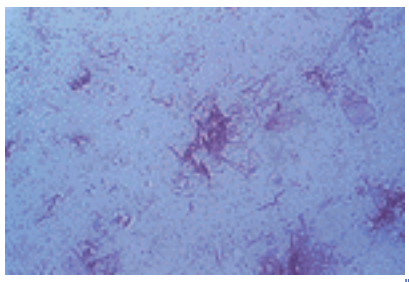

FIGURE 201-3 *Actinomyces israelii* filaments. Gram stain. Magnification, × 1022. (*Courtesy of Maria Cecilia Albornoz, MD, Instituto de Biomedicina, Caracas.*)

Actinomycosis-producing actinomycetes may be distinguished from aerobic, filamentous bacteria such as *Nocardia* species, *Rothia dentocariosa,* or *Corynebacterium (Bacterionema) matruchotii* by the type of carbohydrate metabolism (nocardiae are aerobes), by differences in cell wall composition (nocardiae and *C. matruchotii* contain *meso*-diaminopimelic acid, arabinose and galactose as well as mycolic acids in their walls), by partial acid-fastness and aerial filaments (nocardiae), and by resistance to penicillin (nocardiae). *R. dentocariosa,* which is often difficult to distinguish from aerobically growing *Actinomyces* species, is characterized by its ability to reduce nitrate as well as nitrite.

BIOCHEMISTRY *A. israelii* differs from the other *Actinomyces* species on the basis of acid production from anaerobic fermentative carbohydrates. [14] *P. propionicum* differs from the *Actinomyces* species biochemically on the basis of production of large amounts of propionic acid from glucose fermentation, the presence of ll-diaminopimelic acid in the cell wall, growth in the presence of lysozyme, and acid production from carbohydrates. [15] Differentiation of *Actinomyces* from other anaerobic nonsporulating gram-positive bacilli, such as *Bifidobacterium, Eubacterium,* and *Propionibacterium,* is based on acid production from carbohydrates, hydrolysis of esculin and gelatin, reduction of nitrate, production of indol and catalase, reaction in milk, and gas chromatographic analysis of the organic end products of glucose fermentation (Table 201-2).



TABLE 201-2 **Comparison of** *Actinomyces* **and** *Propionibacterium* **Species to Others of Related Genera***

Pathology

The organisms stain in tissue with Gomori methenamine silver (GMS) and the Brown and Brenn modification of the Gram stain (B&B). They are usually pleomorphic, gram-positive bacilli that appear beaded in older cultures because they take up stain irregularly. The presence of “sulfur granules” is highly suggestive but not diagnostic of actinomycosis. “Sulfur granules” comprise masses of matted, interconnected bacterial filaments that appear in vivo in a characteristic radial arrangement (see “ Actinomycetoma” later in this chapter). Microorganisms may be scarce in pathologic specimens, so detection may require diligent searching of multiple tissue sections. [16]

Serodiagnosis

Serodiagnosis of actinomycosis by detection of precipitating antibodies has not been a particularly useful diagnostic test. However, presumptive identification can be achieved by direct or indirect modification of the immunofluorescence technique. [17] Unfortunately, the fluorescein isothiocyanate-labeled (direct) and unlabeled (indirect) antisera needed for these tests, and used in research laboratories, are not commercially available. Expectorated sputum may be culture positive for *Actinomyces* because of contamination from upper airway secretions. In addition, it is important to collect specimens before initiation of antibiotics and to alert the laboratory to the clinical suspicion of actinomycosis so that anaerobic cultures may be observed for an appropriate period.

Therapy

Penicillin is the antimicrobial therapy of choice for deep-seated actinomycosis. Prolonged treatment with large doses of penicillin is required to achieve serum drug concentrations high enough to ensure drug penetration into areas of fibrosis and suppuration and possibly to penetrate the granules themselves. The goal of therapy is to administer intravenous penicillin G (150,000 to 200,000 U/kg per day or 10 to 20 million units per day in divided doses for adults) for 4 to 6 weeks (or for at least 3 to 4 weeks after the patient appears cured), followed by oral penicillin (e.g., phenoxymethyl penicillin, 2 to 4 g per day, to patient tolerance) for 6 to 12 additional months, or even longer, to prevent relapse. In a given patient, complications including disseminated infection, critical organ involvement (e.g., CNS), and/or associated inability to perform definitive surgery, may alter or extend this regimen. [18] Clinical resistance to penicillin may not be a major problem; however, there have been occasional reports of clinical failures and apparently considerably more therapeutic problems that were not published in the literature following penicillin therapy alone. [19], [20] Although there is some in vitro evidence to support the development of acquired resistance to penicillin, in vivo development of acquired antimicrobial resistance by *Actinomyces* species, particularly to penicillin G, has not been reported. When the clinical response to penicillin is poor, a search should be made for an undrained abscess; in addition, the possibility of a resistant concomitant bacterial species should be considered.

The therapeutic concept outlined above is primarily based on the view that the pathogenic fermentative actinomycetes are the principal or even sole target against which the antimicrobial chemotherapy has to be directed. Considering the impressive amount of bacteriologic data that indicate that human actinomycoses are essentially always synergistic mixed infections, perhaps this concept should be modified. Pulverer and Schaal, [7] as well as several other authors, have reported on characteristic clinical treatment failures of penicillin G therapy. These findings could be related to the presence either of *A. actinomycetemcomitans* or of beta-lactamase producing *Bacteroides* species, *Staphylococcus aureus,* or *Enterobacteriaceae*. Because *Bacteroides* species or *Enterobacteriaceae* are commonly found as concomitant organisms in abdominal and pelvic actinomycoses, the latter usually do not respond well to penicillin G treatment. In contrast, beta-lactamase producers, as well as penicillin G-resistant strains of *A. actinomycetemcomitans,* are less common in the cervicofacial form of the disease so that many of these cases may be effectively treated with high doses of benzoyl penicillin.

Compared with narrow-spectrum penicillins, the aminopenicillins are similarly active against the pathogenic fermentative actinomycetes, but clearly much more effective against *A. actinomycetemcomitans,* both in vitro and in vivo. Thus, therapy with comparatively high doses of aminopenicillins such as ampicillin or amoxicillin (4 to 8 g/day for adults) effectively helps to avoid the characteristic treatment failures or relapses of cervicofacial infections caused by *A. actinomycetemcomitans*. However, aminopenicillins are also susceptible to beta-lactamases so that the presence of bacterial beta-lactamase producers may impair their therapeutic efficacy. Consequently, general treatment schemes for human actinomycoses should include drugs that are effective not only against the causative actinomycetes and *A. actinomycetemcomitans,* but also against potential producers of beta-lactamases such as *Staphylococcus aureus,* various gram-negative anaerobes of the family *Bacteroidaceae,* and, in case of abdominal and pelvic actinomycoses, certain *Enterobacteriaceae*.

On the basis of the above considerations, the current recommendations for antibiotic treatment of human actinomycoses in Germany, according to which several hundred cases were treated essentially without any therapeutic failure or relapse, are as follows [20]: for cervicofacial actinomycosis, a combination of amoxicillin and clavulanic acid is the treatment of choice. The standard dose is 2.2 g amoxicillin plus clavulanic acid every 8 h for 1 week and then a lower dose of 1.1 g of the same combination every 8 h for another week. Only rarely will delayed clinical improvement of long-term chronic cervicofacial infections indicate that antibiotic treatment of 3 or even 4 weeks duration is required. Parenteral administration of the drugs is recommended; prolonged oral treatment was never found to be necessary. [20] For thoracic actinomycosis, the same therapeutic scheme may be sufficient. Although no reduction in the initial dose is

needed, antimicrobial therapy is usually continued for 3 to 4 weeks. In addition, patients with either advanced chronic pulmonary or abdominal disease may require the addition of 2 g ampicillin every 8 h to increase the aminopenicillin tissue levels (ampicillin is used in addition to amoxicillin to avoid possible side effects associated with high doses of amoxicillin). Treatment of abdominal and pelvic actinomycoses occasionally demands the combination of amoxicillin/clavulanic acid with an aminoglycoside such as tobramycin or gentamicin to inhibit resistant concomitant *Enterobacteriaceae.* [20]

In addition to antimicrobial therapy, surgical drainage of empyema and large abscesses and excision of sinus tracts, underlying foreign bodies, necrotic tissues, sequestra, and recalcitrant fibrotic lesions may be indicated in these infected patients.

NOCARDIOSIS (See also Chap. 207)

Epidemiology

Nocardia species are soil bacteria found worldwide as saprophytes on decaying matter and are not normal inhabitants of the respiratory or gastrointestinal tracts. Disease occurs by inhalation and males are three times more likely than females to become infected.

Nocardia spp. infections are rare in humans, occurring most frequently in patients who are severely immunocompromised. [21], [22] Most clinical infections in temperate countries were caused by *N. asteroides* complex, *N. brasiliensis* (Table 201-3), and, rarely, *N. otitidiscaviarum*. *N. asteroides* complex [comprised of *N. abscessus* (formerly *N. asteroides* sensu stricto type I), *N. asteroides* sensu stricto type VI, *N. farcinica, N. nova,* and possibly other unnamed taxa] is considered to be responsible for the majority of serious invasive infections. *N. brasiliensis* is associated particularly with subcutaneous infections and is predominant in tropical countries. [23], [24] A new taxon, *N. pseudobrasiliensis,* was separated from *N. brasiliensis* and appears to be generally associated with noncutaneous (pulmonary, CNS, or systemic) nocardiosis and differs in susceptibility to ciprofloxacin and resistance to minocycline. [25] *N. otitidiscaviarum* is rare and has no typical geographic distribution. [26] *N. transvalensis* is an unusual emerging human pathogenic *Nocardia* species. [22] Four new species of *Nocardia* were recently described: *N. africana,* [27] *N. brevicatena* complex, [28] *N. paucivorans,* [29] and *N. veterana.* [30]



TABLE 201-3 **Distinguishing Features of Systemic and Primary (Cutaneous) Forms of Aerobic Actinomycetes Infections Affecting the Skin**

Nosocomial Infection

Although nocardiosis is most often considered a late-presenting, community-acquired infection, nosocomial outbreaks of nocardiosis in immunocompromised patients attributed to airborne bacterial transmission have been reported. [31], [32], [33] and [34] These outbreaks of nocardiosis have affected patients in a renal transplant unit, [31] children with nocardiosis complicating hematologic malignancies, [32] severely immunocompromised heart transplant patients, [35], [36], [37], [38] and [39] and patients in a special care unit for patients with acute and chronic liver disease and liver transplants. [33]

Recently, three nosocomial endemic or epidemic outbreaks of *N. farcinica* surgical-site infections occurred. [37], [38] and [39] In one outbreak, the transmission of the infection was via an asymptomatic, colonized health care worker and the infectious source was confirmed epidemiologically by genetic methods to be the environment of the health care worker's home. [39] Although definitive sources of the infectious agents could not be identified in the other two outbreaks, it appeared that aerogenic transmission of *N. farcinica* occurred endemically during operative or postoperative treatment in a health care center in Germany. [37] The increase in the number of patients with *N. farcinica* of the same genotype (18 of 20), as identified by pulsed-field gel electrophoresis, correlated with increased construction work during a specific time frame. [37] These authors recommended that because of this correlation, precautions against nocardial infections should be taken in hospitals where renovation work is planned. [37] In the other outbreak involving three heart transplant recipients in France, randomly amplified polymorphic DNA analysis showed one pattern for the epidemiologically related isolates. [38] These outbreaks illustrate the importance of using epidemiologic and laboratory data as the basis for formulating effective control interventions for terminating nosocomial transmission of pathogenic organisms.

Patterson et al. also reported a pseudo-outbreak at a university hospital, in which 18 patient blood cultures were found to be falsely positive for *N. asteroides.* [40] An epidemiologic investigation revealed that the source of contamination was a malfunctioning automated radiometric blood culture machine, and the epidemic strain was confirmed by DNA fingerprinting. Control measures that were instituted and shown to be effective in halting the pseudo-outbreak were changing the needle sterilizer and prolonging needle sterilization time on the machine. [40]

An unusual cluster of nocardiosis cases was also reported among cancer patients who had received therapy in a clinic in the Bahamas. An investigation by the US Centers for Disease Control and Prevention (CDC) determined that the probable cause was contamination of parenterally administered cancer medications. [41] There are also reports of

cutaneous nocardiosis in patients following intravenous heroin abuse. [42], [43]

Clinical Disease

In immunocompromised patients, localized respiratory infection is thought to result from inhalation of *Nocardia* spp. However, in up to half the infected patients, dissemination may occur with a predilection for the CNS and subcutaneous tissues. The clinical manifestations, severity, and prognosis of disease in the infected patient are extremely variable, and may be determined by factors such as the route of infection and the presence or absence of a properly functioning immune system. In immunocompetent hosts, localized subcutaneous infection may result. In severely immunocompromised patients, principal predisposing factors include immunosuppressive therapy, particularly steroid drugs, neoplastic diseases, solid organ and bone marrow transplantation, chronic bronchopulmonary diseases, and the acquired immunodeficiency syndrome (AIDS); the most common clinical presentations are invasive pulmonary infection and disseminated disease. [35], [36], [43], [44] and [45] However, invasive disease may also occur in nonimmunocompromised patients. Underlying pulmonary disorders (e.g., malignancy, tuberculosis) may predispose to respiratory tract colonization with *Nocardia*. In addition, primary cutaneous and subcutaneous infections may develop from inoculation of these microorganisms at the time of surgery or from traumatic inoculation as a result of outdoor activities.

There are four clinical types of cutaneous nocardiosis: mycetoma; lymphocutaneous infection; superficial skin infection (abscess or cellulitis); and secondary cutaneous involvement with disseminated disease.

Localized cutaneous nocardial infections may also present as either a chronically draining, ulcerative lesion or a slowly expanding nodule and, less commonly, pustules, abscesses, cellulitis, or pyoderma. Frequently, there may be spread beyond the initial cutaneous infective focus to involve the regional lymphatics and, in up to one-third of cases, the disease may progress to form lymphatic abscesses. When regional lymph node involvement occurs, this form of the disease is referred to as the lymphocutaneous syndrome and because it bears a striking clinical resemblance to a superficial infection with the dimorphic fungus *Sporothrix schenckii,* it has also been termed the sporotrichoid form of cutaneous nocardiosis. More localized infections may also be misdiagnosed as staphylococcal skin infections. Because skin manifestations may be complications of disseminated disease, the finding of a cutaneous lesion in a patient should not always be attributed to local inoculation.

Differential Diagnosis

The differential diagnosis of cutaneous nocardiosis includes other infections causing granulomas, for example, eumycotic mycetoma; dermal tuberculosis and cutaneous nontuberculous mycobacterial infections; keloid blastomycosis and certain forms of leishmaniasis; sporotrichosis; and botryomycosis. Noninfectious conditions to consider include foreign-body granulomas, soft-tissue sarcomas, and lethal midline granuloma.

Clinical history, epidemiologic considerations, and general pathologic features should alert the clinician to include nocardiosis in the patient's differential diagnosis. A confirmation of the diagnosis may be provided by the presence of granules, histopathologic findings, and culture identification of causative microorganisms. Deep organ involvement may pose more of a diagnostic problem because invasive biopsy procedures may be required and interpretation of the results may be complicated by the occurrence of a mixed infection. Imaging procedures (radiography, and computerized tomographic and nuclear magnetic resonance scans); and invasive procedures (e.g., bronchoscopic biopsy and bronchoalveolar lavage) may be important. A heightened level of clinical suspicion and prompt notification of the clinical microbiology laboratory to perform appropriate tests to screen for the causative organisms may provide the key for early diagnosis of nocardiosis.

Pathophysiology

Nocardia infection is usually acquired by inhalation; rarely, however, direct skin inoculation may be implicated. Inhalation allows establishment of a focal pneumonitis that progresses to necrosis and abscess formation. Rarely, colonization of the skin or respiratory tract by *Nocardia* may occur. Invasive infection in an immunocompetent patient may result in a minimal inflammatory response and negligible residual tissue scarring; however, in immunocompromised hosts, particularly those infected by *N. brasiliensis,* there may be a marked tissue response together with true granuloma formation. The immune status of the patient is crucial in determining whether and to what extent disease progression occurs.

Laboratory Diagnosis

Because *Nocardia* spp. are ubiquitous in nature, the isolation of these microorganisms from microbiologic specimens may be clinically nonsignificant. In a patient's sputum culture, their presence may not always indicate invasive infection and may reflect either laboratory contamination or respiratory colonization. The diagnosis of invasive *Nocardia* species infections is often hindered by their often nonspecific clinical presentation, the requirement for invasive diagnostic biopsy procedures, the difficulty in isolating organisms, and the imperfect taxonomic classification.

DIRECT EXAMINATION If clumps of bacteria or granules are present in the exudate, these should be selectively removed and crushed between two glass microscope slides. In addition, some of the exudate should be examined in a wet mount to exclude the presence of fungal hyphae. Two smears should be stained prior to microscopic examination of the material; one with Gram's stain and the other with modified Kinyoun's stain. [46] The presence of gram-positive filaments with some degree of acid fastness is suggestive of *Nocardia*. Although the gross and microscopic characteristics of the granules may suggest the etiologic agent, definitive identification is dependent upon culture isolation and identification.
ISOLATION Culture isolation of *Nocardia* may be difficult because growth can take up to 3 weeks on routine culture media and *Nocardia* colonies can be obscured by the rapid overgrowth of concomitant bacterial species. Additionally, *Nocardia* is inhibited by antibiotics in fungal culture media and often do not survive the digestive procedures used in

mycobacterial culture isolation. The observation that some nocardial isolates may not survive in respiratory specimens has prompted studies of recovery procedures for aerobic actinomycetes from these sources. [47], [48] Digestion-decontamination of respiratory tract specimens with *N*-acetyl-L-cysteine, sodium hydroxide, and benzalkonium is toxic to *Nocardia.* [49] The Thayer-Martin medium containing vancomycin, colistin, and nystatin, a selective medium commonly used in clinical laboratories for the isolation of *Neisseria* species, is useful as a selective medium for the growth of *Nocardia* species. [49] Other promising media include buffered-charcoal-yeast extract (BCYE) agar, and selective BCYE media containing polymyxin, anisomycin, and vancomycin; these media are commonly used in clinical microbiology laboratories for the isolation of *Legionella* species from respiratory specimens. [50] Pretreatment of clinical specimens with a low pH (2.2) KCL-HCL solution for 4 min is necessary for adequate isolation of *Nocardia* species. [50] Although no optimal methods for isolating the aerobic actinomycetes from potentially contaminated specimens exist, the methods discussed above likely represent an improvement for the recovery of these microorganisms when compared to direct plating of specimens to conventional media (e.g., Sabouraud-dextrose agar, brain–heart infusion agar, blood agar, or Lowenstein-Jensen).

BIOCHEMICAL IDENTIFICATION The final identification of the aerobic actinomycetes depends upon the results of a battery of tests including the hydrolysis of different substrates (e.g., *N. brasiliensis* hydrolyzes casein and tyrosine, but not xanthine, Fig. 201-4), and acid production or utilization of carbohydrates. Importantly, routine identification methods in use in many clinical laboratories often misidentify *N. farcinica* as *N. asteroides* complex, *Rhodococcus*/ *Gordona* complex, or *Mycobacterium* species. Therefore, additional supplemental tests that include comparison of growth on agar slants at 35°C (95°F) and 45°C (113°F), the hydrolysis of acetamide, arylsulfatase production, and antimicrobial susceptibility testing may be needed for the definitive identification of *N. farcinica.* [51], [52], [53], [54], [55], [56] and [57] Table 201-4 lists the characteristics that differentiate the medically important species of the genus *Nocardia*. In addition, newer, rapid, sensitive identification techniques (e.g., use of chromogenic enzyme substrates) have been developed. [58] The diagnostic future will probably rest on DNA amplification and restriction endonuclease analysis. [59]

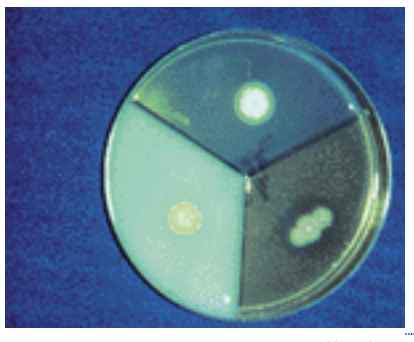

FIGURE 201-4 *Nocardia brasiliensis* is able to hydrolyze casein (*top*) and tyrosine (*right*), but not xanthine (*left*). (*Courtesy of Roberto Arenas, MD, Hospital Manuel Gea González, Mexico City.*



TABLE 201-4 **Characteristics Used to Differentiate the Medically Important** *Nocardia* **Species**

Diagnostic Immunology

Diagnosis by immunologic methods [60], [61] has been hampered by the antigenic complexity of the aerobic actinomycetes, cross-reactivity with other species and genera (including *Mycobacteria*), and development of a generally poor immunologic response against many nocardiae during the infectious process. With the use of affinity chromatography, Boiron and Provost recently purified a 54-kDa antigen from *N. asteroides* for a Western blot assay and found little cross-reactivity with *N. brasiliensis, Rhodococcus rhodochrous, M. tuberculosis,* and *M. leprae.* [60] Although there have been many previous immunologic studies with *N. asteroides,* only recently were data on a sensitive *N. brasiliensis* immunodiagnostic assay published. Salinas-Carmona described an enzyme-linked immunosorbent assay that used the 26- and 24-kDa proteins for the diagnosis of *N. brasiliensis* mycetoma infections and showed its usefulness in assessing the patient's response to treatment. An additional advantage of this particular assay might be its demonstrated cross-reactivity with *N. asteroides.* [61]

Therapy

Sulfonamides or trimethoprim-sulfamethoxazole (TMP-SMX) is the therapy of choice for proven or presumed nocardiosis. [21] Antimicrobial therapy must be adjusted to the particular species of *Nocardia* present, to individual strain antimicrobial susceptibility patterns, and to the site and type of infection. Certain strains of *N. asteroides* complex may be susceptible to sulfonamides or TMP-SMX, and response to treatment may be attained in greater than 90 percent of cases, if the infection is confined to pleuropneumonia. However, in patients with disseminated disease to the CNS, and/or renal transplant recipients and HIV-infected patients, optimal drug therapy is difficult. [22] First, these patients frequently develop side effects (skin rash, fever, neutropenia, hepatotoxicity) with TMP-SMX that may be aggravated by prolonged use of TMP-SMX as prophylactic therapy. Second, the infecting microorganism may develop resistance to prolonged therapy with TMP-SMX, alternative agents, or drug combinations. Third, there are scant data on the efficacy of newer oral alternative antimicrobial agents or combinations that might improve the outcome of patients infected with *Nocardia* species and avoid the problems of TMP-SMX.

Sulfonamides have good penetration into the cerebrospinal fluid (CSF) and achieve high CSF concentrations. [62]

Sulfadiazine is the most commonly prescribed drug, but sulfisoxazole and triple sulfonamide combinations are also effective. Drug therapy should be continued for 6 to 18 months depending on the extent of the disease because of the high incidence of relapse and metastatic abscesses with shorter duration of therapy. [21] For most patients with nocardiosis, clinical improvement is expected within 7 to 10 days after the initiation of empiric therapy with sulfonamides (with or without trimethoprim). For infected patients the exact route of drug administration may be influenced by the assessment of their overall clinical status. In addition, a serum level estimation at least once following institution of antimicrobial therapy may be useful to establish that adequate drug absorption is occurring and provide a basis for any necessary adjustment of the patient's drug dosage to achieve recommended levels in blood of 100 to 150 µg/mL approximately 2 h after an oral dose. It is recommended that therapy with sulfonamides be given at high doses (3 to 6 g/day) for extended periods 6 to 12 months. While primary cutaneous nocardiosis may be cured by a 1- to 3-month course of antimicrobial therapy and uncomplicated pulmonary nocardiosis may respond to therapy for 6 months or less, therapy for 12 months or more is usually required for disseminated infection or if the patient is immunocompromised. Alternative antimicrobial agents in sulfonamide sensitive patients include ampicillin, clindamycin, erythromycin, and minocycline. Minocycline reaches excellent concentrations in the brain and can penetrate into phagocytes to kill intracellular organisms. [21] Ampicillin plus erythromycin or sulfonamide have demonstrated synergism in vitro. [21] Although amikacin is an effective agent in vitro, it does not cross the blood-brain barrier and prolonged outpatient therapy is impractical. Surgical drainage of abscesses and débridement of avascular tissue may be an important adjunct in the successful management of infected patients.

ACTINOMYCETOMA (See also Chap. 207)

Epidemiology

Mycetoma is a late-stage clinical manifestation of a subcutaneous infection produced by either bacteria (actinomycetes causing actinomycotic mycetoma, or actinomycetoma) or fungi (eumycotic mycetoma, or eumycetoma). [63] Patients with these chronic infections may have a history of a specific minor localized traumatic injury. Walking barefooted may be the major mode of acquisition of these infections, because this practice potentially exposes the feet to repeated soil-contaminated puncture wounds. Only actinomycetoma is discussed further in this chapter.

Microorganisms reported to cause actinomycetomas include *N. brasiliensis, Actinomadura madurae, A. pelletieri, Streptomyces somaliensis,* and, less commonly, *N. asteroides, N. otitidiscaviarum, Nocardiopsis dassonvillei,* and *N. transvalensis*. In North America, South America, Mexico, and Australia, *N. brasiliensis* is the chief cause of actinomycetomas; in Africa, Saudi Arabia, and India, *S. somaliensis* and *A. madurae* predominate. These infections most commonly affect patients in the rural areas in third world countries (Table 201-3).

Clinical Disease

Actinomycetoma is a chronic, localized, slowly progressive and often painless subcutaneous disease. The foot is the most common site of involvement; but, the hands (Fig. 201-5 and Fig. 201-6), face, neck, and upper back (Fig. 201-7, Fig. 201-8, and Fig. 201-9) may also be involved. The pathology of the disease is characterized by tumefaction, subcutaneous nodules, destructive granulomata, deformity, and discharging sinus tracts with intercommunicating channels that exude pus, often with macroscopically visible granules of various sizes and colors. Macroscopically, the granules of *Nocardia* usually appear white or yellowish in color, and those of *A. madurae* usually appear tan, orange to deep red. In contrast, *A. pelletieri* granules appear red and those of *S. somaliensis* are usually a cream to brown color macroscopically (Table 201-1).

FIGURE 201-5 Mycetoma of the hand and wrist caused by *Nocardia brasiliensis*. Note gross deformity. (*Courtesy of Roberto Arenas, MD, Hospital Manuel Gea González, Mexico City.*)

FIGURE 201-6 Radiograph from patient in Fig. 201-5 shows associated marked destruction of bones and underlying soft tissues. (*Courtesy of Roberto Arenas, MD, Hospital Manuel Gea González, Mexico City.*)

FIGURE 201-7 Mycetoma of the shoulder caused by *Nocardia brasiliensis*. (*Courtesy of Maria Cecilia Albornoz, MD, Instituto de Biomedicina, Caracas.*)

FIGURE 201-8 Huge scapulothoracic mycetoma caused by *Nocardia brasiliensis*. Note multiple fistulae. (*Courtesy of Maria Cecilia Albornoz, MD, Instituto de Biomedicina, Caracas.*)

FIGURE 201-9 Close-up of mycetoma in Fig. 201-8. Note doughnut-shaped masses and purulent drainage. (*Courtesy of Maria Cecilia Albornoz, MD, Instituto de Biomedicina, Caracas.*)

Histopathology

Actinomycetomas, eumycotic mycetomas and botryomycosis are all associated with a similar tissue response. Typically, in hematoxylin and eosin (H&E)-stained tissue sections, deeply basophilic granules may be present, surrounded by evidence of chronic inflammation (i.e., palisading epithelioid cells and multinucleated giant cells mixed with smaller numbers of plasma cells, lymphocytes, and macrophages). Amorphous, deeply eosinophilic, radially arranged Splendore-Hoeppli material may also be present on the periphery of these granules (Fig. 201-10). Usually, neither the filaments of actinomycetoma and eumycotic mycetoma nor the bacterial agents causing botryomycosis are seen in H&E-stained tissue sections. To further define a granule as being actinomycotic or eumycotic, special stains (i.e., B&B stain for bacteria, the GMS method for both bacteria and fungi, and PAS for fungi only) are needed. If either the B&B- or the GMS-stained sections reveal gram-positive branched bacterial filaments (<1.0 µm in width), this finding suggests a diagnosis of actinomycetoma; however, the presence of a pure population of nonfilamentous bacteria (bacilli, cocci, or coccobacilli) suggests the diagnosis of botryomycosis. If either a GMS- or PAS-stained section shows broad (2 to 6 µm) hyphae, often in addition to the presence of numerous chlamydospores in the mycelium, these findings suggest a diagnosis of eumycotic mycetoma.

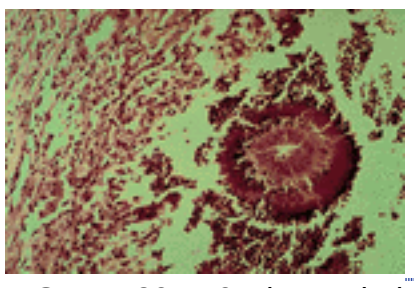

FIGURE 201-10 Histopathologic section of mycetoma featuring a granule of *Nocardia brasiliensis*. Note homogenous center, peripheral clavate area, and surrounding tissue reaction with infiltration by polymorphonuclear leukocytes. Hematoxylin and eosin stain. Magnification, × 100. (*Courtesy of Oscar Reyes-Flores, MD, Instituto de Biomedicina, Caracas.*)

Other nonspecific histopathologic findings include localized abscesses in the dermis that contain granules that may be interspersed with areas of intense infiltration with polymorphonuclear leukocytes, necrotic debris, and dense granulation tissue. Among the agents causing actinomycetomas, the granules of *Nocardia* are small (about 100 µm in diameter) and the granules of *A. madurae* are variable in size (0.5 to 5 mm), whereas the granules of *A. pelletieri* and *S. somaliensis* range from 300 to 500 µm and from 0.5 to 5 mm, respectively. Although several earlier references suggested that the

histologic appearance may enable a species-specific diagnosis, [64] the histopathologic findings, including the appearance of granules, if present, are markedly nonspecific, and culture isolation and identification of the causative agent are essential for confirmation of the diagnosis of aerobic actinomycete infection. This is because recent taxonomic studies (using DNA hybridization and rRNA gene sequencing) have confirmed marked heterogeneity among the genera of aerobic actinomycetes. [59] In addition, the macroscopic granules that may be seen to emerge in the exudate from the sinus tracts in actinomycetoma patients may or may not simulate the corresponding microorganism's colonial characteristics on microbiologic culture.

BOTRYOMYCOSIS

This is usually a chronic or subacute inflammation of the skin and subcutaneous tissues. The bacteria most commonly implicated in causing botryomycosis include *Pseudomonas aeruginosa, Actinobacillus lignieresii, Staphylococcus aureus, Proteus* species, and *Escherichia* species. [65]

Diagnosis

Clinical history, epidemiologic considerations, and general pathologic features should alert the clinician to the possible diagnosis of actinomycetoma. The detection of suggestive microorganisms in stained histologic sections obtained by deep wedge surgical biopsies or preparations from fine-needle aspiration may be of value. [65], [66] Table 201-1 lists the criteria for presumptive microbiologic diagnosis to the genus level. However, it has been suggested that patient isolates should be sent to a specialized reference laboratory for species identification and in vitro susceptibility testing. [21]

Treatment

Therapy for patients with actinomycetoma should be individualized. Economic considerations may influence the choice of therapy, particularly in developing countries. Parenteral treatment is difficult in ambulatory patients. Patient follow-up is always important and clinical progress can be monitored by biopsy or by aspiration and culture. Dapsone (diaminodiphenylsulfone) reportedly is effective and has been used in combination with other antimicrobials. Dapsone is usually prescribed in an oral daily dosage of 3 to 5 mg/kg for periods of 1 to 2 years following clinical cure. [67] In the last two decades, therapy with other sulfonamides (e.g., TMP-SMX) has been reported to be successful. The recommended therapeutic dose of TMP-SMX is 8 and 40 mg/kg per day for periods ranging from 6 months to several years with a reported average success rate of more than 60 percent. [67] This drug should be used with caution in AIDS patients as they may be intolerant of this combination. The use of other agents (e.g., amikacin) has been proposed, but there is no widespread consensus on their use. There are additional reports of patients unresponsive to sulfonamide therapy who were successfully treated with a combination of amikacin (15 mg/kg per day total dose, divided and administered as two intramuscular injections every 12 h) and oral TMP-SMX, each for a total of 3 weeks, followed by oral TMP-SMX alone for an additional 2 weeks. [67], [68] This constitutes “a cycle.” One to three cycles are usually required (5 to 15 weeks of treatment). [67] The patient should be monitored for the development of amikacin-associated ototoxicity. Surgery is effective in early or small lesions and may be the last recourse in extensive mycetomas. Extension of the infection to involve bone may be an important determinant in deciding the extent of surgical debridement. Medical treatment should precede and continue after surgical treatment. Stopping any immunosuppressant medications and other specific measures to enhance the patient's immune status (e.g., antiviral treatment for HIV infection) and surgery (e.g., removal of infected prostheses or foreign bodies) may have an important adjunctive role in the patient's therapy. In a more recent case series of actinomycotic mycetoma patients, Ramam et al. used a two-step regimen that consisted of an intensive phase of therapy with intravenous penicillin (1 MU every 6 h), intravenous gentamicin (80 mg two times per day), and oral TMP-SMX (80 to 400 mg two times per day) for 5 to 7 weeks. [69] One patient with associated leprosy received dapsone (100 mg two times per day) as a substitute for TMP-SMX. After the initial therapy in the hospital, patients were discharged and treatment was continued at home with amoxicillin (500 mg two times per day) and TMP-SMX/dapsone at the same doses as before. Maintenance therapy was continued 2 to 5 months after the lesions became completely inactivated.

Use of trade names and commercial sources is for identification only and does not imply endorsement by the U S Public Health Service or the U S Department of Health and Human Services.

REFERENCES

1. Schaal KP, Hee-Joo Lee: Actinomycete infection in humans-a review. *Gene* **115**:201, 1992

2. Stackebrandt E et al: Proposal for a new hierarchic classification system, *Actinobacteria classis* nov. *Int J Syst Bacteriol* **47**:479, 1997

3. Sarkonen N et al: Phenotypic identification of *Actinomyces* and related species isolated from human sources. *J Clin Microbiol* **39**:3955, 2001

4. Lawson PA et al: Characterization of some *Actinomyces*-like isolates from human clinical specimens: Reclassification of *Actinomyces suis* (Soltys and Spratling) as *Actinobaculum suis* comb. nov., and description of *Actinobaculum schaalii* sp. nov. *Int J Syst Bacteriol* **47**:899, 1997

5. Ramos CP et al: Phylogenetic analysis of the genus Actinomyces based in 16srRNA gene sequences: Description of *Arcanobacterium phocae* sp. nov., *Arcanobacterium bernardiae* comb nov., and *Arcanobacterium pyogenes* comb nov. *Int J Syst Bacteriol* **47**:46, 1997

6. Schaal KP: Actinomycoses, actinobacillosis and related diseases, in *Topley & Wilson's Microbiology and Microbial Infections,* vol 3: *Bacterial Infections,* 9th ed, edited by L Collier, A Balows, M Sussman. London: Arnold, 1998, p 777

7. Pulverer G, Schaal KP: Medical and microbiological problems in human actinomycoses, in Biological, biochemical, and biomedical aspects of actinomycetes, edited by L Ortiz-Ortiz, LF Bojalil, V Yakoleff. Orlando, Academic Press, 1984, p 161

8. Pulverer G, Schaal KP: Human actinomycosis. *Drug Exp Clin Res* **X**:187, 1984

9. Evans DT: *Actinomyces israelii* in the female genital tract: A review. *Genitourin Med* **69**:54, 1993

10. Fiorino AS: Intrauterine contraceptive device-associated actinomycotic abscess and *Actinomycetes* detection on cervical smear. *Obstet Gynecol* **87**:142, 1996

11. Lenoir P et al: Bronchoscopic diagnosis of an unusual presentation of pulmonary actinomycosis. *Pediatr Pulmonol* **16**:138, 1993

12. Coodley EL, Yoshinaka R: Pleural effusion as the major manifestation of actinomycosis. *Chest* **106**:1615, 1994

13. Traynor RM et al: Isolation of actinomycetes from cervical specimens. *J Clin Pathol* **34**:914, 1981

14. Dowell VR, Hawkins TM: Laboratory methods in anaerobic bacteriology. CDC laboratory manual. Atlanta, GA, Department of Health and Human Services, 1990

15. Schofield GM, Schaal KP: A numerical taxonomic study of members of the Actinomycetaceae and related taxa. *J Gen Microbiol* **127**:237, 1981

16. Muller-Holzner E et al: IUD-associated pelvic actinomycosis: A report of five cases. *Int J Gynecol Pathol* **14**:70, 1995

17. Schaal KP, Gatzer R: Serological and numerical phenetic classification of clinically significant fermentative actinomycetes, in *Filamentous Microorganisms, Biomedical Aspects,* edited by T Arai. Tokyo, Japan, Japan Scientific Societies Press, 1985, p 85

18. Weese WC, Smith IM: A study of 57 cases of actinomycosis over a 36-year period. *Arch Intern Med* **135**:1562, 1975

19. Garland SM, Rawling D: Pelvic actinomycosis in association with an intrauterine device. *Aust N Z J Obstet Gynecol* **33**:96, 1993

20. Schaal KP: Actinomycoses, in Oxford textbook of medicine, vol 1, 3rd ed, edited by DJ Weatherall, JGG Ledingham, DA Warrell. Oxford: Oxford University Press, 1996, p 680

21. Lerner PL: Nocardiosis. *Clin Infect Dis* **22**:891, 1996

22. McNeil MM, Brown JM: The medically import aerobic actinomycetes: Epidemiology and microbiology. *Clin Microbiol Rev* **7**:357, 1994

23. Hay RJ: Nocardial infection of the skin. *J Hyg (London)* **91**:385, 1983

24. Smego RD et al: Trimethoprim-sulfamethoxazole therapy for *Nocardia* infections. *Arch Intern Med* **143**:711, 1983

25. Wallace RJ Jr et al: New Nocardia taxon among isolates of *Nocardia brasiliensis* associated with invasive disease. *J Clin Microbiol* **33**:1528, 1995

26. Beaman BL et al: Nocardia and nocardiosis. *J Med Vet Mycol* **30** (Suppl 1):317, 1992

27. Hamid ME et al: *Nocardia africana* sp. nov., a new pathogen isolated from patients with pulmonary infections. *J Clin Microbiol* **39**:625, 2001

28. Brown BA et al: Characterization of a *Nocardia brevicatena* complex among clinical and reference isolates. 97th Meeting of the American Society of Microbiology. Abstract C-65, Miami Beach, FLA. May 11– *May* 17, 1997

29. Yassin AF et al: *Nocardia paucivorans* sp. nov. *Int J Syst Evol Microbiol* **50**:803, 2000

30. Gurtler R et al: *Nocardia veterana* sp. nov., isolated from human bronchial lavage. *Int J Syst Evol Microbiol* **51**:933, 2001

31. Houang ET et al: *Nocardia asteroides* infection—A transmissible disease. *J Hosp Infect* **1**:31, 1980

32. Cox F, Hughes WT: Contagious and other aspects of nocardiosis in the compromised host. *Pediatrics* **55**:135, 1975

33. Sahathevan M et al: Epidemiology, bacteriology and control of an outbreak of *Nocardia asteroides* infection on a liver unit. *J Hosp Infect* **18**(Suppl A): 473, 1991

34. Schaal KP: Medical and microbiological problems arising from airborne infection. *J Hosp Infect* **18**:451, 1991

35. Krick JA et al: *Nocardia* infection in heart transplant patients. *Ann Intern Med* **82**:18, 1975

36. Simpson GL et al: Nocardial infections in the immunocompromised host; a detailed study in a defined population. *Rev Infect Dis* **3**:492, 1981

37. Blumel J et al: Typing of *Nocardia farcinica* by pulsed-field gel electrophoresis reveals an endemic strain as source of hospital infections. *J Clin Microbiol* **36**:118, 1998

38. Exmelin L et al: Molecular study of nosocomial nocardiosis outbreak involving heart transplant recipients. *J Clin Microbiol* **34**:1014, 1996

39. Wenger PN et al: *Nocardia farcinica* sternotomy site infections in patients following open heart surgery. *J Infect Dis* **178**:1539, 1998

40. Patterson JE et al: Pseudoepidemic of *Nocardia asteroides* associated with a mycobacterial culture system. *J Clin Microbiol* **30**:1357, 1992

41. Anonymous: Cutaneous nocardiosis in cancer patients receiving immunotherapy injections—Bahamas. *MMWR Morb Mort Weekly Rep* **33**: 471, 1984

42. Valero-Guillen PL, Martin-Luengo F: *Nocardia* in soils of southeastern Spain: Abundance, distribution, and chemical characterization. *Can J Microbiol* **30**:1088, 1984

43. Gaspar G et al: Primary cutaneous nocardiosis and human immunodeficiency virus infection [letter]. *Med Clin (Barc)* **92**:598, 1989

44. Wilson JP et al: Nocardial infections in renal transplant recipients. *Medicine (Baltimore)* **68**:38, 1989

45. Lucas SB et al: Nocardiosis in HIV-positive patients: An autopsy study in West Africa. *Tuber Lung Dis* **75**:301, 1994

46. Berd D: Laboratory identification of clinically important aerobic actinomycetes. *Appl Microbiol* **25**:665, 1973

47. Hosty TS et al: Prevalence of *Nocardia asteroides* in sputa examined by a tuberculosis diagnostic laboratory. *J Lab Clin Med* **58**:107, 1961

48. Krasnow L, Wayne LG: Comparison of methods for tuberculosis bacteriology. *Appl Microbiol* **18**:915, 1969

49. Murray PR et al: Effect of decontamination procedures on recovery of *Nocardia* spp. *J Clin Microbiol* **25**:2010, 1987

50. Vickers RM et al: Clinical demonstration of isolation of *Nocardia asteroides* on buffered charcoal-yeast extract media. *J Clin Microbiol* **30**:227, 1992

51. Goodfellow M et al: Actinomycete systematics: An unfinished synthesis. *Nova Acta Leopoldina NF* **80**:47, 1999

52. Yassin AF et al: *Nocardia abscessus* sp. nov. *Int J Syst Evol Microbiol* **50**:1487, 2000

53. Ruimy R et al: *Nocardia pseudobrasiliensis* sp. nov., a new species of *Nocardia* which groups bacterial strains previously identified as *Nocardia brasiliensis* and associated with invasive diseases. *Int J Syst Bacteriol* **46**:259, 1996

54. Wallace RJ Jr et al: Antimicrobial susceptibility patterns of *Nocardia asteroides*. *Antimicrobiol Agents Chemother* **32**:1776, 1988

55. Wallace RJ Jr et al: Cefotaxime-resistant *Nocardia asteroides* strains are isolates of the controversial species *Nocardia farcinica*. *J Clin Microbiol* **28**:2726, 1990

56. Wallace RJ Jr et al: Clinical and laboratory features of *Nocardia nova*. *J Clin Microbiol* **29**:2407, 1991

57. National Committee for Clinical Laboratory Standards: *Methods for Dilution Antimicrobial Susceptibility Tests for Bacteria that Grow Aerobically (M7-A2)*. Villanova, PA, National Committee for Clinical Laboratory Standards, 1990

58. Boiron P, Provost F: Enzymatic characterization of *Nocardia* spp. and related bacteria by API ZYM profile. *Mycopathologia* **110**:51, 1990

59. Steingrube VA et al: Rapid identification of clinically significant species and taxa of aerobic actinomycetes, including *Actinomadura, Gordona, Nocardia, Rhodococcus, Streptomyces,* and *Tsukamurella* isolates, by DNA amplification and restriction endonuclease analysis. *J Clin Microbiol* **35**:817, 1997

60. Boiron P, Provost F: Use of the partially purified 54-kilodalton antigen for diagnosis of nocardiosis by Western blot (immunoblot) assay. *J Clin Microbiol* **28**:328, 1990

61. Salinas-Carmona MC et al: Enzyme-linked immunosorbent assay for serological diagnosis of *Nocardia brasiliensis* and clinical correlations with mycetoma infections. *J Clin Microbiol* **31**:2901, 1993

62. Thea D, Barza M: Use of antibacterial agents in infections of the central nervous system. *Infect Dis Clin North Am* **3**:553, 1989

63. Magaña M: Mycetoma. *Int J Dermatology* **23**:221, 1984

64. Rippon JW: Mycetoma, in *Medical Mycology,* 2nd ed. Philadelphia, WB Saunders, 1982, p 79

65. Greenblatt M et al: Bacterial pseudomycosis (“botryomycosis”). *Am J Clin Pathol* **41**:188, 1964.

66. El Hag IA et al: Fine-needle aspiration cytology of mycetoma. *Acta Cytologica* **40**:461, 1996

67. Welsh O: Mycetoma. Current concepts in treatment. *Int J Dermatol* **30**:387, 1991

68. Welsh O et al: Amikacin alone and in combination with trimethoprim-sulfamethoxazole in the treatment of actinomycotic mycetoma. *J Am Acad Dermatol* **17**:443, 1987

69. Ramam M et al: A two-step schedule for the treatment of actinomycotic mycetomas. *Acta Derm Venereol* **80**:378, 2000

T>

Chapter 202

Thomas Rea Robert Modlin

Leprosy

HISTORICAL ASPECTS
EPIDEMIOLOGY
ETIOLOGY AND PATHOGENESIS
GENETICS
PREVENTION
CLINICAL MANIFESTATIONS
A Granulomatous Spectrum
Peripheral Nerve Changes
Dermatologic and Neural Changes
Systemic Associations
Variants
Reactional States
LABORATORY FINDINGS
PATHOLOGY
Microscopic Changes
Immunopathology and Immunology
DIAGNOSIS
False Negatives
False Positives
TREATMENT
REFERENCES

Leprosy (Hansen's disease) can be defined as a chronic granulomatous infection and its sequelae, caused by *Mycobacterium leprae,* and affecting primarily skin and nerves. Leprosy is an important clinical problem, with more than 600,000 new cases yearly, worldwide. Also, despite apparently curative antibacterial therapy, one-quarter to one-third of all patients will have a debilitating and permanent neurologic deficit. Because of its diverse host responses, for clinicians, leprosy is a challenging diagnostic problem, and for immunologists, it is an exemplary model for understanding cell-mediated immunity in humans.

HISTORICAL ASPECTS

Leprosy is an ancient disease; sacred writings from India in the sixth century B.C. give a good description of a similar or identical illness. Greek soldiers returning from Asia in third century B.C. are thought to have introduced the disease into Europe. Stigmatization of patients with leprosy remains an unfortunate but enduring legacy of the European pandemic (1000 to 1500 A.D.). Hansen's attribution of *M. leprae* as its etiologic agent in 1873 marks the beginning of scientific leprology. [1]

Effective chemotherapy began with the introduction of sulfones in 1943. The limited growth of *M. leprae* in the mouse foot pad, in 1961, provided a way to screen for therapeutic agents and to identify drug resistance. [2] Rifampin, in 1970, was the first drug to be identified as bactericidal for *M. leprae* and is now the cornerstone of most therapeutic regimens.

In 1919, the lepromin skin test inaugurated systematic study of host resistance as the source of disease diversity, [3] lymphocyte transformation tests being established in the 1960s as an in vitro correlate. The recognition of leprosy in the nine-banded armadillo, in 1971, provided a source of large quantities of highly purified *M. leprae* for a wide variety of investigations, culminating in the sequencing of the entire genome of *M. leprae* in 2001. [4] This landmark achievement will provide novel avenues of investigation, which, in turn, will provide new methods of intervention.

EPIDEMIOLOGY

Leprosy, primarily a disease of developing countries, is endemic in all continents, except Antarctica. In the Americas, only Canada and Chile are not endemic areas, with Texas and Louisiana being endemic states in the United States. The southern-most nations of Europe have a very low incidence, while leprosy is endemic in many Pacific islands. The Indian subcontinent has two-thirds of the world's leprosy burden. The highest case detection rates are in India, Brazil, Madagascar, Nepal, and Tanzania. During the decade of the 1990s, the prevalence of leprosy fell by 90 percent, because patients completing a course of multiple-drug therapy have been considered to be cured, but the incidence of the disease has remained unchanged. [5]

In all populations studied, lepromatous disease is more common in men than in women by a 2:1 ratio. The tuberculoid form dominates wherever the disease is common. The median age of onset is less in tuberculoid than in lepromatous patients, but in both groups, leprosy is predominantly a young person's disease, the majority of cases occurring before age 35 years. However, age is not protective; new cases of each type occur in the eighth and ninth decades of life. The incubation time for tuberculoid leprosy is up to 5 years and for lepromatous may be 20 years or longer.

The preponderance of opinion supports the traditional view that *M. leprae* is transmitted from human-to-human, but the presence of an *M. leprae* caused lepromatous-like illness in wild armadillos, [6] evidence of armadillo exposure as a risk factor for leprosy in people, [7] and the presence of an *M. leprae*-like organism on sphagnum moss, [8] suggest that nonhuman sources for *M. leprae* may be important. The route of infection is unknown, but current evidence favors

respiratory transmission; evidence for congenital and percutaneous transmission has been presented, but these are probably rare. [9] In leprosy endemic areas, subclinical infection is common, as judged by serologic studies identifying *M. leprae*-specific antibodies. [10]

ETIOLOGY AND PATHOGENESIS

M. leprae, the cause of leprosy, is a noncultivable, gram-positive, obligate intracellular, acid-fast bacillus. The union of bulk extracted *M. leprae* from armadillos with the techniques of molecular biology has proven to be a fruitful marriage, its crowning accomplishment being the sequencing the bacillary genome. [4] The genome of *M. leprae* (3.27 megabases) is notably shorter than that of *M. tuberculosis,* (4.41 megabases). Even more striking, the *M. leprae* genome codes for 1600 genes, *M. tuberculosis* codes for 4000. The two species share 1439 genes in common. In *M. leprae* only one-half of its genome is coding sequence, this evident gene deletion and decay leaving *M. leprae* with few respiratory enzymes, but offering a reasonable explanation for the failure to cultivate the organism in cell-free media, as well as for its obligatory intracellular environment.

The bacillary cell wall consists of a peptidoglycan backbone linked to arabinogalactan and mycolic acids. Immunogenic proteins are associated with the cell wall, and also present in the cytoplasm. These include highly conserved heat shock proteins of molecular weight 10, 65, and 70 kDa, each bearing species-specific and cross-reacting epitopes. A lipoglycan target of both antibody and cellular immune responses, lipoarabanomannan, courses through the outer membrane and inserts into the cell membrane. Phenolic glycolipid I is a major, species specific and immunogenic, constituent of the highly nonpolar outer layer of the bacillus. Entry into nerves is mediated by the binding of the species-specific trisaccharide in phenolic glycolipid I to laminin-2 in the basal lamina of Schwann cell-axon units, [11] providing a rationale as to why *M. leprae* is the only bacterium known to invade peripheral nerves.

In tissues or smears, *M. leprae* is quantified by the biopsy index (BI), a logarithmic scale as to the numbers of bacilli per oil immersion field (OIF): a BI of 6 is 1000 or more bacilli/OIF; a BI of 5 is 100 to 1000/OIF; a BI of 4 is 10 to 100/OIF; a BI of 3 is 1 to 10/OIF; a BI of 2 is 1 bacillus/1 to 10 OIFs; a BI of 1 is 1/10 to 100 OIFs; and a BI of 0 is no bacilli in 100 OIFs.

GENETICS

A twin study has provided compelling evidence that both genetic and environmental factors are important in determining disease susceptibility and disease expression. [12] The recent report of a susceptibility locus for leprosy in India, located on chromosome 10p13, may be the beginning of going beyond the vague rubric of “polygenetic susceptibility.” [13] Major histocompatibility complex class II antigens appear to influence disease expression, that is tuberculoid versus lepromatous, but not susceptibility. [14]

PREVENTION

Protocols endeavoring to control leprosy by vaccination usually consists of BCG alone, viable BCG in combination with killed *M. leprae,* or killed *M. leprae* alone. [15] Most studies support a reduction in leprosy incidence, roughly one-third in tuberculoid cases, considerably less in lepromatous. The recent observation that lipid and lipoglycan antigens are presented to T cells (CD4–, CD8–, CD3+) by CD1+ cells opens the door to entirely new vaccination protocols. [16] Other preventive measures, such as isolation of patients or treatment of patient contacts with antimicrobials, have been disappointing.

CLINICAL MANIFESTATIONS

The diverse clinical manifestations of leprosy can be reduced to two kinds of changes, a granulomatous spectrum and the reactional states.

A Granulomatous Spectrum

The most detailed description of the granulomatous spectrum of leprosy came from Ridley and his associates, [17], [18] integrating both clinical and histologic changes. Ridley's construct is a six-member granulomatous spectrum, ranging from high to low resistance, TT (polar tuberculoid), BT (borderline tuberculoid), BB (borderline), BL (borderline lepromatous), LLs (subpolar lepromatous), and, finally, LLp (polar lepromatous):

$$TT \Leftarrow BT \Leftrightarrow BB \Leftrightarrow BL \Leftrightarrow LLs\ LLp$$

Conceptually, TT and LLp are clinically stable, but, between the poles, the hosts granulomatous posture may change, as indicated by the arrows, upgrading (or reversing) to a posture of higher resistance, often with devastating inflammation, or downgrading to a posture of lower resistance, usually silent but occasionally inflammatory. BT patients may upgrade to TT, thus, becoming stable, but LLs patients do not downgrade to LLp nor do LLp patients upgrade. Putatively, the host's granulomatous posture is the result of the degree of cell-mediated immunity directed against *M. leprae*.

In comparison of pre-Ridley and Ridley terminology, tuberculoid corresponds to TT and BT, borderline or dimorphic to BB and BL, and lepromatous to LLs and LLp. In virtually all TT patients, and in most BT cases, acid-fast bacilli cannot be found, whereas in BB, BL, LLs, and LLp, bacilli are demonstrable with ease. Ridley's construct is useful in classifying patients, especially for immunity. Another classification system is useful for treatment: paucibacillary, that is to say no acid-fast bacilli found, or multibacillary, that is to say one or more bacilli found.

Peripheral Nerve Changes

Four types of peripheral nerve abnormalities are common in leprosy: (1) nerve enlargement (usually perceived as asymmetry), particularly in those close to the skin, such as the great auricular, ulnar, radial cutaneous, superficial peroneal, sural and posterior tibial; (2) sensory loss in skin lesions; (3) nerve trunk palsies either with signs and symptoms of inflammation or without such overt manifestations, that is, silent neuropathy, [19] usually with both sensory and motor loss (weakness and/or atrophy) and, if long-standing, also with contracture; and (4) acral distal symmetric anesthesia, a withering away, so to speak, of the type C fibers, involving heat and cold discrimination before loss of pain or light touch, beginning in acral areas and, over time, extending centrally but sparing the palms, at least for a while. Uncommon peripheral nerve abnormalities include nerve abscesses (palisading granulomas formed about cutaneous sensory nerves) and the carpal tunnel syndrome. Anhidrosis is a common manifestation of sympathetic nerve involvement.

Dermatologic and Neural Changes

POLAR TUBERCULOID LEPROSY In TT, immunity is strong as manifested by spontaneous cure and the absence of downgrading to a posture of less host resistance. The primary skin lesion of TT is a plaque, often assuming an annular configuration secondary to peripheral propagation and central clearing (Fig. 202-1). The border of the plaque or both borders of the annulus are sharply marginated. Typically, the lesion is firmly indurated, elevated, erythematous, scaly, dry, hairless, and hypopigmented, but clinically, considerable variation is encountered.

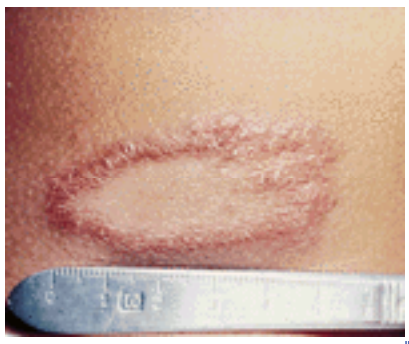

FIGURE 202-1 A solitary, anesthetic, and annular lesion of polar tuberculoid leprosy (TT), which had been present for 3 months. Its sharp margins, erythema, and scale are more evident than its elevation. The central red dots are the sequelae or “footprints” of testing for pinprick perception when it is absent. (If present, the patient withdraws, preventing overtly purpuric consequences.)

A nearby sensory nerve may or may not be enlarged, but the lesion itself is characteristically anesthetic and anhidrotic. Skin lesions are often solitary, particularly in those patients who are TT de novo, as contrasted to those who upgrade to TT from BT, where multiple lesions, usually no more than three, may be found. In both groups, immunity is sufficient to effect cure, thus, placing an upper limit of 10 cm on lesion size, but antibiotic therapy is recommended.
BORDERLINE TUBERCULOID LEPROSY In BT disease, immunologic resistance is strong enough to restrain the infection, in that the disease is limited and bacillary growth retarded, but the host response is insufficient to self-cure. These patients are somewhat unstable—resistance may increase, upgrading to TT, or decrease, downgrading to BL. The primary skin lesions of BT are plaques and papules. As in TT, an annular configuration is common and both borders are sharply marginated but annular lesions or plaques may have satellite papules (Fig. 202-2). Hypopigmentation may be conspicuous in darkly pigmented patients. In contrast to TT, typically, there is little or no scaling, less erythema, less induration, and less elevation, but lesions may become much larger, that is, well over 10 cm in diameter, a single lesion sometimes involving an entire extremity over time. Multiple, asymmetric lesions are the rule, but solitary lesions are not rare.

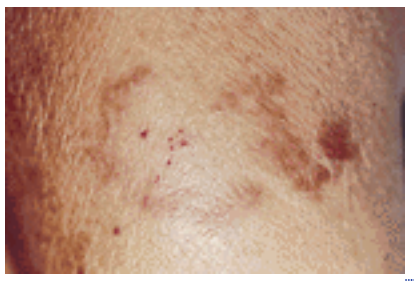

FIGURE 202-2 One of several lesions of borderline tuberculoid (BT), which had an incompletely annular configuration with satellite papules. Compared to the TT lesion in Fig. 202-1, there is less erythema, no evident scales, but sharp margination, and the footprints of absent pinprick perception are also seen.

Loss of sensation in skin lesions is the rule and nerve trunk involvement, enlargement, or palsies, usually in no more than two and asymmetric, are common. Nerve abscesses, when they occur, are most often seen in males with BT disease.
BORDERLINE LEPROSY BB is the immunologic midpoint or mid-zone of the granulomatous spectrum, being its most unstable area, with patients quickly up- or downgrading to a more stable granulomatous posture with or without a clinical reaction. Characteristic skin changes are annular lesions with sharply marginated interior and exterior margins, large plaques with islands of clinically normal skin within the plaque, giving a “Swiss cheese” appearance, or the classic dimorphic lesion. Because of instability, the BB posture is short-lived and such patients are evidently rarely seen; for example, we have yet to see a nonreactional patient meeting both clinical and histologic criteria.
BORDERLINE LEPROMATOUS LEPROSY In BL disease, resistance is too low to significantly restrain bacillary proliferation, but still sufficient to induce tissue destructive inflammation, especially in nerves. Thus, patients with BL may have the worst of both worlds. The BL category is highly variable in its clinical expression. Although seen in only a third of BL patients, the classic dimorphic lesion is the most characteristic, having an annular configuration with a poorly marginated outer border (lepromatous-like) but a sharply marginated inner one (tuberculoid-like, hence, having both morphologies or dimorphic) (Fig. 202-3). Poorly or sharply marginated plaques with “punched out” or “Swiss cheese”

sharply marginated areas of normal skin in the interior of the plaque are also characteristic, and can be viewed as a variant of the classic dimorphic lesion. Annular lesions with sharply marginated exterior and interior borders are not uncommon. When they occur, lepromatous-like, poorly defined papules and nodules may be numerous, but are usually accompanied by some sharply marginated lesions somewhere (Fig. 202-4).

FIGURE 202-3 A characteristic borderline or dimorphic lesion, which is an indurated and elevated annular plaque that has a well defined “tuberculoid” interior margin, but a poorly defined “lepromatous” exterior margin. Having both morphologies, it is termed “dimorphic.” (*From Demis DJ, editor: Clinical Dermatology, 23rd revision,* Vol. 3, unit 16–29, 1996, p 14. Courtesy of Lippincott Williams & Wilkins.)

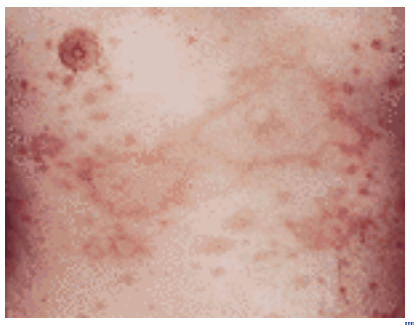

FIGURE 202-4 Multiple lesions in a patient with borderline lepromatous (BL) leprosy. The annular lesions vary in size and are asymmetrically distributed. In contrast, the poorly defined papular and nodular lesions are roughly symmetric. Loss of sensation was present in most lesions.

Lesions range in number from solitary (something happens first, the tip of an inapparent iceberg) to numerous and widespread. Generally speaking, the annular and plaque lesions, however numerous, are asymmetric, but the lepromatous-like nodules, if numerous, are symmetric. Skin lesions are often hypesthetic or anesthetic, but not necessarily so. Nerve trunk palsies have their highest prevalence in BL disease, but are variable in number, ranging from none to serious neurologic deficits, both motor and sensory, in all four extremities. Involvement of both median and ulnar nerves, not infrequently bilateral, is characteristic. When disease is extensive, BL patients may also develop acral distal symmetric anesthesia. Untreated BL patients have slowly relentless progression of skin and nerve changes. With or without treatment, this course may be altered by a reactional state, upgrading reactions being more common than erythema nodosum leprosum (ENL; see below). Also, BL patients may silently downgrade to an LLs granulomatous posture.

LEPROMATOUS LEPROSY In lepromatous leprosy (LL) disease, the lack of cell-mediated immunity toward *M. leprae* permits unrestricted bacillary replication and widely disseminated, multiorgan disease. Poorly defined, skin-colored nodules are the most characteristic lesions, usually up to 2 cm in diameter, and symmetrically distributed (Fig. 202-5). Dermatofibroma-like or histiocytoma-like lesions, usually multiple, are sharply marginated erythematous papules, sometimes confluent into plaques, and are not rare in untreated Mexican-born patients, but are also seen in Filipinos and Samoans (Fig. 202-6). Diffuse dermal infiltration is always present subclinically and may be overtly manifested by widening of the nasal root and fusiform swelling of the fingers, mimicking a rheumatic illness. With progressive bacillary proliferation, further cellular infiltration, and the consequent thickening of the dermis, the skin is thrown into folds producing the leonine faces often in conjunction with nodular lesions. Less-common presenting skin lesions include digitate, barely indurated patches of erythema (Fig. 202-7), which in light-skinned patients are sometimes followed by a mild hyperpigmentation; in dark-skinned patients, multiple hypopigmented macules may originate in such lesions, a veil of melanin concealing the erythema. A clinical clue of LLs is a sharply marginated region in a lesion, perhaps the residual of a BL lesion in a patient who has downgraded to LLs.

FIGURE 202-5 *A, B*. Multiple skin-colored papular and small nodular lesion in a patient with polar lepromatous (LLp) leprosy. The margination of the lesions is variable, some being poorly defined. The absence of clinical inflammation is evident. Some distortion of the normal helix is arising from diffuse infiltration as well as from the nodular lesions.

FIGURE 202-6 Multiple papular lesions, which are solitary and confluent, in a patient with subpolar lepromatous (LLs) leprosy. Their uniformly sharp margins and erythema are in contrast to the lesions in Fig. 202-5.

FIGURE 202-7 These multiple, barely palpable, erythematous, and asymptomatic lesions had been erupting over the previous 2 months in a LLs patient. With treatment, as lesions remitted they became mildly hyperpigmented. Here, the accentuation of the normal skin markings are in contrast to their effacement in the lesions in Fig. 202-5 and Fig. 202-6.

Hair loss, common on the eyebrows, where it progresses laterally to medially, but also on the eyelashes and extremities, may be partially reversible if treated early. Scalp involvement is rare. Loss of eccrine sweating from sympathetic nerve involvement is common but rarely so extensive as to lead to heat intolerance. Any given skin lesion may or may not be hypesthetic but generally, in each patient, some are. Nerve trunk palsies occur, but are less common than in BL. Acral distal symmetric anesthesia is to be expected and may be so severe as to lead to debilitating trophic changes of the hands or feet. Untreated LL disease is relentlessly progressive, but this course may be altered by reactional states. LLs and LLp subjects frequently develop ENL, but LLp patients do not develop reversal reactions (see below), whereas LLs patients may.

Systemic Associations

Because of motor or sensory changes in cranial nerve V, the eye may be at risk in TT and BT disease, as well as in BB, BL, and LL leprosy. In the latter group, numerous changes in the cornea and anterior chamber are possible, iritis being a common serious change, occurring de novo or in association with reactions. Corneal insensitivity is the common, treatable change. Routine ophthalmologic examination is recommended for all patients.

In all LL patients and in BL with extensive disease, wide dissemination of the infection is the rule, but, with the exception of the upper respiratory tract (tip of the nose through the vocal cords with rhinitis, septal perforation, and nasal collapse being not uncommon), eyes and testicles (atrophy, impotence, and infertility), clinically troublesome injury is unusual. With effective chemotherapy, chronic disability from ocular or upper respiratory tract involvement is less common than previously, but has not disappeared, making ophthalmologists and otolaryngologists still vital to the successful management of patients with leprosy, to evaluate and treat acute changes, and to prevent chronic changes.

Variants

PREGNANCY AND POSTPARTUM Pregnancy is a precipitating factor for leprosy in 10 to 25 percent of women patients, presumably because of altered immunity. When pregnant, LL and BL patients are predisposed to develop ENL, but in the postpartum period, they are predisposed to develop reversal reactions, putatively due to reduced immunity in the former and restored immunity in the latter. [20] Of the drugs used to treat leprosy, none have been proven to be safe for the fetus and one is clearly contraindicated. Fetal damage attributable to dapsone evidently has not been observed, hence continuation of dapsone in multibacillary patients is usually recommended. The wishes of the patient should be carefully considered. Untreated, lactating BL and LL patients have viable bacilli in their milk, but no definable risk has been identified in infants ingesting such bacilli. [21] Dapsone in mother's milk may produce hemolysis in baby.

INDETERMINATE LEPROSY Indeterminate leprosy is a term with nearly as many meanings as it has users. We prefer the definition of Khanolkar, [22] designating an early lesion, appearing before the host makes a definitive immunologic commitment to cure or to an overt granulomatous response. Clinically, the indeterminate lesion is a hypopigmented macule, with or without a sensory deficit and acid-fast bacilli, if found, are in very small numbers. Such lesions are rare in our clinic. The term is inappropriately used to describe lesions rich in bacilli but having neither typical tuberculoid or lepromatous histological responses, such patients usually being BL and occasionally LL.

ACQUIRED IMMUNODEFICIENCY SYNDROME OR HIV INFECTION In contrast to the high incidence of tuberculosis and *M. avium-intracellulare* infections in AIDS or HIV patients, leprosy does not behave as an opportunistic infection in these individuals. Also, AIDS or HIV does not appear to influence disease expression (tuberculoid versus lepromatous) or the frequency of reactional states, but may be a risk factor for recurrent reversal reactions. [23]

DISABILITY OF HANDS AND FEET Approximately one-quarter to one-third of newly diagnosed patients with leprosy will eventually have some chronic disability secondary to irreversible nerve injury, usually of the hands or feet, or from eye involvement. Weakness from loss of innervation of muscles is a self-evident cause of disability. Loss of protective sensation is less obvious, but no less real. When a sharp or hot object cannot be perceived as such, injury occurs. Because this injury is more severe than if sensation were normal, infection is more apt to occur. Because the infection can produce no painful signal, the part is not rested, allowing the infection to become extensive before help is sought. Repetitive cycles of injury and infection, permitted by loss of protective pain sensation, is the source of severe tissue destruction in leprosy. Management and prevention of the problems arising from nerve injury require the skills of

orthopedic surgeons, podiatrists, plastic surgeons, physical therapists, orthotists and occupational therapists.
RELAPSING LEPROSY “Multibacillary” patients who are noncompliant or who develop drug resistance are prone to relapse. Such individuals present in several ways, including (1) a reprise of their initial presentation, (2) florid dermatofibroma-like lesions (histoid lesions), (3) a reactional state, and (4) a clinical state of higher resistance than their initial presentation, for example, an initially LLs individual having BL or even BT disease.

Reactional States

Generically, the reactional states of leprosy are distinctive, tissue destructive, inflammatory processes, putatively immunologically driven, that greatly increase the morbidity of the disease and, because of the experience required for optimal patient care, justify leprology as a clinical subspecialty. When present, a reactional state is superimposed upon the underlying granuloma, but it usually dominates the clinical picture. Analogous to the p electron in photobiology, when the granulomas accept immunologically driven “energy,” the excited granuloma is able to injure tissues in ways that it cannot when in its ground state.

DELAYED-TYPE HYPERSENSITIVITY REACTION (JOPLING'S TYPE I REACTION) Although widely regarded as a delayed-type hypersensitivity (DTH) response, the nomenclature is not uniform. Reversal reaction, originally synonymous with “upgrading,” has come to be used as identical to type I, probably because most type I reactions are associated with reversal. Designation by mechanism as a DTH reaction is a rational and acceptable name. DTH reactions are particularly common in BL patients, but are not rare in LLs, BB, or BT. [24] Patients may upgrade to a more-resistant granulomatous posture, remain unchanged, or downgrade to a less-resistant disease state. Clinically, DTH reactions are characterized by the abrupt conversion of previously torpid plaques to tumid lesions, and new tumid lesions arising in clinically normal skin with or without an abrupt onset of neuritis. A purplish color is characteristic, and even if not obvious, the dusky erythema may have a purplish cast (Fig. 202-8). Iritis and lymphedema (elephantiasis graecorum) may be concomitant changes. Lesions are rarely solitary, as can happen in BT upgrading to TT, often multiple, and occasionally myriad, as in BL or LLs upgrading to BT. Neuritis also ranges from mild to severe, potentially disastrous, particularly if involving multiple nerves. DTH reactions may often be a mode of presentation, and DTH reactions occurring soon after presentation and the institution of treatment may well have been DTH reactions from the beginning. Most common in the first year of treatment, DTH reactions may occur up to 7 years after starting therapy, well after treatment has stopped. The diagnosis of a DTH reaction is primarily clinical, but histologic confirmation should be sought.

FIGURE 202-8 Some of the initial presenting lesions in a patient with a DTH reaction who had borderline lepromatous (BL) leprosy. The tumidity, purplish hues, and sharp margination strongly suggest a reversal reaction. The lesions were neither painful nor tender. The differences between these lesions and those shown in Fig. 202-3 and Fig. 202-4 emphasize that the DTH reaction, not the underlying BL disease, dominates the clinical picture. The patient also had an irreversible foot drop of recent onset.

ERYTHEMA NODOSUM LEPROSUM (JOPLING'S TYPE II REACTION) ENL (first described by Murata in 1912) occurs most often in LL, in up to 75 percent of cases, but is not rare in BL patients. (ENL is not erythema nodosum occurring in leprosy; it is a leprosy-specific response, which has some features in common with erythema nodosum.) It may occur before, during, or after chemotherapy. The median time of onset is close to 1 year after onset of treatment. Clinically, this reaction is characterized by crops of painful and tender, bright pink, dermal and subcutaneous nodules arising in clinically normal skin, in association with fever, anorexia, and malaise (Fig. 202-9). Of the other organs involved, arthralgias and arthritis are more common in ENL than are neuritis, adenitis, orchitis/epididymitis, or iritis, but each may rarely be the initial structure affected. Involvement of both upper and lower extremities is the rule and facial lesions occur in one-half of the patients. A neutrophilic leukocytosis is often present, occasionally leukemoid in degree. Severe episodes can be associated with an abrupt fall in hematocrit, up to 5 g/dL, easily mistaken for dapsone-induced hemolysis. The response to thalidomide is dramatic in greater than 90 percent of patients, perhaps qualifying as a diagnostic criterion. When ENL is the presenting mode of leprosy, there may be little or no stigmata of the underlying multibacillary disease. ENL may be precipitated by pregnancy or pyogenic infections.

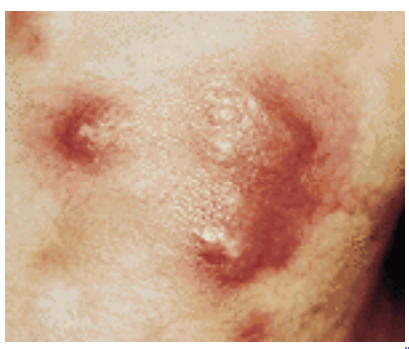

FIGURE 202-9 Lesions of erythema nodosum leprosum (ENL) in a patient with lepromatous leprosy (LL). The bright pink color is characteristic. These lesions are edematous, and pustule formation is suggested. The lesions are painful and tender.

Although episodes of ENL may be occasional or sporadic, in the more severely involved patients, episodes can be frequent to virtually unremitting. In the latter, brawny induration of the anterior thighs and preaxial portion of the arms is

characteristic, perhaps a reversible fibrosis. Other cutaneous variants are annular lesions mimicking erythema multiforme, vesicles or pseudovesicles in association with papillary edema, necrotic lesions, ulcers, frank subcutaneous abscesses, and pustular lesions mimicking pyodermas. The course of ENL, treated or untreated, ranges from sporadic and ephemeral, to frequent and persistent, lasting a matter of years. A severe, difficult to manage, form of ENL is a serious problem in Brazil and other parts of South America. The diagnosis of ENL, if considered, is usually not difficult, the clinical and histologic features being characteristic and the response to thalidomide often dramatic.

THE LUCIO REACTION Clinically, the Lucio reaction, first described by Raphael Lucio in 1853, consists of hemorrhagic infarcts. Particularly prevalent in Mexico and the Caribbean region, it is restricted to patients with Latapi's lepromatosis, described by Fernando Latapi in 1941, [25] a distinctive form of diffuse nonnodular lepromatous leprosy. When fully developed, Latipi's lepromatosis manifests a widening of the nasal root and fusiform enlargement of the fingers, both the consequence of diffuse dermal infiltration, as well as, a purplish suffusion of the hands and feet, numerous telangiectatic mats or eruptive telangiectasias, nasal septum perforation, total alopecia of eye brows and eye lashes, and a well-developed acral distal symmetric anesthesia. Firm subcutaneous nodules are palpable but not visible. Ocular sparing is the rule. The Lucio reaction occurs after Latapi's lepromatosis is well developed but before treatment is initiated. The necrotic lesions, arising in crops, have the serrated margins characteristic of septic infarcts and are painful but not tender (Fig. 202-10). Lesions usually crust and heal with scaring. Ulceration is common, especially below the knees. Lesions vary in size and extent, ranging from a few small lesions on the ankles to many large lesions, placing life in peril. With dapsone alone, lesions may worsen, but in our experiences, new lesions cease within 1 week of beginning rifampin, suggesting a strict requirement for viable bacilli. [26]

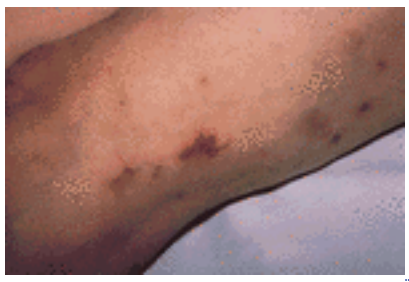

FIGURE 202-10 Lesions of the Lucio reaction, which show the characteristic hemorrhagic infarcts and serrated borders. Lesions are painful but not tender. The patient has Latapi's lepromatosis as manifested by diffuse infiltration, total alopecia of the eyelashes and brows, perforation of the nasal septum, no nodular lesions, and severe acral distal symmetric anesthesia.

LABORATORY FINDINGS

Most laboratory changes occur in LL or extensive BL disease. Hyperglobulinemia is the most common, giving an elevated sedimentation rate. A biologic false-positive serologic test for syphilis, anemia of chronic disease, and mild lymphopenia are also common. Clinically insignificant antiphospholipid antibodies are present in 50 percent of LL patients, and may give rise to a lupus anticoagulant or agglutination of sheep erythrocytes (Rubino factor). [27] If sought, the stained smear of the buffy coat shows bacilli up to 10^5/mL. Elevated serum lysozyme and angiotensin-converting enzyme values reflect the extensive accumulation and activation of macrophages synthesizing these proteases. Proteinuria, not uncommon, is associated with a focal glomerulonephritis, seen mostly in patients with ENL. As manifested by high serum follicle-stimulating hormone (FSH) and luteinizing hormone (LH) values, but low testosterone levels, LL disease involves the testicles in a majority of men with LL, but in a minority of men with BL.

PATHOLOGY

Microscopic Changes

COMMON AND UNCOMMON PATTERNS Granulomatous responses are the common tissue reactions in leprosy, with epithelioid differentiation of macrophages being characteristic of TT, BT, and BB, and undifferentiated or foamy macrophages being the hallmark of BL, LLs, and LLp. Exceptions can occur, sometimes dominating the histologic picture; exceptions include (1) chronic inflammation, particularly in BL and indeterminate disease, (2) lobular panniculitis in ENL, and (3) vasculitis in ENL and the palpable-only nodules of Latapi's lepromatosis. At the level of the low-power objective, a patchy infiltrate throughout the dermis, or a bizarre “sausage-shaped” infiltrate (following neurovascular bundles) should include consideration of leprosy in the differential diagnosis.

SPECTRAL GRANULOMATOUS PATTERNS [17], [18] In de novo TT lesions, small, well-developed epithelioid tubercles are surrounded by large lymphocytic mantles. In TT upgrading from BT, abundant Langhans-type giant cells and a brisk exocytosis into the epidermis are added to the preceding pattern, and caseation may be present. In BT tissues, lymphocytic mantles are less well developed, Langhans-type giant cells are inconstant, and, if present at all, epidermal exocytosis is focal. Acid-fast bacilli are not found in TT and are only rarely seen in BT. The presence of bacilli or plasma cells in what otherwise appears to be BT warrants consideration of a reversal reaction. In BB, lesions are lymphopenic, giant cells are absent, and bacilli are common. The classic BL tissue responses are a moderately dense lymphocytic infiltrate restricted to the space occupied by the macrophages, and lamination of the perineurium with infiltrating inflammatory cells. A chronic lymphohistiocytic infiltrate is an alternate pattern. In LLs, lymphocytes are present focally or sparsely distributed generally, and the laminated perineurium is not infiltrated. In LLp, lymphocytes are fewer than in LLs, and there is no perineural lamination. From BL to LLp, the extent of the granuloma and the numbers of globi (large secondary lysosomes packed with bacilli) are highly variable, but bacilli are always easily found, even if with great quantitative differences.

PATTERNS IN REACTIONAL STATES Reversal reactions, when compared with prereactional tissues, occasionally do not differ, but may show edema, epithelioid change, increased lymphocytes, Langhans-type and foreign-body giant cells, epidermal thickening, and, occasionally, enhanced bacteriolysis. [28] ENL lesions usually have neutrophils, a marked increase in lymphocytes, epidermal thickening, and a gradient of inflammatory cells, scant in the papillae and heavy in the deep dermis or subcutis. Lucio lesions feature ischemic necrosis in both epidermis and dermis, vessel occlusion by

thrombosis or endothelial proliferation, and heavy bacillary parasitization of endothelial cells. [26]

Immunopathology and Immunology

Investigation into the immunology of leprosy offers three promises: (1) a better understanding of the disease itself; in particular, the immunopathogenesis of the granulomatous spectrum and the reactional states; (2) eradication or control of the disease by vaccination; and (3) development of a probe of cell-mediated immunity in humans that, when understood in the model of leprosy, will illuminate other disease processes.

CELLULAR IMMUNITY The great diversity of leprosy is exemplified by comparing its two polar forms. The high-resistance tuberculoid form is characterized by few lesions, rare organisms, epithelioid cell granulomas, and a tendency to self-cure. A sharp margin on a plaque is the inscription of anti- *M. leprae* DTH on the skin; a nerve trunk palsy is its inscription on a peripheral nerve. Tuberculoid leprosy appears to be an entirely different disease than the low-resistance lepromatous form, characterized by wide dissemination, abundant organisms, foamy macrophages, and, if untreated, relentless progression. Strain variation of *M. leprae* is an unlikely explanation for the diverse host responses in leprosy. [29] The observations of a positive lepromin skin test in tuberculoid subjects and unresponsiveness in lepromatous patients was the first objective and reproducible evidence that host immunity was the mechanism of polar diversity. [3] Lymphocyte transformation tests provided an in vitro correlate of the lepromin skin and substantial evidence that mediation of polar diversity was through the cellular-immune response. On the contrary, antibody responses to *M. leprae* were found to be stronger in lepromatous patients, indicating the humoral immunity does not lead to resistance to disease. Immunophenotypic studies established an important difference between the lymphocyte subsets infiltrating skin lesions and tuberculoid subjects having a predominance of the CD4 subset (CD4:CD8 = 2:1), but lepromatous patients having a predominance of the CD8 subset (CD4:CD8 = 1:2). [30] The skewing of T cell subsets in lesions was independent of those in the peripheral blood, because all patients had a normal CD4:CD8 ratio of 2:1. Therefore, it is important to study the immune response of patients at the site of disease activity, that is, the skin lesions. By using the sequential application of reverse transcriptase and polymerase chain reaction techniques to tissue extracts, studies of mRNA cytokine profiles in polar tissues have provided a functional explanation for their immunopathogenesis. [31] Tuberculoid lesions have a type 1 (T_H1 or T_H1-like) proinflammatory profile, in particular abundant mRNA coding for interleukin (IL)-2, interferon (IFN)-?, and IL-12, but scant mRNA coding for IL-4 or IL-10. In contrast, lepromatous tissues have a type 2 (T_H2 or T_H2-like) anti-inflammatory profile, in particular, abundant IL-4 mRNA and IL-10 mRNA, but little mRNA coding for the type 1 cytokines. Furthermore, CD4+ T cells in tuberculoid lesions were shown to produce IFN-?, whereas, CD8 T cells in lepromatous lesions accounted for the production of IL-4. [32] The presence of type 1 cytokines likely results in strong T cell and macrophage activation, the result being cell-mediated immunity to localize the infection. On the other hand, the type 2 cytokines found in lepromatous lesions likely lead to the strong antibody responses, but concomitantly inhibit T cell and macrophage responses resulting in progression of the infection. The importance of this paradigm is reflected in experiments designed to augment cell-mediated immunity in lepromatous patients, where the administration of recombinant IFN-? to lepromatous patients reduced the number of bacilli infiltrating tissues. [33] The decision by the host as to which cytokine profile to make, that is, type 1 or type 2, may rest with the response of the native immune system to *M. leprae*. Cytokines produced by the native immune system may profoundly affect the adoptive response, [34] and some of the Toll-like receptors (TLR) of the native system are triggered by mycobacterial lipoproteins [35] (see Chap. 22 and Chap. 28). Reversal reactions and positive lepromin skin tests (Mitsuda reactions), long considered to be delayed-type hypersensitivity responses, [36] also have a CD4+ T cell predominance and a type 1 cytokine profile, but both differ from tuberculoid lesions by having a relative excess of *M. leprae*-reactive ?d T cells, perhaps related to these being recent lesions. [37] Host cytokine profiles are subject to change. LLs patients undergoing a reversal reaction switch from a type 2 to a type 1 profile; the mechanism of the switching is yet to be determined. [38]

ANTIBODY IMMUNITY ENL is widely regarded to be mediated by immune complexes. There are large amounts of anti-*M. leprae* antibodies in both LL and BL patients. All classes of antibodies are represented and their specificities directed against a number of substrates including specific and cross-reacting peptides, but these antibodies do not confer disease protection. Also, the blood of BL and LL patients contains abundant antigens including intact bacilli, up to 10^5/mL. Therefore, it is readily conceivable that BL and LL patients should be subject to immune complex-mediated tissue injury. The best direct support for the hypothesis that ENL is immune complex mediated is the presence of split complement products in serum, which is consistent with extravascular complement activation within tissues. [39] Inferential evidence is that of neutrophil infiltration, suggesting an Arthus phenomenon, and an excess of glomerulonephritis in ENL patients. Also, the cytokine profile in ENL is type 2, despite a preponderance of the CD4+ subset. [38] However, evidence for immune complex mediation is far from persuasive—it has not been reproduced and it is confounded by a number of observations, including human leukocyte antigen (HLA)-DR framework antigen in lesional epidermis, [40] an increase in IFN-? containing cells by hybridization studies, [41] an excess of IL-2–staining cells as compared with LL tissue, [42] and the precipitation of ENL by the administration of rIFN-?. [43] Also, other thalidomide responsive syndromes, such as rheumatoid arthritis, tuberculosis cachexia, multiple myeloma, and Behçet's syndrome, are not directly immune complex mediated. Perhaps both immune complexes and cellular immunity are important in the pathogenesis of ENL. Little is known concerning the immunopathogenesis of the Lucio reaction. Extant evidence favors immune complex mediation. The abundant acid-fast bacilli in endothelial cells could be the optimum location for presentation of antigen to antibody. Also, the cryoprecipitate from Lucio serum is more indicative of complement activation than that from ENL patients. [44]

DIAGNOSIS

A firm diagnosis of leprosy requires the satisfaction of one of two criteria: a consistent peripheral nerve abnormality or the demonstration of mycobacteria in tissues.

The diagnosis begins with a suspicion of leprosy, which should be aroused by the presence of any of several known risk factors, including (1) birth or residence in an endemic area, which is almost sine qua non for the diagnosis, (2) a blood relative with the disease, which could reflect transmission, common genetic makeup, or common environmental

exposure, and (3) armadillo (seven-banded) exposure in North American.

The possibility of leprosy also should be suggested by particular clinical constellations such as (1) simultaneous skin lesions and peripheral nerve abnormalities, (2) a differential diagnosis that includes granuloma, vasculitis, or lymphoma, (3) a peripheral neuropathy of unknown type in a patient in or from an endemic area, the so called pure neuritic leprosy, and (4) simultaneous palsies of cranial nerves V and VII, considered to be leprosy until proven otherwise.

Because *M. leprae* does not grow in cell-free media, demonstration of mycobacteria by their acid-fast property is used most commonly in diagnosis. Acid-fast bacilli in tissue sections are best shown by carbolfuchsin staining, using modifications of the Ziehl-Neelson method, collectively called Fite-Farraco stains . *M. leprae,* like *Nocardia* species, is only weakly acid-fast. In smears, either the Ziehl-Neelson method or oramine-rhodamine staining with fluorescent microscopy is satisfactory. Because of characteristic clinical and histologic changes, positive specification of *M. leprae* is rarely required.

Characteristic histologic changes are extremely helpful in suggesting or corroborating a diagnosis of leprosy, but, excepting the presence of epithelioid cell granulomas within nerves, are not absolutely diagnostic.

False Negatives

The six errors that lead to missing the diagnosis of leprosy are (1) failure to consider the diagnosis, usually from ignoring birth or residence in an endemic area; (2) failure to inform the pathologist of the suspicion of leprosy—an infiltrate may not be granulomatous, thus no acid-fast bacilli stain will be done by the pathologist if there is no known clinical suspicion; (3) an inadequate neurologic exam, in particular, the patient is not properly instructed to distinguish between dull and sharp (if the patient is not instructable, absence of a histamine-induced axon reflex flare, with a positive symmetric control, is good evidence of type C pain fiber loss); (4) presence of pinprick perception does not exclude loss of heat and cold discrimination; (5) improper staining for bacilli in biopsy specimens—in a conventional Ziehl-Neelson stain *M. leprae,* being only weakly acid-fast, may be decolorized altogether; and (6) tissue sampling error—the advancing border should be selected for biopsy not the clearing center.

False Positives

The four errors that lead to improperly diagnosing leprosy are (1) inflammatory lesions may have blunted pain perception (histamine tachyphylaxis), producing diminished sensation similar to that seen in some leprosy lesions; (2) atypical mycobacterial infection may have the abundant acid-fast bacilli characteristic of lepromatous disease; (3) environmental mycobacteria-like water, including that used to process tissue sections, as suggested by bacilli in the embedding medium, or not associated with cellular infiltrates; (4) from time-to-time, cunning artifacts are misinterpreted as acid-fast bacilli. If a patient, suspected of having leprosy, has no history of residence in a known endemic area, then one of these errors should be seriously considered.

ALTERNATIVE METHODS Alternative methods of establishing a diagnosis have been pursued but, at present, are of limited value. *M. leprae* specific antibodies are most prevalent in multibacillary cases, where there is no need for better diagnosis, and are, in endemic areas, far more prevalent than the disease, thus further restricting their utility. [10] Polymerase chain reaction (PCR) may be negative in up to one-half of paucibacillary cases, making a positive signal of value but a negative signal of no help. PCR should be most helpful in the diagnosis of patients with lesions having acid-fast bacillus, but no stigmata of leprosy, and negative cultures. [45] Lepromin skin testing, because of the high rate of positive reactions in unexposed adults, is not useful in diagnosis, but can be of value in classification of diagnosed patients; all TT and most BT (85 percent in our experience) being positive (3 mm or more of induration at 21 days) and BB through LLp being negative (less than 3 mm).

TREATMENT

Medical management is directed at the infection itself, or if present, at a reactional state. For paucibacillary disease (TT or BT) the World Health Organization (WHO) recommends the combination of unsupervised dapsone (bacteriostatic) 100 mg daily and supervised rifampin (bactericidal) 600 mg monthly for a duration of 6 months. [46] We prefer dapsone 100 mg daily for 2 to 3 years, with or without rifampin 600 mg monthly, with follow-up examination at 1 and 2 years after discontinuing treatment.

For multibacillary disease (BB, BL, and LL) the WHO recommends unsupervised dapsone 100 mg daily, supervised rifampin 600 mg monthly and clofazimine 50 mg daily, unsupervised, and 300 mg monthly supervised for a routine duration of 2 years. [46] The rationale for this regimen is that rifampin will kill all susceptible organisms, including those resistant to dapsone, and dapsone will eventually eliminate all susceptibles, including those resistant to rifampin; clofazimine is added to obviate the risk of primary dapsone resistance. This regimen is considered by the WHO to be curative and is the cornerstone of the anticipated reduction of the prevalence of leprosy to less than 1 case per 10,000 people. The report of a 20 percent relapse rate within 8 years after completion of this regimen suggests a need for alternative approaches, [47] particularly in heavily bacillary patients (biopsy index of 5 or more).

For the treatment of multibacillary disease, other regimens may be used. Because the incidence of primary dapsone resistance is low in our patient population, we often use the combination of rifampin 600 mg daily and dapsone 100 mg daily for 3 years followed by dapsone 100 mg daily indefinitely or cessation of treatment. Alternative regimens of rifampin 600 mg daily in combination with either minocycline (bactericidal) 100 mg daily or clarithromycin (bactericidal) 500 mg daily for 2 to 3 years, followed by monotherapy, has been well tolerated, except for hyperpigmentation from the minocycline. [48] Short-term therapy with three microbicidal agents (rifampin, minocycline, and ofloxacin or moxifloxacin) is currently experimental. [49]

In reversal reactions, because of the risk of permanent nerve damage, prompt institution of prednisone therapy (0.5 to 1 mg/kg per day) is recommended (but still wanting a controlled trial). The dose of prednisone is titrated against overt nerve tenderness, the patient's symptoms, and careful sensory evaluation of hands and feet, for example with graded Weinstein filaments. Once instituted, therapy should be tapered slowly and continued for a minimum of 6 months. If response of neuritis to prednisone is not prompt, then rest, enforced with splinting of effected extremities, is also recommended. In ENL, thalidomide use is dramatically effective in a majority of patients, if not interdicted by its teratogenic effects. For outpatients, we usually start with 100 to 200 mg nightly of thalidomide and, if it is only partially effective, we add prednisone in a 0.5 to 1.0 mg/kg range, tapering the prednisone over the subsequent 6 to 8 weeks. Higher doses of thalidomide are usually restricted to inpatients in whom excessive sleepiness is not a problem. If not available, corticosteroids in conjunction with clofazimine at 200 mg per day may be effective. Thalidomide is slowly tapered to 100 mg and then to 50 mg daily.

Adverse reactions to dapsone seen in the near term include the dapsone syndrome, a rare, potentially fatal infectious mononucleosis-like condition and three kinds of hemolytic anemia, almost universally from a direct membrane effect, uncommonly from a glucose-6-phosphate deficiency, and rarely from an idiosyncratic response (see also Chap. 254). In the long-term, dapsone is associated with peripheral neuropathy, usually motor with a sensory component, and, rarely, bone marrow suppression, especially agranulocytosis.

The serious problem with rifampin is hepatotoxicity. Red urine is alarming but banal. As a P450 inducer, rifampin may lessen the effect of other drugs, for example, oral contraceptives resulting in pregnancy, or reduced anti-inflammatory activity of corticosteroids. Once monthly use is rarely associated with severe hemolysis and acute renal failure.

Clofazimine produces skin darkening from the clofazimine itself in the near-term and from a ceroid-lipofuscin pigment in the long-term. [50] At usual doses of 50 to 100 mg a day, gastrointestinal intolerance, dry skin, and acquired ichthyosis are common. Prolonged administration of large doses may produce a novel enteropathy secondary to mucosal and enteric lymph node drug accumulation. Accumulation in the spleen may predispose to rupture.

Thalidomide, infamous for teratogenicity, may produce constipation and dizziness. Neuritis, a common side effect in nonleprosy patients, appears to be rare in ENL patients (see also Chap. 264).

Long-term use of minocycline may be limited by hyperpigmentation, [48] much more common in leprosy than in acne, perhaps related to the large accumulation of macrophages in leprosy. We have seen both diffuse hyperpigmentation and intense hyperpigmentation at the site of lesions, usually on the legs or feet.

Corticosteroids, in addition to their well-known side effects, may also exacerbate coexisting diseases, for example, tuberculosis, hepatitis B, and some gastrointestinal parasites.

REFERENCES

1. Skinsnes OK: Immunopathology of leprosy: The century in review. *Int J Lepr Other Mycobact Dis* **41**:329, 1973

2. Shepard CC: The experimental disease that follows injection of human leprosy bacilli into foot pads of mice. *J Exp Med* **112**:445, 1960

3. Mitsuda K: On the value of a skin reaction to a suspension of leprous nodules. *Int J Lepr* **21**:347, 1953

4. Cole ST et al: Massive gene decay in the leprosy bacillus. *Nature* **409**:1007, 2001

5. Anonymous. Leprosy—global situation. *Wkly Epidemiol Rec* **75**:226, 2000

6. Walsh GP et al: Leprosy-like disease occurring naturally in armadillos. *J Reticuloendothel Soc* **18**:347, 1975

7. Thomas DA et al: Armadillo exposure among Mexican-born patients with lepromatous leprosy. *J Infect Dis* **156**:990, 1987

8. Mostafa HM et al: Acid-fast bacilli from former leprosy regions in coastal Norway showing PCR positivity for *Mycobacterium leprae*. *Int J Lepr Other Mycobact Dis* **63**:97, 1995

9. Ducan ME et al: A clinical and immunological study of four babies of mothers with lepromatous leprosy, two of whom developed leprosy in infancy. *Int J Lepr Other Mycobact Dis* **51**:7, 1983

10. Cho SN et al: Prevalence of IgM antibodies to phenolic glycolipid I among household contacts and controls in Korea and the Philippines. *Lepr Rev* **63**:12, 1992

11. Ng V et al: Role of the cell wall phenolic glycolipid-1 in the peripheral nerve predilection of *Mycobacterium leprae*. *Cell* **103**:511, 2000

12. Chakravartti MR, Vogel F: A twin study on leprosy, in *Topics in Human Genetics,* edited by PEEA Becher. Stuttgart, Georg Thieme, 1973, p 1

13. Siddiqui MR et al: A major susceptibility locus for leprosy in India maps to chromosome 10p13. *Nat Genet* **27**:439, 2001

14. de Vries RR et al: HLA class-II immune response genes and products in leprosy. *Prog Allergy* **36**:95, 1985

15. Convit J et al: Immunoprophylactic trial with combined *Mycobacterium leprae*/BCG vaccine against leprosy: Preliminary results. *Lancet* **339**:446, 1992

16. Sieling PA et al: CD1-restricted T cell recognition of microbial lipoglycans. *Science* **269**:227, 1995

17. Ridley DS. Histological classification and the immunological spectrum of leprosy. *Bull World Health Organ* **51**:451, 1974

18. Ridley DS: *Pathogenesis of Leprosy and Related Diseases*. London, Wright, Butterworth, 1988, p 158

19. van Brakel WH, Khawas IB: Silent neuropathy in leprosy: An epidemiological description. *Lepr Rev* **65**:350, 1994

20. Lyde CB: Pregnancy in patients with Hansen's disease. *Arch Dermatol* **133**:623 1997

21. Pedley JC: The presence of *M. leprae* in human milk. *Lepr Rev* **38**:239, 1967

22. Khanolkar VR: Pathology of leprosy, in *Leprosy in Theory and Practice,* edited by RG Cochrane, TF Davey. Bristol, John Wright and Sons, 1964, p 125

23. Gebre S et al: The effect of HIV status on the clinical picture of leprosy: A prospective study in Ethiopia. *Lepr Rev* **71**:338, 2000

24. Scollard DM et al: Epidemiologic characteristics of leprosy reactions. *Int J Lepr Other Mycobact Dis* **62**:559, 1994

25. Latapi F, Zamora AC: The “spotted” leprosy of Lucio (la lepra “manchada” de Lucio). *Int J Lepr* **16**:421, 1948

26. Rea TH, Levan NE: Lucio's phenomenon and diffuse non-nodular lepromatous leprosy. *Arch Dermatol* **114**:1023, 1978

27. Panunto-Castelo A et al: The Rubino test for leprosy is a beta $_2$-glycoprotein 1-dependent antiphospholipid reaction. *Immunology* **101**:147, 2000

28. Rea TH, Sieling PA: Delayed-type hypersensitivity reactions followed by erythema nodosum leprosum. *Int J Lepr Other Mycobact Dis* **66**:316, 1998

29. Clark-Curtiss JE, Walsh GP: Conservation of genomic sequences among isolates of *Mycobacterium leprae*. *J Bacteriol* **171**:4844, 1989

30. Modlin RL et al: T lymphocyte subsets in the skin lesions of patients with leprosy. *J Am Acad Dermatol* **8**:182, 1983

31. Yamamura M et al: Defining protective responses to pathogens: Cytokine profiles in leprosy lesions. *Science* **254**:277, 1991

32. Salgame P et al: Differing lymphokine profiles of functional subsets of human CD4 and CD8 T cell clones. *Science* **254**:279, 1991

33. Nathan CF et al: Local and systemic effects of intradermal recombinant interferon-gamma in patients with lepromatous leprosy. *N Engl J Med* **315**:6, 1986

34. Hsieh C-S et al: Development of Th1 CD4+ T cells through IL-12 produced by *Listeria*-induced macrophages. *Science* **260**:547, 1993

35. Brightbill HD et al: Host defense mechanisms triggered by microbial lipoproteins through Toll-like receptors. *Science* **285**:732, 1999

36. Barnetson RS et al: Cell mediated and humoral immunity in “reversal reactions.” *Int J Lepr Other Mycobact Dis* **44**:267, 1976

37. Modlin RL et al: Lymphocytes bearing antigen-specific gamma/delta T-cell receptors in human infectious disease lesions. *Nature* **339**:544, 1989

38. Yamamura M et al: Cytokine patterns of immunologically mediated tissue damage. *J Immunol* **149**:1470, 1992

39. Bjorvatn B et al: Immune complexes and complement hypercatabolism in patients with leprosy. *Clin Exp Immunol* **26**:388, 1976

40. Rea TH et al: Epidermal keratonocyte Ia expression, Langerhans cell hyperplasia, and lymphocytic infiltration in skin lesions of leprosy. *Clin Exp Immunol* **65**:253, 1986

41. Cooper CL et al: Analysis of naturally occurring delayed-type hypersensitivity reactions in leprosy by in situ hybridization. *J Exp Med* **169**:1565, 1989

42. Modlin RL et al: In situ identification of cells in human leprosy granulomas with monoclonal antibodies to interleukin 2 and its receptor. *J Immunol* **132**:3085, 1984

43. Sampaio EP et al: Prolonged treatment with recombinant interferon gamma induces erythema nodosum leprosum in lepromatous leprosy patients. *J Exp Med* **175**:1729, 1992

44. Quismorio FP et al: Lucio's phenomenon: An immune complex deposition syndrome in lepromatous leprosy. *Clin Immunol Immunopathol* **9**:187, 1978

45. Williams DL et al: Detection of *M. leprae* and the potential for monitoring antileprosy drug therapy directly from skin biopsies by PCR. *Mol Cell Probes* **6**:401, 1992

46. WHO Study Group. Chemotherapy of leprosy. *WHO Tech Rep Ser* 847, 1994

47. Jamet P et al: Relapse after long-term follow up of multibacillary patients treated by WHO multidrug regimen. *Int J Lepr Other Mycobact Dis* **63**:195, 1995

48. Rea TH. Trials of daily, long-term minocycline and rifampin or clarithromycin and rifampin in the treatment of borderline lepromatous and lepromatous leprosy. *Int J Lepr Other Mycobact Dis* **68**:129, 2000

49. Ji B, Grosset J: Combination of rifapentine-moxifloxacin-minocycline (PMM) for the treatment of leprosy. *Lepr Rev* **71**(Suppl):S81, 2000

50. Job CK et al: Skin pigmentation from clofazimine therapy in leprosy patients: A reappraisal. *J Am Acad Dermatol* **23**:236, 1990

T>

Chapter 203

Eva Åsbrink Anders Hovmark

Lyme Borreliosis

HISTORICAL ASPECTS
EPIDEMIOLOGY
ETIOLOGY
CLINICAL MANIFESTATIONS
Classification of Clinical Disease
Geographic Differences in the Clinical Picture
CUTANEOUS MANIFESTATIONS
Erythema Migrans
Borrelial Lymphocytoma
Acrodermatitis Chronica Atrophicans
Extracutaneous Manifestations in Patients with ACA
Sclerotic and Other Skin Lesions
EXTRACUTANEOUS MANIFESTATIONS
Neurologic Manifestations
Rheumatic Manifestations
Cardiac Manifestations
Ocular Lyme Borreliosis
Gestational Lyme Borreliosis
LABORATORY EXAMINATION
Detection of B. burgdorferi
Serology of Lyme Borreliosis
TREATMENT
Treatment of Uncomplicated Erythema Migrans
Treatment of Borrelial Lymphocytoma
Treatment of Neuroborreliosis or Cardiac Abnormalities
Treatment of Lyme Arthritis
Treatment of ACA
Jarisch-Herxheimer Reaction
PREVENTION
COURSE AND PROGNOSIS
Natural Course
Posttherapeutic Course

REFERENCES

Lyme borreliosis (Lyme disease) is a vector-borne infection primarily transmitted by *Ixodes* ticks and caused by at least three different but closely related species of *Borrelia*. The disease may affect different organs, and the clinical picture and course may be highly variable. Erythema (chronicum) migrans, borrelial lymphocytoma, and acrodermatitis chronica atrophicans (ACA) are the cutaneous hallmarks.

HISTORICAL ASPECTS

Three dermatologic conditions—erythema migrans, lymphadenosis benigna cutis (LABC), and ACA—have long been well known to European dermatologists. Both the atrophic and the inflammatory forms of ACA were described by different European authors more than a century ago, but the disease was first named and further characterized by Herxheimer and Hartmann in 1902. The first report of an erythema developing after a tick bite was presented by Afzelius in Sweden in 1909, and he gave it the name *erythema migrans*. A few years later, the term *erythema chronicum migrans* was used in an Austrian case report by Lipschütz. The designation *lymphocytoma* was first used by Biberstein in 1923. Bäfverstedt coined the term *lymphadenosis benigna cutis* in his monograph on pseudolymphomas published in 1943. [1]

In 1941 and 1944, the German neurologist Bannwarth described a syndrome, later to be named after him, with focal and often severe radicular pain, lymphocytic meningitis, and cranial nerve paralysis. The association with tick bites and erythema migrans was later observed by Schaltenbrand.

In the United States, erythema migrans was not described until the 1970s. In 1977, Steere et al. reported on an epidemic form of arthritis occurring in several communities around Lyme, Connecticut, on the Connecticut River. [2] Lyme arthritis was soon linked to a preceding erythema migrans, and manifestations in the nervous system and the heart were also found. [2]

In the early 1980s, Burgdorfer et al. [3] showed that Lyme disease was caused by tick-borne spirochetes. With use of modified Kelly medium, [4] cultivation of spirochetes from *Ixodes* ticks, from erythema migrans lesions, and from blood and cerebrospinal fluid specimens from a few patients with Lyme disease was successful. These spirochetes were classified as a new species of *Borrelia* and were named *B. burgdorferi.* Later, spirochetal cultivations and serologic tests also revealed that Bannwarth's syndrome and ACA were caused by *B. burgdorferi* and that these spirochetes may also cause LABC. However, as all cases diagnosed as LABC or pseudolymphomas do not have a borrelial etiology, Weber et al. introduced the term *borrelial lymphocytoma* in 1985. [5]

EPIDEMIOLOGY

Lyme borreliosis is a disease with a wide distribution in the northern hemisphere. Cases have been reported from Canada, 46 of the United States, most European countries, the Federal Republic of China, Korea, and Japan. In the former Soviet Union, cases have been recognized from the Baltic republics to the Pacific Ocean. It is the most common vector-borne disease of bacterial origin in the United States and Europe. There have been discussions as to whether the true incidence is rising or whether the reported increase is mainly attributable to greater recognition and awareness of this infection.

ETIOLOGY

The spirochete causing Lyme borreliosis was discovered unexpectedly in conjunction with a tick survey on Long Island, New York, in 1981 and 1982. [3] Studies of the morphology, antigen profile, and DNA indicated that the spirochete named *B. burgdorferi* was a new species in the genus *Borrelia* (order Spirochaetales). Antigenic heterogeneity was soon found among different strains of *B. burgdorferi*. The three genospecies of *B. burgdorferi sensu lato,* which have been shown to be human pathogens, have been named *B. burgdorferi sensu stricto, B. garinii,* and *B. afzelii*. There are differences in the geographic distribution of these genospecies. [6] Thus, until now, only *B. burgdorferi sensu stricto* has been found in the United States. In Europe, all three species are present, although at least in the Netherlands, Germany, Austria, Scandinavia, and Russia, *B. garinii* and *B. afzelii* seem to dominate. In the Asian parts of the former Soviet Union and in Japan, Korea, and China, *B. garinii* and *B. afzelii,* but not *B. burgdorferi sensu stricto,* have been found.

The primary vectors of Lyme borreliosis are hard ticks belonging to the *Ixodes ricinus* complex, that is, *I. scapularis* (*I dammini*) and *I. pacificus* in North America , *I. ricinus* and *I. persulcatus* in Europe, and *I. persulcatus* and *I. ovatus* in Asia. They are three-host ticks, parasitizing a wide range of animals, including humans. During feeding on a spirochetemic host, the larval or nymphal tick may become infected, and it may then remain infectious throughout the rest of its life by transstadial transmission of spirochetes. The feeding activity of the different stages is often seasonal during the spring, summer, and autumn. The rate of infection in nymphs and adult ticks ranges from a few percent to greater than 50 percent. Transovarial transmission seems to be rare. Instead, the main reservoirs of *B. burgdorferi* are the hosts, mainly considered to be rodents, of the larvae and nymphs. However, birds and many other warm-blooded animals may serve as additional reservoirs. Large animals such as deer may play an important role in feeding adult ticks. In endemic areas, domestic animals are frequently seropositive for antibodies to *B. burgdorferi,* and manifestations of Lyme borreliosis have been demonstrated in such animals.

Tick vectors other than those of the genus *Ixodes* may transmit *B. burgdorferi* but are less efficient vectors. Transmission of *B. burgdorferi* by nontick vectors such as deer flies, horseflies, and mosquitoes, or by direct contact with fluids from infected animals has been reported. However, Lyme borreliosis obtained in other ways than through a tick bite is probably very rare, with many patients unaware of the preceding tick bite because the nymphal tick, which is considered to be the most important vector for transmitting *B. burgdorferi* to humans, is so small that it often escapes detection.

CLINICAL MANIFESTATIONS

Classification of Clinical Disease

By analogy with syphilis, the natural history of Lyme borreliosis can be divided into three stages based on the clinical manifestations. Because the course in the individual patient does not imply a uniform temporal sequence with development of all the stages and because the infection is sometimes not manifest until stage two or three, many clinicians believe that a staging system with numbers may be misleading. It has therefore been proposed that the terms *early localized infection, early disseminated infection,* and *late* or *chronic infection* should be used instead (Table 203-1). Besides the clinical picture, the duration of the disease is probably also important in therapeutic decisions. A definition of chronic or late infection as persistent infection lasting more than 12 months has been suggested. Because many signs and symptoms of Lyme borreliosis are nonspecific, the cutaneous borrelial manifestations may serve as helpful and important landmarks in the identification of Lyme borreliosis.

Early Lyme borreliosis
Localized infection: Erythema migrans and borrelial lymphocytoma without signs or symptoms of disseminated infection. (Regional lymphadenopathy and/or minor constitutional symptoms may be present.)
Early disseminated infection: Multiple erythema migrans–like skin lesions. Early manifestations of neuroborreliosis, arthritis, carditis, or other organ involvement.
Late Lyme borreliosis
Chronic infection: ACA. Neurologic, rheumatic, or other organ manifestations—persistent or remitting for at least 12 months.

*The classification provides a guideline for the timing of different disease manifestations.

TABLE 203-1 **Classification of Lyme Borreliosis***

Geographic Differences in the Clinical Picture

The clinical manifestations caused by the different genospecies of *B. burgdorferi sensu lato* are similar but may vary in some respects. [6] All three strains may cause erythema migrans, neuroborreliosis, and arthritis. With few exceptions, analyses of sera or spirochetes isolated from patients with ACA or borrelial lymphocytoma have indicated that these manifestations are associated with infection with *B. afzelii*. *B. burgdorferi sensu stricto* is associated with a high frequency of articular manifestations. In Europe, *B. garinii* causes neuroborreliosis more often than *B. afzelii*. These findings support the concept of a strain-dependent organotropism of *B. burgdorferi*.

The differences in the geographic distribution of the three genospecies may explain some of the different clinical pictures of Lyme borreliosis described in Europe and the United States. Multiple erythema migrans–like lesions have been found in a higher frequency among American patients (25 to 48 percent) [7] than among Europeans (8 percent or less). [8] A higher frequency of arthritis has also been reported from the United States. In contrast, only a few cases of ACA and borrelial lymphocytoma have been described in Americans.

Within the last decade the risk of concurrent infection with other tick-transmitted agents, such as *Babesia* and *Ehrlichia,* has been described, especially in the northeastern and Great Lakes regions of the United States, but also in Europe. In experimentally coinfected animals, disease appears to be more severe than in those infected by *B. burgdorferi* alone, perhaps because babesial as well as ehrlichial infection may lead to immune suppression. Recent data indicate that coinfection may modify the clinical course of human Lyme borreliosis. [9], [10] Tetracyclines and clindamycin/quinine, respectively, are the treatments of choice for ehrlichiosis and babesiosis.

CUTANEOUS MANIFESTATIONS

Erythema Migrans

CLINICAL FEATURES [7], [8], [11], [12], [13] **and** [14] Erythema migrans, the principal cutaneous hallmark of Lyme borreliosis, starts at the site of a tick bite, but it is not unusual for the bite to pass unnoticed. The incubation period may vary from a few days to 3 months but is usually 1 to 3 weeks. [7], [8], [14] The initial erythema is usually homogeneous (Fig. 203-1), and it sometimes remains so until it heals. In long-standing lesions, the center partly or totally fades, leaving an annular erythema that spreads centrifugally (Fig. 203-2). A central reddish patch, representing the site of the tick bite, may sometimes be apparent. The diameter of the erythema migrans ranges from less than 1 decimeter to several decimeters. The size of the lesion or the distance the erythema has migrated mostly corresponds to the duration of the infection. The peripheral reddish band may be more or less sharply demarcated and is mostly 1 to 2 cm wide. With time, the erythematous border often fades; it may wax and wane and is sometimes visible only after the skin has been warmed up (e.g., in a hot bath). The classic lesion is round, but elliptical or irregular forms may be seen. The duration of an untreated lesion of erythema migrans may vary from some days to about a year, but generally it disappears within weeks or months.

FIGURE 203-1 Homogeneous erythema migrans of 3 weeks' duration.

FIGURE 203-2 Annular erythema migrans of 2 months' duration.

In North America, the lesion is more often of shorter duration than in Europe, and associated with more intense inflammation and signs suggestive of spirochetal dissemination. [14] Erythema migrans may appear almost anywhere on the skin surface, but the lower extremities are most usually affected. Facial involvement is common in children. [11] The clinical spectrum of erythema migrans is wider than previously reported. Atypical appearances with blisters or hemorrhagic or scaling lesions may develop. Other variants are small, stationary erythemas or a localized swelling without any obvious erythema at the site of the tick bite. Erythema migrans may pass unnoticed, as it may be poorly visible and asymptomatic. However, many patients experience local itching or sensations of irritation or heat. [7], [8], [12] In most cases, the local symptoms are mild or moderate, but in a few cases, more intense dysesthesia/hyperesthesia may occur at or near the site of the eruption. Regional lymphadenopathy may be present. In at least half of the patients, constitutional signs or symptoms, such as headache, low-grade fever, malaise, gastrointestinal complaints, and/or myalgia/arthralgia, accompany the skin lesion, or sometimes start before the erythema. [7], [8], [12], [13] Severe fatigue or emotional disturbances, such as irritability and depression, may develop. The constitutional reactions are usually mild or moderate, of an intermittent and changing nature, and last for some days to one or a few weeks. If they are more pronounced or long-lasting, they may signal a disseminated infection with meningitis.

MULTIPLE ERYTHEMA MIGRANS–LIKE LESIONS The development of secondary erythema migrans–like lesions is the cutaneous sign of hematogenous spread of spirochetes and of disseminated infection, as evidenced by successful spirochetal cultivation from secondary lesions. The lesions may follow the initial erythema migrans lesion or sometimes appear almost simultaneously. The multiple lesions may be homogeneous or annular; they are often, but not always, smaller than a solitary erythema migrans lesion and may be nonmigrating.

PATHOLOGY The epidermis is usually unaffected and there is a generally sparse dermal lymphocytic infiltrate with an admixture of a few plasma cells. The infiltrate is mainly confined to the perivascular regions.

DIAGNOSIS The clinical picture and the characteristic evolution of the erythema are most often sufficient to make the correct diagnosis. In atypical cases, the seasonal onset, the history of exposure to an area highly endemic for Lyme borreliosis, the history of a tick bite at the site of the lesion, the nonspecific histopathologic features, and/or elevated serum antibodies to *B. burgdorferi* (see below) are helpful clues. However, seronegativity does not rule out the diagnosis, as many patients with early uncomplicated erythema migrans are seronegative. The diagnosis can be confirmed by cultivation of borreliae from a skin-biopsy specimen. If the lesion does not resolve after adequate antibiotic therapy, the diagnosis of erythema migrans ought to be reconsidered.
DIFFERENTIAL DIAGNOSIS Important differential diagnoses are granuloma annulare, erysipelas, tinea, fixed-drug eruptions, lupus erythematosus, dermatomyositis, erythema gyratum repens, and nonspecific tick or insect bite reactions. In patients with multiple lesions, erythema multiforme and Sweet's syndrome may also be considered. Histopathologic examinations are often helpful.

Borrelial Lymphocytoma

CLINICAL FEATURES [1], [5], [15] Borrelial lymphocytoma often, but not always, starts at the site of the tick bite. The incubation period may vary from a few weeks to several months. [15] Some patients have a history of a preceding erythema migrans, and others may show a concomitant erythema migrans located around or near the lymphocytoma. [1], [5], [15] That a lymphocytoma may start at a distance from the spirochetal inoculation is obvious in cases where it begins close to the periphery of a large migrating erythema migrans lesion. The classic borrelial lymphocytoma presents as a solitary bluish-red nodule, 1 to 5 cm in diameter, often accompanied by regional lymphadenopathy. Predilection sites are the earlobe (Fig. 203-3) and the nipple/areola mammae region. Other sites of predilection are the scrotum and the nose. Ear and scrotal lesions are mostly seen in children, and breast lesions are mostly seen in adults. In many cases, there are no or only slight local symptoms, such as tenderness and itching. However, constitutional symptoms such as headache, fever, and arthralgia/myalgia may occur.

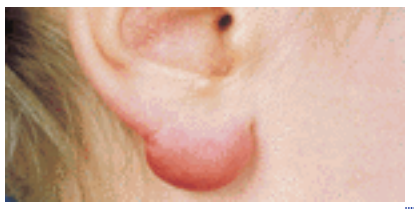

FIGURE 203-3 Borrelial lymphocytoma of 3 months' duration.

PATHOLOGY Usually the epidermis is unaffected. There is a dense dermal lymphocytic infiltrate, dominated by polyclonal B cells. The presence of germinal centers (Fig. 203-4), similar to those seen in reactive lymph nodes, is a helpful clue but not an obligatory diagnostic sign.

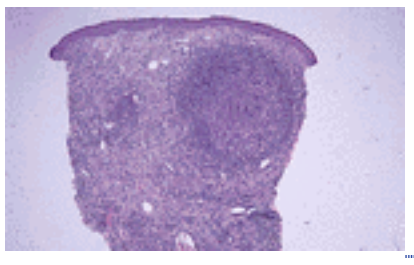

FIGURE 203-4 Borrelial lymphocytoma. Punch biopsy specimen from a scrotal lesion. In the dermis and subcutis there is a dense lymphocytic infiltrate displaying a follicular pattern with a large germinal center. (*Micrograph by Eva Brehmer-Andersson, MD.*)

DIAGNOSIS Besides the clinical picture, a history of a preceding erythema migrans lesion or a tick bite in the vicinity of the lesion supports the diagnosis. Histopathologic findings of a dense dermal lymphocytic infiltrate with germinal centers are suggestive of, but not specific for, borrelial lymphocytoma. Elevated serum antibody titers to *B. burgdorferi* have been found in more than half of the patients.
DIFFERENTIAL DIAGNOSIS Borrelial lymphocytoma of the breast is often primarily suspected of being a malignant tumor. Conventional histopathologic examinations may be decisive in distinguishing a borrelial lymphocytoma from granuloma faciale, granuloma annulare, sarcoidosis, lupus erythematosus, polymorphous light eruptions, and arthropod bite granuloma. Lesions without germinal centers may be difficult to differentiate from malignant lymphoma. In such cases, immunohistochemical characterization of the cell infiltrate is of diagnostic help.

Acrodermatitis Chronica Atrophicans

CLINICAL FEATURES [8], [11] A connection between ACA and a preceding tick bite is rarely suspected by patients. Approximately 20 percent have a history consistent with a preceding untreated erythema migrans, usually on an extremity where ACA lesions developed 6 months to 10 years later. [8], [11] Some patients also have a history of preceding neurologic and/or rheumatic complaints. Among patients with ACA there is a preponderance of females (about 70 percent), and it is generally a disease of the middle-aged or elderly. It usually starts on the extensor aspect of one extremity. The most common site is the lower leg, with initial involvement of the foot, ankle, or knee region. The dorsal aspect of the hand or the olecranon area are other common sites. The fingers, toes, and soles may become involved. With time, more widespread involvement of the extremity may occur, and the lesions usually spread from distal to proximal sites. Additional limbs may become affected, but sometimes not until after several years. More extensive involvement of the trunk or involvement of the face is uncommon. The first cutaneous sign is a bluish-red discoloration, often with edematous swelling. Sometimes the erythema may be very slight and swelling may dominate the clinical picture, suggesting venous stasis or lymphedema. A typical feature is that one of the feet or just the heel gradually increases in size. [11] ACA lesions often develop slowly and insidiously, and initially both the erythema and the swelling may wax and wane. Fibrous thickening of the skin in the form of indurated bands or nodules may develop. The most common bands are ulnar bands (Fig. 203-5A). The same area is also the most common site of single or multiple fibrotic nodules (Fig. 203-5C).

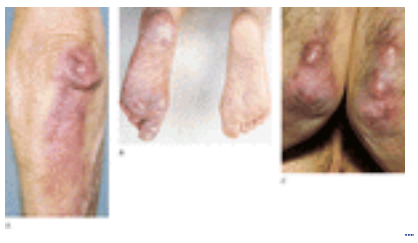

FIGURE 203-5 *A*. Ulnar band in a patient with acrodermatitis chronica atrophicans that has been present for more than 10 years. *B. burgdorferi* has been cultivated from this lesion. *B*. Acrodermatitis chronica atrophicans with bluish-red discoloration and advanced atrophy of the plantar surface of one of the feet. *C*. Acrodermatitis chronica atrophicans with fibrotic nodules on the elbows.

Sclerotic skin lesions that may be clinically and histopathologically indistinguishable from localized scleroderma or lichen sclerosus et atrophicus have been described in 5 to 10 percent of patients with ACA. The term *pseudoscleroderma* has previously been used for the sclerotic skin lesions that may occur in ACA. Inflammatory ACA lesions may persist for years or decades, with gradual conversion to atrophic skin lesions (Fig. 203-5B). Both inflammation and atrophy may occur in different regions in the same patient. In the advanced atrophic phase, the skin becomes cigarette paper–like and wrinkled, appendageal structures disappear, and the vessels become prominent (Fig. 203-6). Besides diffuse atrophy, macular atrophy, which was previously described as atrophia maculosa cutis or dermatitis atrophicans maculosa, may rarely occur.

FIGURE 203-6 Acrodermatitis chronica atrophicans. Typical end-stage cutaneous atrophy is seen on both legs with prominence of the superficial veins.

Extracutaneous Manifestations in Patients with ACA

Enlarged regional lymph nodes are common. Migrating and/or intermittent pain is fairly frequent. A rather common and characteristic feature is pain arising from impacts against bony prominences—such as the knuckles, the olecranon, or the malleoli—underlying ACA skin lesions. As diagnosed by clinical and electroneurographic examinations, more than 50 percent of patients with ACA have peripheral neuropathy, mostly mild or moderate. This neuropathy may be a sensory or motor mono- or polyneuropathy, or patchy dysesthesia, at the sites of the skin lesions. Symptoms such as hyperesthesia, muscular weakness, a feeling of heaviness, and muscle cramps are common in patients with ACA. These symptoms are mainly located in the limb(s) affected by skin lesions. Profound fatigue, emotional disturbances, and personality changes sometimes accompany ACA. However, there are usually no cerebrospinal fluid abnormalities in patients.

Subluxations/luxations of small joints of the fingers or toes and periosteal thickening of bones have been found underneath the skin lesions in patients with long-standing ACA. Periarticular manifestations such as knee or olecranon bursitis and Achilles tendinitis on the same limb as the cutaneous involvement may precede or accompany ACA. Attacks of knee–joint effusions were found to have preceded or to have occurred simultaneously with ACA in approximately one-fifth of patients studied.

PATHOLOGY [16] There are usually no epidermal changes in the early inflammatory phase of ACA, but sometimes the epidermis is thin and shows liquefaction degeneration. The most common dermal findings are telangiectases in combination with a patchy and/or interstitial, often dense lymphocytic infiltrate with a moderate to rich admixture of plasma cells (Fig. 203-7). This infiltrate may involve the whole or part of the dermis, and sometimes also the subcutaneous fat. As the disease progresses, degeneration of elastin and collagen begins. After many years, advanced dermal atrophy develops, including atrophy of hair follicles and of sebaceous glands. In the advanced atrophic phase, the inflammatory cells decrease in number or almost disappear.

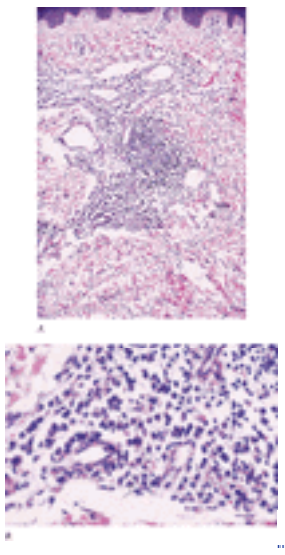

FIGURE 203-7 Acrodermatitis chronica atrophicans. Punch biopsy specimen from the dorsum of the foot. *A*. The dermis contains telangiectasias and a patchy cell infiltrate. Epidermis is not involved. *B*. High-power view of the infiltrate, which consists mainly of plasma cells. (*Micrograph by Eva Brehmer-Andersson, MD.*)

DIAGNOSIS The clinical recognition of ACA may be difficult. If a red-violaceous discoloration, with or without swelling, is observed on a foot or heel, the dorsal aspect of a hand, the olecranon area, or, in more advanced cases, on more than one extremity (especially in an elderly woman), a diagnosis of ACA should be considered. Cutaneous atrophy may not appear for several years and is not an obligatory clinical or histopathologic criterion for a diagnosis of ACA. As compared to the prepenicillin era, patients with advanced atrophy are seen less frequently nowadays. Instead, the diagnostic efforts should be concentrated on recognizing inflammatory ACA lesions. The clinical diagnosis should be further verified by the histopathologic pattern and by elevated serum titers of IgG antibodies to *B. burgdorferi*. The diagnosis may be confirmed by spirochetal cultivation, as borreliae may still be present in the skin even after more than 10 years of ACA. Thus, ACA is a cutaneous example of prolonged survival of *B. burgdorferi* in humans.
DIFFERENTIAL DIAGNOSIS ACA lesions are frequently overlooked or regarded as physiologic changes due to age. A discolored, sometimes swollen and painful leg is often misdiagnosed as circulatory insufficiency in these patients. Fibrotic nodules may be confused with rheumatic nodules.

Sclerotic and Other Skin Lesions

B. burgdorferi may cause skin lesions that are clinically and histopathologically indistinguishable from localized scleroderma and lichen sclerosus et atrophicus (see Chap. 113, Chap. 114, and Chap. 173). A high frequency of elevated serum antibody titers to *B. burgdorferi* has been found in some studies of patients with scleroderma, [17] but this finding could not be confirmed by others. [18] In patients with ACA and pseudoscleroderma, the sclerotic lesions sometimes predominate, the inflammatory ACA lesions are missed, and the patient is diagnosed as suffering from morphea or lichen sclerosus et atrophicus. [18] However, in most cases diagnosed as morphea or lichen sclerosus et atrophicus, there is no evidence of borrelial infection. [19]

As with syphilis, *B. burgdorferi* infection may sometimes mimic other conditions in its clinical and histopathologic features. Granuloma annulare (see Chap. 100), eosinophilic fasciitis (see Chap. 96 and Chap. 173) benign lymphocytic infiltration (Jessner-Kanof) (see Chap. 159), and anetoderma (see Chap. 105) have been described in connection with Lyme borreliosis.

EXTRACUTANEOUS MANIFESTATIONS

Lyme borreliosis is a complex multisystem disease that may affect the nervous system, joints, heart, and eyes in addition to the skin.

Neurologic Manifestations

Neuroborreliosis [20], [21] and [22] may involve both the peripheral and the central nervous system (CNS).

EARLY NEUROBORRELIOSIS This usually begins 4 to 10 weeks after the onset of the infection. The triad of lymphocytic meningitis, cranial neuritis, and radiculoneuritis is a typical feature of neuroborreliosis. Compared with many other bacterial meningitides, the symptoms of a borrelial meningitis may often appear mild and fluctuating. Nonspecific signs or symptoms such as fever, fatigue, malaise, vomiting, weight loss, or headache with or without neck stiffness may be the only clinical manifestations. In such cases, a history of a preceding tick bite and/or erythema migrans is helpful when considering the possibility of a diagnosis of neuroborreliosis. However, approximately one-third of patients lack these important clues. [20] The most common manifestations from the peripheral nervous system are radicular pains and facial palsy. In patients with a preceding erythema migrans, the skin lesion has often been located in the same part of the body as the subsequent radiculoneuritis or facial palsy. Untreated early neuroborreliosis generally heals within 3 to 6 months. However, if less-than-adequate therapy is given, some patients may develop manifestations from other organs or late neuroborreliosis.
LATE NEUROBORRELIOSIS (CHRONIC NEUROBORRELIOSIS) In the United States up to 5 percent of untreated patients may develop chronic neuroborreliosis, sometimes after long periods of latent infection. [22] A mild late neurologic syndrome, without inflammatory changes in the cerebrospinal fluid, called Lyme encephalopathy and manifested primarily by subtle cognitive disturbances, has been reported in North America. One form of late neuroborreliosis seen in Europe is the chronic peripheral neuropathy often associated with ACA. These patients usually lack spinal fluid abnormalities, in contrast to patients with severe CNS syndromes. Progressive encephalomyelitis with hemiparesis, para- and quadriparesis, ataxia, multiple sclerosis–like demyelinating disease, dementia-like deficiencies, mental changes, and/or incapacitating fatigue have been described, but these severe forms of late neuroborreliosis are uncommon. [21]

Rheumatic Manifestations

Reports on Lyme arthritis came first from the United States [2], [7], [23] and later from Europe. [24] Intermittent episodes of arthralgia or migrating musculoskeletal pain may occur early in the development of Lyme borreliosis. Months after the onset of the infection, a single episode or intermittent attacks of mono- or oligoarthritis may occur. In contrast to the symmetric polyarthritis seen in rheumatoid arthritis, Lyme arthritis characteristically affects only one or a few large joints, most commonly the knee joint. Often the pain is not severe, and swelling of the joint usually dominates the clinical picture. Arthritic attacks can recur for months and even years. In children, Lyme arthritis may sometimes mimic juvenile rheumatoid arthritis. Approximately 10 percent of patients in the United States with Lyme arthritis have been reported to develop chronic arthritis with erosion of cartilage and bone.

Cardiac Manifestations

The frequency of cardiac involvement in patients with Lyme borreliosis is not well established. The most common findings have been atrioventricular conduction disturbances, with the majority showing transient first-degree atrioventricular block. Occasionally, complete heart block requiring a temporary pacemaker has developed. Other abnormalities are rhythm disturbances, acute myopericarditis, pancarditis, and heart failure. [25]

Ocular Lyme Borreliosis

Early lyme borreliosis is sometimes accompanied by conjunctivitis. Ocular motor palsies and solitary cases of iritis, iridocyclitis, choroiditis, keratitis, retinal hemorrhage, optic neuritis, ischemic optic neuropathy, and papilledema have been reported. [26]

Gestational Lyme Borreliosis

Most women with documented Lyme borreliosis during pregnancy appear to give birth to normal infants. [27] Solitary cases of fetal death, malformations, and prematurity have been reported.

LABORATORY EXAMINATION

Detection of *B. burgdorferi*

CULTIVATION OF SPIROCHETES In atypical cases, spirochetal cultivation, using modified Kelly medium, [4] is the most specific and reliable way of diagnosing Lyme borreliosis. Spirochetal cultivation from human tissue or fluid has not become a routine diagnostic method as it is laborious and mostly a low-yielding process. One exception might be cultivation from skin specimens, as successful cultivation from more than 60 to 70 percent of skin-biopsy specimens from patients with erythema migrans has been reported. [6], [28]
DEMONSTRATION OF SPIROCHETES IN TISSUES Spirochetes may be demonstrated in biopsy specimens with different silver stains. Polyclonal or monoclonal antibodies to borrelial antigens have also been used to demonstrate spirochetes in tissue specimens. These techniques for visualizing spirochetes are difficult to evaluate, however, and there may be a risk of both over- and underdiagnosis.
POLYMERASE CHAIN REACTION In the analysis of skin biopsies from patients with erythema migrans and ACA, polymerase chain reaction (PCR) has achieved a diagnostic sensitivity at least comparable to that of culture. [29], [30] In the detection of *B. burgdorferi* in joint fluid, PCR testing has been reported to be superior to culture. [31]

Serology of Lyme Borreliosis

Serologic examination is at present the most important laboratory aid in diagnosing Lyme borreliosis. The serologic results must, however, be interpreted with caution, as false-negative as well as false-positive results are common with the currently used tests. In early Lyme borreliosis, particularly in patients with signs or symptoms of disseminated disease, significantly increasing IgM and/or IgG antibody titers to *B. burgdorferi* may be found in consecutive tests performed at an interval of 2 to 3 weeks. Later on, the IgG titers are often stationary, and finding serologic proof of current infection may be difficult. Because high prevalence of seropositivity has been found among asymptomatic sports enthusiasts, outdoor workers, and other control individuals in endemic areas, the diagnostic value of the serologic findings may be limited, particularly in cases where only slightly elevated titers have been found. The lack of standardization also means that there may be great variations in sensitivities and specificities among different laboratories.

The tests most widely used at present for measuring antibodies to *B. burgdorferi* are the indirect immunofluorescence assay and the enzyme-linked immunosorbent assay (ELISA).The tests are of low diagnostic value in the earliest phase of Lyme borreliosis. Only 20 to 50 percent of patients with uncomplicated erythema migrans have been found to be seropositive in IgM and/or IgG ELISA. [32], [33] Patients with multiple erythema migrans–like lesions and those with borrelial lymphocytoma are more often seropositive. In most cases where signs or symptoms of a disseminated infection have been present for several weeks, elevated serum titers to *B. burgdorferi* are found. Almost 100 percent of patients with ACA are seropositive, and they usually show very high serum IgG titers to *B. burgdorferi*. [32], [33]

With use of Western blot techniques, IgM and IgG antibodies to a number of spirochetal polypeptides have been found in sera from patients with Lyme borreliosis. Western blotting is also used as a diagnostic tool but with varying criteria for positivity in different laboratories.

False-positive serologic reactions may occur in patients with relapsing fever and syphilis. In contrast, patients with high serum titers to *B. burgdorferi,* such as those with ACA, often have cross-reactive antibodies to treponemal antigens that

are detectable in the fluorescent treponemal antibody-absorption test.

CEREBROSPINAL FLUID EXAMINATION IN NEUROBORRELIOSIS The presence of cerebrospinal fluid (CSF) abnormalities with a lymphocytic pleocytosis, in combination with the finding of intrathecally synthesized antibodies to *Borrelia,* is diagnostic for neuroborreliosis with CNS involvement. [20]

TREATMENT

Since the 1940s, European dermatologists have treated patients with erythema migrans and ACA with oral penicillin. It is not known whether the antibiotic susceptibility may differ among *B. burgdorferi* strains from different parts of the world. Attempts have been made to determine antibiotic sensitivities of *B. burgdorferi* in vitro and in experimental animals. Because the methodology for such studies is not yet standardized, the studies should be interpreted with caution. Tradition and clinical experience, variations in the clinical spectra, and the advantage of a drug effective against a possible coinfecting agent such as *Ehrlichia* have resulted in varying treatment regimens in different parts of the world. [12], [23], [34], [35] and [36]

Few large, well-controlled treatment studies have been performed on groups of well-defined patients with similar manifestations of Lyme borreliosis. As in syphilis, the difficulties of therapy seem to increase with the duration of the disease. The possibility has been considered that the spirochetal division time may be longer in the late than in the early stage of syphilis, and that a longer period of therapy will be needed for late cases. The same may be true for late Lyme borreliosis.

The recommendations for treatment may be modified in the future, when further treatment trials have been carried out. Current guidelines for treatment of adult patients with different manifestations of Lyme borreliosis are given below.

Treatment of Uncomplicated Erythema Migrans

Doxycycline (100 mg orally, bid), or amoxicillin (500 mg orally, tid) is recommended for 14 to 21 days. [14] In Europe, phenoxymethyl penicillin (1g orally, bid/tid) for 14 days is also used.

In patients with erythema migrans and concurrent manifestations from other organs, the latter may be decisive for the choice of therapy. Such manifestations are particularly common in patients with multiple erythema migrans–like lesions. Before the start of therapy in patients with erythema migrans and signs or symptoms suggestive of neuroborreliosis, a diagnostic spinal tap should be performed. Alternatively, an antibiotic regimen has to be chosen that gives therapeutic CSF concentrations.

Treatment of Borrelial Lymphocytoma

The same treatment regimens as for uncomplicated erythema migrans are proposed. In patients with a disease duration of several months, prolonged courses of antibiotics for up to 20 to 30 days may be required.

Treatment of Neuroborreliosis or Cardiac Abnormalities

In the United States a 2- to 4-week course of intravenous ceftriaxone is most commonly given. Parenteral therapy with cefotaxime or penicillin G may be a satisfactory alternative. [14]

In cases of cardiac abnormalities where only first-degree atrioventricular block is present, and in early neuroborreliosis, oral regimens with doxycycline (100 mg, bid) for 14 days are also used, especially in Europe.

Treatment of Lyme Arthritis

Doxycycline (100 mg orally, bid/tid) or amoxicillin (500 mg orally, tid) for 30 to 60 days or IV regimens with ceftriaxone for 14 to 28 days are recommended in the United States, [14] whereas in many parts of Europe, shorter treatment periods and oral regimens with doxycycline (100 mg orally, bid) have been found to be sufficient.

Treatment of ACA

Doxycycline (100 mg orally, bid) for 20 to 30 days is recommended. Both intravenous penicillin or ceftriaxone have also been used.

Jarisch-Herxheimer Reaction

Mild to moderate Herxheimer reactions may sometimes appear after the institution of antibiotic therapy. Intensification of the current cutaneous rash and of local symptoms or the appearance of new signs or symptoms such as fever have been reported to occur. [36], [37]

PREVENTION

A vaccine for Lyme disease is approved for adults and commercially available in the United States. The efficacy of this vaccine has been reported to be 76 percent after three injections, but booster injections may be needed every 1 to 3 years to maintain protection. [38] In Europe the situation may be more complicated, as three different *Borrelia* species are

involved, but vaccine tests are under investigation in different European countries.

Protection from tick bites by the use of protective clothing in risk areas and body inspection and removal of any attached ticks as soon as possible are the most important prophylactic methods. Prophylactic antibiotic therapy after a tick bite is generally not recommended in the United States or Europe because it is controversial whether the value of such treatment can balance the risk of adverse reactions to antibiotics. Results of animal tests in the United States show that it usually takes at least 24 h of attachment for an infected blood-sucking *I. scapularis* tick to transmit spirochetes to its host. [39] However, data from the former Soviet Union indicate that humans bitten by *I. persulcatus* usually are already infected during the first 24 h of attachment. [40] In this study, prophylactic treatment with doxycycline (100 mg, bid) for 3 to 5 days was an efficient method for preventing humans bitten by *Borrelia*-infected ticks from contracting Lyme borreliosis. More recently, it was shown that a single 200 mg dose of doxycycline given within 72 h after an *I. scapularis* tick bite can prevent Lyme disease, [41] but it has also been suggested that this prophylaxis should be restricted to geographic regions where the incidence of Lyme disease is high. [42]

COURSE AND PROGNOSIS

Natural Course (See Table 203-1)

On ethical grounds, the natural history of untreated Lyme borreliosis cannot be studied today, and no prospective investigations on the natural course have been carried out on large groups of unselected patients. During the preantibiotic era and the era preceding the discovery of the etiologic agent, many of the cases of early borrelial infection probably healed spontaneously. In 1977, Steere et al. reported on 12 patients in the United States with untreated erythema migrans, 6 of whom had multiple skin lesions. Of those patients, 7 developed arthritis or arthralgia. [2] This study was later expanded to 55 untreated patients. Six patients (11 percent) developed neurologic abnormalities, 2 (4 percent) developed cardiac involvement, and 28 (51 percent) developed arthritis. [23] Among 16 untreated Swedish patients with solitary erythema migrans, 2 patients developed recurrent erythema migrans lesions, 2 developed meningitis, and 1 developed ankle arthritis during the follow-up period. [12]

Posttherapeutic Course

Treatment failures have been reported with most of the different regimens. However, in the vast majority of patients, antibiotic therapy results in healing of the infection. Convalescence periods of several months, especially with persisting fatigue, are not uncommon in patients treated for Lyme borreliosis.

Reinfection in patients previously treated for erythema migrans is not unusual. [12], [13]

The resolution time for erythema migrans varies. [23], [34], [36] In most cases, the erythema begins to fade a few days after the start of therapy. In some patients the skin lesion has disappeared by the time the treatment is terminated, but in others it may persist longer. In patients with borrelial lymphocytoma, it might take more than a month after antibiotic therapy before the lesion has disappeared completely.

As a rule, the clinical improvement in ACA after antibiotic therapy occurs gradually and may continue for at least 1 year. The first sign of improvement is an abatement of the swelling. The cyanotic discoloration fades to varying degrees. Histologically there is a reduction in the number of infiltrating cells. Residual erythema, present several months after therapy, is generally caused by hyperemia resulting from remaining dilated vessels. The least satisfactory results are obtained in patients with advanced atrophy of the skin.

Serologic follow-up examination after therapy has shown that seroreversal tends to be slower in late than it is in early Lyme borreliosis. After antibiotic therapy, patients with ACA exhibit gradually decreasing antibody titers to *B. burgdorferi*. However, in only a minority of patients does the titer fall to normal values within 1 year. [32], [34] Serologic reactivity after therapy may perhaps persist indefinitely in patients with long-standing ACA, as in patients treated for late syphilis.

Some patients with chronic joint involvement do not respond to antibiotic therapy, even after repeated courses of different antibiotics. It has been speculated that *B. burgdorferi* may sometimes initiate immunologic reactions that may continue for varying lengths of time, even in the absence of live spirochetes.

Disparate opinions exist about the long-term consequences of borrelial infection. Some authors have described a post-Lyme syndrome and prolonged antibiotic therapy has been recommended. However, recent controlled trials show that antibiotic treatment for 90 days did not improve symptoms more than placebo. [43] In another study, it was shown that persisting nonspecific symptoms in patients treated for Lyme disease are similar to those among age-matched controls without Lyme disease. [44]

REFERENCES

1. Bäfverstedt B: *über Lymphadenosis benigna cutis: Eine klinische und patologisch-anatomische Studie*. Stockholm, PA Norstedt, 1943

2. Steere AC et al: Erythema chronicum migrans and Lyme arthritis: The enlarging clinical spectrum. *Ann Intern Med* **86**:685, 1977

3. Burgdorfer W et al: Lyme disease—A tick-borne spirochetosis? *Science* **216**:1317, 1982

4. Barbour A: Isolation and cultivation of Lyme disease spirochetes. *Yale J Biol Med* **57**:521, 1984

5. Weber K et al: Das Lymphocytom-eine Borreliose? *Z Hautkr* **60**:1585, 1985

6. Van Dam AP et al: Different genospecies of *Borrelia burgdorferi* are associated with distinct clinical manifestations of Lyme borreliosis. *Clin Infect Dis* **17**:708, 1993

7. Steere AC et al: The early clinical manifestations of Lyme disease. *Ann Intern Med* **99**:76, 1983

8. Åsbrink E: Erythema chronicum migrans Afzelius and acrodermatitis chronica atrophicans. Early and late manifestations of Ixodes ricinus-borne *Borrelia* spirochetes. *Acta Derm Venereol (Stockh)* **118**(Suppl):1, 1985

9. Walker DH, Dumler JD: Emergence of the ehrlichioses as human health problems. *Emerg Infect Dis* **2**:1, 1996

10. Krause PJ et al: Concurrent Lyme disease and babesiosis. *JAMA* **21**:1657, 1996

11. Åsbrink E, Hovmark A: Early and late cutaneous manifestations in *Ixodes*-borne borreliosis (erythema migrans borreliosis, Lyme borreliosis). *Ann N Y Acad Sci* **539**:4, 1988

12. Åsbrink E, Olsson I: Clinical manifestations of erythema chronicum migrans Afzelius in 161 patients. A comparison with Lyme disease. *Acta Derm Venereol (Stockh)* **65**:43, 1985

13. Weber K, Neubert U: Clinical features of early erythema migrans disease and related disorders. *Zentralbl Bakteriol Hygiene (A)* **263**:209, 1986

14. Steere AC: Lyme disease. *N Engl J Med* **345**:115, 2001

15. Åsbrink E et al: Lymphadenosis benigna cutis solitaria— *Borrelia* lymphocytoma in Sweden. *Zentralbl Bakteriol Hygiene* **18**(Suppl):156, 1989

16. Brehmer-Andersson E: Histopathologic patterns of acrodermatitis chronica atrophicans. *Clin Dermatol* **11**:385, 1993

17. Aberer E et al: Evidence for spirochetal origin of circumscribed scleroderma (morphea). *Acta Derm Venereol (Stockh)* **67**:225, 1987

18. Halkier-Sörensen L et al: Antibodies to the *Borrelia burgdorferi* flagellum in patients with scleroderma, granuloma annulare and porphyria cutanea tarda. *Acta Derm Venereol (Stockh)* **69**:116, 1989

19. Weide B et al: Morphea is neither associated with features of *Borrelia burgdorferi* infection, nor is this agent detectable in lesional skin by polymerase chain reaction. *Br J Dermatol* **143**:780, 2000.

20. Stiernstedt G et al: Clinical manifestations and diagnosis of neuroborreliosis. *Ann N Y Acad Sci* **539**:46, 1988

21. Ackermann R et al: Chronic neurologic manifestations of erythema migrans borreliosis. *Ann N Y Acad Sci* **539**:16, 1988

22. Logigian EL et al: Chronic neurologic manifestations of Lyme disease. *N Engl J Med* **323**:1438, 1990

23. Steere AC et al: The clinical evolution of Lyme arthritis. *Ann Intern Med* **107**:725, 1987

24. Herzer P et al: Lyme arthritis: Clinical features, serological, and radiographic findings of cases in Germany. *Klin Wochenschr* **64**:206, 1986

25. Van der Linde MR et al: Range of atrioventricular conduction disturbances in Lyme borreliosis: A report of four cases and review of other published reports. *Br Heart J* **63**:162, 1990

26. Mikkila HO et al: The expanding clinical spectrum of ocular Lyme borreliosis. *Ophthalmology* **107**:581, 2000

27. Markowitz LE et al: Lyme disease during pregnancy. *JAMA* **255**:3394, 1986

28. Berger BW et al: Cultivation of Borrelia burgdorferi from erythema migrans lesions and perilesional skin. *J Clin Microbiol* **30**:359, 1992

29. Schwartz I et al: Diagnosis of early Lyme disease by polymerase chain reaction amplification and culture of skin biopsies from erythema migrans lesions. *J Clin Microbiol* **30**:3082, 1992

30. Stedingk LV et al: Polymerase chain reaction for detection of *Borrelia burgdorferi* DNA in skin lesions of early and late Lyme borreliosis. *Eur J Microbiol Infect Dis* **14**:1, 1995

31. Nocton JJ et al: Detection of *Borrelia burgdorferi* DNA by polymerase chain reaction in synovial fluid from patients with Lyme arthritis. *N Engl J Med* **330**:229, 1994

32. Åsbrink E et al: Serologic studies of erythema chronicum migrans Afzelius and acrodermatitis chronica atrophicans with indirect immunofluorescence and enzyme-linked immunosorbent assays. *Acta Derm Venereol (Stockh)* **65**:509, 1985

33. Hansen K et al: Serodiagnosis of erythema migrans and acrodermatitis chronica atrophicans by the *Borrelia burgdorferi* flagellum enzyme-linked immunosorbent assay. *J Clin Microbiol* **27**:545, 1989

34. Weber K et al: Antibiotic therapy of early European Lyme borreliosis and acrodermatitis chronica atrophicans. *Ann N Y Acad Sci* **539**:324, 1988

35. Berger BW: Treating erythema chronicum migrans of Lyme disease. *J Am Acad Dermatol* **15**:459, 1986

36. Steere AC et al: Treatment of the early manifestations of Lyme disease. *Ann Intern Med* **99**:22, 1983

37. Weber K: Jarisch-Herxheimer-Reaktion bei Erythema-migrans-Krankheit. *Hautarzt* **35**:588, 1984

38. Steere AC et al: Vaccination against Lyme disease with recombinant *Borrelia burgdorferi* outer-surface lipoprotein A with adjuvant. *N Engl J Med* **339**:209, 1998

39. Piesman J: Dynamics of *Borrelia burgdorferi* transmission by nymphal *Ixodes* dammini ticks. *J Infect Dis* **167**:1082, 1993

40. Korenberg EI et al: Prevention of borreliosis in persons bitten by infected ticks. *Infection* **2**:187, 1996

41. Nadelman RB et al: Prophylaxis with single-dose doxycycline for the prevention of Lyme disease after an *Ixodes scapularis* tick bite. *N Engl J Med* **345**:79, 2001.

42. Shapiro ED: Doxycycline for tick bites—Not for everyone. *N Engl J Med* **345**:133, 2001

43. Klempner MS et al: Two controlled trials of antibiotic treatment in patients with persistent symptoms and a history of Lyme disease. *N Engl J Med* **345**:85, 2001

44. Seltzer EG et al: Long-term outcomes of persons with Lyme disease. *JAMA* **283**:609, 2000

T>

Chapter 204

Donald Leung Anne Lucky

Kawasaki Syndrome

HISTORICAL ASPECTS
EPIDEMIOLOGY
ETIOLOGY AND PATHOGENESIS
CLINICAL MANIFESTATIONS
Dermatologic Features
Systemic Associations
Cardiac Manifestations
LABORATORY FINDINGS
PATHOLOGY
DIAGNOSIS AND DIFFERENTIAL DIAGNOSIS
TREATMENT AND PROGNOSIS
PROGNOSIS

REFERENCES

Kawasaki syndrome (KS) is an acute multisystem vasculitis that primarily affects infants and young children. Although KS was originally described as a benign illness of early childhood, it is now recognized that this disease is the leading cause of acquired heart disease in children in the United States and western Europe. Children with KS who do not receive appropriate treatment within the first 10 days of onset of fever have a 20 to 25 percent risk of developing coronary artery abnormalities. Early recognition and prompt treatment with the combination of intravenous immunoglobulin and aspirin reduces the prevalence of coronary artery abnormalities to less than 5 percent. Thus acute KS must be diagnosed early and treated promptly. A diagnosis of KS is based on the presence of fever plus at least four of five criteria listed in Table 204-1. [1]

Fever of 5 or more days without other explanation, and at least four of the five following criteria:

- Bilateral, painless, bulbar, nonexudative, conjunctival injection
- One of the following changes in the oropharynx: injected or fissured lips, injected pharynx, or strawberry tongue
- One of the following extremity changes: erythema of the palms or soles, edema of the hands or feet, periungal desquamation
- Polymorphous exanthem
- Acute nonsuppurative cervical lymphadenopathy (≥1.5 cm in diameter)

*A diagnosis of atypical Kawasaki syndrome can be made when less than four criteria are present and when coronary artery aneurysms are present.

TABLE 204-1 **Diagnostic Criteria for Kawasaki Syndrome**

HISTORICAL ASPECTS

KS, originally called mucocutaneous lymph node syndrome, was first recognized and described in Japan in 1967 by Dr. Tomisaku Kawasaki. [2] He reported his experience with 50 children who had been seen during the preceding 6-year period at the Tokyo Red Cross Medical Center. These children appeared to manifest a constellation of findings distinct from any previously described disease. After this description, numerous cases were reported throughout Japan. Dr. Kawasaki's first description in the English language of the disease appeared in 1974. In 1976, the syndrome was first reported in the United States by Melish, Hicks, and Larson in a group of 12 children from Honolulu seen between 1971 and 1973. Since then, KS has been recognized worldwide in children of every racial group.

EPIDEMIOLOGY

Although KS occurs worldwide in children of all racial groups, it is most prevalent in Japan and in children of Japanese ancestry (reviewed in Ref. 3). KS is primarily an illness of young children, with approximately 80 percent of patients being younger than 5 years of age. The ratio of males to females is about 1.5:1. The incidence rate is the highest for Japanese children between 6 and 12 months of age, with equal numbers in the first and second years of life. KS only rarely occurs in the same school, daycare center, or household. Thus, person-to-person transmission of the disease appears to be unlikely. In Japan, the recurrence rate of KS is reported to be 3.9 percent and the proportion of sibling cases 1.4 percent. The rate of recurrence is highest within the first 12 months following the first episode. [4] These studies suggest common exposure to an infectious agent in genetically predisposed individuals.

The incidence of KS in Japan increased from 1967 to the mid-1980s. Nationwide epidemics, with wavelike spread of cases, occurred in 1979, 1982, and in late 1985 to early 1986. Since the mid-1980s the incidence of KS in Japan has increased steadily such that the incidence rate in 1998 was over 1.5 times higher than that in 1987. [5] The endemic annual incidence of KS is approximately 111 cases per 100,000 children younger than age 5 years. Both the endemic and the epidemic form of KS in Japan occur most commonly in the late winter and spring, with another period of slightly increased incidence during late fall. KS has been increasingly recognized in other Asian countries as well.

Epidemiologic findings in the United States and Europe reveal striking similarities to those in Japan. KS has been reported in all parts of the United States and Europe, occurring sporadically or as temporally limited community-wide epidemic outbreaks. Surveillance studies suggest that approximately 3000 patients with KS are hospitalized annually in the United States. The peak age is 18 to 24 months of age. More than 80 percent of cases occur in patients younger than 5 years of age, and most cases occur in patients younger than 2 years of age. Infants younger than 12 months of age,

and particularly those younger than 6 months of age, appear to be at an increased risk of developing coronary artery abnormalities. The prevalence of KS is highest among Asians, intermediate in blacks, and lowest in whites. Regardless of the racial group affected, however, the clinical picture is similar.

ETIOLOGY AND PATHOGENESIS

Although multiple factors are likely to play a role in the pathogenesis of KS, several observations suggest that immune activation is involved in its pathogenesis (reviewed in Ref. 6). First, the acute phase of KS is characterized by increased numbers of activated helper T cells and monocyte/macrophages, as well as a marked polyclonal B cell activation. Second, there is increased production of multiple proinflammatory cytokines. Serum levels of interleukin (IL)-1, tumor necrosis factor (TNF)-a, IL-6, adrenomedullin, and vascular endothelial growth factor have been reported to correlate with the development of coronary artery abnormalities. [7], [8] Third, the histologic lesion in coronary arteries and other medium-sized arteries suggests a role for immune-mediated vascular injury (see pathology section below). Fourth, the acute phase of KS is associated with the appearance of circulating antibodies that are cytotoxic against cardiac myosin and vascular endothelial cells prestimulated with IL-1, TNF-a, or interferon (IFN)-?. [9] Finally, successful treatment of patients with intravenous immunoglobulin plus aspirin reduces the immune activation associated with this disease. [10] In contrast, KS patients treated with aspirin alone have prolonged T and B cell activation.

At present, there is no consensus regarding the etiology of KS. Nevertheless, it is widely agreed that KS is caused by an infectious agent because of the acute, self-limited nature of this disease, seasonal incidence, geographic clustering of outbreaks, and the unique susceptibility of young children. Furthermore, the fever and other clinical findings in acute KS (see Table 204-1) significantly overlap with bacterial toxin-mediated diseases such as toxic shock syndrome (TSS) or scarlet fever.

The activation of T cells and monocytes/macrophages found in acute KS is characteristic of diseases caused by bacterial toxins that act as superantigens. [11] Staphylococcal enterotoxins (SEs), TSS toxin-1 (TSST-1), and streptococcal pyrogenic exotoxins (SPEs) are prototypic superantigens that stimulate a large proportion (up to 35 percent) of T cells in a human leukocyte antigen (HLA)-DR–dependent yet unrestricted manner. These bacterial toxins bind directly to conserved amino acid residues outside of the peptide antigen binding groove on major histocompatibility complex (MHC) class II molecules and selectively stimulate T cells expressing specific T cell antigen receptor (TCR) ß chain variable gene segments. Other variable elements (Dß, Jß; Va, Ja) of the TCR contribute much less to the recognition of these superantigens. In contrast, nominal peptide antigens generally require all five variable elements for optimal T cell recognition and therefore stimulate only a low number of T cells (less than 1 in 1000).

To determine whether the immune activation during acute KS results from stimulation by superantigen(s), T lymphocytes of 19 children with KS were analyzed for TCR Vß gene usage. [12] Patients with acute KS demonstrated marked expansion of Vß2 and, to a lesser extent, Vß8-positive T cells. In contrast, cells from control subjects showed no evidence for overexpression of TCR Vßs. During the convalescence phase of KS, percentages of Vß2-positive and Vß8-positive T cells returned to normal levels. This selective expansion of circulating Vß2-positive T cells is similar to the changes observed in T cells from patients with staphylococcal TSS, an illness with many clinical similarities to acute KS.

Since the initial report there have been confirmatory and nonconfirmatory reports of Vß2 expansion in acute KS. [13], [14], [15] and [16] The ability to find Vß2-positive T cell abnormalities in the peripheral blood of patients with acute KS may depend on the timing of the blood collection, as superantigens stimulate the expression of homing receptors, thereby triggering the migration of T cells into inflamed tissues. [13] Thus, increased Vß2-positive T cells may be observed in the tissue even with normal or decreased Vß2-positive T cell values in the peripheral blood. Indeed, Yamashiro and colleagues have observed a selective expansion of Vß2-positive T cells in the small intestinal mucosa of patients with acute KS. [17] They suggested that the gastrointestinal tract may be the primary site of entry for a superantigen-secreting organism causing acute KS.

To further test the hypothesis that acute KS is triggered by a superantigen, Abe et al. [18] analyzed the sequences of random cDNA clones containing Vß2 gene segments of T cells from patients with acute KS. In patients with a two- to threefold increase in numbers of Vß2-positive T cells, a clonotypic expansion of Vß2-positive T cells might be expected to result in identical junctional sequences in up to 67 percent of the clones. However, none of the acute KS Vß2-positive T cell clones had the same junctional sequence. In view of the selective expansion of Vß2-positive T cells in acute KS, the extensive ß-chain junctional diversity suggests that these Vßs play a dominant role in recognition. This type of recognition is generally not a feature of responses to most peptide antigens. This high frequency of response and the prominent role for Vß2 is most consistent with the hypothesis that T cell activation observed in the peripheral blood of acute KS is mediated by a superantigen that induces Vß2-positive T cell expansion.

To identify potential bacterial superantigen(s) involved in the pathogenesis of KS, Leung et al. [19] analyzed cultures in a blinded manner from the groin, axilla, rectum, and pharynx of 16 patients in the acute phase of KS and 15 age-matched, febrile control patients. All group A beta-hemolytic streptococci and coagulase-positive *Staphylococcus aureus* isolates were screened for toxin production. Superantigen-producing bacteria were found in 13 of 16 patients with acute KS, but only in 1 of 15 control patients ($p < 0001$). Of 13 toxin (superantigen)-positive cultures from patients with KS, 11 were TSST-1, secreting *S. aureus,* and 2 of 13 were *streptococci,* producing streptococcal pyrogenic exotoxin B (SPEB) and streptococcal pyrogenic exotoxin C (SPEC). Importantly, TSST-1 and SPEC are known to possess Vß2 stimulatory activity, whereas SPEC has both Vß2 and Vß8 stimulatory activity.

It should be noted that 12 of 13 culture-positive patients had toxin-producing *S. aureus* isolated from the pharyngeal or rectal cultures. Only 1 of 13 patients had toxin (superantigen)-producing bacteria exclusively on the skin. This suggests that the primary site of bacterial colonization or infection in KS patients is the mucosal surface of the gastrointestinal tract, consistent with the observation by Yamashiro et al. [17] that there is a selective expansion of Vß2-positive T cells in the small intestinal mucosa of patients with acute KS. Furthermore, these data suggest that several staphylococcal or

streptococcal superantigens with TCR Vß2-stimulatory activity may cause the acute clinical features listed in Table 204-1 by inducing fever and tissue inflammation via the massive release of cytokines. Since these sentinel observations, several studies have confirmed this initial report, while others have failed to find superantigen-producing *S. aureus* or *Streptococci* associated with acute KS. [20], [21] A recent multicenter, blinded, controlled study also confirmed an association of TSST-1 producing *S. aureus* and SPEC-producing *streptococci* with acute KS but, interestingly, other superantigens were not associated with KS. [22] Furthermore, the recent description of guttate psoriasis (known to be caused by Vß2-stimulatory superantigens) in a patient following KS with associated *S. aureus* on throat culture, and a series of 10 patients who developed psoriasis during or following acute KS are consistent with a superantigenic etiology in KS. [23], [24] and [25]

CLINICAL MANIFESTATIONS

Dermatologic Features

The mucocutaneous manifestations of KS are varied and not all children exhibit each feature. The major diagnostic criteria for KS are listed in Table 204-1 and are reviewed in references 1 to 3. KS is a triphasic illness beginning with an acute phase that lasts 7 to 14 days, followed by a subacute phase of approximately 25 days and a convalescent phase that lasts nearly 70 days. The cardinal feature of the acute phase is a prolonged high fever that frequently spikes to 40°C (104°F) and is associated with a toxic appearance in virtually all patients. In the absence of anti-inflammatory therapy, the duration of fever is usually 1 to 2 weeks.

Approximately 90 percent of children with KS develop an exanthem in the first days of their acute febrile illness (Fig. 204-1). The eruption favors the trunk and proximal extremities, but can be generalized. It can be quite variable, having been described as macular, papular, morbilliform, urticarial, and even “target-like” resembling erythema multiforme. The initial rash may be indistinguishable from an acute viral exanthem or adverse drug reaction, but is rarely vesicular or bullous. Recently, plaque-type and pustular psoriatic lesions have been described in the acute phase. [25]

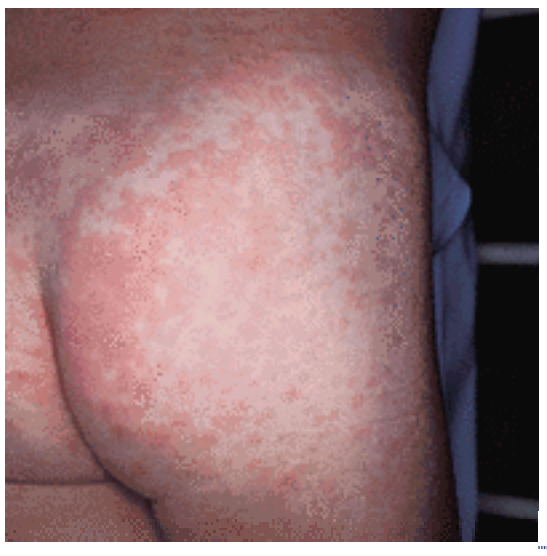

FIGURE 204-1 A generalized morbilliform eruption appearing early in the febrile course of a 5-year-old boy with Kawasaki syndrome.

One of the earliest signs of KS is a characteristic perineal eruption (Fig. 204-2). In one study of 58 children, 67 percent had the perineal eruption. [26] Onset is usually within the first 6 days of the illness and presents as diffuse macular or plaque-type blanching erythema involving part or all of the perineal skin. These involved areas can be warm and tender. Within 48 h, the erythematous areas begin to desquamate. This desquamation occurs earlier than that of the palms and soles.

FIGURE 204-2 Generalized erythema and early desquamation in the perigenital and perineal area of a 4-year-old girl with Kawasaki syndrome. This feature occurs early in the illness and involves 67 percent of affected children.

In 90 percent of patients, a nonexudative conjunctival injection begins shortly after the onset of fever and generally involves the bulbar conjunctivae more severely than the palpebral conjunctivae. Conjunctival vessels become engorged and dilated. There is no purulent discharge or crusting of the eyelashes, as is seen in bacterial conjunctivitis. Conjunctival injection is associated with anterior uveitis in approximately 83 percent of patients examined within the first weeks of illness.

Oral mucosal findings are very characteristic of KS and occur in almost all cases. The lips become “cherry” red, dry, and often cracked, producing small hemorrhagic fissures. In contrast to staphylococcal scalded skin syndrome, there is no

radial crusting of the perioral skin. There are no punctate ulcerations, as are seen in herpes gingivostomatitis or aphthae, and no diffuse erosions with confluent hemorrhagic crusts, as are seen in Stevens-Johnson syndrome. The tongue has been described as “strawberry,” with hypertrophied papillae and hyperemia, but only about half the cases seem to have this feature.

Profound edema and erythema of the distal aspects of the hands and feet with fusiform swelling of the fingers is also noted in almost all cases (Fig. 204-3). Onset is usually within a few days of the start of illness. These hyperemic areas are subject to desquamation 10 to 18 days later, during the subacute phase. The desquamation characteristically begins at the tips of the fingers and toes and may develop either fine peeling or shedding of thick “casts” of palmar and plantar skin, similar to that seen in scarlet fever (Fig. 204-4).

FIGURE 204-3 Erythema and edema of the distal fingertips are characteristic of the early phase of Kawasaki syndrome.

FIGURE 204-4 Desquamation starting at the tips of the fingers occurs 10 to 18 days after the onset of illness, as illustrated in this 3-month-old infant with Kawasaki syndrome.

Generalized fine desquamation, especially in the areas of the skin that had previously been erythematous, is also common at this time. Recurrent skin peeling, especially in those children with nasal staphylococcal colonization, may occur for several years, usually following upper respiratory tract infections. [27] Because of the severe systemic nature of the illness and the prolonged high fever, it is not surprising that some children develop telogen effluvium, with significant but transient hair loss 6 to 12 weeks following the acute phase of the illness. Similarly, Beau's lines of the nails and/or shedding of the nails have been observed weeks to months later. Transient episodes of psoriasis have been described 4 to 12 weeks after the acute phase, but none of these children have developed chronic psoriasis. [23], [25] Lymphadenopathy is the least frequent finding and is seen in less than 75 percent of patients. The adenopathy generally consists of a single enlarged, nonsuppurative cervical node measuring at least 1.5 cm.

Systemic Associations

Table 204-2 lists other associated clinical features of KS. Arthralgia and arthritis occur in approximately one-third of patients. During the acute phase, the arthritis usually involves the small joints, whereas involvement of the large weight-bearing joints usually occurs in the second and third weeks of the illness. Urethritis associated with sterile pyuria is frequently present in acute KS. Aseptic meningitis is usually associated with mild mononuclear cell pleocytosis of the cerebrospinal fluid and with normal glucose and protein. Hydrops of the gallbladder may be present with or without obstructive jaundice. Diarrhea, vomiting, abdominal pain, cranial nerve palsies, otitis media, and infarction of organs whose vascular supply is compromised by thrombosis may also be presenting symptoms. Sensorineural hearing loss has also been associated with KS.

- Cardiovascular abnormalities, including myocarditis, arterial aneurysms, pericarditis, aortic or mitral regurgitation, ventricular arrhythmias
- Arthralgia and arthritis
- Urethritis with sterile pyuria
- Aseptic meningitis
- Hydrops of the gallbladder
- Diarrhea, vomiting, or abdominal pain
- Sensorineural hearing loss
- Uveitis
- Hepatic dysfunction

TABLE 204-2 **Associated Clinical Features of Kawasaki Disease**

During the convalescent phase there is generally a paucity of physical findings. Patients who suffer cardiovascular complications from this illness may have persistent cardiac abnormalities, including chronic myocardial dysfunction, aortic or mitral regurgitation, and cardiac arrhythmias. Occasionally a patient may experience clinical exacerbation, with recurrence of fever and other acute clinical signs, such as rash and conjunctival injection, after they had appeared to resolve. This occurs most often within a few weeks of onset of illness and may be associated with an increased risk of coronary artery disease.

Cardiac Manifestations

Abnormal cardiac findings are a hallmark of KS. Myocarditis is frequently observed during the first week after onset of fever. Pericardial effusion may develop toward the latter part of the acute phase and is secondary to myopericarditis. It is rare that these patients progress to cardiac tamponade, and the pericardial effusion generally resolves spontaneously. Congestive heart failure may occur as a result of myocarditis in the acute phase. During the subacute stage, congestive heart failure is usually caused by myocardial dysfunction secondary to ischemia or infarction.

Coronary artery ectasia or aneurysms occur in nearly 25 percent of patients with KS who are not treated with intravenous immunoglobulin. Dilatation of the coronary arteries may be detected by echocardiography beginning 7 days after the onset of fever, usually peaking 3 or 4 weeks into the illness. A minority of patients (approximately 5 percent) may suffer from aortic or mitral regurgitation due to valvulitis, transient papillary muscle dysfunction, or as a complication of myocardial infarction.

On cardiac examination, patients with acute KS often present with tachycardia and gallop rhythms, both in excess of the fever and anemia associated with the illness. In a minority of patients, a pericardial friction rub, dysrhythmias, aortic and mitral regurgitation, the findings of congestive heart failure, and the appearance of peripheral arterial aneurysms appear during the latter part of the acute phase or during the subacute phase.

LABORATORY FINDINGS

During the acute phase of KS, patients develop a leukocytosis with a predominance of neutrophils and an increase in band count. A normocytic, normochromic anemia without evidence of hemolysis or reticulocytosis presents during the first week of illness and persists until the inflammatory process subsides. Increased platelet turnover occurs together with marked hypercoagulability in the acute phase. Thrombocytosis peaks typically in the third to fourth week after onset of fever. Elevation of liver transaminases, usually two- to threefold, is common in the acute phase, usually with a cholestatic profile of elevated bilirubin and alkaline phosphatase. Sterile pyuria caused by urethritis is observed in up to 75 percent of patients during the first week of illness. Early in the disease, acute-phase reactants such as C-reactive protein and serum a $_1$-antitrypsin, are increased with the onset of fever and persist for 6 to 10 weeks. Similarly, erythrocyte sedimentation rates are uniformly elevated in patients with acute KS. Elevation of the latter typically persists after resolution of fever, a feature that may help to distinguish KS from common viral illness. Although patients with KS have a polyclonal B cell activation, their sera do not contain the usual autoantibodies associated with collagen-vascular disease (i.e., no rheumatoid factor or antinuclear or anti-DNA antibodies). Low serum albumin levels are reported to be a risk factor for the development of coronary artery aneurysms and poor clinical outcome. [28]

Electrocardiographic changes may be present in over half of patients with acute KS. These abnormalities can include prolonged PR interval, left ventricular hypertrophy, abnormal Q waves, ventricular dysrhythmias, and nonspecific ST-T wave changes. Two-dimensional echocardiography has been used extensively for the assessment of ventricular function, the anatomy of the proximal coronary arteries, and the presence of a pericardial effusion. In general, it is preferable to obtain a baseline two-dimensional echocardiogram before the seventh day of illness (prior to onset of coronary dilation) and a repeat echocardiogram 3 to 5 weeks after illness onset (when coronary artery abnormalities are likely to be detected). Coronary arteriography is generally reserved for the patient with persistent abnormalities on echocardiograms or any patient with symptoms of myocardial ischemia. It is especially useful for visualization of coronary artery stenoses or distal coronary artery lesions that are difficult to define by two-dimensional echocardiography.

PATHOLOGY

Extensive gross and microscopic studies have been carried out at autopsy of KS patients who have died in different phases of their illness. The case-fatality rate for KS is approximately 0.4 percent, with most deaths occurring secondary to the cardiovascular complications of this disease. Fujiwara and Hamashima classified the pathology of this syndrome into four stages, according to the duration of illness at death. [29] Stage 1 (0 to 9 days after onset) is characterized by acute vasculitis and perivasculitis of small blood vessels. Microscopically, the acute vascular lesion in KS is associated with evidence for endothelial activation and endothelial cell damage. [29], [30] The lesion is also associated with the infiltration of both neutrophils and mononuclear cells. The mononuclear cells consist of activated T cells and monocyte/macrophages. [31] MHC II antigens are expressed on the coronary arterial endothelium in acute KS but not in normal controls. IFN-? is a potent in vivo inducer of class II MHC antigens, and IL-1, as well as TNF-a, plays an important role in the induction of leukocyte adhesion molecules. The induction of class II MHC antigens on endothelial cells, as well as the observation of leukocyte adhesion to endothelial cells in the vascular lesion of KS, suggests that cytokine-induced endothelial antigens play an important role in the pathogenesis of this disease. In the larger arteries, the initial inflammation involves the intima and the vasa vasorum without inflammation of the media. Pericarditis, myocarditis, inflammation of the atrioventricular conduction system, and endocarditis with valvulitis are also present.

Stage 2 (12 to 25 days after onset) is characterized by a marked infiltration of inflammatory cells into the media of the coronary arteries as well as other medium-sized arteries, and aneurysms with thrombosis begin to form. At this stage, it is presumed that the formation of aneurysms is occurring as the result of destruction of the blood vessel walls that follows release of proteolytic enzymes and inflammatory mediators into the media. In stage 3 (28 to 31 days), the acute inflammatory process regresses, and granulation of the coronary arteries is noted. In stage 4 (40 days to 4 years), scar formation, organization of thrombi, intimal proliferation and neoantiogenesis continue to occur for several years after onset of the disease. [32] This process can result in severe stenosis of the coronary arteries as well as other medium-sized arteries.

The peak time of death is 3 to 4 weeks after onset of the acute illness. Death can occur as early as during the first week of illness and as late as more than 10 years after the acute illness. During stage 1 of KS, patients usually die of acute

myocarditis or cardiac arrhythmia caused by inflammation of the atrioventricular conduction system. In stage 2 of the disease, death can result from rupture of the coronary arteries or myocarditis, including lesions of the atrioventricular conduction system, or myocardial insufficiency caused by thrombosis of the coronary arteries. Sudden death late in the illness (stage 3), or years after recovery from acute KS (stage 4), may occur as the result of myocardial infarction in children with residual coronary artery aneurysms and stenoses.

It is worth emphasizing that although coronary arteries are invariably involved in this disease, almost any other medium- or large-sized blood vessel may be involved when examined at autopsy. Aneurysm formation has been reported in the femoral, iliac, renal, axillary, and brachial arteries. KS is a systemic vasculitis that can affect most small- and medium-sized blood vessels. Cutaneous vasculitis, however, is not a prominent feature of KS.

DIAGNOSIS AND DIFFERENTIAL DIAGNOSIS

According to the guidelines set forth by the American Heart Association, [1] the patient with KS should have fever lasting 5 or more days without other reasonable explanation and satisfy at least four of the five following criteria (Table 204-1): (1) bilateral nonexudative conjunctival injection; (2) at least one of the following mucous membrane changes: injected or fissured lips, diffuse injection of the oral and pharyngeal mucosa, or “strawberry tongue”; (3) at least one of the following peripheral extremity changes: erythema of the palms or soles, edema of the hands or feet during the acute phase, or periungual desquamation during the convalescent phase; (4) polymorphous exanthem; and (5) acute nonsuppurative cervical lymphadenopathy (>1.5 cm in diameter). In atypical cases, patients with fever and fewer than four of the principal symptoms can be diagnosed as having KS when coronary artery disease is detected by two-dimensional echocardiography or coronary angiography. Males younger than 6 months of age are at particularly high risk for atypical KS. The diagnosis of atypical KS should be considered in any infant with prolonged fever (>2 weeks). Findings that should trigger the search for another diagnosis include discrete intraoral ulcerations, exudative conjunctivitis and generalized lymphadenopathy which is rarely seen in acute KS.

KS has clinical features compatible with infection, hypersensitivity reactions, or exposure to environmental toxins. The differential diagnosis includes staphylococcal or streptococcal scarlet fever or toxic shock syndrome; staphylococcal scalded skin syndrome; viral exanthem, particularly measles; Rocky Mountain spotted fever; leptospirosis; infantile polyarteritis nodosa; mercury toxicity (acrodynia); Stevens-Johnson syndrome; erythema multiforme; adverse drug reaction; and juvenile rheumatoid arthritis. KS has a variety of mucocutaneous manifestations, some of which are characteristic, but many of which are shared with these other infectious and reactive disorders. The correct diagnosis of KS hinges on recognizing the cumulative combination of mucocutaneous, systemic, and laboratory findings. Considerations that help in eliminating certain viruses such as measles and influenza from the differential diagnosis include local epidemiology, vaccination history, and culture results.

Because KS is based on diagnostic criteria that use clinical characteristics that overlap with other illnesses, diagnostic dilemmas can arise, particularly in atypical cases that do not completely fulfill the diagnostic criteria, but which are associated with the development of coronary artery abnormalities. Instances of atypical KS are most common in infants, the age group that is at greatest risk of coronary artery abnormalities. The decision to initiate therapy in children who do not satisfy the American Heart Association criteria can be supported by laboratory results showing acute phase reactants (elevated white blood cell count, elevated sedimentation rate), an ultrasound showing a pericardial effusion or a slit lamp exam showing anterior uveitis.

TREATMENT AND PROGNOSIS

Current management is aimed at reducing inflammation in the myocardium and coronary artery wall, and at preventing coronary thrombosis. Aspirin in combination with high-dose intravenous immunoglobulin is the cornerstone of therapy for acute KS. Aspirin is administered in doses of 80 to 100 mg/kg of body weight per day in four divided doses to achieve a serum salicylate level of 20 to 25 mg/dL during the acute phase of the illness. At therapeutic doses, aspirin reduces fever, toxicity, and joint symptoms within 48 h. [33] After defervescence, usually around the fourteenth day of illness, the aspirin dose is reduced to 3 to 5 mg/kg of body weight per day to continue inhibiting platelet activity. Aspirin is discontinued if no coronary abnormalities have been detected by 6 to 8 weeks after onset of the illness and the platelet count and sedimentation rate have normalized. Aspirin therapy is continued indefinitely if coronary artery aneurysms develop and persist. Digitalis and diuretics are used as needed in the patient with congestive heart failure. In patients at risk for cardiovascular complications, some physicians add dipyridamole, 1 mg/kg body weight per day, to further inhibit platelet aggregation. Therapy of the mucocutaneous manifestations of the disease is entirely symptomatic and includes emollients for desquamating skin and antihistamines for pruritus.

No definitive prospective study has demonstrated that high-dose aspirin therapy prevents coronary artery abnormalities. In contrast, several randomized multicenter studies have demonstrated that high-dose (greater than 1 g/kg) IV immunoglobulin in combination with aspirin therapy is safe and effective in reducing the prevalence of coronary artery abnormalities. [34], [35], [36] and [37] IV immunoglobulin both reduces the overall prevalence of coronary artery abnormalities and prevents the formation of giant aneurysms, the most serious form of coronary abnormality caused by KS. Abnormalities of left ventricular systolic function and contractility also improves more rapidly in children treated in the acute phase with high-dose IV immunoglobulin together with aspirin than in those children treated with aspirin alone. [38]

At present, the treatment of choice for acute KS is a single high dose of IV immunoglobulin (2 g/kg) administered over 10 to 12 h with aspirin (80 to 100 mg/kg per day). When compared with multiple-dose regimens of approximately equivalent total dose, this single high dose of IV immunoglobulin has a lower incidence of coronary abnormalities, more rapid resolution of fever and laboratory indices of acute inflammation, and reduction in the duration of hospitalization, as well as higher peak serum IgG levels. [36] Of interest, peak-adjusted serum IgG levels are lower among patients who subsequently develop coronary artery abnormalities and the levels are inversely related to fever duration and laboratory

indices of acute inflammation.

A minority of patients who receive IV immunoglobulin have persistent fever 48 h after completion of the infusion. A subset of patients might also demonstrate initial defervescence but then have recurrence of their fever after being afebrile for 24 h or more. In both situations, a repeat dose of IV immunoglobulin may be indicated. [39]

At present, the use of systemic steroids in the treatment of KS is controversial. Several studies from Japan report that patients treated with steroids alone or in combination with aspirin have a higher frequency of coronary aneurysms and of subsequent myocardial infarction and death. [40] A more recent study of four patients with KS resistant to IV immunoglobulin suggested a response to high-dose pulse methylprednisolone (30 mg/kg per day for 1 to 3 days) therapy. [41] In 1999, Shinohara et al. reviewed the experience with prednisolone in children with KS. [42] The authors concluded that prednisolone resulted in a shorter duration of fever and a lower prevalence of coronary artery aneurysms. However, this study was a retrospective review of patients who received different doses and different schedules of IV immunoglobulin than what is currently used in the United States. Case reports of either oral or intravenous corticosteroid use in patients with unresponsive disease despite at least two adequate doses of IV immunoglobulin suggest a possible role for steroids in the reduction in the acute inflammatory phase, as well as control of the vasculitis. [43], [44] However, controlled studies are needed to determine whether systemic corticosteroids should be used in patients who fail to respond to IV immunoglobulin therapy.

Patients who develop coronary artery aneurysms must be monitored closely for the long-term cardiac sequelae of KS. [45] Stress echocardiography and coronary angiography may be indicated in patients with evidence of myocardial ischemia. For the KS patients with obstructive changes in one or more coronary arteries, anticoagulant therapy may be required. For more severe cardiovascular symptoms, the options include the use of intravenous streptokinase or urokinase when a thrombus is present, balloon angioplasty, and/or coronary artery bypass grafting. [46], [47]

PROGNOSIS

The major long-term morbidity in KS is related to cardiovascular complications from this disease. The majority of children (50 to 67 percent) with arterial aneurysms will show angiographic regression within 6 months to 2 years after onset of their disease. [48] The likelihood of resolution of the aneurysms appears to be determined by the initial size of the aneurysm, with smaller aneurysms having a greater likelihood of regression. Some studies, however, indicate that there is evidence of persisting abnormal vascular wall morphology and vascular dysfunction at the site of regressed coronary aneurysms in patients with previous KS. [49] Patients with giant aneurysms, that is, those with a maximum diameter greater than 8 mm, have the worst prognosis. The majority of patients with giant aneurysms progress to stenosis or obstruction. Nearly all late deaths from KS occur in this subgroup of patients.

Children without known cardiac sequelae during the first month of KS appear to return to their previous state of health without cardiac impairment. A study of patients many years after resolution of acute KS, however, using high-resolution ultrasound to study endothelium-dependent vascular responses, showed evidence of persistent endothelial dysfunction, even in patients without detectable early coronary artery involvement. [50] Increased blood pressure, adiposity and higher fasting triglyceride levels have also been reported in patients with previous KS. Thus, it is generally recommended that children with KS be followed over the long-term by a cardiologist to rule out the development of myocardial dysfunction, late-onset valvular regurgitation, or premature coronary artery disease.

REFERENCES

1. American Heart Association Committee on Rheumatic Fever, Endocarditis, and Kawasaki Disease: Diagnostic guidelines for Kawasaki disease. *Circulation* **103**:335, 2001

2. Kawasaki T: [Acute febrile mucocutaneous syndrome with lymphoid involvement with specific desquamation of the fingers and toes in children]. *Arerugi* **16**:178, 1967

3. Burns JC: Kawasaki disease. *Adv Pediatr* **48**:157, 2001

4. Hirata S et al: Incidence rate of recurrent Kawasaki disease and related risk factors: From the results of nationwide surveys of Kawasaki disease in Japan. *Acta Paediatr* **90**:40, 2001

5. Yanagawa H et al: Incidence survey of Kawasaki disease in 1997 and 1998 in Japan. *Pediatrics* **107**:E33, 2001

6. Leung DY et al: The immunopathogenesis and management of Kawasaki syndrome. *Arthritis Rheum* **41**:1538, 1998

7. Nishida K et al: Increased plasma adrenomedullin levels in Kawasaki disease with coronary artery involvement. *Am J Med* **111**:165, 2001

8. Hamamichi Y et al: Neutrophils and mononuclear cells express vascular endothelial growth factor in acute Kawasaki disease: Its possible role in progression of coronary artery lesions. *Pediatr Res* **49**:74, 2001

9. Cunningham MW et al: Anti-human cardiac myosin autoantibodies in Kawasaki syndrome. *J Immunol* **163**:1060, 1999

10. Leung DY et al: Reversal of lymphocyte activation in vivo in the Kawasaki syndrome by intravenous gamma globulin. *J Clin Invest* **79**:468, 1987

11. Yarwood JM et al: Evidence for the involvement of bacterial superantigens in psoriasis, atopic dermatitis, and Kawasaki syndrome. *FEMS Microbiol Lett* **192**:1, 2000

12. Abe J et al: Selective expansion of T cells expressing T-cell receptor variable regions Vß2 and Vß8 in Kawasaki disease. *Proc Natl Acad Sci U S A* **89**:4066, 1992

13. Curtis N et al: Evidence for a superantigen mediated process in Kawasaki disease. *Arch Dis Child* **72**:308, 1995

14. Leung DY et al: Evidence for superantigen involvement in cardiovascular injury due to Kawasaki syndrome. *J Immunol* **155**:5018, 1995

15. Pietra BA et al: TCR Vß family repertoire and T cell activation markers in Kawasaki disease. *J Immunol* **153**:1881, 1994

16. Yoshioka T et al: Polyclonal expansion of TCRßV2- and TCRßV6-bearing T cells in patients with Kawasaki disease. *Immunology* **96**:465, 1999

17. Yamashiro Y et al: Selective increase of Vß 2+ T cells in the small intestinal mucosa in Kawasaki disease. *Pediatr Res* **39**:264, 1996

18. Abe J et al: Characterization of T cell repertoire changes in acute Kawasaki disease. *J Exp Med* **177**:791, 1993

19. Leung DY et al: Toxic shock syndrome toxin-secreting *Staphylococcus aureus* in Kawasaki syndrome. *Lancet* **342**:1385, 1993

20. Leung DY et al: Association of toxic shock syndrome toxin-secreting and exfoliative toxin-secreting *Staphylococcus aureus* with Kawasaki syndrome complicated by coronary artery disease. *Pediatr Res* **42**:268, 1997

21. Terai M et al: The absence of evidence of staphylococcal toxin involvement in the pathogenesis of Kawasaki disease. *J Infect Dis* **172**:558, 1995

22. Leung DYM et al: Prevalence of superantigen-secreting bacteria in patients with Kawasaki disease. *J Pediatr* **140**:742, 2002

23. Han MH et al: A case of guttate psoriasis following Kawasaki disease. *Br J Dermatol* **142**:548, 2000

24. Leung DY et al: Evidence for a streptococcal superantigen-driven process in acute guttate psoriasis. *J Clin Invest* **96**:2106, 1995

25. Eberhard BA et al: Psoriatic eruption in Kawasaki disease. *J Pediatr* **137**:578, 2000

26. Friter BS, Lucky AW: The perineal eruption of Kawasaki syndrome. *Arch Dermatol* **124**:1805, 1988

27. Michie C et al: Recurrent skin peeling following Kawasaki disease. *Arch Dis Child* **83**:353, 2000

28. Oki I et al: A multicenter collaborative study on the risk factors of cardiac sequelae due to Kawasaki disease: A one-year follow-up study. *Acta Paediatr* **89**:1435, 2000

29. Fujiwara H, Hamashima Y: Pathology of the heart in Kawasaki disease. *Pediatrics* **61**:100, 1978

30. Hirose S, Hamashima Y: Morphological observations on the vasculitis in the mucocutaneous lymph node syndrome. A skin biopsy study of 27 patients. *Eur J Pediatr* **129**:17, 1978

31. Brown TJ et al: CD8 T lymphocytes and macrophages infiltrate coronary artery aneurysms in acute Kawasaki disease. *J Infect Dis* **184**:940, 2001

32. Suzuki A et al: Active remodeling of the coronary arterial lesions in the late phase of Kawasaki disease: Immunohistochemical study. *Circulation* **101**:2935, 2000

33. Koren G et al: Probable efficacy of high-dose salicylates in reducing coronary involvement in Kawasaki disease. *JAMA* **254**:767, 1985

34. Furusho K et al: High-dose intravenous gamma globulin for Kawasaki disease. *Lancet* **2**:1055, 1984

35. Newburger JW et al: The treatment of Kawasaki syndrome with intravenous gamma globulin. *N Engl J Med* **315**:341, 1986

36. Newburger JW et al: A single intravenous infusion of gamma globulin as compared with four infusions in the treatment of acute Kawasaki syndrome. *N Engl J Med* **324**:1633, 1991

37. Durongpisitkul K et al: The prevention of coronary artery aneurysm in Kawasaki disease: A meta-analysis on the efficacy of aspirin and immunoglobulin treatment. *Pediatrics* **96**:1057, 1995

38. Newburger JW et al: Left ventricular contractility and function in Kawasaki syndrome. Effect of intravenous gamma-globulin. *Circulation* **79**:1237, 1989

39. Burns JC et al: Intravenous gamma-globulin treatment and retreatment in Kawasaki disease. US/Canadian Kawasaki Syndrome Study Group. *Pediatr Infect Dis J* **17**:1144, 1998

40. Kato H et al: Kawasaki disease: Effect of treatment on coronary artery involvement. *Pediatrics* **63**:175, 1979

41. Wright DA et al: Treatment of immune globulin-resistant Kawasaki disease with pulsed doses of corticosteroids. *J Pediatr* **128**:146, 1996

42. Shinohara M et al: Corticosteroids in the treatment of the acute phase of Kawasaki disease. *J Pediatr* **135**:465, 1999

43. Dale RC et al: Treatment of severe complicated Kawasaki disease with oral prednisolone and aspirin. *J Pediatr* **137**:723, 2000

44. Raman V et al: Response of refractory Kawasaki disease to pulse steroid and cyclosporin A therapy. *Pediatr Infect Dis J* **20**:635, 2001

45. Fulton DR, Newburger JW: Long-term cardiac sequelae of Kawasaki disease. *Curr Rheumatol Rep* **2**:324, 2000

46. Yoshikawa Y et al: Result of surgical treatments in patients with coronary-arterial obstructive disease after Kawasaki disease. *Eur J Cardiothorac Surg* **17**:515, 2000

47. Suda Y et al: Twenty-two–year follow-up of saphenous vein grafts in pediatric Kawasaki disease. *Ann Thorac Surg* **70**:1706, 2000

48. Kato H et al: Long-term consequences of Kawasaki disease. A 10- to 21-year follow-up study of 594 patients. *Circulation* **94**:1379, 1996

49. Iemura M et al: Long-term consequences of regressed coronary aneurysms after Kawasaki disease: Vascular wall morphology and function.

Heart **83**:307, 2000

50. Dhillon R et al: Endothelial dysfunction late after Kawasaki disease. *Circulation* **94**:2103, 1996

T>

Chapter 205

Michael Nelson Ann Martin Michael Heffernan

Superficial Fungal Infections: Dermatophytosis, Onychomycosis, Tinea Nigra, Piedra

MYCOLOGY
Historical Aspects
Laboratory Procedures
Epidemiology
Pathogenesis
Genetics
DERMATOPHYTOSES
Tinea Capitis
Tinea Favosa
Tinea Barbae
Tinea Corporis (Tinea Circinata)
Tinea Cruris
Tinea Pedis and Tinea Mannum
ONYCHOMYCOSIS
Epidemiology
Etiology and Pathogenesis
Clinical Manifestations
Laboratory Findings
Pathology
Differential Diagnosis
Treatment
TINEA NIGRA
Epidemiology
Etiology
Clinical Manifestations
Laboratory Findings
Pathology
Differential Diagnosis
Treatment
PIEDRA
Epidemiology
Clinical Manifestations
Laboratory Findings
Diagnosis
Treatment

REFERENCES

MYCOLOGY

The dermatophytes are a group of taxonomically related fungi whose ability to form molecular attachments to keratin and use it as a source of nutrients allows them to colonize keratinized tissues, including the stratum corneum of the epidermis, hair, nails, and the horny tissues of animals. [1] Superficial infection caused by a dermatophyte is termed *dermatophytosis,* whereas *dermatomycosis* refers to systemic or deep fungal infections.

Historical Aspects

Systematic study of superficial fungal infection began more than 150 years ago when Remak described the mycelial nature of the clinical disease favus. In 1841, Gruby isolated the organism of favus in culture and experimentally reproduced the disease with inoculation in normal skin. However, it was not until 1910 that Raymond Saboraud published his seminal treatise, *Les Tiegnes,* classifying the dermatophytes into four genera based on their microscopic and clinical characteristics. In 1934, Emmons' critical review of dermatophyte taxonomy resulted in the three genera known today: *Epidermophyton, Microsporum,* and *Trichophyton*.

Laboratory Procedures

The success of laboratory confirmation of clinically diagnosed superficial fungal infection relies on the proper collection of specimens for microscopic examination and culture.

MICROSCOPIC EXAMINATION

Hair Examination of lesions involving the scalp or beard with a Wood lamp may reveal the fluorescent pteridine of certain pathogens (Table 205-1). Hairs must be plucked, not cut, for examination by low-power microscopy, which may reveal three possible patterns of infection:

Ectothrix	Endothrix
Yellow-green fluorescence	Dull gray-green fluorescence
M. audouinii	*T. schoenleinii*
M. canis	
M. ferrugineum	
No fluorescence	No fluorescence
M. fulvum	*T. gourvilii*
M. gypseum	*T. soudanense*
T. megninii	*T. tonsurans*
T. mentagrophytes	*T. violaceum*
T. rubrum	*T. yaoundei*
T. verrucosum	

TABLE 205-1 **Laboratory Characteristics of Dermatophytes that Cause Tinea Capitis**

1. Ectothrix—small or large arthroconidia forming a sheath around the hair shaft (Fig. 205-1);

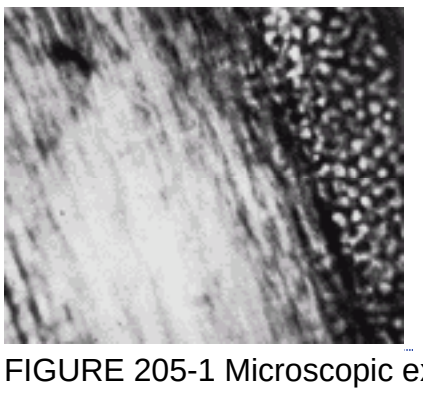

FIGURE 205-1 Microscopic examination of ectothrix hair involvement.

2. Endothrix—arthroconidia within the hair shaft (Fig. 205-2);

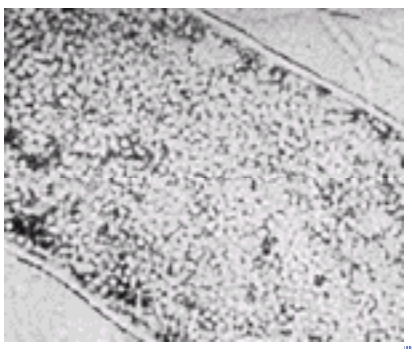

FIGURE 205-2 Microscopic examination of endothrix hair involvement.

3. Favic—hyphae arranged in parallel within and around the hair shaft (Fig. 205-3).

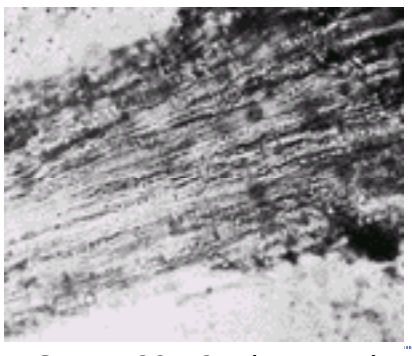

FIGURE 205-3 Microscopic examination of favic hair involvement seen with *T. schoenleinii*.

Skin and nails Skin samples should be taken by scraping with the dull edge of a scalpel outward from the advancing margins of a lesion. Nail specimens must include clippings of the entire thickness of dystrophic areas of nail, as proximal from the distal edge as possible. In a potassium hydroxide (KOH) preparation, fungal hyphae will appear as septate and branching structures (Fig. 205-4); however, culture is required for speciation.

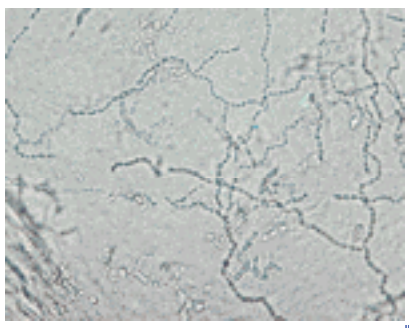

FIGURE 205-4 Microscopic examination of skin scrapings (scales) revealing septate, branching hyphae.

CULTURE PROCEDURES Speciation of superficial fungi is based on the macroscopic, microscopic, and metabolic characteristics of the organism. Sabouraud's dextrose agar (SDA) [dextrose 40 g; agar 20 g; peptone 10 g; distilled water (adjusted to pH 5.5) to 1000 mL] is the most commonly used isolation medium and serves as the basis for most morphologic descriptions. However, contaminant saprobes (organisms that feed on dead or decaying matter) grow rapidly on this medium, masking true pathogens. This necessitates the addition of cycloheximide (0.5 g/L) and chloramphenicol (0.05 g/L) to inhibit saprobes and bacteria, making the medium highly selective for the isolation of dermatophytes. Commercial versions of this agar are Mycosel and Mycobiotic. Dermatophyte test medium (DTM) contains the pH indicator phenol red; it remains yellow with the growth of most saprophytes, but turns red when dermatophyte proteolytic activity increases the pH to 8 or above. Identification of isolated fungi is facilitated by the use of potato dextrose agar (PDA), which stimulates the production of conidia and pigment. Finally, species of *Trichophyton* are often differentiated by their nutritional requirements, revealed on *Trichophyton* agar Numbers 1 through 7. These are a

casein basal medium (T1) with the addition of inositol (T2), thiamine and inositol (T3), thiamine (T4), and nicotinic acid (T5), as well as an ammonium nitrate basal medium (T6) supplemented with histidine (T7). It is essential that each laboratory use standardized media, of which several commercial variants are available. Cultures are incubated at room temperature (26°C/78.8°F) for up to 4 weeks before being discarded as no growth. With more than 40 known dermatophytes, proper identification requires a suitable reference source. [2] Figure 205-5 lists the characteristics of the most common pathogens.

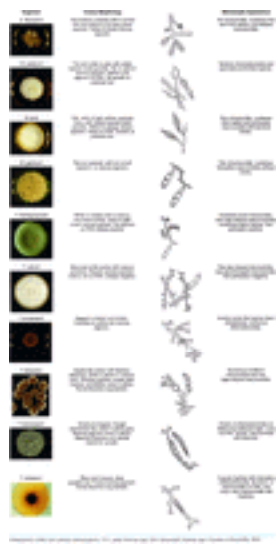

FIGURE 205-5 Characteristics of the most common dermatophytes. PDA, potato dextrose agar; SDA, Sabouraud's dextrose agar. (*Courtesy of David Ellis, PhD.*)

Epidemiology

Classifying superficial fungi by their usual habitat (Table 205-2) is useful for understanding their various clinical presentations and patterns of transmission.



TABLE 205-2 **Usual Habitat of Dermatophytes Known to Cause Human Disease**

Geophilic organisms grow in the soil and only sporadically infect humans; when they do, the result is usually inflammatory. Strains of *M. gypseum,* the most common geophilic pathogen, cultured from humans are more virulent than those from the soil, accounting for occasional epidemic spread under appropriate conditions. [3]

Zoophilic species are found on animals, but are also transmitted to humans sporadically. Domestic animals and pets are becoming an increasing source of these infections in urban areas (e.g., *M. canis* in cats and dogs). Transmission may occur through direct contact with a specific animal species or indirectly by infected animal hair carried on clothing or present in contaminated buildings or feed. Exposed areas such as the scalp, beard, face, and arms are favored sites of infection. Although human infection with zoophiles is often suppurative, animal infection may be clinically silent, demonstrating the unique adaptation of fungi to their animal hosts. [4]

Anthropophilic species have adapted to humans as hosts. Unlike the sporadic geophilic and zoophilic infections, anthropophilic infections are often epidemic in nature. They are transmitted from person to person via direct contact or fomites. Markedly inflammatory reactions can occur because of variability in virulence as well as host susceptibility. Kerion formation, suppuration, or other manifestations of inflammatory tinea facilitate early diagnosis. Noninflammatory disease, in contrast, results in a clinically silent “carrier” state that serves to delay diagnosis and propagate the infection.

Host variability also affects presentation. Immunocompromised individuals are more susceptible to severe or refractory dermatophytoses, and advances in chemotherapy and transplant medicine have led to an increase in opportunistic infections by previously nonpathogenic dermatophytes. [5] Interestingly, only the severity of dermatophytosis is increased with HIV disease, not the prevalence. [6] Age, sex, and race are additional important epidemiologic factors, as dermatophyte infections are five times more prevalent in males than females. [7] However, *T. tonsurans* tinea capitis is more common in female adults than male adults, and most common in African-American children.

T. tonsurans also illustrates how patterns of human travel may rapidly influence the distribution of endemic fungi. Within

the past quarter century, it has replaced *M. audouinii* as the predominant cause of tinea capitis in the United States, correlating well with the immigration of Mexican and Caribbean populations. The relative resistance of *T. tonsurans* to griseofulvin has also contributed to its predominance. [4] Finally, local customs influence rates of dermatophytoses. For example, the use of macerating occlusive footwear has made tinea pedis and onychomycosis much more common in industrialized nations. [6]

Pathogenesis

Superficial fungi must overcome several obstacles in order to colonize keratinized tissue. They must resist the effects of UV light, variation in temperature and moisture, competition from normal flora, and fungistatic fatty acids and sphingosines produced by keratinocytes. After adherence, spores must germinate and penetrate the stratum corneum at a rate faster than desquamation. This penetration is accomplished by the secretion of proteinases, lipases, and mucinolytic enzymes, which also provide nutrients. Trauma and maceration also facilitate penetration. New defenses emerge once the deeper layers of epidermis are reached, including competition for iron by unsaturated transferrin and possibly inhibition of fungal growth by progesterone. From this point, the degree of inflammation is highly dependent on immune system activation.

Immune detection and chemotaxis of inflammatory cells may occur through several mechanisms. Some fungi produce low-molecular-weight chemotactic factors much like those produced by bacteria. Others activate complement, creating complement-derived chemotactic factors. Keratinocytes may also induce chemotaxis by releasing IL-8 in response to antigens such as trichophytin. Accumulating neutrophils produce zinc-binding calprotectin, in addition to numerous oxidants and enzymes. Accumulating macrophages inhibit fungal growth via the free radical nitric oxide. Fungal mannans appear to counteract this response by inhibiting inflammation and phagocytosis. [7]

Type IV, or delayed-type hypersensitivity (DTH), plays a pivotal role in clearing dermatophytoses. This arm of cellular immunity is maintained by interferon-gamma secretion from type 1 T-helper lymphocytes (T_H1 cells). In patients without previous exposure to a dermatophyte, primary infection causes minimal inflammation, and a trichophytin skin test is negative. [8] The infection produces mild erythema and scale, the result of increased keratinocyte turnover. It is hypothesized that dermatophyte antigen is then processed by epidermal Langerhans cells and presented in local lymph nodes to T lymphocytes. The T lymphocytes undergo clonal proliferation and migrate to the dermis and epidermis to attack the fungus. [7] At this time, the lesion becomes abruptly inflammatory, and the epidermal barrier becomes permeable to transferrin and migrating cells. Soon the fungus is cleared and the lesion spontaneously resolves. The trichophytin skin test is now positive, and clearing of a second infection will be more rapid. Patients who display an IgE-mediated, immediate hypersensitivity (IH) reaction to the trichophytin skin test, instead of a DTH response, are prone to chronic dermatophytoses, usually with *T. rubrum*.

Atopic individuals are notoriously susceptible to chronic dermatophytosis. A likely explanation is that atopy, in which overactive type 2 T-helper lymphocytes (T_H2 cells) induce IH responses to antigen, inhibits or overpowers the ability of T_H1 cells to maintain a DTH response. [8]

Dermatophytid reactions, which occur in 4 to 5 percent of patients, are inflammatory reactions of the skin at a site distant from the primary fungal infection. [9] Unlike the primary lesion, these are KOH examination and culture negative. They may take the form of follicular papules, erythema nodosum, vesicular id of the hands and feet, erysipelas-like, erythema annulare centrifugum, or urticaria. [10], [11], [12], [13], [14] and [15] They typically occur at or slightly after the height of infection, or just after initiation of systemic antifungals, [16] and disappear with resolution of the primary lesion. Occasionally an id reaction is widespread or inflammatory enough to warrant concomitant topical or systemic corticosteroids. Although the precise mechanism is unknown, these reactions are associated with a DTH response to the trichophytin test and may involve a local DTH response to systemically absorbed fungal antigen. [9], [10]

Genetics

In households afflicted with *T. concentricum* and *T. rubrum,* relatives are more likely to be infected than conjugal partners, even with equal exposure to the fungus. Also, pedigrees from families with chronic dermatophytoses suggest an autosomal dominant pattern of susceptibility. Potential explanations for this phenomenon include genetic predisposition toward the development of IH responses and autosomal dominant differences in keratins that affect the ability of a fungus to attach to and digest the proteins. [1], [8]

DERMATOPHYTOSES

Tinea Capitis

Tinea capitis is a dermatophytosis of the scalp and associated hair. It may be caused by any pathogenic dermatophyte except *E. floccosum* and *T. concentricum*. The most common cause worldwide is *M. canis,* whereas in the United States it is *T. tonsurans*. [17]

EPIDEMIOLOGY Although the incidence of tinea capitis remains unknown, it is most commonly found in children ages 3 to 14 years; it is uncommon in adults. Transmission is increased with decreased personal hygiene, overcrowding, and low socioeconomic status. Organisms responsible for tinea capitis have been cultured from fomites such as combs, caps, pillowcases, and theater seats, to name a few. Even after shedding, hairs may harbor infectious organisms for over a year. [18] Asymptomatic carriers are common, making tinea capitis difficult to eradicate. [19]
PATHOGENESIS Ectothrix dermatophytes (Table 205-1) typically establish infection in the perifollicular stratum corneum, spreading around and into the hair shaft of mid- to late-anagen hairs before descending into the follicle to penetrate the cortex of the hair. Intrapilary hyphae then descend to the border of the keratogenous zone, where they

grow in equilibrium with the keratinization process, never entering the nucleated zone. The terminal tuft of hyphae at this border zone is termed *Adamson's fringe,* and from here the hyphae proliferate and divide into arthroconidia that reach the cortex of the hair and are transported upward on its surface. Plucked hairs will break just above the fringe, where the hair is now weakest. Microscopically, only the ectothrix arthroconidia may be visualized on plucked hairs, although intrapilary hyphae are present as well. The pathogenesis of endothrix infections is the same except that arthroconidia remain within the hair shaft, replacing the intrapilary keratin and leaving the cortex intact. As a result, the hair is very fragile and breaks at the surface of the scalp where support from the follicular wall is lost, leaving behind a tiny black dot. Thus, “black dot” tinea capitis is observed. Endothrix infections are also more chronic because of their ability to persist past the anagen phase into the telogen phase. [3], [20]

CLINICAL MANIFESTATIONS The clinical appearance of tinea capitis depends on its etiology (Table 205-3).

Inflammatory	Noninflammatory	Black Dot	Favus
M. audouinii	*M. audouinii*	*T. tonsurans*	*M. gypseum*
M. canis	*M. canis*	*T. violaceum*	*T. schoenleinii*
M. gypseum	*M. ferrugineum*		*T. violaceum*
M. nanum	*T. tonsurans*		
T. mentagrophytes			
T. schoenleinii			
T. tonsurans			
T. verrucosum			

*Note that a single organism may have more than one presentation.

TABLE 205-3 **Organisms Associated with Clinical Types of Tinea Capitis***

Noninflammatory, human, or epidemic type This pattern is seen most commonly with the anthropophilic ectothrix organisms *M. audouinii* or *M. ferrugineum*. The lesion begins as a small erythematous papule surrounding a single hair shaft and spreads centrifugally, encompassing nearby hairs. Scaling is usually present, but inflammation is minimal. Hairs in the affected area turn gray and lusterless secondary to their sheath of arthroconidia, and break off just above the level of the scalp (Fig. 205-6). These lesions frequently appear as one or more well-demarcated patches on the occiput or posterior neck. [18]

FIGURE 205-6 Tinea capitis caused by *M. audouinii*.

Inflammatory type This pattern is usually seen with zoophilic or geophilic pathogens, the most common examples being *M. canis* and *M. gypseum,* respectively. The spectrum of inflammation ranges from a pustular folliculitis to kerion (Fig. 205-7), which is a boggy mass studded with broken hairs and follicular orifices oozing with pus. [21] Such inflammation often results in scarring alopecia. Inflammatory lesions are usually pruritic, and may be associated with pain, cervical lymphadenopathy, fever, and additional lesions on glabrous skin.

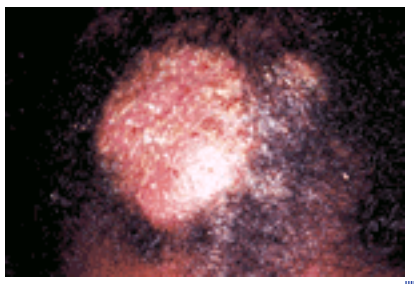

FIGURE 205-7 Kerion of the scalp.

“Black dot” tinea capitis This form of tinea capitis is caused by the anthropophilic endothrix organisms *T. tonsurans* or *T. violaceum*. Hair loss may or may not occur. When it does, hairs broken at the level of the scalp leave behind grouped black dots (Fig. 205-8). Diffuse scaling is again usually present, but inflammation varies from minimal to pustular folliculitis or furuncle-like lesions to kerion. [21] Affected areas are usually multiple or polygonal with poorly demarcated, finger-like margins. Normal hairs commonly remain within patches of alopecia.

FIGURE 205-8 “Black dot” tinea capitis caused by *T. tonsurans*.

PATHOLOGY In tinea capitis, methenamine silver and PAS stains reveal hyphae around and within the hair shaft. The dermis demonstrates a perifollicular infiltrate of mixed lymphocytes, histiocytes, plasma cells, and eosinophils. Follicular disruption leads to an adjacent foreign-body giant cell reaction. Markedly inflammatory lesions such as a kerion demonstrate a more intense infiltrate of polymorphonuclear leukocyte abscesses within the dermis and follicle. [22] Organisms are difficult to visualize, but fungal antigens are detectable with immunofluorescent techniques. [23]

DIFFERENTIAL DIAGNOSIS The differential diagnosis of minimally inflammatory, scaly tinea capitis includes seborrheic dermatitis, atopic dermatitis, and psoriasis. Pronounced alopecia invites the consideration of alopecia areata, trichotillomania, secondary syphilis, and pseudopelade. The hairs of tinea capitis do not display the exclamation point morphology typical of alopecia areata or the artifactual-appearing hairs of different lengths seen with trichotillomania. Inflammatory tinea capitis must be differentiated from the bacterial pyodermas, folliculitis decalvans, and perifolliculitis

capitis abscedens et suffodiens. The differential diagnosis of scarring alopecia also includes discoid lupus erythematosus, lichen planopilaris, pseudopelade, and radiation dermatitis.

TREATMENT Systemic antifungals are necessary for clearance of tinea capitis as they penetrate the hair follicle. Oral griseofulvin has been the gold standard of therapy for the past 40 years, but is being increasingly challenged by simpler regimens of the oral triazole and allylamine antifungals. Because of shorter track records, these alternatives are currently reserved for patients intolerant or unresponsive to griseofulvin.

Griseofulvin The usual dose of griseofulvin is 1 g/day of the microcrystalline form or 0.5 g/day of the ultramicrosize version. The pediatric dosage is 10 to 20 mg/kg per day of the ultramicrosize form taken with a fatty meal to facilitate absorption. [18] Treatment is continued until clinical and mycologic cure is documented, which usually takes 6 to 8 weeks. The dose may be increased to 20 to 25 mg/kg per day for refractory infections. The disadvantages of griseofulvin include poor compliance because of cost, length of treatment, its bitter taste in liquid form, photosensitivity, and gastrointestinal side effects. [17] It also potently induces cytochrome P450 enzymes. [24]

Fluconazole Available as both tablets and a pleasant-tasting liquid, fluconazole at doses of 6 mg/kg per day for 20 days is 89 percent effective in curing *T. tonsurans* tinea capitis. [25] Another effective treatment option appears to be once-weekly dosing of 8 mg/kg fluconazole for 8 to 16 weeks. [26] Absorption of fluconazole is not affected by meals, and gastrointestinal side effects are uncommon. Hepatitis has been reported, but occurs less frequently than with ketoconazole. [24]

Itraconazole At doses of 3 to 5 mg/kg per day, itraconazole effectively eradicates tinea capitis caused by either *Microsporum* or *Trichophyton* species in 4 to 6 weeks. [27], [28] Possible adverse effects of itraconazole include gastrointestinal upset, diarrhea with liquid itraconazole, and peripheral edema, especially when used in conjunction with calcium channel blockers. Like fluconazole, hepatotoxicity occurs at much lower rates than with ketoconazole. [24] Routine monitoring of hematologic and hepatic function is only necessary for therapy continuing beyond 4 weeks.

Terbinafine Doses of 3 to 6 mg/kg per day of terbinafine can cure *Trichophyton* tinea capitis in 2 to 4 weeks, but requires 4 to 8 weeks for treatment of *Microsporum*. [17] A recent randomized comparison of 4 weeks of terbinafine to 8 weeks of griseofulvin showed no statistically significant difference overall. However, a subgroup with *Trichophyton* infection responded better to terbinafine, while *M. audouinii* infections responded better to griseofulvin. [29] Terbinafine also produces gastrointestinal side effects and rare hepatitis. Although it has fewer cytochrome P450 effects than the other oral antifungals, tricyclic antidepressant toxicity has occurred with concomitant terbinafine use as a result of CYP2D6 inhibition. [24] Hepatic function and a complete blood count need only be monitored for therapy extending beyond 6 weeks. [17]

Adjuvant therapy With markedly inflammatory tinea capitis, oral glucocorticoids may reduce the incidence of scarring. Though there is no evidence for differences in cure rates, oral glucocorticoids are beneficial in relieving pain and swelling. The usual dose of prednisone is 1 mg/kg each morning for the first 10 to 15 days of therapy. Household transmission may be prevented through the treatment of infected family members or animals and disinfection of the environment. The use of ketoconazole 2% shampoo or selenium sulfide 2.5% by all household members three times weekly also reduces transmission by decreasing the shedding of spores. [17] Children may attend school during treatment. [30]

Tinea Favosa

Tinea favosa or favus (Latin, “honeycomb”) is a chronic dermatophyte infection of the scalp, glabrous skin, and/or nails characterized by thick yellow crusts (scutula) within the hair follicles which lead to scarring alopecia.

EPIDEMIOLOGY Favus is usually acquired before adolescence and extends into adulthood. [31] Associated with malnutrition and poor hygiene, it has become geographically limited in the past century, as it is now seen almost exclusively in Africa, the Middle East, and parts of South America. [32] Even in these regions, its incidence is dramatically declining. [33]

ETIOLOGY *T. schoenleinii* is the most common cause of human favus, with *T. violaceum* and *M. gypseum* occurring as rare isolates. [32] Although favus occurs in poultry, mice, and horses, there is only a single case report of human favus caused by an organism responsible for animal favus. [34]

CLINICAL MANIFESTATIONS Early favus (usually the first 3 weeks of infection) is characterized by patchy follicular erythema of the scalp with slight perifollicular scaling and mild matting of the hair. Progressive hyphal invasion distends the follicle, first producing a yellowish-red papule, then a yellow concave crust often centered about a single dull, dry hair (Fig. 205-9) that is less brittle than that of endothrix infections. The scutulum may reach 1 cm in diameter, engulfing surrounding hairs and coalescing with other scutula to form large adherent mats with an unpleasant cheese-like or musky odor. Over several years the lesions advance peripherally, leaving central, atrophic clearings of alopecia. [32] Atypical presentations occur in infected individuals with relatively good hygiene, and may include diffuse scaling with small or absent scutula. [35] Glabrous skin involvement may be papular, papulosquamous, or vesicular, with or without scutula. *T. schoenleinii* nail invasion is indistinguishable from other causes of onychomycosis.

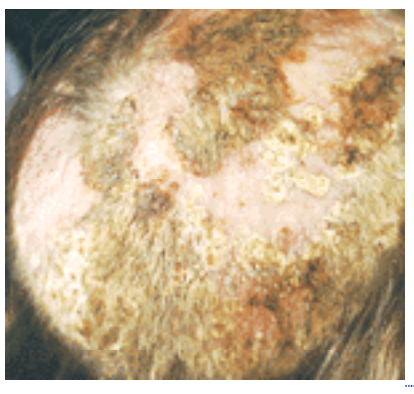

FIGURE 205-9 Favus caused by *T. schoenleinii.* Note the numerous yellow scutula.

LABORATORY FINDINGS *T. schoenleinii* exhibits subtle grayish green fluorescence along the entire hair with Wood lamp examination. Microscopy with KOH preparation reveals hyphae arranged lengthwise around and within the hair

shaft, rare arthroconidia, and vacant air spaces (Fig. 205-3). [32]
PATHOLOGY Hyphae are present in the stratum corneum, inside scutula, and inside and around hairs. The scutula also contain sebum and keratinaceous debris, and lie atop an atrophic epidermis. Acanthosis is often present near the margins of the lesion. In the dermis, particularly beneath scutula, are plasma cell or granulomatous perifollicular infiltrates. Advanced disease may exhibit fibrosis with diminished infiltrates. [36]
DIFFERENTIAL DIAGNOSIS Atypical and early favus may be difficult to distinguish from seborrheic dermatitis, psoriasis, or tinea amiantacea. With the development of cicatricial alopecia, favus must be differentiated from radiation or chemical injury, pseudopelade, folliculitis decalvans, lupus erythematosus, and lichen planopilaris.
TREATMENT Griseofulvin (1 g/day of the microcrystalline form or 0.5 g/day of the ultramicrosize version) is effective in the treatment of favus. Concomitant nail infection, however, requires 6 to 12 months of therapy. Also beneficial are local débridement of crust, improved hygiene, and simultaneous treatment of infected family members. [32] Finally, because epilated hairs may carry viable *T. schoenleinii* for years, their removal from the environment is imperative for controlling transmission. [37]

Tinea Barbae

Tinea barbae (tinea sycosis, barber's itch) is a dermatophytosis of the facial terminal hair of men. Dermatophytosis of the same area in females or prepubertal males involves glabrous skin and is termed tinea faciale.

EPIDEMIOLOGY Tinea barbae is by definition seen only in males. Largely transmitted by contaminated barbers' razors in the past, improved sanitation has reduced its incidence. As a result, tinea barbae is now often contracted by direct exposure to cattle, horses, or dogs, and is thus most commonly seen in rural settings on farmers or ranchers.
ETIOLOGY Tinea barbae is most commonly caused by the zoophilic organisms *T. mentagrophytes* and *T. verrucosum,* and, uncommonly, *M. canis*. Among the anthropophilic organisms, *T. megninii, T. schoenleinii,* and *T. violaceum* may cause tinea barbae in endemic areas, while *T. rubrum* is an infrequent cause. [32]
CLINICAL MANIFESTATIONS Tinea barbae is typically unilateral and more often involves the beard area than the moustache or upper lip. Three forms exist: (1) inflammatory or kerion-like, (2) superficial or sycosiform type, and (3) the circinate, spreading type.
Inflammatory type Usually caused by *T. mentagrophytes* and *T. verrucosum,* inflammatory tinea barbae (Fig. 205-10A) is analogous to kerion formation in tinea capitis. The lesions are nodular and boggy with a crusting seropurulent discharge. [38] Hairs in this area are lusterless, brittle, and easily epilated to demonstrate a purulent mass about the root. Perifollicular pustulation may coalesce to form sinus tracts and abscess-like collections of pus, eventuating in a scarring alopecia. [32]

FIGURE 205-10 *A*. Tinea barbae, kerion. Sharply demarcated red nodule studded with multiple yellowish pustules. The surface is edematous and weeping. *B*. Superficial tinea barbae. Diffuse erythema with scattered follicular papules and pustules.

Superficial type Caused by the less inflammatory anthropophiles, this form of tinea barbae closely resembles bacterial folliculitis, with diffuse erythema and perifollicular papules and pustules (Fig. 205-10B). Hairs that are dull and brittle make endothrix infection with *T. violaceum* a more likely etiology than *T. rubrum*.
Circinate type Much like tinea circinata of glabrous skin, circinate tinea barbae exhibits an active, spreading vesiculopustular border with central scaling and relative sparing of the hair. [38]
PATHOLOGY Histopathologic findings are similar to those seen with tinea capitis. Fungi may be demonstrated in both the hair and stratum corneum, but not in the dermis. A chronic inflammatory response is seen perifollicularly, often with a neutrophilic infiltrate within the follicle. Extremely inflammatory lesions reveal minimal to no fungi. [22]
DIFFERENTIAL DIAGNOSIS Other diagnoses to consider with tinea barbae include bacterial folliculitis (sycosis vulgaris), perioral dermatitis, candidal folliculitis, pseudofolliculitis barbae, acneiform dermatitis, contact dermatitis, halogenoderma, and herpes simplex. Bacterial folliculitis is more often bilateral, more painful, and more commonly involves the upper lip. [32] History, patch testing, Tzanck smears, or viral cultures can identify the other diagnoses.
TREATMENT Microsize griseofulvin at 1g daily until 2 to 3 weeks after clinical resolution is recommended for tinea barbae, particularly chronic cases. However, inflammatory *T. verrucosum, T. mentagrophytes,* and *M. canis* infections usually resolve without treatment in 2 to 4 weeks. [32] Adjunct measures include topical antifungals, warm compresses, shaving, and débridement of crusted discharge. Systemic glucocorticoids are helpful for symptoms of severe inflammatory lesions. [38] No data beyond case reports exist for the other systemic antifungals.

Tinea Corporis (Tinea Circinata)

Tinea corporis refers to all dermatophytoses of glabrous skin except the palms, soles, and groin.

EPIDEMIOLOGY Tinea corporis may be transmitted directly from infected humans or animals, via fomites, or via autoinoculation from reservoirs such as *T. rubrum* colonization of the feet. [1] Children are more likely to contract zoophilic pathogens, especially *M. canis* from dogs or cats. Occlusive clothing and a warm, humid climate are associated with more frequent and severe eruptions. [39] The occlusive clothing, frequent skin-to-skin contact, and minor trauma (mat burns) of competitive wrestling create an environment in which dermatophytes flourish. Numerous outbreaks of "tinea corporis gladiatorum" have resulted, mostly caused by *T. tonsurans*. [40] Preliminary evidence suggests a high prevalence of disease even in the absence of an epidemic. [41] Tinea imbricata, caused by *T. concentricum,* is largely limited to areas of the Far East, South Pacific, and South and Central America, and is more prevalent in natives than resident nonnatives. Explanations for this observation include the necessity to acquire chronic infection in early childhood [42] and genetic susceptibility (see above).

ETIOLOGY Although any dermatophyte can cause tinea corporis, the most common causes are *T. mentagrophytes, T. rubrum,* and *M. canis.* [4] *T. rubrum* and *T. verrucosum* are the most likely candidates in cases with additional follicular involvement. [38]

CLINICAL MANIFESTATIONS Table 205-4 presents the many variants of tinea corporis. The classic presentation is an annular lesion with scale across the entire erythematous border. The border is often vesicular (Fig. 205-11) and advances centrifugally. The center of the lesion is usually scaly, but may exhibit clearing. Concentric vesicular rings suggest tinea incognito caused by *T. rubrum,* whereas the concentric rings of tinea imbricata demonstrate little to no vesiculation. [1] *T. rubrum* infections may also present as large, confluent polycyclic or psoriasiform plaques (Fig. 205-12).



TABLE 205-4 **Variants of Tinea Corporis**

FIGURE 205-11 Tinea corporis with typical "ringworm-like" configuration.

FIGURE 205-12 Polycyclic pattern of tinea corporis.

LABORATORY FINDINGS Any erythematous, scaly eruption should be scraped for KOH examination. Obtaining scales by scraping outward from the active border maximizes sensitivity, while vesicles and bullae harbor the most organisms in their roofs. Because of the high rate of false-negative KOH preparations, fungal culture of scrapings is often necessary for diagnosis. However, in cases with dermal granulomata, culturing biopsy material produces the highest yield.

PATHOLOGY PAS stains of typical tinea circinata reveal red hyphae within the stratum corneum (Fig. 205-13). Hyphae are basophilic with hematoxylin and eosin, and stain black with methenamine silver. If organisms are absent, the histopathology is nonspecific and resembles an acute or chronic dermatitis with or without spongiotic vesiculation. The nodular perifolliculitis variant, caused by *T. rubrum,* displays a perifollicular granulomatous reaction commonly accompanied by central necrosis and suppuration. Organisms are present in the hairs and dermis, and large spores (6 µm) may be found within multinucleated giant cells. [22]

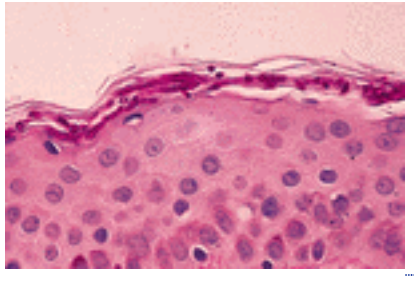

FIGURE 205-13 PAS stain of dermatophyte in stratum corneum. (*Courtesy of Sonia Toussaint, MD.*)

DIFFERENTIAL DIAGNOSIS The differential diagnosis of annular tinea corporis includes erythema annulare centrifugum, nummular eczema, and granuloma annulare. Erythema annulare centrifugum is distinguished by scale at the

trailing edge of the advancing border instead of over the entire border. Nummular eczema tends to produce more numerous and symmetric lesions than tinea corporis, and lacks central clearing. Granuloma annulare consists of intradermal papules without scale. A papulosquamous lesion of tinea corporis may resemble psoriasis, lichen planus, secondary syphilis, seborrheic dermatitis, pityriasis rosea, or pityriasis rubra pilaris. These are usually readily differentiated by their unique clinical features, otherwise a biopsy is diagnostic. Tinea faciei often lacks a distinct raised scaly border, and may mimic a photodermatosis such as lupus erythematosus or dermatomyositis. [43] However, most tinea faciei lack the follicular plugging and poikiloderma of connective tissue diseases. Other photodermatoses to consider include polymorphous light eruption, contact dermatitis, and acne rosacea. For inflammatory variants of tinea corporis, other infectious processes such as bacterial, candidal, or deep fungal infections should be considered. Verrucous and granulomatous lesions can resemble mycobacterial infections or blastomycosis.
TREATMENT For isolated lesions of tinea corporis, topical agents such as the allylamines, imidazoles, tolnaftate, butenafine, or ciclopirox are effective. Most are applied twice daily for 2 to 4 weeks. Oral antifungals are reserved for widespread or more inflammatory lesions. Comparative studies in adults show fluconazole 150 mg weekly for 4 to 6 weeks, itraconazole 100 mg daily for 15 days, and terbinafine 250 mg daily for 2 weeks to be as effective as griseofulvin 500 mg daily for 2 to 6 weeks, with no significant differences in adverse events. [44] Safe and effective regimens for children include ultramicrosize griseofulvin 10 to 20 mg/kg per day for up to 6 weeks, itraconazole 5 mg/kg per day for 1 week, [45] and terbinafine 3 to 6 mg/kg daily for 2 weeks.

Tinea Cruris

Tinea cruris is a dermatophytosis of the groin, genitalia, pubic area, perineal, and perianal skin.

EPIDEMIOLOGY Much like tinea corporis, tinea cruris spreads via direct contact or fomites, and is exacerbated by occlusion and warm, moist climates. Again, autoinfection from distant reservoirs such as tinea pedis caused by *T. rubrum* or *T. mentagrophytes* is common. [1]
ETIOLOGY Most tinea cruris is caused by *T. rubrum, T. mentagrophytes,* and *E. floccosum,* with the latter being most often responsible for epidemics. [32]
CLINICAL MANIFESTATIONS Tinea cruris usually appears as multiple erythematous papulovesicles with a well-marginated, raised border. Pruritus is common, as is pain with maceration or secondary infection. *E. floccosum* tinea cruris is more likely to display central clearing, and is most often limited to the genitocrural crease and the medial upper thigh. In contrast, *T. rubrum* infections are often coalescent with extension to the pubic, perianal, buttock and lower abdominal areas (Fig. 205-14). The genitalia are typically unaffected. [32] Common secondary changes include lichenification caused by chronic scratching or weeping, maceration, and pustulation caused by bacterial superinfection. Finally, many topical treatments may complicate the presentation by causing an allergic or irritant contact dermatitis.

FIGURE 205-14 Tinea cruris. Scaling erythematous plaque with sharp margins.

LABORATORY FINDINGS KOH examination of infected scales reveals septate hyphae. Culture on SDA with antibiotics and incubation at room temperature will reveal growth within 2 to 4 weeks.
PATHOLOGY The histologic findings are identical to those of tinea corporis.
DIFFERENTIAL DIAGNOSIS Similar-appearing diseases with crural involvement include psoriasis, seborrheic dermatitis, candidiasis, erythrasma, lichen simplex chronicus, familial benign pemphigus, and Darier-White disease. Candidiasis displays satellite pustules, peripheral to brightly erythematous plaques and it more often involves the scrotum. Erythrasma fluoresces coral red under Wood lamp, unlike tinea cruris. If KOH and fungal culture are unrevealing, biopsy may be necessary to exclude the other diagnoses.
TREATMENT Most tinea cruris is successfully treated with the topical antifungals used for tinea corporis, preferably as a powder or cream. Minimizing occlusion and moisture in the area are also helpful. As with tinea corporis, oral antifungals are reserved for refractory, widespread, or more inflammatory lesions. Safe and effective treatment for adults includes fluconazole 150 mg weekly for 4 to 6 weeks, itraconazole 100 mg daily for 15 days, terbinafine 250 mg daily for 2 weeks, and griseofulvin 500 mg daily for 2 to 6 weeks. [44] Safe and effective regimens for children include ultramicrosized griseofulvin, 10 to 20 mg/kg per day for up to 6 weeks, itraconazole, 5 mg/kg per day for 1 week, [45] and terbinafine, 3 to 6 mg/kg per day for 2 weeks.

Tinea Pedis and Tinea Mannum

Tinea pedis is a dermatophytosis of the feet, whereas tinea manuum affects the palmar and interdigital areas of the hand.

EPIDEMIOLOGY Present worldwide, tinea pedis and tinea manuum are the most common dermatophytoses. Tinea pedis has risen from obscurity prior to the twentieth century to a prevalence of approximately 10 percent today primarily as a result of modern occlusive footwear, although increased worldwide travel has also been implicated. [32] The incidence of tinea pedis is higher among those using communal baths, showers, or pools. Whether this is caused by increased maceration or increased transmission remains unclear. [46] Tinea manuum may be acquired by direct contact with an infected person or animal, the soil, or autoinoculation from a distant site. [47] However, it is nearly always associated with tinea pedis [32] and has been shown to occur most commonly following tinea pedis in the hand used to excoriate the feet. [48] Manual labor and preexisting inflammatory conditions of the hand are additional risk factors. [47] Both tinea pedis and tinea

manuum are exacerbated by hyperhidrosis, tropical climates, and any anatomic abnormality leading to closed web spaces.

ETIOLOGY Tinea pedis and tinea manuum are caused predominantly by *T. rubrum, T. mentagrophytes* var. *interdigitale,* and *E. floccosum*.

CLINICAL MANIFESTATIONS Tinea pedis may present as any of four forms, or a combination thereof.

Chronic intertriginous type The most common presentation of tinea pedis, the chronic intertriginous type, begins as scaling, erosion, and erythema of the interdigital and subdigital skin of the feet, particularly between the lateral three toes. Under appropriate conditions, the infection will spread to the adjacent sole or instep, rarely involving the dorsum. [32] This pattern is produced by fungal infection alone and has been termed *dermatophytosis simplex*. Occlusion and bacterial coinfection soon produce the interdigital maceration, pruritus, and malodor of *dermatophytosis complex* (Fig. 205-15), or “athlete's foot.” [49]

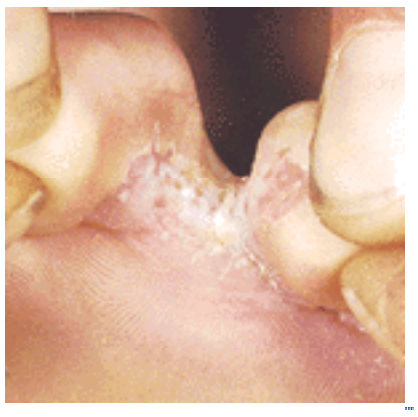

FIGURE 205-15 Tinea pedis, interdigital. The area is macerated and has opaque white scales and some erosions.

Chronic hyperkeratotic type Usually bilateral with patchy or diffuse scaling limited to the thick skin of the feet, this is also known as “moccasin-type” tinea pedis (Fig. 205-16). *T. rubrum,* the most common etiology, produces very few minute vesicles, leaving collarettes of scale less than 2 mm in diameter. Erythema is variable. [1] Unilateral tinea manuum commonly occurs in association with hyperkeratotic tinea pedis, resulting in the “two feet–one hand syndrome” (Fig. 205-17). Oral antifungals are often required for treatment due to the high incidence of concomitant onychomycosis and relapse. [50]

FIGURE 205-16 Tinea pedis. Superficial white scales in a moccasin-type distribution. Note arciform pattern of the scales, which is characteristic.

FIGURE 205-17 “One hand, two feet” presentation of *T. rubrum*.

Vesiculobullous type This form, typically caused by *T. mentagrophytes* var. *interdigitale,* features tense vesicles greater than 3 mm in diameter, vesiculopustules, or bullae on the thin skin of the sole and periplantar areas. Remissions and relapses occur with fluctuations in exposure of the feet to heat and humidity.

Acute ulcerative type Rampant bacterial coinfection, most often from gram-negatives in combination with *T. mentagrophytes* var. *interdigitale,* produces vesiculopustules and large areas of purulent ulceration on the plantar surface. Cellulitis, lymphangiitis, lymphadenopathy, and fever are frequently associated. The vesiculobullous and acute ulcerative types commonly produce a vesicular id reaction, either as a dyshydrotic-like distribution on the hands or on the lateral foot or toes. The vesicles are by definition KOH and culture negative. Tinea manuum (Fig. 205-18) predominantly presents as the hyperkeratotic type, although crescentic, exfoliating, vesicular, folliculopapular, and dorsal erythematous forms are also described. [32]

FIGURE 205-18 Tinea manus. Polycyclic pattern of an eruption composed of scaling vesicles with involvement of the thumb nail; the nail exhibits destruction of the nail plate.

LABORATORY FINDINGS KOH examination of scales reveals septate, branching hyphae. For vesiculobullous lesions, examination of the roofs yields the highest rate of positivity. Fungal cultures should be performed on SDA with cycloheximide and chloramphenicol.
PATHOLOGY Histologically, hyperkeratotic tinea pedis or tinea manuum is characterized by acanthosis, hyperkeratosis, and a sparse, chronic superficial perivascular infiltrate in the dermis. Vesiculobullous forms display spongiosis, parakeratosis, and subcorneal or spongiotic intraepithelial vesiculation. With both types, foci of neutrophils are occasionally seen in the stratum corneum, as well as fungal organisms with PAS or methenamine silver staining.
DIFFERENTIAL DIAGNOSIS If KOH examination and fungal culture are negative, other considerations for interdigital disease include psoriasis, soft corns, bacterial coinfection, candidiasis, and erythrasma. The likelihood of candidal and bacterial infection increases with the severity of maceration, denudation, and pruritus. [51] Unlike tinea pedis, erythrasma fluoresces coral red under a Wood lamp. The hyperkeratotic type must be differentiated from psoriasis, hereditary or acquired keratodermas of the palms and soles, dyshydrosis, pityriasis rubra pilaris, and Reiter's syndrome. Contact dermatitis may also be considered, although it more commonly affects the dorsal foot than tinea pedis. Children are more likely to have peridigital dermatitis or atopic dermatitis. Vesiculobullous or vesiculopustular presentations may be confused with pustular psoriasis, palmoplantar pustulosis, and bacterial pyodermas.
PREVENTION AND TREATMENT Minimizing chronic moisture is important in preventing tinea pedis. This may be achieved through talcum powder, absorbent socks, nonocclusive shoes, and, occasionally, 20 to 25% aluminum chloride hexahydrate powder. Antifungal powders such as undecylenic acid and tolnaftate are also beneficial. [38] Mild interdigital tinea pedis without bacterial involvement can be treated topically with an allylamine, azole, ciclopirox, tolnaftate, or undecenoic acid. [52] Topical terbinafine for 1 week is 66 percent effective, [53] while the other topicals generally require 4 to 6 weeks of application. The newer oral antifungals have replaced griseofulvin as the treatments of choice for severe or refractory tinea pedis. The dosing schedule of terbinafine is 250 mg daily for 2 weeks. Effective regimens of itraconazole for adults are 200 mg twice daily for 1 week, 200 mg daily for 3 weeks, or 100 mg daily for 4 weeks, [44] while children should receive 5 mg/kg per day for 2 weeks. [45] Fluconazole 150 mg weekly for 3 to 4 weeks or 50 mg daily for 30 days is also effective. [44] Associated onychomycosis is common; if present, treatment of the onychomycosis is necessary to prevent recurrence of tinea pedis. Maceration, denudation, pruritus, and malodor obligate a search for bacterial coinfection by Gram stain and culture. Antibiotics should be started once bacterial infection is documented and chosen based on sensitivity studies. Adjunctive topical therapy such as 0.25% acetic acid for *Pseudomonas* and colorless Castellani's paint are also helpful. Finally, because vesiculobullous tinea pedis is the result of a T cell–mediated immune reaction, symptomatic relief with topical or systemic corticosteroids may be warranted during the beginning of antifungal treatment. [54]

ONYCHOMYCOSIS

Onychomycosis denotes any infection of the nail caused by dermatophyte fungi, nondermatophyte fungi, or yeasts. Tinea unguium, however, refers strictly to dermatophyte infection of the nail plate. The four clinical types of onychomycosis are: (1) distal subungual onychomycosis (DSO), (2) proximal subungual onychomycosis (PSO), (3) white superficial onychomycosis (WSO), and (4) candidal onychomycosis.

Epidemiology

Onychomycosis is a common infection, with a prevalence estimated at 2 to 18 percent worldwide and up to 48 percent incidence by age 70. [55] Higher rates of onychomycosis are associated with male gender, age, smoking, and peripheral arterial disease. [56] Finally, 30 percent of patients with dermatophytoses elsewhere also have tinea unguium. The dermatophytosis commonly begins as tinea pedis before extending to the nail bed, where eradication is more difficult. This site then serves as a reservoir for recurrent distal infections, particularly in the setting of a hot and humid environment created by occlusion or tropical climates. [1]

Etiology and Pathogenesis

The dermatophytes, especially *T. rubrum, T. mentagrophytes* var. *interdigitale, T. tonsurans,* and *E. floccosum,* cause the great majority of onychomycosis. Table 205-5 categorizes the most likely causative dermatophytes according to patterns of concurrent infection in other areas. [57]

Tinea unguium + tinea pedis and/or tinea corporis
T. rubrum
T. mentagrophytes var. *interdigitale*
E. floccosum
Tinea unguium + tinea capitis or favus
T. tonsurans
T. violaceum
T. megninii
T. schoenleinii
Tinea unguium + tinea imbricata
T. concentricum

TABLE 205-5 **Causative Organisms According to Anatomic Patterns of Infection**

Yeasts are the source of approximately 5 percent of onychomycosis, the majority of which is caused by *Candida albicans* and occurs in conjunction with chronic mucocutaneous candidiasis. The nondermatophyte molds *Acremonium, Aspergillus, Fusarium, Onychocola canadensis, Scopulariopsis brevicaulis,* and *Scytalidium dimidiatum* account for approximately 4 percent of onychomycosis. [55] The nondermatophyte molds appear to have a predilection for antecedently diseased or aged nails (Fig. 205-19). [38]

FIGURE 205-19 Onychomycosis can be caused by nondermatophyte fungi such as *Aspergillus niger*.

DSO may be caused by any of the organisms listed above, beginning with invasion of the stratum corneum of the hyponychium and distal nail bed. The infection then spreads proximally up the nail bed to the ventral nail plate. Hyperproliferation of the nail bed in response to the infection creates subungual hyperkeratosis, and progressive invasion of the nail plate results in an increasingly dystrophic nail. PSO results primarily from *T. rubrum* and *T. megninii* infection of the proximal nail fold, which then spreads to the proximal ventral nail plate. [58] *T. rubrum* causes PSO almost exclusively in those infected with HIV. [6] WSO is a direct invasion of the dorsal nail plate. Seen only on toenails, it is usually caused by *T. mentagrophytes,* although nondermatophyte molds such as *Aspergillus, Scopulariopsis,* and *Fusarium* are also known etiologies. *Candida* species invade via the hyponychial epithelium to affect the entire thickness of the nail plate. [58]

Clinical Manifestations

DSO (Fig. 205-20), the most common form, begins as a whitish to brownish-yellow opacification at the distal edge of the nail or near the lateral nail fold. As the infection progresses, subungual hyperkeratosis leads to onycholysis. Increasing invasion of the ventral nail plate makes it thick, discolored, and friable. The subungual debris also provides a site for secondary infection by bacteria, other molds, and yeasts.

FIGURE 205-20 Distal subungual onychomycosis.

Early PSO (Fig. 205-21) is evident as a white to beige opacity on the proximal nail plate that may gradually enlarge to affect the entire nail. WSO (Fig. 205-22) is recognized as white to dull yellow sharply bordered patches anywhere on the surface of the toenail. The affected areas are rough and friable, and may coalesce with time. Candidal onychomycosis is rare, affecting either the fingernails or toenails of those with chronic mucocutaneous candidiasis. These lesions resemble DSO as the nail may be thickened, rough, and opaque or darkened. Nailbed thickening also occurs and may be severe enough to create “pseudoclubbing.” [58] In contrast to DSO, a paronychial inflammatory response is often present, and subungual debris does not accumulate. [32]

FIGURE 205-21 Proximal subungual onychomycosis in a patient with AIDS; Kaposi's sarcoma is also seen on the fourth toe.

FIGURE 205-22 White superficial onychomycosis.

Laboratory Findings

Because onychomycosis is responsible for only 50 percent of dystrophic nails, laboratory diagnostic confirmation is often helpful prior to treatment with an oral antifungal. KOH examination, nail biopsy, and fungal culture on SDA (with and without antimicrobials) are most useful. However, microscopy is often negative even when there is a high clinical suspicion of onychomycosis, and nails with positive microscopy often yield negative cultures. As most false-negatives are caused by sampling error, the simplest measures to maximize yield are to maximize sample size and perform repeat collections. [59]

Finally, because of the difficulty in discerning pathogens from contaminants, the following guidelines should be followed: (1) if a dermatophyte is isolated on culture, it is a pathogen; (2) if a nondermatophyte mold or yeast is cultured, it is considered significant only if hyphae, spores, or yeast cells are seen on microscopic examination; and (3) confirmation of an infection by a nondermatophyte requires repeated isolation, classically defined as at least 5 of 20 inocula without concurrent isolation of a dermatophyte. [60]

Pathology

Hyphae are seen lying between the nail laminae parallel to the surface, with a predilection for the ventral nail and nail bed stratum corneum. [61] The epidermis may show spongiosis and focal parakeratosis and there is a minimal dermal inflammatory response. In WSO, the organisms are present superficially on the dorsal nail and display unique “perforating organs” and “eroding fronds.” Candidal onychomycosis displays invasion of pseudohyphae throughout the entire nail plate, adjacent cuticle, granular layer and stratum spinosum of the nail bed, and the hyponychial stratum corneum. [58]

Differential Diagnosis

A variety of disorders may cause nail changes similar to onychomycosis, including hand eczema, pachyonychia congenita, Darier's disease, Reiter's syndrome, lichen planus, exfoliative dermatitis, and Norwegian scabies. Neither the pitting produced by psoriasis nor the typically transverse ridges seen in the dystrophic nails of hand eczema are seen with fungal nail infections. Otherwise, most of the above disorders are differentiated by related skin findings and history. WSO must be distinguished from the acquired and congenital leukonychias. All leukonychia of the fingernails not WSO.

Treatment

The only effective topical agent for tinea unguium is ciclopirox (8% lacquer) applied daily for 48 weeks. When used for mild to moderate disease, it is 34 percent effective in achieving mycologic cure alone and 7 percent effective in achieving mycologic cure and clear nails. [62] Despite its poorer efficacy when compared to the newer oral antifungals, topical ciclopirox is more cost effective because of its relatively low cost. [63]

Oral antifungals may be used for refractory, severe, or nondermatophytic onychomycosis, or when a shorter treatment regimen is desired. Selecting an antifungal should be based primarily on the causative organism, potential adverse effects, and drug interactions. As potent inhibitors of cytochrome P450 3A4, the azole antifungals are contraindicated with drugs such as astemizole, terfenadine, lovastatin, simvastatin, triazolam, and midazolam. Baseline and interval testing of liver enzymes is prudent for each agent discussed below.

Terbinafine is fungicidal against dermatophytes, *Aspergillus,* and *Scopulariopsis,* but demonstrates variable activity against *Candida* species. A course of 250 mg daily for 6 weeks is effective for most fingernail infections, while a 12-week course is required for toenail infections. Most adverse effects are gastrointestinal, and cytochrome P450 interactions are

insignificant.

Itraconazole is fungistatic against dermatophytes, nondermatophyte molds, and yeasts. Safe and effective schedules include pulse dosing at 400 mg daily for 1 week per month or a continuous dose of 200 mg daily, both of which require 2 months of treatment for fingernails and 3 months for toenails. [55] Children may receive 5 mg/kg daily. [45] Elevated liver enzymes occur in 0.3 to 5 percent of patients, returning to normal within 12 weeks of discontinuation.

Fluconazole is fungistatic against dermatophytes, some nondermatophyte molds, and *Candida*. The usual dosage is 150 to 300 mg once per week for 3 to 12 months, although 450 mg weekly may be used in refractory onychomycosis. Adverse effects include gastrointestinal disturbance and elevated liver enzymes. [55]

Griseofulvin is no longer considered standard treatment for onychomycosis because of its adverse effects, drug interactions, prolonged treatment course, and low cure rates. Final options for refractory cases include surgical avulsion or chemical removal of the nail with 40% urea compounds in combination with topical or oral antifungals. [64]

TINEA NIGRA

Tinea nigra is a rare infection, usually of the palmar stratum corneum, caused by the nondermatophyte *Phaeoannellomyces werneckii* (formerly called *Exophiala werneckii*).

Epidemiology

Tinea nigra usually occurs in tropical or subtropical areas, including Central and South America, Africa, and Asia. Of the approximately 150 cases reported in North America since 1950, the majority were associated with tropical travel. [65] However, endemic foci exist in the coastal southeastern United States. Person-to-person transmission is rare. [66]

Etiology

Nearly always caused by *Phaeoannellomyces werneckii,* other dematiaceous fungi may produce the disease. *Stenella araguata,* for example, has been isolated from clinical tinea nigra. Such dematiaceous fungi are commonly found in soil, sewage, and decaying vegetation, [66] although *P. werneckii* was also recently isolated from the surfaces of rocks in the Mediterranean and Northern Europe. [67]

Clinical Manifestations

Tinea nigra presents as an asymptomatic, mottled brown to greenish-black macule with minimal to no scale (Fig. 205-23). The macule is often darkest at the advancing border. Although usually seen on the palm or ventral surface of the fingers, plantar involvement is possible.

FIGURE 205-23 Tinea nigra palmaris. An irregular, brownish-black macule on the palm caused by *P. werneckii*. (*Courtesy of Stuart Salasche, MD.*)

Laboratory Findings

KOH examination of scrapings from the lesion reveals brown to olive-colored hyphae and oval to spindle-shaped yeast cells occurring singly or in pairs with a central transverse septum. Cultures may be performed on SDA with cycloheximide and chloramphenicol. Growth is initially yeastlike and brown to shiny black, appearing as the typical two-celled yeast forms under microscopic examination. With time, mycelial growth predominates as aerial hyphae create a fuzzy grayish-black colony. Deeply pigmented, thick, septate hyphae 7 to 10 µm in diameter are seen microscopically.

Pathology

Skin biopsy shows brown, branching hyphae in the upper stratum corneum on hematoxylin and eosin stain. Hyperkeratosis is present without dermal inflammation.

Differential Diagnosis

Mistaking tinea nigra for a melanocytic lesion such as a junctional nevus or melanoma may lead to unnecessary biopsy. Pigmentation from Addison's disease, syphilis, pinta, or chemical exposure should also be considered. Tinea nigra is easily differentiated from all of these by KOH examination. *Scytalidium* may rarely produce a lesion similar to tinea nigra, but is usually associated with interdigital scaling, palmoplantar scaling, or onychomycosis. [68]

Treatment

Tinea nigra responds easily to topical therapy with a keratolytic (Whitfield's ointment, 2% salicylic acid), tincture of iodine, azole antifungal, or terbinafine. [65], [69] Treatment should be continued for 2 to 4 weeks after clinical resolution to prevent relapse. Oral agents are unnecessary and often ineffective. [66], [69]

PIEDRA

Piedra is an asymptomatic fungal infection of the hair shaft caused by *Piedraia hortae* (black piedra) and *Trichosporon beigelii* (white piedra).

Epidemiology

Black piedra is seen commonly in humans and primates of tropical areas such as South America, the Pacific Islands, and the Far East, and less commonly in Africa and Asia. Scalp hair is most commonly affected. Infestation is encouraged for religious and esthetic reasons by some indigenous cultures. [65]

White piedra is most common in the temperate climates of South America and Asia, and occurs infrequently in the United States and Europe. It affects facial, axillary, and genital hair more commonly than the scalp. [38] Person-to-person transmission is rare, and infection has not been associated with travel to endemic areas. [70] Found commonly in soil, air, and sputum, *T. beigelii* appears to be a ubiquitous fungus capable of producing white piedra only in situations of low hygiene. [65]

Clinical Manifestations

Black piedra is characterized by firmly attached, hard, brown-black nodules on the hair shaft that vary from microscopic to a few millimeters in size, and are gritty to palpation. [65] Black piedra weakens the hair shaft, often resulting in broken hairs.

White piedra consists of softer and less adherent whitish to beige nodules that may be discrete or coalesce into sleeve-like structures. Broken hairs are less common than with black piedra.

T. beigelii may also cause onychomycosis, [70] and is responsible for more than 100 cases of disseminated infection in immunocompromised hosts. [68] Cutaneous manifestations of dissemination may include erythematous or purpuric papules or papulovesicles. In these cases, *T. beigelii* may be cultured from the lesions and visualized in biopsy material. [71]

Laboratory Findings

Nodules of black piedra examined with KOH display a periphery of aligned hyphae and a well-organized center of thick-walled cells packed closely together, sometimes termed “pseudoparenchyma.” These nodules are mostly outside of the hair shaft. *P. hortae* grows well, albeit slowly, on most laboratory media. Colonies are dark-brown to black and glabrous initially, eventually developing aerial mycelia. Microscopy demonstrates septate hyphae, chlamydospores, and irregularly shaped hyphal elements. Most media result in asexual growth. The nodules of white piedra have a less organized and more intrapilar appearance than do the nodules of black piedra, with hyphae arranged perpendicularly to the hair shaft. [65] *T. beigelii* thrives on SDA without cycloheximide. Colonies are at first yeastlike and creamy, but develop radial convolutions with age. Microscopy reveals septate hyphae that easily fragment into 3 to 7 µm arthroconidia. Arthroconidia eventually become oval and exhibit budding.

Diagnosis

Microscopy immediately differentiates piedra from nits, hair casts, developmental hair shaft defects, and trichomycosis axillaris. In addition, the nodules of trichomycosis axillaris are usually smaller and may fluoresce under a Wood lamp.

Treatment

Shaving the infected hair is often curative but may be augmented by the use of a topical azole antifungal. Because of the high rate of relapse and evidence for intrafollicular organisms in white piedra, some authors suggest employing an additional systemic antifungal in this disease. [70]

REFERENCES

1. Rebell G, Zaias N: Session I—Introducing the syndromes of human dermatophytosis. *Cutis* **67**:6, 2001

2. Larone DH: *Medically Important Fungi: A Guide to Identification*. Washington, DC, ASM Press, 1995

3. Greer DL: An overview of common dermatophytes. *J Am Acad Dermatol* **31**:S112, 1994

4. Aly R: Ecology and epidemiology of dermatophyte infections. *J Am Acad Dermatol* **31**:S21, 1994

5. Rinaldi MG: Dermatophytosis: Epidemiological and microbiological update. *J Am Acad Dermatol* **43**:S120, 2000

6. Johnson RA: Dermatophyte infections in human immune deficiency virus disease. *J Am Acad Dermatol* **43**:S135, 2000

7. Ogawa H et al: Dermatophytes and host defence in cutaneous mycoses. *Med Mycol* **36**:S166, 1998

8. Jones HE: Immune response and host resistance of humans to dermatophyte infection. *J Am Acad Dermatol* **28**:S12, 1993

9. Grappel SF et al: Immunology of dermatophytes and dermatophytosis. *Bacteriol Rev* **38**:222, 1974

10. Dahl MV: Host defense: Fungus, in *Clinical Immunodermatology*. Chicago, Year Book, 1988, p 171

11. Calista D et al: Erythema nodosum induced by kerion celsi of the scalp. *Pediatr Dermatol* **18**:114, 2001

12. Frieden IJ, Howard R: Tinea capitis: Epidemiology, diagnosis, treatment, and control. *J Am Acad Dermatol* **31**:S42, 1994

13. Waisman M: Recurrent, fixed erysipelas-like dermatophytid. *Arch Dermatol* **53**:10, 1946

14. Jillson OF: Allergic confirmation that some cases of erythema annulare centrifugum are dermatophytids. *Arch Dermatol* **70**:355, 1954

15. Weary PE, Guerrant JL: Chronic urticaria in association with dermatophytosis: Response to the administration of griseofulvin. *Arch Dermatol* **95**:400, 1967

16. Martinez-Roig A et al: Erythema nodosum and kerion of the scalp. *Am J Dis Child* **136**:440, 1982

17. Elewski BE: Treatment of tinea capitis: Beyond griseofulvin. *J Am Acad Dermatol* **40**:S27, 1999

18. Howard R, Frieden IJ: Tinea capitis: New perspectives on an old disease. *Semin Dermatol* **14**:2, 1995

19. Frieden IJ: Tinea capitis: Asymptomatic carriage of infection. *Pediatr Infect Dis J* **18**:186, 1999

20. Elewski BE, editor: *Topics in Clinical Dermatology: Cutaneous Fungal Infections*. New York, Igaku-Shoin, 1992

21. Smith ML: Tinea capitis. *Pediatr Ann* **25**:101, 1996

22. Langley JB: Fungal diseases, in *Lever's Histopathology of the Skin,* 8th ed, edited by D Elder, R Elenitsas, C Jaworsky, B Johnson, Jr. Philadelphia, Lippincott, 1997, p 517

23. Imamura S et al: Use of immunofluorescent staining in kerion. *Arch Dermatol* **111**:906, 1975

24. Smith EB: The treatment of dermatophytosis: Safety considerations. *J Am Acad Dermatol* **43**:S113, 2000

25. Collins R et al: Fluconazole for the treatment of tinea capitis in children. *J Am Acad Dermatol* **37**:274, 1997

26. Gupta AK et al: Once weekly fluconazole is effective in children in the treatment of tinea capitis: a prospective, multicentre study. *Br J Dermatol* **142**:965, 2000

27. Lopez-Gomez S et al: Itraconazole versus griseofulvin in the treatment of tinea capitis: A double-blind randomized study in children. *Int J Dermatol* **33**:743, 1994

28. Mohrenschlager M et al: Optimizing the therapeutic approach in tinea capitis of childhood with itraconazole. *Br J Dermatol* **143**:1011, 2000

29. Fuller LC et al: A randomized comparison of 4 weeks of terbinafine vs. 8 weeks of griseofulvin for the treatment of tinea capitis. *Br J Dermatol* **144**:321, 2001

30. Honig PJ: Tinea capitis: Recommendations for school attendance. *Pediatr Infect Dis J* **18**:211, 1999

31. Khan KA, Anwar AA: Study of 73 cases of tinea capitis and tinea favosa in adults and adolescents. *J Invest Dermatol* **51**:474, 1968

32. Rippon JW: Dermatophytosis and dermatomycosis, in *Medical Mycology: The Pathogenic Fungi and the Pathogenic Actinomycetes,* 3d ed. Philadelphia Saunders, 1988, p 169

33. Gargoom AM et al: Tinea capitis in Benghazi, Libya. *Int J Dermatol* **39**:263, 2000

34. Garcia-Sanchez MS et al: Favus due to *Trichophyton mentagrophytes* var. *quinkeanum*. *Dermatology* **194**(2):177, 1997

35. Rook A, Dawber R: Infections and infestations, in *Diseases of the Hair and Scalp* 2d ed. Oxford, Blackwell, 1991, p 396

36. Graham JH, Barroso-Tobila C: Dermal pathology of superficial fungal infections, in *Human Infection with Fungi, Actinomycetes, and Algae,* edited by RD Baker et al. New York, Springer, 1971, p 211

37. Guirges SY: Viability of *Trichophyton schoenleinii* in epilated hairs. *Sabouraudia* **19**:155, 1981

38. DeLacerda MH, Caldeira JB, Delfino JP et al: Sycosis of the beard (tinea barbae). Analysis of 42 cases. *Med Cutan Ibero Lat Am* **9**:161, 1981.

39. Taplin D: Dermatophytosis in Vietnam. *Cutis* **67**:19, 2001

40. Kohl TD, Lisney M: Tinea gladiatorum: Wrestling's emerging foe. *Sports Med* **29**:439, 2000

41. Adams BB: Tinea corporis gladiatorum: A cross-sectional study. *J Am Acad Dermatol* **43**:1039, 2000

42. Hay RJ et al: Immune responses of patients with tinea imbricata. *Br J Dermatol* **108**:581, 1983

43. Shanon J, Raubitschek F: Tinea faciei simulating chronic discoid lupus erythematosus. *Arch Dermatol* **82**:268, 1960

44. Rand S: Overview: The treatment of dermatophytosis. *J Am Acad Dermatol* **43**:S104, 2000

45. Gupta AK et al: The use of itraconazole to treat cutaneous fungal infections in children. *Dermatology* **199**:248, 1999

46. Rosenthal SA: Tinea pedis isolates. *Cutis* **67**(5S):20, 2001

47. Richardson MD, Warnock DW: Dermatophytosis, in *Fungal Infection: Diagnosis and Management.* Oxford, Blackwell, 1997, p 59

48. Daniel, CR et al: Two feet–one hand syndrome: A retrospective multicenter survey. *Int J Dermatol* **36**:658, 1997

49. Leyden JJ: Progression of interdigital infections from simplex to complex. *J Am Acad Dermatol* **28**:S7, 1993

50. Seeburger J, Scher RK: Long-term remission of two feet–one hand syndrome. *Cutis* **61**:149, 1998

51. Zaias N: Tinea pedis interdigitalis (interspace). *Cutis* **67**(5S):28, 2001

52. Crawford F et al: Extracts from “clinical evidence”: Athlete's foot and fungally infected toenails. *BMJ* **322**:288, 2001

53. Lebwohl M et al: Efficacy and safety of terbinafine 1% solution in the treatment of interdigital tinea pedis and tinea corporis or tinea cruris. *Cutis* **67**:261, 2001

54. Leyden JJ: Tinea pedis pathophysiology and treatment. *J Am Acad Dermatol* **31**:S31, 1994

55. Scher RK: Onychomycosis: Therapeutic update. *J Am Acad Dermatol* **40**:S21, 1999

56. Gupta AK et al: The epidemiology of onychomycosis: Possible role of smoking and peripheral arterial disease. *J Eur Acad Dermatol Venereol* **14**:466, 2000

57. Midgely G et al: Mycology of nail disorders. *J Am Acad Dermatol* **31**:S68, 1994

58. Zaias N: Onychomycosis. *Arch Dermatol* **105**:263, 1972

59. Ellis DH: Diagnosis of onychomycosis made simple. *J Am Acad Dermatol* **40**:S3, 1999

60. English MP: Nails and fungi. *Br J Dermatol* **94**:697, 1976

61. Scher RK, Daniel CR: *Nails: Therapy, Diagnosis, Surgery,* 2d ed. Philadelphia, Saunders, 1997

62. Gupta AK, Joseph WS: Ciclopirox 8% nail lacquer in the treatment of onychomycosis of the toenails in the United States. *J Am Podiatr Med Assoc* **90**:495, 2000

63. Gupta AK: Pharmacoeconomic analysis of ciclopirox nail lacquer 8% and the new oral antifungal agents used to treat dermatophyte toe onychomycosis in the United States. *J Am Acad Dermatol* **43**:S81, 2000

64. Zaias N: Onychomycosis, in *The Nail: In Health and Disease*. New York, SP Medical & Scientific, 1980, p 91

65. Rippon JW: Superficial Infections, in *Medical Mycology: The Pathogenic Fungi and the Pathogenic Actinomycetes* 3d ed. Philadelphia, Saunders, 1988, p 154

66. Van Velsor H, Singletary H: Tinea nigra palmaris: A report of 15 cases from coastal North Carolina. *Arch Dermatol* **90**:59, 1964

67. Sterflinger K: Temperature and NaCl-tolerance of rock-inhabiting meristematic fungi. *Antonie Van Leeuwenhoek* **74**:271, 1998

68. Richardson MD, Warnock DW: Other cutaneous fungal infections, in *Fungal Infection: Diagnosis and Management*. Oxford, Blackwell, 1997, p 94

69. Shannon PL et al: Treatment of tinea nigra with terbinafine. *Cutis* **64**:199, 1999

70. Kalter DC et al: Genital white piedra: Epidemiology, microbiology, and therapy. *J Am Acad Dermatol* **14**:982, 1986

71. Manzella JP et al: *Trichosporon beigelli* fungemia and cutaneous dissemination. *Arch Dermatol* **118**:343, 1982

T>

Chapter 206

Alison Klenk Ann Martin Michael Heffernan

Yeast Infections: Candidiasis, Pityriasis (Tinea) Versicolor

CANDIDIASIS
Historical Aspects
Etiology
Pathogenesis
Immunology
Clinical Manifestations
Laboratory Findings
"PITYROSPORUM INFECTIONS" OF THE SKIN: PAPULOSQUAMOUS TINEA VERSICOLOR, "PITYROSPORUM" FOLLICULITIS, AND INVERSE TINEA VERSICOLOR
History
Etiology and Pathogenesis
Immunology
Clinical Features
Laboratory Findings
Pathology
Diagnosis
Treatment and Prognosis

REFERENCES

CANDIDIASIS

Candidiasis (or candidosis) indicates a diverse group of infections caused by *Candida albicans* or by other members of the genus *Candida*. These organisms typically infect the skin, nails, mucous membranes, and gastrointestinal tract, but they also may infect internal organs and cause systemic disease.

Historical Aspects

Initially classified as a *Sporotrichum* by Gruby, the organism was placed in the genus *Oidium* (*O. albicans*) by Robin in 1847. Later, it was confused with *Monilia candida,* a fungus isolated from rotting vegetation. The name *Monilia* was stubbornly defended by Castellani and accounts for the term *moniliasis* being used as a synonym for candidiasis in the literature. This term is a misnomer and actually refers to the imperfect stage of certain ascomycetes; it has no relationship to the genus *Candida*. Controversy persists over the nomenclature of *Candida* infections. In the United States, *candidiasis* is the accepted term, although *candidosis* is preferred in Canada, the United Kingdom, France, and Italy.

In 1853, Robin first described systemic candidiasis, whereas cutaneous and chronic mucocutaneous candidiasis were described in 1907 and 1909, respectively. In 1877, Grawitz described the dimorphic nature of the organism. The genus *Candida* was established in 1923, and Martin subsequently classified several species of yeast within this genus. In the antibiotic era of the 1940s, candidiasis was first reported as an opportunistic infection.

Etiology

The genus *Candida* is a heterogeneous group of approximately 150 yeast species. [1] Many species of *Candida* are opportunistic human pathogens, although the majority do not infect humans. *C. albicans* is a dimorphic yeast that is responsible for 70 to 80 percent of all candidal infections, which makes it the most common cause of superficial and systemic candidiasis. [2] All species within the genus *Candida* share the ability to produce pseudomycelia, with the exception of *C. glabrata* (Fig. 206-1). *Candida* do not possess morphologic or biochemical characteristics that would classify them in the genera of imperfect yeast, nor do they produce ascospores or telospores. Other species of *Candida* produce clinical disease under certain circumstances, such as immunosuppression, prolonged hospitalization, and previous antibiotic use. [2], [3] These infections may be systemic or localized (Table 206-1). Recent epidemiologic studies indicate that the relative prevalence of *C. albicans* in clinical isolates is declining, with other species such as *C. glabrata, C. tropicalis, C. krusei,* [2] *C. dubliniensis,* [4] and *C. parapsilosis* [5] emerging as pathogens. The different species of *Candida* can be identified in the laboratory by Delft auxanography, substrate fermentation tests, and microscopic examination of yeast morphology. In addition, polymerase chain reaction (PCR) assays and other molecular techniques for species differentiation are becoming more readily available. [6]

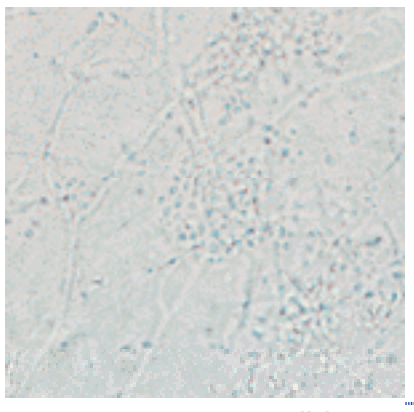

FIGURE 206-1 *Candida* in potassium hydroxide preparation. Pseudomycelia in clusters of grapelike yeast cells.

C. parapsilosis	Paronychia, endocarditis, otitis externa, systemic disease, vaginitis
C. tropicalis	Vaginitis; intestinal, bronchopulmonary, and systemic infections; onychomycosis; bone and joint disease; central nervous system disease
C. stellatoidea	Vaginitis, systemic disease, bone and joint disease
C. guilliermondii	Endocarditis, cutaneous candidiasis, onychomycosis, bone and joint disease
C. krusei	Vaginitis, urethritis
C. glabrata	Esophagitis, vaginitis, endocarditis
C. krusei	Endocarditis, vaginitis
C. zeylanoides	Onychomycosis
C. viswanathii	Central nervous system disease
C. lusitaniae	Systemic disease
C. dubliensis	Oral candidiasis, systemic disease, joint disease

TABLE 206-1 **Candidal Isolates Other than** *C. albicans*

Pathogenesis

C. albicans is often found as a saprophyte and colonizes the mucous membranes of warm-blooded animals. In up to 50 percent of normal individuals, the oropharynx is colonized. [3] In addition, *C. albicans* exists as a commensal organism in the vaginal mucosa of 20 to 25 percent of asymptomatic, healthy women. [7] The yeast is rarely isolated from normal human skin except occasionally from intertriginous areas. Likewise, the organism is seldom found in soil, vegetation, or air samples.

Predisposing factors to *Candida* infection include local skin conditions, nutritional status, altered physiologic states, systemic illness, and iatrogenic causes, as outlined in Table 206-2.

Mechanical factors
Trauma (burns, abrasions)
Occlusion, moisture, and/or maceration
Dentures
Occlusive dressings or garments
Obesity
Nutritional factors
Anhelmintosis
Iron deficiency (chronic mucocutaneous candidiasis)
Generalized malnutrition
Physiologic alterations
Extremes of age
Pregnancy
Menses
Systemic illnesses
Down syndrome
Acrodermatitis enteropathica
Endocrine disease
Diabetes mellitus
Cushing's disease
Hypoadrenalism
Hypothyroidism
Hypoparathyroidism
Uremia
Malignancy (especially hematologic, thymoma)
Immunodeficiency
AIDS
Severe combined immunodeficiency syndrome
Myeloperoxidase deficiency
Chediak-Higashi syndrome
Hyperimmunoglobulinemia E syndrome
Chronic granulomatous disease
DiGeorge syndrome
Nezelof syndrome
Iatrogenic causes
Indwelling catheters and intravenous lines
X-irradiation
Medications
Glucocorticoids
Other immunosuppressive agents
Antibiotics (especially broad-spectrum, extremidazole)
Tranquilizers
Oral contraceptives (especially estrogen-dominant)
Colchicine
Phenylbutazone

TABLE 206-2 **Factors Predisposing to** *Candida* Infections

As a dimorphic fungus, *Candida* has the ability to transform from a budding yeast phase to an invasive mycelial growth phase, which is necessary for tissue infection. Initiation of infection is aided by adherence of the organism to epithelial cells and subsequent invasion into the tissue. [8] Tissue invasion occurs by elaboration of keratinolytic enzymes, phospholipases, or strain-specific proteolytic enzymes. Histopathologically, a clear space is seen around the organisms, suggesting an ongoing process of epithelial tissue lysis. In recent years, investigators have identified multiple virulence genes that mediate tissue adherence and invasion of *Candida* species. [8], [9]

An experimental animal model demonstrates the ability of *Candida* to cause infections of the skin and mucous membranes. [10] Using the staphylococcal toxin epidermolysin to cleave the epidermis selectively below the granular layer, Ray et al. [11] showed that only *C. albicans* and *C. stellatoidea* inoculated into this cleft were capable of invading the stratum corneum and eliciting inflammation. Other species were incapable even under occlusive experimental conditions.

Maibach and Kligman's experiments in human cutaneous candidiasis also demonstrated differences in virulence among *Candida* species. [12] These investigators noted that the cutaneous inoculation of *C. albicans* could produce disease only if the site of inoculation was occluded. Within 36 to 72 h, typical subcorneal, erythematous pustules developed. The severity of the infection was proportional to the size of the inoculum. [13] Staining showed organisms in the stratum corneum but not in the pustules. Cutaneous lesions were produced using a sterile extract of disintegrated candidal cells and a sediment of killed ruptured cells. The authors postulated the existence of an endotoxin-like substance that mediated the pustular response. [12] These experiments provided initial evidence for the host inflammatory response to

Candida infection.

Immunology

The host response to *Candida* infection includes local skin and mucosal defenses as well as the systemic immune response. Local factors include (1) integrity of the stratum corneum, (2) competing microbial flora, (3) epidermal proliferation and skin desquamation due to inflammation, and (4) direct epithelial cell inhibition of yeast growth. [14] Normal skin, with its constant sloughing and regeneration, provides an effective barrier against *Candida*. Skin-surface lipids are partially inhibitory as well. Damage to this barrier by mechanical means or occlusion facilitates infection. The host microbial flora compete with *Candida* for nutrients and epithelial adherence sites and produce by-products toxic to the yeast. As with cutaneous dermatophyte infections, the skin increases its turnover rate significantly during the early stages of infection, which helps shed the organism. [15] Recent in vitro studies have shown that vaginal [16]) and oral [14] epithelial cells inhibit the growth of *Candida,* likely by a mechanism involving direct contact between the yeast and epithelial cell membrane proteins.

The systemic immune response to *Candida* involves both humoral and cell-mediated immunity. In addition, polymorphonuclear leukocytes (PMNs) and macrophages phagocytize and kill yeast. Cell-mediated immunity contributes more to host defense against mucosal *Candida* infection than humoral immunity. [7] In mucocutaneous candidiasis and HIV infection, a defect in cell-mediated immunity may lead to extensive superficial candidiasis despite normal humoral defenses. Serum antibody production to the principal candidal cell-wall glycoprotein antigens occurs in low titers in normal individuals due to colonization of the gastrointestinal tract early in life. [17] However, patients with B cell deficiency states, such as X-linked agammaglobulinemia or severe hypogammaglobulinemia, are not at increased risk for candidal infections. [18]

Numerous immunologic defects are associated with chronic mucocutaneous candidiasis (CMC), although 25 to 35 percent of patients with CMC have no specific immunologic defect. [19] CMC usually involves abnormalities in cell-mediated immunity (CMI), whereas humoral immunity is largely intact. Table 206-3 contains a list of some of the commonly described immunologic abnormalities in patients with CMC. In some cases, the observed immunologic defect is reversed after successful antifungal therapy. This suggests that a massive antigenic load (particularly mannan) may interfere with CMI—perhaps by the generation of specific T-suppressor cells. [20]

1. Complete anergy to common skin test antigens or selective unresponsiveness to *C. albicans* antigen. This group can be further divided based on in vitro lymphocyte transformation and lymphokine production studies to Candida.
   a. Lymphocyte transformation negative and lymphokine production positive
   b. Lymphocyte transformation positive and lymphokine production negative
   c. Both lymphocyte transformation and lymphokine production negative
2. Selective IgA deficiency
3. Plasma inhibitor to lymphocyte transformation by *C. albicans*
4. Serum inhibitor of polymorphonuclear leukocyte chemotaxis and killing of *C. albicans*
5. Abnormal monocyte chemotactic and killing responses
6. Combined abnormality of monocyte mobility and phagocytosis killing
7. Abnormal complement function
8. Abnormal macrophage function
9. Hyperimmunoglobulinemia E and impaired granulocyte chemotaxis
10. Defective suppressor T cell function
11. Defective mannan handling by monocytes
12. Impaired generation of helper T cells

TABLE 206-3 **Immunologic Abnormalities in Chronic Mucocutaneous Candidiasis**

Phagocytosis of yeast organisms is accomplished primarily by PMNs and macrophages after opsonization by the classical or alternative complement pathway. [3] Patients with neutropenia or diseases affecting PMN function (see Table 206-3) are particularly susceptible to candidal infections. In addition, histologic studies show that the PMN is the predominant early inflammatory cell in candidal infections. [17]

Ray et al. [21] demonstrated that a purified mannan cell wall polysaccharide from *C. albicans* exhibits endotoxin-like activity in vitro and is capable of activating complement via the alternative pathway. The generation of factors such as C5a induces neutrophil chemotaxis. The contribution of complement activation to host defense against *Candida* has been demonstrated in rodents that have been complement-depleted (using cobra venom factor) and in hereditary C5-deficient animals. In this setting, experimentally induced candidal infections do not elicit a neutrophil response. The organism invades more rapidly and extensively in these animals than in controls. [10], [22] Both PMNs and macrophages have C3b surface receptors, and the deposition of C3b opsonins on *Candida* organisms therefore may facilitate phagocytosis. [23], [24] Macrophages also exhibit opsonin-independent phagocytosis, perhaps mediated by the mannose receptor on their cell surfaces. [18] Ultimately, PMNs and macrophages accomplish intracellular killing by both the oxidative pathway of myeloperoxide oxidase–halide–hyperoxide and nonoxidative means. [18], [25]

Clinical Manifestations

The cutaneous and mucosal manifestations of candidiasis can be divided into several distinct clinical syndromes.

ORAL CANDIDIASIS Acute pseudomembranous candidiasis or thrush is the most common form of oral candidiasis. Predisposing factors include diabetes mellitus, systemic steroids, antibiotic use, pernicious anemia, malignancies, and cell-mediated immunodeficiency [3], [27] (see Table 206-2). Up to one-third of patients infected with HIV develop oral candidiasis, and over 90 percent of patients with AIDS develop oral candidiasis over the course of their disease. [26] Oral candidiasis appears as discrete white patches that may become confluent on the buccal mucosa, tongue, palate, and gingivae (Fig. 206-2A). This friable pseudomembrane resembles milk curds and consists of desquamated epithelial cells, fungal elements, inflammatory cells, and food debris. Scraping the patches exposes a brightly erythematous

surface underneath. Microscopic examination of this material reveals masses of tangled pseudohyphae and blastospores (see Fig. 206-1). In severe cases, the mucosal surface may ulcerate. Typical oral thrush is characteristic, but the atrophic or ulcerative forms of oral candidiasis can be confused with mucositis due to chemotherapeutic drugs, herpetic infections, erythema multiforme, pemphigus, lichen planus, discoid lupus erythematosus, pernicious anemia, histoplasmosis, leukoplakia, secondary syphilis, or aspirin burn.

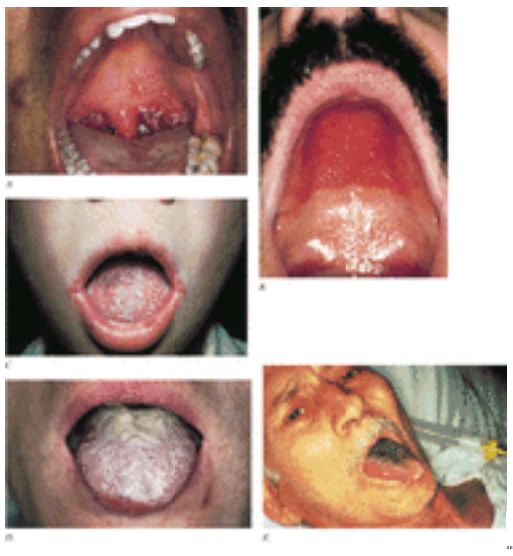

FIGURE 206-2 *A.* Pseudomembranous candidiasis or thrush. Note the characteristic white patches on the palate. *B.* Atrophic candidiasis under dentures. *C. Candida* perlèche with erythema and fissuring at the corners of the mouth. *D.* Hyperplastic candidiasis of the tongue. *E.* Black hairy tongue is characterized by pigmented hypertrophied filiform papillae of the dorsum of the tongue and is usually associated with oral antibiotic therapy.

Acute atrophic candidiasis (erythematous candidiasis) commonly occurs after sloughing of the thrush pseudomembrane. [27] This condition is associated with broad-spectrum antibiotics, glucocorticoids, and HIV. [3] The most common location is on the dorsal surface of the tongue, where there are patchy depapillated areas with minimal pseudomembrane formation. Chronic atrophic candidiasis (denture stomatitis) (see Fig. 206-2B) is a common form of oral candidiasis. Female patients are affected more commonly than males. Clinical findings of chronic erythema and edema of the palatal mucosa that contacts the dentures as well as angular cheilitis are present. Presumably, the chronic low-grade trauma and occlusion provided by dentures predispose to candidal colonization and subsequent infection. [28] Candidal cheilosis (angular cheilitis) or perlèche is characterized by erythema, fissuring, maceration, and soreness at the angles of the mouth (see Fig. 206-2C). This condition is commonly encountered in habitual lip lickers and in elderly patients with sagging skin at the oral commissures. Loss of dentition, poorly fitting dentures, malocclusion, and riboflavin deficiency may be predisposing factors. Cheilosis is often associated with chronic atrophic candidiasis due to denture wear. [27] The differential diagnosis of perlèche includes secondary syphilis, glucagonoma, or iron-deficiency states. Chronic hyperplastic candidiasis or candidal leukoplakia is characterized by adherent, firm plaques on the buccal mucosa or tongue that are translucent to white in color with surrounding erythema (see Fig. 206-2D). Conditions associated with chronic hyperplastic candidiasis include oral leukoplakia and erythroplakia, smoking, and use of dentures. This condition can be resistant to therapy. [27] Median rhomboid glossitis causes central papillary atrophy of the dorsal surface of the tongue. Lesions also may appear as exophytic, lobulated masses in the midline on the tongue. [3] Although median rhomboid glossitis once was thought to be a developmental anomaly, now *Candida* is recognized as its etiology. Black hairy tongue is associated with *C. albicans*. An alteration in normal oral flora allows overgrowth with fungi and bacteria. The filiform papillae hypertrophy, and the surface of the tongue cannot undergo normal desquamation (see Fig. 206-2E). Factors that may worsen the condition include poor oral hygiene, radiation therapy, and use of antacids. The lesion occurs at the same location as median rhomboid glossitis but also can be generalized to cover the entire dorsal surface of the tongue. Patients often complain of a tickling sensation in their mouths due to elongated papillae. Treatment consists of physical debridement and good hygiene. [29] For uncomplicated oral candidiasis, topical antifungal agents are the first line of treatment. [3] The most commonly used drugs include nystatin suspension (400,000 to 600,000 units qid) held in the mouth and then swallowed, clotrimazole troches (10 mg dissolved in the mouth five times per day), 1% to 2% gentian violet, and chlorhexidine rinse. Nystatin, while safe for long-term use, is not as effective as clotrimazole troches. If reinfection of the oral cavity occurs, systemic therapy is indicated. Fluconazole can be given as a single dose of 200 mg or as 100 mg/d for 5 to 14 days. Itraconazole (100–200 mg daily for 14 days) can be used in fluconazole-resistant patients. For denture-wearing patients with candidiasis, proper oral hygiene is an essential component of treatment. Dentures must be removed from the mouth at night and may be soaked in 0.1% hypochlorite solution to eliminate *Candida*. [3]

VAGINAL AND VULVOVAGINAL CANDIDIASIS Approximately three-quarters of all women will experience an episode of vulvovaginal candidiasis (VVC) in their lifetime. *C. albicans* causes 80 to 90 percent of VVC, and *C. glabrata* is the next most common species. [1] Risk factors for VVC include diabetes mellitus, steroid use, intrauterine devices, tight-fitting and synthetic clothing, and immunosuppression. [30] A retrospective study conducted by MacDonald et al. [31] also showed a clear relationship between the use of oral antibiotics and subsequent VVC. These factors disrupt the vaginal lactobacilli that normally inhibit overgrowth of *Candida*. [1] Patients generally present with a thick vaginal discharge associated with burning, itching, and occasional dysuria. Examination shows whitish plaques on the vaginal wall with underlying erythema and surrounding edema that can extend to the labia and perineum. Recurrent vulvovaginal candidiasis is defined as four or more episodes per year. Recurrent VVC occurs in up to 5 percent of women. [1] Changes in the hormonal environment, such as pregnancy and the luteal phase of menstruation, can induce a relapse of VVC. Use of a genital cleansing solution or douche is also associated with recurrent candidiasis. The mechanism may be an allergy or hypersensitivity response that increases susceptibility to *Candida*. Frequent sexual intercourse may predispose women to recurrent VVC. This is due to both vaginal abrasions sustained during intercourse and semen allergy. [32] Numerous vaginal and oral antifungal agents are available to treat candidal vulvovaginitis. Many surveys have demonstrated that most women prefer oral therapy. Patients with severe local symptoms may require topical or intravaginal therapy to relieve itching and burning. Some women may find increased vaginal symptoms after using a topical azole because of allergic contact dermatitis. [33] Available topical imidazoles include butaconazole, miconazole, tiaconazole, and

clotrimazole. Both creams and suppositories may be used for 3 or 7 days. [34] Terconazole 0.4% cream for 7 days, 0.8% cream for 3 days, or 80-mg suppositories for 7 days are also effective. [35] All these topical agents are safe to use during pregnancy. [33] Oral fluconazole, itraconazole, and ketoconazole offer similar efficacy to topical therapy. Ketoconazole, while effective, has the undesirable side effect of hepatotoxicity. [33] Studies have shown better compliance with fluconazole and faster recovery as compared with intravaginal clotrimazole. [36] Itraconazole is also as effective as clotrimazole. Single-dose therapies have been explored for improved convenience and compliance. Options include one 500-mg clotrimazole suppository and one 150-mg fluconazole tablet. These drugs have the ability to maintain therapeutic concentrations in the vagina for 5 days. Severe or recurrent candidal vaginitis should not be treated with single-dose therapy. Prophylactic regimens can be used to prevent recurrent VVC. A weekly application of terconazole 0.8% cream [37] or clotrimazole cream [33] has been shown to prevent recurrences. A single 150-mg dose of fluconazole each month also has been used successfully as prophylaxis [38] in women who are HIV-positive with recurrent vaginal candidiasis.

BALANITIS OR BALANOPOSTHITIS *Candida* species cause 30 to 35 percent of infectious balanitis. Factors predisposing to balanitis include candidal vaginal infection in sexual partners, diabetes mellitus, and an uncircumcised state. [39] *C. albicans* balanitis presents as small papules or fragile papulopustules on the glans or in the coronal sulcus. These break to leave superficial erythematous erosions with a collarette of whitish scale. Infection may spread to the scrotum and inguinal areas. In diabetics or immunosuppressed patients, a severe edematous, ulcerative balanitis may occur. Occasionally, patients present with a transient erythema and burning occurring shortly after intercourse. These symptoms likely represent a hypersensitivity response to candidal vaginitis in their partners. The recommended treatment for candidal balanitis is topical clotrimazole cream or a single 150-mg dose of fluconazole. [39]

CUTANEOUS CANDIDIASIS *C. albicans* has a predilection for colonizing moist, macerated folds of skin. Intertrigo is the most common clinical presentation on glabrous skin. Usual locations for intertrigo include the genitocrural, axillary, gluteal, interdigital (Fig. 206-3A), and inframammary (see Fig. 206-3B) areas and between folds of skin on the abdominal wall. Predisposing conditions include obesity, occlusive clothing, diabetes mellitus, and occupational factors. [40] Cutaneous candidiasis appears as pruritic, erythematous, macerated skin in intertriginous areas with satellite vesicopustules. These pustules break open, leaving a red, macular base with a collarette of easily detachable necrotic epidermis.

FIGURE 206-3 Candidal intertrigo. *A.* Erythematous, eroded plaques involving the scrotum and inguinal area with satellite lesions. *B.* Confluent and discrete erythematous, eroded areas with pustular and erosive satellite lesions. *C.* The infant shows red macular plaques on the vulva surrounded by a delicate collar. Outside the main lesions are a few satellite lesions. *D. Erosio interdigitalis blastomycetica.* Erythematous eroded areas between the fingers occurring in a waitress.

Cutaneous candidal infection is diagnosed by the typical appearance of skin lesions and the presence of satellite vesicopustules. The clinical diagnosis can be confirmed by KOH examination and culture of skin scrapings. Intertriginous candidiasis occasionally can be confused with tinea infections, eczema, seborrheic dermatitis, intertriginous psoriasis, erythrasma, bacterial intertrigo, familial benign pemphigus, Leiner's disease, glucagonoma, or flexural Darier's disease. Intertrigo has been treated successfully with topical antifungals. Nystatin and topical imidazole creams effectively treat cutaneous candidiasis. Nystatin and miconazole powder can dry moist intertriginous areas. Adding a topical steroid to the treatment regimen helps relieve itching, burning, and pain. [40] Several clinical variants of *Candida* intertrigo deserve special mention. Candidal diaper dermatitis is caused by yeast colonization from patients' gastrointestinal tracts. Chronic occlusion by wet diapers furthers the infection. Lesions appear first in the perianal area and spread to the perineum and inguinal creases, which show pronounced erythema [41] (see Fig. 206-3C). *Erosio interdigitalis blastomycetica* refers to interdigital candidal infection of the hands or feet and, because of anatomic considerations, usually affects the third or fourth innerspace (see Fig. 206-3D). *Candida* miliaria often affects the back in bedridden patients. Lesions start as isolated vesicopustules that contain yeast. *Candida* also can colonize and infect the skin around wounds with occlusive dressings. Broad-spectrum topical antibiotics also contribute to *Candida* wound infections. [42] Erythematous pustular folliculitis may be caused by *C. albicans*. Although the lesions are perifollicular in location, true invasion of the hair shaft is usually not observed. [43] These lesions are commonly distributed in the perioral area. A severe form of *C. albicans* folliculitis resembling pyoderma faciale has been described in the perioral area. [44], [45] Candidal paronychia is common in individuals whose hands are chronically involved in wet work (e.g., housekeepers, bakers, fishermen, bartenders). Typically there is redness, swelling, and tenderness of the paronychial area with prominent retraction of the cuticle toward the proximal nail fold (Fig. 206-4). Occasionally, pus can be expressed. Secondary nail changes include onycholysis and transverse depressions of the nail plate (Beau's lines) with a brownish or green discoloration along the lateral borders. [46], [47] Candidal paronychia should be differentiated from bacterial paronychia or paronychia associated with hypoparathyroidism, celiac disease, acrodermatitis enteropathica, Reiter's syndrome, acrokeratosis paraneoplastica, or retinoid therapy.

FIGURE 206-4 Chronic onychia and paronychia from *C. albicans*. *A.* Note the warm but not hot, slightly tender, edematous nail fold with some onycholysis. This is very often misdiagnosed as staphylococcal paronychia. *B.* This is a chronic inflammatory condition of the nail fold that also can involve the nail plate.

Chronic paronychial infections due to *C. albicans* are resistant to therapy. All wet work should be minimized. Topical agents should be applied and allowed to drain under the proximal nail fold. Occlusion using a finger cot may allow better drug penetration. A topical imidazole in solution form is the ideal treatment. [40] Also, 4% thymol in chloroform or absolute alcohol has anticandidal activity and is drying. Oral ketoconazole or surgical marsupialization of the proximal nail fold is recommended in resistant cases. [46] The rare syndrome of congenital candidiasis presents in the first 24 hours of life. Organisms spread to the uterus of pregnant women with *Candida* vaginitis and thus infect the fetus. Affected neonates have a pink maculopapular eruption that progresses to vesicles and pustules with desquamation. Lesions occur predominantly on the upper half of the body and on the palms and soles. While most neonates have a benign course, approximately 20 percent have transient respiratory distress or clinical signs of sepsis. Preterm and low-birth-weight infants are at higher risk for fatal dissemination of the disease. Although congenital cutaneous candidiasis may resolve spontaneously, topical therapy with nystatin is recommended to prevent disseminated disease. Amphotericin B at 0.5–1.0 mg/kg per day should be used to treat systemic neonatal candidiasis. [48], [49] The incidence of disseminated candidiasis is steadily rising as more patients with hematologic malignancies are treated with potent immunosuppressive drugs and other patients undergo bone marrow and organ transplants (see Table 206-2). The organisms responsible include *C. albicans, C. tropicalis, C. lusitaniae, C. krusei,* and *C. parapsilosis.* [50] These organisms may gain hematogenous access from the oropharynx or gastrointestinal tract when the function of the mucosal barrier is compromised (e.g., mucositis secondary to chemotherapy) or through contaminated intravenous catheters. Organs most commonly involved include the lungs, spleen, kidneys, liver, heart, and brain. [51] Candidal endophthalmitis occurs often and correlates well with multiple-organ involvement. [52] Skin lesions occur in some patients with disseminated infection. The recognition of such lesions may be important in early diagnosis because antemortem blood cultures are negative in a high percentage of patients with autopsy-proven systemic candidiasis. [51] The characteristic skin lesions are 0.5- to 1.0-cm erythematous papulonodules that become hemorrhagic. The eruption is located on the trunk and extremities and has a varying number of lesions. Associated findings include fever and myalgias. [53], [54] Necrotic cutaneous lesions also have been described that resemble ecthyma gangrenosum. [55], [56] In intravenous heroin abusers, macronodular and folliculitis-like skin lesions occur in the scalp and other terminal hair-bearing areas when candidal organisms infiltrate the hair follicles. [57] The differential diagnosis of papules in systemic candidiasis includes *Pityrosporum* folliculitis, [58] bacterial sepsis (e.g., gonococcal, meningococcal, pseudomonal, staphylococcal), and other disseminated fungal infections (e.g., aspergillosis). Necrotic cutaneous lesions due to *Candida* may appear identical to *Pseudomonas* ecthyma or deep fungal infections (e.g., cryptococcosis, torulopsosis, or sporotrichosis). The management of disseminated candidiasis includes the early use of amphotericin B. Newer lipid-based formulations may reduce nephrotoxicity. Some studies support the empirical use of amphotericin B in febrile neutropenic patients with antibiotic-resistant infections. Another option in the treatment of disseminated candidiasis is 5-flucytosine (150 mg/kg). Amphotericin B and 5-flucytosine may be combined in the treatment of *Candida* meningitis or hepatosplenic candidiasis. [51]

CHRONIC MUCOCUTANEOUS CANDIDIASIS Chronic mucocutaneous candidiasis (CMC) consists of several clinical syndromes characterized by chronic, treatment-resistant, superficial candidal infections of the skin, nails, and oropharynx. There is virtually no propensity for disseminated visceral candidiasis. In many cases there are specific abnormalities in CMI; in others, the defects are more global. The clinical findings and immunologic defects have been reviewed extensively. [59]

Clinical syndromes Table 206-4 categorizes CMC syndromes and summarizes their distinguishing features. [59], [60], [61] and [62]) In general, the various syndromes may be familial or sporadic. When presenting in childhood, lesions are detected before the age of 3 years. Oral lesions or diaper dermatitis appear first, followed by angular cheilitis (perlèche), lip fissures, nail and paronychial involvement, vulvovaginitis, and cutaneous involvement. In chronic localized mucocutaneous candidiasis, markedly hyperkeratotic, hornlike, or granulomatous lesions may appear (candidal granuloma) on the face, eyelids, scalp, lips, or acral areas (Fig. 206-5). On the scalp they may resemble the lesions of favus and can lead to alopecia. In chronic diffuse candidiasis, lesions may appear with an erythematous, serpiginous border or areas of brownish desquamation on a background of mild erythema (see Fig. 206-5). Concomitant dermatophyte infection of the skin may occur and confuse the clinical presentation. [59] The lesions of CMC may resemble those of tinea (e.g., favus), bacterial pyoderma, acrodermatitis enteropathica, and halogenoderma.

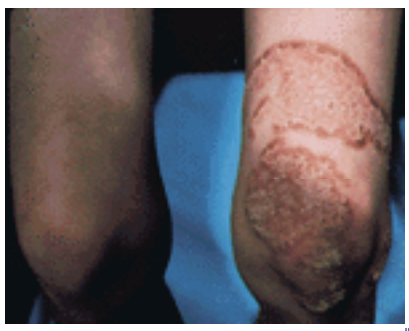

FIGURE 206-5 Mucocutaneous candidiasis. Well-demarcated serpiginous border.

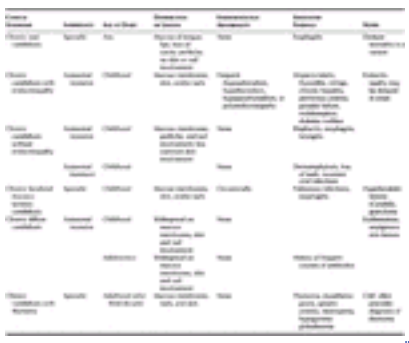

TABLE 206-4 **Classification of Chronic Mucocutaneous Candidiasis**

Nail involvement is characterized by markedly thickened and dystrophic nail plates whose entire thickness is invaded by *Candida.* The paronychial areas are red and edematous, and the fingertips are often bulbous in appearance [46] (see Fig. 206-4). Conditions that have been associated with CMC include candidal esophagitis or laryngitis, endocrinopathies (usually hypoparathyroidism, hypoadrenalism, hypothyroidism), circulating antinuclear antibodies, diabetes mellitus, vitiligo, iron deficiency, chronic active hepatitis, pernicious anemia, malabsorption, alopecia totalis, dental enamel dysplasia, keratoconjunctivitis, pulmonary fibrosis, and keratitis, ichthyosis, and deafness (KID) syndrome. Recurrent pyogenic, viral, or other fungal infections also may occur. When CMC first appears in adulthood, it is often associated with a thymoma and the other conditions listed in Table 206-4. [63] In the past, chronic mucocutaneous candidiasis has been notoriously difficult to treat. The best results are seen with a combination of antifungal drugs and immune deficiency correction. [63] The most important consideration in the treatment of CMC is the specific immune deficiency. Although antifungal treatment will clear the lesions quickly, the infection recurs within a few weeks of stopping the drug unless the underlying immune defect is corrected. Patients with CMC have used oral azoles with good efficacy for years. [59] Several different methods of immune regulation have been used. A patient with DiGeorge syndrome received thymic tissue transplantation and had spontaneous clearing of CMC. The infection of a patient with severe combined immunodeficiency and extensive CMC also cleared after transplantation of cultured fetal thymus donor leukocytes. Infusion with *Candida*-specific transfer factor proteins from donor T lymphocytes also has produced remission of CMC. [63]

Laboratory Findings

Direct microscopic examination of specimens for the presence of yeast and isolation of yeast in culture are needed to diagnose infection definitively. In superficial candidal infections, the diagnosis can be made by examining skin scrapings and observing typical budding yeasts with hyphae or pseudohyphae. *C. albicans* grows readily on bacterial media, but Sabouraud's agar with added antibiotics is usually recommended for isolation. Whitish mucoid colonies grow within 2 to 5 days. Of all superficial infections, chronic paronychiae may have the lowest yield of positive cultures.

In systemic candidiasis with skin lesions, the diagnosis usually can be made from histopathologic examination and culture of appropriate skin biopsy specimens. Blood cultures often are negative in this setting. [51] Serologic studies using immunodiffusion, counterimmunoelectrophoresis, and latex agglutination methods may be somewhat helpful in the diagnosis of systemic candidiasis. However, false-negative and false-positive reactions are common. More promising are techniques to detect circulating candidal antigens (e.g., mannan) or metabolic products (e.g., arabinitol). [64]

MICROSCOPIC STUDIES Since *Candida* species may infect virtually any organ system, specimens for laboratory examination will vary from body fluids to surgical biopsies. Direct microscopic examination for the presence of yeast provides rapid evidence to support the clinical diagnosis. Body fluids such as urine and cerebrospinal fluid should be centrifuged and the sediment examined directly to increase the probability of finding yeast. Sputum, surgical biopsies, and tissue scrapings must be treated with a clearing agent such as 10% potassium hydroxide (KOH) and ink before the material is examined. *Candida* appears as oval budding cells, elongated filamentous cells connected end to end (pseudohyphae), or septate hyphae (see Fig. 206-1). However, this method does not permit species identification.
CULTURE METHODS Sediment from centrifuged body fluids, tissue from biopsies, and skin scrapings should be inoculated promptly onto Sabouraud's dextrose agar containing antibacterial antibiotics. Cultures are incubated at room temperature [25–to 27°C (77–80.6°F)] and examined periodically for growth of yeast. Negative cultures are discarded after 4 weeks. All yeast colonies must be subcultured and tested further for identifying morphologic and biochemical characteristics before they can be speciated.
PATHOLOGY Superficial candidiasis is characterized by subcorneal pustules. Organisms are seldom seen within the pustule but can be visualized in the stratum corneum with the aid of a periodic acid–Schiff (PAS) stain. The histology of a candidal granuloma shows marked papillomatosis and hyperkeratosis and a dense dermal infiltrate consisting of lymphocytes, granulocytes, plasma cells, and multinucleated giant cells. In systemic candidal infections with skin involvement, biopsies show focal areas of yeast in the dermis and within blood vessels. Organisms can be identified using PAS or methenamine silver stains. There may be a surrounding mononuclear cell infiltrate, [65] leukocytoclastic vasculitis, or microabscess formation.

“ *PITYROSPORUM* INFECTIONS” OF THE SKIN: PAPULOSQUAMOUS TINEA VERSICOLOR, “ *PITYROSPORUM*” FOLLICULITIS, AND INVERSE TINEA VERSICOLOR

The genus *Malassezia* includes seven species of lipophilic basidiomycetous yeast: *Malassezia furfur, M. pachydermatis, M. sympodialis, M. globosa, M. restricta, M. slooffiae,* and *M. obtusa*. [66] Previously, *M. furfur, M. pachydermatis,* and *M. sympodialis* were the only members of the genus. In 1996, Gueho et al. [67] proposed a new taxonomic classification based on morphology, ultrastructure, and molecular biology that added four new species. These yeasts cause a wide spectrum of superficial cutaneous disease, including tinea versicolor, folliculitis, and seborrheic dermatitis. [68]

History

Eichstedt first recognized tinea versicolor as a cutaneous fungal infection in 1846. For several years the disease was considered to be dermatophyte in origin, but Baillon, impressed by the yeastlike nature of the organism, coined the name *Malassezia* in 1889 to distinguish this organism from the *Microsporum* species of dermatophytes. [69] In 1951, Gordon isolated and characterized the organism *M. furfur* and renamed it *Pityrosporum orbiculare*. [70] It is now recognized and accepted that *M. furfur* is the correct name and that *P. orbiculare, P. ovale,* and *M. ovalis* are synonyms.

Etiology and Pathogenesis

M. furfur can be cultured from diseased and normal skin and is considered part of the normal flora, particularly in sebum-rich areas of the skin. [71] *M. furfur* is a dimorphic, lipophilic organism that grows in vitro only with the addition of C_{12} to C_{14} fatty acids such as olive oil and lanolin. Under appropriate conditions, it converts from the saprophytic yeast to the predominantly parasitic mycelial morphology associated with clinical disease. Factors responsible for mycelial transition include a warm, humid environment, heredity, Cushing's disease, immunosuppression, and a malnourished state. [71]

The species of *Malassezia* can be differentiated by their nutritional requirements, morphology, and molecular biology. [67], [72] *M. pachydermatis* is the one member of the genus *Malassezia* without an absolute requirement of exogenous lipids for growth. Although previously recognized as a zoophilic organism, it has been identified only recently as a human pathogen. In one study, *M. pachydermatis* caused a series of infections in a neonatal care nursery, where it was presumably spread to patients from health care workers whose pet dogs were colonized with the fungus. [73] Other members of the genus, including *M. sympodialis* and *M. sloofiae,* are part of the normal skin flora. [74] A recent study also linked *M. sympodialis* with neonatal cephalic pustulosis, a skin disorder also known as *neonatal acne.* [75]

M. furfur has long been identified as the fungus causing tinea versicolor. However, recent studies indicate that *M. globosa* may be involved in the pathogenesis of this disease. Crespo Erchiga et al. [74], [76] cultured the lesions of tinea versicolor in 96 patients, and *M. globosa* was found in 97 percent.

Tinea versicolor is an opportunistic infection of the skin. Experimental inoculation of *Malassezia* under occlusion can cause infection. [71] The resulting increase in humidity, temperature, and CO_2 tension appear to be important factors that make the skin susceptible to infection. [70] When the occlusion is terminated, healing occurs, although the organism is not eradicated from the skin and can be cultured from clinically uninvolved areas. [77] It also may colonize follicular structures, and a high recurrence rate is expected.

Immunology

No specific deficiencies in antibodies or complement components have been found in patients with tinea versicolor. Similar titers of specific IgG antibody are seen in healthy controls and tinea versicolor patients. [78] Furthermore, Sohnle and Collins-Lech [79] have shown that *M. furfur* induces IgA, IgG, and IgM antibodies and that it also activates complement through the alternative and classical pathways. The precise role that CMI and other immunologic factors play in the disease process is unknown.

The immune response seen in *Malassezia* folliculitis is likewise poorly understood. Patients with *Malassezia* folliculitis have higher titers of IgG antibodies than those with tinea versicolor or controls. [80] Both nonspecific inflammatory responses and specific cellular immunity are also observed. Faergemann et al. [78] have shown that patients with seborrheic dermatitis and *Malessezia* folliculitis have an increased number of NK1+ and CD16+ cells and complement activation consistent with irritant stimulation of the immune system. In addition, biopsies of involved skin lesions showed an increase in inflammatory cytokines. [78]

Clinical Features

Cutaneous infections with *Malassezia* may take three forms: (1) papulosquamous, (2) folliculitis, and (3) inverse tinea versicolor. The most common presentation is scaly hypo- or hyperpigmented macules observed in characteristic areas of the body, including the chest, back, abdomen, and proximal extremities (Fig. 206-6). Less common areas of involvement include the face, scalp, and genitalia. The characteristic scale is described as dustlike or furfuraceous. This characteristic feature of the disease can be produced by lightly scraping a scalpel blade over the involved skin. [71] The color of the lesions varies from almost white to reddish brown or fawn-colored. The presenting complaint is usually a cosmetic one because lesions often fail to tan with sun exposure. Pruritus is mild or absent.

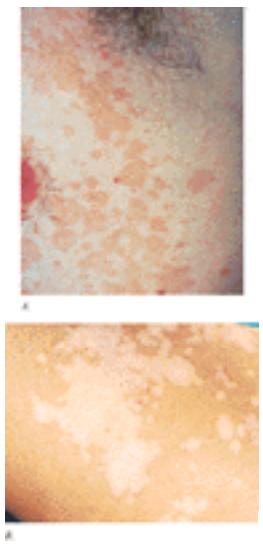

FIGURE 206-6 *A.* Pityriasis versicolor. These lesions are darker because of hyperemia secondary to inflammatory response and increased melanin. *B.* Tinea versicolor. There are sharply marginated, uniformly hypopigmented macules with a fine, sometimes barely perceptible scale, but they are easily scraped off with a glass slide. When the lesions are very large, as on the left, they can be confused with vitiligo.

The yeast may filter the rays of the sun and interfere with normal tanning. [71] Furthermore, the metabolites of *M. furfur* such as azaleic acid, a dicarboxylic acid, can cause depigmentation by inhibiting tyrosinase and injuring melanocytes. [71], [77] This long-standing damage to melanocytes may explain why most hypopigmented lesions persist for months and some persist for years. [71]

In *Malassezia* (*Pityrosporum*) folliculitis, lesions typically appear on the back, chest, and sometimes the extremities (Fig. 206-7A). Pruritus is more common than with typical tinea versicolor. The primary lesion is a perifollicular, erythematous, 2- to 3-mm papule or pustule. Only appropriate culture and KOH examination can distinguish this infection from a bacterial folliculitis. Frequently, biopsy with special stains for fungus is necessary (see Fig. 206-7B). Diabetes mellitus [70] or prior glucocorticoid or antibiotic therapy [77]) can predispose to this disorder.

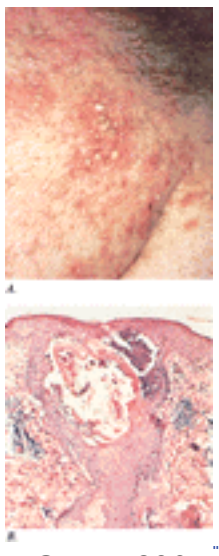

FIGURE 206-7 *A, B. Pityrosporum* folliculitis on the anterior chest. Note the organisms in the follicular ostia on staining with hematoxylin and eosin.

The lesions of inverse tinea versicolor are encountered predominantly in flexural areas. [81] Because of its location, inverse tinea versicolor can be confused with seborrheic dermatitis, psoriasis, erythrasma, candidiasis, and dermatophyte infections.

Rarely, *M. furfur* can infect organs other than the skin. A premature infant on total parenteral nutrition with intravenous lipid supplementation has been reported who showed no skin lesions but had an extensive vasculitis of small pulmonary arteries as well as pneumonia. *M. furfur* was seen microscopically in areas of lipid deposition. The organism has been cultured from peritoneal dialysate and blood and, with increasing frequency, from patients receiving parenteral intravenous lipid supplementation. Presumably, this provides an appropriate growth medium for *M. furfur*. [70]

Each of the cutaneous variants has an equal sex distribution and tends to flare during the summer months, presumably due to increased heat and humidity. These infections are also more common in tropical climates. Although the disease can occur at any age, late adolescents and early adults are predominantly affected. [71]

Laboratory Findings

To identify the *Malassezia* yeast forms, scale from involved skin should be scraped onto a glass slide and treated with 10% KOH. Alternatively, cellophane tape can be used to pick up skin scales from the lesion. The tape is mounted on a glass slide with methylene blue, and the organism is selectively stained. [80]

Sabouraud's dextrose agar overlaid on the surface with sterile olive oil or lanolin readily supports the growth of this

lipophilic yeast. To reduce the growth of contaminating organisms, antibiotics such as penicillin, streptomycin, and cycloheximide are incorporated into this medium. In general, cultures are not required for diagnosis because organisms can be demonstrated with 10% KOH.

Pathology

In tinea versicolor, the organisms inhabit the stratum corneum. There is usually no dermal infiltrate. Yeast may be observed with hematoxylin and eosin (H&E) stain alone. PAS staining is confirmatory. Microscopic examination reveals clusters of oval budding yeast cells 3.5 × 4.5 µm long with short, septate, and occasionally branching hyphae (Fig. 206-8). The microscopic appearance of the yeast is classically described as “spaghetti and meatballs.” In *Malassezia* folliculitis, organisms are noted in widened follicular ostia mixed with keratinous material (see Fig. 206-7B). Rupture of the follicular wall can occur with a resulting mixed inflammatory and foreign-body giant cell response.

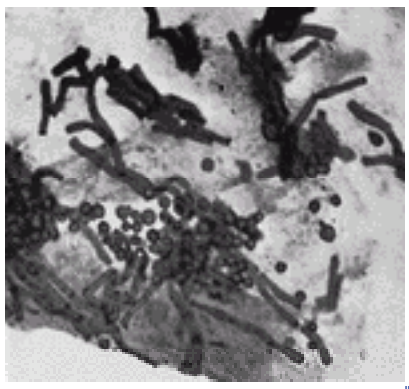

FIGURE 206-8 “Spaghetti and meatballs” appearance of tinea versicolor in a KOH preparation.

Diagnosis

The clinical appearance of tinea versicolor is usually characteristic, and KOH examination is confirmatory. A Wood's lamp examination may show yellowish fluorescence of involved skin. The differential diagnosis includes pityriasis alba, confluent and reticulated papillomatosis of Gougerot and Carteaud, pityriasis rosea, seborrheic dermatitis, vitiligo, or secondary syphilis.

For the folliculitis variant, both bacterial and candidal folliculitis should be considered in the differential diagnosis. The skin lesions of disseminated candidiasis also can be confused with *Malassezia* folliculitis. [83]

Treatment and Prognosis

There are multiple topical products that are useful in treating tinea versicolor. The most widely used has been 2.5% selenium sulfide shampoo. This should be applied liberally over and beyond the affected areas, left on for at least 10 min, and then washed off. The cycle is repeated every day for 2 weeks. Subsequently, we recommend applying the drug once or twice per month to prevent recurrence. All the topical azole antifungals have been effective in the treatment of tinea versicolor. Ketoconazole 2% shampoo may be lathered on affected areas and left for 5 min; this is repeated for 3 consecutive days. [84] Recent studies have shown that topical terbinafine, 1% solution applied twice daily to lesions for 7 days, has cure rates of greater than 80 percent. [85], [86]

While topical therapy is ideal for this condition, systemic treatment may be necessary for patients with extensive disease, frequent recurrences, or failure of topical agents. [87] In addition, patients often prefer the convenience of oral therapy. Cure rates range from 90 to 100 percent with ketoconazole (200 mg daily for 7 days) or itraconazole (200–400 mg daily for 3–7 days). Fluconazole is also effective and can be given as a single dose of 400 mg. [86], [88] Oral terbinafine is not an effective treatment, likely because therapeutic drug levels are not achieved in the stratum corneum. [71] In addition, griseofulvin is not effective in the treatment of tinea versicolor. Whether systemic or oral medications are used, clinical improvement is not seen until 3 to 4 weeks after treatment because the involved epidermis must slough. [86]

Malassezia folliculitis also can be treated successfully with both topical and systemic therapy. As with most types of folliculitis, systemic therapy is more effective. Although there are few controlled trials, oral ketoconazole (200 mg daily for 4 weeks), fluconazole (150 mg weekly for 2–4 weeks), and itraconazole (200 mg daily for 2 weeks) are useful systemic agents in the treatment of this papulopustular folliculitis. [80]

Tinea versicolor is often a chronic, recurrent condition. Prophylactic measures, as discussed earlier, and fastidious cleanliness may lessen the risk of recurrence.

REFERENCES

1. Ferrer J: Vaginal candidosis: Epidemiological and etiological factors . *Int J Gynecol Obstet* **71**:S21, 2000

2. Fidel PL et al: *Candida glabrata*: Review of epidemiology, pathogenesis, and clinical disease with comparison to *C. albicans*. *Clin Microbiol Rev* **12**:80, 1999

3. Farah CS et al: Oral candidosis. *Clin Dermatol* **18**:553, 2000

4. Sebti A et al: *Candida dubliensis* at a cancer center. *Clin Infect Dis* **32**:1034, 2001

5. De Bernardis F et al: Biotyping and virulence properties of skin isolates of *Candida parapsilosis*. *J Clin Microbiol* **37**:3481, 1999

6. Coleman DC et al: Importance of *Candida* species other than *Candida albicans* as opportunistic pathogens. *Med Mycol* **36**:156, 1998

7. Fidel PL, Sobel JD: Immunopathogenesis of recurrent vulvovaginal candidiasis. *Clin Microbiol Rev* **9**:335, 1996

8. Staib P et al: Expression of virulence genes in *Candida albicans*. *Adv Exp Med Biol* **485**:167, 2000

9. Navarro-Garcia F et al: Virulence genes in the pathogenic yeast *Candida albicans*. *FEMS Microbiol Rev* **25**:245, 2001

10. Ray TL, Wuepper KD: Recent advances in cutaenous candidiasis. *Int J Dermatol* **17**:683, 1978

11. Ray TL et al: Experimental cutaneous candidiasis: Role of the stratum corneum. *Clin Res* **24**:495A, 1976

12. Maibach HI, Kligman AM: The biology of experimental human cutaneous moniliasis (*Candida albicans*). *Arch Dermatol* **85**:233, 1962

13. Rebora A et al: Experimental infection with *Candida albicans*. *Arch Dermatol* **108**:69, 1973

14. Steele C et al: Growth inhibition of *Candida* by human oral epithelial cells. *J Infect Dis* **182**:1479, 2000

15. Odds FC: Pathogenesis of *Candida* infections. *J Am Acad Dermatol* **31**:S2, 1994.

16. Steele C et al: Growth inhibition of *Candida albicans* by vaginal cells from naïve mice. *J Med Mycol* **37**:251, 1999

17. Dupont PF: *Candida albicans,* the opportunist. *J Am Podiatr Med Assoc* **85**:104, 1995

18. Marodi L: Local and systemic host defense mechanisms against *Candida*: Immunopathology of candidal infections. *Pediatr Infect Dis J* **16**:795, 1997

19. Jorizzo JL: Chronic mucocutaneous candidosis: An update. *Arch Dermatol* **118**:963, 1982

20. Rogers TJ, Balish E: Immunity to *Candida albicans*. *Microbiol Rev* **44**:660, 1980

21. Ray TL et al: Purification of a mannan from *Candida albicans* which activates serum complement. *J Invest Dermatol* **73**:269, 1979

22. Ray TL, Wuepper KD: Experimental cutaneous candidiasis in rodents: II. Role of the stratum corneum barrier and serum complement as a mediator of a protective inflammatory response. *Arch Dermatol* **114**:539, 1978

23. Solomkin JS et al: Phagocytosis of *Candida albicans* by human leukocytes: Opsonic requirements. *J Infect Dis* **137**:30, 1978

24. Wilton JMA et al: The role of Fc and C3b receptors in phagocytosis by inflammatory polymorphonuclear leukocytes in man. *Immunology* **32**:955, 1977

25. Vazquez-Torres A et al: Macrophages in resistance to candidiasis. *Microbiol Mol Biol Rev* **61**:170 1997

26. Patton LL, van der Horst C: Oral infections and other manifestations of HIV disease. *Infect Dis Clin North Am* **13**:879, 1999

27. Appleton SS: Candidiasis: Pathogenesis, clinical characteristics, and treatment. *J Calif Dent Assoc* **28**:942, 2000

28. Wilson J: The aetiology, diagnosis and management of denture stomatitis. *Br Dent J* **185**:380, 1998

29. McNally MA, Langlais RP: Conditions peculiar to the tongue. *Dermatol Clin* **14**:257, 1996

30. Haefner HK: Current evaluation and management of vulvovaginitis. *Clin Obstet Gynecol* **42**:184, 1999

31. MacDonald TM et al: The risks of symptomatic vaginal candidiasis after oral antibiotic therapy. *Q J Med* **86**:419, 1993

32. Spinillo A et al: Epidemiologic characteristics of women with idiopathic recurrent vulvovaginal candidiasis. *Obstet Gynecol* **81**:721, 1993

33. Sobel JD: Controversial aspects in the management of vulvovaginal candidiasis. *J Am Acad Dermatol* **31**:S10, 1994

34. Tanaka D: Management of vaginal candidiasis: A review. *Pediatr Infect Dis J* **17**:746, 1998

35. Carr PL et al: Evaluation and management of vaginitis. *J Gen Int Med* **13**:335, 1998

36. O-Prasertsawat P, Bourlert, A: Comparative study of fluconazole and clotrimazole for the treatment of vulvovaginal candidiasis. *Sex Transm Dis* **22**:565, 1990

37. Stein GE, Mummaw N: Placebo-controlled trial of itraconazole for the treatment of acute vaginal candidiasis. *Antimicrob Agents Chemother* **37**: 89, 1996

38. Desai PC, Johnson BA: Oral fluconazole for vaginal candidiasis. *Am Fam Phys* **54**:1337, 1996

39. English JC III et al: Dermatoses of the glans penis and prepuce. *J Am Acad Dermatol* **37**:1, 1997

40. Pariser DM: Cutaneous candidiasis. *Postgrad Med* **87**:101, 1990

41. Kazaks EL, Lane AT: Diaper dermatitis. *Pediatr Dermatol* **47**:909, 2000

42. Giandoni MB, Grabski WJ: Cutaneous candidiasis as a cause of delayed surgical wound healing. *J Am Acad Dermatol* **30**:981, 1994

43. Jorizzo JL: The specrum of mucosal and cutaneous candidiasis. *Dermatol Clin* **2**:19, 1984

44. Bradford LG, Montes LF: Perioral dermatitis and *Candida albicans*. *Arch Dermatol* **105**:892, 1972

45. Brandrup F et al: Perioral pustular eruption caused by *Candida albicans*. *Br J Dermatol* **105**:327, 1981

46. Hay RJ: Yeast infections. *Dermatol Clin* **14**:113, 1996

47. Elewski BE: Onychomycosis: Pathogenesis, diagnosis, and management. *Clin Microbiol Rev* **11**:415, 1998

48. Waguespack-LaBiche J et al: Disseminated congenital candidiasis in a premature infant. *Arch Dermatol* **135**:510, 1999

49. Darmstadt GL et al: Congenital cutaneous candidiasis: Clinical presentation, pathogenesis, and management guidelines. *Pediatrics* **105**:438, 2000

50. Lewis RE, Klepser ME: The changing face of nosocomial candidemia: Epidemiology, resistance, and drug therapy. *Am J Health Sys Pharm* **56**:525, 1999

51. Wright WL, Wenzel RP. Nosocomial *Candida*: Epidemiology, transmission, and prevention. *Infect Dis Clin North Am* **11**:411, 1997

52. Edwards JE et al: Ocular manifestations of *Candida* septicemia: Review of seventy-six cases of hematogenous *Candida* endopthalmitis. *Medicine* **53**:47, 1974

53. Jarowski CI et al: Fever, rash, and muscle tenderness: A distinctive clinical presentation of disseminated candidiasis. *Arch Int Med* **138**:544, 1978

54. Kressel B et al: Early clinical recognition of disseminated candidiasis by muscle and skin biopsy. *Arch Intern Med* **138**:429, 1978

55. File TM et al: Necrotic skin lesions associated with disseminated candidiasis. *Arch Dermatol* **115**:214, 1979

56. Fine JD et al: Cutaneous lesions in disseminated candidiasis mimicking ecthyma gangrenosum. *Am J Med* **70**:1133, 1981

57. Collignon PJ, Sorrell TC: Disseminated candidiasis: Evidence of a distinctive syndrome in heroin abusers. *Br J Med* **287**:862, 1983

58. Klotz SA et al: *Pityrosporum* folliculitis: Its potential for confusion with skin lesions of systemic candidiasis. *Arch Intern Med* **142**:2126, 1982

59. Kirkpatrick CH: Chronic mucocutaneous candidiasis. *Eur J Clin Microbiol Infect Dis* **8**:448, 1989

60. Herrod HG: Chronic mucocutaneous candidiasis in childhood and complications of non- *Candida* infection: A report of the Pediatric Immunodeficiency Collaborative Study Group. *J Pediatr* **116**:377, 1990

61. Van Scoy RE et al: Familial neutrophil chemotaxis defect, recurrent bacterial infections, mucocutaneous candidiasis and hyperimmunoglobulinemia E. *Ann Intern Med* **82**:766, 1975

62. Durandy A et al: Mannan-specific and mannan-induced T cell suppressive activity in patients with chronic mucocutaneous candidiasis. *J Clin Immunol* **7**:400, 1987

63. Kirkpatrick CH: Chronic mucocutaneous candidiasis. *J Am Acad Dermatol* **31**:S14, 1994

64. Penn RL et al: Invasitve fungal infections: The use of serologic tests in diagnosis and management. *Arch Intern Med* **143**:1215, 1983

65. Bodey GP, Luna M: Skin lesions associated with disseminated candidiasis. *JAMA* **229**:1466, 1974

66. Midgley G: The lipophilic yeasts: State of the art and prospects. *Med Mycol* **38**(suppl 1):9, 2000

67. Gueho E et al: The genus *Malassezia* with description of four new species. *Antonie van Leewenhoek* **69**:337, 1996

68. Faergemann J: *Pityrosporum* species as a cause of allergy and infection. *Allergy* **54**:413, 1999

69. Baillon H: *Traite de Botanique Medical Cryptoganique*. Paris, Octave Doin Editeur, 1889, p 234

70. Silva-Lizama E: Tinea versicolor. *Int J Dermatol* **34**:611, 1995

71. Sunenshine, PJ et al: Tinea versicolor. *Int J Dermatol* **37**:648, 1998

72. Gupta AK et al: Molecular differentiation of seven *Malassezia* species. *J Clin Microbiol* **38**:1869, 2000

73. Chang HJ et al: An epidemic of *Malassezia pachydermatis* in an intensive care nursery associated with colonization of health care workers' pet dogs. *N Engl J Med* **338**:706, 1998

74. Crespo Erchiga V et al: *Malassezia globosa* as the causative agent of pityriasis versicolor. *Br J Dermatol* **143**:799, 2000

75. Niamba P et al: Is common neonatal cephalic pustulosis (neonatal acne) triggered by *Malassezia sympodialis Arch Dermatol* **134**:995, 1998

76. Nakabayashi A et al: Identification of *Malassezia* species isolated from patients with seborrheic dermatitis, atopic dermatitis, pityriasis versicolor and normal subjects. *Med Mycol* **38**:337, 2000

77. Schmidt A: *Malassezia furfur*: A fungus belonging to the physiological skin flora and its relevance in skin disorders. *Cutis* **59**:21, 1997

78. Faergemann J et al: Seborrhoeic dermatitis and *Pityrosporum* folliculitis: Characterization of inflammatory cells and mediators in the skin by immunohistochemistry. *Br J Dermatol* **144**:549, 2001

79. Sohnle PG, Collins-Lech C: Cell-mediated immunity to *Pityrosporum orbiculare*. *J Clin Invest* **62**:45, 1978

80. Faergemann J: *Pityrosporum* species as a cause of allergy and infection. *Allergy* **54**:413, 1999

81. Burkhart CG et al: An unusual case of tinea versicolor in an immunosuppressed patient. *Cutis* **27**:56, 1981

82. Mayser P et al: Differentiation of *Malassezia* species: Selectivity of Cremophor EL, castor oil and ricinoleic acid for *M. furfur*. *Br J Dermatol*

137:208, 1997

83. Klotz A et al: *Pityrosporum* folliculitis: Its potential for confusion with skin lesions of systemic candidiasis. *Arch Intern Med* **142**:2126, 1982

84. Lange DS et al: Ketoconazole 2% shampoo in the treatment of tinea versicolor: A multicenter, randomized, double-blind, placebo-controlled trial. *J Am Acad Dermatol* **39**:944, 1998

85. Vermeer BJ, Staats CCG: The efficacy of a topical application of terbinafine 1% solution in subjects with pityriasis versicolor: A placebo-controlled study. *Dermatology* **194**(suppl 1):22, 1997

86. Savin R et al: Tinea versicolor treated with terfinabine 1% solution. *Int J Dermatol* **38**:863, 1999

87. Drake LA et al: Guidelines of care of superficial mycotic infections of the skin: Pityriasis (tinea) versicolor. *J Am Acad Dermatol* **34**:287, 1996

88. Hickman JG et al: A double-blind, randomized, placebo-controlled evaluation of short-term treatment with oral itraconazole in patients with tinea versicolor. *J Am Acad Dermatol* **34**:785 1996

T>

Chapter 207

R. Hay

Deep Fungal Infections

SUBCUTANEOUS MYCOSES
Sporotrichosis
Mycetoma (Maduromycosis, Madura Foot)
Chromoblastomycosis (Chromomycosis)
Pheohyphomycosis (Phaeomycotic Cyst, Cystic Chromomycosis)
Lobomycosis (Keloidal Blastomycosis, Lobo's Disease)
Subcutaneous Zygomycosis [Basidiobolomycosis, Subcutaneous Phycomycosis and Conidiobolomycosis, (Rhino)-Entomophthoromycosis]
Rhinosporidiosis
SYSTEMIC MYCOSES
Histoplasmosis
Blastomycosis (North American Blastomycosis, Gilchrist Disease)
Coccidioidomycosis (Coccidioidal Granuloma, Valley Fever, San Joaquin Valley Fever, Desert Rheumatism)
Paracoccidioidomycosis (South American Blastomycosis, Paracoccidioidal Granuloma)
Infections due to Penicillium marneffei (Penicilliosis, Penicilliosis Marneffei)
Cryptococcosis (Torulosis, European Blastomycosis)
Cutaneous Aspects of Systemic Opportunistic Mycoses
Systemic Candidiasis
Zygomycosis (Mucormycosis, Phycomycosis)
Other Opportunistic Mycoses
Actinomycosis
Nocardiosis

REFERENCES

Deep fungal infections comprise two distinct groups of conditions, the subcutaneous and systemic mycoses. Neither are common, and the subcutaneous mycoses, with some exceptions, are largely confined to the tropics and subtropics. In recent years, the systemic mycoses have become important opportunistic infectious complications in immunocompromised patients, including those with AIDS and patients receiving treatment for malignancies. They also include a group of primary respiratory infections such as histoplasmosis and coccidioidomycosis, which may affect otherwise healthy individuals and those with underlying illness. The fungi that cause these respiratory infections are usually dimorphic or exist in a different morphologic phase, e.g., yeast or mold, at different stages of their life cycle.

Patients with subcutaneous fungal infections often present to a physician with signs of skin involvement. By contrast, patients with systemic mycoses only occasionally have skin lesions, either following direct involvement of the skin as a portal of entry or after dissemination from a deep focus of infection. There are a number of excellent texts about fungi and the diseases they cause. [1], [2], [3] and [4]

SUBCUTANEOUS MYCOSES

The subcutaneous mycoses, or mycoses of implantation, are infections caused by fungi that have been introduced directly into the dermis or subcutaneous tissue through a penetrating injury, such as a thorn prick. Although many are tropical infections, some, such as sporotrichosis, are also prevalent in temperate climates; any of these infections may present as an imported disease in a patient who has originated from an endemic area, sometimes after a lapse of many years. The most common subcutaneous mycoses are sporotrichosis, mycetoma, and chromoblastomycosis. Rarer infections include lobomycosis and subcutaneous zygomycosis.

Sporotrichosis

Sporotrichosis is a subcutaneous or systemic fungal infection caused by the dimorphic fungus *Sporothrix schenckii*. [5], [6] The fungus occurs in the natural environment, presumably in mold form, but develops as a yeast in infections. The most frequent site of this infection is the dermis or subcutis. There is also a systemic form of sporotrichosis whose clinical features range from pulmonary infection to arthritis or meningitis. One important characteristic of the diagnosis of cutaneous lesions is the scarcity of organisms in tissue, making confirmation of the diagnosis potentially difficult. [6] Sometimes in tissue, fungal cells are surrounded by an eosinophilic refractile fringe, the asteroid body, that is a characteristic of the organism, although a similar phenomenon may occur with other infections.

HISTORICAL ASPECTS The first published case in Western literature was in 1898 by Schenck from the Johns Hopkins Hospital. Subsequently, a series of reports appeared in France from 1903 onward that described the disease and its treatment with potassium iodide. One important feature of the infection is the development of clusters of cases in defined geographic areas. For instance, there was a major outbreak of sporotrichosis in the South African gold mines from 1941 to 1944.
EPIDEMIOLOGY Infections occur in both temperate and tropical countries. They are seen in North, South, and Central America, including the southern United States and Mexico, as well as in Africa, Egypt, Japan, and Australia. [6] The countries where the highest rates of infection occur are Mexico, Brazil, and South Africa. However, sometimes hyperendemic areas are found where large numbers of cases occur. [7] In the United States, infections are most common

in the midwestern river valleys. Infections are now rare in much of Europe. In nature, the fungus grows on decaying vegetable matter such as plant debris, leaves, and wood. Although it is usually a cause of sporadic infection, *S. schenckii* also may affect groups of workers exposed to the organism, such as those using straw as a packing material, gardeners, and forestry workers and those whose recreational activities bring them into contact with plant debris. The organism is thought to be introduced into the skin through a local injury.

CLINICAL MANIFESTATIONS The two clinical varieties of sporotrichosis are the subcutaneous and systemic forms of disease. [5], [8], [9] Subcutaneous sporotrichosis is by far the more common and includes two main forms: lymphangitic and fixed infections. The lymphangitic form is the more common and usually develops on exposed skin sites such as hands or feet. The first sign of infection is the appearance of a dermal nodule that breaks down into a small ulcer. Draining lymphatics become inflamed and swollen, and a chain of secondary nodules develops along the course of the lymphatic (Fig. 207-1); these also may break down and ulcerate. In the fixed variety, which accounts for about 15 percent of cases, the infection remains localized to one site, such as the face, and a granuloma develops that subsequently may ulcerate. Satellite nodules may form around the rim of the primary lesion. Other clinical variants of subcutaneous sporotrichosis may mimic mycetoma, lupus vulgaris, and chronic venous ulceration. In some cases, deep extension of the infection may affect joints or tendon sheaths. Patients with AIDS who develop sporotrichosis often have multiple cutaneous lesions [9] without prominent lymphatic involvement, but deep infections such as arthritis are also reported (see below).

FIGURE 207-1 Sporotrichosis. An ulcerated nodule is seen on the thumb with proximal lymphangitic spread represented by subcutaneous nodules. (*Courtesy of Takeji Nishikawa, MD.*)

In the much rarer systemic form of sporotrichosis, lesions can develop almost anywhere, although chronic lung nodules, with cavitation, arthritis, and meningitis have been described most frequently. These may coexist with cutaneous lesions of sporotrichosis.

DIFFERENTIAL DIAGNOSIS Conditions commonly confused with sporotrichosis are mycobacterial infections and leishmaniasis. The nontuberculous mycobacterial infection due to *Mycobacterium marinum* (fish-tank granuloma), in particular, closely resembles lymphangitic sporotrichosis.

LABORATORY DIAGNOSIS The best sources of diagnostic material are smears, exudates, and biopsies. *S. schenckii* is seen very rarely in direct microscopic examination because yeasts are usually present only in small numbers; the organism can be isolated readily on Sabouraud's agar. In primary culture, the fungus grows as a mold, with compact, white colonies that darken with age. Microscopically, the hyphae produce small oval or triangular conidia either on specialized hyphae or elsewhere on the mycelium. Ideally, the organism should be converted to yeast phase on enriched media such as brain-heart infusion (BHI) agar at 37°C in order to complete the identification. Pathologically, sporotrichosis causes a mixed granulomatous reaction with neutrophil microabscesses. The fungus, if present, is usually in the form of small (3 to 5 µm) cigar-shaped or oval yeasts that may, on occasion, be surrounded by a thick, radiating eosinophilic fringe forming the distinctive asteroid body. Organisms are usually sparsely distributed in lesions, and it may be necessary to scan several sections in order to identify one yeast. A sporotrichin skin test is available in some Latin American countries and may have a role to play in allowing the physician to identify the most appropriate laboratory investigations to instigate.

TREATMENT While spontaneous remissions may occur, most patients are treated with antifungal chemotherapy. Potassium iodide (saturated solution), 4 to 6 mL tid, is effective in the cutaneous types of sporotrichosis and should be continued for 3 to 4 weeks after clinical cure. The daily dose is built up slowly from 1 mL tid over 2 to 3 weeks to avoid side effects such as hypersalivation and nausea. This is an inexpensive form of therapy, but it is unpalatable. Alternative treatments include itraconazole, 200 mg daily, and terbinafine, 250 mg daily, which are better tolerated, and intravenous amphotericin B for deep infection. In all cases, treatment is continued for at least 1 week after clinical resolution.

Mycetoma (Maduromycosis, Madura Foot)

Mycetoma is a chronic localized infection caused by different species of fungi or actinomycetes. It is characterized by the formation of aggregates of the causative organisms, known as *grains,* that are found within abscesses. These either drain via sinuses onto the skin surface or involve adjacent bone, causing a form of osteomyelitis. Grains are discharged onto the skin surface via these sinuses. The disease advances by direct spread, and distant metastatic sites of infection are very rare. Mycetomas caused by species of fungi are known as *eumycetomas,* and those caused by aerobic actinomycetes or filamentous bacteria are known as *actinomycetomas*. The organisms are usually soil or plant saprophytes [11] that are only incidental human pathogens.

HISTORICAL ASPECTS Although this is a disease of great antiquity, the original description of the disease in the Western literature was in 1694 by Engelbert Kaempfer, a German physician in southern India. Over a century elapsed before the disease was redescribed by an English army surgeon, called Gill, working in southern India in 1842. Subsequent cases from India, Africa, and South America confirmed the presence of the disease in a wide variety of tropical countries.

EPIDEMIOLOGY Mycetomas are mainly, but not exclusively, found in the dry tropics where there is low annual rainfall. [11], [12] They are sporadic infections that are seldom common, even in endemic areas. [13] Occasionally, nonimported cases are reported from temperate climates, although in these cases the most common organism is *Scedosporium apiospermum*. Actinomycetomas due to *Nocardia* species are most common in Central America and Mexico (Table 207-1). In other parts of the world, the most common organism is a fungus, *Madurella mycetomatis*. The actinomycete *Streptomyces somaliensis* is isolated most often from patients originating from Sudan and the Middle East. The causative organisms of mycetoma have been isolated from either soil or plant material, including Acacia thorns, in endemic areas.

Organisms	H&E Section Appearances
Eumycetoma	
Dark grains	
Madurella mycetomatis	Cement present, vesicles sometimes prominent
M. grisea	Cement absent, compact outer layer
Leptosphaeria senegalensis	Cement in outer zone, dark periphery with vesicular center
Exophiala jeanselmei	Cement absent, often hollow
Pyrenochaeta romeroi	Cement lacking, compact outer layer
Pale grains	
Fusarium spp., *Acremonium*, *Scedosporium apiospermum*, *Aspergillus nidulans*, *Neotestudina rosati*	Compact, pigment lacking, interwoven fungal filaments (*S. apiospermum* may have prominent vesicles)
Actinomycetoma	
Pale (white to yellow) grains	
Actinomadura madura	Basophilic-stained fringe in layers
Nocardia brasiliensis	Small, pale blue, eosinophilic fringe
Yellow to brown grains	
Streptomyces somaliensis	Grains fractured, basophilic or pink
Red to pink grains	
A. pelletieri	Small, basophilic layers

Note: H&E, hematoxylin and eosin stain.

TABLE 207-1 **Macroscopic and Histopathologic Features of Mycetoma Grains**

The organisms are implanted subcutaneously, usually after a penetrating injury. It is unusual to find any underlying predisposition in patients with mycetoma, and the persistence of the organism after the initial inoculation appears to be related to its ability to evade host defenses through a variety of adaptations such as cell wall thickening and melanin deposition. [14]

CLINICAL MANIFESTATIONS The clinical features of both fungal and actinomycete mycetomas are very similar. [12] They are most common on the foot, lower leg, or hand, although head or back involvement also may occur. Infection of the chest wall is most characteristic of *Nocardia* infections. The earliest stage of infection is a firm, painless nodule that spreads slowly with the development of papules and draining sinus tracts over the surface (Fig. 207-2). Local tissue swelling, chronic sinus formation, and later bone involvement distort and deform the original site of infection (Fig. 207-3 and Fig. 207-4). Lesions are seldom painful except in the late stages and where sinus tracts are about to emerge onto the skin surface. Dissemination from the initial site is exceptionally rare, although local lymphadenopathy may occur.

FIGURE 207-2 Mycetoma. Brawny edema and crusted papules on the plantar surface.

FIGURE 207-3 Eumycetoma caused by *Scedosporium*.

FIGURE 207-4 Mycetoma. Chronic fibrotic involvement of the foot with lymphatic spread to the popliteal fossa.

X-ray changes include periosteal erosion and proliferation, as well as the development of lytic lesions in the bone. Bone scans or magnetic resonance imaging (MRI) may identify bone lesions at an earlier stage.

DIFFERENTIAL DIAGNOSIS Chronic bacterial or tuberculous osteomyelitis may resemble mycetoma. Actinomycosis (see below) is also similar but usually develops close to certain sites, such as the mouth or the cecum, where the causative organisms are sometimes commensal.

LABORATORY DIAGNOSIS Finding the mycetoma grains is the key to establishing the diagnosis, and these are generally discharged from the openings of sinus tracts. However, they also may be obtained by removing the surface crust from a pustule or sinus tract with a sterile needle and gently squeezing the edges. Grains are 250- to 1000-µm white, black, or red particles that can be picked out with the naked eye. Direct microscopy of grains is important because it will show whether the grain is composed of the small actinomycete or broader fungal filaments. In general, it is not possible to distinguish the fine actinomycete filaments in KOH mounts or, for that matter, in hematoxylin and eosin–stained material. In addition, black grains are always caused by fungi; red grains, by actinomycetes (see Table

207-1). Final identification requires isolation of the causal agent in culture. In view of the number of possible species, a series of different culture media and conditions of incubation should be employed. Morphologic and physiologic characteristics are used to distinguish between the genera and species. Serology is only diagnostically helpful in some cases, e.g., *S. somaliensis,* and even then it is more appropriate as a guide to therapeutic response. Histologically, there is a chronic inflammatory reaction with neutrophil abscesses and scattered giant cells and fibrosis. [11] Grains (50 to 250 µm) are found in the center of the inflammation. Their size and shape may help in the identification, although with nonpigmented fungal causes of mycetoma, this is seldom sufficient (Fig. 207-5).

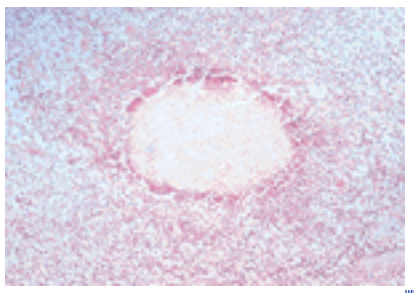

FIGURE 207-5 Pale eumycetoma grain (H&E stain).

TREATMENT Actinomycetomas generally respond to antibiotics such as a combination of dapsone with streptomycin or sulfamethoxazole-trimethoprim plus rifampin or streptomycin. Amikacin also may be used in recalcitrant *Nocardia* infections. The responses in all but a few cases are good. [15] Of the fungal causes of mycetoma, *M. mycetomatis* may respond to ketoconazole, 200 mg daily over several months. For the others, a trial of therapy with griseofulvin, terbinafine, or itraconazole is worth attempting. However, responses to chemotherapy are unpredictable, although antifungals may slow the course of infection. Surgery, usually amputation, is the definitive procedure and may have to be used in advanced cases. However, the value of major surgery in a disfiguring but non-life-threatening infection has to be weighed against the availability of appropriate prosthetic limbs.

Chromoblastomycosis (Chromomycosis)

Chromoblastomycosis is a chronic fungal infection of the skin and subcutaneous tissues caused by pigmented or dematiaceous fungi that are implanted into the dermis from the environment. In the ensuing inflammation, they form thick-walled single cells or cell clusters (sclerotic or muriform bodies), and these may elicit a marked form of pseudoepitheliomatous hyperplasia often accompanied by transepidermal elimination of organisms. The infection can be caused by a number of different pigmented fungi, the most common being *Phialophora verrucosa, Fonsecaea pedrosoi, F. compactum, Wangiella dermatitidis,* and *Cladophialophora carrionii*. [16]

HISTORICAL ASPECTS The first confirmed case was in a patient from New England described by Lane and Medlar in 1915, although subsequently most of the early reports came from Brazil. There is considerable confusion over the correct designation of the first reported isolates because their names have changed considerably over time. This problem of identification is discussed below.

EPIDEMIOLOGY The fungi that cause chromoblastomycosis can be isolated in the environment from wood, plant debris, or soil. [17] The vast majority of infections are caused by *F. pedrosoi* and *P. carrionii*. As with other subcutaneous mycoses, infection follows implantation through a tissue injury. The infection is found as a sporadic condition in Central and South America, although rarely in North America. It occurs in the Caribbean region, Africa (particularly Madagascar), Australia, and Japan. It also may occur as an imported infection outside the usual endemic areas. The disease is most frequent in male rural workers.

CLINICAL MANIFESTATIONS The initial site of the infection is usually on the feet, legs, arms, or upper trunk. The clinical features vary. [17] The initial lesion is often a warty papule that expands slowly over months or years (Fig. 207-6 and Fig. 207-7). Alternatively, lesions may be flatter and plaquelike with an atrophic center. The more common verrucous form spreads slowly and locally. Individual lesions may be very thick and often develop secondary bacterial infection. Satellite lesions around the initial site of infection are local extensions of the infection and usually are produced by scratching. Complications of chromoblastomycosis include local lymphedema leading to elephantiasis and squamous carcinomas in some chronic lesions.

FIGURE 207-6 Chromoblastomycosis. A solitary, large verrucous plaque surrounded by a halo of erythema is seen on the calf. (*Courtesy of Ted Rosen, MD, and Howard Rubin, MD.*)



FIGURE 207-7 Close-up view of chromoblastomycosis.

DIFFERENTIAL DIAGNOSIS The disease must be differentiated from chronic tropical lymphedema with hyperplasia (mossy foot). Other chronic verrucous lesions such as tuberculosis and blastomycosis are often more extensive. The identification of organisms in the lesions of chromoblastomycosis is essential.

LABORATORY DIAGNOSIS The typical sclerotic or muriform fungal cells can be seen in skin scrapings taken from the surface of lesions, particularly areas where there is a small dark spot on the skin surface, using KOH mounts. The lesions also should be biopsied because the pathologic changes and presence of muriform cells are typical. The histology shows a mixed granulomatous response, with small neutrophil abscesses and often exuberant epidermal hyperplasia. [18] The organisms, which are often seen either in giant cells or in neutrophil abscesses, appear singly or in small groups of brown pigmented cells, often with a single or double septum and thick cell wall. In culture, these fungi are very similar in gross macroscopic appearance, producing black colonies with a downy surface. Their cultural identification depends on demonstrating the presence of different but specific types of sporulation, and either single or multiple sporulation mechanisms may be seen in each organism. Accurate differentiation between the different fungi may be difficult. At this stage, the choice of treatment does not depend critically on correct identification of the organisms, although there may be differences in the speed of response to azole drugs (see below).

TREATMENT The main treatments for chromoblastomycosis are itraconazole, 200 mg daily, with or without flucytosine, 30 mg/kg qid (in a patient with normal renal function) [19]; terbinafine, 250 mg daily [20]; and in extensive cases, intravenous amphotericin B (up to 1 mg/kg daily). Thiabendazole is a further alternative, although nausea and vomiting may limit the use of the drug. Lesions can be spread by surgery, which should be used only as an adjunctive therapy after drug treatment. The local application of heat may be helpful in some instances. The responses of these fungi to different antifungal agents do not appear to differ significantly, although there is some evidence that *C. carrionii* responds more rapidly to itraconazole. In any event, treatment is continued until there is clinical resolution of lesions, which usually takes several months. Extensive lesions often respond poorly to treatment.

Pheohyphomycosis (Phaeomycotic Cyst, Cystic Chromomycosis)

Pheohyphomycosis is a rare infection characterized by the formation of subcutaneous inflammatory cysts. It is caused by dematiaceous fungi, the most common of which are *Exophiala jeanselmei* and *Wangiella dermatitidis,* but some 103 species have been described as causal agents. [21] However, unlike in chromoblastomycosis, these organisms form short, irregular, pigmented hyphae in tissue. The infection may occur in any climatic area, although it is more common in the tropics. It also may appear in immunosuppressed patients, particularly those receiving long-term glucocorticoid therapy. The lesions present as cysts and may be mistaken for other similar structures such as Baker's cysts. The diagnosis is usually made after surgical excision. Histologically the cyst wall consists of palisades of macrophages and other inflammatory cells surrounded by a fibrous capsule, and the fungal hyphae are found in the macrophage zone. Although the fungi in tissue lesions are usually pigmented, this is not always the case; if special melanin stains such as Masson-Fontana are used, the organisms will stain, showing that they can produce melanin in small quantities. The treatment is surgical excision, although relapse can occur, particularly in immunocompromised patients.

Lobomycosis (Keloidal Blastomycosis, Lobo's Disease)

This is an uncommon infection seen in Central and South America, often in remote rural areas. The source of the organism is unknown, although similar lesions have been found on freshwater dolphins. Lobomycosis is characterized by the appearance of keloid-like skin lesions on exposed sites. [22] Although it cannot be cultured in vitro, it is caused by a fungus that forms chains of rounded cells in tissue, each joined by a small tubule. Lesions may occur anywhere on the body but usually are found on exposed parts such as the legs, arms, and face. They can spread from site to site by autoinoculation. Antifungal drugs are not effective, and surgical removal is the main treatment.

Subcutaneous Zygomycosis [Basidiobolomycosis, Subcutaneous Phycomycosis and Conidiobolomycosis, (Rhino)-Entomophthoromycosis]

This is a rare tropical subcutaneous mycosis characterized by the development and spread of a chronic, firm swelling involving subcutaneous tissue. There are two main varieties, caused by different organisms. [23] The first, most often caused by *Basidiobolus ranarum* (*B. haptosporus*), is more common in children. It occurs in a wide variety of countries and environments from South America to Africa and Indonesia. The organism can be found in plant debris and in the intestinal tracts of reptiles and amphibians. Lesions usually develop around limb girdle sites and present with a firm, slowly spreading, woody cellulitis. The second form, caused by *Conidiobolus coronatus,* is seen in adults. The organism can be isolated from soil, plant debris, and some insects. The early infection starts in the region of the inferior turbinates of the nose. Spread involves the central part of the face, and once again, the swelling is hard and painless. It may cause very severe deformity of the nose, lips, and cheeks.

Histopathologically, a chronic granulomatous response with large numbers of eosinophils can be seen. The fungi are present as large, straplike hyphae without cross-walls or septa. They are also often surrounded by refractile eosinophilic material (Splendore-Hoeppli phenomenon). The organisms can be cultured readily on Sabouraud's agar. Lesions usually respond to oral treatment with potassium iodide, given in similar doses to those used in sporotrichosis (see above). Ketoconazole (400 mg daily) and itraconazole (100–200 mg daily) also may be useful in this condition, although

experience to date is limited to a few cases.

Rhinosporidiosis

Rhinosporidiosis is a chronic infection caused by the organism *Rhinosporidium seeberi,* which causes the development of polyps affecting the mucous membranes. The organism has never been cultured, and it is now thought to be a member of the Protista. Rhinosporidiosis is seen most often in southern India and Sri Lanka. Cases also have been described in South America, the Caribbean, and South Africa. Exposure to water (lakes, pools) has been associated with the infection. The main site affected is the nasal mucosa, but the conjunctival mucosa also may be affected. [24] The infection causes the development of large polyps that are studded with white flecks; these are small cysts or sporangia containing small spores. These are best seen in histopathologic sections, where the large sporangia or spore sacs in different phases of development are readily seen. The only treatment is surgical excision.

SYSTEMIC MYCOSES

The systemic mycoses are fungal infections whose initial portal of entry into the body is usually a deep site such as the lung, gastrointestinal tract, or paranasal sinuses. They have the capacity to spread via the bloodstream to produce a generalized infection. In practice, there are two main varieties of systemic mycosis: the opportunistic mycoses and the endemic respiratory mycoses.

The chief opportunistic systemic mycoses seen in humans are systemic or deep candidiasis, aspergillosis, and systemic zygomycosis. These affect patients with severe underlying disease states, such as AIDS, or with neutropenia associated with malignancy, solid-organ transplants, or extensive surgery. Where combination antiretroviral therapy is used, the incidence of systemic mycoses in HIV-infected patients has dropped considerably. In the neutropenic patient in particular, other fungi also may cause infection occasionally. Different underlying conditions predispose to different mycoses, and a scheme for this is shown in Table 207-2. Generally, skin involvement is not common with these opportunistic infections, which can occur in any climate and environment. The clinical manifestations of the opportunistic mycoses are also variable because they depend on the site of entry of organism and the underlying disease.

Predisposition	Infection
Neutropenia (whatever cause) functional neutrophil defects	Aspergillosis, oropharyngeal and/or systemic candidiasis, zygomycosis, infections due to rare organisms
CD4 lymphopenia (e.g., AIDS)	Oropharyngeal candidiasis, cryptococcosis and endemic respiratory mycoses such as histoplasmosis, nocardiosis
Diabetes mellitus	Zygomycosis
Heart valve surgery	Various but mainly *C. albicans* and non-albicans *Candida* spp.
Abdominal surgery	Candidiasis

TABLE 207-2 **Underlying Predisposition and Opportunistic Systemic Mycoses**

The endemic respiratory mycoses are histoplasmosis (classic and African types), blastomycosis, coccidioidomycosis, paracoccidioidomycosis, and infections due to *Penicillium marneffei*. The clinical manifestations of these infections are affected by the underlying state of the patient, and many develop in the presence of particular immunodeficiency states, notably AIDS. However, they follow similar clinical patterns in all infections. These infections also may affect otherwise healthy individuals. They have well-defined endemic areas determined by factors that favor the survival of the causative organisms in the environment, such as climate. The usual route of infection is via the lung.

In practice, because of the tendency for both groups of infections to develop in predisposed patients, the distinction between opportunistic and endemic mycoses is blurred. This is particularly the case with the deep infection cryptococcosis, which shares clinical and pathologic features of the two main types of systemic mycosis but is mainly seen now in AIDS patients.

Histoplasmosis

Fungi of the dimorphic genus *Histoplasma* cause a number of different infections in animals and humans. These range from equine farcy, or equine histoplasmosis, a disseminated infection of horses caused by *H. farciminosum,* to two human infections known as *classic* or *small-form histoplasmosis* and *African histoplasmosis*. These are caused, respectively, by two variants of *H. capsulatum: H. capsulatum* var. *capsulatum* and *H. capsulatum* var. *duboisii*. They can be distinguished because their respective yeast phases differ in size, the *capsulatum* variety producing cells from 2 to 5 µm in diameter and the *duboisii* form producing cells of 10 to 15 µm in diameter. The other important differences are in their epidemiology and clinical manifestations. They also show minor antigenic differences that are apparent in serodiagnosis, but their mycelial phases are identical. The two types of human infections will be referred to as *histoplasmosis* and *African histoplasmosis* because this nomenclature is used most widely.

HISTOPLASMOSIS (SMALL-FORM OR CLASSIC HISTOPLASMOSIS OR HISTOPLASMOSIS CAPSULATI)
Histoplasmosis results from infection with the dimorphic fungus *H. capsulatum* var. *capsulatum*. A sexual state of this fungus *Ajellomyces capsulatus* also has been described. The infection starts as a pulmonary infection that, in most individuals, is asymptomatic and heals spontaneously, the only evidence of exposure being the development of a positive intradermal skin test reaction to a fungal antigenic extract, histoplasmin. [25] However, in addition, there is a symptomatic disease that includes respiratory infections and acute or chronic pulmonary histoplasmosis, as well as a disseminated infection that may spread to affect the skin or mucous membrances. Direct inoculation into the skin may occur as a result of a laboratory accident.
Historical aspects Histoplasmosis was first recognized in Panama by Darling in 1905 as the cause of death in a patient from Martinique. The proof that this was caused by a fungus rather than a protozoan came in 1929 when de Monbreun, at

Vanderbilt University, grew the organism in culture. Even so, its importance as a cause of a wider spectrum of infections, including lung disease, was not recognized until the 1940s.

Epidemiology Histoplasmosis occurs in many countries from the Americas to Africa, India, and the Far East. In the United States, it is endemic in the Mississippi and Ohio River valleys, where often more than 80 percent of the population may have acquired the infection asymptomatically. Exposure rates are usually lower in all other endemic areas, although high rates are also found in northern South America and some Caribbean islands. Histoplasmosis is not found in Europe. *H. capsulatum* is an environmental saprophyte that can be isolated from soil, particularly when it is contaminated with bird or bat excreta. The disease is acquired by inhalation of spores, and epidemics of respiratory infection may occur in persons exposed to a spore-laden environment when exploring caves or cleaning sites heavily contaminated with bird droppings, such as bird roosts or barns. Although any person can acquire histoplasmosis through inhalation, it causes a distinctive disseminated infection in patients with disease affecting cellular immune capacity, such as AIDS or lymphoma. [26], [27]

Clinical manifestations The spectrum of histoplasmosis includes asymptomatic as well as benign symptomatic infections and a progressive disseminated variety with bloodstream spread to multiple organs. [25] Skin lesions may develop as a result of immune-complex formation in the primary infection (erythema multiforme) or from direct spread after dissemination from the lungs; rarely, infections may develop at a point of inoculation into the skin. Asymptomatic forms of histoplasmosis are, by definition, without signs or symptoms, but those exposed usually have a positive histoplasmin skin test. The percentage of skin test reactors in the community indicates the chances of exposure, and in endemic areas, this may range from 5 to 90 percent. Occasionally, asymptomatic pulmonary nodules removed at surgical exploration or autopsy are found to contain *Histoplasma*.

ACUTE PULMONARY HISTOPLASMOSIS In this form, patients are often exposed to large quantities of spores such as may be encountered in a cave or after cleaning a bird-infested area. Patients present with cough, chest pain, and fever, often with accompanying joint pains and rash—toxic erythema, erythema multiforme, or erythema nodosum. These skin rashes are not common, occuring in fewer than 15 percent of patients, but they may be precipitated by treatment of the acute infection. On chest x-ray, there is often diffuse mottling, which may calcify with time.

CHRONIC PULMONARY HISTOPLASMOSIS This usually occurs in adults and presents with pulmonary consolidation and cavitation, closely resembling tuberculosis. Skin involvement is not seen.

ACUTE DISSEMINATED HISTOPLASMOSIS In these patients there is widespread dissemination to other organs such as the liver and spleen, lymphoreticular system, and bone marrow. Patients present with progressive weight loss and fever. This form is the type that is most likely to occur in untreated AIDS patients, who often develop skin lesions as a manifestation of disseminated infection [27] (Fig. 207-8). There are papules, small nodules, or small molluscum-like lesions that subsequently may develop into shallow ulcers. Diffuse micronodular pulmonary infiltrates also may develop. Patients have progressive and severe weight loss, fever, anemia, and hepatosplenomegaly.

FIGURE 207-8 Histoplasmosis, disseminated. Multiple erythematous keratotic papules and small plaques resembling guttate pattern psoriasis are seen on the chest and arm of a male with advanced HIV disease. (*Courtesy of JD Fallon, MD.*)

The distinction between acute and chronic dissemination in histoplasmosis is somewhat artificial because these merely represent extremes of behavior, with progression occurring over a few months, on the one hand, and over several years, on the other. Intermediate forms occur, and other organs such as the meninges and heart may be affected.

CHRONIC DISSEMINATED HISTOPLASMOSIS This may appear months or years after a patient has left an endemic area. The most common clinical presenting features are oral or pharyngeal ulceration or adrenal insufficiency (Addison's disease) due to adrenal infiltration. The mouth ulcers are often large, irregular, and persistent and affect the tongue as well as the buccal mucosa. The patients otherwise may appear well, but it is important to investigate them for evidence of infection elsewhere, e.g., by abdominal CT scan. Adrenal infection in particular should be excluded.

PRIMARY CUTANEOUS HISTOPLASMOSIS This form is rare and follows inoculation of the organism into the skin, for instance, after accidental laboratory- or postmortem room–acquired infection. The primary lesion is a nodule or indurated ulcer, and there is often local lymphadenopathy.

Differential diagnosis The organism is the same size as a number of others causing deep mycoses such as *P. marneffei* and small forms of *Blastomyces* and *Cryptococcus* (see below). It is also similar in size to *Leishmania* species, and in the tropics, kala-azar is an important part of the differential diagnosis. These observations emphasize the importance of carrying out appropriate laboratory tests to confirm the diagnosis.

Laboratory diagnosis The diagnosis of histoplasmosis is established by identifying the small intracellular yeast-like cells of *Histoplasma* in sputum, peripheral blood, bone marrow, or biopsy specimens. *Histoplasma* must be separated from *P. marneffei* because the two organisms are of a similar size, although the latter shows characteristic septa formation. The identity of the organism should be confirmed by culture; it grows as a mold at room temperature. The white, cottony colonies develop at room temperature on Sabouraud's glucose agar to produce two types of spores, the larger (8–15 µm), rounded, tuberculate macroconidia being typical; the smaller microconidia are infectious. Confirmation of the identity should be obtained by demonstrating the production of diffusing exoantigen by an immunodiffusion assay (exoantigen test). Mycelial-phase cultures of *H. capsulatum* are very infectious, and laboratories receiving specimens should be warned about the suspected diagnosis. The intradermal histoplasmin skin test is an epidemiologic tool that is

of no help in diagnosis. In patients with disseminated histoplasmosis, it is often negative. By contrast, serology is often useful in diagnosis. A rising complement-fixation titer indicates dissemination. Precipitins detected by immunodiffusion are also valuable because the presence of antibodies to specific H and M antigens correlates well with active or recent infection. [28] A new development, particularly helpful in AIDS patients, has been serologic tests for the detection of circulating *Histoplasma* antigens. [29] In histopathologic sections, *H. capsulatum* is an intracellular parasite often seen in macrophages. The cells are small (2–4 µm in diameter) and oval in shape with small buds (Fig. 207-9). Mycelial forms are seen rarely in tissue.

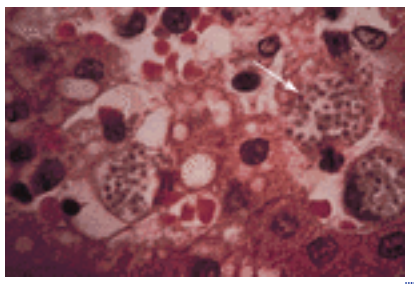

FIGURE 207-9 Histoplasmosis, disseminated. Lesional biopsy specimen shows dermal macrophages packed with dozens of tiny yeast forms of *H. capsulatum*.

AFRICAN HISTOPLASMOSIS (LARGE-FORM HISTOPLASMOSIS OR HISTOPLASMOSIS DUBOISII) This infection is sporadic and uncommon. [30] It is seen in patients from areas south of the Sahara and north of the Zambezi River in Africa. Infections seen outside Africa are all imported. The most common clinically involved sites are the skin and bone, although lymph nodes and other organs, including the lungs, may be affected. Skin lesions range from small papules resembling molluscum contagiosum to cold abscesses, draining sinuses, or ulcers. It is not clear if there is an asymptomatic form of African histoplasmosis as in classic histoplasmosis. The diagnosis is confirmed by culture and microscopy (direct microscopy or histopathology). The organisms of *H. capsulatum* var. *duboisii* are different from the smaller *capsulatum* forms. They are usually 10 to 15 µm in diameter, slightly pear-shaped, and clustered in giant cells. *Histoplasma* serology, using conventional tests, is often negative in African histoplasmosis.

TREATMENT The choice of therapy for histoplasmosis depends on the severity of the illness. For patients with some disseminated or localized forms of the disease, oral itraconazole (200–400 mg daily) is highly effective. It also has been used for long-term suppressive treatment of the disease in AIDS patients after primary therapy either with itraconazole or amphotericin B. [31] However, there is now evidence that provided CD4 counts do not fall in patients on HAART therapy, suppressive treatment can be discontinued. Intravenous amphotericin B (up to 1 mg/kg daily) is given to patients with widespread and severe infections and is the main alternative used. Ketoconazole and fluconazole are also effective in many cases. In African histoplasmosis, itraconazole is also the treatment of choice, but once again, in severe cases amphotericin B may be used. [30]

Blastomycosis (North American Blastomycosis, Gilchrist Disease)

Blastomycosis is a chronic mycosis caused by the dimorphic pathogen *Blastomyces dermatitidis*. [32] Its chief sites of involvement are the lungs, but disseminated forms of the infection may affect skin, bones, CNS, and other sites.

HISTORICAL ASPECTS The infection was first described by Gilchrist in 1894. Many of the early cases were described from the Chicago area, and originally this disease was called *North American blastomycosis* until, in 1952, the first case was described from North Africa. It is now recognized that this infection has a wider distribution, although it is not common anywhere.

EPIDEMIOLOGY The infection is found in North America and Canada. [33] Most cases, though, come from the Great Lakes Region and southern states of the United States. It also occurs sporadically in Africa, with the largest numbers of cases coming from Zimbabwe, [34] and cases also have been reported from the Middle East and India. It is thought that the natural habitat of *Blastomyces* is in some way related to wood debris and is close to rivers or lakes or in areas subjected to periodic flooding. However, it is difficult to isolate *Blastomyces* from the natural environment. [35] Blastomycosis also may affect domestic animals such as dogs.

CLINICAL MANIFESTATIONS As with histoplasmosis, there is a subclinical form of the infection; its prevalence has not been defined in detail because of lack of a commercial *Blastomyces* skin test antigen and the extent of antigenic cross-reactivity with fungi such as *Histoplasma*. Primary cutaneous blastomycosis is also very rare and follows trauma to the skin and the subsequent introduction of fungus, for instance, in laboratory workers or pathologists. [36] After inoculation, an erythematous, indurated area with a chancre appears in 1 to 2 weeks with associated lymphangitis and lymphadenopathy. Pulmonary blastomycosis is very similar in clinical presentation to pulmonary tuberculosis. [33], [36], [37] There may be no symptoms, or there may be low-grade fever, chest pain, cough, and hemoptysis, and unlike histoplasmosis, it often coexists with disseminated disease. Skin lesions are a common presenting feature of disseminated blastomycosis. [36], [38] They are often symmetric and usually affect the face and extremities. The early lesion is a papule or nodule, which may ulcerate and discharge pus. With time, this enlarges to form a hyperkeratotic lesion, often with central scarring or ulceration (Fig. 207-10, Fig. 207-11 and Fig. 207-12). Oral lesions are less common. Multiple skin lesions are often found in disseminated infection. Other patients may present with nodules and abscesses, and in many patients lesions of different morphologies are present. African patients with blastomycosis have a higher frequency of skin and bone involvement. [34] Although blastomycosis can affect almost any organ, other common sites for dissemination include the bone, the epididymis, and the adrenal gland. Less commonly, there is widespread rapid dissemination with multiple organ involvement, and *B. dermatitidis* can produce a form of adult respiratory distress syndrome (ARDS). Skin lesions in widespread disseminated disease are usually papules, abscesses, or small ulcers. Widespread blastomycosis has been described in AIDS patients, but it is not common. [39]

FIGURE 207-10 Blastomycosis. Older lesion, appearing as a verrucous plaque.

FIGURE 207-11 Blastomycosis. Inflammatory plaque with ulceration resembling pyoderma gangrenosum on the calf. (*Courtesy of Elizabeth M. Spiers, MD.*)

FIGURE 207-12 Blastomycosis. Chronic verrucous plaque on the cheek.

DIFFERENTIAL DIAGNOSIS The chronic skin granulomas must be differentiated from those due to tuberculosis, other deep mycoses, nonmelanoma skin cancers, pyoderma gangrenosum, and drug reactions due to bromides and iodides.
LABORATORY IDENTIFICATION The fungus can be found in KOH mounts of pus, skin scrapings, or sputum as thick-walled, rounded refractile spherical cells with broad-based buds (Fig. 207-13). In culture, the fungus grows as a mycelial fungus at room temperature. It produces small, rounded or pear-shaped conidia. At higher temperature (37°C) and on enriched media, it produces yeast forms with the characteristic buds. In tissue sections, the typical organisms with broad buds may be found, although it may be necessary to search several fields to find the characteristic cells.

FIGURE 207-13 Direct preparation (KOH) of *Blastomyces.*

These are often found in giant cells or surrounded by neutrophils (Fig. 207-14). Precipitating antibodies to *B. dermatitidis* are often present in the sera of infected patients, and a characteristic precipitin line, the E band, has been described in a high proportion of proven cases; there is also an enzyme-linked immunosorbent assay for blastomycosis. However, one of the problems with serodiagnosis in blastomycosis is the presence of a high number of false-positive reactions in uninfected persons and cross-reactivity with other fungi.

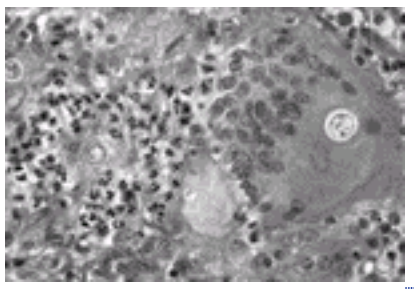

FIGURE 207-14 Blastomycosis. Lesional biopsy specimen shows many thick-walled budding yeast forms.

TREATMENT Treatment is similar to that used for histoplasmosis, itraconazole (200–400 mg daily) is used in the less severe forms of the infection or where there is only localized spread. Treatment is usually given for at least 6 months. Follow-up surveillance is necessary because relapse can occur, particularly where there are deep sites of infection or the patient is immunosuppressed. Amphotericin B (up to 1 mg/kg daily) is generally used for the treatment of widespread

disseminated forms of blastomycosis. Ketoconazole is an alternative therapy.

Coccidioidomycosis (Coccidioidal Granuloma, Valley Fever, San Joaquin Valley Fever, Desert Rheumatism)

Coccidioidomycosis is the infection caused by the fungus *Coccidioides immitis*. It shows an unusual form of dimorphism, with a mold form at room temperature and the development of large, spore-containing structures, spherules, in infected tissue. As with other endemic mycoses, there are asymptomatic, acute and chronic pulmonary, and disseminated forms. The disease can affect otherwise healthy individuals or predisposed patients, including those with AIDS.

HISTORICAL ASPECTS Coccidioidomycosis was first described as a disseminated infection in Argentina by Posadas in 1892. Later, this was connected with a benign self-resolving form, valley fever, in California, and in 1938, studies with an antigen from the organism, coccidioidin, confirmed that there was widespread exposure in endemic areas of the United States.

EPIDEMIOLOGY *C. immitis* is endemic in some semidesert areas of the southwestern states of the United States (e.g., California, Arizona, New Mexico, and Texas) and in parts of Mexico and Central and South America. The climate of the endemic areas is marked by very high summer temperatures and low annual rainfall, demonstrated by a characteristic vegetation with cacti and mesquite bushes. Skin tests with coccidioidin show that the incidence of exposure in endemic areas may be as high as 95 percent. The fungus is found in soil and can affect other animals as well as humans. Exposure may result from a brief visit to an endemic area, and local weather can determine exposure rates. [40], [41] For instance, dust storms may cause infection in large numbers of individuals. The usual route of infection is respiratory, although direct implantation into the skin can occur rarely.

CLINICAL MANIFESTATIONS As with other systemic mycoses, there is an asymptomatic or subclinical form that is common in endemic areas, judging by the percentages of skin test reactors to coccidioidin in the healthy population. The primary pulmonary form, which is the most common clinical type, presents as a chest infection with fever, cough, and chest pain. Complications such as pleural effusion may occur. Erythema multiforme or erythema nodosum, [41] often accompanied by arthralgia or anterior uveitis, occurs from the third to the seventh week in about 10 to 15 percent of patients and is more common in females. Sometimes an early, generalized, macular and erythematous rash is seen in some patients. The chronic pulmonary form of the disease presents with chronic cough and resembles tuberculosis. Skin lesions normally do not occur in this phase. In the rare primary skin infection, following inoculation, there is an indurated nodule that develops 1 to 3 weeks after local trauma. This is followed by regional lymphadenopathy. Disseminated coccidioidomycosis develops in fewer than 0.5 percent of infected individuals. It is mainly seen in patients from certain ethnic backgrounds (American blacks, Filipinos, or Mexicans), in pregnant women, and in immunosuppressed patients, including those with AIDS. [42], [43] In disseminated disease, lesions may develop in the skin, subcutaneous tissues, bones, joints, and all organs. The skin lesions (Fig. 207-15) are abscesses, granulomas, ulcers or discharging sinuses in which there is underlying bone or joint disease. Some lesions appear as flat plaques with central atrophy. Meningitis is an important complication of dissemination and is usually not associated with signs of infection in other sites. In AIDS patients, persistent pneumonia, skin lesions, and widespread dissemination can all occur.

FIGURE 207-15 Coccidioidomycosis, disseminated. Intact and ulcerated papules and nodules are seen on the cheek and nose of this comatose patient with coccidioidomycotic meningitis. (*Courtesy of Francis Renna, MD.*)

DIFFERENTIAL DIAGNOSIS Physicians in endemic areas should be aware of the connection between erythema nodosum and coccidioidomycosis. It also may occur in visitors to endemic areas after only a short stay.

LABORATORY DIAGNOSIS A characteristic of the laboratory findings is the ability of *C. immitis* to form spore-containing spherules. These are large (up to 250 µm) and can be seen in KOH mounts of sputum, cerebrospinal fluid (CSF), or pus. In culture, colonies of *C. immitis* are mycelial, fast-growing, white, and cottony. On microscopy, there are chains of arthrospores at intervals on the older mycelium. *C. immitis* in the mold phase is highly infectious, and cultures should be handled carefully. Serologic tests are of value in the diagnosis and prognosis of coccidioidomycosis. [44] Precipitins develop in about 90 percent of infected individuals within 2 to 6 weeks but are short-lived; complement-fixing antibodies are characteristic of more severe infections and, in active infection, increase to a maximum after 6 months. Skin tests with coccidioidin are of little value in diagnosing infections. Spherulin is an antigen obtained from spherules of *C. immitis* and may be better than coccidioidin for detecting sensitization. However, in severe infections, cutaneous anergy to both is common. Spherules containing large endospores can be seen in tissue sections, although there are a variety of less distinct intermediate stages in spherule formation that also can be seen. Before endospores form, the cytoplasm of the immature spherule is basophilic and subsequently breaks up into spores. Mycelium is seen rarely in histopathologic sections.

TREATMENT No specific therapy apart from rest is necessary in the primary pulmonary infection, and there is little evidence that the symptoms are either improved or shortened by giving an oral azole drug, even though it is widespread practice. For disseminated disease, treatment is still unsatisfactory, but amphotericin B (1 mg/kg daily), itraconazole (200–400 mg daily), or fluconazole (200–600 mg daily) can all be given. [45] Experience with the newer antifungal agents such as voriconazole and posaconazole is limited at present. It is important to follow patients carefully, given the frequency of relapse. Meningitis, arthritis, and progressive disseminated infection involving multiple sites are all particularly refractory to therapy. Generally, soft tissue coccidioidomycosis (skin and joint) has a better prognosis, and the mortality in patients who present with soft tissue lesions is low.

Paracoccidioidomycosis (South American Blastomycosis, Paracoccidioidal Granuloma)

Paracoccidioides brasiliensis is a dimorphic fungus that causes a respiratory infection with a tendency to disseminate to the mucous membranes and lymph nodes. It is confined to Central and South America. [46]

HISTORICAL ASPECTS Paracoccidioidomycosis was first described in Brazil by Lutz in 1908. Although initially thought to be related to coccidioidomycosis, described a few years earlier in Argentina, the organism was isolated in 1912 and shown to be different.
EPIDEMIOLOGY Paracoccidioidomycosis has been reported from most Latin American countries, but the infection is found most commonly in parts of Brazil, Colombia, and Argentina. The infection does not occur in the United States, although it has been reported from Mexico. Exposure rates can be estimated by skin test reactivity and appear to be equal in both males and females, although the prevalence of positive reactors in endemic areas seldom exceeds 25 percent. In contrast, the active infection is seen predominantly in males. The mechanism is thought to be connected to the presence of a cytoplasmic estrogen receptor on the fungus, and in vitro, estradiol suppresses the conversion of mycelium to yeast. [47] The ecologic niche of the organisms is unknown, but the condition is much more frequent in rural areas; exposure has been associated with proximity to water or areas of high atmospheric humidity. [48]
CLINICAL MANIFESTATIONS There are a number of different clinical patterns of infection that depend on the predominant site of clinical involvement. These include the lung (pulmonary form), the mucous membranes (mucocutaneous form), and the lymph nodes (lymphatic form). Many patients have a mixed type of infection with involvement of different organ groups. [46] Patients rarely present with an acute form of pulmonary infection; rather, it tends to be chronic and slowly progressive with weight loss and chronic cough. The lesions may be bilateral and nodular on chest x-ray, and there is often extensive fibrosis. Other sites of involvement include mucocutaneous areas. Oral or circumoral lesions are common in the mucocutaneous forms of paracoccidioidomycosis; lesions also occur in the nose, conjunctivae, or around the anus. These lesions may be small granulomas or ulcers. They heal with scarring, which may cause considerable deformity. The cervical lymph nodes are sometimes enlarged, tender, and tethered to the overlying skin; they rarely suppurate. Other systemic sites of involvement include the spleen, intestines, lungs, and liver. Paracoccidioidomycosis is uncommon in AIDS patients, although there is a widespread variety that is a more rapidly progressive form of disseminated infection occurring in young adults or older children without recognizable predisposition. [49]
DIFFERENTIAL DIAGNOSIS This includes tuberculosis, leishmaniasis, and other deep mycoses.
LABORATORY DIAGNOSIS Sputum, exudates, and scrapings can be screened using KOH. They show numbers of round yeasts with a characteristic form of multiple budding in which a parent cell is surrounded by large numbers of smaller buds. The organism is dimorphic and produces a cottony mycelial-phase growth on primary isolation at room temperature. Once again, the characteristic yeast phase can be induced on enriched media such as BHI agar at 37°C. Serology is very helpful in confirming the diagnosis, the main tests being the immunodiffusion assay and a complement-fixation test. Recently, antibodies to a 43-kDa antigen have been found to be highly specific for this infection in immunoblotting. There is also an antigen-detection test useful in monitoring patients with disseminated disease. Histopathologically, there is a mixed granulomatous response with fibrosis. The organisms can be seen with special fungal stains such as methenamine silver (Grocott modification). In tissue, the characteristic budding pattern can be seen, although it may be necessary to search several fields to find the most typical structures (Fig. 207-16). In widespread infections, masses of small yeast forms may be mistaken for *Histoplasma*.

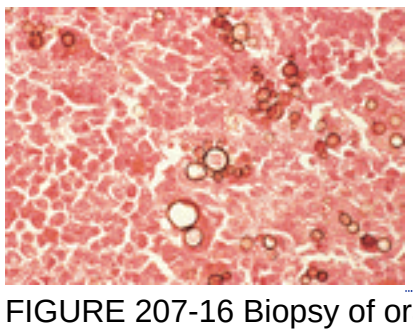

FIGURE 207-16 Biopsy of oral mucosal lesion showing multiple budding *Paracoccidioides brasiliensis.*

TREATMENT The treatment of choice in most cases is itraconazole, which can produce remissions in 3 to 6 months. [50] Ketoconazole is an alternative. Relapses can occur, and where possible, patients should be reviewed periodically after primary therapy. In very extensive infections and in severely ill patients, such as those with the progressive disseminated type of infection, intravenous amphotericin B may be necessary. Severe pulmonary or intraoral fibrosis may remain after treatment.

Infections due to *Penicillium marneffei* (Penicilliosis, Penicilliosis Marneffei)

This infection is a more recently recognized disease found in Southeast Asia. *P. marneffei* is a member of the common genus *Penicillium*. It shows an unusual pattern of dimorphism in that it develops yeast-like cells that reproduce with septal formation, dividing the cells into two. It is inhaled via the lungs, and it is not known whether there is a primary cutaneous form of the infection.

HISTORICAL ASPECTS This disease was first recognized in 1959 by Segretain in a specimen from Vietnam. [51] Subsequent cases in U.S. veterans from Vietnam and then cases from Thailand and China have confirmed the wide geographic extent of this infection.
EPIDEMIOLOGY The natural source of *P. marneffei* is unknown. Infections are confined to Southeast Asia, particularly Thailand, South China, and Vietnam. However, there are reports in other Asian countries, including northeast India, and imported cases are seen in Europe and the United States. Natural infections are known to occur in bamboo rats, which are large burrowing rodents. The infection affects otherwise healthy individuals as well as those with immune defects and is most common after the rainy season. [52] Patients with AIDS appear to be particularly susceptible to this infection.
CLINICAL MANIFESTATIONS There has been no work to demonstrate that there is a subclinical form of *Penicillium*

infection, even though this is likely. Patients usually present with localized pulmonary or disseminated disease. The chest signs are those of chronic pulmonary disease. [53], [54] Over 50 percent of AIDS patients with this infection have multiple skin lesions, which are umbilicated papules that may enlarge and ulcerate. They are usually widely scattered on the face and trunk. Other organs including the liver, gastrointestinal tract, spleen, and bone marrow may be affected.

DIFFERENTIAL DIAGNOSIS The main differential diagnosis is with other disseminated mycoses such as histoplasmosis and cryptococcosis, which also can be found in the endemic area in AIDS patients. Biopsy and, where necessary, culture will distinguish between the different causes.

LABORATORY DIAGNOSIS *P. marneffei* forms characteristic yeastlike cells that are divided by a septum in tissue and are best seen in histopathologic sections stained with methenamine silver. These cells are small (2–4 µm) and difficult to see in blood films or skin or bone marrow smears, but they may be highlighted with stains such as leishmanin. In culture, *P. marneffei* is a green or grayish mold that produces typical *Penicillium* conidiophores and a diffusible red pigment. There is no commercial serologic test as yet.

TREATMENT In severe cases, amphotericin B is necessary. In many cases, however, there is a good response to itraconazole (200–400 mg daily). In AIDS patients, this is continued after initial therapy to prevent relapse. [54]

Cryptococcosis (Torulosis, European Blastomycosis)

Cryptococcosis is the infection caused by the encapsulated yeast *Cryptococcus neoformans*. Although the main portal of entry is through inhalation into the lungs, the disease usually presents with signs of extrapulmonary dissemination such as meningitis. Cutaneous lesions can develop as a result of dissemination or, rarely, through inoculation.

HISTORICAL ASPECTS *C. neoformans* was first demonstrated by Busse and Buschke in a patient with a bone infection in 1894. The capsule was originally misidentified as the result of histolytic action in vivo. In its time, this organism has been assigned to a variety of different fungal genera from *Torula* to *Saccharomyces*. Subsequently, other cases showed that *Cryptococcus* could cause a variety of different clinical forms of disease, notably meningitis. The advent of the AIDS epidemic has affected the epidemiology of this infection considerably, and in areas such as northern Thailand, cryptococcosis is one of the main secondary complications of HIV infection. [55]

EPIDEMIOLOGY Cryptococcosis has a worldwide distribution, although exposure rates probably differ markedly in different countries. *C. neoformans* has two variants: *C. neoformans* var. *neoformans* and *C. neoformans* var. *gattii*. These correspond to two clusters of serotypes: (1) A, D, or AD and (2) B or C. [56] The *neoformans* variety can be isolated from pigeon excreta and is more common in AIDS patients; the *gattii* form is found in the debris of certain eucalyptus trees in the tropics and California, but it is less often isolated from AIDS patients. Two sexual varieties called *Filobasidiella neoformans* and *F. bacillispora* correspond to the *neoformans* and *gattii* varieties, respectively. Patients with certain immunodeficiency states caused by AIDS, malignant lymphomas, sarcoidosis, collagen disease, and carcinoma and those receiving systemic glucocorticoid therapy are particularly susceptible. The incidence of cryptococcosis in patients with established AIDS varies in different countries from 3 to 6 percent in the United States, to 3 percent in the United Kingdom, to over 12 percent in parts of Africa, e.g., Zaire. Strains of serotype D are more likely to be found in skin lesions, which occur in 10 to 15 percent of cases of disseminated cryptococcosis.

CLINICAL MANIFESTATIONS There is probably a subclinical form of cryptococcosis because unaffected individuals may have positive skin tests. However, the most common clinical manifestation of disease is meningoencephalitis. This presents with classic signs of meningismus, changes in consciousness, mental changes, and nerve palsies. In AIDS patients, these signs may be only weakly expressed. Pulmonary infection can be found in about 10 percent of those with meningitis. Chest signs include the appearance of nodular shadows, cavitation, and pleural effusion. Patients with AIDS often present with fever and mild headache and few other features of infection. [55] Cutaneous lesions may develop in about 10 percent of cases but are seldom pathognomonic. [57], [58], [59] and [60] Acneiform papules or pustules progressing to warty or vegetating, crusted plaques, ulcers, and hard infiltrated plaques or nodules are characteristic of widespread systemic infection (Fig. 207-17). Cold abscesses, cellulitis, and nodular lesions also occur. In otherwise healthy patients or those with sarcoidosis, lesions may be solitary, and in such patients they may be the only clinical manifestation of infection.

FIGURE 207-17 Cryptococcosis, disseminated. Multiple, discrete, skin-colored papules and nodules resembling molluscum contagiosum are seen on the face of a male with advanced HIV disease. (*Courtesy of Loïs Vaillant, MD.*)

In primary cutaneous cryptococcosis with direct inoculation of organisms into the skin, the skin lesions are usually solitary nodules that break down and ulcerate. Local lymphadenopathy also develops. The term *primary cutaneous cryptococcosis* is also used loosely to describe solitary lesions of cryptococcosis, but in many such cases there is also evidence of dissemination to other internal organs. It is important to investigate all patients who present with cutaneous lesions for evidence of dissemination to other sites. [58]

DIFFERENTIAL DIAGNOSIS Cryptococcal skin lesions may mimic a range of other conditions, particularly other systemic mycoses in AIDS patients. It is important to biopsy and culture suspicious lesions in immunocompromised patients.

LABORATORY DIAGNOSIS Cryptococci are large (5–15 µm), budding cells with capsules that are best observed by direct microscopy of India ink or Nigrosin mounts (Fig. 207-18). The organism is not difficult to grow in culture. Various biochemical features such as the production of urease and the ability to pigment on Guizotia seed medium are characteristic. Serologic tests are rapid and specific. The main test is an antigen-detection assay using latex agglutination or ELISA, and this is simple and very rapid to perform on blood or CSF. Very high titers are found in AIDS patients in serum and CSF. Non-AIDS patients with single, localized skin lesions are often antigen-negative.



FIGURE 207-18 Cryptococcosis. India ink preparation of cerebrospinal fluid.

In tissue sections, the large pleomorphic yeasts stimulate either a granulomatous reaction or very little inflammation. The capsules of the cells can be stained using the mucicarmine or alcian blue stains.
TREATMENT The most frequently used drug regimen in the non-AIDS patient is intravenous amphotericin B combined with flucytosine. In patients with single skin lesions and no other signs of infection, alternatives such as fluconazole or itraconazole can be used. In AIDS patients, there is a very high relapse rate, and the usual policy is to give a 10- to 14-day course of amphotericin B with or without flucytosine, followed by long-term fluconazole. [61] However, it may be possible to stop suppressive therapy in patients receiving HAART. Fluconazole given on its own is an alternative approach.

Cutaneous Aspects of Systemic Opportunistic Mycoses

Skin lesions are not common with the opportunistic fungal infections, but they can occur in some, particularly in certain predisposed groups. When they occur, their presence may be very helpful because it is possible to biopsy easily accessible lesions in order to establish the diagnosis.

Systemic Candidiasis (See Chapter 206)

This follows dissemination of *Candida* species from the gastrointestinal tract or via the bloodstream. Skin lesions may occur particularly in two situations: (1) In neutropenic patients, there is often a severe disseminated disease with widespread skin nodules and associated muscle pains, [62] and (2) in intravenous drug abusers, candidiasis may present with a follicular, pustular rash in the beard area and scalp. Other lesions include retinal deposits and abscesses around the costochondral junctions. [63]

Systemic candidiasis is usually treated with intravenous amphotericin B (conventional or lipid-associated) or fluconazole. Resistance to some azole drugs, such as fluconazole and ketoconazole, is more common with certain non- *albicans Candida* species, and these antifungal agents should be avoided in infections caused by these species.

Zygomycosis (Mucormycosis, Phycomycosis)

Zygomycosis is a rare disease caused by zygomycete fungi such as *Rhizomucor, Absidia,* and *Rhizopus. Cunninghamella bertholletiae* and *Saksenaea vasiformis* are less common causes. Zygomycetes cause disease in patients with poorly controlled diabetes, neutropenia, or renal disease. They can invade necrotic burned areas or involve the facial skin secondary to invasive infection of the paranasal sinuses (Fig. 207-19). Zygomycete infections also have been associated with close apposition of the skin with contaminated dressing materials in the case of *R. rhizopodiformis* [64] or with wooden tongue depressors in the case of *R. microsporus*. [65] The zygomycete fungi have a tendency to invade blood vessels, causing widespread infarction. Infections may respond to intravenous amphotericin, and recent results with lipid-associated amphotericin B formulations have been encouraging.

FIGURE 207-19 Mucormycosis. *A.* The face of this young woman with diabetes mellitus shows proptosis, unilateral facial edema, and a right-sided facial palsy associated with infection beginning in the right maxillary sinus. *B.* Ulcer. *C.* Hyphae in tissue.

Other Opportunistic Mycoses

Other fungi causing systemic infections also may produce skin lesions in the process of bloodstream dissemination. The best known of these organisms are *Aspergillus, Scedosporium, Trichosporon,* and *Fusarium*. Skin infection is seen mainly in severely immunocompromised patients such as those with neutropenia.

Aspergillus may produce large necrotic lesions such as ecthyma gangrenosum, but smaller papules and cold abscesses also can occur. [66] *Fusarium* infections may produce widely distributed target-like lesions that may undergo central necrosis and, in some cases, digital cellulitis and superficial white onychomycosis. [67] Treatment for all these infections is usually amphotericin B.

LABORATORY DIAGNOSIS OF OPPORTUNISTIC MYCOSES Laboratory confirmation of the diagnosis is fraught with difficulties chiefly because many of the organisms are also commensals in human sites; since they occur in severely ill patients, the capacity to produce diagnostic antibody titers is compromised. The interpretation of laboratory data is consequently difficult and has to be related to the clinical state of the patient. Ideally, a histologic diagnosis should be made, although biopsy may be impossible because of the risk of bleeding. In many cases, the diagnosis of a systemic mycosis is presumptive, and treatment therefore is given empirically.

Actinomycosis

Actinomycosis is an infection caused by filamentous bacteria that form large granules (sulfur granules) in abscess cavities. Draining sinuses communicate from the center of the abscess to the skin or mucosal surface.

HISTORICAL ASPECTS The first human case was described by Israel in 1878, 1 year after the disease had been recognized in cattle. In 1910, it was first recognized that the organism, *Actinomyces israelii,* was carried in the oral cavity and tonsils. Early literature is full of reports of this infection, which fortunately is seen much less frequently nowadays.
EPIDEMIOLOGY The main causative organism, *A. israelii,* an anaerobic actinomycete, is a normal inhabitant of the human mouth. Actinomycosis is therefore an endogenous infection. *A. bovis, A. naeslundii, Arachnia propionica,* and *Bifidobacterium eriksonii,* all inhabitants of the mouth, are rarer causes of human disease. The incidence of the infection is affected by the availability of good dental care, since poor dental hygiene and delayed treatment of intraoral infections lead to a greater risk of actinomycosis. The disease has a worldwide distribution but is not common. Other sites of carriage include the vaginal mucosa, and this also may affect the development of infection. In most cases of actinomycosis, the formation of granules is thought to require cooperation with other bacteria.
CLINICAL MANIFESTATIONS There are five main types of actinomycosis, depending on the primary site of infection. [68], [69] Actinomycosis usually remains localized. The infections are cervicofacial, thoracic, abdominal, pelvic, and primary cutaneous. Cervicofacial actinomycosis is the most common form of this infection (Fig. 207-20). It usually presents with an indurated nodule or plaque on the cheek or submaxillary region. In the later stages, multiple sinuses develop on the surface; these discharge pus and sulfur granules. The initial site of infection is probably a dental abscess, and it is likely that many cases are now treated before the typical features develop. Sulfur granules are sometimes found in tonsillar crypts after elective tonsillectomy, and in this case, they do not appear to be causing symptomatic illness.

FIGURE 207-20 Actinomycosis, cervicofacial form. *A.* Localized lesion with sinus margin. *B.* Chronic cervicofacial, actinomycosis. (*Courtesy of R. Arenas, MD.*)

Thoracic actinomycosis only presents with skin changes if the underlying lung infection, which mimics pulmonary tuberculosis, involves the outer chest wall. Once again, multiple sinuses communicate with the underlying lung infection. Abdominal actinomycosis usually begins with an abscess in the appendix or cecum. Skin involvement, which is now rare, follows extension of the infection to the anterior abdominal wall with the formation of sinuses. Pelvic actinomycosis is a distinct form of actinomycosis associated with the use of intrauterine contraceptive devices. However, the skin is not affected, and the infection presents as an intrapelvic mass associated with signs of chronic pelvic inflammation. Primary cutaneous actinomycosis is very rare. [70] It occurs on exposed skin and clinically mimics mycetoma; the infection is thought to follow implantation of organisms.
DIFFERENTIAL DIAGNOSIS Actinomycosis has a typical appearance, with draining sinuses related to potential sites of infection. Tuberculosis and mycetoma are the main differentials to be excluded.
LABORATORY DIAGNOSIS The presence of sulfur granules is typical. These are yellow granules up to 1 to 2 mm in diameter that on Gram staining contain a mixture of thin bacterial filaments. Cultures of *A. israelii* are incubated under anaerobic conditions at 37°C. Histopathologically, there is a suppurative inflammatory process, and small abscesses contain the granular colonies of the organism surrounded by neutrophils. With hematoxylin and eosin staining, the outer zone of the granule contains a layer of eosinophilic, refractile, clublike structures.
TREATMENT *A. israelii* is sensitive to sulfonamides, streptomycin, penicillin, chloramphenicol, chlortetracycline,

oxytetracycline, tetracycline, rifampicin, and erythromycin. [71] High doses of intravenous or intramuscular penicillin are the usual treatment given for this infection. The course has to be continued for several weeks. Alternative medications include erythromycin, tetracyclines, and imipenem.

Nocardiosis

Nocardiosis is an acute or chronic infection caused by filamentous bacteria of the genus *Nocardia*. These cause localized skin or subcutaneous infections, including abscesses and actinomycetoma, as well as a systemic infection that may disseminate to involve the skin.

HISTORICAL ASPECTS As with actinomycosis, nocardial infection was first described in cattle in 1888 by Nocard. The first human patient had a disseminated infection with involvement of the lungs and brain. Nocardiosis has become more common because it is associated with immunosuppression.
EPIDEMIOLOGY The main pathogenic species of *Nocardia* are *N. asteroides, N. brasiliensis,* and *N. otitidis-caviarum*. These are soil organisms, but generally, *N. asteroides* is environmentally dominant in northern climates, whereas *N. brasiliensis* is more common in the south. *Nocardia* can gain entry through a superficial wound to cause a localized dermal or subcutaneous infection; it also can be inhaled via the lungs to cause a pulmonary infection. In causing systemic disease, *Nocardia* usually behaves as an opportunistic pathogen, causing disease in patients with an underlying predisposition such as AIDS, solid-organ transplant, Cushing syndrome, diabetes, and following the use of corticosteroids in the treatment of various diseases. Occasionally, there are outbreaks of nocardiosis in hospitals, associated with contamination of ventilation systems. [72]
CLINICAL MANIFESTATIONS Rarely, *Nocardia* can cause a subcutaneous abscess or a lymphangitic form (see "Sporotrichosis" above), in which multiple suppurative nodules develop along a lymphatic chain. [73], [74] and [75] Actinomycetoma due to *Nocardia* species has been described earlier. In systemic nocardiosis, the main sites for infection are the lung or the brain. Lung lesions resemble pulmonary tuberculosis, whereas brain lesions present as intracranial space-occupying lesions and with fever. In about 30 percent of cases of systemic infection there are metastatic cutaneous abscesses, which are often multiple [76]; this is a particular feature of infection in patients with AIDS. [77]
LABORATORY DIAGNOSIS Although *Nocardia* species form grains in mycetomas, in other infections they are present as fine-branching filaments. These can be seen in pus from skin lesions or sputum after staining by Gram stain, methenamine silver, and modified acid-fast techniques because *Nocardia* are only partially acid-fast. The organisms can be cultured on Sabouraud's agar. Serology can be useful in the diagnosis of systemic nocardiosis.
TREATMENT The most widely used treatment is co-trimoxazole. Alternatives include ampicillin, minocycline, amikacin, and more recently, imipenem. Unfortunately, the results of in vitro testing for antibiotic sensitivity may not accurately reflect the subsequent clinical responses.

REFERENCES

1. Chandler FW et al: *A Colour Atlas and Text Book of the Histopathology of Mycotic Diseases*. London, Wolfe, 1980, pp 92, 98

2. Warnock DW, Richardson MD (eds): *Fungal Infection in the Compromised Patient*. Chichester, Wiley, 1991

3. Kibbler CC et al: *Principles and Practice of Clinical Mycology*. Chichester, Wiley, 1996

4. Jacobs PH, Nall L (eds): *Fungal Disease: Biology, Immunology and Diagnosis*. New York, Marcel Dekker, 1997

5. Winn RE: A contemporary view of sporotrichosis. *Curr Top Med Mycol* **6**:73, 1995

6. de Albornoz MCB: Sporotrichosis, in *Tropical Fungal Infections, Bailliere's Clinical Tropical Medicine and Communicable Diseases,* vol 4, edited by RJ Hay. London, Bailliere Tindall, 1989, p 71

7. Pappas PG et al: Sporotrichosis in Peru: Description of an area of hyperendemicity. *Clin Infect Dis* **30**:65, 2000

8. Itoh M et al: Survey of 260 cases of sporotrichosis. *Dermatologica* **172**:203, 1986

9. Bibler MR et al: Disseminated sporotrichosis in a patient with HIV infection after treatment for acquired factor VIII inhibitor. *JAMA* **256**:3125, 1986

10. Kauffman CA et al: Practice guidelines for the management of patients with sporotrichosis. For the Mycoses Study Group, Infectious Diseases Society of America. *Clin Infect Dis* **30**:684, 2000

11. 11. Mahgoub ES, Murray IG: *Mycetoma*. London, Heinemann Medical, 1973

12. Hay RJ et al: Mycetoma. *J Med Vet Mycol* **30**(suppl 1):41, 1992

13. Venugopal PV, Venugopal TV: Pale grain eumycetomas in Madras. *Australas J Dermatol* **36**:149, 1995

14. Wethered DB et al: Ultrastructural and immunogenic changes in the formation of mycetoma grains. *J Med Vet Mycol* **25**:39, 1986

15. Welsh O et al: Treatment of eumycetoma and actinomycetoma. *Curr Top Med Mycol* **6**:47, 1995

16. McGinnis MR: Chromoblastomycosis and phaeohyphomycosis: New concepts, diagnosis and mycology. *J Am Acad Dermatol* **8**:1, 1983

17. Bayles MA: Chromomycosis. *Curr Top Med Mycol* **6**:221, 1995

18. Goette DK, Robertson D: Transepithelial elimination in chromomycosis. *Arch Dermatol* **120**:400, 1984

19. Restrepo A: Treatment of tropical mycoses. *J Am Acad Dermatol* **31**:S91, 1994

20. Esterre P: Treatment of chromomycosis with terbinafine: Preliminary results of an open pilot study. *Br J Dermatol* **134**(suppl 46):33, 1996

21. Matsumoto T et al: Developments in hyalohyphomycosis and phaeohyphomycosis. *J Med Vet Mycol* **32**(suppl 1):329, 1994

22. Baruzzi RG, Marcopito LF: Lobomycosis, in *Tropical Fungal Infections, Bailliere's Clinical Tropical Medicine and Communicable Diseases,* vol 4, edited by RJ Hay. London, Bailliere Tindall, 1989, p 97

23. Drouhet E, Ravisse P: Entomophthoromycosis. *Curr Top Med Mycol* **5**:215, 1994

24. Chitravel V et al: Recurrent rhinosporidiosis in man: Case reports. *Mycopathologia* **73**:79, 1981

25. Goodwin RA et al: Histoplasmosis in normal hosts. *Medicine* **60**:231, 1981

26. Cano MV. Hajjeh RA. The epidemiology of histoplasmosis: A review. *Semin Respir Infect* **16**:109, 2001

27. Wheat LJ et al: Histoplasmosis in the acquired immune deficiency syndrome. *Am J Med* **78**:203, 1985

28. Davies SF: Serodiagnosis of histoplasmosis. *Semin Respir Infect* **1**:9, 1986

29. Wheat LJ et al: Diagnosis of disseminated histoplasmosis by detection of *Histoplasma capsulatum* antigen in serum and urine specimen. *N Engl J Med* **314**:83, 1986

30. Drouhet E: African histoplasmosis, in *Tropical Fungal Infections, Bailliere's Clinical Tropical Medicine and Communicable Diseases,* vol 4, edited by RJ Hay. London, Bailliere Tindall, 1989, p 221

31. Wheat J: Endemic mycoses in AIDS: A clinical review. *Clin Microbiol Rev* **8**:149, 1995

32. Lemos LB et al: Blastomycosis: Organ involvement and etiologic diagnosis. A review of 123 patients from Mississippi. *Ann Diagn Pathol* **4**:391, 2000

33. Bradsher RW: Histoplasmosis and blastomycosis. *Clin Infect Dis* **22**(suppl 2):S102, 1996

34. Emerson PA et al: North American blastomycosis in Africans. *Br J Dis Chest* **78**:286, 1984

35. Klein BS et al: Isolation of *Blastomyces dermatitidis* in soil associated with a large outbreak of blastomycosis in Wisconsin. *N Engl J Med* **314**:529, 1986

36. Bradsher RW: A clinician's view of blastomycosis. *Curr Top Med Mycol* **5**:181, 1994

37. McAdams HP et al: Thoracic mycoses from endemic fungi: Radiologic-pathologic correlation. *Radiographics* **15**:255, 1995

38. Weil M et al: Cutaneous lesions provide a clue to mysterious pulmonary process: Pulmonary and cutaneous North American blastomycosis infection. *Arch Dermatol* **132**:822, 1996

39. Herd AM et al: Miliary blastomycosis and HIV infection. *Can Med Assoc J* **143**:1329, 1990

40. Rosenstein NE et al: Risk factors for severe pulmonary and disseminated coccidioidomycosis: Kern County, California, 1995–1996. *Clin Infect Dis* **32**:708, 2001

41. Braverman IM. Protective effects of erythema nodosum in coccidioidomycosis. *Lancet* **353**:168, 1999

42. Bronniman DA et al: Coccidioidomycosis in the acquired immunodeficiency syndrome. *Ann Intern Med* **106**:373, 1987

43. McNeil MM, Ampel NM: Opportunistic coccidioidomycosis in patients infected with human immunodeficiency virus: Prevention issues and priorities. *Clin Infect Dis* **21**(suppl 1):S111, 1995

44. Martins TB et al: Comparison of commercially available enzyme immunoassay with traditional serological tests for detection of antibodies to *Coccidioides immitis. J Clin Microbiol* **33**:940, 1995

45. Graybill JR: Treatment of coccidioidomycosis. *Curr Top Med Mycol* **5**:151, 1994

46. Del Negro G et al (eds): *Paracoccidioidomicose*. Sao Paulo, Sarvier Editora, 1982

47. Restrepo A et al: Estrogens inhibit mycelium to yeast transformation in the fungus *P. brasiliensis:* Implications for resistance of females to paracoccidioidomycosis. *Infect Immun* **46**:346, 1984

48. Restrepo A: The ecology of *P. brasiliensis:* A puzzle still unsolved. *J Med Vet Mycol* **23**:323, 1985

49. Sugar AM et al: Paracoccidioidomycosis in the immunosuppressed host: Report of a case and review of the literature. *Am Rev Respir Dis* **129**:349, 1984

50. Negroni R et al: Oral treatment of paracoccidioidomycosis and histoplasmosis with itraconazole in humans. *Rev Infect Dis* **9**(suppl):S47, 1987

51. Segretain G: Description d'une nouvelle espece de penicillium: *Penicillium marneffei* n.sp. *Bull Soc Mycol Fr* **75**:412, 1959

52. Chariyalertsak S et al: Seasonal variation of disseminated *Penicillium marneffei* infections in northern Thailand: A clue to the reservoir? *J Infect Dis* **173**:1490, 1996

53. Jayanetra P et al: Penicilliosis marneffei in Thailand: Report of five human cases. *Am J Trop Med Hyg* **33**:637, 1984

54. Supparatpinyo K et al: Disseminated *Penicillium marneffei* infection in southeast Asia. *Lancet* **344**:110, 1994

55. Mitchell TG, Perfect JR: Cryptococcosis in the era of AIDS: 100 years after the discovery of *Cryptococcus neoformans. Clin Microbiol Rev* **8**:515, 1995

56. Bennett JE et al: Epidemiologic differences among serotypes of *Cryptococcus neoformans. Am J Epidemiol* **120**:582, 1984

57. Manrique P et al: Polymorphous cutaneous cryptococcosis: Nodular, herpes-like, and molluscum-like lesions in a patient with the acquired immunodeficiency syndrome. *J Am Acad Dermatol* **26**:122, 1992

58. Murakawa GJ et al: Cutaneous *Cryptococcus* infection and AIDS: Report of 12 cases and review of the literature. *Arch Dermatol* **132**:545, 1996

59. Manfredi R et al: Morphologic features and clinical significance of skin involvement in patients with AIDS-related cryptococcosis. *Acta Derm Venereol* **76**:72, 1996

60. Pineski R et al: Cutaneous cryptococcosis in a patient receiving chronic immunosuppressive therapy. *Cutis* **57**:229, 1996

61. Pappas PG et al: Cryptococcosis in human immunodeficiency virus–negative patients in the era of effective azole therapy. *Clin Infect Dis* **33**:690, 2001

62. Bodey G, Luna M: Skin lesions associated with disseminated candidiasis. *JAMA* **229**:1466, 1974

63. Dupont B, Drouhet E: Cutaneous, ocular and osteoarticular candidiasis in heroin addicts: New clinical and therapeutic aspects in 38 patients. *J Infect Dis* **152**:577, 1985

64. Gartenberg G et al: Hospital-acquired mucormycosis (*Rhizopus rhizopodiformis*) of skin and subcutaneous tissue: Epidemiology, mycology and treatment. *New Engl J Med* **299**:1115, 1978

65. Mitchell SJ et al: Nosocomial infection with *Rhizopus microsporus* in preterm infants associated with wooden tongue depressors. *Lancet* **348**:441, 1996

66. Wong J et al: Coexistent cutaneous *Aspergillus* and cytomegalovirus infection in a liver transplant recipient. *J Am Acad Dermatol* **44**:370, 2001

67. Rabodonirina M et al: *Fusarium* infections in immunocompromised patients: Case report and literature review. *Eur J Clin Microbiol Infect Dis* **13**:152, 1996

68. Bennhoff DF: Actinomycosis: Diagnostic and therapeutic considerations and a review of 32 cases. *Laryngoscope* **94**:1198, 1984

69. Smego RA Jr, Foglia G. Actinomycosis. *Clin Infect Dis* **26**:1255, 1998

70. Mert A et al: Primary actinomycosis of the hand: A case report and literature review. *Int J Infect Dis* **5**:112, 2001.

71. Schlech WF et al: Medical management of visceral actinomycosis. *South Med J* **76**:921, 1983

72. Houang ET et al: *Nocardia asteroides* infection: A transmissible disease. *J Hosp Infect* **1**:31, 1980

73. Aydingoz IE et al: Primary cutaneous nocardiosis associated with intraarticular corticosteroid injection. *Int J Dermatol* **40**:196, 2001

74. Tsuboi R et al: Lymphocutaneous nocardiosis caused by *Nocardia asteroides*. *Arch Dermatol* **122**:1183, 1986

75. Freeland C et al: Primary cutaneous nocardiosis caused by *Nocardia otitidiscaviarum*: Two cases and a review of the literature. *J Trop Med Hyg* **98**:395, 1995

76. Smego RA, Gallis HA: The clinical spectrum of *Nocardia brasiliensis* infections in the United States. *Rev Infect Dis* **6**:164, 1984

77. Marquez-Diaz F et al: Nocardiosis in patients with HIV infection. *AIDS Patient Care Stds* **12**:825, 1998.

T>

Chapter 208

Douglas Lowy

Viral Diseases: General Considerations

DEFINITION
CLASSIFICATION
VIRAL REPLICATION
CELLULAR CONSEQUENCES OF VIRAL INFECTION
PATHOGENESIS OF VIRAL INFECTIONS IN THE SKIN
HOST RESPONSE
DIAGNOSIS OF VIRAL INFECTIONS
THERAPY AND PREVENTION

REFERENCES

Skin lesions are a prominent feature of many viral diseases. In some instances, cutaneous lesions suggest a specific viral illness whose diagnosis can be quickly established by appropriate procedures. At other times, the differential diagnosis includes several viral and nonviral conditions. This situation may require costly, specialized, time-consuming, and possibly nondefinitive diagnostic procedures. However, the application of new techniques for laboratory diagnosis can shorten the time for diagnosis. To complement advances in diagnosis, there are several effective antiviral agents for treating at least some viral diseases with cutaneous manifestations, and other potential antiviral agents are in clinical trials. Consequently, making the correct diagnosis in viral infection may have important implications for therapy as well as for prognosis. It may also contribute to the surveillance and control of infectious disease within the community. Preventive vaccines have reduced or eliminated several viral infections, and the development of new vaccines against other viruses could have a similar impact on the diseases they induce.

DEFINITION

Viruses form a diverse group of infectious agents that share a distinctive composition and a unique mode of replication. [1], [2], [3] and [4] Viruses are not cellular organisms. Although certain viruses encode a small number of enzymes, viruses do not possess functional ribosomes or other cellular organelles. These agents therefore lack much of the machinery required for their own multiplication. They multiply only inside cells, where they make use of the cellular synthetic apparatus to produce their components. It is because their replication depends on the host cell that viruses are often referred to as “obligate intracellular parasites.”

The most important element of a virus is its genetic information (the viral *genome*), which may be either deoxyribonucleic acid (DNA) or ribonucleic acid (RNA), depending on the type of virus. [5], [6] The life cycle of a virus may be divided into two parts. In one part, the virus exists as an extracellular particle (also called a *virion*), where the viral genetic information is surrounded by a highly organized protein coat that can be seen by electron microscopy. The virion serves to transmit the viral genetic information, functionally intact, to a susceptible host. The second part of the viral life cycle is that period when the viral genetic information is present inside a cell, where it is usually found in a nonparticulate form. Certain pathogenetic aspects of virus infection occur during the nonparticulate portion of the virus life cycle. The duration of this intracellular phase is extremely variable, from a few hours in acute infections, to years when a virus establishes latency.

CLASSIFICATION

All organisms, from bacteria to humans, are susceptible to infection by a range of viruses, but no single virus is capable of infecting all classes of cells. Each virus is broadly classified as a bacterial, plant, or animal virus based on the type of cell it can infect. The animal viruses are divided into several large families according to the size, shape, and structure of the virion and the type of viral nucleic acid within it, as shown in Table 208-1. In the virion, the viral genome consists of only a single type of nucleic acid—either DNA or RNA. Viruses of a given family can be identified by physical methods, such as the size and shape of their virions by electron microscopy, by antigenic cross-reactivity, or by nucleic acid homology. Although viruses are grouped principally according to their virion morphology and nucleic acid composition, a given family of viruses usually shares functional, genetic, biochemical, and immunologic features.



TABLE 208-1 **Selected Animal Virus Groups**

The virion is composed of the viral genetic core surrounded by a protective protein coat called the *capsid*. In certain virus families (such as herpesviruses and retroviruses), the capsids are located inside a virion envelope (composed of lipid, protein, and carbohydrate), which is required for infectivity (Table 208-1). The viral envelope is sensitive to drying, so that infectivity is lost on dry surfaces. The virions of other viruses (such as papillomaviruses) do not possess an envelope, so their capsids are called “naked.” Because the capsid proteins are usually stable in dry environments,

viruses whose virions lack an envelope typically remain infectious for long periods after drying.

In most viruses, the capsid is arranged in one of two patterns: helical symmetry or icosahedral (cubic) symmetry (Table 208-1). Poxviruses have a more complicated structure, which is classified as “complex.” In viruses with helical symmetry, the protein subunits that form the capsid are assembled in an elongated, helical form. The subunits in viruses with icosahedral symmetry are assembled into an icosahedral structure, which is a symmetric polyhedron with 20 equilateral triangular faces. Viruses within a given family may be further classified according to their relatedness at the nucleic acid level, their antigenic cross-reactivity, and the host cells that they infect.

Figure 208-1 shows examples of virions from the three main families of viruses (papillomaviruses, herpesviruses, and poxviruses) that multiply in the epidermis. The viral genomes of these three families are composed of DNA. As noted above, papillomaviruses possess naked (nonenveloped) capsids, and herpesviruses have enveloped virions. Poxvirus virions are large, have a very complex structure, and are enveloped, but their envelope is not required for their virions to be infectious. Hence, poxviruses can remain infectious after drying.

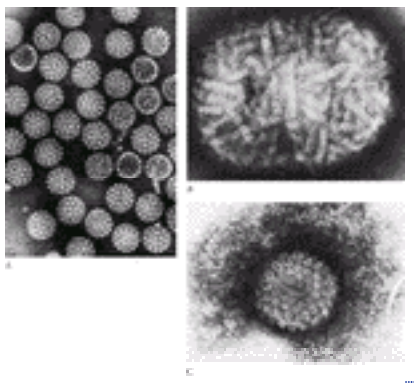

FIGURE 208-1 Electron micrographs of negatively stained virions (×200,000). *A.* Papillomavirus: multiple nonenveloped human papillomavirus (wart) virions showing capsid subunits (capsomeres). *B.* Poxvirus: single molluscum contagiosum virus virion, showing complex tubular structures. *C.* Herpesvirus: single varicella-zoster virus virion showing capsid inside envelope. (*Parts A and B courtesy of AF Howartson, JD Almeida, and MG Williams. Part C by permission of Almeida JD et al: Morphology of Varicella (Chicken Pox) Virus. Virology 16:353, 1962.*)

VIRAL REPLICATION

Viruses replicate inside cells by synthesizing their various structural components separately and then assembling them into multiple virions. [6] This contrasts with cells, which multiply by binary fission (the production of two progeny cells from a single parental cell). Viruses use the host-cell machinery to synthesize and assemble new virions, because these agents do not contain the apparatus required for their own replication.

Viral genomes encode two main classes of proteins. Some virus-encoded proteins are used to form the virions; these proteins are called *structural proteins* or *virion proteins*. Viral genomes also encode *nonstructural proteins*; as their name implies, these proteins do not participate in forming the structural components of the virion. The nonstructural viral proteins often play key roles in the replication of the virus, although they are not usually incorporated into the virion. Acyclovir inhibits herpesvirus replication because the drug is activated inside herpesvirus-infected cells by virus-encoded nonstructural proteins. [7]

Nonstructural proteins of certain viruses may redirect the cell to synthesize the proteins required by the virus at the expense of those required for normal function of the cell. Many tumor viruses, including papillomaviruses, encode nonvirion proteins that increase cell growth and lead to inappropriate control of cell division (see Chap. 37). The intracellular pathogenicity of a virus may be partly due to effects of nonvirion proteins. [8]

The viral replication cycle, which has been studied in detail in tissue culture, involves several more or less sequential steps: attachment (adsorption), penetration, uncoating, biosynthesis, virion assembly, and release. Attachment of virions to cells involves a specific interaction between the viral capsid or envelope (for those viruses that possess enveloped virions) and receptors on the cell surface. For example, HIV enters cells via an interaction between viral envelope protein and two classes of receptors: cellular CD4 receptors and chemokine receptors. [9] Consequently, cells that lack the appropriate cell surface receptors for a particular virus will not be infected by that virus. Although most people are quite susceptible to HIV infection, rare individuals who lack the appropriate chemokine receptors, or who have modified versions of them, may be relatively resistant to HIV infection or the development of AIDS. [10], [11]

Following penetration of the virion into the cell, cellular enzymes degrade the envelope and capsid (uncoating), which begins the nonparticulate phase of the virus life cycle. During biosynthesis, the viral genome instructs the infected cell to produce the proteins encoded by the viral genes. Viruses vary in their size and complexity. The genome of poliovirus, which is a small virus with a simple virion structure, encodes a single precursor protein, which is cleaved to give rise to the structural and nonstructural viral proteins. By contrast, poxviruses, whose virions are more than 10 times larger than poliovirus virions and are much more complex, encode dozens of structural and nonstructural proteins.

The virions of most viruses, including papillomaviruses, herpesviruses, and poxviruses, are assembled inside the cell and released following cell death and lysis. However, enveloped viruses whose virions are assembled at the cell surface (such as retroviruses and paramyxoviruses) are released by budding from intact cells; with these viruses, productive infection and release of virions may or may not be accompanied by toxic effects on the infected cell. Each virus has its characteristic site of replication within the cell. Papillomaviruses and herpesviruses are assembled in the nucleus (Fig. 208-2 and Fig. 208-3). Poxviruses, which are the only DNA viruses that replicate in the cytoplasm, synthesize their

virions in organized cytoplasmic “viral factories” (Fig. 208-4).

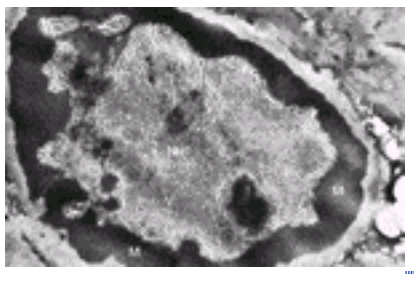

FIGURE 208-2 Papillomavirus-infected cell. Electron micrograph (×20,000). Nucleus (Nuc) of a stratum corneum cell, filled with papillomavirus virions (V); chromatin is marginated (M). Mature keratin can be seen in an adjacent cell (S).



FIGURE 208-3 Varicella-zoster virus (a herpesvirus)-infected cell. Electron micrograph (×24,000). Portion of cell of the stratum spinosum. The nucleus (Nuc) contains varicella-zoster virions (V). Chromatin is marginated at (M). Virions (V) and tonofilaments (T) are shown in the cytoplasm (Cyt).

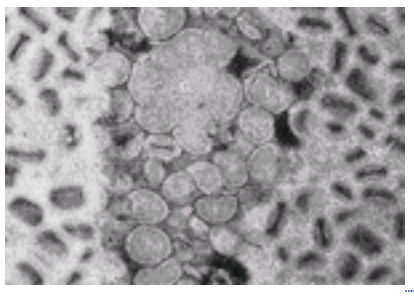

FIGURE 208-4 Molluscum contagiosum (a poxvirus)-infected cell. Electron micrograph (×45,000). Cytoplasm of a spinosum cell filled with mature molluscum contagiosum virions (V), immature virus forms (i), and viroplasm in a gyrate pattern (G).

Typically, hundreds or thousands of new virions are produced from each infected cell, and they, in turn, infect previously uninfected cells. One cycle of virus replication may last from 3 to 36 h, depending on the virus and cell involved. Interruption of any step will prevent the development of new infectious virions.

Each virus can infect and replicate in only a limited number of cell types. The spectrum of susceptible cells depends on the virus. Human papillomaviruses can infect a very narrow range of cells, namely certain differentiating human epidermal cells. Other viruses can infect a much broader range of cells; herpes simplex viruses can replicate in many different human and nonhuman cell types.

Even within a given tissue, a virus may be infectious only for cells with a specific degree of differentiation. The important role of the differentiated state of the cell in determining whether or not a virus will undergo replication is seen in the skin lesions of molluscum contagiosum. Because molluscum contagiosum virus (MCV) particles are sometimes found in cells of the upper dermis, the virus must be capable of attachment and penetration in these cells. MCV does not, however, replicate in dermal cells, indicating that an intracellular block to MCV synthesis exists in the dermal cells. MCV particles are also found in the basal layer of epidermal cells, but synthesis of new viral components does not begin until the cells reach the suprabasal layers. This observation implies that MCV replication can take place only in partially differentiated epidermal cells.

CELLULAR CONSEQUENCES OF VIRAL INFECTION

Typically, infected cells develop gross and often characteristic cytopathic changes and eventually die. Infections of this type are termed *cytocidal* or *lytic*. However, some viruses can replicate without causing irreversible damage to the host cell. Noncytocidal infection of this type may occur in tissue culture with measles virus and many other enveloped RNA viruses, leading to a chronically infected culture. While many retroviruses replicate without killing cells, cell lysis plays an important role in the pathogenesis of HIV infection. [9]

Two other types of noncytocidal infection are neoplastic transformation [12], [13] and viral latency. [14], [15] Tumor viruses, when they transform cells, alter the normal control of cellular proliferation. In general, tumor viruses (such as the polyomavirus SV40) do not synthesize new virions in neoplastically transformed cells, although such transformation requires the continued expression of a portion of the viral genome. It is interesting to note that SV40 is exclusively cytocidal for some cell types (permissive infection), induces transformation exclusively in other cells (nonpermissive infection), and induces both types of infection in still other cell types (semipermissive infection), again underlining the importance of the host cell in affecting the outcome of infection. Epidermal cells are semipermissive for papillomavirus infection. Virus-induced

neoplasia is discussed in greater detail in Chap. 37.

Viral latency, which is a mechanism for evading the host immune response, commonly occurs with herpesviruses and papillomaviruses. Latently infected cells either produce very small numbers of new virions so that spread to uninfected cells is minimal or they synthesize no virions but retain an intact and potentially activatable viral genome.

PATHOGENESIS OF VIRAL INFECTIONS IN THE SKIN

There are several general patterns of viral infection. [15] The most typical is that of acute infection followed by viral clearance, usually by immune mechanisms. This pattern occurs frequently with viruses that produce exanthems, such as measles. Another pattern is that of acute infection followed by latent infection, which may then be followed by viral reactivation. In viruses with cutaneous manifestations, this pattern occurs often with herpes simplex virus, varicella-zoster virus, and papillomavirus. A third pattern is that of chronic infection, as occurs frequently with HIV infection. Often, active infection with some viruses, such as papillomaviruses and MCV, may persist for months or years, even in immunocompetent hosts.

Virus infections may affect the skin by three different routes: direct inoculation, systemic infection, or local spread from an internal focus. In warts, herpes simplex, chickenpox, herpes zoster, molluscum contagiosum, and smallpox, virus shedding from human skin lesions represents an important source in the transmission of virus to other people. Skin lesions may be produced by the direct effect of virus replication on infected cells, the host response to the virus, or the interaction of replication and host response.

The viruses of warts, molluscum contagiosum, vaccinia, orf, milker's nodules, and (primary) herpes simplex, all of which infect the skin by direct inoculation, replicate in the epidermis. Their viral cytopathic effects account for the appearance of early lesions. The immune system presumably contributes to the evolution of those lesions that subsequently develop an inflammatory response. The incubation period is generally short because the lesions develop at the site of inoculation. The incubation period for warts is longer, presumably because the virus replicates slowly or cell-to-cell spread of virus occurs to only a limited extent.

In systemic infections, the skin is infected during viremia, so that the dermis is generally infected earlier than the epidermis. It is not known how the distribution of viral exanthems is determined. In chickenpox and smallpox, the damage from cytocidal infection of the skin is a prime cause of the lesions. On the other hand, there is suggestive evidence from patients with impaired cellular immunity that the lesions of rubella and measles result in part from a cell-mediated immune response to the virus. The basis of most exanthems associated with enteroviral infections remains to be established; there is significant cytocidal viral replication in the skin in hand-foot-and-mouth disease.

Recurrent herpes simplex and herpes zoster represent the local spread of virus to the skin following reactivation of the latent virus present in peripheral nerves. Cytocidal infection clearly plays an important role in these lesions, although lesions may contain less virus than during primary infection, presumably because of immunity.

HOST RESPONSE

The severity of illness induced by a particular virus varies considerably from person to person. While the size of the viral inoculum and the portal of entry play some role, it is believed that host factors usually account for most of this variation. Both immunologic and nonimmunologic responses appear to be important. [8], [15], [16], [17] and [18] Conversely, viral infection may have significant direct and indirect effects on the immune system, especially those viruses that infect lymphoid cells, such as Epstein-Barr virus and HIV. [9]

Antibody responses to viral infection represent the major host defense against reinfection by the same virus; [19] the prophylactic administration of type-specific antibodies can prevent or modify some primary viral infections even in patients with impaired cellular immunity. However, humoral immunity is thought not to contribute to the recovery from most primary viral infections, as viral infection of patients with isolated deficiencies of humoral immunity usually follows a normal course. There are several mechanisms by which antibodies may inhibit the spread of virus. These include neutralization of virus through prevention of viral attachment to target cells (which may be increased by complement); enhancement of viral uptake by phagocytic cells, which then inactivate the virus; and (complement-mediated) immune lysis of infected cells.

Specific cell-mediated immunity (CMI) is also elicited during viral infections and influences the course of many viral infections. CMI is usually protective, although it may sometimes increase the degree of cellular pathology (as in the eruption of measles). Patients with impaired CMI often have difficulty handling primary or recurrent viral infection. Such patients are at risk of developing severe primary virus infections, persistent warts, chronic herpes simplex virus infections, disseminated herpes zoster, and AIDS. The protective antiviral mechanisms have not yet been fully established. Sensitized T cells are known to be capable of lysing infected cells and of liberating lymphokines, which attract phagocytic cells. Natural killer cells, virus-specific cytotoxic lymphocytes, and antibody-dependent cell-mediated cytotoxicity can inhibit infection under experimental conditions.

Inflammatory cells may produce some of their antiviral effects via the production of interferons, a unique family of closely related cytokines that are active against viruses. [20] Interferon, which can be induced by foreign RNA or DNA (including viral nucleic acids), is secreted into the extracellular fluid. Resistance to virus infection is induced in those cells that come in contact with the interferon. Virtually all viruses are capable of inducing interferon and are susceptible to its action, but viruses differ greatly in their degree of interferon induction and in their sensitivity to its action. Interferon is responsible for recovery in several types of virus infection in mice, and the presence of interferon correlates with the recovery phase of several human viral infections. Genetic factors may also play a role in determining the outcome of viral infections. In animal models, cellular genes can determine the susceptibility to viral infection at several levels, including virion

attachment to cells, viral replication, and viral-induced immune responses. [21]

DIAGNOSIS OF VIRAL INFECTIONS

Four major approaches are used in the laboratory to diagnose viral infection: virus isolation, microscopy, detection of viral nucleic acids or viral antigens, and serology. [22], [23] and [24] As with all laboratory tests, the results must be interpreted in the context of the clinical setting. Fortuitous infection with a virus unrelated to the illness should always be considered. For many viruses, considerable progress has been made in the development of relatively rapid assays that are sensitive and specific. [22], [23], [25] Most of these newer assays depend upon the ability to detect small amounts of viral nucleic acids and/or viral antigens.

Cultivation of the virus has represented the traditional “gold standard” for viral diagnosis. Virus isolation is most useful if the suspected pathogen can be readily propagated and positive results can be obtained in a short time. If necessary, more precise identification of the cultured virus can be carried out with specific tests for viral nucleic acid or viral antigen. Culture techniques for herpes simplex virus are quite sensitive, with diagnostic changes in cells often appearing within 1 to 2 days of inoculation. The closely related varicella-zoster virus is much more difficult to grow in culture, leading to frequent false-negative results.

When virus isolation is attempted, specimens should be obtained as early in the disease as possible. In vesicular conditions, fluid from an early vesicle is often a good source of virus. Lesional specimens are less likely to be positive with nonvesicular exanthems. Specimens should also be obtained from additional sites as indicated. Specimens are often collected in a sterile tube with 2 to 5 mL of a buffered isotonic balanced salt solution containing penicillin and streptomycin. Preferably, they should be transported on ice immediately to the laboratory. If this is not practical, specimens should be frozen [at –70°C (–94°F), if possible]. The suspected pathogen(s) should be indicated, because it may determine the type of cell culture or test animal to be inoculated.

The direct identification of a virus in clinical specimens can theoretically be accomplished more quickly than tests that rely on culturing the virus. This approach may be especially useful for detecting those viruses difficult to propagate in culture and those, such as papillomaviruses, for which no reproducible culture system is available. Direct analysis may identify characteristic cells, as with Tzanck smears for herpesviruses (this test will not distinguish between herpes simplex and varicella-zoster viruses) or the histologic appearance of MCV-containing lesions.

The direct identification of virus from clinical material is limited by the sensitivity and specificity of the assay. The use of assays based on detecting viral nucleic acid is having a progressively larger impact on direct identification, initially through molecular hybridization, and more recently through application of the polymerase chain reaction (PCR). [22], [23], [25] This latter technique, which can specifically amplify minute quantities of viral nucleic acid, has revolutionized diagnostic virology. Assays based on PCR and related techniques are extremely sensitive, often being able to detect as few as 1 infected cell in 10,000, and highly specific. The main pitfall of PCR is that its great sensitivity makes it very susceptible to yielding false-positive results via cross-contamination with minute quantities of viral nucleic acid. However, meticulous attention to detail and appropriate controls can usually overcome this potential liability.

More traditional techniques are also available. For those lesions that contain large numbers of viral particles, electron microscopy of a lesion or its extract may provide morphologic identification of the virus. [24] The positive identification of specific viral antigen in clinical material through use of immunologic techniques permits a more specific diagnosis than direct microscopy. For example, immunologic techniques can distinguish between herpes simplex virus and varicella-zoster virus. Radioimmunoassay, enzyme-linked immunosorbent assay, immunoelectron microscopy, fluorescent antibody, or immunoperoxidase techniques identify viral antigen by the use of viral-specific antibody.

Serologic studies to detect viral antibodies may be important for epidemiologic purposes, for identifying infection with viruses such as HIV and hepatitis B, and for those situations where acute sera contain diagnostic antibodies, as with heterophile antibodies in infectious mononucleosis. In most acute viral illness, serologic analysis requires acute and convalescent sera, which limits its use in that setting to making a retrospective diagnosis. Paired sera are required because a positive serology during the acute phase may merely mean the individual was infected previously with a member of that virus family, but it does not have implications for the etiology of the current illness. The acute specimen should be taken as early in the illness as possible and the convalescent specimen 2 to 4 weeks later. Serum should be separated immediately from the coagulated blood and refrigerated or preferably frozen at –20°C (–4°F) until antibody tests can be run simultaneously on both specimens. A fourfold or greater rise in antibody titer between the first and second specimen generally indicates recent infection. A variety of assays are used to measure antibody levels, each detecting a certain type of antigen-antibody reaction. The antibody titer of a given serum is defined as the reciprocal of the highest dilution that gives a positive reaction.

THERAPY AND PREVENTION

Prophylaxis of viral infection has thus far proved more successful than the specific treatment of established infection. Vaccines have been extremely useful in the prevention of a variety of viral illnesses. [19], [26], [27] Recombinant DNA techniques are making it possible to develop effective subunit vaccines composed only of viral protein, rather than traditional vaccines, which represent either an attenuated strain of the pathogen or an inactivated preparation of the entire virus. [28], [29] In addition to vaccines that induce active immunity, the passive administration of type-specific antibody soon after exposure can prevent chickenpox in compromised hosts. Sensitive procedures for the detection of hepatitis B and HIV infection in potential blood donors has drastically reduced the incidence of transmission of these agents by transfusion.

Because viruses are adapted to the cells they infect and because they make use of the cellular machinery, many chemotherapeutic agents that have been considered as potential antiviral agents affect cells to about the same extent as

they affect viruses. However, this difficulty has already been overcome in several instances, and additional antiviral agents are under development (see Chap. 260). [7], [30], [31] Most antivirals seek to exploit a specific property of a particular virus. Azidothymidine (AZT) and several protease inhibitors, which are approved for use in the treatment of HIV infection, interfere with HIV replication by preferentially inhibiting synthesis of the viral genome and the processing of viral proteins, respectively. [9], [32], [33] Acyclovir, an antimetabolite that is approved for use in selected herpesvirus infections, is preferentially activated by herpesvirus-infected cells through its affinity for two herpesvirus enzymes involved in DNA synthesis. Interferon is a potentially potent antiviral agent that inhibits most viruses and at low dosages is relatively nontoxic to cells. Interferon has been approved for use in treatment of certain genital papillomavirus infections and has also been helpful in the management of some children with papillomas of the larynx.

REFERENCES

1. Galasso GJ, Whitley RJ, Merigan TC, editors: *Antiviral Agents and Viral Diseases of Man,* 4th ed. New York, Lippincott-Raven, 1997

2. Richman DD, Whitley RJ, Hayden FG, editors: *Clinical Virology,* 2d ed. Washington, DC, ASM Press, 2002

3. Knipe DM, Howley PM, editors: *Fields Virology,* 4th ed. Philadelphia, Lippincott Williams & Wilkins, 2001

4. Zuckerman AJ, Banatvala JE, Pattison JR, editors: *Principles and Practice of Clinical Virology,* 4th ed. Chichester, UK, John Wiley & Sons, 2000

5. Mattern CFT: Structure and classification of viruses, in *Medical Microbiology,* 3d ed, edited by S Baron. New York, Churchill Livingstone, 1991, p 559

6. Roizman B: Multiplication of viruses, an overview, in *Fields Virology,* 3d ed, edited by BN Fields, DM Knipe, PM Howley. New York, Lippincott-Raven, 1996, p 101

7. Boucher CAB, Galasso GJ: *Practical guidelines in antiviral therapy*. Amsterdam, Elsevier, 2002

8. Tyler KL, Nathanson N: Pathogenesis of viral infections, in *Fields Virology,* 4th ed, edited by DM Knipe, PM Howley. Philadelphia, Lippincott Williams & Wilkins, 2001, p 199

9. Levy JA, editor: *HIV and the Pathogenesis of AIDS,* 2d ed. Washington, DC, ASM, 1998

10. Dean M et al: Genetic restriction of HIV-1 infection and progression to AIDS by a deletion allele of the CKR5 structural gene. *Science* **273**:1856, 1996

11. Smith MW et al: Contrasting genetic influence of CCR2 and CCR5 variants on HIV-1 infection and disease progression. *Science* **277**:959, 1997

12. Nevins JR: Cell transformation by viruses, in *Fields Virology,* 4th ed, edited by DM Knipe, PM Howley. Philadelphia, Lippincott Williams & Wilkins, 2001, p 245

13. Bishop JM, Weinberg RA, editors: *Molecular Oncology*. New York, Scientific American, 1996

14. Stevens JG: Overview of herpesvirus latency. *Semin Virol* **5**:191, 1994

15. Ahmed R et al: Persistence of viruses, in *Fields Virology,* 3d ed, edited by BN Fields, DM Knipe, PM Howley. New York, Lippincott-Raven, 1996, p 219

16. Biron CA et al: Innate immunity and viral infection, in *Immunology of Infectious Diseases,* edited by SHE Kaufmann, A Sher, R Ahmed. Washington, DC, ASM Press, 2002, p 139

17. Szomolanyi-Tsuda E et al: Acquired immunity against viral infections, in *Immunology of Infectious Diseases,* edited by SHE Kaufmann, A Sher, R Ahmed. Washington, DC, ASM Press, 2002, p 247

18. Whitten L, Oldstone MBA: Immune response to viruses, in *Fields Virology,* 4th ed, edited by DM Knipe, PM Howley. Philadelphia, Lippincott Williams & Wilkins, 2001, p 285

19. Murphy BR, Chanock RM: Immunization against virus disease, in *Fields Virology,* 4th ed, edited by DM Knipe, PM Howley. Philadelphia, Lippincott Williams & Wilkins, 2001, p 435

20. Biron CA, Sen GC: Interferons and other cytokines, in *Fields Virology,* 4th ed, edited by DM Knipe, PM Howley. Philadelphia, Lippincott Williams & Wilkins, 2001, p 321

21. Brahic M et al: Immunogenetics of the host response to viral infections, in *Immunology of Infectious Diseases,* edited by SHE Kaufmann, A Sher, R Ahmed. Washington, DC, ASM Press, 2002, p 421

22. Storch GA: Skin and mucous membrane infections, in *Essentials of Diagnostic Virology,* edited by GA Storch. New York, Churchill Livingstone, 2000, p 93

23. Lennette EH, Smith TF, editors: *Laboratory Diagnosis of Viral Infections*. New York, Marcel Dekker, 1999

24. Hsiung GD et al: *Hsiung's Diagnostic Virology: As Illustrated by Light and Electron Microscopy,* 4th ed. New Haven, Yale University, 1994

25. Becker Y, Darai G, editors: *PCR: Protocols for Diagnosis of Human and Animal Virus Diseases*. New York, Springer, 1995

26. Ada GL, Ramsay AJ: *Vaccines, Vaccination, and the Immune Response*. Philadelphia, Lippincott-Raven, 1997

27. Plotkin SA, Orenstein WA, editors: *Vaccines,* 3d ed. Philadelphia, Saunders, 1999

28. Levine MM: *New Generation Vaccines,* 2d ed. New York, Marcel Dekker, 1997

29. Powell MF et al: *Vaccine Design: The Subunit and Adjuvant Approach*. New York, Plenum, 1995

30. Mills J, Volberding P, Corey L, editors: *Antiviral Chemotherapy 4: New Directions for Clinical Application and Research*. New York, Plenum,

1996

31. Jeffries DJ, De Clercq E, editors: *Antiviral Chemotherapy*. New York, Wiley, 1995

32. Sande MA, Volberding P, editors: *The Medical Management of AIDS,* 5th ed. Philadelphia, Saunders, 1997

33. De Clercq E: *Antiretroviral Therapy,* Washington, DC, ASM Press, 2001

T>

Chapter 209

Stephen Gellis

Rubella (German Measles)

EPIDEMIOLOGY
CLINICAL MANIFESTATIONS (Table 209-1)
COMPLICATIONS
LABORATORY FINDINGS
CONGENITAL RUBELLA (Table 209-2)
Diagnosis
IMMUNITY AND IMMUNIZATION
REFERENCES

Rubella (German measles) is a common communicable infection of children and young adults characterized by a short prodromal period; enlargement of cervical, suboccipital, and postauricular glands; and a rash of approximately 2 to 3 days' duration. The disease has rare sequelae and, were it not for its devastating effect on the fetus, would be of relatively little significance in terms of morbidity or complications.

EPIDEMIOLOGY

Prior to immunization programs, epidemics of rubella were noted at 5- to 7-year intervals. The disease is worldwide in its distribution and tends to occur most frequently during the spring months in North America. During the past decade, fewer than 200 cases were reported in most years in the United States. [1] It is rare in young infants and is most common in school-age children, adolescents, and young adults. Recent outbreaks in North America have occurred in young men in Latino communities who have come from countries without immunization programs. [2] Through these outbreaks, viruses that are common abroad have been introduced into the United States. [1] It is spread via the respiratory route, and the period of infectivity extends from the end of the incubation period to the disappearance of the rash. A single attack confers lifelong immunity in most individuals, although subclinical reinfections can be demonstrated by laboratory tests in some “immune” individuals who are subsequently exposed to the wild virus. Two attacks of rubella with rash are most unlikely to be encountered; in such instances, one of the episodes is usually not rubella but is caused by another viral infection.

The virus of rubella may be recovered from the pharynx as early as 7 days before and up to 14 days after the onset of the rash. Viremia is rarely demonstrated after the onset of the rash. [3]

CLINICAL MANIFESTATIONS (Table 209-1)

TABLE 209-1 **Some Distinctive Features of the Rashes of Rubella, Measles, and Scarlet Fever**

The incubation period ranges between 14 and 21 days and is usually 16 to 18 days. Prodromal signs and symptoms are rare in young children, and the rash usually appears without prior complaint. In older children, adolescents, and adults, low-grade fever, headache, conjunctivitis, sore throat, rhinitis, cough, and lymphadenopathy may precede the rash by 1 to 4 days and disappear rapidly after the rash appears. In some adults, however, these symptoms and signs may persist longer and be more severe, and the infection under such circumstances may be difficult to distinguish from rubeola (measles) unless Koplik's spots, characteristic of measles, are observed. The rash of rubella is first noted on the face (Fig. 209-1) and rapidly spreads to the neck, arms, trunk, and legs. It consists of pink-red macules and papules that are discrete and remain so on the extremities, coalescing on the trunk to give a uniform red blush.

FIGURE 209-1 Rubella. Erythematous macules and papules appearing initially on the face and spreading usually within 24 h.

The rash, which usually disappears by the end of 2 or 3 days, clearing first from the face, may occasionally be followed by fine desquamation. This rapid disappearance is in contrast to measles (rubeola), in which the rash persists for longer periods. An enanthem is often seen at the end of the prodromal period or beginning of the rash, consisting of red spots, pinhead in size, scattered over the soft palate. The lymphadenopathy of rubella is striking; it involves all lymph nodes, but enlargement and tenderness are most common in the suboccipital, postauricular, and anterior and posterior cervical nodes. In older children and adults, lymphadenopathy may be noted several days before the rash; but in both children and adults, the enlargement and tenderness are most striking on the first day of the rash. Enlargement of glands may persist for days to weeks, but tenderness rapidly subsides. Splenomegaly may occasionally be detected. The fever of rubella is usually of low grade and seldom lasts beyond the first day or two of the eruption except in individuals who have joint involvement, in whom fever may persist. Arthritis caused by rubella occurs much more frequently in adults than in children, and is usually first noted as the rash fades. Small and large joints may become painful, with or without swelling, possibly simulating rheumatic fever or rheumatoid arthritis. In one epidemic, joint involvement was seen in 25 percent of children younger than 11 of years age and in 52 percent of patients 11 years of age or older. [4] Striking effusions into joints have been reported. The arthritis of rubella usually lasts 1 to 2 weeks but occasionally may persist for longer periods or may be recurrent.

COMPLICATIONS

Rubella is essentially a benign disease. Rarely, it may produce an encephalitis, which tends to be mild and is usually followed by complete recovery and no effect on intellectual function. Thrombocytopenic purpura, which may result from rubella, may be accompanied by epistaxis, petechiae, ecchymoses, intestinal hemorrhage, and hematuria. These manifestations frequently clear within a month of onset but may occasionally persist for longer periods. Rarely, a peripheral neuritis may follow rubella.

LABORATORY FINDINGS

The white blood cell count is usually low but may be normal. Increased numbers of atypical lymphocytes may be noted, and in some cases, increased numbers of plasma cells have been reported. Among patients with meningoencephalitis, varying numbers of lymphocytes may be found in the cerebrospinal fluid (CSF).

CONGENITAL RUBELLA (Table 209-2)

Teratogenic findings—congenital malformations
1. Heart*
a. Patent ductus arteriosus
b. Coarctation of pulmonary vessels
c. Ventricular septal defects
d. Combination of above
e. Others
2. Eye*
a. Cataracts
b. Microphthalmia
c. Retinopathy
d. Glaucoma
e. Cloudy cornea
3. Hearing defects*
4. Central nervous system*
a. Microcephaly
b. Hydrocephaly
5. Bone,* disturbances of growth of skull
6. Abnormal dermatoglyphics
7. Agammaglobulinemia
8. Other organ systems
Other findings
1. Intra- and extrauterine growth retardation*
2. Prematurity*
3. Meningoencephalitis
4. Pneumonitis
5. Hepatitis*
6. Cardiac tissue injury
7. Rarefaction bone*
8. Thrombocytopenia with or without purpura*
9. Anemia
10. Rubelliform skin rash
11. Generalized adenopathy

*Most commonly encountered

SOURCE: Adapted from papers in Rubella Symposium, Am J Dis Child 106:343, 1963.

TABLE 209-2 **Some Manifestations of the Congenital Rubella Syndrome**

Gregg, in 1941, [5] was the first to record the devastating effects of rubella infection in the fetus and to describe the congenital rubella syndrome. Approximately 50 percent of infants who acquire rubella during the first trimester of intrauterine life will show clinical signs of damage from the virus. The earlier the infection, the more severe the fetal damage. In such infants, multiple congenital defects include low birth weight, microcephaly with mental retardation, cataracts, nerve deafness, and congenital heart disease (usually patent ductus arteriosus or ventricular septal defect).

Following completion of organ development in the fetus, infection with rubella may produce a variable clinical picture, which may include hepatitis, splenomegaly, pneumonitis, myocarditis, encephalitis, and osteomyelitis. When the bone marrow is affected, the infant may be born with thrombocytopenia and bleeding into the skin, producing a striking picture of petechiae and ecchymoses given the colorful term “blueberry muffin baby.” In congenital rubella, a retinopathy consisting of a diffuse deposit of black pigmentation is commonly found.

Diagnosis

Infants with congenital rubella may be chronically infected for many months. Virus can be cultured from the nasopharynx, urine, CSF, and even the lens of infants with congenital cataract. As time passes, the amount of virus shed in the nasopharynx and urine gradually declines and disappears. Approximately 85 percent of infants infected in utero will excrete virus in the first month of life; 1 to 3 percent continue to excrete virus in the second year of life. The large amounts of virus from congenitally infected infants are very hazardous to pregnant women working with such infants who may be susceptible to infection. The infant with congenital infection will usually have elevation of IgM as a result of antibody produced by the infant itself, together with elevated IgG caused by passive transfer of antibodies in the maternal blood. IgG traverses the placenta, in contrast to IgM, which does not. The IgG antibodies disappear over the first few months of life. Passively acquired IgG by the fetus from an immune mother may explain the rarity of acquired rubella in early infancy. The antibodies against rubella consist of neutralizing, complement-fixing, and hemagglutination-inhibition antibodies. Neutralizing and hemagglutination-inhibition antibodies usually persist for life. The hemagglutination-inhibition antibodies are easily and quickly measured and serve to determine whether a recent infection can be attributed to rubella by an increase in titer in the convalescent period over the titer in the acute stage. A fourfold increase or more is considered diagnostic of the infection. Testing for these antibodies also enables the physician to determine whether a woman of childbearing age is immune or susceptible to German measles.

More sensitive tests—latex agglutination, fluorescence immunoassay, passive hemagglutination, hemolysis in gel, and enzyme immunoassay—are now available.

IMMUNITY AND IMMUNIZATION

Lifelong immunity usually follows an attack of rubella. Reinfection can occur but is usually not accompanied by clinical signs and symptoms. A rise in antibody level can occur; viremia from subclinical reinfection is very rare. Thus, congenital rubella is very unlikely in an infant whose mother has had an attack of rubella in the past and acquires a reinfection during pregnancy. In these instances, evaluation of fetal blood obtained by cordocentesis for specific rubella IgM antibodies or for evaluation by newer techniques using polymerase chain reaction (PCR) may help to confirm a diagnosis of fetal infection. [6], [7] The availability of rubella vaccine [8], [9] and its widespread use has markedly reduced the frequency of congenital infection.

In the United States, rubella vaccine is usually given together with mumps and measles vaccines in a single injection [mumps, measles, rubella (MMR)] at the age of 12 to 15 months and again at school entry (4 to 6 years of age).

Recommendations have been that rubella vaccine should not be given to a pregnant woman. Recent studies indicate that no cases of congenital rubella syndrome were seen among infants born to women who had been inadvertently vaccinated against rubella within 3 months of or early in pregnancy. Based upon this evidence the recommendation now is that pregnancy should be avoided for 28 days rather than 3 months following immunization. [10] Asymptomatic infections have occurred, but as noted, no cases of congenital defects have been documented. Interruption of pregnancy is not indicated.

The child or adult to whom rubella vaccine is administered does not shed sufficient virus to infect susceptible individuals in close contact. As a result, it is safe to immunize children in a family in which the mother is pregnant. [11]

REFERENCES

1. Reef SE et al: The changing epidemiology of rubella in the 1990s: On the verge of elimination and new challenges for control and prevention. *JAMA* **287**:464, 2002

2. Plotkin SA et al: The eradication of rubella. *JAMA* **281**:561, 1999

3. Cooper LZ, Krugman S: Clinical manifestations of postnatal congenital rubella. *Arch Ophthalmol* **77**:434, 1967

4. Jedelsohn RG, Wyll SA: Rubella in Bermuda: Termination of an epidemic by mass vaccination. *JAMA* **223**:401, 1973

5. Gregg NM: Congenital cataract following German measles in the mother. *Trans Ophthalmol Soc Aust* **3**:35, 1941

6. Zolti M et al: Rubella-specific IgM in reinfection and risk to the fetus. *Gynecol Obstet Invest* **30**:184, 1990

7. Ho Terry L et al: Diagnosis of foetal rubella virus infection by polymerase chain reaction. *J Gen Virol* **71**:1607, 1990

8. Meyer HM Jr et al: Attenuated rubella virus II: Production of an experimental live-virus vaccine and clinical trial. *N Engl J Med* **275**:575, 1966

9. Meyer HM Jr, Parkman PD: Rubella vaccination: A review of practical experience. *JAMA* **215**:613, 1971

10. Revised ACIP recommendation for avoiding pregnancy after receiving a rubella-containing vaccine. *MMWR Morb Mortal Wkly Rep* **50**:1117, 2001

11. American Academy of Pediatrics: Rubella, in *2000 Red Book: Report of the Committee on Infectious Diseases.* 25 th ed, edited by LK Pickering. Elk Grove Village, Ill: AAP 2000

T>

Chapter 210

Louis Cooper

Measles

HISTORICAL ASPECTS
EPIDEMIOLOGY
ETIOLOGY AND PATHOGENESIS
CLINICAL MANIFESTATIONS
Prodromal Symptoms
Rash
Oral Lesions
COMPLICATIONS
LABORATORY FINDINGS
PATHOLOGY
DIAGNOSIS
TREATMENT
PREVENTION23, 24, and 25
COURSE AND PROGNOSIS

REFERENCES

Measles is a universal, highly contagious, acute viral disease of childhood. It is characterized by high fever, cough, coryza, conjunctivitis, and Koplik's spots, which precede the appearance of a florid, generalized macular and papular rash.

HISTORICAL ASPECTS

The term *measles* is thought to come from the Latin *misellus* or *misella,* a diminutive of the Latin *miser,* eaning "miserable," which described the inmate of a medieval leper house. *Morbilli,* the diminutive of *morbus,* was introduced to distinguish minor rash disease from bubonic plague, *morbus,* the major disease. *Morbilliform* is a synonym for *measles-like;* it is still in common use.

No accurate information is available on the early history of measles. The tenth-century Arabian physician Rhazes generally has been credited with distinguishing measles from smallpox, although he cited El Yehudi, a Hebrew physician from the first century, as first describing the disease. However, it was probably not until the severe epidemics of measles during the seventeenth century that these diseases were clearly separated; e.g., the astute clinical and epidemiologic observations of Thomas Sydenham were completed at this time. [1]

In more recent times, transmission of measles to monkeys was first reported by Josias, [2] and other investigators [3], [4] demonstrated that monkeys could be infected with blood or nasopharyngeal secretions obtained from patients.

The isolation of measles virus in tissue culture by Enders and Peebles [5] provided the essential techniques for definitive characterization of virus excretion and antibody response in this disease and for its ultimate control. In 1960, Enders and coworkers successfully attenuated measles virus, [6] and after extensive field trials, a live measles virus vaccine was licensed for general use in the United States in 1963. Since that time, the administration of over 300 million doses of vaccine has almost eliminated indigenous measles within the United States.

EPIDEMIOLOGY

Measles is a universal illness, worldwide in distribution, that occurs primarily in children. However, the age incidence varies according to the environmental setting. In congested urban areas, the highest attack rate occurs in infancy and early childhood. In rural and less crowded areas, the attack rate is highest in the early school years, at ages 5 to 10 years. When measles has been introduced into isolated communities, the attack rate has approached 100 percent among the susceptible population of all ages. Very young infants, under 4 months of age, are usually protected by the persistence of transplacentally acquired maternal measles antibody.

Neither race nor sex affects the attack rate of measles, but the general state of health and nutrition clearly affects morbidity and mortality rates. Measles is primarily a disease of winter and spring in temperate climates, with the peak incidence of infection usually occurring in March or April.

The epidemiology of measles has changed dramatically because of the impact of massive immunization programs for eradication of the disease. The Measles Elimination Program, aided by a policy of school exclusion for those without proof of measles immunization, reduced the total number of reported cases in the United States to approximately 100 in both 2000 and 2001 (CDC/NIP/ESD personal communication to author, July 2, 2002). Almost half these cases can be attributed to importation from other countries. However, this success leaves no room for complacency. Low immunization rates among urban poor infants and young children allowed tragic epidemics of measles during the 3-year period 1989 to 1991, when 18,000, 28,000, and almost 10,000 cases, respectively, were reported nationally. Black and Latino infants and preschool children bore the brunt of the epidemic. Hospitalization and death rates were remarkably high (see "Complications" below). As a consequence of increased efforts targeted at high-risk groups and the requirement that a second dose of measles vaccine be given before school entry, by 1995, the number of confirmed cases of measles in the United States declined to 301. In 1996, the number increased slightly to 508 cases, but the striking finding was that 34 percent of the patients were above 19 years of age. This older group missed the introduction of the second dose of

vaccine. [7] Further local efforts, the impact of the second dose of measles vaccine, and expanded efforts in other countries of the western hemisphere have contributed to the current situation in the United States and, in fact, to only approximately 2000 cases in Central and South America. Isolated, serious outbreaks still occur even in countries with generally high immunization rates. Nearly 3300 cases were reported in the Netherlands in 2000 among a community with religious objections to immunization. Japan still has an estimated 100,000 to 200,000 cases anually, associated with 50 to 100 deaths. In Africa and Asia, approximately 30 million cases of measles still contribute to almost 900,000 fatalities annually. Public and private resources are currently being marshalled to ensure that immunization becomes available in these areas.

ETIOLOGY AND PATHOGENESIS

Measles virus has been classified as a paramyxovirus. Its structure and many of its biologic properties are similar to those of the larger members of the myxovirus group, i.e., mumps, Newcastle disease virus (NDV), and parainfluenza viruses. It is a heat-labile virus with an RNA core and an outer envelope of protein and lipoprotein. The virus is stable at low temperatures (especially in the presence of protein) but is inactivated rapidly by ultraviolet radiation, ether, trypsin, acetone, and beta-propiolactone. Complement fixation, hemagglutination, and hemolysis are properties of the virus that have been used for laboratory diagnosis (see " Diagnosis" below). The virus has been adapted by serial passage to grow well in numerous continuous cell lines.

At the time of the initial isolation of measles virus in tissue culture, certain characteristic cytopathic effects were noted that were strikingly similar to previously well-recognized pathologic changes occurring during natural infection in humans. These included formation of syncytia and multinucleated giant cells with intranuclear and intracytoplasmic eosinophilic inclusions.

Measles virus is antigenically stable and distinct from mumps virus and the other larger myxoviruses. There is some degree of cross-reactivity with the agents of canine distemper and bovine rinderpest, but these cause no difficulty in serodiagnosis in humans.

The natural route of infection is by droplet spread of infectious secretions from an infected patient to the respiratory tract of a person who is susceptible. It is suspected that after local multiplication at this site of entry, there may be an early viremia, but this has not been documented. During the prodromal period, virus can be detected in nasopharyngeal secretions, lymphatic tissue, blood, and urine, [8] and virus may persist in the urine for 4 days after onset of the rash. [9] However, viremia and pharyngeal shedding of virus cease by the second day of rash, a time when measles antibody reaches detectable levels in the serum.

The mechanism of the rash has not been established; rash may be a direct effect of viral invasion on epithelial and vascular endothelial cells, or it may result from the damaging effects of a virus-antibody complex. In support of the latter theory is the temporal relationship between onset of rash and appearance of antibody (the same is true in rubella, another exanthem) and the absence of rash in the few rare children, usually those with leukemia, who have developed chronic measles infection without rash or antibody production but with fatal giant cell pneumonia. [10] The experience of these children is in sharp contrast to that of children with classic (Bruton-type) agammaglobulinemia, who respond to measles infection in a normal fashion. [11] Delayed allergy (tuberculin-type skin sensitivity) is intact in these children, and they may make small quantities of humoral antibody as well. Similarly, two complications of measles, encephalitis and thrombocytopenic purpura, are suspected of having an allergic basis, but direct evidence is not available to clarify these points.

CLINICAL MANIFESTATIONS

The course of measles may be divided into three distinct phases: (1) an essentially asymptomatic incubation period of 10 or 11 days following exposure, (2) a prodromal phase characterized by fever, malaise, and increasingly severe coryza, conjunctivitis, and cough that persists for 3 or 4 days, followed by (3) onset of the rash, which usually reaches its maximum within several days and rarely persists longer than 5 to 6 days. The pathognomonic Koplik's spots usually appear in the mouth 24 to 48 h before onset of the rash and may remain discrete for 2 or 3 days. A typical clinical course is illustrated in Fig. 210-1.

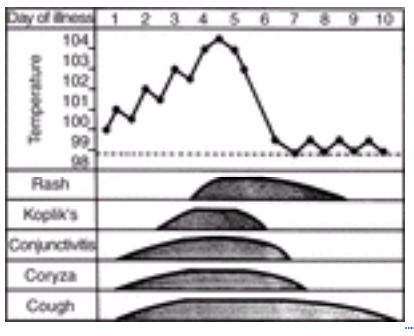

FIGURE 210-1 Schematic diagram illustrating the clinical course of typical measles. (*From Krugman S, Ward R: Infectious Diseases of Children, 3d ed. St. Louis, Mosby, 1964, with permission.*)

Prodromal Symptoms

The coryza, conjunctivitis, cough, and fever that characterize the measles prodrome increase in severity until the rash has reached its peak. The coryza is similar to that in a severe common cold. The conjunctivitis is most strikingly palpebral, extending to the lid margin, so that the eyes appear to be red-rimmed. Lacrimation, lid edema, and

photophobia accompany the conjunctivitis. A brassy or barking cough, due to diffuse involvement of the tracheobronchial tree, may be quite severe even in the absence of a complicating pneumonia and may persist for a week after the coryza. The temperature frequently reaches 40 to 40.5°C (104 to 104.9°F) at the peak of the rash but falls promptly to normal in the absence of complications. Generalized adenopathy is common in measles.

Rash

After a prodromal period of 1 to 7 days, an erythematous, discrete, macular and papular rash (Fig. 210-2B, Fig. 210-2C) appears behind the ears and over the forehead. It spreads down over the neck and trunk and then distally over the upper and lower extremities. The hands and feet are involved. This progression is usually complete, and the rash most intense, within 3 days, which coincides with the peak of the other major clinical signs of fever, cough, and conjunctivitis. Those areas in which the rash appears first tend to be most heavily involved, and confluence of lesions on the face and upper neck is common. Lesions on the legs usually remain discrete and macular and papular. The exanthem begins to fade in the order of its appearance; sometimes clearing of the face begins on the third day while the eruption is still discrete and fresh on the legs. Although the early erythematous rash blanches on pressure, the fading rash consists of brown staining (inflammatory melanosis with old hemorrhage) that does not blanch. [12] Variable degrees of fine, branny desquamation may be present as the rash clears. In the United States, the desquamation is never as extensive as that which may occur in severe scarlet fever, but desquamation has been described as quite marked in other areas of the world, such as Nigeria. [13]

FIGURE 210-2 Measles (rubeola; morbilli) has a characteristic prodrome of 3 to 4 days that consists of coryza, a striking palpebral conjunctivitis with photophobia, and a “barking” cough. The first lesions appear on the soft palate as blotchy erythema, but the most pathognomonic lesions of the prodrome, if present, are Koplik's spots (*A*), which appear as tiny white lesions surrounded by an erythematous ring (“grains of sand”). Koplik's spots precede the onset of the generalized rash by 1 to 2 days, remain for 2 to 3 days, and usually are heavily clustered on the buccal mucosa opposite the second molars. The purplish-red rash on the body appears first behind the ears and over the forehead and then spreads slowly to involve the entire body by the third day: the eruption extends downward over the neck, shoulders, and trunk and then distally over the upper and lower extremities; the spread of this rash over the central parts of the trunk (*B*) first is in contrast with that of German measles, which spreads rapidly to involve the entire body in 1 day. The measles rash remains in its original site while it spreads to the extremities, in contrast with the rash in rubella, which disappears from each site as it spreads. The erythematous macular and popular lesions, which were discrete (*C*), become confluent on the face and upper part of the neck, whereas they may remain discrete on the legs. As the rash disappears, it becomes brownish-yellow owing to capillary hemorrhages.

The severe hemorrhagic measles (“black measles”) associated with extreme toxicity, respiratory tract and gastrointestinal bleeding, hyperpyrexia, and a significant mortality rate is now rare and should not be confused with the purpuric lesions that may be seen in fair-skinned children during the course of ordinary measles.

Oral Lesions

The earliest oral lesions, according to Weinstein, [12] are a series of pinpoint elevations connected by a network of minute vessels on the soft palate. These red dots then coalesce as the entire pharynx becomes reddened. Herrman spots, bluish-gray or white areas on the tonsils, also may be present. Neither of these lesions is pathognomonic of measles. The pathognomonic lesions of measles described by Henry Koplik, [14] a New York pediatrician, begin as small, irregular, bright-red spots that usually precede onset of the rash by 24 to 48 h. In the center of each red spot is a minute bluish-white speck. These Koplik's spots are clustered most heavily on the buccal mucosa opposite the second molars (see Fig. 210-2A), but occasionally they are seen on the conjunctivae at the inner canthus and, at autopsy, in the large intestine. [15] During the first day of rash, Koplik's spots are usually easy to see as a cluster of fine grains of sand on a red background. They normally become less distinct as the rash progresses.

COMPLICATIONS

The complications of measles fall into two categories: those which are due to the measles infection alone and/or the patient's response to the infection and those due to superinfection with pathogenic bacteria. Encephalitis, which occurs in approximately 1 of every 800 cases, is the most dreaded and unpredictable complication of measles. Although most children recover completely, death or permanent brain damage occurs in a significant minority of children who develop measles encephalitis. Purpura, usually associated with thrombocytopenia, may be severe. These complications may be due to a direct effect of measles virus on the target tissues, or there may be an immunologic component. Common bacterial complications are otitis media and pneumonia caused by the pneumococcus, group A hemolytic *Streptococcus, Hemophilus influenzae,* or occasionally, *Staphylococcus aureus*. The onset of these complications is frequently accompanied by a secondary fever spike or prolongation of fever at a time when defervescence ordinarily would be expected.

Complication rates have always been higher among the very young, the malnourished, and those with other underlying diseases. The last serious outbreaks in the United States (1989–1991) were focused in just such inner-city populations.

Approximately one-third of cases were in children under 4 years of age.

Hospitalization rates of 15 to 20 percent, usually attributed to dehydration and/or respiratory distress, were associated with measles itself or bacterial superinfection. Although most of the deaths occurred in young children, almost one-third of the 97 deaths in 1990 were in adults. Some of the deaths in adults were in individuals known to be immunocompromised (e.g., HIV-infected). Death rates reached almost 4 per 1000 cases, far higher than the less than 1 per 1000 experienced in the United States in the prevaccination era but still tenfold lower than the rate seen among malnourished children in developing nations.

Measles may aggravate or exacerbate tuberculosis. The reasons for this and for the transient anergy it produces are unknown. Both measles and measles vaccine may depress the tuberculin skin test reaction for 2 or 3 weeks.

A complication, new since the vaccine era, has been described in children who received killed measles virus vaccine and subsequently were exposed to and infected with natural measles. [16] Some of these children have developed atypical infection characterized by urticarial, vesicular, and petechial rashes, swollen hands and feet, severe pneumonia, high fever, and extreme prostration. Although children may be quite sick with this syndrome, the illness appears to be self-limited. Similarly, administration of the live attenuated measles virus vaccine after prior immunization with the killed vaccine may produce erythema, edema, and even vesiculation at the injection site, with or without fever for several days.

Another late-developing complication of measles is subacute sclerosing panencephalitis (SSPE). Patients with this progressive and usually fatal disease recover uneventfully after acute measles. Months or years later, mental and motor deterioration, often with myoclonic seizures, are associated with a characteristic spike-and-wave pattern of the electroencephalogram, remarkably elevated serum and cerebrospinal fluid (CSF) measles antibody titers, and elevated total CSF IgG. In brain tissue, measles virus antigen has been demonstrated by immunofluorescence, measles-like nucleocapsids have been seen on electron microscopy, and infectious virus with the characteristics of measles has been isolated in tissue culture by meticulous techniques of cocultivation and serial passage. Fortunately, this rare complication (estimated at 5 to 10 cases per million cases of measles) appears to be even less common among children protected by attenuated measles vaccines (1 case per million doses of vaccine).

LABORATORY FINDINGS

In uncomplicated measles, routine laboratory tests are unremarkable and not particularly helpful. There is a mild leukopenia, and the chest roentgenogram frequently reveals an increase in bronchovascular markings. Cytologic examination of nasal secretion and sputum may demonstrate characteristic multinucleated giant cells.

Isolation of measles virus from blood, urine, or pharyngeal secretions during the prodromal and early rash period (see “ Etiology and Pathogenesis” above) requires virus laboratory facilities, which are available in only a limited number of research and reference institutions.

Serologic tests for measles include measurements of neutralizing, complement-fixing (CF), and hemagglutination-inhibiting (HI) antibodies. Paired sera taken shortly after onset of rash and 2 to 3 weeks later will show diagnostic (fourfold or greater) rises in measles antibody measured by each of these tests. Neutralizing and HI antibodies persist at detectable levels for many years after natural infection (probably for life in most instances), but CF antibody persistence is not so predictable. [17] The most sensitive and convenient of these serologic tests are the HI technique [18] and the enzyme-linked immunosorbent assay (ELISA). [19] These tests, which are specific for measles, can be most helpful in clarifying the cause of the unusual case of atypical measles. Bacterial superinfections and measles encephalitis usually are associated with a polymorphonuclear leukocytosis.

PATHOLOGY

The measles exanthem begins with hyaline necrosis of epidermal cells, followed by exudation of serum around the superficial vessels in the dermis and by proliferation of endothelial cells. [20] The epithelial cells become necrotic. Intranuclear inclusions may be seen. In the later stages, there is leukocytic infiltration of the dermis and lymphocytic cuffing of vessels. In uncomplicated measles, the invariable presence of multinucleated giant cells in the respiratory tract and lymphoid tissues (Warthin-Finkeldey cells) throughout the body has been accepted as evidence of measles virus invasion of these tissues (see “ Etiology and Pathogenesis” above). Tracheobronchitis is as much a part of measles as the exanthem. Rarely, a fatal penumonia, characterized by the presence of giant cells in the lungs, occurs in children with underlying disease such as leukemia. The histopathologic characteristics of measles encephalitis are similar to those observed in other postviral encephalitides. Early lesions include lymphocytic infiltration of the walls of small veins in gray and white matter, measured cellular infiltration, degeneration of ganglion cells, and microglial proliferation. Perivascular demyelinization follows these initial changes. Adams et al. [21] described intranuclear and intracytoplasmic inclusions and small giant cells in brain tissue obtained from fatal cases of measles encephalitis. Confirmation of these observations by others would add indirect support to the concept that direct invasion of the CNS by measles virus is of pathogenic significance in measles encephalitis.

DIAGNOSIS

The clinical course of full-blown measles is so characteristic that diagnosis should represent no problem. The 3- to 4-day prodrome of cough, conjunctivitis, and coryza, with appearance of Koplik's spots, followed by a macular and papular rash, is unambiguous. Laboratory confirmation is usually not necessary. However, when measles has been modified by prophylactic administration of human immunoglobulin at the time of exposure (see “ Treatment” below), the disease may be significantly attenuated; it may consist of various combinations of brief fever, cough, and rash, or it may be subclinical.

The unusual clinical picture seen in patients who develop measles despite prior immunization with inactivated (killed)

measles vaccine may be diagnosed on the basis of a prior history of such immunization and recent measles exposure (see " Complications" above).

TREATMENT

As in other systemic viral infections, there is no specific therapy for measles. Supportive therapy consisting of rest, diet, hydration, aspirin, a vaporizer, and mild antitussive agents appropriate for the febrile child with tracheobronchitis is frequently helpful in management of the self-limited disease. The prophylactic administration of antibiotics is unwarranted because it does not prevent bacterial complications and, in fact, may predispose the patient to superinfection with a treatment-resistant organism. [22] Antibiotic therapy should be instituted promptly, however, if bacterial complications develop (see " Complications" above). Therapy for measles encephalitis is also supportive.

PREVENTION [23], [24], and [25]

Measles is preventable. Guidelines for using the highly effective and safe live attenuated measles vaccine (licensed in 1963) have continued to evolve in response to the vaccine-induced changing epidemiology of the disease. A single dose of vaccine produces detectable levels of measles antibody in approximately 95 percent of recipients. Immunity from vaccine is protective against this disease, presumably for life, in most or all of those who seroconvert. However, it has become clear in recent years that the 5 percent of children who fail to respond to an initial dose of measles vaccine have provided a reservoir for continued outbreaks of disease, especially in settings where large numbers of adolescents and young adults congregate (e.g., college and high school campuses).

In 1989, because of the morbidity and costs associated with the outbreaks among young people, public health authorities in the United States adopted a two-dose measles immunization schedule (a practice already in place in 10 European countries). In the United States, the first dose of vaccine is usually given at age 15 months to avoid an interfering effect from maternal measles antibody. The second dose is given prior to school entry or early in elementary school.

The major epidemics of measles experienced in 1990 and 1991 were not due to vaccine failure (i.e., the 5 percent who fail to respond to the first dose of vaccine). The failure has been in distributing vaccine to poor children. Measles vaccination rates for inner-city children 2 years of age dropped to less than 50 percent, setting the stage for epidemics with a lower age distribution and higher complication and death rates than experienced previously in the United States. For control of epidemic measles, the timing and number of subsequent doses of vaccine are now adjusted by local health officials. The first dose may be given as early as 6 months of age. An extra dose after age 15 months but before school entry may be required in certain communities. It is likely that recommendations concerning the timing, number of doses, and perhaps even route of administration of measles vaccine will continue to evolve.

Significant controversy has been generated by unconfirmed but widely publicized reports that measles vaccine (as measles-mumps-rubella vaccine, or MMR) is a cause of autism spectrum disorder. Extensive reviews by respected panels of the Medical Research Council (United Kingdom), the American Academy of Pediatrics, and the Institute of Medicine (IOM) of the National Academy of Sciences have concluded that current scientific evidence favors rejection of a causal association between autism and MMR vaccine (IOM Report, May 2001). Nevertheless, immunization rates have fallen as low as 65 percent in parts of the United Kingdom, and serious concern exists of a resurgence of measles in that country.

Immune serum globulin (ISG) may be used to modify or prevent measles if given within 6 days of exposure. The recommended dose is 0.25 mL/kg of body weight, given intramuscularly. ISG is especially valuable for infants too young for active immunization. For children and adults who are immunosuppressed, the dose is 0.5 mL/kg. The maximum dose is 15 mL. In contrast to other congenital or acquired causes of immunosuppression, HIV infection is not a contraindication for measles vaccination, but when exposed, such children should still receive ISG.

COURSE AND PROGNOSIS

Uncomplicated measles runs a self-limited course, lasting about 10 days, with no sequelae. However, the prognosis varies greatly with the age of the patient, his or her nutritional and general health status, and perhaps access to early and appropriate supportive care. Prior to widespread immunization, approximately 500 deaths were attributed to measles each year in the United States. In the early 1980s, when measles cases dropped to an average of only 3000 yearly, deaths were few. In 1990, with almost 100 deaths, the rate of almost 4 per 1000 greatly exceeded the death rate of 3 per 10,000 that characterized the preimmunization era rate for infants in the United States. Morbidity and mortality in developing nations, where poverty prevents access to care, continue to reflect the general health status of children in these areas, with measles a major contributor to infant mortality. This experience offers ample justification for the World Health Organization's Expanded Program for Immunization.

REFERENCES

1. Katz SL, Enders JF: Measles virus, in *Viral and Rickettsial Infections of Man,* 4th ed., edited by FL Horsfall Jr., I Tamm. Philadelphia, Lippincott, 1965, p 784

2. Josias A: Ré cherches expérimentales sur la transmissibilité de la rugeole aux animaux. *Med Mod* **9**:158, 1898

3. Anderson JF, Goldberger J: Experimental measles in a monkey: A preliminary note. *Public Health Rep* **26**:847, 1911

4. Blake FG, Trask JD Jr: Studies on measles: I. Susceptibility of monkeys to the virus of measles. *J Exp Med* **33**:385, 1921

5. Enders JF, Peebles TC: Propagation in tissue cultures of cytopathogenic agents from patients with measles. *Proc Soc Exp Biol Med* **86**:277, 1954

6. Enders JF et al: Studies on an attenuated measles-virus vaccine: I. Development and preparation of the vaccine: Technics for assay of effects of vaccination. *N Engl J Med* **263**:153, 1960

7. Centers for Disease Control: Measles. *MMWR* **47**:RR08-1, 1998

8. Enders JF: Measles virus: Historical review, isolation and behavior in various systems. *Am J Dis Child* **103**:282, 1962

9. Gresser I, Katz SL: Isolation of measles virus from urine. *N Engl J Med* **263**:452, 1960

10. Mitus A et al: Persistence of measles virus and depression of antibody formation in patients with giant cell pneumonia after measles. *N Engl J Med* **261**:882, 1959

11. Janeway CA, Gitlin D: The gamma globulins. *Adv Pediatr* **9**:65, 1957

12. Weinstein L: *The Practice of Infectious Disease.* New York, McGraw-Hill, 1958

13. Morley DC: Measles in Nigeria. *Am J Dis Child* **103**:230, 1962

14. Koplik H: The diagnosis of the invasion of measles from a study of the exanthema as it appears on the buccal mucous membrane. *Arch Pediatr* **13**:918, 1896

15. Corbett EU: The visceral lesions in measles. *Am J Pathol* **21**:905, 1945

16. Rauh LW, Schmidt R: Measles immunization with killed virus vaccine: Serum antibody titers and experience with exposure to measles epidemic. *Am J Dis Child* **109**:232, 1965

17. Krugman S et al: Studies on immunity to measles. *J Pediatr* **66**:471, 1965

18. Rosen L: Hemagglutination and hemagglutination-inhibition with measles virus. *Virology* **13**:139, 1961

19. Parker JC et al: Sensitivity of enzyme-linked immunosorbent assay, complement fixation, and hemagglutination inhibition serological tests for detection of Sendai virus antibody in laboratory mice. *J Clin Microbiol* **9**:444, 1979

20. Robbins FC: Measles: Clinical features. *Am J Dis Child* **103**:266, 1962

21. Adams JM et al: Inclusion bodies in measles encephalitis. *JAMA* **195**:290, 1966

22. Weinstein L: Failure of chemotherapy to prevent the bacterial complications of measles. *N Engl J Med* **253**:679, 1955

23. Centers for Disease Control: Measles prevention: Recommendations of the Immunization Practices Advisory Committee. *MMWR* **38**(suppl 9): December 1989

24. Markowitz LE, Orenstein WA: Measles vaccines. *Pediatr Clin North Am* **37**:603, 1990

25. National Vaccine Advisory Committee: The measles epidemic, barriers and recommendations. *JAMA* **266**:1574, 1991

T>

Chapter 211

Raphael Dolin

Hand-Foot-and-Mouth Disease

HISTORICAL
EPIDEMIOLOGY
PATHOGENESIS
CLINICAL MANIFESTATIONS
HISTOPATHOLOGY
DIAGNOSIS
DIFFERENTIAL DIAGNOSIS
TREATMENT
COURSE AND PROGNOSIS

REFERENCES

Hand-foot-and-mouth disease (HFMD) is an illness characterized by a distinctive vesicular eruption in the mouth and on the extremities. The causative agents are enteroviruses, most commonly coxsackievirus A16, less commonly A5, A7, A9, A10, B2, and B5, and enterovirus 71, which has been responsible for the largest reported outbreaks. [1] Infection with adenovirus 21 also has been associated with this disease. [2] HFMD caused by coxsackieviruses is usually a benign, self-limited illness, but that caused by enterovirus 71 has been associated with significant morbidity and with fatalities. [3]

HISTORICAL

Robinson et al. [4] first described an outbreak in Canada in 1957, characterized by fever, pharyngeal lesions, and a vesicular exanthem on the extremities, associated with coxsackievirus A16. Alsop et al. [5] reported a similar outbreak in the United Kingdom in 1959 and coined the term *hand-foot-and-mouth disease.* Enterovirus 71 infection was first recognized in 1969 and has been associated with individual cases or outbreaks of HFMD since that time. [5], [6]

EPIDEMIOLOGY

HFMD is worldwide in distribution and occurs in both sporadic cases and in outbreaks. [7], [8] and [9] Extraordinarily large examples of the latter have been reported in association with enterovirus 71 infection, including two recent outbreaks in Taiwan that were estimated to involve more than 100,000 cases. [10] As is the case with enteroviral infections in general, HFMD occurs most commonly during the warmer times of the year, from summer through late fall in temperate climates and throughout the year in tropical areas. Children younger than age 10 are affected most frequently, and intrafamilial spread of infection to other siblings is common. [1], [11] Household members who are adults also may be infected but usually without clinical manifestations.

Most enteroviral infections are transmitted by fecal-oral spread, and it has been assumed that this is also the case with HFMD. However, the rapidity of spread seen in the large enterovirus 71 outbreaks suggests that respiratory or droplet spread might occur, as is the case with respiratory illness caused by coxsackievirus A21. [1], [10]

PATHOGENESIS

The pathogenesis of enteroviral infections has been established largely through studies of polioviruses. [12] It has been assumed that the pathogenesis of nonpoliovirus enteroviruses, such as those which cause HFMD, is similar, and available evidence generally supports this. Infection begins by ingestion of fecal (or possibly respiratory) material that contains virus, which then infects the oropharynx or gastrointestinal tract. The cellular site of initial virus replication is not established but may involve M cells in the gastrointestinal tract. [13] Within 1 to 3 days, virus replication can be detected in regional lymphoid tissue, from which a “minor” viremia ensues. This is not manifested clinically but results in spread of virus to reticuloendothelial tissues such as bone marrow, spleen, liver, and deep lymph nodes. In most cases of enteroviral infection, virus replication is contained at this point by host defenses, and clinical manifestations are not noted. In a minority of infections, virus replication continues in reticuloendothelial tissues or in deep lymph nodes, and a “major” viremia results. This viremia probably accounts for the “nonspecific” or prodromal febrile illness component of many enterovirus-associated illnesses. [14] The major viremia results in dissemination of virus to end organs that are involved with disease, such as the skin and oral mucosa in HFMD, the central nervous system, or the heart. The incubation period of HFMD is believed to be short, lasting 3 to 6 days.

CLINICAL MANIFESTATIONS

HFMD commonly begins with a nonspecific prodromal illness consisting of low-grade fever (38° to 39°C) that lasts 1 to 2 days and is accompanied by malaise and occasionally by upper respiratory tract symptoms or abdominal pain. The presenting complaints are most frequently sore mouth or sore throat, and young children so afflicted may refuse to eat. The characteristic features of the disease are painful oral lesions that are present in virtually all cases (Fig. 211-1). These are generally few in number, usually between 5 and 10, most frequently are found on the tongue, buccal mucosa, or hard palate but can be present anywhere in the oropharynx. [11], [15] The lesions begin as erythematous macules and papules, 2 to 8 mm in diameter, that progress rapidly to vesicles on an erythematous base. The vesicles quickly erode and form yellow to gray shallow ulcerations surrounded by an erythematous halo. Several vesicles may coalesce to form larger lesions that resemble bullae. While vesicular lesions are the hallmark of HFMD, the duration of the vesicles is

sufficiently short that the oral lesions usually have ulcerated by the time patients present to the physician.

FIGURE 211-1 *A.* Shallow ulcerations on the tongue that are part of the oral lesions of hand-foot-and-mouth disease caused by coxsackievirus A16 infection. *B.* Vesicular and popular lesions on the fingers and feet in hand-foot-and-mouth-disease. (From Haley JC, Flood AF: Hand-foot-and-mouth disease, in *Dermatology in General Medicine,* 5 th ed, edited by IM Freedberg, AZ Eisen, K Wolff, KF Austen, LA Goldsmith, SI Katz, and TB Fitzpatrick. New York, McGraw Hill, 1999, p 2405)

Cutaneous peripheral lesions are present in approximately 75 percent of patients and appear either simultaneously with the oral lesions or shortly thereafter. [1], [11] The lesions typically occur on the distal extremities and are more common on the hands than on the feet (Fig. 211-1 and Fig. 211-2). The extensor surfaces and sides of the finger, hands, toes, and feet are involved most frequently, but lesions may be present on the palms and soles as well. Less frequently, lesions occur more proximally on the extremities, as well as on the buttocks or genitalia. Lesions are usually painful and tender but on occasion can be asymptomatic. The number of lesions on the periphery is highly variable and can range from several to more than 100. [16]

FIGURE 211-2 *A, B.* Vesicles and bullae on an erythematous base on the hands and feet in hand-foot-and-mouth-disease. These are usually painful and are associated with a vesicular enanthem. (From Haley JC, Flood AF: Hand-foot-and-mouth disease, in *Dermatology and General Medicine,* 5 th ed, edited by IM Freedberg, AZ Eisen, K Wolff, KF Austen, LA Goldsmith, SI Katz, and TB Fitzpatrick. New York, McGraw Hill, 1999, p 2404)

The evolution of the cutaneous lesions is similar to that described for the oral lesions. Initially, a small (2–10 mm in diameter) erythematous macule or papule is seen that evolves into a clear vesicle surrounded by an erythematous halo. The vesicles collapse and form crusts that resolve gradually in 7 to 10 days without sequelae. A cutaneously disseminated form of HFMD described in an infant with eczema has been called *eczema coxsackium.* [17]

HISTOPATHOLOGY

Cutaneous lesions of HFMD consist of intraepidermal vesicles that are infiltrated with polymorphonuclear leukocytes and mononuclear cells and contain fluid and eosinophilic, proteinaceous material (Fig. 211-3). The epidermis of the blister wall has dyskeratotic and acantholytic cells. [18] As the basal cell layer is lost, vesicles can expand to form subepidermal bullae. Eosinophilic intranuclear inclusions and intracytoplasmic crystalline arrays of picornavirus particles (by electron microscope) have been seen in cells surrounding dermal vessels. [19] The dermis adjacent to vesicles also has a mixed polymorphonuclear and mononuclear cell infiltrate, along with edema fluid.

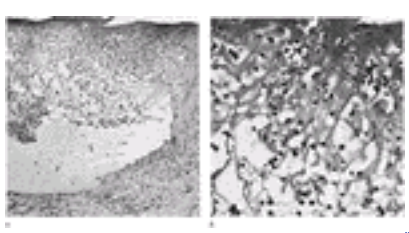

FIGURE 211-3 *A.* Intraepidermal bulla with focal loss of epidermis at base. The cavity is filled with polymorphonuclear leukocytes and mononuclear cells (H&E Stain). *B.* Higher magnification of roof of bulla with dyskeratotic epidermal cells and exocytosis of mononuclear cells (H&E stain). (From Haley JC, Flood AF: Hand-foot-and-mouth disease, in *Dermatology in General Medicine,* 5 th ed, edited by IM Freedberg, AZ Eisen, K Wolff, KF Austen, LA Goldsmith, and TB

Fitzpatrick. New York, McGraw Hill, 1999, p 2405)

DIAGNOSIS

The diagnosis of HFMD is usually based on the characteristic clinical picture of an oral enanthem and a vesicular exanthem on the extremities, usually in association with a low-grade febrile illness. Laboratory diagnosis is rarely required, except in the case of unusual or severe manifestations (see below). Definitive diagnosis is established by isolation of virus from lesions in tissue culture. Isolation of virus from throat or stool provides only presumptive etiologic evidence because enteroviruses may be shed for weeks in the oropharynx and even longer in the stool, and thus the presence of virus may reflect an unrelated, intercurrent infection. The ability to cultivate virus in vitro is highly variable among enterovirus groups and serotypes and may take several days to weeks. [1] The use of polymerase chain reaction (PCR) provides a rapid, sensitive, and specific method to detect enteroviruses in clinical specimens. PCR primers employ a highly conserved portion of the 5' nontranslated portion of the enterovirus genome that can detect most enteroviruses, except for echovirus 22 and 23. [20], [21] The likelihood of a positive culture or PCR detection increases with the number of sites or lesions that are sampled.

Serologic tests are of limited utility in diagnosis of enteroviral infections. There are 67 distinct serotypes of enteroviruses, so type-specific neutralization tests are performed infrequently, unless a specific serotype is being sought (e.g., coxsackievirus A16). Type and group immunoassays employing ELISA or other methodologies appear to be less sensitive and specific than neutralization tests but have been used to detect IgM antibody responses against group B coxsackieviruses in support of the diagnosis of acute infection. [22]

DIFFERENTIAL DIAGNOSIS

The presence of oral lesions and vesicles on the hands and feet forms a characteristic pattern for HFMD that is unlikely to be caused by other illnesses. If only oral lesions are present, they may be confused with herpetic gingivostomatitis, herpangina, or aphthous ulcers. Herpetic gingivostomatitis is usually more extensive than HFMD and frequently is accompanied by higher fever, cervical lymphadenopathy, and more systemic symptoms. Herpangina, caused by any of several enteroviruses, usually involves the posterior orpharynx, fauces, and soft palate. Aphthae may appear anywhere on the oral mucosa or tongue but are not accompanied by fever or systemic symptoms. Chickenpox can include oral lesions, but the cutaneous lesions are usually central and much more extensive than those in HFMD. Patients with erythema muliforme usually have more extensive oral or cutaneous involvement, along with a variety of different lesions, such as target lesions. Drug eruptions also tend to be more extensive than lesions seen in HFMD and frequently are pruritic rather than painful.

TREATMENT

HFMD is usually a benign, self-limited illness that resolves within 7 to 10 days. Treatment usually is not necessary, although analgesics and particularly topical anesthetics may provide relief from painful oral lesions. A single report of benefit in the treatment of HFMD with the use of acyclovir, which does not inhibit RNA viruses, is unconvincing. [23]

COURSE AND PROGNOSIS

As noted earlier, the vast majority of cases of HFMD resolve spontaneously within a week to 10 days without sequelae. Occasionally, cases associated with more prolonged fever, systemic symptoms, diarrhea, and joint pains have been reported. [24] CNS involvement as defined by headache, nuchal rigidity, myoclonus, tremor, and cerebrospinal fluid (CSF) pleocytosis has been reported to be as frequent as 8 to 24 percent of patients in some outbreaks of HFMD caused by enterovirus 71. [25] Encephalitis and flaccid paralysis also have been reported but appear to be considerably less frequent. [25], [26] Rare life-threatening and fatal complications also have been reported, chiefly in cases in the largest outbreaks of enterovirus 71 associated with HFMD (0.083 cases per 1000 children younger than 15 years of age), most of whom had pulmonary edema or hemorrhage as a cause of death. [10] In outbreaks involving both viruses, serious complications were less frequent in cases associated with coxsackievirus A16 than with enterovirus 71. [10], [27] Whether the occurrence of recently reported large outbreaks of HFMD caused by enterovirus 71 that are associated with uncommon but serious complications are recently emerged or merely recently recognized phenomena is unclear at present. [3]

REFERENCES

1. Modlin JF: Coxsackieviruses, echoviruses and newer enteroviruses, in *Principles and Practice of Infectious Diseases,* 5th ed, edited by GL Mandell, JE Bennett, and R Dolin. Philadelphia, Churchill-Livingstone, 2000, p 1904

2. AbuBakar S et al: Adenovirus in EV71-associated hand, foot, and mouth disease. *Lancet* **355**:146, 2000

3. Dolin R: Enterovirus 71—Emerging infections and emerging questions. *New Engl J Med* **341**:984, 1999

4. Robinson CR et al: Report of an outbreak of febrile illness with pharyngeal lesions and exanthema. *Can Med Assoc J* **79**:615, 1958

5. Alsop J et al: Hand-foot-and-mouth disease in Birmingham in 1959. *Br Med J* **2**:1708, 1960

6. Schmidt NJ et al: An apparently new enterovirus isolated from patients with disease of the central nervous system. *J Infect Dis* **129**:304, 1974

7. Chonmaitree T et al: Enterovirus 71 infection: Report of an outbreak with two cases of paralysis and a review of the literature. *Pediatrics* **67**:489, 1981

8. Kennett ML et al: Enterovirus type 71 infection in Melbourne. *Bull WHO* **51**:609, 1974

9. Miwa C et al: Epidemic of hand, foot and mouth disease in Gifu prefecture in 1978. *Jpn J Med Sci Biol* **33**:167, 1980

10. Ho M et al: An epidemic of enterovirus 71 infection in Taiwan. *New Engl J Med* **341**(13): 929, 1999

11. Adler JL et al: Epidemiologic investigation of hand, foot and mouth disease: Infection caused by coxsackievirus A16 in Baltimore, June through September 1968. *Am J Dis Child* **120**:309, 1970

12. Sabin AB: Pathogenesis of poliomyelitis: Reappraisal in light of new data. *Science* **123**:1151, 1956

13. Wolf JL et al: Intestinal M cells: A pathway for entry of reovirus into the host. *Science* **212**:471, 1981

14. Horstmann DM, McCollum RW: Poliomyelitis virus in human blood during the “minor illness” and the asymptomatic infection. *Proc Soc Exp Biol Med* **82**:434,1953

15. Evan AD, Waddington E: Hand, foot, and mouth disease in South Wales, 1964. *Br J Dermatol* **79**:309, 1967

16. Higgins PG, Warin RP: Hand, foot and mouth disease: A clinically recognizable virus infection seen mainly in children. *Clin Pediatr* **6**:373, 1967

17. Nahmias AJ et al: Generalized eruption in a child with eczema due to coxsackievirus A16. *Arch Dermatol* **97**:147, 1968

18. Miller GD: Hand-foot-and-mouth disease. *JAMA* **203**:827, 1968

19. Kimura A et al: Light and electron microscopic study of skin lesions in patients with hand, foot, and mouth disease. *Tohoku J Exp Med* **122**:237, 1977

20. Rotbart HA et al: Diagnosis of enteroviral meningitis by using PCR with a colorimetric microwell detection assay. *J Clin Microbiol* **32**:2590, 1994

21. Yan JJ et al: Complete genome analysis of enterovirus 71 isolated from an outbreak in Taiwan and rapid identification of enterovirus 71 and coxsackievirus A16 by RT-PCR. *J Med Virol* **65**:331, 2001

22. Pozzetto B et al: Comparative evaluation of immunoglobulin M neutralizing antibody response in acute-phase sera and virus isolation for the routine diagnosis of enterovirus infection. *J Clin Microbiol* **27**:705, 1989

23. Shelley WB et al: Acyclovir in the treatment of hand-foot-and-mouth disease. *Cutis* **57**:232, 1996

24. Fields JP et al: Hand, foot and mouth disease. *Arch Dermatol* **99**:243, 1969

25. Ishimaru Y et al: Outbreaks of hand, foot, and mouth disease by enterovirus 71: High incidence of complication disorders of central nervous system. *Arch Dis Child* **55**:583, 1980

26. Huang CC et al: Neurologic complications in children with enterovirus 71 infection. *New Engl J Med* **341**:936, 1999

27. Chang LY et al: Comparison of enterovirus 71 and coxsackievirus A16 clinical illnesses during the Taiwan enterovirus epidemic, 1998. *Pediatr Inf Dis J* **18**:1092, 1999

T>

Chapter 212

David Sirois

Herpangina

EPIDEMIOLOGY
ETIOLOGY/PATHOGENESIS
CLINICAL MANIFESTATION
DIFFERENTIAL DIAGNOSIS
TREATMENT
NATURAL HISTORY AND PROGNOSIS

REFERENCES

Herpangina is an acute viral infection of the oropharynx that presents as multiple, acute ulcerations or gray-white papulovesicular lesions with associated marginal erythema. [1], [2] and [3] The infection usually occurs during warm months, with the highest incidence from June to October. It frequently occurs in epidemics affecting children ages 3 through 10 years. Herpangina is one of three oropharyngeal infections caused by group A coxsackieviruses, the others being hand-foot-and-mouth disease and acute lymphonodular pharyngitis. [4], [5] Of the 24 known types of group A coxsackieviruses, type A4 causes the majority of cases of herpangina. Types A1 to A10 and A16 to A22 have also been implicated, however, as have group B coxsackieviruses (strains 1 to 4), echoviruses, adenoviruses, and other enteroviruses. [6], [7], [8], [9] and [10]

EPIDEMIOLOGY

Herpangina can occur in any age group, but as noted above, it most commonly affects children ages 3 to 10 years. [6], [7] There may be outbreaks of herpangina among groups of children in close contact, such as classmates in school or siblings at home. The incubation period is approximately 4 days. The virus may cause subclinical infection manifest as febrile illness without the characteristic oropharyngeal lesions. During the summertime in a temperate climate, it may be possible to isolate the virus from as many as 1.5 to 7.5 percent of asymptomatic persons. Although it spreads primarily through inhalation of aerosolized drops of saliva (e.g., from sneezing and coughing), group A coxsackieviruses can be recovered not only from saliva, but also from nasal and oropharyngeal washing, and from stool. The disease is worldwide in distribution. There is no sex difference and no known difference by race or national origin in the prevalence of the disease.

ETIOLOGY/PATHOGENESIS

Coxsackieviruses are RNA enteroviruses named for the town in upper New York State where they were first discovered. Coxsackieviruses have been separated into two groups, A (24 known types) and B (6 known types), [2], [3] based upon the lesional pathology produced in laboratory suckling mice. This distinction has limited practical value, however, because virus speciation is rarely necessary in the clinical setting.

Although most often coxsackievirus infection is self-limited, fever, chills, oropharyngeal ulcerations, sore throat, and dysphagia are characteristic. These viruses can also cause hepatitis, meningitis, myocarditis, pericarditis, and acute respiratory disease. Following infection, permanent immunity to the specific infecting strain develops, but because of the many antigenic strains, the illness may appear more than once in the same individual.

CLINICAL MANIFESTATION

The typical presentation of herpangina is a sudden onset of fever, chills, sore throat, headache, and body aches. Most patients experience fever ranging from 38°C to 41°C (100. 4°F to 105.8°F) and mild leukocytosis (10,000 to 15,000/mL ^{3}). Examination of the oral cavity reveals multiple shallow papulovesicular lesions affecting, in order of frequency, the anterior pillars of the tonsillar fauces, soft palate, uvula, and tonsils; the lesions quickly progress to shallow ulcers with brisk marginal erythema (Fig. 212-1). For patients with this clinical presentation and lesions affecting the hands and feet, hand-foot-and-mouth disease is the most likely diagnosis (see Chap. 211 and Fig. 211-1 and Fig. 211-2).

FIGURE 212-1 Typical appearance of the oropharyngeal lesions of herpangina. Acute, multiple papulovesicular lesions quickly progress to form shallow ulcerations with brisk marginal erythema.

DIFFERENTIAL DIAGNOSIS

No reliable, practical definitive laboratory diagnostic test is available or necessary for the diagnosis of herpangina: the diagnosis is based on the clinical presentation. [3], [11], [12] Several disorders can be confused with herpangina, for example, coxsackievirus infection resulting in hand-foot-and-mouth disease or lymphonodular pharyngitis, and primary herpetic gingivostomatitis. Less commonly confusion may arise in regard to oral candidiasis, deficiency diseases and hematologic disorders, infectious mononucleosis, and the enanthems of measles, varicella, scarlatina, and diphtheria. Serologic, microbiologic, hematologic, and histologic examination will differentiate among these disorders when the clinical presentation alone is insufficient to make the diagnosis with confidence. Table 212-1 summarizes the distinguishing features among the disorders commonly confused with herpangina.

TABLE 212-1 **Comparative Features of Disorders that May Be Confused with Herpangina**

TREATMENT

Herpangina resolves with supportive care in 4 to 7 days; no specific treatment is available or necessary. Supportive care includes maintaining proper hydration and administering acetaminophen to control fever. The use of antihistamine mouth rinses can provide symptomatic relief from painful oral lesions. Rapid resolution of oral lesions has been reported with the use of allopurinol mouthwashes. [13]

NATURAL HISTORY AND PROGNOSIS

The fever associated with herpangina rarely lasts more than 4 days; the oral lesions rarely last more than a week. With the exception of the occasional child who suffers a febrile convulsion, the prognosis is good and the course benign. Immunity to one strain does not protect an individual from future infection by a different antigenic strain of the virus.

Because other more virulent and potentially fatal enteroviruses can mimic the presentation of herpangina, signs and symptoms that progress significantly or continue beyond 7 days warrant aggressive exploration. [6], [8], [9] and [10]

REFERENCES

1. Cole RM et al: Studies of Coxsackie viruses: Observations on epidemiological aspects of group A viruses. *Am J Public Health* **41**:1342, 1951

2. Cherry JD, Jahn CL: Herpangina: Etiologic spectrum. *Pediatrics* **36**:632, 1965

3. Hyypia T, Stanway G: Biology of Coxsackie A viruses. *Adv Virus Res* **42**:343, 1993

4. Steigman AJ et al: Acute lymphonodular pharyngitis: Newly described condition due to Coxsackie A virus. *J Pediatr* **61**:331, 1962

5. Adler L et al: Epidemiologic investigation of hand-foot-and-mouth disease. *Am J Dis Child* **120**:309, 1970

6. Nakamura Y et al: Epidemic patterns of infectious diseases from the results of the surveillance of infectious diseases in Japan. *Pediatr Infect Dis J* **7**:262, 1988

7. Yamadera S et al: Herpangina surveillance in Japan, 1982–1989. *Jpn J Med Sci Biol* **44**:29, 1991

8. Nakayama T et al: Outbreak of herpangina associated with Coxsackievirus B3 infection. *Pediatr Infect Dis J* **8**:495, 1989

9. Modlin JF, Rotbart HA: Group B Coxsackie disease in children. *Curr Top Microbiol Immunol* **223**:53, 1997

10. Chang LY et al: Risk factors of enterovirus 71 infection and associated hand, foot, and mouth disease/herpangina in children during an epidemic in Taiwan. *Pediatrics* **109**:88, 2002

11. Eversole LR: Inflammatory diseases of the mucous membranes: Part 1. Viral and fungal infections. *J Can Dent Assoc* **22**:52, 1994

12. Cohen SG et al: The differentiation of intraoral ulcers. *Hosp Pract* **26**:101, 1991

13. Waldfahrer F, Iro H: Successful treatment of herpangina with allopurinol mouthwashes. *Laryngoscope* **105**:1405, 1995

T>

Chapter 213

Karen Wiss

Erythema Infectiosum and Parvovirus B19 Infection

HISTORICAL ASPECTS
EPIDEMIOLOGY
ETIOLOGY AND PATHOGENESIS
PREVENTION
CLINICAL MANIFESTATIONS
Parvovirus B19 in Children
Parvovirus B19 in Adults
Papular Purpuric Gloves-and-Socks Syndrome
COMPLICATIONS
Transient Aplastic Crisis
Chronic B19 Infection
Fetal B19 Infection
Other Complications
LABORATORY FINDINGS
PATHOLOGY
DIAGNOSIS AND DIFFERENTIAL DIAGNOSIS
TREATMENT AND PROGNOSIS
REFERENCES

Erythema infectiosum (fifth disease) is primarily a childhood illness that is characterized by a “slapped cheek” appearance of the face and an erythematous, lacy eruption on the trunk and extremities. Parvovirus B19, the etiologic agent, may also cause arthropathy, aplastic crisis in patients with increased red blood cell turnover, chronic anemia in immunocompromised persons, and fetal hydrops.

HISTORICAL ASPECTS

The first known clinical picture of a patient with erythema infectiosum is drawn in Robert Willan's book *On Cutaneous Diseases* (1808). Throughout the 1800s, the disease was thought to be a mild form of rubella or measles. Tschamer described a distinct illness compatible with erythema infectiosum in 1889, although he thought it was abortive rubella. [1] It was designated fifth disease in the early 1900s when infectious exanthems were numbered first through sixth. [2]

The first clue to the etiologic agent came in 1975 in England. During routine screening of serum from healthy blood donors for hepatitis B surface antigen, nine samples of blood had false-positive results by counterimmunoelectrophoresis (CIE), but were negative by the more sensitive techniques of hemagglutination and radioimmunoassay (RIA). Electron microscopy of these serum samples demonstrated viral particles that were designated B19 after a specimen label from one of the blood donors. [3] The authors postulated that this was an infectious agent because 30 percent of adults had IgG antibody to the viral antigen. It was later confirmed that B19 was a parvovirus. [4] Parvoviruses had previously been thought to infect only animals. In this manner, the virus was discovered, but association with a clinical illness awaited.

Parvovirus was identified as the etiologic agent of an acute febrile illness in two British soldiers in 1980, and was found in the serum of patients with sickle cell anemia and hypoplastic crisis in 1981. The virus was suggested as a cause of aplastic crisis in sickle cell disease. In 1983, there was an outbreak of fifth disease among London schoolchildren. [5] Serum samples from 31 schoolchildren and 6 exposed adults, all with clinical signs of the disease, contained parvovirus-specific IgM antibody. There was no IgM detected in exposed asymptomatic individuals. These findings suggested parvovirus B19 as the cause of erythema infectiosum.

EPIDEMIOLOGY

Fifth disease is worldwide in distribution, can occur throughout the year, and can affect all ages. It tends to occur in epidemics, especially associated with school outbreaks in the late winter and early spring. Serologic studies show increasing prevalence with age. Various studies indicate that from 15 to 60 percent of children 5 to 19 years old and 30 to 60 percent of adults are seropositive. [6] Seroprevalence increases to greater than 90 percent in the elderly. [6] Previous infection with B19 seems to confer lifelong immunity.

The incubation period for erythema infectiosum is from 4 to 14 days. [7] After intranasal inoculation of parvovirus-infected serum to healthy volunteers, low-grade fever and nonspecific complaints occurred at the time of viremia, 6 to 14 days after inoculation, and the rash appeared at day 17 or 18. [8]

Parvovirus B19 is thought to be transmitted primarily by the respiratory route via droplet aerosol during the viremic phase, and B19 DNA has been found in respiratory secretions of viremic patients. [8] After the rash of erythema infectiosum appears, B19 is not found in respiratory secretions and is usually not present in the serum. This suggests that persons with erythema infectiosum are infectious only prior to the onset of the rash.

The virus seems to be effectively spread after close contact. The secondary attack rate among susceptible household contacts is approximately 50 percent. Transmission may occur via blood transfusion, from blood products, and vertically from mother to fetus. [9] The transmission of B19 through blood transfusion is particularly problematic because the

nonenveloped virus is not killed by the solvent detergents or heat that are used to inactivate HIV and hepatitis viruses. [10]

ETIOLOGY AND PATHOGENESIS

The B19 virus belongs to the family *Parvoviridae* and the genus Parvovirus. [11] Two other genera in this family, the Dependoviruses and the Densoviruses, infect other vertebrates and insects. [12] B19 lacks an envelope and contains single-stranded DNA. It is the smallest single-stranded DNA-containing virus known to infect humans, measuring 18 to 26 µm in diameter. Parvoviruses are widespread in veterinary medicine, but animal parvoviruses are not thought to be transmissible to humans. [10]

The pathogenesis of erythema infectiosum is unknown, but the mechanism may involve immune complexes. The more serious manifestations of parvovirus infection relate to the fact that the virus infects and lyses erythroid progenitor cells. Recent evidence suggests that the blood group P antigen (globoside) is a receptor of parvovirus. Because some individuals lack P antigen, they are not susceptible to infection with B19. [13] In patients with increased red blood cell destruction or loss who depend on compensatory increase in red cell production to maintain stable red cell indices, B19 infection may lead to transient aplastic crisis. Such patients include those with anemia associated with acute or chronic blood loss. When parvovirus infects the erythroblasts in a developing fetus with decreased red cell survival, the result may be hemolysis and anemia. [14] Anemia may trigger congestive heart failure, edema (fetal hydrops), and possibly fetal death.

PREVENTION

There is currently no vaccine to prevent parvovirus B19 infection. Candidate vaccines are in clinical trials. [15] It is not known whether immunoglobulin given around the time of exposure will prevent infection or alter the course of the disease.

Because patients with erythema infectiosum are no longer infectious by the time they develop the illness, control measures directed toward these individuals are not likely to be effective. If these persons are hospitalized, no special precautions need to be taken. Because the virus is transmitted before the rash appears, the disease is easily spread in situations of close prolonged contact such as schools, day care centers, workplaces, and homes.

Patients with aplastic crisis or immunosuppression with chronic B19 anemia may have high titer viremia and are particularly infectious. These individuals should be placed in respiratory and contact isolation if hospitalized, and pregnant health care providers should not care for them directly. Hospital workers are at risk of contracting nosocomial infections from these patients [16] and could spread the virus to patients if adequate precautions are not taken.

CLINICAL MANIFESTATIONS

Parvovirus B19 in Children

Most infections caused by B19 are asymptomatic and unrecognized. Fifth disease, the most common clinical picture associated with the virus, usually begins with nonspecific symptoms such as headache, coryza, and low-grade fever about 2 days prior to the onset of the rash. [17] Patients may have headache, pharyngitis, fever, malaise, myalgias, coryza, diarrhea, nausea, cough, and conjunctivitis coinciding with the rash. Approximately 10 percent of children with erythema infectiosum develop arthralgias or arthritis. Large joints are affected more often than small joints. [17] Occasionally, children may present with chronic joint complaints suggestive of juvenile rheumatoid arthritis. [18]

The characteristic rash begins with confluent, erythematous, edematous plaques on the malar eminences, the “slapped cheeks” (Fig. 213-1). As the facial rash fades over 1 to 4 days, pink to erythematous macules or papules appear on the trunk, neck, and extensor surfaces of the extremities. These lesions have some central fading, giving them a lacy or reticulated appearance [17] (Fig. 213-2). The rash can be morbilliform, confluent, circinate, or annular, and there have been reports of palmar and plantar involvement. [7] The eruption typically lasts 5 to 9 days, but can recur for weeks or months with triggers such as sunlight, exercise, temperature change, bathing, and emotional stress. In some outbreaks, pruritus is a major feature of the rash in children. [7]

FIGURE 213-1 Child with the characteristic “slapped cheeks”.

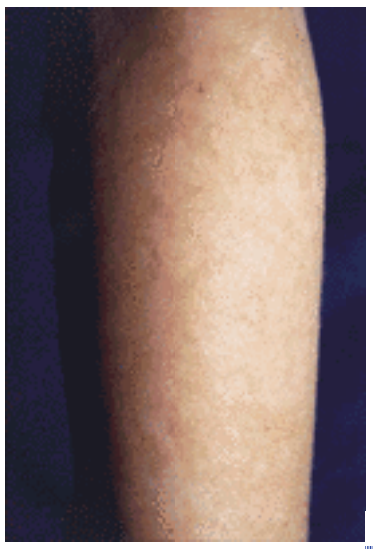

FIGURE 213-2 Reticulate erythematous macules on the extremity.

There have been occasional reports of parvovirus B19 associated with vascular purpura, including Henoch-Schönlein purpura. [19] An enanthem consisting of erythema of the tongue and pharynx and red macules on the buccal mucosa and palate can occur.

Parvovirus B19 in Adults

Acute arthropathy is the primary manifestation of B19 viral infection in adults. [20] It occurs mainly in women and affects the small joints of the hands, the knees, wrists, ankles, and feet. Occasionally, other joints such as the spine and costochondral joints are involved. This symmetric polyarthritis is usually of sudden onset and is self-limited but can be persistent or recurrent for months. It may mimic Lyme arthritis or rheumatoid arthritis.

The constitutional symptoms are usually more severe in adults than in children. [21] Fever, adenopathy, and a mild arthritis without a rash is the usual course. Women are more likely than men to have joint complaints and rash, while men often present with only a flulike illness. [20] Some adults may have fatigue, malaise, and depression for weeks after the infection. Asymptomatic infection can certainly occur in adults as well as in children. In one outbreak, 26 percent of adults were reported to be asymptomatic. [20] Parvovirus B19 can cause numbness and tingling of the fingers with or without other features of fifth disease. [22] Pruritus that is sometimes severe can occur with or without a rash. It has been suggested that if pruritus is a complaint in a patient with acute-onset arthritis, parvovirus should be considered as a possible cause.

The rash in adults, if present at all, is usually macular and blotchy or lacy, often on the extremities, and rarely demonstrates the characteristic slapped-cheek appearance. [20] Other cutaneous manifestations associated with B19 infection in adults include purpura, vesicles and pustules, palmoplantar desquamation, a morbilliform exanthem with Koplik spots, and livedo reticularis.

Papular Purpuric Gloves-and-Socks Syndrome

In 1990, Harms et al. [23] described a unique syndrome of pruritic erythema and edema of the hands and feet with petechiae, fever and oral erosions. This rare exanthem, now known as papular, purpuric gloves-and-socks syndrome (PPGSS), seems to affect teenagers and adults. However, it can affect children also. [24] Patients usually have mild prodromal symptoms of fatigue and low-grade fever, myalgias, and arthralgias. Subsequently, itchy, painful, symmetrical edema and erythema of the distal hands and feet occurs. [25] Purpuric papules appear on the hands and feet with abrupt demarcation at the wrists and ankles. The enanthem, if present, arises on the lips, soft palate, and buccal mucosa. The syndrome resolves spontaneously within 2 weeks. Although many viruses have been implicated as causative agents for PPGSS, B19 is the virus proven to cause the syndrome. [26]

COMPLICATIONS

As more attention is focused on parvovirus B19, an increasing number of complications are recognized. Subclinical infection is quite common. However, this virus can be responsible for a variety of hematologic, rheumatologic, and neurologic abnormalities.

Transient Aplastic Crisis

Parvovirus B19 is the most common cause of transient aplastic crisis in patients with chronic hemolytic anemias. [27] This has been demonstrated in sickle cell anemia, hereditary spherocytosis, heterozygous ß-thalassemia, pyruvate kinase deficiency, and autoimmune hemolytic anemia, as well as in other conditions of decreased red cell production or increased red cell destruction. The aplastic crisis may be the initial manifestation of the underlying hematologic disease. [28]

Patients typically have fever and constitutional complaints, followed 1 week later by fatigue, pallor, and worsening anemia. [29] Rarely is a rash reported with aplastic crisis. There is an absence of reticulocytes, and the hemoglobin may fall below 4 µg/dL. Bone marrow examination shows hypoplasia or aplasia of the erythroid series. Red blood cell transfusion may be necessary, and most patients recover in 1 week, although the problem can be fatal if untreated.

Transient red cell aplasia can occur in healthy persons without underlying hematologic abnormalities. [30] It is likely that the aplasia is missed in individuals without disorders of shortened erythrocyte survival because the hemoglobin does not drop low enough to cause symptoms.

Chronic B19 Infection

In immunocompromised patients, B19 infection can cause a serious, prolonged anemia from persistent lysis of red blood cell precursors. [30] Parvovirus-related chronic anemia has been reported in HIV-infected patients, as well as in transplant recipients and those with congenital immunodeficiencies, acute leukemias, lupus erythematosus, and during the first year of life without immunodeficiency. These patients respond dramatically to intravenous gamma globulin, suggesting that antibody is the main defense to human parvovirus infection. [31]

Fetal B19 Infection

Fetal infection with B19 may result in a normal fetus, spontaneous abortion (especially in the first half of pregnancy), hydrops fetalis in the second half of pregnancy, congenital anemia, and even late fetal death. [32] Nonimmune fetal hydrops is the most common complication of intrauterine infection with B19. Because B19 virus can infect erythroid precursors, extensive hemolysis can occur in the fetus, leading to severe anemia, tissue anoxia, high-output heart failure, and generalized edema. The fetus may show ultrasonographic evidence of subcutaneous edema, ascites, pleural effusion, pericardial effusion, placental edema, and polyhydramnios. The overall risk of fetal death is not clearly known, but recent studies suggest that this risk is about 6.5 percent with maternal infection. [32] The risk of fetal death for a woman with unknown serologic status is estimated to be less than 2.5 percent after a household exposure and less than 1.5 percent after a significant work exposure. It seems that in B19-infected pregnant women, most fetuses are not infected; if they are infected, usually there is not an adverse outcome. [33] Furthermore, about half of women of childbearing age are immune to parvovirus infection because of prior infection.

Because parvoviruses are known teratogens in animals, there has been much concern about whether they cause birth defects in humans. In sera collected from 253 infants with a wide range of congenital abnormalities, there was no parvovirus-specific IgM detected to suggest recent infection. [34] There has been one report of a B19-infected abortus with eye abnormalities, [35] and another of an infected abortus with cleft lip, cleft palate, and micrognathia. [36] Rare reports describe cardiac abnormalities, [37] neurologic problems, [38] and “blueberry muffin” nodules. [39] It has been concluded from these few studies that parvovirus B19 is not a common cause of birth defects.

Other Complications

There are reports of B19 infection causing encephalitis, meningitis, brachial neuritis, a myasthenia-like syndrome, and motor weakness. Parvovirus infection has been blamed for a Wegener's granulomatosis-like illness, [40] polyarteritis nodosa, [41] Kawasaki disease, [42] and a systemic lupus erythematous-like picture. [43] In addition, there are reports of other hematologic complications including idiopathic thrombocytopenic purpura, transient neutropenia, myocarditis, a hemophagocytic syndrome, and the Diamond-Blackfan syndrome.

LABORATORY FINDINGS

In patients with erythema infectiosum, laboratory results are usually normal, including reticulocyte count, hematocrit, and tests of liver and renal function. Patients with aplastic crisis have reticulocytopenia and anemia, the severity of which depends on the degree of the underlying anemia. Reticulocytopenia, anemia, lymphopenia, neutropenia, and thrombocytopenia can occur in healthy individuals with B19 infections, although these are usually not significant enough to cause clinical symptoms. The erythrocyte sedimentation rate is rarely elevated, and rheumatoid factor has been positive in some cases of parvovirus-associated arthritis.

PATHOLOGY

Histologic examination of various tissues demonstrates homogeneous, intranuclear inclusions with peripheral condensation of chromatin in erythroid precursor cells. [44] Electron microscopy of these inclusions reveals parvovirus-like particles. [44] In fetal tissues, a leukoerythroblastic reaction may also be seen. The histopathologic changes in the skin of patients with erythema infectiosum include a sparse superficial perivascular lymphocytic infiltrate that is not considered diagnostic.

DIAGNOSIS AND DIFFERENTIAL DIAGNOSIS

The diagnosis of erythema infectiosum is usually based on the clinical features. The differential diagnosis includes rubella, measles, scarlet fever, roseola, enteroviral infection, erysipelas on the cheek, and drug hypersensitivity. These other disorders may have more significant systemic illness and lack the progression from the slapped cheeks to the lacy extremities that is so characteristic of fifth disease. Because no animal model or easy tissue culture system exists for the B19 virus, laboratory testing for the antibody or the virus is performed only in a limited number of research laboratories. The Centers for Disease Control and Prevention will currently test the serum of patients with aplastic crisis, immunodeficiency, and chronic anemia; pregnant women with B19 exposure; and fetal hydrops cases in which B19 infection is suspected. The testing is not done on a routine basis and is arranged through state health departments.

Detection of recent infection is usually performed with assays for IgM antibody. RIA or enzyme-linked immunosorbent assay (ELISA) techniques can detect IgM within a few days after onset of illness. IgM can be measured for up to 6 months in many cases, although there is a decline in titer in the second month after onset. IgG can be identified with the

same techniques by the seventh day of illness and lasts for years and is therefore best for documenting past infection. Parvovirus antibody is often not detectable in immunodeficient persons. B19 virus can be detected in serum during viremia by a variety of techniques including RIA, CIE, and ELISA. The most specific tests are dot-blot hybridization [45] and the polymerase chain reaction, [46] which may allow identification of B19 DNA in serum, urine, respiratory secretions, cerebrospinal fluid, and bone marrow. B19 DNA can be detected with PCR for up to 4 months after the onset of illness. [47]

TREATMENT AND PROGNOSIS

There is no specific treatment available for parvovirus B19 infection. Erythema infectiosum is a benign condition, and usually no treatment is necessary. Supportive therapy for relief of fatigue, malaise, pruritus, and arthralgia may be needed. The chronic anemia of persistent B19 infection may be treated successfully with commercially available intravenous immunoglobulin, which contains neutralizing anti-B19 antibodies. Transient aplastic crisis, which can be life-threatening, may require oxygen therapy and blood transfusion.

Serologic testing for B19 IgG and IgM should be offered to pregnant women who are exposed to parvovirus B19. Infected pregnant women are followed by frequent ultrasonograms. Evidence of hydrops fetalis warrants umbilical cordocentesis to check for anemia, viral DNA, IgG, and IgM. The management of infected fetuses is controversial. Some physicians advocate observation because spontaneous resolution is common. Fetuses with severe anemia and compromise are usually managed with intrauterine exchange transfusion, but this procedure does carry risk.

Parvovirus B19 infection in healthy individuals is self-limited. The rash of erythema infectiosum and the parvovirus arthropathy usually resolve in 1 to 2 weeks, but can recur or persist for months. If untreated, transient aplastic crisis can be fatal, but most patients recover in 1 week. Chronic anemia from B19 usually resolves if treated with gamma globulin. Fetal hydrops can lead to fetal death if not treated.

REFERENCES

1. Tschamer A: Ueber ortliche Rotheln. *Jahrbuch fur Kinderheilkunde* **29**:372, 1889

2. Shapiro L: The numbered diseases: First through sixth. *JAMA* **194**:210, 1965

3. Cossart YE et al: Parvovirus-like particles in human sera. *Lancet* **1**:72, 1975

4. Summers J et al: Characterization of the genome of the agent of erythrocyte aplasia permits its classification as a human parvovirus. *J Gen Virol* **65**:2527, 1983

5. Anderson MJ et al: Human parvovirus, the cause of erythema infectiosum (fifth disease)? *Lancet* **1**:1378, 1983

6. Cohen BJ, Buckley MM: The prevalence of antibody to human parvovirus B19 in England and Wales. *J Med Microbiol* **25**:51, 1988

7. Plummer FA et al: An erythema infectiosum-like illness caused by human parvovirus infection. *N Engl J Med* **313**:74, 1985

8. Anderson MJ et al: Experimental parvoviral infection in humans. *J Infect Dis* **152**:257, 1985

9. McCarter-Spaulding D: Parvovirus B19 in pregnancy. *J Obst. Gynec & Neonatal Nursing* **31**:107, 2002

10. Cohen B: Parvovirus B19: An expanding spectrum of disease. *BMJ* **311**:1549, 1995

11. Siegl G et al: Characteristics and taxonomy of Parvoviridae. *Intervirology* **23**:61, 1985

12. Anderson MJ, Pattison JR: The human parvovirus: Brief review. *Arch Virol* **82**:137, 1984

13. Brown KE et al: Resistance to parvovirus B19 infection due to lack of virus receptor (erythrocyte P antigen). *N Engl J Med* **330**:1192, 1994

14. Anand A et al: Human parvovirus inception in pregnancy and hydrops fetalis. *N Engl J Med* **315**:183, 1987

15. Bansal GP et al: Candidate recombinant vaccine for human B19 parvovirus. *J Infect Dis* **167**:1034, 1993

16. Bell LM et al: Human parvovirus B19 infection among hospital staff members after contact with infected patients. *N Engl J Med* **321**:485, 1989

17. Feder HM, Anderson I: Fifth disease. A brief review of infections in childhood, in adulthood, and in pregnancy. *Arch Intern Med* **149**:2176, 1989

18. Nocton JJ et al: Human parvovirus B19-associated arthritis in children. *J Pediatr* **122**:186, 1993

19. Lefrere JJ et al: Henoch-Schönlein purpura and human parvovirus infection. *Pediatrics* **78**:183, 1986

20. Woolf AD et al: Clinical manifestations of human parvovirus B19 in adults. *Arch Intern Med* **149**:1153, 1989

21. Thurn J: Human parvovirus B19: Historical and clinical review. *Rev Infect Dis* **19**:1005, 1988

22. Faden H et al: Numbness and tingling of fingers associated with parvovirus B19 infection. *J Infect Dis* **161**:354, 1990

23. Harms M et al: Papular-purpuric gloves and socks syndrome. *J Am Acad Dermatol* **23**:850, 1990

24. Petter G et al: Juvenile papular-purpuric gloves and socks syndrome. *J Eur Acad Derm Ven* **15**:340, 2001

25. Smith PT et al: Papular, purpuric, gloves-and-socks syndrome associated with acute parvovirus B19 infection: Case report and review. *Clin Infect Dis* **27**:164, 1998

26. Grilli R et al: Papular, purpuric, “gloves and socks” syndrome: Polymerase chain reaction demonstration of parvovirus B19 DNA in

cutaneous lesions and sera. *J Am Acad Dermatol* **41**: 793, 1999

27. Young N: Hematologic and hematopoietic consequences of B19 parvovirus infection. *Semin Hematol* **25**:159, 1988

28. Bertrand Y et al: Autoimmune haemolytic anaemia revealed by human parvovirus-linked erythroblastopenia. *Lancet* **2**:383, 1985

29. Ware R: Human parvovirus infection. *J Pediatr* **114**:343, 1989

30. Anderson LJ: Human parvoviruses. *J Infect Dis* **161**:603, 1990

31. Kurtzman G et al: Pure red-cell aplasia of 10 years' duration due to persistent parvovirus B19 infection and its cure with immunoglobulin therapy. *N Engl J Med* **321**:519, 1989

32. Levy R et al: Infection by parvovirus B19 during pregnancy: A review. *Obstet Gynecol Surv* **52**:254, 1997

33. Public Health Laboratory Service Working Party on Fifth Disease: Prospective study of human parvovirus (B19) infection in pregnancy. *BMJ* **300**:1166, 1990

34. Mortimer PP et al: Human parvovirus and the fetus. *Lancet* **2**:1012, 1985

35. Weiland HT et al: parvovirus B19 associated with fetal abnormality. *Lancet* **1**:682, 1987

36. Tiessen RG et al: A fetus with a parvovirus B19 infection and congenital anomalies. *Prenat Diagn* **14**:173, 1994

37. Silver MM et al: Association of prenatal closure of the foramen ovale and fetal parvovirus B19 infection in hydrops fetalis. *Cardiovasc Pathol* **4**:103, 1995

38. Garcia-Tapia AM et al: Spectrum of parvovirus B19 infection: Analysis of an outbreak of 43 cases in Cadiz, Spain. *Clin Infect Dis* **21**:1424, 1995

39. Silver MM et al: Anemia, blueberry-muffin rash, and hepatomegaly in a newborn infant. *J Pediatr* **128**:579, 1996

40. Finkel TH et al: Chronic parvovirus B19 infection and systemic necrotising vasculitis: opportunistic or aetiological agent? *Lancet* **343**:1255, 1994

41. Corman LC, Dolson DJ: Polyarteritis nodosa and parvovirus B19 infection. *Lancet* **339**:491, 1992

42. Nigro G et al: Recurrent Kawasaki disease associated with coinfection with parvovirus B19 and HIV-1. *AIDS* **7**:288, 1993

43. Nesher G et al: Parvovirus infection mimicking systemic lupus erythematosus. *Semin Arthritis Rheum* **24**:297, 1995

44. Caul EO et al: Intrauterine infection with human parvovirus B19: A light and electron microscopy study. *J Med Virol* **24**:55, 1988

45. Anderson MJ et al: Diagnosis of human parvovirus infection by dot-blot hybridization using cloned viral DNA. *J Med Virol* **15**:163, 1985

46. Salimans MMM et al: Rapid detection of human parvovirus B19 DNA by dot-blot hybridization and the polymerase chain reaction. *J Virol Methods* **23**:19, 1989

47. Patou G et al: Characterization of a nested polymerase chain reaction assay for detection of parvovirus B19. *J Clin Microbiol* **31**:540, 1993

T>

Chapter 214

Adriana Marques Stephen Straus

Herpes Simplex

HISTORICAL ASPECTS
EPIDEMIOLOGY
ETIOLOGY AND PATHOGENESIS
The Virus
Immune Response
PREVENTION
Antiviral Therapy
Vaccines
CLINICAL MANIFESTATIONS
Orofacial Infections
Genital Infection
Other Cutaneous Infections
Ocular Infections
Neurologic Disorders
Immunocompromised Host
Neonatal Herpes
LABORATORY FINDINGS
MANAGEMENT
Antiviral Therapy
Antiviral Resistance

REFERENCES

Herpes simplex virus (HSV) infections are very common and are caused by two closely related types of HSV. Their main clinical manifestations are mucocutaneous infections, with HSV type 1 (HSV-1) being mostly associated with orofacial disease, while HSV type 2 (HSV-2) is usually associated with perigenital infection. Studies in past years have brought insights into the molecular biology of HSV, the epidemiology and presentation of its infections, and an expanded menu of options for their treatment and prevention. Treatments that ameliorate the signs and symptoms of herpes have been developed, but a viable general strategy to prevent HSV infections remains elusive.

HISTORICAL ASPECTS

The earliest reference to herpetic infections was made approximately 2,000 years ago by the Roman physician Herodotus who described them as “the herpetic eruptions that appeared about the mouth at the crisis of simple fevers.” John Astruc, a French physician, described genital herpes in 1736, in the “ *De morbis venereis.*” [1] Person-to-person transmission of herpes was recognized in 1893. At the beginning of the twentieth century, histopathologic studies described the multinucleated giant cells associated with herpesviruses infections. The infectious nature of the disease was shown by Lowestein in 1919, who demonstrated that virus from herpetic lesions caused lesions on the rabbit cornea. [2] In 1968, HSV-1 and HSV-2 were first distinguished on the basis of antigenic and other biological features. [3]

EPIDEMIOLOGY

The incidence of primary infection with HSV-1, which is responsible for the vast majority of recurring labial herpes, is greatest during childhood, when 30 to 60 percent of children are exposed to the virus. Rates of infection with HSV-1 increase with age, with 90 percent of adults older than 50 years of age being seropositive for HSV-1. [4] From 20 to 40 percent of the population have had episodes of herpes labialis. [5] The frequency of recurrent episodes is extremely variable, and in some studies averages about once per year, [6] but there is evidence that the frequency and severity of recurrent HSV-1 disease decrease over time.

Acquisition of HSV-2 correlates with sexual behavior and the prevalence of the infection in the pool of one's potential sexual partners. Antibodies to HSV-2 are rare in people before the onset of intimate sexual activity, and rises steadily thereafter. HSV-2 seroprevalence in the United States is 22 percent in persons 12 years of age or older. [7]

Although most patients infected with HSV-1 or HSV-2 are asymptomatic, they still can transmit the virus. Studies using DNA polymerase chain reaction (PCR) assays show that rates of detecting HSV-2 DNA in genital secretions of people who have never recognized herpes outbreaks (asymptomatic persons) are similar to the rates of shedding viral DNA in persons who have experienced symptomatic genital herpes but who are not symptomatic at the moment of testing (subclinical shedding). [8] It is estimated that more than 70 percent of transmission of HSV-2 is associated with asymptomatic and subclinical reactivation and shedding. [9] The average risk of transmission for couples discordant for genital herpes (i.e., one partner has genital herpes and the other does not) is about 10 percent per year, when the couples simply refrain from intercourse during outbreaks. [9] In another study, the overall rate of HSV-2 infection averaged 5.1 cases per 100 person-years in sexually active persons. As with other sexually transmitted infections, the rate of acquisition of HSV-2 infection is higher for women than for men (6.8 versus 4.4 cases per 100 person-years; relative risk, 1.55). Asymptomatic HSV-2 infection is more common among men and persons who are also seropositive for HSV-1, suggesting that prior infection with HSV-1 reduces one's likelihood of experiencing symptomatic HSV-2 infection. [10]

ETIOLOGY AND PATHOGENESIS

The Virus

HSV-1 and HSV-2 are members of the Herpesviridae family, a group of lipid-enveloped double-stranded DNA viruses responsible for a wide variety of common human infections. Both serotypes of HSV and the closely related varicella-zoster virus (VZV) are members of the Alpha-herpesviridae virus subfamily. Alpha herpes viruses infect multiple cell types in culture, grow rapidly, and efficiently destroy the host cells. Infection in the natural host is characterized by lesions in the epidermis, often involving mucosal surfaces, with spread of virus to the nervous system and establishment of latent infections in neurons, from which virus periodically reactivates.

The complete 152-kbp genomic DNA sequence of HSV-1 was published in 1988, [11] and the complete HSV-2 genome was reported a decade later. [12] Both genomes are linear and consist of two regions of unique sequence, each of which is bounded by a pair of inverted repeat elements. There is a high degree of genetic and antigenic homology between HSV-1 and HSV-2, but they are distinct; an analysis of herpesvirus phylogeny estimated that the two HSV types diverged from an ancestral protoherpesvirus approximately 8 million years ago. [13]

Herpesvirus replication is a carefully regulated, multistep process. Shortly after infection, five “immediate-early” genes are transcribed. The proteins encoded by these genes stimulate the synthesis of about a dozen “early” proteins that are required for genome replication. Most current antiviral drugs interact with two of these proteins, the thymidine kinase and the viral DNA polymerase enzyme. After DNA replication, the remaining set of more than 60 “late” HSV-2 genes is expressed. They encode virion structural components and proteins needed for their proper assembly.

In vivo, HSV infections can be divided into three stages: acute infection, establishment and maintenance of the latency, and reactivation of virus. During acute infection, virus replicates at the site of inoculation on mucocutaneous surfaces, resulting in primary lesions from which virus rapidly spreads to infect sensory nerve terminals, where it travels by retrograde axonal transport to neuronal nuclei in regional sensory ganglia. In a subset of infected neurons, a latent infection is established in which viral DNA is maintained as an episome and HSV gene expression is severely restricted: of all of the viral genes, only one is abundantly transcribed during latency. In the last stage, replication reactivates with concomitant anterograde axonal transport of newly assembled virus to a peripheral site, at or near the original portal of entry.

Differences in the ability of HSV strains to use different cell surface receptors may account for serotype and strain differences in tissue tropism and pathogenicity. Initial attachment of HSV to cells is mediated primarily by binding of one or more viral envelope glycoproteins (primarily HSV glycoprotein B and glycoprotein C) to heparan sulfate proteoglycans on the surface of susceptible cells. These interactions facilitate attachment of HSV glycoprotein D to one of a family of specific cellular coreceptors. One such receptor is the herpesvirus entry mediator A (HveA), a member of the tumor necrosis factor receptor super-family. Two other cell surface coreceptors named HveB and HveC are members of the immunoglobulin superfamily and are closely related to the poliovirus receptor. HveB mediates the entry of HSV-2 strains, but fails to mediate the entry of wild-type HSV-1. HveC mediates the entry of HSV-1 and HSV-2, and has been implicated as in spread of HSV-1 and HSV-2 from mucosal surfaces to the nervous system.

The molecular mechanisms underlying the latency and reactivation of HSV are not well understood. In latently infected ganglia, the viral DNA persists as an episome, and within the genome, only parts of the long repeat elements are expressed, yielding the so-called latency-associated transcripts (LATs). LATs are not essential for productive infection or establishment and maintenance of latency, but may modulate reactivation. HSV mutants that are deleted for their ability to express LATs can establish latent infections in mice, guinea pigs, and rabbits as efficiently as their wild-type parental virus, but reactivate less frequently.

HSV-1 reactivates most efficiently and frequently from trigeminal ganglia, while HSV-2 reactivates primarily from sacral ganglia. The rate of reactivation of HSV appears to be influenced more by the quantity of latent viral DNA in the ganglia than by the accumulation of LATs. [14] In addition to the quantity of latent virus being a determinant of the relative rate of HSV reactivation, there are type-specific sequences within the viral LAT-encoding region of the HSV genome that appear to influence recurrence rates in particular anatomic sites. [15] In addition to viral genes, host factors strongly influence HSV reactivation. Reactivation is induced in experimentally infected animals by exposure to UV irradiation, by hyperthermia, by local trauma, and by other physiological stressors. These model systems emulate well what occurs in similarly stressed humans.

Immune Response

Host immunity to HSV clearly influences the risk of acquiring the infection, the severity of disease, and the frequency of recurrences. Through studies in animal models and observations of immune-deficient people, the host genetic background, multiple immune cell types (including macrophages, natural killer cells, and different T cell subpopulations), antibodies that mediate neutralization and/or antibody-dependent cell-mediated cytotoxicity, and cytokine responses have all been implicated as important host defenses against HSV infections.

The humoral immune response is important in reducing virus titers at the site of inoculation and in regional neural tissues during primary infection. Animals are effectively protected from disseminated and neurologic disease by passive transfer of polyclonal or monoclonal antibodies, and by antibody responses elicited actively through vaccination. Moreover, the transfer of HSV-specific antibodies from the mother to the child is a key factor in protecting against neonatal herpes. But, in other human HSV infections, humoral immune responses play less important roles than the cellular immune responses, as disease in patients with deficits in humoral immunity is no more severe that that in normals, while those with defects in cellular immunity can experience severe and recurring infections. Most patients mount antibody responses

to HSV infection within 4 to 6 weeks after infection. Some of these responses are type-specific, while other cross-react with proteins of the other virus type.

The risk of severe HSV disease and the rate of recurrence correlates with the level of cellular immune competence of the host. Patients with mild decreases in cellular immunity may experience only an increased number of recurrences and a slower resolution of lesions, while severely compromised patients are more likely to develop disseminated, chronic, or drug-resistant infections.

Studies of humans and mice have implicated a role for both CD8+ and CD4+ T lymphocyte subsets, for natural killer (NK) cells, and for inflammatory cytokines like interferon-? in mediating protection against HSV. However, the contribution of each cell subset and cytokine in the control of HSV infection has not been clearly defined.

The roles of immunity in sustaining latency and in limiting reactivation of HSV are less clear. There is some evidence that constant immune surveillance and engagement are required to maintain latency. Other findings implicate immunity only in defining whether virus once reactivated would spread and become clinically evident.

PREVENTION

Strategies to prevent HSV infection have proven inadequate to address the growing epidemic of genital herpes. HSV infection can be prevented by total abstinence, as indicated by very low seroprevalence rates in cloistered nuns. Barrier contraceptives reduce rates of transmission if used routinely. [16] Other than these public health approaches, most efforts involve antiviral therapy and vaccines directed at genital herpes.

Antiviral Therapy

As discussed more fully below, antiviral therapy decreases both symptomatic and subclinical shedding of HSV-2. In a double-blinded, placebo-controlled, crossover clinical trial of acyclovir 400 mg twice a day, subclinical shedding decreased from 6.9 percent of the days in the placebo group to 0.3 percent of the days in the treatment group. [17] Studies using PCR show that daily administration of oral acyclovir reduces the frequency of HSV DNA detection by a median of 80 percent. [18] Famciclovir decreases asymptomatic shedding in men from 1.09 to 0.08 percent of the days analyzed. Because of its ability to reduce both symptomatic and subclinical shedding of HSV-2, a mathematical model predicted that antiviral therapy would affect the spread of genital herpes through the populace. [19] The results imply that high rates of treatment would significantly reduce the prevalence of HSV-2, but would also increase the incidence of drug-resistant HSV-2 infection. However, even in the worst-case scenario in this model, the use of acyclovir would prevent at least five new infections for every case that develops resistance to the drug. Based on these findings, chronic suppressive therapy was predicted to be more beneficial than episodic treatment in reducing the transmission of infection and widespread treatment was recommended. A mathematical model for use of topical penciclovir in recurrent herpes labialis, however, did not predict a decrease in the prevalence of HSV-1 infection. [20]

Vaccines

The best public health strategy to reduce infection and morbidity associated with HSV infection is development of effective vaccines. Unfortunately, no vaccine has proven to protect adequately against acquisition of HSV or to reduce the number of recurrent episodes, although there are hopeful developments in these directions. Recombinant glycoprotein vaccines containing immunogenic HSV proteins have been developed and tested by multiple pharmaceutical and biotechnological companies. In a preliminary study, a recombinant HSV-2 glycoprotein D vaccine with alum adjuvant decreased the frequency of symptomatic outbreaks in patients with genital herpes. A modified form of the vaccine (with added glycoprotein B and a lipid emulsion adjuvant known as MF59) was not found, in larger studies, to decrease the number of recurrences in patients with genital herpes, but it was able to decrease the duration and severity of a subsequent study outbreak of genital herpes. [21] Two phase III studies of the effect of this vaccine (one in monogamous seronegative partners of individuals with genital herpes, and the other in seronegative persons attending clinics for sexually transmitted diseases) failed to prevent acquisition of genital herpes infection or disease. A recombinant gD2 vaccine that uses monophosphoryl lipid-A (MPL) as adjuvant has a modest effect in preventing genital herpes in HSV-1 and -2 seronegative women, but not in males or HSV-1 seropositive females. [22]

A major theoretical limitation of recombinant HSV vaccines is their inability to induce broad and protective cellular immune responses. To better do so, investigators have turned their attention to DNA-based and genetically engineered live vaccines. The use of replication-defective HSV mutants has been tested with success as a candidate vaccine in animal models. These viruses are capable of only a single round of replication, and therefore have no pathogenic potential while potentially inducing the full spectrum of immune responses. lso, these mutant constructs open the possibility of engineering agents with additional genes that encode antigens from other infectious agents, envisioning a vaccine that can protect against multiple infections. Also underway, with initial promising results in animal models, are studies of DNA vaccines for HSV. The first phases of human trials of DNA and replication-defective vaccines have begun.

CLINICAL MANIFESTATIONS

The clinical manifestations of HSV infection depend on the site of infection and, as indicated above, the immune status of the host. Primary infections with HSV, namely those that develop in persons without preexisting immunity to either HSV-1 or HSV-2, are usually more severe, frequently with systemic signs and symptoms, and they have a higher rate of complications, than recurrent episodes.

Orofacial Infections

Herpetic gingivostomatitis (Fig. 214-1) and pharyngitis are mostly commonly associated with a primary HSV-1 infection. The symptoms of primary oral herpes may resemble those of aphthous stomatitis and include ulcerative lesions involving the hard and soft palate, tongue, and buccal mucosa, as well as neighboring facial areas. Patients with pharyngitis exhibit ulcerative and exudative lesions of the posterior pharynx that can be difficult to differentiate from streptococcal pharyngitis. Other common symptoms are fever, malaise, myalgias, pain on swallowing, irritability, and cervical adenopathy.

FIGURE 214-1 Primary herpetic gingivostomatitis in a child. (*Courtesy of Clyde S. Crumpacker, MD.*)

Reactivation of virus from these primary infections involves the perioral facial area, mainly the lips, with the outer third of the lower lip being the most commonly affected (Fig. 214-2). Other facial locations include the nose, chin, and cheek, and account for less than 10 percent of the cases. Two-thirds of labial lesions involve the vermilion border, while the rest occur at the junction of the border with the skin. In patients with frequent recurrences, lesions may differ slightly in location with each episode. Immunocompetent patients tend not to experience recurrent intraoral lesions, but can present with clusters of tiny vesicles and ulcers on the gingivae and anterior hard palate that are mildly symptomatic. Prodromal symptoms precede herpes labialis in 45 to 60 percent of episodes. [4] Patients experience pain, burning, or itching at the site of the subsequent eruption. Even in the immunocompetent patient, the severity of recurrent herpes labialis is extremely variable, and may vary from that of prodromal symptoms alone without the subsequent development of lesions (aborted episodes), to extensive disease induced by severe local sunburn.

FIGURE 214-2 Recurrent facial herpes simplex with grouped vesicles and crusting. (*Courtesy of Clyde S. Crumpacker, MD.*)

The progression of the classical herpes lesions has been divided according to the following stages based on their features: prodromal, erythema, and papule (the developmental stages); vesicle, ulcer, and hard crust (disease stages); followed by dry flaking and residual swelling (resolution stages). The lesions usually resolve within 5 to 15 days.

Trigger factors for oral herpes recurrences include emotional stress, illness, exposure to sun, trauma, fatigue, menses, chapped lips, and the season of the year. [23] Other well-documented triggers include exposure to UV irradiation, trigeminal nerve surgery, oral trauma, epidural administration of morphine, and abrasive, laser, and chemical facial cosmetic procedures. The exact mechanism by which these diverse factors triggers HSV reactivation is unknown.

HSV-2 causes a primary orofacial infection that is indistinguishable from that associated with HSV-1 except that it is usually in adolescents and young adults and following genital–oral contact. Moreover, HSV-2 orolabial infections are 120 times less likely to reactivate than is orolabial HSV-1 disease. [6]

Genital Infection

Genital herpes is the major clinical presentation of HSV-2 infection, but it may also result from HSV-1 in 10 to 40 percent of the cases, primarily ones following oral–genital contact. Because of their epidemiology, acquisition of HSV-1 in a person with prior HSV-2 infection is unusual, but HSV-2 acquisition in the presence of previous HSV-1 infection is common, and infection of the genital tract with both HSV-1 and HSV-2 has been described. Patients with previously known HSV-1 genital infection who develop frequent genital herpes recurrences should be tested for HSV-2 infection. [24]

The clinical courses of acute first-episode genital herpes among patients with HSV-1 and HSV-2 infections are similar. These infections are associated with extensive genital lesions in different stages of evolution, including vesicles, pustules, and erythematous ulcers that may require 2 to 3 weeks to resolve (Fig. 214-3). In males, lesions commonly occur on the glans penis or the penile shaft; in females, lesions may involve the vulva, perineum, buttocks, vagina, or cervix. There is accompanying pain, itching, dysuria, vaginal and urethral discharge, and tender inguinal lymphadenopathy. Systemic signs and symptoms are common and include fever, headache, malaise, and myalgias.

Herpetic sacral radiculomyelitis, with urinary retention, neuralgias, and constipation, can occur. HSV cervicitis occurs in more than 80 percent of women with primary infection. It can present as purulent or bloody vaginal discharge, and examination reveal areas of diffuse or focal friability and redness, extensive ulcerative lesions of the exocervix, or, rarely, necrotic cervicitis. Cervical discharge is usually mucoid, but it is occasionally mucopurulent.

FIGURE 214-3 *A*. Primary genital herpes with vesicles. *B*. Primary herpetic vulvitis. (*Courtesy of Clyde S. Crumpacker, MD.*)

The rates of recurrence for genital HSV-2 infections vary greatly among individuals and over time within the same individual. Infections caused by HSV-2 reactivate approximately 16 times more frequently than HSV-1 genital infections, and average 3 to 4 times per year, but may appear virtually weekly. [6] Recurrences tend to be more frequent in the first months to years after first infection. [6] The classical clinical manifestations of recurrent HSV-2 infection include multiple small but grouped vesicular lesions in the genital area. They may ulcerate promptly in women, some days later in men. The recurrence of genital lesions is usually heralded by a prodrome of tenderness, itching, burning, or tingling. Without treatment, the lesions usually heal in 6 to 10 days. Herpetic cervicitis is less common in recurrent disease, occurring in 12 percent of the patients. It may present without external lesions. Signs and symptoms that are less classical for genital HSV infection and which may divert one from the correct diagnosis include small erythematous lesions, fissures, pruritus, and urinary symptoms. HSV can cause urethritis, usually manifested only as a clear mucoid discharge, dysuria, and frequency. Occasionally, HSV can be associated with endometritis, salpingitis, or prostatitis. Symptomatic or asymptomatic rectal and perianal infections are common. Herpetic proctitis presents with anorectal pain, anorectal discharge, tenesmus, and constipation, with ulcerative lesions of the distal rectal mucosa.

FIGURE 214-4 Herpetic whitlow of the middle finger with associated erythema multiforme in a nurse's aide. (*Courtesy of Clyde S. Crumpacker, MD.*)

Other Cutaneous Infections

HSV can infect any skin site. The common theme among virtually all of these cutaneous presentations is the requirement that virus has penetrated otherwise normal and well-keratinized tissues. Herpetic whitlow (Fig. 214-4) is the infection of the fingers by HSV acquired by direct inoculation or by direct spread from mucosal sites at the time of primary infection. Thus, a typical presentation of whitlow would be in children who suck their fingers during a primary gingivostomatitis outbreak. It is also a well-documented occupational hazard for medical personnel. It is usually caused by HSV-1, but HSV-2 whitlow may develop as a manifestation of primary inoculation following manual–genital contact with an infected partner. The infected region becomes erythematous and edematous. Lesions are usually present at the fingertip and can be pustular and very painful. Fever and local lymphadenopathy are common. Whitlow is often misdiagnosed as a bacterial paronychial infection, but the surgical drainage, often needed for a bacterial infection, is unnecessary and potentially harmful, while antiviral therapy speeds healing. Whitlow may recur.

Cutaneous herpes can be transmitted between athletes involved in contact sports, such as wrestling (herpes gladiatorum) and rugby (herpes rugbiaforum or scrum pox), and may do so as outbreaks or small epidemics among team members. In these instances, multiple herpetic lesions may appear across the thorax, ears, face, arms, and hands, caused by facilitation of infection by trauma to the normally keratinized skin sustained during the practice of the sport. Concomitant ocular herpes can occur.

Eczema herpeticum (Kaposi's varicelliform eruption) (Fig. 214-5) results from a widespread infection following inoculation of virus to skin damaged by eczema. It is usually a manifestation of primary HSV-1 infection in a child with atopic dermatitis, but other skin conditions also can be complicated by cutaneous dissemination of HSV. Some of the known predisposing conditions include mycosis fungoides, Sézary syndrome, Darier's disease, various bullous diseases of the skin (particularly if patients are receiving immunosuppressive therapy), and burns of second or third degree. The severity of these infections ranges from mild to fatal, with mortality rates of up to 10 percent being reported before antiviral therapy was available. Mortality was usually primarily caused by bacterial superinfection and bacteremia.

Common pathogens include *Staphylococcus aureus, Streptococcus,* and *Pseudomonas*.

FIGURE 214-5 Eczema herpeticum in areas of atopic dermatitis. (*Courtesy of Clyde S. Crumpacker, MD.*)

In a typical severe primary attack, several days after exposure vesicles develop in large numbers over the areas of active or recently healed atopic dermatitis, particularly the face, and continue to appear in crops for several days more. The vesicles become pustular and markedly umbilicated. Patients commonly have high fever and adenopathy. Viremia with infection of internal organs can be fatal. Recurrences are usually far milder than these first infections. Arriving at the correct diagnosis can be delayed because of secondary impetiginization of the lesions, but it always should be considered in children with infected eczema, particularly if the child is more ill systemically than one might anticipate with impetigo. Eczema herpeticum of the young infant is a medical emergency and early treatment with acyclovir can prove lifesaving.

Recurrent HSV infection is the most common precipitating event in cases of recurrent erythema multiforme (EM) (Fig. 214-5) (see Chap. 58). HSV–associated EM (HSVAEM) is usually an acute, self-limited, recurrent disease. The duration of the disease is usually about 3 weeks. The lesions are usually disseminated and symmetric, occurring on acral extremities and face, and there is grouping of the lesions over the elbow and knees, as well as nail fold involvement; photodistribution and isomorphic phenomenon can occur. Mucosal involvement is usually mild and restricted to the mouth. Constitutional symptoms are rare and the skin lesions heal without scarring.

Ocular Infections

HSV is a leading cause of recurrent keratoconjunctivitis and its associated corneal opacification and visual loss. It is usually caused by HSV-1, except in neonates in whom HSV-2 is more prevalent. The majority of HSV eye disease is caused by reactivation of the virus in the trigeminal ganglia, but primary infections of the eye can also occur. Usually, the initial manifestation of herpetic eye disease is a superficial infection of the eyelids and conjunctiva (blepharoconjunctivitis), or corneal surface (dendritic or geographic epithelial ulcer). Deeper involvement of the cornea (stromal keratitis) or anterior uvea (iritis) represent more serious forms of the disease and can cause permanent visual loss. Acute retinal necrosis is a rare but rapidly progressive disease characterized by retinal arteriolar sheathing, uveitis, and peripheral retinal opacification, with variable pain and visual loss. Bilateral involvement may occur, and retinal detachments are common. It is usually associated with HSV-1 infection, but HSV-2 retinitis has been described and VZV causes a similar process. [25]

Neurologic Disorders

All HSV infections involve the nervous system, as neurons are the sole proven site of virus latency. Neurologic manifestations of HSV infections, however, are not universal, but highly variable in their presentation and severity. HSV meningitis is manifested by headache, fever, and mild photophobia, with lymphocytic pleocytosis in the cerebrospinal fluid (CSF). Most cases result from HSV-2 infection. It resolves spontaneously in 2 to 7 days. It is usually seen in association with primary genital HSV-2 infection. Recurrent lymphocytic meningitis (Mollaret's meningitis) is associated with recurrent HSV-2 infection, often without symptomatic genital disease. Involvement of the sacral nerves with autonomic nervous system dysfunction, numbness, pelvic pain, tingling, urinary retention, constipation, and CSF pleocytosis has been reported in association with HSV infection. Symptoms usually resolve in a few days, but in some cases, the neurologic residua take weeks to months to disappear, occasionally becoming permanent. Rare cases of transverse myelitis and Guillain-Barré syndrome after HSV infection have been reported.

Bell's palsy is an acute, peripheral facial paresis of unknown cause, and is thought to result from inflammation and subsequent mechanical compression of the facial nerve in the temporal bone. Reactivation of HSV and VZV are implicated in the pathogenesis of the disease. [26], [27]

HSV encephalitis is the most commonly identified acute, sporadic viral encephalitis in the United States, accounting for 10 to 20 percent of all cases. Nearly all of the cases arising after the neonatal period (see below) are caused by HSV-1. HSV encephalitis usually presents with acute onset of focal neurologic symptoms and fever. Involvement of the temporal lobe is a characteristic feature of this disease, but overall, it is difficult to differentiate HSV encephalitis clinically from other viral encephalitides. PCR of the CSF for HSV DNA is the most sensitive noninvasive technique to help in the diagnosis. Brain biopsies had been the gold standard method to establish the diagnosis until the advent of PCR. However, even with therapy, neurologic sequelae are frequent, especially in persons older than 35 years of age. Patients with presumed HSV encephalitis should be treated empirically with intravenous acyclovir until the diagnosis is confirmed

or an alternative diagnosis is made.

Immunocompromised Host

All manifestations of HSV infection seen in the immunocompetent host can also be seen in immunocompromised patients, but they are usually more severe, more extensive and difficult to treat, and, for many of them, recurrences are more frequent as well. Patients with defects of T cell immunity are at particular risk for progressive mucocutaneous or visceral infections, but as indicated above, the degree of dissemination depends on the level of immunodeficiency of the host. Recurrent and persistent ulcerative HSV lesions are among the most common and defining opportunistic infections in patients with AIDS. Genital herpes is very common in patients with HIV and can be persistent and severe. Oropharyngeal HSV in immunocompromised patients can present with widespread involvement of the mucosa and extremely painful, friable, hemorrhagic, and necrotic lesions, similar to the mucositis caused by cytotoxic agents or other infectious agents. The lesions can spread locally to involve the esophagus. Esophagitis presents with odynophagia, dysphagia, substernal pain, and multiple ulcerative lesions. Esophagitis can also arise directly by reactivation of HSV and its spread to the esophagus via the vagus nerve. Tracheobronchitis and pneumonitis can also occur by spreading of the virus from oropharyngeal HSV.

HSV can reactivate from visceral ganglia of the autonomic nervous system or disseminate hematogenously to other visceral organs, causing pneumonitis, hepatitis, pancreatitis, other portions of the gastrointestinal tract, as well as adrenal necrosis. Most of these severe infections are caused by HSV-1, but HSV-2 can do so as well. Few are ever diagnosed except at autopsy.

Neonatal Herpes

The neonate is a special category of immune-deficient host. The incidence of neonatal herpes is approximately 1 in 3500 live births. Seventy percent of neonatal HSV cases are caused by HSV-2 inoculated directly by infectious genital secretions at the time of delivery. The category of maternal infection plays a significant role in defining the risk of neonatal herpes. Primary genital herpes is associated with a risk of neonatal infection of 33 to 50 percent for vaginally delivered babies. Risk of transmission to a neonate is highest in women who develop primary herpes in the third trimester. This is because primary infections are usually associated with prolonged excretion of high titers of virus, and there will have been no time for the mother to mount an immune response against the virus and transfer protective antibodies to the child. In contrast, recurrent maternal infection is associated with a risk of transmission of less than 3 percent. [28]

Neonatal herpes infections manifest in one of three forms: skin, eye, and mouth (SEM) involvement; encephalitis; or disseminated disease. The latter two forms account for more than 50 percent of cases of neonatal herpes. Without therapy, the overall mortality of neonatal herpes is 65 percent, and fewer than 10 percent of untreated neonates with central nervous system (CNS) infection will develop normally. With current therapeutic modalities, most babies with SEM disease survive, but approximately 5 percent of these children remain at risk for long-term neurologic sequelae. For treated babies with encephalitis, mortality is 14 percent, with 50 percent developing normally after 1 year. For babies with disseminated disease, mortality is 55 percent, with 85 percent of the survivors apparently developing normally after 1 year. [29]

LABORATORY FINDINGS

The method of choice for diagnosis of HSV infection depends on the clinical presentation. In many instances, the history and clinical findings may be sufficient, but the social, emotional, and therapeutic implications of a diagnosis dictate that it be confirmed by laboratory testing when possible. For patients with lesions, virus isolation by cell culture is the method of choice. In culture, HSV causes typical cytopathic effects and most specimens will prove positive within 48 to 96 h after inoculation. The sensitivity of the culture depends on the quantity of the virus in the specimen. Even in the most experienced centers, only approximately 60 to 70 percent of fresh genital lesions are culture-positive. Isolation of the virus is most successful when lesions are cultured during their vesicular stage, and when specimens are taken from immunocompromised patients or from patients suffering from a primary infection.

Direct fluorescent antibody staining of lesion scrapings and antigen detection assays can also be used, but sensitivity is somewhat lower than that of viral culture. [30] The Tzanck smear can be helpful in the rapid diagnosis of herpesviruses infections, but it is less sensitive than culture and staining with fluorescent antibody, with positive results in fewer than 40 percent of culture-proven cases. It is performed by scraping the base of a freshly ruptured vesicle and staining the slides with Giemsa or Wright stain (the Papanicolaou staining method can also be used), followed by examination for the multinucleated giant cells that are diagnostic of herpetic infection. Both HSV and VZV will cause these changes. PCR is more sensitive than viral isolation, and has been extensively used for the diagnosis of CNS infections, but it is still not available for routine practice settings. It may also be useful for the detection of HSV in late stage ulcerative lesions. Both viral culture and PCR assays enable typing of the isolate as HSV-1 or HSV-2. This information helps to predict the frequency of reactivation after a first-episode of HSV infection. In the skin biopsy specimens, the epithelial cells are enlarged, swollen, and often separated. Multinucleated cells with intranuclear eosinophilic inclusion bodies (Cowdry type A inclusions) can be seen.

Serologic detection of antibodies to HSV can be helpful in certain settings but the results are often misinterpreted. Its main function is in differentiating a primary episode from a recurrent infection (Table 214-1). A positive serologic test result can be useful in patients with recurrent, genital lesions that are not present at times of examination and, therefore, a positive culture cannot be obtained. Serologic testing can also be helpful for counseling patients with initial episodes of disease and their partners, especially during pregnancy, and in counseling partners of patients with genital herpes about their risk of acquiring HSV.

Classification	Virus isolated	Serologic results		Serologic	Comments
		HSV-1	HSV-2	HSV-1	HSV-2
Primary HSV-1	HSV-1	+	+	+	+
Primary HSV-2	HSV-2	+	+	+	+
Primary HSV-1 plus previous HSV-2 infection*	HSV-1	+	+	+	+
Primary HSV-2 plus previous HSV-1 infection	HSV-2	+	+	+	+
Recurrent HSV-1	HSV-1	+	+ or +	+	+ or +
Recurrent HSV-2	HSV-2	+ or +	+	+ or +	+

*Note.

TABLE 214-1 **Classification of Herpes Simplex Infections According to Viral Isolation and Paired Serologic Test Results**

The traditional serologic testing techniques for HSV are seriously deficient because they reflect the substantial cross-reactivity between HSV-1 and HSV-2 antigens. The Western blot assay, in identifying responses to non–cross-reacting herpes glycoproteins can differentiate between HSV-1 and HSV-2 infection, but it is expensive and only available in a few research laboratories. Recently, simple kits for type-specific serologic assays, based on antigenic differences between HSV-1 and HSV-2 glycoprotein G have been tested and have entered the market. [31] It is anticipated that in time they will be in high demand. Guidelines for their use in general clinical practice are not yet available. However, it seems obvious that they should be used only by practitioners who are prepared to counsel patients about the meaning of the test results in terms of the natural history of the disease, available treatment regimens, disease transmission, and the emotional and social implications of the diagnosis.

MANAGEMENT

All sexually active persons should be educated regarding the nature and risks of acquiring and transmitting sexually transmitted infections, including HSV. Studies show that about half of the patients with asymptomatic HSV-2 infection have mild unrecognized disease and can be taught to recognize their symptoms and signs of genital herpes. Also, patients should be counseled regarding safer sex practices. It must be emphasized that the majority of transmission occurs in asymptomatic phases and from people who have no classical lesions. Patients with genital herpes should be counseled to refrain from sexual intercourse during outbreaks and for 1 to 2 days after, and to use condoms between outbreaks. Suppressive therapy may also be an option (see below), but it has not yet proven to decrease transmission.

Pregnant women who are known to have genital herpes should be reassured that the risk of transmitting herpes to the baby during childbirth is extremely low. Recommendations for the management of pregnant women with recurrent genital herpes have been made, but there has been no controlled trial of the overall approach. [32] The recommendations include clinical evaluation at delivery, with delivery by cesarean section indicated if there are signs and symptoms of active infection (including prodrome). Women with primary HSV infection during pregnancy, particularly during the second and third trimesters, should be treated with antiviral therapy. For women at or beyond 36 weeks of gestation who are at risk for recurrent HSV infection, suppressive antiviral therapy also may be considered. Cesarean section delivery may not reliably prevent neonatal HSV infection when membranes are ruptured for long periods of time (=24 h). The role of culturing the mother and/or the baby for HSV is controversial. Current recommendations include culturing for HSV at the time of delivery in women with a history of genital herpes. Women with active genital lesions at delivery and their babies should be cultured serially. Cultures should be taken from eye, oronasopharynx, and suspected sites every 2 to 3 days during the first 4 weeks of life. [33]

Women who are known by history and serologic tests not to have genital herpes should be counseled about signs and symptoms of HSV and how to avoid acquiring the infection during pregnancy. Serology is helpful in counseling a couple in which the male partner has recurrent genital herpes and the pregnant wife is susceptible.

Antiviral Therapy

Many HSV infections require no specific treatment at all. Keeping the lesions clean and dry while they heal by themselves may be all that is required. Treatment is warranted for infections that are likely to prove protracted, highly symptomatic, or complicated. Acyclovir, an acyclic guanosine analogue, was the first compound shown to prevent replication of a virus at concentrations far below those that affect cellular nucleic acid synthesis. This finding was a key factor in establishing antiviral chemotherapy as a major medical intervention. Acyclovir inhibits HSV-1 and HSV-2 replication by 50 percent at a concentration of 0.1 and 0.3 µg/mL (range, 0.01 to 9.9 µg/mL), respectively, but is toxic at concentrations of >30 µg/mL. Any strain that requires more than 3 µg/mL of acyclovir to be inhibited is said to be relatively drug-resistant. Acyclovir must be phosphorylated to be active, and it requires the viral thymidine kinase for efficient monophosphorylation. After this key initial step, the monophosphate is converted to acyclovir triphosphate by cellular kinases. The fully active acyclovir triphosphate competes with the natural substrate, deoxyguanosine triphosphate, and it is more efficiently incorporated into viral DNA by the viral polymerase compared to the cellular polymerase. The incorporated acyclovir triphosphate prevents chain elongation and terminates viral DNA synthesis. Therefore, acyclovir has a highly favorable therapeutic index because of its preferential activation in infected cells and preferential inhibition of the viral DNA polymerase. Acyclovir was approved for the treatment of HSV in 1982. In recent years, various derivative compounds have been developed, each of which offers some modest advantages over acyclovir.

Valaciclovir, the L-valyl ester of acyclovir, is an oral prodrug of acyclovir, designed to overcome the poor gastrointestinal (GI) absorption of acyclovir itself. The bioavailability of acyclovir from oral valaciclovir is three- to fivefold greater than that achieved after oral acyclovir administration, and it can be used in a more convenient dosage regimen. Valaciclovir is usually well tolerated, but in a study of very high-dose valaciclovir (8 g/day) for cytomegalovirus prophylaxis in HIV patients, there was a trend toward earlier deaths in the valaciclovir arm with a possible association with thrombotic microangiopathy. [34] This association was not been observed in other studies of high-dose valaciclovir.

Famciclovir is the well-absorbed oral form of the related guanosine analogue penciclovir. Similar to acyclovir, famciclovir is converted by phosphorylation to its active metabolite penciclovir-triphosphate. The efficacy and adverse effect profile

of famciclovir is comparable to that of acyclovir. Penciclovir 1% cream is approved by the Food and Drug Administration (FDA) for the treatment of herpes simplex labialis.

Docosanol 10% cream is approved by the FDA for over-the-counter treatment of recurrent herpes labialis. Docosanol is a long-chain saturated alcohol that inhibits entry of lipid-enveloped virus into the cell. It decreased the healing time by 18 h when compared with placebo. [35]

The current recommendations for antiviral treatment depend on the clinical disease, on host immune status, and whether one is treating a primary or recurrent episode or considering suppressive therapy. Table 214-2 describes the dosages and regimens for these different scenarios. For disseminated or severe herpes infections, the treatment of choice remains intravenous acyclovir 5 to 10 mg/kg every 8 h. Some experts use acyclovir 15 mg/kg IV every 8 h for life-threatening HSV infection, including encephalitis. The dose of intravenous acyclovir for disseminated or CNS neonatal herpes is 20 mg/kg per dose given every 8 h.

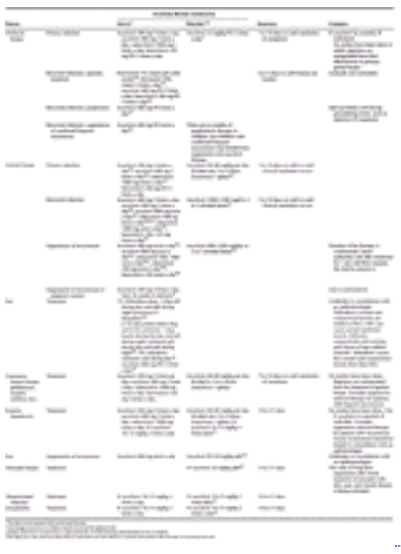

TABLE 214-2 **Recommended Regimens for the Treatment of Herpes Simplex Infections**

For first episodes of genital HSV-2 infections oral acyclovir, famciclovir, and valaciclovir all speed the healing, resolution of symptoms, and decrease viral shedding. When compared with placebo, acyclovir decreases time to healing from 16 to 12 days, the duration of pain from 7 to 5 days, and the duration of constitutional symptoms from 6 to 3 days. [36] Valaciclovir was compared with acyclovir in the treatment of primary episodes, and shown to be equivalent. [37] But antiviral treatment of initial herpes episodes does not decrease subsequent recurrences. The reason for this is that HSV establishes latent infection within hours after inoculation and days before symptoms evolve. While carefully conducted animal studies showed that very early therapy with antivirals (before lesions have appeared) can decrease the amount of latent virus and hence reduce the rate of subsequent reactivation, this is not a practical or appropriate strategy for humans, except perhaps in the setting of a clear laboratory contamination with an infectious inoculum of HSV.

Treatment of recurrent episodes of genital herpes with famciclovir, acyclovir, or valaciclovir has been shown to reduce the time of healing from about 7 to 5 days, time of cessation of viral shedding from 4 to 2 days, and duration of symptoms from 4 to 3 days when compared with placebo. Valaciclovir and acyclovir are equivalent, [38], [39] and it is likely that famciclovir, if tested, would be as well.

For persons with frequent or complicated genital recurrences, long-term suppressive therapy with acyclovir or its analogues is the most effective management strategy. [40], [41] Because genital herpes is not progressive in the normal host, and because the rate of recurrences varies over time and may decrease after some years, it is wise to recommend a “holiday” from treatment every year or so to reassess the person's continuing need for treatment.

The use of antiviral suppressive therapy during the late phase of pregnancy to avoid neonatal herpes has also been advocated, but a formal study of the approach would require a very large number of participants because of the rare incidence of neonatal herpes. A more achievable goal is to decrease the need for cesarean deliveries caused by herpes recurrences during labor. Cost–benefit analyses have been favorable for the use of acyclovir in pregnancy. [42] Pregnant women who had at least one episode of genital herpes during pregnancy were randomized to receive acyclovir 200 mg or placebo four times a day starting at 36 weeks. Acyclovir decreased the rate of cesarean sections from 16.5 to 8.4 percent. Pregnant women who did not have a genital herpes recurrence during pregnancy and who did not receive prophylaxis had a cesarean rate of 9.9 percent. There were no cases of neonatal herpes during the study period and there were no complications as a result of the antiviral treatment administered during pregnancy. [43] Larger studies to define the risks and benefits of antiviral suppressive therapy in pregnancy are needed.

Orolabial HSV infections warrant antiviral treatment less often than do the genital infections. Primary HSV gingivostomatitis should be treated with oral acyclovir. The pediatric dose is 15 mg/kg of acyclovir suspension PO five times a day for 7 days. When it is started within 3 days of onset of the disease, this regimen decreases the duration of oral and extraoral lesions, fever, and eating and drinking difficulties. Valaciclovir and famciclovir may be equally effective, but they have not been studied in this setting and are not currently approved for use in children. Severely ill children may need to be hospitalized for hydration, and intravenous acyclovir may be necessary.

Treatment of recurrent herpes labialis with antiviral drugs in immunocompetent hosts has shown only modest benefits so far. The infections are inherently briefer and less symptomatic than genital herpes. Treatment is only effective if used very early in the disease, especially in the prodromal or erythema lesion stages. Patients who wish treatment should

have the medication available and be vigilant for the earliest signs and symptoms of a recurrence. When treatment is felt to be required, the therapy of choice is penciclovir 1% cream every 2 h while awake for 4 days. [44] Treatment should be initiated as early as possible. When initiated within 1 h of first symptom of recurrence, penciclovir sped the healing of lesions (4.8 days versus 5.5 days) and decreased the duration of pain (3.5 days versus 4.1 days). This regimen is approved by the FDA. Docosanol 10% cream is approved by the FDA for over-the-counter treatment of herpes simplex labialis. It is to be applied five times a day, at the first sign of recurrence of herpes simplex labialis. There has been no direct comparison with topical penciclovir.

Oral acyclovir 400 mg five times a day for 5 days affords marginal benefit if begun in the earliest hour or two of the outbreak. Famciclovir 500 mg three times a day for 5 days, when started within 48 h after experimental ultraviolet radiation, decreased the median time to healing from 6 to 4 days, [45] but is not useful for the more usual sporadic cases of herpes labialis. Valaciclovir should be comparable to acyclovir and famciclovir, but it has not been studied in this setting. Creams and ointments containing 5% and 10% acyclovir are not beneficial in recurrent herpes labialis.

The use of suppressive acyclovir for herpes labialis is controversial. In one small study, oral acyclovir, 400 mg twice a day, was effective in decreasing recurrences of herpes labialis. [46] In studies with skiers (and therefore significant and anticipated sun exposures), acyclovir 400 mg twice a day was shown to reduce recurrences in one study, [47] while acyclovir 800 mg bid failed to prevent recurrences in another study. [48]

Herpetic eye disease should always be treated in consultation with an ophthalmologist. Options usually involve topical antivirals. These include idoxuridine, vidarabine, and trifluridine. Topical antivirals are effective in shortening the duration of dendritic and geographic keratitis, and are used to prevent corneal epithelial disease in patients with blepharitis and conjunctivitis, as well as patients on topical steroid therapy for corneal stromal inflammation and iridocyclitis. Oral acyclovir is also effective for dendritic and geographical epithelial keratitis. Suppressive acyclovir therapy reduces the rates of all types of recurrent ocular HSV disease, and it is most important for patients with a history of HSV stromal keratitis, because it can prevent additional episodes and potential loss of vision.

Antiviral Resistance

The specter of drug resistance hangs over the family of antiherpes drugs as it does over all other classes of antimicrobials. However, virtually all clinically relevant drug resistance has been seen in immunocompromised patients. The primary mechanism of acyclovir resistance is selection of viral mutants defective or deficient in thymidine kinase (TK) expression. Most mutants that are TK deficient are somewhat attenuated in virulence in vivo. In animal models, totally TK-deficient mutants have been severely impaired, most notably failing to reactivate from latency.

The treatment of resistant HSV infection is complicated. First, one must make the diagnosis. Very few people who claim to be “resistant” to one of the antiviral drugs actually harbor resistant virus. There is a common misconception that treatment prevents all recurrences, now and forever. One should suspect resistance only in people who continue to have culture-proven outbreaks of unaltered frequency and severity, especially if the lesions do not heal by themselves. When resistance is suspected, virus should be recovered and tested specifically for sensitivity to acyclovir. These tests are expensive but now widely available through commercial reference laboratories. Second, the options for patients with true resistance are few and far from ideal due to the lack of alternatives that are safe and easy to administer. Foscarnet, an organic analogue of inorganic pyrophosphate, inhibits replication of all known herpesviruses in vitro and does not require activation by TK or other kinases, and therefore can be effective in the treatment of acyclovir-resistant HSV. Foscarnet requires intravenous therapy and can cause numerous adverse reactions including nephrotoxicity, electrolytes disturbances, anemia, and seizures. Also, foscarnet-resistant herpesvirus strains have been described.

Cidofovir is an acyclic nucleoside phosphonate with broad-spectrum activity against a wide variety of DNA viruses including herpesviruses. Being a nucleotide (rather than nucleoside) analogue, it does not require the viral TK for its intracellular phosphorylation to the active form. Cidofovir has been tested in cases of acyclovir-resistant HSV and topical cidofovir has been used with success to treat progressive herpetic lesions. [49] Intravenous cidofovir is associated with considerable nephrotoxicity and requires the coadministration of saline hydration and probenecid.

REFERENCES

1. Hutfield DC: History of herpes genitalis. *Br J Vener Dis* **42**:263, 1966

2. Wildy P: Herpes: History and classification, in *The Herpesviruses,* edited by AS Kaplan. New York, Academic Press, 1973, p 1

3. Nahmias AJ, Dowdle WR: Antigenic and biologic differences in herpesvirus hominis. *Prog Med Virol* **10**:110, 1968

4. Spruance SL et al: The natural history of recurrent herpes simplex labialis: Implications for antiviral therapy. *N Engl J Med* **297**:69, 1977

5. Embil JA et al: Prevalence of recurrent herpes labialis and aphthous ulcers among young adults on six continents. *Can Med Assoc J* **113**:627, 1975

6. Lafferty WE et al: Recurrences after oral and genital herpes simplex virus infection. Influence of site of infection and viral type. *N Engl J Med* **316**:1444, 1987

7. Fleming DT et al: Herpes simplex virus type 2 in the United States, 1976 to 1994. *N Engl J Med* **337**:1105, 1997

8. Wald A et al: Reactivation of genital herpes simplex virus type 2 infection in asymptomatic seropositive persons. *N Engl J Med* **342**:844, 2000

9. Mertz GJ et al: Risk factors for the sexual transmission of genital herpes. *Ann Intern Med* **116**:197, 1992

10. Langenberg AG et al: A prospective study of new infections with herpes simplex virus type 1 and type 2. Chiron HSV Vaccine Study Group.

N Engl J Med **341**:1432, 1999

11. McGeoch DJ et al: The complete DNA sequence of the long unique region in the genome of herpes simplex virus type 1. *J Gen Virol* **69**:1531, 1988

12. Dolan A et al: The genome sequence of herpes simplex virus type 2. *J Virol* **72**:2010, 1998

13. McGeoch DJ et al: Molecular phylogeny and evolutionary time scale for the family of mammalian herpesviruses. *J Mol Biol* **247**:443, 1995

14. Lekstrom-Himes JA et al: The quantity of latent viral DNA correlates with the relative rates at which herpes simplex virus types 1 and 2 cause recurrent genital herpes outbreaks. *J Virol* **72**:2760, 1998

15. Yoshikawa T et al: The characteristic site-specific reactivation phenotypes of HSV-1 and HSV-2 depend upon the latency-associated transcript region. *J Exp Med* **184**:659, 1996

16. Wald A et al: Effect of condoms on reducing the transmission of herpes simplex virus type 2 from men to women. *JAMA* **285**:3100, 2001

17. Wald A et al: Suppression of subclinical shedding of herpes simplex virus type 2 with acyclovir. *Ann Intern Med* **124**:8, 1996

18. Wald A et al: Frequent genital herpes simplex virus 2 shedding in immunocompetent women. Effect of acyclovir treatment. *J Clin Invest* **99**:1092, 1997

19. Blower SM et al: Predicting and preventing the emergence of antiviral drug resistance in HSV-2. *Nat Med* **4**:673, 1998

20. Lipsitch M et al: Effects of antiviral usage on transmission dynamics of herpes simplex virus type 1 and on antiviral resistance: Predictions of mathematical models. *Antimicrob Agents Chemother* **44**:2824, 2000

21. Straus SE et al: Immunotherapy of recurrent genital herpes with recombinant herpes simplex virus type 2 glycoproteins D and B: Results of a placebo-controlled vaccine trial. *J Infect Dis* **176**:1129, 1997

22. Spruance S, Group SBSBHVES: Gender-specific efficacy of a prophylactic SBAS4-adjuvanted gD2 subunit vaccine against genital herpes (GHD): Results of two clinical efficacy trials [abstract], in 40th Interscience Conference on Antimicrobial Agents and Chemotherapy (ICAAC) American Society for Microbiology, Toronto, Canada 2000

23. Young SK et al: A clinical study for the control of facial mucocutaneous herpes virus infections. I. Characterization of natural history in a professional school population. *Oral Surg Oral Med Oral Pathol* **41**:498, 1976

24. Sucato G et al: Evidence of latency and reactivation of both herpes simplex virus (HSV)-1 and HSV-2 in the genital region. *J Infect Dis* **177**:1069, 1998

25. Ganatra JB et al: Viral causes of the acute retinal necrosis syndrome. *Am J Ophthalmol* **129**:166, 2000

26. Murakami S et al: Bell palsy and herpes simplex virus: Identification of viral DNA in endoneurial fluid and muscle. *Ann Intern Med* **124**:27, 1996

27. Furuta Y et al: High prevalence of varicella-zoster virus reactivation in herpes simplex virus-seronegative patients with acute peripheral facial palsy. *Clin Infect Dis* **30**:529, 2000

28. Brown ZA et al: The acquisition of herpes simplex virus during pregnancy. *N Engl J Med* **337**:509, 1997

29. Whitley RJ: Neonatal herpes simplex virus infections. *J Med Virol* **1**:13, 1993

30. Slomka MJ et al: A comparison of PCR with virus isolation and direct antigen detection for diagnosis and typing of genital herpes. *J Med Virol* **55**:177, 1998

31. Groen J et al: Comparison of two enzyme-linked immunosorbent assays and one rapid immunoblot assay for detection of herpes simplex virus type 2-specific antibodies in serum. *J Clin Microbiol* **36**:845, 1998

32. Anonymous: ACOG practice bulletin. Management of herpes in pregnancy. Number 8, October 1999. Clinical management guidelines for obstetrician-gynecologists. *Int J Gynaecol Obstet* **68**:165, 2000

33. Whitley RJ, Kimberlin DW: Treatment of viral infections during pregnancy and the neonatal period. *Clin Perinatol* **24**:267, 1997

34. Feinberg JE et al: A randomized, double-blind trial of valaciclovir prophylaxis for cytomegalovirus disease in patients with advanced human immunodeficiency virus infection. AIDS Clinical Trials Group Protocol 204/Glaxo Wellcome 123–014 International CMV Prophylaxis Study Group. *J Infect Dis* **177**:48, 1998

35. Sacks SL et al: Clinical efficacy of topical docosanol 10% cream for herpes simplex labialis: A multicenter, randomized, placebo-controlled trial. *J Am Acad Dermatol* **45**:222, 2001

36. Mertz GJ et al: Double-blind placebo-controlled trial of oral acyclovir in first-episode genital herpes simplex virus infection. *JAMA* **252**:1147, 1984

37. Fife KH et al: Valaciclovir versus acyclovir in the treatment of first-episode genital herpes infection. Results of an international, multicenter, double- blind, randomized clinical trial. The Valaciclovir International Herpes Simplex Virus Study Group. *Sex Transm Dis* **24**:481, 1997

38. Tyring SK et al: A randomized, placebo-controlled comparison of oval valacyclovir and acyclovir in immunocompetent patients with recurrent genital herpes infections. The Valaciclovir International Study Group. *Arch Dermatol* **134**:185, 1998

39. Bodsworth NJ et al: Valaciclovir versus acyclovir in patient initiated treatment of recurrent genital herpes: A randomised, double blind clinical trial. International Valaciclovir HSV Study Group. *Genitourin Med* **73**:110, 1997

40. Straus SE et al: Acyclovir suppression of frequently recurring genital herpes. Efficacy and diminishing need during successive years of treatment. *JAMA* **260**:2227, 1988

41. Diaz-Mitoma F et al: Oral famciclovir for the suppression of recurrent genital herpes: A randomized controlled trial. Collaborative Famciclovir Genital Herpes Research Group. *JAMA* **280**:887, 1998

42. Scott LL, Alexander J: Cost-effectiveness of acyclovir suppression to prevent recurrent genital herpes in term pregnancy. *Am J Perinatol*

15:57, 1998

43. Braig S et al: Acyclovir prophylaxis in late pregnancy prevents recurrent genital herpes and viral shedding. *Eur J Obstet Gynecol Reprod Biol* **96**: 55, 2001

44. Boon R et al: Penciclovir cream for the treatment of sunlight-induced herpes simplex labialis: A randomized, double-blind, placebo-controlled trial. Penciclovir Cream Herpes Labialis Study Group. *Clin Ther* **22**:76, 2000

45. Spruance SL et al: Peroral famciclovir in the treatment of experimental ultraviolet radiation-induced herpes simplex labialis: A double-blind, dose- ranging, placebo-controlled, multicenter trial. *J Infect Dis* **179**:303, 1999

46. Rooney JF et al: Oral acyclovir to suppress frequently recurrent herpes labialis. A double-blind, placebo-controlled trial. *Ann Intern Med* **118**:268, 1993

47. Spruance SL et al: Acyclovir prevents reactivation of herpes simplex labialis in skiers. *JAMA* **260**:1597, 1988

48. Raborn GW et al: Oral acyclovir in prevention of herpes labialis. A randomized, double-blind, multicentered clinical trial. *Oral Surg Oral Med Oral Pathol Oral Radiol Endod* **85**:55, 1998

49. Lalezari J et al: A randomized, double-blind, placebo-controlled trial of cidofovir gel for the treatment of acyclovir-unresponsive mucocutaneous herpes simplex virus infection in patients with AIDS. *J Infect Dis* **176**:892, 1997

50. Anonymous: Drugs for non-HIV viral infections. *Med Lett Drugs Ther* **41**:113, 1999

51. Antiviral Drugs for Non-Human Immunodeficiency Virus Infections, in *AAP 2000 Red Book: Report of the Committee on Infectious Diseases,* 25th ed. Elk Grove Village, IL, American Academy of Pediatrics, 2000, p 678

52. Goldberg LH et al: Episodic twice-daily treatment for recurrent genital herpes. *Am J Med* **85**:10, 1988

53. Saiag P et al: A double-blind, randomized study assessing the equivalence of valacyclovir 1000 mg once daily versus 500 mg twice daily in the episodic treatment of recurrent genital herpes. Genival Study Group. *J Antimicrob Chemother* **44**:525, 1999

54. Chosidow O et al: Famciclovir vs. acyclovir in immunocompetent patients with recurrent genital herpes infections: A parallel-groups, randomized, double-blind clinical trial. *Br J Dermatol* **144**:818, 2001

55. Reitano M et al: Valaciclovir for the suppression of recurrent genital herpes simplex virus infection: A large-scale dose range-finding study. International Valaciclovir HSV Study Group. *J Infect Dis* **178**:603, 1998

P>56. Mostow SR et al: Suppression of recurrent genital herpes by single daily dosages of acyclovir. *Am J Med* **85**:30, 1988

57. Patel R et al: Valaciclovir for the suppression of recurrent genital HSV infection: A placebo-controlled study of once daily therapy. International Valaciclovir HSV Study Group. *Genitourin Med* **73**:105, 1997

58. Mertz GJ et al: Oral famciclovir for suppression of recurrent genital herpes simplex virus infection in women. A multicenter, double-blind, placebo-controlled trial. Collaborative Famciclovir Genital Herpes Research Group. *Arch Intern Med* **157**:343, 1997

59. Dawson C: Management of herpes simplex eye diseases, in *Clinical Management of Herpes Viruses,* edited by S Sacks, SE Straus, RJ Whitley, P. Griffiths. Amsterdam, Netherlands, IOS Press, 1995, p 127

60. Kimberlin DW: Advances in the treatment of neonatal herpes simplex infections. *Rev Med Virol* **11**:157, 2001

T>

Chapter 215

Stephen Straus Kenneth Schmader Michael Oxman

Varicella and Herpes Zoster

EPIDEMIOLOGY
Epidemiology of Varicella
Epidemiology of Herpes Zoster
ETIOLOGY
PATHOGENESIS
Pathogenesis of Varicella
Pathogenesis of Herpes Zoster
Pathogenesis of Pain in Herpes Zoster and Postherpetic Neuralgia
CLINICAL MANIFESTATIONS
Clinical Manifestations of Varicella
Clinical Manifestations of Herpes Zoster
PATHOLOGY
Cytopathology
Pathology of Varicella
Pathology of Herpes Zoster
CLINICAL AND LABORATORY DIAGNOSES
Clinical Diagnosis of Varicella
Clinical Diagnosis of Herpes Zoster
Laboratory Diagnosis
TREATMENT
Antiviral Agents
Treatment of Varicella
Treatment of Herpes Zoster
Treatment of Postherpetic Neuralgia
PREVENTION AND CONTROL
Prevention and Control of Varicella
Prevention and Control of Herpes Zoster

REFERENCES

Varicella (chickenpox) and herpes zoster (shingles, zoster) are distinct clinical entities caused by a single member of the herpesvirus family, the varicella-zoster virus (VZV). The different clinical manifestations of these two diseases are a result of differences in the host and in the circumstances of infection, not to differences in their etiologic agent. [1], [2]

Varicella, an acute, highly contagious exanthem that occurs most often in childhood, is the result of primary infection of a susceptible individual. In normal children, systemic symptoms are usually mild and serious complications are extremely rare. In adults and in immunologically compromised persons, varicella is more likely to be associated with life-threatening complications.

Herpes zoster is a localized disease characterized by unilateral radicular pain and a vesicular eruption that is generally limited to the dermatome innervated by a single spinal or cranial sensory ganglion. It occurs most often in elderly people. Herpes zoster is the result of the reactivation of endogenous virus that had persisted in latent form within sensory ganglia following an earlier attack of varicella. The incidence of complications increases with immune-impairing conditions. [3]

EPIDEMIOLOGY

Epidemiology of Varicella

Varicella is distributed worldwide, but its age-specific incidence differs in temperate versus tropical climates and in those populations who have received the varicella vaccine. In temperate climates in the absence of vaccination, varicella is endemic, with a regularly recurring seasonal prevalence in winter and spring, and periodic epidemics that depend upon the accumulation of susceptible persons. In Europe and North America, 90 percent of cases occur in children younger than 10 years of age and fewer than 5 percent of cases occur in individuals older than the age of 15. [3] National Health Interview Survey (NHIS) data indicated an incidence of 15 cases per 1000 population per year, with the highest annual incidence (90 per 1000 population per year) among children 5 to 9 years of age. [4] More recent studies report the highest annual incidence among children 1 to 4 years of age (e.g., 154 per 1000 population in Olmstead County, Minnesota). [5] The trend toward younger age of infection may be related to increased attendance at preschools and day care centers. From 1988 to 1995, there were approximately 11,000 hospitalizations and 100 deaths caused by varicella each year in the United States. [6] The risk of hospitalization and death was much higher in infants and adults than in children, and most varicella-related deaths occurred in previously healthy people. [7]

In tropical and semitropical countries, the mean age of varicella is higher and the susceptibility of adults to primary VZV infection is significantly greater than in temperate climates. High levels of susceptibility to varicella among adults emigrating from tropical climates is well documented in the U.S. military, where up to 40 percent of recruits from Puerto Rico and the Philippines have been VZV seronegative.

Varicella is highly contagious. Attack rates of 87 percent among susceptible siblings in households and nearly 70 percent

among susceptible patients on hospital wards have been reported. More than 95 percent of cases of varicella are clinically apparent, although occasionally the exanthem may be so sparse and transient as to pass unnoticed. A typical patient is infectious for 1 to 2 days (rarely, 3 to 4 days) before the exanthem appears, and for 4 or 5 days thereafter, that is, until the last crop of vesicles has crusted. The immunocompromised patient, who may experience many successive crops of lesions for a week or more, is infectious for a longer period of time. The mean incubation period of varicella is 14 or 15 days, with a range of 10 to 23 days. It is often prolonged in patients who develop varicella after passive immunization with varicella-zoster immune globulin (VZIG) or zoster immune plasma (ZIP), or active immunization with the live attenuated Oka strain varicella vaccine. [8]

The major route by which varicella is acquired and transmitted is thought to be the respiratory tract, but infection may also be spread by direct contact. Varicella crusts are not infectious, and the duration of infectivity of droplets containing virus is probably quite limited. Although the infectiousness of patients with varicella is thought to depend largely upon virus shed from the mucous membranes of the upper respiratory tract, VZV has only rarely been cultured from pharyngeal secretions; however, it can be detected in the oropharynx of the majority of patients using polymerase chain reaction (PCR)-based assays. [9]

One attack of varicella generally confers lasting immunity to the disease. Reexposure to the virus boosts humoral and cell-mediated immune responses but rarely leads to clinical illness. Most reported second attacks of varicella involve incorrect diagnoses; others may represent cutaneous dissemination in patients with herpes zoster (see below). With severe immunocompromise, reinfections manifested as varicella have been observed. In addition, persons who develop modified varicella (e.g., because they are infected early in infancy in the presence of maternal antibody or have been immunized with live attenuated varicella vaccine) may respond to exogenous exposure by developing a second, usually mild, episode of “breakthrough” varicella.

Epidemiology of Herpes Zoster

Herpes zoster occurs sporadically throughout the year without seasonal prevalence. The occurrence of herpes zoster is independent of the prevalence of varicella, and there is no convincing evidence that herpes zoster can be acquired by contact with other persons with varicella or herpes zoster. Rather, the incidence of herpes zoster is determined by factors that influence the host-virus relationship.

One strong risk factor is older age (Fig. 215-1A). [3] Experts calculate the lifetime incidence of herpes zoster to be 10 to 20 percent in the general population and an annual incidence of 600,000 to 850,000 cases of herpes zoster in the United States. [10]



FIGURE 215-1 *A*. The epidemiology of herpes zoster and postherpetic neuralgia. The annual incidence of herpes zoster per 1000 persons in a general medical practice. *B*. The percentage of patients with pain persisting after the onset of the herpes zoster rash. These data are from the placebo recipients in one large, double-blind treatment study. *C.* The proportion of patients with postherpetic neuralgia according to age. (*From Kost and Straus,* [17] *with permission.*)

Another major risk factor is cellular immune dysfunction. Immunosuppressed patients have a 20 to 100 times greater risk of herpes zoster than immunocompetent individuals. Herpes zoster is frequently an early manifestation of HIV infection, and thus high-risk individuals who develop herpes zoster should be evaluated for coincident HIV infection.

Second episodes of herpes zoster are uncommon in immunocompetent persons, and third attacks are not unheard of but many of these occur in immunocompromised individuals. [11] Immunocompetent patients suffering multiple episodes of herpes zoster–like disease are far more likely to be suffering from recurrent zosteriform herpes simplex virus infections. [12]

Patients with herpes zoster are less contagious than patients with varicella. The rate at which susceptible household contacts develop varicella after exposure to herpes zoster appears to be one-third that of cases following exposure to varicella. [11] Virus can be isolated from vesicles of uncomplicated herpes zoster for up to 7 days after the appearance of the rash and for much longer periods in some immunocompromised individuals. Patients with uncomplicated dermatomal zoster appear to spread the infection by means of direct contact with their lesions. Patients with disseminated herpes zoster may, in addition, transmit the infection in aerosols, so that airborne and contact isolation is required for such patients.

ETIOLOGY

VZV is a member of the herpesvirus family. [1], [2] Other members pathogenic for humans include herpes simplex viruses type 1 (HSV-1) and type 2 (HSV-2); cytomegalovirus (CMV); Epstein-Barr virus (EBV); human herpesvirus-6 (HHV-6) and human herpesvirus-7 (HHV-7), which cause roseola; and Kaposi's sarcoma–associated herpesvirus, also called human herpesvirus type 8. All herpesviruses are morphologically indistinguishable and share a number of properties, including a propensity for establishing latent infections that persist for life.

The VZV genome encodes about 70 genes, most of which have DNA sequence and functional homology to genes of the other herpesviruses. Immediate early (IE) gene products regulate VZV replication. Early gene products, such as the

virus-specific thymidine kinase and the viral DNA polymerase, support viral replication. Late genes encode virus structural proteins that serve as targets of antibody and cellular immune responses.

There is only one VZV serotype; however, viruses isolated from individual cases of varicella or herpes zoster worldwide are basically similar, but minor variations in their nucleotide sequences allow one to distinguish cases associated with wild-type or vaccine virus strains.

PATHOGENESIS

Pathogenesis of Varicella

Entry of VZV is through the mucosa of the upper respiratory tract and oropharynx. Initial multiplication at this portal of entry results in dissemination of small amounts of virus via the blood and lymphatics (the primary viremia). This virus is cleared by cells of the reticuloendothelial system, the major site of virus replication during the remainder of the incubation period.

The incubating infection is partially contained by innate host defenses [e.g., interferon, natural killer (NK) cells] and by developing immune responses. In most individuals, virus replication eventually overwhelms these still undeveloped defenses, so that about 2 weeks after infection, a much larger (secondary) viremia and associated symptoms and lesions occur. Skin lesions appear in successive crops, reflecting a cyclic viremia, which in the normal host is terminated after about 3 days by VZV-specific humoral and cellular immune responses. Virus circulates in mononuclear leukocytes, primarily lymphocytes. The frequent observations of elevated serum levels of hepatocellular enzymes in the acute stage of uncomplicated varicella suggest the routine, subclinical involvement of many organs; it is merely the ease with which skin involvement in varicella is recognized that makes it so noteworthy.

Effective host immune responses terminate viremia and limit the progression of varicella lesions in the skin and other organs. Humoral immunity to VZV protects against varicella. People with detectable serum antibody do not usually become ill after exogenous exposure. [13] Cell-mediated immunity to VZV also develops during the course of varicella, persists for many years, and protects one from severe infections. [14]

Pathogenesis of Herpes Zoster

During the course of varicella, VZV passes from lesions in the skin and mucosal surfaces into the contiguous endings of sensory nerves and is transported centripetally up the sensory fibers to the sensory ganglia. In the ganglia, the virus establishes a latent infection that persists for life. Herpes zoster occurs most often in dermatomes in which the rash of varicella achieves the highest density—those innervated by the first (ophthalmic) division of the trigeminal nerve and by spinal sensory ganglia from T1 to L2.

Although the latent virus in the ganglia retains its potential for full infectivity, reactivation is sporadic, infrequent, and associated with immunosuppression; irradiation of the spinal column; tumor involvement of the cord, dorsal root ganglion, or adjacent structures; local trauma; surgical manipulation of the spine; and frontal sinusitis as a precipitant of ophthalmic zoster. Most important, though, is the senescence of the cellular immune response to VZV with increasing age. [11], [15]

VZV may also reactivate without producing overt disease. Although asymptomatic reactivation of VZV has not been proven definitively, the small quantity of viral antigen released during such contained reactivations would be expected to stimulate and sustain host immunity to VZV. [16]

When host resistance falls below a critical level, reactivated virus can no longer be contained. [11] Virus multiplies and spreads within the ganglion, causing neuronal necrosis and intense inflammation, a process that is often accompanied by severe neuralgia. Infectious VZV then spreads antidromically down the sensory nerve, risking intense neuritis, and is released around the sensory nerve endings in the skin, where it produces the characteristic cluster of zoster vesicles. Spread of the ganglionic infection proximally along the posterior nerve root to the meninges and cord results in local leptomeningitis, cerebrospinal fluid pleocytosis, and segmental myelitis. Infection of motor neurons in the anterior horn and inflammation of the anterior nerve root account for the local palsies that may accompany the cutaneous eruption, and extension of infection within the central nervous system may result in rare complications of herpes zoster (e.g., meningoencephalitis, transverse myelitis).

Pathogenesis of Pain in Herpes Zoster and Postherpetic Neuralgia

Pain is a major symptom of herpes zoster. It often precedes and generally accompanies the rash, and it frequently persists after the rash has healed—a complication known as postherpetic neuralgia (PHN). A number of different but overlapping mechanisms appear to be involved in the pathogenesis of pain in herpes zoster and PHN (Fig. 215-2). [17], [18]

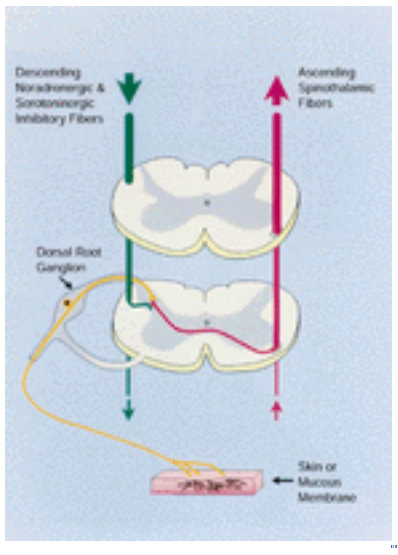

FIGURE 215-2 Pathway of normal pain perception. Noxious stimuli activate free nerve endings in the skin to generate signals that are conveyed through unmyelinated C fibers (*red*) and small Ad fibers to the neuronal bodies in the segmental dorsal root ganglia, then proximally to the dorsal horn of the spinal cord, where they form synapses with second-order neurons. Spinal cord neurons are subject to powerful descending inhibitory signals from the brain (*green*), mediated by the biogenic amines serotonin and norepinephrine. Drugs that potentiate the central effects of biogenic amines, such as tricyclic antidepressant drugs, may act by enhancing these descending pathways. Endogenous opiates also contribute to descending inhibitory input. The net result of peripheral afferent input and descending inhibitory input is projected cephalad, joining other ascending fibers in the contralateral spinothalamic tract (*orange*). Information from the spinothalamic tract is integrated with input from brainstem and cortical areas for the perception of specific aspects of pain as well as more general affective components of pain perception.

Injury to the peripheral nerve and to neurons in the ganglion triggers afferent pain signals. Inflammation in the skin triggers nociceptive signals that further amplify cutaneous pain. The abundant release of excitatory amino acids and neuropeptides induced by the sustained barrage of afferent impulses during the prodrome and acute phase of herpes zoster may cause excitotoxic injury and the loss of inhibitory interneurons in the spinal dorsal horn. Damage to neurons in the spinal cord and ganglion, and to the peripheral nerve, is important in the pathogenesis of PHN. Damaged primary afferent nerves may become spontaneously active and hypersensitive to peripheral stimuli and also to sympathetic stimulation. In turn, excessive nociceptor activity and ectopic impulse generation may sensitize central nervous system neurons, producing prolonged and augmented central responses to innocuous as well as noxious stimuli. Clinically, these mechanisms result in allodynia (pain and/or unpleasant sensations elicited by stimuli that are normally not painful, e.g., light touch) with little or no sensory loss, and explain relief of pain by local lidocaine infiltration.

The anatomic and functional changes responsible for PHN appear to be established early in the course of herpes zoster. Consistent with this is the correlation of initial pain severity and the presence of prodromal pain with the subsequent development of PHN and the failure of antiviral therapy to fully prevent PHN (see below).

CLINICAL MANIFESTATIONS

Clinical Manifestations of Varicella

PRODROME OF VARICELLA In young children, prodromal symptoms are uncommon. In older children and adults, the rash is often preceded by 2 to 3 days of fever, chills, malaise, headache, anorexia, severe backache, and, in some patients, sore throat and dry cough.
RASH OF VARICELLA In unvaccinated persons, the rash begins on the face and scalp and spreads rapidly to the trunk, with relative sparing of the extremities (Fig. 215-3). New lesions appear in successive crops, but their distribution remains central. The rash tends to be denser in the small of the back and between the shoulder blades than on the scapulae and buttocks and more profuse on the medial than on the lateral aspects of the limbs.

FIGURE 215-3 Varicella. *A.* A full spectrum of lesions—that is, erythematous papules, vesicles (“dewdrops on rose petals”), crusts, and erosions at sites of excoriation—is seen in a child with a typical case of varicella. *B.* A wider range of lesions, including many large pustules, is seen in a 21-year-old female who was febrile as well as “toxic” and had varicella pneumonitis.

A striking feature of varicella lesions is their rapid progression from rose-colored macules to papules, vesicles, pustules, and crusts (Fig. 215-3A). The typical vesicle of varicella is 2 to 3 mm in diameter and elliptical, with its long axis parallel to the folds of the skin. The early vesicle is surrounded by an irregular area of erythema, which gives the lesions the

appearance of a “dewdrop on a rose petal.” The vesicular fluid soon becomes cloudy with the influx of inflammatory cells, which convert the vesicle to a pustule (Fig. 215-3B). The lesion then dries, beginning in the center, first producing an umbilicated pustule and then a crust. Crusts fall off spontaneously in 1 to 3 weeks, leaving shallow pink depressions that gradually disappear. Scarring is rare unless the lesions were picked at by the patient or superinfected with bacteria. Healing lesions may leave hypopigmented spots that persist for weeks to months. Vesicles also develop in the mucous membranes of the mouth, nose, pharynx, larynx, trachea, gastrointestinal tract, urinary tract, and vagina. These mucosal vesicles rupture so rapidly that the vesicular stage may be missed. Instead, one sees shallow ulcers 2 to 3 mm in diameter. A distinctive feature of varicella is the simultaneous presence, in any one area of the skin, of lesions in all stages of development. Careful prospective studies have shown that the average number of lesions in healthy children ranges from 250 to 500; secondary cases resulting from household exposure are more severe than primary cases resulting from exposure at school, presumably because more intense and prolonged exposure at home results in a higher virus inoculum. Fever usually persists as long as new lesions continue to appear, and its height is generally proportional to the severity of the rash. It may be absent in mild cases or rise to 40.5°C (105°F) in severe cases with extensive rash. Prolonged fever or recurrence of fever after defervescence may signify a secondary bacterial infection or another complication. The most distressing symptom is pruritus, which is usually present throughout the vesicular stage. The varicella vaccine alters the natural history of the rash. A small percentage of vaccinees develop “breakthrough” varicella after exposure to people with active VZV infections. The usual breakthrough rash is predominately maculopapular with fewer lesions (i.e., less than 60) and fewer vesicles than the rash of natural varicella. The incidence and severity of fever is also less than that in natural varicella. [19]

COMPLICATIONS OF VARICELLA In the normal child, varicella is rarely complicated. The most common complication is the secondary bacterial infection of skin lesions, usually by staphylococci or streptococci, which may produce impetigo, furuncles, cellulitis, erysipelas, and, rarely, gangrene. [20] These local infections often lead to scarring and, rarely, to septicemia with metastatic infection of other organs. Bullous lesions may develop when vesicles are superinfected by staphylococci that produce exfoliative toxins. Invasive group A streptococcal infections are particularly virulent. Up to one-third of invasive group A streptococcal infections are associated with varicella, usually occurring within 2 weeks of the onset of the rash. [21] Secondary bacterial pneumonia, otitis media, and suppurative meningitis are rare complications and typically respond to appropriate antibiotic therapy. Bacterial superinfection is common and potentially life-threatening, however, in leukopenic patients. Other complications reflect a basic defect in the capacity of the host to limit VZV dissemination. [22] In adults, fever and constitutional symptoms are more prominent and prolonged, the rash of varicella is more profuse, and complications are more frequent. [22] Primary varicella pneumonia is the major complication of adult varicella. [23] Some patients are virtually asymptomatic, but others develop severe respiratory embarrassment, with cough, dyspnea, tachypnea, high fever, pleuritic chest pain, cyanosis, and hemoptysis 1 to 6 days after onset of the rash. The severity of the symptoms usually exceeds the physical findings, but the roentgenogram typically reveals diffuse, peribronchial nodular densities throughout both lung fields with a tendency to concentrate in the perihilar regions and at the bases. The mortality in adults with frank varicella pneumonia has been estimated to be between 10 and 30 percent, but it is less than 10 percent if immunocompromised patients are excluded. Varicella during pregnancy is a threat to both mother and fetus. [24] The fetus may die as a consequence of premature labor or maternal death in severe varicella pneumonia, but varicella during pregnancy does not, otherwise, substantially increase fetal morbidity or mortality. Nevertheless, even in uncomplicated varicella, maternal viremia can result in intrauterine (congenital) VZV infection. [25] Perinatal varicella (i.e., varicella occurring within 10 days of birth) is more serious than varicella in infants infected even a few weeks later. The morbidity and mortality of varicella are also markedly increased in immunocompromised patients. In these patients, continued virus replication and dissemination result in a prolonged high-level viremia, a more extensive rash, and a longer period of new vesicle formation. Immunosuppressed and glucocorticoid-treated patients may develop pneumonia, hepatitis, encephalitis, and hemorrhagic complications of varicella, which range in severity from mild febrile purpura to severe and often fatal purpura fulminans and “malignant” varicella. [26], [27] Central nervous system (CNS) complications of varicella occur in fewer than 1 in 1000 cases; they include several distinct syndromes. Varicella-associated Reye's syndrome (acute encephalopathy with fatty degeneration of the liver) typically occurs 2 to 7 days after the appearance of the rash. In the past, from 15 to 40 percent of all cases of Reye's syndrome occurred in association with varicella, particularly when aspirin was administered for fever, with mortality as high as 40 percent. [28] Acute cerebellar ataxia is more common than the other neurologic complications of varicella, occurring in 1 in 4000 cases, and more benign. [29] Encephalitis is much less common, occurring in 1 in 33,000 cases, but causes death or permanent neurologic sequelae. The pathogenesis of cerebellar ataxia and encephalitis remains obscure, but in many cases it is possible to detect VZV antigens, VZV antibodies, and VZV DNA in the cerebrospinal fluid of patients, suggesting direct infection of the CNS. [30] Although elevated aminotransferase levels are common, clinical hepatitis is rare except as a complication of progressive varicella. Other rare complications of varicella include myocarditis, glomerulonephritis, orchitis, pancreatitis, gastritis and ulcerative lesions of the bowel, arthritis, Henoch-Schönlein vasculitis, optic neuritis, keratitis, and iritis. The pathogenesis of many of these complications has not been delineated, but direct parenchymal or endovascular infection, or vasculitis induced by VZV antigen-antibody complexes appear to be responsible in most cases.

Clinical Manifestations of Herpes Zoster

PRODROME OF HERPES ZOSTER Pain and paresthesia in the involved dermatome often precede the eruption by several days and vary from superficial itching, tingling, or burning to severe, deep, boring, or lancinating pain. It may be constant or intermittent and is often accompanied by tenderness and hyperesthesia of the skin in the involved dermatome. The preeruptive pain of herpes zoster may simulate pleurisy, myocardial infarction, duodenal ulcer, cholecystitis, biliary or renal colic, appendicitis, prolapsed intervertebral disk, or early glaucoma, and leads to serious misdiagnosis and misdirected interventions. A few patients experience acute segmental neuralgia without ever developing a cutaneous eruption—a condition known as zoster sine herpete.

RASH OF HERPES ZOSTER The most distinctive feature of herpes zoster is the localization and distribution of the rash, which is nearly always unilateral, does not cross the midline, and is generally limited to the area of skin innervated by a single sensory ganglion (Fig. 215-4A). The area supplied by the trigeminal nerve, particularly the ophthalmic division, and the trunk from T3 to L2 are most frequently affected; the thoracic region alone accounts for more than half of all reported cases, and lesions rarely occur distal to the elbows or knees. [10], [11]

FIGURE 215-4 Herpes zoster. *A.* Early involvement of a thoracic dermatome with erythema within the dermatome and areas of grouped vesicle formation. *B.* Later involvement with crusted sites on the back, where the eruption first appeared, and many confluent hemorrhagic vesicles and bullae on the lateral chest wall, where the eruption appeared more recently; some vesicles are also seen outside the involved dermatome, representing hematogenous dissemination, a not uncommon occurrence. *C.* Ophthalmic zoster. Note the involvement of the tip of the nose, which frequently signals involvement of the eye.

Although the individual lesions of herpes zoster and varicella are indistinguishable, those of herpes zoster tend to evolve more slowly and usually consist of closely grouped vesicles on an erythematous base, rather than the more discrete, randomly distributed vesicles of varicella. This difference reflects intraneural spread of virus to the skin in herpes zoster, as opposed to viremic spread in varicella. [31] Herpes zoster lesions begin as erythematous macules and papules that often first appear where superficial branches of the affected sensory nerve are given off, for example, the posterior primary division and the lateral and anterior branches of the anterior primary division of spinal nerves. Vesicles form within 12 to 24 h and evolve into pustules by the third day. These dry and crust in 7 to 10 days. The crusts generally persist for 2 to 3 weeks (Fig. 215-4B). In normal individuals, new lesions continue to appear for 1 to 4 days (occasionally for as long as 7 days). The rash is most severe and lasts longest in older people, and is least severe and of shortest duration in children. Between 10 and 15 percent of reported cases of herpes zoster involve the ophthalmic division of the trigeminal nerve (Fig. 215-4C). [32] The rash of ophthalmic zoster may extend from the level of the eye to the vertex of the skull, but it terminates sharply at the midline of the forehead. When only the supratrochlear and supraorbital branches are involved, the eye is usually spared. Involvement of the nasociliary branch, which innervates the eye as well as the tip and side of the nose, occurs in 30 to 40 percent of patients with ophthalmic zoster. Thus, when ophthalmic zoster involves the tip and the side of the nose, careful attention must be given to the condition of the eye. Herpes zoster affecting the second and third divisions of the trigeminal nerve (Fig. 215-5) and other cranial nerves may produce symptoms and lesions in the mouth, ears, pharynx, or larynx. The so-called Ramsay-Hunt syndrome (facial palsy in combination with herpes zoster of the external ear or tympanic membrane, with or without tinnitus, vertigo, and deafness), results from involvement of the facial and auditory nerves.

FIGURE 215-5 Cephalic herpes zoster with facial palsy (Hunt syndrome). A 60-year-old female with right-sided facial palsy and vesicles on her (*A*) *tongue and* (*B*) *soft palate.*

COMPLICATIONS OF HERPES ZOSTER (Table 215-1)

Cutaneous	Visceral	Neurologic
Bacterial superinfection	Pneumonitis	Postherpetic neuralgia
Scarring	Hepatitis	Meningoencephalitis
Zoster gangrenosum	Esophagitis	Transverse myelitis
Cutaneous dissemination	Gastritis	Peripheral nerve palsies
	Pericarditis	Motor
	Cystitis	Autonomic
	Arthritis	Cranial nerve palsies
		Sensory loss
		Deafness
		Ocular complications
		Granulomatous angiitis (causing contralateral hemiparesis)

TABLE 215-1 **Complications of Herpes Zoster**

The sequelae of herpes zoster include cutaneous, ocular, neurologic, and visceral complications. Most complications of herpes zoster are associated with the spread of VZV from the initially involved sensory ganglion, nerve, or skin, either via the bloodstream or by direct neural extension. The rash may disseminate after the initial dermatomal eruption has become apparent. When immunologically competent patients are carefully examined, 17 to 35 percent of them are found to have at least a few vesicles in areas distant from the involved and immediately adjacent dermatomes. The disseminated lesions usually appear within a week of onset of the segmental eruption and, if few in number, are easily overlooked. More extensive dissemination (with 25 to 50 lesions or more), producing a varicella-like eruption (generalized herpes zoster; Fig. 215-6), occurs in 2 to 10 percent of unselected patients with localized zoster, most of whom have immunologic defects as a result of acquired immunodeficiency, as seen with HIV infection, underlying malignancy (particularly lymphomas), or immunosuppressive therapy. If the rash spreads widely from a small, painless area of herpes zoster, the initial dermatomal presentation may go unnoticed, and the ensuing disseminated eruption may be mistaken for varicella.

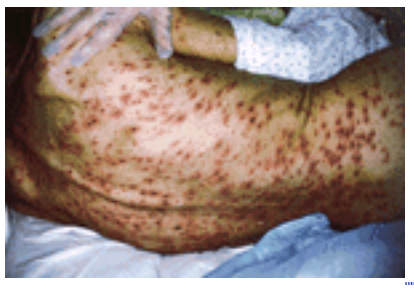

FIGURE 215-6 The back of a patient with chronic lymphocytic leukemia and disseminated herpes zoster. (*From Straus et al.,* [85] *with permission.*)

When the dermatomal rash is particularly extensive, as it often is in severely immunocompromised patients, there may be superficial gangrene with delayed healing and subsequent scarring (Fig. 215-7). Secondary bacterial infection may also delay healing and cause scarring.

FIGURE 215-7 *A.* Acute, necrotic herpes zoster involving the first and second distributions of the fifth cranial nerve in a woman with lymphoma receiving cytotoxic chemotherapy. *B.* Dense scar formation and temporal muscle wasting several weeks later. (*From Straus et al.,* [85] *with permission.*)

The eye is involved in 20 to 70 percent of patients with ophthalmic zoster, with a wide range of possible complications. [32] VZV is also the principal cause of acute retinal necrosis (ARN), a fulminant sight-threatening disease observed primarily in otherwise healthy individuals. [33] Herpes zoster may be attended by a variety of neurologic complications (Table 215-1), of which PHN is the most common and important. [34] PHN has been defined as pain after the rash has healed or pain 1 month or 3 months after rash onset. In clinic and community studies using the first two definitions, the overall incidence of PHN is 8 to 15 percent (Fig. 215-1B). [17], [35], [36] Age is the most significant risk factor for PHN (Fig. 215-1C). In a recent study, patients aged 50 years or older had a 14.7-fold higher prevalence (95 percent CI, 6.8 to 32.0) of pain 30 days after rash onset than patients younger than 50 years of age. [36] Other risk factors for PHN include the presence of prodromal pain, severe pain during the acute phase of herpes zoster, greater rash severity, more extensive sensory abnormalities in the affected dermatome and, possibly, ophthalmic (as opposed to thoracic or abdominal) herpes zoster. [37] PHN usually remits spontaneously over several months; the risk of long-lasting PHN also increases with increasing age. The patient with PHN may suffer from constant pain (described as “burning, aching, throbbing”), intermittent pain (“stabbing, shooting”), and/or stimulus-evoked pain, including allodynia (“tender, burning, stabbing”). Allodynia, the experience of pain elicited by stimuli that are normally not painful, is a particularly disabling component of the disease. Patients with allodynia suffer from severe pain after the lightest touch of the affected skin by things as trivial as a cold wind or a piece of clothing. These subtypes of pain may produce disordered sleep, depression, anorexia, weight loss, chronic fatigue, and social isolation and interfere with dressing, bathing, general activity, traveling, shopping, cooking, and housework.

HERPES ZOSTER IN THE IMMUNOCOMPROMISED HOST Except for PHN, most serious complications of herpes zoster occur in immunocompromised persons. [38] These complications include necrosis of skin and scarring (Fig. 215-7) and cutaneous dissemination with an incidence as high as 25 to 50 percent. Approximately 10 percent of patients with cutaneous dissemination manifest widespread, often fatal, visceral dissemination as well, particularly to the lungs, liver, and brain. [38] HIV-infected patients are fairly unique in their tendency to suffer multiple recurrences of herpes zoster as their disease progresses; herpes zoster may recur in the same or different dermatomes or in several contiguous or noncontiguous dermatomes. Herpes zoster in patients with AIDS may be severe, with cutaneous and visceral dissemination. Patients with AIDS may also develop chronic verrucous, hyperkeratotic, or ecthymatous cutaneous lesions caused by acyclovir-resistant VZV (Fig. 215-8).

FIGURE 215-8 Chronic verrucous lesions of herpes zoster despite long-term acyclovir treatment in a patient with advanced AIDS. (*Courtesy of David Paar, MD.*)

The incidence and severity of herpes zoster are also markedly increased in hematologic malignancies and in recipients of solid organ and bone marrow transplants (BMT). [39] Disseminated infection is common and often occurs without a recognizable cutaneous focus of localized herpes zoster.

PATHOLOGY

Cytopathology

The cutaneous lesions of varicella and herpes zoster are histologically indistinguishable (Fig. 215-9) and similar to those produced by HSV. The characteristic changes include “ballooning degeneration” with the formation of intranuclear inclusion bodies, and multinucleated giant cells. The nuclei exhibit margination of chromatin and contain inclusion bodies (Fig. 215-9B). Early in infection, these inclusion bodies may be homogeneous and moderately basophilic; however, they rapidly evolve into classical Cowdry type A inclusion bodies [sharply demarcated acidophilic (eosinophilic) inclusions that are separated from the deeply basophilic ring of marginated chromatin at the nuclear membrane by a clear zone or halo]. VZV glycoproteins induce pairs and groups of adjacent VZV-infected cells to fuse to form multinucleated giant cells.

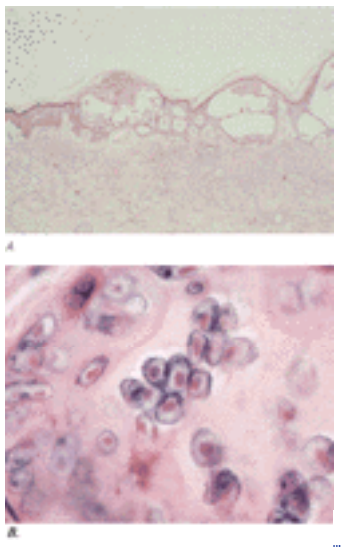

FIGURE 215-9 Herpes zoster, histopathology. *A.* Intraepidermal vesicle, acantholysis, reticular degeneration; underlying dermis shows edema and vasculitis. *B.* Multinucleated giant cells with characteristic nuclear changes.

Pathology of Varicella

The initial event in the formation of cutaneous lesions of varicella is probably infection of capillary endothelial cells in the papillary dermis, with subsequent spread of virus to epithelial cells in the epidermis, hair follicles, and sebaceous glands. [40] In early papular lesions, the epithelium is slightly elevated as a result of swelling of the infected epithelial cells and to edema and vascular congestion of the underlying dermis. In the superficial dermis, capillary endothelial cells are swollen, and their nuclei often contain typical intranuclear inclusion bodies. In the epidermis, the cells initially involved are those of the germinal layer and the deeper portion of the stratum spinosum. These cells show ballooning degeneration with loss of intercellular bridges (acantholysis) and are soon separated by intercellular edema.

The papular lesions rapidly evolve into intraepidermal vesicles as a result of the infection and degeneration of increasing numbers of epithelial cells, the fusion of adjacent areas of microscopic degeneration, and the continuing influx of edema fluid, which elevates the uninvolved stratum corneum to form a delicate clear vesicle. At this stage, the vesicle fluid contains fibrin, degenerating and “ballooned” epithelial cells, and abundant cell-free infectious VZV. As the lesions progress, polymorphonuclear leukocytes and a small number of macrophages invade from the underlying dermis, and the vesicle fluid becomes cloudy; this transforms the vesicle into a pustule. The fluid is then absorbed, with the formation of a flat, adherent crust that is eventually detached by the regrowth of subjacent epithelial cells. The evolution from papule to early crusting normally occurs over a period of 24 to 48 h.

In fatal varicella, focal lesions and viral antigens are found in virtually every organ, the lungs and liver being the most common sites of severe involvement. [41] There is widespread vascular damage, with characteristic acidophilic intranuclear inclusion bodies in endothelial cells lining small blood vessels and lymphatics; capillaries within individual lesions are often destroyed, resulting in thrombosis and hemorrhage.

Pathology of Herpes Zoster

Although the histopathology of the skin lesions of herpes zoster and varicella is the same (Fig. 215-9), herpes zoster is accompanied by acute inflammation of the corresponding sensory nerve and ganglion. The ganglion shows intense lymphocyte infiltration, necrosis of nerve cells and fibers, endothelial cell proliferation and lymphocytic cuffing of small vessels, focal hemorrhage, and inflammation of the ganglion sheath. [42] Satellite cells and neurons contain characteristic acidophilic intranuclear inclusion bodies, virus particles visible by electron microscopy, and VZV antigens demonstrable by immunofluorescence.

The peripheral nerve shows diffuse lymphocytic infiltration and focal hemorrhage, with axonal degeneration and demyelination of sensory fibers. Virus particles and VZV antigens are present in Schwann and perineural cells. The inflammatory reaction in the ganglion also extends proximally to the posterior nerve root and into adjacent regions of the cord or brainstem, producing a segmental myelitis. A mild lymphocytic leptomeningitis is generally present and is most intense over the involved segments and nerve roots.

CLINICAL AND LABORATORY DIAGNOSES

Clinical Diagnosis of Varicella

Varicella can usually be diagnosed readily on the basis of the appearance and evolution of its characteristic rash (see Fig. 215-3), particularly when there is a history of exposure within the preceding 2 to 3 weeks.

Disseminated HSV infections may resemble varicella; however, there is often an obvious concentration of lesions at and surrounding the site of the primary or recurrent infection (e.g., the mouth or external genitalia) and there may be marked toxicity and encephalitis.

The remaining differential diagnosis of varicelliform rashes include impetigo, the vesicular exanthems of coxsackievirus and echovirus infections (e.g., hand-foot-and-mouth disease syndrome), rickettsialpox, insect bites, papular urticaria, scabies, contact dermatitis, dermatitis herpetiformis, drug eruptions, secondary syphilis, and erythema multiforme. The character, distribution, and evolution of the lesions, together with a careful epidemiologic history, usually differentiate these diseases from varicella. The rashes associated with classical measles, rubella, roseola (herpesvirus types 6 and 7 infections), and erythema infectiosum (parvovirus B19 infection) are not vesicular and should not be mistaken for varicella. When any doubt exists, the clinical impression should receive laboratory confirmation.

Clinical Diagnosis of Herpes Zoster

In patients with prodromal pain, herpes zoster is often confused with other causes of localized pain. Once the eruption appears, the diagnosis is usually obvious (Fig. 215-4 and Fig. 215-5).

Disseminated herpes zoster may be mistaken for varicella when there is widespread dissemination of VZV from a small, painless area of herpes zoster or from the affected sensory ganglion in the absence of an obvious dermatomal eruption. This is not infrequent in profoundly immunosuppressed, seropositive persons (Fig. 215-6).

A cluster of vesicles, particularly near the mouth or genitals, may represent herpes zoster, but it may also be a recurrent HSV infection. [12] Zosteriform herpes simplex is often impossible to distinguish from herpes zoster on clinical grounds. A history of multiple recurrences at the same site is common in herpes simplex but does not occur in herpes zoster in the absence of profound and clinically obvious immune deficiency.

Laboratory Diagnosis

The lesions of varicella and herpes zoster are indistinguishable by histopathology (Fig. 215-9). The presence of multinucleated giant cells and epithelial cells containing acidophilic intranuclear inclusion bodies (Fig. 215-9B) distinguishes the cutaneous lesions produced by VZV from all other vesicular eruptions, except those produced by HSV. These cells can be demonstrated in Tzanck smears prepared at the bedside; material is scraped from the base of an early vesicle and stained with hematoxylin-eosin, Giemsa, Papanicolaou, or Paragon multiple stain.

Punch biopsies provide more reliable material for histologic examination than Tzanck smears and facilitate diagnosis in the prevesicular stage and in atypical lesions such as the chronic verrucous lesions produced by acyclovir-resistant VZV in patients with AIDS (Fig. 215-8).

The definitive diagnosis of VZV infection, as well as the differentiation of VZV from HSV, is accomplished by the isolation of virus in cell cultures inoculated with vesicle fluid, blood, cerebrospinal fluid, or infected tissue, or by the direct identification of VZV antigens or nucleic acids in these specimens. [29], [43] Virus isolation is the only technique that yields infectious VZV for further analysis, such as determination of its sensitivity to antiviral drugs; however, VZV is extremely labile, and only 30 to 60 percent of cultures from proven cases are positive. To maximize virus recovery, specimens should be inoculated into cell culture immediately. It is important to select new vesicles containing clear fluid for aspiration, because the probability of isolating VZV diminishes rapidly as lesions become pustular. VZV is almost never isolated from crusts.

VZV can be isolated and propagated in vitro in monolayer cultures of a variety of human (and certain simian) cells. [44] The cytopathic effects induced by the replicating virus in such cell cultures are characterized by the formation of acidophilic intranuclear inclusion bodies and multinucleated giant cells similar to those seen in the cutaneous lesions of the disease. These changes are indistinguishable from those produced by HSV, but whereas HSV rapidly spreads to infect the remaining cells in the culture, the cytopathic effect of VZV remains focal. Cytopathic effects of VZV are generally not apparent until several days after specimen inoculation. Modifications of the cell culture assay in which vesicle fluid or lesion scrapings are centrifuged onto cells growing on coverslips at the bottom of thin glass-walled “shell” vials followed by staining of the cells with fluorescein- or enzyme-labeled monoclonal antibodies to VZV proteins can confirm the presence of VZV in 24 to 72 h, well before cytopathic effects are evident in conventional cell cultures. [44]

Immunofluorescent or immunoperoxidase staining of cellular material from fresh vesicles or prevesicular lesions has become the diagnostic method of choice in many centers; it can detect VZV significantly more often and faster than virus culture, even relatively late in the disease when cultures are no longer positive. [44] Enzyme immunoassays provide another rapid and sensitive method for antigen detection.

Detection of nucleic acids in clinical specimens by nucleic acid hybridization or following amplifications by PCR provides the greatest assay sensitivity and is revolutionizing the diagnosis of VZV infections. [30], [44]

Serologic tests provide a retrospective diagnosis of varicella and herpes zoster reliably when acute and convalescent sera are available for comparison. [13], [44] They can also identify susceptible individuals who may be candidates for

isolation or prophylaxis. The technique most commonly used is a solid-phase enzyme-linked immunosorbent assay (ELISA). This assay, however, often lacks sensitivity and specificity and fails to detect antibody in people who are immune, and sometimes yield false-positive results in susceptible individuals. [44] Several more sensitive techniques have been developed to measure humoral responses to VZV. These include an immunofluorescence assay for antibody to VZV-induced membrane antigens [fluorescent antibody to membrane antigen (FAMA)] that reliably distinguishes immune from susceptible adults and a latex agglutination test that is comparable in sensitivity and specificity to FAMA assays, but is much simpler to perform. [45]

TREATMENT

Antiviral Agents

The nucleoside analogues acyclovir, famciclovir, valaciclovir, and vidarabine; the pyrophosphate analog foscarnet (Fig. 215-10); and human alpha interferons show efficacy in treating VZV infections. [46] Acyclovir is a guanosine analogue that is selectively phosphorylated by VZV thymidine kinases (it is a poor substrate for cellular thymidine kinase) and is thus concentrated in infected cells. Cellular enzymes then convert acyclovir monophosphate to acyclovir triphosphate, which interferes with viral DNA synthesis by inhibiting viral DNA polymerase.

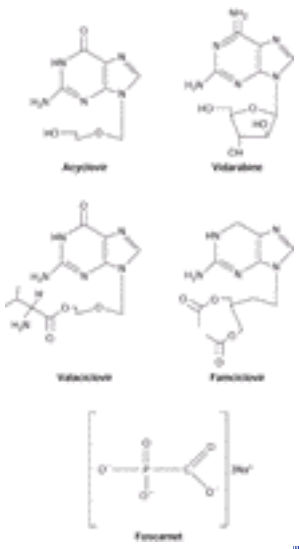

FIGURE 215-10 The chemical structures of five antiviral drugs proven effective in the treatment of varicella-zoster virus infections.

Two prodrugs, valaciclovir and famciclovir, produce higher antiviral blood levels and permit less frequent dosing than acyclovir. [47], [48] Valaciclovir is a valine ester of acyclovir that is converted enzymatically to acyclovir after absorption. Famciclovir is a prodrug of penciclovir, a nucleoside analogue similar to acyclovir in mechanism of action and antiviral activity against VZV and HSV. Famciclovir is converted enzymatically to penciclovir after absorption.

Foscarnet is an analogue of inorganic pyrophosphate that inhibits the replication of all known herpesviruses in vitro. It exerts its antiviral activity by selective inhibition at the pyrophosphate binding site of virus-specific DNA polymerases and reverse transcriptases at concentrations that do not affect cellular DNA polymerases. Foscarnet does not require phosphorylation by thymidine kinase to be activated and is therefore active against acyclovir-resistant VZV mutants that lack thymidine kinase activity.

Vidarabine, which is not a very selective inhibitor of virus replication, is potentially cytotoxic. It must be administered in large volumes of fluid. It is rarely used today.

Although the interferons are active, their cost, toxicity, and inconvenience have virtually eliminated their clinical use in varicella and herpes zoster. [49]

Acyclovir-resistant varicella and herpes zoster have been documented in patients with advanced AIDS (Fig. 215-8). Because of the mechanism of acyclovir resistance by VZV (mutations in the viral thymidine kinase gene), these infections are cross-resistant to ganciclovir, valaciclovir, famciclovir, and penciclovir. They usually respond to foscarnet, 40 mg IV every 8 h; however, the infections commonly recur once treatment has ended.

Treatment of Varicella

TOPICAL In normal children, varicella is generally benign and self-limited. Cool compresses or calamine lotion locally, oral antihistamines, and tepid baths with baking soda or colloidal oatmeal (3 cups per tub of water) may relieve itching. Creams and lotions containing glucocorticoids and occlusive ointments should not be used. Antipyretics may be needed, but salicylates must be avoided because of their association with Reye's syndrome. [28] Minor bacterial infections are treated with warm soaks. Bacterial cellulitis requires systemic antimicrobial therapy that is effective against *Staphylococcus aureus* and group A beta-hemolytic streptococcus.

ANTIVIRAL THERAPY

Normal children (Table 215-2) A large randomized, controlled trial of acyclovir treatment of healthy children 2 to 12 years of age found that early treatment (within 24 h of the appearance of rash) with oral acyclovir (20 mg/kg four times a day for 5 days) modestly reduced the maximum number of lesions, the time to cessation of new lesion formation, and the duration of the rash, fever, and constitutional symptoms when compared to placebo. [50] Because varicella is a relatively benign infection in children and the clinical benefits of treatment are modest, it does not require routine acyclovir

treatment; however, many have favored its use where cost is not a concern, where it can be begun in time to benefit the patient (within 24 h of rash), and where there is a perceived need to speed resolution of the infection so that parents can comfortably return to work. Because secondary cases among susceptible children in the household are generally more severe than the index cases, and because early initiation of treatment is more readily accomplished in secondary cases, treatment with acyclovir seems reasonable.

Patient Group	Regimen
Normal	
• Neonate	• Acyclovir 500 mg/m² q8h × 10 days
• Child	• Symptomatic treatment alone, or acyclovir 20 mg/kg per dose × 5 days
• Adolescent, adult, or glucocorticoids used	• Acyclovir 800 mg per 5 × /day × 7 days
• Pneumonia, pregnancy	• Acyclovir 800 mg per 5 × /day × 7 days, or acyclovir 10 mg/kg IV q8h × 7 days
Immunocompromised	
• MILD varicella or mild compromise	• Acyclovir 800 mg per 5 × /day × 7–10 days
• Severe varicella or severe compromise	• Acyclovir 10 mg/kg IV q8h × 7 days or longer
• Acyclovir-resistant (advanced AIDS)	• Foscarnet 40 mg/kg IV q8h until healed

TABLE 215-2 **Treatment of Varicella in the Normal and Immunocompromised Patient**

Normal adolescents and adults A randomized, controlled trial of acyclovir treatment of healthy adolescents 13 to 18 years of age found that early treatment with oral acyclovir (800 mg five times a day for 5 days) reduced the maximum number of lesions and time to cessation of new lesion formation compared to placebo. [51] A randomized, placebo-controlled trial of oral acyclovir in healthy adults with varicella showed that early treatment (within 24 h of onset of cutaneous lesions) with oral acyclovir (800 mg five times a day for 7 days) significantly reduced the time to crusting of lesions, the extent of disease, and duration of symptoms and fever. [23] Thus, routine treatment of varicella in adults seems reasonable. Although not tested, it is likely that valaciclovir 1000 mg PO q8h or famciclovir 500 mg q8h would be convenient and appropriate substitutes for acyclovir in normal adolescents and adults. Many physicians do not prescribe oral acyclovir in uncomplicated varicella during pregnancy because the risk to the fetus of treatment is unknown. Other physicians recommend oral acyclovir for infections in the third trimester when organogenesis is complete, when there may be a heightened risk of varicella pneumonia, and when infection can be spread to the newborn. Intravenous acyclovir is often considered for pregnant women with varicella who have extensive cutaneous and/or systemic disease.
Complications of varicella in normal persons Uncontrolled studies of immunocompetent adults with varicella pneumonia suggest that early treatment (within 36 h of hospitalization) with IV acyclovir (10 mg/kg q8h) may be useful in reducing fever and tachypnea and improved oxygenation. [52] Other serious complications of varicella in the immunocompetent host, such as encephalitis, meningoencephalitis, myelitis, and ocular complications, should be treated with IV acyclovir.
Immunocompromised patients Controlled clinical trials of IV acyclovir demonstrated a decrease in the incidence of life-threatening visceral complications when administered within 72 h of onset to immunosuppressed patients with varicella. [26] Immune compromise, however, is a continuum ranging from minimal to severe. Intravenous acyclovir has been the standard of care for management of varicella in patients with substantial immunodeficiency. While such oral therapy with valaciclovir or famciclovir might suffice for patients with mild degrees of immune impairment, there are no controlled clinical trials to guide the decision.

Treatment of Herpes Zoster

TOPICAL During the acute phase of herpes zoster, the application of cool compresses, calamine lotion, cornstarch, or baking soda may help to alleviate local symptoms and hasten the drying of vesicular lesions. Occlusive ointments should be avoided, and creams and lotions containing glucocorticoids should not be used. Bacterial superinfection of local lesions is uncommon and should be treated with warm soaks; bacterial cellulitis requires systemic antibiotic therapy. Topical treatment of the herpes zoster rash with antiviral agents is not effective.
ANTIVIRAL THERAPY The major goals of therapy in patients with herpes zoster are to (1) limit the extent, duration, and severity of pain and rash in the primary dermatome; (2) prevent disease elsewhere; and (3) prevent PHN.
Normal patients Table 215-3 lists the current recommendations for treatment of herpes zoster. Oral acyclovir significantly reduced the time to rash healing and the duration of viral shedding and acute pain in randomized controlled trials in patients older than 50 years of age who were treated within 72 h of rash onset. [17], [47] Clinical trials of acyclovir demonstrated conflicting results, however, regarding the efficacy of preventing PHN. Meta-analyses of the individual acyclovir trials indicated a reduction in the duration of chronic pain. [53] Randomized controlled trials comparing acyclovir to famciclovir and valaciclovir to famciclovir demonstrated equivalent results in rash healing, acute pain, and the duration of chronic pain. [48], [54] All three drugs are acceptable agents for older adults, with cost and dosing schedule determining the choice of agent. Because of the lower risk of PHN, antiviral therapy is less valuable or necessary for treatment of uncomplicated herpes zoster in healthy people younger than 50 years of age. The utility of antiviral agents is questionable if more than 72 h have elapsed since the onset of rash, except perhaps for patients who have ophthalmic zoster or who continue to have new vesicle formation.

Patient Group	Regimen
Normal	
• Age < 50 years	• Symptomatic treatment only, or acyclovir 800 mg/dose 5 × /day × 7 days
• Age ≥ 50 years, or with ophthalmic involvement	• Acyclovir 800 mg per 5 × /day × 7 days, or valaciclovir 1 g per q8h × 7 days, or famciclovir 500 mg per q8h × 7 days
Immunocompromised	
• MILD compromise, or HIV	• Acyclovir 800 mg per 5 × /day × 7–10 days or valaciclovir or famciclovir
• Severe compromise	• Acyclovir 10 mg/kg IV q8h × 7–10 days
• Acyclovir-resistant (advanced AIDS)	• Foscarnet 40 mg/kg IV q8h until healed

TABLE 215-3 **Treatment of Herpes Zoster in the Normal and Immunocompromised Patient**

Ophthalmic zoster represents a special therapeutic challenge because of the risk of ocular complications. Examination by an ophthalmologist should be sought in all cases. Oral acyclovir was effective for the prevention of ocular complications of ophthalmic zoster in a randomized, controlled trial. [55] Famciclovir and valaciclovir appear to have comparable efficacy to acyclovir in the treatment of ophthalmic zoster. [56], [57]
Immunocompromised patients A randomized, double-blind, placebo-controlled trial in immunocompromised patients with herpes zoster showed that acyclovir (500 mg/m ^{2} IV q8h for 7 days) halted progression of herpes zoster, both in patients with localized disease and in patients with cutaneous dissemination before treatment. [58] Acyclovir accelerated the rate of clearance of virus from vesicles and markedly reduced the incidence of visceral and progressive cutaneous dissemination. Pain subsided faster in acyclovir recipients, and fewer reported HN, but these differences were not statistically significant. Clinical trials comparing IV acyclovir therapy with vidarabine therapy for the treatment of herpes zoster in immunocompromised patients showed that acyclovir was significantly more effective and less toxic. [38], [58] In

patients with mild immunocompromise and localized herpes zoster, oral acyclovir, valaciclovir, or famciclovir will usually suffice. [59], [60] A randomized, controlled trial of oral famciclovir versus oral acyclovir in localized herpes zoster in immunocompromised patients following bone marrow or organ transplantation or oncology treatment found that the two treatments were equivalent in rash healing and loss of acute pain and that both were well tolerated. [60]

ANTIINFLAMMATORY THERAPY The possibility that PHN may be caused by inflammation of the sensory ganglion and contiguous neural structures has provided the rationale for the use of glucocorticoids during the acute phase of herpes zoster in an attempt to further reduce acute pain and prevent PHN. Randomized controlled trials, however, showed that the addition of glucocorticoids to acyclovir did not change the incidence of chronic pain. [61], [62] The common adverse effects of glucocorticoids argue against their routine use in older patients with herpes zoster; however, glucocorticoids did reduce acute pain in most trials, and in one trial of acyclovir and prednisone, the time to uninterrupted sleep, return to daily activity, and cessation of analgesic therapy was reduced in patients who received glucocorticoids. [62] Consequently, some experts advocate oral glucocorticoids for otherwise healthy older adults whose rash is complicated by moderate to severe pain and who have no contraindications to glucocorticoids. Others, including one of the authors (MO), do not recommend the use of glucocorticoids in this setting.

ANALGESICS Greater acute pain severity is a risk factor for PHN, and ongoing acute pain may contribute to central sensitization and the genesis of chronic pain. Therefore, aggressive pain control is both reasonable and humane. The severity of acute herpes zoster pain should be determined with simple standardized pain scales. Clinicians should prescribe scheduled nonopiate or opiate analgesics with the goal of limiting the severity of pain to below 3 or 4 on a 0-to-10 scale and to a level that does not interfere with sleep. The choice, dosage, and schedule of drugs is governed by the patient's pain severity, underlying conditions, and response to specific drugs. If pain control remains inadequate, then regional or local anesthetic nerve blocks should be considered. The effectiveness of carefully managed opiates, regional anesthetic nerve blocks, anticonvulsants, and tricyclic antidepressants during the acute phase of herpes zoster in reducing the incidence, duration, or severity of PHN is not known and needs to be tested in rigorous clinical trials.

Treatment of Postherpetic Neuralgia

PHN, once established, is difficult to treat. [17] Fortunately, it resolves spontaneously in most patients (Fig. 215-1B). Clinicians have advocated a wide range of treatments, including many oral and topical medications, epidural injection of local anesthetic and glucocorticoids, acupuncture, biofeedback, subcutaneous injections of triamcinolone, *trans*-epidermal electric nerve stimulation (TENS) units, spinal cord stimulators, and systemic administration of a variety of compounds, but most have not been validated by controlled trials.

TOPICAL THERAPY The topical lidocaine patch and EMLA (eutectic mixture of local anesthetics) cream produced significant pain relief in patients with PHN in controlled clinical trials; they are easy to use and are not associated with systemic lidocaine toxicity. [63] The 10 × 14-cm lidocaine patch contains 5% lidocaine base and other ingredients on a polyester backing. One or more patches are applied over the affected area for 12 h a day. EMLA is applied over the affected area under an occlusive dressing once a day. The disadvantages of the patch are application site reactions such as skin redness or rash, and substantial cost. Capsaicin (*trans*-8-methyl- *N*-vanillyl-6-nonenamide), an extract of hot chili peppers, is a chemical known to deplete substance P, an important endogenous neuropeptide that acts as a chemomediator of nociceptive impulses from the periphery to the CNS. A small clinical trial of topical capsaicin for 4 weeks in patients with PHN demonstrated significant effects of this therapy on pain, with 75 percent of patients experiencing substantial pain relief. [64] Unfortunately, the ointment burns too much to be tolerated by approximately one-third of subjects. In the authors' experience, capsaicin is rarely effective in patients with PHN.

ORAL AND ANESTHETIC AGENTS Gabapentin significantly reduced average daily pain scores in patients with PHN in a randomized, placebo-controlled trial. [65] The adverse effects of gabapentin included somnolence (27 percent), dizziness (24 percent), and ataxia (7 percent). Some experts have begun to prescribe gabapentin to patients with severe pain early in the course of herpes zoster, although the efficacy of this approach is unproven. Tricyclic antidepressants produced moderate to good pain relief in 44 to 67 percent of elderly patients with PHN in several randomized, controlled trials. [66], [67] Nortriptyline and desipramine are preferred alternatives to amitriptyline because they cause less sedation, cognitive impairment, orthostatic hypotension, and constipation in the elderly. Scheduled opioid therapy may also reduce PHN. In a randomized, placebo-controlled crossover trial of sustained-release oxycodone in patients with PHN, treated patients reported significant pain relief when compared to placebo. [68] Multiple anecdotal reports have advocated the use of peripheral, sympathetic, epidural, and ganglion blocks with local anesthetics and/or corticosteroids in PHN, but well-designed controlled trials are unavailable to support the efficacy of these treatments. [69] Recently, in patients with intractable PHN for more than a year who had failed oral and topical treatments, Kotani et al. reported good or excellent pain relief for up to 2 years in 90 percent of patients treated with intrathecal methylprednisolone plus lidocaine, compared to 6 percent in patients treated with intrathecal lidocaine alone. [70] These are remarkable results, but the safety and the feasibility of this intervention needs to be confirmed.

PREVENTION AND CONTROL

Prevention and Control of Varicella

VARICELLA VACCINE Several studies conducted in Europe, Japan, and the United States from the 1970s through early 1990s demonstrated that the live attenuated VZV (Oka strain) vaccine was immunogenic, that it was efficacious in protecting against varicella, that breakthrough cases were relatively mild, and that it was well tolerated in children. [71] Similar results were obtained in adults when two doses were given 4 to 8 weeks apart. Vaccinated children and adults developed breakthrough varicella from wild-type virus at a rate of 1 to 3 percent per year, as compared to the attack rate of natural varicella in unvaccinated children of 8 to 13 percent per year. On the basis of these data, the FDA licensed the Oka/Merck vaccine in the United States in 1995. The Advisory Committee on Immunization Practices (ACIP) and American Academy of Pediatrics recommend the varicella vaccine for (1) routine childhood immunization, one dose at 12 to 18 months of age; (2) susceptible, immunocompetent older children, adolescents and adults, using two doses, 4 to 8 weeks apart for persons older than 13 years of age; (3) individuals at high risk for exposure or transmission, including susceptible health care workers, family of immunosuppressed individuals, teachers of children, day care workers,

residents and staff in institutional settings, nonpregnant women of childbearing age, and college students; (4) postexposure prevention and outbreak control; and (5) day care and school entry. [72] The duration of vaccine-induced immunity over the life span is not yet known, but a high percentage of children followed long-term have remained seropositive; [73] however, it is likely that the immunity induced by the vaccine is not as solid as that induced by wild-type VZV infection. In adults, approximately 20 percent of vaccinees lose antibodies to VZV over time but continue to be partially protected—breakthrough varicella is characterized by mild disease and not severe varicella. [71] From the Vaccine Adverse Event Reporting System, the Food and Drug Administration and the Centers for Disease Control and Prevention (CDC) described 6574 case reports of adverse events per 9.7 million doses sold from March 1995 to July 1998. [74] The most common events were rashes (*n* = 3640) and injection site reactions (*n* =575). Of the case reports, 285 (4 percent) were serious, including seizures, neuropathy, encephalitis, ataxia, and thrombocytopenia at a rate of 2.9/100,000 doses. Whether these serious events were causally related to the vaccine was unclear. This rate is much lower than the rate for serious events following natural varicella. Herpes zoster was reported in vaccinees, but it occurred at lower frequency than herpes zoster caused by wild-type virus. Cases of laboratory-confirmed herpes zoster in vaccinees from several studies included some cases caused by reactivation of the vaccine virus and others caused by reactivation of wild-type virus that had been acquired but gone unrecognized. The effectiveness of the vaccine demonstrated in clinical trials has been confirmed in routine clinical practice, and the epidemiology of varicella in the United States is changing. [75], [76] and [77] Active surveillance showed that vaccination rates increased from less than 10 percent of children aged 12 to 23 months in 1995 to approximately 70 percent in 1999. Concomitantly, in 1999 and 2000, varicella incidence declined by approximately 80 percent, with the greatest decline among children 1 to 4 years of age. There was also a marked reduction in varicella-related hospitalizations and an attenuation of varicella seasonality. Many states now mandate the vaccine for school entry. [77] Carefully selected immunosuppressed children may also benefit from the varicella vaccine. When children with acute lymphoblastic leukemia (ALL) in remission and off chemotherapy are vaccinated, fewer than 10 percent develop a papular or papulovesicular rash, and most develop antibody and cell-mediated immunity to VZV. [78] Although not licensed for this indication, vaccine is available from the manufacturer to any physician through a research protocol for use in patients who have ALL and who meet certain eligibility criteria. In addition, the ACIP recommends that the vaccine be considered for asymptomatic or mildly symptomatic HIV-infected children in CDC class N1 or A1 with age-specific CD4+ T lymphocyte percentages greater than or equal to 25 percent. [72]

POSTEXPOSURE PROPHYLAXIS AND INFECTION CONTROL Patients with varicella and herpes zoster may transmit varicella to susceptible individuals. No preventive measures are recommended for a normal child who has been exposed to varicella or herpes zoster. On the other hand, it is desirable to prevent or modify varicella in high-risk immunocompromised individuals. Passive immunization with zoster immune globulin (ZIG) prepared from the plasma of donors recovering from herpes zoster and containing a high titer of antibody to VZV, zoster immune plasma (ZIP) obtained from otherwise healthy individuals during convalescence from varicella or herpes zoster, and varicella-zoster immune globulin (VZIG) harvested from outdated blood from blood banks, all protect immunosuppressed children from severe varicella when administered within 3 to 5 days of exposure. [79] Standard preparations of pooled human immunoglobulins for IV administration (IVIG) are probably also acceptable. Table 215-4 lists recommended criteria for the use of VZIG and related products.

TABLE 215-4 **Criteria for the Use of Varicella-Zoster Immune Globulin (VZIG) for the Prophylaxis of Varicella***

Active immunization with the live attenuated varicella vaccine is also effective in preventing illness or modifying varicella severity in children if used within 3 days of exposure. [80] Whereas protection afforded by VZIG is transient, varicella vaccine induces long-lasting immunity to VZV and protection against subsequent exposures. Chemoprophylaxis with acyclovir also has been studied in susceptible children following household exposure to varicella. Children who received postexposure treatment with acyclovir experienced fewer and lesssevere cases of varicella than children in the control group; [81] however, the appropriate timing is critical, immunity to varicella may not be achieved, and there are always fears that resistant strains will be selected by promiscuous applications of this approach. Hence, it is not recommended for routine use in children. Infection control practices for VZV increase in importance with the age and compromised immune status of the exposed, susceptible individual. There is no need to prevent exposure of susceptible normal children to VZV, but careful isolation procedures should be enforced to prevent infection of susceptible immunocompromised patients, newborn infants, and adults, particularly women of childbearing age. Exposure of susceptible immunocompromised patients to VZV warrants reduction in the dosage of glucocorticoids and immunosuppressive drugs and administration of VZIG. Hospital and long-term care facility personnel without a clear history of varicella or herpes zoster should be tested for antibody to VZV so that appropriate leave from work can be instituted following VZV exposure. In hospitals, airborne and contact precautions are recommended until all lesions are crusted for patients with varicella, immunocompromised patients with localized herpes zoster, and any patient with disseminated herpes zoster. [83] Contact precautions are recommended for immunocompetent patients with localized herpes zoster.

Prevention and Control of Herpes Zoster

Until universal vaccination greatly reduces the number of people harboring large amounts of latent VZV, prevention of herpes zoster must be aimed at preventing reactivation and spread of the virus. Long-term suppressive acyclovir treatment is only practical in immunocompromised patients at proven risk of developing herpes zoster within a defined time period, that is, in the year following bone marrow or solid organ transplantation. For the more general population, other strategies must be devised.

One approach to the prevention of herpes zoster is the stimulation of immunity to VZV, which wanes in elderly and other high-risk individuals. [15] Studies of healthy adults older than 55 years of age with a history of varicella demonstrate an increase in VZV-specific T lymphocytes and humoral immunity after vaccination with live attenuated VZV vaccine that is

similar to the increased immunity to VZV observed after an episode of herpes zoster. [84] These findings suggest that vaccination of this subset of patients may be useful in preventing herpes zoster and its complications. [15] A randomized, double-blind, placebo-controlled Veterans Affairs Cooperative Studies Program trial, involving more than 38,000 healthy adults aged 60 years and older, is currently being carried out in the United States in collaboration with the National Institute of Allergy and Infectious Diseases and Merck & Co., Inc., to determine whether immunization with a more potent formulation of the licensed varicella vaccine can reduce the frequency and severity of herpes zoster and its complications, particularly PHN.

REFERENCES

1. Cohen JI, Straus SE: Varicella-zoster virus and its replication, in *Fields Virology*, edited by DM Knipe, PM Hawley, DE Griffin, RA Lamb, MA Martin, B Roizman, SE Straus. Philadelphia, Lippincott-Williams & Williams, 2001, p 2707

2. Arvin AM: Varicella-zoster virus, in *Fields Virology*, edited by DM Knipe, PM Hawley, DE Griffin, RA Lamb, MA Martin, B Roizman, SE Straus. Philadelphia, Lippincott-Williams & Williams, 2001, p 2731

3. Choo PW et al: The epidemiology of varicella and its complications. *J Infect Dis* **172**:706, 1995

4. Wharton M: The epidemiology of varicella-zoster virus infections. *Infect Dis Clin North Am* **10**:571, 1996

5. Yawn PB et al: Community impact of childhood varicella infections. *J Pediatr* **130**:759, 1997

6. Seward J et al: Epidemiology of varicella, in *Varicella-Zoster Virus. Virology and Clinical Management*, edited by AM Arvin, AA Gershon. Cambridge, Cambridge University Press, 2000, p 187

7. Meyer PA et al: Varicella mortality: Trends before licensure in the United States, 1970-1994. *J Infect Dis* **182**:383, 2000

8. White CJ et al: Varicella vaccine (VARIVAX) in healthy children and adolescents: Results from clinical trials, 1987 to 1989. *Pediatrics* **87**:604, 1991

9. Sawyer MH et al: Detection of varicella-zoster virus DNA in the oropharynx and blood of patients with varicella. *J Infect Dis* **166**:885, 1992

10. Ragozzino MW et al: Population-based study of herpes zoster and its sequelae. *Medicine (Baltimore)* **6**:310, 1982

11. Hope-Simpson RE: The nature of herpes zoster: A long-term study and a new hypothesis. *Proc R Soc Med* **58**:9, 1965

12. Kalman CM, Laskin OL: Herpes zoster and zosteriform herpes simplex infections in immunocompetent adults. *Am J Med* **81**:775, 1986

13. Brunell PA et al: Varicella-zoster immunoglobulins during varicella, latency, and zoster. *J Infect Dis* **132**:49, 1975

14. Arvin AM: Cell-mediated immunity to varicella-zoster virus. *J Infect Dis* **166**:S35, 1992

15. Oxman MN: Immunization to reduce the frequency and severity of herpes zoster and its complications. *Neurology* **45**:S41, 1995

16. Krause PR, Klinman DM: Varicella vaccination: Evidence for frequent reactivation of the vaccine strain in healthy children. *Nat Med* **6**:451, 2000

17. Kost RG, Straus SE: Postherpetic neuralgia: Pathogenesis, treatment, and prevention. *N Engl J Med* **335**:32, 1996

18. Rowbotham M et al: Spectrum of pain mechanisms contributing to PHN, in *Herpes Zoster and Postherpetic Neuralgia,* 2nd ed, edited by CPN Watson, AA Gershon. Amsterdam, Elsevier, 2001, p 167

19. Johnson C et al: A long-term prospective study of varicella vaccine in healthy children. *Pediatrics* **100**:761, 1997

20. Aebi C et al: Bacterial complications of primary varicella in children. *Clin Infect Dis* **23**:698, 1996

21. Kiska DL et al: Invasive group A streptococcal infections in North Carolina: Epidemiology, clinical features and genetic and serotype analysis of causative organisms. *J Infect Dis* **176**:992, 1997

22. Centers for Disease Control: Varicella-related deaths among adults—United States. *JAMA* **277**:1754, 1997

23. Wallace MR et al: Treatment of adult varicella with oral acyclovir: A randomized, placebo-controlled study. *Ann Intern Med* **117**:358, 1992

24. Enders G, Miller E: Varicella and herpes zoster in pregnancy and the newborn, in *Varicella-Zoster Virus. Virology and Clinical Management*, edited by AM Arvin, AA Gershon. Cambridge, Cambridge University Press, 2000, p 317

25. Enders G et al: Consequences of varicella and herpes zoster in pregnancy: Prospective study of 1739 cases. *Lancet* **343**:1548, 1994

26. Nyerges G et al: Acyclovir prevents dissemination of varicella in immunocompromised children. *J Infect Dis* **157**:309, 1988

27. Whitley RJ et al: Vidarabine therapy of varicella in immunosuppressed patients. *J Pediatr* **101**:125, 1982

28. Centers for Disease Control: Reye syndrome—United States, 1984. *MMWR Morb Mortal Wkly Rep* **34**:13, 1985

29. Liu GT, Urion DK: Pre-eruptive varicella encephalitis and cerebellar ataxia. *Pediatr Neurol* **8**:69, 1992

30. Puchhammer-Stockl E et al: Detection of varicella-zoster DNA by polymerase chain reaction in the cerebrospinal fluid of patients suffering from neurological complications associated with chickenpox or herpes zoster. *J Clin Microbiol* **29**:1513, 1991

31. Oxman MN: Clinical manifestations of herpes zoster, in *Varicella-Zoster Virus. Virology and Clinical Management*, edited by AM Arvin, AA Gershon. Cambridge, Cambridge University Press, 2000, p 246

32. Liesegang TJ: Diagnosis and therapy of herpes zoster ophthalmicus. *Ophthalmology* **98**:1216, 1991

33. Holland GN: Standard diagnostic criteria for the acute retinal necrosis syndrome. *Am J Ophthalmol* **117**:663, 1994

34. Gilden DH et al: Neurologic complications of the reactivation of varicella-zoster virus. *N Engl J Med* **342**:635, 2000

35. Hope-Simpson RE: Postherpetic neuralgia. *J R Coll Gen Pract* **25**:571, 1975

36. Choo PW et al: Risk factors for postherpetic neuralgia. *Arch Intern Med* **157**:1217, 1997

37. Dworkin RH, Schmader KE: The epidemiology and natural history of herpes zoster and postherpetic neuralgia, in *Herpes Zoster and Postherpetic Neuralgia*, 2nd ed, edited by CPN Watson, AA Gershon. Amsterdam, Elsevier, 2001, p 51

38. Whitley RJ et al: Disseminated herpes zoster in the immunocompromised host: A comparative trial of acyclovir and vidarabine. *J Infect Dis* **165**:450, 1992

39. Schmader KE: Epidemiology of herpes zoster, in *Varicella-Zoster Virus. Virology and Clinical Management*, edited by AM Arvin, AA Gershon. Cambridge, Cambridge University Press, 2000, p 227

40. Muraki R et al: Hair follicle involvement in herpes zoster: Pathway of viral spread from ganglia to skin. *Virchows Arch* **428**:275, 1996

41. Nikkels AF et al: Distribution of varicella-zoster virus and herpes simplex virus in disseminated fatal infections. *J Clin Pathol* **49**:243, 1996

42. Watson CPN et al: The neuropathology of herpes zoster with particular reference to postherpetic neuralgia and its pathogenesis, in *Herpes Zoster and Postherpetic Neuralgia*, 2nd edition, edited by CPN Watson. New York, Elsevier, 2001, p 167

43. Coffin SE, Hodinka RL: Utility of direct immunofluorescence and virus culture for detection of varicella-zoster virus in skin lesions. *J Clin Microbiol* **33**:2792, 1995

44. Forghani B: Laboratory diagnosis of infection, in *Varicella-Zoster Virus. Virology and Clinical Management,* edited by AM Arvin, AA Gershon. Cambridge, Cambridge University Press, 2000, p 351

45. Steinberg SP, Gershon AA: Measurement of antibodies to varicella-zoster virus by using a latex agglutination test. *J Clin Microbiol* **29**:1527, 1991

46. Hirsch MS et al: Antiviral agents, in *Fields Virology*, 3rd ed, edited by BN Fields, DM Knipe, PM Hawley, DE Griffin, RA Lamb, MA Martin, B Roizman, SE Straus. Philadelphia, Lippincott-Raven, 1996, p 431

47. Tyring S et al: Famciclovir for the treatment of acute herpes zoster: Effects on acute disease and postherpetic neuralgia: A randomized double-blind, placebo-controlled trial. *Ann Intern Med* **123**:89, 1995

48. deGreef H: Famciclovir, a new oral antiherpes drug: Results of the first controlled clinical study demonstrating its efficacy and safety in the treatment of uncomplicated herpes zoster in immunocompetent patients. *Int J Antimicrob Agents* **4**:241, 1995

49. Winston DJ et al: Recombinant interferon alpha-2a for treatment of herpes zoster in immunosuppressed patients with cancer. *Am J Med* **85**:147, 1988

50. Dunkle LM et al: A controlled trial of acyclovir for chickenpox in normal children. *N Engl J Med* **325**:1539, 1991

51. Balfour HH et al: Acyclovir treatment of varicella in otherwise healthy adolescents. *J Pediatr* **120**:627, 1992

52. Haake DA et al: Early treatment with acyclovir for varicella pneumonia in otherwise healthy adults: Retrospective controlled study and review. *Rev Infect Dis* **12**:788, 1990

53. Jackson JL et al: The effect of treating herpes zoster with oral acyclovir in preventing postherpetic neuralgia: A meta-analysis. *Arch Intern Med* **157**:909, 1997

54. Tyring SK et al: Antiviral therapy for herpes zoster: Randomized, controlled clinical trial of valacyclovir and famciclovir therapy in immunocompetent patients 50 years and older. *Arch Fam Med* **9**:863, 2000

55. Cobo LM et al: Oral acyclovir in the treatment of acute herpes zoster ophthalmicus. *Ophthalmology* **93**:763, 1986

56. Colin J et al: Comparison of the efficacy and safety of valaciclovir and acyclovir for the treatment of herpes zoster ophthalmicus. *Ophthalmology* **107**:1507, 2000

57. Tyring S et al: Famciclovir for ophthalmic zoster: A randomized, acyclovir controlled study. *Br J Ophthalmol* **85**:576, 2001

58. Balfour HH Jr et al: Acyclovir halts progression of herpes zoster in immunocompromised patients. *N Engl J Med* **308**:1448, 1983

59. Gnann JW et al: Sorivudine versus acyclovir for treatment of dermatomal herpes zoster in human immunodeficiency virus-infected patients: Results from a randomized, controlled clinical trial. *Antimicrob Agents Chemother* **42**:1139, 1998

60. Tyring et al: A randomized, double-blind trial of famciclovir versus acyclovir for the treatment of localized dermatomal herpes zoster in immunocompromised patients. *Cancer Invest* **19**:13, 2001

61. Wood MJ et al: A randomized trial of acyclovir for 7 days or 21 days with and without prednisolone for treatment of acute herpes zoster. *N Engl J Med* **330**:896, 1994

62. Whitley RJ et al: Acyclovir with and without prednisone for the treatment of herpes zoster: A randomized, placebo-controlled trial. The National Institute of Allergy and Infectious Diseases Collaborative Antiviral Study Group. *Ann Intern Med* **125**:376, 1996

63. Galer BS et al: Topical lidocaine patch relieves postherpetic neuralgia more effectively than a vehicle topical patch: Results of an enriched enrollment study. *Pain* **80**:533, 1999

64. Bernstein JE et al: Treatment of chronic postherpetic neuralgia with topical capsaicin. *J Am Acad Dermatol* **17**:93, 1987

65. Rowbotham M et al: Gabapentin for the treatment of postherpetic neuralgia: A randomized controlled trial. *JAMA* **280**:1837, 1998

66. Kanazi GE et al: Treatment of postherpetic neuralgia. An update. *Drugs* **59**:1113, 2000

67. Watson CPN et al: Efficacy of oxycodone in neuropathic pain: A randomized trial in postherpetic neuralgia. *Neurology* **50**:1837, 1998

68. Watson CPN et al: Nortriptyline versus amitriptyline in postherpetic neuralgia: A randomized trial. *Neurology* **51**:1166, 1998

69. Fine PG: Nerve blocks, herpes zoster and postherpetic neuralgia, in *Herpes Zoster and Postherpetic Neuralgia,* 2nd ed, edited by CPN Watson, AA Gershon. Amsterdam, Elsevier, 2001, p 223

70. Kotani M et al: Intrathecal methylprednisolone for intractable postherpetic neuralgia. *N Engl J Med* **343**:1514, 2000

71. Annunziato PW, Gershon AA: Primary immunization against varicella, in *Varicella-Zoster Virus. Virology and Clinical Management*, edited by AM Arvin, AA Gershon. Cambridge, Cambridge University Press, 2000, p 460

72. Centers for Disease Control: Prevention of varicella: Updated recommendations of the Advisory Committee on Immunization Practices (ACIP). *MMWR Morb Mortal Wkly Rep* **48**(RR06):1, 1999

73. Asano Y et al: Experience and reason: Twenty-year follow-up of protective immunity of the Oka live varicella vaccine. *Pediatrics* **94**:524, 1994

74. Wise RP et al: Postlicensure safety surveillance for varicella vaccine. *JAMA* **284**:1271, 2000

75. Vazquez M et al: The effectiveness of the varicella vaccine in clinical practice. *N Engl J Med* **344**:955, 2001

76. Clements DA et al: Partial uptake of varicella vaccine and the epidemiological effect on varicella disease in 11 day care centers in North Carolina. *Arch Pediatr Adolesc Med* **155**:455, 2001

77. Centers for Disease Control: National, state, and urban area vaccination coverage levels among children aged 19-35 months—United States, 2000. *MMWR Morb Mortal Wkly Rep* **50**:637, 2001

78. Gershon AA et al: Persistence of immunity to varicella in children with leukemia immunized with live attenuated varicella vaccine. *N Engl J Med* **320**:892, 1989

79. Zaia JA et al: Evaluation of varicella-zoster immune globulin: Protection of immunosuppressed children after exposure to varicella. *J Infect Dis* **147**:737, 1983

80. Watson B et al: Postexposure effectiveness of varicella vaccine. *Pediatrics* **105**:84, 2000

81. Asano Y et al: Postexposure prophylaxis of varicella in family contact by oral acyclovir. *Pediatrics* **92**:219, 1993

82. Report of Committee on Infectious Diseases: *Varicella Zoster Infections*, 22d ed. Elk Grove Village, IL, American Academy of Pediatrics, 1991, p 517

83. Garner JS: Guideline for isolation precautions in hospitals. The Hospital Infection Control Advisory Committee. *Infect Control Hosp Epidemiol* **17**:53, 1996

84. Levin MJ et al: Use of a live attenuated varicella vaccine to boost varicella-specific immune responses in seropositive people 55 years of age and older: Duration of booster effect. *J Infect Dis* **178**:S109, 1998

85. Straus SE et al: Varicella-zoster infections: Biology, natural history, treatment and prevention. *Ann Intern Med* **108**:221, 1988

T>

Chapter 216

Francesco Drago Alfredo Rebora

Cytomegalovirus Infection

HISTORICAL ASPECTS
EPIDEMIOLOGY
NATURAL HISTORY
Congenital Infection
Perinatal Infection
Postnatal Infection
Infection in the HIV-Infected Host
IMMUNOLOGY
CLINICAL PRESENTATION
Congenital Infection
Perinatal and Postnatal Infection
Infection in the Normal Host
Postperfusion Syndrome
Infection in the Immunocompromised Host
Skin Lesions
DIAGNOSIS
Culture Methods
Light Microscopic Examination
Electron Microscopy Examination
Immunohistochemistry
In Situ Hybridization
Polymerase Chain Reaction
Serologic Tests
Histopathologic Findings
TREATMENT

REFERENCES

Cytomegaloviruses are widely disseminated in nature and species-specific members of this genera affect many animals, including rodents, domestic animals and primates. Human cytomegalovirus (HCMV) belongs to the Herpesviridae family, subfamily Betaherpesvirinae, and its formal designation is human herpesvirus 5.

HCMV shares many characteristics with other herpesviruses, including the general architecture of the virion, the genome structure and properties, including enzyme and viral DNA synthesis, the assembly of capsids in the nucleus, the irreversible destruction of the infected cells during the productive cycle, and the ability to remain latent in natural hosts after a primary infection, producing overt disease subsequently.

HCMV also has distinguished characteristics, such as salivary gland tropism, species-specificity, and slow growth in cultured cells that undergo typical cytopathic changes. It shows typical herpesvirus morphology with a core containing a linear double-stranded DNA surrounded by a capsid with 162 capsomeres, a tegument region of amorphous material that bridges the nucleocapsid to the envelope, and an envelope mostly derived from altered cell membranes of the host.

The only cell known to be fully permissive for HCMV replication in vitro is the human fibroblast. In these cells, HCMV grows slowly requiring 48 to 72 h to yield detectable levels of progeny virus. In vivo, however, cells infected with HCMV may be found in tissues of epithelial origin (liver, lung, salivary glands, kidneys, bile ducts, gut), in mesenchymal cells (endothelial cells, fibrocytes), in peripheral blood mononuclear cells and, occasionally, in inflammatory cells such as macrophages.

HISTORICAL ASPECTS

Weller coined the term HCMV, in 1957, because of the cytopathic cellular changes the virus produces in cell culture and in the so-called “congenitally acquired cytomegalic inclusion disease (CID).” In tissues, such changes include cell enlargement with the characteristic “owl's eye” intranuclear inclusions that had been described long before the virus was isolated, in the salivary glands of infants dying with CID. For a long time, the inclusions were considered the result of a protozoan infection, until Cole and Kuttner, in 1926, described a filtrable agent present in the submaxillary glands of guinea pigs. [1] Because the histopathologic features observed in the salivary glands of animals were similar to those in humans, the agent became initially known as “salivary gland virus.” Finally, in 1956, three laboratories independently described an identical cytopathic effect and isolated the virus. The virus was found to replicate in human fibroblastic tissue with the appearance of large refractile cells containing intranuclear inclusions identical to those observed earlier in CID patients with salivary gland infections. [2], [3] and [4]

EPIDEMIOLOGY

Worldwide 70 to 90 percent of people are infected with HCMV. HCMV may be considered one of the most successful examples of a human infectious agent, displaying an array of strategies for perpetuating and propagating itself in its natural host. It infects humans both vertically and horizontally, and many of its genetically unique strains continue to

circulate in the general population throughout the world.

HCMV is transmitted to approximately 70 percent of individuals living in good hygienic surroundings and to 90 to 100 percent of people of poor socioeconomic conditions. Transmission occurs during primary infection, reinfection, or reactivation, but the peculiar symbiotic relationship of HCMV with the host usually is manifest by subclinical infections. The infected persons may become reservoirs from which the virus spreads to other susceptible persons. As a consequence, the majority of adults show serologic evidence of HCMV infection.

Because of its lability, close or intimate contact is required for the horizontal dissemination of HCMV. The virus is present in oropharyngeal, cervical and vaginal secretions, urine, semen, breast milk, tears, feces, and blood. [5], [6] and [7] Because of its persistence in a life-long latent state after the primary infection, it is released for years in an occasional or continuous manner. The former occurs mostly during reactivation when infectious virions are shed in the saliva or other body fluids in a significant fraction of seropositive young adults. Reactivation may also lead to vertical (intrauterine) transmission. [7]

NATURAL HISTORY

The natural history of HCMV infection includes a primary infection, the latent infection, and possible reinfections and reactivations. The primary infection may be prenatal (via transplacental [8] or intrauterine transmission [7]), perinatal (via cervical secretion) or postnatal (via infected urine, saliva, breast milk, [8] blood transfusions, or organ transplantation [9]). Because infection occurs more readily in unhygienic environments, the vast majority of children of poor socioeconomic background are primarily infected by the onset of puberty.

After primary infection, HCMV remains in a latent state in specific cells of the host. In these cells, the genome takes the form of a closed circular molecule and expresses only a small fraction of viral genes. Peripheral blood mononuclear cells and other myeloid progenitors have been suggested as the reservoir of latent virus, but salivary glands and kidney cells also may play such a role. [10], [11]

Occasionally, however, the virus reactivates, and infectious virions appear in the saliva and/or urine. Such temporary reactivations are asymptomatic, but allow the virus to spread horizontally and even vertically if the reactivation happens during pregnancy. Reactivation is induced by an alteration of the host–parasite relationship caused by physiologic conditions, such as pregnancy and natural decay of defenses, to concurrent debilitating diseases, immunosuppressive drugs, and operative procedures. Cellular and humoral immune mechanisms are considered important in this regard. During immunosuppression, the rate of HCMV isolation increases presumably as a result of reactivation, although procedures such as allografting or blood transfusion implemented at the same time may provide additional opportunities for reinfection.

Reinfection is caused by a virus of a different antigenic type. Although it may be epidemiologically important to distinguish between reinfection and reactivation, both are clinically similar. The term *recurrent infection,* therefore, is often used to mean both possibilities.

Congenital Infection

Thirty to 40 percent of primary HCMV infections during pregnancy result in congenital infection of the newborn. As in rubella, the fetus is probably infected through maternal viremia and subsequent infection of the placenta, but infection of the myometrium via cervix or infected spermatozoa is also possible. Whether a cell-free virus or a leukocyte-associated virus is required for placental infection and why intrauterine transmission occurs only in one-third of pregnant women with primary infection are still open questions. In the course of a maternal infection, however, intrauterine transmission may also result from reactivation or reinfection with another HCMV strain.

Many factors play a role in this mode of transmission. Women who transmit the virus to their fetus, for example, have a more intense and prolonged HCMV-specific antibody response than those who do not transmit it. [12] In fact, if the antibody response is regarded as an indirect marker of viral replication, women who transmit the virus are those who replicate it more efficiently, supplying, therefore, the placenta with larger amounts of HCMV. Also, the host cell–mediated immune response and the hypothetical barrier function of the placenta are likely to be important.

Perinatal Infection

Eight to 56 percent of infants become infected and excrete HCMV into the urine during the first 6 months of life. Because intrauterine transmission accounts only for 0.4 to 2.5 percent of cases, the wide increase that occurs within the first months of life should be considered, in the absence of blood transfusion, as the result of mother-to-infant transmission. This occurs predominantly via infected genital secretions or breast milk, especially colostrum. [8] After breast milk ingestion, HCMV probably replicates within children's salivary glands.

Postnatal Infection

Forty to 80 percent of children are infected before puberty. HCMV primary infection in a normal host is usually asymptomatic and finding the routes of transmission is difficult. Probably saliva represents one of the most efficient sources of virus. An 80 percent rate of HCMV acquisition has been demonstrated in a group of children attending day care centers where HCMV-containing saliva can be recovered from toys.

Excretion of large quantities of virus is common in infants with congenital infection and may persist for years following birth, regardless of the severity of the infection. This provides an important source of virus and the spread of infection to

other infants and their caretakers. [13] Also, children with subclinical infection may spread the virus and pregnant women are at high risk, with oral and respiratory routes being the probable modalities of transmission. [14]

In normal adults, HCMV infection may be regarded also as a sexually transmissible disease, being more prevalent among women with past or current gonococcal infection. [15] HCMV is shed from the female genital tract, as cultures of cervical secretions show, in 3 to 35 percent of subjects. [16] An extremely high seroprevalence has been observed in sexually active homosexual men. [17] How relevant this route of transmission may be is uncertain, because sexual genital contacts are usually preceded by oral-to-oral contacts and HCMV excretion rate in semen is unknown. [5] By analogy with Epstein-Barr virus (EBV) infection, HCMV infection may represent in young adults a “kissing disease” rather than a classically venereal disease.

Other routes of transmission, though less frequent, are also important. Multiple transfusions or the transfusion of large quantities of blood are a particular problem. Leukocytes are the blood product mainly responsible; in fact, procedures that limit their quantity in transfused blood have reduced the incidence of this type of infection. [18] Screening blood donors has also contributed to a reduction in the incidence of infections. Blood-transfusion transmission is an uncommon event, because only 2.4 percent of blood units taken from HCMV seropositive donors actually lead to infection of seronegative recipients. [19]

HCMV is an important posttransplant pathogen in allograft recipients. Because HCMV is known to replicate actively in the distal convoluted tubules of infected kidneys and in mononuclear inflammatory cells in their interstitial spaces, approximately 50 percent of seronegative renal transplant recipients develop primary HCMV infection. Overall, however, 60 to 100 percent of allograft recipients of solid organs [20] become infected. HCMV reinfection (because of immunosuppression caused by operative procedures, therapies, and most probably HCMV reactivation) occurs in more than 85 percent of patients who are seropositive at the time of transplantation. [21]

Generally, the infection rate is indirectly related to the degree of the recipient immunosuppression. Obviously, the seronegative transplant recipients of organs donated by seropositive subjects are those who run the highest risk (33 to 83 percent infected in the case of kidney transplant). In addition, they usually develop a more severe disease than seropositive recipients. The risk for a seronegative patient who receives a graft from a seronegative donor is lower, but not nil (0 to 30 percent infected). [21]

Usually, not only does a more severe disease develop in transplant recipients who undergo a primary infection as compared to those with reactivation or reinfection, but HCMV infection also seems to have a negative influence on long-term graft function and patient survival. In cardiac allograft recipients, for example, coronary restenosis is caused by accelerated graft arteriosclerosis, while in kidney and hepatic transplantation, the mechanism of the damage is unclear. [22]

HCMV infection is a frequent cause of morbidity and mortality. After allogeneic bone marrow transplantation (BMT), for example, approximately 50 percent of all recipients develop HCMV infection. [9] Many remain asymptomatic, but some develop gastroenteritis, fever, leukopenia and wasting, hepatitis, or retinitis. The average incidence of HCMV pneumonia is 15 percent with 80 to 90 percent mortality.

With regard to HCMV infection, BMT differs from solid organ transplants. For example, the infection rate in seronegative recipients from seropositive marrow donors is lower than in seropositive recipients. In addition, BMT recipients receive less blood product than those patients transplanted with solid organs. All these considerations suggest that the donor marrow has only minor importance as a fomite and that the cause of infection is reactivation of latent virus.

The relevance of HCMV infection in inducing graft-versus-host disease in the posttransplant period is still debated.

Infection in the HIV-Infected Host

In HIV-positive patients, HCMV may influence the natural history of the HIV infection, independently of its role as an opportunistic pathogen, and it may be a possible cofactor in the progression to AIDS. In fact, an in vitro HCMV-HIV interaction has been shown, either directly through transactivation of the HIV genome or indirectly through the production of cytokines.

Although the in vivo evidence of this concept is at present debated, [23], [24] HCMV remains one of the most important opportunistic and life-threatening infections in AIDS patients. The longer survival of HIV patients emphasizes the importance of their HCMV infection by providing more opportunities for primary and recurrent infections to develop when cellular immunity is impaired or absent. In fact, the risk of developing opportunistic infections seems, at least partly, to be correlated with the level of the CD4+ lymphocyte count. In the case of HCMV infection, however, other mechanisms may be involved, such as a functional deficiency of the residual CD4+ cells or infection of other organs. [25]

IMMUNOLOGY

Immune surveillance mechanisms are important in HCMV infection. Probably, all components of the immune system act in concert to control the acute infection and to maintain the latent state, but T cells and the class I major histocompatibility complex (MHC)-restricted CD8+ cytotoxic T lymphocytes, natural killer (NK) cells, and antibody-dependent cellular cytotoxicity all play a central role. [11] This is shown by patients with deficiencies in this arm of the immune system who are at greater risk, and by the observation that a prompt cellular immune response is correlated with a good prognosis. [11] The specific immunity is mediated by CD8+ cytotoxic T lymphocytes that have their major target antigens [26] in the HCMV matrix protein pp65. In fact, patients with acute infection show increased levels of CD8+ T cells and a reversed CD4/CD8 ratio. Expansion of CD8+ T cells, comprising a CD8+ T cell subset that coexpresses the CD57 antigen, persists for

several months. Although the role of the CD8/CD57+ cells is still unclear, they probably mediate contact-dependent suppression and produce an inhibitory soluble factor. [27]

As for CD4 T cell functions, the acute infection is accompanied by a decrease of their antiviral action, but their role is uncertain. Lymphoproliferative responses to mitogens and viral antigens and the reactivity to skin tests are, in fact, diminished and a selective impairment of T cell activation via the T cell receptor/CD3 complex, which can be corrected by addition of exogenous interleukin (IL)-2, has been shown. [28] CD4+ T cells probably intervene by producing cytotoxicity-mediating cytokines and their role in controlling viral replication in salivary glands is influenced by the level of interferon (IFN)-?. [29]

The inhibition of the cell-mediated immunity is a part of the HCMV vast array of immune escape strategies. First of all, HCMV inhibits the cell-surface expression of the MHC class I within the infected cells by a variety of HCMV gene products. In addition, it impairs IFN-?–induced MHC class II-dependent antigen presentation by macrophages and protects infected cells interfering also with IFN-a–stimulated antiviral and immunoregulatory activity. [30] It also encodes proteins that can interfere with the presentation of viral peptide antigens to T cells and interacts with NK cells through a virally encoded MHC class I homologue. This is the UL18 gene product, which binds the host ß $_2$-microglobulin. The UL18 protein acts as a surrogate ligand that engages the NK-cell receptors, preventing recognition and lysis of HCMV-infected cells and may be used by the virus both as mechanism of infection and to evade the host immune response. [31], [32]

Additional mechanisms for the virus to evade the host immune response and facilitate human transmission probably include the possibility of HCMV-infected cells remaining protected from CD8+ cytotoxicity. This is the result of the alteration of MHC class I antigen surface expression [31], [32] and binding of the host ß $_2$-microglobulin. Human cytomegalovirus can survive in body fluids as ß $_2$-microglobulin–coated particles associated with its envelope, masking the antigenic sites necessary for neutralization. [33]

The biologic significance of other mechanisms of viral protection remains unclear. For example, HCMV is able to induce the expression of receptors with high affinity for the Fc portion of human IgG in the cytoplasm and membrane of the infected cells, and to immunoactivate polyclonal B cells, accounting for the increased plasma levels of IgG and the overproduction of autoantibodies.

The host-protective role of the humoral immune response is still controversial. Antibodies of IgG class are produced promptly at the time of primary infection and persist lifelong. IgM class antibodies are produced in primary, but not in the recurrent infections of immunocompetent individuals and they persist for 3 to 4 months. On the contrary, immunosuppressed patients may fail to mount an IgM response during primary infection and only one-third of them have IgM detectable in recurrent infections. During intrauterine infection, IgM antibodies are produced by the fetus together with IgG antibodies that remain detectable when the passively transferred maternal antibodies are cleared. Nonetheless, HCMV can be transmitted in the presence of passively acquired antibodies, though the severity of disease may be reduced if it occurs. Consequently, pooled human gamma globulins can be used in selected allogeneic BMT and renal transplant recipients. [34]

The nature and limits of the protective responses are, however, still largely undefined. Although HCMV-specific immune responses in a normal host may contribute to the limited growth of the virus in the involved tissue and to the fact that rarely do normal hosts exhibit clinical evidence of infection, immunity cannot prevent reinfection. On the other hand, the cell-mediated response may be a cause of disease. There is evidence that HCMV pneumonia can occur in allograft patients and, perhaps, some skin eruptions may be autoimmune conditions. [11] It is unclear what types of cells harbor the virus and support a productive infection, and if leukocytes act as specific carriers of the virus during acute infection. It is also unclear what represents the reservoir of replicating virus and the site of its latency. The cellular receptor for HCMV entry has not been identified, though the salivary glands, kidney, and mononuclear cells are considered the major sites of proliferation in primary infection. Finally, although we know that the most potent reactivators are immunosuppressive therapy, HIV infection, and organ transplants, the mechanism of reactivation remains unknown.

CLINICAL PRESENTATION

The main types of clinical presentation are congenital infection, postnatal infection, infection in the normal host, the postperfusion syndrome, and infection of the immunocompromised host.

Congenital Infection

CID occurs in 0.5 to 2 percent of newborns, often as a result of transplacental transmission of the virus. [8] Clinical manifestations are more severe in the offspring of mothers primarily infected in pregnancy than in those who undergo reactivation, and the earlier the gestational infection the more severe the disease. [8] Disease may develop in fewer than 10 percent of affected newborns and its manifestations may be so diverse as to include hepatomegaly with or without jaundice and splenomegaly, cardiovascular abnormalities (paraventricular calcifications), and gastrointestinal (GI) disorders (esophageal or biliary atresia, ileal or colonic stenosis, pyloric malformation). Neurologic abnormalities (deafness, encephalitis, psychomotor retardation, and paralysis) may be severe. [8] Sequelae, ranging from unilateral hearing loss to multiple central nervous system (CNS) abnormalities, intracranial calcifications, and impaired intellectual performance, develop in 10 to 20 percent of congenitally infected newborns, even if they were asymptomatic at birth. [8], [35] Manifestations may occur alone or in combination and are associated with a high risk of mortality.

Perinatal and Postnatal Infection

Postnatal infection is the most common clinical outcome of primary congenital infection and usually is asymptomatic.

Only occasionally does it present with a symptom complex, which resembles EBV mononucleosis syndrome.

Infection in the Normal Host

HCMV infection in immunocompetent patients often passes unnoticed, most individuals being unaware of their seroconversion. The clinical disease consists of a mononucleosis-like syndrome with a long-term unexplained febrile illness or pharyngitis, tonsillitis, lymphadenopathy, and/or arthralgias. [36] Numerous systemic manifestations are reported affecting one or more organ systems and tissues. Lymphadenopathy is less frequent than in EBV-induced infectious mononucleosis, and the Paul-Bunnell test is invariably negative. An elevated serum transaminase level is the most common evidence of liver involvement, but icteric hepatitis and fatal massive hepatic necrosis have also been observed. Laundry-Guillain-Barré syndrome and involvement of the CNS with encephalitis and meningitis have also been reported. The GI tract is another major site of HCMV involvement, exhibiting ulcerations from the esophagus to the colon. Retinitis and conjunctivitis, myocarditis, pericarditis, pneumonia, and hematologic abnormalities have also been described. [36]

Laboratory findings include atypical lymphocytosis, elevated hepatic transaminases, and a negative heterophile antibody response. Atypical lymphocytes have been shown to be mainly CD8+ T cells, while there is a decrease in CD4+ T cells, resulting in low CD4/CD8 ratios.

Postperfusion Syndrome

The postperfusion syndrome, [37] which occurs after a blood transfusion, is a mononucleosis syndrome in which the liver involvement is usually prominent. Transfused immunocompetent recipients rarely develop HCMV disease and, when it occurs either as primary infection or reactivation–reinfection, most of them are symptomless. Even if they become symptomatic, prognosis remains good without sequelae. In immunocompromised patients, the likelihood of developing a postperfusion syndrome is mostly related to the underlying condition of the recipient. Patients with AIDS and those who require massive transfusion support run a high risk of acquiring infection and developing severe disease.

Infection in the Immunocompromised Host

Organ transplant recipients and those with HIV infection may respond to primary or recurrent HCMV infections by remaining completely asymptomatic, but, more frequently, they develop viremia with bouts of fever and variable liver, lung, GI, and retinal involvement. The mortality rate is very high (80 to 90 percent).

Reactivation of latent intracellular virus is the major cause of HCMV infection in HIV-infected individuals in whom, most often, a disseminated and chronic disease develops with a high frequency of relapses and plurivisceral localization. Human cytomegalovirus retinitis is the most common visceral complication and presents with visual defects or decreased visual acuity. Gastrointestinal disorders caused by HCMV are also frequent in AIDS patients, and may involve all levels of GI tract, from esophagus to rectum. Colitis is a prominent manifestation with diarrhea, abdominal pain, weight loss, and bleeding.

Lungs, adrenal glands, and the CNS with encephalitis may also be involved. [38] Most patients have multiple sites of involvement and most often HCMV infection coexists with other opportunistic infections. Death as a result of HCMV-induced organ failure is possible, but the main cause of demise in AIDS patients remains *Pneumocystis carinii* pneumonia. [38]

Also in immunosuppressed transplanted patients, HCMV reactivation is the major cause of severe infections. Several risk factors predict the outcome: the degree of the immunosuppression, the need to supply blood products, the occurrence of graft-versus-host-disease, and the serologic status of the donor and the patient. [9], [37]

Symptoms occur from 1 to 4 months after transplantation. Gastrointestinal involvement is a major cause of mortality and develops later. Although there is limited evidence that the colon is involved in kidney transplant recipients and the upper GI tract in heart transplant recipients, the entire GI tract may be affected. Symptoms include esophagitis, abdominal pain, diarrhea, and bleeding, or massive hemorrhage in the case of GI perforation. [38] In renal transplant patients HCMV may cause interstitial glomerulonephritis that leads to poor graft function.

In HCMV-seropositive recipients who undergo allogeneic BMT, the risk of developing HCMV disease is great. It has been suggested that allogeneic reactivity triggers HCMV reactivation, but autologous-BMT recipients are at the same risk, and, when the disease develops, it is often as severe as after allogeneic BMT. [9] HCMV interstitial pneumonia is the most serious manifestation, leading to death more frequently than any other infectious agent. [37]

Skin Lesions

During HCMV infection, the skin is involved, especially in immunocompromised patients (Fig. 216-1), with both nonspecific and specific lesions. [39] The specific lesions are those ascribable to HCMV in the affected tissues or to the typical histopathologic features. The nonspecific lesions are mostly a consequence of immunologic abnormalities that follow viral infection or of hypersensitivity manifestations especially arising after antibiotic therapy. [11] The lesions include generalized macular and papular rashes, and urticarial and scarlatiniform eruptions. [36], [40] A widespread eruption, usually pruritic and morbilliform, appears in patients who receive ampicillin and its incidence increases in proportion to the duration of ampicillin treatment, as it occurs in EBV mononucleosis. The mechanism by which ampicillin triggers the development of rashes in patients with HCMV or EBV infection is unknown. High levels of infection-induced cytokines, HCMV-encoded proteins homologous to MHC class I, impaired CD4 T cells, control and expression of HCMV-enhanced adhesion molecules, all are hypothesized mechanisms that might induce the expansion of MHC class I–restricted

ampicillin-specific T cells. [11]

FIGURE 216-1 Papules and nodules on the back of a patient with Hodgkin's disease and disseminated HCMV. (*From Sugiura H et al: Successful treatment of disseminated cutaneous cytomegalic inclusion disease associated with Hodgkin's disease. J Am Acad Dermatol* **24**:346; 1991, *with permission.*)

CID cutaneous manifestations fall into this group. They consist of petechiae, purpura, jaundice, and blueberry muffin lesions [8], [41] (Fig. 216-2). The latter are violaceous or dark blue-red infiltrative papules and nodules that are characterized histologically by dermal erythropoiesis.

FIGURE 216-2 Infant with congenital HCMV infection: “blueberry muffin baby.” (*From Groark SP, Jampel RM: Violaceous papules and macules in a newborn. Dermal erythropoiesis associated with congenital cytomegalovirus infection. Arch Dermatol* **114**:116, 1989, *with permission.*)

The specific lesions differ according to the patient's immunocompetence. In the immunocompromised host, there are localized lesions and widespread eruptions (Fig. 216-3). Histologically, there is evidence of HCMV in the endothelial cells of the dermal vessels. [40] In fact, HCMV has been found in antemortem skin biopsies of hyperpigmented and indurated areas of the thighs, [42] granulating areas of burned patients, [43] a cutaneous ulceration on the chest, [44] a verrucous plaque on the heel, [45] crusted papules on the face, and ulcerations on the oral mucosa. [46] An ulcerative vulvovaginitis in a woman with AIDS has also been attributed to HCMV infection. [47] HCMV and herpes simplex virus have been simultaneously observed in the same skin ulcer of the lower lip and in necrotic papules of the legs in two AIDS patients. [48] HCMV has also been found in biopsies of erythematous and purpuric morbilliform eruptions, [44] scattered verrucous lesions, [45] and in a widespread eruption of perifollicular papulopustules. [49] Generalized urticaria during disseminated HCMV infection and a vesiculobullous eruption with histologic evidence of intraepidermal multinucleate giant cells, consistent with the cytopathic damage usually produced by the herpes group viruses, has also been reported. [40], [50]

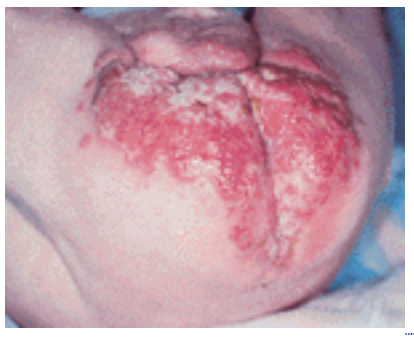

FIGURE 216-3 Infant with AIDS and diaper dermatitis–like disseminated HCMV. (*From Thiboutot DM et al: Cytomegalovirus diaper dermatitis. Arch Dermatol* **127**:396, 1991, *with permission.*)

Although most of the literature of the last 20 years reports cases of patients with ulcerations of the genital area who have been diagnosed later or even at autopsy, [40], [51] the skin is often the initial site of HCMV involvement and may provide the first clue to systemic infection.

Immunocompetent individuals very rarely present with cutaneous HCMV involvement. Only in two cases have specific dermatologic manifestations been reported. They consisted of erythematous, edematous, purpuric papules, and plaques in a livedo pattern on the lower extremities of a 7-year-old girl [52] and a purpuric rash with bullae on the legs in an adult woman. [53] The case of a patient with an acute papular and purpuric dermatosis in a characteristic “gloves-and-socks” distribution is also worth mentioning. [54] Usually, the papular-purpuric gloves-and-socks syndrome is considered a manifestation of parvovirus B19 infection, but in this particular patient, the specific anti-HCMV IgM antibodies detection suggested an active HCMV infection. In addition, HCMV has been found in ulcerated nodules of patients with systemic lupus erythematosus [55] and in skin lesions of 11 of 29 patients with vitiligo. [56] HCMV antibodies have been observed in patients with systemic sclerosis, [57] while, in psoriasis, a symptomless HCMV antigenemia was found associated with anti-HCMV IgG, but not IgM. This cleared with conventional antipsoriatic topical treatment. It may be related to a systemic overexpression of tumor necrosis factor (TNF)-a promoting HCMV activation. Alternatively, HCMV activation might exacerbate psoriasis via proinflammatory cytokines in infected cells. A recent study, however, found no evidence of HCMV-DNA in plaque psoriasis, indicating that cutaneous infection is not strictly necessary in the pathogenesis of the disease. [58]

DIAGNOSIS

Demonstrating HCMV pathogenicity is possible by different techniques and at least two strategies, namely the direct detection of virus and the specific immune response, are needed. However, the concordant results of several methods are necessary to establish a pathogenic relationship. It is quite important, therefore, to have a correct idea of the methods currently employed and of their own diagnostic significance (Fig. 216-4).

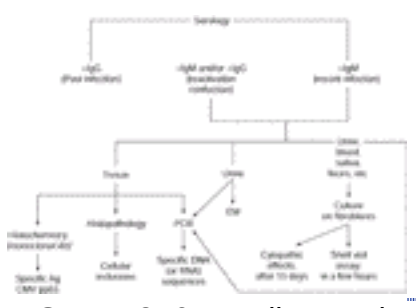

FIGURE 216-4 A diagnostic algorithm.

Culture Methods

Specimens may be collected from saliva, blood, urine, feces, semen, cervical secretions, bronchoalveolar lavage, fluid, and tissue biopsies obtained from target organs like skin, lung, liver, and kidney. [42] Diagnosis of congenital or perinatal infection needs urine or saliva samples and only rarely lumbar puncture or liver biopsy. In adults, urine, and heparinized blood are the best specimens. Culture of HCMV from oral lesions is not considered to be very specific because the virus can be excreted from other sites of the upper GI tract. [46]

Immunocompromised patients should be investigated by repeated cultures of saliva, urine, and blood. In saliva and urine of allograft recipients, HCMV excretion is very common, but it might be a mere coincidence. Viremia is more rare, but more specific and supports the diagnosis of HCMV, mononucleosis, or hepatitis. It is also indicative of a poor prognosis. Detecting HCMV in peripheral blood mononuclear cells does not prove that the virus has caused the disease because it might be in a latent state. By contrast, the detection of HCMV free in the plasma is considered a marker of active viral replication and strongly supports its involvement in the pathogenesis. [39]

HCMV grows only in human fibroblast cell culture. All cultures should be observed at least twice weekly to detect the focal cytopathic effect because the virus grows slowly, in contrast to herpes simplex and varicella-zoster viruses in epithelial cell cultures. [51] Modifications of this assay include the centrifugation enhancement of the specimen and the detection of intracellular HCMV proteins by immunofluorescence (shell vial assay). With the shell vial assay, the nuclear staining that results from immediate early gene expression can be seen within 10 to 15 h after inoculation. The shell vial assay has higher sensitivity (70 to 95 percent when compared to virus isolation) and specificity (100 percent by using monoclonal antibodies) and thus permits chemotherapy to be started earlier.

Light Microscopic Examination

The most commonly available method for diagnosing HCMV infection is histologic examination that, though specific, is less sensitive than cultures. Hematoxylin and eosin–stained sections may show enlarged, irregularly shaped, endothelial cells containing intracytoplasmic and intranuclear inclusions. [40] These Cowdry type A intranuclear inclusions are surrounded by a halo and may be found also in other tissues including liver, lung, gut, kidney, and brain. Cytomegalic changes without the characteristic inclusions have also been reported. These cells may be either present around or within the blood vessels. [49] Some intraluminal cytomegalic cells may have phagocytosis capacity. [40]

Electron Microscopy Examination

Although electron microscopy may show the characteristic viral particles of the Herpesviridae family, it cannot distinguish HCMV from other herpesviruses. The pseudoreplica method, [59] instead, identifies HCMV rapidly in the urine from infected infants in whom it is excreted at high titer. In immunocompetent children, viruria is considered specific because it is very unusual for any other herpesvirus to be found at so high a titer in infantile urine. This is not the case for immunosuppressed patients in whom the rate of virus excretion is usually lower and other herpesviruses are frequently found.

Immunohistochemistry

Indirect immunofluorescence is a rapid and sensitive method to identify numerous cellular antigens in some tissues, especially by using specific monoclonal antibodies against nuclear and cytoplasmic HCMV antigens. The detection of antibody-reactive polypeptides of UL83 (pp65) in circulating leukocytes (HCMV pp65 antigenemia assay) offers a method of estimating the viral burden. The high specificity provided by the use of monoclonal antibodies together with the very short processing time make the HCMV-antigen assay of great value in predicting invasive infection in allograft recipients and in HIV-positive patients, and in monitoring the efficacy of the treatment. A new approach to this method is the application of direct quantification of pp65 using flow cytometry. [60] Immunoperoxidase staining detects HCMV by using monoclonal antibody directed against the virus in paraffin-embedded tissues. [42]

In Situ Hybridization

DNA hybridization technology is based on the detection of particular nucleic acid sequences in biologic material, even in formalin-fixed, paraffin-embedded tissues. A labeled single strand of DNA with sequences complementary to the target nucleic acid (DNA probe) is used to seek and hybridize the viral genome in the test specimen. This test localizes specifically HCMV genomes in a particular cell type, but it is not a first-line test.

Polymerase Chain Reaction

HCMV DNA can be easily detected by polymerase chain reaction (PCR). In contrast to in situ hybridization, PCR does not give evidence about the specific cellular localization of the virus. In addition, detecting a viral genome in a cell or a tissue does not permit one to conclude about its etiopathogenetic role. PCR cannot distinguish between latent and productive infection or between latently infected cells and active replication. Only quantitative PCR gives data on the viral burden and its possible replicative state. It has been used to prove that patients with HCMV disease have more HCMV DNA in plasma (and even more in leukocytes) than those without disease. The viral load in leukocytes has been detected in immunocompromised patients often before the onset of symptoms and has been found to decrease during ganciclovir treatment. In blood and plasma samples, HCMV DNA levels seem to be suitable for screening patients at risk and monitoring the efficacy of antiviral therapy. [61]

Serologic Tests

The evaluation of the antibody titer is obtained by enzyme-linked immunosorbent assay or by complement fixation. Detecting IgG antibodies against HCMV suggests a past infection, while their rising level is often used as a marker of acute infection. Although detecting IgM antibody in acutely ill patients is highly significant for HCMV primary or recurrent infection, attention should be paid to both false-positive and false-negative results. A patient with disseminated HCMV infection has been reported not to show a change in antibody titer during a several month period. In addition, infectious mononucleosis or a positive rheumatoid factor can raise the HCMV IgM titer. [42] In contrast, immunocompromised patients with primary or recurrent infections may fail to produce specific IgM antibodies, leading to a poor prognosis. In transplant patients, the production of IgM antibodies following a recurrent infection is even more unpredictable.

Histopathologic Findings

Cutaneous HCMV is difficult to diagnose both clinically and histopathologically. Often, only a few cells exhibit cytolytic changes in a specimen even if, in severe disseminated disease, evidence of HCMV involvement can be found in virtually all organ systems. In fact, HCMV can be cultured from tissues easier than typical lesions can be seen. Generally, under light microscopy and with routine histologic staining, the typically infected cells appear exceedingly large with limited cytoplasm and prominent central nucleus. The latter often contains marginated chromatin and evident intranuclear inclusions surrounded by a clear halo (“owl's eye” inclusions) [40] (Fig. 216-5). In the skin, the typically affected cells are the endothelial cells, less frequently affected are fibrocytes and inflammatory cells. Only rarely have the epithelial cells (keratinocytes, eccrine ductal cells) been described.

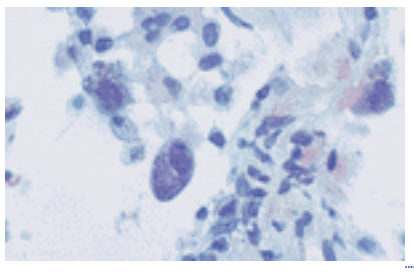

FIGURE 216-5 Intracellular inclusions in a cell infected by HCMV. (*From Konstadt JW et al: Disseminated cytomegalovirus infection with cutaneous involvement in a heart trasplant patient. Clin Cases Dermatol* **2**:2, 1990, *with permission.*)

The cell initially rounds, mainly by progressive swelling of the nucleus that appears basophilic, and it may display a prominent nucleolus and a reticulated pattern of nucleoplasm. Next, the cell continues to enlarge, particularly the nucleus that appears pale and convoluted. The nucleoplasm is marginated and vacuolated, while the cytoplasm is smudged and peripherally darker. Fully developed changes reveal that many, but not all, enlarged nuclei contain a purplish or basophilic inclusion body usually with a halo. Cytoplasm may contain granular, poorly defined, eosinophilic inclusions. The entire cell, however, stains basophil, except for the inclusions. [62]

Various authors differ markedly in their description of the nuclear inclusions, describing them as purplish, eosinophilic, basophilic, or amphophilic. These color variations may be a result of the different stages of nuclear changes in which the cells have been observed.

TREATMENT

Different antiviral agents can be used to treat HCMV infection and their combination (ganciclovir + foscarnet or foscarnet + cidofovir) or association with interferon is recommended because of their potentially decreased toxicity, higher efficacy, and delayed onset of drug resistance.

High-dose acyclovir has been used for prophylaxis in allogeneic BMT recipients and in renal allograft recipients with conflicting results, [63] but now it has been mostly replaced by new drugs.

Ganciclovir is a nucleoside analogue of acyclovir that does not require viral thymidine kinase for phosphorylation and activation. In vitro, it displays potent activity against HCMV and it is administered IV at 10 mg/kg per day for induction therapy and orally at 3000 mg/day for maintenance and prevention. An intraocular implant of 4.5 mg is used in HCMV retinitis. Ganciclovir toxicity includes leukopenia and thrombocytopenia, with abnormalities in spermatogenesis, leading to sterility, also described in experimental animals. The usual course of treatment is 14 days, but retreatment may be needed for some patients who relapse. After solid-organ transplantation, prophylaxis with ganciclovir reduces significantly the rate of both infection and disease, whereas acyclovir affects only the latter. [64]

Valganciclovir is a prodrug of ganciclovir that has been developed for the treatment of HCMV retinitis in AIDS patients. Oral valganciclovir is rapidly hydrolyzed to ganciclovir, providing a daily dose comparable to that of IV ganciclovir and equally effective. High ganciclovir blood levels can be achieved without the complications associated with the long-term access. [65]

Foscarnet interacts directly with the pyrophosphate binding site of the viral DNA polymerase. It is administered IV at 180 mg/kg per day (60 mg/kg every 8 h) for induction therapy and at 120 mg/kg per day for maintenance of HCMV retinitis and of acyclovir-resistant mucocutaneous infections. Dose adjustments for changes in renal function are necessary. Foscarnet has the same efficacy as ganciclovir, but it allows AIDS patients to survive longer, perhaps because of its antiretroviral activity. In fact, after 14 days of foscarnet induction therapy, the p24 HIV antigen levels decrease below the baseline.

Cidofovir is a nucleotide analogue with broad antiviral activity, that is effective in HCMV retinitis of AIDS patients refractory to other antiviral agents. It is administered IV at 5 mg/kg per week with sufficient hydration and under cover of probenecid to prevent nephrotoxicity. It can also be administered topically as 1% gel. [66] Despite such a route of administration, its pharmacokinetic properties allow a once-a-week dosing. Side effects include nephrotoxicity, bone marrow suppression, and ophthalmologic toxicity.

As a result of long-term maintenance therapy or of a subdose regimen, resistance to ganciclovir and foscarnet has been reported. For ganciclovir, the overall resistance rate ranges from 7.6 to 22 percent. For foscarnet, it is 26 percent after a 6-month therapy, rising to 37 percent after 9 months, while the overall resistance rate of cidofovir is 29 percent after 3 months. [67]

Novel agents under clinical development are maribavir and fomivirsen. Maribavir inhibits viral DNA synthesis by blocking terminal DNA processing, while fomivirsen is an antisense oligonucleotide with a sequence complementary to the coding region of the major immediate early HCMV gene of which it blocks the expression. It was recently approved for the local treatment of HCMV retinitis by intravitreal injection.

HCMV retinitis in AIDS patients profited from the advent of the highly active antiretroviral therapy (HAART). Allowing immunocompetency to be restored, HAART may eliminate the need for ongoing antiviral therapy, [68] leading to a dramatic reduction in the rate of HCMV infection and disease. Because AIDS patients were mostly at risk of developing HCMV drug resistance, the rate of the latter has also declined.

Efforts to develop vaccines able to confer immunity against HCMV have been made in recent years, but attenuated laboratory strains of HCMV induced only limited and temporary immunity. The use of replicating viral vaccine for preventing HCMV infection has met with some resistance because of the lack of knowledge of the determinants of HCMV virulence. The risk of vaccinating women of childbearing age with a replicating and possibly teratogenic virus and the oncogenic potential of such a vaccine raised other concerns. More recent interest has focused on the production of HCMV proteins from a recombinant expression system like the major envelope glycoprotein and the pp65 matrix protein, the last being considered an important target of HLA-restricted cytotoxic T cells after natural infection.

REFERENCES

1. Cole R, Kuttner AG: A filtrable virus present in the submaxillary glands of guinea pigs. *J Exp Med* **44**:855, 1926

2. Smith MG: Propagation in tissue cultures of a cytopathogenic virus from human salivary gland virus disease. *Proc Soc Exp Biol Med* **92**:424, 1956

3. Rowe WP et al: Cytopathogenic agents resembling human salivary gland virus recovered from tissue cultures of human adenoids. *Proc Soc Exp Biol Med* **92**:418, 1956

4. Weller TH et al: Isolation of intranuclear inclusion producing agents from infants with illnesses resembling cytomegalic inclusion disease. *Proc Soc Exp Biol Med* **94**:4, 1957

5. Lang DJ, Kummer JF: Cytomegalovirus in semen: Observations in selected population. *J Infect Dis* **132**:472, 1975

6. Reynolds DW et al: Maternal cytomegalovirus excretion and perinatal infections. *N Engl J Med* **289**:1, 1973

7. Stagno S et al: Congenital cytomegalovirus infection: The relative importance of primary and recurrent maternal infection. *N Engl J Med* **306**:945, 1982

8. Epps RE et al: TORCH Syndrome. *Semin Dermatol* **14**:179, 1995

9. Zaia JA, Forman SJ: Cytomegalovirus infection in the bone marrow transplant recipient. *Infect Dis Clin North Am* **9**:879, 1995

10. Kondo K et al: Human cytomegalovirus latent infection of granulocyte-macrophage progenitors. *Proc Natl Acad Sci U S A* **91**:11879, 1994

11. Kano Y, Shiohara T: Current understanding of cytomegalovirus infection in immunocompetent individuals. *J Dermatol Sci* **22**:196, 2000

12. Alford CA et al: Primary cytomegalovirus infection in pregnancy: Comparison of antibody response to virus encoded proteins between women with and without intrauterine infection. *J Infect Dis* **158**:917, 1988

13. Pass RF et al: Increased frequency of cytomegalovirus in children in group day care. *Pediatrics* **74**:121, 1984

14. Pass RF et al: Young children as a probable source of maternal and congenital cytomegalovirus infection. *N Engl J Med* **316**:1366, 1987

15. Lesher JL: Cytomegalovirus infections and the skin. *J Am Acad Dermatol* **18**:1333, 1988

16. Stagno S et al: Cervical cytomegalovirus excretion in pregnant and nonpregnant women: Suppression in early gestation. *J Infect Dis* **131**:522, 1975

17. Collier AC et al: Cytomegalovirus infection in homosexual men. Relationship to sexual practices, antibody to human immunodeficiency virus and cell-mediated immunity. *Am J Med* **23**:593, 1987

18. De Witte T et al: Prevention of primary CMV infection after allogeneic bone marrow transplantation by using leukocyte-poor random blood products from CMV-unscreened blood-bank donors. *Transplantation* **50**:964, 1990

19. Rubin RH et al: Multicenter seroepidemiologic study of the impact of cytomegalovirus infection on renal transplantation. *Transplantation* **40**:243, 1985

20. Pollard AB. Cytomegalovirus infections in renal, heart, heart-lung and liver transplantation. *Pediatr Infect Dis* **7**:97, 1988

21. Gnann JW et al: Inflammatory cells in transplanted kidneys are infected by human cytomegalovirus. *Am J Pathol* **132**:239, 1988

22. Loebe M et al: Role of cytomegalovirus infection in the development of coronary artery disease in the transplanted heart. *J Heart Transplant* **9**:707, 1990

23. Webster A: Cytomegalovirus as a possible cofactor in HIV disease progression. *J Acquir Immune Defic Syndr Hum Retrovirol* **4**:S47, 1991

24. Peterson PK et al: Human cytomegalovirus-stimulated peripheral blood mononuclear cells induce HIV-replication via a tumor necrosis factor-alpha–mediated mechanism. *J Clin Invest* **89**:574, 1992

25. Chaisson RE et al: Impact of opportunistic disease on survival in patients with HIV infection. *AIDS* **12**:29, 1998

26. McLaughlin-Taylor E et al: Identification of the major late human cytomegalovirus matrix protein pp65 as a target antigen for CD8+ virus-specific cytotoxic T lymphocytes. *J Med Virol* **43**:103, 1994

27. Labalette M et al: CD8 Lymphocytosis in primary cytomegalovirus (HCMV) infection of allograft recipients: Expansion of an uncommon CD8+ CD57–subset and its progressive replacement by CD8+ CD57–T cells. *Clin Exp Immunol* **95**:465, 1994

28. Rowbottom AW et al: Cytomegalovirus (HCMV) infection in AIDS patients is associated with a CD3 receptor-mediated T cell hyporesponsiveness. *Clin Exp Immunol* **111**:559, 1998

29. Lucin P et al: Gamma interferon-dependent clearance of cytomegalovirus infection in salivary glands. *J Virol* **66**:1977, 1992

30. Miller DM et al: Human cytomegalovirus inhibits IFN-alfa-stimulated antiviral and immunoregulatory responses by blocking multiple levels of IFN-alfa signal transduction. *J Immunol* **162**:6107, 1999

31. Leong CC et al: Modulation of natural killer cell cytotoxicity in human cytomegalovirus infection: The role of endogenous class I major histocompatibility complex and a viral class I homolog. *J Exp Med* **187**:1681, 1998

32. Lopez-Botet M et al: Human cytomegalovirus and natural killer-mediated surveillance of class I expression: A paradigm of host-pathogen adaptation. *Immunol Rev* **181**:193, 2001

33. Browne H et al: A complex between the MHC class I homologue encoded by human cytomegalovirus and beta 2 microglobulin. *Nature* **347**:770, 1990

34. Zaia JA: Prevention and treatment of cytomegalovirus pneumonia in transplant recipients. *Clin Infect Dis* **17**:S392, 1993

35. Stagno S et al: Primary cytomegalovirus infection in pregnancy. Incidence, transmission to fetus and clinical outcome. *JAMA* **256**:1904,

1986

36. Cohen JI, Corey GR: Cytomegalovirus infection in the normal host. *Medicine (Baltimore)* **64**:100, 1985

37. Tegtmeier GE: Posttransfusion cytomegalovirus infections. *Arch Pathol Lab Med* **13**:236, 1989

38. Katlama C: Cytomegalovirus infection in acquired immune deficiency syndrome. *J Med Virol* **1**(Suppl):128, 1993

39. Drago F et al: Cytomegalovirus infection in normal and immunocompromised humans. *Dermatology* **200**:189, 2000

40. Pariser RJ: Histologically specific skin lesions in disseminated cytomegalovirus infection. *J Am Acad Dermatol* **9**:937, 1983

41. Fine JD, Arndt KA: The TORCH syndrome: A clinical review. *J Am Acad Dermatol* **12**:697, 1985

42. Feldman PS et al: Cutaneous lesions heralding disseminated cytomegalovirus infection. *J Am Acad Dermatol* **7**:545, 1982

43. Swanson S, Feldman PS: Cytomegalovirus infection initially diagnosed by skin biopsy. *Am J Clin Pathol* **87**:113, 1987

44. Yu-Yun Lee J: Cytomegalovirus infection involving the skin in immunocompromised hosts. A clinicopathologic study. *Am J Clin Pathol* **92**:96, 1989

45. Bournirias I et al: Unusual cutaneous cytomegalovirus involvement in patients with acquired immunodeficiency syndrome. *Arch Dermatol* **125**:1243, 1989

46. Schubert MM et al: Oral infections due to cytomegalovirus in immunocompromised patients. *J Oral Pathol Med* **22**:268, 1993

47. Friedmann W et al: CMV virus infection of the vulva and vagina [MEDLINE abstr]. *Geburtshilfe Frauenheilkd* **50**:729, 1990

48. Yu-Yun Lee J, Peel R: Concurrent cytomegalovirus and herpes simplex virus infections in skin biopsy specimens from two AIDS patients with fatal CMV infection. *Am J Dermatopathol* **11**:136, 1989

49. Horn TD, Hood AF: Clinically occult cytomegalovirus present in skin biopsy specimens in immunosuppressed hosts. *J Am Acad Dermatol* **21**:781, 1989

50. Bhawan J et al: Vesiculobullous lesions caused by cytomegalovirus infection in an immunocompromised adult. *J Am Acad Dermatol* **11**:743, 1984

51. Toome BK et al: Diagnosis of cutaneous cytomegalovirus infection: A review and report of a case. *J Am Acad Dermatol* **24**:857, 1991

52. Weigand DA et al: Vasculitis in cytomegalovirus infection. *Arch Dermatol* **116**:1174, 1980

53. Hogarth MB et al: A blistering rash and swollen knees. *Lancet* **353**:978, 1999

54. Carrascosa JM et al: Papular-purpuric gloves-and-socks syndrome related to cytomegalovirus infection. *Dermatology* **191**:269, 1995

55. Colsky AS et al: Diagnosis and treatment of a case of cutaneous cytomegalovirus infection with a dramatic clinical presentation . *J Am Acad Dermatol* **38**:349, 1998

56. Grimes PE et al: Cytomegalovirus DNA identified in skin biopsy specimens of patients with vitiligo. *J Am Acad Dermatol* **35**:21, 1996

57. Neidhart M et al: Increased serum levels of antibodies against human cytomegalovirus and prevalence of autoantibodies in systemic sclerosis. *Arthritis Rheum* **42**:389, 1999

58. Asadullah K et al: A high prevalence of cytomegalovirus antigenaemia in patients with moderate to severe chronic plaque psoriasis: An association with systemic tumour necrosis factor alfa overexpression. *Br J Dermatol* **141**:94, 1999

59. Lee FK et al: Rapid diagnosis of cytomegalovirus infection in infants by electron microscopy. *N Engl J Med* **299**:1266, 1978

60. Poirier-Toulemonde AS et al: Clinical relevance of direct quantification of pp65 antigenemia using flow cytometry in solid organ and stem cell transplant recipients. *J Clin Microbiol* **38**:4143, 2000

61. Zipeto D et al: Human cytomegalovirus (CMV) DNA in plasma reflects quantity of CMV DNA present in leukocytes. *J Clin Microbiol* **33**:2607, 1995

62. Resnik KS et al: Histopathologic findings in cutaneous cytomegalovirus infection. *Am J Dermatopathol* **22**:397, 2000

63. Barkholt L et al: High-dose acyclovir prophylaxis reduces cytomegalovirus disease in liver transplant patients. *Transpl Infect Dis* **1**:89, 1999

64. Van der Bij W, Speich R: Management of cytomegalovirus infection and disease after solid-organ transplantation. *Clin Infect Dis* **33**:S32, 2001

65. Curran M, Noble S: Valganciclovir. *Drugs* **61**:1145, 2001

66. Ljungman P et al: Cidofovir for cytomegalovirus infection and disease in allogeneic stem cell transplant recipients. *Blood* **97**:388, 2001

67. Emery V: Progress in understanding cytomegalovirus drug resistance. *J Clin Virol* **21**:223, 2001

68. Piper H et al: Changing therapeutic paradigms in CMV retinitis in AIDS. *Expert Opin Pharmacother* **1**:1343, 2000

T>

Chapter 217

Jeffrey Cohen

Epstein-Barr Virus Infections

EPIDEMIOLOGY
ETIOLOGY AND PATHOGENESIS
CLINICAL MANIFESTATIONS
Infectious Mononucleosis
Oral Hairy Leukoplakia
Cutaneous Malignancies
Other Skin Findings
DIAGNOSIS
TREATMENT

REFERENCES

Epstein-Barr virus (EBV) is the etiologic agent of infectious mononucleosis and is associated with oral hairy leukoplakia and B cell lymphoma in patients with AIDS or acquired immunodeficiencies. EBV is also associated with malignancies including Burkitt's lymphoma, nasopharyngeal carcinoma, Hodgkin's disease, and certain T cell lymphomas.

In 1964 Epstein, Barr, and Achong described the presence of herpesvirus-like particles in Burkitt's lymphoma tissue. [1] In 1968, the Henles reported that EBV was the causative agent of infectious mononucleosis. [2] EBV DNA was demonstrated in biopsy tissues from patients with Burkitt's lymphoma and nasopharyngeal carcinoma in 1970, [3] in AIDS patients with B cell lymphomas in 1982, [4] and in Reed-Sternberg cells from patients with certain subtypes of Hodgkin's disease in 1989. [5]

EPIDEMIOLOGY

Infection with EBV is usually asymptomatic or presents with nonspecific symptoms in infants and young children. In contrast, infection of adolescents and young adults often results in infectious mononucleosis. While most individuals, especially those in developing countries, are infected at a young age and have few symptoms, persons from higher socioeconomic classes are less likely to have been infected during childhood and therefore are more likely to manifest primary EBV infection as infectious mononucleosis. [6] Most adults in the United States are seropositive for EBV by age 25 and are no longer susceptible to infection.

EBV is usually spread by contact with salivary secretions from asymptomatic persons shedding the virus. The incubation period of infectious mononucleosis is estimated to be 30 to 50 days. Transmission has been documented from blood transfusion and bone marrow transplantation. EBV can be isolated from saliva of asymptomatic seropositive individuals in 15 to 20 percent of attempts. Higher rates of shedding are seen in immunocompromised patients, [7] and in patients with infectious mononucleosis.

ETIOLOGY AND PATHOGENESIS

EBV is a member of the herpesvirus family. [8] The receptor for EBV (CD21) is present on B cells and epithelial cells. Infection of epithelial cells results in replication of the virus with lysis of the cell and release of infectious virus. Infection of B cells in vitro results in transformation and immortalization of the cells. These infected B cells are latently infected and usually do not produce infectious virus.

Humans become infected with EBV from oral secretions. The virus infects epithelial cells in the oropharynx, and B lymphocytes become infected either by direct contact with EBV-containing oral secretions or by contact with infected epithelial cells. The infected B cells proliferate and are controlled by an expansion of reactive T cells resulting in enlargement of lymphoid tissues and the symptoms of infectious mononucleosis. Following acute infection, EBV persists for life as a latent infection of B cells. These EBV-infected B cells remain low in number because of continued T cell surveillance. In the setting of cellular immune deficiency disorders, the EBV-infected B cells proliferate and may become clinically significant.

CLINICAL MANIFESTATIONS

Infectious Mononucleosis

Infectious mononucleosis is associated with the triad of fever, sore throat, and lymphadenopathy. [8] Erythema of the pharynx occurs in 85 percent of cases, and 20 percent of patients have a grayish-white pharyngeal exudate. Pharyngitis may be accompanied by tonsillar enlargement and may be associated with streptococcal infection. Other frequent signs and symptoms include malaise, headache, anorexia, myalgias, chills, and hepatosplenomegaly; less-common findings are nausea, abdominal pain, jaundice, and rash. Infectious mononucleosis is usually self-limited and symptomatic for 2 to 4 weeks; malaise and fatigue, however, can persist for months. Infrequent complications of infectious mononucleosis include autoimmune hemolytic anemia, thrombocytopenia, upper airway obstruction caused by hypertrophy of lymphoid tissue, hepatitis, meningitis, encephalitis, and rupture of the spleen.

A morbilliform or papular rash, usually on the arms or trunk, is present in 5 to 15 percent of cases of infectious

mononucleosis. The rash is more common in young children, is usually present during the first week of the illness, and may persist until the second week. The rash can have atypical features including a vesicular or scarlatiniform eruption, urticaria, or petechiae.

The vast majority of patients with infectious mononucleosis treated with ampicillin develop a maculopapular rash (Fig. 217-1 and Fig. 217-2). Rash has also been reported with amoxicillin, but is less frequent in patients treated with other beta-lactam antibiotics, including penicillin and cloxacillin. The eruption usually begins as erythematous or copper-colored lesions 5 to 10 days after beginning the antibiotic and starts on the trunk and spreads to the face and extremities as it becomes generalized. It may be associated with pruritus and usually resolves within 1 week. The rash associated with ampicillin usually appears later, is more severe and longer in duration, and more often involves the palms and soles than the rash in patients not treated with the antibiotic. It can be associated with other features of hypersensitivity reactions such as arthralgia, edema of the face and extremities, and diarrhea. The eruption is not predictive of future positive skin tests or adverse reactions to ampicillin or penicillin.

FIGURE 217-1 Generalized ampicillin exanthem in a patient with infectious mononucleosis. (*Courtesy of Helmut Hinton, MD, University of Innsbruck.*)

FIGURE 217-2 Closeup of ampicillin rash shown in Fig. 217-1. (*Courtesy of Helmut Hinton, MD, University of Innsbruck.*)

FIGURE 217-3 Oral hairy leukoplakia in a patient with HIV. (*From Cohen JI,* [8] *with permission. Copyright 2000 by the Massachusetts Medical Society. All rights reserved.*)

The etiology of the rash is thought to be caused by formation of antibodies associated with the polyclonal B cell proliferation that occurs with EBV infection and subsequent immune complex formation with activation of complement. Circulating immune complexes composed of immunoglobulins, complement components (C3, C4, and C5), EBV capsid antibody, and viral particles were associated with urticaria in one patient and became undetectable during recovery. [9] Skin reactions (consisting of a wheal =3 mm) to ampicillin were detected in two-thirds of patients with infectious mononucleosis, independent of prior ampicillin therapy. [10] Increased levels of serum antibodies reacting to ampicillin were detected in the serum of patients with infectious mononucleosis whether or not they had been treated with the antibiotic. The presence of these antibodies may be important in immune complex formation resulting in an Arthus reaction in the walls of small arterioles.

Urticaria has been reported in 5 percent of patients during the acute stage of infectious mononucleosis in the absence of antibiotic therapy or prior history of allergy. [11], [12] Cold-induced urticaria associated with cryoglobulinemia has also been seen during infectious mononucleosis in the absence of ampicillin therapy. [13], [14] Cold-induced acrocyanosis and cryoglobulinemia with vasculitis of the small vessels of the skin have each been noted in patients with infectious

mononucleosis.

Other skin lesions, including isolated palmar papules, erythema nodosum, and erythema multiforme, have also been reported in patients with infectious mononucleosis. Painful, bluish-black genital ulcerations have been reported in patients with acute EBV infection, and in one case, EBV was isolated from the ulcers. [15]

Periorbital edema is present in 2 to 35 percent of patients with infectious mononucleosis, and palatal enanthem is present in 3 to 13 percent of cases. The enanthem consists of multiple 0.5 to 1 mm erythematous petechiae, located between the hard and soft palate, which can coalesce to form larger lesions.

Laboratory findings in infectious mononucleosis include lymphocytosis that peaks during the second or third week of illness and >10 percent atypical lymphocytes. The atypical lymphocytes are vacuolated with a large cytoplasm. They may have indentations in the cytoplasmic membrane and are predominantly EBV-specific reactive T cells. Neutropenia, thrombocytopenia, and elevated transaminases and alkaline phosphatase are frequent findings during the first month of illness.

Infection with cytomegalovirus, toxoplasmosis, HIV-1, or hepatitis viruses can also produce the symptoms of infectious mononucleosis.

Oral Hairy Leukoplakia

Oral hairy leukoplakia is a benign hyperplasia of epithelial cells caused by active replication of EBV (Fig. 217-3). Lesions are usually present on the lateral surface of the tongue, but occasionally involve the dorsal and ventral surfaces of the tongue, buccal mucosa, soft palate, floor of the mouth, or pharynx. [16], [17] Patients present with slightly raised white lesions that are not well demarcated and have a corrugated or hairy appearance. The lesions may wax and wane, are not painful, and do not scrape off. Oral hairy leukoplakia is seen predominantly in patients with HIV, but has also been found in other immunosuppressed persons including transplant recipients as well as in persons with no known immunodeficiency. Histologically the lesions show parakeratosis, acanthosis, intranuclear inclusions, ballooning of the cytoplasm or an eosinophilic “ground glass” appearance, and little inflammation in the subepithelial layer. [18] Dysplasia is usually not seen and lesions do not progress to malignancy.

The lesions contain virus in the upper layers of the epithelium, but not in the basal layers. Biopsies from oral hairy leukoplakia contain EBV antigens, viral linear DNA (indicative of replicating virus), and large numbers of herpesvirus particles on electron microscopy. EBV viral capsid and early antigens are present, consistent with virus replication.

The differential diagnosis includes candidiasis, lichen planus, idiopathic or tobacco-associated leukoplakia, carcinoma, and geographic tongue. A presumptive diagnosis is usually made by the typical clinical appearance in an HIV-infected individual. Biopsy may be appropriate in atypical cases, such as patients not infected with HIV. The presence of EBV DNA in tissue or lesion scrapings by in situ hybridization is more specific than cytopathologic changes for the diagnosis of oral hairy leukoplakia. [19]

Cutaneous Malignancies

EBV has been detected in skin lesions from patients with cutaneous T/natural killer (NK) cell lymphomas. Most of these lymphomas are termed *angiocentric T cell lymphomas*. They present with ulcers, vesicles, nodules, or violaceous papules, and usually involve the nose, but may also present with lesions on the cheeks, lips, extremities, or trunk. [20] EBV is more likely to be present in patients with secondary cutaneous angiocentric lymphomas than in those with primary disease. [21] Some patients with NK cell lymphomas have severe hypersensitivity reactions to mosquito bites. Patients with hydroa vacciniforme–like lesions often progress to T cell lymphoma. [22] These patients present with fever and vesiculopapular lesions on the face and dorsum of the hands, and their lesions contain T cells with EBV DNA. A case of cutaneous T cell lymphoma associated with EBV was reported in a patient with AIDS. [23] Many patients with EBV-associated cutaneous T/NK cell lymphomas have a poor response to chemotherapy and progress to a hemophagocytic syndrome with pancytopenia and coagulopathy.

Subcutaneous panniculitic T lymphomas associated with hemophagocytosis and EBV present with indurated plaques, fever, hepatosplenomegaly, and pancytopenia. [24] Biopsies show cytophagic histiocytic panniculitis with lymphocytic infiltration into fat lobules and phagocytic or “beanbag” cells (Fig. 217-4). [25]

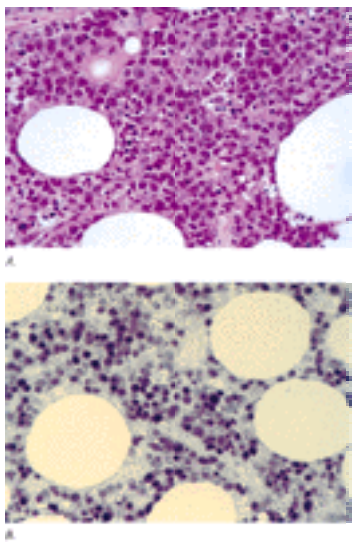

FIGURE 217-4 *A.* Bean-bag cells containing multiple nuclei in a patient with EBV-associated subcutaneous lymphoma, ×400. *B*. In situ hybridization for EBV-encoded RNA of the same subcutaneous lymphoma shows numerous cells expressing EBV RNA stained black, ×400. (*Courtesy of Keiji Iwatsuki, MD, Okayama University, Okayama, Japan.*)

EBV is also associated with B cell lymphomas that occur after transplantation or in persons with AIDS. While most of these patients have lesions in lymph nodes or viscera, some present with ulcerated cutaneous nodules containing EBV DNA. [26], [27] A patient with Hodgkin's disease who presented with skin nodules containing EBV RNA has been reported. [28] EBV–associated cutaneous B cell lymphoma has been reported in patients with rheumatoid arthritis or dermatomyositis who were receiving methotrexate, and many of these tumors resolved when the drug was discontinued. [29] EBV has also been detected in subcutaneous nodules of patients with lymphomatoid granulomatosis, [30] and in the epidermis in a patient with chronic lymphocytic leukemia and a papular rash. [31]

Other Skin Findings

Infantile papular acrodermatitis, or the Gianotti-Crosti syndrome, is associated with EBV and presents with symmetric erythematous lichenoid papules on the face, extremities, and buttocks, usually sparing the trunk (Fig. 217-5). [32] The rash is not pruritic and may be accompanied by splenomegaly, hepatitis, and lymphadenopathy. The rash often occurs in young children after an upper respiratory tract illness, but can occur in adults. The lesions show dermal edema, exocytosis of lymphocytes, and apoptotic keratinocytes. [33] An epidemic of Gianotti-Crosti syndrome caused by EBV was reported in Italy. [34]

FIGURE 217-5 Papules in a patient with Gianotti-Crosti syndrome associated with Epstein-Barr virus infection. (*Courtesy of Thomas Ruzicka, MD, Heinrich Heine University, Dusseldorf, Germany.*)

Kawasaki-like disease [35] and granuloma annulare–like eruption [36] have also been reported in patients with EBV infection. EBV has also been detected in lesions from patients with Kikuchi's histiocytic necrotizing lymphadenitis. [37] This benign condition occurs more often in females and presents with fever, chills, sore throat, cervical adenopathy, erythematous papules, nodules, and ulcers.

DIAGNOSIS

Acute infection with EBV is usually diagnosed by a positive heterophile test (e.g., monospot test). Heterophile antibodies agglutinate sheep or horse erythrocytes and do not recognize EBV antigens. More than 90 percent of patients with signs and symptoms of infectious mononucleosis, atypical lymphocytes, and a heterophile antibody titer of >1:40 have acute EBV infection. Heterophile antibodies may not become elevated until the third week of the illness, and usually persist for only 3 months. Heterophile antibodies are less common in persons who do not present with infectious mononucleosis.

EBV–specific antibody tests are useful for diagnosis of patients with negative heterophile antibodies or those with atypical symptoms. IgM antibody to the viral capsid antigen (VCA) is particularly helpful in the diagnosis of acute infection because it is elevated only during acute infection. Unfortunately, some commercial assays are nonspecific and report elevated levels of IgM anti-VCA antibodies in other settings as well. Antibody to early antigens (EA) is less useful

because it is elevated in 70 percent or fewer of patients with infectious mononucleosis. Seroconversion to IgG VCA or EBNA (EBV nuclear antigen) antibody positivity is useful for diagnosis of acute EBV infection; IgG VCA and EBNA antibodies usually persist for life. EBV DNA, RNA, and proteins can be detected in tissues from patients with oral hairy leukoplakia, lymphoproliferative disease, or EBV-associated malignancies (Fig. 217-4). Isolating EBV from oral secretions is of little value, because the virus is shed in a large percentage of healthy persons.

TREATMENT

Infectious mononucleosis is usually self-limited and therapy for symptoms includes rest and antipyretics. Although acyclovir inhibits virus replication in vitro and limits shedding of the virus, acyclovir is ineffective for reducing the symptoms of infectious mononucleosis. [38] Glucocorticoids are not indicated for patients with uncomplicated illness and may predispose to bacterial superinfection. [39] The combination of acyclovir and glucocorticoids has no significant effect on the duration of symptoms of infectious mononucleosis. [40] Glucocorticoids (1 mg/kg per day of prednisone for 2 to 3 days and tapered off over 1 to 2 weeks) may be useful in some patients with airway obstruction, severe hemolytic anemia, thrombocytopenia, or in very selected cases of encephalitis, myocarditis, pericarditis, or debilitating malaise and fever.

Patients with exudative pharyngitis that is accompanied by beta-hemolytic streptococci should be treated with penicillin or erythromycin. Ampicillin or amoxicillin should not be given during the acute phase of infectious mononucleosis.

Treatment of oral hairy leukoplakia is usually unnecessary. The lesions resolve during treatment with oral acyclovir (400 to 800 mg five times daily); however, they usually recur 2 weeks to 2 months after the drug is stopped. [17] Oral hairy leukoplakia has been reported to resolve with antiretroviral therapy, presumably as a result of better control of the underlying HIV infection. Surgical excision is associated with long-term remissions, but the disease can recur elsewhere on the tongue. [41] Topical tretinoin, [42] podophyllum resin, [43] trichloroacetic acid, and glycolic acid have all been used to remove lesions, but the disease recurs after treatment is discontinued.

REFERENCES

1. Epstein MA et al: Virus particles in cultured lymphoblasts from Burkitt's lymphoma. *Lancet* **1**:702, 1964

2. Henle G et al: Relation of Burkitt's tumor-associated herpes-type virus to infectious mononucleosis. *Proc Natl Acad Sci U S A* **59**:94, 1968

3. ZurHausen H et al: EBV DNA in biopsies of Burkitt's tumors and anaplastic carcinoma of the nasopharynx. *Nature* **228**:1056, 1970

4. Ziegler JL et al: Outbreak of Burkitt's-like lymphoma in homosexual men. *Lancet* **2**:631, 1982

5. Weiss LM et al: Detection of Epstein-Barr viral genomes in Reed-Sternberg cells of Hodgkin's disease. *N Engl J Med* **320**:502, 1989

6. Niederman JC, Evans AS: Epstein-Barr virus, in *Viral Infections of Humans: Epidemiology and Control*, 4th ed, edited by AS Evans, RA Kaslow. New York, Plenum, 1997, p 253

7. Ammatuna P et al: Presence of Epstein-Barr virus, cytomegalovirus, and human papillomavirus in normal oral mucosa of HIV-infected and renal transplant patients. *Oral Dis* **7**:34, 2001

8. Cohen JI: Epstein-Barr virus infection. *N Engl J Med* **343**:481, 2000

9. Wands JR et al: Circulating immune complexes and complement sequence activation in infectious mononucleosis. *Am J Med* **60**:269, 1976

10. Lund BMA, Bergan T: Temporary skin reactions to penicillins during the acute stage of infectious mononucleosis. *Scand J Infect Dis* **7**:21, 1975

11. Cowdrey SC, Reynolds JS: Acute urticaria in infectious mononucleosis. *Ann Allergy* **27**:182, 1969

12. Africk JA, Halprin KM: Infectious mononucleosis presenting as urticaria. *JAMA* **209**:1524, 1969

13. Tyson CJ, Czarny D: Cold-induced urticaria in infectious mononucleosis. *Med J Aust* **1**:33, 1981

14. Lemanske RF, Bush RK: Cold urticaria in infectious mononucleosis. *JAMA* **247**:1604, 1982

15. Portnoy J et al: Recovery of Epstein-Barr virus from genital ulcers. *N Engl J Med* **311**:966, 1986

16. Husak R et al: Oral hairy leukoplakia in 71 HIV-seropositive patients: Clinical symptoms, relation to immunologic status, and prognostic significance. *J Am Acad Dermatol* **35**:928, 1996

17. Triantos D et al: Oral hairy leukoplakia: Clinicopathologic features, pathogenesis, diagnosis, and clinical significance. *Clin Infect Dis* **25**:1392, 1997

18. Fernandez JF et al: Oral hairy leukoplakia: A histopathologic study of 32 cases. *Am J Dermatopathol* **12**:571, 1990

19. Greenspan JS et al: Comparison of cytopathic changes in oral hairy leukoplakia with in situ hybridization for EBV DNA. *Oral Dis* **4**:95, 1998

20. Chang S-E et al: Clinicopathological features of CD56+ nasal-type T/natural killer cell lymphomas with lobular panniculitis. *Br J Dermatol* **142**:924, 2000

21. Wechsler J et al: Differences in Epstein-Barr virus expression between primary and secondary cutaneous angiocentric lymphomas. *Arch Dermatol* **134**:479, 1998

22. Iwatsuki K et al: The association of latent Epstein-Barr virus infection with hydroa vacciniforme. *Br J Dermatol* **140**:715, 1999

23. Dreno B et al: Cutaneous anaplastic T-cell lymphoma in a patient with human immunodeficiency virus infection: Detection of Epstein-Barr

virus DNA. *Br J Dermatol* **129**:77, 1993

24. Iwatsuki K et al: Cutaneous lymphoproliferative disorders associated with Epstein-Barr virus infection: A clinical overview. *J Dermatol Sci* **22**:181, 2000

25. Craig AJ et al: Cytophagic histiocytic panniculitis—A syndrome associated with benign and malignant panniculitis: Case comparison and review of the literature. *J Am Acad Dermatol* **39**:721, 1998

26. Cohen JI: Epstein-Barr virus lymphoproliferative disease associated with acquired immunodeficiency. *Medicine (Baltimore)* **70**:137, 1991

27. McGregor JM et al: Posttransplant cutaneous lymphoma. *J Am Acad Dermatol* **29**:549, 1993

28. Kumar S et al: Primary cutaneous Hodgkin's disease with evolution to systemic disease: Association with Epstein-Barr virus. *Am J Surg Pathol* **20**:754, 1996

29. Tournadre A et al: Cutaneous lymphoma associated with Epstein-Barr virus infection in 2 patients treated with methotrexate. *Mayo Clin Proc* **76**:845, 2001

30. Beaty MW et al: Cutaneous lymphomatoid granulomatosis—Correlation of clinical and biologic features. *Am J Surg Pathol* **25**:1111, 2001

31. Fermand J-P et al: Detection of Epstein-Barr virus in epidermal skin lesions of an immunocompromised patient. *Ann Intern Med* **112**:511, 1990

32. Hofmann B et al: Gianotti-Crosti syndrome associated with Epstein-Barr virus infection. *Pediatr Dermatol* **14**:273, 1997

33. Smith KJ, Skelton H: Histopathologic features seen in Gianotti-Crosti syndrome secondary to Epstein-Barr virus. *J Am Acad Dermatol* **43**:1076, 2000

34. Baldari U et al: An epidemic of infantile papular acrodermatitis (Gianotti-Crosti syndrome) due to Epstein-Barr virus. *Dermatology* **188**:203, 1994

35. Barbour AG et al: Kawasaki-like disease in a young adult: Association with primary Epstein-Barr virus infection. *JAMA* **241**:397, 1979

36. Spencer SA et al: Granuloma annulare-like eruption due to chronic Epstein-Barr virus infection. *Arch Dermatol* **124**:250, 1988

37. Yen A et al: EBV-associated Kikuchi's histiocytic necrotizing lymphadenitis with cutaneous manifestations. *J Am Acad Dermatol* **36**:342, 1997

38. van der Horst C et al: Lack of effect of peroral acyclovir for the treatment of infectious mononucleosis. *J Infect Dis* **164**:788, 1991

39. McGowan JE et al: Guidelines for the use of systemic glucocorticosteroids in the management of selected infections. *J Infect Dis* **165**:1, 1992

40. Tynell E et al: Acyclovir and prednisolone treatment of acute infectious mononucleosis: A multicenter, double-blind, placebo-controlled study. *J infect Dis* **174**:324, 1996

41. Herbst JS et al: Comparison of the efficacy of surgery and acyclovir therapy in oral hairy leukoplakia. *J Am Acad Dermatol* **21**:753, 1989

42. Schofer H et al: Treatment of oral “hairy” leukoplakia in AIDS patients with vitamin A acid (topically) or acyclovir (systemically). *Dermatologica* **174**:150, 1987

43. Gowdey G et al: Treatment of HIV-related hairy leukoplakia with podophyllum resin 25% solution. *Oral Surg Oral Med Oral Pathol* **79**:64, 1996

T>

Chapter 218

Sandy Tsao

Human Herpesvirus 6 and 7 Infections and Exanthem Subitum (Roseola Infantum or Sixth Disease)

HISTORICAL ASPECTS
EPIDEMIOLOGY
HUMAN HERPESVIRUS 6 AND 7
PATHOGENESIS
Human Herpesvirus 6
Human Herpesvirus 7
CLINICAL MANIFESTATIONS
Cutaneous Manifestations
Neurologic Manifestations
Human Herpesvirus 6 and Human Immunodeficiency Virus
Neoplastic Disorders
Bone Marrow Transplantation
Miscellaneous
LABORATORY TESTS
SUSCEPTIBILITY TO ANTIVIRAL AGENTS

REFERENCES

Human herpesvirus 6 (HHV-6) and human herpesvirus 7 (HHV-7) are two newly recognized viruses that share close genetic, biologic, and immunologic features. They differ from all other known human herpesviruses in their primary T cell tropism and their inability to directly induce cellular transformation in vitro. They are present in the normal population in a latent phase and have been implicated as etiologic agents in various conditions, including exanthem subitum.

HISTORICAL ASPECTS

Salahuddin and colleagues first isolated HHV-6 in 1986 after herpes-like particles were identified in the peripheral mononuclear blood cells (PMBCs) of patients with various forms of lymphoproliferative disorders, some of whom were also infected with HIV-1. [1] At the time, only five human herpesviruses were known: herpes simplex virus (HSV or HHV-1 and HHV-2), varicella zoster virus (VZV or HHV-3), Epstein-Barr virus (EBV or HHV-4), and human cytomegalovirus (CMV or HHV-5). As the virus was initially isolated from B lymphoreticular disorders, it was named human B lymphotrophic virus (HBLV). Shortly thereafter, Lusso and associates characterized it as the first preferentially T-lymphotrophic human herpesvirus. [2] Subsequently, HHV-6 has been found to also infect natural killer cells, monocytes, glial cells, and fibroblasts. [3]

Four years later, using similar culture conditions, Frenkel and colleagues isolated HHV-7, a second human herpesvirus with a predominant T-lymphocyte tropism. [4] The role of these organisms as etiologic agents in exanthem subitum has been well established. [5], [6] Recent observations and in vitro studies have provided a greater insight into other disease states in which they may play a causal role, including pityriasis rosea and neoplastic disorders.

EPIDEMIOLOGY

HHV-6 and HHV-7 are ubiquitous in the population. At birth, most children have IgG antibodies to HHV-6 and HHV-7 because of their exposure to maternal immunoglobulin. Primary infection is thought to be acquired largely through oropharyngeal secretions, as suggested by the frequent detection of the virus in salivary secretions. Dahl and associates found peripheral blood HHV-6 DNA by polymerase chain reaction (PCR) assays in 41 to 44 percent of pregnant women, 25 percent of women at delivery, and 24 percent of age-matched controls. HHV-6 to DNA occurred in only 1 percent of cord blood samples. Thus, fetal transfer of HHV-6 is probably rare, and there is currently no indication that congenital infection with HHV-6 is harmful to the fetus. [7] Viral particles have also been recovered from vaginal and cervical secretions.

HHV-6 antibody levels reach a nadir at 4 to 7 months of age, then increase throughout infancy so that by 12 months two-thirds of children have been infected, with peak antibody levels being reached at 2 to 3 years. HHV-7 antibody levels reach a nadir at 6 months, with antibody levels peaking at 3 to 4 years. Adult seroprevalence rates of HHV-6 and HHV-7 show some waning of antibody levels with increased age. Clinical data suggest that HHV-6 and HHV-7 may persist as an active viremia, however, or remain latent in asymptomatic adults.

HUMAN HERPESVIRUS 6 AND 7

HHV-6 and HHV-7 are members of the ß-herpesvirus family. HHV-6 is a double-stranded DNA virus with an enveloped virion and an icosahedral capsid 170 to 200 nm in diameter that encloses the viral genome. The capsid is composed of 162 subunits (capsomeres) that resemble tubular structures. An amorphous integument acquired from the nuclear membrane encapsulates the genome and capsid (nucleocapsid). HHV-6 replicates by a rolling circle mechanism, with the formation of head-to-tail concatamers in infected nuclei. Fusion events with the nuclear membrane result in the release of

the capsids into the cytoplasm of infected cells. They undergo envelopment in cytoplasmic vacuoles, yielding mature virions. Further fusion with the cell membrane releases completed particles into the extracellular space.

More than 30 polypeptides have been identified in virions and infected cells, including 7 glycoproteins. In addition to structural components of the virion, certain enzymes essential for viral replication, including virus-specific DNA-polymerase, are synthesized in infected cells. Thymidine kinase, uracil-DNA-glycosidase, and deoxyuridine triphosphate nucleotidohydrolase, as well as other herpesvirus-specific enzymes, are not synthesized. [8] Ganciclovir kinase, similar to that produced by CMV, is detected.

The HHV-6 genome is 160 to 170 kilobase pairs (kbp) in length. A central segment containing a unique sequence that is rich in A+T and approximately 140 kbp in length has been identified. It is flanked by two identical direct repeat segments, rich in G+C, of approximately 8000 base pairs each. These direct repeats contain essential elements for viral DNA packaging and replication, and possibly for the maintenance of latency. [9] They also contain a tandem repetitive sequence (GGGTTA) that is also present in the genome of the Marek's disease virus. The overall content of G+C is 43 percent, one of the lowest among the Herpesviridae. The genome shares the highest degree of nucleotide sequence homology with HHV-7, while both HHV-6 and HHV-7 are more distantly related to CMV, [10] with approximately 65 percent homology. HHV-6 also possesses a gene with striking homology to the rep gene of adeno-associated virus type-2 (AAV-2), [11] a defective parvovirus dependent on adenovirus for replication. The AAV-2 rep protein inhibits cellular transformation by papillomaviruses. The HHV-6 replike gene product is functional and has been shown to block H- *ras* cellular transformation, to mediate AAV-2 DNA replication, and to alter HIV-1 transcription via the long terminal repeat. [12]

There are two major viral subgroups (A and B) for HHV-6. [13] The overall genetic divergence between the two variants is approximately 5 percent. The prototype of HHV-6A is strain GS. [1] The prevalence and time of primary infection with HHV-6A are still undefined, as type A is detected less frequently than type B. HHV-6A has been frequently detected in the plasma of patients after bone marrow transplantation, [14] serum of patients with multiple sclerosis, [15] and blood of immunocompromised patients such as those with AIDS. Although the detection of virus in these patients suggests a role for the virus in the etiology of these disorders, to date no human disease has been definitely linked to this subgroup. The prototype of HHV-6B is strain Z29. [16] It is responsible for most cases of primary infection of early childhood and has been associated with exanthem subitum. Its prevelance in Western countries is universal.

Characterization of HHV-7 is not yet complete. The HHV-7 genome is approximately 145 kbp. The genome encodes more than 70 proteins, including 2 major capsid proteins, and shares the greatest nucleotide homology with HHV-6A.

PATHOGENESIS

It is believed that HHV-6 and HHV-7 establish latent infections, as observed with other herpesviruses, thereby persisting indefinitely in the infected host. Although no in vitro models of latency exist, infection persists in cultured monocytes. [17] It is postulated that salivary and bronchial gland epithelial cells and circulating monocytes act as reservoirs for these viruses.

Human Herpesvirus 6

HHV-6 is a cytopathic virus. Unlike EBV, HHV-6 does not cause direct immortalization of its target cells. Both EBV and HHV-6 preferentially infect CD4+ T cells, [2] although HHV-6A is also able to infect cytotoxic effector cells, including CD8+ T cells, natural killer cells, and ?d T cells. HHV-6 can also infect, yet ineffectively lyse, nonimmune cells such as fibroblasts, neural cells, muscular cells, and epithelial cells. The receptor for HHV-6 is not known. HHV-6 has been shown to downregulate the expression of CD3 and aß heterodimers on T-cells, [18] thus having a potential immunosuppressive effect. HHV-6 can also transcriptionally activate the expression of CD4 in cells that physiologically do not express it. [19] It is also a powerful inducer of cytokines, including TNF-a and IL-1ß.

Human Herpesvirus 7

The major receptor for HHV-7 is the CD4 glycoprotein, [20] which also serves as the major receptor for HIV. HHV-7 and HIV-1 compete for CD4 occupancy and reciprocally interfere both in CD4+ T cells and in mononuclear phagocytes. HHV-7 downregulates CD4 expression. The use of its envelope in anti-HIV therapy has been proposed.

CLINICAL MANIFESTATIONS

Cutaneous Manifestations

EXANTHEM SUBITUM Zahorsky, in 1913, described exanthem subitum as *roseola infantum* (Latin, “pink rash of infants”). Veeder and Hemplemann introduced the name *exanthem subitum* (Greek, “sudden rash”) in 1921 to describe the most characteristic clinical finding, that of the sudden appearance of a rash on the fourth or fifth day of illness. Exanthem subitum originates in a mild, self-limited illness of short duration that is commonly mistaken for other illnesses that cause fever and rash in children. Exanthem subitum is a nonreportable infection, occurring equally in boys and girls. Although most studies of large groups of affected children showed no characteristic seasonal or monthly incidence, Juretic, in a review of 243 cases, noted a peak occurrence in May. [21] The typical age range is between 6 months and 2 years, with occasional cases described in older children and adults. Maternal antibodies play a role in the prevention of clinical infection prior to 6 months of age. The estimated incubation period is 5 to 15 days. Many viruses have been postulated to be the causative agent of exanthem subitum, including echovirus 16, coxsackieviruses, adenoviruses, and parainfluenzavirus type 1. To date, there is no conclusive evidence to support these hypotheses. In 1988, Yamanishi and colleagues provided evidence that HHV-6 was a causal agent of exanthem subitum. [22] HHV-7 has subsequently been

shown to play a similar causal role. The virus is present in high concentrations within mononuclear blood cells during the febrile stage of the illness. Subsequently, HHV-6 and HHV-7 antibodies develop. The onset of the disease is abrupt. In spite of a high fever, ranging from 38.9°C to 40.6°C (102°F to 105°F), the child is generally in no distress. A bulging anterior fontanelle, tonsillar and pharyngeal inflammation, tympanic injection, and nodal enlargement have been observed. There are generally no other systemic symptoms. The fever drops precipitously on the fourth day, coinciding with the rapid onset of a rash. The exanthem consists of nonpruritic, rose-pink macules and papules, 2 to 3 mm in diameter that blanch on pressure and are surrounded by a white halo (Fig. 218-1). The rash characteristically appears first on the trunk and may spread to the neck, upper extremities, and lower extremities. Fully evolved within 12 hours, it lasts 1 to 2 days. In some cases, the rash appears suddenly and disappears within a few hours. Resolution occurs without desquamation or hyperpigmentation. Palpebral edema (Berliner's sign, “heavy eyelids”) and periorbital edema are quite common.

FIGURE 218-1 Exanthem subitum. Multiple, blanchable macules and papules on the back of a febrile child, which appeared as the temperature fell. (*Courtesy of Karen Wiss, MD.*)

The differential diagnosis of high fever with sudden defervescence and an evanescent exanthematous eruption is quite narrow, but should include rubella, measles, scarlet fever, erythema infectiosum, other viral infections with exanthems (i.e., enterovirus, adenovirus, echovirus, coxsackievirus, rotovirus), and adverse cutaneous drug reactions. The characteristic clinical findings form the basis for diagnosis. Laboratory tests may reveal a transient leukopenia with a relative lymphoctyosis and occasional atypical lymphocytes. The course of exanthem subitum is mild, and there are generally no sequelae. The most common complication is the development of seizures. It is unclear whether the seizures are secondary to fever or to infection. Meningoencephalitis and fulminant hepatitis, confirmed by isolation of either HHV-6 or HHV-7 viral DNA from cerebrospinal fluid in the febrile phase, have been reported as complications of exanthem subitum. Thrombocytopenia has also been observed. Intussusception has been reported in three Japanese children with HHV-6 infection. [23] No treatment is generally required, given the self-limited nature of this disease. Primary infection with HHV-6 and HHV-7 confers lasting immunity.
PITYRIASIS ROSEA (See Chap. 46) Drago and colleagues have postulated that HHV-7 may play a role in patients with pityriasis rosea. [24] For 12 patients with pityriasis rosea, HHV-7 was isolated from sera, PMBCs, and skin biopsies using PCR techniques. Weak PCR signals were detected in PMBCs from 11 of 25 control patients. No HHV-7 was detected in control patient sera or skin biopsies. Further studies are needed to establish causality.

Neurologic Manifestations

HHV-6 may be a potential trigger for multiple selerosis. High levels of the virus have occurred in infected oligodendrocytes near plaque formations in the brains of patients with multiple sclerosis. [26] As well, IgM titers to an early HHV-6 antigen have been elevated during relapses. HHV-6 may act as a cofactor, activating a retrovirus responsible for multiple sclerosis. Active viremia and seroconversion in these children, as well as meningitis and meningoencephalitis, have implicated both HHV-6, and HHV-7 as causal agents of infant febrile seizures. [26], [27] These seizures are thought to be due to direct invasion of the central nervous system (CNS) by the virus.

Sugaya and colleagues recently reported that some cases of influenza encephalopathy were associated with HHV-6 and HHV-7 infection. [28] Of eight patients with encephalopathy, HHV-6 and HHV-7 DNA was detectable in the cerebrospinal fluid of two and three patients, respectively. No influenza virus was found in the cerebrospinal fluid.

Human Herpesvirus 6 and Human Immunodeficiency Virus

HHV-6 is thought to play an important role in the activation and propagation of HIV infection. Given its preferential tropism for CD4+ T cells and its ability to upregulate CD4 expression, HHV-6 may function as a cofactor for infection of these T cells with HIV. In addition, HHV-6 is a potent transactivator of HIV (long terminal repeat), and the HIV Tat transactivator enhances HHV-6 replication, each providing a favorable environment for replication. Active HHV-6 has been detected in multiple organs of patients with terminal AIDS at the time of autopsy. [29] In particular, HHV-6 localized to the white matter in areas of demyelinization in AIDS patients, [30] sparing areas without pathologic changes. It is postulated that HHV-6 may play a direct role in the development of AIDS-associated central nervous system disease. Clinically, HHV-6 has appeared in the cerebrospinal fluid of children with AIDS encephalitis.

Neoplastic Disorders

It has been suggested that HHV-6 may be an etiologic factor in neoplastic disorders such as Hodgkin's disease (via IgG serology and PCR), [31] non-Hodgkin's lymphoma (via Southern blot and PCR), [32] Langerhans cell histiocytosis (via PCR), [33] Kaposi's sarcoma (via PCR), [34] cervical cancer, [35] and angioimmunoblastic lymphadenopathy with dysproteinemia (via

PCR). [36] Unfortunately, no controlled studies have been conducted on these hypothesis. The tumorigenic potential of HHV-6 has nonetheless been well documented in vitro. [37]

Bone Marrow Transplantation

An important cause of idiopathic marrow suppression after bone marrow transplantation is HHV-6, as indicated by the presence of active viremia at the time of suppression. [38] This marrow-suppressive effect is thought to be partially mediated by cytokine- or virus-produced soluble factors. HHV-6A produces a more virulent aplastic anemia than does HHV-6B. The presence of HHV-6 DNA in the plasma, but not PMBCs, of bone marrow transplantation patients suggests reservoirs of HHV-6 other than peripheral blood cells. [14] Interstitial pneumonitis, [39] retinitis, [40] and bone marrow graft failure have also occurred in patients with active HHV-6 infections.

Miscellaneous

Both HHV-6 and HHV-7 have a putative role in the development of chronic fatigue syndrome. A major impediment to a confirmation of this role is the lack of a precise definition for chronic fatigue syndrome. Studies have demonstrated higher antibody titers to HHV-6 and HHV-7, as well as EBV, in patients with chronic fatigue syndrome than in control patients. Confirmation of active viral infection will allow for more supportive data.

Razonable and associates found selective reactivation of HHV-6A in critically ill immunocompetent hosts. [41] However, the incidence and degree of reactivation of the virus was not associated with any specific parameter, nor was it related to disease severity and outcome. Anti–HHV-6 IgM antibodies were also detected in patients who exhibited a drug reaction with eosinophilia and systemic symptoms (DRESS). [42] Neither anti-CMV nor anti-EBV antibodies were detected, suggesting a selective reactivation of HHV-6. Seroconversion occurred in two patients, suggesting a specific immunologic reaction induced by exogenous drugs. Interestingly, HHV-6 DNA was not detectable in the serum of any patient by PCR.

LABORATORY TESTS

The most accurate method of detection of HHV-6 and HHV-7 is the PCR evaluation of serum or plasma. [43] IgM antibody reactivity correlates well with active infection. Immunoglobulin antibody titers do not correlate with actual viral replication. Other methods employed include immunohistochemisty and RNA in situ hybridization, both of which offer the additional advantage of exact lineage identification.

SUSCEPTIBILITY TO ANTIVIRAL AGENTS

The antiviral susceptibilities of HHV-6 and HHV-7 resemble those of CMV. [44] All three viruses lack a thymidine kinase and encode for ganciclovir kinase. HHV-6 and HHV-7 are susceptible to ganciclovir and foscarnet and show minimal susceptibility to acyclovir. At present, these agents are not routinely used in the treatment of HHV-6 or HHV-7. The optimal approach to the prophylactic treatment of transplantation patients has yet to be defined. Ganciclovir should be avoided in patients with marrow suppression, and foscarnet avoided in patients with renal disease. Other drugs with in vitro activity against these viruses include ampligen and kutapressin.

REFERENCES

1. Salahuddin SZ et al: Isolation of a new virus, HBLV, in patients with lymphoproliferative disorders. *Science* **234**:596, 1986

2. Lusso P et al: In vitro cellular tropism of human B-lymphotropic virus (human herpesvirus-6). *J Exp Med* **167**:1659, 1988

3. Downing RG et al: Isolation of human lymphotropic herpesviruses from Uganda. *Lancet* **2**:390, 1987

4. Frenkel N et al: Isolation of a new herpesvirus from human CD4+ T cells. *Proc Natl Acad Sci U S A* **87**:748, 1990

5. Takahashi K et al: Human herpesvirus 6 and exanthem subitum. *Lancet* **1**:1463, 1988

6. Tanaka K et al: Human herpesvirus 7: Another causal agent for roseola (exanthem subitum). *J Pediatr* **125**:1, 1994

7. Dahl H et al: Reactivation of human herpesvirus 6 during pregnancy. *J Infect Dis* **180**:2035, 1999

8. Gompels UA et al: The DNA sequence of human herpesvirus-6: Structure, coding content, and genome evolution. *Virology* **209**:29, 1995

9. Thomson BJ et al: Structure and heterogeneity of the a sequences of human herpesvirus 6 strain variants U1102 and Z29 and identification of human telomeric repeat sequences at the genomic termini. *J Virol* **68**:3007, 1994

10. Berneman ZN et al: Human herpesvirus 7 is a T-lymphotropic virus and is related to, but significantly different from, human herpesvirus 6 and human cytomegalovirus. *Proc Natl Acad Sci U S A* **89**:10552, 1992

11. Thomson BJ et al: Human herpesvirus 6 (HHV-6) is a helper virus for adeno-associated virus type 2 (AAV-2) and the AAV-2 rep gene homologue in HHV-6 can mediate AAV-2 DNA replication and regulate gene expression. *Virology* **204**:304, 1994

12. Araujo JC et al: Human herpesvirus 6A ts suppresses both transformation by H- *ras* and transcription by the H- *ras* and human immunodeficiency virus type 1 promoters. *J Virol* **69**:4933, 1995

13. Ablashi DV et al: Genomic polymorphism, growth properties, and immunologic variations in human herpesvirus-6 isolates. *Virology* **184**:545, 1991

14. Nitsche A et al: Human herpesvirus 6A DNA is detected frequently in plasma but rarely in peripheral blood leukocytes of patients after bone

marrow transplantation. *J Infect Dis* **183**:130, 2001

15. Akhyani N et al: Tissue distribution and variant characterization of human herpesvirus (HHV)-6: Increased prevalence of HHV-6A in patients with multiple sclerosis. *J Infect Dis* **182**:1321, 2000

16. Lopez C et al: Characteristics of human herpesvirus-6. *J Infect Dis* **157**: 1271, 1988

17. Kondo K et al: Latent human herpesvirus 6 infection of human monocytes/macrophages. *J Gen Virol* **72**:1401, 1991

18. Lusso P et al: Productive infection of CD4+ and CD8+ mature human T cell populations and clones by human herpesvirus 6: Transcriptional down-regulation of CD3. *J Immunol* **147**:685, 1991

19. Lusso P et al: Induction of CD4 and susceptibility to HIV-1 infection in human CD8+ T lymphocytes by human herpesvirus 6: *Nature* **349**:533, 1991

20. Lusso P et al: CD4 is a critical component of the receptor for human herpesvirus 7: Interference with human immunodeficiency virus. *Proc Natl Acad Sci U S A* **91**:3872, 1994

21. Jeretic M. Exanthem subitum: A review of 243 cases. *Helv Pediatr Acta* **18**:80, 1963

22. Yamanishi K et al: Identification of human herpesvirus-6 as a causal agent for exanthem subitum. *Lancet* **1**:1065, 1988

23. Asano Y et al: Simultaneous occurrence of human herpesvirus 6 infection and intussusception in three infants. *Pediatr Infect Dis J* **10**:335, 1991

24. Drago F et al: Human herpesvirus 7 in pityriasis rosea. *Lancet* **349**:1367, 1997

25. Challoner PB et al: Plaque-associated expression of human herpesvirus 6 in multiple sclerosis. *Proc Natl Acad Sci U S A* **92**:7440, 1995

26. Kondo K et al: Association of human herpesvirus 6 infection of the central nervous system with recurrence of febrile convulsions. *J Infect Dis* **167**:1197, 1993

27. Torigoe S et al: Clinical manifestations associated with human herpesvirus 7 infection. *Arch Dis Child* **72**:518, 1995

28. Sugaya N et al: Influenza encephalopathy associated with infection with human herpesvirus 6 and/or human herpesvirus 7. *Clin Infect Dis* **34**:461, 2002

29. Corbellino M et al: Disseminated human herpesvirus 6 infection in AIDS. *Lancet* **342**:1242, 1993

30. Knox KK, Carrigan DR. Active human herpesvirus (HHV-6) infection of the central nervous system in patients with AIDS. *J Acquir Immune Defic Syndr Hum Retrovirol* **9**:69, 1995

31. Clark DA et al: The seroepidemiology of human herpesvirus-6 (HHV-6) from a case-control study of leukaemia and lymphoma. *Int J Cancer* **45**: 829, 1990

32. Jarrett RF et al: Identification of human herpesvirus 6–specific DNA sequences in two patients with non–Hodgkin's lymphoma. *Leukemia* **2**:496, 1988

33. Leahy MA et al: Human herpesvirus 6 is present in lesions of Langerhans cell histiocytosis. *J Invest Dermatol* **101**:642, 1993

34. Bovenzi P et al: Human herpesvirus 6 (variant A) in Kaposi's sarcoma. *Lancet* **341**:1288, 1993

35. Chen M et al: Detection of human herpesvirus 6 and human papillomavirus 16 in cervical carcinoma. *Am J Pathol* **145**:1509, 1994

36. Luppi M et al: Frequent detection of human herpesvirus-6 sequences by polymerase chain reaction in paraffin-embedded lymph nodes from patients with angioimmunoblastic lymphadenopathy and angioimmunoblastic lymphadenopathy-like lymphoma. *Leuk Res* **17**:1003, 1993

37. Razzaque A. Oncogenic potential of human herpesvirus-6 DNA. *Oncogene* **5**:1365, 1990

38. Carrigan DR, Knox KK: Human herpesvirus 6 (HHV-6) isolation from bone marrow: HHV-6–associated bone marrow suppression in bone marrow transplant patients. *Blood* **84**:3307, 1994

39. Carrigan DR et al: Interstitial pneumonitis associated with human herpesvirus-6 infection after marrow transplantation. *Lancet* **338**:147, 1991

40. Qavi HB et al: Demonstration of HIV-1 and HHV-6 in AIDS-associated retinitis. *Curr Eye Res* **8**:379, 1989

41. Razonable RR et al: Selective reactivation of human herpesvirus 6 variant A occurs in critically ill immunocompetent hosts. *J Infect Dis* **185**:110, 2002

42. Descamps V et al: Association of human herpesvirus 6 infection with drug reaction with eosinophilia and systemic symptoms. *Arch Dermatol* **137**:301, 2001

43. Secchiero P et al: Quantitative PCR for human herpesviruses 6 and 7. *J Clin Microbiol* **33**:2124, 1995

44. Burns WH: Sandford GR: Susceptibility of human herpesvirus 6 to antivirals in vitro. *J Infect Dis* **162**:634, 1990

T>

Chapter 219

Vincent Fulginiti

Smallpox and Complications of Smallpox Vaccination

SMALLPOX (VARIOLA)
Historical Aspects
Epidemiology
Etiology and Pathogenesis
Clinical Manifestations
Pathology
Diagnosis and Differential Diagnosis
Treatment
Course and Prognosis
Bioterrorism with Smallpox
COMPLICATIONS OF SMALLPOX VACCINATION (VACCINIA)*
Definition and Classification
Historical Aspects
Epidemiology
Etiology and Pathogenesis
Clinical Manifestations
Laboratory Findings
Treatment
Course and Prognosis

SUGGESTED READINGS
Smallpox (Variola)
Complications of Smallpox Vaccination (Vaccinia)

SMALLPOX (VARIOLA)

Smallpox is an acute exanthematous disease caused by infection with poxvirus variolae. The significant clinical features include a 3-day prodromal illness and a generalized centrifugal rash with rapidly successive papules, vesicles, pustules, umbilication, and crusting within 14 days. Although the worldwide eradication of smallpox was officially announced in 1979, it is too soon to give up discussion of this disease in medical texts, and it is treated here as though it still existed. Recent concern about the use of smallpox as an agent of bioterrorism reinforces the thought that the disease cannot be ignored. In addition, many nations are preparing for large-scale vaccinations, furthering the need to enhance professional knowledge of the disease and the vaccine.

Historical Aspects

The first clinical description of smallpox was by Rhazes, an Arabian physician, in the tenth century A.D. Many curious beliefs concerning the cause and pathogenesis of the disease are recorded in the writings of the early physicians. Frequently smallpox was confused with chickenpox, syphilis, and measles. It is of interest that smallpox was known in China 11 centuries before the birth of Christ, and that inoculation to prevent the disease was described in the sixth century B.C., using dried crusts introduced into the nose. It is likely that smallpox was introduced into the Western world in the early centuries after Christ by the migrations of invading armies. Subsequent spread of the disease in Europe and England is intertwined with the history of these areas. As one reads the various accounts of epidemics of this disease in the fifteenth and sixteenth centuries, and later in the United States, it becomes apparent that smallpox represented a major force in life, often affecting dynasties, determining the outcome of military conflicts, as well as influencing daily life. Until the advent of Jennerian vaccination, its widespread application, and the ultimate eradication of smallpox, this disease continued to be a major threat, with widespread attack rates, persistent infection within a community, and a high mortality rate.

Epidemiology

In the past 25 years, a remarkable event occurred in public health. The efforts of many countries, coordinated by the World Health Organization (WHO), resulted in intensive case finding and application of smallpox vaccination across large populations. This resulted in the eradication of smallpox, and there have been no cases anywhere in the world since October 1977. Monkeypox, mainly in central Africa, affects human with lesions resembling variola, has a case fatality rate less than 1 percent, and has not taken over smallpox' ecologic niche.

After the eradication of the disease, smallpox virus (variola) was supposed to be limited to two laboratories (USSR and US) by the WHO. It now appears that several countries possess the virus, including some with potential terrorist relationships.

Etiology and Pathogenesis

Smallpox is caused by infection with poxvirus variola. The entire DNA genome of the virus has been analyzed, and many of the viral proteins have been sequenced. Many of these share identity with the major gene products of the vaccinia virus. It is believed that infection occurs strictly following contact with another infected human being. Evidence suggests

respiratory transmission, and the epidemiologic pattern supports this concept. Skin inoculation and fomite spread may also play a role in some instances.

Following contact, there is an asymptomatic period of 12 to 13 days. Despite the lack of symptoms, viral replication is massive. The pathogenic events that occur in the human being are suggested by analogy with Jenner's experimental mousepox infection. The virus, following introduction via the respiratory tract, undergoes local multiplication in the respiratory mucosa and regional lymphoid tissue. Primary viremia, which spreads the virus widely throughout the reticuloendothelial system, occurs where a massive multiplication occurs. A secondary viremia heralds the onset of the prodromal illness, resulting in spread to many organs and tissues, with primary manifestations in the skin. It has been postulated that serum antibody is not the significant factor in recovery from initial episodes of smallpox, and it appears likely that both delayed hypersensitivity and interferon production play some role in such recovery. Hemorrhagic forms of the disease are of interest in that a profound coagulation disorder is associated with a decrease in the number of serum platelets. Evidence indicates that depression of platelet formation occurs routinely in smallpox infection and that the hemorrhagic forms of the disease bear some similarity to disseminated intravascular coagulation, which results in reduction in coagulation factors, extensive hemorrhage, and death.

Clinical Manifestations

HISTORY An influenzal illness occurring shortly after contact has been described ("illness of contact"). Prior vaccination history and interval to symptoms are important, as the disease pattern may be altered. Prior to the onset of the typical cutaneous lesions, a prodromal period of 3 days' duration occurs, characterized by apprehension, sudden prostrating fever, severe headache, back pain, and vomiting. A prodromal rash is not uncommon; it is macular and papular or petechial, and when it occurs in the characteristic "swimming-trunk" distribution, it is felt to be pathognomonic. The patient is not infectious during the prodrome until an enanthem appears.
CUTANEOUS LESIONS The disease may take various courses. In the nonvaccinated person, a discrete pox eruption is the most frequent form of illness. Severe forms of the disease are associated with confluent eruptions and/or cutaneous hemorrhage. Infrequently, variola may occur without eruption, or with just a few pocks. A flat erythematous macular rash may precede the appearance of tense, deep-seated papules that rapidly vesiculate. These lesions are firm and more deep-seated than those of chickenpox. The rash may be very sparse, or individual vesicles may become confluent to form large patches. As the lesions mature, the classic "pustule" occurs (Fig. 219-1). These lesions do not contain bacteria, and the cloudiness represents accumulated white blood cells, debris, and protein. Central umbilication is characteristic (Fig. 219-1 and Fig. 219-2), and eventually the lesion crusts over and heals, with scar formation. Although this is the classic evolution of smallpox, many variants are encountered, especially in individuals previously vaccinated. Lesions may present a flat disklike appearance, or may undergo resolution without passing through the vesiculopustular stage.

FIGURE 219-1 *A.* Pustular smallpox: tense, clouded vesicles which maintain a firm feel. *B* and *C.* Note tendency to confluence and beginning central umbilication in some lesions.

FIGURE 219-2 Confluent smallpox. Note massive numbers of lesions, all in same stage of development, and confluency of many.

There are two recognized hemorrhagic forms of the disease: one in which hemorrhage occurs in association with prodromal symptoms but death supervenes before any of the characteristic skin lesions can occur; and a second, characterized by hemorrhage into preexisting skin lesions. Both have almost universally fatal outcomes, the first within a week and the second after 8 to 12 days. Bacterial infection of smallpox lesions occurs, and localized abscesses, cellulitis, and the like may result.
OTHER PHYSICAL FINDINGS Secondary viremia with spread to many organs may result in clinically apparent illness. Particularly common are ulceration of the cornea, laryngeal lesions with symptoms of obstruction in the upper part of the airway, central nervous system involvement with encephalitis or acute psychotic behavior, and, less commonly, osteomyelitis, pneumonia, and orchitis.
LABORATORY FINDINGS Usual diagnostic laboratory measurements are of little value in smallpox. The white blood cell

count may be elevated early in the disease, but this is not of diagnostic significance. Virus is present in the blood of patients during the prodrome and occasionally thereafter. Virus is uniformly found in the skin lesions; the early papules and vesicles provide the richest source. In hemorrhagic forms of the disease, severe thrombocytopenia occurs; in addition, marked decrease in the level of accelerator globulin (factor V), moderate decreases in the amount of prothrombin and proconvertin, and a circulating antithrombin are noted in early hemorrhagic smallpox. The late hemorrhagic form of the disease is associated with a decrease in platelets without other coagulation disturbances.

Pathology

In the papular stage of the eruption, capillary dilatation and edema of the papillary layer of the dermis are observed. Perivascular inflammatory changes occur, with lymphocytic and histiocytic infiltration. Thickening and vacuolization in the epithelium result in vesicle formation. The vesicle is deep and, because of the destruction of cells, becomes separate. Leukocyte infiltration results in the “pustule formation” which resolves by epithelial migration and crusting. Typical cytoplasmic eosinophilic inclusion bodies have been described (Guarnieri's bodies). Histopathologic changes in the mucosa are similar, with added ulceration.

Diagnosis and Differential Diagnosis

Typical smallpox in endemic areas could usually be diagnosed clinically, and ancillary virologic laboratory aids were usually unnecessary. However, now that smallpox has been eradicated worldwide, if a case arose, it would probably be confused with severe chickenpox or not suspected at all. For this reason virologic diagnosis would be essential, with confirmation of variola having global public health implications. Rapid means of laboratory diagnosis include (1) polymerase chain reaction (PCR) detection of antigen in clinical specimens, (2) electron microscopic identification of virus in vesicular fluid or scrapings from the base of a papule or early vesicle, and (3) fluorescent antibody staining of the virus from the same material. All these tests yield rapid, presumptive results in the hands of experienced workers, but definite diagnosis can be achieved only by isolation of the virus in appropriate tissue culture systems and specific identification of the virus by neutralization with variola antiserum. Retrospective diagnosis can be afforded by evaluation of serum antibody rises in a 2- to 3-week interval, using paired sera collected during the acute and convalescent phases of the illness.

In summary, the diagnosis of smallpox is primarily clinical and based upon obtaining an adequate history of exposure, the observation of an approximately 2-week incubation period followed by a severe 3-day prodrome, ultimately terminating in a typical rash with centrifugal distribution and all lesions in the same stage of development. One cannot rely on the presence of Guarnieri's bodies to establish the diagnosis, although they may be suggestive.

In the preeruptive phase of smallpox, distinction must be made from dengue, enterovirus infections, and other febrile illnesses. The prodromal rash may be confused with that of measles. History of contact and the appropriate incubation interval should serve to make one suspect smallpox.

Hemorrhagic smallpox may be confused with meningococcal septicemia, coagulation disorders, typhus, and other acute hemorrhagic exanthems. Eruptive smallpox is most frequently mistaken for chickenpox. The lack of prodromal symptoms, the successive appearance of crops of superficial vesicles, the centripetal distribution, and the varying stages of development of chickenpox lesions all serve to distinguish this disease from variola.

Treatment

This disease has been prevented by Jennerian vaccination, but no effective specific treatment is known. Thiosemicarbazone and antivariola or antivaccinia serum and immune globulin failed in the therapy of established smallpox. Cidofovir has shown promise in early in vitro and animal studies.

Good nursing care with attention to the prevention of secondary bacterial infection is critical in treatment. Appropriate antimicrobial therapy for bacterial complications should be employed, and attention should be paid to the nutritional, fluid, and electrolyte needs of patients.

Course and Prognosis

The overall mortality rate of smallpox approximates 30 percent, with confluent disease representing a greater risk than discrete eruptions. Fulminant smallpox is universally fatal, as are the hemorrhagic forms of the illness.

Bioterrorism with Smallpox

Smallpox has been used as a biologic weapon at least since the time of the French and Indian Wars (1754–1767), when blankets of smallpox victims were distributed to the American Indians. The high case fatality rate, the high frequency of secondary spread, and the absence of routine vaccinations for smallpox since 1972 all contribute to the concern about this agent in bioterrorism. In 1998, 42 percent of the US population, 114 million people, had not been vaccinated. It was possible to vaccinate more than 6 million people in New York City in 1947. The last vaccine in the United States was manufactured in the 1970s and has been stored at the Centers for Disease Control and Prevention and at Aventis laboratories in France. Recent studies have shown (1) potency is maintained; (2) a 1/5 dilution is effective, and (3) a new diluent is needed and is being manufactured. Tissue culture vaccine is currently being manufactured and tested.

COMPLICATIONS OF SMALLPOX VACCINATION (VACCINIA)*

Definition and Classification

Vaccination against smallpox consists of the introduction of vaccinia virus into the outer layers of the intact skin. Local multiplication of virus occurs, and in some instances, regional lymphadenopathy and systemic symptoms ensue. The infection is a localized one that heals by scarring and is limited by host response. A complicated vaccination is one in which any of the above components is altered. Complications may be classified as indicated in Table 219-1.

Major Categories	Specific Syndromes	Comment
Noninfectious rashes	Erythema multiforme	Differentiate from generalized
	Macular—toxic eruption	
	Macular and papular	
	Vesicular	
	Urticarial	
Bacterial superinfection	Streptococcal	Often hyperkeratotic
	Staphylococcal	
	Mixed	
Accidental inoculation (may occur in vaccinated individual)	Normal skin	
	Abnormal skin	
	Burns	
	Pyoderma	
	Exanthem	Examples: varicella, herpes
	Eczema	
	Other dermatides:	
	Mucosal	Usually oral or conjunctival
	Corneal	Vaccinal keratitis
Congenital vaccinia		
Generalized vaccinia	Benign	
Progressive vaccinia (vaccinia gangrenosa, vaccinia necrosum)	In immunologically normal persons	
	In hypogammaglobulinemia:	
	Congenital sex-linked	
	thymic alymphoplasia	
	In dysgammaglobulinemia	
	With malignancies:	
	Chronic lymphatic leukemia	
	Hodgkin's disease	
	Lymphoma	
Encephalitis	Postvaccinal	
Miscellaneous	Hemolytic anemia	Unproven
	Arthritis	
	Osteomyelitis	
	Laboratory infections	
	Pericarditis and myocarditis	

TABLE 219-1 **Classification of Complications of Vaccination**

The vaccinia virus is now being used as a vector to express other genes in mammalian cells, including potential vaccines against other diseases.

Historical Aspects

With the eradication of smallpox in the world, the routine application of infant vaccination has been greatly diminished. As a result, complications of vaccinations are seen infrequently in most countries, and not at all in many countries. However, recent concerns with bioterrorism have brought many of these questions back into the concerns of medical decision makers.

Epidemiology

Most complications could occur at any age, but they were usually seen among young infants and children. Primovaccination was most often administered to this age group, and almost all the significant complications occurred most frequently, if not exclusively, after first vaccination. In addition, the infectious complications tended to occur in the immunologically deficient child, which also contributed to the clustering in early childhood. Bacterial superinfection in some instances was related to warm weather, with the opportunity for maceration of skin and with increased exposure of the vaccination site.

Complications were reported more commonly in the Western world, despite the prevalence of vaccination in the east. This undoubtedly represented reporting differences, not a true geographic or racial relationship. The incidence of postvaccinal encephalitis appeared to be higher in the Netherlands. Whether this represented a true racial difference or simply reflected the fact of primovaccination in the adults was not clear.

Etiology and Pathogenesis

The basic mechanisms of the complications of vaccination can be divided into three categories: (1) bacterial superinfection, (2) abnormal viral replication, and (3) altered reactivity, or “allergy,” to some viral component.

Bacteria can invade the vaccination site; indeed, not all vaccine is bacteriologically sterile. That superinfection is not more common is remarkable. Apparently more than contamination is necessary; those factors of greatest importance are concurrent streptococcal infection elsewhere and excessive trauma, maceration, and manipulation of the vaccination site.

Usually the virus remains localized at the site of implantation, but occasionally infection may be transposed to healthy or unhealthy skin elsewhere on the body, or even to another person. Etiologic factors include excessive manipulation, abnormal skin (burns, atopic dermatitis, etc.), inflammatory lesions (blepharitis, herpes), and abnormal immune mechanisms. Any of these may contribute to spread of the virus away from the intended localized vaccination site.

Among the host factors responsible for limitation of viral spread and recovery from vaccination are development of serum antibody, delayed hypersensitivity, and interferon production. Serum antibody and delayed hypersensitivity are specific and are induced soon after infection; antibody appears to be less important in recovery than delayed hypersensitivity. Interferon is nonspecific and has been found in the skin of animals recovering from vaccinia infection who have been rendered deficient in antibodies and in delayed hypersensitivity. It has also been found in human vaccination crusts. Individuals who lack antibody-synthesizing capacity may develop progressive and widespread vaccinal lesions. However, even these patients, if they retain delayed-hypersensitivity responsiveness, may undergo perfectly normal vaccinations. In addition, patients with normal antibody levels, but with absent delayed-hypersensitivity responsiveness, are susceptible to the progressive form of the disease. As indicated, interferon is also important and may account for recovery of animals in the absence of the other two functions. However, data for human beings are lacking, and the

importance of this mechanism of resistance is not known.

Allergy, or presumed altered reactivity, to viral components appears to be responsible for the erythema multiforme type of skin rash observed in some individuals after primovaccination. This mechanism has also been implicated in the pathogenesis of postvaccinal encephalitis; it is assumed the virus or a virus–central nervous system complex invokes an immune response directed against brain antigens, which then results in an antigen–antibody inflammatory reaction and the clinical picture of encephalitis.

Clinical Manifestations

ERYTHEMA MULTIFORME–LIKE ERUPTIONS An intensely erythematous macular rash may follow smallpox vaccination. This rash has the characteristics of erythema multiforme in that iris or bull's-eye lesions appear and tend to coalesce. The rash is often symmetric and florid, involving a large portion of the body. This is a totally benign manifestation representing an allergic reaction.
BACTERIAL SUPERINFECTION Purulent complications of smallpox vaccination involve principally impetiginous infection with *Staphylococcus aureus* or group A beta-hemolytic streptococci. When poultices were employed, tetanus could be introduced by the soil or dung elements incorporated in such primitive techniques.
ACCIDENTAL INOCULATION Vaccinia virus can be implanted from the site of vaccination onto the skin or mucous membrane anywhere on the individual's body. The virus can also be transferred to another individual. Each of the lesions is characteristic of a primary smallpox vaccination except they do not tend to scar. Certain implantations may be more hazardous than the occasional single-site inoculation. These include implantation onto large areas of abnormal skin (burns or other dermatoses), into the eye (vaccinal keratitis may result), extensive mucosal lesions, and implantation around various body orifices which may impede certain bodily functions (Fig. 219-3). A recombinant vaccine caused severe but limited vaccinial lesions in a pregnant woman who had epidermolytic hyperkeratosis.

FIGURE 219-3 Eczema vaccinatum. Lesions are in areas of active eczema. Note typical vaccinal character of individual lesions.

CONGENITAL VACCINIA Vaccination of the pregnant woman, especially in the third trimester, may result in disseminated disease fatal to the fetus. Congenital vaccinia may also occur. The infant may be stillborn or may develop lesions shortly after birth.
GENERALIZED VACCINIA Generalized vaccinia as used in this classification refers to a benign generalized eruption, each lesion of which is identical to its primary smallpox vaccination. Although little is known of the immunology surrounding such a defect, it is clear that some children with isolated IgM deficiency are liable to this complication. Lesions tend to heal rapidly. Occasionally, there may be recurrent crops of lesions.
PROGRESSIVE VACCINIA (VACCINIA GANGRENOSA, VACCINIA NECROSUM) If a smallpox vaccination shows no evidence of normal resolution within 2 weeks of inoculation, a presumptive diagnosis of progressive vaccinia should be made. In this disease, the normal immunologic response to vaccination is impaired. This may occur in an otherwise normal individual or in persons with generalized defects in immunologic capacities. In its complete form, the site of vaccination fails to heal and continues to enlarge, often for months. Usually, no systemic signs of illness are present and, in the absence of some other disease, physical findings are limited to the vaccination. These lesions differ from normal ones in that little inflammatory response is observed. The vaccination initially has a soft, rubbery appearance with little scabbing (Fig. 219-4). As the lesion progresses in size, considerable central necrosis becomes evident, and thick, dark eschars form (hence the synonym *vaccinia necrosum*). The initial lesion may become huge, with the entire upper arm and shoulder involved. In many cases, secondary lesions are evident; in some cases, satellite vaccinations occur close to the primary one, and, in addition, viremic lesions may appear at distant sites. Each of the secondary lesions progresses in the same fashion as the primary one (Fig. 219-5). Variations are observed in that the primary lesion may become ulcerative or may have a piled-up appearance, but the progression is characteristic.

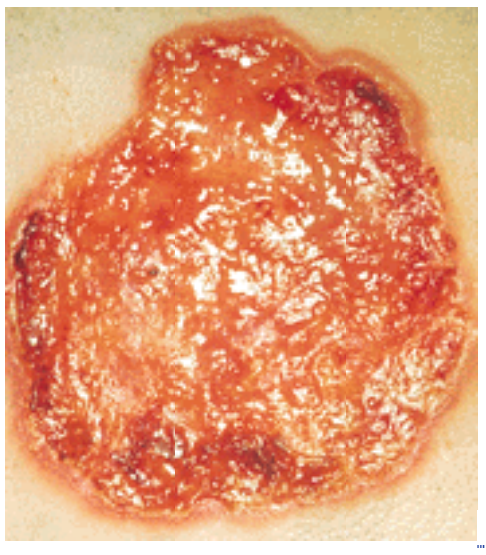
FIGURE 219-4 Progressive vaccinia: large, nonhealing vaccination site with “soft, rubbery” border, high virus content, and lack of surrounding inflammatory response; present 4 months in 10-month-old male with variant of thymic alymphoplasia.

FIGURE 219-5 Secondary viremic lesions in progressive vaccinia. Two lesions on arm, which demonstrate variability, both positive for vaccinia virus, occurred in an elderly female with chronic lymphatic leukemia; complete clearing with thiosemicarbazone therapy.

Untreated disease or illness failing to respond to treatment may be of long duration, during which extensive tissue destruction, secondary bacterial infection and septicemia, mucosal lesions, pneumonia, and other complications may occur. The course is progressively downhill, although the patient may not manifest correspondingly severe constitutional symptoms until relatively late in the disease.
ENCEPHALITIS A meningoencephalitis syndrome occurs rarely as a complication of smallpox vaccination. The sudden onset of headache and vomiting in the second week after vaccination may herald this illness. Convulsions, lethargy, coma, paralysis, signs of cerebral edema, increased intracranial pressure, and focal neurologic findings may occur. In other instances, the disease may resemble aseptic meningitis or myelitis.

Laboratory Findings

VIROLOGIC Specimens from suspected vaccinal lesions can be inoculated into a variety of tissue culture systems. Identification is by typical pock formation or by classic cytopathogenic effect with subsequent neutralization by antisera. Additionally, specific vaccinia antigen can be detected by a variety of methods from specimens obtained from lesions.
IMMUNOLOGIC AND HEMATOLOGIC Response to vaccinia virus may be critical in determining host susceptibility. Vaccinia-neutralizing antibody can be measured, as can a delayed-hypersensitivity reaction. In certain clinical states, total immunologic capacity may need to be surveyed, as the vaccinal infection is simply an indicator of a more comprehensive immunologic defect. Assays for immunoglobulin antibody capacity and for cell-mediated immune function may need to be employed.

Treatment

Complications of vaccination can be reduced by recognizing those predisposing conditions that lead to each of the separate types of complication. Thus, individuals who have eczema or other skin lesions should not be vaccinated or exposed to an individual who is vaccinated. Individuals with immunologic deficiency, receiving immunosuppressive therapy, or suffering from diseases such as lymphatic malignancies that heighten susceptibility should avoid contact with vaccinia virus and should not be vaccinated. If such individuals are exposed, use of either vaccinia immune globulin by injection or methisazone (isatin thiosemicarbazone) reduces the risk.

In the past, administration of vaccinia immune globulin (VIG) for complications of vaccination has been utilized. Some VIG for intramuscular use is stored at the CDC. New lots of VIG, compatible with intravenous or intramuscular administration, are being produced. Children with erythema multiforme or simple autoinoculation disease and vaccinal encephalitis should not receive this preparation as it is of no benefit. On the other hand, those with extensive intradermal involvement such as eczema vaccinatum or burns should be treated with VIG. VIG should be used in conjunction with immunologic therapy in those severe complications such as progressive vaccinia. Early in vitro and animal studies with cidofovir show promise in treating vaccinia infections.

In vaccinia keratis, topical antivirals are the preferred method of treatment. VIG should be avoided because of the potential of increased scarring.

Course and Prognosis

As indicated in the separate sections, prognosis is variable. Most complications are self-limited or respond to simple measures; a few require extraordinary forms of therapy, and even with such treatment a small group remains who are unresponsive.

---

*For more details and up-to-date information, consult http://www.bt.cdc.gov/training/smallpoxvaccine/reactions

SUGGESTED READINGS

Smallpox (Variola)

Albert MR et al: The last smallpox epidemic in Boston and the vaccination controversy, 1901–1903. *N Engl J Med* **344**:375, 2001

Bauer DJ et al: Prophylactic treatment of smallpox contacts with *N*-methylisatin ß-thiosemicarbazone. *Lancet* **2**:494, 1963

Bremen JG, Arita I: The confirmation and maintenance of smallpox eradication. *N Engl J Med* **303**:1263, 1980

Breman JG Henderson DA: Poxvirus dilemmas—Monkeypox, smallpox, and biologic terrorism. *N Engl J Med* **339**:556, 1998

Dixon CW: *Smallpox*. London, Churchill, 1962

Downie AW: Smallpox, in *Medical History of the Second World War,* edited by Z Cope. London, HM Stationery Office, 1952

Downie AW, MacDonald A: Smallpox and related virus infections in man. *Br Med Bull* **9**:191, 1953

Downie AW et al: Studies on the virus content of mouth washings in the acute phase of smallpox. *Bull World Health Organ* **25**:49, 1961

Fenner F: Global eradication of smallpox. *Rev Infect Dis* **4**:916, 1982

Henderson DA et al: Smallpox as a biological weapon: Medical and public health management. Working Group on Civilian Biodefense. *JAMA* **281**:2127, 1999

Kempe CH et al: The use of vaccinia hyperimmune gamma globulin in the prophylaxis of smallpox. *Bull World Health Organ* **25**:41, 1961

Massung RF et al: Analysis of the complete genome of smallpox variola major virus strain Bangladesh 1975. *Virology* **201**:215, 1994

Rao AR et al: A study of 1,000 cases of smallpox. *J Indian Med Assoc* **35**:296, 1960

Wehrle P: A reality in our time—Certification of the global eradication of smallpox. *J Infect Dis* **242**:636, 1980

WHO Expert Committee on Smallpox: *WHO Tech Rep Ser* **283**:1, 1964

Complications of Smallpox Vaccination (Vaccinia)

Adels BR, Oppe TE: Treatment of eczema vaccinatum with *N*-methylisatin beta-thiosemicarbazone. *Lancet* **1**:18, 1966

Barbero GT et al: Vaccinia gangrenosa treated with hyperimmune vaccinal gamma globulin. *Pediatrics* **16**:609, 1955

Daly JJ, Jackson E: Vaccinia gangrenosa treated with *N*-methylisatin ß-thiosemicarbazone. *Br Med J* **2**:1300, 1962

Davidson E, Hayhoe FG: Prolonged generalized vaccinia complicating acute leukemia. *Br Med J* **2**:1298, 1962

Dimson SB: Eczema vaccinatum. *Lancet* **2**:73, 1962

Ellis PP, Wenograd L: Ocular vaccinia. *Arch Ophthalmol* **68**:600, 1962

Flewitt TH, Ker FL: A case of vaccinia necrosum (progressive vaccinia) with severe hypogammaglobulinemia, treated with *N*-methylisatin ß-thiosemicarbazone (33T57). *J Clin Pathol* **16**:271, 1963

Fulginiti VA, Kempe CH: Poxvirus diseases, in *Brennemann's Practice of Pediatrics,* vol II, part 1, edited by V Kelley. Hagerstown, MD, Harper & Row, 1968, p 1

Fulginiti VA et al: Therapy of experimental vaccinal keratitis. *Arch Ophthalmol* **74**:539, 1965

Greenberg M: Complications of vaccination against smallpox. *Am J Dis Child* **76**:492, 1948

Kaufman H et al: A cure of vaccinia infection by 5-iodo-2'-deoxyuridine. *Virology* **18**:567, 1962

Kempe CH: Studies on smallpox and complications of smallpox vaccination. *Pediatrics* **26**:176, 1960

Kempe CH, Benenson AS: Smallpox immunization in the United States. *JAMA* **194**:161, 1965

Kempe CH et al: Hyperimmune vaccinal gamma globulin. *Pediatrics* **18**:177, 1956

Moss B: Genetically engineered poxviruses for recombinant gene expression, vaccination, and safety. *Proc Natl Acad Sci U S A* **93**:11341, 1996

Naidoo P, Hirsch H: Prenatal vaccinia. *Lancet* **1**:196, 1963

Nanning W: Prophylactic effect of antivaccinia gamma globulin against postvaccinal encephalitis. *Bull World Health Organ* **27**:317, 1962

Neff JM: Smallpox vaccination: Minimal complication rates, United States, 1963. Presentation at Annual Epidemiologic Intelligence Service, Communicable Disease Center, April 1965

O'Connel CJ et al: Progressive vaccinia with normal antibodies: A case possibly due to deficient cellular immunity. *Ann Intern Med* **60**:282, 1964

Rupprecht C et al: Human infection due to recombinant vaccinia—Rabies glycoprotein virus. *N Engl J Med* **345**:582, 2001

Sathe PV et al: Prevention of postvaccinal tetanus. *Indian J Pediatr* **31**:306, 1965

Spillane JD, Wells CEC: The neurology of Jennerian vaccination: A clinical account of the neurological complications which occurred during the smallpox epidemic in South Wales in 1962. *Brain* **87**:1, 1964

Sussman S, Grossman M: Complications of smallpox vaccination. Effects of vaccinia immune globulin therapy. *J Pediatr* **67**:1168, 1965

Wielenga G et al: Prenatal infection with vaccinia virus. *Lancet* **1**:258, 1961

T>

Chapter 220

Renee Snyder Dayna Diven

Orf (Contagious Pustular Dermatitis, Contagious Ecthyma)

EPIDEMIOLOGY AND ETIOLOGY
IMMUNE AND INFLAMMATORY RESPONSE
MOLECULAR ANATOMY OF ORF VIRUS
VIRULENCE PROTEINS
CLINICAL MANIFESTATIONS
PATHOLOGY
DIAGNOSIS
TREATMENT

REFERENCES

Orf is a self-limited exanthematic dermatitis caused by a viral infection that is typically seen on the hands of people handling infected animals. The word “orf” is derived from the Anglo-Saxon name for cattle. [1] In 1937, George Peterkin reported the occurrence of orf in humans from contagious pustular dermatitis in sheep. [2] References to the disease date back to the 1520s. The clergy knew of orf as Pope Leo X referred to Martin Luther, founder of the reformation, as a “scabby sheep” infecting “the flock.”. [1]

The agent that causes this contagious pustular dermatitis is a worldwide, zoonotic, epitheliotropic, double-stranded DNA poxvirus of the genus parapoxvirus (PPV). Parapoxvirus ovis (PPOV) causes orf, which is also referred to as ecthyma contagiosum, scabby mouth, sore mouth, contagious pustular dermatitis, or infectious pustular dermatitis. In animals, it is typically located around the commissures of the lips and nostrils of infected sheep and goats, [3] and on the teats of ewes suckling young. [4] The cutaneous and pathologic features of human and ovine orf virus lesions are similar, and in both hosts, infection is confined to the epidermis, with no evidence of systemic spread. [5] Primary lesions generally resolve in 6 weeks. [6]

EPIDEMIOLOGY AND ETIOLOGY

Orf is prevalent worldwide wherever sheep and goats are raised; consequently, it is not uncommon in farming communities. Age and race are not factors for human infection. The disease is most common in kids and lambs 3 to 6 months of age and is seen during the spring, when newborn lambs that lack immunity fall prey to the disease. [7], [8] Infection of older susceptible animals has proven that orf virus can be carried by adult animals either in subclinical lesions or as true persistent infections, which can be exacerbated by the stress of handling and transportation. [9] Susceptible lambs become infected from contact with virus-containing objects such as saliva, lesions and crusts of afflicted animals or fomites (i.e., barn doors, wire fencing, feeding troughs, shears, and bottles). [8], [10] Notably, the virus remains infective on fomites for years at room temperature. It is able to survive heating and drying and is resistant to lipid solvents such as ether and chloroform. [11] The disease is associated with a high morbidity but low mortality rate. Orf is also found in goats, camels, bighorn sheep, reindeer, mountain goats, gazelles, wild sheep, and rams. [9], [12] Transmission to humans occurs via a bite or contact with virus-containing objects into traumatized skin; overt clinical signs of orf virus infection are not a requirement for the spread of virus to man. [9] It can also be transmitted by accidental inoculation with orf vaccines and from infected carcasses. [13] As a zoonosis, orf is a recognized occupational hazard for abattoir workers, farmers, veterinary surgeons and farmers who bottle-feed sheep. [6], [9], [13] Only three cases of human-to-human spread have been reported worldwide. [14]

The true incidence of human orf is unknown. The farming community is so familiar with the disease that it tends not to seek medical attention. This may be a result of the spontaneous healing of the lesion, a lack of effective treatment, or that most attacks occur during the spring, which is the busiest time of the farming year. [13], [15]

Live unattenuated virus from scab material and attenuated orf virus strains have been used for vaccination. In one study, scarification of sheep with the D1701 attenuated orf virus strain caused only mild skin lesions while it induced immunity against orf virus infection that lasted 4 to 6 months. [16] This vaccination is successful in reducing the severity of disease but the lesions induced add to the environmental load of disease-causing virus. [17] It is unlikely that any orf vaccine will be able to stimulate full immunity to reinfection, as wild-type strains of orf virus contain virulence genes [6] (discussed below). In prevention of human infection it may be more prudent to focus on usage of personal protective equipment, such as protective gloves when feeding sheep, and isolating infected animals.

IMMUNE AND INFLAMMATORY RESPONSE

In sheep, primary lesions of orf can be severe and proliferative, taking 4 to 6 weeks to resolve. Reinfection lesions, seen in annual outbreaks of infected flocks, are less severe and resolve faster, usually within 2 weeks. This indicates that viral replication, and therefore lesion development, is influenced by the host immune response. The immune and inflammatory response to orf virus infection has been experimentally studied in sheep. The cell phenotype and cytokine response in ovine local lymph is vigorous and typical of an antiviral response, involving CD4+ helper and CD8+ cytotoxic T cells, interferons, and antibodies. [6] There is evidence in the literature that the immune response to orf virus infection in humans is similar to that reported in sheep. [18] An unusual feature is the accumulation of major histocompatibility complex (MHC) class II dendritic cells in the skin lesions of sheep. [19] Histologically, human orf lesions are similar to those in sheep,

involving epidermal proliferation with areas of swelling, vacuolation, and angiogenesis. A study has not been performed to determine whether dendritic cells accumulate adjacent to the infected cells in humans as they do in sheep. [19] Host-acquired immunity involving CD4+ T cells and antibody is effective in controlling the extent of viral replication in the skin of infected sheep, but it does not prevent reinfection. [3] The CD45R–T cell subset is the principal cellular source of lymphokines [interleukin (IL)-2, interferon (IFN)-?, and granulocyte-macrophage colony-stimulating factor (GM-CSF)] during reinfection in sheep. [20] In humans, however, despite evidence to the contrary from surveys and experimental inoculation, immunity to orf has been reported to be life-long after a single infection. [15], [18]

A number of immunogenic proteins have been visualized in convalescent sera from infected sheep. [21] Murine monoclonal antibodies recognize the identified structural proteins that include the 39- and 42-kDa envelope proteins, and the 10-kDa putative fusion protein. Uncharacterized 22- and 65-kDa antigens have also been described. These proteins can be used to discriminate between the different parapoxviruses. [21], [22] In spite of a high titer of antibody in the sera of orf virus infected sheep, passive transfer of antibody in colostrum or serum of orf-naÏve lambs does not confer protection to infection. [8]

Viral virulence proteins that aid in evading host immunity include homologues of the gene encoding the cytokine IL-10, the mammalian vascular endothelial growth factor (VEGF) gene, granulocyte-macrophage colony-stimulating factor inhibitor, and the orf virus interferon resistance gene.

MOLECULAR ANATOMY OF ORF VIRUS

Members of the genus Parapoxvirus of the family Poxviridae are grouped into PPV bovis 1 [bovine pustular stomatitis (BPS)], PPV bovis 2 [milker's nodule (MN) or pseudo-cowpox virus] and PPV ovis [orf virus (OV)]. More recently, PPV of red deer in New Zealand has been suggested as a fourth species of the genus. [23], [24] OV is the prototype species of the genetically heterogeneous parapoxvirus genus. [16] PPV can be distinguished from other poxviruses by its distinct virion shape; it is an ovoid particle about 250 nm × 160 nm. [11] The surface tubules of parapoxvirus appear as a twinelike structure, 10 to 20 nm wide, forming a long crisscross design that extends for up to 1 µm in length. [11] Electron microscopic demonstration of orf virus in the scabs effectively confirms the presence of disease [25] and helps to distinguish them from orthopoxviruses. [11] Monoclonal antibodies that recognized the 40- to 43-kDa protein of orf virus were found to react against 45- to 48-kDa proteins present in pseudo-cowpox virus and bovine popular stomatitis virus, two other parapoxviruses. [21]

VIRULENCE PROTEINS

An orf virus virulence protein with immunomodulatory function is the orf virus homologue of the ovine gene encoding the cytokine IL-10 that is suggested to have been captured from its host sheep during the evolution of orf virus. [26] IL-10 is a cytokine that exhibits immunosuppressive activity by inhibiting proinflammatory cytokines [IL-1ß, IL-6, tumor necrosis factor (TNF)-a] and chemokine (IL-8) synthesis in macrophages. These cytokines are responsible for the stimulation, recruitment, and activation of neutrophils, monocytes and lymphocytes at the site of inflammation. [27] IL-10 also inhibits antigen-specific T cell proliferation by downregulating MHC class II molecules on antigen-presenting cells. [27]

A homologue of the mammalian VEGF gene was the first of the orf virus virulence genes to be described. [28] Construction of a recombinant orf virus in which viral VEGF was inactivated proved that viral VEGF is responsible for mitogenesis of vascular endothelial cells, induction of vascular permeability, and activations of VEGF receptor 2. [5] Absence of viral VEGF did not affect virus growth in tissue culture, but resulted in substantially reduced clinical indications of infection in the lesions. However, viral replication in the early stage of infection was not impaired. [5] Data supporting VEGF-like factor promoting angiogenesis also support the view that the VEGF receptor VEGFR-2 is predominantly responsible for the signaling of vascular endothelial cell mitogenesis as well as for the induction of dermal vascularization and epidermal hyperplasia. [5]

A soluble protein inhibitor of ovine granulocyte-macrophage colony-stimulating factor (ovGM-CSF) and ovine interleukin-2 (ovIL-2) are also effective in evading host immunity. IL-2 and IFN-? are implicated in protective immunity to orf virus reinfection. [3] IL-2 is also known to be a T cell growth factor produced by T cells that can activate cytotoxic T cells and natural killer (NK) cells. [27] The role of GM-CSF in orf virus infection is less clear; it is known that GM-CSF stimulates hematopoietic progenitor cells to develop into neutrophils, macrophages, eosinophils, and basophils. In nonhematopoietic tissues, GM-CSF recruits these cells to sites of inflammation and activates them. [6] GM-CSF also regulates antigen presentation by dendritic cells. [29]

The presence of an orf virus interferon resistance gene (OVIFNR) may protect the virus from the antiviral effect of IFNs for long enough to allow at least some viral replication, which suggests the importance of interferons in host resistance to orf virus infection.

CLINICAL MANIFESTATIONS

The cutaneous lesions of orf are usually 2 to 3 cm in diameter and present after an incubation period of 5 to 6 days. [13] Characteristically, lesions evolve through six stages lasting approximately 6 days each. The sequential stages include the clinical progression of a slightly elevated, erythematous papule into a target lesion that presents as a nodule with a white middle ring containing a red center and periphery (Fig. 220-1). The acute weeping stage describes the rapidly growing, elevated phase (Fig. 220-2). The regenerative, dry stage is accompanied by the appearance of black dots over the surface of the nodule. Small papillomas develop over the nodule during this papillomatous stage. During the regressive stage the formation of a dry crust and scab develop with resolution and no resultant scar formation (Table

220-1).

FIGURE 220-1 The target phase shows a white circle with central and peripheral erythema.

FIGURE 220-2 In the acute phase, there is weeping of the surface overlying an elevated tumor.

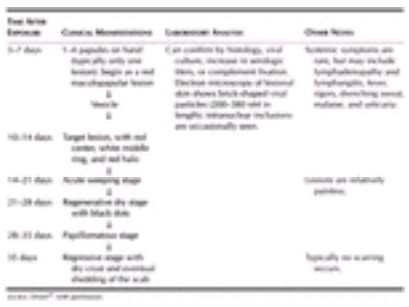

TABLE 220-1 **Clinical Manifestation of Orf**

Accompanying signs that can occur include localized swelling, secondary bacterial infection, lymphangitis, regional lymphadenopathy, and short-lived fever. Other reported complications include 22 cases of secondary erythema multiforme [30] and vesicular eruptions, [31] secondary spread of infection to face and hands associated with active atopic dermatitis, [31] and 5 reported cases of bullous pemphigoid occurring approximately 3 weeks after the lesion. [32]

PATHOLOGY

The first stage, or papular stage, of orf virus infection begins with erythema shortly after infection and coincides with the accumulation of dermal fluid. [5] In the target stage, intranuclear and intracytoplasmic inclusions are present in superficial, vacuolated epidermal cells in areas corresponding to the white ring (Fig. 220-3). There is an accumulation of neutrophils, basophils, dendritic dells, and lymphocytes, including both B and T cells. [33] The acute weeping stage is distinguished by loss of epidermis over the central part of the lesion. Peripherally, there is reticular degeneration and microvesicles are present. There is distention and loss of the epidermal cells of hair follicles followed by regeneration of the epidermis. The black dots observed clinically correspond to an accumulation of cellular breakdown products within the follicles. Many papillary elevations and finger-like downward projections of the epidermis are seen in the papillomatous stage (Fig. 220-4). In the regressive stage, the papillomas are reduced in size, and histiocytes, macrophages, lymphocytes, and plasma cells decrease in number. [10], [11]

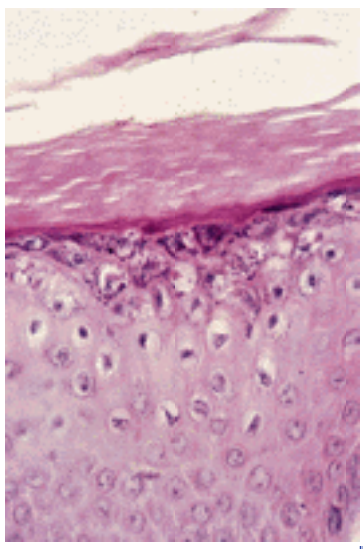

FIGURE 220-3 In the target phase there are superficial vaculated epidermal cells with inclusion bodies.

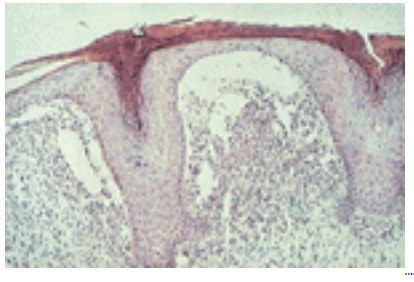

FIGURE 220-4 Later in the target stage there are finger-like projections of the epidermis and a dense inflammatory infiltrate accompanied by massive edema in the papillary body.

The papillomatosis, acanthosis, and the dermal infiltrate are responsible for the size of the growing lesion. These manifestations are consistent with the finding that the VEGF homologue is encoded as an early gene product and is responsible for promoting angiogenesis, and that the receptor VEGFR-2 is predominantly responsible for the signaling of vascular endothelial cell mitogenesis, as well as the induction of both dermal vascularization and epidermal hyperplasia. [5]

Regional lymph node studies in sheep have shown that in the afferent lymph draining infected skin, polymorphonuclear cells, dendritic cells, and lymphocytes and lymphoblasts that are predominantly CD4+ T cells, rather than CD8 T cells or B cells, [20], [34] accumulate. There is also an increase in the production of IFN-a, IFN-?, GM-CSF, IL-1ß, IL-2, and IL-8. [6], [19]

DIAGNOSIS

The self-limited course of the usually solitary lesion can be diagnosed by a careful history and follow-up. A typical evolving skin lesion in a person with a history of contact with sheep or goats is usually sufficient for diagnosis. Orf infection can resemble a pyogenic granuloma, erythema multiforme, cutaneous anthrax, basal or squamous cell carcinomas, or malignant melanoma (Table 220-2). Facial orf lesions particularly may mimic skin tumors. A biopsy can be done if the diagnosis is in question. Laboratory diagnosis can also be made by passage of the virus to cultured sheep cells, fluorescent antibody tests, and electron microscopy, [11] but these are rarely required.

Milker's nodules:	Clinically identical; source of infection is cattle.
Cowpox:	Early lesions of cowpox are similar.
Anthrax:	More hemorrhagic and lesions progresses more rapidly to an eschar.
Tularemia:	Typically, tularemia has systemic symptoms, with high fever, headache, malaise, and myalgias. The skin ulcer is more chancre-like.
Tuberculosis (Primary inoculated):	Most lesions occur in children. A painless shallow ulcer develops and heals poorly.
Mycobacteria infection (atypical):	Lesions often last 1 to 2 years before healing.
Syphilitic chancre:	Lesions typically occur on the genitalia rather than the hand.
Sporotrichosis:	Begins as a single necrotic nodule, but multiple nodules arise in a linear fashion along the lymphatics.
Pyogenic granuloma:	Juicy, red papule that bleeds easily often with an epidermal collarette at the base.
Keratoacanthoma:	Appears as a dome-shaped papule or plaque with a central crater filled with keratin.
Giant molluscum contagiosum:	Lesions do not weep or became necrotic and often appear in clusters.

SOURCE: Dixon[37] with permission.

TABLE 220-2 **Differential Diagnosis of Orf**

TREATMENT

There is no effective treatment for orf. Management is focused on waiting for spontaneous resolution, which typically occurs within 6 weeks with no scarring. Compresses, culture and sensitivity testing, and antibiotics are appropriate measures if secondary bacterial infection occurs. Care must be taken to avoid overtreatment in the form of parenteral antibiotics, primary excision, and cautery, or even repair with a skin graft or flap. The prognosis is excellent.

REFERENCES

1. Bainton RH: *Here I stand. The life of Martin Luther*. New York, Abingdon-Cokesbury Press, 1950

2. Peterkin GAG: The occurrence in humans of contagious pustular dermatitis of sheep (“orf”). *Br J Dermatol* **49**:492, 1933

3. Lloyd JB et al: In vivo T-cell subset depletion suggests that CD4+ T-cells and a humoral immune response are important for the elimination of orf virus from the skin of sheep. *Vet Immunol Immunopathol* **74**:249, 2000

4. Gilray JA et al: Restriction endonuclease profiles of orf virus isolates from the British Isles. *Vet Rec* **143**:237, 1998

5. Savory L et al: Viral vascular endothelial growth factor plays a critical role in orf virus infection. *J Virol* **74**:10699, 2000

6. Haig DM, Mercer AA: Orf. *Vet Res* **29**:311, 1998

7. Gameel A et al: Clinicopathological observations on naturally occurring contagious ecthyma in lambs in Saudi Arabia . *Rev Elev Med Vet Pays Trop* **48**:233, 1995

8. Moriello KA, Cooley J: Difficult dermatologic diagnosis. Contagious viral pustular dermatitis (orf), goatpox, dermatophilosis, dermatophytosis, bacterial pyoderma, and mange. *J Am Vet Med Assoc* **218**:19, 2001

9. Nettleton PF et al: Natural transmission of orf virus from clinically normal ewes to orf-naïve sheep. *Vet Rec* **139**:364, 1996

10. Leavell UW Jr et al: Orf: Report of 19 human cases with clinical and pathological observations. *JAMA* **203**:657, 1968

11. Leavell UW, Jacob RJ: Orf, in *Dermatology in General Medicine,* 5th ed, edited by IM Freedberg, AZ Eisen, K Wolff, KF Austen LA Goldsmith, SI Katz, TB Fitzpatrick. New York, McGraw-Hill, 1999 p 2474

12. Yeruham I et al: Parapox Infection in a gazelle kid. *J Wildl Dis* **30**:260, 1994

13. Crumbie A: The orf virus: A disease of the farming community. *Community Nurse* **4**:44, 1998

14. Buchan J: Orf: An overview. *Dermatol Pract* November/December:9, 1995

15. Inceoglu F: Orf (ecthyma contagiosum): An occasional diagnostic challenge. *Plast Reconstr Surg* **106**:733, 2000

16. Cottone R et al: Analysis of genomic rearrangement and subsequent gene deletion of the attenuated orf virus strain D1701. *Virus Res* **56**:53, 1998

17. Nettleton PF et al: Tissue culture-propagated orf virus vaccine protects lambs from orf virus challenge. *Vet Rec* **138**:184, 1996

18. Yirrell DI et al: Response of efferent lymph and popliteal lymph node in epidermal infection of sheep with orf virus. *Vet Immunol Immunopathol* **28**:219, 1991b

19. Haig DM et al: The immune and inflammatory response to orf virus. *Comp Immun Microbiol Infect Dis* **20**:197, 1997

20. Haig DM et al: The activation status of ovine CD45R+ and CD45R–efferent lymph T cells after orf virus reinfection. *J Comp Pathol* **115**:163, 1996

21. Housawi FM et al: The reactivity of monoclonal antibodies against orf virus with other parapoxviruses and the identification of a 39-kDa immunodominant protein. *Arch Virol* **143**:2289, 1998

22. Czerny CP et al: Identification of three distinct antigenic sites in parapoxviruses. *Arch Virol* **142**:807, 1997

23. Robinson AJ, Mercer AA: Parapoxvirus of the red deer: Evidence of its inclusion as a new member in the genus of parapoxvirus. *Virology* **208**:812, 1995

24. Rziha H et al: Parapoxviruses: Potential alternative vectors for directing the immune response in permissive and non-permissive hosts . *J Biotechnol* **73**:235, 1999

25. Gilray JA et al: Restriction endonuclease profiles of orf virus isolates from the British Isles. *Vet Rec* **143**:237, 1998

26. Fleming SB et al: A homolog of interleukin-10 encoded by the poxvirus orf virus. *J Virol* **71**:4857, 1997

27. Haig DM, Fleming S: Immunomodulation by virulence proteins of the parapoxvirus orf virus. *Vet Immunol Immunopathol* **72**:81, 1999

28. Lyttle DJ et al: Homologs of vascular endothelial growth factor are encoded by the poxvirus orf virus. *J Virol* **68**:84, 1994

29. Deane D et al: Orf virus encodes a novel secreted protein inhibitor of granulocyte-macrophage colony-stimulating factor and interleukin-2. *J Virol* **74**:1313, 2000

30. Mourtada I et al: Human orf and erythema multiforme. *Ann Dermatol Venereol* **127**:398, 2000

31. Diven DG: *Pox Viruses. Cutaneous Manifestations of Viral Diseases*. New York, Marcel Dekker, in press

32. Murphy JK, Ralfs IG: Bullous pemphigoid complicating human orf. *Br J Dermatol* **134**:929, 1996

33. Lear A et al: Phenotypic characterization of the dendritic cells accumulating in the ovine dermis following primary and secondary orf virus infection. *Eur J Dermatol* **6**:135, 1996

34. Yirrell KI et al: Qualitative and quantitative changes in ovine afferent lymph draining the site of epidermal orf virus infection. *Vet Dermatol* **2**:133, 1991

T>

Chapter 221

Douglas Lowy Elliot Androphy

Molluscum Contagiosum

EPIDEMIOLOGY
ETIOLOGY AND PATHOGENESIS
CLINICAL MANIFESTATIONS
PATHOLOGY
DIAGNOSIS AND DIFFERENTIAL DIAGNOSIS
TREATMENT

REFERENCES

Molluscum contagiosum is a common, benign, viral infection of the skin and mucous membranes that generally affects children. In adults, the condition may be transmitted sexually. The fully developed lesion is an umbilicated papule, and most patients have multiple lesions. Molluscum can be extensive in patients with AIDS or other disorders associated with immunologic dysfunction.

EPIDEMIOLOGY

Infections with the molluscum contagiosum virus (MCV) occur throughout the world, but their frequency varies considerably. The disease commonly affects children, sexually active adults, and immunocompromised individuals. On some Pacific islands, 5 percent of children under 10 years of age may be affected. The prevalence in the United States is much lower. Although the infection may develop at any age, the fact that the majority of cases are found in children suggests that adults are resistant to infection.

MCV is transmitted by person-to-person spread and possibly by fomites, as poxviruses are resistant to desiccation. Outbreaks have been reported among children attending swimming pools, and genital lesions in adults are probably transmitted sexually. [1] The incidence of subclinical infection is unknown. The role of humoral immunity is unclear, although many patients possess IgG antibodies against viral antigens. [2], [3] Individuals with impaired cellular immune function may have widespread lesions. Patients with AIDS are at particular risk of MCV infection, with prevalence rates of 5 to 18 percent; [4], [5] the frequency and severity of infection vary inversely with the CD4+ count. Lesions in AIDS patients are often refractory to treatment.

ETIOLOGY AND PATHOGENESIS

MCV is a poxvirus that is distinct morphologically, serologically, and pathologically from other poxviruses. [6], [7] It is a large 200 by 300 nm DNA virus that replicates in the cytoplasm of infected cells and induces hyperplasia, as do other poxviruses. The complete sequence of the MCV DNA genome has been determined. [8] About two-thirds of the viral genes are similar to those of the orthopoxviruses, such as vaccinia virus and variola virus, while about one-third appear to be novel immune defense molecules. [8], [9]

Unlike most other poxviruses, MCV has not been reproducibly propagated in tissue culture. There has been some experimental success in reproducing the lesions and inducing MCV replication using cell-free lesional extracts to infect human foreskin grafts in nude mice. [10], [11] However, serial transmission has not yet been achieved. Experimental transmission to humans with an incubation period of 2 to 7 weeks has been observed. Attempts to transmit the disease to other species have been unsuccessful. Three different MCV strains (I, II, and III) have been identified based on restriction endonuclease digestion patterns. MCVI is more prevalent than MCVII, with MCVIII being extremely uncommon. [12], [13] No clinical differences have been evident among the strains.

Viral growth is confined to the epidermis; virus particles are synthesized in cytoplasmic foci of cells in the malpighian and granular layers. The rate of cell division in the basal layer of lesional skin is twice that of normal skin. It remains unclear how the MCV infection causes this hyperproliferation. The higher rate may be due to the inhibition of the normal keratinocyte apoptotic differentiation program by specific MCV encoded proteins. [14], [15] and [16]

The novel genes of the MCV genome that may interfere with immune recognition and host defense mechanisms include (1) a major histocompatibility complex class I heavy chain homologue that may inhibit presentation of MCV-specific peptides, (2) a chemokine homologue that may inhibit inflammation, and (3) a glutathione peroxidase homologue that may protect the virus and infected cells from oxidative damage by peroxides, which may form in response to infection. [8], [9], [11] These features of the virus may explain the paucity of inflammatory and immune response seen even in lesions of immunocompetent patients. They may also account, at least in part, for the difficulties encountered in treating infection in immunocompromised individuals.

CLINICAL MANIFESTATIONS

Lesions begin as minute papules that usually enlarge to 3 to 6 mm and, rarely, may become as large as 3 cm in diameter. The individual lesions are discrete, smooth, pearly to flesh-colored, dome-shaped papules, often with central umbilication in which lies a white, curdlike core, which may be easily expressed. Lesions may appear on any area of the skin or mucous membranes. They are often grouped in one or two areas (Fig. 221-1), but may be widely disseminated. Most

patients have fewer than 20 lesions, although some may have several hundred. In temperate climates, the virus involves the head, eyelids, trunk, and genitalia most often. In the tropics, lesions occur most commonly on the extremities. Lesions in adults frequently appear on the genitalia (Fig. 221-2). Lesions may resolve spontaneously with or without inflammation.

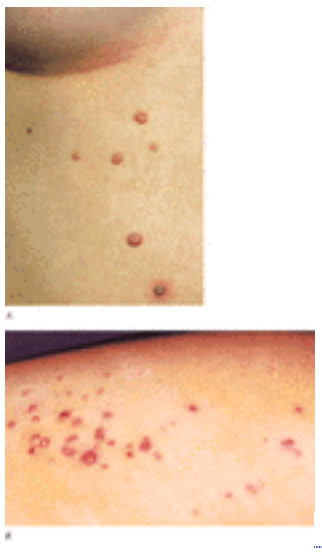

FIGURE 221-1 Molluscum contagiosum. *A*. Discrete, solid, skin-colored papules, 1 to 2 mm in diameter with central umbilication. *B*. Multiple, scattered, and discrete lesions, some of which are inflamed.

FIGURE 221-2 Molluscum contagiosum. Multiple umbilicated papules are seen on the abdomen, thigh, and penis of this 33-year-old HIV-infected male.

Immunocompetent cells are absent from the infected epidermis, even when they are present in the underlying dermis. [17] In adults with AIDS, molluscum often occur exclusively at extragenital sites, although they may be confined to the genitalia. In AIDS patients, lesions may attain a very large size and mimic cutaneous tumors. Although the lesions are usually asymptomatic, pruritus may be present, and an eczematous reaction may develop around some lesions. Conjunctivitis and keratitis may complicate lesions around the eyelid. Patients with atopic dermatitis or other conditions with impaired immune function may develop widespread lesions, and secondary bacterial infection also occurs.

PATHOLOGY

The histologic appearance of the hypertrophied and hyperplastic epidermis is characteristic (Fig. 221-3). [18] Above the normal-appearing basal layer are lobules of enlarged epidermal cells that contain multiple Feulgen-positive intracytoplasmic inclusion bodies (molluscum bodies or Henderson-Paterson bodies). These inclusion bodies, which contain the viral particles, increase in size as the infected cell moves toward the surface. In the horny layer, the molluscum bodies are enmeshed in a fibrous network that dissolves in the center of the lesions, forming the central core, which is composed primarily of molluscum bodies.

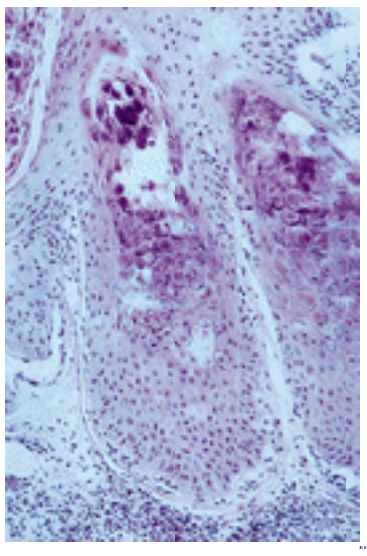

FIGURE 221-3 Molluscum contagiosum. Downgrowth of infected epidermal cells bearing large eosinophilic cytoplasmic inclusion bodies.

DIAGNOSIS AND DIFFERENTIAL DIAGNOSIS

The distinctive clinical appearance of the lesions, stained smears of the expressed core, and biopsy usually lead to the diagnosis. It is necessary to differentiate molluscum contagiosum from warts, varicella, pyoderma, papillomas, epitheliomas, basal cell carcinoma, and lichen planus. In the immunity-impaired host, bacterial and fungal infections should be considered.

TREATMENT

Because the condition is usually self-limited and lesions heal without scarring in the absence of a secondary bacterial infection, treatment is not always mandatory. Individual lesions may last 2 to 4 months, but the development of new lesions by autoinoculation is common. Most cases resolve spontaneously in 6 to 9 months, but some may persist for years, especially in immunosuppressed individuals.

Removal of lesions with a sharp curette or cryotherapy with liquid nitrogen are simple, relatively painless, and effective treatments. More than one treatment session may be necessary, however, either because of recurrence or because of the development of new lesions. Other destructive or inflammatory agents, such as potassium hydroxide [19] and silver nitrate, [20] have been used to treat molluscum lesions. A double-blinded study showed self-administered topical podophyllotoxin cream to be superior to placebo. [21] Historically, canthardin and tretinoin have been used. More recently, topical imiquimod [22], [23], [24], [25] and [26] and cidofir [27], [28] have been reported to be effective in uncontrolled studies. A small clinical trial found topical acidified nitrate led to the resolution of molluscum in children. [29] Treatment with oral cimetidine is controversial, as a controlled regimen has not been reported. [30], [31] and [32]

Cure may be especially difficult in patients with impaired immune function. In HIV-infected patients, treatment of the underlying HIV infection may promote the recovery of immune function and amelioration of the molluscum lesions. [33] Anectodotal studies suggest the topical use of imiquimod and cidofir may be effective for recalcitrant molluscum in HIV-1 immunocompromised patients.

REFERENCES

1. Brown TJ et al: An overview of sexually transmitted diseases: Part II. *J Am Acad Dermatol* **41**:661, 1999

2. Konya J, Thompson CH: Molluscum contagiosum virus: Antibody responses in persons with clinical lesions and seroepidemiology in a representative Australian population. *J Infect Dis* **179**:701, 1999

3. Watanabe T et al: Antibodies to molluscum contagiosum virus in the general population and susceptible patients. *Arch Dermatol* **136**:1518, 2000

4. Goodman DS et al: Prevalence of cutaneous disease in patients with acquired immunodeficiency syndrome (AIDS) or AIDS-related complex. *J Am Acad Dermatol* **17**:210, 1987

5. Schwartz JJ, Myskowski PL: Molluscum contagiosum in patients with human immunodeficiency virus infection: A review of twenty-seven patients. *J Am Acad Dermatol* **27**:583, 1992

6. Diven DG: An overview of poxviruses. *J Am Acad Dermatol* **44**:1, 2001

7. Myskowski PL: Molluscum contagiosum: New insights, new directions. *Arch Dermatol* **133**:1039, 1997

8. Senkevich TG et al: The genome of molluscum contagiosum virus: Analysis and comparison with other poxviruses. *Virology* **233**:19, 1997

9. Moss B et al: Immune-defense molecules of molluscum contagiosum virus, a human poxvirus. *Trends Microbiol* **8**:473, 2000

10. Fife KH et al: Growth of molluscum contagiosum virus in a human foreskin xenograft model. *Virology* **226**:95, 1996

11. Bugert JJ, Darai G: Recent advances in molluscum contagiosum virus research. *Arch Virol Suppl* **13**:35, 1997

12. Porter CD et al: Molluscum contagiosum virus types in genital and non-genital lesions. *Br J Dermatol* **120**:37, 1989

13. Scholz J et al: Epidemiology of molluscum contagiosum using genetic analysis of the viral DNA. *J Med Virol* **27**:87, 1989

14. Gil J et al: MC159L protein from the poxvirus molluscum contagiosum virus inhibits NF-kappaB activation and apoptosis induced by PKR. *J Gen Virol* **82**:3027, 2001

15. Hu S et al: A novel family of viral death effector domain-containing molecules that inhibit both CD-95– and tumor necrosis factor receptor-1–induced apoptosis. *J Biol Chem* **272**:9621, 1997

16. Shisler JL, Moss B: Molluscum contagiosum virus inhibitors of apoptosis: The MC159 v-FLIP protein blocks Fas-induced activation of procaspases and degradation of the related MC160 protein. *Virology* **282**:14, 2001

17. Viac J, Chardonnet Y: Immunocompetent cells and epithelial cell modifications in molluscum contagiosum. *J Cutan Pathol* **17**:202, 1990

18. Cribier B et al: Molluscum contagiosum: Histologic patterns and associated lesions. A study of 578 cases. *Am J Dermatopathol* **23**:99, 2001

19. Romiti R et al: Evaluation of the effectiveness of 5% potassium hydroxide for the treatment of molluscum contagiosum. *Pediatr Dermatol* **17**:495, 2000

20. Niizeki K, Hashimoto K: Treatment of molluscum contagiosum with silver nitrate paste. *Pediatr Dermatol* B>16:395, 1999

21. Syed TA et al: Topical 0.3% and 0.5% podophyllotoxin cream for self-treatment of condylomata acuminata in women: A placebo-controlled, double-blind study. *Dermatology* **189**:142, 1994

22. Barba AR et al: An open label safety study of topical imiquimod 5% cream in the treatment of molluscum contagiosum in children. *Dermatol Online J* **7**:20, 2001

23. Brown CW Jr et al: Recalcitrant molluscum contagiosum in an HIV-afflicted male treated successfully with topical imiquimod. *Cutis* **65**:363, 2000

24. Hengge UR et al: Self-administered topical 5% imiquimod for the treatment of common warts and molluscum contagiosum. *Br J Dermatol* **143**:1026, 2000

25. Skinner RB Jr et al: Treatment of molluscum contagiosum with topical 5% imiquimod cream. *Pediatr Dermatol* **17**:420, 2000

26. Syed TA et al: Treatment of molluscum contagiosum in males with an analog of imiquimod 1% in cream: A placebo-controlled, double-blind study. *J Dermatol* **25**:309, 1998

27. Meadows KP et al: Resolution of recalcitrant molluscum contagiosum virus lesions in human immunodeficiency virus-infected patients treated with cidofovir. *Arch Dermatol* **133**:987, 1997

28. Toro JR et al: Topical cidofovir: A novel treatment for recalcitrant molluscum contagiosum in children infected with human immunodeficiency virus 1. *Arch Dermatol* **136**:983, 2000

29. Ormerod AD et al: Molluscum contagiosum effectively treated with a topical acidified nitrite, nitric oxide liberating cream. *Br J Dermatol* **141**:1051, 1999

30. Dohil M, Prendiville JS: Treatment of molluscum contagiosum with oral cimetidine: Clinical experience in 13 patients. *Pediatr Dermatol* **13**:310, 1996

31. Cunningham BB et al: Inefficacy of oral cimetidine for nonatopic children with molluscum contagiosum. *Pediatr Dermatol* **15**:71, 1998

32. Yashar SS, Shamiri B: Oral cimetidine treatment of molluscum contagiosum. *Pediatr Dermatol* **16**:493, 1999

33. Hicks CB et al: Resolution of intractable molluscum contagiosum in a human immunodeficiency virus-infected patient after institution of antiretroviral therapy with ritonavir. *Clin Infect Dis* **24**:1023, 1997

T>

Chapter 222

Douglas Lowy

Milker's Nodules

ETIOLOGY
EPIDEMIOLOGY
CLINICAL MANIFESTATIONS
PATHOLOGY
DIAGNOSIS AND DIFFERENTIAL DIAGNOSIS
COURSE, PROGNOSIS, TREATMENT, AND PREVENTION

REFERENCES

Milker's nodule is a benign viral skin disease which generally consists of one or a few nodules on the hand or forearm. The virus is usually transmitted to cattle handlers from infected cows.

ETIOLOGY

The etiologic agent is called pseudocowpox virus (PCPV), paravaccinia virus, or milker's node virus. It is a poxvirus from the parapoxvirus subgroup, which also includes orf virus and bovine papular stomatitis virus. [1] PCPV is endemic in cattle. Lesions in cows, which may be chronic and recurrent, appear mainly on the teats, although other areas may be affected. In cows, the condition is called *pseudocowpox.* There is no cross-immunity with the cowpox, vaccinia, or variola orthopox group of poxviruses. Bovine papular stomatitis virus infection of cattle is characterized by lesions around the mouth; [2] it induces lesions in humans that are identical to milker's nodules, and some investigators believe that the two viruses may be identical. [3]

PCPV can be propagated in bovine or human cells in tissue culture. [4], [5] It resembles the virus of orf (ecthyma contagiosum) morphologically and serologically, [6], [7] and [8] but the two viruses can be distinguished by viral DNA hybridization or polymerase chain reaction. [9] As is true of other poxviruses, paravaccinia is a large (150 × 300 nm) brick-shaped DNA virus that contains many enzymes and replicates in foci in the cytoplasm of infected cells. [10] Infection often induces a mild degree of hyperplasia and increased dermal vascularity. The disease has been transmitted experimentally from human to human and from human to cow. [11]

EPIDEMIOLOGY

Milker's nodule has a worldwide distribution, occurring where cattle are found. Most cases are sporadic, but small epidemics have been reported. Because the disease is usually transmitted to humans by direct contact with infected cattle, milkers are most at risk. Cases also occur among stockyard and slaughterhouse workers. Most cases arise in individuals who recently became milkers, and infection in humans usually induces lasting immunity. Indirect transmission from virus-contaminated material to patients with burned skin has been reported. [12] The incidence of subclinical infection is not known. Although infectious virus is found in human lesions, person-to-person transmission under natural conditions has not been documented.

CLINICAL MANIFESTATIONS

The typical case consists of a single asymptomatic or slightly painful 1 cm erythematous nodule on a finger (Fig. 222-1). [13], [14] There are usually no more than four lesions, and they are generally confined to the hand and forearm. Rarely, other areas of the skin may be involved, or numerous lesions may be present. Lymphadenopathy is uncommon.

FIGURE 222-1 Milker's nodule. *A*. Firm, purple, eroded nodule occurred following milking a cow. *B*. Multiple, purple papules and nodules occurred in a second-degree scalding burn sustained in a milking barn.

The incubation period is usually 4 to 7 days, but may be as long as 2 weeks. In the absence of secondary bacterial infection, each lesion usually heals spontaneously in 4 to 6 weeks without scar formation. Leavell and Phillips [14] have described six clinical stages, each lasting about a week. Initially, the lesion begins as an erythematous macule, which soon becomes papular. The target stage is next: the lesion, which is papulovesicular, has a red center, surrounded by a white ring and a red halo. This stage is followed by a period of weeping and erosion. The lesion then becomes a firm, crusted nodule. Next, small papillomatous elevations develop on the nodule. Finally, during the regressive stage, the lesion darkens and sloughs.

PATHOLOGY

Pathologic changes are present in both epidermis and dermis; the precise histologic appearance depends on the clinical stage. [14], [15] The manifestations are similar to those of orf. Epidermal changes include hyperkeratosis, parakeratosis, acanthosis, and striking elongation of the rete ridges. These alterations increase progressively as the lesion develops. In early lesions, the upper portion of the malpighian layer may contain balloon cells and cells with many intracytoplasmic and some intranuclear inclusions. Later, reticular degeneration, multilocular vesicles, spongiosis, and intracellular edema may be the prominent findings. The dermis contains a marked increase in the number of capillaries and a nonspecific inflammatory infiltrate that is most intense during the acute weeping stage. Electron micrographic examination of the superficial portion of a lesion usually reveals the characteristic cytoplasmic viral particles. The hypervascularity in the dermis may be secondary to the production and secretion of a virally encoded homologue of vascular endothelial growth factor (VEGF), a potent stimulator of vascular proliferation. A VEGF homologue in the orf virus contributes to its pathogenicity in sheep, [16] and the close similarity between orf virus and PCPV makes it likely that PCPV also contains an analogous gene.

DIAGNOSIS AND DIFFERENTIAL DIAGNOSIS

The diagnosis is generally based on the history, clinical appearance, and biopsy. It can be established more definitively by the electron microscopic demonstration of viral particles, by propagation of the virus in tissue culture, or by polymerase chain reaction. Orf and bovine papular stomatitis are usually excluded by history.

Milker's nodule must also be differentiated from a large number of other conditions, including true cowpox, herpetic whitlow, pyoderma, anthrax, tularemia, primary inoculation tuberculosis, atypical mycobacterial infection, syphilitic chancre, sporotrichosis, and pyogenic granuloma.

COURSE, PROGNOSIS, TREATMENT, AND PREVENTION

Because the disease is self-limited, only symptomatic therapy is generally indicated. Parapoxviruses are inhibited by cidofovir, and the nonregressing orf lesion in an immunocompromised patient responded to topical treatment. [17] Prevention is limited to the isolation of infected animals.

REFERENCES

1. Robinson AJ, Lyttle DJ: Parapoxviruses: Their biology and potential as recombinant vaccines, in *Recombinant Poxviruses,* edited by M Binns, GL Smith. Boca Raton, FL, CRC Press, 1992, p 285

2. Rossi CR et al: A paravaccinia virus isolated from cattle. *Cornell Vet* **67**:72, 1977

3. Bowman KF et al: Cutaneous form of bovine papular stomatitis in man. *JAMA* **246**:2813, 1981

4. Friedman-Kien AE et al: Milker's nodules: Isolation of a poxvirus from a human case. *Science* **140**:1335, 1963

5. Thomas V: Biochemical and electron microscopic studies of the replication and composition of milker's node virus. *J Virol* **34**:244, 1980

6. Nagington J et al: Milker's nodule virus infections and their similarity to orf. *Nature* **208**:505, 1965

7. Leavell UW et al: Orf: report of 19 human cases with clinical and pathological observations. *JAMA* **204**:657, 1968

8. Lard SL et al: Differentiation of parapoxviruses by application of orf virus-specific monoclonal antibodies against cell surface proteins. *Vet Immunol Immunopathol* **28**:247, 1991

9. Inoshima Y et al: Detection and diagnosis of parapoxvirus by the polymerase chain reaction. *J Virol Methods* **84**:201, 2000

10. Caplen HS, Holowczak JA: Some enzymatic activities associated with purified parapoxvirions. *J Virol* **46**:384, 1983

11. Sonck CE, Penttinen K: Milker's nodules: Transmission from man to man. *Acta Derm Venereol*(*Stockh*) **34**:420, 1954

12. Schuler G et al: The syndrome of milker's nodules in burn injury: Evidence for indirect transmission. *J Am Acad Dermatol* **6**:334, 1982

13. Wheeler CE, Cawley EP: The etiology of milker's nodules. *Arch Dermatol* **75**:249, 1957

14. Leavell UW Jr, Phillips IA: Milker's nodules: Pathogenesis, tissue culture, electron microscopy, and calf inoculation. *Arch Dermatol* **111**:1307, 1975

15. Groves RW et al: Human orf and milkers' nodule: A clinicopathologic study. *J Am Acad Dermatol* **25**:706, 1991

16. Savory LJ et al: Viral vascular endothelial growth factor plays a critical role in orf virus infection. *J Virol* **74**:10699, 2000

17. Geerinck K et al: A case of human orf in an immunocompromised patient treated successfully with cidofovir cream. *J Med Virol* **64**:543,

2001

T>

Chapter 223

Douglas Lowy Elliot Androphy

Warts

HISTORICAL ASPECTS
ETIOLOGIC AGENT
HUMAN PAPILLOMAVIRUS TYPES
EPIDEMIOLOGY
PATHOGENESIS
CLINICAL MANIFESTATIONS
Cutaneous Infections
Extracutaneous (Mucosal) Infections
RELATION OF PAPILLOMAVIRUSES AND MALIGNANCY
HISTOPATHOLOGY
DIAGNOSIS
DIFFERENTIAL DIAGNOSIS
TREATMENT AND PROPHYLAXIS

REFERENCES

Warts, or verrucae, are benign proliferations of the skin and mucosa that result from infection with papillomaviruses. These viruses do not produce acute signs or symptoms, but induce slow-growing lesions that can remain subclinical for long periods of time. A subset of human papillomaviruses (HPVs) has been associated with the development of epithelial malignancies.

HISTORICAL ASPECTS

Cutaneous warts were known to the ancient Greeks and Romans, and until the nineteenth century genital warts were believed to be a form of syphilis or gonorrhea. The viral etiology of warts was implied from the observation that inoculation of wart filtrates from which cellular and bacterial products were removed could induce papillomas at the site of injection. All warts were considered to be derived from a single virus, because isolates from cutaneous, genital, or laryngeal warts could induce papillomas at other sites. However, advances in recombinant DNA technology have now identified more than 100 different HPV genotypes. [1]

ETIOLOGIC AGENT

The papillomaviruses comprise a large family of double-stranded DNA viruses found in humans and many other species. [2] They are distantly related to the polyomaviruses, which include simian virus 40, polyomavirus, BK virus, and JC virus. All papillomaviruses are highly host-specific, which means that those from one species do not induce papillomas in heterologous species. HPVs infect only humans. Rabbits, cows, and dogs are the natural host for some papillomaviruses, but for unknown reasons these viruses are not found in common strains of mice. These limitations place significant restrictions on investigating the mechanism and biologic consequences of papillomavirus infection in a laboratory animal model. Although it is now possible to cultivate HPVs in normal epithelial cell culture (see below), the process results in only minute amounts of virus, and in vitro culture of HPV is not a simple, routine test in any laboratory.

Recombinant DNA technology has enabled the molecular cloning of the complete viral DNA or genome from clinical lesions. The entire nucleotide sequence for the genomes of many human and animal papillomaviruses is now known. Comparison of these papillomavirus DNAs reveals that they share a similar genetic organization (Fig. 223-1) and are predicted to encode related protein products. [3] The papillomavirus genome is present within the viral particle as a single, supercoiled, covalently closed circle of double-stranded DNA. Each genome is composed of approximately 8000 nucleotide base pairs, which is approximately one-twentieth the size of a herpesvirus genome. The papillomavirus genome encodes only eight to nine proteins, which are historically separated into two groups, E (early) and L (late). The E proteins, most of which participate in viral DNA replication, are expressed before the L proteins and are not incorporated into the infectious virus particle. Because the E genes do not encode a DNA polymerase or thymidine kinase, papillomaviruses are not susceptible to inhibition by acyclovir. The L1 and L2 genes encode the structural proteins that form the outer protein shell, called the capsid of the viral particle, which is called the virion. The spherical virion measures 55 nm in diameter and surrounds the viral DNA.



FIGURE 223-1 All papillomavirus genomes are composed of approximately 8000 nucleotide base pairs, represented as a linear sequence but actually a closed circle of double-stranded DNA. The boxes depict the viral genes, each of which encodes a protein. The regulatory region is a DNA segment that does not encode proteins, but participates in the expression of the viral genes and the replication of the viral DNA. In general, E6, E7, and E5 represent transforming genes; E1 and E2 coordinate replication and expression of the viral genome; and the L1 and L2 proteins form the viral capsid. E4 encodes a protein that may be involved in the release of the virus from the cell's keratin framework.

Until recently, clinical lesions have been the only source of infectious papillomavirus particles, except for a limited number of papillomaviruses that have successfully propagated in human keratinocytes grown under the renal capsule of athymic nude mice. [4] The use of the so-called raft culture system, which forms a stratified squamous epithelium, has now produced limited amounts of infectious HPV. [5] In standard tissue culture cells, the application of genetic engineering technology has led to the production of infectious bovine papillomavirus. [6] These and related advances make it likely that the number of infectious HPV types produced in the laboratory, as well as the amount of virus, will increase considerably in the near future.

HUMAN PAPILLOMAVIRUS TYPES

Although more than 80 HPV types have been completely or partially sequenced, [1] the actual number of types may range between 100 and 150. Currently, the relatedness of their DNA sequence distinguishes between HPV types. Until recently, molecular hybridization techniques were used to determine the HPV type of a particular isolate. The ease with which the polymerase chain reaction (PCR), which has both high sensitivity and specificity, can be used to amplify and sequence any viral DNA isolate has now led to HPV types being defined by DNA sequence homology. Fresh tissue is not required, and PCR has been successfully applied to detect and type HPV DNA in paraffin-embedded tissue blocks that are decades old. [7] Two HPV isolates are assumed to be of the same type if the sequences of their L1 genes are at least 90 percent identical. [1] It is likely a new HPV type if, after the viral genome has been molecularly cloned and its L1 gene sequenced, the sequence is less than 90 percent homologous to the closest known HPV type. Using this approach, it has also been possible to study the evolutionary relationships between different HPV genotypes even within the same HPV type. [8]

Often associated with distinct regional predilection, histopathology, and biology, HPV types are separated into three categories: cutaneous (nongenital) types such as HPV-1, -2, -3, and -4; genital-mucosal types such as HPV-6, -11, -16, and -18; and those usually isolated from epidermodysplasia verruciformis (EV) such as HPV-5 and -8 (Table 223-1). A hypothetical evolutionary tree depicting the relationship among the HPV genotypes shows that those closely related by DNA sequence tend to induce similar lesions. [8] Examples include highly related types such as 3 and 10, which induce flat warts; types 6 and 11, which induce genital-mucosal warts (condylomata acuminata); and types 5 and 8, which induce scaly lesions in EV.



TABLE 223-1 **Clinical Associations of Human Papillomavirus (HPV) Types**

Another important distinction is that some HPV genotypes appear to have malignant potential. This was first noted in association with EV. [9] For example, almost all cutaneous squamous cell carcinomas that arise in EV warts contain specific HPV types such as 5 and 8, while benign lesions, even in the same patient, may harbor many other HPV types. Similarly, the majority of cervical carcinomas contain HPV-16, -18, or other so-called high-risk types, while the low-risk HPV-6 and -11, which are found in benign cervical disease, are rarely identified in cervical malignancies. [10]

Many other viruses are typed by the ability of antisera to distinguish their capsid antigens, and antisera made by immunization with intact papillomavirus virions can generate type-specific antibodies. [11] However, serologic typing requires the generation of antisera specific to each HPV type, which is more cumbersome and less sensitive than DNA sequence analysis and may be subject to greater interlaboratory variation. The study of HPV serotyping has been less extensive, because until recently, it was usually necessary to obtain virus from lesions. It has now been determined that the expression of L1 protein molecules of any papillomavirus in cultured cells leads to their self-assembly into virus-like particles (Fig. 223-2) that exhibit the same type-specific epitopes as the authentic virus. [8] Serologic analyses using antisera obtained by immunization with L1 virus-like particles have shown an excellent correlation between the serologic results and DNA typing, with little serologic cross-reactivity between different HPV types and considerable cross-reactivity among isolates of the same HPV type. [12]

FIGURE 223-2 Transmission electron micrograph of HPV-16 virus-like particles composed of the viral L1 and L2 capsid proteins. The L1 and L2 proteins have been expressed in cultured cells, and have self-assembled into 55-nm particles that are similar morphologically to infectious virus, except that they do not contain the viral DNA. The particles in the electron micrograph have been purified from the cells. (*Micrograph courtesy of Heather Greenstone.*)

Detergent-disrupted papillomavirus particles expose common structural antigens shared by all papillomaviruses, but not by other viruses. [11] Antibodies to such shared antigens can be used to detect structural capsid proteins in clinical materials, including formalin-fixed tissue (Fig. 223-3). However, antibodies to structural viral proteins cannot be used to confirm the presence of HPV in cells that do not synthesize large numbers of virions as in genital warts, bowenoid papulosis, dysplasias, and HPV-associated malignancies.

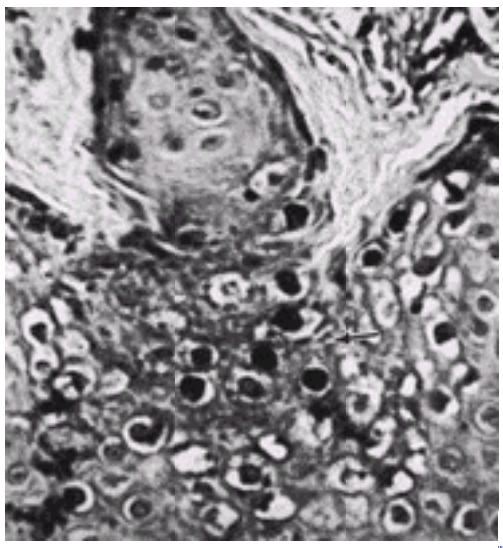

FIGURE 223-3 Immunoperoxidase assay of a verruca in which the darkly stained nuclei (*arrow*) represent cells that contain papillomavirus virion structural antigens. The positive nuclei are found in some, but are not limited to, koilocytotic cells.

EPIDEMIOLOGY

Contagion of HPV probably depends on several factors, including the location of lesions, the quantity of infectious virus present, the degree and nature of the contact, and the general and HPV-specific immunologic status of the exposed individual. Patients with impaired cell-mediated immunity are particularly susceptible to HPV infection, and warts occur in the majority of renal transplant patients on immunosuppressive therapy. [13], [14]

The source or reservoir for HPV is believed to be individuals with clinical or subclinical infection, as well as the environment. Using sensitive PCR detection methods, it is becoming increasingly evident that normal skin in immunocompetent individuals can harbor HPVs, including novel types and those found in EV. [15], [16] Therefore, when these sensitive techniques are used to find HPV DNA in a lesion not usually thought to be caused by HPV, additional evidence should be sought to determine whether the virus has contributed to the development of the lesion.

Nongenital warts occur most frequently in children and young adults, in whom the incidence may approach 10 percent. [17] The age-specific incidence of nongenital warts differs from that of anogenital warts, which are uncommon in children. Anogenital warts behave as a sexually transmitted condition, and partners can transmit the virus with high efficiency. [18] Penile lesions occur frequently in the sexual contacts of women with cervical intraepithelial neoplasia. [19]

Although genital warts in children may be a consequence of sexual abuse, such warts in infants and children commonly result from virus inoculation at birth or from incidental spread from cutaneous warts. In contrast to anogenital lesions in adults, a significant proportion of genital warts in children contain HPV types that are usually isolated from nongenital warts. [20], [21] The majority of respiratory (laryngeal) papillomas, which contain the same HPV types as are found in anogenital papillomas, [22] occur in infants and young children. In this age group, the condition is believed to have been transmitted from mothers with genital HPV infection when the infant aspirates infectious virus during birth. [22] The incidence of respiratory papillomas is much lower than that of genital HPV lesions. Maternal factors that predispose to the development of clinical respiratory lesions in children include first pregnancy and young age. [23]

In addition to causing lesions on the external genitalia, genital-mucosal HPV types also infect the uterine cervix. This sexually transmitted infection, which may involve low- or high-risk HPV types, is especially common in sexually active women younger than 25 years of age, in whom the prevalence of infection may exceed 25 percent. [24] The majority of HPV DNA–positive cervical infections are transient and remain histologically normal. [25] Persistence of HPV DNA strongly correlates with an increased risk for progression to cervical dysplasia and invasive cancer. HPV DNA has also been detected in some clinically normal penile skin. [26] Thus, even normal-appearing genital skin or mucosa may represent a reservoir for contagion.

The most common antibody response to HPV infection is directed against conformational type-specific epitopes present in the L1 protein of the viral particle. [27], [28] and [29] These epitopes are efficiently presented by virus-like particles, which can be produced in large quantity in cultured cells. The availability of virus-like particles has facilitated the development of HPV type-restricted assays to monitor the seroepidemiology of HPV infection. The most extensive use of these assays has focused on the seroprevalence of HPV-16 infection, because this is the HPV type that occurs most frequently in cervical cancer. Most, but not all, infected patients develop low serum antibody titers. The likelihood of becoming antibody-positive increases with the duration of the infection. Once an individual becomes antibody-positive, the antibodies seem to persist for many years, even if the individual becomes viral DNA–negative. Thus, the antibodies detect both past and present infection, and the seroprevalence of HPV-16 antibodies in a given population reflects the

relative prevalence of the virus within that population.

PATHOGENESIS

HPV infection occurs through inoculation of virus into the viable epidermis through defects in the epithelium. [2] Maceration of the skin is probably an important predisposing factor, as suggested by the increased incidence of plantar warts in swimmers who frequent public pools. [29] Although the receptor(s) by which cells take up HPV infection has not been identified, cell surface heparan sulfate, which is encoded by proteoglycans and binds papillomavirus particles with high affinity, is required for HPV infection. [30] To establish the chronic infection characteristic of a wart, it is probably necessary to infect an epidermal stem cell. It is believed that a single copy or at most a few copies of the viral genome are maintained as an extrachromosomal plasmid within the infected epithelial basal cells. When these basal cells divide, the viral genome is also replicated and transported within the daughter cells as they migrate upward to form the differentiating epithelium.

After experimental papillomavirus inoculation, it usually requires 2 to 9 months for a verruca to become clinically apparent. This observation implies a relatively long period of subclinical infection. This state of inapparent infection represents a potential source of infectious virus. Although the epidermis in a wart is acanthotic, hyperplasia of the proliferative basal cell population is not dramatic, in concordance with the observation that warts develop slowly.

Once an infection has taken place, new warts may develop in sites of inoculation over a period of weeks to months. Each new lesion probably results either from the initial exposure or spread from other warts. There is no convincing evidence for blood-borne dissemination. Autoinoculation of virus into apposed skin is commonly seen on adjacent digits (Fig. 223-4) and in the anogenital region.

FIGURE 223-4 *A.* Common wart, periungual. Multiple, confluent kerototic papules are apparent around the proximal periphery of the fingernails. *B.* Common wart, verruca plantaris. *C.* Common wart, mosaic plantar. A large hyperkeratotic plaque is seen on the heel, made up of multiple small coalescing warts.

HPV DNA has been detected in normal-appearing mucosa of the larynx of patients with respiratory papillomatosis who were in clinical remission [31] and in normal-appearing skin and hair adjacent to treatment sites of recurrent genital warts. [16] Whether these represent subclinical states rather than true “latency” (i.e., nonreplicating and transcriptionally inactive virus) is unknown. There is also increasing evidence that HPV DNA can be resident in clinically normal skin. [15], [16], [28] Whether HPV DNA persists in the epithelium after successful treatment of immunocompetent individuals remains an unresolved question.

Viral RNA expression (transcription) remains low until the upper malpighian layer, just before the granular layer, where viral DNA replication may result in hundreds of copies of viral DNA per cell. The viral capsid proteins (L1 and L2; see Fig. 223-1 and Fig. 223-2) are synthesized and assembled into virions in the nuclei of the cells at this level (see Fig. 223-3). The newly synthesized viral DNA is also incorporated into the virions in the nuclei of these differentiated malpighian cells. A viral protein called E1-E4 (the product of a spliced RNA from the E1 and E4 genes) may induce collapse of the cytoplasmic keratin filament network. This is postulated to facilitate release of the virions from the cross-linked cytoskeleton so that they can be inoculated into another site or desquamated into the environment.

Papillomaviruses are not enveloped, because they do not bud from the nuclear or plasma membrane, as do many viruses such as herpes simplex virus or HIV. It is their membrane-derived lipoprotein envelope that causes the rapid inactivation of these latter viruses by environmental conditions, such as freezing or desiccation, or chemicals, such as ethanol. In contrast, papillomavirus virions are resistant to desiccation [32] and to the detergent nonoxynol-9, although exposure of virions to formalin, detergents such as sodium dodecyl sulfate, [33] or high temperature can reduce their infectivity. They can remain infectious for years when warts are stored in glycerol at room temperature. Indeed, L1 and L2 form a tightly packed protein structure that is highly resistant to proteases.

The relative abundance of these stable virus particles in a verruca varies with the clinical setting and the HPV type. Newer lesions tend to contain more virions than do older verrucae. Plantar warts containing HPV-1 have a high number of virions; anogenital verrucae typically have small quantities of mature virus particles; and common warts usually have intermediate numbers. Not only does the quantity of viral DNA present differ among these lesions, but also the proportion that is enclosed within the infectious virions may vary among these verrucae. [34]

Because virions do not appear in the lower epithelial levels in warts, it is believed that the state of differentiation of the infected epithelial cell coordinate viral transcription, DNA replication, and late protein production. The recent propagation of limited amounts of HPVs in cultured cells is a consequence of the ability to reproduce the milieu required for physiologic differentiation. [5], [35] Further support for the belief that the production of virus particles and virion antigens depends on the state of epithelial differentiation is the fact that as benign papillomas progress toward dysplasia, virion production decreases. Capsid proteins are almost never observed in frank malignancies, although HPV DNA is present. It is also possible to cultivate some HPVs by exposing epithelial cells to infectious virions and placing them under the renal capsule of an immunodeficient (nude) mouse for prolonged periods. In this system, the epithelial cells differentiate,

stratify, and resemble a verruca histologically, and the full virus replication cycle occurs, producing infectious virions. [4]

Experimental evidence from cell culture systems has shown that papillomavirus genes can alter cell proliferation, a characteristic common to many tumor viruses. [36], [37] Several different transformation assays have been developed to examine the biologic effects of papillomavirus genes in vitro. For example, cells may lose contact inhibition and continue to divide, exhibit increased DNA synthesis and replication rates, lose growth factor dependence, or become immortal instead of exhibiting a finite life span in vitro. Three different viral genes have been shown to possess some of these properties: E5, E6, and E7 (see Fig. 223-1). They alter cell growth by nonoverlapping, but cooperative, mechanisms.

These experimental systems have been used to examine and compare the in vitro activities of genital-mucosal HPVs. Their relative activity varies with the HPV type. In one assay, keratinocytes or cervical cells were grown as a stratified epithelium on a raft that provided an air-media interface. The introduction of high-risk HPV-16 or -18 DNA induced a disorganized pattern of differentiation with suprabasal mitotic figures resembling squamous cell carcinoma in situ, while the cells retained a normal pattern of stratification with the use of low-risk HPV-6 or -11 DNA. [38] In other in vitro models, the introduction of HPV-16 or -18 DNA into cultured human epithelial cells increased the cells growth rate, resistance to differentiation, and ability to be continuously passaged; HPV-6 and -11 DNA were much less active. Thus, for the genital-mucosal HPVs, there is an excellent correlation between their ability to induce cell transformation in vitro and their association with malignancy.

In cutaneous or cervical epithelial cells, transformation is best achieved with both E6 and E7 from HPV-16 or -18. These two HPV genes are preferentially retained and expressed in cervical cancers, implying that these assays measure a property that is closely related to the oncogenic potential of these viruses in cervical infection. [39], [40] One mechanism by which the E6 and E7 proteins exert their effects is by each binding to a different cellular protein that inhibits normal epithelial cell growth. Apparently, binding to E6 and E7, respectively, inactivates two cellular proteins, p53 and the retinoblastoma susceptibility protein (Rb), and thereby relieves infected cells from the normal growth inhibitory activities of these two cellular proteins. However, the E6 proteins from some HPV types, including those associated with malignancies in EV and immunosuppression, do not interact with p53, although they may prolong the life span of infected cells by an alternate mechanism, such as inactivation of the pro-apoptotic protein Bak. [41], [42] Several studies demonstrate that E6 and E7 must have multiple targets in the cell. [39], [40], [43], [44] The viral E5 genes encode proteins that appear to activate growth factor receptors. In the bovine (cow) papillomavirus, which induces fibropapillomas, E5 appears to preferentially activate the receptors for platelet-derived growth factor, and HPV-16 E5 may stimulate the epidermal growth factor receptor. [45], [46]

The roles of immunity and genetic susceptibility to papillomavirus infection are incompletely understood. [47] The decrease in the frequency of warts with age implies that resistance to infection develops over time, and much of this resistance may be immunologic. In experimental papillomavirus infection in animals, resistance to virus challenge correlates with the presence of neutralizing anticapsid antibodies, and serum or IgG from resistant animals can provide protection through passive transference. [48], [49] It is therefore likely that neutralizing antibodies account for at least some of the resistance to reinfection. Serum antibodies to viral capsids are detectable in some patients with current warts or a past history of warts. In patients with warts, these antibodies, as well as other host factors, may help to limit the spread of warts to new sites.

Although humoral immunity may contribute to resistance to infection, most evidence suggests that cellular immune reactivity plays a significant role in wart regression. Individuals with defective cell-mediated immunity are particularly susceptible to papillomavirus infection, and their infections are notoriously resistant to treatment. In cows, the induction of high levels of neutralizing antibodies, although protective against challenge with a papillomavirus that causes oral papillomas, do not alter established oral papillomas induced by the same virus. [50] Flat warts in patients may regress spontaneously in association with a mononuclear cell infiltrate. There are also instances in which treatment of one or a few warts may lead to resolution of many or all warts in nonimmunosuppressed patients, although this outcome is the exception rather than the rule. In uncontrolled patient studies, vaccination with wart extracts has been reported to be effective in prevention of condylomata acuminata recurrence. [51]

CLINICAL MANIFESTATIONS

Cutaneous Infections

Warts are usually classified by their clinical location or morphology. As shown in Figure 223-5, Figure 223-6, Figure 223-7, Figure 223-8 and Figure 223-9, the cutaneous manifestations of warts are varied. *Common warts* (verruca vulgaris) are scaly, rough, spiny papules or nodules that can be found on any skin surface (see Table 223-1). They occur often as single or grouped papules on the hands and fingers. *Flat warts,* (verruca plana), are 2 to 4 mm, slightly elevated, flat-topped papules that have minimal scale. These are most frequent on the face, hands, and lower legs. Verrucae may also be *filiform* or appear as cutaneous horns. *Plantar and palmar warts* are thick, endophytic, and hyperkeratotic lesions, which may be painful with pressure. Punctate black dots (“seeds”), which become evident after shaving away of the outer keratinous surface, represent thrombosed capillaries in the papilloma. *Mosaic warts* result from the coalescence of plantar or palmar warts into large plaques. Some individuals with an apparently normal immunologic state develop exuberant warts of the palms or soles that are refractory to treatment. *Butcher's warts* are verrucous papules, usually multiple, on the dorsal, palmar, or periungual hands and fingers of meat cutters.

FIGURE 223-5 Common wart. A large hyperkeratotic nodule is seen on the ear.

FIGURE 223-6 *A.* Common wart with koebnerization. A linear arrangement of warts is seen on the elbow, arising at the site of an abrasive injury. *B.* Common wart. A giant wart is seen on the dorsum of the hand in a renal transplant recipient; the lesions were resistant to treatment, but resolved spontaneously when immunosuppressive therapy was discontinued.

FIGURE 223-7 The large, scaly, and horny warts contain HPV-2. The smaller, flatter, less scaly papules are warts that contain HPV-3.

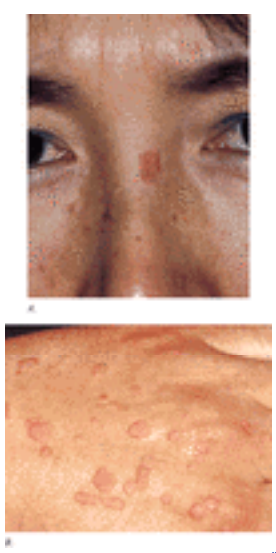

FIGURE 223-8 Common wart, verruca plana. *A.* A single pink, flat-topped lesion is evident on the nose. *B.* Many flat-topped papules occur in a linear configuration as a result of autoinoculation.

FIGURE 223-9 Mucosal wart. *A.* Multiple condyloma acuminata on the shaft of the penis. *B.* Multiple confluent condylomata on the labia minora. *C.* Multiple condylomata on the perineum of a 20-month-old boy. He was infected during vaginal delivery; his mother was not aware of her infection, but examination revealed several small condylomata.

Anogenital warts (also known as condylomata acuminata, genital warts, or venereal warts) consist of epidermal and dermal papules or nodules on the perineum, genitalia, crural folds, and anus. They vary in size and can form large, exophytic (cauliflower-like) masses, especially in the moist environment of the perineum. Discrete 1- to 3-mm sessile warts may occur on the penile shaft.

Lesions that resemble common warts also occur in this region, but are unusual. Warts may extend internally into the vagina, urethra, and perirectal epithelium.

Bowenoid papulosis is a clinicopathologic entity in which HPVs have been identified. [52] Papules, often multiple, appear as 2- to 3-mm lesions on the external male and female genitalia. Histologically, there is cellular atypia resembling Bowen's disease or squamous cell carcinoma in situ. These lesions are usually infected with HPV-16, which suggests that bowenoid papulosis may represent a precursor of penile and vulvar cancer. However, the rate of transition to frank malignancy is much lower for the external genitalia than for the cervix. These small papules should be treated, because they may represent a reservoir for the transmission of potentially oncogenic HPVs. [53] As in all genital warts, virions are difficult to detect in these lesions.

EPIDERMODYSPLASIA VERRUCIFORMIS Representing a unique susceptibility to cutaneous HPV infection, [54] EV usually manifests itself in childhood with widespread warts. The individual lesions typically have either the appearance of flat warts or flat scaly red-brown macules, which resemble lesions of pityriasis rosea or tinea versicolor (Fig. 223-10). The first type of lesion is usually caused by the same HPV types as those found in flat warts in the general population (e.g., HPV-3 and -10), while the second is usually caused by EV HPV types (e.g., HPV-5 and -8). Many EV patients are infected with multiple HPV types. The involvement of large areas of the body with warts or the failure to clear lesions despite adequate treatment is the typical indication to consider with this diagnosis. About 50 percent of EV cases are inherited, usually with an autosomal recessive pattern. At least two different genes can give rise to autosomally inherited EV, because the condition has been mapped to two distinct loci. [55] An X-linked inheritance has also been reported. [56] Viral studies to identify the HPV genotype in the lesions may be suggestive, although such analyses are still limited to research laboratories. EV HPV types may commensually reside in normal skin at very low levels, [15] and it is not clear that they normally cause disease in this setting, although their association with malignant skin tumors is well substantiated in immunosuppressed individuals. [18], [19], [20] and [21] Warts in EV are usually widespread, although there are some patients with only a few classic lesions limited to one extremity. Mucosal warts of the cervix and oropharynx are rare, but can occur. Despite treatment, warts in EV always recur, suggesting failure to mount an effective immune response to the infection. Classically, individuals with EV do not suffer from frequent bacterial or other viral infections. EV patients may have defects of cellular immunity. [54] Immunocompromised individuals, such as those with HIV infection, may have multiple warts that contain EV types and are difficult to eradicate, but this condition is acquired. [57]

FIGURE 223-10 Plane wartlike lesions on the dorsa of the hands and forearms, associated with HPV-5 and -8. The lesions are numerous, flat, reddish, and partly confluent.

Some EV patients are at high risk of developing cutaneous squamous cell carcinomas. [54] These tumors usually arise in pityriasis-like lesions on sun-exposed areas (Fig. 223-11). Most of the malignant tumors remain local, but regional and distant metastases may occur. Although pityriasis-like lesions caused by any EV type may be at increased risk of becoming malignant, the risk appears to be greatest for those caused by HPV-5 and -8. Because the malignant tumors develop on exposed areas, it is believed that UV light acts as an important cofactor in the development of the tumors. The lesions of individuals with EV who have only flat warts caused by non-EV HPV types do not seem to be at increased risk of becoming malignant.

FIGURE 223-11 Invasive cancer in an EV patient infected with numerous HPV types including HPV-5, -8, -9, -14, and others. In the tumor cells, DNA HPV-5 was detected in a high copy number. This large squamous cell carcinoma did not metastasize and did not recur after surgery. There are numerous actinic keratoses on the forehead.

Extracutaneous (Mucosal) Infections

Oral warts are small, slightly elevated, soft, often pink or white papules that may be found on the buccal, gingival, or labial mucosa or on the tongue or hard palate. [58] Verrucous, horny papillomas may occur on the palate. Mucosal lesions of the oropharynx, termed focal epithelial hyperplasia, also contain HPVs. In oral florid papillomatosis, which is thought also to be caused by a papillomavirus, multiple large verrucae appear within the oral cavity. Progression to verrucous carcinoma may occur. Oral condylomata acuminata can result from orogenital contact. Warts may also occur in the urethra, usually when meatal warts are present. [59] They may spread to the urinary bladder.

In respiratory (laryngeal) papillomatosis, patients have multiple benign, noninvasive warts that usually involve the larynx, but may extend to the oropharynx and bronchopulmonary epithelia. [22] Presenting symptoms commonly include hoarseness and stridor. Most cases occur in infants (where the lesions may block the airway), but the condition may develop at any age. These HPV-associated papillomas may spontaneously remit, especially at puberty, but recurrences are frequent, perhaps because of the persistence of viral DNA despite clinical remission. [31] The HPVs isolated from these lesions are the same types as those of cervical warts, and respiratory papillomatosis is thought to result from seeding of the larynx during parturition by virus present in maternal condylomata acuminata or cervical papillomas. [31], [60] Several studies have demonstrated the epidemiologic correlation of condylomata in mothers of infants with this disease. Nonetheless, cervical and external genitalia warts are common in the childbearing age bracket, while respiratory papillomatosis of infants is rare. It is controversial whether mothers with condylomata should undergo cesarean section, because this procedure itself has attendant risk.

As noted earlier, the uterine cervix is an important site of HPV infection. Often termed cervical warts or atypical condylomata, lesions are usually flat or slightly elevated. Their visualization may require colposcopy and enhancement following acetic acid application, which makes them appear as white patches (Fig. 223-12). Atypical condylomata may mimic cervical dysplasia or carcinoma in situ histologically, with nuclear atypia and disorganized differentiation. Cells with a central nucleus and a surrounding clear halo (koilocytotic cells) may be evident histologically in these lesions, as well as in common verrucae, and represent a hallmark of HPV infection as visualized in a Papanicolaou smear.

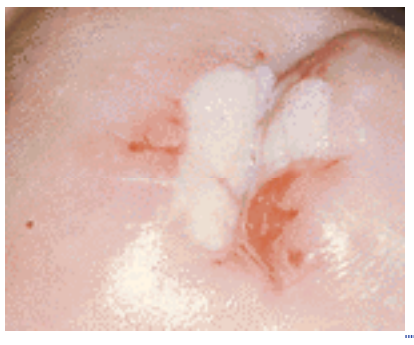

FIGURE 223-12 Colposcopic view of cervical condylomata after treatment with acetic acid for visualization as white, elevated patch.

RELATION OF PAPILLOMAVIRUSES AND MALIGNANCY

Although most papillomaviruses are associated with and limited to biologically benign lesions, epidemiologic and experimental studies indicate that certain papillomavirus genotypes have oncogenic potential. [24], [61] In animals, the benign warts induced in rabbits by the (Shope) cottontail rabbit papillomavirus can spontaneously convert to invasive squamous cell carcinoma. [62] Small doses of chemical carcinogens induce a high rate of malignant conversion in these lesions. In cattle, esophageal papillomas induced by bovine papillomavirus type 4 become malignant if the infected animals graze on bracken fern, which contains a potential carcinogen. [63] These observations and the long latency to malignant progression suggest that papillomaviruses do not induce malignant tumors directly; it is more likely that potentially oncogenic papillomaviruses act by predisposing the infected cell to become malignant. Similar conclusions seem relevant to human malignancies associated with HPVs.

In humans, the link to infection by specific HPV types was first noted in patients with EV. [54] As noted earlier, squamous cell carcinoma frequently develops in sun-exposed warts in EV lesions and is common in those warts containing HPV-5 or -8. Metastatic tumors in EV contain the viral DNA, implying that its presence is not from skin contamination and that retention of the HPV genome is necessary for maintaining the malignant phenotype. Progression of the verrucae in respiratory papillomatosis to invasive squamous cell carcinoma can occur subsequent to X-irradiation.

There is now compelling evidence that cervical infection with high-risk HPVs is the main cause of cervical cancer. [24] Even with high-risk HPVs, however, cervical infection usually has a benign outcome. [25] Patients with impaired cellular immune function, such as renal transplant recipients or those with HIV infection and AIDS, are at much greater risk of having persistent HPV infection that progresses to severe dysplasia and thus to cancer. [64], [65] These observations lead to the conclusion that HPVs usually induce benign lesions, but specific HPV types can induce the development of malignant epithelial tumors. Although HPV infection with these high-risk types may be necessary, it is not sufficient and most likely requires other cofactors to alter the cell to a malignant phenotype.

Epidemiologic and molecular evidence has also linked some penile, vulvar, anal, and oral carcinomas with HPV infection. [61], [66], [67] As with cervical cancer, these tumors are associated primarily with high-risk HPV types, which is consistent with these HPVs as a cause of the malignancies. High-risk HPVs, especially HPV-16, have been identified in some periungual cutaneous tumors. [68]

The giant condyloma acuminatum, also called the Buschke-Lowenstein tumor, is a low-grade, locally invasive squamous cell carcinoma. Low-risk HPVs, such as types 6 and 11, are usually found in these tumors. [69] Verrucous carcinoma of the penis, however, is not usually associated with HPV infection. Epithelioma cuniculatum, another rare type of verrucous carcinoma, is found on the sole and is thought to arise from a plantar wart.

There is also evidence, arising from the use of very sensitive PCR techniques, that HPVs may be found in a high proportion of nonmelanoma cutaneous tumors in patients without obvious immune impairment, as well as in immunosuppressed renal allograft recipients. [13], [14] These provocative findings require careful follow-up to determine the precise relationship between the HPVs and the cutaneous tumors, because the same PCR techniques have also identified small amounts of HPV DNA in normal skin or in dermatologic conditions in which the normal barrier function of the epithelium is impaired. [15], [16]

HISTOPATHOLOGY

Verrucae consist of an acanthotic epidermis with papillomatosis, hyperkeratosis, and parakeratosis (Fig. 223-13); some correlations can be made with HPV type. [70] The elongated rete ridges often point toward the center of the wart. The dermal capillary vessels are prominent and may be thrombosed. Mononuclear cells may be present. Large keratinocytes with an eccentric, pyknotic nucleus surrounded by a perinuclear halo (koilocytotic cells or koilocytes) are characteristic of HPV-associated papillomas. Koilocytes do not usually contain keratohyaline granules, although they occur in the malpighian layer. Papillomavirus-infected cells may have small, eosinophilic granules and dense clumps of basophilic keratohyaline granules. These granules may be composed of or associated with the papillomavirus E4 (E1-E4) protein [71] and do not represent conglomerates of virus particles. Flat warts have less acanthosis and hyperkeratosis and do not have parakeratosis or papillomatosis. Koilocytotic cells are usually abundant, indicating the viral origin of the lesion. Anogenital warts may have from slight to extensive acanthosis and parakeratosis: they lack a granular layer as they are within or adjacent to a mucosal surface. The rete ridges often form thick bands extending extensively into the underlying, highly vascular dermis. Koilocytes are often observed in these viral papillomas.

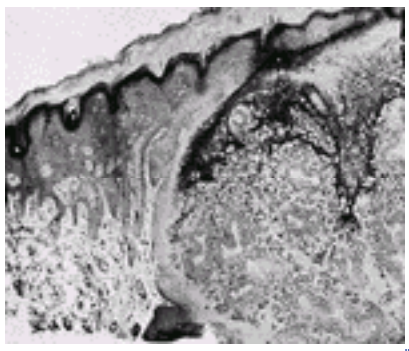

FIGURE 223-13 Verruca vulgaris. The process is one of extensive hyperplasia, and the hyperplastic cells contain both intranuclear and intracytoplasmic inclusion bodies. (*Micrograph by Wallace H. Clark, Jr., MD.*)

Plane warts, which usually contain HPV-3 or -10, have a similar appearance histologically whether in the general population or in patients with EV (Fig. 223-14). The granular and upper spinous layers contain many cells with perinuclear vacuolization. In EV, many cells from lesions containing HPV-5 or -8 have a characteristic basket-weave–like hyperkeratosis with many large clear cells in the granular and spinous layers (Fig. 223-15).

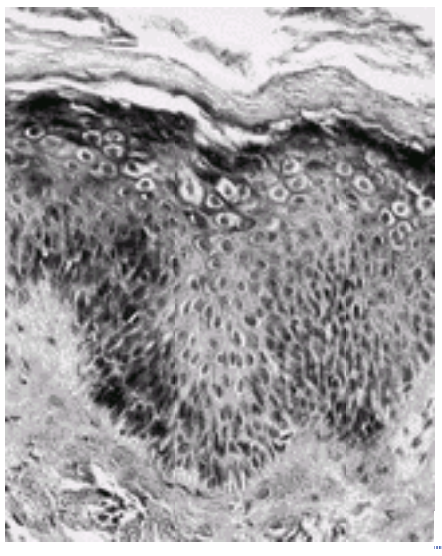

FIGURE 223-14 HPV-3–associated plane wartlike lesion in patient with EV. The histologic pattern is characteristic of a plane wart with numerous cells showing perinuclear vacuolization in the granular and upper spinous layers. H&E.

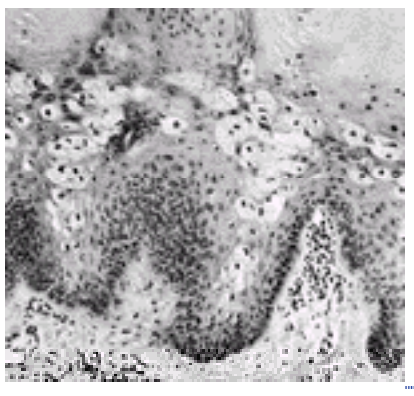

FIGURE 223-15 Characteristic cytopathic effect of EV-specific HPV in a patient found to be infected with HPV-5, -8, and -9. Very abundant clear large cells with small pyknotic nuclei replace almost the entire epidermis. H&E.

DIAGNOSIS

The clinical appearance usually leads to the diagnosis of viral wart, but histologic examination may also suggest the diagnosis. Application of 3 to 5 percent acetic acid to genital warts enhances detection of these lesions, particularly with colposcopic magnification, although diagnosis should not rest only on the presence of white lesions since there may be false-positive results. Immunohistochemical detection of papillomavirus structural proteins may confirm the presence of virus in a lesion. PCR techniques to detect cutaneous HPVs, which are currently limited to research laboratories, may vary in their sensitivity. [72] Diagnostic hybridization tests to identify genital-mucosal HPV type are now commercially available for the common genital HPV types. [73]

Cutaneous warts are common in children and young adults, but also occur in patients over 40 years of age. Multiple warts that do not spontaneously resolve, always recur after treatment, persist for years, or have an unusual morphology (especially if familial) suggest EV. HPV typing may be of benefit in confirming the diagnosis of EV and will also disclose whether the patient is infected with a type that is associated with malignancy. Immunocompromised patients, such as those with AIDS, lymphoproliferative disorders, or on chemotherapeutic drugs, may have multiple warts.

DIFFERENTIAL DIAGNOSIS

Common lesions such as seborrheic and solar keratoses, nevi, irritated achrocordons, clavi, and squamous cell carcinomas may look like verrucae. Papules of lichen planus may resemble flat warts; they may be differentiated by the presence of Wickham's striae and buccal involvement. Acrokeratosis verruciformis and epidermolytic hyperkeratosis are characterized by verrucous papules on the extremities. Syphilitic condylomata must be differentiated from venereal warts.

TREATMENT AND PROPHYLAXIS

The proper approach to the management of warts depends on the age of the patient, the extent and duration of lesions, the patient's immunologic status, and the patient's desire for therapy. [74], [75] Children with common warts may not require therapy. Studies of spontaneous regression of warts in children suggest that two-thirds will remit within 2 years, with remaining verrucae continuing to resolve at this rate. [76] However, new warts may appear while others are regressing.

Many treatments for verrucae involve physical destruction of the infected cells. The existence of multiple treatment modalities reflects the fact that none is uniformly effective or directly antiviral. The choice of treatment depends on the location, size, number and type of wart, as well as on the age and cooperation of the patient. Pain, inconvenience, risk of scarring, and experience of the physician are considerations to evaluate prior to treatment. In patients with anogenital warts (including bowenoid papulosis), sexual partners should be examined and treated if necessary. In females, the condition of the uterine cervix should be evaluated; male contacts of women with cervical disease should also be examined.

Cryotherapy using liquid nitrogen applied with a cotton tip or a spray canister to achieve a halo of ice around the lesion is a common and effective treatment for most warts. [77], [78] Caution must be used near the nail matrix when treating periungual warts. Aggressive cryotherapy with a spray canister can injure underlying structures, such as nerves.

Therefore, its use on the lateral surfaces of the digits and genitalia mandates caution. Warts on the elbows and knees of children may be particularly susceptible to scarring with cryotherapy; although effective, this modality should be used in moderation in these patients.

Warts may be curetted or surgically excised, particularly large anogenital warts unresponsive to topical treatments. Electrodesiccation of condylomata acuminata requires local anesthesia, but may be effective. Laser treatment in several different energy formats, including photodynamic therapies, can be useful for destroying warts that are treatment-resistant or those that require careful control of width and depth, such as large periungual warts. Use of a surgical mask should be routine because infectious papillomavirus has been identified in the vapor plume with laser or with electrocoagulation of warts. [79] Microscopically controlled (Mohs) surgery has been useful in the treatment of verrucous carcinoma. X-irradiation of verrucae is contraindicated because of its association with the development of malignancy in respiratory papillomatosis and EV. Avoidance of and protection from sun exposure is also important in EV. The nucleotide analogue cidofovir has been effective in the treatment of genital warts; however, pain and ulceration were common side effects. [80], [81]

Clinicians have used a variety of chemotherapeutic agents. Topical podophyllin resin is a common treatment, particularly for anogenital warts, as it is more effective on mucosal surfaces. However, podophyllin is contraindicated during pregnancy, and the potency of podophyllin preparations may be variable. Purified podophyllotoxin (Condylox) has activity that is uniform from batch to batch, and it is approved for treatment of genital and perianal warts. [82], [83] Intralesional bleomycin may eradicate verrucae, but should be used cautiously because of the possibility of extensive tissue necrosis. [84]

Caustics and acids such as salicylic acid, lactic acid, and trichloroacetic acid destroy and peel off infected skin. Home use of salicylic acid preparations can be particularly efficacious in young children who cannot tolerate other modalities. Retinoic acid has been used topically for flat warts and probably has a similar mechanism of action. Cantharidin is an extract of the green blister beetle that leads to blistering and focal destruction of epidermis.

Immunotherapies have been attempted in various forms. Induction of allergic contact dermatitis with dinitrochlorobenzene (DNCB), squaric acid dibutylester (SADBE), [85] or diphenylcyclopropenone (DPC) [86] allows localization of inflammation to warts on which the allergen is painted; it has been speculated that this treatment stimulates local immunity. DNCB is positive in the Ames bacterial test of mutagenicity, and its use remains controversial. Cimetidine has been associated with the resolution of cutaneous warts, particularly in children. Although this regimen has its supporters, a double-blind controlled study showed no beneficial effect. [87] Interferon has been effective in short-term studies, reducing warts in laryngeal papillomatosis and EV, but lesions return when therapy is stopped. [31], [88], [89] Recombinant interferon-a was approved for intralesional injection of refractory genital warts in 1989, and other forms of interferon have shown utility. [90] It is not clear that interferon acts through stimulation of immune response. Cytokines were successfully used in the treatment of warts in a patient with cyclic neutropenia. [91] Imiquimod (Aldara), a potent stimulator of the release of several proinflammatory cytokines, has been approved for treatment of genital warts. [92] Uncontrolled reports suggest it may have utility in treatment of cutaneous, plantar, and flat warts.

A variety of prophylactic and therapeutic HPV vaccine trials is contemplated or in progress. [93] Most of these focus on genital HPV infection. For animal papillomaviruses, vaccination of rabbits, dogs, and cows with virus-like particles derived from papillomaviruses that can cause lesions in the respective host have shown good protection against subsequent experimental challenge with the authentic virus. [50], [94] Early phase clinical trials in normal volunteers indicate that HPV virus-like particles are well tolerated and highly immunogenic. [95]

REFERENCES

1. de Villiers EM: Papillomavirus and HPV typing. *Clin Dermatol* **15**:199, 1997

2. Favre M et al: Human papillomaviruses: General features. *Clin Dermatol* **15**:181, 1997

3. Turek LP: The structure, function, and regulation of papillomaviral genes in infection and cervical cancer. *Adv Virus Res* **44**:305, 1994

4. Howett MK et al: Tissue xenografts as a model system for study of the pathogenesis of papillomaviruses. *Clin Dermatol* **15**:229, 1997

5. Meyers C et al: Synthesis of infectious human papillomavirus type 18 in differentiating epithelium transfected with viral DNA. *J Virol* **71**:7381, 1997

6. Roden RBS et al: In vitro generation and type-specific neutralization of a human papillomavirus type 16 virion pseudotype. *J Virol* **70**:5875, 1996

7. Gravitt PE et al: Improved amplification of genital human papillomaviruses. *J Clin Microbiol* **38**:357, 2000

8. Chan SY et al: Analysis of genomic sequences of 95 papillomavirus types: Uniting typing, phylogeny, and taxonomy. *J Virol* **69**:3074, 1995

9. Majewski S, Jablonska S: Human papillomavirus–associated tumors of the skin and mucosa. *J Am Acad Dermatol* **36**:659, 1997

10. Bosch FX et al: Prevalence of human papillomavirus in cervical cancer: A worldwide perspective. *J Natl Cancer Inst* **87**:796, 1995

11. Jenson SB et al: Immunological relatedness of papillomaviruses from different species. *J Natl Cancer Inst* **64**:495, 1980

12. Roden RBS et al: Assessment of the serological relatedness of genital human papillomaviruses by hemagglutination inhibition. *J Virol* **70**:3298, 1996

13. de Villiers EM et al: Prevailing papillomavirus types in non-melanoma carcinomas of the skin in renal allograft recipients. *Int J Cancer* **73**:356, 1997

14. Berkhout RJ et al: Persistence of human papillomavirus DNA in benign and (pre)malignant skin lesions from renal transplant recipients. *J Clin Microbiol* **38**:2087, 2000

15. Astori G et al: Human papillomaviruses are commonly found in normal skin of immunocompetent hosts. *J Invest Dermatol* **110**:752; 1998

16. Boxman IL et al: Detection of human papillomavirus types 6 and 11 in pubic and perianal hair from patients with genital warts. *J Clin Microbiol* **37**:2270, 1999

17. Laurent R, Kienzler JL: Epidemiology of HPV infections. *Clin Dermatol* **3**:64, 1985

18. Kokelj F et al: Study of the partners of women with human papillomavirus infection. *Int J Dermatol* **32**:661, 1993

19. Barrasso R et al: High prevalence of papillomavirus-associated penile intraepithelial neoplasia in sexual partners of women with cervical intraepithelial neoplasia. *N Engl J Med* **317**:916, 1987

20. de Villiers EM: Importance of human papillomavirus DNA typing in the diagnosis of anogenital warts in children. *Arch Dermatol* **131**:366, 1995

21. Obalek S et al: Anogenital warts in children. *Clin Dermatol* **15**:369, 1997

22. Kashima HK et al: Recurrent respiratory papillomatosis. *Obstet Gynecol Clin North Am* **23**:699, 1996

23. Shah KV et al: Risk factors for juvenile onset recurrent respiratory papillomatosis. *Pediatr Infect Dis J* **17**:372, 1998

24. Schiffman MH, Brinton LA: The epidemiology of cervical carcinogenesis. *Cancer* **76**:1888, 1995

25. Hildesheim A et al: Persistence of type-specific human papillomavirus infection among cytologically normal women. *J Infect Dis* **169**:235, 1994

26. Castellsagué X et al: Prevalence of penile human papillomavirus DNA in husbands of women with and without cervical neoplasia: A study in Spain and Colombia. *J Infect Dis* **176**:353, 1997

27. Dillner J: The serological response to papillomaviruses. *Semin Cancer Biol* **9**:423, 1999

28. Favre M et al: Antibodies to human papillomavirus type 5 are generated in epidermal repair processes. *J Invest Dermatol* **114**:403, 2000

29. Gentles JC, Evans EGV: Foot infections in swimming baths. *Br Med J* **2**:260, 1973

30. Giroglou T et al: Human papillomaviruses infection requires heparan sulfate. *J Virol* **75**:1565, 2001

31. Steinberg BM et al: Persistence and expression of human papillomavirus during interferon therapy. *Arch Otolaryngol Head Neck Surg* **144**:27, 1988

32. Roden RB et al: Papillomavirus is resistant to desiccation. *J Infect Dis* **176**:1076, 1997

33. Howett MK et al: A broad-spectrum microbicide with virucidal activity against sexually transmitted viruses. *Antimicrob Agents Chemother* **43**:314, 1999

34. Grussendorf-Conen EI et al: Correlation between content of viral DNA and evidence of mature virus particles in HPV-1, HPV-4, and HPV-6 induced virus acanthomata. *J Invest Dermatol* **81**:511, 1983

35. Frattini MG et al: In vitro synthesis of oncogenic human papillomaviruses requires episomal genomes for differentiation-dependent late expression. *Proc Natl Acad Sci U S A* **93**:3062, 1996

36. zur Hausen H: Papillomaviruses causing cancer: Evasion from host-cell control in early events in carcinogenesis. *J Natl Cancer Inst* **92**:690, 2000

37. Howley PM, Lowy DR: Papillomaviruses and their replication, in *Fields Virology,* 4th ed, edited by DM Knipe et al. Philadelphia, Lippincott Williams & Wilkins, 2001, p 2197

38. McCance DJ et al: Human papillomavirus type 16 alters human epithelial cell differentiation in vitro. *Proc Natl Acad Sci U S A* **85**:7169, 1988

39. Mantovani F, Banks L: The human papillomavirus E6 protein and its contribution to malignant progression. *Oncogene* **20**:7874, 2001

40. Münger K et al: Biological activities and molecular targets of the human papillomavirus E7 oncoprotein. *Oncogene* **20**:7888, 2001

41. Steger G, Pfister H: In vitro expressed HPV 8 E6 protein does not bind p53. *Arch Virol* **125**:355, 1992

42. Jackson S et al: Role of Bak in UV-induced apoptosis in skin cancer and abrogation by HPV E6 proteins. *Genes Dev* **14**:3065, 2000

43. Liu V et al: Multiple functions of human papillomavirus type 16 E6 contribute to the immortalization of mammary epithelial cells. *J Virol* **73**:7297, 1999

44. Funk JO et al: Inhibition of CDK activity and PCNA-dependent DNA replication by p21 is blocked by interaction with the HPV-16 E7 oncoprotein. *Genes Dev* **11**:2090, 1997

45. Stoppler MC et al: The E5 gene of HPV-16 enhances keratinocyte immortalization by full-length DNA. *Virology* **223**:251, 1996

46. DiMaio D, Mattoon D: Mechanisms of cell transformation by papillomavirus E5 proteins. *Oncogene* **20**:7866, 2001

47. Majewski S, Jablonska S: Immunology of HPV infection and HPV-associated tumors. *Int J Dermatol* **37**:81, 1998

48. Breitburd F et al: Immunization with virus-like particles from cottontail rabbit papillomavirus (CRPV) can protect against experimental CRPV infection. *J Virol* **69**:3959, 1995

49. Roden R et al: Papillomavirus L1 capsids agglutinate mouse erythrocytes through a proteinaceous receptor. *J Virol* **69**:5147, 1995

50. Kirnbauer R et al: Virus-like particles of bovine papillomavirus type 4 in prophylactic and therapeutic immunization. *Virology* **219**:37, 1996

51. Abcarian H, Sharon N: Long-term effectiveness of the immunotherapy of anal condyloma acuminatum. *Dis Colon Rectum* **25**:648, 1982

52. Bergeron C et al: Human papillomavirus type 16 in intraepithelial neoplasia (bowenoid papulosis) and coexistent invasive carcinoma of the vulva. *Int J Gynecol Pathol* **6**:1, 1987

53. Obalek S et al: Bowenoid papulosis of the male and female genitalia: Risk of cervical neoplasia. *J Am Acad Dermatol* **14**:433, 1986

54. Orth G: Epidermodysplasia verruciformis: A model for understanding the oncogenicity of human papillomaviruses. *Ciba Found Symp* **120**:157, 1986

55. Ramoz N et al: Evidence for a nonallelic heterogeneity of epidermodysplasia verruciformis with two susceptibility loci mapped to chromosome regions 2p21-p24 and 17q25. *J Invest Dermatol* **114**:1148, 2000

56. Androphy EJ et al: X-linked inheritance of epidermodysplasia verruciformis: Genetic and virologic studies of a kindred. *Arch Dermatol* **121**:864, 1985

57. Berger TG et al: Epidermodysplasia verruciformis–associated papillomavirus infection complicating human immunodeficiency virus disease. *Br J Dermatol* **124**:79, 1991

58. Praetorius F: HPV-associated diseases of oral mucosa. *Clin Dermatol* **15**:399, 1997

59. Sand PK et al: Evaluation of male consorts of women with genital human papilloma virus infection. *Obstet Gynecol* **68**:679, 1986

60. Puranen MH et al: Exposure of an infant to cervical human papillomavirus infection of the mother is common. *Am J Obstet Gynecol* **176**:1039, 1997

61. Lowy DR, Howley PM: Papillomaviruses, in *Fields Virology,* 4th ed, edited by DM Knipe et al. Philadelphia, Lippincott Williams & Wilkins, 2001, p 2231

62. Kreider JW, Bartlett GL: Shope rabbit papilloma-carcinoma complex: A model system of HPV infections. *Clin Dermatol* **3**:20, 1985

63. Campo MS: Bovine papillomavirus and cancer. *Vet J* **154**:175, 1997

64. Palefsky JM et al: Cervicovaginal human papillomavirus infection in human immunodeficiency virus-1 (HIV)-positive and high-risk HIV-negative women. *J Natl Cancer Inst* **91**:226, 1999

65. Frisch M et al: Human papillomavirus–associated cancers in patients with human immunodeficiency virus infection and acquired immunodeficiency syndrome. *J Natl Cancer Inst* **92**:1500, 2000

66. Frisch M: Sexually transmitted infection as a cause of anal cancer. *N Engl J Med* **337**:1350, 1997

67. Gillison ML: Evidence for a causal association between human papillomavirus and a subset of hand and neck cancers. *J Natl Cancer Inst* **92**:709, 2000

68. McHugh RW et al: Metastatic periungual squamous cell carcinoma: Detection of human papillomavirus type 35 RNA in the digital tumor and axillary lymph node metastases. *J Am Acad Dermatol* **34**:1080, 1996

69. Grussendorf-Conen EI: Anogenital premalignant and malignant tumors (including Buschke-Lowenstein tumors). *Clin Dermatol* **15**:377, 1997

70. Jablonska S et al: Cutaneous warts: Clinical, histologic, and virologic correlations. *Clin Dermatol* **3**:71, 1985

71. Rogel-Gaillard D et al: Human papillomavirus type 1 E4 proteins differing by their *N*-terminal ends have distinct cellular localizations when transiently expressed in vitro. *J Virol* **66**:816, 1992

72. Meyer T et al: Frequency and spectrum of HPV types detected in cutaneous squamous-cell carcinomas depend on the HPV detection system: A comparison of four PCR assays. *Dermatol* **201**:204, 2000

73. Schiffman M et al: HPV DNA testing in cervical cancer screening: Results from women in a high-risk province in Costa Rica. *JAMA* **283**:87, 2000

74. Beutner KR, Ferenczy A: Therapeutic approaches to genital warts. *Am J Med* **102**:28, 1997

75. Sterling JC et al: Guidelines for the management of cutaneous warts. *Br J Dermatol* **144**:4, 2001

76. Messing AM, Epstein WL: Natural history of warts: A two year study. *Arch Dermatol* **87**:306, 1963

77. Ahmed I et al: Liquid nitrogen cryotherapy of common warts: Cryo-spray vs. cotton wool bud. *Br J Dermatol* **144**:1006, 2001

78. Connolly M et al: Cryotherapy of viral warts: A sustained 10-s freeze is more effective than the traditional method. *Br J Dermatol* **145**:554, 2001

79. Sawchuk WS et al: Infectious papillomavirus in the vapor of warts treated with carbon dioxide laser or electrocoagulation: Detection and protection. *J Am Acad Dermatol* **21**:41, 1989

80. Matteelli A et al: Efficacy and tolerability of topical 1% cidofovir cream for the treatment of external anogenital warts in HIV-infected persons. *Sex Transm Dis* **28**:343, 2001

81. Snoeck R et al: Phase II double-blind, placebo-controlled study of the safety and efficacy of cidofovir topical gel for the treatment of patients with human papillomavirus infection. *Clin Infect Dis* **33**:597, 2001

82. Beutner KR et al: Patient-applied podofilox for treatment of genital warts. *Lancet* **1**:831, 1989

83. Baker DA et al: Topical podofilox for the treatment of condylomata acuminata in women. *Obstet Gynecol* **76**:656, 1990

84. Hayes ME, O'Keefe EJ: Reduced dose of bleomycin in the treatment of recalcitrant warts. *J Am Acad Dermatol* **15**:1002, 1986

85. Micali G et al: Use of squaric acid dibutylester (SADBE) for cutaneous warts in children. *Pediatr Dermatol* **17**:315, 2000

86. Pollock B, Highet AS: An interesting response to diphencyprone (DPC) sensitization on facial warts: Review of DPC treatment for viral warts. *J Dermatolog Treat* **13**:47, 2002

87. Yilmaz E et al: Cimetidine therapy for warts: A placebo-controlled, double-blind study. *J Am Acad Dermatol* **34**:1005, 1996

88. Haglund S et al: Interferon therapy in juvenile laryngeal papillomatosis. *Arch Otolaryngol* **107**:327, 1981

89. Androphy EJ et al: Response of warts in epidermodysplasia verruciformis to treatment with systemic and intralesional alpha interferon. *J Am Acad Dermatol* **11**:197, 1984

90. Reichman RC et al: Treatment of condyloma acuminatum with three different interferon-alpha preparations administered parenterally: A double-blind, placebo-controlled trial. *J Infect Dis* **162**:1270, 1990

91. Gaspari AA et al: Successful treatment of a generalized human papillomavirus infection with granulocyte-macrophage colony-stimulating factor and interferon gamma immunotherapy in a patient with a primary immunodeficiency and cyclic neutropenia. *Arch Dermatol* **133**:491, 1997

92. Fife KH et al: Treatment of external genital warts in men using 5% imiquimod cream applied three times a week, once daily, twice daily, or three times a day. *Sex Transm Dis* **28**:226, 2001

93. Schiller JT, Lowy DR: Papillomavirus-like particle based vaccines: Cervical cancer and beyond. *Expert Opin Biol Ther* **1**:571, 2001

94. Suzich JA et al: Systemic immunization with papillomavirus L1 protein completely prevents the development of viral mucosal papillomas. *Proc Natl Acad Sci U S A* **92**:11553, 1995

95. Harro C et al: Safety and immunogenicity trial in adult volunteers of a human papillomavirus type 16 L1 virus-like particle vaccine. *J Natl Cancer Inst* **93**:284, 2001

T>

Chapter 224

Erwin Tschachler Marvin Reitz Genoveffa Franchini

Human Retroviral Disease: Human T-Lymphotropic Viruses

VIROLOGY
HTLV-1 TRANSMISSION AND EPIDEMIOLOGY
THE NATURAL COURSE OF HTLV-1 INFECTION AND CLINICAL DISEASE SPECTRUM
Adult T Cell Leukemia/Lymphoma
Diagnosis and Differential Diagnosis of ATL
Prognosis and Therapy of ATL
The Role of HTLV-1–Related Retroviruses in Cutaneous T Cell Lymphoma
Neurologic Disease
Infective Dermatitis
Other Disorders

REFERENCES

Viruses have attracted attention as pathogens in malignant and autoimmune diseases in animals ever since Peyton Rous discovered that a virus could cause solid tumors in fowls at the beginning of the twentieth century. The Rous sarcoma virus, named after its discoverer, turned out to contain an RNA genome, but appeared to exist as a DNA provirus in infected cells. [1], [2] This paradox was resolved when Baltimore and Temin and Mizutani independently discovered a polymerase that was able to use RNA as a template to produce DNA—the reverse transcriptase (RT). Viruses, which contain an RNA genome and an RNA-dependent DNA polymerase, belong to the family of Retroviridae. [1]

Although the history of animal retroviruses dates back to the beginning of the century, the first pathogenic human retrovirus was discovered only in 1980. At that time Poiesz and coworkers isolated a retrovirus from lymphocytes of a patient with cutaneous T cell lymphoma [3] and subsequently from a patient with leukemia classified as Sézary syndrome. [4] Independently of this work, Miyoshi and coworkers later isolated the same retrovirus from a Japanese leukemia patient. [5] The American and Japanese isolates were shown in the following years to be indistinguishable by nucleic acid comparison and the name human T cell leukemia virus type I (HTLV-1) was proposed [6] for all isolates previously called adult T cell leukemia virus (ATLV) in Japan and HTLV in the United States.

In 1982, a second human retrovirus, related to but distinct from HTLV-1, was isolated from a cell line derived from a patient with hairy cell leukemia and was named HTLV-2. [7] Although isolated from a leukemic patient, a clear association with a distinct disease has not yet been accomplished for HTLV-2.

VIROLOGY

HTLV-1 and 2 are related but distinct human retroviruses, which, together with bovine leukemia virus, form their own genus within the retroviridae. [1] Many strains of HTLV-1 have been isolated in different areas of the world, including the United States, the Caribbean islands, Africa, and Japan. [8] From sequencing data it appears that the overall nucleic acid sequence variation among different HTLV-1 strains does not exceed 7 percent. [9] Although the genomic organization of HTLV-1 and -2 is quite similar, the nucleotide sequence conservation between these two viruses is only about 55 percent. [10] Like other enveloped retroviruses, the HTLV-1 genome consists of a dimer of identical RNA subunits. [1] After infection of host cells, the RNA genome is transcribed into DNA by the viral RT and the viral DNA is integrated into the host cell genome (provirus). Like all retroviruses it contains dual long-terminal repeats (LTR) at the 3'and 5'ends and *gag, pol,* and *env* genes, which encode integral components of the virions. In addition to these genes, both the HTLV-1 and -2 genomes contain an extra sequence of approximately 1.6 kb between the *env* and the 3' LTR, which was originally called “pX.” [2] While *gag* and *pol* proteins are translated from the full-length genomic RNA, and the *env* proteins are translated from singly spliced mRNAs, the “pX” genes are expressed from RNAs produced mostly by double-splicing mechanisms. The functions of two of these at least six genes, that is, the transregulatory proteins Tax (transactivator in the region x) and Rex (regulator in the region x) have been elucidated. The 40-kDa HTLV-1 Tax interacts with cellular transcription factors and transactivates the viral LTR thereby increasing viral RNA synthesis. [2] The 27-kDa Rex protein promotes the export of the viral genomic and envelope mRNAs to the cytoplasm where they can be translated. [2] The function of the other proteins of the pX region—p21Rex, p12 [I], p13 [II], p30 [II]—still awaits full elucidation. [2]

Infection of human, monkey, and rabbit T lymphocytes by HTLV-1 in vitro leads to their continuous growth in tissue culture and the development of cell lines with growth characteristics of transformed cells. [11] In infected patients, HTLV-1 is mainly present in CD4+ T cells, [12] but it has also been found in dendritic cells of blood [13] and cells from the synovial lining of arthritic joints. [14]

The steps leading from virus infection to the development of the different HTLV-1–associated diseases are still only partly understood. Only a small percentage of patients infected with HTLV-1 ultimately develop adult T cell leukemia (ATL) and the time from infection to leukemia usually lasts several decades. [15] Unlike acute or chronic leukemia viruses, the HTLV-1 genome neither contains an oncogene nor does it transduce cellular oncogenes by insertion at critical sites within the host cell genome. [2], [11], [15] However, the HTLV-1 regulatory gene *Tax,* which is necessary for in vitro

transformation, is able to transactivate both the viral promoter and certain cellular genes. [2], [15] Transformation of human T cells in vitro is a multistep event, which involves selection of infected T cell clones. At first, T cells proliferate in response to exogenous interleukin (IL)-2 (immortalization) and, in time, lose growth factor requirement for growth (transformation). Tax, the viral transactivator, is necessary but not sufficient to induce T cell transformation inasmuch as it interferes with at least two inhibitors of cell-cycle progression as the tumor suppressor protein p16 ^{ink} and p53. [2], [15] In the transformed state, HTLV-1–infected T cells proliferate in the absence of exogenous growth factors; this event correlates with both the constitutive activation of the Jak/STAT signaling pathway [2] and the constitutive activation of the cyclin E/CDK2 complex. The in vitro model of T cell transformation appears to mirror the event that leads to leukemogenesis. In most cases of ATL, genetic mutation/deletion of p53 or p16 ^{ink} occur [2] and the leukemic cells of 70 percent of patients display constitutive activation of the Jak3 and STAT proteins. [2]

Although HTLV-2 has been less well studied than HTLV-1, most of the properties described for the latter, including the transformation of T cells in vitro and the presence and importance of transregulatory genes, are true also for the former. [15] To date, however, no disease has been associated with HTLV-2 infection.

HTLV-1 TRANSMISSION AND EPIDEMIOLOGY

The mode of transmission of HTLV-1 appears to be quite analogous to that of the human immunodeficiency virus type 1 (HIV-1). However, HTLV-1, which is mainly infectious by cell-to-cell contact, is less infectious than HIV-1, which can readily be transmitted cell free. Based on longitudinal studies, it has become well established that sexual transmission of HTLV-1 from male to female, female to male, and male to male occurs. [15], [16] Although the mechanisms of vertical transmission of HTLV-1 are not completely clarified, transmission from mother to child via breast-feeding appears to play a more important role than perinatal or intrauterine transmission. [15], [16]

In parenteral transmission, approximately one-half of patients received transfusions of an HTLV-1–infected donor seroconvert, [17], [18] whereas cell-free fresh-frozen plasma appears not to be infectious. [18] Transfusion-mediated HTLV-1 infection in Japan has been virtually terminated by mass screening of donated blood. In the United States, a screening program for blood units was initiated in 1989. Parenteral transmission via needle sharing very likely accounts for clusters of HTLV-1/-2 seropositivity in intravenous drug users in certain areas of the United States and Europe. [19] There is no indication that arthropod-borne transmission of HTLV-1 occurs.

The geographic distribution of HTLV-1 and -2 has been studied mainly by serological methods, which cannot distinguish between the two viruses. Therefore seroprevalence data usually refer to both HTLV-1 and HTLV-2. More recently, molecular methods that allow the reliable distinction between HTLV-1 and -2 infection have led to extensive molecular typing of the viruses. [8], [15]

An estimated 10 to 20 million individuals are infected by HTLV-1 worldwide. [8], [15], [16] Extensive seroepidemiologic and molecular surveys confirmed an endemic pattern in southern Japan. In Kyushu, Shikoku, and the Ryuku islands, including Okinawa, seroprevalence ranges from 1 to 36 percent, depending on the location and the age group investigated. [15], [16], [20] Similar patterns can be found in the Caribbean islands, particularly Jamaica, Trinidad, Tobago, Martinique, Haiti, Guadeloupe, and Barbados, and in countries of equatorial Africa such as Gabun, Zaire, and the Ivory Coast. [15], [16], [20] Small clusters of HTLV-1/-2 seropositive populations have been reported from restricted areas in South America, among Australian aborigines, and in the Middle East. [15], [16], [20] In the United States, Europe, and Canada, the incidence of HTLV-1 infection is low, and clusters are found predominately among immigrants from endemic areas, especially from the West Indies and Africa. [15], [16], [21] A seroepidemiologic survey among 39,898 U.S. blood donors in 8 geographically diverse areas showed a seroprevalence for HTLV-1/-2 of 0.025 percent. [16] In the United Kingdom, HTLV-1 infection among blood donors is similarly low, with a seroprevalence of approximately 0.05 percent. [22]

THE NATURAL COURSE OF HTLV-1 INFECTION AND CLINICAL DISEASE SPECTRUM

Adult T Cell Leukemia/Lymphoma

Uchiyama and coworkers first described ATL in 1977 as a distinct malignancy of mature T cells occurring primarily in patients born in southwestern Japan. [23] At the beginning of the 1980s, HTLV-1 was linked to ATL by virus isolation from leukemic cells, by the demonstration of oligoclonal or monoclonal integrated HTLV-1 provirus in leukemic cells and by extensive seroepidemiologic studies. [2], [15], [24] Besides Japan, the West Indies are a major region where HTLV-1 infection and ATL are endemic. [2], [15], [16], [24]

Although HTLV-1 is a prerequisite for ATL development, infection with this virus does not necessarily lead to development of leukemia. More than 90 percent of infected individuals remain asymptomatic carriers. [15], [16] Based on Japanese epidemiologic studies, it appears that the annual incidence rate of ATL among HTLV-1 carriers older than 40 years of age is approximately 0.6 to 1.7/1000. [25] The cumulative incidence rate of ATL in HTLV-1 carriers approximates 2 to 5 percent. The latent period from infection to outbreak of leukemia is 20 years or more, as concluded from studies in migrants. [26] Interestingly, the average age of onset of ATL differs in patients from Japan (56 years) and the Caribbean (43 years). [27]

Acute, prototypic ATL is a fatal malignancy of adult onset with a clinical presentation that appears to be identical in all endemic areas. [23], [24], [28], [29] It is characterized by the variable combination of multiorgan involvement, including hepatosplenomegaly, systemic lymphadenopathy, central nervous system (CNS) involvement, and skin lesions, with the presence of multilobated leukemic cells in the peripheral blood (Fig. 224-1A). Leukemic infiltrates of different organs may determine the clinical presentation and the morbidity. CNS involvement may alter the mental status of the patient; [28],

[29] lymphoma within the liver may lead to abnormalities in liver function tests and jaundice; and lung involvement may lead to tachypnea, cyanosis, and dyspnea. [24], [28], [29]

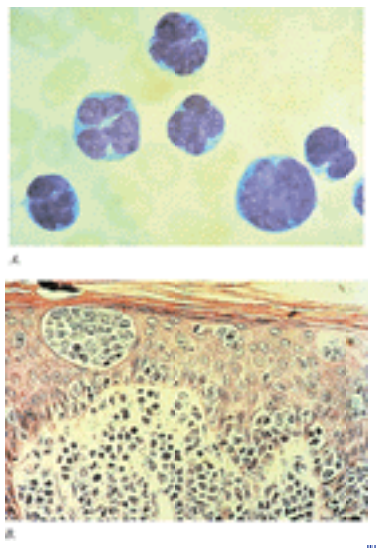

FIGURE 224-1 *A.* Abnormal lymphocyte with multilobated nucleus ("flower cell") from a patient with ATL. (*Courtesy of K Takatsuki, MD, Kumamoto University, Japan.*) *B*. ATL tumor cells are infiltrating the epidermis. (*Courtesy of B Hanchard, MD, University of the West Indies, Jamaica.*)

A striking feature in a high percentage of patients with acute ATL is refractory hypercalcemia, which may represent the first sign of the disease and indicates an aggressive course. [24], [29], [30] Patients may present with weakness, lethargy, polyuria, and polydipsia. Lytic bone lesions resembling those of multiple myeloma are often present at the time of diagnosis and levels of alkaline phosphatase may be elevated. [24], [28], [31] Parathyroid hormone levels and 1,25-dihydroxyvitamin D levels are normal in ATL patients with hypercalcemia; it had been postulated that factors produced by leukemic cells are involved in osteoclast activation, which lead to the clinical symptoms. A variety of cytokines produced by HTLV-1 infected cells and cells derived from ATL patients have been suggested to account for hypercalcemia and bone resorption in ATL patients. [24]

Based on the clinical course and laboratory parameters ATL is classified into four subtypes: (1) smoldering, (2) chronic, (3) lymphoma type, and (4) acute or prototypic ATL, for which diagnostic criteria were recently formulated (Table 224-1). [32], [33]

Smoldering ATL
5% or more abnormal lymphocytes of T cell nature in peripheral blood (PB); normal lymphocyte level (<4 ×10⁹/L; no hypercalcemia; LDH value of up to 1.5 × the normal upper limit; no lymphadenopathy; no involvement of liver, spleen, CNS, bone, and gastrointestinal tract; no ascites or pleural effusion. Skin and pulmonary lesion(s) may be present. In cases where there is less than 5%, abnormal T lymphocytes in PB, at least one histologically proven skin lesion and/or pulmonary lesions should be present.
Chronic ATL
Absolute lymphocytosis (≥4 ×10⁹/L) with T lymphocytosis > 3.5 × 10⁹/L; LDH value up to twice the normal upper limit; no hypercalcemia; no involvement of CNS, bone, and gastrointestinal tract; no ascites or pleural effusion. Lymphadenopathy and involvement of liver, spleen, skin, and lung may be present, and 5% or more abnormal T lymphocytes are seen in PB in most cases.
Lymphoma Type ATL
No lymphocytosis; ≤1% abnormal T lymphocytes; and histologically proven lymphadenopathy with or without extranodal lesions.
Acute ATL
Remaining ATL patients who usually have leukemic manifestations and tumour lesions but are not classified as any of the three other types.

TABLE 224-1 **Distinguishing Features of ATL Subtypes**

In a large series of 818 patients, 57 percent were classified as the acute type, 19 percent as the lymphoma type, 19 percent as chronic, and 5 percent as smoldering-type ATL. [32] Smoldering and chronic ATL may convert into acute ATL, which has led some authors to speak of crisis-type ATL. [28], [32]

The skin involvement in ATL varies considerably among patients but is present to a variable degree in all forms of ATL. [29], [34], [35] and [36] Skin lesions may appear as uncharacteristic erythematous patches, as papular and nodular tumors (Fig. 224-2), and as erythroderma. Nonspecific skin lesions may precede the onset of acute ATL for up to two decades. [37] Specific skin infiltrates may occur as first manifestations of ATL, and show monoclonality of skin infiltrating cells by the criteria both of T cell receptor rearrangement and integration of HTLV-1 DNA. This occurs at a time when circulating T cells of these patients still appear unaffected. [34] For this latter situation, the term *cutaneous type ATL* has been proposed. [34] It is, however, questionable whether this form represents an independent course of ATL or should be included in the smoldering form. Alternatively, it may reflect very early diagnosis of prototypic or chronic ATL, a result of improved diagnostic measures.

FIGURE 224-2 Skin manifestations of ATL. *A*. Generalized papular infiltrates in a patient from Jamaica with prototypic ATL. *B* and *C*. Nodular skin tumors in Japanese ATL patients. (*Courtesy of K Takatsuki, MD, Kumamoto University, Japan.*)

Diagnosis and Differential Diagnosis of ATL

Besides the characteristic clinical course of prototypic ATL, examination of the leukemic cells yields a characteristic picture: numerous multilobated cells called ATL cells or flower cells (Fig. 224-1A) are present in peripheral blood, and can usually be readily distinguished from cells of other T cell leukemias by light microscopy, although sometimes occasional cells indistinguishable from Sézary cells may be present. [24], [28], [29] In smoldering-type ATL and chronic-type ATL, multilobated cells are less frequent, and in lymphoma-type ATL they may comprise less than 1 percent of lymphocytes (Table 224-1). Monoclonal or oligoclonal integration of HTLV-1 DNA [2], [24], [34] has been demonstrated in leukemic cells, as well as in affected organs. By immunophenotyping, leukemic cells display predominantly a mature CD2+/CD3+/CD4+/CD8–/CD25+ phenotype. [24] Although most of these T cell markers can be found on other T cell malignancies, the strong expression of the IL-2 receptor alpha chain (CD25) can be regarded as distinguishing marker between ATL and Sézary syndrome. [38]

The histopathologic features seen in affected organs and lymph nodes are more variable than the picture encountered in peripheral blood, and ATL is associated with lymphomas of several histologic subtypes. Distinction of ATL from other peripheral T cell lymphomas, especially HTLV-1 positive and negative cases on morphologic grounds, cannot be accomplished. No specific pathologic finding distinguishes ATL from other forms of non-Hodgkin's lymphoma. Difficulties can also be encountered in differentiating skin involvement of ATL from mycosis fungoides (MF)/Sézary syndrome because focal epidermal infiltration by T cells or Pautrier's microabscesses (Fig. 224-1B) can be present in skin lesions of ATL. [35], [37], [39] Indeed, the diseases of patients from whom the original U.S. HTLV-1 isolates were obtained were classified as Sézary syndrome [4] and cutaneous T cell lymphoma, [3] respectively. To unequivocally establish the diagnosis of HTLV-1–associated ATL, four diagnostic criteria have been put forward: [28], [32], [33] (1) a histologically or cytologically proven lymphoid malignancy with T cell surface antigens; (2) abnormal T lymphocytes in peripheral blood except in the lymphoma type; (3) anti-HTLV-1 serum antibodies; and (4) the demonstration of clonality of HTLV-1 proviral DNA.

Prognosis and Therapy of ATL

The prognosis of ATL is largely dependent on the subtype. In the most extensive study on the course of ATL to date, 818 newly diagnosed Japanese patients were studied for a median follow-up time of 13.3 months. [27] Median survival time was 6.2 months for the acute type, 10.2 months for the lymphoma type, and 24.3 months for the chronic type. Projected 2- and 4-year survival rates were 16.7 and 5.0 percent for acute type, 21.3 and 5.7 percent for lymphoma type, 52.4 and 26.9 percent for chronic type, and 77.7 and 62.8 percent for smoldering type, respectively. The presence of hypercalcemia, high lactic acid dehydrogenase (LDH) levels, and an excessively high white blood cell count are prognostic factors [27], [32], [33], [38] associated with poor survival. Treatment of prototypic ATL is disappointing and controlled randomized studies comparing different therapeutic protocols have not been performed. Combination cytotoxic therapy used for treatments of non-Hodgkin's lymphoma has little effect on prototypic ATL and ATL lymphoma. [40] Although complete remission can be achieved in up to 40 percent of patients with different combinations of conventional chemotherapy, most of the patients relapse within weeks or months and the 4-year overall survival is below 10 percent. [40] Recently, maintenance chemotherapy with vincristine or methotrexate, prednisolone, etoposide, and cyclophosphamide (OPEC/MPEC), or with daily oral etoposide and prednisolone, was shown to improve both survival and quality of life of ATL patients. [41] Frequent complications of chemotherapy include septicemia and opportunistic infections, which are a consequence of the additive effects on the immune suppression already present in ATL patients. [24], [29], [30] Besides conventional chemotherapy the combination of alpha-interferon and zidovudine, a nucleoside analogue used in anti–HIV-1 therapy, is effective in the treatment of acute and lymphoma-type ATL. [42], [43] Allogeneic bone marrow transplantation, which has been reported in few cases of ATL, [44] as well as the combination of chemotherapy with hemopoietic growth factors, [45] might represent therapeutic options for the future. Cutaneous lesions have been treated successfully with PUVA in one patient. [46]

The course of smoldering and chronic ATL is less dramatic and involvement of inner organs and hypercalcemia are observed less frequently than in ATL lymphoma and acute ATL, [24], [27], [47] and patients have a better prognosis. [24], [27], [40], [47] Because chemotherapy-associated immunosuppression increases immunosuppression caused by the disease, early chemotherapy may be more harmful than beneficial for the patients. Consequently, patients with smoldering and chronic ATL should not be treated by chemotherapy unless they enter a more aggressive phase of their disease.

The Role of HTLV-1–Related Retroviruses in Cutaneous T Cell Lymphoma

The smoldering and the chronic subtypes of ATL can clinically and histologically mimic cutaneous T cell lymphoma (CTCL) and the first HTLV-1 isolates were obtained from patients diagnosed as MF and Sézary syndrome. [3], [4] This, together with earlier reports about the presence of retroviral particles in skin and lymph nodes of patients with these diseases, [48], [49] has incited an intensive search of HTLV-1 in CTCL. Whereas early serologic surveys for HTLV-1 in CTCL patients had revealed HTLV-1 seropositivity rates of less than 1 percent, [50] several reports recently claimed that HTLV-1 DNA sequences are detectable in tumor tissue and in cell lines derived from MF patients and in peripheral blood mononuclear cells (PBMCs) from relatives of MF patients. [51], [52] In contrast to these findings, an overwhelming majority of investigators, studying patients from the same geographic regions with comparable methods, were unable to find HTLV-1 DNA in CTCL samples, [53], [54], [55], [56], [57], [58], [59] and [60] and it is now well accepted by most that HTLV-1 is not involved in the pathogenesis of CTCL.

Neurologic Disease

HTLV-1 infection is associated with chronic progressive myelopathies, which is referred to as tropical spastic paraparesis (TSP) in the Caribbean and HTLV-1–associated myelopathy (HAM) in Japan. [61] Patients suffering from TSP/HAM are generally younger than ATL patients and the latency from infection to development of clinical neurologic symptoms has been described to be very short in individual cases. [62] The lifetime risk to develop HAM/TSP has been estimated at 1 percent. [63] In contrast to ATL, which is associated with HTLV-1 infection very early in life, TSP/HAM patients frequently become infected only in adolescence. In particular, the acquisition of HTLV-1 by blood transfusion has been reported to play an important role for TSP/HAM development. [64]

Infective Dermatitis

Infective dermatitis (Fig. 224-3) is a severe, chronic, relapsing eczema in Jamaican children [65] associated with infection by *Staphylococcus aureus* and beta-hemolytic streptococcus. [66] The association of infective dermatitis with HTLV-1 infection was recently reported. [67] Bacterial infection in infective dermatitis is difficult to control and although it responds to antibiotic treatment, prolonged therapy is necessary and relapses are common after discontinuation. [67] The characteristic clinical picture, the recalcitrant course, and HTLV-1 seropositivity sets infective dermatitis apart from other forms of recurrent eczema, including from atopic eczema. [68] Immunosuppression observed by other investigators in HTLV-1 carriers, as well as in ATL patients, [29], [69], [70] may play a role in the pathogenesis of infective dermatitis. Whereas HTLV-1–infected individuals are overrepresented among patients hospitalized for infectious diseases in Japan, [70] infective dermatitis has been rarely reported from regions outside the Caribbean. [71] Regional, cultural, or genetic factors may play an additive role in the occurrence of infective dermatitis. Evidence that infective dermatitis in childhood might be associated with subsequent development of ATL [72] comes from a recent report on a patient who developed ATL 17 years after having been diagnosed as infective dermatitis in Jamaica. [73]

FIGURE 224-3 Infective dermatitis in an HTLV-1–infected Jamaican girl. (*Courtesy of L. LaGrenade, MD, University of the West Indies, Kingston Jamaica.*)

Other Disorders

Besides the above diseases, certain types of uveitis, [74] polymyositis, [75] chronic inflammatory arthropathy, [76] and peripheral neuropathy [77] have been suggested to be associated with HTLV-1 infection. However, future epidemiologic and virologic studies will be necessary to establish the causative role of the virus in the pathogenesis of these diseases.

REFERENCES

1. Vogt PK: Historical introduction to the general properties of retroviruses, in *Retroviruses,* edited by JM Coffin, SH Hughes, HE Varmus. Cold Spring Harbor, NY, Cold Spring Harbor Laboratory Press, 1997, p 1

2. Johnson JM et al: Molecular biology and pathogenesis of the human T-cell leukaemia/lymphotropic virus type-1 (HTLV-1). *Int J Exp Pathol* **82:**135, 2001

3. Poiesz BJ et al: Detection and isolation of type C retrovirus particles from fresh and cultured lymphocytes of a patient with cutaneous T-cell lymphoma. *Proc Natl Acad Sci U S A* **77:**7415, 1980

4. Poiesz BJ et al: Isolation of a new type C retrovirus (HTLV) in primary uncultured cells of a patient with Sézary T-cell leukemia. *Nature* **294:**268, 1981

5. Miyoshi I et al: Type C virus particles in a cord blood T-cell line derived from cocultivating normal human cord leukocytes and human leukaemic T cells. *Nature* **294:**770, 1981

6. Watanabe T et al: Retrovirus terminology. Science **222:**1178, 1983

7. Kalyanaraman VS et al: A new subtype of human T-cell leukemia virus (HTLV-II) associated with a T-cell variant of hairy cell leukemia. *Science* **218:**571, 1982

8. Gessain A: Epidemiology of HTLV-I and associated diseases in *Human T-Cell Lymphotropic Virus Type I,* edited by P Höllersberg, DA Hafler. Chichester, UK, John Wiley & Sons, 1996, p 33

9. Gessain A et al: Low degree of human T-cell leukemia/lymphoma virus type I genetic drift in vivo as a means of monitoring viral transmission and movement of ancient human populations. *J Virol* **66:**2288, 1992

10. Shimotohno K et al: Complete nucleotide sequence of an infectious clone of human T-cell leukemia virus type II: An open reading frame for the protease gene. *Proc Natl Acad Sci U S A* **82:**3101, 1985

11. Rosenberg N, Jolicoeur P: Retroviral pathogenesis, in *Retroviruses,* edited by JM Coffin, SH Hughes, HE Varmus. Cold Spring Harbor, NY, Cold Spring Harbor Laboratory Press, 1997, p 475

12. Richardson JH et al: In vivo cellular tropism of human T-cell leukemia virus type 1. *J Virol* **64:**5682, 1990

13. Macatonia SE et al: Dendritic cells from patients with tropical spastic paraparesis are infected with HTLV-1 and stimulate autologous lymphocyte proliferation. *AIDS Res Hum Retroviruses* **8:**1699, 1992

14. Kitajima I et al: Detection of human T cell lymphotropic virus type I proviral DNA and its gene expression in synovial cells in chronic inflammatory arthropathy. *J Clin Invest* **88:**1315, 1991

15. Cann AJ, Chen ISY: Human T-cell leukemia virus types I and II, in *Fields Virology,* edited by B Fields, DM Knipe, PM Howley, DE Griffin, RA Lamb, MA Martin, B Roizman, SE Straus. Philadelphia, Lippincott-Raven, 1996, p 1849

16. Edlich RF et al: Global epidemic of human T-cell lymphotropic virus type-I (HTLV-I). *J Emerg Med* **18:**109, 2000

17. Hino S et al: Transfusion-mediated spread of the human T-cell leukemia virus in chronic hemodialysis patients in a heavily endemic area, Nagasaki. *Gann* **75:**1070, 1984

18. Okochi K et al: A retrospective study on transmission of adult T cell leukemia virus by blood transfusion: Seroconversion in recipients. *Vox Sang* **46:**245, 1985

19. Schwebke J et al: Prevalence and epidemiologic correlates of human T cell lymphotropic virus infection among intravenous drug users . *J Infect Dis* **169:**962, 1994

20. Blattner WA: Retroviruses, in *Viral Infections of Humans: Epidemiology and Control,* edited by AS Evans. New York, Plenum, 1989, p 545

21. The HTLV European Research Network: Seroepidemiology of the human T-cell leukaemia/lymphoma viruses in Europe . *J Acquir Immune Defic Syndr Hum Retrovirol* **13:**68, 1996

22. Brennan M et al: Prevalence of antibodies to human T cell leukaemia/lymphoma virus in blood donors in north London. *BMJ* **307:**1235, 1993

23. Uchiyama T et al: Adult T-cell leukemia in Japan: Clinical and hematologic features of 16 cases. *Blood* **50:**481, 1977

24. Bazarbachi A, Hermine O: Treatment of adult T-cell leukaemia/lymphoma: Current strategy and future perspectives. *Virus Res* **78:**79, 2001

25. Kondo T et al: Risk of adult T-cell leukemia/lymphoma in HTLV-I carriers. *Lancet* **ii**:159, 1987

26. Greaves MF et al: Human T-cell leukemia virus (HTLV) in the United Kingdom. *Int J Cancer* **33:**795, 1984

27. Yamaguchi K et al: Pathogenesis of adult T-cell leukemia from clinical pathologic features, in *Human Retrovirology: HTLV,* edited by WA Blattner. New York, Raven Press, 1990, p 163

28. Takatsuki K et al: Adult T-cell leukemia, in *Human T-Cell Lymphotropic Virus Type I,* edited by P Höllersberg, DA Hafler. Chichester, UK, John Wiley & Sons, 1996, p 219

29. Bunn PA et al: Clinical course of retrovirus-associated adult T-cell lymphoma in the United States. *N Engl J Med* **309:**257, 1983

30. Grossmann B et al: Hypercalcemia associated with T-cell lymphoma-leukemia . *Am J Clin Pathol* **75:**149, 1981

31. Blayney DW et al: The human T-cell leukemia/lymphoma virus, lymphoma, lytic bone lesions and hypercalcemia. *Ann Intern Med* **98:**144, 1982

32. Shimoyama M: Diagnostic criteria and classification of clinical subtypes of adult T-cell leukaemia-lymphoma. A report from the Lymphoma Study Group (1984–87). *Br J Haematol* **79:**428, 1991

33. Anonymous. Major prognostic factors of patients with adult T-cell leukemia-lymphoma: A cooperative study. Lymphoma Study Group (1984–1987). *Leuk Res* **15:**81, 1991

34. Dosaka N et al: Examination of HTLV-I integration in the skin lesions of various types of adult T-cell leukemia (ATL): Independence of cutaneous-type ATL confirmed by Southern blot analysis. *J Invest Dermatol* **96:**196, 1991

35. DiCaudo DJ et al: Clinical and histologic spectrum of human T-cell lymphotropic virus type I-associated lymphoma involving the skin. *J Am*

Acad Dermatol **34:**69, 1996

36. Bunker CB et al: Indolent cutaneous prodrome of fatal HTLV-I infection. *Lancet* **i:**426, 1990

37. Chan HL et al: Cutaneous manifestations of adult T cell leukemia/lymphoma . *J Am Acad Dermatol* **13:**213, 1985

38. Waldmann TA et al: Functional and phenotypic comparison of human T cell leukemia/lymphoma virus positive adult T cell leukemia with human T cell leukemia/lymphoma virus negative Sézary leukemia, and their distinction using anti-Tac. *J Clin Invest* **73:**1711, 1984

39. Maeda K, Takahashi M: Characterization of skin infiltrating cells in adult T-cell leukaemia/lymphoma (ATLL): Clinical, histological and immunohistochemical studies on eight cases. *Br J Dermatol* **121:**603, 1989

40. Shimoyama M: Treatment of patients with adult T-cell leukaemia-lymphoma: An overview, in *Advances in Adult T-cell Leukemia and HTLV-I Research,* edited by K Takatzuki, Y Hinuma, M Yoshida. Tokyo, Japan, Japan Scientific Societies Press, 1992 p 43

41. Matsushita K: Long-term maintenance combination chemotherapy with OPEC/MPEC (vincristine or methotrexate, prednisolone, etoposide and cyclophosphamide) or with daily oral etoposide and prednisolone can improve survival and quality of life in adult T-cell leukemia/lymphoma. *Leuk Lymphoma* **36:**67, 1999

42. Gill PS et al: Treatment of adult T-cell leukemia-lymphoma with a combination of interferon alfa and zidovudine. *N Engl J Med* **332:**1744, 1995

43. Hermine O et al: Brief report: Treatment of adult T-cell leukemia-lymphoma with zidovudine and interferon alfa. *N Engl J Med* **332:**1749, 1995

44. Borg A et al: Successful treatment of HTLV-1-associated acute adult T-cell leukaemia lymphoma by allogeneic bone marrow transplantation. *Br J Haematol* **94:**713, 1996

45. Taguchi H et al: An intensive chemotherapy of adult T-cell leukemia/lymphoma: CHOP followed by etoposide, vindesine, ranimustine, and mitoxantrone with granulocyte colony-stimulating factor support. *J Acquir Immune Defic Syndr Hum Retroviro.* **12:**182, 1996

46. Takemori N et al: Satisfactory remission achieved by PUVA therapy in a case of crisis-type adult T-cell leukaemia/lymphoma with generalized cutaneous leukaemic cell infiltration. *Br J Dermatol* **133:**955,1995

47. Kawano F et al: Variation in the clinical course of adult T-cell leukemia. *Cancer* **55:**851, 1985

48. Van der Loo EM et al: C-type virus-like particles specifically localized in Langerhans and related cells of the skin and lymph nodes of patients with mycosis fungoides and Sézary syndrome. *Virchows Arch* **31:**193, 1979

49. Unge T et al: Detection of T-lymphotrophic virus-like particles in cultures of peripheral blood lymphocytes from patients with mycosis fungoides. *Proc Natl Acad Sci U S A* **88:**7630, 1991

50. Gallo RC et al: Association of the human C type retrovirus with a subset of adult T-cell cancers. *Cancer Res* **43:**3892, 1983

51. Ghosh SK et al: Human T-cell leukemia virus type I Tax/Rex DNA and RNA in cutaneous T-cell lymphoma. *Blood* **84:**2663, 1994

52. Zucker-Franklin D et al: Reexamination of human T cell lymphotropic virus (HTLV-I/II) prevalence. *Proc Natl Acad Sci U S A* **94:**6403, 1997

53. Capesius C et al: No evidence for HTLV-I infection in 24 cases of French and Portuguese mycosis fungoides and Sézary syndrome. *Leukemia* **5:**416, 1991

54. Chadburn A et al: Detection and characterization of human T-cell lymphotropic virus type I (HTLV-I) associated T-cell neoplasms in an HTLV-I nonendemic region by polymerase chain reaction. *Blood* **77:**2419, 1991

55. Lisby G et al: No detection of HTLV-I DNA in punch skin biopsies from patients with cutaneous T-cell lymphoma by the polymerase chain reaction. *J Invest Dermatol* **98:**417, 1992

56. Bazarbachi A, et al: HTLV-1 provirus and mycosis fungoides. *Science* **259:**1470, 1993

57. Bazarbachi A et al: Mycosis fungoides and Sézary syndrome are not associated with HTLV-I infection: An international study. *Br J Haematol* **98:**927, 1997

58. Li G et al: Failure to detect human T-lymphotropic virus type-I proviral DNA in cell lines and tissues from patients with cutaneous T-cell lymphoma. *J Invest Dermatol* **107:**308, 1996

59. Fujihara K et al: HTLV-associated diseases: Human retroviral infection and cutaneous T-cell lymphomas. *Immunol Invest* **26:**231, 1997

60. Wood GS et al: Evidence against a role for human T-cell lymphotrophic virus type I (HTLV-I) in the pathogenesis of American cutaneous T-cell lymphoma. *J Invest Dermatol* **107:**301, 1996

61. Izumo S et al: HTLV-I–associated myelopathy. *Neuropathology* **20:**S65, 2000

62. Gout O et al: Rapid development of myelopathy after HTLV-I infection acquired by transfusion during cardiac transplantation. *N Engl J Med* **84:**383, 1990

63. Kaplan JE et al: The risk of development of HTLV-I–associated myelopathy/tropical spastic paraparesis among persons infected with HTLV-I. *J Acquir Immune Defic Syndr* **3:**1096, 1990

64. Osame M et al: Nationwide survey of HTLV-I–associated myelopathy in Japan: Association with blood transfusion. *Ann Neurol* **28:**50, 1990

65. Sweet RD: A pattern of eczema in Jamaica. *Br J Dermatol* **78:**93, 1966

66. Walshe MM: Infective dermatitis in Jamaican children. *Br J Dermatol* **79:**229, 1967

67. LaGrenade L et al: Infective dermatitis of Jamaican children: A marker for HTLV-I infection. *Lancet* **ii:**1345, 1990

68. La Grenade L, et al. Clinical, pathologic, and immunologic features of human T-lymphotrophic virus type I-associated infective dermatitis in

children. *Arch Dermatol* **134:**439, 1998

69. Marsh BJ: Infectious complications of human T cell leukemia/lymphoma virus type I infection. *Clin Infect Dis* **23:**138, 1996

70. Essex ME et al: Seroepidemiology of human T-cell leukemia virus in relation to immunosuppression and the acquired immunodeficiency syndrome, in *Human T-Cell Leukemia/Lymphoma Virus,* edited by RC Gallo, M Essex, L Gross. Cold Spring Harbor, NY, Cold Spring Harbor Laboratory, 1984, p 355

71. LaGrenade L: HTLV-I–associated infective dermatitis: Past, present, and future. *J Acquir Immune Defic Syndr Hum Retrovirol* **13:**S46, 1996

72. Tschachler E, Franchini G: Infective dermatitis: A pabulum for human T-lymphotrophic virus type I leukemogenesis? *Arch Dermatol* **134:**487, 1998

73. Hanchard B et al: Childhood infective dermatitis evolving into adult T-cell leukaemia after 17 years. *Lancet* **ii:**1593, 1991

74. Mochizuki M et al: HTLV-I uveitis. *J Acquir Immune Defic Syndr Hum Retrovirol* **13:**S50, 1996

75. Morgan OSTC et al: HTLV-1 and polymyositis in Jamaica. *Lancet* **ii:**1184, 1989

76. Sato K et al: Arthritis in patients infected with human T lymphotropic virus type I. Clinical and immunopathologic features. *Arthritis Rheum* **34:**714, 1991

77. Vernant JC et al: Pseudo-amyotrophic lateral sclerosis peripheral neuropathy and chronic polyradiculoneuritis in patients with HTLV-I associated paraplegias in HTLV-I and the nervous system, in *Neurology and Neurobiology,* edited by G Roman, JC Vernant, M Osame. New York, Alan R. Liss, 1989, p 361

T>

Chapter 225

Richard Johnson

Cutaneous Manifestations of Human Immunodeficiency Virus Disease

EPIDEMIOLOGY
PATHOGENESIS
NATURAL HISTORY
ACUTE RETROVIRAL SYNDROME (ARS)/PRIMARY HIV INFECTION
COURSE AFTER ARS
ANTIRETROVIRAL DRUG THERAPY (ART) AND HIGHLY ACTIVE ANTIRETROVIRAL THERAPY (HAART)
MUCOCUTANEOUS FINDINGS
CUTANEOUS DISORDERS OCCURRING IN HIV DISEASE
Pruritus and Pruritic Eruptions of HIV Disease
Eosinophilic Folliculitis
Psoriasis Vulgaris
Erythroderma
Pigmentary Disorders
Photosensitivity
CUTANEOUS MANIFESTATIONS OF SYSTEMIC DISORDERS OCCURRING IN HIV DISEASE
DISORDERS OF THE OROPHARYNX
Oropharyngeal Candidiasis
Oral Hairy Leukoplakia (OHL)
Aphthous Ulcers
Neoplasms
OPPORTUNISTIC NEOPLASMS (ONs)
Nonmelanoma Skin Cancer
HIV-Associated KS
HPV-Induced Dysplasias and Cancers
ADVERSE CUTANEOUS DRUG ERUPTIONS
Antiretroviral Agents
Lipodystrophy Syndrome
OPPORTUNISTIC INFECTIONS
BACTERIAL INFECTIONS
FUNGAL INFECTIONS
Dermatophytoses
Mucocutaneous Candidiasis
INVASIVE FUNGAL INFECTIONS
Cryptococcosis
Coccidioidomycosis
Histoplasmosis
Sporotrichosis
Aspergillosis
Penicillinosis
VIRAL INFECTIONS
Herpes Simplex Virus 1 and 2 Infections
Varicella-Zoster Virus (VZV) Infections
Molluscum Contagiosum Virus (MCV)
Human Papillomavirus Infections
SEXUALLY TRANSMITTED DISEASES
SCABIES
REFERENCES

Cutaneous disorders occur nearly universally during the course of human immunodeficiency virus (HIV) disease as a result of the acquired immunodeficiency or are related to treatment. Dermatologic manifestations of HIV disease are a very broad and diverse spectrum. [1] Individuals who have access to highly active antiretroviral therapy (HAART), in most cases those living in North America, western Europe, and Australia, have a markedly altered course of HIV disease if immune restoration is achieved. [2] In most cases, there is a marked reduction in the incidence of opportunistic infections (OIs) and neoplasms (ONs). Globally, however, more than 95 percent of HIV-infected individuals have no access to any medical interventions, and subsequently, many of the cutaneous manifestations associated with HIV disease become chronic and progressive. An estimated 60 million individuals had become infected by the year 2000.

EPIDEMIOLOGY

HIV is a lymphotropic human retrovirus. HIV-1 is the cause of nearly all HIV infection in the United States and Europe; HIV-2 infection has been detected mainly in West Africa. HIV is a blood-borne pathogen, transmitted by sexual contact with an infected person, significant exposures to infected blood or blood products, including needles shared among injecting drug users (IDUs), and perinatally from an infected mother to her child. Both types cause similar clinical HIV disease. HIV-1 has at least 10 subtypes, designated A through J. Subtype B is prevalent in the United States and western Europe and is found mainly among men who have sex with men (MSM) and IDUs. Subtype E—unlike subtype B—is spread very efficiently through heterosexual intercourse.

PATHOGENESIS

Four mechanisms are critical for the establishment and propagation of HIV infection over time and for the progression of HIV disease. HIV is not eliminated after primary infection. Persistent virus replication occurs in lymphoid organs throughout the course of HIV infection. Chronic stimulation of the immune system causes inappropriate immune activation and progressive exhaustion of the immune response. Destruction of lymphoid tissue results in severe impairment of the ability to maintain an effective ongoing HIV-specific immune response and to generate immune responses against new pathogens. Epidermal Langerhans cells (LCs) may become infected by HIV; decreased LC function could account for some of the cutaneous manifestations of HIV disease. [3]

NATURAL HISTORY

HIV disease is a continuum that progresses from primary infection to death, with a sequence of OIs and ONs marking the gradual destruction of the immune system (Table 225-1). Medically, the acquired immune-deficiency syndrome (AIDS) is defined by precise clinical and laboratory parameters. In an individual whose HIV status is unknown or inconclusive and who has no other cause for immunodeficiency, the following mucocutaneous findings are AIDS-defining: *candidiasis* of the esophagus, trachea, bronchi, or lungs (however, not oropharangeal candidiasis alone); *cryptococcosis* with hematogeneous dissemination to skin; *herpes simplex virus mucocutaneous ulcer* that persists longer than 1 month; and *Kaposi's sarcoma* in a patient younger than 60 years of age. In an individual who is HIV-seropositive, the following are AIDS-defining: *coccidioidomycosis* or *histoplasmosis* with hematogenous dissemination to skin and *Kaposi's sarcoma* at any age.

TABLE 225-1 **Stages of HIV Disease**

ACUTE RETROVIRAL SYNDROME (ARS)/PRIMARY HIV INFECTION

The incubation period (from presumed exposure to development of acute febrile illness) ranges from 3 to 6 weeks, varying with the route of infection and the size of the viral inoculum. Commonly reported clinical manifestations include fever (>80–90 percent), fatigue (>70–90 percent), rash (morbilliform, papulosquamous, vesicular on the upper trunk, palms, and soles) (50–60 percent) (Fig. 225-1), myalgia/arthralgia (50–70 percent), pharyngitis (50–70 percent), night sweats (50 percent), and/or nausea, vomiting, and diarrhea (30–60 percent). Less commonly reported manifestations include decreased white blood cell count/platelet count (40–45 percent), weight loss (25 percent), aseptic meningitis (24 percent), anorexia (21 percent), abnormal liver function tests (20 percent), oral ulcers (10–20 percent), and/or genital ulcers (5–15 percent). [4] The laboratory diagnosis of HIV-1 infection is made by four methods: detection of viral antigens, detection of viral nucleic acids, identification of antibodies to viral proteins, and isolation of HIV by viral culture. A delay of 3 to 4 weeks exists between newly acquired HIV-1 infection and development of antibodies, the “window period.” The core structural protein p24 antigen can be detected a week before antibodies can be measured.

FIGURE 225-1 Acute retroviral syndrome: exanthem. Discrete, erythematous macules and papules on the trunk and arm; associated findings were fever, scrotal ulcers, erythematous macules on palate, and lymphadenopathy.

COURSE AFTER ARS

Following the initial burst of viral replication and the peak of viremia, the plasma RNA level decreases and then stabilizes to a level called the *viral set point*. The maximum or peak viral load, the duration of the viral burst, the viral replicative half-life, and the host immune response all influence the viral set point. Antiretroviral intervention has several possible effects on the kinetics of the acute phase of infection. The peak viral load may be reduced without affecting the viral set point, or the peak load may not be affected, but the duration of the viral burst may be shortened with reduction in the viral set point. Cytotoxic T lymphocytes, particularly those specific for Env, help control viral replication and are associated with slower declines in CD4+ cell counts. [5] Approximately 6 months after transmission of HIV, the plasma HIV RNA level reaches a relatively stable set point that dictates the subsequent course. Patients with high viral concentrations (viral load), such as 100,000 or more copies per microliter, will have a relatively rapid course, and those with relatively low concentrations, such as 10,000 copies per microliter, will have relatively slow progression. Undetectable viral load levels may correspond with nonprogression of HIV disease. The average annual decrease in CD4+ cell count is 50 cells per microliter. Early treatment with antiretroviral drugs may reduce the viral set point and alter the prognosis of HIV infection.

Multiple variables are known to influence the rate of progression of HIV disease, contributing to induction of HIV expression, and potentially modify and accelerate the course of HIV disease: size of HIV inoculum, the site of infection,

immune status of the host, variable virulence of certain HIV strains, and reactivation of latent herpesvirus infection. In a cohort of HIV-infected homosexual males from San Francisco studied prior to effective antiretroviral drug therapy, approximately 50 percent developed AIDS within 11 years of becoming infected. Similar data have been reported in other risk groups in the United States. In a cohort of HIV-infected persons from North America, Europe, and Australia whose date of seroconversion was known, the incubation time to the development of an AIDS-defining event varied with the various risk groups, possibly because of different exposures to potential opportunistic pathogens. [6] The rate of disease progression is more rapid in developing nations that cannot afford any medical therapies than in industrialized countries.

ANTIRETROVIRAL DRUG THERAPY (ART) AND HIGHLY ACTIVE ANTIRETROVIRAL THERAPY (HAART)

The three main groups of antiretroviral drugs are nucleoside analogue reverse transcriptase (RT) inhibitors (NRTIs), nonnucleoside RT inhibitors (NNRTIs), and proteinase inhibitors (PIs). Nucleoside analogues that inhibit HIV RT slow or prevent formation of DNA copies of HIV in infected cells. Like the nucleoside analogues, NNRTIs inhibit RT, but by a different mechanism; their toxicity and resistance patterns do not overlap with the nucleosides. PIs prevent cleavage of protein precursors essential for HIV maturation, infection of new cells, and replication. Therapy with PIs in individuals with advanced HIV disease has led to marked clinical improvement and prolonged survival. All PIs can cause hyperglycemia and worsening of diabetes mellitus. NRTIs include zidovudine (ZVD, AZT), didanosine (ddI), zalcitabine (ddC), stavudine (d4T), lamivudine (3TC]), and abacavir. NNRTIs include nevirapine, delavirdine, and efavirenz. PIs include saquinavir, ritonovir, indinavir, nelfinavir, amprenavir, and lopinavir.

MUCOCUTANEOUS FINDINGS

OIs, ONs, dermatoses, adverse cutaneous drug reactions, and pruritus involving skin and/or mucosa occur more commonly as immune function deteriorates, being problematic in more than 90 percent of HIV-infected individuals. Correlated with low CD4 cell counts, cutaneous lesions may become quite atypical. Certain cutaneous disorders correlate with low CD4 cell counts (200–300 cell/µL), including Kaposi's sarcoma, oral hairy leukoplakia, multiple facial molluscum contagiosum, xerosis, and oropharyngeal candidiasis. Mucocutaneous disorders (see Table 225-2) are commonly the indication for initial HIV testing.

Highly indicative of HIV infection (correlated with risk factors for HIV infection)
• Exanthem of acute retroviral syndrome
• Proximal subungual onychomycosis
• Chronic herpetic ulcers
• Oral hairy leukoplakia
• Kaposi's sarcoma
• Eosinophilic folliculitis
• Molluscum contagiosum, multiple facial in adult
Strongly associated with HIV infection (correlated with risk factors for HIV infection)
• Any sexually transmitted disease (indicative of "unsafe" sexual practice)
• Herpes zoster
• Signs of injecting drug use
• Candidiasis: oropharyngeal or recurrent vulvovaginal
May be associated with HIV infection (correlated with risk factors for HIV infection)
• Generalized lymphadenopathy
• Seborrheic dermatitis (extensive, refractory to therapy)
• Aphthous ulcers (recurrent, refractory to therapy)

TABLE 225-2 **Mucocutaneous Disorders as Indications for HIV Serotesting**

Immune restoration syndrome is defined by manifestations of HIV disease, which may worsen despite an adequate response to HAART, as measured by an increase in CD4 cell counts and a decrease/disappearance of serum HIV RNA. With progressive HIV disease, T_H2 immune responses dominate, facilitating development of many dermatologic disorders. With HAART, T_H1 responses are restored, and some skin disorders regress; however, some conditions may worsen, such as VZV infections, HSV infections, eosinophilic folliculitis (EF), HPV infections, and mycobacterial infections. [8] These seemingly paradoxical responses may occur as the host's immune responses recognize silent or latent infections. [9]

CUTANEOUS DISORDERS OCCURRING IN HIV DISEASE

Pruritus and Pruritic Eruptions of HIV Disease

Pruritus, a common complaint in patients with late symptomatic and advanced HIV disease, is a surrogate cutaneous marker for disease progression, occurring commonly in patients with CD4 counts of less than 50 cells per microliter compared with those with counts greater than 250 cells per microliter. In most cases, primary or secondary dermatoses rather than metabolic disorders are the cause of pruritus. [10] The differential diagnosis of primary pruritic skin disorders includes EF, adverse cutaneous drug eruptions, atopic dermatitis, xerosis, dermatographism, allergic contact dermatitis, scabies, and insect bites. [11] Much less commonly, systemic and metabolic disorders such as lymphoma, renal failure, viral hepatitis (hepatitis B or C), and obstructive liver disease are associated with pruritus in the absence of cutaneous findings, i.e., “metabolic” pruritus.

An atopic diathesis may become manifest in individuals with advanced HIV disease and pruritus. Changes secondary to chronic rubbing and scratching include excoriations, atopic dermatitis, lichen simplex chronicus, and prurigo nodularis. Secondary *Staphylococcus aureus* infection (impetiginization, furunculosis, or cellulitis) is very common in any of these traumatized lesions. Ichthyosis vulgaris and xerosis are common in advanced HIV disease and may be associated with mild pruritus. PIs (especially indinavir) frequently cause xerosis with or without eczematous dermatitis, which may be associated with mild or moderate pruritus (see “ Adverse Cutaneous Drug Reactions” below). These changes occur relatively soon after initiation of therapy, presenting xerosis (dry skin) with or without eczematous dermatitis or nummular

eczema.

Eosinophilic Folliculitis

EF is a chronic pruritic dermatosis occurring in persons with advanced HIV disease. It may occur in the immune restoration syndrome. The etiology and pathogenesis are unknown but may be associated with a T_H2 immune response to an unknown antigen. [12] Clinically, small pink to red, edematous, folliculocentric papules (and much less commonly pustules) occur symmetrically above the nipple line on the chest (Fig. 225-2), proximal arms, head, and neck. Secondary changes include excoriations, excoriated papules, lichen simplex chronicus, and prurigo nodularis, as well as secondary *S. aureus* infections. In individuals with darker skin, postinflammatory hyperpigmentation often produces significant cosmetic disfigurement. Once significant immune restoration has been achieved, EF resolves. Histologic findings are specific for EF; peripheral eosinophilia is common, in some cases up to 35 percent.

FIGURE 225-2 Eosinophilic folliculitis. Multiple erythematous pruritic papules and a few pustules on the upper back in an individual with a CD4 cell count of 50/µL.

The most effective therapy for EF is prednisone. Beginning with an initial dose of 70 mg PO, prednisone is tapered by 10 or 5 mg over 7 or 14 days; established lesions resolve, new lesions do not occur, and pruritus resolves. In the majority of persons with successfully treated EF, lesions and pruritus recur within a few weeks after prednisone has been discontinued. In those with severe symptoms, prednisone can be given on alternate days or weekly. Oral isotretinoin is effective and safe in treatment of EF, usually 40 mg bid until lesions and symptoms resolve, then tapered to 40 mg daily for several weeks, and then to 20 mg daily or 40 mg qod. [13] Isotretinoin can raise serum triglyceride levels, which are often high in HIV-infected persons; serum lipids should be monitored regularly. Phototherapy with ultraviolet radiation (UVR), using ultraviolet A (UVA) or UVB with or without topical or systemic psoralen, is considered to be a safe topical treatment modality in HIV-infected persons. [14] UVR does not appear to have a significant deleterious effect on HIV viral load. [15] High-potency topical corticosteroid preparations may reduce the formation of new EF lesions as well as treat eczematous dermatitis, thus providing symptomatic relief; cutaneous atrophy is of concern with chronic application. Topical tacrolimus or pimecrolimus may be effective. Sedating antihistamines such as doxepin are most effective for symptomatic control of nocturnal pruritus; nonsedating antihistamines are ineffective in controlling pruritus.

Psoriasis Vulgaris (See Chap. 42)

The prevalence of psoriasis vulgaris and psoriatic arthritis is increased in HIV disease. The onset of psoriatic lesions may be prior to or following HIV infection. Onset of psoriasis in an individual at risk for HIV disease may be an indication for HIV serotesting. Psoriasis with onset following HIV infection has been observed to improve more with HAART than that with onset prior to HIV infection. For management of psoriasis vulgaris, see Chap. 42. Short-term administration of retinoids such as isotretinoin or acetretin is usually safe. Potential hyperlipidemia is more likely in HAART-treated individuals. Etanercept has been effective for psoriasis/psoriatic arthritis in HIV disease but is associated with infections. [16]

Erythroderma (See Chap. 44)

Erythroderma in HIV disease may be related to drug hypersensitivity, atopic dermatitis, psoriasis vulgaris, photosensitivity dermatitis, the hypereosinophilic syndrome, coexisting human T-cell lymphotrophic virus-I (HTLV-I) infection, or cutaneous T cell lymphoma. [17]

Pigmentary Disorders

Postinflammatory hyper- and hypopigmentation are the most common disorders affecting HIV-infected individuals. With the exception of light-skinned individuals of northern European heritage, significant lightening or darkening of skin occurs following any type of inflammatory dermatosis or infection. In addition to pigmentary alterations, significant atrophic or hypertrophic scarring can follow herpes zoster. This alteration in normal skin color results in significant cosmetic disfigurement, especially when it occurs on highly visible sites such as the face, neck, and upper extremities. If the dermatosis is chronic, the pigmentary change can become persistent and progressive. If the dermatosis resolves, the pigmentary disorder can take months to years to fade gradually to uniform pigmentation. The primary goal in management of these pigmentary disorders is to treat the primary skin disorder. Topical preparations containing 4% hydroquinone may be helpful in treating postinflammatory hyperpigmentation.

Photosensitivity (See Chap. 135 and Chap. 136)

Idiopathic photosensitivity is an uncommon phenomenon in HIV disease but may be the presenting complaint of advanced disease [18] (Fig. 225-3). The most common types of photosensitivity in HIV disease are related to drug therapy.

FIGURE 225-3 Chronic actinic dermatitis. Eczematous dermatitis and hyperpigmentation in the sun-exposed sites of the face, neck, and dorsum of the hands of a 50-year-old black male; no exogenous photosensitizing agents could be identified.

CUTANEOUS MANIFESTATIONS OF SYSTEMIC DISORDERS OCCURRING IN HIV DISEASE

Porphyria cutanea tarda (PCT) in HIV disease is most often associated with an underlying hepatopathy, i.e., hepatitis C virus (HCV) infection, alcoholism, or hepatitis B virus infection. Pseudoporphyria occurs in the absence of abnormalities of porphyrin metabolism and usually is drug-induced.

Cutaneous and systemic vasculitis of many etiologies has been reported to occur in HIV disease, including adverse cutaneous drug reaction, cytomegalovirus infection, polyarteritis nodosa, lymphomatoid granulomatosis, Kawasaki syndrome, and possibly HIV infection itself. [19], [20] Causative drugs should be discontinued if possible. Most other causes are not specifically treatable. Systemic immunosuppressive therapy may be indicated in some cases.

DISORDERS OF THE OROPHARYNX

Nearly all HIV-infected individuals experience disorders of the oropharynx during the course of the disease. [21] Oropharyngeal disorders have been reported to be the first sign of HIV disease in 10 percent of cases, and their detection may be an indication for HIV serotesting. In a study of oropharyngeal disorders (103 consecutive patients with late symptomatic and advanced HIV disease), candidiasis was the most common finding, diagnosed in more than 90 percent. [22] Other disorders of the lips and oropharynx included herpetic ulcers (10 percent), xerostomia (10 percent), exfoliative cheilitis (9 percent), oral hairy leukoplakia (7 percent), Kaposi's sarcoma (4 percent), patchy depapillation of the tongue (6 percent), and ulcers of uncertain cause (3 percent).

Oropharyngeal Candidiasis

(See “ Candidiasis” below)

Oral Hairy Leukoplakia (OHL)

OHL, a lesion specific to HIV disease caused by Epstein-Barr virus, has been reported in up to 28 percent of HIV-infected patients and is a marker for disease progression. [24] In a study of HIV-associated mucocutaneous disorders in 456 patients (1982–1992), [24] OHL was diagnosed in 16 percent of cases when the median CD4 cell count was 235 cells per microliter. Median survival time after OHL diagnosis was 20 months. In patients with a CD4 cell count of 300 or more cells per microliter, the detection of OHL was associated with shorter median survival time of 25 months compared with 52 months in those without the finding. OHL presents as a hyperplastic, whitish epithelial plaque(s) on the lateral tongue with corrugations accentuating the normal tongue ridges, usually bilateral but not symmetric (Fig. 225-4). The differential diagnosis includes hyperplastic oral candidiasis, HPV-induced neoplasia [condyloma acuminatum, squamous intraepithelial lesion (SIL) squamous cell carcinoma in situ (SCCIS), or invasive SCC], geographic tongue, lichen planus, tobacco-associated leukoplakia, mucous patch of secondary syphilis, and occlusive trauma. The diagnosis of OHL is usually made on clinical findings; however, if the diagnosis is uncertain, confirmatory lesional biopsy is advised. For the most part, OHL is asymptomatic, but its presence may be associated with some degree of anxiety. With HAART, OHL usually either does not occur or resolves without additional interventions.

FIGURE 225-4 Oral hairy leukoplakia. White plaques with vertical corrugations on the inferolateral aspect of the tongue. The lesions are fixed, as compared with those of thrush, which can be brushed off with a gauze pad.

Aphthous Ulcers

(See Chap. 112)

Neoplasms

Kaposi's sarcoma (KS) commonly occurs on the palate, gingiva, and tongue. Untreated, KS can evolve into large nodular lesions and ulcerate. Oral presentations of non-Hodgkin's lymphoma usually occur on the palate, gingiva, or consular area. HPV-induced SCC, both in situ and invasive, arises on the buccal mucosa, tongue, and palate.

OPPORTUNISTIC NEOPLASMS (ONs)

The prevalence of the ONs including KS, [25] HPV-induced neoplasia [squamous intraepithelial lesion (SIL), squamous cell carcinoma in situ (SCCIS), and invasive SCC of the cervix, external anogenitalia, and perineum], undifferentiated non-Hodgkin's B cell lymphoma (NHL), and primary CNS lymphoma, is increased in HIV disease. [26] The incidence of nonmelanoma skin cancer, Hodgkin's lymphoma, T cell lymphomas, and seminoma also may be increased. Many of these ONs (NHL, KS, and anogenital in situ and invasive SCC) are associated with oncogenic human viruses (Epstein-Barr virus, HHV-8, HPV) and diminished immune-mediated tumor surveillance.

Nonmelanoma Skin Cancer

The prevalence of UVR-induced SCC appears to be increased in HIV disease, as it is in immunosuppressed renal transplant recipients; as with transplant recipients, UVR-induced SCC in HIV disease may be more aggressive than in the immunocompetent host. [27], [28] Risk factors for the development of SCC and basal cell carcinoma (BCC) were fair skin and excessive sun exposure (>6 h per day during the previous 10 years). SCCs were diagnosed more commonly in individuals with advanced HIV disease than were BCCs. HPV was not an oncogenic factor in the development of these cutaneous tumors; however, p53 overexpression was hypothesized to play an etiologic role. As in immune-suppressed transplant recipients, the incidence of Merkel cell carcinoma may be increased in HIV-infected individuals. [29]

HIV-Associated KS

(See Chap. 104) [30]

HPV-Induced Dysplasias and Cancers

(See " Human Papillomavirus Infection" below)

ADVERSE CUTANEOUS DRUG ERUPTIONS (See Chap. 138)

The incidence of adverse cutaneous drug eruptions (ACDEs) to a variety of drugs is high in HIV disease (100 times more common than in the general population) and increases with advancing immunodeficiency. [31] Drug hypersensitivity complicated 3 to 20 percent of all prescriptions in one large series. In a report of 974 HIV-infected individuals followed for 46 months, 283 ACDEs occurred in 201 patients. [32] ACDEs were noted more commonly in white than in black individuals. The onset of a majority of ACDEs was within 6 to 14 days of initiation therapy. Trimethoprim-sulfamethoxazole (TMP-SMZ), other sulfonamide drugs, and penicillins were the causative agents in 75 percent of cases of ACDE. Exanthematous/morbilliform eruptions were by far the most common ACDEs, occurring in 95 percent of cases; other ACDEs observed were urticaria (4 cases), erythema multiforme (EM, 8 cases; EM major, 2 cases; EM minor, 6 cases), lichenoid eruption (1 case), and fixed drug eruption (2 cases). Systemic symptoms were reported in 20 percent of cases, including fever, headache, myalgia, and arthralgia. In most cases, the implicated or suspected drug should be discontinued. In some, such as with morbilliform eruptions, the offending drug can be continued, and the eruption may resolve. In cases of urticaria/angioedema or early Stevens-Jones Syndrome (SJS)/toxic epidermal necrosis (TEN), the ACDR can be life-threatening, and the drug should be discontinued.

Between 50 and 60 percent of HIV-infected individuals treated with intravenous TMP-SMZ develop an exanthematous eruption (often associated with fever) (Fig. 225-5) 1 to 2 weeks after starting therapy, an incidence 10 times greater than that in the general population. Successful desensitization has been accomplished in patients with prior exanthematous/morbilliform or urticarial reactions to TMP-SMZ, sulfadiazine, and dapsone. [33] Desensitization in patients with prior SJS also has been reported. [34] Coadministration of corticosteroids with TMP-SMX reduced the incidence of adverse cutaneous reactions from 47 to 13 percent. [35] The occurrence of ACDRs to TMP-SMZ also has been noted to be associated with more rapid decline in CD4 cell counts. Severe bullous eruptions appear to be more common in HIV disease. In a report of 6 cases of EM major and 6 of TEN, all adverse reactions were to sulfonamides: sulfadiazine (6 cases), TMP-SMZ (2 cases), and sulfadoxine-pyrimethamine (Fansidar) (2 cases). [36] Of 14 cases of TEN over a 6-year period (1984–1989), sulfa drugs were the most common causative agents. [36] The number of cases of TEN was 375 times that expected. TEN occurred in patients with advanced HIV disease and had a 21 percent mortality rate.

FIGURE 225-5 Adverse cutaneous drug eruption: trimethoprim-sulfamethoxazole. A typical exanthematous eruption occurred on the trunk on the tenth day after initiation of therapy with the drug.

Oral corticosteroid therapy in HIV-infected individuals raises concerns regarding increased immunosuppression with exacerbations of opportunistic infections and neoplasms such as Kaposi's sarcoma or HSV infections. A cohort of 44 asymptomatic HIV-infected individuals (200–799 CD4 cells/µL) was treated with oral prednisolone (0.5 mg/kg for 6 months; 0.3 mg/kg therafter). After 1 year of prednisolone therapy, no major side effects or HIV disease–related events had occurred. Serum p24 antigen and HIV RNA load levels remained stable; CD4 cell counts increased significantly at all time points (median increase at 1 year 119 cell/µL). A more recent study concluded that short-term prednisone was well-tolerated and reasonably safe. [37] Short-term oral corticosteroid therapy appears to be safe in most HIV-infected individuals.

Antiretroviral Agents

Antiretroviral therapy (ART) has a significant incidence of ACDRs, including hypersensitivity reactions, the lipodystrophy syndrome, and drug interactions. [38] Drug hypersensitivity commonly occurs with the nonnucleoside reverse-transcriptase inhibitors (NNRTIs) nevirapine, delavirdine, and efavirenz; the NRTI abacavir; and the PI amprenavir. [31] Approximately half the cases of antiretroviral hypersensitivity resolve despite continuation of therapy. Drug therapy should be discontinued if the following occur: mucosal involvement, blistering, exfoliation, clinically significant hepatic dysfunction, fever greater than 39°C (102.2°F), or intolerable fever or pruritus.

NRTIs currently available include zidovudine, didanosine, lamivudine, zalcitabine, and stavudine. Zidovudine (ZVD)–treated individuals (more commonly blacks than Latinos or whites) experience longitudinal melanonychia with brown-black longitudinal streaks in the nail plate (up to 40 percent of those treated). The pigmentary changes are usually noted in the finger- and/or toenails within 4 to 8 weeks after initiation of ZVD therapy but may occur as late as 1 year later. ZVD pigmented macules of mucous membranes is also common, occurring more commonly in more heavily melanized individuals. Diffuse hyperpigmentation mimicking primary adrenal insufficiency has been reported. Melanonychia and mucocutaneous pigmentation also have been reported with hydroxyurea in HIV disease. [39] Other ZVD ACDRs include hypertrichosis, hypersensitivity, leukocytoclastic vasculitis, and paronychia. Didanosine has few reported ACDRs, which include vasculitis and SJS, systemic adverse effects include pancreatitis and peripheral neuropathy. ACDRs to lamivudine are also uncommon. Zalcitabine may cause aphthous-like ulcers of the oropharynx and esophagus and drug hypersensitivity (2 percent). Rechallenge with abacavir has been associated with several deaths. [40]

NNRTIs currently in use include nevirapine, delavirdine, and loviride. Nearly 20 percent of nevirapine-treated patients experience rash, most commonly an exanthematous eruption and rarely SJS. Nevirapine causes rash in 9 to 32 percent of treated individuals in the first 4 to 6 weeks of therapy; SJS occurs in 1 percent of treated individuals. [41] Drug hypersensitivity syndrome also has been reported. [42] In addition, 18 to 50 percent of delavirdine-treated patients experience rash.

PIs, including indinavir, saquinavir, nelfinavir, and amprenavir, are commonly associated with ACDRs, including lipodystrophy, hypersensitivity reaction, and acute generalized exanthematous pustulosis. Indinavir, which has a retinoid-like effect, caused cheilitis (57 percent); diffuse dryness and pruritus (41 percent); asteatotic dermatitis on the trunk, arms, and thighs (12 percent); and defluvium of the scalp (12 percent) and other sites. Paronychia and pyogenic granuloma, single or multiple, also were reported. Symptoms resolved when indinavir was discontinued. Peripheral lipodystrophy syndrome occurred in 14 percent of subjects. Other ACDRs include acute porphyria, hypersensitivity syndrome, SJS, “frozen shoulder,” and venous thrombosis. [38] Nelfinavir causes a morbilliform eruption in 3 to 28 percent of treated individuals and, less commonly, urticaria. [43]

Lipodystrophy Syndrome

During the past few years, lipodystrophy syndrome (LDS) has been associated with PI therapy. [38], [44], [45] and [46] The HIV-related LDS is characterized by abnormal fat distribution: lipohypertrophy with central obesity, cushingoid habitus (“buffalo hump”), increased neck girth (Fig. 225-6), increased abdominal girth associated with increase intraabdominal fat (protease paunch, “crix belly”), and breast enlargement. Lipoatrophy of subcutaneous fat produces a pseudoathletic appearance, manifested on the face (Fig. 225-7) and extremities as a prominent venous pattern and musculature. Additional findings include insulin resistance, hyperglycemia, and hypertriglyceridemia. [47] Of note, not all components are present in all patients, such that there is significant variability and heterogeneity in presentation. In a study of 581 patients (61 percent were treated with PIs), the overall prevalence of lipodystrophy was 38 percent, of fat wasting 16

percent, of peripheral fat accumulation 12 percent, and of mixed syndromes 10 percent. [48] The prevalence of metabolic abnormalities was 49 percent for lipid disorders and 20 percent for glucose disorders. The pathogenesis of LDS is not known; it is hypothesized that the phenomenon occurs as a result of immune restoration or a metabolic adverse effect of the PI. Discontinuation or replacement of PI therapy does not result in reversal of dysmorphic changes in most persons. [49] Liposuction has been used to treat the buffalo hump, but the result is most often unsatisfactory. Facial lipoatrophy has been treated with fat transfer from the abdominal panniculus and injection or insertion of various inert agents, again with limited cosmetic success.

FIGURE 225-6 Lipohypertrophy. The subcutaneous fatty tissue of the cervicothoracic region as well as the preauricular cheeks and neck are strikingly enlarged in an otherwise thin male. Liposuction improved his appearance to some degree.

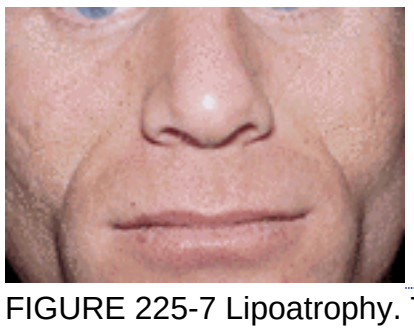

FIGURE 225-7 Lipoatrophy. The cheeks are hollowed, secondary to loss of subcutaneous fat, causing a significant cosmetic concern for the patient. The lipoatrophy remained in spite of a 20-lb weight gain.

OPPORTUNISTIC INFECTIONS

Opportunistic infections (OIs) of the skin and mucosa occurring in HIV disease for the most part represent overgrowth of resident flora (*Candida albicans*), extension beyond sites of colonization (dermatophytosis), reactivation of latent infection (human herpesviruses), or transformation of subclinical to clinical infection (HPV, MCV). The natural history of OIs has changed during the past 5 years, related to HAART and more effective therapies of infections. In individuals responding to HAART, the incidence of all OIs, with the exception of HPV infections, is markedly reduced. [50] OIs continue to be frequent, occurring in more advanced and/or untreated HIV disease.

BACTERIAL INFECTIONS

Staphylococcus aureus is the most common bacterial pathogen causing cutaneous and systemic infections in HIV disease. An increased prevalence of *S. aureus* carriage in the nares and perineum has been noted in asymptomatic and symptomatic HIV-infected individuals (up to 50 percent). Prophylaxis with agents such as TMP-SMX and clarithromycin is associated with a decreased nasal carrier rate as well as a reduced rate of infections. Primary cutaneous infections or secondarily infected dermatoses or breaks in the epidermal integrity usually occur in chronic *S. aureus* carriers. No unique staphylococcal infections occur in HIV disease. Rather, a wide range of *S. aureus* pyodermas and soft tissue infections do occur, the incidence increasing with the degree of immune deficiency. Primary staphylococcal infections include impetigo, bullous impetigo, and ecthyma; folliculitis; furuncles, and carbuncles; cellulitis; botryomycosis; and pyomyositis. Secondary infection of underlying dermatoses and superinfections occur commonly in persons with chronic atopic (eczematous) dermatitis that may be associated with elevated IgE levels, excoriations, herpetic ulcers, Kaposi's sarcoma, molluscum contagiosum (MCV), scabies, injection sites in injecting drug users, and intertrigo. Staphylococcal bacteremia may complicate either primary or secondary cutaneous infections (psoriasis or scabies); however, the most common site for hematogenous dissemination is the intravenous catheter, the source of 73 percent of cases of bacteremia. As with the majority of infections in HIV disease, staphylococcal infections tend to be recurrent. Management (see Chap. 194) should be directed at the acute infection, eradication of any underlying dermatoses, eradication of nasal carriage of *S. aureus* with mupirocin (pseudomonic acid) ointment, and chronic oral prophylaxis for recurrent infections.

Helicobacter cinaedi causes a syndrome characterized by fever, bacteremia, and recurrent and/or chronic cellulitis (resembling erythema nodosum) in compromised patients. [51] The organism is carried as bowel flora in 10 percent of homosexual men (no carriage in other groups). Diagnosis is made by considering it in immunocompromised individuals, demonstrating cellulitis on lesional biopsy (excluding panniculitis), and failure to isolate other pathogens. Bacteremia is intermittent; the organism is difficult to isolate, requiring hydrogen in the culture vial.

Pseudomonas aeruginosa causes primary infections such as cellulitis (i.e., ecthyma gangrenosum), infection at catheter sites, and secondary infection of underlying disorders such as Kaposi's sarcoma in advanced HIV disease. Cutaneous *P. aeruginosa* infection occurs by local invasion, gaining entry through breaks in the skin or by primary infection of skin appendages in the anogenital or axillary regions, or by hematogenous dissemination to the skin. Cutaneous pseudomonal infection may extend into the bloodstream, with resulting bacteremia and seeding of many organ systems.

Tuberculosis is the most common opportunistic infection in HIV disease in developing countries; cutaneous tuberculosis, however, is relatively uncommon. In non-HIV-infected persons with tuberculosis, the incidence of extrapulmonary tuberculosis is 15 percent; in HIV disease, 20 to 40 percent. In advanced HIV disease, the incidence of extrapulmonary disease increases to 70 percent. *Mycobacterium* spp. other than tuberculosis (MOTT) (a.k.a. environmental mycobacteria: *M. chelonae, M. fortuitum, M. kansasii, M. malmoense, M. gordonae, M. marinum,* and *M. hemophilum*) have been reported to cause cutaneous lesions in HIV disease. The most common MOTT agent in advanced HIV disease is *M. avium-intracellulare* complex (MAC); however, this rarely presents with cutaneous infection. The incidence of MAC infections has fallen with primary prophylaxis with azithromycin and, more recently, with HAART.

Bacillary angiomatosis (BA) and bacillary peliosis (BAP), caused by *Bartonella henselae* and *B. quintana,* occur most commonly in the setting of advanced HIV-induced immunodeficiency, characterized by angioproliferative lesions resembling cherry hemangiomas, pyogenic granulomas, or Kaposi's sarcoma. [52] Currently, the prevalence of BA in North America and western Europe is very low due to improved immune function with HAART and to prophylaxis given for infections such as MAC. Clinically, the cutaneous lesions of BA are red to violaceous, dome-shaped papules, nodules, or plaques resembling Kaposi's sarcoma and ranging in size from a few millimeters up to 2 to 3 cm in diameter (dermal vascular lesions with thinned or eroded epidermis) (Fig. 225-8). Less commonly, domed subcutaneous masses occur without the characteristic red color of more superficial vascular lesions. [53] Lesions are soft to firm and may be tender to palpation. The number of lesions ranges from solitary lesions to more than a 100 and, rarely, greater than 1000. Nearly any cutaneous site may be involved, but the palms, soles, and oral cavity are usually spared. Following hematogenous or lymphatic dissemination, the spectrum of internal disease caused by *B. henselae* and *B. quintana* includes soft tissue masses, bone marrow, lymphadenopathy, splenomegaly, and hepatomegaly; internal involvement can occur with or without cutaneous lesions. The course of BA is variable. In some patients, lesions regress spontaneously. BA infection may spread hematogenously or via lymphatics to involve bone marrow, bone, spleen, and liver. As with other OIs in HIV disease, BA can recur. The antibiotics of choice are erythromycin (250–500 mg PO qid) or doxycycline (100 mg bid), continued until the lesions resolve, usually 3 to 4 weeks. Secondary prophylaxis is indicated in patients with recurrent BA.

FIGURE 225-8 Bacillary angiomatosis. A vascular nodule of the shin was associated with disseminated small red papules and subcutaneous nodules in the inguinal areas bilaterally. The lesions appeared suddenly during a one-week period.

FUNGAL INFECTIONS

Cutaneous fungal infections in HIV disease occur as superficial infections (dermatomycoses), invasive cutaneous infections, or systemic fungal infection with hematogenous dissemination to the skin. HAART has markedly diminished the incidence of these infections. [54], [55]

Dermatophytoses

Trichophyton rubrum causes proximal subungual onychomycosis (PSO), an infection of the undersurface of the proximal nail plate. [56] PSO occurs most often in HIV-infected individuals; the diagnosis is an indication for HIV testing. Epidermal dermatophytosis can be extensive in HIV disease. Unless immunocompromise is restored, dermatophyte infections are chronic and recurrent.

Mucocutaneous Candidiasis

Cutaneous *Candida* infections such as intertrigo are relatively uncommon in adults with HIV disease: concomitant diabetes mellitus associated with HAART may increase the prevalence. Candidiasis of moist, keratinized cutaneous sites such as the anogenital region occurs with some frequency. Candidal angular cheilitis occurs at the corners of the mouth as an intertrigo, unilaterally or bilaterally; it may occur in conjunction with oropharyngeal or esophageal disease or as the only manifestation of candidal infection. Children with HIV infection commonly experience candidiasis in the diaper area and intertrigo in the axillae and neck fold. Fingernail chronic *Candida* paronychia with secondary nail dystrophy (onychia) also is common in HIV-infected children. [57]

Candida colonization of the oropharynx is common in HIV-infected individuals, up to 60 percent in the absence of any clinical findings. *C. albicans* was the most prevalent colonizing species, but multiple species may be present. Isolation of non- *albicans* species alone correlates with advanced HIV disease and very low CD4 cell counts. Oropharyngeal

candidiasis (OPC) is a marker of HIV disease progression. In a study of the onset of OPC following documented dates of HIV seroconversion, candidiasis was noted in 4 percent at 1 year after seroconversion, 8 percent at 2 years, 15 percent at 3 years, 18 percent at 4 years, and 26 percent at 5 years; the median CD4 cell count was 392 cells per microliter when OPC was first detected. [58] OPC and esophageal candidiasis (EC) have been reported to occur as a manifestation of primary HIV infection. EC, an AIDS-defining condition, occurs only with advanced CD4 count reduction (<100 cells/µL). OPC presents in four different patterns: pseudomembranous (thrush), atrophic (erythematous), hyperplastic, and as an angular cheilitis. Despite a high prevalence of candidiasis in HIV-infected individuals, disseminated candidiasis is distinctly uncommon, probably because of B cell activation and the presence of anticandidal protective antibody.

HIV-infected women with CD4 counts of 200 to 500 cells per microliter had a 33 percent incidence of vaginal candidiasis and 44 percent if the CD4 count was less than 200 cells per microliter. In a study of 117 HIV-infected women, recurrent candidal vaginitis was the most common initial clinical manifestation of HIV disease (43 of 117 women). [59] Other studies have failed to confirm an increased incidence of candidal vaginitis in HIV-infected women.

INVASIVE FUNGAL INFECTIONS

Invasive fungal infections arise by local invasion of the skin or mucosa, often followed by lymphatic or hematogenous dissemination to viscera or skin or, more commonly, activation of a latent pulmonary focus of infection. Latent pulmonary fungal infections such as cryptococcosis, histoplasmosis, coccidioidomycosis, sporotrichosis, or penicillinosis can reactivate and disseminate to various organs, including meninges and skin, in persons with advanced HIV disease. The cutaneous findings most commonly resemble multiple molluscum contagiosum–like lesions that occur most often on the face and upper trunk. Disseminated deep mycoses are much less common with HAART (see " Cryptococcosis," " Coccidioidomycosis," and " Histoplasmosis" below).

Cryptococcosis

Disseminated cryptococcosis is by far the most common life-threatening fungal infection occurring in advanced HIV disease; cutaneous cryptococcosis occurs in 5 to 10 percent of cases. [60] Skin lesions may be present for weeks or many months before presentation, occurring most commonly on the head and neck (78 percent, but they may be widespread. The most common morphology of cutaneous cryptococcosis is of molluscum contagiosum–like lesions, i.e, umbilicated skin-colored or pink papules or nodules (54 percent) (Fig. 225-9). Other types of cutaneous lesions include pustules, cellulitis, ulceration, panniculitis, palpable purpura, subcutaneous abscesses, vegetating plaques, and pyoderma gangrenosum–like lesions. [61], [62]

FIGURE 225-9 Disseminated cryptococcosis. Multiple skin-colored papules and nodules on the face. At first glance, the lesions mimic molluscum contagiosum, which is very common in advanced HIV disease.

Coccidioidomycosis

Cutaneous lesions of disseminated coccidioidomycosis are usually asymptomatic, beginning as papules and evolving to pustules, plaques, or nodules with minimal surrounding erythema; lesions often resemble molluscum contagiosum. In time, lesions may enlarge and become confluent with the formation of abscesses, multiple draining sinus tracts, ulcers, subcutaneous cellulitis, verrucous plaques, granulomatous nodules, and healing scars.

Histoplasmosis

Disseminated cutaneous histoplasmosis presents with erythematous macules; necrotic or keratin-plugged, molluscum contagiosum–like papules and nodules; pustules, folliculitis, acneform lesions, a rosacea–like eruption, or a guttate psoriasis–like eruption; ulcers; vegetative plaques; or panniculitis. [63] Several different morphologic lesions may occur on a patient. Lesions occur most commonly on the face, followed by the extremities and trunk. Oral mucosal lesions include nodules and vegetations; ulceration occurs on the soft palate, oropharynx, epiglottis, and nasal vestibule. A subtle, widespread exanthematous or psoriasiform eruption occasionally may develop in HIV-infected patients already on systemic antifungal therapy, in whom systemic symptoms are completely lacking. Hepatosplenomegaly and/or lymphadenopathy occur commonly in patients with disseminated histoplasmosis.

Sporotrichosis

In HIV disease, dissemination of local infection to other organs occurs from lung or skin foci. Hematogenously disseminated cutaneous lesions present as papules to nodules that may become eroded, ulcerated, crusted, or hyperkeratotic, usually sparing the palms, soles, and oral mucosa. Ocular involvement results in hypopyon, scleral perforation, and prolapse of the uvea. Other organs involved in disseminated sporotrichosis in HIV disease include joints, [64] lung, liver, spleen, intestine, and meninges.

Aspergillosis

Invasive aspergillosis is rare in HIV diseases, presenting as primary cutaneous infection, occurring under adhesive tape near central venous catheters, [65] or occurring as disseminated infection. Risk factors for invasive aspergillosis in HIV disease include leukopenia and therapy with glucocorticoids, broad-spectrum antibiotics, and antineoplastic agents. Skin lesions appear as skin-colored to pink umbilicated papules resembling molluscum contagiosum. The majority of patients with invasive disseminated aspergillosis die despite treatment with amphotericin B.

Penicillinosis

The dimorphic fungus *Penicillium marneffei* is the third most common opportunistic infection in HIV-infected residents of countries of Southeast Asia and the southern part of China. [66] In a report of 92 patients, [67] the clinical presentation included fever, weight loss, cough, anemia, and disseminated papular skin lesions (71 percent). The most common skin lesions were umbilicated papules, occurring most frequently on the face, pinnae, upper trunk, and arms. Genital ulcers also were reported, ranging in size from less than 1 to 3 cm in diameter. Oral lesions included papules and ulcers.

VIRAL INFECTIONS

Viruses are major pathogens causing OIs in HIV disease, many of which are manifested at mucocutaneous sites, ranging from cosmetically disfiguring facial MCV to extensive common or genital warts to life-threatening/invasive HPV–induced SCC. In the majority of cases, viral OIs represent activation of subclinical infection (HPV, MCV) or of reactivation of latent infection [human herpesviruses: herpes simplex virus 1 (HSV-1), HSV-2, varicella-zoster virus (VZV), cytomegalovirus (CMV), Epstein-Barr virus (EBV), and HHV-8 (Kaposi's sarcoma–associated virus)]. In HIV-infected individuals treated with HAART, the incidence of opportunistic viral infections has diminished markedly, with the exception of those caused by HPV; the incidence of benign and dysplastic HPV-induced lesions is stable or has increased despite immune restoration with HAART.

Herpes Simplex Virus 1 and 2 Infections (See Chap. 214)

With more advanced compromise, lesions tend to be subacute or chronic, indolent, and atypical, responding less promptly to oral antiviral therapy. Chronic herpetic ulcers of greater than 1 month's duration are an AIDS-defining condition. With increasing immunocompromise, recurrent HSV infection may become persistent and progressive. Erosions occurring at the typical sites [perioral (Fig. 225-10), anogenital, and digital] enlarge and deepen into painful ulcers. In addition to ulceration, chronic HSV infections also can present as proliferative lesions of the epidermis with or without scale. Foscarnet and cidofovir are administered intravenously for infections caused by acyclovir-resistant HSV. [68] Cidofovir gel has been effective as a topical therapy of acyclovir-resistant HSV infections. [69] Imiquimod 5% cream is also an effective topical treatment for cutaneous herpetic infections, including those caused by acyclovir-resistant HSV strains. Imiquimod 5% cream is applied to the lesion(s) hs daily or qod if irritation occurs. [70]

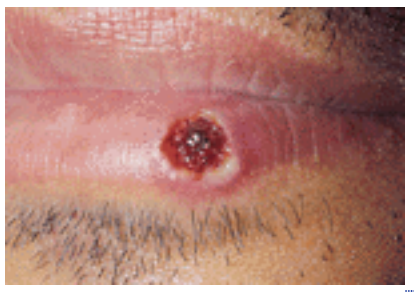

FIGURE 225-10 Herpes simplex virus infection: chronic herpetic ulcer of lip. A crusted ulceration has been present on the lip for 2 months, making it an AIDS-defining condition. The lesion resolved promptly with oral acyclovir.

Varicella-Zoster Virus (VZV) Infections

Primary VZV infection manifests as varicella (chickenpox); reactivation of VZV from a dorsal root ganglion or cranial nerve ganglion manifests as herpes zoster (HZ). [71] In the compromised host, VZV infection can present as severe varicella, persistent varicella, dermatomal HZ, disseminated HZ (sometimes without dermatomal HZ), and chronic [72] (Fig. 225-11) or recurrent HZ. Disseminated HZ is defined as cutaneous involvement by greater than three contiguous dermatomes, more than 20 lesions scattered outside the initial dermatome, or systemic infection (hepatitis, pneumonitis, encephalitis). Disseminated VZV infection in an individual harboring latent VZV can present with a clinical pattern of scattered vesicles in the absence of dermatomal HZ. Acyclovir-resistant VZV is rare. [73]

FIGURE 225-11 Varicella-zoster virus infection: ecthymatous lesions. Two ulcerated, crusted, painful ulcerations on the hip and lateral thigh had been present for 9 months. The lesions resolved with oral acyclovir therapy.

Molluscum Contagiosum Virus (MCV)

MCV commonly infects keratinized skin subclinically and can cause lesions at sites of minor trauma and in the infundibular portion of the hair follicle. [74] The clinical course of MCV infection in HIV disease differs significantly from that in the normal host and is an excellent clinical marker of the degree of immunodeficiency. Large and confluent lesions cause significant morbidity and disfigurement (Fig. 225-12). Prior to HAART, MCV infections were detected in 10 percent of individuals with HIV disease and in 30 percent of those with CD4 cell counts of less than 100 cells per microliter, the number of lesions being inversely related to the CD4 cell count. [25] In HIV-infected individuals, MCV infection tends to be progressive and recurrent after the usual therapies. With response to HAART, MCV infections regress, resolve completely, or do not occur, associated with increased CD4 cell counts and reduced viral load level. [76] For cases resistant to standard therapies, imiquimod 5% cream may be effective in both children and adults. [77] Cidofovir, a nucleotide analogue with activity against several DNA viruses, given either intraveneously or topically as a cream, may be an effective therapy. [78], [79]

FIGURE 225-12 Molluscum contagiosum virus infection: Prior to HAART, multiple facial mollusca would enlarge to cause significant cosmetic disfigurement.

Human Papillomavirus Infections

Human papillomavirus (HPV) infections occur commonly during the course of HIV disease. Of interest, the incidence of HPV infections does not decrease with HAART and immune restoration but actually may be increased. [80]

COMMON WARTS With advancing HIV disease, verrucae can enlarge, become confluent, and become unresponsive to therapy. [81] HPV-5 can cause an unusual pattern of extensive verruca plana and pityriasis (tinea) versicolor–like warts, similar to the pattern seen in epidermodysplasia verruciformis. [82] With moderate or advanced immunodeficiency, warts may become much more numerous, confluent, and refractory to usual treatment modalities. Precancerous lesions identical to mucosal lesions (SIL and SCCIS) can occur periungually and on the nail bed epidermis (usually fingers). In some cases, invasive SCC can arise at one or multiple sites on the fingers and/or nail bed. These tumors are aggressive and invade to the underlying periosteum and bone relatively early due the proximity of the underlying bony structures. Despite immune restitution with HAART, HPV infections often persist and progress unlike other opportunistic viral infections.

GENITAL WARTS HPV-6 and HPV-11 infect non- or minimally-keratinized epithelium such as anogenital sites and oropharynx and cause genital warts; HPV-16 and HPV-18 cause precancerous lesions, low-grade SIL (LSIL), high-grade SIL (HSIL), and invasive SCC. [83], [84]

ORAL WARTS Oropharyngeal HPV-induced lesions resemble anogenital condyloma, pink or white in color. Extensive intraoral condyloma acuminatum (oral florid papillomatosis) presents as multiple large plaques that can transform to verrucous carcinoma.

HPV-INDUCED DYSPLASIA: LSIL, HSIL, INVASIVE SCC The natural history of external anogenital HPV-induced dysplasia is not known. Prolonged, severe immunodeficiency provides the necessary milieu for the emergence of HPV-induced anogenital neoplasia. [85] The incidence of transformation of SCCIS to invasive SCC appears to be low. The relative risk for HPV-related anal invasive SCC is much higher in HIV-infected than in non-HIV-infected homosexual men and is more likely in advanced HIV disease. The most common sites for HPV-induced SIL, SCCIS, and invasive SCC are cervix, anus, perineum, vulva, penis, oropharynx/tongue, conjunctivae, and nail apparatus. [86] Anogenital dysplasias are likely to become more common manifestations of HIV disease because patients with profound immunodeficiency, who previously would have succumbed to OIs, are now surviving for extended periods because of HAART. [87] HAART/immune

restoration may not cause regression of these dysplasias. [88], [89] Cervical, anal, and external anogenital LSIL, HSIL, and invasive SCC have become more common in long-term survivors of HIV disease. Invasive SCC arising on external anogenital sites is usually detected earlier and is less aggressive than that arising on the cervix or anal canal. Management of external anogenital HPV infection in HIV-infected individuals is directed at identifying HSIL before progression to invasive SCC has occurred. All HIV-infected individuals should be examined annually for evidence of HPV infection, especially those with prior HPV infections. Since HPV-induced neoplasia may extend to the cervix and/or anus, direct examination by speculum and anoscope also should be performed; samples for cytology should be obtained using a cervical brush and cytofix solution during the examination. High-resolution anoscopy and biopsy are done on individuals with HSIL. [90] Individuals with documented external anogenital SIL should be followed by periodic follow-up examinations (every 4 to 6 months), noting the appearance of new lesions at these sites or an enlarging nodule or ulcerated site; biopsy of these sites is recommended. For minimally invasive SCC arising on the anal verge (nonkeratinized to keratinized epithelium) or on external anogenital sites (penis, vulva, perineum), surgical excision is recommended with adequate borders around the lesion. Invasive SCC of the anus (transformation zone) is treated by radiation therapy and chemotherapy. Prognosis for invasive anal SCC is better in those with higher CD4 cell counts at time of diagnosis.

SEXUALLY TRANSMITTED DISEASES

The great majority of HIV infections are transmitted during sexual intercourse. Individuals presenting with any sexually transmitted disease (STD) should be screened for HIV infection, syphilis, *Chlamydia,* gonorrhea, and *Trichomonas.* Possible interrelationships of STDs and HIV disease include the potential for STDs to increase the rate of both primary HIV acquisition and transmission, the potential for STDs to accelerate the natural progression of HIV infection, and the potential for HIV coinfection to alter critical clinical and/or serologic parameters used to diagnose and treat STDs. Genital ulcerative diseases (GUDs) such as syphilis, herpes genitalis, and chancroid increase the risk of acquisition of HIV. Gonorrhea and trichomoniasis also increase the risk of HIV transmission.

SCABIES (See Chap. 238)

Scabies is included in the differential diagnosis of pruritus in HIV disease. In individuals with advanced immunocompromise, scabies can occur with minimal or no pruritus but an extensive papulosquamous eruption, i.e, hyperkeratotic, crusted scabies, or Norwegian scabies. Secondary *S. aureus* infection can occur, rarely complicated by bacteremia. Oral ivermectin (200 µg/kg weekly) is the most effective therapy.

REFERENCES

1. Rico MJ et al: Guidelines of care for dermatologic conditions in patients infected with HIV. Guidelines/Outcomes Committee, American Academy of Dermatology. *J Am Acad Dermatol* **37**:450, 1997

2. Calista D et al: Changing morbidity of cutaneous diseases in patients with HIV after the introduction of highly active antiretroviral therapy including a protease inhibitor. *Am J Clin Dermatol* **3**:59, 2002

3. Simonitsch I et al: Cutaneous dendritic cells are main targets in acute HIV-1-infection. *Mod Pathol* **13**:1232, 2000

4. Vanhems P et al: Comprehensive classification of symptoms and signs reported among 218 patients with acute HIV-1 infection. *J Acquir Immune Defic Syndr* **21**:99, 1999

5. Musey L et al: Cytotoxic-T-cell responses, viral load, and disease progression in early human immunodeficiency virus type 1 infection. *N Engl J Med* **337**:1267, 1997

6. Biggar RJ: AIDS incubation in 1891 HIV seroconverters from different exposure groups. International Registry of Seroconverters. *AIDS* **4**:1059, 1990

7. Fauci AS et al: Immunopathogenic mechanisms of HIV infection. *Ann Intern Med* **124**:654, 1996

8. King MD et al: Human papillomavirus-associated oral warts among human immunodeficiency virus-seropositive patients in the era of highly active antiretroviral therapy: An emerging infection *Clin Infect Dis* **34**:641, 2002

9. Cooney EL: Clinical indicators of immune restoration following highly active antiretroviral therapy. *Clin Infect Dis* **34**:224, 2002

10. Rodwell GE, Berger TG: Pruritus and cutaneous inflammatory conditions in HIV disease. *Clin Dermatol* **18**:479, 2000

11. Gelfand JM, Rudikoff D: Evaluation and treatment of itching in hiv-infected patients. *Mt Sinai J Med* **68**:298, 2001

12. Amerio P et al: Role of T_H2 cytokines, RANTES and eotaxin in AIDS-associated eosinophilic folliculitis. *Acta Derm Venereol* **81**:92, 2001

13. Otley CC et al: Isotretinoin treatment of human immunodeficiency virus-associated eosinophilic folliculitis: Results of an open, pilot trial. *Arch Dermatol* **131**:1047, 1995

14. Lim HW et al: UVB phototherapy is an effective treatment for pruritus in patients infected with HIV. *J Am Acad Dermatol* **37**:414, 1997

15. Gelfand JM et al: Effect of UV-B phototherapy on plasma HIV type 1 RNA viral level: A self-controlled prospective study. *Arch Dermatol* **134**:940, 1998

16. Aboulafia DM et al: Etanercept for the treatment of human immunodeficiency virus-associated psoriatic arthritis. *Mayo Clin Proc* **75**:1093, 2000

17. Morar N et al: Erythroderma: A comparison between HIV positive and negative patients. *Int J Dermatol* **38**:895, 1999

18. Vin-Christian K et al: Photosensitivity in HIV-infected individuals. *J Dermatol* **27**:361, 2000

19. Johnson RM et al: Kawasaki-like syndromes associated with human immunodeficiency virus infection. *Clin Infect Dis* **32**:1628, 2001

20. Chetty R: Vasculitides associated with HIV infection. *J Clin Pathol* **54**:275, 2001

21. Weinert M et al: Oral manifestations of HIV infection. *Ann Intern Med* **125**:485, 1996

22. Phelan JA et al: Oral findings in patients with acquired immunodeficiency syndrome. *Oral Surg Oral Med Oral Pathol* **64**:50, 1987

23. Webster-Cyriaque J et al: Epstein-Barr virus and human herpesvirus 8 prevalence in human immunodeficiency virus–associated oral mucosal lesions. *J Infect Dis* **175**:1324, 1997

24. Husak R et al: Oral hairy leukoplakia in 71 HIV-seropositive patients: Clinical symptoms, relation to immunologic status, and prognostic significance (see comments). *J Am Acad Dermatol* **35**:928, 1996

25. Hermans P: Kaposi's sarcoma in HIV-infected patients: Treatment options. *HIV Med* **1**:137, 2000

26. Gallagher B et al: Cancer incidence in New York State acquired immunodeficiency syndrome patients. *Am J Epidemiol* **154**:544, 2001

27. Maurer A et al: Cutaneous squamous cell carcinoma in human immunodeficiency virus–infected patients: A study of epidemiologic risk factors, human papillomavirus, and p53 expression. *Arch Dermatol* **133**:577, 1997

28. Calista D: Five cases of melanoma in HIV positive patients. *Eur J Dermatol* **11**:446, 2001

29. Engles EA et al: Merkel cell carcinoma and HIV infection. *Lancet* **359**:497, 2002

30. Cattelan A et al: Acquired immunodeficiency syndrome-related Kaposi's sarcoma regression after highly active antiretroviral therapy: Biologic correlates of clinical outcome. *J Natl Cancer Inst Monogr* **28**:44, 2001

31. Carr A, Cooper DA: Adverse effects of antiretroviral therapy. *Lancet* **356**:1423, 2000

32. Smith KJ et al: Increased drug reactions in HIV-1–positive patients: A possible explanation based on patterns of immune dysregulation seen in HIV-1 disease. The Military Medical Consortium for the Advancement of Retroviral Research (MMCARR). *Clin Exp Dermatol* **22**:118, 1997

33. Yoshizawa S et al: A 5-day course of oral desensitization to trimethoprim/sulfamethoxazole (T/S) in patients with human immunodeficiency virus type-1 infection who were previously intolerant to T/S. *Ann Allergy Asthma Immunol* **85**:241, 2000

34. Douglas R et al: Successful desensitization of two patients who previously developed Stevens-Johnson syndrome while receiving trimethoprim-sulfamethoxazole. *Clin Infect Dis* **25**:1480, 1997

35. Caumes E et al: Effect of corticosteroids on the incidence of adverse cutaneous reactions to trimethoprim-sulfamethoxazole during treatment of AIDS-associated *Pneumocystis carinii* pneumonia. *Clin Infect Dis* **18**:319, 1994

36. Roujeau JC et al: Toxic epidermal necrolysis (Lyell syndrome). *J Am Acad Dermatol* **23**:1039, 1990

37. McComsey GA et al: Placebo-controlled trial of prednisone in advanced HIV-1 infection. *AIDS* **15**:321, 2001

38. Ward HA, Shrum RG: Cutaneous manifestations of antiretroviral therapy. *J Am Acad Dermatol* **46**:284, 2002

39. Laughon SK et al: Melanonychia and mucocutaneous hyperpigmentation due to hydroxyurea use in an HIV-infected patient. *Int J Dermatol* **39**:928, 2000

40. Staszewski S et al: Abacavir-lamivudine-zidovudine vs indinavir-lamivudine-zidovudine in antiretroviral-naive HIV-infected adults: A randomized equivalence trial. *JAMA* **285**:1155, 2001

41. Warren KJ et al: Nevirapine-associated Stevens-Johnson syndrome. *Lancet* **351**:567, 1998

42. Bourezane Y et al: DRESS (drug rash with eosinophilia and systemic symptoms) syndrome associated with nevirapine therapy. *Clin Infect Dis* **27**:1321, 1998

43. Fortuny C et al: Rash as side effect of nelfinavir in children. *AIDS* **14**:335, 2000

44. Carr A: HIV protease inhibitor-related lipodystrophy syndrome. *Clin Infect Dis* **30**:(suppl 2):S135, 2000

45. Graham NM: Metabolic disorders among HIV-infected patients treated with protease inhibitors: a review. *J Acquir Immune Defic Syndr* **25**(suppl 1):S4, 2000

46. Martinez E et al: Risk of lipodystrophy in HIV-1-infected patients treated with protease inhibitors: A prospective study. *Lancet* **357**:592, 2001

47. Hadigan C et al: Metabolic abnormalities and cardiovascular disease risk factors in adults with human immunodeficiency virus infection and lipodystrophy. *Clin Infect Dis* **32**:130, 2001

48. Thiebaut R et al: Lipodystrophy, metabolic disorders, and human immunodeficiency virus infection: Aquitaine Cohort, France, 1999. Groupe d'Epidemiologie Clinique du Syndrome d'Immunodeficience Acquise en Aquitaine. *Clin Infect Dis* **31**:1482, 2000

49. Panse I et al: Lipodystrophy associated with protease inhibitors. *Br J Dermatol* **142**:496, 2000

50. Detels R et al: Effectiveness of potent antiretroviral therapies on the incidence of opportunistic infections before and after AIDS diagnosis. *AIDS* **15**:347, 2001

51. Hung CC et al: Bacteremia caused by *Helicobacter cinaedi* in an AIDS patients. *J Formos Med Assoc* **96**:558, 1997

52. Gazineo JL et al: Bacillary angiomatosis: description of 13 cases reported in five reference centers for AIDS treatment in Rio de Janeiro, Brazil. *Rev Inst Med Trop Sao Paulo* **43**:1, 2001

53. Schwartz RA et al: Bacillary angiomatosis: presentation of six patients, some with unusual features. *Br J Dermatol* **136**:60, 1997

54. Cassone A et al: Antiretroviral therapy with protease inhibitors has an early, immune reconstitution-independent beneficial effect on

Candida virulence and oral candidiasis in human immunodeficiency virus-infected subjects. *J Infect Dis* **185**:188, 2002

55. Haddad NE, Powderly WG: The changing face of mycoses in patients with HIV/AIDS. *AIDS Read* **11**:365, 2001

56. Johnson RA: Dermatophyte infections in human immune deficiency virus (HIV) disease. *J Am Acad Dermatol* **43**:S135, 2000

57. Prose NS: HIV infection in children. *J Am Acad Dermatol* **22**:1223, 1990

58. Lifson AR et al: Time from HIV seroconversion to oral candidiasis or hairy leukoplakia among homosexual and bisexual men enrolled in three prospective cohorts. *AIDS* **8**:73, 1994

59. Carpenter CC et al: Human immunodeficiency virus infection in North American women: Experience with 200 cases and a review of the literature. *Medicine* **70**:307, 1991

60. Murakawa GJ et al: Cutaneous *Cryptococcus* infection and AIDS: Report of 12 cases and review of the literature. *Arch Dermatol* **132**:545, 1996

61. Dimino-Emme L, Gurevitch AW: Cutaneous manifestations of disseminated cryptococcosis. *J Am Acad Dermatol* **32**:844, 1995

62. Laochumroonvorapong P et al: Disseminated histoplasmosis presenting as pyoderma gangrenosum–like lesions in a patient with acquired immunodeficiency syndrome. *Int J Dermatol* **40**:518, 2001

63. Kucharski LD et al: Disseminated cutaneous histoplasmosis and AIDS: Case report. *Braz J Infect Dis* **4**:255, 2000

64. Edwards C et al: Disseminated osteoarticular sporotrichosis: Treatment in a patient with acquired immunodeficiency syndrome. *South Med J* **93**:803, 2000

65. Stanford D et al: Human immunodeficiency virus–related primary cutaneous aspergillosis. *Australas J Dermatol* **41**:112, 2000

66. Duong TA: Infection due to *Penicillium marneffei,* an emerging pathogen: Review of 155 reported cases. *Clin Infect Dis* **23**:125, 1996

67. Supparatpinyo K et al: Disseminated *Penicillium marneffei* infection in southeast Asia. *Lancet* **344**:110, 1994

68. Saint-Leger E et al: (Efficacy of cidofovir in an HIV infected patient with an acyclovir and foscarnet resistant herpes simplex virus infection). *Ann Dermatol Venereol* **128**:747, 2001

69. Lalezari J et al: A randomized, double-blind, placebo-controlled trial of cidofovir gel for the treatment of acyclovir-unresponsive mucocutaneous herpes simplex virus infection in patients with AIDS. *J Infect Dis* **176**:892, 1997

70. Gilbert J et al: Topical imiquimod for acyclovir-unresponsive herpes simplex virus 2 infection. *Arch Dermatol* **127**:1015, 2001

71. Vafai A, Berger M: Zoster in patients infected with HIV: A review. *Am J Med Sci* **321**:372, 2001

72. Nikkels AF et al: Chronic verrucous varicella zoster virus skin lesions: Clinical, histological, molecular and therapeutic aspects. *Clin Exp Dermatol* **24**:346, 1999

73. Saint-Leger E et al: Clinical and virologic characterization of acyclovir-resistant varicella-zoster viruses isolated from 11 patients with acquired immunodeficiency syndrome. *Clin Infect Dis* **33**:2061, 2001

74. Weinberg JM et al: Viral folliculitis: Atypical presentations of herpes simplex, herpes zoster, and molluscum contagiosum (see comments). *Arch Dermatol* **133**:983, 1997

75. Koopman RJ et al: Molluscum contagiosum: A marker for advanced HIV infection (letter). *Br J Dermatol* **126**:528, 1992

76. Hicks CB et al: Resolution of intractable molluscum contagiosum in a human immunodeficiency virus–infected patient after institution of antiretroviral therapy with ritonavir. *Clin Infect Dis* **24**:1023, 1997

77. Strauss RM et al: Successful treatment of molluscum contagiosum with topical imiquimod in a severely immunocompromised HIV-positive patient. *Int J STD AIDS* **12**:264, 2001

78. Toro JR et al: Topical cidofovir: A novel treatment for recalcitrant molluscum contagiosum in children infected with human immunodeficiency virus 1. *Arch Dermatol* **136**:983, 2000

79. Calista D: Topical cidofovir for severe cutaneous human papillomavirus and molluscum contagiosum infections in patients with HIV/AIDS: A pilot study. *J Eur Acad Dermatol Venereol* **14**:484, 2000

80. Greenspan D et al: Effect of highly active antiretroviral therapy on frequency of oral warts. *Lancet* **357**:1411, 2001

81. Viac J et al: Langerhans cells, inflammation markers and human papillomavirus infections in benign and malignant epithelial tumors from transplant recipients. *J Dermatol* **19**:67, 1992

82. Haas N et al: Remission of epidermodysplasia verruciformis-like skin eruption after highly active antiretroviral therapy in a human immunodeficiency virus–positive patient. *Br J Dermatol* **145**:669, 2001

83. Leigh IM et al: Role of human papillomaviruses in cutaneous and oral manifestations of immunosuppression. *J Acquir Immune Defic Syndr* **21**(suppl 1): S49, 1999

84. Diaz-Arrastia C et al: Clinical and molecular responses in high-grade intraepithelial neoplasia treated with topical imiquimod 5%. *Clin Cancer Res* **7**:3031, 2001

85. Del Mistro A, Chieco Bianchi L: HPV-related neoplasias in HIV-infected individuals. *Eur J Cancer* **37**:1227, 2001

86. Poblet E et al: Human papillomavirus-associated penile squamous cell carcinoma in HIV-positive patients. *Am J Surg Pathol* **23**:1119, 1999

87. Goldstone SE et al: High prevalence of anal squamous intraepithelial lesions and squamous cell carcinoma in men who have sex with men as seen in a surgical practice. *Dis Colon Rectum* **44**:690, 2001

88. Palefsky JM et al: Effect of highly active antiretroviral therapy on the natural history of anal squamous intraepithelial lesions and anal

human papillomavirus infection. *J Acquir Immun Defic Syndr* **28**:422, 2001

89. Minkoff H et al: The effect of highly active antiretroviral therapy on cervical cytologic changes associated with oncogenic HPV among HIV-infected women. *AIDS* **15**:2157, 2001

90. Place RJ et al: Outcome analysis of HIV-positive patients with anal squamous cell carcinoma. *Dis Colon Rectum* **44**:506, 2001

T>

Chapter 226

Johannes Pammer Erwin Tschachler

Prions and the Skin

PRIONS AS INFECTIOUS AGENTS
MANIFESTATIONS OF PRION DISEASES
TRANSMISSION OF PRION DISEASES
THE SKIN IN PRION DISEASES

REFERENCES

Prion diseases are transmissible neurodegenerative disorders [1], [2] that are characterized by cerebral accumulation of amyloid composed of an altered form of the cellular prion protein (PrP^{c}), designated scrapie prion protein (PrP^{Sc}). These diseases include kuru, Creutzfeldt-Jakob disease (CJD) and Gerstmann-Sträussler-Scheinker disease (GSS) in humans, and scrapie and bovine spongiform encephalopathy (BSE) in animals. Recently, a new human-transmissible encephalopathy, variant Creutzfeldt-Jakob disease (vCJD), was identified, which is presumably transmitted from cattle with BSE to humans. To date, vCJD has been diagnosed in more than 100 patients, preferentially in Great Britain, and has attracted considerable attention. [3] Whether these patients represent the tip of an iceberg and the harbinger of a new pandemic, or whether the number of patients with this dreadful disease will be limited to a few hundred as recently suggested, [4] the next few years will tell.

PRIONS AS INFECTIOUS AGENTS

The infectious agents of transmissible spongiform encephalopathies (TSEs) are called prions, which stands for proteinaceous infectious particles. [1], [2] Prions lack nucleic acids and consist mainly, if not entirely, of PrP^{Sc}. [1] Their contact with PrP^{c} is thought to induce conformational changes of the latter, resulting in the PrP^{Sc} isoform, which is resistant to protease digestion. PrP^{Sc} accumulates in brain cells and cerebral interstitium leading to the characteristic pathology of TSEs. [1], [2] Consequently, expression of PrP^{c} in brain cells is the prerequisite for the manifestation of prion diseases. [5] Although some researchers contest this “protein-only” hypothesis, [6] it is accepted by most researchers and it is widely used to explain the pathogenesis of TSE. In addition to brain cells, PrP^{c} is expressed by cells of different lineages, [7], [8] including skin and mucosal keratinocytes. [9], [10]

MANIFESTATIONS OF PRION DISEASES

Clinical manifestations vary slightly between different prion diseases and comprise mental deterioration with dementia and motor disturbances in CJD, cerebellar degeneration with ataxia and tremor in kuru, and early sensory and psychiatric disturbances rather than dementia and motor abnormalities in vCJD. [1], [11] In animals, restlessness, trembling, and pruritus characterize scrapie and altered behavior, including fear or aggressive responses and ataxia, characterize BSE. [12], [13] Neuropathologically, these ultimately fatal diseases are characterized by vacuolar (spongiform) degeneration of the brain, reactive astrocytosis and variable amounts of amyloid composed of PrP^{Sc} depositions. Whereas CJD, kuru, scrapie, and BSE show abundant vacuolization and little or no amyloid plaques, in GSS syndrome, amyloid deposits are abundant with variable vacuolization. Variant CJD exhibits both intense vacuolization and plaque formation. [14]

TRANSMISSION OF PRION DISEASES

Prion diseases may be inherited, they may occur sporadically, and in the laboratory setting, they are mostly transmitted by direct inoculation of infected tissue. [1], [2] In contrast, the routes of transmission in the field have not yet been determined. Although scrapie is among the longest recognized TSEs, its transmission route remains enigmatic. Direct contact with infected animals seems not to be necessary because sheep can acquire the disease even by grazing on pastures that previously have been populated by infected animals. [15] Ingestion of contaminated food has been suggested for kuru [16] and BSE. [13], [17] Supporting evidence for ingestion as route of transmission also comes from the recent demonstration that in primates fed with BSE-infected brain, PrP^{Sc} can be localized in epithelia lining the digestive tract, as well as in nerve tissue. [18], [19]

THE SKIN IN PRION DISEASES

A direct involvement of the skin in TSE has only been reported for scrapie. [12], [15] Naturally infected sheep develop a severe, itching skin disease leading to hair loss and skin ulcers (Fig. 226-1). The pathogenic cause of this skin affection is unknown and prions have not been demonstrated within these lesions. In humans, PrP^{Sc} has not been detected in samples of regular skin of two patients suffering from vCJD. [20] This finding argues against a continuous prion replication in skin of infected individuals. However, it does not preclude that skin plays a role in the transmission of prions. There is at least some suggestive evidence for this assumption. Kuru is thought to have occurred by ingestion of contaminated human organs in the course of ritual funeral ceremonies. Interestingly, a higher proportion of women as compared to men were affected. Because mainly women were involved in the preparation of the ritual meals, which involved treating the contaminated tissue, including the brain, with their bare hands, infection by inoculation was proposed as an alternative route of transmission to explain this epidemiologic finding. Other authors explain excess of kuru in women by the different

partition of body parts at the funeral ceremonies. [15], [16] The recent demonstration that prion diseases could experimentally be transmitted via inoculation into the skin of mice makes transmission via skin a realistic option. [21] In this context, it is important that the target structure of PrP^{c} is expressed in keratinocytes (KC) of normal epidermis and is strongly upregulated in inflammatory skin diseases [9], [10] and in KC in tissue culture; [9] epithelial cells have been shown to sustain prion replication. [22] In addition, infiltrating inflammatory cells strongly express PrP^{c}. [9] Therefore all elements necessary to establish prion infection and to allow it to spread within the organism are present within the skin. Although it is highly improbable that prions are able to cross an intact stratum corneum, there are many instances when this outer barrier is defective, either as a consequence of microtrauma or in the course of inflammatory skin diseases. Such defects would allow macromolecules to enter into deeper layers of the skin.

FIGURE 226-1 Ulcerations and hemorrhagic crusting on the upper hind quarter of a sheep suffering from natural scrapie.

Another potential port of entry relates to the use of in vitro reconstructed skin for transplantation on burn wounds or chronic ulcers. Constituents of bovine origin are frequently added to the tissue culture medium used to grow keratinocytes. Because in vitro cultivated keratinocytes express high amounts of PrP^{c}, [9] it is theoretically possible that prions could contaminate such cultures and be transmitted to patients. At the moment, there is no evidence that the skin represents a target organ for prion disease in humans, but potentially it may serve as a target organ for prion entry. For the dermatologist, this consideration is also important in light of the fact that prions cannot be inactivated by conventional disinfection procedures. [23] It should encourage the preferential use of disposable instruments in dermatosurgical procedures.

REFERENCES

1. Prusiner SB: Prions. *Proc Natl Acad Sci U S A* **95**:13363, 1998

2. Prusiner SB: An introduction to prion biology and diseases, in *Prion Biology and Diseases,* edited by SB Prusiner. Cold Spring Harbor, NY, Cold Spring Harbor Laboratory Press, 1999, p 1

3. Collinge J: Variant Creutzfeldt-Jakob disease. *Lancet* **354**:317, 1999

4. Valleron AJ et al: Estimation of epidemic size and incubation time based on age characteristics of vCJD in the United Kingdom. *Science* **294**:1726, 2001

5. Bueler H et al: Mice devoid of PrP are resistant to scrapie. *Cell* **73**:1339, 1993

6. Manuelidis L: The dimensions of Creutzfeldt-Jakob disease. *Transfusion* **34**:915, 1994

7. Bendheim PE et al: Nearly ubiquitous tissue distribution of the scrapie agent precursor protein. *Neurology* **42**:149, 1992

8. Horiuchi M et al: A cellular form of prion protein (PrPc) exists in many nonneuronal tissues of sheep. *J Gen Virol* **76**:2583, 1995

9. Pammer J et al: Human keratinocytes express cellular prion-related protein in vitro and during inflammatory skin diseases. *Am J Pathol* **153**:1353, 1998

10. Pammer J et al: Cellular prion protein expressed by bovine squamous epithelia of skin and upper gastrointestinal tract. *Lancet* **354**:1702, 1999

11. Will RG et al: Infectious and sporadic prion diseases, in *Prion Biology and Diseases*, edited by SB Prusiner. Cold Spring Harbor, NY, Cold Spring Harbor Laboratory Press, 1999, p 465

12. Laplanche J-L et al: Scrapie, chronic wasting disease and transmissible mink encephalopathy, in *Prion Biology and Diseases*, edited by SB Prusiner. Cold Spring Harbor, NY, Cold Spring Harbor Laboratory Press, 1999, p 393

13. Nathanson N et al: Bovine spongiform encephalopathy and related disease, in *Prion Biology and Diseases*, edited by SB Prusiner. Cold Spring Harbor, NY, Cold Spring Harbor Laboratory Press, 1999, p 431

14. DeArmond SJ, Ironside JW: Neuropathology of prion diseases, in *Prion Biology and Diseases*, edited by SB Prusiner. Cold Spring Harbor, NY, Cold Spring Harbor Laboratory Press, 1999, p 585

15. Ridley RM, Baker HF: *Fatal Protein*. Oxford, Oxford University Press, 1998

16. Gajdusek CD: Infectious amyloids, in *Fields Virology* edited by BN Fields, DM Knipe, PM Howley. Philadelphia, Lippincott-Raven, 1996, p

17. Wilesmith JW et al: Bovine spongiform encephalopathy: Epidemiological studies on the origin. *Vet Rec* **128**:199, 1991

18. Bons N et al: Prion immunoreactivity in brain, tonsil, gastrointestinal epithelial cells, and blood and lymph vessels in lemurian zoo primates with spongiform encephalopathy. *C R Acad Sci III* **320**:971, 1997

19. Bons N et al: Natural and experimental oral infection of nonhuman primates by bovine spongiform encephalopathy agents. *Proc Natl Acad Sci U S A* **96**:4046, 1999

20. Wadsworth JD et al: Tissue distribution of protease resistant prion protein in variant Creutzfeldt-Jakob disease using a highly sensitive immunoblotting assay. *Lancet* **358**:171, 2001

21. Taylor DM et al: Scrapie infection can be established readily through skin scarification in immunocompetent but not immunodeficient mice. *J Gen Virol* **77**:1595, 1996

22. Vilette D et al: Ex vivo propagation of infectious sheep scrapie agent in heterologous epithelial cells expressing ovine prion protein. *Proc Natl Acad Sci U S A* **98**:4055, 2001

23. Taylor DM: Inactivation of transmissible degenerative encephalopathy agents: A review. *Vet J* **159**:10, 2000

T>

Chapter 227

Justin Green Warren Heymann

The Rickettsioses and Ehrlichioses

HISTORICAL ASPECTS
ETIOLOGY AND PATHOGENESIS
THE SPOTTED FEVER GROUP
Rocky Mountain Spotted Fever
Other Spotted Fevers
TYPHUS GROUP
Endemic Typhus (Murine Typhus)
Epidemic (Louse-Borne) Typhus
Scrub Typhus (Tsutsugamushi fever)
Q Fever
EHRLICHIOSIS
Epidemiology
Prevention
Clinical Manifestations
Laboratory Findings
Pathology
Diagnosis and Differential Diagnosis
Therapy and Prognosis

REFERENCES

Rickettsial infections are arthropod-borne diseases belonging to the genus *Rickettsia*. The rickettsioses and ehrlichioses should be considered when a patient is evaluated for fever and a rash. In many endemic areas of the world, rickettsial infections are emerging and reemerging pathogens. [1] New pathogenic species continue to be identified, and it is likely that some “nonpathogenic” species will eventually cause human disease.

HISTORICAL ASPECTS

The rickettsioses have had profound effects upon civilization, particularly during times of war or famine. Hans Zinsser, who recognized Brill's disease as a recrudescent form of epidemic typhus, wrote: “Typhus is not dead. It will live on for centuries, and it will continue to break into the open whenever human stupidity and brutality give it a chance, as most likely they occasionally will.” The first contemporary account of rickettsial disease appeared during the civil wars of Granada in 1489 to 1490, where a typhus-like disease killed 17,000 Spanish soldiers. The eighteenth century physician James Lind astutely recognized that the vector of epidemic typhus was carried on the bodies of men and clothes. In 1909, Charles Nicolle identified the body louse as the vector for epidemic typhus. Howard Tyler Ricketts, who ultimately died from typhus, is credited with first demonstrating the organism in typhus patients and infected lice. During World War I and the Russian Revolution, epidemic typhus caused 3 million deaths.

The earliest serologic test for rickettsiae was based upon the work of Weil and Felix, in 1915, who demonstrated that the serum of patients with typhus agglutinated certain strains of *Proteus vulgaris*.

Rocky Mountain spotted fever was first described in the late 1800s after infection occurred in pioneers in the western states of Idaho and Montana. Ricketts was able to confirm the hypothesis regarding the wood tick as the vector, and S. Burt Wolback at Harvard University Medical School identified the organism within the endothelial cells of vasculitic lesions. [2]

ETIOLOGY AND PATHOGENESIS

The rickettsioses are caused by infection with obligate, intracellular, Gram-negative bacteria. They are pleomorphic and may appear as cocci or bacilli ranging in size from 0.3 µm to 1 µm. Their genome is composed of DNA and RNA and reproduction is achieved through binary fission. *Rickettsia* are propagated by arthropod vectors that use mammals (and sometimes the arthropods themselves) as reservoirs. *Rickettsia* are separated into the typhus group and the spotted fever group on the basis of common genetics, immunologic patterns, and intracellular growth characteristics. [3], [4] The typhus group lives entirely within the cell cytoplasm, while the spotted fever group can reside within the cytoplasm or nucleus. *Rickettsia* spp. and their geographic strains can be differentiated by unique antigenic structures on cell surface proteins. Certain rickettsial cell wall lipopolysaccharides are highly immunogenic and are shared by the gram-negative bacteria *Proteus* and *Legionella*. T lymphocytes, interferon-?, and tumor necrosis factor-a are involved in immune-mediated bacterial killing. [3], [4]

Infection occurs in human beings through arthropod-induced breaks in the skin. Humans can assist this process by, for example, scratching a flea bite and enabling inoculation of *R. typhi* from the flea's feces. The organisms travel via the hematogenous and lymphatic systems until they attach to endothelial cell membranes and are phagocytosed. The clinical manifestations of most rickettsial infections are caused by a proliferation of bacteria within endothelial cells of capillaries, arterioles, and venules, resulting in a multifocal, systemic vasculitis. [4] Pathogenicity is most likely a consequence of direct cell injury.

THE SPOTTED FEVER GROUP

Rocky Mountain Spotted Fever

Rocky Mountain spotted fever (RMSF) is caused by the tick-borne *Rickettsia rickettsii.* It is the most frequently reported rickettsial infection in the United States, and without treatment, it carries a fatality case ratio of approximately 28 percent.

EPIDEMIOLOGY The vector largely responsible for RMSF in the eastern two-thirds of the U.S. is the American dog tick, *Dermacentor variabilis,* while the Rocky Mountain wood tick, *Dermacentor andersoni,* is most prevalent in the western U.S. *Amblyomma cajennense,* in Central and South America, and *Rhipicephalus sanguineus,* in Mexico, also serve as tick vectors. *R. rickettsii* is transmitted by the tick through the salivary glands after at least a 6-h feeding period. Infection can also be acquired in persons exposed to hemolymph during tick removal. [4], [5] The average annual incidence of RMSF in the U.S. from 1993 to 1996 was 2.2 cases per 1 million persons. Children aged 5 to 9 years have the highest age-specific incidence of RMSF. [6] Infection rates in a given locale and time period may be influenced by human recreational activities, use of insecticides, climatic variability, type of serologic tests used, and type of antibiotic therapy. [4] In addition, ticks infected with *Rickettsia* of unknown pathogenicity (e.g., *R. montana*) can compete with *R. rickettsii,* and affect prevalence rates. The south Atlantic region of the U.S. experiences the highest prevalence of RMSF. In the western U.S., men are more often affected than women, and children are disproportionately represented in the southern U.S. Most cases are diagnosed between April and September. [7]
PREVENTION The most effective method for preventing RMSF, as well as other tick- and mite-borne diseases, is to avoid exposure. Wearing protective clothing, using repellants, performing tick checks, and proper tick extractions are important for lowering risk of infection.
CLINICAL MANIFESTATIONS After an incubation period of 2 to 14 days (median, 7 days), RMSF presents with fever, chills, myalgia, fatigue, anorexia, and/or headache. The fever typically reaches 38.9°C (102°F) or higher, and gastrointestinal complaints frequently precede the rash. The components of the classic triad (fever, headache, and rash) are each common at presentation, but only approximately 60 percent of patients present with the complete triad. [7]
Dermatologic The rash of RMSF typically appears 3 to 5 days after the onset of illness, and occurs in 50 percent of patients by the third day. The rash usually appears first at the wrists and ankles, and over the next 6 to 18 h spreads centripetally. However, truncal or diffuse initial presentations occur in up to 10 percent of cases. Palm and sole involvement frequently occurs. [4] Individual lesions are blanchable, red macules that within a few days become papular and display evidence of petechiae or purpura (Fig. 227-1). Showers of petechiae can appear on limbs after sphygmomanometer use (Rumple-Leede test). Necrosis from overwhelming vasculitis is rare (4 percent), and preferentially occurs in peripheral locations such as the digits, penis, and scrotum (Fig. 227-1). [4] Small scars can develop from focal necrosis. “Spotless” fever, which does not imply milder disease, may occur in approximately 10 percent of cases, and is more common in the elderly and darker-complected individuals. [4] Infrequently, eschars and erythema migrans-like eruptions are reported at the site of the tick bite. Postinflammatory hyperpigmentation follows the acute eruption.

FIGURE 227-1 Rocky Mountain spotted fever. *A, B*. Early macular blanchable macules and papules on the palm, soles, and ankles; no truncal lesions were present at this time. *C, D*. Later lesions on the ankles and palm are hemorrhagic and no longer blanch with pressure; truncal lesions were present at this time. *E*. Truncal and facial hemorrhagic macules and papules 7 days after the onset of the rash. *F*. Infarction of fingers in patient whose course was complicated by disseminated intravascular coagulation. (*C, D, and F, courtesy of Charles W. Stratton, MD.*)

Systemic associations Multisystem involvement is the rule in RMSF. Vascular leakage from vasculitis results in hypotension, hypovolemia, and peripheral edema. An inappropriately high tachycardia can occur. Nausea, vomiting, and abdominal pain are common early symptoms, with more severe cases resulting in gastrointestinal bleeding and perforation. Hepatomegaly is seen in up to 25 percent of cases and is found more often in fatal cases. Jaundice is seen in up to 8 percent of cases. A severe headache is often reported and may be accompanied by a vast array of less-common neurologic manifestations (e.g., confusion, delirium, stupor, meningismus, coma, motor deficits, cranial nerve palsy, deafness, photophobia, hallucinations, seizures, Guillain-Barré syndrome). [8] Acute renal failure can result from, in part, a profound prerenal state and/or direct renal vascular injury. [9] Ocular involvement is common with up to 30 percent of cases having conjunctivitis. Periorbital edema may be seen, especially in children. Myocarditis, cardiac arrhythmias, and adult respiratory distress syndrome are infrequent, but potentially fatal complications. In patients with severe RMSF, long-term sequelae are usually the result of neurologic deficits or acral amputation/necrosis. [10]
LABORATORY FINDINGS Laboratory findings that support a diagnosis of RMSF include thrombocytopenia (32 to 52 percent of patients), anemia (5 to 24 percent), and hyponatremia (50 percent). [5] A normal leukocyte count with increased immature cells is more common than leukopenia or leukocytosis. Elevations in transaminases, lactate dehydrogenase, creatine kinase, serum bilirubin, alkaline phosphatase, blood urea nitrogen, and creatinine are variably found. [4]

Coagulopathy with increased prothrombin time and decreased fibrinogen levels, and disseminated intravascular coagulopathy are rare. The cerebrospinal fluid can exhibit increased leukocytes and increased protein concentration, and the glucose is typically normal.

PATHOLOGY Histopathologic examination shows a septic vasculitis (Fig. 227-2). Early lesions show a predominantly perivascular, lymphohistiocytic infiltrate accompanied by extravasated erythrocytes, and dermal edema. A lymphohistiocytic vasculitis can progress to a leukocytoclastic vasculitis. Less often, basal cell vacuolization, lymphocytic exocytosis, fibrin thrombi, and capillary wall necrosis is appreciated. [11] Immunohistology reveals positive staining for *R. rickettsii* in endothelial cells that are involved in the vasculitis.

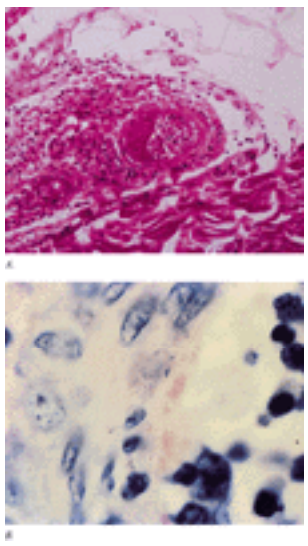

FIGURE 227-2 *A*. The vascular lesion of Rocky Mountain spotted fever as seen in an arteriole in the skin. An early thrombus is present. *B*. *Rickettsiae* are seen in endothelial cells in a skin biopsy.

DIAGNOSIS AND DIFFERENTIAL DIAGNOSIS Serologic examination is the most used confirmatory test. This test detects convalescent antibodies, but is seldom diagnostic before the seventh day. This stresses the necessity for empiric treatment when RMSF is a consideration in the differential diagnosis. Indirect immunofluorescence assay (IFA), latex agglutination, and enzyme-linked immunosorbent assay are available. Of these, IFA is the most widely used, being highly sensitive (94 percent) and specific (up to 100 percent). [5] Positive values include acute titers of 1:64 or greater, or a fourfold rise in titers between acute and convalescent titers. The Weil-Felix test and complement fixation tests are no longer used because of poor sensitivity. Direct immunofluorescent or immunoperoxidase staining and polymerase chain reaction (PCR) tests of skin biopsies can be accurate and more expeditious than serology, but are not widely available. False-negative direct immunofluorescent tests can occur in patients receiving antirickettsial therapy for more than 24 h. Isolation of the organisms is difficult and hazardous, consequently it is performed by few laboratories. The differential diagnosis for RMSF when the patient initially presents without a rash is broad. Viral respiratory infections, intestinal infections, otitis media, encephalitis, and psychiatric conditions have all been confused with early RMSF. During the first few days of illness, other rickettsial infections, tularemia, and leptospirosis should be considered. Measles can mimic RMSF, but is distinguished by presence of coryza, Koplik spots, and cough. In addition, individual lesions fail to become petechial. Atypical measles, seen in patients born in the late 1950s to the mid-1960s, is more difficult to distinguish because of its centripetal location and presence of petechiae. Meningococcemia can look identical to RMSF, especially when gangrene develops in the latter. Helpful clues to support a diagnosis of meningococcemia include a more rapid onset of rash and leukocytosis. [5] Other diseases to consider are rubella, enteroviral infection, secondary syphilis, toxoplasmosis, ehrlichiosis, infectious mononucleosis, erythema multiforme, drug eruption, typhoid fever, toxic shock syndrome, preeclampsia with liver involvement and thrombocytopenia, thrombotic thrombocytopenic purpura, and idiopathic thrombocytopenic purpura.

TREATMENT AND PROGNOSIS Empiric therapy for RMSF is often necessary because of the potential mortality associated with delays in confirming the diagnosis. Treatment recommendations for RMSF are tetracycline (500 mg q6h or 25 to 50 mg/kg per day q6h, maximum daily dose 2 g), doxycycline (100 mg q12h or 1 mg/lb q12h, maximum daily dose 200 mg), or chloramphenicol (50 to 75 mg/kg per day q6h, maximum daily dose 4 g). Antibiotic therapy should be continued for 7 days and continued for 2 days after the patient remains afebrile. [4] In general, the tetracyclines are the preferred drugs for RMSF. Doxycycline is preferable to tetracycline in patients with renal failure. In children, the tetracyclines can stain teeth, but this is dose and duration dependent, and doxycycline is advocated as the treatment of choice. [12] Chloramphenicol is the treatment of choice during pregnancy, [4], [13] but doxycycline could be considered in near-term gravidas. [13] Aggressive supportive care, with particular attention paid to electrolyte and fluid replacement, is necessary in more severe disease. Without antibiotic treatment, classic RMSF results in a mortality rate that approaches 28 percent. Death occurs 8 to 15 days after the onset of symptoms. [4] Fulminant RMSF leads to a more rapid decompensation and has characteristically been reported in black males with glucose-6-phosphate dehydrogenase deficiency (G6PD). [4] G6PD patients may also have a higher risk of cutaneous necrosis. Groups with a worse prognosis include males and older adults. More severe disease is also seen with neurologic manifestations, thrombocytopenia, hepatitis, jaundice, and acute renal failure. Prompt administration of appropriate antibiotic therapy is the most important factor in determining prognosis. Since the beginning of the antibiotic era, the case fatality rate for RMSF has decreased to 2 to 5 percent. Underestimation of actual fatality rates may be a result of reliance on serologic assays with lower sensitivity.

Other Spotted Fevers

TICK-BITE ASSOCIATED

Mediterranean fever There are seven other tick-bite associated spotted fever group species pathogenic to humans (*R. conorii, R. sibirica, R. japonica, R. australis, R. honei, R. africae,* and *R. slovaca*). The prototype of this class of disease is Mediterranean fever (aka Boutonneuse fever, Marseilles fever, Israeli spotted fever) caused by *R. conorii.*

EPIDEMIOLOGY *R. conorii* is endemic in southern Europe, Middle East, southwest Asia, India, and Africa. It is transmitted primarily by the brown dog tick, *Rhipicephalus sanguineus*. Contact with dogs is reported in up to 90 percent of cases of Mediterranean fever. [14] There is a seasonal variation in case reports, with temperate regions having peaks

during the summer months.

CLINICAL MANIFESTATIONS The constitutional symptoms of the tick-bite–associated spotted fevers, including Mediterranean fever, are similar to those of RMSF. The classic cutaneous hallmark of this group is the tache noir, an erythematous, indurated papule with a central necrotic ulcer and eschar that represents locally aggressive endothelial invasion by rickettsiae and occurs in up to 72 percent of cases with *R. conorii* infection. [15] Multiple eschars can be seen in one-half of patients with African tick-bite fever (*R. africae*). The rash of this group of spotted fevers displays similar temporal and morphologic patterns as that of RMSF. However, the eruption may be more diffuse and is less frequently petechial or purpuric. Pox-like vesicular lesions and isolated lymphadenopathy are associated with *R. conorii. R. africae* infection is frequently spotless, although when rash is apparent, it has been described as vesicular. Lymphadenopathy and lymphangitis are common features of African tick-bite fever. [16] Systemic complications of Mediterranean fever are attributed to the multiorgan vasculitis and include meningoencephalitis, hepatitis, and vascular collapse. Coagulation abnormalities have been described resulting in cases of deep vein thrombosis. [4] In murine models, infection with *R. conorii* induced a procoagulant state with decreased tissue plasminogen activator and increased plasminogen activator inhibitor levels. Other laboratory abnormalities resemble those of RMSF.

DIAGNOSIS AND DIFFERENTIAL DIAGNOSIS Serologic tests employing IFA technology are the mainstay of diagnosis for the spotted fevers. More rapid results for detecting *R. conorii* are obtained through direct immunofluorescence of skin biopsies, PCR amplification of skin biopsies, monoclonal antibody-coated separation immunomagnetic beads detecting circulating endothelial cells, and blood and skin cultures using centrifugation-shell vial inoculation. [4], [14] Newer serologic assays and PCR amplification of tissue have also been used for diagnosis of *R. japonica, R. slovaca,* and *R. africae.* The rash of Mediterranean fever generates a similar differential diagnosis as that of RMSF. When the tache noir is appreciated, consideration should be given to brown recluse spider bite, cutaneous anthrax, scrub typhus, rickettsialpox, aspergillosis, and mucormycosis.

TREATMENT AND PROGNOSIS Overall, the other tick-bite–associated spotted fevers run a less-aggressive course than RMSF. However, hospitalized patients with Mediterranean fever have death rates ranging from 1.4 to 5.6 percent. Even higher death rates (33 percent) have been reported when delays in diagnosis and in therapy occur. [14] Milder disease is seen in children. Groups at risk for a more fulminant course include alcoholics, the elderly, and those with diabetes mellitus, heart disease, or G6PD deficiency. [4] Treatment is similar to that of RMSF, with tetracyclines or chloramphenicol. Additionally, ciprofloxacin, azithromycin, and clarithromycin have been efficacious. [17] The newer macrolides offer a safety profile advantageous in the pediatric age group.

MITE-BITE ASSOCIATED

Rickettsialpox Rickettsialpox is an acute, self-limited, febrile disease so named because of its clinical resemblance to varicella (chickenpox) and its etiologic agent *R. akari*. The house mouse (*Mus musculus*) is the reservoir and the vector is the rodent mite, *Liponyssoides sanguineus* (*Allodermanyssus sanguineus*). [18] This rodent mite inflicts a painless bite, and is too small to be readily recognized by the victim.

EPIDEMIOLOGY First recognized in 1946 in a housing development in Queens, New York City, rickettsialpox continues to be found in urban locales infested with mice. Serologic evidence of *R. akari* infection has been demonstrated in New York City dogs, but it is not known whether dogs serve as sentinels for human disease. [19] Cases have been reported from the United States (mostly eastern seaboard), South Africa, Korea, and parts of Russia. Intravenous drug users may be at higher risk, but it is unclear if this is solely attributed to inner-city exposures (e.g., mice).

CLINICAL MANIFESTATIONS A primary lesion occurs at the site of the mite bite as early as 1 to 2 days after transmission. It consists of a frequently painless, erythematous, indurated papule ranging in size from 0.5 to 3.0 cm. Vesicle formation is followed by desiccation and a subsequent eschar (Fig. 227-3). [18] Regional lymphadenopathy is common. Resolution of the primary lesion occurs within 1 month.

FIGURE 227-3 Rickettsialpox: tâche noire. A crusted, ulcerated papule (eschar) with a red halo resembling a cigarette burn at the site of a tick bite.

Approximately 1 week after the primary lesion appears, fever, chills, sweats, malaise, headache, and myalgia, often manifesting as backache, begin. The sweating associated with febrile episodes can be drenching. The fever persists with remissions for about a week before abating. Two to 3 days after the onset of systemic symptoms, a generalized eruption occurs that is typically papulovesicular (Fig. 227-4). Small vesicles or pustules, that later crust, can form at the center of papules. Roughly 5 to 40 lesions can be found. These resolve in 1 week. Less frequently, an enanthem, photophobia, generalized lymphadenopathy, and gastrointestinal symptoms may be noted. [18]

FIGURE 227-4 Rickettsialpox: exanthem. Multiple, erythematous papules and pustules, some with central hemorrhage and crusting, on the back after hematogenous dissemination of the *R. akari* from the tick-bite site.

LABORATORY FINDINGS During the acute febrile illness a mild leukopenia can be seen. This can be accompanied by a relative lymphocytosis.
PATHOLOGY The primary lesions are characterized by extensive necrosis and an acute inflammatory infiltrate. The papulovesicular lesions display a subepidermal split with superficial edema, and a perivascular lymphohistiocytic infiltrate that can lead to vasculitis. In contrast to RMSF, Mediterranean spotted fever, louse-borne typhus fever, and murine typhus, the perivascular macrophage, not the endothelial cell, appears to be the preferentially infected cell.
DIAGNOSIS AND DIFFERENTIAL DIAGNOSIS The Weil-Felix test is generally negative. Instead, diagnosis can be confirmed with complement fixation tests or indirect fluorescent antibody tests. Titers for antibody detection peak after 3 to 4 weeks and could be delayed for up to 8 weeks with antibiotic use. [20] More rapid diagnosis, but perhaps less specific, can be made by using the cross-reactivity of *R. akari* with *R. rickettsii*. Indeed, direct immunofluorescence of primary lesion biopsies can be performed with anti- *R. rickettsii* globulin. The generalized eruption does not contain enough inoculum to become positive by direct immunofluorescence. Varicella can resemble rickettsialpox, but can be differentiated by the morphology of individual lesions. In varicella, the “dewdrop on a rose petal” description, refers to the largely vesicular lesion surrounded by erythema. This is distinct from the erythematous papule surmounted by a vesicle seen with rickettsialpox. [18] A positive Tzanck preparation is observed in varicella, but not in rickettsialpox. Fever occurs with the rash of varicella, but precedes the eruption of rickettsialpox. Other diseases to consider with respect to the initial lesion are scrub typhus, the spotted fever group of illnesses that result in eschar formation, brown recluse spider bite, cutaneous anthrax, aspergillosis, and mucormycosis. The generalized eruption can be confused with smallpox, gonococcemia, infectious mononucleosis, echovirus (types 9 and 16), and coxsackievirus infection (A9, A16, and B5).
TREATMENT AND PROGNOSIS Tetracyclines are the most effective therapy. They can be continued for up to 5 days, although defervescence is typical within 48 h. [20] The disease is self-limited, and even without antimicrobial therapy the illness will resolve within 2 weeks. Scarring can result from the primary eschar, and postinflammatory hyperpigmentation can remain as a result of the papulovesicular lesions.

TYPHUS GROUP

Endemic Typhus (Murine Typhus)

Endemic typhus is caused by *R. typhi,* and is classically transmitted to humans by the rat flea (*Xenopsylla cheopis*) with rats serving as the reservoir. *R. felis* is a recently characterized rickettsiae that has emerged in southern Texas and southern California. In this setting, *R. felis* is thought to be an important cause of endemic typhus-residing in peridomestic animal cycles involving free-ranging cats, dogs, opossums, and their fleas (e.g., cat flea, *Ctenocephalides felis*). [21] Some authors have classified *R. felis* in the spotted fever group based upon molecular characterization.

EPIDEMIOLOGY Endemic typhus occurs worldwide, and typically occurs in temperate and subtropical seaboard regions during warm-weather months. During the early 1940s, thousands of cases occurred along the southeastern and Gulf Coast of the United States, and today, a limited number of cases are reported from southern Texas and southern California. [22] Areas of the world that have experienced outbreaks of endemic typhus include Thailand, Kuwait, and China. In 1998, five cases occurred on southwestern Kauai.
PREVENTION Control of flea populations and their respective reservoirs are effective in decreasing infection rates.
CLINICAL MANIFESTATIONS After an incubation period of 1 to 2 weeks, the illness presents abruptly with fever, and may be accompanied by headache, nausea, vomiting, diarrhea, cough, chills, and myalgia. Initially, only 18 percent of patients exhibit a rash, but this develops in 50 to 60 percent of patients over the course of the illness. [21], [22] The median onset of rash after the fever is 6 days. The rash usually consists of erythematous macules or erythematous macules and papules. Infrequently, petechiae are present. The distribution occurs mainly on the trunk, but the extremities can also be affected. Rarely, palms and soles are involved. Hepatomegaly and splenomegaly can sometimes be appreciated. In Spain, endemic typhus is an important cause of fever of intermediate duration (7 to 28 days). [23] Complications are uncommon, but include seizures, meningoencephalitis, retinitis, acute hepatitis, endocarditis, renal insufficiency, pneumonia, and respiratory failure.
LABORATORY FINDINGS The most frequent laboratory abnormalities in endemic typhus patients are elevations in hepatic enzymes. Serum aspartate aminotransferase can be elevated in up to 90 percent of patients, and elevations greater than fivefold are not unusual. Elevated erythrocyte sedimentation rate, hyponatremia, hypocalcemia, and hypoalbuminemia are also common findings. Mild leukopenia and thrombocytopenia occur during the first week in a minority of patients. A shift toward immature leukocytes can be seen without leukocytosis.
DIAGNOSIS AND DIFFERENTIAL DIAGNOSIS Serologic tests employing IFA are the most widely used. Diagnostic titers are present in 50 percent of patients by 1 week, and in virtually 100 percent of patients by 15 days. [21] These assays do not easily differentiate among epidemic typhus or endemic typhus, however. More specific distinctions can be made by

using a combination of Western blotting and IFA, or by using serum cross-adsorption. [24] Newer methods of diagnosis (immunohistochemical diagnosis using antilipopolysaccharide antibodies) have not been standardized. The differential diagnosis is broad as a result of the nonspecific cutaneous eruption. The list includes other rickettsial infections, ehrlichioses, leptospirosis, drug eruptions, viral exanthems, meningococcemia, Kawasaki disease, and toxic shock syndrome.

TREATMENT AND PROGNOSIS Treatment for endemic typhus is similar to that of RMSF, with tetracyclines being the preferred agents. Single-dose doxycycline therapy is not recommended because of the potential for relapse. Fluoroquinolones have also been used effectively. [21] Fatalities occur in fewer than 5 percent of infected individuals. Approximately 10 percent of patients require intensive care. With institution of appropriate antibiotics, most patients have resolution of fever within 2 to 3 days. Markers for possibly more complicated courses are advanced age, alcoholism, underlying hemolytic disorders, and exposure to sulfa-containing antibiotics. [21], [22]

Epidemic (Louse-Borne) Typhus

Epidemic typhus is caused by *R. prowazekii,* and is transmitted to humans via the body louse (*Pediculus humanus var. corporis*). It may appear in two clinical forms, a primary febrile illness and a recrudescent infection [Brill-Zinsser disease (BZD)].

EPIDEMIOLOGY Louse infestation is associated with times of war, natural disasters, cold weather, and lack of hygiene. The most recent outbreak of epidemic typhus occurred in refugee camps in Burundi during the mid-1990s. [25] The major reservoir for disease seems to be humans, with body lice acquiring infection from feeding on persons with primary illness or BZD. The louse will die of infection within 3 weeks. The lice are spread through close personal or clothing contact. The infected louse will defecate while taking a blood meal, and the organisms in the feces are scratched into the skin. Since 1975 an association has been recognized between contact with southern flying squirrels and epidemic typhus. Along the eastern United States, fleas or lice from these rodents may be important vectors. Most of these cases have occurred in suburban or rural settings during the winter months. [22], [25]

PREVENTION Prevention begins with regular bathing and clothes washing. Delousing with appropriate agents, such as lindane or dichlorodiphenyltrichloroethane is effective. [25] A vaccine is available, but it is only recommended for special-risk groups.

CLINICAL MANIFESTATIONS After an incubation period of 1 week, there is an abrupt onset of headache, fever, chills, and myalgia. Typically, the rash begins in the axillary folds and upper trunk on the fifth day of illness. Initial lesions consist of erythematous macules that then become papular and petechial over several days. The eruption spreads centrifugally, but spares the face, palms, and soles. Indigenously acquired epidemic typhus in the United States appears similarly, but may be a more mild illness. [22], [25] Complications include acral gangrene cerebral thrombosis, and other neurologic sequelae. The severity of disease appears more significant than that of murine typhus, but certainly not as fulminant as RMSF. BZD occurs as a recrudescence of previous infection with *R. prowazekii*. Provocation by immunologic stress induced by poor living conditions may play a role. The illness is usually milder than primary disease.

LABORATORY FINDINGS Laboratory abnormalities include thrombocytopenia, elevated transaminases, and lactic dehydrogenase. A minority of patients has leukocytosis.

DIAGNOSIS AND DIFFERENTIAL DIAGNOSIS The diagnosis of epidemic typhus should be considered when the aforementioned clinical characteristics are combined with a setting where body lice could promulgate. Additionally, in the United States, flying squirrel exposure could be an important clue. The centrifugal spread, lack of eschar, and predilection for colder months helps differentiate epidemic typhus from other *Rickettsia*. The Weil-Felix test has been largely replaced by serologic tests employing IFA. These assays do not easily differentiate among epidemic typhus or endemic typhus, however. More specific distinctions can be reached using a combination of Western blotting and IFA, or by using serum cross-adsorption. Newer methods of diagnosis (PCR and immunohistochemical diagnosis using antilipopolysaccharide antibodies) have not been standardized. The Weil-Felix test is usually negative in BZD, but low titers can be present and consist of immunoglobulin G rather than M (primary disease). [22] The differential diagnosis is similar to that of endemic typhus (see above).

TREATMENT AND PROGNOSIS Treatment consists of tetracycline, doxycycline, or chloramphenicol. In fact, a single-dose of doxycycline, 100 mg, can be curative. [25] However, therapy should be continued for 2 to 3 days after defervescence. BZD is treated identically. Therapy failures have been documented with azithromycin for BZD. [26] The fever of epidemic typhus abates in 2 weeks in untreated cases. Recovery of strength can take 2 to 3 months. With early use of appropriate antibiotics, fever resolves within 48 h. Headaches may take 1 week to resolve. Fatal illness is rare if therapy is begun early. Mortality rates are highest in the elderly. Case fatality rates during recent outbreaks have been less than 5 percent, but have been recorded to be 30 percent in other instances. [22], [25]

Scrub Typhus (Tsutsugamushi fever)

Scrub typhus is a mite-transmitted zoonosis caused by *Orientia tsutsugamushi* (formerly *R. tsutsugamushi*). The vector is the larval stage (chigger) of trombiculid mites (*Leptotrombidium deliense* and several other *Leptotrombidium* sp.). The mites and rodents serve as the major reservoirs.

EPIDEMIOLOGY Scrub typhus is endemic to a region spanning eastern Asia to the western Pacific (Japan, Korea, India, Pakistan, Taiwan, Southeast Asia, and Australia). Scrub typhus is named for the type of vegetation that harbors the mite vector. This vegetation is a transitional terrain between tall forests and cleared land, composed of plantations, fields, groves, and tall grass. [27] Accordingly, the illness is more common in rural settings and is a common occupational disease.

PREVENTION Repellants that target the larval mites, such as diethyltoluamide (DEET) are effective at preventing transmission. These agents can be applied to skin or impregnated in clothing. Chemoprophylaxis with weekly doxycycline (200 mg) may be efficacious to travelers in endemic areas. [22]

CLINICAL MANIFESTATIONS The initial skin lesion is an erythematous papule that appears within 2 days of the chigger bite and undergoes ulceration and eschar formation in one-half to two-thirds of patients. The eschar may be absent in intertriginous areas. [22] Regional lymphadenopathy is followed by generalized lymphadenopathy. One to 2 weeks after the

bite, there is a sudden onset of fever. Chills, headache, cough, myalgia, anorexia, nausea, diarrhea, dyspnea, and conjunctival injection are variably present. A macular and then papular eruption sometimes occurs a few (mean, 4 to 5) days after the fever begins. [27] The eruption starts on the trunk, then spreads to the extremities, and fades within a few days. A relative bradycardia may be appreciated. Complications include pneumonitis, adult respiratory distress syndrome, meningoencephalitis, deafness, tinnitus, myocarditis, pericarditis, disseminated intravascular coagulation, hemophagocytic syndrome, retinal vein occlusion, renal failure, and hepatitis. In one retrospective study of 33 patients, 36 percent experienced pneumonitis. [28] In some HIV-1 patients who were also infected with scrub typhus, viral loads have been observed to diminish. A possible suppressive effect of *O. tsutsugamushi* on HIV has been hypothesized. [29] Clinically, HIV patients infected with *O. tsutsugamushi* do not seem to have more severe manifestations of scrub typhus.
LABORATORY FINDINGS A lymphocytosis with a normal total white blood cell count is common, but leukopenia or leukocytosis can also occur. Atypical lymphocytes are sometimes found, and multilobated nuclei have been reported. Other abnormalities include thrombocytopenia (44 percent of patients), and elevated hepatic transaminases (75 percent of patients). Cerebrospinal fluid (CSF) abnormalities, such as mild pleocytosis and elevated protein, have been documented. In a study of 75 consecutive patients with shrub typhus, 54 (72 percent) had pulmonary radiographic abnormalities. [30] These included reticulonodular opacities and ground-glass opacities.
DIAGNOSIS AND DIFFERENTIAL DIAGNOSIS The Weil-Felix test can be used for diagnosis, but has a low sensitivity. More-sensitive techniques that are readily available are IFA and the indirect immunoperoxidase assay. [27] Tests with even higher sensitivities that are being used in some regions include ELISA, dot blot urine immunoassay, rapid immunochromatographic flow assay, and PCR. The differential diagnosis includes those found with murine typhus and those generated by the tache noire and the eschar of rickettsialpox.
TREATMENT AND PROGNOSIS Tetracycline, doxycycline, and chloramphenicol are effective for scrub typhus. Single dose or short courses (3 days) of doxycycline may prove to be as efficacious as 7-day courses of tetracycline. [27] However, naturally occurring doxycycline- and chloramphenicol-resistant strains of *O. tsutsugamushi* have been found in northern Thailand. Azithromycin, rifampin, and ciprofloxacin are alternatives in this setting. With institution of proper antibiotics, defervescence occurs abruptly, usually within 24 h. In untreated patients, fever lasts for about 2 weeks. Relapses are common, especially when therapy is less than 2 weeks in duration. There is marked strain variation in virulence. Case fatality rates are significantly diminished with use of antibiotics, and were as high as 50 percent in Japan during the preantibiotic era. [22]

Q Fever

Q fever is caused by *Coxiella burnetii,* a rickettsia-like bacteria that is infrequently associated with cutaneous disease.

EPIDEMIOLOGY Unlike the aforementioned rickettsial diseases, it is chiefly acquired through the aerosol route and is most commonly associated with cattle, sheep, and goat reservoirs. Other mammals (including cats and dogs), fish, birds, and ticks can harbor *C. burnetii.* Pregnancy can reactivate the infection and parturition exposes contacts to a heavily infected placenta. The distribution is worldwide. Immunosuppressed patients, particularly those with HIV, are at increased risk. [31]
PREVENTION Preventative measures include an investigational vaccine for those at highest risk (abattoir workers, veterinarians), avoidance of infected animals, especially at parturition, and control of ectoparasites on typical animal reservoirs. [32]
CLINICAL MANIFESTATIONS A wide range of clinical illness can occur after infection. These include a self-limited febrile illness, pneumonia, endocarditis (especially in those with abnormal heart valves or vascular prostheses and aneurysms), hepatitis, osteomyelitis, pericarditis, and meningoencephalitis. [31], [32] Acute illness begins approximately 3 weeks after exposure and presents with fever, headache, malaise, myalgia, and chills. Cutaneous manifestations in acute Q fever are variably reported and may occur in as few as 4 percent or as many as 42 percent of patients. They consist of truncal erythematous macules and papules that present during the febrile episode. Palpable purpura can result from an immune complex vasculitis seen in chronic Q fever with endocarditis. [31] Livedo reticularis, mixed cryoglobulinemia, and arterial emboli can also occur in this setting. Erythema nodosum has also been ascribed to *C. burnetii.*
LABORATORY FINDINGS Common laboratory findings are a normal white blood cell count and elevated hepatic transaminases. Less frequently noted are thrombocytopenia, antiphospholipid antibodies, smooth muscle antibodies, inappropriate secretion of antidiuretic hormone, and hemolytic anemia. [31], [32] Multiple rounded opacities on chest x-ray are suggestive of Q fever caused by infected cat placenta.
PATHOLOGY Leukocytoclastic vasculitis can be appreciated with skin biopsies of palpable purpura in chronic Q fever. With hepatitis, a “doughnut granuloma” is characteristic. The granuloma consists of a dense fibrin ring surrounding a central lipid vacuole.
DIAGNOSIS AND DIFFERENTIAL DIAGNOSIS Diagnosis is usually confirmed with serology (complement fixation tests or others). The differential diagnosis is broad with acute Q fever's exanthem. In chronic disease associated with palpable purpura and a heart murmur, infectious emboli, atrial myxoma, and lupus erythematosus should be considered.
TREATMENT AND PROGNOSIS Tetracyclines such as doxycycline are the primary treatment for Q fever. Macrolides also are efficacious. Acute infections can be treated for 2 to 3 weeks, while chronic infections may require years of therapy. Frequently, other antimicrobials are added in the setting of chronic disease. Quinolones, rifampin, amantadine, and antimalarials have been used. [31], [32] The prognosis of Q fever is variable and ranges from an asymptomatic or self-limited febrile illness to death (2.7 percent).

EHRLICHIOSIS

Ehrlichia species are small, obligate intracellular bacteria that were originally thought to be *Rickettsia* species. Ehrlichioses are tick-borne zoonoses that have tropism for human phagocytic bone marrow-derived cells. The organisms grow within membrane-bound vacuoles, in which they form intracytoplasmic microcolonies called morulae. The main clinical classification of the ehrlichioses is human monocytic ehrlichioses (HME) caused by *E. chaffeensis* and human granulocytic ehrlichioses (HGE) caused by the *E. phagocytophilia* group. [33]

Epidemiology

E. chaffeensis is primarily transmitted by the tick *Amblyomma americanum,* although *Dermacentor variabilis* may also be a vector. HME occurs most often in the southern and south central United States. Peak incidence occurs May through July with increased outdoor exposure and males represent the majority of reported patients. [33] The main reservoirs are deer, dogs, and coyote.

HGE infection occurs in a geographically identical pattern as that of Lyme disease (primarily northeastern United States, with parts of the Pacific Northwest and upper midwest of the United States). The vector for both diseases is the *Ixodes* spp. of ticks. *Ixodes* sp. can also transmit *Babesia microti,* in addition to *Borrelia burgdorferi, Borrelia afzelii, Borrelia garinii,* and the *E. phagocytophilia* group. In the eastern United States, HGE infection peaks in July and again in November. The main reservoir is the white-footed mouse, other small mammals, and deer. [33]

Prevention

Preventative measures include avoidance of tick exposure and careful removal of attached ticks.

Clinical Manifestations

HME has a 1- to 2-week incubation period. Initial symptoms resemble those of many rickettsial diseases, with fever, chills, headache, myalgia, and malaise. Less-common symptoms include gastrointestinal illness, cough, dyspnea, and confusion. A nonspecific macular, papular, or petechial rash occurs in about one-third of patients, and is more common in children. The eruption occurs a few days after symptoms begin and is generally found on the trunk. Other less-common expressions are conjunctival injection, palatal petechiae, and acral edema with desquamation. [34] Severe complications consist of meningoencephalitis, renal failure, respiratory insufficiency, disseminated intravascular coagulation and pericarditis.

HGE greatly resembles HME in its clinical presentation. Rash is not as frequent as HGE, with fewer than 10 percent of patients affected. [33] Severe complications can include shock, renal failure, and respiratory insufficiency. Reported neurologic manifestations are meningoencephalitis, facial diplegia, brachial plexopathy, and demyelinating polyneuropathy. Concurrent illness with ehrlichioses and babesiosis or Lyme disease (up to one-fifth of HGE patients) has been documented.

E. sennetsu causes a mononucleosis-like illness in the Far East. *E. canis* has been reported to cause asymptomatic human infection. *E. ewingii* has infrequently been associated with human illness and may be clinically indistinguishable from HME or HGE infection. [35]

Laboratory Findings

HME and HGE most often result in thrombocytopenia, leukopenia, and elevations of hepatic transaminase levels during the first week of illness. The platelet count in HME usually is between 50,000 and 140,000/µL, whereas the mean white blood count is 3500/µL. [33] In HME, the leukopenia is the result of neutropenia or lymphopenia, or both. HGE results in thrombocytopenia more often than leukopenia. The leukopenia is the result of a relative and absolute lymphopenia with an increased number of band neutrophils during the first week of illness. Anemia is less often found, and occurs after the first week of illness. Serum creatinine is often elevated, especially in HGE. [34]

Pathology

E. chaffeensis primarily infects monocytes and macrophages. In the bone marrow, granulomas, myeloid hyperplasia, and erythrophagocytosis are common. Other findings include hepatic granulomas, hepatocellular necrosis, interstitial mononuclear cell pneumonitis, perivascular lymphohistiocytic infiltrates of various organs, and diffuse mononuclear phagocyte hyperplasia of the spleen and lymph nodes. [33] In contrast to the rickettsioses, vasculitis is not found in pathologic specimens. [33] A single retrospective case study suggests HME may rarely be associated with cutaneous vasculitis such as polyarteritis nodosa. [36]

The *E. phagocytophilia* group primarily infects neutrophils. This selectivity is mediated by adhesion to fucosylated leukocyte P-selectin glycoprotein ligand, PSGL-1. [37] Pathologic findings can include erythrophagocytosis in mononuclear phagocytic organs, hyper- or normocellular bone marrow, and hepatic apoptosis.

Diagnosis and Differential Diagnosis

Microscopic examination of leukocytes for the presence of morulae should be performed if ehrlichioses are suspected. Sensitivity is greater in HGE (20 to 80 percent) than in HME (7 percent). False positives occur with toxic granulation, superimposed platelets, and Döhle bodies. The major diagnostic criterion used for HME and HGE is IFA using acute and convalescent serum samples. Other, less-frequently employed, but more specific techniques are PCR, protein immunoblotting, and direct cultivation.

The differential diagnosis is extensive and includes such entities as RMSF, babesiosis, viral syndromes, pneumonia, gastroenteritis, Lyme disease, relapsing fever, endemic and epidemic typhus, tularemia, Q fever, Colorado tick fever, autoimmune systemic vasculitides, leptospirosis, hepatitis, toxic shock syndrome, thrombotic thrombocytopenic purpura, Kawasaki disease and endocarditis. RMSF is more likely with the presence of rash, normal white blood count, lack of morulae, and pathologic evidence of vasculitis. *Babesia microti* can be visualized in Giemsa- or Wright-stained

erythrocytes as ring forms with a central paler area, tetrads ("Maltese cross"), or as a single chromatic dot. Other findings with babesioses include emotional lability, hemolytic anemia, frequently normal or slightly depressed white blood count, dark urine with proteinuria, and hemoglobinuria.

Therapy and Prognosis

Tetracyclines are the drugs of choice, with doxycycline the most often used. Defervescence occurs within 1 to 2 days. Therapy for 5 to 7 days is generally effective, but one may want to continue therapy for 14 days if coinfection with *B. burgdorferi* is likely. [33] Children should also receive doxycycline (see RMSF therapy discussion for rationale).

The median duration of the ehrlichioses is 1 to 2 weeks. Fatalities have occurred in approximately 2 to 4 percent of patients with HME. [34] The clinical course ranges from asymptomatic seroconversion to multisystem organ failure with death. Initiation of antibiotics leads to decreased morbidity and mortality. Predictors of more fulminant disease include immunosuppression (e.g., organ transplant patients, HIV, glucocorticoid use), and patients with cough, diarrhea, and lymphadenopathy. More aggressive illness has been reported in patients with HME taking trimethoprim-sulfamethoxazole. HGE is also more severe in the immunosuppressed and can lead to opportunistic infections (disseminated candidiasis, aspergillosis, etc.).

REFERENCES

1. Walker DH et al: Emerging bacterial zoonotic and vector-borne diseases: Ecological and epidemiologic factors. *JAMA* **275**:463, 1996

2. Quintal D: Historical aspects of the rickettsioses. *Clin Dermatol* **14**:237, 1996

3. Heymann WR: Rickettsial microbiology. *Clin Dermatol* **14**:243, 1996

4. Walker DH, Raoult D: *Rickettsia rickettsii* and other spotted fever group *Rickettsiae* (Rocky Mountain spotted fever and other spotted fever), in *Principles and Practice of Infectious Diseases,* vol 2, 5th ed, edited by GL Mandell, JE Bennett, R Dolin. Philadelphia, Churchill Livingstone, 2000, p 2035

5. Silber JL: Rocky Mountain spotted fever. *Clin Dermatol* **14**:245, 1996

6. Treadwell TA et al: Rocky Mountain spotted fever in the United States, 1993–1996. *Am J Trop Med Hyg* **63**:21, 2000

7. Kirk JL et al: Rocky Mountain spotted fever. A clinical review based on 48 confirmed cases, 1943–1986. *Medicine (Baltimore)* **69**:35, 1990

8. Toerner JG et al: Guillain-Barré syndrome associated with Rocky Mountain spotted fever: Case report and review. *Clin Infect Dis* **22**:1090, 1996

9. Conlon PJ et al: Predictors of prognosis and risk of acute renal failure in patients with Rocky Mountain spotted fever. *Am J Med* **101**:621, 1996

10. Archibald LK, Sexton DJ: Long-term sequelae of Rocky Mountain spotted fever. *Clin Infect Dis* **20**:1122, 1995

11. Kao GF et al: Cutaneous histopathology of Rocky Mountain spotted fever. *J Cut Pathol* **24**:604, 1997

12. Purvis JJ, Edwards MS: Doxycycline use for rickettsial disease in pediatric patients. *Pediatr Infect Dis J* **19**:871, 2000

13. Stallings SP: Rocky Mountain spotted fever and pregnancy: A case report and review of the literature. *Obstet Gynecol Surv* **155**:37, 2001

14. Kaplan LI: Other spotted fevers. *Clin Dermatol* **14**:259, 1996

15. Cascio A et al: Clinical and laboratory findings of boutonneuse fever in Sicilian children. *Eur J Pediatr* **157**:182, 1998

16. Brouqui P et al: African tick-bite fever. An imported spotless rickettsiosis. *Arch Intern Med* **157**:119, 1997

17. Cascio A et al: Efficacy and safety of clarithromycin as treatment for Mediterranean spotted fever in children: A randomized controlled trial. *Clin Infect Dis* **33**:409, 2001

18. Heymann WR: Rickettsialpox. *Clin Dermatol* **14**:279, 1996

19. Comer JA et al: Serologic evidence of *Rickettsia akari* infection among dogs in a metropolitan city. *J Am Vet Med Assoc* **218**:1780, 2001

20. Saah AJ: *Ricketssia akari* (Rickettsialpox), in *Principles and Practice of Infectious Diseases,* vol 2, 5th ed, edited by GL Mandell, JE Bennett, R Dolin. Philadelphia, Churchill Livingstone, 2000, p 2042

21. Dumler JS, Walker DH: *Rickettsia typhi* (murine typhus), in *Principles and Practice of Infectious Diseases,* vol 2, 5th ed, edited by GL Mandell, JE Bennett, R Dolin. Philadelphia, Churchill Livingstone, 2000, p 2053

22. Baxter JD: The typhus group. *Clin Dermatol* **14**:271, 1996

23. Bernabeu-Wittel M et al: Murine typhus as a common cause of fever of intermediate duration: A 17-year study in the south of Spain. *Arch Intern Med* **159**:872, 1999

24. La Scola B et al: Serologic differentiation of murine typhus and epidemic typhus using cross-adsorption and Western blotting. *Clin Diagn Lab Immunol* **7**:612, 2000

25. Saah AJ: *Rickettsia prowazekii* (epidemic or Louse-Borne typhus), in *Principles and Practice of Infectious Diseases,* vol 2, 5th ed, edited by GL Mandell, JE Bennett, R Dolin. Philadelphia, Churchill Livingstone, 2000, p 2050

26. Turcinov D et al: Failure of azithromycin in treatment of Brill-Zinsser disease. *Antimicrob Agents Chemother* **44**:1737, 2000

27. Saah AJ: *Orientia tsutsugamushi* (scrub typhus), in *Principles and Practice of Infectious Diseases,* vol 2, 5th ed, edited by GL Mandell, JE

Bennett, R Dolin. Philadelphia, Churchill Livingstone, 2000, vol 2, p 2056

28. Tsay RW, Chang FY: Serious complications in scrub typhus. *J Microbiol Immunol Infect* **31**:240, 1998

29. Watt G et al: HIV-1 suppression during acute scrub-typhus infection. *Lancet* **356**:475, 2000

30. Choi YH et al: Scrub typhus: radiologic and clinical findings. *Clin Radiol* **55**:140, 2000

31. Marrie TJ: *Coxiella burnetti* (Q fever), in *Principles and Practice of Infectious Diseases,* vol 2, 5th ed, edited by GL Mandell, JE Bennett, R Dolin. Philadelphia, Churchill Livingstone, 2000, p 2043

32. Gluckman SJ: Q fever and trench fever. *Clin Dermatol* **14**:283, 1996

33. Walker DH, Dumler JS: *Ehrlichia chaffeensis* (human monocytotropic ehrlichiosis), *Ehrlichia phagocytophilia* (human granulocytotropic ehrlichiosis), and other *Ehrlichiae,* in *Principles and Practice of Infectious Diseases,* vol 2, 5th ed, edited by GL Mandell, JE Bennett, R Dolin. Philadelphia, Churchill Livingstone, 2000, p 2057

34. Mounzer KC, Dinubile MJ: Ehrlichial infections. *Clin Dermatol* **14**:289, 1996

35. Buller RS et al: *Ehrlichia ewingii,* a newly recognized agent of human ehrlichiosis. *N Engl J Med* **341**:148, 1999

36. Pick N et al: Ehrlichiosis associated vasculitis. *J Intern Med* **247**:674, 2000

37. Herron MJ et al: Intracellular parasitism by the human granulocytic ehrlichiosis bacterium through the P-selectin ligand, PSGL-1. *Science* **288**:1653, 2000

T>

Chapter 228

Miguel Sanchez

Syphilis

HISTORY
EPIDEMIOLOGY
ETIOLOGY
IMMUNOLOGY
CLASSIFICATION
PATHOGENESIS
CLINICAL MANIFESTATIONS
Primary Syphilis
Differential Diagnosis
Secondary Syphilis
Other Associated Clinical Manifestations
LATENT SYPHILIS
RELAPSING SYPHILIS
TERTIARY SYPHILIS
Late Benign (Tertiary) Syphilis
Mucous Membrane Lesions of Late Benign Syphilis
Cardiovascular Syphilis
Neurosyphilis (Table 228-3)
CONGENITAL SYPHILIS
Clinical Manifestations
SYPHILIS AND HIV INFECTION
DIAGNOSTIC TESTS
Histopathologic Examination
Dark-Field Microscopy
Direct Fluorescence Antibody Test
Serology
Reaginic Tests
Specific Treponemal Tests
CSF Examination
TREATMENT
Primary and Secondary Syphilis (without Neurologic, Ophthalmologic, or Auditory Involvement)47
Early Latent Syphilis47
Indeterminate or Late Latent Syphilis
Tertiary Syphilis (Cardiovascular, Late Benign Syphilis)47
Neurosyphilis47
Treatment in Pregnancy47
Prenatal Syphilis47
Persons Exposed to Syphilis (Epidemiologic Treatment)
Syphilis in HIV-Infected Patients
Complications of Treatment
VACCINES
CONCLUSION

REFERENCES

Syphilis is caused by *Treponema pallidum* (ssp. *pallidum*), a microaerophilic spirochete that infects only humans and a few other primates. The organism is too delicate to be grown in vitro, yet so aggressive that it invades almost any organ in the body, and so evasive that it can elude a miasmal immune attack and occasionally it may even survive massive doses of antibiotics. [1] The infection is usually contracted through sexual contact with infected lesions or body fluids; less commonly, transplacentally from mother to unborn child; and rarely through blood transfusion, accidental inoculation, or puncture with contaminated instruments, such as those used for tattooing.

Dermatologists have a decisive advantage in diagnosing syphilis because of their skill in evaluating skin lesions. However, although the diagnosis is usually made by examination of mucocutaneous lesions, the infection is systemic, even in the absence of symptoms. The variable clinical course and diverse manifestations were recognized long before Sir William Osler dubbed syphilis “the great imitator,” but much remains to be learned about the pathogenesis of this infection, which continues to baffle and challenge even experienced clinicians, investigators, and epidemiologists.

HISTORY

Syphilis probably evolved from yaws between 15,000 and 3000 B.C. However, it is commonly cited that syphilis was contracted by Spanish sailors from Haitian natives during Columbus' first trip to the New World. Columbus, himself, reportedly died from syphilitic aortitis. Several infected sailors joined Spanish troops supporting the struggle of Alfonso II of Naples against Charles VIII of France and infected Neapolitan women. The women, in turn, infected mercenaries from different countries fighting for the French army. After the army's disbandment, the mercenaries spread the disease throughout Europe. Concurrently, Portuguese sailors under Vasco da Gama transmitted the infection in Asia.

Probably, syphilis was already present in a more attenuated form in several continents well before the discovery of the Americas. Ancient documents describe “venereal leprosy” in the populations of Rome, Greece, and China in terms that closely resemble the manifestations of syphilis. However, a devastating epidemic of a virulent, destructive, and disfiguring form of syphilis, that swept through Europe at the end of the fifteenth century stimulated previously

unprecedented preoccupation with the disease. In each country, syphilis was named after a rival nation. The French called it the Neapolitan itch, the Russians named it the Polish disease, and the Italian term *morbus Gallicus* (French disease) became particularly popular. In 1530, the physician and poet Girolamo Fracastoro published the third book of his poem *Syphilis sive Morbus Gallicus,* about the affliction of the handsome shepherd Syphilus with a repulsive disease as punishment for blasphemy to the sun god. The poem included a detailed description of the incubation period, symptoms, prevention, and treatment, and the name of the shepherd became synonymous with the infection. [2] The other name by which the disease is commonly known, *lues* (from the Latin for plague or pestilence), was introduced by the sixteenth century physician-poet Jean Fennel, who first differentiated between the primary and secondary stages. By the end of the sixteenth century, the clinical manifestations and treatment with guaiac wood and mercury (two minutes with Venus, two years with Mercury) were well documented. But the major contributions were made after the eighteenth century (Table 228-1). None had a greater impact than the introduction of penicillin as treatment for syphilis in the 1940s. Within 10 years, the number of cases had so dramatically declined that the extinction of the disease was predicted, prompting the American Academy of Dermatology to drop the term *Syphilology* from its original name.

1797	John Hunter concludes that syphilis and gonorrhea are the same disease after developing both infections from a self-administered inoculation of urethral discharge.
1837	Phillipe Ricord distinguishes syphilis from gonorrhea and classifies primary, secondary, and tertiary stages.
1854	John Diday writes popular manual on congenital syphilis.
1856	Ricord generates definitive description of the biology of syphilis.
1880	Jonathan Hutchinson describes triad of congenital syphilis (keratitis, labyrinthitis, and notched teeth).
1891	Caesar Boeck studies the natural course of the disease in 2181 patients who are not treated for fear that complications of mercury are greater than those of syphilis.
1905	Fritz Schaudinn and Erich Hoffman identify treponemes in chancres.
1909	Paul Erlich treats syphilis with a "magic bullet"—arsenic.
1910	August von Wasserman develops complement fixation diagnostic test.
1933	John Nelson generates a treponemal-specific serologic test.
1943	John Mahoney reports that penicillin cures syphilis.

TABLE 228-1 **Landmarks in Syphilology**

EPIDEMIOLOGY

In the early part of the twentieth century, 10 percent of the population of the United States and Europe was infected with syphilis. [1] During World War I, the US Congress launched several public health measures after syphilis was detected in 13 percent of military draftees. These included quarantines and compulsory premarital screening. The incidence of syphilis peaked between 1935 and 1947 as efforts to combat the disease were restrained by a conspiracy of silence. Surgeon General Thomas Parran, in his ambitious campaign to wipe out the "shadow on the land," called for a serologic dragnet to screen the population and to institute partner notification through "shoe leather" epidemiology. These aggressive public health policies were largely ineffective.

During World War II, the armed forces instituted successful preventive interventions that included public education, prostitution control, distribution of condoms, and availability of immediate treatment without punitive repercussions. As treatment with penicillin became widely available, the incidence decreased dramatically. The resurgence of sexually transmitted diseases seen in the 1960s was blamed on looser sexual attitudes (permissiveness, promiscuity, and the pill), but in the 1970s, enhanced control efforts again lowered the number of syphilis cases. Since then, the pattern has been sudden bursts in the rate of infected cases followed approximately every 5 to 10 years by periods of low prevalence. [3] The most effective public health strategies have been the selection and confidential screening of high-risk populations, partner notification, free treatment of infected persons and partners, behavior counseling, and rapid response to outbreaks. Still, kindled by the exchange of sex for money to buy crack cocaine, the rate of infectious syphilis catapulted in 1991 to a 50-year high of 102.3/100,000 population, only to decline in 1999 to an all-time low rate of 2.5/100,000 population. [4] Encouraged by this success, the Centers for Disease Control launched a National Plan for Elimination of Syphilis from the United States. However, recently, several outbreaks of syphilis among homosexual and bisexual men, including those who are HIV-seropositive, have been reported. [5] The facilitation of casual sex promoted by Internet sites may prove to be an important cause for future outbreaks in industrialized countries.

In many parts of the world, syphilis continues to be a major public health problem. Despite therapeutic "magic bullets," the disease has proven to be a formidable opponent.

ETIOLOGY

The cause of syphilis is *T. pallidum,* a motile, corkscrew-shaped, prokaryotic bacterium with a flexible, helically coiled cell wall (Fig. 228-1). The organism is microscopically indistinguishable from treponemes that cause pinta, yaws, or endemic syphilis, and closely resembles the bacteria that cause Lyme disease, borreliosis, and leptospirosis.

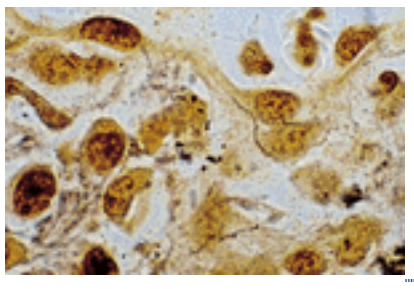

FIGURE 228-1 Silver stain of syphilis lesion showing the corkscrew-shaped treponemes.

T. pallidum measures between 6 and 15 µm in length and 0.10 and 0.18 µm in width. It has tapered ends between which are 6 to 14 regularly spaced tight spiral coils. When fixed, the spirals impart a wavelike configuration. Its narrow width renders the organism undetectable by light microscopy without silver staining. Under dark-field microscopic examination, the treponemes resemble strings of beads with a characteristic rotatory motion and a flexion and back-and-forth squiggle. This motion is said to be characteristic of virulent treponemes and to facilitate penetration through tissue. However, in fluid medium, the bacteria lack locomotion, which distinguishes them from most saprophytic treponemes.

The spirochete has three main components. The protoplast is the central part of the treponeme and contains the genome and the organelles responsible for metabolism. [6] The axial filament (flagellum) consists of six to eight elastic fibrils twisted around the protoplast. It imparts a helicoid shape and contributes to the spirochete's mobility. The outer envelope contains a heteropolymer peptidoglycan macromolecule that preserves the organism's shape, protects the fragile cytoplasm against injury, and filters large molecules. An extracellular amorphous slime layer may protect the organism against phagocytosis. Because the outer envelope contains a paucity of integral transmembrane proteins that stimulate specific antibodies, the organism more easily evades immune attack.

Replication occurs through fission, with an interval of 30 to 33 h between divisions. The outer envelope, where growth requires approximately 30 steps and several enzymes, is susceptible to damage by antibiotics.

IMMUNOLOGY

Our knowledge of the disease has been hampered by the difficulty of growing the organism in culture and the laboriousness involved in growing treponemes in rabbits, the only animal model. In addition, the immune responses in patients with syphilis may differ during the various stages of infection. For this reason, contradictory conclusions have been reported.

T. pallidum penetrates mucosal surfaces and abraded skin of humans. Chemotactic factors attract neutrophils to the inoculation site. Skin breakdown results in a chancre, initiating the *primary stage*. In more mature chancres, neutrophils are replaced by lymphocytes that, through secretion of lymphokines, attract and activate macrophages. In the presence of exogenous antibody, macrophages ingest and destroy the organisms. Consistent with a T_H1-predominant local cellular response, the lesions contain interleukin (IL)-2, interferon-?, IL-10, and IL-12. [7] Plasma cells are also present in the infiltrate and a humoral response is elicited. Antibodies to *T. pallidum* are detectable at the time or shortly after the chancre appears. Production of IgM precedes that of IgG. The combined humoral and cell-mediated immune responses appear to eliminate the spirochetes locally, resulting in the end of the primary stage. PCR studies indicate that *T. pallidum* spirochetemia occurs during the primary stage (as well as the secondary and relapsing stages). [8]

After a few weeks, proliferation of spirochetes markedly increases, and the disease becomes generalized. During this *secondary stage,* antibody levels skyrocket in response to the huge numbers of organisms. The antibody response modifies the appearance of the secondary syphilis lesions, which would otherwise resemble primary chancres. At this time, resistance to new infection develops, although delayed-type hypersensitivity to *T. pallidum* becomes unexpectedly deficient. This suppression of cell-mediated immunity allows proliferation of the organisms despite rising antibody levels.

The secondary stage is followed by an asymptomatic stage called *latency*. During this period, delayed-type hypersensitivity reappears. In *the tertiary stage,* the immune response results in the formation of granulomas, although treponemes are rarely detected, even by immunofluorescence.

Immunity to reinfection develops only in untreated patients. After treatment, most reinfected patients develop typical chancres. The majority of patients with congenital syphilis are refractory to reinoculation and do not develop lesions or elevated antibody levels. A few develop dark-field–negative lesions associated with high antibody titers or gummas at the inoculation site.

The means by which some treponemes resist the immune attack, which effectively clears practically every organism from early lesions, is unknown. Possible explanations include inhibition of cell-mediated responses, refuge of treponemes in anatomic sites (central nervous system, eye, aorta, bone, lymph nodes, or perilymph of middle ear) that shield the organisms from detection by the immune system, and protection by the slimy mucopolysaccharide coat surrounding the spirochetal cell wall. Some answers are provided by experimental infection in rabbits. Early on, immunity is normal, resulting in annihilation of most treponemes. However, treponemal antigens are able to induce the host macrophages to secrete twice as much prostaglandin E_2. As a result, IL-2 synthesis by these cells is halved and, consequently, T cell proliferation is inhibited, leading to suppressed immunity that enables the remaining intact organisms to proliferate, even in the presence of antibody. The suppression persists for at least 1 month and can be reversed by indomethacin or a combination of IL-1 and IL-2. [9]

CLASSIFICATION

Syphilis has been described as an on- and off- and on-again disease. Its course is divided into three clinically distinct stages and two asymptomatic epidemiologic stages. Early syphilis includes the primary stage (chancre), secondary disease (mucocutaneous lesions and/or lymphadenopathy, with or without organ involvement), and subsequent clinical relapses. Latent disease is subdivided into early (less than 1 year) and late (1 year or longer) stages. Tertiary (late) disease can present with cutaneous, cardiovascular, or neurologic involvement (Table 228-2).



TABLE 228-2 **Stages of Syphilis**

PATHOGENESIS

The natural course of syphilis was studied in three large studies. In the Oslo study conducted in Oslo, Norway, between 1891 and 1910, the records of 953 patients with untreated syphilis were analyzed. The data has been criticized for its emphasis on autopsies, death certificates, and hospital admissions, which biased the results toward a more serious prognosis. In the notorious Tuskegee experiment, 412 African American men with untreated latent syphilis were followed from 1936 to 1972, during which time they were discouraged from receiving treatment. [10] The conclusions of this unfortunate study are limited by its restriction to a single race, sex, and socioeconomic class, and by the lack of a unified protocol. Furthermore, the study has been accused of having as a prime objective the procuring of body tissues and fluids to create and commercialize serologic tests. Conclusions from the Rosahn study, the third in this series, which was a review of autopsies, are distorted by the obviously poor prognosis of the studied population.

In the Oslo study, the median duration of the primary stage was 30 days in men and 27 days in women. [11] The secondary stage lasted 2.1 months in men and 3.5 months in women. Approximately 25 percent of patients experienced relapsing syphilis, and in this group, one-quarter had multiple episodes. Six months after contracting syphilis, 95 percent of patients become uninfectious, even without treatment. Although the danger of direct transmission is exceedingly low after 5 years of infection, inoculation from gummas has been reported. Latent syphilis follows the secondary stage and may persist for life in an asymptomatic form in about two-thirds of untreated patients. The rest develop tertiary syphilis, which usually becomes manifest as cutaneous (16 percent), cardiovascular (9.6 percent), or central nervous system (CNS) (6.5 percent) disease (see Table 228-2). Syphilis was the cause of death in 11 percent of the patients in the Oslo study. In African American men with untreated syphilis, the mortality appears to be even higher as cardiovascular disease was found in approximately half of autopsies from persons participating in the Tuskegee experiment. [10]

More recent analyses indicate that 1 in 25 persons with untreated syphilis become crippled, 1 in 44 insane, and 1 in 200 blind.

CLINICAL MANIFESTATIONS

Primary Syphilis

Approximately one-third of persons who come in contact with a lesion of early syphilis become infected. At the site of treponemal penetration, after an incubation period that ranges from 10 to 90 days (average 3 weeks), a dusky red macule appears that grows into a papule and becomes a chancre by ulcerating in the center (Fig. 228-2). The length of the incubation period varies inversely with the number of inoculated treponemes. The chancre is round or oval, approximately 1 cm in diameter, with sharply defined, regular, raised, indurated borders (Fig. 228-3). It is firm, rubbery, and, if uncomplicated by trauma or impetiginization, nontender. The ulcer base is smooth, brownish-red, and it may be covered with a yellowish or grayish slough. [12] Untreated, the chancre persists from 1 to 6 weeks; it resolves within 1 to 2 weeks after treatment and heals without scarring. However, deviation from the above description is common, and the classic “Hunterian” chancre is now seen in only approximately 60 percent of cases. In 15 to 30 percent of cases, the lesions go unnoticed. Multiple chancres (Fig. 228-4) may be present in up to 47 percent of cases, and edema, phimosis, erosive balanitis, lymphangitis, and thrombophlebitis of the dorsal vein may be found. In industrialized countries, coinfection with herpes genitalis is the most plausible explanation for the presence of multiple chancres. In men, the commonly involved locations are the glans, the coronal sulcus, and the foreskin. Chancres in the urethral orifice have been reported to cause an inflammatory phimosis that may eventuate in penile gangrene. Retraction of the foreskin with a chancre in its mucosal surface causes the foreskin to flip briskly, a sign known as the “dory flop.”

FIGURE 228-2 Early chancre presenting as a flat, eroded papule with raised, indurated borders and a smooth, clean base.

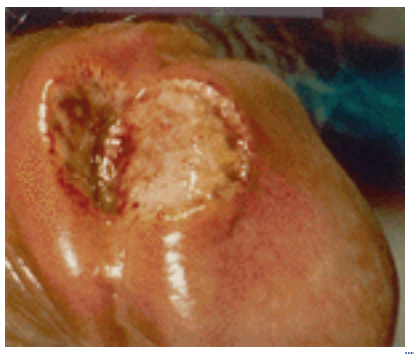

FIGURE 228-3 Classic “Hunterian” chancre with raised, indurated borders and a slightly hemorrhagic necrotic base.

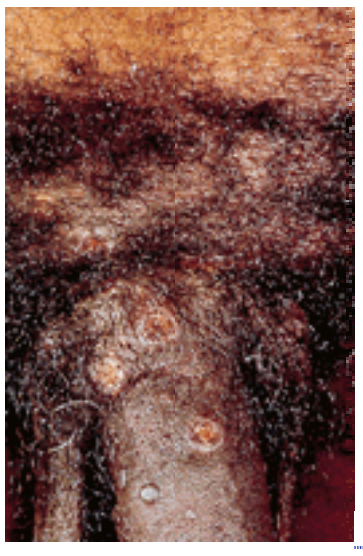

FIGURE 228-4 Multiple chancres at the base of the penis and adjacent pubis. Chancres in this location are associated with use of condoms.

In women, the labia, fourchette, urethra (Fig. 228-5), and perineum are affected, in descending order of frequency. Chancres in women tend to have an edematous rather than a cartilaginous induration. *Edema indurativum* is a unilateral labial swelling with rubbery consistency and intact surface, characteristic of a deep-seated chancre in this site. Chancres develop in the cervix in as many as 44 percent of infected women but are rarely detected. Kissing chancres are common in areas of skin-to-skin contact such as the vulva.

FIGURE 228-5 Chancre in a female. An ulcer covered with fibrin and necrotic slough at the orifice of the urethra.

Extragenital chancres are more commonly related to oral sex. Approximately two-thirds of extragenital chancres occur above the neck, and approximately half of these are seen on the lips, the perioral region, or in the oral cavity (Fig. 228-6). The rest appear on the fingers, breasts, trunk, abdomen, and extremities. Chancres on the fingers may be painful. Anorectal chancres constitute at least 4 to 10 percent of extragenital primary syphilis cases and are common in men who have sex with men. Anorectal primary syphilis is underdiagnosed and should be considered in any at-risk person with rectal pain, bloody stools, anal fissures, or a precipitously appearing mass or ulcer in the anorectal area.

FIGURE 228-6 Extragenital chancre. A deep ulcer with an indurated border and base. Most extragenital chancres are located on the lips or the perioral region.

In 70 to 80 percent of all primary syphilis cases, enlarged, rubbery, movable, nontender, nonsuppurative, discrete lymph nodes (buboes, also scleradenitis) appear during the first week of infection. The nodes are usually unilateral at first and most commonly palpated in the inguinal area, although in women the femoral nodes are often enlarged. In one study, the nodes were tender in 14 percent of patients. Relapses of primary syphilis, called monorecidive syphilis or chancre redux, are rare.

Differential Diagnosis

The diseases most frequently misdiagnosed as primary syphilis are chancroid, traumatic ulcers, and herpes genitalis. The differential diagnosis also includes granuloma inguinale, lymphogranuloma venereum, bacterial infections, squamous or basal cell carcinoma, lymphoma, Behçet's disease, aphthous ulcers, fixed-drug eruption, and balanitis or vulvitis caused by candidiasis, psoriasis, or lichen planus.

Secondary Syphilis

Lesions of secondary syphilis erupt 3 to 12 weeks after the appearance of the chancre but may develop months later or, in up to 15 percent of cases, before the chancre disappears. The secondary stage usually recedes in 4 to 12 weeks. [12] Not all patients present with the classic textbook presentation. In fact, the symptoms and clinical findings may be subtle, transient, and easily overlooked or so severe that hospitalization is required. Almost 60 percent of patients with latent or late syphilis deny ever experiencing signs or symptoms of secondary disease. One-quarter of these patients cannot recall the appearance of a chancre. Patients with secondary syphilis may experience symptoms such as malaise, appetite loss, fever, headache, stiff neck, lacrimation, myalgias, arthralgias, nasal discharge, and depression. However, the majority of patients present with only an eruption. The frequency of organ involvement differs among studies. In a series of 2269 cases of secondary syphilis, the skin was involved in 81.1 percent, the oral cavity and pharynx in 36.3 percent, the genitalia in 19.9 percent, the CNS in 9.9 percent, the eyes in 4 percent, and visceral organs in 0.2 percent. Wise clinicians learn to consider the “great imitator” when confronting a combination of signs and symptoms that cannot be readily explained.

Skin eruptions develop in 80 to 95 percent of cases. Greater than 95 percent of the eruptions are macular, maculopapular, papular, or annular. [12] Nodular and pustular eruptions occur infrequently, and vesiculobullous lesions are seen only in prenatal syphilis, and not at all in adults. Lesions of secondary syphilis often have a symmetric pattern early in the disease and become polymorphic later. In 8 to 42 percent of cases the lesions are pruritic. Itching may be more common among African Americans. With or without treatment, all secondary lesions heal without scar formation in 2 to 10 weeks.

Macular eruptions (roseola syphilitica) consist of .05- to 2-cm, pink, discrete, nonscaling, oval macules and patches, which predominantly involve the trunk and flexor aspects of the upper extremities (Fig. 228-7). The face is usually spared, but any area, including the palms and soles, may be involved.

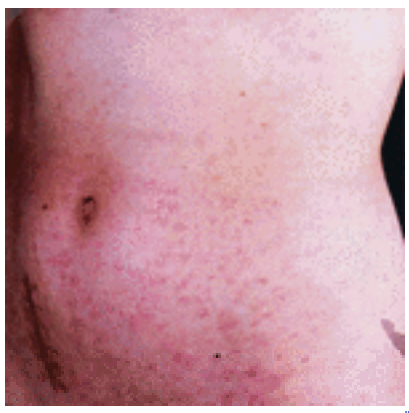

FIGURE 228-7 Macular syphilis (roseola syphilitica) with nonscaling, oval pink, ill-defined macules and patches on the chest and abdomen.

Maculopapular eruptions represent an evolution of the macular lesions toward papules and plaques, as some macules

become thickened and develop a dark coppery hue (Fig. 228-8 and Fig. 228-9). Lesions are often present on the genitalia, face, palms, and soles. Lesions around the hairline form a crown-like pattern known as the “corona veneris.”

FIGURE 228-8 Syphilis showing a combination of erythematous macules and coppery papules.

FIGURE 228-9 Generalized papulopustular syphilitic eruption. Note coppery tone of the papules and central crusting of some of the pustular lesions.

Papular eruptions include papulosquamous, follicular, lenticular, corymbose, nodular, annular, and follicular varieties. They may be disseminated and generalized (Fig. 228-9) or grouped, aggregated, and localized to defined sites (Fig. 228-10 and Fig. 228-11).

FIGURE 228-10 Papulosquamous syphilitic eruption with erythematous, well-demarcated, flattened plaques covered with scales (Biette's collarette).

FIGURE 228-11 Lichenoid syphilitic eruption with pink to violaceous, planar, polygonal papules resembling lichen

planus.

Papulosquamous eruptions have discoid, copper-colored or erythematous, oval or circular, indurated papules or plaques with a flat, shiny, scaly surface (Fig. 228-10). When the lesions are pruritic and lichenoid, the eruption may be difficult to distinguish from lichen planus (Fig. 228-11) and, when hyperkeratosis is pronounced, the eruption may resemble psoriasis. The occasional presence of the Koebner's phenomenon further contributes to this confusion. A thin, white ring of scales on the surface of a lesion (Biet's collarette) is a valuable but not pathognomonic diagnostic sign. The palms and soles are often involved (Fig. 228-12). On the soles, the lesions may become hyperkeratotic and be mistaken for calluses (clavi syphilitici) or tinea pedis.

FIGURE 228-12 Characteristic secondary syphilis lesions on the palms (**A**) and soles (**B**). Palmoplantar lesions may be macular or papular, discrete or diffuse, and nonscaling, slightly scaly, or hyperkeratotic (“syphilitic corn”).

Lenticular eruptions consist of pinhead to lentil-size, brown to red papules with smooth surfaces or fine scaling. The face, especially the forehead, oral commissures, nasolabial folds, and the genitalia, are favored sites.

Corymbose (bombshell) eruptions are rare and seldom occur before 6 to 8 months of infection. Typically a large central papule or plaque is surrounded by smaller satellite papules (Fig. 228-13).

FIGURE 228-13 Corymbose syphilitic eruptions occur late in the secondary stage, usually after 6 to 8 months of infection. A larger papule or plaque is surrounded by smaller satellite papules.

Nodular eruptions consist of dermal nodules, which are frequently misdiagnosed as lymphoma or a granulomatous disease (Fig. 228-14).

FIGURE 228-14 Nodular secondary syphilis on the face of a man. Such lesions are frequently misdiagnosed as lymphoma or a granulomatous disease, such as sarcoidosis, leprosy, or lupus vulgaris.

Annular eruptions consist of oval or round ringlike papules and plaques with a predilection for the face, anogenital area, body folds, palms, and soles. The eruption is often misdiagnosed as sarcoid, granuloma annulare, or tinea corporis. Serpiginous, concentric, or arcuate configurations may be seen.

Follicular eruptions consist of pinpoint, acuminate or rounded, erythematous papules that arise in crops on the torso and extremities. This eruption is uncommon and has been reported predominantly in debilitated persons such as alcoholics.

Pustular eruptions include several morphologic variants. In miliary pustular eruptions, small acuminate pustules and papules resolve with depressed pigmented scars. In acneiform, varioliform, or obtuse eruptions, there are large, acuminate perifollicular pustules, often with polymorphism (Fig. 228-9). In impetiginoid or ecthymiform eruptions, flat pustules become confluent and covered with a large crust called a carapace. Malignant syphilis (lues maligna, rupial syphilis, pustuloulcerative syphilis) presents with widespread papulopustules or nodules that become necrotic and break down into ulcers covered by layers of rupioid crust resembling an oyster shell (Fig. 228-15). The eruption is associated with toxicity, fever, arthralgias, and, occasionally, hepatitis. Oral ulcers and mucous patches may develop. Most patients have abnormal immune systems or poor health. Infected contacts usually have a more benign course, and there is no evidence that the treponemes causing the infection are more virulent. Noduloulcerative syphilis with or without systemic symptoms is more common in immunocompromised HIV-infected persons.

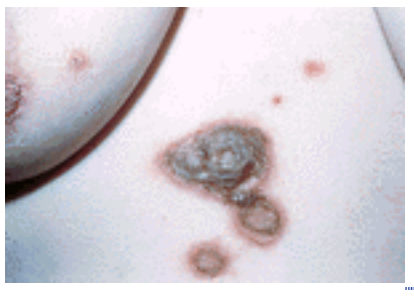

FIGURE 228-15 Sharply marginated, necrotic ulcers covered by “rupioid,” thick dirty crusts (like oyster shells) are the characteristic lesions of malignant syphilis.

Pigmentary changes may remain after healing of lesions. On the sides of the neck an interesting pattern consisting of hypopigmented macules superimposed on linear pigmented reticulated patches, has been called leukoderma colli syphiliticum or the necklace of Venus. In dark-skinned individuals, intense loss of pigment within the affected areas may resemble vitiligo. Hypopigmentation in syphilis results from partial inhibition of melanogenesis as the number of melanocytes is normal or only slightly reduced. When dermal atrophy, possibly related to inflammation-induced elastin degradation, is present, the appearance resembles anetoderma.

Mucous membrane lesions are extremely infectious. The three manifestations are condylomata lata, mucous patches, and pharyngitis. The last two heal spontaneously within 2 to 3 weeks, but condylomata may persist for months.

Condylomata lata consist of flesh-colored or hypopigmented, moist, oozing papules that become flattened and macerated (Fig. 228-16). They have been reported in 9 to 44 percent of cases. Their surface may be smooth, papillated, or covered with cauliflower-like vegetations. The common sites are the genital and anal areas and, less frequently, the oral commissures, face, axillae, inframammary folds, and toe webs (Fig. 228-17). [13] Lesions in intertriginous areas may erode or proliferate, forming elevated, brown velvety plaques or grouped hypertrophic, nodular lesions that resemble raspberries (frambesiform syphilis). Overgrowth of bacteria produces a foul odor.

FIGURE 228-16 Rounded, gray, moist, vegetating papules (condylomata lata) develop most frequently on the anogenital area, but may arise on the lips, groin, and toe webs. The lesions are often confused with condylomata acuminata (venereal warts).

FIGURE 228-17 Coppery, eroded, and crusted papules of secondary syphilis may also be found in the toe webs, where they may be mistaken for tinea, erythrasma or, as in this case, Kaposi's sarcoma.

Mucous patches are painless, shallow, rounded erosions covered with gray macerated scaling (Fig. 228-18). Present in 7 to 12 percent of secondary syphilis cases, the lesions may appear anywhere in the mouth but are more common on the tongue and lips. [14] The tonsils and epiglottis may be affected, resulting in hoarseness. Confluence of several denuded lesions on the tongue has been termed *plaques fauches en prairie*. Mucous patches also arise on the glans penis, inner vulva, and anus. In these areas, the lesions are more likely to become eroded or ulcerated due to friction. Split papules are elevated mucous patches with central fissures in the oral commissures (Fig. 228-18).

FIGURE 228-18 Mucous patches on the lips. These erosions covered with gray-white, macerated scales are seen on the lips, oral mucosa, tonsils, and larynx. Lesions in the buccal commissure are fissured in the center (split papules).

Pharyngitis of variable severity may occur in up to a quarter of cases, although soreness is rare. Diffuse redness of the pharynx, palate, and tonsils may be very mild or severe with edema and erosions. Pseudomembranes and necrosis have been reported, and laryngeal involvement may produce hoarseness.

NAIL DISEASE In secondary syphilis, nail changes may result from involvement of either the nail matrix or the nail folds. In the nail plate, brittleness, splitting, onycholysis, pitting, lunular elkonyxis (pits) with fissuring, and dystrophy have been described. The nail plate growing during the infectious episode may become dull, dry, thickened, and Beau's lines or latent *onychomadesis* (separation) may appear. Paronychia of the lateral and proximal nail folds may develop. The nail bed may become ulcerated, producing an exudate that may cause separation, shedding, and even permanent deformity of the nail plate. Amber-colored plates resembling artificial nails have been reported to be characteristic of late secondary syphilis. Cyanotic, painful toes (the blue-toe syndrome) are an unusual manifestation. [15] Alopecia may be the only sign of secondary syphilis. It has been described in 3 to 7 percent of cases, and may be either patchy, diffuse, or both. [16] The more characteristic type consists of small irregular patches of nonscarring alopecia throughout the scalp but predominantly on the occipital and parietal regions. Because the margins are not sharp, the term *moth-eaten* is often used descriptively (Fig. 228-19). In some cases, the lesions resemble trichotillomania or alopecia areata. Occasionally the eyebrows, beard, and other hair-bearing areas are affected. Diffuse hair loss may occur as a result of scalp involvement by secondary syphilis or as a telogen effluvium, clinically noticeable 3 to 5 months after the infection begins.

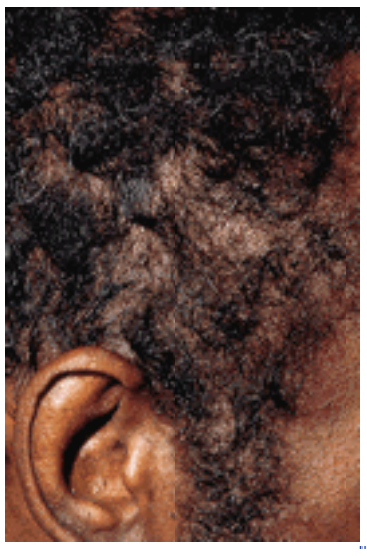

FIGURE 228-19 Moth-eaten alopecia is the more common form of hair loss. Irregular, patchy, nonscarring alopecia is present more frequently on the occipital scalp, and occasionally affects the eyebrows and beard.

Other Associated Clinical Manifestations

LYMPHORETICULAR SYSTEM Enlarged lymph nodes are present in 50 to 80 percent of cases. In descending order of frequency, the inguinal, axillary, cervical, epitrochlear, femoral, and superclavicular chains are involved. Typically, the nodes are movable, firm, rubbery, discrete, bilateral, symmetric, and nontender. [12] Mild splenomegaly is common.
OPHTHALMOLOGIC Iritis, the most common eye complication, occurs in fewer than 3 percent of all cases, late in the course of secondary syphilis, or in relapsing syphilis. The patient presents with red, injected eyes and complains of pain, lacrimation, and photophobia. Uveitis, chorioretinitis, and, rarely, vasculitic occlusion of the central retinal vein and artery are also observed. A recent report concluded that 4.3 percent of 552 cases of uveitis were syphilitic. [17] Symptoms include photophobia; lacrimation; red, painful eyes; and blindness. Topical glucocorticoids without antibiotics are contraindicated.
AUDITORY There are a few reports of sensorineural hearing loss in early acquired syphilis. The condition worsens rapidly and tends to be bilateral. Vestibular involvement with labyrinthitis is uncommon. However, 6 percent of all cases of Ménière's disease are caused by congenital or acquired syphilis. [18] The pathogenesis is usually basilar meningitis with damage to the eighth nerve. Immediate treatment with antibiotics and a prolonged course of prednisone preserves hearing in almost all cases.
MUSCULOSKELETAL Because bone and joint involvement are not readily apparent, the impression has been that they are rare. However, different studies have found rates ranging from 0.15 to 4 percent clinically and 9 percent by imaging. The principal symptoms are local pain, erythema, doughy tumefaction, and warmth. Favored affected sites are the long bones of the extremities, especially the tibia, and the skull, with resulting persistent headaches. Radiographs and more sensitive bone scans demonstrate various combinations of periostitis, osteomyelitis, bone destruction, and sclerosis. Radiographic changes may take up to 11 months for complete resolution after appropriate therapy. Back pain, arthralgias, arthritis, tenosynovitis, and bursitis may be severe and persist for several months. Patients may experience generalized myalgias and muscle weakness that resembles an inflammatory myopathy.
HEMATOLOGIC Abnormalities include anemia, leukocytosis, relative lymphopenia, and elevated sedimentation rate.
RENAL Acute membranous glomerulonephritis, usually manifested by the nephrotic syndrome, is reversible with treatment.
HEPATIC Although usually subclinical, the incidence of luetic hepatitis was 9.7 percent in one study. Jaundice is seldom detected.
GASTRIC Epigastric pain and postprandial vomiting may be caused by eroded, ulcerated, or polypoidal stomach lesions, which heal with antibiotics. Erosive syphilitic gastritis usually affects the antrum of the stomach.

LATENT SYPHILIS

The secondary stage is followed by an asymptomatic stage with no clinical findings in which the only evidence of the disease is reactive serologic testing. Latency may remain indefinitely, be interrupted by a relapse of secondary syphilis, or progress to the tertiary stage. Being a diagnosis of exclusion, careful examination for mucocutaneous lesions and organ involvement is required. Ultrasound evaluation of the aorta to exclude cardiovascular disease should be considered. Although neurosyphilis should be excluded by examination of the cerebrospinal fluid (CSF), spinal taps are not routinely done because of concern about complications, unless neurologic signs or symptoms are present or the patient is HIV-infected. The duration of infection should be determined by history and previous serologic tests, because, for therapeutic and epidemiologic purposes, the latent stage is divided into early (less than 1 year) and late (1 year or longer) stages. However, this determination may not always be possible, and the clinician must settle for a diagnosis of indeterminate latency, which is treated in the same manner as late latent syphilis.

In clinical practice, patients who were adequately treated but who continue to have low titers of nontreponemal tests are commonly seen. If previous treatment or lack of reinfection cannot be confirmed, then, from a public health standpoint, these patients should be assumed to be infected and treated. A record of the nontreponemal test titer and the administered therapy should be given to the patient. Too often patients are unnecessarily retreated repeatedly because such records are not readily available.

RELAPSING SYPHILIS

Approximately 25 percent of untreated patients experience a relapse of secondary lesions despite the absence of reinfection. More than two-thirds of the relapses occur within 6 months, 90 percent occur within the first year, and 95 percent occur within 2 years. Relapses may present with the reappearance of chancres or, more frequently, an eruption of secondary syphilis, including mucous patches and condylomata lata. Relapsing syphilis lesions tend to be less extensive and are frequently confined to the anogenital and oral areas. Because patients may be unaware of the lesions

or insufficiently concerned to seek medical help, relapsing syphilis is particularly alarming from an epidemiologic standpoint. Other presentations include periostitis (usually tibial), iritis, and hepatitis.

TERTIARY SYPHILIS

Approximately one-third of patients with untreated latent syphilis develop tertiary syphilis, while the other two-thirds remain in perpetual latency. The three principal presentations during this stage are late benign syphilis, cardiovascular disease, and neurosyphilis.

Late Benign (Tertiary) Syphilis

Late benign syphilis includes any symptomatic syphilitic manifestation after the secondary and relapsing stages that does not involve the cardiovascular or nervous systems. The lesions are caused by a cell-mediated inflammatory response to a small number of treponemes present in the affected tissues. At the beginning of the twentieth century, the incidence in untreated men and women was 14.4 and 16.7 per 100,000 population, respectively, but now this stage is rare, possibly as a result of widespread use of antibiotics for other infections. The more commonly involved organs are the skin (70 percent), mucous membranes (10.3 percent), and bones (9.6 percent), but gummas may appear in practically any organ, including the parotid glands, thyroid, esophagus, stomach, liver, breasts, pancreas, kidneys, adrenal glands, spleen, bladder, and cervix, as well as the brain and heart. Chronic iritis, chorioretinitis, interstitial keratitis, and atrophy of the optic nerve are rare. Painless, fibrosing interstitial orchitis can result in atrophy.

LATE BENIGN SYPHILIS OF THE SKIN Tertiary skin lesions can be divided into three types: granulomatous nodules, psoriasiform granulomatous plaques, and gummas. “Precocious” lesions develop within the first 2 years after the resolution of the secondary stage, and “late” lesions at any time after that. Most lesions develop within 3 to 7 years, but gummas have appeared as long as 60 years after infection. The longer the interval before the appearance of the skin lesions, the more solitary and destructive the process. Precocious tertiary syphilis develops during the first 2 years of infection and occasionally within weeks. Infiltrated grouped papules that tend to ulcerate may be localized to one site or be more widespread. The papules have features of both secondary stage lesions and tertiary stage granulomas. Bacteria are rarely detected. The lesions heal with little or no scarring. Nodular and noduloulcerative tertiary lesions (Fig. 228-20) are superficial, firm, painless, dull-red, shiny, flat cutaneous nodules that measure several millimeters to 2 cm in size. The nodules appear in a grouped configuration and coalesce into plaques. [19] The skin overlying the lesions breaks down, resulting in irregular ulcers covered with crust. Over weeks or months, central healing and advancing borders produce plaques with annular, arciform, serpiginous, or polycyclic configurations that may grow to more than 30 cm (Fig. 228-21). Some plaques may be psoriasiform (Fig. 228-22). The lesions are most commonly seen on the arms, back, and face. Even without treatment the granulomas heal over the years, leaving noncontractile, atrophic scars with increased or decreased pigmentation.

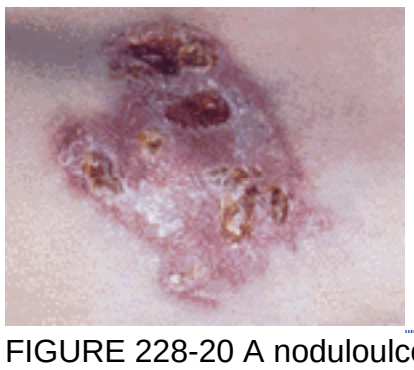

FIGURE 228-20 A noduloulcerative tertiary syphilitic lesion is a sharply defined and irregularly shaped flat nodule of a dull red color, firm consistency and superficial ulcerations.

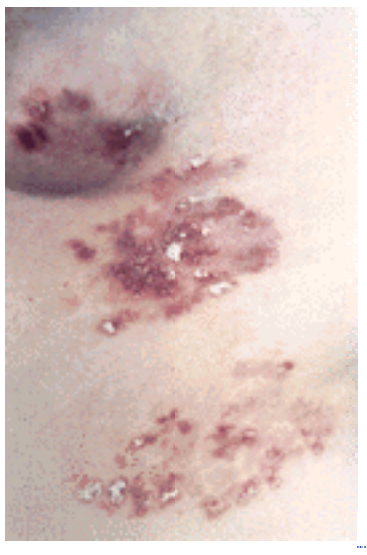

FIGURE 228-21 Crusted and scaly noduloulcerative tertiary syphilis plaques with characteristic serpiginous borders and scarring.

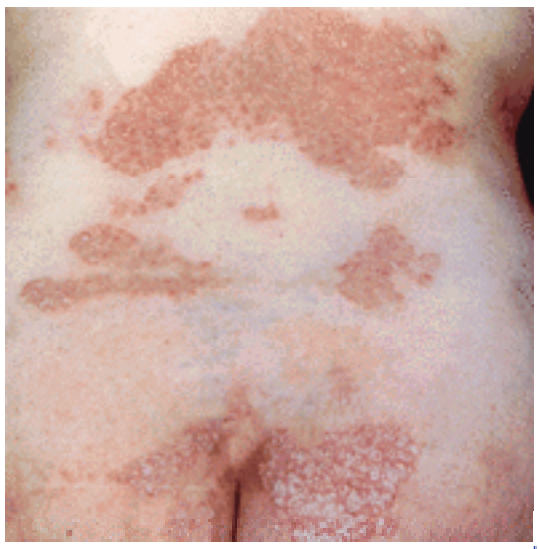

FIGURE 228-22 Plaque of tertiary syphilis may be brick-red in color, covered with scales, and may be indistinguishable from psoriasis.

Gummas are nontender pink to dusky-red nodules or plaques that vary in size from millimeters to many centimeters in diameter. [20] They favor sites of previous trauma and may arise anywhere in the body but are more common on the scalp, forehead (Fig. 228-23), buttocks, and presternal, superaclavicular or pretibial areas. The nodule is initially firm but develops a gummy consistency due to accumulation of necrotic tissue. Gummas may grow horizontally as well as vertically. Small ulcerations and abscesses may be present within the lesions (Fig. 228-23). Various geometric configurations are assumed. As the central gumma heals, new lesions may develop on the periphery, forming scalloped borders. Gummas are more destructive and deeper than noduloulcerative lesions (Fig. 228-24). Tissue necrosis eventuates in cylindrical, punched-out ulcers with clean granulomatous bases covered with adherent yellow-white slough (Fig. 228-25). The ulcer may enlarge, remain unchanged, or heal spontaneously even as the gumma enlarges. More superficial gummas heal with noncontractile atrophic scars, whereas deeper lesions leave thickened, pitted, ridged scars. Gummas are rarely contagious, but infection following contact with gummas has been reported.

FIGURE 228-23 Disfiguring gummatous infiltration of the glabella and forehead with scattered ulcerations in a 60-year-old female with late benign syphilis.

FIGURE 228-24 Aggressive gumma of the forehead causing destruction of the calvarium, mimicking advanced, destructive basal cell carcinoma.

FIGURE 228-25 Two deep, punched-out ulcers in the popliteal fossa, covered with an adherent yellow slough at the base. This is the classical appearance of nodular gummas.

Mucous Membrane Lesions of Late Benign Syphilis

Discrete gummas or diffuse gummatous infiltration may involve mucous membranes, especially the palate, nasal mucosa, tongue, tonsils, and pharynx. The lesions ulcerate and are disfiguring. Destruction of the nasal cartilage and bone (saddle nose) (Fig. 228-26A) and perforation of the nose and palate are disease hallmarks (Fig. 228-26B). Chronic interstitial glossitis remains premalignant even after penicillin treatment (Fig. 228-27). Gummas of the larynx, trachea, and bronchi are rare. Pulmonary findings include chronic infection with miliary lesions, a nodule, or pleural effusion. Pseudochancre redux is a solitary gumma of the penis.

FIGURE 228-26 *A*. Destruction of the nasal cartilage and bone by a gumma leads to a saddle nose and (*B*) to the perforation of the nasal cartilage and skin and thus to considerable mutilation.

FIGURE 228-27 Premalignant, chronic interstitial glossitis secondary to gummatous infiltration of the tongue.

Skeletal late syphilis includes gummatous osteitis, periostitis, and sclerosing osteitis. The bones most commonly affected are the tibia, clavicle, skull, fibula, femur, and humerus, but the disease can involve almost any bone. Symptoms include nocturnal pain, swelling, and tenderness.

Cardiovascular Syphilis

Although currently regarded as a medical curiosity, new cases of cardiovascular syphilis continue to be reported. In early syphilis, cardiovascular disease is rare and limited to conduction defects. However, cardiovascular disease is a common manifestation of tertiary disease. In the Oslo study, the disease was clinically apparent in 13.6 percent of men and 7.6 percent of women, and was the primary cause of death in 15.1 percent of men and 8.2 percent of women. Before the availability of penicillin, syphilis constituted 25 to 30 percent and 5 to 10 percent of all cardiac diseases in African Americans and whites, respectively. Symptoms usually develop 15 to 30 years after the initial infection. Only 7 percent of patients with cardiovascular syphilis develop symptoms or signs within 5 years of infection.

Presumably, during the early stages of syphilis, treponemes invade the aortic wall, where they can remain dormant indefinitely. The treponemes have a predilection for the aortic vasa vasorum and produce chronic low-grade inflammation

that eventuates in an obliterative endarteritis. This results in necrosis of the muscular and elastic tissues and scarring. Fibrous thickening of the adventitia and atherosclerotic plaques in the intima impart the tree bark appearance that is highly suggestive of syphilis. The most common complications are aortitis, aortic aneurysm, aortic valve incompetence, coronary ostial stenosis, and myocardial gummatous disease.

Uncomplicated aortitis occurs predominantly in the ascending aorta, with fewer than 10 percent of the cases involving the abdominal aorta and only 2 percent affecting the portion below the renal artery. [21] The disease comprises between 27 and 36 percent of cardiovascular syphilis cases, but is asymptomatic and is usually found inadvertently at postmortem examination. The diagnosis is suspected when linear eggshell calcifications of the anterolateral aortic wall are present in chest radiographs.

Aortic aneurysms comprise 20 percent of cases of cardiovascular syphilis. The proportion is actually 40 percent if patients who also have coronary ostial or aortic valvular disease are included. Focal weakening of the wall results in a saccular aneurysm, whereas diffuse weakening produces fusiform involvement of the ascending and transverse aorta with subsequent dilation of the aortic ring. More than 60 percent of aneurysms involve the ascending aorta, and 25 percent the transverse arch. Abdominal aneurysms usually form above the renal arteries.

Coronary ostial stenosis constitutes 25 to 30 percent of cases of cardiovascular syphilis. Like ischemic heart disease, the main symptoms are angina pectoris and congestive heart failure. Clues to the diagnosis are the relative young age of the patient, absence of arteriosclerotic changes, reactive syphilis serology, poor response to vasodilators, and concomitant aortic regurgitation. Acute myocardial infarctions rarely occur because the stenosis is gradual and stimulates the development of an adequate collateral circulation.

Aortic valvular incompetence is found in approximately 30 percent of patients with tertiary disease. It is a late complication caused by aortic ring dilation and stretching of the valve. The soft diastolic blowing murmur of aortic regurgitation is best heard over the second right intercostal space. Myocardial disease occurs in only 2.4 percent of cardiovascular syphilis patients. In diffuse gummatous myocarditis, the most common locations are the left ventricle and septum, where gummas can cause heart block and conduction defects.

Neurosyphilis (Table 228-3)

I. Asymptomatic
II. Meningeal
A. Acute meningitis (headache, fever, photophobia, stiff neck, confusion)
1. With hydrocephalus (severe headache, nausea, vomiting, papilledema)
2. With vertex involvement (seizures, aphasia, hemiplegia)
3. With basilar involvement (tinnitus, deafness, Bell's palsy)
B. Spinal pachymeningitis (cervical pain, muscle atrophy, sensory loss, spastic paraplegia)
III. Meningovascular
A. Cerebral (prodromal symptoms, hemiparesis, hemiplegia, aphasia, seizures)
B. Spinal
1. Meningomyelitis (paresthesia, spastic weakness of legs, sensory loss, sphincter disturbances)
2. Acute transverse meningitis (sudden flaccid paraplegia, hemiparesis, sensory loss, urinary retention)
IV. Parenchymatous
A. General paresis (impaired judgement, irritability, delusions, dysarthria, tremors, incontinence)
B. Tabes dorsalis (paresthesia, lightning pains, ataxia, incontinence, impotence, pupillary disturbances)
C. Optic atrophy (visual loss)
V. Gummatous
A. Cerebral
B. Spinal

TABLE 228-3 **Classification of Neurosyphilis**

Hematogenous invasion of the meninges by *T. pallidum* occurs early. The resulting infection may resolve spontaneously or proceed to either chronic asymptomatic or acute symptomatic meningitis. Meningitis may progress to involve other areas of the CNS. In one study, *T. pallidum* was recovered from half the patients with secondary syphilis, the only patient with primary syphilis, and from no patient with latent syphilis. In another report, 16 percent of patients with indeterminate latent syphilis had reactive CSF serologies and pleocytosis, and one-quarter of these patients were asymptomatic.

After resolution of secondary syphilis, the spirochetes presumably remain dormant in the CNS of untreated, and even in some treated, patients. In 9.4 percent of men and 5 percent of women, this asymptomatic state progresses to clinically overt neurologic disease.

Symptoms occur from 5 to 35 years after the initial infection. The clinical manifestations of neurosyphilis are protean, but the classification (Table 228-3) is useful and widely used. Neurosyphilis is divided into asymptomatic, meningeal, meningovascular, parenchymatous, and gummatous disease.

Asymptomatic neurosyphilis is the presence of CNS infection as indicated by CSF abnormalities in the absence of neurologic signs or symptoms. CSF findings, such as reactive serologic or elevated cell counts and protein, peak at 12 to 18 months after infection, but disappear in 70 percent of cases even without treatment. Nontreponemal tests may be nonreactive in up to 39 percent of patients, but treponemal tests are usually positive in the serum as well as in the CSF. [21]

Meningeal syphilis may occur early or late. Most cases of acute syphilitic meningitis occur during the first year of infection. Meningitis is the initial presentation of syphilis in up to 25 percent of patients. Fewer than 10 percent of these patients have skin eruptions at the onset of their meningitis. The symptoms are consistent with any aseptic meningitis and include headache, fever, photophobia, stiff neck, confusion, nausea, and vomiting. One-third of patients present with

acute hydrocephalus and one-quarter of all cases of syphilitic meningitis have focal involvement of the cerebral vertex (vertex meningitis) or posterior fossa, possibly resulting in seizures, aphasia, and hemiplegia. Cranial nerve palsies caused by basilar involvement are a common complication of meningitis. The more frequent palsies involve the oculomotor, auditory, and facial nerves. Reversible sensorineural deafness, which characteristically involves the higher frequencies, develops within days in up to 20 percent of patients, even in the absence of meningitis or other signs of secondary syphilis. The hearing loss is often preceded by tinnitus. Response of meningeal syphilis to penicillin is usually good.

Spinal pachymeningitis with inflammation and thickening of the dura mater usually involves the cervical area and causes pain, muscle atrophy, sensory loss, diminished tendon reflexes, and, ultimately, spastic paraplegia with sensory loss.

Meningovascular syphilis constitutes 10 percent of all neurosyphilis cases. The disease may involve the cerebrum (cerebrovascular) or spinal cord (spinal meningovascular).

Cerebrovascular syphilis is caused by endarteritis of the medium and large arteries (Heubner's arteritis) or small arteries and arterioles (Nissl arteritis) that results in thrombotic infarction. The name is somewhat misleading because the underlying pathogenesis is a chronic meningitis. Because the neurologic signs are focal, the clinical picture resembles atherosclerotic occlusive disease, but the typical patient is an adult 30 to 50 years of age. Symptoms may develop as early as 2 years, but usually develop between 4 and 7 years after the initial infection. Weeks to months before the abrupt onset, approximately half the cases experience prodromes, with symptoms such as dizziness, headaches, insomnia, memory loss, and mood changes. [22] Depending on the artery involved, patients may present with almost any neurologic deficit. The most frequent is hemiparesis or hemiplegia, followed in frequency by aphasia and seizures. [22] Therefore, this diagnosis should be considered in anyone with adult-onset epilepsy or strokes.

Spinal meningovascular syphilis is divided into meningomyelitis and acute transverse myelitis. Meningomyelitis, the more common form, usually begins more than 20 years after the initial infection, with paresthesia and spastic weakness of the legs. These symptoms are followed by combinations of sensory loss, sphincter disturbances, pain, and muscular atrophy. Acute transverse myelitis produces sudden flaccid paraplegia, sensory deficits, and urinary retention.

Parenchymatous neurosyphilis is divided into three well-known syndromes: tabes dorsalis, general paresis, and optic atrophy. [21]

Tabes dorsalis is caused by infection of the parenchyma of the posterior columns and posterior root of the spinal cord. It once developed in 5 percent of patients with untreated syphilis of 20 to 25 years duration, but is now rare. The three stages are preataxia, ataxia, and paralysis. The early symptoms are recurrent attacks of paresthesia and paroxysms of lightning pain. Stabbing pains in visceral organs such as the abdomen, rectum, and larynx (10 to 15 percent of cases) may simulate surgical emergencies. As the disease progresses, the patient may develop impotence, urinary retention, visual loss, and rectal incontinence. Locomotor ataxia begins with stumbling and difficulty in walking. Because position sense is lost, the ataxia is more prominent in the dark and is compensated by visual orientation. The Romberg sign is positive, which means that the patient stumbles when the feet are held close together with the eyes closed. Pupil reactivity becomes sluggish early and is seen in 90 percent of cases. The distinctive Argyll-Robertson pupils in which the pupil accommodates (to objects), but does not react (to light) are seen later. Hearing loss as a result of eighth nerve involvement is found in approximately 25 percent of cases. Charcot joints are enlarged, painless, uninflamed joints, with or without deformity or effusion, in the lower extremities and spine and result from repeated traumatic injury. Serum and CSF serologic tests are reactive in early tabes dorsalis but may be negative late in the course. The disease is rarely fatal, but patients become disabled and dependent.

General paresis, a chronic meningoencephalitis that severely disturbs cerebrocortical function and results in gross atrophy of the frontal and temporal lobes, is characterized by granulations in the ventricles, hydrocephalus, and widened cerebral sulci. Depending on the damaged area, the symptoms may be psychiatric, neurologic, or, more commonly, both. [21] Untreated, the course of this process spirals downward towards death. In the Oslo study, general paresis developed in 2.5 percent of men and 1.4 percent of women. The disease begins about 15 to 20 years after infection. The onset may be sudden but is more commonly insidious, with changes in personality and behavior. Irritability, forgetfulness, inability to concentrate, and headaches are followed by impaired judgment, emotional lability, and inappropriate social or moral behavior. [21] Delusions of grandeur with marked euphoria occur in 20 percent of the cases. It has been said that everyone in contact with the paretic suffers but the patient. Paranoia, tantrums, and alcohol abuse may appear. Full-blown psychosis is followed by a period of neurologic deterioration. Tremors of the hands, lips, or tongue; seizures of any type; and incontinence of urine and feces are common. At this point, a paralytic facies devoid of facial expression is typical. Mental and neurologic deterioration progresses to death in an average of 2 to 12 years from pneumonia, infected pressure ulcers, or septicemia. The clinical spectrum is summarized in the clever Holmes mnemonic, *paresis*: *p*ersonality disorder, *a*ffect (flat), *r*eflexes (hyperactive), *e*ye changes (unequal pupils that react poorly to light), *s*ensorium (delusions), *i*ntellect impairment, and *s*peech dysarthria. Serum and CSF serologic tests are reactive in almost all cases. Adequate antibiotic treatment halts progression of the disease in 80 percent of patients.

Optic atrophy may occur as an isolated finding. The visual loss begins in one eye, but soon involves the other. Optic atrophy also results from syphilitic optic neuritis. In both conditions, the CSF is usually abnormal. Penicillin does not restore vision but prevents further loss.

Focal (gummatous) cerebral meningeal syphilis is caused by compression and invasion of the brain by a gumma, which usually arises from the pia mater. Because serologic tests can be unreactive in the serum and the CSF, a biopsy may be required for diagnosis. The symptoms produced by spinal gummas are caused by compression. Cerebral gummas respond poorly to antibiotics, so surgical resection may be necessary. [23]

In clinical practice, an unusual combination of signs and symptoms may be present, resulting in a puzzling neurologic picture. Perhaps as a result of the liberal use of antibiotics, which may partially treat CNS infection, the classic forms of

neurosyphilis are becoming less common and the presentations more atypical. There are reports of patients with blurring of vision accompanied by Argyll-Robertson pupils or with isolated bilateral oculomotor nerve paresis or with tinnitus accompanied by variable auditory deficits. The presentation may be ophthalmic symptoms, confusion, personality changes, the Guillain-Barré syndrome, or persistent dizziness. The diagnosis of neurosyphilis should be strongly considered in a young adult with a stroke, new seizure disorder, confusional syndrome, or dementia. Detection relies on a combination of clinical manifestations, serum serologic tests, CSF examination, and radiographic scans.

CONGENITAL SYPHILIS

As early as 1529, Paracelsus recognized that syphilis could infect the fetus, although “genetically from father to son” rather than transplacentally. At that time, because of another popular misconception, wet nurses were publicly paraded and flogged (with the approval of medical practitioners) for supposedly transmitting the disease to their previously healthy charges. In time, the mode of transmission became clear, but not until the nineteenth century was the disease studied systematically. In 1854, Paul Diday described the syphilitic newborn as “a little wrinkled potbellied old man with a cold in his head” (see Fig. 228-28). The definition of congenital syphilis was recently updated (Table 228-4); however, because most infants have no clinical or serologic evidence of syphilis at birth and develop abnormalities months to years later, all potentially infected infants should be treated with penicillin. [24] Despite the popularity of the term *congenital syphilis,* prenatal syphilis better indicates that the signs and symptoms may develop before or after delivery rather than always being present at birth, and are not hereditary, as congenital implies. Mothers usually transmit the infection to the fetus transplacentally and possibly during delivery through contact with an infectious genital lesion. Syphilis is not transmitted through breast-feeding unless an infectious lesion is present on the breast. [25]

FIGURE 228-28 Early prenatal syphilis in a newborn. The skin is dry and wrinkled with a yellowish-brownish hue. There is hemorrhagic rhinitis. This is what Diday described as “a little wrinkled potbellied (not seen here) old man with a cold in his head.” Note also the aged appearance of the fingers in this newborn.

Type	Definition
Confirmed	An infant in whom *T. pallidum* is identified in lesions, placenta, umbilical cord, or autopsy tissue
Presumptive	Any infant whose mother was untreated or treated with antibiotics other than penicillin before delivery, regardless of findings in the infant or Any infant or child with a reactive treponemal test for syphilis and any one of the following: Evidence of congenital syphilis on physical examination or X-ray of long bones Presence in the CSF of lymphocytosis and elevated protein (without other cause) Reactive CSF VDRL or Infant RPR fourfold higher than mother (both drawn at birth) or Reactive IgM-treponemal antibody test in serum
Syphilitic stillbirth	A fetal death in which the mother had untreated or inadequately treated syphilis at delivery of a fetus after a 20-week gestation or of a fetus weighing >500 g

*Congenital syphilis includes cases of prenatally acquired syphilis in infants and children, as well as syphilitic stillbirths.
NOTE: RPR, rapid plasma reagin; VDRL, Venereal Disease Research Laboratory

TABLE 228-4 **Definition of Congenital Syphilis***

In a recent study, 66 percent of fetuses of women diagnosed with infectious syphilis had hepatomegaly, and some also had abnormal transaminases, thrombocytopenia, and anemia. [26]

Approximately 25 percent of infants from mothers with untreated primary or secondary syphilis die in utero. Of those infants born, almost half develop the disease, another quarter are seropositive without clinical manifestations, and one-quarter are not infected. About 40 percent of infants born to mothers with early latent syphilis are infected, and an additional 20 percent are premature, 10 percent stillborn, and 4 percent die perinatally. In late latent syphilis, 10 percent develop congenital syphilis and another 10 percent are stillborn or premature. [25] One-quarter of newborns with signs and symptoms of congenital syphilis die shortly after birth unless treated. Syphilis is the most common cause of nonimmune hydrops fetalis, resulting in pallor, edema, and a bloated abdomen.

Spirochetes have been detected in fetuses as young as 9 weeks, but before the fifth month of gestation the fetus seems to escape harm, probably as a result of an inability to mount an inflammatory response. Even at birth, the inflammation

affects the placenta more than the infant. A fibrosed, large, thick, and pale placenta and a diseased umbilical cord with alternating streaks of red, pale blue, and chalky white may be the only clue to the diagnosis of congenital syphilis. Some infants may develop the disease after birth from colonization of *T. pallidum* in the nasopharynx and gastrointestinal system.

Clinical Manifestations

Prenatal syphilis is divided into early (first 2 years) and late (after 2 years) stages. In 80 percent of cases, the diagnosis is missed during the first year of life, and in one study, the average age at diagnosis was 30 years. Most infants are asymptomatic, and even when manifestations develop, these are often subtle and nonspecific.

EARLY PRENATAL SYPHILIS Clinical manifestations develop within the first 2 years of life. This stage is comparable to the secondary stage of acquired syphilis because treponemes disseminate throughout the fetus. Without treatment, almost half of symptomatic infants die. However, with improved perinatal care and treatment, the prognosis is now good. Infants tend to be small for dates or they are premature, irritable, and cry feebly. In descending order of frequency, the manifestations found are low birth weight, hepatosplenomegaly, anemia, jaundice, thrombocytopenia, skin lesions, respiratory distress, rhinitis, and pseudoparalysis. [26] Rhinitis ("snuffles") has been reported in 73 percent of infants. It usually develops in the second to third week of life and may be the earliest clinical sign. Initially thin, a mucoid nasal discharge, teeming with spirochetes, can become purulent or bloody (Fig. 228-28). The nasal septum may become perforated. If untreated, flattening of the nasal bridge results in the characteristic saddle or *fleur de lis* nose. [27] The skin of the syphilitic neonate is often dry and wrinkled and, in newborns with fair skin, has a café au lait hue (see Fig. 228-28). Mucocutaneous manifestations occur in about half of patients younger than 6 months of age and, like secondary syphilis lesions, usually consist of an eruption of copper- to red-colored macules and papules, with or without scale, predominantly on the palms, soles, and diaper area. Condylomata lata and mucous patches may also be present. Annular or corymbiform eruptions may also occur. [25] Rare, but characteristic for the disease, are bullae between 1 and 5 cm in diameter. They are highly infectious and may be generalized or, more often, limited to the extremities including the palms and soles (Fig. 228-29). Commonly known as syphilitic pemphigus, the blisters are invariably a sign of severe disease. Pustules may appear on the fingers, toes, and at the angles of the mouth. Ulcerations around the mouth, nose, or anus may heal with rhagades (Parrot's lines), depressed linear scars that persist to adulthood and radiate from the orifice like the spokes of a wheel (Fig. 228-30).

FIGURE 228-29 Bullous eruptions on the soles of a newborn with early prenatal syphilis. Bullae have ruptured and now present as erosions ("syphilitic pemphigus").

FIGURE 228-30 Perioral rhagades are linear scars that result from ulcerations that appear during early congenital syphilis and persist to adulthood.

Lymphadenopathy occurs in half the cases but may not be prominent. The presence of firm, movable, nontender epitrochlear nodes is especially characteristic for prenatal syphilis. Bone disease, although usually asymptomatic, is the most common early manifestation, having been reported in 97 percent of autopsied infants younger than 6 months of age. The most frequently observed osseous lesion, osteochondritis, is diagnosed by its characteristic radiographic *sawtooth* appearance in the metaphysis. In the medial aspect of the proximal tibial metaphysis, this defect occurs in one-fifth of early cases and has been called the *Wimberger* or *cat-bite sign*. Longitudinal lines of rarefaction like "celery sticks" may expand into the diaphysis. Pain from osteochondritis of the long bones, or epiphysitis, is exacerbated by movement, so the child keeps the affected limb still, a sign known as *pseudoparalysis of Parrot*. Painful periostitis, commonly observed in the latter half of the first year, may lead to blunting of the scapular spines and anterior tibial margins in later life. The resulting multiple layers of new bone produce the radiographic "onion-peel periosteum" sign. Osteitis of the fingers is uncommon but may produce dactylitis during the first 2 years of life. Neurosyphilis occurs in 40 to 60 percent of all syphilitic infants. However, only 10 percent of these infants develop symptomatic neurosyphilis, which does not usually become clinically evident until the third to sixth month of life. It is essentially meningovascular and can present as various neurologic syndromes.

LATE PRENATAL SYPHILIS Manifestations appear after the age of 2 years, but rarely past the age of 30, and can be divided into two groups: malformations (stigmata) and active pathologic processes (Table 228-5). Most manifestations are not specific, with the exception of the Mulberry molars and the characteristic interstitial keratitis. Late congenital syphilis is not infectious. The order of frequency of late syphilis signs varies in different reports.

Stigmata	Active Disease
Ophthalmic	Retinitis
Corneal clouding	Interstitial keratitis
Oral	
Hutchinson's teeth	Gummas in nose or palate
Mulberry molars	
High-arched palate	
Ears, nose, throat	
Saddle nose	
Orthopedic	
Frontal bossing	Periostitis
Short maxilla	Dactylitis
Protuberant mandible	Clutton's joints
Saber shins	
Scaphoid scapula	
Thickened medial clavicle	
Neurologic	Eighth nerve deafness
	Neurosyphilis
Mucocutaneous	Gummas
Gastrointestinal	Hepatomegaly
	Splenomegaly

TABLE 228-5 **Clinical Manifestations in Late Prenatal Syphilis**

Interstitial keratitis occurs in 8.8 percent of cases, and the average age of onset is 13.5 years for men and 27.1 years for women. The course eventuates in corneal clouding (syphilitic nebulae) (Fig. 228-31A) or glaucoma. Iritis and iridocyclitis may also be found, but usually earlier. Corneal transplantation often restores vision.

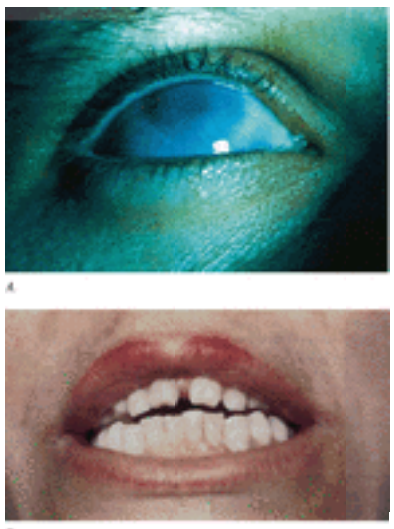

FIGURE 228-31 *A*. Interstitial keratitis with corneal clouding in late prenatal syphilis. *B*. The presence of small, notched, peg-shaped upper incisors (Hutchinson's teeth) is also part of the late congenital syphilis triad.

Asymptomatic neurosyphilis occurs in 30 to 50 percent of patients and is diagnosed only through abnormal CSF findings. Symptomatic neurosyphilis is rare and usually delayed until puberty. Juvenile paresis, the most common pattern, affects 1 to 5 percent of all patients with congenital syphilis. The presentation often involves personality and behavior changes such as deteriorating school performance and inappropriate emotional responses. Within a year, any combination of ataxia, dysarthria, tremors, and seizures develop. Other CNS complications include mental retardation and cranial nerve palsies. Bilateral eighth-nerve disease with vertigo, tinnitus, and deafness has been reported in 3 to 38 percent of patients, usually adolescents. The deafness progresses despite antibiotics, but the response to systemic glucocorticoids has been encouraging. Skin manifestations consist of granulomatous lesions and gummas, just as in late benign syphilis. Bone manifestations, such as arthritic perisynovitis, chondroosteoarthritis, epiphysitis, and periostitis, may also occur in late prenatal infection. A thickened, prominent forehead produced by localized periostitis of the frontal and parietal bones (*frontal bossing of Parrot*) is present in approximately 87 percent of patients. A short maxilla, with a shallow dish configuration, results from impaired development caused by syphilitic rhinitis and is present in up to 83 percent of patients. The *Higoumenakis sign,* which is a rather nonspecific finding, is a unilateral, irregular enlargement of the sternoclavicular portion of the clavicle resulting from previous periostitis. Anterior bowing and thickening from periostitis of the midportion of the tibia (*saber shins*) occur in 4 percent of patients. *Scaphoid scapulae,* a concavity of the vertebral border of the scapulae, is observed in 0.7 percent of patients. Mandibular protuberance, *or bulldog jaw,* was found in 25.8 percent of patients. The size is normal but appears proportionally larger in comparison to the size of the maxilla. *Clutton joints* are symmetric, nontender swellings of the knees, which often follow trauma and produce bilateral hydrarthrosis. Deformities such as painless perforation of the nasal septum or soft palate and deep ulcers of the pharynx and tongue can result from damage by gummas. Dental abnormalities are caused by treponemal invasion of the tooth buds. The pathognomonic *Hutchinson's teeth* refer to widely spaced, small permanent incisors that are screwdriver or peg-shaped, wider at the gingival margin, and notched at the biting edge because of defective enamel production (Fig. 228-31B). *Mulberry* or *Moon's molars,* found in 65 percent of cases, are dome-shaped and have numerous diminutive cusps arrayed in a tight circle at the top of the dome. The first lower molars most commonly show these changes. As a consequence of defective enamel, these teeth are predisposed to caries and rarely persist beyond adolescence. Dental abnormalities can be prevented if treatment is initiated before the third month of age. Congenital syphilis can be a difficult diagnosis in the absence of physical signs and symptoms. Maternal IgG antibodies can cross the placenta, but nontreponemal tests become nonreactive within 3 to 6 months and treponemal tests within 6 to 12 months after birth. There is an interval of 2 to 3 months between the onset of the infection and fetal production of IgM antibodies, so serologic reactivity at birth depends on when the fetus became infected. The presence of reactive IgM tests in the serum of newborns is considered to prove the diagnosis of congenital syphilis, but the FTA-ABS IgM may be falsely negative in 35 percent of infants. The umbilical cord should be sent for pathologic examination with special stains for treponemes. Nasal secretions and mucocutaneous lesions should be examined by dark-field microscopy. Radiographs showing periostitis of the tibia suggest the diagnosis.

SYPHILIS AND HIV INFECTION

Infection with syphilis imparts a greater risk for acquiring HIV infection, at least in part because the genital ulceration provides an easier entry to the virus into the systemic circulation. Numerous studies demonstrate that syphilis is more common in HIV-infected than in HIV-seronegative persons.

Surprisingly, HIV infection does not significantly influence the clinical course, serologic response, or treatment outcome of most patients with early syphilis. [28], [29] The appearance of primary chancres is typical, but patients with primary syphilis

present more frequently with multiple ulcers and chancres may persist up to the secondary stage. The course of secondary syphilis is usually unchanged, although rarely, rapidly progressive disease, and unusual manifestations have been reported. [30] Nodular and noduloulcerative lesions (Fig. 228-32) are more common, but most of these cases have no constitutional symptoms associated with malignant syphilis. [31] Perforation of the palate has been rarely reported. There are several reports of eye involvement, but syphilis is an uncommon cause of uveitis in HIV infection (0.6 percent). [32]

FIGURE 228-32 Ulcerated papules in an HIV-infected man. This was the initial presentation of HIV infection.

Although most cases of early syphilis in HIV-positive patients respond to conventional doses of penicillin, serologically defined treatment failures are more common, and for this reason closer evaluation after therapy is mandatory. In one study, 18 percent of patients treated with intramuscular penicillin had serologically defined treatment failures at 6 months and 14 percent at 12 months, but this rate was similar to the HIV-seronegative control group. [33] Clinical relapses occurred in 1 percent of patients in a prospective study, and more frequently in retrospective studies. Rarely, patients experience multiple relapses.

Neurosyphilis may be the first clinical manifestation of HIV infection. In one study, investigators recovered *T. pallidum* from the CSF of 26 percent of HIV-infected patients with early syphilis before treatment and 20 percent after treatment. [33] These percentages are similar to those of HIV-seronegative patients. [33] In a prospective, multicenter, randomized, controlled trial that compared HIV-seropositive and HIV-uninfected persons with syphilis, no differences in neurologic status were apparent. [34] The presence of *T. pallidum* in the CSF in early syphilis does not differ according to HIV status and is not predictive of treatment failure. Most cases of neurosyphilis comprise asymptomatic or meningovascular neurosyphilis, but focal gummas and other types of neurosyphilis have also been reported. Manifestations include cranial nerve palsies, optic neuritis or neuroretinitis, polyradiculopathy, transient ischemic episodes, and strokes. A rare fulminant form (necrotizing neurosyphilis) is reported more frequently in AIDS patients.

Not only is the prevalence of neurosyphilis higher in patients coinfected with both syphilis and HIV, but the progression to symptomatic forms of neurosyphilis is accelerated, even after conventional therapy. [34] In a small but significant study, which included 15 HIV-infected and 25 HIV-seronegative patients with primary or secondary syphilis, *T. pallidum* was isolated from the CSF by rabbit inoculation in a similar proportion from both groups. [35] Only CSF leukocytosis was more common (67 versus 25 percent) in the HIV-seropositive group. Notably, one injection of benzathine penicillin failed to eradicate the CNS infection in three of the four HIV-infected cases with positive treponeme cultures. Since then, several unsettling reports have alluded to the unexpected frequency of neurorelapse after benzathine penicillin therapy in HIV-infected patients. Serologic response and CSF abnormalities usually resolve successfully in HIV-infected patients with neurosyphilis, but 8 percent may fail therapy even by the recommended high doses of intravenous penicillin the first time, and 23 percent have persistent pleocytoses. [35] Patients with CSF abnormalities should be cautiously diagnosed as having asymptomatic neurosyphilis, because CSF leukocytosis or elevated protein is present in up to 60 percent of nonsyphilitic HIV-infected patients who are not taking effective antiretroviral therapy.

Dysregulation of the humoral immune response may result in uncontrolled production of antibodies with extremely elevated titers. In a study, the median rapid plasma reagin (RPR) titers (see below) were four times higher (1:128 versus 1:32) in HIV-infected patients than in HIV-uninfected patients with their first episodes of early syphilis. [36] Furthermore, B cell activation occasionally results in a higher rate of biologic false-positive, nontreponemal serologic tests. Conversely, an occasional patient may have a nonreactive nontreponemal test during early syphilis, and the sensitivity of treponemal tests appears to be lower in patients treated for past syphilis if they are HIV infected (80 versus 97 percent). [37]

In view of the occasional unreliability of serologic testing, the threshold to biopsy skin lesions should be lower. The classic pathologic findings of secondary syphilis are usually present, although some cases with lymphoid infiltrate resembling cutaneous T cell lymphoma have been reported.

DIAGNOSTIC TESTS

The definitive test in early syphilis is demonstration of spirochetes in lesional exudate or tissue either by dark-field microscopy or by direct immunofluorescence. Unless the diagnosis is unequivocal as a result of these examinations or from clinical evaluation of typical lesions coupled with reactive serologic results, skin biopsy is recommended in primary, secondary, and certainly in tertiary syphilis lesions.

Histopathologic Examination

The epidermis of a chancre is acanthotic at the margins and becomes thinner and more edematous towards the eroded center. A dermal infiltrate, composed predominantly of lymphocytes, plasma cells, some histiocytes, and a few neutrophils, is dense in the central portion and perivascular in the periphery of the chancre. In untreated cases, the spirochetes stain gray with an impregnated silver stain such as the Warthin-Starry stain. In contrast to immunofluorescence with fluorescein-labeled syphilitic rabbit serum, which requires fresh tissue, immunoperoxidase testing can be done on paraffin-embedded tissue. The spirochetes are more easily found in the epidermis and around dermal capillaries. Under electron microscopy, *T. pallidum* is predominantly found extracellularly. Less commonly, it is found intracellularly within the endothelial cells of capillaries and inside the vacuoles and phagolysosomes of plasma cells, macrophages, and neutrophils; and, occasionally, within fibroblasts and nerve fibers. Syphilitic buboes show follicular hyperplasia, endothelial proliferation, and a chronic inflammatory infiltrate with plasma cells and many spirochetes. Occasionally, noncaseating sarcoidal granulomas are present at the end of the primary stage.

Characteristically, secondary syphilis lesions show dilatation and thickening of blood vessels with a proliferation of endothelial cells and a superficial and deep perivascular dermal infiltrate containing numerous plasma cells. The infiltrate often becomes lichenoid, may obscure the dermal epidermal interface, and, in a third of cases, surrounds adnexal structures and nerves. Other changes depend on the biopsied lesion. Macules show mild or no epidermal changes.

Papulosquamous plaques show psoriasiform epidermal hyperplasia, parakeratosis and, often, focal spongiosis, basal vacuolar changes, and microabscesses with neutrophils. Other common epidermal changes are epidermal pallor, keratinocyte necrosis, extravasated red blood cells, and exocytosis of mononuclear cells. The dermal vessels show endothelial proliferation and swelling. There is a deep and superficial perivascular infiltrate arranged in a coat-sleeve pattern and composed of lymphocytes, histiocytes, and many plasma cells. The infiltrate assumes a lichenoid pattern that may involve the superficial and deep dermis and, in one-third of the cases, surrounds adnexal, vascular, and neural structures. The infiltrate may also be T-shaped or perivascular. Small epithelioid granulomas, which may have Langhans or foreign-body–type giant cells, may be present, even in young lesions. In lesions of pustular syphilis, neutrophils within the subcorneal pustules may infiltrate the hair follicles. In ulcerating lesions, there is infarction necrosis of the epidermis and dermis because of occlusion of blood vessels by fibrinoid material. The epidermis may be absent from the specimen.

In nodular tertiary syphilis, there is a dermal lymphohistiocytic and plasma cell infiltrate with small granulomas and islands of epithelioid cells intermingled with some multinucleated giant cells. A mild degree of caseation necrosis may be present. In gummas, the infiltrate contains numerous epithelioid and multinucleated giant cells and extends throughout dermis to the subcutaneous tissues. Extensive caseation necrosis surrounded by epithelioid and giant cells is present in the center of the lesion. Nodular tertiary syphilis may be difficult to differentiate from lupus vulgaris, and gummatous syphilis from scrofuloderma and erythema induratum.

Dark-Field Microscopy

Dark-field examination is the diagnostic test of choice in chancres and moist lesions of secondary syphilis, especially condylomata lata and mucous patches. The test is invalid in oral membranes because saprophytic treponemes, which cannot be differentiated from *T. pallidum,* are common in the mouth. Here, a lymph node aspirate can be examined by dark-field microscopy.

The surface of the lesion should be cleaned and gently abraded with a sterile gauze soaked in 0.9 percent sterile saline, carefully avoiding bleeding as blood cells obscure detection of the treponemes. After squeezing the base of the lesion with two gloved fingers, a serous exudate accumulates on the surface and can be scraped off with a scalpel or drawn off with a pipette. The exudate is mixed with one or two drops of saline on a glass slide and covered with a plastic slip. The slide is examined under a dark-field microscope for the presence of treponemes.

Direct Fluorescence Antibody Test

The lesion exudate on the glass slide is stained with fluorescein-labeled anti- *T. pallidum* immunoglobulin. In contrast to dark-field microscopic examination, the smear can be held for later evaluation and oral or anal lesions can be examined because only *T. pallidum* is stained. The sensitivity of the test is greater than 90 percent. [38]

Serology

Serologic tests for syphilis are divided into two types. The simpler cardiolipin-based nontreponemal tests are used for screening and to follow therapeutic response. The more elaborate *T. pallidum*-based treponemal tests are used for diagnostic confirmation and to improve diagnosis of early, congenital, and neurosyphilis. [39]

A presumptive diagnosis of syphilis is made by a reactive nontreponemal test, such as the *RPR test* or the *Venereal Disease Research Laboratory* (VDRL) test, confirmed by a treponemal test, such as *the microhemagglutination assay with T. pallidum antigen* (MHA-TP) or the *fluorescent treponemal antibody-absorption test* (FTA-ABS) (Table 228-6). [40] Although treponemal tests have higher specificity and sensitivity, because of their higher cost they are not used for screening but rather to corroborate the accuracy of reactive nontreponemal tests.

RPR	MHA-TP	Capia (IgM) EIA	
–	–	–	No syphilis or incubating syphilis
–	–	+	Early primary syphilis
+	+	+	Primary or secondary syphilis
+	–	+	Early infection
+	+	–	Late secondary or latent syphilis
+	–	–	Biologic false-positive, late syphilis
–	+	–	Late infection, treated syphilis, or false-positive treponemal test
↑	+	↑	Reinfection, relapse

Note: ↑, rising titers; EIA, enzyme immunoassay; MHA-TP, microhemagglutination assay with *T. pallidum* antigen; RPR, rapid plasma reagin.

TABLE 228-6 **Interpretation of Serologic Tests**

Reaginic Tests

These tests are inexpensive and are widely used for screening. The antigen (reagent) is a combination of cardiolipin, cholesterol, and lecithin. The VDRL and RPR become reactive 4 to 5 weeks after infection and revert to negative in 25 to 30 percent of cases during late latency. Results are reported qualitatively as reactive, weakly reactive, or nonreactive or quantitatively as a titer of the sample diluted with saline in a geometric progression by a factor of 2 (1:2, 1:4, 1:8, and so on). The highest dilution that gives a positive result is reported as the titer. Titers may differ slightly between laboratories. A high titer (=1:32) usually indicates active disease, while low titers (=1:8) may remain unchanged for years following therapy of late disease. Titers decline more slowly in patients with previous episodes of syphilis. After treatment, the titers should decline fourfold (a titer of 1:32 decreases to 1:4 or lower) within 6 months in primary or secondary syphilis, and within 24 months in latent syphilis. In patients treated for primary syphilis, the tests become nonreactive in 60 percent by 4 months and in nearly all patients by 12 months. In secondary syphilis, the tests usually become nonreactive in 12 to 24 months after treatment. If therapy is administered in the early latent stage, low titers may remain for up to 5 years or longer. In one study, 18 percent of patients treated for secondary syphilis had reactive tests at low titers after 30 to 35 years, and 44 percent of patients treated during the late latent stage had reactive tests after 35 years. In tertiary syphilis, the tests may revert to nonreactive in 20 to 30 percent of cases, even without treatment. A titer that neither decreases nor increases fourfold after treatment is referred to as serofast. If an initially high titer (=1:32) fails to decrease after treatment, the patient should be evaluated for neurosyphilis and retreated appropriately. A fourfold titer increase indicates reinfection or treatment failure. Weakly reactive qualitative tests should be repeated, because up to a third will be eventually positive.

False-negative results occur during very early infection or in latent and late syphilis. In 1 percent of secondary syphilis cases, results are falsely reported as nonreactive as a result of the prozone phenomenon, because, unless the serum is diluted, the high levels of antibody prevent flocculation.

Biologic false-positive results constitute 1 to 2 percent of reactive tests, depending on the population studied. In 90 percent of patients, the titers are less than 1:8. Biologic false-positive results may be transient and acute (6 months) or longer lasting and chronic (6 months) (Table 228-7). In narcotic addicts, false-positive reactions may persist even after 14 months of drug abstinence. [37]

	Acute	Chronic
Physiologic	Pregnancy	Advanced age
Spirochete infection	Leptospirosis	Endemic syphilis
	Lyme disease	Pinta
	Rat-bite fever	Yaws
	Relapsing fever	
Viral infection	Cytomegalovirus	Human T cell leukemia/lymphoma virus I
	Infectious mononucleosis	HIV infection
	Hepatitis	
	Herpes simplex	
	Herpes zoster-varicella infection	
	Measles	
	Mumps	
	Mycoplasma pneumonia	
	Toxoplasmosis	
	Viral sepsis	
Bacterial infection	Pneumonia	Lepromatous leprosy
		Lymphogranuloma venereum
		Tuberculosis
Protozoan infection	Malaria	Kala azar
		Trypanosomiasis
Autoimmune disease		Autoimmune hemolytic syndrome
		Autoimmune thyroiditis
		Idiopathic thrombocytopenic purpura
		Mixed connective-tissue disease
		Polyarteritis nodosa
		Primary biliary cirrhosis
		Rheumatoid arthritis
		Sjögren's syndrome
		Systemic lupus erythematosus
Other		Drug abuse
		Dysproteinemias
		Hepatic cirrhosis
		Malnutrition
		Malignancy
		Lymphoproliferative disorders

TABLE 228-7 **Causes of Biologic False-Positive Nontreponemal Tests**

Specific Treponemal Tests

These tests use whole or fragments of *T. pallidum* as antigen. Compared to nontreponemal tests, they are more cumbersome to perform but have greater sensitivity in the primary and late stages and slightly higher specificity (Table 228-8). They are widely used to confirm reactive, nontreponemal test results. [39]

	Sensitivity, %				
	Primary	Secondary	Latent	Tertiary	Specificity, %
VDRL	80 (74–87)	100	80 (75–100)	71 (55–86)	98
RPR	86 (81–100)	100	80 (75–100)	73 (55–86)	98
FTA-ABS	98 (93–100)	100	99	97 (95–100)	99
MHA-TP	82 (50–95)	100	99	96 (90–99)	99
Capia (IgM) EIA	82	60	53	34	100

Note: For explanation of serologic tests, see text.

TABLE 228-8 **Sensitivity and Specificity of Serologic Tests**

The FTA-ABS test is the most sensitive serologic test in primary syphilis, and reactivity begins during the third week of infection, but the MHA-TP, which is less expensive and cumbersome to perform, is more popular. The tests rarely

become nonreactive in untreated patients, and reactivity usually continues even after treatment. Although 15 to 25 percent of patients become unreactive after treatment of primary syphilis, long-term reactivity persists in many after appropriate treatment of secondary syphilis.

The specificity and sensitivity of both tests range between 94 and 100 percent during the secondary and the late phases of the disease (Table 228-8). Their high sensitivity permits detection of very small amounts of antibodies, so the tests are not useful to assess the efficacy of treatment. False-negative results are very rare. False-positive FTA-ABS results are usually caused by autoantibodies (rheumatoid factor) or antibodies to spirochetal infections (Table 228-9).

Infectious mononucleosis
Lepromatous leprosy
Leptospirosis
Lyme disease
Malaria
Relapsing fever
Systemic lupus erythematosus

TABLE 228-9 **Common Causes of False-Positive Treponemal Tests**

Treponemal-based *enzyme immunoassays* (EIA) are more specific (99.5 percent) than the RPR when used for screening, and more sensitive than the FTA-ABS in patients with past infection. [41]

IgM tests, such as the *Captia syphilis (IgM) EIA,* are the serologic test of choice in primary infection, assessment of reinfection, and congenital syphilis. IgM antibodies can be detected in the serum toward the end of the second week of infection. The test is the first to become positive and has a 93 percent sensitivity in primary infection. However, because memory cells do not synthesize IgM antibodies, the sensitivity is only 85 percent in secondary infection and 64 percent in early latent infection. Reactivity ceases within 3 to 9 months after therapy of early syphilis, but may persist for 12 to 18 months after treatment of late infection. In untreated persons, a reactive result indicates almost with certainty the need for therapy, but a nonreactive result does not exclude infection. Persistence of reactivity after therapy indicates treatment failure or false-positive results because of autoantibodies of the IgM class.

Because IgM antibodies cannot pass through the placenta or the intact blood–CSF barrier, IgM reactivity in the serum of a newborn confirms prenatal infection, and detection of antitreponemal IgM in the CSF indicates neurosyphilis. The sensitivity of the Captia (IgM) EIA is very high in congenital syphilis (100 percent), but less so in primary (82 percent), neurosyphilis (34 percent), and treated syphilis (11 percent). [40] The test is highly specific because there appears to be no interference by rheumatoid factors or competitive inhibition by antitreponemal IgG. Values below 0.9 are nonreactive, between 0.9 and 1.0 are equivocal, and above 1.0 are reactive.

Immunoblots have a very high sensitivity and near-perfect specificity. Although laborious, they are the tests of choice to confirm a false-positive test, and are promising as a replacement of other confirmatory treponemal tests. [39]

PCR assays have achieved a sensitivity and specificity of over 95 percent in identifying *T. pallidum* in genital ulcers. [42] They have also become essential investigational tools.

CSF Examination

Examination of the CSF by lumbar puncture to exclude asymptomatic neurosyphilis offers marginal benefits as the risk of developing neurosyphilis in HIV-seronegative patients after standard parenteral penicillin treatment is very small. However, lumbar puncture should be performed if there is clinical evidence of neurologic involvement. Because no clinical presentation is specific for neurosyphilis, reliable criteria by laboratory examinations are particularly important (Table 228-10). Elevated white blood cell count (5 cells per µL) and total protein (>400 mg/L) indicate inflammation and presumed infection. Of course, these findings are found in other types of aseptic meningitis. However, both may be normal or slightly elevated in asymptomatic disease as well as in tabes dorsalis.

Strongly indicative
Reactive VDRL (or RPR)
Reactive MHA-TP (or FTA)
Reactive western blot, PCR, or IgM tests
TPHA index >500
Strongly suggestive (in absence of other CNS disease)
Cell count >5 cells per µl
Protein >40 mg/100 mL
IgG index >0.7
Practically excluded
Nonreactive MHA-TP (or FTA)
TPHA index <70

TABLE 228-10 **Diagnosis of Neurosyphilis through CSF Testing**

A reactive CSF VDRL result indicates neurosyphilis. Blood contamination may increase titers but this only occurs when CSF is visibly bloody. Unfortunately, the CSF VDRL is not reactive in up to 70 percent of patients with neurosyphilis, particularly in asymptomatic cases and in tabes dorsalis. [43] The CSF FTA-ABS is unreliable because of false-positive results; however, a nonreactive test virtually excludes CNS involvement. [44] In certain cases, the diagnosis of neurosyphilis is particularly challenging. A patient with adequately treated syphilis and no neurosyphilis may have abnormal CSF serology, cell counts, and protein as a result of nonsyphilitic CNS infection (HIV, malaria) or a neoplasm.

TREATMENT

Parenteral penicillin is the treatment of choice for all stages of syphilis. Treatment failures are rare and regularly respond

to a second course of penicillin at the same or higher doses. The concentration of penicillin in the CSF is less than 10 percent of the serum level. However, even a single injection of benzathine penicillin produces effective levels in the perivascular areas where treponemes are found in the CSF. [45] Parenteral penicillin is the only treatment with documented efficacy in neurosyphilis, HIV infection, and pregnancy.

A concentration of penicillin above 0.018 mg/L is considered treponemicidal. However, the maximally effective in vitro level of concentration (0.36 mg/L), is recommended for a minimum duration of 7 to 10 days in early syphilis, and longer in late syphilis. [46]

Recommended doses of long-acting benzathine penicillin provide treponemicidal levels for 3 to 4 weeks. Oral penicillins can produce adequate serum and tissue levels, but is not recommended because of reduced efficacy because of lack of compliance. [47]

Tetracyclines, erythromycin, and third-generation cephalosporins have strong antitreponemal activity in experimental and clinical trials. Clinically, however, their efficacies are less than penicillin, and numerous treatment failures have been reported. Although less investigated and more expensive than tetracycline, doxycycline is preferred because of better compliance and absorption, which is less affected by food. [47] Erythromycin is slightly less effective than tetracycline. However, therapeutic results with another macrolide, azithromycin, administered in a single 2 g dose, are encouraging, and this antibiotic may eventually replace erythromycin, and even doxycycline, as the alternative treatment of choice. [48] Ceftriaxone at a dose of 500 mg daily for 10 days has also been studied. [48] 1 g intramuscularly or intravenously daily for 8 to 10 days appears to be effective in primary, secondary, and early latent syphilis, although experience with this treatment is limited. [49] Additionally, although not recommended, the drug can be safely administered during pregnancy. [46] HIV serology is recommended for all patients with syphilis, and should be repeated in 6 months in patients living in areas with high HIV prevalence. [47]

Primary and Secondary Syphilis (without Neurologic, Ophthalmologic, or Auditory Involvement) [47]

A single dose of benzathine penicillin G, 2.4 million units intramuscularly, is the preferred treatment.

PENICILLIN ALLERGY Patients with uncomplicated syphilis may be treated with doxycycline, 100 mg orally twice daily for 2 weeks. Compliance is better than with tetracycline, 500 mg orally four times daily, or erythromycin, 500 mg orally four times daily. Ceftriaxone, 250 mg daily or 1 g every other day intravenously for 10 days, is an alternative.
PREGNANCY Pregnant women should be treated with penicillin as discussed below. If there is allergy to penicillin the patient should be desensitized.
HIV INFECTION Three doses of weekly injections of benzathine penicillin G are preferred by some experts because of higher prevalence of neurosyphilis in these patients (although there is no evidence that this is more effective). Enhanced therapy with ampicillin and probenecid after treatment with benzathine penicillin injections does not improve responses. [33]
CHILDREN Children should be evaluated for congenital syphilis through examination and review of maternal and prenatal records. If CNS is abnormal, treat for neurosyphilis. If infection was acquired postnatally, consult with a child protection agency after treating with a single intramuscular injection of benzathine penicillin G, 50,000 units/kg up to 2.4 million units.
CSF EXAMINATION If there are signs or symptoms of CNS, eye, or hearing involvement, examine the CSF. Do a slit lamp examination if there is ophthalmologic disease. If CSF findings suggest neurosyphilis, treat accordingly.
FOLLOW-UP Patients should be reexamined clinically and serologically at 6 and 12 months (if HIV-seropositive, then at 3, 6, 9, 12, and 24 months).
TREATMENT FAILURES Patients should be retreated if there is a fourfold (or greater) increase in RPR or VDRL titer within 6 months. HIV serology should be repeated. Unless reinfection is definite, CNS examination is indicated. If CSF abnormalities indicate neurosyphilis, treat with intravenous penicillin. If neurosyphilis is excluded, treat with benzathine penicillin G, 2.4 million units intramuscularly for three doses 1 week apart. The management of patients who remain serofast, with RPR titers that do not decline by a fourfold factor in 6 months, is unclear. At the very minimum, clinical evaluation and HIV testing are indicated. If the patient is HIV seropositive, do a spinal tap and treat accordingly. If HIV seronegative but compliance cannot be assured, retreatment (preferably with three injections of benzathine penicillin G 1 week apart) is recommended.

Early Latent Syphilis [47]

A single dose of benzathine penicillin G, 2.4 million units intramuscularly, is the recommended treatment.

PENICILLIN ALLERGY If the patient is neither pregnant nor HIV-infected, treat with doxycycline, 100 mg orally twice daily for 4 weeks.
PREGNANCY Treat with penicillin. If there is allergy to penicillin, desensitize.
CHILDREN The treatment is the same as for primary syphilis.
FOLLOW-UP As in ate latent syphilis, below.

Indeterminate or Late Latent Syphilis

Benzathine penicillin G, 2.4 million units intramuscularly 1 week apart for three doses, is the treatment of choice. If the patient misses a dose, the treatment may be resumed as long as the interval between injections has not exceeded 2 weeks.

PENICILLIN ALLERGY Doxycycline, 100 mg orally twice daily, or tetracycline, 500 mg orally four times daily for 28 days, may be prescribed.
PREGNANCY Treat with penicillin as discussed below.

HIV INFECTION Treat with penicillin.
CHILDREN After appropriate evaluation to exclude congenital syphilis and sexual abuse, treat with weekly injections of benzathine penicillin G, 50,000 units/kg (up to 2.4 million units) intramuscularly for three doses.
CSF EXAMINATION In asymptomatic individuals, the yield of positive findings in lumbar punctures is low, but CSF examination is clearly indicated in certain cases:

- Cardiovascular, neurologic, eye, or auditory symptoms or in late benign syphilis
- HIV infection
- RPR titer =1:32
- Treatment failure
- Treatment other than penicillin

If the CSF examination demonstrates abnormal, unexplainable findings, patients should be treated for neurosyphilis. The outcome of treatment has not been conclusively studied, but in 469 treated patients with uncomplicated late latent syphilis who were followed for up to 12 years, the CSF remained normal and no cases of cardiovascular syphilis were reported.
TREATMENT FAILURES Patients with a normal CSF examination should be retreated for latent syphilis if signs or symptoms of syphilis develop, if a high titer (>1:32) fails to decline fourfold within 12 to 24 months, or if titers increase fourfold or higher.
FOLLOW-UP Quantitative nontreponemal serologic tests should be repeated at 6, 12, and 24 months (6, 12, 18, and 24 months if the patient is HIV infected). After treatment, the patient should be reevaluated for neurosyphilis and retreated accordingly if (1) titers increase fourfold, (2) an initially high titer (=32) fails to decrease fourfold within 12 to 24 months, or (3) the patient develops signs or symptoms attributable to tertiary syphilis.

Tertiary Syphilis (Cardiovascular, Late Benign Syphilis) [47]

Benzathine penicillin G, 2.4 million units 1 week apart for three doses, is the recommended treatment.

PENICILLIN ALLERGY If the patient is not HIV infected and the CSF is negative, treat with doxycycline, 100 mg orally twice daily for 2 weeks.
CSF EXAMINATION All patients should have spinal taps, and if abnormalities are found, treat for neurosyphilis.
PROGNOSIS After treatment of late benign syphilis, gummas heal slowly over several months, depending on the extent of tissue destruction. Gummas of the brain or spinal cord may need surgical excision. Because advanced symptomatic disease in cardiovascular syphilis is associated with poor prognosis even with recommended doses of benzathine penicillin, some experts prefer to treat cardiovascular disease with high-dose intravenous penicillin. The evidence suggests that penicillin has a beneficial effect in the majority of patients, although efficacy is difficult to evaluate as most symptomatic patients receive therapy to improve cardiac function. In studies, 63 percent of patients with aortic insufficiency, aneurysms, or both experienced symptomatic improvement from 6 to 12 months after penicillin treatment. The disease progressed in 4 percent of asymptomatic and 4.5 percent of symptomatic patients.

Neurosyphilis [47]

Aqueous crystalline penicillin G, 18 to 24 million units administered daily as 3.5 to 4 million units intravenously every 4 h for 10 to 14 days, is the treatment of choice. [47]

Alternatively, treatment with a single injection of procaine penicillin G, 2.4 million units intramuscularly daily; and probenecid, 500 mg orally every 6 h for 10 to 14 days, can be instituted in patients whose compliance can be assured. Treatment of neurosyphilis with ceftriaxone (1 g intravenously daily for 14 days) is not as effective as penicillin.

PENICILLIN ALLERGY Desensitize and treat with penicillin.
FOLLOW-UP Reexamine the CSF every 6 months until normal. Cell counts should decrease by 6 months, and CSF VDRL and protein levels by 2 years. If not, retreat with intravenous penicillin.
PROGNOSIS In one study, penicillin cured, improved, or stabilized the disease in 91 percent of patients with asymptomatic neurosyphilis, 81 percent with meningovascular disease or meningitis (78 percent cured), 75 percent with general paresis (48 percent cured), 72 percent with tabes dorsalis (47 percent cured), and 88 percent with miscellaneous neurologic abnormalities. If symptoms worsen during treatment, the dose may need to be increased. Optic atrophy, alone or in conjunction with tabes dorsalis, and eighth-nerve-related deafness are notoriously more resistant to treatment. No case of blindness because of optic atrophy is reversible with penicillin, although lack of progression or improvement occurs in up to 60 percent of cases. Eighth-nerve-related deafness benefits from the combination of long-term penicillin and prednisone.
RELAPSE Neurosyphilis relapses usually respond to additional courses of intravenous penicillin at equal or higher doses.

Treatment in Pregnancy [47]

The penicillin regimen appropriate for the stage of the infection should be used. In primary, secondary, and early latent syphilis, a second benzathine penicillin injection 1 week later is recommended by some experts.

PENICILLIN ALLERGY Desensitize and treat with penicillin. Erythromycin's ability to cross the placenta is fair to poor. Infants born to mothers who any of received erythromycin for syphilis during pregnancy should be thoroughly evaluated for active disease, treated with penicillin, and closely followed. Tetracycline is avoided because of dental staining as a result of deposition in enamel.
EVALUATION Perform fetal ultrasound, and if signs (hydrops, hepatomegaly) of fetal syphilis are present, consult with an experienced obstetrician.
SCREENING Pregnant women should be screened at their initial prenatal visit, and those with seropositive results should

be considered infected unless treatment can be verified and sequential serologic antibody titers convincingly demonstrate an appropriate response. In case of doubt, retreatment is warranted as the potential benefits outweigh the possible risks. Screening should be repeated in the third trimester and again at delivery.
FOLLOW-UP Repeat serologic titers monthly if there is risk of reinfection; otherwise, repeat in the third trimester and at delivery.
COMPLICATIONS A potential adverse effect of penicillin treatment is the Jarisch-Herxheimer reaction, which may precipitate labor (placental shock). However, the association of spontaneous abortion with this phenomenon is debatable and should not delay treatment.
PROGNOSIS In 414 pregnant women with early syphilis who were treated with variable doses of penicillin, only 5 percent of their newborns had syphilis, and an expected rate of stillbirths was reported. The failures were observed in women reinfected or treated late in pregnancy. In another study, the success of therapy in preventing congenital syphilis was as follows: primary syphilis, 27 of 27; secondary syphilis, 71 of 75; early latent syphilis, 100 of 102; and late latent syphilis, 136 of 136. [50]

Prenatal Syphilis [47]

Neonatal period: Aqueous penicillin G, 50,000 units/kg intravenously every 12 h for the first 7 days of life and every 8 h for the next 3 days, or procaine penicillin G, 50,000 units/kg intramuscularly daily for 10 to 14 days.

Postneonatal period: Benzathine penicillin G, 50,000 units/kg (up to 2.4 million units) intramuscularly if CSF examination is negative. If neurosyphilis, aqueous penicillin G, 50,000 units/kg every 4 to 6 h intravenously for 10 to 14 days.

ADDENDUM Infants should be treated for presumed congenital syphilis regardless of evaluation if born to mothers with any of the following:

- Untreated syphilis at delivery
- Treatment other than with penicillin
- History of treatment before becoming pregnant but no documentation of a fourfold decrease in titers
- Treatment for syphilis within 1 month of delivery
- Inadequate documentation of appropriate treatment
- Serologic evidence of relapse or reinfection after treatment
- No fourfold decrease in RPR titers after treatment during pregnancy

If the infant has signs of congenital syphilis on physical examination or serologic evidence of syphilis (infant's RPR titer is two dilutions greater than mother's), the evaluation should include complete blood count with differential and platelets and CSF examination for cell count, protein, and RPR. Other tests that can be ordered as clinically indicated include long-bone radiographs, chest radiograph, cranial ultrasound, ophthalmologic examination, auditory–brainstem response, and liver function tests. If the infant's clinical, CSF, serologic, and blood evaluation are normal and compliance is indisputable, the infant may be treated with a single intramuscular injection of benzathine penicillin G, 50,000 units/kg. If the mother was adequately treated and had an appropriate serologic decline in titers, evaluation of an infant with a nontreponemal titer equal to or less than the mother's titer is not necessary, but a single dose of benzathine penicillin is recommended. If the infant's titer is not reactive, no treatment is necessary.
FOLLOW-UP Seropositive infants (or infants born to mothers who were seroreactive at delivery) must be reexamined clinically and serologically every 2 to 3 months until the test becomes nonreactive or the titer has decreased fourfold. If the reactive test result was caused by passive transplacental transfer, nontreponemal antibody titers should decrease by 3 months and disappear by 6 months of age. If the child was infected and treated, the serologic decline may be slower. If the titers are stable or increasing after 8 to 12 months of age, the child should be reevaluated (including CSF analysis) and retreated with a 10-day course of intramuscular penicillin G. Treponemal tests may remain positive for 15 months if the disease was acquired transplacentally, but if the tests are reactive after 18 months, they indicate congenital syphilis. Close neurologic follow-up is indicated for infants with initially abnormal CSF examinations. If CSF pleocytosis was present, spinal taps should be done every 6 months until the cell count is normal. If the cell count remains abnormal after 2 years, or if a downward trend is not present at each examination, the infant should be retreated. The CSF VDRL should also be checked at 6 months, and retreatment administered if still reactive.

Persons Exposed to Syphilis (Epidemiologic Treatment)

If compliance cannot be assured, examine the patient, do a serologic test, and treat the patient prophylactically for primary syphilis. If the patient is reliable, examine and do RPR monthly for 3 months from the last exposure.

Syphilis in HIV-Infected Patients

A penicillin regimen should be instituted according to the stage of the disease.

PENICILLIN ALLERGY Desensitize and treat.
CSF EXAMINATION Spinal fluid analysis should be performed on patients with indeterminate or late latent disease or with early disease with neurologic symptoms. Some experts recommend CSF examination before treatment of early syphilis as well as 6 months after treatment, but there is no evidence of improved outcomes.
FOLLOW-UP A closer follow-up with clinical and serologic tests is needed for these patients. CSF examination is indicated if there is serologic evidence of treatment failure at any time, or if the serofast response continues after 12 months.
NEUROSYPHILIS Treat according to recommended regimens for neurosyphilis. Neurorelapse is more common in these patients, even after adequate treatment.

Complications of Treatment

The Jarisch-Herxheimer reaction is a clinical syndrome consisting of fever, headache, flare of mucocutaneous lesions, tender lymphadenopathy, pharyngitis, malaise, myalgias, and leukocytosis. It occurs within 12 h of therapy. The fever peaks in 6 to 8 h usually around 39°C (102.2°F), but it can be as high as 42°C (107.6°F). Patients should be warned about the possibility of developing this reaction prior to receiving treatment. Symptoms are controlled with nonsteroidal antiinflammatory agents or aspirin. The pathogenesis of the Jarisch-Herxheimer reaction is unknown. It has been proposed that destruction of spirochetes is followed by massive phagocytosis with release of pyrogenic cytokines. Systemic glucocorticoids modify the febrile reaction without affecting the skin lesions or the leukocytosis; if administered 12 h prior to or at the time of treatment, they suppress or mitigate the reaction.

Patients with neurosyphilis not uncommonly become febrile after treatment with penicillin. Febrile reactions are more common when the CSF contains high numbers of cells and protein. Convulsions, dementia, psychosis, and meningismus have been reported to occur in up to 2 percent of neurosyphilis patients treated with penicillin. Death is rare. About 50 percent of infants with early and 39 percent of those with late disease develop febrile reactions. Rare cases of elevated liver function tests and the nephrotic syndrome have been reported.

Therapeutic paradox, or deterioration of tertiary syphilis after therapy, results from rapid decomposition of gummatous tissue. Worsening of the aortic insufficiency murmur has been reported from this complication.

Hoigné syndrome (pseudoanaphylactic reaction) is a complication associated with intramuscular procaine penicillin treatment and is seen in approximately 1 case per 1000 treated patients. The reaction occurs immediately after the injection and is characterized by tachycardia, elevated blood pressure, fear of imminent death, violent combativeness, unusual taste sensation, auditory or visual disturbances, neuromuscular twitching, occasional seizures, and even loss of consciousness. It rarely lasts longer than 30 min. Treatment consists of observation and sedatives or anticonvulsants. Inadvertent intracapillary infusion of procaine or, less likely, penicillin during intramuscular injection resulting in microembolization has been proposed as the mechanism.

Anaphylaxis from administration of penicillin injection is a life-threatening emergency that is managed by intramuscular injection of epinephrine and diphenhydramine with hydrocortisone intravenously. [46]

VACCINES

A protective vaccine against syphilis will require considerably more investigation. In one promising study, repeated immunization of rabbits with purified antiendoflagellar antigen over 32 weeks did not prevent reinfection, but the lesions occurred earlier, had a flatter, softer appearance, and resolved more rapidly. [51] Twelve surface proteins that may be suitable components for designing a vaccine were identified after mapping of the genome. [52]

CONCLUSION

The preceding discussion leaves no doubt that syphilis is a disease with an exceptional diversity of possible organ involvement. However, the skin is affected in most cases with active disease. The study and treatment of syphilis had a pivotal influence in the development of dermatology as a specialty. Even today, a number of dermatology departments from around the world have retained the word syphilology in their names. No practitioner is more capable than a dermatologist of evaluating, diagnosing, or treating syphilis and preventing its daunting complications. The occasional need for consultation with other specialties does not detract from the dermatologist's expertise. In fact, it is appropriate and essential for dermatologists to contribute their experience and skills whenever syphilis is considered as a potential diagnosis by other primary care providers and specialists. The physician who understands syphilis is a more astute and competent clinician. This conclusion was reached long ago by the renowned physician William Osler who wrote, “Know syphilis in all its manifestations and relations, and all other things clinical will be added unto you.” With the mapping of the *T. pallidum* genome a new era dawned for understanding syphilis, developing new tests and treatments, and designing a vaccine to prevent infection.

REFERENCES

1. Lukehart SA: Modern syphilis—Still a shadow on the land. *West J Med* **163**:587, 1995

2. Hudson MM, Morton RS: Fracastoro and syphilis: 500 years on. *Lancet* **348**:14, 1995

3. Nakashima AK et al: Epidemiology of syphilis in the United States, 1941–1993. *Sex Transm Dis* **23**:16, 1996

4. Primary and secondary syphilis—United States, 1999. *MMWR Morb Mortal Wkly Rep* **50**:113, 2001

5. Outbreak of syphilis among men who have sex with men—Southern California, 2000. *MMWR Morb Mortal Wkly Rep* **50**:117, 2001

6. Fraser CM et al: Complete genome sequence of *Treponema pallidum,* the syphilis spirochete. *Science* **281**:375, 1998

7. Van Vorrhis WC et al: Primary and secondary syphilis lesions contain mRNA for Th-1 cytokines. *J Infect Dis* **173**:491, 1996

8. Marfin AA et al: Amplification of the DNA polymerase I gene of *Treponema pallidum* from whole blood of persons with syphilis. *Diagn Microbiol Infect Dis* **40**:163, 2001

9. Baker-Zander SA et al: VDRL antibodies enhance phagocytosis of *Treponema pallidum* by macrophages. *J Infect Dis* **167**:1100, 1993

10. Roy B: The Tuskegee syphilis experiment: Biotechnology and the administrative state. *J Natl Med Assoc* **87**:56, 1995

11. Fyrand O, Granholt A: The history of venereology in Norway. *Genitour Med* **70**:215, 1994

12. Sanchez MR: Infectious syphilis. *Semin Dermatol* **31**:134, 1994

13. Rosen T et al: Pedal interdigital condylomata lata: A rare sign of secondary syphilis. *Rev Sex Transm Dis* **28**:184, 2001

14. Ban M et al: A case of secondary syphilis with mucous patches on the hard palate. *J Dermatol* **22**:52, 1995

15. Federman DG et al: Syphilis presenting as the blue toe syndrome. *Arch Intern Med* **154**:1029, 1994

16. Cuozzo DW et al: Essential syphilitic alopecia revisited. *J Am Acad Dermatol* **32**:840, 1995

17. Barile GR, Flynn TE: Syphilis exposure in patients with uveitis. *Ophthalmology* **104**:1605, 1997

18. Peilec JL: Ménière's diseases of syphilitic etiology. *Ear Nose Throat J* **76**:508, 1997

19. Sule RR et al: Late cutaneous syphilis. *Cutis* **59**:135, 1997

20. Sekkat A et al: Cutaneomucous tertiary syphilis. *Ann Dermatol Venereol* **121**:146, 1994

21. Scheck DN, Hook EW III: Neurosyphilis. *Infect Dis Clin North Am* **8**:769, 1994

22. Tyler KL et al: Medical medullary syndrome and meningovascular syphilis: A case report in an HIV-infected man and a review of the literature. *Neurology* **44**:2231, 1994

23. Horowitz HW et al: Brief report: Cerebral syphilitic gumma confirmed by PCR in a man with human immunodeficiency virus infection. *N Engl J Med* **331**:1488, 1994

24. Glaser JH: Centers for Disease Control and Prevention guidelines for congenital syphilis. *J Pediatr* **129**:488, 1996

25. Sanchez PJ, Wendel GD: Syphilis in pregnancy. *Clin Perinatol* **24**:71, 1997

26. Hollier LM et al: Fetal syphilis: Clinical and laboratory characteristics. *Obstet Gynecol* **97**:947, 2001

27. Benc M et al: Syphilis in pregnancy. *Sex Transm Infect* **76**:73, 2000

28. Rompalo AM et al: Syphilis and HIV Study Group. Clinical manifestations of early syphilis by HIV status and gender: Results of the syphilis and HIV study. *Sex Transm Dis* **28**:158, 2001

29. Marra CM et al: Diagnosis of neurosyphilis in patients infected with human immunodeficiency virus type 1. *J Infect Dis* **174**:219, 1996

30. O'Mahony C et al: Rapidly progressive syphilis in early HIV infection. *Int J STD AIDS* **8**:275, 1997

31. Sands M et al: Lues maligna, or ulceronodular syphilis, in a man infected with human immunodeficiency virus: Case report and review. *Clin Infect Dis* **20**:387, 1995

32. Shalaby IA et al: Syphilitic uveitis in human immunodeficiency virus infected patients. *Arch Ophthalmol* **115**:469, 1997

33. Rolfs RT et al: A randomized trial of enhanced therapy for early syphilis in patients with and without human immunodeficiency virus infection. The Syphilis and HIV Study Group. *N Engl J Med* **337**:307, 1997

34. Gordon SM et al: The response of symptomatic neurosyphilis to high-dose intravenous penicillin G in patients with human immunodeficiency virus infection. *N Engl J Med* **331**:1469, 1994

35. Marra CM et al: Resolution of serum and cerebrospinal fluid abnormalities after treatment of neurosyphilis. Influence of concomitant human immunodeficiency virus infection. *Sex Transm Dis* **23**:184, 1996

36. Yinnon AM et al: Serologic response to treatment of syphilis in patients with HIV infection. *Arch Intern Med* **156**:321, 1996

37. Nandwani R, Evans DT: Are you sure it's syphilis? A review of false-positive serology [review]. *Int J STD AIDS* **6**:241, 1995

38. Jethwa HS et al: Comparison of molecular and microscopic techniques for detection of *Treponema pallidum* in genital ulcers. *J Clin Microbiol* **33**:180, 1995

39. Meyer JC: Laboratory diagnosis of syphilis. *Curr Probl Dermatol* **24**:1, 1996

40. Eaglestone SI, Turner AJL: Serological diagnosis of syphilis. *Commun Dis Public Health* **3**:158, 2000

41. Young H: Guidelines for serological testing for syphilis. *Sex Transm Infect* **76**:403, 2000

42. Liu H et al: New tests for syphilis: Rational design of a PCR method for detection of *Treponema pallidum* in clinical specimens using unique regions of the DNA polymerase I gene. *J Clin Microbiol* **39**:1941, 2001

43. Luger AF et al: Significance of laboratory findings for the diagnosis of neurosyphilis. *Int J STD AIDS* **11**:224, 2000

44. Marra CM et al: Cerebrospinal fluid treponemal antibodies in untreated early syphilis. *Arch Neurol* **52**:68, 1995

45. Goldmeier D, Hay P: A review and update on adult syphilis, with particular reference to its treatment. *Int J STD AIDS* **4**:70, 1993

46. Goh B: European guidelines for the management of syphilis. *Int J STD AIDS* **12**:14, 2001

47. 2002 Guidelines for Treatment of Sexually Transmitted Diseases. Centers for Disease Control. *MMWR Recomm Rey* **51(RR-6)**:18, 2002

48. Hook EW et al: Azithromycin compared with penicillin G benzathine for treatment of incubating syphilis. *Ann Intern Med* **131**:434, 1999

49. Marra CM et al: A pilot study evaluating ceftriaxone and penicillin G as treatment agents for neurosyphilis in human immunodeficiency virus-infected individuals. *Clin Infect Dis* **30**:540, 2000

50. Alexander JM et al: Efficacy of treatment for syphilis in pregnancy. *Obstet Gynecol* **93**:5, 1999

51. Adimora AA et al: Vaccines for classic sexually transmitted diseases. *Infect Dis Clin North Am* **8**:859, 1994

52. Pennisi E: Genome reveals wiles and weak points of syphilis. *Science* **281**:324, 1998

T>

Chapter 229

Miguel Sanchez

Endemic (Nonvenereal) Treponematoses

PINTA (CARATE, MAL DE PINTA, AZUL)
Primary Stage
Secondary Stage
Tertiary Stage
YAWS (FRAMBOESIA TROPICA, PIAN, BUBA, PARU, PARANGI)
Primary Stage
Secondary Stage
Tertiary Stage
ENDEMIC SYPHILIS (BEJEL, FIRJAL, BELESH, NJOVERA)
Primary Stage
Secondary Stage
Tertiary Stage
DIAGNOSIS OF THE NONVENEREAL TREPONEMATOSES
HISTOPATHOLOGY
TREATMENT
CONCLUSION
REFERENCES

The nonvenereal treponematoses (pinta, yaws, and endemic syphilis) constitute a group of three distinct spirochetal infections that have remained confined to endemic foci in indigent, remote, rural regions of tropical and subtropical countries. [1] The causative spirochetes cannot be distinguished morphologically or serologically from *Treponema pallidum* and, like syphilis, the diseases progress through successive clinical stages separated by periods of latency. However, in contrast to syphilis, transmission occurs from skin-to-skin contact rather than sexually. Infants contract the infections from their mothers during breast feeding, and children contract them from direct contact with mucocutaneous lesions of infected family members and playmates.

Without treatment, patients remain infectious indefinitely, although the skin lesions may become mild or subclinical. They do not develop lifelong immune resistance. Cross-immunity is absent in the early stages of syphilis, yaws, and pinta, but is variable in late stages. Patients with late pinta are resistant to syphilis but those with yaws or syphilis at any stage are susceptible to pinta.

The nonvenereal treponematoses are not fatal but are disfiguring and disabling, and patients suffer the effects of social ostracism.

PINTA (CARATE, MAL DE PINTA, AZUL)

Pinta, which means *colored spot* in Spanish, is caused by *Treponema carateum*, named after the Colombian name for the disease (*carate*).

The disease predominantly affects poor, undernourished infants, children, and adolescents who live in small, remote, crowded villages in hot, semiarid coastal areas. Twenty years ago, approximately 750,000 cases were estimated, but now only a few hundred new cases are reported each year, mainly from southern Mexico, Brazil, Colombia, Venezuela, Peru, and Ecuador. [1]

Transmission occurs from repeated, direct contact of the exposed skin of a healthy person with a cutaneous or mucous membrane lesion from an infected person.

Pinta is the only treponematosis with clinical manifestations confined to the skin, [1] although cardiovascular disease formerly was considered to be a complication of late pinta. As in syphilis, there are three distinct clinical stages, but in contrast to syphilis, lesions from different stages may be present in a single patient. Because cell-mediated immunity is not completely effective, the infection persists indefinitely, and people of all ages are infected. However, 40 to 60 percent of all patients are younger than 15 years of age.

Primary Stage

Between 3 and 60 days (average, 1 to 3 weeks) after contact with an infected lesion, one or more small, erythematous papules develop at the site(s) of inoculation. These primary lesions may be pruritic, become slightly scaly and enlarge, or coalesce with other lesions to achieve a size of 1 to 3 cm within 3 months. The resulting plaques are irregular, hyperkeratotic, lichenified and up to 20 cm in diameter (Fig. 229-1). [2] Primary lesions usually develop in exposed areas, especially the hands, feet, arms, legs, face, and neck. They can persist for years, and eventually heal spontaneously with residual hypopigmentation.

FIGURE 229-1 Lichenified patch in primary pinta with dyschromic changes.

Secondary Stage

Secondary lesions (*pintids*) usually appear 1 to 12 months, but sometimes years, after the appearance of the primary lesions. They may encircle the sites of the primary lesions, or erupt generally on the body. Pintids may appear on the palms, soles, and groin. [1] Secondary lesions may be indistinguishable from primary lesions, but are smaller and usually not pruritic. Some lesions may be circinate or annular with raised borders where the number of treponemes is highest. Over time, the lesions turn brown or copper-colored and eventually slate blue, gray, or black. More than one color may be present within a plaque. Lesions can recur up to 10 years after the initial infection. [2]

Tertiary Stage

Late lesions develop between 3 months and 10 years after the appearance of the secondary stage. Typically, patients have dyschromic patches that are hyperchromic, hypochromic, and achromic, imparting a mottled pattern with a variegated palate of white, brown, blue, red, and violet. [3] The lesions have irregular borders and vary in size. The more commonly involved areas are the wrists, palms, ankles, and elbows as well as the skin around and within old lesions (Fig. 229-2). In such areas, the lesions appear scarred and atrophic (cicatricial lesions of pinta). [3] Lymphadenopathy may develop during any stage of pinta. Patients with only late-stage lesions may appear to have vitiligo (vitiligo of pinta).

FIGURE 229-2 Depigmented and hyperpigmented, mottled patches in late pinta.

YAWS (FRAMBOESIA TROPICA, PIAN, BUBA, PARU, PARANGI)

Yaws is caused by *T. pallidum* (ssp. *pertenue*). Approximately 75 percent of new cases arise in children younger than 15 years of age. [4] /SUP>, [5] Yaws is contracted from direct contact with abraded, bitten, or excoriated skin with oozing lesions. Some experts contend with scant evidence that the disease can be transmitted by flies or through domestic utensils. [6]

The infection occurs in countries along the tropical belt in lowlands adjacent to forests characterized by heavy rainfall, high humidity, and hot temperatures that do not fall below 27°C (80.6°F). [5] Owing to mass treatment campaigns and improved living conditions, the disease has been eradicated in many areas, and greatly reduced in others. [4] However, sizeable foci were recently reported in several tropical regions of West and Central Africa (Ghana, Togo, Benin, and Central African Republic), and residual foci remain in South America (Colombia, Peru, Ecuador, and Brazil), Indonesia, Papua New Guinea, the Solomon Islands, Haiti, and Dominica. [6] Currently, at least 100 million children are estimated to be at risk of becoming infected. [1]

Primary Stage

After an incubation period of 9 to 90 days (average, 3 weeks), the primary lesion or mother yaw (*buba madre*) appears at the site of inoculation, which is usually an exposed body part, such as the face, neck, buttock, leg, foot, arm, or hand. [7] Characteristically, the lesion is a nontender, occasionally pruritic, infiltrated, erythematous small nodule that grows horizontally to a size of 1 to 5 cm. Its surface frequently becomes papillomatous and crusted. The primary lesion is usually single, but satellite papules may be present, becoming confluent into a plaque. The lesion eventually becomes an ulcer (chancre of yaws) with a raspberry-like (frambesial) base that may be covered by yellow crust (Fig. 229-3). Regional buboes are common. [1] The “mother yaw” heals spontaneously in 2 to 6 months leaving atrophic scarring and central hypopigmentation. Constitutional symptoms are rare.

FIGURE 229-3 Ulcerated primary-stage nodule (“mother yaw”). The genital location is unusual.

Secondary Stage

Resolution of the primary stage is typically followed by a period of latency, lasting weeks to months, which is then interrupted by an eruption of disseminated skin lesions with generalized lymphadenopathy. Constitutional symptoms, such as malaise, fever, and anorexia, are often present. The lesions (*daughter yaws* or *pianomas*) are soft, warty or vegetating, nonpruritic, scaly, yellow-red papules and plaques not unlike the mother yaws (frambesiomas) but smaller (up to 2 cm) (Fig. 229-4A). As the lesions grow, they become eroded and covered by a highly infectious fibrinous exudate, which dries into a crust (Fig. 229-4B and *C*). The exudate attracts flies that torture the afflicted persons. [7] *Pianic onychia* (paronychia) may develop.

FIGURE 229-4 *A*. Early secondary lesions of yaws (“daughter yaws”) showing eroded and crusted papules and plaques. *B*. Warty secondary-stage papillomas (“daughter yaws”). *C*. Eroded papillomas covered by fibrinous exudate. (*B and C Courtesy of HJH Engelkens, MD, J. van der Stek, MD, and E. Stolz, MD.*)

Pianomas may appear in any body area. In addition, dry, papulosquamous patches and plaques *(pianides)*, which resemble the lesions of secondary syphilis, may be present on any part of the body. [7] In body folds, they resemble condylomata lata; in mucous membranes, they resemble hypertrophic mucous patches. Thick, hyperkeratotic plaques of the palms and soles become fissured and ulcerated (worm-eaten soles). This painful involvement of the soles is also called *crab yaws* (Fig. 229-5) because patients walk with a deliberate slow, crustacean gait. Some lesions may be annular or circinate (*tinea yaws*). Lesions on the face are often seborrheic or psoriasiform. [7] Painful osteoperiostitis is common in early yaws. [6] The appearance of turnip-like, fusiform soft-tissue swelling of the proximal, but not the distal, phalanges because of periostitis is classic (ghoul hands). The metatarsal, metacarpal, and tibial bones are also commonly involved. [7] Infected persons then enter a latent period with serologic reactivity but no signs or symptoms of the disease. All lesions resolve without scarring, but relapses may develop during the initial 5 years of infection. In relapsing yaws, lesions tend to be confined to the perioral, perianal, and periaxillary areas.

FIGURE 229-5 Fissured hyperkeratotic plantar keratoderma in secondary yaws (“crab yaws”).

A less-contagious form of yaws with one or few dry, gray, transient patches predominantly in the axillae and perianal areas has been described. [1]

Tertiary Stage

In approximately 10 percent of cases, latency is interrupted after 5 to 10 years by a late stage with skin and skeletal lesions, and possibly with ophthalmologic and neurologic involvement. Cutaneous and subcutaneous gummatous nodules (*gumma framboesiodes*) necrose centrally and ulcerate, causing deep, mutilating damage. [6] Coalescence of the ulcers may result in the formation of circinate, serpiginous tracts that heal with deforming scars and contractures. [5] Palmoplantar hyperkeratosis may lead to keratoderma. Juxtaarticular nodes may form on the elbows and knees.

Late skeletal changes include hypertrophic periostitis, hydrarthrosis, gummatous osteitis and periostitis, and osteomyelitis. Considerable bone hypertrophy as a result of chronic osteitis may result in curvature of the tibia (saber shins). Bilateral hypertrophic osteitis of the nasal process of the maxillae with persistent swelling of the nasal bridge (*goundou*) slowly progresses over 5 to 20 years. The most dreaded consequence of yaws is rhinopharyngitis mutilans (*gangosa*), which leads to extensive destruction of the nose, maxillae, upper lip, and central face with eventual perforation of the nose and palate. It occurs in approximately 1 percent of untreated, infected persons.

Although eye, neurologic, and cardiovascular disease is not usually associated with yaws, there are rare reports of optic disk atrophy, myeloneuropathy, and aneurysms. [1]

ENDEMIC SYPHILIS (BEJEL, FIRJAL, BELESH, NJOVERA)

This nonvenereal infection caused by *T. pallidum* (ssp. *endemicum*) favors arid climates in rural areas bordering deserts. It has been reported to be a common health problem in children from Burkina Faso and in the Bedouin tribes of Saudi Arabia, Iraq, and Syria. Foci also remain in Saharan Africa (Sudan, southern Zimbabwe, and South Africa), in Southeast Asia, Turkey, and the Western Pacific. [2] Approximately 80 percent of cases occur in children and adolescents younger than 15 years of age. [8] Transmission occurs during skin or mucous membranes contact with infected skin lesions or saliva, or by drinking from contaminated flasks or from sharing pipes. [1] Anecdotal reports that the common fly, *Musca domestica*, is a disease vector have not been substantiated. The mucocutaneous lesions resemble those of venereal syphilis.

Primary Stage

The incubation period is 10 to 90 days. The primary lesion is a slimy patch that becomes eroded. It is frequently missed probably because the chancre is often present in the oropharyngeal mucosa. Because of the small inoculum, regional lymphadenopathy is rare. A primary chancre may develop in the nipple of a mother nursing an infected child. Primary lesions heal in 1 to 6 weeks. [2]

Secondary Stage

Usually a few nontender, oval or round, macerated, eroded, mucous patches erupt on the lips, tongue, and tonsils. Vegetating or hypertrophic condylomata lata appear on the anogenital area and the axillae. [4] Split papules are fissured mucous patches in the labial commissures. Occasionally, macular, papular, annular, and circinate eruptions, similar to those seen in secondary syphilis, develop. Nontender, generalized lymphadenopathy is common. Nocturnal lower extremity pain is caused by periostitis of the long bones.

The secondary stage persists for 6 to 9 months and is followed by a latency period, which may continue for only a few months but usually lasts 5 to 15 years. At this point, a tertiary stage with cutaneous skeletal and systemic manifestations develops. [9]

Tertiary Stage

Late lesions consist of gummas of the skin, bone, nasopharynx, and larynx. [6] The gummas develop destructive ulcerations, but the lesions are not as mutilating as those of yaws (Fig. 229-6). The ulcerations eventually heal, leaving atrophic, depigmented scars bordered by hyperpigmentation. Saddle-nose deformity, palate perforation, or gangosa are disfiguring complications. [2]

FIGURE 229-6 Cutaneous gummas in late endemic syphilis. Note the involvement of the elbow.

Skeletal involvement is common, but most patients are not significantly bothered by pain. Clinically apparent tibial bowing or tenderness are exceptions. However, bone defects may be radiologically present, most commonly on the tibia and fibula, and sometimes in the ulna and radius. Systemic involvement is rare. Uveitis, chorioretinitis, and optic atrophy have been observed. Aortitis and saccular aneurysms of the aortic arch have infrequently been reported. [2]

An attenuated form of endemic syphilis with fewer, more-rapidly healing cutaneous lesions but more frequent periostitis has been reported.

DIAGNOSIS OF THE NONVENEREAL TREPONEMATOSES

The diagnosis of these diseases is made through clinical evaluation of the lesions (Table 229-1) in inhabitants or former residents of endemic areas, and confirmed by detection of treponemes under dark-field microscopic examination of lesional exudate. In the absence of a positive dark-field examination, histologic or serologic confirmation is required. In yaws and endemic syphilis, nontreponemal tests become reactive in 2 to 3 weeks after the onset of the primary lesion. In pinta, these tests become reactive in 80 percent of cases within 3 months after the appearance of primary lesions and are reactive in all patients with the late stage of the disease. Other treponemal tests, including enzyme immunoassays (EIA), have not shown greater specificity than the fluorescence treponemal antibody absorption (FTA-ABS) test. [10] A finger-prick indirect hemagglutination test is advantageous for screening children. [11]

	Pinta	Yaws	Endemic Syphilis
Causative organism	T. carateum	T. pertenue	T. pallidum
Transmission	Skin-to-skin contact	Skin-to-skin contact	Skin or mucosal contact with infected skin or saliva, drinking vessels
Peak ages	1–15 years	1–15 years	Months–15 years
Incubation	3–60 (average, 1–2 weeks)	9–90 days (average, 2 weeks)	10–90 days
Primary lesions	Erythematous papules becoming psoriasiform plaques	Vegetating, soft, ulcerating papule (mother yaws), with satellites	Small eroded papule (often absent)
Secondary lesions	Erythematous scaly and psoriasiform plaques; primitiv develop; increased and decreased pigmentation	Warty or hyperkeratotic nodules, papulovegetanous plaques, palmoplantar "crab claws"	Mucous patches, condylomata lata, syphilis-like eruptions
Tertiary lesions	Dyschromic, hyperchromic, achromic, and polychromic patches	Cutaneous, pinkish dyschromia, juxtaarticular nodes, gangrena, gonoides, keratoderma	Serpiginous gummas, juxtaarticular nodes on elbows only
Reactive serology	2–3 months after primary lesion	2–3 weeks after primary lesion	2–3 weeks after primary lesion
Treatment	Penicillin	Penicillin	Penicillin

TABLE 229-1 **Nonvenereal Trepanomatoses—Clinical Manifestations**

HISTOPATHOLOGY

In a primary lesion of pinta, epidermal changes consist of mild acanthosis, epidermal edema, exocytosis of lymphocytes, liquefaction degeneration of the basal cell layer, and loss of melanin. In the upper dermis there is a dense infiltrate of plasma cells, lymphoid cells, some neutrophils and histiocytes, and many melanophages. In contrast to syphilitic chancres, endothelial swelling is minimal or absent.

Histologically, secondary lesions are indistinguishable from primary lesions. In the hyperpigmented patches of tertiary pinta, the epidermis is atrophic and the basal cell layer shows no melanin, but in the upper dermis there is an infiltrate of many melanophages and some lymphoid cells. As the lesions become increasingly depigmented, the infiltrate is milder and treponemes become scarcer to the point that neither is present. Treponemes are found in silver impregnation between epidermal cells in primary, secondary, and late-stage hyperpigmented lesions, but not in late hypopigmented patches.

The epidermal changes in a primary lesion of yaws are acanthosis, papillomatosis, edema, and neutrophilic microabscesses. In the dermis, there is a dense mixed-cell infiltrate of neutrophils, lymphocytes, histiocytes, fibroblasts, a few eosinophils, and many plasma cells. No endothelial proliferation is seen in the vessels. Secondary yaws lesions have a similar appearance to the primary lesions. In late yaws, the lesions are very similar to late benign syphilitic lesions. In the first two stages, treponemes are easily detected on silver-stained tissue, almost exclusively between epidermal cells. [12]

The lesions of endemic syphilis are histopathologically identical to those of venereal syphilis.

TREATMENT

The recommended treatment for pinta, yaws, and endemic syphilis is a single intramuscular injection of 1.2 million units of benzathine penicillin in adults or children older than 10 years of age and 0.6 million units in younger children. [6] Patients become noninfectious within 24 h. Children older than 8 years of age who are allergic to penicillin may be treated for 15 days with tetracycline 250 mg four times daily, or, if younger, with erythromycin 8 mg/kg four times daily. [8] Penicillin-allergic adults are treated for 15 days with tetracycline 500 mg four times daily, doxyclycline 100 mg twice daily. Erythromycin 500 mg four times daily and other macrolide antibiotics are also probably effective, despite a dearth of in vivo experience. In pinta, primary and secondary lesions disappear after treatment, but achromic patches persist for life. The effect of HIV infection on nonvenereal treponematosis is not known, but based on the experience with venereal syphilis, it appears prudent to screen those persons at risk with HIV serology and to consider closer follow-up. Recommendations for epidemiologic treatment depend on the number of seropositive children younger than 6 years of age (Table 229-2).

Area (Percentage of Seropositive Children)	Recommendation
Hyperendemic (>50%)	Treat the entire population
Mesoendemic (10–50%)	Treat all active cases, their contacts, and all children 15 years of age or younger
Hypoendemic (<10%)	Treat all active cases, their household members, and other obvious contacts

TABLE 229-2 **Epidemiologic Treatment**

CONCLUSION

The means to eradicate the nonvenereal treponematoses is available. However, history has shown that mass treatment campaigns alone are insufficient. [13] In some areas where the diseases had been thought to be eradicated, new cases are being reported at a surprising rate. [14] In 1997, the World Health Organization estimated the number of new cases of endemic treponematosis at 460,000 annually. [4] Treatment of those infected and those at risk must be followed by such sound public health measures as prolonged serosurveillance and periodic screenings. [15] Resurveys should begin 6 months after initial treatment and continued at least every 2 years. City dwellers are not at risk and the diseases are practically unknown in the West, where a single case usually stimulates a published case report. The western medical establishment regards these diseases as curiosities that are extinct or almost extinct.

REFERENCES

1. Koff AB, Rosen T: Nonvenereal treponematoses: Yaws, endemic syphilis, and pin *J Am Acad Dermato* **29**:519, 1993
2. Engelkens HJ et al: Endemic treponematoses: Part II. Pinta and endemic syphilis [revie *Int J Dermato* **30**:231, 1991
3. Fuchs J et al: Tertiary pinta: Case reports and overvie *Cutis* **51**:425, 1993
4. Walker ST et al. Yaws—A review of the last 50 year *Int J Dermato* **39**:258, 2000
5. Sehgal VN et al: Yaws control/eradicatio *Int J Dermato* **33**:16, 1994
6. Engelkens HJ et al: Nonvenereal treponematoses in tropical countri *Clin Dermato* **17**:143, 1999
7. Engelkens HJ et al: Endemic treponematoses: Part I. Yaw *Int J Dermato* **30**:77, 1991
8. Parish JL: Treponemal infection in the pediatric populatio *Clin Dermato* **18**:687, 2000
9. Yakinci C et al: Bejel in Malatya, Turke *J Trop Pediat* **41**:117, 1995
10. Backhouse JL, Hudson BJ: Evaluation of immunoglobulin G enzyme immunoassay for serodiagnosis of ya *J Clin Microbio* **33**:1875, 1995
11. Backhouse JL et al: Modified indirect hemagglutination test for detection of treponemal antibodies in finger-prick bl *J Clin Microbio* **30**:561, 1992
12. Engelkens HJ et al: The localization of treponemes and characterization of the inflammatory infiltrate in skin biopsies from patients with primary or secondary syphilis, or early infectious yaws. *Genitourin Mec* **69**:102, 1993
13. Engelkens HJ et al: The resurgence of yaws: Worldwide consequence *Int J Dermato* **30**:99, 1991
14. Meheus A, Antal GM: The endemic treponematoses: Not yet eradicat *World Health Sta* **45**:228, 1992
15. Anselmi M et al: Yaws in Ecuador: Impact of control measures on the disease in the province of Esmeral *Genitourin Mec* **71**:343, 1995

T>

Chapter 230

Stephan Lautenschlager Alfred Eichmann

Chancroid

DEFINITION
HISTORICAL ASPECTS
EPIDEMIOLOGY
ETIOLOGY
Taxonomy
Biochemistry
Growth Requirements
Genetics and Virulence
PATHOGENESIS
CLINICAL MANIFESTATIONS
Clinical Variants of Soft Ulcer
LABORATORY AND SPECIAL EXAMINATION
DIFFERENTIAL DIAGNOSIS
TREATMENT
RELATIONSHIP BETWEEN HIV-INFECTION AND CHANCROID
PREVENTION
COURSE AND PROGNOSIS
REFERENCES

DEFINITION

Chancroid is a sexually transmitted, acute ulcerative disease, usually localized at the anogenital area and often associated with inguinal adenitis or bubo. The disease is caused by infection with *Haemophilus ducreyi,* a gram-negative, facultative anaerobic bacillus that requires hemin (X factor) for growth.

HISTORICAL ASPECTS

Chancroid, or soft chancre (*ulcus molle*) was first distinguished from syphilis by Basserau in France in 1842. The causative bacillus was discovered and described by Ducrey, a bacteriologist at the University of Naples, in 1889. Unna described the histology of the chancroidal ulcer and found the chains of gram-negative rods in the lesion. It is still unclear who was the first to culture *H. ducreyi*. In his review, Albritton [1] credited Himmel (1901) with the first convincing isolation of *H. ducreyi,* but other authors in the same period also claimed priority.

EPIDEMIOLOGY

Chancroid is most common in many of the world's poorest regions with the weakest public health infrastructure, such as areas of Africa, Asia, and the Caribbean. More recently, chancroid prevalence has declined markedly in countries such as the Philippines, Senegal, and Thailand. [2] Outbreaks have been reported in a number of cities in industrialized countries during the last two decades, predominantly in the United States. [3] After an epidemic in California in 1981, the number of cases increased, peaking in 1987 at 5035 cases. In 2000, only 78 cases of chancroid were reported to the Centers for Disease Control and Prevention (CDC). [4] Chancroid occurred 10 times less frequently than syphilis. In a 10-city study, chancroid was confirmed in 12 percent of genital ulcers in Chicago, and in 20 percent of genital ulcers in Memphis. [5] Interpreting chancroid surveillance data is difficult because confirmatory culture media are not commercially available and the true incidence is probably vastly underreported.

The prevalence of chancroid is higher in lower socioeconomic groups. Recent epidemics in the industrialized countries usually were associated with prostitution, the use of crack cocaine, syphilis, and an increased risk of HIV infection. [6], [7] Lower-class prostitutes appear to be a reservoir in all reported outbreaks of this disease. Men have a markedly higher incidence of chancroid than do women. [3] Data from Africa and Thailand show that chancroid-ulcer is an important risk factor for the heterosexual spread of HIV-1. [2] Until now epidemiology of chancroid has been poorly documented because of little interest and lack of accurate and simple diagnostic tools (phenotypic markers for strain-typing). It is still not clear whether there is an asymptomatic reservoir of *H. ducreyi* and what the risks of transmission are. [8]

ETIOLOGY

Taxonomy

H. ducreyi is a gram-negative, facultative anaerobic bacillus that requires hemin (X factor) for growth. The organism is small, nonmotile, and non–spore-forming, and shows typically streptobacillary chaining, especially in cultures. The exact taxonomy is still controversial. The current classifications list *H. ducreyi* as a true Haemophilus species. Some biochemical properties, however, put this organism close to the Pasteurellaceae. [1]

Biochemistry

H. ducreyi has few distinguishing biochemical features. Nitrate reduction is a characteristic of the genus. All reported strains are oxidase-positive and catalase-negative and have a broad range of phosphatase activity. The alkaline

phosphatase reaction is used in its identification. [1] Differentiation from other hemin-requiring strains of *Haemophilus* is made by the lack of requirement for nicotinamide adenine dinucleotide (NAD, V factor) and its failure to produce hydrogen sulfide, catalase, or indole. [1], [9]

Growth Requirements

H. ducreyi is a fastidious bacillus. To get optimal rates of positive cultures, Nszane et al. [10] recommend the use of two media simultaneously: gonococcal agar supplemented with bovine hemoglobin and Mueller-Hinton agar supplemented with chocolate horse blood, each with 5% fetal calf serum. Growth is best at 30°C to 33°C (86°F to 91.4°F) in a water-saturated atmosphere.

Genetics and Virulence

The strains of *H. ducreyi* appear to be serologically and biochemically homogenous. *H. ducreyi* shares a significant gene pool with members of the Pasteurellaceae and the Enterobacteriaceae. The core plasmid conferring ampicillin resistance in *H. ducreyi* is found in other species of *Haemophilus* and *Neisseria*. [1] A number of plasmids mediating beta-lactamase production have been described and the reassortment of the different plasmids in various isolates can be used as a partial typing system. Isogenic mutants of *H. ducreyi* now can be constructed and the virulence properties of specific mutants can be determined. Recently, an isogenic hemoglobin receptor-deficient mutant of *H. ducreyi* was reported that showed an attenuated infection in a human model. [11]

PATHOGENESIS

Three major problems seem to be important in the pathogenesis of *H. ducreyi* infection: the adherence to the epithelial surface, the rate of exotoxins, and the resistance of the host defense mechanism. Many questions about pathogenesis are still unclear. In the absence of appropriate experimental model systems, attachment factors are not well understood. [12]

CLINICAL MANIFESTATIONS

The incubation period is between 3 and 7 days; rarely more than 10 days. No prodromal symptoms are known. The chancre begins as a soft papule surrounded by erythema. After 24 to 48 h it becomes pustular, eroded, and ulcerated; vesicles are not seen. The edges of the ulcers are often ragged and undermined. The ulcer is usually covered by a necrotic, yellowish-gray exudate and its base is composed of granulation tissue that bleeds readily on manipulation. In contrast to syphilis, chancroid ulcers are usually tender and quite painful. Half of the males present with a single ulcer. The diameter varies from 1 mm to 2 cm. Most lesions in males are found on the external or internal surface of the prepuce, on the frenulum, and on the glans (Fig. 230-1). The urethral meatus, shaft of the penis, and the anal orifice are involved less frequently. Edema of the prepuce is often seen. Rarely, if the chancre is localized in the urethra, *H. ducreyi* causes purulent urethritis.

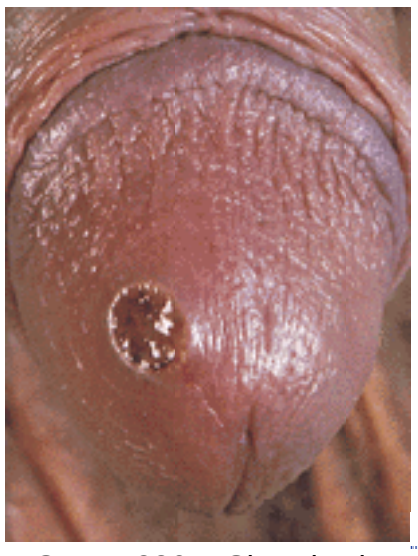

FIGURE 230-1 Sharply circumscribed ulcer on the glans.

In females, the lesions are mostly localized on the vulva, especially on the fourchette, the labia minora, and the vestibule. Vaginal, cervical, and perianal ulcers have also been described. Extragenital lesions of chancroid have been reported on the breasts, fingers, thighs, and inside of the mouth. Trauma and abrasion may be important for such extragenital manifestations.

Painful inguinal adenitis (bubo) occurs in up to 50 percent of patients within a few days to 2 weeks (average, 1 week) after onset of the primary lesion (Fig. 230-2). The adenitis is unilateral in most patients, and erythema of the overlying skin is typical. Buboes can become fluctuant and may rupture spontaneously. The pus of the bubo is usually thick and creamy. Lymphadenitis and buboes are less common in female patients.

FIGURE 230-2 Small chancroid ulcer on the internal surface of the prepuce with inguinal adenitis.

Clinical Variants of Soft Ulcer

Besides the common types of chancroid described above, a number of clinical variants have been reported:

- Giant chancroid: a single lesion extends peripherally and shows extensive ulceration.
- Large serpiginous ulcer: a lesion that becomes confluent, spreading by extension and autoinoculation. The groin or thigh may be involved (ulcus molle serpiginosum).
- Phagedenic chancroid: a variant caused by superinfection with fusospirochetes. Rapid and profound destruction of tissue can occur (ulcus molle gangrenosum).
- Transient chancroid: small ulcer that resolves spontaneously in a few days. It may be followed 2 to 3 weeks later by acute regional lymphadenitis (French: *chancre mou volant*).
- Follicular chancroid: multiple small ulcers in a follicular distribution.
- Papular chancroid: a granulomatous ulcerated papule that might resemble donovanosis or condylomata lata (ulcus molle elevatum).

Mild systemic symptoms rarely accompany chancroid, but systemic infection by *H. ducreyi* has never been observed.

LABORATORY AND SPECIAL EXAMINATION

Bacterial culture of *H. ducreyi* currently remains the main tool for the diagnosis of chancroid in the clinical setting. However, the advent of more-sensitive DNA amplification techniques has demonstrated that the sensitivity of culture of *H. ducreyi* reaches only 75 percent at best. [13] The bacillus will survive only 2 to 4 h on a swab unless refrigerated. Swabs from the purulent ulcer base should be examined directly or inoculated to appropriate culture medium because no satisfactory transport system is available. Cotton or calcium-alginate swabs are recommended for specimen collection.

The simultaneous use of two primary isolation media supplemented with hemoglobin and serum are recommended for high culture sensitivity [10] (see Etiology, above). Small, nonmucoid, yellow-gray, translucent colonies appear 2 to 4 days after inoculation. Typically, these colonies remain intact when they are pushed across the agar surface. The identification of *H. ducreyi* is performed following the recommendations of Lubwama: [14] demonstration of hemin requirement, oxidase and catalase test, beta-lactamase test, hydrogen sulfide (H_2S) and indole activity. Testing of antibiotic susceptibility is recommended because clinically significant antimicrobial resistance of *H. ducreyi* has become common.

Direct examination of clinical material by Gram or Giemsa stain may be helpful, but reported sensitivity and specificity values are low, being 10 to 63 percent and 51 to 99 percent, respectively. [15] The bacilli are usually found in small clusters or parallel chains of two or three organisms streaming along strands of mucus. This pattern has been described as a “school of fish” or “railroad-track” appearance (Fig. 230-3). This arrangement, said to be characteristic of *H. ducreyi,* is nevertheless not pathognomonic, because most genital ulcers have a polymicrobial flora. Some authors do not recommend direct microscopy in the routine diagnosis of chancroid. [1]

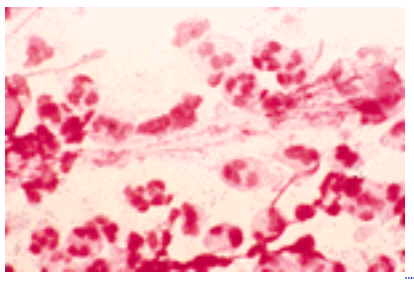

FIGURE 230-3 Smear from chancroid ulcer (Giemsa stain).

Characteristic histologic features with three vertically arranged zones (superficial necrotic zone, beneath a zone of new blood vessel formation, and a deep zone consisting of dense lymphocytic and plasma cell infiltrate) have been described in chancroid, [16] although tissue biopsy is not a recommended diagnostic method.

Histologic examination is useful as a means to exclude malignancy in nonhealing or atypical ulcers. [15]

Many attempts have been made to develop serologic tests for chancroid. Because of limited sensitivities for detection of circulating antibodies to *H. ducreyi,* serology has limited usefulness in the routine diagnosis of chancroid infection, but may be useful in population-based epidemiologic research as a screening method for past infection. [15], [17] Polymerase chain reaction (PCR) procedures with different primers showed superior sensitivity for the diagnosis of chancroid when compared to bacterial culture. [15] A multiplex PCR (M-PCR) assay has been developed for the simultaneous amplification

of DNA targets from *H. ducreyi, T. pallidum,* and herpes simplex types 1 and 2, [18] which seems to be a particularly attractive diagnostic tool in the investigation of patients presenting with genital ulcers. None of these PCR-based methods are commercially available yet, but their use for routine diagnostic purposes would be clearly advantageous.

In resource-poor settings where diagnostic facilities are not readily available, the World Health Organization advocates the use of a syndromic management approach for patients with genital ulcer disease. [19]

DIFFERENTIAL DIAGNOSIS

The three classic etiologic agents for anogenital ulceration are *H. ducreyi, Treponema pallidum,* and herpes simplex. The clinical appearance of the diseases caused by these three organisms can be extremely variable in both men and women and, therefore, clinical diagnosis of genital ulcer disease can be made with reasonable certainty only for a minority of patients. [20] The etiology of genital ulcers also differs considerable by geographic region. In a high percentage of genital ulcers, no pathogen can be isolated.

Clinical diagnosis alone is inadequate and the majority of authors consider even direct microscopic examination of smears from genital ulcers insufficient for diagnosis of chancroid. [1] Isolation of *H. ducreyi* on appropriate media and subsequent biochemical identification is necessary.

Syphilis may be eliminated by dark-field examination and repeated serologic testing for antibodies. Herpes simplex virus (HSV) infection can be diagnosed by culture, HSV DNA detection by PCR, or HSV antigen detection. Lymphogranuloma venereum (LGV) can be eliminated by a negative LGV complement-fixation test (titer less than 1:16) and by failure to demonstrate a significant rise in the titer on repeated testing after 3 weeks.

Donovanosis, superinfected traumatic lesions, and noninfectious causes of genital ulcerations, such as Crohn's disease or Behçet's syndrome must be considered in the differential diagnosis.

Mixed infections (chancroid and syphilis, chancroid and herpes simplex) are possible.

TREATMENT

Since the 1970s, beta-lactamase–producing strains of *H. ducreyi* emerged and treatment failures were common. Subsequently, further plasmid-mediated resistance to tetracycline, sulfonamides, chloramphenicol, and aminoglycosides has been reported. [21] Little is known about chromosomally mediated resistance in *H. ducreyi,* but decreased susceptibilities to various antibiotics in absence of identifiable resistance plasmids suggests evolution of such mechanisms. [21] Since the 1993 treatment guidelines for sexually transmitted diseases were published by the CDC, experience has indicated that the regimens recommended remain largely effective. [22] Based on in vitro susceptibility, the most active drugs against *H. ducreyi* are azithromycin, ceftriaxone, ciprofloxacin, and erythromycin. The in vitro findings of resistance to amoxicillin/clavulanate suggest that it may be less effective than when it was recommended as a second-line drug in 1993, and therefore it can no longer be recommended for the treatment of chancroid. [22] Newer quinolones show promise as effective agents. Table 230-1 lists the regimens recommended by the CDC. [23]

TABLE 230-1 **CDC Recommended Regimens for the Treatment of Chancroid**

Local treatment consists of antiseptic dressings (i.e., povidone-iodine). Suppurative nodes should not be incised; if necessary, they can be punctured to prevent spontaneous rupture and sinus tract formation. A large syringe should be used and the fluctuant buboes entered laterally through normal skin. In patients with phimosis, a circumcision may be necessary when all active lesions have healed.

Even after correct treatment, relapses occur in approximately 5 percent of patients. Retreatment with the original regimen is recommended. If a sexual partner was not treated, reinfection is probably the cause of relapse. HIV infection and lack of circumcision appear to be associated with an increased likelihood of treatment failure.

RELATIONSHIP BETWEEN HIV-INFECTION AND CHANCROID

Over the past decade, renewed interest in chancroid has led to evidence that genital ulcers promote the heterosexual transmission and acquisition of HIV-1. [24] Effective treatment of genital ulcers can reduce the incidence of HIV-1, and this strategy has become a cornerstone of HIV prevention programs in many parts of the world. [25] Furthermore, it was shown that concomitant HIV-infection has clinically significant effects on the course of the chancroid disease, and failure of single-dose or short-course therapy for chancroid in men is associated with HIV-1 seropositivity. [24] A wide variation in the clinical picture of chancroid has been observed in HIV-infected patients. [24] Epidemiologic control of chancroid may be a very important strategy to interrupt the heterosexual spread of HIV in some parts of the world. Accordingly, patients with chancroid should also be tested for HIV-antibodies. HIV-seropositive patients with culture-proven chancroid should be monitored closely and treated with a multiple-day regimen.

PREVENTION

The augmentation of the HIV epidemic by *H. ducreyi* has made chancroid control an urgent priority. Patients should be advised to abstain from sexual activity until all clinical lesions have cleared. Sexual contacts of the patient should be examined and treated regardless of whether symptoms of the disease are present, because asymptomatic carriage of *H. ducreyi* is possible. [9] Chancroid survives in populations in which many men are having sex with a few women. As a result, programs to trace and treat contacts are essential. Eradication of chancroid is considered to be a feasible public health objective. [2]

COURSE AND PROGNOSIS

The disease is self-limited and systemic spread does not occur. Occasionally, without treatment, genital ulcer and inguinal abscess have been reported to persist for years. Local pain is the most frequent complaint. If no clinical improvement is evident 1 week after the start of therapy, incorrect diagnosis, coinfection with another sexually transmitted disease, concomitant HIV infection, poor compliance, or a resistant strain of *H. ducreyi* must be considered. Infections do not confer immunity and reinfections are possible. To avoid reinfections, patients must be instructed to use condoms properly.

REFERENCES

1. Albritton WL: Biology of *Haemophilus ducreyi. Microbiol Rev* **53**:377, 1989

2. Steen R: Eradicating chancroid. *Bull World Health Organ* **79**:818, 2001

3. Ronald AR, Albritton W: Chancroid and *Haemophilus ducreyi,* in *Sexually Transmitted Diseases,* edited by KK Holmes, PF Sparling, P-A Mårdh, SM Lemon, WE Stamm, P Piot, and JN Wasserheit. New York, McGraw-Hill, 1999, p 515

4. Division of STD Prevention: Sexually transmitted disease surveillance, 2000. US Department of Health and Human Services, Public Health Service. Atlanta: Centers for Disease Control and Prevention, 2001. http://www.cdc.gov/std/stats/Tables/2000

5. Mertz KJ et al: Etiology of genital ulcers and prevalence of human immunodeficiency virus coinfection in 10 US cities. The Genital Ulcer Disease Surveillance Group. *J Infect Dis* **178**:1795, 1998

6. DiCarlo RP et al: Chancroid epidemiology in New Orleans men. *J Infect Dis* **172**:446, 1995

7. Mertz KJ et al: An investigation of genital ulcers in Jackson, Mississippi, with use of a multiplex polymerase chain reaction assay: High prevalence of chancroid and human immunodeficiency virus infection. *J Infect Dis* **178**:1060, 1998

8. O'Farrell N: Chancroid in the United Kingdom. *Sex Transm Infect* **76**:67, 2000

9. Trees DL, Morse SA: Chancroid and *Haemophilus ducreyi*: An update. *Clin Microbiol Rev* **8**:357, 1995

10. Nsanze H et al: Comparison of media for the primary isolation of *Haemophilus ducreyi*. *Sex Transm Dis* **11**:6, 1984

11. Al Tawfiq JA et al: An isogenic hemoglobin receptor-deficient mutant of *Haemophilus ducreyi* is attenuated in the human model of experimental infection. *J Infect Dis* **181**:1049, 2000

12. Lewis DA: The use of experimental animal and human models in the study of chancroid pathogenesis. *Int J STD AIDS* **10**:71, 1999

13. Morse SA et al: Comparison of clinical diagnosis and standard laboratory and molecular methods for the diagnosis of genital ulcer disease in Lesotho: association with human immunodeficiency virus infection. *J Infect Dis* **175**:583, 1997

14. Lubwama SW et al: Isolation and identification of *Haemophilus ducreyi* in a clinical laboratory. *J Med Microbiol* **22**:175, 1986

15. Lewis DA: Diagnostic tests for chancroid. *Sex Transm Infect* **76**:137, 2000

16. Sheldon WH, Heyman A: Studies in chancroid: Observations on the histology with an evaluation of biopsy as a diagnostic procedure. *Am J Pathol* **22**:415, 1946

17. Elkins C et al: Development of a serological test for *Haemophilus ducreyi* for seroprevalence studies. *J Clin Microbiol* **38**:1520, 2000

18. Orle KA et al: Simultaneous PCR detection of *Haemophilus ducreyi, Treponema pallidum,* and herpes simplex virus types 1 and 2 from genital ulcers. *J Clin Microbiol* **34**:49, 1996

19. Bogaerts J et al: Simple algorithms for the management of genital ulcers: Evaluation in a primary health care centre in Kigali, Rwanda. *Bull WHO* **73**:761, 1995

20. DiCarlo RP, Martin DH: The clinical diagnosis of genital ulcer disease in men. *Clin Infect Dis* **25**:292, 1997

21. Erbelding E, Quinn TC: The impact of antimicrobial resistance on the treatment of sexually transmitted diseases. *Infect Dis Clin North Am* **11**:889, 1997

22. Schmid GP: Treatment of chancroid, 1997. *Clin Infect Dis* **28**(Suppl 1): S14, 1999

23. Centers for Disease Control and Prevention (CDC): Sexually Transmitted Diseases: Treatment Guidelines 2002 *MMWR Recomm Rep* **51**: RR-6, 2002.

24. Abeck D, Ballard RC: Chancroid. *Curr Probl Dermatol* **24**:90, 1996

25. Grosskurth H et al: Impact of improved treatment of sexually transmitted diseases on HIV infection in rural Tanzania: Randomised controlled trial. *Lancet* **346**:530, 1995

Chapter 231

Richard Rothenberg

Lymphogranuloma Venereum

HISTORY
EPIDEMIOLOGY
ETIOLOGY
CLINICAL MANIFESTATIONS
PATHOLOGY
DIAGNOSIS
DIFFERENTIAL DIAGNOSIS
TREATMENT

REFERENCES

Lymphogranuloma venereum (LGV) is a sexually transmitted disease of chlamydial etiology with protean clinical manifestations involving the lymphatic system. It should be considered in the differential diagnosis of benign and malignant lymphadenopathy, genital lesions, proctocolitis, and rectal stricture. LGV, along with other causes of genital ulcer disease, is increasingly important as a potential facilitator of human immunodeficiency virus (HIV) transmission. [1]

HISTORY

The disease has a colorful nosologic history including such designations as tropical or climatic bubo; third, fourth, fifth, or sixth venereal disease; lymphopathia venerea; and Nicolas-Favre disease, but the current name is now universally accepted. The first major clinical description appeared in 1913, and inclusion bodies in material from lesions were demonstrated 10 years later. In 1930, the disease was produced experimentally by intracerebral inoculation of monkeys with pus from a bubo of LGV. [2] In 1940, Rake [3] grew the organism, then thought to be a filterable virus, in the yolk sac of embryonated eggs. In the 1960s and 1970s the organism was successfully grown in tissue culture by using cycloheximide-treated McCoy cells, [4] and microimmunofluorescence techniques were developed for speciation and recognition of serovariants. [5] During the 1980s and 1990s, the study of chlamydial infection benefited from the considerable advances in the techniques of microbial genetics and diagnostic methods with the development of polymerase chain reaction and ligase chain reaction techniques for genus identification. No commercial products are yet available for LGV identification, however.

EPIDEMIOLOGY

LGV probably occurs all over the world, with endemic foci in tropical and subtropical countries, but few, if any, systematic data describe incidence or prevalence. Most surveys are actually reports of proportional morbidity in clinic series, and the results are highly variable: Singapore, <1 percent; [6] Australia, rare with a recommendation to intensify surveillance; Durban, South Africa, 6 percent; [7] Madagascar, 24 percent in 1994 [8] and 14 percent in 1999; [9] Rwanda, 10 percent; [10] Paris, 0 percent; [11] Kuala Lumpur, 0 percent; [12] and Jamaica, about 4 percent over the decade of the 1980s [13] with a decrease to 3 percent by 1999 [14]. Several studies from Africa found very few cases, [15] but a substantial proportional morbidity (8 percent) was noted in Nigeria during the period 1993 to 1997. [16] In the United States, the number of cases reported yearly declined from a peak in 1944 of 2858 cases to a stable level of 200 to 300 during the 1980s, and a subsequent decline to 69 reported cases in 1999 (Fig. 231-1). [17] The chief foci of activity have been the District of Columbia and the southeastern United States, affecting predominantly African Americans of low socioeconomic status. Age-specific attack rates are highest in the 20- to 40-year-old group. The disease is spread by direct inoculation from genital fluids, but transmission efficiency is not known. Women may be asymptomatic and culture positive, and may serve as a reservoir for infection, as they do for gonorrhea and other genital chlamydial infections.

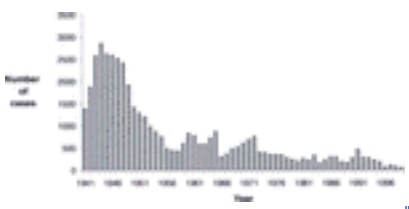

FIGURE 231-1 Cases of lymphogranuloma venereum, United States, 1941 to 1999.

ETIOLOGY

The disease is caused by members of the genus *Chlamydia* (previously known as *Bedsonia*) whose structure, metabolism, DNA and RNA content, and method of reproduction make them similar to *Rickettsia*. [18] The genus is composed of three species: *psittaci, pneumoniae,* and *trachomatis*. The species *Chlamydia trachomatis* has two major biologic varieties (biovars): trachoma or TRIC organisms, and LGV organisms. The latter, in turn, are characterized by three major serologic varieties (or serovars)-L1, L2, L3, and the more recently recognized L2'. [19] The LGV serovars are distinguished by their preferential infectivity for lymph nodes, intracerebral lethality for mice, and different behavior in cell culture. Experimentally, the LGV serovars produce severe hemorrhagic proctitis in monkeys, while TRIC serovars do not. [20] The two biovars, however, share a major cross-reacting antigen which complicates serologic distinction between them.

Distinction among types is now actively pursued with modern biochemical and molecular biologic methods, including exploration of mechanisms for immune-mediate lysis, [21] use of restriction fragment length polymorphism, [22] response to heparin sulfate lysis, [23], [24] use of pooled antibody to distinguish between genital and nongenital infection, [15] and structural genetic differences. [25]

CLINICAL MANIFESTATIONS

LGV is contracted by direct contact with infectious secretions, almost exclusively through sexual activity. The portal of entry and the initial symptoms are determined by the nature of the sex act; inoculation is usually genital, but it may be rectal or pharyngeal. The incubation period varies from 3 to 30 days if primary lesions occur, but it may be longer if adenopathy is the only manifestation. The period of infectiousness and transmission rates are not clearly defined.

Acute and chronic manifestations characterize both the genital (or inguinal) and rectal syndromes. The primary lesion is a 5- to 8-mm soft, erythematous, painless erosion (Fig. 231-2) that heals spontaneously in a few days. Occasionally, a button-like papule may appear that is also transient. Such lesions are reported by a fourth to a third of patients. Secondary inguinal adenopathy begins 1 to 2 weeks after the primary lesion as discrete, movable, tender nodes that later coalesce to form a firm, fist-sized, elongated, immovable mass. These may occur above and below Poupart's ligament, giving rise to the “groove” sign (Fig. 231-3). Nodes are bilateral in one-third of cases. Rupture of fluctuant nodes may lead to chronic sinus formation. Initially, the overlying skin is often slightly reddened and edematous, but it later may become thickened and develop a characteristic purplish hue. Generalized systemic symptoms such as fever, chills, and malaise may be prominent. Meningoencephalitis, hepatosplenomegaly, arthralgia, stiff neck, and headache may also occur. A strong association of LGV and other chlamydial infections has been established, [26] but the relationship of chlamydial treatment to improvement of arthritis is more tenuous. [27] Conjunctivitis with marginal corneal ulceration has been reported. [28] In untreated cases, the lymphadenopathy usually subsides spontaneously in 8 to 12 weeks.

FIGURE 231-2 Lymphogranuloma venereum. Soft painless erosion on the prepuce.

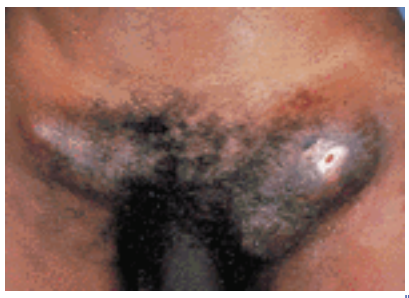

FIGURE 231-3 Lymphogranuloma venereum. Bilateral, firm, immovable masses above Poupart's ligament.

Late complications of the male inguinal syndrome are rare. Elephantiasis of the penis and scrotum characterized by infiltrative, ulcerative, and fistular lesions occur in approximately 4 percent of cases. [29] LGV may mimic cervical lymphoma, as reported in a homosexual male practicing fellatio and a heterosexual male engaging in cunnilingus. [31] In another report, clinical presentation and computerized tomography of intrapelvic nodes suggested cervical cancer in a 24-year-old woman with LGV, [32] and LGV has also been associated with tonsillar infection. [33] In keeping with the diagnostic confusion associated with lymphoproliferative syndromes, LGV has also been mistaken for cat-scratch fever.

The acute rectal syndrome occurs more frequently in women than men. In men, direct inoculation of the anal canal is believed to be the mode of entry, whereas the internal lymphatic drainage of the proximal two-thirds of the vagina has been invoked as the source for women. In both sexes, acute manifestations include rectal pain, tenesmus, and mucosanguineous rectal discharge, with typical findings of proctocolitis on sigmoidoscopy. It is important to distinguish LGV from other forms of inflammatory bowel disease, particularly in homosexual men. [34] The major late manifestation is rectal stricture. [35] In women, late scarring, fistulas, ulceration, and elephantiasis of the perineum, called esthiomene, may require radical surgical intervention. [36]

Various dermatologic conditions have been reported in association with acute manifestations, including erythema nodosum, erythema multiforme, scarlatiniform exanthem, and urticaria. [2] In addition, photosensitivity has been reported in

as many as 35 percent of patients, occasionally associated with conjunctivitis, joint involvement, and erythema nodosum. [2] Sonck [37] observed a photosensitivity reaction in 140 of 400 LGV cases studied. This reaction was manifest 1 to 2 months after the onset of bubo formation and occurred in 60 percent of the chronic and about 20 percent of subacute cases. Punctiform, red papules appeared on the skin 30 min to 3 h after exposure to sunlight. Accompanying this photosensitivity reaction was conjunctivitis in 19 percent, joint involvement in 33 percent, and erythema nodosum in 16 percent of patients. The possible allergic or autoimmune nature of these phenomena is supported by the frequent appearance of biologic false-positive tests for syphilis (estimated at 20 percent of cases), the high incidence of cryoprecipitins and rheumatoid factor, and the high serum levels of IgA and IgG in both acute and chronic syndromes. [38]

As noted, as a cause of genital ulceration LGV may play a role in facilitating transmission of HIV. Because of its lymphatic manifestations and potential effects on the immune system, it may also play a role in the differential diagnosis of acquired immunodeficiency syndrome (AIDS). [39] In one reported case, for example, disseminated Kaposi's sarcoma mimicked LGV in its initial presentation. [40] The syndrome of angioimmunoblastic lymphadenopathy has been reported in association with LGV, [41] and may, as occurred in one case, lead to progressive immunologic deterioration and rapidly fatal immunoblastic lymphoma.

PATHOLOGY

In general, histopathologic changes of LGV are nonspecific. Primary ulcers are characterized by an exudate of fibrin, polymorphonuclear leukocytes, and cellular debris. [42] Skin test sites or rectal lesions may contain epithelioid nodules, plasma cells, and occasional giant cells, but these changes are not diagnostic. Stellate triangular abscesses may be observed in biopsy specimens of lymph nodes and are characteristic, but not pathognomonic, of LGV. [43] The pathology of LGV-induced proctocolitis is characterized by crypt distortion, submucosal fibrosis, neuromatous hypertrophy, follicular inflammation, and occasional granuloma formation. It may be difficult to distinguish these changes from those associated with Crohn's disease, although localization of lesions is of considerable help (proximal in Crohn's disease, distal in LGV). [44] It is likely that LGV is not etiologically associated with Crohn's disease.

DIAGNOSIS

One of the earliest diagnostic techniques, the Frei test, used an intradermal inoculation of killed LGV organisms and was important to diagnosis for many years. Its sensitivity and specificity are in serious doubt, however, [45] and the test is now of historical interest only, because the antigen is no longer commercially available. The diagnostic accuracy of the clinical diagnosis is variable. In one study from South Africa, diagnostic accuracy (defined as true positives divided by true positives plus false positives plus false negatives) was found to be 66 percent in men and 40 percent in women, but these figures are based on a small number of cases. [7] In another attempt from South Africa, the diagnostic accuracy was 20 percent overall. [46] Although algorithmic approaches to genital ulcer disease is important in many clinical settings, clinical diagnosis alone may not be dependable.

Definitive diagnosis is possible through isolation of the organism from tissue or body fluids, and distinction among the four serovars can be made by using microimmunofluorescence techniques. [47] Because tissue culture may not be readily available, the clinician must often rely on serologic methods. First developed in the 1930s, the complement fixation test has long been the mainstay of diagnosis of LGV. It suffers from lack of specificity: virtually all members of the genus *Chlamydia* share the target antigen. [48] Although less than 3 percent of the general population has a titer as high as 1:16, [45] 40 to 50 percent of women with uncomplicated TRIC-agent cervical infection had titers of 1:16 to 1:32; similar titers occurred in 15 to 20 percent of men with TRIC-associated urethritis. A titer of 1:64 or greater is, however, highly suggestive of LGV. Coupled with a fourfold change in titer (which is not uniformly detected), a high titer greatly increases diagnostic assurance. The microimmunofluorescence test, originally developed as a guide to identification of organisms, has been successfully adapted as a serologic test. It responds, similar to the complement fixation test, to the broadly reactive range of antibodies produced by patients with LGV. Again, very-high titers of IgG antibody are usual in patients with acute infection. Other tests, including enzyme-linked immunosorbent assay (ELISA) and radioimmunoassay methods, are also available but appear to offer little advantage over the microimmunofluorescence test. [49]

DIFFERENTIAL DIAGNOSIS

In view of the nonspecific nature of signs and symptoms, acute LGV should be considered in the differential diagnosis of syphilis, herpes progenitalis, granuloma inguinale, and chancroid, as well as in bacterial, fungal, or tuberculous skin infection. Adenopathy may require consideration of benign and malignant lymphoproliferative disorders (e.g., infectious mononucleosis, Hodgkin's disease), particularly in the presence of oral and cervical infection. Late manifestations must be distinguished from neoplastic skin disease, filariasis, rectal cancer, inflammatory bowel disease, and hidradenitis suppurativa.

TREATMENT

Antibiotics are effective in the acute illness but may have little or no effect on late lymphatic pathology. Standard recommended treatment is doxycycline 100 mg orally twice a day for 21 days. An alternative regimen is erythromycin base 500 mg orally four times a day for 21 days. [50] To avoid formation of fistulous tracts, buboes should be aspirated rather than incised and drained. With treatment, prognosis for avoidance of late complications is excellent.

REFERENCES

1. Piot P et al: Retrospective seroepidemiology of AIDS virus infection in Nairobi populations. *J Infect Dis* **155**:1108, 1987

2. Koteen H: Lymphogranuloma venereum. *Medicine (Baltimore)* **24**:2, 1945

3. Rake G: Agent of lymphogranuloma venereum in the yolk sac of the developing chick embryo. *Proc Soc Biol Med* **43**:332, 1940

4. Evans RT, Woodland RM: Detection of chlamydiae by isolation and direct examination. *Br Med Bull* **39**:181, 1983

5. Wang SP: Microimmunofluorescence method. Study of antibody response to TRIC organisms, in *Trachoma and Related Disorders Caused by Chlamydia Agents,* edited by RL Nichols. Amsterdam, Excerpta Medica, 1971, p 273

6. Chua SH, Cheong WK: Genital ulcer disease in patients attending a public sexually transmitted disease clinic in Singapore: An epidemiologic study. *Ann Acad Med Singapore* **95**:510, 1995

7. O'Farrell N et al: Genital ulcer disease in men in Durban, South Africa. *Genitourin Med* **91**:327, 1991

8. Harms G et al: Pattern of sexually transmitted diseases in a Malagasy population. *Sex Transm Dis* **94**:315, 1994

9. Behets FM et al: Chancroid, primary syphilis, genital herpes, and lymphogranuloma venereum in Antananarivo, Madagascar. *J Infect Dis* **180**:1382, 1999

10. Bogaerts J et al: The etiology of genital ulceration in Rwanda. *Sex Transm Dis* **89**:123, 1989

11. Casin I et al: [Microbiological study of male genital ulcers. Apropos of 75 cases] [French]. *Pathol Biol (Paris)* **90**:710, 1990

12. Zainah S et al: A microbiological study of genital ulcers in Kuala Lumpur [published erratum appears in *Med J Malaya* 47(2):iv, 1992]. *Med J Malaysia* **91**:274, 1991

13. Brathwaite AR et al: A comparison of prevalence rates of genital ulcers among persons attending a sexually transmitted disease clinic in Jamaica. *West Indian Med J* **46**:67, 1997

14. Behets FM et al: Genital ulcers: Etiology, clinical diagnosis, and associated human immunodeficiency virus infection in Kingston, Jamaica. *Clin Infect Dis* **28**:1086, 1999

15. Duncan ME et al: Chlamydial infection in a population of Ethiopian women attending obstetric, gynaecological and mother and child health clinics. *Cent Afr J Med* **42**:1, 1996

16. Fawole OI et al: Genital ulcers disease among sexually transmitted disease clinic attendees in Ibadan, Nigeria. *Afr J Med Med Sci* **29**:17, 2000

17. Division of STD Prevention, Centers for Disease Control and Prevention. *Sexually Transmitted Disease Surveillance, 1999*. Atlanta, GA, Centers for Disease Control and Prevention, 2000

18. Schachter J: Chlamydial infection. *N Engl J Med* **298**:428, 490, 540, 1978

19. Wang SP et al: Immunotyping of *Chlamydia trachomatis* with monoclonal antibodies. *J Infect Dis* **152**:791, 1985

20. Quinn TC et al: Experimental proctitis due to rectal infection with *Chlamydia trachomatis* in nonhuman primates. *J Infect Dis* **86**:833, 1986

21. Beatty PR et al: Cross-reactive cytotoxic T-lymphocyte-mediated lysis of *Chlamydia trachomatis*- and *Chlamydia psittaci*-infected cells. *Infect Immun* **65**:951, 1997

22. Meijer A et al: Species identification of *Chlamydia* isolates by analyzing restriction fragment length polymorphism of the 16S-23S rRNA spacer region. *J Clin Microbiol* **35**:1179, 1997

23. Chen JC, Stephens RS: *Chlamydia trachomatis* glycosaminoglycan-dependent and -independent attachment to eukaryotic cells. *Microb Pathog* **22**:23, 1997

24. Chen JC et al: Structural requirements of heparin binding to Chlamydia trachomatis. *J Biol Chem* **271**:11134, 1996

25. Herrmann B et al: Differentiation of *Chlamydia* spp. by sequence determination and restriction endonuclease cleavage of RNase P RNA genes. *J Clin Microbiol* **34**:1897, 1996

26. Taylor-Robinson D: *Chlamydia* species in human arthritides [review]. *Rev Rhumat* **66**:9S, 1999

27. Bardin T, Schumacher HR: Antibiotic trials in reactive arthritis. [Review]. *Rev Rhumat* **66**:63S, 1999

28. Buus DR et al: Lymphogranuloma venereum conjunctivitis with a marginal corneal perforation. *Ophthalmology* **88**:799,1988

29. Hopsu-Havu VK, Sonck CE: Infiltrative, ulcerative, and fistular lesions of the penis due to lymphogranuloma venereum. *Br J Venereol Dis* **49**:193, 1973

30. Thorsteinsson SB: Lymphogranuloma venereum. A cause of cervical lymphadenopathy. *JAMA* **235**:1882, 1976

31. Andrada MT. Oral lymphogranuloma venereum. A cause of cervical lymphadenopathy: Case report. *Mil Med* **139**:99, 1974

32. Zweizig S et al: Computed tomography of lymphogranuloma venereum mimicking cervical cancer. *Comput Med Imaging Graph* **91**:97, 1991

33. Watson DJ et al: Lymphogranuloma venereum of the tonsil. *J Laryngol Otol* **90**:331, 1990

34. Bauwens JE et al: Infection with *Chlamydia trachomatis* lymphogranuloma venereum serovar L1 in homosexual men with proctitis: Molecular analysis of an unusual case cluster. *Clin Infect Dis* **95**:576, 1995

35. Papagrigoriadis S, Rennie JA: Lymphogranuloma venereum as a cause of rectal strictures. *Postgrade Med J* **74**:168, 1998

36. Hirschberg SM, Horton CE: Radical perineal resection for far-advanced lymphogranuloma venereum. *Plast Reconstr Surg* **51**:217, 1973

37. Sonck CE: On the occurrence of solar dermatitis in lymphogranuloma inguinale. *Acta Derm Venereol (Stockh)* **20**:529, 1939

38. Sonck CE: Autoimmune serum factors in active and inactive lymphogranuloma venereum. *Br J Venereol Dis* **49**:67, 1973

39. Czelusta A et al: An overview of sexually transmitted diseases. Part III. Sexually transmitted diseases in HIV-infected patients [review]. *J Am Acad Dermatol* **43**:409, 2000

40. Aghadiuno PU et al: Kaposi sarcoma in the acquired immune deficiency syndrome (AIDS), presenting as lymphogranuloma venereum (LGV) in a promiscuous Trinidadian male. *Trop Geogr Med* **87**:88, 1987

41. Senitzer D et al: Infectious antecedent of immunoblastic lymphoma; progressive immunosuppression in a patient with lymphogranuloma venereum. *Am J Med* **8**:163, 1985

42. Smith EB, Custer RP: The histopathology of lymphogranuloma venereum. *J Urol* **63**:546, 1950

43. Robbins SL. *Pathology*. Philadelphia, Saunders, 1967

44. de la Monte SM, Hutchins GM: Follicular proctocolitis and neuromatous hyperplasia with lymphogranuloma venereum. *Hum Pathol* **16**:1025, 1985

45. Schachter J: Lymphogranuloma venereum. I. Comparison of the Frei test, complement-fixation test and isolation of the agent. *J Infect Dis* **120**:372, 1969

46. Dangor Y et al: Accuracy of clinical diagnosis of genital ulcer disease. *Sex Transm Dis* **90**:184, 1990

47. Kellock DJ et al: Lymphogranuloma venereum: Biopsy, serology, and molecular biology. *Genitourin Med* **73**:399, 1997

48. Treharne JD et al: Chlamydial serology. *Br Med Bull* **39**:194, 1983

49. Darougar S: The humoral immune response to chlamydial infection in humans. *Rev Infect Dis* **7**:726, 1985

50. Centers for Disease Control and Prevention: 1998 Guidelines for treatment of sexually transmitted diseases. *MMWR Recomm Rep* **47**: RR-1, 1998

T>

Chapter 232

Richard Rothenberg

Granuloma Inguinale

HISTORY
EPIDEMIOLOGY
ETIOLOGY AND PATHOGENESIS
CLINICAL MANIFESTATIONS
PATHOLOGY
DIAGNOSIS
TREATMENT

REFERENCES

Granuloma inguinale is an indolent, progressive, ulcerative, and granulomatous skin disease caused by *Calymmatobacterium granulomatis*. It is probably spread by both homosexual and heterosexual venereal contact, as well as by nonvenereal means. [1] Untreated it exhibits no tendency to go into spontaneous remission, and in later stages, it may be severely debilitating.

HISTORY

The first description is credited to McLeod in 1882, who termed the illness *serpiginous ulcer*. [2] Many other names have been suggested, but aside from granuloma inguinale, only the term *donovanosis* persists. Donovan, in 1905, first described the bipolar-staining, intracellular inclusions in macrophages from lesion exudate (termed *Donovan bodies*). These organisms were grown in embryonated eggs in 1943; [3] requirements for growth on artificial media were established in 1959. [4]

EPIDEMIOLOGY

Small numbers of sporadic cases of granuloma inguinale have been reported from developed countries. Since 1970, fewer than 100 cases per year have been reported in the United States; in 1989, there were only 7; in 1995, no cases were reported; and in 1999, 19 cases were reported. [5] Endemic foci are usually seen only in tropical and subtropical environments such as New Guinea, Brazil, central Australia, the Caribbean, and parts of India. [6], [7] Recently, a focus was recognized in South Africa, after an apparent eclipse of 50 years. [8] Investigators in Durban, South Africa, noted a peak in case reports in the late 1980s, [9] and recognized that, by 1995, granuloma inguinale accounted for almost 10 percent of cases of genital ulcer disease seen at one clinic in that city. [10] Several large case series [11], [12] and [13] confirmed a strong association with syphilis and HIV infection, but the influence of the latter infection on the course of granuloma inguinale remains controversial. No special effect has been noted on the course of pregnancy, [12] but a case control study in India of patients with and without HIV infection observed 40 percent faster healing of similarly treated lesions in those patients without HIV. [14]

Certain ethnic predispositions have been noted—higher incidence in African Americans than in whites in the United States; in natives than in Europeans in Papua, New Guinea; in Hindus than in Moslems in India—but there is no evidence for specific ethnic susceptibility. Rather, socioeconomic status and living conditions are a major risk factor.

The venereal nature of transmission has been debated for many years and is supported by the genital site of early lesions, the prominence of perirectal disease in male homosexuals, and the predominant occurrence of infection in the sexually active group. [7] The possibility of nonvenereal transmission is suggested by the occurrence of disease in sexually inactive children, the infrequency of infection in partners repeatedly exposed to open lesions, and the infrequency of infection in sexually active people (e.g. prostitutes) in some endemic areas. [1], [7], [15] It seems clear, however, that granuloma inguinale is one of a class of diseases that causes genital ulceration that may predispose persons to the transmission of HIV. [16] One investigator suggests that a global program to eradicate granuloma inguinale could retard the spread of HIV. [17]

ETIOLOGY AND PATHOGENESIS

The causative agent (formerly termed *Donovania granulomatis*) is a gram-negative rod that in early studies was purported to be found in fecal flora, [4] supporting the hypothesis that disease transmission may occur through fecal contamination in environments with lower levels of hygiene. This may also explain the occurrence of disease in males practicing rectal intercourse. Recently, it was shown to have a close phylogenetic relationship to the *Klebsiella* group, with which it has 95 percent homology. Its reclassification as *Klebsiella granulomatis* [18] has been proposed, based on a similarities demonstrated using polymerase chain reaction (PCR) diagnostics. [19] Long resistant to in vitro cultivation, the organism has now been propagated in a monocyte coculture system, [20], [21] and in Hep-2 cell culture. [22] A colorimetric test, linked to the PCR that has been developed, [19] promises to provide simple field methods for testing. [23]

Antibody against the organism may be detected by a complement-fixation test, although the test has little diagnostic value. Circulating antibody, which does not affect the relentless course of untreated disease, has raised the possibility that a defect in cell-mediated immunity may predispose the patient to clinical illness, as is the case in the other diseases

caused by intracellular organisms (e.g., leprosy and tuberculosis). [24]

CLINICAL MANIFESTATIONS

The primary lesion may be a button-like papule, a subcutaneous nodule, or an ulcer. The incubation period is poorly defined and may range from 2 weeks to 3 months. Experimental human inoculation has produced lesions after latency of 21 days. [25] Papules or nodules are quickly denuded and ulcerate within several days. The subcutaneous nodules, if large enough, may be mistaken for lymph nodes, giving rise to the term *pseudobubo*. True adenopathy is rare. In men, the penis, scrotum, and glans are the most common sites of primary lesions; in females, the labia minora, mons veneris, and fourchette are the most common sites. Lesions of the cervix may occur in as many as 10 percent of infected women, and the disease may also involve the uterus and adnexa. Typically, the disease spreads, either by direct extension or autoinoculation, to the inguinal and perineal skin.

Four major clinical varieties are described: [7], [26] the *nodular* variety is characterized by soft, red nodules that eventually ulcerate and present a bright-red granulating surface (Fig. 232-1); the *ulcerovegetative* variety (most common) (Fig. 232-2) develops from the nodular type and consists of large, spreading, exuberant ulcers; the *hypertropic* form (relatively rare) exhibits a proliferative reaction and formation of large vegetating masses; and the *cicatricial* type produces spreading scar tissue formation that is a direct consequence of disease spread per se, rather than of healing. Superinfection with fusospirochetal organisms may give rise to necrotic lesions with massive tissue destruction, similar to the situation in so-called *phagedenic* chancroid. The disease may rarely progress to destroy genital and inguinal tissue. Elephantiasis of the penis, scrotum, or vulva is a mutilating potential sequela.

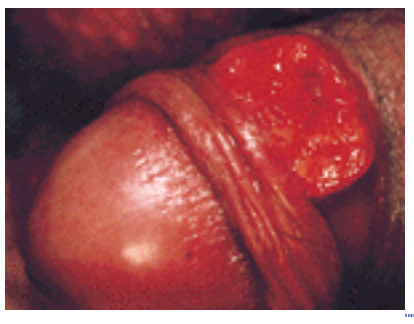

FIGURE 232-1 Granuloma inguinale: nodular variety evolving into large, exuberant ulcer. (*Courtesy of A. Eichmann, MD.*)

FIGURE 232-2 Granuloma inguinale: large ulcerovegetative type.

Extragenital lesions are infrequently reported, with occasional systemic involvement, notably of bone, [27] but involving nongenital skin as well, for example, the orbit, [28] the foot, [29] the chin, [30] the thigh, [31] and the axilla. [32] Chronic ulcerating oral mucosa lesions may occur with or without associated genital lesions [33] and may resemble actinomycosis. [34] Granuloma inguinale may affect cervical lymph nodes both in adults (resembling tuberculous lymphadenitis), [35] and in infants. [36], [37] Rarely, systemic abscesses have been reported, manifested as otitis media with mastoiditis [38] and as a psoas abscess. [39] The disease shows no tendency toward spontaneous healing, although lesions may be stable for long periods of time. There is believed to be an increased incidence of squamous cell carcinoma of the genital skin in granuloma inguinale, [40] although the relative rarity of the infection renders this observation difficult to document.

PATHOLOGY

Histologically, the skin exhibits a massive cellular reaction, predominantly polymorphonuclear, with plasma cells, foamy histiocytes, and, rarely, lymphocytes. [41], [42] The marginal epithelium demonstrates acanthosis, elongation of rete pegs, and pseudoepitheliomatous hyperplasia. [43] These latter changes can be suggestive of early malignancy and squamous cell carcinoma. Hypertropic and cicatricial forms demonstrate an increase in fibrous tissue. Typically, large mononuclear cells containing numerous cytoplasmic inclusions (the Donovan bodies) are scattered throughout the lesions. These are considered to be diagnostic of granuloma inguinale and are often best demonstrated with special stains, such as Giemsa's stain, Delafield's hematoxylin, Dieterle's silver stain, and the Warthin-Starry stain. [41]

Although the histopathology of granuloma inguinale is well recognized, the pathophysiology is not understood. Some investigators suggest the transepithelial elimination (TEE) of irritative dermal substances through intact epidermis, [44] citing the finding of pseudoepitheliomatous hyperplasia and other markers found in processes classically associated with

TEE. The investigators recognize, however, that the sequence of events remains unelucidated.

DIAGNOSIS

The clinical diagnosis of granuloma inguinal, based on history and appearance, may be fairly accurate in endemic areas. In one study from South Africa, the diagnostic accuracy was 63 percent and the positive predictive value between 71 percent and 83 percent. [45] Despite the cited advances in microbiology, laboratory diagnosis usually requires a crush or touch preparation stained with Wright's or Giemsa's stain from a punch biopsy specimen. [46] Superficial curettings can be inadequate because of bacterial contamination. The diagnostic Donovan bodies are seen as deeply staining, bipolar, safety pin-shaped rods in the cytoplasm of macrophages (Fig. 232-3). Diagnosis may require multiple specimens because clinical varieties differ in the quantity of organisms present. Rapid-staining techniques [such as the RapiDiff stain (Clinical Science Diagnostics Ltd.)] are available and suitable for use under a variety of field conditions. [47] As noted, serologic tests, such as the use of complement fixation, have evoked some research interest, but have little practical application.

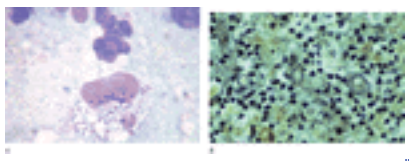

FIGURE 232-3 Granuloma inguinale: tissue smear showing Donavan bodies, which are gram-negative (*A*) and readily stained with Giemsa stain (*B*).

In its typical form, granuloma inguinale is easily differentiated from other ulcerative and granulomatous skin diseases, but atypical forms may be difficult to distinguish from syphilis, chancroid, lymphogranuloma venereum, tuberculosis of skin, cutaneous amebiasis, and filariasis. Squamous cell carcinoma with metastases may be closely mimicked by granuloma inguinale.

TREATMENT

Numerous drugs have been used to treat granuloma inguinale, including streptomycin, chloramphenicol, tetracycline, ampicillin, and gentamicin. Case series, usually assembled over a decade or more, offer a variety of regimens, as do numerous case reports, but few controlled trials are available. The US Public Health Service recommends either trimethoprim-sulfa, one double-strength tablet orally twice a day for 3 weeks minimum or doxycycline, 100 mg orally twice per day for 3 weeks minimum. Erythromycin, 500 mg four times a day orally for 3 weeks minimum and ciprofloxacin 750 mg twice a day orally for 3 weeks minimum are offered as alternatives. [48] Considerable recent interest in azithromycin has developed, and one pilot-controlled trial has been performed. [49] The Australian Antibiotic Guidelines now recommend azithromycin, 1 g orally per week or 500 mg orally daily for 3 weeks minimum. [50] Response may be monitored by clinical appearance and serial biopsy specimens examined for persistent presence of Donovan bodies. In early cases, prognosis for complete healing is good. In late cases, irreparable tissue destruction may have supervened, and radical surgery may be required.

REFERENCES

1. Goldberg J: Studies on granuloma inguinale. VII. Some considerations of the disease. *Br J Venereol Dis* **40**:140, 1964

2. McLeod K: Précis of operations performed in the wards of the first surgeon, Medical College Hospital, during the year 1881. *Indian Med Gazette* **11**:113, 1882

3. Anderson K et al: An etiologic consideration of *Donovania granulomatis* cultivated from granuloma inguinale (three cases) in embryonic yolk. *J Exp Med* **81**:25, 1943

4. Goldberg J: Studies on granuloma inguinale: IV. Growth requirements of *Donovania granulomatis* and its relationship to the natural habitat of the organism. *Br J Venereol Dis* **35**:266, 1959

5. Division of STD Prevention, Centers for Disease Control and Prevention (CDC): *Sexually Transmitted Disease Surveillance, 1999*. Atlanta, GA, Department of Health and Human Services, 2000

6. Hart CA, Rao SK: Donovanosis [review]. *J Med Microbiol* **48**:707, 1999

7. Hart G: Donovanosis [review]. *Clin Infect Dis* **25**:24, 1997

8. Freinkel AL: The enigma of granuloma inguinale in South Africa. *S Afr Med J* **77**:301, 1990

9. O'Farrell N: Trends in reported cases of donovanosis in Durban, South Africa. *Genitourin Med* **92**:366, 1992

10. Pham-Kanter GB et al: Sexually transmitted diseases in South Africa [review]. *Genitourin Med* **96**:160, 1996

11. Bassa AG et al: Granuloma inguinale (donovanosis) in women. An analysis of 61 cases from Durban, South Africa. *Sex Transm Dis* **93**:164, 1993

12. Hoosen AA et al: Granuloma inguinale in association with pregnancy and HIV infection. *Int J Gynaecol Obstet* **96**:133, 1996

13. O'Farrell N: Clinico-epidemiological study of donovanosis in Durban, South Africa. *Genitourin Med* **93**:108, 1993

14. Jamkhedkar PP et al: Clinico-epidemiologic features of granuloma inguinale in the era of acquired immune deficiency syndrome. *Sex*

Transm Dis **25**:196, 1998

15. Kuberski T. Granuloma inguinale (donovanosis). *Sex Transm Dis* **7**:29, 1980

16. Fleming DT, Wasserheit JN: From epidemiological synergy to public health policy and practice: The contribution of other sexually transmitted diseases to sexual transmission of HIV infection. *Sex Transm Infect* **75**:3, 1999

17. O'Farrell N: Global eradication of donovanosis: An opportunity for limiting the spread of HIV-1 infection [review]. *Genitourin Med* **95**:27, 1995

18. Carter JS et al: Phylogenetic evidence for reclassification of *Calymmatobacterium granulomatis* as *Klebsiella granulomatis* comb. nov. *Int J Syst Bacteriol* **49**:1695, 1999

19. Carter J et al: Diagnostic polymerase chain reaction for donovanosis. *Clin Infect Dis* **28**:1168, 1999

20. Kharsany AB et al: Culture of *Calymmatobacterium granulomatis*. *Clin Infect Dis* **22**:391, 1996

21. Kharsany AB et al: Growth and cultural characteristics of *Calymmatobacterium granulomatis*—the aetiological agent of granuloma inguinale (donovanosis). *J Med Microbiol* **46**:579, 1997

22. Carter J et al: Culture of the causative organism of donovanosis (*Calymmatobacterium granulomatis*) in HEp-2 cells. *J Clin Microbiol* **35**:2915, 1997

23. Carter JS, Kemp DJ: A colorimetric detection system for *Calymmatobacterium granulomatis*. *Sex Transm Infect* **76**:134, 2000

24. Maddock I: Donovanosis in Papua New Guinea. *Br J Venereol Dis* **52**:190, 1976

25. Rajam RV, Rangiah PN: Donovanosis (granuloma inguinale, granuloma venereum). *WHO Monogr Ser* **24**, 1954

26. D'Aunoy R, Von Haam E: Granuloma inguinale. *Am J Trop Med Hyg* **17**:747, 1967

27. Paterson DL: Disseminated donovanosis (granuloma inguinale) causing spinal cord compression: case report and review of donovanosis involving bone [review]. *Clin Infect Dis* **26**:379, 1998

28. Endicott JN: Granuloma inguinale of the orbit with bony involvement. *Arch Otolaryngol* **96**:457, 1972

29. Rao MV et al: Extragenital donovanosis of the foot. *Sex Transm Infect* **74**:298, 1998

30. Sanders CJ: Extragenital donovanosis in a patient with AIDS. *Sex Transm Infect* **74**:142, 1998

31. Cliff S et al: Disseminated granuloma inguinale secondary to cervical infection. *J Infect* **36**:129, 1998

32. Spagnolo DV et al: Extragenital granuloma inguinale (donovanosis) diagnosed in the United Kingdom: A clinical, histological, and electron microscopical study. *J Clin Pathol* **37**:945, 1984

33. Rao M: Oral lesions of granuloma inguinale. *J Oral Surg* **34**:1112, 1976

34. Coovadia YM et al: Granuloma inguinale (donovanosis) of the oral cavity: A case report. *S Afr Med J* **68**:815, 1985

35. Freinkel AL: Granuloma inguinale of cervical lymph nodes simulating tuberculous lymphadenitis: Two case reports and review of published reports. *Genitourin Med* **64**:339, 1988

36. Bowden FJ et al: Donovanosis causing cervical lymphadenopathy in a five-month-old boy. *Pediatr Infect Dis J* **19**:167, 2000

37. Govender D et al: Granuloma inguinale (donovanosis) presenting as a neck mass in an infant. *Pediatr Surg Int* **15**:129, 1999

38. Govender D et al: Granuloma inguinale (donovanosis): An unusual cause of otitis media and mastoiditis in children. *Am J Clin Pathol* **108**:510, 1997

39. Mein J et al: Intrapelvic donovanosis presenting as a psoas abscess in two patients. *Sex Transm Infect* **75**:75, 1999

40. Stewart DB: Ulcerative and hypertrophic lesions of the vulva. *Proc R Soc Med* **61**:363, 1968

41. Sehgal VN, Shyam Prasad AL: Donovanosis: Current concepts. *Int J Dermatol* **25**:8, 1986

42. Sehgal VN, Sharma HK: Donovanosis [review]. *J Dermatol* **92**:932, 1992

43. Dodson RF: Donovanosis: A morphologic study. *J Invest Dermatol* **62**:611, 1974

44. Ramdial PK et al: Transepithelial elimination of cutaneous vulval granuloma inguinale. *J Cutan Pathol* **27**:493, 2000

45. O'Farrell N et al: Genital ulcer disease: Accuracy of clinical diagnosis and strategies to improve control in Durban, South Africa. *Genitourin Med* **94**:7, 1994

46. Van Dyck E, Piot P: Laboratory techniques in the investigation of chancroid, lymphogranuloma venereum and donovanosis [review]. *Genitourin Med* **92**:130, 1992

47. O'Farrell N et al: A rapid stain for the diagnosis of granuloma inguinale. *Genitourin Med* **66**:200, 1990

48. Centers for Disease Control and Prevention: 1998 Guidelines for treatment of sexually transmitted diseases. *MMWR Recomm Rep* **47**: RR-1, 1998

49. Bowden FJ et al: Pilot study of azithromycin in the treatment of genital donovanosis. *Genitourin Med* **72**:17, 1996

50. Clinical Effectiveness Group AfGM: National guideline for the management of donovanosis. *Sex Transm Infect* **75**(Suppl 1):S38, 1999

T>

Chapter 233

David Feingold Claire Mansur

Gonorrhea

HISTORY
EPIDEMIOLOGY
ETIOLOGIC AGENT AND PATHOGENESIS
CLINICAL MANIFESTATIONS
Males
Females
DISSEMINATED GONOCOCCAL INFECTION
MISCELLANEOUS CLINICAL MANIFESTATIONS
PATHOLOGY
DIAGNOSIS
DIFFERENTIAL DIAGNOSIS
TREATMENT AND CONTROL

REFERENCES

Gonorrhea is a bacterial infection caused by *Neisseria gonorrhoeae,* a gram-negative diplococcus whose only natural reservoir is humans. The infection is almost always contracted during sexual activity.

The usual presentation in males is acute urethritis; in females, it is cervicitis, which may be asymptomatic. Other parts of the genitourinary apparatus, as well as the rectum, pharynx, and eye, may be infected. Occasionally bacteremia occurs, which is regularly associated with arthralgia and skin lesions; metastatic infection in joints or other foci may ensue. Although good treatment is available, the disease remains an important public health problem, causing a large percentage of female sterility and considerable morbidity in both sexes.

HISTORY

The name *gonorrhea* is attributed to Galen, who thought the urethritis represented abnormal flow of semen, hence the combination of *gonos* (seed) and *rhoea* (flow). The slang name for gonorrhea, *clap,* likely derives from a French word for brothel, *clapoir*.

Early confusion among the venereal diseases was augmented by the unfortunate experiment of John Hunter in 1767. He inoculated himself with a presumed gonococcal urethral exudate, only to develop syphilis. With isolation of the causative organism of gonorrhea by Neisser in 1879, positive identification of the disease became possible.

Treatment for gonorrhea has progressed from sandalwood oil to urethral irrigations with potassium permanganate to sulfonamides in the 1930s. Resistance to sulfonamides developed rapidly, but, fortunately, in the 1940s, the exquisite sensitivity of gonococcal strains to penicillin was discovered. The emerging problem of the organism's resistance to penicillin and other antibiotics is discussed below.

EPIDEMIOLOGY

The incidence of gonorrhea in the United States increased dramatically in the 1960s and early 1970s to more than 1 million reported cases annually. It is estimated that fewer than one-third of the new cases are reported. In the 1980s, there was a slow decline in reported cases to about 700,000 per year. This gradual decline has continued with fewer than 400,000 cases of gonorrhea reported in 2000. [1] The downward trend in infections slowed, but continued through 1997. Why has this two-phase trend occurred? [2] The epidemic was intensified, first, by behavioral factors, including increased sexual activity, changes in birth control methods, high population mobility, and an increase in repeated infections, and, second, by increased reporting when the federal gonorrhea screening effort was introduced in 1972. The subsequent decrease in incidence in the United States resulted from the Herculean efforts of the US Public Health Service through the national control program to detect and treat asymptomatic gonococcal infections. The practice of safer sex in the era of acquired immunodeficiency syndrome (AIDS) had additional impact on decreasing the incidence of all sexually transmitted diseases. In 1998, the number of reported cases rose slightly from 327,000 to 360,000, where it remained through 2000. Increased screening and sensitivity of tests are partially responsible for this increase, but true increases in certain populations appear to have occurred. [3]

The disease is spread almost exclusively by sexual activity, although newborns may be infected by exposure during parturition. Although all age groups are susceptible, infection is more prevalent in the 15- to 35-year-old age group. Among women in 2000, 15- to 19-year-olds had the highest incidence (715.6 per 100,000), while among men, 20- to 24-year-olds had the highest rate (589.7 per 100,000). [3] The disease is concentrated in high-density population centers, with a core group of active transmitters. [4] However, the mobility of individuals results in the occurrence of gonorrhea everywhere.

A signal event that has affected the epidemiology of gonorrhea is the dramatic increase in resistance of *N. gonorrhoeae* to antibiotics. Since the availability of sulfonamides and penicillin in the 1940s, antimicrobial resistance in *N. gonorrhoeae* has been evolving. The appearance of penicillinase-producing strains of *N. gonorrhoeae* in the United States in 1975 accelerated the trend toward greater antibiotic resistance. Penicillinase (beta-lactamase) synthesis in these organisms depends on the presence of plasmids, extrachromosomal packets of DNA, which can be transferred among organisms. At least five beta-lactamase plasmids of *N. gonorrhoeae* have been reported. Chromosomal

resistance to penicillin and tetracycline is also occasionally at levels sufficient to result in treatment failure. [5] For all practical purposes, in most areas penicillin is no longer the treatment of choice for gonorrhea.

In 1987, the Gonococcal Isolate Surveillance Project (GISP) was established by the Centers for Disease Control (CDC) to periodically monitor national trends in *N. gonorrhoeae* antibiotic resistance. [6] Of all isolates collected by GISP in 2000, 24.7 percent were resistant to penicillin, tetracycline, or both. Ciprofloxacin resistance was first identified in 1991 and is fairly widespread in Asia; the rate of resistance in the United States, however, has remained low (0.4 percent of isolates in 1999 and 2000) and largely restricted to specific geographic areas. Of note, ciprofloxacin resistance in Hawaii was 14.3 percent of GISP isolates in 2000, and the CDC has recommended that fluoroquinolones not be used to treat gonorrhea in that state. The proportion of isolates with elevated minimum inhibitory concentrations (MICs) to azithromycin also has risen. In 1992, 0.9 percent of isolates had azithromycin MIC >0.5, compared with 2.4 percent in 2000. In contrast, no cephalosporin resistance has been identified by GISP. In 2000 all isolates were sensitive to ceftriaxone and cefixime. [7]

ETIOLOGIC AGENT AND PATHOGENESIS

N. gonorrhoeae is a gram-negative diplococcus with distinctive morphology; the cocci are flattened and the long axes of the bean-shaped organisms are parallel. Gonococci tolerate oxygen but usually require 2 to 10 percent CO_2 in the growth atmosphere. The organisms have narrow temperature [35°C to 37°C (95°F to 98.6°F)] and pH (7.2 to 7.6), optimal for growth. Although fragile, they have relatively simple growth requirements. Defined media are now available on which the organisms will grow readily. Different strains have somewhat different growth requirements. Careful study of these requirements has led to a system of typing gonococcal isolates called auxotyping. [8], [9] Auxotyping was an important advance, because the ability to distinguish one *N. gonorrhoeae* isolate from another made epidemiologic studies feasible. Several other systems for typing gonococci were developed subsequently, including sensitivity to bacteriocins, the presence of specific lipopolysaccharide antigens, the use of monoclonal antibodies, and identification of specific opa genes. [10]

Kellogg and coworkers recognized four colony types of *N. gonorrhoeae*. [11] Only types 1 and 2 were pathogenic for humans. These types were also found to possess surface hairlike structures termed *pili*. The nature of pili as virulence factors has not been clarified; pili may foster adherence of gonococci to mucosal surfaces or resistance to phagocytosis. Other virulence factors are being identified, and might include capsular production in vivo, resistance to the immune bactericidal action of serum, and the ability of gonococci to survive in the presence of various competing commensal organisms. Griffiss and Artenstein [12] point out that all *Neisseria* are adapted to moist mucous membranes. Of them, the meningococcus and the gonococcus are the ones capable of escaping from host restraints, proliferating rapidly, and even invading the bloodstream. The reason why certain organisms occupy particular ecologic niches and the factors conferring virulence are only beginning to be understood.

CLINICAL MANIFESTATIONS

Signs, symptoms, complications, and the natural history of gonorrhea differ dramatically between males and females. However, careful studies have exposed the myth that males with gonorrhea are symptomatic and females asymptomatic.

Males

After a single exposure to an infected contact, approximately 25 percent of males will develop gonorrhea. It is estimated that 85 percent of men with gonococcal urethritis develop an acute process, with discomfort, dysuria, and purulent discharge usually ensuing from 2 to 10 days after exposure. Figure 233-1 shows a typical purulent discharge. Fifteen percent of urethritis in the male is minimally symptomatic or asymptomatic. Because these patients may not receive treatment, they tend to accumulate in the population. The resultant point prevalence of minimally symptomatic or asymptomatic male gonorrhea may be as high as 40 percent. [13] Clearly these men are capable of spreading disease. Untreated symptomatic urethritis subsides over several days to weeks, but occasionally local complications such as epididymitis, seminal vesiculitis, and prostatitis occur. Anorectal [14] and pharyngeal [15] gonococcal colonizations are uncommon. The incidence of positive cultures correlates with the practices of passive rectal intercourse and fellatio, respectively. Because symptoms of proctitis and pharyngitis correlate poorly with positive cultures, colonization of these areas rather than overt infection is likely to be what occurs.

FIGURE 233-1 Purulent urethral discharge.

Females

When an uninfected woman is exposed to an infected man, gonorrhea ensues over half the time. Once infected, the specific symptoms and signs of acute salpingitis may occur (20 to 40 percent) or the less-specific symptoms of dysuria,

increased discharge, or abnormal bleeding (20 to 30 percent) may be seen within a few days to a few weeks. Thirty to 60 percent of infected women will be minimally affected or asymptomatic, yet remain long-term carriers capable of transferring the infection. [16], [17] As described for men, these cases will accumulate, because symptomatic gonorrhea is treated preferentially. Because none of the symptoms or signs is diagnostic of gonorrhea, cultures of endocervix, urethra, rectum, and pharynx should be carried out if the disease is suspected or the patient is reported as a contact of gonorrhea.

Pelvic inflammatory disease (PID) is the most important complication of gonococcal infection. PID is the result of ascending infection from the endocervix, causing endometritis and/or salpingitis and/or pelvic peritonitis. Clinical findings can vary from crampy abdominal pain with minimal tenderness in mild cases to fever, severe abdominal pain, and exquisite tenderness with adnexal masses in florid cases. Prompt diagnosis and aggressive treatment are mandatory because infertility, ectopic pregnancy, and chronic pelvic pain are frequent complications. Several organisms other than *N. gonorrhoeae* may cause PID. The etiologic diagnosis, which is discussed below, may be difficult. Tragically, the role of silent or asymptomatic PID in causing adverse reproductive sequelae is becoming increasingly appreciated.

DISSEMINATED GONOCOCCAL INFECTION

Spread of *N. gonorrhoeae* to the bloodstream is estimated to occur in 1 to 3 percent of patients with gonorrhea, [18] with the majority of cases in females. Although endocarditis and meningitis have been reported, they are rare complications. Arthritis and skin lesions, on the other hand, are regularly associated with disseminated gonococcal infection (DGI). The syndrome is so characteristic that a presumptive diagnosis can usually be made on clinical grounds alone; the syndrome has been labeled the arthritis–dermatitis syndrome. The onset of gonococcal bacteremia usually occurs with menstruation or pregnancy in females. In males, DGI is most often seen in association with asymptomatic infection. Fever, chills, polyarthralgias, arthritis, and tenosynovitis are common. In the early stages of the disease, skin manifestations occur that are quite characteristic (Fig. 233-2). The skin lesions typically are few in number (often fewer than a dozen) and concentrated on the extremities, usually acral, and often around the joints. The lesions may be petechial or papular; however, they usually evolve into vesicles or pustules on an erythematous base, which may become hemorrhagic. Sometimes they present as hemorrhagic bullae. Prompt diagnosis and therapy are mandatory, because delay may result in frank pyogenic arthritis with potential for joint destruction.

FIGURE 233-2 Disseminated gonococcal infection. Lesions on the fingers and palm consisting of pustules and hemorrhagic, necrotic pustules, which are slightly tender.

It has been recognized that organisms causing DGI often differ from those causing urethritis. Most strains of gonococci are susceptible to the complement-mediated bactericidal action of normal serum; the strains causing DGI are resistant. [18] This important observation may explain why some gonococci are capable of causing bacteremia while others are restricted to mucous membranes. In support of the necessity for serum resistance in strains causing DGI are the reports that patients deficient in the late complement components, which are required for serum killing, are peculiarly susceptible to recurrent neisserial sepsis. [19]

The pathogenesis of the arthritis–dermatitis syndrome is unclear. Bacteremia regularly occurs early in the course of DGI, but it has been suggested that most signs and symptoms of DGI are manifestations of immune-complex formation (see also Chap. 197).

MISCELLANEOUS CLINICAL MANIFESTATIONS

In rare cases, an ulcer or abscess may appear on the raphe of the penis. Gonococcal perihepatitis is a complication of gonococcal peritonitis with hepatic capsular fibrosis and adhesions (Fitz-Hugh-Curtis syndrome). [20] Adhesions such as those between the hepatic capsule and the anterior abdominal wall can cause discomfort, which may be persistent and difficult to diagnose.

Gonococcal ophthalmia neonatorum is neonatal purulent conjunctivitis contracted by the newborn in passage through an infected birth canal. Reappearance of this problem in greater numbers in the 1970s was probably a reflection of the higher incidence of gonorrhea combined with a more casual use of silver nitrate prophylaxis in newborns. [21]

Cornified squamous epithelium is quite resistant to infection with *N. gonorrhoeae,* hence vulvovaginitis is infrequent in adult women. However, in children, the vagina is lined with columnar epithelium; acute vulvovaginitis is the usual manifestation of genital gonococcal infection in the prepubescent female.

PATHOLOGY

The picture of active gonococcal infection is usually that of an acute or subacute inflammatory response with

polymorphonuclear leukocytes predominating. The histopathology of the vesiculopustular lesions of DGI consists of infiltrates of neutrophils admixed with some mononuclear cells and red blood cells. Fibrinoid necrosis of vessel walls may be seen. The bullae are subepidermal in location. [22] Bacteria are rarely seen in or grown from the skin lesions.

DIAGNOSIS

Definitive diagnosis of gonorrhea depends upon identification of the organisms by Gram stain and/or culture. A positive Gram stain consists of characteristic gram-negative diplococci in the cytoplasm of neutrophils (Fig. 233-3). Such a Gram stain from the male urethra is considered diagnostic. Gram stain of endocervical discharge is not usually done because even a positive smear is not considered diagnostic; culture confirmation is required. In women, endocervical cultures give a higher yield of positives than vaginal cultures. In males without exudate, swabs for culture should be inserted several centimeters into the urethra. In women with gonorrhea, endocervical cultures as well as rectal, urethral, and pharyngeal cultures should be obtained. In DGI, blood, skin lesions, and joint effusions should be cultured. Skin lesions are regularly negative; joint fluid is usually negative until acute purulent arthritis occurs. Blood cultures are positive only early in the disease. Thus, the diagnosis of DGI must frequently be made on clinical grounds only. This rarely presents a problem, because the clinical picture, especially the skin lesions and the tenosynovitis, is quite characteristic.

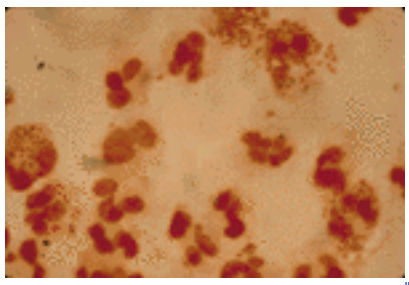

FIGURE 233-3 Diagnostic Gram-stained smear of urethral exudate of a man with gonococcal urethritis.

When culturing an area in which a mixed bacterial flora is unusual, for example, synovial fluid or male urethra, chocolate agar may be used for isolation. When culturing an area that has an exuberant flora, such as the throat, rectum, or endocervix, one should use selective media containing antimicrobials that inhibit organisms other than *Neisseria*. Modified Thayer-Martin medium is usually employed. Transgrow is a similar medium, but it also contains CO_2 and is a good transport medium for gonococci.

In addition to *N. gonorrhoeae,* several other organisms cause PID, including *Chlamydia trachomatis,* endogenous anaerobic and aerobic bacteria, and, probably, genital mycoplasmas. It is clearly advantageous for proper therapy to know the causative organism. Endocervical cultures are the only practical way to distinguish between gonococcal and nongonococcal PID; patients in whom gonococci are grown from the cervix are assumed to have gonococcal PID. [23] A DNA probe assay (Gen-Probe) has been tested as an alternative to culture for diagnosis of gonorrhea. [24], [25] The DNA probe does not require viable organisms; this is a major advantage that obviates the need for rapid and careful transport of the specimen to the laboratory. Another important advantage of the probe versus culture is that simultaneous testing for *C. trachomatis* on the same specimen is possible. In many institutions, the DNA probe assay has replaced culture as the routine screening and diagnostic test for gonorrhea.

DIFFERENTIAL DIAGNOSIS

The differential diagnosis of genitourinary gonococcal disease in the female includes the following:

- *Trichomonas vaginalis* infection. This usually presents as a profuse, frothy, foul vaginal exudate, at times with urethritis. A positive saline preparation for the protozoa is diagnostic.
- *Candida albicans* infection. Often this presents as a pruritic infection with creamy or curdy exudate, and diagnosis depends on identification of the organism by smear and/or culture.
- *Gardnerella vaginalis* or bacterial vaginosis. There is still dispute about the role of various organisms in bacterial vaginosis. However, the syndrome is well defined, with a malodorous, gray, acidic discharge that shows clue cells on smear and yields a fishy, amine odor on alkalinization with potassium hydroxide. All patients with vaginal discharge should be cultured for gonococci. Even though inflammatory vaginitis is rarely seen with gonorrhea alone, mixed infections do occur rather commonly.

In men, urethritis can also be caused by multiple organisms. *T. vaginalis* and *C. albicans* can infect the male and be asymptomatic or cause urethritis or balanitis. Some urethritis has been attributed to *Herpesvirus hominis*. However, even more common than gonorrhea as a cause of urethritis in many populations is so-called nongonococcal or nonspecific or postgonococcal urethritis.

Urethritis with an identified pathogen (except gonococci) is referred to as a *nongonococcal urethritis* (NGU). The term *nonspecific urethritis* describes a urethritis caused by an unidentified organism. NGU may be the most common sexually transmitted disease in humans in most industrialized countries, although reporting is not required in the United States. It is characterized by dysuria, often by urethral discharge or urinary frequency, and by the absence of *N. gonorrhoeae*. In contrast to classic gonococcal urethritis, NGU usually has a longer incubation period, a less-acute onset, and scanty urethral discharge; at times, no discharge is evident, only urethral discomfort or tenderness. Occasionally, coinfection with *N. gonorrhoeae* occurs, and urethritis remains following effective antibiotic therapy for gonorrhea; this has been labeled *postgonococcal urethritis*.

Until the mid-1970s, causative agents of NGU were not identified; however, it was clear that symptoms usually yielded to

therapy with tetracyclines. Now there is good evidence that at least two organisms are responsible for NGU. *C. trachomatis* has been demonstrated convincingly to cause most of the cases of NGU. *Ureaplasma urealyticum* and possibly a few other organisms may be responsible for some of the remaining cases of NGU. Because NGU has been the subject of such intensive study recently and is so common, it is also discussed separately in Chap. 234.

TREATMENT AND CONTROL

Ideal therapy for gonococcal urethritis has the following attributes in addition to curing urethritis: it should be given as a single dose; it should abort coincubating syphilis; and it should cure coexisting chlamydial infections. No single-drug regimen achieves these ideals. Previously recommended penicillin or tetracycline regimens are no longer indicated because of widespread resistance of *N. gonorrhoeae* to these antibiotics.

Multiple regimens have merit: (1) ceftriaxone 125 mg IM in a single dose; (2) cefixime 400 mg PO in a single dose; (3) azithromycin 1 g PO in a single dose; (4) ciprofloxacin 500 mg PO in a single dose; and (5) ofloxacin 400 mg PO in a single dose. [26]

When using a cephalosporin regimen for gonorrhea, additional treatment for coexisting chlamydial infection should be given, often doxycycline 100 mg bid for 7 days. Although the cephalosporins have been used widely to treat gonorrhea, no significant resistance has yet developed. Azithromycin as a single dose effectively treats gonococcal and chlamydial infections. The drawbacks of this regimen are high cost, lack of FDA approval for gonorrhea treatment, and concern regarding increased MICs to azithromycin in strains with chromosomal resistance to penicillin or tetracycline. [7] The single-dose fluoroquinolone regimens for gonorrhea treatment may not be adequate for treatment of chlamydial infections. Gonococcal strains with decreased susceptibility to ciprofloxacin have emerged, causing concern about the future efficacy of these agents. [7] The GISP of the Centers for Disease Control and Prevention periodically monitors antimicrobial susceptibility of *N. gonorrhoeae*. [7] These surveillance data are valuable for predicting the efficacy of the various antibiotic regimens for gonorrhea treatment.

Control of the gonorrhea epidemic probably depends more on other factors than on the details of therapy of acute disease. It is essential to educate the public about venereal disease, including signs and symptoms, methods of prevention, and resources available. Medical personnel must also be made aware of the most effective case-finding techniques, including screening of at-risk populations and aggressive search for contacts of patients with gonorrhea. More controlled sexual activity in the wake of the AIDS epidemic, including widespread use of condoms, will probably help ameliorate the epidemic of gonorrhea.

REFERENCES

1. Centers for Disease Control and Prevention: Summary of notifiable diseases, United States 2000. *MMWR* **49**:No 53, 2002

2. Schnell D et al: A time series analysis of gonorrhea surveillance data. *Stat Med* **8**:343, 1989

3. Centers for Disease Control and Prevention: Gonorrhea—United States, 1998. *MMWR* **49**:538, 2000

4. Rothenberg RB, Potterat JJ: Temporal and social aspects of gonorrhea transmission: The force infectivity. *Sex Transm Dis* **15**:88, 1988

5. Johnson SR, Morse SA: Antibiotic resistance in *Neisseria gonorrhoeae*: Genetic mechanisms of resistance. *Sex Transm Dis* **15**:217, 1988

6. Fox KK et al: Antimicrobial resistance in *Neisseria gonorrhoeae* in the United States, 1988–1994: The emergence of decreased susceptibility to the fluoroquinolones. *J Infect Dis* **175**:1396, 1997

7. Centers for Disease Control and Prevention: *Sexually Transmitted Disease Surveillance 2000 Supplement: Gonococcal Isolate Surveillance Project (GISP) Annual Report 2000*. Atlanta, GA: US Department of Health and Human Services, 2001

8. Carifo K, Catlin BW: *Neisseria gonorrhoeae* auxotyping: Differentiation of clinical isolates based on growth responses on chemically defined media. *Appl Microbiol* **26**:223, 1973

9. Moyes A, Young H: Typing of *Neisseria gonorrhoeae* by auxotype, serovar and lectin agglutination. *Br J Biomed Sci* **50**:295, 1993

10. O'Rourke M et al: Opa typing: A high-resolution tool for studying the epidemiology of gonorrhoeae. *Mol Microbiol* **17**:865, 1995

11. Kellogg DS et al: *Neisseria gonorrhoeae*: II. Colonial variation and pathogenicity during 35 months in vitro. *J Bacteriol* **96**:596, 1968

12. Griffiss JM, Artenstein MS: The ecology of the genus *Neisseria*. *Mt Sinai J Med* **43**:746, 1976

13. Handsfield HH et al: Asymptomatic gonorrhea in men—Diagnosis, natural course, prevalence, and significance. *N Engl J Med* **290**:117, 1974

14. Klein EJ et al: Anorectal gonococcal infection. *Ann Intern Med* **86**:340, 1977

15. Wiesner PJ et al: Clinical spectrum of pharyngeal gonococcal infection. *N Engl J Med* **288**:181, 1973

16. McCormack WM et al: Clinical spectrum of gonococcal infection in women. *Lancet* **1**:1182, 1977

17. Weisner PJ, Thompson SE III: Gonococcal diseases. *Dis Mon* **26**:2, 1980

18. Schoolnik GK et al: Gonococci causing disseminated gonococcal infection are resistant to the bactericidal action of normal human sera. *J Clin Invest* **58**:1163, 1976

19. Petersen BH et al: Human deficiency of the eighth component of complement. *J Clin Invest* **57**:283, 1976

20. Reichert JA, Valle RF: Fitz-Hugh-Curtis syndrome. *JAMA* **236**:266, 1976

21. Snowe RJ, Wilfert CM: Epidemic reappearance of gonococcal ophthalmia neonatorum. *Pediatrics* **51**:110, 1973

22. Elder D, Elenitsas R, Jaworsky C, Johnson B Jr, editors: *Lever's Histopathology of the Skin,* 8th ed. Philadelphia, PA, Lippincott-Raven, 1997

23. Eschenback DA et al: Polymicrobial etiology of acute pelvic inflammatory disease. *N Engl J Med* **293**:166, 1975

24. Vlaspolder F et al: Value of a DNA probe assay (Gen-Probe) compared with that of culture for diagnosis of gonococcal infection. *J Clin Microbiol* **31**:107, 1993

25. Schwebke JR, Zajackowski ME: Comparison of DNA probe (Gen-Probe) with culture for the detection of *Neisseria gonorrhoeae* in an urban STD programme. *Genitourin Med* **72**:108, 1996

26. Centers for Disease Control and Prevention; 2002 Guidelines for treatment of sexually transmitted diseases. *MMWR* **51**:RR06, 2002

T>

Chapter 234

Alfred Eichmann Stephan Lautenschlager

Other Venereal Diseases

GENITAL CHLAMYDIA INFECTIONS
Epidemiology
Etiology and Pathogenesis
Clinical Manifestations
Laboratory Examinations
Diagnosis
Treatment
Prevention
GENITAL MYCOPLASMAS
Pathogenesis
Detection and Treatment
TRICHOMONAS VAGINALIS
Clinical Manifestations
Diagnosis
Therapy
BACTERIAL VAGINOSIS

REFERENCES

GENITAL CHLAMYDIA INFECTIONS

Fifteen different serovars of *Chlamydia trachomatis* are presently known: A, B, Ba, and C are considered to be the causative agents of trachoma; D, E, F, G, H, I, J, and K are associated with genital tract infections, conjunctivitis, and childhood pneumonia; and serovars L_1, L_2, and L_3 cause lymphogranuloma venereum (LGV) (see Chap. 231). Although serotypes E, F, and D account for 60 to 70 percent of urogenital *C. trachomatis* infections, there is no evidence that specific genital syndromes are serotype specific. [1]

Epidemiology

In 1997, more than 500,000 *C. trachomatis* infections (~200/100,000 population) were reported to the CDC. This is obviously a considerable underestimate of the actual number of cases (estimated at 3 to 4 million) in the United States each year. The World Health Organization (WHO) currently estimates that there are approximately 90 million infections annually worldwide attributable to *C. trachomatis.* [2]

Etiology and Pathogenesis

Chlamydiae have a cell wall and cell membrane and contain DNA and RNA in their cytoplasm; they are bacteria endowed with a characteristic metabolism. However, they are energy-requiring parasites that can multiply only within other cells, where they form inclusions in the cytoplasm. Reproduction occurs by binary fission and in cell culture, and the cycle of development takes 48 to 72 h. [3] Chlamydial infection leads to an immune response in the form of circulating antibodies and cellular immunity. The major chlamydial antigens are the major outer-membrane proteins (MOMP), the lipopolysaccharides, and the heat-shock proteins (HSP). [4]

Clinical Manifestations

INFECTIONS OF THE FEMALE GENITAL TRACT Urogenital infection in women is symptomatic in approximately 30 percent of the cases. The most important manifestations include mucopurulent cervicitis, purulent vaginal discharge, lower abdominal pain, postcoital or intermenstrual bleeding, dysuria, and pelvic inflammatory disease (PID). Sequelae include extrauterine pregnancy, tubal infertility, and cervical cellular atypia.
Cervicitis *Chlamydia trachomatis* attacks the cylindrical epithelium of the cervix, where the cervicitis cannot be distinguished clinically from other inflammatory cervical processes. Approximately 30 to 50 percent of women with proven chlamydial cervicitis show no clinical symptoms. In women who do, the principal symptom is mucopurulent discharge, followed by hypertrophic ectopia, postcoital bleeding, and spotting. Simple objective criteria for the presumptive diagnosis of mucopurulent cervicitis include an increased number (>10 per high-power field) of polymorphonuclear leukocytes in cervical smears, a positive swab test, erythema, edema, and induced mucosal bleeding in the area of ectopy and the transformation zone. [1] Epidemiologic studies suggest that *C. trachomatis* serotype G infections are associated with subsequent development of cervical squamous cell carcinoma. [5]
Pelvic inflammatory disease PID is the most severe complication of infection of the lower genital tract. The clinical spectrum of chlamydial PID has a wide range: subclinical endometritis, salpingitis, pelvic peritonitis, periappendicitis, and perihepatitis. Consequently, the traditional clinical and laboratory criteria for diagnosis of PID are inaccurate. Laparoscopy, endometrial biopsy, transvaginal ultrasonography, or magnetic resonance imaging are recommended to improve the accuracy of the diagnosis. Laparoscopy is generally accepted as the gold standard for diagnosis of PID. [1] Concern about silent PID and its sequelae has led to a change in the recommendations for clinical diagnosis of PID. The minimal criteria for clinical diagnosis of PID are:

- Lower abdominal tenderness

- Bilateral adnexal tenderness
- Cervical motion tenderness
- No evidence of a competing diagnosis (e.g., positive pregnancy test, acute appendicitis)

When a proper diagnosis of chlamydial PID is uncertain or delayed, adequate antibiotic treatments should be started if the above mentioned criteria are observed. [1]

Perihepatitis (Fitz-Hugh-Curtis syndrome) Chlamydia can pass from the cervix via the endometrium and the uterine tubes to reach the region of the right diaphragm. There it causes a perihepatitis, which does not involve the liver parenchyma. Clinically, it is characterized by piercing pain below the right costal margin. Symptoms are reminiscent of those seen in acute cholecystitis or pleuritis. Perihepatitis appears to be more common in chlamydial infections than in gonorrhea. [6]

INFECTIONS IN MEN Urogenital infection in men is symptomatic in approximately 75 percent of the cases. The most frequent symptoms are urethral discharge, dysuria, signs of epididymitis, and prostatitis. The genital manifestations of chlamydial infection are very similar to those of gonococcal infection, but the symptoms start later and are milder. Mucous membranes are infected first; later, more-invasive infection occurs. Infection by the serotypes D through K can result in the following diseases in men: nongonococcal urethritis (NGU), postgonococcal urethritis, prostatitis, vas deferentitis, epididymitis, and proctitis. In 30 to 50 percent of the patients with NGU, *Chlamydia* can be found. The incubation period ranges from 7 to 21 days. Urethritis caused by *Chlamydia* is more often asymptomatic than urethritis caused by *Neisseria gonorrhoeae*. Coinfection with *Chlamydia* in men is found in about 15 to 35 percent of patients with gonorrhea. *Chlamydia* causes postgonococcal urethritis in 70 to 80 percent of patients, [6] and is the cause of acute vas deferentitis and epididymitis in men younger than 35 years of age in more than 50 percent of cases. Untreated vas deferentitis/epididymitis produces an obliteration of the vas deferens; sterility can result if both sides are affected. Identification of the causative pathogen in an aspirate and increased levels of IgG and IgM antibodies in the serum provide verification of the diagnosis. [7] The role of *Chlamydia* in prostatitis is still controversial. Chlamydial proctitis is frequently seen in homosexual men, caused by the serotypes D through K. Approximately 50 percent of the men with proctitis present clinical symptoms, including anorectal pain and bleeding, mucous discharge, and diarrhea. Crohn's disease must be excluded in these patients. [6] *Chlamydia* is present in approximately 80 percent of patients with the genitourinary form of Reiter's syndrome, [8] where it is considered to have a trigger function.

INFECTIONS IN NEWBORN CHILDREN These infections are a direct consequence of a genital chlamydial infection of the mother.

Chlamydial pneumonia in the newborn Patients with chlamydial pneumonia are often afebrile with a pertussis-like cough and mucous sputum. X-ray reveals symmetric interstitial infiltrates. Laboratory findings include marked eosinophilia, hypergammaglobulinemia, and IgM antibodies to *Chlamydia*. Tracheal aspirates and lung biopsy specimens should be tested if available. [9]

Inclusion-particle conjunctivitis *Chlamydia* can be isolated from 15 to 20 percent of all children with postnatal blennorrhea. The conjunctivitis appears between days 5 to 15 and is often unilateral. The eyelids are edematous and inflamed and a suppurative secretion is observed. For confirmation of the diagnosis, material is taken from the conjunctiva of the lower eyelid. [9]

Laboratory Examinations

Laboratory diagnosis for *Chlamydia* has rapidly developed during the last few years. [9], [10] and [11]

The following techniques are used to detect *C. trachomatis:* [12]

- Cell culture
- Direct fluorescent antibody assays (DFA) (Fig. 234-1)

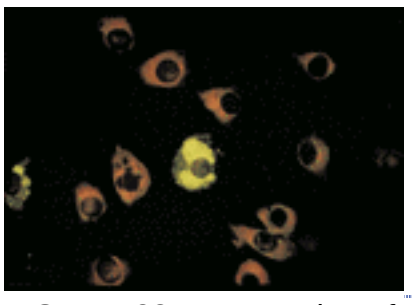

FIGURE 234-1 Detection of *Chlamydia trachomatis* by direct immunofluorescence with monoclonal antibodies.

- Enzyme immunoassays (EIA)
- RNA-DNA hybridization [polymerase chain reaction (PCR) and ligase chain reaction (LCR)]

The nucleic acid amplification tests (PCR, LCR) have a sensitivity of at least 90 percent and a high specificity (97 to 99 percent). A further advantage is that noninvasive samples (urine and vulvovaginal) can be used. Sensitivity seems to be highest from cervical samples. [13]

SEROLOGY All organisms of the genus *Chlamydia* possess a common group-specific antigen that stimulates the formation of IgM, IgA, and IgG antibodies in infected patients. The antibodies can be detected using a microimmunofluorescence (MIF) test or the enzyme-linked immunosorbent assay (ELISA) technique in the case of invasive forms of the infection. Serologic methods are without significance in localized chlamydial infections. The MIF is very useful for epidemiologic studies. [10], [12]

Diagnosis

The definitive diagnosis results from the direct identification of the causative pathogen by one or more of the tests

mentioned above. For invasive forms of chlamydia infection an additional serologic investigation can be helpful.

Treatment

Tetracyclines and the macrolides are the antibiotics of choice for uncomplicated genital chlamydial infections. A single dose of azithromycin (1 g) is effective in treating *Chlamydia* but at a much greater cost than a 7-day course of doxycycline. [14] In patients for whom compliance is in question, azithromycin may be cost effective. Sexual partners and the mothers of infected newborns must be examined and treated. For chlamydial PID and perihepatitis, more extensive treatment regimens are necessary. [15]

Prevention

Effective prevention consists of the careful examination and treatment of all sexual partners. If techniques for appropriate diagnosis are not available, it is recommended that patients with NGU and nongonococcal mucopurulent cervicitis undergo tetracycline or azithromycin therapy, just as is used for proven chlamydial infections. Patients at risk during pregnancy must be examined and treated prophylactically when indicated with erythromycin (500 mg orally four times daily for 7 days) or amoxicillin (500 mg orally three times daily for 7 days).

GENITAL MYCOPLASMAS

Mycoplasmas are the smallest self-replicating microorganisms. In the genital region, three species, *Mycoplasma hominis, Ureaplasma urealyticum,* and *M. genitalium,* have been detected and correlated with genital disease. Whether these mycoplasmas have definite pathogenic properties is still a matter of controversy. Mycoplasmas are found relatively frequently on the genital mucosa in sexually active people without giving rise to any manifest disease. The frequency of the colonization of the genital mucosa increases with sexual experience and the number of partners. [16]

Pathogenesis

It has still not been definitely determined whether *M. hominis* and *U. urealyticum* cause NGU. Newer investigations indicate that *Ureaplasma* is not a cause of NGU and vaginitis. [17], [18] *M. genitalium* is strongly associated with acute NGU in men, and there is good evidence that it is a cause. The involvement of *M. genitalium* in genital tract disease of women needs further investigation. [19]

Detection and Treatment

Mycoplasmas can be detected by culture from swabs. Until now, seven serotypes of *M. hominis* and 14 serotypes of *U. urealyticum* are known. Whether a relationship exists between individual serotypes and particular diseases is unknown. In addition to NGU, mycoplasmas have been considered as possible etiologic agents in other diseases: adnexitis, puerperal fever, fever after abortion, natural miscarriage, prostatitis, and bartholinitis. [20] Mycoplasmas are sensitive to tetracyclines and macrolides. Dosage and duration of treatment are the same as those used against chlamydial infections.

TRICHOMONAS VAGINALIS

Since the reporting of sexually transmitted diseases (STDs) is not obligatory in most countries, reliable figures for incidence are hard to find. In most western countries, however, trichomonal infections seem to be declining. [21] Transmission results from sexual contact. Perinatal infection is the most frequent nonvenereal form of transmission. The causative pathogen can survive for several hours on moist objects and in body fluids.

Clinical Manifestations

The most common clinical symptoms in women are a yellow vaginal discharge, abnormal vaginal odor, pruritus, reddening and swelling of the vulva, and punctate petechiae of the cervix (“strawberry cervix”) (Fig. 234-2). More than half of all infected women show symptoms. [22] The majority of infected men are asymptomatic. In males, the most common symptoms are milky discharge and dysuria. Serious complications are unknown.

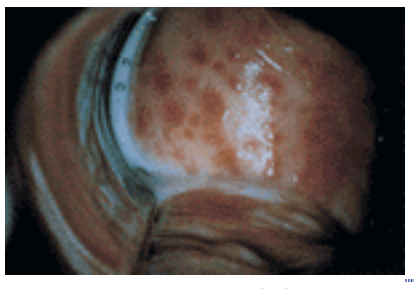

FIGURE 234-2 *Trichomonas vaginalis* infection: “strawberry” appearance of cervix with punctate bleeding erosions. (*Courtesy of U. Lauper, MD.*)

Diagnosis

The 10- to 20-µm protozoan with four to five flagellae can be directly detected on a wet mount. Phase-contrast or dark-field microscopy is helpful (Fig. 234-3). In women, the specimen must be taken from the vagina, because the

causative pathogen attacks only multilayered squamous epithelia. Attempts to demonstrate the causative organism in men are not always successful, but *Trichomonas vaginalis* can be detected in the urinary sediment. Various culture media are available from industrial sources. Culture is the current “gold-standard” for diagnosis. The PCR-based detection of *T. vaginalis* needs further investigation. [23]

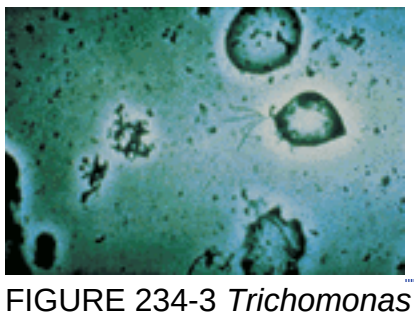

FIGURE 234-3 *Trichomonas vaginalis,* phase-contrast microscopy. (*Courtesy of U. Lauper, MD.*)

Therapy

The therapy of choice is a nitroimidazole such as metronidazole. This can be given orally as a single 2 g dose or as 250 mg three times daily for 7 days. In some individuals, metronidazole has a disulfiram-like effect. Thus, it can produce symptoms such as nausea and flushing.

BACTERIAL VAGINOSIS

Bacterial vaginosis (BV) is characterized microbiologically by a shift in the vagina away from a lactobacillus-predominant flora and toward a predominantly anaerobic milieu. The cause of BV is unknown, but the epidemiology of the syndrome suggests an association with sexual activity. BV is the most frequent vaginal infection in sexually active women. The prevalence ranges from 5 percent (in women during a routine gynecologic checkup) to 40 percent (in women visiting an STD clinic). [24] BV can be diagnosed by four clinical criteria:

- Thin, homogeneous vaginal discharge
- Vaginal pH >4.5
- Release of a fishy odor from vaginal discharge after alkalinization with 10% potassium hydroxide
- Clue cells (see below) on wet mount (Fig. 234-4)

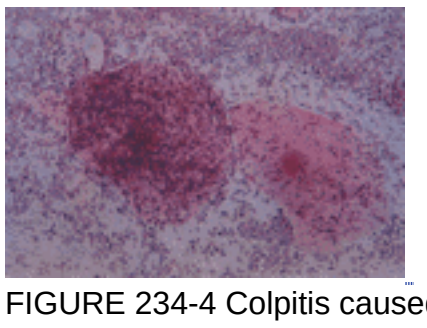

FIGURE 234-4 Colpitis caused by *Haemophilus vaginalis*. Clue cells, Gram-staining. (*Courtesy of U. Lauper, MD.*)

Gram stain gives excellent results with regard to sensitivity and specificity. Routine vaginal microbiologic cultures in women with suspected BV are of no diagnostic value. [25]

Clue cells are epithelial cells coated with bacteria (predominantly *Gardnerella vaginalis*). *G. vaginalis* is found in high concentrations in the vaginal fluid of more than 90 percent of women with BV. Patients with BV have only few or no lactobacilli in the vaginal flora. [25] BV in nonpregnant women is treated successfully with metronidazole orally or locally. A single oral dose of 2 g metronidazole is as successful as a 5- to 7-day course of 1 g daily. Intravaginal clindamycin cream (2%) for 5 to 7 days is the drug of choice in pregnancy. [26] Routine treatment of male partners is not recommended as no study has shown that treatment of the male partner decreases the risk of recurrence.

REFERENCES

1. Paavonen J: *Chlamydia trachomatis:* A major cause of mucopurulent cervicitis and pelvic inflammatory disease in women. *Curr Probl Dermatol* **24**:110, 1996

2. Schachter J: Epidemiology of human chlamydial infections, in *Proceedings of 4th Meeting of the European Society for Chlamydia Research,* edited by P Saikku. Universitas Helsingiensis, Helsinki 2000, p 307

3. Schachter J: Biology of *Chlamydia trachomatis,* in *Sexually Transmitted Diseases,* 3d ed, edited by KK Holmes, Sparling PF, Mårdh PA, Lemon SM, Stamm WE, Piot P, Wasserheit JN. New York, McGraw-Hill, 1999, p 391

4. Stephens RS: Cell biology of *Chlamydia* infection, in *Chlamydial Infections,* edited by J Orfila et al. Bologna, Esculapio, 1994, p 377

5. Anttila T et al: Serotypes of *Chlamydia trachomatis* and risk for development of cervical SCC. *JAMA* **285**:47, 2001

6. Stamm WE: *Chlamydia trachomatis* infections of the adult, in *Sexually Transmitted Diseases,* 3d ed, edited by KK Holmes, Sparling PF, Mårdh PA, Lemon SM, Stamm WE, Piot P, Wasserheit JN. New York, McGraw-Hill, 1999, p 407

7. Doble A et al: Acute epididymitis: A microbiological and ultrasonographic study. *Br J Urol* **63**:90, 1989

8. Kousa M et al: Frequent association of chlamydial infection with Reiter's syndrome. *Sex Transm Dis* **5**:57, 1978

9. Schachter J: Evolution of diagnostic tests for *Chlamydia trachomatis* infections, in *Proceedings of 3rd Meeting of European Society for Chlamydial Research,* edited by A Stary. University of Vienna, Vienna, 1996 p 243

10. Taylor-Robinson D: Tests for infection with *Chlamydia trachomatis*. *Int J STD AIDS* **7**:19, 1996

11. Schachter J: Which test is best for *Chlamydia*? *Curr Opin Infect Dis* **12**:41, 1999

12. Van Dyck E et al: Laboratory Diagnosis of Sexually Transmitted Diseases. Geneva, WHO, 1999

13. Thomas BJ et al: Qualitative and quantitative aspects of the ligase chain reaction assay for *Chlamydia trachomatis* in genital tract samples and urines. *Int J STD AIDS* 12:589, 2001

14. Hillis SD et al: Doxycycline and azithromycin for prevention of chlamydial persistence or recurrence one month after treatment in women. A use-effectiveness study in public health settings. *Sex Transm Dis* **25**:5, 1998

15. Centers for Disease Control and Prevention: 1998 Guidelines for treatment of sexually transmitted diseases. *MMWR Recomm Rep* **47**:1, 1998

16. Taylor-Robinson D: Genital mycoplasma infections. *Clin Lab Med* **9**:501, 1989

17. Horner P et al: Role of *Mycoplasma genitalium* and *Ureaplasma urealyticum* in acute and chronic nongonococcal urethritis. *Clin Infect Dis* **32**:995, 2001

18. Arya OP et al: Is *Mycoplasma hominis* a vaginal pathogen? *Sex Transm Infect* **77**:58, 2001

19. Taylor-Robinson D, Horner PJ: The role of *Mycoplasma genitalium* in non-gonococcal urethritis. *Sex Transm Infect* **77**:229, 2001

20. Taylor-Robinson D et al: Genital mycoplasmas, in *Sexually Transmitted Disease,* edited by KK Holmes, Sparling PF, Mårdh PA, Lemon SM, Stamm WE, Piot P, Wasserheit JN. New York, McGraw-Hill, 1999, p 533

21. Dragsted DM et al: Occurrence of trichomoniasis in women in Denmark, 1967–1997. *Sex Transm Dis* **28**:326, 2001

22. Wolner-Hanssen P et al: Clinical manifestations of vaginal trichomoniasis. *JAMA* **261**:571, 1989

23. Lawing LF et al: Detection of trichomoniasis in vaginal and urine specimens from women by culture and PCR. *J Clin Microbiol* **38**:3585, 2000

24. Martius J: Bacterial vaginosis, in *Vulvo-Vaginitis,* edited by P Elsner, J Martius. New York, Marcel Dekker, 1993, p 345

25. Hellberg D et al: The diagnosis of bacterial vaginosis and vaginal flora changes. *Arch Gynecol Obstet* **265**:11, 2001

26. Martius J: Bacterial vaginosis. *Curr Probl Dermatol* **24**:105, 1996

T>

Chapter 235

Sidney Klaus Shoshana Frankenburg A. Dhar

Leishmaniasis and Other Protozoan Infections

LEISHMANIASIS
Characterization of Leishmania Parasites
Immunobiology
Immunologic Response
Clinical Patterns
Histopathology
Diagnosis
Other Types of Leishmaniasis
Treatment
AFRICAN TRYPANOSOMIASIS
Pathogenesis
Clinical Features
Diagnosis
Treatment
AMERICAN TRYPANOSOMIASIS (CHAGAS DISEASE)
Epidemiology
Pathogenesis
Clinical Features
Diagnosis
Treatment
CUTANEOUS AMEBIASIS
Pathogenesis
Clinical Features
Diagnosis
Treatment
CUTANEOUS ACANTHAMEBIASIS
CUTANEOUS TOXOPLASMOSIS

REFERENCES

Protozoa are ubiquitous, unicellular, nonphotosynthetic, eukaryotic organisms that are microscopic or near microscopic in size. Although most are free-living, some have adapted to a parasitic existence; it is this group that is of major medical importance.

The basic structure of protozoa consists of a cell membrane surrounding cytoplasm in which one or more nuclei are embedded. Each of the major classes of protozoa has evolved distinctive organelles to mediate locomotion and provide for metabolic activity.

The taxonomy of the protozoa subkingdom is complex. Table 235-1 lists a simplified classification of those protozoan species that cause diseases of dermatologic interest.



TABLE 235-1 **Protozoa Causing Dermatologic Disease**

LEISHMANIASIS

Leishmaniasis is the result of infection with intracellular protozoan parasites belonging to the genus *Leishmania*. The infections cause a wide spectrum of clinical changes that divide leishmaniasis into four broad divisions based on the extent and severity of involvement in the human host: cutaneous leishmaniasis (CL), diffuse cutaneous leishmaniasis (DCL), mucocutaneous leishmaniasis (MCL), and visceral leishmaniasis (VL).

The prevalence of all forms of leishmaniasis worldwide is in excess of 18 million cases. Movement of new immigrants into endemic areas, an increase in tourism to “exotic” areas of the globe, a decrease in the use of insecticides, and improvement in diagnostic methods have all contributed to raising the incidence of cutaneous leishmaniasis, which the World Health Organization estimates will soon exceed 1.5 million new cases annually. The more serious forms of the disease, such as MCL and VL, cause the death of more than 80,000 persons annually.

Characterization of *Leishmania* Parasites

The parasites that cause leishmaniasis are members of the order Kinetoplastida, family Trypanosomatidae. They are found in two morphologic forms during their life cycle. In humans and other mammalian hosts, they exist within

macrophages as round to oval nonflagellated amastigotes, 2 to 3 µm in diameter. In the arthropod vectors (sandflies belonging to the genus *Phlebotomus* or *Lutzomyia*), the parasites exist as elongated flagellated promastigotes, 10 to 15 µm in length and 2 to 3 µm in width. Both forms of the parasites have a nucleus and a smaller DNA-containing kinetoplast. Although promastigotes of different *Leishmania* species vary slightly in the width-to-length ratio, amastigotes show no significant differences, and it is not possible to distinguish species of *Leishmania* by their morphology in tissue smears.

Until the 1980s, different species of *Leishmania* were identified largely by the pattern of their clinical involvement. The Old World forms of CL were thought to be caused by *L. tropica*, New World MCL was attributed to *L. braziliensis*, New World CL to *L. mexicana*, and VL to *L. donovani*. Recently, more precise techniques for identifying *Leishmania* species have been developed, such as monoclonal antibodies, isoenzyme characterization, DNA hybridization, and the polymerase chain reaction (PCR). Based on findings using these techniques, the older clinical categories have been subdivided and now include recently identified species. Table 235-2 provides a practical, somewhat simplified classification scheme.



TABLE 235-2 **Classification of Leishmaniasis**

VECTORS *Leishmania* parasites are transmitted by phlebotomine sandflies of the genus *Phlebotomus* in the Old World and *Lutzomyia* in the new world. Sandflies are small mosquito-like insects, 1.5 to 4 mm in length. Their small size enables them to pass through ordinary mesh screens and mosquito netting. Sandflies are widely distributed throughout the tropics and subtropics in a variety of habitats, including deserts, rain forests, and highlands. Only the females are hematophagous (blood sucking).
LIFE CYCLE Parasites, in the form of amastigotes from infected tissue or blood, are taken up from the mammalian host during feeding by female sandflies. Within the midgut of the sandflies, the parasites undergo a change to the promastigote form and multiply. Once the promastigotes are fully developed, they migrate from the gut to the pharynx and proboscis, where they remain until they are injected into a new mammalian host during a subsequent blood meal. Between 10 and 200 promastigotes enter the dermis during each feeding by an infected sandfly. Many of the “free” promastigotes are thought to be destroyed by polymorphonuclear leukocytes and serum complement. The exact details of the early stages of infection are still unknown. Some of the promastigotes become attached to receptors on the surface of dermal macrophages and are phagocytosed. It has been shown that sandfly saliva, injected with the parasites, enhances parasite virulence, mainly because of its impressive vasodilatory properties. Studies in animals suggest that the saliva also has an immunomodulatory effect, delaying a protective cell-mediated response. [1] Within the macrophage, the promastigotes transform into amastigotes (also called Leishman-Donovan bodies) and are incorporated into the cells' phagolysosomes (parasitophorous vacuoles). Within the phagolysosome, the parasites are able to resist destruction and multiply readily by binary fission. When a macrophage becomes filled with amastigotes, the macrophage is disrupted. The amastigotes reenter the extracellular space and are taken up again by other macrophages. The duration of the extracellular stage is unknown. Dissemination of the parasites from the inoculation site depends in large measure on the species of the parasite. Some species, such as *L. donovani* and *L. infantum*, can spread to macrophages elsewhere in the reticuloendothelial system early in the course of the illness. Other species, such as members of the *L. braziliensis* complex, travel to specific locations in the host, including the mucosal surfaces of the nose, pharynx, and upper respiratory tract. Amastigotes of dermatotropic species, such as *L. major* and *L. tropica*, generally remain confined to the skin and probably to the draining lymph nodes. The cycle of infection continues when an infected mammal is again bitten, and amastigotes are taken up by a female sandfly.
RESERVOIRS Each species of *Leishmania* favors one or more animal reservoirs, except *L. donovani*, which is thought to be largely anthroponotic. *L. tropica* is probably not anthroponotic, but in many countries the specific animal reservoir has not yet been identified. Identification and control of the reservoir may have a profound influence on the epidemiology of the disease. For example, in southern France and Spain, where dogs serve as the main reservoir for VL (caused by *L. infantum*), destruction of infected animals has led to a marked decrease in the frequency of the disease in humans. In an area of Turkmenistan, as a result of a zoonotic control program, CL was practically eliminated.

Immunobiology

Leishmaniasis can be pictured as an immunologic spectrum that in many aspects parallels leprosy. At one end lies CL, in which the host usually develops a protective immune response; at the other is VL, in which the host shows little evidence of resistance and may show signs of immunosuppression. In the middle are MCL, which provokes an intense inflammatory reaction, and DCL, in which there is extensive and widespread proliferation of the organisms of the skin, but without much inflammation or tendency for visceralization. Unlike leprosy, the extent and pattern of leishmaniasis that develop are strongly influenced by the specific species of *Leishmania* involved.

Additional factors that affect the clinical picture include the number of parasites inoculated, the site of inoculation, the nutritional status of the host, and even the nature of the last nonblood meal of the vector. In some cases, the sandfly vector is heavily infected, and a large load of parasites may partially block the insect's pharynx, often requiring the sandfly to make multiple probes to obtain an adequate blood meal. [2] This may result in a localized cluster of cutaneous lesions in the host. Rather broad differences in the disease pattern may develop from apparently similar or identical strains of *Leishmania*. Some patients infected by *L. major* develop inapparent infections, whereas others infected by identical *Leishmania* species show deep or widespread lesions that involve subcutaneous tissue and lymph nodes. Although CL caused by *L. aethiopica* results in spontaneous cure in 80 percent of patients, widespread diffuse cutaneous

lesions develop in the remaining 20 percent.

Immunologic Response

Cell-mediated immunoregulation plays a central role in the outcome of leishmanial infection. On the one hand, the clinical expression of the disease is a result of immunologic processes rather than the number of parasites in the lesions; on the other hand, cell-mediated immunity is crucial for healing and development of long-lasting immunity. Although antileishmanial antibodies are produced during infection, their presence does not correlate with resolution of the disease. In experimental animals, disease progression is associated with T_H2 lymphocytes, which produce interleukin (IL)-4, IL-5, IL-10, and transforming growth factor (TGF)-ß; control and resolution of infection are mediated by T_H1 lymphocytes, which produce interferon (IFN)-? and IL-2. Experiments using transgenic mice and selective gene disruption have shown that both cytokines and chemokines are major regulators of the immune response. For example, IL-12 has been found to play a central role in both the induction and maintenance of long-term protection to infection by *L. major*. [3] And natural killer (NK)-cell–activating chemokines have been shown to induce NK cells to promote parasite containment and stimulate a T_H1 protective immune response. [4]

Parasites are eliminated by an effector mechanism which involves IFN-?–mediated activation of infected macrophages. Recent evidence suggests that parasite killing within macrophages is mediated largely through the upregulation of nitric oxide synthetase (NOS) and the generation of nitric oxide (NO). The expression of inducible NOS is upregulated by T_H1 cytokines and suppressed by T_H2 cytokines. [5], [6] In general, the murine leishmania model has served as a model for diseases exhibiting the T_H1/T_H2 dichotomy, such as leprosy.

Although it is suggested that similar mechanisms may be operative in human CL, the picture that emerges from human studies is less clear. Several researchers have measured cytokine production in CL lesions, and mostly a mixture of T_H1 and T_H2 cytokines has been found, without a clear correlation with healing. [7] Other studies show that patients with active CL have circulating lymphocytes that produce IFN-? in response to leishmanial antigen, thus supporting a role for T_H1 lymphocytes in healing. It is not known how parasites are killed in humans. Although it has been shown that human macrophages in vitro can kill parasites by the generation of NO, it is unclear if this represents the operative mechanism during the disease process.

In general, infection and recovery are followed by lifelong immunity to reinfection by the same species of *Leishmania*. In some cases, interspecies immunity has also been reported. An effective vaccine for the prevention of leishmaniasis is still unavailable. Leishmanization, the injection of viable infective parasites in a controlled manner, has been used in some parts of the world as a means of preventing infection upon reexposure under field conditions.

Clinical Patterns

OLD WORLD

CL caused by L. major CL is found in widely scattered parts of Asia, Africa, and Europe, largely in tropical and subtropical zones, and in much of the Middle East, especially Iran, Iraq, eastern Saudi Arabia, the Jordan Valley (of Israel and Jordan), and the Sinai Peninsula. The disease begins as a small erythematous papule, which may appear immediately after the bite of the sandfly, but usually appears 2 to 4 weeks later. The papule slowly enlarges in size (to 2 cm or more) over a period of several weeks and assumes a more dusky violaceous hue (Fig. 235-1). Eventually the lesion becomes crusted in the center. When the crust is removed, a shallow ulcer is found, often with a raised and somewhat indurated border. In some cases, the central part of the nodule becomes hyperkeratotic, and a firmly adherent horn develops over the lesion. Small satellite papules (Fig. 235-2) may also be found at the periphery of the lesion, and occasionally subcutaneous nodules develop along the course of the proximal lymphatics. Rarely, lesions become locally invasive and extend to subcutaneous tissue and even muscle. This latter occurrence may be related to specific deficiencies in the host's immune response.

FIGURE 235-1 Cutaneous leishmaniasis. Large moist plaque on the cheek caused by *L. major*.

FIGURE 235-2 Cutaneous leishmaniasis, late plaque-stage. Central plaque with peripheral satellite papules (*L. major*) is

seen near the ankle.

After the lesion has been present for 2 months or more, peripheral spread stops and the ulcerated nodule remains approximately the same size for another 3 to 6 months, or even longer (Fig. 235-3). The lesion then heals, usually leaving a slightly depressed scar. In some cases, CL has been found to remain “active,” that is, with positive smears, for 24 months or even longer. Such cases have been designated *nonhealing chronic cutaneous leishmaniasis*.

FIGURE 235-3 Cutaneous leishmaniasis, Old World. A deep ulcerated lesion on the leg, caused by *L. major*, in a man with specific deficit in cell-mediated response to the parasite.

The number of lesions that develop in *L. major* CL depends largely on the circumstances of exposure and the extent of the infection within the sandfly vector. Infection with *L. major* may result in multiple lesions (Fig. 235-4); up to 100 or more have been reported in a single individual. The reservoir for *L. major* is desert rodents, and the incidence of the disease is highest in areas close to the burrows of the infected animals.

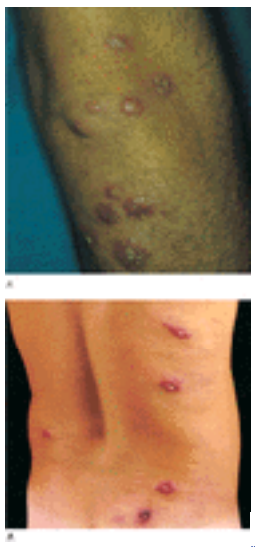

FIGURE 235-4 Cutaneous leishmaniasis, multiple lesions. *A*. Multiple nodules on the arm caused by *L. major. B*. Multiple, nodular, ulcerated lesions on the trunk at the sites of sandfly bites. Note that the ulcerated nodules look like volcanoes seen from above (“volcano sign”).

CL caused by L. tropica CL caused by *L. tropica* is found in parts of southern Europe, Iran, Iraq, the Middle East, and the southern republics of the former USSR. The disease is more common in urban areas than is CL from *L. major*. *L. tropica* is largely a disease of humans although recent evidence suggests that hyrax and rats may serve as reservoirs. The clinical pattern of *L. tropica* infection is similar to that of *L. major*, although lesions are more apt to be solitary and tend to be somewhat more inflammatory. They last longer and are usually more difficult to treat.
CL caused by L. infantum CL caused by *L. infantum* is found in countries bordering the Mediterranean, including southern Europe and northern Africa. The skin lesions are similar to those in the *L. major* form of the disease, but their duration is usually shorter. Wild canines and dogs serve as the reservoir. Reports from endemic areas in Spain have shown that up to 20 percent of dogs tested for the presence of *L. infantum* were harboring parasites in the skin and in internal organs.
CL caused by L. aethiopica This is found in Kenya, the Sudan, and Ethiopia. The common form of the disease seen in these areas is similar to CL caused by *L. major*. However, in a significant number of patients, widespread skin involvement develops (DCL) that resembles lepromatous leprosy (see below).
NEW WORLD CL
CL caused by L. mexicana complex In the New World form, the skin lesions of CL are caused by parasites of the *L. mexicana* complex. The disease is found in Mexico, Central America, as far north as Texas, and as far south as Brazil. The vectors for this form of CL are *Lutzomyia* sandflies. The lesions develop in a similar fashion to those caused by *L. major* in the Old World form. A small erythematous papule develops at the site of the bite of an infected sandfly and gradually develops into an ulcerated nodule. Eventually, the lesion heals, leaving a depressed scar. Although lesions can develop on any part of the body, in Mexico and Central America sores characteristically involve the pinna of the ears (chiclero ulcers).
CL caused by L. braziliensis Most cases are caused by transmission from forest rodent to sandfly to human, with the latter serving as a sporadic host when entering into the habitat of the forest rodent reservoirs. The clinical symptoms of the cutaneous lesions are similar to those caused by the Old World species of *Leishmania*, except that some of the strains of the *L. braziliensis* complex can invade the mucous membranes of the mouth, nose, pharynx, and larynx, giving rise to MCL (see below).

Histopathology

In acute CL, the epidermal changes are highly variable and can range from atrophy or ulceration to hyperplasia, which may be pseudoepitheliomatous. The most constant feature is a diffuse dermal inflammatory cell infiltrate composed of varying proportions of histiocytes, lymphocytes, plasma cells, and neutrophils. Specific diagnosis requires the identification of amastigotes within the cytoplasm of dermal macrophages. In general, the number of parasites present is

inversely proportional to the duration of the lesion. The amastigotes measure from 2 to 4 µm and are a dull blue-gray color with hematoxylin and eosin (H&E) staining. Infected macrophages are usually present in clusters. Although the parasites are more apparent with Giemsa stain, in the authors' experiences, it is rare to find them with Giemsa stain if they are not visible with H&E. An immunoperoxidase, monoclonal antibody stain can be performed on paraffin sections and is sometimes more helpful than either H&E or Giemsa staining in locating amastigotes.

In chronic CL, the dermal infiltrate is nodular and is characterized by tuberculoid-type histiocytic granulomas with lymphocytes and plasma cells surrounding them. Amastigotes are usually not detectable. Necrosis rarely occurs. This histology generates a differential diagnosis that includes other causes of tuberculoid type granulomas such as lupus vulgaris, tuberculoid leprosy, and granulomatous rosacea. A specific diagnosis at this stage requires clinicopathologic correlation.

Diagnosis

PARASITOLOGIC DIAGNOSIS [8] The diagnosis of CL rests on finding parasites in the skin. The most effective method for detecting parasites is a tissue smear from a lesion. Tissue smears are obtained by making a shallow slit in the skin with a scalpel blade at the edge of the lesion. After staining with Giemsa, the amastigotes are seen as pale-blue oval bodies with a dark-blue nucleus and a small point-shaped kinetoplast within the cytoplasm of tissue macrophages (Fig. 235-5). Occasionally, abundant organisms are located in an extracellular location. These extracellular amastigotes are generally somewhat larger than the intracellular forms and often have an elongated profile.

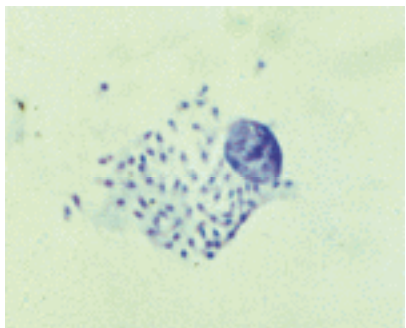

FIGURE 235-5 Amastigotes within a macrophage in a Giemsa-stained smear of a CL lesion.

Parasites can also be cultured from tissue fluid obtained from a lesion. The material is cultured in a biphasic medium, such as Novy-MacNeal-Nicolle (NNN), or a liquid medium, such as Schneider's insect culture medium, in the presence of fetal calf serum. Promastigote forms appear after several days and can be detected in the culture medium. Cultures should not be discarded as negative before 4 weeks. Strains that do not grow in culture media may be inoculated into susceptible animals, but this method is not very practical for routine diagnosis. In regions of the world where more than one species of *Leishmania* is found, emphasis should be on species identification, because characterization of the parasite may influence treatment. PCR has proven useful for this purpose, and primers have been developed than can detect different parasite species, using very small amounts of tissue material. [9]

IMMUNOLOGIC DIAGNOSIS Although both circulating and cellular responses can be demonstrated during the course of the illness, animal studies show that protective immunologic reaction is based solely on cell-mediated immunity. Generally, tests of immune function are of more value in following the course of the disease than they are for diagnosis. Enzyme-linked immunosorbent assays (ELISA) for circulating antibodies that use purified leishmanial products as the test antigen are available. Antibody levels are often elevated in the early stages of CL, but they are not considered a useful diagnostic sign. The cell-mediated immune response can be measured by the leishmanin (Montenegro) skin test, in which phenol-killed preparations of promastigotes are injected into the dermis; the extent of the inflammatory response is measured at the end of 48 and 72 h. Biopsy of a positive Montenegro test at 72 h shows a diffuse cellular infiltrate in the upper dermis, with occasional histiocytes and eosinophils. An in vitro lymphocyte proliferation assay for cell-mediated immunity is also available. In this test, the proliferation of peripheral blood lymphocytes in response to a crude extract of promastigotes is measured after 6 days of incubation. Like the Montenegro test, this assay reflects both present and past infection. [10] The assay is useful in the diagnosis of CL in infants, where it is easier to obtain a drop of blood from a finger prick than a biopsy, especially when the face is involved.

Other Types of Leishmaniasis

DIFFUSE CUTANEOUS LEISHMANIASIS In both the Old and New Worlds, a form of CL is found in which large areas of the dermis are invaded by leishmania-containing macrophages, without a tendency toward visceralization. In the Old World, the disease is caused by *L. aethiopica*; DCL is found in 20 percent of leishmaniasis patients in Ethiopia and the Sudan. In South America, DCL is attributed to a poorly characterized member of the *L. braziliensis* complex. DCL usually presents as a single nodule, which then spreads locally, often through extension from satellite lesions, and eventually by metastasis. In time, the process becomes widespread, with nonulcerating nodules appearing diffusely over the face and trunk; these lesions show a close clinical resemblance to lepromatous leprosy (Fig. 235-6). DCL usually runs a protracted course but does not visceralize. It responds poorly to treatment. Parasites are abundant in skin smears and skin biopsies from DCL and circulating antibodies are present, but tests for cell-mediated immune response, such as the Montenegro skin test and lymphocyte proliferation assay, are negative. There is still some question about the pathogenesis of this form of leishmaniasis, but most workers attribute it to deficiencies in the host's immune response, rather than to an especially virulent strain of leishmania.

FIGURE 235-6 Disseminated anergic cutaneous leishmaniasis. Confluent nodules on the foot resembling lepromatous leprosy; there was generalized cutaneous involvement as well. (*Courtesy of David Wyler, MD.*)

MUCOCUTANEOUS LEISHMANIASIS MCL is characterized by involvement of both skin and the upper respiratory tract. The disease is caused by parasites of the *L. braziliensis* complex in South America and by *L. aethiopica* in Africa. In the form of the disease caused by *L. braziliensis*, mucosal lesions develop from cutaneous lesions in more than 75 percent of those infected. However, in infections caused by less virulent species in the complex, such as *L. braziliensis guyanensis*, nasal involvement develops in only 5 percent of infected cases. In the Old World, MCL can be found infrequently in patients infected by *L. aethiopica*. MCL begins with a cutaneous lesion that is identical to that of CL; a small red papule develops at the site of a sandfly bite and gradually enlarges, ulcerates, and finally heals. However, rather than showing eventual resolution, as in CL, the infection extends to the mucosa of the mouth, nose and pharynx and eventually to the cartilages of the upper respiratory tract, especially the nose and the larynx (Fig. 235-7). Edema and inflammatory changes occur that lead to epistaxis and coryzal symptoms. Eventually there is destruction of the cartilaginous structures in the area, including the nasal septum, and there is also destruction of the floor of the mouth, and the tonsilar areas. Bony structures are usually spared. The disease leads to marked disfigurement, known as espundia in South America (Fig. 235-7). If this form of the disease is not arrested, death usually results from superimposed bacterial infection or pharyngeal obstruction leading to acute respiratory failure or malnutrition.

FIGURE 235-7 Mucocutaneous leishmaniasis, South American. Painful, mutilating ulceration with destruction of portions of the nose. (*Courtesy of Eric Kraus, MD.*)

The diagnosis of MCL rests largely on clinical grounds. The parasites are often difficult to demonstrate or isolate from the mucosa of the respiratory tract.

VISCERAL LEISHMANIASIS In VL, also called kala azar, the parasite establishes itself mainly in the bone marrow, spleen, and liver. The disease, if untreated, is often fatal, but in some areas, many subclinical cases have been reported. It is a disease of all age groups. The disease is present in China, India, the former USSR, the Middle East, from east Africa through the Sudan to west Africa, and across South America. The main *Leishmania* species involved are *L. donovani* in India and Africa, *L. chagasi* in South America, and *L. infantum* in the Mediterranean countries. In India, the disease is transmitted directly from person to person by sandflies; post-kala azar dermal leishmaniasis (PKDL; see below) may represent the human reservoir of the parasite. In other types of VL, foxes, jackals, and dogs are naturally infected, and humans are regarded as accidental hosts. The disease in this case is not believed to be transmitted directly from person to person. In India, VL is mostly an urban disease; elsewhere, it is mostly rural. As in CL, the incubation period may last from weeks to months; there is often a febrile onset that may be so severe as to be fatal, or so slight that it may be little remarked upon. The next symptom to appear is usually splenomegaly, then pancytopenia, fever, wasting, and serious imbalance of serum proteins. There is a high death rate among untreated cases. Definite diagnosis of VL requires the demonstration of parasites; they can be detected in smears or cultures prepared from bone marrow biopsies or spleen aspirates, or in histologic sections from the spleen. Specific serologic tests are often positive in the acute stage of the disease, but cell-mediated immunity, is suppressed. This suppression is reversed after treatment and cure. In a small number of Gulf War veterans who developed a systemic illness characterized by fever, fatigue, malaise, cough, and intermittent diarrhea, but without either lesions of CL or the typical features of VL, *L. tropica* was isolated from bone marrow or lymph nodes; this form of VL has been termed *viscerotropic leishmaniasis*. [11]

LESS-COMMON FORMS OF LEISHMANIASIS

Leishmaniasis recidivans Leishmaniasis recidivans (LR) is a distinctive form of chronic cutaneous leishmaniasis that is a complication of an *L. tropica* infection. Lesions are characterized by dusky-red plaques, with active, spreading borders and healing centers, giving rise to gyrate and annular forms. LR most commonly affects the face and can cause tissue destruction and severe deformity. Generally, the smear and culture are negative, but the patients have a strongly positive leishmanin test, and tests for cell-mediated immunity are positive. Reactivation of *Leishmania* parasites in the scars of cutaneous lesions long thought to be clinically cured may account for LR. Persistence of *Leishmania* has been found by PCR in scars of patients with healed CL up to 11 years after treatment. [12]

Post-kala azar dermal leishmaniasis PKDL is a sequel to VL that has apparently been cured spontaneously or following adequate treatment. The skin lesions usually appear within a year after a course of therapy and consist of macular, papular, and nodular lesions on the face, trunk, and extremities. Many of the lesions take the form of

hypopigmented macules and plaques. The nodules rarely ulcerate. When the lesions are numerous, the clinical picture resembles lepromatous leprosy. *L. donovani* can be recovered from the skin lesions by culture, and smears are usually positive. PKDL has been reported to develop in almost 20 percent of Indian patients treated for VL, and in more than 50 percent of patients in the Sudan. [13] Because there is no known animal reservoir for VL in India, it is thought that patients with PKDL serve as an important human reservoir for this disease.

Treatment

The treatment of leishmaniasis depends on the clinical form of the disease. [14] CL in the Old World is usually self-limited and in most cases does not require specific treatment. Treatment in this form of the disease should be given for extensive lesions, especially involving the face, or for those lesions that invade deeper tissues. The most successful therapy consists of intralesional injections of pentavalent antimonials (Pentostam), usually administered at weekly intervals. Up to 1 mg/kg body weight of the drug may be injected in the borders of the lesions. For very extensive lesions, Pentostam is administered intravenously. Other measures that have been advocated for the treatment of CL include freezing, local heat, oral ketoconazole, and topical amphotericin B. A topically applied aminoglycoside antibiotic, paromomycin, is sometimes effective for the treatment of CL. Trials using these modalities have not been widespread, however, and their efficacy is unconfirmed. Treatment of DCL and VL usually requires parenteral Pentostam.

AFRICAN TRYPANOSOMIASIS

Trypanosomiasis, also known as sleeping sickness, is a potentially fatal protozoan infection of the central nervous system that occurs in sub-Saharan Africa, in a band between N15° and S20°. Although approximately 45,000 cases were reported in 1999, the World Health Organization estimated that the real number of people affected was ten times greater.

The disease exists in two rather distinct forms: Gambian trypanosomiasis (West African sleeping sickness), caused by the subspecies *Trypanosoma brucei gambiense*, is found mainly in the lowland rain forests of West and Central Africa, and is characterized by a relatively slow progression of systemic involvement, leading to mental deterioration, somnolence, and progressive emaciation over a period of months or years. Rhodesian trypanosomiasis, caused by *T. b. rhodesiense* is endemic in the eastern regions of Africa and generally follows a more rapid course, with signs of an acute infection (fever, chills, arthralgias, and anemia) overlapping with a diffuse encephalopathy that generally ends fatally within a few months.

The parasites of both forms of trypanosomiasis are transmitted by the bite of male and female tsetse flies (*Glossina* spp.) These insects are vigorous fliers. They are active mainly during daylight hours and are attracted by dark clothing and moving objects.

In the western regions endemic for *T. gambiense*, humans are the natural hosts. East African trypanosomiasis is a zoonosis, and reservoirs for this form of the disease include wild and domestic animals (such as antelope and cattle) as well as infected humans. [15]

Pathogenesis

Parasites that enter the skin following the bite of an infected fly remain within the local area for about 10 days, and then enter the bloodstream as trypomastigotes. In the blood, the two subspecies of *T. brucei* are morphologically identical; they have an elongated body, 10 to 30 µm long, with a large central nucleus, a kinetoplast, and an undulating membrane that extends the length of the organism. A single flagellum emerges from the anterior end of the body. Some of the signs and symptoms of sleeping sickness are the direct result of the parasites, while other effects are related to circulating immune complexes.

Researchers have shown that the inability of an infected patient to mount a successful immune response stems from the parasites' abilities to express distinct surface antigens (variant surface glycoproteins). Once the parasites enter the host's bloodstream, antibodies are produced that result in the clearing of the majority of trypanosomes. However, the surviving parasites undergo a series of antigenic variations, resulting in subsequent waves of parasitemia. Thus, the host is induced to manufacture antibodies that have little protective value, and the parasites are able to escape total immune elimination.

Clinical Features

GAMBIAN TRYPANOSOMIASIS Three stages of the infection are recognized, although not all those infected demonstrate the complete range of symptoms. During the early stage, usually within a week after the bite of an infected fly, about one-third or fewer of patients will develop an inflammatory skin lesion at the site of inoculation. The lesion, known as a *trypanosome chancre*, is a local response to the proliferation of parasites in the dermis. It consists of a red or violaceous, indurated nodule surrounded by a pinkish halo. It is tender and accompanied by regional adenopathy. Occasionally, an eschar develops in the center of the lesion. The chancre persists for a few weeks and then disappears spontaneously. During the second stage of the disease—6 to 8 weeks later— transient erythematous macules or urticarial lesions develop, often showing an annular or irregular pattern, most commonly on the trunk. [15] During this stage the patient begins to show evidence of systemic involvement, including fever, headache, arthralgias, malaise, and dizziness. Facial or peripheral edema may also be present. Winterbottom's sign (enlargement of lymph nodes along the posterior cervical chain) is a characteristic finding. The third and final stage of the disease evolves slowly over a period of 2 to 3 years, with signs of central nervous system involvement, including lassitude, weakness, personality change, and apathy, that eventually progress to somnolence, coma, and death.
RHODESIAN TRYPANOSOMIASIS Trypanosomiasis caused by *T. b. rhodesiense* follows a similar but more fulminant course. Skin involvement, in the early stages of the disease, occurs more commonly and tends to be more severe (Fig. 235-8).

FIGURE 235-8 East African trypanosomiasis. The trypanosome chancre is a lighly inflammatory, erythematous lesion with bulla formation and a necrotic center. This patient was treated with Suramin and survived (From Case Records of the Massachusetts General Hospital, Case 20-2002, *N Engl J Med* 346:2069, 2002, with permission of the Massachusetts Medical Society.)

A trypanosome chancre is found in more than half of those infected and is often more pronounced than in the Gambian form of the disease. Winterbottom's sign, however, is commonly absent. A transient macular eruption may occur in the second stage of the illness, along with fever, malaise, and headache. There may also be edema of the hands and feet. Disseminated intravascular coagulation may complicate the clinical picture. The major feature characterizing East African sleeping sickness is the rapidity with which the systemic changes develop; trypanosomes enter the circulation within 2 or 3 weeks, and symptoms of central nervous system involvement, such as changes in behavioral and sleep patterns, may appear within 6 to 8 weeks. This form of trypanosomiasis may be fatal within months, even before marked changes of the central nervous system develop. Mild cases of both forms of trypanosomiasis have been reported among indigenous inhabitants, but generally the course of the disease is progressive and the ultimate prognosis is poor. Without treatment trypanosomiasis is regularly fatal.

Diagnosis

During the early stages the diagnosis depends on the identification of parasites in blood, bone marrow, or spinal fluid or in material aspirated from the skin lesion at the site of inoculation or from an enlarged lymph node. Parasites are identified in thick or thin blood films, in tissue aspirates stained with Giemsa, or in unstained wet preparations, by using high-power microscopy. Serologic tests, which may provide additional evidence of infection, are available, but are not diagnostic.

The early skin lesion of trypanosomiasis should be distinguished from the skin lesions of other infectious disorders seen in Africa, including tick-borne relapsing fever, cutaneous diphtheria, anthrax, and African spotted fever. [16]

Treatment

Suramin (naphthylamine sulfonic acid) or pentamidine are useful in the early stages of infection. Once central nervous system involvement has been confirmed, specific therapy consists either of Melarsoprol B (a trivalent organic arsenical) or eflornithine (an ornithine decarboxylase inhibitor), given by intravenous injection, in slowly increasing doses.

Prior to a lumbar puncture, Suramin is given intravenously to clear peripheral parasitemia.

AMERICAN TRYPANOSOMIASIS (CHAGAS DISEASE)

This is a systemic disease caused by the pleomorphic trypanosome *Trypanosoma cruzi*. The disease is endemic in rural areas of Central and South America and affects 16 to 18 million people. Chagas disease is characterized by an acute phase with fever, tissue edema, lymphadenopathy, and diffuse acute myocarditis, and by a chronic phase with cardiomyopathy and megacolon. Skin lesions with characteristic features may develop during the early stage of the illness.

Epidemiology

The disease is usually spread when parasites, in the feces of infected reduviid bugs, are deposited on the skin at the time of biting, and penetrate through the puncture wound or excoriations. The insect vectors (*Reduviidae* spp.) are 3 to 4 cm long and are recognized by their elongated “snout” (“cone-nosed” bugs). They inhabit cracks found along the walls and floors of mud or wooden houses in rural areas and come out at night to feed. Transmission can also occur directly from person to person by transfusion of infected blood.

A Chagas disease control program, now in effect in the southernmost countries of South America, has achieved remarkable success. The program, which consists of insecticide spraying of thatched and adobe houses, has reduced the incidence of the disease in Argentina by 85 percent and in Chile and Uruguay by 99 percent. The goal of the control program is the elimination of Chagas disease by 2010. [17]

Pathogenesis

Trypanosomes exist in the epimastigote form in the gut of the insect vector, as free-living trypomastigotes in the

bloodstream of a vertebrate host, and as amastigotes within tissue cells. The organisms are taken up by reduviid bugs during a blood meal and proliferate in the insects' hindguts. When the bugs feed again, epimastigotes are excreted on the skin surface in the insects' feces. From the skin surface, the epimastigotes invade the skin (or conjunctiva) through the bite wound or through an abrasion and are taken up by macrophages and other cells. They differentiate into trypomastigotes and are spread by way of the bloodstream to other organs and are found in macrophages of the spleen and the Kupffer cells of the liver. Organisms may persist for years in the heart and walls of the gastrointestinal tract, inducing both inflammatory and immunologic disturbances. [18]

Clinical Features

The cutaneous lesion that may develop early in the course of the illness at the site of inoculation consists of a small and often painful erythematous nodule, 1 to 3 cm in diameter, surrounded by a halo of edema, and associated with local adenopathy. Occasionally, necrosis develops in the skin overlying the lesion, a presentation known as a chagoma. If inoculation occurs through the conjunctiva, or nearby on the face (a favorite location for the reduviid bug's blood meal), the resulting conjunctivitis and edema of the orbital area is known as Romaña's sign.

Signs of systemic involvement appear about a week after inoculation (between 4 and 12 days) and consist of fever, headache, generalized adenopathy, arthralgias, and malaise. During this stage a widespread and transient morbilliform eruption may also be seen, along with hepatosplenomegaly. Acute cardiac involvement (giving rise to hypotension and electrocardiographic changes) or acute meningoencephalitis may also be present.

The chronic phase of Chagas disease may last 20 years or more. During this phase, involvement of the heart and gastrointestinal tract is found, eventually leading to congestive failure and/or achalasia of the esophageal sphincter, megaesophagus, and megacolon.

Diagnosis

The diagnosis of American trypanosomiasis is suggested by the appearance of the characteristic chagoma or by Romaña's sign in patients living in endemic areas. The diagnosis is confirmed by finding parasites in thick or thin blood smears, in material from a lymph node biopsy or aspirate, or in blood cultures. Skin biopsy from an involved area may also reveal amastigotes within macrophages.

Serologic tests for the presence of IgM anti- *T. cruzi* antibodies are positive early in the course of the disease. Complement fixation and hemagglutination tests are also available, but they are more useful in identifying cases during the chronic phase.

Treatment

Treatment during the acute phase consists of either benznidazole (a nitroimidazole) or nifurtimox (a nitrofuran). Both drugs may cause significant side effects. The management of patients with chronic infection is based on individual circumstances. [19]

CUTANEOUS AMEBIASIS

Amebae are unicellular protozoa that belong to the subphylum Sarcodina; they are characterized by pseudopod-dependent motility and by reproduction by binary fission. *Entamoeba histolytica*, the causative agent of intestinal amebiasis, occasionally invades the skin, causing cutaneous amebiasis.

It is estimated that as many as 48 million people worldwide (about 1 percent of the world's population) develop intestinal amebiasis each year, although not all cases are symptomatic. The death toll from amebiasis is estimated to be between 50,000 and 70,000 persons annually, mainly infants and children. Amebiasis is found in all regions of the globe, but its prevalence is higher in the tropics and in rural areas, especially in areas where sanitary conditions are poor. Skin involvement occurs infrequently, more commonly among malnourished individuals. [20]

Pathogenesis

Intestinal amebiasis is contracted by the ingestion of food or water contaminated with cyst forms of *E. histolytica*. In the bowel, the cysts transform into trophozoites (ameba forms) and invade the intestinal wall, where they cause little or no irritation or may become invasive, penetrating through the mucosa into the muscular layers. In the cecum, appendix, or ascending colon, the organisms may cause ulcers and eventually perforations into the peritoneal cavity. *E. histolytica* amebae can also penetrate venules and lymphatics and be carried to the liver by the portal circulation to give rise to hepatic amebic abscesses.

If local conditions become unfavorable to the amebae, they encyst, giving them the capability of survival for long periods. Cysts usually do not induce clinical signs of disease, but they are important in the transmission of the disease by apparently healthy individuals.

Clinical Features

Cutaneous lesions in amebiasis are usually the result of direct invasion of the parasites into the skin from an underlying amebic abscess. Typical sites of involvement include the perianal area (as direct extension of rectal involvement) (Fig. 235-9) or the abdominal wall (at the outlet of a sinus draining an abscess in the colon or liver). The penis or vulva may become involved through direct transfer of parasites during intercourse. Amebic skin lesions have also been reported at sites of surgical incisions that were contaminated with amebae during a procedure to remove an abdominal or hepatic

amebic abscess. Rarely, cutaneous lesions have been reported in more remote sites, such as the face, spread by autoinoculation.

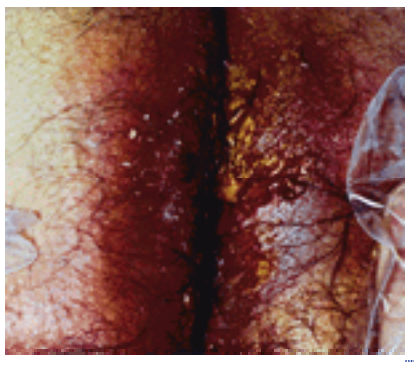

FIGURE 235-9 Cutaneous amebiasis. A painful, ragged, foul-smelling ulcer with an erythematous halo in the perianal region.

The skin lesion usually begins as an indurated pustule or as a localized area of redness that quickly becomes purulent, breaks down, and develops into a painful ragged ulcer with an erythematous halo (see Fig. 235-9). The lesions are often foul-smelling and covered by a layer of pus or necrotic tissue. The borders of the cutaneous lesions are raised and undermined, and regional lymphadenopathy is common. The ulcers tend to expand rapidly and can be especially destructive in children and in poorly nourished adults. The course of the cutaneous lesions tends to be progressive, and large areas of tissue may be destroyed. Without treatment the disease usually ends fatally.

Diagnosis

The appearance of a rapidly enlarging, painful, and foul-smelling ulcer in a patient with a history of dysentery is suggestive of cutaneous amebiasis, and a careful search for trophozoites (ameba forms) within the border of the skin lesion should be carried out.

The diagnosis is made by finding typical trophozoites in tissue scrapings or biopsy material from the border of an ulcer. The tissue is suspended in saline and examined under a microscope for the presence of amebae. The organisms measure 20 to 40 µm and show active movement of pseudopodia in fresh preparations. In biopsy specimens stained with H&E, the organisms are identified by their large size and finely granular pink cytoplasm. *E. histolytica* can be distinguished from nonpathogenic amebae by the presence of ingested erythrocytes within their cytoplasm.

Serologic tests for amebiasis are available, but they may not be positive until several weeks after tissue invasion. The presence of intestinal amebiasis should be confirmed by stool examinations.

Because the clinical features of cutaneous amebiasis are not specific, other causes of ragged-looking skin ulcers must be considered, including other infectious granulomas (such as syphilis, chancroid, and cutaneous tuberculosis) and malignancies. [21]

Treatment

In the past, the standard treatment for cutaneous amebiasis consisted of intramuscular injections of emetine (1 mg/kg daily, not to exceed 60 mg/day), but today newer “mixed” antiamebic agents (effective both in tissues and in the intestinal lumen) are replacing emetine. The most effective of these mixed amebicides are metronidazole and tinidazole, a nitroimidazole derivative. [22]

CUTANEOUS ACANTHAMEBIASIS

Accidental inoculation by free-living amebae (*Acanthamoeba* spp.) may cause granulomatous skin lesions. These parasites are usually introduced at a site of trauma from a contaminated environmental source, including streams, ponds, and swimming pools. Widespread cutaneous involvement may also occur in patients who are immunocompromised and present with a disseminated form of the disease. [23], [24]

Skin lesions initially appear as indurated red or violaceous deep nodules or large pustules, which soon ulcerate. The histologic picture at the border of the ulcer is one of a granulomatous inflammation. Cysts or trophozoites (ameba forms) are formed in scrapings or in biopsy specimens. In wet preparations, the trophozoites of *Acanthamoeba* are actively motile, and show slender, pointed projections (acanthopodia) that continuously form and disappear.

CUTANEOUS TOXOPLASMOSIS

Toxoplasmosis, in its systemic form, is widespread throughout the world. The causative organism, *Toxoplasma gondii,* is an obligate intracellular parasite that infects many animal species. Human infection is usually contracted from contact with infected house cats (*Felix domestica*) or other large cats. Cats acquire the infection by eating rodents, which serve as intermediate hosts of the parasite.

Cutaneous involvement occurs in only a small proportion of individuals with the systemic form of the disease. In neonates, toxoplasmosis is acquired during pregnancy, usually when the mother comes in contact with cat feces or soil containing oocysts of the parasite. In children and adults, the disease may be acquired by eating raw or undercooked

meats from infected animals.

Skin manifestations of toxoplasmosis are rare. A variety of skin lesions have been described in the acquired form of the disease, including roseola and erythema multiforme-like eruptions, prurigo-like nodules, urticaria, and maculopapular lesions. In neonates toxoplasmosis may present as punctate macules, ecchymoses, or “blueberry muffin” lesions.

The diagnosis of cutaneous toxoplasmosis rests upon the demonstration of *T. gondii* in the skin. The form of the parasite seen in the skin, the tachyzoite, is about 6 µm long and 2 µm wide, bow-shaped, with a large nucleus about one-third the size of the body. The organism may be found in all levels of the epidermis. In formalin-fixed paraffin embedded tissue stained with Giemsa, the cytoplasm of the parasite appears blue and the nucleus appears red. Tachyzoites also may be identified by electron microscopy. [25]

In confirmed cases of congenital or acquired disease, or in recurrent infections in immunosuppressed patients, pyrimethamine and sulfadiazine or clindamycin are the drugs of choice. In immunocompetent individuals, the duration of treatment is generally 4 to 6 weeks. Curtailing the ingestion of undercooked or raw meats has been suggested as one measure to lower the incidence of toxoplasmosis. In addition, pregnant women should avoid handling cat litter boxes.

REFERENCES

1. Qureshi A et al: Immunomodulatory properties of maxadilan, the vasodilator peptide from sandfly salivary gland extracts. *Am J Trop Med Hyg* **54**:665, 1996

2. Schlein Y et al: *Leishmania* infections damage the feeding mechanism of the sandfly vector and implement parasite transmission by bite. *Proc Natl Acad Sci U S A* **89**:9944, 1992

3. Stobie L et al: The role of antigen and IL-12 in sustaining Th1 memory cell in vivo: IL-12 is required to maintain memory/effector Th1 cells sufficient to mediate protection to an infectious parasite challenge. *Proc Nat Acad Sci U S A* **97**:8427, 2000

4. Vester B et al: Early gene expression of NK cell-activating chemokines in mice resistant to *Leishmania major*. *Infect Immun* **67**:3155, 1999

5. Stenger S et al: Tissue expression of inducible nitric oxide synthase is closely associated with resistance to *Leishmania major*. *J Exp Med* **180**:783, 1994

6. Stenger S et al: Reactivation of latent leishmaniasis by inhibition of inducible nitric oxide synthase. *J Exp Med* **183**:1501, 1996

7. Melby PC et al: In situ expression of interleukin-10 and interleukin-12 in active human cutaneous leishmaniasis. *FEMS Immunol Med Microbiol* **15**:101, 1996

8. Schnur LF, Jacobson RL: *Parasitological Techniques in the Leishmaniases*, vol 1. London, Academic, 1987, p 499

9. Eisenberger CL, Jaffe CL: *Leishmania*: Identification of old world species using a permissively primed intergenic polymorphic-polymerase chain reaction. *Exp Parasitol* **91**:70, 1999

10. Frankenburg S: A simplified microtechnique for measuring human lymphocyte proliferation after stimulation with mitogen and specific antigen. *J Immunol Methods* **112**:177, 1988

11. Kreutzer, RD et al: Identification and genetic comparison of leishmanial parasites causing viscerotropic and cutaneous disease in soldiers returning from Operation Desert Storm. *Am J Trop Med Hyg* **49**:357, 1993

12. Schubach A et al: Cutaneous scars in American tegumentary leishmaniasis patients: A site of *Leishmania* (*Viannia*) *braziliensis* persistence and viability eleven years after antimonial therapy and clinical cure. *Am J Trop Med Hyg* **58**:824, 1998

13. Zijulstra EE et al: Endemic kala azar in eastern Sudan—Post-kala azar dermal leishmaniasis. *Am J Trop Med Hyg* **52**:299, 1995

14. Berman, JD: Human leishmaniasis: Clinical, diagnostic and chemotherapeutic developments in the last 10 years. *Clin Infect Dis* **24**:684, 1997

15. McGovern TW et al: Cutaneous manifestations of African trypanosomiasis. *Arch Dermatol* **131**:1178, 1995

16. Panosian CB et al: Fever, leukopenia, and a cutaneous lesion in a man who had recently traveled in Africa. *Rev Infect Dis* **13**:1130, 1991

17. Moncayo A: Progress towards interruption of transmission of Chagas disease. *Mem Inst Oswaldo Cruz* **94**:401, 1999

18. DosReis GA: Cell-mediated immunity in experimental *Trypanosoma cruzi* infection. *Parasitol Today* **5**:355, 1997

19. Luquetti AO: Etiological treatment for Chagas disease. *Parasitol Today* **13**:127, 1997

20. Fujiita WH et al: Cutaneous amebiasis. *Arch Dermatol* **117**:309, 1981

21. Mendoza JB, Barba EJR: Cutaneous amebiasis of the face: A case report. *Am J Trop Med Hyg* **35**:69, 1986

22. Martinez-Palomo A, Cantellano ME: Update on antiamebic agents development: Clinical results and experience, in *Burger's Medicinal Chemistry and Drug Discovery*, edited by ME Wolff. New York, Wiley, 1997, p 453

23. Rosenberg AS, Morgan MB: Disseminated acanthamoebiasis presenting as lobular panniculitis with necrotizing vasculitis in a patient with AIDS. *J Cutan Pathol* **28**:307, 2001

24. Wurtman PD: *Acanthamoeba* infection. *Int J Dermatol* **35**:48, 1996

25. Leyva WH, Santa Cruz DJ: Cutaneous toxoplasmosis. *J Am Acad Dermatol* **14**:600, 1986

T>

Chapter 236

Leslie Lucchina Mary Wilson

Cysticercosis and Other Helminthic Infections

ASCARIASIS10,11

Synonyms
Etiology
Pathogenesis
Geographic Distribution
Epidemiology
Clinical Features
Laboratory Findings
Diagnosis
Differential Diagnosis
Treatment
Prevention

CERCARIAL DERMATITIS12,13

Synonyms
Etiology
Life Cycle
Pathogenesis
Geographic Distribution
Epidemiology
Clinical Features
Laboratory Findings
Diagnosis
Differential Diagnosis
Treatment
Prevention

COENUROSIS14,15

Synonyms
Etiology
Life Cycle
Pathogenesis
Geographic Distribution
Epidemiology
Clinical Features
Laboratory Findings
Diagnosis
Differential Diagnosis
Treatment
Prevention

CUTANEOUS LARVA MIGRANS16,17 and 18

Synonyms
Etiology
Life Cycle
Pathogenesis
Geographic Distribution
Epidemiology
Clinical Features
Laboratory Findings
Diagnosis
Differential Diagnosis
Treatment
Prevention

CYSTICERCOSIS19,20 and 21

Synonyms
Etiology
Life Cycle
Pathogenesis
Geographic Distribution
Epidemiology
Clinical Features
Laboratory Findings
Diagnosis
Differential Diagnosis
Treatment
Prevention

DIROFILARIASIS22,23 and 24

Synonyms
Etiology
Life Cycle

Pathogenesis
Geographic Distribution
Epidemiology
Clinical Features
Laboratory Findings
Diagnosis
Differential Diagnosis
Treatment
Prevention

DRACUNCULIASIS25,26 and 27

Synonyms
Etiology
Life Cycle
Pathogenesis
Geographic Distribution
Epidemiology
Clinical Features
Laboratory Findings
Diagnosis
Differential Diagnosis
Treatment
Prevention

ECHINOCOCCOSIS28,29 and 30

Synonyms
Etiology
Life Cycle
Pathogenesis
Geographic Distribution
Epidemiology
Clinical Features
Laboratory Findings
Diagnosis
Differential Diagnosis
Treatment
Prevention

ENTEROBIASIS31,32

Synonyms
Etiology
Life Cycle
Pathogenesis
Geographic Distribution
Epidemiology
Clinical Features
Laboratory Findings
Diagnosis
Differential Diagnosis
Treatment
Prevention

FASCIOLIASIS33,34 and 35

Synonyms
Etiology
Life Cycle
Pathogenesis
Geographic Distribution
Epidemiology
Clinical Features
Laboratory Findings
Diagnosis
Differential Diagnosis
Treatment
Prevention

FILARIASIS, LYMPHATIC36,37 and 38

Synonyms and Diseases
Etiology
Life Cycle
Pathogenesis
Geographic Distribution
Epidemiology
Clinical Features
Laboratory Findings
Diagnosis
Differential Diagnosis
Treatment
Prevention

GNATHOSTOMIASIS39,40

Synonyms
Etiology
Life Cycle
Pathogenesis

Geographic Distribution
Epidemiology
Clinical Features
Laboratory Findings
Diagnosis
Differential Diagnosis
Treatment
Prevention

HOOKWORM DISEASE41,42

Synonyms and Diseases
Etiology
Life Cycle
Pathogenesis
Geographic Distribution
Epidemiology
Clinical Features
Laboratory Findings
Diagnosis
Differential Diagnosis
Treatment
Prevention

LOIASIS43,44,45 and 46

Synonyms
Etiology
Life Cycle
Pathogenesis
Geographic Distribution
Epidemiology
Clinical Features
Laboratory Findings
Diagnosis
Differential Diagnosis
Treatment
Prevention

ONCHOCERCIASIS47,48,49 and 50

Synonyms
Etiology
Life Cycle
Pathogenesis
Geographic Distribution
Epidemiology
Clinical Features
Laboratory Findings
Diagnosis
Differential Diagnosis
Treatment
Prevention

PARAGONIMIASIS35,51

Synonyms
Etiology
Life Cycle
Pathogenesis
Geographic Distribution
Epidemiology
Clinical Features
Laboratory Findings
Diagnosis
Differential Diagnosis
Treatment
Prevention

SCHISTOSOMIASIS52,53,54 and 55

Synonyms
Etiology
Life Cycle
Pathogenesis
Geographic Distribution
Epidemiology
Clinical Features
Laboratory Findings
Diagnosis
Differential Diagnosis
Treatment
Prevention

SPARGANOSIS56,57

Synonyms
Etiology
Life Cycle
Pathogenesis
Geographic Distribution

Epidemiology
Clinical Features
Laboratory Findings
Diagnosis
Differential Diagnosis
Treatment
Prevention

STRONGYLOIDIASIS58,59,60 and 61

Synonyms
Etiology
Life Cycle
Pathogenesis
Geographic Distribution
Epidemiology
Clinical Features
Laboratory Findings
Diagnosis
Differential Diagnosis
Treatment
Prevention

TRICHINOSIS62,63 and 64

Synonyms
Etiology
Life Cycle
Pathogenesis
Geographic Distribution
Epidemiology
Clinical Features
Laboratory Findings
Diagnosis
Differential Diagnosis
Treatment
Prevention

VISCERAL LARVA MIGRANS65,66 and 67

Synonyms
Etiology
Life Cycle
Pathogenesis
Epidemiology
Clinical Features
Laboratory Findings
Diagnosis
Differential Diagnosis
Treatment
Prevention

REFERENCES
GENERAL
ASCARIASIS
COENUROSIS
CUTANEOUS LARVA MIGRANS
CYSTICERCOSIS
DRACUNCULIASIS
ECHINOCOCCOSIS
ENTEROBIASIS
FASCIOLIASIS
FILARIASIS, LYMPHATIC
GNATHOSTOMIASIS
HOOKWORM DISEASE
LOIASIS
ONCHOCERCIASIS
PARAGONIMIASIS
SCHISTOSOMIASIS
SPARGANOSIS
STRONGYLOIDIASIS
TRICHINOSIS
VISCERAL LARVA MIGRANS

Although many helminthic diseases occur sporadically in the United States, helminthic diseases are a common cause of morbidity and mortality worldwide, particularly in tropical and developing countries. Common helminthic infections include ascariasis, cysticercosis (the most common helminthic infection of the central nervous system), enterobiasis, hookworm disease, lymphatic filariasis, onchocerciasis, and schistosomiasis. Because of the increase in global migration of populations—including immigration of persons from tropical countries to the United States, travel, and prolonged visits of people from industrialized to tropical regions—the dermatologist must be familiar with skin manifestations of helminthic diseases (Table 236-1).

TABLE 236-1 **Summary of Helminths Included in This Chapter**

For many helminthic infections, skin lesions may provide important diagnostic clues (Table 236-2, Table 236-3, Table 236-4 and Table 236-5). A thorough history and physical examination are essential. The patient history should include exact geographic location(s) and durations of stay; means of transportation; occupation; lifestyle; housing; dietary habits (food and water); clothing and shoes worn; exposures (beach, fresh or salt water, insects, plants, animals); personal contacts; history of similar signs and symptoms in other family members, fellow travelers, or persons who have visited same areas; use of preventive measures (insect repellent, mosquito netting); and any known recent outbreaks or diseases endemic to geographic areas previously lived in or visited. The history should also include a thorough review of medications and other preparations (including herbal and local treatments) that the patient may have used. The dermatologic history should include any alterations in skin integrity and underlying skin diseases prior to presentation, description of initial presentation and progression of lesions, time of onset relative to potential exposures, duration of lesions, anatomic distribution, and any associated local and systemic signs and symptoms.

TABLE 236-2 **Helminthic Causes of Dermatologic Nodules and Cysts**

Disease	Helminth(s)	Comments
Dracunculiasis	*Dracunculus medinensis*	Ulcer at site of eruption of worm

TABLE 236-3 **Helminthic Cause of Ulcerative Dermatologic Lesions**



TABLE 236-4 **Helminthic Causes of Migratory Dermatologic Lesions**

TABLE 236-5 **Helminthic Causes of Pruritic Lesions***

The laboratory and diagnostic evaluation of a patient with a suspected helminthic infection is based on the history and clinical findings. Many helminthic infections are associated with a peripheral eosinophilia; however, the peripheral eosinophilia may be low-grade or absent (Table 236-6). Other laboratory evaluations (including serologic tests and biopsy of skin lesions for identification of the parasite) and radiologic studies may be warranted, depending on the suspected parasite. [1], [2], [3], [4], [5], [6], [7], [8] and [9] The treatment of these diseases is summarized in Table 236-7.



TABLE 236-6 **Helminthic Infections and Eosinophilia**

Download image
in PDF format

TABLE 236-7 **Treatment for Parasitic Infections Discussed in This Chapter**

ASCARIASIS [10], [11]

Synonyms

Roundworm infection, ascaridiasis

Etiology

Ascariasis is caused by *Ascaris lumbricoides* and occasionally by *Ascaris suum,* the pig roundworm. *Ascaris lumbricoides* is the largest intestinal nematode. The female measures 20 to 35 cm in length and 3 to 6 mm in thickness, and the male measures 11 to 22 cm in length.

Pathogenesis

Humans are the only host of *A. lumbricoides*. After a human ingests the eggs, larvae emerge from the eggs in the duodenum and penetrate the intestinal wall via the mesenteric lymphatics and venules. Five to 14 days after ingestion, the larvae reach the heart, lungs, trachea, and pharynx. Swallowed larvae reach the intestines (primarily jejunum) and, within 60 to 75 days, mature into adults capable of producing eggs that are passed in the feces. Under the appropriate environmental conditions (temperature, humidity), these eggs embryonate over the course of 2 to 4 weeks. If the infective eggs are ingested by another human, the cycle repeats.

Geographic Distribution

Ascariasis is found worldwide. The number of persons infected may be as high as 1.3 billion. The highest rates of infection are in children, in hot and humid climates, and in areas with crowding and poor sanitation. Clay soils are especially suited for the survival of *Ascaris* species.

Epidemiology

ACQUISITION Infection with *A. lumbricoides* follows the ingestion of infective eggs in soil contaminated with human feces. Such soil may contaminate fruits, vegetables, water, and hands. Infection may also occur through the inhalation of eggs in dust, on footwear, and on dog fur. In some areas, prevalence of infection exceeds 90 percent.
INCUBATION PERIOD AND TIME FRAME Pulmonary symptoms and eosinophilia may begin 10 to 14 days after ingestion of *A. lumbricoides* eggs. Gastrointestinal symptoms may precede the shedding of eggs in feces, which begins 50 to 75 days after ingestion of infective eggs. Initial symptoms may be noted weeks or months after onset of infection. Most adult worms survive 8 to 12 months; occasionally, as long as 24 months.

Clinical Features

The dermatologic manifestation of ascariasis is urticaria, although the majority of infections are asymptomatic or mild. The rare fatalities occur primarily in children with heavy worm burdens. Patients may have a cough, wheezing, fever, and vague gastrointestinal symptoms. Complications arise from intestinal obstruction by worms, usually in the terminal ileum. In its migration, the adult worm can perforate the bowel wall, obstruct biliary or pancreatic ducts, or be associated with acute appendicitis. Cases involving the migration of a worm to the eye, brain, and heart have been reported. General anesthesia and fever may precipitate the migration of adult worms.

Partial immunity follows infection, but reinfection is common.

Laboratory Findings

A peripheral eosinophilia may accompany the stage of pulmonary migration in ascariasis.

Diagnosis

Finding eggs in the feces usually leads to the diagnosis of ascariasis. The diagnosis can also follow identification of the adult worm in stool, pharynx, or an operative specimen. Rarely, larvae appear in sputum or on gastric lavage. Transient bilateral infiltrates on chest x-ray films are seen early in infection. Gastrointestinal contrast study will reveal a filling defect.

Differential Diagnosis

The causes of acute and chronic urticaria are among the differential diagnosis of the skin findings.

Treatment

For ascariasis, treatment options include albendazole, mebendazole, or pyrantel pamoate.

Prevention

Proper waste disposal and avoidance of ingestion of fecally contaminated soil can prevent ascariasis. The embryonated eggs of *A. lumbricoides* can remain viable in soil for years.

CERCARIAL DERMATITIS [12], [13]

Synonyms

Clam digger's dermatitis, schistosome dermatitis, sedge pool itch, swimmer's itch

Etiology

Cercarial dermatitis (Fig. 236-1) results from the infestation of the skin by cercariae (larvae) of nonhuman schistosomes, whose usual hosts are birds and small mammals. Many nonhuman schistosomes have been implicated, including *Trichobilharzia, Gigantobilharzia, Ornithobilharzia, Microbilharzia* and *Schistosomatium*. (Also, see the discussion of Schistosomiasis.)

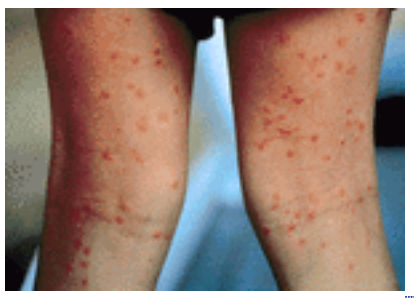

FIGURE 236-1 Cercarial dermatitis. (*Courtesy of Jay S. Keystone, MD, FRCPC.*)

Life Cycle

The adult schistosome inhabits a primary host (e.g., finch, marshbird, mouse, muskrat, vole, waterfowl). Eggs produced by adult schistosomes living in animals are shed with animal feces into the environment. On reaching water, the schistosome eggs hatch, releasing miracidia (fully developed larvae). If the miracidia reach appropriate snail hosts (e.g., *Lymnaeidae* and *Physidae*) before dying, they penetrate the snail and mature in its digestive gland as sporocysts. After 4 to 6 weeks of maturation, they emerge from the snail as fork-tailed cercariae, which must penetrate the skin of a vertebrate host to continue development. Humans cannot support the development of these schistosomes and, hence, are incidental, dead-end hosts.

Pathogenesis

The free-swimming, fork-tailed stage of the parasite, the cercariae, penetrate intact human skin and die without invading other tissues. The schistosomes elicit an inflammatory response. Schistosomes capable of causing invasive disease in humans (e.g., *Schistosoma mansoni, S. haematobium,* and *S. japonicum*) may cause a similar skin eruption shortly after penetration, as well as late visceral complications.

Geographic Distribution

Cercarial dermatitis occurs worldwide. It involves both fresh and salt water that is inhabited by the appropriate molluscan hosts. Sporadic reports come from all continents.

Epidemiology

ACQUISITION Cercarial dermatitis is acquired by skin exposure to fresh or salt water infested with cercariae. It occurs in swimmers and in people whose occupations lead to water exposures (e.g., aquarists, clam diggers, paddy workers, rice farmers).
INCUBATION PERIOD AND TIME FRAME Typically, pruritus and skin changes begin within hours of exposure to the schistosomes. In persons with previous exposures to cercariae, the rash may begin sooner and may be more severe. The eruption peaks in 2 to 3 days and usually resolves over 1 to 2 weeks. Occasionally, lesions first appear days after the exposure.

Clinical Features

A prickling sensation begins during or within minutes of exposure to the cercariae. Approximately 1 hour later, a pruritic, erythematous macular eruption develops that persists for several hours. Ten to fifteen hours after exposure, papular, papulovesicular, and urticarial lesions develop, with marked pruritus. Purpura may develop as well. The distribution of the eruption includes skin surfaces that were exposed to the water and typically spares parts of the body that were covered

by clothing. The severity of the eruption increases with repeat exposures. Secondary bacterial infection can complicate the dermatitis.

Laboratory Findings

In most instances, laboratory studies are not performed because the process is self-limited. Biopsy of skin lesions will show an inflammatory infiltrate with eosinophils.

Diagnosis

The basis for the diagnosis of cercarial dermatitis is usually the characteristic clinical findings and appropriate epidemiologic exposures. Documenting the presence of schistosomal cercariae in epidemiologically incriminated water provides supportive evidence.

Differential Diagnosis

Clinicians should consider seabather's eruption; contact dermatitis due to marine plants, hydroids, and corals; insect bites; and causes of urticaria in the differential diagnosis.

Treatment

Cercarial dermatitis resolves without specific antiparasitic therapy. The systemic use of antihistamines and the topical use of steroids may reduce the symptoms. The systemic administration of steroids has been helpful in severe cases.

Prevention

Avoidance of contaminated water prevents cercarial dermatitis. If contact does occur, vigorous towel drying as soon as the swimmer leaves the water may reduce the penetration of the cercariae.

COENUROSIS [14], [15]

Synonyms

Disease in sheep is named gid and staggers.

Etiology

Coenurosis is caused by the larval stages of several species of *Multiceps,* a cestode (tapeworm). Some authors consider these parasites to belong to the genus *Taenia*. The species that cause human disease most often are *M.(Taenia) multiceps, M.(Taenia) serialis,* and *M.(Taenia) brauni*.

Life Cycle

Definitive hosts of multiceps are the dog, fox, and wolf. Eggs shed in the feces by the infected definitive host are ingested by the intermediate host—herbivorous mammals such as sheep (most commonly), antelope, cattle, gazelle, goat, horse, monkey, and rarely, humans. In the intermediate host, the parasite develops into the larvae in various tissues that the definitive hosts eat, thus completing the cycle.

Pathogenesis

In humans, oncospheres hatch from ingested eggs in the intestine, penetrate the intestinal wall, and may reach many parts of the body, including the central nervous system, subcutaneous muscle tissue, and eye. In these tissues, the larval stage (coenurus) develops. Degenerating or dying larvae provoke an inflammatory reaction and fibrosis.

Geographic Distribution

Reported human cases of coenurosis are sporadic and rare, with the majority from Africa. Infections have occurred in Asia, Europe, and North America, particularly in areas where sheep are common. In tropical Africa, infections are more commonly located in subcutaneous or muscle tissue, or the eye and orbit (particularly in children). In nontropical Africa, infections occur primarily in the central nervous system of adults.

Epidemiology

ACQUISITION Humans acquire coenurosis by ingesting eggs in water or food or on contaminated fingers.
INCUBATION PERIOD AND TIME FRAME The incubation period is months. The disease may be present for years before the infection is recognized. Limited information suggests that the pathogen may survive in the human for at least 15 years.

Clinical Features

Soft tissue coenurosis typically presents as a subcutaneous or intramuscular nodule that is a solitary unilocular cyst. Size varies from 2 to 6 cm in diameter. The lesion is often painless. The most common anatomic locations are the trunk, intercostal region, and anterior abdominal wall, although cysts do occur on the head, neck, and limbs. The parasite has a

tropism for the eye and central nervous system. In these sites, signs and symptoms reflect the presence of a mass lesion. Systemic signs and symptoms are usually absent.

Laboratory Findings

There is usually no peripheral eosinophilia.

Diagnosis

CT or MRI may be useful to determine the exact location of the mass lesion. Definitive diagnosis requires histologic examination of tissues and identification of the parasite. Currently, specific serologic tests are not available.

Differential Diagnosis

Included in the differential diagnosis of coenurosis are cysticercosis, echinococcosis, epidermal inclusion cyst, lipoma, ganglion, and neurofibroma. In the central nervous system, the differential diagnosis includes space-occupying lesions, including neurocysticercosis and cerebral echinococcosis.

Treatment

Complete surgical excision is curative. Follow-up physical examinations for further cysts is important. The prognosis depends on the location and extent of the cysts.

Prevention

Avoiding close contact with infected animals and food contaminated with their feces prevents coenurosis. Limited studies suggest praziquantel may be effective in treating infected sheep.

CUTANEOUS LARVA MIGRANS [16], [17] and [18]

Synonyms

Creeping eruption, creeping verminous dermatitis, sandworm eruption, plumber's itch, duckhunter's itch. Term describes a clinical finding caused by several different parasites.

Etiology

Most often, the larvae of hookworms (nematodes) of dogs, cats, and other mammals cause cutaneous larva migrans (Fig. 236-2). *Ancylostoma braziliense* is the most common cause. Other skin-penetrating nematode larvae that produce cutaneous larva migrans include *A. caninum, Uncinaria stenocephala* (hookworm of European dogs), and *Bunostomum phlebotomum* (hookworm of cattle). Filariform larvae of *Strongyloides stercoralis* can penetrate the skin (usually on the buttocks) and cause similar lesions, larva currens. Cutaneous larva migrans usually refers to lesions produced by nonhuman hookworms, but other parasites, including *Gnathostoma spinigerum, Strongyloides procyonis, Dirofilaria repens, Fasciola hepatica,* and some forms of myiasis can cause migratory skin lesions.

FIGURE 236-2 Cutaneous larva migrans. (*Courtesy of Jay S. Keystone, MD, FRCPC.*)

Life Cycle

The human is usually an aberrant, dead-end host who acquires the parasite from an environment contaminated with animal feces. The infective larvae may remain viable in soil for several weeks.

Pathogenesis

Third-stage larvae penetrate human skin and migrate up to several centimeters a day, usually between the stratum germinativum and stratum corneum. This induces a localized eosinophilic inflammatory reaction. Most larvae are unable to undergo further development or to invade deeper tissues and die after days to months.

Geographic Distribution

Cutaneous larva migrans is widely distributed and most commonly found in tropical and subtropical areas, especially the southeastern United States, Caribbean, Africa, Central and South America, India, and Southeast Asia.

Epidemiology

ACQUISITION Skin contact with the infective larvae in the soil is the means of infection. Activities that pose a risk include contact with sand or soil contaminated with animal feces, such as playing in a sandbox, walking barefoot on a beach, and working in crawl spaces under houses.
INCUBATION PERIOD AND TIME FRAME The time from exposure to onset of symptoms is usually a few (1 to 6) days. The eruption usually lasts between 2 and 8 weeks, though rarely it has been reported to last up to 2 years.

Clinical Features

The lesions of cutaneous larva migrans are characteristically erythematous, raised, and vesicular (Fig. 236-3), linear, or serpentine. Lesions are approximately 3 mm wide and may reach 15 to 20 cm in length. Lesions can be single or multiple, are intensely pruritic, and may be painful. The hookworm advances a few millimeters to a few centimeters daily. The most common anatomic sites (usually 3 to 4 cm from the penetration site) include the feet, buttocks, and genitalia. The oral mucosa has been involved. Excoriation and impetiginization are common. Systemic signs and symptoms (wheezing, dry cough, urticaria) have been reported in patients with extensive infection. *Ancylostoma caninum* larvae can migrate to the small intestine and cause eosinophilic enteritis.

FIGURE 236-3 Cutaneous larva migrans. Note vesicular and bullous lesions. (*Courtesy of Jay S. Keystone, MD, FRCPC.*)

Laboratory Findings

There may be a transient peripheral eosinophilia.

Diagnosis

Characteristic clinical findings, as well as known epidemiologic exposure, are the basis for the diagnosis of cutaneous larva migrans.

Differential Diagnosis

For cutaneous larva migrans, the differential diagnosis includes cercarial or contact dermatitis, bacterial or fungal infection, scabies, myiasis, loiasis, and several other migratory parasites (see Table 236-4).

Treatment

Therapy for cutaneous larva migrans due to dog or cat hookworm includes the use of ivermectin or albendazole, or the topical application of thiabendazole. There should be no attempt to extract the worm, because it has already migrated beyond the visible lesion by the time the infection is identified.

Prevention

Infection with animal hookworms is prevented by avoiding direct skin contact with fecally contaminated soil.

CYSTICERCOSIS [19], [20] and [21]

Synonyms

Cysticercus cellulosae, larval taeniasis

Etiology

The larval stage of the pork tapeworm, *Taenia solium,* causes cysticercosis.

Life Cycle

Humans are the definitive host for *T. solium*. Swine are the intermediate host. Eggs from the adult worm in human small intestine are passed in feces and may remain viable for weeks. If humans or swine ingest the eggs, the outer shell disintegrates in the small bowel, releasing embryos that penetrate the wall of the small bowel and enter the circulation. They disseminate widely, lodging in tissues, most often subcutaneous tissue, brain, eye, and skeletal muscle and developing into the larval stage (cysticerci), which leads to the clinical disease known as cysticercosis. In humans, *T. solium* infection causes both intestinal taeniasis and cysticercosis. The human host can have either form of infection alone. Intestinal infection with the adult parasites follows eating raw or undercooked pork containing cysticerci. The larval cysts attach to the small bowel mucosa and develop into adult worms.

Pathogenesis

Cysticerci in tissues are surrounded by a connective tissue membrane and cause little host reaction while they are alive. When the cysticerci die, however, they may release foreign antigens that provoke granulomatous changes and infiltration of plasma cells, eosinophils, lymphocytes, and macrophages. Calcification may follow. Cysts in muscle collapse and calcify, giving the characteristic spindle shape.

Geographic Distribution

Taenia solium is a common parasite in Central and South America, Africa, parts of Asia, and Eastern Europe. In the United States, this disease appears primarily in immigrants from endemic areas where poor sanitation and pig farming are common, although acquisition of infection has been well documented in the United States. Cysticercosis is the most common helminthic infection of the central nervous system.

Epidemiology

ACQUISITION Humans acquire cysticercosis by ingesting eggs in food, water, or on fingers contaminated with human feces. Humans infected with adult worms may acquire cysticercosis by ingesting eggs passed in their own feces.
INCUBATION PERIOD AND TIME FRAME The time from infection to the appearance of subcutaneous nodules is highly variable and may be from months to years. Cysticerci can survive in humans for 10 to 15 years. Symptoms may begin or continue long after the parasites are dead.

Clinical Features

The clinical features range from asymptomatic to fatal. Fifty-four percent of patients with cysticercosis present with subcutaneous nodules. The skin findings include single or multiple firm, mobile, round, well circumscribed subcutaneous nodules that may be tender or asymptomatic. The nodules vary in size from millimeters to centimeters, but are generally about 2 cm in diameter. The most common anatomic locations are the extremities and trunk. In a series from Nepal, 10 percent of patients had nodules in the oral mucosa.

Systemic manifestations reflect the presence of mass lesions. Although the central nervous system (Fig. 236-4), subcutaneous tissue, skeletal muscle, and eye (Fig. 236-5) are the most commonly affected sites, the heart, kidneys, liver, lungs, and pancreas may be involved. Seizures are the most common manifestation of neurocysticercosis. Almost 50 percent of patients with central nervous system cysticerci found at autopsy had no history of central nervous system symptoms. Intestinal taeniasis is evident in 25 to 50 percent of patients with cysticercosis. Persons with intestinal infection with the adult worms may have abdominal pain, anorexia, constipation, and diarrhea.

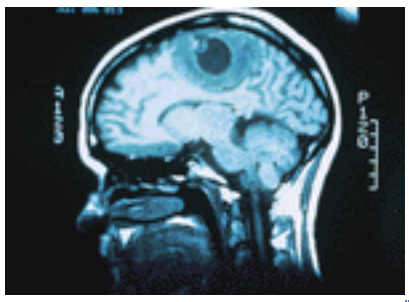

FIGURE 236-4 MRI scan of central nervous system cysticercosis. (*Courtesy of Jay S. Keystone, MD, FRCPC.*)

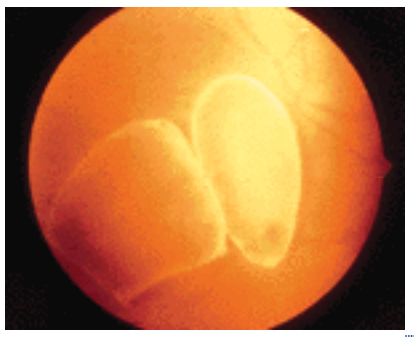

FIGURE 236-5 Cysticercosis in retina. (*Courtesy of William S. Kammerer, MD.*)

Laboratory Findings

Peripheral eosinophilia is absent in 85 percent of patients with neurocysticercosis. High-grade eosinophilia in a patient with cysticercosis should lead clinicians to a search for another process to explain the eosinophilia.

Diagnosis

Surgical excision of a nodule and identification of the parasite by characteristic morphology is the basis for a definitive diagnosis. Serologic tests are also available. High sensitivity and specificity have been reported with an enzyme-linked immunoelectrotransfer blot (EITB) assay and with an enzyme-linked immunosorbent assay (ELISA). Sensitivity is high in patients with multiple lesions, but, in one study, only 28 percent of patients with a single lesion had positive EITB results. Other immunologic tests, such as complement fixation, direct immunofluorescence, immunoelectrophoresis, and indirect hemagglutination, have been less sensitive and less specific.

For neurocysticercosis, MRI allows the evaluation of the developmental stages of larval cysts. Cerebrospinal fluid may be normal or may contain increased protein and cells, including eosinophils and plasma cells.

Differential Diagnosis

For subcutaneous lesions of cysticercosis, the differential diagnosis includes echinococcosis, onchocerciasis, benign cysts, soft tissue tumors, and other causes of nodules (see Table 236-2).

Treatment

The use of anthelmintic drugs for parenchymal cysticercosis remains controversial. Decisions about treatment depend on the location and characteristics of the lesions (viability of the cysts) and may include surgery as well as medical therapy with anticonvulsants and an anthelmintic drug. If a few subcutaneous lesions are present, they need treatment only if symptomatic or for cosmetic reasons. If multiple subcutaneous lesions are present, the drug of choice is albendazole or praziquantel. The Food and Drug Administration (FDA) considers praziquantel an investigational drug for cysticercosis. Concomitant intestinal taeniasis due to *T. solium,* if present, should be treated to eliminate a potential ongoing source of infection for the patient and contacts.

Albendazole should be taken with a fatty meal to increase absorption. In the treatment of neurocysticercosis with praziquantel or albendazole, the administration of glucocorticoids before and during treatment may reduce the inflammatory reaction that follows the death of cysticerci. Plasma levels of praziquantel may decrease by up to 50 percent when given with glucocorticoids.

The prognosis of subcutaneous cysticercosis is excellent. Prognosis involving other organ systems depends on the anatomic location of the lesions. Untreated, symptomatic cerebral cysticercosis has a mortality of 10 to 26 percent. Mortality may reach 50 percent in patients with untreated cysticercal meningitis.

Prevention

Preventive measures include proper disposal of feces, avoidance of fecal contamination of food and drink, and treatment of intestinal taeniasis.

DIROFILARIASIS[22], [23] and [24]

Synonyms

Dog heartworm infection

Etiology

The organisms responsible for dirofilariasis include the filarial nematodes of several species of the genus *Dirofilaria*. These include, most importantly, *D. immitis* (the dog heartworm), as well as *D. tenuis* (raccoon), *D. repens* (dog), and *D. ursi* (bear). *Dirofilaria immitis* causes pulmonary disease and, rarely, soft tissue infection.

Life Cycle

Dirofilaria immitis lives in the right ventricle and pulmonary artery of dogs, producing microfilariae that are ingested with a blood meal by the mosquito. The microfilariae develop into the infective larvae stage in the mosquito.

Pathogenesis

The bite of the mosquito (blackfly for *D. ursi*) introduces the infective larvae of *D. immitis*, and they undergo a growth period in subcutaneous and deeper tissues. The parasite does not complete its development in humans, so no microfilariae are produced. *Dirofilaria immitis* may enter the circulation and occlude a small pulmonary artery, resulting in an infarct. The necrotic and granulomatous tissue contains the worm and eosinophils, and may calcify.

Geographic Distribution

Widespread in dogs, *D. immitis* is thought to be most prevalent in North and South America, Australia, Europe, Japan, India, and China. Sporadic infections with other *Dirofilaria* species have been reported from all continents. In the United States, this infection occurs in the eastern, midwestern, and southern states.

Epidemiology

ACQUISITION Humans acquire the infection when bitten by a mosquito containing infective larvae. The larvae emerge from the mouth parts of the mosquito and enter through the puncture wound.
INCUBATION PERIOD AND TIME FRAME The interval between exposure and development of symptoms is usually at least 2 to 3 months. The parasite occasionally survives for years. Rarely, mature worms have been found in the heart. Dead and calcified worms may be found years after the disease was acquired.

Clinical Features

Soft tissue dirofilariasis is characterized by erythematous to skin colored, well defined, firm subcutaneous nodules that are usually single, but may be multiple. The lesion is typically 1 to 2 cm in diameter and may be tender. There may be initial soft tissue swelling, which evolves into a well circumscribed nodular lesion. Occasionally, lesions are migratory. The most common anatomic sites are the head, neck, breast, arm, leg, and scrotum. Parasites may appear in the conjunctiva and oral cavity. Subcutaneous dirofilariasis has been associated with acute arthritis.

Pulmonary dirofilariasis can cause cough, chest pain, and, rarely, hemoptysis and low-grade fever. More than 50 percent of persons with pulmonary dirofilariasis are asymptomatic.

Laboratory Findings

Peripheral eosinophilia is usually absent or low grade.

Diagnosis

The definitive diagnosis of dirofilariasis comes from surgical excision of the nodule and identification of the worm. Serologic studies using ELISA may be positive in 75 percent of patients with pulmonary dirofilariasis. However, cross-reaction with other helminthic infections (strongyloidiasis, toxocariasis, schistosomiasis, and filariasis) may limit the usefulness of ELISA particularly in tropical locations. Chest x-ray films of pulmonary dirofilariasis show a coin lesion that is usually single and may be calcified.

Differential Diagnosis

Loiasis, cysticercosis, onchocercosis, paragonimiasis, as well as epidermal inclusion cyst, lipoma or other benign tumor, and malignant tumor or metastatic disease, make up the differential diagnosis of subcutaneous dirofilariasis.

Treatment

Surgical excision of the nodule containing the worm is curative.

Prevention

Dirofilariasis caused by *D. immitis* can be prevented by controlling the heartworm infection in dogs. Prevention of other dirofilarial infections requires avoiding bites of arthropods with infective larvae.

DRACUNCULIASIS [25], [26] and [27]

Synonyms

Dracunculosis, dracontiasis, Guinea worm disease, Medina worm infection, dragon worm disease, serpent worm disease

Etiology

The nematode *Dracunculus medinensis* causes dracunculiasis (Fig. 236-6). The female is 70 to 80 cm in length and rarely exceeds 100 cm.

FIGURE 236-6 Dracunculiasis. (*Courtesy of Jay S. Keystone, MD, FRCPC.*)

The ancient symbols of medicine, the caduceus and staff of Aesculapius, may have been drawn from the practice of using sticks to extract the *D. medinensis* worm from its host.

Life Cycle

Larvae are released into water from an infected human and ingested by copepods (tiny aquatic arthropods), in which they develop. Humans ingest the copepods (*Cyclops*) to complete the cycle. Although some animals may be infected, humans are the definitive host and main reservoir of infection.

Pathogenesis

In humans, gastric acid dissolves the ingested copepods, which results in the release of larvae that then migrate through the stomach wall and reach loose connective tissue. The larvae mature into adult worms over 10 to 14 months without causing a tissue reaction. Migration of the gravid female to skin leads to a localized bulla containing inflammatory cells and many eosinophils. Over a period of 4 weeks, the worm emerges. The bulla ruptures on contact with water, releasing larvae from the uterus of the female worm, which prolapses through the skin.

Geographic Distribution

Dracunculiasis is now confined to 13 countries in Africa. It remains a serious health problem in Sudan. As of 2000, cases reported from Sudan represented approximately 73 percent of all cases reported in the world.

Epidemiology

ACQUISITION Humans acquire dracunculiasis by ingesting infected copepods, usually in drinking water taken from shallow lagoons, step wells, and other surface water.
INCUBATION PERIOD AND TIME FRAME The adult worm emerges about 1 year (range, 10 to 18 months) after the larvae are ingested. Symptoms associated with the migration of the worm may precede the emergence of the worm. The adult worm typically dies (or is removed) after reaching the skin and releasing larvae. Disabling symptoms may persist for weeks to months. Fatalities rarely result from complications.

Clinical Features

The characteristic clinical findings of dracunculiasis include a papule, 2 to 7 cm in size, that progresses over 1 to 3 days to a vesicle with an indurated border. An intense burning sensation is relieved, at least in part, by submerging the affected body part in water. The bulla ruptures and larvae are ejected into the water. The rupture of the worm in tissues provokes an intense inflammatory response and cellulitis, and may lead to abscess formation. Disruption of the skin by the worm predisposes the person to secondary bacterial infection, including tetanus. Most infected persons have only one or a small number (usually fewer than six) of worms. In 85 to 90 percent of cases the lesion is on the lower extremity, but the worm may emerge on the hands, arms, trunk, and even jaw. Systemic symptoms of nausea, vomiting, diarrhea, urticaria, and pruritus may precede the skin lesion by a few hours. The systemic symptoms improve once the larvae are ejected into the water.

Rarely, worms have been found in the pericardium, spinal canal, eye, broad ligament, testicle, and other deep tissues. Arthritis and ankylosis may result if a joint is infected. No protective immunity to this parasite develops. Reinfection is common.

Laboratory Findings

Peripheral eosinophilia is common during tissue migration.

Diagnosis

Visual inspection of the morphology of the parasite as it emerges and identification of the discharged motile larvae confirm the diagnosis. X-ray examination may reveal dead calcified worms.

Differential Diagnosis

In cases of dracunculiasis, the differential diagnosis includes a carbuncle or cellulitis associated with bacterial infection, onchocerciasis, loiasis, and syphilitic gumma.

Treatment

In endemic areas, the treatment of dracunculiasis includes extracting the worms by slowly winding them around a stick. This poses the risk of rupturing the worm, however, resulting in a severe inflammatory reaction. Medical therapy with metronidazole is not curative, but decreases inflammation and facilitates extraction of the worm. Mebendazole has been reported to kill the worm directly. Although the FDA has approved the use of metronidazole for other disorders, it is considered investigational for dracunculiasis.

Prevention

Using water that has been filtered or obtained from safe sources avoids infection. Boiling water or treating water with temephos also renders it safe.

ECHINOCOCCOSIS [28], [29] and [30]

Synonyms

For disorders associated with *Echinococcus granulosus*—unilocular echinococcosis, hydatid disease caused by *E. granulosus,* classic cystic hydatid disease; for disorders associated with *E. multilocularis*—multilocular echinococcosis, alveolar hydatid disease

Etiology

The larval stages of the cestodes (tapeworms) *E. granulosus* and *E. multilocularis* cause most cases of human echinococcosis.

Life Cycle

The definitive hosts for *E. granulosus* are dogs and other members of the family Canidae. Sheep, moose, horses, and other animals serve as intermediate hosts. The adult worm in the gut of the definitive host produces eggs that are shed into the environment and ingested by the intermediate host, where they develop into hydatid cysts in tissues that are eaten by the definitive host to complete the cycle. Humans are incidental intermediate hosts. The life cycle of *E. multilocularis* is similar to that of *E. granulosus,* except that the definitive hosts are foxes and the intermediate hosts are small rodents.

Pathogenesis

With *E. granulosus,* the oncosphere (larva) hatches from an ingested egg in the gut, penetrates the intestinal mucosa, enters the venous and lymphatic pathways, and then settles in tissue anywhere in the body and begins cystic development. The cyst increases in size at a rate of about 1 to 5 cm per year. The hydatid cyst (metacestode) has an inner germinative layer of cells, surrounded by an acellular, laminated membrane and variable granulomatous reaction. Secondary cysts bud internally from the germinative layer and produce multiple protoscolices, which, if released from the hydatid cyst by rupturing, may establish new sites of infection. The cysts may reach volumes of several liters. The cysts may cause local pressure and mechanical problems due to their large size.

Echinococcus multilocularis has no limiting membrane of parasitic or host origin, and the cyst gives rise to new cysts by exogenous budding. This produces an enlarging mass of contiguous vesicles that may invade and replace host tissue (usually the liver). *Echinococcus multilocularis* grows more rapidly than *E. granulosus* (commensurate with the short life span of its usual intermediate host, a rodent) and remains in the proliferative stage indefinitely. The mass may undergo central necrosis with cavitation. Hematogenous dissemination leads to metastatic infection.

Geographic Distribution

Echinococcus granulosus is present on all continents. Infections are sporadic in North America, Central America, northern South America, northern Europe, Australia, and New Zealand. There is a high prevalence of infection in southern South America, parts of southern Europe, parts of the former Soviet Republics, Middle Eastern countries, and northern and East Africa. The infection is present in most Asian countries. *Echinococcus multilocularis* is more limited in distribution because of greater host specificity. There are documented cases in North America, Europe, Asia, India, and Iran; one case was reported from northern Africa (Tunisia) in 1981.

Epidemiology

ACQUISITION Infection with *E. granulosus* is acquired by the ingestion of infective eggs with food or fluid or on fingers. Eggs are dispersed by wind, water, and arthropods from the site of fecal deposition. They may survive for a year or more in the environment. Transmission by inhalation of infective eggs may account for rare infections. In some highly endemic areas, the prevalence of infection may reach as high as 5 percent or more of the population. In the United States, approximately 200 cases are diagnosed yearly, with more than 90 percent being acquired outside the country. Persons at

highest risk are those who live in endemic areas, have close contact with dogs, and have poor personal hygiene. Many persons become infected in childhood. Like that with *E. granulosus,* infection with *E. multilocularis* is acquired by ingestion of infective eggs in food or fluid or on fingers. The latter is an uncommon infection in humans. In some areas, 40 to 100 percent of foxes are infected. Trappers, hunters, and persons who work with fox fur are at increased risk of infection.

INCUBATION PERIOD AND TIME FRAME The interval between acquisition of infection and onset of symptoms is usually years and may be decades for *E. granulosus*. Both of these parasites live for years, sometimes for the lifetime of the host.

Clinical Features

Most infections with *E. granulosus* are asymptomatic and go unrecognized. Skin and soft tissue manifestations are rare, occurring in less than 2 percent of infected patients. Cysts may manifest as firm subcutaneous or intramuscular nodules or masses that are fluctuant and nontender to palpation. There is no epidermal change. Skin fistulas from a hydatid cyst in a patient known to have an infection with *E. granulosus* have been reported. Infection with *E. multilocularis* may cause multiple supraumbilical cutaneous and subcutaneous nodules associated with ulceration, surrounding inflammation, and painless cutaneous fistulas. One report described an inflamed epigastric nodule where the mechanism of skin involvement was the progression of larva from the liver to the skin by the falciform ligament.

The clinical features of infection with *E. granulosus* are highly variable and reflect the location and size of cysts (Fig. 236-7 and Fig. 236-8). Mechanical pressure of a mass or an allergic reaction to foreign antigens from leaking cyst fluid causes most symptoms. Cysts are single most often, although they can be multiple (25 percent). They appear in the liver (50 to 75 percent), lung (20 to 30 percent), and other sites: kidney, spleen, heart, bones, muscles, and central nervous system (less than 2 percent). The cyst may reach a large size within the abdomen before symptoms develop. If the cyst leaks fluid, the patient may have wheezing, urticaria, or anaphylaxis.

FIGURE 236-7 Abdominal bulge from intraperitoneal cyst of echinococcosis. (*Courtesy of Jay S. Keystone, MD, FRCPC.*)

FIGURE 236-8 Surgical removal of intraperitoneal echinococcal cyst. (*Courtesy of Jay S. Keystone, MD, FRCPC.*)

Patients with an *E. multilocularis* infection remain asymptomatic for years. The signs and symptoms are epigastric and right upper quadrant pain, a palpable mass, jaundice, and hepatomegaly. Initial symptoms occasionally are related to metastatic lesions in the central nervous system and lung.

Laboratory Findings

Peripheral eosinophilia is present in one-third or fewer of patients with cysts; however, leakage of cyst fluid causes eosinophilia in a higher percentage.

Diagnosis

Examination of the contents of the cyst and identification of the parasite confirm the diagnosis. Characteristic morphology of the parasite as seen by imaging (e.g., ultrasound, CT scan, and MRI) can suggest the diagnosis and can detect clinically silent lesions. Serologic studies can aid in the diagnosis and may be useful in following patients after surgical treatment. In *Echinococcus* granulosus, negative antibody test results do not exclude the diagnosis, as some persons with cysts do not have detectable antibodies. Lesions in the liver are more often associated with positive serologic studies than are lung lesions. A combination of serologic tests may provide the best information. False-positive results can occur in persons with other helminthic infections. Tests that assess circulating antigen, including molecular

techniques using polymerase chain reaction (PCR) are being actively developed. Serologic tests are usually positive at high titers in patients infected with *E. multilocularis*.

Differential Diagnosis

When there is skin involvement, the differential diagnosis includes cysticercosis, paragonimiasis, dirofilariasis, and other cystic lesions of soft tissues.

Treatment

In the past, surgical treatment was the only option available for infection with *E. granulosus*. The use of an alternative approach, chemotherapy and puncture–percutaneous aspiration–injection of chemicals–reaspiration (PAIR), is becoming increasingly common, especially when lesions are inoperable or would pose high surgical risk. It is important to evaluate the patient's condition for silent lesions and follow the patient for recurrence. Albendazole may be useful before surgery or in the event that the cysts rupture or leak during surgery, or that surgery is contraindicated. The operative mortality of *E. granulosus* is 0.9 to 3.6 percent, which increases with subsequent surgeries. The mortality for symptomatic patients who are not treated surgically is as high as 22 to 60 percent in some series. The clinical outcome depends on the anatomic location, number, and size of the lesions.

Surgical resection can be curative in *E. multilocularis* infection if the diagnosis is made early. Albendazole may slow the progression of the infection, but will not cure late infection. Liver transplantation has been used in about 20 patients with inoperable infection. One report describes improvement in a patient with cutaneous alveolar echinococcus after treatment with albendazole. The mortality rate from infection with *E. multilocularis* has been 50 to 75 percent in the past, but may be lower with newer forms of therapy.

Prevention

The incidence of *E. granulosus* infection may be decreased by preventing dogs and other canines from feeding on infected offal.

ENTEROBIASIS [31], [32]

Synonyms

Threadworm, pinworm or seatworm infection, oxyuriasis

Etiology

Enterobiasis is caused by the nematode (roundworm) *Enterobius vermicularis*.

Life Cycle

Humans are the only host for *E. vermicularis*. See below for its life cycle.

Pathogenesis

Humans ingest the infective eggs, which hatch in the intestine and develop into adult worms in the cecum. Female worms migrate from the anus and deposit eggs in the perianal area. The eggs remain viable for up to 13 days. Worms may be found in surgically resected appendices. The migration of worms to the vagina, uterus, fallopian tubes, and peritoneal cavity may be associated with local granulomatous inflammation and peritonitis.

Geographic Distribution

Enterobiasis is found worldwide. It is the most common helminthic infection in industrialized countries. The highest rates of infection are among children.

Epidemiology

ACQUISITION The ingestion of infective *E. vermicularis* eggs can occur by direct anus-to-mouth transfer by fingers or sexual activities, contact with contaminated objects (e.g., bed linens, clothing, bathroom fixtures), and the inhalation and ingestion of airborne eggs in dust. Eggs become infective within a few hours of being deposited by the female worm in the perianal area.
INCUBATION PERIOD AND TIME FRAME A period of 4 to 6 weeks is required before eggs can be found. Symptoms may begin weeks to months after the ingestion of infective eggs. The parasite may live months or longer in the human. Autoinfection by anus-to-mouth transfer of eggs by fingers allows infection to continue indefinitely and to amplify.

Clinical Features

Nocturnal anal and perianal pruritus is the primary clinical feature. The skin may become impetiginized. Other findings have included perianal masses with recurrent cellulitis. Localized urticaria on the buttocks has occurred. In females, vulvovaginitis and vaginal discharge are common, and a nodular lesion of the vulva has been described. Rare complications include appendicitis, inguinal hernia, peritonitis, salpingitis, and urethritis. Reinfection is common.

Laboratory Findings

The results of laboratory studies are usually normal. Eosinophilia occurs only with tissue invasion (e.g., peritonitis).

Diagnosis

The identification of *E. vermicularis* eggs in the perianal area leads to the diagnosis of enterobiasis. This is most effectively done by pressing transparent tape on a glass slide to the skin in the perianal area, then reviewing it under a microscope for identification of the eggs (Fig. 236-9). Eggs may also be found in stool (less than 5 percent) and in subungual material. Occasionally, the adult worm is found in the perianal area, vagina, or underclothes. If ectopic sites are involved, the parasite may be identified in tissue sections.

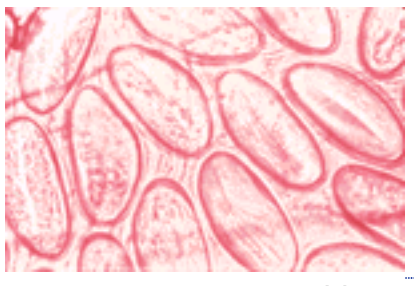

FIGURE 236-9 *Enterobius vermicularis* ova as seen under microscope (collected on transparent tape from perianal area). (*Courtesy of Herman Zaiman, MD.*)

Differential Diagnosis

Allergic and hypersensitivity reactions, neurodermatitis, and strongyloidiasis are part of the differential diagnosis.

Treatment

The administration of pyrantel pamoate, mebendazole, or albendazole is the treatment of choice.

Prevention

Treatment of infected cases and good personal hygiene are the most effective preventive measures.

FASCIOLIASIS [33], [34] and [35]

Synonyms

Sheep liver fluke disease

Etiology

Trematodes (flukes) residing in the human bile ducts cause fascioliasis. These flukes include *Fasciola hepatica,* the sheep liver fluke, and *F. gigantica*. Human infection with *F. gigantica* is rare.

Life Cycle

In water, miracidia released from eggs penetrate snails and develop into cercariae that encyst on water plants (e.g., watercress) and become metacercariae, which are ingested by herbivores (e.g., sheep and cattle).

Pathogenesis

If humans ingest metacercariae, the cyst envelope releases larvae in the duodenum; the larvae then pass through the intestinal wall and peritoneal cavity to penetrate the capsule of the liver. The parasite enters the bile ducts, where it matures and produces eggs that are released into the bile and passed in the feces. The parasite may cause hyperplasia of the bile duct epithelium, periductal fibrosis, and obstruction of the bile ducts. Flukes occasionally migrate to extrabiliary sites, most commonly to subcutaneous tissue.

Geographic Distribution

Fasciola hepatica is found worldwide in sheep- and cattle-raising areas. Sporadic human infections have been reported from all continents.

Epidemiology

ACQUISITION Fascioliasis is acquired by the ingestion of the metacercariae, usually on watercress and other plants (e.g., dandelion leaves and lettuce), or in contaminated water.
INCUBATION PERIOD AND TIME FRAME Eggs are first found in the stool 3 to 4 months after the ingestion of metacercariae. The earliest symptoms, which are related to the migration of the young fluke in the liver, may occur as

early as 2 weeks after exposure. The parasite can survive 10 years or longer in the human host.

Clinical Features

Symptoms may be absent or mild in patients with fascioliasis. In a small percentage of patients, more severe disease develops, and these patients may have acute, relapsing, or chronic symptoms. Early changes that begin during liver migration and may persist for weeks to months include hepatomegaly, fever, right upper quadrant pain, nausea, and diarrhea. Jaundice may occur. Patients may have repeated episodes of urticaria, sometimes accompanied by wheezing. Chronic infection is often asymptomatic, but may be associated with episodic cholangitis, cholecystitis, and obstructive jaundice.

The most frequent site of ectopic fascioliasis is the subcutaneous tissue. Typical findings are erythematous, painful, and pruritic subcutaneous nodules. The most common anatomic locations include the abdomen, back, and extremities. Migratory tracks cause necrosis and local inflammation, and they may lead to fibrosis. Fascioliasis may also present as eosinophilic panniculitis. Other documented ectopic sites include the brain, lung, cecum, epididymis, stomach, appendix, pancreas, peritoneum, spleen, skeletal muscle, orbit, and lymph nodes. Ectopic fascioliasis is not always associated with hepatobiliary disease.

Laboratory Findings

Marked leukocytosis and eosinophilia characterize acute infection with *F. hepatica*. In chronic infection, eosinophilia may wax and wane. Liver function test results are abnormal.

Diagnosis

The identification of eggs in the stool, duodenal contents, or bile confirms the diagnosis of fascioliasis. Eggs are typically present in small numbers in stool; hence, they may be difficult to find. Adult worms may be recovered during hepatobiliary surgery. When ectopic sites are involved, adult worms can be identified in surgical specimens. Serologic tests may aid in the diagnosis of early infection and ectopic infection, although their value is limited because of cross-reactions with other helminthic infections.

Differential Diagnosis

Included in the differential diagnosis are viral hepatitis, infection with other liver flukes, schistosomiasis (Katayama fever), toxocariasis, amebiasis, and biliary tract disease. When subcutaneous tissue is involved, the differential diagnosis includes lymphadenitis, epidermal inclusion cyst, abscess, cellulitis, and other parasites causing nodular skin lesions.

Treatment

Fascioliasis is treated with triclabendazole or bithionol available in the United States only from the manufacturer. Surgery may also be necessary.

Prevention

Preventive measures include avoiding freshwater plants, especially watercress, and untreated water.

FILARIASIS, LYMPHATIC[36], [37] and [38]

Synonyms and Diseases

Malayan filariasis *(Brugia malayi*), Timor filariasis *(B. timori*), Bancroft's filariasis, filariasis bancrofti, and wuchereriasis *(Wuchereria bancrofti*). Some of these parasites can cause elephantiasis and tropical pulmonary eosinophilia. The disease process depends on the etiologic agent. See Table 236-8 for a summary of filarial parasites.

TABLE 236-8 **Summary of Filarial Parasites***

Etiology

Lymphatic filariasis (Fig. 236-10) is caused by three filarial nematodes: *B. malayi, B. timori,* and *W. bancrofti*.

FIGURE 236-10 Lymphatic filariasis secondary to *Wuchereria bancrofti*. (*Courtesy of Jay S. Keystone, MD, FRCPC.*)

Life Cycle

Microfilariae produced by adult worms in the human are taken up by the mosquito during a blood meal. Over several days, the microfilariae develop into larvae within the mosquito, which can transmit infection to other humans when taking blood meals. *Brugia malayi* can follow an alternative life cycle that involves the leaf monkey instead of humans as the definitive host.

Pathogenesis

Infective larvae emerge from the mosquito during its feeding and migrate through the puncture wound produced by the feeding mosquito. The larvae enter the lymphatic vessels, and when they become mature adult worms, they mate in the lymphatics or lymph nodes and release sheathed microfilariae into the bloodstream. Maturing adult worms provoke an eosinophilic and chronic inflammatory cell infiltrate around lymphatic vessels, leading to dilatation and hypertrophy, damaging the lymph valves with eventual scarring, and obstructing lymphatic flow. The death of worms in lymphatics and lymph nodes results in an intense inflammatory reaction with granulomatous changes and necrosis. Late calcification may result.

Geographic Distribution

For *B. malayi,* the geographic distribution includes South and East Asia (from India to Korea), as well as adjacent islands. *Brugia timori* is limited to the small volcanic islands of southeastern Indonesia surrounding the Savu Sea (Timor, Flores, Alor, Sumba, Roti, and Savu). *Wuchereria bancrofti,* which infects 120 million people worldwide, is found in the tropical and subtropical areas of Africa, Asia, Pacific islands, Central and South America, and the Caribbean. Figure 236-11 shows the geographic distribution of *W. bancrofti* in Africa, the Americas, and the Eastern Mediterranean region. Figure 236-12 shows the geographic distribution of *W. bancrofti, B. malayi,* and *B. timori* in the Southeast Asian and Western Pacific regions.

FIGURE 236-11 Distribution of *Wuchereria bancrofti* in the African region, region of the Americas, and Eastern Mediterranean region. (*Reprinted from* Lymphatic filariasis: The disease and its control. *Fifth report of the WHO Expert Committee on Filariasis. Geneva, World Health Organization, 1992 [WHO Technical Report Series No. 821], with permission.*)

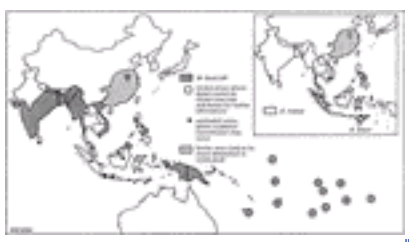

FIGURE 236-12 Distribution of *Wuchereria bancrofti, Brugia malayi,* and *B. timori* in the Southeast Asian and Western Pacific Regions. (*Reprinted from* Lymphatic filariasis: The disease and its control. *Fifth report of the WHO Expert Committee on Filariasis. Geneva, World Health Organization, 1992 [WHO Technical Report Series No. 821], with permission*.)

Epidemiology

ACQUISITION Lymphatic filariasis is acquired by the bite of an infective mosquito. Microfilariae that pass into the

bloodstream by means of transfusion or those that cross the placenta are unable to develop in humans and disappear within a few weeks. Worldwide, the filarial parasites are estimated to infect more than 100 million people. Infection is uncommon in persons who have spent only brief periods in endemic areas. Multiple bites from infective mosquitoes are generally necessary to establish symptomatic infection. In the United States, infection appears primarily in immigrants from endemic areas.
INCUBATION PERIOD AND TIME FRAME The incubation period is 5 to 18 months, although *B. malayi* microfilaremia may occur as early as 2 to 3 months after exposure. *Wuchereria bancrofti* microfilariae first appear in peripheral blood 8 to 12 months after exposure, but symptoms can begin as early as 1 to 3 months after exposure. Adult worms live an average of 10 to 15 years; the microfilariae, probably 6 to 12 months. Symptoms and sequelae can persist after the death of all parasites.

Clinical Features

The clinical presentation and course of lymphatic filariasis depend on the age at first exposure and the presence of immunity. In endemic areas, the prevalence increases after age 20, with most new cases occurring between the ages of 25 and 40 years old. The clinical course ranges from asymptomatic to severely disabling (less than 1 percent of those infected). Manifestations may be acute, chronic, and recurrent. Early findings are lymphangitis with a characteristic retrograde progression, lymphadenitis, orchitis, epididymitis, and sometimes fever. During the resolution of the acute phase of *W. bancrofti* filariasis, there may be extensive exfoliation of the skin of the affected limb. Lymphangitis is typically recurrent with 6 to 10 episodes per year, usually lasting 3 to 7 days each; the affected body part clinically appears normal between early episodes. Intermittent fevers and lymphangitis can recur for as long as 20 years after an infected person leaves the endemic area.

After 10 to 15 years of infection, chronic disease is evident in sequelae of lymphatic obstruction including lymphedema, elephantiasis, hydrocele, and chyluria. The skin over the involved area is hypertrophic, verrucous, and fibrotic with redundant folds of skin. Fissures, ulceration, and gangrene may occur. Secondary bacterial infection invariably occurs. The anatomic locations most commonly afflicted with elephantiasis include the lower extremity, scrotum, and penis. Less commonly, the upper extremity, breast, and vulva are involved, and rarely, an amputation stump, ears, oral mucosa, periorbital area, and panniculus. Treatment does not reverse the late findings of scarring and lymphatic obstruction. *Wuchereria bancrofti* has been reported to cause a skin nodule on the breast.

Tropical pulmonary eosinophilia develops in some patients with filarial infections. Clinical findings include cough, wheezing, dyspnea, chest pain, and fever accompanied by marked eosinophilia and pulmonary infiltrates. Tropical pulmonary eosinophilia may be associated with progressive restrictive pulmonary disease.

Filariasis due to *B. malayi*, usually involves the lower extremities, lymphangitis is not severe, and genital lesions are uncommon. In filariasis due to *B. timori,* lymphatic abscesses are common. Genital lesions, chyluria, and tropical pulmonary eosinophilic syndrome are not reported with *B. timori*.

Travelers to endemic areas do not manifest classic findings when first infected. Instead, they have a hyperresponsive clinical presentation, with more intense inflammatory reactions to filarial parasites. The clinical findings may include lymphangitis, lymphadenitis, and groin pain from the associated lymphatic inflammation, urticaria, and a peripheral eosinophilia. Microfilaremic patients have hyporesponsiveness to filarial antigens and a limited host response to the parasite. Persons with a more vigorous immune response may clear the microfilariae from the blood, but have more prominent local pathology and systemic symptoms.

Laboratory Findings

Patients with lymphatic filariasis have a peripheral eosinophilia, which may be high grade, and an elevated IgE. More than half of microfilaremic patients with *W. bancrofti* infection have hematuria and/or proteinuria.

Diagnosis

The basis for diagnosis is the demonstration of microfilariae in blood, urine, and other body fluids, and tissue or the demonstration of the adult worm in lymphatics or other tissues. The usefulness of serologic tests has been limited by cross-reactions with other antigens, but newer tests with better specificity are becoming available. Persons with active filarial infection may not be microfilaremic, and persons with microfilaremia may be asymptomatic. Persons with tropical eosinophilic syndrome will have pulmonary infiltrates on chest x-ray films.

Differential Diagnosis

The stage of the infection determines the differential diagnosis. Acute infection may be confused with a bacterial lymphangitis. The differential diagnosis for the chronic stage includes other filarial infections such as infection with *Onchocerca volvulus,* recurrent bacterial lymphangitis, deep fungal infection, disruption of lymphatic channels due to trauma, chronic venous insufficiency, pretibial myxedema, lymphosarcoma, fibrosarcoma, and congenital diseases such as Milroy's disease and Klippel-Trenaunay-Weber syndrome.

Treatment

The drug of choice for infections with *B. malayi* and *W. bancrofti* is diethylcarbamazine, which is active against microfilariae, but has a limited effect on adult worms. A single dose of ivermectin has been reported to be effective for the treatment of microfilariae. Tropical pulmonary eosinophilia syndrome is treated with diethylcarbamazine. When treating filariasis with diethylcarbamazine, clinicians may use antihistamines of glucocorticoids to decrease the allergic reaction that may result from disintegration of microfilariae. Severe reactions may follow the administration of diethylcarbamazine to persons infected with filariasis who also have loiasis or onchocerciasis. Combined therapy with albendazole and

ivermectin looked promising in early trials, and additional studies are under way.

Management strategies for patients with lymphedema include elevation of the affected body part, compression stockings, antiinflammatory drugs, skin care of the affected area, treatment of superficial fungal infections, as well as protection of the affected area from trauma. Surgical treatment includes debulking of the affected area, wide excision of chronic draining areas, and lymphatic shunts.

Prevention

The avoidance of mosquito bites in endemic areas is the primary means of prevention. Prophylaxis with diethylcarbamazine (500 mg/d for 2 days each month) is effective for *W. bancrofti* and could be considered for adults who plan to spend more than a month in endemic areas and are likely to have extensive exposures to mosquitoes.

GNATHOSTOMIASIS [39], [40]

Synonyms

Yangtze River edema (China), tau-chid (Thailand), choko-fushu (Japan), wandering swelling, Consular disease (Nankung), Shanghai's rheumatism, nodular eosinophilic panniculitis (Ecuador), Woodbury bug (Australia)

Etiology

The nematodes (roundworm) *Gnathostoma spinigerum* and less frequently, *G. hispidum, G. nipponicum,* and *G. doloresi* cause gnathostomiasis (Fig. 236-13 and Fig. 236-14)

FIGURE 236-13 Subcutaneous swellings of gnathostomiasis. (*Courtesy of Jay S. Keystone, MD, FRCPC*.)

FIGURE 236-14 Subcutaneous swellings of gnathostomiasis. (*Courtesy of Jay S. Keystone, MD, FRCPC*.)

Life Cycle

The adult parasite lives in the stomachs of the definitive hosts, cats and dogs. Eggs are passed in the stool and hatch in water. The larvae are then ingested by *Cyclops* (a type of copepod, which are small aquatic arthropods) that are eaten by fish, frogs, and snakes; in these hosts, the larvae develop into third-stage larvae. When vertebrates who are unsuited to be definitive hosts (including humans) ingest the third-stage larvae, the larvae do not complete development, but encyst or wander in tissues.

Pathogenesis

The ingested larvae penetrate the wall of the stomach and migrate in tissues, causing inflammation, edema, hemorrhage, and necrosis. Chronic lesions are associated with eosinophilic and granulomatous inflammation. The parasite may reach any location within the body.

Geographic Distribution

Human gnathostomiasis is endemic in Southeast Asia, especially Thailand and Japan. Since the 1970s, the prevalence of gnathostomiasis has increased in Peru, Ecuador, and Mexico. Imported fish and other animal flesh can be the source of infection outside of endemic areas. Sporadic cases have been reported in the Americas, Africa, Europe, and Australia.

Epidemiology

ACQUISITION Humans acquire gnathostomiasis by ingesting larvae in undercooked or raw flesh (e.g., fish, chicken, duck, pork, frog). Transmission may also occur by ingestion of infective copepods in water or by skin penetration when handling infected fish.
INCUBATION PERIOD AND TIME FRAME Soft tissue swellings usually begin 3 to 4 weeks after exposure, but may not

develop until months or years later. The parasite can survive in the human for 10 years or longer. One report documents recurrences for 20 years.

Clinical Features

The signs and symptoms of gnathostomiasis range from mild to severe. Within 1 to 2 days after ingestion of the larvae, fever, malaise, anorexia, nausea, vomiting, diarrhea, epigastric pain, and urticaria may develop. Migration of the larvae in the skin and subcutaneous tissue results in intermittent, migratory swellings that are associated with erythema, pruritus, and pain. The lesions may be single or multiple, and up to several centimeters in diameter. The swellings develop rapidly, persist for 1 to 4 weeks, then resolve—only to reappear in a different anatomic location after an asymptomatic interval of a week to months. Over time, episodes become less frequent, less intense, and shorter in duration. However, cutaneous gnathostomiasis may continue for months to years. Gnathostomiasis may present as a cutaneous larva migrans–like eruption and, rarely, as a skin abscess or nodule. The most common anatomic locations include the trunk, upper body, and thighs.

Visceral gnathostomiasis, involving deeper tissues and organs, may occur in the eye, lungs, gastrointestinal and genitourinary tracts, and the central nervous system. Fewer than 1 percent of patients with cutaneous disease have central nervous system infection. Signs and symptoms reflect the location and activity of the larvae. Facial migratory swellings are a sign of increased risk for both ocular involvement and possible permanent visual loss, as well as central nervous system involvement, should the worm migrate through a cranial foramen. Deaths from central nervous system involvement have been reported.

Laboratory Findings

Peripheral eosinophilia may be high grade. Leukocytosis may be present during larval migration. When the infection involves the central nervous system, the cerebrospinal fluid may be bloody or xanthochromic and contains eosinophils.

Diagnosis

The characteristic morphology of larvae in surgical specimens or at autopsy confirms the diagnosis. ELISA is available in some endemic areas to aid in the diagnosis.

Differential Diagnosis

The differential diagnosis of soft tissue gnathostomiasis includes loiasis, onchocerciasis, sparganosis, cutaneous myiasis, cutaneous larva migrans, visceral larva migrans, dirofilariasis, cutaneous paragonimiasis, and eosinophilic cellulitis.

Treatment

Surgical excision plus albendazole is the treatment of choice. Ivermectin has been shown to be effective in animals and appeared to be effective in the treatment of a human with gnathostomiasis.

Prevention

Infection can be prevented by avoiding raw and undercooked flesh of fish, eel, chicken, duck, pork, snake, dogs, cats, and frog; drinking only treated water; and wearing gloves when handling potentially infected flesh.

HOOKWORM DISEASE [41], [42]

Synonyms and Diseases

New World hookworm disease, American hookworm disease, uncinariasis, or necatoriasis (for disease caused by *Necator americanus*); Old World hookworm infection or ancylostomiasis (for disease caused by *Ancylostoma* duodenale); ground itch, hookworm folliculitis. (See also cutaneous larva migrans.)

Etiology

The major causes of hookworm disease are *A. duodenale* and *N. americanus*. Pathologic effects show some variation by species. *Ancylostoma ceylanicum* has a more limited distribution. *A. caninum* causes eosinophilic enteritis as well as cutaneous disease.

Life Cycle

Eggs embryonate and hatch in the soil and develop into infective larvae over 5 to 10 days. Humans are the main reservoir host for *A. duodenale* and *N. americanus*. Cats and dogs are hosts for *A. ceylanicum* and *A. caninum*.

Pathogenesis

The larvae penetrate the skin, reach superficial venules, and enter the circulation. They reach the lungs and penetrate the alveoli. Larvae are carried up the respiratory tract to the pharynx then swallowed. Parasites mature and attach to villi, mainly in the jejunum, where they suck blood and cause bleeding at the site of mucosal attachment. Eggs are shed in the feces. When *A. duodenale* larvae enter the host by means of ingestion instead of via the skin, they develop without

passing through the lung.

Proteolytic enzymes secreted by the infective larvae of *N. americanus* enhance skin penetration by degrading collagen types I, III, IV, and V, fibronectin, laminin, and elastin.

Geographic Distribution

The various species that cause hookworm disease have distinct, but overlapping geographic distributions. Hookworm disease is most common in rural tropical and subtropical areas but can also occur in temperate areas when sanitation is poor. In 1996, the World Health Organization (WHO) estimated that hookworm disease affected 151 million persons and caused 65,000 deaths. The majority of persons who harbor hookworms have no or few symptoms; disease develops in approximately 25 percent as a consequence of infection.

Epidemiology

ACQUISITION Humans acquire infection by penetration of intact skin or mucosa by infective larvae, or ingestion of food (e.g., raw vegetables) contaminated by *A. duodenale* larvae. Transmammary infection is possible with *A. duodenale*. There is probable infection in utero by transplacental spread. Skin contact with fecally contaminated soil poses a high risk. Walking barefoot is the most common way to acquire infection.
INCUBATION PERIOD AND TIME FRAME Skin changes usually begin 1 to 2 days after skin penetration. Eggs are found in the stool 4 to 6 weeks after skin penetration. Pulmonary symptoms may occur 1 to 3 weeks after percutaneous penetration; gastrointestinal symptoms, 1 month after penetration. *Ancylostoma duodenale* survives for approximately 1 year (and up to 5 to 7 years), and *N. americanus* survives for 2 to 6 years (and up to 15 to 20 years) in the human.

Clinical Features

The majority of hookworm infections are asymptomatic or mild. Heavy infections are debilitating and can contribute to death. Within 1 to 2 days, the area of skin penetrated by the larvae may have localized erythema, edema, and papular or papulovesicular lesions. This eruption, known as “ground itch,” is most commonly located on the feet and lasts 1 to 2 weeks. There may be an associated generalized urticaria. The area involved may also present as folliculitis, where the hookworm is identified within a hair follicle. In a minority of patients, the pulmonary migration phase produces cough, wheezing, and shortness of breath. Heavy infections are associated with abdominal pain, diarrhea, and gastrointestinal bleeding. Chronic infection is associated with signs and symptoms of hypoproteinemia and chronic anemia: edema, pallor, weakness, shortness of breath, and tachycardia. Hookworm infection in children can retard growth and intellectual development. Previous infection does not prevent re-infection, but may have a limiting effect on the worm population.

Laboratory Findings

A peripheral eosinophilia begins as early as 2 to 3 weeks after skin penetration by the infective larvae and may be high grade during tissue migration. Chest x-ray films may reveal transient pulmonary infiltrates. In chronic infection, abnormal laboratory values include iron deficiency anemia and hypoalbuminemia. There is gross or occult blood in the stool.

Diagnosis

Characteristic clinical findings in a person with appropriate epidemiologic exposure suggest a presumptive diagnosis of “ground itch.” At the time a patient presents with skin changes and pulmonary infiltrates, the results of stool examinations will be negative. A period of 4 to 6 weeks after exposure must pass before eggs can be found on stool examination. The eggs of *A. duodenale* and *N. americanus* are indistinguishable by routine light microscopy.

Differential Diagnosis

For hookworm disease, the differential diagnosis includes cutaneous larva migrans and folliculitis.

Treatment

Effective treatment includes albendazole, mebendazole, or pyrantel pamoate (considered investigational by the FDA for this infection). Albendazole appears to be more effective than mebendazole.

Prevention

The sanitary disposal of human feces can prevent hookworm infections.

LOIASIS [43], [44], [45] and [46]

Synonyms

Calabar swellings, fugitive swellings, loa loa filariasis, African eyeworm infection

Etiology

The filarial nematode (roundworm), *Loa loa,* is the parasite responsible for loiasis.

Life Cycle

The *Chrysops* (a type of fly) bites an infected human and ingests microfilariae along with the blood meal. The microfilariae develop into larvae, which are transmitted when the fly bites another human.

Pathogenesis

Larvae from the biting fly enter the human through the puncture wound. The larvae mature into adult worms that live in subcutaneous tissue and migrate along fascial planes to all parts of the body. The adult worms produce microfilariae that enter the bloodstream during the day and may reside in the lungs when not circulating.

Geographic Distribution

Loiasis is endemic in Central and West Africa.

Epidemiology

ACQUISITION The bite of the infective day-biting flies of the genus *Chrysops* spreads loiasis. The microfilariae can be transmitted via transfused blood, but will not develop into adult worms in the human host. Flies live in the canopy of the rain forest and lay eggs in muddy streams and swamps. The flies are attracted by dark clothing, wood smoke, and movement of people or vehicles. In endemic areas, infection rates exceed 50 percent in some human populations. Infections in visitors from nonendemic areas occur primarily in persons who spend at least 3 months in endemic areas.
INCUBATION PERIOD AND TIME FRAME Symptoms usually begin 1 year or longer after exposure, although first findings can appear as early as 4 months or as long as 8 years after the acquisition of infection. Microfilariae first appear in the bloodstream 5 to 6 months after the person becomes infected. The adult worm can live longer than 10 years in the human host.

Clinical Features

Loiasis is manifested by pruritus, urticaria, and Calabar swellings (Fig. 236-15), which are localized areas of angioedema associated with the migration of the adult worms through the subcutaneous tissues. Often erythematous and warm, Calabar swellings range from 5 to 10 cm in diameter. They may be associated with pruritus or pain. The lesions last several days and may recur multiple times. They occur predominantly on the extremities (upper more commonly than lower), especially around joints such as the wrist or knee. Fatigue, myalgias, arthralgias, and fever may be associated with the lesions. A migrating adult worm may be seen crossing the conjunctivae or the bridge of the nose (hence, the term “eyeworm”; Fig. 236-16). This is associated with swellings on the face, particularly of the periorbital region. Other, less common systemic findings include arthritis, lymphadenopathy, lymphedema, peripheral neuropathy, cardiomyopathy (endomyocardial fibrosis), hematuria, proteinuria, and encephalopathy.

FIGURE 236-15 Calabar swelling of loiasis. (*Courtesy of Jay S. Keystone, MD, FRCPC*.)

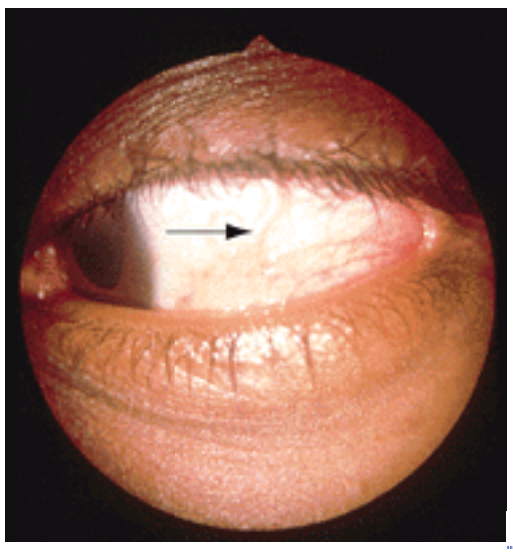

FIGURE 236-16 Loiasis. Adult worm crossing eye. (*Courtesy of Murray Wittner, MD, PhD*.)

Individuals living in endemic areas may be microfilaremic, with a wide range of symptoms. Persons from nonendemic regions who become infected often do not have detectable microfilaremia, but have prominent symptoms and immunologic hyperresponsiveness.

Laboratory Findings

Those with loiasis have a peripheral eosinophilia that may be high grade, leukocytosis, and elevated IgE. *Loa loa*–specific IgG4 is elevated. These findings are much less prominent in infected persons who have always resided in endemic areas.

Diagnosis

The basis for diagnosis is the identification of microfilariae in blood (during the day) or, occasionally, in urine, cerebrospinal fluid, sputum, or other body fluid or by the identification of an adult worm removed from the eye or other tissues. Calcified worms may be seen on x-ray films. Although the usefulness of older serologic tests is constrained by cross-reactivity with other parasites, newer approaches are being developed, including the use of PCR amplification of *L. loa* DNA from the blood.

Differential Diagnosis

The differential diagnosis includes other filarial infections, gnathostomiasis, and toxocariasis.

Treatment

The surgical removal of the worm from the eye or other tissue, if feasible, is a component of treatment. Patients may be infected with multiple worms (usually not more than 10 to 20 adult worms). Diethylcarbamazine (DEC) is currently the drug of choice for persons who are not microfilaremic. Local inflammatory manifestations may occur within 1 to 2 days of DEC treatment. These include pruritus and subcutaneous nodules that, when biopsied, reveal the adult worm. Neurologic complications, including encephalitis and death, may follow treatment of microfilaremic loiasis patients with DEC.

For patients who have an infection refractory to DEC, albendazole may be effective. Alternative approaches in patients with heavy infections have included the use of ivermectin or albendazole or apheresis to reduce microfilaremia. Encephalopathy may occur when patients with a heavy *L. loa* infection are given ivermectin for the treatment of another parasitic infection.

Prevention

Prevention includes protection from *Chrysops* bites in endemic areas to prevent infection. Prophylaxis with DEC is effective for *L. loa* in adults who may spend more than a month in endemic regions and expect to have frequent exposures to biting flies.

ONCHOCERCIASIS [47], [48], [49] and [50]

Synonyms

Onchocercosis, blinding filariasis, river blindness, coastal erysipelas, erysipela de la costa (Mexico and Guatemala), onchocercomata, onchodermatitis, sowda (Arabic speaking areas), craw-craw (West Africa)

Etiology

Onchocerciasis is caused by the filarial nematode (roundworm) *Onchocerca volvulus*.

Life Cycle

Blackflies of the genus *Simulium* bite an individual infected with *O. volvulus*. The microfilariae develop into infective larvae within the blackfly, which passes larvae to another human when taking a blood meal.

Pathogenesis

After entering the human skin when the blackfly takes a blood meal, the infective larvae mature to adult worms that are encapsulated in fibrous tissue and reside in nodules in the subcutaneous tissue and deep fascia. Necrosis and calcification may follow the death of the worm. Microfilariae migrate from adult worms and may enter the bloodstream. The presence of microfilariae in the skin, connective tissue, eyes, and lymph nodes is associated with significant pathologic findings.

Geographic Distribution

The greatest concentration of *O. volvulus* infections is in equatorial Africa. Endemic foci also appear in Latin America, Yemen, and Saudi Arabia. Fig. 236-17 shows the geographic distribution of onchocerciasis in Africa and the Arabian peninsula. Fig. 236-18 shows the geographic distribution of endemic onchocerciasis in the Americas. Onchocerciasis affects primarily people living near fast-flowing rivers where blackflies breed.

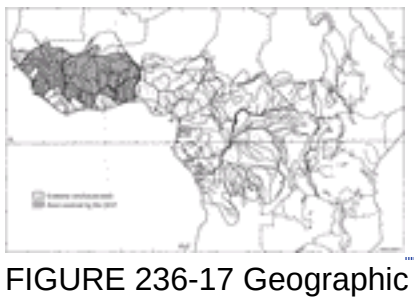

FIGURE 236-17 Geographic distribution of onchocerciasis in Africa and the Arabian peninsula. (*Reprinted from* Onchocerciasis and its control. *Report of a WHO Expert Committee on Onchocerciasis Control. Geneva, World Health Organization, 1995 [WHO Technical Report Series No. 852], with permission*.)

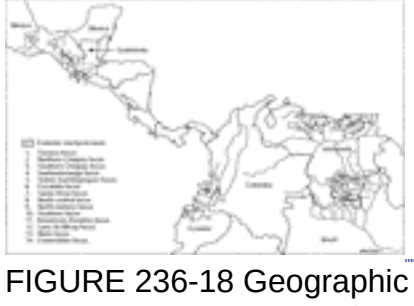

FIGURE 236-18 Geographic distribution of endemic onchocerciasis in the Americas. (*Reprinted from* Onchocerciasis and its control. *Report of a WHO Expert Committee on Onchocerciasis Control. Geneva, World Health Organization, 1995 [WHO Technical Report Series No. 852], with permission*.)

Epidemiology

ACQUISITION Onchocerciasis is acquired by the bite of an infective blackfly. Microfilariae from an infected mother can infect the fetus, and the potential exists for transmission of microfilariae by blood transfusion. It is estimated that approximately 17.5 million persons are infected and 85 million are at risk for infection. An estimated 1 million persons have significant visual impairment due to onchocerciasis, and 3 to 4 million infected persons have onchocercal skin disease. Symptomatic infection generally occurs only in persons who have lived in endemic areas for several months and usually longer. Severe disease develops only after repeated exposures over many years.
INCUBATION PERIOD AND TIME FRAME The incubation period is usually 1 to 2 years with a range of months to several years. Microfilariae may first appear 3 to 15 months after exposure. The initial symptoms can precede the presence of microfilariae in tissue, but often develop only after months or years of infection. The microfilariae can survive in humans for up to 2 to 3 years, the adult worms, for 10 to 15 years.

Clinical Features

Persons with onchocerciasis may be asymptomatic, or they may have a severe impairment, including loss of vision. The skin and the eye are the two most commonly involved organ systems.

The skin manifestations of onchocerciasis have six different patterns, including acute papular onchodermatitis (Fig. 236-19), chronic papular onchodermatitis, lichenified onchodermatitis, atrophy, depigmentation, and palpable onchocercal nodules. More than one pattern of skin involvement may be present simultaneously, or one pattern of skin involvement may evolve into another pattern. Pruritus is often the first symptom of infection. Acute papular onchodermatitis, which most often involves the face, extremities, and trunk, includes widespread small pruritic papules that may progress to vesicles and pustules in the most severe cases. There may be associated erythema and edema. Ivermectin and DEC can precipitate a rash similar to acute papular onchodermatitis. In Mexico and Guatemala, the combination of erythema, edema, and pruritus of the face is known as “erisipela de la costa” and is an acute onchocercal reaction.

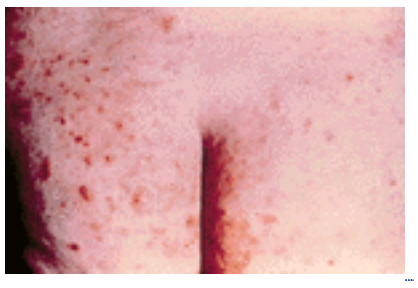

FIGURE 236-19 Onchocercal dermatitis. (*Courtesy of Herman Zaiman, MD*.)

The skin lesions of chronic papular onchodermatitis are macules and lichenoid papules varying in size from 3 to 9 mm in diameter. Pruritus is common, and postinflammatory hyperpigmentation may be present. The most commonly affected anatomic areas are the buttocks, shoulders, and waist.

Lichenified onchodermatitis, also known as “sowda” (Arabic for “black”) in Arabic-speaking regions, most commonly affects teenagers and young adults and most commonly occurs in Yemen and Sudan. Hyperkeratotic and hyperpigmented pruritic plaques become more confluent and lichenified with increased severity and time. The plaques have an asymmetric distribution with the lower extremity being the most frequently affected anatomic location. There is often associated lymphadenopathy.

Atrophy, also known as “lizard skin” in its most severe presentation, makes middle-aged persons appear elderly. The most commonly involved anatomic location is the buttocks; the secondmost, the extremities.

Depigmentation (Fig. 236-20) associated with onchocerciasis is also known as “leopard skin.” Depigmentation is associated with perifollicular pigmentation within macular or minimally depressed areas. In black skin, there may be yellow-brown hypopigmentation. Pruritus is rare in this pattern of skin involvement by onchocerciasis. The anatomic location most commonly involved is the shin area bilaterally. A previous report described the depigmentation of the shins as a useful method to screen for onchocerciasis in endemic areas. Less commonly, the buttocks, lateral groin, and lower abdomen are involved.

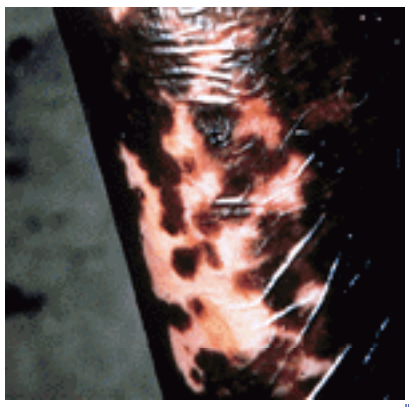

FIGURE 236-20 Depigmentation secondary to onchocerciasis. (*Courtesy of Jay S. Keystone, MD, FRCPC*.)

Palpable onchocercal nodules, containing the adult worm, involve the deep dermis and subcutaneous tissue (Fig. 236-21). Typically asymptomatic, the nodules occur over bony prominences such as the skull, iliac crest, knee, rib, sacrum, scapula, and trochanter.

FIGURE 236-21 Onchocercal nodule over iliac crest. (*Courtesy of Jay S. Keystone, MD, FRCPC*.)

Other clinical findings associated with onchocerciasis include “hanging groin,” which consists of folds of inelastic skin in the inguinal area, and associated lymphadenopathy. Groin hernias, lymphedema of external genitalia or limbs, and lymphadenopathy may occur. Ocular involvement is the most devastating aspect of this disease, as blindness is a potential outcome. Ocular findings include chorioretinitis, iritis, optic atrophy, punctate keratitis, and sclerosing keratitis.

Many psychosocial issues surround onchocerciasis, given the potential ocular involvement as well as the obvious skin manifestations that are easily recognizable to those individuals in endemic areas. The most common presentations in visitors to endemic areas are pruritus and rash. Skin nodules and eye involvement are usually absent, and microfilariae are absent or evident only in low numbers in the skin.

Laboratory Findings

Peripheral eosinophilia and elevated IgE levels are common findings.

Diagnosis

Onchocerciasis is most commonly diagnosed by the identification of the microfilariae in a skin snip or of an adult worm in an excised nodule. In heavily infected individuals, microfilariae may appear in the blood (up to one-third of cases), sputum, cerebrospinal fluid, urine, or other fluids. Microfilariae are clearly visible in the anterior chamber of the eye on slit-lamp examination. Antibody and PCR testing are being developed.

Differential Diagnosis

The skin pattern at presentation determines the differential diagnosis of the skin manifestations of onchocerciasis. Acute papular onchodermatitis may resemble miliaria, insect bites, or a hypersensitivity reaction. Chronic papular

onchodermatitis may resemble a chronic or lichenoid hypersensitivity reaction or atopic dermatitis. The differential diagnosis for lichenified onchodermatitis is broad and includes essentially any diagnosis that involves significant pruritus or rubbing of the involved area. Atrophy associated with onchocerciasis resembles that associated with aging. Onchocercal depigmentation may be confused with postinflammatory hypopigmentation or depigmentation. The differential diagnosis for onchocercal nodules includes cysticercosis, histoplasmosis, paragonimiasis, and epidermal inclusion cysts.

Treatment

The drug of choice in the treatment of onchocerciasis is ivermectin. Surgical excision of the nodules, especially if located on the head, is recommended.

Prevention

The primary means of preventing onchocerciasis is through vector control and mass treatment with ivermectin of the population in endemic areas.

PARAGONIMIASIS [35], [51]

Synonyms

Lung fluke infection, oriental lung fluke disease

Etiology

The trematode (fluke) *Paragonimus westermani* and more than 10 species of *Paragonimus* infect humans.

Life Cycle

Eggs hatch in water and release free-swimming miracidia that enter snails and develop into cercariae. The cercariae leave the snail and invade tissues of freshwater crabs, shrimp, or crayfish, where they encyst as metacercariae. The crustaceans are eaten by the definitive host, which may be a human, although other animals are more important in maintaining the life cycle.

Pathogenesis

In humans, the ingested metacercariae excyst in the small intestine, migrate through the gut wall, and enter the abdominal cavity, where they remain for several days. They migrate across the diaphragm into the pleural cavity and lungs, where they mature and produce eggs that are expectorated in sputum or swallowed. A fibrous capsule surrounds the flukes in the lungs, forming a cyst that may rupture, thus releasing ova and necrotic material into the bronchioles. The eggs provoke a granulomatous reaction. Flukes may migrate anywhere within the body, including subcutaneous tissues, and cause an eosinophilic, granulomatous reaction or abscess.

Geographic Distribution

Paragonimus westermani is widely distributed in East and Southeast Asia and Africa. Other species of *Paragonimus* are found in Asia, Africa, and the Americas.

Epidemiology

ACQUISITION Human hosts acquire paragonimiasis by ingesting metacercariae in raw or undercooked freshwater crayfish, crab, or shrimp or with other foods or fluids contaminated with metacercariae during preparation. Worldwide, an estimated more than 10 million persons are infected with paragonimiasis. The rates of infection are high in parts of Asia, where raw, undercooked, salted, pickled, or marinated crustaceans are frequently eaten. Juices from raw crustaceans are used for medicinal purposes in Korea and Japan. Paragonimiasis is also acquired by eating raw or undercooked field rats and wild boar.
INCUBATION PERIOD AND TIME FRAME Urticaria and gastrointestinal symptoms can begin within a few days of ingestion. Migratory subcutaneous nodules may appear as early as 2 weeks, and pulmonary symptoms occur as early as a few weeks after infection. Central nervous system involvement typically manifests 12 to 16 months after the onset of infection. Eggs are first produced approximately 10 weeks after the ingestion of metacercariae. The diagnosis may not be made for years. The life span of the fluke within humans is usually 10 years or less, but can be as long as 20 to 30 years.

Clinical Features

Depending on the intensity of infection and the anatomic location involved, the clinical features of paragonimiasis range from asymptomatic to fatal. The acute phase corresponds to fluke migration and tissue invasion. This is manifested by urticaria, abdominal pain, and diarrhea, followed by cough, hemoptysis, production of rusty-colored sputum, wheezing, pleuritic pain, and low-grade fever. These findings can continue for weeks. Patients with chronic infection have pulmonary and, sometimes, extrapulmonary findings. Ten percent of patients with *P. westermani* infection and 20 to 60 percent of patients with (*P. skrjabini P. szechuanensis*) infection have subcutaneous swelling or nodules (containing immature flukes). These lesions may be up to 6 cm in diameter, migratory, firm, slightly mobile, and tender to palpation. The lesions are most commonly located on the lower abdomen and inguinal region. Cerebral involvement occurs in less than 1 percent of patients and is more common in children. Five percent of central nervous system infections are fatal. Presenting findings include meningoencephalitis (early) and signs and symptoms of a space-occupying lesion (late).

Abdominal involvement may result in abdominal pain, bloody diarrhea, and palpable abdominal masses.

Laboratory Findings

A peripheral eosinophilia occurs in 80 percent of patients with paragonimiasis, but may be low grade or absent when the parasites are encysted. Eosinophils may be found in fluids adjacent to the parasite, for example, in cerebrospinal fluid, sputum, pleural fluid, and pericardial fluid.

Diagnosis

The identification of eggs in the sputum, feces, pleural fluid, or cerebrospinal fluid or the identification of the adult parasite or eggs in tissue confirms the diagnosis. An immunoblot serologic test that has high sensitivity and specificity is available from the Centers for Disease Control and Prevention (CDC) in Atlanta. Chest x-ray films may reveal many findings, including diffuse infiltrates, nodules, cavities, ring cysts, calcification, and pleural effusions.

Differential Diagnosis

For the subcutaneous nodules of paragonimiasis, the differential diagnosis includes gnathostomiasis, sparganosis, and onchocerciasis. The differential diagnosis of pulmonary involvement includes tuberculosis, lung abscess, fungal infections, malignant tumor, melioidosis, and echinococcosis. The differential diagnosis for central nervous system involvement includes cysticercosis, echinococcosis, angiostrongyloidiasis, gnathostomiasis, fungal infection, tuberculosis, schistosomiasis, and a benign or malignant tumor.

Treatment

The drug of choice in the treatment of paragonimiasis is praziquantel. Although it is an approved drug, the FDA considers it investigational for paragonimiasis. When treating cerebral paragonimiasis, clinicians can give glucocorticoids along with praziquantel to blunt the inflammatory reaction that follows the release of antigens from the dying worms. Bithionol is an alternative mode of therapy and is available under an Investigational New Drug (IND) protocol from the CDC. Triclabendazole may also be effective.

Prevention

Paragonimiasis may be prevented by eating only well cooked crustaceans.

SCHISTOSOMIASIS [52], [53], [54] and [55]

Synonyms

Bilharziasis, snail fever, Katayama fever

Etiology

Schistosomiasis is caused by trematodes (flukes) that, in the adult stage, live in blood vessels. These include primarily *Schistosoma mansoni, S. japonicum, S. haematobium, S. mekongi,* and *S. intercalatum*. (See also " Cercarial Dermatitis," above, for a discussion of disease caused by nonhuman schistosomes.)

Life Cycle

Schistosome eggs excreted by a human or animal hatch in water, releasing free-swimming miracidia that penetrate the intermediate host, the snail, where they develop over 4 to 6 weeks, then emerge as free-swimming cercariae. The cercariae must penetrate the skin of a vertebrate host to continue development to the adult stage. Humans are the only important reservoir for *S. haematobium*. In parts of Africa, baboons are important hosts for *S. mansoni*. Animals (e.g., cows, dogs) are important hosts for *S. japonicum*.

Pathogenesis

Cercariae penetrate the skin over 30 seconds to 10 minutes, become schistosomulae, and may elicit a local inflammatory response. Schistosomulae enter venules and reach pulmonary capillaries in 1 week after skin penetration. Worms mature in the hepatic sinusoids after several weeks, mate, and migrate to the mesenteric venules (*S. intercalatum, S. japonicum, S. mansoni, S. mekongi*) or rectovesical plexus and branches of the vesical plexus (*S. haematobium*), where the mature worm pairs begin to produce eggs 1 to 3 months after infection. Mature adult females lay eggs daily, of which 60 percent remain in tissues or enter the bloodstream. The remainder of the eggs reach the bowel or bladder and are excreted. Granulomas with epithelioid cells, foreign body giant cells, and many eosinophils characterize the host response to the eggs. Necrosis, fibrosis, and calcification occur late in the disease. Worms do not multiply in the human host.

Geographic Distribution

Schistosoma haematobium is widespread in Africa, western Asia, and possibly a focal area of middle Asia (India). *Schistosoma japonicum* is found in several areas in eastern and Southeast Asia. *Schistosoma mekongi* is localized to a small area in Southeast Asia. *Schistosoma mansoni* is found in more than 50 countries in Africa, tropical South America, the Caribbean, and western Asia (eastern Mediterranean region). *Schistosoma intercalatum* has been found in at least

six central African countries. Figure 236-22 shows the geographic distribution of schistosomiasis due to *S. haematobium, S. japonicum,* and *S. mekongi*. Figure 236-23 shows the geographic distribution of schistosomiasis due to *S. mansoni* and *S. intercalatum*.

FIGURE 236-22 Global distribution of schistosomiasis due to *Schistosoma haematobium, S. japonicum,* and *S. mekongi*. (*Reprinted from* The control of schistosomiasis. *Second report of the WHO Expert 5 Committee*. *Geneva, World Health Organization, 1993 [WHO Technical Report Series No. 830], with permission*.)

FIGURE 236-23 Global distribution of schistosomiasis due to *Schistosoma mansoni* and *S. intercalatum.* (*Reprinted from* The control of schistosomiasis. *Second report of the WHO Expert 5 Committee. Geneva, World Health Organization, 1993 [WHO Technical Report Series No. 830], with permission.*)

Epidemiology

ACQUISITION Schistosomiasis is acquired by coming into contact with water that contains live cercariae (which penetrate intact skin and mucous membranes) and by drinking infested water. An estimated more than 200 million persons in the world are infected, and 500 to 600 million live in endemic areas. Infection can be acquired after a brief exposure in an endemic area (e.g., during travel). Activities associated with risk in endemic areas include swimming, wading, rafting, and bathing in infested water. Pools, ponds, shores of lakes, and small dams pose a greater risk than rapidly flowing streams. Invasive schistosomes are not found in saltwater. Chlorination, iodination, and boiling eliminate infective cercariae.
INCUBATION PERIOD AND TIME FRAME The skin manifestations of infection begin within minutes. Schistosomal fever (Katayama fever), which develops in a minority of those infected, begins 2 to 10 weeks after exposure. Other symptoms may begin after weeks to years. The usual life span of the adult worm within the human is 3 to 10 years, but survival of more than 30 years has been documented.

Clinical Features

Schistosomal infections in humans produce clinical features that range from inapparent to fatal. Most light infections are asymptomatic, and even heavy infections may cause few symptoms. Serious sequelae can develop in a small percentage of those who are infected, however, typically after many years of infection.

There are several different cutaneous manifestations of schistosomiasis. Schistosomal dermatitis occurs shortly after exposure to water infested with cercariae and reflects a hypersensitivity response to the cercariae. An urticarial and erythematous papular eruption associated with pruritus develops in persons who have been previously sensitized. The rash usually resolves over 1 week. In individuals without previous exposure to the parasites, the first exposure results in erythema and pruritus that resolves within hours. A similar rash may appear after exposure to nonhuman schistosomes (sometimes also called schistosomal dermatitis). (See Cercarial Dermatitis.)

Symptoms of acute schistosomiasis, also known as Katayama fever or Katayama syndrome, are most prominent in primary infection in nonimmune persons. The findings are due to a hypersensitivity response to schistosome antigens, as well as circulating immune complexes. Symptoms include fever, myalgias, and headache that may persist for 2 to 10 weeks, sometimes longer. Patients may also have lymphadenopathy, abdominal pain, anorexia, and diarrhea. The skin manifestations include urticaria, purpura, and edema of the face, and, particularly, edema of the extremities, genitals, and trunk. Katayama fever occurs with *S. japonicum* and *S. mansoni,* but rarely with *S. haematobium*.

Late skin involvement, bilharziasis cutanea tarda, occurs in persons with visceral disease. The cutaneous manifestations result from the granulomatous, inflammatory reaction to the deposition of eggs in the dermis (Fig. 236-24). It is evident primarily in persons who live in endemic regions. When lesions are present, they manifest as skin-colored or slightly pigmented, 2- to 4-mm, oval papules that may form clusters. The lesions are firm on palpation and are associated with pruritus. The lesions appear in crops and, without treatment, remain unchanged.

FIGURE 236-24 Ectopic deposition of *Schistosoma mansoni* ova.

The trunk, particularly the periumbilical region, is the most common anatomic location for the lesions of schistosomiasis. A zosteriform distribution has been described. Soft tissue involvement that presented as a breast mass has also been described. Lesions also appear in the genital and buttocks areas, especially on the vulva in women and the scrotum and penis in men. Early in the disease, the lesions in these locations may also manifest as papules or nodules. The presentation late in the disease is that of painless, skin-colored, pink or brown erosive papules and warty, vegetative, polypoid lesions that may be ulcerated and necrotic, with fistulous tracts. Lymphedema and elephantiasis can occur. These lesions may be complicated by secondary bacterial infection and squamous cell carcinoma.

Ectopic egg deposition can involve many tissues, including the central nervous system, ovaries, fallopian tubes, uterus and cervix, eyes, and gallbladder.

The manifestations of infection with *S. mansoni, S. japonicum, S. mekongi,* or *S. intercalatum,* include hepatomegaly, portal and pulmonary hypertension and complications of such due to fibrosis, and intestinal polyps, fistulae, and strictures. Glomerulonephritis occurs in up to 10 percent of patients with hepatosplenic *S. mansoni* infection. With *S. haematobium,* patients have dysuria, hematuria, urinary frequency, chyluria, secondary bacterial urinary tract infection, renal calculi, hydroureter, hydronephrosis, renal failure from obstructive uropathy, and bladder carcinoma. Recurrent bacteremia with *Salmonella* species is a frequent complication of schistosomiasis.

Laboratory Findings

Prominent eosinophilia may be present in early infection.

Diagnosis

Clinicians can diagnose schistosomiasis by identifying viable eggs in the stool (*S. japonicum* and *S. mansoni*), urine (*S. haematobium*), or biopsy of rectal, bladder, or other tissue. Diagnosis may be difficult to establish in early infection (Katayama fever) before the worms are producing large numbers of eggs. The eggs of *S. haematobium* have a terminal spine; those of *S. japonicum,* no spine; and those of *S. mansoni,* a lateral spine (Fig. 236-25). Several serologic tests are available, although they vary in their sensitivity and specificity. Serologic tests also do not indicate the intensity or duration of infection.

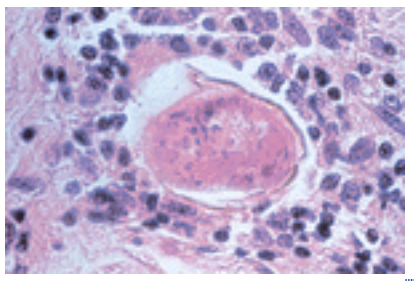

FIGURE 236-25 Skin biopsy of the patient shown in Figure 236-24, revealing *Schistosoma mansoni* ovum. (*Courtesy of Robert F. Cheek, MD.*)

In infection with *S. haematobium,* x-ray films of the pelvis may show linear calcification in the submucosa of the bladder and ureters.

Differential Diagnosis

For acute schistosomiasis, the differential diagnosis includes visceral larva migrans, infection with liver flukes, and the migration phase of strongyloides or other helminths. The differential diagnosis of bilharziasis cutanea tarda of the genital and buttocks area includes atypical syphilis or condyloma latum, condyloma acuminatum, elephantiasis and its causes, amebiasis, other granulomatous diseases, malignancy, and hemorrhoids.

Treatment

Praziquantel is the treatment of choice for *S. haematobium, S. japonicum, S. mansoni,* and *S. mekongi* infections.

Oxamniquine is an alternative treatment for *S. mansoni* infection.

Prevention

Avoiding contact with infested water in endemic areas, as well as snail control in those areas, can help to prevent schistosomiasis. Feces and urine of infected humans should be eliminated in a way that precludes contamination of freshwater.

SPARGANOSIS [56], [57]

Synonyms

Spirometrosis, sparganum infection

Etiology

The tapeworm larvae of the genus *Spirometra,* including *Spirometra mansoni, S. erinaceri,* and *S. mansonoides,* cause sparganosis (Fig. 236-26). At least 10 cases have been caused by *S. proliferum*.

FIGURE 236-26 Soft tissue swelling of sparganosis. (*Courtesy of Jay S. Keystone, MD, FRCPC*.)

Life Cycle

The development of *spirometra* involves definitive hosts (e.g., dogs, cats) and two intermediate hosts, a copepod (a tiny planktonic crustacean) and a vertebrate (e.g., amphibians, reptiles, birds). Humans are incidental hosts for the second-stage larvae, which do not mature in human tissues.

Pathogenesis

When ingested by humans, the larvae migrate widely and usually lodge in subcutaneous tissue or muscle. They provoke an inflammatory response of lymphocytes, plasma cells, neutrophils, and eosinophils. When the larvae die, there is increased inflammation and tissue eosinophilia, as well as tissue necrosis. Usually, only one or a few larvae are present. When infected flesh is applied to the skin, the larva migrate directly into the skin or wound, resulting in a localized acute inflammatory reaction.

Spirometra proliferum develops branched proliferating processes that may detach from the parent larva and develop into separate organisms, thus leading to a massive infection.

Geographic Distribution

The parasite is found in animals on all continents, but most human cases are from China, Japan, and Southeast Asia. Cases have also been reported from Africa, Australia, Caribbean islands, Southern Europe, and the Americas.

Epidemiology

ACQUISITION Sparganosis is acquired by drinking water contaminated with the copepod infected with larvae; by ingesting larvae in the raw or undercooked flesh of frog, snake, poultry, or pork; or by applying flesh that contains larvae to human skin or wound as a poultice.
INCUBATION PERIOD AND TIME FRAME The incubation period depends on the route of acquisition, with the range being 20 days to 14 months for those who eat infected frogs. Symptoms appear much sooner when transmission has taken place via direct larval migration from infected animal flesh into human flesh. The larvae can live in the human for at least 9 years.

Clinical Features

The severity of infection depends on the route of infection, the number of parasites, and the anatomic locations involved.

Sparganosis caused by ingestion of the infective larvae presents as a slow-growing, subcutaneous nodule that is occasionally migratory. The lesion may be pruritic and either tender or nontender. The infection is located in the subcutaneous tissue or skeletal muscle. Other organs affected include the brain, breast, bowel, eye, epididymis, urethra, and lung. Sparganosis due to the use of infected flesh results in localized pruritus, then erythema, edema, and subcutaneous nodules that are painful on palpation. Infection with *S. proliferum* may present as a massive systemic. infection with fever and many subcutaneous nodules.

Laboratory Findings

Peripheral eosinophilia and leukocytosis may be present during tissue migration.

Diagnosis

The definitive diagnosis is made by the identification of the parasite in the surgically excised tissue.

Differential Diagnosis

Included in the differential diagnosis for sparganosis are cysticercosis, visceral larva migrans, cutaneous larva migrans, gnathostomiasis, paragonimiasis, as well as a benign or malignant tumor, lipoma, and epidermal inclusion cyst.

Treatment

The surgical excision of the larvae is a component of treatment. Only palliative measures are available for *S. proliferum*.

Prevention

Steps to prevent sparganosis include boiling or filtering water; avoiding the ingestion of raw or undercooked frog, snake, poultry, or pork; and avoiding the use of raw flesh of such animals for poultices.

STRONGYLOIDIASIS [58], [59], [60] and [61]

Synonyms

Strongyloidosis, strongyloidal ground itch, larva currens

Etiology

Strongyloidiasis results from infection by the nematode (roundworm) *Strongyloides stercoralis*. *Strongyloides fuelleborni,* a common parasite of primates, infects humans in limited geographic areas. Other *Strongyloides* species that do not mature in humans affect the skin only.

Life Cycle

Under appropriate conditions, the parasite can multiply for several generations in the soil. Although animals can be infected with *S. stercoralis,* humans are the main reservoir host for human infection.

Pathogenesis

Filariform larvae penetrate the skin, enter blood vessels, and then travel to the lungs, where they break into alveoli and migrate up the respiratory tree to the pharynx. When they reach the upper gastrointestinal tract, the females embed themselves in the mucosa, mature, and produce partially embryonated eggs that hatch in the mucosal epithelium. The larvae migrate into the intestinal lumen and are either eliminated in the feces or develop into infective larvae that repeat the pulmonary migration, resulting in internal autoinfection. The larvae eliminated in the feces may penetrate the perianal or other skin and reinfect the host, resulting in external autoinfection.

Geographic Distribution

The distribution of *strongyloides* is worldwide, but the parasite is most common in tropical and subtropical areas. *Strongyloides fuelleborni* is endemic in parts of tropical Africa and Asia.

Epidemiology

ACQUISITION Humans acquire strongyloidiasis by the penetration of skin or mucous membranes by the infective larvae, usually from soil. Transmammary infection of *S. fuelleborni* may account for some infections in infants. Transmission also occurs via oral-anal sexual intercourse. Strongyloidiasis is a common infection with rates as high as 80 percent in some populations in tropical areas. High rates of infection are reported in institutionalized mentally impaired persons and in former prisoners of war. The risk of infection is high for persons with frequent soil contact (e.g., being barefoot) in warm, moist areas where human feces frequently contaminate the soil. Long-term glucocorticoid and immunosuppressive therapy, malnutrition, and particularly conditions that compromise cell-mediated immunity [e.g., human T-cell leukemia/lymphoma virus (HTLV-1) infection] predispose to hyperinfection and disseminated strongyloidiasis. Slow intestinal transit and achlorhydria may also contribute to an increased risk.
INCUBATION PERIOD AND TIME FRAME Larvae appear in the stool 2 to 3 weeks after exposure. Skin and pulmonary manifestations can begin within days of exposure. Because autoinfection can occur, infection can persist indefinitely.

Infection may first be recognized years after it was acquired.

Clinical Features

The signs and symptoms of strongyloidiasis occur irregularly with prolonged asymptomatic intervals. Nonspecific gastrointestinal complaints include abdominal pain, nausea, vomiting, diarrhea, constipation, malabsorption, and weight loss. Transient pulmonary infiltrates appear during pulmonary migration. Cough and wheezing may be present during this phase.

The characteristic skin manifestation of chronic strongyloidiasis is larva currens (Latin for tracing larva). The filariform larvae invade the perianal skin and travel within the skin, resulting in an urticarial serpiginous eruption. Larva currens is associated with intense pruritus. This eruption is unique in that it migrates at a rate of up to 5 to 10 cm per hour. Anatomic locations commonly include the buttocks, groin, and trunk. The duration of the eruption is hours to a few days, but it may be recurrent over the course of weeks to years. Persons chronically infected with *strongyloides* may also experience pruritus ani and chronic urticaria, consisting of fixed nonmigratory wheals on the trunk, wrists, and ankles. The secondary skin changes associated with strongyloidiasis include prurigo nodularis and lichen simplex chronicus.

Hyperinfection may cause abdominal pain, nausea, vomiting, diarrhea, and anorexia that are secondary to mucosal edema or ulcers. Malabsorption, ileus, or gastrointestinal bleeding sometimes develops. Pneumonia, adult respiratory distress syndrome, and respiratory failure may develop with disseminated infection. Filariform larvae can penetrate multiple extraintestinal sites, such as the brain, liver, and urinary tract. Bacteremia with bowel flora, carried from the gut by the larvae, and meningitis are frequent complications. The mortality rate is high in disseminated strongyloidiasis given the underlying diseases, impaired immune system, damage from the parasite, and bacterial superinfection.

The dermatologic manifestation of hyperinfection and disseminated strongyloidiasis is a rapidly and progressively diffuse petechial and purpuric eruption caused by massive filariform larvae dissemination to the skin (Fig. 236-27). The eruption typically involves the trunk and proximal extremities. The “thumbprint sign” has been used in disseminated strongyloidiasis to describe a unique pattern of periumbilical purpura that resembles multiple thumbprints.

FIGURE 236-27 Nonpalpable purpura secondary to disseminated strongyloidiasis. (*Reprinted with permission from: Grossman ME, Roth J:* Cutaneous Manifestations of Infection in the Immunocompromised Host. *Baltimore, Williams & Wilkins, 1995*.)

Laboratory Findings

Peripheral eosinophilia is common and may be high grade during larval migration. Eosinophilia may be absent when patients are on glucocorticoids or are severely immunocompromised.

Diagnosis

The identification of larvae in the stool, small bowel contents, and rarely in other body fluids confirms the diagnosis. Multiple stool examinations are often necessary to make the diagnosis. Serologic testing by ELISA has a sensitivity of approximately 90 percent.

Diagnosis of larva currens is made by its characteristic clinical morphology. Skin biopsy of the larva currens eruption typically fails to reveal larvae. Biopsy of the purpuric and petechial eruption of hyperinfection and disseminated strongyloidiasis will reveal larvae (Fig. 236-28).

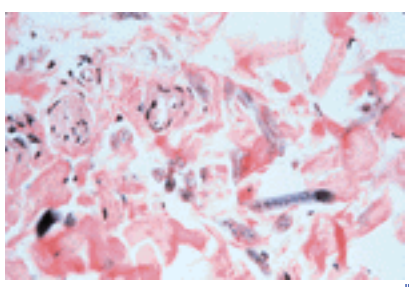

FIGURE 236-28 Skin biopsy of patient shown in Figure 236-27, revealing *Strongyloides stercoralis* larvae. (*Reprinted with permission from: Grossman ME, Roth J:* Cutaneous Manifestations of Infection in the Immunocompromised Host. *Baltimore, Williams & Wilkins, 1995*.)

Persons with a history of prior residence or activities in areas that place them at an increased risk for strongyloidal

infection should undergo screening for unrecognized infection prior to intentional immunosuppression.

Differential Diagnosis

Infection with other intestinal parasites and other causes of eosinophilic pneumonia make up the differential diagnosis. For larva currens, the differential diagnosis is cutaneous larva migrans. For the petechial and purpuric eruption, the differential diagnosis includes sepsis and causes of diffuse bleeding.

Treatment

Ivermectin or thiabendazole may be components of treatment for strongyloidiasis. Repeated courses or prolonged therapy may be necessary for patients who are immunocompromised or who have disseminated infection.

Prevention

Avoiding skin-soil contact in endemic areas can help prevent infection.

TRICHINOSIS [62], [63] and [64]

Synonyms

Trichinellosis, trichiniasis, trichinelliasis

Etiology

The pathogen in trichinosis is *Trichinella spiralis,* a filariform nematode.

Life Cycle

Animals ingest muscle containing infective larvae and become infected. Humans are incidental dead-end hosts.

Pathogenesis

Cysts surrounding larvae are digested in the upper gastrointestinal tract, releasing larvae that attach to villi in the small intestine, where the parasites mature and mate. Over 2 to 4 weeks, each female worm produces 500 to 1500 larvae that penetrate the intestinal wall and enter lymphatics and blood vessels to reach tissues throughout the body. Larvae enter striated muscle cells, where they grow, provoking an inflammatory reaction that is followed by the formation of a fibrous capsule around the larvae and an eosinophilic granulomatous infiltrate.

Geographic Distribution

Trichinosis is present in most countries, but there is marked variation in the incidence. The parasite is thought to be absent from Australia and many South Pacific islands. Sporadic infections occur worldwide via shipped meat.

Epidemiology

ACQUISITION The ingestion of raw or undercooked infected meat is the means by which humans acquire trichinosis. Sources of infection have included flesh from swine, bears, wild boars, cougars, walruses, horses, dogs, and cats. Swine fed uncooked scraps are more likely to be infected. Human infection tends to be sporadic and epidemic. Since 1947, trichinosis has been a reportable condition in the United States. State health departments reported 32 cases during 1994. Laws in the United States prohibit the feeding of offal to swine.
INCUBATION PERIOD AND TIME FRAME The usual incubation period for trichinosis is 10 to 30 days. Gastrointestinal symptoms may begin as early as 1 to 2 days after eating infected meat. Symptoms occur during larval migration, before encystment. The adult parasite is excreted within 2 to 3 months. The encysted larvae may remain viable for 5 to 10 years.

Clinical Features

The severity of trichinosis ranges from asymptomatic to fatal. The case fatality rate is 1 to 2 percent for recognized infections, usually related to complications of central nervous system or cardiac involvement.

Abdominal pain, diarrhea, and vomiting during the first week of infection are followed by fever, fatigue, myalgias, periorbital edema, and a macular and papular (sometimes urticarial) rash on the extremities. Hand swelling and volar surface erythema followed by desquamation have been reported. Subconjunctival and splinter hemorrhages are common (Fig. 236-29) Headache, cough, and shortness of breath may be reported. The central nervous system is involved in 10 to 20 percent of cases of trichinosis, as manifested by meningitis, encephalitis, paresis, and paralysis. Cardiac involvement includes myocarditis that leads to cardiac failure and arrhythmias.

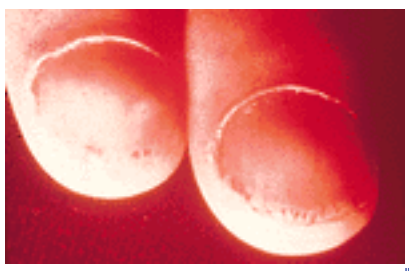

FIGURE 236-29 Subungual hemorrhage secondary to trichinosis. (*Courtesy of Herman Zaiman, MD*.)

Laboratory Findings

A peripheral eosinophilia may be marked and may persist for months.

Diagnosis

The definitive diagnosis comes from the identification of the parasite in surgically excised tissue (e.g., muscle biopsy; Fig. 236-30). Serologic testing with ELISA or indirect immunofluorescence is not useful in early infection. Antibody levels are usually low before the third week of the illness.

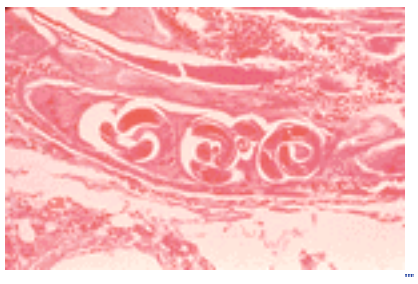

FIGURE 236-30 Muscle biopsy showing *Trichinella spiralis* larvae. (*Courtesy of Murray Wittner, MD, PhD*.)

Differential Diagnosis

The differential diagnosis includes allergic reactions, vasculitis, Katayama fever, visceral larva migrans, and eosinophilia-myalgia syndrome due to ingested tryptophan.

Treatment

Mebendazole is the treatment of choice. Although mebendazole is an approved drug, the FDA considers it an investigational drug for trichinosis. Albendazole and flubendazole (not available in the United States) may also be effective. Patients should receive steroids concomitantly when symptoms are severe.

Prevention

It is important to avoid raw and undercooked meat. Cooking the meat to a temperature of 170°F (77°C) will destroy the trichinae. Smoking and drying meat will not kill the infective larvae. Salt curing solutions may kill the trichinae, but the temperature and duration are important factors in this method.

VISCERAL LARVA MIGRANS[65], [66] and [67]

Synonyms

Toxocariasis, toxocaral visceral larva migrans, ocular toxocariasis, ocular larva migrans

Etiology

Visceral larva migrans is caused by the common dog roundworm, *Toxocara canis,* and much less frequently by the cat roundworm, *T. catis*.

Life Cycle

Dogs acquire *T. canis* infection by ingesting infective eggs or larvae, by transplacental transmission, or by the transmammary passage of larvae in milk. The eggs are passed in the stool and contaminate soil.

Pathogenesis

In humans, ingested embryonated *Toxocara* eggs reach the small intestine and release larvae that penetrate the mucosa and, by way of the portal circulation, reach the liver, lungs, and systemic circulation. When the larvae reach blood vessels that are too narrow to allow passage, the larvae bore through the vessel wall and migrate in tissues. The organs involved include the liver, heart, brain, spinal cord, eyes, and muscle. The larvae provoke hemorrhage, necrosis, and an eosinophilic and granulomatous tissue response. Because the parasite cannot mature in humans, the larvae may remain

dormant or wander in tissues for years.

GEOGRAPHIC DISTRIBUTION Visceral larva migrans is a common infection that is found worldwide. It is most common in tropical and temperate climates where both humans and dogs reside.

Epidemiology

ACQUISITION Humans become infected by ingesting the eggs from contaminated soil on fingers, fruits, vegetables, and other foods. Other reported sources of human infection include ingestion of larvae in raw liver from chickens, cattle, sheep, and other animals. Direct contact with dogs is not necessary. Warm, moist clay soil is the most favorable condition for the eggs, which must embryonate for 1 to 3 weeks before they become infective. Children and persons with a history of pica are at an increased risk. *Toxocara* eggs contaminate the soil in 10 to 30 percent of public playgrounds and parks.
INCUBATION PERIOD AND TIME FRAME The incubation period is typically 1 month or longer with a range of 1 to 2 weeks to years. The larvae may remain viable in the human for 10 years or longer.

Clinical Features

Most infections are asymptomatic or mild. Occasionally, however, infection leads to a prolonged, debilitating illness, loss of an eye, or death. Clinical findings reflect the intensity and chronicity of infection, and the anatomic location of larvae. Signs and symptoms, which may include fever, cough, wheezing, abdominal pain, anorexia, arthralgias, myalgias, fatigue, restlessness, and hepatomegaly, usually resolve over time. In heavy infections, the heart and central nervous system may be affected.

Skin manifestations may include subcutaneous nodules that may be tender, purpura, urticaria, pruritus, and an erythematous and urticarial eruption that evolves into pruritic papules on the abdomen and extremities. The palms and soles may be involved.

Patients with eye involvement, termed ocular larva migrans, usually lack systemic symptoms and have findings restricted to the eye (Fig. 236-31). Eye infection typically occurs unilaterally in children or young adults with the subacute presentation of decreased vision, strabismus, leukocoria, a fixed pupil, or a red eye. Clinically, ocular larva migrans can resemble neuroblastoma.

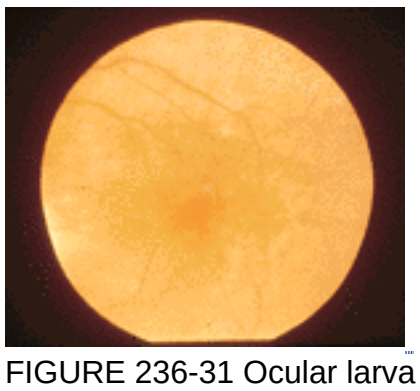

FIGURE 236-31 Ocular larva migrans. (*Courtesy of Murray Wittner, MD, PhD*.)

Laboratory Findings

Common findings are peripheral eosinophilia that may be high grade and persistent, leukocytosis, an elevated serum level of IgG, and elevated liver function test results.

Diagnosis

The identification of larvae in tissue or the combination of serologic evidence of infection and compatible clinical findings is the basis for diagnosis. ELISA testing has a sensitivity of 75 to 90 percent. Eggs and larvae are not found in human feces.

Differential Diagnosis

The differential diagnosis includes trichinellosis, schistosomiasis, strongyloidiasis, ascariasis, ancylostomiasis, fascioliasis, gnathostomiasis, filariasis, paragonimiasis, sparganosis, and infection with the raccoon roundworm, *Baylisascaris procyonis*. Ocular larva migrans may mimic toxoplasmosis, histoplasmosis, diffuse unilateral subacute neuroretinitis, Coats' disease, persistent hyperplastic primary vitreous, and retinoblastoma.

Treatment

Albendazole is the treatment of choice for visceral larva migrans. Alternative therapy is mebendazole. Although the FDA has approved albendazole and mebendazole, these medications are considered investigational in the treatment of visceral larva migrans. For severe symptoms or eye involvement, glucocorticoids can be used in addition to anthelmintic drugs. It is important to treat infected dogs.

Prevention

Avoiding exposure to soil contaminated with animal feces and treating infected dogs are primary preventive measures.

REFERENCES

GENERAL

1. Centers for Disease Control and Prevention: *Health Information for International Travel 2001–2002*. Atlanta, GA, U.S. Department of Health and Human Services, Public Health Service, 2001.

2. *International Travel and Health*. Geneva, WHO, 2002

3. Allen JE, Maizels RM: Immunology of human helminth infection. *Int Arch Allergy Immunol* **109**:3, 1996

4. Chin J (ed): *Control of Communicable Diseases Manual,* 17th ed. Washington, DC, American Public Health Association, 2000

5. Caumes E et al: Dermatoses associated with travel to tropical countries: A prospective study of the diagnosis and management of 269 patients presenting to a tropical disease unit. *Clin Infect Dis* **20**:542, 1995

6. Horton J: Albendazole: A review of antihelminthic efficacy and safety in humans. *Parasitology* **121**: S113, 2000

7. Liu LX, Weller PF: Antiparasitic drugs. *N Engl J Med* **334**:1178, 1996

8. Ottensen EA, Campbell WC: Ivermectin in human medicine. *J Antimicrob Chemother* **34**:195, 1994

9. Stephenson I, Wiselka M: Drug treatment of tropical parasitic infections recent achievements and developments. *Drugs* **60**:985, 2000

ASCARIASIS

10. O'Lorcain P, Holland CV: The public health importance of *Ascaris lumbricoides*. *Parasitology* **121**:S51, 2000

11. De Silva NR et al: Morbidity and mortality due to ascariasis: Re-estimation and sensitivity analysis of global numbers at risk. *Trop Med Int Health* **2**:519, 1997

12. Lindblade KA: The epidemiology of cercarial dermatitis and its association with limnological characteristics of a northern Michigan lake. *J Parasitol* **84**:19, 1998

13. Baster J et al: Aquarium dermatitis: Cercarial dermatitis in an aquarist. *Dermatology* **197**:84, 1998

COENUROSIS

14. Ing MB et al: Human coenurosis in North America. *Clin Infect Dis* **27**:519, 1998

15. Templeton AC: Anatomical and geographical location of human coenurus infection. *Trop Geogr Med* **23**:105, 1971

CUTANEOUS LARVA MIGRANS

16. Caumes E: Treatment of cutaneous larva migrans. *Clin Infect Dis* **30**:811, 2000

17. Richey TK et al: Persistent cutaneous larva migrans due to *Ancylostoma* species. *South Med J* **89**:609, 1996

18. Tremblay A et al: Outbreak of cutaneous larva migrans in a group of travelers. *Trop Med Int Health* **5**:330, 2000

CYSTICERCOSIS

19. Amatya BM, Kimula Y: Cysticercosis in Nepal: A histopathologic study of sixty-two cases. *Am J Surg Pathol* **23**:1276, 1999

20. Garcia HH, Del Brutto OH: *Taenia solium* cysticerosis. *Infect Dis Clin North Am* **14**:97, 2000

21. Sloan L et al: Evaluation of enzyme-linked immunoassay for serological diagnosis of cysticercosis. *J Clin Microbiol* **33**:3124, 1995

22. Orihel TC, Eberhard ML: Zoonotic filariasis. *Clin Microbiol Rev* **11**:366, 1998

23. Pampiglione S et al: Dirofilariasis due to *Dirofilaria repens* in Italy, an emergent zoonosis: Report of 60 new cases. *Histopathology* **38**:344, 2001

24. Shenefelt PD et al: Elusive migratory subcutaneous dirofilariasis. *J, Am Acad Dermatol* **35**:260, 1996

DRACUNCULIASIS

25. Centers for Disease Control: Progress toward global eradication of dracunculiasis. *MMWR Morb Mortal Wkly Rep* **49**:731, 2000

26. Hopkins DR et al: Dracunculiasis eradication: Delayed, not denied. *Am J Trop Med Hyg* **62**:163, 2000

27. World Health Organization International Commission for the Certification of Dracunculiasis Eradication: *Fourth meeting: Report and recommendations*. Geneva, Switzerland, February 15–17, 2000. (WHO/CDS/CPE/ CEE/2000.6).

ECHINOCOCCOSIS

28. Cannon CP et al: Soft tissue echinococcosis: A report of two cases and review of the literature. *Clin Orthop* **385**:186, 2001

29. Siles-Lucas M, Gottstein B: Review: Molecular tools for the diagnosis of cystic and alveolar echinococcis. *Trop Med Int Health* **6**:463, 2001

30. World Health Organization Informal Working Group on Echinococcus: Guidelines for the treatment of cystic and alveolar echinococcosis in humans. *Bull WHO* **74**:100, 1996

ENTEROBIASIS

31. Grencis RK et al: Enterobius, trichuris, capillaria, and hookworm including *Ancylostoma caninum*. *Gastroenterol Clin North Am* **25**:579, 1996

32. Sun T et al: Enterobius egg granuloma of the vulva and peritoneum: Review of the literature. *Am J Trop Med Hyg* **45**:249, 1991

FASCIOLIASIS

33. Arjona R et al: Fascioliasis in developed countries: A review of classic and aberrant forms of the disease. *Medicine (Baltimore)* **74**:13, 1995

34. Graham CS et al: Imported *Fasciola hepatica* infection in the United States and treatment with triclabendazole. *Clin Infect Dis* **33**:1, 2001

35. Harinasuta T et al: Trematode infections: Opisthorchiasis, clonorchiasis, fascioliasis, and paragonimiasis. *Infect Dis Clin North Am* **7**:699, 1993

FILARIASIS, LYMPHATIC

36. Addiss DB et al: Randomized placebo-controlled comparison of ivermectin and albendazole alone and in combination for *Wuchereria bancrofti* microfilaremia in Haitian children. *Lancet* **350**:480, 1997

37. Burri H et al: Skin changes in chronic lymphatic filariasis. *Trans R Soc Trop Med Hyg* **90**:671, 1996

38. World Health Organization: Weekly epidemiological record. *Bull WHO* **76**:149, 2001

GNATHOSTOMIASIS

39. Camacho SPD et al: Clinical manifestations and immunodiagnosis of gnathostomiasis in Culiacan, Mexico. *Am J Trop Med Hyg* **59**:908, 1998

40. Rusnak JM, Lucey DR: Clinical gnathostomiasis: Case report and review of the English-language literature. *Clin Infect Dis* **16**:33, 1999

HOOKWORM DISEASE

41. Brown A et al: *Necator americanus* (human hookworm) aspartyl proteinases and digestion of skin macromolecules during skin penetration. *Am J Trop Med Hyg* **60**:840, 1999

42. Sacko M et al: Comparison of the efficacy of mebendazole, albendazole and pyrantel in treatment of human hookworm infections of the southern region of Mali, West Africa. *Trans R Soc Trop Med Hyg* **93**:195, 1999

LOIASIS

43. Case Records of the Massachusetts General Hospital, Case 1-2002. *N Engl J Med* **346**:115, 2002

44. Klion AD et al: Albendazole therapy for loiasis refractory to diethylcarbamazine treatment. *Clin Infect Dis* **29**:680, 1999

45. Gardon J et al: Serious reactions after mass treatment of onchocerciasis with ivermectin in an area endemic for *Loa loa* infection. *Lancet* **350**:18, 1997

46. Wahl G, Georges AJ: Current knowledge on the epidemiology, diagnosis, immunology, and treatment of loiasis. *Trop Med Parasitol* **46**:287, 1995

ONCHOCERCIASIS

47. Burnham G: Ivermectin treatment of onchocercal skin lesions: Observations from a placebo-controlled, double-blind trial in Malawi. *Am J Trop Med Hyg* **52**:270, 1995

48. Hagan M: Onchocercal dermatitis: Clinical impact. *Ann Trop Med Parasitol* **92**:S85, 1998

49. Henry NL et al: Onchocerciasis in a nonendemic population: Clinical and immunologic assessment before treatment and at the time of presumed care. *J Infect Dis* **183**:512, 2001

50. Vincent JA et al: A comparison of newer tests for the diagnosis of onchocerciasis. *Ann Trop Med Hyg* **94**:253, 2000

PARAGONIMIASIS

51. Nawa Y: Re-emergence of paragoniamiasis. *Intern Med* **39**:353, 2000

SCHISTOSOMIASIS

52. Amer M: Cutaneous schistosomiasis. *Dermatol Clin* **12**:713, 1994

53. Elliott DE: Schistosomiasis: Pathophysiology, diagnosis and treatment. *Gastroenterol Clin North Am* **25**:599, 1996

54. Hamilton JV et al: Diagnosis of schistosomiasis: Antibody detection, with notes on parasitological and antigen detection methods.

Parasitology **117**:S41, 1998

55. Whitty CJM et al: Presentation and outcome of 1107 cases of schistosomiasis from Africa diagnosed in a non-endemic country. *Trans R Soc Trop Med Hyg* **94**:531, 2000

SPARGANOSIS

56. Chang JH et al: Subcutaneous sparganosis—A case report and a review of human sparganosis in Taiwan. *Kaohsiung J Med Sci* **15**:567, 1999

57. Suh J, Cho J: Subcutaneous and musculoskeletal sparganosis: Imaging characteristics and pathologic correlation. *Skeletal Radiol* **29**:402, 2000

STRONGYLOIDIASIS

58. Bank DE et al: The thumbprint sign: Rapid diagnosis of disseminated strongyloidiasis. *J Am Acad Dermatol* **23**:324, 1990

59. Gordon SM et al: Disseminated strongyloidiasis with cutaneous manifestations in an immunocompromised host. *J Am Acad Dermatol* **31**:255, 1994

60. Jacob CI, Patten SF: *Strongyloides stercoralis* infection presenting as generalized prurigo nodularis and lichen simplex chronicus. *J Am Acad Dermatol* **41**:357, 1999

61. Mahmoud AAF: Strongyloidiasis. *Clin Infect Dis* **23**:949, 1996

TRICHINOSIS

62. Mahannop P et al: Immunodiagnosis of human trichinellosis and identification of specific antigen for *Trichinella spiralis*. *Int J Parasitol* **25**:87, 1995

63. Murrell KD, Pozio E: Trichinellosis: The zoonosis that won't go quietly. *Int J Parasitol* **30**:1339, 2000

64. Walsh DS et al: Hand rash in trichinosis. *Clin Dermatol* **26**:272, 2001

VISCERAL LARVA MIGRANS

65. Boschetti A; Kasznica J: Visceral larva migrans induced eosinophilic cardiac pseudotumor: A cause of sudden death in a child. *J Forensic Sci* **40**:1097, 1995

66. Humbert P et al: Skin manifestations associated with toxocariasis: A case-control study. *Dermatology* **201**:230, 2000

67. Wolfrom E et al: Chronic urticaria and *Toxocara canis*. *Lancet* **345**:196, 1995

T>

Chapter 237

Mark Scharf Jennifer Daly

Bites and Stings of Terrestrial and Aquatic Life

ANIMAL BITES
Specific Bacterial Infections Caused by Animal Bites
Viral Infections Caused by Animal Bites
SNAKE BITES
AQUATIC BITES AND STINGS
Seal Bite
Injuries Caused by Jellyfish, Portuguese Man-of-War, Sea Anemones, and Corals
Dermatitis from Sponges
Injuries Caused By Echinoderms: Sea Urchins, Starfish, and Sea Cucumbers
Dermatitis and Bites from Marine Worms
Seabather's Eruption
Injuries Caused By Mollusks
Injuries Caused by Venomous Fish Spines
Fish Bites
WATERBORNE INFECTIONS
CUTANEOUS MANIFESTATIONS OF SEAFOOD INGESTION AND OF SEAFOOD POISONING

REFERENCES

The Book of Genesis promised humans dominion over the fish of the sea and every living thing that moved on the face of the earth. Unfortunately, it did not guarantee that every encounter between human and beast would be free from harm. The first two sections of this chapter consider the harmful effects of landborne animal bites, as well as the bacterial and viral infections they may transmit. The last section reviews bites and stings and other forms of injury that may be inflicted by marine life.

ANIMAL BITES

An estimated 2 million mammalian bites involving humans occur each year in the United States. [1] Dog bites constitute the largest number of these injuries, accounting for 80 to 90 percent. [1] The human victim is often a 7- to 9-year old boy, who may have been teasing or playing with the dog. Sometimes the bite occurs when a person is trying to break up a pair of fighting dogs, or the victim is the postal delivery person. Most bites are delivered by so-called friendly dogs, known to the victim. [1] Most of these injuries involve the upper extremity, especially the hands; the lower extremities are involved slightly less frequently. [1] Cat bites comprise the second most common type of mammalian bite, but the wounds are nearly twice as likely to develop an infection as wounds from dog bites. [2]

The evaluation and treatment of all bite wounds should include a careful history of the incident, the type of animal, the site of the bite, and the geographic setting. Hand wounds, puncture wounds, and crush injuries are likely to become infected. Infected bites should be cultured and a Gram-stained smear prepared; the wound should then be washed, well irrigated, and left open. Selection of an antibiotic depends on the bite history and Gram's stain results. [3] Most patients with deep cat bites, deep cat scratches, and sutured wounds should be treated with penicillin, amoxicillin-clavulanic acid, cefuroxime, or tetracycline because of the increased incidence of *Pasteurella multocida* infection. [1], [4] Tetanus immune status should be evaluated and rabies immunization considered.

Human bites and monkey bites deserve special mention as 30 percent become infected with aerobic or anaerobic mouth organisms. Anaerobic infection may spread through the metacarpal–phalangeal space and cause severe damage. The same procedure as for other animal bites should be followed; that is, culture and Gram's stain, thorough washing, and debridement. Wounds should be left open if possible, especially hand wounds. Patients with human bites should be treated prophylactically with amoxicillin/clavulanate for 7 to 10 days. Clenched fist injuries should be evaluated by a hand surgeon because of the high likelihood of infectious complications including septic arthritis and osteomyelitis. [1]

Specific Bacterial Infections Caused by Animal Bites

PASTEURELLA MULTOCIDA A common organism infecting bite wounds is *P. multocida.* Disease caused by this organism is now diagnosed more frequently; thus, its presence in the nasopharynx in 50 to 66 percent of dogs and 70 to 90 percent of cats is of public health importance. Most infections in humans fall into one of three clinical patterns:

1. The most common pattern is that of local infection with adenitis after a dog or cat bite or scratch. *P. multocida* is the most common pathogen in cat bite infections and may also complicate 26 percent of dog bite wounds. [2] The infection usually presents within 24 to 48 h, often within several hours. [2] *P. multocida* is the most common organism to be found in patients whose infection presents within the first 24 h. [5] In patients with a cat bite, the infection may be followed by tenosynovitis or osteomyelitis as a result of inoculation of the organism into the periosteum by the long, sharp tooth of the animal. Canine teeth are more blunt and less likely to penetrate the periosteum. *Pasteurella* infections have also been reported after bites of large cats, such as lions and tigers.
2. The second pattern is *chronic pulmonary infection,* in which *P. multocida* may occur as the primary pathogen or in association with other organisms. Bacteria may enter the respiratory tract through the inspiration of contaminated barn dust, or by inhalation of infectious droplets sprayed by the sneeze of an animal. In such cases, the bacteria

probably colonize the respiratory tract and lie dormant in the patient with chronic lung disease. Acute infection occurs only after trauma to the bronchial tree. Bronchiectasis, emphysema, peritonsillar abscess, and sinusitis have all been described with this organism.

3. Finally, systemic infection with bacteremia or meningitis may occur.

P. multocida is a small, gram-negative, ovoid bacillus that grows well on blood agar but does not grow on selective gram-negative media such as MacConkey agar. Because of the superficial resemblance of *P. multocida* to *Haemophilus influenzae* and *Neisseria* organisms, infections of the respiratory tract and central nervous system with this bacillus may be misdiagnosed initially. Failure of growth on routine gram-negative media is an important clue. Treatment of the patient with presumptive *P. multocida* infection (i.e., any patient with a deep cat bite or scratch or a deep dog bite) should consist of careful washing of the wound and an attempt to leave it open. The antibiotic of choice is penicillin, orally for 7 to 10 days, with careful follow-up of the wound. Ampicillin, tetracycline, ciprofloxacin, and trimethoprim-sulfamethoxazole are alternatives. To treat possible pathogens in addition to *P. multocida,* amoxicillin-clavulanic acid is the best empirical choice before culture or Gram-stain results are available.

STAPHYLOCOCCUS INTERMEDIUS *S. intermedius* is an organism associated with dogs weighing more than 40 pounds. It is more commonly found in canine gingival flora than *S. aureus* (39 percent versus 10 percent). [6] It is a gram-positive, coagulase-positive coccus that can be differentiated from *S. aureus* in the laboratory by biochemical testing. In comparison with *S. aureus, S. intermedius* does not produce acetoin from glucose and has ß-galactosidase activity. If these tests are not performed, the laboratory may mistakenly report an isolate as *S. aureus*. Antibiotic treatment is the same as that for infections with *S. aureus,* as approximately 55 percent (slightly less than *S. aureus*) are resistant to penicillin because of production of beta-lactamase.

CAPNOCYTOPHAGA CANIMORSUS *C. canimorsus* is a capnophilic, facultatively anaerobic slow-growing, gram-negative rod associated with dog bites. [7] The organism has been found in the oral cavity of 17 percent of cats and 24 percent of dogs. [8] Most infections occur in the splenectomized or immunocompromised host and present as overwhelming sepsis. Meningitis has been reported in a child. [5]

PORPHYROMONAS SPECIES *Porphyromonas* species are slow-growing anaerobic bacteria that require media enriched with vitamin K and hemin for optimal growth. They are difficult to culture, requiring 4 to 6 days for colony formation, and they have been recognized as a cause of infection in patients with dog and cat bites. [9] These organisms are found in the deep gingival pockets and cause destructive periodontitis in animals and humans. Citron and coworkers [10] found *Porphyromonas* species in 28 percent of culture specimens from patients with infected dog and cat bite wounds.

EDWARDSIELLA TARDA This bacterium is found most frequently in freshwater fish and reptiles, but has been isolated from seals living in salt water, amphibians, mammals, and birds. It is a gram-negative rod that is a member of the family *Enterobacteriaceae* and resembles *Salmonella* in various biochemical attributes. It is an unusual cause of clinical disease in humans. The most commonly identified infection in humans is gastroenteritis, but soft-tissue infection, including cellulitis or abscess, has been reported after bites or scratches from animals, including a pet turtle. [11] Osteomyelitis, intraabdominal and pulmonary infections, meningitis, and septic shock have been reported.

MARINE VIBRIOS *Vibrio carchariae,* a salt water-loving (halophilic) gram-negative bacillus, was reported as the cause of a wound infection after a shark bite. [12]

CAT-SCRATCH DISEASE *Bartonella henselae* is the most common etiologic agent of cat-scratch disease. *Afipia felis* and other *Bartonella* species may cause some cases (see Chap. 198).

PLAGUE (See Chap. 199)

TULAREMIA (See Chap. 199)

RAT-BITE FEVER (See Chap. 199)

Viral Infections Caused by Animal Bites

RABIES The most notorious viral disease caused by an animal bite is rabies. Its epidemiology has changed in the past few years as a result of improved control of rabies in the domestic animal population. Now, nonimmune dogs and domestic animals account for only 10 percent of cases, whereas sylvatic animals, such as skunks, raccoons, red and gray foxes, bats, and domestic dogs, represent the greatest potential danger; rodents, such as squirrels and hamsters, are probably inconsequential as sources of rabies. [13] Postexposure prophylaxis that is nearly 100 percent effective has reduced the number of cases of human rabies from more than 100 per year a century ago to an average of 1 to 3 cases a year in the United States today. Live virus is introduced into nerve tissue at the time of the bite. The virus multiplies at the site and then spreads to the central nervous system. It replicates in gray matter and then spreads along autonomic nerves to the salivary glands, adrenal glands, and heart. The incubation period varies with the site of the bite—from 5 days to as long as several years. Clinical features include a prodromal period of 1 to 4 days, followed by high fever, headache, and malaise. Paresthesia at the site of inoculation occurs in 80 percent of patients. The next sequence of events is familiar: agitation, hyperesthesia, dysphagia, excessive thirst, paralysis, and death.

Diagnosis The diagnosis of clinical rabies is difficult and is often not made until after death of the patient. Viral isolation may be positive in specimens of saliva or cerebral spinal fluid during the first 2 weeks of the illness. Serum antibodies may be detected as early as day 6 and usually by day 13. The fluorescent antibody method for detection of the viral antigen is the most rapid and sensitive means of making the diagnosis, and can be used on a biopsy of skin from the highly innervated hair-covered area of the neck or brain tissue.

Prevention and treatment The most effective prevention for rabies is to avoid contact with any wild animal or any unfamiliar domestic animal. Persons at risk of unavoidable contact with rabies, such as spelunkers, veterinarians, virologists, and travelers spending time in countries where rabies is enzootic, should receive preexposure prophylaxis. For people who cannot avoid exposure, a human diploid cell vaccine series (three intramuscular injections, days 0, 7, and 21 or 28) should be given in the deltoid muscle [13] and repeated every 2 years. In persons vaccinated intradermally, the neutralizing antibody titer should be followed to assess immunity. A case of rabies occurred in a Peace Corps volunteer who had been immunized by the intradermal route. Immunity may or may not be as fully protective in persons vaccinated intradermally as it is in patients who are vaccinated intramuscularly. [14] The need for postexposure prophylaxis can be determined by the answers to these questions: What is the status of animal rabies in the locale where the exposure took place? Was the attack provoked or unprovoked? Of what species and size was the animal? What was the state of health and vaccination record of the animal? Will the brain of the animal be examined within 48 h? Most animals transmit rabies virus in saliva only a few days before becoming ill themselves (dog and skunk, 5 days; fox, 3 days; cat, 1

day; bats, however, may harbor the virus for many months).

Bites by household pets If the dog or cat is healthy and available for observation for 10 days, do not treat the patient unless the animal develops rabies. At the first sign of rabies in the animal, treat the patient with rabies immune globulin (RIG) and human diploid cell rabies vaccine (HDRV). The symptomatic animal should be killed and tested as soon as possible. If the animal is rabid, or suspected of being rabid, or if it does not have up-to-date vaccination records, treat the patient with RIG and HDRV. [13] In certain states, ferrets may be kept as pets. These animals should be vaccinated against rabies, as they are large enough to survive a bite by a rabid animal and become infected.

Bites by wild animals All skunks, bats, groundhogs, foxes, coyotes, raccoons, bobcats, and other carnivores should be regarded as rabid unless laboratory tests prove negative. Treat the patient with RIG and HDRV.

Bites by other animals Consider other animals (livestock, rodents, lagomorphs, e.g., rabbits, hares) individually. [13] Local and state public health officials should be consulted about the need for prophylaxis. Bites by squirrels, hamsters, guinea pigs, gerbils, chipmunks, rats, mice, and other small rodents almost never call for antirabies prophylaxis.

Specifics of treatment The most important step is to cleanse the wound immediately with a brush and soap so as to remove as much virus as possible. Rinse well, and then perform a second scrub with green soap or alcohol, which is rabicidal. If vaccine treatment is indicated, both RIG and HDRV should be given as soon as possible, regardless of the interval after exposure, unless the patient has been previously vaccinated and a serologic assay shows current immunity. In this case, only HDRV is needed and should be given on day 0 and day 3. [13] The administration of RIG is the more urgent procedure. If HDRV is not immediately available, start RIG and give HDRV as soon as it is obtained. RIG (20 IU/kg) should be given to the patient immediately—50 percent around the site of the bite and 50 percent in the thigh or the arm. This passive immunization will result in the early appearance of antibody but will also inhibit development of the active antibody from the human diploid vaccine—thus, the reason for prolonged dosage of the vaccines. Active immunization is accomplished with the human diploid cell vaccine. HDRV is given intramuscularly for a total of five doses. The doses are given on days 0, 3, 7, 14, and 28. Serum for rabies antibody testing should be collected 2 weeks after the fifth dose. If there is no antibody response, an additional booster should be given.

Management of the patient with clinical rabies When the rare patient is admitted with the clinical diagnosis of rabies, several steps should be taken immediately. First, the diagnosis must be made rapidly by fluorescent antibody staining of various tissues, as well as mouse inoculation with the source animal's brain tissue. Elevated antibody titers in the absence of immunization are clear evidence of infection. The first signs of clinical rabies are usually nonspecific, such as malaise, anorexia, fatigue, headache, and fever. The acute neurologic illness that follows is most commonly characterized by intermittent episodes of hyperactivity. In some cases, however, a progressive paralysis is most common. The usual period from onset of symptoms to onset of coma is 10 days. Risk of exposure for hospital staff includes contamination of open wounds or mucous membranes with saliva or other potentially infectious material such as neurologic tissue, spinal fluid, or urine. Blood, serum, and stool are not considered infectious. [15] The basic clinical management consists of anticipating and preventing all treatable complications of the rabies infection. Pulmonary hypoxia should be prevented by tracheostomy at the first sign of respiratory difficulty, monitoring of actual PO_2, and use of supplemental oxygen. There are no specific antiviral treatments for rabies. Anticonvulsant therapy should also be instituted. Extreme increases in intracranial pressure may be prevented by insertion of a cerebrospinal fluid reservoir connected to the lateral ventricle, allowing withdrawal of the intraventricular fluid and measurement of intracranial pressure. Cardiac arrhythmias may be anticipated with careful monitoring. Rabies has been regarded as uniformly fatal. There have now been several patients who have survived with prolonged cardiorespiratory support, and there is serologic evidence that some animals have survived. An aggressive approach to the patient with known rabies infection is certainly worthwhile.

LYMPHOCYTIC CHORIOMENINGITIS Lymphocytic choriomeningitis (LCM) virus is an infectious agent common to the house mouse but rarely transmitted to humans. The mode of transmission is unknown. [16] Recently, outbreaks of LCM virus infection in the United States and Germany have been traced to pet hamsters. Hamsters, like mice, may excrete LCM virus for several months and may become lifelong carriers. When humans are infected, there may be three major manifestations: a grippe-like illness, meningitis, or encephalitis. The cerebrospinal fluid usually reveals an increased mononuclear leukocyte count and hypoglycorrhachia. Symptomatic therapy is all that is available.

HERPESVIRUS SIMIAE (B VIRUS) Herpesvirus simiae (B virus) is enzootic in old world monkeys, especially rhesus, cynomolgus, and other macaques. The illness in monkeys is similar to that caused by herpes simplex in humans, and asymptomatic monkeys may shed the virus in saliva. Most cases in humans have occurred after direct exposure to macaque monkeys or monkey tissue through bites, scratches, or cuts. [17] A vesicular lesion develops at the wound site with progressive lymphadenitis and fever. Over the next few days to weeks patients develop a severe illness, which is characterized by rapidly progressive ascending neuropathy and encephalitis. [17] The illness is rare, with only 22 well-documented cases described from 1937 to 1990. Of cases diagnosed before 1987, 72 percent were fatal. A cluster of four cases occurring in 1987 in Pensacola, Florida, were treated with acyclovir. The two patients who received acyclovir when their infections were localized responded well to therapy and have been maintained on oral prophylaxis. The diagnosis can be made by viral culture, serology, or the presence of intranuclear inclusions in lymph nodes. All macaques should be presumed to be shedding B virus and should be handled accordingly. All monkey-inflicted injuries should be cleansed, specimens should be collected for viral culture, and the patient should be evaluated by a physician. Clinical and serologic monitoring is critical, and high-risk or infected patients should be treated according to established guidelines. [17] The use of acyclovir or ganciclovir initially and acyclovir for years has led to improved survival in infected patients.

SNAKE BITES

In the United States, there are approximately six deaths from snake bites and several thousand snake bite envenomations each year. [18] The largest number of venomous snake bites occur in the southwestern and Gulf states. Arizona, Florida, Georgia, and Alabama are the states with the highest incidence of snake bites. Worldwide as many as 30,000 fatal snake bites may occur each year. Because of regional differences in varieties of snakes, management recommendations differ geographically.

The two major poisonous snakes in the Americas are the pit viper (family Viperidae, subfamily Crotalinae, which includes the rattlesnake, water moccasin, and copperhead) and the coral snake (family Elapidae). Two poisonous snakes are native to New England. The northern copperhead, also called the highland moccasin, is pink or reddish brown and is

marked with large chestnut-brown barrels resembling dumbbells or hourglasses (Fig. 237-1). The bite is painful but rarely fatal. The timber rattler is dark brown with chevrons of black and brown (Fig. 237-2).



FIGURE 237-1 Northern copperhead.

FIGURE 237-2 Timber rattlesnake.

The degree of toxicity of a snake bite depends on the potency of the venom, the amount injected, the size and condition of the snake, and the size of the person bitten. [19] There are immediate local clinical manifestations of a pit viper bite. Pain occurs at the site of the bite (usually within 5 min). Signs and symptoms of the bite site include wheal with local edema, numbness, and, within moments, ecchymosis and painful lymphadenopathy (Fig. 237-3). Nausea, vomiting, sweating, fever, drowsiness, and slurred speech may develop. Bleeding of the gums and hematemesis are common hemorrhagic manifestations. If edema and erythema have not developed within 8 h after the bite, it can be assumed that significant envenomation did not occur. Recent mortality rate estimates for victims who receive antivenom in a health care facility are less than 1 percent, and probably less than 0.1 percent. [18]

FIGURE 237-3 Copperhead snake bite.

For proper treatment, it is extremely important to establish that the bite is from a poisonous snake. The patient should have distinct fang punctures and immediate local pain, followed by edema and discoloration within 30 min. It is helpful to inspect the snake, because those that are poisonous may be differentiated from those that are not by the presence of fangs and the shape of the pupils (Fig. 237-4). A photograph of snakes common to a specific geographic area is important for all hospital emergency wards to aid practitioners in deciding if the patient has been bitten by a poisonous snake.

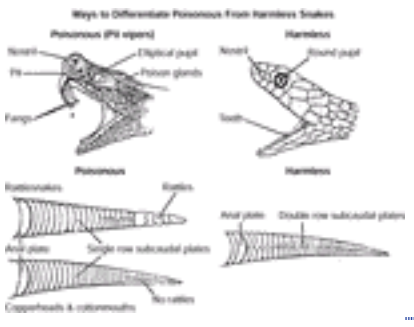

FIGURE 237-4 Identification of poisonous and nonpoisonous snakes. (*From Wingert WA, Wainschel W: A quick handbook on snake bites. Resident & Staff Physician, p 56, 1977. Reprinted with permission.*)

Although there are still insufficient evidence-based data for first aid and out-of-hospital treatment for snake bite envenomations, a rational approach based on currently available information includes these recommendations [20]:

1. The patient should be stabilized and transported as rapidly as possible to a health care facility capable of administering antivenom. [20]
2. The affected site should be immobilized and kept in a position at or slightly below the level of the heart, and the patient should be kept at strict bedrest. [20]
3. The use of venous compression bands or pressure immobilization (PIM) remains controversial. These techniques

(which should not be confused with arterial tourniquets) are designed to impede the return of venous and lymphatic flow from the bite site without sacrificing blood flow to the extremity. The potential advantage of employing these maneuvers is to forestall the systemic spread of the venom when transport to a medical facility will be measured in hours rather than minutes. In cases where there is likely to be a significant delay in transport, and the victim is developing systemic signs of envenomation such as hypotension, these techniques may be of value. [20] Arguments against using these techniques include the time that it takes to apply the treatments, which may further delay transport time. Additional arguments against the use of these techniques include the potential for concentrating the venom in the affected limb, which may worsen local necrosis, along with the possibility of a bolus effect when the compression is released. [20] Another possible disadvantage of these compression techniques is the potential for them to become arterial compression tourniquets as the affected limb swells in reaction to the toxin. If a decision is made to use a venous compression band or PIM in the field, arterial pulses should be palpable distal to the ligature, and the dressing should be checked frequently to be sure that it is has not become too tight. If a venous compression dressing has been applied in the field and is not causing vascular compromise, it should be left in place until the patient reaches a health care facility and antivenom is at the bedside. [20]

4. The value of suction devices to extract venom from the bite site remains uncertain. A mechanical suction device called the Sawyer Extractor vacuum pump can be used without incision of the bite site. If such a device is applied in the field and fluid is accumulating in the suction cup, it can be left in place until the patient reaches a medical facility. [20]
5. The use of cryotherapy, incision or excision of the bite site, arterial tourniquets, and electroshock therapy as part of emergency field therapy should be discouraged.

The role of surgical intervention in the treatment of snake bite envenomations is limited in most cases. Debridement of truly necrotic skin and subcutaneous tissues is recommended 4 to 5 days after envenomation. [21] In cases of bites to a digit, if there is severe swelling and the finger is tense, blue, or pale, a digit dermotomy may be of use. [21] This technique involves making a longitudinal excision through the skin on the medial or lateral side of the digit under local anesthesia. The purpose of this procedure is to avoid the complications of a compartment syndrome affecting the involved finger. True compartment syndrome involving an extremity is a rare complication of snake bite envenomation. Fasciotomy should be used only in cases of compartment syndrome that have been properly documented with increased compartment pressures that have not responded to prompt and sufficient treatment with antivenom. [21]

The primary treatment for crotaline snake venom poisoning is prompt and adequate dosing with antivenom. Antivenom is most effective if given within 4 h of the snake bite. Emergency information and antivenom are available in the United States through a nationwide poison control center network, which can be reached 24 h a day by calling 1-800-222-1222.

A polyvalent antiserum derived from horse serum, Antivenin (Crotalidae) Polyvalent (ACP), has been used since 1954 to treat bites of North American and South American crotaline snakes. ACP is still available from Wyeth-Ayerst (Philadelphia, PA), but a new antivenom derived from sheep serum is now available. This antivenom, Crotalidae Polyvalent Immune Fab (Ovine), trade name CroFab, is manufactured by Protherics Inc. (Nashville, TN) and is distributed by Savage Laboratories (Melville, NY). The potential advantages of the new antivenom are decreased immunogenicity and increased potency relative to that of ACP. [18] CroFab is less likely to cause acute or delayed allergic reactions because most of the more immunogenic Fc portion of the antibody is removed during the manufacturing process. Unlike ACP, which requires bedside testing with an intradermal injection to rule out hypersensitivity to horse serum, CroFab does not require pretesting. [19], [22]

Polyvalent pit viper antivenin should be used for all severe American crotaline snake bites except those of the coral snake. The dosage should be guided by the severity and progression of local changes and systemic clinical signs. [22]

The dosage of ACP antivenin for a moderate rattlesnake bite is 4 to 7 vials (10 mL); severe cases may require 15 to 20 vials. A water moccasin bite requires 1 to 4 vials. For copperhead bites, antivenin usually is necessary only if the patient is a child or is elderly. The vials should be diluted in 500 mL of normal saline and given intravenously over 30 min.

The initial recommended dose of CroFab is 4 to 6 vials. If symptoms are not controlled with the first dose, additional doses of 4 to 6 vials should be administered repeatedly until symptoms of envenomation are under control. Once the envenomation syndrome is controlled, additional 2-vial doses should be infused at 6, 12, and 18 h. [18]

Supportive treatment is important, that is, hospitalization, and careful evaluation of baseline hematocrit, platelet count, and prothrombin time. The wound should be cleansed and covered. Antitetanus therapy and antibiotic prophylaxis with penicillin, 2 g/day, or tetracycline, 2 g/day, should be initiated for severe bites.

AQUATIC BITES AND STINGS

Seal Bite

Normally, a seal bite occurs on the finger of a trainer or a seal hunter—thus the term seal finger or Spaek finger. [23] The etiologic agent is unclear; *Mycoplasma phocidae* was isolated in one case. The incubation period of 4 to 8 days is followed by throbbing pain, erythema at the site, and swelling of the joint proximal to the bite. Untreated, Spaek finger progresses to cellulitis, tenosynovitis, and arthritis. The treatment before antibiotics were available was amputation of the affected finger to relieve the severe pain and deformity. Tetracycline, 500 mg orally four times a day for 10 days, is now the antibiotic of choice. It is also helpful to immobilize and elevate the finger as well as soak it several times a day.

Injuries Caused by Jellyfish, Portuguese Man-of-War, Sea Anemones, and Corals

Stings caused by jellyfish, Portuguese man-of-war, sea anemones, and corals are the most common envenomations

encountered by humans in marine environments. All of these creatures are members of the phylum Cnidaria, formerly known as Coelenterata. They are divided into three major classes. The first class, Hydrozoa, includes the Portuguese man-of-war, fire corals, and hydroids. Jellyfish belong to the second class, Scyphozoa. The third class, Anthozoa, encompasses sea anemones and true corals. Approximately 100 of the 9000 species of Cnidaria that have been identified may cause injury to humans. [24]

Cnidarians are radially symmetric animals with body walls formed by an inner and outer layer of cells enclosing a jelly-like substance. [25] They may be either free floating in the water like jellyfish, or sessile like corals. [24] Almost all cnidarians possess nematocysts, or stinging capsules, which are usually concentrated on some form of tentacle. Each nematocyst contains a toxin or group of toxins and a coiled threadlike apparatus with a barbed end that functions like a flexible hypodermic syringe (Fig. 237-5). When the nematocyst comes into contact with a victim, the barbed end is discharged and the toxin is injected into the skin.

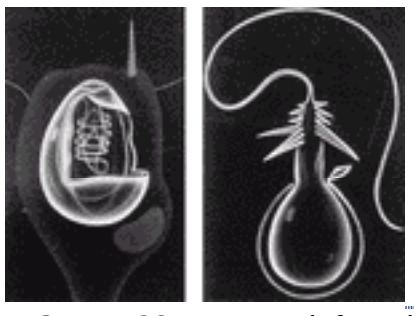

FIGURE 237-5 From left to right, a diagrammatic view of an intact and discharged coelenterate nematocyst. (*R Kreuzinger, courtesy of World Life Research Institute.*)

Cnidarian stings range from mild, self-limited irritations to extremely painful and serious injuries, depending on the toxin of the species involved and the magnitude of the envenomation. Stings from certain species such as the cubomedusae, or box jellyfish, can be fatal.

In most cases, jellyfish stings elicit toxic rather than allergic types of reactions. These toxic reactions may be localized and/or systemic in nature and are discussed below. Although they occur less frequently, immediate-type hypersensitivity reactions, including urticaria, angioedema, and anaphylaxis, require prompt medical intervention because shock and death may ensue in highly sensitized individuals. Allergic contact dermatitis, delayed and persistent hypersensitivity reactions, [26] granuloma annulare, [27] and erythema nodosum [28] are several of the possible cutaneous reactions to jellyfish stings. Table 237-1 summarizes reactions to jellyfish stings.



TABLE 237-1 **Local and Systemic Reactions to Jellyfish Stings**

INJURIES CAUSED BY JELLYFISH

Sea nettles Among the most common causes of jellyfish stings are the sea nettles, which comprise two different species, both of which inhabit Atlantic as well as Indo-Pacific waters. *Cyanea capillata,* and its relatives, is the larger of the two species, with a bell measuring up to 1 m and numerous tentacles reaching 30 m in length [29] (Fig. 237-6). *Chrysaora quinquecirrha* is smaller, with a white or rusty bell that may reach 30 cm with four digestive tentacles hanging from it. [29]

FIGURE 237-6 *Cyanea capillata,* also known as the sea nettle or lion's mane, is a common cause of jellyfish stings. (*BW Halstead, courtesy of World Life Research Institute.*)

Although sea nettle stings are seldom lethal, they can be quite painful. [36] Initially the victim experiences a sharp burning pain in the area contacted by the tentacles. Within minutes, the sting area develops a zig-zag shaped, whiplike pattern of raised red welts 2 to 3 mm wide (Fig. 237-7). The duration of acute pain may vary, but it often begins to subside in 30 min. The wheals usually subside by 1 h, but purplish-brown petechial and postinflammatory pigmentation may persist for several days in the sites of tentacle contact.

FIGURE 237-7 Whiplike sting pattern caused by *Cyanea capillata* in a young boy. (*JH Barnes, courtesy of World Life Research Institute.*)

Portuguese man-of-war *Physalia physalis* is the species name for the Portuguese man-of-war, which is a member of the class Hydrozoa and is therefore not a true jellyfish. *P. physalis* is encountered in both Atlantic and Mediterranean waters, and is easily recognized by its translucent blue to pink or purple, bladder-like float with multiple tentacles suspended from it (Fig. 237-8). Both the floating bell and the tentacles are composed of large colonies of hydroids. *P. physalis* is distinguished from its Pacific ocean relative *P. utriculus,* commonly known as the blue bottle, in that *P. physalis* has a larger bell ranging in size from 10 to 30 cm with multiple fishing tentacles extending up to 30 m, whereas *P. utriculus* has only a single tentacle that rarely exceeds 5 m. [29] These tentacles are armed along their entire length with hundreds of thousands of nematocysts arranged in stinging batteries, with each battery containing hundreds of nematocysts. The nematocysts remain active even after portions of the tentacles are broken off in storms or when these animals are stranded on the shoreline by high winds or waves. Beached Portuguese man-of-war can cause a severe sting when stepped on or touched. Children who are stung after handling these animals cry and rub their eyes and may develop an acute conjunctivitis.

FIGURE 237-8 *Physalia physalis,* the Portuguese man-of-war, is distinguished by its bladder-like float and numerous trailing tentacles. (*BW Halstead, courtesy of World Life Research Institute.*)

Stings from *P. physalis* are more painful and severe than those caused by sea nettles and are more extensive and serious than those caused by *P. utriculus.* At the moment of contact with the tentacles of *P. physalis,* the victim experiences a sharp, shocklike, burning pain. There may be painful paresthesias or numbness in the sting area. Initially, the sting area appears as an irregular single line or multiple lines composed of red papules, beaded streaks, or erythematous welts that correspond to the areas of tentacle contact. The wheals resolve in several hours but may progress to vesicular, hemorrhagic, necrotic, or ulcerative stages before healing [25] (Fig. 237-9). Postinflammatory striae may persist for weeks to months. Permanent scarring may occur in some instances. [31] Severe localized complications of *P. physalis* stings may also include arterial spasm in the sting site that can result in distal digital gangrene of the affected limb. [37]

FIGURE 237-9 This diver surfaced directly under a large Portuguese man-of-war and suffered a severe sting with bulla formation and tissue necrosis. (*S Anderson, courtesy of World Life Research Institute.*)

Within 10 to 15 min of a *Physalia* sting, the victim may develop symptoms of an envenomation reaction characterized by nausea, abdominal cramps, muscular pains, backache, irritability, dyspnea, and chest tightness. Intravascular hemolysis and acute renal failure have been reported in a 4-year-old girl after a severe sting by *P. physalis*. [38] Until recently, reports of deaths as a result of stings from *P. physalis* were not well documented; however, in 1989, there were two separate well-substantiated case reports of human fatalities caused by *P. physalis* envenomation. [39], [40]

Cubomedusae (box jellyfish or sea wasps) Of all the species of jellyfish that cause painful stings and distress to swimmers, the species with the most established record of lethality is the box jellyfish, *Chironex fleckeri.* [41] Since 1884, it has been responsible for at least 63 confirmed deaths in tropical Australian waters. [42] At least one death occurs each year in Australia. [41] The fatality is usually a child, presumably because the size of the victim and the total area of the sting determine the likelihood of death. Until recently, most of the published cases involving *C. fleckeri* stings reported fatal or near fatal stingings. [43] Of 40 patients presenting with jellyfish stings to an emergency department in a hospital in coastal tropical Australia over a 1 year period, 28 were typical of *C. fleckeri* envenomation. [43] None of the stings in this series were serious enough to require antivenom, or were life-threatening. [43] *C. fleckeri* nematocysts were confirmed microscopically by the tape-stripping technique in 23 of the 28 cases thought to be caused by *C. fleckeri*. [43] *C. fleckeri* (commonly known as the sea wasp) is an advanced species of jellyfish, with a semitransparent cubic bell that may grow to a volume of 9 L and weigh more than 6 kg [41] (Fig. 237-10). Trailing from the bell are up to 60 stinging tentacles, which may reach 2 to 3 m in length. [41] When a human comes into contact with a box jellyfish, some of the tentacles are torn off and adhere to the skin. Rescuers of *C. fleckeri* sting victims must exercise extreme caution, as they also are at risk of envenomation until the tentacles have been neutralized and removed.

FIGURE 237-10 The deadly box jellyfish, *Chironex fleckeri,* is found in Indo-Pacific waters off the coast of Northern Australia. (*Courtesy of R Hartwick.*)

The stings appear initially as linear welts that give the patient the appearance of having been whipped. [41] Fresh stings of *C. fleckeri* are easily recognized because they display a diagnostic frosted cross-hatched or ladder-like appearance (Fig. 237-11). Microscopic diagnosis is also possible from blade scrapings or tape strippings from the sting site. [44] Conscious victims who suffer sublethal stings describe the pain as instantaneous and excruciating. The pain may persist for many hours. Severely stung areas of skin take on a dusky cyanotic appearance and may go on to blister formation and necrosis. The healing process is slow and may be complicated by bacterial superinfection. Scarring is often permanent.

FIGURE 237-11 Characteristic frosted cross-hatched tentacle marks diagnostic of a sting caused by *Chironex fleckeri*. (*Courtesy of Townsville General Hospital, Department of Medical Illustration, Townsville, Queensland*, Australia.)

Death may ensue within minutes if >6 m of tentacles have made contact with the victim. Pharmacologic analysis of the venom of *C. fleckeri* has resulted in the isolation of dermatonecrotic, hemolytic, and lethal fractions. [45] The lethal fractions contain cardiotoxic and neurotoxic agents. [45], [46] Intravascular hemolysis caused by hemolytic fractions in the toxin can precipitate acute renal failure. The potent cardiotoxins can produce ventricular arrhythmias and cardiac arrest, and the neurotoxins lead to respiratory failure. First aid for these victims frequently requires cardiopulmonary resuscitation. Intravenous verapamil has been proposed for both treatment and prophylaxis of ventricular arrhythmias in sting victims. [47] Antivenin is available for *C. fleckeri* stings, and its early use in severe envenomations may be lifesaving. In addition to blocking or reversing the systemic effects of the toxins, the antivenin also significantly reduces the pain and inflammation at the sting site. [41], [48]

PREVENTION AND TREATMENT OF JELLYFISH STINGS

Prevention [47]

1. Swim only at patrolled beaches with properly trained lifeguards and adequate treatment facilities.
2. Avoid swimming in infested waters, especially after a storm, as stings may result from remnants of floating damaged tentacles.
3. Beware of apparently dead or beached jellyfish.
4. Wear protective clothing when snorkeling or scuba diving, such as wet suits, long-sleeved shirts, pants or long

woolen underwear, and gloves.
5. Close bathing beaches during periods of high jellyfish infestation.

Treatment

First Aid Treatment [24], [25], [29], [39], [49], [50]

1. Remove or rescue the victim from the water.
2. Stabilize vital functions: airway, breathing, circulation.
3. Immobilize the affected part to prevent further envenomation by adherent tentacles.
4. Identify the type of jellyfish sting by considering locale, time of year, and indigenous species and by observing the sting pattern. Preserve a portion of the tentacle for future identification. Tape strip or scrape the sting site for microscopic analysis of the nematocysts if no tentacles are available.
5. To prevent further envenomation of the victim and to reduce the chance of a sting to the rescuer, disarm the nematocysts before removing the adherent tentacles.
   a. If *C. fleckeri* or other box jellyfish species are suspected, douse or spray dilute acetic acid (3 to 10%) or household vinegar over all areas of tentacle contact for at least 30 s. [51]
   b. For sea nettles, mix sodium bicarbonate (baking soda) with water to form a slurry and pour over the affected area or apply the powder directly to the tentacles. [49]
   c. For *P. physalis* stings a slurry of baking soda is indicated. Vinegar had been reported to neutralize nematocysts of *P. physalis,* but work with species from Australia indicate that it may cause a discharge of nematocysts in some cases. [49], [51]
   d. If vinegar or baking soda is unavailable, papain, available as a powdered meat tenderizer, may be applied directly as a powder or mixed in water as a slurry to sting areas and tentacles of both sea nettles and Portuguese man-of-war. [24]
   e. If nothing else is available, the tentacles can be rinsed off with seawater.
   f. Do not use fresh water, methylated spirits, or alcohol in any form to deactivate tentacles as these all may cause a rapid massive discharge of nematocysts. [24]
6. After the tentacles have been disarmed, they may be carefully removed with a forceps or gently scraped away from the skin with a plastic card, shell, or knife. [50]

Treatment of Systemic Reactions

1. Support vital functions with cardiopulmonary resuscitation, oxygen, and intravenous fluids as required. [48]
2. Treat symptoms of anaphylaxis or shock with systemic epinephrine, glucocorticoids, and antihistamines. [28]
3. A venous-lymphatic constriction bandage applied proximally to the wounded site should be considered in the case of severe stings when systemic reactions are present or likely to occur, when topical deactivation of tentacles is not possible, and when transport to an acute care facility will be delayed. [28], [50]
4. Specific antivenin is available for *C. fleckeri* stings. It is prepared by Commonwealth Serum Laboratories, Parkville, Victoria, Australia. [28] The antivenin is prepared from sheep serum and may therefore pose a risk of allergic reaction in sensitive individuals. [28] The preferred route of administration is intravenous, but it may be given intramuscularly. In severe stingings, it has proved lifesaving. It is also the only treatment that can alleviate the intense pain (often within minutes of administration). It may also reduce the cutaneous inflammation at the sting site and decrease the chance of scarring.
5. Intravenous verapamil has been advocated for both treatment and prophylaxis of arrhythmias. [47]
6. For pain in severe stingings, consider parenteral narcotic analgesics, ice packs, and antivenin in cases involving *C. fleckeri.*

Treatment of Local Reactions

1. Apply topical anesthetic ointments, creams, lotions, or sprays to relieve itching or burning pain. (Benzocaine preparations should be avoided because of the risk of contact dermatitis.) [24]
2. Cleanse ulcerated or open wounds three times daily, apply a nonsensitizing antiseptic or antibiotic cream or ointment, and cover as needed with a light dressing.
3. Treat secondary infections with the appropriate parenteral antibiotics.
4. For delayed-type hypersensitivity reactions, use topical glucocorticoids, antihistamines, and systemic glucocorticoids if necessary. [29]
5. Antitetanus therapy should be considered, if indicated.
6. Ice or cold packs can relieve the pain of mild to moderate stings from many types of jellyfish.
7. Aspirin or acetaminophen, alone or in combination with codeine, can be used to relieve persistent pain. [44]

SEA ANEMONE DERMATITIS Sea anemones are members of the phylum Cnidaria, class Anthozoa. They are sessile creatures with graceful flowery tentacles armed with nematocysts (Fig. 237-12). Although stings caused by sea anemones are not as common as those caused by fire corals and jellyfish, they are a frequent cause of dermatitis in sponge fishermen, sponge divers, and beachcombers who gather snails and crabs from rocky hollows along the shore. Their toxicity to humans depends on the species. As with jellyfish stings, the acute symptoms of pain and burning from sea anemone envenomation are a result of the effects of toxins injected by nematocysts. After the immediate reaction has subsided, it is possible to see delayed-type hypersensitivity reactions develop in the sting site from sea anemones (Fig. 237-13).

FIGURE 237-12 The flowery tentacles of the sea anemone can cause envenomations similar to jellyfish stings. (*Courtesy of Marty Gilman, Worcester, MA.*)

FIGURE 237-13 Delayed-type hypersensitivity reaction to a presumed sea anemone sting. This 11-year-old girl stepped into a hole while wading in shallow waters on the South Carolina coast. She experienced an immediate burning pain with erythema and swelling of both lower legs that subsided within a day. Several days later she developed a pruritic linear eruption. A diagnosis was made of a delayed-type hypersensitivity reaction that developed in the sting site and corresponded with the tentacle marks from what was presumed to be a sea anemone envenomation.

The genus *Sagartia* is the cause of “sponge fisherman's disease.” [24] This anemone lives at the base of sponges sought by commercial fishermen. When they harvest or sort the sponges with their bare hands or forearms, they are likely to come into contact with the tentacles of *Sagartia.* Itching and burning occur at the sting site within minutes of the exposure and are accompanied by erythema, edema, and vesicles. [24] Other species of sea anemones with especially venomous stings include *Actinodendron, Anemonia sulcata,* and *Triactis producta.* Severe stings may progress to vesiculation, ulceration, necrosis, and, occasionally, abscess formation. Systemic symptoms may follow the exposure and can include headache, nausea, vomiting, fever, chills, muscle spasms, abdominal pain, malaise, thirst, and prostration. [24] The only known death caused by anemone sting resulted from fulminant hepatic failure in an individual stung by a *Condylactis* species found in the Caribbean Sea. [52] One case of acute renal failure (a result of acute tubular necrosis) was reported to occur after a probable exposure to a sea anemone. [53] Treatment of sea anemone stings is similar to that of jellyfish envenomations (see above). [54] The tentacles, if still adherent, should be removed carefully with a gloved hand and the sting area rinsed with seawater. [24] Both vinegar and Stingose (an aqueous solution of 20% aluminum sulfate and 11% surfactant) have been suggested for neutralizing the sting sites of anemones. [54] Sea anemone sting sites often heal slowly and may require treatment with antibiotics.

INJURIES CAUSED BY FIRE CORAL AND CORAL CUTS Corals are colonial organisms belonging to the phylum Cnidaria. They form calcified structures of various sizes and shapes by cementing together their limestone exoskeletons or polyps. True corals are members of the class Anthozoa. Fire corals are members of the class Hydrozoa and are not true corals, although they are similar in many ways. Coral injuries may be divided into two major types: superficial injuries caused by nematocyst stings and lacerations. Both injuries may occur at the same time. Coral injuries may be complicated by foreign-body reactions, bacterial infections, and localized eczematous reactions. Nematocyst envenomation in most true corals is a relatively innocuous experience, resulting in mild pruritic erythema that requires little if any treatment. Calamine lotion or antipruritic lotions may bring relief. [55] In contrast to true corals, the sting from the fire coral, *Millepora alcicornis,* is quite painful, as many scuba divers and snorkelers from the Florida Keys to the Caribbean will attest (Fig. 237-14). The wet mucous membrane surrounding the organism contains numerous nematocysts that readily discharge on contact with the skin, causing immediate burning and stinging pain. Within 1 to several hours a pruritic erythematous papular eruption appears, which in severe cases may become pustular, and in rare cases, may progress to necrosis and eschar formation. [56] Lesions heal in 1 to 2 weeks, often with postinflammatory hyperpigmentation. A delayed and persistent allergic contact dermatitis has also been reported to occur from a fire coral sting from the Red Sea. [57]

FIGURE 237-14 The mustard-colored finger-like outcropping in the upper left quadrant of this formation of coral and hydroids is a typical example of fire coral.

The sting may be prevented by wearing protective clothing. Fire coral stings should be rinsed with seawater to remove

undischarged nematocysts. The sting area can then be compressed with either 5% acetic acid (vinegar) or 40 to 70% isopropyl alcohol for 15 to 30 min or until the pain is relieved. [36] Seawater compresses, hot to the point of tolerance, are also reported to inactivate the toxin. A topical steroid cream or ointment may relieve pruritus and promote healing. Lacerations from the razor-sharp exoskeletons of coral are known collectively as coral cuts. Beach walkers, waders, fishermen, swimmers, surfers, and scuba and skin divers are at risk for these injuries. Coral cuts can be prevented by avoiding dangerous shorelines and by wearing protective clothing such as reef boots, gloves, long pants made of a thick cut-resistant material, or a wet suit. Coral cuts are notorious for their slow healing and propensity for secondary infection. Factors that complicate healing include the following:

1. Wounds often involve the lower extremities and these generally heal more slowly because of decreased tissue blood supply.
2. Wound edges are often irregular, contused, crushed, and abraded.
3. Contamination of wounds is likely because of pathogenic bacteria in shore waters.
4. Foreign bodies, including marine algae growing on the coral or portions of the coral itself, may be implanted in the wound.
5. Victims of coral cuts are often actively engaged in water sports and may not comply with optimal wound care.

Treatment of coral cuts should begin with vigorous cleansing of the wound with soap and water with a soft brush or rough towel, followed by copious irrigation with saline to remove foreign bodies. If the wound is extensive, local anesthesia may be required in order to adequately cleanse, explore, debride, and achieve good hemostasis. Hydrogen peroxide washing of the wound before dressing it is recommended. The decision to close a coral cut wound primarily or to allow it to heal by secondary intention depends on the location of the wound, the degree of tissue trauma at the wound margins, and the likelihood of subsequent infection. Facial and scalp wounds can often be converted to surgically clean wounds by debridement and closed primarily. Trunk and arm wounds may be closed primarily, but require more surgical judgment. Lower extremity wounds in most cases heal slowly by secondary intention. Tape stripping is preferable to suturing of leg wounds because sutured leg wounds have a high chance of abscess formation. Once the wound has been closed, an antibiotic ointment covered with a nonstick dressing, with an outer dressing applying light pressure for 24 to 48 h, is advisable. Rest and elevation promote healing. Because coral cuts are tetanus prone, the patient may require tetanus prophylaxis, depending on immunization history. Failure to remove foreign debris after a coral injury may result in foreign-body reactions. Localized episodes of dermatitis have been reported after contact with coral (Fig. 237-15). The lesions may appear within several hours as erythematous papules; these coalesce to form plaques, which may become vesicular. Biopsy of these lesions reveals a superficial and mid-dermal perivascular infiltrate of lymphocytes, eosinophils, and plasma cells resembling an arthropod bite reaction. In some patients, these eruptions have been recurrent. Topical glucocorticoids may be helpful in treating these eczematous reactions.

FIGURE 237-15 A contact dermatitis-like eruption resembling poison ivy on the unprotected leg of a scuba diver 24 to 48 h after contact with an unknown type of coral. The eruption persisted for several weeks and cleared after treatment with topical steroid creams.

Dermatitis from Sponges

Sponges are members of the phylum Porifera, class Desmospongiae. They are simple multicellular animals that live attached to the sea bottom. Sponges grow by forming a series of hollow-centered branching tubes composed of a fibrous material called spongin, which contains spicules of calcium carbonate or silica. [24], [58] Spicules from certain species of sponges are capable of penetrating the skin, causing a localized irritant or foreign-body reaction. Treatment of sponge spicule dermatitis involves tape stripping of the affected area.

At least 13 species of sponges can cause a toxic dermatitis. [59] Of these, the most commonly encountered are the West Indian and Hawaiian fire sponge, *Tedania ignis;* the poison bun sponge, *Fibula nolitangere* (Fig. 237-16); and the red sponge, *Microciona prolifera,* found in the northeastern United States. [59] These creatures are covered by a surface liquid, or slime, that produces an irritant or toxin-induced dermatitis when contacted by bare skin. [58]



FIGURE 237-16 The poison bun sponge, *Fibula nolitangere,* can cause a severe irritant or toxin-induced contact dermatitis.

Symptoms of itching, prickling, stinging, or burning appear within minutes of exposure and are followed within a few hours by pain, swelling, and stiffness. [24], [58], [59] If the fingers are involved, they often become immovable within 24 h. [43] The first cutaneous sign of sponge poisoning is local erythema, which progresses to a papular, vesicular, or bullous eruption with weeping of a serous or purulent fluid. [58], [59] Desquamation of the site occurs within several days. Erythema multiforme and anaphylactoid reactions have been reported in highly sensitized individuals.

Treatment of sponge dermatitis is similar to that of severe poison ivy. The acute dermatitis can be treated with cool dilute vinegar soaks [30 mL of vinegar per liter of water (2 tbsp/qt water)] several times a day. [59] Soothing lotions, topical glucocorticoids, and antihistamines may relieve symptoms, which usually begin to subside in several days. Systemic glucocorticoids may be indicated for severe reactions.

Injuries Caused By Echinoderms: Sea Urchins, Starfish, and Sea Cucumbers

SEA URCHINS Sea urchins are spiny creatures that belong to the phylum Echinodermata, class Echinoidea. They are encased in a fragile, roughly spherical, calcareous shell, which is protected by a formidable array of mobile spines and pincer-like organs known as *pedicellariae* [60] (Fig. 237-17).

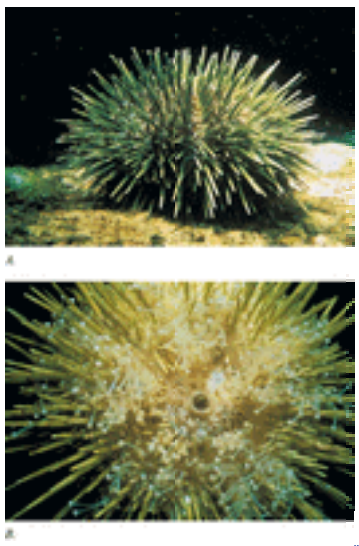

FIGURE 237-17 Lateral (*A)* and ventral (*B)* views of a sea urchin demonstrate this animal's protective spines and venomous pedicellaria underneath. (*Courtesy of Marty Gilman, Worcester, MA.*)

Bathers, surfers, divers, and fishermen are all at risk for sea urchin injuries. These may occur when the victim steps on an urchin, driving the spines into an unprotected foot, or as a result of loss of balance or wave action, in which case the hands or other body parts may be impaled. Sea urchin spines are composed of calcium carbonate and are covered with a proteinaceous membrane. [61] Injuries from sea urchins may be inflicted either by penetrating wounds from the animal's spines, which often break off and become imbedded in the wound, or by bites from the pedicellaria. In certain species, the spines or pedicellaria are venomous. This fact may explain why the pain of some sea urchin wounds is so excruciating and out of proportion to the apparent injury. Encounters with sea urchins can result in both immediate and delayed reactions. Immediate reactions are usually localized and are initially manifested by a severe burning pain in the wound site, which quickly becomes red and swollen and may bleed profusely. [59] There may be a black or purple discoloration at the site of the spine penetration due to either retained spines in the wound or to a tattoo-like effect from dye released by the spines that have exited intact. Paresthesias may develop in the wound area. Systemic symptoms are not common but can occur in injuries due to particularly venomous species. Symptoms may include nausea, syncope, paresthesias, ataxia, muscle cramps, paralysis, and respiratory distress. [59] Delayed reactions to sea urchin wounds may be nodular or diffuse; they result from a foreign-body reaction to the retained spine fragments. Delayed-type hypersensitivity reactions may occur with erythema and intense pruritus days after the initial injury. [62] In one of these cases, the diagnosis was confirmed by patch testing with extracts of the ground sea urchin spines. [63] Nodular reactions are localized to the area of spine penetration and are not usually painful. They consist of small firm nodules, which may be flesh colored, pink, or cyanotic, or may take on colors from the dye in the spines. [24], [64] Nodules may have a central umbilication or a keratotic surface [64] (Fig. 237-18).

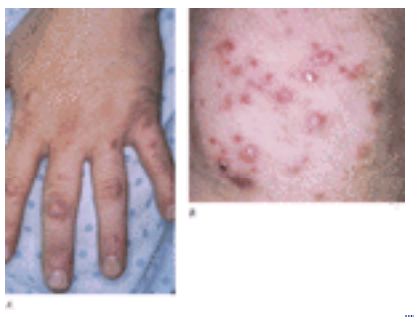

FIGURE 237-18 *A* and *B.* Nodular reactions to imbedded sea urchin spines. (*Courtesy of Karen Rothman, MD.*)

The diffuse form more commonly involves the fingers or toes and is manifested by a fusiform swelling of the affected digit with accompanying pain and loss of function. [59], [60] Two cases of sea urchin granuloma involving the nail apparatus and resulting in permanent nail deformity have been reported. [65] In addition to joint synovitis and arthritis, additional osteoarticular complications of sea urchin spine penetration may include tenosynovitis with or without destruction of the underlying bone, fasciitis, and bursitis. [61], [66] Sea urchin spine wounds may also cause direct mechanical injuries to nerves and may be complicated by secondary infection. [59] Histopathologically, a granulomatous inflammatory reaction is the most common presentation, with foreign body and sarcoidal types the most frequent patterns observed in 50 biopsy specimens in one study. [60], [67] Other histologic patterns less commonly seen in the study included tuberculoid, necrobiotic, and suppurative granulomas as well as nonspecific chronic inflammation or suppurative dermatitis. [67] Because a few of the specimens showed changes suggestive of mycobacterial infection, the same investigators reevaluated the 50 biopsy specimens with the polymerase chain reaction technique and found *M. marinum*-specific restriction patterns in three of the samples. [68] Initial first aid for the pain from immediate reactions calls for soaking the affected area in hot water [43°C to 46°C (110°F to 115°F)] for 30 to 90 min until maximal relief is obtained. [50], [59] Infiltration of the wound site with 1 to 2% lidocaine without epinephrine may be required in some cases to produce significant pain relief. [50] Spines protruding from the wound may be carefully removed. They are very fragile, however, and it is difficult to extract the entire spine intact. Tumescence of the skin with local anesthetic may allow superficially imbedded spines to be extracted when radiographs demonstrate no evidence of joint or bony impingement. [69] More invasive attempts at spine removal should not be performed without the benefit of aseptic surgical facilities and radiographs to confirm the spine locations. Removal of the spines may be aided by the use of an operating microscope. [59] There are anecdotal reports of pounding the wound site with a stone for the purpose of breaking up the spines into smaller fragments, which are more easily absorbed. This practice has been criticized. [59] The application of ammonia compresses or freshly voided urine has also been recommended, but again these remedies are anecdotal and their value has not been proved. [60] Antibiotics are indicated for secondary infections, and tetanus prophylaxis should be given if indicated. Most sea urchin wounds resolve without complications; however, those involving the digits, joint spaces, or nerves require surgical intervention. Delayed nodular reactions may resolve slowly with time. Topical and intralesional glucocorticoids may be efficacious for nodular reactions, and systemic glucocorticoids have been recommended for diffuse reactions, but their benefit has not been clearly substantiated. [24], [59], [70] Symptomatic nodular or diffuse reactions may not resolve until the spines and granulomatous tissue have been surgically removed.

STARFISH Certain species of starfish may produce puncture wound injuries similar to those caused by sea urchins. The crown-of-thorns starfish, *Acanthaster planci,* accounts for most severe starfish envenomations. [59] The ice pick-like spines of *A. planci,* which may reach 4 to 6 cm in length, are covered with a thin skin and glandular tissue that produce a poisonous slime. [50], [70] The resulting wound is quite painful and may be accompanied by numbness and paresthesias. [59] Systemic symptoms including nausea, vomiting, and muscle weakness are infrequent and short lived. [59] Fragments of spines and their surrounding integument may become imbedded in the wounded area, resulting in granulomatous reactions. Treatment is similar to that of sea urchin wounds. Initial first aid should include soaking the affected area in hot water for 30 to 90 min until there is maximal pain relief. [50] In addition to causing spinous injuries, some species of starfish may secrete a toxic substance directly into the water. When these starfish are present in large numbers, there may be sufficient amounts of this toxin to produce a pruritic papulourticarial eruption. [24], [59]

SEA CUCUMBER DERMATITIS Sea cucumbers are sausage-shaped bottom-feeding echinoderms that can produce a papular contact dermatitis by means of a toxic liquid substance, known as holothurin, which is secreted from their body walls. [24] Conjunctivitis, even blindness, can result from corneal involvement if the toxin comes in contact with the eyes. [59] These animals have also been reported to ingest intact nematocysts from marine coelenterates, which they may later secrete for defensive purposes. Prevention of sea cucumber dermatitis involves protecting the skin and eyes from contact with these creatures and educating children and curious divers about the risk of handling them. Treatment consists of washing the affected area with soap and water to remove the toxin and then treating as for a mild contact dermatitis.

Dermatitis and Bites from Marine Worms

BRISTLEWORM DERMATITIS Bristleworms are multisegmented marine worms of the phylum Annelida, class Polychaeta (which means “many bristles”) (Fig. 237-19). Each segment of the worm is armed with rows of silky or bristle-like, hollow, venom-filled setae that can easily penetrate and break off in the unprotected skin of a victim in a fashion similar to cactus spines. [70] Contact with the bristleworm results in an erythematous papular or urticarial eruption at the site, accompanied by symptoms of paresthesias, intense itching, or burning pain. [24], [70] The bristles are too small and fragile in most cases to be removed with a forceps; however, tape stripping with cellophane adhesive tape can be effective. [24] After the setae have been removed, the application of ammonia soaks or alcohol or water compresses may bring symptomatic relief. [24]

FIGURE 237-19 *Hermodice carunculata,* the West Indian bristleworm, can inflict a painful wound with its hollow, venom-filled bristle-like setae. (*Courtesy of Marty Gilman, Worcester, MA.*)

LEECHES Leeches are another class of segmental worms whose bites may be encountered in fresh or salt water as well as on land. They are members of the phylum Annelida, class Hirudinea. Leeches have specialized biting jaws that allow them to attach to their host in order to feed on a meal of blood. Although freshwater leeches are capable of attaching painlessly to their human host, salt water leeches produce bites with pain similar to that of a bee sting. [24] Leeches inject a

powerful anticoagulant, hirudin, into the wound, as well as other antigenic substances that are capable of eliciting allergic reactions (including anaphylaxis) in sensitized individuals. [24] Local symptoms of leech bites include bleeding from the puncture marks, pain, swelling, redness, and severe pruritus; urticarial, bullous, or necrotic reactions may occur in sensitized persons. [24] Severe ulcerations may result if the leech is removed forcibly and its mouth parts are left behind in the bite site. Leeches must be induced to fall off by applying a noxious agent (such as alcohol, vinegar, brine, or a match flame) to their site of attachment. [24] After the leech has been removed, the wound should be carefully cleansed and minor bleeding controlled by the application of a styptic pencil. [24] Secondary infections may be prevented by cleansing the bite site for several days with antiseptic solutions containing alcohol or boric acid. [24]

CERCARIAL DERMATITIS (CLAM DIGGER'S ITCH) Cercarial dermatitis, also known as schistosome dermatitis or swimmer's or clam digger's itch, is an acute pruritic eruption resulting from the penetration of the skin by the cercarial forms of certain parasitic flatworms of the family Schistosomatidae. Symptoms of cercarial dermatitis begin with urticarial-like lesions and a prickling sensation of the skin, which lasts about half an hour after exposure to cercarial-infested waters. Severe pruritus of the affected area occurs 10 to 12 h later. Within 24 h, erythematous papules appear that may progress to vesicles and later to pustules. Pain and swelling of the area accompanies the intense itching, which usually peaks in 48 to 72 h. Headache, fever, and superinfection with lymphangitis are occasionally present. In the Great Lakes region, several species of schistosome cercariae that cause swimmer's itch have been reported, and many other species have been discovered throughout the world in both fresh and salt water. [71] The economic impact on regions with recreational lakes in which the parasites are known to occur can be substantial. A severely disabling form of cercarial dermatitis affects the paddy workers and rice farmers of the Far East. Cercarial dermatitis has also been described in shallow coastal waters, notably on Long Island Sound where the condition affects clam diggers, giving rise to the name, “clam digger's itch” (Fig. 237-20). There is one reported case of cercarial dermatitis occurring on the hands and arms of a patient after he cleaned the aquarium in which he kept native watersnails. [72]

FIGURE 237-20 Intensely pruritic papulovesicles suggestive of a severe reaction to flea bites in a patient with clam digger's itch. The left hand, which was not in the water and was holding the pail for collecting the clams, was spared.

Humans are accidental hosts in the life cycle of dermatitis-producing schistosomes. The cycle begins when the primary host, a waterfowl, marsh bird, finch, muskrat, mouse, or deer, passes schistosomal eggs in its feces into a body of water. Each egg hatches in 10 to 15 min, releasing a secondary stage miracidium. The miracidia are free-swimming and must locate and infect their definitive snail host within 12 h or they will die. The miracidia migrate to the snail's digestive gland, where they develop into multiple sporocysts. In about 5 weeks the sporocysts give rise to hundreds of fork-tailed cercariae that measure 0.75 mm in length. The cercariae are released from the snail under favorable conditions of light and heat, and are carried toward the shore by prevailing winds and currents. [71] When an appropriate host is encountered, the cercaria attach to the skin with their oral suckers and penetrate the epidermis and dermis by means of histolytic enzymes. They lose their tails in this process and are now called schistosomula. The schistosomula migrate via the blood vessels through the heart and lungs to the intrahepatic veins, where they mature into adult male and female trematode flukes. When the worms mate, they pass in pairs through the mesenteric venules of the intestinal wall where the female lays hundreds of eggs. [71] The eggs then penetrate the gut wall and are discharged in the feces, and the cycle is repeated. When cercariae that do not cause schistosomiasis in humans accidentally attach to the skin, they may penetrate the epidermis but are unable to reach the bloodstream. The organisms die in the superficial papillary dermis and undergo total histolysis within 3 to 4 days. The cercarial protein residua stimulate a delayed-type hypersensitivity response, which may increase in severity with repeated exposures. Skin biopsies taken at 3 to 4 days reveal an amorphous eosinophilic mass at the site of the dissolved cercaria, with an intense lymphocytic infiltrate. Later, histiocytes appear in the middle and deep papillary dermis. The differential diagnosis of cercarial dermatitis includes insect bites from chiggers, mosquitoes, and fleas; contact dermatitis from poison ivy, and the stings of other marine coelenterates. In Africa, Asia, South America, and Puerto Rico, swimmer's itch must be distinguished from the dermatitis associated with human schistosomiasis, which produces an eruption with very similar but milder and more transient symptoms. [71], [73] Swimmer's itch must also be distinguished from sea bather's eruption, which is discussed in the next section. Prevention of cercarial dermatitis in waters where swimmer's itch is known to be a problem is difficult. Avoidance of all aquatic activity is not a reasonable solution, and most swimmers or workers are not willing to apply a protective coat of petrolatum before exposure. Some investigators have advocated a brisk rubdown with a towel immediately after bathing in the belief that the cercaria can be wiped off before they can penetrate the skin, but other investigators have shown that both this and alcohol rubdowns are of little benefit. Various chemical repellents have been tried, including copper sulfate and bathing with hexachlorophene soap before exposure, but the effectiveness of these methods remains unproved. Clothing barriers may be of some help, as cercarial dermatitis occurs more commonly on uncovered skin. Another preventive alternative involves the elimination of the molluscan host by a variety of means. The waters can be treated with various molluscicides, copper sulfate, or niclosamide. Drainage of lakes or ponds with the removal of aquatic vegetation can deprive the snails of shelter and nourishment. [71] In smaller ponds, hand removal of the snails from the banks of the water may be helpful. The most radical efforts reported involve draining the affected ponds and destroying the snails with flame throwers. Many of these methods are too expensive or dangerous to the environment to be practical.

Treatment of cercarial dermatitis is largely symptomatic. In mild cases, antipruritic or drying lotions, oatmeal or starch baths, and antihistamines may alleviate pruritus. Aspirin may be helpful for the pain and swelling, and a bedtime sedative may be required to allow the patient much-needed sleep. Proper washing and hygiene should be maintained to prevent bacterial superinfection. In severe cases, potent topical glucocorticoids and occasionally systemic glucocorticoids may be required.

Seabather's Eruption

Seabather's eruption (SE), also known as marine dermatitis, and more commonly as “sea lice,” is an acute dermatitis that begins shortly after bathing in seawater. Seabather's eruption is often confused with swimmer's itch (cercarial dermatitis), not only because they both occur after exposure to water, but also because the common names of these two conditions are easily confused. For many years, the cause of SE remained a mystery, but it is now known that the responsible agents in at least two types of the SE are the larval forms of marine coelenterates. In waters off the coast of Florida and in the Caribbean, the tiny larvae of the thimble jellyfish, *Linuche unquiculata,* are to blame. [74] Off the coast of Long Island, NY, researchers found that the larval forms of the sea anemone *Edwardsiella lineata* were responsible for the eruption. [75]

In addition to a different etiology, SE can be distinguished from cercarial dermatitis by several other factors (Table 237-2). Seabather's eruption primarily involves areas of the body covered by bathing suits where water evaporates slowly, as opposed to the uncovered areas typical of swimmer's itch. Most symptoms are not noted until the bather has left the water (although some of those affected have complained of a prickling sensation while still in the water.)



TABLE 237-2 **Comparison of Swimmer's Itch and Seabather's Eruption**

The eruption is caused by minute stings from the nematocysts of the coelenterate larvae that become trapped underneath swimwear or may adhere to hairy areas of the body. In addition to the larvae, which are most abundant in May and June, swimmers and bathers may also develop SE after contact with the other two free-swimming stages of *L. unguiculata,* the ephyrae and medusae stages. [76] Ephyrae are released in late January through March from scyphistoma, which are the sessile stage of the thimble jellyfish. The medusae stage is the adult form of the thimble jellyfish and is present in affected waters from early April until mid May. [76] Seabather's eruption is believed to be caused by an allergic reaction to these nematocyst stings. Factors that may cause the nematocysts to fire include mechanical pressure from a bathing suit or swim cap, or from lying on a surfboard or sitting on a car seat in a wet bathing suit; and changes in osmotic pressure as the bathing suit dries out or when the bather rinses off with fresh water while wearing swimwear.

The lesions begin within 4 to 24 h after exposure as erythematous macules, papules, or wheals that may itch or burn (Fig. 237-21). [24] These lesions may progress to vesiculopapules, which crust over and heal in 7 to 10 days. [24] Associated systemic symptoms may include chills and a low-grade fever as well as nausea, vomiting, diarrhea, headache, weakness, muscle spasms, and malaise. Febrile and systemic symptoms are more common in children and adolescents. [77] In the presence of such constitutional symptoms, caregivers who fail to recognize the pattern of the eruption or who fail to take a history of exposure to salt water may mistakenly make the diagnosis of a viral syndrome.

FIGURE 237-21 Seabather's eruption in a young girl after a swim at a Florida beach. (*Courtesy of Karen Rothman, MD.*)

In waters along the coast of south Florida, the season for SE is between March and August with a peak in May. The incidence among bathers during May and June 1993 in Palm Beach County was reported to be 16 percent. [77] The strongest risk factor for developing SE is a previous history of the condition, which is consistent with the theory that SE represents a hypersensitivity response to the nematocyst stings. [77] Other risk factors include age younger than 16 years and surfing. [77] Showering with swimwear removed was found to be a protective measure. [77]

Prevention of SE includes the following measures:

1. Bathers should remove their swimwear and shower as soon as possible after leaving the water. Because fresh water may cause discharge of the nematocysts, it is important that the suits be removed before showering begins. Showering with salt water may be preferable, but impractical. Bathing suits should be rinsed with soap and water and heat dried, as the eruption can recur when the suit is air dried. Persons who have had a severe case of SE may want to consider discarding the suit worn at the time of the exposure.

2. T-shirts should not be worn in the water. Women may consider wearing a two-piece suit to reduce the surface area under which larvae may be trapped. Swimming without a bathing suit may be advantageous (assuming it is permitted and proper care is taken to prevent sunburning); but because the larvae easily attach to hair-bearing areas, showering after a swim in infested waters is still required.
3. Whole-body Lycra swimsuits or wetsuits with snug-fitting collars and cuffs may be protective, but the eruption may still occur along the collar or cuff edges.
4. Highly sensitized individuals should avoid swimming in waters during outbreaks of SE.

Treatment of SE is symptomatic with antipruritic lotions, colloidal baths with starch or oatmeal, antihistamines, and topical glucocorticoids. Severe unremitting cases may warrant systemic glucocorticoids. [74] Secondary bacterial infections may complicate the condition and should be diagnosed and treated appropriately.

Injuries Caused By Mollusks

CONE SHELL ENVENOMATIONS Cone shells are univalvular gastropods whose ornate cone-shaped shells are highly prized by shell collectors and divers. A number of species have a highly developed venom apparatus that can inflict a lethal sting. Most of the dangerous cone shell species are found in shallow waters of the Indo-Pacific. Cone shells are carnivorous. They live on the ocean bottom and, depending on the species, may hunt worms, other mollusks, or fish. Cone shells kill their prey by means of a spearlike venomous radular tooth that is thrust out from the animal's proboscis. Cone shell venom contains several different kinds of neurotoxins, and death may result from respiratory paralysis. There is as yet no antivenin for cone shell envenomations, and mortality rates for the more dangerous species (*Conus geographicus* and *C. magus*) may be as high as 15 to 20 percent. [24] Injuries from cone shells are of the puncture wound variety. The degree of pain is variable, ranging from a mild stinging sensation, similar to that of an insect bite, to severe excruciating pain. Early symptoms may include edema, ischemia, numbness, and paresthesias of the wound site. Paresthesias may become widespread, with the lips and mouth commonly affected. [24], [59] Localized muscular paralysis may progress to generalized weakness or paralysis with eventual respiratory distress and cardiopulmonary failure. Neurotoxic symptoms that indicate severe envenomations include diplopia, blurred vision, aphonia, dysphagia, and coma. [24], [59] Rare cases of disseminated intravascular coagulation have been reported after cone shell envenomation. Great care must be exercised in handling live cone shells. Thick protective gloves should be worn, and the soft underportion of the animal should be avoided. Cone shells should never be placed in pockets of clothing or swimwear as they have been known to sting through clothing. [50] Treatment of cone shell envenomations is supportive. The victim should be kept at rest, and the sting area kept dependent and immobilized. A compression dressing should be applied to occlude lymphatic-venous, but not arterial, flow. [50] Local suction may be helpful if it can be applied immediately to the wound site with a plunger device, such as the Extractor (Sawyer Products, Safety Harbor, Florida). No incision of the wound is required with this device. Compresses or immersion of the sting area in hot water may be indicated in those cases where it is not practical to apply a lymphatic-venous compression dressing or to relieve pain in milder stings. [24], [50], [59] Advanced life support measures, including artificial ventilation, may be required while victims are being transported to a hospital, where they may require mechanical ventilatory support. [50]

OCTOPUS BITES Octopuses are an advanced class of mollusks belonging to the class Cephalopoda. The octopus bites with a parrot-like chitinous beak located on the ventral side of the head in the middle of its eight tentacles (Fig. 237-22). Species of octopi range in size from a few centimeters to 1 to 2 m in diameter. [78] They are shy and reclusive creatures that tend to avoid encounters with humans; however, bites can occur when curious divers, fishermen, or beachgoers encounter these animals and handle them carelessly. Most octopus bites are not life-threatening to humans. The bite site may be immediately painful, like a bee sting, and is recognized by the presence of two small puncture wounds, which may bleed profusely. [24] Symptoms from octopus bites are usually mild and transient and consist of redness, swelling, and itching. [79] One case of granuloma annulare has been reported to have developed around the site of an octopus bite [79] (Fig. 237-23). Paresthesias and numbness may develop at the site if the species is venomous. In more severe envenomations, these symptoms may be followed by more generalized neurologic symptoms similar to those occurring in cone shell stingings.

FIGURE 237-22 Ventral view of the underside of an octopus exposing the animal's centrally located mouth and parrot-like beak. (*From DD Fulghum,* [79] *with permission.*)

FIGURE 237-23 Granuloma annulare on the back of the hand of a commercial fisherman several days after being bitten by a small octopus at the same site. (*From DD Fulgham,* [79] *with permission.*)

The most dangerous species of octopus, the Australian blue-ringed octopus, *Hapalochlaena maculosa,* is found in Australian coastal waters. Mortality rates due to bites caused by *H. maculosa* may be as high as 25 percent. *H. maculosa* produces a toxin in its salivary glands, which is introduced into the bite site by the animal's powerful beak. The toxin contains a fraction identical to tetrodotoxin, which blocks peripheral nerve conduction, resulting in paralysis of the victim with subsequent respiratory failure. The bite of the blue-ringed octopus may or may not be painful, so that victims may not realize that they have been bitten until neurologic symptoms develop. [59] There is no antivenin for bites from *H. maculosa.* Treatment is supportive and similar to that recommended above for severe cone shell envenomations. Immersion of the wound in hot water does not seem to be beneficial. [59] The use of the pressure–immobilization technique with a lymphatic–venous occlusive pressure dressing or the immediate application of suction to the wound site with a suction device may be of value. [50] Excision of the bite site down to fascia has been recommended by some authors, but its value is unproven. [24], [59]

Injuries Caused by Venomous Fish Spines

Ichthyoacanthotoxicosis is the proper term for envenomations as a result of puncture wounds or lacerations inflicted by the spines of venomous fish. There are more than 200 species of venomous fish in the world that can cause injury to humans. [59] The most notorious of these species includes the stingrays, catfish, lionfish, scorpionfish, stonefish, weeverfish, toadfish, and spiny dogfish. All of these fish have in common a venom apparatus consisting of a single spine or multiple spines, in various locations, which are covered by an integumentary sheath enclosing various forms of venom glands. When the spine of the animal penetrates the victim, the sheath is torn and the venom glands release their toxins into the wound. The toxins from some of these fish may remain potent for 24 to 48 h after the death of the fish. [80]

STINGRAYS Stingrays represent one of the most common causes of venomous fish stings confronting humans, with as many as 1500 to 2000 stingray attacks reported each year in the United States alone. [70], [81] Rays are grouped into one of four categories; gymnurid (butterfly rays), urolophid (round stingrays), myliobatid (bat or eagle rays), and dasyatid (proper stingrays). The groupings are based on their relative stinging ability, which depends on the size, number, and location of the caudal stinging appendages. The most dangerous group, the dasyatid or true stingrays, have the largest spines located further out on their tails, making theirs the most potent striking weapons. The spines have retroserrated teeth, which makes removal difficult (Fig. 237-24).

FIGURE 237-24 A close-up view of a stingray stinger devoid of its outer membrane and venom glands, demonstrating the retroserrated spine. (*Courtesy of David Fulghum, MD.*)

Most stingray injuries occur when bathers, waders, or fishermen accidentally step on rays as they lie partially covered with sand in shallow waters. Severe lacerations and puncture wounds are inflicted by the ray as it defensively whips its tail upward and forward when stepped on or threatened [82] (Fig. 237-25). The majority of wounds, therefore, are located on the dorsum of the foot or lower leg. Penetrating wounds to other locations have occurred to fishermen stung while attempting to remove rays from their lines or nets; in a freak accident when a ray leapt from the water, striking a young boy in a small boat; and to divers engaged in feeding rays at popular dive locations. [82] When stingray spines penetrate the thorax or abdomen, the resulting wounds may prove fatal. [82]

FIGURE 237-25 Stingrays reflexively swing their barbed tails up when stepped on, causing painful lacerations and puncture wounds. (The leg used for this photograph was a prosthesis; the stingray was alive.) (*Courtesy of David Fulghum, MD.*)

In addition to their spines, stingrays can produce an abrasive wound with their mouths known as a “two-fathom hickey.” [83] These injuries occur when divers and snorkelers attempt to feed stingrays at popular dive sites. The rays occasionally miss the food that is being offered and may press their mouths against the unprotected hand or arm of the diver feeding them. A superficial abrasion results from the sucking action of the mouth and their abrasive rasplike-teeth.

CATFISH Both fresh- and saltwater catfish are armed with stout sharp spines located immediately in front of the soft rays of their dorsal and pectoral fins. [69] Catfish defensively lock these spines into an extended position when they are handled or threatened. Bathers may sustain stings on their feet or legs if they step on a catfish, but most catfish stings involve the hand or upper extremity of fishermen or seafood processors. [84] Fishermen are commonly stung while attempting to remove catfish from the hooks of their fishing lines. Heavy gloves, pliers, and pincer-like jaws for holding the fish afford some protection. The safest approach in the absence of these devices is to maintain a safe distance from the fish and to cut the line. Fishermen and seafood processors may even be stung while cleaning dead catfish. To prevent these injuries, it has been suggested that the offending spines be removed with a pair of pliers before attempting to clean the fish. Although most catfish stings are mild, they occasionally can result in severe necrosis and even gangrenous tissue loss, which in one case required digital amputation. One of the most dangerous venomous fish in the world whose sting can be fatal is a species of catfish, *Plotosus lineatus,* which is found in waters of Japan, the Philippines, Southeast Asia, East Africa and Australia. [85] Swimmers and bathers in the Amazon river are at risk for urologic injuries if they encounter a very small species of catfish called “candiru,” which has the ability to enter the human urethra. Barbs on the head of this fish prevent it from swimming backward out of the orifice, and surgical intervention is often required to extract the fish.

SCORPIONFISH Scorpionfish, family Scorpaenidae, are divided into three main groups on the basis of their stinging apparatus. All have venomous spines of varying sizes and toxicity that may be found, depending on the species, on the dorsal, pelvic, and anal locations. Lionfish, genus *Pterois,* live in tropical waters and are prized by fish fanciers because of their colorful and ornate fins. The spines of lionfish are long and slender with small venom glands. [59] Their stings are relatively mild and not life-threatening. [70], [86] Stings among amateur fish collectors are occurring more frequently because of the increasing popularity of these fish. [86] Scorpionfish, genus *Scorpaena,* have stings that are of intermediate severity. They are bottom dwellers with superior camouflage abilities that allow them to blend in almost invisibly with their surroundings (Fig. 237-26). Their spines are long and heavy and have moderate-sized venom glands.

FIGURE 237-26 *Scopaena plumieri,* a species of scorpion fish, is found in the waters of the West Indies. Its camouflage abilities are exceeded only by its painful sting.

Stonefish, genus *Synanceja,* are the most dangerous members of the scorpionfish family. They live in shallow waters, sometimes partially buried in sand or mud, or in holes of rocky shoals, reef areas, or tidal pools. [70] Injuries occur when a wader steps on the erect venomous dorsal spine that the stonefish raises in defense. Stonefish spines are short and thick and have very large and well-developed venom glands. [59] The wounds caused by stonefish are quite severe and may be fatal. A stonefish antivenin is available from the Commonwealth Serum Laboratories, Melbourne, Australia. [24]

WEEVERFISH In European coastal waters, the weeverfish is one of the most common and severe causes of venomous fish spine injuries. [87] These fish are equipped with between five and eight venomous dorsal spines and two venomous opercular spines (one on each side of the head near the gill plate). [88] Waders and bathers are at risk when they step on weeverfish that lie partly buried in mud or sand in shallow waters. Fishermen may suffer stings while trying to remove these fish from nets or fishing lines. Weeverfish stings produce severe pain and significant local tissue reaction characterized initially by erythema and edema. There may be associated ecchymoses, regional lymphangitis, and lymphadenitis. [88] Systemic signs and symptoms may include headache, nausea, vomiting, diaphoresis, hypotension, syncope, and respiratory depression. [87], [88] Fatalities from weeverfish stings are extremely rare and have been attributed to respiratory failure. [88]

LOCAL AND SYSTEMIC SYMPTOMS OF FISH-SPINE ENVENOMATIONS The toxicity of a given sting depends on a number of factors, including the species of fish involved, the location and severity of the wound, the amount of venom released, and the first aid and subsequent medical care provided to the victim. In general, these wounds produce pain out of proportion to the apparent severity of the injury. The pain is immediate and intense. In the case of scorpionfish stings, the pain may be so severe as to cause the victim to thrash about wildly, scream, and finally lose consciousness. Initially, the sting site may appear pale or cyanotic. The area around the wound may be anesthetic or hyperesthetic. [59] Erythema and edema soon develop, giving the appearance of a cellulitis. Vesicles may form. In severe stingings, especially those caused by stonefish, the wounded area may become indurated and develop areas of ischemic necrosis

with subsequent sloughing and ulcer formation. Fish-spine wounds may be complicated by foreign-body reactions to bits of retained spines or remnants of integumentary sheath. Secondary infections from a variety of organisms must be anticipated. Healing is slow, especially in cases plagued by abscess or ulcer formation. Systemic symptoms from toxic fish spine envenomations may range from mild to severe, depending on the species involved and the amount of venom entering the wound. They can include headache, nausea, vomiting, diarrhea, abdominal cramps and pain, fever, local lymphangitis and lymphadenitis, joint aches, muscle weakness, diaphoresis, peripheral neuropathy, limb paralysis, restlessness, delirium, seizures, cardiac arrhythmias, myocardial ischemia, pericarditis, hypotension, respiratory distress, and death. [49], [86]

PREVENTION Prevention of toxic fish-spine wounds begins with a knowledge of and an appreciation for the various venomous species that may be encountered in a given area. Waders and bathers should shuffle their feet to scare away and avoid stepping on rays or scorpionfish. Fishermen must exercise care when removing rays or catfish from their fishing lines or when cleaning fish with venomous spines. Fish hobbyists and divers should wear protective clothing and avoid handling venomous species.

TREATMENT Puncture wounds and lacerations from venomous fish spines should be irrigated immediately with sterile saline or water, if available, and with seawater as a last resort. [50] The wounded area should then be soaked as quickly as possible in hot (not scalding) water of approximately 43°C to 46°C (110°F to 115°F) for 30 to 90 min or until maximal pain relief is achieved. Hot soaks may be repeated if the pain returns. Because the wound or extremity may be partially anesthetic, it is necessary for the person administering first aid to test the water's temperature for the victim. [82] One source of hot water that is often overlooked and may be useful in an emergency is hot seawater from a boat motor's cooling system. [82] Local infiltration of the wound with 1 to 2% lidocaine without epinephrine may bring about significant pain relief and allow for exploration of the wound after x-rays have been performed to locate retained portions of spines. [70], [82] Longer-acting anesthetics such as procaine and bupivacaine may be chosen to provide a longer period of pain relief. The wound should be thoroughly cleaned to remove any remnants of integumentary sheath. Cleansing with a toothbrush and a solution of hexachlorophene in 70% alcohol has been recommended. [82] Abdominal and thoracic wounds and deep wounds to the hands, feet, or fascial compartments of the legs should be explored in the operating room. [70] Debridement of necrotic tissues may be required at the time of exploration, and sequential debridement may be necessary. [70] In general, these wounds should be left open or closed loosely with tape or suture to allow for adequate drainage and to prevent abscess formation. Tetanus prophylaxis should be administered, if indicated, and antibiotics are recommended if the wound is more than 6 h old, is extensive, or involves deep puncture wounds to the hand or foot. [70] The choice of antibiotic should be based on the bacteriology of the marine environment in which the wound occurred and subsequently on deep wound or tissue cultures. Empiric antibiotic therapy for infections of wounds occurring in salt water should include coverage for *Vibrio* species. Before final wound culture results are known, initial choices of parenteral antibiotics include IV ciprofloxacin, imipenem-cilastatin, cefoperazone, cefotaxime, ceftazidime, gentamicin, tobramycin, chloramphenicol or trimethoprim-sulfamethoxazole. [89] Choices for oral antibiotic therapy include ciprofloxacin, doxycycline, and trimethoprim sulfamethoxazole. [89] Organisms reported to cause secondary infections in catfish spine wounds include *Erysipelothrix, Nocardia, Chromobacterium, Mycobacterium terrae, Sporothrix, Actinomyces, E. tarda, Aeromonas hydrophila,* and *Vibrio* species. [90] Deep wound or tissue cultures should guide the choice of antibiotic therapy. Empiric therapy for catfish wounds may include cephalosporins or ciprofloxacin. [84] Stonefish stings complicated by severe reactions may be treated with antivenin by slow intravenous infusion. Antivenin is not usually required for the stings of lionfish and other species of scorpionfish, except for stonefish. [70] Stonefish antivenom is available from the Australian Commonwealth Serum Laboratory, (Melbourne, Australia). It is supplied in 1.2-mL ampules. The amount of antivenin given depends on the number of puncture wounds sustained by the victim and the response to treatment. The initial dosing schedule is 1, 2, or 3 ampules for 1, 3, or more than 4 puncture wounds. [91] Stonefish antivenin is prepared from horse serum, and its administration may be complicated by anaphylaxis and serum sickness in sensitized individuals. [91]

Fish Bites

There are many species of fish whose bites are dangerous to humans. Among the best known are the sharks and barracudas, whose bites may cause severe injuries.

Although they are well publicized by the news media, shark attacks are relatively rare events. The average number of shark attacks worldwide is between 30 and 100 annually. Only 32 of the 350 known species of sharks have been reported to attack humans. Most shark attacks involve surfers, scuba divers, and swimmers. Because sharks are attracted to bright or shiny objects, as well as to contrasting colors, these items should not be worn in the water. They are also attracted by any sort of blood in the water; therefore women who are menstruating should refrain from water sports in areas where sharks may be prevalent, and no one should swim with an open bleeding wound. Spearfishermen should never tie their catch to themselves, and they should place their catch in the dive boat as soon as possible. Although most shark bites are not life-threatening, more severe attacks may cause extensive soft tissue loss with massive hemorrhage, which, in the worst cases, can result in amputation of a limb or death. [92], [93]

Barracuda attacks are even more rare than shark bites. They tend to occur in murky turbid waters where these predators may mistake jewelry or other brightly colored objects worn by bathers for the baitfish on which they feed. Barracuda bites typically produce straight or V-shaped lacerations.

Other gamefish such as flounder, mackerel, and bluefish may occasionally cause bites if they are handled carelessly by fishermen. Bluefish, which run in large schools, present a menace to swimmers and surfers and to fishermen who are not wary of their vicious bites. [50]

Divers and aquarium hobbyists must be careful when feeding or handling moray eels, which have powerful jaws and knifelike teeth. Although not considered venomous by most sources, they can produce deep puncture wounds and lacerations [50] (Fig. 237-27). When biting, moray eels tend to lock onto their prey; decapitation of the eel or disarticulation of its jaw may be required to release the victim. [94] As with all deep puncture wounds or lacerations, victims of moray eel

bites should receive tetanus prophylaxis. Empiric antibiotic therapy for prophylaxis or treatment can include ciprofloxacin or cefuroxime for coverage of *Vibrio* or *Pseudomonas* species. [95]

FIGURE 237-27 Moray eel bites are uncommon but have increased because of divers feeding these animals at popular dive sites. (*Courtesy of Marty Gilman, Worcester, MA.*)

WATERBORNE INFECTIONS

A variety of infections may result from exposures to aquatic environments. Pathogenic organisms may be actively introduced into wounds of the bites, stings, or lacerations caused by marine life; preexisting wounds may be passively infected when exposed to contaminated waters. Table 237-3 summarizes those organisms commonly associated with waterborne infections. A host of other agents, such as *Streptococcus* and *Staphylococcus* spp., *Bacteroides fragilis, Clostridium perfringens, Escherichia coli, Salmonella enteritidis,* other marine *Vibrio* species, *Chromobacterium violaceum,* and *Chlorella,* also require consideration when dealing with infections derived from aquatic settings. [70]



TABLE 237-3 **Wound Infections Associated with Waterborne Organisms**

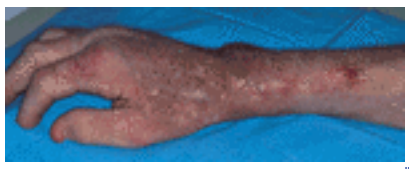

FIGURE 237-28 Fish fancier's finger with sporotrichoid spread to the wrist and arm caused by a *Mycobacterium marinum* infection, which responded to minocycline. (*Courtesy of Lori Herman, MD.*)

CUTANEOUS MANIFESTATIONS OF SEAFOOD INGESTION AND OF SEAFOOD POISONING

Several dermatologic reactions may appear after the ingestion of seafood. Urticaria, angioedema, and, rarely, leukocytoclastic vasculitis may occur in individuals sensitized to fish or shellfish (Fig. 237-30). Many seafoods, such as kelp, contain large amounts of iodine, which may cause acneiform eruptions.

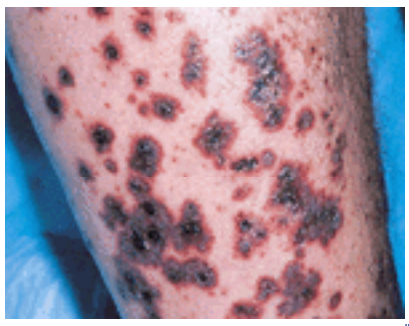

FIGURE 237-29 Leukocytoclastic vasculitis occurring in a patient, allergic to shellfish, who consumed a chowder containing quahogs, a type of clam.

Scombroid food poisoning involves the ingestion of spoiled fish from the Scombroidae family of fish, which includes tuna, mackerel, bonita, and their relatives. If these fish are not kept cold enough after being caught, their flesh develops scombrotoxins as a consequence of the bacterial breakdown of histidine into histamine, saurine, and possibly other toxic byproducts. These can cause striking erythema and flushing of the face, neck, and upper trunk, as well as pruritus and urticarial and angioedematous eruptions. Administration of antihistamines can provide symptomatic relief in severe cases.

Ciguatera toxin, which is produced during blooms of toxic dinoflagellates, is incorporated into the marine food chain and concentrated in the flesh of a variety of fish. Dermatologic symptoms of ingesting these fish may include generalized pruritus and diffuse erythematous macular and papular exanthems that may progress to blister formation and

desquamation.

FIGURE 237-30 When patients present with a bullous hemorrhagic cellulitis after eating shellfish (as was the case with this patient) or after having suffered a wound in salt water, *Vibrio vulnificus* cellulitis should be suspected.

Pufferfish poisoning, also known as Fugu poisoning, may be lethal. The toxin responsible for this illness is tetrodotoxin, a powerful neurotoxin, which can be found in the skin, entrails, and flesh of these fish. Initially, it was thought that pufferfish produced tetrodotoxin intrinsically, but it now appears to be produced by commensal microorganisms. [97] When deaths occur, they are because of an ascending paralysis of respiratory muscles. Cutaneous manifestations of Fugu poisoning may rarely include a severe erythrodermic eruption followed by extensive desquamation. Although these fish are considered a delicacy in Japan and other cultures of the Indo-Pacific, diners must take exceptional care when ordering this fare. The safest approach is to avoid eating pufferfish completely. Individuals not willing to abstain should eat only at restaurants of the highest caliber where properly licensed and experienced pufferfish cooks are employed.

The authors wish to thank Dr. Bruce Halstead of the World Life Research Institute, Colton, California, for allowing us to reprint the photographs from the first and second editions of *Poisonous and Venomous Marine Animals of the World.*

REFERENCES

1. Griego RD et al: Dog, cat, and human bites: A review. *J Am Acad Dermatol* **33**:1019, 1992

2. Garcia VF: Animal bites and *Pasteurella* infections. *Pediatr Rev* **18**:127, 1997

3. Goldstein EJC: Bite wounds and infection. *Clin Infect Dis* **14**:633, 1992

4. Goldstein E et al: Outpatient therapy of bite wounds: Demographic data, bacteriology and a prospective randomized trial of amoxicillin-clavulanic acid versus penicillin ± dicloxacillin. *Int J Dermatol* **26**:123, 1987

5. Callaham M: Prophylactic antibiotics in common dog bite wounds: A controlled study. *Ann Emerg Med* **9**:410, 1980

6. Barnham M, Holmes B: Isolation of CDC group M-5 and *Staphylococcus intermedius* from infected dog bites. *J Infect* **25**:332, 1992

7. Blanche P et al: *Capnocytophaga canimorsus* lymphocytic meningitis in an immunocompetent man who was bitten by a dog. Clin Infect Dis *Clin Infect Dis* **18**:654, 1994

8. Westwell AJ et al: DF-2 infection. *BMJ* **298**:116, 1989

9. Hudspeth MK et al: Growth characteristics and a novel method for identification (the WEE-TAB system) of *Porphyromonas* species isolated from dog and cat bite wounds in humans. *J Clin Microbiol* **35**:2450, 1997

10. Citron DM et al: Incidence and characterization of *Porphyromonas* species isolated from infected dog and cat bite wounds in humans by biochemical tests and PCR fingerprinting. *Clin Infect Dis* **23**(Suppl 1):S78, 1996

11. Darrow M et al: Zoonotic transmission of turtle-borne *Edwardsiella tarda*. *Infect Med* **11**:33, 1993

12. Pavia AT et al: *Vibrio carchariae* infection after a shark bite. *Ann Intern Med* **111**:85, 1989

13. Fishbein DB, Robinson LE: Rabies. *N Engl J Med* **329**:1632, 1993

14. Kositprapa CC et al: Immune response to simulated postexposure rabies booster vaccinations in volunteers who received preexposure vaccinations. *Clin Infect Dis* **25**:614, 1997

15. Anderson LJ: Human rabies in the United States. *Ann Intern Med* **100**:728, 1984

16. Glaser C et al: Pet-, animal-, and vector-borne Infections. *Pediatr Rev* **21**:219, 2000

17. Holmes GP et al: Guidelines for the prevention and treatment of B-virus infections in exposed persons. *Clin Infect Dis* **20**:421, 1995

18. Dart RC, McNally J: Efficacy, safety, and use of snake antivenoms in the United States. *Ann Emerg Med* **37**:181, 2001

19. Gold BS, Barish RA: Venomous snakebites: Current concepts in diagnosis, treatment, and management. *Emerg Med Clin North Am* **10**:249, 1992

20. McKinney PE: Out-of-hospital and interhospital management of crotaline snakebite. *Ann Emerg Med* **37**:168, 2001

21. Hall EL: Role of surgical intervention in the management of crotaline snake envenomation. *Ann Emerg Med* **37**:175, 2001

22. Gold BS, Wingert WA: Snake venom poisoning in the United States. *South Med J* **87**:579, 1994

23. Eadie P, Lee T: Seal finger in a wildlife ranger. *Ir Med J* **83**:117, 1990

24. Fisher AA: Aquatic dermatitis, Part I. Dermatitis caused by coelenterates. *Cutis* **64**:84, 1978

25. Halstead BW: Coelenterate (cnidarian) stings and wounds, aquatic dermatology. *Clin Dermatol* **5**:8, 1987

26. Reed KM et al: Delayed and persistent cutaneous reactions to coelenterates. *J Am Acad Dermatol* **10**:462, 1984

27. Mandojana RM: Granuloma annulare following blue bottle jellyfish (*Physalia utriculus*) sting. *J Wilderness Med* **1**:220, 1990

28. Auerbach PS, Hays JT: Erythema nodosum following a jellyfish sting. *J Emerg Med* **5**:487, 1987

29. Burnett JW et al: Local and systemic reactions from jellyfish stings. *Clin Dermatol* **5**:14, 1987

30. Mathelier-Fusade P, Leynadier F: Acquired cold urticaria after jellyfish sting. *Contact Dermatitis* **29**:273, 1993

31. Ingram DM et al: Mondor's disease of the breast resulting from jellyfish sting. *Med J Aust* **157**:836, 992

32. Burnett JW et al: Mononeuritis multiplex after coelenterate sting. *Med J Aust* **161**:320, 1994

33. Al-Ebrahim K et al: Jellyfish—Venom-induced deep venous thrombosis. *Angiology* **46**:449, 1995

34. Pang KA, Schwartz MS: Guillain-Barré syndrome following jellyfish stings. *J Neurol Neurosurg Psychiatry* **56**:1133, 1993

35. Little M et al: Life-threatening cardiac failure in a healthy young female with Irukandji syndrome. *Anaesth Intensive Care* **29**:178, 2001

36. Auerbach PS: Envenomations from jellyfish and related species. *J Emerg Nurs* **23**:555, 1997

37. Adiga KM: Brachial artery spasm as a result of a sting. *Med J Aust* **140**:181, 1984

38. Guess HA, Saviteer PL: Hemolysis and acute renal failure following a Portuguese man-of-war sting. *Pediatrics* **70**:979, 1982

39. Burnett JW, Gable WD: A fatal jellyfish envenomation by the Portuguese man-o'war. *Toxicon* **27**:823, 1989

40. Stein MR et al: Fatal Portuguese man-o'-war (*Physalia physalis*) envenomation. *Ann Emerg Med* **18**:312, 1989

41. Sutherland S: Lethal jellyfish. *Med J Aust* **143**:536, 1985

42. Fenner PJ, Williamson JA: Worldwide deaths and severe envenomation from jellyfish stings. *Med J Aust* **165**:658, 1996

43. O'Reilly GM et al: Prospective study of jellyfish stings from tropical Australia, including the major box jellyfish *Chironex fleckeri*. *Med J Aust* **175**:652, 2001

44. Currie BJ, Wood YK: Identification of *Chironex fleckeri* envenomation by nematocyst recovery from skin. *Med J Aust* **162**:478, 1995

45. Chand RP, Selliah K: Reversible parasympathetic dysautonomia following stinging attributed to the box jellyfish (*Chironex fleckeri*). *Aust N Z J Med* **14**:673, 1984

46. Currie B: Clinical implications of research on the box-jellyfish *Chironex fleckeri*. *Toxicon* **32**:1305, 1994

47. Burnett JW, Calton GJ: Response of the box-jellyfish (*Chironex fleckeri*) cardiotoxin to intravenous administration of verapamil. *Med J Aust* **153**:363, 1990

48. Fenner PJ et al: Successful use of Chironex antivenom by members of the Queensland Ambulance Transport Brigade. *Med J Aust* **151**:708, 1989

49. Burnett JW et al: First aid for jellyfish envenomation. *South Med J* **76**:870, 1983

50. Halstead BW, Auerbach PS, editors: *Dangerous Aquatic Animals of the World: A Color Guide, with Prevention, First Aid, and Emergency Treatment Procedures*. Princeton, NJ, Darwin Press, 1990

51. Fenner PJ et al: First aide treatment of jellyfish stings in Australia. Response to a newly differentiated species. *Med J Aust* **158**:498, 1993

52. Garcia PJ et al: Fulminant hepatic failure from a sea anemone sting. *Ann Intern Med* **120**:665, 1994

53. Mizuno M et al: Acute renal failure after a sea anemone sting. *Am J Kidney Dis* **36**:E10, 2000

54. Nicholis D: Sea anemone sting while scuba diving. *N Z Med J* **105**(936): 245, 1992

55. Weedon D et al: Coral dermatitis. *Aust J Dermatol* **22**:104, 1981

56. Sagi A et al: “The fire coral” (*Millepora dichotoma*) as a cause of burns: A case report. *Burns* **13**:325, 1987

57. Camarasa JG et al: Red Sea coral contact dermatitis. *Contact Dermatitis* **29**:285, 1993

58. Burnett JW et al: Dermatitis due to stinging sponges. *Cutis* **39**:476, 1987

59. Kizer KW: Marine envenomations. *J Toxicol Clin Toxicol* **21**:527, 1983

60. Baden HP: Injuries from sea urchins. *Clin Dermatol* **51**:12, 1987

61. Liram N et al: Sea urchin puncture resulting in PIP joint synovial arthritis: Case report and MRI study. *J Travel Med* **7**:43, 2000

62. Burke WA et al: Delayed hypersensitivity reaction following a sea urchin sting. *Int J Dermatol* **25**:649, 1986

63. Asada M et al: A case of delayed hypersensitivity reaction following a sea urchin sting. *Dermatologica* **180**:99, 1990

64. Baden HP, Burnett JW: Injuries from sea urchins. *South Med J* **70**:459, 1977

65. Haneke E et al: Sea urchin granuloma of the nail apparatus: Report of 2 cases. *Dermatology* **192**:140, 1996

66. Guyot-Drouot MH et al: Arthritis, tenosynovitis, fasciitis and bursitis due to sea urchin spines. A series of 12 cases in Reunion Island. *Joint Bone Spine* **67**:94, 2000

67. De La Torre C, Toribio J: Sea-urchin granuloma: Histologic profile. A pathologic study of 50 biopsies. *J Cutan Pathol* **28**:223, 2001

68. De la Torre C et al: Identification of *Mycobacterium marinum* in sea-urchin granulomas. *Br J Dermatol* **145**:114, 2001

69. Burnett JW, Burnett MG: Sea urchins. *Cutis* **64**:21, 1999

70. Auerbach PS: Marine envenomations. *N Engl J Med* **325**:486, 1991

71. Hoeffler DF: “Swimmers's itch” (cercarial dermatitis). *Cutis* **19**:461, 1977

72. Bastert J et al: Aquarium dermatitis: Cercarial dermatitis in an aquarist. *Dermatology* **197**:84, 1998

73. Gonzalez E: Schistosomiasis, cercarial dermatitis, and marine dermatitis. *Dermatol Clin* **7**:291, 1989

74. Tomchik RS et al: Clinical perspectives on seabather's eruption, also known as “sea lice.” *JAMA* **269**:1669, 1993

75. Freudenthal AR, Joseph PR: Seabather's eruption. *N Engl J Med* **329**:542, 1993

76. Segura-Puertas L et al: One *Linuche* mystery solved: All 3 stages of the coronate scyphomedusa *Linuche unguiculata* cause seabather's eruption. *J Am Acad Dermatol* **44**:624, 2001

77. Kumar S et al: Risk Factors for seabather's eruption: A prospective cohort study. *Public Health Rep* **112**:59, 1997

78. Burnett JW: Aquatic adversaries: Human injuries induced by octopi. *Cutis* **62**:124, 1998

79. Fulghum DD: Octopus bite resulting in granuloma annulare. *South Med J* **79**:1434, 1986

80. Soppe GG: Marine envenomations and aquatic dermatology. *Am Fam Physician* **40**:97, 1989

81. Germain M et al: The cutaneous cellular infiltrate to stingray envenomization contains increased TIA+ cells. *Br J Dermatol* **143**:1074, 2000

82. Fenner PJ et al: Fatal and nonfatal stingray envenomation. *Med J Aust* **151**:621, 1989

83. Falcone RE, Miller AP: Two-fathom hickey. *N Engl J Med* **325**:521, 1991

84. Das SK et al: Catfish stings in Mississippi. *South Med J* **88**:809, 1995

85. Pearn J: The sea, stingers, and surgeons: The surgeon's role in prevention, first aid, and management of marine envenomations. *J Pediatr Surg* **30**:105, 1995

86. Trestrail JH, Al-Mahasneh QM: Lionfish sting experiences of an in poison center: A retrospective study of 23 cases. *Vet Hum Toxicol* **31**:173, 1989

87. Davies RS, Evans RJ. Weever fish stings: A report of two cases presenting to an accident and emergency department. *J Accid Emerg Med* **13**:139, 1996

88. Borondo JC et al: Fatal weeverfish sting. *Hum Exp Toxicol* **20**:118, 2001

89. Link KW et al: A new hazard for windsurfers: Needlefish impalement. *J Emerg Med* **17**:255, 1999

90. Hall JT et al: Chronic tenosynovial hand infection from *Mycobacterium terrae*. *Arthritis Rheum* **22**:1386, 1979

91. Burnett JW: Aquatic adversaries: Stonefish. *Cutis* **62**:269, 1998

92. Woolgar JD et al: Shark attack: Review of 86 consecutive cases. *J Trauma Injury Infect Crit Care* **50**:887, 2001

93. Byard RW et al: Pathologic features of fatal shark attacks. *Am J Forensic Med Pathol* **21**:225, 2000

94. Auerbach PS, Halstead BW: Hazardous aquatic life, in *Management of Wilderness and Environmental Emergencies,* 2nd ed, edited by PS Auerbach, EC Beehr. St Louis, CV Mosby, 1989, p 933

95. Erickson T et al: The emergency management of moray eel bites. *Ann Emerg Med* **21**:212, 1992

96. Mlot C: *Pfisteria piscicida* puts focus on harmful aquatic microbes. *ASM News* **63**:590, 1997

97. Mines D et al: Travel-related emergencies, poisonings. *Emerg Med Clin North Am* **15**:157, 1997

T>

Chapter 238

Stephen Stone

Scabies and Pediculosis

HUMAN SCABIES
Etiology and epidemiology
Clinical Features
Differential Diagnosis
Diagnosis
Complications
Treatment
Antipruritic Medications
Treatment of Special Forms of Scabies
PEDICULOSIS
Clinical Manifestations
Pediculosis Capitis (Head Lice)
Pediculosis Corporis (Body Lice)
Pediculosis (Pthiriasis) Pubis (Pubic Lice)
Treatment and Control

REFERENCES

HUMAN SCABIES

Etiology and epidemiology

Scabies is the term for infestation with the itch mite, *Sarcoptes scabiei var humanus.* The mite was first described in 1687, making scabies one of the first infectious diseases with a known cause. [1] The disease is found worldwide, in all races and in all age groups. It can be transmitted sexually as well as by nonsexual close skin-to-skin contact, especially within the family and at school. When more than one member of a household is afflicted with an intensely pruritic eruption, scabies infestation must be considered.

Clinical Features

CLASSIC SCABIES The hallmark of scabies is intractable pruritus, characteristically more severe at night. The itching, often disproportionately severe, is associated with lesions that initially appear on the web spaces, then the sides of the fingers, the flexor surfaces of the wrists, elbows and anterior axillary folds. Other common sites of lesions are the penis (Fig. 238-1) and scrotum, the areolae in women, the buttocks, and the sacral and periumbilical areas. Lesions may be eczematous and often are excoriated, but the pathognomonic lesion is the burrow (Fig. 238-2), a short, wavy, dark line. The classical features are often obscured by excoriations, impetiginization or eczematization.

FIGURE 238-1 Scabies, with nodular lesions. The penis and scrotum are common sites for scabies infestations; crusted excoriated papules are seen on the glans and shaft, and nodular scabies lesions on the scrotum.

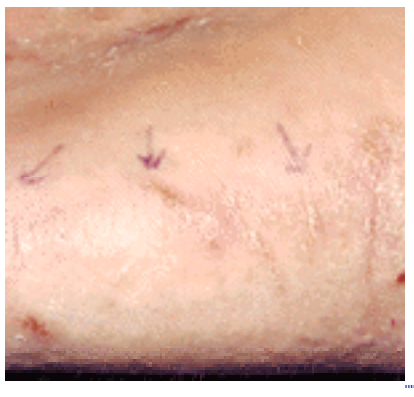

FIGURE 238-2 Scabies. Several, slightly scaling, threadlike burrows are seen on the medial aspect of the palm, associated with a more generalized eczematous process; scrapings of a burrow have the highest yield in detection of a scabies mite. (*Courtesy of M. Hebert, MD.*)

SPECIAL FORMS Orkin [2] described presentations of scabies that may present diagnostic difficulties or may suggest the diagnosis.

Scabies in patients with good hygiene Easily misdiagnosed because lesions are sparse and burrows difficult to find.

Scabies incognito Originally described in patients taking glucocorticoids, other immunosuppressive drugs also may lead to confusing presentations of scabies, including crusted scabies mimicking contact dermatitis or Darier's disease. Scabies must be considered whenever a widespread, scaly, pruritic dermatosis develops in an immunosuppressed patient.

Nodular scabies The lesions are reddish-brown, pruritic papules and nodules (Fig. 238-1) on covered areas (most frequently the male genitalia, groin, and axillary regions), which often persist long after adequate treatment for scabies. They probably represent a hypersensitivity reaction to retained mite parts or antigens.

Scabies in infants and young children In this age group, the face, scalp, palms, and soles may be involved; the most common presenting lesions are still papules, vesicopustules, and nodules, but the distribution may be atypical. [3] The diagnosis is frequently missed because of a low index of suspicion. Secondary eczematization and impetigenization are common, and burrows difficult to find. The prevalence of scabies is highest in infants younger than 2 years of age; the youngest child in the household is often affected because he or she is carried and hugged by affected adults.

Scabies in the elderly In this age group, scabies may be missed because the cutaneous changes may be minimal or atypical. The intense itching may be attributed to “senile pruritus,” xerosis, drugs or psychogenic causes. Older patients who spend prolonged periods of time in bed or in chairs may have involvement of the back. Scabies epidemics are frequently reported in group care facilities such as nursing homes, where a single patient with crusted scabies may be the index case leading to infection of other patients as well as health care workers and their families.

Crusted (Norwegian) scabies Historically, this condition has been associated with advanced age, debility, and developmental disabilities such as Down's syndrome. It is now also seen with immunosuppression of all types. Hyperkeratotic, nonpruritic lesions are most common, but the condition may range from crusting with or without pruritus to a pruritic, papular dermatitis and may mimic Darier's disease or psoriasis. Finger- and toenail involvement may simulate psoriasis or onychomycosis. Thousands to millions of organisms may be present in the scales and the nails. In the absence of other predisposing conditions, patients with crusted scabies should be tested for AIDS. Patients with crusted scabies have developed bacteremias—occasionally fatal—as a consequence of infection of the fissured and excoriated skin.

Scabies and HIV/AIDS Scabies occurs in at least 2 to 4 percent of patients with AIDS. Unusual forms of scabies in AIDS can be divided into crusted scabies (Fig. 238-3) and atypical papular scabies. [4] Patients with HIV/AIDS may present with classical scabies, and as the CD4 count drops, they may develop crusted scabies and the pruritus may decrease or disappear. Because of the atypical appearance, diagnosis may be delayed, increasing the risk of spread to others.

FIGURE 238-3 Scabies. Crusted or Norwegian scabies in an AIDS patient. The clinical presentation of generalized hyperkeratosis and scaling is often misdiagnosed; rather than an infestation with a dozen mites, many thousands to millions are present. (*Courtesy of M. Hebert, MD.*)

Scabies of the scalp Scabies rarely involves the adult scalp; when it does, it may accompany or simulate seborrheic dermatitis. However, scalp lesions do occur in infants and children, the elderly, nursing home patients, those residing in tropical areas, and patients with crusted scabies, AIDS and, recently reported, patients with dermatomyositis.

Bullous scabies Vesicles are common in children with scabies but uncommon in adults. Bullous scabies may occur in adults, associated with an eruption indistinguishable from bullous pemphigoid clinically, pathologically, and immunopathologically. [5] Patients are generally older than 65 years of age and in otherwise good health. Often, they are treated with oral glucocorticoids when routine and immunofluorescent biopsies point to a diagnosis of bullous pemphigoid, but, if sought, burrows are present in most cases. Because of the significant delay in diagnosis, there is an opportunity for spread of the disease to others.

Differential Diagnosis

Scabies can be confused with almost any pruritic dermatosis but is most commonly confused with atopic dermatitis, papular urticaria, pyodermas, insect bites, and dermatitis herpetiformis. Certain animal mites may transiently infest humans, and should be suspected in pruritic dermatoses of uncertain cause. Mite species known to cause such transient eruptions include *Sarcoptes scabiei* var *. canis, S. scabiei* var *. bovis, Notoedres cati, Cheyletiella yasguri, Cheyletiella blakei, Dermanyssus gallinae,* and *Ophionyssus natricis.* The eruption associated with these mites does not share the classical distribution of human scabies, nor have these mites been reported to cause crusted scabies. [6]

Diagnosis

Burrows are often difficult to find, and the usual clue to the diagnosis is the characteristic distribution; in males, papules, nodules and, rarely, ulcers on the penis, are a significant diagnostic feature. Definitive diagnosis rests on microscopic identification of the mites, eggs, or fecal pellets (*scyballa*). Often mites cannot be found in spite of classical lesions of nodular scabies on the genitalia, or the typical rash with a history of other family members itching. It may be appropriate to treat such a patient with a presumptive diagnosis, but both overdiagnosis and underdiagnosis are common. Useful

diagnostic methods include the following techniques.

DIRECT EXAMINATION One or two drops of mineral oil are applied to the lesion, which is scraped or shaved with a scalpel blade to remove the tops of the burrows or papules. The scrapings, along with the oil, covered with a coverslip, are examined microscopically under low power. Potassium hydroxide should not be used, because it can dissolve the fecal pellets (*scyballa*). Alternatively, the papule or burrow can be curetted with a small dermal curette. A toothpick or applicator stick may be used to clear the tissue/oil mixture from the curette, and the specimen is then examined microscopically. This technique is not frightening to children and uncooperative or anxious patients, and may be a preferred method in patients suspected of having HIV/AIDS.
DERMOSCOPY Argenziano et al. reported epiluminescence microscopy, or dermoscopy, to be an effective *in vivo* means of diagnosing scabies. The magnified view shows small, dark, triangular structures corresponding to the pigmented anterior section of the mite, and a subtle linear segment behind the triangle containing small air bubbles; together resembling a “jet with contrail” and thought to be the burrow along with the eggs and fecal pellets. [7]
POLYMERASE CHAIN REACTION Bezold et al. reported the use of PCR to prove scabies in a patient presenting with clinically atypical eczema. Epidermal scales were PCR positive for *S. scabiei* DNA before, and negative 2 weeks after, therapy. [8]

Complications

Eczema, particularly in atopics, may be prominent both during the active infestation and after the scabies has cleared. Excoriation may lead to secondary pyoderma, and colonization with nephritogenic strains of streptococci may lead to acute glomerulonephritis. This complication is seen most commonly in tropical areas. Patients who have been successfully treated for scabies (or have never had scabies) may develop *acarophobia* or delusions of parasitosis (see also Chap. 40).

Treatment

PRINCIPLES There are a number of effective treatments for scabies: selection may depend primarily on cost and potential toxicity. Patients will often apply medications more frequently and for longer periods than recommended, so knowing the appropriate quantity to prescribe can prevent irritation from overuse, which, in turn, is misinterpreted as treatment failure. Scabicides should be applied thoroughly to the area behind the ears and from neck to soles, with special attention to intertrigenous areas such as between the fingers and the toes, the umbilicus, the groin, between the buttocks, and under the fingernails and toenails. Medication should be thoroughly washed off after the recommended time period. The morning after treatment, underwear, bed linens, and towels should be machine-washed and dried, using the hot cycles. Patients should be cautioned that while the infestation has been adequately treated, itching and eczematization might persist for up to a month. All members of the affected household should receive topical treatment, although some physicians treat only those asymptomatic family members who have intimate contact with the patient (sharing a bed, sexual contact).
SPECIFIC TOPICAL SCABICIDES 1. *Permethrin 5% cream* (Elimite, Acticin), a synthetic pyrethroid, is an excellent scabicide, with low toxicity in humans even with overuse. It is minimally absorbed and rapidly metabolized. The cream is applied as described above and left on overnight. Many physicians prefer to use a second application 5 to 7 days later. Clinically significant resistance (properly termed tolerance) has not been reported. Permethrin should not be used in infants younger than 2 months of age or in pregnant or nursing women. The most common adverse reactions are mild and transient; burning, stinging or exacerbation or recurrence of pruritus, and rarely contact dermatitis may occur. 2. *Lindane 1%* (gamma-benzene hexachloride) in some studies was about as effective as permethrin. Other studies showed lindane to be somewhat inferior. Lindane is left on for 8 h and then washed off. As with permethrin, some physicians prefer to retreat 1 week later. Central nervous system toxicity may occur, generally because of failure to follow instructions, either because too much of the medication was applied or it was applied too many times. Since January 1, 2002, the state of California has forbidden the use of lindane in any products used or sold for the treatment of lice or scabies in humans. Lindane should not be used in infants, young children, or pregnant or nursing women, or in patients with seizure disorders or other neurologic diseases. Clinically significant tolerance to lindane has not been reported. 3. *Sulfur,* usually prescribed as precipitated sulfur (6%) in petrolatum, must be compounded by the pharmacist. It may be applied nightly for 3 nights and washed off thoroughly 24 h after the last application. It smells, stains, and is greasy, but it is safe, effective, and appropriate for infants younger than 2 months of age and during pregnancy or lactation. [9] 4. *Benzyl Benzoate 25%* is an effective scabicide, but is not commercially available in the United States. It is probably as effective as lindane. 5. *Crotamiton cream* (Eurax) is not believed to be highly effective in the treatment of scabies; it is inferior to permethrin, but may be about as effective as benzyl benzoate and sulfur. [10]
IVERMECTIN Ivermectin is an antiparasitic agent, approved by the FDA for onchocerciasis and strongyloidiasis in humans. Since 1993, there have been numerous reports indicating that ivermectin given in one or two oral doses of 200 µg/kg body weight is an effective treatment for scabies. Other studies suggest that higher dosages may be more effective, especially in immunosuppressed patients such as those with AIDS. Further controlled studies are needed to determine the most effective dosage and means of administration in both healthy and immunosuppressed patients, as well as the place of combined topical and oral therapy with ivermectin. Topical preparations of ivermectin such as a 1% solution in propylene glycol are also being investigated as a possible alternative treatment. [11]

Antipruritic Medications

The pruritus of scabies often persists for several weeks after adequate therapy. Sedating antihistamines may reduce the pruritus, but a short course of topical or systemic glucocorticoids is generally more effective. In children, 1% hydrocortisone cream may be helpful; in adults triamcinolone cream (0.1%) may be used. For more severe itching, a 7- to 14-day course of prednisone or intramuscular triamcinolone acetonide, 40 to 60 mg, may give relief.

Where excoriation has led to impetiginization, antibiotic therapy with topical mupirocin or a broad-spectrum antibiotic is appropriate.

Treatment of Special Forms of Scabies

CRUSTED SCABIES The scabicides used for classical scabies are effective in crusted scabies as well; however, repeated applications are usually required, clearing is slower than in noncrusted scabies, and sometimes the sequential use of two or more different agents is necessary. The entire skin should be treated, including the scalp, face (excluding the areas around the eyes, nose, and mouth), and particularly under the fingernails and toenails, brushing the medication under the free edges of the nails. Ivermectin, 200 to 250 µg/kg of body weight may be appropriate, alone or in combination with permethrin cream, followed by lindane or 6% to 10% sulfur ointment if necessary. Pretreatment with keratolytic agents (creams or lotions containing salicylic acid) may be helpful. Because the patient with crusted scabies carries huge numbers of mites (reportedly up to 2 million), the patient should be isolated until treatment is complete, and the environment and fomites should be treated. Compliance is also of concern: the scabicides should be applied under supervision. Prophylactic therapy of exposed individuals including family members and health care workers is indicated.
SCABIES IN HIV/AIDS Management is similar to that of crusted scabies. The more profound the immunosuppression, the more atypical may be the morphology and the less predictable the response to therapy. Repeated applications of scabicides, sequential use of several different agents, nd/or systemic therapy with ivermectin may be required. Isolation of the patient, supervision of treatment and treatment of contacts are appropriate as with crusted scabies.

PEDICULOSIS

Lice have infested humans for millennia. They are mentioned in the Hebrew Bible, and nits have been identified intact in ancient artifacts such as combs. There are three types of lice known to infest humans; whether they are three or only two different species is controversial. The head and body lice may be variants within a single species, but are thought by most biologists to represent two distinct species, which can hybridize or interbreed under special circumstances. They are best-termed *Pediculus humanus* and *P. capitis,* although if a single species, they are properly termed *P. humanus* var. *capitis,* and *P. humanus* var. *corporis.* The lice are tiny (1 to 4 mm) elongated, soft-bodied, wingless, dorsoventrally flattened, blood-sucking insects with six legs all terminating in small claws, which enable them to grasp hair shafts or clothing fibers. The third species, *Pthirus pubis,* is morphologically distinct from the others. The common term “crab louse” is an excellent description, the body being somewhat rounded like that of a crab, with small claws on the front pairs of legs and larger claws on the two rear pairs, which allow the louse to grip the widely spaced hairs of the pubic area, eyebrows and lashes, and other areas of short hairs.

Both head lice and pubic lice feed and reproduce on the human host, cementing their nits to the hair. Body lice, however, take their blood meals from the human host, but reproduce by attaching their eggs to the fibers of clothing. This has significance when treatment is considered. After an incubation period of 9 to 12 days, the nymphal stage emerges from the egg, or nit, and matures into an adult within another 10–15 days. Head and body lice may move as rapidly as 23 cm/min; the slower crab lice may travel only up to 10 cm/day.

Clinical Manifestations

The bite of the louse is painless, but because of hypersensitivity to the saliva of the mite, or to the anticoagulant injected at the time of feeding, the human host may develop an inflammatory lesion at the site. This lesion may be an immediate urticarial lesion, a small 2- to 3-mm red macule or papule developing hours to days later, or the classic *macula cerulea* (see pediculosis corporis). Pruritus is the most common symptom in any type of pediculosis.

Pediculosis Capitis (Head Lice)

ETIOLOGY AND EPIDEMIOLOGY Head lice are most common among children, infesting millions of elementary school students annually, spread by close physical contact as well as by the sharing of head gear, combs, brushes, and pillows. The lice are believed to survive for only about 24 to 48 h away from the human host, and therefore fumigation of homes is unnecessary. Head lice are a growing problem in the United States and around the world, and it is believed that the incidence is usually underestimated: there are numerous reports of surveys of school children showing varying incidences in different geographic areas. Head lice affect all levels of society and all ethnic groups, although in the United States, the incidence is low among African Americans. Hair length is not an important factor.
CLINICAL MANIFESTATIONS Pediculosis capitis is typically confined to the scalp (Fig. 238-4). The most common symptom is itching, often intense, and the sight of schoolchildren scratching their heads often leads to the diagnosis. There may occasionally be a tiny hemorrhagic crust at the site to indicate the louse has taken its blood meal. According to one study, bite reactions, pruritus, excoriations, lymphadenopathy, and conjunctivitis were the most common signs and symptoms, although lymphadenopathy was equally common in unaffected children of the same age. [12]

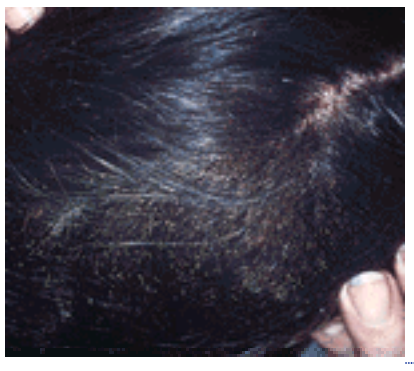

FIGURE 238-4 Pediculosis capitis. Myriads of oval, grayish-white egg capsules (nits) are firmly attached to the hair shafts. (*Courtesy of DA Burns, MD.*)

DIAGNOSIS AND DIFFERENTIAL DIAGNOSIS The most common diagnostic sign of head lice is the live nits on the proximal part of the hair shaft. These eggs are cemented to the hair by the female louse at the point where the hair exits the scalp. Thus the distance of the nit from the scalp along the hair shaft is evidence of the duration of the infestation.

When all of the nits are noted to be a significant distance from the scalp (i.e., >1 cm) it is likely that the infection is no longer active and that these nits are not fertile. It is best to examine the hair under the microscope to assure that there are live larvae present within the nits and to exclude seborrheic scales, hair casts, and artifacts on the hair (e.g., hair spray) that may be brushed off easily. Finding live adult lice, immature nymphs, and/or viable-appearing eggs confirms the diagnosis. One recent study suggested that fine combing hair that has been saturated with water and conditioner yields more positive results and fewer false positives than traditional scalp examination. [13]

Pediculosis Corporis (Body Lice)

ETIOLOGY AND EPIDEMIOLOGY Pediculosis corporis is a disease of poverty, found almost exclusively among the indigent, the homeless, and groups living in crowded unsanitary conditions, such as refugees and, in wartime, the military—these patients are seen mainly in urban public hospitals. The body louse is about 30 percent larger than the head louse, but has essentially the same morphology. The infestation is usually transmitted by contaminated clothing or bedding.

CLINICAL MANIFESTATIONS AND DIAGNOSIS Occasionally, the *macula cerulea* (literally, sky-blue spot), a blue to slightly slate-colored macule, can be seen, particularly in areas where clothing binds, such as the waistband, and on the buttocks and thighs. It is an asymptomatic to slightly pruritic, somewhat bruiselike lesion, up to approximately 1.5 cm in diameter and often with a central punctum. More commonly, the only sign of body lice is excoriations, often linear and primarily on the trunk. These serve as evidence of the intense pruritus, and secondary infection of these excoriations is not uncommon. Postinflammatory pigmentation is seen in more chronic cases. Adult lice are rarely seen except in heavy infestations. Diagnosis is made by closely examining the lining of the clothing, particularly at the seams, for the presence of nits. The clothing may also be shaken out over a sheet of newsprint, at which time the lice may be seen moving about on the paper. Body lice are medically important not because of the pruritus and secondary impetiginization, but because they may act as vectors for *Rickettsia prowazekii* and *R. quintana* (typhus and trench fevers; see Chap. 227) and *Borrelia recurrentis* (relapsing fever).

Pediculosis (Pthiriasis) Pubis (Pubic Lice)

ETIOLOGY AND EPIDEMIOLOGY Most often pubic lice are a sexually transmitted disease, commonly associated with other sexually transmitted diseases. There are no racial differences in incidence (unlike pediculosis capitis). The infestation is common and tends to recur in gay men. [14]

CLINICAL MANIFESTATIONS As suggested by its name, this louse is most commonly found in the pubic hair (Fig. 238-5), although in hirsute individuals the short hairs of the thighs, trunk, and perianal area may also be involved. All the hair-bearing skin should be examined. Occasionally, the beard, moustache, and even eyelashes (Fig. 238-6) may be involved. Infestation of the eyelashes and periphery of the scalp occur mainly in children, probably a result of contact with an infested parent. Meinking and Taplin [14] reported as much as 60 percent of a homeless population had crab lice in areas of the body besides the pubic hair. Secondary infection because of excoriation may obscure the infestation and can lead to local lymphadenitis and fever. *Maculae ceruleae* (sky-blue macules) may be present as in pediculosis corporis and capitis (Fig. 238-7).

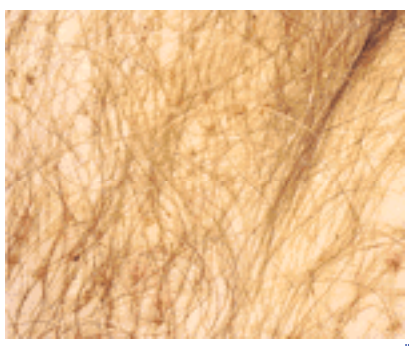

FIGURE 238-5 Pediculosis pubis. Several crab lice and their dot-like nits attached to the hair shafts can be seen in the pubic area of this patient. (*Courtesy of DA Burns, MD.*)

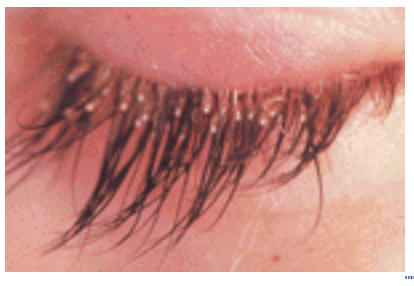

FIGURE 238-6 Pediculosis pubis. Eyelash infestation with *Pthirus pubis*. Nits can be seen attached to the eyelashes. (*Courtesy of DA Burns, MD.*)

FIGURE 238-7 Pediculosis pubis. Maculae caeruleae, slate-gray or blue-gray macules, are seen on the buttocks. (*Courtesy of DA Burns, MD.*)

DIAGNOSIS The diagnosis is most frequently made by the patient him- or herself, often identifying the louse in the pubic area. Infested patients reportedly have an average of 10 to 25 or more adult organisms (Fig. 238-8) on the body. When the lice themselves cannot be found, nits may be identified near the base of the hair. As in pediculosis capitis, the duration of infestation can be approximated by the distance of the nit from the skin surface. The diagnosis is confirmed by microscopic examination of the plucked hair to identify the nits (Fig. 238-9). Empty nits may indicate a prior infestation.

FIGURE 238-8 Pediculosis pubis. Microscopic view of an adult female louse containing an egg. (*Courtesy of DA Burns, MD.*)

FIGURE 238-9 Pediculosis pubis. Microscopic view of an egg, containing an unhatched louse, attached to a hair shaft. (*Courtesy of DA Burns, MD.*)

Treatment and Control

PEDICULOSIS CAPITIS The vast majority of patients with head lice are not treated by dermatologists, but by school nurses, primary physicians, pediatricians, and pharmacists. The dermatologist is likely to see those patients in whom initial treatment has failed. There are numerous published reports of tolerance to each of the approved topical medications for the treatment of pediculosis capitis. As drug resistance emerges in areas, it is impossible to be certain of the comparative effectiveness of these products. The “best” choice will now depend on local resistance patterns. [15] As a treatment becomes unpopular in a given area, susceptibility of the head lice in that area might return. In 2000, Meinking et al. studied the effects of pediculicides available in the United States, and most of the information that follows is based on that work. [16]
Topical pediculicides 1. Natural *pyrethrin* products synergized with piperonyl butoxide (RID, A-200, R&C shampoo and others) are available over-the-counter. They are applied to saturate the scalp and allowed to remain on for 10 min. The hair is then washed thoroughly, dried, and the nits can be removed with a fine-toothed comb which is often sold with the product. Meinking's study, using RID, showed only 49 percent of lice killed in 10 min, and 47 percent of lice exposed to RID survived more than 3 h, whereas A-200 killed 97 percent of lice within 20 min. The two preparations also showed significant ovicidal activity, but a second treatment is advisable 7 to 10 days later to kill the nymphs hatched after the treatment. 2. *Permethrin,* a synthetic pyrethrin, is marketed over the counter as Nix, a 1% cream rinse. After shampooing with regular shampoo, the hair and scalp are toweled dry and allowed to further air dry so as not to dilute the lotion. The hair and scalp are thoroughly saturated with the permethrin lotion, which is left in place for 10 min, rinsed thoroughly, and dried with a clean towel. The hair should be combed with a fine-toothed comb to remove any remaining nits. 3. *Malathion* lotion 0.5% (Ovide; prescription only) appears to be the fastest-acting pediculicide, killing 100 percent of lice tested in less than 10 min. In the same study, malathion showed 100 percent ovicidal activity after a 10-min exposure. The FDA-approved directions recommend application to dry hair until the hair and scalp are thoroughly moistened, then allow it to dry and remain on the hair and scalp for 8 to 12 h, before washing out with nonmedicated shampoo. 4. *Lindane* (gamma-benzene hexachloride) 1% shampoo was for many years the best known pediculicide. There has been a well-reported decline in its efficacy, and its potential toxicity has lead to its being banned in California since 2002. It remains available by prescription elsewhere. Enough shampoo is applied to dry hair (1 ounce or less for short hair, 2 ounces or less for long hair) to thoroughly wet the hair and scalp or skin of the affected and surrounding hairy areas. It is allowed to remain in place for 4 min, then, using just enough water to work up a good lather, it is rinsed out. The patient should also thoroughly rinse the entire body to remove any lindane on the skin. Lindane should not be used in infants, preschool children and pregnant or lactating females. A large number of alternative methods such as herbal treatments are being promoted on the Internet, but there is little to no published scientific evidence of their efficacy. Physical treatment methods such as extensive combing, specially designed combs, and even electrified combs that are being marketed have either not been studied or have been shown to be ineffective. Because of resistance to topical therapy a

number of alternative treatments for pediculosis capitis have been proposed. These include ivermectin 200 µg/kg, two doses given 10 days apart. Although the reports to date are all anecdotal, ivermectin may emerge as the preferred treatment for the first half of the twenty-first century. There are also reports of the use of cotrimoxazole [trimethoprim-sulfamethoxazole (TMP-SMX)] for resistant head lice infestations, but it is premature to recommend the therapy at this time. Because neither ivermectin nor TMP-SMX is ovicidal, if used, they should be readministered in 7 to 10 days.

Environmental control The only definite evidence of treatment failure is the presence of adult organisms, which clearly requires retreatment. The presence of nits does not necessarily indicate ongoing infection. With any pediculicidal treatment, it is best to follow-up by using a fine-toothed comb to remove as many of the nits as possible. An 8 percent formic acid rinse (such as Step 2) may be helpful to dislodge the nits from their attachment to the hair. All members of the affected household should be examined. Although some physicians recommend treating all household members, others recommend treating affected individuals only. Following therapy, the treated individuals should wear clean clothing, and both clothing and bedding should be washed and dried using the hot cycle; nonwashables should be dry cleaned, ironed, put in the clothes dryer without washing, or stored in a sealed plastic bag in a warm area for 2 weeks. Combs and brushes may be washed in very hot water (such as the dishwasher) and may be coated with the pediculicide first, for 10 or 15 minutes. Floors, play areas, and furniture should be carefully vacuumed to remove any hairs with viable eggs attached. Fumigation of living spaces is of no value. “No nit” policies requiring exclusion from school and treatment for all children with nits alone are likely excessive. [17]

PEDICULOSIS PUBIS Topical therapy is much the same as that for pediculosis capitis. The preparation should be applied to the infested area, paying particular attention to the pubic and perianal regions and adjacent hairy areas. A common cause of failure is treating only the pubic area in hairy individuals: the pediculicide should be applied to the thighs, trunk, and axillary regions because the mite can infest these areas as well. Sexual contacts should be treated simultaneously, even if no lice can be seen, but other family members need not be treated if there is no evidence of infestation. After the treatment, the patients should use fresh underclothing, nightwear, and bedding; used articles should be washed and dried in the hot cycle of the washer and dryer. Ironing woolens and bedding may also be helpful.

Specific agents Synergized pyrethrins (RID, A-200, and other preparations available over the counter) appear to be safe and effective. They are applied undiluted until the infested areas are entirely wet, and allowed to remain in place for 10 min. The area is then washed thoroughly with warm water and soap and dried. Dead lice and eggs are removed with a fine-toothed comb (provided with some products). A second application is used in 7 to 10 days to kill any nymphs newly hatched from eggs that survive the first treatment. Lindane shampoo may be lathered into the affected area for 5 min. The area should be rinsed thoroughly and towel-dried. Remaining nits should be removed with a fine-toothed comb or forceps. Some physicians routinely prescribe a second treatment in 1 week to kill any newly hatched nymphs. Treatment failure is usually a result of failure to follow instructions, neglecting to treat sexual contacts, or reinfestation. Persistent itching may be caused by irritation from the pediculicide (usually because of overuse) or patient anxiety. Parasitophobia is fairly common after infestation and is difficult to treat. Therapy for eyelash involvement is petrolatum applied twice daily for 8 days followed by removal of any nits. Some authors recommend use of 1% malathion ointment, 1% lindane ointment, or 0.25% physostigmine ointment. Patients with HIV/AIDS tend to have more severe infestations with pediculosis pubis and to be unresponsive to conventional therapy.

PEDICULOSIS Corporis Because lice reproduce in the clothing and not on the skin, bathing, discarding or laundering infested clothing, and restoring proper hygiene should cure the infestation. Bedding should also be laundered with hot water, boiled, or discarded. Woolens and other nonwashables may be dry cleaned or ironed at home, with special attention given to the seams. Some physicians believe that, following appropriate disposition of clothing, the patient should be treated from head to toe with a single application of permethrin 5% cream, left on for 8 to 10 h and then washed off thoroughly. [18]

REFERENCES

1. Orkin M, Maibach HI: Ectoparasitic diseases, in *Dermatology,* edited by M Orkin, HI Maibach, MV Dahl. Norwalk, CT, Appleton and Lange, 1991, p 205

2. Orkin M: Today's scabies. *JAMA* **233**(8):882, 1975

3. Paller AS: Scabies in infants and small children. *Semin Dermatol* **12**:3, 1993

4. Orkin M: Scabies in AIDS. *Semin Dermatol* **12**:9, 1993

5. Konishi N et al: Bullous eruption associated with scabies: Evidence for scabetic induction of true bullous pemphigoid. *Acta Derm Venereol* **80**:281, 2000

6. Beck W: Tierische Milben als Epizoonoseerreger und ihre Bedeutung in der Dermatologie. *Hautarzt* **47**:744, 1996

7. Argenziano G et al: Epiluminescence microscopy. A new approach to in vivo detection of *Sarcoptes scabiei*. *Arch Dermatol* **133**:751, 1997

8. Bezold G et al: Hidden scabies: Diagnosis by polymerase chain reaction. *Br J Dermatol* **144**:614, 2001

9. Maibach HI et al: Sulfur revisited. *J Am Acad Dermatol* **28**:154, 1990

10. Walker GJA, Johnstone PW: Interventions for treating scabies (Cochrane Review). The Cochrane Library, Issue 3, 2001. Oxford: Update Software.

11. Victoria J, Trujillo R: Topical ivermectin: A new successful treatment for scabies *Pediatr Dermatol* **18**:63, 2001

12. Mumcuoglu KY et al: Clinical observations related to head lice infestation. *J Am Acad Dermatol* **25**:248, 1991

13. De Maeseneer J et al: Wet combing versus traditional scalp inspection to detect head lice in schoolchildren: Observational study *BMJ* **321**:1187, 2000

14. Meinking TL, Taplin D: Infestations: Pediculosis, in *Sexually Transmitted Diseases: Advances in Diagnosis and Treatment,* edited by P Elsner, A Eichmann. Basel, Karger, 1996, p 157

15. Dodd CS. Interventions for treating head lice (Cochrane Review). The Cochrane Library, Issue 2, 2001. Oxford: Update Software

16. Meinking TL et al: Comparative efficacy of treatments for pediculosis capitis infestations: Update 2000. *Arch Dermatol* **137**:287, 2001

17. Williams LK et al: Lice, nits, and school policy. *Pediatrics* **107**:1011, 2001

18. Taplin D, Meinking TL: Infestations, in *Pediatric Dermatology,* 2d ed, edited by LH Schachner, RC Hansen. New York, Churchill Livingstone, 1995, p 1465

T>

Chapter 239

David Wilson Michael Smith Lloyd King

Arthropod Bites and Stings

HISTOPATHOLOGY
ARACHNIDA
Acarina
Araneae
CHILOPODA AND DIPLOPODA
Centipedes
Millipedes
INSECTA
Anoplura
Coleoptera
Diptera
Hemiptera
Hymenoptera
Lepidoptera
Siphonaptera
PREVENTION
REFERENCES

The bites and stings of arthropods cause many patients to consult physicians for relief from these vexatious creatures. Occasionally, death is caused by envenomation, particularly in infants. The clinician primarily diagnoses and treats skin lesions and systemic illnesses produced or transmitted by only five of the nine classes of arthropods: Arachnida, Chilopoda, Diplopoda, Crustacea, and Insecta. [1] All arthropods are invertebrates with a chitinous exoskeleton, bilateral symmetry, true segmentation, and jointed true appendages that vary from few to many (Fig. 239-1 and Table 239-1).



FIGURE 239-1 Pictorial key to groups of human ectoparasites. (*Courtesy of CJ Stojanovich and HG Scott, US Department of Health, Education, and Welfare, Public Health Service.*)

I. Arachnida—mites, ticks, spiders, scorpions (four pairs of legs)
  A. Acarina
    1. Mites—follicle, food, fowl, grain, harvest, murine, scabies
    2. Ticks
  B. Araneae—spiders
  C. Scorpionida
II. Chilopoda and Diplopoda—centipedes, millipedes
III. Insecta (three pairs of legs)
  A. Anoplura—lice
  B. Coleoptera—beetles
  C. Diptera—flies, mosquitoes
  D. Hemiptera—bedbugs, kissing bugs
  E. Hymenoptera—ants, bees, wasps
  F. Lepidoptera—butterflies, moths
  G. Siphonaptera—fleas

TABLE 239-1 **Arthropods That Infest, Bite, or Sting Humans**

HISTOPATHOLOGY

Most arthropod bites have a similar histologic reaction pattern. In the acute phase, there is variable epidermal necrosis, spongiosis, and parakeratosis with plasma exudate and a dermal inflammatory infiltrate extending upward. Dermal inflammation tends to extend into the deep dermis in a wedge-shaped pattern, surrounding vessels with some extension into dermal collagen. The infiltrate is typically of mixed composition including eosinophils, neutrophils, lymphocytes, and histiocytes in varying proportions. Eosinophils are usually prominent, although neutrophils may predominate in reactions to fleas, mosquitoes, fire ants, and brown recluse spiders. Bullae can form secondary to marked edema, especially in children. Insect parts are rarely seen, except for the burrowed mites of scabies within the stratum corneum and the mouth parts of ticks, which may remain within the dermis after ticks are removed.

Chronic lesions most commonly result when a portion of the arthropod lodges within the skin, although hypersensitivity to the bite can be the sole cause. Chronic lesions can present diagnostic problems when they take on a pseudolymphomatous appearance. [2]

ARACHNIDA

The Arachnida class includes three orders of medical interest: Acarina (ticks and mites), Araneae (spiders), and Scorpionida (scorpions). All adults in this class have four pairs of legs; the cephalothorax may vary, but it is typically fused. An exception to this rule is the larval stage of ticks (seed ticks), which have only three pairs of legs.

Acarina

The mites in the order Acarina of most interest to the clinician are the follicle mites, food mites, fowl mites, grain mites, harvest mites, murine mites, and scabies mites. With the exception of *Demodex* mites and scabies mites, these mites do not burrow and are known to drop off after feeding. [3] All mites may produce pruritus and/or allergic reactions through salivary proteins deposited during feeding. Although it is not possible to group all mites that cause human diseases into convenient categories, most of the more common mites can be grouped into three suborders:

Trombidiiformes: Harvest/chigger mites, family Trombiculidae; grain mites, family Pyemotidae; follicle mites, family Demodicidae.
Mesostigmata: Bird/rodent mites, family Dermanyssidae; straw mites, family Hemoganasidae.
Sarcoptiformes: Scabies mites, family Sarcoptidae; food mites, family Acaridae, family Glycyphagidae; mange, family Psoroptidae.
FOLLICLE MITES *Demodex* mites can be detected in sebaceous glands and hair follicles by skin biopsy of symptomatic and asymptomatic humans. [4] Whether *Demodex* is the etiologic agent in rosacea and other dermatoses, or whether its presence reflects asymptomatic commensalism, is not well documented. Symptoms produced by demodicidosis, if any, are more likely a result of immunologic rather than toxicologic reactions.
FOOD MITES Several species of mites that infest foodstuffs have been described. The grain mite, *Acarus,* the cheese mite, *Glyciphagus,* and the grocery mite, *Tyrophagus,* produce papular urticaria or vesiculopapular eruptions. An occupational history and negative skin scrapings are frequently required to separate these food mite–induced problems from scabies and other causes of papular urticaria. [5]
FOWL MITES Office workers, homemakers, poultry workers, and bird fanciers are all affected by mites that infest birds, especially pigeons that have nests or roosts near air conditioner intake ducts. *Dermanyssus gallinae* and *D. avium* are the most common fowl ectoparasites identified in the United States. These mites only temporarily infest humans. *Ornithonyssus bursa* transmit Western equine encephalomyelitis virus. [6]
GRAIN MITES The best studied grain mite of medical importance is the straw itch mite, *Pyemotes ventricosus*. *P. ventricosus* is primarily a parasite of insect larvae that feed on grain. *P. ventricosus* infests both animals and humans, occasionally producing unusual epidemics after an exposure to infested hay, grains, grasses, or straw. Affected patients often have systemic symptoms such as fever, diarrhea, anorexia, and malaise. Clinically, the lesions vary from bright red macules to varicelliform eruptions. However, *P. ventricosus* is often not identified in grain products because of a low index of suspicion. [5]
HARVEST MITES Perhaps the best-known cause of “bites” from mites in the United States is the chigger, mower, or harvest mite (*Eutrombicula alfreddugesi* and *E. splendeus*). In other parts of the world, trombiculid mites (*Leptotrombidium akamushi* and *L. deliense*) are the vectors for *Rickettsia tsutsugamushi,* the cause of scrub typhus. Contact with the chigger mite usually occurs during the summer and fall when outdoor activities are maximal. Frequently, the only sign of exposure is intense pruritus on the ankles, legs, or belt line, because the bright red mites (“red bugs”) typically fall off after feeding or may be scratched off. In nonsensitized individuals, usually only 1- to 2-mm pruritic macules are seen, which require minimal treatment. In sensitized or allergic individuals, the reaction to the chigger infestation may be papular urticaria, vesiculation, or a granulomatous reaction with fever and lymphadenopathy. Clinically, the distribution of the lesions may be confused with other dermatoses because the type of exposure and the clothing worn greatly affect where the mites attach. Occasionally, the mites can be identified by visual inspection. A unique clinical syndrome called “summer penile syndrome” is seen in toddler to school-age boys. Edema, pruritus, and excoriation of the glans and foreskin result from hypersensitivity to chigger bites. Partial phimosis may reduce urine stream. The mean duration is 4 days but the condition may last up to 18 days. [7]
ANIMAL MITES Two species of murine mites are of medical importance throughout the world: *Ornithonyssus bacoti* (tropical rat mite; vector of endemic/murine typhus), and *Allodermanyssus sanguineus* (the housemouse mite, a vector of rickettsialpox). Papular urticaria from bites are often acral and may exhibit secondary eczematization. Cheyletiellid mites are frequently harbored by dogs and cats, producing a condition sometimes referred to as “walking dander.” The pet may be asymptomatic, or may have seborrhea-like scale or crusted annular lesions, while the person holding the pet experiences marked pruritus when the mites penetrate clothing and temporarily feed on that individual's skin. Diagnosis depends on finding the mites on the pet by microscopically examining cellophane tape applied to the pet's skin or brushings from the animal. Treatment of the pet by a qualified veterinarian resolves the symptoms. [5], [6] Sarcoptic mange of dogs (*Sarcoptes scabiei* var. *canis*) and cats (*Notoedres cati*) may also affect humans. Lesions range from papular to pustular with intense pruritus, excoriation and crusting. The condition resolves after pets are cured. [8]
SCABIES MITES Scabies is discussed in Chap. 238. Because nonscabetic mites other than *Demodex* do not burrow into the skin, their treatment consists of a warm soapy bath to kill remaining larvae, an important step in the prevention of scrub typhus transmitted by trombiculid mites. The ultimate success of treatment in these nonscabetic cases also depends on treatment of the animal or food sources. Antipruritics are used as needed. Application of persistent pyrethroid compounds such as Permanone to cuffs, socks, shoes, and waistbands may reduce the attachment of chiggers in susceptible individuals. *N, N*-diethyl-3-methylbenzamide (DEET)-based insect repellants are of no value in preventing mite infestation. [5]
TICKS Ticks are the largest members of the order Acarina. They are important worldwide as vectors of systemic disease. Reactions to tick bites include foreign-body reactions, reactions to salivary secretions, reactions to injected toxins, and

hypersensitivity reactions. [3] Ticks are divided into the Argasidae (soft tick) and Ixodidae (hard tick) families (Fig. 239-1). The Ixodidae family is responsible for most tick-related diseases. Ticks are separated from other mites by the presence of a barbed hypostome, which they use for feeding. Using their toothed chelicerae, ticks tear open the epidermis and then insert the barbed hypostome. Salivary secretions are used to soften the epidermis as well. During the insertion process, a cement-like substance is secreted that hardens and firmly anchors the hypostome to the skin. Ticks feed for about 7 days until engorged and then drop off to continue their life cycle. [3] Tick bites occur most commonly in the spring and summer, coinciding with the life cycle of the tick. Ticks have four stages of the life cycle: egg, larva, nymph, and adult. All stages require a blood meal to advance to the next stage except the egg. Eggs are deposited in early spring and develop to larvae by summer. The larvae feed once on small rodents and then are inactive over winter. The following spring larvae develop to nymphs and again find a suitable host and feed. Generally this host is a small rodent, but larger animals and humans may also become hosts. Nymphs molt to become adults in summer. After finding a suitable host for a blood meal, the adult female survives through the winter to begin the life cycle with egg laying the following spring. Many different species of ticks are responsible for local tick bite reactions and transmission of diseases in humans. Among those most common in the United States are *Ixodes scapularis, I. pacificus, Amblyomma americanum* (Lone Star tick), *Dermacentor andersoni* (American wood tick), and *D. variabilis* (American dog tick). In Europe, *I. ricinus* and *I. persulcatus* are important vectors of disease, especially Lyme disease. Lyme disease is discussed in greater detail in Chap. 203. Depending on the species of tick, the bite of the tick may or may not be painful or pruritic. In many instances, victims are not even aware that they have been bitten and there may be only a red papule at the bite site. This papule can progress to local swelling and erythema. Blistering, severe pruritus, and ecchymosis can be seen. A cellular reaction to the bite can lead to induration and nodularity after a few days. Central necrosis and ulceration rarely occur. [3] The usual bite heals in 2 to 3 weeks, although chronic tick bite granulomas may persist for months to years. Persistent papules respond to intralesional glucocorticoid injections.

Tick paralysis Tick paralysis is thought to be caused by a toxin secreted in the saliva of the tick, although the exact nature of the toxin is unknown. Typically, the tick is attached from 4 to 7 days before the onset of symptoms. The paralysis is an acute ascending lower motor neuron paralysis that rapidly resolves after the tick is removed. [9], [10] Treatment, which may require respiratory support, is merely supportive until the symptoms resolve.

Ehrlichiosis Two new forms of ehrlichiosis transmitted by tick vectors now occur in the United States. Monocytic ehrlichiosis is caused by *Ehrlichia chaffeensis* invading mononuclear white blood cells. The more recently described human granulocytic ehrlichiosis (HGE) is caused by an organism identical to *E. equi.* The invasion of neutrophils in this disorder leads to the characteristic intracytoplasmic inclusions (morulae) in peripheral blood neutrophils. Patients present with nonspecific findings of fever, chills, headache, and myalgias along with leukopenia, anemia, and thrombocytopenia. No cutaneous findings have been reported in HGE, but a diffuse macular erythema is noted in 36 percent of patients with monocytic ehrlichiosis. [11], [12]

Southern erythema migrans A new Lyme disease–like condition has been reported in many southern U.S. states. Clinical features include erythema migrans, fever, stiff neck, headache, myalgia, and arthralgia. No neurologic, arthritic, or cardiac sequelae have been noted. The putative etiologic agent is *Borrelia lonestari,* transmitted by *Amblyomma americanum* from its primary lizard host. Although *B. burgdorferi* is found in the southern United States, lizards are poor hosts for this organism. Serologic testing with a Lyme disease enzyme-linked immunosorbent assay (ELISA) shows cross-reactivity. No cross-reactivity is seen with the Western blot technique. [11], [12] Ticks are important vectors of many other diseases to humans. They play a role in transmitting viruses, rickettsia, parasites, spirochetes, and bacteria. [11], [12] and [13] Preventing bites is the most important measure in controlling both local and systemic tick-related diseases. When exposure is anticipated, proper clothing should be worn and appropriate repellents used. Immediately after potential exposures, the skin should be carefully inspected for ticks in an attempt to remove them before they become embedded or transmit disease. Evidence suggests that the tick must remain attached for more than 24 h in most cases to transmit Lyme disease. Once the tick's hypostome is secure to the skin, the tick must be forced to remove it. A colorful array of remedies has been recommended for removing the tick. Physical methods such as slow steady pulling on the tick, with or without twisting, are advised. If the hypostome is retained in the skin when the tick is extracted, it should be removed surgically. Foreign-body reactions and persistent papules are produced if tick parts remain in the wound.

Araneae

Spiders belong to the class Arachnida and are differentiated from insects by the presence of two separate body parts with five paired appendages and the absence of antennae. Spiders are carnivorous and either capture their prey in webs or attack them and inject venom through their chelicera (mandibles). In the United States, the genera *Loxosceles, Latrodectus,* and *Tegenaria* are the only species whose venom produces significant toxic effects in humans. Wolf spiders, tarantulas, jumping spiders, orb weavers, and crab spiders rarely produce cutaneous lesions by other mechanisms, such as the trauma of the bite or secondary infection. [1]

LOXOSCELES There are 13 different species of *Loxosceles* in the United States, and five of them, *L. reclusa, L. deserta, L. arizonica, L. laeta,* and *L. rufescens,* are associated with cutaneous loxoscelism. [1], [14] The brown recluse spider, *L. reclusa,* typifies the species and is widely distributed throughout the Southeast and the Midwest. It is often called the violin or fiddleback spider because of the violin-shaped figure on its dorsal cephalothorax (Fig. 239-2). Adult body size is 8 to 9 mm, with leg span up to 5 cm, depending on diet and habitat. Although its natural habitat is outdoors under dry overhanging rocks and cliffs, human environmental controls have caused it to move indoors and expand its range. Despite its usually timid nature, this spider will bite when trapped or threatened via chance encounters with humans. Because the brown recluse spider hibernates in the winter, most bites occur between March and October when humans disturb their habitat (closets, attics, outbuildings).

FIGURE 239-2 Brown recluse spider. Characteristically there are six eyes in three pairs and fiddle-shaped markings on the cephalothorax.

The venom of the brown recluse spider contains at least nine protein fractions. [15] These include sphingomyelinase D, alkaline phosphatase, 5'-ribonucleotide phosphohydrolase, hyaluronidase, and esterase. A major fraction is the 32- to 34-kDa protein sphingomyelinase D. This venom fraction aggregates platelets, generates leukocyte chemoattractants, and liberates thromboxane B_2 in vitro. It is also responsible for direct erythrocyte lysis in a calcium-dependent mode. In addition, the venom induces release of granulocyte-macrophage colony-stimulating factor, interleukin-8, and E-selectin, effects similar to those of tumor necrosis factor-a. The venom produces typical skin necrosis when injected into rabbits. Reported responses to envenomation range from a mild local urticarial reaction to full-thickness skin necrosis. The bite itself is generally painless, and findings of a central papule and associated erythema may not be seen for 6 to 12 h. Few envenomations, perhaps less than 10 percent, lead to severe skin necrosis or other systemic manifestations. Wounds destined for necrosis generally show signs of progression within 48 to 72 h of the bite. [16] Central blistering with a surrounding gray to purple discoloration of the skin may be seen at the bite site. A surrounding ring of blanched skin is itself surrounded by a large area of asymmetric erythema leading to the typical “red, white, and blue” sign of a brown recluse bite (Fig. 239-3A). At this stage of evolution, these bites may be associated with significant pain related to incipient necrosis of skin and subcutaneous tissues. The resultant necrotic skin ulcer heals slowly (Fig. 239-3B) and may require skin grafts or flaps to reconstruct the defect. A retrospective review of confirmed cases demonstrated correlation between severity and healing time. Grade 3 lesions (necrosis >1 cm) required an average of 74 days to heal.

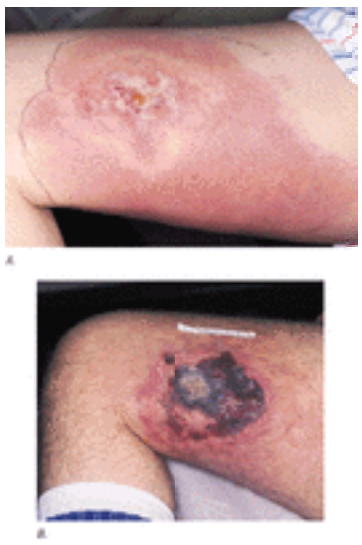

FIGURE 239-3 *A*. Clinically typical brown recluse spider bite showing the “red, white and blue” sign. *B*. Late ulcerative brown recluse spider bite with overlying eschar.

A systemic reaction may be seen in the first 24 to 48 h after envenomation. Features may include a diffuse macular erythema, fever, chills, malaise, arthralgias, headache, nausea, and vomiting. Thrombocytopenia, hemolytic anemia, transient leukocytosis, and consumptive coagulopathy have been noted. Hemolysis, if severe, may induce profound hemoglobinuria and renal insufficiency. Renal failure, seizures, and death have been reported, although the cases are often unconfirmed. Death is rare with brown recluse bites. The histologic findings of bites are nonspecific, and such studies should not generally be pursued unless other etiologies are strongly considered. Findings include acute vasculitis, platelet thrombi, and leukocyte infiltrates. [15], [16], [17], [18] and [19] Because the clinical appearance of a brown recluse spider bite is nonspecific, diagnosis may be difficult. The potential for exposure to *Loxosceles* spiders, identification of the arachnid, appearance of the lesion, and clinical course must all be considered. Of these, only identification of the captured spider allows for definitive diagnosis of *Loxosceles* envenomation. Laboratory tests for diagnosis are not currently available. Laboratory tests to assess for potential complications such as hemolysis are in order, particularly in children. A broad differential diagnosis must be entertained to include reactions to other biting organisms, allergic reactions, trauma, herpetic eruptions, skin abscesses, and pyoderma gangrenosum. The treatment of brown recluse spider bites remains controversial. Rest, ice compresses, and elevation are useful in reducing erythema and swelling. Aspirin may help reduce platelet aggregation and thrombosis. Tetanus prophylaxis must be current. Antibiotics have been found useful to reduce the comorbid secondary infection risk. Analgesics may be required. A controversial remedy used successfully by the authors, both experimentally and clinically, is the sulfone-based leukocyte-inhibitor dapsone. [15], [16], [17], [18] and [19] Years of successful anecdotal use, supportive animal studies, an uncontrolled human trial, and the neutrophil-dominant pathophysiology of the bite reaction combine to support its use. Glucocorticoids have not proved useful for the local necrotic wound but do have a role in systemic reactions with hemolysis, especially in children. The steroid membrane–stabilizing effect and relative renal protection may improve outcome. Acute excision of the bite site should be avoided because the inflammatory reaction produced by the venom will inhibit wound healing and produce an inferior clinical result. [15], [16], [17] and [18] Surgical management should be postponed until wounds have stabilized with medical management and are no longer progressing.

TEGENARIA The bite of the Hobo spider, *T. agrestis,* has become an important consideration in the differential diagnosis of necrotic skin lesions in the Pacific Northwest regions of the United States. This relatively large spider in the family Agelenidae has a body length of 10 to 13 mm with a leg span of approximately 4 cm. Funnel webs are built in bushes, cracks in masonry, window wells, stacked firewood, and other crevices. When disturbed, the spider inflicts a painless to slight pinprick bite. Erythema, induration, and local paresthesia develop within minutes. Vesicle formation occurs within 36 h, often with hemorrhage into the vesicles. Local necrosis may ensue, covered by eschar within a few days. The main systemic feature is a severe, and perhaps prolonged, headache. Nausea, weakness, paresthesias, vomiting, and diarrhea have been reported. The venom effects and appropriate treatment have not been elucidated. [17], [20], [21], [22] and [23]

LATRODECTUS Several different species of *Latrodectus* spiders exist in the United States, but the fame and fear of *L. mactans,* the black widow, far exceed the others. *L. mactans* is the most common of the North American “widow” spiders, but *L. variolus* and *L. hesperus* can also be commonly found in a more limited distribution. All three of these spiders have the characteristic red hourglass or double triangle on the ventral surface of the abdomen; the age of the spider determines the relative amount of red on the abdomen (Fig. 239-4). The red-legged widow, *L. bishopi,* is found only in southern Florida, while the brown widow, *L. geometricus,* is rarely found in the United States. Females are significantly

larger than males (leg span up to 40 mm) and are the only spiders capable of envenomation. Black widows spin their large irregular “tangled” webs close to the ground under debris, over hollow stumps, under woodpiles, or in front of rodent burrows. Clinging upside down to the web, they wait for prey to become entangled in the web and then quickly paralyze the prey with a bite. [24]

FIGURE 239-4 Black widow spider, with eight eyes; it is shiny black, usually with a red hourglass marking on the underside of its abdomen.

The venom of the black widow spider contains a neurotoxin known as alpha-latrotoxin. This toxin acts to destabilize nerve cell membranes by opening ionic channels at the synapses. Acetylcholine is then irreversibly released at motor endplates of neuromuscular synapses. The sympathetic and parasympathetic nervous systems are affected as well, with release of adrenaline and noradrenaline from peripheral nerves. [25] Clinically, bites may be sensed as a pinprick or a sharp pinch. Dull aching pain or a numb sensation ensues 30 to 40 min after the bite. Skin manifestations are limited to slight erythema, local piloerection, mild edema or urtication, local perspiration, and possibly lymphangitis. Systemic symptoms peak at 1 to 8 h after the bite and may last 24 to 48 h. Severe pain in local muscle groups spreads to regional muscle groups. The characteristic crampy abdominal and chest pain may lead to confusion with acute appendicitis, renal colic, or acute myocardial infarction. Headache, restlessness, anxiety, fatigue, insomnia, salivation, lacrimation, diaphoresis, tremors, tachycardia, bradycardia, hypertension, shock, seizures and, coma have all been associated with latrodectism. Death from documented bites occurs in fewer than 1 percent of reported cases. [26] Diagnosis depends on recognition of a consistent history and typical physical findings. Most bites do not result in severe symptoms. In a study of bites of the red-back spider in Australia, 76 percent of victims had only local symptoms. [27] Laboratory evaluation is not helpful, although hemoglobinuria, albuminuria, and leukocytosis may be found. Treatment of most cases of latrodectism is supportive and generally does not require hospitalization. Exceptions to this rule include the very young and the very old and persons with cardiovascular disease, who are at greater risk for complications. Traditional treatment with intravenous calcium gluconate (10%) and muscle relaxants (methocarbamol, diazepam) has proved effective in most patients. Relief of pain with narcotics may reduce the severity of symptoms and muscle spasms. [26] Because antivenin is prepared in horses, it should be used only for severe envenomations in persons not allergic to horse serum.
TARANTULAS Tarantula injuries (family Theraphosidae) include mild transient bite reactions, and more severe cutaneous and ocular injury from abdominal urticating hairs. When cornered or threatened, tarantulas use their hind legs to flick needle-like hairs off the dorsal abdomen. These embed in the skin, producing local pruritus to granulomatous foreign-body reactions. Topical glucocorticoids provide prompt relief. Ocular injuries range from brief keratoconjunctivitis responsive to topical steroids, to severe pan-uveitis with corneal granulomas, iritis, cataract, vitreitis, and chorioretinitis. Ophthalmologic evaluation is mandatory. [28] Numerous other spiders have been implicated in human envenomation, including the Australian funnel-web spider *Atrax robustus*. Detailed consideration of all dangerous spiders is beyond the scope of this text. [17]
SCORPIONS Scorpions are of medical interest primarily in tropical and/or arid areas such as parts of the southwestern United States, Mexico, India, and the Middle East. Although capable of producing painful local wounds, the primary concern over scorpion envenomation involves the potential for serious cardiovascular complications, which can be lethal. [3]

CHILOPODA AND DIPLOPODA

Centipedes and millipedes superficially resemble each other, having one pair of legs and two pairs of legs per segment, respectively.

Centipedes

Centipedes are nocturnal carnivores and may produce painful wounds by discharging venom through their claws as they grip the victim. In addition to severe pain, localized sweating, erythema, edema, bleeding, secondary infection, and ulceration may be seen. [29] Local injections of an anesthetic may be used to control pain. Antibiotics to control infection and glucocorticoids to control inflammation may be necessary.

Millipedes

Millipedes are generally harmless vegetarians that neither bite nor envenomate. However, when disturbed or threatened they emit a toxic substance from repugnatorial glands on each side of each segment. This fluid may produce burning, blistering, and pigmentation of the skin. If introduced into the eye, it may cause severe inflammation. For skin contact, no treatment is usually necessary other than thorough washing of the skin as soon as possible. [30]

INSECTA

Anoplura

Only two species of Anoplura, *Phthirius pubis* and *Pediculus humanus,* are host-specific parasites of humans. [1] Diseases associated with lice are detailed in Chap. 238.

Coleoptera

Five families of Coleoptera produce chemicals that induce blistering or vesiculation upon contact with human skin: Meloidae, Staphylinidae, Paussidae, Coccinellidae, and Edemeridae. The Spanish fly, *Lytta vesicatoria* (family Meloidae), is the most famous of the blister beetles. Although these beetles neither bite nor sting, they produce blisters because of the chemical cantharidin contained in their bodies. This chemical may be emitted by the beetle, but it is most often encountered when the beetle is crushed against the skin. Several other beetle species, which contain chemicals similar to cantharidin, may be the cause of blisters in various geographic areas. [31] A characteristic clinical feature of blisters from beetles is kissing or touching lesions, which may produce infection and ulceration. Rove beetles (genus *Paederus*) contain the vesicant pederin. These beetles are associated with a blistering dermatitis, *Paederus dermatitis,* in various areas of the world. [32] The common carpet beetle (*Anthrenus scrophulariae*) is associated with a papulovesicular dermatitis. This condition appears to be caused by an allergic response to the larvae of the beetle and not to the beetle itself. [33] If contact with a beetle is suspected early, washing the skin with soap and water may prevent vesiculation. Symptomatic treatment with wet compresses and topical or systemic glucocorticoids may be needed.

Diptera

The order Diptera consists of the two-winged, or true, flies. Collectively, its members are responsible for the transmission of more diseases worldwide than any other arthropod order.

MOSQUITOES The mosquitoes of the family Culicidae are vectors for disease throughout the world. These include malaria, yellow fever, dengue, and filariasis, as well as encephalitis viruses. In the continental United States, females of the genus *Aedes* are the most common cause of mosquito bites. The cutaneous reaction is produced when the female mosquito's serrated jaws disrupt the skin and she inserts her blood tube. Irritating salivary secretions are injected to anticoagulate the blood and are responsible for the edema, pruritus, and papular lesions. Mosquito bites may have an urticarial, eczematoid, or granulomatous appearance, depending on the sensitivity of the victim. Mosquitoes prefer the young to the old, warm to cool skin, and scented to unscented victims. They also are attracted to bright colors and elevated carbon dioxide concentrations in the air.
BLACK FLIES The black flies of the family Simuliidae are also bloodsuckers. Also known as buffalo gnats, these hump-backed insects are found in tremendous swarms near fast-moving water in the late spring and early summer. Because this black fly injects an anesthetic into the wound, the initial bite is painless. However, the bite subsequently becomes extremely painful with itching, erythema, and edema, which may lead to nummular eczema, vesicles, or hard pruritic papules. A systemic reaction, termed *black fly fever,* which produces headache, fever, nausea, and generalized lymphadenitis, has been reported. [1] Black flies are vectors in the transmission of onchocerciasis (river blindness) and tularemia (see Chap. 236 and Chap. 199, respectively).
MIDGES The biting midges of the genus *Culicoides* (family Ceratopogonidae), are also called punkies, no-see-ums, and sand flies. Although ordinarily producing only a painful bite, they can be the vectors for filariasis caused by *Mansonella* species. The midge bites produce immediate pain with erythema at the bite site and 2- to 3-mm papulovesicles, followed by indurated nodules of up to 1.0 cm which persist for many months. [34]
TABONIDS The large family Tabanidae are ferocious bloodsucking flies and include horseflies, deerflies, clegs, breeze flies, greenheads, and mango flies. Species of the genus *Chrysops* (deerfly) are known to transmit loiasis and tularemia. [1] Because they are large flies (6 to 25 mm) with bladelike mouth parts, their bite is painful and may bleed vigorously. The cutaneous welt that is produced may be accompanied by urticaria, dizziness, weakness, wheezing, or angioedema.
MYIASIS Cutaneous myiasis occurs when various species of fly larvae penetrate the skin or are deposited onto open wounds. Larvae may be fixed to one site or may be migratory, simulating larva migrans. Larvae of the human botfly, *Dermatobia hominis,* are a cause of furuncular myasis. This fly is distributed throughout Central and South America. These painful lesions resemble a pyogenic furuncle, but lack of response to antibiotics points to the correct diagnosis (Fig. 239-5). [35]

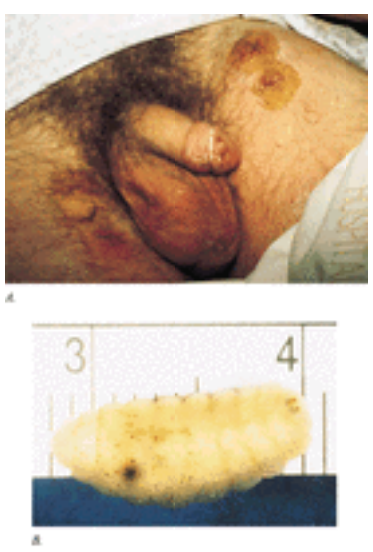

FIGURE 239-5 Myiasis. *A.* Abscesses which contain the larval form of *Dermatobia hominis* are seen in the genital area and thighs. *B.* Larva removed from the abscess.

SANDFLIES Phlebotomid sandflies are aggressive biters that produce pruritic, inflamed, indurated lesions. More importantly, they are responsible for transmission of leishmanial parasites throughout the world. Leishmania is discussed further in Chap. 235.
TSETSE FLIES The tsetse fly (*Glossina* species) serves as the vector for African trypanosomiasis. The bite produces minimal cutaneous reaction. African trypanosomiasis is discussed in Chap. 235.
TREATMENT The treatment of Diptera bites requires meticulous attention to wound care by cleansing with soap or other antiseptics to avoid secondary infection. Local application of steroid ointment and systemic treatment with antihistamines

will reduce itching and redness. Although systemic allergic reactions are rare, they should be treated aggressively with epinephrine, fluids, glucocorticoids, and supportive care. Furuncular myiasis is best treated by local surgical excision of the larva and surrounding tissue.

Hemiptera

Most of the Hemiptera order feed on plants. Only the Cimicidae and Reduviidae families commonly feed on animals, including humans.

CIMICIDAE (BEDBUGS) Several genera have members that are commonly grouped as bedbugs: *Cimex, Leptocimex, Oeciacus,* and *Hematasiphon*. Bedbugs are characteristically very flat dorsoventrally with broad bodies measuring up to 8 mm long. Given their small size and nocturnal feeding habits, the diagnosis of bedbug bites may not be clinically obvious. Bedbugs are not vectors for disease, but large numbers of pruritic bites can lead to considerable distress. The clinical findings may range from a few linear purpuric macules to generalized allergic reactions in sensitized individuals.
REDUVIIDAE (KISSING BUGS, ASSASSIN BUGS, CONE-NOSED BUGS) Several species of Reduviidae transmit *Trypanosoma cruzi,* the etiologic agent in Chagas disease. Genera involved in transmission of Chagas disease include *Triatoma, Rhodnius,* and *Panstrongylus*. Most species are encountered in the Americas with a few in Africa, Asia, and Europe. While the defensive bites of many reduviids are extremely painful, the feeding bites are typically painless. Clinically, the lesions produced by Reduviidae are similar to those from other arthropods and depend on the species, type of exposure, and individual sensitivity. However, defensive reduviid bites may produce severe local reactions, occasionally resulting in necrosis and ulceration. The pathogenesis and clinical findings of Chagas disease are discussed in Chap. 235.

Hymenoptera

The general family Hymenoptera includes bees (Apidae and Bombidae), wasps and hornets (Vespidae), and ants (Formicidae). [1] These insects are notorious for their painful stings, which may be associated with an anaphylactic reaction and/or death.

BEES, WASPS, HORNETS Stings by the female bee, hornet, or wasp from the modified ovipositor (stinger apparatus) produce immediate burning and pain followed by an intense, local, erythematous reaction with swelling and urticaria. The honeybee leaves a barbed ovipositor and paired venom sacs impaled in the victim. The method of removal of the stinger appears less important than the speed with which it is removed. [36] The honeybee dies after stinging. Other Hymenoptera do not lose their stinging units and may use them repeatedly. Severe systemic reactions occur in 0.4 to 0.8 percent of patients and are divided into three categories: angioedema or generalized urticaria; respiratory insufficiency from laryngeal edema or bronchospasm; and shock. Occasionally, major local reactions may persist at the bite site, presumably mediated by cellular immune mechanisms. [37] The acute treatment of Hymenoptera stings is based on the severity of patient response. Cutaneous reactions may be managed by application of ice and local injection of lidocaine to relieve pain. Hypotension and respiratory failure must obviously be treated vigorously. Systemic reactions require administration of subcutaneous epinephrine, while glucocorticoids and antihistamines may be helpful for urticaria or edema. If a patient experiences an anaphylactic reaction and has a positive skin test, desensitization should be strongly considered. [38]
ANTS Fire ants of the genus *Solenopsis* are aggressive and produce local skin necrosis and systemic reactions when they sting. [39] Imported fire ant venom contains a nonproteinaceous, hemolytic factor identified as a dialkylpiperidine derivative, solenopsin D, which induces the lytic release of histamine and other vasoactive amines from mast cells. Clinically, the bite site starts as an intense local inflammatory reaction that becomes a sterile pustule. [39] The imported fire ants (*S. invicta*) are particularly vicious because they attack in groups. By securing its jaw in the victim's skin, the fire ant is able to pivot, thereby leaving a ring of pustules. Because there is no specific therapy for ant stings, therapy is symptomatic. Systemic reactions occur frequently and may require glucocorticoids or antihistamines. Desensitization may be helpful to protect allergic patients. [39]

Lepidoptera

The Lepidoptera order is medically important solely because of the irritant and allergenic properties of the hairs from caterpillars and moths. Contact with caterpillars results in burning and itching or even a stinging reaction in the case of the puss caterpillar (*Megalopyge* species) (Fig. 239-6). Skin lesions typically appear as papular urticaria, which can become generalized in severe cases. Systemic reactions to some species have been reported. [40] At least one caterpillar species (gypsy moth, *Lymantria dispar*) may cause irritation because of histamine contained in the lancet hairs, but the allergic potential of the same caterpillar hairs has also been demonstrated. [41] Wind-borne dissemination of these hairs may lead to dermatitis as well as keratoconjunctivitis. [42] Whether most urticating caterpillar dermatoses are caused by histamine, by allergic reactions, or by both is not clear. [40] The caterpillars and moths most commonly assumed to cause these problems in the United States and Latin America are the following:

Caterpillars: Brown-tailed moth (*Euproctis chrysorrhoea*); io moth (*Automeris io*); puss or flannel moth (*M. opercularis*); saddleback moth (*Sibine stimulae*).
Moths: Lymantriidae family, tussock moths; brown-tailed moth (*E. chrysorrhoea*); gypsy moth (*L. dispar*); Douglas fir tussock moth (*Hemorocampa pseudotsugata*); silk or peacock moth (Saturniidae family); silk moth (*Hylesia* species); io moth (*A. io*).

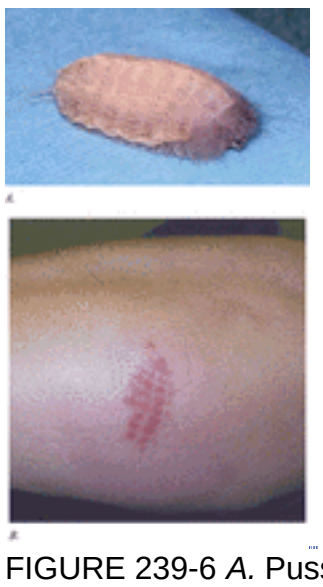

FIGURE 239-6 *A.* Puss caterpillar (*Megalopyge opercularis*) demonstrating the corresponding gridlike pattern of its hairs. *B.* Cutaneous reaction from contact with a puss caterpillar showing the typical gridlike pattern.

Siphonaptera

Fleas have a unique body shape that is flattened laterally rather than dorsoventrally. Their ability to jump to a height of 18 cm aids in their movement from host to host.

The Pulicidae family is of interest because certain species, most notably the rat fleas (*Xenopsylla cheopis* and *x*. *brasiliensis*), transmit bubonic plague and endemic typhus. Cat fleas (*Ctenocephalides felis*), dog fleas (*C*. *canus*), and bird fleas (*Ceratophyllus gallinae*) also transmit diseases. *C*. *felis* can be the vector for cat-scratch disease, bacillary angiomatosis, and endemic typhus. [43] All species bite humans because host specificity is relatively low; severe attacks may occur where infested domestic animals and birds have recently resided. Survival of adult fleas for months in the absence of host animals makes flea-borne epidemics difficult to detect and eradicate. Usually, flea bites cause minimal irritation in a nonsensitized person and produce typically linear or clustered urticarial papules. Bites are frequently found on the lower leg. In allergic individuals, lesions are much more severe; blisters and even erythema multiforme can develop (Fig. 239-7).

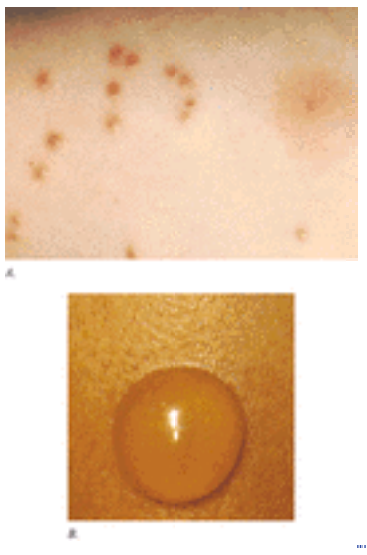

FIGURE 239-7 Insect bites. *A.* Papular urticaria. Bites of fleas and bedbugs can present with the clinical picture of multiple, extremely pruritic, edematous papules. *B.* Bullous lesions occur most commonly with flea bites, but also occur with bedbugs or contact with blister beetles on the skin.

In the Tungidae family, only *Tunga penetrans,* the chigoe or sand flea, is well known to produce problems. The female sand flea burrows into the dermis of the animal host. A painful necrotic abscess forms around the site of the female sand flea and her eggs. Secondary infection and scarring are the usual major complications, although tetanus can develop in these wounds. Treatment consists of systemic antibiotics after sterile removal of early lesions, or killing the adult female with a suitable agent. Late lesions resolve by spontaneous ulceration. [44]

PREVENTION

Insect repellents containing DEET are the most effective preventive agents for persons bothered by fleas, flies, mosquitoes, and ticks. For most circumstances, products containing 10% to 35% DEET provide protection. This product has an excellent safety record, but there are reports of encephalopathy in children exposed to excessive amounts of higher concentration products. For this reason, children should use products containing no more than 10% DEET. Passive measures such as screens, nets, and clothing, are also effective in preventing bites. Permethrin spray can be applied to clothing or other fabrics such as tents. Permethrin acts as a contact insecticide rather than as a repellent. Combined use of permethrin-treated clothing with DEET applied to skin gives maximum protection. While the protective effects of permethrin applied to fabrics remains fairly stable over time, DEET efficacy falls over several hours. Heat and humidity accelerate this loss of efficacy. Under such circumstances, slow-release formulations may provide more effective protection. [45]

Plant-derived products, such as citronella, are available. These products generally demonstrate less efficacy and shorter

duration of action relative to DEET. [45]

No preventive measures other than killing the adult or larval forms of bees, spiders, or wasps are currently available.

A variety of insecticides are available for individual or professional use. Proper use of these agents is important in the eradication of field ectoparasites inhabiting inanimate objects such as clothing, furniture, carpets, draperies, and pet bedding. Optimal results from insecticides may require consultation with a professional exterminator.

REFERENCES

1. Harwood RF, James MT, editors: *Entomology in Human and Animal Health,* 7th ed. New York, Macmillan, 1979

2. Ackerman AB: *Histopathological Diagnosis of Cutaneous Inflammatory Skin Disease,* 2d ed. Baltimore, Williams & Wilkins, 1997

3. Alexander JO: *Arthropods and Human Skin*. Berlin, Springer-Verlag, 1984

4. Bonnar E et al: The *Demodex* mite population in rosacea [see comments]. *J Am Acad Dermatol* **28**:443, 1993

5. Millikan LE: Mite infestations other than scabies. *Semin Dermatol* **12**:46, 1993

6. Fraser CM et al: *The Merck Veterinary Manual,* 7 th ed. Rahway, NJ, Merck, 1991.

7. Smith GA et al: The summer penile syndrome: Seasonal acute hypersensitivity reaction caused by chigger bites on the penis. *Pediatr Emerg Care* **14**:116, 1998

8. Parish LC, Schwartzman RM: Zoonoses of dermatological interest. *Semin Dermatol* **12**:57, 1993

9. Abbott KH: Tick paralysis: A review. *Proc Mayo Clin* **18**:39, 1943

10. Centers for Disease Control and Prevention: Tick paralysis—Washington, 1995. *MMWR Morb Mortal Wkly Rep* **45**:325, 1996

11. Walker DH: Tick-transmitted infectious diseases in the United States. *Annu Rev Public Health* **19**:237, 1998

12. Edlow JA: Lyme disease and related tick-borne illnesses. *Ann Emerg Med* **33**:680, 1999

13. Jacobs RF: Tick exposure and related infections. *Pediatr Infect Dis J* **7**:612, 1988

14. Gertsch WJ: The spider genus *Loxosceles* in North America, Central America and the West Indies. *Am Museum Novitates* **1907**:1, 1958

15. Truett AP III, King LE Jr: Sphingomyelinase D: A pathogenic agent produced by bacteria and arthropods. *Methods Enzymol* **26**:275, 1993

16. Wilson DC, King LE Jr: Spiders and spider bites. *Dermatol Clin* **8**:277, 1990

17. Sams HH et al: Necrotic arachnidism. *J Am Acad Dermatol* **44**:561, 2001

18. King LE Jr, Rees RS: Treatment of brown recluse spider bites. *J Am Acad Dermatol* **14**:691, 1986

19. Cole HP III et al: Brown recluse spider envenomation of the eyelid: An animal model. *Ophthal Plast Reconstr Surg* **11**:153, 1995

20. Vest DK: Necrotic arachnidism in the northwest United States and its probable relationship to *Tegenaria agretis* (Walckenaer) spiders. *Toxicon* **25**:175, 1987

21. Centers for Disease Control and Prevention. Necrotic arachnidism—Pacific Northwest, 1988–1996. *MMWR Morb Mortal Wkly Rep* **45**:433, 1996

22. Roe AH: The aggressive house spider (hobo spider). Utah State University, Fact Sheet No. 86:1, 1993

23. Fisher RG et al: Necrotic arachnidism. *West J Med* **160**:570, 1994

24. Gertsch WJ: *American Spiders*. New York, Van Nostrand Reinhold, 1979

25. Binder LS: Acute arthropod envenomation. *Med Toxicol Adverse Drug Exp* **4**:163, 1989.

26. Anderson PC: Spider bites in the United States. *Dermatol Clin* **15**:307, 1997

27. Jelinek GA et al: Red-back spider bites at Fremantle Hospital, 1982–1987. *Med J Aust* **150**:693, 1989

28. Blaikie AJ et al: Eye disease associated with handling pet tarantulas: Three case reports. *BMJ* **314**:1524, 1997

29. Elston DM: What's eating you? Centipedes (Chilopoda). *Cutis* **64**:83, 1999

30. Elston DM: What's eating you? Millipedes (Diplopoda). *Cutis* **67**:452, 2001

31. Nichols DSH et al: Oedermerid blister beetle dermatosis: A review. *J Am Acad Dermatol* **22**:815, 1990

32. Claborn DM et al: Staphylinid (rove) beetle dermatitis outbreak in the American southwest? *Mil Med* **164**:209, 1999

33. Ahmed AR et al: Carpet beetle dermatitis. *J Am Acad Dermatol* **5**:428, 1981

34. Steffen C: Clinical and histopathological correlation of midge bites. *Arch Dermatol* **117**:785, 1981

35. Millikan L: Myiasis. *Clin Dermatol* **17**:191, 1999

36. Visscher PK et al: Removing bee stings. *Lancet* **348**:301, 1996

37. Elgart GW: Ant, bee and wasp stings. *Dermatol Clin* **8**:229, 1990

38. Valentine MD et al: The value of immunotherapy with venom in children with allergy to insect stings. *N Engl J Med* **323**:1601, 1990

39. Reschly MJ et al: Multiple fire ant stings: Report of 3 cases and review of the literature. *Cutis* **66**:179, 2000.

40. Gardner TL, Elston DM: Painful papulovesicles produced by the puss caterpillar. *Cutis* **60**:125, 1997

41. Allen VT et al: Gypsy moth caterpillar dermatitis revisited. *J Am Acad Dermatol* **24**:979, 1991

42. Vissenberg I et al: Caterpillar induced keratoconjunctivitis. *Bull Soc Belge Ophthalmol* **249**:107, 1993

43. Elston DM: What's eating you? Ctenocephalides fleas (dog and cat fleas). *Cutis* **62**:15, 1998

44. Lowry MA et al: A case of tungiasis. *Mil Med* **161**:128, 1996

45. Fradin MS: Mosquitoes and mosquito repellents: A clinician's guide. *Ann Intern Med* **128**:931, 1998

T>

Chapter 240

Michael Bigby Moyses Szklo

Evidence-Based Dermatology

A BRIEF HISTORY OF EVIDENCE-BASED MEDICINE
WHAT IS "THE BEST EVIDENCE?"
FINDING THE BEST EVIDENCE
CRITICALLY APPRAISING THE EVIDENCE
EVIDENCE ABOUT THERAPY AND PREVENTION
EVIDENCE ABOUT DIAGNOSTIC TESTS
EVIDENCE ABOUT HARM
APPLYING EVIDENCE TO SPECIFIC PATIENTS
SAVING THE CRITICAL APPRAISAL OF THE EVIDENCE

REFERENCES

A BRIEF HISTORY OF EVIDENCE-BASED MEDICINE

Medical practitioners have had to face the problem of distinguishing treatments that are effective from those that are ineffective or harmful since the beginning of medicine. Evidence-based medicine is a method designed to help practitioners best meet this challenge. The origin of evidence-based medicine is most often traced to Pierre Charles Alexander Louis, who introduced the teaching of statistical methods into the study of medicine in postrevolutionary France. [1], [2] Epidemiologists and public health researchers have developed excellent quantitative skills, traceable in part to his "methode numerique," which is credited as forming the basis of epidemiology. [3]

There is some debate as to the identity of the first controlled clinical trial. [4] In 1545, Ambroise Paré compared the treatment of wounds with dressings of onions, traditional dressings, or no dressings. Crushed onions seemed to be more effective. In 1753, James Lind compared six alternative treatments on 12 sailors with scurvy and noted that the two sailors prescribed oranges and limes recovered more quickly than did the others. Johanes Fibiger used alternate-day allocation of patients admitted to the hospital with diphtheria to demonstrate that diphtheria serum was more effective than no serum. [4]

However, these early efforts at controlled clinical trials had little impact on medical decision making. Prior to the 1940s, determination of treatment efficacy was based on expert opinion, trial and error, uncontrolled observation, and small case series. The only treatments that could be distinguished as effective were those that produced dramatic increases in survival, such as streptomycin for tuberculosis meningitis. The publication of the randomized controlled clinical trial (RCT) that demonstrated that streptomycin was effective in the treatment of pulmonary tuberculosis was a landmark event. [5] Since then, the RCT has become the gold standard for determining the efficacy of therapeutic interventions.

Hundreds of RCTs were conducted between 1950 and the 1970s. However, their results were not catalogued or used systematically to inform medical decision making. In 1971 Archie Cochrane, a British epidemiologist and physician, published his response to being asked to evaluate the effectiveness of the British National Health Service in delivering health care to the population of the United Kingdom. In his analysis, he concluded that medical science was poor at distinguishing interventions that were effective from those that were not, and that physicians were not using available evidence from clinical research to inform their decision making. [6]

Groups of like-minded epidemiologists and physicians responded to Archie Cochrane's challenge by examining the methods by which medical decisions and conclusions were reached and proposed an alternative based on finding, appraising, and using available data from clinical research done on intact patients. [7] In 1985, Sackett, Haynes, Guyatt, and Tugwell published *Clinical Epidemiology: A Basic Science for Clinical Medicine,* which detailed the rationale and techniques of this evidence-based approach. [7] These authors and others reduced the rules of evidence to a small subset of principles that were easier to teach and to understand, and reintroduced the concept in 1992. [8] They named this technique "evidence-based medicine" (EBM). It was defined as the conscientious, explicit, and judicious use of the best current evidence in making decisions about the care of individual patients. [8] Although making decisions about therapy has been the primary focus of EBM, its principles have been extended to diagnosis, prognosis, harmful effects of interventions, cost effectiveness, and economic analyses.

Results from well-designed clinical studies on patients are at the pinnacle of the hierarchy of evidence used to practice evidence-based medicine. When reading recommendations about treatment, diagnosis, and harm made in this textbook and in other sources, one should take into account the validity, magnitude, precision, and applicability of the evidence upon which it is based.

The introduction of EBM was met with considerable hostility. It was perceived as cook book medicine, old hat, too restrictive, and an insult to those already trying to practice good medical care. The definition was softened to include the integration of individual clinical expertise, best available external clinical evidence from systematic research, and patient's values and expectations. [2]

The Cochrane Collaboration was formed to an extent in response to Archie Cochrane's challenge to organize a critical summary, by specialty or subspecialty, adapted periodically, of all relevant randomized controlled trials. [9] Through collaborative efforts of volunteers, the Cochrane Library is an impressive and useful compendium of systematic reviews, abstracts of systematic reviews, and the Cochrane Controlled Trials Registry, a database of more than 300,000

controlled clinical trials (http://www.cochrane.org/). The Cochrane Library is the most complete and best indexed database of RCTs and controlled clinical trials, and is the best and most efficient place to find evidence about therapy.

Evidence-based medicine acceptance in the specialty of dermatology has been slow. The term and principles are understood by few and misunderstood by many. It is perceived as an attempt to cut costs, impose rigid standards of care, and to restrict physician freedom to exercise individual judgment. Practicing EBM in dermatology is hampered by the continued belief among dermatologists that clinical decision can be guided by understanding the pathophysiology of disease, logic, trial and error, and nonsystematic observation. [1], [10] It is hampered also by a lack of sufficient data in many areas. This chapter reviews the guiding principles and techniques of EBM. As with EBM in general, we concentrate primarily on therapy; however, evidence-based approaches to diagnoses and harm are briefly covered.

WHAT IS “THE BEST EVIDENCE?”

Practicing EBM is predicated on finding and using the best evidence. Potential sources of evidence include understanding the etiology and pathophysiology of disease and logic, personal experience, colleagues or experts, textbooks, articles published in journals, and systematic reviews. An important principle of EBM is that the quality (strength) of evidence is based on a hierarchy of evidence. The order of the hierarchy of evidence is dependent on the type of question being asked (Table 240-1). [11] This hierarchy consists of results of systematic reviews of well-designed studies (especially if the studies have results of similar magnitude and direction, and if there is statistical homogeneity among studies), results of one or more well-designed studies, results of large case series, expert opinion, and personal experience in descending order. [9], [10] The hierarchy was created to encourage the use of the evidence that is most likely to be true and useful in clinical decision making. The ordering of this hierarchy has been widely discussed, actively debated, and sometimes hotly contested. [12]



TABLE 240-1 **Grades of Evidence*†**

A systematic review is an overview that answers a specific clinical question, contains a thorough, unbiased search of the relevant literature, explicit criteria for assessing studies, and structured presentation of the results. A systematic review that uses quantitative methods to summarize results is a meta-analysis. [13], [14] Meta-analysis provides an objective and quantitative summary of evidence that is amenable to statistical analysis. [13] Meta-analysis is credited with allowing recognition of important treatment effects by combining the results of small trials that individually lacked the power to demonstrate differences among treatments. For example, the benefits of intravenous streptokinase in acute myocardial infarction were recognized by the results of a cumulative meta-analysis of smaller trials at least a decade before it was recommended by experts and before it was demonstrated to be efficacious in large clinical trials. [15], [16] Meta-analysis has been criticized for the discrepancies between the results of meta-analysis and the results of large clinical trials. [16], [17], [18] and [19] For example, results of a meta-analysis of 14 small studies of calcium to treat preeclampsia showed benefit of treatment, whereas a large trial failed to show a treatment effect. [16] The frequency of discrepancies ranges from 10 to 23 percent. [16] Discrepancies can often be explained by differences in treatment protocols, heterogeneity of study populations, or changes that occur over time. [16]

Publication bias is an important concern about systematic reviews. It results from allowing factors other than the quality of the study to influence its acceptability for publication. Several studies show that factors such as sample size, direction, and statistical significance of findings, or investigators' perception of whether the findings are “interesting,” are related to the likelihood of publication. [20], [21] For example, in a study by Dickersin et al., reasons given that completed studies were not published included “negative results” (28 percent), “lack of interest” (12 percent), and “sample size problems” (11 percent). [20] Studies with small samples are less likely to be published especially if they have negative results. [20], [21] This type of publication bias jeopardizes one of the main goals of meta-analysis (i.e., an increase in power when pooling results of small studies). Creation of study registers and advance publication of research designs have been proposed as ways to prevent publication bias. [22], [23] Publication bias can be detected by using a simple graphic test (funnel plot) or by calculating the “fail-safe N.” [24], [25] In addition, for many diseases, the studies published are dominated by drug company–sponsored trials of new, expensive treatments. The needs for studies to answer clinical questions of most concern to practitioners are not addressed because sources of funding are inadequate.

Not all systematic reviews and meta-analyses are equal. A systematic review can only be as good as the clinical trials that it contains. The criteria to critically appraise systematic reviews and meta-analyses are shown in Table 240-2. Detailed explanations of each criterion are available. [13], [26]

Are the results of this systematic review valid?
Did the review address a focused clinical question?*
Were the criteria used to select articles for inclusion appropriate?*
Is it unlikely that important, relevant studies were missed?*
Was the validity of the included studies appraised?*
Were assessments of studies reproducible?†
Were the results similar from study to study?†
Are the valid results of this systematic review important?
What are the overall results of the review?
How precise were the results?
Can you apply this valid, important evidence in caring for your patient?
Can the results be applied to my patient's care?
Were all clinically important outcomes considered?
Are the benefits worth the harms and costs?

*Primary guides.
†Secondary guides.
SOURCE: Reproduced with permission Sackett D, et al.[26]

TABLE 240-2 **Critical Appraisal of a Systematic Review**

The type of clinical study that constitutes best evidence is determined by the category of the question being asked. Questions about therapy and prevention are best addressed by randomized controlled trials. [13], [26], [27] and [28] Questions about diagnosis are best addressed by cohort studies. [13], [26], [29], [30] Randomized controlled trials, cohort studies, or case-control studies best address questions about harm. [13], [26], [31] Methods for assessing the quality of each type of evidence are available. [13], [26]

With regard to questions about therapy and prevention, the RCT has become the gold standard for determining treatment efficacy. Thousands of RCTs have been conducted. Studies have demonstrated that failure to use randomization or adequate concealment of allocation resulted in larger estimates of treatment effects, predominantly caused by a poorer prognosis in nonrandomly selected control groups compared with randomly selected control groups. [32] However, studies comparing randomized and nonrandomized clinical trials of the same interventions have reached disparate and controversial results. [32], [33] and [34] Some found that observational studies find stronger treatment effects than randomized controlled trials. [32] Others found that the results of well-designed observational studies (with either a cohort or a case-control design) do not systematically overestimate the magnitude of the effects of treatment as compared with randomized controlled trials on the same topic. [33], [34] Sifting through the controversy leads to the following limited conclusions. Trials that use historical controls do result in larger estimates of treatment effects when compared to randomized controlled trials. Large, inclusive, fully blinded randomized controlled trials are likely to provide the best possible evidence about effectiveness. [12], [35], [36]

Whereas personal experience is an invaluable part of becoming a competent physician, the pitfalls of relying too heavily on personal experience have been widely documented. [7], [37], [38] Nisbett and Ross extensively reviewed people's ability to draw inferences from personal experience and documented several pitfalls [39] including:

- Overemphasis on vivid, anecdotal occurrences and underemphasis on significant statistically strong evidence;
- Bias in recognizing, remembering, and recalling evidence that supports preexisting knowledge structures (e.g., ideas about disease etiology and pathogenesis) and parallel failure to recognize, remember and recall evidence that is more valid;
- Failure to accurately characterize population data because of ignorance of statistical principles, including sample size, sample selection bias, and regression to the mean;
- Inability to detect and distinguish statistical association and causality; and
- Persistence of beliefs in spite of overwhelming contrary evidence.

Nisbett and Ross provide examples from controlled clinical research. Simple clinical examples abound. Physicians may remember patients who improved, often assume that patients who did not return for followup improved and conveniently forget the patients who did not improve. A patient treated with a given medication may develop a severe life-threatening reaction. On the basis of this single undesirable experience, the physician may avoid using that medication for many future patients, although, on average, it may be more efficacious and less toxic than the alternative treatments that the physician chooses. Few physicians keep adequate, easily retrievable records to codify results of treatments with a particular agent or of a particular disease; and even fewer actually carry out analyses. Few physicians make provisions for tracking those patients who are lost to follow-up. Therefore statements made about a physician's “clinical experience” may be biased. Finally, for many conditions, a single physician sees far too few patients to enable reasonably firm conclusions to be drawn about the response to treatments. For example, suppose a physician has treated 20 patients with lichen planus with tretinoin and found that 12 (60 percent) had an excellent response. The confidence interval for this response rate (i.e., the true response rate for this treatment in the larger population from which this physician's sample was obtained) ranges from 36 to 81 percent. Thus the true response rate might well be substantially less (or more) than the physician concludes from personal experience.

Expert opinion can be valuable particularly for rare conditions in which the expert has the most experience or when other forms of evidence are not available. However, several studies demonstrate that expert opinion often lags significantly behind conclusive evidence. [7] Experts suffer from relying on bench research, pathophysiology, treatments based on logical deduction from pathophysiology, and from the same pitfalls noted for relying on personal experience. Experts should be aware of the quality of evidence that exists.

It is widely believed that a clinical decision can be made on the basis of understanding the etiology and pathophysiology of disease and logic. [1], [10] This paradigm is problematic because the accepted hypothesis for the etiology and pathogenesis of disease changes over time. Therefore the logically deduced treatments change over time. For example, in the last 20 years, hypotheses about the etiology of psoriasis have shifted from a disorder of keratinocyte proliferation and homeostasis, to abnormal signaling of cyclic adenosine monophosphate, to aberrant arachidonic acid metabolism, to aberrant vitamin D metabolism, to the current favorite—a T cell–mediated autoimmune disease. Each of these hypotheses spawned logically deduced treatments. The efficacy of many of these treatments has been substantiated by rigorous controlled clinical trials, whereas others are used even in the absence of systematically collected observations. Therefore, we have many options for treating patients with severe psoriasis (e.g., UV-B, Goeckerman, psoralen–UVA, methotrexate, and cyclosporin) and mild to moderate psoriasis (e.g., anthralin, topical corticosteroids, calcipotriene, and

tazarotene). However, we lack a clear sense of which is best, in what order they should be used, or in what combinations. We do not know how well methotrexate works or the optimal dose or dosing schedule for it. [10], [40] Treatments based on logical deduction from pathophysiology may have unexpected consequences. For example, the observation that antiarrhythmic drugs could prevent abnormal ventricular depolarization after myocardial infarction logically led to their use to prevent sudden death after myocardial infarction. However, an RCT showed increased mortality of patients treated with antiarrhythmic drugs compared to placebo. [28], [41], [42]

Textbooks can be valuable particularly for rare conditions and for conditions for which the evidence does not change rapidly over time. However, textbooks have several well-documented shortcomings. They tend to reflect the biases and shortcomings of the experts who write them. By virtue of how they are written, produced, and distributed, most are about 2 years out of date at the time of publication. Most textbook chapters are narrative reviews that do not consider the quality of the evidence reported. [7], [13]

FINDING THE BEST EVIDENCE

The ability to find the best evidence to answer clinical questions is crucial for practicing EBM. Finding evidence requires access to electronic searching, searching skills, and available resources. Evidence about therapy is easiest to find. The best sources for finding the best evidence about treatment include:

- The Cochrane Library
- Searching the Medline and Embase databases
- Secondary journals and books (e.g., ACP Journal Club, *Evidence Based Medicine Journal,* and *Clinical Evidence*)
- Primary journals
- The National Guideline Clearinghouse (http://www.jcaai.org/)
- Bandolier (http://www.jr2.ox.ac.uk/Bandolier)

The Cochrane Library contains systematic reviews of the treatment of diseases, a Database of Abstracts of Reviews of Effectiveness (DARE), and the Cochrane Controlled Trials Registry (CCTR) (http://www.update-software.com/Cochrane/default.HTM).

Volunteers, according to strict guidelines developed by the Cochrane Collaboration, write the systematic reviews in the Cochrane Library. The Cochrane Library contains over 1200 completed systematic reviews. The number of reviews of dermatologic topics is steadily increasing.

The CCTR is a database of more than 300,000 controlled clinical trials. The Cochrane Controlled Trials Registry is compiled by searching the Medline and Embase databases, and hand searching many journals. Hand searching journals to identify controlled clinical trials and RCTs was undertaken because members of the Cochrane Collaboration noticed that many trials were incorrectly classified in the Medline database. As an example, Dr. Finola Delamere of the Cochrane Skin Group, hand searched the *Archives of Dermatology* from 1990 through 1998 and identified 99 controlled clinical trials. Nineteen of the trials were not classified as controlled clinical trials in Medline, and 11 trials that were not controlled clinical trials were misclassified as control clinical trials in Medline. [43] DARE is a database of abstracts of systematic reviews published in the medical literature. It contains 2100 abstracts and bibliographic details on more than 800 other published systematic reviews.

The Cochrane Library is the best source for evidence about treatment. It is easily searched by using simple Boolean combinations of search terms, as well as by more sophisticated search strategies. The Cochrane Library of systematic reviews, DARE, and the CCTR can be searched simultaneously. The Cochrane Library is available on a subscription basis on CD, and on the World Wide Web from Update Software (www.update-software.com/cochrane/default.html). Subscriptions to the Cochrane library are updated quarterly. The Cochrane Library is, or should be, available at medical libraries.

The second-best method for finding evidence about treatment and the best source for finding most other types of best evidence in dermatology is by searching the Medline database by computer. [44], [45] Medline is the National Library of Medicine's (NLM) bibliographic database covering the fields of medicine, nursing, dentistry, veterinary medicine, the health care system, and the preclinical sciences. The MEDLINE file contains bibliographic citations and author abstracts from approximately 3900 current biomedical journals published in the United States and 70 foreign countries. The file contains approximately 9 million records dating back to 1966. [46]

Medline searches have inherent limitations that make their reliability less than ideal. [45] For example, Spuls et al. conducted a systematic review of systemic treatments of psoriasis. [47] Treatments analyzed included UVB, PUVA, methotrexate, cyclosporin A, and retinoids. The authors used an exhaustive strategy to find relevant references including Medline searches, contacting pharmaceutical companies, polling leading authorities, reviewing abstract books of symposia and congresses, and reviewing textbooks, reviews, editorials, guideline articles, and the reference lists of all papers identified. Of 665 studies found, 356 (54 percent) were identified by Medline search (range, 30 to 70 percent for different treatment modalities). No references beyond those identified by Medline searching were provided by the 17 of 23 authorities who responded. Specific search strategies (“filters”) have been developed to help find relevant references while excluding irrelevant references for best evidence about diagnosis, therapy, prognosis, harm, and prevention. [48] These filters have been incorporated into the PubMed Clinical search engine of the National Library of Medicine and are available at http://www.ncbi.nlm.nih.gov/entrez/query/static/clinical.html. [49] Pub- Med Clinical Search is the preferred method for searching the Medline database for best evidence. It can be freely used by anyone with Internet access.

More than 20 vendors of Medline online and on CD are available. Haynes et al. compared several vendors of Medline online and on CD to determine which was best in terms of finding relevant articles and excluding irrelevant articles. Assessed on combined rankings for the highest number of relevant and the lowest number of irrelevant citations

retrieved, SilverPlatter's CD-ROM Medline clinical journal subset performed best for librarians' searches, whereas PaperChase's online system worked best for clinicians' searches. For cost per relevant citation, Dialog's Knowledge Index performed best for both librarian and clinician searches. [50]

Embase is Excerpta Medica's database covering drugs, pharmacology, and biomedical specialties. [13] The overlap in journals covered by Medline and Embase is about 34 percent (range, 10 to 75 percent depending on the subject). [51], [52] Unfortunately, most currently available platforms for physician Medline searches in the United States are not capable of searching the Embase database. Embase searches are available in many libraries.

Structured abstracts of articles are published in secondary journals (e.g., ACP Journal Club, *Evidence-Based Medicine,* and the *Evidence-based Dermatology*). The articles are strictly selected on the basis of methodologic quality and are accompanied by commentary putting the information in clinical perspective. All of the articles from ACP Journal Club and *Evidence-Based Medicine* are available on the CD, *Best Evidence*. It is available through the American College of Physicians and the British Medical Association. It is updated annually. *Evidence-based Dermatology* is published quarterly in the *Archives of Dermatology*. *Clinical Evidence* is a six monthly-updated compendium of evidence on the effects of common clinical interventions. Skin-related diseases are included. It is available through the British Medical Association.

Full text versions of many primary journals are available on the Internet. Journals in this category include the *British Medical Journal,* the *New England Journal of Medicine, Annals of Internal Medicine, JAMA,* the *Lancet,* and the *Canadian Medical Association Journal*. The following Web site provides a handy portal to these journals (http://www.uib.no/isf/people/atle/ebm.htm#BM4_secondary).

The National Guideline Clearinghouse maintains a database of guidelines for the treatment of disease written by panels of experts following strict guidelines of evidence. The database is accessible through the Internet (http://www.guideline.gov/index.asp). The current coverage of dermatologic topics is limited. Bullet points of EBM (reviews and EBM-related articles) are published in *Bandolier,* which is available on the Internet at http://www.jr2.ox.ac.uk/Bandolier/. Reviews of treatment of warts and on the new oral antifungals have appeared in it.

CRITICALLY APPRAISING THE EVIDENCE

After finding evidence, the next step in practicing EBM involves critically appraising the quality of the evidence and determining its magnitude and its precision. The criteria to critically appraise papers about treatment, diagnostic tests, and harmful effects of exposures are shown in Table 240-3, Table 240-4, and Table 240-5. [13], [26] Papers that meet these criteria are more likely to provide information that is true and useful in the care of patients. [13], [26] Detailed explanation of each criterion [13], [26] and an example using a patient with a dermatologic complaint are available. [45]

TABLE 240-3 **Critical Appraisal of a Paper about Therapy**



TABLE 240-4 **Critical Appraisal of a Paper About a Diagnostic Test**



TABLE 240-5 **Critical Appraisal of a Paper About Harm**

Critically appraising evidence consists of three steps: determining whether the results are (1) *valid* (i.e., as unbiased as possible), (2) *clinically important*, and (3) *applicable* to the specific patient being seen.

Determining the validity of evidence centers on ascertaining whether the evidence was produced in a manner most likely to eliminate and avoid bias. The critical questions to ask to determine validity for papers about therapy, diagnostic tests, and harm are shown at the tops of Table 240-3, Table 240-4 and Table 240-5 respectively.

EVIDENCE ABOUT THERAPY AND PREVENTION

Therapeutic studies should have concealed randomization, nearly complete follow-up of all entered patients, an intent-to-treat analysis of results, blinding where possible, equal treatment of groups, and similar prognostic variables among treatment groups. These criteria represent only a small subset of features of a well-designed and reported clinical trial. [37] A more complete set of criteria has been published and is required by many of the leading medical journals. [53]

Important terms and concepts that must be understood to determine whether the results of a paper about therapy are clinically important include the magnitude of the treatment effect, its precision, the difference in response rates, its reciprocal, the number needed to treat, and the confidence interval.

In evaluating a clinical trial, look for clinical outcome measures that are clear-cut and clinically meaningful to you and your patients. [37] For example, in a study of a systemic treatment for warts, complete disappearance of warts is a meaningful outcome, whereas a decrease in the volume of warts is not. Historically, two principal methods are used to determine patient outcomes in dermatologic clinical trials. The first involves examining patients before, during, and at the conclusion of treatment, and reporting how the patients appear at the various time points. The second involves determining the degree of improvement during treatment. [54] A third method, determining the impact of therapy on the quality of the patient's life, is being increasingly used in dermatologic trials. [37]

An example of the first method is commonly encountered in therapeutic trials of psoriasis. A common practice is to assign numerical values to the amount of erythema, scaling, and degree of infiltration, to determine the area of the body surface involved, and to formulate an “index” by calculating a derivative of some product of these four numbers. [55], [56] The overall condition of the patient can then be represented by this index. A common example is the psoriasis area and severity index (PASI) which ranges from 0 to 72. [55] The major problem with indices is that they confound area of involvement with severity of disease. [54] For example, a patient with thick plaque-type psoriasis of the knees, elbows, and scalp may have the same index as a patient with diffuse but minimal psoriasis of the trunk and arms. Whereas the former patient is notoriously difficult to treat, the latter will generally respond rapidly and easily to many forms of therapy. [54] The second problem with indices is that they lend an air of accuracy to the analysis and presentation of data that are not warranted. [54] For example, Tiling-Grosse and Rees demonstrated that physicians and medical students were poor at estimating the area of skin disease; consequently, some of the components that make up indices may be inaccurate. [57] Finally, calculating the means, differences in means, and percentages of change in indices in response to treatment often do not convey an accurate clinical picture of the changes that have occurred. [54]

The second method of assessment groups patients according to their degree of improvement. Treatments are then compared by their ability to move patients to higher degrees of improvement. There are two major problems with this form of assessment. The first is that the categories of improvement are often not well defined. The second problem is that the categories are not additive. [54] That is, 60 to 80 percent improvement is often assumed to be twice as good as 20 to 40 percent, although no such numerical relationship exists between these subjectively defined categories.

To be most useful, the outcome variables to measure must be clearly defined, as objective as possible, and have clinical and biologic significance. [37], [54] The best indices and scales are the ones that accurately reflect the state of the disease and the ones whose validity and reliability have been verified by previous work. [37], [54], [58] The development of scales and indices for cutaneous diseases and testing their validity, reproducibility, and responsiveness has been inadequate. [37], [54], [59] Therefore a lack of clearly defined and useful outcome variables remains a major problem in interpreting dermatologic clinical trials.

Until better scales are developed, trials with the simplest and most objective outcome variables are the best. They lead to the least amount of confusion and have the strongest conclusions. Thus, trials in which a comparison is made between death and survival, patients with recurrence of disease and those without recurrence, or patients who are cured and those who are not cured are studies whose outcome variables are easily understood and verified. For trials in which the outcomes are less clear-cut and more subjective in nature, a simple ordinal scale is probably the best choice. [54] The best ordinal scales involve a minimum of human judgment, have a precision that is much smaller than the differences being sought and are sufficiently standardized that they can be used by others and produce similar results. [38]

In addition to being clearly defined, outcome variables should have clinical and biological significance. [27], [28] For example, in a therapeutic trial of patients with severe acne, treatment was associated with a decrease in lesion count from a mean of 400 to a mean of 350. This numerical difference may be of statistical significance, but it does not convey what the biologic significance of the change in lesion number represents. [54] This result may mean that some patients with severe acne cleared completely, whereas other patients remained the same or got worse. It could also mean that most patients got slightly better. Furthermore, does an individual patient look better when their lesion number has been reduced from 400 to 350? Are scarring and complications less?

To strengthen clinical trials and to help validate their conclusions, the outcome variables should be few in number and should be chosen before initiation of the study. Many outcome variables increase likelihood that spurious, chance differences will be detected. An ineffective treatment may be found efficacious when tested using poorly designed outcome assessment tools. Conversely, an effective therapy may be found ineffective by an insensitive scale.

Special precautions are recommended in recognizing and being skeptical of “substitute or surrogate end points” especially when no differences are detected in clinically important outcomes. [28], [60] Examples of such end points include CD4/CD8 ratios instead of survival in studies of treatments of AIDS, antinuclear antibody (ANA) levels, or sedimentation rates instead of clinical measures of disease activity in lupus erythematosus, and volume of warts instead of proportion of patients cleared of warts. Carefully chosen and validated surrogate end points often enable studies to provide answers to questions that would typically require much larger or longer trials if the targeted clinical end point were used. For example, a well-designed, short clinical trial may be sufficient to demonstrate that a new drug effectively lowers serum cholesterol or that another drug is effective in controlling hypertension. In both cases, much longer and larger studies would be required to demonstrate that the cholesterol lowering drug and the antihypertensive drug reduced morbidity and mortality from atherosclerotic and hypertensive cardiovascular diseases respectively. Surrogate end points must, however, correlate with clinical outcomes and their validity must be demonstrable in prior studies.

Once sound, clinically relevant outcome measures are chosen, the magnitude of the difference between the treatment groups in achieving these meaningful outcomes should be determined. The precision of the estimate of the differences among treatments should be estimated. Useful measures of the magnitude of the treatment effect are the difference in response rate and its reciprocal, the number needed to treat (NNT). [13], [26], [45] The NNT represents the number of patients one would need to treat to achieve one additional cure.

The confidence interval provides a useful measure of the precision of the treatment effect. [13], [26], [45], [61], [62] The calculation and interpretation of confidence intervals has been extensively described. [63] In simple terms, the reported result (known as the “point estimate”) provides the best estimate of the treatment effect. Values become increasingly less likely as they move away from the reported result within the confidence interval. [13], [26], [45] The confidence interval provides a range of values in which the “population” or true response to treatment is likely to lie.

Examples of the application of the concepts of numbers needed to treat and confidence intervals are given by a paper identified by a search of the Cochrane Library for treatment of herpes zoster with corticosteroids or antivirals that reported a randomized-controlled trial comparing placebo, acyclovir, prednisone, and acyclovir-prednisone in the treatment of herpes zoster. [64] At day 30 of the trial, 48 of 52 patents treated with acyclovir were totally healed compared to 22 of 52 patients who received placebo. The response rates for acyclovir and placebo were .92 and .42, respectively, and the difference in response rates was .5. The NNT was 2 (1/.5). This result means that for every two patients treated with acyclovir instead of placebo, one additional patient would be totally healed by day 30. The 95 percent confidence interval for the difference in response rates is from .35 to .65, and the 95 percent confidence interval for the NNT is 2 to 3.

What does the fact that the confidence interval for the difference in response rates in the example above is .35 to .65 actually mean? If the investigators of this study had the opportunity to repeat this study many times using the same design and procedures, sampling variability would prevent obtaining the same exact results in each study. Repeated trials were simulated using resampling (resampling is a computer-intensive method that uses the reported results of a trial to simulate results that would be obtained if the trial were to be repeated many times). [45], [65] The results when the trial was repeated 10 or 1000 times are shown in Fig. 240-1A and Fig. 240-1B, respectively. The 95 percent confidence interval of .35 to .65 means that if the trial is repeated many times, and a confidence interval is calculated for each trial, the true result or response to treatment will be included in 95 percent of the confidence intervals so produced. Alternatively, if the trial were repeated multiple times, the results would lie within that interval (.35 to .65) 95 percent of the time.



FIGURE 240-1 If the acyclovir trial were repeated (*A*) 10 or (*B*) 1000 times, the results in *A* and *B* might be obtained. CI, confidence interval.

The population or true response to treatment will most likely lie near the middle of the confidence interval and will rarely be found at or near the ends of the interval. The population or true response to treatment has only a 1 in 20 chance of being outside of the 95 percent confidence interval. Unless a patient is very different from the patients included in the study, his or her response will most likely lie near the middle of the confidence interval. If the 95 percent confidence interval of the difference in response rates excludes the zero difference, one can reject the null hypothesis that the two treatments are the same. [26], [45], [61], [62]

Misinterpreting trials that fail to show statistically significant differences among treatments is a common error of

interpretation in dermatology clinical trials. It is important to remember that “not statistically significant” means that a difference has a reasonably high probability of having been a result of chance; it does not mean that there is no difference or that treatment is necessarily ineffective. [37] Significant differences in treatment effects in comparison trials may be missed if the number of subjects tested is small. For example, in a 1978 survey of 71 published trials with negative results, Freiman et al. found that a 25 or 50 percent improvement in outcome might have been missed in 57 (80 percent) and 34 (48 percent) of the studies, respectively. [66] A follow-up study conducted by Moher et al. in 1994 indicated that 25 or 50 percent improvements in outcome might have been missed in 84 and 64 percent of 102 negative studies, respectively. [67] The sample sizes of many dermatologic trials are often inadequate to detect clinically important differences.

The acceptance of a significance level of .05 as the cutoff for rejecting the null hypothesis is a tradition based on quality control standards and is not an absolute truth. At times, more stringent standards are required (e.g., treatments with substantial side effects) and, paradoxically, tests that do not meet the P=.05 standard sometimes may be clinically significant. For example, consider a hypothetical trial of new chemotherapeutic agent involving 30 randomized patients with metastatic melanoma that produced a 5-year survival of 7 of 15 patients treated with the new agent, and of 3 of 15 in control patients treated with conventional surgery, chemotherapy, and radiation. Whereas the result does not achieve statistical significance when compared by chi-square testing (Yates corrected chi-square = 1.35; P=.25), the result is, nonetheless, potentially significant. If the therapy is beneficial and the estimated difference in response rates is the true difference in response rates, it may result in the saving of 2400 lives annually (based on 7200 deaths from melanoma annually and the improvement in survival in this hypothetical example). Because of the biologic and clinical importance of the results suggested by the study, the treatment should be subjected to study in a larger patient population with more power to detect a significant difference if one exists. [37]

The potential benefit of the treatment may be further revealed by the use of confidence intervals. To determine whether a treatment effect may have been missed in a study reporting negative (not statistically significant) results, one should look at the upper boundary of the 95 percent confidence interval. If this value would be clinically important if it were the true response, then an important treatment effect may have been missed in the study. Consider our hypothetical new treatment for metastatic melanoma. The cure rates for the new treatment and conventional treatment were 47 and 20 percent, respectively, and the difference between them was 27 percent. The 95 percent interval for the difference in cure rates was -10 to +51 percent. The upper boundary of the difference in cure rates was 51 percent. This difference would clearly have a significant impact on the treatment of patients with metastatic melanoma (the NNT is 2!); consequently, a significant treatment advance may have been missed in this study. Also note that the 95 percent confidence interval of the difference in proportions includes the zero difference; therefore, we cannot conclude with a high degree of confidence that the response rates of the two treatments are different. However, when zero is included as one of the values in the confidence interval, the inference that the therapy is not efficacious fails to consider the fact that the best estimate of effect is the point estimate (e.g., the observed difference in cure rates of 27 percent in our hypothetical example). [68] In other words, the values contained in the confidence interval are not equally likely, and become less and less likely as they move away from the point estimate. Thus, in the example, a difference of 25 percent (close to the observed 27 percent) is much more likely than one of -5 percent (far from the observed 27 percent). [37]

EVIDENCE ABOUT DIAGNOSTIC TESTS

To be valid, studies about diagnostic tests should include blind comparison with a criterion (“gold”) standard, evaluation in an appropriate spectrum of patients, and consistent application of the criterion standard. Few studies in dermatology meet this standard.

Important terms and concepts that must be understood to determine whether the results of a paper about a diagnostic test is clinically important include likelihood ratio, pretest probability, posttest probability, and threshold for action.

The likelihood ratio is the percentage of people with the disease who have a positive test divided by the percentage of people who do not have the disease who have a positive test. [45] The likelihood ratio is traditionally taught as the *sensitivity/1 - the specificity* and provides an estimation of how much higher the likelihood of the disease is, given a positive test (posttest probability), when compared to the probability before the test is done (pretest probability). [13], [26] An ideal test is one that will almost always be positive when the disease is present and negative when the disease is absent. Thus, it is one with a high sensitivity and specificity. Such a test would have a very high likelihood ratio.

In order for the likelihood ratio to be useful, one has to have an idea of how likely the disease is to be present before the test is done (i.e., the pretest probability) and a sense of how certain one needs to be to conclude that the patient has the disease and to act on it (i.e., the threshold for action). [45], [69] The pretest probability is determined from available published data or based on physician experience and judgment. [26], [45] Once the pretest probability is known or estimated, and the likelihood ratio determined, a nomogram can be used to estimate the post-test probability (Fig. 240-2). [26]



FIGURE 240-2 Nomogram for determining the posttest probability. To determine the posttest probability, draw a straight line through the pretest probability and the likelihood ratio, and read the posttest probability on the right. (Reproduced with permission from Sackett D, et al. [26]

If the nomogram is not available, the calculations can be done manually, but require conversion of probabilities to odds. The odds of disease is defined as the probability of disease divided by one minus the probability (*odds = probability/1 - probability*). For a defined group of individuals or patients, it can be also calculated as the ratio of the number those with disease to those without disease. Thus, if the probability (proportion) of a disease is 0.20 (20 percent), the odds of that disease is 0.20/1 - 0.20, or 0.20/0.80, or 1:4. This result means that for every person with the disease, there are four people without the disease. The posttest odds are equal to the pretest odds times the likelihood ratio (*posttest odds = pretest odds × likelihood ratio*). [26] The formula *probability = odds/odds + 1* is used to convert odds back to probability.

For example, suppose that based on clinical judgment the estimated probability that a patient with a cluster of vesicles on his cheek has herpes zoster is 0.6 (60 percent), then his odds of having zoster are 1.5:1 (0.6/1 - 0.6). Assume, for this example, that the sensitivity and specificity of antibody tests for herpes zoster are 80 percent and 96 percent, respectively. Then the likelihood ratio for a positive antibody test is 20 (.80/1 - .96). If this patient's antibody test is positive, his posttest odds are 30 (1.5 × 20) and the posttest probability of herpes zoster is .97 (97 percent) (30/30 + 1). This probability is certainly high enough to act upon.

Whether formally or informally, physicians develop thresholds of certainty at or above which they are comfortable with establishing a diagnosis and acting on the diagnoses. Action may take the form of communicating the diagnosis or prognosis to the patient, prescribing treatment, or referring the patient. When historical and physical evidence leads a clinician to suspect a diagnosis but the degree of certainty does not exceed the threshold for establishing a diagnosis, a test is done to increase the probability that the disease is present above the clinician's threshold for action. [69]

EVIDENCE ABOUT HARM

To be valid, studies about the harmful effects of exposures should include cohorts with comparable groups of exposed and unexposed individuals, or cases and controls, objective outcome measures, and adequate follow-up. In addition, the results should make clinical and biologic sense. [13], [26] Few dermatologic studies meet these criteria.

Important terms and concepts that must be understood to determine whether the results of a paper about harmful effects of exposures is clinically important include case-control and cohort studies, risk ratios, and odds ratios.

In a cohort study a group of individuals who are exposed to an agent is compared with an appropriately selected unexposed control group and both groups are followed until an event of interest occurs or for a prespecified length of time. The association of exposure to the harmful outcome is expressed as the relative risk (see Table 240-5 for relative risk calculations). A relative risk of 1 implies no association. If the relative risk is greater than 1, then the result implies a positive association between exposure and the harmful outcome. If it is less than 1, then the implication is of an inverse association. However, in order to infer a causal association reflected by either an increase in risk (relative risk greater than 1), or a protective effect (relative risk less than 1), it is important to evaluate the validity and precision of the relative risk estimate. The precision can be readily assessed by means of the 95 percent confidence interval. A confidence interval that does not include 1.0 denotes a statistically significant association. Because the most the likely result of a study is the point estimate (i.e., the reported result), the observed association (expressed by the point estimate) may be causal, even if the confidence interval includes 1.0 as a result of a small sample size. [13], [26]

Case-control studies are used when the bad outcome is recognized and the causative agent is not yet discovered. They are also used when there is a very long time lag between exposure and outcome, or when the frequency of adverse events is very small. In a case-control study, patients with a disease of interest are compared with appropriately selected controls. The odds of exposure to suspected etiologic agents are ascertained in cases and controls (Table 240-5). Recall that the odds of an event are the ratio of the number of events to the number of nonevents. [70] Events are exposures to potentially harmful risk factors in case-control studies. The odds of exposure of cases are divided by the odds of exposure among controls to derive the odds ratio, which is a good estimate of the relative risk when the outcome (e.g., disease, death) is relatively rare (i.e., when it is less than 5 percent in exposed subjects). The association between exposure and outcome is expressed as the odds ratio in case-control studies. An odds ratio of 1 implies no association. If the odds ratio is greater than 1, then the result implies a positive association between exposure and the harmful outcome. If the odds ratio is less than 1, then the result implies a protective effect of the exposure. [13], [26] As noted above, it is important to evaluate the validity and precision of the odds ratio estimate by examining the 95 percent confidence

interval.

For example, suppose a case-control study was performed to study the relationship between limb deformity and exposure to thalidomide. The results of the study indicated that patients with limb deformities were more likely than controls to have been exposed to thalidomide in utero. The odds ratio for thalidomide exposure was 3.5 and the confidence interval was from 1.8 to 6.6. Thus the odds that patients with limb deformities were exposed to thalidomide in utero was 3.5 times the odds of thalidomide exposure in controls. Because the odds ratio is greater than 1, and its 95 percent confidence interval does not include 1, the result implies a positive association between thalidomide use and limb deformities, not likely to have been the result of random error. These results (an odds ratio of 3.5 and confidence interval of 1.8 to 6.6) were actually the results of a study by Wolf et al. who studied the relationship between sunscreen use and melanoma in a case-control study in Austria. [71] Their results indicated that patients with melanoma were more likely than controls to have used sunscreen often. In order to infer causality, it is important to assess whether the results could have resulted from bias and that the results are biologically plausible.

To add confusion to an already difficult area, clinical researchers will often report results of meta-analyses, cohort studies, and randomized-controlled trials by using odds ratios. Odds ratios are used because they have stronger statistical properties than other measures. [70] For example, odds ratios can take any value between zero and infinity, are symmetric in a log scale, and can be used to make adjustments for confounding factors by using multiple regression. [70] Unfortunately, they are the measure of association least intuitively understood. If a meta-analysis, controlled trial, or cohort study is reported by using odds ratios, the relative risk, difference in response rates, or NNT can often be calculated if the primary data are provided. Alternatively, these more readily understandable measures can be derived if the number of subjects in each group, odds ratio and overall event rate are provided.

APPLYING EVIDENCE TO SPECIFIC PATIENTS

Applying the evidence to specific patients involves determining whether the evidence from studies is applicable to a specific patient. This decision is based on the patient's condition and values. It involves asking a series of questions that are specific to the type of evidence being considered (see Table 240-3, Table 240-4 and Table 240-5). When faced with the task of determining whether the results of a particular study are applicable to specific patients, physicians should determine whether there are any compelling reasons that the result should not be applied. [37] Applying evidence to a specific patient always involves physician judgment.

SAVING THE CRITICAL APPRAISAL OF THE EVIDENCE

Once you have made the effort to ask a clinical question, find the best evidence, and critically appraise it, you should save your analysis in a place and format in which it can be easily retrievable for future use. Worksheets for recording evidence about papers dealing with diagnosis, therapy and prevention, prognosis, and harm, are available (http://ftp://cebm.jr2.ox.ac.uk/pub/centre/docs/workshee.doc). [26] These worksheets can be saved electronically or filed physically.

REFERENCES

1. O'rourke A: Seminar 3: An introduction to evidence-based practice. http://www.shef.ac.uk/uni/projects/wrp/sem3.html. Last update April 10, 1998. Accessed January 17, 2003

2. Sackett DL et al: Evidence-based medicine: What it is and what it isn't. *BMJ* **312**:71, 1996

3. Etheridge EW: *Sentinel for health: A history of the Centers for Disease Control*. Berkeley: University of California Press, 1992

4. Royal College of Physicians of Edinburgh: Controlled trials from history—Control of selection biases. http://www.james/indlibrary.org/selection.html. Accessed January 17, 2003

5. Anonymous. Medical research council streptomycin in tuberculosis trials committee. Streptomycin treatment of pulmonary tuberculosis. *Br Med J* **ii**:769, 1948

6. Cochrane A: *Effectiveness and efficiency. Random reflections on health services*. London: Nuffield Provincial Hospital Trust, 1972

7. Sackett DL et al: *Clinical epidemiology: A basic science for clinical medicine*. Boston: Little, Brown, 1991, p 441

8. Evidence Based Medicine Working Group: Evidence-based medicine: A new approach to teaching the practice of medicine. *JAMA* **268**:2420, 1992

9. Cochrane A: *1931–1971: A critical review, with particular reference to the medical profession. Medicines for the year 2000.* London: Office of Health Economics, 1979, p 1

10. Bigby M: Paradigm lost. *Arch Dermatol* **136**:26, 2000

11. Ball C et al: Levels of evidence and grades of recommendations. http://www.indigojazz.co.uk/cebm/levels_of_evidence.asp. Last update May 2001. Accessed January 17, 2003

12. Bigby M: Challenges to the hierarchy of evidence: Does the emperor have no clothes? *Arch Dermatol* **137**:345, 2001

13. Greenhalgh T: *How to read a paper: The basics of evidence based medicine*. London: BMJ Publishing, 1997, p 196

14. Chalmers I, Altman D, editors. *Systematic reviews*. London, BMJ Publishing, 1995.

15. Lau J et al: Cumulative meta-analysis of therapeutic trials for myocardial infarction [see comments]. *N Engl J Med* **327**:248, 1992

16. Lau J et al: Summing up evidence: One answer is not always enough. *Lancet* **351**:123, 1998

17. Villar J et al: Predictive ability of meta-analyses of randomised controlled trials [see comments]. *Lancet* **345**:772, 1995

18. Cappelleri JC et al: Large trials vs meta-analysis of smaller trials: How do their results compare? *JAMA* **276**:1332, 1996

19. LeLorier J et al: Discrepancies between meta-analyses and subsequent large randomized, controlled trials. *N Engl J Med* **337**:536, 1997

20. Dickersin K et al: Factors influencing publication of research results. Follow-up of applications submitted to two institutional review boards. *JAMA* **267**:374, 1992

21. Easterbrook PJ et al: Publication bias in clinical research. *Lancet* **337**:867, 1991

22. Dickersin K: Report from the panel on the case for registers of clinical trials at the eighth annual meeting of the Society for Clinical Trials. *Control Clin Trials* **9**:76, 1988

23. Piantadosi S, Byar DP: A proposal for registering clinical trials. *Control Clin Trials* **9**:82, 1988

24. Egger M et al: Bias in meta-analysis detected by a simple, graphical test. *BMJ* **315**:629, 1997

25. Abramson J: *Making sense of data: A self-instruction manual on the interpretation of epidemiological data*. New York, Oxford University Press, 1994

26. Sackett D et al: *Evidence-based medicine: How to practice and teach EBM.* Edinburgh, Churchill Livingstone, 1996, p 250

27. Guyatt GH et al: Users' guides to the medical literature II. How to use an article about therapy or prevention. A. Are the results of the study valid? *JAMA* **270**:2598, 1993

28. Guyatt GH et al: Users' guides to the medical literature II. How to use an article about therapy or prevention. B. What were the results and will they help me in caring for my patients? *JAMA* **271**:59, 1994

29. Jaeschke R et al: Users' guides to the medical literature III. How to use an article about a diagnostic test. A. Are the results of the study valid? *JAMA* **271**:389, 1994

30. Jaeschke R et al: Users' guides to the medical literature III. How to use an article about a diagnostic test. B. What are the results and will they help me in caring for my patients? *JAMA* **271**:703, 1994

31. Levine M et al: Users' guides to the medical literature IV. How to use an article about harm. *JAMA* **271**:1615, 1994

32. Kunz R, Oxman AD: The unpredictability paradox: Review of empirical comparisons of randomised and non-randomised clinical trials. *BMJ* **317**:1185, 1998

33. Benson K, Hartz AJ: A comparison of observational studies and randomized, controlled trials. *N Engl J Med* **342**:1878, 2000

34. Concato J et al: Randomized, controlled trials, observational studies, and the hierarchy of research design. *N Engl J Med* **342**:1887, 2000

35. Barton S: Which clinical studies provide the best evidence: The best RCT still trumps the best observational study. *BMJ* **321**:255, 2000

36. Kunz R, Oxman A: *BMJ* (serial online). Two systematic reviews two different answers [electronic reply]? http://bmj.com/cgi/letters/319/7205/3124411 . Accessed January 17, 2003

37. Bigby M, Gadenne A-S: Understanding and evaluating clinical trials. *J Am Acad Dermatol* **34**:555, 1996

38. Hines DC, Goldheizer JW: Clinical investigation: A guide to its evaluation. *Am J Obstet Gynecol* **105**:450, 1969

39. Nisbett R, Ross L: *Human Inference: Strategies and Shortcomings of Social Judgment.* Englewood Cliffs, NJ, Prentice-Hall, 1980, p 330

40. Griffiths CE et al: A systematic review of treatments for severe psoriasis. *Health Technol Assess* **4**:1, 2000

41. Echt DS et al: Mortality and morbidity in patients receiving encainide, flecainide, or placebo: The cardiac arrhythmia suppression trial. *N Engl J Med* **324**:781, 1991

42. The Cardiac Arrythmia Suppression Trial II Investigators: Effects of the antiarrhythmic agent moricizine on survival after myocardial infarction. *N Engl J Med* **327**:227, 1992

43. Delamere FM, Williams HC: How can hand searching the dermatological literature benefit people with skin problems? *Arch Dermatol* **137**:332, 2001

44. Oxman AD et al: Users' guide to the medical literature I. How to get started. *JAMA* **270**:2093, 1993

45. Bigby M: Evidence-based medicine in a nutshell. A guide to finding and using the best evidence in caring for patients. *Arch Dermatol* **134**:1609, 1998

46. PubMed Overview: http://www.ncbi.nlm.nih.gov/PubMed/overview.html . Last update 9/25/02. Date accessed 10/23/02.

47. Spuls PI et al: A systematic review of five systemic treatments for severe psoriasis. *Br J Dermatol* **137**:943, 1997

48. Haynes RB et al: Developing optimal search strategies for detecting clinically sound studies in MEDLINE. *J Am Med Inform Assoc* **1**:447, 1994

49. Haynes B: PubMed clinical queries using research methodology filters. http://www.ncbi.nlm.nih.gov/PubMed/clinical.html Last update March 22, 2002. Date accessed 10/23/02.

50. Haynes RB et al: Performances of 27 MEDLINE systems tested by searches with clinical questions. *J Am Med Inform Assoc* **1**:285, 1994

51. Smith B et al: Modern methods of searching the medical literature. *Med J Aust* **157**:603, 1992

52. Mulrow C, Oxman A, editors: Cochrane Collaboration handbook (updated 1 March 1997), in *The Cochrane Library* (Database on disk and CDROM). Oxford, The Cochrane Collaboration, 1997.

53. The Standard of Reporting Trials Group: A proposal for the structured reporting of randomized controlled trials. *JAMA* **272**:1926, 1994

54. Allen AM: Clinical trials in dermatology, part 3: Measuring responses to treatment. *Int J Dermatol* **19**:1, 1980

55. Fredriksson T, Pettersson U: Severe psoriasis—Oral therapy with a new retinoid. *Dermatologica* **157**:238, 1978

56. Fleisher AB et al: Patient measurement of psoriasis disease severity with a structured instrument. *J Invest Dermatol* **102**:967, 1994

57. Tiling-Grosse S, Rees J: Assessment of area of involvement in skin disease: A study using schematic figure outlines. *Br J Dermatol* **128**:69, 1992

58. Feinstein AR: An additional basic science for clinical medicine: IV. The development of clinimetrics. *Ann Intern Med* **99**:843, 1983

59. Charman C, Williams H: Outcome measures of disease severity in atopic eczema. *Arch Dermatol* **136**:763, 2000

60. Nyberg G: Assessment of significant differences. *Med J Aust* **1**:328, 1974

61. Gardner MJ, Altman DG: Estimating with Confidence, in *Statistics with Confidence*, edited by MJ Gardner, DG Altman. London: British Medical Journal, 1989, p 3

62. Gardner MJ, Altman DG: Estimation rather than hypothesis testing: Confidence intervals rather than P values, in *Statistics with Confidence,* edited by MJ Gardner, DG Altman. London: British Medical Journal, 1989, p

63. Gardner MJ, Altman DG, editors: *Statistics with Confidence*. London, British Medical Journal, 1989, p 140

64. Whitley R et al: Acyclovir with and without prednisone for the treatment of herpes zoster. *Ann Intern Med* **125**:376, 1996

65. Simon JL, Bruce P: The new biostatistics of resampling [see comments]. *MD Computing* **12**:115, 1995

66. Freiman JA et al: The importance of beta: The type II error and sample size in the design and interpretation of the randomized control trial. *N Engl J Med* **299**:690, 1978

67. Moher D et al: Statistical power, sample size, and their reporting in randomized controlled trials. *JAMA* **272**:122, 1994

68. Rothman KJ et al: Casual inference. *Epidemiology* **4**:555, 1993

69. Bigby M: Ruling out the diagnosis. *Arch Dermatol* **132**:697, 1996

70. Deeks J: Swots corner: What is an odds ratio? *Bandolier* **25**:6, 1996

71. Wolf P et al: Phenotypic markers, sunlight-related factors and sunscreen use in patients with cutaneous melanoma: an Austrian case-control study. *Melanoma Res* **8**:370, 1998

T>

Chapter 241

Hans Schaefer Thomas Redelmeier Gerhard Nohynek

Pharmacokinetics and Topical Applications of Drugs

DIFFUSION
Fick's Laws
THREE-COMPARTMENT MODEL
THE SKIN SURFACE
Surface Applications of Formulations
Reservoir
Formulations
Liposomes as Transdermal Delivery Systems
THE SKIN BARRIER
Corneocytes
Intercellular Lipid
Appendages
Pathways Across the Stratum Corneum
Inter- and Intraindividual Variation in Skin Barrier Function
VIABLE TISSUE
Skin Metabolism
Resorption
The Influence of Pathologic Processes on Skin Barrier Function

REFERENCES

Pharmacokinetics related to topical applications of drugs describes the time-dependent drug concentration following the application of the drug to the skin surface, its subsequent passage through the skin barrier into the underlying skin layers and its distribution into the systemic circulation. The subject continues to hold the attention of research scientists and clinicians alike because of its relevance to dermatologic therapy and the possibility of topical application of current systemic medication, such as peptides or proteins. However, this is an inherently complex subject, despite the advent of new insights into the principal factors that govern diffusion of a drug into and across the skin.

The major difficulty in developing an accurate description of the percutaneous absorption of a drug is related to the size of the compartments. A topical application of a cream or ointment is generally spread to a thickness of not greater than 10 µm. The thickness of the *stratum corneum* is also approximately 10 µm, whereas the viable epidermis, dermis, and, to a greater extent, the systemic compartment represent a large sink in which absorbed drugs undergo dilution to levels that often remain undetectable to all but the most sensitive techniques. The determination of the time-dependent changes in the concentration of a drug in individual compartments is technically challenging. Following topical application of a drug formulation, these parameters can affect this process:

1. Formulations may undergo drastic changes in composition and structure;
2. The drug or its formulation may affect effectiveness of the skin barrier, resulting in time-dependent changes of the barrier function;
3. The skin barrier may be affected by the type and progression of a disease;
4. There are significant regional variations in the barrier properties of the skin;
5. Viable skin tissues themselves may respond to a topical application of a drug formulation resulting in enhancement or retardation of percutaneous absorption;
6. Skin has a significant metabolic capacity; often enough, the resulting systemic exposure may be not only to the parent drug, but also to pharmacologically more or less active metabolite(s);

DIFFUSION

Compounds applied topically to the skin surface migrate along concentration gradients according to well-described laws governing diffusion of solutes in solutions and/or their diffusion across membranes. For a detailed discussion of relevant equations, readers are referred to several comprehensive reviews. [1], [2], [3] and [4]

Fick's Laws

Diffusion of uncharged compounds across a membrane or any homogenous barrier is described by Fick's first and second laws. The first law states that the steady state flux of a compound (J = moles/cm per second) per unit path length (d, cm) is proportional to the concentration gradient (?C) and the diffusion coefficient (D, cm^2/s).

$$J = -D(\Delta C/\Delta \delta)$$

The negative sign indicates that the net flux is in the direction of the lower concentration. This equation applies to diffusion-mediated processes in isotropic solutions under steady-state conditions. Fick's second law predicts the flux of compounds under non–steady-state conditions. It is worthwhile to point out that diffusion is a very effective transport mechanism over very short distances but not over long ones. The relationship between the time (?t) it takes for a

molecule to migrate along a path length (x) and its diffusion coefficient is governed by the following equation:

$$\Delta t = x^2/2D$$

For example, the diffusion coefficient for water in an aqueous solution is: 2.5×10^{-5} cm^2/s, suggesting that a water molecule would migrate over a 10-µm path (the equivalent of the width of the stratum corneum) in 0.4 ms. However, because diffusion depends upon the square of the distance, longer distances are not efficiently covered; a 100-µm path would take 40 ms.

THREE-COMPARTMENT MODEL

Although pharmacokinetic analysis of topical preparations may require the description of a relatively large number of compartments, this discussion is confined to the three outlined in Fig. 241-1: the skin surface, the stratum corneum, and the viable tissue. The formulation itself forms a reservoir, from which the compound must be released; in order to undergo percutaneous absorption, the compound then must penetrate the stratum corneum, diffuse into and through the viable epidermis into the dermis, and, finally, gain access to the systemic compartment through the vascular system. In addition, the substance may diffuse through the dermal and hypodermal layers to reach underlying tissues. As summarized in Table 241-1, within each compartment, the compound may diffuse down along its concentration gradient, bind to specific components, or be metabolized. The size or characteristics of each compartment may alter with time, and the factors determining diffusion within each compartment may be affected by disease state as well as the nature or the pharmacologic/biologic activity of the drug or its excipients.

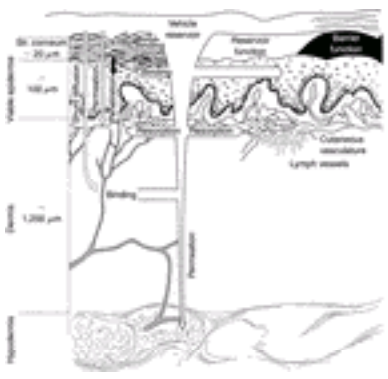

FIGURE 241-1 Diagrammatic representation of three compartments of the skin: surface, stratum corneum, and viable tissues. Following surface applications, evaporation and structural/compositional alterations in the applied formulation may play an important role in determining the bioavailability of drugs. The stratum corneum, the outermost layer, plays the most significant role in determining the diffusion of compounds into the body. Following absorption, compounds may bind or diffuse within the viable tissues, or become resorbed by the cutaneous vasculature.

Compartment	Processes	General Relevance to Bioavailability[a]
Vehicle	diffusion	++
	thermodynamic activity	++
	evaporation	+
	precipitation	+/–
Stratum corneum	reservoir function	+++
	diffusion	+++
	binding	–/+
	metabolism	–
Epidermis	diffusion	+/–
	metabolism	+/–
	binding	++
Cutaneous vasculature	resorption	+
Underlying tissues including dermis	diffusion	+/–
	metabolism	+/–
	binding	–

[a]–, Although theoretically possible, this process is probably not of general relevance; +/–, this process is of direct relevance, but only in a restricted number of cases; +, the process is generally relevant, but not as important as ++ or +++.

TABLE 241-1 **Compartments Encountered by Substances Undergoing Percutaneous Absorption: General Relevance of Processes to Bioavailability**

THE SKIN SURFACE

Surface Applications of Formulations

Formulations differ in their physicochemical properties, and, as discussed below, this influences the kinetics of release and/or absorption. However, the principal consideration is that topically applied drug products represent a physically small compartment, which limits the amount of compound that can be applied to the skin surface. When a patient applies a dermatologic preparation, the layer of a formulation covering the skin is very thin (approximately 0.5 to 2 mg/cm^2). Thicker layers are felt as “unpleasant” and are consciously or subconsciously rubbed off or spread to larger surfaces. This restricts the amount of compound that can effectively come in contact with the skin surface to approximately 5 to 20 $\mu g/cm^2$ for a 1% (wt/wt) topical formulation.

However, even after being rubbed in, formulations do not remain homogeneous over the time course of penetration. For example, topical applications containing water, alcohol, or similar solvents undergo rapid evaporation.[5] This phenomenon is readily recognized by patients as a cooling sensation. The evaporation results in rapid concentration of nonvolatile substances on the skin surface, which may result in the formation of supersaturated “solutions” or, alternatively, precipitation of active ingredients. Formulations may also mix with skin-surface lipids or undergo

time-dependent changes in their composition as excipients and drugs undergo absorption. Altogether, these considerations suggest that dramatic changes in the composition and structure of formulations may occur following surface application, all of which may determine the subsequent bioavailability of active ingredients.

Reservoir

The reservoir function was first described by Vickers, [6] who observed that simple occlusion lead to the renewed onset of a glucocorticoid mediated vasoconstriction several hours after it had declined. He interpreted this effect as renewed liberation of the glucocorticoid from a “reservoir” stored in the upper skin layers.

We define as reservoir the amount of an active ingredient, that is still in contact with the nonvolatile constituents of its formulation after the latter had been massaged into the skin surface. The compound has not yet penetrated, but it cannot be removed by simple rubbing or contact with clothing or other tissues. The reservoir thus adheres to the skin surface and resides in the wrinkles and the upper layers of the stratum corneum. Reservoirs on eczematous skin may become even more prominent because of the scaliness of the skin. Recently, we discovered that the upper volume of the follicular channels serves also as a reservoir, which may result in a relative increase in absorption through appendages. This phenomenon may be increased in formulations that contain particles or precipitates given the evidence that appropriately sized particles can rapidly penetrate along the shafts of hair follicles to a depth of up to 100 to 500 µm. [7], [8], [9] and [10]

Formulations

Formulations can be differentiated on the basis of whether they are designed to remain on the skin surface (sunscreen products and cosmetics), to be delivered to compartments in the skin (topical formulations), or to migrate across the skin into the central compartment (transdermal formulations).

Formulations may affect the kinetics and the degree of percutaneous absorption and, subsequently, the onset, duration, and extent of a biologic response. In the context of percutaneous absorption, there are several different parameters that should be considered when selecting a formulation: [1], [11] the thermodynamic activity of the active ingredient; [12] the amount of compound that can be incorporated into the formulation; [13] the stability of the formulation on the skin surface (e.g., emulsions should break easily); [14] the partition coefficient of the active ingredient between the vehicle and the stratum corneum; [15] and the enhancer activity.

In general, percutaneous absorption is proportional to the thermodynamic activity of the compound. Thus, the greatest flux is observed at the active ingredient's maximum solubility in a vehicle. Vehicles that are very good solvents should be avoided because they may retain the active ingredient on the skin surface.

Liposomes as Transdermal Delivery Systems

Liposomes are microscopic spheres comprising a bilayer that encloses an inner aqueous core. A wide variety of cosmetics contain liposomes. Liposome-based formulations have proved to be safe, cosmetically attractive, and well accepted. There is considerable evidence that, at least for some preparations, application of liposomes is mildly occlusive and improves the hydration level of the stratum corneum. Interest in the use of liposomes to enhance the delivery of drugs across the skin has been spurred by several observations in animal models: liposome formulations were believed to enhance the penetration of compounds across the skin or to optimize the retention of bioactive compounds in target tissues. [16] However, these early studies, which rested largely on animal models, were followed by relatively few in vivo studies for humans [17] conducted under standard conditions.

There is good evidence that particles can penetrate along the hair shaft and this route may be appropriate for delivery of bioactive compounds into sebaceous glands or hair follicles. [9], [10]

THE SKIN BARRIER

The primary compartment that limits the percutaneous absorption of compounds is the stratum corneum. This thin (10 to 20 µm) layer effectively surrounds the body and represents a highly differentiated structure that determines the diffusion of compounds across the skin. The physical description of the stratum corneum is well documented, [18] and it can be accurately described as “bricks” of bundled, water-insoluble proteins, embedded in a “mortar” of intercellular lipid (see Chap. 9).

The general consensus today is that the stratum corneum is a highly organized, differentiated structure. To participate fully in forming an effective barrier to diffusion, the biogenesis of the corneocytes as well as the synthesis and processing of the intercellular lipid must proceed in an orderly manner. Recent evidence suggests that disruption in the kinetics of skin barrier formation by accelerating the division of the keratinocytes in the underlying layers will lead to a disruption in the barrier properties of the skin. [19] Thus, the concept of dead or dying skin forming a passive barrier to diffusion is now replaced by a model of the stratum corneum as a highly differentiated structure with unique properties that are particularly suited for its role in forming the skin barrier. [20]

Corneocytes

Fully 85 percent of the stratum corneum is protein (as a percentage of dry mass), mostly associated with the cornified cells, termed *corneocytes*. These structures contain a core of keratins surrounded by an envelope made up of cross-linked proteins. [21] The keratins may account for up to 80 percent of the total dry mass of the corneocytes, and thus represent their most important constituent. In addition to these fibrous proteins, the core contains low-molecular-weight polar compounds, such as amino acids, urocanic acid, and pyrrolidone carboxylic acid. These compounds play a role in

maintaining the hydration properties of the stratum corneum. Unlike living cells, which contain approximately 80 to 90 percent water by weight, corneocytes contain only 15 to 30 percent water by weight.

Recent investigations into the nature of the corneocytes have focused on the role of the corneocyte envelope proteins, because they may be responsible for the integrity of the stratum corneum as well as for its resistance to irritants. The composition of the envelope was recently reviewed. [21] It is composed of several proteins termed *loricrin, involucrin,* a family of proline-rich proteins (also termed *cornifin* and *pancornullin*), and *cystatin,* also termed *keratolinin*.

Intercellular Lipid

Interspersed between corneocytes, the intercellular lipid is organized into sheets that provide the primary barrier to diffusion across the stratum corneum. [19] This lipid is located in an extracellular domain and thus is not morphologically equivalent to a cellular membrane. The lipid accounts for approximately 15 percent of the dry weight of the stratum corneum or 20 percent of the volume. It is composed of roughly equimolar mixtures of ceramides, cholesterol, and long-chain free fatty acids. There is now substantial evidence that these lipids form structures [22] wherein diffusion of the lipids is more than 1000-fold less than that found in normal cellular membranes. [23]

These properties of the intercellular lipid are particularly suited to its role as a barrier to diffusion. [18], [24]

Appendages

A variety of appendages penetrate the stratum corneum and epidermis, facilitating thermal control and providing a protective covering. Appendages are potential sites of discontinuity in the integrity of the skin barrier. Though appendages account for only 0.1 to 1 percent of the area of the skin, they appear to present the predominant pathways for percutaneous absorption in nondiseased skin. [9], [10] This can be explained by the fact that only the upper wall of the follicular apparatus (the *acroinfundibulum*) is protected by a coherent stratum corneum, whereas in the lower part (*infrainfundibulum*) the corneocytes appear undifferentiated and protection is incomplete, if not absent. Even solid particles may enter deep into the follicular orifice, [7], [8], [18] a phenomenon that lends itself to the concept of follicular targeting of drugs. [18]

It follows that in relationship to the integral protection against the passage of xenobiotics in general, and drugs specifically, the barrier function of the interfollicular stratum corneum is even more potent than thought, whereas more research is needed relative to the follicular pathway. Recent investigations hint to the presence of active follicles (open to penetration) and passive ones. [9]

Pathways Across the Stratum Corneum

Several studies have directly visualized penetration pathways across the stratum corneum electron microscopically. Osmium vapor can be used to precipitate *n*-butanol that has penetrated the stratum corneum. [25] Following a brief (5 to 60 s) exposure of murine or human stratum corneum, the alcohol was found to be enriched in the intercellular spaces (threefold), although significant levels were also found in the corneocytes. By using a different approach that involved rapid freezing, water, ethanol, and cholesterol were also found preferentially concentrated in the intercellular lipid spaces. [26] Similarly, the penetration of mercury chloride through the intercellular lipid can be detected following precipitation with ammonium sulfide vapor. [27]

However, in most of these investigations, there was also significant localization of compounds in the corneocytes, more prevalent in the upper layers (stratum disjunctum). Thus, corneocytes undergoing desquamation appear to be relatively permeable, even to rather bulky ions such as mercury. There is additional evidence that other compounds can and do penetrate corneocytes. It is well established, for example, that occlusion or immersion of skin in a bath leads to swelling of the corneocytes, consistent with the entry of water. Other compounds have also been localized in corneocytes, such as the anionic surfactants that are bound to keratins. Low-molecular-weight moisturizers such as glycerol are likely to partition into the corneocytes and alter their water-binding capacity. Thus, the penetration of compounds into corneocytes cannot be excluded from considerations of percutaneous absorption pathways. The relevance of this step is related to whether it is rate-determining, that is, whether the diffusion of compounds within the intercellular lipid is restricted by the corneocytes.

Inter- and Intraindividual Variation in Skin Barrier Function

Finally, it is worthwhile to consider the level of inter- and intraindividual variation in skin barrier activity, including that of follicles. The most accurate and reproducible measurement of skin barrier activity is transepidermal water loss (TEWL). [28] The extent of interindividual variation in this parameter for the same individual are estimated to be 8 percent by site and 21 percent by day to day. The variations between individuals are reported to be somewhat larger, ranging from 35 to 48 percent. [29] There appear to be no significant gender- or ethnic-dependent differences in skin barrier activity. The skin barrier activity of premature babies (delivered more than 3 weeks premature) [30] is markedly impaired, although skin barrier function appears normal for full-term infants. There seems to be no significant alteration in skin barrier activity as a function of age. Differences in skin barrier activity among different sites have been observed; barrier function can be ranked as arm ˜ abdomen > postauricular > forehead. [28]

VIABLE TISSUE

Although the primary barrier to percutaneous absorption lies within the stratum corneum, diffusion within the viable tissue, as well as metabolism and resorption, also influence the bioavailability of compounds in specific skin compartments. These processes are interrelated, and factors that increase the rate of one of these processes inevitably

influence the others. Because the development of dermatologic formulations is often focused on “targeted” delivery to living tissues, the manipulation of these processes offers a clear-cut rationale for increasing therapeutic efficacy.

The passage of compounds from the stratum corneum into the viable epidermis results in a substantial dilution. This reflects not only the relatively larger size of the epidermis as compared with the stratum corneum, but also the lower resistance to diffusion within viable tissues, approximately corresponding to that of an aqueous protein gel. [29] Drug concentrations of 10^{-4} to 10^{-6} M may be attained in the epidermis and dermis for substances that permeate readily. Although the actual concentration gradient of a compound is influenced both by the physicochemical properties of the compounds as well as by the time of application, the presence of a concentration gradient is visible at all times. In other words, strategies to enhance percutaneous absorption generally result in a relatively uniform increase in the concentration of compounds in all compartments.

Skin Metabolism

The skin contains a wide range of enzymatic activities, including phase I oxidative, reductive, hydrolytic, and phase II conjugation reactions, as well as a full complement of drug-metabolizing enzymes. [31] Metabolic activity is a primary consideration in the design of prodrugs and may influence the bioavailability of drugs delivered via dermatologic or transdermal formulations. Alterations in skin metabolism have been implicated in a range of diseases including hirsutism and acne, and they may be relevant to risk assessment of topical exposure to carcinogens. Metabolic processing of antigens by Langerhans cells is involved in the presentation of allergens to the immune system. Thus, metabolism in skin compartments plays a significant role in determining the fate of a topically applied active compound.

Significant cutaneous metabolism has been demonstrated for a wide variety of compounds of differing physicochemical properties, including the steroid hormones estrone, estradiol, and estriol, as well as glucocorticoids, prostaglandins, retinoids, benzoyl peroxide, aldrin, anthralin, 5-fluorouracil, nitroglycerin, theophylline, and propranolol. [31] For example, cutaneous metabolism reduced the systemic bioavailability of nitroglycerin administered in a transdermal drug formulation in rhesus monkeys by 16 to 21 percent and hydrolyzed virtually 100 percent of a salicylate diester. [32] It is convenient to classify metabolic reactions in terms of their cofactor dependence. Processes that require cofactors are likely to be energy dependent, and these are located within viable tissues. Among the best-studied examples are the interconversion of steroids (e.g., estrone and estradiol), and the oxidation of polycyclic aromatic hydrocarbons with mixed-function monooxygenases. In contrast, cofactor-independent processes involve catabolism and may be located outside of viable tissues, that is, in the transition region between the stratum corneum and stratum granulosum. The best-characterized of these involve hydrolytic reactions such as nonspecific ester hydrolysis.

Metabolic activity is found in (1) skin-surface microorganisms, (2) appendages, (3) the stratum corneum, (4) the viable epidermis, and (5) the dermis. In considering the site of the most significant metabolism, one has to take into account the relevant enzymes and their specific activity, as well as their capacity relative to the size of the compartment. Thus, although the level of many enzymes is highest in the epidermis, the relatively large size of the dermal compartment may result in a significant role in the metabolism of topically applied substances. A further consideration is that enzymes involved in cutaneous metabolism may be induced upon exposure to xenobiotics. This has been well described for various mixed-function monooxygenases. [33] Finally, the qualitative and quantitative extrapolation of results from animal models to humans is uncertain owing to the significant species differences in the metabolism of compounds.

Percutaneous absorption and metabolism of compounds can be viewed as two events in kinetic competition with each other. [34] Generally, compounds that remain in the skin for longer periods of time undergo significantly more metabolism. Furthermore, the type of metabolism of a substance may also be influenced by the nature of its formulation, as illustrated by investigations on the metabolism of several transdermal nitroglycerin formulations. [35] The inclusion of enhancers in the formulation not only increased the bioavailability of the nitroglycerin but also the ratio of one metabolic compound (1,2-glyceryl dinitrate) in relation to another (1,3-glyceryl dinitrate). This may limit the suitability of in vitro experiments for estimating the significance of cutaneous metabolism, because the vasculature is not functional in vitro. It further emphasizes that it is difficult to extrapolate quantitatively the level of metabolism obtained for different formulations. This has significant implications for the estimation of bioequivalence.

However, despite the variety of skin-associated metabolic processes, the extent of metabolism is normally modest, that is, in the order of 2 to 5 percent of the absorbed compounds. Metabolism is limited not only by the relatively short period of time that a compound spends in the viable layers of the skin, but also by the overall low level of enzyme activity. Thus, under many circumstances, the available enzymes are saturated by the level of compound undergoing percutaneous absorption. [31]

Resorption

Resorption, defined as the uptake of compounds by the cutaneous microvasculature, is directly related to the surface area of the exchanging capillaries as well as their blood flow. Total blood flow to the skin may vary up to 100-fold, a process primarily regulated by vascular shunts, but also by recruitment of new capillary beds. It is estimated that under resting conditions only 40 percent of the blood flow passes via exchanging capillaries capable of acting as a sink for absorbed compounds. However, this value demonstrates considerable variation between body sites, individuals, and species and is influenced by disease states and environmental conditions. In particular, changes in temperature and humidity as well as the presence of vasoactive compounds may directly influence skin blood flow. [36]

For most compounds and situations, resorption does not limit the delivery of compounds to the central compartment after topical applications. This is a result of the relatively high resistance to diffusion within the stratum corneum as compared with uptake by the vasculature. However, for compounds or situations in which diffusion across the stratum corneum is rapid, resorption limits the maximum rate of absorption. [36] The evidence that resorption can limit the delivery of compounds to the central compartment comes primarily from studies that examine the influence of blood flow on this

process. The percutaneous absorption of methylsalicylate is increased by elevated ambient temperature or strenuous exercise, an observation consistent with increased resorption as a result of cutaneous blood flow. [37] Moreover, intravenously administered nicotine (a vasoconstrictor) reduces the percutaneous absorption of topically applied nicotine. [38] Regional differences in the percutaneous absorption of piroxicam, a nonsteroidal anti-inflammatory agent, are dependent upon the local vasculature rather than upon skin barrier function. [39] Perhaps the most convincing evidence that resorption can limit delivery to the vasculature comes from in vitro studies on the perfused porcine skin flap. [40]

An additional consideration is that the rate of resorption may indirectly influence the diffusion of compounds to the underlying musculature, tissues, and joints. [41] The principle of locally enhanced delivery to underlying musculature has been demonstrated for piroxicam as well as several local anesthetic preparations. [42]

The Influence of Pathologic Processes on Skin Barrier Function

Reduced skin-barrier function has been observed in a number of pathologic conditions including the ichthyoses, [43], [44] psoriasis, [18], [45] atopic dermatitis, [46] and contact dermatitis. [47] It is generally accepted that this is attributable to structural alterations in the stratum corneum. [18] These structural deficiencies may arise from an absence of an enzyme or structural protein in the underlying viable tissues or may be related to the improper formation of the stratum corneum resulting from an increase in keratinocyte proliferation. Thus, in individuals predisposed to a defective barrier, a minor perturbation may become amplified as the skin “attempts to compensate” by increasing keratinocyte proliferation. [48] A further consideration is that the homeostatic mechanisms responsible for recovery of barrier activity after perturbation may be altered in some diseases or physiologic states.

For example, whereas the skin of aged people exhibits normal barrier function, the recovery of barrier activity after perturbation is markedly reduced. [43], [44] This kinetic basis for reduced barrier function may also account for interindividual variation in barrier function and/or the apparently increased susceptibility of certain individuals to contact dermatitis. [47]

In summary, the principal factors determining the pharmacokinetics of a topical application are the physiochemical properties of the bioactive molecule. Hydrophobicity, molecular weight, and ionic charge determine the feasibility of transdermal delivery for any particular compound. Formulations influence the pharmacokinetics largely from considerations of the thermodynamic activity of the compound. However, one should not exclude the impact of changes in the formulation that occur following topical application. Evaporation, and changes in the structure of emulsions, may result in dramatic changes in the thermodynamic activity of the compound at the skin surface. Under some circumstances, this may lead to the retention of the drug on the skin surface, that is, the reservoir.

The rate-limiting step for percutaneous absorption of most compounds is their penetration through the stratum corneum. There is substantial evidence that this is related to diffusion through a tortuous path around the corneocytes within the highly structured intercellular lipid, the constituents of which exhibit diffusional properties consistent with their role in the skin barrier. The follicular pathway is also important. For skin diseases exhibiting reduced skin-barrier function, the absence of a differentiated stratum corneum may account for the decreased barrier activity. The progression of a disease and the inherent biologic variability makes predictions of percutaneous absorption for diseased skin inherently difficult. This contributes significantly to the challenges of developing topical drugs.

Processes occurring in viable tissues can have a significant, though generally less important, influence on the bioavailability of compounds undergoing percutaneous absorption. It has been difficult to establish in vivo the level of skin-related metabolism of drugs undergoing percutaneous absorption. Effective manipulation of the rates of resorption with vasodilators or vasoconstrictors offers an attractive opportunity to influence the delivery of compounds to underlying tissues. However, this is likely to be of most importance with those compounds that, on their own, exhibit rapid rates of percutaneous absorption.

REFERENCES

1. Guy RH, Hadgraft J: Mathematical models of percutaneous absorption, in *Percutaneous Absorption,* edited by RL Bronaugh, HI Maibach. New York, Marcel Dekker, 1989, p 13

P>2. Jain MK: in *Introduction to Biological Membranes,* edited by MK Jain, RC Wagner. Toronto, Wiley, 1980, p 117

3. Gennis RB: *Biomembranes: Molecular Structure and Function*. New York, Springer-Verlag, 1989

4. Anissimov YG, Roberts MS: Diffusion modelling of percutaneous absorption kinetics. *J Pharm Sci* **88**:1201, 1999

5. Flynn GL: General introduction and conceptual differentiation of topical and transdermal drug delivery systems, in *Topical Drug Bioavailability: Bioequivalence and Penetration,* edited by VP Shaw, HI Maibach. New York, Plenum, 1993, p 369

6. Vickers CFH: Existence of reservoir in the stratum corneum. *Arch Dermatol* **88**:20, 1963

7. Rolland A et al: Site-specific drug delivery to pilosebaceous structures using polymeric micro spheres. *Pharm Res* **10**:1738, 1993

8. Rolland A: Particulate carriers in dermal and transdermal drug delivery: Myth or reality, in *Pharmaceutical Particulate Carriers: Therapeutic Applications,* edited by KA Walters, J Hadgraft. New York, Marcel Dekker, 1993, p 367

9. Lademann J et al: Investigation on follicular penetration of topically applied substances. *Skin Pharmacol Appl Skin Physiol* **14**:17, 2001

10. Schaefer H: The role of follicular penetration. *Skin Pharmacol Appl Skin Physiol* **14**:23, 2001

11. Higuchi T: Physical chemical analysis of percutaneous absorption process from creams and ointments. *J Soc Cosmet Chem* **11**:85, 1960

12. Guy RH et al: A pharmacokinetic model for percutaneous absorption. *Int J Pharm* **11**:119, 1982

13. Gupta SK et al: Pharmacokinetic and pharmacodynamic modeling of transdermal products: In vivo methods, problems, and pitfalls, in *Topical Drug Bioavailability: Bioequivalence and Penetration,* edited by VP Shah, HI Maibach. New York, Plenum, 1993, p 311

14. Kuboto K et al: Percutaneous absorption: A single model. *J Pharm Sci* **82**:450, 1993

15. Williams PL, Riviere JE: A biophysically based dermatopharmacokinetic compartment model for quantifying percutaneous penetration and absorption of topically applied agents: 1. Theory. *J Pharm Sci* **84**:599, 1995

16. Egbaria K et al: Liposomes as topical drug delivery system. *Adv Drug Del Rev* **5**:287, 1990

17. Korting HC et al: Liposome encapsulation improves efficacy of betamethasone dipropionate in atopic eczema but not in psoriasis vulgaris. *Eur J Clin Pharmacol* **39**:349, 1991

18. Schaefer H, Redelmeier TE: *Skin Barrier Principle of Percutaneous Absorption*. Basel, Karger, 1996

19. Elias PM, Menon GK: Structural and lipid biochemical correlates of the epidermal permeability barrier. *Adv Lipid Res* **24**:1, 1991

20. Elias PM et al: Coordinate regulation of epidermal differentiation and barrier homeostasis. *Skin Pharmacol Appl Skin Physiol* **14**:28, 2001

21. Reichert U et al: The cornified envelope: A key structure of terminally differentiating keratinocytes, in *The Keratinocytes,* edited by M Darmon, M Blumenberg. San Diego, Academic Press, 1993, p 107

22. Hou SYE et al: Membrane structures in normal and essential fatty acid-deficient stratum corneum: Characterization by ruthenium tetroxide staining and x-ray diffraction. *J Invest Dermatol* **96**:215, 1991

23. Bouwstra JA et al: Structure of human stratum corneum as a function of temperature and hydration: A wide angle x-ray diffraction study. *Int J Pharm* **84**:205, 1992

24. Flynn GL: Physiochemical determinants of skin absorption, in *Principles of Route-to-Route Extrapolation for Risk Assessment,* edited by TR Gerrity, CJ Henry. New York, Elsevier, 1990, p 93

25. Nemaniac MK, Elias PM: In situ precipitation: A novel cytochemical technique for visualization of permeability pathways in mammalian stratum corneum. *J Histol Cytochem* **28**:573, 1980

26. Squier CA, Lesch CA: Penetration pathways of different compounds through epidermis and oral epithelial. *J Oral Pathol* **17**:512, 1988

27. Boddé HE et al: Visualization of normal and enhanced $HgCl_2$ transport through human skin in vitro. *Int J Pharm* **53**:13, 1989

28. Pinnagoda J et al: Guidelines for transepithelial water loss (TEWL) measurements. A report from the Standardization Group of the European Society of Contact Dermatitis. *Contact Dermatitis* **22**:164, 1990

29. Scheuplein RJ: Mechanism of percutaneous absorption: II. Transient diffusion and the relative importance of various routes of skin penetration. *J Invest Dermatol* **45**:334, 1967

30. Rutter N: Clinical consequences of an immature barrier. *Semin Neonatol* **5**:281, 2000

31. Kao J, Carver MP: Cutaneous metabolism of xenobiotics. *Drug Metab Rev* **22**:363, 1990

32. Guzek DB et al: Transdermal drug transport and metabolism: I. Comparison of in vitro and in vivo results. *Pharm Res* **6**:33, 1989

33. Mukhtar H, Khan WA: Cutaneous cytochrome P-450. *Drug Metab Rev* **20**:657, 1989

34. Hadgraft J: Theoretical aspects of metabolism in the epidermis. *Int J Pharm* **4**:229, 1980

35. Higo N et al: Cutaneous metabolism of nitroglycerin. *Pharm Res* **9**:299, 1992

36. Riviere JE et al: The effect of vasoactive drugs on transdermal lidocaine iontophoresis. *J Pharm Sci* **80**:615, 1991

37. Danon A et al: Effect of exercise and heat exposure on percutaneous absorption of methylsalicylate. *Eur J Clin Pharmacol* **31**:49, 1986

38. Benowitz NL et al: Intravenous nicotine retards transdermal absorption of nicotine: Evidence of blood flow-limited percutaneous absorption. *Clin Pharmacol Ther* **52**:223, 1992

39. Monteiro-Riviere NA et al: Topical penetration is dependent on the distribution of the local vasculature. *Pharm Res* **10**:1326, 1993

40. Rogers RA, Riviere JE: Pharmacologic modulation of the cutaneous vasculature in the isolated perfused porcine skin flap. *J Pharm Sci* **83**:1682, 1994

41. Singh P, Roberts MS: Blood flow measurements in skin and underlying tissues by microsphere method: Application to dermal pharmacokinetics of polar non-electrolytes. *J Pharm Sci* **82**:873, 1993

42. Kushla GP et al: Non-invasive assessment of anaesthetic activity of topical lidocaine formulations. *J Pharm Sci* **82**:1118, 1993

43. Williams ML: Ichthyosis: Mechanisms of disease. *Pediatr Dermatol* **9**:365, 1992

44. Lavrijsen APM et al: Reduced skin barrier function parallels abnormal stratum corneum lipid organization in patients with lamellar ichthyoses. *J Invest Dermatol* **105**:619, 1995

45. Schaefer H et al: *Skin Permeability*. Berlin, Springer, 1982

46. Werner Y, Linberg M: Transepidermal water loss in dry and clinically normal skin in patients with atopic dermatitis. *Acta Derm Venereol* **65**:102, 1985

47. Wilhelm KP et al: Effect of sodium lauryl sulfate-induced skin irritation on in vivo percutaneous absorption of four drugs. *J Invest Dermatol*

97:927, 1991

48. Ghadially R et al: The aged permeability barrier: Structural, functional, and lipid biochemical abnormalities in humans and a senescent murine model. *J Clin Invest* **95**:2281, 1995

T>

Chapter 242

Bruce Strober Ken Washenik Jerome Shupack

Principles of Topical Therapy

CUTANEOUS DRUG DELIVERY
OTHER FACTORS THAT AFFECT ABSORPTION
Stratum Corneum
Occlusion
Frequency of Application
Quantity of Application
Miscellaneous Factors
CLASSIFICATION AND CLINICAL APPLICATION OF TOPICAL FORMULATIONS
Powders
Poultices
Ointments
Pastes
Liquids
Aerosols
Stabilizers
Thickening Agents
TOXICITY OF TOPICAL DRUGS
Local Effects
Systemic Effects

REFERENCES

After correctly diagnosing a cutaneous disease, the dermatologist must consider a myriad of options in formulating an effective treatment plan. Sensible topical drug therapy involves not only the selection of an appropriate agent, but also a thoughtful consideration of the areas of the body affected, the state of the diseased skin, the concentration of the drug in a suitable vehicle (i.e., ointment, cream, lotion, etc.), the method of application, and a defined duration of use that both maximizes efficacy and minimizes adverse side effects. Behind each of the aforementioned considerations are basic principles that help guide the practitioner toward a rational plan of therapy.

CUTANEOUS DRUG DELIVERY

The therapeutic efficacy of a topical drug relates to both its inherent potency and the ability of that drug to penetrate the skin. In fact, many potent agents, such as hydrocortisone and fluocinolone acetonide, are quite poorly absorbed into the skin. Conversely, many well-absorbed agents with weak potency have negligible therapeutic use. Percutaneous absorption requires a drug to pass through the stratum corneum, epidermis, papillary dermis, and into the bloodstream. But for most drugs, the limiting barrier to absorption is solely the stratum corneum.

When a thin layer of a finite amount of drug is applied to the skin, its rate of absorption, or *flux,* can be described in three phases: the lag, rising, and falling phases. [1] The lag phase reflects the period when no drug has transversed the stratum corneum, and thus no drug can be measured in the bloodstream. After a period of time, the rising phase begins as some drug crosses the stratum corneum and ultimately enters the dermal capillaries, and thus can be detected in the bloodstream. As it leaves the applied surface film, the drug increasingly fills the stratum corneum. This increase in concentration within the stratum corneum will lead to an increased rate of drug delivery to the epidermis, dermis, and dermal capillaries. Of course, because the amount of drug in the surface film is finite the amount delivered to the stratum corneum will ultimately diminish. The falling phase of absorption reflects the exhaustion of drug from the surface film and the resultant lower supply of the agent within the stratum corneum that can be delivered to the dermal capillaries. It should be noted that in addition to absorption, other factors, such as exfoliation, rub-off, and wash-off, reduce the drug's surface concentration. The pharmacokinetics of topical drugs are discussed in Chap. 241.

OTHER FACTORS THAT AFFECT ABSORPTION

Stratum Corneum

As mentioned previously, the stratum corneum is the rate-limiting barrier to percutaneous drug delivery. Of course, the stratum corneum thickness, and thus drug penetration, varies depending on body site. [1] Table 242-1 lists varying body sites and their relative resistance to percutaneous absorption. An important consideration in topical therapy is that diseased skin may have an altered (increased, decreased, or absent) stratum corneum, thus changing the body site's barrier function; for example, abraded or eczematized skin presents less of a barrier.

1. Mucous membrane
2. Scrotum
3. Eyelids
4. Face
5. Chest and back
6. Upper arms and legs
7. Lower arms and legs
8. Dorsa of hands and feet
9. Palmar and plantar skin
10. Nails

*Have penetration with number 1 and low penetration with increasing numbers.

TABLE 242-1 **Regional Differences in Penetration***

Occlusion

Occlusion via closed, airtight dressings or greasy ointment bases increases the hydration and temperature of the stratum corneum and limits rub-off/wash-off of the drug, enhancing drug penetration. To derive the greatest benefit from occlusion, the patient should hydrate the skin by immersion in water for approximately 5 min prior to the application of a cream or ointment. With many drugs, occlusion increases drug delivery by 10 to 100 times the amount of drug delivered when not occluded. [2] On the other hand, occlusion may also lead to a more rapid appearance of the drug's adverse effects such as the ability of topical corticosteroids to induce local skin atrophy or suppression of the hypothalamus-pituitary-adrenal axis. Occlusion might also promote infection, folliculitis, and miliaria.

Frequency of Application

The frequency of drug application likely has little effect on increasing a topical drug's overall efficacy. [3], [4] One daily application is enough for most topical glucocorticoids, for example, but the nonspecific emollient or protective effect of creams and ointments are likely enhanced by more frequent applications. Regardless, increasing the contact time for a topical drug augments its total absorption.

Quantity of Application

The quantity of the drug applied likely has a negligible effect on drug absorption, but enough must be dispensed and spread to cover the affected areas. Furthermore, the quantity of drug applied can affect patient adherence to prescribed regimen. For example, too much applied drug might negatively alter the subjective experience of having the salve on the skin, that is, either the drug feels “wrong” (greasy, caked, chalky, etc.) or is cosmetically unattractive. Regardless, the amount prescribed must be adequate to treat the affected body surface area for the necessary length of time. In this regard, patient education is critical to prevent wasteful overuse or ineffective underuse of the medication. Table 242-2 presents the amounts of topical medications to dispense based on the estimated body surface area, frequency of application, and duration of therapy.



TABLE 242-2 **Suggested Amounts of Topical Medications to Dispense—Cream or Ointment**

Miscellaneous Factors

Vigorous rubbing or massaging of the drug into the skin not only increases the surface area of skin covered, but also increases blood supply to the area locally, augmenting systemic absorption. The presence of hair follicles on a particular body site also enhances drug delivery, with the scalp and beard areas presenting less of a barrier than the relatively hairless body sites. While having a thinner stratum corneum, the skin of older individuals is poorly hydrated and has fewer hair follicles, and therefore may impede drug delivery. Reducing the particle size of the active ingredient increases its surface area to volume ratio, allowing for a greater solubility of the drug in its vehicle. This forms the basis for the increased absorption of certain micronized drugs. [5]

CLASSIFICATION AND CLINICAL APPLICATION OF TOPICAL FORMULATIONS

The vehicle is the preparation that brings a drug in contact with the skin. Prior to the mid-1970s pharmaceutical companies performed limited testing of the impact of the vehicle on the potency of a given formulation. The lack of a scientific analysis of the vehicle led to the marketing of topical drugs that, while having different concentrations of the same active ingredient, displayed similar bioavailability and potency. For example, older preparations of triamcinolone acetonide showed no real differences in potency among the 0.025%, 0.1%, and 0.5% concentrations. By contrast, modern drug development attempts to maximize drug bioavailability by optimizing the vehicle formulation. Additionally, during the current drug development process dose–response studies determine the maximal effective concentration within a given vehicle, above which any further increase in concentration serves no therapeutic benefit.

The vehicle of a topical formulation often has beneficial nonspecific effects by possessing cooling, protective, emollient, occlusive, or astringent properties. Rational topical therapy leads to an appropriate vehicle that contains an effective concentration of the drug. The vehicle functions optimally when it is stable both chemically and physically and does not inactivate the drug. The vehicle also should be nonirritating, nonallergenic, cosmetically acceptable, and easy to use. Additionally, the vehicle must release the drug into the pharmacologically important compartment of the skin. Finally, the patient must like the vehicle or else compliance will be poor. For example, while ointments are often pharmacodynamically better than creams, patients generally prefer creams, and thus it should not surprise that more prescriptions are written for cream-based formulations. Table 242-3 lists many commonly used ingredients in topical preparations. Many of these compounds may serve more than one function in a particular formulation.

Emulsifying agents	Solvents
Cholesterol	Alcohol
Disodium monooleamidosulfo-succinate	Diisopropyl adipate
Emulsifying wax	Glycerin
Polyoxyl 40 stearate	1,2,6-Hexanetriol
Polysorbates	Isopropyl myristate
Sodium laureth sulfate	Propylene carbonate
Sodium lauryl sulfate	Propylene glycol (PG)
Auxiliary emulsifying agents/emulsion stabilizers	Water
Carbomer	Thickening agents
Cetearyl alcohol	Beeswax
Cetyl alcohol	Carbomer
Glyceryl monostearate	Petrolatum
Lanolin and lanolin derivatives	Polyethylene
Polyethylene glycol (PG)	Xanthan gum
Stearyl alcohol	Emollients
Stabilizers	Caprylic/capric triglycerides
Benzyl alcohol	Cetyl alcohol
Butylated hydroxyanisole (BHA)	Glycerin
Butylated hydroxytoluene (BHT)	Isopropyl myristate
Chlorocresol	Isopropyl palmitate
Citric acid	Lanolin and lanolin derivatives
Edetate disodium	Mineral oil
Glycerin	Petrolatum
Parabens	Squalene
Propyl gallate	Stearic acid
Propylene glycol (PG)	Stearyl alcohol
Sodium bisulfite	Humectants
Sorbic acid/potassium sorbate	Glycerin
	Propylene glycol (PG)
	Sorbitol solution

TABLE 242-3 **Vehicle Ingredients Commonly Used in Topical Preparations**

Powders

Powders absorb moisture and decrease friction. Because they adhere poorly to the skin, their use is limited to cosmetic and hygienic purposes. Generally, powders are used in intertriginous areas and on the feet. Adverse effects of powders include caking (especially if used on weeping skin), crusting, irritation, and granuloma formation. Furthermore, powders may be inhaled by the user. Most powders contain zinc oxide for its antiseptic and covering properties, talc (primarily composed of magnesium silicate) for its lubricating and drying properties, and a stearate for improved adherence to the skin. Calamine is a popular skin-colored powder composed of 98% zinc oxide and 1% ferric oxide that acts as an astringent to relieve pruritus. Other drugs formulated as powders include some over-the-counter antifungals. [5]

Poultices

A poultice, also referred to as a cataplasm, is a wet solid mass of particles, sometimes heated, that is applied to diseased skin. Historically, poultices contained meal, herbs, plants, and seeds. The modern poultice often consists of porous beads of dextranomer. Poultices are used as wound cleansers and absorptive agents in exudative lesions, such as decubiti and leg ulcers. [5]

Ointments

Ointments are semisolid preparations that spread easily. They can be protective, hydrating, and lubricating. Ointment bases used in dermatology can be classified into five categories: hydrocarbon bases, absorption bases, emulsions of water-in-oil, emulsions of oil-in-water, and water-soluble bases. Dermatologists commonly refer to the hydrocarbon bases and absorption bases as “ointments,” and the water-in-oil/oil-in-water emulsion bases as “creams.” In pharmaceutical terms, all of these preparations are ointments.

HYDROCARBON BASES Also called oleaginous bases, hydrocarbon bases are often referred to as emollients because they prevent the evaporation of moisture from the skin, and are composed of a mixture of hydrocarbons of varying molecular weights, with petrolatum being the most commonly used (white petrolatum, except for being bleached, is identical to yellow petrolatum). They are also greasy and can stain clothing. The silicon ointments are composed of alternating oxygen and silicon atoms bonded to organic groups such as phenyl or methyl and are excellent protectants. They can be used for diaper rash, incontinence, bedsores, and colostomy sites. Hydrocarbon bases are generally stable and do not contain preservatives. They cannot absorb aqueous solutions and thus are not used for water-soluble drugs. [6]

ABSORPTION BASES Absorption bases contain hydrophilic substances that allow for the absorption of water-soluble drugs. The hydrophilic (polar) compounds may include lanolin and its derivatives, cholesterol and its derivatives, and the partial esters of polyhydric alcohols such as sorbitan monstearate. These ointments are lubricating, hydrophilic, and can form emulsions. They function well as emollients and protectants. They are greasy to apply, but are easier to remove than the hydrocarbon bases. They do not contain water. Examples include anhydrous lanolin and hydrophilic petrolatum. [5]

WATER-IN-OIL EMULSIONS (CREAMS) Emulsions are two-phase systems involving one or more immiscible liquids dispersed in another with the assistance of an emulsifying agent. A water-in-oil emulsion by definition contains less than 25 percent water, with oil being the dispersion medium. The two phases may separate unless shaken. The emulsifier (or surfactant) is soluble in both phases and surrounds the dispersed drops to prevent their coalescence. Examples of surfactants used include sodium lauryl sulfate, the quaternary ammonium compounds, Spans (sorbitan fatty acid esters), and Tweens (polyoxyethylene sorbitan fatty acid esters). Preservatives are frequently added to increase the emulsion's shelf life. Water-in-oil emulsions are less greasy, spread easily on the skin, and provide a protective film of oil that remains on the skin as an emollient, while the slow evaporation of the water phase provides a cooling effect. [5]

OIL-IN-WATER EMULSIONS An oil-in-water emulsion contains greater than 31 percent water. In fact, the aqueous phase may comprise up to 80 percent of the formulation. This type of formulation is the one most commonly chosen to deliver a dermatologic drug. Clinically, oil-in-water emulsions spread very easily, are water washable and less greasy, and are easily removed from the skin and clothing. Invariably, they contain preservatives such as the parabens to inhibit the growth of molds. Additionally, oil-in-water emulsions contain a humectant (an agent that draws moisture into the skin) such as glycerin, propylene glycol, or polyethylene glycol to prevent the cream from drying out. The oil phase may contain either cetyl or stearyl alcohol (paraffin alcohols) to impart a stability and velvety smooth feel upon application to the skin. After application, the aqueous phase evaporates leaving behind both a small hydrating layer of oil and a concentrated deposit of the drug. [5]

WATER-SOLUBLE BASES Water-soluble bases consist either primarily or completely of various polyethylene glycols (PEGs). Depending on their molecular weight, PEGs are either liquid (for example, PEG 400) or solid (PEG 4000). These

formulations are water soluble, will not decompose, and will not support the growth of mold; consequently, they do not require preservative additives. They are much less occlusive than water-in-oil emulsions; in addition, they are nonstaining, greaseless, and easily washed from the skin. Without water this ointment poorly delivers its coformulated drug. Therefore, it will be useful in scenarios where the practitioner desires a high surface concentration and low percutaneous absorption of the drug. For example, topical antifungal drugs and topical antibiotics (i.e., mupirocin) are formulated in this type of base. *Gels* are made from water-soluble bases by formulating water, propylene glycol, and/or PEGs with a cellulose derivative or carbopol. A gel consists of organic macromolecules uniformly distributed in a lattice throughout the liquid. After application, the aqueous or alcoholic component evaporates, and the drug is deposited in a concentrated form. This provides a faster release of the drug independent of its water solubility. Gels are popular because of their clarity and ease of both application and removal. They are also easy to use on the hair-bearing body sites. Nevertheless, they lack any protective or emollient properties. If they contain high concentrations of alcohol or propylene glycol they tend to be drying or cause stinging. Gels require preservatives. [5]

Pastes

Pastes are simply the incorporation of high concentrations of powders (up to 50 percent) into an ointment such as a hydrocarbon base or a water-in-oil emulsion. The powder must be insoluble in the ointment. Invariably, they are “stiffer” than the original ointment. The powders commonly used are zinc oxide, starch, calcium carbonate, and talc. Pastes function to localize the effect of a drug that may be staining or irritating (i.e., anthralin). They also function as impermeable barriers that serve as protectants or sunblocks. Pastes are less greasy than ointments, more drying, and less occlusive. [5]

Liquids

Liquids can be subdivided into solutions, suspensions, and emulsions (discussed in the section on ointments).

SOLUTIONS A solution involves the dissolution of two or more substances into homogenous clarity. The liquid vehicle may be aqueous, hydroalcoholic, or nonaqueous (alcohol, oils, or propylene glycol). An example of an aqueous solution is aluminum acetate or Burow's solution. A hydroalcoholic solution with a concentration of alcohol of approximately 50 percent is called a *tincture*. A *collodion* is a nonaqueous solution of pyroxylin in a mixture with ether and ethanol, and is applied to the skin with a soft brush. *Flexible collodions* have added castor oil and camphor and are used, for example, to deliver 10% salicylic acid as a keratolytic agent and cantharidin for the treatment of warts. *Liniments* are nonaqueous solutions of drugs in oil or alcoholic solutions of soap. The base of oil or soap facilitates application to the skin with rubbing or massage. Liniments can be used as counterirritants, astringents, antipruritics, emollients, and analgesics. [5]
SUSPENSIONS (LOTIONS) A suspension, or *lotion,* is a two-phase system consisting of a finely divided, insoluble drug dispersed into a liquid in a concentration of up to 20 percent. Nonuniform dosing can result if the suspended particles coalesce and separate out of a homogeneous mixture, therefore shaking of the lotion prior to application may be required. Examples include calamine lotion, steroid lotions, and emollients containing urea or lactic acid. The applied lotion leaves the skin feeling cooler via evaporation of the aqueous component. Lotions are easier to apply and allow for uniform coating of the affected area, and are often the favorite preparation in treating children. Lotions are more drying than ointments, and preparations with alcohol tend to sting eczematized or abraded skin. [5]
SHAKE LOTIONS These are lotions to which a powder is added in order to increase the surface area of evaporation. As a result of the increased evaporation, the application of shake lotions effectively dries and cools wet and weeping skin. Generally, shake lotions consist of zinc oxide, talc, calamine, glycerol, alcohol, and water, to which specific drugs and stabilizers may be added. Shake lotions tend to sediment, and derive their name from the need to shake the preparation prior to each use in order to obtain a homogeneous suspension. In addition, after water has evaporated from the lotion, the powder component may clump together and become abrasive. Therefore, patients should be instructed to remove the residual particles prior to the reapplication of shake lotions. [5]

Aerosols

Topical aerosols may be used to deliver drugs formulated as solutions, suspensions, emulsions, powders, and semisolids. Aerosols involve formulating the drug in a solution within a propellant. Usually, the propellant is a blend of nonpolar hydrocarbons. When applied to abraded or eczematized skin, aerosols lack the irritation of other formulations, especially when the quality of the skin makes direct application painful or difficult. Further, aerosols dispense a drug as a thin layer with minimal waste, and the unused portion cannot be contaminated. Aerosol foams, a relatively new vehicle for drug delivery, are commonly used to deliver corticosteroids such as betamethasone valerate and clobetasol propionate. The foam contains the drug within an emulsion formulated with a foaming agent (a surfactant), a solvent system (such as water and ethanol), and a propellant. Upon application, a foam lattice forms transiently until it is broken by both the heat of the skin and the heat of rubbing the foam onto the skin. Foams that are alcohol based leave very little residue within seconds of their application. Furthermore, a given corticosteroid formulated in a foam vehicle demonstrates comparable potency when compared to the same corticosteroid in other vehicles. [6] While aerosols allow for the ease of application (especially to hair-bearing areas) and high patient satisfaction, they suffer from the disadvantages of being expensive and potentially ecologically damaging. [5]

Stabilizers

Stabilizers are nontherapeutic ingredients and include the *preservatives, antioxidants,* and *chelating agents*. Preservatives protect the formulation from microbial growth. Ideally, preservatives are effective at a low concentration against a broad spectrum of organisms, and are nonsensitizing, odor-free, color-free, stable, and inexpensive. Unfortunately, the ideal preservative does not exist. The parabens are the most frequently added preservatives, and are active against molds, fungi, and yeasts, but less effective against bacteria. Alternative agents include the halogenated phenols, benzoic acid, sodium benzoate, formaldehyde and the formaldehyde-releasing agents, and thimerosal. Most

commonly used preservatives can act as contact sensitizers.

Antioxidants prevent the drug or vehicle from degrading via oxidation. Examples include butylated hydroxyanisole (BHA) and butylated hydroxytoluene (BHT), used in oils and fats. Ascorbic acid, sulfites, and sulfur-containing amino acids are used in water-soluble phases. Chelating agents, such as sodium ethylenediaminetetraacetic acid (EDTA) and citric acid, work synergistically with antioxidants by complexing heavy metals in aqueous phases.

Thickening Agents

These are agents that serve to increase the viscosity of products or to suspend ingredients in the formulation. Examples include beeswax and carbomers. In addition to functioning as an ointment vehicle, petrolatum may be added to an emulsion to increase its viscosity. Therefore, an ingredient simultaneously may be both therapeutic and nontherapeutic.

TOXICITY OF TOPICAL DRUGS

Local Effects

Either the vehicle or its active ingredients may cause local toxicity to the applied site. Local toxic effects are usually minor and reversible. Major cutaneous side effects include irritation, allergenicity, atrophy, comedogenicity, formation of telangiectases, pruritus, stinging, and pain. The mechanism of toxicity might be as simple as the desiccation of the stratum corneum (the removal of sebum and oils by the preparation's emulsifiers, for example), or involve a more complex effect on either the cells of the epidermis or dermis and the structures these cells comprise (i.e., epidermis, adnexae, etc.). Local damage may occur either directly at, or within close proximity to, the treated site. Furthermore, irritation and damage may appear even after the drug has been discontinued. Often the therapeutic effects of the active ingredient mask or immediately treat the toxic effects of the formulation so that the acutely toxic effects are transient. [7]

Irritation relies less on drug penetration and more on drug concentration. Thus, lowering the concentration of an irritating drug may lower the risk of side effects. But such a change in formulation may reduce the preparation's efficacy. Nevertheless, often using a less-concentrated preparation over a greater period of time is as therapeutically efficacious while minimizing adverse effects; for example, using benzoyl peroxide 2 to 5% preparations instead of 10% preparations. [7] In some instances, however, skin irritancy might be central to drug efficacy. For example, although not conclusively shown, the power of immunomodulating agents such as imiquimod might rely on an increased innate (inflammatory or irritant) immune response.

In contrast to local irritation, the development of contact allergy depends on local penetration. Allergy, of course, relies on antigen recognition and presentation; consequently, percutaneous absorption of the drug must be at a level that guarantees interaction with the immune effector cells of the epidermis and dermis. Therefore, the contact allergic properties of a drug relate to all of the parameters that influence percutaneous absorption.

Systemic Effects

Although not always considered while formulating a treatment plan, one should be aware of the potential systemic toxicities of topical drugs. While generally safer than the other routes of administration, topical application can result in systemic toxicities ranging from end-organ toxicity (central nervous system, cardiac, renal, etc.), teratogenicity and carcinogenicity, to drug interactions. These outcomes may relate to the drug itself, its metabolites, or a component of the vehicle.

The kinetics of topically applied drugs differ significantly from those administered by other routes. An important consideration is the lack of hepatic first-pass metabolism of a topical drug. This is especially relevant to drugs such as salicylic acid that are relatively innocuous when given enterally, but may manifest central nervous system toxicity when applied topically. Additionally, acting as a reservoir, the stratum corneum may store large amounts of a topical drug and a subsequently long diffusion period of many days may ensue, delivering a steady supply of drug to the systemic circulation.

Percutaneous toxicity directly relates to percutaneous absorption. Therefore, factors that modulate absorption also influence toxicity: the concentration of the drug, its vehicle, the use of occlusion, the body site treated, frequency of dosage, the duration of therapy, and the nature of the diseased skin. For example, 6% salicylic acid in Eucerin used for 11 days in the treatment of psoriasis results in epistaxis and deafness, while the same concentration of salicylic acid in hydrophilic cream under occlusion for 4 days for the treatment of dermatitis (involving the same amount of body surface area) may result in hallucination. [7] Similar to their effect on systemically administered drugs, renal and hepatic diseases, by influencing drug clearance, also contribute to an increased potential for drug toxicity.

Young children have a greater surface area-to-volume ratio, and thus are at greater risk of percutaneous toxicity than adults. This phenomenon necessitates alternative drugs, formulations, and dosing schedules for children with widespread cutaneous disease. Patients with acute flares of cutaneous illness (e.g., psoriasis or atopic dermatitis) may require the treatment of a larger body surface area in a relatively abbreviated period of time. These patients may also increase their dose and frequency of application during such flares. Coupled with the likely increased percutaneous absorption of the diseased skin, these scenarios exponentially increase the possibility of systemic toxicity, and patient education is vital to prevent adverse outcomes. [8] To reduce the risk of toxicity from topical drugs and to increase treatment efficacy, many practitioners rationally will advocate nontopical approaches (e.g., methotrexate, cyclosporine, or ultraviolet radiotherapy) to patients whose disease exceeds 20 to 25 percent of their body surface area.

In rare instances, anaphylactic shock can be precipitated by topical drug application. For example, when applied to diseased or abraded skin, bacitracin ointment can induce an immediate-type (type I) hypersensitivity reaction in

susceptible individuals. Such reactions might be represented by a local and then subsequently generalized pruritus leading to cardiopulmonary arrest. [8] Nonimmunologic acute toxicity results from substances such as pesticides and chemical warfare agents that rapidly diffuse through the skin and reach target organs.

REFERENCES

1. Feldman RJ, Maibach HI: Regional variation in percutaneous penetration of 14C cortisol in man. *J Invest Dermatol* **48**:181, 1967

2. Ryan TJ, editor: *Beyond Occlusion: Dermatology Proceedings*. No. 137 of International Congress Symposium Series. London/New York, Royal Society of Medicine Series, 1988

3. Eaglstein WH et al: Topical corticosteroid therapy: Efficacy of frequent application. *Arch Dermatol* **110**:955, 1974

4. Wester RL et al: Frequency of application on percutaneous absorption of hydrocortisone. *Arch Dermatol* **113**:620, 1977

5. Ricciatti-Sibbald D, Sibbald RG: Dermatologic vehicles. *Clin Dermatol* **7**:11, 1989

6. Franz TJ et al: Betamethasone valerate foam 0.12%: A novel vehicle with enhanced delivery and efficacy. *Int J Dermatol* **38**:628, 1999

7. Zesch A: Short- and long-term risks of topical drugs. *Br J Dermatol* **115**(Suppl 31):63, 1986

8. Bashir SJ, Maibach HI: Topical drug testing, in *Comprehensive Dermatologic Drug Therapy,* edited by SE Wolverton. Philadelphia, Saunders, 2001, p 911

T>

Chapter 243

Isabel Valencia Francisco Kerdel

Topical Glucocorticoids

PHARMACOLOGY
CLINICAL USES
Pediatric Uses
Geriatric Uses
Uses in Pregnancy
DOSAGE SCHEDULES AND FORMULATIONS
ADVERSE EFFECTS
DRUG INTERACTIONS

REFERENCES

Hydrocortisone, the first topically effective glucocorticoid, was introduced by Sulzberger and Witten in 1952. [1] The success associated with hydrocortisone led to the design and development of an ever-growing list of more potent analogues. Currently, topical steroids are the most frequently prescribed of all dermatologic drug products.

PHARMACOLOGY

Modifications of cortisol, the basic molecule (Fig. 243-1) by addition or alteration of functional groups at certain positions, have led to compounds of varying potencies and side effects. Addition of a fluorine molecule at positions 6 and/or 9 enhances the potency of the steroid, but is accompanied by an increased mineralocorticoid activity. [2] Substitution at the position 16 with an a-hydroxyl (triamcinolone), a-methyl (dexamethasone) or ß-methyl (betamethasone) increases efficacy without a concomitant increase in the sodium-retaining properties. [3] The removal, replacement or masking of hydroxyl groups increases the molecule's lipophilicity, therefore rate of percutaneous absorption as well as the glucocorticoid receptor-binding activity. Masking of hydroxyl groups can be achieved by esterification at positions C16, C17, and C21 (i.e., butyric acid at position 17 in the hydrocortisone molecule yields hydrocortisone butyrate); or formation of acetonide groups by addition of a 16-a-hydroxy substituent, producing triamcinolone acetonide and fluocinolone acetonide. Replacement of the 21-hydroxyl group in the betamethasone molecule with a chlorine moiety, creates clobetasol 17-propionate, the strongest molecule to date. [3], [4] and [5]

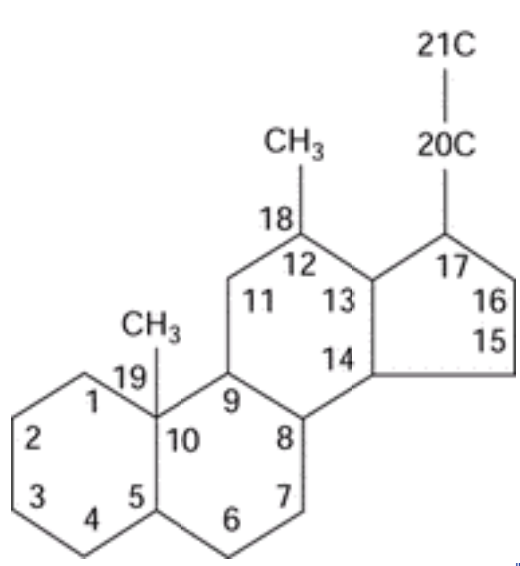

FIGURE 243-1 Basic steroid molecule.

The clinical potency of a topical corticosteroid depends not only on the inherent potency of the molecule but also on factors such as the vehicle and the nature of the skin onto which it is applied. The vehicle in which the steroid is incorporated may be as important as the steroid molecule itself because the vehicle affects the amount of steroid that is released in any given period of time (see Chap. 242). Very occlusive vehicles, such as ointments, potentiate glucocorticoid effects because they provide increased hydration of the stratum corneum and increase its permeability. By covering the skin with an occlusive dressing such as plastic wrap, this effect can be heightened as much as 100-fold. The solubility of the glucocorticoid in the vehicle also affects penetration into the epidermis. Propylene glycol is one agent commonly used to dissolve the glucocorticoid in the vehicle, and it is found in many topical glucocorticoid preparations. [6] In general, compounds that contain higher amounts of propylene glycol tend to be more potent.

Treatment of the skin prior to application of the topical steroid may also affect the absorption of the compounds into the skin. For example, use of keratolytics or fat solvents such as acetone enables increased penetration by disrupting the epidermal barrier. Tape stripping of the skin also increases the absorption of hydrocortisone by 78 to 90 percent. [7]

Topical glucocorticoid research has focused on strategies to optimize potency while minimizing side effects. One strategy is to develop compounds with enhanced anti-inflammatory effects and minimal unwanted atrophogenic and adrenal suppressive effects. In this sense, progress has been made with the development of glucocorticoid molecules that, while retaining high activity in the skin following topical application, are quickly broken down into inactive metabolites, thereby

mitigating systemic and possibly some local toxic effects (“soft” glucocorticoids). Examples of these compounds include fluticasone propionate, prednicarbate and methyl prednisolone aceponate. [8] However, data on long-term safety following prolonged topical application of these agents is currently lacking. Research to develop a nonsteroidal compound with the same anti-inflammatory effects of glucocorticoids but without the side effects is currently ongoing. [9]

CLINICAL USES

The clinical effectiveness of glucocorticoids is related to four basic properties: vasoconstriction, antiproliferative effects, immunosuppression, and anti-inflammatory effects. Topical steroids cause capillaries in the superficial dermis to constrict, thus reducing erythema. The ability of a given glucocorticoid agent to cause vasoconstriction usually correlates with its anti-inflammatory potency, and thus vasoconstriction assays are often used to predict the clinical activity of an agent. These assays in combination with double-blind clinical trials have been used to separate the topical glucocorticoids into seven classes based on potency. Class 1 includes the most potent, while class 7 contains the least potent. Table 243-1 lists many of the available topical glucocorticoids according to this classification.

TABLE 243-1 **Potency Ranking of Some Commonly Used Brand-Name Glucocorticoids**

The antiproliferative effect of topical glucocorticoids is mediated by inhibition of DNA synthesis and mitosis. Control of cellular proliferation is a complex process composed of cascades of stimulating influences that are counteracted by multiple inhibitory circuits. Many of these processes are probably influenced by glucocorticoids. [10]

The effectiveness of glucocorticoids, in part, may also be due to their immunosuppressive properties. The mechanisms responsible for immunosuppression are poorly understood. Several studies have shown that glucocorticoids can cause mast cell depletion in the skin. [11] This may explain the utility of topical glucocorticoids in patients with urticaria pigmentosa. Experiments also show that topical glucocorticoids cause a local inhibition of chemotaxis of neutrophils [12] in vitro, and decrease the number of Ia+ Langerhans cells [13] in vivo. In addition, several cytokines are directly affected by glucocorticoids, including interleukin (IL)-1, tumor necrosis factor-a, granulocyte-macrophage colony-stimulating factor, and IL-8. These effects may also be a result of the steroid action on antigen presenting cells. [14]

It is believed that glucocorticoids exert their potent anti-inflammatory effects by inhibiting the formation of prostaglandins and other derivatives of the arachidonic acid pathway. [15] It is known that glucocorticoids inhibit the release of phospholipase A_2, the enzyme responsible for liberating arachidonic acid from cell membranes, thus inhibiting the arachidonic acid pathway. For many years it was believed that glucocorticoids caused macrophages and other cells to release a specific protein, lipocortin, that was thought to have a direct inhibitory action on phospholipase A_2. [16] Although lipocortins have since been purified and their genes cloned and sequenced, their role in the anti-inflammatory action of glucocorticoids has been questioned. [17] It is the current belief that glucocorticoids inhibit phospholipase A_2 in cells by directly inducing phosphorylation of the enzyme. [18] Other proposed mechanisms for the anti-inflammatory effects of glucocorticoids include inhibition of phagocytosis and stabilization of lysosomal membranes of phagocytizing cells. [19]

Certain variables must be considered when treating skin disorders with topical glucocorticoids. For example, the responsiveness of diseases to topical glucocorticoids varies. In this setting, diseases can be divided into the three categories shown in Table 243-2: highly responsive, moderately responsive, and least responsive. Highly responsive diseases will usually respond to weak steroid preparations; less-responsive diseases require medium potency steroids; and the least-responsive category requires high-potency topical steroids.



TABLE 243-2 **Responsiveness of Dermatoses to Topical Application of Corticosteroids**

Before choosing a topical glucocorticoid preparation, one must consider the area of the body that is to be treated because regional differences greatly affect the activity of the topical agent. Penetration of the glucocorticoid varies according to the skin site, which, in turn, is related to the thickness of the stratum corneum and the vascular supply to the area. For example, penetration of topical steroids through the eyelids and scrotum is 4 times greater than for the forehead and 36 times greater than for the palms and soles. Inflamed, moist, and denuded skin also shows increased penetration. Areas of the body where the skin is inherently thin not only allow for increased penetration of the drug but are more susceptible to develop side effects than other areas where the skin is thick (see Table 242-3). Potent topical steroids (classes 1 and 2) should rarely, if ever, be used in the areas with the highest level of penetration, such as the

eyelids.

Pediatric Uses

Topical glucocorticoids are highly effective, and few side effects are observed when a low-potency preparation is used for brief periods of time without occlusion in children. Infants, however, are at an increased risk for side effects for several reasons. Because they have a higher ratio of skin surface area to body weight, application to a given area results in a greater potentially systemic dose of steroid. Infants may also be less able to metabolize potent glucocorticoids rapidly. [20] Premature infants are especially at risk because their skin is thinner and the penetration rate of topically applied drugs is greatly increased. [21] Application of topical steroids to the diaper area results in occlusion of the steroid by the diaper, and increased penetration occurs. Excess absorption of topical glucocorticoids can suppress endogenous cortisol production. Consequently, subsequent cessation of topical steroid therapy after an extended treatment period can result in an addisonian crisis characterized by nausea, anorexia, postural hypotension, and vascular collapse. Deaths from addisonian crisis have been reported with the use of topical steroids, [22] and the risk of this occurring is greater in children. Chronic suppression of cortisol production can also lead to growth retardation. A morning plasma cortisol level can be performed to screen for adrenal suppression. If suppression is present, the child should be slowly weaned from the steroids to prevent these complications.

Geriatric Uses

Elderly patients similarly can have thin skin, which allows for increased penetration of topical glucocorticoids. They are also more likely to have preexisting skin atrophy secondary to aging and may be diaper-dependent, so the same precautions used in the treatment of infants should be used when treating elderly patients. Topical glucocorticoids should be used infrequently, for brief periods, or under close supervision in those patients with preexisting skin atrophy to avoid unwanted side effects.

Uses in Pregnancy

Appropriate human studies using topical glucocorticoids in pregnancy have never been undertaken. Studies in animals, however, show that topical steroids are systemically absorbed and may cause fetal abnormalities, especially when used in excessive amounts, under occlusive dressings, for prolonged periods of time, or when the more potent agents are used. However, numerous studies of pregnant patients taking systemic glucocorticoids throughout pregnancy show no increases in the incidence of fetal abnormalities. Most topical steroids are rated by the US Food and Drug Administration (FDA) as category C drugs, which implies that caution must be exercised when used in pregnancy. It is currently unknown whether topical glucocorticoids are excreted in breast milk; however, they should be used with caution in breast-feeding mothers and should never be used on the breasts prior to breast feeding.

DOSAGE SCHEDULES AND FORMULATIONS

Twice-a-day topical application of glucocorticoids is recommended on the labels of most formulations, although no scientific evidence has ever established this as the optimal schedule. To decrease the risks of side effects, it is best to establish, with the aid of the patient, the longest elapsed time between successive applications that still controls the disease. This method may help to decrease the development of side effects and tachyphylaxis. Tachyphylaxis has been demonstrated in experimental conditions by diminished vasoconstriction, rebound of DNA synthesis, and recovery of histamine wheals after application of topical steroids in patients with a history of long-term topical steroid usage. [23]

Topical steroids come in many different vehicles and dosage forms. Ointments are water-insoluble mixtures of oil and petrolatum and are the best preparation when treating dry skin conditions because they provide the most moisture of the available preparations. They are also useful for treating conditions on areas of the body with thick skin, such as the palms and soles. The occlusive nature of the ointment and its ability to moisturize the stratum corneum allow for increased penetration and enhanced potency of the drug. Peanut oil has also been combined with steroids to form a preparation that is thinner and easier to apply while retaining the hydrating capability of ointments. However, patients may feel that ointments and oils are too greasy. New emollient creams have been devised that contain an increased amount of petrolatum but with less greasiness than ointments, and some patients find them more cosmetically appealing.

Creams are suspensions of oil in water. They vary in their composition and generally are far less greasy than ointments, but they do not provide the same degree of hydration to the skin. Many patients find creams easier to spread on the skin and more cosmetically pleasing than ointments. However, creams may contain emulsifiers and preservatives that can lead to allergic reactions in some patients.

Lotions are suspensions of oil in water and are similar to creams. They contain agents to help solubilize the glucocorticoids and to allow them to be spread more easily on the skin. Solutions contain no oil but are composed of water, alcohol, and propylene glycol. Gels are solid components at room temperature but melt on contact with the skin. Lotions, solutions, and gels have less penetration than ointments but are useful in treating hair-bearing areas such as the scalp where greasiness is cosmetically displeasing to the patient. Steroid-impregnated tapes are useful because they provide occlusion with increased penetration and provide protection of the skin lesion from manipulation, such as scratching, by the patient. Sprays containing steroids are available, and while they represent a convenient mode of applying these agents, the inefficiency of the delivery system is such that they are seldom recommended.

More recently, foam products have been added to currently available topical formulations. They are highly efficacious, cosmetically superior, and well tolerated. When first dispensed, the foam is stable; but when applied to skin, body heat causes the foam structure to break down and the active ingredient is deposited on the skin with very little residue. [24] (For a more complete discussion of vehicles for topical preparations, see Chap. 242.)

ADVERSE EFFECTS

Side effects from the use of topical steroids have become more prevalent since the introduction of the higher potency topical steroids. Using these products on thin or denuded skin, on the elderly or pediatric population, or under occlusion increases the incidence of side effects. Striae and atrophy, the most commonly observed side effects, occur with prolonged use and are more likely to occur in areas of sweating, occlusion, or high penetration such as the axilla or groin. In general, atrophy does not occur until the agent has been used for 3 to 4 weeks and is usually reversible. Striae, which develop when the weakened skin is stretched, are not reversible. Prolonged treatment can also result in “steroid acne,” which is characterized by crops of dense, inflamed pustules in the same developmental stage. These lesions occur on the face, chest, and back. Perioral and periocular dermatitis have been associated with the use of topical steroids and usually improve with cessation of the steroid. Patients with rosacea who are given topical steroids may initially improve, but a severe rebound phenomenon consisting of edema and pustules may occur. For these reasons, in most situations steroid use should be discouraged in the treatment of rosacea and perioral and periocular dermatitis. Purpura, which represents easy bruising, may develop when steroids are used in areas of thin skin.

Topical steroids can also cause suppression of the pituitary–adrenal axis. Growth retardation and iatrogenic Cushing's syndrome are known, but rare, complications of topical steroid therapy. Morning plasma cortisol serologic tests can be performed to screen for adrenal suppression. If these levels are abnormal, adrenal function can be assessed further by using the cosyntropin stimulation test. Most topical and systemic side effects are readily reversible if recognized early by the clinician. The incidence of side effects, however, can be significantly reduced if appropriate guidelines for topical steroid use are followed.

Patients treated with topical glucocorticoids may develop a contact or irritant dermatitis to the steroid itself or, more commonly, to one of the ingredients used as a preservative. An increase in contact dermatitis caused by the steroid component has been reported. [25] Most topical steroid ointments are free of preservatives and are less likely than other topical agents and steroid creams to cause an allergic or irritant contact dermatitis. The most common preservatives that cause allergic contact dermatitis include parabens, polyethylene glycol, and benzyl alcohol (Table 243-3). Fragrance and local anesthetics are also sensitizers that may be included in the topical preparations.

Parabens
Propylene glycol
Benzyl alcohol
Chlorocresol
Ethylenediamine hydrochloride
Isopropyl palmitate
Polysorbate 60
Stearyl alcohol

TABLE 243-3 **Common Sensitizers in Topical Steroids**

DRUG INTERACTIONS

Topical glucocorticoids have few, if any, known drug interactions. For this reason they are often mixed with other topical medications, such as antifungals and antibiotics, to form combination products. Although a few combination products are available, development of new combination products has not been encouraged by the FDA. In fact, the FDA recently rejected new drug applications for combinations of topical antibacterials such as neomycin, bacitracin, and hydrocortisone, because the manufacturers were unable to provide proof of effectiveness of each component. However, many of these combination products are found in many countries outside the United States. Theoretically, there should be no need for a combination when each component can be obtained separately.

REFERENCES

1. Sulzberger MD, Witten VH: The effect of topically applied compound 1 in selected dermatoses. *J Invest Dermatol* **19**:101, 1952

2. Brattsand R: Influence of 16a, 17a-acetyl substitution and steroid nucleus fluorination on the topical to systemic activity ratio of corticosteroids. *J Steroid Biochem* **16**:779, 1982

3. Phillips GH: Locally active corticosteroids: Structure-activity relationships, in *Mechanisms of Topical Corticosteroid Activity*, edited by L Wilson, R Marks. Edinburgh, Churchill-Livingstone, 1976, p 1

4. Ponec M: Glucocorticoids and cultured human skin cells: Specific intracellular binding and structure-activity relationships. *Br J Dermatol* **107** (Suppl 23):24, 1982

5. Ponec M et al: Glucocorticoids: binding affinity and lipophilicity. *J Pharm Sci* **75**:973, 1986

6. Stoughton RB, Cornell RC: Topical steroids in dermatology, in *Topical Corticosteroid Therapy: A Novel Approach to Safer Drugs*, edited by E Christophers, E Schopf, AM Kligman. New York, Raven, 1988, p 1

7. Hepburn D et al: Topical steroid treatment in infants, children and adolescents in *Advances in Dermatology,* vol 9, edited by J Callen, M Dahl, L Golitz, H Greenway, L Schachner. St Louis, Mosby, 1994, p 225

8. Korting HC et al: Topical glucocorticoids with improved benefit-risk ratio: Do they exist? *J Am Acad Dermatol* **27**:87, 1992

9. Flower RJ: A molecular biology approach to the design of safer steroid-like drugs, in *Topical Corticosteroid Therapy: A Novel Approach to Safer Drugs,* edited by E Christopher. New York, Raven, 1988, p 27

10. Almawi WY et al: Partial mediation of glucocorticoid antiproliferative effects by lipocortins. *J Immunol* **157**:5231, 1996

11. Lavker RM et al: Cutaneous mast cell depletion results from topical corticosteroid usage. *J Immunol* **135**:2368, 1985

12. Norris DA et al: The effect of epicutaneous glucocorticosteroids on human monocyte and neutrophil migration in vivo. *J Invest Dermatol* **78**:386, 1982

13. Furue M, Katz SI: Direct effects of corticosteroids on epidermal Langerhans cells. *J Invest Dermatol* **92**:342, 1989

14. Guyre PM et al: Glucocorticoid effects on the production and actions of immune cytokines. *J Steroid Biochem Mol Biol* **30**:89, 1988

15. Naray-Fejes-Toth A et al: Glucocorticoid effect on arachidonic acid metabolism in vivo. *J Steroid Biochem Mol Biol* **30**:155, 1988

16. Blackwell GJ et al: Macrocortin: A polypeptide causing antiphospholipase effects of corticosteroids. *Nature* **287**:147, 1980

17. Duval D, Freyss-Beguin M: Corticosteroids and prostaglandin synthesis: We cannot see the wood for the trees. *Prostaglandins Leukot Essent Fatty Acids* **45**:85, 1992

18. Bailey JM: New mechanism for effects of anti-inflammatory corticosteroids. *Biofactors* **3**:97, 1992

19. Katchman SD et al: A transgenic mouse model provides a novel biological assay of topical corticosteroid potency. *Arch Dermatol* **131**:1274, 1995

20. West DP et al: Pharmacology and toxicology of infant skin. *J Invest Dermatol* **76**:147, 1981

21. Holbrook K, Sybert V: Basic science, in *Pediatric Dermatology,* edited by L Schachner, R Hansen. New York, Churchill Livingstone, 1995, p 17

22. Cook LJ et al: Iatrogenic hyperadrenocorticism during topical steroid therapy: Assessment of systemic effects by metabolic criteria. *J Am Acad Dermatol* **6**:1054, 1982

23. Singh G et al: Tachyphylaxis to topical steroids measured by histamine-induced wheal suppression. *Int J Dermatol* **25**:324, 1986

24. Feldman SR et al: Topical corticosteroid in foam vehicle offers comparable coverage compared with traditional vehicles. *J Am Acad Dermatol* **42**:1017, 2000

25. Lutz ME et al: Allergic contact dermatitis due to topical application of corticosteroids: Review and clinical implications. *Mayo Clin Proc* **72**:1141, 1997

T>

Chapter 244

Sewon Kang John Voorhees

Topical Retinoids

PHARMACOLOGY
Nomenclature
Metabolism of Retinoids in Human Skin
The Retinoid Receptors
Receptor-Selective Retinoids
The Retinoid Receptors in Human Skin
Retinoid Target Genes and Their Activation Cascade in Human Skin
CLINICAL USE
DOSAGE SCHEDULES AND FORMS
ADVERSE EFFECTS
DRUG INTERACTION AND INCOMPATIBILITIES

REFERENCES

The term *retinoid* was coined by Michael Sporn and his colleagues in 1976. The original description referred both to the naturally occurring compounds with vitamin A activity and to synthetic analogues of retinol. Hence, retinoids were defined in both functional (vitamin A activity) and structural (retinol-derivative) terms. The discovery of intranuclear retinoic acid receptors (RARs) in 1987, by two independent groups, [1], [2] was pivotal to our understanding of the mechanism of retinoic acid action because it demonstrated for the first time the existence of a retinoid-responsive transcription factor. This also gave rise to the concept that retinoids are like hormones. Therefore, a retinoid can be defined as any molecule that, by itself or through metabolic conversion, binds to and activates the RARs, thereby eliciting transcriptional activation of retinoic acid-responsive genes that results in specific biologic responses.

PHARMACOLOGY

Nomenclature

Vitamin A is a 20-carbon molecule that consists of a cyclohexenyl ring, a side chain with four double bonds (all arranged in *trans* configuration), and an alcohol end group. Hence, it is also known as all- *trans* retinol. Oxidation of the alcohol end group of all- *trans* retinol results in the formation of an aldehyde (all- *trans* retinaldehyde), which can be further oxidized to carboxylic acid (all- *trans* retinoic acid = tretinoin) (Fig. 244-1A). The numbering of the carbon atoms is as shown in Fig. 244-1B. The terms 9- *cis* and 13- *cis* retinoic acid refer to stereoisomers of all- *trans* retinoic acid in which the double bond that begins with the ninth and thirteenth carbon atoms, respectively, is in the *cis*- rather than *trans*-configuration. The fourth carbon atom is located in the cyclohexenyl ring of all- *trans* retinoic acid and is involved in a hydroxylation reaction to generate 4-hydroxy-all- *trans* retinoic acid (Fig. 244-1C). The addition of a hydroxyl group to the cyclohexenyl ring renders the molecule more polar, making it more amenable for excretion/elimination from cells and organisms. It is also much less active biologically. 4-Hydroxy-all- *trans* retinoic acid can be further oxidized to 4-oxo retinoic acid.

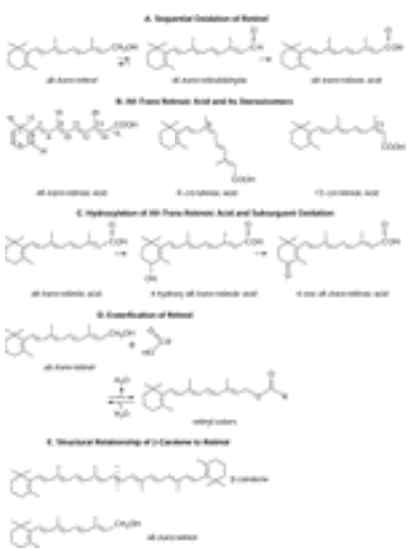

FIGURE 244-1 Nomenclature of natural retinoids.

A group of compounds referred to as *retinyl esters* functions as the molecular storage form of retinol. The compounds are formed by esterification of retinol with fatty acids (Fig. 244-1D). The fatty acids involved specify the ester. For example, retinyl palmitate is generated when retinol is esterified with palmitic acid. Hydrolysis of retinyl esters regenerates retinol. Finally, beta-carotene is a symmetric 40-carbon molecule (twice the number of retinol or retinoic acid) present in green and yellow-orange fruits and vegetables. As suggested by stoichiometry, one molecule of this carotenoid can potentially generate two molecules of retinol (cleavage of the central double bond) (Fig. 244-1E).

Metabolism of Retinoids in Human Skin

As the vitamin designation implies, all- *trans* retinol cannot be synthesized in the body and is thus an essential nutrient. Retinyl esters and beta-carotene are the two major precursors of retinol present in our diet. Once taken in from the diet, retinyl esters and beta-carotene are converted to all- *trans* retinol in the intestine and stored in the liver after reconversion to retinyl esters. Retinol released from the liver is carried in the circulation by plasma retinol-binding proteins. Once transported to target cells, it is taken up, apparently through passive diffusion. Consistent with the fact that retinol is a hydrophobic molecule, it associates intracellularly with a ubiquitously expressed binding protein called cellular retinol-binding protein (CRBP). In human skin, CRBP-bound all- *trans* retinol (holoCRBP) can be metabolized to at least three important products: retinyl esters, all- *trans* retinoic acid, and all- *trans* 3,4-didehydroretinol (vitamin A_2) and its esters. The functional significance of vitamin A_2 formation is unknown.

ESTERIFICATION AND OXIDATION OF RETINOL Topical treatment of human skin with all- *trans* retinol increases retinyl ester levels in the epidermal layer by more than tenfold. [3] This reaction is catalyzed by two enzymes: lecithin/retinol acyltransferase (LRAT) and acyl-CoA/retinol acyltransferase (ARAT). In human keratinocytes, LRAT is the predominant retinol-esterifying activity. [4] All- *trans* retinoic acid is formed by sequential oxidation of all- *trans* retinol, with all- *trans* retinaldehyde as the intermediate metabolite. The first step (oxidation of all- *trans* retinol to all- *trans* retinaldehyde) is rate limiting for all- *trans* retinoic acid formation. Topical application of all- *trans* retinol to human skin results in histologic and molecular alterations that mimic those following all- *trans* retinoic acid treatment. [3] These include epidermal hyperplasia caused by keratinocyte proliferation, epidermal spongiosis, compaction of the stratum corneum, and induction of CRBP, cellular retinoic acid binding protein (CRABP) II, and retinoic acid 4-hydroxylase. [3], [5] In retinol-treated skin, all- *trans* retinoic acid is minimally detectable, which is no different from untreated normal skin. The lack of significant accumulation of all- *trans* retinoic acid in retinol-treated skin is a result of the tightly regulated conversion of retinol to retinaldehyde and the effective hydroxylation of all- *trans* retinoic acid that is formed by retinoic acid 4-hydroxylase. The observation that all- *trans* retinol and retinoic acid elicit similar responses in human skin but that retinol does so without detectable increases in retinoic acid levels indicates that endogenously synthesized retinoic acid is a much more efficient activator of retinoid pathways than exogenously supplied retinoic acid. Metabolically formed all- *trans* retinoic acid is bound to CRABP. This cytoplasmic protein, of which there are two species (CRABP I and II), binds all- *trans* retinoic acid selectively and with high affinity. The fact that the CRABPs are highly conserved proteins found in multiple species showing distinct patterns of expression in developing embryo and adult organisms suggests that their functions are important in retinoid signaling. In addition to all- *trans* retinoic acid, 9- *cis* and 13- *cis* retinoic acid have been isolated from tissues. It is not known whether the interconversion among the retinoic acid occurs through specific isomerases. When equal amounts (0.1 percent) of all- *trans,* 9- *cis,* or 13- *cis* retinoic acid are applied topically to human skin, all- *trans* retinoic acid is extracted in significant amounts (36 to 72 percent of retinoic acid isomers) regardless of the isomer applied. [5]

HYDROXYLATION OF ALL- *TRANS* RETINOIC ACID In human skin all- *trans* retinoic acid is catabolized primarily to the more polar 4-hydroxy-all- *trans* retinoic acid, which is further metabolized to 4-oxo retinoic acid. 4-Hydroxy retinoic acid is tenfold less potent in inducing retinoid responses in human keratinocytes and mouse skin than is all- *trans* retinoic acid. [6] In untreated normal human skin, all- *trans* retinoic acid 4-hydroxylase activity is minimally detectable. Topical administration of all- *trans* retinoic acid or all- *trans* retinol to human skin, however, increases its activity several fold. [5], [7] The 4-hydroxylase is a cytochrome P450 enzyme (now termed CYP26) whose activity can be effectively inhibited by ketoconazole and a related azole, liarozole. [7], [8] By blocking this major inactivation pathway of all- *trans* retinoic acid pharmacologically, topical liarozole can amplify human skin responses to all- *trans* retinol and retinoic acid. [8] Although this hydroxylase activity is also induced in skin treated with 9- *cis* or 13- *cis* retinoic acid, remarkably it has substrate specificity for the all- *trans* retinoic acid isomer only and it does not hydroxylate 9- *cis* or 13- *cis* retinoic acid, retinol, or retinaldehydes. [5] With all- *trans* retinoic acid, the 4-hydroxylase activity is maximally induced after 24 h of occlusive treatment.

The Retinoid Receptors

The landmark discovery of RARs and characterization of their molecular features revealed the similarity of RARs to steroid/thyroid hormone receptors. [1], [2] A characteristic common to these receptors is that they bind to regulatory regions in DNA called hormone response elements, or target sequences, and activate gene transcription in a ligand-dependent manner. Hence, they are referred to as ligand (hormone)-dependent transcription factors. At the amino acid level, the nuclear receptor superfamily members are organized into six domains, each with a distinct function. Two domains of major importance are the DNA-binding domain and the ligand-binding domain. A short sequence within the DNA-binding domain, called the P box, has allowed categorization of the receptors into at least four different subfamilies. RARs, vitamin D receptors (VDRs), and thyroid hormone receptors (TRs) all possess the same P-box amino acid sequence. When their respective ligands are bound, these receptors bind to similar DNA recognition sequences located in the promoter region of target genes. The recognition sequences (hormone-response elements) are composed of two half-sites, each 6 base pairs long (AGGTCA). The base pair spacing between the half-sites determines, in part, the specificity of the receptor recognition sequences. The two half-sites are arranged as direct repeats for RAR, VDR, and TR, whereas for classic steroid hormone receptors (e.g., glucocorticoid, mineralocorticoid, progesterone), the two are in a palindromic (i.e., inverted repeat) configuration. These nuclear receptors bind to their response elements as dimers. Unlike receptors for the steroid hormones, which form homodimers (two identical monomers), RAR, VDR, and TR bind to their elements with greater affinity as heterodimers (two different monomers). The key partner for heterodimerization and ultimate functioning of RAR, VDR, and TR is the retinoid X receptor (RXR). [9] 9- *cis* retinoic acid is a key physiologic ligand for RXR. [10] In addition to RARs, VDRs, and TRs, RXRs heterodimerize with other receptors. This ability of RXRs to interact with many receptors suggests their importance as regulatory proteins. There are three different members of RAR (a, ß, and ?) and RXR (a, ß, and ?), each encoded by different genes. In addition, each of the receptors has isoforms, adding to the diversity of retinoid receptors.

Receptor-Selective Retinoids

Identification and functional characterization of these families of retinoid receptors provided an attractive target for drug discovery. Synthetic molecules could be screened for their ability to bind and activate the specific receptors. Many of these compounds have no structural similarities to all- *trans* retinol or retinoic acid, yet by virtue of their ability to activate the receptor(s), they can mediate the retinoid effect and thus be considered retinoids. Two synthetic retinoids that fit this description and have been used topically in humans are adapalene and tazarotene (Fig. 244-2). Adapalene has restricted receptor specificity, possessing poor affinity for RAR-a, higher affinity for RAR-ß and -?, and no interaction with RXR-a. [11] Although adapalene does not bind to CRABPs, it is capable of inducing CRABP II mRNA like all- *trans* retinoic acid. [12] Unlike retinoic acid, however, adapalene does not induce clinical erythema, epidermal hyperplasia, or spongiosis following a short-term (4 days) occlusive treatment. Tazarotene is another synthetic molecule that has biologic activity when topically applied. Tazarotene cannot directly bind to RARs or RXRs. However, its acid metabolite (AGN 190299) has a weak, but relative, receptor selectivity for RARs (RAR-ß > RAR- ? > RAR-a), [13] and is felt to be the principal active form.

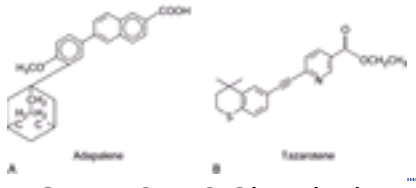

FIGURE 244-2 Chemical structures of the synthetic retinoids adapalene and tazarotene.

The Retinoid Receptors in Human Skin

Skin remains the only human tissue in which systematic analysis of the relative levels of each RAR and RXR protein has been made. Human epidermis expresses RAR-a, RAR-?, RXR-a, and RXR-ß mRNAs. [14] RXR-? mRNA is undetectable, and the transcript for RAR-ß is barely detectable. A similar pattern is observed in cultured human keratinocytes and dermal fibroblasts. These relative levels of retinoid receptor mRNAs mirror their relative protein levels. In nuclei from human epidermal cells, there are five times more total RXRs than RARs. [15] For RAR proteins, 87 percent are RAR-? and 13 percent are RAR-a with no detectable RAR-ß. Of the RXR proteins, 90 percent are RXR-a. In gel-shift studies performed on nuclei isolated from human skin and cultured keratinocytes, which in both cases are expressing their normal endogenous receptors, only RXR-a and RAR (mostly ?) heterodimers bind to retinoic acid-response elements (RAREs) spaced by two (DR-2) or five nucleotides (DR-5). [15], [16] Neither RAR nor RXR homodimers are detectable. Therefore, normal human epidermis is regulated by RXR-a and RAR-? heterodimers. In terms of the ligands needed to activate RXR/RAR-bound RAREs, based on chloramphenicol acetyltransferase reporter gene activity in keratinocytes, the heterodimer requires only the RAR ligand. Furthermore, the presence of RXR ligand does not confer additional transactivation induced by RAR ligand. Therefore, at their physiologic levels, RARs and RXRs in human skin bind RAREs (DR-2 or DR-5) as heterodimers and transactivate these response elements in response to RAR, but not to RXR, ligands. However, the RXR is key as the heterodimer will not bind to the RARE without the presence of the RXR protein. Ultraviolet (UV) irradiation of human skin causes a rapid and significant reduction of retinoid receptors, both RAR-? and RXR-a. [17] Although the decrease in the receptor levels is transient, returning to pre-UV treatment levels within 2 days, topical application of all- *trans* retinoic acid shortly after UV irradiation fails to activate CRABP-II and RA-4 hydroxylase genes which contain functional RAREs in their promoters. This indicates that the reduction of RAR and RXR by UV results in functional impairment of receptor-dependent retinoid responsiveness in human skin. Interestingly, pretreatment of skin with all- *trans* retinoic acid before UV irradiation reduces receptor loss and accelerates receptor recovery. [17]

Retinoid Target Genes and Their Activation Cascade in Human Skin

Based on current information, retinoid actions are primarily, if not solely, mediated by retinoid receptors. Given that the receptors are transcription factors, the ultimate skin effects of retinoids (phenotypic changes) must be accomplished through regulated gene expression. The best-established mechanism by which retinoid receptors modulate gene expression is activation of retinoid target genes through direct binding to RARE in the gene promoter, thereby stimulating the basal transcriptional machinery. In skin, CRABP II, CRBP, and keratin 6, all of which contain RAREs, are regulated by all- *trans* retinoic acid. [3], [18], [19] and [20] However, the products of these genes are probably not the effectors of the retinoid response and hence cannot account for the pleiotropic effects of retinoids in skin. Undoubtedly, additional RARE-regulated genes will be identified that encode for proteins that function to modulate cutaneous growth and differentiation directly or indirectly. A likely scenario is that these protein products, in turn, activate other non–RARE-containing genes in a cascading reaction to produce the clinical features of retinoid action in skin (Fig. 244-3). Because most genes expressed within the cascade would contain no functional RAREs, their activation by retinoids would be indirect. Therefore, the retinoid response in human skin is mediated both by direct and indirect activation of genes, initiated by a retinoid signal.

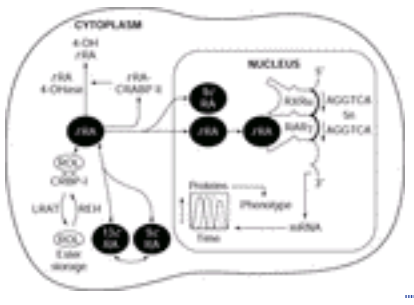

FIGURE 244-3 Cellular metabolism of natural retinoids and molecular mechanism of retinoid-specific gene activation.

CLINICAL USE

Until quite recently, clinical use of topical retinoids has been limited to all- *trans* retinoic acid (tretinoin). Although the initial use of this retinoid was in actinic keratosis, currently the only approved dermatologic indications in the United States are for acne and photoaged skin. Topical adapalene and tazarotene have also received approval from the U.S. Food and Drug Administration for acne; tazarotene has also received approval for psoriasis. For acne therapy, it is widely accepted that, especially for the comedonal variant, topical retinoids are extremely effective. Of the different classes of antiacne medications, retinoids are thought to be the best, if not the only, agents to normalize the abnormal follicular epithelial differentiation/desquamation viewed to be important in the pathogenesis of acne lesions. Therefore, the use of retinoids would also provide protection against the development of new lesions. This prophylactic property is the basis for including topical retinoid in almost all antiacne regimens. A potential for aggravating inflammation exists in treating inflammatory acne (i.e., papules and pustules) with topical retinoids, but when properly administered, this type of acne also responds well to retinoids (see " Dosage Schedule and Forms"). Fine wrinkles and dyspigmentation are two salient features of photoaged skin that are improved by topical tretinoin. Several weeks of treatment are required before clinical improvement is appreciated. For the effacement of fine wrinkles by topical tretinoin, partial restoration of markedly reduced levels of collagen in sun-exposed skin toward those seen in sun-protected skin appears to be responsible. [21] Tretinoin's ability to improve photoaging is specific and does not result from the irritation or retinoid dermatitis frequently produced by this compound. [22] Although the molecular basis of photoaging prevention by topical tretinoin was recently demonstrated, [23] its value in clinical practice is as yet unstudied. Neither topical adapalene nor tazarotene are approved for the treatment of photoaging. However, recent studies indicate that both retinoids hold promise in ameliorating the clinical features of photodamage. [24], [25]

Besides the approved indications, topical retinoids have been demonstrated, through well-controlled studies, to be effective in the treatment of several other conditions. Most of these have been with tretinoin because it is the first topical retinoid to be developed and has been available the longest. Studied conditions include, but are not limited to, postinflammatory hyperpigmentation in blacks, [26] actinic dyspigmentation in Chinese and Japanese individuals, [27] melasma, [28], [29] and early stretch marks. [30] The controlled studies show more than therapeutic efficacies. They also provide valuable information to dispel some of the myths about retinoid use in humans. For example, African Americans and Asians tolerate topical tretinoin as well as, if not better than, [26], [27], [29] whites. [24], [28], [30] Furthermore, the often observed retinoid dermatitis does not usually lead to postinflammatory hyperpigmentation in those with greater constitutive pigmentation.

Many other skin disorders have been reported to be improved by topical retinoids, but most of these have not been as rigorously studied and their therapeutic claims should thus be interpreted with caution. Molluscum contagiosum, warts, and various forms of ichthyosis may be improved by topical retinoids to a variable degree. In psoriasis, especially, irritation of treated skin has limited the use. Topical tazarotene, which is approved for psoriasis, does not appear to have fully overcome the irritation problem; [31] thus, it is typically used in combination with topical steroids. The beneficial effects of topical retinoids in treating actinic keratoses have been confirmed through clinical trials. However, there is no role for topical retinoids in the treatment of established cutaneous tumors.

With such a wide variety of skin conditions treatable by topical retinoids, their use has included practically all age groups, perhaps with the exception of neonates. Similar considerations in dose schedule and forms are made in both young and old patients. The use of topical retinoids in pregnancy is an emotional issue. As discussed below, based on fact, teratogenicity is not caused by topical retinoids (see " Adverse Effects"). However, because none of the dermatologic conditions seen in pregnancy that may respond to topical retinoids (i.e., acne, melasma, stretch marks) are life-threatening to the mother or the fetus, it seems prudent to delay the treatment until after delivery. In a study which demonstrated that early, inflammatory stretch marks were improved by topical tretinoin, all pregnancy-related stretch marks were treated postpartum. [30] Therefore, even in this pregnancy-associated condition, the therapeutic benefit could be achieved by instituting the treatment after delivery.

DOSAGE SCHEDULES AND FORMS

Until very recently, tretinoin was the only topical retinoid available for clinical use. Under the trade name Retin-A, three different formulations are available for acne therapy: cream (0.025%, 0.05%, 0.1%), gel (0.01%, 0.025%), and solution (0.05%). For photoaging treatment, tretinoin (0.05%, 0.02%) was introduced as Renova cream. A recent addition to acne therapy, adapalene (Differin) is available in 0.1% gel and lotion formulations. For acne and psoriasis, topical tazarotene (0.05% and 0.1%) is available in gel and cream formulations. Different formulations allow some flexibility in terms of tailoring the therapy to an individual's skin dryness or oiliness.

Regardless of the retinoid preparation or the patient's age, the most important element in topical therapy is patient/guardian education. It must be explained clearly to each patient that, as part of the treatment, local skin irritation, characterized by redness and peeling, can be expected. It was once believed, especially for the treatment of photoaged skin, that clinical improvement correlated with the degree of irritation. This concept was erased through a large,

controlled clinical study in which 0.025% and 0.1% tretinoin were shown to be equally efficacious, but the former was significantly less irritating than the latter. [22] Therefore, unlike most medications for which the dosing schedule may be set as once or twice daily, administration of a topical retinoid should be titrated depending on the skin reaction. For some individuals it may be applied only twice a week, for others four times a week, and so on. The frequency of drug application can be increased, as tolerated, to a once-daily regimen. This method of individualizing topical therapy minimizes unwanted acute retinoid dermatitis.

Under the nonprescription category, there are countless “natural retinoid” preparations with various claims (mostly antiaging) being sold throughout the world. Most of these contain retinyl esters, especially retinyl palmitate, retinaldehyde, or retinol. Whether any of these products can deliver retinoid activity to human skin is subject to question. Percutaneous absorption (especially for retinyl esters), adequate concentrations, and stable formulations (especially for retinol) are some of the important unknowns for this group of products. Based on human in vivo work, all- *trans* retinol and all- *trans* retinaldehyde hold the most promise of these natural retinoids in being biologically active, [3], [32] provided the stability of the compound can be maintained with a proper formulation. When the sun-protected skin of individuals older than 80 years of age was treated for 7 days with 1% retinol, the fibroblast growth and dermal collagen were increased significantly. [33] Concomitantly, retinol markedly reduced the levels of matrix-degrading metalloproteinases that are elevated in the aged skin as compared to the young skin. These findings suggest that retinol may reverse and partially prevent skin atrophy that accompanies intrinsic aging.

ADVERSE EFFECTS

By far the most common adverse effect associated with topical retinoid use is local skin irritation characterized by erythema, peeling, dryness, and pruritus. This is a predictable skin response that is temporary, but troubling, for many patients. The so-called retinoid dermatitis tends to peak within the first month of treatment and diminishes thereafter. It responds to a temporary reduction in the frequency or amount of retinoid application and to liberal use of emollients.

It has been well documented that the most striking histologic feature of all- *trans* retinoic acid-treated skin is the marked thickening of the epidermis [3], [8], [22] caused by the increased proliferation of basal keratinocytes. An increase is also seen in the number of cell layers expressing the differentiation markers involucrin, loricrin, filaggrin, and epidermal transglutaminase. [20] These epidermal changes collectively translate to clinical desquamation and peeling. This hyperproliferative response of epidermis to retinoic acid is mediated by its nuclear receptor, as was recently demonstrated in transgenic mice expressing either a dominant-negative (dn) RXR-a [34] or dn RAR-a [35] mutant proteins targeted to the suprabasal epidermis by the keratin 10 promoter. The mutant proteins impaired retinoid signaling by competing with endogenous RAR-?/RXR-a heterodimers. In these mice, the ability of topically applied retinoic acid to stimulate proliferation of undifferentiated keratinocytes in the basal layer and resultant peeling of stratum corneum from the surface was significantly reduced. [34], [35] Therefore, the peeling component of retinoid dermatitis is a part of the retinoid-specific skin response. Among the genes regulated by retinoid receptors involved in the cell growth control (keratinocyte proliferation), heparin-binding epidermal growth factor (HB-EGF) appears to be a critical one. Retinoid induction of HB-EGF stimulates basal cell growth via the cell surface EGF receptor activation. The importance of this signaling pathway in the hyperplastic response of the epidermis to topical retinoid was recently demonstrated when pharmacologic antagonists of EGF receptor tyrosine kinase activity blocked retinoid-induced epidermal thickening in human skin organ culture. [36] This observation suggests that it may be possible to reduce the clinically undesirable effects of retinoids on epidermal keratinocytes. The erythema response, however, may not to be retinoid-receptor mediated, because all- *trans* retinol, which induces epidermal hyperplasia and CRABP II mRNA-like retinoic acid (two indicators of receptor activation), is unassociated with clinical erythema. [3]

Systemic retinoid exposure has been well documented and established as a cause of embryonic death and congenital malformation. Therefore, concerns about potential teratogenicity from long-term topical retinoid use are completely justified. However, systemic absorption of retinoids from topical application is negligible, and the levels of endogenous retinoic acid in the blood are not increased by twice daily application of 0.025% tretinoin to more than 40 percent of body area over 1 month. Furthermore, controlled topical administration of tretinoin at doses used for acne therapy (2 g of 0.025% gel applied daily to the face, neck, and upper part of the chest for 14 days) has less influence on plasma levels of endogenous retinoids than diurnal and nutritional factors. [37] Indeed, a large population-based study demonstrated no excess risk of birth defects in offspring born to mothers who were exposed to topical tretinoin during pregnancy. [38] Therefore, no evidence exists for teratogenicity of topical tretinoin in humans. As mentioned under “Pharmacology,” topical use of tretinoin induces in the skin the enzyme retinoic acid 4-hydroxylase that inactivates tretinoin. Therefore, the induction of this enzyme would serve as a protective mechanism to partially reduce the amount of tretinoin for systemic absorption. In this regard, topical use of natural retinoids would be even safer than any of the synthetic compounds, because there already exists self-inducible enzymatic machinery that will inactivate excess tretinoin, but probably not synthetic retinoids.

“Sun sensitivity” is a frequently discussed subject with topical retinoid use and requires clarification. When formally tested in humans, topical tretinoin does not lower the minimal erythema dose of UVB light. [23] Because its presence in human skin does not increase the likelihood of sunburn reaction, tretinoin is not a phototoxic agent. When one talks to patients who complain of such sun sensitivity, they describe an uncomfortable skin sensation that is felt within minutes of being in the sun rather than hours later. This time line is certainly in disagreement with a typical sunburn reaction which takes longer to be noticed (hours to a day). Furthermore, this sensation is often said to be accentuated in warmer temperatures, which suggests participation of infrared irradiation (heat).

Related to the sun-sensitivity is the issue of photocarcinogenesis. In an animal model of photocarcinogenesis, topical tretinoin has caused skin cancer. However, this seems to be restricted to susceptible animals under contrived experimental conditions, and no evidence exists of a comparable process in humans. Indeed, by using a model in which human skin was grafted onto mice with severe combined immunodeficiency disease, gross inadequacy of the commonly used rodent model of photocarcinogenesis was demonstrated. [39] Specifically, the traditional rodent models significantly

overestimate the human carcinogenic potential of tested agents. Topical retinoids, on the contrary, appear to have a protective effect against UV-induced premalignant and malignant lesions. In those predisposed by nevoid basal cell carcinoma syndrome or xeroderma pigmentosum to the development of nonmelanoma skin cancer, systemic retinoids have provided effective protection. In this regard, topical tretinoin's ability to prevent UV induction of c-Jun is relevant. [40] c-Jun is a protooncoprotein that is minimally detectable in normal human skin in vivo. Its partner c-Fos, however, is constitutively expressed. UV irradiation to human skin does not affect the level of c-Fos expression, but it markedly induces c-Jun protein which can then heterodimerize with c-Fos, forming a complete active AP-1 transcription factor. [40] The critical importance of AP-1 in mediating carcinogenic transformation of papillomas has been demonstrated. [41] In human squamous cell carcinomas, c-Jun expression is elevated and systemic retinoids prevent carcinomas of the head and neck. Mechanisms involved in this chemopreventive effect of the retinoid likely include c-Jun suppression. These clinically observed anticarcinogenic activities of retinoids are also supported by in vitro data demonstrating that tretinoin treatment of human skin upregulates the antigen-presenting activity of Langerhans cells without concomitant increase in autoreactivity. [42] Such a retinoid effect would improve cutaneous immune responsiveness to tumor antigens. Therefore, topical retinoic acid is not a carcinogen in humans.

DRUG INTERACTION AND INCOMPATIBILITIES

Retinoids in general are photolabile and therefore can be photoinactivated. Based on this chemistry, it is prudent to apply the agents in the evening rather than before the start of the day. Because the major avenue of tretinoin inactivation is through a cytochrome P450 retinoic acid 4-hydroxylase, drugs that modulate the activity of this enzyme can potentially cause drug interactions. Ketoconazole and liarozole are effective inhibitors of this hydroxylase. [7], [8] Therefore, concurrent use of these azoles and topical tretinoin can increase the amount and prolong the half-life of tretinoin locally in the skin, thereby aggravating the local side effect. Indeed, this was observed in one topical tretinoin study when a patient inadvertently started oral ketoconazole for tinea infection and experienced a severe and prolonged dermatitis, which could be reproduced by ketoconazole challenge. Other than retinoids, no other compounds have been shown to induce the retinoic acid 4-hydroxylase.

The use of vitamin D_3 and its analogues has increased in dermatology (see Chap. 251). Vitamin D effects in human skin are largely mediated via its nuclear receptor VDR. As previously discussed, VDR is a member of the steroid/retinoic acid/thyroid hormone receptor superfamily. Like RAR, VDR functions in human skin mainly as a heterodimer with RXR (VDR-RXR). In contrast with retinoid signaling via RAR-RXR in which the presence of RXR-ligand confers no additional effect, RXR-ligand provides a synergistic effect with VDR-ligand in vitamin D signaling. [43] Therefore, topical retinoids that possess, or through metabolic conversion, acquire RXR selectivity can positively influence vitamin D pharmacology in human skin.

REFERENCES

1. Petkovich M et al: A human retinoic acid receptor which belongs to the family of nuclear receptors. *Nature* **330**:444, 1987

2. Giguére V et al: Identification of a receptor for the morphogen retinoic acid. *Nature* **330**:624, 1987

3. Kang S et al: Application of retinol to human skin in vivo induces epidermal hyperplasia and cellular retinoid binding proteins characteristic of retinoic acid but without measurable retinoic acid levels or irritation. *J Invest Dermatol* **105**:549, 1995

4. Kurlandsky SB et al: Auto-regulation of retinoic acid biosynthesis through regulation of retinol esterification in human keratinocytes. *J Biol Chem* **271**:15346, 1996

5. Duell EA et al: Retinoic acid isomers applied to human skin in vivo each induce a 4-hydroxylase that inactivates only *trans* retinoic acid. *J Invest Dermatol* **106**:316, 1996

6. Reynolds NJ et al: Retinoic acid metabolites exhibit biological activity in human keratinocytes, mouse melanoma cells and hairless mouse skin in vivo. *J Pharmacol Exp Ther* **266**:1636, 1993

7. Duell EA et al: Human skin levels of retinoic acid and cytochrome P-450-derived 4-hydroxyretinoic acid after topical application of retinoic acid in vivo compared to concentrations required to stimulate retinoic acid receptor-mediated transcription in vitro. *J Clin Invest* **90**:1269, 1992

8. Kang S et al: Liarozole inhibits human epidermal retinoic acid 4-hydroxylase activity and differentially augments human skin responses to retinoic acid and retinol in vivo. *J Invest Dermatol* **107**:183, 1996

9. Yu VC et al: RXRß: A co-regulator that enhances binding of retinoic acid, thyroid hormone, and vitamin D receptors to their cognate response element. *Cell* **67**:1251, 1991

10. Levin AA et al: 9- *cis* retinoic acid stereoisomer binds and activates the nuclear receptor RXR-a. *Nature* **355**:359, 1992

11. Bernard BA: Adapalene, a new chemical entity with retinoid activity. *Skin Pharmacol* **6**(Suppl 1):61, 1993

12. Griffiths CEM et al: Comparison of CD271 (adapalene) and all- *trans* retinoic acid in human skin: Dissociation of epidermal effects and CRABP-II mRNA expression. *J Invest Dermatol* **101**:325, 1993

13. Nagpal S et al: Separation of transactivation and AP1 antagonism functions of retinoic acid receptor a. *J Biol Chem* **270**:923, 1995

14. Elder JT et al: Differential regulation of retinoic acid receptors and binding proteins in human skin. *J Invest Dermatol* **98**:673, 1992

15. Fisher GJ et al: Immunological identification and functional quantitation of retinoic acid and retinoid X receptor proteins in human skin. *J Biol Chem* **269**:20629, 1994

16. Xiao JH et al: Endogenous retinoic acid receptor-retinoid X receptor heterodimers are the major functional forms regulating retinoid-responsive elements in adult human keratinocytes. *J Biol Chem* **270**:3001, 1995

17. Wang, Z et al: Ultraviolent irradiation of human skin causes functional vitamin A deficiency, preventable by all- *trans* retinoic-acid

pretreatment. *Nat Med* **5**:418, 1999

18. Aström A et al: Retinoic acid induction of human cellular retinoic acid-binding protein-II gene transcription is mediated by retinoic acid receptor-retinoid X receptor heterodimers bound to one far upstream retinoic acid–responsive element with 5-base pair spacing. *J Biol Chem* **269**:22334, 1994

19. Fisher GJ et al: All- *trans* retinoic acid induces cellular retinol-binding protein in vivo. *J Invest Dermatol* **105**:80, 1995

20. Rosenthal DS et al: Acute or chronic topical retinoic acid treatment of human skin in vivo alters the expression of epidermal transglutaminase, loricrin, involucrin, filaggrin, and keratins 6 and 13 but not keratins 1, 10, and 14. *J Invest Dermatol* **98**:343, 1992

21. Griffiths CEM et al: Restoration of collagen formation in photodamaged human skin by tretinoin (retinoic acid). *N Engl J Med* **329**:530, 1993

22. Griffiths CEM et al: Two concentrations of topical tretinoin (retinoic acid) cause similar improvement of photoaging but different degrees of irritation: A double-blind, vehicle controlled comparison of 0.1% and 0.025% tretinoin creams. *Arch Dermatol* **131**:1037, 1995

23. Fisher GJ et al: Molecular basis of sun-induced premature skin ageing and retinoid antagonism. *Nature* **379**:335, 1996

24. Kang S et al: Tazarotene cream for the treatment of facial photodamage: A multicenter, investigator-masked, randomized, vehicle-controlled, parallel comparison of 0.01%, 0.025%, 0.05%, and 0.1% tazarotene creams with tretinoin emollient cream applied once daily for 24 weeks. *Arch Dermatol,* **137**:1597, 2001

25. Kang S et al: Randomized efficacy and safety assessment of adapalene gel (0.1% and 0.3%) and vehicle for the treatment of actinic keratoses and lentigines. *J Am Acad Dermatol,* in press

26. Bulengo-Ransby SM et al: Topical tretinoin (retinoic acid) therapy for hyperpigmented lesions caused by inflammation of the skin in black patients. *N Engl J Med* **328**:1438, 1993

27. Griffiths CEM et al: Topical tretinoin (retinoic acid) treatment of hyperpigmented lesions associated with photoaging in Chinese and Japanese patients: A vehicle-controlled trial. *J Am Acad Dermatol* **30**:76, 1994

28. Griffiths CEM et al: Topical tretinoin (retinoic acid) improves melasma: A vehicle-controlled clinical trial. *Br J Dermatol* **129**:415, 1993

29. Kimbrough-Green CK et al: Topical retinoic acid (tretinoin) for melasma in black patients: A vehicle-controlled clinical trial. *Arch Dermatol* **130**:727, 1994

30. Kang S et al: Topical tretinoin (retinoic acid) improves early stretch marks. *Arch Dermatol* **132**:519, 1996

31. Esgleyes-Ribot T et al: Response of psoriasis to a new topical retinoid, AGN 190168. *J Am Acad Dermatol* 30:581, 1994

32. Saurat JH et al: Topical retinaldehyde on human skin: Biologic effects and tolerance. *J Invest Dermatol* **103**:770, 1994

33. Varani J et al: Vitamin A antagonizes decreased cell growth and elevated collagen-degrading matrix metalloproteinases and stimulates collagen accumulation in naturally aged human skin. *J Invest Dermatol* **114**:480, 2000

34. Feng X et al: Suprabasal expression of a dominant-negative RXRa mutant in transgenic mouse epidermis impairs regulation of gene transcription and basal keratinocyte proliferation by RAR-selective retinoids. *Genes Dev* **11**:59, 1997

35. Xiao J-H et al: Identification of heparin-binding EGF-like growth factor as a target in intercellular regulation of epidermal basil cell growth by suprabasal retinoic acid receptors. *EMBO J* **18**:1539, 1999

36. Varani J et al: Heparin-binding, epidermal-growth-factor-like growth factor activation of keratinocyte ErbB receptors mediates epidermal hyperplasia, a prominent side-effect of retinoid therapy. *J Invest Dermatol,* 1170:1335, 2002

37. Bucha P et al: Repeated topical administration of all-trans-retinoic acid and plasma levels of retinoic acids in humans. *J Am Acad Dermatol* **30**:428, 1994

38. Jick SS et al: First trimester topical tretinoin and congenital disorders. *Lancet* **341**:1181, 1993

39. Soballe PW et al: Carcinogenesis in human skin grafted to SCID mice. *Cancer Res* **56**:757, 1996

40. Fisher GJ et al: Retinoic acid inhibits induction of c-JUN protein by ultraviolet radiation that occurs subsequent to activation of mitogen-activated protein kinase pathways in human skin in vivo. *J Clin Invest* **101**:1432, 1998

41. Saez E et al: C-fos is required for malignant progression of skin tumors. *Cell* **82**:721, 1995

42. Meunier L et al: Retinoic acid upregulates human Langerhans cell antigen presentation and surface expression of HLA-DR and CD11c, a $ß_2$ integrin critically involved in T-cell activation. *J Invest Dermatol* **103**:775, 1994

43. Kang S et al: The retinoid X receptor agonist 9- *cis*-retinoic acid and the 24-hydroxylase inhibitor ketoconazole increase activity of 1,25-dihydroxyvitamin D_3 in human skin in vivo. *J Invest Dermatol* **108**:513, 1997

T>

Chapter 245

Mark Bonner Paul Benson William James

Topical Antibiotics

AGENTS USED IN THE TOPICAL TREATMENT OF ACNE
Erythromycin
Clindamycin
Tetracycline
Metronidazole
Azelaic Acid
AGENTS USED FOR THE TOPICAL THERAPY OF SUPERFICIAL BACTERIAL INFECTIONS
Mupirocin
AGENTS USED TO PREVENT INFECTION FOLLOWING SURGICAL PROCEDURES OR INJURIES OR TO TREAT CHRONIC DERMATITIS
Bacitracin
Polymyxin B
TOPICAL AMINOGLYCOSIDES, INCLUDING NEOMYCIN, GENTAMICIN, AND PAROMOMYCIN
MISCELLANEOUS AGENTS
Gramicidin
Chloramphenicol
Sulfonamides
Clioquinol
Nitrofurazone
Fusidic Acid
REFERENCES

Topical antibiotics play an important role in the management of many common dermatologic conditions. They are prescribed most often by dermatologists for the management of mild to moderate acne vulgaris or as adjunctive treatment with oral agents. For localized superficial infections, such as impetigo, the use of a topical agent (e.g., mupirocin) may eliminate the need for oral antibiotics and the accompanying problems of compliance, gastrointestinal side effects, and potential drug interactions. Lastly, topical antibiotics frequently are prescribed as prophylactic agents following minor surgery or cosmetic procedures (dermabrasion, laser resurfacing) to reduce the risk of postoperative wound infections and to speed wound healing. The usefulness of topical antibiotics for prophylaxis following such minor procedures has been questioned recently and will be discussed more fully below.

AGENTS USED IN THE TOPICAL TREATMENT OF ACNE

The efficacy of topical antibiotics for the treatment of acne vulgaris and rosacea may be due to their direct antibiotic effect, but there are some suggestions that many of the topical antibiotics exhibit anti-inflammatory properties by suppressing neutrophil chemotactic factor or by other mechanisms. There are mounting concerns about the use of topical antibiotics in the treatment of acne vulgaris because of the increasing levels of antibiotic resistance to common topicals. This has led investigators to look at combination therapy for acne vulgaris that reduces the development of antibiotic resistance.

Erythromycin

Erythromycin belongs to the group of macrolide antibiotics and is active against both gram-positive cocci and gram-negative bacilli. It is a fermentation product of *Streptomyces erythreus* and is used principally as a topical agent for the treatment of acne. Erythromycin binds to the bacterial 50S ribosome and blocks translocation of the peptidyl-tRNA molecule from the acceptor to the donor site, interfering with the formation of the polypeptide chain and inhibiting protein synthesis. [1] In addition to its antibacterial properties, erythromycin has anti-inflammatory activity, which makes it especially useful in the management of acne. [2]

Erythromycin is available as a 1.5% to 2% solution, gel, pledgets, and ointment as a single agent (Table 245-1). It is also available in combination with benzoyl peroxide, which may slow the development of antibiotic resistance to erythromycin. [3] The combination of 1.2% zinc acetate and 4% erythromycin may be superior to clindamycin, although it is not currently available in the United States.



TABLE 245-1 **Topical Antibiotics**

Clindamycin

Clindamycin is a semisynthetic lincosamide antibiotic that is derived from lincomycin. The mechanism of action is very similar to that of erythromycin, with binding to the 50S ribosome and suppression of bacterial protein synthesis. [1] Clindamycin is used topically as a 1% gel, solution, and suspension (lotion) (see Table 245-1) primarily for the treatment of acne. It is also available as a combination with benzoyl peroxide, which may slow the development of antibiotic resistance to clindamycin. Pseudomembranous colitis rarely has been reported to occur with the topical use of clindamycin. [4]

Tetracycline

Topical tetracyclines, in the form of meclocycline sulfosalicylate and tetracycline hydrochloride solution, have been available in the past for the treatment of acne but have never gained wide acceptance. Meclocycline sulfosalicylate currently is not available, probably because of a lack of efficacy. Undesirable side effects of tetracycline topical solution include odor and yellow staining of skin.

Metronidazole

Metronidazole, a topical nitroimidazole, is currently available as a 0.75% gel, lotion, or cream and as a 1% cream for the topical treatment of rosacea. In the lower strength, it is applied twice daily, and in the higher strength, it is used once daily. Orally, metronidazole has broad-spectrum activity against many protozoal organisms and anaerobes. The mechanism of action of topical metronidazole in the skin is unknown; however, the antirosacea effect may be due to the antibiotic, antioxidant, and anti-inflammatory properties of the drug. [5]

Azelaic Acid

Azelaic acid is a dicarboxylic acid found in food (whole-grain cereals and animal products). There is a normal human plasma level (20–80 ng/mL), but topical application does not significantly alter this level. The mechanism of action is thought to be normalization of the keratinization process (decreased thickness of the stratum corneum, decreased number and size of keratohyaline granules, and decreased amount of filaggrin). There are reports of in vitro activity against *Propionibacterium acnes* and *Staphylococcus epidermidis,* which may be due to inhibition of bacterial protein synthesis (the exact site is not known at this time). In aerobic microorganisms, there is inhibition of oxidoreductive enzymes (such as tyrosinase, mitochondrial enzymes of the respiratory chain, 5-alpha-reductase, and DNA polymerases). In anaerobic bacteria, there is disruption of glycolysis. Azelaic acid is used principally in the treatment of acne vulgaris, although there are some advocates for its use in the treatment of hyperpigmentation (such as melasma). However, the U.S. Food and Drug Administration (FDA) has not approved the drug for this indication. Azelaic acid is available as a 20% cream preparation. [6]

AGENTS USED FOR THE TOPICAL THERAPY OF SUPERFICIAL BACTERIAL INFECTIONS

Mupirocin

Mupirocin, which was formerly known as pseudomonic acid A, is a topical antibiotic agent derived *from Pseudomonas fluorescens*. The drug reversibly binds to isoleucyl-tRNA synthetase and inhibits bacterial protein synthesis. The activity of mupirocin is limited to gram-positive bacteria, especially staphylococci and most streptococci. Its activity is enhanced in an acid pH environment (5.5), which is the normal pH of the skin. Mupirocin is somewhat temperature-sensitive and thus should not be exposed to high temperatures. Mupirocin ointment 2% is applied three times daily and is principally indicated for the treatment of localized impetigo caused by *S. aureus* and *Streptococcus pyogenes*. [7] However, widespread impetigo or disease occurring in immunocompromised individuals should be treated with systemic therapy to reduce the risk of serious complications. Bacterial resistance to mupirocin was first reported in 1987. [8] Since then, there have been additional reports of mupirocin resistance with the widespread use of the topical antibiotic to control methicillin-resistant *S. aureus* (MRSA) carriage in health care facilities. [9], [10] A recent study at a Tennessee Veterans' Affairs Hospital demonstrated that prolonged use of mupirocin ointment to control MRSA carriage, especially in bedridden patients with decubitus ulcers, led to significant resistance. [11] Further, Japanese researchers found that low concentrations of mupirocin are achieved after intranasal application and postulated that this might explain the selection of mupirocin-resistant strains of *S. aureus.* [12] A small pilot study using intranasal application of a combination antibiotic ointment containing bacitracin, polymyxin B, and gramicidin successfully decolonized 80% (9 of 11) of patients who remained clear after a mean follow-up period of 2 months. [13] All cases (6 of 6) of mupirocin-sensitive MRSA were eradicated, whereas only 3 of 5 cases of mupirocin-resistant MRSA were eliminated. New formulations that involve the use of the calcium salt of mupirocin (the calcium aids in chemical stability in the intranasal preparation) are available for intranasal use as a 2% ointment and a 2% topical cream.

AGENTS USED TO PREVENT INFECTION FOLLOWING SURGICAL PROCEDURES OR INJURIES OR TO TREAT CHRONIC DERMATITIS

It is common practice to use topical antibiotics to reduce the potential for wound infections following minor surgical procedures, in cases of chronic dermatitis such as stasis dermatitis or atopic dermatitis, or following minor abrasions of the skin. Recent studies have focused on the incidence of infection after skin biopsy or minor surgery with the use of topical antibiotics or their vehicles. In some cases, the topical antibiotic seemed to decrease the rate of wound healing. In other studies, use of the vehicle alone appeared to be as effective as the topical antibiotic in wound healing without the risk of irritant or allergic contact dermatitis to the antibiotic agent. The results of one large study comparing bacitracin and petrolatum in over 1200 minor surgical procedures and biopsies demonstrated that the active agent, bacitracin, did not statistically decrease the already low rate of infection during such procedures but was associated with a small risk of

allergic contact dermatitis. [14]

Bacitracin

Bacitracin is a topical polypeptide antibiotic originally isolated from the Tracy-I strain of *Bacillus subtilis,* which was cultured from a patient with a compound fracture contaminated with soil. Thus the baciportion is derived from *Bacillus,* and the *-tracin* from the name of the patient who had the compound fracture (Tracy). Bacitracin is a cyclic polypeptide antibiotic with multiple components (A, B, and C). Bacitracin A is the major component of commercial products and is often used as the zinc salt. [1] Bacitracin interferes with bacterial cell wall synthesis by binding to and inhibiting the dephosphorylation of a membrane-bound lipid pyrophosphate. [15] It is active against gram-positive cocci such as staphylococci and streptococci. Most gram-negative organisms and yeast are resistant to the drug. It is available as bacitracin ointment and as zinc bacitracin, with 400 to 500 units per gram.

Topical bacitracin is effective for the treatment of superficial bacterial infections of the skin such as impetigo, furunculosis, and pyodermas. It is often combined with polymyxin B and neomycin as a triple antibiotic ointment applied several times daily for the treatment of secondarily infected eczematous dermatitis such as atopic dermatitis, nummular dermatitis, or stasis dermatitis. [1] Unfortunately, the topical application of bacitracin carries with it the risk of allergic contact sensitization [8] and, rarely, anaphylactic shock. [16]

Polymyxin B

Polymyxin B is a topical antibiotic derived from a spore-forming soil aerobe *B. polymyxa,* which was isolated originally from a soil sample in Japan. Polymyxin B is a mixture of polymyxin B_1 and B_2, which are both cyclic polypeptides. They function as cationic detergents that interact strongly with bacterial cell membrane phospholipids, thus disrupting the integrity of the cell membrane. [1]

Polymyxin B is active against a wide range of gram-negative organisms, including *P. aeruginosa, Enterobacter,* and *Escherichia coli.* [1] Polymyxin B is available in ointment form (5000–10,000 units per gram) in combination with bacitracin or bacitracin and neomycin. It should be applied one to three times a day. [15]

TOPICAL AMINOGLYCOSIDES, INCLUDING NEOMYCIN, GENTAMICIN, AND PAROMOMYCIN

The aminoglycosides are an important group of antibiotics used both topically and systemically for the treatment of infections caused by gram-negative bacilli. Aminoglycosides exert their bactericidal effects by binding to the 30S ribosomal subunit and interfering with protein synthesis. [17]

Neomycin sulfate, the aminoglycoside most often used topically, is a fermentation product of *Strep. fradiae.* Commercial neomycin is a mixture of neomycin B and C, whereas framycetin, used in Canada and some European countries, is pure neomycin B. [18] Neomycin sulfate has activity against aerobic gram-negative bacteria and is used most commonly for prophylaxis against infection in superficial abrasions, cuts, and burns. [17] It is available in ointment form (3.5 mg/g) and is packaged in combination with other antibiotics such as bacitracin, polymyxin, and gramicidin. Other agents, such as lidocaine, pramoxine, or hydrocortisone, also may be found in combination with neomycin. [19]

Neomycin is not recommended by many dermatologists because of the allergic contact dermatitis that occurs after widespread, indiscriminate use of the drug, especially in over-the-counter products. [16] The prevalence of contact dermatitis is high, with 6 to 8 percent of patients undergoing patch testing being positive. [20] Neomycin sulfate (20%) in petrolatum is used to assess for contact allergy. [20]

Gentamicin sulfate is derived as a fermentation product from *Micromonospora purpurea.* It is available as a topical 0.1% cream or ointment. [21] It is used by some dermatologic surgeons when operating on the ear, especially in diabetic or other immunocompromised patients, to provide prophylaxis against malignant otitis externa due to *P. aeruginosa.* [22]

Paromomycin is closely related to neomycin and has antibacterial and antiparasitic activities. A topical formulation consisting of paromomycin sulfate and methylbenzethonium chloride is used in Israel to treat Old World cutaneous leishmaniasis. [23]

MISCELLANEOUS AGENTS

Gramicidin

Gramicidin is a topical antibiotic derived from *B. brevis.* [15] The gramicidins are linear peptides that form stationary ion channels in susceptible bacteria. The antibiotic activity of gramicidin is restricted to gram-positive bacteria. [24]

Chloramphenicol

Chloramphenicol is available in the United States with use limited to the treatment of minor bacterial skin infections. Chloramphenicol was isolated originally from *Strep. venezuelae,* but it is now synthesized because of its simple chemical structure. The mechanism of action is similar to that of erythromycin and clindamycin, with inhibition of the 50S ribosome blocking translocation of peptidyl tRNA from the acceptor to the donor site. [16] Chloramphenicol is available as a 1% cream. It is used infrequently because fatal aplastic anemia or dose-related bone marrow suppression has been reported

following topical exposure. [25]

Sulfonamides

The sulfonamides are structurally similar to *para*-aminobenzoic acid (PABA) and compete with it during the synthesis of folic acid. Sulfonamides are used infrequently as topical agents, with the exception of silver sulfadiazine (Silvadene) cream and mafenide acetate cream. Silver sulfadiazine is thought to release silver slowly. The silver exerts its effect on the bacterial cell walls and membranes. [26] The mechanism of action of mafenide is not the typical sulfonamide mechanism of action because PABA does not antagonize its performance. [27] Mafenide acetate, if used over large areas of skin, has the potential to cause a metabolic acidosis, and it can cause intense pain on topical administration. Both agents are broad-spectrum antibacterials useful in the treatment of burns. *Candida* superinfection may be a problem with mafenide cream. [27]

Clioquinol

Clioquinol (also known as *iodochlorhydroxyquin*) is a broad-spectrum antibacterial/antifungal topical that is currently indicated for the treatment of inflammatory skin disorders and tinea pedis and has been used for minor bacterial infections. It is a synthetic hydroxyquinoline whose mechanism of action is unknown. [28] The disadvantages of clioquinol include discoloration of clothing, skin, hair, and nails and the potential to cause irritation. Clioquinol may interfere with thyroid function determination because the iodine moiety interferes with tests that rely on iodine uptake (this effect can last for up to 3 months after application). However, clioquinol does not interfere with testing for T3 or T4. [28]

Nitrofurazone

Nitrofurazone (Furacin) is a nitrofuran derivative used for the treatment of burn patients. The mechanism of action involves the inhibition of bacterial enzymes involved in the aerobic and anaerobic degradation of glucose and pyruvate. Nitrofurazone is available as a 0.2% cream, solution, or soluble dressing, and its spectrum of activity includes staphylococci, streptococci, *E. coli, Clostridium perfringens, Aerobacter enterogenes,* and *Proteus* spp. [29]

Fusidic Acid

Fusidic acid is a topical preparation that is not currently available in the United States but is in use in Canada and Europe as an antibacterial available as a cream, ointment, and impregnated gauze. [30] Fusidic acid is a steroidal antibiotic with a mechanism of action that interferes with the function of the elongation factor (EF-G) by stabilizing the EF-G-GDP-ribosome complex, preventing translocation of the ribosomes and EF-G from recycling. [24]

REFERENCES

1. Kapusnik-Uner JE et al: Tetracyclines, chloramphenicol, erythromycin, and miscellaneous antibacterial agents, in *Goodman and Gilman's The Pharmacological Basis of Therapeutics,* 9th ed, edited by JG Hardman, LE Limbird, AG Gilman. New York, McGraw-Hill, 1996, p 1123

2. Esterly NB et al: The effect of antimicrobial agents on leukocyte chemotaxis. *J Invest Dermatol* **70**:51, 1978

3. Thiboutot DM: Acne: An overview of clinical research findings. *Dermatol Clin* **15**:97, 1997

4. Clindamycin (topical), in *Drug Information for the Health Care Professional (USP DI)*. Englewood, CO, Micromedex, 2000, p 930

5. Metronidazole (topical), in *Drug Information for the Health Care Professional (USP DI).* Englewood, CO, Micromedex, 2000, p 2131

6. Azelaic Acid (topical), in *Drug Information for the Health Care Professional (USP DI).* Englewood, CO, Micromedex, 2000, p 507

7. Mupirocin (nasal and topical), in *Drug Information for the Health Care Professional (USP DI)*. Englewood, CO, Micromedex, 2000, p 2191

8. Rahman M et al: Mupirocin-resistant *Staphylococcus aureus. Lancet* **2**:387, 1987

9. Watanaabe H et al: Emergence and spread of low-level resistance in methicillin-resistant *Staphylococcus aureus* isolated from a community hospital in Japan. *J Hosp Infect* **47**:294, 2001

10. Miller MF et al: Development of mupirocin resistance among methicillin-resistant *Staphylococcus aureus* after widespread use of nasal mupirocin ointment. *Infect Control Hosp Epidemiol* **17**:811, 1996

11. Vasquez JE et al: The epidemiology of mupirocin resistance among methicillin-resistant *Staphylococcus aureus* at a Veteran's Affairs hospital. *Infect Control Hosp Epidemiol* **21**:459, 2000

12. Watanabe H et al: Low concentrations of mupirocin in pharynx following intranasal application may contribute to mupirocin resistance in methicillin-resistant *Staphylococcus aureus. J Clin Microbiol* **39**:3775, 2001

13. Fung S et al: The utility of Polysporin ointment in the eradication of methicillin-resistant *Staphylococcus aureus* colonization: a pilot study. *Infect Control Hosp Epidemiol* **21**:653, 2000

14. Smack DP et al: Infection and allergy incidence in ambulatory surgery patients using white petrolatum versus bacitracin ointment. *JAMA* **276**:972, 1996

15. Neomycin, polymyxin B, and bacitracin (topical), in *Drug Information for the Health Care Professional (USP DI).* Rockville, MD, United States Pharmacopeial Convention, 1997, p 2111

16. Farley M et al: Bacitracin anaphylaxis. *Am J Contact Dermatitis* **6**:28, 1995

17. Chambers HF, Sande MA: The aminoglycosides, in *Goodman and Gilman's The Pharmacological Basis of Therapeutics,* 9th ed, edited by

JG Hardman, LE Limbird, AG Gilman. New York, McGraw-Hill, 1996, p 1123

18. Budavari S: *The Merck Index,* 12th ed. Whitehouse Station, NJ, Merck & Co, 1996, p 1108

19. Olin BR (ed): *Drug Facts and Comparisons.* St. Louis, MO, Facts and Comparisons, 1996, p 2829

20. Marks JG, DeLeo VA: Standard allergens, in *Contact and Occupational Dermatology.* St. Louis, MO, Mosby Year Book, 1992, p 59

21. Edwards DI: Biosynthesis of antimicrobial drugs, in *Antimicrobial Drug Action.* Baltimore, MD, University Park Press, 1980, p 31

22. Scherbenske JM et al: Acute *Pseudomonas* infection of the external ear (malignant external otitis). *J Dermatol Surg Oncol* **14**:165, 1988

23. Teva Pharmaceutical Industries, Ltd: Package insert for Leshcutan (Paromomycin sulfate, 15%, and Methylbenzethonium chloride, 12%, Ointment), Petah-Tikva, Israel

24. Lancini G et al: The mechanism of action of antibiotics, in *Antibiotics: A Multidisciplinary Approach*. New York, Plenum, 1995, p 70

25. Chloramphenicol (Topical), in *Drug Information for the Health Care Professional (USP DI).* Englewood, CO, Micromedex, 2000, p 795

26. Mandell GA, Petri WA: Sulfonamides, trimethoprim-sulfamethoxazole, quinolones, and agents for urinary tract infections, in *Goodman and Gilman's The Pharmacological Basis of Therapeutics,* 9th ed., edited by JG Hardman, LE Limbird, AG Gilman. New York, McGraw-Hill, 1996, p 1061

27. Mafenide (topical), in *Drug Information for the Health Care Professional (USP DI).* Rockville, MD, United States Pharmacopeial Convention, 1997, p 1912

28. Clioquinol (topical), in *Drug Information for the Health Care Professional (USP DI).* Englewood, CO, Micromedex, 2000, p 934

29. 1996 Roberts package insert for Furacin (nitrofurazone cream), in *Physicians' Desk Reference,* 51st ed. Montvale, NJ, Medical Economics, 1997, p 3044

30. Additional Products & Indications, in *Drug Information for the Health Care Professional (USP DI).* Englewood, CO, Micromedex, 2000, p 3044

T>

Chapter 246

James Fitzpatrick

Topical Antifungal Agents

DERMATOPHYTE INFECTIONS
CANDIDIASIS (CANDIDOSIS)
PITYROSPORUM (MALASSEZIA) INFECTIONS

REFERENCES

Superficial fungal infections such as dermatophytoses, candidiasis, and pityriasis versicolor are typically restricted to epithelial tissues. When presented with such infections, the option is to treat with either systemic or topical antifungal therapy. The decision requires consideration of numerous factors, including extent of infection, severity of infection, site of infection (e.g., nails as opposed to glabrous skin), underlying diseases, efficacy of treatment, potential drug interactions, side effects, known allergies, cost, the patient's health care plan, ease of use, patient's preference, and finally the physician's familiarity with different antifungal therapies. In general, patients with limited disease and fungal infections confined to glabrous skin are best treated with topical antifungal therapy while patients with extensive disease and infections of hair and nails are best treated with systemic therapy. In some cases, either option can be used. Topical antifungal therapy has numerous advantages over systemic antifungal therapy, including the absence of serious side effects (e.g., hepatitis as seen with the oral imidazoles), absence of drug interactions, no requirement to monitor laboratory tests, ability to localize treatment to affected sites, over-the-counter availability of some medications, and ease of use for patients who experience difficulty swallowing pills. The oral medications are discussed in Chap. 261.

Today there are numerous topical antifungal drugs available (Table 246-1). Prior to 1945, specific antifungal drugs were not available and nonspecific therapies such as keratolytics (e.g., salicylic acid) and antiseptics (e.g., gentian violet, Castellani's paint) were the cornerstones of therapy. Although topical antifungal drugs have been available since the development of undecylenic acid in 1945, there is no consensus as to the best topical antifungal agent. The ideal topical antifungal agent should demonstrate these properties:

- Fungicidal at therapeutic concentration
- Absence of resistance
- Broad spectrum of action that includes all known superficial fungal pathogens
- Keratinophilic
- Penetrates keratin but is not absorbed systemically
- Hypoallergenic
- Nonirritating
- Anti-inflammatory properties
- Once-per-day (or less) application
- Short duration of therapy required for cure
- Availability in a wide variety of formulations (e.g., cream, solution) and sizes
- Inexpensive

Class/Generic Name	Name	Availability
Allylamines		
Naftifine	Naftin	Prescription
Terbinafine	Lamisil	Prescription
	Lamisil AF	OTC
	Desenex Max	OTC
Benzylamine		
Butenafine	Mentax	Prescription
Hydroxypyridone		
Ciclopirox olamine	Loprox	Prescription
	Penlac	Prescription
Imidazoles		
Clotrimazole	Lotrimin	Prescription
	Mycelex	Prescription
	Desenex AF	OTC
	Lotrimin AF	OTC
Clotrimazole/betamethasone dipropionate	Lotrisone	Prescription
Econazole	Spectazole	Prescription
Ketoconazole	Nizoral	Prescription
Miconazole	Monistat-Derm	Prescription
	Micatin	OTC
Oxiconazole	Oxistat	Prescription
Sulconazole	Exelderm	Prescription
Polyenes		
Amphotericin B	Fungizone	Prescription
Nystatin	Mycostatin	Prescription
	Nystop	Prescription
Nystatin/triamcinolone	Mycolog II	Prescription
Miscellaneous		
Tiacetin/sodium propionate/benzalkonium chloride/cetylpyridinium chloride/chlorocresol	Fungoid	Prescription
Tolnaftate	Equate	OTC
	Tinactin	OTC
Undecylenic acid/zinc undecylenate	Cruex	OTC
	Desenex	OTC
Undecylenic acid/chlorocresol	Cordo/Kem	OTC

OTC, over the counter

TABLE 246-1 **Topical Antifungal Agents**

None of the drugs developed to date fully meets all of the desired properties. Despite the fact that topical antifungal agents have been used for decades and there are numerous studies that demonstrate the efficacy of each drug, it remains difficult to compare the efficacy of the various agents. In part this is because the pharmaceutical companies sponsor most antifungal studies and the antifungal therapy is often compared to the vehicle. Comparing the results among these studies is fraught with error because the studies differ in design, duration of therapy, site of infection, patient selection, method of determining response, and duration of follow-up. There are a number of studies that compare one topical antifungal agent with another, but the conclusions are always limited to that study and the data cannot be compared with data from other studies. Because the two most important medical factors are the type of

pathogen and the site of infection, the discussion of topical antifungal therapy that follows is organized in this fashion.

DERMATOPHYTE INFECTIONS

Dermatophyte infections are limited to three genera (i.e., *Trichophyton, Microsporum,* and *Epidermophyton*) that use keratin as a substrate (see Chap. 205). The specific species producing infection is usually not a consideration in the selection of topical therapy, although in vitro studies show that *T. mentagrophytes* species are less sensitive to most antifungal drugs than are other species. Because the location of infection (i.e., hair, glabrous skin, nails) is critical in selecting therapy, the treatment of dermatophyte infections is individually discussed for each area.

Dermatophyte infections of hair most commonly present as tinea capitis but may also present as tinea barbae or Majocchi's granuloma. In follicular dermatophyte infections, viable hyphae can invade as deep as the bottom one-third of the hair follicle to a region referred to as Adamson's fringe. It is at this level that there is a transition from keratin to viable keratinocytes, which cannot serve as a substrate for dermatophyte growth. Because of the depth of Adamson's fringe, topical antifungal agents should probably not be used as primary therapy for hair infections, although studies regarding their use in this situation are lacking. Ketoconazole shampoo and selenium sulfide have both been demonstrated to decrease the shedding of viable organisms and are useful adjunctive therapies to prevent the spread of infection to other family members.[1], [2] Although, ketoconazole shampoo as a monotherapy for tinea capitis reportedly produces long-term clinical and mycologic cures in as many as one-third of children,[2] this is a low cure rate when compared to systemic therapy and it is not recommended as a primary therapy.

Dermatophyte infections of glabrous skin, which are classified by site of involvement including face (tinea faciei), trunk and extremities (tinea corporis), groin (tinea cruris), hands (tinea manuum), and feet (tinea pedis), are the most common indication for topical antifungal therapy. Topical therapies may be used interchangeably among these sites with the possible exception of tinea cruris, where the skin is sensitive and easily develops an irritant contact dermatitis to some topical antifungals.

The two earliest topical antifungal agents, undecylenic acid and tolnaftate, are still available but are only rarely used. Undecylenic acid, which is often combined with one of its salts (i.e., zinc undecylenate), is the original specific topical antifungal agent. Although the initial study reported a high cure rate, subsequent studies reported cure rates as low as 27 percent. In addition this antifungal also has a disagreeable odor and may require prolonged use (up to 26 weeks in some studies). Tolnaftate, synthesized in Japan and introduced as a topical antifungal agent in 1964, is a thiocarbamate derivative, not related to any other antifungal drug. Its mode of action is similar to the allylamines in that it inhibits squalene epoxidase, which results in accumulation of squalene in the fungal cell. Although early studies reported cure rates as high as 73 to 93 percent, at least one study reported a 0 percent cure rate for tinea pedis.[3] While earlier studies suggested that tolnaftate was superior to undecylenic acid preparations, later studies concluded that the two drugs were equivalent. Although definitive comparative studies are lacking, it is probably less effective than newer antifungal agents and is only rarely used.

The advent of the topical imidazoles in the early 1970s produced the class of drugs that are most commonly used on fungal infections of glabrous tissue. The imidazoles are considered to be fungistatic drugs, although at very high levels some are fungicidal. The imidazoles act by inhibiting the cytochrome P450-dependent enzyme, lanosterol 14a-demethylase, that is necessary for the conversion of lanosterol to ergosterol, a fungal cell wall sterol necessary for normal cell membrane permeability and structural integrity. The topical antifungals currently available in this class include miconazole, clotrimazole, econazole, ketoconazole, oxiconazole, and sulconazole. Although all of these drugs have the same mechanism of action, in vitro studies have shown that not all dermatophytes are uniformly susceptible to different imidazoles at identical concentrations. The clinical significance of this finding is not yet resolved.

The reported cure rates for the imidazole class of drugs are highly variable and depend on the design of the study; as stated earlier, it is impossible to compare cure rates between different studies. For example, one may conclude that topical miconazole produces either a 63 percent cure rate[4] or a 100 percent cure rate[5] in dermatophyte infections, depending on the study quoted. A review of the literature of topically applied imidazole agents does not provide convincing evidence that there is a significant difference among any of the members of this group in overall cure rate or relapse rate, although they appear to be marginally superior to both undecylenic acid products and tolnaftate. Miconazole and clotrimazole are the two drugs in the class that are also available over the counter at a considerable savings over their prescription counterparts (Table 246-2). Although mycologic cure rate is not a determining factor in drug selection within this group, there is a difference in irritancy between different preparations, particularly in sensitive areas such as the groin. In at least one study of clotrimazole, it was reported that it produced severe erosive irritant reactions in 4 of 27 patients when used to treat tinea cruris. In the same study, sulconazole did not produce any irritant reactions, was well tolerated, and seemed to accelerate healing in denuded areas.[6] In a second study, it was reported that there were severe irritant reactions in miconazole-treated patients, but not in sulconazole-treated patients.[5] Until better studies regarding irritant reactions of topically applied imidazoles are available, sulconazole is an excellent choice for sensitive or macerated skin.

TABLE 246-2 **Topical Antifungal Cost (Retail)**

Topical imidazoles are available in creams and lotions. Limited studies from manufacturers seem to indicate that creams are marginally more effective than lotions. For example, oxiconazole cream is reported by the manufacturer to produce a clinical and mycologic cure in 52 percent of cases of tinea pedis, whereas oxiconazole lotion only produces a 41 percent cure. [7]

A second issue is that of how often the drug should be applied. Several imidazoles, including econazole, ketoconazole, and oxiconazole, have received once-daily application approval from the US Food and Drug Administration, while the remaining imidazole regimens recommend twice-daily application. Sulconazole is recommended by the manufacturer to be applied twice daily, but a study comparing once-daily to twice-daily application regimens for the treatment of tinea cruris and tinea corporis reported identical cure rates. [6] This result is not unexpected, because all imidazoles have the same mechanism of action. This is an important point because drug companies with once-per-day indications promote their drugs as being more economical than drugs with twice-daily regimens.

A third important issue is the use of topical imidazoles combined with topical glucocorticoids. The combination of clotrimazole and betamethasone dipropionate is the most frequently prescribed topical agent in the United States, with the majority of the prescriptions being written by primary care providers. The rationale for this combination has been that the addition of a topical glucocorticoid will relieve symptoms of pruritus and burning more quickly and produce quicker resolution of erythema and scaling. Early studies reported that the clotrimazole and betamethasone dipropionate combination was more effective than clotrimazole alone in producing resolution of erythema and pruritus. The mycologic cure rate was reported to be equivalent to that of clotrimazole, although these studies had short follow-up periods that did not permit proper assessment of the relapse rate. Subsequent striae and persistent dermatophyte infections have prompted many dermatologists to eschew the use of this combination product. [8] In a subsequent study comparing naftifine to clotrimazole/betamethasone dipropionate, it was reported that the combination was less efficacious than naftifine alone. In contrast to prior studies, this study had an 8-week follow-up period that demonstrated a high relapse rate (36 percent) for the antifungal/steroid combination. [9] In sum, based on limited studies and anecdotal reports, this antifungal/steroid combination is more likely to produce permanent side effects and a high relapse rate.

Ciclopirox olamine, a broad-spectrum antifungal agent, is a hydroxypyridone and is not related to any other known antifungal agent. In contrast to the imidazoles, which are fungistatic, ciclopirox olamine is both fungicidal and fungistatic. This antifungal acts by chelating trivalent cations such as Fe^{3+}, thus inhibiting metal-dependent enzymes required for the degradation of toxic metabolites. This affects cell membrane synthesis, alters cell permeability, and inhibits respiratory activity. Resistance of dermatophytes to ciclopirox olamine has not been reported. The compound also demonstrates anti-inflammatory activity by inhibiting prostaglandin and leukotriene synthesis and has been shown to be more effective than either imidazoles or allylamines in suppressing UVB-induced erythema. [10] Ciclopirox olamine also penetrates keratin easily, with cadaveric studies demonstrating levels in the dermis that are 10 to 15 times that of minimum inhibitory concentrations (MICs). [11] In clinical trials, ciclopirox olamine has demonstrated excellent mycologic and clinical response rates. [12] Despite its excellent pharmaceutical properties, its efficacy has not been compared to that of other antifungal agents in treatment of glabrous skin, and it has been used interchangeably with the imidazoles, allylamines, and benzylamines. Although allergic contact dermatitis to ciclopirox olamine has been documented, it is rare.

Another of the newer classes of topical antimycotic drugs are the allylamines (naftifine and terbinafine). These drugs act by specific inhibition of squalene epoxidase. As with the imidazoles, this inhibits ergosterol biosynthesis, which is a fungistatic effect, but it also produces an accumulation of intracellular squalene, which is a fungicidal effect. In vitro studies to determine MICs on 80 strains of dermatophytes revealed that naftifine was superior to clotrimazole, miconazole, and ketoconazole as determined by both the dilution method and the disk-diffusion method. In addition to their antifungal effects, naftifine and terbinafine demonstrate anti-inflammatory activity as measured by their ability to suppress UVB-induced erythema. [10] Naftifine is also lipophilic and demonstrates penetration to deep portions of the hair follicle. Terbinafine, the newest allylamine, demonstrates properties similar to naftifine except that it demonstrates in vitro activity that is 10 to 100 times greater. [13] Pharmokinetic studies have shown that topical application of 1% terbinafine on hyperkeratotic tinea pedis produces concentrations that are 50,000 times higher than the minimum inhibitory concentration needed to treat dermatophyte infection. [14] Numerous clinical studies compare the allylamines to the imidazoles, often producing conflicting results. In some studies, topical naftifine has been comparable to topical imidazoles, whereas in other studies, it has demonstrated marginal superiority to topical imidazoles. When compared to topical miconazole combined with hydrocortisone cream, naftifine was markedly superior in the treatment of inflammatory dermatophyte infections. [15] The number of studies comparing topical terbinafine to other antimycotics is limited, but in two large multicenter comparisons of topical terbinafine with clotrimazole in the treatment of tinea pedis, a significantly higher cure rate and lower relapse rate for terbinafine was reported. [16], [17] In summary, topical allylamines, especially terbinafine,

are marginally superior to topical imidazoles in cure rates and probably require shorter duration of therapy. Terbinafine is now available over the counter.

Butenafine, the newest topical antifungal agent, is the only member of the benzylamine class of antifungals. It is structurally similar to the allylamines, and like the allylamines, it works by inhibiting squalene epoxidase. Like the allylamines it is both fungistatic and fungicidal. The minimal fungicidal concentrations for butenafine are 4 to 130 times lower than for naftifine, tolnaftate, clotrimazole, and bifonazole. [18] Like the allylamines, this drug also demonstrates anti-inflammatory effects as measured by reduced cutaneous erythema in response to UVB irradiation. [19] Results in clinical trials suggest that it is very similar to the allylamines in terms of clinical responses.

Tinea unguium is the third major category of superficial dermatophytoses. Although pharmacokinetic studies demonstrate that imidazoles and allylamines are capable of penetrating the nail plate in concentrations sufficient to exceed the MICs of most dermatophytes, [20] they typically fail to produce clinical cures. A prescription product composed of triacetin, sodium propionate, benzalkonium chloride, cetylpyridium chloride, and chloroxylenol has been marketed in a tincture base (Fungoid) for the treatment of onychomycosis. An uncontrolled study has reported a 100 percent cure rate after 12 months of treatment; however, treatment also included monthly nail débridement and there was only a 2-month follow-up. Because of its excellent penetration of the nail plate, ciclopirox nail lacquer 8% solution was developed and introduced for the topical treatment of onychomycosis. The most commonly used treatment regimen is to apply the lacquer to the affected nail once per day for 48 weeks. The reported mycologic cure rates have ranged from 29 to 85.7 percent with the meta-analytic average cure rate being 53 percent. The reported relapse rate is 21 percent. [21] Ciclopirox nail lacquer has an advantage over systemic antifungal agents in that it does not require physician monitoring, laboratory testing is not required, and it has a reduced cost per mycologic cure. [21]

CANDIDIASIS (CANDIDOSIS)

Candida albicans is the primary pathogen in most cases of superficial candidiasis, although other species, such as *C. parapsilosis* and *C. guilliermondii,* may also produce infection (see Chap. 206). *Candida* species are commensal organisms that usually require a change in the host milieu, usually alterations in nutrition (e.g., diabetes mellitus), microbial flora (e.g., antibiotic therapy), or host immune defenses (e.g., neutropenia) to produce infections. This is an important consideration in assessing the efficacy of topical therapies, since the recurrence rate is very high if the underlying disease is not corrected.

Before the advent of the imidazoles, the polyenes were the mainstay of topical candidial therapy. There are more than 80 polyene antibiotics, but only nystatin and amphotericin B have been used as topical agents. Polyene antimycotics are primarily fungistatic at low concentrations and fungicidal at high concentrations. They act by binding irreversibly with ergosterol in the cell membrane, which leads to altered cellular permeability and leakage of cell contents. Nystatin is available in powder, suspension, lozenges, and as creams for topical therapy. The suspension and lozenge formulations are used for oral candidiasis, and the powder and creams are used for cutaneous infections. Older studies comparing topical nystatin with imidazoles suggested that the two were comparable in efficacy, but more recent studies suggest that imidazole drugs are more effective than nystatin in vaginal candidiasis. [22] This may be related to the increased nystatin resistance which is now observed in up to 20 percent of isolates. Nystatin resistance may be encountered in wild strains (primary resistance) but may also be induced during therapy (secondary resistance). Nystatin and amphotericin, while effective against candidial infections, are not effective against dermatophytes.

Topical imidazoles are the mainstay of topical therapy for candidiasis. Imidazoles are available as lotions, creams, and troches (clotrimazole). Clotrimazole troches are used for the management of oral candidiasis, and imidazole lotions and creams are used for superficial cutaneous candidiasis. The susceptibility of different strains of *C. albicans* to imidazoles is highly variable (MIC of 0.5 to 100 µg/mL). The implication of this difference in susceptibility to imidazoles has not been studied to determine if it is clinically significant in terms of response rates. All of the topical imidazoles are clinically and mycologically effective in treating superficial candidal infections and can be used interchangeably. As discussed in the management of dermatophyte infections, there is evidence to suggest that clotrimazole and miconazole are potentially irritating and may not be the preferred imidazoles in sensitive flexural areas infected with *Candida*.

Ciclopirox olamine, like the imidazoles, is a broad-spectrum antimycotic drug that is effective against *Candida* species. Ciclopirox olamine is indicated for the management of cutaneous candidial infections but it does not come in formulations for oral use. Head-to-head studies comparing this drug to the topical imidazoles have not been done, but ciclopirox olamine appears to be equivalent to the topical imidazoles in terms of clinical efficacy.

Topical allylamines (naftifine, terbinafine) demonstrate moderate activity against yeast, including *Candida* species. In vitro studies demonstrate that *Candida* species are more sensitive to the imidazole class of drugs than the allylamines. [8] Despite the higher measured in vitro MICs for yeasts, clinical studies have demonstrated that most cases of cutaneous candidiasis can be successfully treated with topical allylamines; they compare with topical imidazoles in terms of mycologic cure. Despite the therapeutic efficacy of the allylamines, they should not be considered as a primary topical therapy for candidiasis because they are expensive, have not received approval for this indication, and demonstrate less-favorable MICs.

PITYROSPORUM (*MALASSEZIA*) INFECTIONS

Pityrosporum orbiculare is a lipophilic yeast that produces superficial fungal infections in the form of tinea (pityriasis) versicolor and, less commonly, as a folliculitis (see Chap. 206). Because these two forms of infection respond to the same topical therapies, they are discussed together. Because this yeast is a normal component of the skin flora, its total eradication is usually not possible by using topical therapies. The ubiquitous nature of the organism also accounts for the high recurrence rate following treatment. For this reason, it is difficult to compare different studies since the follow-up periods are usually of different lengths. Patients with extensive involvement are usually best treated with oral

antimycotics, whereas patients with limited involvement may be treated with either systemic or topical antimycotics. A number of less-conventional agents that are not regarded as antimycotics have been reported in the literature, including salicylic acid, propylene glycol, and zinc pyrithione. These are not discussed because they do not appear to offer significant advantages over specific antimycotic agents.

Selenium sulfide (2.5%) lotion has been shown in uncontrolled and controlled studies to be useful in the management of both tinea versicolor and *Pityrosporum* folliculitis. A variety of different methods and durations of applications have been utilized but one of the most common regimens is to have patients apply the lotion daily for 10 min for 7 consecutive days. [23] Cure rates have been reported to be as high as 87 percent [23] in tinea versicolor and 90 percent in *Pityrosporum* folliculitis. [24] Advantages of this treatment modality include low cost and the ability to treat large areas of the body since the lotion is easy to apply. The major disadvantage that limits its use is that the lotion is irritating, with almost one in five patients developing an irritant dermatitis that may range from mild to severe. Some patients also find the odor objectionable.

Numerous studies demonstrate the efficacy of topical imidazoles for the treatment of both tinea versicolor and *Pityrosporum* folliculitis. The clinical and mycologic cure rates vary from 76 to 100 percent in different studies. The most common regimen for all imidazoles is a once-daily application for 2 weeks. The results of all studies, including those in which there is a head-to-head comparison between different imidazoles, do not demonstrate a significant difference between any of the antifungals in this class. The choice of topical imidazole is primarily based on price. Topical ciclopirox olamine is also effective against *Pityrosporum* species and can be used interchangeably with the imidazoles, although at least one head-to-head study between ciclopirox olamine and clotrimazole demonstrated marginally higher cure rates with ciclopirox olamine.

Although topical allylamines are clinically and mycologically effective against *Pityrosporum* infections, they have not received an indication for use in this disorder. Although in vitro data suggest that allylamines have higher MIC values than imidazoles against yeast, MIC values do not always correlate with clinical efficacy. There are only a limited number of studies using topical allylamines in *Pityrosporum* infections, but the clinical and mycologic cure rates appear to be equivalent to that of topical imidazoles. Despite the clinical efficacy, topical allylamines are not a good choice for the treatment of either tinea versicolor or *Pityrosporum* folliculitis because this is the most expensive class of topical antimycotics and they have not received an indication for treatment of these infections.

REFERENCES

1. Allen HB et al: Selenium sulfide: Adjunctive therapy for tinea capitis. *Pediatrics* **69**:81, 1982

2. Greer DL: Successful treatment of tinea capitis with 2% ketoconazole shampoo. *Int J Dermatol* **39**:302, 2000

3. Smith EB: New topical agents for dermatophytosis. *Cutis* **17**:54, 1976

4. Fredriksson T: Treatment of dermatomycoses with topical tioconazole and miconazole. *Dermatologica* **116**(Suppl 1):14, 1983

5. Tanenbaum L et al: Sulconazole nitrate 1.0 percent cream: A comparison with miconazole in the treatment of tinea pedis and tinea cruris/corporis. *Cutis* **30**:105, 1982

6. Tanenbaum L et al: Sulconazole nitrate cream 1 percent for treating tinea cruris and corporis. *Cutis* **44**:344, 1989

7. *Physicians' Desk Reference,* 55th ed. Montvale, NJ, Medical Economics Data Production, p 1151, 2001

8. Barkey WF: Striae and persistent tinea corporis related to prolonged use of betamethasone dipropionate 0.05 percent; cream/clotrimazole 1 percent; cream (Lotrisone cream). *J Am Acad Dermatol* **17**:518, 1987

9. Smith EB et al: Double-blind comparison of naftifine cream and clotrimazole/betamethasone dipropionate cream in the treatment of tinea pedis. *J Am Acad Dermatol* **26**:125, 1992

10. Rosen T et al: Anti-inflammatory activity of antifungal preparations. *Int J Dermatol* **36**:788, 1997

11. Gupta AK et al: Antifungal agents: An overview. Part I. *J Am Acad Dermatol* **30**:677, 1994

12. Kligman AM et al: Evaluation of ciclopirox olamine cream for the treatment of tinea pedis: Multicenter, double-blind comparative studies. *Clin Ther* **7**:409, 1985

13. Stiller MJ et al: Treatment of dermatophytoses II: Newer topical antifungal drugs. *Int J Dermatol* **32**:638, 1993

14. Tanuma H et al: Usefulness of 1% terbinafine HCl (Lamisil) cream hyperkeratotic-type of tinea pedis and its transfer into the horny layer. *Mycoses* **43**:417, 2000

15. Nada M et al: Naftifine versus miconazole/hydrocortisone in inflammatory dermatophyte infections. *Int J Dermatol* **33**:570, 1994

16. Bergstresser PR et al: Topical terbinafine and clotrimazole in interdigital tinea pedis: A multicenter comparison of cure and relapse rates with 1- and 4-week treatment regimens. *J Am Acad Dermatol* **28**:648, 1993

17. Evans EGV et al: Comparison of terbinafine and clotrimazole in treating tinea pedis. *BMJ* **307**:645, 1993

18. McNeely W, Spencer CM: Butenafine. *Drugs* **55**:405, 1998

19. Nahm WK et al: The antifungal agent butenafine manifests anti-inflammatory activity in vivo. *J Am Acad Dermatol* **41**:203, 1999

20. Stütten G, Bauer E: Bioavailability, skin and nail penetration of topically applied antimycotics. *Mykosen* **25**:74, 1981

21. Gupta AK: Pharmacoeconomic analysis of ciclopirox nail lacquer solution 8% and the new oral antifungal agents used to treat dermatophyte

toe onychomycosis in the United States. *J Am Acad Dermatol* **43**:S81, 2000

22. Young GL, Jewell D: Topical treatment for vaginal candidiasis (thrush) in pregnancy (Cochrane Review). *Cochrane Database Syst Rev* **4**:CD000225, 2001

23. Sànchez JL, Torres VM: Double-blind efficacy study of selenium sulfide in tinea versicolor. *J Am Acad Dermatol* **11**:235, 1984

24. Bäck O et al: Pityrosporum folliculitis: A common disease of the young and middle-aged. *J Am Acad Dermatol* **12**:56, 1985

T>

Chapter 247

Francis Gasparro Douglas Brown Brian Diffey John Knowland Vivienne Reeve

Sun Protective Agents: Formulations, Effects, and Side Effects

SUNSCREEN ACTIVE INGREDIENTS
MEASURING AND RATING EFFECTIVENESS: UVB AND UVA
The Sun Protection Factor
Sunscreens and UVA Protection
Perspective: Sunscreens, UVA, and Public Health
EVALUATION OF SUNSCREEN PRODUCT EFFICACY
SIDE EFFECTS OF SUNSCREENS
Indirect Effects of Photoactivated Sunscreen Ingredients
Direct Effects of Photoactivated Sunscreen Ingredients
SUNSCREENS AND IMMUNE PROTECTION IN HUMANS
Sunscreen Protection from Suppression of DTH or CHS
Sunscreen Protection from Epidermal Langerhans Cell Depletion
Does UVA Suppress Immunity?
Does UVA Modify UVB-Induced Damage?
REFERENCES

With the start of the twenty-first century, we mark more than 50 years of sunscreen use. Over this period of time sunscreens have evolved from a topical preparation used to prevent sunburn to agents with the desired capability of protecting the skin against various kinds of damage—both short-term and long-term. Regarding the former, this was a simple goal and concept that was easily measured for effectiveness, and hence quite easily achieved. If the exposure of skin to sunlight caused sunburn and this process could be stopped by a topical application of a UVR-absorbing chemical, the effects were observable by visual inspection. However, the protection versus long-term effects such as photoaging and skin cancer present a different challenge—the analysis of long-term effects (most likely extending over years). While this is an admirable and desirable goal, its solution cannot be met with simple procedures and must not be based on faith alone. Skin aging and skin cancer are complicated biologic processes with myriad interlocking steps, many of which may be affected by the exposure to sunlight. Furthermore, certain effects may arise from particular regions of the solar spectrum and/or potential synergistic or antagonistic wavelength interactions. There are several recent reviews available and Chap. 133 contains much relevant data. [1], [2], [3], [4], [5], [6], [7], [8] and [9] This chapter presents cutting edge issues regarding sunscreens.

There is no question that sunscreens prevent sunburn on the basis of their UVR-absorbing capacity to attenuate the amount of “burning” rays of the sun that reach skin cells. Skin cancer, the most common type of cancer in humans, is primarily caused by exposure to sunlight. Therefore, reducing the exposure of skin to solar UVR would be expected to prevent skin cancer. However, although public health authorities have advocated use of sunscreens for skin cancer prevention for many years, there is little actual human data to support this recommendation. In the summer of 2000, a panel of experts in sunscreen-related fields was convened by The International Agency for Research on Cancer (IARC), part of the World Health Organization (WHO). The results of this meeting have been published by IARC, [9] and its overall evaluation for cancer-preventive activity of sunscreens is shown in Table 247-1.



TABLE 247-1 **Evaluation of Sunscreens for Cancer-Preventive Activity**

There are three major types of skin cancer: the highly curable basal cell and squamous cell carcinomas and the highly malignant cutaneous melanoma. The scientific evidence concerning the impact of sunscreens on the development of skin cancer was evaluated by the IARC panel of experts. The Working Group concluded that the appropriate use of sunscreens probably prevents squamous cell carcinoma, the most frequent type of skin cancer, which mainly develops at exposed sites (face, arms, and hands). For malignant melanoma, which is potentially metastatic—with fatal consequences, the impact of sunscreen use is more complex. The relevant epidemiologic studies show significantly higher risks for melanoma in users of sunscreens than in nonusers of sunscreens. Although this apparent paradoxical observation has been attributed to the possibility that sunscreen users, feeling they are protected, may deliberately spend more time in the sun, this is unproven. Further research is needed to determine if the protective effect of sunscreens can be outweighed by overexposure based on the false assumption that sunscreens are an invincible armor against the adverse effects of UV light.

As shown in Table 247-1 the IARC Working Group concluded that sunscreens do prevent sunburn and may reduce the risk of squamous cell carcinoma, but only if people do not extend their outdoor exposure time. The Working Group recommended that sunscreens should be part of an overall sun avoidance program that includes seeking shade whenever possible, wearing protective clothing, scheduling outdoor activities for times of least solar insolation, and using

sunscreens with a sun protection factor (SPF) of at least 15.

SUNSCREEN ACTIVE INGREDIENTS

Sunscreens are commonly referred to as chemical and nonchemical. Of course, all sunscreens are made up of chemicals. The chemical versus nonchemical concept refers to whether the active ingredient—ultraviolet radiation absorbing chemical (UVRAC)—is organic (made up of carbon-containing compounds) or inorganic (not containing carbon). The former include active ingredients such as the cinnamates and benzophenones. The nonchemical group includes pigment agents that, as originally developed, form a visible layer on the skin. The inorganic sunscreens are also commonly known as physical agents. The distinction between these two categories of sunscreens is arbitrary. In fact, while once thought to differ in their mechanism, recent studies show that both agents act by the direct absorption of solar UVR.

Organic sunscreens have been the primary ingredient(s) for sunscreen formulation from their original development early in the last century. Although inorganic sunscreens are gaining in popularity, organic sunscreens are still used in greater amounts. Table 247-2 lists the most common chemicals used in sunscreens, as well as the maximum percentage that can be used. [10] These compounds usually contain conjugated aromatic structures and therefore absorb a specific portion of the UVR spectrum. Depending on the details of each compound's molecular structure, the absorbance may be effective for UVB or UVB and some UVA.

	Ingredient	Maximum Amount (%)	UVB Protection	UVA Protection
Chemical absorbers	Avobenzone (Parsol 1789)	3	No	Yes
	Cinnamates	7.5	Yes	No
	Octocrylene	10	Yes	No
	Oxybenzone (benzophenones)	6	Yes	Yes
	PABA (para-aminobenzoic acid)	15	Yes	No
	Padimate-O (octyl dimethyl paba)	8	Yes	No
	Salicylates	5	Yes	No
Physical blockers	Titanium dioxide	25	Yes	Yes
	Zinc oxide (including transparent)	25	Yes	Yes

*[illegible]

TABLE 247-2 **Common Sunscreen Ingredients***

The absorption of photons creates an excited state in the molecule that persists only for a very short time before the energy is dissipated. [10] Dissipation may occur by one or some combination of the following: release of heat, emission of longer wavelength (lower energy) photons, and/or photochemical transformation. Although the exact fate of the excited state photon of sunscreens applied to skin has not been studied under in vivo conditions, it is generally assumed that there is a reemission of photons at a less energetic, longer wavelength (i.e., heat or light). In some cases, these photons may be used in a photochemical reaction, such as *cis-trans* or keto-enol photochemical isomerization that probably cannot lead to any kind of adverse effect, or perhaps minimally causes a slight change in effective SPF for the sunscreen. However, recent studies show that some UVRACs are transformed into ineffective agents. Prime among these are studies on avobenzone, the major UVA-absorbing chemical sunscreen. Several studies show that avobenzone (also called parsol 1789) undergoes photodegradation when exposed to the very wavelength against which it is designed to protect skin.

Although there are 16 organic sunscreen agents currently available in the United States for use in over-the-counter (OTC) sunscreen products, just 9 are commonly used in sunscreen products (see Table 247-2). The organic sunscreens are almost always used in combination because no single organic sunscreen agent, used at levels currently allowed by the US FDA, can provide a high SPF (=15). The intended use of the product, recreational or daily photoprotection, and its attributes, such as waterproof or sweatproof, dictates which combinations of sunscreens will be used. Recently, formulations with the combination of organic and inorganic sunscreens became very popular and inorganic compounds have been used with increasing frequency. To some degree this shift has been driven not only by the effectiveness of the inorganic compounds, but also by a concern regarding potential adverse effects of the organic sunscreens. Generally, inorganic sunscreens are viewed as harmless pigments that cannot enter the skin and are largely unaffected by light energy. The two most commonly used physical sunscreens are titanium dioxide (TiO_2) and zinc oxide (ZnO). These two metal oxides differ substantially in their appearance and attenuation spectra. [11] Both are odorless white powders that have a normal distribution of particle sizes. Microfine powders are used in sunscreen products because their particle size does not scatter light and hence does not appear white on the skin. In fact, they function on the basis of their UVR absorbance properties just like organic sunscreens. These pigments have also found photochemical uses. Therefore, when used in sunscreen preparations they are often coated with other materials such as silicones, fatty acids, or oxides of aluminum, silicon, or zirconium, to render them less reactive. [12]

MEASURING AND RATING EFFECTIVENESS: UVB AND UVA

The Sun Protection Factor

The concept of the SPF was originally proposed by the Austrian scientist Franz Greiter and subsequently adopted by many regulatory authorities and the cosmetic and pharmaceutical industries. It is popularly interpreted as how much longer skin covered with sunscreen takes to burn as compared to unprotected skin. More precisely, the sun protection factor is defined as the ratio of the least amount of ultraviolet energy required to produce a minimal erythema on sunscreen-protected skin to the amount of energy required to produce the same erythema on unprotected skin. [1] Internationally agreed procedures define protected skin as that to which a 2 mg/cm^2 layer of sunscreen has been applied.

Determination of SPFs by in vivo phototesting is subject to increasing variability with increasing SPF. Table 247-3 shows the results of a series of interlaboratory ring tests performed by seven major European sunscreen manufacturers. [13] It can

be seen that, even under the same laboratory conditions, there is a threefold variation in measured SPF for the high factor (SPF 20 to 25) sunscreen. The principal factor accounting for variability in measured SPF between individuals is differences in topology of the skin surface.

Nominal SPF	Measured SPFs	
	Mean	Range
4	4.2	3.9–4.6
15	12.7	11.1–14.1
15	15.5	14.2–18.2
20–25	22.4	11.3–33.9

TABLE 247-3 **SPF Obtained on Four Products Tested in Seven Laboratories Using the COLIPA SPF Test Method** [13]

The numerical value of the SPF appearing on sunscreen products is usually not identical to the measured mean SPF, because other factors, such as regulatory requirements and commercial considerations, also influence the choice of the declared SPF. In 1990, most commercially available sunscreen products had SPFs less than 10, but by 2000 there was a trend for higher factors, with most manufacturers producing products with factors of 15 to 20 and, not uncommonly, products claiming a factor of 50 or higher.

Sunscreens and UVA Protection

A number of in vivo and in vitro methods have been described to measure sunscreen photoprotection in the UVA region. [14], [15] In vivo methods rely on using erythema or tanning as the end point when the skin is irradiated with or without prior sensitization with, for example, psoralens. In vitro methods are based on the spectral transmission of UV radiation through either a dilute solution of the sunscreen or, preferably, the sunscreen applied to a substrate with a roughened surface. No one method has yet met with universal acceptance and the relative strengths and weaknesses of the different methods have been reviewed. [14], [15]

Additionally, ex vivo methods using excised human epidermis as the substrate have been described. [16], [17] This “middle way” shares the speed and simplicity of in vitro methods, but at the same time accounts for sunscreen–skin interactions that are inherent in in vivo methods.

Perspective: Sunscreens, UVA, and Public Health

The increasing concern over the past 20 years of the known and postulated deleterious effects of UVA exposure in human skin resulted in considerable efforts made during the 1990s to establish a robust and meaningful assay of the UVA, or broad spectrum, protection provided by topical sunscreens. A number of in vivo and in vitro methods have been proposed, [16], [17] but none has yet met with universal approval by manufacturers and adoption by regulatory authorities. This intense activity by academic and industrial researchers has led to a somewhat narrow approach to photoprotection. Yet the spectral profile of a sunscreen, and its summary by some “UVA index” is just one component of the role of sunscreens in reducing the burden of solar ultraviolet A exposure to the population.

From a public health perspective, it is clear that the UVA exposure of sunscreen-protected skin depends not just on the absorption characteristics of the product but also on a number of other factors, including the amount of sunscreen applied, how it is spread over the skin, resistance to water immersion and sand abrasion, and when and how often sunscreen is reapplied. A mathematical study [18] that examined the relative importance of three of these factors—amount applied, how it is spread, and UVA-absorbing properties of sunscreens—found that in a population of sunscreen users, approximately 75 percent of the variance in UVA protection achieved depends upon how much sunscreen is applied, with how well it is applied and how well it absorbs UVA contributing approximately equally to the remaining 25 percent of variance. So what advice should be given to someone who wishes to achieve the maximum benefit in terms of UVA protection from applying a sunscreen of a given SPF? This analysis demonstrated that by far the most important factor is to apply a liberal quantity. However, many studies [19] show that users feel uncomfortable with applications of 2 mg/cm^2 (the thickness used when the SPF is measured), and prefer to apply quantities averaging half this thickness. It is likely, therefore, that campaigns to encourage people to apply a greater quantity of sunscreen at a single application will fail. Another important factor in sunscreen performance is the uneven nature of the skin surface. If an opaque sunscreen is applied to the skin, particularly at the low surface densities typical of practical usage, the epidermal markings become visible as the surface grooves, or sulci, are filled. With further application, the intervening ridges are also covered and the surface becomes more featureless. The situation is analogous to painting a wall with a textured surface when two coats of paint are almost always required for satisfactory coverage. In the same way two “coats of sunscreen” may be required for adequate protection.

Advising people to reapply sunscreen early in their sun exposure period will result in better protection [20] than will the common public health recommendation [21] to reapply every 2 to 3 h. The summary advice given to sunscreen users should be as follows:

- Apply sunscreen liberally to exposed sites 15 to 30 min before going out into the sun.
- Reapply sunscreen to exposed sites 15 to 30 min after sun exposure begins.
- Further reapplication of sunscreen is necessary after vigorous activity that could remove sunscreen, such as swimming, toweling, or excessive sweating and rubbing.

EVALUATION OF SUNSCREEN PRODUCT EFFICACY

Conceptually, sunscreen products are quite simple. The UV filter or filters in these topically applied products absorb,

reflect, or scatter sunlight, thereby reducing the amount or a “dose” of energy to which the skin might otherwise be exposed. Based on this empirical construct, when evaluating sunscreen product efficacy it is important to consider (1) the wavelengths of sunlight human skin needs protection from; (2) which end point(s) can be measured reproducibly and are a biologically meaningful consequence of sunlight exposure; and (3) how this information regarding protection can be communicated to patients and consumers in an understandable manner.

Sunlight reaching the surface of the earth consists of UV, wavelengths (?) < 400 nm, visible, between 400 and 700 nm, and infrared, ? > 700 nm, radiation. Experimental and observational evidence supports the view that solar UV has the most pronounced impact on biologic systems. As such, it has become the practice of many to divide specific wavebands of the terrestrial UV spectrum as UVB (290 to 320 nm) and UVA (320 to 400 nm). In addition, the UVA waveband is often subdivided into UVA II (320 to 340 nm) and UVA I (340 to 400 nm), generally reflecting the higher erythemogenic efficiency of shorter UVA wavelengths. Importantly, the division between these UV wavebands is arbitrary and humans are exposed simultaneously to all UV wavebands from the sun (see also Chap. 133).

A reduction in all wavelengths of UV would apparently afford the greatest protection to human skin against sunlight-induced damage. However, many biologic responses to UV exposure are weighted with the shorter, more energetic wavebands between 290 and 330 nm producing the greatest effects, as much as 100 to 1000 times that of longwave UV, that is, ? > 340 nm. Thus, knowledge of the action spectrum, [22] the relative biologic response versus wavelength of UV, is critical and possibly essential for understanding the current and any future end points used to evaluate sunscreen product efficacy. Regardless, it is empirically obvious that a reduction in all wavelengths of UV would provide the greatest protection against solar damage much as clothing and staying indoors do.

It should not be surprising then that erythema continues to be the most universally recognized end point in sunscreen photobiology. Considering its widespread appeal—that is, noninvasive threshold end point, relatively reproducible, UV-dose reciprocity, and short duration of exposure—it has become the standard for evaluating sunscreen products. Specifically, the SPF test measures erythema as an end point.

The protection factor, displayed as a number on most sunscreen products, is dependent on a number of variables and as such should be viewed as a relative measure, which is more meaningful as a product comparison. This is particularly true as the SPF exceeds 30 because the relationship between absorption of erythema energy versus SPF is nonlinear, as illustrated in Fig. 247-1. Despite several shortcomings of the SPF test method and labeling, it remains the most recognized efficacy measure of sunscreen products. More important, the end point—erythema—is biologically meaningful and a likely surrogate for chronic effects of UV exposure such as nonmelanoma skin cancer.

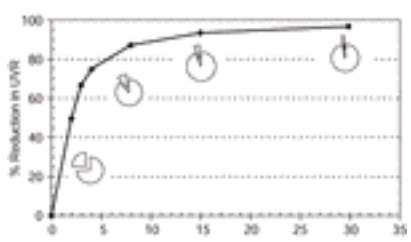

FIGURE 247-1 The theoretical effectiveness of sunscreens with different SPF values at reducing the amount of UVR reaching skin. Also shown are pie chart representations for SPFs 4, 8, 15, and 30.

Beyond erythema, long wavelengths of solar UV (i.e., >340 nm) can contribute to skin damage. This assertion is based on both clinical evidence and theoretical considerations. The studies by Lavker et al. [23], [24], Lavker and Kaidby, [25] and Lowe et al. [26] provide evidence that repeated exposure to an artificial source of long wavelength UVA produces morphologic changes in human skin indicative of photodamage. These data corroborate studies in animals where exposure to UVA was reported to accelerate photodamage [27] and the induction of skin tumors. [28], [29] Because the overwhelming majority of sunscreen products available to consumers provide protection primarily limited to UVB and short wavelength UVA II (320 to 340 nm), it has been hypothesized that the use of such products may paradoxically increase exposure to long wavelength UVA I (340 to 400 nm) [30] by selectively changing the spectrum of solar sunlight received by the skin. [31]

Given the need for long wavelength UVA protection and the absence of meaningful information regarding such protection on currently marketed sunscreen products, there is an urgent demand for a reliable, versatile, and universally applicable method that provides purposeful, SPF-independent information regarding UVA photoprotection. Several in vivo methods using human subjects have been proposed, [32], [33], [34], [35] and [36] but not widely accepted. Although there are several reasons for this, the limitation of all proposed human studies of UVA photoprotection is the absence of an end point measure that is a true surrogate marker for long wavelength (i.e., >340 nm) UVA-induced skin damage. From a more practical perspective, the existing human studies use end points that (1) are redundant with SPF testing, that is, erythema; (2) are oxygen and, by definition, UV dose-rate dependent; (3) are skin-type dependent; (4) have a high degree of variability; and (5) may require extraordinary exposures to an artificial UVA source, the human health consequences of which are unknown.

SIDE EFFECTS OF SUNSCREENS

That sunscreens, when liberally and frequently applied, [18] reduce sunburn is beyond dispute. As sunburn is the most obvious and immediate form of damage, it seems intuitively obvious that agents that reduce the intensity of the sunlight that reaches the skin must be universally protective. It is very tempting to conclude that sunscreens will also protect against other forms of damage. Support for that view stems mainly from a large body of work on hairless mice, which shows that sunscreens reduce, or at least delay the onset of, skin cancers. But the WHO is not convinced that what

applies to mice applies to men. As noted above, the WHO conclusion is that “there is sufficient evidence [in mice] for a [squamous cell carcinoma] preventive effect of sunscreen formulations,” but that corresponding evidence in humans is only “limited” and that “evidence in humans for a cancer-preventive effect [of topical sunscreens] against cutaneous malignant melanoma and basal cell carcinoma [is] inadequate.” Consequently, the recommendation that “sunscreens should not be used as a means of extending the duration of solar exposure, such as prolonging sunbathing,” sits uneasily with the perception that the sun protection factor describes the “allowable” increase in exposure. In other words, the advantage of using sunscreens to extend exposure without burning may be offset by a potential failure to protect against the skin cancer that is associated with increased exposure of skin to solar wavelengths transmitted by the sunscreen. We need to explain this paradox in which protection against one kind of damage does not necessarily confer corresponding protection against another, more serious kind. Here, it is important to distinguish indirect effects of sunscreens from potential direct effects such as sensitization reactions (Table 247-4).

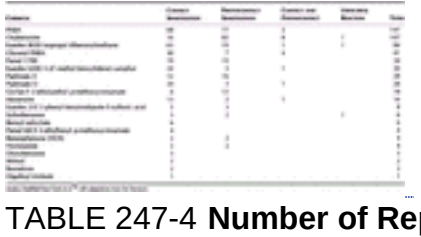

TABLE 247-4 **Number of Reports of Sunscreen Sensitization Reactions**

Indirect Effects of Photoactivated Sunscreen Ingredients

Indirect effects are largely attributable to (1) increasing exposure and (2) receiving, in consequence, unusually large doses of UVR not attenuated by the sunscreen. Until recently, many sunscreens absorbed UVB very effectively, but UVA much less effectively. Sunburn is caused almost entirely by UVB, so that sunbathers who increased their exposure according to the SPF of their sunscreens received almost as much UVA as they would have done had they not used a sunscreen and had endured the sunburn that the increased time in the sun would have caused. While the relation between UVA and carcinogenesis remains uncertain in humans, it may be that the action spectrum will turn out to be similar to that for the induction of melanoma in a hybrid fish, [37] in which case excess melanoma in sunscreen users could be ascribed simply to excess UVA.

The potential dangers of UVA led to the incorporation of UVA-absorbers in sunscreens. When examined individually in simple systems, some absorbers, both UVA and UVB, exhibit varying degrees of instability. [38] High-performance liquid chromatographic methods have been used for the comparison of the photostability of five sunscreen agents. [39] A problem with this approach is that stability depends upon the solvent used, [38] a finding that resembles the fact that widely used solvents such as ethanol and dimethylsulfoxide can quench DNA-damaging effects of some illuminated sunscreens, [40] so that when measuring photostability, studies on the actual products may be more valuable. Maier et al. showed that in 7 of 16 products exposure to simulated sunlight reduced absorption of UVA by up to 48 percent while UVB absorption was not affected. [41] Furthermore, the photochemical behavior of the products was not predictable from the ingredients, emphasizing the need for measurements on actual commercial products. Partly for such reasons, there is increasing interest in “physical” sunscreens (i.e., titanium dioxide and zinc oxide). They have the merit of photostability, are far less likely to penetrate human skin than organic sunscreens, and, unlike many organic sunscreens, do not induce allergic reactions which, although limited to a small fraction of users, can pose severe problems for those affected.

Direct Effects of Photoactivated Sunscreen Ingredients

Concern about direct effects stems from the fact that all sunscreens are energy transducers. Their function is to absorb UV energy and convert it to other forms, and for that reason the terms “sunscreen” and “sunblock” are somewhat misleading. In most cases, the mechanisms by which they absorb and convert are uncertain, but in some cases there is direct evidence for the formation of reactive oxygen species. [10] In others, free radicals are formed, [42] and the generation of excited states can be deduced from the ability of illuminated sunscreens to attack organic chemicals, [43] DNA, [44] or cells in culture. [45], [46]

Animal and epidemiologic studies have suggested a role for UVA radiation in the induction of melanoma. [37], [47] Melanin in the upper layer of the epidermis protects against direct attack by light on DNA in viable cells deeper down, but melanin found deeper down can absorb light that penetrates and, acting as a sensitizer, forms excited states that then attack DNA. If an endogenous chemical can behave in this way, an exogenous one could, too. However, most work to date on DNA damage in human cells, and its modulation by sunscreens, has concentrated on direct photoproducts rather than on other lesions such as nonligatable strand breaks. A vital point here is that while direct photoproducts are repaired by mechanisms that restore the original DNA sequence, both single- and double-strand breaks can initiate recombinogenic events, which, although regenerating an intact DNA molecule, can lead to disruption of the sequence of the gene originally affected. [48] In other words, the process of “repair” does not restore the original sequence, with potentially serious results. Such disruptions in tumor-suppressor genes are associated with various tumors, including some melanomas. [49] For these reasons it is very important to define the damage induced and to examine its consequences by using appropriate assays; concentrating on suppression of direct photoproducts may mean that other, equally important aspects are overlooked.

SUNSCREENS AND IMMUNE PROTECTION IN HUMANS

The question of whether sunscreens protect humans from the immunosuppressive effects of solar UVR, and how well, remains one of the most complex issues in sunscreen development. Animal experimentation has progressed from the

earliest studies using unfiltered UVB sources (280 to 320 nm) containing environmentally irrelevant UVC (280 to 290 nm), to solar-simulated UVR (SSUV; 290 to 400 nm), and has taught us clearly that the latter source is essential for assessing sunscreen effects. [50] Furthermore, small doses administered through highly protective sunscreens have been of limited usefulness, because this does not simulate the conditions under which humans acquire their sunlight exposure—conditions most commonly encompassing prolonged sunlight exposure (in spite of official warnings to dissuade this behavior). The available data from animal experimentation is far more substantial than from human studies, but very confusing as the results of the studies vary greatly, with the effectiveness of sunscreens in preventing immune suppression ranging from no protection, through partial protection to total protection. A comprehensive review highlights the interpretative difficulties. [51] From studies in mice, it seems that most sunscreens do afford some protection from immune suppression by UVR, but that the protection is less than that from sunburn for which the products were designed. However equivalent data in humans are lacking. Current controversies about the need to filter out the UVA waveband (320 to 400 nm) in addition to the UVB, by using broad spectrum sunscreens, were initially driven by the evidence that the UVA waveband is the prime cause of photoaging. [52] On the other hand, the contributory role of the UVA waveband to erythema, immune suppression, and carcinogenesis, remains unclear. Certainly, UVA at high doses that would not be easily attained in daily sunlight exposure, can induce erythema in humans, and even carcinogenesis in chronically exposed mice.

Several relevant immune markers and functions has been used to measure sunscreen immune protection: contact hypersensitivity (CHS) and delayed-type hypersensitivity (DTH) induced either locally at the irradiated skin site or at nonirradiated distant sites, epidermal Langerhans cell numbers, nickel allergy elicitation, or mixed epidermal cell lymphocyte reactions, combined with various UV spectra, dosages, and treatment regimes.

Sunscreen Protection from Suppression of DTH or CHS

Several studies provide evidence for protection from the immune functions by sunscreens. Simple sunscreens blocking predominantly UVB have been compared with broad spectrum sunscreens that also provide varying degrees of added UVA protection. In addition, the DTH response induced at the site of irradiation, known as the “local” response, has been compared with DTH induced at a distant nonirradiated site, known as the “systemic” response. Serre et al. [53] used an SPF 15 broad spectrum sunscreen (UVA protection factor 9) to examine protection in humans from a single exposure of 3 × MED of SSUV. The irradiation suppressed the CHS reaction to dinitrochlorobenzene (DNCB) in 50 percent of the subjects, but sunscreened SSUV did not impair the reaction at all. Moyal et al. reported that a UVB sunscreen failed to prevent both local and systemic immune suppression after repeated SSUV exposures, whereas a broad-spectrum sunscreen prevented the systemic effects and significantly reduced the local immune suppression. [54] Further trials with two sunscreens matched at SPF 9, but with different UVA protection (9 versus 2) showed that the systemic suppression induced by 10 exposures to SSUV was prevented, and the local suppression was reduced, by the superior UVA-protecting sunscreens, whereas the inferior UVA sunscreen failed to protect. [55] These findings suggested that UVA must play a more important role in establishing local immune suppression than systemic, however the possible immunologic pathways by which the local and the systemic impairments are induced remain unclear.

Other studies have used daily sunlight exposures. Moyal tested two sunscreens of different capacity: SPF 15 with UVA protection factor of 6, and SPF 30 with UVA protection factor of 12, against the sunlight suppression of the DTH reaction [56] and showed that SPF 15 did not protect, but that SPF 30 protected significantly. More recently, two SPF 25 sunscreens (with UVA protection factors of 14 versus 6) were compared in subjects treated with six daily sunlight exposures, and the superior UVA protection again prevented the suppression of DTH, while the inferior UVA sunscreen failed to protect. [55] The implication from these findings is that a higher SPF, and superior UVA protection from a broad-spectrum sunscreen, provides the best immune protection from the sun.

CHS to a topical nickel challenge in nickel-allergic subjects is suppressed by UVR, an impairment that has been used to assess the protection by sunscreens from elicitation of the existing immune response. Damian et al. compared two sunscreens with SPF of 9 and 24, and reported similar protection from the SSUV-elicited nickel reaction as predicted by the SPF. [57] This study attempted to produce SSUV dose response data and to establish, as for the sunscreen SPF, similarly derived sunscreen immune protection factors (IPF). Human subjects were irradiated with suberythemal doses of SSUV through three SPF 10 sunscreens differing in their UVA protection capacity, and their nickel allergic reactions were monitored. [58] The SSUV suppressed the nickel reaction to 35 percent, which remained unaffected by the UVB-blocking sunscreen, but the suppression was reduced to 7 to 10 percent by the broad-spectrum sunscreens. This suggested again that UVA does contribute to the systemic suppression of nickel CHS, although little is understood about the pathways involved.

Sunscreen Protection from Epidermal Langerhans Cell Depletion

An early response to UVR is the depletion of the epidermal Langerhans cells with the concomitant failure of normal antigen presentation by the skin. Measurement of Langerhans cell number has been a useful assessment of local immune competence in human skin following UV exposure, and has been used to assess sunscreen efficacy in immune protection. Le Vee et al. investigated the ability of an SPF 4 UVB-blocking sunscreen to protect from Langerhans cell depletion by increasing SSUV doses. [59] They found complete protection from 2 MED, partial protection from 4 MED, and no protection from 8 MED. Thus, protection from this immune marker appeared to match the sunscreen SPF, and it is apparent that the immune protection fails as the ratio of the SSUV dose to sunscreen SPF becomes too great.

That the depletion of the epidermal Langerhans cells might be caused primarily by UVAI (340 to 400 nm) was examined when Dumay et al. irradiated human skin with a large dose of UVAI. [60] A decreased Langerhans cell number resulted, and partial protection was observed by a predominantly UVB sunscreen. It was predicted that a higher UVA protection factor would provide better protection, but the role of UVA in Langerhans cell depletion remains unclear. Langerhans cells were also found to be significantly and chronically depleted in sun-exposed skin sites compared with sun-protected skin sites of subjects enrolled in a long-term skin cancer prevention trial, in spite of their regular sunscreen usage during

the past 3 years. This suggests that chronic immunologic damage of the skin is not prevented by sunscreens. However, further Langerhans cell depletion by recent high sun exposure in these subjects was reduced by sunscreen usage. [61]

In general, these studies lead us to believe that protection from the UVA waveband provides better immune protection for the skin. However, studies that conform to the prerequisite of the correct UV spectrum for testing sunscreen protection are few. It has also been pointed out that, in addition to the use of SSUV, dose responses need to be constructed in order to establish correct and reliable data for sunscreen protection from immune defects resulting from environmentally feasible exposures. [51] Furthermore, only limited models of immune function have been appropriately assessed in human subjects, whereas murine models have identified numerous additional immune impairments that probably apply equally to SSUV-exposed humans.

Does UVA Suppress Immunity?

A number of studies in experimental animals report that UVA has no effect on immune function when administered at suberythemogenic doses from a defined UVR source. Both hairless and haired mice have been UVA-exposed acutely or chronically for 4 weeks, and the local CHS reaction was found to be normal (Ref. [62] and references cited therein). Two studies in the marsupial *Monodelphus domestica,* also found no immunosuppression caused by UVA, [62], [63] and a study in mice and guinea pigs reported systemic potentiation of CHS by UVA. [64] When Langerhans cell structure and function were the targets in mice, these were unaffected by repeated high doses of UVAI. [65] In contrast, chronic suberythemal UVA suppressed the local, but not the systemic CHS in mice, [66] with the cumulative UVA dose equating to the innocuous UVA administered as a single exposure in other studies. [62]

In humans, UVAI resulted in Langerhans cell depletion from the epidermis and reduced epidermal antigen-presenting cell function, [60] as did UVAII. [67] However, Dittmar et al. reported that UVAI did not alter the mixed epidermal cell leukocyte reaction in human subjects, nor the functional upregulation of Langerhans cell costimulatory molecules. [68] Skov et al. described a decrease in the production of the immunosuppressive cytokine tumor necrosis factor (TNF)-a in suction blister fluid from UVAI-irradiated human skin, as compared to an increase in TNF-a release in response to UVB. [69] In cultured human keratinocytes, UVA caused the release of the proinflammatory immune-protective cytokine interleukin (IL)-12, with no evidence of release of immunosuppressive IL-10. [70] That the human immune-altering effects of UVA and UVB differ was suggested by an altered time course for detectable UVA immunosuppression compared with UVB, and the transience of the UVA-induced defect reported by Damian et al. [71]

Does UVA Modify UVB-Induced Damage?

Some recent studies in mice indicate that immunologically innocuous suberythemal UVA effectively protects from the immunosuppressive effect of UVB by inactivating the immunosuppressive pathways initiated by *cis*-urocanic acid produced in the epidermis by UVR. [62], [72], [73] The immune function was assessed either by the systemic CHS reaction or by the DTH reaction to infection by *Listeria* monocytogenes. These observations are consistent with a moderating function of UVA on other UVB effects, such as from UVB-induced erythema, melanogenesis, and photocarcinogenesis observed in mice. [74] A pioneering study of photocarcinogenesis in hairless mice some years ago also noted an apparent UVA protective effect, although the authors had no plausible explanation for this observation at the time. [75]

It is important to obtain evidence for such waveband interactions in human skin. Evidence has existed, almost unnoticed for many years, of an ameliorating effect of UVA-induced pigmentation on UVB-induced erythema and sunburn cell formation in human subjects. [76] Most convincingly, Skov et al. provided the first study in which pretreatment with UVAI significantly reduced the UVB-induced suppression of CHS to diphenylcyclopropenone in 22 subjects. [77] Thus far the evidence is sparse and needs further confirmation in human subjects. If substantiated, it might argue against the use of broad-spectrum sunscreens for optimal immune protection from solar UV.

Unfortunately, the data regarding sunscreen prevention of immune suppression by solar UVR in humans are few and inconsistent. Until there is further clarification of the immunosuppressive role of the UVA and the potential interactions of the UVA and UVB wavebands, it is difficult to assess or design improvements for immune protection by topical sunscreens. More human studies with appropriate sources and rigorous treatment regimens that enable reliable comparisons to be made between sunscreens offering differing UVB and UVA protection factors, as well as different active ingredients and/or vehicles, are urgently needed.

REFERENCES

1. Gasparro FP, editor. *Sunscreen Photobiology*. Georgetown, TX RG Landes Co, Medical Intelligence Unit, 1997

2. Gasparro FP et al: A review of sunscreen safety and efficacy. *Photochem Photobiol* **68**:243, 1998

3. Gasparro FP: Sunscreens, skin photobiology, and skin cancer: The need for UVA protection and evaluation of efficacy. *Environ Health Perspect* **108**(Suppl 1):71, 2000

4. Gasparro FP: Photodermatology: Progress, problems, and prospects. *Eur J Dermatol* **10**:250, 2000

5. Food and Drug Administration: Sunscreen drug products for over-the-counter human use. Tentative final monograph, Proposed rule. Fed Reg, vol 64, No 98, May 21, 1999, p 27666

6. Fairhurst D, Miltchnick MA: Particulate sunblocks: General principles, in *Sunscreens: Development, Evaluation, and Regulatory Aspects,* 2d ed, edited by NJ Lowe et al. New York, Marcel Dekker, 1997, p 313

7. Liffrig JR: Phototrauma prevention. *Wilderness Environ Med* **12**(3):195, 2001

8. Fischetti M: Tan or burn. *Sci Am* **285**:91 2001

9. International Agency for Research on Cancer: *IARC Handbooks of Cancer Prevention,* vol 5, Sunscreens, edited by H Vainio, F Bianchini. Lyon, World Health Organization, 2001

10. Martincigh BS et al: Sunscreens: The molecules and their photochemistry, in *Sunscreen Photobiology,* edited by FP Gasparro. New York, Springer, 1997

11. Sayre RM et al: Physical sunscreens. *J Soc Cosmet Chem* **41**:103, 1990

12. Fairhurst D: Surface coating and the optimization of microfine oxides in sunscreen formulations. *Cosmet Toilet* **112**:81, 1997

13. Ferguson J: European guidelines (COLIPA) for evaluation of sun protection factors, in *Sunscreens: Development, Evaluation, and Regulatory Aspects,* 2nd ed, edited by NJ Lowe, NA Shaath, MA Pathak. New York, Marcel Dekker, 1997, p 513

14. Cole C: Sunscreen protection in the ultraviolet A region: How to measure effectiveness. *Photodermatol Photoimmunol Photomed* **17**:2, 2000

15. Forestier S: Sunscreens in vivo versus in vitro testing: Pros and cons, in *Measurements of Optical Radiation Hazards,* edited by R Matthes, D Sliney. International Commission on Non-Ionizing Radiation Protection, 1998, p 413

16. Brown S, Diffey BL: The effect of applied thickness on sunscreen protection: In vivo and in vitro studies. *Photochem Photobiol* **44**:509, 1986

17. Marginean G et al: New ex vivo method of evaluating the photoprotective efficacy of sunscreens. *Int J Cosmet Sci* **17**:233, 1995

18. Diffey BL: Sunscreens and UVA Protection: A major issue of minor importance. *Photochem Photobiol* **74**:61, 2001

19. Diffey BL: Has the sun protection factor had its day? *BMJ* **320**:176, 2000

20. Diffey BL: When should sunscreen be reapplied? *J Am Acad Dermatol* **45**:882, 2001

21. Mackie RM: *Skin Cancer,* 2nd ed. London, Martin Dunitz 1996, p 331

22. de Gruijl F: Biological action spectra. *Radiat Protect Dosimetry* **91**:57, 2000

23. Lavker RM et al: Cumulative effects from repeated exposures to suberythemal doses of UVB and UVA in human skin. *J Am Acad Dermatol* **32**:53, 1995

24. Lavker RM et al: Quantitative assessment of cumulative damage from repetitive exposures to suberythemogenic doses of UVA in human skin. *Photochem Photobiol* **62**:348, 1995

25. Lavker R, Kaidbey K: The spectral dependence for UVA-induced cumulative damage in human skin. *J Invest Dermatol* **108**:17, 1997

26. Lowe NJ et al: Low doses of repetitive ultraviolet A induced morphologic changes in human skin. *J Invest Dermatol* **105**:739, 1995

27. Bissett DL et al: Wavelength dependence of histological, physical, and visible changes in chronically UV-irradiated hairless mouse skin. *Photochem Photobiol* **50**:763, 1989

28. Harrison JA et al: Sunscreens with low sun protection factor inhibit ultraviolet B and A photoaging in the skin of the hairless albino mouse. *Photodermatol Photoimmunol Photomed* **8**:12, 1991

29. Sterenborg HJCM, van der Leun JC: Tumorigenesis by a long wavelength UV-A source. *Photochem Photobiol* **51**:325, 1990

30. Autier P et al: Sunscreen use and duration of sun exposure: A double-blind randomized trial. *J Natl Cancer Inst* **91**:1304, 1999

31. Diffey BL: The need for sunscreens with broad-spectrum protection, in *Biological Responses to Ultraviolet A Radiation,* edited by F Urbach. Overland Park, KS, Valdenmar Publishing, 1992, p 321

32. Kaidbey K, Gange RW: Comparison of methods for assessing photoprotection against ultraviolet A in vivo. *J Am Acad Dermatol* **16**:346, 1987

33. Roelandts R: Evaluating the UVA protection of sunscreens. *J Am Acad Dermatol* **21**:56, 1989

34. Roelandts R: Shedding light on sunscreens. *Clin Exp Dermatol* **23**:147, 1998

35. Standfield JW et al: Ultraviolet A sunscreen evaluations in normal subjects. *J Am Acad Dermatol* **20**:744, 1989

36. Cole C: Sunscreen protection in the ultraviolet A region: How to measure the effectiveness. *Photodermatol Photoimmunol Photomed* **17**:2, 2001

37. Setlow RB et al: Wavelengths effective in induction of malignant melanoma. *Proc Natl Acad Sci U S A* **90**:6666, 1993

38. Schwack A, Rudolf T: Photochemistry of dibenzoyl methane UVA filters Part 1 . *J Photochem Photobiol B* **47**:229, 1995

39. Vanquerp V et al: High-performance liquid chromatographic method for the comparison of the photostability of five sunscreen agents. *J Chromatogr A* **832**:273, 1999

40. McHugh PJ, Knowland J: Characterization of DNA damage inflicted by free radicals from a mutagenic sunscreen ingredient and its location using an in vitro genetic reversion assay. *Photochem Photobiol* **66**:276, 1997

41. Maier H. et al: Change of ultraviolet absorptance of sunscreens by exposure to solar simulated radiation. *J Invest Dermatol* **117**:256, 2001

42. Damiani E et al: Nitroxide radicals protect DNA from damage when illuminated in vitro in the presence of dibenzoylmethane and a common sunscreen ingredient. *Free Radical Biol Med* **26**:809, 1999

43. Dunford R et al: Chemical oxidation and DNA damage catalysed by inorganic sunscreen ingredients. *FEBS Letts* **418**:87, 1997

44. Stevenson C, Davies RJH: Photosensitization of guanine-specific DNA damage by 2-phenylbenzimidazole and the sunscreen agent 2-phenylbenzimidazole-5-sulfonic acid. *Chem Res Toxicol* **12**:38, 1999

45. Xu C et al: Photosensitisation of the sunscreen octyl *p*-dimethylaminobenzoate by UVA in human melanocytes but not in keratinocytes. *Photochem Photobiol* **73**:600, 2001

46. Gulston M, Knowland J: Illumination of human keratinocytes in the presence of the sunscreen ingredient Padimate-O and through an SPF 15 sunscreen reduces direct photodamage to DNA but increases strand breaks. *Mutat Res* **444**:49, 1999

47. Moan J et al: Epidemiological support for an hypothesis for melanoma induction indicating a role for UVA radiation. *Photochem Photobiol* **70**:243, 1999

48. Friedberg EC et al: *DNA Repair and Mutagenesis*. Washington, DC, ASM Press, 1995

49. Hayward NK: The current situation with regard to human melanoma and genetic inferences. *Curr Opin Oncol* **8**:136, 1996

50. Roberts LK et al: Ultraviolet spectral energy differences affect the ability of sunscreen lotions to prevent ultraviolet-radiation-induced immunosuppression. *Photochem Photobiol* **63**:874, 1996

51. Wolf P, Kripke ML: Immune aspects of sunscreens in *Sunscreen Photobiology: Molecular, Cellular, and Physiological Aspects,* edited by F Gasparro. Georgetown, TX, Landes Bioscience, 1997, p 99

52. Lowe NJ et al: Low doses of repetitive ultraviolet A induce morphological changes in human skin. *J Invest Dermatol* **105**:739,1995

53. Serre I et al: Immunosuppression induced by acute solar-simulated ultraviolet exposure in humans—Prevention by a sunscreen with a sun protection factor of 15 and high UVA protection. *J Am Acad Dermatol* **37**:187, 1997

54. Moyal D et al: Immunosuppression induced by chronic solar-simulated irradiation in humans and its prevention by sunscreens. *Eur J Dermatol* **7**:223, 1997

55. Moyal DD, Fourtanier AM: Broad-spectrum sunscreens provide better protection from the suppression of the elicitation phase of delayed-type hypersensitivity response in humans. *J Invest Dermatol* **117**:1186, 2001

56. Moyal D: Immunosuppression induced by chronic ultraviolet irradiation in humans and its prevention by sunscreens. *Eur J Dermatol* **8**:209, 1998

57. Damian DL et al: Measurement of in vivo sunscreen immune protection factors in humans. *Photochem Photobiol* **70**:910, 1999

58. Damian DL et al: Broad-spectrum sunscreens provide greater protection against ultraviolet-radiation-induced suppression of contact hypersensitivity to a recall antigen in humans. *J Invest Dermatol* **109**:146, 1997

59. LeVee GJ et al: Effect of sunscreen on human immunosuppression by simulated solar radiation. *J Invest Dermatol* **104**:600, 1995

60. Dumay O et al: Ultraviolet A-1 exposure of human skin results in Langerhans cell depletion and reduction of epidermal antigen-presenting function: Partial protection by a broad spectrum sunscreen. *Br J Dermatol* **144**:1161, 2001

61. Neale R et al: Sun exposure, sunscreen, and their effects on epidermal Langerhans cells. *Photochem Photobiol* **66**:260, 1997

62. Reeve VE et al: Ultraviolet A radiation (320–400nm) protects hairless mice from immunosuppression induced by ultraviolet B radiation (280–320nm) or *cis*-urocanic acid. *Int Arch Allergy Immunol* **115**:316, 1998

63. Applegate LA et al: Identification of the molecular target for the suppression of contact hypersensitivity by ultraviolet radiation. *J Exp Med* **170**:1117, 1989

64. Morison WL et al: Effect of sunlight and its component wavebands on contact hypersensitivity in mice and guinea pigs. *Photodermatol* **2**:195, 1985

65. Gruner S et al: Studies on the effects of a high dose UVA-1 radiation therapy on surface and function of epidermal Langerhans cells. *Arch Dermatol Res* **285**:283, 1993

66. Bestak R, Halliday GM: Chronic low-dose UVA irradiation induced local suppression of contact hypersensitivity, Langerhans cell depletion and suppressor cell activation in C3H/HeJ mice. *Photochem Photobiol* **64**:969, 1996

67. LeVee GJ et al: UVAII exposure of human skin results in decreased immunization capacity, increased induction of tolerance and a unique pattern of epidermal antigen-presenting cell alteration. *Photochem Photobiol* **65**:622, 1997

68. Dittmar HC et al: In vivo UVA-1 and UVB irradiation differentially perturbs the antigen-presenting function of human epidermal Langerhans cells. *J Invest Dermatol* **112**:322, 1999

69. Skov L et al: Contrasting effects of ultraviolet A1 and ultraviolet B exposure on the induction of tumour necrosis factor-alpha in human skin. *Br J Dermatol* **138**:216, 1998

70. Kondo S, Jimbow K: Dose-dependent induction of IL-12 but not IL-10 from human keratinocytes after exposure to ultraviolet light A. *J Cell Physiol* **177**:493, 1998

71. Damian DL et al: Low-dose UVA and UVB have different time course for suppression of contact hypersensitivity to a recall antigen in humans. *J Invest Dermatol* **112**:939, 1999

72. Reeve VE et al: Interferon-gamma is involved in photoimmuno-protection by UVA (320 to 400nm) radiation in mice. *J Invest Dermatol* **112**:945, 1999

73. Garssen J et al: UVA exposure affects UVB and *cis*-urocanic acid-induced systemic suppression of immune responses in *Listeria* monocytogenes-infected Balb/c mice. *Photochem Photobiol* **73**:432, 2001

74. Bech-Thomsen N et al: Pre-treatment with long wavelength ultraviolet light inhibits ultraviolet-induced skin tumor development in hairless mice. *Arch Dermatol* **124**:1215, 1988

75. Forbes PD et al: Experimental ultraviolet photocarcinogenesis: Wavelength interactions and time-dose relationships. *Natl Cancer Inst Monogr* **50**:31, 1978

76. Roser-Maass E et al: Protection against UV-B by UV-A-induced tan. *Arch Dermatol* **118**:483, 1982

77. Skov L et al: Long-wave UVA offers partial protection against UVB-induced immune suppression in human skin. *APMIS* **108**:825, 2000

78. Funk JO et al: Contact sensitization and photocontact sensitization of sunscreening agents, in *Sunscreens: Development, Evaluation, and Regulatory Aspects,* 2d ed, edited by NJ Lowe et al. New York, Marcel Dekker, 1997, p 631

T>

Chapter 248

Howard Baden Lynn Baden

Keratolytic Agents

GENERAL PRINCIPLES OF KERATOLYSIS
KERATOLYTIC AGENTS
MECHANISM
RETINOIDS AS KERATOLYTICS
SPECIAL KERATOLYTICS

REFERENCES

Keratolysis describes the shedding of stratum corneum cells, although the rate of loss varies in different body areas. [1] The adhesion of viable epidermal cells is primarily a result of the interaction of desmosomes [2] and cadherins, [3] calcium-dependent glycoproteins, on the surfaces of adjacent cells. The intercellular structures of cells change in the stratum corneum, with modification of desmosome morphology and secretion of lamellar bodies rich in nonpolar lipids, giving rise to an orderly layered structure. [4] There is evidence that the lipids are cross-linked to the cornified envelopes by ester bonds. [5] A number of hydrolytic enzymes are also present in the secreted lamellar bodies, and these are thought to play a role in natural keratolysis. [6] The desmosomes undergo a progressive series of morphologic changes in the upper layers of the stratum corneum, leading to their apparent disappearance. In diseases associated with hyperkeratosis, the progressive alteration in desmosome morphology is markedly lessened, pointing to their role in cell adhesion. [7], [8]

The mechanism by which the intercellular lipid, covalently linked to the cornified envelope of one cell, is bound to lipids attached to adjacent cells has not been clarified. Extraction of stratum corneum in vitro with organic solvents followed by aqueous solutions, even when they contain a surface-active agent or detergent, does not disperse the tissue into a single cell suspension. This extraction removes considerable intercellular lipid, but it is hypothesized that the residual lipid covalently linked to the envelope alters the configuration of the surface, so that dispersion by aqueous solvents is not possible. However, prolonged treatment of trypsin-treated stratum corneum with an aqueous solution of sodium lauryl sulfate does result in such dispersion. The use of a proteolytic enzyme may alter structural proteins attached to lipids or activate other hydrolytic processes in the intercellular spaces.

GENERAL PRINCIPLES OF KERATOLYSIS

Accumulation of excessive stratum corneum is a common problem; it may be a result of a primary disorder of keratinization such as ichthyosis vulgaris, or a result of a secondary change in the epidermis, as in cutaneous fungal infection. The clinical presentation is a scaly, white skin surface, which often results in shedding of stratum corneum when the skin is rubbed. The color is white because of light scattering from air trapped in the scale; the normal skin color can be restored by moistening the skin or rubbing on a lubricant that displaces the air.

Removal of the excess stratum corneum necessitates loosening the cohesive attachment of the cornified cells by topical treatment followed by mechanical débridement. When thickening of the stratum corneum is minimal, this may be accomplished by applying a cream or ointment that moisturizes the skin by the addition of water and/or produces an occlusive film that prevents loss of water, which has diffused outward from below. Numerous products sold as moisturizers or emollients can accomplish this. The increased water content allows the normal mechanism of cell separation described above to occur, and gentle rubbing of the skin during bathing mechanically removes the cornified tissue. Such a treatment is particularly effective for the xerosis that occurs during the winter months in cold regions of the country. Water-binding materials added to moisturizing creams are said to diffuse into the stratum corneum and help bind water. Two common compounds used for this purpose are urea [9] and lactic acid. [10] The latter is much more widely used and is an example of an a-hydroxy acid, discussed below. [11] These are generally well tolerated except in young children in whom a-hydroxy acids often cause a burning sensation. Glycerin has also been used to increase water binding and has been shown to result in enhanced desmosomal degradation. [12]

KERATOLYTIC AGENTS

The oldest keratolytic agent used in dermatology is salicylic acid, which is usually prepared in an ointment or cream base at a concentration of 3 to 6%. [13] Salicylic acid decreases the cell-to-cell cohesion as measured by the ease by which layers of cells can be stripped from the surface of treated skin. Excessive use of ointments containing salicylic acid can result in salicylism and its use should not exceed 30 g of a 6% preparation in a 24-h period. This is especially important in children.

The application of propylene glycol at a concentration of 40 to 60% in water will result in the removal of scales, particularly when used under an occlusive plastic dressing. Although the glycol is not toxic, an occasional patient may develop an unpleasant burning sensation of the skin with its use. Propylene glycol has been used at lower concentrations with organic acids, and that combination has proved effective.

Lactic acid, in addition to being a humectant, acts as a keratolytic agent and results in the separation of stratum corneum cells as judged by the peeling off of scales from the surface of the skin. Stirring stratum corneum in solutions of lactic acid results in the release of desmogleins, suggesting that its mode of action is breakdown of desmosomes. Lactic acid

comes in a variety of commercial preparations and can be sold over the counter at a concentration of no higher than 5%. Epilyt, which is a liquid preparation containing 5% lactic acid and propylene glycol as the active agents, is extremely effective relieving the symptoms of dryness and removing scales [14] (Fig. 248-1). Being a liquid preparation, it can be easily used in the scalp to remove scales and has been a popular treatment for the management of seborrheic dermatitis and psoriasis. It is applied to the scalp at bedtime and shampooed out in the morning. A popular prescription cream preparation of lactic acid (Lac-Hydrin) contains 12% lactate neutralized to pH 5.0 in order to make a stable emulsion possible. [15] One can compound lactic acid at different concentrations in a suitable base such as Aquaphor. Adults will tolerate concentrations up to 12%, and this is very effective in scale removal. If the ointment is applied to moist skin, as after a bath, it spreads much more easily and is more cosmetically acceptable to the patient. Lactic acid in Aquaphor is well tolerated by children, particularly at low concentrations of the acid.

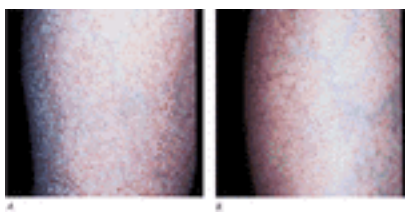

FIGURE 248-1 *A* and *B.* Treatment of ichthyosis vulgaris with Epilyt twice a day for 1 week; before (*A*) and after (*B*) treatment.

Lactic acid is an a-hydroxy acid, and this family of acids has received considerable attention as peeling agents for sun-damaged skin. The a-hydroxy acids derive their name from the presence of a hydroxyl group on the a carbon atom. Glycolic acid [16] is probably the most popular as judged from the number of products that have appeared on the market. There is no compelling evidence, however, indicating an advantage of one acid over another; the ability of an acid to loosen scales is more related to its concentration and the composition of the base in which it is compounded. Molecular weights and dissociation constants of glycolic and lactic acids are almost identical. In general, more anhydrous preparations are less irritating and allow the use of higher concentrations of acid without side effects.

Some general principles must be kept in mind in considering the use of keratolytic agents. A plastic occlusive dressing, although not necessary, in many situations will enhance the therapeutic effect and result in more rapid and complete clearing. In treating the palmoplantar surface, occlusive dressings are essential and little effect will be observed without their use. In treating the scalp, wearing a lightweight plastic shower cap enhances the effect of the treatment and prevents staining of the pillow. In combining topical corticosteroids with keratolytics, as in the management of psoriasis, it is important to choose a drug that is stable in the presence of acid (e.g., fluocinolone). Although keratolytic agents loosen scales, they do not dissolve them, so that mechanical removal is necessary. Patients should be told to rub the skin with a washcloth or rough sponge while bathing. This will result in the shedding of large quantities of scale after the skin has been treated for several days.

Children are very sensitive to a-hydroxy acid, and small areas of the skin should be tested before applying it over wide areas. The irritation occurs rather quickly, so it is easy to determine whether a particular product is a problem. This sensitivity usually disappears at the time of puberty. It must be remembered that salicylic acid can be absorbed through the stratum corneum, and no more than 2.0 g of salicylic acid should be applied to a child's skin over a 24-h period.

MECHANISM

The mechanism of action of all organic acids is thought to be the same, and release of desmogleins indicating disintegration of the desmosomes is a consistent finding. It is possible that the acids work directly by solubilizing the protein components of desmosomes. An alternative explanation is that they activate an endogenous proteolytic or other hydrolytic enzyme as a result of a change in pH. However, no acid proteases have been described in the stratum corneum. [17] The desmosome is unlikely to be the only site of action of the acids, because the lipid layer between cells is important in holding cells together. Furthermore, in some of the ichthyoses (e.g., X-linked), it would appear that an abnormality of the lipid layer is responsible for increased coherence of cells, so one would not expect disintegration of the desmosomes by acids to result in cell separation. It seems likely that, in addition to a direct effect on desmosomes, there is an indirect one involving activation of some endogenous pathway responsible for normal cell separation.

RETINOIDS AS KERATOLYTICS

Retinoids exhibit a keratolytic effect, but this is mediated by alteration in the keratinization pathways in the epidermis. This has been demonstrated for retinoic acid used topically and acitretin and isotretinoin given orally. The application of retinoic acid to the skin of patients with psoriasis and ichthyosis resulted in shedding of thickened stratum corneum. [18] Later studies using retinoic acid for acne suggested loss of cohesion of cornified cells in the sebaceous duct. [19] A side effect of the treatment was scaling of the skin, indicating loss of cell cohesion in the interfollicular stratum corneum. Retinoic acid is now approved for the treatment of photoaging, and a number of changes in the epidermis have been reported. The stratum corneum changed from a basket-weave structure to a more compact form. [20] There was a reduction in turnover time of the stratum corneum and an increase in transepidermal water loss. Altered cell surface glycosylation has been reported as well. Patients with photoaging have reported a smoother feel to the skin surface and removal of keratotic lesions. [21] Tazarotene is a new topical retinoid with keratolytic effects that is effective in acne and psoriasis.

Isotretinoin is used to treat a number of inherited disorders of keratinization and has proven very effective in reducing the thickness of the stratum corneum in, for example, lamellar ichthyosis (Fig. 248-2). [22] The mechanism for this decrease in cell cohesion is unknown, but reduction in the number of desmosomes and altered glycosylation of cell surface proteins

has been mentioned. Acitretin has had a similar effect on the scale of patients with psoriasis and in addition has resulted in clearing of the lesions.

FIGURE 248-2 Treatment of lamellar ichthyosis (*A*) with isotretinoin at 2 mg/kg per day for 6 weeks (*B*).

SPECIAL KERATOLYTICS

The hyperkeratosis associated with calluses, clavi, and warts is treated with high concentrations of salicylic and/or lactic acid in a liquid formulation or incorporated into a tape. A 40 percent salicylic acid preparation in tape is available, which results in marked softening of these lesions. They can then be abraded to remove the hyperkeratotic surface. A personal preference is to mix an equal volume of flexible collodion and 85% lactic acid. After thorough stirring, the solution is applied to the lesion, allowed to dry, and covered with waterproof tape. The lesion is mechanically débrided following hydration on a regular basis. This process is extremely effective in removing thickened stratum corneum, but can be very irritating if applied to normal skin. The softened thick skin must be hydrated before it is removed with an abrasive such as a pumice stone.

Hyperkeratosis of the nail bed has been treated by an ointment containing 40% urea, 5% paraffin, 20% anhydrous lanolin, 25% white petrolatum, and 10% silica gel type H. [23] The normal skin around the nail is protected by adhesive tape. The urea ointment is applied to the involved nail, covered with an occlusive dressing, and left in place for 1 week. The treated nail is then soaked in water and the keratotic material removed by gentle brushing. A second application may be necessary. Others have modified the ointment without much change in efficacy.

REFERENCES

1. Dover R, Wright NA: The cell proliferation kinetics of the epidermis, in *Physiology, Biochemistry, and Molecular Biology of the Skin,* 2nd ed, edited by LA Goldsmith. New York, Oxford University Press, 1991, p 239

2. Steinberg MS et al: On the molecular organization, diversity and functions of desmosomal proteins, in *Junctional Complexes of Epithelial Cells,* edited by G Bock, S Clark. New York, Wiley, 1987, p 3

3. Horiguchi Y et al: Ultrastructural localization of E-cadherin cell adhesion molecule on the cytoplasmic membrane of keratinocytes in vivo and in vitro. *J Histochem Cytochem* **42**:1333, 1994

4. Elias PM, Feingold KR: Lipids and the epidermal water barrier: Metabolism regulation and pathophysiology. *Semin Dermatol* **11**:176, 1992

5. Lazo ND et al: Lipids are covalently attached to rigid corneocyte protein envelopes existing predominantly as beta-sheets: A solid-state nuclear magnetic resonance study. *J Invest Dermatol* **105**:296, 1995

6. Menon GK et al: Lamellar bodies as delivery systems of hydrolytic enzymes: Implications for normal and abnormal desquamation. *Br J Dermatol* **126**:337, 1992

7. Suzuki Y et al: The role of proteases in stratum corneum: Involvement in stratum corneum desquamation. *Arch Dermatol Res* **286**:249, 1994

8. Elsayed AH et al: Stereological studies of desmosomes in ichthyosis vulgaris. *Br J Dermatol* **126**:24, 1992

9. Muller KH, Pflugshaupt C: Urea in dermatology I. *Hautarzt* **40**(Suppl 9):1, 1989

10. Van Scott EJ, Yu RJ: Control of keratinization with alpha-hydroxy acids and related compounds. I. Topical treatment of ichthyotic disorders. *Arch Dermatol* **110**:586, 1974

11. Van Scott EJ, Yu RJ: Alpha hydroxy acids: Procedures for use in clinical practice. *Cutis* **43**:222, 1989

12. Rawlings A et al: The effect of glycerol and humidity on desmosome degradation in stratum corneum. *Arch Dermatol Res* **287**:457, 1995

13. Loden M et al: Distribution and keratolytic effect of salicylic acid and urea in human skin . *Skin Pharmacol* **8**:173, 1995

14. Baden HP: Management of scaly skin with Epilyt, in *Seminars in Dermatology, Dermatopharmacology, and Therapeutics,* vol 6, edited by HI Maibach. Philadelphia, Grune & Stratton, 1987, p 55

15. Wehr R et al: Controlled two-center study of lactate 12 percent lotion and a petrolatum-based cream in patients with xerosis. *Cutis* **37**:205, 1986

16. Stiller MJ et al: Topical 8% glycolic acid and 8% L-lactic acid creams for the treatment of photodamaged skin: A double-blind vehicle-controlled clinical trial. *Arch Dermatol* **132**:631, 1996

17. Suzuki Y et al: The role of two endogenous proteases of the stratum corneum in degradation of desmoglein-1 and their reduced activity in the skin of ichthyotic patients. *Br J Dermatol* **134**:460, 1996

18. Frost P, Weinstein GD: Topical administration of vitamin A acid for ichthyosiform dermatoses and psoriasis. *JAMA* **207**:1863, 1969

19. Tagami H et al: Functional assessment of the stratum corneum under the influence of oral aromatic retinoid (etretinate) in guinea-pigs and

humans: Comparison with topical retinoic acid treatment . *Br J Dermatol* **127**:470, 1992

20. Ellis CN et al: Sustained improvement with prolonged topical tretinoin (retinoic acid) for photoaged skin. *J Am Acad Dermatol* **23**:629, 1990

21. Griffiths CE et al: Topical retinoic acid changes the epidermal cell surface glycosylation pattern towards that of a mucosal epithelium. *Br J Dermatol* **134**:431, 1996

22. Baden HP et al: Treatment of ichthyosis with isotretinoin. *J Am Acad Dermatol* **6**:716, 1982

23. South DA, Farber E: Urea ointment in nonsurgical avulsion of nail dystrophies: Reappraisal. *Cutis* **21**:609, 1980

T>

Chapter 249

Lesley Clark-Loeser Ken Washenik Jerome Shupack

Topical Cytotoxic Agents

5-FLUOROURACIL
MECHLORETHAMINE (NITROGEN MUSTARD)
BCNU (CARMUSTINE)
VINBLASTINE
BLEOMYCIN

REFERENCES

5-FLUOROURACIL

5-Fluorouracil (5-FU) has been used in clinical practice since the 1960s and has proved to be efficacious as a topical cytotoxic drug for a variety of diseases. Current developments in the use of this drug focus on different methods of delivery and use in an increasing variety of skin diseases. 5-FU is a structural analogue of thymine, halogenated with fluorine at position 5. It interferes with pyrimidine metabolism and action by conversion to 5-fluoro-2'-deoxyuridine-5'-phosphate (F-dUMP). F-dUMP is a potent inhibitor of thymidylate synthetase; thus, DNA synthesis is blocked. 5-FU itself is also incorporated into RNA and DNA.

Systemic absorption of topically applied 5-FU is limited to approximately 6 percent of the applied dose. [1] Absorption is selectively higher from abnormal skin than from surrounding normal skin. [2] Normal skin appears to be unaffected clinically, but there are ultrastructural changes. [1] Systemic effects of 5-FU include nausea and anorexia, stomatitis, diarrhea, myelosuppression, alopecia, neurologic manifestations, and cardiac toxicity.

Topical or parenteral 5-FU should not be used in patients with dihydropyrimidine dehydrogenase (DHD) enzyme deficiency, [3] a rare pharmacogenetic syndrome that is inherited as an autosomal codominant trait. Approximately 3 to 5 percent of the population may be heterozygous for the syndrome. Because 80 to 90 percent of an administered dose of 5-FU is catabolized by the enzyme DHD, DHD enzyme deficiency can result in elevated systemic levels of 5-FU, leading to cytotoxic activity and potential toxicities. Rarely, life-threatening toxicities such as diarrhea, neutropenia, and neurotoxicity occur following intravenous administration of 5-FU in patients with DHD deficiency. A case of life-threatening systemic toxicity in a DHD deficient patient after treatment with topical 5-FU has been reported. This patient was found to be homozygous for the mutation. Homozygosity for the mutation appears to be the most common one responsible for DHD deficiency. Symptoms included severe abdominal pain, bloody diarrhea, vomiting, fever, and chills. Physical examination revealed stomatitis, erythematous skin rash, neutropenia, thrombocytopenia and inflammation of the esophagus, stomach, and small bowel. After cessation of treatment, the patient experienced a complete reversal of the toxicity. Although this case was observed when 5% fluorouracil cream was used, it is unknown whether patients with profound DHD enzyme deficiency would develop systemic toxicity with lower concentrations of topically applied fluorouracil. [3] Currently, phenotypic and genotypic tests to diagnose DHD deficiency exist. However, these tests are complex and labor intensive and cannot be recommended for routine screening. For further information and updated references visit http://www.dpdenzyme.com/. [3]

Topical 5-FU is commercially available as a solution (1%, 2%, and 5%) and as a cream (0.5%, 1%, and 5%). A 20% ointment can be compounded by using commercially available intravenous 5-FU solution. The intravenous solution can also be used for intralesional injection. Side effects of the topical preparation are generally local cutaneous reactions of irritation, erythema, pain, swelling, pruritus, hyper- and hypopigmentation, allergic contact dermatitis, and photosensitivity. Unusual reactions may include onycholysis, onychodystrophy, and the appearance of telangiectasias. [1] The use of injectable preparations may be complicated by local ulceration, erosion, and desquamation.

Successful use of topical 5-FU has been reported in many skin diseases (Table 249-1); however, its use is most established in the treatment of actinic keratoses, [4] particularly in patients with many lesions. It is used twice daily until an inflammatory response is seen, usually 2 to 4 weeks. This inflammation of actinic keratoses is also seen in patients undergoing systemic 5-FU treatment for malignancy, and it is this observation that initially led to the development of the drug as a topical treatment for actinic keratoses. Pretreatment with a keratolytic agent may be useful for particularly hyperkeratotic lesions. Irritation during treatment sometimes requires reduction or interruption of treatment and the addition of emollients or topical steroids. Another strategy to reduce irritant dermatitis caused by 5-FU is weekly pulse dosing. This involves applying the medication for 1 to 2 days per week for 6 to 7 weeks. [5] During 5-FU treatment, other actinic keratoses may be revealed, and basal and squamous cell carcinomas may become unmasked. [6] Occasionally the therapeutic response is inadequate, and occlusive dressings, more frequent applications, prolonged therapy, or the use of an adjunctive agent such as tretinoin cream is required. Continuous use of 5-FU as a prophylactic measure for actinic keratoses is not of proven benefit, [6], [7] and [8] although its use in xeroderma pigmentosum has been advocated. There are reports of cutaneous resistance to 5-FU treatment after 18 months of use. [9]

Precancerous lesions
Actinic keratoses
Actinic cheilitis, leukoplakia
Radiodermatitis
Xeroderma pigmentosum
Bowen's disease
Bowenoid papulosis
Erythroplasia of Queyrat
Porokeratosis of Mibelli*
Tumors
Keratoacanthoma
Warts
Basal cell carcinoma
Dermatoses
Psoriasis
Darier's disease
Pityriasis rubra pilaris
Kyrle's disease

*On rare occasion, porokeratosis of Mibelli is associated with Bowen's disease, squamous cell carcinoma, and invasive squamous cell carcinoma.

TABLE 249-1 **Diseases in Which 5-Fluorouracil Is Useful**

Basal cell carcinomas have been extensively investigated for treatment with topical 5-FU. [3] Some researchers report adequate tumor clearance, [10] but others find unacceptable recurrence rates and persistence of tumor on biopsy. [11] The 5% cream is approved by the US Food and Drug Administration for treatment of superficial basal cell carcinomas.

Warts such as verrucae vulgaris, verrucae plana, plantar warts, and condylomata acuminata, can be treated with varying response rates to topical and intralesional injection of 5-FU. Condyloma acuminata have been reported to have response rates to topical 5-FU of up to 69 percent in men and 90 percent in women. [12], [13] Most clinicians, however, would reserve this treatment for warts not easily treated with conventional therapy or for recalcitrant or extensive condylomata. [14]

Actinic cheilitis and mucosal leukoplakia have been well managed with topical 5-FU. [15], [16] and [17] Topical treatment of the lip has the advantage of good cosmetic results, and it may preclude the necessity for surgery. Several reports have shown varying responses to the treatment of radiodermatitis with topical 5-FU. [7], [18] Bowen's disease, Bowenoid papulosis, and erythroplasia of Queyrat have all been reported as having a range of poor to excellent responses to treatment with topical 5-FU. [19], [20] and [21] Topical 5-FU as well as intralesional injection have been reported to cure most keratoacanthomas, [22] and porokeratosis of Mibelli has reportedly been cured after treatment with topical 5-FU. [23]

Over the past decade there has been experimental use of topical and intralesional 5-FU for the treatment of psoriasis. Continuous topical fluorouracil under occlusion can be given for 2 to 3 days per week for about 16 weeks or until clearance occurs. [24] Alternatively, weekly intralesional fluorouracil has been tried for treatment of psoriatic papules and portions of larger psoriatic plaques with some beneficial effect. [25] The responses observed after injection of 5-FU in an investigational sustained-release gel suggest clinical usefulness in treatment of chronic, recalcitrant, plaque psoriasis that is unresponsive to other therapies. [26] However, this preparation remains commercially unavailable.

MECHLORETHAMINE (NITROGEN MUSTARD)

Mechlorethamine [methyl- *bis* (2-chloroethyl) amine hydrochloride] was the first nitrogen mustard to be used in clinical medicine. Sulfur mustard, of which mechlorethamine is a nitrogen analogue, is a vesicant and was developed as a chemical warfare agent. Mechlorethamine acts as an alkylating agent and is not cell-cycle specific; however, it has most effect on cells in the late G1 or S phases. The primary target of mustard is the 7-nitrogen atom of guanine, although other bases may also be alkylated.

Topical preparations of nitrogen mustard are used primarily for cutaneous T cell lymphoma (CTCL). They are generally very well tolerated. Systemic side effects from IV nitrogen mustard include nausea, vomiting, myelosuppression, menstrual irregularities, oligospermia, alopecia, cardiac abnormalities, hypocalcemia, and central nervous system abnormalities. The drug is also teratogenic. There are no reports of systemic side effects following topical nitrogen mustard application. [27] Exposure to vapors released during topical application does not induce pulmonary fibrosis.

The side effects of topical mustard include contact sensitivity (both immediate and delayed), hyperpigmentation, irritant dermatitis, telangiectases, bullous eruptions, and an increased incidence of skin cancers. Delayed-type hypersensitivity (DTH), also known as cutaneous intolerance to topical mechlorethamine (CIM), may occur in 35 to 60 percent of patients on long-term treatment. [28], [29] This reaction consists of erythema and pruritus, and histologically is typical allergic contact dermatitis. If hypersensitivity occurs, discontinuation of therapy is not necessarily required. Desensitization has been achieved using intravenous [30] and topical [31] methods. UV therapy can delay development of contact sensitization to mustard; however, this modality is not recommended because nitrogen mustard is radiomimetic and, when coupled with UV, will increase the incidence of skin cancers. Although desensitization may be achieved, it may not be desirable as DTH is possibly of therapeutic benefit. CTCL may resolve clinically after the development of DTH, and regression has been reported after application of dinitrochlorobenzene to induce DTH. [27] Most clinicians continue topical mustard in individuals who have developed DTH, employing dilutions below the threshold for clinically observable contact dermatitis. Up to 8 percent of patients may develop an immediate-type hypersensitivity to topical mechlorethamine, manifesting as urticaria. Treatment must be discontinued if urticaria develops to avoid a potential anaphylactic reaction. Desensitization is not achievable in this situation. The incidence of hypersensitivity is reported to be less with the ointment preparation than with the aqueous solution of nitrogen mustard. [32]

Changes in pigmentation may also occur secondary to use of topical mechlorethamine. Hyperpigmentation is especially prone to develop in areas of previous CTCL and tends to resolve spontaneously, although slowly. [27], [30], [31] Hypopigmentation occurs rarely.

A potential troubling property of topical nitrogen mustard is its carcinogenicity. It is associated with an increased risk of basal and squamous cell carcinomas and keratoacanthomas, and a report exists of lentigo maligna. [33], [34] It is difficult to determine the exact extent of the problem as topical nitrogen mustard is often used in patients who have had other known

carcinogenic therapies such as PUVA. Overall the risk is small, [35] and because the lesions are easily treatable, this should not dissuade one from using topical nitrogen mustard. Nevertheless, it is important to advise patients to avoid sun exposure during therapy to minimize the risk.

Whether or not topical nitrogen mustard increases the incidence of internal malignancies in patients with CTCL remains unclear. [36] Some studies have reported an increased risk of colon cancer, whereas others have not. CTCL itself is associated with an increased incidence of systemic lymphoma. High-dose systemic mechlorethamine is not associated with these other malignancies, so perhaps CTCL patients have an underlying increased risk for these second malignancies. [28]

The main role of topical mustard in dermatology is in the treatment of CTCL patches and plaques. [28] There are reports of topical mustard producing complete remission in up to 75 percent of patients, [36] particularly if used in the early stage. [28], [37] Topical nitrogen mustard has also been used with some success in the treatment of psoriasis, [38] alopecia areata, [39] and histiocytosis X. [40] One of the authors (JLS) has used topical mustard successfully in the treatment of alopecia mucinosis.

Topical mustard is usually prepared as either an aqueous solution or an ointment preparation. The aqueous solution needs to be prepared daily by the patient. This is done by mixing 10 mg of nitrogen mustard with 60 mL of water. The solution should be applied immediately with a gauze pad to the entire body but sparingly to intertriginous sites. The genitalia should be excluded. The solution has a shelf life of approximately 1 day. However, refrigeration of the solution extends the usefulness for up to 6 months. With proper application, there is minimal contamination to the surrounding environment. [32] Those assisting in the application of the drug should limit their exposure by wearing protective gloves, avoiding direct contact, and washing thoroughly after handling the preparation. Effort should be made to dispose of empty vials or unused solution in accordance with Environmental Protection Agency guidelines. Dissolving the mustard in anhydrous petrolatum provides an alternative to the aqueous preparation. Generally, 10 mg of nitrogen mustard powder is first dissolved in 99% isopropyl alcohol, and then compounded with 100 g of anhydrous petrolatum. This creates an ointment with 0.01% concentration of mechlorethamine. The ointment has a shelf life of approximately 50 days.

BCNU (CARMUSTINE)

Carmustine [bischloroethylnitrosourea (BCNU)] is a nitrosourea that acts by alkylation to inhibit DNA, RNA, and protein synthesis. Its action is not cell-cycle specific. The topical formulation, introduced in 1971, is used predominantly in the treatment of CTCL. BCNU is effective in patch- and plaque-stage CTCL, with complete clinical response rates of 48 to 86 percent and remission durations of 18 to 66 months. [41]

Systemic side effects include profound myelosuppression, renal failure, mucositis, pulmonary fibrosis, alopecia, nausea and vomiting, and azoospermia. These side effects have not been seen resulting from topical treatment, apart from mild myelosuppression. Cutaneous reactions are very common with the topical formulations. Erythema is seen in almost all patients and generally appears after 4 to 8 weeks of therapy. If severe, this may be associated with skin tenderness and telangiectasia. Allergy is uncommon and occurs in fewer than 10 percent of patients, manifesting as DTH. Urticaria is not seen, and an increased incidence of skin cancers is not observed. Mild bone marrow depression can be found, and patients should have regular blood counts while undergoing topical BCNU treatment.

BCNU is available as a powder for reconstitution as a solution or ointment. A 0.2% alcoholic stock solution is made by mixing 300 mg of BCNU with 150 mL of 95% ethanol. This solution is stable for 3 to 12 months if refrigerated. The patient is instructed to mix 5 mL (10 mg) of the stock solution daily with 60 mL of water. This should be applied immediately to the skin, avoiding the face, hands, genitals, and intertriginous areas, unless these are directly involved with CTCL. The applications should be continued until clearing is seen, usually in 8 to 16 weeks. If the response to 10 mg daily is inadequate, the dose may be doubled for a further 4 to 8 weeks if tolerated. The ointment is prepared by combining BCNU powder in 95% alcohol and then mixing with white petrolatum USP up to concentrations of 10 mg% (10 mg/100 g base), 20 mg%, and 40 mg%. The ointment is easier for patients to use and leads to fewer cutaneous reactions. However, it is associated with an increased incidence of myelosuppression. The ointment is stable for about 6 months if kept refrigerated.

VINBLASTINE

Vinblastine is a vinca alkaloid. It is an antimitotic agent and acts by disrupting microtubules, blocking cell division in metaphase. In dermatologic practice, this agent is used primarily as an intralesional injection for cutaneous and oral lesions of Kaposi's sarcoma.

Potential systemic side effects are myelosuppression, neuropathy, anorexia, nausea, vomiting and diarrhea, alopecia, mucositis, and dermatitis. Side effects of intralesional injection are usually limited to pain, ulceration, and hyperpigmentation at the injection site. To reduce the pain involved with injection, local anesthesia before injection has been tried, as has mixing lidocaine into the vinblastine solution. [42], [43] This does not reduce postinjection pain, which may persist for up to 48 h. Pain can usually be managed with simple oral analgesics.

The method of intralesional injection generally reported is 0.1 to 0.2 mg of vinblastine per mL of normal saline, with doses escalating to 0.6 mg/mL. Some authors use one injection only, whereas others recommend injections every 2 to 4 weeks until complete response is seen. [44] Complete or partial clinical response is of the order of 88 percent. [43] However, as treatment is local, progression of Kaposi's sarcoma may occur at other sites.

BLEOMYCIN

The bleomycins are a group of antibiotics produced by *Streptomyces verticillatus*. The drug in clinical use is a mixture of

bleomycins A2 and B2. Bleomycin acts by disrupting DNA synthesis, causing cells to accumulate in G2. At 48 h after injection, apoptotic keratinocytes are seen in the epidermis. [45] Systemic toxicity from bleomycin includes myelosuppression, hyperpigmentation, hyperkeratosis, ulceration, pulmonary fibrosis, headache, nausea, vomiting, hyperthermia, and hypotension.

Intralesional bleomycin has largely been used as a successful treatment for recalcitrant warts. Additionally, intralesional injections of bleomycin have yielded some success in the treatment of keratoacanthomas. [46] Significant systemic exposure does occur, although systemic toxicity has not been found. [45], [47] Local side effects of pain, swelling, and Raynaud's phenomenon have been reported. [48] Local injection for periungual warts may result in permanent nail loss or dystrophy. Lidocaine may reduce the pain associated with the injection.

Bleomycin is available as a powder. It should be reconstituted with 0.9% sodium chloride into a 1 U/mL solution. Stability in this formulation has been shown at 6 to 8 weeks if the preparation is refrigerated at 4°C (39.2°F), and for several months if stored at -20°C (-4°F). [45] The solution should be injected intralesionally until the wart blanches; one to two injections may be required. Using this technique, a 77 percent cure rate has been found for warts on extremities; however, the rate falls to about 48 percent for plantar warts. [49] A multiple puncture technique has been employed by one group, which may result in a more uniform distribution of drug into the wart. [50]

REFERENCES

1. Goette DK: Topical chemotherapy with 5-fluorouracil. A review. *J Am Acad Dermatol* **4**:633, 1981

2. Krebs HB: Treatment of genital condylomata with topical 5-fluorouracil. *Dermatol Clin* **9**:333, 1991

3. Johnson MR et al: Life-threatening toxicity in a dihydropyrimidine dehydrogenase-deficient patient after treatment with topical 5-fluorouracil. *Clin Cancer Res* **5**:2006, 1999

4. Breza T et al: Noninflammatory destruction of actinic keratoses by fluorouracil. *Arch Dermatol* **112**:1258, 1976

5. Pearlman DL: Weekly pulse dosing: Effective and comfortable topical 5-fluorouracil treatment of multiple facial actinic keratoses. *J Am Acad Dermatol* **25**:665, 1991

6. Belisario JC: Topical cytotoxic therapy of solar keratoses. *Med J Aust* **2**:1136, 1969

7. Neldner KH: Prevention of skin cancer with topical 5 fluorouracil. *Rocky Mt Med J* **63**:74, 1966

8. Dillaha CJ et al: Selective cytotoxic effect of topical 5-fluorouracil. *Arch Dermatol* **88**:247, 1963

9. Reed WB et al: Xeroderma pigmentosum. Clinical and laboratory investigation of its basic defect. *JAMA* **207**:2073, 1969

10. Klein E et al: Tumors of the skin. XII. Topical 5-fluorouracil for epidermal neoplasms. *J Surg Oncol* **3**:331, 1971

11. Reymann F: Treatment of BCC with 5FU ointment. A 10-year follow-up study. *Dermatologica* **158**:368, 1979

12. Pareek S: Treatment of condyloma acuminatum with 5% fluorouracil. *Br J Vener Dis* **55**:65, 1979

13. Sanders BB, Stretcher GS: Warts: Diagnosis and treatment. *JAMA* **235**:2859, 1976

14. Kling AR: Genital warts-therapy. *Semin Dermatol* **11**:247, 1992

15. Epstein E: Treatment of actinic cheilitis with topical fluorouracil. *Arch Dermatol* **113**:906, 1977

16. Klein E: Tumors of the skin. IX. Local cytostatic therapy of cutaneous and mucosal premalignant and malignant lesions. *N Y State J Med* **68**:886, 1968

17. Williams AC: Experiences with local chemotherapy and immunotherapy in premalignant and malignant skin lesions. *Cancer* **25**:450, 1970

18. Dillaha CJ et al: Further studies with topical 5-fluorouracil. *Arch Dermatol* **92**:410, 1965

19. Jansen GT et al: Bowenoid conditions of the skin: Treatment with topical 5-fluorouracil. *South Med J* **69**:185, 1967

20. Wade TR et al: Bowenoid papulosis of the penis. *Cancer* **42**:1890, 1978

21. Goette DK et al: Erythroplasia of Queyrat: Treatment with topically applied 5-fluorouracil. *JAMA* **232**:934, 1975

22. Odom RB, Goette DK: Treatment of keratoacanthomas with intralesional 5-fluorouracil. *Arch Dermatol* **114**:1779, 1978

23. Goncalves JCA: Fluorouracil ointment treatment of porokeratosis of Mibelli. *Arch Dermatol* **108**:131, 1973

24. Pearlman DL et al: Weekly pulse dosing schedule of fluorouracil: A new topical therapy for psoriasis. *J Am Acad Dermatol* **15**:1247, 1986

25. Pearlman DL et al: Weekly psoriasis therapy using intralesional fluorouracil. *J Am Acad Dermatol* **17**:78, 1987

26. Lowe NJ et al: Intradermal fluorouracil and epinephrine injectable gel for treatment of psoriatic plaques. *Arch Dermatol* **131**:1340, 1995

27. Ramsay DL et al: Topical treatment of early cutaneous T-cell lymphoma. *Hematol Oncol Clin North Am* **9**:1031, 1995

28. Vonderheid EC et al: Long-term efficacy, curative potential, and carcinogenicity of topical mechlorethamine chemotherapy in cutaneous T-cell lymphoma. *J Am Acad Dermatol* **20**:416, 1989

29. Esteve E et al: A prospective study of cutaneous intolerance to topical mechlorethamine therapy in patients with cutaneous t-cell

lymphoma. *Arch Dermatol* **135**:1349, 1999

30. Van Scott EJ, Kalmanson JD: Complete remissions of mycosis fungoides lymphoma induced by topical nitrogen mustard (HN2). *Cancer* **32**:18, 1973

31. Constantine VS et al: Mechlorethamine desensitization in therapy for mycosis fungoides: Topical desensitization to mechlorethamine (nitrogen mustard) contact hypersensitivity. *Arch Dermatol* **111**:484, 1975

32. Breneman DL et al: Topical mechlorethamine in the treatment of mycosis fungoides. Uniformity of application and potential for environmental contamination *J Am Acad Dermatol* **25**:1059, 1991

33. Lee LA et al: Second cutaneous malignancies in patients with mycosis fungoides treated with nitrogen mustard. *J Am Acad Dermatol* **7**:590, 1982

34. Abel EA et al: Cutaneous malignancies and metastatic squamous cell carcinoma following topical therapies for mycosis fungoides. *J Am Acad Dermatol* **14**:1029, 1986

35. Smoller BR, Marcus R: Risk of secondary cutaneous malignancies in patients with long-standing mycosis fungoides. *J Am Acad Dermatol* **30**:201, 1994

36. Price NM et al: Ointment-based mechlorethamine treatment for mycosis fungoides. *Cancer* **52**:2214, 1983

37. Hoppe RT et al: Mycosis fungoides: Management with topical nitrogen mustard. *J Clin Oncol* **5**:1796, 1987

38. Handler RM, Medansky RS: Treatment of psoriasis with topical nitrogen mustard. *Int J Dermatol* **18**:758, 1979

39. Arrazola JM et al: Treatment of alopecia areata using topical nitrogen mustard. *Int J Dermatol* **24**:608, 1985

40. Berman B et al: Histiocytosis X treated with topical nitrogen mustard. *J Am Acad Dermatol* **3**:23, 1980

41. Zackheim HS: Topical carmustine (BCNU) for patch/plaque mycosis fungoides. *Semin Dermatol* **13**:202, 1994

42. Epstein JB: Treatment of oral Kaposi sarcoma with intralesional vinblastine. *Cancer* **71**:1722, 1993

43. Boudreaux AA et al: Intralesional vinblastine for cutaneous Kaposi's sarcoma associated with acquired immunodeficiency syndrome. A clinical trial to evaluate efficacy and discomfort associated with infection. *J Am Acad Dermatol* **28**:61, 1993

44. Conant MA: Management of human immunodeficiency virus-associated malignancies. *Recent Results Cancer Res* **139**:423, 1995

45. James MP et al: Histologic, pharmacologic, and immunocytochemical effects of injection of bleomycin into viral warts. *J Am Acad Dermatol* **28**:993, 1993

46. de la Torre C et al: Keratoacanthoma centrifugum marginatum: Treatment with bleomycin. *J Am Acad Dermatol* **37**:1010, 1997

47. Shumer SM, O'Keefe EJ: Bleomycin in the treatment of recalcitrant warts. *J Am Acad Dermatol* **9**:91, 1983

48. Gregg LJ: Intralesional bleomycin and Raynaud's phenomenon. *J Am Acad Dermatol* **27**:279, 1992

49. Amer M et al: Therapeutic evaluation for intralesional injection of bleomycin sulfate in 143 resistant warts. *J Am Acad Dermatol* **18**:1313, 1988

50. Shelley WB, Shelley ED: Intralesional bleomycin sulfate therapy for warts: A novel bifurcated needle puncture technique. *Arch Dermatol* **127**:234, 1991

T>

Chapter 250

Robert Sidbury Jon Hanifin

Topical Immunomodulators

TOPICAL MACROLACTAM IMMUNOSUPPRESSIVES

Tacrolimus (FK506)

PIMECROLIMUS AND OTHER MACROLACTAM AGENTS
IMIQUIMOD

Other Clinical Uses

REFERENCES

The topical immunomodulators represent an entirely new realm of therapeutic agents that act via immunologic pathways to either inhibit or enhance immune and inflammatory reactions in the skin. The immunosuppressive agents are all within the macrolactam class of immunophilin-binding cytokine inhibitors. In the immune-enhancing category, there is currently only one drug, the interferon-inducing agent, imiquimod.

Therapy with topical immunomodulators is presently in a relatively primitive phase. The range of indications is limited, yet the full potential for such agents might be perceived as almost limitless. Knowledge of mechanisms of action is sketchy, as are basic pharmacologic parameters such as absorption kinetics, metabolism (cutaneous and systemic), and tissue retention. In general, short-term safety has been assured, but side effects over many years must be a continuing concern. The outlook seems bright at present and many investigations can be foreseen as we expand the range of diseases that can be helped by the current and future immunomodulators.

TOPICAL MACROLACTAM IMMUNOSUPPRESSIVES

Tacrolimus (FK506)

This drug was originally isolated from *Streptomyces tsukubaensis* and developed for use in organ transplantation. The mechanism of action involves tacrolimus binding to the immunophilin-binding protein (FKBP), in turn blocking calcineurin dephosphorylative activation of NFAT (nuclear factor of activated T cells), which translocates to the nucleus where it initiates cytokine gene expression (Fig. 250-1).In vitro effects include inhibition of T cell proliferation and inhibition of production of a variety of cytokines including interleukin (IL)-2, IL-3, IL-4, IL-12, tumor necrosis factor (TNF) and interferon (IFN)-?. [1], [2]

FIGURE 250-1 Tacrolimus: Mechanism of action. Calcineurin-dependent inhibition of inflammatory cytokine gene transcription.

Tacrolimus is one to two logs more potent than cyclosporin, its molecular weight is less, and its ability to penetrate the skin is greater. These properties provided a basis for experiments demonstrating topical inhibition of contact hypersensitivity and then development as an ointment for treating atopic dermatitis.

Tacrolimus ointment, 0.03% and 0.1% applied twice daily, was studied extensively in clinical trials that included adults and children as young as 2 years of age. [1], [3] Pharmacokinetic studies showed percutaneous absorption initially in 10 to 20 percent of patients with atopic dermatitis, but generally blood levels were undetectable by 1 week as healing and reestablishment of the skin barrier occurred. Rarely were blood levels greater than 2 ng/mL (compared to trough levels of 5 to 15 ng/mL in transplant patients treated systemically).

With topical tacrolimus therapy, more than 70 percent of patients have had moderate to excellent improvement in 3-week controlled trials, and 30 to 40 percent have had greater than 90 percent improvement. [4], [5] In general, response to therapy with topical tacrolimus has been best and most rapid in thinner skin areas such as the face, neck, and trunk. During remissions, dosing may be reduced in frequency but flares occur with discontinuance. Responsiveness is slow and often incomplete on extremities, especially hands and feet, and in patients with lichenified lesions. Roughly 25 percent of patients, especially those with the most severe disease, do not have a satisfactory therapeutic response. Additionally, patients should realize that exacerbations of atopic dermatitis may occur and require occasional intervention with topical or systemic corticosteroid therapy. The main advantage of topical tacrolimus is the provision of chronic maintenance therapy without the need for continuous topical corticosteroids. Long-term therapy with tacrolimus has shown no evidence of cutaneous atrophy, increased infection, hypertension, renal toxicity, or cumulative blood levels.

Adverse effects have been primarily an intense burning and itching in 30 to 40 percent of patients at application sites, especially in areas of flaring, excoriation and erosion. [3], [5] These symptoms usually subside in a few days, in concert with

healing of the skin. However, some patients continue to have bothersome burning, and this effect seems to be more prominent when the skin is exposed to heat such as summer weather, baths, or hot tubs. In general, these problems with burning sensations seem to be less in children. Up to 10 percent of adults experience symptoms of flushing with alcohol ingestion. Infections have not been a notable problem in tacrolimus-treated patients. [4] Occasional staphylococcal skin infections occur, but they are no worse than before treatment, and studies actually demonstrate a reduction in *S. aureus* colonization during prolonged therapy. In spite of the theoretical concern about immunosuppression, there have been no significant increases in frequency or severity of herpes simplex, wart, varicella, or molluscum contagiosum infections. All continue to occur as usual in these patients with atopic dermatitis but severity is unremarkable. Immunosuppression also carries the theoretical risk of cutaneous cancer and lymphoma predisposition but, to date, there has been no evidence of increased occurrence. However, such effects would likely require many years of constant immunosuppression and thus close surveillance is indicated along with careful counseling of patients to use sun protection.

OTHER CLINICAL USES One can envision an almost endless list of inflammatory dermatoses that might benefit from topical tacrolimus therapy (Table 250-1). Anecdotal reports suggest value in oral lichen planus, vitiligo, and pyoderma gangrenosum, but no evidence-based information yet exists. Psoriasis responses have been disappointing, presumably because of impaired drug penetration, but there are indications of efficacy for facial and intertrigenous lesions. Increased hair growth in animal models suggests a possible role for tacrolimus in alopecia areata but evidence of clinical success is lacking. [1]

Cutaneous	Mucosal
Psoriasis (especially flexural)	Aphthae
Miscellaneous eczemas	Lichen planus
Stasis dermatitis	Pemphigus, pemphigoid
Eyelid dermatitis	Vernal conjunctivitis
Bullous disease	Keratoconus
Cutaneous lupus erythematosus	Pruritus ani
Alopecia areata	Vulvovaginal inflammation
Vitiligo	
Hidradenitis suppurativa	
Inflammatory scalp disease	

TABLE 250-1 **Conditions Potentially Amenable to Treatment with Topical Macrolides**

PIMECROLIMUS AND OTHER MACROLACTAM AGENTS

The ascomycin derivative pimecrolimus (ASM 981) has been studied extensively as a topical 1% cream. The drug has a very similar structure to tacrolimus and interacts with the same binding protein to inhibit calcineurin activation of NFAT. Cutaneous effects appear to be lower, however, as reflected in the need for the higher drug concentration in the topical cream and the necessity for twice daily application. [6] Available information indicates that the drug's lipophilicity helps keep it in the skin, enhancing the local effect and reducing clearance. It also appears to have little systemic immunosuppressive effect, which may reflect a wider margin of safety. Clinical trials have included infants as young as 3 months of age. Prolonged therapy up to 1 year has shown no significant adverse events in adults or children. [7] Blood levels have been detected in occasional patients but no high or prolonged levels were seen. Pimecrolimus is also being tested as an oral agent and to date, no renal, hypertensive, or other side effects have been noted in short-term study. This aspect may provide greater safety assurance for use of the topical agent and may eventually give us a much-needed oral agent for patients with widespread disease.

A third topical macrolactam agent, ABT281, has undergone preclinical testing in vitro and in animal contact allergy models. The potency appears, from these early studies, to be intermediate between tacrolimus and pimecrolimus but its safety and efficacy for human use remains to be demonstrated.

IMIQUIMOD

Imiquimod, an imidazoquinolone amine, was initially found to protect guinea pigs from herpes virus infection. Subsequent animal studies revealed both an antiviral and antitumor effect. Imiquimod is unique in that it appears to enhance both acquired and innate immune function. In comparison, tacrolimus functions to inhibit pathways involved in immune activation. The precise mechanism is unknown but appears related to induction of inflammatory cytokines. In vitro and in vivo studies demonstrate that topically applied imiquimod induces local cytokine production from keratinocytes and other cells. [8] In vitro effects include induction of interferon (IFN)-a, tumor necrosis factor (TNF)-a, IL-1, IL-1 RA (interleukin-1 receptor antagonist), IL-6, IL-10, IL-12, G-CSF (granulocyte colony-stimulating factor), GM-CSF (granulocyte-monocyte colony-stimulating factor), as well as the chemokines IL-8, macrophage inflammatory protein (MIP)-1a, and monocyte chemotactic proteins (MCP)-1. [8] Imiquimod also stimulates the innate immune response by increasing natural killer cell activity, activating macrophages, inducing proliferation and maturation of B lymphocytes, and activating Langerhans cells. The major systemic metabolite of imiquimod, S26704, is a hydroxylation product that achieves plasma concentrations 25 times greater than imiquimod. The half-life of intravenously administered imiquimod is 14 h, and less than 1 percent of the drug is recovered in the urine after a single topical application. [8]

Many published reports show that imiquimod is an effective treatment for anogenital warts. A 16-week study of 311 immunocompetent adults with external anogenital warts compared three times weekly 5% imiquimod cream, 1% imiquimod cream, and placebo. Clearance was achieved in more than 70 percent of women and 30 percent of men with the 5% cream, both significantly better than placebo. [9] This greater response in females has been demonstrated in a number of trials. Comparable response rates have been seen in uncircumcised males treated under the foreskin, suggesting that increased moisture may account for this gender discrepancy. Similarly, local factors may account for lower response rates seen in nongenital warts. The primary benefit of imiquimod cream relative to other available wart therapies is ease of administration. In adults, home therapy for genital warts is preferred given the sensitive nature of this problem. Likewise in children, genital warts may be a result of sexual abuse, and an atraumatic topical therapy that can be rapidly applied in a nonthreatening environment is ideal.

Recurrence rates following use of imiquimod cream have ranged from 13 to 19 percent. Adverse effects relate primarily to cutaneous irritation at the application site, especially with thrice weekly application leading to moderate erythema and

erosion in roughly one-third and one-tenth of patients, respectively. [9] Further studies suggest that both the response rate, particularly in males, and the likelihood of side effects will increase with daily therapy. Imiquimod is a category B drug, and it is not known to what extent topically applied imiquimod is excreted in the breast milk of nursing mothers. Imiquimod has not been thoroughly studied in children younger than 18 years of age. Other infectious conditions for which imiquimod holds promise include acyclovir-resistant herpes simplex, [10] molluscum contagiosum, [11] and leishmaniasis. [12]

Other Clinical Uses

In vitro antitumor effects formed the basis for evaluation of imiquimod's efficacy in the treatment of cutaneous neoplasia. Beutner et al. conducted a double-blind, dose-escalating placebo-controlled pilot trial that suggested a role for imiquimod in the treatment of superficial basal cell carcinoma (sBCC). [13] A multicenter, randomized, open-label dose-response trial subsequently showed an almost 90 percent histologic clearance rate of sBCC when 5% imiquimod cream was applied daily for 6 weeks. Increased frequency of application again led to an improved response rate, but a higher incidence of local skin reactions. [14] Response has also been demonstrated in nonfacial BCC in a patient with basal cell nevus syndrome. [15] Imiquimod is presently being evaluated as a treatment for a number of other neoplastic conditions including actinic keratosis, superficial squamous cell carcinoma, Bowen's disease, and lentigo maligna. Analogues of imiquimod such as S28463 and R848 (resiquimod) may prove to be more potent inducers of inflammatory cytokines.

REFERENCES

1. Ruzicka T et al: Tacrolimus—The drug for the turn of the millennium? *Arch Dermatol* **135**:574, 1999

2. Mollison KW et al: A macrolactam inhibitor of T helper type 1 and T helper type 2 cytokine biosynthesis for topical treatment of inflammatory skin diseases. *J Invest Dermatol* **112**:729, 1999

3. Paller AS: Use of nonsteroidal topical immunomodulators for the treatment of atopic dermatitis in the pediatric population. *J Pediatrics* **138**:163, 2001

4. Reitamo S et al: Safety and efficacy of 1 year of tacrolimus ointment monotherapy in adults with atopic dermatitis. *Arch Dermatol* **136**:999, 2000

5. Kang S et al: Long-term safety and efficacy of tacrolimus ointment for the treatment of atopic dermatitis in children. *J Am Acad Dermatol* **44**:S58, 2001

6. Van Leent EJ et al: Effectiveness of the ascomycin macrolactam SDZ ASM 981 in the topical treatment of atopic dermatitis. *Arch Dermatol* **134**:805, 1998

7. Boguniewicz M et al: Pimecrolimus (Elidel, SDZ ASM 981) cream 1% is safe in long-term use in pediatric atopic eczema. Presented at the IX World Congress of Pediatric Dermatology, Cancun, Mexico, 20–24 October 2001

8. Sauder DN: Immunomodulatory and pharmacologic properties of imiquimod. *J Am Acad Dermatol* **43**:S6, 2000

9. Edwards L et al: Self-administered topical 5% imiquimod cream for external anogenital warts. *Arch Dermatol* **134**:25, 1998

10. Conant MA: Immunomodulatory therapy in the management of viral infections in patients with HIV infection. *J Am Acad Dermatol* **43**:S27, 2000

11. Liota E et al: Imiquimod therapy for molluscum contagiosum. *J Cut Med Surg* **4**:76, 2000

12. Arevalo I et al: Successful treatment of drug-resistant cutaneous leishmanaisis in humans by use of imiquimod, an immunomodulator. *Clin Infect Dis* **33**:1847, 2001

13. Beutner KR et al: Therapeutic response of basal cell carcinoma to the immune response modifier imiquimod 5% cream. *J Am Acad Dermatol* **41**:1002, 1999

14. Marks R et al: Imiquimod 5% cream in the treatment of superficial basal cell carcinoma: Results of a multicenter 6-week dose-response trial. *J Am Acad Dermatol* **44**:807, 2001

15. Kagy MK, Amonette R: The use of imiquimod 5% cream for the treatment of superficial basal cell carcinomas in a basal cell nevus syndrome patient. *Dermatol Surg* **26**:577, 2000

T>

Chapter 251

Adam Rubin Nicole LaNatra Matthew Stiller

Other Topical Medications

ACNE THERAPIES
Adapalene
a-Hydroxy Acids
Azelaic Acid
Benzoyl Peroxide
Clindamycin
Erythromycin
Tazarotene
Tretinoin (Vitamin A Acid)
ANALGESICS
Capsaicin
Eutectic Mixture of Local Anesthetic (EMLA)
Topical Anesthetics
ANTIFUNGALS
Allylamines
Azoles
Castellani's Paint
Ciclopirox
Haloprogin
Polyenes
Selenium Sulfide
Tolnaftate
Undecylenic Acid
Whitfield's Ointment
Zinc Pyrithione
ANTI-HAIR LOSS
Minoxidil
ANTI-INFLAMMATORY AGENTS
Coal Tar
Shale Tar
Wood Tar
ANTIMICROBIAL AGENTS
Chlorhexidine
Dyes
Hydrogen Peroxide
Iodinated Compounds
Metronidazole
Mupirocin
Silver Sulfadiazine
ANTIPARASITIC AGENTS
Crotamiton
Gamma Benzene Hexachloride
Malathion
Permethrin
Pyrethrin
ANTIPERSPIRANTS
Aluminum Compounds
Aldehydes
Methenamine
ANTIPRURITIC AGENTS
Antihistamines
Doxepin
Menthol
Phenol
Pramoxine Hydrochloride
ANTIVIRALS
Acyclovir
ASTRINGENTS
Aluminum Salts
Potassium Permanganate
Silver Nitrate
BLEACHING AGENTS
Retinoic Acid
Azelaic Acid
Hydroquinone
KERATOLYTIC AGENTS
a-Hydroxy Acids
Propylene Glycol
Salicylic Acid
Urea
PSORIASIS THERAPIES

Anthralin
Calcipotriol
Tazarotene
WART THERAPIES
Dinitrochlorobenzene (DNCB)
Diphenylcyclopropenone
5-Fluorouracil
Formaldehyde
Glutaraldehyde
Imiquimod
Mono-, Di-, Trichloroacetic Acids
Podophyllin Resin
Podofilox
Salicylic Acid

REFERENCES

Topical therapies are one of the foundations of a dermatologist's therapeutic armamentarium. This chapter reviews the latest additions to the dermatologist's repertoire of treatments and reevaluates many of the older therapies that are still highly effective.

ACNE THERAPIES

Adapalene

Adapalene, derived from naphthoic acid, has potent retinoid and anti-inflammatory properties. As a 0.1% gel, it was developed for use in acne vulgaris and has slightly lower irritant effects than tretinoin. Adapalene has comedolytic, antiproliferative, and anti-inflammatory activity. [1] It acts on cell proliferation and differentiation via retinoic acid receptor-binding proteins, and gene transcription. [1] Follicular penetration is observed with adapalene, which presents an advantage in treating acne. In 12-week international multicenter studies comparing adapalene gel 0.1% to tretinoin gel 0.025%, adapalene was as effective and in some cases superior to tretinoin. [2] Side effects associated with adapalene 0.1% gel include burning, pruritus, dryness, and scaling.

a-Hydroxy Acids

The a-hydroxy acids are keratolytic. These drugs reduce follicular hyperkeratosis and facilitate stratum corneum desquamation.

Azelaic Acid

Azelaic acid is a naturally occurring aliphatic dicarboxylic acid that is a competitive inhibitor of tyrosinase. Azelaic acid is a reversible inhibitor of cytochrome P450 reductase and 5a-reductase in microsomes and a reversible inhibitor of some enzymes in the respiratory chain. [3] Its efficacy is attributed to activity against *Propionibacterium acnes,* normalization of keratinization, and a direct anti-inflammatory effect. [4] A beneficial effect may not be observed until 4 weeks after initiation of treatment, which may need to be continued for several months.

Benzoyl Peroxide

Benzoyl peroxide rapidly improves both inflammatory and noninflammatory acne lesions. It can be used effectively as monotherapy for mild disease. Benzoyl peroxide has antibacterial activity, reducing the population of *P. acnes* by generating reactive oxygen species. Benzoyl peroxide can initially irritate skin, and bleaching of skin and hair have been reported. It is available in a variety of formulations, including gels, lotions, creams, and washes with a concentration of 2.5% to 10%, or by prescription in a variety of formulations.

Clindamycin

Clindamycin 1% is available in several topical formulations (gel, solution, lotion). Two recent clinical trials showed that the combination of 5% benzoyl peroxide and 1% clindamycin gel was superior in acne improvement than clindamycin alone. [5] Antibiotic therapy may be discontinued for 1 month then resumed or an alternative agent substituted if resistance develops.

Erythromycin

Topical erythromycin reportedly reduces acne lesions by 50 to 60 percent. It decreases comedogenic free fatty acids and exerts an anti-inflammatory effect by suppressing neutrophil chemotaxis. Topical erythromycin has a low potential for sensitization. A recent study suggests that erythromycin acts as a catalyst to increase benzoyl peroxide radical activity. [6]

Tazarotene

Tazarotene is a topical acetylenic retinoid that normalizes keratinization of the follicular epithelium, preventing the formation of microcomedones, thereby helping to reduce the proliferation of *P. acnes.* [7] A recent multicenter, double-blind, randomized, trial showed comparable efficacy of alternate day tazarotene 0.1% gel and once-daily adapalene 0.1% gel. [8]

Tretinoin (Vitamin A Acid) (See also Chap. 244)

The actions of tretinoin include influencing desquamation of abnormal epithelium, altering the microclimate of the microcomedo, resolving mature comedones, preventing new lesions, and enhancing the penetration of other drugs. [9] By increasing mitotic activity and turnover of follicular epithelial cells and regulating maturation of epidermal cells, tretinoin induces thickening of the granular layer and normalization of parakeratosis. Tretinoin treatment in acne enhances epithelial turnover, loosening keratin debris; it promotes the drainage of preexisting comedones and inhibits formation of new ones.

Initially, tretinoin may cause erythema and tenderness of the skin, but the comedones then start to extrude and do not usually reform if therapy is continued. The irritation can be minimized by using the mildest formulation (0.025% cream) first and initiating its use on alternate days. Maximal therapeutic results take up to 6 weeks, and maintenance therapy may be required to prevent exacerbations. Tretinoin is available in cream, gel, and solution formulations in an assortment of concentrations.

ANALGESICS

Capsaicin

Capsaicin is an active ingredient of cayenne peppers and other plants of the Capsicum family. The mechanism of pain relief is not known; however, it may be a result of reduction in afferent input following depletion of substance P. Consequently, pain impulses cannot be transmitted to the brain. When applied topically, capsaicin causes vasodilatation and a burning sensation. After repeated exposures, the burning sensation may diminish. Capsaicin is applied four or five times per day for 4 to 6 weeks. Patients should be instructed to wash their hands after each application and to avoid inadvertent eye contact. Capsaicin has been used to treat postherpetic neuralgia, painful diabetic neuropathy, postmastectomy pain syndrome, nostalgia paresthetica, meralgia paresthetica, and cluster headaches. Its effect appears to be modest, but it is quite safe.

Eutectic Mixture of Local Anesthetic (EMLA)

EMLA cream contains a eutectic mixture of 50 percent lidocaine and 50 percent prilocaine in an oil-in-water emulsion. EMLA is applied to intact skin and covered with an occlusive dressing. Anesthesia develops in hours at a depth in the skin proportional to the duration of application. Maximal penetration occurs 30 min after the removal of EMLA, and analgesia persists for several hours. EMLA is safe and particularly useful in children.

Topical Anesthetics

Topical anesthetics, such as benzocaine, are sensitizers that should be avoided. Lidocaine (United States) or lignocaine (United Kingdom) and other “amide” type agents are rare sensitizers and may be used.

ANTIFUNGALS (See also Chap. 246)

Allylamines

This group of topical antifungals includes terbinafine and naftifine. The fungicidal allylamines inhibit ergosterol synthesis, specifically squalene epoxidase, and thus alter the cell wall. They are lipophilic, allowing binding to the stratum corneum layer. Terbinafine is at least as effective as miconazole 2% cream and naftifine 1% gel in tinea pedis. [10] The side effects of both terbinafine and naftifine include a low incidence of local burning, pruritus, dryness, and erythema.

Azoles

The first- and second-generation imidazoles include clotrimazole, econazole, ketoconazole, miconazole, and sulconazole as topical therapies; they have similar spectrums of efficacy and activity. They function by blocking synthesis of ergosterol, which plays an integral role in cell membrane structure and function. Ketoconazole is available in a shampoo formulation, which leads to more rapid clearing of lesions in tinea versicolor.

Castellani's Paint

Named after Sir Aldo Castellani, this mixture contains resorcinol (8 g), acetone (4 mL), magenta (0.4 g), phenol (4.0 g), boric acid (0.8 g), industrial methylated spirit 90% (8.5 mL), and water (to 100 mL). It is fungicidal and bactericidal with local anesthetic effects, [11] and stains the skin red. Castellani's paint, usually applied to the intertriginous areas of the skin, is particularly effective in inflammatory ntertriginous tinea and acute *Candida paronychia*. It has also been used to treat seborrheic eczema and tinea pedis. It has drying ability, which makes it useful in treating leg ulcers. It is applied daily for 2 weeks, usually at bedtime.

Ciclopirox

Ciclopirox acts by interfering with the uptake and availability of components required for membrane synthesis. Ciclopirox is fungicidal and fungistatic with anti-inflammatory properties. It is also effective against certain gram-positive and gram-negative aerobic bacteria, including resistant strains of *Staphylococcus aureus,* yeasts, dermatophytes, and nondermatophyte molds. [12]

Haloprogin

Haloprogin exhibits activity against a variety of organisms, including dermatophytes and Candida, and against pityriasis versicolor and erythrasma. In yeast infections, it interferes with respiration and disrupts cell membranes. However, its mode of action in dermatophytic infections is not clearly elucidated. The side effects associated with its use include local irritation, pruritus, and contact dermatitis.

Polyenes

The polyenes, such as nystatin, act by increasing fungal cell membrane permeability by binding to membrane sterol. Nystatin is both fungicidal and fungistatic. It has been the standard therapy for candidiasis, especially oral thrush. Topical nystatin has limited systemic absorption but can rarely cause nausea, vomiting, and diarrhea.

Selenium Sulfide

Selenium sulfide is reported to increase fungal shedding by decreasing corneocyte production through its cytostatic effect on cells. It also has sporicidal activity. It is commonly used as adjunctive therapy in tinea capitis to reduce the period of infectivity and in the treatment of pityriasis versicolor and seborrheic dermatitis. For the treatment of tinea versicolor the solution is applied and left on for 10 min before thoroughly rinsing. This is done on a daily basis for 7 days. There are many other effective regimens for using selenium sulfide in tinea versicolor. Associated side effects include skin irritation and increased hair loss and discoloration.

Tolnaftate

Tolnaftate inhibits squalene epoxidation, and is fungicidal. It is not as effective as other antifungals in treating dry trichophyton rubrum infections and candidiasis. Uncommon side effects of tolnaftate include contact dermatitis, urticaria, pruritus, and erythema. Stevens-Johnson syndrome and toxic epidermal necrolysis have also been reported.

Undecylenic Acid

When combined with zinc, calcium, and sodium, undecylenic acid has fungistatic activity.

Whitfield's Ointment

Whitfield's ointment, composed of 12% benzoic acid and 6% salicylic acid, is the least-expensive preparation to treat dermatophytoses. Effective only against dermatophytes, it is fungistatic and keratolytic. Whitfield's ointment has the ability to kill spores and remove infected debris, although many patients discontinue use because of its local irritant effect. [13]

Zinc Pyrithione

Zinc pyrithione is a general inhibitor of membrane transport in fungi. It has fungistatic and antimicrobial activity, [14] but its exact mode of action is unknown. Zinc pyrithione has been used to treat dandruff and psoriasis with variable effectiveness. It has been reported to cause allergic contact dermatitis.

ANTI-HAIR LOSS

Minoxidil

Minoxidil was originally developed as an oral antihypertensive agent. It is a potent vasodilator that acts directly on peripheral arterioles, decreasing blood pressure with resultant tachycardia. It was serendipitously observed that patients on minoxidil developed hypertrichosis. Subsequently, it has been reformulated into a topical solution, which lacks the systemic effects, to treat alopecia. The exact mode of action of minoxidil is unknown, although it has been postulated that minoxidil increases cutaneous blood flow to the scalp. It is available in 2% and 5% formulations. Approximately 30 percent of patients with male pattern baldness achieve some beneficial results. Currently, only 2% minoxidil is approved by the FDA for treatment of androgenetic alopecia in women. [15]

ANTI-INFLAMMATORY AGENTS

Coal Tar

Coal tar is manufactured as the by-product of processing coke and gas from bituminous coal (coal tars). It contains at least 10,000 different chemicals, including aromatic hydrocarbons such as benzenes, naphthalenes, creosols, and phenols. The cruder the coal tar, the more therapeutically effective it is. The method by which coal tar exerts its influence is still not well understood. Studies suggest that tars depress DNA synthesis and have an antimitotic effect. Coal tar applied to normal skin produces early suppression of epidermal DNA synthesis followed by a proliferative response. [16] Tars have phototoxic or photodynamic activity, with an action spectrum in the UVA and visible range. Tar is known to be carcinogenic in animals. However, there are very few reports of squamous epithelioma resulting from the therapeutic use of crude coal tar. The most common adverse effects of tar are folliculitis and irritation. Other side effects include tar acne, phototoxicity, and allergic contact sensitivity. Tar application is messy and can stain clothing. Therapeutic results in chronic eczema, especially atopic dermatitis, are gratifying. Coal tars are frequently formulated as gels, shampoos, and

tar baths.

Shale Tar

Shale tar (ichthammol) originates from shale oil that undergoes chemical degradation with ammonia and sulfuric acid to form a sulfur-rich substance. It is most often formulated with glycerin and is thought to have both anti-inflammatory and vasoactive properties. Ichthammol is a safe, time-honored standard in the treatment of eczema, seborrheic dermatitis, and rosacea, and has also been used in the treatment of otitis externa when mixed with glycerol. The effects of shale tar on neutrophils include inhibiting the release of leukotriene B_4 (LTB_4) and blocking migration. [17] In contrast to coal tar, shale tars are less irritating, not photosensitizing, and less effective.

Wood Tar

Wood tars are obtained by distilling wood under controlled conditions. Oil of cade from juniper is the most common wood tar and has a strong and distinctive odor. Other wood tars include oil of beech, birch, and pine. They can be added to arachis oil (peanut oil) or simple bases as an application to the scalp in seborrheic dermatitis and psoriasis. Oil of cade is also a major ingredient in the 20-10-5 ointment, which consists of 20 percent oil of cade, 10 percent sulfur, and 5 percent salicylic acid. Like shale tars, wood tars are not photosensitizers. [18]

ANTIMICROBIAL AGENTS

Chlorhexidine

Chlorhexidine is a bisbiguanide that has bactericidal and fungicidal activity. However, it does not kill bacterial spores or mycobacteria, although it does inhibit their growth. Because it does not lose its effectiveness in the presence of whole blood, it is an important antiseptic, disinfectant, and preservative.

Dyes

Dyes are useful as topical treatment because they are inexpensive and chemically and physically stable. The two dyes, gentian violet (methylrosaniline chloride) and brilliant green (*p*-diethylamine triphenylmethanol) are both derivatives of triphenylmethane. Gentian violet has been used as a dye for fabrics, wood, and cosmetics, and in food. It is also used as a biologic stain (Gram stain, nucleic acid stain), mycostatic agent in poultry feed, antiseptic, astringent, and anthelminthic, and as a blood additive to prevent the transmission of Chagas' disease by transfusion. [19] The dyes are effective against *Candida* species, streptococci, and staphylococci, including methicillin-resistant *Staphylococcus aureus*. Several hypotheses exist as to gentian violet's mode of antimicrobial activity, including (1) inhibition of bacterial cell wall formation, (2) protein synthesis inhibition, (3) redox potential alteration, (4) inhibition of glutamine synthesis, and (5) formation of a dye-bacteria un-ionized complex. [19]

Hydrogen Peroxide

Hydrogen peroxide has been used for a number of years as a cleansing agent and for the removal of debris. It has antibacterial properties against both gram-positive and -negative bacteria, and its effervescent quality helps to débride wounds. Hydrogen peroxide does not induce bacterial resistance.

Iodinated Compounds

Iodine solution is bactericidal, sporicidal, and viricidal. Iodophors are complexes of iodine with a carrier that slowly liberates inorganic iodine on contact with reducing substances. This preserves the antimicrobial activities of iodine without the irritant effects of the free tincture. Iodophors may be inactivated after contact with whole blood, and have a slower onset of action than iodine solution.

POVIDONE-IODINE Povidone-iodine has a wide spectrum of in vitro activity against gram-negative and -positive bacteria, fungi, and viruses. Wound exudate, however, inactivates povidone. Systemic absorption can occur with resultant renal and thyroid dysfunction.
CLIOQUINOL Clioquinol, 5-chloro-8-hydroxy-7-lodoquinolinol, is weakly antifungal and antibacterial. It is a yellowish-white to brownish-yellow powder available in 1% and 3% cream and ointment bases. It is effective alone or combined with a topical steroid to treat inflammatory dermatoses, especially in intertriginous areas. Adverse reactions include a yellowish discoloration on clothing or skin, delayed contact hypersensitivity, and primary contact dermatitis.

Metronidazole

Metronidazole is an imidazole with the ability to inhibit fungi and *Trichomonas,* and is most useful in rosacea. Its mode of action involves the impedance of leukocyte chemotaxis and selective suppression of cellular immunity.

Mupirocin

Formerly known as pseudomonic acid A, mupirocin is obtained from the fermentation of *Pseudomonas fluorescens*. It is bactericidal at the concentration achieved with topical application to the skin and mucous membranes. Mupirocin prevents the incorporation of isoleucine into proteins by inhibiting bacterial isoleucyl-t-RNA synthetase. Its unique mechanism of action prevents cross-resistance. [20] It has activity against staphylococci, streptococci, and certain gram-negative bacteria (*Haemophilus influenzae, Neisseria* species , *Pasteurella multocida*), but is inactive against

normal skin flora (*Micrococcus, Corynebacterium, Propionibacterium* species).

Silver Sulfadiazine

This compound was originally synthesized in 1968 from silver nitrate and sodium sulfadiazine. It is available as a 1% cream and is effective against a wide spectrum of microbial pathogens. Its antimicrobial activity is thought to occur by inhibiting DNA replication and modifying the cell membrane. It is largely used to treat burn patients, but has been used to treat a variety of other skin conditions including Stevens-Johnson syndrome. Side effects are very few. Of these, transient leukopenia is a side effect encountered with clinical use. Early postburn leukopenia is mild and self-limited. After 2 to 4 days of use, silver sulfadiazine can cause formation of a “pseudoeschar” which is caused by the interaction of proteinaceous exudate in the wound with the drug.

ANTIPARASITIC AGENTS (See also Chap. 238)

Crotamiton

Crotamiton (crotonyl- *N*-ethyl- *O*-toluidine) is a colorless or pale yellow oil used in the treatment of scabies and pediculosis capitis. Other antiparasitic formulations, such as lindane 1% and permethrin cream 5%, are more effective than crotamiton, [21] which is rarely a sensitizer. Its mode of action is unknown. It has some antipruritic activity and is safe. [22]

Gamma Benzene Hexachloride

Gamma benzene hexachloride, a chlorinated hydrocarbon pesticide, is very effective against lice and fleas as a 1% solution. It is amongst the slowest acting ovicides of several antiparasitic agents. Scabies resistant to gamma benzene hexachloride has been reported. Side effects of topical application include central nervous system toxicity, seizures, and aplastic anemia. [23]

Malathion

Malathion is a moderately toxic organophosphate insecticide and is the fastest acting ovicide in comparison with other antiparasitic agents. It acts by irreversibly binding to acetylcholinesterase, [24] and is used for the treatment of head lice. Contact dermatitis has been reported with its use.

Permethrin

Permethrin is a synthetic pyrethroid modeled after the natural insecticide found in the pyrethrum flower, *Chrysanthemum cinerariaefolium,* which has been used for centuries in Iran as an insecticide. It acts on parasitic nerve cell membranes, causing paralysis and death. It is available as a 1% cream rinse, which is left on for 10 min. A single application is effective against head lice and nits, with activity detectable at least 10 days after use. Permethrin is the treatment of choice for treatment of scabies and lice. [25] There is a lack of safety data for its use in children younger than 2 months of age, and in pregnant and breast-feeding women. Permethrin is also effective against pediculosis pubis, and mites infestations including cheyletiella. [25] It was recently used in combination with oral ivermectin in the treatment of rosacea-like demodicidosis. [26]

Pyrethrin

Pyrethrin is the naturally occurring ester of chrysanthemumic acid. In combination with piperonyl butoxide, it is available as a liquid, gel, and shampoo. For the treatment of head lice, it is as cosmetically acceptable as permethrin, but does not kill all unhatched eggs and has no residual activity. [22] Pyrethrin is a neurotoxin, and piperonyl butoxide inhibits its metabolism, potentiating its effects. It is also effective against fleas, mosquitoes, and houseflies.

ANTIPERSPIRANTS

Aluminum Compounds

Aluminum chloride, in solution in anhydrous ethyl alcohol (6 to 20%), has been used to treat hyperhidrosis. The solution is applied to the axillae or the palms and soles for at least 6 to 8 h. Shaving of the axillae should be avoided for 24 to 48 h before application of aluminum chloride. Occlusion, used to increase efficacy, increases the likelihood of irritation. Once excessive sweating is under control, use may be decreased to once or twice a week as maintenance therapy. The mechanism of action is controversial and may occur by blockage of the sweat duct or by atrophy of the secretory cells. [27]

Aldehydes

Glutaraldehyde solution applied to palms or soles has been used to control hyperhidrosis. It may be used on alternate days until desired results are achieved and then decreased to once a week or as needed. Glutaraldehyde as a 10% solution may leave brown pigmentation on the skin. A 2% solution will not produce this discoloration, but is less effective. Formaldehyde is a sensitizer and is not commonly used.

Methenamine

Methenamine is a six-carbon, four-nitrogen compound that has been used for a number of years to treat bacterial infections of the urinary bladder. At acid pH, it releases ammonia and formaldehyde. A 10% solution is effective in mild to

moderate hyperhidrosis, rarely producing allergic reactions. As a 5% firm gel stick, it is effective in reducing palmoplantar hyperhidrosis after 1 month of use, and the effect continues for up to 3 weeks after discontinuation of the product. [28]

ANTIPRURITIC AGENTS

Antihistamines

Topical antihistamines, such as diphenhydramine, are associated with a high incidence of contact sensitization [29] and cross-reactivity, and rarely with photoallergic reactions. [30] Given the availability of other effective topical agents, topical antihistamines should be avoided.

Doxepin

Tricyclic compounds, particularly doxepin hydrochloride, given orally are known to have antipruritic properties. Doxepin cream 5% may be used to treat pruritus, although the mechanism of its effect is uncertain. However, doxepin has an affinity for H_1 and H_2 receptors and may also exert its antipruritic effect through the antagonism of a-adrenergic, muscarinic, and serotonergic receptors and through inhibition of norepinephrine and serotonin neuronal reuptake and the inhibition of platelet-activating factor production. Topical doxepin has a potential for sensitization. It is effective for atopic dermatitis, chronic urticarias, prurigos, and neurodermatitis. [31] Doxepin cream may also be used as an adjuvant to glucocorticoids in treatment of pruritus.

Menthol

Menthol is a highly lipid-soluble cyclic terpene alcohol, often used interchangeably with or in addition to camphor. It is a naturally occurring plant oil obtained from the Mentha species. Menthol is a known chemical activator of cold-sensitive A delta fibers. Menthol does not decrease the duration or magnitude of histamine-induced pruritus. [32]

Phenol

Phenol in low concentrations acts as an antipruritic agent through its anesthetic effect. It may be percutaneously absorbed and should be avoided in pregnant women and infants. [33] It is a common ingredient in over-the-counter preparations for pruritus.

Pramoxine Hydrochloride

Pramoxine hydrochloride, a topical anesthetic, is effective in cases of mild to moderate pruritus. It is available in combination with menthol, petrolatum, and hydrocortisone. It is a sensitizer less frequently than other topical anesthetics.

ANTIVIRALS

Acyclovir

Acyclovir, 9-(2-hydroxyethoxymethyl) guanine, has specific antiviral activity against herpes simplex virus (HSV), varicella, Epstein-Barr virus, and cytomegalovirus. Acyclovir completely inhibits viral DNA synthesis by inactivating viral DNA polymerase. [34] It is more active against HSV-1 than HSV-2. Because frequent application of acyclovir 5% ointment has lower efficacy than systemic formulations, it is only topically indicated in initial genital HSV infections and limited mucocutaneous HSV infection of immunocompromised patients. [35] Some patients with ulceration may experience pain with application of acyclovir. A recent clinical trial showed comparable clinical efficacy between topical acyclovir 3% cream and penciclovir 1% cream when used for up to 7 days of treatment. [36] Penciclovir is a novel acyclic nucleoside analogue that has shown efficacy against HSV types 1 and 2 and VZV in cell culture. [36]

ASTRINGENTS

Aluminum Salts

Aluminum acetate tablets diluted 1:10 to 1:40 (Burow's solution) are an effective astringent. Over-the-counter aluminum sulfate and calcium acetate (Domeboro) are available and, when dissolved in water, make a modified Burow's solution. These solutions may be used as wet dressings, compresses, or soaks.

Potassium Permanganate

Potassium permanganate is a strong oxidizing agent and has non-specific activity against *Candida* species. Solutions of 1:4,000 to 1:16,000 may be used as wet compresses to reduce weeping. Alternatively, a 1:25,000 solution may be used as a medicated bath. Undissolved crystals can burn the skin. The use of this agent is limited because of bright purple staining, which may be removed with a weak solution of oxalic acid or sodium thiosulfate.

Silver Nitrate

Silver nitrate in 0.5% aqueous solution is an astringent and antimicrobial that is valuable in the treatment of infected eczema, gravitational ulcers, and other weeping and/or infected skin lesions. It is effective against *S. aureus, S. epidermidis,* and *P. aeruginosa*. At low concentration (0.5% formulation, used clinically) it is bacteriostatic, while bactericidal at higher concentrations (10%). The precise mode of its action is unknown. It is applied as a wet dressing

and stains the skin black. Its cosmetic disadvantage is often outweighed by the rapid resolution of weeping and superficial infection, often by resistant organisms. A 40% silver nitrate solution in alcohol is helpful in the management of severe folliculitis, and in solid form it may be used as a hemostat. In its concentrated form, it is extremely toxic to tissues, and methemoglobinemia has been noted secondary to topical treatment. [37]

BLEACHING AGENTS

Retinoic Acid

Retinoic acid is an effective acne therapy that has also been used successfully to treat melasma. Retinoic acid combined with 2% to 3% hydroquinone has synergistic effects and causes a rapid decrease in skin pigmentation. It has also been used to treat melasma in black patients effectively.

Azelaic Acid

This agent originally was intended for use in disorders of hyperpigmentation, and was later extended to acne treatment. Azelaic acid exhibits antityrosinase activity and is effective in melanosis caused by hyperfunction or proliferation of melanocytes. It has been used to treat melasma, lentigo maligna, [38] and melanoma. [39] Local irritation with azelaic acid is more common than with hydroquinone. Azelaic acid does not affect normal melanocytes and fibroblasts, and leukoderma and ochronosis are not associated with its use.

Hydroquinone

A hydroxyphenolic compound, hydroquinone is used extensively as a skin bleaching agent. It targets tyrosinase, inhibiting conversion of dopa to melanin. It is an effective depigmenting agent in many disorders of hyperpigmentation, including melasma, ephelides, and postinflammatory hyperpigmentation. Hydroquinone has been combined with retinoic acid and/or dexamethasone to enhance efficacy. The most serious side effect of hydroquinone use is development of ochronosis, seen with prolonged use of strong concentrations (6%). Other adverse events seen with hydroquinone use are development of irritant and allergic contact dermatitis, nail discoloration, and postinflammatory hyperpigmentation. Hydroquinone is available over the counter at concentrations less than 2%.

KERATOLYTIC AGENTS (See also Chap. 248)

a-Hydroxy Acids

a-Hydroxy acids (lactic acid, glycolic acid, citric acid, glucuronic acid, and pyruvic acid) are found in a variety of natural products including cane sugar, fruits, and yogurt. They are extremely effective keratolytics. a-Hydroxy acids reduce the thickness of hyperkeratotic stratum corneum by reducing corneocyte adhesion in the lower levels. These agents are effective in the treatment of disorders of keratinization (e.g., ichthyosis, hyperkeratotic eczema) and photoaging, and have also been used in acne and hyperpigmentation. The pHs of the various a-hydroxy acid preparations, including cleansers, moisturizers, and chemical peeling agents, are important in determining their efficacy.

Propylene Glycol

Propylene glycol and lactic acid have been used for hyperkeratotic conditions since the 1970s. A recent study showed that a combination of 20% propylene glycol with 5% lactic acid in a semiocclusive cream base was both highly effective and well tolerated in patients with lamellar ichthyosis. [40] This drug combination may be very effective in other types of nonbullous ichthyosis, as well as hyperkeratotic forms of eczema and psoriasis. [40] Propylene glycol is also available as a gel containing 6% salicylic acid.

Salicylic Acid

Salicylic acid may be used in concentrations ranging from 0.5% to 60% in almost any base. In concentrations of 3% to 6%, it causes shedding of scales by softening the horny layers. In concentrations higher than 6%, salicylic acid is destructive to tissue. It is for this reason that it is employed in wart therapy. Salicylism has been reported with widespread and prolonged use, especially in children. Sensitization is rare, and irritation can be minimized if introduced at lower concentrations. Salicylic acid's keratolytic effect occurs by dissolving the intracellular matrix and softening the stratum corneum, causing scale shedding. A loss of connectivity between corneocytes causes skin desquamation. [41]

Urea

Urea is proteolytic at high concentrations. It has been indicated for use in dry skin and the associated pruritus, ichthyosis vulgaris, atopic dermatitis, hand dermatitis, and nonsurgical avulsion of nails. [42] Urea has been added to some topical glucocorticoid preparations. In various bases, 5 to 10% urea is used in the management of ichthyosis. However, some patients experience burning with this therapy.

PSORIASIS THERAPIES

Anthralin

Anthralin (USP) or dithranol (BP) is a synthetic derivative of chrysarobin derived from chrysarophanic acid. Anthralin's exact mode of action is unknown. It may affect DNA synthesis (probably mitochondrial DNA), reducing cell turnover, or affect various enzyme systems (e.g., leukotriene synthesis, polyamines, respiratory function). [43] The most common

adverse events seen with anthralin use are erythema, irritancy, and contact dermatitis. Anthralin stains normal skin dark brown or black. Consequently, it is usually prepared in a paraffin base so that it does not spread to normal skin. Anthralin is available in pastes, ointments, and creams.

Calcipotriol

Calcipotriol is a vitamin D analogue. A recent review of treatment for mild to moderate chronic plaque psoriasis noted that topical calcipotriol 0.005% cream or ointment was more effective than calcitriol, coal tar, allantoin 2%, hydrocortisone 0.5%, short-contact dithranol, and tacalcitol. [44] It possesses the same therapeutic properties as vitamin D_3, including inhibition of epidermal proliferation, induction of differentiation, and anti-inflammatory effects. Hypercalcemia may occur if more than 100 g is used per week. It is applied initially twice daily, and maximal improvement can be expected within 6 to 8 weeks. Cutaneous irritation may occur in up to 20 percent of patients. This agent should be used cautiously on the face, groin, or intertriginous areas. In view of the risk of hypercalcemia and high cost, this preparation is not recommended for patients with extensive psoriasis.

Tazarotene

Tazarotene is useful in treatment of mild to moderate plaque psoriasis. Tazarotene normalizes abnormal keratinocyte differentiation, has antihyperproliferative activity, and is anti-inflammatory. [45] It is nonsensitizing, nonphototoxic, and nonphotoallergenic. Tazarotene is available in a 0.05% and 0.1% gel. It is effective as a once-daily application, and clearing can occur in 12 weeks. The most common side effect is local skin irritation.

WART THERAPIES

Dinitrochlorobenzene (DNCB)

DNCB is a potent sensitizer. The mechanism of action of topical DNCB may be to systemically stimulate T_H1 cell responses. [46] DNCB is mutagenic and potentially carcinogenic.

Diphenylcyclopropenone

Diphenylcyclopropenone is also used in contact immunotherapy in much the same way as DNCB. However, it is not mutagenic.

5-Fluorouracil

5-Fluorouracil is a pyrimidine analogue that inhibits thymidine synthetase, thereby inhibiting DNA synthesis. In addition to its use in actinic keratosis, it has been used successfully in the treatment of flat, mosaic, and genital warts. Its effectiveness may be heightened by an occlusive dressing or in combination with salicylic acid.

Formaldehyde

Formaldehyde acts similarly to glutaraldehyde. It is useful in the treatment of mosaic plantar warts, which are especially resistant to therapy. A 3% solution is used to soak the infected area for 15 to 20 min daily. The solution can be reused.

Glutaraldehyde

Glutaraldehyde is viricidal. It hardens the wart surface, thereby facilitating paring. It stains skin brown, making it less cosmetically appealing. The benefit to using this agent is that it reduces viral shedding from the wart surface, thus reducing the infectious risk.

Imiquimod

Imiquimod belongs to a class of imidazoquinolinamines that has antitumor and antiviral activity. The mechanism of action is uncertain. It exerts no direct antiviral effect within the mammalian cell in vitro, but does activate the immune system via cytokine induction. [47] Imiquimod is available in a 5% cream (see also Chap. 250).

Mono-, Di-, Trichloroacetic Acids

Eighty percent monochloroacetic acid penetrates the skin and may produce necrosis of the epidermis by blister formation. Saturated dichloroacetic acid or trichloroacetic acid in concentrations of 50% to 80% are less powerful but still effective in the management of warts. [48] Occlusive dressings enhance effectiveness. The application needs to be repeated at 1- to 2-week intervals until complete resolution.

Podophyllin Resin

Podophyllin is an extract from the dried roots of either *Podophyllum peltatum* or *P. emodi*. It acts as an antimitotic agent by preventing the formation of mitotic spindles. It is available in a range of concentrations in various vehicles, such as tincture of benzoin, alcohol, or flexible collodion, and is used as a treatment for genital warts.

Podofilox

Podofilox is the active ingredient obtained upon purification of the podophyllin resin. It does not contain any of the ingredients responsible for the toxicity of podophyllin.

Salicylic Acid

The use of salicylic acid in treating warts lies in the destruction of the epidermis in which the virus is present. Salicylic acid is more irritating than some other over-the-counter preparations.

REFERENCES

1. Shroot B: Pharmacodynamics and pharmacokinetics of topical adapalene. *J Am Acad Dermatol* **39**:S17, 1998

2. Cunliffe WJ et al: Clinical efficacy and safety comparison of adapalene gel and tretinoin gel in the treatment of acne vulgaris: Europe and US multicenter trials. *J Am Acad Dermatol* **36**:S126, 1997

3. Nazzaro-Porro M: Azelaic acid. *J Am Acad Dermatol* **17**:1033, 1987

4. Webster G: Combination azelaic acid therapy for acne vulgaris. *J Am Acad Dermatol* **43**:S47, 2000

5. Ellis CN et al: Therapeutic studies with a new combination benzoyl peroxide/clindamycin topical gel in acne vulgaris. *Cutis* **67**:13, 2001

6. Burkhart CN et al: Synergistic activity of benzoyl peroxide and erythromycin. *Skin Pharmacol Appl Skin Physiol* **13**:292, 2000

7. Menter A: Pharmacokinetics and safety of tazarotene. *J Am Acad Dermatol* **43**:S31, 2000

8. Leyden J et al: Comparison of treatment of acne vulgaris with alternate-day applications of tazarotene 0.1% gel and once-daily applications of adapalene 0.1% gel: A randomized trial. *Cutis* **67**:10, 2001

9. Webster GF: Topical tretinoin in acne therapy. *J Am Acad Dermatol* **39**:S38, 1998

10. McClellan KJ, Wiseman LR, Markham A: Terbinafine. An update of its use in superficial mycoses. *Drugs* **58**:179, 1999

11. Rogers SC et al: Percutaneous absorption of phenol and methyl alcohol in Magenta Paint B.P.C. *Br J Dermatol* **98**:559, 1978

12. Bohn M, Kraemer KT: Dermatopharmacology of ciclopirox nail lacquer topical solution 8% in the treatment of onychomycosis. *J Am Acad Dermatol* **43**:S57, 2000

13. Holti G: A double-blind controlled trial of Whitfield's ointment and Variotin in ringworm infections with a two year “follow-up.” *Acta Derm Venereol* **50**:229, 1970

14. Khattar MM et al: The influence of pyrithione on the growth of micro-organisms. *J Appl Bacteriol* **64**:265, 1988

15. Olsen EA: Female pattern hair loss. *J Am Acad Dermatol* **45**:S70, 2001

16. Walter JF, DeQuoy PR: Anthracene with near ultraviolet light inhibiting epidermal proliferation. *Arch Dermatol* **114**:1463, 1978

17. Schmid MH, Korting HC: Coal tar, pine tar, and sulfonated shale oil preparations: Comparative activity, efficacy, and safety. *Dermatology* **193**:1, 1996

18. Kaidbey KH, Kligman AM: Clinical and histological study of coal tar phototoxicity in humans. *Arch Dermatol* **113**:592, 1977

19. Docampo R, Moreno SN: The metabolism and mode of action of gentian violet. *Drug Metab Rev* **22**:161, 1990

20. Williford PM: Opportunities for mupirocin calcium cream in the emergency department. *J Emerg Med* **17**:213, 1999

21. Elgart ML: A risk-benefit assessment of agents used in the treatment of scabies. *Drug Saf* **14**:386, 1996

22. Burkhart CG et al: An assessment of topical and oral prescription and over-the-counter treatments for head lice. *J Am Acad Dermatol* **38**:979, 1998

23. Hall RC, Hall RC: Long-term psychological and neurological complications of lindane poisoning. *Psychosomatics* **40**:513, 1999

24. Downs AM et al: Evidence for double resistance to permethrin and malathion in head lice. *Br J Dermatol* **141**:508, 1999

25. Roos TC et al: Pharmacotherapy of ectoparasitic infections. *Drugs* **61**:1067, 2001

26. Forstinger C et al: Treatment of rosacea-like demodicidosis with oral ivermectin and topical permethrin cream. *J Am Acad Dermatol* **41**:775, 1999

27. Holzle E, Braun-Falco O: Structural changes in axillary eccrine glands following long-term treatment with aluminium chloride hexahydrate solution. *Br J Dermatol* **110**:399, 1984

28. Cullen SI: Topical methenamine therapy for hyperhidrosis. *Arch Dermatol* **111**:1158, 1975

29. Coskey RJ: Contact dermatitis caused by diphenhydramine hydrochloride. *J Am Acad Dermatol* **8**:204, 1983

30. Horio T: Allergic and photoallergic dermatitis from diphenhydramine. *Arch Dermatol* **112**:1124, 1976

31. Greiding L, Moreno P: Doxepin incorporated into a dermatologic cream: An assessment of both doxepin antipruritic action and doxepin action as an inhibitor of papules, in allergen and histamine-caused pruritus. *Allergol Immunopathol (Madr)* **27**:265, 1999

32. Yosipovitch G et al: Effect of topically applied menthol on thermal, pain, and itch sensations and biophysical properties of the skin. *Arch Dermatol Res* **288**:245, 1996

33. Pascher F: Systemic reactions to topically applied drugs. *Int J Dermatol* **17**:768, 1978

34. Furman PA et al: Acyclovir triphosphate is a suicide inactivator of the herpes simplex virus DNA polymerase. *J Biol Chem* **259**:9575, 1984

35. Brown TJ et al: Antiviral agents: Non-antiviral drugs. *J Am Acad Dermatol* **47**:581, 2002

36. Chen XS et al: A comparison of topical application of penciclovir 1% cream with acyclovir 3% cream for treatment of genital herpes: A randomized, double-blind, multicentre trial. *Int J STD AIDS* **11**:568, 2000

37. Chou TD et al: Methemoglobinemia secondary to topical silver nitrate therapy—A case report. *Burns* **25**:549, 1999

38. Gaspar ZS, Dawber RP: Treatment of lentigo maligna. *Australas J Dermatol* **38**:1, 1997

39. Nazzaro-Porro M et al: A case of recurrent (following surgery ×2) invasive malignant melanoma with satellitosis (stage IIIA) successfully resolving after azelaic acid treatment administered by several routes. *Clin Exp Dermatol* **21**:321, 1996

40. Ganemo A et al: Improved topical treatment of lamellar ichthyosis: A double-blind study of four different cream formulations. *Br J Dermatol* **141**:1027, 1999

41. Jennings MB et al: Comparison of salicylic acid and urea versus ammonium lactate for the treatment of foot xerosis. A randomized, double-blind, clinical study. *J Am Podiatr Med Assoc* **88**:332, 1998

42. Fisher AA: Urea in topical medications and cosmetics. *Cutis* **62**:68, 1998

43. Steigleder GK et al: Autoradiographic in vitro examination of psoriatic skin before, during, and after dithranol treatment. *Arch Dermatol Forsch* **246**:231, 1973

44. Ashcroft DM et al: Systematic review of comparative efficacy and tolerability of calcipotriol in treating chronic plaque psoriasis. *BMJ* **320**:963, 2000

45. Chandraratna RA. Tazarotene—First of a new generation of receptor-selective retinoids. *Br J Dermatol* **135**(Suppl 49):18, 1996

46. Yoshizawa Y et al: Topical dinitrochlorobenzene therapy in the treatment of refractory atopic dermatitis: Systemic immunotherapy. *J Am Acad Dermatol* **42**:258, 2000

47. Sauder DN: Immunomodulatory and pharmacologic properties of imiquimod. *J Am Acad Dermatol* **43**:S6, 2000

48. Baker GE, Tyring SK: Therapeutic approaches to papillomavirus infections. *Dermatol Clin* **15**:331, 1997

T>

Chapter 252

Patricia Engasser Howard Maibach

Cosmetics and Skin Care in Dermatologic Practice

EFFICACY AND SAFETY OF COSMETICS
ADVERSE REACTIONS TO COSMETICS
Irritation Syndrome
Contact Urticaria Syndrome
Delayed Hypersensitivity Reactions
FRAGRANCES
PRESERVATIVES
Cosmetic Intolerance Syndrome and "Sensitive Skin"
SKIN CARE COSMETICS
Cleansing Agents
Shaving Products
Hair Removers
Deodorants/Antiperspirants
Moisturizers
Self-Tanning Agents
Whitening Agents
Makeup
HAIR CARE COSMETICS
Shampoos and Conditioners
Hair Dyes
Bleaches
Permanents
Ethnic Hair Products
NAIL COSMETICS
Nail Polish
Nail Elongation Materials
OCCUPATIONAL HAZARDS
CONCLUSION

REFERENCES

Consulting with patients and the public about cosmetics is part of the dermatologist's role as the skin care expert. The increasing application of biophysical measurement techniques to study skin allows more accurate assessment of the safety and efficacy of cosmetics. Notwithstanding this advance, published evidenced-based clinical data on which dermatologists can support this advice are limited, and advertising and press reports create unrealistic public expectations. Information technology allows international experts to communicate easily about the dermatotoxicology of cosmetics, and manufacturers frequently sell products internationally; this situation enables global market forces and regulations to determine the nature of available products.

EFFICACY AND SAFETY OF COSMETICS

In response to scientific, economic, and social influences, the definition of cosmetics varies. In the United States, the 1938 Food, Drug, and Cosmetic Act defines cosmetics as "articles intended to be rubbed, poured, sprinkled, or sprayed on, introduced into, or otherwise applied to the human body or any part thereof for cleansing, beautifying, promoting attractiveness, or altering the appearance." Drugs in part are defined as "articles…intended to affect the structure or any function of the body." [1] These definitions are not mutually exclusive, and products such as antiperspirants and whitening agents are regulated both as over-the-counter drugs and as cosmetics. Hutt details not only the law and regulations but also their ambiguities. In Japan, these ambiguities are managed by the classification of "quasi-drug."

In the United States, drugs must meet strict premarket safety and efficacy requirements. Regulatory penalties make cosmetic scientists reluctant to explore the physiologic effects of topical compounds or the nature of their placebo effects. To deal with these contradictory forces, Kligman [2] proposed a separate category—cosmeceuticals—for products that have cosmetic purposes but also affect skin structure and function. This term could describe topical minoxidil used to treat physiologic balding, some topical retinoids that might reverse signs of aging, and some moisturizers applied to treat xerosis. In the last two decades, dermatologic studies have established that the stratum corneum—the "playground" for cosmetics—has a modifiable metabolic activity that influences the structure and function of viable epidermis, [3] making the 1938 definition of a cosmetic outdated and irrational. The advancing field of cutaneous biometrics [4] can bring efficacy claims from fanciful to provable, and consumers' desire for readily available cosmeceuticals will ensure their development.

Physical attractiveness is deemed socially advantageous and results in perceptions of "goodness" and success as well as a sense of well-being. [5] Improvement in attractiveness and consequent psychological benefit promoted by effective cosmetic use extend to the elderly and should be recognized by physicians.

An important consideration in cosmetic innovation and toxicology is the growing concern about animal testing. Some manufacturers have voluntarily abandoned testing final products on animals. The European Union's Sixth Amendment to the Cosmetic Directive proposal that animal testing of ingredients cease was activated on June 30, 2002. [6] Complete, timely compliance with this ban is unfeasible because development validation of alternative testing methods has been

slow and problematic.

In the United States, manufacturers' reporting of adverse cosmetic reactions to the Food and Drug Administration (FDA) is a voluntary program. The Cosmetic, Toiletries, and Fragrance Association (CTFA), the manufacturers' trade organization, sponsors the Cosmetic Ingredient Review (CIR) to review the safety of cosmetic ingredients and publishes its final reports in the *International Journal of Toxicology*. In the United States, ingredient labeling has been mandated for retail cosmetics since 1978. Ingredients are listed in descending order of amount, using nomenclature published in the *International Cosmetic Ingredient Dictionary*. [7] Fragrances (complex mixtures) are described simply as fragrance. Voluntary compliance with these regulations for cosmetics used or sold in beauty spas and salons was adopted in 1989. Beginning in 1998, European cosmetics were also required to have ingredient labeling. Listing of two dozen fragrance allergens may shortly be mandated on European labels. In cooperation with the American Contact Dermatitis Society, the CTFA publishes *Cosmetic Industry On Call,* a list of industry scientists who will aid dermatologists in evaluating patients who may have reactions to cosmetics. [8] Irritant, urticarial, allergic, or photosensitive eruptions, as well as pigmentary, hair, and nail disorders, or systemic reactions, can result from cosmetic use. To diagnose affected patients, dermatologists must appreciate the diversity of these reactions.

ADVERSE REACTIONS TO COSMETICS (See also Chap. 120)

Irritation Syndrome

Previously considered monomorphous, the irritation syndrome (Table 252-1) is a heterogeneous process. It often has an eczematous appearance, notwithstanding disparate mechanisms. Several clinical and biologic entities have been described, and others await clinical or basic science definition.

Objective Irritation	Subjective Irritation
Acute or corrosive reaction	Sensory irritation
Irritant dermatitis	
Irritant reaction	
Cumulative irritation	
Mechanical irritation	
Acneiform and pustular eruption	
Phototoxic reaction (photoirritation)	

TABLE 252-1 **Irritation Syndrome Related to Use of Cosmetics**

OBJECTIVE IRRITATION Skin irritation is defined as localized inflammation that is not mediated through the immune system and is caused by endogenous and environmental factors. Hair straighteners, permanents, and depilatories can cause *acute reactions* if directions for their safe use are not strictly followed. Cleansers are frequently responsible for causing *irritant dermatitis*. Moisturizers or emollient creams, in which water and oleacous materials are blended, contain surfactants and emulsifiers that are often mild irritants. When these cosmetics are applied to the face or to dry or eczematous skin, where the stratum corneum is a less-efficient barrier, *irritant reactions* may result. Morphologic features include scaling, which may rapidly clear with avoidance of exposure but becomes erythematous with recurrent dosing and may evolve into chronic irritant dermatitis. Some cosmetics produce irritation only after repeated application; this phenomenon is termed *cumulative irritation*. Friction, injury, and *mechanical irritation* can be caused by popular cosmetics containing granules or by devices (e.g., synthetic sponges) used to exfoliate the skin. Sensitive bioengineering techniques used to evaluate the pathophysiology of irritation include transepidermal water loss, skin impedance, conductance resistance, and blood flow velocity. [9] By using predictive testing in animals and humans, manufacturers can recognize strong or moderate irritant ingredients or products. In premarket testing, mild irritants are more difficult to detect and quantify. Some skin and hair care cosmetics cause acneiform eruptions. *Acnegenicity* encompasses both comedogenicity, which refers to follicular keratin impaction [10] and papulopustular formation. [11] The time course for the appearance of facial papulopustules and comedones is different: papulopustules may appear in just a few days, whereas the appearance of comedones is delayed. Considerable confusion derives from the testing techniques: for example, isopropyl myristate in concentrations as low as 10% in petrolatum rapidly induces comedones in the rabbit ear but yields papulopustules in humans. Even common emulsifiers such as sodium lauryl sulfate produce pustules in a dose-related manner. The mechanisms appear to be related in spite of varied morphology. The European Community's proposed ban on animal testing of final products will result in stronger reliance on human testing, whether this takes the form of use tests or application of a cosmetic under occlusion to the back for 4 weeks and subsequent cyanoacrylate or cationic polymer biopsies (to identify microcomedones), or both. [11] The clinical significance of cosmetics in precipitating postadolescent acne in women was recently called into question by one of the authors of the original paper on “acne cosmetica.” [10], [12] To avoid total confusion in light of this development, it seems prudent to advise female acne patients to keep their cosmetic regimen of care simple and gentle, using products from manufacturers who test for acnegenicity. Bergamot oil (5-methoxypsoralen) is a *phototoxic* fragrance ingredient that was used in cosmetics but has been removed. As interest in “natural” ingredients increases, [13] new phototoxins may be inadvertently introduced and have serious consequences when they are not recognized clinically.

SUBJECTIVE IRRITATION Burning, stinging, or itching caused by application of a cosmetic or topical medicament without detectable visible or microscopic change is termed *sensory irritation*. The afferent limb of this reaction is carried by C nerve fibers that are present throughout the dermis and viable epidermis. The stinging occurs on the face within an hour of application in susceptible individuals. In a segment of the population, this sensory response is caused by many ingredients at dosages that do not produce clinical objective irritation. Examples of such ingredients are propylene glycol, benzoic acid, hydroxy acids, and ethanol. To identify susceptible persons (“stingers”), Frosch and Kligman [14] applied 5% lactic acid to the nasolabial fold when the subject was sweating profusely; about 20 percent of the population experiences an unpleasant sensation under these circumstances. “Stingers” do not have a higher incidence of atopy or dry skin, but do report frequent adverse reactions to cosmetics. Strontium nitrate and chloride inhibit sensory irritation caused by a-hydroxy acids, ascorbic acid, and aluminum salts. [15] These blockers are being incorporated into skin care products such as those containing a-hydroxy acids.

Contact Urticaria Syndrome

Contact urticaria syndrome typically consists of a wheal-and-flare response developing within 30 to 60 min after the skin is exposed to certain agents. Symptoms range from the mildest manifestations (e.g., itching, tingling, burning, and erythema) to the most severe (e.g., anaphylaxis and death). Diagnosis of immediate contact urticaria is based on a thorough medical history (including notation of burn, sting, or itch resulting from skin contact; urticaria; or respiratory symptoms) and skin testing using suspected substances as summarized by Amin and Maibach. [16]

Contact urticaria syndrome is divided into two subtypes—nonimmunologic and immunologic—based on proposed pathophysiologic mechanisms. [16] Nonimmunologic contact urticaria, the most common form, occurs in the absence of previous exposure and remains localized, causing no systemic symptoms. Typically, the strength of the reaction varies by ingredient concentration and location of use. The mechanism is not completely delineated. Benzoic acid, cinnamic acid, and cinnamal are commonly used in cosmetics and are potent substances capable of eliciting this response.

Immunologic contact urticaria is an immediate type I allergic reaction that occurs in sensitized individuals and is induced more frequently in atopic individuals. The eliciting chemicals react with specific IgE molecules on mast cell membranes. Localized urticaria can extend beyond the site of contact, or may be accompanied by other symptoms such as rhinitis, conjunctivitis, asthma, and anaphylaxis. In this manner, methylparaben, ethylparaben, henna, and ammonium persulfate have been associated with systemic reactions. [16], [17]

Delayed Hypersensitivity Reactions

Adverse reactions to cosmetics constitute a small but significant portion of contact dermatitis cases treated by dermatologists. In a study conducted by the North American Contact Dermatitis Group (NACDG), patch testing showed contact dermatitis related to cosmetics in 5 percent of more than 13,000 patients evaluated; [18] similar percentages have been reported from Europe. [19] These figures underestimate the total number of cases, because most mild reactions are not investigated by dermatologists. In the NACDG study, 59 percent of the cosmetic-induced reactions occurred on the face and 79 percent were seen in women, but a relation to cosmetics was suspected by the dermatologist or patient initially in fewer than half the cases. Diagnosis of allergic contact dermatitis is based on a compatible history and examination supported by results of patch testing. Most cosmetics are not strong irritants and can be patch tested closed in the usual manner; however, notable exceptions exist (Table 252-2). Weakly positive reactions should be confirmed by medical history, test repetition, and patch testing of ingredients. Ingredient testing is a problem in the United States because of the limited number of chemicals available on the T.R.U.E. (thin-layer rapid use epicutaneous) test screening tray. It is important to recognize which of these allergens are found in cosmetics (Table 252-3). Cosmetic Industry on Call [8] provides information for contacting manufacturers who may provide ingredients for patch testing. De Groot et al. [19] provide reference information on chemical concentrations and vehicles to use in testing cosmetic ingredients.

Shampoos	Cuticle removers
Soaps	Nail polish removers
Detergent foaming cleansers	Nail glues
Foaming bath products	Nail extenders
Shaving lathers	Depilatories
Dentifrices	Bleaching creams
Hair bleach or boosters	Permanent-waving solutions
Straighteners	Hair dyes
Dry thoroughly before covering in closed patch tests:	
Mascara	Hair spray
Nail polish	Perfumes

TABLE 252-2 **Cosmetics Not Safely Applied "As Is" in Closed Patch Tests**

Colophony (rosin)
Fragrance mix
Paraphenylenediamine
Lanolin alcohol (wool alcohols)
Formaldehyde
Quaternium-15
Balsam of Peru
Paraben mix
Thimerosal*
Methylchloroisothiazolinone + methylisothiazolinone

*Thin-layer rapid-use epicutaneous test.
*Patch for mercury sensitivity.

TABLE 252-3 **Ingredients Found in Cosmetics Included on T.R.U.E.* Test**

The provocative use test (PUT), also called the repeat open application test (ROAT), [20] is a practical way to screen for allergy to cosmetics including fragrances [21] or to confirm the clinical significance of weak positive reactions. The cosmetic is applied twice daily for up to 4 weeks to an approximately 5-cm area on the flexor surface of the forearm near the cubital fossa.

Most photoallergic ingredients in cosmetics are sunscreening agents or fragrances. To test for photoallergy, the patch site is exposed to between 5 and 10 J of ultraviolet A (UVA) 24 h after application; after 48 h, the photopatch site is compared with a nonirradiated site similarly patch tested.

Most allergic reactions to cosmetics are caused by fragrances, preservatives, and a small number of miscellaneous ingredients. [18], [19] Familiarity with these allergens will enable clinicians to diagnose many of these cases accurately.

FRAGRANCES

Fragrance allergy is common, affecting approximately 1 percent of the general population; dermatitis may develop on the

face, neck, hands, and axillae, or it may be generalized. [22]

Fragrances are ubiquitous: in addition to cosmetics and toiletries, they are added to household goods or cleansers in the workplace, and some are used as flavorings. Paradoxically, “unscented” cosmetics may contain a masking fragrance. A new method of promoting fragrances is to claim that scents have mood-altering effects—so-called aromatherapy. Inevitably, troublesome sensitization has occurred in consumers who have doused themselves and their surroundings with fragrance. Since 1966, toxicologic information related to fragrance ingredients has been assembled and assessed by the industry-sponsored Research Institute for Fragrance Materials (RIFM). [22], [23] Based on this information, the International Fragrance Association (IFRA) publishes guidelines that industry members generally agree to follow.

Photosensitization occurred more commonly before methyl coumarin and musk ambrette were eliminated from fragrances. Sensitization to musk ambrette left an extensive legacy of so-called persistent light eruptions. Because fragrance allergy is frequently not suspected by either the patient or the physician, patch testing is an important tool for reaching this diagnosis. Balsam of Peru, cinnamal, fragrance mix, and colophony are recognized markers for fragrance allergy on patch-test screening series. At present, the fragrance mix (marketed by Hermal and by Chemotechnique and also marketed in the T.R.U.E. test) contains eight ingredients: eugenol, isoeugenol, oak moss absolute, geraniol, cinnamal, a-amyl cinnamic aldehyde, hydroxycitronellal, and cinnamic alcohol. In an international study of 165 patients with probable fragrance allergy, the fragrance mix detected 86 percent of positive reactions. [24] Addition of ylang-ylang oil, narcissus oil, sandalwood oil, and balsam of Peru raised this percentage to 96 percent. Racial and geographic distinctions exist; for instance, Japanese patients tested were more frequently reactive to benzyl salicylate. Such racial differences were highlighted by the epidemic of bizarre facial hyperpigmentation seen in Japanese women in the 1960s and 1970s caused by allergy to fragrances and coal-tar dyes used in some cosmetics; elimination of these allergens solved the problem. [25]

Allergy to fragrance can be tested by using ROAT for up to 4 weeks. [21] Balsams, cinnamic alcohol, cinnamaldehyde, benzyl alcohol, and benzaldehyde are among the fragrance ingredients that can evoke contact urticaria not detected by closed patch testing. [17]

PRESERVATIVES

Preservatives are added to prevent contamination of cosmetics by microorganisms, which degrade the product or cause infection in consumers; but the term *preservative* may encompass agents that prevent degradation induced by oxidation or ultraviolet light. Approximately 60 chemicals are commonly used as preservatives in cosmetics. Preservatives may consist of a single ingredient or a mixture of ingredients (e.g., Euxyl 400 is a mixture of methyldibromoglutaronitrile and phenoxyethanol). Use of specific preservatives varies among American, European, and Asian markets; consequently, the incidence of allergic reactions to individual agents also varies. Adverse reactions have prompted development of preservative-free cosmetics. Strategies for developing such products include modification of the manufacturing and packaging processes as well as use of botanicals, which have antimicrobial activity. The increasing complexity of cosmetics and their vehicles makes this goal even more difficult to achieve.

Paraben esters, the most popular group of preservatives, are effective against fungi and gram-positive (but not gram-negative) bacteria. Parabens rarely sensitize but may do so when applied to eczematous skin. Sensitized patients frequently tolerate parabens in cosmetics applied to normal skin.

Propylene glycol, a popular solvent and humectant, has antimicrobial properties but is used in some “preservative-free” cosmetics. Review of the literature and observations in patch tested patients suggest that propylene glycol is a mild irritant that only occasionally sensitizes. [26]

Formaldehyde and formaldehyde releasers are widely used. [27] Formaldehyde is formulated in wash-off products such as shampoos. Quarternium-15, imidazolidinyl urea, diazolidinyl urea, DMDM hydantoin, and 3-bromo-2-nitropropane-1-3-diol are commonly used preservatives that release formaldehyde. They may sensitize themselves or cause reactions secondary to formaldehyde release in formaldehyde sensitive patients, and cross-reactions in the group are reported. Patients' tolerance of products containing preservatives to which they are sensitive is modified by the site of application and their degree of sensitivity. For example, some formaldehyde sensitive individuals can tolerate low levels of formaldehyde releasers on normal skin.

When introduced into Europe as a preservative, methylchloroisothiazolinone/methylisothiazolinone was used extensively in concentrations, that frequently caused sensitization. [19] Benefiting from the European experience and in an effort to diminish the problem, CIR set guidelines restricting concentration to =15 ppm in wash-off products and to =7.5 ppm in leave-on products.

A mixture of methyldibromoglutaronitrile and phenoxyethanol (Euxoyl 400) used initially in Europe has gained popularity and is being reported more frequently as an allergen. [28] Butylated hydroxyanisole (BHA), butylated hydroxytoluene (BHT), tocopherol, propyl gallate, and t-butyl hydroquinone used as antioxidants are sometimes reported as allergens. Other ingredients reported frequently as allergens in cosmetics include paraphenylenediamine, toluene sulfonamide/formaldehyde resin (tolysamide/formaldehyde resin), acrylates, lanolin, glyceryl thioglycolate, and UV light-absorbing agents. These will be discussed below in reviewing cosmetic categories.

Cosmetic Intolerance Syndrome and “Sensitive Skin”

Cosmetic intolerance syndrome is not a single entity but rather a symptom complex of multiple exogenous and endogenous factors (Table 252-4). The syndrome is an uncommon clinical entity in which patients complain bitterly of facial burning and discomfort associated with application of most skin care products. Their skin may show overt inflammatory changes, or symptoms may be only subjective. These patients seriously challenge practitioners' empathy

and diagnostic skills because the severity of symptoms does not match objective signs of disease. Many patients affected with this syndrome have tried numerous cosmetics and topical medications. Gradually, over the past two decades, most of these individuals have been recognized to have an organic rather than a functional basis for their complaints.

Exogenous Causes	Endogenous Causes
Subjective irritation	Seborrhea/psoriasis
Objective irritation	Rosacea and perioral dermatitis
Contact urticaria	Atopic dermatitis
Allergic contact dermatitis	Dysmorphobia
Photoallergic contact dermatitis	

Source: Adapted and reproduced by permission of the publisher from Malbach and Engasser[29]

TABLE 252-4 **Types and Causes of Facial Skin Intolerance to Cosmetics**

Fisher [29] coined the term *status cosmeticus* for the condition in which patients no longer tolerate use of any facial cosmetic product. Some of these patients initially experience subjective or objective irritation in response to use of cosmetics and become intolerant to many other topical agents during the evolution of this disorder. Other patients have occult allergic contact dermatitis, allergic photocontact dermatitis, contact urticarial reaction, or a combination of these conditions. In this group, causal agents can be documented by careful clinical review and patch testing. Other patients have a seborrheic-rosacea diathesis which flares and is accompanied by facial erythema and scaling when use of soap and water is abandoned and cleansing creams and emollients are overused. Atopic dermatitis and dry skin are other factors that predispose patients to this condition.

Strictly observing a prolonged program of eliminating cosmetics is an important therapeutic intervention (Table 252-5). Some patients are able to return gradually to using other cosmetics after 6 to 12 months. Subsequent additions to the skin care regimen can be made one at a time every 2 weeks. For the final regimen, the number of cosmetics and frequency of their use should remain limited.

Examine every cosmetic and skin care product
Administer patch and photo patch test to rule out occult allergic and photoallergic dermatitis
Test for contact urticaria
Do careful repeat open application testing (ROAT)
Treat endogenous inflammatory disease
Limit skin care to
Water washing without soap or detergent
Lip cosmetics as desired if lips are clear
Eye cosmetics as desired if eyelids are asymptomatic
Face powder
Glycerin and rose water as a moisturizer if necessary
Avoiding other cosmetics for 6 to 12 months

TABLE 252-5 **Diagnosis and Treatment of Patients Whose Skin Is Intolerant to Cosmetics**

Other patients experience facial burning continuously, without showing objective signs. Cotterill [30] described these patients as having “dermatologic nondisease.” Many of these patients have a disturbed body image or dysmorphobia—that is, they complain of physical defects that lack objective evidence. Many are depressed and need psychiatric help, which they frequently reject.

Sensitive skin covers the same range of pathophysiology as the cosmetic intolerance syndrome, but it is generally less severe. Sensitive skin is a lay term coined to describe the condition of consumers who believe their skin is less tolerant than that of the average person's to environmental conditions and topical preparations. This is a common perception. In a recent British survey, 51 percent of the women and 38 percent of the men believed that they have sensitive skin, and 19 percent of this population reported an adverse reaction to a cosmetic product in the last year. [31] The largest segment of these consumers manifests sensory skin irritation.

SKIN CARE COSMETICS

Cleansing Agents

Cleansing the skin removes environmental contaminants, sweat, sebum, desquamated cells, and microorganisms. Soap bars are manufactured by saponification of fat and alkali, and “syndet” bars contain synthetic detergents to emulsify lipids, which will then be rinsed off with water. Originally, wipe-off cleansing creams containing mineral oil and borax were commonly used as cleansing agents. Detergents are often used in rinse-off foaming lotions. Lipid-free cleansing lotions contain fatty alcohols and may be wiped or rinsed off. In the 1950s, liquid soaps were developed for cleansing workers' hands and were perceived as harsh; liquid cleansers and gels evolved in the 1970s and 1980s to become popular as gentle hand, face, or body washes using blends of surfactants (including nonionics), which are claimed to be less irritating. Fatty acids and polymers are added to enhance mildness. Antimicrobial agents such as chloroxylenol (PCMX) or triclosan are used in cleansers whose manufacturers make antibacterial claims.

Use of cleansers may cause irritation, to which subsets of the population (such as persons who are elderly or who have atopic eczema) are susceptible. The irritant potential of cleansers is gauged by soap-chamber tests or by use tests, which may be exaggerated. Visually or with instrumentation, these tests indicate barrier injury, inflammation, dryness, or skin roughness. Testing is refined to detect subclinical damage and define the depth of injury in the stratum corneum using squamometry. [32] Factors that influence irritancy are the structure and quantity of surfactant, mechanical trauma, water temperature, and duration and frequency of cleansing.

Because wash-off products contact the skin briefly, they infrequently cause allergic contact dermatitis; however, some surfactants (cocamidopropyl betaine), preservatives (methylchloroisothiazolinone/methylisothiazolinone), antimicrobials (PCMX), and fragrances have been reported as allergens in these products. Cocamidopropyl betaine is the most

commonly used amphoteric surfactant in cosmetics, and some of the allergic reactions are caused by impurities. Purification of this surfactant may lead to reduced incidence of sensitization. [33]

Shaving Products

Foaming shaving creams or gels are designed to wet and soften the beard hair in order to reduce the friction caused by a metal blade cutting the hair. Lubricants are added to these fatty acid soaps to decrease frictional forces as the blade traverses the skin. Preshave cosmetics for use with electric razors are fragranced alcohol products that dry the skin and reduce friction. Aftershaves are fragranced cosmetics applied to freshly shaven skin with a compromised barrier, which partially accounts for the frequency of allergic and photoallergic reactions reported in the past when photosensitizers such as musk ambrette were present. [22]

Hair Removers

Superfluous hair may be disguised by bleaching or removed by shaving, waxing, plucking, chemical dissolution, or electrolysis. Laser hair removal is becoming an increasingly popular alternative. For some patients who have curly beard hair and who are susceptible to pseudofolliculitis barbae, use of barium sulfide depilatories is a helpful but malodorous and irritating alternative to shaving.

Most modern depilatories contain substituted thiols. Calcium thioglycolates are the least irritating. They act more slowly than sulfides but are safer. Thioglycolates attack keratin and may injure the epidermis; manufacturers' directions should be followed closely.

Eflornithine hydrochloride cream has been approved by the FDA for the reduction of unwanted facial hair in women by inhibiting the enzyme ornithine decarboxylase. This drug may be used to complement facial hair removal, and its effect is reversed when the drug is discontinued.

Deodorants/Antiperspirants

These popular cosmetics are designed for use in the axillae, whose apocrine sweat glands produce organic chemicals metabolized by bacteria to produce an odor generally considered undesirable. [34] Eccrine sweat distributes these chemicals more broadly. Deodorants contain antimicrobial agents (e.g., triclosan) as well as fragrance to mask odor. Antiperspirants use aluminum salts, which theoretically cause temporary plugging of the eccrine sweat glands to reduce their output and decrease the bacterial population. Aluminum salts may cause irritant reactions, but the allergic reactions associated with these products are caused by fragrance or other ingredients.

Moisturizers

Most dermatologists are conversant with the promotional faces of moisturization, as detailed by dermatologic, cosmetic, and occupational specialty firms. The word is beguilingly simple; the mechanism of action and biology are highly complex and incompletely understood.

It is probable that branded moisturizers appreciated by the consumer vary depending on the anatomic site intended for use. Materials for the face may be highly regarded when they produce a slight swelling and improve cosmetic feel and appearance. Hand care presents a different situation; the consumer does not need or desire swelling and instead, appreciates the healing effects of certain lipid-rich moisturizers that are formulated to avoid greasiness that interferes with the consumer's tasks. Legs present another clinical situation—the consumer/patient desiring a diminution in itch and scaling is more tolerant of increasing lipid content, and in some moisturizers, keratolytics are incorporated successfully.

The chemistry—in spite of a century of extensive development by various industries involved—remains incompletely understood, in terms of both formulation and mechanism of action. Lipids provide the underpinnings of most moisturizing products. These (see below) depend highly at one extreme on the greasiness of petrolatum and on the other extreme, the more esthetic qualities of the lanolins. Glycerin, highly popular in the nineteenth century, has regained its prominence in recent years in consumer acceptance studies and the marketplace. Other formulating materials include urea (shown to be effective in controlled consumer studies but far less so in the marketplace) and a mixture named *natural moisturizing factor.* In most formulations, water constitutes the major component.

Moisturizers improve the appearance and tactile properties of dry and aging skin by acting on the stratum corneum to diminish scaling and to enhance suppleness, presumably by increasing its water content. [35] Traditionally, moisturizers inhibit transepidermal water loss by occlusion. The “bricks and mortar” model illuminates the stratum corneum's role as an active membrane [36] (see Chap. 9). Loss of intercellular lipids (i.e., ceramides, cholesterol, and fatty acids that form bilayers) damages the water-barrier function and calls into play repair mechanisms signaled into action by the stratum corneum. In this way, treating dry skin has consequences in the viable epidermis.

Usually containing mixtures of water and fatty substances such as petrolatum, lanolin, lanolin derivatives, and fatty alcohols, moisturizers decrease scale and transiently increase water content in the stratum corneum. Several putative mechanisms are popular: (1) occlusion, that is, allowing water to percolate up from the viable epidermis; (2) replacement or assisted synthesis of lipid mixtures in the intercellular spaces; [3], [37] and (3) use of humectants, which bind water in the stratum corneum. Success of these maneuvers is determined in the laboratory by measuring transepidermal water loss, impedance, and conductance, [38] as well as by epidermal capacitance and regression testing. But discerning consumers judge by the feel and appearance of their skin, which introduces the criterion of esthetics. In recent years, several experiments confirm conventional wisdom—moisturizers decrease irritant dermatitis, [39], [40] and their efficacy is related to

their lipid mass. [41] It is likely that moisturizers are equal or more important than glucocorticoids in this regard.

What is not clear is the prophylactic value of moisturizers in preventing irritant dermatitis. Several studies on acute exposure in highly controlled environments demonstrate their value; however, in the one chronic administration study, [42] this benefit was not only not confirmed, but showed an exacerbation of surfactant-induced irritant dermatitis. The clinical experience and literature on barrier creams is beyond the province of this brief chapter. Zhai summarizes much of this information. [43]

Petrolatum, a semisolid mixture of hydrocarbons obtained from dewaxed heavy mineral oils, is a uniquely effective moisturizer as a result of mechanisms not fully understood. Petrolatum delays water evaporation from the stratum corneum. In contrast to a vapor-impermeable membrane (e.g., latex), petrolatum does not impede barrier lipid repair in acetone-stripped stratum corneum and enhances immediate repair. [3], [44] Petrolatum is not a primary or cumulative irritant and can protect against irritant effects of detergents. Kligman [12] has questioned the acnegenicity and comedogenicity of petrolatum, and high-quality, cosmetic-grade petrolatum appears to be safe in this regard. Unfortunately, large amounts impart a tacky feel, which consumers do not like.

Lanolin and its derivatives are more esthetically acceptable and are good emulsifiers. Lanolin is a mixture of esters and polyesters of high-molecular-weight alcohols and fatty acids. Analysis of tape strippings shows that lanolin penetrates the entire stratum corneum and appears to emulsify intercellular water. [45] Although lanolin has been reported to be an allergen in 2 to 5 percent of patients who received patch tests, [46], [47] it infrequently causes reactions on normal skin but can sensitize when applied to eczematous skin, especially in stasis dermatitis. Cronin [47] reported 26 cases of lanolin-cosmetic facial dermatitis in women, for half of whom the eyelids were affected to a striking degree. Wool alcohols (30% in petrolatum) and Amerchol L-101 (50% in petrolatum) are used in patch tests to screen for allergy.

Three types of lipid—cholesterol, free fatty acids, and ceramides—are required for maintaining the epidermal permeability barrier. All three lipids in proper molar proportions are alleged to be necessary. These data are being used to formulate moisturizers. [37]

Glycerin and propylene glycol function as humectants. Studies of moisturizers containing glycerin showed formation of a glycerin reservoir in the stratum corneum, suggesting a role in barrier repair and in preventing transition of stratum corneum lipids to a solid crystalline state. [48]

The hygroscopic properties of urea allow it to bind water quickly in the stratum corneum, especially at high humidity. [38] Incorporating urea in hydrophilic ointment enhances the water binding capacity for at least several hours, but this function is lost at lowered humidity.

Smoothing rough skin and minimizing signs of aging fit the consumer's broad definition of moisturizing. Consequently, keratolytic agents (i.e., hydroxy acids and salicylic acid) are extremely popular ingredients in skin care products (see also Chap. 248). In 1974, a-hydroxy acids were proposed for treatment of keratinizing disorders, [49] and lactic acid was noted to improve dry skin; however, no major launch of a cosmetic containing a-hydroxy acid occurred until 1992. Hydroxy acids at low concentrations diminish corneocyte adhesion at the lower level of the stratum corneum, stimulate epidermal cell proliferation, and increase the thickness of viable epidermis. The thinner stratum corneum they create is more flexible. The a-hydroxy acids can stimulate glycosaminoglycan and perhaps collagen synthesis. Consumers perceive improved skin texture, brightness, and firmness, as well as less wrinkling and pigmentation. [50] Like the drug tretinoin, hydroxy acids modify some of the adverse effects of sun exposure, photoaging. Topical retinoids, which two decades ago revolutionized dermatologic therapy of photoaging, are discussed in Chap. 244. If formulated properly, a-hydroxy acids may be useful for treating acne, and salicylic acid, which is lipid soluble, has been used for decades for this purpose.

Improved formulations reduced the irritation and unpleasant odor of skin care products. In general, lower pH and higher concentration increases penetration of these ingredients. The CIR concluded that glycolic acid, lactic acid, and their common salts and esters are safe for use in cosmetics at concentrations =10 percent when the product is at pH =3.5 and formulated to avoid increasing sun sensitivity or when directions for use specify daily use of sun protection. [51] The FDA has proposed further toxicologic study.

Reactive oxygen species (e.g., free radicals) arise from UV light and from other insults that damage cells. Theoretically these chemical species are partly responsible for aging. Antioxidants such as vitamins A, C, and E and their derivatives are added to cosmetics in an attempt to block this injury, and mixtures of antioxidants may have a synergistic benefit improving efficacy. [52] To prove that this can be accomplished by using any of these agents as currently administered, the complex chemistry of these oxidative processes must be further studied.

Sun-screening agents are added to many cosmetics to prevent photodamage to skin. In the United States, sunscreens are regulated as over-the-counter drugs when a sun protection factor (SPF) is tested. The list of permitted ingredients, methods of efficacy testing, and labeling standards are published as regulations in the Federal Register. [53]

Many so-called antiaging and photoprotective products have vehicles that are, in fact, identical to moisturizers. Many of the studies provided to dermatologists only show a before and after difference, rather than demonstrating a difference between an active and a placebo. It is unclear how much of the value comes from the active agent and how much comes from the moisturizer-like composition.

Self-Tanning Agents

“Sunless” or “self-tanning” lotions containing dihydroxyacetone are regulated as cosmetics, although they do provide some protection from longwave UVA light. [54] Dihydroxyacetone binds to the skin's surface keratin, producing a brown

stain that fades only as corneocytes desquamate. These products have become popular because they can give the illusion of a tan. Allergic contact dermatitis may occur rarely from dihydroxyacetone or other ingredients in the formulation. A system called Turbo-PUVA, which uses dihydroxyacetone to photoprotect noninvolved psoriatic skin during PUVA therapy, allows higher UVA exposure and faster clearing. [54]

Whitening Agents

There is wide consumer interest in agents that lighten skin tone and improve irregular pigmentation. In vivo and in vitro investigation of potential whitening agents have been conducted, and some are available in the nonprescription market. [55] Hydroquinone inhibits the tyrosinase conversion of tyrosine to melanin. Nonprescription bleaching creams containing up to 2.0% hydroquinone are modestly effective in treating postinflammatory hyperpigmentation, lentigines, and melasma. In 2002, the FDA approved for the first time a skin whitening prescription agent. It contains fluocinolone acetonide 0.01%, hydroquinone 4%, and tretinoin 0.05%. Successful treatment of melasma requires strict protection from UV light. Adverse effects associated with the use of hydroquinone include irritant and allergic reactions, hypopigmentation, hyperpigmentation, exogenous ochronosis, and staining of nails.

Hydroxyacids have been used to enhance hydroquinone, and there is evidence in a double-blind study that 5.0% lactic acid or greater acts as a whitening agent alone. [56] Kojic acid, a fungal metabolic product, suppresses tyrosinase by chelating copper. First marketed in Japan at a 1% concentration in nonprescription preparations in 1988, it remains popular there and is now used in United States. [55] Stable derivatives of vitamin C, vitamin E, and linoleic acid are being studied for their effectiveness in suppressing pigment production. Also, “natural” agents have been sought. Arbutin, extracted from pear tree leaves, is a source of hydroquinone, and glycyrrhizinate from licorice root can lighten pigment in clinical studies. [56] These cosmetic ingredients, as well as the prescription combination products, offer the consumer a wider choice for treating pigment disorders.

Makeup

Makeup has been used since ancient times to normalize, glamorize, and accentuate features, or to create a stylized appearance. Camouflage techniques using specially designed opaque cosmetics have been developed by skilled makeup artists and can be taught to patients with disfiguring disorders, greatly benefiting these patients' psychological well-being. [34], [57]

Sales of ethnic cosmetics burgeoned in the 1990s, and jet-milled and coated pigments enabled the development of darker makeup shades, which require more pigment. An important trend in mass-market color cosmetics is the use of silicone technology to produce long-lasting formulations for lipsticks, foundations, and related products. To be permitted in makeup, colors must be government-certified for use; they seldom cause adverse reactions. The United States has certified 34 colors, but only 13 of these are certified in all three major markets (Japan, Europe, and the United States). Most makeup can be tested for contact allergy in the standard manner by using a closed patch test. Waterproof mascara is an important exception: it contains volatile solvents and must be dried thoroughly to avoid severe irritant reactions. Upper-eyelid dermatitis syndrome is related to multiple endogenous and exogenous causes. Irritant and allergic contact dermatitis caused by cosmetics accounts for a small percentage of these cases. Mercury preservatives are permitted only in cosmetics designed for use in the eye area owing to the danger of *Pseudomonas* infection. Eye infections are rarely traced to use of eye cosmetics that have not been adequately preserved.

HAIR CARE COSMETICS

Shampoos and Conditioners

Shampoos are cleansing agents designed to remove sebum, scale, microorganisms, and environmental debris. Thorough cleansing can leave hair dry, statically charged, and without luster. Modern shampoos contain single or combined anionic, amphoteric, cationic, or nonionic surfactants that vary in their ability to clean as well as to leave hair manageable. Products designed for use on dry, normal, or oily hair inform consumers regarding cleansing intensity, which is determined by type and concentration of surfactants. Baby shampoos contain amphoteric surfactants that do not sting the eyes and which cleanse moderately well.

Conditioning agents are used in hair care products for many purposes—to enhance combability of wet and dry hair, to neutralize static charges, and to promote the appearance, feel, fullness, luster, and general manageability of hair. Long hair, hair that is frequently shampooed, chemically exposed and treated hair, and dry hair require conditioners to aid grooming, prevent damage, and enhance appearance. Quaternium compounds, hydrolyzed proteins, cationic surfactants, polymers, lipids, glycols, and silicones are the most commonly used conditioners. Some recently marketed shampoos simultaneously cleanse and deposit conditioning agents on the hair shaft. [58] Conditioning can be modified to enhance volume of fine, straight hair without causing buildup. For hair damaged extensively by chemicals, application of conditioner separately after shampooing allows deposition of more material. Shampoos also contain thickeners, foam boosters, colors, and preservatives.

Shampoos and conditioners are only briefly in contact with the skin and infrequently cause adverse contact reactions. Allergic reactions have been reported to occur both in consumers and in beauticians using the “mild” amphoteric surfactant cocamidopropyl betaine. [33] Formaldehyde and a combination of methylchloroisothiazolone and methylisothiazolone also are preservatives that have caused allergic contact dermatitis. [19]

Hair Dyes

Hair coloring is increasingly popular worldwide; in the United States alone, an estimated 50 million consumers color their hair. These versatile cosmetics allow men and women to add highlights, change color, or disguise gray hair. In addition

to bleaches, hair dyes are classified as temporary, progressive, semipermanent, or permanent.

Temporary colors are deposited on the surface of the hair and are removed by shampooing. They make minor changes in shade or blend gray hair. Dyestuffs used can include basic dyes, indolamine, indophenols, and azo, azine, or thiazine derivatives, and are generally harmless. Progressive lead acetate dyes deposit lead oxides and sulfides, which build on the hair shaft when applied repeatedly. Used almost exclusively by men to conceal graying, these dyes preclude successful perming or use of other color systems. Use of metallic dyes is not considered to put consumers at risk for acute toxicity except when such dyes are accidentally ingested by children. [59] In 1980, the FDA approved these dyes after reviewing available data on human absorption of lead during simulated use. Concerns about lead in the environment remain.

Color from semipermanent dyes lasts through about a dozen shampoos. When used on unbleached hair, these dyes can add new tones to natural hair, cover as much as 50 percent of gray hair, and occasionally improve the appearance of permanently tinted hair. Semipermanent hair-coloring products use low-molecular-weight dyes that penetrate the hair cuticle. These dyes are mostly derivatives of nitroanilines, nitrophenylenediamines, and nitroaminophenols. Recently, some of these products were modified by blending in oxidative precursors and adding a low percentage of peroxide for a more lasting effect. These formulations are called tone on tone.

Permanent hair dyes contain colorless precursors that react with hydrogen peroxide inside the hair shaft to produce permanent hair colors. Primary intermediates such as *p*-phenylenediamine or *p*-aminophenol are oxidized by hydrogen peroxide and react with many different couplers (e.g., resorcin) to produce a range of shades. Owing to their esthetic appeal, coal-tar hair dyes are popular; however, they can cause allergic reactions (mostly to *p*-phenylenediamine) and satisfactory substitutes are often unavailable. Semipermanent dyes often do not induce a cross-reaction, but they do not cover gray nearly as successfully as permanent dyes. Adverse reactions to *p*-phenylenediamine include type IV acute and chronic dermatitis rarely leading to depigmentation, and rare type I urticaria and anaphylaxis.

Bleaches

Hair bleaches—hydrogen peroxide solutions that oxidize melanin to a lighter color—may be supplemented with persulfate boosters. Ammonium persulfate does cause types I and IV allergic contact reactions. [16], [17] The type I reaction has rarely progressed to systemic reaction in consumers, whereas type IV can result in hand dermatitis for frequent users such as hairdressers.

Permanents

Permanents allow reconfiguration of the hair fiber while it remains wound around a curling rod. In this process, mercaptans cleave the disulfide bonds in hair so that they can later be reformed in a new configuration when neutralized: [58]

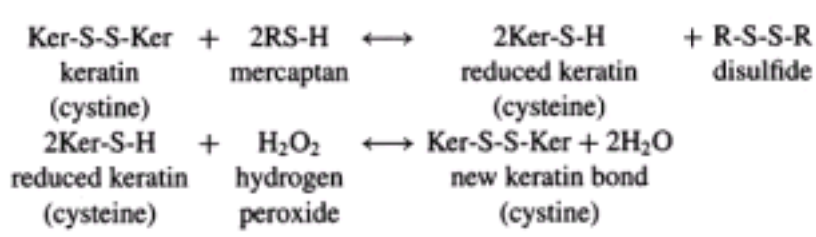

Neutralizers contain hydrogen peroxide, potassium or sodium bromate, perbromates, percarbonates, or sodium borate perhydrate. Curled hair appears more voluminous, so women with fine, thin hair often use permanents to give the illusion of a fuller head of hair.

Ammonium thioglycolate applied improperly can cause extensive hair damage and acute irritant dermatitis; dithiodiglycollic acid is added to “self-timing” permanents to prevent over processing. [58] Glyceryl thioglycolate used in “acid” permanents initiates allergic contact dermatitis. [60] Sodium sulfite is used in some home permanent kits, and cystine waving solutions have become popular in Japan.

Ethnic Hair Products

Extremely curly hair may be straightened temporarily, mechanically by pressing, or permanently by using chemical relaxers. After the pressing oils are applied, heated metal combs or round tongs are used to straighten the hair. In the early 1900s, pressing oils consisted of heavy waxes in a petrolatum base; lanolin, phenyldimethicone, and dimethicone now allow production of lighter preparations that leave hair silkier and less greasy.

In the 1940s, sodium and potassium hydroxide-containing preparations were introduced as chemical straighteners that permanently changed the configuration of kinky hair, and a petrolatum “base” was applied to the scalp for protection. Gentler to the scalp are “no-lye” relaxers: lithium hydroxide and guanidine hydroxide (made by mixing calcium hydroxide and guanidine carbonate). Neutralizing acid shampoos are applied after the hair has been relaxed; these shampoos contain mixtures of anionic and amphoteric surfactants combined with cationic polymers for conditioning. Relaxing damages the hair; therefore, particular care must be taken when relaxing new growth not to overlap and double-process the hair, causing breakage. Alkaline thioglycolates formulated in viscous emulsions and neutralized with an oxidative step are used as straighteners also. [58] Grooming—combing, brushing, heat setting, coloring, bleaching, waving, and straightening—all damage the hair shaft to a varying degree. True repair or reversal of this damage is not feasible at present, which is why prevention by gentle care is important.

NAIL COSMETICS

Used judiciously, nail cosmetics can protect and enhance the esthetic appearance of nails. Professional manicures are complex procedures involving many products; most adverse reactions (aside from mechanical trauma) are caused by nail polish or by acrylates used for nail enhancement.

Nail Polish

Nail polishes, including base and top coats, are of a similar composition, containing the following types of ingredients: (1) a film former of nitrocellulose; (2) resins to improve adhesion and gloss; (3) plasticizers to increase flexibility; (4) solvents and diluents to modify viscosity; (5) colors; and (6) suspending agents to prevent pigments from settling. Most reported allergic reactions to nail enamel have been caused by tolysamide/formaldehyde resin [toluene sulfonamide/formaldehyde resin (TSFR)]. In a study of approximately 3500 patients patch-tested between 1996 and 1998, 1.5 percent of the positive reactions were caused by this resin and 68 percent of these reactions were clinically relevant. [61] Allergic contact dermatitis to nail polish can be misdiagnosed because it frequently affects the face, eyelids, sides of the neck, or mouth, and may spare the hands and fingers. In a study of TSFR-allergic patients referred to an occupational dermatology clinic, the allergen had not previously been detected; instead the cause was mistakenly attributed to work conditions. [62] The consequences of this mistake were dramatic: 11 of the 18 patients in the study erroneously took sick leave or modified or changed their jobs. Results of patch tests using 10% TSFR in petrolatum established the diagnosis, and closed patch tests of dry nail polish were positive in 17 of the 18 patients. [62] California legislation has prohibited the use of the solvent toluene, and cosmetic manufacturers in a legal settlement agreed to reformulate nail polish, in most cases eliminating toluene and TSFR. Salon-distributed products may still contain TSFR. [63] New formulations of nail enamels use other resins, so different allergens may emerge, for example, methyl acrylate and phthalic anhydride/trimellite/glycol copolymer. [64], [65] and [66]

Nail Elongation Materials

Manicurists enhance natural nails by gluing on preformed prostheses, wrapping and gluing nails with strips of fine cloth, molding acrylic extensions, or adding layers of photodeveloped plastic gels.

Prostheses may consist of plastic nails that cover the entire nail plate, but using cyanoacrylate glue to attach plastic tips to the distal portion of the nail has become popular because their application requires less skill than creating sculptured acrylic extensions. Allergy to instant cyanoacrylate glue can cause nail dystrophy and periungual dermatitis. Acrylics, gels, or wraps are used to smooth and strengthen this form.

Sculptured nails are molded (by using liquid acrylic monomers mixed with powdered polymers) onto templates that surround the nail; the sculptured nails are then filed to the desired shape. The liquid may contain a stabilizer such as hydroquinone, plasticizers, and solvents, and the powder contains an initiator (e.g., benzoyl peroxide). Before application, the nail plate is prepared by abrading it with a file and/or by painting it with methacrylic acid. As the nail grows out, the base must be filled with new applications of the resin. Infections, paresthesia, nail dystrophies, and allergic dermatitis surrounding the nail and at distant sites have all been reported as a consequence of this procedure. [67] Most patients who have inflammatory reactions to sculptured nails are never patch tested, and their reactions are not reported. The chemistry is complex, patterns of cross-reaction are common, and labeling of ingredients in salon products is voluntary and often inadequate. Patch-test data from patients sensitized by the use of acrylic nails suggests that five chemicals may be used as screening patch-test materials: ethyl acrylate, 2-hydroxy ethyl acrylate, ethylene glycol dimethacrylate, ethyl cyanoacrylate, and triethylene glycol diacrylate. In a series of 11 patients, 0.1% ethyl acrylate in petrolatum detected 91 percent of the patients sensitized to these nails. [68]

Ultraviolet light–cured acrylates, known as gels, are also popular for nail enhancement. In studying women sensitized to photobonded acrylic nails, 2-hydroxyethyl methacrylate and ethylene glycol dimethacrylate are useful screening materials for patch testing. [69] Professionals applying these gels had reactions to 15 of the 31 acrylates tested. [70] Complex occupational cases are best evaluated at centers prepared for extended patch testing.

The CIR published a final report on ethyl methacrylate, a frequent ingredient of sculptured nails, and declared it safe as used by professionals; however, it advised against retail sale of products containing ethyl methacrylate because they can sensitize when contacting the skin. [71] However, in a Finnish study, 6 of 23 acrylate-sensitive patients were sensitive to ethyl methacrylate, demonstrating its considerable sensitizing potential. [72]

Despite the adverse reactions seen by dermatologists, the popularity of these cosmetics is great: myriad of nail salons have opened in the United States during the past decade, supporting the $8-billion-per-year nail care industry.

OCCUPATIONAL HAZARDS

Occupational hand eczema frequently develops in hairdressers. Novice beauticians' hands become dry and chapped from shampooing many clients. A history of atopic hand eczema heightens the risk for irritant contact dermatitis. Educating hairdressers on safe practices and having them apply low irritancy moisturizing creams before and after work mitigates this condition. Hairdressers are constantly exposed to sensitizers such as hair dyes, ammonium persulfate, preservatives, surfactants, fragrances, and glyceryl thioglycolate. Glyceryl thioglycolate penetrates most protective gloves and remains on customers' hair despite shampooing, making avoidance difficult for the sensitized hairdresser. [60] Rubber gloves worn for protection may prove to be sensitizing. When chronic hand eczema interferes with a beautician's career, patch testing is mandatory to determine whether a relevant allergen is causing or aggravating the dermatitis. Many epidemiologic studies of hairdressers working with hair dyes have looked for a relation between exposure to health

hazards and carcinogenesis, but the findings have been equivocal or contradictory. [59], [73]

A recent epidemiologic study of 897 bladder cancer patients in Los Angeles County showed women who used permanent hair dyes monthly had a 2.1-fold risk as compared to nonusers. Subjects who worked as hairdressers for 10 years or more experienced a fivefold risk of bladder cancer. [74] Manicurists are at risk for developing contact allergy to acrylates but proper training in protection and “no touch” techniques enhanced their safety. [63], [66]

There is evidence that artificial fingernails worn by health care workers harbor pathogens and may pose a risk to their patients. [75] In response, a major HMO has banned their use by health care workers at all their medical centers in California.

CONCLUSION

Consumers consider cosmetics useful, industry introduces innovation to enhance their efficacy, and physicians should recognize their functional and psychological importance for patients. Safety considerations must also not be forgotten. We are alerted to this fact by a report of mercury poisonings in the United States resulting from use of a mercury-containing cosmetic manufactured in Mexico. [76] Except for small amounts permitted as eye cosmetic preservatives, mercury has long been banned from use in cosmetics sold in major markets. International trade and less-stringent laws in some countries can lead unsuspecting consumers to disaster. Skin is not an impermeable membrane, and substances applied for beautification must be monitored carefully.

REFERENCES

1. Hutt PB: The legal distinction in the United States between a cosmetic and a drug, in *Cosmeceuticals: Drugs vs Cosmetics,* edited by P Elsner, HI Maibach. New York, Marcel Dekker, 2000, p 223

2. Kligman AM: Cosmeceuticals: Do we need a new category? in *Cosmeceuticals: Drugs vs Cosmetics,* edited by P Elsner, HI Maibach. New York, Marcel Dekker, 2000, p 1

3. Mao-Qiang M et al: Exogenous nonphysiologic vs physiologic lipids: Divergent mechanisms for correction of permeability barrier dysfunction. *Arch Dermatol* **131**:809, 1995

4. Schwindt DA, Maibach HI, editors: *Cutaneous Biometrics*. New York, Kluwer Academic/Plenum, 2000

5. Alam M, Dover JS: On beauty: Evolution, psychosocial considerations, and surgical enhancement. *Arch Dermatol* **137**:795, 2001

6. Van Essche R: EEC cosmetic directive and legislation in Europe, in *Handbook of Cosmetic Science and Technology,* edited by AO Barel, M Paye, HI Maibach. New York, Marcel Dekker, 2001, p 729

7. Wenninger JA, Canterbery RC, McEwen GN Jr, editors: *International Cosmetic Ingredient Dictionary and Handbook,* 9th ed. Washington, DC, Cosmetic, Toiletry, and Fragrance Association, 2000

8. Curry AS, McEwen GN, Duelly MM: *Cosmetic Industry on Call 2002*. Washington, DC, Cosmetic, Toiletry and Fragrance Association, 2002

9. Berardesca E, Distante F: Bioengineering: Methods, in *The Irritant Contact Dermatitis Syndrome,* edited by PGM van der Valk, HI Maibach. Boca Raton, FL, CRC Press, 1996, p 313

10. Kligman AM, Mills OH Jr: “Acne cosmetica.” *Arch Dermatol* **106**:843, 1972

11. Simion AF: Acnegenicity and comedogenicity testing for cosmetics, in *Handbook of Cosmetic Science and Technology,* edited by AO Barel, M Paye, HI Maibach, New York, Marcel Dekker, 2001, p 837

12. Kligman AM: Petrolatum is not comedogenic in rabbits or humans: a critical reappraisal of the rabbit ear assay and the concept of “acne cosmetica.” *J Soc Cosmet Chem* **47**:41, 1996

13. Levin C, Maibach H: Exploration of “alternative” and “natural” drugs in dermatology. *Arch Dermatol* **138**:207, 2002

14. Frosch PJ, Kligman AM: A method for appraising the stinging capacity of topically applied substances. *J Soc Cosmet Chem* **28**:197, 1977

15. Hahn GS: Anti-irritants for sensory irritation, in *Handbook of Cosmetic Science and Technology*, edited by AO Barel, M Paye, HI Maibach, New York, Marcel Dekker, 2001, p 285

16. Amin S, Maibach HI: Immunologic contact urticaria definition, in *Contact Urticaria Syndrome,* edited by S Amin, A Lahti, HI Maibach. Boca Roton, FL, CRC Press, 1997, p 11

17. Hannuksela M: Cosmetics, cosmetic ingredients, emulsifiers, and moisturizers, in *Contact Urticaria Syndrome,* edited by S Amin, A Lahti, HI Maibach. Boca Raton, FL, CRC Press, 1997, p 111

18. Adams RM, Maibach HI: A five-year study of cosmetic reactions. *J Am Acad Dermatol* **13**:1062, 1985

19. de Groot AC et al: *Unwanted Effects of Cosmetics and Drugs Used in Dermatology,* 3d ed. New York, Elsevier, 1994

20. Nakada T et al: Use tests: ROAT (repeated open application test)/PUT (provocative use test): An overview. *Contact Dermatitis* **43**:1, 2000

21. Andersen KE et al: The time-dose-response relationship for elicitation of contact dermatitis in isoeugenol allergic patients. *Toxicol Appl Pharmacol* **170**:166, 2001

22. de Groot AC, Frosch PJ: Adverse reactions to fragrances: A clinical review. *Contact Dermatitis* **36**:57, 1997

23. Opdyke DLJ: Monographs on fragrance raw materials. *Food Cosmet Toxicol* **11**:95, 477, 855, 1011, 1973; **12**:385, 517, 703, (Suppl):807, 1974; **13**:91, 1975

24. Larsen W et al: Fragrance contact dermatitis: A worldwide multicenter investigation (part I). *Am J Contact Dermat* **7**:77, 1996

25. Nakayama H et al: Pigmented cosmetic dermatitis. *Int J Dermatol* **23**:299, 1984

26. Funk JO, Maibach MI: Propylene glycol dermatitis: Re-evaluation of an old problem. *Contact Dermatitis* **31**:236, 1994

27. Fransway AF: The problem of preservation in the 1990s: I. Statement of the problem, solution(s) of the industry, and the current use of formaldehyde and formaldehyde-releasing biocides. *Am J Contact Dermat* **2**:6, 1991

28. Geier J et al: Patch testing with methyldibromoglutaronitrile. *Am J Contact Dermat* **11**:207, 2000

29. Fisher AA: Cosmetic actions and reactions: Therapeutic irritant, and allergic. *Cutis* **26**:22, 1980

30. Cotterill JA: Clinical features of patients with dermatologic nondisease. *Semin Dermatol* **2**:203, 1983

31. Williams CM et al: Sensitive skin: An epidemiological study. *Br J Dermatol* **145**:258, 2001

32. Charbonnier V et al: Open application assay in investigation of sub-clinical irritant dermatitis induced by SLS in man: Advantage of squamometry. *Skin Res Technol* **4**:244, 1998

33. McFadden JP et al; Clinical allergy to cocamidopropyl betaine: Reactivity to 3-dimethylaminoprpylamine and lack of reactivity to 3-dimethylaminopropylamine. *Contact Dermatitis* **45**:72, 2001

34. Draelos ZD: *Cosmetics in Dermatology,* 2d ed. New York, Churchill Livingstone, 1995

35. Rawlings AV et al: Stratum corneum moisturization at the molecular level. *Prog Dermatol* **28**:1, 1994

36. Elias PM, Feingold KR: Lipids and the epidermal water barrier: Metabolism, regulation, and pathophysiology. *Semin Dermatol* **1**:176, 1992

37. Mao-Qiang M et al: A natural lipid mixture improves barrier function and hydration in human and murine skin. *J Soc Cosmet Chem* **47**:157, 1996

38. Obata M, Tagami H: A rapid in vitro test to assess skin moisturizers. *J Soc Cosmet Chem* **41**:235, 1990

39. Hannuksela A, Kinnunen T: Moisturizers prevent irritant dermatitis. *Acta Derm Venereol* **72**:42, 1992

40. Lodén M, Andersson A-C: Effect of topically applied lipids on surfactant-irritated skin. *Br J Dermatol* **134**:215, 1996

41. Held E, Lund H, Agner T: Effect of different moisturizers on SLS-irritated human skin. *Contact Dermatitis* **44**:229, 2001

42. Held E et al: Effect of long-term use of moisturizer on skin hydration, barrier function and susceptibility to irritants. *Acta Derm Venereol* **79**:49, 1999

43. Zhai H, Maibach HI: Efficacy of barrier creams, in *Cosmeceuticals: Drugs vs. Cosmetics* edited by P Elsner, Maibach HI. New York, Marcel Dekker, 2000, p 249

44. Ghadially R et al: Effects of petrolatum on stratum corneum and function. *J Am Acad Dermatol* **26**:387, 1992

45. Clark EW, Steel I: Investigations into biomechanisms of moisturizing function of lanolin. *J Soc Cosmet Chem* **44**:181, 1993

46. Henderson CA et al: The frequency of lanolin contact allergy. *Contact Dermatitis* **32**:52, 1995

47. Cronin E: *Contact Dermatitis*. New York, Churchill Livingstone, 1980

48. Froebe CL et al: Prevention of the stratum corneum lipid phase transitions in vitro by glycerol: An alternative mechanism for skin moisturization. *J Soc Cosmet Chem* **41**:51, 1990

49. Van Scott EJ, Yu RJ: Control of keratinization with alpha hydroxy acids and related compounds: I. Topical treatment of ichthyotic disorders. *Arch Dermatol* **110**:586, 1974

50. Stiller MJ et al: Topical 8% glycolic acid and 8% l-lactic acid creams for the treatment of photodamaged skin: A double-blind vehicle-controlled clinical trial. *Arch Dermatol* **132**:631, 1996

51. Cosmetic Ingredient Review: Report on glycolic acid, lactic acid. *Int J Toxicol* **17**(Suppl 1):215, 1998

52. Theile JJ et al: Antioxidant defense systems in the skin, in *Cosmeceuticals: Drugs vs. Cosmetics* edited by P Elsner, HI Maibach. New York, Marcel Dekker, 2000, p 145

53. *Fed Reg* **58**:28194, May 12, 1993

54. Levy SB: Tanning preparations. *Dermatol Clin* **18**:591, 2000

55. Zhai H, Maibach HI: Skin-whitening agents. *Cosmet Toiletries* **116**:20, 2001

56. Zuidhoff, HW, van Rijsbergen JM: Whitening efficacy of frequently used whitening ingredients. *Cosmet Toiletries* **116**:53, 2001

57. Rayner VL: Camouflage cosmetics, in *Textbook of Cosmetic Dermatology*, 2nd ed, edited by R Baran, HI Maibach. London, Martin Dunitz, 1998, p 417

58. Wolfram L: Hair cosmetics, in *Handbook of Cosmetic Science and Technology* edited by AO Barel, M Paye, HI Maibach. New York, Marcel Dekker, 2001, p 581

59. Engasser PG, Maibach HI: Hair dye toxicology, in *Hair and Hair Diseases,* edited by CE Orfanos, R Happle. Berlin, Springer-Verlag, 1990, p 927

60. Storrs FJ: Permanent wave contact dermatitis: Contact allergy to glyceryl monothioglycolate. *J Am Acad Dermatol* 11:74, 1984

61. Marks JG Jr et al: North American Contact Dermatitis Group patch test results, 1996 to 1998 [letter]. *Arch Dermatol* **136**:272, 2000

62. Lidén C et al: Nail varnish allergy with far-reaching consequences. *Br J Dermatol* **128**:57, 1993

63. Schoon DD: *Milady's Nail Structure and Product Chemistry*. Albany, NY, Milady Publishing, 1996

64. Kanerva L et al: Methyl acrylate: A new sensitizer in nail lacquer. *Contact Dermatitis* **33**:203, 1995

65. Moffit DL, Sansom JE: Allergy to phthalic anhydride/trimellite/glycol copolymer, a component of nail varnish. *Br J Dermatol* **145**(Suppl 59):100, 2001

66. Engasser PG et al: Cosmetologists, in *Handbook of Occupational Dermatology* edited by P Elsner, JE Wahlberg, HI Maibach. Berlin, Springer-Verlag, 2000, p 893

67. Freeman S et al: Adverse contact reactions to sculptured acrylic nails: 4 case reports and a literature review. *Contact Dermatitis* **33**:381, 1995

68. Koppula SV et al: Screening allergens for acrylate dermatitis associated with artificial nails. *Am J Contact Dermat* **6**:78, 1995

69. Hemmer W et al: Allergic contact dermatitis to artificial fingernails prepared from UV light-cured acrylates. *J Am Acad Dermatol* **35**:377, 1996

70. Kanerva L et al: Occupational allergic contact dermatitis caused by photobonded sculptured nails and a review of (meth)acrylates in nail cosmetics. *Am J Contact Dermat* **7**:109, 1996

71. Cosmetic Ingredient Review Expert Panel: Final report of safety assessment of ethyl methacrylate. Washington, DC, Cosmetic, Toiletry and Fragrance Association, Sept 12, 1994

72. Kanerva L et al: Statistics on allergic patch test reactions caused by acrylate compounds, including data on ethyl methacrylate. *Am J Contact Dermat* **6**:75, 1995

73. La vecchia C, Tavina A: Epidemiological evidence on hair dyes and risk of cancer in human. *Eur J Cancer Prev* **4**:31,1995

74. Gago-Dominauez M et al: Use of permanent hair dyes and bladder cancer risk. *Int J Cancer* **91**:575, 2001

75. McNeil SA et al: Effect of hand cleansing wih antimicrobial soap or alcohol–based gel on microbial colonization of artificial fingernails worn by health care workers. *Clin Infect Dis* **32**:367, 2001

76. Mercury poisoning associated with beauty cream—Texas, New Mexico, and California, 1995–1996. *Arch Dermatol* **132**:1533, 1996

T>

Chapter 253

Victoria Werth

Systemic Glucocorticoids

BIOLOGY
PHARMACOLOGY
DISEASES TREATED WITH GLUCOCORTICOIDS
COMPLICATIONS OF SYSTEMIC GLUCOCORTICOID THERAPY
Osteoporosis
Avascular Necrosis
Atherosclerosis
Suppression of the Hypothalamic-Pituitary-Adrenal Axis
Drug Interactions
Immunologic Side Effects
Concerns during Pregnancy and Lactation
THERAPEUTIC USE OF GLUCOCORTICOIDS
Fundamental Principles
Choosing among Glucocorticoids
Route of Administration and Dosage Schedules
STRATEGIES TO REDUCE GLUCOCORTICOID SIDE EFFECTS
Evaluation before Treatment
Evaluation during Treatment
Preventive Measures (Table 253-4)

REFERENCES

Glucocorticoids are a mainstay of dermatologic therapy because of their potent immunosuppressive and anti-inflammatory properties. In 1949, Hench and co-workers [1] described the beneficial effects of cortisone in patients with rheumatoid arthritis. By understanding the properties and mechanisms of action of glucocorticoids, one can maximize their efficacy and safety as therapeutic agents.

BIOLOGY

The major naturally occurring glucocorticoid is cortisol (hydrocortisone). It is synthesized from cholesterol by the adrenal cortex. Normally, less than 5 percent of circulating cortisol is unbound; this free cortisol is the active therapeutic molecule. The remainder is inactive because it is bound to cortisol-binding globulin (CBG, also called transcortin) (95 percent) or to albumin (5 percent). The daily secretion of cortisol ranges between 10 and 20 mg, with a diurnal peak around 8 A.M. [2] Cortisol has a plasma half-life of 90 min. It is metabolized primarily by the liver, although it exerts hormonal effects on virtually every tissue in the body. The metabolites are excreted by the kidney and the liver.

The mechanism of glucocorticoid action involves passive diffusion of the glucocorticoids through the cell membrane, followed by binding to soluble receptor proteins in the cytoplasm. [3] This hormone-receptor complex then moves to the nucleus and regulates the transcription of a limited number of target genes; some of the most important appear to be inhibitory effects on the transcription factors AP-1 and NF-?B, coupled with increased I?Ba, an inhibitor of NF-?B. [4] Glucocorticoids decrease the synthesis of a number of proinflammatory molecules, including cytokines, interleukins, adhesion molecules, and proteases, largely through their effects on transcription. [4] Similarly, other mediators of inflammation, such as cyclooxygenase-2 and the inducible form of nitric oxide synthase, are inhibited.

Glucocorticoids increase the synthesis of other important molecules, such as annexins 1 and 2. Annexins reduce phospholipase A_2 activity, which reduces the release of arachidonic acid from membrane phospholipids, [5], [6] limiting the formation of prostaglandins and leukotrienes. [7], [8] There is usually a delay in the onset of pharmacologic activity of glucocorticoids relative to their peak blood concentrations, which is probably consequent to altering the transcription of genes, [4] although some actions appear to be independent of transcription. [9] Glucocorticoids may also exert their effects by nongenomic mechanisms such as membrane-bound receptors and/or physicochemical interactions with cellular membranes. [10] Some effects of glucocorticoids are too rapid to be mediated by genomic glucocorticoid action. [11] This mechanism might explain additive benefits of very high-pulse glucocorticoids.

Glucocorticoids profoundly affect the replication and movement of cells. They induce monocytopenia, eosinopenia, and lymphocytopenia and have a greater effect on T cells than on B cells. [12] The lymphocytopenia appears to be caused by a redistribution of cells as they migrate from the circulation to other lymphoid tissues, and it has been suggested that glucocorticoids induce apoptosis. [13] The increase in circulating polymorphonuclear leukocytes is related to demargination of cells from the bone marrow and a diminished rate of removal from the circulation, at least partially mediated by the increase in annexin 1 [14]; there also appears to be inhibition of neutrophil apoptosis. [15]

Glucocorticoids affect cell activation, proliferation, and differentiation. They modulate the levels of mediators of inflammation and immune reactions, as seen with the inhibition of interleukin (IL)-1, IL-2, IL-6, and tumor necrosis factor synthesis (or release). [16], [17] Macrophage functions—including phagocytosis, antigen processing, and cell killing—are decreased by cortisol, [18], [19] and this decrease affects immediate and delayed hypersensitivity.

Glucocorticoids suppress monocyte and lymphocyte function (both T_H1 and T_H2 cells) more than polymorphonuclear leukocyte function. [20] This effect is clinically important because granulomatous infectious diseases, such as tuberculosis, are prone to exacerbation and relapse during prolonged glucocorticoid therapy. The antibody-forming cells, B lymphocytes and plasma cells, are relatively resistant to the suppressive effects of glucocorticoids. Very high doses of glucocorticoids are needed to suppress antibody production. [21]

The multiplicity of biologic effects produced by glucocorticoids emphasizes that currently there is no unifying hypothesis to explain the therapeutic efficacy of these extremely potent anti-inflammatory and immunosuppressive agents.

PHARMACOLOGY

When hydrocortisone is given in moderate to high doses, its mineralocorticoid effects can be deleterious, and thus synthetic analogues of cortisol have been developed that have greater anti-inflammatory properties and less sodium retention. Small substitutions on the basic steroid structure of three hexanes and a pentane ring (Fig. 253-1, Table 253-1) account for the differences in plasma half-life and the relative anti-inflammatory and sodium-retaining potencies (Table 253-2). In general, most synthetic analogues bind less efficiently to CBG (about 70 percent binding). This property may explain, in part, their tendency to cause side effects at lower dosages. The 11-betahydroxyl group in cortisol is essential for activity. Because cortisone and prednisone are 11-keto compounds, they are active only after being converted in the liver to the corresponding 11-betahydroxyl compounds (cortisol and prednisolone) (Table 253-1). Patients with severe liver disease generally maintain their ability to convert the 11-keto compounds; nevertheless, some authorities suggest that only the converted active compounds should be administered to these patients. [22]

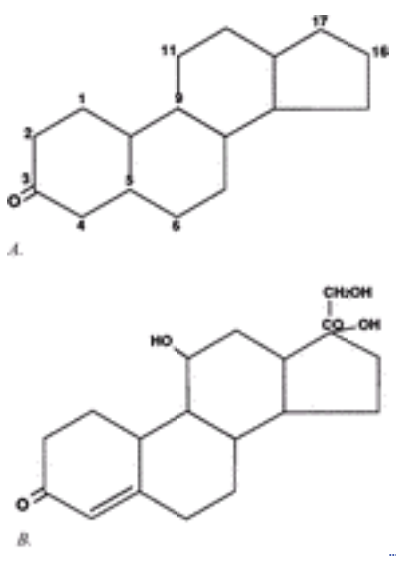

FIGURE 253-1 *A.* Basic steroid skeleton. *B.* The structure of hydrocortisone (cortisol).

	Position				
	1–2	6	9	11	16
Cortisol	—	—	—	–OH	—
Cortisone	—	—	—	=O	—
Prednisone	Double bond	—	—	=O	—
Prednisolone	Double bond	—	—	–OH	—
Methylprednisolone	Double bond	CH3	—	–OH	—
Triamcinolone	Double bond	—	F	–OH	OH
Dexamethasone	Double bond	—	F	–OH	CH3

TABLE 253-1 **Comparative Structures of Glucocorticoids**

	Equivalent Glucocorticoid Potency (mg)	Mineralocorticoid Potency	Plasma Half-Life (min)	Duration of Action (h)
Short-acting				
Hydrocortisone (Cortisol)	20	0.8	90	8–12
Cortisone	25	1	30	8–12
Intermediate-acting				
Prednisone	5	0.25	60	24–36
Prednisolone	5	0.25	200	24–36
Methylprednisolone	4	0	180	24–36
Triamcinolone	4	0	300	24–36
Long-acting				
Dexamethasone	0.75	0	200	36–54

TABLE 253-2 **Glucocorticoids**

DISEASES TREATED WITH GLUCOCORTICOIDS

Skin diseases commonly treated with oral glucocorticoids include serious blistering diseases (pemphigus, bullous pemphigoid, cicatricial pemphigoid, linear IgA bullous dermatoses, epidermolysis bullosa acquisita, herpes gestationis, erythema multiforme, toxic epidermal necrolysis); connective-tissue diseases (dermatomyositis, systemic lupus erythematosus, mixed connective-tissue disease, eosinophilic fasciitis, relapsing polychondritis); vasculitis; neutrophilic dermatoses (pyoderma gangrenosum, acute febrile neutrophilic dermatosis, Behçet's disease); sarcoidosis; type I reactive leprosy; capillary hemangiomas; panniculitis; and urticaria/angioedema. Short courses of glucocorticoids, under appropriate conditions, may be used for severe dermatitis (contact dermatitis, atopic dermatitis, photodermatitis, exfoliative dermatitis, erythrodermas). Acne and hirsutism consequent to adrenogenital syndromes can be treated with low doses of glucocorticoids at bedtime if these conditions are unresponsive to more conservative therapy. The use of glucocorticoids is controversial in the treatment of erythema nodosum, lichen planus, cutaneous T cell lymphoma, and discoid lupus erythematosus.

COMPLICATIONS OF SYSTEMIC GLUCOCORTICOID THERAPY

Complications associated with systemic glucocorticoid therapy (Table 253-3) [23], [24] increase with higher doses, longer duration of therapy, and more frequent administration. However, osteoporosis and cataracts develop with alternate-day dosing, and avascular necrosis can be seen after only short courses of glucocorticoids.

Central nervous system	Endocrinologic
Pseudotumor cerebri and psychiatric disorders	Suppression of HPA*
Musculoskeletal	Growth failure
Osteoporosis with spontaneous fracture	Secondary amenorrhea
Aseptic necrosis of bone	Metabolic
Myopathy	Hyperglycemia and unmasking genetic predisposition to diabetes mellitus
Ocular	Nonketotic hyperosmolar states
Glaucoma and cataracts	Hyperlipidemia
Gastrointestinal	Alterations of fat distribution (typical cushingoid appearance)
Peptic ulceration	Fatty infiltration of the liver
Intestinal perforation	Drug interactions (decreased anticoagulant effect of ethyl biscoumacetate)
Pancreatitis	Fibrinolytic inhibition
Cardiovascular and fluid retention	Inhibition of wound healing
Hypertension	Subcutaneous tissue atrophy (striae, purpura, ecchymosis)
Sodium and fluid retention	Suppression of host defenses
Hypokalemic alkalosis	Immunosuppression, allergy
Atherosclerosis	Effects on phagocyte kinetics and function
Hypersensitivity reactions	Increased incidence of infections
Urticaria	
Anaphylaxis	

*HPA, hypothalamic-pituitary-adrenal axis.

TABLE 253-3 **Complications of Glucocorticoid Therapy**

Osteoporosis

Osteoporosis occurs in 40 percent of individuals treated with systemic glucocorticoids; it is especially prominent in children, adolescents, and postmenopausal women. [25] Approximately one-third of patients have evidence of vertebral fractures after 5 to 10 years of glucocorticoid treatment, but this proportion is higher in postmenopausal women. [26], [27] Bone loss occurs most rapidly in the first 6 months of glucocorticoid use, but continues at a slower rate after that, with loss of 3 to 10 percent of bone per year in many patients. [25], [28] Some of the bone loss may be reversible after glucocorticoids are stopped, at least in the young. [29]

Glucocorticoids inhibit osteoblasts, increase calcium excretion by the kidney, decrease intestinal calcium absorption, and, concomitantly, increase bone resorption by osteoclasts. [30] They also reduce estrogen and testosterone levels, which is likely to be an important factor in the pathogenesis of osteoporosis. Serum osteocalcin, a measure of osteoblast function, decreases within a day after a dosage regimen of as little as 10 mg of prednisone a day is begun; a dosage regimen of 7.5 mg of prednisone a day or more often causes significant bone loss and an increased fracture rate. [31], [32] and [33] Trabecular bone is primarily affected, leading to painful vertebral fractures.

Avascular Necrosis

Avascular necrosis (AVN) is manifest by pain and limitation of motion in one or more joints. There is intraosseous hypertension, leading to bone ischemia and necrosis. [34] It is likely that intraosseous lipocyte hypertrophy causes this intraosseous hypertension in persons taking glucocorticoids. In addition, glucocorticoids induce apoptosis of osteoblasts, likely contributing to AVN. Underlying diseases, such as systemic lupus erythematosus (SLE), increase the likelihood of steroid-induced AVN. [35] Studies suggest that many patients who develop AVN have either thrombophilia or hypofibrinolysis, which leads to thrombotic occlusion of venous outflow from the bone, decreased arterial perfusion, and subsequent infarction of bone. [36]

Atherosclerosis

Glucocorticoids enhance many risk factors that are associated with atherosclerosis, including arterial hypertension, insulin resistance, glucose intolerance, hyperlipidemia, and central obesity. It is thus not surprising that patients taking glucocorticoids have an increased risk of atherosclerosis. [37] Patients with untreated Cushing's disease have a four times higher mortality rate from cardiovascular complications, including coronary artery disease, congestive heart failure, and cardiac stroke. [38] The risk factors for atherosclerosis persist for at least 5 years after normalization of the serum cortisol level in Cushing's disease, and similar findings may be true in those treated with chronic glucocorticoids. [39]

Suppression of the Hypothalamic-Pituitary-Adrenal Axis

The hypothalamic-pituitary-adrenal (HPA) axis is rapidly suppressed after the onset of glucocorticoid therapy. However, if therapy is limited to 1 to 3 weeks, the recovery of the HPA axis is rapid. Longer daily glucocorticoid therapy is associated with suppression of the HPA axis for up to 1 year after therapy is terminated. [40] Symptoms of adrenal suppression include lethargy, weakness, nausea, anorexia, fever, orthostatic hypotension, hypoglycemia, and weight loss.

There also exists a steroid withdrawal syndrome, in which patients experience symptoms of adrenal insufficiency despite having an apparently normal cortisol response to adrenocorticotropic hormone (ACTH). Symptoms most commonly include anorexia, lethargy, malaise, nausea, weight loss, desquamation of the skin, headache, and fever. Less commonly, vomiting, myalgias, and arthralgias occur. These patients have adjusted to high levels of glucocorticoids, and symptoms disappear after the glucocorticoids are restarted. This problem can be treated by slower tapering of the glucocorticoids, often by 1 mg of prednisone every few weeks. [41]

Drug Interactions

Glucocorticoids are associated with a number of important drug interactions. Drugs such as barbiturates, phenytoin, and rifampin, which induce hepatic microsomal enzymes, may accelerate the metabolism of glucocorticoids. [42] Drugs such as

cholestyramine, colestipol, and antacids, impair absorption of glucocorticoids. Glucocorticoids reduce the serum salicylate level and necessitate a higher dose of warfarin (Coumadin) for anticoagulation.

Immunologic Side Effects

Glucocorticoids impair delayed-type hypersensitivity reactions because of their inhibition of lymphocytes and monocytes. Prednisone at daily doses of 15 mg or more suppresses the response to tuberculin, although it takes an average of 13.6 days for oral prednisone at 40 mg/day to inhibit the response to tuberculin. [43] Thus, even in situations requiring immediate use of prednisone, it is possible to perform simultaneously a purified protein derivative of tuberculin (PPD) test and an anergy panel. Overall, there is an increased incidence of infections attributable to both the glucocorticoids and the immunologic changes related to the underlying disease. [44]

Concerns during Pregnancy and Lactation

Glucocorticoids cross the placenta, but they are not teratogenic. Exposed infants as well as breast-fed infants of mothers receiving glucocorticoids should be monitored for adrenal suppression and growth suppression.

THERAPEUTIC USE OF GLUCOCORTICOIDS

Fundamental Principles

Before therapy with glucocorticoids is begun, the benefit that can realistically be expected should be weighed against the potential side effects. Alternative or adjunctive therapies should be considered, especially if long-term treatment is contemplated. Coexisting illnesses such as diabetes, hypertension, or osteoporosis need to be considered. The predisposition of the patient to side effects should be included in an assessment of risk.

Choosing among Glucocorticoids

A number of considerations bear on the choice of glucocorticoids. First, a preparation with minimal mineralocorticoid effect is usually picked to decrease sodium retention. Second, the long-term oral use of prednisone or a similar drug, with an intermediate half-life and relatively weak steroid-receptor affinity, may reduce side effects. Long-term use of drugs like dexamethasone, which has a longer half-life and high glucocorticoid-receptor affinity, may produce more side effects without any better therapeutic effects. Third, if a patient does not respond to cortisone or prednisone, the substitution of the biologically active form, cortisol or prednisolone, should be considered. In general, even in severe liver disease, substitution has not proved to be very important. Fourth, methylprednisolone is used for pulse therapy because of its low sodium-retaining characteristics and high potency.

Route of Administration and Dosage Schedules

Systemic glucocorticoids can be administered intralesionally, orally, intramuscularly, and intravenously. The route and regimen are determined by the nature and extent of the disease being treated.

Intralesional glucocorticoid administration allows direct access to either a relatively few lesions or a particularly resistant lesion. The concentration depends on the site of injection and the nature of the lesion. Lower concentrations (2 to 3 mg/mL) are used on the face to prevent atrophy of the skin, whereas keloids may require concentrations of 40 mg/mL. In conditions requiring sustained effects, such as keloids and alopecia areata, longer-acting glucocorticoids, such as Aristospan, can be administered alone or mixed with the more typically used Kenalog. It is best to limit the total monthly dose of Kenalog to 20 mg to assure that the HPA axis will not be suppressed. [45]

There are serious drawbacks to intramuscular administration because of erratic absorption and lack of daily control of the dose. Because Kenalog is longer-acting than prednisone, there are more potential side effects, including increased HPA suppression and myopathy.

When oral glucocorticoids are prescribed, prednisone is most commonly selected. Glucocorticoids are usually administered daily or every other day, although for acute disease split daily doses can be administered. The initial dose is most often daily to control the disease process and can range from 2.5 mg to several hundred milligrams daily. If used for less than 3 to 4 weeks, glucocorticoid therapy can be stopped without tapering. The lowest possible dose of a short-acting agent every other morning minimizes side effects. Because cortisol levels peak at around 8 A.M., the HPA axis is least suppressed with this morning dosage, and maximal feedback suppression of ACTH secretion by the pituitary is already occurring. The low levels of glucocorticoids at night allow for normal secretion of ACTH. Low doses of prednisone (2.5 to 5 mg) at bedtime have been used to maximize adrenal suppression in cases of acne or hirsutism of adrenal origin.

Intravenous glucocorticoids are used in two situations. One is for stress coverage for patients who are acutely ill or are undergoing surgery and who have adrenal suppression from daily glucocorticoid therapy. The other is for patients with certain diseases—such as resistant pyoderma gangrenosum, severe pemphigus or bullous pemphigoid, serious SLE, or dermatomyositis—to gain rapid control of the disease and thus minimize the need for long-term, high-dose oral steroid therapy. [46] Methylprednisolone is used at a dose of 500 mg to 1 g daily because of its high potency and low sodium-retaining activity. Serious side effects associated with intravenous administration include anaphylactic reactions, seizures, arrhythmias, and sudden death. Other adverse reactions include hypotension, hypertension, hyperglycemia, electrolyte shifts, and acute psychosis. Slower administration over 2 to 3 h has minimized many of the serious side effects, and as long as vital signs are determined frequently, patients without underlying renal or cardiac disease do not need to be treated in a monitored bed. [47] It is important to monitor serum electrolytes before and after pulse therapy,

particularly when patients are on concomitant diuretic therapy.

STRATEGIES TO REDUCE GLUCOCORTICOID SIDE EFFECTS

Evaluation before Treatment

To minimize potential problems, the baseline evaluation should include a personal and family history, with special attention to predisposition to diabetes, hypertension, hyperlipidemia, glaucoma, and associated diseases that could be affected by steroid therapy. Baseline blood pressure and weight should be measured. If prolonged administration is anticipated, an eye examination and a PPD test should be performed and an anergy panel applied. Examination for other covert infections should be based on history and physical examination. For instance, a stool culture for *Strongyloides* should be performed for immigrants from third-world countries and for Vietnam veterans. [48] If long-term administration of glucocorticoids is anticipated, baseline spinal bone-density measurement should be obtained by quantitative computed tomography (CT), dual-photon absorptiometry, or dual-energy x-ray absorptiometry (DEXA). [49]

Evaluation during Treatment

At follow-up visits, patients receiving chronic glucocorticoid therapy should be questioned about polyuria, polydipsia, abdominal pain, fevers, sleep disturbances, and psychological effects. There may be serious effects on affect and even psychosis in patients with high doses of glucocorticoids. Weight and blood pressure should be monitored. Serum electrolytes, fasting blood sugar, and cholesterol and triglyceride levels should be measured on a regular basis. Stool should be examined for occult blood. Follow-up eye examinations should be performed with careful monitoring for the development of cataracts and glaucoma.

Preventive Measures (Table 253-4)



TABLE 253-4 **Prevention of Side Effects with Chronic (= 3 months) Glucocorticoid Use**

DIET Diet should be low in calories, fat, and sodium, and high in protein, potassium, and calcium. Protein intake is important to reduce steroid-induced nitrogen wasting. [50] Use of alcohol, coffee, and nicotine should be minimized. Exercise should be encouraged.

INFECTIONS Patients with a positive PPD should be given prophylaxis with isoniazid. [51] Anergic patients should have a baseline chest x-ray to search for evidence of previous tuberculosis. Fevers or focal findings should be evaluated with appropriate cultures and diagnostic approaches. Some advocate use of Bactrim prophylaxis (1 DS Bactrim 3 days a week) against *Pneumocystic carinii* when patients receive concomitant cytotoxic therapy. [22]

GASTROINTESTINAL COMPLICATIONS Although there is controversy about whether an increase in the incidence of peptic ulcer disease occurs in otherwise unaffected patients receiving glucocorticoids, there is almost a ninefold increase in patients taking both glucocorticoids and nonsteroidal anti-inflammatory agents. [52], [53] In patients with two or more risk factors (such as those taking nonsteroidal anti-inflammatory medications, a previous history of peptic ulceration, advanced malignant disease, or a total dose of glucocorticoids >1000 mg), prophylaxis may be considered. Prophylaxis can include antacids, H_2-receptor blockers (cimetidine, ranitidine, nizatidine, or famotidine with the evening meal), or proton pump inhibitors (Prilosec or Prevacid).

ADRENAL SUPPRESSION Patients receiving daily glucocorticoid therapy for longer than 3 to 4 weeks must be assumed to have adrenal suppression that requires tapering of the glucocorticoids to allow for recovery of the HPA axis. Tapering is best performed by switching from a single daily dose to alternate-day doses, followed by a gradual reduction of the amount of the drug. The daily dose is first gradually tapered to 40 or 50 mg of prednisone. Then either the dose can be kept constant on one day and reduced on the alternate day by 5-mg decrements down to 5 mg/day, or, the steroid dose can be increased on one day and reduced by a similar amount on the alternate day. After the prednisone dose is tapered to 5 mg on alternate days, the need for maintenance therapy must be assessed. The 8 A.M. plasma cortisol level is measured 4 weeks after the 5-mg dose has been reached. The morning dose of prednisone is held until the plasma cortisol level is determined. If the plasma cortisol level is less than 10 µg/dL, the alternate-day prednisone dose should be decreased by 1 mg every 1 to 2 weeks to a maintenance dose of 2 mg/day. Then the 8 A.M. plasma cortisol level should be rechecked every 2 months until it is greater than 10 µg/dL, at which point maintenance glucocorticoids can be terminated. [54] Recovery of the HPA axis can take longer than 9 months. [40] At that point and at any point when the patient is receiving tapering doses of steroids, a stress caused, for example, by trauma, surgery, diarrhea, or fever >38°C (101°F) can precipitate acute adrenal insufficiency related to an inadequate stress response. Patients should wear bracelets or carry cards indicating that they are receiving glucocorticoids. During such stressful situations, it is necessary to give high doses of glucocorticoids, generally 25 to 70 mg/day of prednisone or 100 to 300 mg/day of cortisol in divided doses. [55] Patients must be educated about the need for stress coverage. The amount of glucocorticoids to give for coverage for surgery should probably be individualized to the severity of the operation. Minor operations lasting less than 1 h are associated with, at most, 50 mg/day (12.5 mg prednisone) of cortisol in response to the surgery. Moderate to major surgeries are associated with the production of 75 to 200 mg/day of cortisol. [56], [57] Thus, recent guidelines suggest that adrenally suppressed patients receive 25 mg of hydrocortisone equivalents for minor surgeries, 50 to 75 mg for

moderate surgeries, and 100 to 150 mg for major surgery for 2 to 3 days, beginning when the patient is on call for surgery. [56] No trials have been done, and one recent study suggested even lower doses are adequate. [58] In general, adrenal insufficiency resolves within 1 year of the termination of glucocorticoid therapy. An ACTH (cosyntropin) stimulation test may be performed after maintenance glucocorticoids are terminated to assess adrenal reserve. This test is performed in the office by determining a baseline cortisol level, giving an intramuscular injection of 0.25 mg of cosyntropin, and measuring the serum cortisol level again 1 h later. [54] The adrenal response is suppressed if the serum cortisol level fails to increase by at least 5 µg/dL to a stimulated value 60 min later of more than 20 µg/dL. If adequate adrenal response to stress is demonstrated, there is less concern about the endogenous cortisol response to stress. [22] However, such a response is not a guarantee of adequate adrenal reserves if severe stress occurs, and many physicians would choose routine stress coverage with glucocorticoids without performing an ACTH stimulation test.

OSTEOPOROSIS Attention to the prevention of osteoporosis is becoming increasingly important as newer therapies that may deter bone loss become available. Calcium and vitamin D supplements, sex hormone replacement, a weight-bearing exercise program, and sodium restriction are suitable first-line therapies. [59], [60] Calcium and vitamin D together, but not calcium alone, preserve bone mass in patients receiving long-term treatment with glucocorticoids at an average of 15 mg/day. [59], [61] Patients taking glucocorticoids should be given elemental calcium, 1500 mg/day, and vitamin D_2, 400 units twice daily. Activated forms (alfacalcidiol, 1 µg/day, or calcitriol, 0.5 to 1 µg/day) can be given, but more frequent monitoring is required for hypercalciuria and hypercalcemia. Patients with a history of renal stones should not receive supplemental calcium and vitamin D. For patients receiving calcium and vitamin D_2, calcium levels should be measured in serum and in 24-h urine collections every 3 months or whenever glucocorticoid doses are substantially altered. If the urinary calcium level exceeds 250 to 350 mg/dL, the addition of 12.5 to 25 mg/day of thiazide will reduce the renal excretion of calcium. [62] If thiazide is not added, calcium and vitamin D supplementation should be adjusted. Postmenopausal and premenopausal women who become amenorrheic because of glucocorticoids benefit from hormone replacement therapy (HRT). Such therapy helps to prevent the effects of glucocorticoids on bone. [63], [64] Postmenopausal women should receive oral conjugated estrogen (Premarin), 0.625 mg/day. Women with a uterus should also receive medroxyprogesterone (Provera), 2.5 mg/day, which prevents the increased endometrial carcinoma that occurs in women receiving estrogen alone. [65] Transdermal estradiol is also a common route of drug delivery. Newer selective estrogen receptor modulators, such as Raloxifene, offer the option of HRT to women previously unable to tolerate estrogens, and mimic the effects of estrogen on bone and blood lipid levels without the stimulatory effects on the breast and uterus. Raloxifene has more modest effects than conjugated estrogens on bone resorption and formation parameters, and is less effective in increasing bone mineral density; its role in glucocorticoid-induced osteoporosis has not been specifically studied. [66] Women who are to receive hormonal therapy should not have a history of benign or malignant breast disease or other hormone-sensitive tumors, thrombophlebitis, smoking, gallstones, or a family history of breast cancer. Breast and pelvic examinations should be performed initially and at regular 6- to 12-month intervals during hormone therapy. Glucocorticoids suppress serum testosterone in men. [67] Low serum testosterone is associated with low bone density in hypogonadal men; bone density increases in these men when they receive supplemental testosterone. [68] One study suggests that testosterone partially reverses the effects of glucocorticoids on bone. [69] Men with low serum testosterone levels who are receiving glucocorticoids should have testosterone supplementation. Based on recommendations published by the American Association of Clinical Endocrinologists and the American College of Endocrinology, men with serum testosterone levels below the physiologic range (<300 ng/mL) should receive replacement therapy. [70] Replacement is administered either by the intramuscular route (testosterone enanthate or cypionate, 200 mg IM every 2 weeks or 100 mg every week to avoid cycling) or by testosterone patches (Androderm, 4 or 6 mg applied daily). Serum testosterone should be checked after replacement to assure adequate treatment. The increased osteolysis caused by steroids has led to the use of a number of agents that inhibit bone resorption, such as the bisphosphonates and calcitonin. Inhibition of bone resorption leads to recoupling of the remodeling unit, thereby preventing further bone loss. In addition, because bone formation proceeds at a much slower pace than resorption, antiresorptive drugs produce a period of time up to 2 years where formation is greater than resorption. Several bisphosphonates are now available and have revolutionized the approach to prevention and treatment of steroid-induced osteoporosis. These include alendronate, 70 mg/week or 5 mg/day (10 mg/day for postmenopausal women not on HRT); risedronate, 30 mg/week or 5 mg/day; etidronate, 400 mg/day for 2 weeks every 13 weeks; and pamidronate, 30 to 60 mg intravenously every 6 to 12 months. All four agents increase vertebral bone mineral density and decrease vertebral fractures in patients receiving glucocorticoids, and alendronate and risedronate are currently recommended for prevention and treatment of glucocorticoid-induced osteoporosis. [71], [72] Intranasal calcitonin may increase bone mineral density, but less effectively than the bisphosphonates, and it does not reduce the risk of vertebral fractures. [73], [74] Calcitonin offers a treatment for patients unable to tolerate the bisphosphonates or unwilling to add another pill to their regimen. It is considered a second-line agent for treatment of osteoporosis and is not recommended for prevention of bone loss in early glucocorticoid therapy. [59] It is used as one spray to one nostril daily, alternating nostrils each day to minimize local irritation. Calcitonin is often helpful in relieving the pain of compression fractures. [75] Current recommendations include baseline measurements of bone density and a sequential study to identify early those who are rapidly losing bone density. [24], [59] Bone density is best measured in the lumbar spine in patients younger than 60 years of age and in the femoral neck in patients older than 60 years of age. All men and postmenopausal women in whom long-term glucocorticoid treatment at =5 mg/day is being initiated or who have below normal bone mineral density T-scores should receive bisphosphonates at the time glucocorticoids are prescribed. Premenopausal women treated with bisphosphonates should prevent pregnancy. A decrease in bone mineral density of 5 percent or greater warrants changing or starting additional treatment strategies.

ATHEROSCLEROSIS Blood pressure, serum lipids, and glucose levels should be measured serially. Abnormalities should be treated with dietary manipulation and medication as necessary. Patients who smoke should be encouraged to stop. Female sex hormones protect against the development of atherosclerosis, and thus HRT for postmenopausal women on glucocorticoids makes sense. [76] However, recent data suggest that women with established atherosclerosis actually do worse with HRT, and there was a 58 percent increase in coronary heart disease events in the first year after myocardial infarction in patients treated with an estrogen/progestin combination. [77] If patients develop increased levels of cholesterol or triglycerides while taking glucocorticoids, there are now good approaches to treatment, particularly with some of the newer statins, that impact on the development of atherosclerosis and prevent myocardial infarctions. Patients should be treated or referred for treatment on the basis of guidelines that emphasize the importance of assessing the risk of atherosclerosis. These guidelines recommend treatment when patients have low-density lipoprotein (LDL) cholesterol

levels greater than 160 mg/dL and fewer than two coronary heart disease risk factors (high LDL cholesterol, smoking, hypertension, diabetes, male sex, family history of premature heart disease), LDL cholesterol levels greater than 130 mg/dL with two or more additional risk factors for heart disease, and LDL cholesterol levels greater than 100 mg/dL for patients with established coronary artery disease. [78] High-density lipoprotein (HDL) cholesterol levels lower than 35 mg/dL independently predict increased coronary mortality rates in men and should be taken into account in therapeutic decisions. Several trials have demonstrated reduction in both coronary heart disease and total mortality rates with statin therapy. [79], [80] and [81] Patients should supplement the diet with folate and B_6 to control any elevations in homocysteine.

AVASCULAR NECROSIS Early detection is important because early intervention may prevent progression to degenerative joint disease requiring joint replacement. Twenty percent of patients with AVN have normal x-rays. Bone scan and magnetic resonance imaging (MRI) are more sensitive techniques for evaluating AVN. Patients should be regularly questioned about pain and limitation of motion of joints. If abnormalities develop, an x-ray, bone scan, or MRI should be ordered. If imaging shows AVN, an orthopedic surgeon skilled in early intervention with core decompression may be able to halt progression of the disease. Patients with AVN have an increased risk that other joints will be affected. The progression of AVN to destructive joint disease may require joint replacement surgery. [82]

REFERENCES

1. Hench PS et al: The effect of a hormone of the adrenal cortex (17-hydroxy-11-dehydrocorticosterone (compound E)) and of pituitary adrenocorticotropic hormone on rheumatoid arthritis. *Mayo Clin Proc* **24**:181, 1949

2. Esteban NV et al: Daily cortisol production rate in man determined by stable isotope dilution/mass spectrometry. *J Clin Endocrinol Metab* **72**:39, 1991

3. Bloom E et al: Nuclear binding of glucocorticoid receptors: Relations between cytosol binding, activation and the biological response. *J Steroid Biochem* **12**:175, 1980

4. Adcock IM, Ito K: Molecular mechanisms of corticosteroid actions. *Monaldi Arch Chest Dis* **55**:256, 2000

5. Flower RJ, Rothwell NJ: Lipocortin-1: Cellular mechanisms and clinical relevance. *Trends Pharmacol Sci* **15**:71, 1994

6. Croxtall JD et al: Lipocortin 1 and the control of cPLA2 activity in A549 cells. Glucocorticoids block EGF stimulation of cPLA2 phosphorylation. *Biochem Pharm* **52**:351, 1996

7. Pepinsky RB et al: Five distinct calcium and phospholipid binding proteins share homology with lipocortin I. *J Biol Chem* **263**:10799, 1988

8. Wallner BP et al: Cloning and expression of human lipocortin, a phospholipase A_2 inhibitor with potential anti-inflammatory activity. *Nature* **320**:77, 1986

9. Croxtall JD et al: Glucocorticoids act within minutes to inhibit recruitment of signalling factors to activated EGF receptors through a receptor-dependent, transcription-independent mechanism. *Br J Pharmacol* **130**:289, 2001

10. Buttgereit F et al: A new hypothesis of modular glucocorticoid actions. *Arthritis Rheum* **41**:761, 1998

11. Groner B et al: Transcription initiation of transfected mouse mammary tumor virus LTR DNA is regulated by glucocorticoid hormones. *Nucleic Acids Res* **11**:4713, 1983

12. Cupps TR, Fauci AS: Corticosteroid-mediated immunoregulation in man. *Immunol Rev* **65**:133, 1982

13. Cidlowski JA et al: The biochemistry and molecular biology of glucocorticoid-induced apoptosis in the immune system. *Recent Prog Horm Res* **51**:457, 1996

14. Goulding NJ et al: Novel pathways for glucocorticoid effects on neutrophils in chronic inflammation. *Inflamm Res* **47**(Suppl 3):S158, 1998

15. Liles WC et al: Glucocorticoids inhibit apoptosis of human neutrophils. *Blood* **86**:3181, 1995

16. Amano Y et al: Inhibition by glucocorticoids of the formation of interleukin-1 alpha, interleukin-1 beta, and interleukin-6: Mediation by decreased mRNA stability. *Mol Pharmacol* **43**:176, 1993

17. Kitajima T et al: A novel mechanism of glucocorticoid-induced immune suppression: the inhibition of T cell-mediated terminal maturation of a murine dendritic cell line. *J Clin Invest* **98**:142, 1996

18. Balow JE, Rosenthal AS: Glucocorticoid suppression of macrophage migration inhibitory factor. *J Exp Med* **137**:1031, 1973

19. Hogan MM, Vogel SN: Inhibition of macrophage tumoricidal activity by glucocorticoids. *J Immunol* **140**:513, 1988

20. Parrillo JE, Fauci AS: Mechanisms of glucocorticoid action on immune processes. *Annu Rev Pharmacol Toxicol* **19**:179, 1979

21. Butler WT, Rossen RD: Effects of corticosteroids on immunity in man. I. Decreased serum IgG concentration caused by 3 or 5 days of high doses of methylprednisolone. *J Clin Invest* **52**:2629, 1973

22. Baxter JD: Advances in glucocorticoid therapy. *Adv Intern Med* **45**:317, 2000

23. Williams LC, Nesbitt LT Jr: Update on systemic glucocorticosteroids in dermatology. *Dermatol Clin* **19**:63, 2001

24. Vittorio CC, Werth VP: Preventive techniques to limit glucocorticoid-induced side effects. *Adv Dermatol* **16**:273, 2000

25. Lukert BP, Raisz LG: Glucocorticoid-induced osteoporosis: Pathogenesis and management. *Ann Intern Med* **112**:352, 1990

26. Adachi JD et al: Intermittent etidronate therapy to prevent corticosteroid-induced osteoporosis. *N Engl J Med* **337**:382, 1997

27. Luengo M et al: Vertebral fractures in steroid dependent asthma and involutional osteoporosis: A comparative study. *Thorax* **46**:803, 1991

28. Reid IR, Heap SW: Determinants of vertebral mineral density in patients receiving long- term glucocorticoid therapy. *Arch Intern Med*

150:2545, 1990

29. Rizzato G, Montemurro L: Reversibility of exogenous corticosteroid-induced bone loss. *Eur Respir J* **6**:116, 1993

30. Reid IR: Glucocorticoid osteoporosis—Mechanisms and management. *Eur J Endocrinol* **137**:209, 1997

31. Godschalk MF, Downs RW: Effect of short-term glucocorticoids on serum osteocalcin in healthy young men. *J Bone Miner Res* **3**:113, 1988

32. Pons F et al: The effect of systemic lupus erythematosus and long-term steroid therapy on bone mass in pre-menopausal women. *Br J Rheum* **34**:742, 1995

33. Buckley LM et al: Effects of low dose corticosteroids on the bone mineral density of patients with rheumatoid arthritis. *J Rheumatol* **22**:1055, 1995

34. Solomon L: Idiopathic necrosis of the femoral head: Pathogenesis and treatment. *Can J Surg* **24**:573, 981

35. Zizic TM et al: Corticosteroid therapy associated with ischemic necrosis of bone in systemic lupus erythematosus. *Am J Med* **79**:596, 1985

36. Glueck CJ et al: Thrombophilia and hypofibrinolysis: Pathophysiologies of osteonecrosis. *Clin Orthop* **334**:43, 1997

37. David DS et al: Adrenal glucocorticoids after twenty years. A review of their clinically relevant consequences. *J Chronic Dis* **22**:637, 1970

38. Etxabe J, Vazquez JA: Morbidity and mortality in Cushing's disease: An epidemiological approach. *Clin Endocrinol (Oxf)* **40**:479, 1994

39. Colao A et al: Persistence of increased cardiovascular risk in patients with Cushing's disease after five years of successful cure. *J Clin Endocrinol Metab* **84**:2664, 1999

40. Graber AL et al: Natural history of pituitary-adrenal recovery following long-term suppression with corticosteroids. *J Clin Endocrinol Metab* **25**:11, 1995

41. Dixon RB, Christy NP: On the various forms of corticosteroid withdrawal syndrome. *Am J Med* **68**:224, 1980

42. Gustavson LE, Benet LZ: Pharmacokinetics of natural and synthetic glucocorticoids, in *The Actual Cortex,* edited by DC Anderson, JSD Winters. Cornwall, England, Butterworth, 1985, p 235

43. Bovomkitti S et al: Reversion and reconversion rate of tuberculin skin reactions in correlation with the use of prednisone. *Dis Chest* **38**:51, 1960

44. Aucott JN: Glucocorticoids and infection. *Endocrinol Metab Clin North Am* **23**:655, 1994

45. Firooz A et al: Benefits and risks of intralesional corticosteroid injection in the treatment of dermatological diseases. *Clin Exp Dermatol* **20**:363, 1995

46. Sabir S, Werth VP: Pulse glucocorticoids. *Dermatol Clin* **18**:437, 2000

47. White KP et al: Severe adverse cardiovascular effects of pulse steroid therapy: is continuous cardiac monitoring necessary? *J Am Acad Dermatol* **30**:768, 1994

48. Genta RM: Global prevalence of strongyloidiasis: Critical review with epidemiologic insights into the prevention of disseminated disease. *Rev Infect Dis* **11**:755, 1989

49. Levis S, Altman R: Bone densitometry: Clinical considerations. *Arthritis Rheum* **41**:577, 1998

50. Cogan MG et al: Prevention of prednisone-induced negative nitrogen balance. Effect of dietary modification on urea generation rate in patients on hemodialysis receiving high-dose glucocorticoids. *Ann Intern Med* **95**:158, 1981

51. American Thoracic Society: Treatment of tuberculosis and tuberculosis infection in adults and children. *Am Rev Resp Dis* **134**:355, 1986

52. Piper JM et al: Corticosteroid use and peptic ulcer disease: role of nonsteroidal anti- inflammatory drugs. *Ann Intern Med* **114**:735, 1991

53. Hernandez-Diaz S, Rodriguez LA: Steroids and risk of upper gastrointestinal complications. *Am J Epidemiol* **153**:1089, 2001

54. Grinspoon SK, Biller BM: Clinical review 62: Laboratory assessment of adrenal insufficiency. *J Clin Endocrinol Metab* **79**:923, 1994

55. Baxter JD: Minimizing the side effects of glucocorticoid therapy. *Adv Intern Med* **35**:173, 1990

56. Salem M et al: Perioperative glucocorticoid coverage. A reassessment 42 years after emergence of a problem. *Ann Surg* **219**:416, 1994

57. Krasner AS: Glucocorticoid-induced adrenal insufficiency. *JAMA* **282**:671, 1999

58. Glowniak JV, Loriaux DL: A double-blind study of perioperative steroid requirements in secondary adrenal insufficiency. *Surgery* **121**:123, 1997

59. American College of Rheumatology Ad Hoc committee on Glucocorticoid-Induced Osteoporosis: Recommendations for the prevention and treatment of glucocorticoid-induced osteoporosis. *Arthritis Rheum* **44**:1496, 2001

60. Amin S et al: The role of vitamin D in corticosteroid-induced osteoporosis: A meta-analytic approach. *Arthritis Rheum* **42**:1740, 1999

61. Reid DM et al: Efficacy and safety of daily risedronate in the treatment of corticosteroid-induced osteoporosis in men and women: A randomized trial. *J Bone Miner Res* **15**:1006, 2000

62. Lane NE: An update on glucocorticoid-induced osteoporosis. *Rheum Dis Clin North Am* **27**:235, 2001

63. Hall GM et al: Effect of hormone replacement therapy on bone mass in rheumatoid arthritis patients treated with and without steroids. *Arthritis Rheum* **37**:1499, 1994

64. Lukert BP et al: Estrogen and progesterone replacement therapy reduces glucocorticoid-induced bone loss. *J Bone Miner Res* **7**:1063, 1992

65. Gambrell RD: Prevention of endometrial cancer with progestogens. *Maturitas* **8**:159, 1986

66. Khovidhunkit W, Shoback DM: Clinical effects of raloxifene hydrochloride in women. *Ann Intern Med* **130**:431, 1999

67. MacAdams MR et al: Reduction of serum testosterone levels during chronic glucocorticoid therapy. *Ann Intern Med* **104**:648, 1986

68. Finkelstein JS et al: Osteoporosis in men with idiopathic hypogonadotropic hypogonadism. *Ann Intern Med* **106**:354, 1987

69. Reid IR et al: Testosterone therapy in glucocorticoid-treated men. *Arch Intern Med* **156**:1173, 1996

70. Petak SM et al: AACE clinical practice guidelines for the evaluation and treatment of hypogonadism in adult male patients, 1996. http://www.aace.com/clin/guides/hypogonadism.html

71. Struys A et al: Cyclical etidronate reverses bone loss of the spine and proximal femur in patients with established corticosteroid-induced osteoporosis. *Am J Med* **99**:235, 1995

72. Adachi JD et al: Two-year effects of alendronate on bone mineral density and vertebral fracture in patients receiving glucocorticoids: A randomized, double-blind, placebo-controlled extension trial. *Arthritis Rheum* **44**:202, 2001

73. Cranney A et al: Calcitonin for the treatment and prevention of corticosteroid-induced osteoporosis. *Cochrane Database Syst Rev* CD001983, 2001

74. Reid IR: Glucocorticoid-induced osteoporosis. *Baillieres Best Pract Res Clin Endocrinol Metab* **14**:279, 2000

75. Pun KK, Chan LW: Analgesic effect of intranasal salmon calcitonin in the treatment of osteoporotic vertebral fractures. *Clin Ther* **11**:205, 1989

76. Grodstein F et al: Postmenopausal estrogen and progestin use and the risk of cardiovascular disease. *N Engl J Med* **335**:453, 1996

77. Hulley S et al: Randomized trial of estrogen plus progestin for secondary prevention of coronary heart disease in postmenopausal women. Heart and Estrogen/progestin Replacement Study (HERS) Research Group. *JAMA* **280**:605, 1998

78. Expert Panel on Detection Evaluation, and Treatment of High Blood Cholesterol in Adults: Executive summary of the third report of The National Cholesterol Education Program (NCEP) Expert Panel on Detection, Evaluation, and Treatment of High Blood Cholesterol in Adults (Adult Treatment Panel III). *JAMA* **285**:2486, 2001

79. The Long-Term Intervention with Pravastatin in Ischaemic Disease (LIPID) Study Group: Prevention of cardiovascular events and death with pravastatin in patients with coronary heart disease and a broad range of initial cholesterol levels. *N Engl J Med* **339**:1349, 1998

80. Randomised trial of cholesterol lowering in 4444 patients with coronary heart disease: The Scandinavian Simvastatin Survival Study (4S). *Lancet* **344**:1383, 1994

81. Sacks FM et al: The effect of pravastatin on coronary events after myocardial infarction in patients with average cholesterol levels. Cholesterol and Recurrent Events Trial investigators. *N Engl J Med* **335**:1001, 1996

82. Mont MA et al: Core decompression for osteonecrosis of the femoral head in systemic lupus erythematosus. *Clin Orthop* **334**:91, 1997

T>

Chapter 254

Stephen Katz

Sulfones

PHARMACOLOGY
INDICATIONS
ADVERSE EFFECTS
MONITORING OF DAPSONE THERAPY
MECHANISM OF ACTION

REFERENCES

In 1940, Costello [1] first described the dramatic success of sulfapyridine in treating a patient with dermatitis herpetiformis, a disease he believed to be a form of bacterial allergy. Swartz and Lever [2] later reported the regular response of all their patients with dermatitis herpetiformis to sulfapyridine therapy. In the early 1950s, a group of drugs chemically related to sulfapyridine, the sulfones (dapsone and related compounds), were first used in treating patients with this disease. Because dapsone is the most widely used drug among these compounds, there has been an enormous amount of research into its metabolism, mechanisms of action, and toxicity. This chapter focuses on the effect of dapsone on inflammatory skin diseases.

PHARMACOLOGY

Figure 254-1 shows the chemical structure of dapsone [4,4'-diaminodiphenylsulfone (DDS)]. Derivatives of dapsone such as sulfoxone (no longer available in the United States) are thought to be metabolized to the parent dapsone structure. Sulfapyridine resembles dapsone in that it has an aminophenyl group attached to a sulfone (SO_2); however, on the other side of the sulfone, there is a pyridine group (Fig. 254-1). Although other sulfonamides have an aminophenyl group attached to a sulfone, they have different groups on the other side of the sulfone, and none is as effective as sulfapyridine in the treatment of inflammatory diseases. The pyridine group was thought to contribute to the beneficial effect of sulfapyridine, and other compounds, such as pyribenzamine and nicotinamide, were said to be useful in treating patients with dermatitis herpetiformis. After many years, sulfapyridine is still available only under an investigational new drug (IND) application.

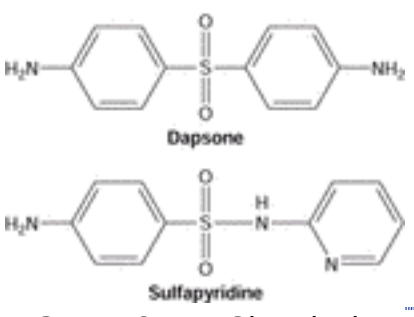

FIGURE 254-1 Chemical structure of dapsone and sulfapyridine.

After oral administration of dapsone, approximately 80 to 85 percent is absorbed, with peak levels being reached 2 to 6 h after a single dose. In patients taking 50 to 300 mg/day of dapsone, the peak levels of dapsone and its major metabolite reach 0.5 to 7 mg/L and 0.2 to 5 mg/L, respectively. [3] The half-life of dapsone in the circulation is approximately 30 h. [4] Its retention in the body, however, is prolonged, perhaps because of its enterohepatic recirculation, since high concentrations have been detected in the bile. Dapsone and its metabolites may be transmitted through human milk [5] and are excreted by the kidneys. [4]

Dapsone is metabolized in the liver. The two major metabolic pathways involve acetylation and *N*-hydroxylation (Fig. 254-2). As with isoniazid and certain hydrazides and sulfonamides, dapsone and its derivatives are acetylated polymorphically, that is, some patients rapidly acetylate dapsone to monoacetyldapsone (MADDS), the major metabolite, whereas in others, this process occurs slowly. However, in humans, MADDS is rapidly deacetylated. Thus, an equilibrium between MADDS and dapsone is rapidly reached and sustained. The half-life in the body seems to be unrelated to the rate of acetylation. From a clinical standpoint, it seems that in dapsone's control of symptoms of dermatitis herpetiformis and even in its efficacy as an antileprosy drug, the dapsone dosage requirement is unrelated to acetylator phenotype. [3], [6]

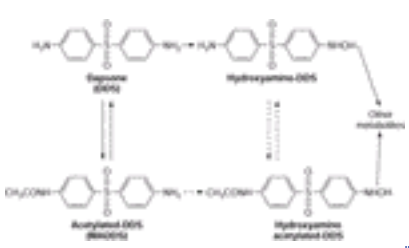

FIGURE 254-2 Dapsone metabolism in humans.

The other major metabolic pathway involves hydroxylation of one of the amino groups to form aminohydroxylaminodiphenylsulfone. This compound is responsible for the methemoglobinemia, hemolysis, and Heinz-body formations that occur regularly when dapsone is administered. [7], [8] and [9] Thus, these pharmacologic side effects must be anticipated.

A number of drugs interfere with the effect of dapsone, including probenecid, [10] rifampicin, [11] cimetidine, [12] omeprazole, [13] and trimethoprim. [14]

INDICATIONS

Since its introduction into clinical medicine, dapsone has had therapeutic trials in a multitude of diseases. Long lists of inflammatory diseases that have responded to dapsone therapy have been generated. [15], [16] Some of the individual reports are difficult to assess critically. Two diseases that invariably respond to dapsone therapy are dermatitis herpetiformis and erythema elevatum diutinum. [17] The dramatic dependence of patients on dapsone is best exemplified by the prompt exacerbations that follow withdrawal of the drug.

Other diseases for which dapsone therapy reportedly has been effective in some patients are rheumatoid arthritis; idiopathic or autoimmune thrombocytopenic purpura; acne conglobata; actinomycetoma; pyoderma gangrenosum; bullous pemphigoid; linear IgA disease; scarring pemphigoid; relapsing polychondritis; the bullous eruption of systemic lupus erythematosus (SLE); granuloma faciale; subcorneal pustular dermatosis; necrotic arachnidism; and certain forms of leukocytoclastic vasculitis. As a unifying feature, most of these diseases have granulocytes (neutrophils or eosinophils) as the predominant infiltrating cell. In most diseases, the neutrophils appear early in the pathologic process. The response to dapsone therapy is not as rapid, regular, or predictable in any of these diseases as it is in dermatitis herpetiformis or erythema elevatum diutinum.

Prospective controlled trials show dapsone therapy to be modestly effective in the treatment of some patients with rheumatoid arthritis. [18] Similarly, 50 percent of patients with thrombocytopenic purpura respond to dapsone therapy. [19] High dosages (up to 400 mg/day) are usually required in the treatment of otherwise unresponsive patients with cystic acne. With the advent of the synthetic retinoids, however, a trial of dapsone therapy may no longer be necessary. A few patients with bullous pemphigoid have responded fairly dramatically to dapsone therapy. [20] Indeed, some authors have advocated its use as a regularly effective treatment for bullous pemphigoid, [21] while others have found its efficacy in bullous pemphigoid to be limited. [22] Dapsone and sulfapyridine are effective in ocular cicatricial pemphigoid, particularly in the early inflammatory phases (reviewed in Ref. [23]), and dapsone is effective in patients with superficial pemphigus who have a low or negative pemphigus antibody titer. [24]

Patients with SLE occasionally have subepidermal vesicular lesions that closely simulate dermatitis herpetiformis histologically. These patients do not have an “admixture” of dermatitis herpetiformis and SLE, although the eruption is extraordinarily responsive to dapsone therapy. [25] Therapeutic responses to dapsone have occurred in occasional patients with subacute cutaneous lupus erythematosus. [26] Granuloma annulare has also been reported to respond to dapsone treatment. [27] Some patients with subcorneal pustular dermatosis respond to and become dependent on dapsone, whereas others are unresponsive. This difference may reflect the heterogeneity of this disease, whose nosologic features have been a source of considerable debate. [28]

Although several reports suggest that dapsone therapy is remarkably effective in the treatment of relapsing polychondritis, my experiences with dapsone therapy in several patients with this condition have been uniformly unsuccessful. Occasionally, there are patients with chronic leukocytoclastic vasculitis in addition to those with erythema elevatum diutinum in whom dapsone therapy induces the prompt cessation of lesions. Because there is no uniformly successful therapy for these patients, many of whom do not seem to have associated internal problems, a short trial of dapsone therapy is warranted. In general, when a pathologic lesion is characterized by a neutrophilic infiltrate and is unassociated with an infectious agent, a trial of dapsone therapy should be considered. Even if a therapeutic trial is successful, the dose of dapsone should be decreased to a point at which lesions recur to be sure that the improvement was indeed due to dapsone and that there is a continuing need for the drug.

In the early 1990s there was considerable enthusiasm for the potential of dapsone as a prophylactic agent for *Pneumocystis carinii* pneumonia (PCP). It is now considered less effective than trimethoprim-sulfamethoxazole (TMP-SMX). However, dapsone is a reasonable choice for PCP prophylaxis in patients who are unable to take TMP-SMX. [29]

ADVERSE EFFECTS

Dapsone therapy produces hemolysis and methemoglobinemia. The metabolite responsible for both these pharmacologic effects of sulfones has been identified as aminohydroxylaminodiphenylsulfone. Patients taking more than 50 mg/day of dapsone probably will have some degree of hemolysis that will be reflected in a lowered hemoglobin level. At 150 mg/day, dapsone may produce a decrease of as much as 2 g of hemoglobin. Patients with glucose-6-dehydrogenase deficiency have a greater decrease in the hemoglobin level. Most patients tolerate a 2-g fall in the level of hemoglobin well, but older patients or those with cardiopulmonary problems should be closely monitored or they should be given sulfapyridine. An increase in the reticulocyte count accompanies the fall in the hemoglobin level. Several months after treatment has begun, the hemoglobin level may rise almost to pretreatment levels but usually remains about 1 g below the original level.

Methemoglobinemia also regularly occurs in patients treated with sulfones but not as often as in patients treated with sulfapyridine. Methemoglobinemia is not a major problem in most patients. Even in patients taking 200 mg/day of

dapsone, the level usually does not exceed 12 percent of the total hemoglobin level and is often less than 5 percent. The methemoglobin level is more pronounced at the onset of treatment and, as with hemolysis, it is dose-dependent. The cyanosis (which may seem more gray than blue) that results from methemoglobinemia may be seen in anyone with a methemoglobin level greater than 3 percent but may not be apparent in some patients with a level as high as 12 percent. Symptoms of methemoglobinemia include weakness, tachycardia, nausea, headache, and abdominal pains, which should not be attributed to methemoglobinemia until levels reach 20 percent or greater. Dapsone-induced methemoglobinemia can be reduced by coadministration of cimetidine. [30]

Other than these pharmacologic side effects, the adverse effects of dapsone may be idiosyncratic or allergic in nature [15], [31], [32] (Table 254-1). Peripheral neuropathy is one such example, and usually occurs at high dosage levels. Loss of motor function is the most common type of neuropathy, and it is reversible by decreasing the dose of dapsone. Sensory neuropathy is rare. Other side effects include the induction of acute psychosis [33], [34] and a potentially fatal mononucleosis-like “dapsone” syndrome that occurs during the induction of dapsone therapy in patients with leprosy, [35] but also in patients with vasculitis and dermatitis herpetiformis. [36], [37] Severe hypoalbuminemia with anasarca has also been reported. [38]

Pharmacologic effects	Morbilliform eruptions
Hemolysis	Erythema nodosum
Methemoglobinemia	Erythema multiforme
Headache	Exfoliative dermatitis
Gastric irritation	Toxic epidermal necrolysis
Nausea	Severe hypoalbuminemia
Anorexia	Psychosis
Fatigue	Leukopenia
Hepatitis, infectious mononucleosis-like with adenopathy	Agranulocytosis
Cholestatic jaundice	Peripheral neuropathy (almost always motor)

SOURCE: Modified from Lang,[15] Klemmer,[31] and Kato et al.[32]

TABLE 254-1 **Adverse Reactions to Sulfones**

Agranulocytosis has been estimated to occur in 0.2 to 0.4 percent of patients treated with dapsone. [39] If agranulocytosis occurs, its onset is almost always during the first 3 months of therapy. [39], [40] Although it is usually reversible when patients stop therapy, it may be fatal. Patients should be warned to seek medical care immediately if an infection develops during the first several months of therapy. Generally, when adverse reactions occur as a result of therapy with dapsone, dapsone derivatives and even sulfapyridine cause the same types of problems.

Information from two independent studies of carcinogenicity suggests that dapsone is a “weak carcinogen” in rats. [41], [42] There is no similar evidence from studies in humans.

A frequently asked question is whether dapsone is safe to use during pregnancy. In one study, 2 of 56 infants born to patients with leprosy who were being treated with dapsone had congenital malformations. [43] There are no controlled studies in animals or humans that address this point. As mentioned earlier, dapsone may be found in breast milk. [5]

MONITORING OF DAPSONE THERAPY

Before therapy with the sulfones or sulfapyridine is started, a complete blood cell (CBC) count should be obtained. In addition, Asians, blacks, or persons of Mediterranean descent should be tested for glucose-6-phosphate dehydrogenase deficiency, because sulfones can cause profound hemolysis in persons lacking this enzyme. After therapy is begun, a leukocyte count with a differential and hemoglobin levels should be obtained weekly for the first month and then twice a month during the next 2 months. Thereafter, CBC counts should be obtained periodically. Liver and renal function also should be tested before therapy starts and periodically thereafter. Once the disease being treated is under control, the dosage of dapsone should be reduced to be sure that the patient is using the minimum amount of drug required. Although in some diseases, such as dermatitis herpetiformis, the patients may alter the drug dosage according to the severity of the disease, they should be reminded not to increase the dosage by large amounts abruptly. Because the blue-gray color of methemoglobinemia may be attributed to other causes by emergency room physicians, patients should be advised to carry a medication card in their wallets.

MECHANISM OF ACTION

The mechanisms of action of dapsone in leprosy and inflammatory diseases have been the subject of considerable study. Dapsone and its derivatives are potent oxidants with a notable influence on glutathione. Interference with the folate biosynthetic pathway of bacteria accounts for their bacteriostatic effect. Less-well-known activities of dapsone involve its inhibition of choline incorporation into the lecithin of the cell membranes, thereby decreasing phospholipid synthesis. [44] Also, dapsone administered in the diet decreases visceral lesions and mortality in chickens infected with Marek's disease, in which a herpesvirus induces a lymphocytic malignant neoplasm in chickens. [45]

Numerous studies have attempted to determine how dapsone exerts its anti-inflammatory effect. Evidence suggests that its antiinflammatory effect is not related to its antibacterial effect. Dapsone inhibits lysosomal enzyme activity, [46] interferes with the myeloperoxidase-H_2O_2-halide-mediated cytotoxic system, [47], [48] and inhibits the generation of 5-lipoxygenase products in polymorphonuclear leukocytes. [49] Dapsone and its analogues also inhibit the zymosan-mediated human neutrophil respiratory burst. [50] Although these findings may account for the effect of the drug on neutrophils or on their lysosomal enzymes at the site of injury, they probably do not account for the lack of influx of neutrophils into the dermis in treated patients. There is little evidence to support suggestions that dapsone interferes with complement activation and deposition. Some in vivo studies have shown that dapsone at doses of 100 to 200 mg/kg

inhibits adjuvant-induced arthritis and carrageenan-induced inflammation in rats. [51]

Several studies suggest that dapsone and its derivatives do not affect the response of neutrophils to chemotactic stimuli. However, other studies suggest that dapsone inhibits leukotriene B_4 binding to and chemotaxis of neutrophils. [52], [53] Yet others demonstrate that dapsone inhibits the neutrophil response to some selected chemotactic stimuli. [54] More extensive studies with chemotactic stimuli in varied concentrations are required to evaluate the possibility that dapsone may interfere with a specific chemotactic factor or with the response of neutrophils to such a factor. Another possibility for the beneficial effect of dapsone on neutrophil-rich dermatoses may be its ability to inhibit (1) interleukin 1–stimulated neutrophil adhesion to endothelial cells, [50] (2) neutrophil adherence to antibodies deposited in skin, [55] (3) integrin-mediated neutrophil adherence functions, [56] or (4) chemoattractant-induced signal transduction. [57] More recent studies suggest that dapsone may inhibit the release of chemotactic stimuli from keratinocytes. [58]

REFERENCES

1. Costello MJ: Dermatitis herpetiformis treated with sulfapyridine. *Arch Dermatol Syphilol* **41**:134, 1940

2. Swartz JH, Lever WF: Dermatitis herpetiformis: Immunology and therapeutic considerations. *Arch Dermatol Syphilol* **47**:680, 1943

3. Ellard GA et al: Dapsone acetylation in dermatitis herpetiformis. *Br J Dermatol* **90**:441, 1974

4. Zuidema J et al: Clinical pharmacokinetics of dapsone. *Clin Pharmacokinet* **11**:299, 1986

5. Edstein S et al: Excretion of chloroquine, dapsone and pyrimethamine in human milk. *Br J Clin Pharmacol* **22**:733, 1986

6. Ellard GA et al: Dapsone acetylation and the treatment of leprosy. *Nature* **239**:159, 1972

7. McMillan DC et al: Dapsone induced hemolytic anemia: Effect of dapsone hydroxylamine on sulfhydryl status, membrane skeletal proteins, and morphology of human and rat erythrocytes. *J Pharmacol Exp Ther* **274**:540, 1995

8. Grossman SJ, Jollow DJ: Role of dapsone hydroxylamine in dapsone-induced hemolytic anemia. *J Pharmacol Exp Ther* **244**:118, 1988

9. Coleman MD et al: The effect of acetylation and deacetylation on the disposition of dapsone and monoacetyl dapsone hydroxylamine in human erythrocytes in vitro. *J Pharm Pharmacol* **48**:401, 1996

10. Goodwin CS, Sparell G: Inhibition of dapsone excretion by probenecid. *Lancet* **1**:884, 1969

11. Balakrishnan S, Seshadri PS: Drug interactions—The influence of rifampicin and clofazimine on the urinary excretion of DDS. *Lepr India* **53**:17, 1981

12. Rhodes LE et al: Cimetidine improves the therapeutic/toxic ratio of dapsone in patients on chronic dapsone therapy. *Br J Dermatol* **132**:257, 1995

13. Caraco Y et al: Differences between white subjects and Chinese subjects in the in vivo inhibition of cytochrome P450s 2C19, 2D6, and 3A by omeprazole. *Clin Pharmacol Ther* **60**:396, 1996

14. Lee BI et al: Dapsone, trimethoprim, and sulfamethoxazole plasma levels during treatment of *Pneumocystis* pneumonia in patients with the acquired immune deficiency syndrome (AIDS): Evidence of drug interactions. *Ann Intern Med* **110**:606, 1989

15. Lang P: Sulfones and sulfonamides in dermatology today. *J Am Acad Dermatol* **1**:479, 1979

16. Zhu YI, Stiller MJ: Dapsone and sulfones in dermatology: Overview and update. *J Am Acad Dermatol* **45**:420, 2001

17. Katz SI et al: Erythema elevatum diutinum: Skin and systemic manifestations, immunologic studies, and successful treatment with dapsone. *Medicine (Baltimore)* **56**:443, 1977

18. Chang DJ et al: Dapsone in rheumatoid arthritis. *Semin Arthritis Rheum* **25**:390, 1996

19. Godeau B et al: Dapsone for chronic autoimmune thrombocytopenic purpura: A report of 66 cases. *Br J Haematol* **97**:336, 1997

20. Person JR, Rogers RS III: Bullous pemphigoid responding to sulfapyridine and the sulfones. *Arch Dermatol* **113**:610, 1977

21. Venning VA et al: Dapsone as first line treatment for bullous pemphigoid. *Br J Dermatol* **120**:83, 1989

22. Bouscarat F et al: Treatment of bullous pemphigoid with dapsone: Retrospective study of thirty-six cases. *J Am Acad Dermatol* **34**:683, 1996

23. Kirtschig G et al: Interventions for mucous membrane pemphigoid/cicatricial pemphigoid and epidermolysis bullosa acquisita. *Arch Dermatol* **138**:380, 2002

24. Basset N et al: Dapsone as initial treatment in superficial pemphigus: Report of nine cases. *Arch Dermatol* **123**:783, 1987

25. Hall RP et al: Bullous eruption of systemic lupus erythematosus: Dramatic response to dapsone therapy. *Ann Intern Med* **97**:165, 1982

26. Callen J: Treatment of cutaneous lesions in patients with lupus erythematosus. *Dermatol Clin* **12**:201, 1994

27. Steiner A et al: Sulfone treatment of granuloma annulare. *J Am Acad Dermatol* **13**:1004, 1985

28. Chimenti S, Ackerman AB: Is subcorneal pustular dermatitis of Sneddon and Wilkinson an entity sui generis? *Am J Dermatopathol* **3**:363, 1981

29. Beumont MG et al: Safety of dapsone as *Pneumocystis carinii* pneumonia prophylaxis in human immunodeficiency virus-infected patients with allergy to trimethoprim-sulfamethoxazole. *Am J Med* **100**:611, 1996

30. Coleman MD, Coleman NA: Drug-induced methaemoglobinemia: Treatment issues. *Drug Saf* **14**:394, 1996

31. Alexander JO: Dermatitis herpetiformis, in *Major Problems in Dermatology,* edited by A Rook. Philadelphia, Saunders, 1975, p 291

32. Katz SI et al: Dermatitis herpetiformis: The skin and the gut. *Ann Intern Med* **93**:857, 1980

33. Fine JD et al: Psychiatric reaction to dapsone and sulfapyridine. *J Am Acad Dermatol* **9**:274, 1983

34. Gawkrodger D: Manic depression induced by dapsone in patient with dermatitis herpetiformis. *Br Med J* **299**:860, 1989

35. Frey AM et al: Fatal reaction to dapsone during treatment of leprosy. *Ann Intern Med* **94**:777, 1981

36. Prussick R, Shear NH: Dapsone hypersensitivity syndrome. *J Am Acad Dermatol* **35**:346, 1996

37. McKenna KE, Robinson J: The dapsone hypersensitivity syndrome occurring in a patient with dermatitis herpetiformis. *Br J Dermatol* **137**:657, 1997

38. Kingham JGC et al: Dapsone and severe hypoalbuminemia. *Lancet* **2**:662, 1979

39. Hörnsten P et al: The incidence of agranulocytosis during treatment of dermatitis herpetiformis with dapsone as reported in Sweden, 1972 through 1988. *Arch Dermatol* **126**:919, 1990

40. Coleman MD: Dapsone-mediated agranulocytosis: Risks, possible mechanisms and prevention. *Toxicology* **162**:53, 2001

41. *Bioassay of Dapsone for Possible Carcinogenicity*. US Department of Health, Education, and Welfare publication 77–820. National Cancer Institute Carcinogenesis Technical Reports Series, Washington, DC, 1977

42. Griciute L, Tomatis L: Carcinogenicity of dapsone in mice and rats. *Int J Cancer* **25**:123, 1980

43. Maurus JM: Hansen's disease in pregnancy. *Obstet Gynecol* **52**:22, 1978

44. Shigeura HT et al: Metabolic studies on dapsone and sulfone derivatives in chick macrophages. *Biochem Pharmacol* **24**:687, 1975

45. Shen TY et al: Read before the American Chemical Society Abstracts Meeting. September 12–16, 1971

46. Mier PD, Van Den Hurk JJMA: Inhibition of lysosomal enzymes by dapsone. *Br J Dermatol* **93**:471, 1975

47. Stendahl O et al: The inhibition of polymorphonuclear leukocyte cytotoxicity by dapsone: A possible mechanism in the treatment of dermatitis herpetiformis. *J Clin Invest* **62**:214, 1978

48. Kazmierowski JA et al: Dermatitis herpetiformis: Effects of sulfones and sulfonamides on neutrophil myeloperoxidase-mediated iodinations and cytotoxicity. *J Clin Immunol* **4**:55, 1984

49. Wozel G, Lehmann B: Dapsone inhibits the generation of 5-lipoxygenase products in polymorphonuclear leukocytes. *Skin Pharmacol* **8**:196, 1995

50. Coleman MD et al: Studies of the inhibitory effects of analogues of dapsone on neutrophil function in vitro. *J Pharm Pharmacol* **49**:53, 1997

51. Williams K et al: Anti-inflammatory actions of dapsone and its related biochemistry. *J Pharm Pharmacol* **28**:555, 1976

52. Maloff BL et al: Dapsone inhibits LTB4 binding and bioresponse at the cellular and physiologic levels. *Eur J Pharmacol* **158**:85, 1988

53. Wozel G et al: Dapsone hydroxylamine inhibits the LTB_4-induced chemotaxis of polymorphonuclear leukocytes into human skin: Results of a pilot study. *Inflamm Res* **46**:420, 1997

54. Harvath L et al: Selective inhibition of neutrophil chemotaxis to *N*-formyl-methionyl-leucyl-phenylalanine by sulfones. *J Immunol* **137**:1305, 1986

55. Thuong-Nguyen V et al: Inhibition of neutrophil adherence to antibody by dapsone: A possible therapeutic mechanism of dapsone in the treatment of IgA dermatoses. *J Invest Dermatol* **100**:349, 1993

56. Booth SA et al: Dapsone suppresses integrin-mediated neutrophil adherence function. *J Invest Dermatol* **98**:135, 1992

57. DebolSM et al: Anti-inflammatory action of dapsone: Inhibition of neutrophil adherence is associated with of chemoattractant-induced signal transduction. *J Leukoc Biol* **62**:827, 1997

58. Schmidt E et al: The IL-8 release from cultural human keratinocytes, mediated by antibodies to bullous pemphigoid autoantigen 180, is inhibited by dapsone. *Clin Exp Immunol* **124**:157, 2001.

T>

Chapter 255

Jeffrey LaDuca Anthony Gaspari

Aminoquinolines

PHARMACOLOGY, PHARMACOKINETICS, DISTRIBUTION, AND DOSING
MECHANISMS OF ACTION
Photodermatologic Properties
Immunologic and Anti-inflammatory Effects
Interaction with Cellular DNA
Other Effects
INDICATIONS FOR USE OF ANTIMALARIAL DRUGS
Lupus Erythematosus
Porphyria Cutanea Tarda
Polymorphous Light Eruption
Sarcoidosis
SPECIAL CONSIDERATIONS
SIDE EFFECTS AND DRUG INTERACTIONS

REFERENCES

The 4-aminoquinolines are a family of compounds derived from quinine. Chloroquine (CQ) and hydroxychloroquine (HCQ) are the principal members of this class of compounds and are those most often used as therapeutic agents in dermatology. Quinacrine (QE), a quinine derivative classified as an acridine, has also been used in dermatology. Quinine is extracted from the bark of the cinchona tree. It is said that, in 1638, Anna del Chinchon, the wife of the viceroy of Peru, was cured of malaria by the bark from this tree. Although the validity of this claim is debated, the tree from which the bark was taken still bears her name. By 1645, news of the use of cinchona bark to treat intermittent fevers reached Rome via a delegate from Peru who convinced Roman Jesuits of its efficacy. By the 1670s, the bark was being used throughout Europe. In the mid-1700s the French explorer De la Condamine identified the tree and named it quinquina (the word comes from *quina,* which is Peruvian vernacular for cinchona). In 1852, a Dutch expedition succeeded in transplanting cinchona seeds and plants to Java in the Dutch East Indies, and by the end of the nineteenth century, 90 percent of the world's supply of quinine came from Java. (For a more detailed history of quinine, see Hofheinz and Merkli. [1])

The research and development of synthetic antimalarials derived from quinine stemmed from military demand. After World War I, supplies of quinine dwindled. CQ was first synthesized in Germany in 1934. QE and other synthetic quinine derivatives were also produced in the 1930s. During World War II, Japan occupied Java and cut off supplies, again creating a need for alternative sources. More than 17,000 compounds were tested for antimalarial properties in the United States and England, and, as a result of this research, HCQ was synthesized in 1946. These antimalarial drugs were first used for dermatologic conditions in 1894, when Payne reported the treatment of lupus erythematosus (LE) with quinine. [2] In 1951, Page reported that during World War II he had observed that 18 American soldiers taking quinine noted an improvement of their cutaneous lupus and inflammatory arthritis. [3] Since that time antimalarial drugs (primarily CQ, HCQ, and QE) have been studied for dermatologic use. QE was first synthesized as an alternative to quinine for the treatment of malaria and was subsequently found to be much more efficacious, with greater bioavailability and better tolerance. It became an important agent for the treatment of *Giardia* infections. Its production in the United States was discontinued in 1992. These agents, their pharmacology, mechanisms, clinical applications, and side effects are described below.

PHARMACOLOGY, PHARMACOKINETICS, DISTRIBUTION, AND DOSING

CQ, HCQ, and QE are closely related structures (Fig. 255-1). CQ and HCQ are 4-aminoquinolines, whereas QE, with an additional benzene ring, is classified as an acridine. The pharmacology and pharmacokinetics of these antimalarial compounds are similar (Table 255-1). They are bitter, water-soluble, and readily absorbed from the gastrointestinal tract. All have a relatively good bioavailability and achieve peak concentrations within hours. Both CQ and HCQ have large volumes of distribution and prolonged half-lives. [4], [5] QE is extensively bound to plasma proteins, whereas CQ and HCQ are only partially bound. [4], [5] and [6] The half-life of QE is substantially less than that of the other compounds. [6] CQ is metabolized (dealkylated) in the liver by P450 enzymes into desethylchloroquine (DECQ) and bisdesethylchloroquine (BDCQ). [4] CQ and its metabolites are stored in relatively high concentrations in the liver, spleen, lungs, and adrenals, and in melanin-containing cells. [4] Approximately 50 percent of CQ is eliminated by the kidneys unchanged. [4] HCQ is also metabolized in the liver (*N*-de-ethylation) into three chief metabolites: desethylhydroxychloroquine (DHCQ), DECQ, and BDCQ. [5] The parent compound and metabolites are taken up by lysosomes and concentrated in lysosome-rich tissues. Approximately 15 to 25 percent of the total clearance is through the kidneys. [5] As with CQ, renal excretion can be enhanced with acidification of the urine. [4], [5] QE is excreted in urine, bile, sweat, and saliva, [6] with renal excretion accounting for only about 11 percent. The highest tissue concentrations are in the liver and spleen. [6] Equivalent doses of these compounds are 250 mg of CQ, 400 mg of HCQ, and 100 mg of QE. The usual doses used in dermatology are 250 to 500 mg/day for CQ, 400 mg/day for HCQ, and 100 to 200 mg/day for QE. Evidence of efficacy is generally seen after 1 to 3 months of use, after which the dose may be tapered to a minimum effective dose. Because the mechanism of action, metabolism, clearance, and side-effect profile of QE are sufficiently different from those of HCQ and CQ, no crossover reactivity is thought to occur between QE and the 4-aminoquinolines. [7]

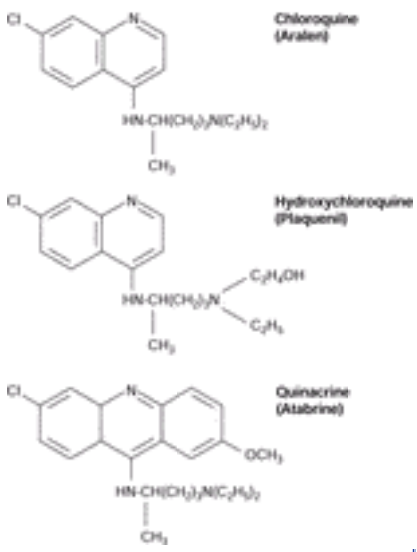

FIGURE 255-1 Antimalarial drugs used in dermatology.



TABLE 255-1 **Pharmacology and Pharmacokinetics of Antimalarial Compounds**

MECHANISMS OF ACTION

The precise mechanism by which antimalarial compounds exert their action is still a subject of debate. However, several discrete mechanisms have been determined and attributed to the drugs' efficacy. Generally, antimalarial drugs are felt to be anti-inflammatory. For the treatment of malaria, the aminoquinolines concentrate in the *Plasmodium* digestive vacuole and prevent polymerization of toxic heme released during proteolysis of hemoglobin. [8] Other important actions of antimalarial compounds are summarized below.

Photodermatologic Properties

The 4-aminoquinolines bind in the epidermis in high concentrations, probably because of their affinity for pigment. However, studies of the photoprotective effects of antimalarials have yielded conflicting data. Both in vitro and in vivo studies indicate that CQ absorbs ultraviolet light in the UVB range. [9], [10] The effect on the minimal erythema dose (MED) is less certain. One study showed that QE prolonged the MED in two patients with lupus. [3] Another study showed that CQ had no effect on the MED in 21 patients with polymorphous light eruption. [11]

Immunologic and Anti-inflammatory Effects

CQ and HCQ are weak diprotic bases that are protonated, become trapped, and accumulate to 100 times concentration inside acidic vesicles such as lysosomes. [12] QE inhibits Na-K ATPase activity, stabilizes cell membranes, and concentrates in lysosomes. The effects are most evident in macrophages and phagocytic cells, where phagocytosis and chemotaxis are impaired. [13] Cellular enzymes and receptors dependent on lysosomes for function or activation are also affected, thus altering the cell's responsiveness to mitogenic stimuli. [12] Decreases in the T cell release of interleukin (IL)-1, IL-6, tumor necrosis factor (TNF), and interferon-? have been observed. [14] The fact that IL-1, IL-6, and TNF play a role in the hepatic production of acute phase reactants may contribute to their anti-inflammatory properties. [15] Inhibition of calcium signaling within the T cell may be involved. [16] Low concentrations of CQ and QE inhibit the pro-IL-6 stimulatory effect of cytosine-phosphorothiolated guanine (CpG)-oligodeoxynucleotides on human peripheral blood mononuclear cells. [17] CQ has also been implicated in the inhibition of natural killer (NK) cell activity, decreased production of IL-2 by activated lymphocytes, and alteration of antigen-antibody complexes. QE also inhibits NK cells and blocks the primary proliferative response of cytotoxic T cells to non-T cell antigens. [15] Lastly, the arachidonic acid pathway is affected by antimalarial compounds. CQ inhibits phospholipases A_2 and C, [15] and QE also inhibits phospholipase A_2. Thus, important mediators of inflammation such as prostaglandins, leukotrienes, bradykinin, and histamine can all be decreased by antimalarial therapy.

Interaction with Cellular DNA

Both QE and CQ bind cellular DNA by intercalation between base pairs, thus stabilizing the DNA. [18], [19] Gene transcription and subsequent translation are inhibited.

Other Effects

Antimalarial compounds exhibit many effects. HCQ improves lipid profiles. Both CQ and HCQ improve glucose profiles and inhibit platelet aggregation. High doses of CQ may produce an antioxidant effect. Through membrane stabilization, antimalarials can produce a local anesthetic effect. In vitro, HCQ induces apoptosis in B-chronic lymphocytic leukemia cells. CQ, HCQ, and QE all interfere with HIV-1 replication and function.

INDICATIONS FOR USE OF ANTIMALARIAL DRUGS

The FDA-approved indications for the use of CQ, HCQ, and QE are limited. Nonetheless, antimalarial drugs have been used to treat a myriad of dermatologic and nondermatologic conditions (Table 255-2). The treatment of malaria is the only indication shared by all three drugs. CQ is approved for the treatment of extraintestinal amebiasis, and QE is approved for the treatment of giardiasis. HCQ, the drug most extensively studied, is indicated for rheumatoid arthritis, discoid lupus and other forms of cutaneous lupus erythematosus, and systemic lupus erythematosus. It has also been found efficacious in a long list of dermatologic conditions. CQ has been used to treat many of these diseases, although not to the same extent. The current difficulty in obtaining QE may account for the relatively fewer indications. The following sections discuss the more accepted uses of these drugs in dermatology.



TABLE 255-2 **Medical and Dermatologic Uses of Antimalarial Agents**

Lupus Erythematosus (See also Chap. 171)

Antimalarial drugs have been used for the cutaneous manifestations of lupus for more than a century. During World War II, CQ and QE were also found to be effective as well. [3] Ninety to 95 percent of patients receiving HCQ are thought to benefit. [20] A double-blind trial of HCQ for chronic discoid lupus showed a 70 percent response rate. [21] QE has a 73 percent response rate in 20 clinical trials in patients with LE. [22] Each of the antimalarials is effective as a glucocorticoid-sparing agent in the treatment of LE. [23] Typically, these drugs are used to treat patients whose symptoms cannot be controlled by topical glucocorticoids and sun protection. Widespread cutaneous lesions, hypertrophic and verrucous lesions, and long-standing discoid lesions do not respond as well. Antimalarials are not effective for systemic symptoms of fever or renal and hematologic abnormalities in systemic SLE. The onset of action for antimalarial therapy is 4 to 8 weeks. More rapid response has been achieved with QE. [22] Anecdotal reports suggest that when HCQ is ineffective as a monotherapy, CQ may be efficacious. The use of QE alone or in combination with either HCQ or CQ has also been suggested as eliciting a response in patients with recalcitrant disease. Triquin, a combination of all three drugs, had been used for discoid lupus and cutaneous LE. Although the manufacturers have discontinued making the drug, it can be compounded.

Porphyria Cutanea Tarda (See also Chap. 149)

The first reported case of porphyria cutanea tarda treated with CQ was published in 1957. [24] Since then, mechanisms of action have been suggested, side effects described, and treatment regimens identified. Phlebotomy remains the principal treatment for porphyria cutanea tarda after exacerbating factors are identified and removed. Antimalarial therapy is used with phlebotomy as an adjuvant therapy or when phlebotomy is not possible. CQ inhibits porphyrin synthesis and mobilizes lysosomal stores of porphyrins, allowing for the formation of water-soluble complexes that are then excreted by the kidney. [25] Headache, nausea, fever, elevated transaminase levels, and urinary excretion of porphyrins occur 3 to 4 days after the initiation of therapy with CQ at 250 mg/day. [26] Multiple treatment regimens have been found effective. High doses of HCQ (250 mg tid) for short courses induce a prolonged remission. Marked increases in liver transaminase levels require hospitalization during the initiation of therapy. Low-dose CQ therapy, consisting of 125 mg twice a week for 2 weeks followed by 250 mg twice a week thereafter has been proposed. Alternatively, HCQ, at 100 mg three times a week for a month, then 200 mg three times a week for a month, then advanced to 200 mg daily can be used. These lower dosing schedules appear to alleviate the severe hepatotoxicity. Finally, phlebotomy prior to the initiation of CQ therapy may also reduce the severity of hepatotoxicity. [27] Laboratory monitoring of liver function is recommended during therapy.

Polymorphous Light Eruption (See also Chap. 136)

Polymorphous light eruption is an inflammatory reaction in sun-exposed areas of the skin. IL-1, -6, and -8 may play a role in the inflammatory process. [28] CQ decreases IL-1 and IL-6 production. Additionally, it absorbs UVB light. CQ has been used to treat this reaction for a number years, [11] and placebo-controlled trials have proven its efficacy. [29] HCQ at doses of 200 to 400 mg/day is effective. Topical sunscreens should be used in conjunction with antimalarial therapy. In northern climates, discontinuation of therapy during the winter months may decrease the cumulative side effects of antimalarial therapy.

Sarcoidosis (See also Chap. 183)

Antimalarial therapy for cutaneous manifestations of sarcoidosis was first described nearly 50 years ago. A review concluded that antimalarials were highly effective, with a greater than 70 percent response rate. Two to 3 mg/kg per day of HCQ was reported as being effective in 12 of 17 patients treated. CQ therapy initiated at a dose of 500 mg/day for 2 weeks, then lowered to a maintenance dose of 250 mg/day, has been described as safe and effective. [30] Therapy may also be effective for associated hypercalcemia.

SPECIAL CONSIDERATIONS

CQ and HCQ have been used to treat children. However, reports of fatal toxicity suggested that antimalarial drugs were contraindicated in the pediatric population. [31] It was later determined that, milligram per kilogram, antimalarials are generally safe in the treatment of children with connective tissue diseases, juvenile rheumatoid arthritis, morphea, panniculitis, and porphyria cutanea tarda. [32] The risk for toxicity in children is felt to be no greater than in adults.

The use of antimalarial drugs in pregnancy is controversial, but is now generally accepted as safe. The 4-aminoquinolines cross the placenta and accumulate in fetal tissues. [4], [5] Congenital defects are rarely reported in newborn children of women with malaria who were taking antimalarial drugs. [33] However, the extended half-life of these drugs does suggest significant fetal exposure, even if the drug is discontinued once pregnancy is detected. One study of 24 women exposed to CQ or HCQ during 27 pregnancies uncovered no congenital anomalies. [34] Another retrospective review of 33 women with lupus exposed to HCQ during 36 pregnancies reported no evidence of teratogenic effects. [35] Larger reviews of the British and North American experiences with antimalarial drugs also support the use of 4-aminoquinolines during pregnancy. [36], [37] Conversely, discontinuation of antimalarial therapy for the treatment of lupus may cause a significant flare, which can be associated with prematurity, growth retardation, and increased fetal loss. The safety of QE is less well documented.

The use of antimalarials during breast-feeding is relatively contraindicated. CQ and HCQ are both excreted in breast milk. [38] Infants are exposed to 2 percent of the maternal dose of HCQ per kilogram per day and 1 percent of the maternal dose of CQ. [7] As the half-life is long and elimination is slow, the potential exists for the accumulation of drug in the infant.

SIDE EFFECTS AND DRUG INTERACTIONS

Antimalarial drugs are safe and effective when used responsibly. Without proper monitoring, however, they have the potential for serious side effects, most of which are reversible with decreased doses or drug withdrawal. Retinopathy is the most severe side effect and may be permanent even after therapy is discontinued (Table 255-3).

Organ System	Toxic Reaction
Gastrointestinal	Anorexia, nausea, vomiting, diarrhea, weight loss, hepatotoxicity
Hematologic	Hemolytic anemia (G6PD deficiency), aplastic anemia, agranulocytosis, pancytopenia
Mucocutaneous	Pigmentation-blue gray, yellow (QE), rashes (urticaria, morbilliform, lichenoid, exfoliative dermatitis, AGEP) pruritus, worsening psoriasis
Ophthalmologic	Neuromuscular eye toxicity (diplopia, blurred vision, loss of accommodation), corneal deposits (halos around lights, photophobia), retinopathy (premaculopathy-reversible and true retinopathy-irreversible; not seen with QE therapy)
Neuromuscular	Nightmares, vertigo, tinnitus, nervousness, irritability, toxic psychosis, seizures, neuromyotoxicity, myasthenia-like syndrome, ototoxicity
High doses	Cardiovascular toxicities, hypotension, neurotoxicity, respiratory or cardiac arrest, death

NOTE: AGEP, acute generalized exanthematous pustulosis; G6PD, glucose-6-phosphate dehydrogenase.

TABLE 255-3 **Possible Side Effects from Antimalarial Compounds**

At therapeutic doses gastrointestinal complaints of anorexia, nausea, vomiting, diarrhea, and weight loss are most commonly encountered (10 percent for HCQ; 20 percent for CQ; 30 percent for QE). [39] Nightmares are also reported. Acute symptoms from high doses of CQ and HCQ include blurred vision, cardiovascular toxicities, hypotension, neurotoxicity, and respiratory or cardiac arrest. [4], [5] As little as 0.75 g in children and 2.25 to 3.0 g in adults of CQ can be fatal, with a direct action on the myocardium as the cause of death. Lethal doses of HCQ are considered to be in the similar range. [4], [5] Management of overdose consists of gastric lavage, ventilation, and inotropic support. [4], [5] A lethal dose of QE has not been determined.

Hematologic effects can be seen with antimalarial therapy. Patients with glucose-6-phosphate dehydrogenase (G6PD) deficiencies are susceptible to CQ- and HCQ-induced hemolytic anemia, although rarely when the drugs are used in therapeutic ranges. Aplastic anemia, agranulocytosis, neutropenia, and thrombocytopenia are rare, potentially fatal, adverse reactions. [4], [5]

Cutaneous adverse effects occur with antimalarial therapy, including the exacerbation of preexisting psoriasis. It is estimated that up to 18 percent of patients with psoriasis develop an exacerbation of their disease while on antimalarial therapy. [40] One review of the literature suggested that CQ was responsible for most psoriatic flare-ups, QE was more likely to induce exfoliative erythroderma, and HCQ was much less likely to exacerbate psoriasis. [41] These same authors concluded that the use of antimalarial drugs in patients with psoriasis was associated with a 31 percent risk of severe cutaneous reaction. In the general population, the incidence of pruritus and rashes secondary to antimalarial use is reported to be 10 to 20 percent, [42] although this rate may be an overestimate. Dose-related QE-induced drug eruptions were reported during World War II. One in 2000 soldiers taking QE, 100 mg qd, reported a reaction, whereas 1 in 600 soldiers taking 200 mg qd had a cutaneous reaction. Lichenoid reactions accounted for approximately 20 percent of the reactions in this series. CQ has an affinity for melanin and thus concentrates in the skin. The binding of drug molecules to melanin may cause a blue-black discoloration of the skin in 10 to 25 percent of patients treated with these compounds

for a prolonged course. The shins, face, hard palate, and nail beds are commonly affected. [43] The discoloration may fade slowly over months after the drug is discontinued. QE also binds melanin and may cause hyperpigmentation similar to that seen with CQ. More commonly, a dose-related yellowish staining occurs and affects the skin, sclera, and bodily secretions. This discoloration also tends to fade over time after drug withdrawal.

Ocular toxicity is the most worrisome side effect of antimalarial therapy. Neuromuscular eye toxicity, corneal deposits, and potentially irreversible retinopathy can all occur. During the initial weeks of therapy blurred vision and reduction in accommodation power can occur from the depressive effect on ocular muscles; this effect is transient and typically self-limited. CQ is deposited in the basal epithelium of the cornea. Deposition of HCQ can also occur, but is less likely at therapeutic doses. [44] These depositions can be responsible for patient complaints of blurred vision, halos around lights, and photophobia. [45] The corneal deposits are dose related, reversible with cessation of therapy, and not a contraindication for continued therapy. CQ has an affinity for retinal pigment epithelium and can be stored there for years, even after discontinuation of therapy. Retinopathy induced by antimalarial therapy can be reversible (premaculopathy) or irreversible (true retinopathy). Premaculopathy includes changes of visual fields or funduscopic exam not associated with visual loss, but with potential to progress to irreversible disease if the offending drug is not discontinued. True retinopathy is associated with bilateral, permanent visual field abnormalities. The risk of true retinopathy from antimalarial therapy has been studied and debated, but it is generally accepted that the risk of retinopathy is greater for CQ than HCQ. [44] Doses considered to be safe for preventing retinopathy are less than 4.0 mg/kg per day for CQ and less than 6.5 mg/kg per day for HCQ. [46] Higher doses and impaired renal function may contribute to the risk of retinopathy. As HCQ-induced retinopathy is felt to be quite rare, screening as a cost-effective measure is questioned. Current American guidelines include a baseline slit lamp, funduscopic, visual field, and acuity examination by an ophthalmologist every 6 months for a year, and then yearly. The patient should also self-administer the Amsler grid test each month and report changes. [47] More recent Canadian and British guidelines are less stringent. [48], [49] QE does not appear to cause retinal toxicity. Other less likely side effects of antimalarial therapy include neuromyotoxicity [50] and myasthenia-like syndrome, [51] ototoxicity, [52] and acute generalized exanthematous pustulosis (AGEP). [53]

Drug interactions with antimalarial agents are few. Penicillamine or digoxin levels may be increased with concurrent use of CQ or HCQ. [4], [5] Cyclosporine levels may be increased by CQ, [4] and metoprolol levels by HCQ. [54] CQ may reduce the bioavailability of ampicillin. [4] Antacids and kaolin may decrease the gastrointestinal absorption of CQ, and their administration should be separated by at least 4 h. [4] Cimetidine may increase CQ levels, [4] raising the potential for other side effects. The concurrent use of CQ and mefloquine may increase the risk of seizures. Hepatotoxic drugs taken with CQ increase the risk of hepatotoxicity. [4] Finally, smoking may alter the bioavailability of antimalarial therapy by inducing the cytochrome P450 enzyme system; a report of decreased efficacy of antimalarial therapy in smokers has been published. [55]

In conclusion, antimalarial drugs are useful therapeutic anti-inflammatory agents that are well established in the dermatologic armamentarium. Although these drugs are typically well tolerated, the risk of ocular toxicity and irreversible retinopathy warrant judicious monitoring and use. For many dermatologic conditions, the benefits of therapy significantly outweigh the risks.

REFERENCES

1. Hofheinz W, Merkli B: Quinine and quinine analogues, in *Antimalarial Drugs II: Current Antimalarials and New Drug Development,* edited by W Peters, WHG Richards. New York, Springer-Verlag, 1984, p 61

2. Payne JF: A post-graduate lecture on lupus erythematosus. *Clin J* **4**:223, 1894

3. Page F: Treatment of lupus erythematosus with mepacrine. *Lancet* **2**:755, 1951

4. United States Pharmacopeial Convention: Chloroquine, in *Drug Information for the Health Care Professional,* 20th ed. Rockville, MD, United States Pharmacopeial Convention, 2000, p 876

5. United States Pharmacopeial Convention: Hydroxychloroquine, in *Drug Information for the Health Care Professional,* 20th ed. Rockville, MD, United States Pharmacopeial Convention, 2000, p 1735

6. United States Pharmacopeial Convention: Quinacrine, in *Drug Information for the Health Care Professional,* 18th ed. Rockville, MD, United States Pharmacopeial Convention, 1998, p 2469

7. Griffin JP: Drug interactions with antimalarial agents. *Adverse Drug React Toxicol Rev* **18**:25, 1999

8. Sullivan DJ et al: On the molecular mechanism of chloroquine's antimalarial action. *Proc Natl Acad Sci USA* **93**:11865, 1996

9. Sams WM, Carroll NV: The “spectral shift” phenomenon of chloroquine . *Arch Dermatol* **93**:123, 1966

10. McChesney EW et al: Rationale for the treatment of lupus erythematosus with antimalarials. *J Invest Dermatol* **29**:97, 1957

11. Cahn MM et al: Polymorphous light ruption—the effect of chloroquine phosphate in modifying reactions to ultraviolet light. *J Invest Dermatol* **26**:201, 1956

12. Homewood CA et al: Lysosomes, pH and the antimalarial action of chloroquine. *Nature* **235**:50, 1972

13. Ward PA: The chemosuppression of chemotaxis. *J Exp Med* **7**:302, 1964

14. Van den Borne BE et al: Chloroquine and hydroxychloroquine equally affect tumor necrosis factor-alpha, interleukin 6, and interferon-gamma production by peripheral blood mononuclear cells. *J Rheumatol* **24**:55, 1997

15. Fox R: Anti-malarial drugs: Possible mechanisms of action in autoimmune disease and prospects for drug development. *Lupus* **5**(Suppl

1):S4, 1996

16. Goldman FD et al: Hydroxychloroquine inhibits calcium signals in T cells: A new mechanism to explain its immunomodulatory properties. *Blood* **95**:3460, 2000

17. Strekowski L et al: Structure activity relationship analysis of substituted 4-quinolinamines, antagonists of immunostimulatory cpG-oligodeoxynucleotides. *Bioorg Med Chem* **9**:1819, 1999

18. Kurnick NB, Radcliffe IE: Reaction between DNA and quinacrine and other anti-malarials. *J Lab Clin Med* **60**:669, 1962

19. Cohen SN, Yielding KL: Stabilization of the structure of native DNA by chloroquine and observations on the nature of the chloroquine-DNA complex. *Arthritis Rheum* **6**:767, 1963

20. Dubois EL: Antimalarials in the management of discoid and systemic lupus erythematosus. *Semin Arthritis Rheum* **8**:33, 1978

21. Kraak JH et al: The value of hydroxychloroquine (Plaquenil) for treatment of chronic discoid lupus erythematosus: A double-blind trial. *Dermatologica* **130**:293, 1965

22. Wallace DJ: The use of quinacrine (Atabrine) in rheumatic diseases: A reexamination. *Semin Arthritis Rheum* **18**:282, 1989

23. The Canadian Hydroxychloroquine Study Group: A randomized study of the effect of withdrawing hydroxychloroquine sulfate in systemic lupus erythematosus. *N Engl J Med* **324**:150, 1991

24. London ID: Porphyria cutanea tarda: Report of a case successfully treated with chloroquine. *Arch Dermatol* **75**:801, 1957

25. Chinarro S et al: Studies on “in vitro” formation of complexes between porphyrins and chloroquine. *Biochem Int* **6**:565, 1983

26. Cripps DJ, Curtis AC: Toxic effect of chloroquine on porphyria hepatica. *Arch Dermatol* **86**:575, 1962

27. Swanbeck G, Wennersten G: Treatment of porphyria cutanea tarda with chloroquine and phlebotomy. *Br J Dermatol* **97**:77, 1977

28. Noris P et al: The role of interleukins 1, 6, and 8 as lymphocyte attractants in the photodermatoses polymorphic light eruption and chronic actinic dermatitis. *Clin Exp Dermatol* **24**:321, 1999

29. Murphy GM, Hawk JLM, Magnus IA: Hydroxychloroquine in polymorphic light eruption. A controlled trial with drug and visual sensitivity monitoring. *Br J Dermatol* **116**:379, 1987

30. Zic JA et al: Treatment of cutaneous sarcoidosis with chloroquine: Review of the literature. *Arch Dermatol* **127**:1034, 1991

31. Markowitz HA, McGinley JM: Chloroquine poisoning in a child. *JAMA* **189**:950, 1964

32. Ziering CL et al: Antimalarials for children. Indications, toxicities, and guidelines. *J Am Acad Dermatol* **28**:764, 1993

33. Lewis R et al: Malaria associated with pregnancy. *Obstet Gynecol* **42**:696, 1973

34. Levy M et al: Pregnancy outcome following first trimester exposure to chloroquine. *Am J Perinatol* **8**:174, 1991

35. Buchanan NMM et al: The safety of hydroxychloroquine in lupus pregnancy: Review of a series of 36 cases. *Ann Rheum Dis* **55**:486, 1996

36. Khamashta MA et al: The use of hydroxychloroquine in lupus pregnancy: The British experience. *Lupus* **5**(Suppl 1):S65, 1996

37. Parke AL, Rothfield NF: Antimalarial drugs in pregnancy: The North American experience. *Lupus* **5**(Suppl 1):S67, 1996

38. Parke AL. Antimalarial drugs, pregnancy and lactation. *Lupus* **2**(Suppl 1):S21, 1993

39. Wallace DJ: Antimalarial drugs. *Rheum Dis Clin North Am* **20**:243, 1994

40. Wolf R, Ruocco V: Triggered psoriasis. *Adv Exp Med Biol* **445**:221, 1999

41. Slagel GA, James WD: Plaquenil-induced erythroderma. *J Am Acad Dermatol* **12**:857, 1985

42. Wintroub BU, Stern R: Cutaneous drug reactions. Pathogenesis and clinical classification. *J Am Acad Dermatol* **13**:167, 1985

43. Granstein RD, Sober AJ: Drug-and heavy metal-induced hyperpigmentation. *J Am Acad Dermatol* **5**:1, 1981

44. Easterbrook M: An ophthalmological view on the efficacy and safety of chloroquine versus hydroxychloroquine. *J Rheumatol* **26**:1866, 1999

45. Hobbs RF, Calnan CD: Visual disturbances with anti-malarial drugs with particular reference to chloroquine keratopathy. *Arch Dermatol* **80**:557, 1959

46. Mackenzie AH: Dose refinements in long term therapy of rheumatoid arthritis with antimalarials. *Am J Med* **75**(1A):40, 1983

47. Rynes RI, Bernstein HN: Ophthalmic safety profile of antimalarial drugs. *Lupus* **2**(Suppl 1):S17, 1993

48. Easterbrook M: Screening for antimalarial toxicity [editorial]. *Can J Ophthalmol* **28**:51, 1993

49. Jones SK: Ocular toxicity and hydroxychloroquine: guidelines for screening. *Br J Dermatol* **140**:3, 1999

50. Stein M et al: Hydroxychloroquine neuromyotoxicity. *J Rheumatol* **27**:2927, 2000

51. Sghirlanzoni A et al: Chloroquine myopathy and myasthenia-like syndrome. *Muscle Nerve* **11**:114, 1988

52. Seckin U et al: Hydroxychloroquine ototoxicity in a patient with rheumatoid arthritis. *Rheumatol Int* **19**:203, 2000

53. Assier-Bonnet H et al: Acute generalized exanthematous pustulosis induced by hydroxychloroquine. *Dermatology* **193**:70, 1996

54. Somer M et al: Influence of hydroxychloroquine on the bioavailability of oral metoprolol. *Br J Clin Pharmacol* **49**:549, 2000

55. Rahman P et al: Smoking interferes with efficacy of antimalarial therapy in cutaneous lupus. *J Rheumatol* **25**:1716, 1998

T>

Chapter 256

Christopher Cassetty Jerome Shupack Ken Washenik

Cytotoxic and Antimetabolic Agents

ANTIMETABOLIC AGENTS

Methotrexate

Thiopurines

ALKYLATING AGENTS

Cyclophosphamide

Chlorambucil

Anthracyclines

REFERENCES

Cytotoxic and antimetabolic agents can often control skin disease that is otherwise refractory to topical therapy. Discussion in this chapter focuses on the agents clinically relevant to practicing dermatologists. Most of the drugs discussed in this chapter are used by dermatologists at immunomodulatory rather than cytotoxic doses. Despite widespread use of these drugs to treat dermatologic disease, none of the drugs discussed here, except methotrexate, is approved by the FDA for the treatment of inflammatory dermatoses.

Systemic cytotoxic and antimetabolic drugs can be used to modulate the behavior of inflammatory cells. These agents exert their effects primarily through the inhibition of cell proliferation. Depending on the dose, their action can range from modulation of cellular activity to induction of apoptosis or cell death. An understanding of the mechanisms of action, toxicities, and clinical effects of these drugs is essential for optimal use.

The cell cycle is the sequence of growth phases on which all cells of the body depend. The cycle begins with the G_1 phase, in which cell metabolism is directed toward preparing for DNA synthesis. The S phase, which follows G_1, is devoted to DNA synthesis. At the end of DNA synthesis, the G_2 phase occurs. The G_2 phase is followed by the M phase, cell division. Cells may also enter a resting state of variable length, termed G_0, from either the G_1 or the G_2 phase (Fig. 256-1; see Chap. 7). Cytotoxic drugs are effective at specific stages of the cell cycle (e.g., methotrexate in the S phase).

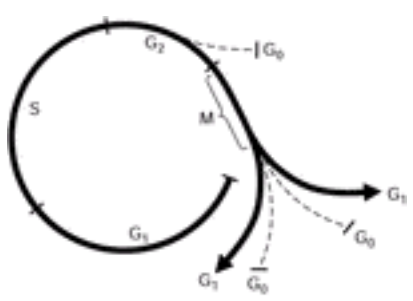

FIGURE 256-1 Diagram of the cell cycle.

Most systemic cytotoxic drugs that are useful in dermatology fall into two broad groups, the antimetabolites and the alkylating agents. Antimetabolites mimic natural molecules and are most active while DNA is being synthesized in the S phase. [1] These drugs require a target cell population that is proliferating in order to exert their effect. A corollary of this principle is that side effects of this class of drugs are most prominent in cells of the body that have an innately high proliferative index, such as visceral epithelium and bone marrow. Alkylating agents exert their effects through an actual physicochemical interaction with preformed DNA molecules. [1] These interactions include alkylation, cross-linking, and carbamylation. Alkylating agents affect not only proliferating populations of cells but also cells that are not actively synthesizing DNA. Their adverse effects are not limited to proliferating cell populations, and they have a greater potential for mutagenicity.

The immunosuppressive potency of cytotoxic drugs has benefits and risks. Dramatic clinical improvement is a major benefit, but infections of lethal proportion may arise quickly and quietly in immunosuppressed patients. Patients should be assessed at each visit for symptoms of infection, including fever, chills, sweats, shortness of breath, cough, headache, dysuria, and arthritis; and they should be instructed to report any new symptoms promptly.

ANTIMETABOLIC AGENTS

Methotrexate

Aminopterin, a folate antagonist, was introduced in 1948. It was followed by methotrexate (amethopterin), which remains one of the most commonly used antimetabolic agents. [2] Methotrexate was initially used to treat hematologic malignancies and various epithelial-derived tumors, but it has been used subsequently to treat nonmalignant diseases, including rheumatoid arthritis, asthma, graft-versus-host disease, and cutaneous conditions such as psoriasis, cutaneous T cell lymphoma, and cutaneous sarcoidosis. Dermatologists have used this drug since the early 1960s and have generated an

impressive record of safety with careful monitoring. Despite this safety record, some dermatologists are reluctant to initiate methotrexate therapy. Many concerns can be alleviated through drug awareness, careful patient selection, laboratory monitoring, and the use of folic acid supplementation.

PHARMACOLOGY Methotrexate is a synthetic analogue of folic acid that differs structurally from folate in two regions (Fig. 256-2). The folate vitamins function as 1-carbon carriers and are essential for the synthesis of purines and thymidylic acid, which are required for the production of RNA and DNA, as well as for gene synthesis and cell division (Fig. 256-3). Of the two forms of folate, the polyglutamated form is preferentially retained within cells and is a more efficient cofactor than the monoglutamated form. To be active, these folate cofactors must be reduced to tetrahydrofolate by the enzyme dihydrofolate reductase (DHFR). Methotrexate is a competitive inhibitor of DHFR.

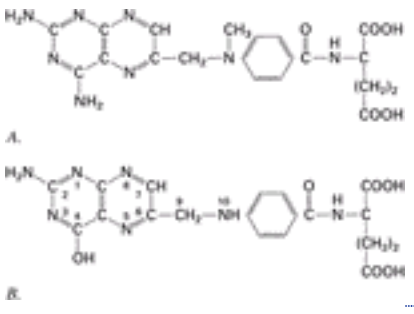

FIGURE 256-2 Chemical structure of methotrexate and folic acid. *A.* Methotrexate. *B.* Folic acid.

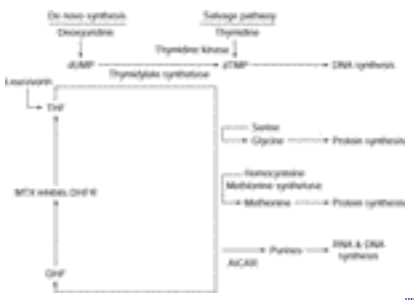

FIGURE 256-3 Contribution of folate to pathways for DNA synthesis. AICAR, 5-aminoimidazole-4-carboxamide ribonucleotide transformylase; DHF, dihydrofolate; DHFR, dihydrofolate reductase; dTMP, deoxythymidine-5-monophosphate; dUMP, deoxyuridine-5-monophosphate; MTX, methotrexate; THF, tetrahydrofolate. (*Modified from Said et al.,* [5] *used by permission of Elsevier Science Inc.*)

Oral methotrexate is variably absorbed at higher dose concentrations, and its absorption is influenced by food and milk in children, but not in adults. [3], [4] In adults, mean bioavailability is 67 percent of the administered dose with plasma peaks between 1 and 3 h after the administration of 10 mg/m ^{2}. Divided oral doses of methotrexate (for example, three 5-mg doses separated by 12 h) result in blood levels ranging from 0.17 to 0.5 µg/mL. For doses higher than 25 mg per week, intramuscular administration may be preferable because of erratic oral absorption above this level. [5] Methotrexate blood levels peak approximately 1 to 1.5 h after absorption, and there is low central nervous system penetration. [5] The mean half-life of the drug is approximately 4 to 5 h. [5] The weak organic acid property of methotrexate contributes to its renal elimination; it is excreted 60 to 95 percent unchanged. [6], [7] A decrease in glomerular filtration or tubular secretion can rapidly lead to toxic levels of methotrexate. Various weak organic acids, including aspirin, other nonsteroidal agents, and probenecid, interfere with methotrexate excretion caused by displacement from serum proteins and changes in renal function. Decreased excretion leads to increased drug concentration and increased cytotoxic properties such as leukopenia. Therefore, it is important to follow markers of renal function as toxicity can develop quickly. Biliary excretion accounts for less than 10 percent of methotrexate elimination. [6] Liver metabolism largely contributes to polyglutamated forms of methotrexate that remain in the body longer and may contribute to overall toxicity.
MECHANISM OF ACTION Methotrexate binds to dihydrofolate reductase and competitively and irreversibly inactivates the enzyme. Methotrexate also partially inhibits thymidylate synthetase. [7] Inhibiting these enzymes decreases the available reduced folate and thymidylate necessary for RNA and DNA synthesis during the S phase of the cell cycle (Table 256-1).

Folate antagonisms/decreased cell proliferation
Suppression of inflammatory cell chemotaxis
Inhibition of monocyte/macrophage activation
Inhibition of histamine release from basophils (and mast cells?)
Inhibition of lymphocyte function

TABLE 256-1 **Potential Mechanisms of Methotrexate Activity in Skin Disease**

In psoriasis, the efficacy of methotrexate was initially related to its effect on epidermal cell proliferation. However, in vitro studies demonstrating that methotrexate has a more significant effect on cells of lymphoid origin [8] followed the findings that psoriasis is a T cell–mediated immunologic disease. The activity of methotrexate is enhanced by polyglutamylation, as is the activity of the natural substrate folic acid. These polyglutamated derivatives form rapidly within cells, increase with the concentration of the drug and the duration of exposure, and bind more tightly to dihydrofolate reductase than does unaltered methotrexate. Glutamylation also broadens the spectrum of enzyme inhibition, shown by studies suggesting that methotrexate has other anti-inflammatory properties. [9] First, by inhibiting aminoimidazole carboxamide ribonucleoside (AICAR) transformylase, methotrexate-polyglutamate increases the local tissue concentration of adenosine, which has potent anti-inflammatory properties. Inflammatory exudates from methotrexate-treated mice were found to have higher concentrations of adenosine than inflammatory exudates from saline-treated mice. [9] Second, methotrexate decreases the production of S-adenyl methionine (SAM) by decreasing available tetrahydrofolate and thereby inhibiting methionine synthetase. The enzyme methionine synthetase converts homocysteine to methionine, which is later converted to SAM. The decreased SAM results in decreased inflammation. [9] Consequently, methotrexate produces a greater anti-inflammatory effect than was previously understood. This fact is an important consideration in the design of treatment regimens, adjustment of dosages, and minimization of adverse effects.

CLINICAL USES The largest and most widely accepted dermatologic use for methotrexate in nonneoplastic disease is in the treatment of psoriasis. In 1987, Peckham and colleagues [10] reported that more than half of the dermatologists in the United States use methotrexate to treat severe psoriasis. Methotrexate was second only to ultraviolet (UV) radiation as a treatment modality for severe disease. The use of methotrexate dates from 1951, when it was reported that a patient's psoriasis unexpectedly cleared during treatment with the drug. [2] The 12-h dosing regimen used today was originally based on the cell cycle kinetics of the psoriatic keratinocyte, which runs 36 h versus 311 h in the normal keratinocyte. [11] Although dosing variations of methotrexate were based on response of disease, tolerability of side effects may better explain the use of the divided-dose regimen. [5] Current use of methotrexate to treat psoriasis is most common in patients with severe or refractory plaque-type disease that requires systemic treatment. It is also very useful for erythrodermic and pustular psoriasis, as well as psoriatic arthritis. [12] Other diseases for which methotrexate is beneficial include pityriasis lichenoides et varioliformis acuta, lymphomatoid papulosis, pityriasis rubra pilaris, granulomatous vasculitis, rheumatoid vasculitis, polymyositis, pemphigus vulgaris, lupus erythematosus, pyoderma gangrenosum, Reiter's syndrome, and sarcoidosis. [7] In severe steroid-responsive cutaneous diseases, the concomitant use of a cytotoxic agent such as methotrexate may allow reduction of the systemic dose of the glucocorticoid. The dermatologist must use caution when administering methotrexate to patients with diseases known to affect the kidney, liver, bone marrow, and lungs, as toxicity may be potentiated in these patients.

PATIENT SELECTION Excluding inappropriate patients by careful selection is a priority for the dermatologist initiating methotrexate therapy. The ideal patient has severe skin disease but is otherwise healthy and compliant. Methotrexate is relatively contraindicated for patients with histories of renal or hepatic disease; excessive alcohol use or hepatitis; evidence of laboratory abnormalities in renal, hepatic, or hematologic function; and those wishing to conceive children. [13] Geriatric patients are less than optimal because of the decrement in renal function that occurs as part of the aging process. Administration of the drug to pregnant women or nursing mothers is absolutely contraindicated. [13] Conception should be avoided during treatment and afterward for at least 3 months in males and one ovulatory cycle in females. [13] The question of whether HIV+ individuals with psoriasis can be safely treated with methotrexate is still unsettled. Published reports reveal varying rates of opportunistic infection in HIV+ patients treated with a range of doses of methotrexate for psoriasis. [14] Methotrexate in low doses may be tolerated by some HIV+ individuals for whom other psoriasis therapies have failed. Careful laboratory monitoring for HIV status and methotrexate toxicity is mandatory as is avoidance of concomitant medications, such as trimethoprim-sulfamethoxazole, that alter methotrexate metabolism. However, with the theoretical possibility of added immunosuppression by methotrexate in HIV+ patients, the authors recommend that first-line systemic treatment for these patients should be a nonimmunosuppressive agent such as a retinoid (e.g., acitretin). Attention to detail is critical when caring for patients receiving methotrexate. Such attention includes regular follow-up, detailed review of systems at each visit, monitoring of appropriate laboratory parameters (Table 256-2), tracking of cumulative methotrexate dosing, and communication with the patient's general physician when appropriate. Laboratory examinations should be performed 5 to 7 days after each dose to ensure normalization of expected increases in liver transaminases before the administration of the next dose. Optimal patient compliance should be promoted by detailed instructions (Table 256-3).

Renal
Urine analysis
Creatinine clearance
BUN/creatinine
Hematopoietic
Complete blood count
Folate level
Hepatic
Transaminase levels
Alkaline phosphatase level
Total bilirubin
Albumin

TABLE 256-2 **Premethotrexate Tests**

1. Follow instructions faithfully.
2. Take methotrexate weekly, not daily.
3. Call your physician immediately if overdose is suspected.
4. Notify your physician if fever, cough, or shortness of breath develops.
5. Tell your physician about all side effects.
6. Inform all of your physicians that you are taking methotrexate.
7. Drink no alcoholic beverages and take no other medications without physician approval.
8. Do not take methotrexate while pregnant or while trying to conceive.
9. Do not take methotrexate if you have an active infection (including but not limited to cold/flu, urinary tract infection, pneumonia) without notifying your physician.
10. Allow no one else to take this medication.

TABLE 256-3 **Instructions for Patients Receiving Methotrexate**

DOSAGE SCHEDULE The effects of methotrexate vary with the dose. Higher doses are more directly cytotoxic. High oncologic doses of methotrexate (for example, 100 to 250 mg/m ^{2} per week) depress the antibody response to common antigens, whereas lower doses suppress rheumatoid factor production. Low immunomodulating doses of methotrexate (for example, 7.5 to 15 mg/week) also suppress the division of mononuclear cells, inhibit the cellular response to interleukin-1, suppress neutrophil and monocyte chemotaxis in vitro and in vivo, and depress Langerhans cell activity and leukotriene B_4 synthesis by neutrophils. [9], [15] Dosages in dermatologic use are usually less than 30 mg per week. Dermatologists most often prescribe methotrexate for oral dosing in one of two regimens: a single dose weekly or a weekly dose divided into three portions, each separated by 12 h. Beginning therapy with the administration of a small test dose is a common practice that is included in the most recent guidelines. [13] Patients deemed to be appropriate candidates on the basis of disease severity, general health, and personal habits, and whose baseline laboratory results are acceptable may be started on a test dose of 5 to 10 mg orally. The patient should return in 1 week for repeat laboratory tests [complete blood count (CBC), plus differential, blood urea nitrogen (BUN)/creatinine (Cr), liver enzymes], a skin examination, and a review of systems. Weekly therapy may be continued at a therapeutic dose of 7.5 to 15 mg per week in a single dose or in divided doses. If a patient does not achieve a sufficient clinical response, the dose can be increased slowly by 2.5 to 5 mg per week until adequate control is achieved. Concomitant topical therapy is usually helpful and can minimize the methotrexate dose needed to provide satisfactory disease control. Patients continue periodic visits until their disease is quiescent and their drug dosage is stable (usually 2 to 3 months). Patients are followed monthly for laboratory safety monitoring and drug effectiveness, unless dose increases require more frequent monitoring. When improvement has stabilized, the dose can be tapered to the point where the disease activity increases slightly. The goal of therapy should allow some mild disease activity to avoid using a dose that is too high. In some

cases, the drug may be discontinued entirely and mild recurrences treated with topical medications. If a patient does not demonstrate acceptable improvement on a dose of 20 to 25 mg per week, consideration should be given to switching to another drug. Occasional patients with refractory disease respond better to parenteral methotrexate, usually intramuscular. In refractory cases, combining methotrexate with UVB phototherapy can enhance therapeutic efficacy without significantly increasing toxicity.

ADVERSE EFFECTS There is a large collected experience in the rheumatologic and dermatologic literature regarding the toxicity of low-dose methotrexate. [13], [16] Adverse reactions (Table 256-4) may be life-threatening or trivial. Several principles regarding the side effects of methotrexate are generally applicable. First, as with many drugs, higher doses cause more side effects. Second, patients who experience side effects early in therapy will probably continue to do so, whereas patients who are free of early complaints may be more likely to remain so during long-term treatment. Third, sicker, older, or more debilitated patients seem to experience more problems than do patients who are in good health. Finally, the use of divided drug dosing is often helpful in reducing side effects (e.g., nausea), likely a result of decreased peak levels. Toxicity can develop with either the single- or the three-dose regimens.

Gastrointestinal: nausea, vomiting, stomatitis, diarrhea, ulceration
Hepatic: abnormal transaminase levels, hepatitis, fibrosis, cirrhosis
Hematopoietic: anemia, thrombocytopenia, leukopenia, pancytopenia
Pulmonary: acute hypersensitivity, fibrosis
Systemic: anaphylaxis

TABLE 256-4 **Adverse Reactions to Methotrexate**

The most common complaints of patients being treated with methotrexate involve the gastrointestinal tract, particularly nausea and vomiting, and these are largely dose related. [13], [16] These side effects can also occur with intramuscular injection. Indeed, 10 to 30 percent of all patients experience some difficulty taking methotrexate. Because some patients experience symptoms before a dose, or even 24 to 36 h after a dose, it has been suggested that these symptoms may have a psychological or centrally active basis. [17], [18] Mucocutaneous complaints are not uncommon. Oral ulcerations and soreness are most often noted. Skin ulcerations are much less frequent and may herald bone marrow toxicity. The authors recommend laboratory evaluations (e.g., CBC, BUN/Cr, liver enzymes) and dosage reduction or discontinuation with mucocutaneous ulcerations. A major limitation of methotrexate therapy is the induction of liver fibrosis. [6], [16], [19], [20] and [21] Methotrexate is a hepatotoxic drug, and elevations in liver enzymes commonly occur in patients taking the drug. Although disquieting, these elevations are of limited value in predicting which patients will develop cirrhosis. For unknown reasons, patients with psoriasis seem to have a higher incidence of liver fibrosis than do patients with rheumatoid arthritis who are treated with similar methotrexate regimens. [13] Fibrosis relates to the duration of therapy, total dose, patient age, and comorbid risk factors. Between 0 and 26 percent of patients receiving methotrexate have demonstrated cirrhotic changes on liver biopsy. [6] A somewhat larger number may show fatty infiltration and a clinically less significant or insignificant fibrosis. [6] The course of methotrexate-induced liver disease is thought to be relatively nonaggressive and, depending on the normalization of liver enzyme levels in the blood, can be continued in some patients. [20] Low-risk patients receiving total doses of less than 1.5 g have a negligible incidence of fibrosis. [6] Patients with prior liver disease, diabetes, obesity, significant alcohol intake, and intravenous drug use are all at increased risk for hepatic fibrosis and cirrhosis. [6] The only acceptable method for verifying methotrexate-induced cirrhosis is percutaneous needle biopsy of the liver. [19] This procedure is usually safe, especially when ultrasound guided. The approximate risk of minor bleeding is 1 in 1000, and the risk of death is estimated as 1 in 10,000. [22] Biopsy results are classified according to liver architecture, degree of inflammation and fibrosis, and the presence of fat, and are graded on a scale of I to IV (Table 256-5). Roenigk and colleagues [13] recommend that patients with grades I and II histology may continue methotrexate therapy, those with grade IIIA histology may continue therapy with a repeat liver biopsy in 6 months, and those with grades IIIB and IV histology should discontinue therapy. According to a study published by Newman and colleagues, [23] 8 of 11 patients with fibrosis or cirrhosis secondary to methotrexate therapy showed meaningful improvement in liver histologic findings after methotrexate treatment had been discontinued for 6 months or more; none had progression of abnormalities.

Grade I	Normal to mild fatty infiltration, portal inflammation, and nuclear variability
Grade II	Moderate to severe fatty infiltration, nuclear variability, portal tract expansion and inflammation, and necrosis
Grade IIIA	Mild fibrosis
Grade IIIB	Moderate to severe fibrosis
Grade IV	Cirrhosis

TABLE 256-5 **Liver Histology Grading Scale**

Perhaps the most important acute adverse effect of methotrexate is the induction of bone marrow suppression. [24], [25] Marrow cells are rapidly proliferating, and they are particularly susceptible to methotrexate. Severe bone marrow suppression caused by low-dose oral methotrexate has been reported. [24] Anemia, neutropenia, and thrombocytopenia, with sepsis and severe bleeding disorders can result. Factors that appear to put patients at increased risk for marrow toxicity include advanced age, low creatinine clearance, and concurrent administration of certain drugs (see " Drug Interactions"). Methotrexate can cause mutations in laboratory animals. However, there has been no associated increase in cancer in patients treated with dermatologic doses of methotrexate. [26], [27] and [28] There was a report of Epstein-Barr virus-associated lymphoma in a patient with psoriasis treated with methotrexate. [29] Because methotrexate is teratogenic and may act as an abortifacient, administration during pregnancy is absolutely contraindicated. [13] There is no apparent effect on the outcome of pregnancies that occur after the discontinuation of methotrexate therapy. [5] There are no reports of abnormal children fathered by men receiving methotrexate therapy, although sperm motility may be abnormal during treatment. [30] However, men treated with methotrexate should wait 3 months after therapy is stopped before attempting conception, and women treated with methotrexate should wait one full menstrual cycle. [13] Pulmonary toxicity (acute pneumonitis and subtle pulmonary fibrosis) has been reported in patients receiving methotrexate therapy for psoriasis. [31] It does not appear to be directly associated with any one risk factor and may be an idiosyncratic reaction. Normal chest radiographs should still be followed up with pulmonary function tests in patients with pulmonary complaints during therapy. Pulmonary toxicity may be related to high-dose regimens more than to cumulative exposure. Withdrawal of therapy is recommended for these patients. [31] Opportunistic infections (pneumocystis pneumonia, cryptococcosis, and histoplasmosis) have been reported in otherwise healthy individuals who are receiving low-dose methotrexate. However,

these patients were often taking a concomitant immunosuppressive medication (e.g., prednisone). [14]

OVERDOSAGE Overdosage is a dangerous side effect that can present in patients with decreased renal function, daily ingestion of methotrexate, or concomitant use of another folate antagonist such as trimethoprim-sulfamethoxazole. Overdosage with methotrexate should be treated promptly with leucovorin (folinic acid). [13] Leucovorin is metabolized in vivo directly to tetrahydrofolate in the absence of dihydrofolate reductase and acts as an antidote to methotrexate overdose by providing a continued supply of thymidine until the methotrexate is cleared from the body. Thymidine is converted to thymidylate by thymidine kinase and thus bypasses the enzyme thymidylate synthetase. This provides the necessary precursors for the synthesis of RNA and DNA. The optimal timing of leucovorin rescue for low-dose methotrexate therapy is critical. [32] An initial dose of 10 mg of folinic acid per square meter (about 20 mg) should be given immediately, either orally or parenterally. An initial oral dose of leucovorin is more beneficial than waiting for intravenous administration. The blood level of methotrexate should be determined every 12 to 24 h, and repeat doses of leucovorin should be given every 6 h on the basis of drug level (Table 256-6). If creatinine clearance decreases by 50 percent, then 100 mg/m ^{2} should be given every 3 h. Leucovorin administration should continue until the level of serum methotrexate falls below 10 $^{-8}$ M. [13]

Serum Methotrexate Level	Leucovorin Dosage*
0.5×10^{-8} M	20 mg q6h
0.1×10^{-7} M	100 mg q6h
0.2×10^{-7} M	200 mg q6h

*Increase proportionately for higher methotrexate levels.

TABLE 256-6 **Potential Drug Interactions with Methotrexate**

Cases of systemic anaphylaxis caused by low-dose methotrexate have been reported, but anaphylaxis usually occurs in patients on high doses. [33] Many of these patients had previously received uneventful methotrexate treatments at comparable doses.

DRUG INTERACTIONS There are three major groups of drug interactions: the first results from alterations in protein binding, the second from altered renal excretion, and the third from hepatotoxicity. [34] Although any drug that may enhance methotrexate toxicity should be avoided, there are several near-absolute contraindications (Table 256-7).

Mechanism	Drugs
Decreased renal elimination of methotrexate	Nephrotoxins (e.g., aminoglycosides, cyclosporine)
	Many nonsteroidal anti-inflammatory agents
	Sulfonamides*
	Probenecid
	Salicylates
	Penicillins
	Colchicine
	Cisplatin and all renal-toxic drugs*
Additive or synergistic toxicity	Trimethoprim-sulfamethoxazole*
	Ethanol
	Pyrimethamine
Displacement of methotrexate from protein binding	Salicylates
	Probenecid
	Barbiturates
	Phenytoin
	Retinoids
	Sulfonamides*
	Sulfonylureas
	Tetracyclines
Intracellular accumulation of methotrexate	Thyroid hormones
Hepatotoxicity	Retinoids
	Ethanol*
Other	Allopurinol

*Other absolute contraindications.

Source: Modified from Hoekzema et al.,[a] used by permission of Mosby Publishing. For a more complete list, see From and Christensen.[b]

TABLE 256-7 **Leucovorin Treatment of Methotrexate Overdosage**

EVIDENCE-BASED MEDICINE Two questions continue to arise about methotrexate use. First, when should liver biopsies be performed? Second, should folic acid supplementation be given routinely to patients on methotrexate? Roenigk and associates, [13] in a consensus conference, recommend that a liver biopsy be performed after administration of the first 1 to 1.5 g of methotrexate in patients with no risk factors, and at or near the beginning of treatment in patients with risk factors. Waiting 2 to 4 months after initiating therapy may decrease the need for liver biopsy in patients who may not require or tolerate long-term therapy. It is recommended that once patients reach 1.5 g of methotrexate, a liver biopsy should be performed with a repeat biopsy at 3 g, and then every 1 to 1.5 g thereafter. Because normal liver function tests and routine ultrasound may not indicate the presence of liver changes, Zachariae [35] proposes the use of newer techniques to identify those patients who would benefit from liver biopsy to identify hepatotoxicity. One method is radioimmunoassay of the amino-terminal propeptide of type III procollagen (PIIINP). PIIINP is produced by the liver during fibrogenesis, but it is also found in other tissues and is increased in patients with psoriatic arthritis. The proposed use is for serial testing at 3-month intervals to detect active fibrogenesis. Another method is dynamic hepatic scintigraphy (DHS), which monitors the portal contribution of blood flow to the liver. Combining these tests with patient history and appropriate laboratory monitoring may lead eventually to a decreased number of liver biopsies. [35] However, these tests are not currently accepted as substitutes for liver biopsy. Folic acid supplementation in patients on methotrexate has received much attention recently, mostly as it relates to use in patients with rheumatoid arthritis. Folic acid enters cells by active transport, without competing with methotrexate, but methotrexate does compete with folinic acid. [17] Folic acid supplementation from 1 mg per day up to a weekly ratio of 3:1 to methotrexate reduced side effects such as nausea, vomiting, stomatitis, elevated liver transaminase levels, and mild myelosuppression without reducing efficacy of methotrexate. Although folinic acid appeared to reduce these side effects, it also decreased the efficacy of methotrexate. [17] Side effects such as liver fibrosis, cirrhosis, pneumonitis, and moderate myelosuppression did not seem affected by folate supplementation. However, folic acid supplementation also decreased the associated increase in homocysteine levels found in patients taking methotrexate. [36] Homocysteine is elevated when folate levels are decreased, because folate is needed to convert homocysteine to methionine. Elevated homocysteine levels are independent risk factors for cardiovascular disease. [36] A drawback to folate supplementation is the potential masking of vitamin B_{12} deficiency macrocytosis in red blood cells. Some patients tolerate methotrexate without supplementation. Other patients may benefit from a trial of folic acid supplementation, if side effects result in the consideration of discontinuation of treatment. Clear guidelines for folate supplementation have not been established.

Thiopurines

AZATHIOPRINE The thiopurine drugs are synthetic analogues of the natural purine bases. They were first synthesized in the 1950s, and many derivatives have subsequently been produced. Azathioprine is the derivative most commonly used in dermatology.

Pharmacology Azathioprine was first developed as a prodrug of 6-mercaptopurine with better bioavailability than that of 6-mercaptopurine alone (Fig. 256-4). Azathioprine and 6-mercaptopurine are equally potent when administered

parenterally, but 6-mercaptopurine is much-less effective when given by mouth. Azathioprine absorption after oral administration is fairly complete. [37]

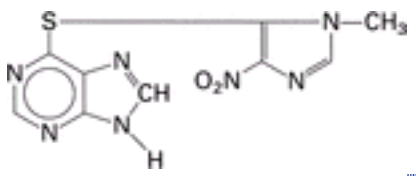

FIGURE 256-4 Chemical structure of azathioprine.

Mechanism of action The clinical activity of all the thiopurine drugs is believed to stem from the inhibition of RNA and DNA synthesis and function. Three specific enzymes are involved in the metabolism of azathioprine: hypoxanthine-guanine phosphoribosyl transferase (HGPRT); xanthine oxidase (XO); and thiopurine methyltransferase (TPMT). [38] Azathioprine is a prodrug that is metabolized to 6-mercaptopurine, which is then converted to active analogues by HGPRT. These monophosphate nucleotide analogues, including 6-thioguanine, block purine synthesis at the initial step. Triphosphorylated 6-mercaptopurine is also incorporated into DNA, rendering the molecule susceptible to strand breaks and point mutations. Patients with Lesch-Nyhan syndrome (HGPRT deficiency) and certain tumor cells that lack HGPRT are resistant to the cytotoxic effects of azathioprine. [39] 6-Mercaptopurine also undergoes oxidations to inactive metabolites by XO. Concomitant administration of allopurinol should be avoided as it may lead to the accumulation of toxic metabolites through the inhibition of XO. Through S-methylation, TPMT is another enzyme involved in the catabolism of 6-mercaptopurine to inactive metabolites. Variations among patients in the activity of TPMT affect the efficacy of drug administration, therapeutic dosage, and amount of toxicity experienced. The TPMT gene is autosomal codominant in inheritance with high activity in approximately 89 percent of individuals, intermediate activity in 11 percent, and low activity in less than 1 percent (1 in 300). [40] TPMT is essential in the metabolism of the active metabolite 6-thioguanine. Thus, genetic polymorphism may contribute to excessive myelosuppression in some patients treated with azathioprine.

Clinical uses The immunopathology of the pemphigus group of diseases makes immunosuppressive drugs a logical therapeutic choice. In 1969, Wolff and Schriener [41] reported the successful treatment of pemphigus with azathioprine. Although the drug may be used as a monotherapy, it is most commonly used as an adjunct to steroid treatment. In a prospective long-term study of patients with pemphigus who were treated with glucocorticoids and azathioprine, 45 percent achieved apparent remission. [42] The starting dose of azathioprine was 2 to 3 mg/kg per day combined with 80 to 200 mg per day of methylprednisolone. The glucocorticoid was maintained for several months, then tapered, and eventually discontinued. The onset of therapeutic effect of azathioprine in pemphigus is delayed by up to several weeks. Other bullous diseases respond to azathioprine. Case reports endorse the use of the drug for steroid-resistant bullous pemphigoid. [43] Treatment regimens are similar to those used for patients with pemphigus. The addition of cytotoxic drugs to glucocorticoid therapy has greatly increased the survival of patients with systemic vasculitis. [44] Cyclophosphamide is the cytotoxic drug of choice for this application because azathioprine seems more able to maintain a remission than to induce one. [44] Azathioprine does not appear to induce gonadal dysfunction, and therefore it is sometimes used in patients who wish to conceive after treatment for their disease. Other inflammatory diseases that have been targets for azathioprine therapy include lupus erythematosus, [45] polymyositis, [46] and various photodermatoses. [47] Because of the differences in azathioprine metabolism among individuals, it may be necessary for researchers and clinicians to consider the genetic polymorphism when evaluating the success or failure of the drug. Any episode of leukopenia in an azathioprine-treated patient may indicate a genetically determined sensitivity to the drug. This occurrence may require a new, lower maintenance dose of azathioprine, or alternatively, the substitution of a different oral agent.

Dosage schedule Azathioprine is supplied as 50-mg tablets and in injectable form. Before therapy begins, baseline blood count, BUN, creatinine, and liver function tests should be performed. Impaired renal function may be associated with greater toxicity even though mercaptopurine metabolites have less activity than the parent drug. During therapy, blood counts and liver function tests should be obtained weekly during the first month, and every 2 or 3 weeks thereafter. Dosage increases require more frequent testing. Azathioprine therapy (1 to 2 mg/kg per day) can be initiated early in the course of disease treatment, usually after the first week or two, if 60 to 80 mg of prednisone has failed to control new blister formation. The addition of azathioprine speeds glucocorticoid tapering without exacerbating the disease.

Adverse effects Azathioprine is generally a safe drug when used with careful monitoring. A comparison of adverse reactions in patients with rheumatoid arthritis treated with methotrexate and those treated with azathioprine failed to reveal significant differences. [48] Adverse effects tend to occur in patients with lower TPMT activity, higher doses of azathioprine, or concomitant use of allopurinol (Table 256-8).

Myelosuppression
Infection
Drug fever
Gastrointestinal
Nausea, vomiting, diarrhea
Hepatitis
Pancreatitis
Induction of malignancy
Shock

TABLE 256-8 **Adverse Reactions to Azathioprine**

Myelosuppression is the major toxic side effect of azathioprine administration. A generalized depression of leukocytes is the most common type of myelosuppression, but any cell line may be exclusively suppressed. Because platelets have the shortest life span of all the formed elements, thrombocytopenia is the most common presentation of toxic marrow suppression. Bone marrow suppression usually occurs only at the higher dosage ranges of dermatologic azathioprine therapy and with lower TPMT activity. [49] Most patients treated with this drug also receive large doses of glucocorticoids as part of their treatment regimen, and therefore it is difficult to assess the exact role of azathioprine in predisposing them to infection. [49] Unlike cyclophosphamide-mediated immune suppression, suppression mediated by azathioprine is not proportional to the peripheral leukocyte count. Rather, the actual function of T cell–mediated immunity and B-cell antibody production is decreased. [39] Thus, infection may occur at normal white blood cell levels. Most commonly, patients receiving high doses of azathioprine may experience nausea, vomiting, and diarrhea. [49], [50] The symptoms are usually not severe and may be minimized by using a divided dose or taking the medication with food. Toxic hepatitis developed in about 1 percent of patients with rheumatoid arthritis who received azathioprine. This hepatitis is characterized by

extremely high alkaline phosphatase levels and is usually reversible. Other reported adverse effects include hepatic venoocclusive disease, pancreatitis, and, infrequently, drug fever. [51], [52] and [53] Discontinuation of therapy is indicated. Azathioprine-induced shock and hypersensitivity-like reactions have also been reported in dermatology patients. [54], [55] In most cases of azathioprine-induced shock, the hypotensive collapse occurred within hours of the first dose. The most recent analysis of patients with rheumatoid arthritis suggests that hematologic malignancies, particularly non-Hodgkin's lymphoma, may be promoted by azathioprine. The relative risk is roughly ten- to thirteenfold, or one lymphoma per 1000 patient years of azathioprine treatment. [56] There is an increased incidence of azathioprine-related lymphoma in renal transplant, Sjögren's syndrome, and rheumatoid populations. [50] In general, dermatologic doses are lower than those used to treat patients with renal or rheumatologic disease. Likewise, the duration of therapy for skin disease is usually shorter. It is the opinion of the authors that the risk of lymphoma is probably significantly less in azathioprine-treated patients with dermatologic disease than in transplant patients or patients with arthritis. Skin cancers were increased in transplant patients. The skin cancers were thought to be related to metabolites of azathioprine imidazoles, which sensitize skin to light and thioguanine. [57] Squamous cell skin cancers were noted in three patients receiving long-term azathioprine therapy for dermatologic disorders. [58] Roubenoff and associates [59] reviewed the incidence of azathioprine-associated birth defects. The rate of congenital malformation is only 4.3 percent. The prevalence of neonatal immunosuppression may be significant. There appears to be no adverse effect on fertility. Azathioprine and its active metabolites readily cross the placenta, and newborns frequently have hematologic abnormalities. [49] Some believe that patients who previously received alkylating agents may have a greatly increased risk for subsequent malignancy after thiopurine therapy. The thiopurines should be avoided in these patients when possible.

Drug interactions The major drug interaction is with allopurinol through the inhibition of xanthine oxidase. This allows toxic metabolites to accumulate and leaves TPMT as the only catabolic reaction for azathioprine metabolism.

Evidence-based medicine Providing the proper dose of azathioprine to treat the disease effectively, while minimizing side effects is often difficult. Armstrong and Oellerich [60] note that a polymerase chain reaction test can screen for all eight of the known TPMT mutations. They report that 6-thioguanine levels measured in erythrocytes correlate well with TPMT activity. However, measuring TPMT activity directly through assays with 6-thioguanine was shown to have flaws as a consequence of contaminants in the thioguanine substrate lots. [61] With this finding, many clinicians will likely delay TPMT testing until patients develop adverse reactions or demonstrate sub-therapeutic responses.

MYCOPHENOLIC ACID AND MYCOPHENOLATE MOFETIL Originally named by Alsberg and Black in 1913, mycophenolic acid (MPA) is a lipid-soluble, weak organic acid that is antifungal, antibacterial, antiviral, and immunosuppressive. [62] MPA was used as an oral agent for the treatment of moderate to severe psoriasis since the early 1970s, but was discontinued because of unwanted side effects. Mycophenolate mofetil (MMF) is a morpholinoester derivative of MPA, with greater bioavailability and immunosuppressive capability. It is also tolerated better than MPA.

Pharmacology MMF is well absorbed after oral ingestion and is quickly converted to MPA, which is then converted to its inactive glucuronide in the liver. The inactive glucuronide lacks the ability to penetrate the cell membranes of most tissue types and is subsequently excreted by the kidneys. Certain tissue types, such as the lining of the gastrointestinal tract and the epidermis, have ß-glucuronidase activity that converts the inactive MPA glucuronide into its active form. MPA can then readily penetrate the eukaryotic cell membrane. [62], [63]

Mechanism of action MPA acts as a noncompetitive inhibitor of the eukaryotic inosine monophosphate dehydrogenases by blocking the conversion of inosine-5-phosphate and xanthine-5-phosphate to guanosine-5-phosphate. By blocking the production of the necessary precursors of DNA and RNA synthesis, MPA interferes with de novo purine biosynthesis. MPA therefore is cytotoxic for cell types that rely predominantly on de novo purine biosynthesis (lymphocytes) rather than the purine salvage pathway. MPA blocks the proliferative responses of T and B lymphocytes and inhibits antibody formation and the generation of cytotoxic T cells. [64] The mechanism by which MPA successfully controls psoriasis is unknown. MPA may act selectively on lymphocytes, the predominant inflammatory cell type in psoriatic lesions. Lymphocytes rely on de novo purine biosynthesis and are susceptible to the action of MPA. Alternatively, MPA may act via direct antiproliferative effects on keratinocytes. A third possibility is that MPA may exert an antiproliferative effect indirectly through the inhibition of cytokine production.

Clinical uses MMF is currently marketed for the prevention of renal allograft rejection but is used off-label as a therapy for psoriasis. MPA has been investigated as an oral agent for the treatment of moderate to severe psoriasis. In a pilot study of MPA in psoriasis, Jones and colleagues [65] demonstrated that it is an effective mode of treatment. This study was then followed by a multicenter, double-blind, placebo-controlled study and by a long-term, follow-up study. These investigations found that MPA was safe and effective at doses ranging from 3000 to 4800 mg/day. Another potential application of MPA is as a steroid-sparing agent, in lieu of azathioprine, in the treatment of dermatologic diseases. Numerous reports suggest MMF improves autoimmune blistering diseases when used in conjunction with oral glucocorticoids, and may act as a steroid-sparing agent. Its anecdotal use has also been reported in pyoderma gangrenosum and systemic vasculitis. [66] MMF has been used to treat rheumatoid arthritis. [67] Topical MPA improved experimental allergic contact dermatitis. [68]

Dosage schedule An MMF dose of 1.3 g to 2 g/day is the presumed effective dose range based on the bioavailability of MMF, which is 43 percent greater than that of MPA (whose dose range was typically 3 to 4.8 g). [62] A recent study with 11 patients found that MMF in doses of 1 g bid was more effective than in doses of 0.5 g bid for treatment of severe psoriasis. [69] Daily doses of 2 g or less of MMF appear to be better tolerated. [69], [70] Monitoring guidelines have not been formally established, but cautious laboratory observation is recommended.

Adverse effects There is a large collection of information detailing the known side effects of MPA. [62], [71] Briefly, MPA has dose-dependent side effects on the gastrointestinal system that decrease dramatically after the first year. There are reports of reversible dose-related bone marrow toxicity, although this complication did not contraindicate therapy. Genitourinary complaints with MPA were common, dose and time-dependent, and without significant nephrotoxicity. [72] Opportunistic infections have not been associated with MPA, and there was not an increased age-adjusted rate of cancer development. [71] MPA is pregnancy category C and its potential teratogenic effect is unknown. MMF is better tolerated and has fewer side effects than MPA. In comparison to azathioprine, MMF acts as a noncompetitive inhibitor of guanine nucleotide synthesis and has not been shown to cause chromosome breaks. Conversely, azathioprine is metabolized into a purine analogue, with the potential of becoming incorporated into DNA, thus causing chromosome breaks with a potential mutagenic risk. [72] MMF is safe for long-term therapy, has no clinically significant hepatotoxicity, and causes less bone marrow toxicity than azathioprine. [73]

Drug interactions Several drug interactions have been studied for MMF and MPA. [66] Antacids containing magnesium and aluminum hydroxide decrease the absorption of MMF, while acyclovir and ganciclovir increase drug levels by competing with MMF for renal tubular secretion. Cholestyramine decreases levels of MPA, possibly through the interruption of enterohepatic recirculation. [66]

THIOGUANINE Elion and Hitchings first described thioguanine, a structural analogue of guanine, in 1955. [74] It is another member of the thiopurine family of drugs, and has a metabolism and mechanism of action similar to those of azathioprine.

Pharmacology Thioguanine is administered orally and has incomplete and unpredictable absorption; there may be more than a tenfold variation in plasma concentrations. Peak levels occur 2 to 4 h after ingestion. Unlike azathioprine and mercaptopurine, thioguanine may be administered concurrently with allopurinol without a dosage reduction.

Mechanism of action Thioguanine is a nucleoside analogue and acts as a prodrug. It generates guanine analogues in the tissues via the action of purine nucleoside phosphorylase. The guanine analogues must undergo enzymatic conversion to the nucleotide to display cytotoxic activity by incorporating thioguanine into cellular DNA. According to one study, the mechanism of action appears to be the induction of apoptosis in activated T lymphocytes. [75] The number of T lymphocytes in skin lesions is decreased, while levels of overall circulating leukocytes remain near normal. Contrary to previous theories about the association of clinical response with decreased total leukocytes counts, Murphy and colleagues [75] found that clinical response was more closely related to decreased T lymphocyte counts in psoriatic skin lesions.

Clinical uses The predominant dermatologic use of thioguanine is for the treatment of psoriasis, particularly in patients who have failed other systemic therapies or who have a contraindication to other systemic therapies such as liver disease. [75], [76] In a recent retrospective study of patients with recalcitrant psoriasis, 14 of 18 patients had greater than 90 percent improvement with thioguanine, including patients with psoriatic arthritis, as well as palm, sole, and scalp involvement. [77] When Zackheim and colleagues [76] treated 81 patients with psoriasis with thioguanine, they found that 49 percent of the patients with plaques were effectively maintained with 6-thioguanine for a median of 33 months and that 4 of 5 patients with palmoplantar pustular psoriasis experienced a substantial benefit. Thioguanine is also used to treat acute granulocytic leukemia, acute lymphocytic leukemia, and chronic granulocytic leukemia.

Dosage schedule Thioguanine is supplied in 40-mg tablets. Treatment can be initiated at a dose of 40 mg/day, with close monitoring for signs of bone marrow depression. After 1 month, if the clinical response is inadequate, the dose may be increased to 80 to 120 mg/day. At the higher doses, significant bone marrow suppression often occurs. Pulse dosing is another reportedly effective treatment option, beginning at doses of 80 mg to 100 mg twice weekly, and increasing as necessary up to 160 mg three times per week. [78]

Adverse effects Adverse effects of thioguanine include bone marrow depression and gastrointestinal disturbances. A toxic hepatic venoocclusive disease also has been described in association with 6-thioguanine therapy for psoriasis. [75], [79] Frequent hematologic monitoring is important in patients treated with thioguanine. Pulse dosing of thioguanine may be a way to decrease side effects.

HYDROXYUREA Hydroxyurea was discovered in 1869, but its effectiveness in the treatment of psoriasis was not appreciated until 100 years later. [80] Outside of dermatology, it is primarily used in the treatment of hematologic malignancies.

Pharmacology Hydroxyurea is well absorbed after oral administration. Its serum level peaks within 2 h, and its cerebrospinal fluid level peaks within 3 h. [81] Eighty percent of an oral dose can be recovered in the urine after 12 h, and at 24 h levels are negligible.

Mechanism of action Hydroxyurea is a low-molecular-weight drug that causes immediate inhibition of DNA synthesis (Fig. 256-5). The drug inhibits ribonucleotide diphosphate reductase, which converts ribonucleotides to their deoxy form. Inhibiting this enzyme limits the supply of DNA bases and thereby decreases the rate of DNA synthesis. Strand breakage and cell death result. Hydroxyurea also prevents cells from repairing damage from ultraviolet and ionizing radiation, thereby acting as a radiosensitizer. [82] Finally, hydroxyurea causes hypomethylation of the fetal hemoglobin gene, a benefit to patients with sickle cell disease. This hypomethylation is also thought to lead to normalization of psoriatic skin by inducing differentiation. Hydroxyurea is most active in cells with a high proliferative index, and exists in higher concentrations in leukocytes than in erythrocytes. [81], [83], [84]

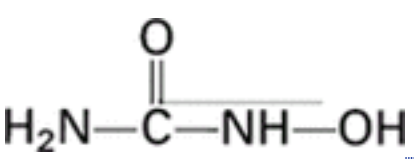

FIGURE 256-5 Chemical structure of hydroxyurea.

Clinical uses The major dermatologic use of hydroxyurea is for the treatment of psoriasis. In 1970, Leavell and Yarbro [83] found in a double-blind study that 9 of 10 patients with severe psoriasis demonstrated clinical and histopathologic responses to hydroxyurea. When Moschella and Greenwald [84] treated 60 patients with psoriasis with hydroxyurea, they achieved a 50 to 60 percent response rate. The authors note that clinical improvement of psoriasis is apparent only if the total white blood cell count is reduced below 4000. Initial response can be expected within 2 to 3 weeks and maximum response by 6 to 8 weeks. [80] Patients should have a baseline chemistry profile, CBC, and urinalysis, with repetition of the CBC at regular intervals. Because hydroxyurea has relatively little hepatic toxicity, it may be a good choice for patients who are excluded from methotrexate therapy because of liver disease. Hydroxyurea seems to be neither as effective nor as rapid in onset of action as methotrexate or azathioprine; however, it is clearly beneficial in some patients.

Dosage schedule Smith [80] recommends that patients should initially receive a dose of 1 g once daily, and the total dose should not exceed 2000 mg/day. Older patients and patients with renal impairment are more susceptible to hydroxyurea and should receive starting doses of 500 mg/day. [80] Hydroxyurea should be taken with food, and patients should add milk or antacids if gastric discomfort occurs. Hydroxyurea is usually well tolerated.

Adverse effects Layton and colleagues [85] found that 57 percent of patients who received 1.5 g/day of the drug experienced no adverse effects and that only 18 percent stopped hydroxyurea therapy because of side effects. The most significant adverse effects of hydroxyurea are bone marrow suppression and teratogenesis. Bone marrow suppression occurs in nearly all patients who are treated with therapeutic levels of the drug and reflects the susceptibility of proliferating cell populations to hydroxyurea. Bone marrow suppression usually resolves rapidly after hydroxyurea is discontinued. Patients taking hydroxyurea may experience adverse cutaneous effects, including but not limited to a

lichen planus-like eruption, a benign dermatomyositis-like eruption, and hyperpigmentation of the skin and nails. Other reported effects include lupus erythematosus, leg ulcers, mild gastrointestinal effects, and the development of secondary malignancies when used in patients being treated for primary malignancies such as polycythemia vera. [80], [86] A rare but important adverse effect of hydroxyurea is fever and a flulike illness. [87] In patients treated for myeloproliferative disorders, nonmelanoma skin cancers were reported. [82] Conception should be avoided when either partner is taking hydroxyurea.
Drug interactions Hydroxyurea appears to have few significant drug interactions, with the exception of other myelosuppressive agents and cytarabine. [80] This caution is because of the potential for additive bone marrow toxicity.

ALKYLATING AGENTS

Cyclophosphamide

Cyclophosphamide is a derivative of nitrogen mustard (Fig. 256-6). As with other nitrogen mustards, cyclophosphamide acts primarily as a DNA cross-linker. [88] It is used as an antineoplastic agent in oncology. However, in certain diseases, especially the autoimmune blistering disorders and systemic vasculitis diseases, it can be used as a steroid-sparing agent or for its inherent efficacy.

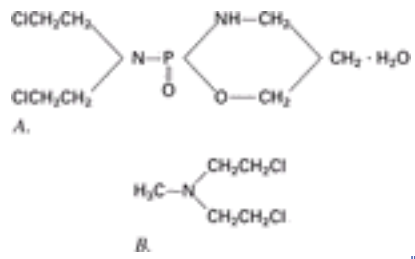

FIGURE 256-6 Chemical structure of the alkylating agents. *A*. Cyclophosphamide *B.* Mechlorethamine (nitrogen mustard).

PHARMACOLOGY Cyclophosphamide is a prodrug that undergoes hepatic conversion by the cytochrome P450 system. It has good oral bioavailability and reaches peak plasma levels within 2 h; its half-life is between 3 and 12 h. Important metabolites are 4-hydroxycyclophosphamide and phosphoramide mustard, both of which are active, and acrolein, an inactive metabolite. [1] Aldehyde dehydrogenase is responsible for the production of another inactive metabolite.
MECHANISM OF ACTION Because cyclophosphamide interacts with preformed DNA and RNA (cell-cycle nonspecific), the drug is active against cells with a low proliferative index. Results from alkylation include DNA cross-linking, abnormal base-pair formation, imidazole ring cleavage with depurination, and chain scission. These mutations can lead to cell death or mutagenesis and carcinogenesis. [81] Cyclophosphamide is more active on B lymphocytes than on T lymphocytes. [81]
CLINICAL USES The major dermatologic use of cyclophosphamide is for the treatment of severe life-threatening diseases resistant to other forms of therapy. Cyclophosphamide is used either to maintain remission after withdrawal of systemic steroids, or as a steroid-sparing agent. The latter usage in patients who have not responded to azathioprine therapy is based on a single report. [89] Pemphigus vulgaris in particular may be treated with cyclophosphamide in combination with prednisone. [89], [90] Recent reports on intravenous pulse therapy of cyclophosphamide and combined pulse dexamethasone-cyclophosphamide therapy in the treatment of pemphigus vulgaris described a curative effect. [90], [91] The survival of patients with systemic vasculitis was enhanced with the introduction of combined steroid/cytotoxic therapy. [44] Diseases that were once lethal are now controllable with such therapy. Wegener's granulomatosis and lymphomatoid granulomatosis often require cyclophosphamide therapy for sustained remission. [92], [93] Other diseases may also respond to cyclophosphamide, including Behçet's disease, pyoderma gangrenosum, lichen planus, and lichen myxedematosus. [81] With the availability of cyclosporine and related drugs, however, cyclophosphamide may not be the drug of choice for steroid-resistant but nonlethal inflammatory diseases. However, in a recent controlled trial, cyclosporine was ineffective as an adjuvant to glucocorticoids for the treatment of pemphigus. [94]
DOSAGE Cyclophosphamide can be given orally or parenterally through intravenous administration. Oral dosages are usually 1 to 3 mg/kg per day either in divided doses or as a single morning dose for nonmalignant diseases. Intravenous pulse dosing of 0.5 to 1 g/m ^{2} monthly may be associated with fewer side effects than daily oral dosing. [90], [95] Vigorous hydration 24 h before and continuing through therapy is strongly recommended to prevent serious bladder toxicity.
ADVERSE EVENTS The side effects of cyclophosphamide are significant. [95] Nausea and vomiting are the most common gastrointestinal side effects associated with cyclophosphamide administration, but ondansetron combined with dexamethasone can significantly reduce these effects. Alopecia, mucosal ulcerations, cardiotoxicity, syndrome of inappropriate antidiuretic hormone secretion (SIADH), squamous cell skin cancer, and hematologic malignancies are associated with cyclophosphamide use. [88], [95] As teratogenicity is of concern with cyclophosphamide, avoidance of pregnancy is stressed and males may consider banking sperm before initiation of therapy. Infertility is another major risk of cyclophosphamide therapy. [90] Hematologic disturbances are frequent, especially leukopenia and thrombocytopenia. [88] The leukocyte nadir is usually around 8 to 12 days after initiation of therapy, with a goal for the absolute neutrophil count to remain above 2000/mm ^{3}. It is not necessary to induce myelosuppression to induce immunosuppression. [81] In some cases with immunoablation through high-dose cyclophosphamide, hematopoietic stem cells appear resistant to the cytotoxic effects of cyclophosphamide through the enzyme aldehyde dehydrogenase. [96] Many forms of bladder toxicity exist in association with cyclophosphamide. Hemorrhagic cystitis occurs in 5 to 40 percent of patients treated with oral cyclophosphamide. [81], [95] This cystitis occurs during therapy and is believed to be caused by the metabolite acrolein. [97] A scavenging agent, mesna (sodium 2-mercaptoethane sulfonate), binds acrolein in the bladder and prevents severe bladder irritation. It is used primarily with high-dose cyclophosphamide regimens and is administered orally or intravenously. Chronic hemorrhagic cystitis and untreated bladder toxicity are thought to be responsible for the development of transitional cell carcinoma of the bladder, which is associated with a thirty-one– to thirty-threefold increase with chronic daily oral cyclophosphamide. [90] Stein and colleagues [98] reported two rare cases of

cyclophosphamide-induced squamous cell carcinoma of the bladder. Cancers may arise many years after therapy, and therefore continued monitoring of the lower urinary tract is indicated. The importance of vigorous hydration and frequent bladder clearance during cyclophosphamide therapy cannot be overemphasized.
DRUG INTERACTIONS Because the microsomal enzyme systems responsible for cyclophosphamide activation are involved in the metabolism of other drugs, there is great potential for drug interaction during cyclophosphamide therapy. Allopurinol, cimetidine, and chloramphenicol increase cyclophosphamide toxicity. Cyclophosphamide has other important drug interactions with succinylcholine, halothane, nitrous oxide, doxorubicin, digoxin, and barbiturates. [81]

Chlorambucil

Chlorambucil is another cell-cycle nonspecific alkylating agent derived from nitrogen mustard that interferes with DNA synthesis and cellular proliferation with effects similar to cyclophosphamide. It is well absorbed orally and undergoes hepatic metabolism with a plasma half-life of approximately 1.5 h. [1] Commonly used in the treatment of chronic lymphocytic leukemia, Waldenström's macroglobulinemia, and lymphomas, it is rarely used in dermatology. However, there are recent reports of treatment of pemphigus and erythrodermic cutaneous T cell lymphoma with various regimens of chlorambucil as a steroid-sparing agent. [99], [100] Although chlorambucil is considered the least toxic nitrogen mustard, its side effects include induction of other malignancies, nausea and vomiting, azoospermia, amenorrhea, pulmonary fibrosis, seizures, dermatitis, and, rarely, hepatotoxicity. [1], [100] Because of infrequent use, dosage schedules of chlorambucil for the treatment of dermatologic disease have not been standardized and must be determined on an individual basis.

Anthracyclines

Anthracyclines are antibiotic molecules with antineoplastic properties that are cell-cycle specific for the S phase of cell division. The mechanism of antineoplastic activity is thought to involve intercalation with DNA and inhibition of DNA and RNA synthesis by template disordering and steric obstruction. This usually results in cell death, but also leads to mutagenesis and carcinogenesis. [1] Pegylated (methoxypolyethylene glycol) liposomal doxorubicin hydrochloride (Doxil) is approved for the treatment of AIDS-related Kaposi's sarcoma. The encapsulating liposomes avoid detection by the reticuloendothelial system and increase the blood circulation time of doxorubicin. [101] These protected liposomes result in a 55-h half-life and allow improved penetration of the compromised vasculature of the Kaposi's sarcoma, thus accumulating within the tumors. [101], [102] Doxorubicin is administered intravenously at a recommended dose of 20 mg/m ^{2} over 30 min once every 3 weeks, as tolerated by the individual patient.

Liposomal doxorubicin has toxicities similar to those of nonliposomal doxorubicin, but it generally is considered to be better tolerated. Careful hematologic monitoring is required, as a transient myelosuppression is expected during the second week of therapy. [1] A small percentage of patients may experience an initial infusion reaction, which typically resolves and does not occur in later infusions if not present initially. Palmar–plantar erythrodysesthesia is not unusual, and hepatotoxicity has also been reported. [101], [102] Doxorubicin is embryotoxic and abortifacient and should be avoided in women who plan to conceive. It should be assumed that liposomal doxorubicin may have myocardial toxicity similar to that of other preparations of doxorubicin. In addition, a history of the use of other anthracyclines or anthracenediones will lower the total dose of doxorubicin required to cause cardiotoxicity. Also reported was recurrence of postradiation skin reaction in patients receiving this drug. Other minor side effects occurred in more than 5 percent of the patients with AIDS-related Kaposi's sarcoma receiving doxorubicin therapy.

Cytotoxic agents are associated with important risks and benefits in the treatment of severe dermatologic disease. Meanwhile, the use of steroids to induce disease remission is also often complicated by serious side effects during prolonged therapy. Many of the discussed cytotoxic agents demonstrate steroid-sparing benefit and may be used successfully with careful attention to laboratory and clinical monitoring. However, with the continued introduction of newer, targeted, immunomodulatory agents, many of the cytotoxic drugs discussed in this chapter will likely be used less often to treat dermatologic disease.

REFERENCES

1. Chabner BA et al: Antineoplastic agents, in *Goodman and Gilman's the Pharmacological Basis of Therapeutics*, 9th ed., edited by JG Hardman, LE Lambird. New York, McGraw-Hill, 1996, p 1233

2. Gubner R et al: Therapeutic suppression of tissue reactivity: II. Effect of aminopterin in rheumatoid arthritis and psoriasis. *Am J Med Sci* **221**:176, 1951

3. Dupuis LL et al: Influence of food on the bioavailability of oral methotrexate in children. *J Rheumatol* **22**:1570, 1995

4. Hamilton RA, Kremer JM: The effects of food on methotrexate absorption. *J Rheumatol* **22**:630, 1995

5. Said S et al: Methotrexate. *Clin Dermatol* **15**:781, 1997

6. Roenigk HH et al: Methotrexate in psoriasis: Revised guidelines. *J Am Acad Dermatol* **19**:146, 1988

7. Callen JP et al: Methotrexate, in *Comprehensive Dermatologic Drug Therapy,* edited by SE Wolverton. Philadelphia, WB Saunders, 2001, p 147

8. Jeffes EWB et al: Methotrexate therapy of psoriasis: Differential sensitivity of proliferating lymphoid and epithelial cells to cytotoxic and growth inhibitory effects of methotrexate. *J Invest Dermatol* **104**:183, 1995

9. Cronstein BN: The mechanism of action of methotrexate. *Rheum Dis Clin North Am* **23**:739, 1997

10. Peckham PE et al: The treatment of severe psoriasis: A national survey. *Arch Dermatol* **123**:1303, 1987

11. Van Scott EJ, Ekel TM: Kinetics of hyperplasia in psoriasis. *Arch Dermatol* **88**:373, 1963

12. Pigatto PD et al: Methotrexate in psoriatic polyarthritis. *Acta Derm Venereol Suppl (Stockh)* **186**:114, 1994

13. Roenigk HH et al: Methotrexate in psoriasis: Consensus conference. *J Am Acad Dermatol* **38**:478, 1998

14. Maurer TA et al: The use of methotrexate for treatment of psoriasis in patients with HIV infection. *J Am Acad Dermatol* **31**:372, 1994

15. Ternowitz T, Herlin T: Neutrophil and monocyte chemotaxis in methotrexate treated psoriasis patients. *Acta Derm Venereol (Stockh)* **120**:23, 1985

16. Weinblatt ME: Toxicity of low-dose methotrexate in rheumatoid arthritis. *J Rheumatol* **12**(Suppl):35, 1985

17. Endresen GKM, Husby G: Folate supplementation during methotrexate treatment of patients with rheumatoid arthritis. *Scand J Rheumatol* **30**:129, 2001

18. Duhra P: Treatment of gastrointestinal symptoms associated with methotrexate therapy for psoriasis. *J Am Acad Dermatol* **28**:466, 1993

19. Weinblatt ME, Kremer JE: Methotrexate in rheumatoid arthritis. *J Am Acad Dermatol* **19**:126, 1988

20. Zachariae H, Sogaard H: Methotrexate-induced liver cirrhosis: A follow-up. *Dermatologica* **175**:178, 1987

21. Mitchell D et al: Ultrasound and radionuclide scans—Poor indicators of liver damage in patients treated with methotrexate. *Clin Exp Dermatol* **12**:243, 1987

22. Tugwell P et al: Methotrexate in rheumatoid arthritis. *Ann Intern Med* **110**:581, 1989

23. Newman MN et al: The role of liver biopsies in psoriatic patients receiving long-term methotrexate treatment. *Arch Dermatol* **125**:1218, 1989

24. Shupack JL, Webster GF: Pancytopenia following low-dose oral methotrexate therapy for psoriasis. *JAMA* **259**:3594, 1988

25. Thomas DR et al: Pancytopenia induced by the interaction between methotrexate and trimethoprim-sulfamethoxazole treatments. *J Am Acad Dermatol* **17**:1055, 1987

26. Stern RS et al: Methotrexate used for psoriasis and the risk of cutaneous and non-cutaneous malignancy. *Cancer* **50**:869, 1982

27. Nyfors A, Jensen H: Frequency of malignant neoplasm in 248 long-term methotrexate-treated psoriatics. *Dermatologica* **167**:260, 1983

28. Jensen MK, Nyfors A: Cytogenic effect of methotrexate on human cells in vivo: Comparison between results obtained by chromosome studies on bone marrow cells and blood lymphocytes and by the micronucleus test. *Mutat Res* **64**:339, 1979

29. Paul C et al: Epstein-Barr virus-associated lymphoproliferative disease during methotrexate therapy for psoriasis. *Arch Dermatol* **133**:867, 1997

30. Sussman A, Leonard JM: Psoriasis, methotrexate, and oligospermia. *Arch Dermatol* **116**:215, 1980

31. McKenna KE, Burrow D: Pulmonary toxicity in a patient with psoriasis receiving methotrexate therapy. *Clin Exp Dermatol* **25**:24, 2000

32. Shupack JL et al: Methotrexate with leucovorin rescue: A therapeutic alternative in severe psoriatics with a history of methotrexate-induced pancytopenia and diminished renal or hepatic function. *J Dermatol Treat* **4**:145, 1993

33. Alkins SA et al: Anaphylactoid reactions to methotrexate. *Cancer* **77**:2123, 1996

34. Evans WE, Christensen ML: Drug interactions with methotrexate. *J Rheumatol* **12**(Suppl):15, 1985

35. Zachariae H: Liver biopsies and methotrexate: A time for reconsideration. *J Am Acad Dermatol* **42**:531, 2000

36. Morgan SL et al: Folic acid supplementation prevents deficient blood folate levels and hyperhomocysteinemia during long-term, low-dose methotrexate therapy for rheumatoid arthritis: Implication for cardiovascular disease prevention. *J Rheumatol* **25**:441, 1998

37. Chabner BA, Myers CE: Clinical pharmacology of cancer chemotherapy, in *Principles and Practices of Oncology,* 2nd ed, edited by VT DeVita et al. Philadelphia, Lippincott, 1985, p 287

38. Snow JL, Gibson LE: A pharmacogenetic basis for the safe and effective use of azathioprine and other thiopurine drugs in dermatologic patients. *J Am Acad Dermatol* **32**:114, 1995

39. Badalamenti S, Kerdel F: Azathioprine, in *Comprehensive Dermatologic Drug Therapy,* edited by SE Wolverton. Philadelphia, WB Saunders, 2001, p 165

40. Snow JL, Gibson LE: The role of genetic variation in thiopurine methyltransferase activity and the efficacy and/or side effects of azathioprine therapy in dermatologic patients. *Arch Dermatol* **131**:193, 1995

41. Wolff K, Schreine E: Immunosuppressive therapy for pemphigus vulgaris. *Arch Klin Exp Dermatol* **235**:63, 1969

42. Aberer W et al: Azathioprine in the treatment of pemphigus vulgaris. *J Am Acad Dermatol* **16**:527, 1987

43. Korman N: Bullous pemphigoid. *J Am Acad Dermatol* **16**:907, 1987

44. Leavitt RY, Fauci AS: Pulmonary vasculitis. *Am Rev Respir Dis* **134**:149, 1986

45. Felson DT, Anderson J: Evidence for the superiority of immunosuppressive drugs and prednisone over prednisone alone in lupus nephritis. *N Engl J Med* **311**:1528, 1984

46. Bunch TW: Prednisone and azathioprine for polymyositis. *Arthritis Rheum* **24**:45, 1981

47. Murphy GM et al: Azathioprine treatment in chronic actinic dermatitis: A double-blind controlled trial with monitoring of exposure to ultraviolet radiation. *Br J Dermatol* **121**:639, 1989

48. Bacon BR et al: Azathioprine induced pancytopenia: Occurrence in two patients with connective tissue diseases. *Arch Intern Med* **141**:223, 1981

49. Younger IR et al: Azathioprine in dermatology. *J Am Acad Dermatol* **25**:281, 1991

50. Nashel DJ: Mechanisms of action and clinical applications of cytotoxic drugs in rheumatic disorders. *Med Clin North Am* **69**:817, 1985

51. Kawanishi H et al: Azathioprine induced pancreatitis. *N Engl J Med* **289**:357, 1973

52. McKendry RJ, Cyr M: Toxicity of methotrexate compared with azathioprine in the treatment of rheumatoid arthritis. *Arch Intern Med* **149**:685, 1989

53. Pandhi RK et al: Azathioprine-induced drug fever. *Int J Dermatol* **33**:198, 1994

54. Jones JJ, Ashworth J: Azathioprine-induced shock. *J Am Acad Dermatol* **29**:795, 1993

55. Knowles SR et al: Azathioprine hypersensitivity-like reactions—A case report and a review of the literature. *Clin Exp Dermatol* **20**:353, 1995

56. Silman AJ et al: Lymphoproliferative cancer and other malignancy in patients with rheumatoid arthritis treated with azathioprine. *Ann Rheum Dis* **47**:988, 1988

57. Penn I: Cancers in cyclosporine-treated vs azathioprine-treated patients. *Transplant Proc* **28**:876, 1996

58. Bottomley WW et al: Aggressive squamous cell carcinomas developing in patients receiving long-term azathioprine. *Br J Dermatol* **133**:460, 1995

59. Roubenoff R et al: Effect of anti-inflammatory and immunosuppressive drugs on pregnancy and fertility. *Semin Arthritis Rheum* **18**:88, 1988

60. Armstrong VW, Oellerich M: New developments in the immunosuppressive drug monitoring of cyclosporine, tacrolimus, and azathioprine. *Clin Biochem* **34**:9, 2001

61. Kroplin T et al: Inhibition of thiopurine S-methyltransferase activity by impurities in commercially available substrates: A factor for differing results of TPMT measurements. *Eur J Clin Pharmacol* **55**:285, 1999

62. Kitchin JES et al: Rediscovering mycophenolic acid: A review of its mechanism, side effects, and potential uses. *J Am Acad Dermatol* **37**:445, 1997

63. McDonald CJ: Chemotherapy of psoriasis. *Int J Dermatol* **14**:563, 1975

64. Eugui EM et al: Lymphocyte-selective anti-proliferative and immunosuppressive effects of mycophenolic acid in mice. *Scand J Immunol* **33**:175, 1991

65. Jones EL et al: Treatment of psoriasis with oral mycophenolic acid. *J Invest Dermatol* **65**:537, 1975

66. Myers SA: Update on new immunomodulatory agents. *Adv Dermatol* **16**:213, 2000

67. Goldblum R: Therapy of rheumatoid arthritis with mycophenolate mofetil. *Clin Exp Rheum* **11**(Suppl 8):S117, 1993

68. Shoji Y et al: Effect of topical preparation of mycophenolic acid on experimental allergic contact dermatitis of guinea pigs induced by dinitrofluorobenzene. *J Pharm Pharmacol* **46**:643, 1994

69. Geilin CC et al: Mycophenolate mofetil as a systemic antipsoriatic agent: Positive experience in 11 patients. *Br J Dermatol* **144**:583, 2001

70. Grundman-Kollman M et al: Treatment of chronic plaque-stage psoriasis and psoriatic arthritis with mycophenolate mofetil. *J Am Acad Dermatol* **42**:835, 2000

71. Epinette WW et al: Mycophenolic acid for psoriasis: A review of pharmacology, long-term efficacy and safety. *J Am Acad Dermatol* **17**:962, 1987

72. Platz KP et al: RS-61443: A new, potent immunosuppressive agent. *Transplantation* **51**:27, 1991

73. Ensley RD et al: The use of mycophenolate mofetil (RS-61443) in human heart transplant recipients. *Transplantation* **56**:75, 1993

74. Elion GB, Hitchings GH: The synthesis of 6-thioguanine. *J Am Chem Soc* **77**:1676, 1955

75. Murphy FP et al: Clinical clearing of psoriasis by 6-thioguanine correlates with cutaneous T-cell depletion via apoptosis: Evidence for selective effects on activated T-lymphocytes. *Arch Dermatol* **135**:1495, 1999

76. Zackheim HS et al: 6-Thioguanine treatment of psoriasis: Experience in 81 patients. *J Am Acad Dermatol* **30**:452, 1994

77. Mason C, Krueger GG: Thioguanine for refractory psoriasis: A 4-year experience. *J Am Acad Dermatol* **44**:67, 2001

78. Silvis NG, Levine N: Pulse dosing of thioguanine in recalcitrant psoriasis. *Arch Dermatol* **135**:433, 1999

79. Kao NL, Rosenblate HJ: 6-Thioguanine therapy for psoriasis causing toxic hepatic veno-occlusive disease. *J Am Acad Dermatol* **28**:1017, 1993

80. Smith CH: Use of hydroxyurea in psoriasis. *Clin Exp Dermatol* **24**:2, 1999

81. Pan TD, McDonald CJ: Cytotoxic agents, in *Comprehensive Dermatologic Drug Therapy,* edited by SE Wolverton. Philadelphia, WB Saunders, 2001, p 180

82. Best PJ, Petitt RM: Multiple skin cancers associated with hydroxyurea therapy. *Mayo Clin Proc* **73**:961, 1998

83. Leavell UW, Yarbro JW: Hydroxyurea: A new treatment for psoriasis. *Arch Dermatol* **102**:144, 1970

84. Moschella SC, Greenwald MA: Treatment of psoriasis with hydroxyurea—An 18-month study of 60 patients. *Arch Dermatol* **107**:363, 1973

85. Layton AM et al: Hydroxyurea in the management of therapy resistant psoriasis. *Br J Dermatol* **121**:647, 1989

86. Donovan PB et al: Treatment of polycythemia vera with hydroxyurea. *Am J Hematol* **17**:329, 1984

87. Starmans-Kool MJF et al: An unwanted side effect of hydroxyurea in a patient with idiopathic myelofibrosis. *Ann Hematol* **70**:279, 1995

88. Fosdick WM et al: Long-term cyclophosphamide therapy in rheumatoid arthritis. *Arthritis Rheum* **11**:151, 1968

89. Bystryn JC, Steinman NM: The adjuvant therapy of pemphigus: An update. *Arch Dermatol* **132**:203, 1996

90. Fleischli ME et al: Pulse intravenous cyclophosphamide therapy in pemphigus. *Arch Dermatol* **135**:57, 1999

91. Pasricha JS, Das SS: Curative effect of dexamethasone-cyclophosphamide pulse therapy for the treatment of pemphigus vulgaris. *Int J Dermatol* **31**:875, 1992

92. Fauci AS et al: Cyclophosphamide therapy of severe systemic necrotizing vasculitis. *N Engl J Med* **301**:235, 1979

93. Jambrosic J et al: Lymphomatoid granulomatosis. *J Am Acad Dermatol* **17**:621, 1987

94. Ioannides D et al: Ineffectiveness of cyclosporine as an adjuvant to corticosteroids in the treatment of pemphigus. *Arch Dermatol* **136**:868, 2000

95. Ortmann RA, Klippel JH: Update on cyclophosphamide for systemic lupus erythematosus. *Rheum Dis Clin North Am* **26**:363, 2000

96. Nousari HC et al: Immunoablative high-dose cyclophosphamide without stem cell rescue in paraneoplastic pemphigus: Report of a case and review of this new therapy for severe autoimmune disease. *J Am Acad Dermatol* **40**:750, 1999

97. Cox PJ: Cyclophosphamide cystitis: Identification of acrolein as the causative agent. *Biochem Pharmacol* **28**:2045, 1979

98. Stein JP et al: Squamous cell carcinoma of the bladder associated with cyclophosphamide therapy for Wegener's granulomatosis: A report of 2 cases. *J Urol* **149**:588, 1993

99. Coors EA, Von Den Driesch P: Treatment of erythrodermic cutaneous T-cell lymphoma with intermittent chlorambucil and fluocortolone therapy. *Br J Dermatol* **143**:127, 2000

100. Shah N et al: The use of chlorambucil with prednisone in the treatment of pemphigus. *J Am Acad Dermatol* **42**:85, 2000

101. Hengge UR et al: Long-term chemotherapy of HIV-associated Kaposi's sarcoma with liposomal doxorubicin. *Eur J Cancer* **37**:878, 2001

102. Northfelt DW et al. Pegylated-liposomal doxorubicin versus doxorubicin, bleomycin, and vincristine in the treatment of AIDS-related Kaposi's sarcoma: Results of a randomized phase III clinical trial. *J Clin Oncol* **16**:2445, 1998

T>

Chapter 257

Stéphane Kuenzli Jean-Hilaire Saurat

The Retinoids

MECHANISMS OF ACTION
PHARMACOLOGY
Vitamin A
Etretinate and Acitretrin
Isotretinoin (13-cis-Retinoic Acid)
Bexarotene
CLINICAL USES (Table 257-1)
Psoriasis
Acne
Cutaneous T Cell Lymphoma (CTCL)
FDA-Unapproved Clinical Uses
Ichthyosis
Darier's Disease
Pityriasis Rubra Pilaris (PRP)
Rosacea
Premalignant and Malignant Skin Lesions
Graft-Versus-Host Disease (GVHD)
Lichen Sclerosus et Atrophicus
Lupus Erythematosus
ADVERSE EFFECTS
Teratogenicity
Skin and Mucous Membrane Adverse Effects (Type I)
Systemic Toxic Effects (Type II)
Laboratory Abnormalities
DRUG INTERACTIONS
FACTORS IN THE DECISION TO USE RETINOIDS

REFERENCES

Retinoids is a generic term for both naturally occurring molecules and synthetic compounds with specific biologic activities that resemble those of vitamin A. Since the early twentieth century, animal experiments in conditions of vitamin A deficiency have revealed alterations of epithelia such as epidermal hyperkeratosis, squamous metaplasia of mucous membranes, various keratinization disorders, and certain precancerous conditions. [1] In view of the “antikeratinizing properties” of vitamin A, the profound clinical impact of synthetic retinoids was first observed and described in patients with dermatologic disease. In initial clinical investigations, synthetic vitamin A was either ineffective at well-tolerated doses or too toxic. Because of this narrow therapeutic index, a large program of chemical synthesis of derivatives was launched to engineer synthetic retinoids that would offer the highest therapeutic activity with the lowest toxicity.

All- *trans*-retinoic acid (tretinoin, ATRA), a naturally occurring metabolite of retinol, was the first retinoid to be synthesized. Its systemic use provided no significant advantages over vitamin A, [2] and hence its dermatologic use is as a topical treatment for disorders of keratinization such as acne vulgaris, ichthyosis, actinic keratosis, and basal cell carcinoma, as well as pityriasis rubra pilaris. ATRA has been used widely as a differentiation-inducing agent for acute promyelocytic leukemia, leading to renewed interest in its effects. [3]

Isotretinoin (13- *cis*-retinoic acid), first synthesized in 1955, was tested only later in clinical trials that were hampered initially by concern about the thalidomide tragedy and about its teratogenicity. Initially, Orfanos and coworkers [4] obtained equivocal results in treating psoriasis with isotretinoin. Subsequently, etretinate, either alone [5] or in combination with topical dithranol, [6] was found to be very effective in treating psoriasis. These findings led to the temporary abandonment of isotretinoin. Interest in isotretinoin was rekindled after the discovery that it was effective in the treatment of lamellar ichthyosis and other cutaneous disorders of keratinization [7] and in producing complete responses with prolonged remissions in patients with previously treatment-resistant cystic and conglobata acne. [8] It also was found to be partially effective in the treatment and prevention of basal cell carcinoma. [9]

In 1972, Bollag, in his chemical program directed at finding retinoids with better therapeutic margins, developed two aromatic retinoids, etretinate and acitretin. These compounds showed a therapeutic index 10 times more favorable than that of ATRA in the chemically induced rodent papilloma test model. Etretinate and its free acid metabolite, acitretin, the second generation of retinoids, achieved a real breakthrough in the treatment of psoriasis.

The recent discovery of retinoic acid receptors (RARs) [10], [11] allows research directed toward third-generation retinoids with a safer therapeutic index and a selective action. Bexarotene for systemic use and adapalene and tazarotene for topical use are at the forefront of this research.

This chapter summarizes the pharmocokinetics, mechanisms of action, efficacy, and toxicity of oral synthetic retinoids in dermatology, with emphasis on acne, psoriasis, and other off-labeled indications.

MECHANISMS OF ACTION

Retinoids are involved in the regulation of diverse biologic functions. They affect cell growth and differentiation, morphogenesis, tumor promotion, and malignant cell growth; exert immunomodulatory action; and alter cellular adhesiveness.

A major breakthrough in the understanding of retinoid action came from the discovery of nuclear receptors for retinoids. [10], [11] Retinoids exert their physiologic effects through two distinct families of nuclear receptors, RARs and retinoid X receptors (RXRs). RARs and RXRs belong to a superfamily of nuclear receptors that act as ligand-activated transcription factors and include the steroid, vitamin D, and thyroid hormone receptors and peroxisome proliferator–activated receptors. Each family contains three receptor isotypes—a,ß, and ?—encoded by different genes. Whereas ATRA binds only to RARs, 9- *cis*-retinoic acid binds to both RARs and RXRs. RARs function as heterodimers with RXRs, whereas RXRs may act as homodimers, as well as participate in the formation of heterodimers, with various other nuclear receptors, including vitamin D, thyroid hormone, and peroxisome proliferator– activated receptors. Such heterodimers can provide a mechanism for cross-talk between nuclear hormone-signaling pathways. Dimers of retinoid receptors (RAR/RXR or RXR/RXR) are localized in the nucleus and bind even in the unliganded state to specific DNA regulatory sequences called *hormone response elements* in the promoters of retinoid-responsive genes. The unliganded receptors bind to corepressor molecules and repress transcription. However, when the receptor binds its ligand, it undergoes a conformational change that results in the release of corepressors and in the recruitment of coactivators. These molecules include histone acetylases that change the conformation of the chromatin and allow access to the DNA by transcriptional machinery. Finally, the retinoid-receptor complex modulates the transcription of specific sets of genes. Retinoids have both direct and indirect effects on gene transcription. Their direct effects are mediated through binding to their hormone response element (retinoid hormone response element, or RARE) in the promoter region of target genes. In contrast, the indirect effects of retinoids result from the downregulation of genes that do not contain RARE in their promoter region. The retinoid-receptor complex probably antagonizes various transcription factors involved in proliferative and inflammatory responses such as activator protein 1 (AP-1) or nuclear factor–interleukin 6 (NF–IL-6) by competing for commonly required coactivator proteins, resulting in a nonproductive complex. [12] Synthetic “dissociating retinoids” have been synthesized that induce the indirect anti-AP-1 function but not the direct gene transactivation function. Finally, the nongenomic effect of retinoids and the reversible phosphorylation of retinoid receptors are still a matter of investigation.

The existence of several types and distribution of receptors, dimers, hormone response elements, mechanisms of action, and regulatory proteins means that retinoid action is mediated by multiple pathways and results in the complex activation or inhibition of a large set of coordinately regulated genes.

PHARMACOLOGY

ATRA, isotretinoin, etretinate, acitretin, and bexarotene, the oral retinoids (Fig. 257-1) that are or have been available commercially, differ not only in their spectra of clinical efficacy but also in their toxicities and pharmacokinetics. Thus each retinoid should be studied as a unique drug, and the lack of a disease response to one retinoid does not equate with unresponsiveness to the others. Three generations of synthetic retinoids have been developed. Members of the first generation of monoaromatic retinoids (isotretinoin, ATRA) are produced by chemically modifying the polar end group and the polyene side chain of vitamin A. Those in the second generation of monoaromatic retinoids are formed by replacing the cyclic end group of vitamin A with diverse substituted and nonsubstituted ring systems (etretinate, acitretin). The third-generation polyaromatic retinoids (also called *arotinoids*) are synthesized through cyclization of the polyene side chain and include bexarotene, adapalene, and tazarotene.

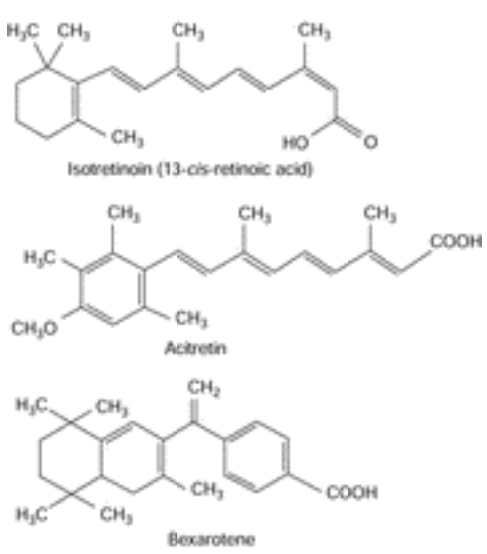

FIGURE 257-1 Chemical structures of systemic retinoids.

Due to their lipophilicity, the oral bioavailability of all retinoids is enhanced when administrated with food, especially with fatty meals. Retinoids are metabolized mainly in the liver. Metabolism involves oxidation and chain shortening to biologically inactive and hydrophilic metabolites, facilitating biliary and/or renal elimination. The oxidative metabolism is induced primarily by the retinoids themselves and possibly also by other agents that induce hepatic cytochrome P-450 isoforms. [13]

Vitamin A

Vitamin A (retinol), one of the fat-soluble vitamins, is required for the visual cycle of dark adaptation, physiologic growth, reproduction, regulation of embryonic development, morphogenesis, and immunomodulation. Most vitamin A must be

acquired through the diet from ingested retinyl esters and provitamin A carotenoids, of which beta-carotene is the most active. In the intestinal lumen, these esters are hydrolyzed to retinol, which is absorbed and stored in the liver in the ester form (especially retinol palmitate). Retinol represents the main dietary source, transport, and storage form of vitamin A. Once in the bloodstream, after the retinol ester/storage form is released, retinol is transported bound to a complex of retinol-binding protein (RBP) and transthyretin. The basic cellular pathway leading to the conversion of retinol to ATRA, the biologically active ligand that binds to nuclear receptors, consists of two steps. In a reversible process, retinol (vitamin A alcohol) is oxidized to retinal (vitamin A aldehyde) and is irreversibly converted to retinoic acid (vitamin A acid). A binding protein, designated *cellular RBP* (CRBP-I), facilitates these enzymatic reactions by delivering retinol to the appropriate enzymes. Two additional intracellular carriers, cellular retinoic acid–binding proteins (CRABP-I and CRABP-II), are thought to act to transport retinoic acid to the nucleus and to buffer the level of free ATRA in the cell. CRABP-I enhances retinoic acid metabolism to inactive derivatives, thereby dampening a cell's ability to respond to retinoic acid; in contrast, CRABP-II sensitizes cells to retinoic acid by channeling it to RARs through protein-protein interactions and enhances retinoic acid–induced transcriptional activity. [14] Retinoic acid is found in both all- *trans* and 9-*cis* configurations. Physiologically, ATRA is the predominant retinoic acid form; only a small fraction is transported as 13-*cis*-retinoic acid. ATRA is the active ligand that binds to the three known nuclear RARs that mediate, at least in part, the molecular and cellular effects of retinoic acid. Retinoic acid can substitute for retinol in growth, morphogenesis, and epithelial differentiation. However, it cannot substitute completely for retinol in reproductive function, nor can it replace retinal in the visual cycle.

Etretinate and Acitretrin

Etretinate is an ethylester that undergoes extensive hydrolysis in the body to yield the corresponding acid metabolite (acitretin). It appears from cellular and molecular pharmacology studies that the pharmacologically active compound of etretinate is acitretin, and therefore, etretinate may be considered as a prodrug. In animal studies and in clinical studies in patients with severe keratinizing disorders, [15] acitretin is as effective as etretinate. However, acitretin has a profound pharmacokinetic advantage because it is eliminated more rapidly than etretinate. [16] Etretinate is approximately 50 times more lipophilic than acitretin and binds strongly to plasma proteins, particularly lipoproteins and albumin. This fact has a profound influence on the respective pharmacokinetic properties of the two drugs.

When etretinate or acitretin is taken with a meal, the absorption of the drug is increased two- to fivefold, and the amount absorbed is more consistent. [16] It is therefore recommended that etretinate or acitretin be taken with the main meal of the day. However, even when the drugs are taken with food, their absorption varies. Marked interindividual variations in plasma retinoid concentration occur and appear not to depend on body weight. [17] The main adverse effect associated with synthetic retinoids is teratogenicity, and the length of time that these drugs are present in the body is thus of great interest. Etretinate is stored in adipose tissue, including subcutaneous fat, from which it is released slowly. It has a long terminal half-life of up to 120 days. In contrast, under identical conditions, acitretin carries a negatively charged group and, not being as lipophilic as etretinate, does not accumulate in adipose tissue and is eliminated from the body more rapidly. Acitretin has an elimination half-life of 2 days. [18] With etretinate, there is a significant first-pass hepatic metabolism by hydrolysis to the active metabolite. Acitretin metabolism involves isomerization instead of oxidation. The major metabolite of acitretin is its *cis* isomer. Paradoxically, acitretin activates all three RAR subtypes but binds poorly to them. [19]

The initial publication of data indicating that etretinate can be formed in patients receiving acitretin [20] has been confirmed by others. This esterification seems to occur when acitretin is taken simultaneously with alcohol. [21] This finding prompted the manufacturer to extend the time of compulsory contraception in patients taking acitretin to 2 years, as it is for etretinate. [22] Indeed, the Food and Drug Administration (FDA) approved the required contraceptive period of at least 3 years for acitretin, based on the pharmacokinetics of acitretin and etretinate in clinical trials and on previous safety experience with etretinate. The pharmacokinetic advantage of acitretin over etretinate still holds true, however, for all women who strictly avoid alcohol during treatment and for 2 months thereafter. [18] For all these reasons, acitretin represents a therapeutic alternative with greater clinical potential than etretinate. In June 1997, acitretin was approved by the FDA as a substitute for etretinate for similar indications. [18]

Isotretinoin (13- *cis*-Retinoic Acid)

Isotretinoin is a naturally occurring physiologic compound that results from the metabolism of vitamin A. Isotretinoin and ATRA are two interconvertable isomers that differ in their elimination half-lives—approximately 20 h for isotretinoin and 1 h for ATRA. Absorption of isotretinoin is increased considerably with food intake. Isotretinoin undergoes first-pass metabolism in the liver and subsequent enterohepatic recycling. In plasma, isotretinoin is more than 99 percent bound to plasma protein, mainly albumin. There is neither liver storage nor adipose tissue storage, in sharp contrast to vitamin A. The major metabolite of isotretinoin is produced by oxidation, which forms 4-oxoisotretinoin. Isotretinoin and its major metabolites are excreted in urine and feces. After the end of treatment, endogenous concentrations of isotretinoin and its major metabolite are reached within 2 weeks, ranging from 2 days for ATRA to 10 days for 4-oxoisotretinoin. Therefore, a 1-month posttherapy contraceptive period provides an adequate safety margin. [23] No clear affinity for any retinoid receptors has been identified with isotretinoin.

Bexarotene

Bexarotene, a specific RXR-selective retinoid (rexinoid), was approved in 1999 in the United States for the treatment of cutaneous T cell lymphoma. This compound is about 100-fold more potent for RXR relative to RAR. Its absorption is particularly increased by fatty meals. In plasma, bexarotene is highly bound (>99 percent) to proteins that have not yet been characterized, and the ability of bexarotene to displace drugs bound to plasma proteins and the ability of drugs to displace bexarotene is unknown. Bexarotene probably has a clearance profile similar to that of isotretinoin with a terminal half-life of between 7 and 9 h. [24] Bexarotene is metabolized by cytochrome P-450 3A4 (CYP 3A4) and generates its own oxidative metabolites via hepatic CYP 3A4 induction. 6/7-Hydroxybexarotene and, to a lesser extent, 6/7-oxobexarotene

appear to be the major metabolites, which exhibit insignificant in vitro receptor retinoid affinity and transactivation. [25] Neither bexarotene nor its metabolites are excreted in urine; elimination is thought to occur primarily via the hepatobiliary system. [24]

CLINICAL USES (Table 257-1)

TABLE 257-1 **Use of Systemic Retinoids in Dermatologic Disease States***

Psoriasis

The retinoids of first choice for the treatment of psoriasis are etretinate and subsequently acitretin. Several randomized multicenter trials have been performed to ascertain the efficacy of acitretin on plaque-type [26], [27], [28], [29] and [30] and pustular psoriasis and to compare its efficacy with that of etretinate. [26] Acitretin appears to be as effective as etretinate and can be used in the same combination regimens. Adverse effects appear to be similar in quality and incidence. The best results have been obtained in palmoplantar or generalized (von Zumbusch) type pustular psoriasis, in which etretinate and acitretin are considered to be the treatments of first choice. [31], [32] Both localized and generalized pustular psoriatic lesions as well as those of erythrodermic psoriasis cleared more rapidly with etretinate or acitretin monotherapy than with most other therapies. [31], [32] and [33] Rebound does not usually occur after acitretin or etretinate treatment is stopped, [34] and reintroduction of the drug when it does occur produces a beneficial response. [34] The most common form of psoriasis, plaque-type psoriasis, responds variably to both drugs. Although complete clearing of the lesions is achieved in only about 30 percent of treated patients, significant improvement is obtained in a further 50 percent. [35], [36] The decrease in the psoriasis area and severity index (PASI) score is approximately 60 to 70 percent, depending on the dosage. [15] Approximately 20 percent of patients may be considered treatment failures. [15], [36]

One of the main reasons for treatment interruption is initial worsening of the disease with increased erythema. Another is an increase in the extent of the lesions, which may occur within a few days of the start of treatment at doses of 0.5 to 1 mg/kg per day (30–70 mg/day). A therapeutic dosage scheme with an initially low dose (10 mg/day) of etretinate or acitretin, followed by progressively increasing doses, seems to avoid this initial worsening. [17] To define the efficacy of acitretin as monotherapy, different doses (10–75 mg/day) were compared in a double-blind fashion with placebo in patients with psoriasis. At the end of an 8-week treatment period, acitretin at doses of 25 and 50 mg/day [37] and 50 and 75 mg/day [38] was superior to placebo in two studies. The efficacy of a dose of 10 mg/day was not significantly different from that of placebo in either study. [17]

Total clearing of the lesions usually requires a combination of treatment such as retinoids plus topical glucocorticoids, topical vitamin D derivatives, dithranol (anthralin), or photochemotherapy (psoralen plus ultraviolet A, or PUVA).

COMBINATION WITH ULTRAVIOLET THERAPY One of the major developments for the treatment of widespread plaque-type psoriasis in recent years has been the combined use of PUVA photochemotherapy with the retinoids etretinate or acitretin (Re-PUVA therapy), in which retinoids are given 14 days before PUVA is started. The effects of etretinate and PUVA appear to be additive. [39] Studies with acitretin have demonstrated the superiority of Re-PUVA. In a double-blind comparative trial, [40] patients with psoriasis received either retinoid (acitretin or etretinate, 50 mg/day) or placebo without PUVA for 2 weeks. This monotherapy phase was followed by a combined-therapy phase of retinoid (acitretin or etretinate, 25 mg/day) or placebo plus PUVA three times a week until remission occurred. Although etretinate plus PUVA was more effective than placebo plus PUVA, statistically significant differences in the number of PUVA exposures and total dose of ultraviolet A (UVA) until remission were shown only between acitretin plus PUVA and placebo plus PUVA. The efficacy of acitretin was confirmed in another study that showed that the mean cumulative UVA dose was 42 percent less in the acitretin plus PUVA group than in the placebo plus PUVA group. [41] The main advantages of the Re-PUVA combination are the acceleration of the response rate of psoriatic lesions and the clearing of lesions that could not be cleared with retinoid or PUVA alone. A further advantage is that the ultraviolet exposure necessary to produce remission is significantly lower with Re-PUVA. The lower dosage is likely to diminish the risk of PUVA-induced carcinogenic effects, which are clearly UVA-dose-dependent. Oral retinoids also can be combined with bath PUVA (psoralen bath plus UVA), which also allows a reduction in the effective dose of UVA. The combination of etretinate or acitretin with ultraviolet B (UVB) phototherapy also has been shown to be more effective in patients with psoriasis than retinoid or UVB phototherapy alone. [40], [42], [43]

TREATMENT OF PATIENTS WITH HIV INFECTIONS The frequency of psoriasis in patients with HIV infection does not differ significantly from that in persons who do not have HIV infection. However, the psoriasis in HIV-infected patients tends to be more aggressive, and treatment poses a unique challenge. Topical agents are usually not sufficient to control the disease process. Potentially immunosuppressive treatments for psoriasis, including phototherapy and the use of glucocorticoids, methotrexate, and cyclosporine, are contraindicated. Eleven patients with psoriasis associated with HIV infection were enrolled in a 20-week treatment protocol. Six (54 percent) of the 11 achieved good to excellent responses with acitretin monotherapy. Both skin and joint manifestations responded to acitretin therapy in most patients. Optimal results were achieved with a dosage of 75 mg/day. The adverse effects were moderate and well tolerated, and

parameters of immunosupression were not exacerbated in most patients. Thus acitretin does not appear to have immunosuppressive properties. Its mode of action in psoriasis is unknown, regardless of HIV status. [44]
ISOTRETINOIN Isotretinoin has a lesser effect on psoriasis than acitretin or etretinate, although some efficacy has been shown in combination with PUVA. [22] Nevertheless, some dermatologists use isotretinoin to treat women with psoriasis who need systemic retinoids in order to avoid the long postacitretin contraception period.

Acne

The retinoid of first choice for the treatment of acne is isotretinoin. The introduction of isotretinoin was a key step in the history of dermatologic treatment. It is still the only compound that really cures acne because it is the only one that affects, albeit not to the same degree, all etiologic factors implicated in the pathogenesis of acne: sebum production, comedogenesis, and colonization with *Propionobacterium acnes.* [45] Among the natural and synthetic retinoids used in humans, only isotretinoin suppresses sebum excretion and significantly improves acne. The “sebospecificity” of oral isotretinoin cannot be explained on the basis of the molecular biology of retinoid nuclear receptors because it has no special affinity to any of the identified retinoid nuclear receptors. Attempts have been made to relate the sebosuppressive effect to a metabolite; 4-oxoisotretinoin has been considered as a candidate, but little supporting evidence has been presented so far. The antiacne effect of isotretinoin relates mainly to its potential to inhibit the production of sebum by inhibition of sebaceous gland differentiation and proliferation, reduction of sebaceous gland size, decrease of skin dihydrotestosterone, and downregulation of skin androgen receptors. Other mechanisms include desquamative effects on poral occlusion, antibacterial action, and anti-inflammatory effects. In the early 1980s, isotretinoin treatment was restricted to patients suffering from severe nodulocystic acne. With increasing experience, however, its use has been extended to patients with less severe disease who respond unsatisfactorily to conventional therapies such as long-term antibiotics because of the increased resistance of *P. acnes* to many antibiotics, in particular erythromycin and tetracycline. [46] Patients with moderate acne that may induce scars also have been treated. Current isotretinoin usage policies and treatment recommendations are being reviewed by expert panels to provide treatment guidelines based on clinical experience. [47]

Acne morbidity is related to more than physical appearance. The significant psychosocial impact of acne includes depression, anxiety, interpersonal and work-related difficulties, and attempted suicide. Studies with quality-of-life instruments have shown that isotretinoin treatment significantly improves mental health, social function, and self-esteem.

It initially had been considered that optimal benefit would be achieved with a high daily dose, about 1 mg/kg of body weight per day. [45] This high dose induces undesirable side effects, and similar short-term therapeutic results are obtained with a dose below 0.5 mg/kg of body weight per day. This approach implies that the treatment is maintained over a longer period of time in order to reach the threshold of the cumulative dose, a concept introduced in 1989. [48] The cumulative dose (mg/kg of body weight) is the total amount of oral isotretinoin taken by the patient during treatment divided by body weight. Thus a patient weighing 50 kg and receiving 25 mg/day of isotretinoin for 100 days would receive a cumulative dose of 50 mg/kg (25 mg × 100 days divided by 50 kg). Data from several centers indicate that posttherapy relapse is minimized by a treatment course amounting to a cumulative dose of at least 120 mg/kg [49] with no further therapeutic gain beyond about 150 mg/kg. [47] A lag period of 1 to 3 months may exist before the onset of the therapeutic effect. Continued healing after the discontinuation of therapy regularly occurs. Consequently, treatment need not be maintained until total clearance is achieved. Approximately one-third of patients with acne require a second course of therapy for either persistent disease or relapse. The only predictive factors of resistance to isotretinoin treatment are closed comedonal acne and microcystic acne. [50] A flareup of disease during the first few weeks of treatment and the evolution of acne cysts into lesions resembling pyogenic granuloma may be observed with isotretinoin treatment; these reactions may be due to the cessation of previous systemic antibiotics in association with impaired cutaneous barrier function leading to *Staphylococcus aureus* colonization and formation of granulation tissue. Furthermore, retinoids may alter directly or indirectly the expression of pro- or antiangiogenic growth factors such as vascular endothelial growth factor/vascular permeability factor (VEGF/VPF). Women with a history of acne refractory to isotretinoin or repeated relapses should be examined for hirsutism, questioned about abnormal patterns of menstruation, and considered for an endocrinologic workup for evaluation of ovarian or adrenal dysfunction. Adrenal dysfunction and 5a-reductase hyperactivity have been reported in such cases. [51]

Women of childbearing potential must have a negative pregnancy test and must practice effective contraception during and for 1 month after the completion of therapy. A 1-month posttherapy contraceptive period affords a sufficient safety margin because plasma concentrations of isotretinoin return to physiologic levels within 10 days of therapy completion. [52] The SMART (System to Manage Accutane Related Teratogenicity) has been put into effect by the FDA and the manufacturer of isotretinoin.

Isotretinoin has limited effect on hidradenitis suppurativa; surgical treatment is the first choice for all intertriginous lesions. Some investigators recommend oral isotretinoin during the weeks or months preceding the surgery and perhaps also during the postoperative period. [53]

Cutaneous T Cell Lymphoma (CTCL)

Etretinate may induce clinical improvement in patients with CTCL (e.g., mycosis fungoides or Sézary syndrome) with no internal involvement; better results were obtained when etretinate was combined with PUVA treatment or interferon-a. The combination of acitretin or isotretinoin with oral vitamin D_3 calcitriol to obtain synergistic effects for the treatment of CTCL has been reported. [54], [55]

Both oral and topical bexarotene have produced improvement in patients with CTCL; the topical formulation also has shown efficacy in Kaposi's sarcoma. In early (IA-IIA) and advanced (IIB-IVB) stages of CTCL, oral bexarotene monotherapy produced about 60 and 50 percent response rates, respectively, at a dose of 300 mg/m^2 or higher per day

within the first 2 months in most patients. [56], [57] The FDA approved bexarotene in December 1999 as oral therapy for the treatment of CTCL that is refractory to at least one systemic therapy and in June 2000 as a gel formulation for cutaneous manifestations of early-stage refractory or persistent CTCL. [57] The recommended initial dose is 300 mg/m ^{2} per day, administered as a single oral dose with meals. Based on the severity of adverse effects, the dose may be adjusted down to 100 or 200 mg/m ^{2} per day or may be suspended temporarily. If the tumor does not respond after 8 weeks of therapy, the dose may be increased to 400 mg/m ^{2} per day with careful monitoring.

FDA-Unapproved Clinical Uses

The pleomorphic effects of the retinoids, as well as the relatively selective targeting of skin structures, explain their broad potential benefit for patients with skin disease. Multiple other skin disorders respond to retinoids (see Table 257-1), but only for a few of them is the effect established in controlled studies. [58] In many skin conditions, reports were confined to etretinate before acitretin was developed, and the choice of etretinate/acitretin rather than isotretinoin was based not on pharmacologic considerations but on availability of the product.

Ichthyosis

Among the different types of ichthyoses, the best results are obtained with acitretin in nonbullous congenital ichthyosis such as erythrodermic and nonerythrodermic lamellar ichthyosis. Treatment of bullous ichthyosiform erythroderma may lead to an initial increase in bullae. Good results also have been achieved in recessive X-linked ichthyosis and ichthyosis vulgaris; however, in contrast to lamellar ichthyosis, the limited severity of the disease often does not require retinoid therapy.

Darier's Disease

Severe forms of Darier's disease are good indications, and care should be taken to initiate therapy with a very low dose, such as 10 mg/day of acitretin, to prevent initial exacerbation of the disease; usually 20 mg/day is sufficient for significant improvement.

Pityriasis Rubra Pilaris (PRP)

Early treatment with retinoids appears to offer the best chance for clearing of PRP. In extensive cases, concomitant use of methotrexate may be advantageous. Etretinate is considered to be superior to isotretinoin in the treatment of adult-onset PRP. [59]

Rosacea

In severe forms or treatment-resistant rosacea, isotretinoin may be more effective on inflammatory lesions than on vascular lesions. [60] A low daily dose (10 mg) is often sufficient. The best indications are severe cases of rosacea associated with significant seborrhea.

Premalignant and Malignant Skin Lesions

Etretinate and acitretin are effective in the treatment of premalignant skin lesions, including human papillomavirus–induced tumors and actinic keratoses. In the basal cell nevus syndrome and in xeroderma pigmentosum, these drugs reduce dramatically the incidence of malignant degeneration of the skin lesions. A double-blind study demonstrated that acitretin at a dose of 30 mg/day for 6 months prevented the development of premalignant and malignant skin lesions in renal transplant recipients. [61]

Graft-Versus-Host Disease (GVHD)

In an open study, 3 months of therapy with etretinate produced an encouraging response among patients with refractory sclerodermatous chronic GVHD resulting from allogeneic bone marrow transplantation. [62]

Lichen Sclerosus et Atrophicus

Acitretin is an effective treatment for severe lichen sclerosus et atrophicus of the vulva and may be recommended intermittently for patients who are intolerant of or resistant to local therapies.

Lupus Erythematosus

Both isotretinoin and acitretin have been used successfully by patients with various forms of lupus erythematosus. However, the lesions recurred after completion of the treatment as quickly as the initial improvement had appeared. Acitretin and hydroxychloroquine are equally effective in the treatment of chronic discoid lupus erythematosus and subacute cutaneous lupus erythematosus.

ADVERSE EFFECTS

Teratogenicity is the most troublesome adverse effect of oral retinoids. The side-effects profile of systemic retinoids (Table 257-2) resembles qualitatively that of the clinical toxic effects of vitamin A or hypervitaminosis A syndrome, although important differences exist. These effects can be globally divided into two types: skin and mucous membrane adverse effects (Type I) and systemic toxic effects (Type II) (Table 257-3). The acute retinoid toxicities include

mucocutaneous lesions (most patients) and laboratory abnormalities (less common but may be severe), whereas the chronic retinoid toxicities involve bony changes (rare).

TABLE 257-2 **Adverse Effects of Systemic Retinoids**



TABLE 257-3 **Types of Side Effects with Oral Retinoids**

Teratogenicity

Isotretinoin and etretinate are potent teratogens, and fetal deformities are the major concern in treating fertile women with oral retinoids. The teratogenic threshold has not been established for synthetic retinoids in humans in contrast to vitamin A. [63] Therefore, there is no safe minimal dose during pregnancy. Retinoid-induced birth defects (retinoid acid embryopathy) include auditory, cardiovascular, craniofacial, ocular (microphthalmia), axial and acral skeletal, central nervous system (hydrocephalus, microcephaly), and thymus gland abnormalities. [64] Etretinate is less likely to induce cardiac malformations and more likely to induce acral skeletal malformations. In some instances, the abnormalities may lead to death, spontaneous abortions, and premature birth. The putative mechanism involves toxic effects on neural crest cells, particularly with exposure during the fourth week of gestation. [65]

In men, retinoid therapy does not appear to produce abnormalities in spermatogenesis, sperm morphology, and sperm motility. [66] However, it is not known whether retinoids present in human semen interfere with normal embryogenesis. No typical retinoid embryopathy malformations have been reported in pregnancies where the male partner was taking acitretin at the time of the conception. No conclusions can be drawn from these limited data, and it is usually recommended that men who are actively trying to father children avoid systemic retinoid therapy.

The recommended duration of contraception after discontinuation of oral retinoid therapy varies with the different retinoid compounds, reflecting mainly their pharmacologic profiles (half-life, deposition in adipose tissue).

Skin and Mucous Membrane Adverse Effects (Type I)

MUCOCUTANEOUS Undesirable dose-related effects on the skin and mucous membranes during treatment with systemic retinoids reflect mainly decreased sebum production, reduced stratum corneum thickness, and altered skin barrier function. [67] Most patients receiving retinoids develop dryness and chapping of the lips, skin, and mucous membranes. Cheilitis is the most common toxicity occurring in almost all patients receiving isotretinoin. Cheilitis is the earliest and the most frequent sign appearing after the start of acitretin treatment, followed by blepharoconjunctivitis, dry eyes, dry nose, and dry mouth. [67] Dryness of the mouth with thirst and dryness and fragility of the nasal mucosa, leading to epistaxis, are observed frequently. Xerosis of the skin, associated with pruritus and peeling, especially of the palms and soles, occurs very frequently. Etretinate and acitretin in particular lead to palm, sole, and fingertip peeling and skin fragility. [67] Skin fragility and fissuring of fingertips sometimes create a problem, especially for those who work with their hands. Photosensitivity is particularly observed with isotretinoin and probably reflects the reduction of thickness of the stratum corneum. Bexarotene appears to induce fewer mucocutaneous and ocular side effects than other classes of retinoids; localized or extensive exfoliative dermatitis is the most common cutaneous side effect with bexarotene. [24] *S. aureus* colonization tends to correlate with isotretinoin-induced reduction in sebum production and may lead to overt cutaneous infections. [68] Various ill-defined skin eruptions, called *retinoid dermatitis,* are observed frequently. The erythema is sometimes difficult to differentiate from the underlying psoriasis, which might become erythrodermic. In atopic patients, eczema may be worsened and pruritus exacerbated by oral retinoids.
OCULAR Blepharoconjunctivitis occurs with varying severity in about one-third of patients and may prevent the use of contact lenses. *S. aureus* has been cultured from the eyelids of patients with isotretinoin-induced blepharoconjunctivitis, and *S. aureus* colonization of the conjunctival sac increases significantly during isotretinoin therapy. However, bacterial

conjunctivitis occurs to a lesser extent than *S. aureus* colonization. [69] If artificial tears and topical ophthalmologic antibiotic therapy fail to alleviate the conjunctivitis, ophthalmologic consultation should be sought.

HAIR AND NAILS Diffuse or localized hair loss (telogen effluvium), which is more severe during treatment with etretinate than with isotretinoin, is a common complaint, although objective alopecia tends to occur only at higher dosage levels. Systemic retinoids may induce undesirable effects on the nail apparatus, such as nail thinning, fragility, and shedding; paronychia-like changes; and periungual granulation tissue.

Systemic Toxic Effects (Type II)

BONE Bone toxicity was first observed in retinoid-treated patients maintained on a high dose and after an extended period of continuous treatment for disorders of keratinization. Bone pain without objective evidence of any abnormalities and without sequelae is frequent in retinoid-treated patients. Although these minor complaints appear to have no long-term pathologic effects on the skeleton, several reports with conflicting results have implicated synthetic retinoids, including etretinate and isotretinoin, in the formation of diffuse hyperostoses of the spine [diffuse idiopathic skeletal hyperostosis (DISH) syndrome–like bone changes] and in calcification of tendons and ligaments, particularly involving the ankles. [70] Specific findings include anterior spinal ligament calcification, osteophytes, extraspinal calcifications, and bony bridges but no narrowing of the disk space. Rarely, ossification of the spinal posterior longitudinal ligament has been reported; this change, if progressive, may lead to spinal cord compression with signs of partial spastic paraplegia. [71] Based on data from retrospective studies, it was concluded that although many of the bone changes could not be positively attributed to etretinate or acitretin therapy, spurs and interosseous membrane and tendon calcifications probably were treatment-related. [72] Subsequent prospective studies have shown that the effects of retinoids on bone, if present at all, likely involve worsening of preexisting skeletal overgrowth rather than de novo changes. [73] The long-term use of isotretinoin by patients with acne does not usually cause clinically significant radiologic abnormalities, and most hyperostoses are asymptomatic and clinically insignificant. [74] Osteoporosis has been observed with hypervitaminosis A and after long-term therapy with etretinate but not with isotretinoin. [75] However, recently, a loss of bone density of 4.4 percent without measurable alterations of calcium metabolism was identified in patients after 6 months of isotretinoin use compared with control subjects. [76] In children, only a few cases of skeletal abnormalities including osteoporosis, periostal thickening, slender long bones, and premature epiphyseal closure [67], [77], [78] and [79] have been reported. No baseline x-rays are required, although monitoring high-risk patients receiving prolonged high-dose retinoid treatment may be useful.

MUSCLE Muscle pain and cramps occur in patients taking etretinate or acitretin; however, these muscle effects are associated mostly with isotretinoin, particularly in individuals involved in vigorous physical activity. Sometimes myalgias are accompanied by elevations in creatine phosphokinase levels. Increased muscle tone and axial muscle rigidity and myopathy were reported to be related to etretinate and acitretin therapy, respectively. [80]

CENTRAL NERVOUS SYSTEM (CNS) AND PSYCHIATRIC CNS side effects are rare. Although individual signs of increased intracranial pressure such as headache, nausea, and vomiting are observed occasionally, the complete syndrome with papilledema (pseudotumor cerebri) and impaired vision is exceptional. [81] Concomitant use in isotretinoin-treated patients of tetracycline, doxycycline, or minocycline, which rarely produce increased intracranial hypertension, is the major risk factor for developing pseudotumor cerebri. Combined therapy with isotretinoin and these antibiotics should be avoided. Examination for papilledema should be performed immediately when a patient receiving retinoid therapy complains of headache, visual changes, nausea, or vomiting or if pseudotumor cerebri is otherwise suspected. There have been anecdotal reports suggesting a causal association between isotretinoin therapy in acne patients and severe depression, psychosis, and suicide attempts. [82] However, large-scale epidemiologic studies provide no evidence that isotretinoin exposure compared with antibiotics is associated with increased risk of newly diagnosed depression, suicidal behavior, psychosis, or other psychiatric disorders. [83] Two patients have been reported to undergo a definite change in their dream patterns with a story-like script 2 to 3 weeks after starting treatment with isotretinoin. [84]

OCULAR The most common retinoid effects on eyes are dryness and irritation. Alterations in visual function, mainly poor night vision, excessive glare sensitivity, and changes in color perception, also have been reported. [85]

PANCREATITIS In contrast to first- or second-generation retinoids, acute hemorrhagic pancreatitis has been encountered with a high incidence in patients taking bexarotene. One case of fatal fulminant pancreatitis with acitretin treatment has been reported. [86] Pancreatitis occured in three patients treated with oral bexarotene, 300 mg/m ^{2} or more per day, in association with marked elevations of fasting serum triglycerides. [56] For safety reasons, an initial dose of 300 mg/m ^{2} or less per day is recommended.

HYPOTHYROIDISM Clinical and biochemical central hypothyroidism occurred in 40 percent of patients in the CTCL trials with bexarotene. It was rapidly and completely reversible with cessation of therapy without any clinical sequelae. [56], [87] This effect probably is mediated through suppression of thyrotropin ß subunit (TSHß) secretion by the thyrotrope cells of the anterior pituitary, which express RXR?.

RENAL Renal toxicity has not been a characteristic consequence of retinoid administration. Isotretinoin has been administered safely to patients with end-stage kidney disease who were undergoing hemodialysis. However, case reports describing reversible renal function impairment with elevated creatinine levels during etretinate therapy advise monitoring renal function during retinoid therapy, particularly in patients with a history of renal disorders. [88]

INFLAMMATORY BOWEL DISEASE Isotretinoin rarely has been linked to inflammatory bowel disease (IBD). Four cases of IBD that were induced or exacerbated by isotretinoin have been reported. There was a history of IBD in most of these patients prior to the introduction of isotretinoin. Thus isotretinoin may be used with caution in the presence of IBD. A 5-year prospective study did not demonstrate an increased risk of IBD or of cancer, diabetes, and cardiovascular disease in association with long-term etretinate use for psoriasis. [86] Similar safety with long-term acitretin therapy has not been established.

Laboratory Abnormalities

HYPERLIPIDEMIA Serum lipid changes are the most frequent laboratory abnormalities of retinoid therapy. Isotretinoin and etretinate/acitretin elevate triglycerides in 50 percent and cholesterol in 30 percent of treated patients, [66], [89] whereas bexarotene elevates triglycerides and cholesterol in approximately 79 and 48 percent of patients, respectively. [56]

Disturbance of blood lipids is generally higher with isotretinoin. In cases of severe retinoid-induced hypertriglyceridemia, eruptive xanthomas and acute hemorrhagic pancreatitis may occur. Obtaining baseline serum lipids before initiating retinoid therapy and additional values every 1 to 2 weeks until they are stable (generally in 4 to 8 weeks) may be desirable. In practice, however, monitoring levels monthly for the first 2 months and then at 2- to 3-month intervals is adequate in patients with normal baseline lipid levels and absence of risk factors (obesity, high alcohol intake, diabetes). Discontinuation of therapy is required if the triglyceride level reaches 800 mg/dL. A less severe increase may be treated by dose reduction, therapy withdrawal until normalization of serum lipids, or reduction in alcohol and tobacco consumption. In some instances, lipid-lowering agents may be indicated. [90] Coadministration of atorvastatin with bexarotene is recommended to lower the risk of hyperlipidemia and pancreatitis. [24] The effects of retinoid-induced hyperlipidemia and its management during long-term therapy on the development of atherosclerotic cardiovascular disease are unknown. Retinoids probably cause hyperlipidemia by interfering with lipid clearance. Transactivation of RXRs increases the expression of apolipoprotein C-III, which prevents the uptake of lipids from very low density lipoproteins (VLDL) into cells. [91]

LIVER TOXICITIES Transitory abnormal elevations in serum transaminases have been reported in approximately 20 percent of patients treated with either etretinate or acitretin and occur much less frequently with isotretinoin and bexarotene. Alkaline phosphatase, lactate dehydrogenase, and bilirubin also may be abnormal. Liver function test changes usually occur between 2 and 8 weeks after therapy is begun. Severe or persistent hepatotoxic reactions appear in less than 1 percent of patients. Acitretin therapy elicited no biopsy-proven hepatotoxicity in a 2-year prospective study, suggesting that periodic liver biopsy should not be necessary. [92] No specific studies evaluate the use of retinoids in patients with hepatic insufficiency. However, because retinoids are metabolized by hepatic cytochrome P-450 isoenzymes (CYP 3A4) and undergo partial biliary elimination, significant hepatic insufficiency may interfere with drug elimination. Transaminase elevations greater than three times the upper normal range should lead to discontinuation of retinoid therapy. With two- to threefold transaminase elevations, therapy should be withdrawn until liver function tests are normalized. [24]

HEMATOLOGIC TOXICITIES A high incidence (28 percent) of dose-related leukopenia has been reported with bexarotene in the CTCL studies, occuring as early as 2 to 4 weeks, and due to a decrease in neutrophils rather than lymphocytes. [56] Hematologic abnormalities are much less common with other retinoids. However, careful hematologic monitoring in HIV-infected patients is warranted. Most adverse effects associated with retinoids are preventable and manageable with proper patient selection, dose adjustments, discontinuation of treatment, and routine monitoring for potential toxicity. Absolute contraindications are pregnancy or women contemplating becoming pregnant, noncompliance with contraception, breast-feeding, and hypersensitivity to parabens (preservatives present in acitretin's capsule). Relative contraindications are leukopenia, cholesterol or triglyceride elevations, significant hepatic (especially bexarotene) or renal dysfunction, and hypothyroidism (bexarotene). Patients should be advised not to take other vitamin A supplements.

DRUG INTERACTIONS

The concurrent use of retinoids with other therapies having similar side effects may increase the risk of these adverse events. Tretracycline, minocycline, and doxycycline (increased intracranial pressure and increased phototoxicity), alcohol (increased conversion to etretinate, hepatoxicity), metothrexate (synergistic liver toxicity with retinoids), and vitamin A supplements (hypervitaminosis A) should be avoided. [86] The concomitant administration of bexarotene and gemfibrozil results in a substantial increase in plasma concentrations of bexarotene and its potential toxicity, probably at least partially related to CYP450 3A4 inhibition by gemfibrozil. The concomitant administration of atorvastatin does not affect bexarotene plasma levels and is the recommended concomitant antilipemic therapy. In rare instances, patients with diabetes may have more difficulty controlling glucose while taking a retinoid; however, a causal relationship is uncertain. In addition, acitretin may possibly reduce the efficacy of progestin-only contraceptives. Retinoid drug levels and resultant potential for toxicity may increase with CYP 3A4 inhibitors such as azole and macrolides. In contrast, antituberculosis drugs (rifampicin) and anticonvulsants (phenytoin and carbamazepine) may decrease the drug levels of retinoids via CYP 3A4 induction. Retinoids may also increase the drug levels of cyclosporine via competition for CYP 3A4 metabolism. [24] Neomycin induces malabsorption syndrome, especially with regard to the absorption of vitamin A.

FACTORS IN THE DECISION TO USE RETINOIDS

As with other medications, the risk-benefit ratio should be used to determine whether or not to treat a dermatologic patient with synthetic retinoids. Factors to be considered include the following:

1. *Responsiveness of the disorder to retinoids.* The treatment of severe acne vulgaris with isotretinoin is optimal, with short-term exposure leading to long-term remission.
2. *Dose of retinoid required.* The use of retinoids in combination with other effective treatments, such as RePUVA (combination photochemotherapy) for psoriasis, may enhance efficacy and allow dose reduction with fewer side effects.
3. *Availability of alternative treatments.* In some diseases (severe Darier's disease, pustular psoriasis, pityriasis rubra pilaris, epidermolytic hyperkeratosis), synthetic retinoids may be the only effective treatment.
4. *Acute and chronic toxicity of retinoid therapy.* Major systemic adverse effects, such as teratogenicity, and ocular, bone, lipid, and liver adverse effects make careful patient selection and ongoing laboratory surveillance critical. Diseases that relapse rapidly on withdrawal of synthetic retinoids require continuous retinoid administration and, therefore, are associated with increased risk of chronic skeletal toxicity, particularly in children.
5. *Severity of the disease.* Disease-induced limitations on educational, psychological, or physical development should be considered. For example, early retinoid treatment of lamellar ichthyosis may prevent the development of ectropion.
6. *Age of the patient.* Children with disorders of cornification requiring chronic moderate- to high-dose retinoid therapy are at highest risk of developing bone toxicity. They are at risk of premature epiphyseal closure, and because of longer lifetime exposure to the drug, they are at higher risk for future development of the vertebral changes resembling DISH syndrome–like bone changes.
7. *Sex of the patient.* Retinoid teratogenicity entails special risks for the female patient of childbearing potential.

Current guidelines are that adequate contraception should be used for at least 1 month before therapy with all systemic retinoids. Isotretinoin and bexarotene require contraception for 1 month after cessation of therapy, whereas acitretin and etretinate require contraception for 3 years after cessation of therapy in the United States and 2 years in Europe.

8. *Presence of other disorders that may be aggravated by retinoid use.* Renal or hepatic compromise, preexisting hyperlipidemia, or a family history of hyperlipidemia or premature atherosclerotic cardiovascular disease should be considered in the therapeutic assessment.
9. *Concomitant use of other drugs.* Drugs interacting with hepatic CYP 3A4 metabolism should be administered carefully in association with systemic retinoids. Other drugs that are hepatotoxic (methotrexate), elevate serum lipids (estrogens, glucocorticoids), or rarely produce benign intracranial hypertension (tetracycline, doxycycline) should be avoided, if possible, or the patient must be monitored carefully during the clinical course.

After more than two decades of experience with isotretinoin and etretinate/acitretin in the treatment of dermatologic diseases, synthetic retinoids are firmly established as efficacious therapeutic agents. New retinoids (agonists, inverse agonists, or neutral antagonists) are being designed to interact with selected nuclear retinoic acid receptors (RARs, RXRs) to focus on a specific therapeutic goal and to improve the therapeutic index.

REFERENCES

1. Wolbach SB, Howe PR: Tissue changes following deprivation of fat-soluble A vitamin. *J Exp Med* **42**:753, 1925

2. Von Stüttgen G et al: The therapeutic use of vitamin A acid. *Acta Derm Venereol (Stockh)* **55** (suppl 74):174, 1975

3. Huang ME et al. Use of all- *trans* retinoic acid in the treatment of acute promyelocytic leukemia. *Blood* **72**:567, 1988

4. Orfanos CE et al: Effect of vitamin A acid (VAA) on psoriasis: Topical combined therapy using corticoids. Two new VAA preparations for oral administration. *Arch Dermatol Forsch* **244**:424, 1972

5. Ott F, Bollag W: Therapie der Psoriasis mit einem oral wirksamen neuen Vitamin A Säure-Derivat. *Schweiz Med Wochenschr* **105**:439, 1975

6. Orfanos CE, Runne U: Systemic use of a new retinoid with and without local dithranol treatment in generalized psoriasis. *Br J Dermatol* **95**:101, 1976

7. Peck GL, Yoder FW: Treatment of lamellar ichthyosis and other keratinising dermatoses with an oral synthetic retinoid. *Lancet* **21**:1172, 1976

8. Peck GL et al: Prolonged remissions of cystic and conglobata acne with 13- *cis*-retinoic acid. *N Engl J Med* **300**:329, 1979

9. Peck GL: Treatment of basal cell carcinomas with 13- *cis*-retinoic acid. *Proc Am Assoc Cancer Res* **20**:56, 1979

10. Petkovich M et al: A human retinoic acid receptor which belongs to the family of nuclear receptors. *Nature* **330**:444, 1987

11. Giguere V et al: Identification of a receptor for the morphogen retinoic acid. *Nature* **330**:624, 1987

12. DiSepio D et al: Retinoic acid receptor–nuclear factor–interleukin 6 antagonism: A novel mechanism of retinoid-dependent inhibition of a keratinocyte hyperproliferative differentiation marker. *J Biol Chem* **272**:25555, 1997

13. Howell SR et al: Effects of retinoid treatment of rats on hepatic microsomal metabolism and cytochromes P450: Correlation between retinoic acid receptor retinoid X receptor selectivity and effects on metabolic enzymes. *Drug Metab Dispos* **26**:234, 1998

14. Budhu A et al: Localization of the RAR interaction domain of cellular retinoic acid binding protein-II. *J Mol Biol* **305**:939, 2001

15. Geiger JM, Czarnetzki BM. Acitretin (Ro 10-1670, etretin): Overall evaluation of clinical studies. *Dermatologica* **176**:182, 1988

16. Brindley CJ: Overview of recent clinical pharmacokinetic studies with acitretin (Ro 10-1670, etretin). *Dermatologica* **178**:79, 1989

17. Geiger JM, Saurat JH: Acitretin and etretinate. *Dermatol Clin* **11**:117, 1993

18. Wiegand UW, Chou RC: Pharmacokinetics of acitretin and etretinate. *J Am Acad Dermatol* **39**:S25, 1998

19. Tian K et al. The isolation and characterization of purified heterocomplexes of recombinant retinoic acid receptor and retinoid X receptor ligand binding domains. *Biochemistry* **36**:5669, 1997

20. Wiegand UW, Jensen BK: Pharmacokinetics of acitretin in humans, in *Retinoids: 10 Years On,* edited by JH Saurat. Basel, Karger, 1991, p 192

21. Gronhoj Larsen F et al: Acitretin is converted to etretinate only during concomitant alcohol intake. *Br J Dermatol* **143**:1164, 2000

22. Saurat JH: Systemic retinoids. What's new? *Dermatol Clin* **16**:331, 1998

23. Wiegand UW, Chou RC: Pharmacokinetics of oral isotretinoin. *J Am Acad Dermatol* **39**:S8, 1998

24. Nguyen E-QH, Wolverton SE: Systemic retinoids, in *Comprehensive Dermatologic Drug Therapy*, edited by SE Wolverton. Philadelphia, Saunders, 2001, p 269

25. Howell SR et al: Bexarotene metabolism in rat, dog, and human, synthesis of oxidative metabolites, and in vitro activity at retinoid receptors. *Drug Metab Dispos* **29**:990, 2001

26. Lassus A, Geiger JM: Acitretin and etretinate in the treatment of palmoplantar pustulosis: A double-blind comparative trial. *Br J Dermatol* **119**:755, 1988

27. Kragballe K et al: A double-blind comparison of acitretin and etretinate in the treatment of severe psoriasis: Results of a Nordic multicentre study. *Acta Derm Venerol (Stockh)* **69**:35, 1989

28. Ledo A et al: Acitretin (Ro 10-1670) in the treatment of severe psoriasis: A randomized double-blind parallel study comparing acitretin and

etretinate (Tigason). *Int J Dermatol* **27**:656, 1988

29. Gollnick H et al: Acitretin versus etretinate in psoriasis: Clinical and pharmacokinetic results of a German multicenter study. *J Am Acad Dermatol* **19**:458, 1988

30. Bjerke JR, Geiger JM: Acitretin versus etretinate in severe psoriasis: A double-blind randomized Nordic multicenter study in 168 patients. *Acta Derm Venereol Suppl* **146**:206, 1989

31. White SI et al: Etretinate in pustular psoriasis of palms and soles. *Br J Dermatol* **113**:581, 1985

32. Ozawa A et al: Treatments of generalized pustular psoriasis: A multicenter study in Japan. *J Dermatol* **26**:141, 1999

33. Wolska H et al: Etretinate therapy in generalized pustular psoriasis (Zumbusch type). *Dermatologica* **171**:297, 1985

34. Dubertret L et al: Maintenance treatment of psoriasis by Tigason: A double-blind randomized clinical trial. *Br J Dermatol* **113**:323, 1985

35. Ellis CN, Voorhees JJ: Etretinate therapy. *J Am Acad Dermatol* **16**:267, 1987

36. Lowe NL: When systemic retinoids fail to work in psoriasis, in *Retinoids: 10 Years On,* edited by JH Saurat. Basel, Karger, 1991, p 341

37. Lassus A et al: Treatment of severe psoriasis with etretin (Ro 10-1670). *Br J Dermatol* **117**:333, 1987

38. Goldfarb MT et al: Acitretin improves psoriasis in a dose-dependent fashion. *J Am Acad Dermatol* **18**:655, 1988

39. Lauharanta J et al: A clinical evaluation of the effects of an aromatic retinoid (Tigason), combination of retinoid and PUVA and PUVA alone in severe psoriasis. *Br J Dermatol* **104**:325, 1981

40. Saurat JH et al: Randomized double-blind multicenter study comparing acitretin-PUVA, etretinate-PUVA and placebo-PUVA in the treatment of severe psoriasis. *Dermatologica* **177**:218, 1988

41. Tanew A et al: Photochemotherapy for severe psoriasis without or in combination with acitretin: A rendomized, double-blind comparison study. *J Am Acad Dermatol* **25**:682, 1991

42. Roenigk HH Jr: Acitretin combination therapy. *J Am Acad Dermatol* **41**:S18, 1999

43. Lebwohl M: Acitretin in combination with UVB or PUVA. *J Am Acad Dermatol* **41**:S22, 1999

44. Buccheri L et al: Acitretin therapy is effective for psoriasis associated with human immunodeficiency virus infection. *Arch Dermatol* **133**:711, 1997

45. Layton AM et al: Isotretinoin for acne vulgaris: 10 years later: A safe and successful treatment: *Br J Dermatol* **129**:292, 1993

46. Eaddy EA et al: Antibiotic resistant propionibacteria in acne: Need for policies to modify antibiotic usage. *Br Med J* **306**:555, 1993

47. Cunliffe WJ et al: Roaccutane treatment guidelines: Results of an internation survey. *Dermatology* **194**:351, 1997

48. Harms M et al: Isotretinoin for acne: Should we consider the total cumulative dose? in *Acne and Related Disorders,* edited by R Marks, G Plewig. London, Martin Dunitz, 1989, p 203

49. Lehucher-Ceyrac D, Weber-Buisset MJ: Isotretinoin and acne: A prospective analysis of 188 cases over 9 years. *Dermatology* **186**:123, 1993

50. Lehucher-Ceyrac D et al: Predictive factors for failure of isotretinoin treatment in acne patients: Results from a cohort of 237 patients. *Dermatology* **198**:278, 1999

51. Chaspoux C et al: Acne in the male resistant to isotretinoin and responsibility of androgens: 9 cases, therapeutic implications. *Ann Dermatol Venereol* **126**:17, 1999

52. Wiegand UW et al: Treatment of female patients with isotretinoin: What is the safe post-therapy contraceptive period? Clinical Dermatology 2000 meeting, Vancouver, Canada, 1996

53. Boer J, van Gemert MJ: Long-term results of isotretinoin in the treatment of 68 patients with hidradenitis suppurativa. *J Am Acad Dermatol* **40**:73, 1999

54. French L et al: Remission of cutaneous T-cell lymphoma with combined calcitriol and acitretin. *Lancet* **344**:686, 1994

55. Thomsen K: Cutaneous T-cell lymphoma and calcitriol and isotretinoin treatment. *Lancet* **345**:1583, 1995

56. Duvic M et al: Phase 2 and 3 clinical trial of oral bexarotene (Targretin capsules) for the treatment of refractory or persistent early-stage cutaneous T-cell lymphoma. *Arch Dermatol* **137**:581, 2001

57. Duvic M et al: Bexarotene is effective and safe for treatment of refractory advanced-stage cutaneous T-cell lymphoma: multinational phase II-III trial results. *J Clin Oncol* **19**:2456, 2001

58. Arechalde A, Saurat JH: Retinoids: Unapproved uses or indications. *Clin Dermatol* **18**:63, 2000

59. Clayton BD et al: Adult pityriasis rubra pilaris: A 10-year case series. *J Am Acad Dermatol* **36**:959, 1997

60. Erdogan FG et al: Efficacy of low-dose isotretinoin in patients with treatment-resistant rosacea. *Arch Dermatol* **134**:884, 1998

61. Bavinck JNB et al: Prevention of skin cancer and reduction of keratotic skin lesions during acitretin therapy in renal transplant recipients: A double-blind, placebo-controlled study. *J Clin Oncol* **13**:1933, 1995

62. Marcellus DC et al: Etretinate therapy for refractory sclerodermatous chronic graft-versus-host disease. *Blood* **93**:66, 1999

63. Miller RK et al: Periconceptional vitamin A use: How much is teratogenic? *Reprod Toxicol* **12**:75, 1998

64. Lammer EJ et al: Retinoic acid embryopathy. *N Engl J Med* **313**:837, 1985

65. Sulik KK: Teratogenicity of the retinoids, in *Retinoids: 10 Years On,* edited by JH Saurat. Basel, Karger, 1991, p 282

66. Koo J et al: Advances in psoriasis therapy. *Adv Dermatol* **12**:47, 1997

67. Murray HE et al: A 12-month treatment of severe psoriasis with acitretin: Results of a Canadian open multicenter study. *J Am Acad Dermatol* **24**:598, 1991

68. Williams RE et al: *Staphylococcus aureus* and intranasal mupirocin in patients receiving isotretinoin for acne. *Br J Dermatol* **126**:362 1992

69. Egger SF et al: Ocular side effects associated with 13- *cis*-retinoic acid therapy for acne vulgaris: Clinical features, alterations of tearfilm and conjunctival flora. *Acta Ophthalmol Scand* **73**:355, 1995

70. Carey BM et al: Skeletal toxicity with isotretinoin therapy: A clinico-radiological evaluation. *Br J Dermatol* **119**:609,1988

71. Tfelt-Hansen P et al: Spinal cord compression after long-term etretinate. *Lancet* **2**:325, 1989

72. Kilcoyne RF. Effects of retinoids in bone. *J Am Acad Dermatol* **19**:212, 1988

73. van Dooren-Greebe R et al: Prolonged treatment with oral retinoids in adults: No influence on the frequency and severity of spinal abnormalities. *Br J Dermatol* **134**:71, 1996

74. Ling TC et al: What is the cumulative effect of long-term, low-dose isotretinoin on the development of DISH? *Br J Dermatol* **144**:630, 2001

75. DiGiovanna JJ et al: Osteoporosis is a toxic effect of long-term etretinate therapy. *Arch Dermatol* **131**:1263, 1995

76. Leachman SA et al: Bone densities in patients receiving isotretinoin for cystic acne. *Arch Dermatol* **135**:961, 1999

77. Gilbert M et al: Lack of skeletal radiographic changes during short-term etretinate for psoriasis. *Dermatologica* **172**:160, 1986

78. Halkier-Sörensen L et al: Bone changes in children on long-term treatment with etretinate. *J Am Acad Dermatol* **16**:999, 1987

79. Nishimura G et al: Generalized metaphyseal modification with cone-shaped epiphyses following long-term administration of 13- *cis*-retinoic acid. *Eur J Pediatr* **156**:432, 1997

80. Lister RK et al: Acitretin-induced myopathy. *Br J Dermatol* **134**:989, 1996

81. Bonnetblanc JM et al: Intracranial hypertension with etretinate. *Lancet* **2**:974, 1983

82. Chu A, Cunliffe WJ: The inter-relationship between isotretinoin/acne and depression. *J Eur Acad Dermatol Venereol* **12**:263, 1999

83. Jick SS et al: Isotretinoin use and risk of depression, psychotic symptoms, suicide, and attempted suicide. *Arch Dermatol* **136**:1231, 2000

84. Gupta MA, Gupta AK: Isotretinoin use and reports of sustained dreaming. *Br J Dermatol* **144**:919, 2001

85. Safran AB et al: Ocular side-effects of oral treatment with retinoids, in *Retinoids: 10 Years On,* edited by JH Saurat. Basel, Karger, 1991, p 315

86. Katz HL et al: Acitretin in psoriasis: An overview of adverse effects. *J Am Acad Dermatol* **41**:S7, 1999

87. Sherman SI et al: Central hypothyroidism associated with retinoid X receptor-selective ligands. *N Engl J Med* **340**:1075, 1999

88. Cribier B et al: Renal impairment probably induced by etretinate. *Dermatology* **185**:266, 1992

89. David M et al: Adverse effects of retinoids. *Med Toxicol* **3**:273, 1998

90. Vahlquist C et al: Effects of gemfibrozil (Lopid) on hyperlipidemia in acitretin-treated patients. *Acta Derm Venereol* **75**:377, 1995

91. Vu Dac N et al: Retinoids increase human apo C-III expression at the transcriptional level via the retinoid X receptor: Contribution to the hypertriglyceridemic action of retinoids. *J Clin Invest* **102**:625, 1998

92. Roenigk HH Jr et al: Effects of acitretin on the liver. *J Am Acad Dermatol* **41**:584, 1999

T>

Chapter 258

Nicholas Soter

Antihistamines

TRADITIONAL, CLASSIC, OR FIRST-GENERATION H1-TYPE ANTIHISTAMINES
Pharmacology
Mechanism of Action
Clinical Uses
Dosage Schedules and Formulations
Adverse Effects
Drug Interactions
LOW-SEDATING OR SECOND- AND THIRD-GENERATION H1-TYPE ANTIHISTAMINES
Pharmacology
Mechanism of Action
Clinical uses
Dosage Schedules and Formulations
Adverse Effects
Drug Interactions
H2-TYPE ANTIHISTAMINES
Pharmacology
Mechanism of Action
Clinical Uses
Dosage Schedules and Formulations
Adverse Effects
Drug Interactions
OTHER THERAPEUTIC AGENTS WITH ANTIHISTAMIC ACTIVITY
Tricyclic Antidepressants
Ketotifen

REFERENCES

In 1937, Bovet and Staub demonstrated that some of the effects of histamine in experimental animals could be antagonized by amines containing a phenolic ether moiety. Subsequent research led to the development of histamine-receptor antagonists, or antihistamines, that became available for clinical use as therapeutic agents in the 1940s. The fact that these antihistamines were unable to block the effects of histamine on the gastric mucosa suggested that histamine might exert its effects via different receptors, which were designated H_1 and H_2. This observation led to the synthesis of compounds that selectively blocked histamine at the H_2-receptor site. H_3 receptors have been recognized in the brain and lung, but not in the skin, in humans [1]; intracellular histamine receptors and H_4 receptors have been described in certain cells and tissues, but, again, not in the skin.

TRADITIONAL, CLASSIC, OR FIRST-GENERATION H_1-TYPE ANTIHISTAMINES

The traditional, classic, or first-generation H_1-type antihistamines have a substituted ethylamine moiety as an integral part of the molecule (Fig. 258-1). The activity of an H_1-type antihistamine is increased by the substitution of a halogen in the *para* position of the phenyl or benzyl group of R^1. For maximum activity, the terminal nitrogen of the ethylamine group should be a tertiary amine with methyl groups or a cyclic moiety in R^2 and R^3. The dextro isomers are more active than are the levo isomers. In addition, H_1-type antihistamines have a tertiary amino group linked by a two- or three-atom chain to two aromatic substituents. Traditional H_1-type antihistamines have been divided into six groups (Table 258-1) on the basis of substitution at the X position with nitrogen, oxygen, or carbon. The presence of multiple aromatic or heterocyclic rings and alkyl substituents results in their lipophilic properties. Evidence that with prolonged use H_1-type antihistamines may produce tachyphylaxis or lose their efficacy appears to reflect decreased compliance rather than an increased rate of metabolism.

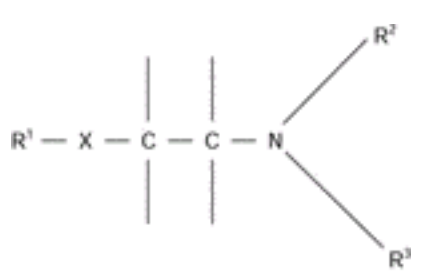

FIGURE 258-1 Ethylamine moiety present in H_1-type antihistamines. R^1, aromatic and/or heterocyclic groups; X, linkage such as nitrogen, oxygen, or carbon.

Chemical Class	Generic Name
Alkylamine (propylamine)	Brompheniramine maleate
	Chlorpheniramine maleate and tannate
	Dexbrompheniramine maleate
	Dexchlorpheniramine maleate
	Dimethindene maleate
	Triprolidine hydrochloride
Ethanolamine (aminoalkyl ether)	Carbinoxamine maleate
	Clemastine fumarate
	Diphenhydramine citrate and hydrochloride
	Doxylamine succinate
	Embramine hydrochloride
	Melenditamium methylsulfate
	Trimethobenzamine citrate
Ethylenediamine	Mepyramine maleate
	Pyrilamine maleate
	Tripelennamine citrate and hydrochloride
Phenothiazine	Dimethothiazine mesylate
	Methdilazine
	Methdilazine and methdilazine hydrochloride
	Promethazine hydrochloride and theoclate
	Trimeprazine tartrate
Piperidine	Azatadine maleate
	Cyproheptadine hydrochloride
	Diphenylpyraline hydrochloride
	Phenindamine tartrate
Piperazine	Hydroxyzine hydrochloride and pamoate

TABLE 258-1 **Traditional, Classic, or First-Generation H_1-Type Antihistamines**

Pharmacology

H_1-type antihistamines are absorbed from the gastrointestinal tract after oral administration. Their effects can be observed within 30 min, are maximal within 1 to 2 h, and persist for 4 to 6 h; however, some of these therapeutic agents may have a longer duration of action. For example, after the oral administration of a single dose, the serum half-lives of brompheniramine, chlorpheniramine, and hydroxyzine exceeded 20 h in adults. The serum half-lives of brompheniramine, [2] chlorpheniramine, diphenhydramine, and hydroxyzine are shorter in children and longer in elderly individuals. H_1-type antihistamines are metabolized by the hepatic cytochrome P450 (CYP) enzyme system CYP3A4, in which they are conjugated to form glucuronides. Excretion of these compounds in the urine is almost complete 24 h after administration.

The H_1-type antihistamines suppress wheal-and-erythema reactions induced by the intracutaneous injection of histamine for various time intervals depending on the agent studied. Their potency can be compared by their inhibition of the cutaneous wheal-and-erythema response. Clemastine, diphenhydramine, promethazine, and triprolidine are excreted in breast milk.

Mechanism of Action

H_1-type antihistamines are competitive inhibitors of the actions of histamine at tissue receptor sites. Their binding is reversible and they can be displaced by high levels of histamine. In addition to their antihistamine actions, H_1-type antihistamines also have sedative effects, anticholinergic activity, local anesthetic effects, antiemetic activity, and anti–motion-sickness effects. Some H_1-type antihistamines possess a-adrenergic receptor or cholinergic muscarinic receptor blocking properties, while others possess antiserotonin effects. Some H_1-type antihistamines may have additional antiallergic properties. For example, azatadine inhibits IgE-mediated histamine release and cysteinyl leukotriene generation and release in vitro from mast cells and basophils.

Clinical Uses

H_1-type antihistamines have been used for the relief of pruritus and for the treatment of urticaria, angioedema, and physical urticaria. In double-blind, placebo-controlled studies, H_1-type antihistamines were statistically superior to placebos in the treatment of urticaria and angioedema. However, comparative studies of the groups of H_1-type antihistamines have shown them to be of equal efficacy. If an agent from one therapeutic group of H_1-type antihistamine proves ineffective, then an agent from another group should be administered. H_1-type antihistamines from different groups may be combined. H_1-type antihistamines are of benefit to patients with a history of reactions to radiocontrast media and transfusion reactions.

H_1-type antihistamines are used to treat pruritus in patients with atopic dermatitis. Their efficacy may in part be related to the suppression of anxiety and to their sedative effect. Pruritus associated with other conditions, such as allergic contact dermatitis and other forms of eczematous dermatitis, lichen planus, mosquito bites, infestations, and pruritus secondary to underlying medical disorders or of an idiopathic nature, also may be relieved by H_1-type antihistamines, although controlled trials do not exist.

There are limited guidelines for the use of H_1-type antihistamines to treat pregnant women. Most H_1-type antihistamines are classified as United States Food and Drug Administration (FDA) pregnancy category B or category C. Although it is recommended that all H_1-type antihistamines be avoided in the first trimester of pregnancy, [3] a meta-analysis of malformations caused by H_1-type antihistamine use in pregnancy showed an odds ratio of 0.76, which suggested that the risk of fetal malformations in early pregnancy was less than that of controls. [4]

Dosage Schedules and Formulations

H_1-type antihistamines are conventionally administered in divided doses at intervals between 4 and 6 h. However, the observation that one oral dose of certain of these agents is associated with longer serum half-lives suggests that some H_1-type antihistamines may not require administration so frequently as was previously indicated. H_1-type antihistamines of the ethylenediamine group are no longer available in the United States.

Adverse Effects

Approximately 25 percent of patients receiving H_1-type antihistamines experience an adverse reaction. Sedation is the most common problem because H_1-type antihistamines cross the blood-brain barrier. This sedative effect is pronounced with the ethanolamine and the phenothiazine groups and is less marked with the alkylamine group. The sedative effect ameliorates in most individuals within a few days of continual administration of H_1-type antihistamines. If tolerance to the sedative manifestations does not occur, an agent from another group should be used.

The use of H_1-type antihistamines has been associated with increased occupational injuries at work, and the risk of injury is enhanced with an odds ratio of 1.5. [5] Other central nervous system (CNS) effects include dizziness, tinnitus, disturbed coordination, inability to concentrate, blurred vision, and diplopia. Stimulatory CNS effects, which occur especially with the alkylamine group, include nervousness, irritability, insomnia, and tremor.

Studies to demonstrate the CNS effects of H_1-type antihistamines include the multiple sleep latency test, critical flicker fusion test, choice reaction time, digit symbol substitution test, tests involving brain stem-evoked potentials, acuity tests, cognitive skill tests, and actual and simulated driving tests. [6] In brain stem-evoked potential studies, the individual's attention and processing speed are impaired by H_1-type antihistamines. In multiple studies, driving skills were impaired after the use of H_1-type antihistamines. Fatal automobile accidents have been reported.

Gastrointestinal complaints, which are the second most frequent side effect and are noted especially with the ethylenediamine group, include anorexia, nausea, vomiting, epigastric distress, diarrhea, and constipation. The administration of these agents with food may eliminate some of these manifestations.

H_1-type antihistamines have anticholinergic effects, which include dry mucous membranes, difficulty in micturition, urinary retention, dysuria, urinary frequency, and impotence. These clinical manifestations occur with the ethanolamine, the phenothiazine, and the piperazine groups. The anticholinergic effects of H_1-type antihistamines preclude their use in patients with narrow-angle glaucoma and require that they be used with caution in patients with prostatic hypertrophy.

The cardiovascular effects of H_1-type antihistamines are not usually experienced after oral administration. Transient hypotension may develop after intravenous therapy, especially if the drug is administered rapidly.

Cutaneous reactions occurring after the administration of H_1-type antihistamines are uncommon; they include eczematous dermatitis, allergic contact dermatitis, urticaria, petechiae, fixed drug eruptions, and photosensitivity.

In children, acute poisoning may develop; hallucinations, ataxia, incoordination, athetosis, and convulsions are the major features. Anticholinergic effects include flushing, dilated pupils, and hyperthermia.

Drug Interactions

The H_1-type antihistamines diphenhydramine, chlorpheniramine, clemastine, promethazine, hydroxyzine, and tripelennamine inhibit CYP2D6 in vitro. [7] The levels of metoprolol increase with the administration of diphenhydramine in healthy men with high CYP2D6 activity. [8] Diphenhydramine inhibits CYP2D6-mediated metabolism of venlafaxine. [9]

When H_1-type antihistamines are consumed in combination with alcohol or other therapeutic agents with CNS depressant effects, such as diazepam, the central depressive effects may be accentuated. Antihistamines of the phenothiazine group may block and reverse the vasopressor effect of epinephrine. If individuals receiving a phenothiazine require a vasopressor agent, norepinephrine or phenylephrine should be used. H_1-type antihistamines are contraindicated for patients receiving monoamine oxidase inhibitors.

LOW-SEDATING OR SECOND- AND THIRD-GENERATION H_1-TYPE ANTIHISTAMINES

Low-sedating or second- and third-generation H_1-type antihistamines (Table 258-2) are less lipophilic, minimally cross the blood-brain barrier, and preferentially bind to peripheral H_1 receptors. Some of these agents possess membrane-stabilizing or quinidine-like effects on cardiac muscle, and are responsible for a prolongation of the refractory period of the heart and the ventricular arrhythmia torsade de pointes. The administration of low-sedating H_1-type antihistamines has not been associated with the development of tachyphylaxis.



TABLE 258-2 **Low-Sedating, Second- and Third-Generation H_1-Type Antihistamines**

Pharmacology

The low-sedating H_1-type antihistamines are absorbed from the gastrointestinal tract and achieve peak plasma concentrations within 2 h (Table 258-2). They suppress the wheal-and-erythema reaction from 1 to 24 h. [10], [11], [12] and [13] Terfenadine, astemizole, loratadine, acrivastine, mizolastine, ebastine, and oxatomide are metabolized in the liver via the hepatic CYP enzyme system CYP3A4. Cetirizine, the carboxylic acid metabolite of hydroxyzine, fexofenadine, the carboxylic acid metabolite of terfenadine, and desloratadine are not metabolized in the liver.

Astemizole is a long-acting agent with a slow onset of action and with a steady-state concentration reached in 3 to 4 weeks. Its plasma half-life after a single dose is biphasic, with an initial phase of 1.1 days and a second phase of 9.5 days, owing to its metabolite desmethylastemizole. The effects of astemizole are long lasting, and the drug should be discontinued 4 to 6 weeks before diagnostic prick skin tests are performed. Cetirizine and fexofenadine have similar elimination half-life values in children and adults. The plasma half-life of fexofenadine is greater in individuals older than 65 years of age and in those individuals with renal impairment; however, the pharmacokinetics in patients with hepatic disease do not differ from those in healthy individuals. Desloratadine has a half-life of 27 h with steady-state serum concentrations achieved within 7 days. [14] In pharmacokinetic studies, approximately 7 percent of all subjects and 20 percent of African Americans were slow metabolizers of desloratadine. There are no restrictions on the use of desloratadine in patients with renal or hepatic failure. Food and grapefruit juice have no effect on its bioavailability and absorption. Pharmacokinetics of mizolastine in elderly individuals were similar to those in healthy volunteers. Ebastine, which is metabolized to form its carboxylic acid metabolite, carebastine, [15] has a half-life of 15 h. Impaired renal function alters the pharmacokinetics of emedastine, and the dose should be adjusted in such patients. [16] Terfenadine, cetirizine, loratadine, fexofenadine, and desloratadine are excreted in breast milk.

Mechanism of Action

Low-sedating H_1-type antihistamines bind in a noncompetitive manner to the H_1 receptor, are not easily displaced by histamine, dissociate slowly, and have a longer duration of action. Some low-sedating H_1-type antihistamines affect the trafficking of cells in the skin and other tissues, the release or generation and release of inflammatory mediators, and the expression of adhesion molecules.

Cetirizine inhibits chemotaxis in a variety of models. After the administration of cetirizine, the challenge of allergic subjects was associated with a decrease in the influx of eosinophils into the skin, as assessed by a skin-window technique in one study. Cetirizine has an inhibitory effect on eosinophil chemotactic responses in vitro to *N*-formyl-methionyl-leucyl-phenylalanine (FMLP) and platelet-activating factor (PAF), and in vivo to the influx of eosinophils induced by PAF. In skin chambers, the migration of eosinophils, neutrophils, and basophils was attenuated with cetirizine, but not with terfenadine, promethazine, chlorpheniramine, and diphenhydramine. Desloratadine and emedastine [17] inhibited PAF-induced eosinophil chemotaxis, TNF-a–induced eosinophil adhesion, and spontaneous and phorbol myristate-induced superoxide generation. [18]

Cetirizine in vitro inhibited the chemotactic responses of monocytes and T lymphocytes of unspecified types to stimulation with FMLP and leukotriene (LT) B_4. [19] After administration of cetirizine to healthy human subjects, peripheral blood monocytes and T lymphocytes showed a diminished chemotactic responses to the aforementioned stimuli.

Cetirizine reduced the wheal-and-flare reaction but not the release of histamine, tryptase, prostaglandin (PG) D_2, and eosinophil cationic protein in a microdialysis study. [20] Oxatomide inhibited the release of histamine and tryptase and the generation and release of PGD_2 and LTC_4 from human basophils and mast cells in vitro [21] and inhibited the synthesis of LTB_4 and PAF in neutrophils in vitro. [21] In other studies, terfenadine, cetirizine, and loratadine decreased expression of intercellular adhesion molecule (ICAM)-1 on human keratinocytes, Langerhans cells, and endothelial cells. Mizolastine inhibited antigen-induced ICAM-1 expression in skin blister aspirates. [22]

Clinical uses

In double-blind, placebo-controlled, or parallel studies, the lowsedating H_1-type antihistamines, terfenadine, astemizole, [23] cetirizine, [23] loratadine, fexofenadine, desloratadine, [24] acrivastine, mizolastine, [25], [26] azelastine, [27] ebastine, [27] and oxatomide, [28] were found to be statistically superior to placebo in the treatment of chronic idiopathic urticaria and angioedema. In studies in which low-sedating H_1-type antihistamines are compared with each other and with traditional H_1-type antihistamines, no single therapeutic agent commands preeminence. No objective evidence exists to support the effectiveness of low-sedating H_1-type antihistamines in the treatment of the pruritus in atopic dermatitis. [29] Azelastine suppressed the pruritus in patients with mastocytosis.

Most low-sedating H_1-type antihistamines are classified as FDA pregnancy category B or category C. In a prospective trial, astemizole administered to pregnant women was not associated with intrauterine growth retardation or perinatal complications. The rate of birth malformations was identical to that of the control group and to that of the general population.

Dosage Schedules and Formulations

Most low-sedating H_1 antihistamines are administered once daily. Those currently available in the United States include cetirizine, loratadine, fexofenadine, and desloratadine. Although azelastine is available as an oral preparation in other countries, it has been approved in the United States only as a nasal spray for allergic rhinitis. In the United States, acrivastine exists only in combination with pseudoephedrine hydrochloride for the treatment of allergic rhinitis. Ebastine, emedastine, mizolastine, and oxatomide are not available in the United States, and terfenadine and astemizole are no

longer available in the United States. Tazifylline, temelastine, noberastine, and setastine are investigational agents and are not discussed in this chapter.

Adverse Effects

The low-sedating H_1-type antihistamines lack both sedative and anticholinergic side effects, and have fewer adverse effects when compared with the traditional H_1-type antihistamines. [30]

With the use of terfenadine and astemizole, a ventricular tachycardia known as torsade de pointes was associated with prolongation of the QT interval and has been reported to occur after drug overdose and as the result of drug interactions. Perhaps individuals with hepatic dysfunction or those susceptible to conditions associated with a prolonged QT interval also may be at risk. Loratadine does not increase the QT interval; however, a prolonged QT interval developed in a single patient with coronary artery disease after the administration of loratadine and quinidine. The QT interval was not affected when fexofenadine was administered with erythromycin or ketoconazole. [31] Desloratadine, acrivastine, mizolastine, [26] and emedastine [32] have no effect on the QT interval. Changes in the QT interval were noted with the administration of ebastine with ketoconazole and with erythromycin, [33] but not with ebastine alone.

Cetirizine is less sedating than its parent compound hydroxyzine. When assessed by actual driving, the critical tracking test, and the divided attention test, cetirizine was more sedating [34] than were placebo, loratadine, and terfenadine. When assessed by tests of cognitive function and psychomotor performance in healthy volunteers, cetirizine at 10 mg was not more sedating than loratadine at 40 mg. One case of cholestasis has been reported after the administration of cetrizine. [35]

In a study of alertness and performance on a flight simulator, the skills of airline pilots who received 10 mg of loratadine were as unaffected as the skills of those who received placebo. In a study of the effects of antihistamines on children's learning, loratadine caused less learning impairment than did diphenhydramine. As assessed by the critical flicker fusion test, choice reaction time, and continuous tracking task test, cetirizine and loratadine were indistinguishable from placebo. [36] The elimination of loratadine is not decreased in individuals with renal impairment. Two cases of hepatotoxicity with liver failure have been reported.

Fexofenadine does not affect actual driving and psychomotor performance, and it attenuated alcohol's adverse effect on driving. [37], [38] Desloratadine has no sedative side effects as assessed by the maintenance of wakefulness test, which measures the ability to stay awake, and the multiple sleep latency test, which measures the time to fall asleep. Desloratadine did not impair driving performance during an over-the-road driving test. [39]

Sedation is a side effect of acrivastine. In a questionnaire study, [40] acrivastine was 2.8 times more likely to result in sedation than were loratadine and fexofenadine. CNS effects are produced by its interactions with alcohol. As assessed by positron emission tomography, ebastine causes brain histamine H_1 receptor occupation of 10 percent, which is consistent with its low incidence of sedative side effects. [41]

Astemizole and oxatomide are associated with increased appetite and weight gain.

Drug Interactions

Prolongation of the QT interval has been reported to occur in patients taking terfenadine and concomitant ketoconazole and itraconazole, but not fluconazole; macrolide antibiotics, such as erythromycin and clarithromycin, but not azithromycin or dirithromycin; troleandomycin; lovastatin; protease inhibitors; and flavonoids, such as naringin in grapefruit juice. There are no interactions between terfenadine and theophylline or between terfenadine and phenytoin. Terfenadine does not enhance the depressant effects of alcohol or benzodiazepines. Astemizole metabolism studied in human liver microsome preparations in vitro is less sensitive to the effects of ketoconazole than is the metabolism of terfenadine. It is recommended, however, that astemizole not be administered with ketoconazole, itraconazole, erythromycin, quinine, lovastatin, nefazodone, and fluvoxamine. There are no restrictions on the ability to take cetirizine with other medications. Electrocardiographic abnormalities and cardiac side effects have not been reported. Although erythromycin and ketoconazole inhibit the metabolism of loratadine, [42] electrocardiographic abnormalities and cardiac side effects have not been reported. Desloratadine has no clinical drug interactions with erythromycin or ketoconazole or with grapefruit juice, [11] and no effect has been demonstrated on the QT interval with these combinations. There is no increased psychomotor impairment with associated alcohol use. [39] Mizolastine is associated with increased levels of theophylline. [43] There are no interactions with lorazepam or ethanol. Ebastine taken with either erythromycin or ketoconazole results in the increased accumulation of ebastine in plasma. [33] Ebastine does not interact with diazepam or alcohol.

H_2-TYPE ANTIHISTAMINES

H_2-type antihistamines possess an imidazole ring and lack the aryl ring of H_1-type antihistamines. These therapeutic agents are lipophobic, which presumably accounts for their lack of CNS effects. Famotidine and nizatidine differ from cimetidine and ranitidine in that they contain a thiol ring.

Pharmacology

H_2-type antihistamines are rapidly absorbed from the gastrointestinal tract with peak levels occurring between 1 and 2 h;

they undergo renal clearance with hepatic metabolism.

Only a small proportion of cimetidine is absorbed from the stomach; most of its absorption occurs in the small intestine. The half-life of cimetidine in plasma is 2 h; approximately 69 percent is excreted unchanged in the urine. The plasma half-life of ranitidine is 2 to 3 h in adults, and it is prolonged in the elderly and in individuals with liver or kidney diseases. The drug and its metabolites are excreted principally in the urine. Famotidine has a plasma half-life of 3 to 8 h. In patients with renal failure, the half-life of famotidine may exceed 20 h. Nizatidine has a plasma half-life of 1 to 2 h, and its duration of action is up to 10 h. Nizatidine is primarily eliminated by the kidneys within 16 h. The oral bioavailability of nizatidine is not affected by food. Cimetidine, ranitidine, famotidine, and nizatidine are present in breast milk.

Mechanism of Action

Although H_2-antihistamines were developed to treat peptic ulcer disease, they have been used in the treatment of dermatologic disorders because of the presence of H_2 receptors on the cutaneous microvasculature. Inasmuch as the skin microvasculature contains both H_1 and H_2 receptors, increased venular permeability depends on the interaction of histamine with both of these receptors.

The presence of an H_2-histamine receptor on CD8 T lymphocytes may partly explain the augmentation of delayed-type hypersensitivity reactions with increased erythema and induration after the intradermal administration of antigens. In healthy volunteers, the oral administration of cimetidine was associated with an increase in the mitogen-induced proliferation of lymphocytes, a decrease in the number of CD8 T lymphocytes, and an increase in the number of CD4 T lymphocytes.

Clinical Uses

The combination of H_1- and H_2-type antihistamines is of benefit to a few patients with acute and chronic idiopathic urticaria and angioedema as well as to those with certain forms of physical urticaria. The combination of H_1- and H_2-type antihistamines should be considered for patients with refractory chronic idiopathic urticaria, in whom H_1-type antihistamines, alone or in combination, are ineffective. The pruritus and whealing in systemic mastocytosis and urticaria pigmentosa were modified in a double-blind trial of chlorpheniramine and cimetidine.

In anecdotal reports, cimetidine was reported to be of value in the treatment of the pruritus resulting from myelofibrosis, polycythemia vera, and carcinoid flush. Anecdotal reports also suggest that the combination of H_1- and H_2-type antihistamines was of value in the treatment of carcinoid flush and alcohol-induced flushing. High doses of cimetidine were successful in the treatment of verruca vulgaris in some individuals.

The H_2-type antihistamines are classified as FDA pregnancy category B.

Dosage Schedules and Formulations

H_2-type antihistamines are administered twice daily, except cimetidine, which is administered four times daily. The H_2-type antihistamines are available without a prescription in the United States and many other countries.

Adverse Effects

Mental confusion may develop in elderly patients with impaired hepatic or renal function who take regular doses of cimetidine, and in younger individuals who take high doses of cimetidine. Other side effects include headache, dizziness, drowsiness, malaise, muscular pain, diarrhea, and constipation. There are rare reports of granulocytopenia.

Uncommon side effects of cimetidine include gynecomastia with or without elevated prolactin levels in men; galactorrhea with elevated prolactin levels in women; and loss of libido, impotence, and reduction of sperm counts in young men. Modest elevations in serum creatinine levels are common and are reversible after the drug is withdrawn. Elevated levels of serum transaminases have been reported and are reversible. Interstitial nephritis, fever, and cutaneous eruptions that include urticaria and erythema multiforme have occurred. Although cimetidine binds to nitrites in the gastrointestinal tract and may yield potential carcinogenic nitroso compounds, the prolonged administration of cimetidine in high doses to rats and dogs failed to result in the development of gastric neoplasms. Cimetidine, however, may mask symptoms associated with gastric carcinoma in humans. Cimetidine increases the concentration of blood alcohol levels due to an inhibitory effect on gastric alcohol dehydrogenase activity.

Ranitidine does not bind to androgen receptors and does not enhance cell-mediated immune responses. Ranitidine may affect physiologic autonomic control of the cardiovascular system by altering indices of parasympathetic and sympathetic control as assessed by power spectral analysis of heart rate variability and calculation of spontaneous baroreflex sensitivity. [44] This altered cardiac sympathovagal balance indicates a shift toward sympathetic predominance and susceptibility to arrhythmias. Ranitidine inhibits gastric alcohol dehydrogenase activity and leads to increased blood alcohol levels. Minor adverse effects include headache, dizziness, malaise, nausea, constipation, and abdominal pain. Serum transaminase and creatinine levels temporarily increase but return to baseline levels with continued treatment.

Adverse reactions to famotidine are infrequent and include headache, dizziness, constipation, and diarrhea. No interference with the hepatic oxidative metabolism of diazepam, phenytoin, theophylline, or warfarin has been observed. Famotidine does not inhibit gastric alcohol dehydrogenase activity; it lacks antiandrogenic side effects.

Minor gastrointestinal side effects occur with nizatidine. Elevations of serum transaminases and uric acid levels, without

adverse clinical consequences, develop, and antiandrogenic effects are absent.

Drug Interactions

Drug interactions have been reported with cimetidine therapy and most importantly include prolonged bleeding and prothrombin times in patients receiving concomitant oral anticoagulants and cimetidine. Cimetidine should be used with caution in patients receiving phenytoin, propanolol, nifedipine, diazepam, and theophylline, because blood levels of these drugs are elevated and their excretion is delayed.

Although ranitidine interacts with other medications less frequently than does cimetidine, interactions with fentanyl, metoprolol, midazolam, nifedipine, theophylline, and warfarin have been observed. Ranitidine may decrease the absorption of diazepam and reduce its plasma concentration by 25 percent.

In healthy volunteers, drug interactions were not reported with the concomitant administration of nizatidine and chlordiazepoxide, diazepam, lidocaine, lorazepam, theophylline, or warfarin.

OTHER THERAPEUTIC AGENTS WITH ANTIHISTAMIC ACTIVITY

Tricyclic Antidepressants

Tricyclic antidepressants act on both H_1 and H_2 receptors. Doxepin was more potent than chlorpheniramine in inhibiting experimental wheals induced by histamine. Doxepin has been used successfully in the treatment of chronic idiopathic urticaria and physical urticaria. In a double-blind, vehicle-controlled trial, topical doxepin cream reduced pruritus in patients with atopic dermatitis. Topical doxepin hydrochloride cream can cause allergic contact dermatitis. Systemic doxepin has been classified as FDA pregnancy category C; topical doxepin is classified as FDA pregnancy category B. Systemic doxepin is contraindicated close to delivery, and systemic and topical doxepin are contraindicated during lactation. Doxepin is present in breast milk.

Ketotifen

Ketotifen, a benzocycloheptathiophene derivative, is an H_1-type antihistamine and calcium channel blocker that prevents histamine release from mast cells induced by IgE and compound 48/80 in vitro and inhibits passive cutaneous anaphylaxis in experimental animals in vivo. Ketotifen has been used successfully in the treatment of chronic idiopathic urticaria, physical urticaria, urticaria pigmentosa in a controlled clinical trial, and the pruritus of neurofibromatosis. Sedation and weight gain are side effects. Ketotifen is available in the United States as an ophthalmic solution.

REFERENCES

1. Kavanagh GMK et al: The intradermal effects of the H_3 receptor agonist R a methylhistamine in human skin. *Br J Dermatol* **138**:622, 1998

2. Simons FER et al: The clinical pharmacology of brompheniramine in children. *J Allergy Clin Immunol* **103**:223, 1999

3. Passalacque G et al: The clinical safety of H_1-receptor antagonists. *Allergy* **50**:666, 1996

4. Seto A et al: Pregnancy outcome following first trimester exposure to antihistamines: Meta-analysis. *Am J Perinatol* **14**:119, 1997

5. Gilmore TM et al: Occupational injuries and medication use. *Am J Ind Med* **30**:234, 1996

6. Hindmarch I, Shamsi Z: Antihistamines: Models to assess sedative properties, assessment of sedation, safety and other side-effects. *Clin Exp Allergy* **29**(Suppl 3):133, 1999

7. Hamelin BA et al: In vitro characterization of cytochrome P450 206 inhibition by classic histamine H_1 receptor antagonists. *Drug Metab Dispos* **26**:536, 1998

8. Hamelin BA et al: Significant interaction between the nonprescription antihistamine diphenhydramine and the CYP2D6 substrate metoprolol in healthy men with the high or low CYP2D6 activity. *Clin Pharmacol Ther* **67**:466, 2000

9. Lessard E et al: Diphenhydramine alters the disposition of venlafaxine through inhibition of CYP2D6 activity in humans. *J Clin Psychopharmacol* **87**:48, 2001

10. Jansen B et al: Pharmacokinetics and pharmacodynamics of the novel H_1-receptor antagonist emedastine in healthy volunteers. *Eur J Clin Pharmacol* **55**:837, 2000

11. Deschamps C et al: Pharmacokinetic and pharmacodynamic modeling of mizolastine in healthy volunteers with an indirect response model. *Clin Pharmacol Ther* **68**:647, 2000

12. Grant JA et al: A double-blind, randomized, single-dose, crossover comparison of levocetirizine with ebastine, fexofenadine, loratadine, mizolastine, and placebo: Suppression of histamine-induced wheal-and-flare response during 24 hours in healthy male subjects. *Ann Allergy Asthma Immunol* **88**:190, 2002

13. Devalia JL et al: A randomized, double-blind, crossover comparison among cetirizine, levocetirizine, and ucb 28557 on histamine-induced cutaneous responses in healthy adult volunteers. *Allergy* **56**:50, 2001

14. Geha RS, Meltzer EO: Desloratadine: A new, nonsedating, oral antihistamine. *J Allergy Clin Immunol* **107**:751, 2001

15. Rohatagi S et al: Effect of age and gender on the pharmacokinetics of ebastine after single and repeated dosing in healthy subjects. *Int J Clin Pharmacol Ther* **39**:126, 2001

16. Joukhadar C et al: Pharmacokinetics of emedastine difumarate, a new anti-histamine agent in patients with renal impairment. *Eur J Clin*

Pharmacol **56**:905, 2001

17. el-Shazly AE et al: Inhibition of human eosinophil chemotaxis in vitro by the anti-allergic agent emedastine difumarate. *Immunopharmacol Immunotoxicol* **18**:587, 1996

18. Aguawal DK et al: Desloratadine attenuation of eosinophil chemotaxis, adhesion, and superoxide generation. *Allergy* **55**(Suppl 63):276, 2000

19. Jinquan T et al: Cetirizine inhibits the in vitro and ex vivo chemotactic response of T lymphocytes and monocytes. *J Allergy Clin Immunol* **95**:979, 1995

20. Nielsen PN et al: Cetirizine inhibits skin reactions but not mediator release in immediate and developing late-phase allergic cutaneous reactions: A double-blind, placebo-controlled study. *Clin Exp Allergy* **31**:1378, 2001

21. Marone G et al: Antiinflammatory effects of oxatomide. *J Investig Allergol Clin Immunol* **9**:207, 1999

22. Baroody FM, Naclerio RM: Antiallergic effects of H1-receptor antagonists. *Allergy* **55**(Suppl 64):17, 2000

23. Breneman D et al: Cetirizine and astemizole therapy for chronic idiopathic urticaria: A double-blind, placebo-controlled comparative trial. *J Am Acad Dermatol* **33**:192, 1995

24. Ring J et al: Once-daily desloratadine improves the signs and symptoms of chronic idiopathic urticaria: A randomized, double-blind, placebo-controlled study. *Int J Dermatol* **40**:1, 2001

25. Leynadier F et al: Comparative therapeutic effect and safety of mizolastine and loratadine in chronic idiopathic urticaria: URTILOR study group. *Eur J Dermatol* **10**:205, 000

26. Lorette G et al: One-year treatment of chronic urticaria with mizolastine: Efficacy and safety. URTOL study group. *Eur Acad Dermatol Venereol* **14**:83, 2000

27. Camarasa JM et al: Azelastine tablets in the treatment of chronic idiopathic urticaria: Phase iii, randomised, double-blind, placebo and active controlled multicentric clinical trial. *Skin Pharmacol Appl Skin Physiol* **14**:77, 2001

28. LaRosa M et al: Double-blind multicenter study on the efficacy and tolerability of cetirizine compared to oxatomide in chronic idiopathic urticaria in preschool children. *Ann Allergy Asthma Immunol* **87**:48, 2001

29. Klein PA, Clark RAF: An evidence-based review of the efficacy of antihistamines in relieving pruritus in atopic dermatitis. *Arch Dermatol* **135**:1522, 1999

30. Horak F, Stübner UP: Comparative tolerability of second generation antihistamines. *Drug Saf* **20**:385, 1999

31. Markham A, Wagstaff AJ: Fexofenadine. *Drugs* **55**:269, 1998

32. Herran ZU et al: Emedastine-ketoconazole: Pharmacokinetic and pharmacodynamic interactions in healthy volunteers. *Int J Clin Pharmacol Ther* **39**:102, 2001

33. Moss AJ, Morganroth J: Cardiac effects of ebastine and other antihistamines in humans. *Drug Saf* **21**(Suppl 1):69, 1999

34. Shamsi Z et al: An investigation into the effects of cetirizine on cognitive function and psychomotor performance in healthy volunteers. *Eur J Clin Pharmacol* **56**:865, 2001

35. Fong DG et al: Cetirizine-induced cholestasis. *J Clin Gastroenterol* **31**:250, 2000

36. Hindmarch I et al: The acute and sub-chronic effects of levocetirizine, cetirizine, loratadine, promethazine and placebo on cognitive function, psychomotor performance, and weal and flare. *Curr Med Res Opin* **17**:241, 2001

37. Vermeeren A, O'Hanlon JF: Fexofenadine's effects, alone and with alcohol, on actual driving and psychomotor performance. *J Allergy Clin Immunol* **101**:306, 1998

38. Hindmarch I et al: A double-blind, placebo-controlled investigation of the effects of fexofenadine, loratadine and promethazine on cognitive and psychomotor function. *Br J Clin Pharmacol* **48**:200, 1999

39. Scharf MB et al: Desloratadine has no effect on wakefulness or psychomotor performance. *Allergy* **55**(Suppl 63):280, 2000

40. Mann RD et al: Sedation with “non-sedating” antihistamines: Four prescription-event monitoring studies in general practice. *BMJ* **320**:1187, 2000

41. Tagawa M et al: Neuroimaging of histamine H_1-receptor occupancy in human brain by positron emission tomography (PET): A comparative study of ebastine, a second-generation antihistamine, and (+)-chlorpheniramine, a classical antihistamine. *Br J Clin Pharmacol* **52**:501, 2001

42. Brannan MD et al: Loratadine administered concomitantly with erythromycin: Pharmacokinetic and electrocardiographic evaluations. *Clin Pharmacol Ther* **58**:269, 1995

43. Lebrun-Vignes B et al: Clinical pharmacokinetics of mizolastine. *Clin Pharmacokinet* **40**:501, 2001

44. Nauet MA et al: Effects of the selective H1 and H2 histamine receptor antagonists loratadine and ranitidine on autonomic control of the heart. *Anesthesiology* **96**:336, 2002

T>

Chapter 259

Jan Hirschmann

Overview of Antibiotics

MECHANISMS OF ACTION AND ANTIMICROBIAL RESISTANCE
ANTIMICROBIAL SUSCEPTIBILITY TESTING
BACTERICIDAL VERSUS BACTERIOSTATIC ACTION
USE OF ANTIBIOTICS DURING RENAL FAILURE, PREGNANCY, AND LACTATION
INDIVIDUAL ANTIBIOTICS
Penicillins
Cephalosporins
Tetracyclines
Macrolides
Fluoroquinolones
Clindamycin
Trimethoprim-Sulfamethoxazole
SYSTEMIC ANTIMICROBIAL PROPHYLAXIS IN DERMATOLOGY
Recurrent Bacterial Skin Infections
Prevention of Wound Infections after Dermatologic Surgery
Antibiotic Prophylaxis for Patients with Heart Disease or Prosthetic Material
REFERENCES

Strictly speaking, antibiotics are chemicals produced by various microbes, such as bacteria, actinomycetes, and fungi, that inhibit the growth of other organisms. In common usage, however, *antibiotic* generally refers to a medication with antibacterial action, whether it is a natural or a synthetic substance. Since the late 1930s, when the sulfonamides emerged as therapeutic agents, and the 1940s, when penicillin came into clinical use, the number and variety of these antibacterial agents have multiplied to the point where the amount of information required to prescribe them intelligently is daunting. Because many of these antibiotics are very expensive and have a wide spectrum of antimicrobial activity, their improper use increases the cost of medical care and encourages the emergence of resistant organisms, which has become a widespread and frightening problem throughout the world. Regrettably, office-based clinicians in the United States (and elsewhere) are prescribing more broad-spectrum, expensive antibiotics than ever before, often from the erroneous belief that newer agents are necessarily better than the older, less expensive ones. For nearly all skin conditions requiring antibiotic therapy that a dermatologist is likely to encounter, however, inexpensive, generic preparations from one of four categories will suffice: (1) penicillins—penicillin and dicloxacillin; (2) first-generation cephalosporins; (3) tetracyclines, usually doxycycline; and (4) erythromycin. Penicillins, cephalosporins, and erythromycin are alternative options for treating streptococcal and staphylococcal infections. Doxycycline or erythromycin is appropriate for acne or rosacea; penicillin or doxycycline for the cutaneous manifestations of Lyme disease; and erythromycin for bacillary angiomatosis. Other primary bacterial infections of the skin are rare. This chapter is focused on these agents, which dermatologists should know thoroughly. Table 259-1 delineates the astonishing differences in price between these medications and some of the newer, more expensive antibiotics for which very few dermatologic indications exist. Table 259-2 lists the antibiotic choices for bacterial and rickettsial skin infections.

Medication	Dose	Cost (7 Days)*
Penicillins		
Penicillin V	250 mg qid	$1.49
Dicloxacillin	250 mg qid	$5.32
Amoxicillin-clavulanate	250 mg qid	$53.55
Cephalosporins		
Cephalexin	250 mg qid	$4.48
Cephradine	250 mg qid	$8.40
Tetracyclines		
Doxycycline	100 mg bid	$2.17
Minocycline	100 mg bid	$26.86
Tetracycline	250 mg qid	$1.61
Macrolides		
Azithromycin	250 mg qd (5 days)	$39.19
Clarithromycin	250 mg bid	$52.96
Erythromycin	250 mg qid	$5.04
Fluoroquinolones		
Ciprofloxacin	500 mg bid	$60.48
Ofloxacin	200 mg bid	$57.89
Other		
Clindamycin	150 mg qid	$16.67
Trimethoprim-sulfamethoxazole	1 DS tablet bid	$1.54

*Price to the pharmacist based on average wholesale cost in *Red Book 2001* of lowest-priced manufacturer. Prices vary considerably among different pharmaceutical companies for generic preparations. The amount actually charged to the patient is substantially more.

TABLE 259-1 **Costs of Oral Antibiotics for Dermatologic Use**



TABLE 259-2 **Antibiotic Choices for Dermatologic Infections**

An understanding of how to prescribe these systemic antimicrobial agents properly requires an acquaintance with some fundamental concepts, such as mechanisms of action, susceptibility testing, drug resistance, and use in special circumstances, such as renal failure and pregnancy.

MECHANISMS OF ACTION AND ANTIMICROBIAL RESISTANCE

Antibacterial agents exert their effects in one of four ways: (1) Some, such as the penicillins and cephalosporins, inhibit cell-wall synthesis, usually leading to the organism's death. (2) Others, by interfering with the 30S or 50S subunit of ribosomes, inhibit protein synthesis. The result may be reversible, temporarily halting growth of the microbe but not killing it—the mechanism for the tetracyclines and erythromycin—or the effect may be lethal, as with the aminoglycosides, such as gentamicin or amikacin. (3) The quinolones (e.g., ciprofloxacin or levofloxacin) affect nucleic acid metabolism, typically killing the bacteria. (4) Sulfonamides and trimethoprim block an essential step in the organism's metabolism by interfering with the folic acid metabolic pathway. The process only inhibits some microbes but kills others.

Microorganisms develop resistance against these antimicrobial effects by the following general mechanisms: (1) The organism may elaborate substances that inactivate the antibiotic. For example, many bacteria, such as penicillin-resistant *Staphylococcus aureus,* produce beta-lactamase that attacks an important ring structure of penicillins and cephalosporins. (2) The microbe may change to prevent the drug from reaching its target or may alter that target. In the former instance, an alteration in the organism's outer membrane may make it impermeable to the drug or the microbe may develop a new membrane transport system that actively extrudes the antibiotic from the cell. In the latter instance, changes occur in the organism's ribosomes, to which the antibiotic ordinarily adheres, thereby preventing the drug from binding to its target and exerting its effect on protein synthesis. Alternatively, by changing its metabolic pathway, the microbe may make the previously effective antimetabolite, such as a sulfonamide, impotent.

These mechanisms of bacterial resistance to antimicrobial agents can arise from random mutations in the organism's chromosomes that are unrelated to drug exposure, with the modified genetic material then passed to its progeny. More commonly, however, resistance comes from extrachromosomal DNA, which other, often unrelated, bacteria transfer to the microbe. This genetic material may reside in plasmids, autonomously replicating pieces of DNA, or transposons, mobile pieces of DNA that can insert themselves into various locations in the bacterial chromosome or plasmids. Some bacteria have numerous plasmids and transposons that confer resistance to several different antibiotics, making treatment of infections caused by these organisms difficult or impossible. This multiresistance typically develops in settings of intensive antibiotic use, such as critical care units. Any indiscriminate prescribing of antimicrobial agents, however, whether in a hospital or an outpatient setting, contributes to the emergence and dissemination of these organisms, because the presence of an antibiotic in a patient allows resistant microbes to flourish while it inhibits the competing susceptible ones. Accordingly, all clinicians must use antibiotics wisely, employing them only when necessary and preferentially prescribing an agent with a narrow spectrum of activity—one that inhibits the pathogen without significantly affecting the rest of the patient's flora.

ANTIMICROBIAL SUSCEPTIBILITY TESTING

After the clinician has submitted an appropriate sample for culture, the laboratory can isolate the infecting organism and determine its susceptibility to a panel of agents with potential activity against the category of bacteria to which the pathogen belongs. The test employs a concentration of 10^5 to 10^6 organisms per milliliter and assesses the effect of various concentrations of the antibiotics on the bacterium's growth after overnight incubation. The minimum inhibitory concentration (MIC) is the lowest amount of the drug that inhibits growth of the organism. The microbe is “sensitive” or “susceptible” when the MIC is less than a concentration (“breakpoint”) of antibiotic ordinarily achievable in the serum of patients given conventional doses of the drug. Because the serum level of antibiotic may differ from its concentration at the site of infection and because the susceptibility test may not reflect local factors that affect drug activity such as pH, the results of the test are potentially misleading, especially in areas such as the cerebrospinal fluid where some antibiotics penetrate poorly. With dermatologic infections, however, the susceptibility results are very reliable.

BACTERICIDAL VERSUS BACTERIOSTATIC ACTION

Laboratory tests can also distinguish between antibiotics that temporarily inhibit the growth of organisms (bacteriostatic) and those that kill (bactericidal). After overnight incubation with the drug, an inoculum of organisms is subcultured onto an antibiotic-free medium for 18 to 24 h. By arbitrary definition, a bactericidal antibiotic has killed 99.9 percent or more of the original bacteria at that time. In general, antibiotics that interfere with cell-wall synthesis, such as penicillins or cephalosporins, are bactericidal. Those that impair protein synthesis or block steps in metabolic pathways may be either bacteriostatic or bactericidal. Furthermore, some agents may kill certain organisms, but only inhibit others. Usually, bactericidal agents have no clinical superiority over bacteriostatic ones, and for almost all infections that a dermatologist is likely to confront the distinction is unimportant. The special circumstances where killing rather than inhibiting growth is significant are infective endocarditis, bacterial meningitis, infections in neutropenic hosts, and, possibly, osteomyelitis.

USE OF ANTIBIOTICS DURING RENAL FAILURE, PREGNANCY, AND LACTATION

For antibiotics eliminated by renal excretion, dose adjustments may be necessary in patients with impaired kidney function to avoid toxic serum levels. Recommended alterations in dose usually depend on an assessment of creatinine clearance. In the absence of a direct measurement, the following formula provides a reasonable estimate for men:

$$\text{Creatinine clearance in men} = \frac{\text{ideal weight in kg} \times (140 - \text{patient's age})}{72 \times \text{serum creatinine in mg/dL}}$$

The value for women is 0.85 of the calculated value for men. These calculations use the ideal body weight, which for men is 50.0 kg + [2.3 kg × (patient's height in inches - 60)] and for women is 45.5 kg + [2.3 kg × (patient's height in inches - 60)]. Patients with creatinine clearances greater than 50 mL/min require no dose adjustments for any antibiotic, but those with lower levels of renal function require either a reduction in the individual dose given of some medications or a greater interval between doses. Because hemodialysis removes a substantial portion of some antibiotics from patients, those undergoing this procedure may require an additional dose afterward. Specific recommendations for these adjustments appear in the discussions of the individual antibiotics.

Because of the risk of affecting the fetus or the newborn (for women near term), clinicians should avoid prescribing antibiotics during pregnancy if possible. Those considered safe include the penicillins, the cephalosporins, and erythromycin (except the estolate form). Clindamycin should be used with caution; and contraindicated drugs include the tetracyclines, the fluoroquinolones, and trimethoprim-sulfamethoxazole. Nursing mothers should avoid taking antibiotics, if possible, but especially the tetracyclines, which stain teeth, and the fluoroquinolones, which may damage joint cartilage in newborns.

INDIVIDUAL ANTIBIOTICS

Penicillins

MECHANISM AND SPECTRUM OF ACTIVITY Penicillins, [1] which exert their antimicrobial action by interfering with bacterial cell-wall synthesis, are active primarily against gram-positive organisms. Those most useful to dermatologists include two oral agents, penicillin V and dicloxacillin, and two parenteral preparations, penicillin G and an intravenous penicillinase-resistant drug such as oxacillin or nafcillin. Penicillin V and penicillin G are effective for skin infections such as cellulitis, blistering distal dactylitis, and impetigo when caused by streptococci and penicillin-sensitive *S. aureus*. As indicated below, however, most strains of *S. aureus* in both the hospital and community settings are penicillin-resistant, and either a penicillinase-resistant penicillin or a cephalosporin is a better choice for infections when *S. aureus* is suspected and its susceptibility to penicillin unknown. Penicillin G and V are appropriate agents to treat *Pasteurella multocida,* an organism often associated with infected cat and dog bites; *Streptobacillus moniliformis* and *Spirillum minus,* the two bacteria responsible for rat-bite fever; *Erysipelothrix rhusiopathiae,* the cause of erysipeloid; *Bacillus anthracis,* which causes anthrax; and *Borrelia burgdorferi,* the pathogen in Lyme disease. Penicillin G, but not V, is the drug of choice for all forms of infection with *Treponema pallidum,* the spirochete responsible for syphilis. Most strains of *S. aureus* produce penicillinase, a beta-lactamase enzyme that splits the beta-lactam ring of some penicillins, including V and G, producing substances with no antibacterial activity. Certain semisynthetic penicillins, however, are penicillinase-resistant, including dicloxacillin, an oral agent, and both nafcillin and oxacillin, which are primarily used as intravenous medications. These penicillins are also effective against *Streptococcus pyogenes* (group A streptococci) and streptococci of other groups, such as F or G, that are responsible for skin infections such as cellulitis. Accordingly, the penicillinase-resistant penicillins are good choices to treat disorders such as impetigo and ecthyma, which either *S. aureus* alone or a mixture of staphylococci and streptococci can cause. Some isolates of *S. aureus* ("methicillin-resistant" strains) are impervious to all penicillins. Alterations of the penicillin molecule have created agents with considerable activity against gram-negative organisms. Such preparations include the aminopenicillins, ampicillin and amoxicillin, which are effective against many isolates of *Escherichia coli* and *Haemophilus influenzae*. These antibiotics have little use in dermatologic practice, but are common causes of drug-induced eruptions. Organisms that produce beta-lactamase inactivate amoxicillin and ampicillin. To prevent this effect and thereby increase the spectrum of activity of these agents, drug manufacturers have combined them with beta-lactamase inhibitors (which preferentially and irreversibly bind the enzyme) to produce a parenteral preparation, ampicillin-sulbactam (Unasyn) and an oral formulation, amoxicillin-clavulanic acid (Augmentin). [2] These drugs are active against beta-lactamase–producing stains of *S. aureus, H. influenzae, Neisseria gonorrhoeae, E. coli, Klebsiella* species, and some other gram-negative bacilli. They are also effective against anaerobes that produce beta-lactamase, such as *Bacteroides fragilis*. Despite this increased spectrum of activity, these agents have little application in dermatologic infections. One exception is in the treatment of bite wounds, for these drugs are active against the likely pathogens—oral anaerobes, *Eikenella corrodens, H. influenzae,* and *S. aureus* in human bites, and *P. multocida,* streptococci, anaerobes, and staphylococci in dog and cat bites. [3] Another use is for serious skin and soft-tissue infections with a complex flora of both aerobic and anaerobic organisms, such as severe diabetic foot infections. Modifications of the ampicillin molecule have created the carboxypenicillins (carbenicillin and ticarcillin) and the ureidopenicillins (mezlocillin, piperacillin, and azlocillin). These "extended-spectrum" parenteral penicillins have much greater activity against many gram-negative bacilli, including *Pseudomonas aeruginosa,* than other penicillins. Two preparations include beta-lactamase inhibitors: ticarcillin-clavulanic acid and piperacillin-tazobactam. Rarely is any of these agents appropriate for treating dermatologic infections, but they commonly cause drug-induced rashes in hospitalized patients.

DOSAGE AND DRUG INTERACTIONS The adult dose of penicillin V is 250 to 500 mg by mouth four times a day. No adjustment is necessary for patients in renal failure, but those undergoing dialysis should receive an extra dose after the procedure. The doses of penicillin G vary according to the infection treated; the reader should refer to the appropriate chapter for details. Patients with creatinine clearance rates between 10 and 50 mL/min should receive 75 percent of the recommended dose, and those with rates of less than 10 mL/min should receive 50 percent of the recommended dose. Patients undergoing hemodialysis should receive an extra dose after the procedure. The intramuscular injection of 1.2 to 2.4 million units of benzathine penicillin provides effective serum levels for 2 to 4 weeks and represents a particularly attractive and dependable approach for the therapy or prophylaxis of streptococcal infections in patients who take medicines unreliably. The adult dose of dicloxacillin is 250 to 500 mg orally four times a day. For infections requiring intravenous treatment of infection from penicillinase-producing *S. aureus,* the adult dose of nafcillin or oxacillin is 1 to 2 g four times a day. No adjustment for renal failure is necessary for any of these agents, and they are not significantly removed by hemodialysis. Amoxicillin-clavulanic acid is available in tablets containing 125 mg potassium clavulanate plus either 250 or 500 mg amoxicillin. The usual adult dose is one of the tablets containing 250 mg of amoxicillin three times a day. Patients with creatinine clearances of 10 to 50 mL/min should receive one tablet twice a day, and those with clearances less than 10 mL/min should receive one tablet a day. Patients undergoing hemodialysis should receive a supplemental dose after the procedure. The parenteral agent ampicillin-sulbactam contains a 2:1 ratio of the two

constituents, respectively. The usual dose is 1.5 g (1 g ampicillin, 0.5 g sulbactam) or 3 g of the combination every 6 h. For patients with a creatinine clearance of 10 to 50 mL/min, the interval should be 12 h; for those with a creatinine clearance less than that, the interval should be every 24 h. Patients undergoing hemodialysis should receive a supplemental dose after the procedure.

ADVERSE EFFECTS The most serious complication of penicillin use is anaphylaxis, which occurs about 10 times in every 100,000 treatment courses, with about a 10 percent fatality rate. [4] Anaphylaxis is not more frequent in atopic patients than in the general population. It begins within the first hour, usually within the first 30 min, after drug administration, and is much less common with oral than with parenteral therapy. Clinical features may include hypotension, wheezing, laryngeal edema, and urticaria or angioedema. As opposed to this immediate response, some patients have an “accelerated” allergic reaction from 1 to 72 h after the dose; the characteristics include urticaria or angioedema, wheezing, and laryngeal edema. These are IgE-mediated events in which the antigens are breakdown products of penicillin (not the intact molecule) bound covalently to proteins. One of these is benzylpenicilloyl, also called the major determinant because it is the most abundant of the penicillin derivatives; it is the antigen involved in accelerated reactions. Several other breakdown products of penicillin, called minor determinants, form in small quantities and are the antigens responsible for anaphylaxis. Penicilloyl polylysine, a manufactured skin-test reagent, tests for IgE against the major determinant; a negative test means that the patient can receive penicillin without developing an accelerated allergic reaction, but it does not exclude the possibility of anaphylaxis. Unfortunately, no commercial preparation of the minor determinants is available in the United States. Studies with noncommercial minor determinant mixtures indicate that a negative skin test predicts that the patient can receive penicillin without developing anaphylaxis. Such skin testing is very safe and quite valuable in assessing the risks of penicillin therapy, because about 80 percent of patients with a history of adverse reactions to penicillin have negative skin tests and can receive the drug without developing anaphylaxis or accelerated reactions. [5] Unless such material is available and the skin testing is negative, however, patients with a history of immediate or accelerated reactions should not receive any kind of penicillin, because the allergic cross-reactivity among all the penicillins appears to be quite high. Skin testing has no predictive value in reactions not mediated by IgE, which include the remaining major adverse effects. Drug fever tends to occur after the first week of therapy in patients without previous exposure, but it can begin earlier in those who have received penicillin in the past. No characteristic pattern of temperature elevation occurs, and the patient's response may range from an unawareness of fever to rigors, hypotension, and delirium. Eosinophilia or a rash accompanies the fever in a minority of cases. The temperature should return to normal within 72 h of discontinuing the medication. Only recurrence of the fever, usually within a few hours, after reexposure to the drug definitively identifies penicillin as the cause, as no reliable laboratory test exists. Such a challenge is safe unless the patient has suffered organ damage, such as nephritis or hepatitis. Rare reactions include hemolytic anemia, usually only with high-dose intravenous therapy; neutropenia; and interstitial nephritis, which typically causes fever, worsening renal function, a morbilliform rash, and the presence of protein, neutrophils, red cells, and eosinophils in the urine. More frequent are gastrointestinal complaints of nausea, vomiting, and diarrhea; but the last is much more likely with ampicillin or amoxicillin than with penicillin or dicloxacillin. Diarrhea is even more frequent with amoxicillin-clavulanic acid. Occasionally, primarily in hospitalized patients, diarrhea related to amoxicillin or ampicillin arises from colitis caused by *Clostridium difficile*. The mechanism of most of the dermatologic reactions to the penicillins is unknown. Because they are not mediated by IgE, skin tests cannot predict their occurrence, indicate definitively that they are drug-related, or confirm that they arise specifically from penicillins in patients concurrently receiving other medications. The most common type of cutaneous reaction to the penicillins by far is a diffuse erythematous eruption with both macules and papules that usually begins on the trunk and spreads to involve the extremities but typically spares the palms, soles, and mucous membranes. It can begin within hours after the first dose, but most commonly develops about 7 to 10 days later. Occasionally, it starts several days after the drug is discontinued; irrespective of when it begins, however, it usually resolves within 7 days. This kind of eruption is most common and has been most extensively studied in patients receiving amoxicillin and ampicillin. With these agents, the eruptions are especially likely to occur in patients with chronic lymphocytic leukemia, those receiving concurrent allopurinol, and those with infectious mononucleosis and cytomegalovirus infections, in whom the incidence is nearly 100 percent. [6] It commonly fails to recur when the patient receives the medication again, and its development is not an indication that the patient is “allergic” to penicillin in the sense of being at greater risk for developing life-threatening adverse reactions. Other skin rashes are distinctly unusual with the penicillins. Serum sickness-like reactions—characterized by fever, arthralgias, lymph node enlargement, and cutaneous eruptions that are morbilliform or urticarial—tend to occur 7 to 10 days after the medication is begun. Other rare skin complications include erythema multiforme, Stevens-Johnson syndrome, toxic epidermal necrolysis, fixed drug eruption, vasculitis, erythroderma, pemphigus, and acute generalized pustulosis.

Cephalosporins

MECHANISM AND SPECTRUM OF ACTIVITY Like the penicillins, the cephalosporins impair cell-wall synthesis and kill susceptible organisms. These agents have been grouped into four “generations” according to the spectrum of their antibacterial activity. [7] First-generation cephalosporins, which include the parenteral agents cephalothin and cefazolin and the oral preparations cephalexin and cephradine, are active against streptococci (but not enterococci), methicillin-sensitive *S. aureus,* and some gram-negative bacilli, including most *E. coli, Proteus mirabilis,* and *K. pneumoniae*. Second-generation cephalosporins have increased activity against many gram-negative bacilli. Cefamandole, cefaclor, and cefuroxime are effective against *H. influenzae,* and cefoxitin and cefotetan against anaerobic gram-negative bacilli. The third-generation cephalosporins are less active than first- and second-generation agents against gram-positive cocci, but are effective against a larger number of gram-negative bacilli, including some that are resistant to many other agents. The fourth-generation cephalosporin, cefepime, has an extended spectrum of activity against both gram-positive cocci and gram-negative bacilli, including *Pseudomonas aeruginosa*. It has poor activity against anaerobes. Like all other cephalosporins, it is not effective for treating infections caused by *Listeria monocytogenes* or *Enterococcus* species.

DOSAGE AND DRUG INTERACTIONS For dermatologists, cephalosporins are primarily useful for treating streptococcal and staphylococcal infections, especially in patients with previous reactions to the penicillins that are not life-threatening. The preferable parenteral agent is cefazolin, 0.5 to 1 g IM or IV q8h, and the preferable oral preparation is cephalexin administered as 250 to 500 mg qid. In patients with renal failure, the appropriate interval between doses of cefazolin is 12 h for those with creatinine clearances between 10 and 50 mL/min, and 24 h for those with values less than 10 mL/min. For cephalexin, the interval should be 12 h when the value is less than 10 mL/min. For both agents, a supplemental dose

after hemodialysis is advisable. Two third-generation cephalosporins are useful in treating sexually transmitted diseases. Ceftriaxone given as a single intramuscular dose of 125 mg is effective against urethral, cervical, rectal, and pharyngeal gonorrhea; a single dose of 400 mg of the oral agent cefixime is another option. Ceftriaxone, 1 g IV daily, is the agent of choice for gonococcal bacteremia, arthritis, or disseminated disease. A single intramuscular dose of 250 mg is one option for treating chancroid.

ADVERSE EFFECTS Patients with a history of penicillin reactions have a higher incidence of adverse reactions with cephalosporins than do patients without such a history, but the frequency is only about 5 percent, and the manifestations are usually mild, even in patients with positive skin tests to the major and minor determinants of penicillin. [8] Most importantly, the risk of anaphylaxis or accelerated reaction is extremely low except in patients with a history of such an allergy to penicillin, who should not receive cephalosporins. Cephalosporins are generally well tolerated. Gastrointestinal symptoms of nausea, vomiting, abdominal cramps, and diarrhea may occur. Sometimes, primarily in hospitalized patients, the diarrhea may arise from *C. difficile* colitis. Candidal vulvovaginitis and pruritus ani are occasional complications, as is blood eosinophilia, which is usually unattended by any other significant findings. Anaphylaxis and urticaria are rare. Macular and papular eruptions, which occur in 1 to 3 percent of patients, resemble those of penicillin, typically beginning on the trunk and extending to the extremities. Reactions resembling serum sickness have developed primarily with cefaclor. Other rare cutaneous complications include toxic epidermal necrolysis, erythema multiforme, Stevens-Johnson syndrome, fixed drug reaction, erythroderma, pemphigus, and acute generalized exanthematous pustulosis. H4>Tetracyclines

MECHANISM AND SPECTRUM OF ACTIVITY Tetracyclines [9] are bacteriostatic antibiotics that impair protein synthesis by interfering with the 30S subunit of bacterial ribosomes. The most commonly used agents in dermatology are tetracycline, doxycycline, and minocycline. They are active against *Propionibacterium acnes,* considered the most important bacterial species in the pathogenesis of acne. They are also useful in treating rosacea and perioral dermatitis, although the microbial etiology, if any, of those disorders is unknown. Tetracyclines are important in the therapy of certain sexually transmitted diseases. Because of their activity against *Chlamydia trachomatis,* they are useful for urethritis, cervicitis, epididymitis, and pelvic inflammatory disease caused by this organism and for lymphogranuloma venereum. They are the drugs of choice in treating syphilis for adults (except pregnant or nursing women) unable to tolerate penicillin and for granuloma inguinale, which is caused by *Calymmatobacterium granulomatis*. They are active in primary skin infections caused by *Bacillus anthracis* (anthrax), *P. multocida* (infected dog or cat bites), *Vibrio vulnificus* (from wounds contaminated with saltwater), *B. burgdorferi* (the cause of Lyme disease), *Spirillum minus* and *S. moniliformis* (the causes of rat-bite fever), and *Mycobacterium marinum* (the cause of fish-tank granuloma). Tetracyclines are also effective in certain systemic infections that may have cutaneous manifestations, including tularemia, plague, brucellosis, bacillary angiomatosis, psittacosis, ehrlichiosis, *Mycoplasma pneumoniae* infection causing Stevens-Johnson syndrome, and rickettsial diseases (Rocky Mountain spotted fever, typhoid fever, and rickettsialpox).

DOSAGE AND DRUG INTERACTIONS The usual adult dose of tetracycline is 250 to 500 mg qid. Because of its less frequent dosage, approximately equivalent cost, and fewer side effects, especially diarrhea, doxycycline at 100 mg bid is the tetracycline of choice for most infections. The same dose is used intravenously for patients requiring parenteral therapy. Some dermatologists prefer minocycline for treating difficult acne, but little objective evidence demonstrates any superiority to doxycycline [10] and it is much more expensive. Its usual dose is 100 mg qd or bid. Because they increase azotemia by inhibiting protein synthesis and are eliminated by renal mechanisms, most tetracyclines are not recommended for patients in renal failure, but doxycycline, which is metabolized in the liver, can be given in its usual dose to patients with all levels of kidney function, and no supplemental dose is required after hemodialysis. Metals chelate the tetracyclines, impairing their absorption; patients, therefore, should avoid concurrent ingestion of medicinal iron or compounds, primarily antacids, containing aluminum, calcium, and/or magnesium. Sodium bicarbonate, milk, and milk products also decrease absorption of the tetracyclines. Phenytoin, carbamazepine, barbiturates, and alcohol use increase the metabolism of doxycycline; standard, twice-daily dosing, however, is satisfactory for patients receiving these substances.

ADVERSE EFFECTS Because they can stain the teeth and impair bone growth in fetuses and in young children, tetracyclines are contraindicated in pregnant women, nursing mothers, and children younger than 12 years of age. Otherwise, they are generally quite safe. Tetracyclines may cause nausea, vomiting, and diarrhea, and *C. difficile* colitis may be a complication, primarily in hospitalized patients. For some, oral or vulvovaginal candidiasis is a problem. Idiopathic intracranial hypertension, pulmonary eosinophilia, and pancreatitis are rare adverse effects. Esophageal ulcerations and strictures occasionally occur from prolonged exposure of the esophageal mucosa to the drug; taking the medication with copious amounts of water and avoiding its ingestion just before the patient is likely to be recumbent, as at bedtime, should prevent these problems. Minocycline can cause neurologic complications—consisting of dizziness, vertigo, light-headedness, tinnitus, and imbalance—that usually begin within a few days of treatment. These occur more frequently in women and subside several days after the drug is discontinued. Minocycline also can cause a syndrome that includes autoimmune hepatitis and features of systemic lupus erythematosus. All the tetracyclines can cause phototoxic eruptions that resemble severe sunburn, and onycholysis may occur in sun-exposed nails of the fingers and toes. Long-term minocycline therapy can result in various forms of pigmentation. Blue-black macules may develop in areas of previous inflammation or in scars, especially those due to acne. Hyperpigmentation, either macular or diffuse, may occur on sun-exposed areas, particularly the extensor surfaces of the legs and forearms as well as on the hard palate. These forms generally abate over a few months after discontinuation of the minocycline. A more persistent type is a brown-gray discoloration, especially in sun-exposed areas, that may also affect the nails, sclera, and teeth. Other cutaneous reactions to tetracycline are uncommon. Erythema multiforme, erythroderma, Stevens-Johnson syndrome, erythema nodosum, and toxic epidermal necrolysis have been reported, and tetracyclines can cause fixed drug eruptions.

Macrolides

MECHANISM AND SPECTRUM OF ACTIVITY Macrolides—consisting of erythromycin, azithromycin (which belongs to a subclass called azalides), and clarithromycin—interfere with protein synthesis by binding to the 50S ribosomal subunit of susceptible organisms. They are generally bacteriostatic. Clarithromycin and azithromycin are structurally similar to erythromycin, but small alterations have created three major differences. [11] They are more stable in gastric acid, promoting better oral absorption and decreasing the degradation of the drugs into inactive metabolites that cause gastrointestinal side effects. Their penetration into cells is superior to that of erythromycin, achieving concentrations in most tissues, but not the brain or cerebrospinal fluid, that considerably exceed those in the blood. They also have longer serum half-lives, which allows less frequent dosage. These agents are considerably more expensive than erythromycin,

however, and their apparent advantages have little relevance to the treatment of most cutaneous infections. The macrolides are active against most streptococci and *S. aureus* but not methicillin-resistant strains. Unfortunately, azithromycin and clarithromycin are ineffective against erythromycin-resistant *S. aureus,* which is common in some areas. Because of its action against *P. acnes,* topical or systemic erythromycin is an option for treating acne, and it is effective in rosacea and perioral dermatitis as well. It is useful for erythrasma, an infection caused by *Corynebacterium minutissimum,* and is an option for anthrax, erysipeloid (which is caused by I>E. rhusiopathiae), and Lyme disease (which is caused by *B. burgdorferi*). Erythromycin is also useful in sexually transmitted diseases, including chancroid and infections caused by *C. trachomatis,* such as nongonococcal urethritis, cervicitis, epididymitis, conjunctivitis, proctitis, and lymphogranuloma venereum. It is the drug of choice for these infections during pregnancy. Clarithromycin and azithromycin have advantages for two special circumstances of potential relevance to dermatologists. In sexually transmitted diseases, single-dose therapy is ideal, because it can be observed and compliance assured, unlike with regimens requiring further doses. Azithromycin as a single 1 g dose is effective for chancroid and for infections caused by *C. trachomatis,* except lymphogranuloma venereum, which requires protracted therapy (21 days) with erythromycin or doxycycline. These macrolides are also active against various mycobacteria, including both rapidly growing (*M. chelonae, M. abscessus*) and slow-growing species (*M. gordonae, M. szulgai, M. scrofulaceum, M. marinum, M. nonchromogenicum*). Azithromycin and clarithromycin, therefore, may be useful in treating cutaneous mycobacterial infections caused by susceptible organisms.
DOSAGE AND DRUG INTERACTIONS The usual adult dose of erythromycin is 250 to 500 mg qid. No changes are necessary in renal failure, and no supplemental doses are required in hemodialysis. Erythromycin increases the levels of several medications, including theophylline, warfarin, carbamazepine, and cyclosporine. Clarithromycin may increase the blood levels of several drugs, including theophylline, cyclosporine, warfarin, and carbamazepine. The usual adult regimen for azithromycin is 500 mg the first day followed by 250 mg daily thereafter. For clarithromycin, the usual adult dose is 250 to 500 mg twice daily. No adjustment is necessary for renal disease.
ADVERSE EFFECTS The most common adverse effects of the macrolides are gastrointestinal, including abdominal cramps, nausea, vomiting, and diarrhea. Occasionally, *C. difficile* colitis occurs, primarily in hospitalized patients. Cholestatic hepatitis rarely develops with erythromycin, almost exclusively with the estolate preparation. Patients typically have nausea, vomiting, and abdominal pain, followed by jaundice and fever. Laboratory findings include abnormal liver function tests consistent with cholestatic changes and occasionally eosinophilia. Angioedema and photosensitivity are rare dermatologic complications of azithromycin.

Fluoroquinolones

MECHANISM AND SPECTRUM OF ACTIVITY Fluoroquinolones [12] inhibit enzymes involved in the coiling of the DNA helix and are usually bactericidal. Agents in this rapidly expanding class of antibiotics include ciprofloxacin, ofloxacin, sparfloxacin, gatifloxacin, grepafloxacin, moxifloxacin, and levofloxacin. Clinicians extravagantly (and very often inappropriately) prescribe them for diverse infections, but they have few potential uses in dermatology. They are active against *S. aureus,* including some methicillin-resistant strains, but resistance of this organism has emerged from widespread use of these agents. Except for ciprofloxacin and ofloxacin, the fluoroquinolones are active against streptococci. They are effective against many gram-negative organisms, including *N. gonorrhoeae,* and against several mycobacteria, such as *M. tuberculosis, M. fortuitum,* and *M. xenopi*. Most fluoroquinolones are also active against *C. trachomatis*. The dermatologic use of the fluoroquinolones is primarily as treatment options for sexually transmitted diseases. Some of these agents are efficacious, but very expensive alternatives to doxycycline for urethritis, cervicitis, conjunctivitis, and proctitis caused by *C. trachomatis*. Several of these agents are effective in single doses for urethral, rectal, cervical, or pharyngeal gonorrhea; 3-day courses are alternatives for treating chancroid.
DOSAGE AND DRUG INTERACTIONS Patients should avoid the concurrent use of sucralfate, supplements containing zinc or iron, and antacids with aluminum, calcium, or magnesium, all of which inhibit the absorption of the fluoroquinolones. Some fluoroquinolones can increase the serum levels of warfarin, theophylline, and cyclosporine, and they can alter the blood glucose level, causing either hyper- or hypoglycemia in some patients taking oral antidiabetic agents or insulin. The proper adjustment in renal dysfunction varies among the fluoroquinolones, and clinicians should consult appropriate sources to determine the recommended approach.
ADVERSE EFFECTS The most frequent adverse effects are nausea, diarrhea, insomnia, headache, and dizziness. Uncommon complications include serum sickness, a morbilliform eruption, anaphylaxis, and vasculitis. Phototoxic reactions can occur, even when patients use a sunscreen. Occasional abnormal laboratory tests include eosinophilia, increased levels of liver enzymes, and leukopenia. Because studies demonstrate cartilage erosions in the joints of young animals given high doses, the fluoroquinolones are not recommended for children. They should not be used in pregnant women or nursing mothers.

Clindamycin

MECHANISM AND SPECTRUM OF ACTIVITY Clindamycin, [13] a bacteriostatic drug, inhibits protein synthesis by binding to the 50S portion of the ribosome. It is active against streptococci, most *S. aureus,* and most anaerobic bacteria, including *P. acnes*. Its major use in dermatology is as an alternative in treating streptococcal and staphylococcal infections in penicillin-allergic patients and in treating acne. It achieves high levels in the nasal secretions and is one of the most effective agents in eradicating nasal carriage of *S. aureus* and in preventing further episodes in those with recurrent staphylococcal skin infections.
DOSAGE AND DRUG INTERACTIONS The usual adult dose is 150 to 300 mg qid. No adjustment is necessary for renal failure, and no supplemental dose is required for patients receiving hemodialysis. Since clindamycin primarily undergoes hepatic metabolism, it accumulates in patients with severe liver disease, a situation that warrants cautious use, although no specific dose adjustments are available. [14] For the prevention of recurrent staphylococcal skin infection, a reasonable program is 150 mg qd for 3 months. [15]
ADVERSE EFFECTS Morbilliform rashes are frequent, but anaphylaxis, urticaria, and erythema multiforme are rare. Hepatotoxicity is also very uncommon. The most notorious adverse effect is diarrhea, which may occur in up to 20 percent of recipients. In nearly all outpatients and most inpatients, the cause seems related to the antibiotic itself, and the diarrhea abates after the clindamycin is discontinued. In patients in the hospital or recently hospitalized, however, clindamycin, like many other antibiotics, predisposes to colitis due to *C. difficile*. This organism is not part of the normal bowel flora, but it commonly colonizes hospitalized patients, especially those who have received broad-spectrum

antibiotics that eradicate the normal intestinal bacteria. The diarrhea ranges from mild to very severe, when fever, leukocytosis, and intravascular volume depletion may occur. It usually begins during clindamycin administration but may start days or even weeks after the course has ended. The diagnosis is established by finding *C. difficile* or its toxin in the stools of symptomatic patients. Mild cases respond to discontinuation of the clindamycin; more severe ones warrant therapy with oral metronidazole. In general, because of the tendency of this drug to cause diarrhea, either as a direct effect of the antibiotic or through predisposing to *C. difficile* colitis, patients with inflammatory bowel disease should not receive clindamycin.

Trimethoprim-Sulfamethoxazole

MECHANISM AND SPECTRUM OF ACTIVITY This combination of antimicrobial agents, [16] also called co-trimoxazole, blocks two separate steps in the folic acid metabolism of susceptible organisms. It is active against a wide variety of gram-negative bacteria and against most *S. aureus,* including many methicillin-resistant strains. Its main use is for urinary tract and respiratory infections, including sinusitis, otitis media, and pneumonia. Because of its activity against *Pneumocystis carinii,* it is effective in treating and preventing pneumonia and other infections due to that organism, and it is widely used for that purpose in patients infected with HIV. It has few indications in dermatology; it may be useful for acne refractory to tetracycline, and it is effective in treating some patients with mild or moderately severe Wegener's granulomatosis and in preventing recurrent episodes in that disorder. Other agents have generally replaced it in the therapy of sexually transmitted diseases.
DOSAGE AND DRUG INTERACTIONS The usual adult dose is one double-strength tablet (containing 800 mg of sulfamethoxazole and 160 mg of trimethoprim) bid. It may increase the serum levels of phenytoin and enhance the hypoglycemic effects of chlorpropamide and tolbutamide. It displaces warfarin and methotrexate from their albumin-binding sites, potentiating the effects of these drugs, and it decreases the serum levels of cyclosporine.
ADVERSE EFFECTS Gastrointestinal side effects—including nausea, vomiting, and abdominal discomfort—occur in approximately 3 percent of patients. Diarrhea develops in fewer than 1 percent of patients, and *C. difficile* colitis is rare. Trimethoprim-sulfamethoxazole can cause mild nephrotoxicity in patients with underlying renal insufficiency, and the drug is not recommended in this circumstance. Hematologic complications include neutropenia, which is more likely in those undergoing hemodialysis and in patients with preexisting folate or vitamin B_{12} deficiency, concurrent phenytoin administration, malnutrition, and alcoholism. Hemolytic anemia can develop in those with glucose-6-phosphate dehydrogenase (G6PD) deficiency. In patients with HIV infection, neutropenia and thrombocytopenia are frequent. Patients with HIV infection frequently develop rashes with this medication. Morbilliform eruptions occur in 30 to 85 percent of those who receive the drug, commonly during the second week of therapy. [17] The findings are itchy or asymptomatic macules and papules that become generalized and usually resolve quickly after the agent is discontinued. A similar rash occurs in about 3 percent of the general population. More severe eruptions develop in about 13 percent of HIV-infected patients, as compared to approximately 1/100,000 of others receiving the drug. These eruptions include erythema multiforme, Stevens-Johnson syndrome, and toxic epidermal necrolysis. Indeed, trimethoprim-sulfamethoxazole is one of the most common causes of these drug reactions. Other occasional cutaneous complications include vasculitis, erythema nodosum, erythroderma, fixed drug eruption, and serum sickness.

SYSTEMIC ANTIMICROBIAL PROPHYLAXIS IN DERMATOLOGY

Clinicians use antibiotics primarily to treat infections, but a considerable amount of antimicrobial administration is devoted to preventing them. Much of this prophylactic use is unnecessary, and in dermatology only a few indications exist, primarily in patients with recurrent bacterial skin infections. [18] Prophylactic antibiotics are rarely indicated to prevent postoperative infections in cutaneous surgery, which seldom imposes a risk for hematogenous infection of implanted prosthetic material in patients with such devices as artificial heart valves and joints. [18]

Recurrent Bacterial Skin Infections

One study of patients with recurrent staphylococcal skin infections demonstrated that oral clindamycin, 150 mg qd for 3 months, impressively decreased the incidence of further episodes. [15] Among the placebo recipients, 64 percent of patients had a recurrent skin abscess in the 3 months, compared to 18 percent of those receiving clindamycin. Of those who were free of infection while taking the antibiotic, 67 percent had no recurrence for at least 9 months after discontinuing the clindamycin. Although the study did not specifically evaluate this issue, this long-term benefit probably came from eradication of staphylococcal nasal carriage, for which clindamycin is one of the few very effective antimicrobials. No patient had gastrointestinal complaints, including diarrhea. Clinicians considering this prophylaxis should perform appropriate cultures of the skin lesions to ensure that the dermatologic lesions are genuinely due to *S. aureus,* because many cutaneous abscesses and other pustular skin diseases are caused by other organisms or have a noninfectious etiology.

Patients with recurrent bouts of cellulitis typically have predisposing factors including tinea pedis, chronic lymphedema, persistent swelling from other causes, poor hygiene, and trauma. When repeated infections occur despite therapy of these underlying conditions, penicillin or erythromycin (250 mg bid) is very effective in preventing further episodes. In one study, for example, the recurrence rate over 18 months was 50 percent among patients who received no systemic antibiotics, compared with zero percent among those taking twice-daily erythromycin. [19] Monthly or twice-monthly injections of benzathine penicillin represent another option, particularly in patients who do not take medications reliably.

Prevention of Wound Infections after Dermatologic Surgery

To justify the expense and potential complications of antimicrobials prescribed to prevent postoperative wound infections, such infections should be either quite frequent or very severe. Most dermatologic procedures are “clean” surgery, which involves incisions through uninfected skin without transecting mucosal surfaces. The expected infection rate without antimicrobial prophylaxis is less than 5 percent, and in most centers, it is less than 1 percent. Because such infections are rarely severe, preventive antibiotics are unjustified. Even in surgery that is “clean-contaminated”—involving the

transection of mucosal surfaces, such as removing a deep basal cell carcinoma from the nose—the infection rate is low and the infections relatively mild. The 10 percent infection rate quoted for this type of operation derives from studies primarily involving major surgery, such as laryngectomies or gastrointestinal resections, not dermatologic procedures. This kind of skin surgery does not warrant antibiotic prophylaxis. Similarly, in patients with acute nonpurulent inflammation or major breaks in aseptic technique ("contaminated surgery"), where the expected infection rate in major surgery is 20 to 30 percent, the incidence is probably lower in dermatologic procedures, and the infections are usually mild. Even with operations involving purulent lesions ("infected or dirty surgery") in which postoperative infections occur in 30 to 40 percent of patients with major surgery, the risks for patients with cutaneous suppuration are low and the consequences mostly mild. Incision and drainage of skin abscesses, for example, lead to few postoperative infections, and antibiotics seem not only unnecessary but ineffective in this setting. [20], [21]

Some practitioners use prophylactic antibiotics for patients undergoing full-face laser resurfacing for removal of wrinkles, but the available information, which is poor, fails to demonstrate a benefit in this setting. Use of antibiotics, however, does seem to increase the isolation of gram-negative bacilli from the wounds, although these organisms rarely cause clinical problems. [22]

While a procedure with extensive and deep surgery involving a mucosal surface may warrant preoperative antibiotics, such operations are uncommon for most dermatologists. For these unusual dermatologic procedures, one of the most important elements in the use of prophylactic antibiotics is the timing of their administration. Because contamination usually occurs only from the beginning of the incision to the time of wound closure, a single preoperative dose of an antibiotic that sustains good tissue levels throughout this period suffices. Further preoperative or postoperative doses are unnecessary and wasteful. Another important consideration is the choice of the agent; the goal is not to eradicate every microbe potentially present but to reduce the concentration of the most likely contaminating organisms to a level that the host can handle without developing an infection. Most studies on prophylactic antibiotics in surgery have used a parenteral cephalosporin, especially cefazolin, 1 g of which results in good, sustained serum and tissue levels of the antibiotic. Furthermore, it is active against streptococci, staphylococci, and most of the upper respiratory flora that are likely to cause infections in procedures transecting the upper airway mucosa.

Antibiotic Prophylaxis for Patients with Heart Disease or Prosthetic Material

The transient bacteremia that occurs with various dental and surgical procedures can sometimes lead to infections of abnormal cardiac valves, both native and prosthetic ones, and possibly to infections of such implanted devices as artificial joints and vascular grafts. The risk of bacteremia with dermatologic surgery involving incisions through either intact or eroded skin is very low, [18] however, and no prophylaxis is required for patients with either abnormal heart valves or indwelling prosthetic material.

Only with incision and drainage of infected tissue is the frequency of bacteremia likely to be high enough to justify antimicrobial prophylaxis, and even in that or, indeed, any other situation, its efficacy is unknown. A reasonable approach for such an uncommon circumstance is to give a single dose of an agent about 1 h before the procedure in patients with implanted prostheses. An oral antibiotic is usually feasible, but occasionally a parenteral agent may be required—for example, in patients with nausea or with evidence of systemic infection, in whom blood cultures should precede antimicrobial administration. Appropriate choices include a first-generation cephalosporin (cephalexin 1 g PO or cefazolin 1 g IM or IV), a penicillinase-resistant penicillin (dicloxacillin 1 g PO or nafcillin 1 g IV), or clindamycin for patients with serious penicillin allergies (300 mg PO or IV).

REFERENCES

1. Wright AJ: The penicillins. *Mayo Clinic Proc* **74**:290 1999

2. Sensakovic JW, Smith LG: Beta-lactamase inhibitor combinations. *Med Clin North Am* **79**:695, 1995

3. Goldstein EJC: Current concepts on animal bites: bacteriology and therapy. *Curr Clin Top Infect Dis* **19**:99, 1999

4. Lin RY: A perspective on penicillin allergy. *Arch Intern Med* **152**:930, 1992

5. Sogn DD et al: Results of the National Institute of Allergy and Infectious Diseases collaborative clinical trial to test the predictive value of skin testing with major and minor penicillin derivatives in hospitalized patients. *Arch Intern Med* **152**:1025, 1992

6. Sher TH: Penicillin hypersensitivity—A review. *Pediatr Clin North Am* **30**:161, 1983

7. Marshall WF, Blair JE: The cephalosporins. *Mayo Clin Proc* **74**:187, 1999

8. Saxon A et al: Immediate hypersensitivity reactions to beta-lactam antibiotics. *Ann Intern Med* **107**:204, 1987

9. Smilack JD: The tetracyclines. *Mayo Clin Proc* **74**:727, 1999

10. Webster GF: Acne. *Curr Probl Dermatol* **8**:237, 1996

11. Alvarez-Elcoro S, Enzler MJ: The macrolides: Erythromycin, clarithromycin, and azithromycin. *Mayo Clin Proc* **74**:613, 1999

12. Walker RC: The fluoroquinolones. *Mayo Clin Proc* **74**:1030, 1999

13. Kasten MJ: Clindamycin, metronidazole, and chloramphenicol. *Mayo Clin Proc* **74**:825, 1999

14. Tschida SJ et al: Anti-infective agents and hepatic disease. *Med Clin North Am* **79**:895, 1995

15. Klempner MS, Styrt B: Prevention of recurrent staphylococcal skin infections with low-dose clindamycin therapy. *JAMA* **260**:2682, 1988

16. Smilack JD: Trimethoprim-sulfamethoxazole. *Mayo Clin Proc* **74**:730, 1999

17. Zalla MJ et al: Dermatologic manifestations of human immunodeficiency virus infection. *Mayo Clin Proc* **67**:1089, 1992

18. Hirschmann JV: Antimicrobial prophylaxis in dermatology. *Semin Cutan Med Surg* **19**:2, 2000

19. Kremer M et al: Long-term antimicrobial therapy in the prevention of recurrent soft-tissue infections. *J Infect* **22**:37, 1991

20. Meislin HW et al: Cutaneous abscesses: Anaerobic and aerobic bacteriology and outpatient management. *Ann Intern Med* **87**:145, 1977

21. Macfie J, Harvey J: The treatment of acute superficial abscesses: A prospective clinical trial. Br J Surg **64**:264, 1977

22. Gaspar Z, et al: Antibiotic prophylaxis for full facial laser resurfacing: Is it necessary? *Arch Dermatol* **137**:313, 2001

T>

Chapter 260

Raphael Dolin

Antiviral Drugs

DRUGS FOR THE TREATMENT OF HERPES SIMPLEX VIRUS AND VARICELLA-ZOSTER VIRUS INFECTIONS
Acyclovir
Valacyclovir
Famciclovir and Penciclovir
DRUGS FOR THE TREATMENT OF CMV INFECTIONS
Ganciclovir
Valganciclovir
Foscarnet
Cidofovir
INTERFERONS
DRUGS FOR THE TREATMENT OF HIV INFECTION
Reverse Transcriptase Inhibitors
Protease Inhibitors
Other Antiretroviral Drugs
REFERENCES

Antiviral drugs have been developed at an extraordinary pace during the past decade. As late as the mid-1980s, only three antiviral drugs were approved for treatment of systemic viral infections. Currently, there are over 30 approved antiviral drugs, and additional ones are likely to be forthcoming. Progress has been accelerated by recent advances in knowledge of the molecular biology and pathogenesis of certain viral infections, of which AIDS has been the most notable. Nonetheless, the field of antiviral drugs still lags considerably behind that of antibacterial antibiotics, both in the numbers of available drugs and in the clinical application of techniques such as pharmacokinetic measurements and in vitro assessment of resistance. These areas are under active development.

This chapter focuses on drugs to treat those viral infections that are most likely to be encountered by dermatologists, such as those caused by herpes simplex virus (HSV) and varicella-zoster virus (VZV). Antiviral drugs used to treat cytomegalovirus (CMV) infections, the interferons, and antiretroviral drugs to combat HIV infection are discussed in less depth, and the reader is referred to reviews of these subjects for more information.

DRUGS FOR THE TREATMENT OF HERPES SIMPLEX VIRUS AND VARICELLA-ZOSTER VIRUS INFECTIONS

Acyclovir

ANTIVIRAL ACTIVITY Acyclovir {9-[(2-hydroxyethoxy) methyl] guanine, Zovirax} (Fig. 260-1) is an antiviral drug widely used for the treatment of HSV and VZV infections. [1] It is highly active against HSV-1, slightly less active against HSV-2, and approximately eightfold less active against VZV in vitro. The activity of acyclovir against CMV is variable, and isolates are frequently resistant. Acyclovir has good activity against Epstein-Barr virus (EBV) in vitro, and at higher concentrations it inhibits human herpesvirus (HHV)-6. The active antiviral moiety of acyclovir is acyclovir triphosphate, which is a potent inhibitor of certain herpesvirus-induced DNA polymerases, but has relatively little effect on host cell DNA polymerase. Acyclovir triphosphate also acts as a terminator of the nascent viral DNA chain because it lacks the 3' hydroxyl group. The initial phosphorylation of acyclovir to acyclovir monophosphate is efficiently carried out by herpesvirus-induced thymidine kinases but not by cellular kinases. Thus, acyclovir monophosphate is concentrated in virus-infected cells, which contributes to its highly selective mechanism of action. [2] Resistance to acyclovir in HSV and VZV isolates occurs most commonly by mutations that result in absent or markedly decreased thymidine kinase activity. Less-frequent mechanisms of resistance are alterations in substrate specificity of the thymidine kinase or changes in the viral DNA polymerase. [3] Resistant viruses have been usually, but not invariably, associated with prolonged use of acyclovir in immunosuppressed patients. Viruses that are resistant to acyclovir on the basis of thymidine kinase mutations are also resistant to ganciclovir and famciclovir, but are generally sensitive to foscarnet and cidofovir (see below). Viruses resistant to acyclovir on the basis of a DNA polymerase mutation are also usually resistant to foscarnet but may retain sensitivity to cidofovir.

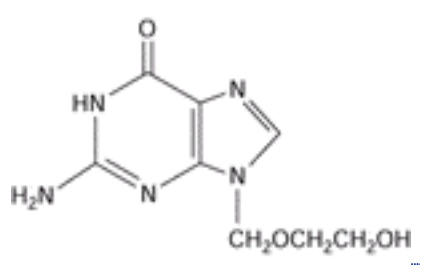

FIGURE 260-1 Acyclovir.

PHARMACOKINETICS Acyclovir is available in oral, intravenous, and topical formulations. The oral bioavailability of acyclovir is low (15 to 30 percent). A 200-mg oral dose of acyclovir results in a peak plasma concentration of 0.4 to 0.8 µg/mL approximately 1.5 h after administration, while an 800-mg oral dose results in a peak plasma concentration of 1.6 µg/mL. [4], [5] Oral absorption may be somewhat less in transplant patients. The plasma half-life of acyclovir is from 2.1 to 3.5 h in patients with normal renal function. Acyclovir is almost entirely eliminated by the renal route, largely

unmetabolized (85 percent), while the remainder is metabolized to a 9-carboxymethoxymethylguanine. Therefore, dosage reductions are required for patients with creatinine clearances of <50 mL/min. [6] Acyclovir is widely distributed in body fluids, including cerebrospinal fluid, vesicle fluids, and vaginal secretions. Acyclovir is available as a 5% ointment in a polyethylene glycol base in the United States, and topical administration results in detectable drug concentrations in lesions but little, if any, systemic absorption.

ADVERSE EFFECTS Acyclovir is generally well tolerated. The major toxicity associated with acyclovir is renal, as a result of crystallization of the drug in renal tubules, which has been reported with high dosage, dehydration, or rapid intravenous administration. Interstitial nephritis associated with acyclovir has also been reported. [7] Central nervous system toxicity has been described, including lethargy, tremors, obtundation, and seizures. [8] These side effects have usually been associated with high plasma levels of acyclovir and with underlying diseases involving the central nervous system. The concomitant use of interferon or other nucleoside analogues may contribute to neurotoxicity.

CLINICAL INDICATIONS The efficacy of acyclovir is well established in the treatment of HSV infections in several clinical settings. These include mucocutaneous HSV infections in immunocompromised patients, which generally respond to either intravenous (5 mg/kg IV q8h) or oral administration (400 mg PO five times per day). These infections are usually treated for 7 to 10 days, but more severe cases may require longer therapy. Acyclovir is also effective as prophylaxis in patients who are seropositive for HSV and who undergo intensive immunosuppression as part of transplantation or chemotherapeutic regimens. Acyclovir administered intravenously or orally to patients with primary genital herpes results in shortened duration of symptoms, acceleration of healing, and reduction of virus shedding. [9] Intravenous and oral therapies have similar efficacies, and the choice between routes of administration should be based on the severity of disease, the need for hospitalization, and the ability of the patient to take oral medications. Acyclovir therapy for primary genital HSV does not reduce the frequency or severity of subsequent recurrences. In recurrent HSV genital infections, oral acyclovir has a modest beneficial effect on the length of time to healing and on the duration of viral shedding, particularly when it is initiated within 24 h of the onset of symptoms. [10] Suppressive therapy with 400 mg of acyclovir PO bid reduces the number of recurrences and is recommended for patients with recurrences that are particularly frequent (more than six times per year) or troublesome. [11] The need for continuation of suppressive therapy should be assessed on an annual basis by stopping the drug to see whether recurrences develop. Chronic suppressive therapy does not eliminate the latent stage of HSV infection, and asymptomatic shedding of virus can occur. Acyclovir therapy for orofacial HSV infections has been less-extensively studied than for genital infections. Oral therapy for herpes labialis produced a modest beneficial clinical effect, particularly if treatment was started early in the recurrence and if higher doses were used (500 mg PO five times per day for 5 days). [12] Primary HSV gingivostomatitis has not been well studied, but anecdotal reports suggest acyclovir may be of some benefit in such cases. The administration of acyclovir prophylactically to patients who experience reactivation of herpes labialis with sunlight may decrease the number of lesions associated with such recurrences but does not appear to have an otherwise beneficial effect. The topical use of acyclovir as a 5% ointment in polyethylene glycol has been largely supplanted in the United States by oral administration of the drug. Acyclovir ointment is beneficial in the treatment of primary genital infections, but less so than oral or intravenous therapy. [13] Topical acyclovir is also modestly beneficial in immunocompromised patients with localized mucocutaneous HSV infections. Topical therapy with acyclovir ointment has not been demonstrated to be of clinical benefit in the treatment of herpes labialis in immunocompetent patients. [14] Intravenous acyclovir is the drug of choice for treatment of life-threatening HSV infections such as encephalitis [15] or neonatal infection. [16] Acyclovir is also effective in the treatment of VZV infection. Because VZV is less sensitive to acyclovir than HSV, higher doses of the drug should be used (10 mg/kg IV q8h or 800 mg PO five times per day for 7 days). In immunocompromised patients with herpes zoster, intravenous acyclovir reduces the frequency of visceral complications and of cutaneous dissemination. [17] Orally administered acyclovir has a modest beneficial effect on the dermatomal lesions of localized herpes zoster in immunocompetent patients. [18] The effect of acyclovir on postherpetic neuralgia is unclear, and a clinical trial suggested that valacyclovir may be more effective in resolution of zoster-associated pain [19] (see below). The use of glucocorticoids along with acyclovir to prevent the development of postherpetic neuralgia remains controversial. One study showed no benefit from the addition of prednisolone to acyclovir in herpes zoster in immunocompetent patients, [20] whereas another showed a beneficial effect of the combination of prednisone and acyclovir in overall quality-of-life measurements, although not on postherpetic neuralgia specifically. [21] Orally administered acyclovir (600 mg five times per day) is effective in the treatment of herpes zoster ophthalmicus. [22] Intravenous acyclovir has been reported to be clinically beneficial in immunosuppressed patients with varicella (chickenpox) and may reduce the rate of visceral complications. [23] Oral acyclovir therapy for varicella in immunocompetent children, adolescents, or adults results in only a modest overall clinical benefit, even if begun within 24 h of onset of lesions. [24], [25] Such therapy has not been demonstrated to reduce the rate of serious complications in these patients. With respect to infections caused by other herpesviruses, acyclovir is not effective in the treatment of CMV infections but has shown efficacy in the prophylaxis of CMV infections in patients undergoing bone marrow, liver, or renal transplantation; it has been used in many transplant centers for that purpose. Acyclovir therapy has no clinical benefit for EBV-induced infectious mononucleosis, although shedding of EBV in the oropharynx was reduced during acyclovir administration. Oral hairy leukoplakia in patients with AIDS frequently responds to acyclovir therapy. Anecdotal reports have described the use of acyclovir to treat EBV-associated posttransplantation lymphoproliferative disorders, but the overall effectiveness of acyclovir in that setting is unclear.

Valacyclovir

Valacyclovir{2-[2-amino-1, 6-dihydro-6-oxo-9 *H*-purin-9-yl-methoxy] ethyl-L-valinate hydrochloride, Valtrex} (Fig. 260-2) is the L-valine ester of acyclovir; it was developed to provide increased oral bioavailability for acyclovir. [26] It is rapidly absorbed from the gastrointestinal tract and is converted almost entirely to acyclovir through intestinal and hepatic esterases. Thus, the mechanism of action and spectrum of activity of valacyclovir is that of acyclovir. After a 1-g oral dose of valacyclovir, peak plasma concentrations of acyclovir of 5.7 µg/mL are achieved in 1.75 h, with area under the curve (AUC) concentrations that are similar to those achieved with 5 mg/kg of acyclovir given intravenously. [27] The pharmacokinetics of acyclovir, once it has been converted from valacyclovir, are those of the parent compound, acyclovir, and adverse effects are those that would be expected with acyclovir. However, severe and even fatal cases of the thrombotic thrombocytopenic purpura/hemolytic uremic syndrome (TTP/HUS) have been reported in patients with AIDS and transplant recipients who were taking high doses of valacyclovir. [28] The basis and causal relationship to valacyclovir

of this observation have not been established, and TTP/HUS has not been reported in patients taking conventional doses (up to 3 g/day) of valacyclovir.

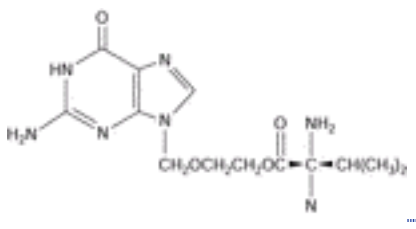

FIGURE 260-2 Valacyclovir.

CLINICAL USEFULNESS Valacyclovir is currently approved for the treatment of initial [29] and recurrent HSV genital infections, [30] for the suppression of frequently recurring genital HSV infections, [31] and for the treatment of herpes zoster in immunocompetent patients. [19] The treatment of initial HSV genital infection with 1 g PO bid for 10 days [29] or recurrent HSV genital infections with 500 mg PO bid for 5 days [30] was as effective and more convenient than when the drug was given at 200 mg five times a day. Clinical episodes of recurrent HSV infections were effectively suppressed with doses of 1 g/day PO in patients with very frequent recurrences (nine or more episodes per year) and with a lower dose (500 mg/day) in those with fewer than nine episodes per year. [31] Suppressive regimes of valacyclovir have been reported to be well tolerated for at least 1 year, and many clinicians have successfully maintained patients on suppressive therapy for even longer periods of times. Valacyclovir is effective in the treatment of herpes zoster in immunocompetent patients if administered within 72 h of the onset of lesions at a dose of 1 g PO tid for 7 days, and it appears to be somewhat superior to acyclovir in the resolution of zoster-associated pain. [19], [32] In a trial comparing valacyclovir with famciclovir (see below) in the treatment of herpes zoster, the two drugs were similarly effective in the resolution of zoster-associated pain. [33] Valacyclovir has been reported to be effective as prophylaxis against recurrences of facial HSV after facial resurfacing. [34] The drug is also being studied as prophylaxis for HSV, VZV, and CMV infections in a variety of immunosuppressed patients, particularly those undergoing transplantation. [35] Because of its favorable pharmokinetic properties and convenience of dosing, many clinicians substitute valacyclovir for acyclovir in the treatment of HSV or VZV infections, even in those in which studies of valacyclovir are not available, such as in immunosuppressed patients or in those with chickenpox.

Famciclovir and Penciclovir

ANTIVIRAL ACTIVITY Famciclovir [9-(4-hydroxy-3 hydroxymethylbut-1-yl) guanine, Famvir] (Fig. 260-3) is a prodrug of penciclovir [9-(4-hydroxy-3-hydroxy-3-hydroxymethylbut-1-yl) guanine]. Penciclovir is phosphorylated to penciclovir triphosphate, which has antiviral activity against HSV-1, HSV-2, VZV, and EBV, and also against hepatitis B virus (HBV). [36], [37] The initial phosphorylation of penciclovir to penciclovir monophosphate is carried out by HSV- or VZV-induced thymidine kinases in a manner analogous to that of the initial phosphorylation of acyclovir. Phosphorylation to di- and triphosphate forms of penciclovir is carried out by cellular kinases. Penciclovir triphosphate inhibits viral DNA polymerases and also inhibits extension of the nascent viral DNA chain. [37] Because of the presence of the hydroxyl group on the acyclic side chain of penciclovir, some DNA chain extension may occur.

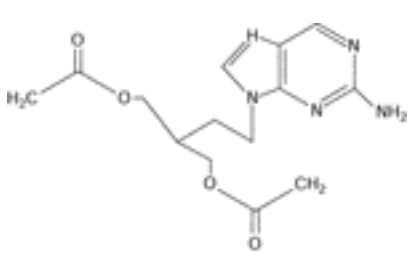

FIGURE 260-3 Famciclovir.

PHARMACOKINETICS Famciclovir is available as an oral formulation, which is converted to penciclovir by deacetylation and oxidation in the liver and intestine. The bioavailability of famciclovir is 77 percent, and a peak penciclovir plasma concentration of 3.3 µg/mL is reached 1 h after oral administration of 500 mg of famciclovir. [38] The plasma half-life of penciclovir is 2 h, and 60 to 70 percent of the drug is excreted unchanged in the urine by both glomerular filtration and tubular secretion. The dose of penciclovir should be reduced in cases of advanced renal dysfunction. [39] Compared to the intracellular half-life of acyclovir triphosphate, that of penciclovir triphosphate is markedly prolonged in HSV-infected cells (10 to 20 h) and VZV-infected cells (9 h). [36], [37] This prolonged intracellular half-life is the rationale for the longer interval of administration of famciclovir (q12h), as compared to that recommended for acyclovir (q4h). HSV and VZV isolates that lack thymidine kinases are resistant to penciclovir just as they are to acyclovir. However, some acyclovir-resistant viruses with altered thymidine kinases remain sensitive to penciclovir.

ADVERSE EFFECTS Famciclovir is well tolerated, and serious clinical and laboratory toxicities are uncommon. Prolonged, high-dose administration of famciclovir to rats was associated with an increased incidence of mammary adenocarcinomas in females, but the clinical significance of this observation is unknown.

CLINICAL USEFULNESS Famciclovir is approved for the treatment of acute herpes zoster, [33], [40] for the treatment or suppression of recurrent genital HSV infections in immunocompetent patients, [41], [42] and [43] and for the treatment of recurrent mucocutaneous herpes simplex infections in HIV-infected patients. [44] Famciclovir is not approved for the treatment of initial genital HSV infections. In immunocompetent patients with herpes zoster treated within 72 h of the onset of lesions, 500 mg of famciclovir PO tid for 7 days had a beneficial effect on the resolution of skin lesions and on the duration of postherpetic neuralgia. In a comparative trial, famciclovir was as effective as valacyclovir for the treatment of herpes zoster in immunocompetent patients. [33] In immunocompromised patients with herpes zoster, famciclovir (500 mg PO tid for 7 days) was as effective as acyclovir (800 mg PO five times day). [40] In studies of recurrent genital HSV infections, famciclovir at a dose of 125 mg PO bid for 5 days reduced the duration of symptoms by 0.6 days, accelerated

healing by 1 day, and reduced the median duration of viral shedding by 2.6 days. [41] Famciclovir appeared to be as effective as acyclovir in the treatment of recurrent genital HSV infection in a comparative trial. [42] Suppression of clinical recurrences of genital HSV infections has been reported with administration of famciclovir, 250 mg PO bid, for up to 1 year. [43] Famciclovir at a dose of 500 mg PO bid for 7 days was as effective as acyclovir at a dose of 400 mg five times per day in the treatment of mucocutaneous HSV infections in HIV infected patients. [44] Famciclovir has also been reported to be efficacious in prophylaxis of HSV recurrences after laser facial resurfacing procedures. [45] Penciclovir is available as a 1% cream in propylene glycol and petrolatum. It is approved for the treatment of recurrent herpes labialis (cold sores) on the face or lips in immunocompetent adults on the basis of two double-blind, placebo-controlled trials involving 3057 patients. In these trials, patients initiated therapy within 1 h of signs or symptoms of lesions and continued to apply the study medication every 2 h while awake, for 4 days. Those patients receiving penciclovir cream experienced a modest benefit, which consisted of a decrease of a half-day in duration of lesions and in pain associated with lesions. [46], [47] Penciclovir cream was well tolerated.

TRIFLURIDINE Trifluridine (5-trifluoromethyl-2'-deoxyuridine, Viroptic) (Fig. 260-4) is a pyrimidine nucleoside analogue with activity against HSV-1, HSV-2, CMV, vaccinia, and, to some degree, certain adenoviruses. [48] Trifluridine monophosphate is an irreversible competitive inhibitor of thymidylate synthetase, and trifluridine triphosphate inhibits HSV DNA polymerase. [48] Trifluridine triphosphate also inhibits cellular DNA polymerases, although to a lesser extent than viral DNA polymerases. Trifluridine shows mutagenesis and teratogenesis in experimental systems.

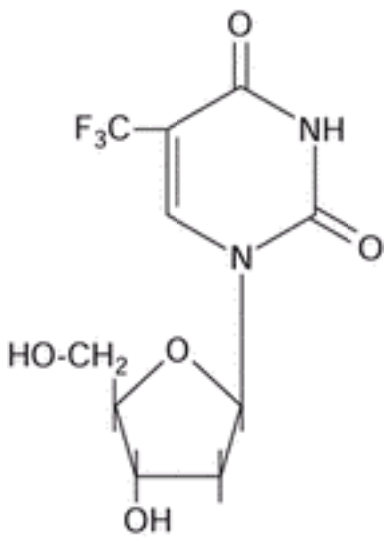

FIGURE 260-4 Trifluridine.

Because of systemic toxicity, trifluridine is approved only for topical application in the form of a 1% ophthalmic aqueous solution for the treatment of primary conjunctivitis and recurrent epithelial keratitis caused by HSV. In comparative trials, it was more effective than topical idoxuridine and similarly effective to topical vidarabine, neither of which is commercially available in the United States. Some patients with herpes simplex keratitis that was unresponsive to idoxuridine or vidarabine have responded to treatment with topical trifluridine. Topical trifluridine, either alone or in combination with interferon (IFN)-a, has been reported to be beneficial in the treatment of acyclovir-resistant mucocutaneous HSV infections in patients with AIDS. [49]

DRUGS FOR THE TREATMENT OF CMV INFECTIONS

Ganciclovir

Ganciclovir [9-(1,3-dihydroxy-2 propoxymethyl) guanine, Cytovene] (Fig. 260-5) is a nucleoside analogue that is similar in structure to acyclovir but is markedly more active than acyclovir against CMV. [50] Ganciclovir has good in vitro activity against HSV-1, HSV-2, VZV, and EBV, and is active against HHV-6 and HBV. The mechanism of action of ganciclovir is similar to that of acyclovir. Ganciclovir is initially phosphorylated by virus-encoded kinases, which, in the case of CMV-infected cells, is a protein kinase encoded by the UL97 gene of CMV. Ganciclovir triphosphate competitively inhibits herpesvirus DNA polymerases and also inhibits elongation of the nascent DNA chain. HSV and VZV viruses may be resistant to ganciclovir through thymidine kinase deficiency and thus would be expected to share cross-resistance with viruses that are resistant to acyclovir on the same basis. Ganciclovir-resistant viruses may also arise through mutations in the viral DNA polymerase, which may be at a different locus than that found with acyclovir-resistant DNA polymerase mutants. Thus, viruses resistant to acyclovir on the basis of DNA polymerase mutation may retain sensitivity to ganciclovir. Ganciclovir-resistant CMV isolates may arise through mutations in the UL97 gene, in which case such viruses remain susceptible to foscarnet or cidofovir (see below). CMV isolates that are resistant to ganciclovir on the basis of DNA polymerase mutations may also be resistant to cidofovir and foscarnet.

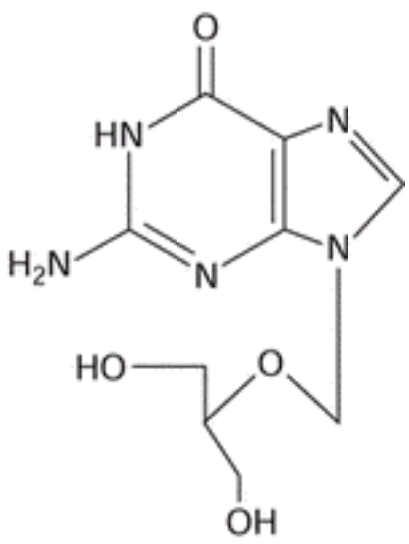

FIGURE 260-5 Ganciclovir.

PHARMACOKINETICS Ganciclovir is available as either an intravenous or an oral preparation. Because of low oral bioavailability (5 to 9 percent), relatively large doses of ganciclovir need to be administered orally (1 g PO three times per day) to achieve an effect. [51] Its use has been largely supplanted by the use of valganciclovir, which is much better absorbed orally (see below). Intravenous administration of ganciclovir at a dose of 5 mg/kg results in a peak plasma concentration of 8 to 11 µg/mL with a serum half-life of 3.5 h. Oral administration of 1 g of ganciclovir results in a peak plasma concentration of 1 µg/mL approximately 4.5 h after administration. [53] Ganciclovir is excreted primarily by the kidney unmetabolized, and the dosage should be reduced in patients with renal dysfunction. Ganciclovir has also been administered intraocularly by intravitreous injection and by the implantation of sustained-release devices in the eye.
ADVERSE EFFECTS The major toxicity associated with ganciclovir is bone marrow suppression, particularly neutropenia and thrombocytopenia. [52] This effect occurs most frequently in patients with underlying bone marrow compromise and is worsened by concomitant administration of other hematotoxic drugs, such as zidovudine. The rates of hematologic toxicity are lower when ganciclovir is administered orally, presumably as a result of poor systemic absorption. Neurotoxicity, fever, liver function abnormalities, and a variety of gastrointestinal symptoms, especially diarrhea, have also been noted. Gastrointestinal intolerance may be a particular problem in patients taking the drug orally. The risk of seizures may be increased when ganciclovir and imipenem are administered concurrently.
CLINICAL USEFULNESS Ganciclovir is widely used for treatment and, in a more limited way, for prophylaxis of CMV infections in immunosuppressed patients. Its most well-established use is for the treatment of CMV retinitis in patients with AIDS, [53] for whom an initial regimen of 5 mg/kg intravenously twice a day for 14 to 21 days is followed by a maintenance regimen of 5 mg/kg intravenously five times per week, indefinitely. Oral ganciclovir (1 g PO tid) and ocular ganciclovir implants have been used as alternative modes for maintenance therapy but are likely to be supplanted by valganciclovir which is under study as maintenance therapy (see below). Ganciclovir is effective for the treatment of gastrointestinal disease caused by CMV in immunosuppressed patients. It is also used for the treatment of CMV-associated pneumonia and neurologic disease, although responses are poor in these cases. Ganciclovir is used for the treatment of CMV infections in patients who are immunosuppressed as a result of organ transplantation. Responses have been variable and, in general, have been etter in patients receiving solid organ transplants than in those receiving bone marrow transplants. Strategies to prevent the development of CMV disease in transplant recipients have included prophylactic administration of ganciclovir during the time of intensive immunosuppression and “preemptive therapy” when CMV virus is detected in the blood by highly sensitive assays but before disease is manifested clinically. The use of ganciclovir in combination with anti-CMV immunoglobulin and in combination with other anti-CMV drugs such as foscarnet (see below) is being evaluated.

Valganciclovir

Valganciclovir or L-valine {2-[(2-amino-1,6 dehydro-6-oxo-9H-purin-9-yl) methoxy]-3-hydroxypropyl ester} (Fig. 260-6) is the L-valyl ester of ganciclovir that acts as a prodrug for ganciclovir in a manner similar to that which valacyclovir serves for acyclovir. After oral administration, valganciclovir is rapidly converted to ganciclovir by intestinal and hepatic esterases. The oral availability of valganciclovir in terms of ganciclovir is approximately 60 percent, and is increased by administration with food. After a 900-mg dose of valganciclovir, the maximum plasma concentration of ganciclovir is 5.61 µg/mL, and the plasma concentration time curve (AUC) is similar to that achieved with ganciclovir given intravenously at a dose of 5mg/kg. [54], [55] The toxicity of valganciclovir is that of its active compound, ganciclovir.

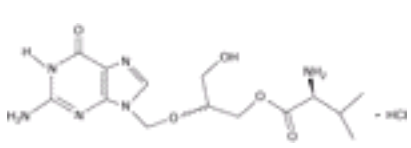
FIGURE 260-6 Valganciclovir.

Valganciclovir is approved for the treatment of CMV retinitis in patients with AIDS. This approval was based on a study of 160 patients in which valganciclovir, initiated at a dose of 900 mg PO bid for 21 days, and then given every day for 7 days, was equivalent in efficacy to standard therapy with intravenous ganciclovir given at 5 mg/kg bid for 21 days and every day for 7 days. After 4 weeks, all patients received valganciclovir for maintenance therapy (900 mg PO qd), thus its efficacy for maintenance therapy was not studied. However, on the basis of pharmacokinetic data, valganciclovir should be at least as effective, if not more so, as oral ganciclovir, which is approved for maintenance therapy of CMV retinitis. [56] Valganciclovir is also currently under study as prophylaxis for CMV infection in immunosuppressed patients in a variety of clinical settings.

Foscarnet

ANTIVIRAL ACTIVITY Foscarnet (trisodium phosphonoformate, Foscavir) (Fig. 260-7) is a pyrophosphate-containing compound that is active in vitro against HSV-1, HSV-2, VZV, CMV, EBV, HHV-6, HBV, and HIV. Foscarnet noncompetitively inhibits viral DNA polymerases at the pyrophosphate-binding site. [57] In contrast to the nucleoside analogues discussed above, foscarnet does not require phosphorylation for its antiviral activity and is therefore active against viruses that are resistant to acyclovir, famciclovir, or ganciclovir on the basis of absent or altered kinase activities. CMV isolates resistant to ganciclovir on the basis of DNA polymerase mutations may also be resistant to foscarnet, although foscarnet-resistant HSV and CMV isolates are variable in their sensitivities to ganciclovir. Some isolates that are resistant to both acyclovir and foscarnet may remain sensitive to cidofovir (see below).

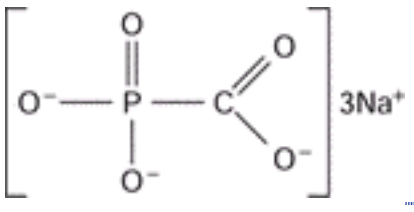

FIGURE 260-7 Foscarnet.

PHARMACOKINETICS Foscarnet is currently available only in an intravenous preparation that has poor solubility and must be administered by an infusion pump in a dilute solution over 1 to 2 h. The plasma half-life of the drug consists of an initial phase of 4 to 8 h and a terminal component of 88 h or more, which reflects a deposition in bone of up to 20 percent of the dose. [58] Eighty percent of the dose is excreted unmetabolized by the kidney, and the dosage should be reduced in patients with renal dysfunction.

ADVERSE EFFECTS The major toxicity associated with foscarnet involves the kidney, and its use requires close monitoring of renal function, particularly during the initial phases of therapy. Saline hydration before administration and slow infusion of the drug appear to reduce nephrotoxicity. Electrolyte abnormalities such as hypo- and hypercalcemia, hypo- and hyperphosphatemia, hypomagnesemia, and hypokalemia have been described. Some of these electrolyte abnormalities appear to be related to the ability of foscarnet to bind divalent cations, whereas the mechanism for others may be related to the interaction of foscarnet with renal function or with bone metabolism. Neurologic toxicities, including tremors, seizures, and altered consciousness, have also been described. Although anemia and, to a lesser extent, neutropenia have been reported with foscarnet administration, hematologic toxicity is less than that with ganciclovir, and foscarnet can often be administered along with myelosuppressive agents. Genital ulcerations have occurred as a result of high concentrations of foscarnet in the urine. [59]

CLINICAL USEFULNESS The major use for foscarnet is in the treatment of CMV retinitis in patients with AIDS. A comparative clinical trial demonstrated that foscarnet was as effective as ganciclovir as first-line treatment of CMV retinitis but was associated with longer survival than ganciclovir, a finding that is perhaps related to the anti-HIV activity of foscarnet. The initial dosage of foscarnet is 60 mg/kg intravenously q8h for 14 to 21 days, followed by a maintenance dose of 120 mg/kg per day. Foscarnet is also used for the treatment of HSV or VZV infection resistant to acyclovir [60] and for ganciclovir-resistant CMV infection. [61] Foscarnet-resistant CMV viruses may emerge on therapy.

Cidofovir

ANTIVIRAL ACTIVITY Cidofovir {(S)-1-[3-hydroxy-2 (phosphonylmethoxy)-propyl] cytosine, Vistide} (Fig. 260-8) is a phosphonate nucleotide analogue with activity against a broad range of herpesviruses, but its major use is against CMV. [62] Cidofovir does not require initial phosphorylation by virus-induced kinases, but is converted by host cell enzymes to cidofovir diphosphate, which is a competitive inhibitor of viral DNA polymerases and, to a lesser extent, of host cell DNA polymerases. Cidofovir is usually active against CMV isolates that are resistant to ganciclovir and foscarnet, although viruses that are resistant to all three drugs have been described. Cidofovir also has antiviral activity against pox viruses, including vaccinia and variola (smallpox), in which there has been renewed interest recently because of bioterrorism concerns. [63]

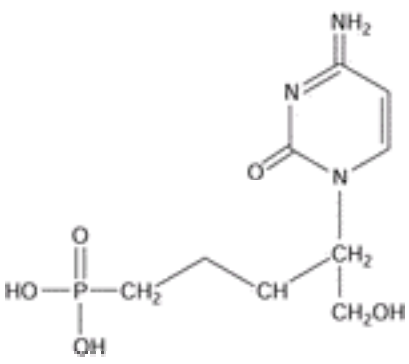

FIGURE 260-8 Cidofovir.

PHARMACOKINETICS Cidofovir is approved for intravenous administration, and a topical formulation and ocular implant have been investigated. An intravenous dose of 5 mg/kg results in a peak plasma concentration of 11.5 µg/mL. The plasma half-life of cidofovir is 2.6 h, and the drug is excreted almost entirely by the kidney. [64] Cidofovir diphosphate has a markedly prolonged intracellular half-life (more than 48 h), which is the basis for the recommended dosing regimen of 5 mg/kg twice a week for the first 2 weeks, followed by one dose every 2 weeks. [65]

ADVERSE EFFECTS The major toxicity associated with cidofovir is renal tubular damage, manifested by proteinuria and elevated serum creatinine levels. [66] Hydration, along with the administration of probenecid before and after administration, appears to protect against nephrotoxicity. Rashes have been reported in patients receiving cidofovir and probenecid.

CLINICAL USEFULNESS Cidofovir is approved for the treatment of CMV retinitis in patients with AIDS who have either failed treatment with ganciclovir and foscarnet or are intolerant of those drugs. Intravitreous administration of cidofovir

has also been used as a maintenance regimen but has been associated with serious toxicities.

INTERFERONS

Interferons are cytokines that have broad antiviral, immunomodulating, and antiproliferative effects. The antiviral activities of interferons are multiple and complex and vary according to the cell type and virus being examined. Interferons have been studied in a variety of viral infections, as well as in a number of diseases of noninfectious etiology. For viral infections, interferon (IFN)-a has been studied most extensively, and four such preparations are currently approved for the treatment of certain viral infections: IFN-a2a (Roferon-A), IFN-a2b (Intron-A), leukocyte-derived IFN-an3 (Alferon N), and IFN alphacon-1 (Infergen). Interferon may be administered intravenously, or, more commonly, subcutaneously or intramuscularly. The plasma half-life after intravenous administration of IFN-a is 2 to 3 h and after subcutaneous or intramuscular administration is 4 to 6 h. [67] A markedly prolonged half-life is seen with the use of "pegylated" interferons, which were recently approved (see below).

The most common adverse effects of interferon are fever, chills, headache, myalgia, arthralgia, and gastrointestinal symptoms. [68] These effects are generally dose-related and are often most prominent with the initial doses of therapy. Granulocytopenia, thrombocytopenia, various neurotoxicities, alopecia, hepatotoxicity, and autoantibody formation have also been noted. [68]

Recombinant IFN-a2b and leukocyte-derived IFN-an3 have been approved for the intralesional treatment of condylomata acuminata, for which purpose they have proved to be modestly effective in placebo-controlled studies. Interferon is most commonly administered in a volume of 0.1 mL through a 30-gauge needle directly into each wart. The recommended dose of IFN-a2b is 1 million units to each wart three times a week for 3 weeks. Significant systemic absorption and associated side effects can result from the intralesional administration of interferon. Systemic (parenteral) administration of interferon has been evaluated as therapy for extensive and refractory warts. In these studies, parenterally administered interferon was associated chiefly with a reduction in the size of warts but not with a decrease in recurrence rates compared to placebo, although there was some variability in findings among the studies. [69], [70]

Interferons have been extensively evaluated in the treatment of chronic HBV and chronic hepatitis C virus (HCV) infection. [68] The administration of recombinant IFN-a2b at a dose of 5 million units per day for 16 weeks resulted in disappearance of HBV DNA in 37 percent of patients and loss of hepatitis B e antigen in 33 percent of patients. [71] Approximately 8 percent of all patients lost hepatitis B surface antigen. In most patients who responded, improvements were sustained for extended periods of time after therapy was discontinued. Predictors of a response to interferon therapy are low HBV DNA levels, high alanine and aspartate aminotransferase levels, short duration of infection, and histopathologic evidence of active hepatitis. [68]

Interferon-a2b, interferon-a2a, and interferon alfacon-1 have been approved for the treatment of chronic HCV infection. [68], [72] Favorable responses were associated with short duration of infection, lower levels of circulating HCV RNA, minimal amounts of hepatic fibrosis, and low hepatic iron stores, as well as with certain HCV genotypes that appear to be more sensitive to interferon. [68] The addition of ribavirin (Rebetol), 1000 to 1200 mg PO daily for 24 to 48 weeks, to interferon therapy increased the rates of responses and was demonstrated to be beneficial for patients with HIV infection who relapsed after interferon therapy had been stopped. [73] The FDA has approved the use of combined IFN-a2b and ribavirin for this purpose. Recently, the FDA approved two "pegylated" interferons, peginterferon-a2b (PEG-Intron) and peginterferon-a2a (PEGASYS), which are covalent conjugates of interferon-a2b or interferon-a2a with monomethoxy polyethylene glycol. This agent reduces the clearance of these interferons markedly and therefore decreases the frequency of administration to once per week. Peginterferon-a2b has been approved for therapy of HCV in combination with ribavirin, as well as by itself. Pegylated interferon-a2a is also currently approved for treatment of chronic HCV. Currently, the optimal regimens for treatment of chronic HCV infection appear to be combinations of pegylated interferon a and ribavirin which result in sustained viral responses of 42–46 percent in patients with genotype 1 infections and 72–82 percent in patients with genotype 2 infections. [74]

DRUGS FOR THE TREATMENT OF HIV INFECTION

The development of antiretroviral drugs to combat HIV infection has been an area of intense preclinical and clinical research activity. Currently there are 16 approved antiretroviral drugs, and it is likely that additional drugs will receive approval in the near future. Strategies for the use of antiretrovirals have emerged from large-scale clinical trials, as well as from advances in the understanding of the pathogenesis of HIV-1 infection. These studies established two important principles on which recommendations for the use of antiretroviral drugs are based: (1) combination therapy with at least three drugs should be used to maximize the clinical and antiviral effects and to minimize the emergence of resistant viruses [75]; and (2) virus load, as well as CD4 counts, should be monitored as an important parameter of the effectiveness of antiviral therapy. The availability of phenotypic and genotypic assays to determine resistance of HIV isolates to antiretroviral drugs also provides increasingly important information for the appropriate use of such drugs. [76]

Recommendations for the use of antiretroviral therapy in various clinical settings, including the optimal time to begin therapy in HIV-infected patients, are still in evolution. For a discussion of those recommendations, and detailed descriptions of individual properties of each antiretroviral drug, itself, the reader is referred to several excellent recent reviews. [75], [77], [78] The major properties of the antiretroviral drugs that are currently available are presented below.

Reverse Transcriptase Inhibitors

Nucleoside analogues that inhibit HIV-1 and HIV-2 reverse transcriptases are the most extensively studied antiretroviral drugs. Six of the currently available drugs—zidovudine, didanosine, zalcitabine, stavudine, lamivudine, and abacavir—are nucleoside analogues, while the seventh, tenofovir, is a nucleotide (nucleoside monophosphate). All

require phosphorylation to the triphosphate form to inhibit viral reverse transcriptases. Resistance to each drug can develop by one or more amino acid substitutions in the HIV reverse transcriptase. Each nucleoside analogue has its own pharmacokinetic profile and characteristic set of toxicities, which determine its suitability for use in individual patients and in combination with other antiretrovirals. The major toxic effects of the nucleoside analogues are as follows: zidovudine, myelosuppression; didanosine, pancreatitis, and peripheral neuropathy; zalcitabine, peripheral neuropathy, mucosal ulcerations, and pancreatitis; stavudine, peripheral neuropathy and pancreatitis in children; and lamivudine, neutropenia at high doses. Abacavir has a hypersensitivity syndrome that consists of fever, usually with a maculopapular or urticarial rash. This syndrome, although uncommon, can be severe; and life-threatening and fatal reactions have been reported when hypersensitive patients are rechallenged with the drug.

Two nucleoside analogues are included in many recommended combination regimens. The most common combinations include zidovudine and lamivudine, zidovudine and didanosine, and stavudine and lamivudine. Zidovudine and stavudine appear to be antagonistic in vitro, and probably in vivo; didanosine and zalcitabine are rarely used together because of overlapping toxicities. The two nucleoside analogue combinations are usually used with at least one other drug from another class of antiretroviral drugs, either a protease inhibitor or a non-nucleoside reverse transcriptase inhibitor (see below). A combination consisting entirely of three nucleoside analogues, zidovudine, lamivudine, and abacavir, is also recommended and is available in a single tablet (Trizivir), which adds to the convenience of such a regimen. A fixed combination of zidovudine and lamivudine (Combivir) is also available as a single capsule.

Nonnucleoside reverse transcriptase inhibitors (NNRTIs) have also demonstrated antiviral efficacy. Of this class of drugs, efavirenz, nevirapine, and delavirdine are approved for use against HIV-1. NNRTIs are compounds of diverse chemical structure that inhibit HIV-1 reverse transcriptase at a characteristic region of the enzyme, generally through noncompetitive allosteric binding. These compounds are active against HIV-1 reverse transcriptases but not against HIV-2 reverse transcriptases. NNRTIs have potent HIV-1 activity in vitro and in vivo, but their use as single agents has resulted in the rapid emergence of resistance across the entire class. Thus, the appropriate use of NNRTIs is as part of combination therapy regimens, with at least two drugs outside of the NNRTI class.

Of this class of drugs, efavirenz, nevirapine, and delavirdine are approved for use against HIV-1. Efavirenz is the most strongly recommended and frequently used member of the class, because of both the convenience of its once-daily dosing schedule and the most extensive clinical experience with the drug. The most common adverse effects associated with the NNRTIs are maculopapular rashes; if they are not severe, they can be managed with antihistamines or glucocorticoids without necessarily discontinuing the drug. Rashes may be particularly frequent with nevirapine, and initiation of therapy with lower doses of nevirapine for two weeks, followed by an escalation to full therapeutic doses has been recommended as a measure to reduce the frequency of skin eruptions.

Protease Inhibitors

The protease inhibitors are an important new class of anti-HIV-1 drugs. [79] These compounds inhibit a virus-specific enzyme that is responsible for the proteolytic cleavage of viral polypeptide precursors. Currently, the protease inhibitors that have been approved for use against HIV-1 infections in the United States are saquinavir, indinavir, ritonavir, nelfinavir, amprenavir, and lopinavir. Each protease inhibitor has a unique pharmacokinetic profile, but all are metabolized through the hepatic cytochrome P450 system. Thus, they have important interactions with the drugs that induce, inhibit, or are, themselves, metabolized by cytochrome P450. Ritonavir has the most profound effect in this regard, and is used frequently at a lower dose in combination with other protease inhibitors to inhibit their metabolism and thus raise their blood levels. A fixed combination of lopinavir and ritonavir (Kaletra) is available as a capsule or a liquid to take advantage of this interaction.

Saquinavir was initially available only as a hard-gel capsule that had poor oral availability. Its use has now largely been supplanted by a soft-gel capsule that gives higher blood levels. Indinavir is poorly soluble and has been associated with both nephrolithiasis and elevated indirect bilirubin levels. The major toxicity associated with ritonavir is gastrointestinal intolerance, although tolerance is improved when lower doses of the drug are used in combination with other protease inhibitors. All of the protease inhibitors can cause disturbances in lipid metabolism, including elevations in serum cholesterol and triglycerides. Diabetes mellitus and fat redistribution syndromes also appear in association with use of protease inhibitors. The molecular basis for resistance to protease inhibitors is complex, but resistance clearly develops when the drugs are used as monotherapy. Therefore, the appropriate use of protease inhibitors is as part of potent multidrug combination regimens.

Other Antiretroviral Drugs

Other steps in the HIV replication pathway have been targeted for the development of antiviral drugs. These include inhibitors of virus-cell fusion, synthesis of virus envelope, nucleocapsid assembly, and integrase activity. Several of these are already in clinical trials, and it is likely that other novel approaches to inhibit virus replication will also be entering clinical evaluation in the coming years.

REFERENCES

1. Whitley RJ et al: Acyclovir: A decade later. *N Engl J Med* **327**:782, 1992

2. Elion GB: Mechanism of action and selectivity of acyclovir. *Am J Med* **73**:7, 1982

3. Schnipper LE et al: Resistance of herpes simplex virus to acycloguanosine: Role of viral thymidine kinase and DNA polymerase loci. *Proc Natl Acad Sci USA* **77**:2270, 1980

4. Van Dyke RB et al: Pharmacokinetics of orally administered acyclovir in patients with herpes progenitalis. *Am J Med* **73**(Suppl):172, 1982

5. McKendrick MW et al: Oral acyclovir in acute herpes zoster. *Br Med J* **293**:1529, 1986

6. Laskin OL et al: Effect of renal failure on the pharmacokinetics of acyclovir. *Am J Med* **73**(Suppl):197, 1982

7. Rashed A et al: Acyclovir-induced acute tubulointerstitial nephritis. *Nephron* **56**:436, 1990

8. Haefeli WE et al: Acyclovir-induced neurotoxicity: Concentration-side effect relationship in acyclovir overdose. *Am J Med* **94**:212, 1993

9. Corey L et al: Intravenous acyclovir for the treatment of primary genital herpes. *Ann Intern Med* **98**:914, 1983

10. Reichman RC et al: Treatment of recurrent genital herpes simplex infections with oral acyclovir. A controlled trial. *JAMA* **251**:2103, 1984

11. Straus SE et al: Suppression of frequently recurring genital herpes: A placebo-controlled double-blind trial of oral acyclovir. *N Engl J Med* **310**:1545, 1984

12. Spruance SL et al: Treatment of recurrent herpes simplex labialis with oral acyclovir. *J Infect Dis* **161**:185, 1990

13. Corey L et al: A trial of topical acyclovir in genital herpes simplex infections. *N Engl J Med* **306**:1313, 1992

14. Spruance SL et al: Treatment of herpes simplex labialis with topical acyclovir in polyethylene glycol. *J Infect Dis* **146**:85, 1982

15. Whitley RJ et al: Vidarabine versus acyclovir therapy in herpes simplex encephalitis. *N Engl J Med* **314**:144, 1986

16. Whitley RJ et al: A controlled trial comparing vidarabine with acyclovir in neonatal herpes simplex virus infection. *N Engl J Med* **324**:444, 1991

17. Balfour HH Jr et al: Acyclovir halts progression of herpes zoster in immunocompromised patients. *N Engl J Med* **308**:1448, 1983

18. Huff C et al: Therapy of herpes zoster with oral acyclovir. *Am J Med* **85**:84, 1988

19. Beutner KR et al: Valacyclovir compared with acyclovir for improved therapy for herpes zoster in immunocompetent adults. *Antimicrob Agents Chemother* **39**:1546, 1995

20. Wood MF et al: A randomized trial of acyclovir for 7 days or 21 days with and without prednisolone for treatment of acute herpes zoster. *N Engl J Med* **330**:896, 1994

21. Whitley RJ et al: Acyclovir with and without prednisone for the treatment of herpes zoster. *Ann Intern Med* **125**:376, 1996

22. Cobo LM et al: Oral acyclovir in the treatment of acute herpes zoster ophthalmicus. *Ophthalmology* **93**:763, 1986

23. Nyerges G et al: Acyclovir prevents dissemination of varicella in immunocompromised children. *J Infect Dis* **157**:309, 1988

24. Dunkel L et al: A controlled trial of oral acyclovir for chickenpox in normal children. *N Engl J Med* **325**:1539, 1991

25. Wallace MR et al: Treatment of adult varicella with oral acyclovir. A randomized, placebo-controlled trial. *Ann Intern Med* **117**:358, 1992

26. Beutner KR: Valacyclovir: A review of its antiviral activity, pharmacokinetic properties, and clinical efficacy. *Antiviral Res* **28**:281, 1995

27. Hoglund M et al: Comparable acyclovir exposures produced by oral valacyclovir and intravenous acyclovir in immunocompromised cancer patients. *J Antimicrobial Chemotherapy* **47**:855, 2001

28. Bell WR et al: Manifestations resembling thrombotic microangiopathy in patients with advanced human immunodeficiency virus (HIV) disease in a cytomegalovirus prophylaxis trial CA (T6 204). *Medicine (Baltimore)* **76**:369,1997

29. Fife KH et al: Valacyclovir versus acyclovir in the treatment of first-episode genital herpes infection. Results of an international, multicenter, double-blind, randomized clinical trial. The Valacyclovir International Herpes Simplex Virus Study Group. *Sex Transm Dis* **24**:481, 1997

30. Tyring SK et al: A randomized, placebo-controlled comparison of oval valacyclovir and acyclovir in immunocompetent patients with recurrent genital herpes infections. The Valacyclovir International Study Group. *Arch Dermatol* **134**:185, 1998

31. Baker DA et al: Once-daily valacyclovir hydrochloride for suppression of recurrent genital herpes. *Obstet Gynecol* **94**:103, 1999

32. Ormrod D, Goa K: Valacyclovir: A review of its use in the management of herpes zoster [review; 94 refs]. *Drugs* **59**:1317, 2000

33. Tyring SK et al: Antiviral therapy for herpes zoster: Randomized, controlled clinical trial of valacyclovir and famciclovir therapy in immunocompetent patients 50 years and older. *Arch Fam Med* **9**:863, 2000

34. Gilbert S, McBurney E: Use of valacyclovir for herpes simplex virus-1 (HSV-1) prophylaxis after facial resurfacing: A randomized clinical trial of dosing regimens. *Dermatol Surg* **26**:50, 2000

35. Steer CBJ et al: Varicella-zoster infection after allogeneic bone marrow transplantation: Incidence, risk factors and prevention with low-dose acyclovir and ganciclovir. *Bone Marrow Transplant* **25**:657, 2000

36. Weinberg A et al: In vitro activities of penciclovir and acyclovir against herpes simplex virus types 1 and 2. *Antimicrob Agents Chemother* **36**:2037, 1992

37. Vere Hodge RA: Famciclovir and penciclovir. The mode of action of famciclovir including its conversion to penciclovir. *Antiviral Chem Chemother* **4**:67, 1993

38. Pue MA et al: Linear pharmacokinetics of penciclovir following administration of single oral doses of famciclovir 125, 250, 500 and 750 mg to healthy volunteers. *J Antimicrob Chemother* **33**:119, 1994

39. Boike SC et al: Pharmacokinetics of famciclovir in subjects with varying degrees of renal impairment. *Clin Pharmacol Ther* **55**:418, 1994

40. Tyring S et al: A randomized, double-blind trial of famciclovir versus acyclovir for the treatment of localized dermatomal herpes zoster in

immunocompromised patients. *Cancer Invest* **19**:13, 2001

41. Sachs SL et al: Patient initiated, twice daily oral famciclovir for early recurrent genital herpes. A randomized, double-blind multi-center trial. Canadian Famciclovir Study Group. *JAMA* **276**:44, 1996

42. Chosidow O et al: Famciclovir vs. acyclovir in immunocompetent patients with recurrent genital herpes infections: A parallel-groups, randomized, double-blind clinical trial. *Br J Dermatol* **144**:818, 2001

43. Diaz-Mitoma F et al: Oral famciclovir for the suppression of recurrent genital herpes: A randomized controlled trial. Collaborative Famciclovir Genital Herpes Research Group. *JAMA* **280**:928, 1998

44. Romanowski B et al: Efficacy and safety of famciclovir for treating mucocutaneous herpes simplex infection in HIV-infected individuals. Collaborative Famciclovir HIV Study Group. *AIDS* **14**:1211, 2000

45. Wall SH et al: Famciclovir as antiviral prophylaxis in laser resurfacing procedures. *Plast Reconstr Surg* **104**:1103; discussion 1109, 1999

46. Denavir, package insert. East Hanover, NJ, Novartis Pharmaceuticals, Jan. 2001

47. Spruance SL et al: Penciclovir cream for the treatment of herpes simplex labialis: A randomized, double-blind, multicenter, placebo-controlled trial. Topical Penciclovir Collaborative Study Group. *JAMA* **277**:1374, 1997

48. Carmine AA et al: Trifluridine: A review of its antiviral activity and therapeutic use in the topical treatment of viral eye infections. *Drugs* **23**:329, 1982

49. De Koning EWJ et al: Combination therapy for dendritic keratitis with human leukocyte interferon and trifluorothymidine. *Br J Ophthalmol* **66**:509, 1982

50. Plotkin SA et al: Sensitivity of clinical isolates of human cytomegalovirus to 9-(1,3-dihydroxy-2-propoxymethyl) guanine. *J Infect Dis* **152**:833, 1985

51. Spector SA et al: Pharmacokinetic, safety, and antiviral profiles of oral ganciclovir in persons infected with human immunodeficiency virus: A phase I/II study. *J Infect Dis* **171**:1431, 1995

52. Markham A et al: Ganciclovir: An update of its therapeutic use in cytomegalovirus infection. *Drugs* **48**:455, 1994

53. Masur H et al: Advances in the management of AIDS-related cytomegalovirus retinitis. *Ann Intern Med* **125**:126, 1996

54. Pescovitz MD: Oral ganciclovir and pharmacokinetics of valganciclovir in liver transplant recipients. *Transplant Infect Dis* **1**(Suppl 1):31, 1999

55. Brown F et al: Pharmacokinetics of valganciclovir and ganciclovir following multiple oral dosages of valganciclovir in HIV- and CMV-seropositive volunteers. *Clin Pharmacokinet* **37**:167, 1999

56. Jung D, Dorr A: Single-dose pharmacokinetics of valganciclovir in HIV- and CMV-seropositive subjects. *J Clin Pharmacol* **39**:800, 1999

57. Crumpacker CS: Mechanism of action of foscarnet against viral polymerases. *Am J Med* **92**(Suppl 2A):2A, 1992

58. Wagstaff AJ et al: Foscarnet: A reappraisal of its antiviral activity, pharmacokinetic properties and therapeutic use in immunocompromised patients with viral infections. *Drugs* **48**:199, 1994

59. Van Der Pijl JW et al: Foscarnet and penile ulceration. *Lancet* **1**:266, 1990

60. Hardy WD: Foscarnet treatment of acyclovir-resistant herpes simplex virus infection in patients with acquired immunodeficiency syndrome: Preliminary results of a controlled, randomized, regimen-comparative trial. *Am J Med* **92**(Suppl 2A):30S, 1992

61. Drobyski WR et al: Foscarnet therapy of ganciclovir-resistant cytomegalovirus in marrow transplantation. *Transplantation* **52**:155, 1991

62. Neyts J et al: Mechanism of action of acyclic nucleoside phosphonates against herpes virus replication. *Biochem Pharmacol* **47**:39, 1995

63. Institute of Medicine: *Assessment of Future Scientific Needs for Live Variola Virus*. Washington, DC, National Academy Press, 1999, p 48

64. Cundy KC et al: Clinical pharmacokinetics of cidofovir in HIV-infected patients. *Antimicrob Agents Chemother* **39**:1247, 1995

65. Bronson JJL et al: (S)-1-(3-Hydroxy-2-(phosphonylmethoxy)propyl) cytosine (HPMPC): A potent antiherpesvirus agent, in *Immunobiology and Prophylaxis of Human Herpesvirus Infections*, edited by C Lopez et al. New York, Plenum, 1991, p 277

66. Polis MA et al: Anticytomegaloviral activity and safety of cidofovir in patients with human immunodeficiency virus infection and cytomegalovirus viruria. *Antimicrob Agents Chemother* **39**:882, 1995

67. Wills RJ: Clinical pharmacokinetics of interferons. *Clin Pharmacokinet* **19**:390, 1990

68. Hoofnagle JH et al: The treatment of chronic viral hepatitis. *N Engl J Med* **336**:347, 1997

69. Reichman RC et al: Treatment of condyloma acuminatum with three different alpha interferon preparations administered parenterally: A double-blind, placebo-controlled trial. *J Infect Dis* **162**:1270, 1990

70. Condylomata International Collaborative Study Group: Recurrent condylomata acuminata treated with recombinant interferon alfa-2a. A multicenter double-blind placebo-controlled clinical trial. *JAMA* **265**:2684, 1991

71. Wong DKH et al: Effect of alpha-interferon treatment in patients with hepatitis B e antigen–positive chronic hepatitis B: A meta-analysis. *Ann Intern Med* **119**:312, 1993

72. Poynard T et al: Meta-analysis of interferon randomized trials in the treatment of viral hepatitis C: Effects of dose and duration. *Hepatology* **24**:778, 1996

73. Reichard O et al: Randomized, double-blind, placebo-controlled trial of interferon a2b with and without ribavirin for chronic hepatitis C. *Lancet* **351**:83, 1996

74. National Institutes of Health Consensus Development Conference Statement Management of Hepatitis C: 2002. Bethesda, MD, September 12, 2002

75. Carpenter CCJ et al: Antiretroviral therapy for HIV infection in adults: Updated recommendations of the International AIDS Society–USA panel. *JAMA* **283**:381, 2000

76. Hirsch MS et al: Antiretroviral drug resistance testing in adult HIV-a infection: Recommendations of an International AIDS Society–USA panel. *JAMA* **283**:2417, 2000

77. Hanna GJ, Hirsch MS: Antiretroviral therapy of human immunodeficiency virus infection, in *Principles and Practice of Infectious Diseases,* edited by GL Mandell, JE Bennett, R Dolin. Philadelphia, Churchill-Livingstone, 2001, p 1479

78. Saag MS; Strategic use of antiviral therapy, in *AIDS Therapy,* edited by R Dolin, H Masur, MS Saag. Philadelphia, Harcourt Brace, 2003, p 359

79. Deeks SG et al: HIV-1 protease inhibitors. *JAMA* **277**:145, 1997

T>

Chapter 261

Nellie Konnikov Helen Raynham

Oral Antifungal Agents

ALLYLAMINES
Terbinafine
TRIAZOLES
Itraconazole
Fluconazole
IMIDAZOLES
Ketoconazole
Griseofulvin
REFERENCES

Oral antifungal agents are now widely and frequently used for the treatment of superficial fungal infections. [1] The first and the only synthetic agent was griseofulvin. Subsequently, other drugs, including amphotericin B and ketoconazole, were introduced. As a result of recent advances in antifungal chemotherapy, new drugs with a broad spectrum of activity, high efficacy, tolerability, and rare, mild side effects are now available. The three newer, released oral antifungal agents are the first oral allylamine, terbinafine, and the triazoles fluconazole and itraconazole.

ALLYLAMINES

Terbinafine

Terbinafine hydrochloride is a synthetic antimycotic agent that belongs to a new family of compounds known as the allylamines. All allylamine derivatives possess a tertiary allylamine, a structural component crucial for antifungal activity (Fig. 261-1). [2] In vitro the drug is primarily a fungicidal agent and highly active against dermatophytes, but less active against molds, dimorphic fungi, and various yeasts.

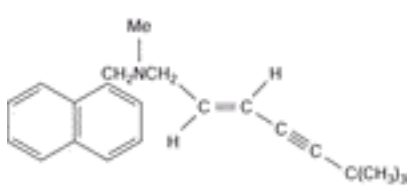

FIGURE 261-1 Terbinafine.

PHARMACOLOGY Terbinafine is well absorbed from the gastrointestinal tract, mostly in chylomicrons. The distribution half-life is 1.5 h, and the elimination half-life is approximately 22 h. [3] Terbinafine is highly lipophilic and keratophilic in nature and, therefore, is widely distributed upon absorption throughout skin and adipose tissue. Terbinafine is extensively biotransformed by the liver, mostly through oxidation by a very small fraction of P450 isoenzymes. More than 80 percent of the drug is excreted in urine; the rest is eliminated with feces. [4]

MECHANISM OF ACTION Terbinafine inhibits the enzyme squalene epoxidase in the fungal membrane, thereby blocking the biosynthesis of ergosterol. [5] Squalene epoxidase, a complex, microsomal, noncytochrome P450 enzyme, catalyzes the first enzymatic step of ergosterol synthesis—the conversion of squalene into squalene epoxide. Consequently, terbinafine causes an abnormal intracellular accumulation of squalene and deficiency in ergosterol. [6] Accumulation of squalene accounts for the drug's fungicidal activity, whereas in vitro deficiency of ergosterol is associated with the drug's fungistatic activity. [6]

CLINICAL USES

Pediatric For the treatment of tinea capitis in children, the dosage guidelines are 3 to 6 mg/kg per day. [7] Children weighing 10 to 20 kg can be given 62.5 mg/day; children weighing 20 to 40 kg can be given 125 mg/day; and those children weighing more than 40 kg can be given 250 mg/day. [8] The treatment course for *Trichophyton* infections is 4 weeks. In a study of tinea capitis in children, comparing a 4-week course of terbinafine with an 8-week course of griseofulvin (10 mg/kg day), oral terbinafine was shown to have efficacy similar to griseofulvin. [9] Other studies suggest that for treatment of *M. canis* with terbinafine, 6 or more weeks may be needed. [8], [10]

Adult Terbinafine is indicated for the treatment of onychomycosis of the toenails and fingernails caused by dermatophytes. [11] In a study comparing continuous terbinafine with intermittent itraconazole in the treatment of toenail onychomycosis, terbinafine was significantly more effective than itraconazole in the treatment of toenail dermatophyte onychomycosis. [12] At week 72, the mycologic cure in those patients treated with a 3-month course of terbinafine was 75.5 percent, compared with a mycologic cure rate of 38.3 percent in those patients treated with a 3-month course of intermittent pulse therapy with itraconazole. Terbinafine is superior to itraconazole in maintaining mycologic and clinical cure for at least 2 years after completion of therapy. [13] In a study of 22 patients with tinea corporis and tinea cruris who used terbinafine 250 mg daily for 1 week, 100 percent clinical and mycologic clearing was observed at 6 weeks. [14] In a study of moccasin tinea pedis and tinea manuum, after a 2-week course of terbinafine 250 mg daily, there was an 86 percent mycologic cure rate at 8 weeks. [15] A placebo-controlled trial demonstrated that a 4-week course of terbinafine 250 mg daily was effective in the treatment of seborrheic dermatitis. [16] Terbinafine is not effective orally for the treatment

of tinea versicolor. [14]

Geriatric Terbinafine is well tolerated by the elderly. [17]

Pregnancy considerations Terbinafine is a pregnancy category B drug and should not be taken by nursing mothers. [11]

DOSAGE SCHEDULES AND FORMULATIONS Terbinafine is supplied as a 250 mg tablet and should be taken once daily for 6 weeks for fingernail onychomycosis and once daily for 12 weeks for toenail onychomycosis. Pretreatment serum transaminase tests are advised for all patients before taking terbinafine, and the drug is not recommended for patients with liver disease. [18] Because of transient lymphopenia observed in patients on terbinafine, complete blood counts should be monitored in patients with immunodeficiency who are receiving terbinafine for longer than 6 weeks. If signs or symptoms of secondary infection occur in patients while on terbinafine, a complete blood count should be performed to rule out neutropenia.

ADVERSE EFFECTS Because of its high selectivity, terbinafine is generally well tolerated with a low incidence of adverse side effects. The most common side effects following oral administration are of a gastrointestinal nature (3.5 to 5 percent). [19] Other rare side effects include headache, exanthematous eruption, acute generalized exanthematous pustulosis (AGEP), pustular psoriasis, subacute cutaneous lupus erythematosus, chest pain, elevated laboratory parameters, loss of taste, tiredness, and malaise. [19], [20], [21], [22], [23] and [24] A few cases of hepatocellular injury (including fulminant hepatic failure), [25] reversible agranulocytosis, [26] and severe skin reactions, including toxic epidermal necrolysis and erythema multiforme, were also reported. [27], [28]

DRUG INTERACTIONS Terbinafine is metabolized by cytochrome P450 enzymes and plasma clearance of terbinafine is increased by the P450-inducer rifampin and decreased by the P450-inhibitor cimetidine. [29] Terbinafine is also reported to decrease cyclosporine levels by increasing cyclosporine clearance. [18], [30] Isolated reports of interactions with warfarin have been reported; however, prospective pharmacokinetic studies have not revealed any clinically significant reactions. [31] It was recently shown that terbinafine inhibits CYP2D6, a cytochrome P450 isoenzyme that metabolizes tricyclic antidepressants and other psychotropic drugs. [32] Other drugs predominantly metabolized by this enzyme include beta-blockers, selective serotonin reuptake inhibitors (SSRIs), and monoamine oxidase inhibitors (MAOIs) type B. [18] In a postmarketing surveillance study of patients on terbinafine, no adverse drug interactions with CYP2D6 substrates were reported. [33] However, there have been two reports of nortriptyline intoxication induced by terbinafine. [34], [35]

TRIAZOLES

Both itraconazole and fluconazole are triazole antimycotic agents sharing a common structural moiety—a triazole ring—not found in azoles of the imidazole family.

Itraconazole

Itraconazole (Fig. 261-2) is a highly lipophilic compound [36] that has a wide spectrum of activity. In vitro it is fungistatic and effective against dermatophytes, yeast, molds, and dimorphic and dematiaceous fungi. [37], [38] and [39]

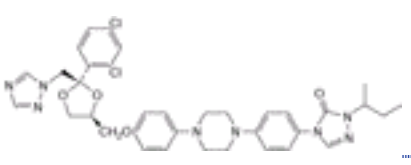

FIGURE 261-2 Itraconazole.

PHARMACOLOGY The serum concentration of itraconazole is influenced by several parameters, including food and gastric acidity. [40], [41] Itraconazole is extensively metabolized, primarily by the cytochrome P450 3A4 isoenzyme system (CYP3A4) to more than 30 metabolites. Hydroxyitraconazole is the main metabolite. Approximately 54 percent of the metabolized drug is excreted in the feces, and 34 percent is excreted in the urine. After single-dose administration, the terminal elimination half-life is 21 h for itraconazole and 12 h for its active metabolite. The pharmacokinetic variables of itraconazole are not affected in patients with renal insufficiency. [42] In patients with liver cirrhosis, the absorption is slightly increased, and the half-life is prolonged, because of a reduced first-pass metabolism. The absorption is decreased in AIDS patients as a result of gastric hypochlorhydria. [42]

MECHANISM OF ACTION Itraconazole inhibits 14-a-demethylase, a microsomal cytochrome P450 enzyme, in the fungal membrane. [43] 14-a-Demethylase is necessary for the conversion of lanosterol to ergosterol, which is the principal structural component of the fungal cell membrane. [38] Consequently, the accumulation of 14-a-methylsterols leads to the impairment of membrane permeability and membrane-bound enzyme activity and to the arrest of fungal cell growth.

CLINICAL USES

Pediatric Recently, itraconazole has been used to treat tinea capitis in children. It is prescribed with food in the capsule formulation because the liquid form of itraconazole contains cyclodextrin, which causes diarrhea and might be carcinogenic in animal models. [37] It is dosed at 5 mg/kg per day for 4 to 6 weeks. [7] Children who weigh between 15 and 30 kg require one 100 mg capsule daily; children weighing 30 to 40 kg require 100 mg one day alternating with 200 mg the next day, to average 150 mg daily. [44] Tinea capitis caused by *T. tonsurans* requires a course lasting 4 weeks; however, a longer treatment course is recommended for *M. canis* [45].

Adult Itraconazole has been approved for the treatment of onychomycosis caused by dermatophytes, [46] and is effective as continuous or pulse therapy. A 2-month course of itraconazole pulse therapy is necessary for fingernail onychomycosis, while toenail onychomycosis requires a 3-month course. A single course consists of 200 mg twice daily for 1 week per month. Itraconazole pulse therapy is at least equal in efficacy, if not superior, in the treatment of toenail onychomycosis, when compared to continuous itraconazole therapy. [47] Itraconazole has been used for the treatment of tinea pedis. A 1-week course of itraconazole 200 mg twice daily is more effective than 200 mg or 100 mg daily for 2 to 4 weeks. [48] Itraconazole at a dose of 200 mg daily is effective in the treatment of tinea versicolor. [49]

Geriatric Itraconazole (pulse) therapy is effective and safe in the elderly. [17]

Pregnancy considerations Itraconazole is a pregnancy category C drug and is not recommended while nursing because it is excreted in human milk.

DOSAGE SCHEDULES AND FORMULATIONS Itraconazole is supplied in 100 mg capsules and can also be given intravenously. Capsules should be taken with a full meal to ensure maximum absorption. [46] Dosage schedules are discussed above. The manufacturers of itraconazole recommend monitoring of hepatic function in patients with preexisting liver disease, or if receiving continuous treatment for more than 1 month. [50]

ADVERSE EFFECTS The most common reported side effects associated with itraconazole therapy are of a gastrointestinal nature. [51] Less-frequent adverse effects are hypertriglyceridemia, edema, [52] urticaria, anaphylaxis, erythema multiforme, [46] headache, neuropathy, impotence, hypertension, leukopenia, nephrotic syndrome, and mildly elevated liver enzymes. [51] Instances of hepatic injury and, rarely, fulminant hepatotoxicity are associated with the administration of itraconazole. There are also rare reports of congestive heart failure and pulmonary edema. When administered intravenously to dogs and healthy human volunteers, negative inotropic effects were noted. [50] Therefore, administration of itraconazole to patients with a history of heart failure is contraindicated, and it is not recommended for patients with a history of liver disease.

DRUG INTERACTIONS Itraconazole inhibits 14-a-demethylase, a fungal P450 enzyme [43] and a member of the same group of enzymes present in the human liver that is responsible for the metabolism of many drugs. Itraconazole specifically inhibits the cytochrome P450 3A4 isoenzyme system (CYP3A4), and, consequently, may increase plasma concentrations of drugs metabolized by this pathway. Itraconazole is also known to increase the levels of digoxin; certain anticonvulsants; antiarrhythmics; antimycobacterials; antihistamines; antipsychotics; benzodiazepines; calcium channel blockers; gastric acid suppressors/neutralizers; gastrointestinal motility agents; 3-hydroxy-3-methylglutaryl coenzyme A (HMG-CoA)–reductase inhibitors; macrolide antibiotics; nonnucleoside reverse transcriptase inhibitors; protease inhibitors; polyenes; oral hypoglycemic agents; antineoplastic agents; and immunosuppressants [5], [50] (Table 261-1). The concomitant use of itraconazole and sildenafil can lead to a reduction in sildenafil clearance. [53] Cisapride, terfenadine, quinidine, dofetilide, oral midazolam, pimozide, triazolam, and HMG-CoA–reductase inhibitors metabolized by CYP3A4, such as lovastatin and simvastatin, are contraindicated with itraconazole. Because itraconazole is itself metabolized by CYP3A4, any inducers or inhibitors may respectively decrease or elevate itraconazole levels (Table 261-1). Absorption of itraconazole may be decreased by the concomitant administration of antacids, H_2-blockers, and proton pump inhibitors. [5]

TABLE 261-1 **Examples of CYP3A4 Subfamily Substrates, Inducers, and Inhibitors***

Fluconazole

Fluconazole (Fig. 261-3) is fungistatic [37] and is effective against many yeasts (with the exception of *C. krusei*) and dermatophytes. [54]

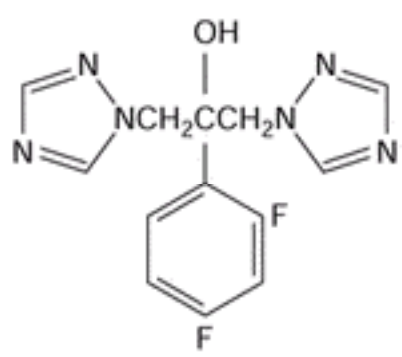

FIGURE 261-3 Fluconazole.

PHARMACOLOGY The pharmacokinetic parameters of fluconazole are similar following either intravenous or oral administration. [54] Extensive absorption (>90 percent) of the triazole appears to be comparable in both postprandial and fasting states and not dependent on stomach acidity. [41], [55] Fluconazole exhibits a long half-life of 25 to 30 h, and a steady-state level is reached after 7 days of once-daily administrations. Fluconazole is only weakly bound to plasma proteins, with about 90 percent of the drug circulating free in the plasma. The drug is resistant to hepatic metabolism, and hence approximately 80 percent of fluconazole is excreted unchanged in urine, with 2 percent in feces and approximately 11 percent as metabolites in urine. [56] The ability to diffuse substantially into the cerebrospinal fluid (CSF) distinguishes this compound from many other antimycotic agents. [57] The levels of fluconazole in cerebrospinal fluid, saliva, vaginal tissue, sputum, skin, and blister fluids are reported to be comparable with or to exceed simultaneous plasma

concentrations. [58] Altered fluconazole pharmacokinetics, including decreased plasma clearance, are detected in patients with cirrhosis [59] and renal impairment. [60]

MECHANISM OF ACTION Fluconazole, like itraconazole, inhibits 14-a-demethylase, a microsomal cytochrome P450 enzyme, in the fungal membrane. [43]

CLINICAL USES

Pediatric In the treatment of tinea capitis, fluconazole has been used successfully at 6 mg/kg per day for 20 days for *T. tonsurans* infection, [61] and at 5 mg/kg per day for 30 days. [44] When *M. canis* is present, a longer treatment course is recommended. [45]

Adult For the treatment of tinea pedis, weekly doses of fluconazole 150 mg were given for a period of 3 to 4 weeks, [62] with a 75 percent mycologic cure rate at 4 weeks. Fluconazole at a dose of 150 mg weekly for 24 weeks is significantly inferior to terbinafine 250 mg daily for 12 weeks in the treatment of onychomycosis. [63] Tinea versicolor can be treated with a single 400 mg dose of fluconazole. [64]

Geriatric Fluconazole is well tolerated in the elderly; [65] however, dose modification is required in elderly patients with renal impairment. [58]

Pregnancy considerations Fluconazole is a pregnancy category C drug and is not recommended in nursing mothers. [66]

DOSAGE SCHEDULES AND FORMULATIONS Fluconazole is available in 50 mg, 100 mg, 150 mg, and 200 mg tablets, and in a liquid form at concentrations of 10 mg/mL and 40 mg/mL. Because it is cleared primarily by renal excretion, dosage should be adjusted in patients with impaired renal function. Fluconazole is indicated for the treatment of vaginal, oropharyngeal, and esophageal candidiasis, cryptococcal meningitis, and for prevention of candidiasis in bone marrow transplant patients. [66] It is approved for use in children age 6 months and older, but not specifically for tinea capitis.

ADVERSE EFFECTS The most common recognized side effects of fluconazole therapy are gastrointestinal. [67] Adverse reactions such as fixed drug eruptions, thrombocytopenia, transient amenorrhea, elevated liver function tests, mild increase in levels of serum creatine phosphokinase, dizziness, anorexia, and alopecia have been observed, and most resolve with continuing fluconazole therapy. [66], [68]

DRUG INTERACTIONS In humans, fluconazole inhibits both CYP3A4 and CYP2C9 in a dose-dependent manner, [5] and consequently may increase plasma concentrations of drugs metabolized by these pathways. Therefore, a number of drugs that are metabolized by CYP3A4 or CYP2C9 are contraindicated or require close monitoring (Table 261-1 and Table 261-2). Coadministration of terfenadine or cisapride with fluconazole is contraindicated. [66]

CYP2C9 Substrates	CYP2C9 Inducers	CYP2C9 Inhibitors
Amitriptyline	Carbamazepine	Amiodarone
Diazepam	Dexamethasone	Disulfiram
Diclofenac	Phenobarbital	Fluconazole
Glipizide	Rifampin	Fluvastatin
Glyburide		Miconazole
Ibuprofen		Omeprazole
Losartan		Ritonavir
Mefenamic acid		Troglitazone
Naproxen		Zafirlukast
Phenytoin		
Piroxicam		
Propranolol		
Terbinafine		
Tolbutamide		
Torsemide		
Zafirlukast		

*This is not a complete list, and readers should refer to the manufacturer's individual package insert for current information

TABLE 261-2 **Examples of CYP2C9 Subfamily Substrates, Inducers, and Inhibitors***

IMIDAZOLES

Ketoconazole

Ketoconazole was introduced in the 1970s as the first effective oral azole antifungal. However, because of the drug's many adverse reactions, it is not used as a first-line agent for the treatment of dermatophyte infections or candida.

Griseofulvin

Griseofulvin has been used since 1958 for the treatment of dermatophyte infections. [45]

PHARMACOLOGY The absorption of griseofulvin is enhanced by several factors, including concurrent intake of a fatty meal and a smaller particle size formulation. Griseofulvin is mainly metabolized by the liver before excretion. [69]

MECHANISM OF ACTION Griseofulvin is fungistatic in vitro, [45] and has a narrow spectrum of antimycotic activity. It disrupts microtubule mitotic spindle formation, thereby causing mitotic arrest at the metaphase stage. [70]

CLINICAL USES

Pediatric Griseofulvin is the drug of choice for the treatment of tinea capitis, but this may alter with new studies emerging about shorter effective courses with the newer antifungal agents. [37] Griseofulvin is recommended at a dosage higher than that suggested by the manufacturers at 20 to 25 mg/kg per day (microsize), or 15 to 20 mg/kg per day (ultramicrosize) to complete a minimum course of 6 to 8 weeks for *T. tonsurans.* [44] However, longer treatment with griseofulvin is recommended for *M. canis* infections. [44]

Adult Although griseofulvin is indicated for the treatment of fingernail and toenail onychomycosis, therapy is prolonged with low cure and high relapse rates, requiring approximately 6 months for the treatment of fingernails and 12 months for toenails. [70]

Geriatric The safety of griseofulvin therapy in the elderly has not been formally evaluated in trials.

Pregnancy considerations Griseofulvin is a pregnancy category C drug. Because griseofulvin interferes with chromosomal distribution during cell division, males should wait at least 6 months after completing griseofulvin therapy before fathering a child. [71]

DOSAGE SCHEDULES AND FORMULATIONS Griseofulvin is indicated for the treatment of dermatophytosis, onychomycosis, and tinea capitis. [71] Griseofulvin is formulated as ultramicrosize tablets in 125 mg, 165 mg, 250 mg, and 330 mg doses. [72] It is also formulated as griseofulvin microsize and is available as 250 mg and 500 mg tablets and in a

125 mg/5 mL suspension. [71] To maximize absorption it should be taken with fatty foods. The manufacturers' recommended dosing is 5 to 10 mg/kg per day (ultramicrosize) or 10 to 20 mg/kg per day (microsize).

ADVERSE EFFECTS The most common side effects are related to the gastrointestinal tract and the central nervous system. [70] The drug is reported to precipitate lupus erythematosus and severe skin reactions. As a result of impaired porphyrin metabolism, griseofulvin therapy is associated with photoallergic reactions. Griseofulvin is contraindicated in patients with porphyria and hepatocellular failure. [45]

DRUG INTERACTIONS Griseofulvin induces CYP3A4, leading to lower plasma levels of drugs metabolized by this pathway (Table 261-1). [5]

EVIDENCE-BASED MEDICINE CONSIDERATIONS Multiple studies looking at the treatment of dermatophytoses have been performed. Criticisms of these studies include the fact that many were open label, leading to investigator bias. [73] Interpretation of competing studies has been difficult as their end points have not been uniform. Such end points may be mycologic cure, clinical cure, complete cure, and effective treatment. Many studies failed to take into account the physiology of nail growth. [13] Toenails can take up to 18 months to grow out fully. Therefore studies at 48 to 52 weeks might not accurately reflect clinical or mycologic cure. Several studies of the treatment of tinea pedis did not always specify the type of tinea pedis, despite known variations amongst forms of tinea pedis in response rate to therapy. Studies of moccasin tinea pedis are preferred as successful treatment usually indicates that the antifungal drug will be effective in the milder forms of tinea pedis as well as tinea corporis and tinea cruris. [73] Finally, the efficacy of antifungal agents depends on the sensitivity of the dermatophyte. For example, in the treatment of tinea capitis, if the causative organism is *M. canis,* longer treatments may be needed than if the organism is *T. tonsurans.* [45] In North America, most tinea capitis is caused by *T. tonsurans,* while surveys in the United Kingdom demonstrate that the predominant dermatophyte is *M. canis.* [45] Consequently, trials assessing the efficacy of a drug may be influenced by the culprit dermatophyte and indirectly by the location of the study.

REFERENCES

1. Elewski BE, Hay RJ: Novel treatment strategies for superficial mycoses: Introduction. *J Am Acad Dermatol* **40**:S1, 1999

2. Favre B, Ryder NS: Characterization of squalene epoxidase activity from the dermatophyte *Trichophyton rubrum* and its inhibition by terbinafine and other antimycotic agents. *Antimicrob Agents Chemother* **40**:443, 1996

3. Jensen JC: Clinical pharmacokinetics of terbinafine (Lamisil). *Clin Exp Dermatol* **14**:110, 1989

4. Balfour JA, Faulds D: Terbinafine. A review of its pharmacodynamic and pharmacokinetic properties, and therapeutic potential in superficial mycoses [erratum appears in *Drugs* **43**:699, 1992]. *Drugs* **43**:259, 1992

5. Katz HI: Drug interactions of the newer oral antifungal agents. *Br J Dermatol* **141**(Suppl 56):26, 1999

6. Ryder NS: Terbinafine: Mode of action and properties of the squalene epoxidase inhibition. *Br J Dermatol* **126**(Suppl 39):2, 1992

7. Elewski BE: Treatment of tinea capitis: Beyond griseofulvin. *J Am Acad Dermatol* **40**:S27, 1999

8. Nejjam F et al: Pilot study of terbinafine in children suffering from tinea capitis: evaluation of efficacy, safety, and pharmacokinetics. *Br J Dermatol* **132**:98, 1995

9. Fuller LC et al: A randomized comparison of 4 weeks of terbinafine vs. 8 weeks of griseofulvin for the treatment of tinea capitis. *Br J Dermatol* **144**:321, 2001

10. Haroon TS et al: An open clinical pilot study of the efficacy and safety of oral terbinafine in dry non-inflammatory tinea capitis. *Br J Dermatol* **126**(Suppl 39):47, 1992

11. Lamisil, in *Physicians' Desk Reference,* 55th ed. Montvale, NJ, Medical Economics, 2001, p 2179

12. Sigurgeirsson B et al: L.I.ON. Study: Efficacy and tolerability of continuous terbinafine (Lamisil) compared to intermittent itraconazole in the treatment of toenail onychomycosis. Lamisil vs. itraconazole in onychomycosis. *Br J Dermatol* **141**(Suppl 56):5, 1999

13. De Cuyper C, Hindryckx PH: Long-term outcomes in the treatment of toenail onychomycosis. *Br J Dermatol* **141**(Suppl 56):15, 1999

14. Villars V, Jones TC: Clinical efficacy and tolerability of terbinafine (Lamisil)—A new topical and systemic fungicidal drug for treatment of dermatomycoses. *Clin Exp Dermatol* **14**:124, 1989

15. White JE et al: Successful 2-week treatment with terbinafine (Lamisil) for moccasin tinea pedis and tinea manuum. *Br J Dermatol* **125**:260, 1991

16. Scaparro E et al: Evaluation of the efficacy and tolerability of oral terbinafine (Daskil) in patients with seborrhoeic dermatitis. A multicentre, randomized, investigator-blinded, placebo-controlled trial. *Br J Dermatol* **144**:854, 2001

17. Gupta AK et al: Single-blind, randomized, prospective study on terbinafine and itraconazole for treatment of dermatophyte toenail onychomycosis in the elderly. *J Am Acad Dermatol* **44**:479, 2001

18. Lamisil [prescribing information]. East Hanover, NJ, Novartis Pharmaceuticals, 2001

19. Roberts DT: Oral terbinafine (Lamisil) in the treatment of fungal infections of the skin and nails. *Dermatology* **194**(Suppl 1):37, 1997

20. Wilson N, Evans S: Severe pustular psoriasis provoked by oral terbinafine. *Br J Dermatol* **139**:168, 1998

21. Bong JL et al: Persistent impairment of taste resulting from terbinafine. *Br J Dermatol* **139**:747, 1998

22. Brooke R et al: Terbinafine-induced subacute cutaneous lupus erythematosus. *Br J Dermatol* **139**:1132, 1998

23. Kovacs MJ et al: Neutropenia and pancytopenia associated with oral terbinafine. *J Am Acad Dermatol* **31**:806, 1994

24. Dupin N et al: Acute generalized exanthematous pustulosis induced by terbinafine. *Arch Dermatol* **132**:1253, 1996

25. Gupta AK et al: Hepatitis associated with terbinafine therapy: Three case reports and a review of the literature. *Clin Exp Dermatol* **23**:64, 1998

26. Ornstein DL, Ely P: Reversible agranulocytosis associated with oral terbinafine for onychomycosis. *J Am Acad Dermatol* **39**:1023, 1998

27. Lowe G et al: Hepatitis associated with terbinafine treatment. *BMJ* **306**:248, 1993

28. Carstens J et al: Toxic epidermal necrolysis and erythema multiforme following therapy with terbinafine. *Acta Derm Venereol* **74**:391, 1994

29. Brodell RT, Elewski BE: Clinical pearl: Systemic antifungal drugs and drug interactions [see comments]. *J Am Acad Dermatol* **33**:259, 1995

30. Smith EB: The treatment of dermatophytosis: Safety considerations. *J Am Acad Dermatol* **43**:S113, 2000

31. Guerret M et al: Evaluation of effects of terbinafine on single oral dose pharmacokinetics and anticoagulant actions of warfarin in healthy volunteers. *Pharmacotherapy* **17**:767, 1997

32. Abdel-Rahman SM et al: Investigation of terbinafine as a CYP2D6 inhibitor in vivo. *Clin Pharmacol Ther* **65**:465, 1999

33. Hall M et al: Safety of oral terbinafine: Results of a postmarketing surveillance study in 25,884 patients. *Arch Dermatol* **133**:1213, 1997

34. van der Kuy PH, Hooymans PM: Nortriptyline intoxication induced by terbinafine. *BMJ* **316**:441, 1998

35. Schmutz JL et al: Surdosage en nortriptyline lors d'un traitement par terbinafine (1er cas rapporte). *Annal Dermatol Venereol* **126**:647, 1999

36. Heykants J et al: The clinical pharmacokinetics of itraconazole: An overview. *Mycoses* **32**(Suppl 1):67, 1989

37. Friedlander SF: Tinea capitis—Past, present, and future. *Curr Probl Dermatol* **12**:126, 2000

38. Haria M et al: Itraconazole. A reappraisal of its pharmacological properties and therapeutic use in the management of superficial fungal infections [erratum appears in *Drugs* **52**:253, 1996]. *Drugs* **51**:585, 1996

39. Van Cutsem J: The in-vitro antifungal spectrum of itraconazole. *Mycoses* **32**(Suppl 1):7, 1989

40. Barone JA et al: Food interaction and steady-state pharmacokinetics of itraconazole capsules in healthy male volunteers. *Antimicrob Agents Chemother* **37**:778, 1993

41. Zimmermann T et al: Influence of concomitant food intake on the oral absorption of two triazole antifungal agents, itraconazole and fluconazole. *Eur J Clin Pharmacol* **46**:147, 1994

42. Negroni R, Arechavala AI: Itraconazole: Pharmacokinetics and indications. *Arch Med Res* **24**:387, 1993

43. Vanden Bossche H et al: Biochemical basis for the activity and selectivity of oral antifungal drugs. *Br J Clin Pract Suppl* **71**:41, 1990

44. Elewski BE: New developments in cutaneous fungal infections. *Curr Probl Dermatol* **12**:81, 2000

45. Gupta AK et al: Tinea capitis: An overview with emphasis on management. *Pediatr Dermatol* **16**:171, 1999

46. Sporanox, in *Physicians' Desk Reference,* 55th ed. Montvale, NJ, Medical Economics, 2001, p 1584

47. Havu V et al: A double-blind, randomized study comparing itraconazole pulse therapy with continuous dosing for the treatment of toe-nail onychomycosis. *Br J Dermatol* **136**:230, 1997

48. Gupta AK et al: Itraconazole for the treatment of tinea pedis: A dosage of 400 mg/day given for 1 week is similar in efficacy to 100 or 200 mg/day given for 2 to 4 weeks. *J Am Acad Dermatol* **36**:789, 1997

49. Hickman JG: A double-blind, randomized, placebo-controlled evaluation of short-term treatment with oral itraconazole in patients with tinea versicolor. *J Am Acad Dermatol* **34**:785, 1996

50. Sporanox [prescribing information]. Titusville, NJ, Janssen Pharmaceutica, 2001

51. Tucker RM et al: Adverse events associated with itraconazole in 189 patients on chronic therapy. *J Antimicrob Chemother* **26**:561, 1990

52. Rosen T: Debilitating edema associated with itraconazole therapy. *Arch Dermatol* **130**:260, 1994

53. Viagra [prescribing information]. New York, Pfizer, 2000

54. Montero-Gei F: Fluconazole: Pharmacokinetics and indications. *Arch Med Res* **24**:377, 1993

55. Thorpe JE et al: Effect of oral antacid administration on the pharmacokinetics of oral fluconazole. *Antimicrob Agents Chemother* **34**:2032, 1990

56. Dudley MN: Clinical pharmacology of fluconazole. *Pharmacotherapy* **10**:141S, 1990

57. Tucker RM et al: Treatment of coccidioidal meningitis with fluconazole. *Rev Infect Dis* **12**(Suppl 3):S380, 1990

58. Brammer KW et al: Pharmacokinetics and tissue penetration of fluconazole in humans. *Rev Infect Dis* **12**(Suppl 3):S318, 1990

59. Ruhnke M et al: Single-dose pharmacokinetics of fluconazole in patients with liver cirrhosis. *J Antimicrob Chemother* **35**:641, 1995

60. Toon S et al: An assessment of the effects of impaired renal function and haemodialysis on the pharmacokinetics of fluconazole. *Br J Clin Pharmacol* **29**:221, 1990

61. Solomon BA et al: Fluconazole for the treatment of tinea capitis in children. *J Am Acad Dermatol* **37**:274, 1997

62. Del Aguila R et al: Once-weekly oral doses of fluconazole 150 mg in the treatment of tinea pedis. *Clin Exp Dermatol* **17**:402, 1992

63. Havu V et al: A double-blind, randomized study to compare the efficacy and safety of terbinafine (Lamisil) with fluconazole (Diflucan) in the treatment of onychomycosis. *Br J Dermatol* **142**:97, 2000

64. Faergemann J: Treatment of pityriasis versicolor with a single dose of fluconazole. *Acta Derm Venereol* **72**:74, 1992

65. Martin MV: The use of fluconazole and itraconazole in the treatment of *Candida albicans* infections: A review [erratum appears in *J Antimicrob Chemother* **45**:555, 2000]. *J Antimicrob Chemother* **44**:429, 1999

66. Diflucan, in *Physicians' Desk Reference,* 55th ed. Montvale, NJ, Medical Economics, 2001, p 2487

67. Anonymous: Oral fluconazole for vaginal candidiasis. *Med Lett Drugs Ther* **36**:81, 1994

68. Pappas PG et al: Alopecia associated with fluconazole therapy [see comments]. *Ann Intern Med* **123**:354, 1995

69. Meinhof W: Kinetics and spectrum of activity of oral antifungals: The therapeutic implications. *J Am Acad Dermatol* **29**:S37, 1993

70. Gupta AK et al: Antifungal agents: An overview. Part I. *J Am Acad Dermatol* **30**:677, 1994

71. Grifulvin V, in *Physicians' Desk Reference,* 55th ed. Montvale, NJ, Medical Economics, 2001, p 2321

72. Gris-PEG, in *Physicians' Desk Reference,* 55th ed. Montvale, NJ, Medical Economics, 2001, p 2466

73. Rand S: Overview: The treatment of dermatophytosis. *J Am Acad Dermatol* **43**:S104, 2000

T>

Chapter 262

H. Nousari Grant Anhalt

Immunosuppressive and Immunomodulatory Drugs

BASIC PHARMACOLOGIC CONCEPTS IN IMMUNOSUPPRESSIVE THERAPY
MACROLACTAM IMMUNOMODULATORS
CYCLOSPORINE A
Mechanism of Action
Pharmacokinetics
Dosages and Monitoring
Side Effects
Dermatologic Uses
TACROLIMUS
Dermatologic Uses
SIROLIMUS
Dermatologic Uses
PIMECROLIMUS
OTHER IMMUNOSUPPRESSIVE DRUGS
Mycophenolate Mofetil
LEFLUNOMIDE
REFERENCES

BASIC PHARMACOLOGIC CONCEPTS IN IMMUNOSUPPRESSIVE THERAPY

Immunosuppressive and immunomodulatory drugs play a crucial role in the management of organ transplantation, as well as in the therapy of autoimmune and inflammatory disorders. The most significant progress in the field of immunosuppression has come from the management of organ transplantation.

The main goal in immunosuppressive therapy is to find the most selective and least toxic regimen. [1] Although, there has been significant progress in the search for selective immunomodulation, the most significant advance in immunosuppressive therapy has been the reduction in the exposure to systemic glucocorticoids. This therapeutic intervention is associated with a significant reduction in morbidity and mortality and is achieved by the avoidance of high doses of systemic glucocorticoids and by the early introduction of steroid-sparing immunosuppressive and immunomodulatory drugs as adjuvant therapy.

The highest level of “safety and effectiveness” in immunosuppressive therapy is currently accomplished by the use of “combination therapy.” [2] Briefly, three major pharmacodynamic effects are obtained by combining these drugs. The first effect is synergistic, whereby the immunologic effect of the drug combination is higher than the one obtained by an individual drug. This allows the use of drugs at lower doses than the ones recommended as sole therapy. Thus, a synergistic combination not only exerts an effective therapeutic dose but also minimizes dose-dependent side effects. The ideal synergistic combination is the one that combines drugs that have different mechanisms of action and have different side effect profiles. Cyclosporine plus mycophenolate mofetil is a commonly used synergistic combination in transplantation and graft-versus-host disease. Certain dermatologic diseases in which this combination may have a synergistic effect include pyoderma gangrenosum, paraneoplastic pemphigus, and lichen planus.

The second major pharmacologic effect obtained with combination therapy is additive, whereby the combination of half of the dosages of individual drugs achieves an immunologic effect that is the similar to the one achieved by the use of a full dose of an individual drug. This is the most common combination used in immunology, especially if only two drugs are combined and one of them is a systemic glucocorticoid. The additive effect in immunosuppressive therapy is the origin of the concept of “steroid sparing agents” in adjuvant therapy. An example of this additive effect is the combination of prednisone and mycophenolate mofetil in organ transplantation and in the treatment of pemphigus.

The third effect of combination therapy is antagonistic, whereby the combining half of the dosages of individual drugs causes a lesser immunologic effect than the one achieved by a full dose of these individual drugs. An example of this effect is the combination of cyclosporine and tacrolimus in transplantation or azathioprine with mycophenolate mofetil in pemphigus. Antagonistic combinations are easy to predict since these drugs usually share similar mechanisms of action and therefore compete for the same intracellular targets.

There are two major obstacles to optimizing immunosuppressive therapy: (1) a low therapeutic index (narrow window between the toxic and the therapeutic range) and (2) intra- and interindividual variation of the pharmacokinetics of these agents. Several concentration-controlled regimens have been developed to overcome these obstacles, including dosing of drugs by ideal (lean) body weight and body surface area. This concept is commonly misinterpreted by some physicians who prescribe these drugs by the actual body weight and not the ideal (lean) body weight of the patient. Another regimen is measurement of drug levels (parent and metabolite serum peak and trough levels). Other more complex methods for prescribing these drugs are less-commonly used, including area under the curve (AUC) and AUC/dosing interval.

The most useful pharmacologic tool that combines the aforementioned pharmacologic concepts is the “median effect formula” of Chou and Talalay (Fig. 262-1). This formula derives from the mass action law and relates dose to biologic effect of drugs. The two major applications of this formula are determination of the therapeutic window of the drug and the type of interactions between agents when used in combination versus individually (i.e., synergistic, antagonistic, or

additive effect). This formula has been used extensively in the design of immunosuppressive regimens. [3]

$$Fa = \frac{D\,m}{Fu\,Dm}$$

A.

$$Cix = \frac{\text{A combined with B}}{\text{A alone}} + \frac{\text{B combined with A}}{\text{B alone}}$$

Cix: combination index necessary for an arbitrary x% inhibition.

Cix: = 1 are additive
< 1 are synergistic
> 1 are antagonistic

B.

FIGURE 262-1 *A.* Median effect formula of Chou and Talalay. D, drug dose; Dm, dose for 50 percent inhibition (median effect); Fa, fraction affected (percent inhibition); Fu, uninhibited fraction (1-Fa); m, slope (Hill) coefficient. *B.* Modified median-effect formula for combined immunosuppressants.

In the scientific design of safe and effective immunosuppressive therapy, it is mandatory to integrate the aforementioned pharmacologic concepts with a full knowledge of the pathogenesis of the disease. Figure 262-2 shows a practical algorithm for the design of immunosuppressive therapy.

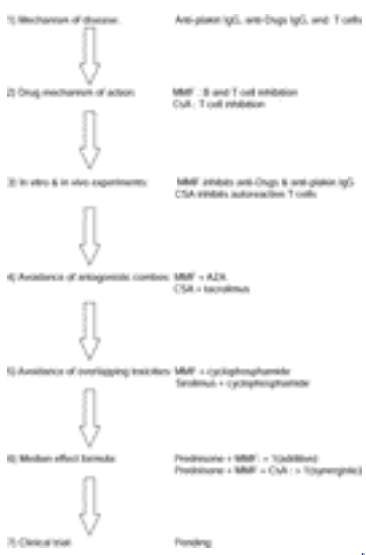

FIGURE 262-2 Paraneoplastic pemphigus as an example for the design of an algorithm of combined immunosuppressive therapy. CsA, cyclosporine A; DsG, desmoglein; MMF, mycophenolate mofetil.

MACROLACTAM IMMUNOMODULATORS

This group of immunomodulators is derived from microorganism fermentation products and includes the three classic calcineurin inhibitors (cyclosporine, tacrolimus, and pimecrolimus) and sirolimus. [4] Macrolactams are versatile immunomodulators that have synergistic therapeutic effects when they are combined with virtually any other immunosuppressive drug. The immunomodulatory effects of these drugs are intricate and subject to constant discoveries. The macrolactams selectively suppress T cell response through the inhibition of calcium-dependent signal transduction mechanisms. It is known that the T cell proliferation/stimulation process involves the orchestration of complex interacting mechanisms, most of which are not completely understood. The pharmacodynamic can be summarized as suppression of gene transcription of proinflammatory cytokines and a complex inhibition of the cell cycle of activated cells. These effects are reflected in the primary inhibition of T cell responses. A simplified explanation of the mechanism of action of these drugs is presented in the following sections and is illustrated in Fig. 262-3.

FIGURE 262-3 This diagram outlines the key mechanisms by which calcineurin inhibitors (cyclosporine, tacrolimus, pimecrolimus) and sirolimus inhibit T cell activation triggered by presentation of antigen via the T cell receptor. The first step in antigen presentation involves presentation of a peptide that is bound within the peptide binding groove of the major histocompatibility complex (MHC) class II molecule. This complex is then presented to the T cell receptor (TCR). This causes transmembrane signaling that increases intracellular calcium concentrations. The liberated calcium, bound to calmodulin, interacts with calcineurin, a calcium-dependent serine/threonine phosphatase that dephosphorylates nuclear factor of activated T cells (shown here as NFATc) and this causes NFAT to translocate to the nucleus. There it binds to other nuclear components of NFAT (shown here as NFATn). This complex regulates the transcription of many cytokine genes, shown in the diagram. Cyclosporine, tacrolimus, and pimecrolimus diffuse freely into the cytoplasm of T cells, and bind with their respective immunophilins. This drug/immunophilin complex binds to calcineurin and blocks its ability to dephosphorylate NFAT, and thereby inhibits the production of cytokines that would normally be induced after T cell activation via the TCR. Sirolimus has a more complex intracellular mechanism of action. Although sirolimus binds macrophilin-12, the immunophilin of tacrolimus and pimecrolimus, its mechanism of action does not appear to be

mediated by calcineurin inhibition.

CYCLOSPORINE A

Cyclosporine A (CsA) is a hydrophobic lipophilic undecapeptide extracted from fungi.

Mechanism of Action

CsA and the other calcineurin inhibitors inhibit T cell stimulation initiated by several pathways, of which the T cell receptor (TCR) CD3 is the best understood. Mechanisms involving B-7 and CD28/CTLA-4, and other costimulatory pathways seem not to be affected by CsA or other calcineurin inhibitors. The high-affinity receptor for CsA is a 17-kDa immunophilin called cyclophilin A (CyPA). The other calcineurin inhibitors (tacrolimus and pimecrolimus) and sirolimus bind a structurally unrelated different immunophilin called macrophilin-12. The drug-immunophilin complex binds to calcineurin. Calcineurin is a serine/threonine protease composed of two subunits: calcineurin A (CnA) and calcineurin B (CnB). CnA constitutes the catalytic unit possessing binding sites for CnB and calmodulin. Calcineurin activity strictly correlates with interleukin (IL)-2 production via CD3 activation. Calcineurin is also involved in the induction of apoptosis and degranulation of cytotoxic T lymphocytes. It is well established that calcineurin activation is not only a rate-limiting step but also a crucial propagating factor in calcium-dependent T cell signaling pathways. Although sirolimus binds to macrophilin-12, this drug-immunophilin complex inhibits gene transcription through a complex mechanism that seems to be independent from the one involving calcineurin.

Subsequently, calcineurin regulates the transcription factor NFAT (nuclear factor of activated T cells), which is implicated in the regulation of the cytokine-encoding genes, including the gene regulating IL-2 production. NFAT is a heterodimer complex composed of two molecules: NFATn and NFATc. One of the substrates of calcineurin is the cytoplasmic component of this complex, NFATc. Once NFATc is dephosphorylated by calcineurin, the protein translocates into the nucleus where it binds NFATn, a nuclear AP-1 family member whose synthesis is induced by protein kinase C-dependent signals. Experimental data show that the CsA, tacrolimus, and pimecrolimus/calcineurin complex inhibits the nuclear translocation of the NFATc by blocking its dephosphorylation. This is thought to be the key step by which these drugs uncouple T cell receptor activation from IL-2 transcription. Tacrolimus is 10- to 100-fold more potent than CsA in vitro in the inhibition of calcineurin activity. [5]

Other less-understood mechanisms of action have been postulated for the immunosuppressive and immunomodulatory effects of calcineurin inhibitors, especially in psoriasis. [6] In summary, CsA inhibits the T cell activation mediated by antigen, but it does not inhibit the early phases of lymphocyte signal transduction occurring after antigen-mediated activation. New cellular mechanisms of action of CsA are being explored.

Pharmacokinetics

The microemulsion-based formulation of CsA (Neoral) was developed to improve the bioavailability of the drug. [7] This formulation does no seem to be influenced greatly by food ingestion and is associated with faster, more extensive, and more predictable absorption even in the presence of malabsorption states. CsA can also be administered intravenously as a 50 mg/mL solution made up in an ethanol-polyoxythylated castor oil mixture. The accumulation of CsA in erythrocytes and leukocytes is the reason that whole-blood monitoring of CsA levels is much more accurate than measurement of plasma levels.

It has not been possible to formulate a preparation of CsA in any topical form that has significant penetration of the epidermal barrier. CsA solution does have some penetration of mucosal surfaces, but this is not true of cornified epithelium. Intralesional injections of CsA do provide some local effects in psoriasis, but they are not widely used. The bioavailability of ingested drug ranges from 25 to 35 percent. Peak levels occur from 1.3 to 4 h after oral administration. After gaining access to the circulation, CsA distributes widely and has a large apparent volume of distribution (13 L/kg). CsA is metabolized into greater than 30 cyclic metabolites by the liver cytochrome P450 3A enzyme. It is believed that metabolites retain some biologic and toxic activities.

Because the primary metabolism of the drug is by the hepatic P450 3A enzyme, drugs that compete for binding to P450 3A will increase CsA levels, and drugs that induce P450 will accelerate metabolism and decrease blood levels (Table 262-1). [8] Certain foods rich in bioflavonoids, especially grapefruit, seem to increase the drug's bioavailability through an interaction with cytochromes. [9] Its elimination half-life is 6 to 12 h in the absence of severe hepatic disease, and biliary excretion accounts for more than 90 percent of its elimination.

TABLE 262-1 **Medications that Commonly Alter the Metabolism of Cyclosporine through the Cytochrome P-450 3A Pathway***

Dosages and Monitoring

Unlike organ transplantation, in dermatology, recommended doses rarely exceed 8 mg/kg per day, with no initial loading doses. Dosage increases should not exceed 0.5 to 1 mg/kg per day at 2- to 4-week intervals. Patients who are unable to tolerate the oral formulation, can receive the diluted intravenous formulation, infused slowly over a period of 2 to 6 h at about one-third of the usual oral dose, or about 2 to 3 mg/kg per day.

The National Academy of Clinical Biochemistry/American Association for Clinical Chemistry Task Force on Cyclosporine Monitoring recommends that whole blood be used for CsA assays, that EDTA is the recommended anticoagulant, and that the assay should be specific for the parent drug. Trough levels should be used, with samples obtained before the next dose. The two most common assays for trough levels are high-performance liquid chromatography (HPLC) and radioimmunoassay (RIA), and the recommended range is 200 to 400 ng/mL. It is important to monitor trough CsA blood concentrations, but one must remember that they do not necessarily correlate well with either toxicity or efficacy in individual patients. Children have comparable bioavailability of orally ingested CsA, but have a higher renal drug clearance rate (11.8 mL/min per kg versus 5.7 mL/min per kg in adults), and a correspondingly shorter blood level half-life (7.3 h versus 10.7 h in adults). Children may therefore require somewhat higher dosages and more frequent administration to achieve comparable trough levels to adults. [10]

From a practical standpoint, adequate monitoring of CsA dosage can be achieved by the avoidance of CsA doses higher than 5 mg/kg per day, evaluation of clinical response, and vigilance for signs of toxicity. This requires a detailed physical examination, including blood pressure monitoring with threshold concern triggered by a persistent diastolic blood pressure above 95 to 100 mmHg, a complete history with emphasis on concomitant drug ingestion and medical conditions that may potentiate CsA toxicity, and laboratory evaluations for complete blood count, creatinine and blood urea nitrogen, uric acid, liver enzymes, serum electrolytes and magnesium (because cyclosporin can induce hypomagnesemia), and a urinalysis. In patients receiving long-term CsA therapy (>6 months), the serum creatinine is a poor predictor of altered renal function and potentially irreversible chronic cyclosporine nephrotoxicity may ensue. In such circumstances more reliable studies for the evaluation of renal function may be indicated. [11], [12] and [13]

Side Effects

RENAL Three types of nephrotoxicity have been described with the use of CsA. The first occurs immediately after renal transplantation and occurs in the context of kidneys already damaged by ischemia. Obviously, this type of renal toxicity is not relevant to dermatologic patients. [14] The second type of nephrotoxicity appears during the first 2 to 3 weeks after transplantation and it is usually associated with high CsA blood levels. In this toxicity, there is an insidious decrease in glomerular filtration rate (GFR), along with hypertension, and tubular dysfunction (renal tubular acidosis, hyperkalemia, hyperuricemia, and decreased fractional excretion of sodium) in association with a recovery of renal function upon lowering the CsA dosage. The lack of specific histologic findings for CSA-induced nephrotoxicity poses a challenge in the differentiation from acute organ rejection. This type of nephrotoxicity can also be seen in patients with skin diseases within a few weeks of initiation of therapy. Reduction of CsA dosages or cessation of CsA is generally associated with recovery of renal function. Finally, there is chronic renal toxicity, which is likely a result of cumulative subclinical toxicity. This form of toxicity may occur in the absence of any detectable elevation of creatinine or blood pressure. Histologic changes include interstitial fibrosis, tubular atrophy, and some degree of vasculopathy. Although renal function can improve somewhat after discontinuation of the drug, this type of toxicity is generally irreversible. In the treatment of dermatologic diseases, this is the form of toxicity that is most likely to occur. In psoriatic patients receiving 5 mg/kg per day CsA, elevation of serum creatinine may persist for more than 4 months after discontinuation of the drug. Overall, one in four patients taking CsA develops clinical and laboratory evidence of altered renal function. A crucial mechanism of CsA nephrotoxicity appears to be the failure of downregulation of renal vasoconstriction, caused by both an increase in endothelin (ET)-1–mediated vasoconstriction and a decrease of prostaglandin-mediated vasodilatation. [15] ET-1 decreases the GFR, increases vascular resistance, and possesses mitogenic properties. The inhibition of ET-1 by diltiazem appears to provide renal protection in CSA-treated patients. [16] Nephrotoxicity can be potentiated by nephrotoxic drugs (Table 262-1). Hypertension is another very common adverse effect of CsA and occurs in approximately 30 percent of psoriatic patients. Calcium channel antagonists also exert a beneficial effect on CsA-induced hypertension, presumably through the inhibition of ET-1. On the other hand, angiotensin-converting enzyme inhibitors are not as effective in the therapy of CsA-induced hypertension. Diuretics should be used with caution because of their potential nephrotoxic effects. Another uncommon adverse renal complication is the development of hemolytic-uremic syndrome (HUS), especially in allogenic bone marrow transplant patients receiving CsA for acute graft-versus-host disease (GVHD). [17] Hypomagnesemia and hyperkalemia also reportedly occur.

GASTROINTESTINAL Nausea, vomiting, anorexia, and diarrhea commonly occur with the use of CsA. Hyperbilirubinemia and transient mild elevation of liver enzymes are also reported in CsA-treated patients. Elevations of liver enzymes greater than 100 percent over baseline should be managed by reduction of the CsA dose by 25 percent weekly, until enzyme levels normalize. [18] Avoidance of drugs with potential hepatotoxicity should be emphasized.
NEUROLOGIC Headache is a common complaint, especially in patients with a history of migraines. It tends to resolve spontaneously as therapy continues. CSA-induced seizures appear to be associated with hypomagnesemia and concomitant use of high doses of systemic corticosteroids, Thus, serum magnesium levels should be always monitored and kept above the lower normal range in CsA-treated patients. Cortical blindness, lethargy, confusion, seizures, hemiplegia, tremors, and paresthesias have also been described in patients receiving CsA. [19]
HEMATOLOGIC There is evidence of impaired fibrinolysis and endothelial damage associated with CsA. Hypercoagulability seems to contribute to the progression of atherosclerosis and glomerular damage in CsA-treated patients. Significant cytopenias have rarely been reported with the use of CsA.
METABOLIC Hypercholesterolemia, elevation of low-density lipoproteins (LDL), and hypertriglyceridemia may be seen with CsA, although the precise mechanism of this adverse effect remains unknown. Preventive measures such as weight reduction, avoidance of alcohol, and increased physical activity should be instituted. Caution should be taken with the use of drugs to treat hyperlipidemias because bile acid-binding resins may interfere with CsA absorption and the use of 3-hydroxy-3-methylglutaryl coenzyme A (HMG-CoA) reductase inhibitors such as lovastatin or simvastatin may cause rhabdomyolysis.
NEOPLASTIC There is an increased incidence of neoplasms in transplant patients, but this risk does not seem to be greater in patients treated with CsA when compared to those patients treated with other immunosuppressive drugs. The relative risk for lymphoma in patients treated with CsA is 27.5, versus a relative risk of 33.8 to 58.6 in patients treated with immunosuppressive regimens that do not include the use of CsA. There also are reports of an increased incidence of non-Hodgkin's B cell lymphomas in patients receiving CsA in conjunction with other immunosuppressants. For example, the incidence of lymphoma in transplant patients receiving CsA alone or in combination with corticosteroids is less than 1 percent, whereas the incidence in transplant patients receiving CsA in conjunction with other immunosuppressive drugs is as high as 8 percent. In contrast to the high mortality rate attributed to lymphomas arising in immunosuppressed patients, lymphomas developing in CsA-treated patients seem to carry a better prognosis and the latency period seems to be shorter. [20] In a recent study in a large number of rheumatoid arthritis patients treated with CsA there was no increase in malignancies in comparison with a matched control group of patients with rheumatoid arthritis who were not treated with CsA. [21] The incidence of lymphoma in CsA-treated dermatologic patients is less than 0.2 percent. Most of these are B cell non-Hodgkin's lymphoma, but T cell non-Hodgkin's and Hodgkin's lymphomas have also been reported. An increased incidence of skin cancer is a known complication of immunosuppression, and CsA-treated transplant recipients have a relative risk for all skin cancers of 6.8 versus 2.2 to 5.5 in patients receiving other immunosuppressive therapies. CsA-treated dermatologic patients also have a higher risk of skin cancers, including squamous cell carcinomas (SCCs), basal cell carcinomas, Bowen's disease, and Kaposi sarcoma, and perhaps melanoma. There is a high incidence of squamous cell carcinoma in psoriatic patients treated with CsA, but this could be biased by previous exposures to PUVA or UVB. Kaposi sarcoma with visceral involvement that develops during CsA treatment often fails to respond to therapy, but approximately 25 percent of nonvisceral Kaposi sarcomas can be expected to undergo complete or partial remission following cessation or reduction of immunosuppressive therapy. An increased incidence of carcinoma of the penis, vulva, and anus has also been reported, and some of these carcinomas arise from preexisting viral warts. Cessation or reduction of the immunosuppressive regimen, as well as of retinoid therapy, could be considered as therapeutic strategies for prevention and control of viral induced SCC and dysplastic lesions. Because of the potential carcinogenic potential of viral warts, total eradication of these lesions has been proposed as a way to prevent the future development of SCC, but the validity of this approach is very controversial. Epstein-Barr virus (EBV)–associated posttransplant lymphoproliferative disorder (PTLD) is quite rare in dermatologic patients. PTLD frequently fails to respond to chemotherapy but it may regress spontaneously after reduction and/or cessation of immunosuppression. For PTLD that fails to regress after discontinuation of CsA, therapies include intravenous immunoglobulin, alpha interferon and high doses of IV acyclovir. Other tumors, are also reported in CsA-treated patients, although their true incidence is unknown.
MUCOCUTANEOUS Hypertrichosis is a well-known complication, and probably occurs in 100 percent of patients on long-term CsA therapy. It seems to be more common in dark-skinned patients, is not confined to androgen-dependent hair-bearing areas, and is independent of sex hormone levels. Hypertrichosis tends to worsen with further treatment and shows no tendency to spontaneous remission. Gingival hypertrophy is reported in 8 to 70 percent of patients on CsA therapy. It tends to develop first on the anterior gingival mucosae and the peak incidence occurs within 6 months of the initiation of CsA therapy. This complication is more common in children and is found in individuals with poor oral hygiene. Gingival sensitivity is a common complaint. The underlying histologic finding is fibrous hyperplasia, similar to that seen in patients on phenytoin and calcium channel blockers. This is an important issue because calcium channel drugs are important in the management of CsA-induced hypertension, and the risk for development of this side effect may be much higher with the use of this drug combination. [22] An acneiform eruption, indistinguishable from that seen in steroid-induced acne, is frequently reported. A disseminated comedonal or cystic acneiform eruption can also occur. These side effects can appear at any time during CsA therapy, although they are more commonly described at the time of initiation of CsA therapy. Keratosis pilaris is reported in 21 percent, sebaceous hyperplasia in 15 percent, and epidermal inclusion cysts in 28 percent of CsA-treated patients. Some of the epidermal cysts are small and located on the face, and typically decrease in size and number as time progresses. Flushing, angioedema, urticaria, and anaphylaxis have also been reported with the use of CsA. An increased incidence of keratoacanthomas, sebaceous hyperplasia, and viral warts have been reported.
MUSCULOSKELETAL Osteoporosis occurs in organ transplant patients receiving CsA and seems to result from the drug's action on osteoblasts, and osteoclasts, and by altering lymphokine release. [23] CsA can induce hyperuricemia in up to 15 percent of patients, apparently secondary to decreased urate clearance. [24] Gout appears to be more common in men, in patients with preexisting renal impairment, and in those concomitantly using diuretics. Myopathy has been reported in transplant patients receiving high doses of CsA.
REPRODUCTIVE CsA does not seem to be mutagenic or teratogenic, although there is a high incidence of preterm newborns, fetal growth retardation, abortions, preeclampsia, and hypertension in mothers taking CsA, and these occurrences are magnified in transplant patients. There are no reports of neonatal complications in children born to fathers receiving CsA. Adequate contraceptive measures are recommended in women of childbearing potential. CsA crosses the placenta and is excreted in breast milk. Because preexistent conditions such as hypertension, diabetes, and

renal dysfunction are risk factors in pregnant transplant patients who take CsA, close monitoring during pregnancy, labor, and postpartum is mandatory. [25]
IMMUNOLOGIC There is controversy as to whether there is an increased incidence of life-threatening infections in nontransplant patients receiving low-dose CsA as a sole immunosuppressive therapy. CsA-treated transplant patients seem to have a relative risk for infectious complications that is lower than that seen in patients receiving azathioprine and prednisolone. However, increased vigilance for infectious complications is recommended in CsA-treated patients.

Dermatologic Uses

Vast experience has been gained in the use of CsA in organ transplantation and autoimmune disorders. The usual dosage for these indications ranges from 5 to 8 mg/kg of the microemulsion-based formulation. The medical literature is replete with anecdotal reports of the therapeutic uses of CsA in dermatologic diseases. The most responsive dermatoses are psoriasis, atopic dermatitis, pyoderma gangrenosum, cutaneous and oral lichen planus, GVHD, epidermolysis bullosa acquisita, Behçet's disease, and paraneoplastic pemphigus. Lesser efficacy is reported in dermatomyositis, alopecia areata, recurrent aphthous stomatitis, and others. [26]

CsA is indicated as part of a rotational therapeutic regimen for refractory cases of psoriasis. Although, CsA has been successfully used in all forms of psoriasis with a wide range of success, the vast experience with this drug comes from its use in plaque-type psoriasis. [27], [28] and [29] The FDA has approved CsA for psoriasis in doses up to 4 mg/kg per day. The recommended starting dose is 2.5 mg/kg per day. Dosage increases should be performed after 4 weeks of therapy, and dose reductions are permitted at any time. Doses higher than 5 mg/kg per day are not advisable. In patients going into remission, defined as PASI (psoriasis area and severity index) reduction greater than 75 percent, the CsA dose should be down titrated at 4-week intervals, usually starting at week 16.

Serum creatinine levels should be carefully monitored during CsA therapy. If creatinine levels increase more than 30 percent above baseline, the dosage should be reduced for 1 to 2 weeks. If, after that time, the creatinine levels decrease below the 30 percent elevation mark, continuation at the lower dose is advisable. In cases where the creatinine remains elevated by more than 30 percent, discontinuation of CsA is recommended until the creatinine returns to levels within 10 percent of pretreatment levels. More accurate studies monitoring the GFR clearance are used in individualized cases. Long-term CsA therapy produces significant clinical improvement, although exacerbation was noted in about 50 percent of patients after CsA was withdrawn. Guidelines for the use of CsA in psoriasis have been published. [30], [31]

There is a vast European experience in the use of CsA in atopic dermatitis (AD). Its safety and efficacy in children have been studied and it seems to be a safe alternative short-term therapy for severe atopic dermatitis in children and adults with doses of 3 to 5 mg/kg per day. [32], [33] Relapses within weeks after discontinuation of CsA are common.

Refractory cutaneous lichen planus has been reported to respond to 4 weeks of CsA therapy at a dose of 6 mg/kg per day. Oral lichen planus is the only disease in which the use of topical CsA has been demonstrated to be effective and safe. [34]

Pyoderma gangrenosum usually responds to initial doses of 5 mg/kg per day, with maintenance therapy at 3 mg/kg per day. Significant improvement is expected within 3 months of initiation of therapy. [35] CsA is very effective in the prevention and treatment of graft-versus-host disease. [36] CsA seems to be an effective immunosuppressive drug for the treatment of some cases of paraneoplastic pemphigus, at a dose of 5 to 7 mg/kg per day. It is generally more effective when used in combination with prednisone or other immunosuppressive agents such as mycophenolate mofetil, thalidomide, or azathioprine. [37] CsA doses in the range of 5 to 10 mg/kg per day are superior to conventional therapy in controlling ocular, and also perhaps extraocular, symptoms in Behçet's syndrome. [38]

TACROLIMUS

This immunosuppressant, formerly known as FK506, is a macrolide antibiotic, which was first isolated from the soil microorganism *Streptomyces tsukubaensis*. This drug is also known to inhibit calcium-dependent events mediated by calcineurin. [39] Tacrolimus can be administered intravenously or orally. A topical formulation has also been developed [40] and is discussed in Chap. 250. The usual adult IV dosage is 25 to 50 µg/kg and 50 to 100 µg/kg for pediatric patients. Oral dosages range between 150 and -200 µg/kg for adults and between 200 and 300 µg/kg for children. The topical formulations have a concentration of 0.3% and 0.1% in an ointment vehicle.

The pharmacokinetics of systemic tacrolimus are characterized by a two-compartment model with a rapid initial drop and a long terminal elimination half-life of 12 to 21 h. Tacrolimus is metabolized in the liver with less than 1 percent of the drug excreted intact.

Tacrolimus has not proven to be more effective than CsA as a first-line agent in renal transplantation, but it appears to have a little better bioavailability. Mucocutaneous and metabolic side effects seem to be less frequent with the use of tacrolimus. However, major neurotoxicities and glucose intolerance are somewhat higher than with CsA use. [41] Nephrotoxicity seems to be comparable to that seen with the use of CsA. The histopathology of the renal toxicity is similar to that seen with CsA nephrotoxicity. The dosage of tacrolimus should be reduced in the presence of hepatic dysfunction. The risk for PTLD seems to be particularly high in children with hepatic transplants who received both tacrolimus and anti-OKT3. [42]

There is a good correlation between enzyme-linked immunosorbent assay (ELISA) and HPLC-MS (mass spectrometry) measurements in monitoring of blood concentrations of tacrolimus. However, ELISA assays may also detect metabolites of the drug, which could make this method less accurate in conditions with altered metabolism of tacrolimus, such as hepatic disease. Levels greater than 20 ng/mL in whole blood are associated with toxicity, so that 5 to 15 ng/mL blood

levels are now widely recommended.

Dermatologic Uses

The European Tacrolimus Multicenter Psoriasis Study Group has shown systemic tacrolimus to be effective for recalcitrant plaque-type psoriasis. This was a double-blind, placebo-controlled study in which the efficacy and side effects of tacrolimus in 27 patients were evaluated. An initial dose of 0.05 mg/kg per day for 6 to 9 weeks produced significant improvement in PASI scores, with relatively few side effects—predominantly diarrhea, paresthesia, and insomnia. [43]

Tacrolimus is very effective in the prevention of acute GVHD. (However, a less graft-versus-leukemia effect in comparison to the one seen with CsA was observed in these patients. [44]) There are isolated reports of the effective and safe use of systemic tacrolimus in atopic dermatitis and pyoderma gangrenosum. [45], [46]

In general, systemic tacrolimus can be used in any inflammatory and autoimmune skin disease in which systemic CsA has proven effective.

Topical tacrolimus has shown its consistent effectiveness in the treatment of certain inflammatory skin disorders, namely atopic dermatitis (see Chap. 250). These effects appear to be related to the inhibitory effects on interleukins (IL-2, 4, 5, and 11 a and ß), chemokines, tumor necrosis factor (TNF)-a, granulocyte-macrophage colony-stimulating factor (GM-CSF), macrophage inflammatory protein (MIP)-2, and interferon (IFN)-?, as well as modulatory effects of tacrolimus on Langerhans cell IgE receptors and mast cell degranulation. [47], [48]

SIROLIMUS

Sirolimus, also known as rapamycin, is a macrolide that was first isolated from the microorganism *Streptomyces hygroscopicus*. After binding macrophillin-12, the immunophilin–sirolimus complex targets kinases (C-rel, RAFT, and others) that are required for T cell proliferation in the presence of IL-2. Sirolimus also inhibits IL-2–mediated signal transduction pathways, and the calcium-independent mechanisms responsible for the activation of T cells, acting in the late phases in the cell cycle, specifically between the late phase of G1 and S.

This mechanism differs from the mechanism of calcineurin inhibitors as the latter block the cell cycle at earlier phases G0/G1. Other mechanisms of action of sirolimus, including the inhibition of IL-4–driven lymphocyte proliferation, have been described.

Sirolimus has some unique properties that differentiate it from CsA and tacrolimus. In addition to its immunosuppressive effects, it inhibits smooth muscle cell proliferation and migration. This property may be helpful in preventing the intimal hyperplasia that is characteristic of CsA and tacrolimus-induced renal vascular toxicity. [49] The drug is sequestered by erythrocytes. It is metabolized by the same P450 3A enzyme that is involved in the metabolism of CsA and tacrolimus. Its half-life is long, with a 24-h trough concentration, and there is a good correlation between trough levels and administered doses. Further protocols are being explored to delineate its pharmacology and therapeutic uses. [50]

Dermatologic Uses

In vitro sirolimus is very effective in inhibiting the role of Langerhans cells by inhibiting transforming growth factor ß. [51] Sirolimus is effective in preventing GVHD. [52] This drug has a potential use in inflammatory conditions such as atopic dermatitis and psoriasis; however, patients with extensive inflammatory skin disorders treated with sirolimus should be monitored closely for capillary leak syndrome caused by induction of massive apoptosis. [53], [54]

Sirolimus inhibits, in vitro, the proliferation and activation of cells in cutaneous large anaplastic lymphoma and Sézary syndrome. Sirolimus seems to exert this action through the inhibition of the basal activation of the Jak/STAT pathway involved in IL-2R signal transduction in these lymphoma cells. [55]

PIMECROLIMUS

This macrolactam, also known as ASM 981, is a derivative of the parent compound ascomycin. Ascomycin was originally isolated from the fermentation products of *Streptomyces hygroscopicus* var. *ascomyceticus*. [56] Pimecrolimus is a cell-selective inhibitor of inflammatory cytokines, specifically developed for the treatment of inflammatory dermatoses.

Pimecrolimus has a similar mechanism of action as that of other calcineurin inhibitors. [57] Pimecrolimus forms a complex with macrophilin-12 that inhibits calcineurin (Fig. 262-3). Calcineurin inhibition leads to inhibition of synthesis of proinflammatory T_H1 and T_H2 cytokines. [58] Other immunomodulatory effects, including stabilization of mast cells and inhibition of TNF-a and other late-phase cytokines, have also been observed with the use of pimecrolimus. [59]

Pimecrolimus is formulated in vehicle cream at concentrations of 0.2%, 0.6%, and 1%. Early studies showed that pimecrolimus is safe and effective in children with atopic dermatitis. Pimecrolimus also appears to have similar effectiveness to that of tacrolimus in treating psoriasis. [60] It has been reported that pimecrolimus does not induce skin atrophy and the systemic absorption rate appears to be clinically insignificant. [61]

Although, preliminary studies have not shown that pimecrolimus is superior to topical tacrolimus, this ascomycin derivative probably has a role in the topical therapeutic armamentarium of T cell–mediated skin disorders (see Chap.

250). [62]

OTHER IMMUNOSUPPRESSIVE DRUGS

Mycophenolate Mofetil

Mycophenolate mofetil (MMF) is an ethyl ester of mycophenolic acid that is metabolized to the active drug mycophenolic acid (MPA). MPA is a product of several *Penicillium* species. The active metabolite, MPA, had been used in the past for the treatment of severe recalcitrant psoriasis. [63] MMF is the reformulated product of MPA, but with enhanced bioavailability. MPA inhibits the type II isoform of inosine monophosphate dehydrogenase (IMPDH) in the de novo pathway of purine synthesis. Lymphocytes are quite susceptible to this drug effect, because they minimally use the hypoxanthine–guanine phosphoribosyl transferase salvage pathway for purine synthesis. MMF inhibits lymphocyte proliferation, antibody formation, leukocyte recruitment, and glycosylation of lymphocyte glycoproteins involved in adhesion to endothelial cells. The drug is rapidly absorbed after oral administration and antacids and cholestyramine may decrease its absorption. Approximately 5 percent of the drug is bound to albumin. It is nearly completely metabolized by glucuronyl transferase and more than 90 percent of the drug is eliminated by the kidneys. The MMF glucuronide metabolite, which is increased in renal failure, increases MMF clearance by competing for its binding sites on albumin. MMF pharmacokinetics seem not to be affected by the concomitant administration of CsA.

The usual dose is 30 mg/kg per day (1 g every 12 h). Expected toxicities include nausea, upset stomach, vomiting, and diarrhea. There is no increase in nephrotoxicity, hepatotoxicity, hypertension, or neurotoxicity when MMF is used in conjunction with CsA and corticosteroids. The hematologic and gastrointestinal side effects are dose dependent and usually clinically insignificant. An increased incidence of lymphoproliferative diseases and lymphoma is reported with its use, as is some predisposition for infectious complications. Therapeutic drug monitoring measured by IMPDH activity, or by measurement of serum levels of mycophenolic acid, shows inconsistent predictive value to monitor effectiveness and toxicity in MMF-treated patients.

MMF is commonly used in synergistic and safe combination with CsA and glucocorticoids to prevent renal graft rejection. The therapeutic and toxic profiles of MMF make this drug a very attractive substitute for azathioprine in several circumstances. For example, it could be useful in those patients who cannot tolerate azathioprine because of nausea or hepatotoxic reactions, or in those patients who are at risk for azathioprine-induced toxicities as a result of deficiency of the enzyme thiopurine methyl transferase.

MMF is effective and safe in several autoimmune and inflammatory skin disorders including pemphigus, pemphigoid, lupus erythematosus, dermatomyositis, pyoderma gangrenosum, lichen planus, graft-versus-host disease, chronic actinic dermatitis, and cutaneous vasculitis. [64], [65], [66], [67], [68], [69] and [70]

In autoantibody-mediated skin disorders, such as pemphigus vulgaris and foliaceus (antidesmogleins antibodies) and hypocomplementemic urticarial vasculitis syndrome (anti-C1q antibodies), higher doses of MMF (35 to 50 mg/kg per day) are often required to achieve a full corticosteroid-sparing agent effect. [71] and [72] On the other hand, in inflammatory and autoimmune disorders where T cells play a predominant pathogenic role, the standard dose of 30 mg/kg per day is usually effective as adjuvant therapy. The effectiveness, safety, and versatility of MMF in the treatment of a wide range of autoimmune and inflammatory skin disorders, have made this drug an important addition in the therapeutic armamentarium of dermatology within the last 5 years.

LEFLUNOMIDE

Leflunomide (LEF) is an isoxazole derivative that inhibits the proliferation of T and B cell lines, as well as polymorphonuclear cells. The immunosuppressive effects of LEF are mediated by the inhibition of pyrimidine biosynthesis, blocking production of uridine monophosphate by the de novo pathway. The anti-inflammatory effects of LEF are very complex, and tyrosine kinase and STAT 6 inhibition appear to be the most important mechanisms of action. Its efficacy in the prevention of heart, kidney, intestine, lung, and skin allograft rejection has been studied in animal models. Because LEF is activated by the liver, renal failure has fewer effects on its kinetics. Its elimination half-life is approximately 11 days, and the kidneys mainly excrete its metabolite. Toxicities may include the liver, gastrointestinal tract, and morbilliform skin eruptions. Long half-life and the potential teratogenic effect of this drug and its metabolites prompt a comprehensive plan of “washing out” for women as well as for men planning conception. This plan includes, reporting to the pharmaceutical company, cholestyramine oral administration, and measuring serum drug levels. A loading dose of LEF is commonly used for rheumatoid arthritis patients. However, this form of administration does not seem to be necessary for patients with skin diseases. The safety profile, along with its combined immunosuppressive (anti-B and -T cell) and anti-inflammatory effects (anticytokine), makes this drug an important glucocorticoid-sparing agent in the treatment of bullous pemphigoid. [73] The authors have successfully expanded the use of LEF to the management of lichen planus and urticarial vasculitis. LEF is a promising immunomodulator in the treatment of autoimmune and inflammatory skin disorders, especially in elderly patients.

REFERENCES

1. Kahan BD et al: Prospects for synergistic immunosuppressive drug therapy in the coming decade. *Transplant Proc* **2**:1263, 1992

2. Kahan BD: The matrix of clinical immunosuppression for transplantation. *Transplant Proc* **33**:3035, 2001

3. Kahan BD, Kramer WG: Median effect analysis of efficacy versus adverse effects of immunosuppressants. *Clin Pharmacol Ther* **70**:74, 2001

4. Bornhovd E et al: Macrolactam immunomodulators for topical treatment of inflammatory skin diseases. *J Am Acad Dermatol* **45**:736, 2001

5. Wiederrecht GJ et al: The mechanism of action of FK-506 and cyclosporine A. *Ann N Y Acad Sci* **696**:9, 1993

6. Cooper KD et al: Effects of cyclosporine on immunologic mechanism in psoriasis. *J Am Acad Dermatol* **23**:118, 1990

7. Kovarik JM et al: Evidence of earlier stabilization of cyclosporine pharmacokinetics in de novo renal transplant patients receiving a microemulsion formulation. *Transplantation* **62**:759, 1996

8. Watkins PB: The roles of cytochromes P-450 in cyclosporine metabolism. *J Am Acad Dermatol* **23**(6 Suppl: II):1301, 1990

9. Min DI et al: Effect of grapefruit juice on cyclosporine pharmacokinetics in renal transplant patients. *Transplantation* **62**:123, 1996

10. Hoppu K et al: Comparison of conventional oral cyclosporine microemulsion formulation in children with a liver transplant. *Transplantation* **62**:66, 1996

11. Mockli G et al: Laboratory monitoring of cyclosporine levels: Guidelines for the dermatologist. *J Am Acad Dermatol* **23**:275, 1990

12. Gilbert SC et al: Cyclosporine therapy for psoriasis: Serum creatinine measurements are an unreliable predictor of decreased renal function. *J Am Acad Dermatol* **21**:470, 1989

13. Messana JM et al: Effects of cyclosporine on renal function in psoriasis patients. *J Am Acad Dermatol* **23**(6 Suppl II):1289, 1990

14. Watschinger B, Sayegh MH: Endothelin in organ transplantation. *Am J Kidney Dis* **27**:151, 1996

15. Fry L et al: Long-term cyclosporine in the management of psoriasis. *Transplant Proc* **20**:23, 1988

16. Chrysostomon A et al: Diltiazem in renal allograft recipients receiving cyclosporine. *Transplantation* **55**:300, 1993

17. Katznelson S et al: Cyclosporine-induced hemolytic uremic syndrome: Factors that obscure its diagnosis. *Transplant Proc* **28**:2608, 1994

18. Klintmalin GB et al: Cyclosporine A hepatotoxicity in 66 allograft recipients. *Transplantation* **32**:488, 1981

19. Edwards LL et al: Neurophysiologic evaluation of cyclosporine toxicity associated with bone marrow transplantation. *Acta Neurol Scand* **92**:423, 1995

20. Nalesnik M et al: Experience with posttransplant lymphoproliferative disorders in solid organ transplant patients. *Clin Transplant* **69**:249, 1992

21. van Der Borne BE et al: No increased risk of malignancies and mortality in cyclosporine A-treated patients with rheumatoid arthritis. *Arthritis Rheum* **41**:1930, 1998

22. Bencini PL et al: Cutaneous lesions in 67 cyclosporine-treated renal transplant recipients. *Dermatologica* **172**:24, 1986

23. Epstein S et al: Organ transplantation and osteoporosis. *Curr Opin Rheumatol* **7**:255, 1995

24. Lin HY et al: Cyclosporine-induced hyperuricemia and gout. *N Engl J Med* **321**:287, 1989

25. Olshan AF et al: International Commission for Protection Against Environmental Mutagens and Carcinogens: Cyclosporine A: Review of genotoxicity and potential for adverse human reproductive and developmental effects. Report of a working group on the genotoxicity of cyclosporine A. *Mutat Res* **317**:163, 1994

26. Ruzicka T: Cyclosporin in less common immune-mediated skin diseases. *Br J Dermatol* **135**:40, 1996

27. Va Joost TH et al: Low-dose cyclosporin A in severe psoriasis. A double blind study. Br J Dermatol 118:183, 1988

28. Dubertret L et al: Cyclosporin in psoriasis: A long-term randomized study on 37 patients. *Acta Derm Venereol Suppl (Stockh)* **146**:136, 1989

29. Ellis CN et al: Cyclosporin for plaque-type psoriasis: Results of multidose double-blind trial. *N Engl J Med* **324**:277, 1991

30. Lebwohl M et al: Cyclosporine consensus conference with emphasis on the treatment of psoriasis. *J Am Acad Dermatol* **39**:464, 1998

31. Solganik J et al: Adverse effects of systemic cyclosporine: Psoriasis. *Forum (Genova)* **4**:5, 1998

32. Zaki I et al: Treatment of severe atopic dermatitis in childhood with cyclosporin. *Br J Dermato1* **35**:21, 1996

33. Zonneveld IM et al: The long-term safety and efficacy of cyclosporin in severe refractory atopic dermatitis: A comparison of two dosage regimens. *Br J Dermatol* **135**:15, 1996

34. Eisen D et al: Cyclosporine swish and spit improves oral lichen planus: A double-blind analysis. *N Engl J Med* **323**:290, 1990

35. Elgart G et al: Treatment of pyoderma gangrenosum with cyclosporin: Results in seven patients. *J Am Acad Dermatol* **24**:83, 1991

36. Vogersang GB et al: Acute graft-versus-host disease: Clinical characteristics in the cyclosporine era. *Medicine* **67**:163, 1988

37. Nousari HC, Anhalt GJ: Pemphigus and pemphigoid. *Lancet* **354**:667, 1999

38. BenEzra D et al: Revaluation of conventional therapy versus cyclosporin A in Behçet's syndrome. *Transplant Proc* **20**:136, 1988

39. Thomson AW et al: Mode of action of tacrolimus (FK506): Molecular and cellular mechanism. *Ther Drug Monit* **17**:584, 1995

40. Lauerma AI, Maibach HI: Topical FK506: Clinical potential or laboratory curiosity? *Dermatology* **188**:173, 1993

41. Eidelman BH et al: Neurologic complications of FK506. *Transplant Proc* **23**:3175, 1991

42. Newell KA et al: Posttransplant lymphoproliferative disease in pediatric liver transplantation. *Transplantation* **62**:370, 1996

43. The European FK 506 Multicentre Psoriasis Study Group. Systemic tacrolimus (FK 506) is effective for the treatment of psoriasis in a

double-blind, placebo-controlled study. *Arch Dermatol* **132**;419, 1996

44. Hiraoka A et al: The Japanese FK506 BMT (Bone Marrow Transplantation) Study Group phase III study comparing tacrolimus (FK506) with cyclosporine. *Bone Marrow Transplant* **28**:181, 2001

45. Lyon CC et al: Recalcitrant pyoderma gangrenosum treated with systemic tacrolimus. *Br J Dermatol* **140**:562, 1999

46. Bergman J, Rico MJ: Tacrolimus clinical studies for atopic dermatitis and other conditions. *Semin Cutan Med Surg* **20**:250, 2001

47. Wakugawa M et al: Interferon-gamma–induced RANTES production by human keratinocytes is enhanced by IL-1beta, TNF-alpha, IL-4 and IL-13 and is inhibited by dexamethasone and tacrolimus. *Dermatology* **202**:239, 2001

48. Panhans-Gross A et al: Human epidermal Langerhans cells are targets for the immunosuppressive macrolide tacrolimus (FK506). *J Allergy Clin Immunol* **107**:345, 2001

49. Pon M et al: Rapamycin inhibits vascular smooth muscle cell migration. *J Clin Invest* **98**:2277, 1996

50. Yatscoff RW et al: Rapamycin: Distribution, pharmacokinetics, and therapeutic range investigations. *Ther Drug Monit* **17**:666, 1995

51. Borkowski TA et al: A role for endogenous transforming growth factor beta 1 in Langerhans cell biology: The skin of transforming growth factor beta 1 null mice is devoid of epidermal Langerhans cells. *J Exp Med* **184**:2417,1996

52. Chen BJ et al: Graft-versus-host disease prevention by rapamycin: Cellular mechanisms. *Blood Marrow Transplant* **6**:529, 2000

53. Trautmann A et al: Targeting keratinocyte apoptosis in the treatment of atopic dermatitis and allergic contact dermatitis. *J Allergy Clin Immunol* **108**:839, 2001

54. Kaplan MJ et al: Systemic toxicity following administration of sirolimus (formerly rapamycin) for psoriasis: Association of capillary leak syndrome with apoptosis of lesional lymphocytes. *Arch Dermatol* **135**:553, 1999

55. Zhang Q et al: Activation of Jak/STAT proteins involved in signal transduction pathway mediated by receptor for interleukin 2 in malignant T lymphocytes derived from cutaneous anaplastic large T-cell lymphoma and Sézary syndrome. *Proc Natl Acad Sci USA* **93**:9148,1996

56. Rappersberger K et al: Clearing of psoriasis by a novel immunosuppressive macrolide. *J Invest Dermatol* **106**:701, 1996

57. Grassberger M et al: A novel anti-inflammatory drug, SDZ ASM 981, for the treatment of skin diseases: In vitro pharmacology. *Br J Dermatol* **141**:264, 1999

58. Mollison KW et al: A macrolactam inhibitor of T helper type 1 and T helper type 2 cytokine biosynthesis for topical treatment of inflammatory skin diseases. *J Invest Dermatol* **112**:729, 1999

59. Zuberbier T et al: The ascomycin macrolactam pimecrolimus (Elidel, SDZ ASM 981) is a potent inhibitor of mediator release from human dermal mast cells and peripheral blood basophils. *J Allergy Clin Immunol* **108**:275, 2001

60. Mrowietz U et al: The novel ascomycin derivative SDZ ASM 981 is effective for psoriasis when used topically under occlusion. *Br J Dermatol* **139**:992, 1998

61. Queille-Roussel C et al: The new topical ascomycin derivative SDZ ASM 981 does not induce skin atrophy when applied to normal skin for 4 weeks: A randomized, double-blind controlled study. *Br J Dermatol* **144**:507, 2001

62. Ling MR: Topical tacrolimus and pimecrolimus: Future directions. *Semin Cutan Med Surg* **20**:268, 2001

63. Gomez EC et al: Efficacy of mycophenolic acid for the treatment of psoriasis. *J Am Acad Dermatol* **1**:531, 1979

64. Nowack R et al: Mycophenolate mofetil for systemic vasculitis and IgA nephropathy. *Lancet* **349**:774, 1997

65. Nousari HC et al: The effectiveness of mycophenolate mofetil in refractory pyoderma gangrenosum. *Arch Dermatol* **134**:1509, 1998

66. Nousari HC et al: Successful treatment of resistant hypertrophic and bullous lichen planus with mycophenolate mofetil. *Arch Dermatol* **135**:1420, 1999

67. Gelber AC et al: Mycophenolate mofetil in the treatment of severe skin manifestations of dermatomyositis: A series of 4 cases. *J Rheumatol* **27**:1542, 2000

68. Nousari HC et al: Mycophenolate in psoralen-UV-A desensitization therapy for chronic actinic dermatitis. *Arch Dermatol* **135**:1128, 1999

69. Goyal S, Nousari HC: Treatment of resistant discoid lupus erythematosus of the palms and soles with mycophenolate mofetil. *J Am Acad Dermatol* **45**:142, 2001

70. Nousari HC et al: Successful therapy for bullous pemphigoid with mycophenolate mofetil. *J Am Acad Dermatol* **39**:497, 1998

71. Nousari HC, Anhalt GJ: The role of mycophenolate mofetil in the management of pemphigus. *Arch Dermatol* **135**:853, 1999

72. Nousari HC et al: Mycophenolate mofetil in autoimmune and inflammatory skin disorders. *J Am Acad Dermatol* **40**:265, 1999

73. Nousari HC, Anhalt GJ: Bullous pemphigoid treated with leflunomide: A novel immunomodulatory agent. *Arch Dermatol* **136**:1204, 2000

T>

Chapter 263

James Krueger Alice Gottlieb

Immunobiologicals in Dermatology

PHARMACOLOGY AND MECHANISM OF ACTION
CLINICAL USES
DOSAGE, SCHEDULE, AND FORMULATIONS
ADVERSE EFFECTS
DRUG INTERACTIONS
EVIDENCE-BASED MEDICINE CONSIDERATIONS
FDA-Approved Biologics for Dermatologic Indications
Investigational Drugs

REFERENCES

Immunobiologicals are a diverse set of molecules that can be used to modify normal or pathologic cellular immune reactions. In general, immunobiologicals are rationally designed agonists or antagonists of previously defined pathways that regulate lymphocyte activation, cytokine production, or cytokine actions. Inflammatory skin diseases such as psoriasis or atopic dermatitis and neoplastic infiltrates in cutaneous T cell lymphoma (CTCL) are candidates for treatment with this group of engineered therapeutics. In addition, immunotherapeutics can be used to enhance immune responses to vaccines, virally infected cells, or tumor antigens. At present, most of the agents discussed in this chapter are investigational, but it is expected that some of the agents discussed will become future dermatologic therapeutics. Most immunobiologicals are protein-based molecules and can be categorized as antibodies, antibody-like fusion proteins, cytokines, or immunotoxins (see Table 263-1). These molecules react mainly with cell surface molecules expressed selectively on leukocytes or with molecules secreted by inflammatory cells. Nucleic acid-based molecules, for example, antisense oligonucleotides, can also be considered as immunobiologicals, but they target primarily intracellular biochemical pathways. Small (chemical-based) molecules are not considered in this chapter, although many agents affect biologic responses of immune cells in a specific fashion. The agents listed in Table 263-1 are limited to immunobiologicals that are approved drugs for dermatologic indications and to investigational agents for dermatologic indications. Numerous other immunobiologicals are being studied in organ transplants and in inflammatory diseases of other organs. Hence, it can be anticipated that many other agents will eventually be tested for dermatologic indications.

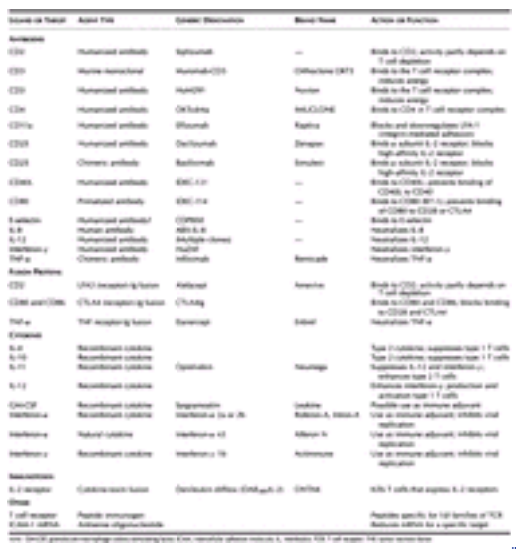

TABLE 263-1 **Immunobiologicals with Potential Use in Dermatology**

PHARMACOLOGY AND MECHANISM OF ACTION

Figure 263-1 shows the general structure of different types of immunobiologicals. Antibodies are currently the most common type of agent in clinical trials. Antibodies can be murine monoclonals, chimeric monoclonals, humanized monoclonals, primatized monoclonals, or human sequence monoclonals. Murine monoclonals are very immunogenic in humans and thus can be used only for short-term treatment. In contrast, humanized and human antibodies are much less immunogenic and better suited for chronic use in humans. [1] However, variation in constant region amino acid sequences between different individuals (allovariation) or glycosylation differences produced by cultured cell lines (all therapeutic antibodies are produced in tissue-culture cell lines) cause all therapeutic antibodies, even fully human sequence antibodies, to be potentially immunogenic in humans. Antibody-like fusion proteins are composed of the ligand-binding domains of human cellular receptors linked to hinge and CH2/CH3 constant region domains of human IgG. The resulting protein is thus composed of a ligand-binding region (like the variable region of an antibody) and a set of immunoglobulin sequences that confer solubility in the plasma and stability similar to antibodies. While protein sequences are fully human, these molecules also have immunogenic potential due to non-natural domain junctions, allovariation, and glycosylation in cell lines. Cytokines are relatively small proteins synthesized based upon human gene sequences. The immunotoxin DAB $_{389}$IL-2 is a fusion protein composed of human interleukin (IL)-2 sequences linked to domains of bacteria-derived diphtheria toxin sequences. This combination protein is highly immunogenic as a consequence of its associated bacterial sequences. Peptides that are homologous to short sequence segments (20 to 40 amino acids) of specific T cell receptor families, for example, Vß 3 or Vß 13, have been constructed as immune “regulatory” immunogens. Antisense oligonucleotides are constructed so that sequences are complementary to coding nucleotides in mRNA for

specific genes.

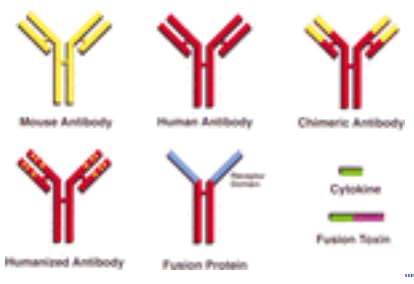

FIGURE 263-1 Structure diagrams of protein-based immunotherapeutics: antibodies, fusion proteins, cytokines, and fusion toxins. For antibodies, mouse sequences are shown in yellow, whereas human sequences are shown in red. The fusion protein contains human immunoglobulin sequences (red) fused to a human sequence receptor domain (blue). The fusion toxin shown combines a human sequence cytokine (green) with a bacterial sequence toxin domain (cyan).

The use of immunobiologicals is predicated on a prior understanding of the role of specific immune receptors, adhesion proteins, and cytokines or chemokines in regulating the immune response or in producing “inflammatory” tissue reactions. A comprehensive discussion of these molecular control points is beyond the scope of this chapter, but Fig. 263-2 presents a simplified view. In addition, a recent review provides a more detailed introduction to cutaneous immunology with a focus on therapeutic ligands or cellular targets that are listed in Table 263-1.[2] Immunobiologicals affect one or more of the six stages of a cutaneous immune response that are diagrammed in Fig. 263-2. These stages are (1) antigen uptake and maturation (activation) of Langerhans cells or other professional antigen-presenting dendritic cells (DCs); (2) activation of T cells through the T cell receptor (TCR) complex; (3) activation of T cells though accessory signals (costimulation); (4) mitotic and differentiation signals delivered by regulatory cytokines; (5) migration of differentiated T cells to skin tissue; and (6) effector actions of T cells in skin tissue, including release of inflammatory cytokines.

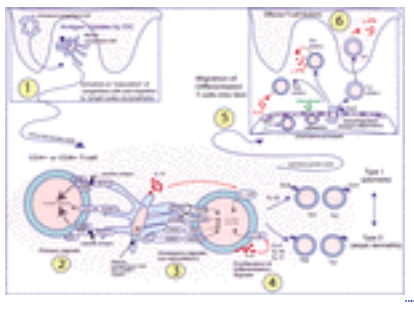

FIGURE 263-2 Cellular processes in the generation of a cutaneous T cell dependent immune response are diagrammed in 6 steps. These steps are (1) antigen capture and processing by Langerhans cells followed by migration of antigen-containing Langerhans cells to a skin-draining lymph node; (2) formation of immune synapes between a T cell and an activated Langerhans cell that initiates T cell activation; (3) enhancement of T cell activation by interactions of coreceptors on T cells and Langerhans cells; (4) proliferative activation of T cells by cytokine mitogens and differentiation of T cells into Type 1 versus Type 2 cells; (5) migration/homing of effector T cells to sites of cutaneous inflammation and transmigration of cells into the dermis; (6) effector immune responses, including release of cytokines, within the cutaneous environment. In general, T cell accumulations in the dermis are CD4-predominant, whereas those in the epidermis are CD8-predominant. The nature of the effector immune response is controlled by the type of antigen encountered and differentiation signals produced within the lymph node.

A cutaneous immune response is initiated by Langerhans cells or other DCs after antigen uptake and processing so that immunogenic peptides reside in major histocompatibility complex (MHC) molecules. Antigen-bearing Langerhans cells migrate to skin-draining lymph nodes upon activation, where naïve T cells are activated and become differentiated memory T cells that have a skin-homing receptor [the cutaneous lymphocyte antigen (CLA) antigen]. The activation of T cells requires physical contact between many different cell surface receptors on DCs and counterreceptors on the T cells, as diagrammed in Fig. 263-2. T cells differentiate into type 1 effectors (which synthesize interferon-?) or type 2 effectors (which make IL-4) in lymph nodes. Differentiated, CLA+ T cells then exit lymph nodes and return to the skin via the blood stream. In postcapillary venules, CLA+ T cells bind to E-selectin or P-selectin, expressing endothelial cells, slowing transit through the vessel. Activation of these “rolling” T cells by various chemokines then stimulates T cells to arrest and attach firmly to endothelial cells via integrins that are expressed on T cells, for example, integrins leukocyte factor antigen (LFA)-1 or very-late antigen (VLA)-1. After firm binding, T cells can migrate through endothelial cells and become extravascular in the dermis. Some T cells, for example, type 1 CD8+ T cells (Tc1 cells), show preferential migration into the epidermis, whereas other T cells remain mostly in the dermis. The relative accumulation of type 1 versus type 2 cells in skin lesions is determined by the nature of the activating antigen, the disease process, and the mixture of chemokines in skin (chemokines stimulate movement of T cell subtypes according to concentration gradients). Once effector T cells have entered the dermis or epidermis, they can recognize activating antigens and release various other “inflammatory” cytokines such as interferon-?, tumor necrosis factor (TNF)-a, or IL-4. In turn, these cytokines induce synthesis of numerous other cytokines and chemokines from skin-resident cells. For example, numerous chemokines induced by interferon-? or TNF-a are upregulated in psoriasis vulgaris skin lesions [this includes IL-8; MIG; gamma-inducible protein 10(IP-10); macrophage inflammatory protein (MIP)-3a; Gro-a; regulated on activation, normal T cell expressed and secreted (RANTES); and MIP-1a]. “Inflammation” results from the effects of these cytokines and chemokines on vascular structure/adhesion, leukocyte trafficking, and biologic activation of skin-resident cells.

Figure 263-3 diagrams the interaction of different immunobiologic agents with molecular or cellular targets in the immune activation sequence described in Fig. 263-2. In this scheme, molecules that inhibit ligand/receptor interactions or

receptor/coreceptor interactions are drawn in orange color. In contrast, agents that activate receptors on DCs and/or T cells are drawn in blue-colored boxes. From this scheme, it can be seen that all stages of an immune response can be affected—either in a stimulatory or inhibitory fashion—by engineered biologic therapeutics. Agents shown can stimulate recruitment of dendritic cells into skin or boost synthesis of antigen-processing and presenting molecules on DCs [granulocyte-macrophage colony-stimulating factor (GM-CSF), interferon-a] or stimulate the differentiation of type 1 (IL-12) or type 2 (IL-4, IL-10, IL-11) T cells. The use of therapeutic cytokines to influence T cell differentiation in a fashion opposite to that of the underlying disease is a strategy termed *immune deviation*. As inhibitors, engineered biologics can prevent T cell activation by modifying activation signals delivered through the TCR; by blocking adhesive or costimulatory interactions between DCs and T cells; by blocking mitogenic or differentiation signals delivered by cell surface receptors; by reducing T cell migration into skin lesions though adhesion-disrupting effects; and by neutralizing cytokines and chemokines that regulate inflammatory effects in tissues. [2], [3] and [4] Immune antagonists that bind to cellular targets can produce reversible blockade of cellular adhesion/activation (such that inhibited function depends on continued presence of the antagonist), T cell anergy (defined as reduced responsiveness of viable T cells to an antigen), or T cell depletion (by apoptotic or cytotoxic mechanisms). [4] To the extent that many antibody responses require T cell “help,” some of the therapeutics listed in Table 263-1, for example, CTLA4-Ig and anti-CD11a, may be able to diminish pathogenic immune responses in antibody-mediated autoimmune diseases. A humanized antibody to CD40L, a molecule expressed on activated CD4+ T and B cells, may have direct inhibitory effects on immunoglobulin production in autoimmune diseases, and it has recently entered clinical studies in systemic lupus erythematosus. [5]

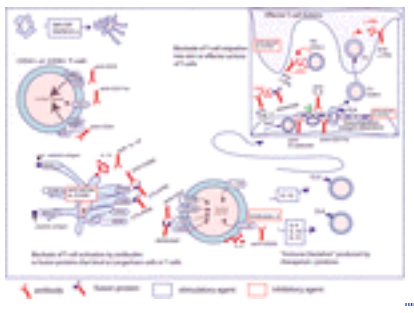

FIGURE 263-3 A diagram of stimulatory and inhibitory biologic agents in the cutaneous immune response according to the activation sequence shown in Fig. 263-2. In this figure, stimulatory agents are shown in blue boxes. Antibodies and fusion proteins can antagonize steps 2–6 of the immune response and their site of action is diagrammed on the figure. A further explanation of the agents shown in this figure can be found in Table 263-1.

Immunobiologicals are mainly proteins that are functionally stable only in neutral pH aqueous buffers. These agents are designed for parenteral administration by SQ., IM, or IV routes. Most agents are large protein molecules that circulate in plasma and have a relatively limited volume of distribution. These agents have variable half-lives that are influenced by the intrinsic nature of the protein, concentrations attained in vivo, and variable human antibody responses to that agent. The half-life of therapeutic antibodies in the circulation is similar to that of naturally occurring human antibodies (however, low concentrations of proteins may be cleared immediately by receptor-mediated uptake). Some agents, for example, the immunotoxin DAB $_{389}$IL-2, have very short circulating half-lives (approximately 1 h), because of receptor-mediated clearance and/or antibody responses to “foreign” or highly immunogenic regions of the fusion protein.

CLINICAL USES

Theoretically, immunobiologicals can be applied to any dermatologic condition where stimulation or inhibition of a cellular immune response might prove beneficial. Commonly considered indications are T cell–mediated inflammatory diseases (psoriasis, atopic dermatitis, alopecia areata), graft-versus-host disease, cutaneous T cell lymphomas, melanoma and other neoplasms (for immunotherapy), viral diseases (for inhibiting viral replication or stimulating immune responses), and some antibody-mediated autoimmune diseases (where T cell help is required for antibody production). To the extent that systemic immunosuppressive agents are used as therapeutics, the extent, chronicity, and severity of skin disease must be factored into the risk-to-benefit equation. The safety of long-term immune suppression with most of the agents listed in Table 263-1 still must be determined. Even so, these agents offer potential benefits over use of current immunosuppressives that have known toxicity for noncutaneous organs. Potential complications of long-term immune suppression (whether with conventional agents or novel immunobiologicals) include increased risk of infections (bacterial, viral, fungal, and mycobacterial), lymphomas, and other neoplasms.

At present, most of the immune antagonists listed in Table 263-1 should be considered as generally contraindicated in pregnancy and pediatric cases. Antibodies and antibody-like fusion proteins would be transferred transplacentally and might have unintended effects on the developing fetal immune system. Likewise, the cellular immune system is “educated” intensively in young children, and immunity to most infectious diseases is acquired during this period. Hence, suppressive immunobiologicals should be considered only after normal immunity is established (from vaccination or spontaneous disease) in childhood. In contrast, therapeutic cytokines, which mainly act as immune-enhancing agonists, might have some use in younger individuals. One agent, interferon-?, is used to enhance antimicrobial immunity in chronic granulomatous disease and much of its use is in pediatric patients.

DOSAGE, SCHEDULE, AND FORMULATIONS

Of the agents listed in Table 263-1, only denileukin diftitox (DAB $_{389}$ IL-2) and the interferons are presently approved for dermatologic indications. Denileukin diftitox, approved for the treatment of CTCL, is administered as an IV infusion on 5 sequential days at a dose of 9 or 18 µg/kg per day, with repeat administration every 21 days (number of administration cycles depends on the clinical response). Interferon-a preparations are variously approved for treatment of condyloma acuminata, Kaposi sarcoma, and melanoma. Treatments range from local injection of 250,000 to 1 million IU into skin lesions of condyloma to IV administration of up to 20 million IU 5 times a week in inductive treatment of melanoma.

Interferon-? is approved as a treatment for chronic granulomatous disease at a dose of 50 µg/m ^{2} administered SC on a three-times-per-week schedule (a dose of 1.5 µg/kg is recommended for patients with a body surface area <0.5 m ^{2}). No formal dose, schedule, or formulation information is available for experimental therapeutics listed in Table 263-1, as related to dermatologic conditions. Muromab-CD3, daclizumab, basiliximab, infliximab, etanercept, IL-11, and GM-CSF are FDA-approved drugs for nondermatologic indications and have recommended doses and schedules for those conditions. However, eventual use in dermatologic conditions may involve significantly different doses or schedules.

ADVERSE EFFECTS

Where available, prescribing guidelines should be consulted for a complete list of adverse effects seen with individual immunobiologicals. All protein-based drugs must be considered as potentially immunogenic and thus capable of producing classic immediate (IgE-mediated) or delayed (T cell–mediated) hypersensitivity reactions. In addition, several T cell–binding antibodies or fusion proteins have a “first-dose reaction,” that consists of flulike or constitutional symptoms, including fever, chills, nausea, and headache. With several antibodies, this effect is related to increased release of cytokines (TNF-a, interferon-?, and IL-6) within 4 to 6 h of administration, and is associated with immunoglobulin isotypes that bind Fc receptors. [1] The underlying mechanism of this effect is thought to be T cell–stimulated production of cytokine synthesis/release from natural killer (NK) cells (bridged with T cells by therapeutic antibodies via Fc receptors), but ligation of only some T cell surface proteins produces this effect. [1] Similar immune activation symptoms (fever, chills, nausea, headache, myalgias) are seen following interferon administration, but symptoms usually persist with repeat administrations. Immune activation or agonist side effects of this type are often dose dependent and may result in dose-limiting toxicity for different immunobiologic agents. Denileukin diftitox, which is ultimately an immune antagonist (through inducing apoptosis of T cells), initially activates T cells through the IL-2 receptor. This agent induces a range of acute “hypersensitivity-type” reactions, which are similar to first-dose effects of immune-activating antibodies and cytokines. In addition, a delayed “vascular leak” reaction (edema, hypoalbuminemia, hypotension) has occurred in a subset of lymphoma patients treated with denileukin diftitox. [6] These effects may be related to the mechanism-of-action of diphtheria toxin sequences (this toxin inhibits protein synthesis in cells that internalize the drug). Injection-site reactions and “rashes” are seen with many different immunobiologicals. Many of these reactions may be mechanistic, that is, related to agonist or immune activating effects of the agents, but true hypersensitivity (allergic) reactions are also possible. Anyone administering protein-based therapeutics should be prepared to treat anaphylactic reactions.

An unresolved concern with immune-modifying biologics is their potential for increasing the incidence of cancer and life-threatening infections if they are used chronically and/or used in combination regimens that produce intense immunosuppression. Several agents, including CD3-antibodies, CD2-antibodies, and alefacept, induce moderate to marked depletion of T cells from the peripheral circulation for variable time periods. The long-term safety of T cell–depleting and/or chronic immunosuppressive treatments need to be determined in unique subsets of dermatologic patients. For example, immunobiologicals may be used mainly as monotherapy in dermatologic diseases as compared to other indications, thus potentially increasing safety. However, compared to patients with internal diseases, more patients with skin disorders may have been treated previously with mutagenic therapies (UVB, PUVA, topical alkylating agents) and thus will be more at risk for cutaneous cancers with immune suppression.

DRUG INTERACTIONS

There are few formal studies of (chemical) drug interactions with immunobiologicals. It is known that interferons can suppress microsomal P450 levels and this could reduce metabolism of some drugs metabolized by P450 enzymes. There is potential for unexpected immune effects when two or more immunosuppressive agents are combined. As judged from experimental systems or other human indications, combinations of immunobiologicals with other immunosuppressives (whether chemical or biologic in nature) often produce increased immunosuppression, but it cannot be predicted whether immunosuppression will be additive or more than additive (synergistic). [3], [4] Sometimes, however, there is unanticipated interference of two agents (less immunosuppression is produced than with either agent alone). Hence, use of immunobiologicals in combination should be based on validated therapeutic protocols.

EVIDENCE-BASED MEDICINE CONSIDERATIONS

FDA-Approved Biologics for Dermatologic Indications

Immunobiologicals are highly successful treatments for some skin diseases. For example, the majority of condyloma and verrucae treated with various interferon-a preparations respond to treatment, whereas response to placebo treatment is quite low. [7] Likewise, interferon-? produces marked reductions in the rate of serious infections in patients with chronic granulomatous disease as compared to placebo treatment. [8] Hence, immunobiologicals can be highly effective drugs that show clinical activity in most patients. However, other diseases treated with immunobiologicals have more variable clinical benefits. This has led to the view that therapeutic activity of immunobiologicals is less predictable than traditional drugs. For instance, the use of interferon a2b in high-risk melanoma patients is based on results of a pivotal study in which 26 percent of placebo-treated versus 37 percent of interferon-treated patients were disease-free with a median follow-up time of 6.9 years. [9] The high doses of interferon used in this study produced dose-limiting toxicity in more than half of treated patients during the trial. Hence, while interferon-a2b is an FDA-approved drug for prophylactic treatment of high risk melanomas, a decision to use it in individual patients often weighs high toxicity versus uncertain benefit. FDA approval of denileukin diftitox for treatment of CTCL was based on a pivotal study in which 71 patients were treated with this agent after failing standard therapies—30 percent of patients had an objective response to treatment (20 percent partial response, 10 percent complete response). [6] While dose-limiting toxicity also occurred in many patients treated aggressively with denileukin diftitox, it remains a viable option for patients with CTCL resistant to other forms of treatment. Likewise, only a small subset of patients with Kaposi sarcoma have disease regression after interferon-a

treatment, [7] but this option is needed less often in an era of highly active antiretroviral therapies.

Investigational Drugs

Immunobiologicals hold promise for treatment of many chronic inflammatory skin diseases, but psoriasis vulgaris has become a particularly important test disease for new immune-regulating drugs. At present, more than half of the agents listed in Table 263-1 are being tested as investigational therapeutics in psoriasis. Psoriasis can be viewed as a T cell–mediated or autoimmune disease in which local infiltration of activated, type 1-biased T cells causes characteristic skin changes. Immunobiologicals geared to psoriasis are thus mainly immunosuppressive and/or target type 1 T cells. [2] The potential utility of immunobiologicals in psoriasis was initially suggested by case reports of clinical improvement brought about by murine monoclonal antibodies to CD3 and CD4. [10] A small study conducted with DAB $_{389}$IL-2 (denileukin diftitox) showed complete clinical and histologic disease reversal in a subset of psoriasis patients, [11] but this agent also commonly causes a poorly tolerated set of side effects. [12] CTLA4-Ig produced more consistent clinical improvements in patients with psoriasis vulgaris, [13] while also reversing pathologic activation of keratinocytes, T cells, dendritic cells, and endothelial cells. [14] However, quite large amounts of protein (25 or 50 mg/kg) were required for consistent clinical activity. Nonetheless, results obtained with DAB $_{389}$IL-2 and CTLA4-Ig were extremely important in showing the underlying immune basis of psoriasis and, to a large extent, these results spurred current investigational studies. Subsequently, improvements in psoriasis have been reported from administration of engineered antibodies to CD2, CD3, CD4, CD25, and CD80, or from therapeutic administration of the “deviating” cytokines IL-4, IL-10, and IL-11 (reviewed in Ref. [2]). Two new agents, a humanized antibody to CD11a [15] and the fusion protein alefacept, [16] have successfully completed placebo-controlled phase II or phase III studies. The latter agent, alefacept, is now approved for treatment of patients with cutaneous psoriasis. Recently, the TNF-a antagonists infliximab, [17] a chimeric antibody, and etanercept, [18] a receptor-domain fusion protein, have shown impressive results in treating cutaneous psoriasis vulgaris or psoriatic arthritis. As many other agents are currently in early phase trials for psoriasis vulgaris, this disease may become the first dermatologic disease for which a wide range of immunotherapeutics is available. In theory, many antipsoriatic biologics could be used in other diseases mediated by activated T lymphocytes, such as graft-versus-host disease, atopic dermatitis, and alopecia areata.

CTCL is viewed not only as a problem in unregulated growth of lymphocytes, but also as a depressed immune state caused by excess production of suppressive (type 2 cytokines). Hence immune-activating (regulatory) cytokines may become important therapeutic tools to treat CTCL and other forms of cancer where immune suppression is a component. IL-12, which activates type 1 T cells (and additionally stimulates cytotoxic T lymphocytes), has shown remarkable activity in some patients with CTCL. [19] Potentially, this immune-enhancing cytokine will find use in treatment of other cancers or “type 2”-deviated diseases such as atopic dermatitis. In addition, the cytokines IL-2, interferon-a, and interferon-? (all of which have immune enhancing effects) have shown activity in some cases of CTCL. [20], [21]

It is important to acknowledge that clinical experience with immunobiologicals is quite limited in comparison to experimental autoimmune diseases and tissue transplant studies. Fortunately, there are major similarities in molecular regulation of immune responses in humans and other species, and, for the most part, clinical trials of immunotherapeutics have helped to solidify similar mechanisms and concepts. Even so, human autoimmune diseases (particularly as related to skin disease) have a number of unique aspects that are not modeled well in experimental systems. Hence, immunobiologicals used in clinical trials become important scientific tools that can help us understand cellular and molecular pathways that ultimately underlie many inflammatory and immunologic skin diseases in people. We have much to learn about pathologic/therapeutic immune regulation in humans, and we must strive to couple investigative medicine and scientific study wherever possible in the emerging era of molecular medicine.

REFERENCES

1. Isaacs JD: From bench to bedside: discovering rules for antibody design, and improving serotherapy with monoclonal antibodies. *Rheumatology (Oxford)* **40**:724, 2001

2. Krueger JG: The immunologic basis for the treatment of psoriasis with new biologic agents. *J Am Acad Dermatol* **46**:1, 2002

3. Salomon B et al: Complexities of CD28/B7: CTLA-4 costimulatory pathways in autoimmunity and transplantation. *Annu Rev Immunol* **19**:225, 2001

4. Yu X-Z et al: Advances in transplantation tolerance. *Lancet* **357**:1959, 2001

5. Davis JC Jr et al: Phase I clinical trial of a monoclonal antibody against CD40-ligand (IDEC-131) in patients with systemic lupus erythematosus. *J Rheumatol* **28**:95, 2001

6. Olsen E et al: Pivotal phase III trial of two dose levels of denileukin diftitox for the treatment of cutaneous T-cell lymphoma. *J Clin Oncol* **19**:376, 2001

7. Stadler R et al: Interferons in dermatology. *J Am Acad Dermatol* **20**:650, 1989

8. The International Chronic Granulomatous Disease Cooperative Study Group: A controlled study of interferon-gamma to prevent infection in chronic granulomatous disease. *N Engl J Med* **325**:1516, 1991

9. Kirkwood JM et al: Interferon alfa-2b adjuvant therapy of high-risk resected cutaneous melanoma: The Eastern Cooperative Oncology Group Trial EST 1684. *J Clin Oncol* **14**:7, 1996

10. Weinshenker BG et al: Remission of psoriatic lesions with muromonab-CD3 (orthoclone OKT3) treatment. *J Am Acad Dermatol* **20**:1132, 1989

11. Gottlieb SL et al: Response of psoriasis to a lymphocyte-selective toxin (DAB $_{389}$IL-2) suggests a primary immune, but not keratinocyte, pathogenic basis. *Nat Med* **1**:442, 1995

12. Bagel J et al: Administration of DAB $_{389}$IL-2 to patients with recalcitrant psoriasis: A double-blind, phase II multicenter trial. *J Am Acad Dermatol* **38**:938, 1998

13. Abrams JR et al: CTLA4Ig-mediated blockade of T-cell costimulation in patients with psoriasis vulgaris. *J Clin Invest* **103**:1243, 1999

14. Abrams JR et al: Blockade of T lymphocyte costimulation with cytotoxic T lymphocyte-associated antigen 4-immunoglobulin (CTLA4Ig) reverses the cellular pathology of psoriatic plaques, including the activation of keratinocytes, dendritic cells, and endothelial cells. *J Exp Med* **192**:681, 2000

15. Papp K et al: The effective treatment of moderate to severe psoriasis with a new anti-CD11a monoclonal antibody. *J Am Acad Dermatol* **45**:665, 2001

16. Ellis CN et al: Treatment of chronic plaque psoriasis by selective targeting of memory effector T lymphocytes. *N Engl J Med* **345**:248, 2001

17. Chaudhari U et al: Efficacy and safety of infliximab monotherapy for plaque-type psoriasis: A randomized trial. *Lancet* **357**:1842, 2001

18. Mease PJ et al: Etanercept in the treatment of psoriatic arthritis and psoriasis: A randomized trial. *Lancet* **356**:385, 2000

19. Rook AH et al: Interleukin-12 therapy of cutaneous T-cell lymphoma induces lesion regression and cytotoxic T-cell responses. *Blood* **94**:902, 1999

20. Vittorio CC et al: Therapeutic advances in biological response modifiers in the treatment of cutaneous T-cell lymphoma. *Biodrugs* **15**:431, 2001

21. Duvic M et al: Emerging new therapies for cutaneous T-cell lymphoma. *Dermatol Clin* **18**:147, 2000

T>

Chapter 264

Gerhard Tappeiner Klaus Wolff

Thalidomide

PHARMACOLOGY
EFFECTS OF THALIDOMIDE
Tumor Necrosis Factor
Angiogenesis
Adhesion Molecules
Cytokines
Human Immunodeficiency Virus
MONITORING THE USE OF THALIDOMIDE
CLINICAL USES
Erythema Nodosum Leprosum
Aphthosis and Behçet's Disease in Immunocompetent Patients
Lupus Erythematosus
Chronic Graft-versus-Host Disease
Complications of HIV Infection
Langerhans Cell Histiocytosis
Actinic Prurigo and Polymorphous Light Eruption
CONTRAINDICATIONS
DOSAGE OF THALIDOMIDE
ADVERSE EFFECTS OF THALIDOMIDE THERAPY
Teratogenesis
Peripheral Neuropathy
Other Side Effects

REFERENCES

Beginning in 1957, thalidomide was marketed as an over-the-counter drug under various brand names in Europe, Canada, Australia, and several African and Asian countries; only samples for “clinical trials” were dispensed in the United States. A Japanese pharmaceutical company synthesized and marketed thalidomide independently at the same time in Japan. The drug quickly found wide use as a barbiturate-free sedative with potent antiemetic properties, and it was believed safe even for pregnant women. Thus, it was widely used for hyperemesis and insomnia during pregnancy, as well as for a host of other conditions.

Peripheral neuropathy was noted in 1959 as the first serious side effect of thalidomide. Because the neuropathy was not initially ascribed to the use of thalidomide, prescribing physicians were not adequately informed. As a result, an unknown number of patients developed polyneuropathy that was sometimes severe. Beginning in 1961, an increasing number of newborns with severe limb malformations were noted in West Germany; soon, thalidomide was identified as the cause, and the drug was taken off the market—in Europe in 1961 and in Japan in 1962. Nevertheless, more than 10,000 children fell victim to thalidomide embryopathy. Following this tragedy, more appropriate procedures to evaluate the safety, efficacy, adverse effects, and risk:benefit ratio of drugs were instituted worldwide. The “thalidomide tragedy” was a driving force behind the evolution of the ethical principles governing clinical studies today (Good Clinical Practice; Declaration of Helsinki).

The anti-inflammatory effects of thalidomide soon became clear, but no one investigated this activity at first. In 1964, Sheskin noted a rapid anti-inflammatory and analgesic effect of thalidomide in patients with erythema nodosum leprosum (type II leprosy reaction). [1] This beneficial effect occurs in more than 90 percent of patients, which vastly improves the therapeutic options for patients with multibacillary leprosy [2] (see Chap. 202). Initially, and erroneously, interpreted as immunosuppressive, this action of thalidomide has been under investigation since the mid-1960s and is now considered its most relevant activity. Thalidomide has turned out to be an important drug for some inflammatory skin conditions, and the Food and Drug Administration (FDA) approved it as a therapeutic agent for erythema nodosum leprosum in 1998. Thalidomide has been found to be beneficial as an adjuvant drug in the treatment of tuberculosis and in one of the *Mycobacterium avium* complex infections. [3], [4] and [5]

PHARMACOLOGY

Thalidomide (a:- *N*-phthalimidoglutarimide; 2-(2,6-dioxo-piperidine-3-yl)-isoindole-1,3-dione) is a racemic mixture of its (-)(S) and (+)(R) isomers. It is poorly soluble in water and in lipids, which accounts for its very low acute toxicity. Its rapid racemization ($T_{1/2}$ about 2.25 h) hampers studies on pure isoforms of thalidomide. Most of the reliable data on the activities of the isoforms of thalidomide have come from the use of configuration-stable methylated analogues. These studies indicate that the (-)(S) form is the active compound and that its beneficial and untoward effects cannot be separated. The search for more effective and less toxic thalidomide derivatives continues. [6]

In a study of healthy male volunteers, [7] an absorption half-life of 1.7 ± 1.05 h, an elimination half-life of 8.7 ± 4.11 h, and a peak plasma concentration of 1.15 ± 0.2 mg/L at 4.39 ± 1.27 h were seen after a single oral dose of 200 mg thalidomide. The plasma concentration-versus-time curve fits a one-compartment model with first-order kinetics. Excretion is primarily nonrenal, as shown by the fact that after a single oral dose, only 0.6 percent of the total could be recovered in the patients' urine. Elimination of the drug is thought to take place primarily through hydrolysis. Correspondingly, accumulation does not occur in patients with severely compromised organ function, (e.g., in patients

with renal insufficiency).

Accumulation of thalidomide has been weak, except for the kidneys and the hepatobiliary tract, where the increased accumulation is thought to be related to excretion. Thalidomide does not seem to have pharmacologic activities in itself; rather, it requires metabolism in the liver, which yields more than 100 different compounds. Some species (e.g., rats) seem to be unable to metabolize thalidomide effectively, and this may account for the fact that no untoward effects of the drug were detected in the initial toxicologic investigations.

EFFECTS OF THALIDOMIDE

Investigations of the effects of thalidomide in mammals in vitro and in vivo have yielded copious amounts of data, some of which are not easy to interpret. The following activities are rather well established.

Tumor Necrosis Factor

Thalidomide decreases the production of tumor necrosis factor (TNF)-a in stimulated human monocyte cultures, but has no effect on total protein synthesis or the expression of various other cytokines. A reduction in the half-life of TNF-a messenger RNA causes this decrease in synthesis; this is a selective and dose-dependent effect, but does not lead to a complete arrest of TNF-a production. Patients with lepromatous leprosy and manifestations of erythema nodosum leprosum have high levels of circulating TNF-a and other cytokines. The administration of thalidomide to these patients leads to an often dramatic amelioration of their symptoms and to a concomitant decrease of TNF-a levels. [8] In patients with active tuberculosis with or without HIV-infection, thalidomide treatment likewise results in a decrease of TNF-a and interleukin 1 (IL-1) levels, and an increase in interferon (IFN)-? levels. The weight loss often associated with active tuberculosis is probably due at least in part to the high levels of TNF-a in these patients. This may explain why the administration of thalidomide results in a reversal of this weight loss. [9]

Angiogenesis

Thalidomide can inhibit angiogenesis, [10] probably via an antiproliferative effect on vascular endothelia. This antiangiogenic effect is increasingly exploited by the use of thalidomide as an antineoplastic agent, [11] and analogues with enhanced antiangiogenic properties are being developed.

Adhesion Molecules

Thalidomide downregulaties adhesion molecules, at least in animal models. [12] The extent and importance of this is not yet entirely clear. Thalidomide has been shown to downregulate ß $_2$-integrin (CD18) and, to a lesser degree, ß $_1$-integrin (CD29) and a $_4$-integrin on circulating leukocytes of humans; the effect on intercellular adhesion molecule 1 (ICAM-1; CD54) expression was increased on granulocytes, but abolished on monocytes. A highly teratogenic analogue of thalidomide administered to pregnant mice resulted in a profound and consistent suppression of ß $_3$-integrin (CD61) in the fetus. In this study, ß $_1$- and a $_4$-integrin subunits were decreased in the limb buds, but not elsewhere. [12] If this also holds for humans, it may explain the teratogenic action and the type of embryotoxic lesions caused by thalidomide.

Cytokines

Thalidomide has been shown to be a potent suppressor of IL-12 production by human monocytes. [13] This suppression was dose-dependent, additive to that of dexamethasone, and independent of endogenous inhibitors of IL-12 production; IL-12 stimulates IFN-? production and thus plays a critical role in the development of cellular immune responses mediated by T helper T $_H$1 cells. The suppression of IL-12 is not yet entirely understood, and it is not clear whether this contributes to the therapeutic activity of thalidomide; [13] however, it may help explain some of the unexpected phenomena seen when thalidomide is used to treat tuberculosis in HIV-infected patients or chronic graft-versus-host disease.

In cultures of human peripheral blood monocytes, thalidomide inhibited IFN-? production and enhanced IL-4 and IL-5 synthesis. [14] The effects on other lymphokines have varied, probably because of the different experimental settings in which they were obtained.

Thus, thalidomide has potent anti-inflammatory activities, presumably mainly through the inhibition of the pathway of TNF-a—this seems to be mediated by accelerating the decay of its mRNA—and of IL-12. Therefore, it should suppress immunity mediated by T helper cells, but this effect has not yet been unequivocally demonstrated.

Human Immunodeficiency Virus

It has been known for some time that opportunistic infections increase HIV replication. This is very likely due to the induction of TNF-a synthesis, which, in turn, activates the nuclear transcription factor, NF?B, a cytoplasmic protein that enhances HIV transcription and is a regulatory component in the gene transcription of several mediators of inflammation, including TNF-a; the result is a feedback amplification loop. Tat, a protein initiating HIV replication, also activates NF?B. Viral replication is abolished in tat-defective strains and can be restored by TNF-a; NF?B-defective T cell lines are resistant to infection with HIV. Thus, the pathways for the transcription of TNF-a (and probably other cytokines) and of HIV appear to depend on the same regulatory mechanism.

By inhibiting TNF-a production, thalidomide blocks a pathway for the activation of NF?B and, hence, the replication of HIV. In addition to inhibiting the synthesis of TNF-a, thalidomide suppresses I?B-kinase activity, a key in NF?B synthesis [15], [16] and thus interferes at two sites with the positive feedback amplification loop for TNF-a and HIV production. In

summary, the effect of thalidomide or its metabolites on the immune system seems to be a reduction of mediators of inflammation (further effects include inhibition of cyclooxygenase–2 [17]) and a downregulation to normal of an overly activated state.

MONITORING THE USE OF THALIDOMIDE

CELGENE, the U.S. manufacturer of thalidomide, and the FDA have created a unique monitoring program for its distribution and monitoring—the System for Thalidomide Education and Prescribing Safety (STEPS) program. It is designed to make drugs, such as thalidomide, that offer important clinical benefits but carry the potential for serious harm, available for medical purposes while minimizing uncontrolled and potentially dangerous (ab)use. To achieve this, the program uses a threefold approach: [18] (1) controlling access to the drug; (2) educating prescribing physicians, pharmacists, and patients; and (3) monitoring compliance. Clinicians who wish to prescribe thalidomide must register in the STEPS Prescriber Registry administered by CELGENE and must agree to prescribe the drug in accordance with STEPS patient eligibility criteria and monitoring procedures. Pharmacies must also register and agree to comply with patient identification and monitoring criteria. Finally, patients receive visual aids, including a videotape, written material, and verbal counseling about the benefits and risks of thalidomide therapy, the importance of not becoming pregnant during therapy, and the types of contraception required (including emergency contraception) and their availability. Women able to bear children must agree to undergo pregnancy testing before starting therapy and on a regular schedule during therapy. All patients must agree to complete a confidential survey about their compliance with contraception, testing, and drug therapy. The manufacturer not only monitors survey results and outcome data, but also is ready to make whatever modifications to the STEPS program are necessary to ensure its effectiveness.

CLINICAL USES

In 1965, clinicians began to recognize thalidomide's potential as an anti-inflammatory drug, first for the treatment of erythema nodosum leprosum and subsequently for a wide variety of conditions:

Bullous pemphigoid [19]
Cicatricial pemphigoid [19]
Erythema multiforme [19]
Jessner-Kanof disease [20]
Lichen planopilaris [21]
Lichen planus, erosive [22]
Melanoma [23]
Multiple myeloma [24]
Palmoplantar pustulosis [25]
Porphyria cutanea tarda [26]
Postherpetic neuralgia [19]
Prurigo nodularis [27]
Pyoderma gangrenosum [28]
Sarcoidosis [29]
Uremic pruritus [30]
Weber-Christian disease [31]

More possible indications are being added. However, many of these observations have been published as case reports or small series and, thus, await confirmation by larger formal studies.

Although the drug cannot now be recommended for these conditions, thalidomide may provide a therapeutic alternative in selected patients who do not respond to more conventional regimens. Currently, efforts are being made to make better use of thalidomide's unique properties, to gain approval for the use of thalidomide in selected indications, and to develop analogues with better pharmacologic properties (e.g., with more pronounced antiangiogenic activity or even with no teratogenic potential) for use in a variety of neoplastic and inflammatory diseases.

Erythema Nodosum Leprosum

In 4522 patients with erythema nodosum leprosum, 99 percent responded to thalidomide. Lesions resolve within 24 to 48 h after treatment is begun; other symptoms (headache, myalgia, anorexia, vomiting, orchitis, leukocytosis, elevated sedimentation rate) also respond quickly. Motor nerve conduction velocity returns to almost normal within 2 weeks. All this can be ascribed to thalidomide's anti-inflammatory effects, as it does not act directly on *Mycobacterium leprae*. Because of this impressive efficacy, thalidomide may currently be considered the therapeutic standard for erythema nodosum leprosum (see Chap. 202).

Aphthosis and Behçet's Disease in Immunocompetent Patients

Thalidomide therapy is one of the main therapeutic options in complex aphthosis and in Behçet's disease. In one larger study, approximately one-third to more than one-half the patients with aphthosis of varying severity had full remissions; almost all had some benefit from treatment, with thalidomide, but relapses were common after its discontinuation. In a retrospective study of 25 patients with recurrent aphthous stomatitis followed for 1 year, 6 were able to stop treatment with only minor recurrences, 10 needed further maintenance treatment with low doses of thalidomide, 7 did not respond, 1 had to stop because of side effects, and 1 was lost to follow-up. [32] Oral and genital lesions of all 22 patients with Behçet's syndrome studied healed very rapidly in response to thalidomide (400 mg/day for 5 days, then 200 mg/day for up to 2 months); however, no effect on ocular lesions was seen. [33] After cessation of therapy, recurrences were milder

and less frequent.

Lupus Erythematosus

Thalidomide is an effective and relatively well tolerated treatment modality for the lesions of chronic cutaneous and subacute cutaneous lupus erythematosus. The value of this therapeutic measure is hardly debated, as the results of the first observations published in the early 1980s [34] are essentially the same as those in the larger series published more recently. [35] The following facts emerge:

- In a survey of 61 lupus centers from 19 countries around the world, 35 percent reported using thalidomide as a therapeutic option. [36]
- When given thalidomide, 50 to 90 percent of patients with subacute or chronic cutaneous lupus erythematosus achieve complete or near complete remissions of skin lesions; in all studies, at least 80 percent of patients responded.
- Thalidomide dosages used in these studies range from 50 to 300 mg/day, the maximum benefit being achieved within 16 weeks. [35], [37], [38] The higher dosages seem to be associated with somewhat higher response rates, but not with lower relapse rates. However, the use of low-dose regimens is becoming more common, as approximately 50 percent of patients respond and have fewer and milder side effects on such a regimen. [39] Thus, starting at a lower dose (50 to 100 mg/day) and increasing it if there is no adequate response in 2 to 3 months may be an appropriate way to treat lupus with thalidomide: presumably, fewer patients would have to discontinue therapy because of side effects. [37], [39]
- Response may be maintained with 25 to 50 mg/day and, rarely, even lower doses. Relapses after cessation of thalidomide medication occur in 70 to 75 percent of patients, but are usually responsive to a new course of the drug.
- Thalidomide must be discontinued early owing to unacceptable side effects in 10 to 25 percent of patients.
- Thalidomide's effect on the skin lesions of lupus erythematosus notwithstanding, it has no influence on the course and severity of the systemic disease.

Some of these studies are flawed in that it is not clear whether concomitant systemic glucocorticoid therapy was given; one of these studies does address the problem, stating that the use of thalidomide allowed the average daily glucocorticoid dose to be reduced from 40 to 17.5 mg. A Ro antibody–positive patient exemplifies the effect of thalidomide on the skin lesions of subacute cutaneous lupus erythematosus: [34] Azathioprine, 150 mg/day, and 6-methylprednisone, 60 mg/day, given previously had completely failed to control his rash (Fig. 264-1A). Thalidomide at 300 mg/day led to a considerable improvement of the skin disease within 3 weeks and to a complete remission within 10 weeks (Fig. 264-1B), with no additional immunosuppressive/glucocorticoid medication. This remission was maintained with thalidomide, 100 mg/day, and the treatment was tolerated well, with only minor side effects due to sedation. Nonetheless, there was progression, albeit slow, of his renal disease.

FIGURE 264-1 Patient with subacute cutaneous lupus erythematosus unresponsive to treatment with azathioprine/methylprednisone. Skin lesions of the face and neck (*A*) shortly after withdrawal of conventional immunosuppression and at the beginning of treatment with thalidomide, 300 mg/day; (*B*) complete resolution of the skin lesions after 10 weeks of therapy.

Chronic Graft-versus-Host Disease

Besides anecdotal reports, there are three studies of thalidomide in the treatment of chronic graft-versus-host disease after bone marrow transplantation in adults and one in children. [40], [41] and [42] In one, a survival rate of 76 percent among patients with graft-versus-host disease refractory to conventional therapy and of 48 percent of patients with high graft-versus-host disease-risk who received thalidomide was observed, with a complete response in 14, a partial response in 12, and no response in 18 patients. [40] There were only minor side effects. In another, 80 patients who failed to respond to conventional therapy (glucocorticoids with or without cyclosporine) were treated with thalidomide. Of these patients, 36 percent had to discontinue thalidomide because of side effects; 20 percent had a sustained favorable response. Five children with severe glucocorticoid-dependent chronic graft-versus-host disease were treated with thalidomide, 12 to 25 mg/kg per day. [41] All children responded to therapy, which allowed a reduction in immunosuppressive medication. There were only minimal side effects that did not necessitate withdrawal of the drug.

These studies clearly demonstrate that patients with chronic graft-versus-host disease refractory to conventional immunosuppressive/glucocorticoid therapy may benefit from the additional administration of thalidomide at doses of up to 1200 mg/day(!) if they can tolerate the side effects. This beneficial effect seems to be even more pronounced in children, possibly because they tolerate the drug better than adults do.

Although thalidomide is an effective therapeutic agent in chronic graft-versus-host disease, it cannot be used for prevention. In a double-blind, randomized trial with 59 patients who received 400 mg of thalidomide starting on day 80 after transplantation, both the incidence of chronic graft-versus-host and the survival rate were unfavorable, as compared

with a placebo group. [42] Thus, thalidomide cannot be used for the prophylaxis of chronic graft-versus-host disease.

Complications of HIV Infection

Thalidomide has a beneficial effect on the complications of HIV disease. Aphthous ulcers and AIDS wasting associated with tuberculosis have been shown to respond well; other complications, such as prurigo nodularis, proctitis, and refractory microsporidial diarrhea, may also respond. Furthermore, thalidomide may inhibit HIV replication in AIDS patients with active mycobacterial infections. However, HIV-infected patients are at greater risk for developing untoward effects from this therapy and must be selected and monitored accordingly.

APHTHOUS ULCERS Patients with advanced HIV disease develop painful aphthous ulcerations of the mouth and the oropharynx resembling the aphthous ulcerations typically found in patients with Behçet's disease. These aphthous ulcers are usually progressive and can be large (more than 1 cm^2), deep, and destructive; furthermore, they can lead to or aggravate HIV-associated weight loss. These aphthae were generally treated with the local or systemic administration of glucocorticoids, but have been shown to respond very well to thalidomide at daily doses of 100 to 300 mg. In a double-blind, randomized, placebo-controlled study, patients received a 4-week course of either 200 mg of thalidomide or placebo. [43] Complete healing of ulcers after 4 weeks occurred in 55 percent of treated patients, as compared with 7 percent in the placebo-treated group; 6 had to discontinue the drug because of toxicity; somnolence and a skin rash were each noted in 7 patients. Contrary to expectations, [44] plasma levels of TNF-a and of HIV RNA increased in the thalidomide-treated group; the significance of these findings remains to be studied. Similarly, 11 of 12 patients with esophageal ulceration had a complete symptomatic remission; in 9 of them, there was complete healing after they received 200 mg of thalidomide daily for 4 weeks. [45]
AIDS-ASSOCIATED WASTING A double-blind study of the efficacy and safety of thalidomide in AIDS-associated wasting showed a significant weight gain in the thalidomide group. However, rashes, fevers, and the sedation, but not neuropathy, limit its usefulness. [46]
MICROSPORIDIOSIS A common cause of chronic diarrhea in HIV patients, microsporidiosis contributes to their often severe wasting problems. In a study of 19 patients with chronic diarrhea due to microsporidiosis, 7 had a complete and 3 a partial clinical remission when given 100 mg of thalidomide daily. [47] Remarkably, all stages of the life cycle of the causative organism, *Enterocytozoon intestinale,* were disrupted.
KAPOSI'S SARCOMA The response to thalidomide was favorable in several phase II Kaposi's sarcoma trials. [48] Partial responses occurred in about 40 percent of patients treated with thalidomide doses of 400 to 1000 mg/day. This effect is thought to be related to thalidomide's antiangiogenic properties.

Langerhans Cell Histiocytosis

Rather than a neoplastic process (see Chap. 160), Langerhans cell histiocytosis is considered reactive. TNF-a has been shown to play an important role in the induction of proliferation of Langerhans cells, and this process can be reversed by thalidomide's inhibition of TNF-a production. So far, there are reports on seven patients treated with thalidomide, all of them responding. [49] Thus, thalidomide may be considered as treatment of Langerhans cell histiocytosis.

Actinic Prurigo and Polymorphous Light Eruption

Although they do not occur exclusively in Amerindians actinic prurigo and polymorphous light eruption occur primarily in this group (see Chap. 135). More than 90 percent of 99 patients with this condition responded well to thalidomide at initial doses of 100 to 300 mg/day within 3 weeks to 3 months. [50] Some of these patients enjoyed prolonged remissions, but most required maintenance therapy, usually of 50 to 100 mg/day, but occasionally as little as 15 mg/day. The rationale for this therapy comes from the observation that keratinocytes in lesional skin from patients with actinic prurigo contain high levels of TNF-a. [51] Good to excellent results have also been achieved in about 90 percent of patients with polymorphous light eruption, a related condition, in an average of 2 weeks. [52]

CONTRAINDICATIONS

Because of the disastrous effects of thalidomide on the development of the embryo, patients of childbearing age and their partners must understand and take the necessary contraceptive measures. The prescribing physician is responsible for informing them. In addition, it is essential to minimize the risk of thalidomide being dispensed through a “black market.” To these ends, the implementation of the (STEPS) [18] program is part of the recent FDA approval for use of thalidomide in certain diseases (see above). [18]

Thalidomide can be excreted with seminal fluid. Because no information is available on the amount of thalidomide required to cause birth defects, males should be advised to use barrier contraception while on thalidomide therapy. Contrary to earlier concerns, there does not seem to be a danger of second-generation birth defects. [53]

As the possible development of peripheral neuropathy (see below) is one of the major drawbacks of thalidomide therapy, patients with peripheral neurologic disorders should not be considered for this treatment modality.

Despite earlier impressions of a favorable effect, toxic epidermal necrolysis should *not* be treated with thalidomide. In a double-blind, randomized placebo-controlled study, there was a threefold higher mortality rate in the thalidomide group (10 of 12 patients) compared to the placebo group (3 of 10 patients). [54]

DOSAGE OF THALIDOMIDE

In the absence of acute toxicity, the dosage of thalidomide is determined by clinical effectiveness and limited by the side

effects of sedation and constipation. Practical doses range between 100 and 400 mg/day, but they are occasionally as high as 600 mg/day in patients with subacute cutaneous lupus and up to 1200 mg in patients with chronic graft-versus-host disease refractory to more conventional anti-inflammatory/immunosuppressive therapy. There is no strict correlation between plasma levels and clinical effects; sedation, healing of oral ulcers, or complete suppression of cutaneous lupus may occur at doses that do not produce detectable thalidomide plasma levels.

ADVERSE EFFECTS OF THALIDOMIDE THERAPY

The most important adverse effect of thalidomide is the well-known teratogenic effect. Thus, as noted earlier, it is mandatory that female patients of childbearing age for whom thalidomide therapy is planned be carefully selected, informed, and monitored and that they take reliable contraceptive measures.

Teratogenesis

Thalidomide embryopathy has affected an estimated 12,000 to 15,000 patients worldwide; more than 4000 cases have been reported, 3000 of them in West Germany alone. Malformations due to thalidomide embryopathy are related to the time of exposure to the drug in utero, the sensitive period being the embryonal ages from the third to the fifth week; they may be caused by the action of thalidomide on embryonal adhesion receptors. [12] Most prominent are malformations of the extremities, including malformations or aplasia of the thumbs, radiate aplasia, phocomelia or amelia of the upper and/or lower limbs, anotia, facial palsy, microphthalmia, and ophthalmoplegia. In addition, neural tube defects, cardiac malformations, renal malformations, esophageal fistulas, duodenal stenosis or atresia, anal atresia, vaginal obstruction, and midline hemangiomas may occur. These malformations must be differentiated from other dysmelic diseases and radial defects, of which Holt-Oram syndrome, an autosomal dominant disease, is the one most similar to thalidomide embryopathy.

Peripheral Neuropathy

Another serious side effect of thalidomide therapy is a peripheral sensory neuropathy that may later progress to involve motor neurons. Estimates of the incidence of this neuropathy range from more than 60 percent to less than 1 percent of HIV-negative patients who receive thalidomide. Not much is known about its incidence in HIV-infected patients, but as with other thalidomide side effects, such individuals may be at greater risk. Patients treated for chronic graft-versus-host disease may also be at risk because of pretreatment with cytotoxic drugs and the higher doses of thalidomide used in this condition. As this neuropathy can become irreversible, preexistent peripheral neuropathy should be excluded before patients receive thalidomide, and their neurologic status should be assessed frequently.

Other Side Effects

Other dose-related and usually mild side effects are sedation, nausea, mood changes, increased appetite, edema of the face and limbs, menstrual abnormalities, decreased libido, constipation, dizziness, and dryness of the mouth. These effects tend to disappear with time, but can be dose-limiting on occasion.

RASH AND FEVER Occuring predominantly in HIV-infected patients, [55] rash and fever may develop with the use of thalidomide—similar to the well-known reaction to trimethoprim-sulfamethoxazole in these patients. More than 30 percent of such patients, especially those with low CD4+ lymphocyte counts, develop this problem, which requires a cessation of therapy. An erythematous rash with peripheral blood eosinophilia has been observed in two patients with renal insufficiency who received thalidomide for prurigo nodularis. [27] The rash resolved promptly upon withdrawal of the drug.
TOXIC EPIDERMAL NECROLYSIS One female patient receiving thalidomide for the treatment of leioblastoma developed toxic epidermal necrolysis after 5 weeks of therapy. [56]

REFERENCES

1. Sheskin J: The treatment of lepra reaction in lepromatous leprosy: Fifteen years' experience with thalidomide. *Int J Dermatol* **19**:318, 1980

2. Welsh O et al: A new therapeutic approach to type II leprosy reaction. *Int J Dermatol* **38**:931, 1999

3. Gori A et al: Clinical and immunological benefit of adjuvant therapy with thalidomide in the treatment of tuberculosis disease. *AIDS* **14**:1859, 2000

4. Gori A et al: Clinical and immunological improvement in a patient who received thalidomide treatment for refractory *Mycobacterium avium* complex infection. *Clin Infect Dis* **26**:184, 1998

5. Stephens T, Brynner R: *Dark Remedy. The Impact of Thalidomide and Its Revival as a Vital Medicine*. Cambridge, MA, Perseus, 2001.

6. Hashimoto Y: Novel biological response modifiers derived from thalidomide. *Curr Med Chem* **5**:163, 1998

7. Chen TL et al: Plasma pharmacokinetics and urinary excretion of thalidomide after oral dosing in healthy male volunteers. *Drug Metab Dispos* **17**:402, 1989

8. Sampaio EP et al: The influence of thalidomide on the clinical and immunologic manifestation of erythema nodosum leprosum. *J Infect Dis* **168**:408, 1993

9. Haslett P et al: The metabolic and immunologic effects of short-term thalidomide treatment of patients infected with the human immunodeficiency virus. *AIDS Res Hum Retroviruses* **13**:1047, 1997

10. D'Amato RJ et al: Thalidomide is an inhibitor of angiogenesis. *Proc Natl Acad Sci USA* **91**:4082, 1994

11. Amato RJ: Thalidomide: An antineoplastic agent. *Curr Oncol Rep* **4**:56, 2002

12. Neubert R et al: Down-regulation of adhesion receptors on cells of primate embryos as a probable mechanism of the teratogenic action of thalidomide. *Life Sci* **58**:295, 1995

13. Moller DR et al: Inhibition of IL-12 production by thalidomide. *J Immunol* **159**:5157, 1997

14. McHugh SM et al: The immunosuppressive drug thalidomide induces T helper cell type 2 (Th2) and concomitantly inhibits Th1 cytokine production in mitogen- and antigen-stimulated human peripheral blood mononuclear cell cultures. *Clin Exp Immunol* **99**:160, 1995

15. Rowland TL et al: Differential effect of thalidomide and dexamethasone on the transcription factor NF-kappa B. *Int Immunopharmacol* **1**:49, 2001

16. Keifer JA et al: Inhibition of NF kappa B activity by thalidomide through suppression of IkappaB kinase activity. *J Biol Chem* **276**:22382, 2001

17. Fujita J et al: Thalidomide and its analogues inhibit lipopolysaccharide-mediated induction of cyclooxygenase-2. *Clin Cancer Res* **7**:3349, 2001

18. Zeldis JB et al: S.T.E.P.S.: A comprehensive program for controlling and monitoring access to thalidomide. *Clin Ther* **21**:319, 1999

19. Naafs B, Faber WR: Thalidomide therapy: An open trial. *Int J Dermatol* **24**:131, 1985

20. Guillaume JC et al: Crossover study of thalidomide vs placebo in Jessner's lymphocytic infiltration of the skin. *Arch Dermatol* **131**:1032, 1995

21. George SJ, Hsu S: Lichen planopilaris treated with thalidomide. *J Am Acad Dermatol* **45**:965, 2001

22. Camisa C, Popovsky JL: Effective treatment of oral erosive lichen planus with thalidomide. *Arch Dermatol* **136**:1442, 2000

23. Kudva GC et al: Thalidomide for malignant melanoma. *N Engl J Med* **345**:1214, 2001

24. Sjak Shie NN et al: Recent advances in multiple myeloma. *Curr Opin Hematol* **7**:241, 2000

25. Hamza M: Behçet's disease, palmoplantar pustulosis and HLA-B27 treatment with thalidomide [letter; comment]. *Clin Exp Rheumatol* **8**:427, 1990

26. Monastirli A et al: Treatment of porphyria cutanea tarda with oral thalidomide. *Skin Pharmacol Appl Skin Physiol* **12**:305, 1999

27. Winkelmann RK et al: Thalidomide treatment of prurigo nodularis. *Acta Derm Venereol* **64**:412, 1984

28. Federman GL, Federman DG: Recalcitrant pyoderma gangrenosum treated with thalidomide. *Mayo Clin Proc* **75**:842, 2000

29. Estines O et al: Sarcoidose: Traitement par thalidomide chez 10 malades. *Ann Dermatol Venereol* **128**:611, 2001

30. Silva SRB et al: Thalidomide for the treatment of uremic pruritus: A crossover randomized double-blind trial. *Nephron* **67**:270, 1994

31. Eravelly J, Waters MF: Thalidomide in Weber-Christian disease [letter]. *Lancet* **1**:251, 1977

32. Bonnetblanc JM et al: Thalidomide and recurrent aphthous stomatitis: A follow-up study. *Dermatology* **193**:321, 1996

33. Saylan T, Saltik I: Thalidomide in the treatment of Behçet's disease. *Arch Dermatol* **118**:536, 1982

34. Volc-Platzer B, Wolff K: [Treatment of subacute cutaneous lupus erythematosus with thalidomide]. *Hautarzt* **34**:175, 1983

35. Stevens RJ et al: Thalidomide in the treatment of the cutaneous manifestations of lupus erythematosus: Experience in sixteen consecutive patients. *Br J Rheumatol* **36**:353, 1997

36. Vitali C et al: International survey on the management of patients with SLE: I. General data on the participating centers and the results of a questionnaire regarding mucocutaneous involvement. *Clin Exper Rheumatol* **14** (suppl 16):S17, 1996

37. Kyriakis KP et al: Experience with low-dose thalidomide therapy in chronic discoid lupus erythematosus. *Int J Dermatol* **39**:218, 2000

38. Ordi Ros J et al: Thalidomide in the treatment of cutaneous lupus refractory to conventional therapy. *J Rheumatol* **27**:1429, 2000

39. Duong DJ et al: American experience with low-dose thalidomide therapy for severe cutaneous lupus erythematosus. *Arch Dermatol* **135**:1079, 1999

40. Browne PV et al: Response to thalidomide therapy in refractory chronic graft-versus-host disease. *Bone Marrow Transplant* **26**:865, 2000

41. Cole CH et al: Thalidomide in the management of chronic graft-versus-host disease in children following bone marrow transplantation. *Bone Marrow Transplant* **14**:937, 1994

42. Chao NJ et al: Paradoxical effect of thalidomide prophylaxis on chronic graft-vs.-host disease. *Biol Blood Marrow Transplant* **2**:86, 1996

43. Jacobson JM et al: Thalidomide for the treatment of oral aphthous ulcers in patients with human immunodeficiency virus infection. National Institute of Allergy and Infectious Diseases AIDS Clinical Trials Group. *N Engl J Med* **336**:1487, 1997

44. Moreira AL et al: Thalidomide and thalidomide analogs reduce HIV type 1 replication in human macrophages in vitro. *AIDS Res Hum Retroviruses* **13**:857, 1997

45. Alexander LN, Wilcox CM: A prospective trial of thalidomide for the treatment of HIV-associated idiopathic esophageal ulcers. *AIDS Res Hum Retroviruses* **13**:301, 1997

46. Kaplan G et al: Thalidomide for the treatment of AIDS-associated wasting. *AIDS Res Hum Retroviruses* **16**:1345, 2000

47. Sharpstone D et al: Thalidomide: A novel therapy for microsporidiosis. *Gastroenterology* **112**:1823, 1997

48. Little RF et al: Activity of thalidomide in AIDS-related Kaposi's sarcoma. *J Clin Oncol* **18**:2593, 2000

49. Dallafior S et al: [Successful treatment of a case of cutaneous Langerhans cell granulomatosis with 2-chlorodeoxyadenosine and thalidomide]. *Hautarzt* **46**:553, 1995

50. Lovell CR et al: Thalidomide in actinic prurigo. *Br J Dermatol* **108**:467, 1983

51. Arrese JE et al: Effectors of inflammation in actinic prurigo. *J Am Acad Dermatol* **44**:957, 2001

52. Saul A et al: Polymorphous light eruption: Treatment with thalidomide. *Australas J Dermatol* **17**:17, 1976

53. Smithells D: Does thalidomide cause second generation birth defects? *Drug Saf* **5**:339, 1998

54. Wolkenstein P et al: Randomised comparison of thalidomide versus placebo in toxic epidermal necrolysis. *Lancet* **352**:1586, 1998

55. Haslett P et al: Adverse reactions to thalidomide in patients infected with human immunodeficiency virus. *Clin Infect Dis* **24**:1223, 1997

56. Horowitz SB, Stirling AL: Thalidomide-induced toxic epidermal necrolysis. *Pharmacotherapy* **19**:1177, 1999

T>

Chapter 265

Jean Krutmann Akimichi Morita

Therapeutic Photomedicine: Phototherapy

PHOTOTHERAPY OF PSORIASIS
311-nm UVB: The Phototherapy of Choice for Psoriasis
Practical Aspects
Combination Therapy
PHOTOTHERAPY OF ATOPIC DERMATITIS
UVA1 Phototherapy for Acute, Severe Atopic Dermatitis
Phototherapy of Chronic, Moderate Atopic Dermatitis
PHOTOTHERAPY OF OTHER DISORDERS
Phototherapy of Polymorphous Light Eruption and Other Photodermatoses
Phototherapy of Scleroderma
Phototherapy of Urticaria Pigmentosa
Phototherapy of Miscellaneous Disorders
MECHANISMS OF ACTION

REFERENCES

Over the past few years, the development of irradiation devices with new emission spectra has led to an expanded role for phototherapy in the treatment of skin disease. [1] This development is best illustrated by the increasing frequency with which 311-nm ultraviolet B (UVB) phototherapy is employed for the treatment of psoriasis. [2] In fact, in Europe 311-nm UVB (narrowband UVB or 312-nm UVB) is currently used more often than psoralens plus ultraviolet A (PUVA) therapy for psoriasis and several other cutaneous diseases. Another example of a new device that has improved and expanded the spectrum of skin diseases amenable to phototherapy is ultraviolet A-1 (UVA1). [3] With this modality, doses of UVA1 (340 to 400 nm) up to 130 J/cm ^{2} are delivered to diseased skin. UVA1 was first used to treat patients with atopic dermatitis, but it has since been found to be efficacious in several other skin diseases, such as localized scleroderma, where other therapeutic options are limited. These two examples demonstrate that the introduction of new spectra into dermatologic phototherapy has not only broadened and improved phototherapy as it relates to established indications but, in addition, has fostered the development of new indications for phototherapy such as connective tissue diseases.

PHOTOTHERAPY OF PSORIASIS

One important element in the long-term management of moderate to severe psoriasis is UVB phototherapy. Within recent years, the availability of new fluorescent bulbs with an emission spectrum that closely conforms to the peak of the action spectrum for clearing psoriasis has significantly improved the efficacy of UVB phototherapy for psoriasis, making it as efficient as PUVA therapy.

311-nm UVB: The Phototherapy of Choice for Psoriasis

Parrish et al. demonstrated that wavelengths shorter than 295 nm displayed no antipsoriatic effect, even if used at erythemogenic doses, whereas wavelengths between 300 and 313 nm caused the greatest remission of skin lesions. [4] These seminal observations provided the rationale for the development of more selective UVB phototherapy (SUP) irradiation devices. These units have a spectrum that is still broadband UVB but is enhanced in the range of 300 to 320 nm. As predicted, these light sources proved to be superior to conventional UVB phototherapy for clearing of psoriasis. A major breakthrough was achieved by the development of the Philips TL-01 fluorescent lamp, emitting a narrow UV band at 311/312 nm and thereby matching closely the assumed therapeutic optimum for psoriasis. [2] A large number of clinical trials comparing broadband versus 311-nm UVB phototherapy for psoriasis have been conducted mainly in Europe, and more recently in the United States. Based on these studies, it is now generally accepted that 311-nm UVB therapy is superior to broadband UVB therapy for psoriasis. [5] Patients treated with a 311-nm spectrum show faster clearance of skin lesions, fewer episodes of excessive erythema, and a longer period of remission (Fig. 265-1). This difference in efficacy has been attributed to the fact that 311-nm UVB is capable of more efficiently depleting skin-infiltrating T cells from the epidermis and dermis of psoriatic plaques as compared with broadband UVB. [6] Also, comparative studies of 311-nm UVB phototherapy and PUVA demonstrate that these two modalities are equally effective. [7], [8] and [9] This is of particular interest, because 311-nm UVB therapy, in comparison to PUVA, does not require psoralens, is cheaper, can be used in pregnancy and childhood, and does not require posttreatment eye protection. It has also been suggested that 311-nm UVB may be less carcinogenic than PUVA. [10] For these reasons, 311-nm UVB therapy currently represents the phototherapeutic modality of choice for the treatment of psoriasis in Europe, and is being used increasingly in the United States.

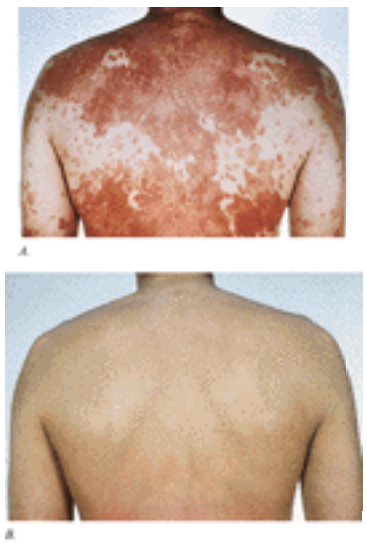

FIGURE 265-1 Patient with severe generalized psoriasis before (*A*) and after (*B*) 15 treatments with 311-nm UVB phototherapy. (*Courtesy of J. Ferguson, MD, Dundee, Scotland.*)

Practical Aspects

For 311-nm UVB therapy, no specific irradiation devices are needed because the Philips TL-01 fluorescent lamps can be fitted into conventional PUVA cabinets. Regardless of whether 311-nm UVB or conventional broadband UVB from fluorescent bulbs (such as Westinghouse FS, Philips TL12, Sylvania UV21) or medium-pressure mercury arc lamps with or without metal halides [8] are used, a number of guidelines should be followed. [11]

In particular, prior to phototherapy, the patient's minimal erythema dose (MED) must be determined in order to establish the optimal dosage schedule. For determination of the MED and subsequent phototherapy, either the same irradiation device or different devices with identical emission spectra must be used. For 311-nm therapy, the initial dose should equal 0.7 MED (Table 265-1). Patients are treated three to five times per week. If the initial dose is tolerated, a 20 percent incremental increase of the previous dose is used at each visit. [12] When a previous treatment results in erythema, no treatment is given the next scheduled visit or the dose is decreased, depending on whether the erythema is asymptomatic or severe and painful (Table 265-1). It should be noted that 311-nm UVB is also very efficient when used at suberythemogenic doses. [13]

1. Determination of minimal erythema dose (MED):	
2. First exposure: 70% of MED	
3. Subsequent exposure:	
a. If no erythema	Increase by 20% at each visit
b. Minimal erythema	Same dose
c. Asymptomatic, well-defined erythema	Postpone exposure until next visit, then same dose; and thereafter 10% increments at each visit
d. Painful erythema ± edema or buller	Omit further exposure until recovery, reduce exposure dose by half, thereafter 10% increments at each visit

[a] According to Hönigsmann and Krutmann[17]

TABLE 265-1 **311-nm UVB Phototherapy Regimen**

For broadband UVB therapy, one MED is given on the first treatment and is increased by 50 percent, 40 percent, 30 percent, and so on, in subsequent treatments. Because ultraviolet radiation is a complete carcinogen, the genitalia and chronically light-exposed areas (e.g., the face, neck, dorsa of hands), if unaffected, should be shielded or protected (with sunscreen) prior to irradiation.

For limited psoriasis, 308-nm excimer laser therapy may represent an option. [14] The 308-nm excimer laser appears to be highly effective even in otherwise therapy-resistant psoriasis. It is selectively directed at lesional skin, thus sparing the surrounding normal skin from unnecessary exposure.

The end point of phototherapy is complete clearance of all psoriatic skin lesions. Psoriasis, however, is a chronic disease and the remission induced by UVB phototherapy is transient. In a randomized, prospective, multicentered trial, postclearing phototherapy was found to significantly increase the disease-free interval, indicating that patients may profit from maintenance phototherapy. [15] On the other hand, maintenance therapy results in a greater cumulative UVB dose, increasing the risk of skin cancer and photoaging. It is therefore preferable, if possible, to maintain remissions with other antipsoriatic modalities. To minimize potential carcinogenic risks from chronic UVB phototherapy, a rotational therapeutic approach including a number of primary and secondary agents has been suggested. [16] Primary agents include UVB, PUVA, methotrexate, and etretinate. If these are no longer effective, then secondary agents, such as cyclosporine, hydroxyurea, and low-dose combination regimens (e.g., retinoids + PUVA + topicals), should be considered.

Combination Therapy (See also Chap. 42)

Along the same lines, phototherapy of psoriasis is frequently used in combination regimens in order to achieve higher clearance rates, longer disease-free intervals, and a lower carcinogenic risk. [16] Phototherapy may be combined with topical or systemic agents. Topical agents include anthralin, vitamin D analogues, retinoids, glucocorticoids, emollients, saltwater baths, and tar. Among these, anthralin and tar are mainly of historical interest and are not discussed.

Antipsoriatic vitamin D analogues include calcipotriol, tacalcitol, and calcitriol, which have antiproliferative, as well as antiinflammatory, effects. [17] Local side effects are limited to moderate skin irritation. [18] To avoid systemic side effects—in particular hypercalcemia with consequent nephrocalcinosis—from percutaneous absorption, the treated body surface should not exceed 30 percent. Under these conditions, long-term safety may be assured. [19] Main indications are psoriatic plaques of limited extent and lesions on the scalp, face, palms, and soles and in the intertriginous areas. The

combination of either broadband UVB or 311-nm UVB therapy with calcipotriol increases the therapeutic efficacy of phototherapy alone. [20] This observation is of particular interest because UVB therapy reduces the irritation caused by calcipotriol. A combination of calcipotriol with UVA radiation or a combined UVA/UVB regimen should be avoided, because UVA radiation leads to degradation of vitamin D_3. Consequently, vitamin D analogues should be applied after (not before) phototherapy.

Another promising combination phototherapy of psoriasis is narrowband UVB irradiation and topical tazarotene gel. Tazarotene is a topical acetylenic retinoid that is efficacious in plaque-type psoriasis. The addition of tazarotene to broadband or narrowband UVB phototherapy was found to promote more effective, faster clearing of psoriasis when compared to either type of phototherapy alone. [21], [22] Pretreatment with tazarotene gel three times per week for 2 weeks before phototherapy significantly reduces the mean minimal erythema dose for UVB and the mean UVA exposure required to induce immediate pigment darkening. Thus, UVB and PUVA therapy can be initiated at lower doses than usual when used in combination with tazarotene. [23]

Several studies have addressed the question whether the efficacy of UVB phototherapy for psoriasis may be enhanced through combination with topical glucocorticoids. Data from these studies are conflicting and the beneficial effects seem to be limited. [24] Topical glucocorticoids are useful, however, for treating psoriatic lesions in skin areas not reached by UV irradiation during phototherapy (e.g., scalp, groin, perianal area, umbilicus), or for the treatment of lesions recalcitrant to standard phototherapy. They may also be used in the early, highly inflammatory state of psoriasis to achieve a quick improvement.

Topical application of emollients alters the optical properties of psoriatic lesions. [25] Lubricants improve transmission of UVB, and a combination of topical lubricants with UVB therapy increased efficacy. [26] This is in contrast to thick applications of petrolatum and water-in-oil type creams and salicylic acid, which act as sunscreens.

Balneophototherapy comprises the combination of saltwater baths with UVB phototherapy, which, under natural conditions, has been successfully employed at the Dead Sea for the treatment of patients with recurrent, severe psoriasis. [27] Modern approaches to balneophototherapy employing synthetically generated Dead Sea salt or sodium chloride solutions for saltwater baths (usually between 5 to 15 percent) are hampered by logistics (the requirement for bathtubs) and environmental problems (caused by the salt consumption). The beneficial effects of saline solutions on psoriasis are thought to involve elution of leukocyte elastase from psoriatic skin [28] and anti-inflammatory effects of magnesium ions. [29] Controlled studies demonstrating a synergistic effect between saltwater baths and phototherapy are still lacking. Similarly, the efficacy of balneophototherapy in comparison with established combination regimens for psoriasis remains to be assessed.

Systemic agents that may be used to treat psoriasis include retinoids, glucocorticoids, cyclosporin A, and methotrexate. Retinoids are the most widely used agents for systemic treatment in combination with phototherapy. In contrast, the systemic use of glucocorticoids in combination with photo(chemo)therapy is limited to special indications, such as generalized pustular psoriasis. Also, combination regimens of UVB therapy with methotrexate or cyclosporin A are not advisable, because both substances increase the possibility of UV-induced skin tumors.

From a theoretical point of view, the advantage of combining retinoids and UVB irradiation is twofold: (1) retinoids exert antipsoriatic effects, which might act synergistically with UVB phototherapy; and (2) they have anticarcinogenic effects and thereby could lower the increased skin cancer risk resulting from long-term UVB therapy. Because of potentially severe side effects, the use of retinoids should be limited to pustular or erythrodermic variants of psoriasis. Combination regimens with broadband UVB or SUP therapy together with etretinate induced improvement in psoriatic patients more quickly than with phototherapy alone, and reduced the number of treatments and cumulative UV doses. [30] Similar results were obtained when acitretin, the major metabolite of etretinate, was used in combination with broadband UVB or 311-nm UVB therapy. [31]

PHOTOTHERAPY OF ATOPIC DERMATITIS (See also Chap. 122)

In the past few years, several new phototherapeutic modalities, including UVA/UVB, [32] 311-nm UVB, [33] and UVA1 phototherapy, [34] were developed to treat atopic dermatitis. As a consequence, dermatologists now have a diverse spectrum of phototherapeutic modalities from which to choose to tailor their treatment to the particular needs of a particular patient. Treatment decisions can now be based on the effectiveness of a given form of phototherapy for a specific stage of atopic dermatitis—i.e., acute and severe versus chronic and moderate disease activity. We recently developed a phototherapeutic approach for atopic dermatitis [34] that should result in phototherapy for atopic dermatitis that is both as effective and as safe as possible. In general, phototherapy of an acute, severe exacerbation of atopic dermatitis may be achieved with high- or medium-dose UVA1 therapy, whereas conventional UVA, UVA/UVB, 311-nm UVB, and low-dose UVA1 phototherapy represent phototherapeutic modalities that are primarily suited for treatment of chronic stages of this disease (Table 265-2).

Indication	Modality	Comment
Acute, severe	High-dose UVA1	Monotherapy; alternative to glucocorticoids; long-term side effects unknown
Chronic, moderate	311-nm UVB UVA/UVB Broadband UVB Broadband UVA Low-dose UVA1	Combination therapy to save glucocorticoids; suited for maintenance therapy

TABLE 265-2 **Concept-Linked Phototherapeutic Approach for Atopic Dermatitis**

UVA1 Phototherapy for Acute, Severe Atopic Dermatitis

UVA1 phototherapy is a highly effective modality that can be used as monotherapy for a limited period of time (10 to 15 exposures). It is most effective for the treatment of patients with a severe, acute exacerbation of atopic dermatitis (Fig. 265-2). Because potential long-term risks of UVA1 phototherapy are not known, patients should not be treated over extended periods of time, for example, for maintenance therapy. For the same reasons its use is not recommended for patients younger than 18 years of age. The therapeutic effectiveness of UVA1 irradiation in the management of patients with atopic dermatitis was first evaluated in an open study in patients with acute, severe exacerbations of atopic dermatitis. [35] They were exposed to 130 J/cm ^{2} UVA1 daily for 15 consecutive days. Its therapeutic effectiveness was assessed by means of a clinical scoring system as well as by monitoring serum levels of eosinophil cationic protein (ECP), a laboratory parameter that can be measured objectively and that correlates well with disease activity in atopic dermatitis. In that study, UVA1 phototherapy was found to be highly efficient in promptly inducing clinical improvement and reducing elevated serum ECP levels. Patients treated with UVA1 were compared with subjects who had been treated with UVA/UVB phototherapy. Significant differences in favor of UVA1 therapy were observed. [35] These results were recently corroborated and extended in a randomized, controlled multicenter trial in which UVA1 therapy, as compared with glucocorticoid treatment, was significantly better at day 10 in reducing the clinical score. [36]

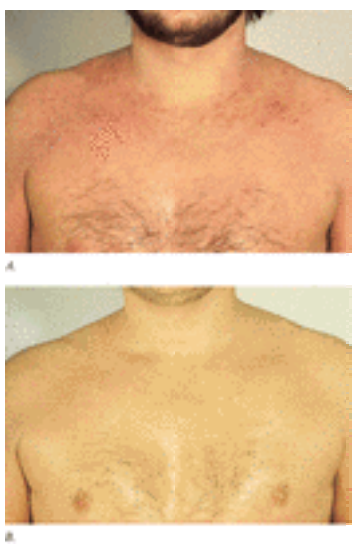

FIGURE 265-2 Patient with severe, acute exacerbation of atopic dermatitis before (*A*) and after (*B*) high-dose UVA1 therapy (15 × 130 J/cm ^{2} UVA1).

The therapeutic effectiveness of UVA1 therapy is dose-dependent. Low-dose UVA1 (30 J/cm ^{2}) is less effective than UVA/UVB therapy, [37] whereas high-dose UVA1 therapy (130 J/cm ^{2}) is superior to UVA/UVB phototherapy. [35], [36] In addition, a medium-UVA1 dosage schedule (50 J/cm ^{2}) was superior to a low-dose UVA1 regimen (10 J/cm ^{2}), whereas no significant difference was detected in a bilateral comparison study between a medium- and a high-dose regimen. [38]

High-dose UVA1 phototherapy may not be used on patients with UVA-sensitive atopic dermatitis or photodermatoses. It is necessary to exclude these diseases prior to initiation of high-dose UVA1 therapy. This can easily be accomplished by photoprovocation testing. Except for eczema herpeticum, no acute side effects have been observed in any of the patients treated with high-dose UVA1 therapy. No other side effects have been observed, although its potential carcinogenic risk is a theoretical concern. It is important to note that exposure of hairless albino Skh-hr1 mice to high doses of UVA1 radiation induced squamous cell carcinoma. [39] The actual contribution of UVA radiation to the development of malignant melanoma in humans is currently under debate and at this point cannot be excluded. [40] Until more is known about high-dose UVA1 therapy, its use should be limited to periods of acute exacerbation of atopic dermatitis and, in general, one treatment cycle should not exceed 10 to 15 continuously applied exposures and should not be repeated more than once per year. [34]

Phototherapy of Chronic, Moderate Atopic Dermatitis

Broadband UVB, [41] combined UVA/UVB, [32], [42] broadband UVA, [43] low-dose UVA1, [37] and, in particular, 311-nm UVB phototherapy [43] are effective treatments in mild and moderate atopic dermatitis. They are not particularly effective in patients with acute, severe exacerbations of their disease. In contrast to UVA1 therapy, these forms of UV therapy are usually not employed as monotherapy. Rather, they are used in combination regimens together with topical glucocorticoids in order to reduce the need for glucocorticoid application. All of these therapies are considered to be relatively safe, even if used over extended periods of time, and they should be used to induce long-term improvement. Patients do best if severe disease is initially controlled by more potent but also more aggressive modalities. For example, 311-nm UVB phototherapy has proved to be an ideal modality for maintenance therapy after high-dose UVA1 has been used in the initial phase of management of an acute, severe exacerbation of atopic dermatitis. [34] If high-dose UVA1 therapy is not available, severe atopic dermatitis should be controlled prior to start of phototherapy by aggressive topical glucocorticoid therapy or systemic immunosuppressive modalities such as glucocorticoids or cyclosporin A.

Studies directly comparing all the different forms of UV therapy for chronic, moderate atopic dermatitis have not been performed, but recent trials indicate that either UVA/UVB combination therapy [37] or narrowband 311-nm UVB therapy [33], [43] is superior to conventional broadband UVB, broadband UVA, or low-dose UVA1 therapy. Also, narrowband UVB appears to be equivalent to bath-PUVA for this indication. [44] The actual choice made for a particular patient also depends on what irradiation devices are available. At the moment, UVA/UVB is more widely available than 311-nm UVB therapy.

Jekler and Larkö, in a paired comparison study, observed significant differences in favor of UVA/UVB therapy over broadband UVB therapy. [37] In this trial, patients were allowed to continue the use of topical glucocorticoids and were irradiated three times per week for a maximum of 8 weeks in a UVB MED-dependent manner.

The therapeutic effectiveness of 311-nm UVB therapy for chronic, moderate atopic dermatitis was first shown in an open trial conducted by George et al. [33] and was recently confirmed in a randomized controlled study. [43] In their well-designed study, George et al. irradiated patients with chronic, moderate atopic dermatitis with 50 100-W TL-01 lamps equipped with reflectors, resulting in a UVB output of 5 mW/cm ^{2} and maximum treatment times of less than 10 min. [44] The irradiation regimen used with 50 lamps was identical to that previously described for 311-nm therapy of psoriasis (Table 265-1). Patients were monitored for severity of clinical symptoms as well as glucocorticoid use 12 weeks prior to phototherapy, during the 12 weeks of phototherapy, and for another 24 weeks after cessation of phototherapy. The 311-nm UVB phototherapy not only decreased the clinical severity, it also significantly reduced the use of glucocorticoids. These beneficial effects were still present in the majority of patients 6 months after cessation of 311-nm UVB therapy. In this study, a specially constructed air-conditioned irradiation unit was used for 311-nm UVB phototherapy. Equivalent therapeutic results could also be achieved if TL-01 lamps were fitted into a conventional PUVA irradiation device, indicating that higher temperatures during 311-nm UVB phototherapy did not lead to heat-induced irritation of eczema. [45] As discussed previously, 311-nm UVB therapy may be associated with a reduced risk of skin cancer compared to broadband UVB or to PUVA therapy. [10] The recent demonstration of 311-nm UVB therapy's effectiveness for treating childhood atopic eczema is therefore of particular interest. [46]

If neither a UVA/UVB nor a 311-nm UVB irradiation device is available, broadband low-dose (0.5 MED) UVB therapy can be used. Placebo-controlled studies show it to be effective for this disease. [41]

PHOTOTHERAPY OF OTHER DISORDERS

In addition to psoriasis and atopic dermatitis, UV therapy is increasingly used for a growing number of skin diseases that previously had mainly been treated with PUVA (e.g., polymorphous light eruption, urticaria pigmentosa, vitiligo, cutaneous T cell lymphoma) or for which no phototherapeutic approach had been available (e.g., scleroderma and lupus erythematosus).

Phototherapy of Polymorphous Light Eruption and Other Photodermatoses

Patients with polymorphous light eruption (PMLE) respond abnormally to ultraviolet radiation (in particular UVA radiation), resulting in an increased and sustained expression of proinflammatory molecules (cytokines, adhesion molecules) and subsequent development of skin lesions (see Chap. 135). In the majority of PMLE patients, exposure to early season sunlight results in induction of tolerance, a process that is termed *hardening*. Artificial induction of hardening or artificial photoprotection constitutes the major principle underlying phototherapy of PMLE. [47] The precise molecular mechanisms responsible for hardening are not yet known, but it is generally believed that phototherapy-induced photoprotection is based on the induction of epidermal thickening, pigmentation, and as-yet-to-be-defined immunologic effects. To maintain phototherapy-induced photoprotection, it is important that patients expose themselves to sunlight, because strict avoidance of sunlight exposure will result in a quick loss of the therapeutically induced hardening effect. The use of phototherapy for PMLE is restricted to severe cases that fail to respond to more simple measures such as light avoidance, photoprotective clothing, and use of broadband sunscreens. For these patients, broadband UVB and PUVA therapy have previously been found to be effective, with PUVA giving better results than UVB therapy. [47] Recent studies, however, indicate that 311-nm UVB therapy represents an effective alternative to PUVA for PMLE-induced photoprotection. In a recent study, 25 patients were randomly assigned to either PUVA treatment or 311-nm UVB therapy, which was administered as previously described (see Table 265-1). [48] When patients were monitored for 4 months following treatment, there was no difference between PUVA and 311-nm UVB therapy with respect to severity of disease and restriction of outdoor activities. For the reasons given above, 311-nm UVB therapy may therefore be considered the treatment of choice for PMLE. The efficacy of 311-nm UVB therapy for photodermatoses other than PMLE has not yet been assessed in controlled studies, but observations from a pilot study indicate that patients with actinic prurigo (in particular), hydroa vacciniforme, and erythropoietic porphyria, but not with solar urticaria, may also benefit from 311-nm UVB therapy. [49] In severe, otherwise therapy-resistant forms of solar urticaria UVA “rush hardening” therapy may represent an option. [50] This novel approach includes multiple UVA irradiations at 1-h intervals per day; it provides significant protection within 3 days.

Phototherapy of Scleroderma

Localized scleroderma has a self-limited course, but skin lesions can cause significant morbidity and discomfort, particularly if they extend over joints and cause flexion contractures, or if they lead to muscle atrophy and disfigurement. [51] In the past, numerous modalities including penicillin, penicillamine, antimalarial drugs, cyclosporin A, interferon-?, and topical or systemic glucocorticoids have been employed. In general, the efficacy of each of these agents is poor. It was therefore of considerable interest to learn that UVA1 phototherapy was of benefit for patients with localized scleroderma [52], [53] (Fig. 265-3).

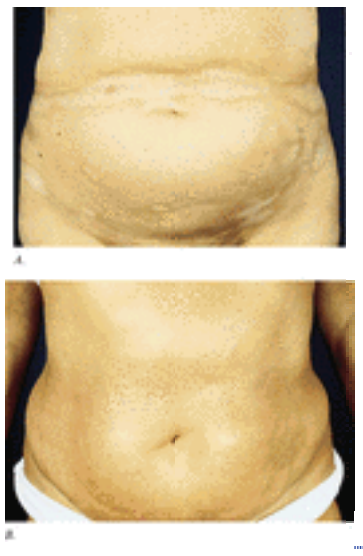

FIGURE 265-3 Patient with localized scleroderma before (*A*) and after (*B*) high-dose UVA1 therapy (30 × 130 J/cm ^{2} UVA1).

In an open study, 10 patients with histologically proven localized scleroderma were exposed 30 times to a single dose of 130 J/cm ^{2} UVA1 radiation. [53] In all patients, high-dose UVA1 therapy significantly reduced thickness and increased elasticity of sclerotic plaques as assessed by 20-MHz sonography. Complete clearance was observed in 4 of 10 patients. These changes were not a result of spontaneous remissions, because they were present only in UVA1-irradiated, but not in unirradiated control, plaques in the same patients. Similar therapeutic benefit could also be achieved by employing a low-dose UVA1 regimen. [52] Direct comparison of low-dose versus high-dose UVA1 therapy revealed that high-dose UVA1 therapy was superior, indicating that the therapeutic efficacy is dose-dependent. [53] Termination of phototherapy was not associated, over a 3-month period, with loss of the beneficial effects achieved by high-dose UVA1 irradiation in 9 of 10 patients, indicating that maintenance therapy may not be required. The precise mechanism by which UVA1 therapy acts in localized scleroderma is unknown, but most likely involves upregulation of collagenase I expression, which was induced about 20-fold in sclerotic skin lesions after successful UVA1 phototherapy. [53], [54]

In addition to localized scleroderma, UVA-1 phototherapy is also effective in patients with systemic sclerosis and chronic graft-versus-host disease. [55], [56]

Phototherapy of Urticaria Pigmentosa

Several studies have demonstrated that PUVA therapy is effective in reducing pruritus and urtication associated with urticaria pigmentosa. [57] In the majority of patients, however, cessation of PUVA therapy leads to recurrence of urticaria pigmentosa after 5 to 8 months. A recent study suggests that beneficial effects may also be achieved in these patients by UVA1 phototherapy. In an open study, four adult patients with severe generalized urticaria pigmentosa were treated with high-dose UVA1 phototherapy, which was given as monotherapy once daily five times per week for 2 consecutive weeks. [58] The initial dose was 60 J/cm ^{2}, which was subsequently increased to 130 J/cm ^{2}. High-dose UVA1 therapy induced reduction of pruritus and loss of urtication from stroking (Darier's sign) after three exposures, whereas hyperpigmented skin lesions faded more slowly. Increased histamine in 24-h urine was reduced to normal levels. In two patients with systemic manifestations of urticaria pigmentosa, such as migraine and diarrhea, relief from systemic symptoms and reduction of serum serotonin to normal levels was observed after 10 exposures. No relapse has occurred in any of these four patients for more than 2 years after cessation of high-dose UVA1 therapy. This is in contrast to PUVA therapy and may be because of the possibility that high-dose UVA1, but not PUVA, therapy leads to depletion of dermal mast cells. [57], [58]

Phototherapy of Miscellaneous Disorders

Several reports indicate that 311-nm UVB is a useful and well tolerated therapy for vitiligo that results in rapid repigmentation in many patients, including Fitzpatrick's skin types IV and V, as well as children. [60], [61] These therapeutic responses were achieved with twice weekly irradiations, the initial dose was 0.25 J/cm ^{2}, independent of the skin type, and the dose was increased by 20 percent each treatment. It should be noted, however, that similar to PUVA or khellin (a furocoumarin) plus UVA (KUVA) therapy, certain anatomic sites (hands and digits, feet and toes) did not respond. There have been no controlled studies comparing 311-nm UVB phototherapy with PUVA or KUVA for this indication.

It has been suggested that daily low-dose UVA1 irradiation is beneficial to patients with lupus erythematosus (Fig. 265-4). In an open study, 10 patients with systemic lupus erythematosus were treated with low-dose UVA1 irradiation (6 J/cm ^{2} daily) for various time periods (15 days to 8 months). [62] A decrease in clinical indices of disease activity, which was most pronounced after 8 months of phototherapy, was observed in all patients. The UVA1 irradiation decreased fatigue, arthritis, photosensitivity, skin rashes, and often depression, headaches, and sleeplessness. In addition, anti-SSA or antinuclear antibodies decreased or even disappeared in most patients. These promising results have been confirmed in an 18-week two-phase study using 6 J/cm ^{2}. [63] No side effects were noted, although UVA1 irradiation, at least at higher doses, may exert detrimental effects on some lupus erythematosus patients.

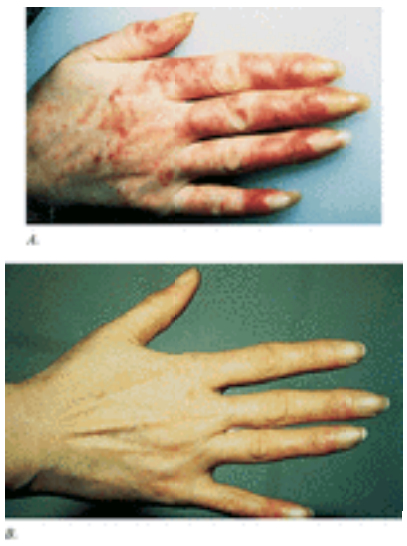

FIGURE 265-4 Hand of a 37-year-old woman with subacute cutaneous lupus erythematosus before (*A*) and after (*B*) low-dose UVA1 therapy. Treatment consisted of irradiation daily for 5 days a week with 6 J/cm ^{2} UVA1 for 3 consecutive weeks. (*Courtesy of H. McGrath, Jr., MD, New Orleans, LA.*)

UVA-1 phototherapy was recently used to treat patients with cutaneous T cell lymphoma (CTCL). In an open pilot study, three of three patients with early stage mycosis fungoides (CTCL stages IA and IB) were treated effectively with a high, as well as medium dose UVA-1 regimen. [64] In a second uncontrolled trial, 11 of 13 patients with widespread plaque-type, nodular and erythrodermic mycosis fungoides (CTCL stages IB, IIB, and III) showed complete clinical and histologic responses upon treatment with a high-dose UVA-1 regimen. [65] These observations are of particular interest because UVA-1 phototherapy offers significant advantages over PUVA therapy. Unwanted side effects resulting from the systemic application of methoxsalen, such as nausea, long-lasting skin photosensitivity and requirement for eye protection are completely avoided. It was recently proposed that 311-nm UVB phototherapy be used to treat early stages of mycosis fungoides. [66]

Local UVA-1 phototherapy appears to be an interesting option in the management of patients with chronic vesicular dyshidrotic hand eczema. In an open pilot study, palms and backs of hands of 12 patients with an acute exacerbation of their disease were exposed to 15 UVA-1 irradiations with a dose of 40 J/cm ^{2} per day over a period of 3 weeks. After 1 week, all but one patient reported a marked relief of itch. After the third week, significant clinical improvement was noted in 10 of 12 patients. [67]

UVA-1 phototherapy has also been used for patients with keloids and hypertrophic scars, [68] pityriasis rubra pilaris, [69] and hypereosinophilic syndrome. [70]

Phototherapy with UVB may be used to treat pityriasis lichenoides acuta et chronica, [71] pityriasis rosea, [72] severe seborrheic dermatitis, [73] and pruritic folliculitis of pregnancy. [74]

MECHANISMS OF ACTION

Through the induction of DNA photoproducts, UVB radiation transiently inhibits cell proliferation. As a result, it was thought that the therapeutic effectiveness of UVB phototherapy in psoriasis is mainly due to its antiproliferative effects. Since the introduction of UVB radiation into dermatologic therapy, however, the number of skin diseases showing a favorable response to phototherapy has grown substantially. The vast majority are immunologic in nature. Studies on the role of UV radiation-induced immunosuppression in photocarcinogenesis and on the effects of UV radiation on the function of epidermal Langerhans cells have provided increasing evidence that UVB, as well as UVA (and in particular UVA1) radiation exert profound effects on the skin immune system (reviewed in Ref. [75]). As a consequence, UVB and UVA phototherapy are currently regarded as modalities whose mechanism of action depends upon immunomodulatory effects that are not specific for a single type of light source. The in vivo relevance of these immunomodulatory effects is dependent on the physical properties of the UV radiation employed. On a per-photon basis, wavelengths within the UVB spectrum possess greater energy than does UVA radiation, but because of their shorter wavelength, they have a more superficial depth of penetration within the skin. As a result, UVB phototherapy primarily affects the function of epidermal keratinocytes and Langerhans cells, whereas UVA1 radiation additionally affects dermal fibroblasts, dermal dendritic cells, endothelial cells, T lymphocytes within the dermis, mast cells, and granulocytes (Fig. 265-5). Photoimmunologic effects induced by UVB and UVA1 radiation fall into three major categories: (1) effects on soluble mediators; (2) modulation of the expression of cell surface–associated molecules; and (3) the induction of apoptosis in pathogenetically relevant cells. The apoptotic effect is currently thought to be of key importance for phototherapy. [75] Both UVB and UVA (particularly UVA1) radiation are highly efficient in inducing apoptosis in human cells. T cells, as compared with monocytes or keratinocytes, have an increased susceptibility to UV radiation-induced apoptosis; this mechanism is, therefore, of particular importance for phototherapy of T cell–mediated skin diseases such as atopic dermatitis and psoriasis. For example, UVA1 phototherapy of patients with atopic dermatitis was shown to induce apoptosis in skin-infiltrating T helper cells, thereby leading to a gradual reduction of the inflammatory infiltrate and concomitant improvement of patients' skin disease. Similarly, successful UVB phototherapy of psoriasis reduced the number of intraepidermal T cells and subsequently normalized keratinocyte morphology. Depletion of T cells was a result of UVB-induced T cell apoptosis. A very detailed, up-to-date review of photoimmunologic mechanisms that are responsible for the efficacy of phototherapy is found in Ref. [75].

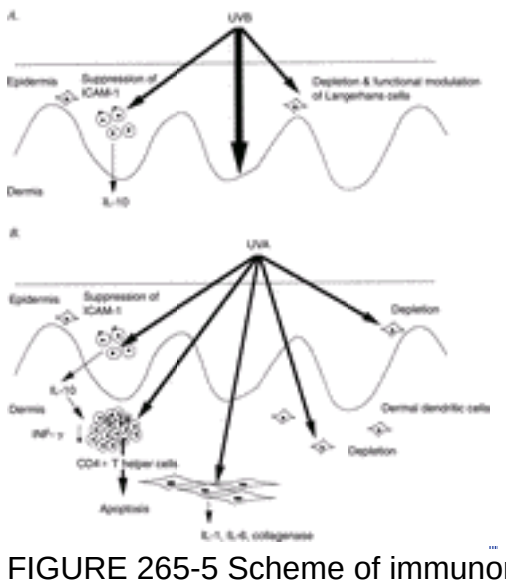

FIGURE 265-5 Scheme of immunomodulatory effects induced by UVB or UVA phototherapy. ICAM-1, intercellular adhesion molecule-1; IFN-?, interferon-?; IL-10, interleukin-10.

REFERENCES

1. Krutmann J et al, editors: *Dermatological Phototherapy and Photodiagnostic Methods.* New York, Springer, 2001.

2. van Welden H et al: A new development in UVB phototherapy of psoriasis. *Br J Dermatol* **119**:11, 1988

3. Krutmann J et al: Ultraviolet-A1 phototherapy: Indications and mode of action, in *Dermatological Phototherapy and Photodiagnostic Methods,* edited by J Krutmann, H Hönigsmann, CA Elments, P Bergstresser New York, Springer, 2001, p 261

4. Parrish JA, Jaenicke KF: Action spectrum for phototherapy of psoriasis. *J Invest Dermatol* **76**:359, 1981

5. Ferguson J: The use of narrowband UV-B (tube lamp) in the management of skin disease. *Arch Dermatol* **135**:589, 1999

6. Ozawa M et al: 312-nanometer ultraviolet B light (narrow-band UVB) induces apoptosis of T-cells within psoriatic lesions. *J Exp Med* **189**:711, 1999

7. van Weelden H et al: Comparison of narrow-band UVB phototherapy and PUVA photochemotherapy in the treatment of psoriasis. *Acta Derm Venereol Suppl (Stockh)* **70**:212, 1990

8. Green C et al: A comparison of the efficacy and relapse rates of narrow band UVB (TL01) monotherapy vs. etretinate (re-TL-01) vs. etretinate-PUVA (re-PUVA) in the treatment of psoriasis. *Br J Dermatol* **127**:5, 1992

9. Tanew A et al: Halfside comparison study on narrow-band UVB phototherapy versus photochemotherapy (PUVA) in the treatment of severe psoriasis. *J Invest Dermatol* **106**:841, 1996

10. Young A: Carcinogenicity of UVB phototherapy assessed. *Lancet* **346**:1431, 1995

11. Hönigsmann H, Krutmann J: Practical guidelines for broadband UVB, narrowband UVB, UVA-1 phototherapy, and PUVA photochemotherapy—A proposal, in *Dermatological Phototherapy and Photodiagnostic Methods,* edited by J Krutmann, H Hönigsmann, CA Elments, P Bergstresser New York, Springer, 2001, p 371

12. Wainwright J et al: Narrowband ultraviolet B (TL-01) phototherapy for psoriasis: Which incremental regimen? *Br J Dermatol* **139**:410, 1998

13. Walters IB et al: Suberythemogenic narrow-band UVB is markedly more effective than conventional UVB in treatment of psoriasis vulgaris. *J Am Acad Dermatol* **40**:893, 1999

14. Bonis B et al: 308-nm UVB excimer laser for psoriasis [letter]. *Lancet* **350**:1522, 1997

15. Stern RS et al: Effect of continued ultraviolet B phototherapy on the duration and remission of psoriasis: A randomized study. *J Am Acad Dermatol* **15**:546, 1986

16. Mentener MA et al: Proceedings of the psoriasis combination and rotation therapy conference. *J Am Acad Dermatol* **34**:315, 1996

17. Berth-Jones J, Hutchinson PE: Vitamin D analogues and psoriasis. *Br J Dermatol* **127**:71, 1992

18. Kragballe K et al: Efficacy, tolerability, and safety of calcipotriol ointment in disorders of keratinization: Results of a randomized, double-blind, vehicle-controlled, right/left comparative study. *Arch Dermatol* **131**:556, 1995

19. Ramsay CA et al: Long-term use of topical calcipotriol in chronic plaque psoriasis. *Dermatology* **189**:260, 1994

20. Kerscher M et al: Combination phototherapy of psoriasis with calcipotriol and narrow-band UVB. *Lancet* **342**:923, 1993

21. Koo JYM et al: Tazarotene plus UVB phototherapy in the treatment of psoriasis. *J Am Acad Dermatol* **43**:821, 2000

22. Behrens S et al: Combination phototherapy of psoriasis with narrow-band UVB irradiation and topical tazarotene gel. *J Am Acad Dermatol* **42**:493, 2000

23. Hecker D et al: Interactions between tazarotene and ultraviolet light. *J Am Acad Dermatol* **41**:927, 1999

24. LeVine MJ, Parrish JA: The effect of topical fluocinonide ointment on phototherapy of psoriasis. *J Invest Dermatol* **78**:157, 1989

25. Anderson RR, Parrish JA: Optical properties of human skin, in *The Science of Photomedicine* **,** edited by JD Regan, JA Parrish. New York, Plenum, 1980, p 147

26. Lebwohl M: Effects of topical preparations on the erythemogenicity of UVB: Implications for psoriasis therapy. *J Am Acad Dermatol* **32**:469,

1995

27. Abel EA et al: Psoriasis treatment at the Dead Sea: Second international study tour. *J Am Acad Dermatol* **19**:362, 1988

28. Wiedow O et al: Freisetzung humaner Leukozytenelastase durch hypertone Salzbäder bei Psoriasis. *Hautarzt* **40**:518, 1989

29. Ludwig P et al: Inhibition of eicosanoid formation in human polymorphonuclear leukocytes by high concentrations of magnesium ions. *Biol Chem Hoppe-Seyler* **376**:739, 1995

30. Orfanos CE et al: Oral retinoid and UVB radiation: A new alternative treatment for psoriasis on an outpatient basis. *Acta Derm Venereol Suppl (Stockh)* **59**:241, 1979

31. Lowe N et al: Acitretin plus UVB therapy for psoriasis. *J Am Acad Dermatol* **24**:591, 1991

32. Jekler J, Larkö O: Combined UV-A–UV-B versus UVB phototherapy for atopic dermatitis. *J Am Acad Dermatol* **22**:49, 1990

33. George SA et al: Narrow-band (TL01) UVB air-conditioned phototherapy for chronic severe adult atopic dermatitis. *Br J Dermatol* **128**:49, 1993

34. Krutmann J, Morita A: Photo(chemo)therapy for atopic dermatitis, in *Dermatological Phototherapy and Photodiagnostic Methods,* edited by J Krutmann, H Hönigsmann, CA Elments, P Bergstresser. New York, Springer, 2001, p 93

35. Krutmann J et al: High-dose UVA1 therapy in the treatment of patients with atopic dermatitis. *J Am Acad Dermatol* **26**:225, 1992

36. Krutmann J et al: High-dose UVA1 therapy for atopic dermatitis. *J Am Acad Dermatol* **38**:589, 1998

37. Jekler J, Larkö O: Phototherapy for atopic dermatitis with ultraviolet A (UVA), low-dose UVB, and combined UVA and UVB: Two paired comparison studies. *Photodermatol Photoimmunol Photomed* **8**:151, 1991

38. Tzaneva S et al: High-dose versus medium-dose UVA-1 phototherapy for patients with severe generalized atopic dermatitis. *J Am Acad Dermatol* **45**:503, 2001

39. Sterenbroigh HCJM, van der Leun JC: Tumorigenesis by a long wavelength UV-A source. *Photochem Photobiol* **51**:325, 1990

40. Setlow RB et al: Wavelengths effective in induction of malignant melanoma. *Proc Natl Acad Sci U S A* **90**:6666, 1993

41. Jekler J, Larkö O: UVB phototherapy of atopic eczema. *Br J Dermatol* **119**:697, 1988

42. Falk ES: UV-light therapies in atopic dermatitis. *Photodermatol Photoimmunol Photomed* **2**:241, 1985

43. Reynolds NJ et al: Narrow-band ultraviolet B and broad-band ultraviolet A phototherapy in adult atopic eczema: A randomized controlled trial. *Lancet* **357**:2012, 2001

44. Der Petrossian M et al: Half-side comparison study on the efficacy of 8-methoxypsoralen bath-PUVA versus narrow-band ultraviolet B phototherapy in patients with severe chronic atopic dermatitis. *Br J Dermatol* **142**:39, 2000

45. Hudson-Peacock MJ et al: Narrow-band UVB phototherapy for severe atopic dermatitis. *Br J Dermatol* **135**:330, 1996

46. Collins P, Ferguson J: Narrow-band (TL-01) UVB air-conditioned phototherapy for atopic eczema in children. *Br J Dermatol* **133**:653, 1995

47. Tanew A, Ferguson J: Phototherapy and photochemotherapy of the idiopathic photodermatoses, in *Dermatological Phototherapy and Photodiagnostic Methods,* edited by J Krutmann, H Hönigsmann, CA Elments, P Bergstresser. New York, Springer, 2001, p 109

48. Bilsland D et al: A comparison of narrow band phototherapy (TL-01) and photochemotherapy (PUVA) in the management of polymorphous light eruption. *Br J Dermatol* **129**:708, 1993

49. Collins P, Fergusson J: Narrow-band UVB (TL-01) phototherapy: An effective preventive treatment for the photodermatoses. *Br J Dermatol* **132**:956, 1995

50. Beissert S et al: UVA rush hardening for the treatment of solar urticaria. *J Am Acad Dermatol* **42**:1030, 2000

51. Fleischmajer R: Localized and systemic scleroderma, in *Connective Tissue Diseases of the Skin,* edited by CM Lapiere, T Krieg. New York, Marcel Dekker, 1993, p 295

52. Kerscher M et al: Treatment of localized scleroderma by UVA1 phototherapy. *Lancet* **346**:1166, 1995

53. Stege H et al: High-dose ultraviolet A1 radiation therapy of localized scleroderma. *J Am Acad Dermatol* **36**:938, 1997

54. Takeda K et al: Decreased collagenase expression in cultured systemic sclerosis fibroblasts. *J Invest Dermatol* **103**:359, 1994

55. Morita A et al: Ultraviolet A-1 (340–400 nm) phototherapy for scleroderma in systemic sclerosis. *J Am Acad Dermatol* **43**:670, 2000

56. Grundmann-Kollmann M et al: Chronic sclerodermic graft-versus-host disease refractory to immunosuppressive treatment responds to UVA1 phototherapy. *J Am Acad Dermatol* **42**:134, 2000

57. Kolde G et al: Response of cutaneous mast cells to PUVA in patients with urticaria pigmentosa: Histophotometric, ultrastructural, and biochemical investigations. *J Invest Dermatol* **83**:175, 1984

58. Stege H et al: High-dose UVA1 for urticaria pigmentosa. *Lancet* **347**:64, 1996

59. Grabbe J et al: High-dose UVA1 therapy, but not UVA/UVB therapy, decreases IgE binding cells in lesional skin of patients with atopic eczema. *J Invest Dermatol* **107**:419, 1996

60. Njoo MD et al: Treatment of generalized vitiligo in children with narrow-band (TL-01) UVB radiation therapy. *J Am Acad Dermatol* **42**:245, 2000

61. Scherschun L et al: Narrow-band ultraviolet B is a useful and well-tolerated treatment for vitiligo. *J Am Acad Dermatol* **44**:999, 2001

62. McGrath H Jr: Ultraviolet-A1 irradiation decreases clinical disease activity and autoantibodies in patients with systemic lupus erythematosus. *Clin Exp Rheumatol* **12**:129, 1994

63. McGrath H Jr et al: Ultraviolet-A1 (340–400 nm) irradiation in systemic lupus erythematosus. *Lupus* **5**:269, 1996

64. Plettenberg H et al: Ultraviolet A1 (340–400 nm) phototherapy for cutaneous T-cell lymphoma. *J Am Acad Dermatol* **41**:47, 1999

65. Zane C et al: “High-dose” UVA1 therapy of widespread plaque-type, nodular, and erythrodermic mycosis fungoides. *J Am Acad Dermatol* **44**:629, 2001

66. Hofer A et al: Narrowband (311-nm) UV-B therapy of small plaque parapsoriasis and early stage mycosis fungoides. *Arch Dermatol* **135**:1377, 1999

67. Schmidt T et al: UVA1 irradiation is effective in treatment of chronic vesicular dyshidrotic hand eczema. *Acta Derm Venereol Suppl (Stockh)* **78**:318, 1998

68. Asawanonda P et al: UVA-1 for keloid. *Arch Dermatol* **135**:348, 1999

69. Herbst RA et al: Combined ultraviolet A1 radiation and acitretin therapy as a treatment option for pityriasis rubra pilaris. *Br J Dermatol* **142**:574, 2000

70. Plötz G et al: UVA1 for hypereosinophilic syndrome. *Acta Derm Venereol Suppl (Stockh)* **80**:221, 2000

71. LeVine MJ: Phototherapy of pityriasis lichenoides. *Arch Dermatol* **119**:387, 1983

72. Arndt A et al: Treatment of pityriasis rosea with UV radiation. *Arch Dermatol* **119**:381, 1983

73. Pirkhammer D et al: Narrow-band ultraviolet B (TL-01) phototherapy is an effective and safe treatment option for patients with severe seborrheic dermatitis. *Br J Dermatol* **143**:964, 2000

74. Reed J, George S: Pruritic folliculitis of pregnancy treated with narrowband (TL-01) ultraviolet B phototherapy. *Br J Dermatol* **141**:154, 1999

75. Krutmann J et al: Mechanism of photo(chemo)therapy, in *Dermatological Phototherapy and Photodiagnostic Methods,* edited by J Krutmann, H Hönigsmann, CA Elments, P Bergstresser. New York, Springer, 2001, p 54

T>

Chapter 266

Herbert Hönigsmann Rolf-Markus Szeimies Robert Knobler Thomas Fitzpatrick Madhukar Pathak Klaus Wolff

Photochemotherapy and Photodynamic Therapy

PHOTOCHEMOTHERAPY (PUVA)
Historical Aspects
Principles of PUVA Therapy
Treatment Protocols
PUVA for Psoriasis
PUVA for Cutaneous T Cell Lymphoma (Mycosis Fungoides)
PUVA for Atopic Dermatitis
PUVA for Lichen Planus
PUVA for Cutaneous Mastocytosis
PUVA for Miscellaneous Dermatoses
PUVA for Chronic Graft-versus-Host Disease (GVHD)
PUVA for Vitiligo
PUVA as Prevention Treatment for Photodermatoses
PUVA in HIV-Infected Patients
Side Effects and Toxicity of PUVA
Patient Selection and Contraindications
Conclusions and Perspectives
EXTRACORPOREAL PHOTOCHEMOTHERAPY (PHOTOPHERESIS, ECP)
Treatment Method
Treatment Results
Perspectives
PHOTODYNAMIC THERAPY
Historical Aspects
Principles of Photodynamic Therapy
PDT in Dermatology
Perspectives

REFERENCES

PHOTOCHEMOTHERAPY (PUVA)

Psoralen photochemotherapy is a combination of psoralen (P) and long-wave ultraviolet radiation (UVA) that brings about a therapeutically beneficial result not produced by either the drug or radiation alone. This particular form of therapy is currently used in the treatment of several common and uncommon skin diseases. Psoralens can be administered orally or applied topically in the form of solutions, creams or baths with subsequent UVA exposure.

Historical Aspects

Topical application of extracts, seeds, and parts of plants that contain natural psoralens followed by exposure to sunlight has been used as a remedy for vitiligo for thousands of years, beginning with the ancient Egyptian and Indian healers. In modern medicine, the first clinical studies in vitiligo with topical and oral psoralens were performed originally by El Mofty in 1948, and later by Lerner et al. (for references see Ref. [1]).

In 1974, it was shown that orally administered 8-methoxypsoralen (8-MOP) and subsequent irradiation with artificial UVA was a highly effective treatment for psoriasis. This new therapeutic concept was termed photochemotherapy or PUVA, [2] and its efficacy was confirmed in a parallel study. [3] Within a few years the beneficial effects of PUVA were documented worldwide. Subsequently, the use of psoralen baths and subsequent UVA exposure became increasingly popular for reasons that are detailed below. This type of treatment, termed bath-PUVA, originated in Scandinavia. [4] The effectiveness of all variants of PUVA has been widely confirmed and has profoundly influenced dermatologic therapy in general, providing treatment for a number of diverse disorders besides psoriasis (Table 266-1).

Therapy of Disease	Prevention of Disease
Psoriasis	**Polymorphous light eruption**
Palmoplantar pustulosis	Hydroa vacciniforme*
Mycosis fungoides (stages IA, IB)	Solar urticaria
Vitiligo	Erythropoietic protoporphyria*
Atopic dermatitis	Chronic actinic dermatitis*
Generalized lichen planus	
Urticaria pigmentosa	
Cutaneous graft-versus-host disease	
Generalized granuloma annulare	
Pityriasis lichenoides*	
Lymphomatoid papulosis*	
Pityriasis rubra pilaris*	
Localized scleroderma*	

*Experience is limited to a small number of patients.

TABLE 266-1 **PUVA-Responsive Diseases**

Principles of PUVA Therapy

The rationale for PUVA therapy is to induce remissions of skin diseases by repeated, controlled phototoxic reactions. These reactions occur only when psoralens are photoactivated by UVA. According to the penetration characteristics of UVA, absorption of photons is confined to the skin. However, there is also some evidence that PUVA may exert systemic effects through circulating blood cells. Clinically, PUVA-induced phototoxic reactions are characterized by a delayed sunburn-like erythema and skin inflammation.

PSORALENS Psoralens are naturally occurring tricyclic furocoumarins present in a large number of plants, but some synthetic psoralen compounds also exist. Most widely used for oral and bath-PUVA is 8-MOP (methoxsalen, xanthotoxin), which is of plant origin but is also available as a synthetic drug. 4,5', 8-Trimethylpsoralen (TMP, trioxsalen) is a synthetic compound that is less phototoxic after oral administration, but more phototoxic when used for bath-PUVA. Also 5-MOP (bergapten) is therapeutically effective by the oral route and bathwater delivery; it is less erythemogenic in oral photochemotherapy and does not induce intolerance reactions.

Psoralen photochemistry [5], [6] ***and*** [7] Psoralens intercalate between DNA base pairs without UV radiation. Absorption of photons in the UVA range results in the formation of a 3,4- or 4',5'-cyclobutane addition product with pyrimidine bases of native DNA. In the first step of this photochemical reaction, a monofunctional adduct with thymine or cytosine is formed. Some psoralens, including 8-MOP, TMP, and 5-MOP, can absorb a second photon, and this reaction leads to the formation of a bifunctional adduct with a 5,6 double bond of the pyrimidine base of the opposite strand, thus producing an interstrand cross-link of the double helix. [8] This intercalation of psoralens with epidermal DNA produces a suppression of both DNA synthesis and cell division, and it is generally assumed, although not proved, that this effect may be the therapeutic mechanism in psoriasis. However, cross-linking does not appear to be a prerequisite for the therapeutic effect, and successful PUVA treatment of other skin diseases is unlikely to be directly caused by this molecular reaction; psoralens also react with RNA, proteins, and other cellular components, and indirectly modify proteins and lipids via singlet oxygen-mediated reactions or by generating free radicals. [7] Perhaps these mechanisms contribute to the effects of PUVA in diseases that are not hyperproliferative in nature. The formation of mono- and bifunctional photoadducts in DNA results in the immediate inhibition of DNA synthesis. The interstrand cross-links are believed to be largely responsible for eliciting skin photosensitization reactions of linear psoralens such as 8-MOP. Excessive production of these cyclobutane adducts causes cell death. The events of mutation and skin carcinogenesis appear to be the consequence of photoconjugation of psoralens to DNA. Psoralens that form monofunctional adducts as well as bifunctional adducts (interstrand cross-links) can be carcinogenic because the cells surviving DNA damage and undergoing DNA replication tend to repair DNA damage through an error-prone repair process. In type II reactions, reactive oxygen species ($^1O_2$, O_2 or OH) induce the oxidation of cellular lipoprotein membrane lipids, destruction of membrane-bound cytochrome P450, and the activation of the cyclooxygenase pathway. The membrane-damaging events activate the arachidonic acid metabolism pathway, which results in an increase of secondary oxidation products that contribute to the increased synthesis of eicosanoids. Furthermore, the reactive oxygen species can directly damage DNA by generating DNA strand breaks.

Mechanisms of photochemotherapy Hypotheses about the mechanism of photochemotherapy of psoriasis are based on the fact that PUVA causes photoconjugation of psoralens to DNA and a subsequent suppression of mitosis, DNA synthesis, and cell proliferation. This would indeed suffice to revert increased cell proliferation rates in psoriasis to normal. On the other hand, PUVA downregulates certain lymphocyte and antigen-presenting cell functions, influences adhesion molecule expression, and diminishes Langerhans cell numbers within the epidermis. In addition, PUVA may affect specific cells such as lymphocytes or polymorphonuclear leukocytes. Because there is evidence that psoriasis is caused primarily by the action of blood-derived immunocytes [9], it is reasonable to speculate that PUVA therapy may possibly act by an effect on normal or abnormal immune function involving a direct phototoxic effect on lymphocytes in skin infiltrates or on an abnormal immune function. This is in keeping with the observation that several other disorders that are not hyperproliferative in nature also respond well to PUVA. PUVA can revert the pathologically altered pattern of keratinocyte differentiation markers and reduce the number of proliferating epidermal cells. Infiltrating lymphocytes are strongly suppressed by PUVA, with variable effects on different T cell subsets. PUVA is far more potent in inducing apoptosis in lymphocytes than in keratinocytes [10], which may explain the high efficacy in cutaneous T cell lymphoma (CTCL), as well as in inflammatory skin diseases. Although much is known about pathways and mechanisms in psoralen photosensitization, the interactions and relative contributions to the clearing of a specific disease are not well understood. Psoralens also stimulate melanogenesis. This involves the photoconjugation of psoralens to DNA in melanocytes, mitosis and subsequent proliferation of melanocytes, an increased formation and melanization of melanosomes, an increased transfer of melanosomes to keratinocytes, and activation and increased synthesis of tyrosine mediated by stimulation of cAMP activity.

Pharmacokinetics The important steps between the ingestion of a psoralen and its arrival at the site of action include absorption, first-pass effect, blood transportation, and tissue distribution. The absorption rate of a psoralen from the gut depends mainly on the physical characteristics of the preparation and the fat content of the concomitant food intake. Liquid preparations of 8-MOP and 5-MOP give higher and earlier peak serum levels than do crystalline formulations. In addition, peak serum levels are achieved by liquid preparations after a relatively reproducible time interval in all subjects, whereas wide time variability occurs with crystalline formulations. Before reaching the skin via the circulation, psoralens are metabolized during passage through the liver. Plasma levels of 8-MOP administered orally at different doses show a strong nonlinearity, indicating a saturable first-pass effect. The unpredictable pharmacokinetic behavior is probably due to inter- and intraindividual variations of intestinal absorption, first-pass effect, blood distribution in the body, metabolism, and elimination of the drug. Within the same individual, serum levels of 8-MOP correspond fairly well with skin reactivity, the peak of skin phototoxicity coinciding with peak serum levels. However, phototoxic responses to PUVA show large interindividual variations. A correlation between 8-MOP and 5-MOP serum levels and epidermal concentrations has been demonstrated and individuals with low maximum serum concentration usually show an unsatisfactory therapeutic result. The pharmacokinetics of 8-MOP following topical treatment depend on the method of application. 8-MOP topically applied as a 0.15% emulsion or solution leads to plasma levels comparable to those found with oral treatment if large areas of the body are treated. In contrast, plasma levels following bath-PUVA treatment of almost the total body surface are very low. Bathwater-delivered psoralens are readily absorbed in the skin but are promptly eliminated without cutaneous accumulation. [10]

UVA RADIATION UVA sources commonly used for PUVA therapy are fluorescent lamps or igh-pressure metal-halide lamps. The typical fluorescent PUVA lamp has an emission peak at 352 nm and emits approximately 0.5 percent in the UVB range. UVA doses are given in J/cm ^{2}, usually measured with a photometer with a maximum sensitivity at 350 to 360 nm. Although the action spectrum of antipsoriatic activity and phototoxic erythema peaks at 335 nm, longer wavelengths have proved equally effective for clearing psoriasis if delivered in an adequate dose to obtain an equal erythemogenic response. [11]

Photosensitivity effects of PUVA PUVA treatment produces an inflammatory response that manifests as delayed phototoxic erythema. The reaction is related to the dose of both the drug and UVA as well as to the individual's sensitivity to phototoxic reactions. Recently, it was shown that changes in the 8-MOP dose had no detectable effect on the maximum slope of the psoralen plus ultraviolet A erythema dose-response curve. Thus, 8-MOP dose changes within individuals, over a narrow but clinically relevant range, appears to significantly alter the threshold response to PUVA erythema, but not the rate of increase in erythema with increasing ultraviolet A dose. [12] PUVA erythema differs from sunburn or UVB erythema that appear after 4 to 6 h and peak 12 to 24 h after exposure. PUVA erythema does not appear before 24 to 36 h and it peaks at 72 to 96 h, or even later. PUVA erythema has a shallower dose-response curve than UVB erythema (by a factor of approximately 2) and this difference is maintained even at the point of maximum erythema. [11] Severe PUVA reactions may lead to blistering and to superficial skin necrosis. Overdoses of UVA are frequently followed by swelling, intense pruritus and sometimes by a peculiar stinging sensation in the affected skin area, possibly as a consequence of damage of superficial nerve endings. Erythema is at present the only available parameter that allows an assessment of the magnitude of the PUVA reaction with psoralens; thus, it represents an important criterion for UVA dose adjustments. [13] Pigmentation is the second important effect of PUVA. It may develop without clinically evident erythema, especially when oral 5-MOP or TMP is used; this is particularly important in the treatment of vitiligo and for the preventive therapy of certain photodermatoses. In normal skin, PUVA pigmentation maximizes about 7 days after a PUVA exposure and may last from several weeks to months. As with sun-induced pigmentation, the individual's ability to tan is genetically determined, but the dose-response curve is much steeper. A few PUVA exposures result in a much deeper tan than that produced by multiple exposures to solar radiation.

Treatment Protocols

TOPICAL TREATMENT Application of 8-MOP in creams, ointments or lotions followed by UVA irradiation is effective in clearing psoriasis but has several disadvantages. The nonuniform distribution on the skin surface induces unpredictable phototoxic erythema reactions and irregular patches of cosmetically unacceptable hyperpigmentation. Furthermore, if numerous lesions are present, the application is laborious and time-consuming and the treatment does not prevent the development of new active lesions in previously unaffected, untreated areas. Therefore, topical PUVA with psoralen creams, ointments or lotions is now used only for limited plaque psoriasis and for palmoplantar disease.

BATH-PUVA The use of bathwater delivery of psoralens is increasingly popular because it provides for a uniform drug distribution over the skin surface, very low psoralen plasma levels, and rapid elimination of free psoralens from the skin, thereby reducing the risk of accidental sunburns. Bathwater delivery of 8-MOP circumvents gastrointestinal side effects and possible phototoxic hazards to the eyes because there is no systemic photosensitization. Skin psoralen levels are highly reproducible, and photosensitivity lasts no more than 2 h. The higher incidence of unwanted phototoxicity can be prevented by a lower starting dose [50 percent of the minimal phototoxic dose (MPD)] and a more cautious dosimetry in the initial treatment phase. Originally, bath-PUVA was performed with TMP, but 8-MOP and 5-MOP are now being used as well. Bath-PUVA consists of 15 to 20 min of whole-body immersion in solutions of 0.5 to 5.0 mg 8-MOP per liter of bathwater. Irradiation needs to be performed immediately, as photosensitivity decreases rather rapidly. TMP is more phototoxic after topical application and is used at lower concentrations than 8-MOP. MPD testing for bath-PUVA must take into account that the phototoxic threshold declines during the early treatment phase, in contrast to oral PUVA. The MPD obtained with four consecutive daily determinations is approximately 50 percent of the MPD obtained with only one determination. [10] Guidelines for bath, local immersion, and other topical PUVA forms recently published by the British Photodermatology Group are based, where possible, on the results of controlled studies, or otherwise on the consensus view on current practice. [14]

ORAL TREATMENT In oral PUVA, 8-MOP is administered orally (0.6 to 0.8 mg per kilogram body weight) 1 to 3 h before exposure, depending on the absorption characteristics of the particular drug brand. Liquid drug preparations are absorbed faster and yield higher and more reproducible serum levels than microcrystalline forms. For 5-MOP the usual dosage is 1.2 to 1.8 mg per kilogram body weight. The initial UVA doses are established by either skin typing [15], [16] or by MPD testing. [13], [17] In the United States, skin reactivity is determined by the classical skin phototype scheme according to sunburn history. Therapeutic doses of UVA are then given according to an empirical scheme based on this classification [15] (Table 266-2). In Europe, dosimetry commonly relies on MPD determination. [13] The MPD is defined as the minimal dose of UVA that produces a barely perceptible, but well-defined, erythema when template areas of the skin are exposed to increasing doses of UVA. Erythema readings are performed 72 h after testing, at which time the psoralen phototoxicity reaction usually reaches its peak. The MPD test should be performed on previously nonexposed skin (e.g., buttocks). Although the MPD test is more time-consuming than phototyping, it allows for more accurate and higher UVA doses during initial treatment.

	Skin Phototype[a]	Recommended Dose (J/cm^2)
I	Always burn, never tan[b,c]	0.5
II	Always burn, but sometimes tan	1.0
III	Sometimes burn, but always tan	1.5
IV	Never burn, always tan	2.0
V[d]	Moderately pigmented	2.5
VI[d]	Blacks	3.0

[a]Types I to IV are determined by history; types V and VI are determined by physical examination (racial descent).
[b]Patients with erythrodermic psoriasis are to be classified as skin phototype I for determination of UVA dosage.
[c]Patients with natural pigmentation of these types should be classified into a lower skin phototype category if the sunburning history so indicates.
SOURCE: Adapted from Melski et al.[15]

TABLE 266-2 **Skin Phototypes**

Repeated exposures are required to clear PUVA-responsive diseases, with gradual dose increments as pigmentation develops. Lower doses quite frequently result in failure of treatment except in those diseases in which induction of pigmentation is the desired objective. In most dermatoses amenable to PUVA, the frequency of treatments is reduced after satisfactory clearing of disease, and the last UVA dose is used as a maintenance dose if maintenance treatment is

planned. The duration of this maintenance phase and the frequency of treatments depend on the particular disease being treated and its propensity to relapse.

PUVA for Psoriasis

Before the advent of oral PUVA, topical psoralen photochemotherapy was used. This may still be indicated for the treatment of resistant plaques and particularly palmoplantar lesions, in conjunction with total-body oral PUVA. In contrast, bath-PUVA therapy, with whole-body immersion in TMP or 8-MOP baths followed by total-body irradiation, does yield satisfactory results. Bathwater delivery of 8-MOP represents a useful alternative to oral PUVA; because of the higher degree of photosensitivity, the UVA dose can be kept much lower.

The effectiveness of oral PUVA in inducing and maintaining remission of psoriasis has been widely documented and confirmed by large-scale clinical trials (Fig. 266-1, Fig. 266-2, and Fig. 266-3). The first two controlled multicenter clinical trials were conducted between 1975 and 1980 in the United States [15] and Europe. [16] The results of these trials are now the standard of reference for all claims of efficacy of PUVA therapy. Both studies reported similar remission rates, but because of the different treatment schedule in the US Cooperative Clinical Trial (Table 266-3), [15] the duration of the clearing phase was twice as long as in the European study. [16] In addition, total UVA requirements in the US study were more than twice as high, and the final single doses differed by about 90 percent (Table 266-4).

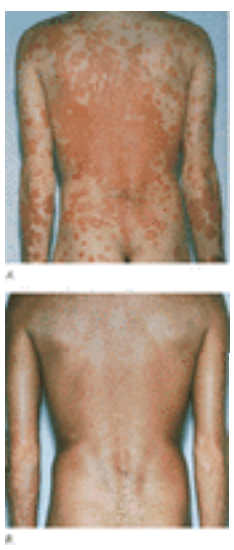

FIGURE 266-1 Twenty-three-year-old patient with generalized psoriasis (seborrheic type). *A*. Before PUVA treatment. *B.* After treatment. (*From Wolff et al.,* [3] *with permission.*)

FIGURE 266-2 Twenty-three-year-old patient with generalized psoriasis (plaque-type). *A.* Before PUVA treatment. *B.* After treatment. (*From Wolff et al.,* [17] *with permission.*)

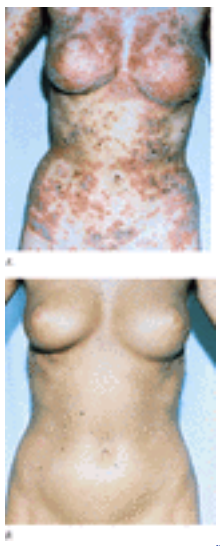

FIGURE 266-3 Eighteen-year-old patient with pustular psoriasis (von Zumbusch type). *A.* Before PUVA treatment. *B.*

After treatment. (*From Hönigsmann H et al., Photochemotherapy for pustular psoriasis (von Zumbusch). Br J Dermatol 97:119, 1977, with permission.*)

	United States	Europe
UVA dosimetry	Predetermined dose according to skin phototype	Individualized dose according to MPD determination
Frequency of treatments	Two to three times per week	Four times per week
Dose increments	Predetermined	Individualized
Principle of approach	Rigid, cautious	Flexible, aggressive
Goal	To clear without persistence testing and acute side effects	To clear rapidly before maximum pigmentation develops

TABLE 266-3 **Differences between US and European Protocols**

	United States	Europe
Number of patients	1139	3175
Result better than marked improvement	1005 (88%)	2785 (89%)
Exposures required for clearing (median)	25	20
Duration of treatment (weeks)	12.7	5.3
Cumulative UVA dose (J/cm^2) (all patients and skin phototypes)	245	96

SOURCE: US adapted from Melski et al.[13] Europe adapted from Hönigsmann et al.[14]

TABLE 266-4 **Treatment Results**

Three studies have compared bathwater delivery of 8-MOP with oral administration. In two reports, initial doses were determined by skin typing, and treatments were given two to three times weekly. Dose increments were instituted with every treatment in one study, whereas smaller increments were given every third treatment in the other. The most recent report, in which patients were treated according to the guidelines of the standard European regimen for oral PUVA, showed the lowest incidence of treatment failures and overdose episodes. In comparison with the results obtained with oral 8-MOP, bath-PUVA showed equal clearing rates with lower numbers of exposures. [10] The greater therapeutic efficacy could be because of a higher penetration of psoralens through the abnormal stratum corneum overlying psoriatic plaques, as compared with healthy perilesional skin where phototoxicity is monitored during the therapy. The incidences of erythema and pruritus were similar or lower compared to oral therapy. Episodes of systemic intolerance such as nausea and vomiting were only recorded with oral PUVA.

As mentioned above, oral 5-MOP–PUVA represents an alternative to 8-MOP–PUVA. Psoriatic lesions are cleared with a comparable number of exposures, but 5-MOP requires significantly higher cumulative UVA doses. This difference is a result of the lower phototoxicity potential of 5-MOP and of its higher tanning activity. Nevertheless, 5-MOP–PUVA therapy seems particularly valuable because of the absence of nausea and vomiting and the lower incidence of pruritus and severe phototoxic skin reactions. [10]

Upon complete clearing, patients are often assigned to maintenance therapy, during which the frequency of treatments is gradually reduced. [18] The purpose of maintenance therapy is to achieve longer remission. Maintenance therapy recommended in the original European regimen consisted of 1 month of twice-weekly treatments, with the last UVA dose used for clearing, followed by another month of once-weekly exposures. According to other recommendations (British Photodermatology Group), [19] maintenance treatment should be considered only upon rapid relapses, because patients with a stable remission may be overtreated, and long-term risks of PUVA are related to the total cumulative phototoxic doses delivered to the skin during continuous or long-term treatment. Although PUVA has now been in use for more than 28 years, the question of whether maintenance therapy can prevent early relapses, particularly in psoriasis, remains unanswered.

Erythrodermic and generalized pustular psoriasis (von Zumbusch type) respond to PUVA (Fig. 266-3), but the time required to induce remission is considerably longer, more treatments are needed, and higher failure rates are reported, as compared to plaque or guttate varieties. Pustular eruptions of palms and soles are quite recalcitrant to treatment, regardless of whether they are true localized pustular psoriasis, nonpsoriatic palmoplantar pustulosis or pustular psoriasis, or pustular eczema. Oral PUVA alone can produce a slow but definite remission in many cases, but a considerable number of patients require adjunctive therapy for clearing. As mentioned above, the combination with topically applied 8-MOP can be beneficial, but bath-PUVA appears to be also quite effective in such cases. The addition of oral retinoids will help to clear the majority of patients (see below).

COMBINATION TREATMENTS

Topical combination PUVA has been combined with other treatment forms to improve efficacy and to reduce possible side effects. Topical adjuvant therapies with glucocorticoids, anthralin, and tar preparations, and, more recently, the combination with calcipotriol and tazarotene have yielded good results. However, adjunctive topical therapy is found unacceptable by some patients because it is considered a step backward to conventional treatment.

Methotrexate A combination of PUVA and methotrexate can reduce the duration of treatment, number of exposures, and total UVA dose and is also effective in clearing patients unresponsive to PUVA or UVB alone. [20] This combination appears to be safe if used during the clearing phase only. However, if used for long-term treatment, PUVA and methotrexate may act synergistically in the development of skin cancers. [21]

Cyclosporin Cyclosporin plus PUVA therapy and retinoids plus PUVA (RePUVA) therapy cleared widespread plaque-type psoriasis in a comparable time. However, RePUVA was significantly superior regarding the cumulative UVA dose required for clearance and the incidence of severe and early relapses. Particularly in view of possible long-term side effects (immune suppression, skin carcinogenesis), the combination of PUVA plus cyclosporin cannot be recommended. [10], [22]

Retinoids The therapeutic efficacy of PUVA therapy is dramatically increased when combined with daily oral retinoid (etretinate, acitretin, isotretinoin; 1 mg/kg) administration 5 to 10 days before the initiation of PUVA, and when this combined treatment is continued throughout the clearing phase. RePUVA was reported to reduce the number of exposures by one-third and the total cumulative UVA dose by more than one-half. RePUVA was also shown to clear “poor PUVA responders” who could not be brought into complete remission by PUVA alone. [23] The mechanism of the

synergistic action of retinoids and PUVA is unknown, but may be a result of the accelerated desquamation that optimizes the optical properties of the skin and to the reduction of the inflammatory infiltrate. As an additional beneficial effect, etretinate and other retinoids may theoretically protect against long-term carcinogenic effects of PUVA, mainly by reducing the number of exposures and by their potential cancer-protective effect. Retinoid toxicity is not a concern because the administration is limited to the clearing phase. The potential teratogenicity of retinoids represents a serious concern. For women of child-bearing age, the use of isotretinoin can be considered because contraception is necessary for only 2 months after discontinuation of therapy, in contrast to etretinate and acitretin, which require 2 years of contraception. [10]

PUVA for Cutaneous T Cell Lymphoma (Mycosis Fungoides) (See Chap. 157)

Based on the known beneficial effect of natural sunlight on early mycosis fungoides, several prospective studies evaluated the effect of photochemotherapy in this disease.

Since the first promising results with photochemotherapy in 1976 [24] (Fig. 266-4), numerous investigators from the United States and Europe have confirmed its efficacy. [25] Treatment schedules and dosimetry in photochemotherapy of CTCL are essentially the same as for psoriasis. The treatment consists of a clearing phase, a maintenance phase, and a follow-up phase without therapy. Remission should be confirmed by histologic examination of previously involved skin sites. The initial treatments are followed by maintenance consisting of two exposures per week for 1 month and one exposure per week for another month. Thereafter, therapy is discontinued and the patient monitored monthly and later bimonthly. If a relapse occurs, the patient is again subjected to a full PUVA course. Some investigators advocate permanent maintenance treatment consisting of treatments once monthly or every other month. Because the course of CTCL varies considerably from patient to patient the final answer remains to be determined. Clinical experience indicates that patients benefit most from individualized schedules. [10]

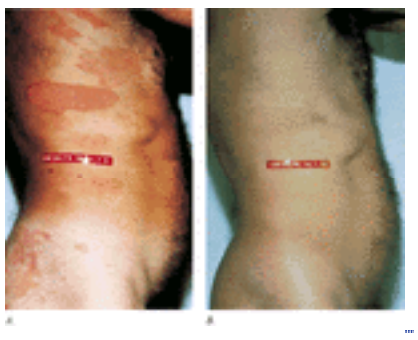

FIGURE 266-4 Forty-six-year-old patient with cutaneous T cell lymphoma (mycosis fungoides), stage IB. *A.* Before PUVA treatment. *B.* After treatment.

Relapses respond as well as the initial lesions when PUVA is resumed. Clinical remissions appear to be directly related to phototoxic destruction of the malignant infiltrate. Thus, complete clearing may be induced when the cells are confined to the epidermis and the superficial dermis and do not exceed the depth of UVA penetration into the skin. Present knowledge indicates that photochemotherapy may induce long-lasting disease-free intervals in CTCL if used in the early stages of the disease. [25] In later stages, PUVA may reduce the tumor cell burden and thus may act synergistically with other treatment. It improves the quality of life and may prolong survival when used in combination with more aggressive treatment modalities. Prolonged remissions were observed with combinations of PUVA with retinoids and with interferon a-2a. [26], [27]

Patients with tumor-stage CTCL exhibit a high rate of early recurrences, which require permanent maintenance treatment, and only the combination of PUVA with local x-ray treatment and/or systemic chemotherapy can result in complete tumor resolution. Most follow-up studies have demonstrated that the great majority of patients with early disease can be kept in remission with or without maintenance therapy for several years. Tumor-stage patients (IIB) usually experience multiple recurrences despite aggressive combination therapies and eventually die within a few years. [25] Currently, no therapeutic regimen is known to arrest the eventual progression of CTCL to tumor formation, dissemination, and fatal outcome. While PUVA therapy is very effective in inducing remission as long as the lymphoma is confined to the skin, the influence of this therapy on the natural course of CTCL and on patient survival is not yet determined. However, data from Sweden show a significant drop in the death rate of patients since the introduction of PUVA. [28]

Successful treatment of the erythrodermic type of CTCL (Sézary syndrome) has been reported with extracorporeal PUVA (photopheresis) (see below). Possible long-term hazards related to frequent PUVA treatments are probably meaningless for patients with CTCL, as compared to patients with benign conditions.

PUVA for Atopic Dermatitis (See Chap. 122)

Many patients with atopic eczema can benefit from PUVA therapy. [29] The treatment guidelines are essentially the same as for psoriasis. However, the condition is more difficult to treat, and quite often a higher number of treatments are required to clear the eczema. There is a high and early recurrence rate, requiring frequent maintenance exposures. As the average patient is young, one should hesitate to initiate long-term maintenance therapy until the possible risks of such treatment are better understood. A combination of PUVA with topical glucocorticoids appears to be superior to PUVA alone in maintaining remissions. The mechanism of action of photochemotherapy in atopic eczema is unclear; current concepts support an alteration of lymphocyte function in the dermal infiltrate.

PUVA for Lichen Planus (See Chap. 49)

In generalized lichen planus, PUVA can provide an effective alternative to systemic glucocorticoid treatment. As indicated by two studies, lichen planus proves to be more resistant to PUVA than psoriasis when treated according to a similar schedule. More exposures and higher cumulative UVA doses are required for clearing, and not all patients respond satisfactorily. An exacerbation during PUVA treatment has been reported in a few patients. In patients who have been cleared, relapses respond equally well when PUVA is resumed. Also, bath-PUVA can clear lichen planus. A combined PUVA-etretinate regimen may accelerate clearing. [30]

PUVA for Cutaneous Mastocytosis (See Chap. 163)

In cutaneous mastocytosis (urticaria pigmentosa), photochemotherapy leads to a temporary involution of skin lesions. [31] The treatment results in loss of Darier's sign, relief of itching, and flattening and even complete disappearance of cutaneous papules and macules. Surprisingly, even systemic symptoms such as histamine-induced migraine and flushing fade gradually as treatment is continued. [31] In most patients reported so far, the manifestations of the disease recurred several months after discontinuation of PUVA, but the recurrences respond as well as the original lesions. The mechanisms that lead to this response are a matter of debate. Both a decrease and no change in mean mast cell counts have been found after clinical clearing of skin lesions. [30], [31]

Despite this uncertainty concerning its mode of action, PUVA seems to be warranted in patients with urticaria pigmentosa when the disease is causing severe distress. Because the treatment of the cutaneous lesions of mastocytosis has been unrewarding with other modalities, the use of PUVA, although not curative, is at present the only therapy available to control the skin lesions in this condition.

PUVA for Miscellaneous Dermatoses

Both acute and chronic pityriasis lichenoides [30] respond to photochemotherapy, and favorable results have been reported for lymphomatoid papulosis. [32] The experience with these conditions is limited to a few anecdotal cases. In pityriasis rubra pilaris, the results are quite inconsistent. Some cases seem to respond well, others may flare, and some require combination treatment with retinoid or methotrexate therapy. Generalized granuloma annulare has been reported to clear completely, but long-term maintenance treatment was required to maintain remissions. [33] Regrowth of hair was noted in alopecia areata with either topical or systemic PUVA exposures localized to the alopecia areas. Follow-up studies of larger patient groups concluded that PUVA is generally not an effective treatment for alopecia areata. [34] The authors' experience has also not been encouraging. Localized scleroderma and pansclerotic morphea have been successfully treated with bath-PUVA and oral PUVA. [35], [36]

PUVA for Chronic Graft-versus-Host Disease (GVHD) (See Chap. 118)

An indication of increasing importance may be acute and chronic cutaneous GVDH. Because of the clinical and histologic similarities of idiopathic lichen planus and lichenoid GVHD, PUVA treatment was evaluated for the latter. [37] The beneficial effects of PUVA in lichen planus-like eruption were demonstrated in patients who had not responded to conventional immunosuppressive therapy alone. PUVA can also improve acute graft-versus-host disease. [38] Reports on the results of PUVA treatment of scleroderma-like variants of cutaneous GVHD are controversial. According to our own experience the more circumscribed, localized forms appear to respond to PUVA more rapidly, concomitantly with softening of the fibrotic, sclerotic connective tissue. However, the more widespread, disseminated lesions hardly respond to PUVA.

Unlike other conditions, PUVA may exert both local and systemic effects because an initial improvement of mucosal erosions followed by healing was observed upon treatment of chronic lichenoid GVHD with PUVA, but this could also be mere coincidence. Apparently, there is no improvement of GVHD of other organs such as the liver.

The therapeutic regimen used for the treatment of chronic GVHD is basically the same as for psoriasis. UVA doses should not be increased too aggressively, in order to avoid erythema and possible (re)activation of GVHD. In general, increase of the UVA dosage by 0.5 J/cm ^{2} at maximum after every second to fourth exposure can be recommended. Patients are exposed to UVA radiation three to four times weekly. After clearing of skin lesions, exposures are reduced according to the outlined maintenance schedule.

Because there may be an overall increased risk of secondary malignancies for all bone marrow/peripheral stem cell recipients, no matter whether they had experienced cutaneous GVHD and whether or not they have been treated with PUVA, these patients must be examined on a regular basis for the development of cutaneous malignancies.

PUVA for Vitiligo (See Chap. 90)

Vitiligo was the first disease treated with an ancient form of psoralen photochemotherapy in folk medicine in India and Egypt. PUVA in its modern form stimulates melanogenesis, melanocyte proliferation and migration, and reconstitutes the normal skin color in more than 50 percent of vitiligo patients.

TREATMENT PROTOCOLS AND RESULTS Oral 8-MOP or TMP are the photosensitizers most frequently used, followed by exposure to sunlight or artificial UVA radiation. From a large controlled clinical trial by the Harvard group, detailed information became available on different treatment schedules and efficacy of treatment. [1] Also, 5-MOP has been studied in a large trial in India, and is used in some European countries with success (Fig. 266-5) (for references see Ref. [10]). To induce repigmentation, patients need constant long-term therapy (12 to 24 months). Because oral TMP is much less phototoxic than 8-MOP, it is preferred for treatment, with sunlight as the radiation source. Treatments should

be given two or three times a week. If there is no response after 6 months or approximately 50 treatments, PUVA should be terminated. Responsiveness is defined as the development of perifollicular macules of repigmentation. If treatment is discontinued, this newly acquired repigmentation may be lost unless treatment is continued until the lesion has completely repigmented. Completely repigmented areas can be stable for a decade or more without relapse. [39]

FIGURE 266-5 Twelve-year-old patient with generalized vitiligo of 4-years duration. *A* and *C.* During the initial phases of PUVA treatment. *B* and *D.* One month after treatment (8-MOP + artificial UVA) with thrice-weekly exposures for 10 months.

Another photochemotherapeutic regimen for vitiligo, using khellin (a furanochromone) as the photosensitizer and UVA irradiation (KUVA), was introduced some years ago. This substance does not lead to phototoxic erythema and exhibits a substantially lower mutagenic activity than do psoralens. Its efficacy and failure rate in vitiligo treatment are comparable to those of PUVA. [40] The major advantage of khellin is that it does not induce phototoxic erythema and thus can be considered safe for home treatment or treatment with natural sunlight. Khellin (not available in the United States) is administered orally at a dose of 100 mg 2 h before treatment or applied topically as a 5% cream. Cream preparations of khellin in concentrations of 5% proved to be effective for topical KUVA. As with psoralens, there is evidence that drug availability and clinical response does not only depend on khellin concentration, but that the vehicle may be of critical importance. The efficacy of topical KUVA in comparison with oral PUVA or other therapeutic modalities has not been established. Patient selection appears to be particularly important in vitiligo treatment. The patients should be age 12 or over and must be available for 12 to 24 months of continuous therapy. Lips, distal dorsal hands, tips of fingers and toes, areas of bony prominences, palms, soles, and nipples are very refractory to treatment, and patients with involvement limited to these areas should be excluded. Segmental vitiligo tends to show a variable response. On average, a complete treatment course consists of at least 150 exposures. However, because of the different response in different body areas, total repigmentation is only rarely achieved, and some 30 percent of patients do not respond at all despite many months of therapy. The mechanisms by which PUVA induces repigmentation in vitiligo skin remain mostly speculative. Bearing in mind the modulating effect of UV radiation on a number of immunologic reactions, one might postulate a hypothetical suppressor cell population generated by PUVA that suppresses the stimulus for melanocyte destruction during therapy.

PUVA as Prevention Treatment for Photodermatoses (See Chap. 135)

Tolerance to sunlight can be induced in several photodermatoses with PUVA. In polymorphous light eruption, the most common photodermatosis, PUVA is the most effective preventive treatment. [41] In approximately 70 percent of patients with this condition, a 3- to 4-week PUVA course of two to three treatments per week suffices to suppress the disease upon subsequent exposure to sunlight. The initial exposure and dose increments during therapy should be performed according to the guidelines outlined above for psoriasis. PUVA has the advantage of a rapid and intense pigment induction at relatively low UVA doses that usually remain well below the threshold doses for eliciting the rash. Approximately 10 percent of patients develop typical lesions during the initial phase of PUVA, but these usually disappear when treatment is continued. The authors' treatment schedule consists of three to four treatments per week for 3 to 4 weeks in early spring; PUVA preventive treatment protects only temporarily, but subsequent sun exposures will maintain protection. However, a considerable number of patients remain protected for 2 to 3 months, even after pigmentation has faded.

The mechanisms by which phototherapy induces tolerance to sunlight are not completely clear. Hyperpigmentation and thickening of the stratum corneum may be important factors for the protective effect. However, other mechanisms may also be involved, because polymorphous light eruption does occur in dark-skinned individuals. In this context, modulations of cutaneous immune functions are being discussed, although there is presently no evidence to confirm the possible role of immune mechanisms. [41]

There is also some experience with PUVA prophylaxis of other photodermatoses. In solar urticaria, PUVA therapy appears to be the most effective preventive treatment available and is certainly better than antihistamines. Tolerance to sunlight can be increased tenfold or more after a single treatment course. The suppressive effect may last throughout the summer if the patients have regular sunlight exposures, which seem to be necessary to maintain tolerance. Problems may arise during the first PUVA exposures, because in some patients the urticaria threshold dose appears to be lower than their MPD. In these cases, careful conditioning by stepwise UVA irradiation of single quadrants of the body surface a few hours before each PUVA treatment have proved useful. Treatments with PUVA are then given during the refractory period.

Successful photochemotherapy has also been reported in occasional cases of chronic actinic dermatitis and hydroa vacciniforme. Limited experience in patients with erythropoietic protoporphyria indicates that, with a very cautious approach and in combination with beta-carotene, PUVA may increase light tolerance considerably. [42], [43]

Considerations about long-term hazards are important, especially in benign disorders such as the photodermatoses. However, extended treatment duration is usually not required in polymorphous light eruption, but in solar urticaria and chronic actinic dermatitis, prolonged therapy may be necessary. There exist no ready-to-use schedules for these latter

conditions and PUVA is usually just one part of the management. [42]

PUVA in HIV-Infected Patients

The use of phototherapy and photochemotherapy in HIV-infected patients with skin diseases is controversial. First, both therapies can induce systemic immune suppression and may modify the immune status of the patient in a way that would lead to a worsening of HIV disease. [44] Second, both UV radiation and psoralen photosensitization were demonstrated to activate the HIV promoter, which could boost viral gene transcription and, eventually, virus production. [45] In addition, HIV-induced immune suppression could support an accelerated development of skin carcinomas in UVB- or PUVA-treated patients. With oral PUVA, treatment of psoriasis did not induce progression of HIV disease or an increase in side effects. [46], [47] It was concluded from these studies that PUVA may be safe for HIV-positive patients with psoriasis. Theoretical modeling of the UVB- and PUVA-induced HIV promoter activation in human skin indicated that UVB is more likely than PUVA to activate viral transcription in vivo. [48] Data from long-term observations are currently awaited. Thus, it is presently impossible to advocate the use of PUVA in (HIV-) immunosuppressed individuals in general, but major hazards are unlikely. The available data and theoretical considerations indicate that UVB is more likely to be a hazard than PUVA in an HIV-infected population. [48], [49]

Side Effects and Toxicity of PUVA

ACUTE SIDE EFFECTS The side effects of PUVA include drug intolerance reactions as well as side effects of the combined action of psoralens plus UVA radiation. Oral 8-MOP (0.6 to 0.8 mg/kg) has a high incidence of nausea (30 percent of patients) and vomiting (10 percent of patients), and this may occasionally require discontinuation of the treatment. These side effects are more common with liquid preparations than with crystalline preparations, probably because of higher psoralen serum levels. With 5-MOP, nausea is almost absent, even with doses of up to 1.8 mg/kg body weight. [8] Undesired acute effects of the combined action of psoralens and UVA can range from an increased delayed erythema reaction to severe burns with blistering. Some patients experience persistent pruritus during PUVA treatment, particularly after slight UVA overdosage, and in rare cases a stinging pain may develop in circumscribed areas. The mechanism is unknown, and the symptoms are unresponsive to antihistamines. These complaints usually subside upon continuation of treatment. Overdosage phenomena occur mostly in body areas not usually exposed to natural sunlight. Careful observation of the criteria for dosimetry can minimize these side effects to acceptable levels. The danger of overdosage is much less with 5-MOP. Very rare side effects of PUVA include polymorphous light eruption-like rashes, acne-like eruptions, subungual hemorrhages caused by phototoxic reactions of the nail beds, and occasional hypertrichosis of the face. These are transient and disappear when treatment is discontinued. Single case reports include exacerbation of systemic lupus erythematosus and bullous pemphigoid during photochemotherapy.
LABORATORY DATA Analysis of laboratory data in several large-scale studies showed no significant abnormal findings in patients receiving PUVA over prolonged periods of time. [15], [16], [50] Serial laboratory examinations performed over a period of several years have not revealed any substantial evidence for an impairment of hepatic function. [18] Liver biopsies after 1 year of therapy did not reveal signs of hepatotoxicity. [51] No evidence exists suggesting impairment of renal function. [15] Several large-scale studies have negated a possible relation between PUVA therapy and the occurrence of antinuclear antibodies. [52]
POTENTIAL LONG-TERM RISKS OF PUVA
Chronic actinic damage Repeated phototoxic injury to the skin can be expected to result in cumulative actinic damage regardless of whether it is induced by sunlight, artificial UV radiation, or PUVA. Chronic exposure to PUVA may produce changes in the skin that resemble photoaging and that may add to the injury induced by sunlight. PUVA lentigines and generalized PUVA lentiginosis result from repeated and prolonged treatment and are commonly associated with high cumulative doses of UVA and a large number of treatments. [16] They exhibit irregular borders and show uneven pigmentation. So far, no increased risk of cutaneous melanoma associated with these lentigines has been recorded, but the cosmetic effect may be quite disturbing.
Carcinogenesis Cutaneous carcinogenicity is the major concern about long-term and repeated PUVA treatment associated with high cumulative UVA doses. In laboratory animals, 8-MOP and 5-MOP have been unequivocally shown to induce skin cancer at levels of drug and UVA irradiation comparable to those used in PUVA therapy. [53], [54] Obviously the risk is related to DNA damage, but PUVA-induced downregulation of immune responses may play an additional role. Although animal studies provide important evidence for the carcinogenic potential, in the human situation this risk has to be assessed against the potential therapeutic benefit. All long-term follow-up studies suffer from the fact that patients are likely to have been exposed previously to other carcinogenic treatments such as ionizing radiation, UVB therapy methotrexate, tar, or arsenic. Correct adjustment for all these factors may be quite problematic, particularly because accurate data are often missing. In PUVA patients, the risk of squamous cell carcinoma, but not of basal cell carcinoma, is significantly increased in comparison with matched controls and the magnitude of the increase appears to be dose-dependent. [21], [54] However, there is uncertainty about PUVA being the sole factor—many of the affected patients had previous exposure to excessive sunlight and to treatments with carcinogenic potential, including arsenic, UVB, and antimetabolite therapy. [55] According to a single study, male genitalia appeared to be particularly susceptible to carcinogenic stimuli of PUVA in patients previously treated with tar and UVB, [56] but the risk seemed not to be increased if only PUVA was used. [57] In a retrospective study from France comprising 5400 patients treated between 1978 and 1998 no case of genital skin cancer was found, despite the fact that the genital area had not been protected during UVA exposure and this makes it unlikely that genital shielding may be indeed absolutely necessary. [58] Carcinogenicity of 5-MOP–UVA therapy in PUVA-treated patients is unknown but 5-MOP has shown a similar activity to 8-MOP in in vitro photomutagenicity studies and photocarcinogenicity studies in mice. Only a few anecdotal cases of malignant melanoma have been observed in long-term PUVA treated psoriatics, and no increased risk of melanoma was found in all large-scale studies. However, Stern et al. reported from the cohort of 1380 patients enrolled in the PUVA Follow-up Study (16-Center Study) that since 1975, 23 patients have developed 26 invasive or in situ cutaneous melanomas. Beginning 15 years after first exposure to PUVA, an increased risk of melanoma was observed in their cohort of PUVA-treated patients. [59], [60] This risk was greater in patients exposed to high doses of PUVA and appeared to be increasing with the passage of time. The conclusions of this study have been questioned, [61] and the authors now agree [60] that the observed

risk of melanoma does not represent an absolute contraindication to PUVA or that PUVA therapy should be abandoned. Rather, the risks of both melanoma and squamous cell carcinoma in PUVA should be weighed against the substantial efficacy of PUVA and the risks of other therapies. [61] Perhaps PUVA has been treated unfairly. Its long-term risks have been subject to much greater scrutiny than the risks of other therapies advocated for severe psoriasis, such as methotrexate and, particularly, immunosuppressive therapies such as cyclosporine; these therapies greatly increase some cancer risks in populations who are less likely to have substantial exposures to known cutaneous carcinogens such as sunlight, or who have attributes such as fair skin, than are patients with severe psoriasis. Early detection through careful long-term follow-up, perhaps lifetime monitoring and education of patients exposed to PUVA, may help to reduce the long-term morbidity and mortality associated with PUVA therapy. Nonetheless, the potential risk of melanoma has to be taken seriously as have the guidelines for PUVA. The cumulative dosages must be kept low and therefore UVA-saving aggressive regimens without prolonged maintenance therapy may be safer than continuous nonaggressive regimens. [62] Based on a recent study of 944 Swedish and Finnish patients, [63] bath-PUVA with TMP seems to bear no relevant risk of carcinogenesis. In addition, no association between cutaneous cancer and 8-MOP bath-PUVA was found in 158 Finnish psoriatic patients. [64] Although hard to understand, these data on the long-term safety of bath-PUVA are encouraging, but premature conclusions should not be drawn. It is important to compare the risks of PUVA with UVB phototherapy. Animal studies show that UVB is carcinogenic but mathematical model studies indicate that the observed risk of squamous cell carcinoma is much higher with PUVA than the calculated risk with UVB. [65] There is a recent trend toward the use of narrowband UVB. The carcinogenic risk of this source in comparison with PUVA is unknown, and it will be crucial to monitor its long-term effects in psoriatics.

Ophthalmologic effects Despite data from animal studies, which indicate a risk of premature cataract formation, clinical evaluation shows no increase in lens opacities, even in patients who neglected careful eye protection. Several studies have shown no indication that psoralen-induced cataracts occur in patients undergoing long-term photochemotherapy. The majority of prospective studies did not report an increased incidence of lens opacities in patients who used eye protection following psoralen ingestion. [66] Obviously, there is no risk with topical or bath-PUVA.

Patient Selection and Contraindications

In view of the potential long-term hazards, the assignment of patients to photochemotherapy should be based on consideration of the risks and the benefit for the individual patient. If only a short-term course of therapy is planned, as, for example, in prevention of photodermatoses, the benefit outweighs the risk. In the treatment of a malignant condition such as CTCL, long-term risks may be meaningless because other treatment options bear the risk of even greater long-term toxicity. The major concerns relate to long-term treatment of psoriasis because this condition represents by far the most common indication for PUVA. As long as the risks of long-term use are not clearly known, careful patient selection appears to be mandatory. Guidelines of care have been published by the American Academy of Dermatology. [17]

Photochemotherapy should not be used during pregnancy, and women should be advised to use contraceptive measures while on PUVA. This precaution is only for reasons of absolute safety as there exists no evidence that either 8-MOP alone or photochemotherapy is teratogenic, as confirmed in a retrospective study in 256 deliveries among the cohort of the 16-Center PUVA Follow-Up Study. [67] However, it has to be emphasized that RePUVA bears the risk of retinoid teratogenicity.

Severe impairment of hepatic and renal functions is usually considered a contraindication to PUVA because metabolism and excretion of psoralens may be inadequate. PUVA is also contraindicated in patients with known light-aggravated or light-induced diseases such as lupus erythematosus, porphyria (but as mentioned above, light tolerance can be induced by PUVA in erythropoietic protoporphyria), and xeroderma pigmentosum. Pemphigus and bullous pemphigoid may be exacerbated by PUVA. Patients with chronic actinic damage and a history of skin cancers may be at higher risk for the development of new cancers. Previous arsenic intake and previous treatment with ionizing radiation also seem to increase the risk of nonmelanoma skin cancers. Immunosuppressed patients should probably not receive PUVA, although this is not yet clearly defined. As outlined above, PUVA can be used in HIV-positive patients. Cataracts and aphakia are not real contraindications if adequate eye protection is guaranteed.

Conclusions and Perspectives

Photochemotherapy is a highly effective treatment for several dermatologic diseases, but it does not lead to permanent cure in most conditions. An exception may be vitiligo, in which PUVA-induced repigmentation may last for many years, or even a lifetime. Although there exists comprehensive clinical experience documenting PUVA's short-term safety when used according to standardized methods, as outlined in this chapter, the risk of potential long-term sequelae has still not been clearly determined. Thus, strategies for treatment should take into account whether other forms of therapy are available that carry a lower risk but are equally effective. Risk-versus-benefit decisions should weigh potential long-term hazards against severity and morbidity of the disease and therefore will vary with the disease being treated. In early stages of mycosis fungoides, the risk-versus-benefit ratio will clearly be in favor of PUVA as an alternative for other treatment options. For polymorphous light eruption, the number of treatments each year necessary to provide relief of discomfort is so small that long-term risks may be negligible. The major concern relates to the treatment of severe psoriasis, as this is the most common indication for PUVA that may require repeated long-term therapy. In many patients with disabling psoriasis, PUVA is more effective than topical therapy, the Goeckerman regimen, or UVB therapy not only in clearing of disease but also in maintaining remission. Regarding chronic toxicity, PUVA appears to be a most valuable alternative to methotrexate and other antimetabolites. Treatment with broadband and narrowband UVB also causes actinic skin changes, alterations of the immune system, and skin carcinomas; and apart from the fact that UVB is not equally effective in all forms of psoriasis, there is no convincing evidence at present that it may be safer than PUVA for long-term use.

Severe widespread psoriasis is a devastating disease that may result in disruption of professional, social, and private life. After almost 28 years of experience with PUVA for the treatment of psoriasis, it has become evident that this therapy offers innumerable patients the chance to resume a normal life. For disabling psoriasis the choice of therapies lies not

between risk and safety but among alternative choices of action (methotrexate, cyclosporine, and UVB), none of which is absolutely safe. [61]

EXTRACORPOREAL PHOTOCHEMOTHERAPY (PHOTOPHERESIS, ECP)

Since 1987, ECP, consisting of extracorporeal irradiation of blood fractions in the presence of 8-MOP, has been used for the palliative treatment of erythrodermic CTCL. [68] The initial success was confirmed by subsequent clinical trials so that ECP can be considered a valuable treatment alternative for erythrodermic lymphoma. [69]

ECP has a very low side-effect and toxicity profile, which has led to its evaluation for other indications. The rational basis for the additional treatment spectrum was supported by a number of experimental studies evaluating the effect of ECP on the immune system. [70], [71], [72] and [73] Under the assumption that ECP can suppress pathogenically relevant T cell clones, a number of studies have been performed in order to evaluate the efficacy of ECP in other inflammatory diseases where autoreactive T cells play a causative role. Initial studies have been performed in systemic sclerosis, pemphigus vulgaris, rheumatoid arthritis, and, to a lesser extent, in psoriatic arthritis, systemic lupus erythematosus, dermatomyositis, atopic dermatitis, and inflammatory bowel disease. Recent studies show that ECP may have a considerable impact on the course of acute and chronic organ graft rejection as well as GVHD after allogeneic bone marrow transplantation.

Treatment Method

The procedure involves passage of blood fractions from one arm vein through a photopheresis machine and back. In the machine, subsequent separation of plasma and the white blood cell fraction (buffy coat, peripheral blood mononuclear cells) from the red cell fraction of nonnucleated cells takes place. The latter is returned to the patient without further treatment. Dissolved 8-MOP, as described by Knobler et al., [74] is added to the heparinized plasma and buffy coat fraction as it flows through an UVA exposure system before it is returned to the patient. This treatment is, on average, repeated on 2 successive days with 2- to 4-week intervals.

Treatment Results

CUTANEOUS T CELL LYMPHOMA Erythrodermic CTCL (Sézary syndrome) was the first disease for which ECP was evaluated. Its efficacy was confirmed in several clinical studies, which led to FDA approval for use of ECP for the palliative treatment of this lymphoma type. In the original study by Edelson et al., [68] 27 of 37 patients responded either with a partial or a complete remission. In a follow-up study in which ECP was compared to historical controls ECP appeared to increase survival from a median of 30 months to over 66 months. Subsequent reports confirmed the initially observed efficacy. [69] These studies report grossly a response rate in up to 75 percent of the patients with complete remissions of up to 25 percent and no response in 25 percent. Based on clinical, immunologic, and laboratory data, the attempt was made to better characterize those patients that are more likely to respond to ECP. A normal CD4/CD8 ratio, a normal absolute count of CD8-positive cells in the peripheral blood, presence of Sézary cells and a malignant clone, as well as short disease duration, appear to be predictors of satisfactory therapeutic response. [69] Because a subpopulation of Sézary syndrome patients does not sufficiently respond to ECP, ongoing studies are evaluating possible synergistic effects with other treatments such as interferon-a, methotrexate, and total-skin electron-beam therapy. [69], [75], [76]

PEMPHIGUS VULGARIS Rook et al. [77] first reported on a therapeutic response in three of four patients with drug-resistant pemphigus vulgaris. Significant remissions with concomitant substantial reduction in glucocorticoid and immunosuppressive therapy was obtained. So far six cases have been treated apparently successful with ECP, [78], [79] but controlled randomized trials have not yet been performed.

PROGRESSIVE SYSTEMIC SCLEROSIS Early T lymphocyte infiltration of affected organs as well as the presence of autoreactive antibodies supports the autoimmune concept of progressive systemic sclerosis (PSS), indicating that photopheresis may be useful in PSS. Following a pilot study in two patients with refractive, rapidly progressive disease, a single-blinded, randomized eight-center trial was conducted, comparing photopheresis to D-penicillamine. Seventy-nine patients with systemic sclerosis of recent onset (mean symptom duration, 18 years) and documented progressive cutaneous involvement 6 months before the study entered this trial. In the 10-month study period ECP was shown to be significantly superior to increasing doses of D-penicillamine, both in reversing skin changes as well as stopping progression of skin involvement. Although a number of questions remain to be answered, ECP may have a beneficial effect, at least on the cutaneous manifestations of PSS. [80], [81] and [82]

RHEUMATOID ARTHRITIS In a pilot study on seven patients with rheumatoid arthritis resistant to conventional therapy, improvement was noted in four patients after 4 months of treatment. This was taken as evidence that it may be unlikely to represent a placebo effect not uncommon in patients with this disease. [83] The observation that all patients who did respond experienced a relapse several months after discontinuation of ECP could support this assumption, suggesting that ECP may be of short-term benefit in selected patients with rheumatoid arthritis. However, no confirmatory report has appeared since.

TRANSPLANTATION AND GRAFT-VERSUS-HOST DISEASE ECP may prove to be important in organ transplantation. Small clinical trials have demonstrated that ECP can be a valuable adjunct in the control and prevention of heart transplant rejection with or without immunosuppressive therapy. [84] ECP significantly decreased cardiac rejection episodes without increasing the incidence of infections. [84] Likewise, beneficial effects have been reported in studies on patients with other organ transplants [85], [86], [87] and [88] and graft-versus-host disease, suggesting that ECP may have increasing indications in the field of transplantation medicine. [89], [90]

SYSTEMIC LUPUS ERYTHEMATOSUS Ten patients who met the criteria of the American Rheumatism Association (ARA) for lupus erythematosus were treated with ECP. [91] For the purpose of this pilot study, only patients whose systemic involvement was not life-threatening, who had mild to moderate disease adequately controlled with conventional treatment, and who experienced repeat consecutive flares of disease activity upon attempted reduction and/or elimination of medication, were included. In this uncontrolled study, response to treatment was significant in seven of eight patients completing the trial. The clinical activity score decreased significantly, but the laboratory abnormalities did not change. Clinical improvement of arthritis and cutaneous manifestations was noted. ECP can thus also be used in patients with

known photosensitivity without inducing an exacerbation.

Perspectives

Extracorporeal photochemotherapy was originally conceived for the treatment of cutaneous T cell lymphoma but there are indications that this treatment modality may have beneficial effects in a number of other conditions, particularly in graft-versus-host disease after allogeneic bone marrow transplantation. The data available so far is based on mostly uncontrolled studies and thus remains controversial. Advances in understanding the mechanisms involved have been made, but additional work leading to a better understanding of these is desirable.

PHOTODYNAMIC THERAPY

Photodynamic therapy (PDT) aims to destroy the desired target selectively, thereby avoiding or minimizing damage to vital structures. The photodynamic reaction consists of the excitation of photosensitizers (mainly porphyrins) by visible light in the presence of oxygen, resulting in the generation of reactive oxygen species, particularly singlet oxygen. These reactive oxygen species mediate cellular and vascular effects depending on the tissue localization of the photosensitizer. This results in a direct or indirect cytotoxic effect on the target cell. [92] In dermatology, PDT has been used effectively for precancerous and malignant conditions such as actinic keratosis, basal cell carcinoma, Bowen's disease, and superficial squamous cell carcinoma, as well as for inflammatory dermatoses such as psoriasis or localized scleroderma.

Historical Aspects

In 1904, von Tappeiner coined the term *photodynamic therapy* for the oxygen-dependent destruction of tissue after photosensitization and subsequent irradiation with visible light. [93] Together with Jesionek, a dermatologist, he treated human skin tumors effectively by applying a 5% solution of eosin dye followed by exposure to lamps or sunlight. [94] The first report on successful PDT in psoriasis with oral and intramuscular porphyrin administration appeared in 1937. [95] Systemic administration of hematoporphyrin derivative (HpD) and subsequent laser irradiation became the standard of PDT because these substances showed a relatively selective accumulation in different tumor tissues, and thus led to selective cell destruction. Meanwhile, PDT found its way into the treatment of a variety of internal malignancies and some skin conditions. The main disadvantage of systemic PDT is prolonged cutaneous photosensitivity that may last for several weeks after one single treatment. PDT-treated patients are thus at risk of severe accidental phototoxic reactions. To avoid generalized photosensitivity, the interest has now focused on the topical application of sensitizers or on the local induction of endogenous porphyrin synthesis in the target tissue.

Principles of Photodynamic Therapy

PHOTOSENSITIZERS The ideal photosensitizer for PDT in dermatology should meet the following criteria: (1) chemical purity; (2) high singlet-oxygen quantum yield; (3) significant light absorption at wavelengths that penetrate the skin sufficiently deeply; (4) high tissue selectivity; and (5) efficacy after topical application. Photofrin, a mixture of several HpD ethers and esters, has a low selectivity to skin tumors and leads to long-lasting photosensitivity; consequently, it is not ideal for dermatologic use. In contrast, “endogenous” sensitizers such as 5-aminolevulinic acid (ALA), a metabolite of heme biosynthesis, induce the synthesis of the actual photosensitizer (protoporphyrin IX) in the target tissue. [96] In this case, the concentration of the photosensitizer depends on the metabolic status of the diseased tissue. ALA was approved by the FDA in 1999, in combination with blue light for the treatment of actinic keratoses. In Europe, ALA-methyl ester has also been registered for actinic keratoses and superficial basal cell carcinomas. Most of the photosensitizers generate singlet oxygen with a quantum yield between 5 and 20 percent. A high quantum yield means that less sensitizer is required in the target tissue to induce sufficient PDT effects. The absorption maxima of the current sensitizers range from 600 to 700 nm. In this range, light penetration in tissue is only up to 3 mm, limiting PDT to superficial tumors, unless interstitial light propagation is used. A high selectivity for sensitizer accumulation in target tissue is necessary to avoid damage to surrounding normal tissue, and this is particularly important when larger areas are treated (e.g., actinic keratoses). So far, only ALA or ALA-methyl ester shows reasonably high selectivity after topical application. The ratio of porphyrin induction in skin tumors to the surrounding tissue is higher than 10:1. [97]
LIGHT SOURCES AND DOSIMETRY Light penetration into skin increases with longer wavelengths (? =1100 nm). To match the absorption maxima of porphyrin-based photosensitizers, wavelengths around 630 nm are necessary. Therefore argon-pumped dye lasers (? = 630 nm) represent appropriate irradiation sources. However, these laser systems are quite expensive and require regular maintenance. Meanwhile, laser diodes that are smaller, more powerful, and less expensive are replacing these sources. In contrast to other applications, dermatologic applications need no fiberoptics for endoscopic treatment, thus simpler incoherent light sources represent a valuable alternative. With regard to therapeutic results, there is no difference between coherent and incoherent light. New lamps, fluorescent lamps or light-emitting diodes (LEDs), are commercially available with appropriate red or blue light emission designed for treatment of large surface areas. A standardized light dosimetry for PDT does not exist. Dosimetry depends on the photosensitizer used and on the condition to be treated. For PDT of skin tumors and actinic keratoses, light doses of 100 to 150 J/cm ^{2} are necessary. With current incoherent light sources, the treatment duration is about 15 to 20 min. For treating inflammatory dermatoses (psoriasis), lower doses will suffice because the goal appears not to be tissue destruction but rather sublethal cell damage or modulation of cellular functions.
MECHANISM OF ACTION PDT-induced effects are mediated by photooxidative reactions. During irradiation, the photosensitizer absorbs light (energy) and is converted to an excited (triplet) state. The energy can then be transferred to molecular oxygen (type II photooxidative reaction), resulting in the generation of reactive oxygen species, mainly singlet oxygen. The biologic effects can be divided into primary cellular and secondary vascular damage. With HpD, early visible damage consists of cell membrane defects as a consequence of lipid peroxidation with consecutive cell lysis. Depending on the intracellular localization of the photosensitizers, damage to subcellular structures such as mitochondria, lysosomes, or endoplasmic reticulum also occurs, whereas DNA is not a primary target. Besides these direct effects, which probably play a key role in topical PDT, vascular effects after systemic application of photosensitizers appear to be the decisive event for the treatment of solid tumors. These effects consist of vasoconstriction, blood stasis, and

thrombosis of tumor vessels leading to tumor ischemia and subsequent necrosis. [98]

PDT in Dermatology

Table 266-5 lists the potential indications for PDT. In contrast to other organs, the skin can be sensitized by either intravenous administration or direct topical or intralesional application of the sensitizers.

Oncologic	Nononcologic
Actinic keratosis	Psoriasis vulgaris
Bowen's disease	Localized scleroderma
Superficial basal cell carcinoma	HPV-associated dermatoses
Nevoid BCC syndrome	Epidermodysplasia verruciformis
Keratoacanthoma	Verrucae vulgares
Superficial squamous cell carcinoma	Condylomata acuminata
Kaposi's sarcoma	
Cutaneous metastases	
Cutaneous T cell lymphoma	

TABLE 266-5 **Potential Indications for Photodynamic Therapy**

SYSTEMIC PHOTODYNAMIC THERAPY So far, HpD and porfimer sodium are the best-studied sensitizers. PDT following systemic application of these dyes has been performed in both skin cancers and inflammatory dermatoses. However, the treatment protocols (dose of sensitizer, time interval between drug application and irradiation, use of laser versus incoherent light, wavelengths, etc.) differ significantly. Thus a comparison of efficacy is difficult. Phase III studies comparing dermatologic PDT with standard therapeutic procedures do not yet exist.

Systemic PDT for oncologic indications Systemic PDT with porfimer sodium for Bowen's disease is very effective. [99] In contrast, squamous cell carcinomas (SCCs) respond less well to systemic PDT, with recurrence rates of up to 50 percent being reported within 6 months. Systemic PDT for basal cell carcinomas (BCCs) with HpD was first employed by Dougherty in 1981. [100] Feyh treated 67 BCCs with HpD and an argon-pumped dye laser. Only three recurrences were reported in the 4.5-year follow-up period. [101] Schweitzer and Visscher treated five patients with AIDS-associated Kaposi sarcoma with porfimer sodium and red light in the form of surface and interstitial illumination. Complete or partial remission of cutaneous or mucosal nodular lesions was observed in 54 of 92 lesions. [102] Almost the same results were presented later for 8 patients with 83 Kaposi sarcoma lesions. Although the remission rate was 60 to 70 percent, the cosmetic result was rated unsatisfactory because of extensive hyperpigmentation and scarring. [103] Benzoporphyrin-derivative monoacid ring A (BPD-MA) also offers a significantly shorter cutaneous photosensitization time than porfimer sodium (<72 h), [104] and is currently being investigated for BCC.

Systemic PDT for nononcologic indications As early as 1937, Silver reported the use of PDT in the treatment of psoriasis. Six patients received HpD intramuscularly and orally on consecutive days and were irradiated with UV light. After 2 weeks, an improvement of psoriasis plaques was noted. [95] Better results were reported by Weinstein et al. when red light was used instead of UVA. [105] Systemic PDT with BPD-MA is currently being investigated for its efficacy in psoriasis. In a phase I study (using 8 mg/m ^{2}, 690 nm, 60 J/cm ^{2}), clinical severity scores of psoriatic plaques dropped from 4.0 to 2.5 in 15 patients after five weekly injections and consecutive irradiation. [106]

TOPICAL PDT Topical application of photosensitizers avoids generalized cutaneous photosensitivity. Unfortunately, because of their high molecular weight (˜900 g/mol), porphyrins cannot penetrate into the skin in sufficient amounts. In contrast, small hydrophilic molecules such as ALA penetrate well into the skin, particularly if it is covered by a parakeratotic layer as is the case in some epidermal tumors or in psoriasis. [96] ALA application selectively induces the production of intracellular porphyrins in epidermal cells and the pilosebaceous unit. These structures synthesize porphyrins to a much higher amount than fibroblasts, myocytes, or endothelial cells. [96], [107] Epithelial tumors synthesize much higher amounts of protoporphyrin IX than the surrounding tissue and can therefore be destroyed without damage to healthy skin [96], [108], [109] (Fig. 266-6). Topical ALA-induced photosensitivity is restricted to the target area. Systemic porphyrin induction is not observed following topical application. [110] The only significant acute side effect of ALA-PDT is a stinging pain during and shortly after irradiation.

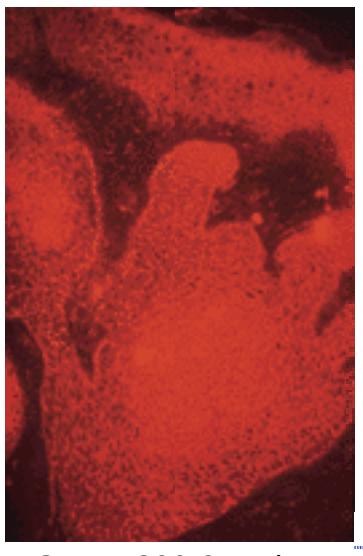

FIGURE 266-6 Endogenous porphyrin fluorescence after topical application of 20% ALA formulation to a solid basal cell carcinoma. Twelve hours after ALA application, there was strong fluorescence of the tumor-bearing areas, and weak to no fluorescence of the surrounding dermis. Also visible is fluorescence in the overlying epidermis (marked by *white arrows*). (*From Szeimies et al.,* [109] *with permission.*)

Topical PDT for oncologic indications [111], [112], [113], [114], [115] ***and*** [116] The experience with treatment of epithelial cancers and precancerous conditions with PDT so far reported in the literature suggest that actinic keratoses, [111], [112] Bowen's disease [114] (Fig. 266-7), superficial BCCs, [115], [116] and initial SCCs (tumor thickness less than 2 mm) are the only tumors that are suitable for topical ALA-PDT with curative intent. For this purpose, ALA is applied topically using 20% in

proprietary cream base formulations with occlusion for 4 to 6 h. Afterwards light is applied; using red light, the light intensity is in the range of 100 to 150 mW/cm ^{2} and the fluence 100 to 150 J/cm ^{2}. For actinic keratoses, topical application of a 20% ALA solution for 14 to 18 h followed by irradiation with blue light at 417 nm for 1000 s (10 J/cm ^{2}) resulted in response rates of 86 percent and 81 percent. It is important to note that neither cutaneous metastases of malignant melanoma, pigmented BCC, nor sclerodermiform variants of BCC respond to ALA-PDT, [117], [118] probably because of insufficient porphyrin synthesis and penetration of light. [109] Tumor thickness appears to be crucial and should not exceed 2 to 3 mm when a single treatment session is planned. Treatment efficacy can be enhanced by repeated treatment sessions. [115], [118]

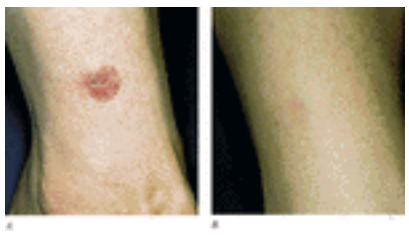

FIGURE 266-7 Bowen's disease. *A.* Lesion located on the right lower leg. *B.* Twelve months after topical ALA-PDT [10% ALA ointment, application for 4 h, irradiation with Argon-pumped dye laser (175 mW/cm ^{2}; 180 J/cm ^{2})], clinically and histologically there were no signs of tumor residue.

CTCL (mycosis fungoides) also responded in experimental trials to ALA-PDT after several treatment sessions. [117] Controlled investigations are currently not available, and, as with PUVA treatment of single lesions, this treatment would not be expected to prevent the appearance of new lesions in other areas.

Topical PDT for nononcologic indications [119], [120], [121], [122] ***and*** [123] Few data are available regarding the treatment of inflammatory skin conditions. Weinstein and co-workers treated psoriatic plaques once weekly using 10, 20, or 30% ALA and dye laser irradiation (10 to 150 J/cm ^{2}). The best results were obtained with 30% ALA and repeated treatments. [119] Boehncke compared the efficacy of ALA-PDT with dithranol in three patients with chronic plaque-type psoriasis with thrice weekly treatments using 10% ALA ointment for 5 h and an incoherent light source (25 J/cm ^{2}). In one patient, the PDT-treated side cleared 1 week earlier than the side treated with dithranol. [120] Karrer studied the efficacy of topical ALA-PDT in five patients with localized scleroderma, in whom conventional therapies had failed. They were treated by application of a gel containing 3% ALA followed by irradiation with red light (40 mW/cm ^{2}, 10 J/cm ^{2}). The treatment was performed once or twice weekly for 3 to 6 months. In all patients, the therapy was highly effective for sclerotic plaques as measured by a quantitative durometer score and a clinical skin score. The only side effect was a transient hyperpigmentation of the treated lesions. [120] Other possible indications for topical PDT are human papilloma virus (HPV)-associated skin diseases. The advantages of PDT for these conditions are the lack of a laser plume, in contrast to CO_2 laser treatment, and perhaps a lower recurrence rate as a result of eradication of subclinical lesions. Complete remission of anogenital condylomata acuminata was achieved in four of seven patients after topical ALA-PDT (20% ALA, 14-h incubation, argon dye laser 100 J/cm ^{2}). [121] Control of disease by topical ALA-PDT was achieved in multiple skin tumors in a patient with epidermodysplasia verruciformis, although in situ hybridization still revealed HPV type. [122] Recently, in a double-blinded, randomized trial, repetitive ALA-PDT with 20% ALA cream and red light (50 mW/cm ^{2} and 70 J/cm ^{2}) resulted in 56 percent clearance rate versus 42 percent in the sham-irradiated placebo group. [123]

Perspectives

The efficacy of PDT in the treatment of superficial neoplastic skin lesion, particularly actinic keratoses, Bowen's disease, and superficial BCCs, has been sufficiently documented. PDT may also find a place in the treatment of selected patients with inflammatory dermatoses. Nonetheless, the limitations of PDT, including its topical variant, have to be kept in mind. Crucial parameters are the depth of the penetration of light, as well as of the sensitizer, into the skin. Moreover, for the treatment of skin cancers with metastatic potential, patients need to be selected carefully, and histologic diagnosis and determination of tumor thickness are a prerequisite. There is still need for controlled studies and for standardized treatment protocols.

REFERENCES

1. Pathak MA, Fitzpatrick TB: The evolution of photochemotherapy with psoralens and UVA (PUVA): 2000 BC to 1992 AD. *J Photochem Photobiol B Biol* **14**:3, 1992

2. Parrish JA et al: Photochemotherapy of psoriasis with oral methoxsalen and long wave ultraviolet light. *N Engl J Med* **291**:1207, 1974

3. Wolff K et al: Photochemotherapie bei Psoriasis. Klinische Erfahrungen bei 152 Patienten. *Dtsch Med Wschr* **100**:2471, 1975

4. Fischer T, Alsins J: Treatment of psoriasis with trioxsalen baths and dysprosium lamps. *Acta Derm Venereol Suppl (Stockh)* **56**:383, 1976

5. Dall'Acqua F et al: Principles of psoralen photosensitization, in *The Fundamental Bases of Phototherapy,* edited by H Hönigsmann, G Jori, AR Young. Milan, OEMF SpA, 1996, p 1

6. Schmitt IM et al: Photobiology of psoralens, in *The Fundamental Bases of Phototherapy,* edited by H Hönigsmann, G Jori, AR Young. Milan, OEMF SpA, 1996, p 17

7. Averbeck D: Recent advances in psoralen phototoxicity mechanism. *Photochem Photobiol* **50**:859, 1989

8. Tanew A et al: 5-Methoxypsoralen and other new furocoumarins in the treatment of psoriasis, in *Light in Biology and Medicine,* edited by RH Douglas, J Moan, F Dall'Acqua. New York, Plenum, 1988, p 183

9. Prinz JC: Psoriasis vulgaris—A sterile antibacterial skin reaction mediated by cross-reactive T cells? An immunological view of the pathophysiology of psoriasis. *Clin Exp Dermatol* **26**:356, 2001

10. Hönigsmann H: Phototherapy for psoriasis. *Clin Exp Dermatol* **6**:343, 2001

11. Ibbotson SH, Farr PM: The time-course of psoralen ultraviolet A (PUVA) erythema. *J Invest Dermatol* **113**:346, 1999

12. Ibbotson SH et al: The effect of methoxsalen dose on ultraviolet-A-induced erythema. *J Invest Dermatol* **116**:813, 2001

13. Wolff K et al: Phototesting and dosimetry for photochemotherapy. *Br J Dermatol* **96**:1, 1977

14. Halpern SM et al: Guidelines for topical PUVA: A report of a workshop of the British Photodermatology Group. *Br J Dermatol* **142**:22, 2000

15. Melski JW et al: Oral methoxsalen photochemotherapy for the treatment of psoriasis: A cooperative clinical trial. *J Invest Dermatol* **68**:328, 1977

16. Henseler T et al: The European PUVA study (EPS): Oral 8-methoxypsoralen photochemotherapy of psoriasis: Cooperative study among 18 European centres. *Lancet* **i**:853, 1981

17. American Academy of Dermatology Committee on Guidelines of Care: Guidelines of care for phototherapy and photochemotherapy. *J Am Acad Dermatol* **31**:643, 1994

18. Wolff K, Hönigsmann H: Clinical aspects of photochemotherapy. *Pharmacol Ther* **12**:381, 1981

19. British Photodermatology Group: British Photodermatology Group guidelines for PUVA. *Br J Dermatol* **130**:246, 1994

20. Morison WL: Phototherapy and photochemotherapy. *Adv Dermatol* **7**:255, 1992

21. Stern RS, Laird N for the Photochemotherapy Follow-up Study: The carcinogenic risks of treatments for severe psoriasis. *Cancer* **73**:2759, 1994

22. Marcil I, Stern RS: Squamous-cell cancer of the skin in patients given PUVA and ciclosporin: Nested cohort crossover study. *Lancet* **358**:1042, 2001

23. Hönigsmann H, Wolff K: Results of therapy for psoriasis using retinoid and photochemotherapy (RePUVA). *Pharmacol Ther* **40**:67, 1989

24. Gilchrest BA et al: Oral methoxsalen photochemotherapy of mycosis fungoides. *Cancer* **38**:683, 1976

25. Herrmann JJ et al: Ultraviolet radiation for treatment of cutaneous T-cell lymphoma. *Hematol Oncol Clin North Am* **9**:1077, 1995

26. Tanew A, Hönigsmann H: UVB and PUVA phototherapy for cutaneous T-cell lymphoma. *Dermatol Ther* **4**:38, 1997

27. Stadler R et al: Prospective randomized multicenter clinical trial on the use of interferon-2a plus acitretin versus interferon-2a plus PUVA in patients with cutaneous T-cell lymphoma stages I and II. *Blood* **92**:3578, 1998

28. Swanbeck G et al: Indications of a considerable decrease in the death rate in mycosis fungoides by PUVA treatment. *Acta Derm Venereol Suppl (Stockh)* **74**:465, 1994

29. Morison WL: *Phototherapy and Photochemotherapy of Skin Disease,* 2 ed. New York, Raven, 1991, p 148

30. Honig B et al: Photochemotherapy beyond psoriasis. *J Am Acad Dermatol* **31**:775, 1994

31. Christophers E et al: A PUVA treatment of urticaria pigmentosa. *Br J Dermatol* **98**:701, 1978

32. Lange Wantzin G, Thomsen K: PUVA-treatment in lymphomatoid papulosis. *Br J Dermatol* **107**:687-90, 1982

33. Kerker BJ et al: Photochemotherapy of generalized granuloma annulare. *Arch Dermatol* **126**:359, 1990

34. Taylor C, Hawk JLM: PUVA treatment f alopecia areata partialis, totalis and universalis: Audit of 10 years' experience at St. John's Institute of Dermatology. *Br J Dermatol* **133**:914, 1995

35. Kerscher M et al: Treatment of localized scleroderma with PUVA-bath photochemotherapy. *Lancet* **343**:1233, 1994

36. Scharfetter-Kochanek K et al: PUVA therapy in disabling pansclerotic morphoea of children. *Br J Dermatol* **132**:830, 1995

37. Volc-Platzer B et al: Photochemotherapy improves chronic cutaneous graft-versus-host disease. *J Am Acad Dermatol* **23**:220, 1990

38. Kunz M et al: Treatment of severe erythrodermic acute graft-versus-host disease with photochemotherapy. *Br J Dermatol* **144**:901, 2001

39. Ortel B et al: Vitiligo treatment. *Curr Probl Dermatol* **15**:265, 1986

40. Ortel B et al: Treatment of vitiligo with khellin and ultraviolet A . *J Am Acad Dermatol* **18**:693, 1988

41. Hönigsmann H: Polymorphous light eruption, in *Clinical Photomedicine,* edited by HW Lim, NA Soter. New York, Marcel Dekker, l993, p 167

42. Tanew A, Ferguson J: Phototherapy and photochemotherapy of the idiopathic photodermatoses, in *Dermatological Phototherapy and Photodiagnostic Methods,* edited by J Krutmann, H Hönigsmann, CA Elmets, PR Bergstresser. Berlin, Springer, 2001, p 122

43. Roelandts R: Photo(chemo)therapy and general management of erythropoietic protoporphyria. *Dermatology* **190**:330, 1995

44. Ullrich SE: Does exposure to UV radiation induce a shift to a Th-2-like immune reaction? *Photochem Photobiol* **64**:254, 1996

45. Morrey JD et al: In vivo activation of human immunodeficiency virus type I long terminal repeat by UV type A (UV-A) light plus psoralen and UV-B light in the skin of transgenic mice. *J Virol* **65**:5045, 1991

46. Ranki A et al: Effect of PUVA on immunologic and virologic findings in HIV-infected patients. *J Am Acad Dermatol* **24**:404, 1991

47. Horn TD et al: Effects of psoralen plus UVA radiation (PUVA) on HIV-1 in human beings: a pilot study. *J Am Acad Dermatol* **31**:735, 1994

48. Zmudzka BZ et al: Medical UV exposures and HIV activation. *Photochem Photobiol* **64**:246, 1996

49. Morison WL: PUVA therapy is preferable to UVB phototherapy in the management of HIV-associated dermatoses. *Photochem Photobiol* **64**:267, 1996

50. Hönigsmann H: Psoralen photochemotherapy—Mechanisms, drugs, toxicity. *Curr Probl Dermatol* **15**:52, 1986

51. Nyfors A et al: Liver biopsies from patients with psoriasis related to photochemotherapy (PUVA): findings before and after 1 year of therapy in twelve patients. A blind study and review of literature on hepatotoxicity of PUVA. *J Am Acad Dermatol* **14**:43, 1986

52. Calzavara-Pinton PG et al: Antinuclear antibodies are not induced in uncomplicated psoriatic patients by PUVA treatment. *J Am Acad Dermatol* **30**:955, 1994

53. Dunnick JK et al: Tumors of the skin in the HRA/Skh mouse after treatment with 8-methoxypsoralen and UVA radiation. *Fundam Appl Toxicol* **16**:92, 1991

54. Stern RS et al: Oral psoralen and ultraviolet-A light (PUVA) treatment of psoriasis and persistent risk of nonmelanoma skin cancer. PUVA Follow-up Study. *J Natl Cancer Inst* **90**:1278, 1998

55. Henseler T et al: Skin tumors in the European PUVA study: Eight-year follow-up of 1643 patients treated with PUVA for psoriasis. *J Am Acad Dermatol* **16**:108, 1987

56. Stern RS, Members of the Photochemotherapy Follow-up Study: Genital tumors among men with psoriasis exposed to psoralens and ultraviolet A (PUVA) radiation and ultraviolet B radiation. *N Engl Med J* **322**:1093, 1990

57. Wolff K, Hönigsmann H: Genital carcinomas in psoriasis patients treated with photochemotherapy. *Lancet* **i**:439

58. Aubin F et al: Genital squamous cell carcinoma in men treated by photochemotherapy. A cancer registry-based study from 1978 to 1998. *Br J Dermatol* **144**:1204, 2001.

59. Stern RS and the PUVA Follow-up Study: The risk of melanoma in association with long-term exposure to PUVA. *J Am Acad Dermatol* **44**:755, 2001

60. Stern RS et al: Malignant melanoma in patients treated for psoriasis with methoxsalen (psoralen) and ultraviolet A radiation (PUVA). *N Engl J Med* **336**:1041, 1997

61. Wolff K: Should PUVA be abandoned [editorial]? *N Engl J Med* **336**:1090, 1997

62. Young AR: Photochemotherapy and skin carcinogenesis: A critical review, in *The Fundamental Bases of Phototherapy,* edited by H Hönigsmann, G Jori, AR Young. Milan, OEMF, 1996, p 77

63. Hannuksela-Svahn A et al: Trioxsalen bath PUVA did not increase the risk of squamous cell skin carcinoma and cutaneous malignant melanoma in a joint analysis of 944 Swedish and Finnish patients with psoriasis. *Br J Dermatol* **141**:497, 1999

64. Hannuksela-Svahn A et al: Cancer incidence among Finnish psoriasis patients treated with 8-methoxypsoralen bath PUVA. *J Am Acad Dermatol* **40**:694, 1999

65. Young AR: Carcinogenicity of UVB phototherapy assessed. *Lancet* **345**:1431, 1995

66. Stern RS: Ocular lens findings in patients treated with PUVA. Photochemotherapy Follow-Up Study. *J Invest Dermatol* **103**:534, 1994

67. Stern RS, Lange R: Outcomes of pregnancies among women and partners of men with a history of exposure to methoxsalen photochemotherapy (PUVA) for the treatment of psoriasis. *Arch Dermatol* **127**:347, 1991

68. Edelson RL et al: Treatment of cutaneous T-cell lymphoma by extracorporeal photochemotherapy. *N Engl J Med* **316**:297, 1987

69. Knobler R, Girardi M: Extracorporeal photoimmunotherapy in cutaneous T cell lymphomas. *Ann N Y Acad Sci* **941**:123, 2001

70. Yoo EK et al: Apoptosis induction by ultraviolet light A and photochemotherapy in cutaneous T-cell lymphoma: relevance in mechanism of therapeutic action. *J Invest Dermatol* **107**:235, 1996

71. Berger CL et al: Inhibition of autoimmune disease in a murine model of systemic lupus erythematosus induced by exposure to syngeneic photoinactivated lymphocytes. *J Invest Dermatol* **94**:52, 1990

72. Vowels BR et al: Extracorporeal photochemotherapy induces the production of tumor necrosis factor-a by monocytes: Implications for the treatment of cutaneous T-cell lymphoma and systemic sclerosis. *J Invest Dermatol* **96**:686, 1992

73. Berger CL et al: Induction of human tumor loaded dendritic cells. *Int J Cancer* **91**:438, 2001

74. Knobler RM et al: Parenteral administration of 8-methoxypsoralen in photopheresis. *J Am Acad Dermatol* **28**:580, 1993

75. Zic J et al: Long term follow-up with cutaneous T-cell lymphoma treated with extracorporeal photochemotherapy. *J Am Acad Dermatol* **356**:935, 1996

76. Gottlieb S et al: Treatment of cutaneous T-cell lymphoma with extracorporeal photopheresis monotherapy and in combination with recombinant interferon alpha: A 10-year experience at a single institution. *J Am Acad Dermatol* **35**:946, 1996

77. Rook AH et al: Extracorporeal photochemotherapy for drug-resistant pemphigus vulgaris. *Ann Intern Med* **112**:303, 1990

78. Liang G et al: Pemphigus vulgaris treated with photopheresis. *J Am Acad Dermatol* **26**:779, 1992

79. Gollnick H et al: Unresponsive severe generalized pemphigus vulgaris successfully controlled by extracorporeal photopheresis. *J Am Acad Dermatol* **28**:122, 1993

80. DiSpaltro F et al: Extracorporeal photochemotherapy in progressive systemic sclerosis. *Int J Dermatol* **32**:1, 1993

81. Rook AH et al: Treatment of systemic sclerosis with extracorporeal photochemotherapy - results of a multicenter trial. *Arch Dermatol*

128:337, 1992

82. Zachariae H et al: Photopheresis and systemic sclerosis. *Arch Dermatol* **128**:1651, 1992

83. Malawista SE et al: Treatment of rheumatoid arthritis by extracorporeal photochemotherapy: A pilot study. *Arthritis Rheum* **34**:646, 1991

84. Barr ML: Immunomodulation in transplantation with photopheresis. *Artif Organs* **20**:971, 1996

85. Sunder-Plassman G et al: Renal allograft rejection controlled by photopheresis. *Lancet* **346**:506

86. Wolfe J et al: Reversal of acute renal allograft rejection by extracorporeal photopheresis: A case presentation and review of the literature. *J Clin Apheresis* **11**:36, 1996

87. Slovis BS et al: Photopheresis for chronic rejection of lung allografts. *N Engl J Med* **332**:962

88. Andreu G et al: Extracorporeal photochemotherapy treatment for acute lung rejection episode. *J Heart Lung Transplant* **14**:793, 1995

89. Greinix TH et al: Successful use of extracorporeal photochemotherapy in the treatment of severe acute and chronic graft-versus-host disease. *Blood* **92**:3098, 1998

90. Greinix TH et al: Extracorporeal photochemotherapy in the treatment of severe steroid-refractory acute graft-versus-host disease: A pilot study. *Blood* **96**:2426, 2000

91. Knobler RM et al: Extracorporeal photochemotherapy for the treatment of systemic lupus erythematosus. A pilot study. *Arthritis Rheum* **35**:319, 1992

92. Pass HI: Photodynamic therapy in oncology: Mechanisms and clinical use. *J Natl Cancer Inst* **85**:443, 1993

93. von Tappeiner H, Jodlbauer A: Über die Wirkungen der photodynamischen (fluorescierenden) Stoffe auf Infusorien. *Dtsch Arch Klin Med* **80**:427, 1904

94. Jesionek A, von Tappeiner H: Zur Behandlung der Hautcarcinome mit fluorescierenden Stoffen. *Dtsch Arch Klin Med* **85**:223, 1905

95. Silver H: Psoriasis vulgaris treated with hematoporphyrin. *Arch Dermatol Syphilol* **36**:1118, 1937

96. Kennedy JC, Pottier RH: Endogenous protoporphyrin IX, a clinically useful photosensitizer for photodynamic therapy. *J Photochem Photobiol B Biol* **14**:275, 1992

97. Fritsch C et al: Ex vivo application of a-aminolevulinic acid induces high and specific porphyrin levels in human skin tumors: Possible basis for selective photodynamic therapy. *Photochem Photobiol* **66**:114, 1997

98. Penning LC, Dubbelman TM: Fundamentals of photodynamic therapy: Cellular and biochemical aspects. *Anticancer Drugs* **5**:139, 1994

99. Jones CM et al: Photodynamic therapy in the treatment of Bowen's disease. *J Am Acad Dermatol* **27**:979, 1992

100. Dougherty TJ: Photoradiation therapy for cutaneous and subcutaneous malignancies. *J Invest Dermatol* **77**:122, 1981

101. Feyh J: Photodynamic treatment for cancers of the head and neck. *J Photochem Photobiol B Biol* **36**:175, 1996

102. Schweitzer VG, Visscher D: Photodynamic therapy for treatment of AIDS-related oral Kaposi's sarcoma. *Otolaryngol Head Neck Surg* **102**:639, 1990

103. Hebeda KM et al: Photodynamic therapy in AIDS-related cutaneous Kaposi's sarcoma. *J Acquir Immune Defic Syndr Hum Retrovirol* **10**:61, 1995

104. Lui H, Anderson RR: Photodynamic therapy in dermatology. *Arch Dermatol* **128**:1631, 1992

105. Weinstein GD et al: Low-dose photofrin II photodynamic therapy of psoriasis. *Clin Res* **39**:509A, 1991

106. Boehncke WH et al: Systemic photodynamic therapy is a safe and effective treatment for psoriasis. *Arch Dermatol* **136**:271, 2000

107. Oseroff AR: Photodynamic therapy, in *Clinical Photomedicine,* edited by HW Lim, NA Soter. New York, Marcel Dekker, 1993, p 387

108. Abels C et al: In vivo kinetics and spectra of 5-aminolevulinic acid-induced fluorescence in an amelanotic melanoma of the hamster. *Br J Cancer* **70**:826, 1994

109. Szeimies RM et al: Penetration potency of topical applied a-aminolevulinic acid for photodynamic therapy of basal cell carcinoma. *Photochem Photobiol* **59**:73, 1994

110. Fritsch C et al: Influence of topical photodynamic therapy with 5-aminolevulinic acid on porphyrin metabolism. *Arch Dermatol Res* **288**:517, 1996

111. Szeimies RM et al: Topical photodynamic therapy with 5-aminolevulinic acid in the treatment of actinic keratoses: A first clinical study. *Dermatology* **192**:246, 1996

112. Jeffes EW et al: Photodynamic therapy of actinic keratosis with topical 5-aminolevulinic acid. *Arch Dermatol* **133**:727, 1997

113. Kurwa HA et al: A randomized paired comparison of photodynamic therapy and topical 5-fluorouracil in the treatment of actinic keratoses. *J Am Acad Dermatol* **41**:414, 1999

114. Morton CA et al: Comparison of photodynamic therapy with cryotherapy in the treatment of Bowen's disease. *Br J Dermatol* **135**:766, 1996

115. Haller JC et al: Routine double treatments of superficial basal cell carcinomas using aminolaevulinic acid-based photodynamic therapy. *Br J Dermatol* **143**:1270, 2000

116. Wang I et al: Photodynamic therapy vs. cryosurgery of basal cell carcinomas: results of a phase III clinical trial. *Br J Dermatol* **144**:832,

2001

117. Wolf P et al: Topical photodynamic therapy with endogenous porphyrins after application of 5-aminolevulinic acid. *J Am Acad Dermatol* **28**:17, 1993

118. Calzavara-Pinton PG: Repetitive photodynamic therapy with topical delta-aminolevulinic acid as an appropriate approach to the routine treatment of superficial non-melanoma skin tumours. *J Photochem Photobiol B Biol* **29**:53, 1995

119. Weinstein GD et al: Photodynamic therapy (PDT) of psoriasis with topical delta aminolevulinic acid (ALA): A pilot dose ranging study. *Photodermatol Photoimmunol Photomed* **10**:92, 1994

120. Karrer S et al: Topical photodynamic therapy for localized scleroderma. *Acta Dermatol Venereol* **80**:26, 2000

121. Frank RGJ et al: Photodynamic therapy for condylomata acuminata with local application of 5-aminolevulinic acid. *Genitourin Med* **72**:70, 1996

122. Karrer S et al: Epidermodysplasia verruciformis treated using topical 5-aminolevulinic acid photodynamic therapy. *Br J Dermatol* **140**:935, 1999

123. Stender IM et al: Photodynamic therapy with 5-aminolaevulinic acid or placebo for recalcitrant foot and hand warts: randomized double-blind trial. *Lancet* **355**:963, 2000

T>

Chapter 267

Graeme Lipper R. Anderson

Lasers in Dermatology

ELECTROMAGNETIC RADIATION AND THE LASER BEAM
DOSIMETRY AND LASER CHARACTERISTICS
SKIN OPTICS AND PRINCIPLES OF LASER–SKIN INTERACTION
Surface Reflectance
Epidermal Optics and Melanin
Dermal Optics
Photothermal Interactions
Photomechanical Interactions
Selective Photothermolysis
Avoiding the Epidermal Melanin Barrier
LASER SAFETY
Eye and Skin Hazards
Mechanical Hazards: Fire, Explosions, Electrocution
Respiratory and Infectious Hazards
CLINICAL APPLICATIONS
Vascular Lesions
Port-Wine Stains (Nevus Flammeus)
Capillary Hemangiomas
Telangiectases and Leg Venulectases
Additional Vascular Neoplasms and Malformations
Lesions Featuring Prominent Vasculature
Melanin-Containing Pigmented Lesions
Hamartomas: Becker's Nevus, Epidermal Nevus, Nevus Sebaceus
Melasma, Drug-Induced and Postinflammatory Hyperpigmentation
Exogenous Dermal Pigment: Tattoos
Laser and IPL Hair Removal
Infrared, Ablative Lasers: CO2 and Erbium:YAG
Nonablative Dermal Remodeling
Ultraviolet Lasers for the Treatment of Psoriasis and Vitiligo
DIAGNOSTIC APPLICATIONS: CONFOCAL SCANNING LASER MICROSCOPY

REFERENCES

Lasers in medicine defy simple characterization. New technology and new surgical and diagnostic applications for lasers are steadily being conceived. Lasers serve goals as diverse as revascularization of ischemic cardiac tissue, precise sculpting of the cornea, pulverizing urinary stones, and imaging cancers in vivo. Dermatology has been deeply affected by lasers, using them as precise and tissue-selective surgical tools.

ELECTROMAGNETIC RADIATION AND THE LASER BEAM

For centuries, physicists debated the nature of light. While Maxwell and his English colleagues argued that visible light behaved as particles, Fresnel and the French physicists maintained that light behaved as a wave, accounting for phenomena such as diffraction, constructive and destructive interference. Both views are correct, a “duality” now pervasive in quantum physics. Proof that electromagnetic radiation (EMR) travels as discrete particles, or *quanta,* of energy came when Einstein demonstrated that light can liberate single electrons off of a metal foil plate. This led to the present view that all matter and energy—everything in the universe—is quantized. EMR is now conceptualized as a fundamental form of energy, propagating through space at a constant speed *c*, as a wave but comprised of discrete quanta known as photons. As expressed by Planck's law (*E* = *h?* = *hc/?*, where *E* = energy, ? = frequency, ? = wavelength, *c* = speed of light, and *h* = Planck's constant), photon energy is proportional to wave frequency and inversely related to wavelength. Consequently, shorter wavelength photons carry more energy. The EMR spectrum ranges from long-wavelength, low-energy radiowaves and microwaves to short-wavelength, high energy x-rays.

When EMR encounters skin, photons are absorbed by individual molecules, called *chromophores,* and/or scattered by structures in the skin. Scattering is a change in the direction of propagation of light, and accounts for reflection from skin. Absorption extinguishes a photon, and all of the photon energy is transferred to the chromophore molecule that absorbed the photon. Without energy absorption, no photon–tissue interaction can occur. Ionizing forms of EMR such as x-rays and shortwave ultraviolet (UV) light impart enough energy to strip electrons from the absorbing molecules entirely. In contrast, optical radiation has the right quantum energy for moving electrons between their molecular orbit levels. This is the basis for photochemistry, in which a photon provides the activation energy for chemical reactions. For example, visible light is visible because its photon energy exactly matches the activation energy for rhodopsin to isomerize, initiating a retinal action potential. Optical wavelengths are generally expressed in nanometers (1 nm = 10^{-9}m). Infrared radiation, which has a longer wavelength and lower photon energy than visible light, generally excites vibrational and rotational motions, generating kinetic energy (heat).

LASER is an acronym for light amplified by stimulated emission of radiation—a process that explains how the unique characteristics of laser light are obtained, illustrated in Fig. 267-1(*A*). The creation of light is conceptually the inverse of absorption—a photon is created when an electron jumps to a lower-energy orbital. In most light sources, this is a spontaneous, random process. In contrast, laser photons are stimulated into existence by each other. Electrons in the

laser medium are first excited to a metastable state, which will eventually return to the preferred ground state by emitting energy. In stimulated emission, a photon triggers the release of metastable state energy in the form of a second, identical photon. Thus, amplification of light is achieved. The laser chamber or *optical cavity* contains two mirrors at each end in parallel alignment, favoring photons that cycle back and forth through the *lasing medium*. Energy is provided by a *pumping source*. The wavelength of the laser is determined primarily by the lasing medium—which may be a gas, liquid, or solid—and to some extent by the mirrors used.



FIGURE 267-1 Schematic of various continuous wave and pulse lasers.

In contrast to natural light, laser light is monochromatic, intense, coherent, and highly collimated. The clinical utilities of lasers stem directly from these fundamental traits. High intensity and collimation allow truly impressive power to be delivered, and focused to spots about equal to the wavelength of light (less than 1 µm). Coherence refers to highly organized waves, which make holograms and a new kind of medical imaging called optical coherence tomography (OCT) possible, for example. Monochromaticity (pure wavelength) allows optimum selective absorption of light by “target” chromophores such as hemoglobin and melanin. Most lasers now in dermatology use the principles of selective absorption and thermal confinement, described by Anderson and Parrish as *selective photothermolysis.* [1], [2]

DOSIMETRY AND LASER CHARACTERISTICS

Light is measured in fundamental *energy* units called *joules* (J). *Power* is the rate of energy delivery, measured in *watts* (1 W = 1 J/s). The “dose” of laser exposure is typically given as energy delivered per unit area (J/cm ^{2}) called *fluence*. Similarly, *irradiance* is the power delivered per unit area (W/cm ^{2}). For pulsed lasers, *peak power* is delivered during the pulse, and *average power* is the time-averaged power delivered. For pulsed lasers, fluence is equal to irradiance multiplied by laser pulse duration, also known as *pulsewidth*. Pulse repetition rate (measured in Hertz) defines the number of laser pulses delivered per second. Wavelength, exposure duration, fluence, and spot size are key determinants of laser–tissue interactions. Wavelength, and to some extent spot size, determine the sites of energy absorption, while pulse duration sets the time over which laser energy is applied. Lasers currently used in dermatology employ pulse durations ranging from seconds to nanoseconds (1 ns = 10 $^{-9}$ s). The same wavelength can exert profoundly different tissue effects depending on pulse duration. For example, in a man with nevus of Ota in the beard area, a 694-nm ruby laser can permanently remove the nevus without removal of hair, or permanently remove hair without removal of the nevus, depending on the pulse duration used. Spot size also affects dosimetry when using visible and near-infrared lasers. For a given fluence, larger spot size yields deeper tissue effect and greater true energy density inside the skin, due to scattering of light.

Continuous wave (CW) lasers emit energy steadily over time (Fig. 267-1B). First-generation CW lasers included the blue-green argon-ion laser (488 or 514 nm) used to treat vascular lesions such as port-wine stains (PWSs), and the carbon dioxide (CO_2) infrared CW laser used for tissue ablation and coagulation. Subsequent CW lasers in dermatology include the argon-pumped tunable dye (577–630 nm), krypton (520, 531, and 570 nm), and CW neodymium-yttrium-aluminum-garnet (Nd:YAG, 1064 nm). The relatively low peak power of CW lasers tends to necessitate long exposure times, allowing heat transfer to produce nonspecific thermal damage. As a rule, CW lasers are safest when used at high power and low exposure duration with a beam scanning or shutter system. Despite the dominance of pulsed CO_2 and erbium lasers for skin resurfacing, CW CO_2 lasers are still popular when delivered by a focused, rapid beam scanner. These lasers “behave” like a pulsed CO_2 laser, delivering a millisecond dwell time (dwell time = spot size/scanning velocity).

Pulsed lasers (Fig. 267-1C) emit energy in so-called long-pulses (millisecond), short-pulses (microsecond and nanosecond), or ultrashort-pulses (picosecond and femtosecond), all of which have been studied in skin. High peak power, short and ultrashort pulses produce unique laser-tissue interactions that are likely to be exploited further in dermatology. When focused inside skin, extreme peak irradiance is achieved (e.g., 10^{18} W/cm ^{2}, a trillion times greater than at the sun's surface), and multiphoton quantum effects appear. For example, multiphoton fluorescence microscopy for imaging live human skin has been reported, using femtosecond lasers. The attosecond barrier was recently crossed, producing optical pulses in the 10^{-18} second domain. For perspective, 1 attosecond is to a second, as a second is to the age of the universe. However, the shortest pulsed lasers routinely used in dermatology are nanosecond Q-switched lasers (Q-switched ruby at 694 nm, Q-switched alexandrite at 755 nm, Q-switched Nd:YAG at 532 or 1064 nm), which contain a photo-optical switch that suddenly releases stored metastable state energy from the laser (Fig. 267-1F). Q-switched lasers typically deliver fluences up to 10 J/cm ^{2} in 10 to 30 nanoseconds (a peak irradiance of about 1 billion

W/cm ^{2}). These lasers are used for selective destruction of very small targets, melanosomes, and tattoo ink particles.

Just as rapidly scanned, high-energy CW lasers can interact with skin in a pseudopulsed fashion, so, too, can rapidly pulsed, low-power systems such as the copper-vapor (512 or 577 nm) and certain potassium titanyl phosphate (KTP) (frequency-doubled Nd:YAG, 532 nm) lasers “behave” in a CW fashion. These *quasicontinuous-wave* (QCW) lasers (Fig. 267-1D), like true CW lasers, tend to produce unwanted thermal damage unless delivered by a scanner to minimize this risk.

“Stuttered” pulses consist of several high-energy pulses separated on the millisecond time scale (Fig. 267-1E). Stuttered pulses are used as a way of mimicking some of the effects of true long pulses, with sources that are technically difficult to operate over a wide range of pulse durations. Stuttered pulse devices are almost always based on a flashlamp. Flashlamp-pumped lasers (dye, ruby, alexandrite, Nd:YAG) and flashlamps themselves [intense pulsed light sources (IPLs), see below] operate efficiently at pulse durations of about 0.3 to 3 msec. When longer pulses are desired, for example, for hair removal, large-vessel treatment, or reduction of purpura, a stuttered pulse can be used in which the interval between several pulses is varied on the millisecond time scale. The skin response to a stuttered pulse can be a combination of short and long pulse effects, not necessarily equal to that after a true, long pulse of similar duration. For example, a stuttered pulsed dye laser emitting several 0.4 msec pulses over approximately 20 msec was developed to reduce purpura associated with classical 0.4 msec dye laser pulses. While reducing purpura substantially in comparison with previous pulsed dye lasers, this device produces more purpura than a true, 20 msec pulse at similar wavelength and fluence. The combination of short and long pulse effects afforded by stuttered pulses may be beneficial in some settings.

IPLs are filtered xenon flashlamps that provide one alternative to long-pulse laser energy. IPLs emit a mixture of wavelengths over a wide range, and cannot produce the peak power of lasers. However, they are less expensive than most long-pulse lasers. Present IPL applications include hair removal, treatment of vascular lesions and lentigines, and, recently, nonablative treatment of facial rhytides. To achieve adequate fluence, IPLs must deliver a far broader spectrum than lasers deliver. Fluences up to 90 J/cm ^{2} are delivered in single, double, or triple pulses. Adjustable parameters include individual pulse duration (2 to 20 msec), interpulse delay, and total fluence delivered. While the ability to deliver wavelengths over a wide range (approximately 500 to 1200 nm) and relatively large “spot” size (e.g., 8 × 35 mm rectangular glass piece) are potential advantages, results vary greatly with operator experience and technique. Table 267-1 lists some CW, QCW, and pulsed lasers and IPLs commonly used in current dermatologic practice.

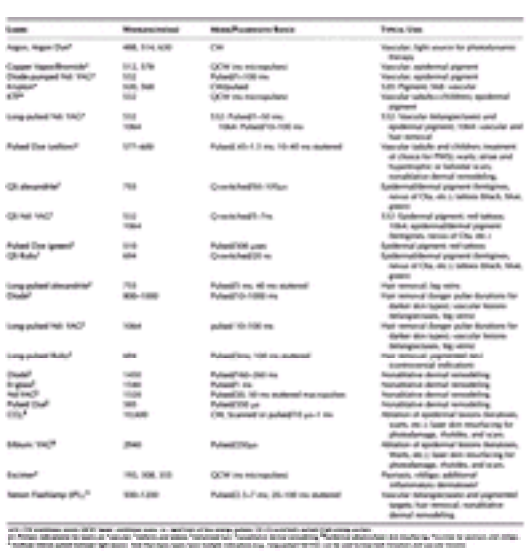

TABLE 267-1 **Commonly Used Lasers in Dermatology**

SKIN OPTICS AND PRINCIPLES OF LASER–SKIN INTERACTION

Laser interactions depend on optical properties of the skin, which are dynamic. Skin color changes subtly with every heartbeat, after a sun exposure, seasonally, and over decades of aging. Skin optics is introduced here anatomically, although the topic could just as well be presented by wavelength region or prominent chromophore. The absorption spectra of the major skin chromophores are diagrammed in Fig. 267-2.

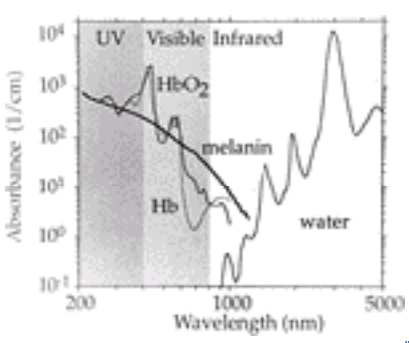

FIGURE 267-2 Optical absorption spectra of the major chromophores in skin. (*Courtesy of S. Prahl, PhD.*)

Surface Reflectance

Approximately 5 to 7 percent of incident light at all wavelengths is reflected from the skin surface, because of the large change in refractive index between air (n = 1.0) and stratum corneum (n ˜1.5). Surface reflectance imparts almost all of

our visual cues regarding the texture of skin, and follows Fresnel's equations for regular reflectance. When surface reflectance is eliminated from view by using polarized light techniques, it is nearly impossible to see wrinkles but easier to see sub-surface structures such as blood vessels and pigmented lesions. Skin examination devices are now available based on this principle.

Epidermal Optics and Melanin

The 93 to 95 percent of incident light not reflected by the skin surface enters the skin, where it is both scattered and absorbed. In the epidermis, UV and visible light absorption by melanin tends to dominate over scattering—therefore it is often appropriate to view the epidermis as a thin, light-absorbing layer on top of the thick, typically more light-scattering dermis. UV wavelengths less than 320 nm are strongly absorbed by both melanin and proteins. For example, about 90 percent of the radiation from the 308 nm XeCl excimer laser, recently introduced for psoriasis phototherapy, is absorbed in the epidermis of even a fair-skinned patient.

Normal and abnormal melanin are frequent targets for laser treatment, and damage to the pigmented epidermis is a frequent cause of unwanted side effects when treating dermal targets. Appropriate laser treatment spares the epidermis, by proper choice of parameters for a given laser and skin pigmentation, and use of skin cooling techniques, discussed below. In hair follicles, a mixture of eumelanin (brown or black hues) and pheomelanin (blonde, red, auburn hues) is present. Safe laser hair removal depends on absorption by hair melanin, without damage to the overlying pigmented epidermis. Melanin absorption extends from the ultraviolet through the visible and near-infrared to about 1200 nm, with a featureless spectrum. Absorption by melanin over this very broad region decreases gradually with increasing wavelength. This absorption spectrum accounts for the brownish hues imparted to normal skin and hair by melanin. Epidermal melanin content varies by at least an order of magnitude across the range of human skin colors from “white” to “black.”

In the mid- and far-infrared wavelengths, water and other molecules absorb photons because of vibrational (kinetic) excitations. Because of a very strong absorption band of water at 2940 nm, this wavelength penetrates only 1 µm into skin, and can therefore be used for precise skin ablation with pulsed erbium:YAG lasers. When a Q-switched Er:YAG laser is used, layers of epidermis can be vaporized with residual thermal injury limited to only a few cells. Dermatologic Er:YAG lasers use longer (microsecond-domain) pulses, which leave somewhat greater residual thermal injury and hence, better hemostasis. CO_2 laser emission at 10,600 nm is also strongly absorbed by water, with a skin-penetration depth of about 20 µm.

Dermal Optics

The dermis is a thick, light-scattering layer punctuated by light-absorbing blood vessels and hair follicles, which have distinct absorption bands associated with hemoglobins and melanin, respectively. Almost all of the visible light returned from within the skin is back-scattered by the dermis, passing twice through the overlying epidermis. Skin color is a result of this back-scattered light component of skin reflectance. The dermis is structurally, functionally, and optically different from epidermis. Dermis has a very large amount of extracellular connective tissue matrix. Collagen, which comprises about 70 percent of dermal protein content, strongly scatters light. Dermal light scattering varies inversely with wavelength, approximately as $?^{-1.5}$. Thus, short (blue) wavelengths are scattered more than long (red) wavelengths. The wavelength-dependence of dermal light scattering accounts for “blue” skin colors induced by nonblue chromophores in dermis, such as hemoglobin (veins), melanin (blue nevi), drug hyperpigmentation (e.g., minocycline), and carbon (blue-black tattoos). Also because of wavelength-dependent light scattering, depth of penetration into the dermis is greater with longer wavelengths across the ultraviolet, visible and near-infrared spectrum to about 1200 nm. The most skin-penetrating wavelength is near 1200 nm, at which approximately 25 percent of incident energy passes entirely through the skin. Intradermal scattering also influences the effective depth of treatment with different laser spot sizes. Small spot sizes (e.g., radius less than 10 times the mean free path between photon-scattering events) suffer attenuation with depth, because photons are easily scattered outside of a narrow beam. Therefore, when treating deep dermal targets such as tattoos, nevus of Ota, hair follicles, PWSs, leg veins, and the like, it is generally best to use the largest feasible spot size. Conversely, smaller spot sizes tend to enhance treatment of superficial targets such as lentigines or small telangiectasias, relative to deeper targets.

Within dermis, hair follicles and blood vessels are the only structures with substantial absorption of visible and near-infrared light. Hemoglobin and oxyhemoglobin have very strong absorption bands at blue, green, and yellow visible wavelengths. The longest wavelength oxyhemoglobin band (577 nm) was initially chosen for targeting microvascular malformations, using pulsed dye lasers in the first example of selective photothermolysis. Present pulsed dye lasers emit slightly longer wavelengths of 585 to 600 nm, which penetrate somewhat deeper into the dermis. Recently, the weak near-infrared absorption bands of hemoglobin and oxyhemoglobin have been used for selective photothermolysis of leg veins using long-pulse alexandrite (755 nm), diode (800 nm), and Nd:YAG (1064 nm) lasers. Because absorption by blood at these wavelengths is less than one-tenth of that for pulsed dye lasers, higher fluences are needed. For hair removal, melanin pigment in the hair shaft and matrix is the target chromophore. Temporary removal of pigmented hair is easily accomplished with red or near-infrared pulses over a wide range of pulse durations. In contrast, nonpigmented stem cells located at the external margin of the outer root sheath appear to be an important target for permanent hair removal. High fluences (e.g., 20 to 50 J/cm^2) and long pulses (e.g., 3 to 100 msec) using ruby, alexandrite, diode, or Nd:YAG lasers delivered in combination with skin surface cooling, permanently remove approximately 30 to 50 percent of coarse dark hairs per treatment.

Photothermal Interactions

Laser surgery consists largely of controlling the anatomic distribution of photothermal injury, that is, controlling the sites and amount of heat generated by light absorption. Temperature is a measure of average molecular kinetic energy—the random translation, rotation, and vibration of molecules. At low temperature, liquids freeze; at high temperature, complex macromolecules unravel. Life operates between these lethal temperature extremes. Thermal denaturation of macromolecules is a rate process, such that both time and temperature influence thermal damage. A useful

time-and-temperature “cookbook” can therefore be constructed for thermal events in skin. For example, fibroblasts and most other human cells are killed at 47°C (116.6°F) in about 20 min, but can withstand 100°C (212°F) for about 10^{-3} seconds. For effective selective photothermolysis with pulsed sources, high temperatures must be briefly achieved in cellular targets such as nevi, blood vessels, and hair follicles. Sublethal thermal injury of cells triggers a complex range of responses including altered metabolism, stress and repair signaling pathways, and/or delayed cell death by apoptosis. Even subtle, controlled thermal injury may be useful. Recently, pulsed dye and mid-infrared lasers were used for “nonablative skin rejuvenation,” by stimulating subtle photothermal injury in the photoaged dermis. Thermal behavior of the extracellular matrix also plays a major role in laser dermatology. Type I collagen is a semicrystalline protein with well-defined melting points. Although soluble collagen monomers melt just above body temperature, fibrillar collagen is much more stable and melts between 60°C (140°F) and 70°C (158°F), or higher depending upon the degree of cross-linking. When denatured, fibrillar collagen shrinks dramatically. Laser resurfacing immediately shrinks the superficial dermis, which may play a role in the final extent of skin tightening.

At temperatures above 100°C (212°F), tissue water vaporizes. Laser skin resurfacing uses pulsed or focused-and-scanned erbium (Er) or CO_2 lasers to vaporize a thin layer at the skin surface with each pass, leaving a layer of residual thermal coagulation caused by heat conduction during the vaporization process. The thickness of this residual thermal injury is critical, both for hemostasis and wound healing. If thinner than approximately 30 µm, hemostasis is a problem; if thicker than approximately 150 µm, retarded wound healing is a problem. The minimum thermal damage layer is at least three times the optical penetration depth, and can be increased by using longer pulse durations. The clinical outcomes of laser resurfacing depend mainly on anatomic depth of injury, which is controlled by fluence per pass and number of passes, and on postoperative care. The choice of laser is somewhat important. In general, Er lasers are easier to use for treating mildly photodamaged skin. When used at equivalent anatomic depth of injury, however, Er and CO_2 lasers produce equivalent clinical results.

Photomechanical Interactions

Q-switched and other short laser pulses can cause predominantly mechanical damage. Rapid vaporization inside the skin causes *cavitation,* the violent expansion and collapse of vapor bubbles. Cavitation occurs around melanosomes and tattoo particles during Q-switched laser treatment of pigmented lesions and tattoos, selectively killing the target cells. Residual gas bubbles remaining after cavitation cause a striking, immediate white color that correlates with clinical efficacy. Immediate whitening is therefore a useful end point during Q-switched laser treatment of tattoos or pigmented lesions. Other mechanical effects can be caused by extremely rapid heating. Q-switched lasers heat intracellular tattoo ink particles by approximately 200°C (392°F) in 10 ns, a heating rate of 20 billion degrees per second! Thermal expansion stresses may alter and/or fragment the particles, which are then removed mainly by lymphatic transport. Extremely rapid heating also produces stress waves, which are positive and/or negative pressure waves. At very high pressure, a “shock” wave forms that travels faster than the speed of sound. Laser-induced shock waves have been shown to nonlethally permeabilize cell membranes, and experimentally to enhance transcutaneous drug and gene delivery.

Selective Photothermolysis

Heat is created at the sites where light is absorbed in skin, and then begins to diffuse by conduction. When a pulse of selectively-absorbed light is delivered within the time for cooling of light-absorbing “targets,” heat is confined to those targets during the laser pulse. This combination of selective absorption plus thermal confinement in desired target structures, is the basis for *selective photothermolysis* (SP). The primary clinical advantages of SP are target-specific efficacy and minimal risk of scarring. Initially conceived for treating pediatric port-wine stains, SP has provided a rationale for nonscarring treatments of pigmented lesions, tattoos, and hypertrichosis. Wavelength and beam geometry (e.g., spot size and focusing) are chosen for optimum absorption in desired targets, exposure duration (e.g., pulsewidth or dwell time) is chosen for the desired degree of thermal confinement to targets, and fluence is chosen to produce the degree of target injury required. The concept of *thermal relaxation time* (t) is useful to describe heat conduction from different target structures. In general, t is defined as the time required for cooling of a structure to 1/e [e = 2.3058] of the temperature difference between the target structure and its surroundings. Thermal relaxation time is proportional to the square of the structure's diameter (d), and inversely proportional to thermal diffusivity (?). Specifically, $t = d^2/4?g$, where g is a factor related to the target shape. A useful approximation is simply $t ? d^2$, when t is expressed in seconds and d is expressed in millimeters. For example, a 1-mm leg vein has a thermal relaxation time of about 1 s, a 0.1-mm port-wine stain vessel has a thermal relaxation time of about 10 msec, a 10-µm nevus cell has a thermal relaxation time of about 100 µs, and a 1-µm tattoo ink particle has a thermal relaxation time of about 1 µs.

Pulses much longer than t for a given target structure tend to cause unwanted gross heating of the skin. However, a pulsewidth less than t is not always desirable. For example, follicular stem cells appear to be an important target for permanent hair removal, but these cells are located at the outer margin of the root sheath, away from the actual site of light absorption, the pigmented hair shaft. Similarly, the target when treating vascular malformations is not blood, which contains the target chromophore oxyhemoglobin, but the surrounding vessel wall. Therefore, it is advantageous to use a pulse duration about equal to t for the actual, intended target geometry—allowing heat to diffuse into the hair follicle or vessel wall during the laser pulse. Other factors, such as the need to protect the epidermis by skin cooling during delivery of an optical pulse, may also affect the choice of pulse duration. For example, the thermal relaxation time of the whole epidermis, which is approximately 0.1 mm thick, is about t ? 10 msec. Skin cooling during a pulse >>10 msec is therefore far more protective than during a pulse <<10 msec.

Avoiding the Epidermal Melanin Barrier

In both plants and animals, skin melanin is used mainly for camouflage; melanins also play roles for vision and neural tissue. In humans, a long life span and lack of fur have fostered the additional adaptation of skin melanin for photoprotection. “White” skin arose in nontropical humans for unknown reasons. Because epidermal melanin is a strong absorber of UV, visible, and to some extent near-infrared light, epidermal injury is a concern when using lasers,

especially when treating dermal targets in dark skin. There are several ways to combat this problem.

DIFFERENTIAL THERMAL RELAXATION TIMES When a laser pulsewidth is delivered that lies between thermal relaxation times for a given large and a small target, the small target tends to escape injury because of a lack of thermal confinement. A good example is pulsed dye laser treatment (pulsewidth ? 1 msec) of microvascular malformations and telangiectasias. Small, normal capillaries (t? 0.1 msec) are spared from injury, while target vessels larger than about 30 µm diameter (t > 1 msec) are selectively photocoagulated. Similarly, the pulse duration of some hair-removal lasers and IPLs can be adjusted to optimally damage terminal hair follicles (t ? 20 to 100 msec) rather than epidermis (t < 10 msec). A combination of long pulsewidth, long wavelength, and skin cooling can be used to safely treat very dark skin, e.g., using very long pulse diode or Nd:YAG lasers for pseudofolliculitis barbae in African-American men.
SKIN COOLING Skin cooling before, during and after a laser pulse helps to protect the epidermis and superficial dermis from thermal injury, and to reduce pain and swelling. Skin cooling is especially useful when treating vascular lesions, leg veins, and hair, and for nonablative dermal remodeling. All methods of skin cooling extract heat from the skin surface into an external medium. The anatomic depth of cooling depends on cooling time. [3] Cooling the epidermis takes about 0.1 s of good contact with a cold, heat-conducting medium, whereas bulk cooling of the skin takes tens of seconds. Icing a PWS before argon laser treatment was shown long ago to reduce scarring, [4] an example of bulk skin cooling. Cooling technology now uses a variety of chilled contact (solid, liquid, or gas) or cryogen spray devices. Dynamic precooling with tetrafluoroethane cryogen spray [boiling point –26°C (–14.8°F); 20 to 100 msec duration] is the most aggressive epidermal precooling technique, but provides little or no cooling during and after a laser pulse. Cryogen spray cooling is excellent when used with pulsewidths shorter than about 10 msec, for example, when treating PWSs with a pulsed dye laser. In a retrospective review of 196 Asian patients with PWSs treated with a 585-nm, 450-msec pulsewidth laser, either with (n = 98) or without (n = 98) cryogen spray cooling, cooling allowed higher fluences to be used (8 to 10 J/cm ^{2} versus 5 to 7 J/cm ^{2}), and was associated with improved clearance, and decreased incidence of scarring and pigmentary side effects. [5] Contact-cooling handpieces typically cool before, during, and after each laser pulse. Cold sapphire windows are an excellent cooling medium, being transparent, hardy, and with high thermal conductivity. In contrast with cryogen spray cooling, contact cooling is best suited for use with long pulses, e.g., hair removal. Forced cold [as low as –30°C (–22°F)] air was tested as a bulk cooling method on 166 patients treated for various indications with different laser systems (long-pulse alexandrite for hirsutism, pulsed dye laser for PWSs and hemangiomas, Q-switched ruby and Nd:YAG lasers for tattoos). [6] There was improved analgesia and epidermal protection (reduced purpura, crusting) in comparison with ice gel precooling.
FOCUSED LASER BEAMS Lasers can deliver very-high-power density at a focal spot, which can be as small as 1 µm, and as deep as about 1.5 mm into the skin. It is possible, and may eventually be practical, to cause precise, selective thermal injury by aiming a laser beam at various targets. Such a system would need to be automated, but the basic technology for this exists. For example, computer writable-CD drives now use a focused laser to record millions of data bits per second inside the disk. Computer-driven focused lasers are already used for skin resurfacing, but could become much more sophisticated, in theory targeting non-pigmented structures such as sebaceous glands and immune effector cells. A combination of emerging technologies would be required: small solid-state lasers, noninvasive microscopy, computer vision, and fast optical scanners.

LASER SAFETY

The importance of safe, intelligent laser practice cannot be overemphasized; every year, laser mishaps are responsible for accidental blindness, skin burns, explosions and electrocution in medicine and industry. IPLs pose most of the same risks as lasers. To minimize these risks, all individuals should receive comprehensive safety training prior to performing any type of laser or IPL therapy. In addition, both the operative environment and procedural format should be designed to protect patients, physicians, and support staff from inadvertent laser or IPL injury. While specific precautions may vary depending on the type of laser in use, all laser procedures require appropriate eye protection, fire precautions, and fume extraction if ablation is involved. All laser personnel should have a mandatory baseline ophthalmologic examination, followed by annual screening for early signs of retinal damage.

Anyone in the operative area is at risk for laser-related injury. This includes the laser surgeon, support staff, patient, and bystanders such as family members. The major laser hazards include eye injury, skin burns, and accidental ignition of clothing, hair, flammable substances, or surgical drapes. Rarer but significant risks include explosion and electrocution caused by electrical malfunction. Respiratory hazards such as transmission of bacterial, viral and fungal pathogens, inhalation of pulmonary irritants and potential carcinogens, remain the subject of active debate. The major laser-associated hazards are summarized in Table 267-2.



TABLE 267-2 **Commonly Used Lasers and Associated Hazards**

Eye and Skin Hazards

Of all human organs, the eye is the most vulnerable to accidental laser injury because of its optical focusing properties. Crucial ocular structures such as the retina, cornea, and lens may be damaged irreversibly by an errant laser beam within microseconds, long before the lid reflex has had time to protect them. The melanin-rich retina is especially vulnerable to lasers operating in the visible to near-infrared wavelengths (400 to 1400 nm)—the so-called retinal hazard region. These wavelengths readily transmit through the clear ocular media, with the cornea and optic lens concentrating the incident laser beam 100,000-fold onto a retinal spot measuring between 10 and 20 µm. While this injury zone may

appear to be small, central retinal or foveal damage from a single incident beam may be enough to cause almost total loss of visual acuity in the affected eye. Because retinal neural tissue has minimal regenerative capacity, such damage is typically permanent.

While all lasers in the 400 to 1400 nm wavelength range are capable of causing significant retinal damage, lasers with high peak powers, such as Q-switched (e.g., QS-Nd:YAG, QS-ruby, QS-alexandrite) and pulsed devices, pose an especially high risk. Special caution should be taken when using high-energy optical pulses near the eyes. For example, all hair removal lasers and IPLs are specifically designed to damage melanized tissues through several mm of tissue. The ocular retina and choroid have the highest melanin concentration in the body, such that retinal injury can be caused even by exposure through the sclera. Laser or IPL hair removal should not be attempted within the bony orbit. Collimated lasers present an added danger, because the energy of highly collimated beams does not diminish significantly over distance. Hence, a collimated beam reflected off of a remote metal surface could be as dangerous as one aimed directly into the eye. Collimated lasers include the CO_2 laser many Q-switched lasers, and some pulsed dye and green lasers, used for tissue ablation and photocoagulation. Most surgical lasers are focused, typically limiting the zone of maximal eye or skin injury to 1 to 2 meters from the focal point, which typically includes the surgeon, patient, and other personnel.

Anterior ocular structures are also susceptible to laser injury. The cornea can be damaged by ultraviolet (e.g., XeCl excimer at 308 nm) and infrared wavelengths beyond 1400 nm (e.g., CO_2 at 10.6 µm; erbium:YAG at 2940 nm; holmium:YAG at 2100 nm). The depth of corneal injury depends on both incident laser fluence and dwell time. Although superficial corneal injury is reversible, deeper photothermal damage to the stroma and corneal stem cells will cause permanent scarring, with corneal transplantation needed to restore normal vision. Of note, UV lasers such as the 308-nm XeCl excimer laser can damage the protein-rich optic lens, causing immediate cataract formation.

Eye damage can be prevented by ensuring that the surgeon, staff, patient, and observers wear appropriate protective eyewear (wraparound glasses, goggles, or eye shields) at all times during any laser procedure. Eyewear should be labeled clearly with both filtered laser wavelength and optical density parameters, and lenses and fittings should be checked regularly for damage and replaced as needed. For CO_2 and Er:YAG lasers, prescription glasses or wraparound plastic goggles made of burn-through-resistant polycarbonate provide adequate protection. The risk of reflected beams should be minimized by using only rough, black polymer-coated metallic objects (such as eye shields) in the surgical field. When not in use, the laser should always be kept on standby, with foot pedal and triggering devices well-labeled and positioned safely to avoid inadvertent triggering.

In contrast to their effects on the eye, isolated accidental laser pulses typically produce reversible thermal skin injury (first- or second-degree burns). Nevertheless, conduction of heat into the deeper dermis can cause third-degree burns and permanent scarring. This becomes especially problematic in sedated or anesthetized patients, who may lack the withdrawal reflexes necessary to protect them from thermal injury. As discussed below, accidental ignition of clothing, hair, flammable compounds, surgical drapes, rubber tubing, or oxygen in the surgical field are factors more likely to cause significant burns.

Mechanical Hazards: Fire, Explosions, Electrocution

Significant and even life-threatening third-degree skin burns have been caused by inadvertent laser ignition of surgical drapes, clothing, hair, oxygen, and endotracheal tubing. While any laser poses a potential fire hazard, CO_2 and Er:YAG lasers present the greatest risk. Ignition of hair, especially when a leaking oxygen mask is present, can be rapid and impressive. To prevent accidental combustion, the laser surgeon should remove all flammable materials from the operative field and avoid using flammable skin preparations containing alcohol. Patients should not wear combustible substances (e.g., hair sprays, gels) on the day of surgery. In addition, treatment areas must always be draped with moistened towels or gauze, and all potentially exposed hair-bearing areas (e.g., hairline and eyebrows during facial resurfacing) should be covered with a protective layer of water or hydrophilic gel.

The use of supplemental oxygen in the surgical field poses a special combustion risk, especially for procedures taking place near the nose and mouth. There are horrific case reports including instances of endotracheal tube ignition and patient demise. Most fires occur from laser exposure to combustible material rather than exposure to skin. While lasers are designed to minimize any electrocution risk, their high-voltage requirements pose significant danger to repair staff or individuals foolish enough to tamper with the device without adequate maintenance training.

Respiratory and Infectious Hazards

The “plume” produced by laser or electrosurgical vaporization, poses both respiratory and infectious hazards, with some risks being more well defined than others. At one extreme, inhaled laser smoke clearly irritates the respiratory mucosa, potentially exacerbating pulmonary diseases such as asthma and emphysema. Long-term inhalation of laser smoke causes interstitial pneumonia, bronchiolitis and emphysema in rats. Hair removal lasers may cause asthmatic flares, triggered by noxious smoke. Particles inhaled from the laser plume may also pose an infectious risk. Viable bacterial skin pathogens (e.g., *Staphylococcal aureus* and *Neisseria*) and fungi have been isolated from laser plumes, especially those produced by the CO_2 and Er:YAG lasers. Laser plumes also contain potentially infectious fragments of human papillomavirus (HPV), a viral pathogen linked to genital and mucosal condylomata, cutaneous warts, cervical dysplasia, and squamous cell carcinoma. While the risk of acquiring HPV from the laser plume remains unclear, the risk of developing nasopharyngeal warts has been noted to be slightly higher in a group of CO_2 laser surgeons when compared to population-based controls from the same region. [7] Proviral HIV DNA has been detected by polymerase chain reaction (PCR), in debris collected from CO_2-vaporized, HIV-infected tissue-culture pellets. [8] With this data in mind, all laser debris should be handled following universal infectious precaution guidelines, including the use of gloves, eye protection, face masks, and frequent hand washing. In addition, laser plumes should be viewed as biohazards and contained by using vacuum smoke evacuators equipped with ULPA-rated (ultralow-penetration air) filters.

Laser pyrolysis products have been shown to be mutagenic in vitro by using a *Salmonella* mutagenicity assay. Any real-life carcinogenic risk remains to be determined. Nevertheless, laser smoke inhalation should be minimized, especially because any cancer risk, however small, is likely to be cumulative. There is no evidence that the laser-induced plume differs from that of electrosurgery; it is prudent to evacuate smoke during any surgical procedure.

CLINICAL APPLICATIONS

Vascular Lesions

One of the first uses for laser light in dermatology was the selective targeting of vascular lesions in the skin, including capillary malformations (e.g., port-wine stains) and hemangiomas. Whether continuous or pulsed, all modern vascular lasers target intravascular oxyhemoglobin (HbO_2) as the primary chromophore. Intuitively, laser wavelengths that closely approximate the absorption peaks of hemoglobin in the blue, green, and yellow bands (418, 542, and 577 nm) should be most effective at targeting blood vessels for selective photothermolysis. Yet additional variables, such as blood vessel depth, caliber, and the pigmentation of overlying epidermis, play equally important roles in determining the ultimate clinical outcome. Skin optics are such that longer wavelengths tend to be preferable, in order to minimize melanin absorption and maximize depth of penetration.

Different vascular lesions often demand different laser parameters for good results. For instance, dilated capillaries and venules in superficial PWSs respond well to the flashlamp-pumped pulsed dye laser (FPDL, 585 to 600 nm) used at pulsewidths ranging from 450 µs to 1.5 msec. These parameters are logical, as the laser has excellent HbO_2 absorption, sufficient penetration into the papillary and upper reticular dermis, adequate energy delivery to induce irreversible vessel damage, and a pulsewidth range approximating the thermal relaxation time of the target vessels (t ? 1 msec for vessel diameters of 30 µm). In contrast, reticular leg veins respond best to systems with deeply penetrating wavelengths in the near-infrared range with longer pulse durations, such as the long-pulse Nd:YAG (1064 nm) and diode (810 nm) lasers, operating at high fluences in the >10 msec pulsewidth range.

Surprisingly, the mechanisms of laser-induced irreversible vessel damage in vivo remain unclear, although complete and irreversible cessation of blood flow appears to be one prerequisite. Lasers delivering high energies over short pulsewidths (e.g., FPDL) tend to induce a combination of photothermal and photomechanical injury, such as intravascular cavitation, vessel wall fragmentation, and hemorrhage. [9] In contrast, longer pulsewidths approximating or exceeding the target vessels' thermal relaxation times cause mainly photothermal damage, with intravascular coagulation and collagen contraction within the vessel wall and surrounding tissue. Both photothermal and photomechanical mechanisms of vessel damage cause clinically visible purpura, providing a helpful end point when using pulsed dye lasers. For all vascular laser systems, epidermal cooling devices (e.g., cryogen spray or contact cooling) help to reduce epidermal damage, especially when using higher fluences or treating darker skin types. A phase of local vasculitis occurs several days after pulsed dye laser treatment, which appears to be important for clinical results. This delayed purpura should be distinguished from the immediate purpura caused by conventional pulsed dye lasers. Patients should be warned that delayed purpura caused by vasculitis often develops following treatment with a stuttered pulsed dye laser that is marketed to be “purpura-free.”

Port-Wine Stains (Nevus Flammeus)

PWSs (nevus flammeus) are cosmetically disfiguring, congenital capillary and venular malformations that affect up to 0.5 percent of newborns. At birth, lesions are first noted as subtle, light pink patches, commonly appearing on the face and often in a trigeminal dermatomal distribution. Approximately 5 percent of these trigeminal PWS are associated with underlying leptomeningeal, ocular, and central nervous system (CNS) involvement, meeting criteria for the Sturge-Weber syndrome. In addition, PWSs may occur on the trunk and extremities, with extremity lesions occasionally developing progressive lymphectasia and soft-tissue hypertrophy (Klippel-Trenaunay-Weber syndrome). Although similar in appearance, congenital “stork-bite” (occipital) and “angel's kiss” (glabellar) telangiectatic patches are extremely common, tend to regress over time, do not merit treatment, and may represent focal areas of persistent fetal circulation.

On histopathology, PWSs consist of dilated, ectatic vessels in the superficial papillary dermis. In contrast to capillary hemangiomas, these vessels are not proliferative and therefore only grow proportionally with the individual. Unfortunately, while hemangiomas undergo spontaneous regression, PWS vessels become progressively tortuous, dilated, and engorged over time. Unless treated, larger PWS will eventually evolve into disfiguring violaceous plaques containing areas of nodular hypertrophy. Prior to the advent of laser surgery, such cosmetically disfiguring lesions were treated with nonspecific, destructive modalities, including cryosurgery, ionizing radiation, dermabrasion, and surgical excision with skin grafting. Although most of these techniques could improve function and to some extent cosmesis, none could avoid the problem of potentially disfiguring scarring.

In contrast, selective photothermolysis can specifically target PWS vessels while sparing surrounding tissue. Despite promising initial results in adult patients with PWSs, the CW argon laser (488 and 514 nm) fell short of this ideal, causing significant scarring in up to 38 percent of treated children younger than 12 years of age. [10] This was mainly a result of nonspecific thermal injury, because the original CW argon exposure time (around 200 msec) far exceeded the t of PWS vessels (1 to 10 msec).

After observing encouraging results in adults with PWSs, Tan et al. conducted a clinical trial using a 577-nm FPDL (360 µsec) to treat pediatric PWSs in 35 white children 3 months to 14 years of age (mean age, 7.2 years). Treated lesions were all located on the head or neck, macular, and pink to red in color. By using minimally overlapping spots (5-mm spot size, 6±0.25 J/cm^2 fluence), they observed impressive fading in all 35 patients after the first treatment, with complete clearing after a mean of 6.5 treatments. [11] Laser-associated adverse effects were minimal, with two children (5.7 percent) developing superficial, depressed scars. Twenty treated children (57 percent) developed transient facial

hyperpigmentation, which cleared within 4 months. In general, this early report is viewed as being overly optimistic in light of subsequent studies. Of note, PWSs over bony prominences and in children younger than 7 years old achieved clearance with fewer treatments. Subsequent studies question both of these findings; instead of PWS location and patient age, Van der Horst et al. found lesion size and depth to be the key predictors of treatment response. [12]

Over the past decade, FPDL treatment of cosmetically significant PWSs has become the standard of care. Most pediatricians advocate early treatment of PWSs to prevent hypertrophy and progression, especially because these lesions can cause significant psychological distress during childhood and adolescence. To attain deeper penetration and faster treatment, FPDLs have been shifted toward using longer wavelengths (585 to 600 nm) and larger spot sizes (7 to 10 mm). As a result of reduced HbO_2 absorption at these longer wavelengths, somewhat higher fluences are used to achieve adequate vessel damage, typically 8 to 12 J/cm ^{2}, delivered in pigmented skin with cryogen spray cooling. As Dierickx et al. demonstrated, target vessel damage may be ideal using longer pulsewidths (1 to 10 msec) that better approximate the t of PWS vessels. [13]

Adverse effects such as scarring, pain, and pigmentary alterations can be reduced significantly by using cryogen spray or contact cooling devices. Cryogen spray cooling has greatly improved the ability to treat darker skin types with PDLs, because the epidermis is specifically cooled prior to arrival of the laser pulse. Although bulk cooling may somewhat reduce efficacy at a given treatment fluence by cooling target vessels, bulk cooling greatly increases tolerance to high fluences. The enticing combination of bulk skin cooling and pulsed dye laser treatment at high fluence has not been adequately studied in clinical trials.

Mature PWSs pose additional therapeutic challenges, including the presence of deeper vessels and overlying hypertrophy. Deeper, violaceous vessels respond better to longer wavelength lasers, higher fluences, and longer pulse durations. Treatment during diascopy to blanch superficial vessels is a useful approach to facilitate destruction of deeper vessels, because superficial overlying vessels often shield deeper targets from photothermal injury. A glass slide is used to press gently on the hypertrophic vascular lesion, until the color is seen to lighten. At this point, a laser pulse is delivered. After one pass in this manner, a second pass can be performed to treat the superficial component. PWSs resistant to pulsed dye laser treatment may improve significantly when treated with alternative lasers such as the modulated KTP laser system (532 nm; 1 to 50 msec; 5 to 50 J/cm ^{2}) or IPL. Both IPL and one version of the pulsed dye laser offer tunable wavelengths. Raulin, et al. [14] used an IPL with 550-nm (for red to pink PWSs) or 515-nm (for purple PWSs) cutoff filters, pulsewidths of 2.5 to 5.0 msec, and high fluences of up to 60 J/cm ^{2} with coupling gel, and observed minimal adverse effects comparable to those seen with standard PDL treatment. Potential advantages of the IPLS include the ability to set multiple wavelengths, deliver high fluences, and use split pulses. However, a prospective trial comparing IPL and PDL treatment over a range of fluences has yet to be done.

Factors to consider when evaluating any PWS for treatment include patient age, skin type, prior treatment response (if any), lesion location and anatomy. It is unknown why some PWS are resistant to therapy with lasers or IPLs. Emerging noninvasive imaging techniques such as high-resolution ultrasound, confocal microscopy, and optical Doppler tomography may help to better guide laser therapy of PWSs in the future. A “cookbook” approach to the treatment of PWSs should be discouraged, and laser parameters and cryogen spray settings must be tailored to each individual.

Capillary Hemangiomas

Hemangiomas are benign vascular endothelial cell tumors found in the skin and, less frequently, other organ systems such as the liver. Hemangiomas typically present in infancy, and may be found in 1 to 2 percent of neonates, with an estimated prevalence of 10 to 12 percent by 1 year of age. Premature infants show an even higher prevalence of up to 20 percent. Fortunately, growth of infantile hemangiomas is restricted to an early proliferative phase, followed by growth arrest and spontaneous involution. As a rule, 50 percent of hemangiomas show regression by 5 years, 70 percent regress by 7 years, and more than 90 percent ultimately regress by adolescence. Lesions classically evolve from pink-red, telangiectatic macules and patches to raised nodules, although congenital hemangiomas may present in the nodular phase or as bleeding ulcerated plaques. While some regressed hemangiomas leave normal skin in their wake, more than 50 percent leave residual changes such as hyper or hypopigmentation, telangiectases, “anetoderma-like” scarring, and atrophy. This can be especially distressing in cosmetically sensitive areas such as the head and neck, where an estimated 50 percent of infantile hemangiomas occur. Up to 30 percent of infants have multiple lesions, and neonates with numerous small (<1 to 2 cm) cutaneous hemangiomas should be evaluated for potential visceral involvement of the liver and gastrointestinal tract—a condition known as multiple neonatal hemangiomatosis. Large, rapidly growing purpuric lesions suggestive of kaposiform hemangioendothelioma should prompt evaluation for Kasabach-Merritt syndrome.

Three main types of infantile hemangioma are recognized: the common, superficial or “strawberry” hemangioma (50 to 60 percent); the mixed hemangioma, consisting of both superficial and deeper cavernous components (25 to 35 percent); and the deep or “cavernous” hemangioma (15 percent). Histologically, all of these lesions show clusters of thin-walled vascular spaces surrounded by sheets of proliferative but benign-appearing endothelial cells. Mixed and cavernous subtypes have deeper, more dilated vessels. Additional features common to most hemangiomas include dermal mast cells and variable atrophy of the overlying epidermis. Small, superficial hemangiomas in cosmetically innocuous areas generally do not require treatment, and should regress spontaneously without significant sequelae. The major indications for treatment include life- or function-threatening hemangiomas, such as those obstructing airways or impairing vision; hemangiomas that tend to leave disfiguring scars or deformities in cosmetically sensitive areas, such as the nose, glabella, lips, ears, and breasts; large facial hemangiomas, especially those with deep components; hemangiomas in exposed areas such as the face and hands; and pedunculated or ulcerated hemangiomas. Therapeutic decisions should be tailor-made to each individual lesion, and should always take into account psychosocial factors, including the emotional well being of both child and parents. Because no treatment is without risks, all potential complications should be detailed prior to initiation of therapy.

Treatment options range from conservative monitoring to local (FPDL or Nd:YAG laser, cryotherapy, intralesional glucocorticoids, surgical excision, embolization) and systemic [oral glucocorticoids or interferon (INF)-a] modalities. Individual treatment risks differ, but all procedures may result in scarring. Laser treatment, for example, with pulsed dye lasers, appears to reduce the risk of spontaneous ulceration and scarring. Treatment choice may vary depending on factors such as lesion location, size and depth, growth phase, presence or absence of functional impairment, and parental preference. Systemic glucocorticoids, IFN-a, and embolization are often reserved for function- or life-threatening lesions, because these treatments carry significant risks (e.g., spastic paresis in infants receiving IFN-a). As a rule, lasers such as the 585-nm flashlamp- pumped pulsed dye laser are most effective when used to treat superficial capillary hemangiomas. The role of laser therapy for these lesions remains somewhat controversial.

FPDL were specifically designed for treating PWS, which are structurally very different from hemangiomas. In theory, a shorter pulsewidth and much longer wavelength selectively absorbed by blood, might work better for these lesions. However, FPDL treatment of hemangiomas appears to accelerate lesion involution, leading to significant lightening with minimal complications. Hohenleutner et al. recently reported long-term results of 617 childhood hemangiomas treated with the FPDL (585 nm; 5 to 7 mm spot; 0.45 msec pulsewidth; 5 to 10 J/cm ^{2} fluence; 10 percent pulse overlap). Forty-nine percent of these were localized to the head and neck. [15] After a mean of 2.5 treatments (1 to 12 treatments given at intervals of 4 to 6 weeks), 96.6 percent of hemangiomas showed no further growth, with 13.8 percent showing total regression and 14.9 percent showing marked regression. These results differ markedly from the expected time-course of involution without treatment, but specific age and lesion-matched controls were not reported. Small, atrophic scars were noted in 4 percent of cases, with transient hypo- or hyperpigmentation seen in 7 percent of cases. Patient age did not appear to influence treatment results. As expected, treatment response varied with lesion depth, with complete remission seen in 42.6 percent of small superficial lesions (<5 mm), 14.5 percent of nodular lesions, and only 6.5 percent of compound lesions. Larger superficial lesions fared poorer than small lesions, with only 19 percent showing complete regression. Infantile hemangiomas also may respond well to the frequency-doubled Nd:YAG (532 nm), KTP (532 nm), and other similar laser systems. Laser treatment causes purpura, is painful, and often requires pretreatment with topical or intralesional anesthetics, or general anesthesia.

Cavernous and mixed hemangiomas with deep, dilated vessels pose a special therapeutic challenge sometimes met by a combination of medical, laser, and excisional surgery. Deep hemangiomas respond to penetrating infrared lasers such as the 1064-nm Nd:YAG, which has been used in both pulsed and CW modes to treat arteriovenous malformations and cavernous hemangiomas. Intense pulsed light sources have also been reported for treatment of deeper hemangiomas. Scarring is common. The best future approach to treating deep hemangiomas will likely involve combination therapies, and/or specific inhibitors of angiogenesis inherent in these lesions.

Telangiectases and Leg Venulectases

Facial telangiectases are extremely common, superficial dilated vessels 0.1 to 1 mm in diameter, generally localized to the nose, malar cheeks, and chin in fair-skinned individuals, particularly those with rosacea. Telangiectasia formation is attributed to a combination of genetic, hormonal and environmental factors such as chronic sun exposure. Vasomotor flushing with centrofacial telangiectasia is a cardinal feature of rosacea, and several inflammatory, metabolic and hereditary skin disorders feature telangiectatic vessels of varying caliber and distribution. Facial telangiectases are located superficially in the papillary dermis, making them simple targets for selective photothermolysis using vascular lasers in the blue, green and yellow wavelength range (418 to 585 nm). Most vessels will clear using relatively low fluences, and more than two sessions per treatment area are seldom required. Both the flashlamp-pumped (585 nm; 450 µs) and long-pulsed (595 to 600 nm; 1.5 msec) dye lasers provide reliable clearance, leaving purpura that typically fades over 1 to 2 weeks. Additional effective systems include the Nd:YAG (1064 nm) and frequency-doubled (532 nm) Nd:YAG, copper bromide, and krypton lasers. Many of these are equipped with cooling devices, and purpura is not required to obtain vessel clearance.

Other telangiectatic processes responsive to vascular laser treatment include generalized essential telangiectasia, hereditary hemorrhagic telangiectasia, radiotherapy-induced telangiectases, telangiectasia macularis eruptiva perstans (TMEP), angioma serpiginosum, nevi aranei (spider nevi), and unilateral nevoid telangiectasia syndrome, although the latter condition tends to recur even after multiple treatments. Spider nevi have a central arteriolar trunk, which must be eradicated to achieve clearance. Treatment during diascopy is helpful for this purpose. Lasers such as the PDL and long-pulsed 532-nm Nd:YAG have also been used to treat poikiloderma of Civatte, which features both telangiectatic and pigmentary changes in a “V”-shaped distribution on the neck and anterior chest. However, this common photoinduced condition should be approached with caution, using low fluences and minimally overlapping treatment spots to avoid the potential problems of irregular “checkerboard” hypopigmentation and scarring. Initial treatment of a small test area is advised, followed by treatment of the entire cosmetic unit. Facial laser skin resurfacing in patients with poikiloderma commonly results in striking pseudohypopigmentation at the margin of the resurfaced areas.

Numerous laser and intense pulsed light systems have been marketed specifically for the treatment of leg venulectases (spider veins). The lasers use higher energies, longer wavelengths, and contact cooling devices to achieve selective photothermolysis of both superficial and deeper leg vessels, which generally range in diameter from 0.1 to 1 mm. Superficial, arborizing networks of spider veins are often fed by reticular veins and varicosities, and treatment of these deeper vessels is a prerequisite for effective, durable clearing. Optimal results usually require a combination approach that incorporates conventional therapies such as venous compression, sclerotherapy, and ambulatory phlebectomy for larger-caliber feeding vessels. At present, most “sclerolasers” seem best suited for the treatment of isolated, superficial telangiectases, vessels too small to inject, and for those cases of postsclerotherapy matting that do not spontaneously resolve. Although needle-phobic patients may prefer the concept of laser treatment over sclerotherapy, the latter is typically *less* painful, more effective, and has lower risk of local side effects, in competent hands.

Initial trials using the 585-nm FPDL at 450 µs showed poor efficacy for leg vessels larger than 0.2 mm in diameter, with a disappointingly high rate of posttreatment hyper- and hypopigmentation. Recently, more promising results were reported

by using high-fluence, longer wavelength, long-pulsewidth lasers and intense pulse light sources equipped with contact cooling devices (Fig. 267-3). Some examples include the long-pulsed FPDL (595 to 600 nm), long-pulsed frequency-doubled Nd:YAG (532 nm), long-pulsed Nd:YAG (1064 nm), long-pulsed alexandrite (755 nm) and long-pulsed diode (800 and 940 nm). Good clearance of reticular veins as large as 4 mm in diameter has been reported using a long-pulsed 1064 nm Nd:YAG laser (7 msec; 130 J/cm ^{2}; 6-mm spot size, one to three treatments). Treatment was well tolerated, with adverse effects limited to transient postinflammatory hyper- and hypopigmentation. [16]

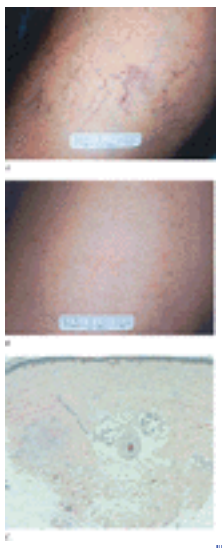

FIGURE 267-3 Leg venulectases in a patient with Fitzpatrick skin phototype I, before (*A*) and 6 months after (*B*) a single treatment with a long-pulsed Nd:YAG laser (350 J/cm ^{2}, 50-msec pulse duration). Histology taken 1 month after treatment shows an organized thrombus with fibrosis occluding the vascular lumen (*C)*. (*Images are courtesy of Kittisak Suthamjariya, MD.*)

Additional Vascular Neoplasms and Malformations

Hemoglobin-targeting lasers such as the PDL, argon, krypton, long-pulsed frequency-doubled Nd:YAG, copper vapor, and KTP, can also clear a wide range of benign vascular ectatic processes including cherry hemangiomas, venous lakes, and angiokeratomas. These lesions all feature relatively superficial blood-filled aneurysmal dilatations, rendering them susceptible to laser-induced selective photothermolysis. As in the case with PWSs, lesion anatomy (depth, size, location, blood flow, etc.) should influence both laser selection and treatment parameters. For instance, venous lakes may persist unless pulse stacking and diascopy are used to reach the deep portions. Long pulsed, near-infrared vascular lasers delivered with cooling (diode, alexandrite, Nd:YAG) are especially useful for deep lesions. Vascular lasers may also be used to improve cosmesis and reduce the risk of traumatic hemorrhage in syndromes featuring prominent vascular ectases such as hereditary hemorrhagic telangiectasia (Osler-Weber-Rendu), blue rubber bleb nevus syndrome (with multiple venous dilatations), and Fabry's disease (angiokeratoma corporis diffusum).

Lesions Featuring Prominent Vasculature

Vascular lasers have also been used to target lesions in which proliferative vasculature is a component, such as fibrous papules, angiofibromas, acne cysts, sebaceous hyperplasia, hypertrophic scars, keloids, HPV-induced viral warts, and local plaques of psoriasis. In such instances, the mechanism of action is often obscure, and results are mixed. Warts, for instance, have a rich supply of papillary dermal capillary loops that are precisely destroyed by vascular lasers such as the FPDL. This alone might lead to ischemia of the overlying epidermis, with subsequent wart involution. Yet heat can also diffuse away from capillary loops into the surrounding papillary dermis and overlying epidermis, causing nonspecific thermal effects, including tissue necrosis, cellular apoptosis, and localized induction of antiviral cytokines and heat shock proteins. This mechanistic complexity has direct clinical implications, because even subtle differences between laser treatment protocols may result in different therapeutic outcomes. Not surprisingly, the literature reflects this ambiguity.

WARTS Lasers are useful, among the list of many other wart treatments. Laser treatment, however, is not particularly more effective than standard therapies. Reported clearance rates vary dramatically from 21 to 95 percent. In the initial study examining pulsed dye laser (PDL) treatment of warts, 39 patients were treated, with warts on the fingers and hands (n = 14), plantar surfaces (n = 6), periungual skin (n = 7), and other body sites (n = 12, including three patients with flat warts), that had been refractory to cryotherapy, CO_2 laser ablation, caustic topical agents, or surgery. [17] Warts were pared, then treated with single nonoverlapping PDL pulses (585 nm; 450 µsec pulsewidth; 6.25 to 7.5 J/cm ^{2} fluence; 5-mm spot size). This induced immediate gray discoloration of the wart, which turned into a black residuum similar to that seen after cryotherapy or topical agents. Pain was minimal during and after the procedure, and 28 patients (72 percent) experienced clearance after an average of 1.68 treatments, spaced 1 to 3 weeks apart. Only one patient developed wart recurrence during a follow-up period that was limited to an average of 5 months. Histology showed intravascular thrombosis of the dermal papillary vessels attributed to laser treatment. Robson et al. reported a prospective randomized trial comparing pulsed dye laser versus “conventional” therapy in 40 patients with 223 common, plantar, or periungual warts. [18] Fifteen of these patients received PDL treatment (585 nm; 450 µsec pulsewidth; 9.0 to 9.5 J/cm ^{2} fluence; 5-mm spot size with 1- to 2-mm overlap) and 20 were treated with either standard cryotherapy (n = 17; 15 s freeze/thaw cycles ×2), topical cantharidin (n = 1), or both cryotherapy and cantharidin (n = 2). Most treatment sessions were spaced 3 to 4 weeks apart. Results for patients in the PDL and conventional groups were statistically comparable by all parameters, including the percentage of complete responders (66 percent with PDL versus 70 percent with conventional therapy), percentage of partial responders showing >50 percent clearance (87 percent with PDL versus 82 percent with cryotherapy) and mean number of treatments needed for complete response (2.00 with PDL versus 2.06 with cryotherapy). Interestingly, warts that had been recalcitrant to prior therapies—including cryotherapy, CO_2 laser

ablation, topical cantharidin, and electrodesiccation—seemed to be no less responsive than treatment-naïve warts in either group. Based on this and other available data, the overall success rate of PDL wart treatment seems to depend on multiple factors, including wart anatomy, laser type and settings, prior treatment history, and treatment intervals. Clinical experience suggests that pulse stacking greatly increases the efficacy of PDL for wart treatment, although this has yet to be assessed in a controlled fashion.

SCARS Laser treatment of hypertrophic and keloidal scars is even more controversial than treating warts. Both types of pathologic scarring feature fibrocytic hyperplasia, excess collagen deposition, prominent telangiectasia and variable inflammation (primarily with mast cells and lymphocytes), yet keloids also contain hyalinized, thick collagen bundles and clinically tend to extend beyond original wound margins. The impetus for treating hypertrophic scars and keloids with vascular lasers stems from a lack of satisfactory alternatives, because traditional therapies, such as intralesional steroid injections, excision, radiation therapy, silicone gel sheeting, and CO_2 laser ablation, are of limited efficacy and may even exacerbate the scarring process. Keloids and hypertrophic scars clearly feature a prominent vascular component, especially during the early stages of development. There is some evidence that early pulsed dye laser treatment of immature scars may lead to improved cosmesis in areas prone to hypertrophic scarring, suggesting a potential prophylactic role. [19] The effects of 585-nm FPDL treatment on keloidal median sternotomy scars were initially reported by Alster and Williams in 16 patients (skin phototypes I to III), treating only one half of each sternotomy scar and leaving the other half as an internal control. [20] The scars had been present for a mean of 17 months, were uniformly hypertrophic, and had not received any prior treatment. Following two treatment sessions (585 nm; 450 µs; 6.5 to 7.25 J/cm ^{2}; 5-mm spot size) spaced 6 to 8 weeks apart, the investigators reported significant improvement in scar characteristics, including erythema, scar height, pliability, texture, and symptoms (pruritus, burning, and tenderness). Biopsy specimens taken from control and laser-treated sites revealed an apparent reduction in collagen fiber density and in the number of fibroblasts and mast cells in the latter. Intrigued by these results, Reiken et al. implanted fragments of human hypertrophic scar (HS) into the fascia of athymic mice, allowing these transplants to grow for 5 days before subjecting them to variable FPDL fluences and wavelengths. [21] They noted a fluence and wavelength-dependent reduction in HS implant size that correlated directly with the extent of vessel damage. Optimal vessel damage and implant size reduction was observed at higher fluence. These results suggest that selective laser-induced vessel damage can cause hypertrophic scars to regress, at least ex vivo. In contrast, a randomized, observer-blinded, controlled trial comparing FPDL (585 nm; 450 µs; 6.5 to 8 J/cm ^{2}; 5-mm spot size; 10 to 20 percent overlap) treatment of hypertrophic scars with silicone gel sheeting failed to show any difference between these two modalities and nontreated control sites. [22] Paradoxically, some PDL-treated scar segments actually showed evidence of increased blood flow following laser irradiation. This well-designed study failed to show efficacy, raising the need for further understanding and confirmation. Interestingly, high-fluence treatment may be detrimental, while low fluences may be effective. A similar situation may hold for an even more controversial use of pulsed dye lasers, “nonablative rejuvenation.” Manuskiatti et al. recently reported that PDL-treated sternotomy scars tended to show more improvement in erythema, induration and height scores when treated using lower laser fluences (3 to 5 J/cm ^{2} versus 7 J/cm ^{2}). [23]

Melanin-Containing Pigmented Lesions

Melanin is well adapted for both coloration and photoprotection in humans, strongly absorbing DNA-damaging ultraviolet radiation, with absorption decreasing steadily with increasing wavelength. Melanin (specifically eumelanin) absorbs well throughout the visible light spectrum, rendering it vulnerable to photothermal and photomechanical injury from a broad range of laser types. Although the absorption spectra of melanin and oxyhemoglobin overlap, preferential absorption by melanin occurs in the 600- to 1100-nm region, providing a useful “window” for selective photothermolysis of melanin-laden targets. Most melanin-targeting lasers, including the Q-switched ruby, alexandrite, and Nd:YAG, operate in this region of the spectrum, and are capable of reaching dermal melanin at various depths. Short pulses from Q-switched lasers are capable of targeting individual pigmented cells, while long pulses (millisecond domain) are capable of targeting collections of pigmented and nonpigmented cells, such as occur in some nevi. In contrast to dermal pigmented lesions, laser-responsive epidermal pigmented lesions have been successfully treated with almost any wavelength/pulsewidth combination at appropriate fluences.

Pulse durations of less than 1 µs can achieve thermal confinement within melanosomes, the subcellular organelle of pigmentation. Nanosecond-pulsed lasers (e.g., Q-switched ruby, alexandrite, and Nd:YAG) operate under these conditions, rapidly heating melanosomes to temperatures high enough to induce cavitation and rupture. Electron microscopy has elucidated this process, which begins with the formation of central zones of lucency within the melanosomes followed by melanosomal membrane rupture. This latter event occurs at a threshold fluence, and correlates with the clinical appearance of immediate epidermal whitening. Subthreshold fluences appear to enhance melanin production by unknown mechanisms. In contrast, suprathreshold fluences cause blebbing and rupture of the melanosome membranes, followed by vacuolar cell degeneration with the appearance of “ring cells.” Ring cells represent damaged basal keratinocytes and melanocytes containing peripherally dispersed melanin and nuclear debris. Animal studies have demonstrated a wide action spectrum for selective photothermolysis of pigmented cells, which correlates well with melanin absorption from UV through near infrared.

In the practice of treating pigmented lesions, thermal confinement within individual melanosomes or melanocytes is not always desired. For instance, compound and congenital nevi are composed of nests or complex aggregates of cells, only some of which may be pigmented. In the case of permanent laser hair removal, the putative target—the stem cell-containing bulge region of the follicle—does not contain melanin except in very darkly pigmented skin. Thermal conduction from the major site of light absorption in hair follicles—a heavily pigmented hair shaft—is needed for stem cell necrosis. Using the same wavelength, a laser can be “tuned” to target melanin-containing structures of varying sizes by altering the pulse duration and fluence parameters. This approach is what separates the actions of Q-switched and long-pulsed lasers. The former is used primarily for targeting pigmented cells, while the latter is used for targeting larger structures which contain some pigment.

EPIDERMAL MELANOCYTIC AND MELANIN-CONTAINING LESIONS: EPHELIDES, LENTIGINES, PIGMENTED SEBORRHEIC KERATOSES, AND CAFÉ AU LAIT MACULES Given their superficial location, one would expect all epidermal melanocytic lesions to be highly responsive to virtually any laser modality, even those that are not especially

melanin selective. Indeed, simple epidermal ablation with pulsed CO_2 or erbium:YAG lasers will remove benign epidermal lesions such as lentigines and ephelides. Pigmented seborrheic keratoses appear to respond equally well to a broad range of melanin-selective and nonselective lasers (and also to cryotherapy). Targeting of individual pigmented cells is not important for their destruction. In contrast, café au lait macules and melasma are far less responsive to both selective and nonselective laser removal, for reasons that are still poorly understood. Lentigines are benign epidermal lesions consisting of variable epidermal and melanocytic hyperplasia with basal keratinocytic hypermelanosis. Solar lentigines follow a photodistribution and accumulate with age, whereas the far-less-common lentigo simplex may occur as an isolated lesion or in association with genetic disorders such as Peutz-Jeghers, LEOPARD [lentigines, electrocardiographic (conduction abnormalities), ocular (hypertelorism), pulmonary (stenosis), abnormal (genitalia), retardation (of growth), and deafness], and Carney's syndromes. Ephelides (freckles) are exceedingly common, especially in Celtic skin types, and represent photodistributed foci of basal keratinocytic hypermelanosis. Lentigines and ephelides have been treated successfully using both nonspecific (CO_2, erbium:YAG) and melanin-selective (510-nm copper vapor, 532-nm KTP, frequency-doubled Q-switched Nd:YAG, Q-switched ruby, Q-switched alexandrite, etc.) wavelength lasers (Fig. 267-4). Although all of these modalities can achieve comparable lesion lightening at relatively low energy settings, distinguishing criteria include treatment expense, risks of adverse effects (scarring, erythema, pain, pigmentary changes), and overall patient preference. Based on these considerations, not all systems are equal, and some may be no better than far cheaper, conventional therapies. For instance, Stern et al. reported that in their hands, solar lentigines lightened more with liquid nitrogen cryotherapy than with low-fluence carbon dioxide (CW) or argon laser treatment. [24] The Q-switched ruby laser is excellent for treatment of lentigines on mucosal surfaces such as those seen in Peutz-Jeghers syndrome. Caution must be taken when treating clinically atypical lentigines, because these may be lentigo maligna, which can recur even years after apparently successful laser treatment. [25]

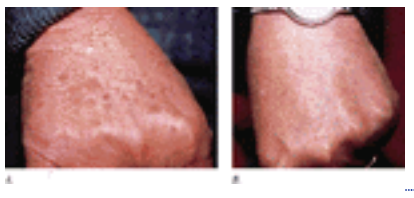

FIGURE 267-4 Solar lentigines on dorsal hand before (*A*) and after (*B*) treatment with Q-switched Nd:YAG 532-nm laser.

In contrast to lentigines, café au lait macules (CALMs) show less-predictable response to laser treatment, running the gamut from clearance to persistence, recurrence, or even darkening. These tan- to brown-colored macular skin lesions are present in approximately 10 percent of the population, occurring sporadically or in association with neurocutaneous genodermatoses such as neurofibromatosis and McCune-Albright syndrome. Both isolated and syndrome-associated CALMs are characterized histologically by the presence of basal keratinocyte hypermelanosis, variable degrees of melanocytic hyperplasia and macromelanosome production. Most attempts to clear CALMs have employed nanosecond-pulsed, melanin-selective lasers such as the Q-switched ruby and frequency-doubled Q-switched Nd:YAG. Grossman et al. used both of these systems to treat nine CALMs, all located on the trunk or proximal extremities in adult patients with skin phototypes I to III. [26] Although some lesions lightened significantly after one treatment, others failed to respond or even showed paradoxical darkening with histopathologic evidence of melanocyte activation. Eight of the nine CALMs had recurred by 6 months, and the remaining CALM recurred at 7 months following sunlight exposure. Two types of CALMs were defined using histopathologic criteria: those with melanocytic hyperplasia and those with only basal keratinocyte hypermelanosis. In addition, three patients had type I neurofibromatosis, and their CALMs contained prominent macromelanosomes. Unfortunately, none of these differences correlated clearly with treatment response. In contrast, Somyos et al. reported more durable CALM clearing (>70 percent at 22 months follow-up) in 15 of 16 Asian patients treated with a scanned, continuous mode 511-nm copper vapor system. [27] Unfortunately, response to laser treatment of CALMs remains an enigma. At present, patients with CALMs seeking treatment should be advised that they will likely require multiple treatments to achieve unpredictable results. Multiple treatments at closely spaced intervals may yield the best chance for durable lightening, but this approach has not been subjected to prospective, blind studies. Specific criteria for predicting CALM response to laser irradiation remain ill-defined, and are largely based on anecdotal experience. Childhood CALMs appear to clear more frequently after laser treatment than adult lesions, however this observation has yet to be confirmed objectively. Transient improvement of CALMs is often followed by recurrence after a few months. Impressive clearing of a large facial CALM, which had failed to lighten despite multiple prior treatments with Q-switched lasers and topical bleaching creams, was reported following two resurfacing treatments with an erbium:YAG laser, and remained clear at 18 months follow-up. [28] This and Somyos' study suggest that some degree of nonspecific epidermal or dermal injury may be important for CALM response to laser treatment.

MELANOCYTIC NEVI: NEVUS SPILUS, NEVOCELLULAR MELANOCYTIC NEVI, CONGENITAL NEVI, AND DYSPLASTIC NEVI Nevus spilus presents as a speckled, localized or segmental pigmented lesion consisting of both CALM and nevocellular melanocytic nevus components, although variants containing foci of Spitz nevi, lentigines, blue nevi, dysplastic nevi, or even melanoma have been described. As in the case with CALMs, larger lesions may be associated with systemic abnormalities such as neurofibromatosis. Laser treatment of nevi spilus is hindered by three main concerns: (1) the CALM component may be refractory to treatment and prone to recurrence; (2) the speckled nevus component may contain deeper nests of cells that are hard to eradicate using nanosecond-pulsed melanin-selective lasers; and (3) while exceedingly small, the risk of melanoma developing within some larger nevi spilus raises additional treatment concerns. Despite these concerns, an excellent and durable clinical response of the speckled lentiginous portion of these lesions can often be obtained by treatment with either Q-switched or normal ruby or alexandrite lasers. When treating nevi spilus, it seems prudent to biopsy any atypical components prior to initial laser irradiation, and to avoid treating patients with a personal or strong family history of melanoma. Patients should be monitored closely for recurrence. Laser treatment of nevomelanocytic nevi remains a problematic area, especially when nevi have clinically atypical features suggestive of dysplastic nevus syndrome. Laser treatment of these lesions is not recommended. While no clinical data to date suggest that laser treatment increases the risk of malignant transformation, there are concerning reports of melanoma occurring within previously laser-treated pigmented lesions. In addition, pseudomelanoma can arise within congenital and acquired melanocytic nevi shortly after CO_2 or argon laser ablation. [29] These CW systems destroy melanocytic lesions through nonselective thermal destruction—a process that denatures dermal collagen and typically leads to some degree of scarring. Residual nevomelanocytic cells may repopulate the scar in irregular nests, clinically

and histologically mimicking regressing melanoma. While CO_2 laser vaporization has recently been used for the palliative debulking of inoperable melanoma and cutaneous metastases, Strobbe et al. reported rapid recurrence in 469 in-transit or satellite lesions following laser treatment, [30] suggesting that even this indication is very limited. At present, there is little or no role for nonselective CW lasers in the treatment of nevomelanocytic lesions, especially those with a dermal component. Instead, most recent attempts to treat nevomelanocytic nevi have employed melanin-selective lasers such as the Q-switched ruby, Q-switched alexandrite, and normal-mode ruby, with the goal of selectively destroying pigmented nevi cells and nests. Vibhagool et al. showed that the Q-switched ruby laser (694 nm; 8 J/cm ^{2}; 28 ns; 5-mm spot size) is highly effective at treating small nevomelanocytic nevi, especially when these benign pigmented lesions are confined to the epidermis. [31] Sixty-seven percent of the treated nevi showed complete clinical and histologic clearance, with no recurrence after a limited follow-up period of 10 weeks. The 33 percent of treated nevi that failed to clear contained persistent melanocytes at depths of 0.10 to 0.40 mm. However, none of these showed irregular nesting or any other features of pseudomelanoma. The Q-switched ruby laser is less effective at clearing congenital nevi, apparently because these lesions contain deeper dermal melanocytic nests, occasional adnexal involvement and amelanotic components. [32], [33] Grevelink et al. noted that Q-switched Nd:YAG (1064 nm) or Q-switched ruby (694 nm) lasers were only capable of removing the superficial portions of congenital nevi, leaving residual nests at depths of 0.16 mm and 0.44 mm, respectively. [33] Primarily in Japan, congenital nevi have been treated with normal-mode, long-pulsed ruby lasers (694 nm; 0.3 to 1.0 ms; 10 to 30 J/cm ^{2}, 10- to 15-mm spot sizes). After an initial report showing impressive clinical results in three patients with extensive congenital nevi, Ueda et al. reported a larger case series with histologic follow-up to 8 years. All nevi faded significantly following four laser treatments, with minimal clinical scarring and an overlying skin appearance approaching that of adjacent normal skin. Despite these impressive cosmetic results, long-term follow-up showed the persistence of residual melanocytic nests, located 1 mm or more beneath the epidermal surface and covered by zones of dermal fibroplasia. [34] This superficial layer of “masking” fibrosis may account for at least some of the observed cosmetic improvement. The long-term risk from leaving residual melanocytic nests remains unclear, and theoretical considerations such as laser-induced melanocyte activation remain. Fibrosis induced by prior laser treatments can complicate the interpretation of subsequent histopathology, and superficial dermal fibrosis could conceivably conceal an evolving focus of melanoma, potentially delaying diagnosis. For these reasons, it is hard to advocate laser treatment for congenital nevi that are amenable to surgical excision. Lesions that are treated using lasers warrant close clinical follow-up. Data on laser treatment of dysplastic nevi is understandably sparse. In one small study, Duke et al. treated a combined group of benign, congenital and atypical nevomelanocytic nevi with either the Q-switched ruby laser, the normal-mode ruby laser, or both lasers together. [35] Although a single treatment yielded significant clinical lightening in 52 percent of the nevi, no lesion demonstrated complete histologic destruction of all nevomelanocytes. Whether or not multiple treatment sessions could achieve complete eradication of atypical nevi remains to be determined, but destruction of purely epidermal lesions might be attainable. Although surgical excision should remain the standard of care for treatment of dysplastic nevi, a better understanding of how lasers interact with these common lesions is sorely needed, because dysplastic nevi may easily be treated inadvertently as benign nevi or during laser hair removal.

DERMAL MELANOCYTIC LESIONS The group of dermal melanocytic lesions includes nevus of Ota, nevus of Ito, dermal melanosis (mongolian spot), and blue nevi. While these latter two lesions are far more prevalent, most attention has focused on laser treatment of the nevus of Ota (nevus fuscoceruleus ophthalmomaxillaris)—a cosmetically disfiguring accumulation of dermal dendritic melanocytes presenting with bluish gray discoloration along one or more branches of the trigeminal nerve. This hamartomatous lesion, which typically presents during childhood, is primarily found in Asian populations but may affect other ethnic groups. A rarer variant of nevus of Ota occurs in association with an ipsilateral or contralateral capillary malformation (PWS)—a condition termed phakomatosis pigmentovascularis. Before the advent of Q-switched melanin-selective lasers such as the Q-switched ruby, alexandrite, and Nd:YAG, no practical, nonscarring treatment options for nevi of Ota existed. In the early 1990s, impressive clearance of nevi of Ota was reported [36] using the Q-switched ruby. Subsequent larger studies by Watanabe and Takahashi [37] and others confirm that the Q-switched ruby, alexandrite, and Nd:YAG lasers are all capable of selectively destroying dermal melanocytes without inducing significant scarring or surface epidermal change. The Q-switched ruby laser selectively destroys melanocytes to a depth of 1.5 mm below the skin surface—a depth that approximates the thickness of the entire epidermis and dermis in the temporal area where nevi of Ota are typically located. Variables affecting treatment response include pigment depth and color, with deeper lesions tending to be more refractory to treatment and prone to recurrence. Color, which reflects both melanocyte depth and density, appears to be an especially useful clinical predictor of treatment response. To this end, Ueda et al. recently found that predominantly brown nevi of Ota required only three treatments to achieve >75 percent clearance. In contrast, all blue-green nevi in their study group needed at least six treatments to obtain comparable clearance, while brown-violet and violet-blue nevi showed an intermediate response. [38] For most nevi of Ota, excellent clearance can be obtained by using Q-switched laser fluences ranging from 5 to 10 J/cm ^{2}, although lower fluences are associated with less hypopigmentation. [39] While multiple treatments increase the response rate, some nevi of Ota will show substantial clearance following a single treatment, with progressive fading noted for months after laser irradiation. Multiple treatments are typically spaced 2 to 3 months apart, but should be delayed, if necessary, until transient hyperpigmentation has resolved. Hypertrophic scarring and textural changes rarely occur, however mottled hypopigmentation was reported in up to 16.8 percent of Asian nevus of Ota patients treated with the Q-switched ruby laser at fluences of 5 to 7 J/cm ^{2}. [40] Risk factors for this hypopigmentation, which persisted for at least 12 months after treatment, included darker patient skin type, the use of multiple treatments, and higher fluence settings. [40], [41] Chan et al. noted an especially high incidence of hypopigmentation in patients receiving combined laser therapy with both the Q-switched alexandrite and Q-switched Nd:YAG lasers (38 percent), although some of these cases may have been temporary in nature. In contrast, they noted posttreatment hypopigmentation in 10.5 percent of patients treated with the Q-switched alexandrite alone and in only 7.6 percent of those treated with the Q-switched Nd:YAG alone. [41] Laser-treated nevi of Ota rarely recur. While nevi of Ota clear well in most locations independent of size, the persistence of periorbital pigmentation may be more common than previously thought—a phenomenon Chan et al. recently termed the “panda's sign.”

Hamartomas: Becker's Nevus, Epidermal Nevus, Nevus Sebaceus

Becker's nevus typically presents during puberty as a tan- to brown-toned hypertrichotic plaque located on the shoulders, upper back, chest, or proximal arms. The lesion, which is far more prevalent in males and usually presents during

puberty, is rarely associated with underlying soft-tissue hypoplasia or musculoskeletal abnormalities. Histologically, Becker's nevi feature variable degrees of basilar keratinocytic hypermelanosis, epidermal hyperkeratosis, and acanthosis with underlying hypertrichosis and smooth muscle fascicles. The combination of hypertrichosis and epidermal pigmentation makes Becker's nevi appealing targets for melanin-selective photothermolysis. Unfortunately, laser treatment has yielded disappointing results characterized by partial response and recurrence. Although good response has been reported after long-pulse ruby laser treatment, [42] large case series addressing the average treatment response in Becker's nevi are lacking.

Epidermal nevi represent a range of hamartomatous processes characterized by epidermal and adnexal hyperplasia with variable ectodermal differentiation. They are classified according to the predominant type of differentiation (epidermal, sebaceous, follicular, etc.) and distribution, ranging in extent from localized plaques to generalized streaks and whorls distributed along Blaschko's lines. While localized, sporadic lesions are relatively common (occurring in an estimated 1 per 1000 live births), extensive and generalized lesions may be associated with a wide range of systemic abnormalities, including musculoskeletal, neurological and ocular defects—a constellation termed the epidermal nevus syndrome. Treatment options for epidermal nevi include surgical excision, dermabrasion, cryosurgery and laser ablation. Topical therapies such as retinoic acid and 5-fluorouracil are far less effective. Epidermal nevi featuring hamartomatous dermal components tend to recur when treatment is confined to the epidermis; unfortunately, procedures that also ablate the dermis tend to produce significant scarring. For localized epidermal nevi amenable to surgical excision, this remains the best treatment option. Nevertheless, laser ablation using CO_2 or argon CW devices can yield impressive and durable cosmetic improvement (Fig. 267-5), even in cases of generalized epidermal nevi. Scarring, which was especially problematic with the earlier generation of CW argon and CO_2 lasers, can now be minimized by using a combination of pulsed or scanned CO_2 and erbium:YAG lasers. Michel et al. obtained encouraging results using a super-pulsed CO_2 laser to treat 10 linear epidermal nevi, 5 of which were inflammatory linear verrucous epidermal nevi (ILVEN). They observed only two recurrences within a 2-year follow-up period, both occurring in younger patients who had been treated with lower energy parameters. [43] Pigmented epidermal nevi have also responded favorably to either Q-switched or normal-mode ruby laser treatment.

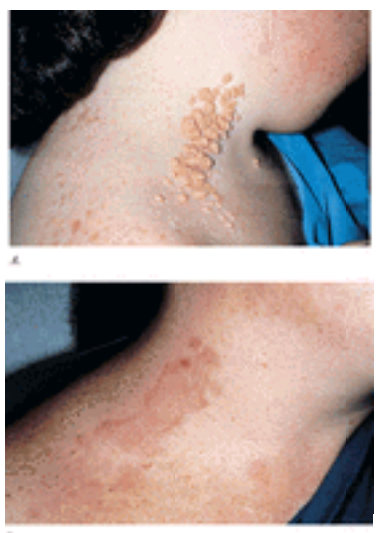

FIGURE 267-5 Epidermal nevus in the neck before (*A*) and after (*B*) treatment with a rapidly scanned CO_2 laser.

Nevus sebaceus of Jadassohn—a relatively common form of epidermal nevus featuring epidermal papillomatosis, prominent sebaceous and apocrine gland hyperplasia—typically presents as a solitary verrucous lesion during childhood. Characteristically located on the scalp, this yellow- to pink-colored hamartoma responds to hormonal stimuli, flattening during childhood but then becoming raised and verrucous during puberty. Although CO_2 laser ablation may yield significant cosmetic improvement in inoperable cases, nevus sebaceus should be completely excised surgically whenever possible given the lesion's known malignant potential.

Melasma, Drug-Induced and Postinflammatory Hyperpigmentation

Melasma is a very common pigmentary disorder featuring smoky brown, photodistributed discoloration, classically involving the face in a masklike distribution. Women are primarily affected, with exacerbating factors including sun exposure, hormonal influences such as pregnancy and oral contraceptive use, ethnicity (Hispanic, Asian, African American) and hereditary predisposition. Three clinical variants are recognized: (1) epidermal melasma, in which melanin deposition is limited to the basal and suprabasal epidermal layers; (2) dermal melasma, featuring perivascular and dermal melanophages; and (3) mixed melasma, in which pigmentation is found in both epidermal and dermal locations. Wood's lamp illumination will enhance epidermal pigmentation alone, providing a convenient bedside diagnostic tool. This distinction is useful, because the epidermal type of melasma is responsive to topical hydroquinone and retinoids. In contrast, dermal pigmentation is notoriously difficult to treat.

Melasma should be responsive to Q-switched lasers capable of selectively targeting melanin, yet this has not been the case in practice. Rather, all forms of melasma have proven refractory to laser treatment, with recurrence or even pigment darkening being the rule. There is little doubt that Q-switched laser treatment destroys the dermal melanophages present in the dermal form of melasma, but treatment necessarily damages the epidermis in the process, potentiating further melasma. Patients with refractory facial melasma or postinflammatory hyperpigmentation typically do not improve after Q-switched ruby laser treatment. [44] Transient improvement had been noted after using erbium:YAG skin resurfacing to treat refractory facial melasma; however, all patients experienced significant postinflammatory hyperpigmentation. [45] At present, laser treatment of melasma cannot be advocated as a single-line therapy, although judicious use of Q-switched laser irradiation or erbium:YAG resurfacing in combination with topical bleaching creams and sun protection may yield

cosmetic improvement in some individuals.

Laser treatment of postinflammatory hyperpigmentation is less disappointing, but variable, especially in darker skin types prone to laser-induced pigment alteration. In lighter skin types, however, Q-switched lasers such as the ruby, alexandrite, and Nd:YAG have been used to treat postsclerotherapy, or drug-induced, hyperpigmentation with good results. In contrast to postinflammatory hyperpigmentation, which is caused by melanin pigment incontinence, postsclerotherapy hyperpigmentation is caused by vessel rupture, erythrocyte extravasation, and perivascular hemosiderin deposition. Tafazzoli et al. used the Q-switched ruby laser (5.6 to 10.5 J/cm ^{2}; 4-mm spot size) to treat this common sclerotherapy complication in eight patients, noting significant lightening in 92 percent of treated areas. [46]

Drug-induced hyperpigmentation may be caused by dermal and epidermal deposition of drug metabolites, hemosiderin, melanin, or a combination of pigment types. The unwanted pigmentation—which can vary from slate-gray to blue, lilac, brown, yellow, or red depending on the culprit drug—often follows a photodistribution (e.g., amiodarone, imipramine), but may also occur on mucosal surfaces, nails, teeth, or in a generalized distribution (e.g., minocycline, busulfan). Q-switched ruby, alexandrite, and 1064 nm-Nd:YAG lasers have all been used to lighten minocycline-induced cutaneous hyperpigmentation with good results. Significant cosmetic improvement has also been reported by using Q-switched lasers to treat amiodarone- and imipramine-induced hyperpigmentation.

Exogenous Dermal Pigment: Tattoos

Prior to the advent of Q-switched laser technology, individuals desiring tattoo removal had to choose between keeping their tattoo or accepting a scar in its place. While a major step forward, Q-switched laser treatment of tattoos is still far from ideal. In skilled hands, ablative techniques, including salabrasion, dermabrasion, cryotherapy, excision, and CO_2 laser vaporization, are capable of yielding cosmetically acceptable results, yet none can promise uniform, scar-free tattoo removal. With the introduction [47] and subsequent refinement of Q-switched laser technology for the treatment of tattoos, selective removal of tattoo pigment without scarring became a real clinical possibility.

An ideal treatment should remove all traces of tattoo pigment without leaving residual scarring. Most tattoo pigment particles are localized to lysosomes, primarily within dermal fibroblasts, macrophages, and occasional mast cells. [48] Pigment particle size ranges from about 2 to 400 nm, with the predominant pigment type being an oval-shaped 40-nm granule. Q-switched lasers produce nanosecond pulses, thereby achieving thermal confinement within individual lysosomes. With Q-switched laser treatment, the irradiated pigment particles reach peak temperatures in excess of 300°C (572°F) within nanoseconds, producing internal changes such as mechanical rupture and chemical alteration (e.g., combustion for carbon-based particles). Taylor et al. and others have described the morphologic appearance of such irradiated pigment particles as “lamellated” or “shell-like,” with central zones of lucency and diminished opacity. [48] These intrinsic structural and chemical changes alone may account for some of the tattoo lightening that follows Q-switched laser irradiation. Each heated pigment particle also vaporizes a shell of water surrounding it, creating a shock wave and cavitation that may contribute to the mechanical rupture and dispersion of the pigment throughout the host cell. Cell rupture and release of pigment fragments into the extracellular space occurs, and the ink is partially eliminated via lymphatic drainage, rephagocytosis, or transepidermal elimination—all proposed mechanisms of posttreatment tattoo clearance. Strategies to augment these “pigment-elimination pathways” may hasten the process of tattoo lightening. In addition, there is some evidence that a new generation of picosecond-pulsed lasers may be even more effective at achieving both thermal and inertial confinement within individual tattoo pigment particles, leading to enhanced photoacoustic effects and more effective tattoo pigment clearance. [49] At present, technological and cost constraints have limited the clinical availability of picosecond lasers.

Over the past decade, the term “laser tattoo removal” has found its way into popular culture, and there is a current misconception that modern lasers can simply erase any tattoo. Recently, the incidence of decorative body art in the United States has skyrocketed to in excess of 10 million people. While many of these new tattoos will lighten with appropriate Q-switched laser treatment, the majority of multicolored tattoos cannot be removed completely. This has become increasingly true as the complexity of tattoo inks continues to increase.

Cosmetically, the best results are obtained when treating blue-black, amateur tattoos, which are produced with carbon-based pigment such as India ink. Using the Q-switched ruby laser at settings of 4–10 J/cm ^{2} (5-mm or 6.5-mm spot size), these tattoos clear without scarring after four to six treatment sessions, spaced 3 to 4 weeks apart. In contrast, professional tattoos often contain multiple pigment types (black, blue, green, red, yellow, orange, purple, etc.), typically deposited in a dense band in the papillary and upper reticular dermis. While some professional tattoos will clear, treatment response can be difficult to predict, especially for tattoos featuring bright, iridescent colors. In general, one should use a Q-switched laser wavelength that is complementary to the tattoo color. For example, green tattoos are best treated with red laser light, and red tattoos are best treated with green laser light. Blue, black, and green tattoos are responsive to Q-switched ruby (694 nm) or Q-switched alexandrite (755 nm) treatment. Both lasers produce significant but transient hypopigmentation in darker skin types. The 1064-nm Q-switched Nd:YAG laser is better tolerated by darkly pigmented skin, and is probably the laser of choice for most black tattoos, but is usually incapable of removing green tattoos. Yellow and orange pigments absorb minimally at any of the commercially-available laser wavelengths, making these colors notoriously difficult to remove.

Theoretically, in vivo absorption spectra can guide laser wavelength selection by providing absorption profiles for any tattoo pigment regardless of its composition. Absorption, however, does not necessarily translate into clinical efficacy. Green tattoo pigment, for instance, absorbs Q-switched ruby laser energy well, as evidenced by the formation of a vigorous epidermal whitening reaction during treatment with this device. Nevertheless, green tattoos often resist laser lightening for unclear reasons that may relate to the chemical composition of the ink itself (e.g. copper or chromium content) (Fig. 267-6). Chemical analysis of tattoo ink stock samples reveals that they are complex mixtures of metallic salts, organic dyes and solvents containing crystalline structures of various sizes (20 to 900 nm) and shapes (cubes, needles, bars, platelets, etc.). For colored tattoos, industrial organic azo and polycyclic dyes have largely replaced

inorganic metallic pigments such as chromium, cobalt, iron, mercury, and cadmium—a trend that is of special concern because organic dyes are known to produce carcinogenic compounds (e.g., aromatic amines) when heated above 200°C (392°F). [50]

FIGURE 267-6 Professional tattoo before (*A*) and after (*B*) multiple Q-switched ruby laser treatments. Note resistant green and red colors and mild hypopigmentation. Red pigment should be responsive to treatment with a Q-switched Nd:YAG 532-nm laser, while green is commonly refractory to “appropriate” wavelength lasers.

Laser-induced chemistry can also induce unwanted color changes within tattoos. When laser-irradiated tattoo particles reach high temperatures, tattoo compounds such as ferric oxide (Fe_2O_3, rust-colored) and titanium dioxide (TiO_2) may shift from their oxidized to reduced states, producing dramatic color changes. In particular, flesh-toned, pink or red cosmetic tattoos, such as those used for “permanent lip-liner,” can permanently blacken immediately after Q-switched laser irradiation. Titanium dioxide, an inert compound that is commonly used to lighten tattoo colors, also darkens from white to blue-black following in vitro Q-switched Nd:YAG laser irradiation—a phenomenon that may contribute to the treatment resistance or paradoxical darkening seen in some modern colored tattoos. [51] Consequently, cosmetic tattoos on the face should be approached cautiously, using test spots before any broad treatment attempt is made. Alternative methods for cosmetic tattoo removal, such as gentle pulsed CO_2 or Er:YAG laser ablation, should also be considered. Finally, patients must be questioned for any history of oral or parenteral gold use before initiating Q-switched laser treatment, because these patients are at risk for laser-induced chrysiasis—an iatrogenic blue-purple skin discoloration caused by laser-induced fragmentation of dermal gold deposits. [52]

Laser and IPL Hair Removal

Photoepilation is one of the most popular dermatologic applications of laser and intense pulsed light. Emphasis has been placed on the potential permanence of laser hair removal, but long-lasting temporary hair removal by lasers or IPLs is also useful. Optical devices may someday challenge the dominance of even the conventional razor blade.

Although often considered a “cosmetic” procedure, important medical indications for photoepilation include the treatment of hypertrichosis and hirsutism, both of which are potentially disfiguring. Hypertrichosis may be caused by genetic, endocrine, or acquired endogenous (e.g., paraneoplastic hypertrichosis lanuginosa, malnutrition) or exogenous factors (e.g., cyclosporine use). In contrast, hirsutism features increased terminal hair growth in androgen-dependent areas such as the upper lip, chin, jaw line, chest, lower abdomen, and upper thighs. Hirsutism caused by polycystic ovary disease is very common, and responds well to laser treatment. Excess hair often causes significant emotional distress and poor self-image in affected individuals, depending to some extent on cultural context. Traditional hair removal methods such as shaving, waxing, plucking, and chemical epilation can only provide temporary improvement and often cause irritation. Electrolysis (direct current) and electrothermolysis (RF current) destroy both pigmented and nonpigmented hairs, but these techniques require the passage of electrical current into individual hair follicles, making them time-consuming, painful, and highly dependent on the operator. It should be emphasized, however, that electrolysis provides advantages not yet achieved by laser hair removal, notably the ability to treat white hair.

In 1996, Grossman et al. first reported the successful, selective destruction of pigmented hair follicles using a normal-mode ruby laser (694 nm; 270 µs; 6-mm spot size) set at high fluence parameters (30 to 60 J/cm^2), and delivered through a cold sapphire lens to minimize epidermal injury. [53] Histologically, hair loss in treated areas correlated with selective thermal injury of individual follicular units, and there was a fluence-dependent growth delay at treatment sites for up to 6 months. Four of the 13 patients in this small cohort had nonscarring alopecia in the laser-treated areas 2 years later. [54] Histologically, there was an increase in vellus-like, miniaturized hairs without scarring, mimicking the appearance of androgenetic alopecia. Laser-induced alopecia was greater in areas that had been shaved rather than plucked prior to treatment, suggesting that the presence of a pigmented hair shaft within the follicle is one prerequisite for efficacy. Terminal hair loss was greatest at sites treated with the highest fluence (60 J/cm^2).

An impressive variety of laser hair removal devices has ensued, and largely eclipsed the stately ruby laser. The most popular laser for hair removal at present is a high-powered diode array (800 nm, 5 to 100 msec), delivered with contact skin cooling. Other popular systems include a long-pulse alexandrite (755 nm, 3 msec) delivered in combination with cryogen spray cooling, and long-pulse Nd:YAG lasers with skin-cooling handpieces. There are at least two key follicular targets: the matrix region of the hair bulb and the bulge region of the outer root sheath. The follicular unit is a dynamic structure, changing as the terminal hair cycles between periods of active growth (anagen), transition (catagen) and rest (telogen). The hair bulb, for instance, varies in depth from 2 to 7 mm below the epidermal surface and is located most superficially during early anagen, which may be somewhat more susceptible to laser-induced injury. [55] The bulb region is responsible for hair shaft growth and contains matrix cells and melanocytes that are highly active during anagen but undergo apoptosis and regression during catagen and telogen. Injury to the bulb during anagen will precipitate premature but temporary hair loss. In contrast, the bulge region of the follicle is a poorly melanized, subtle structure located 1 to 1.5 mm below the epidermis near the insertion of the arrector pili muscle, and at the maximum distance from the hair shaft, at the margin of the outer root sheath. Destruction of the bulge is probably a prerequisite for permanent hair removal (Fig. 267-7), because this region contains stem cells thought to be essential for follicular bulb renewal and hair cycling.

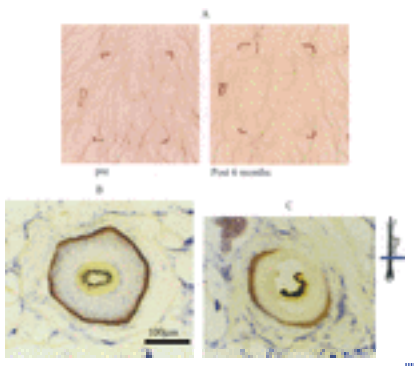

FIGURE 267-7 Laser hair removal using a diode laser with chilled-sapphire cooling tip (810 nm; 40 J/cm ^{2}; 30 msec). Representative clinical pictures of thigh hair at baseline and 6 months following a single laser treatment (*A*) are shown, along with pre- (*B*) and immediately posttreatment (*C)* histology images (Giemsa stain) taken from ex vivo diode-laser treated human scalp hair. Note the laser-induced thermal damage (loss of NBTC staining) to outer root sheath cells that stain positive with the stem-cell marker C8/144B, correlating with stem cell damage (*C)*. (*Images are courtesy of Dieter Manstein, MD.*)

Longer wavelength lasers, such as the diode (810 nm) and long-pulsed Nd:YAG (1064 nm), achieve deeper penetration than the long-pulsed ruby laser (694 nm) and alexandrite (755 nm). Campos et al. reported fluence-dependent permanent hair loss following one to four treatments with a sapphire-chilled 800-nm pulsed diode laser array system [parameters: 10 to 40 J/cm ^{2}; mean fluence = 33.4 J/cm ^{2}; pulsewidth (msec) = 50% of fluence (J/cm ^{2}); 9 × 9 mm ^{2} spot size]. They noted only sparse regrowth in 59 percent of their test subjects after a mean follow-up period of 8.7 months. [56] Alster et al. used a long-pulsed Nd:YAG laser to induce permanent hair reduction in patients with darkly pigmented skin (phototypes IV to VI), observed 12 months after the last of three monthly treatment sessions. Even though high treatment fluences of up to 50 J/cm ^{2} were used in most patients, only 5 percent experienced transient pigmentary alteration and vesiculation was seen in only 1.5 percent. [57] African Americans with hirsutism or pseudofolliculitis barbae tend to respond well to treatment with either diode or Nd:YAG lasers, with minimal side effects when used at lower fluences. While not exact, the general correlation between skin color and hair color appears to be such that high fluences are not necessary in many darkly pigmented patients. The best combination of safety and efficacy for dark skin is achieved by long pulse duration (30 to 100 msec or more), low fluence settings, and aggressive contact skin cooling to minimize epidermal injury.

IPLs are also useful for hair removal. As with many lasers, pulsewidth can be adjusted to some extent using stuttered pulses; unlike lasers, there is also wavelength flexibility by filtering the IPL output. The IPLs can generate fluences of up to 90 J/cm ^{2}, delivered in single, double, or triple pulses. Long-term epilation has been demonstrated using fluences of 34 to 42 J/cm ^{2}, comparable to laser devices. [58] IPL-associated adverse effects such as transient hyperpigmentation and crusting are similar to those seen with lasers.

Because all of these photoepilation devices target melanin within the hair follicle, blonde, white, and gray hairs pose a treatment challenge. Unfortunately, there has yet to be a demonstrated solution to this problem. Exogenous, topical chromophores capable of infiltrating the hair follicle could in theory be employed, but have thus far failed to produce permanent hair removal. Pigmented and nonpigmented hair follicles should be equally susceptible to photochemical injury—a concept that has fueled recent interest in the use of photodynamic therapy (PDT) as an alternative means for hair removal. One promising approach utilizes topically applied aminolevulinic acid (ALA)—a heme precursor that is rapidly metabolized in vivo to the potent photosensitizing compound protoporphyrin IX (PP IX). Several hours after ALA application, PP IX is concentrated within follicular units and sebaceous glands, where it releases singlet oxygen upon exposure to red light (e.g., 635 nm). If adequate ALA concentrations are paired with a sufficiently high fluence, the resulting follicular damage can lead to partial hair loss, reported to persist for up to 6 months in one small study. [59]

Infrared, Ablative Lasers: CO_2 and Erbium:YAG

Both CO_2 and Er:YAG lasers emit light in the infrared portion of the electromagnetic spectrum, a region that is strongly absorbed by tissue water. Specifically, the water absorption coefficients for CO_2 (10,600 nm) and Er:YAG wavelengths are 800 cm $^{-1}$ and 13,000 cm $^{-1}$ respectively, making both of these lasers well-suited for selective ablation of the water-rich epidermis. The earliest CW CO_2 lasers were used for tissue cutting (in the focused mode) or ablation (in the defocused mode), with ablation primarily limited by excessive residual thermal damage and the associated high risk of scarring.

With the introduction of short-pulsed and rapidly scanned, high-energy infrared lasers, it became possible to ablate the epidermis while limiting residual thermal damage to a predictable, superficial dermal zone. This type of controlled ablation has proven to be especially useful for the destruction of primarily epidermal lesions such as seborrheic and actinic keratoses, epidermal nevi, and warts. In addition, both CO_2 and Er:YAG lasers have been used effectively to debulk lymphangiomas and a variety of appendageal tumors, including syringomas, xanthomas, xanthelasma, trichilemmomas, and angiofibromas. Although recurrence rates are high for many of these conditions, cosmetic improvement can be dramatic and potentially life altering.

Despite their clinical versatility, infrared lasers such as the CO_2 and Er:YAG are most commonly used in dermatology to treat photodamaged skin and acne scarring. The dual properties of high water absorption and predictable residual thermal damage make these lasers especially useful for these indications. For a detailed review of laser skin resurfacing, see Chap. 271.

Nonablative Dermal Remodeling

Enthusiasm for the long-term benefits of laser skin surfacing has been tempered by short-term adverse effects including pain, prolonged downtime, persistent erythema, postinflammatory hyperpigmentation, and the need for diligent and time-consuming postoperative wound care. Furthermore, permanent hypopigmentation or scarring, while rare, remain potentially disfiguring complications. To address these challenges, recent attention has focused on various lasers and IPLs capable of inducing selective dermal injury without epidermal ablation. The physical principles behind such nonablative dermal remodeling or “subsurfacing” are not new, but the actual efficacy and potential biological response mechanisms involved have yet to be elucidated in detail. It is clear that photothermal injury is the stimulus. Injury to vascular endothelial cells and fibroblasts may initiate a dermal remodeling process through the induction and release of soluble factors involved in normal wound healing such as collagenase, type I collagen and platelet derived growth factor. [60], [61] Ideally, thermal injury is confined to the dermis, thereby circumventing the prolonged wound healing, erythema and pain associated with ablative modalities such as laser skin resurfacing (LSR).

The first report of nonablative dermal remodeling stems from the anecdotal observation that pulsed dye laser treatment of facial telangiectases is associated with subtle softening of rhytides in the treated areas. Pulsed dye lasers have also been used to treat atrophic striae distensae with modest success, suggesting that selective injury of dermal vessels may influence dermal collagen remodeling. [62] Encouraged by these preliminary observations, Zelickson et al. used a pulsed dye laser (585 nm; 450 msec; 7- or 10-mm spot size with 10 to 15 percent overlap; 3.0 to 6.5 J/cm ^{2}) to treat 20 subjects with photodamaged facial skin. [63] They observed subtle PDL-induced improvement in 9 of 10 patients with moderate and 4 of 10 patients with severe sun-induced rhytides. Representative skin biopsies taken 6 and 12 weeks after treatment showed that areas of solar elastosis had been replaced by superficial, thickened, grenz zones of organized collagen. These features, combined with the findings of increased dermal mucin and active fibroblasts, were all suggestive of dermal collagen remodeling. Interestingly, lower fluences may be more effective. The FDA has cleared a 0.3-msec pulsed dye laser operating at low fluence without skin cooling for this indication; comparative studies are lacking.

More recently, lasers and IPLs capable of inducing nonablative dermal remodeling with little or no associated purpura have been developed and marketed specifically for this indication. The lasers, including the 1320-nm Nd:YAG, 1540-nm erbium glass, and 1440-nm diode lasers, all feature penetrating wavelengths absorbed by water, with essentially zero melanin or hemoglobin absorption. Epidermal sparing is achieved via a combination of approaches including contact or cryogen spray cooling and intradermal beam focusing. Nelson et al. first reported using a 1320-nm Nd:YAG laser in combination with cryogen spray cooling to achieve selective dermal injury in porcine dermis, using laser fluences of up to 36 J/cm ^{2}. Similar fluences without cryogen spray cooling caused epidermal blistering and necrosis. [64] Subsequently, Menaker et al. used a cryogen spray-cooled 1320-nm Nd:YAG laser to treat periocular rhytides and postauricular skin in 10 healthy volunteers (three treatments, every 2 weeks; parameters: 1.32 µm; 20-msec macropulses; 32 J/cm ^{2}; 5-mm spot size; 33 percent overlap; DCD (or dynamic cooling device) 20 ms spray time/10 ms delay time. [65] They assessed rhytid severity, pigment alterations, scarring and patient discomfort at 1 and 3 months posttreatment, noting minimal rhytid improvement in 4 of 10 patients. Four of 10 postauricular skin biopsies (taken 1 month after treatment) showed a statistically insignificant increase in dermal collagen. Of note, four patients developed posttreatment hyperpigmentation, and three patients developed periocular blistering followed by pitted scarring. [65] A larger study by Kelly et al. found statistically significant improvement only in subjects with severe periorbital rhytides, assessed at 6 months follow-up. They also noted blistering when the surface temperature of treated skin exceeded 50°C (122°F), with pinpoint scarring occurring at four sites in two blistered subjects (2.8 percent). [66]

Ultraviolet Lasers for the Treatment of Psoriasis and Vitiligo

Excimer lasers employ a mixture of a noble gas and halogen to produce a molecule that only exists in its excited (metastable) state within the laser cavity. Such molecules are called excited dimers, or excimers. Excimer lasers produce high-average power quasicontinuous trains of nanosecond UV pulses, and are widely used in industry and ophthalmology for extremely precise ablation. The 193-nm, KrF excimer laser ablates about 0.1 µm of corneal tissue per pulse, which allows precise permanent correction of refractive disorders such as myopia.

Recently, a fiber-optic–coupled 308-nm XeCl excimer laser was used in dermatology as a source for local narrow-band UVB therapy of psoriasis and vitiligo. UVB phototherapy is a well-established treatment for a variety of inflammatory dermatoses. Bonis et al. first reported the efficacy of narrow-band conventional UVB versus excimer laser therapy for the treatment of chronic plaque psoriasis in 10 patients. [67] Some plaques were treated with progressively escalating doses of the excimer laser, applied thrice weekly. This regimen yielded uniform plaque clearance following 7 to 11 treatments, requiring a mean cumulative irradiation dose of 4.45 J/cm ^{2}. In contrast, UVB-treated plaques took 2.27 times longer to clear and required significantly larger cumulative doses of UVB (mean 31.1 J/cm ^{2}). At 2 years follow-up, the authors reported that 8 of the 10 original patients still remained plaque-free in excimer-treated areas. [68] A subsequent dose-response study solidified the 308-nm excimer laser's role as an effective treatment for localized chronic plaque psoriasis, especially when used at high energy settings [4 to 6 minimal erythema doses (MEDs) or greater]. [69] Treatment at very high doses (8 to 16 MEDs) frequently causes a blister, which heals without scarring and often without psoriasis after a single treatment. At medium fluences (2, 3, 4, and 6 MED multiples), multiple treatments (twice per week for up to 20 treatments) correlated with greater plaque clearance, however fluence was the main determinant of clinical response. Of note, blistering doses were painful, while lower fluences produced no discomfort or adverse effects. A main advantage of excimer laser over conventional phototherapy is the ability to limit unnecessary, cumulative UVB exposures to unaffected skin. Other sources of narrow-band UVB may become available based on the excellent results obtained by the excimer laser. Narrow-band UVB phototherapy is also an effective vitiligo therapy, capable of inducing at least partial repigmentation in most treated patients. Initial reports suggest that the 308-nm XeCl excimer laser is effective treatment for localized vitiligo. [70]

DIAGNOSTIC APPLICATIONS: CONFOCAL SCANNING LASER MICROSCOPY

While this chapter has focused on the therapeutic use of lasers in dermatology, novel diagnostic applications for laser light warrant attention, especially in view of recent developments and refinement of confocal scanning laser microscopy (CSLM) and optical coherence tomography (OCT). These evolving technologies have made it possible to obtain clear, detailed cross-sectional images of human skin in vivo (Fig. 267-8). Confocal microscopic images are created by detecting backscattered or fluorescence emission coming from a small, scanned focus of light inside the tissue. The focal spot, usually provided by a laser, is in a *con*jugate *focal* plane to a pinhole aperture, which filters unwanted light from above or below the plane within the tissue. This creates a virtual "section" image in vivo, comparable to actual sectioning of the tissue but without the need for a biopsy. A near-infrared confocal microscope was constructed specifically for imaging skin. [71] The device achieves resolution similar to regular light microscopy, and is capable of imaging cells, some subcellular organelles, and extracellular matrix to a depth of about 0.4 mm in skin. The device produces a real-time "histology movie," of horizontal sections inside the living skin. Changes in refractive index within the tissue are responsible for light scattering, which provides the image contrast for reflectance confocal microscopy. Melanin provides the strongest contrast in human skin since its high refractive index (n = 1.7) is much greater than that of the surrounding cytoplasm. [72] Already a useful research tool, clinical applications for confocal microscopy are under investigation, including tumor margin detection, analysis of pigmented lesions, and differentiation of contact from irritant dermatitis.

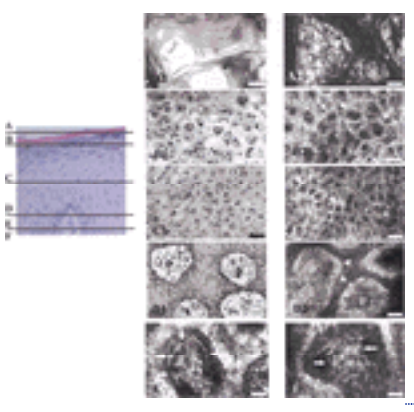

FIGURE 267-8 Correlation between vertical and transverse sections [hematoxylin and eosin (H& E) and in vivo confocal] of normal skin. In confocal images, the corneocytes appear as bright polygonal shapes (*A2, arrows*), and measure 10 to 30 µm in diameter. Granular cells (*B2, arrows*) are regularly seen at depths of 10 to 15 µm. The dark oval areas correspond to nuclei within the bright cytoplasm. Spinous keratinocytes (*C2, arrows*) are seen at 20 to 100 µm below the stratum corneum. Note that the basal keratinocytes (*D2, arrows*), located around dermal papillae (*p, D*), are brighter than the keratinocytes of the stratum spinosum (*ss, C2*) and granulosum layers (*sg, B2*). Blood vessels (*arrows, E*) and collagen bundles (*arrows, F*) are also seen (A1, A2, B1, C1, D1, ×40/0.65 NA dry objective lens; B2, C2, D2, E, F, ×30/0.9 NA water immersion objective lens; scale bar, 25 µm). (*From Rajadhyaksha M et al: In vivo confocal scanning laser microscopy of human skin II: Advances in instrumentation and comparison to histology. J Invest Dermatol 113:293, 1999. Reprinted by permission of Blackwell Science, Inc.*)

Optical coherence tomography is another technique for virtual-section imaging of light reflected from tissue. OCT relies on the coherence properties of light, detected by wave interference in a device called an interferometer. A low-coherence optical source is split into two beams, one of which travels to the tissue, while the other provides a reference path. When the optical pathlength of light traveling in each arm of the device is equal, wave interference can be detected. Thus, OCT is conceptually similar to detecting optical "echoes" from the tissue, and like ultrasound echoes, provides a vertical section. The resolution of OCT is not yet capable of imaging individual cells, but structures such as hair follicles, sweat glands, and tumors are easily seen. Doppler and polarization-sensitive versions of OCT and confocal microscopy are under development, which emphasize functional imaging of blood flow and collagen structure, respectively. It is likely that laser-based imaging will play some role in dermatology in the future.

REFERENCES

1. Anderson RR, Parrish JA: Selective photothermolysis: precise microsurgery by selective absorption of pulsed radiation. *Science* **220**:524, 1983

2. Anderson RR, Parrish JA: Microvasculature can be selectively damaged using dye lasers: A basic theory and experimental evidence in human skin. *Lasers Surg Med* **1**:263, 1981

3. Zenzie HH et al: Evaluation of cooling methods for laser dermatology. *Lasers Surg Med* **26**:130, 2000

4. Gilchrest BA et al: Chilling port wine stains improves the response to argon laser therapy. *Plast Reconst Surg* **69**:278, 1982

5. Chang CJ, Nelson JS: Cryogen spray cooling and higher fluence pulsed dye laser treatment improve port-wine stain clearance while minimizing epidermal damage. *Dermatol Surg* **25**:767, 1999

6. Raulin C et al: Cold air in laser therapy: first experiences with a new cooling system. *Lasers Surg Med* **27**:404, 2000

7. Gloster HM Jr, Roenigk RK: Risk of acquiring human papillomavirus from the plume produced by the carbon dioxide laser in the treatment of warts. *J Am Acad Dermatol* **32**:436, 1995

8. Baggish MS et al: Presence of human immunodeficiency virus DNA in laser smoke. *Lasers Surg Med* **11**:197, 1991

9. Garden JM et al: Effect of dye laser pulse duration on selective cutaneous vascular injury. *J Invest Dermatol* **87**:653, 1986

10. Dixon J et al: Hypertrophic scarring in argon laser treatment of port-wine stains. *Plast Reconstr Surg* **73**:771, 1984

11. Tan O et al: Treatment of children with port-wine stains using the flashlamp-pulsed tunable dye laser. *N Engl J Med* **320**:416, 1989

12. Van der Horst C et al: Effect of the timing of treatment of port-wine stains with the flash-lamp-pumped pulsed dye laser. *N Engl J Med* **338**:1028, 1998

13. Dierickx C et al: Thermal relaxation of port-wine stain vessels probed in vivo: The need for 1–10-millisecond laser pulse treatment. *J Invest Dermatol* **105**:709, 1995

14. Raulin C et al: Treatment of port-wine stains with a noncoherent pulsed light source. *Arch Dermatol* **135**:679, 1999

15. Hohenleutner S et al: Long-term results in the treatment of childhood hemangioma with the flashlamp-pumped pulsed dye laser: an evaluation of 617 cases. *Lasers Surg Med* **28**:273, 2001

16. Sadick N: Long-term results with a multiple synchronized-pulse 1064 nm Nd:YAG laser for the treatment of leg venulectasias and reticular veins. *Dermatol Surg* **27**:365, 2001

17. Tan O et al: Pulsed dye laser treatment of recalcitrant verrucae: A preliminary report. *Lasers Surg Med* **13**:127, 1993

18. Robson K et al: Pulsed-dye laser versus conventional therapy in the treatment of warts: A prospective randomized trial. *Arch Dermatol* **43**:275, 2000

19. McCraw J et al: Prevention of unfavorable scars using early pulsed dye laser treatment: A preliminary report. *Ann Plast Surg* **42**:7, 1999

20. Alster T, Williams C: Treatment of keloid sternotomy scars with 585 nm flashlamp-pumped pulsed-dye laser. *Lancet* **345**:1198, 1995

21. Reiken et al: Control of hypertrophic scar growth using selective photothermolysis. *Lasers Surg Med* **21**:7, 1997

22. Wittenberg G et al: Prospective, single-blinded, randomized, controlled study to assess the efficacy of the 585-nm flashlamp-pumped pulsed-dye laser and silicone gel sheeting in hypertrophic scar treatment. *Arch Dermatol* **135**:1049, 1999

23. Manuskiatti W et al: Energy density and number of treatments affect response of keloidal and hypertrophic sternotomy scars to the 585-nm flashlamp-pumped pulsed-dye laser. *J Am Acad Dermatol* **45**:557, 2001

24. Stern R et al: Laser therapy versus cryotherapy of lentigines: A comparative trial. *J Am Acad Dermatol* **30**:985, 1994

25. Lee P et al: Failure of Q-switched ruby laser to eradicate atypical-appearing solar lentigo: Report of two cases . *J Am Acad Dermatol* **38**:314, 1998

26. Grossman M et al: Treatment of café au lait macules with lasers. *Arch Dermatol* **131**:1416,1995

27. Somyos K et al: Copper vapour laser treatment of café-au-lait macules. *Br J Dermatol* **135**:964, 1996

28. Alora M, Arndt K: Treatment of a café-au-lait macule with the erbium:YAG laser. *J Am Acad Dermatol* **45**:566, 2001

29. Dummer R et al: Pseudo-melanoma after laser therapy. *Dermatology* **197**:71, 1998

30. Strobbe L et al: Carbon dioxide laser for cutaneous melanoma metastases: indications and limitations. *Eur J Surg Oncol* **23**:435, 1997

31. Vibhagool C et al: Treatment of small nevomelanocytic nevi with a Q-switched ruby laser. *J Am Acad Dermatol* **36**:738, 1997

32. Waldorf H et al: Treatment of small and medium congenital nevi with the Q-switched ruby laser. *Arch Dermatol* **132**:301, 1996

33. Grevelink J et al: Clinical and histological responses of congenital melanocytic nevi after single treatment with Q-switched lasers. *Arch Dermatol* **133**:349, 1997

34. Imayama S, Ueda S: Long- and short-term histological observations of congenital nevi treated with the normal-mode ruby laser. *Arch Dermatol* **135**:1211, 1999

35. Duke D et al: Treatment of benign and atypical nevi with the normal-mode ruby laser and the Q-switched ruby laser. *Arch Dermatol* **135**:290, 1999

36. Geronemus R: Q-switched ruby laser therapy of nevus of Ota. *Arch Dermatol* **128**:1618, 1992

37. Watanabe S, Takahashi H: Treatment of nevus of Ota with the Q-switched ruby laser. *N Engl J Med* **331**:1745, 1994

38. Ueda S et al: Response of naevus of Ota to Q-switched ruby laser treatment according to lesion color. *Br J Dermatol* **142**:77, 2000

39. Taylor C et al: Treatment of nevus of Ota by Q-switched ruby laser. *J Am Acad Dermatol* **30**:743, 1994

40. Kono T et al: A retrospective study looking at the long-term complications of Q-switched ruby laser treatment of nevus of Ota. *Lasers Surg Med* **29**:156, 2001

41. Chan H et al: A retrospective study looking at the complications of Q-switched alexandrite (QS alex) and Q-switched Neodymium:Yttrium-Aluminum-Garnet (QS Nd-YAG) lasers in the treatment of nevus of Ota. *Dermatol Surg* **26**:1000, 2000

42. Nanni C, Alster T: Treatment of a Becker's nevus using a 694-nm long-pulsed ruby laser. *Dermatol Surg* **24**:1032, 1998

43. Michel J et al: Resurfacing CO_2 laser treatment of linear verrucous epidermal nevus. *Eur J Dermatol* **11**:436, 2001

44. Taylor C, Anderson R: Ineffective treatment of refractory melasma and postinflammatory hyperpigmentation by Q-switched ruby laser. *J Dermatol Surg Oncol* **20**:592, 1994

45. Manaloto R, Alster T: Erbium:YAG laser resurfacing for refractory melasma. *Dermatol Surg* **25**:121, 1999

46. Tafazzoli A et al: Q-switched ruby laser treatment for post-sclerotherapy hyperpigmentation. *Dermatol Surg* **26**:653, 2000

47. Reid W et al: Q-switched ruby laser treatment of black tattoos. *Br J Plast Surg* **36**:455, 1983

48. Taylor C et al: Light and electron microscopy analysis of tattoos treated by Q-switched ruby laser. *J Invest Dermatol* **97**:131, 1991.

49. Ross E et al: Comparison of responses of tattoos to picosecond and nanosecond Q-switched neodymium:YAG lasers. *Arch Dermatol* **134**:167, 1998

50. Baumler W et al: Q-switched laser and tattoo pigments: First results of the chemical and photophysical analysis of 41 compounds. *Lasers Surg Med* **26**:13, 2000

51. Ross E et al: Tattoo darkening and nonresponse after laser treatment. A possible role for titanium dioxide. *Arch Dermatol* **137**:33, 2001

52. Trotter M et al: Localized chrysiasis induced by laser therapy. *Arch Dermatol* **131**:1411, 1995

53. Grossman M et al: Damage to hair follicles by normal-mode ruby laser pulses. *J Am Acad Dermatol* **35**:889, 1996

54. Dierickx C et al: Permanent hair removal by normal-mode ruby laser. *Arch Dermatol* **134**:837, 1998

55. Lin T et al: Hair growth cycle affects hair follicle destruction by ruby laser pulses. *J Invest Dermatol* **111**:107, 1998

56. Campos V et al: Hair removal with an 800-nm pulsed diode laser. *J Am Acad Dermatol* **43**:442, 2000

57. Alster T et al: Long-pulsed Nd:YAG laser-assisted hair removal in pigmented skin. *Arch Dermatol* **137**:885, 2001

58. Sadick N et al: Long-term photoepilation using a broad-spectrum intense pulsed light source. *Arch Dermatol* **136**:1336, 2000

59. Grossman M et al: PDT for hirsutism [abstract]. *Lasers Surg Med* **7**(Suppl):44, 1995

60. Mordon S et al: Mechanism induced by selective laser targeting of the dermis microvasculature: an in-vivo experimental study [abstract]. *Lasers Surg Med* **13**(Suppl):4, 2001

61. Zelickson B, Kist D: Pulsed dye laser and photoderm treatment stimulates production of type I collagen and collagenase transcripts in papillary dermis fibroblasts [abstract]. *Lasers Surg Med* **13**:33, 2001

62. McDaniel D et al: Treatment of stretch marks with the 585 nm flashlamp-pumped pulsed dye laser. *Dermatol Surg* **22**:332, 1996

63. Zelickson B et al: Pulsed dye laser therapy for sun damaged skin. *Lasers Surg Med* **25**:229, 1999

64. Nelson J et al: Clinical study of non-ablative laser treatment of facial rhytides. *Lasers Surg Med* **95**:32, 1997

65. Menaker G et al: Treatment of facial rhytides with a nonablative laser: A clinical and histologic study. *Dermatol Surg* **25**:440, 1999

66. Kelly K et al: Cryogen spray cooling in combination with nonablative laser treatment of facial rhytides. *Arch Dermatol* **135**:691, 1999

67. Bonis B et al: 308-nm UVB excimer laser for psoriasis [letter]. *Lancet* **350**:1522, 1997

68. Kemeny L et al: 308-nm excimer laser therapy for psoriasis [letter]. *Arch Dermatol* **137**:95, 2001

69. Asawanonda P et al: 308-nm excimer laser for the treatment of psoriasis. *Arch Dermatol* **137**:619, 2001

70. Baltas E et al: Repigmentation of localized vitiligo with the xenon chloride laser [letter]. *Br J Dermatol* **144**:1262, 2001

71. Rajadhyaksha M et al: Video-rate confocal scanning laser microscope for imaging human tissue in vivo. *Appl Opt* **38**:1, 1999

72. Rajadhyaksha M et al: In vivo confocal scanning laser microscopy of human skin: Melanin provides strong contrast. *J Invest Dermatol* **104**:946, 1995

T>

Chapter 268

June Robinson George Hruza

Dermatologic Surgery: Introduction and Approach

PATIENT SELECTION
INFECTION CONTROL
SURGICAL ANATOMY: DANGER ZONES
LOCAL ANESTHESIA
Mechanism of Action
Types of Anesthetics
Side Effects
Epinephrine
Topical Anesthetics
Local Anesthesia
SUTURING TECHNIQUES
Suture Materials
Interrupted Sutures
Running Sutures
Suture Removal
Stainless Steel Staple Closure
Tissue Adhesive
Wound Closure Tapes
EXCISIONAL SURGERY
ELECTROSURGERY
HEALING BY SECOND INTENTION
LOCAL SKIN FLAPS
SKIN GRAFTS

REFERENCES

Over the past 30 years, dermatology has become an organ-specific specialty combining medical and surgical approaches to the skin and its appendages. The expansion of technology and treatment options by dermatologists has widened the scope of practice in cutaneous surgery, laser surgery, Mohs micrographic urgery, and cosmetic surgery. The 1980s and 1990s were a time of explosive development of laser technology and growth of dermatologic uses (see Chap. 267 and Chap. 271). The next decade promises to be one of growth in tissue augmentation. In the 1980s, there was a steady rise in the use of collagen as injectable material. Other emerging biologic nonautologous materials (e.g. hyaluronic acid, cadaver materials), as well as nonbiologic materials (e.g., expanded polytetrafluoroethylene, polymethylmethacrylate microspheres) promise to support similar growth in the next decade. As dermatologists explore the aesthetic uses of these new materials, reconstructive indications will evolve. The two aspects of dermatologic surgery, aesthetic and reconstructive, support one another. This chapter introduces the basic concepts of dermatologic surgery and provides the framework for subsequent chapters focusing on specific dermatologic surgery techniques.

PATIENT SELECTION

Before performing dermatologic surgery, a careful history, review of systems, and focused physical examination are essential. Special attention should be paid to atherosclerotic heart disease, hypertension, presence of a cardiac pacemaker, renal disease, diabetes, immunosuppression, healing ability (poor healing, keloids, or hypertrophic scars), bleeding tendency, allergies to systemic and topical agents, pregnancy, and a history of syncope, especially from injections or phlebotomy. A detailed medication history should be obtained, with special attention to platelet-inhibiting agents such as aspirin, nonsteroidal anti-inflammatory drugs, and dipyridamole; coagulation-inhibiting agents, such as Coumadin; beta-blocking agents; phenothiazines; tricyclic antidepressants; thyroid hormones; and monoamine oxidase inhibitors. A history of abnormal heart valves, heart murmur, or prosthetic joints, valves, or vessels should be ascertained, as some of these patients may require preoperative prophylactic antibiotics to prevent bacterial endocarditis or prosthesis infection. [1] Smoking may interfere with the survival of skin grafts or flaps because of vasoconstriction, [2] while alcohol ingestion may increase the patient's bleeding tendency by causing qualitative platelet inhibition.

Aspirin, nonsteroidal anti-inflammatory drugs, and warfarin increase intraoperative bleeding, [3] but have not been clearly demonstrated to increase postoperative bleeding. [3] If the patient's medical condition allows and these medications are stopped, warfarin and nonsteroidal anti-inflammatory drugs should be held for 3 days preoperatively, while aspirin should be held for at least 10 days because it causes irreversible inhibition of platelet function. [4] Alcohol and cigarettes should be stopped during the perioperative period. Epinephrine should be used with caution in patients taking beta-blocking agents, tricyclic antidepressants, thyroid hormones, and monoamine oxidase inhibitors because of the risk of severe hypertension. However, in routine dermatologic surgery where small amounts of local anesthetic with epinephrine are used, the risk of this problem is remote. [5] A detailed oral and written informed consent discussing the potential benefits, risks, and alternative treatments should be obtained from the patient or, if the patient is mentally incompetent or younger than age 18 years, from the patient's legal guardian.

INFECTION CONTROL

Skin preparation before surgery is designed to reduce but not eliminate the extensive bacterial flora present on intact skin. For minor procedures such as biopsies and electrodesiccation, cleansing with isopropyl alcohol and barrier protection with nonsterile gloves is sufficient. As the procedure increases in complexity to excisional surgery with skin

closure, the skin should be prepared with a povidone-iodine (Betadine) or chlorhexidine scrub followed by draping the surgical field with sterile towels. Hair in the surgical field should be clipped with scissors. Preoperative shaving of hair is associated with an increase in wound infections. [6]

Povidone-iodine is active within a few minutes, but once it has dried, is wiped away, or comes in contact with blood, it loses its bactericidal activity. Some patients are allergic to the iodine, [7] which attacks cell membranes and is bactericidal for most bacteria, has a rapid onset of action, and is preferred as an antiseptic agent by many. It binds to cell membranes, with bactericidal activity lasting several hours after application. Because it is toxic to the cornea [8] and tympanic membrane, it should be avoided for use around the eyes and ears. As povidone-iodine and chlorhexidine are toxic to tissue in open wounds, they should not be used within such wounds. Because hexachlorophene and quaternary ammonium compounds are not bactericidal against many gram-negative organisms, they are rarely used for skin preparation. In addition, hexachlorophene is absorbed through intact skin and is potentially neurotoxic, especially in neonates. [9]

All patients are considered as being infected with HIV, hepatitis B or C, or other blood-borne agents. Therefore, universal precautions must be adhered to in order to protect the surgical staff, as well as patients, against cross-contamination. [10] For skin surgery, this means wearing sterile surgical gloves, masks, and protective eyewear. Double-gloving reduces the risk of glove perforation during surgery by a factor of 3 to 8. [11] If significant exposure to body fluids is anticipated, waterproof gowns and caps should be worn as well. Healthcare workers are most commonly exposed to blood by needle sticks. To reduce the risk of needle-stick injury, needles should never be recapped, suture needles should be handled only with instruments, and all sharps should be disposed of in puncture-proof containers immediately after use. All instruments that come in contact with a patient's blood or tissue must be carefully sterilized or discarded.

The risk of wound infection after skin surgery is quite small. [12] Therefore, prophylactic antibiotics are usually not indicated except for patients or anatomic sites at greatest risk for infection. If such antibiotics are given, they must be in the bloodstream at the time surgery starts in order to be effective. [13] Infections are more likely to develop in patients who are immunosuppressed or debilitated, or who have reduced blood flow to the surgical site, such as the legs in patients with peripheral vascular disease or diabetes. Anatomically, the ears, [12] perineum, legs, and feet seem to be the areas at greatest risk for postoperative wound infection. Open wounds almost never become infected, while closed wounds with hematomas or a large amount of necrotic tissue are at increased risk for infection. For surgery around the lips, prophylactic antiherpesvirus medications are indicated to prevent activation of herpes labialis. [14]

The risk of bacteremia after surgery of intact skin by using proper sterile techniques is slight; this risk is similar to that among normal human volunteers not undergoing surgery. [15] Recommendations for the use of prophylactic antibiotics in skin surgery have been extrapolated from situations with a much higher incidence of bacteremia, such as urologic or dental procedures. One approach recommends prophylactic antibiotics for patients with eroded skin lesions satisfying the American Heart Association (AHA) criteria for being at high risk for developing bacterial endocarditis (e.g., patients with artificial heart valves, mitral valve prolapse with regurgitation, congenital cardiac malformations, rheumatic or other valvular dysfunction, and history of previous endocarditis). [1] However, according to the AHA, if the skin is intact and surgically scrubbed prior to incision, antibiotic prophylaxis is not indicated. [16] If the skin lesion to be surgically manipulated is infected or the patient has active infection elsewhere on the skin, prophylactic antibiotics should be given to those in the AHA's high-risk groups as well as to patients with orthopedic prostheses or internal shunts. [1] Traditionally, antibiotics such as dicloxacillin, with good coverage for gram-positive organisms, and especially *Staphylococcus aureus,* should be given 1 to 2 h before surgery, with a second dose given 6 h after the first. Single dosing is possible with cephalexin 2 g 30 to 60 min before surgery.

SURGICAL ANATOMY: DANGER ZONES

Anatomic structures at risk for damage during surgery, such as motor nerves, lie deep to the fascia. Muscles of facial expression are innervated by the facial nerve, which exits the base of the skull through the stylomastoid foramen and enters the deep lobe of the parotid gland. Within the parotid gland, the facial nerve divides into five major branches that travel within the parotid gland, between the superficial and deep lobes. Once the branches have left the parotid gland and before they have significantly arborized, they are at risk during surgery, as transection of one of these branches will result in permanent motor paralysis of the related muscle group. This danger zone is approximately between the anterior surface of the parotid gland and a vertical line drawn from the lateral canthus to the inferior border of the mandible at the insertion of the masseter muscle. [17]

The temporal (frontal) branch of the facial nerve is at risk as it crosses the temple after having left the parotid gland and before it has entered the deep surface of the frontalis muscle. It is very superficial, located within or on top of the superficial fascia. [18] Transection of the temporal nerve may result in unilateral eyebrow ptosis. This deficit, if permanent, can be corrected through a unilateral eyebrow lift. [19] Undermining in the temporal and zygomatic region should be carried out in the superficial fat. The temporal artery is a useful guide to depth of undermining, as it lies superficial to the temporal nerve.

The zygomatic branch of the facial nerve is at greatest risk as it crosses the zygoma after exiting the parotid gland and before entering the deep surface of the orbicularis oculi muscle. Transection of the zygomatic nerve may result in unilateral inability to close the eyelid and ectropion, with resultant exposure conjunctivitis. Partial correction of the deficit can be achieved by placing gold weights into the upper eyelid, which will allow the eyelids to close properly. [20]

The buccal branch of the facial nerve is at risk as it crosses the masseter muscle in the middle of the cheek after leaving the parotid gland parallel with the parotid duct. It is located on top of the masseter muscle fascia, which is covered by a thick fat pad in most patients. Therefore, injury to this nerve during dermatologic surgery is quite rare. If the nerve is severed, the patient will develop significant facial asymmetry and an inability to pucker his or her lips, with a resultant

difficulty in keeping fluids in the mouth. Nerve grafting and/or repair offer the best chance for restoring function. [21]

The marginal mandibular branch of the facial nerve is at risk as it crosses the mandible at the insertion of the masseter muscle, where it is located within the subcutaneous fat in close proximity to the facial artery. Injury to this nerve may result in facial asymmetry. Nerve grafting or repair may be necessary in order to restore normal muscle function. The cervical branch of the facial nerve exits the inferior pole of the parotid to innervate the platysma. Injury to this branch is not usually associated with any functional impairment.

The spinal accessory nerve traverses the posterior triangle of the neck deep to the superficial cervical fascia, from the posterior surface of the sternocleidomastoid muscle to the anterior surface of the trapezius muscle. The posterior triangle of the neck is bounded by the sternocleidomastoid muscle anteriorly, the trapezius muscle posteriorly, and the clavicle inferiorly. The spinal accessory nerve exits the posterior surface of the sternocleidomastoid muscle at the junction of the superior and middle thirds of the sternocleidomastoid muscle. Injury to the spinal accessory nerve will cause weakness of the shoulder and winged-scapula deformity. [22]

Transection of sensory nerves may result in permanent anesthesia of the denervated area. The anesthetic area may regain sensation over 2 to 3 years with tingling or burning starting at 6 months. Occasionally, a painful traumatic neuroma develops at the site of nerve injury. The possibility of permanent sensory loss in an area of surgery should be included in the informed consent prior to surgery.

The blood supply of the face has extensive anastomoses between the various arteries. Therefore, transecting the facial arteries has no clinical significance as long as effective hemostasis is achieved. Small vessels can be electrocoagulated. But larger, named vessels, such as the temporal artery, should usually be tied off with a suture to reduce the risk of delayed bleeding, which can develop after the vasoconstricting effect of epinephrine has dissipated. In the elderly, atherosclerosis may limit vasoconstriction and even smaller vessels need to be ligated. The external and internal carotid systems communicate in the periorbital and perinasal areas via anastomoses between the angular artery (external carotid system) and branches of the ophthalmic artery (internal carotid system). [22] Therefore, injection of any material, such as a sclerosant, has the potential for retrograde diffusion into the internal carotid system, with the possibility of cavernous sinus thrombosis. Interruption of lymphatic drainage with skin surgery in the head and neck area causes brief periods of edema, except in the infraorbital region. A long horizontal incision in the infraorbital area may lead to prolonged lymphedema of the lower eyelid. On the extremities, incisions should involve less than 50 percent of the circumference of the limb in order to prevent distal lymphedema.

LOCAL ANESTHESIA

Mechanism of Action

Local anesthetics diffuse through the tissue to the nerves and pass through the nerve cell membrane to block Na+ influx during depolarization. This blocks action potentials from occurring. Smaller unmyelinated C-type nerve fibers that conduct temperature and pain sensation are blocked more easily than myelinated A-type nerve fibers, which carry pressure sensations and motor fibers.

Local anesthetics are weak organic bases that, to be water-soluble and injectable, require the addition of a hydrochloride salt. In aqueous solution, the salt equilibrates between the ionized and nonionized form. The ionized form is water-soluble and allows injection into the tissues, but it is the nonionized, lipid-soluble base that diffuses through the tissue to the nerve cell membrane, where the ionized cation is responsible for blocking nerve conduction. At physiologic pH of 7.4, some 80 percent or more of most local anesthetics is in the cationic ionized form. Cocaine is vasoconstricting, but all other local anesthetics are vasodilating.

Types of Anesthetics

Local anesthetics consist of a hydrophobic aromatic end and a hydrophilic secondary or tertiary amine end. The two ends are joined together by an ester or amide linkage (Table 268-1). Esters include benzocaine, chloroprocaine, cocaine, procaine, and tetracaine. They are hydrolyzed in plasma and liver by cholinesterases and subsequently excreted by the kidneys. Amides include bupivacaine, dibucaine, etidocaine, lidocaine, mepivacaine, and prilocaine. They are N-dealkylated and subsequently hydrolyzed by microsomal liver enzymes.



TABLE 268-1 **Local Anesthetics**

Lidocaine 1% with 1:100,000 epinephrine is the standard local anesthetic used for skin surgery. This mixture is very acidic in order to keep the epinephrine component from becoming inactivated. The addition of 1 mL of 1 mEq/mL $NaHCO_3$ to 10 mL of lidocaine with epinephrine before injection neutralizes the anesthetic solution, reducing burning on injection and facilitating anesthetic diffusion but also somewhat reducing the hemostatic effect. [23] For anesthetic effects that are to last more than 1 to 2 h, bupivacaine or etidocaine can be used.

Side Effects

Contraindications to local anesthetics include severe blood pressure instability, history of true allergy to the anesthetic, psychological instability, severe liver compromise (for amide-type anesthetics), and severe renal compromise (for ester-type anesthetics). The most frequent side effect encountered is a vasovagal reaction manifest by hypotension and bradycardia. Injecting with the patient recumbent or in the Trendelenburg position will usually keep the vasovagal reaction from becoming symptomatic. Local side effects include bruising and edema, especially in the periorbital area, and transient motor nerve paralysis. Prolonged paresthesia from sensory nerve injury can occur with nerve blocks if the needle traumatizes the nerve being anesthetized.

Overdosage is rarely a problem in dermatologic procedures as long as the maximum recommended doses of 5 mg/kg of 1% lidocaine or 7 mg/kg of 1% lidocaine with 1:100,000 epinephrine are respected. For tumescent anesthesia, the maximum safe dose appears to be at least 55 mg/kg of 0.05 to 0.1% lidocaine with 1:1,000,000 epinephrine. [24] Signs of overdosage start with circumoral numbness and tingling and can progress to seizures and cardiovascular collapse with severe overdosage. [25] Toxic effects are exacerbated by acidosis and hypoxia.

Local anesthetic allergic reactions are usually IgE-mediated type I reactions that are manifest by urticaria, angioedema, or anaphylaxis with hypotension and tachycardia. True allergic reactions to ester anesthetics are infrequent, but there is cross-reactivity with para-amino benzoic acid, sulfonamides, sulfonylureas, thiazides, and paraphenylene diamine. Patients who are allergic to one of the ester anesthetics can cross-react to other ester anesthetics but not to the amide anesthetics. Amide anesthetics do not cross-react with other drugs and true allergic reactions are extremely rare. Many multidose bottles of local anesthetics contain methylparaben and/or bisulfite preservatives, which can cause allergic reactions and may be the most frequent cause of local anesthetic “allergy.” Management of patients with local anesthetic allergy includes skin testing, use of a preservative-free anesthetic, or substitution of amide for ester, or vice versa. [26] Diphenhydramine hydrochloride (Benadryl) 12.5 mg/mL can be used for local anesthesia, but the patient may develop systemic antihistamine side effects. Normal saline injected intradermally can achieve very brief anesthesia.

Prilocaine metabolizes to orthotoluidine. This is an oxidizing agent capable of converting hemoglobin to methemoglobin—an effect that can be significant with large doses of <500 mg. Bupivacaine poses a greater risk of cardiac toxicity—with ventricular arrhythmias and cardiovascular collapse—than lidocaine.

Epinephrine

Epinephrine prolongs the duration of anesthesia by 100 to 150 percent and decreases the anesthetic's systemic toxicity by slowing its absorption. It is hemostatic in a dilution of up to 1:1,000,000. It is absolutely contraindicated in patients with hyperthyroidism and pheochromocytoma. Relative contraindications include hypertension, severe cardiovascular disease, pregnancy, and narrow-angle glaucoma as well as in patients taking beta blockers, phenothiazines, monoamine oxidase inhibitors, or tricyclic antidepressants. Injection of epinephrine into digits and the penis should be avoided, especially in patients with peripheral vascular disease. When a relative contraindication is present, epinephrine should be used with caution by diluting it to 1:500,000 and using it sparingly.

Side effects of epinephrine include self-limited palpitations, anxiety, fear, diaphoresis, headache, tremor, weakness, and tachycardia. Serious side effects include arrhythmias, ventricular tachycardia, ventricular fibrillation, cardiac arrest, and cerebral hemorrhage. Serious side effects are extremely rare when appropriate dosages are used in patients without significant contraindications. Skin necrosis can occur in patients with poor perfusion or in anatomic sites with limited perfusion or limited collateral circulation, such as the digits.

Topical Anesthetics

The conjunctiva can be anesthetized with proparacaine or tetracaine eyedrops. Superficial mucous membrane anesthesia can be achieved with various topical anesthetics including Surfacaine, Topicale, Dyclone, Anbesol, viscous lidocaine, and lidocaine jelly. For more thorough anesthesia, especially of the intranasal mucosa, a 4 to 10% cocaine solution is effective, with the added benefit of being hemostatic. Partial anesthesia of intact skin can be achieved with eutectic mixture of local anesthetics (EMLA) cream [27] or 30 to 40% lidocaine in acid-mantle cream applied under occlusion 1 to 2 h before the procedure. The resulting anesthesia is variable and in general effective only for very superficial surgery and some laser procedures. [28], [29] Iontophoresis of lidocaine can also achieve superficial skin anesthesia. [30] Cryoanesthesia with several agents can achieve sufficient anesthesia for superficial procedures and is especially useful for dermabrasion.

Local Anesthesia

Minimizing the pain of anesthetic infiltration is for many patients the most important part of the procedure. Minimizing pain starts with verbal reassurance and distraction, accompanied by mechanical distraction through pinching at the injection site, using small, 30-gauge needles and small 1- to 3-mL syringes to reduce the pressures generated on injection. A buffered anesthetic solution is helpful to reduce the burning sensation of the anesthetic being injected. Injections should be made very slowly, with additional sticks through already anesthetized tissue. Injection into the subcutis is less painful than into the dermis. Injection is started on the side where the sensory innervation originates and proceeds distally. Cryoanesthesia or EMLA is used before injecting sensitive areas or in children. Before injection, oral sedatives such as diazepam can be useful for very anxious patients. Long-acting local anesthetics may serve as supplements for prolonged procedures.

Large areas such as the scalp for hair transplantation can be anesthetized with field-block anesthesia, in which infiltration is into the tissues surrounding the surgical field. In certain areas a specific nerve can be blocked by injecting 1 to 2 mL of

anesthetic into its vicinity. Blocks of the supraorbital and supratrochlear nerves anesthetize the central forehead and frontal scalp. Block of the infraorbital nerve anesthetizes the medial cheek, upper lip, and nasal ala, and block of the mental nerve anesthetizes the lower lip. [31] The entire foot can be anesthetized with nerve blocks of the tibial, sural, superficial peroneal, and deep peroneal nerves. [32]

SUTURING TECHNIQUES

Correct suturing technique [33] is crucial for functionally and cosmetically outstanding results from skin surgery. In addition to approximation of wound edges, properly placed sutures are important for skin-edge eversion, minimization and redistribution of tension, elimination of dead space, and maintenance or restoration of natural anatomic contours, while avoiding the formation of permanent suture marks on the skin surface. The suturing technique chosen for a specific wound closure depends on the anatomic location and thickness of the wound edges.

Suture Materials

The two main characteristics differentiating suture materials are the suture configuration and its absorbability (Table 268-2). Sutures can have either monofilament (single-strand) or multifilament (braided) construction. Advantages of monofilament sutures include decreased tendency of infection or suture reaction and ease of passage through tissue, including easy removal. The main advantage of braided sutures is low memory. Memory is the tendency of the suture to retain its original shape. Low suture memory increases knot security and ease of handling. Monofilament suture, with its high memory, has reduced knot security and less ease of handling. Braided sutures pose a greater risk of causing suture reactions and infections and are more difficult to pass through tissue and remove.



TABLE 268-2 **Suture Materials**

Sutures that lose at least 50 percent of their tensile strength within 2 months are considered absorbable, even though such sutures may not dissolve completely for many months. Absorbable sutures are used mainly as buried sutures. They can also be used as surface sutures in cases when suture removal is impractical, as in the case of patients who live far away from the surgeon's office; those who are difficult to treat, such as young children; and in the case of skin grafts, where the wound bed should not be disturbed. Nonabsorbable sutures maintain their tensile strength for more than 2 months and are used mainly on the surface, with the intention of removing them as soon as the wound edges have fully reepithelialized. They are used for skin-edge approximation and exact alignment, with any tension across the wound having been eliminated by the deeper absorbable sutures. Occasionally, permanent sutures are used as buried sutures that are left in place indefinitely in order to provide long-lasting support, as in rhytidectomy.

Synthetic sutures have almost entirely replaced natural sutures in dermatologic surgery. Because natural sutures—including silk and catgut—are much more reactive than synthetic sutures, they are used only in very limited situations. Silk, a nonabsorbable braided natural suture, is useful near mucous membranes, as it is a very soft and pliable suture with low memory. This makes it much less irritating to the mucous membrane than a stiff monofilament suture. Fast-absorbing catgut or mild chromic catgut suture is a monofilament suture that is rapidly absorbed; it is useful for securing skin grafts and for eyelid skin closure.

Selection of suture size depends on skin thickness, body site, and amount of tension across the wound. Small-gauge 5–0 and 6–0 sutures should be used on facial skin, with eyelid skin receiving only 6–0 sutures. The trunk, extremities, and scalp can be sutured with 3–0 and 4–0 sutures and the neck, digits, and genitals with 4–0 and 5–0 sutures. If a larger suture than that recommended above is needed to close a defect, the wound is under too much tension and additional manipulation is in order, such as increased undermining, relaxing incisions, or redesign of the closure plan.

Interrupted Sutures

The simple interrupted suture is the most basic and versatile suture used by dermatologic surgeons. If the suture is placed close to the wound edges, very precise coaptation of the wound edges can be achieved, even in wounds with edges of unequal thickness. If it is placed further from the wound edges, deeper tissues can be pulled in with redistribution of tension across the wound. When the suture is properly placed in a flask-shaped configuration, eversion of the wound edges can be achieved (Fig. 268-1). Wounds in which the edges are of unequal thickness can be aligned by taking a larger bite from the thinner edge and a smaller bite from the thicker edge. Wounds in which one edge appears higher than the other can be similarly aligned. The simple interrupted suture can also be used as a temporary tacking suture to align complex wound edges or position a flap properly.

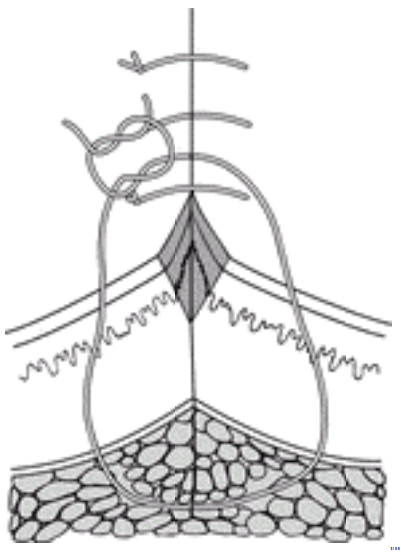

FIGURE 268-1 “Flask-shaped” simple interrupted suture.

The risk of crosshatch marks across the suture line can be minimized by removing the sutures within 5 to 7 days before the formation of epithelial suture tracks is complete, using minimally reactive monofilament suture such as polypropylene and eliminating tension across the wound with appropriate planning of wound closure, adequate undermining, and the use of buried sutures. A simple interrupted suture is more time-consuming to place and remove than is a running suture. In settings where wound healing may be impaired because of the patient's advanced age or underlying disease, interrupted suture techniques may be preferred, as interrupted sutures may have, with all other factors being equal, greater tensile strength and less potential to cause edema, induration, and impaired microcirculation than running sutures. In addition, the progress of wound healing may be monitored by removing alternate sutures. If it seems that dehiscence will occur, the remaining sutures may be left in place for 3 to 4 additional days.

The vertical mattress suture provides wound-edge eversion, reduces dead space and minimizes tension across the wound (Fig 268-2). It does the job of both a buried dermal suture and a skin suture. Because this suture requires four entry points in the skin, significant crosshatching can be expected if the suture is not removed within 5 to 7 days. Even though the vertical mattress suture can be used anywhere on the body, its use on the trunk and extremities results in significant suture marks because it must be left in place longer than 7 days. Even when deep dermal sutures are used, a few vertical mattress sutures can be placed along the wound for maximal wound-edge eversion, [34] and the intervening areas can be precisely approximated with simple interrupted sutures.

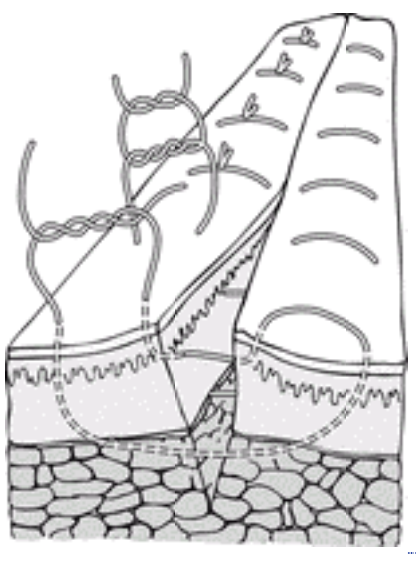

FIGURE 268-2 Vertical mattress suture.

The half-buried vertical mattress suture is a modification of the standard vertical mattress suture; it is designed to eliminate half of the four suture marks in areas such as the face, where minimal scarring is important. This suture is intermediate between a simple interrupted and standard vertical mattress suture in terms of relieving tension across the wound and achieving eversion of the wound edges. It is sometimes used along the hairline, where the buried component is placed on the face and the exposed part of the suture is placed in the hairline.

Classically, the horizontal mattress suture has been used to reduce tension across wound closures that are under significant tension (Fig. 268-3). This suture can be placed as an initial tension-reducing or holding suture and to bring the wound edges closer together, so that subcutaneous sutures can be placed to distribute tension and close the wound. At this point, if the tension has been adequately distributed, the horizontal mattress suture may be removed. If tension across the wound persists, the horizontal mattress suture may be left in place for a few days while early wound healing proceeds and removed before suture tracks have had a chance to form. In areas at high risk for wound dehiscence, such as the lower extremities, the horizontal mattress suture may even be left in place for a few days after the skin sutures have been removed. However, when left in place for more than 7 days and sometimes even less time, significant suture tracks are almost certain to form.

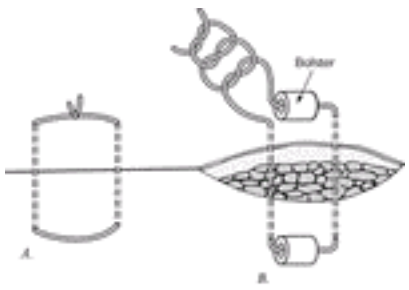

FIGURE 268-3 Horizontal mattress suture (*A*) without and (*B*) with a bolster.

Alternatively the horizontal mattress suture may be used to presuture 12 to 24 h before a proposed excision that may be under considerable tension. This short-term tension on the wound edges may allow as much as 30 percent more tissue to be removed at the time of definitive excision. Presuturing has been used successfully in alopecia reduction, rhytidectomy, and congenital nevus excision. [35]

The main disadvantage of this suture is the possibility of wound-edge necrosis, as this suture can easily strangulate the dermal plexus between its limbs. This problem is minimized by taking large bites with the needle to encompass large amounts of tissue, by using bolsters, by tying the suture only as tight as necessary to accomplish the task of bringing the wound edges together, and by removing the suture as soon as possible, ideally within 2 days of wound closure. Prior to contemplating the use of a horizontal mattress suture for tension reduction, the surgeon should consider other means of reducing tension across the wound, including appropriate use of undermining and closure orientation, flaps from areas of tissue excess, preoperative or intraoperative tissue expanders, serial excisions, and subcutaneous sutures.

Another effect of the horizontal mattress suture is prominent wound-edge eversion. This is accomplished by using a relatively fine suture material and taking relatively small bites when placing the suture across a tension-free wound that has been closed with buried sutures. This method achieves wound-edge eversion and, if the suture is not tied too tightly, wound-edge necrosis is unlikely to develop. [36]

The half-buried horizontal mattress suture is primarily indicated for the positioning of various corners and tips including flap tips, M-plasty tips, and V-Y closure tips (Fig. 268-4). It can also align the edges of tangential flaps and flaps with ischemic wound edges. The buried limb of this suture is placed in the potentially ischemic area in order to minimize interference with the dermal vascular plexus. [36] This reasoning has been challenged, because a superficial simple interrupted suture through a flap tip does not appear to result in increased risk of flap tip necrosis. [37]

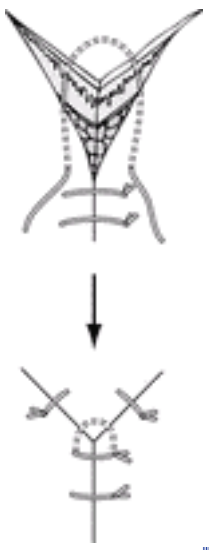

FIGURE 268-4 Half-buried horizontal mattress suture.

A wound gains only 7 percent of its final strength after 2 weeks. [38] As most skin sutures are removed within 1 week of placement, absorbable buried sutures are used as part of layered wound closure. This provides support for the wound until tensile strength has increased sufficiently to prevent wound dehiscence. Deep, buried sutures are placed into wounds to reduce or eliminate tension on the wound edges. On the trunk and extremities, where tension across wounds is greatest, the use of buried sutures may reduce the amount of scar spread. Buried sutures can align the wound edges, so that the skin edges are closely approximated even before the placement of skin sutures. Deep sutures can eliminate dead space and align deep structures such as skeletal muscle or fascia. Deep sutures can also be used to anchor overlying tissue to underlying fixed structures, such as periosteum, to maintain proper facial contour and function. This is exemplified by the anchoring to the maxillary periosteum of a melolabial flap used to close a nasal defect. [39]

The buried dermal suture is used routinely as part of layered closures in dermatologic surgery to eliminate tension across the superficial wound edges and align the wound edges properly. A properly placed buried dermal suture will allow the easy placement of skin sutures without tension. As this suture is placed at the junction of dermis and fat, the knot must be buried so as to minimize tissue reaction to the suture and extrusion through the wound.

The deep subcutaneous suture is entirely subcutaneous. It is used to decrease the amount of dead space, to anchor flaps, and to align deep structures. Because it is deep, tissue reaction to the suture or suture extrusion through the wound is very unlikely even if nonabsorbable suture material is used. Therefore the knot need not be buried.

The buried horizontal mattress suture is a “purse-string” suture that is occasionally used to eliminate dead space or reduce tension across wounds in areas where there is not enough room to place vertical sutures, as in defects on the

nose, with its stiff dermis and minimal subcutaneous tissue. Also, this suture can be used to close off dead space in other areas, such as after the removal of an epidermal cyst. It must be placed deeply and not tied too tightly, as the enclosed tissue can easily become strangulated.

One disadvantage of the standard buried dermal suture is that the wound edges are pulled flat without significant wound-edge eversion. The buried vertical mattress suture incorporates a modification of the buried dermal suture, which maximizes prolonged wound-edge eversion with resulting improved wound healing. [40] The buried vertical mattress suture can be visualized as a standard vertical mattress suture that is completely moved below the skin surface while maintaining its shape. The suture is more superficial further from the wound edge than at the wound edge.

Running Sutures

The simple running suture can be used in situations where the wound edges are of equal thickness without tension, closely approximated, and with an absence of subcutaneous dead space (Fig. 268-5). This suture is most useful for wounds that have already been closed by buried sutures, for the attachment of full-thickness or split-thickness skin grafts, and in areas of thin skin such as the eyelids, ears, neck, and scrotum. By eliminating all but two knots, there is less suture material resting against the skin, resulting in the development of fewer scars from suture marks. However, fine adjustments along the suture line are difficult to make and the uture has a tendency to pucker when very lax and thin skin, such as eyelid skin, is being sutured. In thin skin, the knots at each end may be tied over small bolsters to prevent them from cutting into the tissue. [34]

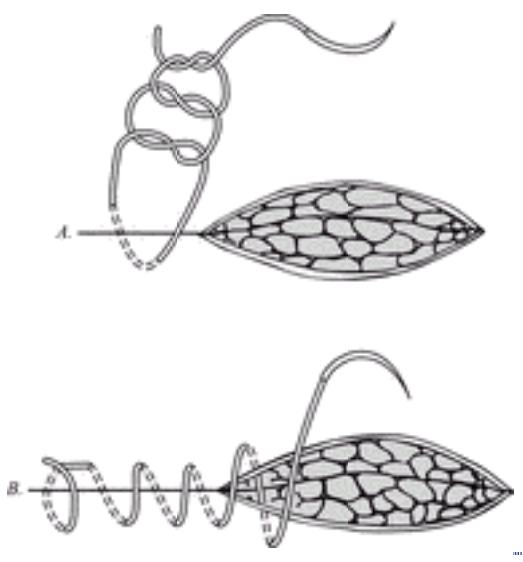

FIGURE 268-5 Simple running suture.

The running locked suture is a variant of the simple running suture in which, after the placement of each loop, the needle is passed through the previous loop prior to starting the next loop. It is intended for the closure of well-vascularized wounds under a moderate amount of tension. The wound edges should be stiff and of equal thickness without a tendency for inversion. It is stronger than a simple running suture. However, if it is placed too tightly or if significant postoperative swelling develops, tissue strangulation with wound-edge necrosis may ensue. It is used primarily on the scalp for the closure of scalp reduction defects and hair transplant donor sites. This suture is strong but should be used sparingly and only when clearly indicated because of the potential for tissue strangulation if it is not placed properly. [34]

The running horizontal mattress suture is primarily a skin-edge–everting suture. It is the ideal suture for closure of wounds with a significant tendency for wound-edge inversion. In addition, by pulling in additional tissue to the wound edge, spreading of facial scars (as seen in young patients) can be minimized. If it is tied too tightly, wound-edge strangulation and necrosis may develop.

The running subcuticular suture is basically a buried running horizontal mattress suture (Fig. 268-6). It is ideal for the closure of wounds in areas such as the trunk and extremities where the suture must remain in place for more than 7 days. As the suture is buried, there are no suture marks and the suture may be left in place for several weeks; when absorbable suture material is used, it may be left in place until it is absorbed. [41] As this suture is capable of only modest wound-edge alignment, it should be reserved for wounds in which the tension has been eliminated with deep sutures and the wound edges, of approximately equal thickness, are closely approximated. The running subcuticular suture should be placed with a nonreactive monofilament suture such as polypropylene to facilitate suture removal and prevent suture breakage within the wound. Some surgeons advocate the use of permanent sutures left in place indefinitely, as this can reduce scar stretching. [42] If nonabsorbable sutures are to be used and to be totally buried, clear, nonreactive suture material such as polypropylene should be used. [34]

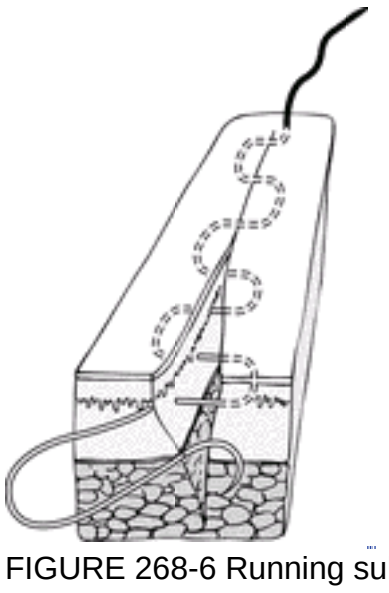

FIGURE 268-6 Running subcuticular suture.

The running subcutaneous suture is designed for the closure of the deep component of relatively long surgical defects that are under only moderate tension. It replaces the buried dermal interrupted suture in selected situations. The main advantage of this suture over interrupted sutures is the speed of placement. However, if the suture material were to rupture anywhere along the suture line, the entire wound might dehisce or a subcutaneous dead space could form under the skin edge without being apparent at the surface. [43]

Suture Removal

Suture marks are caused by epidermal downgrowth along the suture track that is seen within 5 to 7 days of suture placement and aggravated if sutures have been tied too tightly. [34], [36] Sutures should be removed at the earliest possible time to prevent or minimize suture reaction, infection, and suture marks. However, they should remain in place long enough to prevent wound dehiscence and scar spread. In general, the less blood supply to an area and the greater the tension across a wound, the longer the sutures should be left in place. On the face and ears, most skin sutures should be removed within 5 to 7 days, with eyelid sutures being removed in 3 to 5 days. Neck sutures should be removed in 7 days and scalp sutures in 7 to 10 days. On the trunk and extremities, risk of wound dehiscence takes precedence over suture marks. Sutures on the trunk and upper extremities should be left in place for 10 to 14 days. Lower extremities may require 14 to 21 days of suture support.

Absorbable sutures are left in place. However, some patients develop suture reactions, consisting of suture abscesses and suture extrusion through the wound. If this happens, the suture should be picked up carefully with small forceps and cut out of the wound. Any purulent material should also be drained.

Stainless Steel Staple Closure

Staple closure of wounds is an alternative to suture closure. The staples have the advantage of very quick placement, minimal tissue reaction, and very strong wound closure. [44] Staples are most often used with long wounds, especially on the scalp, where the suture line is hidden by scalp hair. Potentially contaminated wounds that are closed with staples appear to be more resistant to infection than wounds closed with sutures. [45] Staples provide efficient wound closure; but when exact wound-edge alignment is required, sutures should be used. Also, surgical staples are far more expensive than suture material. [44] Staples are removed with a staple remover.

Tissue Adhesive

Tissues adhesives, which have been studied for over 40 years, work by polymerizing in an exothermic reaction when they contact a fluid or basic medium, thus forming a strong bond when applied to moist skin. A new tissue adhesive, 2-octyl cyanoacrylate (Dermabond; Ethicon Inc., Norwood, MA) was approved by the Food and Drug Administration and is used most often in the emergency department and for children. Tissue adhesive is less time-consuming to apply, leading to short, more efficient patient encounters with less need for sedation in children. In large studies of laceration wounds, tissue adhesive was shown to be comparable to suture-repaired wounds. [46] However, the cosmetic outcome of cutaneous excisional surgery closed with standard suturing was found to be superior to that of wounds closed with octyl cyanoacrylate. [47]

Wound Closure Tapes

Wound closure tapes are used to provide additional support to a suture line, especially when a running subcuticular suture has been used. [34] In addition, they are helpful in supporting the wound edges after the skin sutures have been removed. Wounds closed with wound closure tapes have a lower risk of wound infection than sutured wounds. [48] However, as they fail to achieve adequate wound-edge eversion and tension reduction, wound closure tapes are rarely used as primary wound closure materials. [49] /SUP>Keeping them in place for several weeks may reduce the amount of scar spreading. [50]

EXCISIONAL SURGERY

A fusiform (elliptical) excision is indicated for the removal of small to moderate-size benign or malignant neoplasms as well as for excisional biopsy. Fusiform closure can be used wherever there is sufficient skin laxity to allow direct side-to-side closure of the defect, after adequate undermining, under minimal tension, and without distortion or functional impairment of surrounding structures. For optimal cosmetic results, the

long axis of the fusiform excision should be oriented along the relaxed skin tension lines, which are generally perpendicular to the muscle pull in the area, without crossing over cosmetic unit boundaries, such as the nose-cheek concavity. [51] If relaxed skin tension lines are not obvious, testing skin tension between the surgeon's index finger and thumb will indicate the direction of least tension. An alternative to fusiform excision is disk excision. The lesion is excised as a circle with adequate margins and the wound is either allowed to heal by second intention or the defect is closed into a straight line with excision of the resulting bilateral standing cones of excess tissue.

ELECTROSURGERY

Electrosurgery is a simple, quick, and effective technique for the treatment of various benign and malignant lesions. Electrosurgery is often combined with curettage in debulking the lesion and removing charred tissue. The main disadvantage of electrosurgery is that there is no histologic confirmation of the lesion having been destroyed. Therefore, if there is any doubt as to the diagnosis, a biopsy should be performed prior to destroying it with electrosurgery. Also, when used to destroy malignant lesions, electrosurgery does not provide tissue for histologic checking of margins. If tissue is obtained from an area subjected to significant electrosurgery, significant tissue artifact is generated, making reliable histologic interpretation very difficult.

Electrodesiccation and electrocoagulation are the most frequently used forms of electrosurgery. They both consist of a high-frequency, high-voltage, low-amperage damped current. [52] The main difference is that in electrodesiccation, there is no dispersive electrode, and the voltage, frequency, and current damping are all greater, while amperage is lower than with electrocoagulation. The observed tissue effect is from contact of the treatment electrode with tissue, generating resistive heating of tissue with resultant tissue dehydration and coagulation. Electrodesiccation is less destructive than electrocoagulation, as less current passes into the tissue and there is less channeling of current along conductive structures such as blood vessels and nerves. Electrodesiccation is most often used for the destruction of verrucae, seborrheic keratosis, superficial nonmelanoma skin cancer, and actinic keratoses. Epidermal lesions can be effectively removed by electrodesiccating their surface. This causes dermal–epidermal separation, which can be taken advantage of with a dermal curette to scrape the lesion away. Electrocoagulation, with its affinity for tracking along blood vessels, is ideally suited for achieving hemostasis during scalpel surgery. In bipolar electrocoagulation, there is no dispersive electrode; instead, both electrodes are part of a forceps. The tissue to be coagulated, usually a blood vessel, is gently picked up by the forceps and current is applied to coagulate it.

Electrofulguration uses a current of very-high voltage, very-high frequency, and very-low amperage that is highly damped without a dispersive electrode. [52] Treatment is performed by holding the electrode tips slightly above the lesion surface in order to generate a spark that carbonizes the surface through resistive heating. The carbonized surface protects deeper tissue from additional fulguration. Therefore, this modality is ideal for very superficial benign lesions, such as dermatosis papulosa nigra and skin tags. Healing is rapid and scarring rare.

Electrodesiccation uses a high-voltage, low-amperage, high-frequency undamped current to cause tissue separation with extremely localized molecular oscillations and heat generation. As the effect is very localized, there is minimal tissue damage; consequently, no hemostasis is achieved with a pure undamped current. To make electrical cutting more practical by achieving hemostasis as the tissue is separated with the current, most devices deliver a blended current that damps the current slightly with increased tissue coagulation and hemostasis. [52] Electrodesiccation is useful in patients with bleeding disorders or on anticoagulants that cannot be stopped before the procedure. By this method, as compared with scalpel surgery, the wound heals more slowly with decreased tensile strength early on, due to the thermally coagulated tissue left in the wound.

In electrocautery, a high-amperage, low-voltage direct or alternating current is passed through a treatment tip that becomes red hot through resistive heating. The heated tip is applied to tissue to coagulate it through direct conduction of heat. As compared with electrodesiccation, electrocautery can cause greater tissue damage through heat conduction from the treatment site. One advantage of electrocautery is that it can work in a bloody surgical field and on nonconductive surfaces such as cartilage, bone, or nails.

Galvanic current is a direct low-voltage, low-amperage current in which the treatment electrode is negative and the dispersive electrode positive. The negative polarity of the treatment electrode generates hydroxides and hydrogen gas in the tissue. These hydroxides liquefy the tissue. Only very small areas can be destroyed with galvanic current, minimizing the risk of scarring, but slowing the treatment process down significantly. [53] The most frequent use of galvanic current is for electrolysis of unwanted hair and destruction of small facial telangiectasias. However, as this technique is so slow, it has generally been replaced by electrodesiccation and electrocoagulation, which is referred to as thermolysis. [53]

Modern pacemakers are very well shielded from standard electrosurgical current. However, it is prudent not to use electrosurgical current near the heart or the pacemaker; when the current is used, it should be applied in short bursts so that any interference would be limited in duration. [54] The best option is to use bipolar electrocoagulation where the current passes between the two tips of the forceps or electrocautery where no current enters the body.

Electrosurgery can cause fire, especially in an oxygen-enriched environment or in the perianal area from the release of methane gas. [55] Electrosurgery generates a significant amount of smoke, which is not only carcinogenic, [56] but may contain viable tissue fragments containing infectious particles, such as HIV. Therefore, the use of smoke evacuators is advisable when electrosurgery is being performed. Electrode tips should be changed after each patient, as electrodes can transmit viral particles. [57]

HEALING BY SECOND INTENTION

Healing of full-thickness skin wounds by second intention is indicated for patients who are poor surgical risks for reconstructive surgery and those who refuse reconstructive surgery. It is also used for infected wounds, to allow observation of the wound bed after resection of tumors at high risk for recurrence, for selected pathologic ulcers, and when the anticipated cosmetic result is at least as good as that achieved by reconstruction. Wounds that are allowed to granulate are very resistant to infection and cannot form a hematoma. The locations that lend themselves best to wound healing by second intention, with superior cosmetic results, are concave areas such as the nose-cheek junction, medial canthus, ear

concha, preauricular cheek, and retroauricular scalp. [58] Wounds allowed to heal by second intention may decrease in size as much as 50 percent or more. [59] Superficial wounds heal with less wound contraction, since there is less deposition of collagen. Therefore, a superficial wound, even on a convex surface such as the forehead or the nose, will usually heal well. Because all wounds contract to some degree, it is important that there be no “free” margin along one side of the wound that can be pulled up during wound contracture and cause distortion at the site. This may be encountered along the eyelid margins, ear margins, eyebrow, nasal ala, and lip vermilion border. These areas are better managed with appropriate reconstructive surgery. [58] Disadvantages of healing by second intention include prolonged healing time of several weeks, the need for daily wound care by the patient, and the somewhat unpredictable cosmetic results.

LOCAL SKIN FLAPS

When simple primary closure cannot be done because a wound is too large, there is too much tension on the wound edges, or an unacceptable functional or cosmetic result would ensue, a tissue-movement procedure such as a flap or a graft should be considered. A local skin flap is a portion of full-thickness skin transferred from a donor site into a surgical defect while maintaining its blood supply from the donor site via a random or axial vascular pedicle that remains attached to the donor site. For random flaps, the blood supply is provided by the skin that remains attached to the surrounding dermis; the length-to-width ratio should not exceed 3:1 or 4:1 on the face, and 2:1 on the trunk and extremities. [56] Flap incisions should, whenever possible, be made so that they fall into relaxed skin tension lines. The two movements involved in placing a flap are the action of placing the flap into the defect, which is the primary movement, and the secondary movement of tissue in the donor area, which closes the secondary defect and facilitates primary flap movement. Both movements are important in terms of distributing tension in the proper direction and over a larger area so as to minimize tension on the flap itself, which might compromise its survival. [60]

The primary motion of the flap provides its name. In an advancement flap, the tissue movement is in a straight line from the donor area to the recipient site. [56] A classic example is the advancement flap to close a defect of the rim of the ear helix by relying on excess tissue present in the earlobe. [61] A bilateral advancement flap is an A-to-T flap, in which incisions extend from the base of a triangular defect and the two sides are slid together along this baseline. Common areas for the use of advancement flaps include defects of hair-bearing skin in the eyebrow [62] (Fig. 268-7) or mustache area, where orientation of the hair shafts is critical. The rotation flap slides skin into the defect by rotating it on its axis. It is classically used to close relatively large defects on the cheek, forehead, or scalp. A rotation flap with a back cut can increase tissue movement in areas of limited tissue laxity, such as the nose.

FIGURE 268-7 *A.* Right eyebrow surgical defect after tumor resection. *B.* Immediately after repair with a laterally based advancement flap and a medially based island pedicle flap. *C.* Final result (7 months postoperative).

Transposition flaps move skin from one site to another, crossing normal skin as the flap moves into its new location, which is often on the face. The classic transposition flap is the rhombic flap (Fig. 268-8). The defect is visualized in the shape of a rhombus with equal sides and angles opposite each other of 60 and 120 degrees, respectively. The flap is created by drawing a line out from and bisecting either of the 120-degree angles. The line is equal in length to one side of the rhombus. The next line creates a 60-degree angle with that line and is parallel to and equal to the side of the rhombus. [63] Other transposition flaps include the note flap, banner flap, nasolabial (melolabial) flap, bilobed flap, Webster's 30-degree modified rhombic flap, and Z-plasty.

FIGURE 268-8 Rhombic transposition flap: (*I*) design with shaded area representing surgical defect, (*II*) transposition after undermining, and (*III*) final suture line.

A subcutaneous island pedicle flap may be considered as a variation of an advancement flap that has had all of its connections to the epidermis and dermis severed, maintaining its blood supply only through a subcutaneous tissue pedicle (see Fig. 268-7). [64] This flap is usually slid from the defect apex into the center to close an area that would be under great tension if closed by side-to-side approximation of the wound edges. [65] , [66]

The most commonly used axial vascular pedicle flap on the face is the paramedian forehead two-stage transposition flap [67] (Fig. 268-9). Tissue is mobilized from the forehead, based on one of the supratrochlear arteries, and transposed to repair large distal nasal defects with the pedicle remaining attached in the glabellar region. Division of the pedicle is performed in 2 to 3 weeks after the flap has established a local blood supply from the original defect's wound bed. [67]

FIGURE 268-9 *A.* Dorsal nose surgical defect after tumor resection. *B.* Immediately after first stage of paramedian forehead flap with upper forehead donor area to heal by second intention healing. *C.* Final result 8 months after flap division and inset.

Flaps require careful postoperative wound care to assure that vascular compromise does not occur. Tightly applied bandages may compromise the blood supply to the flap and cause necrosis. The area under the flap must be free of any bleeding or oozing as hemorrhage or hematoma formation may jeopardize flap survival and increase the risk of infection. Patients who smoke may compromise the blood supply to the flap, and large defects in smokers may require grafting rather than risking failure of a flap. [68] The “trapdoor” effect occurs with some flaps when the center of the flap becomes elevated and the suture line becomes depressed. It may resolve spontaneously over a period of 6 to 12 months. However, if it fails to resolve, it may respond to intralesional glucocorticoids and/or flap elevation with flap thinning, possibly combined with multiple Z-plasties to break up the curved scar line. [69] The trapdoor effect may be prevented with wide undermining around the primary defect, proper thinning of the flap, proper size of the flap, and the use of a geometric shape for the flap. [69]

SKIN GRAFTS

Grafts are totally detached from the donor site and receive all nutrients from the wound bed of the recipient site. They are named for their composition (epidermis, dermis, fat, hair, cartilage, bone). Full-thickness skin grafts (FTSG) consist of epidermis with full-thickness dermis, while split-thickness skin grafts (STSG) consist of epidermis with a varying thickness of dermis.

A STSG is used to cover large defects to allow better wound bed surveillance, to line a large pedicle flap or cover the donor site of a large FTSG, or to resurface mucosa. [70] It is usually harvested from the upper inner arm, thigh, buttock, scalp, or abdomen. The STSG is placed on the wound and fixed in place with absorbable sutures or staples. The main advantage of a STSG is that it will survive even in locations with poor vascularization, such as a leg ulcer. Cosmetically, this graft is suboptimal, with absent appendages, poor color match, and frequent wound contracture under the graft. The donor site will reepithelialize rapidly and relatively painlessly with the use of bio-occlusive dressings. [71]

A FTSG is generally indicated for relatively shallow full-thickness facial defects that may not be amenable to primary closure or local flap repair or to temporarily cover a defect that needs to be observed for possible tumor recurrence. A FTSG contracts less than a STSG and skin color match is better than with a STSG. It is usually harvested from the preauricular, nasolabial, postauricular, conchal bowl, supraclavicular, or eyelid areas. The donor site is chosen so as to match the recipient site in skin texture, thickness, color, and appendiceal structure density. [72] The graft is trimmed to exactly fit the defect and defatted. The donor site is closed with a primary side-to-side closure or second intention healing. The graft is sutured onto the recipient site, including basting sutures as needed. A bolster dressing may be placed over the graft to keep it in place and to prevent fluid accumulation underneath it. Because skin grafts do not bring any blood supply with them, they are more vulnerable to necrosis than simple closures or flaps. Skin color match is difficult to predict. Fairer-skinned individuals with even pigmentation and less sun damage do well with FTSGs. The more darkly pigmented or mottled the surrounding skin, the less likely a good color match will be. Uneven edges around the graft may be smoothed out with dermabrasion 6 to 8 weeks after surgery. [73], [74]

Composite grafts include a component in addition to the epidermis and dermis. The most common composite graft includes cartilage and is used for the correction of full-thickness nasal ala defects. The graft is harvested from the ear helix so that it contains a sandwich of skin surrounding a piece of cartilage. After being sutured in place, the graft receives its blood supply only from its lateral margins. Therefore, only up to 1 cm of nasal ala rim can be replaced with a composite graft, as a larger graft will not receive sufficient nutrients to allow its central portion to survive. [75]

REFERENCES

1. Haas AF, Grekin RC: Antibiotic prophylaxis in dermatologic surger *J Am Acad Dermato* **32**:155, 1995

2. Goldminz D, Bennett RG: Cigarette smoking and flap and full-thickness graft necros *Arch Dermato* **127**:1012, 1991

3. Billingsley EM, Maloney ME: Intraoperative and postoperative bleeding problems in patients taking warfarin, aspirin, and nonsteroidal antiinflammatory a *Dermatol Surg* **23**:381, 1997

4. Goldsmith SM et al: Management of patients taking anticoagulants and platelet inhibitors prior to dermatologic sur *J Dermatol Surg Onco* **19**:578, 1993

5. Dzubow LM: The interaction between propranolol and epinephrine as observed in patients undergoing Mohs' sur *J Am Acad Dermato* **15**:71, 1986

6. Alexander JW et al: The influence of hair-removal methods on wound infectio *Arch Surg* **118**:347, 1983

7. Brown TR et al: A clinical evaluation of chlorhexidine gluconate spray as compared with iodophor scrub for preoperative skin prepar *Surg Gynecol Obste* **158**:363, 1984

8. Nasser RE: The ocular danger of Hibiclens *Plast Reconstr Surg* **89**:164, 1992

9. Shuman RM et al: Neurotoxicity of hexachlorophene in humans: A clinicopathologic study of 46 premature infants: P *Arch Neurol* **32**:320, 1975

10. Centers for Disease Control: Update: Universal precautions for prevention of transmission of human immunodeficiency virus, hepatitis B virus, and other bloodborne pathogens in health-care settings. *MMWR Morb Mortal Wkly Rep* **37**:377, 1988

11. Greco RJ, Garza JR: Use of double gloves to protect the surgeon from blood contact during aesthetic procedu *Aesthetic Plast Surg* **19**:265, 1995

12. Futoryan T, Grande D: Postoperative wound infection rates in dermatologic surge *Dermatol Surg* **21**:209, 1995

13. Classen DC et al: The timing of prophylactic administration of antibiotics and the risk of surgical wound infecti *N Engl J Med* **326**:281, 1992

14. Perkins SW, Sklarew EC: Prevention of facial herpetic infections after chemical peel and dermabrasion: New treatment strategies in the prophylaxis of patients undergoing procedures of the perioral area *Plast Reconstr Surg* **98**:427, 1996

15. Sabetta JB, Zittelli JA: The incidence of bacteremia during skin surger *Arch Dermatol* **123**:213, 1987

16. Dajani AS et al: Prevention of bacterial endocarditis: Recommendations by the American Heart Associat *JAMA* **277**:1794, 1997

17. Bernstein L, Nelson RH: Surgical anatomy of the extraparotid distribution of the facial ner *Arch Otolaryngol* **110**:177, 1984

18. Campiglio GL, Candiani P: Anatomical study on the temporal fascial layers and their relationships with the facial ne *Aesthetic Plast Surg* **21**:69, 1997

19. Grabski WJ, Salasche SJ: Management of temporal nerve injurie *J Dermatol Surg Oncol* **11**:145, 1985

20. Freeman MS et al: Surgical therapy of the eyelids in patients with facial paraly *Laryngoscope* **100**:1086, 1990

21. Conley J, Baker DC: The surgical treatment of extratemporal facial paraly *Head Neck Surg* **1**:12, 1978

22. Otani A et al: The superficial neurovasculature of the head and ne *Semin Dermatol* **13**:43, 1994

23. Stewart JH et al: Neutralized lidocaine with epinephrine for local anesthe *J Dermatol Surg Oncol* **15**:1081, 1989

24. Ostad A et al: Tumescent anesthesia with a lidocaine dose of 55 mg/kg is safe for liposucti *Dermatol Surg* **22**:921, 1996

25. de Jong RH: Toxic effects of local anesthetics *JAMA* **239**:1166, 1978

26. Glinert RJ, Zachary CB: Local anesthetic allerg *J Dermatol Surg* **17**:491, 1991

27. Hruza GJ: EMLA cream: Painless local anesthesia *Fitzpatrick's J Clin Dermatol* **2**:50, 1994

28. Sherwood KA: The use of topical anesthesia in removal of port-wine stai *J Pediatr* **122**:S36, 1993

29. Gupta AK, Sibbald RG: Eutectic lidocaine/prilocaine 5% cream and patch may provide satisfactory analgesia for excisional biopsy or curettage with electrosurgery of cutaneous lesions. *J Am Acad Dermatol* **35**:419, 1996

30. Maloney JM: Local anesthesia obtained via iontophoresis as an aid to shave biop *Arch Dermatol* **128**:331, 1992

31. Randle HW et al: Know your anatomy: Local anesthesia for cutaneous lesions of the head and neck—practical applications of peripheral nerve b *J Dermatol Surg Oncol* **18**:231, 1992

32. Cohen SJ, Roenigk RK: Nerve blocks for cutaneous surgery on the fo *J Dermatol Surg Oncol* **17**:527, 1991

33. Hruza GJ: Suturing techniques, ir *Principles and Techniques of Cutaneous Surger*, edited by GP Lask, RL Moy. New York, McGraw-Hill, 1996, p 171

34. Speer DP: The influence of suture technique on early wound healir *J Surg Res* **27**:385, 1979

35. Stegman SJ: Suturing techniques for dermatologic surger *J Dermatol Surg Oncol* **4**:63, 1978

36. Liang MD et al: Presuturing: A new technique for closing large skin defects: Clinical and experimental stud *Plast Reconstr Surg* **81**:694, 1988

37. Perry AW, McShane RH: Fine tuning of the skin edges in the closure of surgical wounds: Controlling inversion and eversion with the path of the needle: The right stitch at the right time. *J Dermatol Surg Oncol* **7**:471, 1981

38. McQuown SA et al: Gillies' corner stitch revisite *Arch Otolaryngol* **110**:450, 1984

39. Harris DR: Healing of the surgical wound: I. Basic consideration *J Am Acad Dermatol* **1**:197, 1979

40. Robinson JK: Suspension sutures aid facial reconstructio *Dermatol Surg* **25**:189, 1999.

41. Zitelli JA, Moy RL: Buried vertical mattress sutur *J Dermatol Surg Oncol* **15**:17, 1989

42. Herron J: Skin closure with subcuticular polyglycolic acid suture *Med J Aust* **2**:535, 1974

43. Elliot D, Mahaffey PJ: The stretched scar: The benefit of prolonged dermal suppo *Br J Plast Surg* **42**:74, 1989

44. Ftaiha Z, Snow SN: The buried running dermal subcutaneous suture techniqu *J Dermatol Surg Oncol* **15**:264, 1989

45. Gatt D et al: Staples for wound closure: A controlled tri *Ann R Coll Surg Eng* **67**:318, 1985

46. Stillman RM et al: Skin wound closure: The effect of various wound closure methods on susceptibility to infect*Arch Surg* **115**:674, 1980

47. Quinn JV et al: A randomized, controlled trial comparing a tissue adhesive with suturing in the repair of pediatric laceratio*Ann Emerg Mec* **22**:1130, 1993.

48. Bernard L et al: A prospective comparison of octyl cyanoacrylate tissue adhesive (Dermabond) and suture for the closure of excisional wounds in children and adoles*Arch* . *Dermato* **137**:1177, 2001.

49. Edlich RF et al: Wound healing and wound infection, i*Wound Healing and Wound Infection: Theory and Surgical Practic*, edited by TK Hunt. New York, Appleton-Century-Crofts, 1980

50. Bunker TD: Problems with the use of Op-Site sutureless skin closures in orthopaedic procedur*Ann R Coll Surg Eng* **65**:260, 1983

51. Hodges JM: Management of facial lacerations*South Med J* **69**:1413, 1976

52. Meirson D, Goldberg LH: The influence of age and patient positioning on skin tension lin*J Dermatol Surg Onco* **19**:39, 1993

53. Sebben JE: *Cutaneous Electrosurgery*. Chicago, Year Book, 1989

54. Wagner RFJ et al: Electrolysis and thermolysis for permanent hair remov*J Am Acad Dermato* **12**:441, 1985

55. Miller JM: Explosion in sigmoid colon during colonoscopic polypecton*V A Mec* **107**:296, 1980

56. Tomita Y et al: Mutagenicity of smoke condensates induced by CO_2-laser irradiation and electrocauterizatio*Mutat Res* **89**:145, 1981

57. Tromovitch TA et al: *Flaps and Grafts in Dermatologic Surger*. Chicago, Year Book, 1989

58. Sheretz EF et al: Transfer of hepatitis B virus by reusable needle electrodes after electrodesiccation in simulated *J Am Acad Dermato* **15**:1242, 1986

59. Zitelli JA: Wound healing by secondary intention: A cosmetic apprais*J Am Acad Dermato* **9**:407, 1983

60. McGrath MH, Simon RH: Wound geometry and the kinetics of wound contractio*Plast Reconstr Surg* **72**:66, 1983

61. Dzubow LM: Flap dynamics*J Dermatol Surg Onco* **17**:116, 1991

62. Calhoun KH et al: Biomechanics of the helical rim advancement fla*Arch Otolaryngol Head Neck Sur* **122**:1119, 1996

63. Whitaker DC, Birkby CS: Mohs surgery report: An approach to cutaneous surgical defects of forehead and eyebrow following Mohs micrographic sur*J Dermatol Surg Onco* **13**:1312, 1987

64. Borges AF: Choosing the correct Limberg flap*Plast Reconstr Surg* **62**:542, 1978

65. Hruza GJ: Subcutaneous island pedicle flap revisite*Fitzpatrick's J Clin Dermato* **2**:35, 1994

66. Tomich JM et al: Subcutaneous island pedicle flaps*Arch Dermato* **123**:514, 1987

67. Dzubow LM: Subcutaneous island pedicle flaps*J Dermatol Surg Onco* **12**:591, 1986

68. Quatela VC et al: Esthetic refinements in forehead flap nasal reconstructio*Arch Otolaryngol Head Neck Sur* **121**:1106, 1995

69. Salasche SJ, Grabski WJ: Complications of flaps*J Dermatol Surg Onco* **17**:132, 1991

70. Koranda FC, Webster RC: Trapdoor effect in nasolabial flaps*Arch Otolaryngo* **111**:421, 1985

71. Wheeland RG: Skin grafts, in*Dermatologic Surgery: Principles and Practic*, edited by RK Roenigk, HH Roenigk Jr. New York, Marcel Dekker, 1989, p 323

72. Weber RS et al: Split-thickness skin graft donor site management: A randomized prospective trial comparing a hydrophilic polyurethane absorbent foam dressing with a petrolatum gauze dressing. *Arch Otolaryngol Head Neck Sur* **121**:1145, 1995

73. Hruza GJ: Guide to full-thickness skin grafts*Fitzpatrick's J Clin Dermato* **2**:35, 1994

74. Katz BF, Oca MAGS: A controlled study of the effectiveness of spot dermabrasion ("scarabrasion") on the appearance of surgical sc*J Am Acad Dermato* **24**:462, 1991

75. Robinson JK. Improvement of the appearance of full-thickness skin grafts with dermabrasi*Arch Dermato* **123**:1340, 1987.

76. Konior RJ: Free composite grafts*Otolaryngol Clin North Am* **27**:81, 1994

77. Melton JL, Hanke WC: Wound closure materials, i*Principles and Techniques of Cutaneous Surgery*, edited by GP Lask, RL Moy. New York, McGraw-Hill, 1996, p 77

78. Garrett AB: Wound closure materials, i*Cutaneous Surgery*, edited by RG Wheeland. Philadelphia, Saunders, 1994, p 199

T>

Chapter 269

Harold Brody

Skin Resurfacing: Chemical Peels

HISTORICAL ASPECTS
HISTOLOGIC CLASSIFICATION
INDICATIONS FOR CHEMICAL PEELING
PATIENT SELECTION—RELATIVE CONTRAINDICATIONS
Rejuvenation Regimen for the Skin before and after Peeling
PRINCIPLES OF WOUNDING AGENT APPLICATION
Superficial Peeling
Medium-Depth Peeling
Deep Peeling
COMPARISON OF DEEP PEELING WITH CO2 RESURFACING LASER
COMPLICATIONS ARISING FROM CHEMICAL PEELS
COMBINATION SKIN RESURFACING—COMBINING CHEMICAL RESURFACING WITH LASER OR DERMABRASIVE RESURFACING

REFERENCES

Chemical peeling, also called chemical resurfacing, chemexfoliation, or chemosurgery, involves the application of one or more exfoliating agents to the skin, resulting in the destruction of portions of the epidermis and/or dermis with subsequent regeneration. This produces a controlled wound and reepithelialization.

HISTORICAL ASPECTS

Dermatologists pioneered skin peeling for therapeutic benefit. In 1882, P.G. Unna, a German dermatologist, described the properties of salicylic acid, resorcinol, phenol, and trichloroacetic acid (TCA); and during the first half of the twentieth century, phenol and TCA were used in several centers. The combination of two agents, solid carbon dioxide followed by TCA, to produce the first medium-depth combination peel was reported in 1986. These peels have replaced the more risk-prone 50 percent TCA peel. a-Hydroxy acids (AHAs) became available as superficial peeling agents in the late 1980s and the 1990s. Presently, resurfacing lasers can be used in combination with or in addition to peeling agents.

HISTOLOGIC CLASSIFICATION

Based on the study of histologic changes in wound depth, a classification of peels can be developed (Table 269-1). The strength of a dermal wounding agent is based on evaluating the reaction at its peak by noting the depth of the wound as opposed to the depth of inflammation. Examination of the wound at 90 days to evaluate the mid-dermis is imperative for proper evaluation of dermal collagen remodeling. [1]



TABLE 269-1 **Chemical Peeling Wounding Classification***

Epidermal injury (superficial wounding) without clinical vesiculation results from Jessner's solution (JS), the AHAs [2], [3], [4], [5], [6] and [7] and solid carbon dioxide (CO_2), with results similar to those from tretinoin application. [8], [9]

Upper dermal injury (medium-depth wounding) follows the use of 40 to 60% TCA and the medium-depth 35% TCA peeling combinations. Ninety days after peeling, a normal-appearing zone of expanded papillary dermis, referred to as a Grenz zone, is seen. The thickness of this zone varies with the strength of the wounding agent used and the depth of the wound. A band of thick, amorphous brown fibers in the middle to upper dermis is composed of elastotic fibers and glycosaminoglycans (GAGs). The thickness and depth of staining of this band increases with the strength of wounding agents. [10], [11]

Mid-dermal injury (deep wounding) with phenol formulas results in a deeply stained elastotic dermal band. The new subepidermal, horizontally arranged collagen band in the papillary dermis is probably responsible for the lessening of wrinkles. [12], [13]

Dermal peeling can be compared with CO_2 laser treatments. A single or double pass with a superpulse laser at 400-mJ, 10-W, 0.33-s interval in sun-protected and sun-exposed periauricular skin produces a depth of injury approximating that seen with medium-depth chemical peels. Healing at 90 days occurs in a similar fashion as with chemical peeling, but perhaps with less inflammation. [14], [15]

INDICATIONS FOR CHEMICAL PEELING

Actinic keratoses and sun-induced rhytides respond to chemical peeling. Medium-depth peels will reduce the number of visible actinic keratoses by 75 percent with results sustained for as long as 30 months in a majority of patients. This is comparable to 5-fluorouracil (5-FU). [1], [16] Regeneration of the actinic damage may occur and necessitate repeat treatment after 2 to 4 years. Pigmentary dyschromias in the form of melasma or postinflammatory hyperpigmentation also respond. Serial repetitive peels of increasing strength are used to treat melasma. In a study that compared 70% glycolic acid to Jessner's solution in the treatment of melasma resistant to medical therapy, there was a 63 percent reduction in the patients' melasma area and severity index, statistically significant lightening on colorimetry, and equal response to both agents. [17] Glycolic acid caused mild irritancy. Topical glycolic acid can be used between peels, but is not imperative for good results. Depressed scarring responds variably to chemical peeling. Dermabrasion or the resurfacing laser are generally more effective. Medium-depth peeling with solid CO_2 to efface the rims or the edges of depressed scars, combined with the immediate repetitive application of 35 to 50% TCA to the rims, has resulted in substantial improvement. [11], [15] Acne vulgaris may be improved by superficial chemical peeling, although medium peeling can aggravate or actually produce acne. In rosacea the existing erythema of the disease makes medium peeling more risky because of persistent tenderness or erythema.

PATIENT SELECTION—RELATIVE CONTRAINDICATIONS

Prior to peeling, patients must be evaluated for relative contraindications (Table 269-2). [15], [18], [19] Fitzpatrick's classification measures pigmentary responsiveness of the skin to ultraviolet light, most often based on the ethnic background. Skin types I to III are ideal for peeling. Types IV through VI can also be peeled with all peeling agents, but the risk of unwanted pigmentation is greater. A classification of photoaging is helpful in assessing sun damage (Table 269-3). [20] The past or present use of systemic isotretinoin must be ascertained, since retinoids may be associated with a greater risk of scarring after peeling. If the patient has a past history of superficial x-ray treatment for acne, the adnexal structures should be assessed by observing the presence of vellus hairs or by punch biopsy to ensure adequate reepithelialization. Smoking may multiply the wrinkling effects of sunlight. There are few absolute contraindications to the entire spectrum of chemical peeling, since superficial peeling may be tolerated with little risk in all patients of all skin types regardless of their general state of health. Postmenopausal estrogens and oral contraceptives may sensitize the skin to the sun or may produce postinflammatory splotching. Patients infected with HIV may experience delayed healing or be at risk for secondary infection after peeling. Patients with a history of recurrent herpes simplex may be given prophylactic acyclovir, valacyclovir, or famciclovir during medium-depth or deep peeling. True hypertrophic scar or keloid formers may be at greater risk to scar with deep as opposed to medium-depth peeling. A method to document the evaluation prior to peeling includes the mapping and detailing of the defects on a diagram as well as good photography (Fig. 269-1). An interval of 4 to 12 weeks is recommended between peeling and procedures involving undermining such as rhytidectomy, a coronal brow lift, or blepharoplasty. Following peeling, patients must use sunscreens to prevent continuing damage.

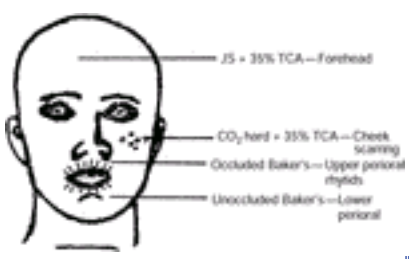

FIGURE 269-1 Example of rubber-stamp diagram mapping the defects and types of peels performed on a given patient.

Fitzpatrick skin type
Degree of actinic damage and photoaging
Philosophy of sun exposure
Present and past sebaceous gland density; previous isotretinoin or radiation
Prior cosmetic surgery
Philosophy of smoking
General state of physical and mental health
Medications
Pregnancy history
History of herpes simplex
History of hypertrophic scarring
Realistic expectations

TABLE 269-2 **Factors in the Assessment for Relative Contraindications**

Group I: Mild, usually age 28–35 years
No keratoses
Little wrinkling
No scarring
Little or no makeup
Group II: Moderate, usually age 35–50 years
Early actinic keratoses—slight yellow skin discoloration
Early wrinkling—parallel smile lines
Mild scarring
Little makeup
Group III: Advanced, usually age 50–65 years
Actinic keratoses—obvious yellow skin discoloration
Wrinkling—present at rest
Moderate acne scarring
Makeup always worn
Group IV: Severe, usually age 60–75 years
Actinic keratoses and skin cancers have occurred
Wrinkling—actinic, gravitational, and dynamic
Severe acne scarring
Makeup is worn; does not cover but cakes on skin

TABLE 269-3 **Photoaging Groups: Glogau's Classification**

Rejuvenation Regimen for the Skin before and after Peeling

The daily, morning use of a sunscreen and the nightly application of tretinoin will reduce solar pigmentation as well as

promote faster healing in the immediate postpeel period. Tretinoin application before and after TCA does not significantly enhance the efficacy of the peel. It potentiates the action of hydroquinone, although the role of hydroquinone in prepeel treatment, to prevent pigment return after peeling, is unsubstantiated. [19] Hydroquinone gel 4%, for example, may be used twice daily for at least a month prior to peeling to test the patient's reactivity to the product and begin bleaching epidermal pigment. It can be reinstituted after reepithelialization. Prolonged use of high concentrations of hydroquinone may paradoxically produce ochronosis in Fitzpatrick types V and VI skin. This is much more common in South African black skin. Kojic acid has a similar tyrosinase-suppressive mechanism and may be used in the program.

PRINCIPLES OF WOUNDING AGENT APPLICATION

Prior to the application of all wounding agents, cutaneous lipids are removed by cleansing with alcohol or acetone-soaked sponges. [15] Excessive defatting prior to 70% glycolic acid peels may cause untoward peeling, erythema or pigmentation. The amount of wounding agent applied, the degree of rubbing, and the duration of skin contact must be carefully monitored to ensure good results. Documentation of application with one or two cotton-tipped applicators, with a more aggressive 4 × 4-inch gauze sponge, or with a sable brush should be written into the patient's record. Frosting with different wounding agents is variable in rate and appearance and depends on the preexisting degree of photodamage, the choice of applicator, and the adequacy of defatting. Observation of the frost itself as a measure of depth is not as valuable as the actual selection of proper wounding technique or wounding agent. [21] The appearance of the frost does give an index of protein agglutination and indicates how evenly the agent has been applied. “Neutralization” of TCA with alcohol or water immediately after frosting is useless to reverse the effect of the application of the wounding agent. Once complete frosting has occurred, penetration is already achieved, and dilution with water is not necessary. AHAs are dependent upon the contact time with the skin, and washing them from the skin after a given amount of time is important.

Superficial Peeling

Superficial peels, which are generally epidermal and pose little risk of scarring, usually require multiple weekly or monthly applications for effectiveness. [15] They do not vesiculate, and patients generally continue normal activities. They can be used on all Fitzpatrick skin types, skin colors, and body areas. These agents may amplify 5-fluorouracil and are preparatory agents to make papillary dermal peeling agents (e.g., TCA 35%) penetrate deeper. It has been postulated that superficial peeling agents induce increased upper dermal collagen production in response to repeated epidermal sloughs. Minimal postoperative care is needed for superficial peels, and patients may return to their normal daily activities immediately, wearing cosmetics to conceal erythema.

TRICHLOROACETIC ACID 10 TO 35% TCA should be prepared by the weight-to-volume (wt/vol) method, mixing the desired concentration in grams of United States Pharmacopeia (USP) TCA crystals with the appropriate volume of distilled water to make 100 mL. [15] Although TCA is marketed as a paste mask application, it is more expensive in this form and offers no clear therapeutic advantage over the aqueous application. Strengths of TCA from 10 to 35% are used to accomplish superficial chemical peeling on facial and nonfacial areas; such peels may be repeated every 7 to 28 days. **MODIFIED UNNA'S RESORCINOL PASTE** In the late 1800s, Unna described the use of resorcinol paste as a peeling agent in concentrations of 10 to 30%. Letessier's modified formula to treat acne, melasma, and sun damage avoids excessive erythema by using axungia, a derivative of pig fat or lard added to a clay-bearing soil with 40% resorcin. [22] **JESSNER'S SOLUTION** Jessner's combination of resorcinol, salicylic acid, and lactic acid in ethanol was formulated to lower the concentration and toxicity of any one agent and to enhance the keratolytic effects (Table 269-4). Application can be light or heavy, and may be repeated after 3 to 4 min. [16], [23] The advantages of Jessner's solution are that only a single solution is needed, timing the duration of application is unnecessary, and dilution or “neutralization” is not performed. The lactic acid in Jessner's solution is an AHA, and it is very effective in the treatment of melasma (Fig. 269-2). The combination in which Jessner's solution or glycolic acid amplifies the effects of 5-FU is called the fluor-hydroxy pulse peel.

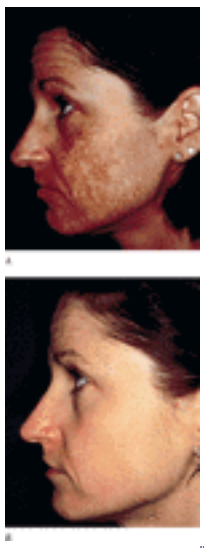

FIGURE 269-2 *A.* Melasma on cheek prior to the application of Jessner's solution. *B.* Improvement after three monthly peels, allowing increased penetration of hydroquinone. (*Photos courtesy of Sue Ellen Cox, MD, and Naomi Lawrence, MD.*)

Resorcinol	14 g
Salicylic acid	14 g
Lactic acid (85%)	14 mL
Ethanol (95%) qs ad*	100 mL

*Quantity sufficient to add up to.

TABLE 269-4 **Jessner's Solution**

SALICYLIC ACID Salicylic acid, a ß-hydroxy acid, can be used as a 50% ointment under occlusion to peel lentigines,

pigmented keratoses, and actinically damaged skin from the dorsa of the hands and forearms. [24] The dressing is removed after 48 h, and mild salicylism with tinnitus and headache is expected. A peeling solution of 35% salicylic acid in ethanol has been applied to the face with cotton-tipped applicators for improvement of comedones. Erythema and edema are minimal, and the peel can be repeated every 2 to 4 weeks.

SOLID CARBON DIOXIDE Solid CO_2 (dry ice) is a physical modality for peeling and not a true chemical peeling agent. It may be used alone or to amplify TCA as a medium-depth peel. [15] The dry ice is wrapped in a small hand towel and dipped as needed in a solution of approximately 3:1 acetone and alcohol, which serves to facilitate application to the skin. A moderate application of 8 seconds to excoriated areas will serve to improve acne excoriée.

a-HYDROXY ACIDS AHAs are naturally occurring but synthetically mass-produced carboxylic acids normally found in many foods. The AHAs include glycolic, lactic, malic, citric, and tartaric acids. The two acids with the shortest carbon chains, glycolic and lactic, are most commonly used in dermatology and are naturally found in sugar cane and sour milk, respectively. Although irritancy of a product is often directly related to lower pH, vehicle irritancy must be considered also. The available free acid, which is difficult to ascertain, is the best method to judge concentration and irritancy. [2], [5] The factors that determine whether AHA peels result in desquamation or epidermolysis are the concentration of the acid, the pH, the degree of buffering or neutralization with sodium bicarbonate, the vehicle formulation, the frequency of application, the conditions of delivery, the amount of acid delivered to the skin over a given period, and, most importantly, the length of time that the acid remains on the skin. Glycolic acid peels become more unpredictable following overzealous scrubbing. The agent is applied in any cosmetic unit order, rapidly—covering the entire face within about 20 seconds—with a large cotton applicator. A starting application time for a weekly or monthly application with 50 or 70% unbuffered glycolic acid is generally in the range of 3 min, and the time is increased with subsequent peels. Neutralizers with sodium bicarbonate have no advantage over water rinsing as long as all acid is removed thoroughly from all rhytides and cosmetic units. This peeling is very forgiving, complications are very rare, and results are slow to appear. Patients should be realistic about subtle results. [25], [26]

TRETINOIN Topical tretinoin, all- *trans*-retinoic acid, is a supplement to most peel regimens along with daily application of sunscreen. [9], [19] Daily application of 0.1% tretinoin cream for 2 weeks prior to a 35% TCA peel significantly enhanced the healing time of the facial, forearm, and hand skin in a double-blind, placebo-controlled study. However, tretinoin application before and after TCA does not significantly enhance the clinical efficacy of the peel. [19], [27], [28]

Medium-Depth Peeling

Medium-depth peels are usually performed as a single procedure to remove actinic keratoses, mild rhytides, or pigmentary dyschromias or to flatten depressed scars. They may be repeated approximately every 3 to 12 months based on the amount of actinic damage still remaining or recurring after the peel or for continued scar effacement. The classic peel for this depth category was the 50% TCA peel. Because TCA is prone to produce increased scarring and hypopigmentation with higher concentrations, the use of a more superficial epidermal peeling agent such as solid CO_2, [1], [11], [15] Jessner's solution, [16], [21], [23] or glycolic acid [29] prior to the application of 35% TCA will produce a wound equivalent in depth to the higher-strength 50% solution or full strength 88% phenol. This technique is called combination medium-depth peeling.

The addition of emulsifiers or additives to TCA may increase its penetration to the lower dermis, leading to overtreatment and scarring. Combinations of medium-depth peels to blend cosmetic units are effective and useful. Resurfacing of the perioral region with the laser, dermabrasion, or deep phenol peel and blending the rest of the face with combination medium-depth peeling is very effective, as is discussed below. Wet to dry soaks of tap water or povidone-iodine skin cleanser twice daily in the shower, followed by application of an occlusive ointment such as bacitracin or petrolatum to minimize crusting, is the optimal aftercare for rapid healing.

Deep Peeling

The traditional chemical peel formula with phenol was described in 1961 by Baker and Gordon (Table 269-5). The application of waterproof tape for 48 h will increase penetration. More aggressive cleaning of the skin prior to application of the wounding agent and the application of more peel solution may eliminate taping. Occlusive petrolatum may be substituted for the tape. The 55% phenolic Baker-Gordon formula has always been thought to penetrate further into the dermis than full-strength undiluted phenol because the latter causes immediate coagulation of epidermal keratin proteins and blocks further penetration of phenol. [10], [12], [13] The concentration of croton oil may be the principal ingredient in the formula responsible for the effects and occasional accompanying hypopigmentation. The phenol may act as a carrier for the croton oil. [14]

Phenol USP	3 mL
Tap water or distilled water	2 mL
Septisol liquid soap	8 drops
Croton oil	3 drops

TABLE 269-5 **The Baker-Gordon Phenol-Croton Oil Formula**

For full-face application, regional nerve blocks or preoperative sedatives and analgesics such as Diprivan and midazolam are employed. Because phenol is partially detoxified in the liver and excreted by the kidney and because phenol may induce cardiac arrhythmias, hydration with 500 mL of lactated Ringer's solution prior to the procedure, and 1000 mL during and after the peel, will prevent phenol toxicity on these organ systems.

The face is degreased prior to the application of the wounding agent and divided into six esthetic units: forehead, perioral, right and left cheeks, nose, and periorbital areas. [15], [20] Peel solution is usually applied in this order, allowing 10 to 15 min between units to minimize renal and cardiac toxicity; thus the entire procedure would take 60 to 90 min. If indicated, tape is applied to each segment. After 48 h, the exudate has lifted the tape considerably, with drainage from

the mask's lower edge, and it is easily removed. Wet-to-dry soaking three to five times daily in the shower using tap water, half-strength boric acid, or dilute antiseptic povidone-iodine skin cleanser will dry the exudative edema. An occlusive moisturizer (e.g., petrolatum) should then be used.

Application of Baker's phenol to one cosmetic unit or less does not require intravenous hydration or cardiac monitoring. The amount of phenol applied to the skin in this fashion is equivalent to or less than that applied for a phenol nail matrixectomy. Oral hydration may be given in the form of 8 to 16 oz of water prior to the peel if patients have not been drinking much fluid on the day of the procedure. After phenol has been applied to the perioral area, for example, medium-depth peeling or other resurfacing modalities may be utilized on other cosmetic units [30] (Fig. 269-3).

FIGURE 269-3 Fitzpatrick type II and Glogau photoaging type IV skin with the most severe defects in the perioral area (*A*). Three months later, there is no perceptible color change after application of perioral occluded Baker-Gordon formula and CO_2 plus TCA 35% on the remainder of the face (*B*). (*From Brody,* [15] *with permission.*)

COMPARISON OF DEEP PEELING WITH CO_2 RESURFACING LASER

Clinical comparison between the laser and Baker's solution reveals that the laser improves severe photodamage by approximately 50 percent. [14] The laser may eliminate mild wrinkles in one treatment with little risk of pigmentary change. The peel does the same but may be more likely to cause slight hypopigmentation. In contrast, very severe rhytides may require multiple touchups by the laser for adequate treatment. However, the Baker's peel can eliminate the vast majority of deep rhytides in one treatment. [30] Neither procedure for severe rhytides leaves bothersome residual hypopigmentation, but mild pigment loss is not unexpected with both peel and laser for this indication.

COMPLICATIONS ARISING FROM CHEMICAL PEELS

A favorable test spot result in patients at higher risk for pigmentation or scarring does not guarantee the behavior of the rest of the facial skin, but it may ease the patient's fears. [15], [20]

Pigmentary changes in the form of hyperpigmentation may occur in darker skin types and is caused by sunlight, estrogens, photosensitizing drugs, or pregnancy. [31] Hypopigmentation after Baker's phenol application is a function of patient selection and mode of application as well as subsequent wound care. The hypopigmentation is proportional to the amount of phenol and croton oil applied, and a small loss of pigment is an expected result and not a complication. The rate of hypopigmentation with laser resurfacing is not uncommon, depending on depth and skin type, and can be as high as 16 percent. Treatment of such hyperpigmentation with hydroquinone regimens is effective.

The risk of hypertrophic scarring is less than 1 percent with the three combination medium-depth peels. By itself, 50% TCA is capable of unpredictable hypertrophic scarring while 35% TCA is relatively safe. The incidence of scarring with the traditional Baker's phenol formula in a series of more than 1000 patients was less than 2 percent. The rate of scarring may increase with deviations in technique, the use of preliminary treatments or topicals to increase absorption, recent isotretinoin use, or improper patient selection. Comparison with the CO_2 laser reveals comparable safety with less than 3 percent complications. The delayed healing syndrome, probably caused by a defect in transepidermal water loss, has been noted after TCA and phenol peeling, as well as after laser resurfacing. [15], [32] The constellation of symptoms includes friable, stellate, nonindurated, painful, unhealed erosions with serous granulation tissue persisting for 10 days after peeling. The areas may heal with hypopigmented flat scars and should be treated with artificial semipermeable dressings or very dilute triamcinolone injections into the wound margins. Other treatments for scars include topical, intralesional, or tape-impregnated glucocorticoids, silicone gel sheeting, or the 585-nm flashlamp-pumped pulsed dye laser (FPDL). [33]

Bacterial, viral, or fungal infection may occur after peeling. Toxic shock syndrome, induced by Staphylococcus aureus exotoxin, has been reported rarely following Baker's phenol face peels. Patients with a positive history of herpes should be treated prophylactically during healing with therapeutic doses of acyclovir, valacyclovir, or famciclovir beginning on the day of the peel. Unusual and unexpected postpeel pain may reflect the onset of herpes viral infection. Candidiasis has been reported more frequently after dermabrasion and CO_2 laser resurfacing, probably because of the partially protective presence of a nonviable epidermis remaining after peeling and because of the lack of occlusive dressings. [15]

Prolonged erythema, which may occur after peeling, may be treated with topical hydrocortisone. Isotretinoin administration prior to peeling, atopic problems in the patient, rosacea, contact dermatitis, or minimal amounts of alcoholic beverages may also affect redness. Textural changes in the form of large pores may occur temporarily after peeling. Milia or acne occurring after peeling may be aggravated by thick ointments. A poor physician/patient relationship in the face of minor, manageable complications can result in a loss of follow-up and litigation.

Skin atrophy, cardiac arrhythmias, laryngeal edema, and exacerbation of a Koebnerizing pemphigus-like disease may occur with phenol/croton oil peels. [34]

COMBINATION SKIN RESURFACING—COMBINING CHEMICAL RESURFACING WITH LASER OR

DERMABRASIVE RESURFACING

As discussed above, deep phenol peeling will eliminate rhytides in the perioral area and medium peels can be used on the remainder of the face if warranted. [15] The resurfacing CO_2 laser or dermabrasion can also be used to eliminate rhytides or reduce scars in the perioral, periorbital, or cheek areas. [14], [35] The remainder of the face can be blended with chemical peeling. Operator-sensitive differences in technique in the three modalities make comparison of the three resurfacing modalities difficult.

REFERENCES

1. Brody HJ: Variations and comparisons in medium depth chemical peeling. *J Dermatol Surg Oncol* **15**:953, 1989

2. Moy LS et al: Glycolic acid peels for the treatment of wrinkles and photoaging. *J Dermatol Surg Oncol* **19**:243, 1993

3. Moy L et al: Comparison of the effect of various chemical peeling agents in a mini-pig model. *Dermatol Surg* **22**:429, 1996

4. Moy L et al: Glycolic acid modulation of collagen production in human skin fibroblast cultures in vitro. *Dermatol Surg* **22**:439, 1996

5. Becker FF et al: A histological comparison of 50% and 70% glycolic acid peels using solutions with various pHs. *Dermatol Surg* **22**:463, 1996

6. Ditre CM et al: The effects of alpha hydroxy acids on photoaged skin: A pilot clinical, histological and ultrastructural study. *J Am Acad Dermatol* **34**:187, 1996

7. Griffin TD et al: Increased factor XIIIa transglutaminase expression in dermal dendrocytes after treatment with alpha hydroxy acids: Potential physiologic significance. *J Am Acad Dermatol* **34**:196, 1996

8. Bhawan J et al: Reversible histologic effects of tretinoin on photodamaged skin. *J Geriatr Dermatol* **3**:62, 1995

9. Griffiths CEM et al: Two concentrations of topical tretinoin (retinoic acid) cause similar improvement of photoaging but different degrees of irritation. *Arch Dermatol* **131**:1037, 1995

10. Stegman SJ: A comparative histologic study of the effects of three peeling agents and dermabrasion on normal and sun-damaged skin. *Aesthetic Plast Surg* **6**:123, 1982

11. Brody HJ, Hailey CW: Medium-depth chemical peeling of the skin: A variation of superficial chemosurgery. *J Dermatol Surg Oncol* **12**:1268, 1986

12. Kligman AM et al: Long-term histologic follow-up of phenol face peels. *Plast Reconstr Surg* **75**:652, 1985

13. Brown AM et al: Phenol-induced histologic skin changes: Hazards, technique and uses. *Br J Plast Surg* **13**:158, 1960

14. Hetter GP: An examination of the phenol-croton oil peel: Parts I–IV. *Plast Reconstr Surg* **105**:227, 240, 752, 1061, 2000.

15. Brody HJ: *Chemical Peeling and Resurfacing*, 2nd ed. St Louis, Mosby-Year Book, 1997

16. Lawrence N et al: A comparison of the efficacy and safety of Jessner's solution and 35% trichloroacetic acid vs 5% fluorouracil in the treatment of widespread facial actinic keratoses. *Arch Dermatol* **131**:176, 1995

17. Lawrence NL, Cox SE, Brody HJ: A comparison of Jessner's solution versus glycolic acid: A comparison of clinical efficacy. *J Am Acad Dermatol* **36**:589, 1997

18. Brody HJ: The art of chemical peeling. *J Dermatol Surg Oncol* **15**:918, 1989

19. Humphreys TR et al: Treatment of photodamaged skin with trichloroacetic acid and topical tretinoin. *J Am Acad Dermatol* **34**:638, 1996

20. Glogau RG, Matarasso SL: Chemical peels. *Dermatol Clin* **13**:263, 1995

21. Brody HJ: Trichloroacetic acid application in chemical peeling. *Oper Tech Plast Reconstr Surg* **2**:127, 1995

22. Letessier SM: Chemical peel with resorcin, in *Dermatologic Surgery: Principles and Practice,* 2nd ed, edited by RK Roenigk, HH Roenigk. New York, Marcel Dekker, 1996, p 1115

23. Monheit GD: The Jessner's + TCA peel: A medium depth chemical peel. *J Dermatol Surg Oncol* **15**:945, 1989

24. Swinehart JM: Salicylic ointment peeling of the hands and forearms. *J Dermatol Surg Oncol* **18**:495, 1992

25. Newman N et al: Clinical improvement of photoaged skin with 50% glycolic acid: A double-blind vehicle-controlled study. *Dermatol Surg* **22**:455, 1996

26. Brody H et al: Round table discussion of alpha hydroxy acids. *Dermatol Surg* **22**:475, 1996

27. Kimbrough-Green CK et al: Topical retinoic acid (tretinoin) for melasma in black patients. *Arch Dermatol* **130**:727, 1994

28. Hevia O et al: Tretinoin accelerates healing after trichloroacetic acid chemical peel. *Arch Dermatol* **127**:678, 1991

29. Coleman WP, Futrell JM: The glycolic acid + trichloroacetic acid peel. *J Dermatol Surg Oncol* **20**:76, 1994

30. Matarasso SL, Brody HJ: Deep Chemical peeling. *Semin Cutan Med Surg* **15**:155, 1996

31. Brody HJ: Complications of chemical peeling. *J Dermatol Surg Oncol* **15**:1010, 1989

32. Szachowicz EH, Wright WK: Delayed healing after full-face chemical peels. *Facial Plast Surg* **6**:8, 1989

33. Goldman MP, Fitzpatrick RE: Laser treatment of scars. *Dermatol Surg* **21**:685, 1995

34. Detwiler SP, Saperstein HW: Physically induced pemphigus after cosmetic procedures. *Int J Dermatol* **32**:100, 1993

35. Hruza GJ, Dover JS: Laser skin resurfacing. *Arch Dermatol* **132**:451, 1996

T>

Chapter 270

Christopher Harmon John Yarborough

Skin Resurfacing: Dermabrasion

HISTORICAL FACTORS
INDICATIONS
PATIENT SELECTION
EQUIPMENT
ANESTHESIA
WOUND CARE
COMPLICATIONS
MICRODERMABRASION

REFERENCES

Over the past decade, the availability of many pulsed and shuttered CO_2 lasers has rekindled an interest in resurfacing treatments of the skin. Many of the current laser surgery practices such as patient selection, postoperative dressings, and management of complications are based on years of experience with dermabrasive resurfacing and chemical peeling. While chemical peeling uses the application of exfoliating chemicals to remove epidermal and dermal layers of the skin, dermabrasion surgically abrades or planes the epidermis and dermis with the use of a rapidly rotating wire brush or diamond fraise. A working knowledge of the limitations and advantages of each of these resurfacing options is requisite in optimizing surgical outcomes for the entire spectrum of clinical presentations.

HISTORICAL FACTORS

Armed with the success of 200 cases performed over a 2-year period, Dr. Abner Kurtin presented “corrective surgical planing of skin” to the Dermatologic Section of Mount Sinai Hospital New York, in January 1953. [1] His technique combined the use of high-speed rotary dermabraders, intraoperative freezing, and various cutting-end pieces for resurfacing facial skin. [2] This office-based surgical procedure laid the groundwork for modern dermabrasion and introduced the subspecialty of cosmetic dermatologic surgery.

INDICATIONS

The indications for dermabrasion include those lesions and defects of the epidermis, papillary dermis, and upper reticular dermis that can be partially or completely removed by surgically planing to the level of the reticular dermis. Wound healing by second intention allows re-epithelialization to occur from the underlying adnexal structures. During the maturation phase of wound healing, fibroblasts replace and remodel collagen bundles in the papillary and upper reticular dermis. [3] These mechanisms allow the superficial and saucer-shaped scars of facial acne to be greatly improved, while ice-pick scars and deep post-varicella scars may require elevation or punch grafting prior to dermabrasion. [4]

Programmed dermabrasion of surgical and traumatic scars performed 6 to 8 weeks following injury frequently yields complete elimination of visible evidence of scar formation. [5] While the cellular mechanisms of this phenomenon are not completely understood, ultrastructural studies have demonstrated an increase in collagen bundle density and size with a tendency toward a more normal unidirectional fiber orientation, parallel to the epidermal surface. Furthermore, immunohistochemical assays have shown a postabrasive upregulation in tenascin expression in the papillary dermis, and an alteration in integrin expression in the spinous layer of the epidermis. These observations suggest that dermabrasive scar revision produces a less-perceptible scar by modifying the extracellular ligand expression of the primary cicatrix, thereby influencing epithelial cell-to-cell interaction and the reorganization of underlying connective tissue. [6]

As a resurfacing treatment for photoaging, dermabrasion can be used to treat actinic keratoses, solar elastosis, and wrinkles [7] (Fig. 270-1). Benign conditions, such as rhinophyma, adenoma sebaceum, epidermal nevi, syringomas, small cysts, milia, and seborrheic keratoses can easily be removed. Abrasion can also be used to eradicate superficial malignancies, including Bowen's disease and superficial basal cell carcinomas. [8] Pigmentary disorders, such as melasma, tattoos, and lentigines, can be improved with dermabrasion when it is used in conjunction with bleaching and tretinoin creams. [9]

FIGURE 270-1 *A.* Perioral rhytides prior to wire brush dermabrasion. *B.* Improved perioral rhytides 6 months following wire brush dermabrasion.

PATIENT SELECTION

In evaluating patients for dermabrasive procedures, a complete history and comprehensive consultation are paramount. A review of “before” and “after” photographs is often helpful in preparing the patient and providing realistic expectations of improvement. The risks of preoperative, intraoperative, and postoperative care should be discussed in obtaining informed consent. A recent history of isotretinoin therapy is a contraindication because of many reports of hypertrophic scarring and poor healing attributed to concomitant or recent isotretinoin usage. Generally, 6 months is considered an adequate interval between isotretinoin treatment and any abrasive surgery. [10], [11], [12] and [13] Similarly, dermabrasions should not be performed for at least 6 months following any extensive undermining (i.e., face lifts, brow lifts, etc.) so as to allow reestablishment of the vascular bed of the area to be abraded. [14]

Drug allergies, clotting disorders, abnormal scarring, cold intolerance, pigmentary disorders, or Koebnerizing skin conditions are other important historical factors to be considered. Preoperative antiviral prophylaxis obviates the great potential for activation of herpes simplex with perioral or full-face abrasions. Furthermore, the risk of aerosolization of viral particles mandates universal precautions. [15], [16]

EQUIPMENT

Various manufacturers produce hand engines capable of providing 15,000 to 60,000 rpms for driving the cutting-end pieces. The wire brush and diamond fraise are the most commonly used. The fraises come in a variety of shapes, sizes, and grades of coarseness. Pear-shaped fraises and cones are often used around the nose and oral commissure, whereas the wheels can be used over broad, flat surfaces. Diamond fraises can be used without cryogenic spray and offer a broader safety margin than the wire brush. The wire brush removes greater amounts of tissue with less thermal injury, thereby allowing the surgeon to plane deeply into the mid-reticular dermis with less risk of scarring. For more aggressive abrasions with a wire brush or a coarse diamond fraise, the use of intraoperative cryogenic sprays provide a firm surface on which to work and prevents the skin from grabbing or gouging. However, excessive freezing or the use of sprays with extremely low boiling points can produce unwanted tissue damage and scarring. The products containing Freon 114 and Freon 114–ethylchloride mixtures are safe, while products using Freon 11 and Freon 12, which lower skin temperatures more, may cause excessive skin damage. [17], [18]

ANESTHESIA

Today, most dermabrasions are performed as outpatient procedures in offices, ambulatory surgery facilities, or hospital operating rooms. Regional or spot dermabrasions can usually be performed with local anesthesia and no additional analgesia. However, full-face abrasions may require oral or IM sedation in conjunction with cryoanesthesia, local or tumescent anesthesia, or nerve blocks. Intravenous sedation or general anesthesia is rarely necessary. Like cryoanesthesia, the tumescent technique offers local anesthesia and a solid surface for planing. Some surgeons prefer the increased hemostasis of tumescence, and choose to eliminate the refrigerant spray because of the chance of unintended tissue damage. [19] A topical eutectic mixture of local anesthetic may provide supplemental surface anesthesia, but its use should be limited to less than 10 g. [20] The controversial and potential benefit of abrading scars frozen into place may be lost with the distention of tumescence.

WOUND CARE

Following dermabrasion, white petroleum ointment or an antibiotic ointment is applied to the abraded area. Significant advances have been made in the development of semipermeable hydrogel dressings that can be applied directly on top of the ointment. By maintaining a critical plane of humidity for epithelial cell migration, these dressings have reduced the time of reepithelialization to only 5 or 6 days. [21], [22] During this time, the ointment and dressing can be changed daily. A mild soap or nonmentholated shaving cream can be used to clean the area and to prevent any buildup or crust formation. Once the treated area has been reepithelialized, the new skin is pink-to-red in color and requires the frequent application of moisturizer. The pinkness can be covered with makeup and usually fades over a period of 6 to 12 weeks.

COMPLICATIONS

Postoperative complications include scarring, pigmentary changes, persistent erythema, and infection. The deeper the

dermabrasion, the greater the risk of scarring, especially over the upper lip, mandible, and bony prominences. Because of the decreased number of adnexal structures in nonfacial skin, dermabrasions performed away from the face are also more likely to produce scarring. Hypertrophic scars and keloids may be treated with topical flurandrenolide tape, intralesional steroids, or silicone gel sheeting. [23] Some 30 to 50 percent of all patients may experience some degree of hypopigmentation following dermabrasion. The chance of hyperpigmentation is greatest during the first 6 weeks after surgery, especially in skin types III and IV, and can often be prevented with the postoperative use of hydroquinone and retinoic acid creams. Because of the low incidence of bacterial infections following dermabrasion, prophylactic antibiotics can produce more harm than good by promoting gram-negative superinfections. Primary bacterial infections are extremely rare and best managed with culture-directed antibiotic regimens. Antiviral prophylaxis, on the other hand, should be performed on a routine basis for full-face abrasions and perioral treatments (see Chap. 260). Careful patient selection, attentive surgical technique, state-of-the-art postoperative dressings, and prompt management of any developing problem can greatly reduce the risk of postabrasive complications and significantly enhance surgical outcomes.

MICRODERMABRASION

Microdermabrasion is a recently developed resurfacing technique that uses aluminum oxide or sodium chloride microcrystals to superficially remove the stratum corneum and epidermis. The microcrystals circulate through a high-speed system and are collected in a waste container. With this method of abrasive resurfacing, the depth of ablation is easily controlled by dialing in the appropriate pressure setting on the machine.

Histologic evaluation of biopsies taken immediately following microdermabrasion demonstrates compaction and homogenization of the epidermis. After six treatments, thickening of the epidermis and an increased number of elastic fibers is seen within the dermis. Clinically, the treated skin has a smoother contour and visible erythema that persists for 2 to 3 days postoperatively. This technique is useful in treating early photodamage, fine wrinkles, dyschromia, and superficial scarring. [24], [25] and [26] Simple postoperative wound care with a hydrating moisturizer allows for rapid recovery and minimal discomfort. Treatments are usually successive, 2 to 4 weeks apart, and maintenance of results requires periodic repeating procedures.

REFERENCES

1. Robbins N: Dr. Abner Kurtin, father of ambulatory dermabrasion. *J Dermatol Surg Oncol* **14**:425, 1988

2. Kurtin A: Surgical planing of the skin. *Arch Dermatol Syphilol* **68**:389, 1953

3. Burks JW: *Wire Brush Surgery*. Springfield, IL, CC Thomas, 1956

4. Yarborough JM: Dermabrasion by wire brush. *J Dermatol Surg Oncol* **13**:610, 1987

5. Yarborough JM: Ablation of facial scars by programmed dermabrasion. *J Dermatol Surg Oncol* **14**:292, 1988

6. Harmon CB et al: Dermabrasive scar revision: Immunohistochemical and ultrastructural evaluation. *Dermatol Surg* **21**:503, 1995

7. Benedetto AV et al: Dermabrasion: Therapy and prophylaxis of the photoaged face. *J Am Acad Dermatol* **27**:439, 1992

8. Roenigk HH: Dermabrasion for miscellaneous cutaneous lesions (exclusive of scarring from acne). *J Dermatol Surg Oncol* **3**:322, 1977

9. Mandy SH: Tretinoin in the preoperative and postoperative management of dermabrasion. *J Am Acad Dermatol* **15**:878, 1986

10. Roenigk HH et al: Acne, retinoids, and dermabrasion. *J Dermatol Surg Oncol* **11**:396, 1985

11. Rubenstein R et al: Atypical keloids after dermabrasion of patients taking isotretinoin. *J Am Acad Dermatol* **15**:280, 1986

12. Katz BE et al: Atypical facial scarring after isotretinoin therapy in a patient with previous dermabrasion. *J Am Acad Dermatol* **30**:852, 1994

13. Stegman SJ et al: Dermabrasion, in *Cosmetic Dermatologic Surgery*, edited by SJ Stegman, TA Tromovitch, RG Glogau. Chicago, Year Book, 1990, p 59

14. Kamer FM, Lefkoff LA: Injectable collagen, chemical peeling, and dermabrasion as an adjunct to rhytidectomy. *Facial Plast Surg* **8**:89, 1992

15. Vaughn RY et al: HIV and the dermatologic surgeon. *J Dermatol Surg Oncol* **16**:1107, 1990

16. Kemsley GM: Transmission of hepatitis B in dermabrasion. *Plast Reconstr Surg* **56**:440, 1975

17. Hanke CW et al: Complications of dermabrasion resulting from excessively cold skin refrigerant. *J Dermatol Surg Oncol* **11**:896, 1985

18. Hanke CW et al: Laboratory evaluation of skin refrigerants used in dermabrasion. *J Dermatol Surg Oncol* **11**:45, 1985

19. Coleman WP et al: Use of the tumescent technique for scalp surgery, dermabrasion, and soft tissue reconstruction. *J Dermatol Surg Oncol* **18**:130, 1992

20. Goodman G: Dermabrasion using tumescent anesthesia. *J Dermatol Surg Oncol* **20**:802, 1994

21. Pinski JB: Dressings for dermabrasion: New aspects. *J Dermatol Surg Oncol* **13**:673, 1987

22. Mandy SH: A new primary wound dressing made of polyethylene oxide gel. *J Dermatol Surg Oncol* **9**:2, 1983

23. Gold MH: Topical silicone gel sheeting in the treatment of hypertrophic scars and keloids. *J Dermatol Surg Oncol* **19**:912, 1993

24. Shim EK et al: Microdermabrasion. A clinical and histopathologic study. *Dermatol Surg* **27**:524, 2001

25. Hernandez-Perez E et al: Gross and microscopic findings in patients undergoing micro-dermabrasion for facial rejuvenation. *Dermatol Surg* **27**:637, 2001

26. Lloyd J: The use of microdermabrasion for acne: A pilot study. *Dermatol Surg* **27**:329, 2001

T>

Chapter 271

George Hruza Jeffrey Dover Kenneth Arndt

Skin Resurfacing: Laser

THEORETICAL CONSIDERATIONS
The CO2 Laser
Erbium:YAG Laser
Variable Pulse Er:YAG Laser
HISTOLOGY
INDICATIONS
Rhytides
Scars
Other Indications
TECHNIQUE
Preoperative Considerations
Surgical Procedure
Carbon Dioxide Lasers
Er:YAG lasers
Long-Pulse Er:YAG Laser
Nonfacial Resurfacing
Wound Care
SIDE EFFECTS AND COMPLICATIONS
FUTURE CONSIDERATIONS

REFERENCES

In the 1980s and early 1990s continuous wave CO_2 lasers were used in an effort to resurface photoaged skin. Although the results of this procedure performed by a few were quite impressive, the risk:benefit ratio of the procedure was very high. Dwelling too long on a specific area led to excessive thermal diffusion and thermal damage resulting in scarring. The technique was never widely used for this specific reason. However, with the development of short-pulse high-peak power and rapidly scanned focused-beam CO_2 lasers and normal mode erbium:yttrium aluminum garnet (Er:YAG) lasers, the ability to remove photodamaged skin layer by layer in a precisely controlled manner while leaving behind a very narrow zone of thermal damage became possible (see Chap. 267). [1], [2]

THEORETICAL CONSIDERATIONS

The CO_2 Laser

The CO_2 laser, first developed in 1964, has an emission wavelength of 10,600 nm in the infrared part of the electromagnetic spectrum, where the major chromophore is water. The thickness of water that absorbs 90 percent of the radiant energy of the incident beam from the CO_2 laser is approximately 30 µm. [3] However, when the energy is delivered in a continuous beam, thermal coagulation occurs to a depth of up to 1 mm because of heat diffusion. To control the depth of thermal damage that occurs in tissue, the continuous wave CO_2 laser beam needs to be scanned at a rate that results in a tissue dwell time of less than the thermal relaxation time or the energy must be delivered in a pulse shorter than this time. The thermal relaxation time of the 30 µm tissue layer heated by the CO_2 laser has been calculated to be less than 1 msec. [4] The necessary pulse energy fluence to achieve pulsed CO_2 laser ablation of skin tissue is approximately 5 J/cm ^{2}. [3] Delivering 5 J/cm ^{2} in less than 1 msec to skin limits the thermal damage zone to 20 to 150 µm depending on how many passes are done with the depth of thermal damage increasing with increasing number of laser passes. [5] Several resurfacing CO_2 lasers that meet the above criteria have been developed (Table 271-1).



TABLE 271-1 **Representative Resurfacing Lasers**

Erbium:YAG Laser

The 2940-nm wavelength of the Er:YAG laser has 16 times greater water absorption than the CO_2 laser. Its shallower skin penetration (1 µm as compared with 30 µm for CO_2 laser light) allows more precise ablation with less thermal damage. In addition, Er:YAG laser light is efficiently absorbed by collagen. The Er:YAG laser has been tested in a pulsed (normal) mode with a pulse width of 200 µsec and in a Q-switched mode with a pulse width of 90 nsec. At fluences below 25 J/cm ^{2}, 2.5 to 30 µm of tissue was ablated and the zone of damage was limited to 10 to 40 µm with normal mode laser and 5 to 10 µm with the Q-switched laser when tested in guinea pig skin. [6] In the Q-switched mode, residual thermal damage is insufficient to coagulate blood vessels, leaving a bloody surgical field limiting its clinical utility. In the normal

mode, skin vaporization leaves a relatively bloodless field after two to three passes. Bleeding becomes a greater problem with successive passes. [7]

The normal mode Er:YAG laser ablates approximately 4 µm of tissue for every J/cm ^{2}. The residual thermal damage is in the range of 10 to 40 µm in clinical practice. Unlike the CO_2 lasers, pulse stacking with an Er:YAG laser does not seem to increase the thickness of thermal damage. Each pass ablates a reproducible thickness of tissue so that with a sufficient number of passes, the laser can ablate into the subcutaneous fat. However, bleeding becomes a problem as the laser ablates into the deep papillary dermis making deeper ablation difficult to achieve in a controlled manner and, unlike the CO_2 laser, there is no immediate tissue shrinkage from thermal coagulation.

Variable Pulse Er:YAG Laser

In the belief that immediate tissue contraction is important for long-term laser resurfacing results, variable pulse Er:YAG laser systems have been introduced. Clinical use of these lasers demonstrates immediate tissue contraction along with a rate of healing intermediate between that of the resurfacing CO_2 lasers and short-pulse Er:YAG lasers. [8]

HISTOLOGY

Resurfacing lasers are designed to ablate a superficial zone of skin, leaving minimal thermal damage. Macroscopically, shrinkage is seen during CO_2 and long-pulse Er:YAG laser treatment and appears to be directly proportional to the number of passes. [9] Contraction has not been measured in photoaged human skin, but shrinkage in pig skin was proportional to the number of passes and to fluence, resulting in a 10 to 30 percent reduction in area. [10]

A study of porcine skin compared the CO_2 laser with trichloroacetic acid and phenol peels and dermabrasion. [11] The depth of residual thermal necrosis was 40 µm, but it was up to 53 and 106 µm with second and third passes, respectively, and increased with increased pulse energy. Dermal vaporization plus necrosis depth was directly proportional to pulse energy; that is, with each pass, the depth of vaporization decreased while the residual thermal damage increased.

One study examined the depth of ablation and residual damage with each pass. [5] Three different laser systems, were compared with a continuous wave (CW) CO_2 laser as a control. One was a pulsed laser with a computerized scanner; another was a scanned CW laser; and the third a superpulsed laser. At the settings used, which were those proposed for optimal response to each laser, the CW laser caused a zone of thermal necrosis 400 to 500 µm thick. Both the scanned CW laser and the superpulsed laser ablated 30 to 50 µm of tissue and completely removed the epidermis. Subsequent passes with these lasers ablated into the dermis. The zone of coagulation necrosis also increased with each pass. Another report of 40 patients tested the flashscanner and superpulsed lasers and confirmed that the first pass ablated the epidermis, the third pass removed the papillary dermis, and the fourth pass penetrated into the reticular dermis. [12]

In summary, the following statements can be made about CO_2 laser resurfacing: (1) With each laser pass, there is a reproducible tissue effect with three distinct zones. (2) The depth of tissue vaporization increases with each pass. (3) The residual thermal damage increases with each pass. (4) A repair zone with new collagen is seen in follow-up biopsies.

The histologic changes with the Er:YAG show minimal thermal damage, but vaporization that is additive after each pass. Therefore, ablation can be carried out all the way through the dermis and into the fat. There is little, if any, additive residual thermal damage. With longer pulses the thermal damage zone increases, but as each pass ablates the previous thermal damage, the thermal damage zone remains constant. [6] With long Er:YAG laser pulses, visible contraction similar to that seen with the CO_2 laser can be observed.

Skin tightening after laser resurfacing seems to be related to biphasic contraction. There is immediate contraction due to thermally denatured and altered collagen (CO_2 and long pulse Er:YAG). This effect seems to diminish during the first couple of weeks as the thermally denatured collagen is sloughed off. A second phase of contraction develops over 3 to 18 months as fibroblasts lay down new collagen as part of long-term wound repair (CO_2, Er:YAG, and long-pulse Er:YAG). Histologically, this is manifested by horizontally oriented collagen fibers in the papillary dermis consistent with mild fibrosis (scar).

INDICATIONS

Rhytides

To evaluate the severity of wrinkling and photodamage present and therefore achieve some degree of predictability of response to resurfacing, a clinical classification and numeric scoring system was devised. [1], [2] Use of this scoring system allows broad classification into mild, moderate, and severe categories, as well as a more objective numerical severity score.

Assessing patients both before and after CO_2 laser resurfacing in studies with an average follow-up of about 90 days revealed that the average patient's preoperative score decreased approximately 50 percent as a result of resurfacing (Fig. 271-1). [1], [2] This means that mild wrinkles generally resolve completely, and that moderate and severe wrinkles improve by one class. These are realistic expectations for the patient, although, occasionally, even severe wrinkles may completely resolve. The treated area continues to improve up to 18 months after laser resurfacing as collagen remodeling takes place. Periorbital, perioral, and other actinically induced rhytides improve, whereas dynamic rhytides such as glabellar and nasolabial folds show only minimal and temporary improvement. In general, both wrinkling and photodamage of the epidermis and dermis are responsive to treatment. Neck and hand photodamage and wrinkles

should be approached with extreme caution as the risk of scarring and hypopigmentation is far higher than on the face. [13]

FIGURE 271-1 *A.* Prior to CO_2 laser resurfacing. *B.* Three days after full-face laser skin resurfacing. *C.* Ten days after full-face laser skin resurfacing. *D.* Three weeks after full-face laser skin resurfacing.

As far as epidermal pathology associated with aging is concerned, actinic keratoses, squamous cell carcinoma in situ, lentigines, and seborrheic keratoses are all removed with stripping of the epidermal layer. Photodamage of the dermis results in fragmentation of elastin and collagen fibers, most profoundly in the papillary dermis. This is seen clinically as altered surface texture and pallor with crepe-like changes progressing to those of severe photoaging with cream yellow discoloration and deep creases. These layers of altered dermal tissue may be removed by vaporization and thermal necrosis and replaced with new healthy collagen developed over a tightened matrix of shrunken collagen. The ability to change these tissues dramatically relates to the depth of damage with the more superficial damage being more responsive. These dermal changes result in loose, sagging, or folded skin. These folds may be particularly visible under the eyes, on the medial lower cheeks, on the lateral cheeks anterior to the ears and to a certain extent at the nasolabial folds. These areas tend to be very responsive to the tightening effects achieved with CO_2 laser resurfacing. [1], [2], [14]

When resurfacing with the traditional, short-pulsed Er:YAG laser, more passes than with the CO_2 lasers are required to ablate to the same depth. The CO_2 lasers ablate more tissue per pass and leave a larger zone of thermal damage, with associated immediate collagen contraction. Studies comparing equivalent combined thickness ablation and coagulation with CO_2 and Er:YAG lasers have shown the CO_2 laser to achieve better wrinkle improvement but the postlaser recovery is faster with the Er:YAG laser. [15]

With the variable pulse Er:YAG lasers, thermal damage zones intermediate between that of the CO_2 and normal mode Er:YAG laser are achieved. Studies comparing a pulsed CO_2 laser with a computerized scanner on one half of the face and a variable pulse Er:YAG laser on the other half suggest that for equivalent depths of combined ablation and coagulation the wrinkle improvement is very similar while the reepithelization times and post-laser erythema duration are shorter for the variable Er:YAG laser–treated patients. [8]

Scars

The treatment of facial acne scars was found to be less effective than wrinkle treatment. [16] Mild to moderate acne scarring has improved significantly more than severe scarring. The procedure is most suited for distensible depressed or elevated acne scars. [16], [17] The edges of the scars are sculpted and more tissue is vaporized in the areas of scar tissue while doing only superficial resurfacing in the rest of the cosmetic unit being treated. Ice-pick and bound-down scars should first be removed with subcision, punch excision, linear excision, punch elevation or punch grafting, [17] with laser resurfacing being performed 6 to 8 weeks later. Alternatively, the surgical procedures may be performed at the time of the laser resurfacing either immediately before or after resurfacing. Any suturing is done immediately after resurfacing. [18]

Facial crateriform varicella scars can be improved with spot laser resurfacing. The area around and over the scar is vaporized with one pass of the laser. Additional passes are concentrated along the edge of the scar crater until it has been completely effaced. When done 6 to 10 weeks after varicella, the scar can be almost totally effaced. Older scars respond, but less completely. Postsurgical and traumatic scars can be dramatically improved, especially if resurfaced 6 to 10 weeks after the surgery or injury. [14] Immediate resurfacing after surgery of well-vascularized wound edges just prior to skin suture placement can make the final scar less noticeable. [19] Immediate resurfacing and sculpting of wound edges of nasal wounds that are to be allowed to heal by second intention enhances the final cosmetic result by allowing the scar to blend in better with the surrounding skin. [20]

Other Indications

Actinic cheilitis can be successfully treated by performing a laser vermilionectomy using one of the resurfacing lasers. [14], [21] Depending on its thickness, this usually requires one to several passes over the vermilion region. This has significantly reduced postlaser healing to approximately 10 days, in contrast to the 4 weeks it took when the conventional CO_2 laser was used. The risk of scarring seems to be greatly reduced as the extent of thermal damage is much less. The end point of treatment is complete epidermal ablation with superficial submucosal coagulation. Ablating only the epidermis has resulted in frequent actinic cheilitis recurrence. Actinic keratoses unresponsive to conventional treatment with liquid

nitrogen and topical 5-fluorouracil can be removed by ablating the epidermis and superficially ablating the upper papillary dermis to remove follicular involvement using one of the resurfacing lasers. This is especially useful on the dorsal hands and scalp.

Pigmentation irregularities such as postinflammatory hyperpigmentation and dark circles under the eyes can sometimes be improved with laser resurfacing. It is very important to use tretinoin and hydroquinones for an extended period of time before and after the procedure. Other lasers more specific for melanin or medium depth chemical peels are often preferable as they do not require anesthesia and the recovery time is much shorter. Melasma responds variably similar to other modalities used for its treatment.

Rhinophyma, epidermal nevi, and various small benign growths such as syringoma, trichoepithelioma, dermatosis papulosa nigra, xanthelasma, adenoma sebaceum, and sebaceous hyperplasia have traditionally been treated with the conventional CO_2 laser. [21] Using a resurfacing laser may reduce the healing time and risk of scarring by reducing the extent of unwanted thermal damage. [21] Sometimes a combination approach can be employed. For example, a rhinophyma can be debulked using the CO_2 laser in the superpulse mode, and the remaining tissue can be removed with the resurfacing mode of the laser to finish the procedure. When treating epidermal nevi, it is important to cause damage into the papillary dermis with residual hypopigmentation expected. Failure to cause some degree of dermal fibrosis often results in nevus recurrence.

TECHNIQUE

Preoperative Considerations

As with any cosmetic procedure, patient expectations are the most important determinant of patient satisfaction. Realistic expectations, an understanding of the postoperative care involved, and excellent preoperative photographs are essential. Resurfacing can improve wrinkling caused by photodamage, while dynamic rhytides need to be managed with other methods, such as botulinum toxin A injections.

Skin that was recently undermined, as in a facelift or blepharoplasty, has an altered blood circulation for several months. Resurfacing procedures done at the same time as or soon after skin undermining increase the risk of skin necrosis with associated scarring. [22] Therefore, laser resurfacing of undermined skin should be deferred for 6 months after the original surgical procedure. It is unknown how long after laser resurfacing a patient can safely undergo a procedure that undermines the resurfaced skin but a wait of 3 to 6 months would seem prudent.

Prior isotretinoin treatment has been reported, in case reports, to be associated with atypical scarring after dermabrasion or chemical peel even if the procedure was performed more than 1 year after isotretinoin treatment. Whether this represents a true increased risk or is only coincidental is unknown. Therefore, patients who have received isotretinoin should receive additional warnings about the possibility of scarring from laser resurfacing and the procedure should probably be done more conservatively. Waiting at least 1 to 2 years before undergoing laser resurfacing after isotretinoin treatment, because of the unknown effects on wound healing presented by isotretinoin, would seem prudent.

Tretinoin speeds reepithelialization after dermabrasion [23] and chemical peels, and it may work similarly after laser resurfacing. Therefore, tretinoin is usually prescribed for at least 6 weeks before laser resurfacing. Postinflammatory hyperpigmentation develops in a majority of Fitzpatrick type IV patients, as well as in almost all darker-skinned individuals. [1] To reduce the incidence of postinflammatory hyperpigmentation, sun avoidance for several weeks before and for several months after the procedure is recommended. While there is debate over whether preparing the skin with lightening agents prior to resurfacing decreases the risk of hyperpigmentation, many laser surgeons give skin types III to VI patients hydroquinone, kojic acid, or azelaic acid. To be effective, bleaching creams have to be used for a number of weeks before the procedure. The ideal time for laser resurfacing is late fall and winter.

All patients, regardless of cold sore or fever blister history, are prophylactically given either acyclovir 400 mg PO tid, valacyclovir 500 mg PO bid, or famciclovir 250 mg PO bid starting up to 2 days before and continuing for at least 10 days after the procedure. After laser resurfacing, there is a layer of necrotic, thermally coagulated dermis that will slough over several days. This material serves as an ideal bacterial culture medium. Therefore, patients are usually given prophylactic antibiotics, such as dicloxacillin 250 mg PO QID or, in penicillin allergic individuals, azithromycin 500 mg followed by 250 mg PO QD starting up to 1 day prior to surgery and continuing for a total of 5 days. Since introducing oral antibiotics, impetiginization of the treated areas has been almost totally eliminated. A few laser surgeons recommend a dose of fluconazole on the day of resurfacing to reduce the risk of candidal infection in the treated area.

Surgical Procedure

Except for the most superficial laser resurfacing, complete anesthesia of the treated area is required. For limited areas, local anesthesia is sufficient, but when treating the entire face, intravenous sedation or general anesthesia is usually preferred. However, there are some surgeons that have been able to successfully resurface the entire face under topical anesthesia alone. [24] To minimize visible lines of demarcation, the entire cosmetic unit with feathering at the edges is recommended. Patients with actinic bronzing or those in whom more than one anatomic unit is to be treated should have the entire face from the hairline to below the jaw line treated.

Carbon Dioxide Lasers

The various laser systems available will have different recommended power and energy fluence setting. The key thing is to limit the number of passes to achieve effacement of the offending pathology while keeping the thermal damage within the papillary or upper reticular dermis and minimizing adjacent pulse overlap, because pulse stacking (overlap of laser-irradiated sites, especially after the first pass) can increase the depth of thermal injury significantly. When the

dermis is entered, visible shrinkage because of collagen denaturation is clearly visible and desired when treating rhytides. At the conclusion of treatment, the tissue will have a yellowish tinge to it, which represents thermal damage within the dermis. Wiping away the thermally altered debris between passes, but not after the last pass is recommended to reduce the depth of thermal damage. Not wiping the debris after the final pass seems to speed reepithialization. [25] There is rarely a reason to perform more than four passes with a CO_2 resurfacing laser in any given area, as studies show that, with the energy fluences used, both vaporization and collagen tightening plateau at three to four passes, while residual thermal damage gradually increases with each additional pass. [26] After the final pass, one to two passes with an Er:YAG laser will remove some of the residual thermal damage and seems to speed healing with a reduced duration of post-resurfacing erythema. [27]

Er:YAG lasers

The treatment field is covered with moderately overlapping laser pulses. Overlapping of laser pulses seems to achieve a more even result. Pulse stacking is acceptable with the Er:YAG laser as additive thermal damage does not develop. Approximately 4 µm of tissue is vaporized per J/cm ^{2} of energy. [7] Settings are adjusted depending on how much tissue one wishes to ablate per pass taking into account any overlapping of pulses. With 50 percent overlap one “pass” will remove tissue equal to two nonoverlapped passes. With an energy fluence of 5 J/cm ^{2}, the epidermis is vaporized away in four passes. At 8 to 12 J/cm ^{2}, the epidermis is vaporized away with two passes. Additional passes are performed until the lesion or rhytid has been effaced, bleeding has been encountered or a maximum safe number of laser passes has been completed. Wiping the tissue between passes, except when the epidermis is ablated, is not necessary. It is important to keep track of the number of laser passes to determine the level of ablation. Er:YAG laser ablation in the papillary dermis gives a smooth, glistening surface. Once the reticular dermis is entered, the surface becomes uneven with sebaceous gland lobules becoming visible. At this point bleeding begins to interfere with deeper treatment. No immediate tissue shrinkage is evident with Er:YAG laser resurfacing.

Long-Pulse Er:YAG Laser

When using the variable pulse Er:YAG laser in the long-pulsed mode, heat is delivered to tissue in a manner very similar to the pulsed CO_2 laser. Therefore, immediate tissue tightening because of collagen denaturation is evident and the procedure is relatively bloodless because of coagulation of small dermal blood vessels. The short-pulsed mode may be used for purely ablative functions such as fine sculpting of tissue irregularities and removal of the final necrotic layer of thermal damage.

The settings used will be similar to the short-pulse Er:YAG laser. A fluence of 10 J/cm ^{2} will remove 40 µm of tissue per pass. The ablation is done overlapping spots by 50 percent so that one pass achieves tissue ablation equivalent to two passes. The variable pulse duration gives this laser added versatility. The pulse duration used will depend on the degree of thermal coagulation and visible shrinkage desired. Deeper wrinkles are best treated with the longest pulse durations available while fine lines and minimal photodamage are treated with the short-pulse option.

Nonfacial Resurfacing

Laser resurfacing other than on the face should be approached with caution as the risk of complications increases dramatically. [13] With the minimal residual thermal damage left behind by the Er:YAG laser, it is useful for the treatment of nonfacial photodamage and may have a role to play in the treatment of nonfacial rhytides, including the dorsal hands and neck. [28] The CO_2 laser is generally not used for resurfacing below the face. However, aggressive hydration of the skin with a topical anesthetic under occlusion seems to reduce the depth of thermal injury sufficiently to allow a CO_2 resurfacing laser to be used for superficial treatment of the neck. [29] Only the epidermis should be ablated with the expectation that dyspigmentation of the skin will be improved while the associated rhytides are only minimally affected. The main indication for neck resurfacing is to reduce color mismatch between the laser resurfaced face and sun-damaged bronze color neck.

Wound Care

Reepithelialization takes 3 to 10 days, depending on the depth of ablation and thermal coagulation (Fig. 271-1). Pretreatment with tretinoin and the use of bio-occlusive dressings during the first few days seems to speed reepithelialization. During the first few days, the thermally denatured collagen is sloughed off. The edema that develops in the first 48 hours can be controlled with ice packs, head elevation at night, and oral glucocorticoids. Once dressings are stopped, continued moist wound healing is achieved with frequent 0.25% acetic acid, normal saline or cool tap water soaks followed by application of a nonocclusive water-in-oil emulsion. Polysporin and bacitracin ointment cause frequent allergic contact dermatitis in these patients and petrolatum may cause a folliculitis, especially if it is not stopped immediately after reepithelialization is complete.

Moderate burning discomfort experienced by some patients during the first 24 h after laser resurfacing is controlled most effectively with bio-occlusive dressings. In patients treated with the open technique, ice packs, cold compresses and analgesics are helpful. Pruritus frequently develops during the first few weeks after resurfacing and responds to antihistamines and topical glucocorticoids. Many patients experience a tightness in the treated areas lasting several weeks to several months.

After reepithelialization, there is a variable period of erythema lasting 1 to 4 months (Fig. 271-1). The intensity and duration of the erythema is related to the depth of ablation and the thickness of the residual thermal damage. The redness can be successfully camouflaged with makeup containing green foundation. Sun avoidance during the entire period of postlaser erythema is essential to reduce the risk of postinflammatory hyperpigmentation.

SIDE EFFECTS AND COMPLICATIONS

Side effects following CO_2 laser resurfacing are frequent and predictable. They are similar to those following medium to deep chemical peels and dermabrasion, but they are less common and can be prevented if excellent technique is followed and postoperative management is fastidious. They can be divided into six categories: immediate, predictable effects; pigmentary changes; infection; follicular effects; eczematous effects; and scarring (Table 271-2).

TABLE 271-2 **Side Effects and Complications Associated with Laser Resurfacing**

Erythema is universal and is considered part of the normal healing process. It lasts an average of 6 to 12 weeks, while erythema and flushing, which develop in the treated site with exertion or emotional upset, are frequent up to a year after resurfacing. Some individuals do have persistent continual erythema lasting up to 12 months; this may be related to the depth of ablation. [2]

The most frequent complication is pigmentary alteration. Transient hyperpigmentation has been reported in up to 36 percent of patients, mainly affecting those with Fitzpatrick types III and IV skin. [16] More recent studies demonstrate rates of hyperpigmentation as low as 2.8 percent. Pretreatment with tretinoin and hydroquinone and fastidious sun avoidance after the procedure during the period of erythema may account for the lower incidence. Hyperpigmentation can last up to 6 months. Resolution may be hastened by continued treatment with tretinoin and hydroquinone. Permanent hypopigmentation has also been reported in up to 16 percent of individuals. [30] It is most frequent in patients with skin bronzing induced by actinic damage. In most patients it is a relative hypopigmentation with the resurfaced skin lacking visible changes of actinic damage. However, in some patients it is true hypopigmentation. Hypopigmentation is more common in patients who have previously been treated with dermabrasion [16] and appears to be related to depth of treatment.

Milia are a result of follicular reepithelialization compounded by the use of occlusive moisturizers and develop during the first 3 months after resurfacing. They are seen far less often after laser resurfacing than after dermabrasion. Treatment with tretinoin and extraction of persistent milia are effective in resolving the problem. Ointments should be discontinued as soon as reepithelialization is complete. Acne is a frequent postoperative event, especially in patients with a past history of acne. It usually develops in the first few weeks after resurfacing and responds to usual acne treatments. Occasionally, aggravation of rosacea and/or perioral dermatitis can be seen from a few weeks to a number of months after resurfacing.

Contact dermatitis, noted with the use of some topical antibiotic preparations, does not correspond with patch-test findings but resolves with appropriate treatment. [1], [2] This occurrence increases the chances of postoperative erythema and hyperpigmentation. For this reason, topical antibiotics are usually not recommended after resurfacing. Eczematous dermatitis occasionally develops in the first 4 weeks after treatment. It responds rapidly to moisturizers and topical mid-potency glucocorticoids.

Hypertrophic scarring is seldom seen following laser resurfacing. [2] It may result from a large number of passes or use of excessive energy that results in overly deep ablation and residual thermal damage. Pulse stacking with the CO_2 laser causes excessive thermal damage and an increased risk of scarring. [26] Pulse stacking with the Er:YAG laser is not a problem as each pulse ablates the thermal damage from the previous pulse so there is very limited additive thermal damage. Infection that is not recognized and treated promptly is another frequent cause of scarring. In rare cases, scars develop as a result of delayed reepithelialization that may take up to 1 year after resurfacing. Early management of incipient scars with topical and intralesional glucocorticoids, pulsed dye laser photocoagulation, silicone gel sheeting, and 5-fluorouracil injections may significantly reduce or even eliminate permanent scarring.

In a procedure that removes the epidermis and part of the dermis, infection is a concern. Laser surgeons have learned from past experience with dermabrasion and have avoided bacterial infection through the judicious use of prophylactic antibacterials. Antiviral chemoprophylaxis was originally confined to those with a history of herpes simplex infection, but results suggest that subjects with no past history of infection frequently develop activation of herpes simplex in treated areas. [1], [2] It is now standard practice to use antiviral prophylaxis in all laser resurfacing treatments. Yeast infections can be seen, but they respond well to oral treatment. [2] Some laser surgeons add oral antifungal medications to their wound care regimen.

The main advantage of the Er:YAG laser is thought to be the improved side-effects profile. However, the side-effect profile is dependent on the combined depth of ablation and thermal damage. If the ablation is carried out to the same depth as with the CO_2 laser, the risk of complications is similar. If the procedure is done superficially, it is less painful and may be completed under topical anesthesia. There is less oozing and crusting and the subsequent erythema, although dependent on the number of passes, lasts a shorter time than that following CO_2 laser treatment.

FUTURE CONSIDERATIONS

CO_2 laser resurfacing technology has matured. However, new indications and technique refinements are being

developed. Treatments are less aggressive than in the early days of laser resurfacing. This enables the procedure to be done with a greater safety margin and faster recovery time at the cost of slightly reduced efficacy. The greatest current interest from both laser surgeons and the public is in minimally invasive procedures that have minimal to no downtime or adverse effects. With this in mind, nonablative laser resurfacing using lasers and intense pulsed light sources with several different wavelengths and pulse durations has been developed and are being studied for dermal remodeling without epidermal damage (see Chap. 267).

REFERENCES

1. Fitzpatrick RE et al: Pulsed carbon dioxide laser resurfacing of photo-aged facial skin. *Arch Dermatol* **132**:395, 1996

2. Waldorf HA et al: Skin resurfacing of fine to deep rhytides using a char-free carbon dioxide laser in 47 patients. *Dermatol Surg* **21**:940, 1995

3. Walsh JJ, Deutsch TF: Pulsed CO_2 laser tissue ablation: Measurement of the ablation rate. *Lasers Surg Med* **8**:264, 1988

4. Walsh JJ et al: Pulsed CO_2 laser tissue ablation: Effect of tissue type and pulse duration on thermal damage. *Lasers Surg Med* **8**:108, 1988

5. Kauvar AN et al: A histopathological comparison of “char-free” carbon dioxide lasers. *Dermatol Surg* **22**:343, 1996

6. Walsh JT, Deutsch TF: Er:YAG laser ablation of tissue: Measurement of ablation rates. *Lasers Surg Med* **9**:327, 1989

7. Kaufmann R, Hibst R: Pulsed erbium:YAG laser ablation in cutaneous surgery. *Lasers Surg Med* **19**:324, 1996

8. Adrian MA: Pulsed carbon dioxide and long pulse 10-ms erbium:YAG laser resurfacing: A comparative clinical and histologic study. *J Cutan Laser Ther* **1**:197, 2000

9. Gardner ES et al: In vitro changes in non-facial human skin following CO_2 laser resurfacing: A comparison study. *Lasers Surg Med* **19**:379, 1996

10. Ross EV et al: Effects of CO_2 laser pulse duration in ablation and residual thermal damage: Implications for skin resurfacing. *Lasers Surg Med* **19**:123, 1996

11. Fitzpatrick RE et al: Pulsed carbon dioxide laser, trichloroacetic acid, Baker-Gordon phenol, and dermabrasion: A comparative clinical and histologic study of cutaneous resurfacing in a porcine model. *Arch Dermatol* **132**:469, 1996

12. Lask G et al: Laser resurfacing with the SilkTouch flashscanner for facial rhytides. *Dermatol Surg* **21**:1021, 1995

13. Fitzpatrick RE et al: Resurfacing of photodamaged skin on the neck with an UltraPulse carbon dioxide laser. *Lasers Surg Med* **28**:145, 2001

14. Hruza GJ: Skin resurfacing with lasers. *Fitzpatrick's J Clin Dermatol* **3**:38, 1995

15. Khatri KA et al: Comparison of erbium:YAG and carbon dioxide lasers in resurfacing of facial rhytides. *Arch Dermatol* **135**:391, 1999

16. Alster TS, West TB: Resurfacing of atrophic facial acne scars with a high-energy, pulsed carbon dioxide laser. *Dermatol Surg* **22**:151, 1996

17. Jacob C et al: Acne scarring: A classification system and review of treatment options. *J Am Acad Dermatol* **45**:109, 2001

18. Grevelink JM, White VR: Concurrent use of laser skin resurfacing and punch excision in the treatment of facial acne scarring [see comments]. *Dermatol Surg* **24**:527, 1998

19. Greenbaum SS, Rubin MG: Surgical pearl: The high-energy pulsed carbon dioxide laser for immediate scar resurfacing. *J Am Acad Dermatol* **40**:988, 1999

20. Ammirati C et al: Immediate postoperative laser resurfacing improves second intention healing on the nose: 5-year experience. *Dermatol Surg* **27**:147, 2001

21. Hruza G: Laser treatment of epidermal and dermal lesions. *Dermatol Clin* **20**:147, 2002

22. Hayes DK et al: Dermal healing fter local skin flaps and chemical peel. *Arch Otolaryngol Head Neck Surg* **116**:794, 1990

23. Alt TH: Technical aids for dermabrasion. *J Dermatol Surg Oncol* **13**:638, 1987

24. Kilmer SL et al: Full-face laser resurfacing utilizing topical anesthesia alone. *Lasers Surg Med* **24**(Suppl 11):30, 1999

25. Ross EV et al: The effect of wiping on skin resurfacing in a pig model using a high energy pulsed CO_2 laser system. *Dermatol Surg* **25**:81, 1999

26. Fitzpatrick RE et al: Depth of vaporization and the effect of pulse stacking with a high-energy, pulsed carbon dioxide laser. *J Am Acad Dermatol* **40**:615, 1999

27. Goldman MP, Manuskiatti W: Combined laser resurfacing with the 950-microsec pulsed CO_2 + Er:YAG lasers. *Dermatol Surg* **25**:160, 1999

28. Goldberg DJ, Meine JG: Treatment of photoaged neck skin with the pulsed erbium:YAG laser. *Dermatol Surg* **24**:619, 1998

29. Kilmer SL et al: Resurfacing of the neck with the CO_2 UltraPulse. *Lasers Surg Med* **24**(Suppl 11):24, 1999

30. Bernstein LJ et al: The short- and long-term side effects of carbon dioxide laser resurfacing. *Dermatol Surg* **23**:519, 1997

T>

Chapter 272

Michelle Choucair Ysabel Bello Tania Phillips

Wound Dressings

HISTORICAL ASPECTS
EFFECT OF MOIST ENVIRONMENT ON ACUTE WOUNDS
Enhancing Débridement and Reepithelialization
Dermal Effect
Angiogenesis
Retention of Wound Fluid
Protection against Infection
EFFECT OF MOIST ENVIRONMENT ON CHRONIC WOUNDS
DRESSING CATEGORIES
Hydrogels
Alginates
Hydrocolloids
Foams
Films
Antimicrobial Dressings
Hydrofiber Dressings
Hyaluronic Acid Dressings
Collagen Dressings

REFERENCES

An “occlusive” or moisture-retentive dressing is one that maintains its moisture vapor transmission rate (MVTR) to permit optimal healing for a given wound. Moisture-retentive dressings maintaining MVTRs of less than 35 g/m^2 per hour in partial-thickness wounds such as donor sites permit moist wound healing.

HISTORICAL ASPECTS

Prior to the twentieth century, wounds were left open to dry, allowing the wound to “breathe.” [1] In 1958, Odland first observed that a blister healed faster when left unbroken. [2] In 1962, a landmark article by Winter demonstrated the beneficial effect of a polyethylene film on wounds in domestic pigs. [3] This study, which showed that wounds in pigs reepithelialize faster under occlusion, revolutionized the approach to wound care and paved the way for the development of occlusive dressings. The first experimental work performed on human volunteers, conducted by Hinman and colleagues in 1963, established the beneficial effect of occlusion on wounds. [4] Since then, a large number and variety of wound dressings have become available, accounting for more than $200 million in sales in 1987, as compared with practically no sales in 1980. [5] In 2000, there were more than 30 different companies offering more than 300 different dressings capable of creating or maintaining a physiologically moist local wound environment. [6]

EFFECT OF MOIST ENVIRONMENT ON ACUTE WOUNDS

Acute wounds are wounds with no underlying healing defect that proceed to heal in an orderly and timely fashion. The beneficial effects of a moist environment have been well studied in this type of wound.

Enhancing Débridement and Reepithelialization

A moist environment enhances the rate of epithelialization. Covered wounds resurface up to 40 percent faster than those exposed to air. [7] Enzymes that débride wounds of necrotic tissue or fibrin need water to become active. Thus, water retained at the wound surface plays a vital role in enhancing débridement and subsequent reepithelialization. Rovee and co-workers stressed that greater epidermal cell movement rather than mitosis accounts for the faster healing time. [8] Keratinocyte migration is facilitated by the absence of necrotic tissue. However, the formation of a functional stratum corneum is delayed under occlusion, as demonstrated by an elevated transepidermal water loss (TEWL) in epithelialized wounds as compared with unwounded skin. [9]

Keeping a wound moist maintains a lateral voltage gradient that aids the repair process. [5] Fibroblasts exposed to electrical energy proliferate and increase the synthesis of collagen by increasing the number of growth factor receptors. [10]

Dermal Effect

The beneficial effects of occlusion extend to the dermis. The dermis of occluded acute wounds—as opposed to the dermis of air-exposed wounds—demonstrates a modified cell infiltrate. [11] Occlusion seems to accelerate the transition from a predominantly neutrophilic to a macrophage-rich infiltrate. In pigs, full-thickness wounds demonstrated an acceleration of the inflammatory and proliferative phases of dermal repair under moist as compared with dry conditions. [12] Initial breaking strength in a wound, which is largely related to collagen tissue deposition, is delayed under occlusion. Interstitial collagenase, a crucial enzyme for initiating collagen degradation, is increased under occlusion and is closely

associated with keratinocyte migration and reepithelialization. [13] Actual in vivo collagen deposition has not been measured, and the exact relationship between the rate of epidermal resurfacing and dermal collagen synthesis remains to be determined. However, occluded wounds remain cosmetically superior, suggesting a modulation of the inflammatory process and accelerated remodeling and wound contraction.

Angiogenesis

Oxygen is both stimulatory and inhibitory to the wound-healing process. Nucleated cells require oxygen for cellular activities such as mitosis or migration, and it is well established that hypoxia is a potent stimulus of angiogenesis. The oxygen gradient between the wound's edge and its center stimulates capillary ingrowth toward the relatively hypoxic center. [14] The accumulation of factors stimulating angiogenesis under occlusion, such as heparin and tumor necrosis factor (TNF), may partly account for this enhanced angiogenesis.

In vitro trials have demonstrated that optimal growth of fibroblasts in tissue culture occurs at a low PO_2 (5 to 10 mmHg), and that epidermal cell growth is inhibited at an O_2 level higher than that of the surrounding air. Thus a delicate O_2 balance is reached under occlusion that may facilitate the formation of granulation tissue.

Retention of Wound Fluid

Acute wound fluid beneath occlusive dressings stimulates the proliferation of the various cells involved in wound healing. Katz and co-workers have demonstrated that acute wound fluid obtained up to 3 days postoperatively stimulates growth of both human dermal fibroblasts and umbilical vein endothelial cells in vitro. [15] Identified growth factors included platelet-derived growth factor (PDGF), basic fibroblast growth factor (bFGF), epidermal growth factor (EGF), transforming growth factor (TGF)-ß, and interleukin (IL)-1. [16] PDGF and PDGF-like peptides may be particularly involved in fibroblast stimulation, as well as being chemotactic to neutrophils and mononuclear cells. [17] Other growth factors important for cell migration and matrix formation are TGF-ß and EGF. [18] TGF-ß stimulates the production of fibronectin by fibroblasts and keratinocytes, promotes angiogenesis, and regulates collagen synthesis. EGF stimulates keratinocyte proliferation and locomotion and inhibits fibroblast proliferation. Alteration of the expression or action of endogenous growth factors occurs within 24 h after wounding. The dressing may be removed between 24 to 48 h without loss of rapid reepithelialization. [19]

Protection against Infection

The presence of either aerobic or anaerobic organisms does not influence wound healing, and there is no relationship between the rate at which the ulcer heals and the appearance or disappearance of the organisms. Although there might be an increased rate of bacterial colonization of occluded wounds, the rate of infection remains lower than in nonoccluded wounds.

Hutchinson, in his extensive review of clinical and research studies, reported an infection rate of 7.1 percent with conventional dressings, compared with 2.6 percent with occlusive dressings ($p < .001$). [20] Hydrocolloids fostered the lowest infection rate, followed by the foams and the hydrogels. In vivo hydrocolloids prevent the invasion of a heavy external inoculum of *Staphylococcus aureus* and *Pseudomonas aeruginosa* applied to the outer surface of the dressing and the skin around it. A polyurethane foam dressing prevented wound contamination by organisms applied to the dressing but not by those inoculated around it.

Several mechanisms account for the low infection rate under occlusion. [21] First, there are enhanced defense mechanisms, as demonstrated by enhanced phagocytic and lysosomal activity under occlusion. Neutrophils infiltrate moist wounds more easily than dry wounds and their presence may be bactericidal. Second, necrotic tissue, which may act as a foreign body predisposing to wound infection, is absent under occlusion. Third, the dressing acts as a physical barrier against exogenous bacteria and viruses. Fourth, the relatively hypoxic environment under occlusion results in an acidic pH that inhibits bacterial growth, particularly of *Pseudomonas*.

EFFECT OF MOIST ENVIRONMENT ON CHRONIC WOUNDS

Chronic wounds are wounds with an underlying pathology that do not heal in a timely fashion. The effect of occlusion on chronic wounds is less well studied due to the paucity of good animal models and well-controlled clinical trials. Chronic wound fluid, unlike acute wound fluid, was found to be inhibitory to cell proliferation and contained fibronectin and vitronectin degradation products, which are inhibitory to keratinocyte migration. [22]

In venous ulcers, moisture-retentive dressings increased the rate of healing over the first month of treatment; but at the end of 12 weeks, controlled studies failed to show any difference between compression plus occlusion versus compression alone. [21] In clinical trials comparing moist saline gauze and other types of moist wound dressings in the treatment of pressure ulcers, no significant differences in healing outcomes were noted. [23]

For patients with chronic wounds, moisture retentive dressings offer the advantage of pain relief, painless wound débridement, containment of wound exudate, reduction in incidence of complications, and improved quality of life.

DRESSING CATEGORIES

There are five basic types of moistures-retentive dressings: the hydrogels, alginates, foams, films, and hydrocolloids (Table 272-1). New categories of dressings are emerging that combine some of the above characteristics. The choice of a dressing is dictated by the location of the wound, the nature of the wound bed, the amount of exudate, the surrounding skin, and the patient's comfort level. On many occasions, several different categories of wound dressing will be needed

during the healing process.

Predictable	Erythema, pruritus, swelling, oozing, crusting
Pigmentary	Hyperpigmentation; permanent hypopigmentation
Infection	Bacterial; viral; yeast
Dermatitis	Eczema
Scarring	Delayed healing (3 to 12 months); atrophic, hypertrophic, keloidal
Follicular	Acne; acneiform eruption; milia

TABLE 272-1 **Wound Dressings**

Hydrogels

Hydrogels consist of a matrix of polymers with up to 96 percent water content. [24] They are semitransparent, nonadherent, and semipermeable to gas and water vapor. These dressings have a soothing and cooling effect when placed over a wound, reducing the temperature by up to 5°C (9°F) for up to 6 h. Hydrogels interact with aqueous solutions by swelling (at 200 to 300 percent saline absorption, their absorbing capacity is high), but their rate of absorbency is low. They are not good bacterial barriers. A secondary dressing is usually needed to secure them in place. They are primarily indicated for treatment of dry to mildly exudating wounds and second-degree burns, split-thickness skin grafts, donor sites, and chronic wounds.

Alginates

Alginates are naturally occurring polysaccharides found in the cell walls of brown seaweeds (*Phaeophyceae*). The principal constituent is isomeric alginic acid present in varying proportions, depending on the seaweed source. The building blocks are mannuronic and guluronic acids. They occur in different ratios and with different structures, depending on the algal species. The higher the amount of guluronic acid in the fiber, the greater its integrity or the tendency to remain in one piece. This characteristic allows for easy removal of the hydrated dressing with a forceps. In comparison, the higher the mannuronic acid content, the greater the speed of absorption, resulting in the formation of a soft gel that can be irrigated from the wound for complete removal (Fig. 272-1).

FIGURE 272-1 An alginate dressing on a wound. The alginate forms a gel over the wound surface but stays dry around the wound margins.

When in contact with a small volume of sodium-rich solution, such as saline or wound exudate, calcium alginate fibers gel at the interface, owing to ion exchange of sodium for calcium-generating free calcium ions; this amplifies the clotting cascade and creates a gel-like substance that conforms to the wound and provides a soft, moist healing environment. [1] Some alginates can absorb up to 20 times their weight, allowing the wound to remain undisturbed for several days at a time and minimizing dressing changes.

Being nonadherent, alginates require a secondary dressing over them. They are useful in heavily exudating wounds and can be packed into deep wounds and sinuses. They are also used as hemostatic dressings and are to be avoided on dry wounds.

Hydrocolloids

Hydrocolloids consist of a mixture of adhesive, absorbent polymers and a gelling agent (sodium carboxymethyl cellulose). They are opaque and impermeable to gas and water. In the presence of wound exudate, they interact with wound fluid to form a gel over the wound (Fig. 272-2).

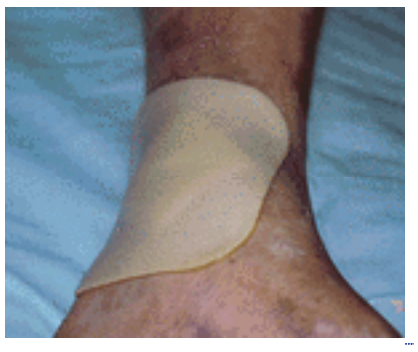

FIGURE 272-2 An opaque hydrocolloid dressing placed over a chronic wound.

Hydrocolloids have been well studied in vivo and in vitro. When factor VIII–related antigen antibodies were used to stain sections of tissue from porcine full-thickness wounds, there was significant enhancement of angiogenesis under certain hydrocolloid dressings compared to a dry dressing on days 3, 6, and 9 after surgery. [25] Macrophages in wounds elicit an angiogenic response through the release of growth factors, and hydrocolloid dressings stimulate macrophages. Furthermore, the relatively hypoxic environment under hydrocolloids is another potent stimulus for angiogenesis. The hydrocolloids have fibrinolytic activity, as demonstrated by the promotion of clot dissolution in a lysis assay in vitro and resolution of ^{131}I-labeled clots in experimental wounds. [26]

Some of the therapeutic benefits of the hydrocolloid dressings in the treatment of chronic wounds may be related to their ability to suppress excessive keratinocyte proliferation and activation and stimulation of epidermal migration. Hydrocolloids inhibit bacterial overgrowth by their physical barrier properties and by their provision of an acidic microenvironment.

Hydrocolloid dressings are convenient to use, offering infrequent dressing changes, ease of application, and a water-resistant surface that allows patients to bathe or take showers. They may cause maceration of the surrounding skin, and patients should be warned about the malodorous, yellow-brown exudate that can form underneath them. In wounds heavily contaminated by anaerobes or caused by hemoglobinopathies such as sickle cell anemia, oxygen-permeable dressings rather than hydrocolloids should be used.

Hydrocolloids are used to treat mild to moderate exudating wounds, pressure ulcers, venous ulcers, donor sites, ulcerative lesions of scleroderma, and epidermolysis bullosa.

Foams

Polyurethane foam dressings contain a hydrophilic surface that comes into contact with the wound and a hydrophobic backing to prevent leakage. They are semiocclusive and permeable to both gas and water vapor. [24] Their absorptive ability varies with the manufacturer and depends partly upon agents impregnated in the dressing. Being nonadherent, they are good alternatives for wounds with surrounding dermatitis and on bony prominences. They are used for mild to moderately exudating wounds and after dermabrasion or Mohs surgery. [1] They are opaque, can adhere to wounds if exudate dries, and sometimes require a secondary dressing to keep them in place. Foams with adhesive borders are now commercially available.

Films

Films are clear polyurethane dressing materials with an acrylic adhesive that facilitates adherence to the wound margins. They are thin and transmit moisture vapor and gases but are impermeable to fluid and bacteria. Being transparent, they allow the physician to inspect the progress of healing without disturbing the dressing or the wound. Clinical trials on surgical incisions have demonstrated that film dressings offer advantages over conventional postoperative dressings in reducing discomfort, edema, redness, and discharge and facilitating wound maturation. [27] They are used in the treatment of skin donor sites, stasis and decubitus ulcers, and superficial burn wounds (Fig. 272-3).

FIGURE 272-3 A transparent film dressing on a wound.

Films require frequent dressing changes. The problem with leakage primarily depends on the amount of fluid accumulated and the technique of application. Needle puncture to aspirate large amounts of fluid and careful observance of the recommended technique of application on the package insert will reduce the incidence of leakage. [28] Good preparation of the surrounding skin by cleaning with hydrogen peroxide and thorough drying with a dry gauze pad helps to assure good adhesion. As secondary dressings, films may be used as waterproof coverings over polyurethane foams, alginates, and hydrogels.

Many new dressings have emerged, such as antimicrobial dressings, hydrofiber dressings, hyaluronic acid dressings, and collagen dressings.

Antimicrobial Dressings

Slow-release antimicrobial dressings combine antibacterial properties with moist, interactive healing. A slow-release formulation of iodine, cadexomer iodine, seems to be useful in contaminated venous ulcers. Cadexomer iodine is composed of microspheres of starch cross-linked with ether bridges and iodine. It absorbs moisture and slowly releases iodine, in low concentrations, which have antibacterial activity yet are non cytotoxic. [29] Cadexomer iodine should be used with caution in patients with iodine allergy or thyroid disease. Slow-release ionized or nanocrystalline silver dressings (Fig. 272-4), also have antibacterial activity. In a pilot study in human chronic wounds, silver dressings were observed to decrease metalloproteinase activity, a possible mode of enhancing wound healing. [30] These slow-release antimicrobials have a broad spectrum of antibacterial activity and can decrease the bacterial burden of the wound bed surface.

FIGURE 272-4 Slow-release silver dressing covering the wound bed of a venous leg ulcer.

Hydrofiber Dressings

Hydrofiber dressings are composed of carboxymethyl cellulose, the main ingredient of hydrocolloids. Fluid is absorbed directly into the fibers. The fibers swell, resulting in a reduction of interstitial space and the formation of a gel. These dressings are highly absorbent and useful in very exudative wounds. In a small multicenter, prospective, randomized study in leg ulcers, there were less dressing changes required per week in wounds treated with hydrofibers as compared to alginate dressings. [31]

Hyaluronic Acid Dressings

Hyaluronic acid is a biodegradable absorbent biopolymer that forms a hydrophilic gel with serum or wound fluid. In chronic wounds, there is depolymerization and degradation of mucopolysaccharides, particularly hyaluronic acid. [32] Topical application of hyaluronic acid may facilitate granulation tissue formation and reepithelialization.

Collagen Dressings

Collagen-containing dressings, with or without hydrogel or alginate, are available in gels, pads, and particles. They are postulated to provide a matrix for cellular migration.

The choice of an appropriate dressing for a wound depends on the nature of the wound, the amount of exudate, the condition of the skin around the wound, and the patient's history. Treatment of the underlying cause is paramount, particularly in the case of chronic wounds. Frequent reassessment of the wound is important, to determine the need to change to a different type of dressing.

REFERENCES

1. Kannon GA et al: Moist wound healing with occlusive dressings: A clinical review. *Dermatol Surg* **21**:583, 1995

2. Odland G: The fine structure of the interrelationship of cells in the human epidermis. *J Biophys Biochem Cytol* **4**:529, 1958

3. Winter GD: Formation of a scab and the rate of epithelialization of superficial wounds in the skin of the young domestic pig. *Nature* **193**:293, 1962

4. Hinman CD et al: Effect of air exposure and occlusion on experimental human skin wounds. *Nature* **200**:377, 1963

5. Eaglstein WH et al: Wound dressings: Current and future, in *Clinical and Experimental Approaches to Dermal and Epidermal Repair. Normal and Chronic Wounds,* edited by A Barbul, MD Caldwell, WH Eaglstein, TK Hunt, D Marshall, E Pines, G Skover. New York, Wiley-Liss, 1991 p 257

6. Ovington L, Pierce B; Wound dressings: Form, function, feasibility, and facts, in *Chronic Wound Care: A Clinical Source Book for Healthcare Professionals,* 3rd ed, edited by DL Krasner, GT Rodeheaver, RG Sibbald. Wayne, PA, HMP Communications, 2001, p 311

7. Eaglstein WH: Experiences with biosynthetic dressings. *J Am Acad Dermatol* **12**:434, 1985

8. Rovee DT et al: Effect of local wound environment on epidermal healing, in *Epidermal Wound Healing,* edited by HI Maibach, DT Rovee.

Chicago, Year Book, 1972, p 159

9. Silverman RA et al: Effects of occlusive and semiocclusive dressings on the return of barrier function to transepidermal water loss in standardized human wounds. *J Am Acad Dermatol* **20**:755, 1989

10. Falanga V et al: Electrical stimulation increases the expression of fibroblast receptors for transforming growth factor beta. *J Invest Dermatol* **88**:488, 1987

11. Falanga V: Occlusive wound dressing: Why, when, which? *Arch Dermatol* **124**:872, 1988

12. Dyson M et al: Comparison of the effects of moist and dry conditions on dermal repair. *J Invest Dermatol* **91**:434, 1988

13. Inoue M et al: Collagenase expression is rapidly induced in wound edge keratinocytes after acute injury in human skin, persists during healing, and stops at re-epithelialization. *J Invest Dermatol* **104**:479, 1995

14. Field CK et al: Overview of wound healing in a moist environment. *Am J Surg* **167**:2S, 1994

15. Katz MH et al: Human wound fluid from acute wounds stimulates fibroblast and endothelial cell growth. *J Am Acad Dermatol* **25**:1054, 1991

16. Bolton LL et al: Occlusive dressings: Therapeutic agents and effects on drug delivery. *Clin Dermatol* **9**:573, 1992

17. Deuel TF et al: Growth factors and wound healing: Platelet-derived growth factor as a model cytokine. *Annu Rev Med* **42**:567, 1991

18. King LE et al: Epidermal growth factor, in *Biochemistry and Physiology of the Skin,* edited by LA Goldsmith. New York, Oxford University Press, 1983, p 269

19. Eaglstein WH: Occlusive dressings. *J Dermatol Surg Oncol* **19**:716, 1993

20. Hutchinson JJ: Prevalence of wound infection under occlusive dressings: A collective survey of reported research. *Wounds* **1**:123, 1989

21. Cordts PR et al: A prospective, randomized trial of Unna's boot versus DuoDERM CGF hydroactive dressing plus compression in the management of venous leg ulcers. *J Vasc Surg* **15**:480, 1992

22. Grinell F et al: Degradation of fibronectin and vitronectin in chronic wound fluid: Analysis by cell blotting, immunoblotting, and cell adhesion assays. *J Invest Dermatol* **98**:410, 1992

23. US Department of Health and Human Services: *Treatment of Pressure Ulcers: Clinical Practice Guideline No. 15*. AHCPR Publication No. 95-0652. Washington, DC, USDHHS, December 1994

24. Choucair M et al: A review of wound healing and dressing materials. *Wounds* **8**:165, 1996

25. Pickworth JJ, De Sousa N: Angiogenesis and macrophage response under the influence of DuoDERM, in *Fibrinolysis and Angiogenesis in Wound Healing*. Amsterdam, Excerpta Medica 1988, p 45

26. Lydon MJ et al: Dissolution of wound coagulum and promotion of granulation tissue under DuoDERM. *Wounds* **1**:95, 1989

27. Holland KT et al: A comparison of the in vitro antibacterial and complement activation effect of OpSite and Tegaderm dressing. *J Hosp Infect* **5**:323, 1984

28. Gardezi SAR et al: Role of polyurethane membrane in postoperative wound management. *J Pak Med Assoc* **33**:219, 1983

29. Sibbald RG et al: Preparing the wound bed-debridement, bacterial balance and moisture balance. *Ostomy/Wound Manage* **46**:14, 2000

30. Kirsner RS et al: Matrix metalloproteinases in normal and impaired wound healing: A potential role of nanocrystalline silver. *Wounds* **13**:4C, 2001

31. Armstrong SH, Ruckley CV: Use of a fibrous dressing in exuding leg ulcers. *J Wound Care* **6**:322, 1997

32. Ortonne JP: A controlled study of the activity of hyaluronic acid in the treatment of venous leg ulcers. *J Dermatol Treat* **7**:75, 1996

T>

Chapter 273

Robert Weiss Margaret Weiss

Treatment of Varicose and Telangiectatic Veins

HISTORICAL ASPECTS
PATIENT SELECTION—VENOUS ANATOMY AND PHYSIOLOGY, SYMPTOMS AND CONTRAINDICATIONS
Contraindications to Treatment of Spider Veins (Table 273-1)
TREATMENT TECHNIQUES
Pretreatment Evaluation
Sclerosing Solutions
Sclerotherapy Technique
SIDE EFFECTS AND COMPLICATIONS OF SCLEROTHERAPY
Postsclerotherapy Hyperpigmentation
Telangiectatic Matting
Cutaneous Necrosis and Ulceration
Superficial Thrombophlebitis
Pulmonary Embolism
Arterial Injection
MODERN MINIMAL SURGICAL APPROACHES FOR VARICOSE VEINS
Endovenous Occlusion Techniques
Surgical Ligation and Limited Stripping
Ambulatory Phlebectomy
Lasers and Light Sources

REFERENCES

Bulging varicose veins and unsightly “roadmap” telangiectatic webs affect millions of patients. Telangiectases comprise the most common of cosmetic complaints, occurring in up to 50 percent of women, while larger varicose veins are seen in up to 20 percent of the American population. [1] Varicose veins may cause significant morbidity including chronic stasis dermatitis, ankle edema, spontaneous bleeding, superficial thrombophlebitis, recurrent cellulitis, lipodermatosclerosis, and ulceration on the ankle and foot.

The incidence of varicose veins increases with each decade of life. Increased incidence has led to increased demand for treatment of varicose and telangiectatic veins as the average age of the US population grows. While 41 percent of women in the fifth decade have varicose veins, this number rises to 72 percent in the seventh decade. [2] Statistics for men are similar, with a 24 percent incidence in the fourth decade, increasing to 43 percent by the seventh decade. Six million workdays per year may be lost in the United States as a result of complications of varicose veins. [3]

The main techniques employed in the dermatologist's office for treatment of cosmetic spider veins are sclerotherapy and lasers. For larger varicose veins, dermatologic surgeons employ sclerotherapy (with or without Duplex ultrasound guidance), ambulatory phlebectomy and endovenous occlusion by radiofrequency or laser. Sclerotherapy which is defined as the intravascular introduction of a sclerosing substance, is the most frequently used procedure. Sclerotherapy gained acceptance as a highly effective treatment during the early 1990s because it can be used for veins of all sizes. [4] It also serves as an effective addition to techniques such as ambulatory phlebectomy for saphenous tributaries [5], [6] or endovenous obliteration of refluxing saphenous veins. [7], [8] Knowledge of venous anatomy and physiology, principles of venous insufficiency, methods of diagnosing venous abnormality, uses and actions of sclerosing solutions and proper use of compression are essential elements of successful venous therapy.

HISTORICAL ASPECTS

Primitive stripping and cauterization were practiced by Celsus, while ligation was mentioned by Antillus (30 A.D.). In the second century A.D., Galen proposed tearing out the veins with hooks, a precursor to the modern day technique of ambulatory phlebectomy originated by the Swiss dermatologist Robert Muller in the late 1960s.

A crude concept of sclerotherapy appeared in 1682, as Zollikofer described injection of acid into a vein to create a thrombus. By the late 1700s, the critical role of saphenofemoral reflux in the pathogenesis of varicose veins had been recognized by the Swiss surgeon Rima. Reports of use of absolute alcohol as a sclerosing agent appeared from 1835 to 1840. In 1851, Pravaz attempted sclerotherapy with ferric chloride using his new invention, the hypodermic syringe.

The foundation of modern sclerotherapy can be traced to World War I when Linser and Sicard both noticed the sclerosing effect of intravenous injections used to treat syphilis that often resulted in vein sclerosis. Tournay greatly refined the sclerotherapy technique in Europe. It was not until 1946, when a safe sclerosant, Sotradecol (sodium tetradecyl sulfate), had been tested and described that sclerotherapy began to be studied seriously in the United States. [9]

Another key to success and acceptance of the treatment of varicose veins by sclerotherapy was the addition of compression. Sigg and Orbach in the 1950s, and Fegan in the 1960s, emphasized the importance of combining external compression immediately following injections. Starting in the 1980s, Duffy promoted the technique among dermatologists and advocated the use of polidocanol and hypertonic saline as safe and effective sclerosing solutions. [10] In March 1999, the first endovenous obliteration technique using radiofrequency was cleared by the US Food and Drug Administration.

Dermatologic surgeons were instrumental in developing this technique. [8] Goldman's first American textbook of sclerotherapy integrated the world's phlebology literature, introduced new sclerosing solutions and validated dermatology's claim to expertise in vein treatment. [11] Several additional textbooks by dermatologic surgeons have now firmly established phlebology within the domain of dermatology. [12], [13]

PATIENT SELECTION—VENOUS ANATOMY AND PHYSIOLOGY, SYMPTOMS AND CONTRAINDICATIONS

The venous system is comprised of a primary deep venous compartment and superficial compartment with thousands of small veins (perforating veins) connecting the two systems. The deep compartment, “the muscle pump,” normally acts as a conduit for 85 to 90 percent of venous return from the leg. During contraction of the calf muscles, the valves of the perforating veins and associated superficial veins close, allowing blood to flow only proximally at high pressures through the deep system. This generates the primary propulsive force returning venous blood to the heart (Fig. 273-1).

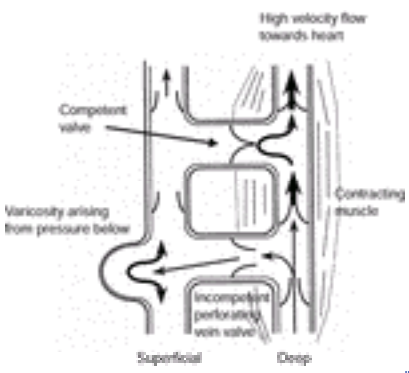

FIGURE 273-1 Schematic of the calf muscle pump with malfunctioning perforating vein connecting the superficial and deep system. High pressures are generated when the gastrocnemius muscle contracts to pump blood proximally. A malfunctioning valve is shown diverting pressure to the skin surface. Competent valve directs flow proximally.

The superficial venous system consists of three primary territories: the greater saphenous vein, the lesser saphenous vein and the subdermic lateral venous system (Fig. 273-2). Comprising the three major patterns are multiple collateral veins (accessory) and multiple tributary veins emptying into each respectively. The points of connection (perforating veins) between the superficial and the deep system play important roles as these are sites through which reflux or reverse flow often develops (Fig. 273-3).

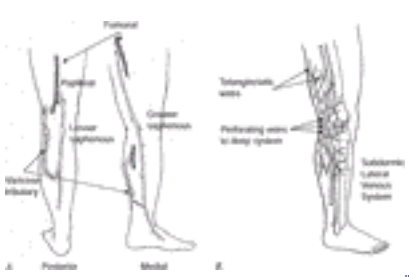

FIGURE 273-2 Schematic of the major portions of the superficial venous system. *A.* Greater saphenous vein and lesser saphenous vein. *B.* Subdermic lateral venous system. When varicosities or telangiectatic webs are present within the distribution of these saphenous veins, the source of pressure must be elucidated. The lateral venous system is the most common source of telangiectasias.

FIGURE 273-3 Diagram indicating major junction points of the superficial venous system with the deep venous system. Larger varicose veins may originate from any of these points.

Due to gravitational hydrostatic pressure, sequential retrograde breakdown of venous valve function often follows a leak at one point leading to propagation of a varicosity. Increased diameter between valve leaflets with failure to oppose properly, caused by a genetically weak venous wall or venous valve structure, may initiate these events. Calf muscle pump pressure plus gravitational hydrostatic forces are transmitted directly via the incompetent perforating vein or

communicating veins to the surface veins. Venous pressure may reach as high as 300 mmHg in the cutaneous venules with the patient erect. Transmission of this pressure may result in venular dilatation over a wide area of skin including the formation of telangiectatic webs.

When present in significant quantity, the volume of blood sequestered and stagnant in reticular veins and associated telangiectatic webs (particularly of the lateral venous system) may cause enough distention to produce symptoms. [14] Symptoms are relieved by the wearing of support hose or with rest and elevation of the legs. Prolonged standing or sitting worsens symptoms. The size of the vessels causing moderately severe symptoms may be as small as 1 to 2 mm in diameter. Sclerotherapy has been reported to yield an 85 percent reduction in these symptoms, as well as superb cosmetic results. [14]

Contraindications to Treatment of Spider Veins (Table 273-1)

TABLE 273-1 **Indications and Contraindications for Sclerotherapy**

Vein treatment, particularly sclerotherapy, may be performed safely and effectively in virtually all types of veins, except when reflux exists at the saphenofemoral junction. Because the goal of sclerotherapy is to eliminate reflux at its origin, the goal of noninvasive diagnostic evaluation is to uncover primary sources of high reverse flow pressure. A high rate of recurrence for sclerotherapy is commonly seen when reflux originates at the major saphenous junctions. The techniques of endovenous occlusion by radiofrequency or laser have been developed to address reflux occurring at the termination point of the saphenous veins. Two-year data indicates that these techniques are as effective as the surgical techniques of ligation and stripping to eliminate saphenous veins. [15]

Venous treatment is contraindicated in a bedridden patient because ambulation is important for minimizing risks of thrombosis. Similarly, patients under general anesthesia for nonrelated procedures should not undergo simultaneous sclerotherapy. Severely restricted arterial flow to the legs necessitates postponement of vein treatment. A history of deep venous thrombosis (DVT) or previous trauma to the leg (e.g., auto accident) should preclude sclerotherapy until adequately evaluated by duplex ultrasound. Previous urticaria or suspected allergy to a sclerosing agent should serve as a relative contraindication to use of that particular sclerosing agent.

Pregnancy should be considered a contraindication during the first and second trimesters, although extremely painful or bleeding varices may be treated in the last trimester. Treatment is typically postponed since many varicosities and telangiectasias will resolve spontaneously 1 to 6 months postpartum.

Obesity should be considered a relative contraindication since maintaining adequate external compression is difficult. Sclerotherapy of larger varicosities should be postponed until weight reduction is achieved. During hot summer months, heat-induced vasodilatation and inability to comply with wearing of compression hose may also require postponement of treatment.

TREATMENT TECHNIQUES

Pretreatment Evaluation

Physical examination is performed by viewing the patient's legs in a 360-degree rotation. Palpation is performed along the saphenous vein distributions to rule out early large axial varicosities that cannot be seen. Based on the history and physical examination noninvasive diagnostic vascular tests are performed as necessary. [16] Those patients with a family history of large varicose veins are more likely to have early axial (saphenous) reflux, even when presenting with telangiectasias alone. [5] Previous venous surgery may warrant further testing before proceeding.

Once the patient is judged to be a candidate for vein treatment, informed consent is obtained. Any veins visible or palpable suggestive of saphenous system involvement should be minimally evaluated by handheld Doppler ultrasound, which is equivalent to using an enhanced “stethoscope” to hear vein flow. In order to generate or augment an audible signal of flow, a maneuver such as manual compression of the calf must be performed by the examiner. When compression is released, gravitational hydrostatic pressure causes reverse flow to cease within 0.5 to 1 second when valves are competent, but a long flow sound is audible when valves are incompetent.

The most essential part of the Doppler examination is the examination of the saphenofemoral junction below the inguinal fold just medial to the femoral arterial signal. During a Valsalva maneuver, a continuous and pronounced reflux signal is a reliable sign of valvular insufficiency. An equivocal result may require a duplex ultrasound examination for a definitive answer. Methods of complete Doppler examination are detailed elsewhere. [5]

Another noninvasive method used to quantify reflux is photoplethysmography (PPG). PPG permits assessment of the physiologic significance of anatomic Doppler findings. Digital (quantitative) PPG measures total venous insufficiency, changes in venous function after treatment and allows evaluation of deep venous function (venous ejection fraction)

during a defined series of calf muscle movements. [17]

The gold standard of noninvasive examination of the venous system is duplex ultrasound. This allows direct visualization of the veins and identification of flow through venous valves. An image is created by an array of Doppler transducers, which are switched on and off sequentially. The duplex examination is often used to uncover hidden sources of reflux prior to beginning any method of treatment or to delineate reflux sources when patients experience poor results from sclerotherapy.

Sclerosing Solutions

Sclerosing solutions are classified into groups based on chemical structure and effect: hyperosmotic, detergent and corrosive agents (chemical toxins—salts, alcohols, and acid or alkaline solutions). Table 273-2 summarizes commonly employed sclerosing solutions.



TABLE 273-2 **Comparison of Commonly Employed Sclerosing Agents**

HYPERTONIC SALINE Although approved by the FDA only for use as an abortifacient, it is a commonly employed solution in the United States. Used at a concentration of 23.4%, a theoretical advantage of hypertonic saline (HS) is its total lack of allergenicity when unadulterated. HS has been commonly used in various concentrations from 10 to 30%, with occasional addition of heparin, procaine or lidocaine. Additional agents typically provide no benefit. Therefore, HS is used either unadulterated or diluted to 11.7% with sterile water for smaller telangiectasias. [18] With hypertonic solutions, damage of tissue adjacent to injection sites may easily occur. Skin necrosis may be produced by extravasation at the injection site particularly when injecting very close to the skin surface. Injection of hyaluronidase into sites of extravasation may significantly reduce the risks of skin necrosis with HS. [19]

HYPERTONIC SALINE AND DEXTROSE Hypertonic saline and dextrose (HSD) is a viscous mixture of dextrose 250 mg/mL, sodium chloride 100 mg/mL, propylene glycol 100 mg/mL, and phenethyl alcohol 8 mg/mL. HSD is a relatively weak sclerosant for local treatment of small vessels, with a total volume of injection not to exceed 10 mL per visit with 0.1 mL to 1.0 mL per injection site. HSD is marketed predominately in Canada. Although a slight burning sensation occurs, pain is far less than with HS.

POLIDOCANOL The detergent-based polidocanol (POL) a urethane compound, was originally developed as an anesthetic, but was found to have the property of sclerosing small diameter vessels after intradermal injection. POL contains hydroxypolyethoxydodecane dissolved in distilled water with 5% ethanol as a stabilizer. First used as a sclerosing agent in the late 1960s in Germany, POL is popular worldwide for smaller vessels because of painless injection and lowest incidence of cutaneous necrosis with intradermal injection. Lower concentrations of POL were initially suspected to have a lower incidence of hyperpigmentation than HS or sodium tetradecyl sulfate (STS), but recent clinical trials indicate a significant percentage of hyperpigmentation occurs. [20] The FDA has not yet approved POL.

SODIUM TETRADECYL SULFATE STS is a long-chain fatty acid salt with strong detergent properties. It is a highly effective sclerosing agent used worldwide. Approved for use in the United States since 1946, it has been popular with vascular surgeons since the 1960s and first described for use in telangiectasias in the 1970s. A relatively high incidence of postsclerosis pigmentation was reported at inappropriately high doses (1% STS). More appropriate concentrations for superficial telangiectasias are 0.1 to 0.2%. Other concentrations are 0.2 to 0.5% for reticular veins or small varicosities (1- to 3-mm diameter), and 0.5 to 3% for larger varicosities related to major sites of valvular reflux.

SODIUM MORRHUATE Sodium morrhuate (Scleromate, Palisades Pharmaceuticals, Inc., Tenafly, NJ) is a 5% solution of the salts of saturated and unsaturated fatty acids in cod liver oil. Approximately 10 percent of its fatty acid composition is unknown and use is limited by reports of fatalities secondary to anaphylaxis. [11] Although sodium morrhuate is approved by the FDA for the sclerosis of varicose veins, use in treatment of telangiectasias is not common because of the caustic qualities with potential for cutaneous necrosis and higher risks of allergy. This agent is reserved primarily for sclerosis of esophageal varices.

CHEMICAL IRRITANTS The chemical irritants include polyiodinated iodine (very caustic) and chromated glycerin (very weak), and are believed to have a direct toxic effect on the endothelium. After injection of polyiodinated iodine salt, the endothelium near the site of injection is destroyed within seconds. The corrosive action is limited because of rapid inactivation by blood proteins. At the sites of endothelial destruction the chemical can penetrate further and diffuse into deeper layers of the vessel wall causing further destruction. These agents are not approved by the FDA.

Sclerotherapy Technique

A basic principle of treatment is to begin at the largest (reflux sources) and progress to the smallest varicosities. Sclerotherapy of telangiectasias is approached by combined injection of visibly connected reticular veins, venulectases, and telangiectatic webs or networks. Progression from proximal to distal regions will focus initial treatment on vessels most likely to be proximal pressure sources.

Reticular veins are treated only after all sources of reflux from major varicosities have been treated by sclerotherapy and/or surgery. When no clear feeder vessel is seen or identified by Doppler, the transillumination (Veinlite, 3Gen, Dana Point, CA) method can be used to identify the “feeding” reticular vein (Fig. 273-4). When unable to locate an associated reticular vein, then the point at which the telangiectasias begin to branch out is the site at which to begin injection. Injection of telangiectasias is simultaneously performed with injection of reticular veins in the hopes of decreasing the

number of treatments. [21]

FIGURE 273-4 Transillumination of a reticular vein. The reticular vein shows up as a dark curvilinear object against a light background.

The injection method for telangiectasia is basically as previously described by Duffy and Goldman. [10], [22] The sclerotherapy tray is prepared with the necessary equipment (Table 273-3). A 30-gauge needle, bent to an angle of 10 to 30 degrees with the bevel up, is placed on the skin so that the needle is parallel to the skin surface. A 3 cc syringe filled with 1.5 to 2 cc of solution is held between the index and middle fingers, while the fourth and fifth finger support the syringe against the leg in a fixed position, facilitating accurate penetration of the vessel. The nondominant hand is used to stretch the skin around the needle and may offer additional support for the syringe (Fig. 273-5). Magnifying lenses or operating loops on the order of 1.5 to 3× may help cannulation of the smallest telangiectasias.

FIGURE 273-5 Position of the hands for sclerotherapy. While the dominant hand holds the syringe and creates a platform with the fifth digit, the nondominant hand stretches the skin and acts as a support for the needle hub so that fine changes in position are permitted.

- Cotton balls soaked with 70% isopropyl alcohol
- Protective gloves
- 3 cc disposable syringes
- 30-gauge disposable transparent hub needles
- Cotton balls or STD pads for compression
- Transpore and/or paper tape
- 2% Nitroglycerine paste (for prolonged blanching or extravasation)

Sclerosing solutions:

1. Sodium tetradecyl sulfate (concentrations from 0.1 to 0.5%)
2. Hypertonic saline (11.7 to 23.4%)
3. Hypertonic saline (10%) and dextrose (25%) (may be mixed by local pharmacy)
4. Polidocanol (0.25 to 1%) (pending FDA clearance)

TABLE 273-3 **Sclerotherapy Tray**

The initial treatment of telangiectatic webs begins with the lowest possible concentration that will cause a telangiectasia to sclerose over a period of 1 to 6 months postinjection. This typically occurs with 0.1% sodium tetradecyl sulfate or 0.2% polidocanol. When ineffective sclerosis occurs judged at a subsequent visit, the concentration, but not the volume per site of sclerosing solution, is increased. Posttreatment compression consists of graduated 20 to 30 mmHg or 30 to 40 mmHg support hose for 2 weeks for larger veins and over-the-counter 15 mmHg compression support hose for smaller veins. Treatment intervals vary but allowing 4 to 8 weeks between treatments helps to minimize the number of necessary sessions. Figure 273-6 shows typical results.

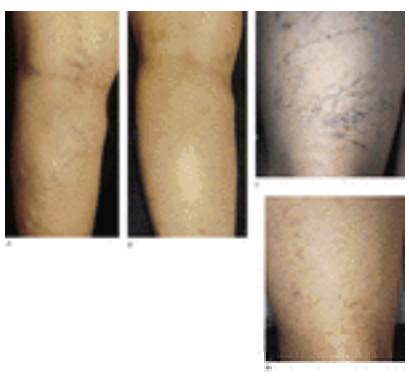

FIGURE 273-6 Typical results following sclerotherapy. *A.* Large varicose vein treated twice with 0.5% STS. *B.* Excellent clinical results at 15-month follow-up. *C.* Sixty-two-year-old patient with focal burning symptoms on anterior thigh. *D.* Results 5 months later and after three treatments with 0.1% STS and 0.5% POL.

SIDE EFFECTS AND COMPLICATIONS OF SCLEROTHERAPY

Postsclerotherapy Hyperpigmentation

Postsclerosis pigmentation is defined as the appearance of increased visible pigmentation along the course of a treated vein of any size. Initially perivascular hemosiderin deposition and not increased melanin production causes this appearance; [23] however, over time, the hemosiderin is replaced by melanin. The incidence of pigmentation is related to dilution and type of sclerosing agent as well as diameter of treated vessel. [24] Pigmentation incidence ranges from 11 to 30 percent after using HS, [14] 11 to 30 percent after using POL, [10], [25] and up to 30 percent with STS. The incidence of pigmentation may be reduced in varicose veins by expressing the dark, viscous blood thought to be a liquefied coagulum or intravascular hematoma, which may accumulate 1 to 4 weeks following sclerotherapy.

Pigmentation clears in 70 percent within 6 months, and rarely persists for more than a year. [24] Attempts to hasten resolution of pigmentation have been mostly unsuccessful as the pigment is dermal hemosiderin and not epidermal melanin. Bleaching agents, exfoliants such as trichloroacetic acid or phenol, cryotherapy, various lasers and intense pulsed light have achieved limited success. [26], [27] The Q-switched ruby laser is the most consistently effective for treatment of postsclerosis pigmentation. [28]

Telangiectatic Matting

Telangiectatic matting is defined as the appearance of groups of new, fine (<0.2 mm diameter) telangiectasias surrounding or replacing a previously treated area in a blushlike manner. A retrospective analysis of more than 2000 patients reports an incidence of 16 percent in patients treated with HS and POL. [29] Resolution usually occurs spontaneously within a 3- to 12-month period with 70 to 80 percent spontaneous resolution within the first 6 months. [30]

Matting may also occur as a result of trauma to the leg, in association with pregnancy or hormonal therapy, or in scars around previous sites of surgical stripping. Predisposing factors include predilection for certain areas of the leg, such as the medial lower thigh, obesity, hormonal therapy with estrogen, family history, and a longer history of telangiectasias. [29] The relative risk factor for development of telangiectatic matting is 3.17 times greater for female patients taking hormonal supplements. [31] Successful treatment of matting with flashlamp-pumped pulsed dye laser (FPDL)is reported accompanied by temporary hyperpigmentation. [32] The use of enhanced visualization with a cross-polarized light source (Syris Scientific, LLC, Grey, MA) assists injection of sclerosing solution into telangiectatic matting. Treatment is often not required because matting will resolve spontaneously except when caused by a source of reflux superiorly.

Cutaneous Necrosis and Ulceration

Cutaneous ulceration may occur with all sclerosing solutions in spite of the most skilled technique. Unavoidably, a tiny amount of sclerosing solution may be left along the needle tract as the needle is withdrawn. Sclerosing solution may also leak out into the skin through the small puncture sites of vessel cannulation. The varicose vein may have a fragile, thin wall, with the injection causing rapid injury leading to sudden unexpected rupture with perivascular accumulation of sclerosant. Additionally, injection may inadvertently occur into a small arteriole associated with telangiectatic varicosities with resultant necrosis and ulceration.

When the dermatologic surgeon recognizes that extravasation has occurred, the risk for necrosis can be minimized by injecting normal saline in a ratio of 10:1 into the extravasation site. Extensive massage of small subcutaneous blebs to spread the trapped sclerosing agent as quickly as possible will minimize prolonged blanching of the area. We have found that application of topical 2% nitroglycerin paste applied immediately to the suspected extravasation site greatly reduces the risks of necrosis, but will not always prevent it.

Superficial Thrombophlebitis

This complication is most commonly mistaken for the normal nodular fibrosis (endosclerosis) that occurs with proper sclerotherapy. After sclerotherapy, a nontender, nonpigmented, nonerythematous fibrotic cord may normally be palpable along the course of a treated 4- to 8-mm vein. This frequent finding is caused by a liquefied intravascular hematoma with surrounding vein wall sclerosis and is not a thrombosis. In contrast, superficial thrombophlebitis is characterized clinically by a very tender, indurated, linear erythematous swelling. Incidence of superficial thrombophlebitis is quite variable estimated at 0.01 to 1% following sclerotherapy, [33] although a recent report indicates that the incidence is higher than previously suspected. [34] Treatment consists of leg elevation and/or compression and regular administration of aspirin or other nonsteroidal anti-inflammatory drugs. Extension of superficial thrombophlebitis into the deep system is extremely rare.

Pulmonary Embolism

Pulmonary emboli probably occur from extension of a superficial thrombus into the deep venous system. Evidence of extension from superficial thrombus to deep thrombophlebitis should be treated promptly by anticoagulation. The incidence of pulmonary embolism is associated with injection of large quantities of sclerosant at a single site. The incidence is extremely low, with fewer than 1 case in 40,000.

Arterial Injection

This dreaded medical emergency is fortunately extremely rare. Classic warning signs include immediate intense pain far beyond the normal discomfort at the initiation of injection, although leakage of sclerosant into the arterial circulation may present in an atypical fashion. Continuous intense burning pain with immediate bone-white cutaneous blanching over an area of several square centimeters is the usual initial sign. Progression to a sharply demarcated cyanosis within minutes

is typical for arterial injection. Emergency treatment involves immediate application of ice, attempts to flush the inadvertently injected artery with normal saline and/or heparin, injection of 3% procaine to inactivate STS, and vascular surgery consultation for intravenous anticoagulation. Rarely, arterial injection may not be accompanied by any pain or cutaneous signs. The atypical cases are suspected to arise from arteriovenous malformations. [35] Arterial injection may lead to wide areas of skin necrosis and damage to subcutaneous tissue and muscle which take months to heal.

MODERN MINIMAL SURGICAL APPROACHES FOR VARICOSE VEINS

Endovenous Occlusion Techniques

When it has been determined by ultrasound that the originating point of reverse flow or reflux is the greater saphenous vein, endovenous radiofrequency (RF) or laser techniques are now the methods of treatment. The efficacy for RF elimination of reflux is 90 percent at 2 years. [15] This method involves the placement of a catheter or fiberoptic within the varicose vein through a small puncture or incision. The catheter is threaded up to the saphenofemoral junction typically under duplex ultrasound guidance. Following placement of tumescent local anesthesia between the vein and the skin and or in a perivenous location, energy is applied as the catheter is slowly withdrawn. This results in a collagen shrinkage of the vein wall accompanied by complete occlusion. Studies suggest a very favorable comparison to traditional ligation and stripping, with far less morbidity and without the risks of general anesthesia.

Surgical Ligation and Limited Stripping

For larger varicose veins, particularly originating from an incompetent valve at the saphenofemoral junction, ligation of the greater saphenous vein with short stripping of its proximal half in the thigh is the traditional surgical method. After proximal ligation without stripping of the saphenous vein, varicography has shown persistent mid-thigh perforator incompetence in 34 percent, a patent portion of saphenous vein in 54 percent, and residual or recurrent femoral-saphenous communication in 80 percent of patients. [36] High ligation combined with sclerotherapy or with varicosity excision is inferior to high ligation and stripping of the saphenous vein. [37]

Ambulatory Phlebectomy

This technique, originally described by Robert Muller and further refined by Albert-Adrien Ramelet, another Swiss dermatologist, involves the use of tiny incisions through which the varicose vein is removed by a small hook. [38], [39] This safe, outpatient technique performed with local anesthesia allows removal of almost any varicose vein except the saphenofemoral or saphenopopliteal junction. Areas or veins that are resistant to sclerotherapy (axial) are particularly indicated for ambulatory phlebectomy (Fig. 273-7). Deep venous thrombosis, postsclerotherapy pigmentation, skin necrosis, and superficial phlebitis occur less frequently with ambulatory phlebectomy than with sclerotherapy. In many cases, larger varicose veins coexist with smaller reticular veins and associated telangiectatic webs. It is reasonable to treat larger varicose veins by various surgical techniques and follow up with sclerotherapy of the remaining reticular networks.

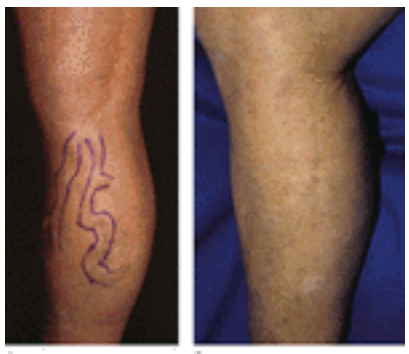

FIGURE 273-7 Ambulatory phlebectomy of a large truncal varicose vein. *A.* Marked just prior to surgery. *B.* Clinical results with complete disappearance at 6 weeks. Bruising usually lasts no longer than 2 weeks.

Lasers and Light Sources

New trends for improved results with lasers and light sources for spider veins include longer wavelengths, larger spot sizes, and cooling to protect the skin. The first report of 1064nm Nd:YAG laser indicated that at 3 months 75 percent improvement was possible after a single treatment. [40] These findings were confirmed and the mechanism of action explained as heat-induced vessel damage and subsequent fibrosis. [41] Recent reports also indicate effectiveness of the 940-nm diode laser. [42] Shorter wavelengths used in the past, such as the pulsed dye laser, have limited utility on leg veins, although many devices are now being adapted to longer pulse durations up to 40 msec. A broadband, noncoherent pulsed light (IPL) has been reported to improve 70 percent of patients responding, with up to 5 treatments per region. [43] In our practice, the vast majority of laser treatments are performed using the 1064-nm Nd:YAG laser in the millisecond domain on isolated telangiectasias, sclerotherapy-resistant telangiectasias, ankle telangiectasias, and suspected arteriovenous malformations.

REFERENCES

1. Biegeleisen K: Primary lower extremity telangiectasias relationship of size to color. *Angiology* **38**:760, 1987

2. Engel A et al: Health effects of sunlight exposure in the United States: Results from the first national health and nutrition examination survey,

1971–1974. *Arch Dermatol* **124**:72, 1988

3. Lofgren KA: Varicose veins: Their symptoms, complications, and management. *Postgrad Med* **65**:131, 1979

4. Weiss RA et al: Physicians' negative perception of sclerotherapy for venous disorders: Review of a 7-year experience with modern sclerotherapy. *South Med J* **85**:1101, 1992

5. Goldman MP et al: Diagnosis and treatment of varicose veins—A review. *J Am Acad Dermatol* **31**:393, 1994

6. Weiss RA, Weiss MA: Ambulatory phlebectomy compared to sclerotherapy for varicose and telangiectatic veins: Indications and complications. *Adv Dermatol* **11**:3, 1996

7. Weiss RA: Endovenous techniques for elimination of saphenous reflux: A valuable treatment modality. *Dermatol Surg* **27**:902, 2001

8. Goldman MP: Closure of the greater saphenous vein with endoluminal radiofrequency thermal heating of the vein wall in combination with ambulatory phlebectomy: Preliminary 6-month follow-up. *Dermatol Surg* **26**:452, 2000

9. Cooper WM: Clinical evaluation of Sotradecol, a sodium alkyl sulfate solution, in the injection therapy of varicose veins. *Surg Gynecol Obstet* **83**:647, 1946

10. Duffy DM: Small vessel sclerotherapy: an overview. *Adv Dermatol* **3**:221, 1988

11. van Haarst EP et al: The development of valvular incompetence after deep vein thrombosis: A 7 year follow-up study with duplex scanning. *Eur J Vasc Endovasc Surg* **12**:295, 1996

12. Weiss RA et al: *Vein Diagnosis and Treatment: A Comprehensive Approach.* New York, McGraw-Hill, 2001

13. Sadick NS: *Manual of Sclerotherapy*. New York, Lippincott Williams and Wilkins, 2000

14. Weiss RA, Weiss MA: Resolution of pain associated with varicose and telangiectatic leg veins after compression sclerotherapy. *J Dermatol Surg Oncol* **16**:333, 1990

15. Weiss RA, Weiss MA: Controlled RF endovenous occlusion using a unique RF catheter under duplex guidance to eliminate saphenous reflux: Two-year follow-up. *Dermatol Surg* **28**:38, 2002

16. Weiss RA. Vascular studies of the legs for venous or arterial disease [review]. *Dermatol Clin* **12**:175, 1994

17. Kerner J et al: Quantitative Photoplethysmographie bei gesunden Erwachsenen, Kindern und Schwangeren und bei Varizenpatienten. *Phlebologie* **21**:134, 1992

18. Sadick NS: Sclerotherapy of varicose and telangiectatic leg veins. Minimal sclerosant concentration of hypertonic saline and its relationship to vessel diameter [see comments]. *J Dermatol Surg Oncol* **17**:65, 1991

19. Zimmet SE: The prevention of cutaneous necrosis following extravasation of hypertonic saline and sodium tetradecyl sulfate. *J Dermatol Surg Oncol* **19**:641, 1993

20. Conrad P et al: The Australian polidocanol (aethoxysklerol) study. Results at 2 years. *Dermatol Surg* **21**:334, 1995

21. Weiss RA, Weiss MA; Painful telangiectasias: Diagnosis and treatment, in *Varicose Veins and Telangiectasias: Diagnosis and Treatment,* 2nd ed., edited by JJ Bergan, RA Weiss, MP Goldman. St. Louis: Quality Medical Publishing, 1999, p 389

22. Goldman MP, Bennett RG: Treatment of telangiectasia: A review. *J Am Acad Dermatol* **17**:167, 1987

23. Goldman MP et al: Postsclerotherapy hyperpigmentation: A histologic evaluation. *J Dermatol Surg Oncol* **13**:547, 1987

24. Weiss RA, Weiss MA: Incidence of side effects in the treatment of telangiectasias by compression sclerotherapy: Hypertonic saline vs. polidocanol. *J Dermatol Surg Oncol* **16**:800, 1990

25. Goldman PM: Sclerotherapy for superficial venules and telangiectasias of the lower extremities. *Dermatol Clin* **5**:369, 1987

26. Thibault P, Wlodarczyk J: Postsclerotherapy hyperpigmentation. The role of serum ferritin levels and the effectiveness of treatment with the copper vapor laser. *J Dermatol Surg Oncol* **18**:47, 1992

27. Goldman MP: Postsclerotherapy hyperpigmentation. Treatment with a flashlamp-excited pulsed dye laser. *J Dermatol Surg Oncol* **18**:417, 1992

28. Tafazzoli A et al: Q-switched ruby laser treatment for postsclerotherapy hyperpigmentation. *Dermatol Surg* **26**:653, 2000

29. Davis LT, Duffy DM: Determination of incidence and risk factors for postsclerotherapy telangiectatic matting of the lower extremity: A retrospective analysis. *J Dermatol Surg Oncol* **16**:327, 1990

30. Goldman MP et al: Cutaneous necrosis, telangiectatic matting, and hyperpigmentation following sclerotherapy. Etiology, prevention, and treatment [review]. *Dermatol Surg* **21**:19, 1995

31. Weiss MA, Weiss RA: Efficacy and side effects of 0.1% sodium tetradecyl sulfate in compression sclerotherapy of telangiectasias: Comparison to 1% polidocanol and hypertonic saline. *J Dermatol Surg Oncol* **17**:90, 1991

32. Goldman MP, Fitzpatrick RE: Pulsed-dye laser treatment of leg telangiectasia: With and without simultaneous sclerotherapy. *J Dermatol Surg Oncol* **16**:338, 1990

33. Goldman MP: Sclerotherapy treatment for varicose and telangiectatic leg veins, in *Cosmetic Surgery of the Skin,* edited by WP Coleman, CW Hanke, TH Alt, S Asken. Philadelphia, BC Decker, 1991, p 197

34. Feied CF: Deep vein thrombosis: The risks of sclerotherapy in hypercoagulable states. *Semin Dermatol* **12**:135, 1993

35. Bergan JJ et al: Extensive tissue necrosis following high-concentration sclerotherapy for varicose veins. *Dermatol Surg* **26**:535, 2000

36. Corbett CR et al: Reasons to strip the long saphenous vein. *Phlebol* **41**:766, 1988

37. Neglen P: Treatment of varicosities of saphenous origin: Comparison of ligation, selective excision, and sclerotherapy, in *Varicose Veins and Telangiectasias: Diagnosis and Management,* edited by JJ Bergan, MP Goldman. St. Louis, Quality Medical Publishing, 1993, p 148

38. Ramelet AA: Muller phlebectomy. A new phlebectomy hook. *J Dermatol Surg Oncol* **17**:814, 1991

39. Ramelet AA: Le Traitement Des Telangiectasies: Indications De La Phlebectomie Selon Muller. *Phlebol* **47**:377, 1995

40. Weiss RA, Weiss MA: Early clinical results with a multiple synchronized pulse 1064-nm laser for leg telangiectasias and reticular veins. *Dermatol Surg* **25**:399, 1999

41. Sadick NS et al: Clinical and pathophysiologic correlates of 1064-nm Nd:Yag laser treatment of reticular veins and venulectasias. *Arch Dermatol* **137**:613, 2001

42. Kaudewitz P et al: Effective treatment of leg vein telangiectasia with a new 940-nm diode laser. *Dermatol Surg* **27**:101, 2001

43. Goldman MP, Eckhouse S: Photothermal sclerosis of leg veins. ESC Medical Systems, LTD Photoderm VL Cooperative Study Group. *Dermatol Surg* **22**:323, 1996

T>

Chapter 274

Rhoda Narins Arnold Klein Jeffrey Klein

Tumescent Liposuction

REFERENCES

The modern phase of fat transplantation began in the late 1970s when Fischer and Fischer reported on the “extraction of fat with the cellusuctiotome.” [1] This was the forerunner of liposuction. In the late 1970s, Yves-Gerard Illouz introduced the technique known today as liposuction and revolutionized the field of fat harvesting and transplantation when he reported reinjecting viable fat that had been obtained during liposuction surgery. [2], [3] and [4] The innovations that made this liposuction procedure possible were the development of a blunt cannula and the injections of small amounts of a hypotonic saline solution into the subcutaneous tissue, both of which diminished bleeding. [3]

In 1987, Klein [5] introduced tumescent anesthesia. The technique involves directly infiltrating and tumescing the targeted fatty tissue with large volumes of dilute anesthetic solution consisting of lidocaine, epinephrine, and sodium bicarbonate in physiologic saline, enabling the procedure to be done under local anesthesia alone. This approach revolutionized liposuction surgery [6], [7] and also the ability to obtain fresh fat for grafting. Klein's procedure involves significantly less blood loss, decreased anesthetic risk, and longer-lasting anesthesia, with no need for postoperative analgesia as compared to the previously used methods of liposuction. [6] Also, when using the tumescent technique, there is no need to replace intravenous fluids. There are better aesthetic results as liposuction can be done more accurately and uniformly because the patient can get into any position necessary for exact removal of fat, thus making the procedure more precise. There is also a more rapid postoperative recovery. [7] With this technique, the patient avoids general anesthesia and has a milder postsurgical course. Tumescent liposuction is the most evolved form of liposuction. [8], [9] Indeed, with the advent of liposuction surgery, the technique of fat transplantation was dramatically reawakened. [2], [10], [11], [12], [13], [14] and [15]

Liposuction surgery is a procedure that can be performed on many areas of the body. The lateral cheeks, jowls, and upper neck are common areas for liposuction that respond beautifully in both men and women. [16], [17] The most common body areas in younger women are the lateral thighs with or without the hips and buttocks and in older women the abdomen. In addition, the waist, back, breast, inner and anterior thigh, arms, calf and ankle fat can be treated. Circumferential liposuction is excellent for the abdominal area in patients where the waist, lower back, and hips are done at the same time as the abdomen for a more youthful, hourglass shape. [18] The most common body areas in men are the flanks and the abdomen. Gynecomastia and pseudogynecomastia can be treated in males. Disorders such as lipomas, buffalo humps, lipodystrophy, and axillary hyperhidrosis can also be treated. [19], [20] Liposuction can be used in association with skin reconstruction. It can be employed to assist in flap elevation and movement and can also serve as means of subcutaneous debulking. [21] Liposuction has revolutionized facelift procedures and has been reported useful in treating lymphedema and type I diabetes, and in harvesting stem cells. [22], [23] and [24]

Presently, the available anesthesia techniques for liposuction are the rarely used dry technique, which uses general anesthesia without preinfiltration of vasoconstrictive solution; [1], [25], [26] the wet technique, which uses general anesthesia and preinfiltration with a low volume of vasoconstrictive solution, which is fairly commonly used, especially by plastic surgeons; [27], [28] the use of tumescent anesthetic solution with general or IV anesthesia, a technique also used mostly by plastic surgeons who understand the benefits of high volume tumescent anesthesia; and the tumescent technique of local anesthesia alone, with no general anesthesia and the preinfiltration of a high volume of low-dosage lidocaine/epinephrine anesthetic solution. It is this latter technique, used mostly by dermatologic surgeons, that has essentially revolutionized the liposuction process and is the current state of the art for this procedure. [29], [30], [31], [32] and [33]

Liposuction surgery is done to improve the contour of the patient's body and to rearrange deposits of adipose tissue without changing the surface of the skin. It is not a treatment for obesity, striae, spider veins, or cellulite, nor does it tighten the overlying skin. It is important to choose a patient with realistic expectations for the procedure and to do an extensive preoperative evaluation and consultation. [34], [35]

The hallmark of the tumescent technique of local anesthesia is the concentration of lidocaine, which is usually 0.05%, 0.075%, or 0.1%, and the concentration of epinephrine, which is usually 1:1 million. Table 274-1 provides formulas for these solutions. For smaller areas, a 250-mL bag of saline can be used rather than a 1000-mL bag. The total safe concentration of lidocaine is based on the published figure of 55 mg/kg. [36] Thus, if a patient weights 150 lb, this is divided by 2.2, giving 68 kg. Multiplying 68 kg by 55 mg/kg would allow the safe use of approximately 3740 mg of lidocaine. A 1000-cc bag of 0.1% lidocaine anesthetic solution has 1000 mg of lidocaine and a 1000-cc bag of .05% lidocaine anesthetic solution has 500 mg of lidocaine. This 68 kg patient can use approximately 3.75 bags of 0.1% solution or 7 bags of .05% solution to stay under the safe limit of 3740 mg of lidocaine. If greater amounts of fluid are necessary for the surgery (a large number of treatment areas), then the 0.05% solution can be used. Indeed, any mixture of solutions that totals 3740 mg of lidocaine is acceptable in a patient who weighs 150 lb. The preceding calculations and formulas can easily be extrapolated to determine the “safe” amount and concentration that can be used in a given patient.

Normal saline	0.9%	1000 mL	1000 mL	250 mL
Lidocaine	2%	25 mL	50 mL	12.5 mL
Epinephrine	1/1000	1 mL	1 mL	0.25 mL
Bicarbonate	8.4%	12.5 mL	12.5 mL	4 mL
Total		500 mg	1000 mg	230 mg
Lidocaine		0.05%	0.1%	0.1%
Epinephrine		1:1 million	1:1 million	1:1 million

TABLE 274-1 **Tumescent Liposuction Solutions**

In the tumescent technique, the anesthesia is delivered in a three-step procedure wherein the incision sites (the openings through which the cannulas are inserted) are first injected with a small amount of local anesthetic using a syringe and a 30-gauge needle. [37] The second stage is the delivery of a small amount of anesthetic solution through a spinal needle radially through these incision sites, fanning out to achieve preliminary anesthesia. This preliminary anesthetic can be pushed in with a pressure cuff around a bag of saline or by the use of an infiltration machine on settings 1 to 3. [37], [38] and [39] Finally, the tumescent anesthetic is delivered through an infiltration cannula with multiple openings. During this final step in the anesthetic process, the infiltration machine is on settings 5 to 7 and the tissue is infiltrated ("tumesced") until firm. After the fatty tissue has been tumesced, it is necessary to wait 30 min or so for the full vasoconstricting effect of the epinephrine solution. The anesthesia is injected at deep as well as intermediate levels to obtain a full effect.

Liposuction surgery is the removal of fatty tissue through tiny excisions in the skin using small, blunt cannulas. [40] It is remarkably safe and should be performed using a sterile technique. The surgery is done using cannulas of various sizes and designs, which are introduced into the incision sites and criss-crossed over the area to produce a smooth, even result. Suction is used at many levels throughout the fatty tissue during the procedure. Suction can be obtained with an aspiration machine or with syringes. [41], [42] and [43]

Sometimes, especially if the area of surgery is very large or very fibrous (male breasts, back anterior thighs, areas of previous liposuction, etc.), ultrasonic or powered liposuction cannulas may be used prior to, or instead of, conventional liposuction cannulas. The ultrasonic devices (ultrasonic liposuction) cavitate the fat, liquefying it and enabling it to be extracted more easily. [44], [45] Ultrasonic liposuction is rarely used by dermatologic surgeons, except occasionally for a short time to make tunnels through fibrous tissue, because of problems with burns, seromas, and hematomas. [46] Some plastic surgeons use ultrasonic liposuction for the entire procedure. Ultrasonic liposuction requires tumescent anesthesia to work and initially the benefits were thought to be a result of the use of ultrasound until it was realized that the tumescent anesthesia was responsible. After this many plastic surgeons kept on using tumescent anesthesia along with general anesthesia to continue to reap these benefits that include decreased bleeding and no need for transfusions and minimal postoperation discomfort. This technique is mistakenly referred to as the tumescent anesthesia technique, even though general or IV anesthesia is used. All of the problems that have been reported with so-called tumescent anesthesia have been with this type of anesthesia. [47], [48] and [49] The true tumescent anesthesia technique is with local anesthesia alone and is extremely safe, as has been reported in several surveys by Hanke et al. [7], [50], [51] When dermatologic surgeons use this technique with local anesthesia alone, there are additional benefits, including the ability of the patient to move into the position required to remove the fat; no risk of general anesthesia; feeling better and recovering more quickly postoperatively; the patient being able to move during surgery and walk out of the operating room, which minimizes the occurrence of pulmonary emboli; and the procedure being much safer. Powered liposuction is also used by many dermatologic surgeons. It has been reported to make the surgery easier for the physician and the patient. [52]

While the results from fat removal are almost immediate, subsequent normal elastic retraction of the skin may take up to 6 or more months to occur. Complications from tumescent liposuction are extremely rare, with the usual postoperative sequelae. [7], [54], [55] and [56] Occasionally, dysesthesia and ecchymosis may occur, with the former lasting a few months and the latter 2 to 3 weeks.

Guidelines for liposuction surgery have been written be the American Academy of Dermatology [57] and the American Society for Dermatologic Surgery. [58] The tumescent technique of local anesthesia is extremely safe and efficacious [24] for removing adipose tissue to effect a change of contour.

REFERENCES

1. Fischer A, Fischer GM: Revised technique for cellulitis fat. Reduction in riding breeches deformity. *Bull Int Acad Cosmet Surg* **2**:40, 1977

2. Illouz YG: The fat cell "graft," a new technique to fill depressions. *Plast Reconstr Surg* **78**:122, 1986

3. Illouz YG: Body contouring by lypolisis: A five-year experience with over 3000 cases. *Plast Reconstr Surg* **72**:591, 1983

4. Illouz YG: D l'utilisation de la graisse aspiree pour combler les defects cutanes. *Rev Chir Esthet Lang Franc* **10**:13, 1985

5. Klein JA: The tumescent technique for liposuction surgery. *Am J Cosmet Surg* **4**:236, 1987

6. Lillis PJ: Liposuction surgery under local anesthesia: Limited blood loss and minimal lidocaine absorption. *J Dermatol Surg Oncol* **14**:1145, 1988

7. Hanke CW et al: Safety of tumescent liposuction in 15,336 patients. *Dermatol Surg* **21**:459, 1995

8. Klein JA: Anesthesia for liposuction in dermatologic surgery. *J Dermatol Surg Oncol* **14**, 1988

9. Narins RS: Liposuction and anesthesia. *Dermatol Clin* **8**:421, 1990

10. Westmore SJ: Injection of fat for soft tissue augmentation. *Laryngoscope;* **99**:50, 1980

11. Teimourian B: Blindness following fat injections [letter]. *Plast Reconstr Surg* **82**:361, 1988

12. Illouz YG: Present results of fat injection. *Aesthetic Plast Surg* **12**:175, 1988

13. Gormley DE, Eremia S: Quantitative assessment of augmentation therapy. *J Dermatol Surg Oncol* **16**:1147, 1990

14. Agris J: Autologous fat transplantation: A 3-year study. *Am J Cosmet Surg* **4**:111, 1987

15. Smahel J: Adipose tissue in plastic surgery. *Ann Plast Surg* **16**:444, 1986

16. Cook W Jr: Regional liposuction face/neck and arms. Paper given at American Society of Dermatological Surgery (ASDS), Palm Desert, California, 1996

17. Narins RS: Liposuction of the face and neck, in *Evaluation and Treatment of the Aging Face,* edited by ML Elson. New York, Springer-Verlag, 1995, p 93–100

18. Narins RS: Abdomen, hourglass abdomen, flanks and modified abdominoplasty, in *Safe Liposuction,* edited by RS Narins. New York, Marcel Dekker 2003, p 95–119

19. Narins RS: Liposuction surgery for a buffalo hump caused by Cushing's disease. *J Am Acad Dermatol* **21**:307, 1989

20. Lillis PJ, Coleman, WP III: Liposuction for treatment of axillary hyperhidrosis. *Dermatol Clin* **8**:479, 1990

21. Field LM, Novy FG III: Flap elevation and mobilization by blunt liposuction cannula dissection to repair temple defect. *J Dermatol Surg Oncol* **13**:1302, 1987

22. Chrisman BB: Liposuction with facelift surgery. *Dermatol Clin* **8**:501, 1990

23. Hanner H, Olbrisch RR: The treatment of type I diabetes with insulin-induced lipohypertrophy by liposuction. *Dtsch Med Wochenschr* **119**:414, 1994

24. Brorson H, Svensson H: Complete reduction of lymphedema of the arm after breast cancer. *Scand J Plast Reconstr Surg Hand Surg* **31**:137, 1997

25. Elam M, Fournier P: *Liposuction: The Franco-American Experience*. Beverly Hills, CA, Medical Aesthetics, 1986

26. Fournier P, Otteni F: Lipodessection in body sculpturing: The dry procedure. *Plast Reconstr Surg* **72**:598, 1983

27. Courtiss EH et al: Large-volume suction lipectomy: An analysis of 108 patients. *Plast Reconstr Surg* **89**:1068, 1992

28. Teimoriun B: *Suction Lipectomy and Body Sculpturing*. St. Louis, Mosby, 1987.

29. *Am J Cosmet Surg* (special liposuction issue), 1986

30. Field LM: Liposuction surgery: A review. *J Dermatol Surg Oncol* **10**:530, 1984

31. Hanke CW: Liposuction under local anesthesia [editorial]. *J Dermatol Surg Oncol* **15**:12, 1989

32. Newman J, Dolsky R: Liposuction surgery: History and development. *J Dermatol Surg Oncol* **10**:467, 1984

33. Stegman S, Tromovitch T: Liposuction, in *Cosmetic Dermatologic Surgery,* Chicago, Year Book, 1983, p 226

34. Cook W Jr: Preoperative consultation and evaluation. Paper given at American Society of Dermatological Surgery (ASDS), Palm Desert, California, 1996

35. Field L, Narins R: Liposuction surgery, in *Skin Surgery,* 6th ed, edited by E Epstein, E Epstein Jr. Philadelphia, Saunders, 1987, p 370.

36. Ostaad A et al: Tumescent anesthesia with lidocaine dose of 55 mg/kg is safe for liposuction. *Dermatol Surg* **22**:921, 1996

37. Narins RS, Coleman WP III: Minimizing pain for liposuction anesthesia. *Dermatol Surg* **23**:1137, 1997.

38. Butterwick KJ et al: Lidocaine levels during the first 2 hours of infiltration of dilute anesthetic solution for tumescent liposuction: Rapid versus slow delivery. *Dermatol Surg* **25**:681, 1999

39. Hanke CW et al: Infusion rates and levels of premedication in tumescent liposuction. *Dermatol Surg* **23**:1131, 1997

40. Cook W Jr: Technical aspects of liposuction. Paper given at American Society of Dermatological Surgery (ASDS), Palm Desert, California, 1996

41. Field LM: The dermatologic surgeon and liposculpting, in *Liposculpture: The Syringe Technique,* edited by PF Fournier. Paris, Arnette Blackwell, 1991, p 265

42. Fournier P: *Body Sculpting through Syringe Lipo-Extractions and Autologous Fat Reinjection*. Solana Beach, CA, Samuel Rolf International, 1988

43. Fournier PF: *Liposculpture: The Syringe Technique*. Paris, Arnette Blackwell, 1991, p 163

44. Zocchi M: Ultrasonic liposculpturing. *Aesthetic Plast Surg* **16**:287, 1992

45. Zocchi M: Clinical aspects of ultrasonic liposculpture. *Perspect Plast Surg* **7**:153, 1993

46. Troilius C: Ultrasound-assisted lipoplasty: Is it really safe? *Aesthetic Plast Surg* **23**:307, 1999

47. Grazer FM, de Jong RH: Fatal outcomes from liposuction: Census survey of cosmetic surgeons. *Plastic Reconstr Surg* **105**:436, 2000

48. Rao RB et al: Deaths related to liposuction. *N Engl J Med* **340**:1471, 1999

49. Coleman WP III et al: Does the location of the surgery or the specialty of the physician affect malpractice claims in liposuction? *Dermatol Surg* **25**:343, 1999

50. Bernstein G, Hanke CW: Safety of liposuction: a review of 9478 cases performed by dermatologists. *J Dermatol Surg Oncol* **14**:1112, 1988

51. Jackson RF, Dolsky RL: Liposuction and patient safety. *Am J Cosmet Surg* **16**:21, 1999

52. Coleman WP III et al. The efficacy of powered liposuction. *Dermatol Surg* **27**:735, 2001

53. Coleman WP III: Powered liposuction. *Dermatol Surg* **26**:315, 2000

54. Coleman WP III et al. Guidelines of care for liposuction. *J Am Acad Dermatol* **45**:438, 2001

55. Lawrence N et al: American Society for Dermatologic Surgery guidelines of care for liposuction. *Dermatol Surg* **26**:265, 2000

56. Coleman WP III: The history of dermatologic liposuction. *Dermatol Clin* **8**:381, 1990

57. Dillerud E: Suction lipoplasty: A report on complications, undesired results, and patient satisfaction based on 3511 procedures. *Plast Reconstr Surg* **88**:239, 1995

58. Hetter G: *Lipoplasty, The Theory and Practice of Blunt Suction Lipectomy*. Boston, Little, Brown, 1984.

T>

Chapter 275

Arnold Klein

Substances for Soft-Tissue Augmentation

INJECTABLE BOVINE COLLAGEN
FAT TRANSPLANTATION
OTHER MATERIALS

REFERENCES

Soft-tissue augmentation has become increasingly important as more individuals seek aesthetic improvement without major surgical procedures. Today, physicians have a much larger armamentarium of techniques and implant materials with which to improve facial contours, ameliorate wrinkles, and stall the tell-tale signs of the aging face. There is reinterest in the concept of the two-dimensional look of the overpulled face because the youthful face has a much fuller look, not a pulled, flat look. Filling has replaced pulling.

For a substance or device to be amenable for soft tissue augmentation by the general medical community, it must have certain intrinsic properties. It must have both a high “use” potential, producing pleasing cosmetic results with a minimum of untoward reactions, and a low “abuse” potential, such that widespread and possibly incorrect or indiscriminate use would not result in significant morbidity. [1] Additionally, it must be nonteratogenic, noncarcinogenic, and nonmigratory. Moreover, the agent must provide predictable persistent correction through reproducible implantation techniques. Finally, if not autologous, the substance, agent, or device must be FDA approved. The search for the perfect material to eradicate rhytides, smooth scars, and fill traumatic defects continues. New products appear, sometimes with great fanfare, which often fail to fulfill the promise of a better alternative to what we use now. Although no currently available implant fulfills all of these criteria, many options exist that are adequate for a given task, satisfy patients, and offer excellent safety profiles. Of course, safety should be the primary concern when using any implant material and to do no harm.

Currently, in the United States, the commonly available injectable filling agents include autologous fat and Zyderm/Zyplast collagen. These are discussed in this chapter. Newer injectable agents, such as the hyaluronic acid products and Artecoll, techniques such as subcision, and surgically implanted agents, such as Gore-Tex, have become part of the field of soft tissue augmentation and are briefly addressed.

INJECTABLE BOVINE COLLAGEN

Injectable bovine collagen, Zyderm collagen implant, has been in use since 1977, receiving FDA approval in 1981. This was the first approved injectable xenogenic agent in the United States for soft-tissue augmentation and its approval reawakened interest in the entire field of filling agents. At present an estimated 1,900,000 individuals worldwide have received injectable collagen implants. Following the release of Zyderm I (ZC-I), two additional forms, Zyderm II (ZC-II) and Zyplast (ZP), received approval. [2] They are regarded as the “gold standards” of injectable or implantable fillers and are standards against which newer materials are measured. ZC-I, ZC-II, and ZP are suspensions of bovine dermal collagen. Processing of the material involves purification, pepsin digestion, and sterilization. Pepsin digestion removes the more antigenic end portions of the bovine collagen molecule (the telopeptides) without disturbing the natural helical structure. The resulting agent is more immunologically compatible with the human host. Zyderm collagen implants are all 95 to 98 percent type I collagen; the remainder is type III. [3] The products are suspended in phosphate-buffered physiologic saline containing 0.3% lidocaine. It should be noted that these substances are all taken from the skin of a closed American herd, negating the possibility of contamination with the bovine spongiform encephalopathy virus or prions. [4] ZC-I, the original material, and ZC-II differ only in concentration. ZC-I is 3.5 percent by weight bovine collagen whereas ZC-II (introduced in 1983) is 6.5 percent by weight bovine collagen. ZP, approved in 1985, is the third form of implantable collagen, which is lightly cross-linked by the addition of 0.0075% glutaraldehyde. These cross-links are intramolecular and intermolecular, as well as between fibrils, resulting in a more robust implant that is essentially an injectable latticework of bovine collagen. [5] ZP is more resistant to proteolytic degradation and less immunogenic. [6], [7] Furthermore, the more substantive nature of ZP makes it applicable for deeper contour defects that are unresponsive to ZC-I or ZC-II. [8], [9] All the products are provided in preloaded syringes that are stored at low temperature (4°C/39.2°F) so that the dispersed fibrils remain fluid and small. Once implanted, the human body temperature causes the products to undergo consolidation into a solid gel.

Treatment with injectable collagen requires an initial screening skin test. Approximately 0.1 cc of the material is placed intradermally in the volar area of the forearm and the site is evaluated after 1 month. A positive test, which is an absolute contraindication to treatment, consists of redness, swelling, or both occurring 6 h or more after test implantation. Approximately 3 to 3.5 percent of persons will have a positive skin test. [10], [11] and [12] Nevertheless, despite one negative skin test, 1.3 to 6.2 percent of patients will have treatment-associated hypersensitivity responses. [10], [11], [12] and [13] To reduce the possibility of these reactions, which usually occur shortly after the first treatment, it is advisable to turn the first treatment exposure into a second test. This second skin test is administered 2 to 4 weeks after the first, in either the contralateral arm or in a cosmetically inconspicuous area of the face. Treatment is then begun 2 to 4 weeks after a negative second test. [2], [14], [15] and [16] If a patient has not been treated or tested within a 12-month period, it is advisable to retest once to reduce the possibility of a treatment reaction.

Zyderm collagen is implanted in the superficial dermis by serial punctures of the skin with syringes prefilled with the

material. With ZC-I a 30- or 32-gauge needle is used. Many experienced practitioners prefer the 32-gauge metal hub needle that produces less trauma to the skin and ultimately has a better cosmetic result. With more viscous ZC-II, a 30-gauge needle is used. When implanting ZC-I and ZC-II, a serial puncture technique is employed with the syringe held almost parallel to the skin surface. Barely penetrating the skin with the needle tip, one must “flow” the material in the superficial dermis observing a flat yellow blanching of the skin. While injecting, each subsequent injection volume should be placed at the advancing edge of the previously injected quantity, generating a continuous “flow” of material that smoothly fills in defects. Because ZC-I and ZC-II contain bovine collagen in the form of microfibrils, it has excellent flow characteristics. “As superficial as possible” placement of ZC-I and ZC-II is no longer employed, nor is excessive overcorrection in that persistent whiteness at the injection site and elevation can be observed. [17], [18] Nevertheless, a slight overcorrection (25 percent) should still be sought when injecting ZC-I and ZC-II.

With ZP, a 30-gauge needle is used to create a mid-dermal flow of material, again by using a serial puncture technique. Zyplast should be placed neither too superficially nor in the subdermal space. In the former location, it will result in persistent overcorrection with beading; in the latter location, it will not provide lasting correction. With ZP, the syringe is held at a 45-degree angle during the injection process and the material placed slightly deeper than ZC-I or ZC-II. While implanting ZP the resistance of the dermal matrix is felt against the injecting hand and the plane of the injected site should elevate as the material is being placed. Deliberate overcorrection should be avoided. With Zyplast there is a greater resistance to flow upon implantation than with ZC-I and ZC-II because of its more robust nature (cross-linking) and the absence of microfibrils. Increased longevity of correction and improved aesthetic results can often be achieved by the “layering” technique wherein ZC-I or ZC-II is immediately implanted over Zyplast injection sites. Full correction can be achieved at one treatment session if enough material is employed.

Correction with all forms of bovine collagen is temporary and requires periodic maintenance at 4- to 12-month intervals. [19] In humans, while histologic studies of ZP (as opposed to ZC-I/ZC-II) have revealed some deposition of host collagen, there is no convincing evidence that this deposition contributes to longevity of correction. [20], [21] Indeed, correction with all forms of bovine collagen appears to be lost as the material is displaced from its site of implantation in the dermis into the subcutaneous space. [22]

Indications for ZC-I/ZC-II include horizontal forehead lines, glabellar lines, crow's-feet, nasolabial lines, fine lip lines, marionette lines, acne scars, excisional scars, and the like. Deep nasolabial folds, marionette grooves, deep acne scars, and the like respond best to ZP with or without ZC-I/ZC-II overlay. ZP is also best suited to resurface the vermilion border between the lip and skin for lip enhancement. Additionally, true “mucosal” injection of ZC-I, ZC-II, and ZP, is often employed in the lip enhancement process, although the mucosal location is not an FDA-approved site for collagen implantation. As one gains more experience, the practitioner will realize that while ZC-I is the most forgiving, it is also the most technique sensitive and versatile. Furthermore, as one's implantation techniques evolve, ZC-I rather than ZC-II will be the preferred filler for shallow defects in that, as one becomes more proficient at superficial placement, ZC-II can often be associated with whiteness at the injection site. The injection of bovine collagen in the circumoral area is the largest single indication for which these products are used. Even a small volumetric increase in the size of the lips in selected individuals can produce a most pleasing cosmetic result. Lip augmentation thus addresses both the age-related contour loss found in the lips and, by enhancing their size, the radial grooves. The ideal technique for lip enhancement is variable, and is certainly not uniform between physicians or even from patient to patient.

Adverse treatment responses to injectable collagen can be divided into nonhypersensitive and hypersensitive. Nonhypersensitive reactions include bruising and reactivation of herpetic eruptions, as well as bacterial infection. Additionally, local necrosis caused by vascular interruption at the treatment site has been noted with ZP and rarely ZC-I/ZC-II. [23] Because 56 percent of these locally necrotic events occur in the glabellar area, physicians are cautioned against using ZP at this site. If, upon injection, there is severe blanching of the area and pain, the procedure should be stopped immediately, as local necrosis may have occurred. The value of massage, cool compresses, or nitroglycerin gel in this situation is, as yet unsubstantiated. Two reports of partial vision loss after Zyderm collagen therapy have been noted. [24] These are probably the result of an occlusive event involving the retinal artery. These serious consequences of a cosmetic procedure underscore the need to ensure the dermal site is the proper locale for collagen implantation.

Treatment associated hypersensitivity reactions to bovine collagen implants are, for the most part, cosmetic problems consisting of redness and swelling at the treatment site. It is rare, but mild systemic symptoms can accompany these reactions. Hypersensitive reactions are almost uniformly associated with anti-Zyderm antibodies. These antibodies do not cross-react with human collagen. [13], [25] “Cyst–abscess” formation is a rare but severe hypersensitivity response occurring at a rate of 4 per 10,000 treated individuals. [23] Clinically, individuals develop painful, swollen cysts at the sites of treatment. These reactions are usually associated with ZP and rarely with ZC-I/ZC-II. Eighty-six percent of these individuals have associated antibovine antibodies. Incision and drainage, as well as intralesional glucocorticoids, have been advocated to manage this most undesirable sequela. This is a long-lasting, severe hypersensitivity response that can persist for more than 2 years. Analysis of extruded material from these abscesses has revealed bovine collagen implant. As to the possibility of bovine collagen inducing connective tissue disease in the human host, retrospective studies as well as an expert panel convened by the FDA have found no supporting evidence. [25]

FAT TRANSPLANTATION

Injectable fat, or autologous fat transplantation, is the oldest material used for tissue augmentation. Indeed, Neuber reported almost l00 years ago the technique of free fat grafts for tissue augmentation. [26] Although Brunings, in 1919, reported fat injection as a technique for soft-tissue augmentation, fat injection or transplantation was ignored in favor of pedicle flaps and the use of paraffin and silicone as filling agents. [27] In the 1980s, a dramatic change occurred. With the advent of liposuction, and especially tumescent liposuction, it was possible to return the viable fat to the body. A new age of fat transfer had begun, but its methodology was marked more by physician to physician variability than by uniformity.

Clinical experience has clearly supported the assumption that fat grafting is most successful when cellular transfer is

placed in areas already occupied with adipocytes. Simply stated, fat works best when injected into the fat. The vast majority of surgeons reporting success in fat-grafting procedures have selected the low-pressure harvest with a syringe system technique. Autologous fat has long been tried as a material for soft-tissue augmentation in aesthetic and reconstructive surgery. [26], [27], [28], [29], [30], [31] and [32] The harvest is relatively easy and there are numerous, easily accessed, donor sites. The avoidance of allogeneic or alloplastic materials and the potential antigenic and/or inflammatory responses inherent with such agents is also of great benefit. Nevertheless, the persistence of clinical augmentation with adipose transplants remains controversial. [33], [34]

Freezing fat for use at a later time is considered by many to be a useful adjunct to autologous fat transfer. After harvesting, some of the material is injected into the recipient site and the rest is fast frozen in liquid nitrogen and kept frozen until subsequent injections are necessary, but not longer than 6 to 12 months. Whether the fat cells remain viable after freezing, thawing, manipulation, and reinjection through 18-gauge or smaller needles is open to question. [35] While many physicians prefer to gently harvest the fat in a syringe, others prefer to remove fat by liposuction. [35], [36]. Whether the size of the lipocyte, the metabolic rate, the site of removal, or washing and stabilizing agents are important in the application of fat transplantation is as yet unclear. [36] Similarly, the most amenable sites for transplantation have not been totally defined. [35] In regards to longevity, additional controversy still exists. In an excellent subjective evaluation of autologous fat transplantation follow-up, Pinski and Roenigk revealed that only 25 to 30 percent of the original transplanted fat remained at 1 year in the forehead, nasolabial folds, and cheeks. [35] In another excellent study, Gormley and Eremia found microlipoinjection of fat unpredictable, yet a good result at 6 months usually was maintained at 1 year. [37] Other authorities have found fine rhytides not amenable to correction with injectable fat, although the fat may be used to fill in hollow cheeks, the perioral area, the glabellar area, facial hemiatrophy, depressed temples, and hands, and for lip augmentation. In an attempt to use autologous fat to correct fine wrinkles, the process of “lipocytic dermal augmentation” was developed. In this technique, centrifuged fat is mechanically manipulated and injected at the level of the dermis through a 25-gauge needle. Indeed, Coleman et al. presented histologic evidence in two patients at 3 months, and other anecdotal clinical subjective evaluations support their hypothesis that this technique of fat injection elicits host collagen deposition and results in the correction of dermal defects. [38]

Despite what appears to be a confusing area, a consensus appears to be evolving. [36], [37], [39], [40] The thighs, buttocks, knees, and abdomen appear to be the donor sites most often used. Individual preference and donor fat availability appear to be directing forces in choosing the proper donor site. After adequate anesthesia, the fat is removed as atraumatically as possible either by syringe extraction or by a machine-assisted method. In the former, almost any size syringe is employed with either a 1.5-inch 14- to 16-gauge needle or microcannula. Once extracted, treatment of the fat appears to vary greatly, but, in general, individuals appear to either use gentle centrifugation or gravity to separate the extracted fat from the fluids. While some individuals continue to wash the extracted lipocytes, others have abandoned this portion of the process. To place the fat, appropriate anesthesia is used and a 16- to 18-gauge needle is attached to the injecting syringe. An 11-gauge scalpel is employed to prick the skin and the syringe containing the fat is then inserted at this recipient site and the material injected at the level of the subcutaneous space. Molding after implantation is frequently used. Sites most amenable for correction with microlipoinjection, by consensus, appear to be the dorsal hand, depressed temples, hollow cheeks, deep nasolabial grooves, and defects caused by liposuction or lipodystrophy. Fat implantation has also been advocated for malar and chin augmentation. [35], [39], [40]

While swelling and bruising are fairly common and usually minor at the recipient site, occasionally persistent edema, asymmetry, punctate scarring, lumping, and bleeding occur. On the other hand, infection is a rare occurrence. There has been a single case of unilateral blindness reported following autologous fat transplantation. This is the most serious adverse consequence reported to date. [41]

OTHER MATERIALS

In addition to the above agents, there are numerous products and techniques whose position in the field of soft-tissue augmentation has not yet been fully defined. Fibrel, Autologen, Dermalogen, Isolagen, and Softform are no longer available.

AcHyal is a 1% solution of the sodium salt of hyaluronic acid. It is provided in 2.5 cc prefilled syringes with 30-gauge needles. It can be stored at room temperature and has a shelf life of 3 years. Indications are for wrinkles, scars, lip, and contour deformities. Adverse reactions are listed as reddening, inflammation, or bruising which dissipate in 2 to 3 days. There is no experience with the material in the United States.

Alloderm is a decellularized, processed, nonimmunogenic human dermal allograft that is inserted through dissected dermal tunnels for soft tissue augmentation. It is a protein framework without cells. It has been used since 1992 on more than 3500 patients. Alloderm is available in solid sheets for grafting or implanting.

Artecoll is a suspension of 20% PMMA (polymethylmethacrylate) microspheres of 30 to 42 µm diameter in 80% collagen solution. The collagen is degraded following injection with the resultant permanent deposition of PMMA. Artecoll is supplied in 0.6 mL syringes and designed for implantation into the deep reticular dermis. Artecoll is distributed worldwide, except in Japan and the United States. Clinical trials in the United States have been conducted. [42], [43] Because of its long lasting effect, Artecoll is not forgiving. Uneven distribution, long lasting itching and redness are common side effects.

Artecoll was preceded by Resoplast and Arteplast, and is basically a combination of these two products. Gottfried Lemperle published results of a prospective study in 118 patients. [44] Other studies [45], [46] have disputed Lemperle's results, and some authors claim that particles of this size are phagocytized, with the subsequent death of the engulfing macrophage and release of enzymes leading to a chronic inflammatory response. Lemperle [45] states that this is less likely given the smooth surface of PMMA microspheres. There have also been problems reported with the collagen

vehicle used for this product. [46] Other impurities were also found in the vehicle.

Biocell Ultravital is also called Biopolymere III. It is a biopolymer developed in Switzerland and contains Silicium (a derivative of silicon). According to the manufacturer, there is no need for allergy tests prior to treatment and results may be permanent. It is commonly used in South America.

Bioplastique is a suspension of textured composite silicone polymer of solid, vulcanized methylsiloxane rubber particles from 100 to 400 µm in size in a carrier vehicle (biocompatible plasdone hydrogel). [47] It is an investigational material for soft-tissue augmentation with a controlled foreign-body response. The size of the particles reportedly reduces migration. There are several reports of granulomas requiring excision. Because of the controversy and resultant bad press surrounding silicone gel implants, it is unlikely to be FDA approved and thus studies have been largely abandoned.

Cosmoderm and Cosmoplast are new products that are not yet on the market. They are recombinant human collagen. They have the same consistency and injection properties as Zyderm and Zyplast bovine collagen. They are grown from a single tissue cell line to avoid the possibility of disease transmission. They are currently undergoing clinical testing. They should eliminate potential allergenicity to collagen injections and may not require skin testing.

Cymetra is micronized cryofractured Alloderm. The material in rehydrated with 1 cc of Xylocaine. No allergy prescreening or testing is required, according to the manufacturer. Donor screening and viral inactivation are performed. The material is obtained from American Association of Tissue Banks (AATB) guideline-compliant tissue banks. It is implanted with a 26-gauge needle into the subcutaneous space. Clinical studies on 200 patients to date evidenced no allergic or immunologic reactions. Adverse reactions are bruising, redness, swelling, and wrinkling of skin. Eye pain with temporary vision loss has been reported. All the adverse reactions are reported as transient and occur at a rate of 2.1 percent.

Dermal grafting is a very unique process championed by Dr. James Swinehart in which postauricular dermis is harvested and inserted in dermal tunnels for soft-tissue augmentation and correction of scars. [48]

Dermalive is composed of hyaluronic acid and acrylic hydrogel fragments. It is nonanimal in origin. The particle sizes are 45 to 65 µm. Skin tests are reportedly unnecessary.

Endoplast-50 is a new product of elastin-solubilized peptides with bovine collagen for intradermal injection. Two skin tests are performed at 15-day intervals prior to treatment. Test syringes are available. It is provided in 0.5 or 1 mL syringes. It is injected with a 30-gauge needle in a serial puncture technique in the reticular dermis and is then massaged. There is a rare possibility of hypersensitivity. After treatment, inflammation is expected for 24 to 48 h. The material influences proliferation of fibroblasts to produce collagen. Duration of correction is said to be 8 to 12 months.

Fascian is preserved, particulate fascia lata derived from screened human cadavers. The material is freeze-dried and typically preirradiated. This material can be injected when soft tissue augmentation is desired. In a clinical trial, Burres followed 81 subjects for 6 to 9 months after implantation without incidence of infection, allergic reaction, or acute rejection. [49] Soft-tissue augmentation was evident 3 to 4 months after grafting, or longer in most cases. Injectable material is supplied in particle sizes of <0.25 mm, <0.5 mm, or <2.0 mm. The Fascian particles are hydrated in 3 to 5 cc of 0.3% lidocaine solution prior to injection. The injected area is pre-undermined with a 20-gauge needle and the material injected into the preformed tunnel with a 16- to 25-gauge needle, depending on the size of the particles used.

Gore-Tex is expanded polytetrafluoroethylene (ePTFE) that has been in medical use in general, cardiovascular, urologic, and reconstructive surgery since 1971. In 1993, it was approved by the FDA for facial plastic and reconstructive surgery. This solid material is inserted under the skin as tied strips, strings, or through a trocar that contains the product. Indications are for nasolabial folds, glabellar folds, lip lines, and lip augmentation. Adverse reactions are infection (0 to 3 percent), foreign-body extrusion, and three-dimensional elevation.

Maas et al. [46] performed studies in the porcine model comparing the implantation of solid strips, rolled sheets, and tubular implants of ePTFE. This work led to the development of the version of ePTFE marketed as Soft-Form, approved by the FDA, and made available in 1997. Softform is no longer available but the material is still available as Conform and Ultrasoft.

Hyaluronic acid derivatives are exciting new materials for soft tissue augmentation with great future potential. Hyaluronic acid is a mammalian polysaccharide found naturally in the dermis. Its ability to bond water assists in hydration and provides skin turgor. Unlike collagen, it is identical across all species and is produced by many types of cells. Hyaluronic acid itself is broken down quickly within the dermis, then eliminated by the lymphatics and eventually the liver. Hylan gels are cross-linked derivatives and have longer dwell times in tissues, but are eventually broken down into their original molecules and eliminated in the same fashion. [51]

Hylaform gel is processed from the cock's combs of domestic fowl. In clinical trials in wrinkles and scars, 80 percent of patients reported moderate or greater satisfaction at 12 weeks. Hylaform is used for facial augmentation throughout most of the world. It is especially popular for volume augmentation of the lips. However, it is not available for this purpose in the United States. It is available in a more concentrated form as Synvisc for use in osteoarthritis of the knee. There is reportedly no immunologic activity, although there have been some reports of redness that persisted at the sites of implantation. Reported adverse reactions are less than 2 percent and include erythema, ecchymoses, and acne. While the major problem reported has been the occurrence of a certain degree of redness, others have reported severe hypersensitivity-like reactions. Recently, two new forms, Hylaform-Fine and Hylaform-Plus became available.

The hyaluronic acid derivative Restylane has been available for soft-tissue augmentation in Europe for more than 5 years. Restylane is stabilized, partially cross-linked hyaluronic acid created via bacterial fermentation from streptococci bacteria and, thus, this is not animal material. It is biocompatible and biodegradable. It has a higher concentration of

hyaluronic acid than Hylaform gel increasing the filler's solubility. Restylane is provided in 0.7 cc preloaded syringes containing 20 mg/cc of stabilized hyaluronic acid. Initially the investigators recommended a linear threading, not a serial puncture technique, but now the serial puncture technique is being used with a 30-gauge needle and no overcorrection. With the second generation of this product, problems with intermittent swelling of the lips apparently have been eliminated. However, there are recent reports of patients developing acute hypersensitivity reaction to Restylane with facial extrusion of the material. It is indicated for rhytides and depressions, but the best indication is for lip augmentation, putting it into the potential space and then actually the mucosa itself, creating excellent volume lip enhancement. Restylane-fine is a new, less viscous form of Restylane for use with a 32-gauge needle. Perlane is a more robust form of Restylane for use with a 27.5-gauge needle. It is placed at the subcutaneous–dermal border.

Hylan Rofilan Gel is hyaluronic acid cross-linked with a natural acid instead of a chemical compound.

Koken Atelocollagen implant is a 2% monomolecular solution of collagen of Japanese origin. It is supplied in cartridges to be injected with a dental syringe through a 30-gauge needle. The indications, contraindications, testing, and injection techniques are the same as those for Zyderm collagen implant. Unlike, Zyderm, Koken Atelocollagen does not contain lidocaine. It is a 2% aqueous solution of monomolecular collagen molecules, whereas Zyderm is a suspension containing molecules, fibers, and fibrils of collagen.

Meta-crill is composed of microspheres of methacrylate in a colloidal suspension without protein. It is similar to Arteplast.

New-fill is a polylactic acid, and is not of animal origin. It is provided as freeze-dried material and can be stored at room temperature. After reconstitution with water, it is 4.45% polylactic acid. The material is biocompatible, biodegradable, and immunologically inert. It is injected into the superficial dermis or subdermally, using a 26-gauge needle. Indications are for nasolabial folds, lips, lipodystrophy of cheeks, acne scars, wrinkles, hands, and liposuction contour deformities.

Permacol is a permanent, cross-linked, solid porcine collagen implant (not injectable), presently available only in sheets. It allows ingrowth of host tissue cells and blood vessels. In Europe it is a CE Mark Class III and is thus approved for implantation. No US studies exist on this porcine product. It is available in 5 × 5 cm and 5 × 10 cm sheets in two thicknesses, 1.5 and 0.75 mm.

Plasmagel is an autologous, blood-derived augmenting material. Ascorbic acid and lidocaine are added to blood plasma. The material is heated to form a gel and injected. It is applicable for wrinkles, contour defects, acne scars, and lip augmentation. [52]

PMS-350 achieved CE certification in Europe after 15 years. It is silicone with a viscosity of 350 centistokes. It is indicated for glabellar lines, nasolabial folds, perioral lines, lip augmentation, atrophic disorders and scars.

Profill is provided as a translucent gel. It is a block copolymer of polyoxyethylene and polyoxypropylene with mineral salts, amino acids and vitamins. The material contains no animal proteins. It is a liquid that can be refrigerated until used. No skin test is required. The liquid material turns to gel upon implantation and can, therefore, be molded after implantation. It is provided in 1 mL syringes and injected with a 30-gauge needle in a serial puncture fashion. Several hours of redness are expected postimplantation. Correction reportedly lasts 6 to 9 months. Profill is frequently used in concert with Endoplast-50.

Reviderm-intra contains 40 to 60 µm dextran beads of the Sephadex type in hylan gel. It is of nonanimal origin. The material is nonimmunogenic, biocompatible, and biodegradable. Intradermal injection is used with a 30-gauge needle. EMLA or a topical anesthetic can be used. No overcorrection is necessary. The material can be molded after injection to disperse the beads. In a clinical study of 274 patients, the material was resistant to resorption and migration.

Silicones are synthetic compounds that do not occur naturally. The liquid silicones used for medical purposes are long polymers of dimethylsiloxanes. [53] Siloxane is an acronym used to describe compounds containing repeating units of silicon, oxygen, and methane. During the 1940s, there was significant German, Swiss, and Japanese experience with injectable silicone. There have been two major American protocols involving the use of highly refined, liquid silicone.

Silicone has a very high use potential, providing pleasing aesthetic results in many patients, but, unfortunately, it also has a high abuse potential. Numerous disastrous complications have resulted from the use of adulterated or impure silicones. Foreign-body–type silicoma can occur up to 11 years after implantation, even with the highly refined, medical grade silicon. Other adverse reactions which have been reported are movement or drift of the implant, peau d'orange, beading, discoloration, site reactions in 12 to 14 percent of patients, and immunologic reactions. [54] While injectable silicone has a long history of use in the United States, its use for soft-tissue augmentation was declared illegal by the FDA. Nevertheless, two forms of silicone—Adatosil-5000 and Silikon-1000—were recently approved as ophthalmic devices for injection into the eye for use as a prolonged retinal tamponade in selected cases of complicated retinal detachment. These are highly viscous agents. Some physicians are injecting this high-viscosity material into the face, but this may not be legal in some states in the United States.

Surgisis is derived from porcine small intestine submucosus. All cells are removed but the complex acellular matrix is retained. It works as a scaffold for host cells and tissue remodeling. It is available in sheets of various sizes and strengths. No immunologic human rejections or sensitization have been seen, although it is not applicable for patients with a known hypersensitivity to porcine products.

REFERENCES

1. Klein AW, Rish DC: Injectable collagen: An adjunct to facial plastic surgery. *Facial Plast Surg* **4**:87, 1987

2. Knapp TR et al: Injectable collagen for soft tissue augmentation. *Plast Reconstr Surg* **60**:389, 1997

3. Wallace DG et al; Injectable collagen for tissue augmentation, in *Collagen,* Vol. III. *Biotechnology,* edited by ME Nimni. Boca Raton, FL, CRC Press, 1988, p 117

4. Bulletin Collagen Corporation: *Bovine Spongiform Encephalopathy*.

5. McPherson JM et al. The preparation and physiochemical characterization of an injectable form of reconstituted, glutaraldehyde crosslinked, bovine corium collagen. *J Biomed Mater Res* **20**:79, 1986

6. DeLustro F et al: Reaction to injectable collagen in human subjects. *J Dermatol Surg Oncol* **14**(Suppl 1):49, 1988

7. Elson ML: Clinical assessment of zyplast implant: A year of experience for soft tissue contour correction. *J Am Acad Dermatol* **116**:707, 1988

8. Klein AW: Indications and implantation techniques for the various formulations of injectable collagen. *J Dermatol Surg Oncol* **14**(Suppl 1):49, 1988

9. Elson ML: Corrections of dermal contour defects with the injectable collagens: Choosing and using these materials. *Semin Dermatol* **6**:77, 1987

10. Castrow FF II, Krull EA: Injectable collagen implant—Update. *J Am Acad Dermatol* **9**:889, 1983

11. Cooperman LS et al: Injectable collagen: A six-year clinical investigation. *Aesthetic Plast Surg* **9**:145, 1985

12. Kamer FM, Churukian XM: The clinical use of injectable collagen: A three-year retrospective study. *Arch Otolaryngol* **110**:93, 1984

13. Siegle RJ et al. Intradermal implantation of bovine collagen: Humoral responses associated with clinical reaction. *Arch Dermatol* **120**:183, 1984

14. Klein AW: In favor of double testing. *J Dermatol Surg Oncol* **15**:263, 1989

15. Elson ML: The role of skin testing in the use of collagen injectable materials. *J Dermatol Surg Oncol* **15**:301, 1989

16. Klein AW, Rish DC: Injectable collagen update. *J Dermatol Surg Oncol* **10**:519, 1984

17. Klein AW: Implantation techniques for injectable collagen: Two-and-one-half years of personal clinical experience. *J Am Acad Dermatol* **9**:224, 1983

18. Bailin PL, Bailin MD: Collagen implantation: Clinical applications and lesion selection. *J Dermatol Surg Oncol* **14**(Suppl 1):49, 1988b

19. Klein AW: Indications and implantation techniques for the various formulations of injectable collagen. *J Dermatol Surg Oncol* **14**(Suppl 1):27, 1988

20. Kligman AM, Armstrong RC: Histologic response to intradermal Zyderm and Zyplast (glutaraldehyde cross-linked) collagen in humans. *J Dermatol Surg Oncol* **12**:351, 1986

21. Kligman AM: Histologic responses to collagen implants in human volunteers: Comparison of Zyderm collagen with Zyplast implant. *J Dermatol Surg Oncol* **14**(Suppl 1):35, 1988

22. Stegman SJ et al: A light and electron microscopic evaluation of Zyderm collagen and Zyplast implants in aging human facial skin: A pilot study. *Arch Dermatol* **123**:1644, 1987

23. Hanke CW et al: Abscess formation and local necrosis after treatment with Zyderm or Zyplast collagen implant. *J Am Acad Dermatol* **25**:319, 1991

24. DeLustro F et al. Reaction to injectable collagen: Results in animal models and clinical use. *Plast Reconstruct Surg* **79**:581, 1987

25. Klein AW: “Bonfire of the wrinkles.” *J Dermatol Surg Oncol* **17**:543, 1991

26. Neuber F: Fettransplantation. *Chir Kongr Verhandl Dsch Gesellch Chir* **22**:66, 1893

27. Broeckaert TJ: Contribution a l'Etude des Greffes Adipeueses. *Bull Acad R Med Belgique* **28**:440, 1919

28. Neuhof H: *The Transplantation of Tissues*. New York: Appleton & Company, 1923

29. Lexer E: Euber Freie Fettransplantation. *Klin Ther Wehnschr* **18**:53, 1911

30. Smith V: Morphological studies of human subcutaneous adipose tissue in vitro. *Anat Rec* **169**:97, 1971

31. Gurney CE: Studies on the fate of free transplants of fat. *Proc Staff Meet Mayo Clin* **12**:317, 1937

32. Hausberger FX: Uber die Waschtums und Entwicklungsfahigkeit Transplantierter Fettgewebskeim-lager von Ratten. *Virchows Arch Pathol Anat* **302**:640, 1938

33. Peer LA: Loss of weight and volume in human fat grafts with postulation of “cell survival theory.” *Plast Reconstr Surg* **5**:217, 1950.

34. Ersek RA. Transplantation of Purified Autologous Fat: a 3-Year Follow-up is Disappointing. *Plast Reconstr Surg* **87**:219, 1991

35. Pinski KS, Roenigk HH: Microlipoinjection, in *Surgical Dermatology: Advances in Current Practice,* edited by RK Roenigk, HH Roenigk. London, Martin Dunitz, 1993, p 451.

36. Asken S: Autologous fat transplantation, in *Dermatologic Surgery, Principles and Practices,* edited by RK Roenigk, HH Roenigk. Marcel Dekker, New York, 1988, p 1179.

37. Gormley DE, Eremia S: Quantitative assessment of augmentation therapy. *J Dermatol Surg Oncol* **16**:1147, 1990

38. Coleman WP et al: Autologous collagen? Lipocytic dermal augmentation: A histopathologic study. *J Dermatol Surg Oncol* **19**:1032, 1993

39. Guidelines of care for soft tissue augmentation: Fat transplantation, in *Dermatology World Supplement—Guidelines of Care*, 1995, p 20

40. Monheit GD: Soft tissue augmentation, in *Cutaneous Surgery*, edited by RG Wheeland. Philadelphia, WB Saunders, 1994, p 446

41. Teimourian B: Blindness following fat injections [letter]. *Plast Reconstr Surg* **82**:361, 1988

42. Hamilton D: A pilot study of the first patients treated in United States with Artecoll implantation for the aging face. *Cosmet Dermatol* **Sept**:147, 2000.

43. Cohen SR et al: The clinical trial of Artecoll in the US. *Plast Reconstr Surg*. In press

44. Lemperle G et al: PMMA microspheres (Artecoll) for skin and soft tissue augmentation. Part II: Clinical investigations. *Plast Reconstr Surg* **96**:627, 1995

45. McClelland M et al: Evaluation of Artecoll polymethylmethacrylate implant for soft-tissue augmentation: Biocompatibility and chemical characterization. *Plast Reconstr Surg* **100**:1466, 1997

46. Constantino PD, Friedman CD: Soft-tissue augmentation and replacement in the head and neck. General considerations. *Otolaryngol Clin North Am* **27**:1, 1994

47. Ersek RA, Beisang AA: Bioplastique: A new textured copolymer microparticle promises permanence in soft-tissue augmentation. *Plast Reconst Surg* **87**:693, 1991

48. Swinehart JM: Pocket grafting with dermal grafts: Autologous collagen implants for permanent correction of cutaneous depressions. *Am J Cosmet Surg* **12**:321, 1996

49. Burres S: Recollagenation of acne scars. *Dermatol Surg* **22**:364, 1996

50. Maas CS et al: Evaluation of ePTFE as a soft tissue filling substance: An analysis of design-related implant behavior employing the porcine skin model. *Plast Reconstr Surg* **101**:1307, 1998

51. Balazs EA, Leshchiner EA: Hyaluronan, its crosslinked derivative hylan, and their medical applications, in *Cellulosics Utilization: Research and Rewards in Cellulosics,* edited by H Inagake, GO Phillips. New York, Elsevier Applied Science, 1989, p 233.

52. Krajcik R et al: Plasmagel: A novel injectable autologous material for soft tissue augmentation. *J Aesthetic Dermatol Cosmet Surg* **1**:109, 1999

53. Barondes R et al: The silicones in medicine. *Mil Surg* **63**:168, 1950

54. Ellenbogen R et al: Injectable fluid silicone therapy: Human morbidity and mortality. *JAMA* **234**:308, 1975

T>

Chapter 276

Richard Glogau

Botulinum Toxin

HISTORY
PHARMACOLOGY
Toxin Structure
Mechanism of Action
Immunology
INDICATIONS
TREATMENT
The Glabellar Brow Furrow
Horizontal Forehead Lines
Crow's-feet
Hyperhidrosis
SIDE EFFECTS AND COMPLICATIONS

REFERENCES

On April 15, 2002, the Federal Food and Drug Administration granted Allergan, Inc. (Irvine, California) approval to Botox Cosmetic (botulinum toxin type A) for the “temporary improvement in the appearance of moderate to severe glabellar lines in adult men and women 65 or younger.” This is the first approved indication for elective cosmetic use of any commercially available botulinum toxin in the US market. However, the FDA's approval merely gilded the lily because off-label usage of the toxin had already propelled annual sales to a quarter of a billion dollars a year in 2002.

HISTORY

The Napoleonic wars eroded rural hygiene and spread poverty throughout southern Germany from 1795 to 1813. [1] A 29-year-old health official, Justinus Kerner, observed a connection between sausage fat and a paralytic illness, which he reported to medical authorities in 1815, and published as a monograph in 1820. His observations provided compelling epidemiologic evidence for causation of a disease eventually known as botulism, after *botulus,* the Latin word for sausage. In 1822, he published a series of experiments, first on animals and later on himself, in which he demonstrated that a poison could be extracted from affected sausage that would induce weakness and anhidrosis. In a fascinating example of forward thinking, Kerner speculated that minimal doses of the toxin might be useful to treat a variety of disorders of the nervous system. Seventy-five years later, Emile-Pierre van Ermengen published the initial description of the causative organism, *Clostridia botulinum,* demonstrating production of a toxin that produced weakness in animals.

In 1944, Schantz began purification of botulinum toxin A in crystalline form, and in the 1950s, Brook first demonstrated that botulinum toxin A blocked release of acetylcholine from motor neurons at the neuromuscular junction. [2] In the early 1970s, Scott, with Schantz, sought a biologic toxin that would be useful in paralyzing muscular action around the eyes. He identified botulinum toxin as an agent useful in treating human strabismus, [3] and predicted it would be used in other conditions of muscle spasm or hyperactivity.

In 1987, Dr. Jean Carruthers, an oculoplastic surgeon visiting Scott's laboratory, and her husband, Dr. J. Alastair Carruthers, a dermatologist, noticed the smoothing effect of the toxin on the glabellar brow furrow when treating a patient for blepharospasm. They pursued their observations on the cosmetic effectiveness of botulinum toxin, which they first published in 1992. [4] By this time the toxin was in use for blepharospasm, strabismus, torticollis, hemifacial spasm, and other focal dystonias. [5] Other therapeutic uses for botulinum toxin have evolved since 1992, including hyperhidrosis, [6] migraine headaches, [7] and low back pain. [8]

PHARMACOLOGY

Toxin Structure

Botulinum neurotoxins are currently categorized into eight distinct serotypes: A, B, Ca, Cß, D, E, F, and G. [9] The molecules vary in their biosynthesis, size, cellular sites of action, binding kinetics, duration of effect, and stability. The two currently available serotypes, A and B, are derived from different strains of *C. botulinum*. They both have 150 kDa dichain polypeptides with a heavy chain and light chain linked by disulfide bonds. During biosynthesis, the molecules of A and B are surrounded by proteins to form a neurotoxin complex, ranging from 500 kDa to 900 kDa.

Mechanism of Action

The toxin enters the nerves by binding to surface protein receptors and undergoing endocytosis into internalized vesicles. The light chain is released into the nerve cytosol, and the SNARE protein complex is cleaved to inhibit exocytosis of the neurotransmitters such as acetylcholine. Type A toxin cleaves SNAP-25, while type B cleaves vesicle-associated membrane protein (VAMP), also called synaptobrevin.

There were three commercially available preparations of botulinum neurotoxin on the market at the time this chapter was written. Type A is available worldwide as Botox or Botox Cosmetic and in Europe as Dysport. Type B is marketed in the

US as Myobloc. Botox and Dysport are sold in lyophilized form and must be reconstituted with normal saline. Myobloc is sold in aqueous solution at pH of 5.6. While the molecule complexes are unique, very approximate equivalencies have been derived from clinical observations. One mouse unit of Botox is equal to approximately 3 to 4 units of Dysport and 100 units of Myobloc. In dermatologic uses, Botox Cosmetic is usually diluted with 1.0 or 2.5 mL saline, producing concentrations of 40 U/mL or 100 U/mL. Contrary to the package insert instructions, clinicians find that the toxin is stable at room temperature, and when diluted, it remains stable at refrigeration for extended periods of time without significant loss of potency. The use of preserved saline lessens the sting of injection with Botox Cosmetic. Myobloc causes more discomfort on injection because of its low pH, but it is stable in liquid form at room temperature for many months.

Immunology

The possibility of antibody-mediated resistance appears to be largely theoretical. Original Botox batch #79-11, widely used in ophthalmology and neurology for years, produced rare cases of nonresponders in torticollis and blepharospasm. Newer batches introduced in 1997, #91223US and #BCB2024, have significantly less protein load. Although the occasional primary nonresponder may be encountered, clinical resistance to Botox/Botox Cosmetic does not appear to be clinically relevant in dermatology, even with the doses used in hyperhidrosis, which can average 400 units per treatment session. In addition, the treatment interval does not appear to be a significant factor in clinical resistance with the use of the newer batches.

INDICATIONS

Botulinum toxin is used primarily in dermatology for treatment of the dynamic expression lines of the upper third of the face: glabellar brow furrow, the horizontal frontalis forehead lines, the periocular crow's-feet rhytides, and axillary hyperhidrosis. Less common and therapeutically more challenging indications are platysmal banding in the neck, perioral rhytides, marionette lines at the corners of the mouth from the action of the depressor anguli oris, and postsurgical synkinesis in the lower face.

TREATMENT

The Glabellar Brow Furrow

A firm understanding of the underlying facial anatomy is the sine qua non of successful aesthetic therapy with botulinum toxin. Depending on the muscle mass present and degree of atrophy from prior treatment, 25 to 35 U of Botox Cosmetic is placed in five separate injection points to treat the corrugators and procerus muscle in the average brow (Fig. 276-1). A 30-gauge needle and a tuberculin or diabetic syringe are used to minimize the trauma of the intramuscular injections. The corrugator injections are placed just at or above the medial brow and in or just lateral to the mid-pupillary line, 1 cm above the bony orbital rim. The fifth injection is placed in the procerus at the midline. Patients are instructed to remain upright for 2 to 3 h to limit incidence of eyelid ptosis, which occurs with diffusion of the toxin down into the levator muscles of the lid. With experience, incidence of ptosis following injection of the brow should be less than 2 percent. Temporary stimulation of Müller's muscle in the lid can be achieved with 0.5% apraclonidine or 2.5% phenylephrine eyedrops. These will produce 2 to 3 mm of elevation of the lash margin and may be repeated at intervals until the distant diffusion effect of the botulinum toxin on the levator muscle disappears, usually in 2 to 3 weeks.

FIGURE 276-1 The corrugator and procerus muscles are weakened by carefully positioning five injections of Botox Cosmetic of 5 units each. Forceful knitting of the brow is prevented. Before treatment (*upper figure*) and 1 week posttreatment (*lower figure*).

Horizontal Forehead Lines

The frontalis is treated at the horizontal equator of the forehead or above to avoid inactivation of the lower third of the frontalis muscle, which is responsible for suspension and movement of the eyebrows (Fig. 276-2). Twelve to 20 U of Botox are placed in four or five divided doses along the forehead equator equidistant. If too large a dose is applied, or injection sites placed too low, brow ptosis and loss of brow arch are produced, giving an unpleasant heavy sensation to the brow, as well as an aesthetically unattractive appearance.

FIGURE 276-2 The upper half of the frontalis muscle is weakened by injecting four or five sites equidistantly along the equator of the forehead, totalling 16 to 20 units of Botox Cosmetic. Before treatment (*upper figure*) and 1 week posttreatment (*lower figure*).

Unlike the treatment of eyelid ptosis, there is no comparable adrenergic agent available to reverse brow ptosis induced by botulinum, and the patient must wait several weeks for the effect to wear off. In the patient who has never received Botox before, it is wise to separate the glabellar area from the forehead area, giving a couple of weeks interval between the two to avoid the possibility of overtreatment and brow ptosis.

Crow's-feet

The rhytides at the corners of the eye will respond favorably to injections of toxin at an injection point approximately 1 cm lateral to the lateral canthus. Great care must be taken to make the injections into the skin only, raising wheals or blebs that can be gently massaged down. Intramuscular injection in this area will reliably produce unwanted bruising because of the rich venous plexus underlying the skin in this area. The toxin will readily diffuse from the blebs into the underlying orbicularis muscle, relaxing the grip on the overlying skin and smoothing out the wrinkles. Care must be taken to avoid injecting too low down onto the malar eminence where diffusion may affect the zygomaticus major muscle and disrupt the symmetrical movement of the corner of the mouth in smiling. In addition, the patient must have good lower eyelid tarsal tone to avoid the appearance of senile ectropion from too much laxity of the lower eyelid. Pretreatment of the crow's-feet area is very useful as an adjunctive technique prior to laser resurfacing, preventing the problem of rhytides being readily reformed by repeated squinting during the postoperative healing period.

Hyperhidrosis

Focal axillary hyperhidrosis is successfully treated with botulinum toxin by using Minor's starch iodine test to map out the extent of surface area in the axillary vault that is affected and then placing 2.5 to 4.0 U of Botox every 1 to 2 cm as intradermal injections in axillary skin. Reliable anhidrosis is produced within 72 h, which will last for 8 to 12 months with doses of 50 U per axilla. The duration of effect appears to be dose related, and doses up to 200 U per axilla have been reported to produce dryness up to 29 months. [10] Aside from insignificant bruising from the needle trauma, there are no apparent side effects.

Palmar hyperhidrosis is more challenging because of (1) more limited diffusion of the toxin in palmar skin, (2) pain on injection, and (3) the generally predictable incidence of temporary weakness in the hand. Anesthesia is achieved with wrist blocks of the median, ulnar, and radial nerves. Approximately 100 to 150 U of Botox are needed for a single palm, divided into 50 to 60 intradermal injection sites of 2 to 3 U each. Onset of anhidrosis peaks in about 5 to 7 days, and is accompanied by minor weakness of the intrinsic muscles of the hand, which makes tasks requiring strength and stability difficult, for example, pushing a button through a button hole. The weakness usually subsides within 3 weeks, while the anhidrosis persists for several months. There is a wider variety of response to palmar treatment with durations lasting from 4 to 12 months, probably mirroring the technical difficulties in achieving even dispersion of the toxin through the palmar skin.

SIDE EFFECTS AND COMPLICATIONS

Minor needle trauma and bruising upon injection with a 30-gauge needle are insignificant short-term complications. The more problematic complications to consider are eyelid ptosis, which can occur with injections in the glabellar brow; headaches with injections anywhere in the upper third of the face; and palmar weakness following injections for hyperhidrosis. Antibody-mediated resistance appears to be an exceedingly rare event and of little clinical consequence in dermatologic uses of botulinum toxin.

REFERENCES

1. Erbguth FJ, Naumann M: Historical aspects of botulinum toxin: Justinus Kerner (1786–1862) and the “sausage poison.” *Neurology* **53**:1850, 1999

2. Jankovic J, Hallett M: *Therapy with Botulinum Toxin*. New York, Marcel Dekker, 1994

3. Scott AB: Botulinum toxin injection into extraocular muscles as an alternative to strabismus surgery. *Ophthalmology* **87**:1044, 1980

4. Carruthers JD, Carruthers JA: Treatment of glabellar frown lines with *C. botulinum* A exotoxin. *J Dermatol Surg Oncol* **18**:17, 1992

5. Schantz EJ, Johnson EA: Properties and use of botulinum toxin and other microbial neurotoxins in medicine. *Microbiol Rev* **56**:80, 1992

6. Naumann M: Evidence-based medicine: Botulinum toxin in focal hyperhidrosis. *J Neurol* **248**(Suppl 1):31, 2001

7. Binder WJ et al: Botulinum toxin type A (BOTOX) for treatment of migraine. *Semin Cutan Med Surg* **20**:93, 2001

8. Foster Let al: Botulinum toxin A and chronic low back pain: A randomized, double-blind study. *Neurology* **56**:1290, 2001

9. Aoki KR: Pharmacology and immunology of botulinum toxin serotypes. *J Neurol* **248**(Suppl 1):3, 2001

10. Wollina U et al: High-dose botulinum toxin type A therapy for axillary hyperhidrosis markedly prolongs the relapse-free interval. *J Am Acad Dermatol* **46**:536, 2002

T>

Chapter 277

Walter Unger Robin Unger

Hair Transplantation and Alopecia Reduction

HAIR TRANSPLANTATION
Patient Selection and Planning
Graft Types
TECHNIQUE
Anesthesia
The Donor Area
Graft Preparation and Insertion
The Recipient Area
Laser Transplanting
Bandaging
Postoperative Course
Complications
ALOPECIA REDUCTION
Technique
Complications
Major Reductions
Scalp Extension
Alopecia Reduction Preceded by Soft-Tissue Expansion

REFERENCES

The first written account of autografting of hair was a doctoral thesis by Dieffenbach, in 1822, in Konigsberg, Germany. [1] However, the concept did not really capture the medical profession's imagination or the general public's enthusiasm until 1959, when Norman Orentreich published an article including an account of successful hair transplantation in male-pattern baldness (MPB). [2] In addition, in the late 1970s, the concept of alopecia reduction (AR) or serial excision of areas of MPB was introduced by the Blanchards and Ungers. [3], [4] This chapter summarizes the present state of graft hair transplantation and AR. Controversial aspects and alternative approaches for hair restoration cannot be dealt with here because of space constraints, but are available in detailed form elsewhere. [5]

HAIR TRANSPLANTATION

Patient Selection and Planning

Hair transplantation is based on the concept of “donor dominance” in MPB. [2] If a graft is taken from an area destined to be permanently hair-bearing and transplanted into an area of MPB or future MPB, it will, after an initial short effluvium, continue to grow in its new site for as long as it would have in its original one. Thus, all planning is predicated on an accurate assessment of the eventual extent of MPB and the size and characteristics of the permanent donor rim. A careful family history, physical examination, and consideration of the patient's age are all important factors to consider as this assessment is made.

Conceptually, the recipient area is now dealt with in thirds [6] (Fig. 277-1A). The anterior third, or “frontal” area, frames the face and extends from the chosen hairline to a line drawn perpendicularly from the tragus. The middle third or “mid-scalp” area extends from the posterior point of the anterior third to the region where the scalp changes from its more horizontal orientation to a more vertical one. The posterior third or “crown” area extends from the posterior border of the mid-scalp to the superior border of the permanent rim hair. If one transplants the anterior two thirds, the patient will appear to have a full head of hair when viewed from frontally and laterally. The crown area is usually not treated unless the individual is not going to treat the frontal third or is also willing to undergo AR or scalp extension and the long-term donor/recipient area ratio is thereby converted to one that is satisfactory for this objective.

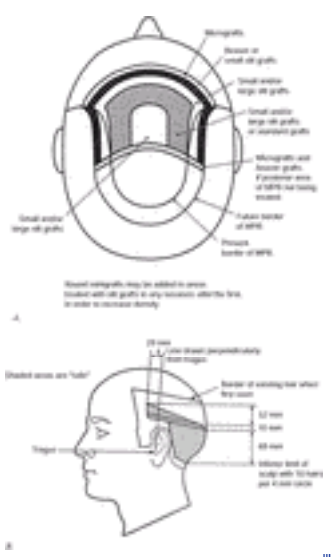

FIGURE 277-1 *A.* Schematic of the distribution of various types of grafts used in hair transplantation. The periphery of this area is always composed of small grafts. If MPB progresses beyond its anticipated extent, one can either treat the new areas or leave them as empty “alleys” adjacent to a relatively large “isolated frontal forelock.” Round mini-grafts and/or slot grafts may be added to any area treated with slit grafts, after the first session, to add greater density. *B.* A safe donor area for 80 percent of patients younger than 80 years of age. The hair density within this zone is greater than or equal to 8 hairs per 4 mm circle and it is approximately 69 mm high in the occipital midline. These boundaries were arrived at by studying 328 men, 65 years of age or older.

If one wants to be sure of *never* overestimating how large an area can be treated, one can create only an “isolated frontal forelock” (IFF), which will look natural standing on its own as long as the periphery is completed with small grafts. [7] This latter objective avoids any need for an accurate prognosis of the eventual boundaries of the area of MPB and is most suitable for those who are likely to develop type VI or VII MPB (see also Chap. 71). However, it appears that less than 24 percent of men who reach the age of 80 years will develop type VI or VII MPB. [8], [9] In addition, a “safe” donor area that is only 50 to 60 mm wide, extending approximately from ear to ear, is usually sufficient to produce enough grafts for four to five relatively large hair transplant sessions (see below). Even men with type VI MPB maintain “safe” donor areas of that width (Fig. 277-1B). In this light, limiting most patients to an IFF seems excessively conservative. A more reasonable course is to attempt to transplant all present and future areas of at least the anterior half to two-thirds of the area of MPB. The transplanted area should have a hair density that is appropriate given the expected donor/recipient area ratio and the borders of the entire area should be completed with small grafts (Fig. 277-1A). If hair loss does eventually exceed the originally estimated extent of MPB, one can treat the new areas or leave them as empty “alleys” adjacent to a relatively large IFF. With today's techniques, few patients are totally unacceptable candidates.

It is not necessary, nor advantageous, to wait until an area is totally alopecic before transplanting is initiated. Existing hair in a patient with relatively “early” androgenetic alopecia, allows for better postoperative camouflage with longer and more convenient intervals between sessions that are timed to keep pace with the rate of hair loss (Fig. 277-2). Transplanting does not, in our opinion, accelerate future hair loss, but the more hair that is present, the more skill is required; incisions must be made in the same direction and at the same angle as the original hair or MPB *will* be accelerated. [6] Similarly, no absolute rules apply to the correct age at which to begin—experience and skill extend the limits, although it is very uncommon to begin before age 21 or after age 80. [6]

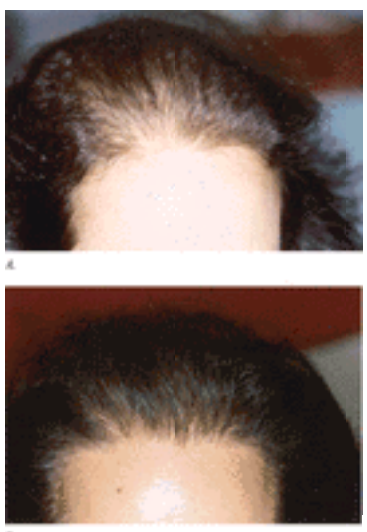

FIGURE 277-2 *A.* A female patient with androgenetic alopecia before transplantation. *B.* Nine months after one session of micrografts, mini-slit, and slit grafts. In our experience, transplanting into hair-bearing areas does not accelerate hair loss, whether in a female or a male with relatively “early” MPB. Subsequent additional transplant sessions may be carried out in pace with the rate of future hair loss.

Women now represent a larger percentage of hair transplant patients, as newer techniques perfected over the last 10 years are ideal for their treatment. Because of these advancements, most women we see are now felt to be acceptable candidates (Fig. 227-2). [10] A minority of women develop diffuse thinning that affects all areas of the scalp hair and are therefore not candidates for hair transplanting. Hair transplantation can also be used to treat cicatricial alopecia, including those from cosmetic surgery, and for the creation of eyelashes and eyebrows.

The less contrast between the color of the hair and skin, the better. Other advantageous hair characteristics are good density, frizziness, and curl or wave. Fine-textured hairs allow transplanted hair to blend in less perceptibly in areas of moderate or advanced thinning, without contrasting too much against hair that gradually becomes finer as MPB progresses. It is also ideal for the creation of very natural looking hairlines. Coarser hair produces more hair bulk and is best used in areas where high hair mass is the objective. An increase in hair diameter of only .01 mm increases hair bulk by an astounding 36 percent.

AR can be used to decrease both the width of an area of MPB and its length by making more superior hairlines cosmetically acceptable, and will therefore result in substantial graft savings. [6] Potentially negative sequelae of AR, such as significantly decreased hair density in future donor areas, disorientation of hair direction, permanently noticeable and/or poor scars, and partial loss of initial gains or “stretch-back” are minimal or can be totally avoided by appropriate planning and technique. [11], [12] and [13] AR can usually be done prior to any transplanting or between sessions.

Graft Types

Grafts are defined by the number of follicular units (FU) they contain, and the instruments used for making their recipient site. FU, first described by Headington, are single follicles or small groups of two to five closely spaced follicles, that are separated from other similar groups by slightly larger alopecic spaces (Fig. 277-3A). [14] Table 277-1 summarizes the definitions of the types of grafts that can be used in hair transplanting (see also graft preparation below).

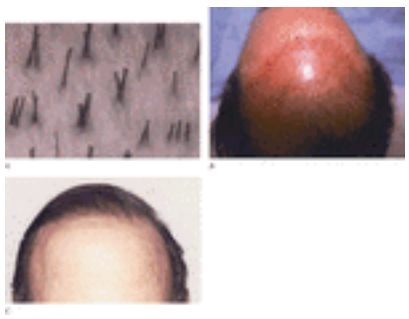

FIGURE 277-3 *A.* Densitometry illustrating the natural follicular groupings in the donor area of a patient with average hair density. Note that only 15 to 20 percent of hairs emerge singly, most are in groups of two and three hairs. *B.* Pattern of a follicular unit transplant (FUT) on a bald scalp. *C.* Frontal view of the same patient 5 months after one session of micrografts; the result will become thicker over the next 5 months.

Micrograft (always a single follicular unit)	1–4	Puncture hole	1 or less	No
Mini-slit graft	3–5	Beaver mini-EL Sharpoint or stitch knife	2	No
Mini-graft "small"	5–8	Hole or slot	3	Yes
Mini-graft "large"	6–12	Hole or slot	3–4	Yes
Slit graft "small"	5–8	Blade slit	3	No
Slit graft "large"	6–12	Blade slit	3–4	No
Standard graft	8–30	1.0+ mm Hole	6–12	Yes

TABLE 277-1 **Graft Terminology**

Three variables are considered in choosing the type of graft to be employed: hair characteristics, density objectives, and the amount of persisting recipient area hair.

The finer the hair texture, the less skin/hair color contrast, and the more hair wave or curl, the less plugginess will be noticed with grafts containing more than one FU. Sessions composed exclusively of FU [follicular unit transplant (FUT)], should be used if density objectives are not high. FUT is also ideal for the first session in a totally alopecic patient, as it produces the most even and natural distribution of hair in such individuals (Fig. 277-3). In addition, FUT is sometimes used as a last session in individuals with coarse hair and/or greater degrees of hair to skin color contrast. FUT is the least efficient way of producing substantial hair density.

Transplanting with mixtures of micrografts, mini-slit, and slit grafts is ideal for producing moderate density, while slot grafts (Fig. 277-4) and round grafts are better for creating greater density. It is popular to assume that round grafts will always produce noticeable "plugginess." This is not so if patients are properly selected and a combination of grafts of proper types and sizes are skillfully used.

FIGURE 277-4 *A.* Intraoperative pattern of a first frontal session. A mixture of micrografts, mini-slit, slit, and slot grafts has been used. *B.* The same patient shown after three sessions. *C.* A critical close-up lateral view of the hairline. Note the absence of any "plugginess" despite the use of some larger grafts.

Initially, micrografts, mini-slit, and slit grafts of whatever type will produce a greater increase in hair density than will slot or round grafts in a recipient area with persisting hair. With micrografts, mini-slit, and slit grafts, the net gain will be equal to the number of hairs being transplanted, as no hair is removed when micrograft holes and slits are correctly made between them. In the long-term, however, the more slot and round grafts that are used, the greater the density that will be achieved. This is the case because alopecic or potentially alopecic skin is also being removed, and because the hairs in the slot and round grafts are closer together than FU or slit grafts can ever be placed.

From the preceding discussion it should be clear that each graft type has advantages as well as disadvantages. Using only one or two types of grafts for all patients and circumstances unnecessarily limits the artistic options available to the hair restoration surgeon and the eventual density a patient can attain.

"Megasessions" consisting of several thousand FU and "dense packing" of the FU (e.g., 40 to 50 FU/cm ^{2}) in a single session were once suggested as a means of producing more coverage and density in fewer sessions and therefore less

time. [15], [16] Unfortunately sessions of 8 h or longer are necessary and may be medically unwise for some individuals. There is also considerable concern as to whether hair survival is as good as it is with smaller sessions and lower FU densities. [17], [18], [19] and [20] Nearly all hair restoration surgeons now limit the number of FU they will transplant in a single session to 1500 to 2000, and FU densities to 20 to 25 FU/cm ^{2}.

TECHNIQUE

Anesthesia

Diazepam 20 mg is given orally 30 min before surgery to minimize anxiety and, more importantly, the possibility of anesthetic toxicity. Oral meperidine hydrochloride (Demerol) 50 mg can be added to the diazepam for patients with low pain thresholds. For patients with extreme anxiety, premixed and self-administered 50% nitrous oxide and 50% oxygen, or intravenous propofol—the latter administered by a fully qualified anesthetist—can also be employed for 10 to 15 min as the local anesthetic is being injected. Field blocks are used in both donor and recipient areas and are produced, respectively, with buffered 1 to 2% lidocaine with 1:100,000 epinephrine and unbuffered 2 to 4% lidocaine with 1:50,000 epinephrine. [21] The buffering minimizes the stinging associated with the initial donor area injections. A tumescent anesthetic technique is used superior to the donor area field block.

For the frontal recipient area, 2 to 4% lidocaine with 1:50,000 epinephrine is used to produce three wheals along the proposed hairline: one in the midline and two midway between the midline and the left and right lateral ends of the hairline. The unanesthetized gaps between these wheals are gradually anesthetized by periodically inserting a needle into the anesthetized sections and injecting more lidocaine bilaterally, until a solid line of anesthesia is created. This field block is produced very slowly, over a period of at least 30 min. Injections are made superficially and the block is not started until 30 to 45 mins after the donor area is anesthetized, thus minimizing the potential for lidocaine and epinephrine toxicity. [21] Approximately 15 to 20 min after the recipient area block is completed, 1:50,000 epinephrine solution is infiltrated superior to it in order to minimize intraoperative bleeding.

The Donor Area

Improved donor area harvesting technique has revolutionized what can be accomplished with hair transplanting even in patients who have a very limited “safe” donor area (SDA). [9] Conceptually, one excises a donor area of appropriate size and sections it into the desired number and types of grafts. The authors employ two donor zones in most patients: one inferiorly in the occipital area and the other on the contralateral side more superiorly, extending from the midline into the parietal area and as far as 28 mm anterior to a line drawn perpendicularly from the tragus. The former is taken from an area with the finest caliber hair that is judged to be permanent and is ideal for use in the hairline zone. The superior donor zone contains hair that is coarser and can be used to produce greater density posterior to the hairline zone. It also contains temporal hair that will become gray or white earlier than that from occipital and parietal areas, and will therefore result in a sprinkling of gray hair in the frontal recipient area in pace with similar changes in the temporal area. During the second session, donor strips are taken contralateral to those obtained in the first session. If the SDA is narrower than usual, only one long donor strip is employed and one attempts to find the different hair textures along different areas on the same strip. Using figures obtained in a study of 328 men 65 years of age or older, a donor area of acceptable density and one that is “safe” to use in 80 percent of the patients younger than the age of 80 years was established. It is shown in Fig. 277-1B. [9] It is not uncommon to be able to excise 7- to 10-mm–wide strips of donor tissue bilaterally in four to six separate sessions, without the rim hair density appearing to be significantly decreased. Each session typically consists of 1500 to 1750 FU or 700 to 900 grafts of various types.

Incisions in the donor areas are made into the mid-subcutaneous tissue and the blades are always held parallel to the angle of exiting hair. Tissue harvested with a multibladed knife is used to prepare all types of grafts, while a strip excised with a two-bladed knife is used to obtain FU. Donor sites are usually closed in a single layer employing a 2–0 Supramid suture; these are removed in 7 to 10 days. Appropriate spacing of blades and donor sites is an important consideration. [9] Overzealous “harvesting” can lead to larger than necessary scars in the donor area. Scars from previous donor harvests are usually excised as part of any new donor areas, so that only one or two scars will ultimately be left no matter how many operations are carried out. Wide scars and needless patient discomfort are usually the result of overestimating what can be removed, or being too zealous in producing large numbers of grafts in a single session.

Graft Preparation and Insertion

After the donor strips obtained with a multibladed knife have been excised, they are separated from each other and oriented on a moistened piece of plastic sheeting with a good back light so that a clear view of the hair follicles is possible. These multiblade strips are used to create primarily slit grafts, slot grafts, and round grafts, but also are a source for additional micrografts. Elliptical blocks of donor tissue, obtained with the two-bladed knives, are first carefully slivered into sections that are one FU wide. [22], [23] These “slivers” are then further divided into pieces containing one, two, or three FU for, respectively, micrografts, mini-slit, and slit grafts. All grafts are immediately placed into saline-filled petri dishes that sit on a cup filled with ice. Most technicians use 6 to 10× stereo microscopes for creating the “slivers” and FU and 1 to 2× magnifying glasses for all other grafts. Although we currently expend considerable effort on keeping FU intact, the importance of this practice is far from certain. Transected follicles often grow hair—although sometimes of smaller caliber—and may, in fact, produce more hair than was originally transplanted.

The grafts are sorted according to hair texture, color, and size and must be kept moist at all times. They are gently eased into the recipient sites using small serrated forceps or jewelers' forceps. They are positioned flush with or slightly above the surrounding skin.

The Recipient Area

The hairline should begin and end at the *ultimate* anterior–superior points of the temporal hair. The midline point should be placed such that (1) the hairline runs approximately parallel to the ground when viewed laterally, and (2) it is situated in the transition area between the more or less vertical forehead and the horizontal caudal plane of the head. Approximately 500 to 600 micrografts are used in the hairline zone, which should always have a very irregular anterior border. Posterior to the micrografts, a zone of mini-slit grafts is usually used, with micrografts scattered between them. Although one is ultimately looking for a random and therefore natural-looking distribution of hair in the hairline zone, the authors have found that a careful “organized disorganization” produces a better short-term as well as long-term appearance. [24] Mini-slit, small and/or large slit grafts are employed for the rest of the recipient area in most patients, excepting the center of the whorl of the vertex, where only micrografts are used (Fig. 277-1A).

After 4 or more months have elapsed, similar grafts are placed between those transplanted during the first session. However, if hair characteristics are good and greater density is preferred, some large slit grafts and/or slot or small round minigrafts may be used during the second session. Six or more months later, a third session may be done. It is common to carry out three sessions in an alopecic frontal area, although some patients are content with two and a few require four sessions to satisfy their density objectives. In the mid-scalp and vertex areas no more than two sessions are usually necessary to produce cosmetically satisfying results. The size of the grafts can be increased from session to session to increase density without increased graft noticeability. The combination of micrografts, mini-slit grafts and slit grafts described above is used for a large majority of patients. However, as noted earlier, if the recipient area is initially alopecic, a first session of FUT may be used. FUT may also be employed for patients who do not want to commit to more than one session.

In 10 to 15 percent of male patients, if the objective is greater hair density, an organized pattern of square grafts placed into round holes may be employed in a zone that is approximately 2 to 2.5 cm posterior to the hairline and medial to the most lateral frontal area grafts (Fig. 277-1A). Generally the square grafts are prepared from 2- or 3.5-mm–wide strips and are placed into holes made respectively with a 2- or 3- to 3.25-mm trephine. Any given area of alopecia can be solidly filled with either three or four sessions of round grafts. [25] The intervals between sessions of round grafts should be the same as those employed for slit grafts. In the authors' view, reports of the demise of the round graft are premature. Such grafts are appropriate for most patients who want more than moderate hair density.

In women, nearly all grafts used are FU or mini-slit grafts. For African American patients, a combination of micrografts and slit grafts for the hairline zone and round or slot grafts of various sizes posterior to the hairline zone should be used. For all other races, the use of this combination of graft types is optional.

The need for consistent direction and angling of recipient sites (mimicking the original direction and angle of hair in the area) cannot be overemphasized. Slight changes in the angle at which one prepares a recipient site, especially for slot and round grafts, can result in injury to or excision of adjacent original or previously transplanted hair matrices and the creation of new small areas of alopecia.

Laser Transplanting

A variety of carbon dioxide lasers were tried and reported on by one of the authors over a period of 5 years. [26], [27] The main objective was to produce slotlike recipient sites that would result in an appearance that was cosmetically superior to that created with micrografts, slit grafts, or round grafts. Unfortunately, the problems of inconsistent degrees of lateral thermal damage, increased postoperative crusting, delayed hair regrowth, and variable rates of hair survival were never overcome. More recently, erbium lasers and combination erbium-CO_2 lasers have shown lesser amounts of all the preceding problems; however, they have thus far been used only for the production of round recipient sites. [28] Therefore, while these lasers allow for better control of bleeding than do trephines and blades, they do not result in better cosmesis, especially when compared to the new “slot” punches. If and when a laser is perfected that combines minimal thermal damage and the rapid production of “slot” sites—especially if it were combined with a scanner to create those sites in a specific pattern with consistent spacing between the sites—then lasers might finally enjoy the potential that the technology has always promised.

Bandaging

Most physicians continue to use a small turban-like postoperative overnight dressing. However, if FUT or micromini-grafting is employed, and if there is no more than the usual amount of bleeding, many patients can leave the office 30 to 120 min after completion of the surgery without a bandage. All patients should ideally return the next day to confirm that the grafts are still positioned properly as well as to carefully clean away any blood clots that may have developed overnight. Properly trained assistants then carefully wash, style, and dry the hair.

Postoperative Course

Patients are supplied with three analgesics to be used as required: acetaminophen tablets with 30 mg of codeine, oxycodone, and meperidine hydrochloride 50 mg. Most patients use only the acetaminophen and codeine tablets and only for the first night. Unless it is contraindicated, patients are also given an intramuscular injection of ketorolac tromethamine, 30 to 60 mg, which generally eliminates all postoperative pain for 6 to 8 h. Nearly all hair restoration surgeons administer an intramuscular glucocorticoid, such as 80 mg of methyl prednisolone acetate, to reduce postoperative edema.

A small amount of crusting forms over the grafts. Most of this is removed during the first cleaning and washing the day after surgery, and it is gone in 7 to 14 days. The grafts will usually lose their hair in 2 to 6 weeks while new hair growth

normally begins 10 to 20 weeks after surgery. The ultimate cosmetic effect of any given session is seen 9 to 12 months after surgery. A 3% solution of minoxidil used twice daily for 5 to 6 weeks postoperatively will often accelerate regrowth and decrease the chance of postoperative telogen effluvium of existing hair in the recipient area. Some hypoesthesia of the scalp can be expected to occur postoperatively in nearly everyone. This is usually temporary, but it may sometimes persist in one or more small areas.

Complications

True infection in the recipient area occurs in fewer than 0.1 percent of patients, while a few usually self-resolving ingrown hairs are seen in 1 to 5 percent. Hot compresses and topical, as well as systemic, antibiotics are prescribed if pathogens grow from the exudate or if there is clearly infection present. Grafts may be slightly elevated ("cobblestoning") or slightly depressed, although both are very uncommon with FU, mini-slit, and slit grafts. Cobblestoning can be treated with light electrodesiccation, while depressed grafts should be excised and repositioned at that site or replaced with new grafts that lie flush with the skin. Other complications include epidermal cysts; keloids; hypertrophic scars; poor hair survival; arteriovenous fistulae; osteomyelitis; telogen effluvium; chronic folliculitis; accelerated hair loss; temporary curly or lusterless hair; indented skin or "grooves" in the recipient area; "hyperfibrotic" healing; and wound dehiscence. All of the above potential complications are either rare, temporary, minor, or avoidable sequelae of hair transplanting, and should be viewed from that perspective. [5] There has, however, been one reported case of an arteriovenous fistula in the donor area leading to septic pulmonary emboli.

ALOPECIA REDUCTION

AR, or scalp reduction, can be defined as the excision of an area of alopecia or future alopecia. The larger the area that can be removed, the smaller the remaining area of alopecia will be, with the result that fewer grafts will be required to treat the reduced area or produce the same hair density in the reduced area. In general, the authors recommend that one or more ARs be employed any time the objective of the patient is maximum coverage of frontal and vertex alopecia.

Technique

AR is usually carried out on an outpatient basis using only local anesthesia but under sterile conditions. [29] If the excision pattern is an ellipse, a variant of an ellipse, or shaped like a "lazy S," an incision is made down to and through the galea along one side of its entire length, usually in a staged fashion, stopping to control bleeding with cautery where required. Care is taken to angle the blade so as to not injure any adjacent follicles. Mayo scissors and blunt finger dissection are used to undermine between the periosteum and galea aponeurotica. Recent studies by Raposio and Seery suggest that 5 cm of undermining will allow the surgeon to excise the same width of tissue when compared to more extensive undermining. [30]

The amount of redundant scalp tissue is estimated by overlapping the tissues, followed by perpendicular incisions made through the top flap, stopping at the points where the flaps meet. The ends of the perpendicular cuts are then joined by a long incision parallel to the original one, and the excess tissue is thereby removed. If the AR is done in the shape of an inverted Y, each "arm" of the Y is treated as a separate ellipse. ARs are closed in two layers—galea and skin—and an overnight dressing is applied.

Complications

Complications of AR include postoperative bleeding, infection, nerve damage, persistent hair thinning or loss in the fringe areas, disorientation of hair direction, and poor scars. All of these rarely occur.

Major Reductions

Major reductions have been described by numerous authors. Brandy suggested calling them bilateral occipital parietal flaps and bilateral temporal flaps. [5] Major reductions are distinguished from standard ARs by more extensive undermining involving the severing of temporal and/or postauricular and/or occipital arteries and nerves bilaterally. The efficacy of these procedures in excising substantial areas of alopecia is beyond question. However, potential complications include wound dehiscence, permanent hypoesthesia, persisting marked thinning of existing scalp hair, and necrosis of large areas of the scalp. Although they are infrequent, they are serious enough that the authors are not aware of anyone presently doing these types of reductions.

Scalp Extension

Scalp extension was first described by Frechet in 1993. [31] As part of a conventional AR, he inserted a thin stretched sheet of silicone elastomer in the subgaleal space. Rows of titanium hooks attached to the lateral ends of this "extender" were hooked into the galea. The wound was then sutured closed in two layers. The extender has a natural tendency to return to its original size, thus stretching the tissue located lateral to the hooks and contracting the scalp between them. After a period of approximately 30 days, the extender is removed. Substantial scalp laxity is then present and another AR is carried out. Frechet's studies revealed that if the extender had been stretched to twice its original length, approximately twice the expected area of alopecia could be removed on this second occasion, and as soon as 30 days after the first (instead of the more usual 2 to 3 months between ARs). Another extender can be inserted at the time of the second, so even a third AR can be carried out. Remarkable results can be achieved very quickly (Fig. 277-5). Disadvantages include substantial discomfort during the postoperative period that lasts from 1 to 2 weeks, an infection rate of approximately 0.5 percent, and a "slot" defect that must be repaired if the entire area of alopecia is excised.

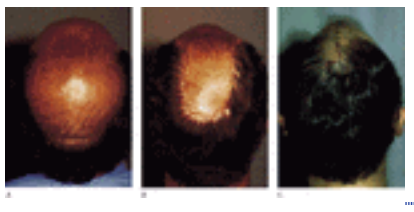

FIGURE 277-5 *A.* Before reduction. *B.* Immediately after the second alopecia reduction (AR), 30 days after the first AR, during which a Frechet extender was inserted. *C.* Immediately after a third AR, which was done 60 days after the first and 30 days after the second, and included a three-flap corrective procedure for the slot that would have otherwise been present. (*Photos courtesy of Dr. Patrick Frechet*)

Alopecia Reduction Preceded by Soft-Tissue Expansion

Tissue expansion has been used prior to AR for more than two decades. In brief, a specially designed surgical “balloon” is inserted as a separate procedure prior to a planned AR. It is gradually inflated with injections of saline every 1 or 2 weeks for 6 to 12 weeks. The expander is then removed and an AR is carried out. The use of such expanders enabled physicians to excise as much as 10 to 12 cm of alopecia in one AR. An infection rate of less than 0.5% is the only additional complication over those that can occur with modified major AR. Anderson described elegant procedures that use soft-tissue expansion prior to bilateral advancement transposition (BAT) and triple advancement transposition (TAT) flaps that produce excellent cosmetic results. [5] Despite this, the cosmetic disability caused by the gradually inflated expanders, which produce a hydrocephalic appearance toward the end of the inflation period, has to a large extent limited this technique to individuals with cicatricial alopecia. Unger recently described the use of what he terms prolonged acute tissue expansion (PATE) during the course of a conventional modified major AR. [29] A U-shaped expander is inserted under the hair-bearing skin and is expanded over 2 to 3 h while the patient remains in the operating room under local anesthesia. The AR is then carried out and generally will result in the removal of approximately twice the area that would have been removed with a conventional modified major AR. This technique offers a reasonable compromise approach to the advantages of tissue expansion while eliminating most of its disadvantages.

REFERENCES

1. Dieffenbach JF: *Nonnulla de regeneration et transplantation*. Konigsberg, Germany, Dissertation inauguralis, 1822

2. Orentreich N: Autografts in alopecias and other selected dermatological conditions. *Ann N Y Acad Sci* **83**:463, 1959

3. Blanchard G, Blanchard B: Obliteration of alopecia by hair lifting: A new concept and technique. *J Natl Med Assoc* **69**:639, 1977

4. Unger MG, Unger WP: Management of alopecia of the scalp by a combination of excisions and transplantations. *J Dermatol Surg Oncol* **4**:670, 1978

5. Unger WP, Shapiro R, editors: *Hair Transplantation,* 4th ed. New York, Marcel Dekker, 2003

6. Unger WP, Beehner M: General principles of recipient site organization and planning, in *Hair Transplantation,* 4th ed., edited by W Unger, S Shapiro. New York, Marcel Dekker, 2003

7. Marritt E, Dzubow L: Re-assessment of male pattern baldness: A re-evaluation of treatment, in *Hair Replacement,* edited by D Stough. St Louis, Mosby, 1995, p 30

8. Norwood OT: Senile alopecia, in *Hair Transplant Surgery,* edited by OT Norwood, R Shiell. Springfield, IL, CC Thomas, 1984, p 10

9. Unger W, Cole J: The donor area, in Hair Transplantation 4th ed., edited by W Unger, S Shapiro. New York, Marcel Dekker, 2003

10. Unger W: Hair transplanting in females, in Hair Transplantation, 4th ed., edited by W Unger, S Shapiro. New York, Marcel Dekker, 2003

11. Unger MG: Alopecia reduction and stretch-back. *Clin Dermatol* **10**:345, 1992

12. Hitzig GC, Sadick NS: A new technique for curvilinear scalp reduction. *J Dermatol Surg Oncol* **15**:1108, 1989

13. Nordstrom R: “Stretch-back” in scalp reductions for male pattern baldness. *Plast Reconstr Surg* **73**:422, 1984

14. Headington JT: Transverse microscopic anatomy of the human scalp. *Arch Dermatol 1* **120**:449, 984

15. Rassman W: The art and science of small graft hair transplantation, in *Hair Replacement, Surgical and Medical,* edited by D Stough, S Haber. St. Louis, Mosby, 1996, p 151

16. Norwood OT: 2000 Grafts per session. *Hair Transpl Forum* **4**(3):2, 1994

17. Pomerantz M: More problems with megasessions. *Hair Transpl Forum* **5**:4, 1995

18. Unger W: Innovations in hair transplanting: Progress versus promotion, in *Adv Dermatol* **16**:427, 2000

19. Greco J: The H-factor in micrografting procedures. *Hair Transpl Forum Int* **6**:8, 1996

20. Shiell R: Editor's notes. *Hair Transpl Forum Int* **4**:12, 1996

21. Unger W: Anesthesia, editor's commentary, in *Hair Transplantation,* 4th ed., edited by W Unger, S Shapiro. New York, Marcel Dekker, 2003

22. Limmer R: Elliptical donor harvesting, in *Hair Replacement Surgical and Medical,* edited by D Stough, R Haber. St Louis, Mosby, 1995, p 142

23. Seager D: Classic microscopic dissection for follicular units, in *Hair Transplantation,* 4th ed., edited by W Unger, S Shapiro. New York, Marcel Dekker, 2003

24. Unger W: Hair transplantation, in *Atlas of Cosmetic Surgery,* edited by S Kaminer, J Dover, K Arndt, Philadelphia, WB Saunders, 2002, p 231

25. Unger W: The recipient area, in *Hair Transplantation,* 4th ed., edited by W Unger, S Shapiro. New York, Marcel Dekker, 2003

26. Unger W, David L: Laser hair transplanting. *J Dermatol Surg Oncol* **20**:515, 1994

27. Unger W: Laser hair transplantation II. *Dermatol Surg* **21**:759, 1995

28. Sadick et al: A comparative clinical and histological study of hair transplantation using Er:Yag, Er:Yag/CO_2 and standard punch techniques. *Dermatol Surg* **27**:807, 2001

29. Unger M: Scalp reduction, in *Hair Transplantation,* 4th ed., edited by W Unger, S Shapiro. New York, Marcel Dekker, 2003

30. Seery G: Improved scalp surgery results by controlling tension vector forces in the tissues by galea to pericranium fixation sutures. *Dermatol Surg* **27**:569, 2001

31. Frechet P: Scalp extension. *J Dermatol Surg Oncol* **19**:616, 1993

T>

Chapter 278

Gloria Graham K. Cerveny James SanFilippo

Cryosurgery

HISTORY
PATIENT SELECTION
CRYOBIOLOGY
EQUIPMENT
TREATMENT OF BENIGN LESIONS
Technique
PREMALIGNANT LESIONS
MALIGNANT LESIONS
Technique
Postoperative Management
SIDE EFFECTS AND COMPLICATIONS
Infection
Abnormal Scarring
Pigment Alteration
Nerve Damage
Insufflation of Soft Tissue
Alopecia
Loss of Mucosa
Reactive Changes
Cartilage Necrosis
Syncope
OTHER INDICATIONS FOR CRYOSURGERY
Full-Face Cryosurgical Peels
Ultrasound
Granuloma Annulare
Lentigines
Keloids
Psoriasis
Seborrheic Keratosis
Prurigo Nodularis
Myxoid Cyst
Verruca
Condylomata Acuminata
Kaposi Sarcoma
Basal Cell Carcinoma

REFERENCES

HISTORY

Cold has been an important adjunct in medicine since the Egyptians used it to treat injuries and inflammation around 2500 B.C. [1] Similarly, Hippocrates used cold to relieve the pain of injury and illness from 460 to 370 B.C. [2] Baron Dominique Jean Lorrey used cold to stop hemorrhage after amputations done in Napoleon's historic retreat from Moscow. [3] Using a brine solution, Arnott, [4] a London physician, lowered temperatures to –24°C (–11.2°F) for treatment of neuralgia and as palliation in terminally ill cancer patients.

New York became the “cradle of cryosurgery” in the United States in 1899, when White, a dermatologist, first dipped a cotton-tipped applicator into liquid air and successfully treated warts, nevi, keratoses, and skin cancers. [5] Whitehouse, another New York dermatologist, developed a spray from a laboratory wash bottle in 1907. [6] In the mid-1960s, Zacarian used this concept to develop a spray of liquid nitrogen after first working with copper probe tips. [7] Around the same time, another New York dermatologist, Torre, treated multiple types of skin lesions with an instrument originally designed by Cooper for use in the brain. [8]

Carbon dioxide was the primary cryogen used from the early 1900s until Allington introduced liquid nitrogen applied with a cotton swab in 1948. [9] This technique is still widely in use.

Cryosurgery is effective in treating a wide array of skin conditions including many benign, premalignant, and malignant lesions. Because it also offers partial anesthesia, numerous lesions may be treated at one sitting. This efficient, effective, and economical method is now widely used by physicians who manage skin lesions.

PATIENT SELECTION

Dermatologists now have a variety of treatment methods available for benign and malignant skin lesions including excision, electrodesiccation, chemical peeling, laser, the Mohs technique, radiation, and topical agents such as 5-fluorouracil, glycolic acid, and retinoids. The selection of treatment depends on the patient as well as his or her skin type, general health, and overall expectations. Not all methods are available in every office, but freezing and

electrodesiccation are extensively used by many dermatologists.

Cryosurgery is unique in its versatility for treatment of multiple warts or keratoses in fair-skinned patients. Patients who are allergic to local anesthesia, take anticoagulants, or have anticipated poor wound healing are excellent candidates for the procedure. Cryosurgery is often selected for lesions larger than 3 to 4 mm, while for multiple 1- to 2-mm lesions, electrodesiccation may be preferable. Laser is usually preferred over freezing for port-wine stains and some other vascular lesions, but freezing may be more cost-effective than laser for treatment of multiple lentigines. [10] For physicians managing patients infected with HIV, the “blood-free” aspect of cryosurgery is a unique advantage, especially in the treatment of warts, molluscum contagiosum, and Kaposi sarcoma. [11]

CRYOBIOLOGY

Cryosurgery is a technique that removes heat from the skin by applying a cryogenic agent. The mechanism of injury involves direct cellular freezing as well as vascular stasis, which develops after thawing. These changes depend on several factors, including the rate of temperature fall, the rate of rewarming, the solute concentration, the length of time cells are exposed to a temperature in the 0°C to –50°C (32°F to –58°F) range, and the coldest temperature reached in the target tissue. [12] Slow cooling produces extracellular ice formation, whereas rapid cooling leads to intracellular ice formation. The latter results in more cellular damage, because the cells are ruptured during the thawing process. Slow thawing also causes an increased concentration of electrolytes. The recrystallization that takes place is damaging to cells. [13] The local inflammatory response contributes to the final cellular destruction [14] and consequent vascular stasis assures greater cell destruction.

EQUIPMENT

Cryosurgery can be performed with a number of cryogens (Table 278-1) and various forms of equipment. The Kidde apparatus uses carbon dioxide to freeze tissue. It is rarely used today, but some offices still use a combination of pulverized carbon dioxide, sulfur, and acetone, which forms a dry ice slush. The application of liquid nitrogen with a cotton swab is still in use, but most physicians in the United States, as well as in numerous foreign countries, frequently apply it using a small hand-held spray unit. These units come equipped with interchangeable apertures and probe tips of varying size. Some of the units available include the Frigitronics Cryo-Surg, Brymill Cry-AC units, Nitrospray, and Wallach Ultra Freeze. Liquid nitrogen may be purchased from many welding supply companies at a cost of approximately $1.50 to $2.40/L. It is stored in 20- to 30-L Dewar flasks.

Cryogens	Boiling Point STP (C°)
Carbon dioxide (solid)	−78.5 (−109.3°F)
Nitrous oxide (liquid)	−89.5 (−129.1°F)
Liquid nitrogen	−195.8 (−320.4°F)

TABLE 278-1 **Cryogens and Their Temperatures**

There is evidence that viral contamination of liquid nitrogen may occur when warts are treated by the dipstick method. [15] Use of a Styrofoam or stainless steel cup is recommended for holding liquid nitrogen prior to dipping the cotton swab in order to avoid this possible complication.

TREATMENT OF BENIGN LESIONS

Many benign tumors and conditions may be managed by cryosurgery. A number of factors must be considered before deciding that cryosurgery is the treatment of choice. These include the depth and location of the lesion, the patient's skin type, the total number of lesions being treated, the desired cosmetic result, and the anticipated discomfort that might result from treatment of lesions in certain locations such as the plantar surface of the foot.

Technique

In general, it is sufficient to freeze a benign tumor until a 1- to 2-mm rim of normal tissue has been frozen around it. Some lesions, such as the seborrheic keratosis, may be especially stubborn to eradicate and need longer freeze times (Table 278-2). The use of intermittent freezing allows for better control than one would have using a continuous spray, especially for small lesions. Probes are advantageous for small vascular lesions and sebaceous hyperplasia. The approximate freeze times for eradication of common benign lesions and the anticipated cosmetic results are given in Table 278-3.

TABLE 278-2 **Treatment Chart***

Lesion	Freeze Times seconds	Range of Expected Cosmetic Results
Acne scarring	10	Good to fair
Actinic keratoses	5–10	Excellent to good
Cherry angioma	15–20 (probe)	Good to fair
Chondrodermatitis	30	Good to fair
Granuloma faciale	30	Good to fair
Hemangioma	60+	Good to fair
Hypertrophic scarring	20	Good to fair
Keloidal scarring	30	Excellent to good
Keratoacanthoma	30	Excellent to good
Lentigines	10	Excellent to good
Lentigo maligna	60–120	Good to fair
Morphea-type basal cell	90–120	Good to fair
Nevi	10	Excellent to good
Nodular basal cell	60–90	Excellent to good
Sebaceous hyperplasia	5–10 (spray or probe)	Good to fair
Seborrheic keratoses	10	Excellent to good
Superficial basal cell	60	Excellent to good

*Using intermittent spray, unless otherwise specified.

TABLE 278-3 **Comparison of Freeze Times for Benign and Malignant Lesions and Range of Expected Cosmetic Results***

PREMALIGNANT LESIONS

The actinic keratosis is one of the most common lesions treated by cryosurgery. The specific type of keratosis and its size determine the duration of freeze. A relatively macular lesion with a thin scale may be eradicated by a 5- to 7-second freeze, whereas a thicker hypertrophic lesion may require up to 20 or 30 seconds of freezing (Table 278-2). The comedonal type of actinic keratosis may require at least 20 seconds. Outlining the lesion with a marking pen prior to freezing is helpful in making certain the entire lesion is treated adequately. A cryopattern develops as a keratosis is frozen, and this is useful in determining lesion size. In some patients, prethinning of lesions with emollients (especially glycolic acid compounds) results in lesions that necessitate an even shorter freeze time of 4 to 6 seconds.

A 2- to 4-mm margin of freeze around the lesion should be sufficient. Thermocouple monitoring for determining depth of cold is not necessary when treating benign lesions.

MALIGNANT LESIONS

Sufficient experience has been gained by numerous cryosurgeons who agree that a freeze time of approximately 60 seconds using an intermittent spray is adequate treatment for a malignancy such as a basal cell carcinoma (BCC) or squamous cell carcinoma (SCC), especially a SCC arising from an actinic keratosis. To measure the depth of freeze by thermocouple monitoring requires inserting a needle beneath the tumor. While many experienced cryosurgeons no longer do this, it can be quite advantageous for learning the proper technique.

Technique

The tumor is frozen with an intermittent spray until a zone of approximately 5 mm of frozen tissue is reached around the lesion (Fig. 278-1, Fig. 278-2 and Fig. 278-3). This usually requires about 60 seconds of freezing. If a neoprene or other type of cone is used, this may shorten the freeze time to 45 seconds or less. The halo thaw time will be approximately 60 seconds, and the complete thaw time for the entire lesion is 2 to 5 min. If a thermocouple needle is used, freezing should continue until the monitor registers around –50°C (–58°F). The thaw time to 0°C (32°F) is often around 1 min. For the greatest destruction, a double freeze–thaw cycle is used.

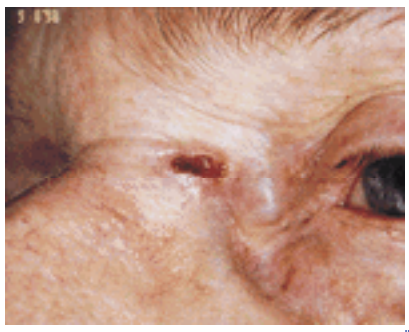

FIGURE 278-1 Basal cell carcinoma on the nasal bridge.

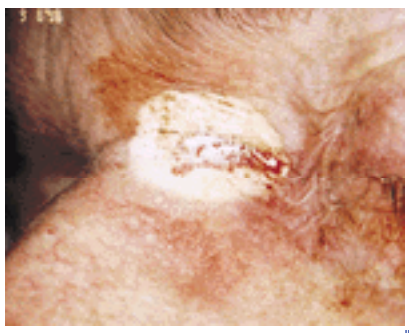

FIGURE 278-2 A double freeze–thaw cycle was used after biopsy confirmation. Freeze time was 1 min for each cycle. Halo around tumor is 5 mm. Halo thaw time was 90 seconds.

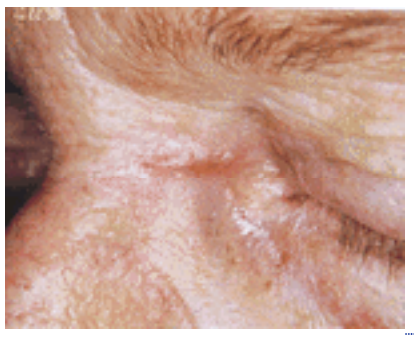

FIGURE 278-3 The site has healed with a linear scar.

Mallon and Dawber [16] found that for facial lesions, a double freeze–thaw cycle yields a higher cure rate; but for superficial basal cell carcinomas on the trunk, a single freeze–thaw cycle is sufficient to yield a 95.5 percent cure rate. Freeze and thaw times should be recorded in the medical record.

Many physicians prefer to debulk the tumor by curettage or razor blade saucerization prior to freezing. [17] This provides an adequate specimen for the pathologist and allows for better judgment in terms of tumor depth and lateral extent of the tumor. Freezing is then performed on the tumor bed. Lesions 3 to 4 cm in size may be divided into 1- to 2-cm portions but may be treated at one visit. More extensive lesions may be treated over several months.

When treating lesions on the ear, the external auditory canal should be protected with a cotton pledget or with one's hand. When treating the nose or eye, protection with a tongue blade or a Jaeger retractor (for the eye) is useful. When proper technique is used, cryosurgery is especially effective in treating lesions overlying cartilage.

Postoperative Management

While simple, the care of the cryosurgical wound requires specific instructions to the patient. Washing the lesion with soap and water once to twice daily is the most useful approach. Although some locations will need a dressing because of the bullous reaction and drainage that freezing can induce, most sites may be left open. These wounds actually seem to heal better this way, because the eschar is not inadvertently removed by adherence to dressings. The cryowound is its own biologic dressing and is wet from its inception (Fig. 278-4). Benign and premalignant lesions heal in 10 days to 2 weeks, although the final eschar separates and comes off at about 1 month postoperatively for most skin cancers. Those on the back and leg, especially if over 1 to 2 cm in diameter, may require 6 weeks to 3 months to heal. If the eschar becomes dry and adherent, it may be removed and the base treated with antibiotic ointment twice daily until healed. If an ulcer is present upon the removal of the eschar, DuoDERM or a similar dressing may be used.

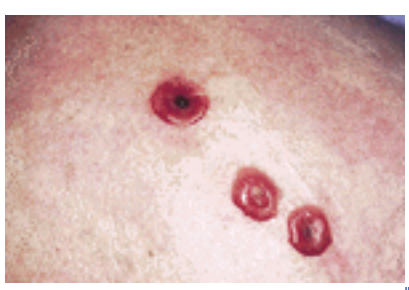

FIGURE 278-4 The bulla resulting from freezing is its own biologic dressing and heals in 10 to 14 days when 10 to 20 seconds of intermittent freeze time is used.

SIDE EFFECTS AND COMPLICATIONS

The expected effects following freezing are edema, vesicles, bullae, weeping, and eschar formation. Periorbital edema may be lessened by the use of systemic glucocorticoids [18] or potent topical glucocorticoids twice daily [19] for 3 to 4 days. Pain following freezing is more likely to occur when lesions on the palms, soles, fingers, toes, scalp, and temple are treated. Rarely are analgesics other than aspirin or acetaminophen required. Bleeding following freezing is uncommon, but should be considered while treating patients who take anticoagulants.

Infection

The incidence of infection following freezing is very low, probably because of destruction of skin flora, maintenance of the basement membrane, and the rapid reepithelialization that occurs after treatment. Patients should be cautioned that if increased heat, redness, or purulent drainage develops, they should return to see the physician promptly.

Abnormal Scarring

The maintenance of a normal dermal fibrous network after freezing allows many wounds to heal with little or no scarring. The most common scar is soft and hypopigmented. Linear hypertrophic scarring may be seen following treatment of cancers on the nose, upper lip, and chest. Ectropion may result following freezing of eyelid carcinoma, but this is rare. Loss of eyelashes is routine after such treatment. Notching of the ala of the nose and helix of the ear is seen when large tumors are treated.

Pigment Alteration

Pigment loss due to sensitivity of the melanocytes, which are destroyed at –4°C (24.8°F), is common after freezing, [20] but when freezing times under 20 to 30 seconds are used, this pigment loss is often temporary. Peripheral hyperpigmentation may be noted especially on the leg and back. Use of topical steroids, glycolic acids, and retinoids as well as hydroquinones may decrease this effect.

Nerve Damage

Damage to nerves is rare following the freezing of benign and premalignant lesions and is also uncommon after freezing malignancies. Digital neuropathy after treating a wart on the finger has been reported. [21] Sensory loss following freezing usually resolves in 6 to 12 months. The sense of touch recovers more quickly than the sensations of pain and cold. [22]

Insufflation of Soft Tissue

Nitrogen gas may escape into perilesional skin when freezing follows a biopsy. Pressure on the crepitant area will result in expulsion of the gas. The use of a cone surrounding the biopsy site can prevent this from occurring.

Alopecia

Freeze times longer than 20 seconds may result in alopecia of the scalp hair, eyebrows, eyelashes, or beard. Alopecia is more common after freezing skin cancer than after treating benign lesions.

Loss of Mucosa

Adherence of probes to mucous membranes can result in loss of mucosa upon removal of the probe. This can be prevented by prechilling the probe or by applying K-Y jelly. If the probe does adhere, it should be allowed to defrost so that it pulls away from the mucosa without tearing it. [17] Pseudotumor recidive and exuberant granulation tissue are occasionally seen.

Reactive Changes

Formation of a pyogenic granuloma after using liquid nitrogen to treat a venous lake on the lip has been reported. Pyogenic granuloma formation has also been noted after freezing basal cell carcinomas and actinic keratoses. [23] Erosive pustular dermatosis of the scalp following cryotherapy for actinic keratosis has been documented, [24] as well as the development of a keratoacanthoma following treatment of prurigo nodularis with cryotherapy. [25]

Cartilage Necrosis

This complication is rare but occurs most frequently on the helix of the ear. Cartilage necrosis is seen most commonly after treating a malignancy because of the deeper cold penetration achieved from longer freeze times. [17]

Syncope

Syncope occurs infrequently but should be anticipated after freezing warts on the digits. A patient who experiences syncope should be cared for with standard supportive measures.

OTHER INDICATIONS FOR CRYOSURGERY

Full-Face Cryosurgical Peels

Full-face cryopeeling was carried out for more than 40 years by using a mixture of carbon dioxide, acetone, and sulfur to create a dry ice sludge that was applied with a gauze ball. Graham first used liquid nitrogen for spraying acne and acne scarring, and performed full-face peeling in lieu of dermabrasion for scarring. [26]

Chiarello used a similar but modified technique called the “cryopeel” for the treatment of sun-damaged skin, actinic keratoses, seborrheic keratoses, lentigines, and wrinkles. [27] He has since combined freezing and “derma sanding” with tumescent anesthesia. With this technique he reports excellent, consistent, and reproducible results with minimal complications in the treatment of rhytids. [28]

Ultrasound

The use of ultrasound in determining the depth and lateral extent of a tumor aids in the decision-making process with regard to the type of procedure to be used for the treatment of a particular cancer. If the tumor has indefinite margins, a procedure such as Mohs surgery should be selected over cryosurgery. The dermatopathologist can aid in this determination by describing the location of the tumor on biopsy, that is, upper, mid, or lower dermis. [17], [29]

Abramovits et al. [30] found ultrasound useful for the accurate placement of thermocouples. They located the thermocouples by using ultrasound and accurately measured their distance from the skin surface. The use of ultrasound significantly benefits the cryosurgeon who uses thermocouples routinely for the treatment of skin malignancies.

Granuloma Annulare

Although cryosurgery has been used for years in the treatment of granuloma annulare, a prospective trial carried out in Germany, in 1993, found that applying liquid nitrogen or nitrous oxide for one freeze–thaw cycle for 10 to 60 seconds produced excellent results. Twenty-five of 31 lesions (80.6 percent) resolved after one treatment. One patient relapsed during a 2-year follow-up. [31]

Lentigines

These common, hyperpigmented macules on the hands and face may be satisfactorily removed by freezing. Pretreating the skin with topical tretinoin, hydroquinone, or glycolic acid helps to thin these lesions prior to freezing and makes the final cosmetic result much better. Approximately 5 to 7 seconds of intermittent freezing will clear a significant portion of the lesions. Cryopeeling also works well on these. [27]

Stern et al. compared laser therapy with cryotherapy and found that freezing worked as well as or better than laser and was more cost-effective in the treatment of lentigines. [10]

Keloids

Freezing may be very effective in some keloids. [26] The variability in size, age, consistency, skin color, and location play a role in deciding which treatment to use. Numerous modifications have been added, such as freezing in conjunction with intralesional steroids with or without prior debulking. The addition of an Epiderm dressing for a few weeks prior to the freezing is helpful. Some have used radiation therapy for treatment prior to freezing. Comparison of intralesional steroid and cryosurgery in acne keloids was carried out by Layton et al. [32] and showed an average of 80 percent improvement in early lesions treated with cryosurgery.

Psoriasis

Although there are few publications attesting to its effectiveness, freezing is used widely by clinicians in treating small and medium-sized plaques of psoriasis. [17], [33]

Nouri [34] reported success in using average freeze times of 12 seconds/cm ^{2}. There was complete resolution of lesions in 5 of 9 subjects. Two others improved substantially and one worsened. Graham [17] has noted Koebnerization in one patient with a brief freeze of only 5 seconds on an elbow. With freeze times of 10 to 15 seconds, this did not occur.

Seborrheic Keratosis

Cryosurgery alone or followed by curettage is an effective form of therapy for this lesion, whose treatment is covered by only a few insurance companies. Some patients experience disabling pruritus but may be helped by using an a-hydroxy body cleanser applied with a polyethylene sponge followed by an a-hydroxy lotion. Castor oil applications are also helpful. Thin lesions are treated with 10 to 15 seconds of freeze. Some very thick lesions may be treated successfully by curettage and cryosurgery. [17]

Prurigo Nodularis

Cryosurgery is one of the treatments of choice for recalcitrant lesions. The C fibers of the nerves are altered by freezing, thereby decreasing pruritus and ameliorating the itch-scratch cycle. [17] Because of differences in lesion size, shape, and thickness, freeze times vary from 15 to 30 seconds. Spray or a contact probe may be used. Topical and oral antipruritic agents and topical steroids help to prevent recurrence. [35]

Myxoid Cyst

There are numerous reports of resolution of myxoid cysts following cryosurgery with one double freeze–thaw cycle. [36] Healing occurs in 2 to 3 weeks with good cosmetic results.

Verruca

The treatment of verruca can be frustrating. [37] Combined treatment of warts with topical salicylic acid and cryotherapy results in an improved cure rate. [38] Pain experienced after the procedure can be minimized by administering aspirin or acetaminophen before freezing. The dipstick method is preferred by some, while many others prefer the spray technique. Kuflik [39] was able to eradicate 97.4 percent of 80 periungual warts with the dipstick technique. Although the spray technique alone will cure some plantar warts, combining spraying with salicylic acid pads and paring will clear more. Failures may respond to bleomycin. [40]

Condylomata Acuminata

Complete cure of these lesions is quite difficult if not impossible despite the use of freezing, surgical excision, laser surgery, and interferon. The use of podofilox or imiquimod on reliable patients enhances resolution of the lesions. The safety of such agents used by pregnant women has not yet been established. [41] Damstra and Van Vloten [42] did a controlled study of 64 patients with small penile and vulvar condylomas. They used a fine needle-spray technique and achieved 92 percent remission rate after 3 months.

Kaposi Sarcoma

Cryosurgery is frequently used to treat Kaposi sarcoma. Tappero et al found treatment using a double freeze–thaw cycle every 3 weeks for three treatments to be effective. [11] Freezing may be combined with vinblastine or other therapies. [11]

Basal Cell Carcinoma

Mallon and Dawber studied the virtues of one versus two freeze–thaw cycles for treatment of basal cell carcinoma (BCC). [16] They treated 84 facial BCCs with a single or double 30-second freeze–thaw cycle. The double freeze–thaw cycle on the face achieved a 95.3 percent cure rate, while the single cycle had a 79.4 percent cure rate. Twenty-nine superficial BCCs on the trunk achieved a 95.5 percent cure rate with the single freeze–thaw cycle. Graham et al. [43] and Torre [44] have used a single freeze–thaw cycle successfully for BCCs 3 mm or less in depth, whether on the trunk or face. The size and depth of the lesions should be defined with reasonable certainty. Kuflik and Gage reported a 5-year cure rate of 99 percent for 628 BCCs ranging from 0.5 to 2 cm in diameter by using a double freeze–thaw cycle. [45]

Over 32 years of performing cryosurgery, Zacarian consistently achieved cure rates around 97.3 percent. [46] He maintained that double freeze–thaw cycles were necessary. Graham [43] compared shave excision or curettage plus cryosurgery with single and double freezes, achieving a higher cure rate with the combination. A double freeze coupled with curettage yielded a 98.4 percent cure rate. Her freeze times are usually 60 seconds or longer, whereas Dawber's were for 30 seconds. [43] This may account for the lower cure rate in his series.

The use of ultrasound for depth determination and placement of a thermocouple needle would probably improve the cure rates in most series. [29], [30] Patient selection is of paramount importance. The cure rate in our series [43] improved over a 30-year period, especially after a Mohs surgeon became available in North Carolina for referral of larger, more difficult tumors. Despite the severe sun damage seen in many of our patients who spend their lives in the sun during the entire year, healing after freezing has been remarkable. Treating tumors with indefinite borders is discouraged unless the treatment is used in a palliative way, as may effectively be done in the nursing home setting.

There is increasing use of cryosurgery in the management of some larger tumors. Biro, [47] Kuflik, [48] Gage, [49] and Goncalves [50] reported on the eradication of large tumors by freezing. Stolar and Turjansky in Argentina have managed many large tumors effectively, and their series supports the effectiveness of this procedure for both therapy and palliation. [51]

REFERENCES

1. Squazzi A, Bracco D: A historical account of the technical means used in cryotherapy. *Minerva Med* **65**:3718, 1974

2. Hippocrates: *Greek Medicine*, translated by AJ Brock. London, Dent, 1929

3. Lorrey DJ: *Memoires de Chirurgie Militaire et Campagnes*. Philadelphia, Carey & Lea, 1832, pp 1812

4. Arnott J: *On the Treatment of Cancers by Regulated Application of an Anaesthetic Temperature*. London, Churchill Livingstone, 1855

5. White AC: Liquid air in medicine and surgery. *Med Rec* **56**:109, 1899

6. Whitehouse HH: Liquid air in dermatology: Its indications and limitations. *JAMA* **49**:371, 1907

7. Zacarian SA, Adham MI: Cryotherapy of cutaneous malignancy. *Cryobiology* **2**:212, 1966

8. Torre D: Cradle of cryosurgery. *N Y State J Med* **67**:465, 1967

9. Allington HD: Cryosurgery. *Calif Med* **72**:153, 1950

10. Stern RS et al: Laser therapy versus cryotherapy of lentigines: A comparative trial. *J Am Acad Dermatol* **30**:985, 1994

11. Tappero JW et al: Kaposi's sarcoma. *J Am Acad Dermatol* **28**:371, 1993

12. Zacarian SA: *Cryosurgery for Skin Cancer and Cutaneous Disorders*. St. Louis, Mosby, 1985, p 18

13. Gage AA: Experimental cryogenic injury of the palate; observations pertinent to cryosurgical destruction of tumors. *Cryobiology* **15**:415, 1978

14. Johnson JF: Immunologic aspects of cryosurgery: Potential modulation of immune recognition and effector cell maturation, in *Clinics in Dermatology: Advances in Cryosurgery*, edited by EW Breitbart, E Siwiec. New York, Elsevier, 1990, p 39

15. Jones SK, Darville JM: Transmission of virus by cryotherapy and multi-use caustic pencils: A problem to dermatologists? *Br J Dermatol* **121**:481, 1989

16. Mallon E, Dawber R: Cryosurgery in the treatment of basal cell carcinoma: Assessment of one and two freeze–thaw cycle schedules. *Dermatol Surg* **22**:854, 1996

17. Graham GF: Cryosurgery for benign, premalignant and malignant lesions, in *Cutaneous Surgery*, edited by RG Wheeland. Philadelphia, Saunders, 1994, p 835

18. Kuflik EG, Webb W: Effects of systemic corticosteroids on post-cryosurgical edema and other manifestations of the inflammatory response. *J Dermatol Surg Oncol* **11**:464, 1985

19. Holt P: Cryotherapy for skin cancer: Results over a 5-year period using liquid nitrogen spray cryotherapy. *Br J Dermatol* **119**:231, 1988

20. Gage AA, Meenaghan M: Sensitivity of pigmented mucosa and pigmented cells in skin due to freezing injury. *Cryobiology* **16**:348, 1979

21. Nix TW Jr: Liquid nitrogen neuropathy. *Arch Dermatol* **92**:185, 1965

22. Dawber RPR: Cold kills! *Clin Exp Dermatol* **13**:138, 1988

23. Cecchi R, Giomi A: Pyogenic granuloma as a complication of cryosurgery for venous lake. *Br J Dermatol* **140**:373, 1999

24. Rongioletti F et al: Erosive pustular dermatosis of the scalp following cryotherapy and topical tretinoin for actinic keratoses. *Clin Exp Dermatol* **24**:499, 1999

25. Okuyama R et al: Keratoacanthoma developing in prurigo nodularis treated with cryotherapy. *Dermatology* **194**:290, 1997

26. Graham GF: Cryotherapy in the treatment of acne, in *Skin Surgery*, edited by E Epstein, E Epstein, Jr. Springfield, IL, CC Thomas, 1982, p 680

27. Chiarello SE: Cryopeeling. *J Dermatol Surg Oncol* **18**:329, 1992

28. Chiarello SE: Tumescent derma sanding with cryospraying: A new wrinkle on the treatment of rhytides. *Dermatol Surg* **22**:601, 1996

29. Graham GF: High cure rates reported with cryosurgical methods. *Cosmet Dermatol* **7**:43, 1994

30. Abramovits W et al: Ultrasound-guided thermocouple placement for cryosurgery. *Dermatol Surg* **22**:771, 1996

31. Blume-Peytavi U et al: Successful outcome of cryosurgery in patients with granuloma annulare. *Br J Dermatol* **130**:494, 1994

32. Layton AM et al: A comparison of intralesional triamcinolone and cryosurgery in the treatment of acne keloids. *Br J Dermatol* **130**:495, 1994

33. Scoggins RB: Cryotherapy of psoriasis. *Arch Dermatol* **123**:427, 1987

34. Nouri K et al: Cryotherapy for psoriasis. *Arch Dermatol* **133**:1608, 1997

35. Stoll DM et al: Treatment of prurigo nodularis: Use of cryosurgery and intralesional steroids plus lidocaine. *J Dermatol Surg Oncol* **9**:922, 1983

36. Kuflik EG: Specific indications for cryosurgery of the nail unit: Myxoid cysts and periungual verrucae. *J Dermatol Surg Oncol* **18**:702, 1992

37. Keefe M, Dich DC: Cryotherapy of hand warts—A questionnaire survey of “consumers.” *Clin Exp Dermatol* **15**:260, 1990

38. van Brederode RL, Engel ED: Combined cryotherapy/70% salicylic acid treatment for plantar verrucae. *J Foot Ankle Surg* **40**:4, 2001

39. Kuflik EG: Cryosurgical treatment of periungual warts. *J Dermatol Surg Oncol* **10**:673, 1984

40. Barbosa P: Plantar verrucae and HIV infection. *Clin Podiatr Med Surg* **15**:317, 1998

41. Miller KE, Graves JC: Update on the prevention and treatment of sexually transmitted diseases. *Am Fam Physician* **61**:379, 2000

42. Damstra RJ, van Vloten WA: Cryotherapy in the treatment of condylomata acuminata: A controlled study of 64 patients. *J Dermatol Surg Oncol* **17**:273, 1991

43. Graham GF, Clark LC: Statistical analysis in cryosurgery of skin cancer, in *Clinics in Dermatology: Advances in Cryosurgery*, vol 8, edited by EW Breitbart, E Dachow-Siwiec. New York, Elsevier, 1990, p 101

44. Torre D: Cryosurgery of basal cell carcinomas. *J Am Acad Dermatol* **15**:917, 1986

45. Kuflik EG, Gage AA: The five-year cure rate achieved by cryosurgery for skin cancer. *J Am Acad Dermatol* **24**:1002, 1991

46. Zacarian SA: Cryosurgery for cancer of the skin, in *Cryosurgery for Skin Cancer and Cutaneous Disorders*, edited by SA Zacarian. St Louis, Mosby, 1985, p 96

47. Biro L, Price E: Cryosurgery for benign and malignant skin tumors, in *Skin Surgery*, edited by M Harahap. St Louis, Green, 1985, p 767

48. Kuflik EG: Cryosurgical treatment for large malignancies on the upper extremities. *J Dermatol Surg Oncol* 12:575, 1986

49. Gage AA: Cryosurgery of advanced tumors, in *Clinics in Dermatology: Advances in Cryosurgery*, edited by EW Breitbart, E Dachow-Siwiec. New York, Elsevier, 1990 p 86

50. Goncalves JA: Cryosurgery of advanced cancer of the extremities. *Skin Cancer* **1**:211, 1986

51. Turjansky E, Stolar E: Our experience in the treatment of cancer of the skin, in *Cryomedicine*, edited by Montserrat. Buenos Aires, Argentina, 1996, p 187

T>

Chapter 279

Ken Lee Neil Swanson

Mohs Micrographic Surgery

HISTORY
TECHNIQUE
INDICATIONS
Basal Cell Carcinoma
Squamous Cell Carcinoma
Melanoma
Other Cutaneous Malignancies

REFERENCES

Mohs micrographic surgery (MMS) is a precise method of treating skin cancer that results in the highest cure rate with maximal tissue conservation. Developed by Dr. Frederic E. Mohs, the procedure combines microscopic evaluation of tumor margins (“micro”) with detailed mapping of the tumor orientation (“graphic”). The hallmarks of MMS are tangential excision that allows theoretically 100 percent of the tumor margin to be examined and the surgeon serving a dual role as surgeon and pathologist. Commonly referred to as Mohs surgery, other names have been used to describe the procedure, including chemosurgery, microscopically controlled excision, and microscopically oriented histographic surgery.

HISTORY

In the 1930s Dr. Mohs, a general surgeon at the University of Wisconsin discovered that 20% zinc chloride paste was a good in situ fixative. He applied a thin layer of the preparation to skin cancers under an occlusive dressing for 12 to 24 h. The tissue was then excised, mapped, marked, and color-coded. It was sectioned horizontally so that the epidermis as well as the entire undersurface could be evaluated simultaneously under the microscope. If tumor remained at the excision margins then the fixation process was repeated. Tumor-free wounds were allowed to heal by second intention as the zinc chloride caused tissue sloughing. While the procedure yielded high cure rates, the technique was labor and time intensive and quite uncomfortable for the patient.

Mohs first published “Chemosurgery, microscopically controlled method of skin cancer excision” in 1941. [1] Despite the high cure rates, it was not well accepted within general surgery, but became adopted and advanced by the field of dermatology. To this day, MMS is recognized as a procedure unique to dermatology.

A key advancement in MMS was the change to the fresh tissue technique using frozen-section processing. Mohs had initially used frozen sections only on a few eyelid tumors. It was not, however, until 1970 that Dr. Theodore Tromovitch presented a more widespread use of the fresh tissue technique eliminating the use of zinc chloride paste and the associated disadvantages. Tromovitch and Stegman subsequently published their results of long-term follow-up of patients having basal cell carcinomas (BCCs) treated with cure rates comparable to the previous fixed tissue technique. [2] With a faster turnaround time and lack of tissue slough allowing for same day reconstruction, the fresh-tissue technique was adopted and represents the standard of MMS today. Although the original “chemosurgery” is rarely used today, Mohs' original concepts of tangential excision and the surgeon serving as the pathologist are still an integral part of the technique which carries his name.

TECHNIQUE

The MMS set up requires an appropriately equipped procedure room, well-trained nursing staff, and a laboratory with a histotechnician trained in the specialized MMS tissue processing. The latter cannot be overemphasized as the quality of the microscopic slides and the efficiency in which they are produced are paramount in order to perform MMS at its highest level.

MMS is usually performed on ambulatory patients in an outpatient setting (Fig. 279-1). [3] The tumor is initially identified, marked, and infiltrated with local anesthesia. It is then debulked using a curette, which further delineates the size. The scalpel blade is held at approximately 45 degrees to the skin surface and the tumor is excised 2 to 3 mm beyond the curetted margin, producing a saucer-shaped piece of tissue. Anatomic orientation is carefully maintained. The remaining skin edge, as well as the surface of the removed tissue, is scored to preserve this orientation. The depth of the excision usually encompasses the entire dermis but can vary depending on the depth of the curettage. The wound is bandaged and the patient waits for the processing which usually takes 30 to 45 min.

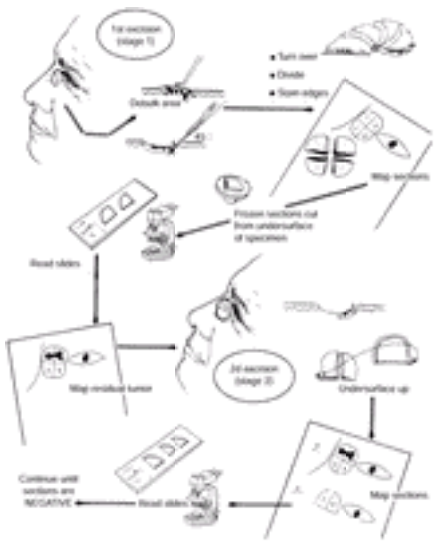

FIGURE 279-1 Schematic of Mohs micrographic surgery technique. See text for detailed explanation.

The tissue is sectioned into smaller pieces along the scored lines, turned over and inked with two to three different colors for precise orientation. An anatomic map is drawn with markings correlating with the scored lines and inked margins. The tissue is then laid flat on a cryostat chuck so that the epidermis and the deepest margin are on one plane (allowing for theoretically 100 percent of the tumor margins to be visualized). The tissue is then frozen, sectioned horizontally, placed on a slide, and stained, usually with hematoxylin and eosin.

A unique aspect of MMS is that the surgeon has a dual role as the pathologist; therefore, the clinicopathologic correlation is precise. This leads to accuracy that is difficult to duplicate when there is a separate surgeon and pathologist. The Mohs surgeon examines the slides microscopically, correlating them with the anatomic map he or she has drawn. If there is persistent tumor on the margin(s), it is marked on the map and the patient is brought back into the procedure room for the second stage. Additional section(s) are again tangentially excised but limited only to the area(s) of persistent tumor. This process continues until the margins are tumor free.

In comparison, with traditional excisions the scalpel blade is placed perpendicular to the skin surface, the tissue is processed in a “bread loaf” fashion and sectioned through the center of the tumor. Less than 1 percent of the tumor margin is visualized. In MMS, the goal is to visualize the outer as well as deep margins, and therefore only the tumor on the margins is represented on the slide. The tumor in the center is not seen unless it extends to the margins.

Since the introduction of the fresh-tissue technique, MMS has been refined to an efficient, highly successful surgery. Reconstructive surgery has become an important and integral aspect of the specialty. The original chemosurgery defects healed by second intention, whereas today's Mohs surgeon also uses side-to-side closures, flaps, and grafts (Fig. 279-2). As a result, advances in reconstructive surgery have been significant in the evolution of MMS.

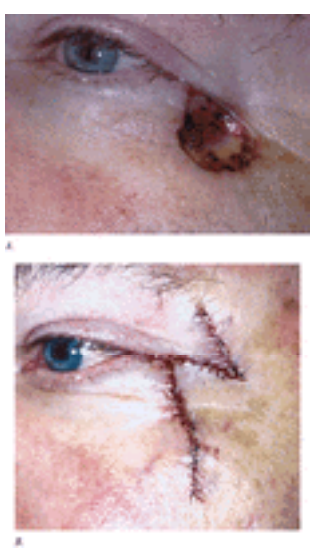

FIGURE 279-2 *A.* Postoperative defect after two stages of MMS. *B.* Reconstruction with rhombic transposition flap.

INDICATIONS

MMS has been used for different types of skin cancers. The overwhelming majority of the cases, however, are BCCs and squamous cell carcinomas (SCCs). MMS is not needed for all skin cancers and should be reserved for those cases that meet specific indications. The American Academy of Dermatology has outlined specific guidelines, which broadly include (1) high risk of local recurrence, (2) areas of tissue preservation, and (3) high risk of metastasis. [4] There are other treatment modalities such as simple excision, electrodessication and curettage, cryosurgery, topical chemotherapy, and irradiation that may be appropriate for other situations. Conversely, MMS should not be employed as the only treatment for some complex cancers. A multidisciplinary approach may be more appropriate for these cases.

Basal Cell Carcinoma

BCC is the most common skin cancer in the United States. Although the potential for metastasis is very low, it can cause significant local destruction. Four important factors that determine the successful treatment of primary BCCs are histologic characteristics, location, size, and clinical nature (Fig. 279-3). Histology ranges from less-aggressive patterns,

such as nodular and superficial, to more-aggressive patterns, such as infiltrative, micronodular, and sclerosing (morpheaform). Perineural involvement also constitutes an aggressive pattern. The aggressive subtypes typically are more ill-defined clinically with less predictable radial growth patterns leading to a greater subclinical extension of tumor. When viewed in the traditional “bread loaf” fashion, these areas of tumor extension can be missed leading to a false negative result. [5] MMS is ideally suited for visualizing these extensions as 100 percent of the margins are inspected.

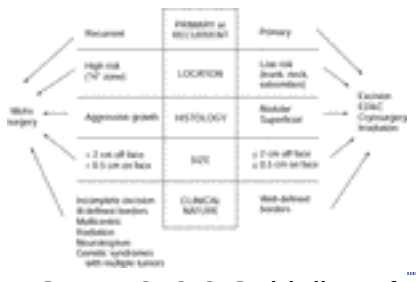

FIGURE 279-3 Guidelines for consideration for Mohs micrographic surgery. The *right* side of the figure represents less-aggressive presentations of BCCs that can be treated with standard treatment regimens. The *left* side of the figure represents more-aggressive presentations for which Mohs micrographic surgery should be considered.

BCCs located on the ear, nose, eyelid, and lip are part of the “H” zone where MMS is indicated because of the high recurrence rate (Fig. 279-4). [6] In these locations, tumors tend to be more destructive and invasive and are in close proximity to vital structures. Tumors spread along perichondrium, periosteum, perineurium and fascial planes. They also spread along embryonic fusion planes to unexpected depths in areas such as the nasal ala/nasolabial fold junction, preauricular sulcus, and columella, as well as penetrating deeply in areas like the medial canthus where there is minimal deep structural support. Furthermore, MMS is important in maximally preserving normal tissue in these cosmetically and functionally sensitive regions.

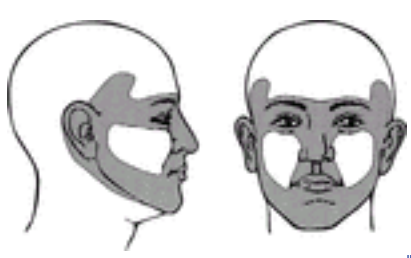

FIGURE 279-4 “H” zone on face. Shaded regions represent high-risk areas where Mohs micrographic surgery is indicated. These areas typically have higher recurrence rates from standard treatment modalities.

Size and clinical nature are also important considerations in determining the appropriate treatment. BCCs greater than 2 cm are more likely to recur or be incompletely excised. Ill-defined clinical borders also make simple excisions more difficult. [7] Overall, MMS has a 99 percent cure rate for primary BCCs, compared with 91.3 percent for all other treatment modalities previously mentioned. [8]

Beyond primary BCCs, MMS is even more significant in the treatment of incompletely excised and recurrent BCCs. MMS is indicated irrespective of histologic subtypes or location as the other treatment modalities have already failed. Incompletely excised BCCs recur between 12 and 41 percent of the time on the face if left untreated. [9] These can be readily treated with MMS by narrow margin excision around the previous scar. This results in precise localization of the persistent tumor.

Recurrent BCCs, by their very nature, are more aggressive and difficult to treat. Clinically, they can be subtle and therefore the diagnosis is usually delayed. By the time the recurrence is noted on the skin surface, there may be large tumor burden buried in the scar. For these recurrences, MMS yields the best cure rate of 94.4 percent, compared to all other modalities, which average only 80 percent. [10]

Squamous Cell Carcinoma

SCC is the second most common skin cancer in the United States. Although SCC and BCC are treated similarly, it would be dangerous to think that they are biologically the same. SCC metastasizes at a much higher rate and accordingly has a higher mortality rate. The indications for MMS are similar to BCC, but additionally involves identifying and reducing the risk for metastasis. As with BCC, histologic pattern is important in determining the potential aggressiveness. Tumors that are poorly differentiated and/or have perineural involvement have a worse prognosis. Locations such as the ear, penis, lip, and digits, lesions greater than 2 cm, deeper lesions, and those occurring in scars carry a higher risk of metastasis and local recurrence. Five-year cure rate for primary SCC of the skin is 96.9 percent with MMS versus 92.1 percent for all other modalities combined (irradiation, curettage and electrodessication, and excision). The difference is greater for primary SCCs of the lip (97.7 percent versus 89.5 percent) and ear (94.7 percent versus 81.3 percent). For recurrent tumors, it is 90 percent with MMS versus 77.7 percent with excision. [11] Immunosuppressed transplant patients have a disproportionate number of SCCs and also carry a greater risk of more aggressive disease.

MMS is an integral part of SCC management and can be especially valuable in special situations like tracking perineural involvement. It is important to note, however, that radiation therapy and surgical lymph node assessment may also be needed for proper management of more aggressive disease.

Melanoma

MMS for treatment of melanoma is controversial. Two issues have given rise to this controversy: interpretation of melanocytes by frozen section and determination of proper excision margins for melanoma. MMS is most useful for lentigo maligna type melanoma in situ and melanoma on the head and neck region, which are notorious for significant subclinical spread that often extends beyond the standard recommended excision margins. Although there have been reports of successful treatment of melanoma with MMS, the variability in the frozen section quality and interpretation places a limit on consistency and accuracy. The method that is commonly employed at many centers is a modified MMS in which a 2- to 3-mm margin is excised beyond the final frozen section margin and submitted for permanent paraffin embedded sections. These sections are processed in the MMS style so that 100 percent of the peripheral margins are visualized. The obvious disadvantage of this method is significant increase in the turnaround time delaying the final closure of the wound. [12], [13]

A newer method that potentially improves both the speed and accuracy is the use of immunohistochemistry stains. S-100 and HMB-45 have traditionally been used to mark melanocytes with variable sensitivity and specificity. Melan-A is a newer addition with better consistency and easier interpretation. [14] Although the turnaround time is shorter than with paraffin sections, it is still more labor intensive than traditional hematoxylin and eosin (H&E)-based frozen sections. Long-term studies determining efficacy are still needed.

Other Cutaneous Malignancies

MMS has been used on many different cutaneous malignancies. The consensus indications outlined by the American Academy of Dermatology include verrucous carcinoma, keratoacanthoma, dermatofibrosarcoma protuberans, atypical fibroxanthoma, malignant fibrous histiocytoma, leiomyosarcoma, adenocystic carcinoma of the skin, sebaceous carcinoma, extramammary Paget's disease, erythroplasia of Queyrat, oral and central facial paranasal sinus neoplasms, microcystic adnexal carcinoma, apocrine carcinoma of the skin, certain aggressive locally recurrent benign tumors, and Merkel cell carcinoma. All cutaneous malignancies that exhibit a contiguous pattern of radial growth and that can be interpreted on frozen section should theoretically be amenable to MMS.

Taken together, MMS is cost-effective although it should be reserved for those cases that meet appropriate indications. [15] It is a highly technical field that requires meticulous attention to detail and considerable training and experience in order to achieve the expected high cure rates.

REFERENCES

1. Mohs FE: Chemosurgery: A microscopically controlled method of skin cancer excision. *Arch Surg* **42**:279, 1941

2. Tromovitch TA, Stegman SJ: Microscopic-controlled excision of cutaneous tumors: Chemosurgery; fresh-tissue technique. Cancer **41**:653, 1978

3. Swanson NA: Mohs surgery: Technique, indications, applications, and the future. *Arch Dermatol* **119**:761, 1983

4. Drake LA et al: Guidelines of care for Mohs micrographic surgery. *J Am Acad Dermatol* **33**:271, 1995

5. Salasche SJ, Amonette RA: Morpheaform basal cell epitheliomas. A study of subclinical extensions in a series of 51 cases. *J Dermatol Surg Oncol* **7**:387, 1981

6. Swanson NA, Johnson TM: Management of basal and squamous cell carcinoma, in *Otolaryngology Head & Neck Surgery,* 3rd ed, edited by CW Cummings, JM Fredrickson, LA Harker, CJ Krause, DE Schuller, MA Richardson. St Louis, Mosby, 1998, p 486

7. Freeman RH, Duncan WC: Recurrent skin cancer. *Arch Dermatol* **107**:395, 1973

8. Rowe DE et al: Long-term recurrence rates in previously untreated (primary) basal cell carcinoma: Implications for patient follow-up. *J Dermatol Surg Oncol* **15**:315, 1989

9. Bieley HC et al: The use of Mohs micrographic surgery for determination of residual tumor in incompletely excised basal cell carcinoma. *J Am Acad Dermatol* **26**:754, 1992

10. Rowe DE et al: Mohs surgery is the treatment of choice for recurrent (previously treated) basal cell carcinoma. *J Dermatol Surg Oncol* **15**:424, 1989.

11. Rowe DE et al: Prognostic factors for local recurrence, metastasis, and survival rates in squamous cell carcinoma of the skin, ear, and lip, implications for treatment modality selection. *J Am Acad Dermatol* **26**:976, 1992

12. Zitelli JA et al: Mohs micrographic surgery for the treatment of primary cutaneous melanoma. *J Am Acad Dermatol* **37**:236, 1997

13. Stonecipher MR et al: Management of lentigo maligna and lentigo maligna melanoma with paraffin-embedded tangential sections: Utility of immunoperoxidase staining and vertical sections. *J Am Acad Dermatol* **29**:589, 1993

14. Zalla, MJ et al: Mohs micrographic excision of melanoma using immunostains. *Dermatol Surg* **26**:771, 2000

15. Cook J, Zitelli JA: Mohs micrographic surgery: A cost analysis. *J Am Acad Dermatol* **39**:698, 1998

T>

Chapter 280

Robert Baran

Nail Surgery

ANATOMY AND PHYSIOLOGY
INSTRUMENTS AND DRAPING
ANESTHESIA
Proximal Digital Block (Fig. 280-3)
Distal Digital Block (Fig. 280-4)
Transthecal Block
Wrist Block
TOURNIQUETS
DRESSING AND POSTOPERATIVE CARE
POSTOPERATIVE COMPLICATIONS
Bleeding
Pain
Infection
Misaligned Nail
Relapse
Residual Dystrophy
Unpredictable Complications
NAIL AVULSION
Distal Approach (Fig. 280-7A)
Proximal Approach (Fig. 280-7B)
Partial Nail Avulsion
SURGICAL APPROACHES TO THE DIFFERENT TISSUES OF THE NAIL APPARATUS
Surgery of the Nail Matrix
Surgery of the Nail Bed
Surgery of the Proximal Nail Fold
Lateral Nail Fold
INGROWN NAILS
Distal Toenail Embedding
Juvenile (Subcutaneous) Ingrown Nails
Pincer Nail5
Hypertrophy of the Lateral Nail Fold
Congenital Malalignment of the Big Toenail

REFERENCES

The main objectives of nail surgery are to aid diagnosis by biopsy, to treat infection, to alleviate pain, to remove local tumors, and to ensure the best cosmetic results in acquired and/or hereditary and congenital abnormalities. Many of the problems that require nail surgery are discussed in Chap. 72; nail biology is also described in Chap. 72.

An exact illustration of the operation is helpful to give the patient insight into the procedure and its expected outcome. A thorough discussion regarding postoperative morbidity is essential. Preoperative photographs as well as any taken during surgery may be useful medicolegally. A careful history may reveal systemic disease such as diabetes mellitus, blood dyscrasias, vascular disease, collagen disease (scleroderma), allergy, chronic pulmonary disease and immune impairment. Any of these may at times be contraindications to surgery, or may alter the technique to be performed. Surgery of the nail is not recommended in high-risk patients. A history of concomitant administration of drugs may be relevant because these may affect anesthesia (monoamine oxidase inhibitors or phenothiazines), prolong bleeding (aspirin and anticoagulants), delay healing (glucocorticoids) or have toxic effects on the nail apparatus (retinoids). There may be a history of allergy to lidocaine or mepivacaine (Carbocaine) or parabens (contained in both as a preservative). A knowledge of previous antitetanus immunization is important because tetanus toxoid may be advisable in association with surgery in the toenail or in traumatic lesions that come into contact with soil.

A magnifying lens may be useful to observe the color, surface, and structure of the periungual tissue and to compare the unaffected contralateral digit. It may be necessary to probe in order to localize pain, to obtain an x-ray to rule out underlying bone involvement, or to ask for sonography and MRI when a tumor is suspected.

The basic requirements for nail surgery include a detailed knowledge of the anatomy and physiology of the nail apparatus. Full aseptic conditions, regional block anesthesia, and local hemostasis are indispensable.

ANATOMY AND PHYSIOLOGY

The nail plate (NP) is the permanent product of the nail matrix. Its normal appearance and growth depend on the integrity of several components; the surrounding tissues, or perionychium, and the bony phalanx all form parts of the nail apparatus (Fig. 280-1). The nail is a semihard horny plate covering the dorsal aspect of the tip of the digit. The nail is inserted proximally in an invagination that is practically parallel to the upper surface of the skin and laterally in the lateral nail grooves. This pocket-like invagination has a roof, the proximal nail fold, and a floor, the matrix from which the nail is derived. The matrix extends approximately 6 mm under the proximal nail fold and its distal portion is only visible as the white semicircular lunula. The general shape of the matrix is a crescent, concave in its posteroinferior portion. The lateral horns of this crescent are more developed in the great toe and located at the coronal plane of the bone. The ventral aspect of the proximal nail fold encompasses both a lower portion, continuing the matrix, and an upper portion (roughly

three quarters of its length), called the eponychium (Fig. 280-2A). The germinal matrix forms the bulk of the NP. The proximal element forms the superficial third of the NP, whereas the distal element provides its inferior two-thirds (Fig. 280-2B).

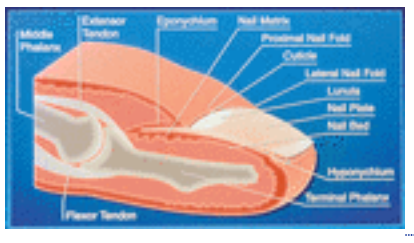

FIGURE 280-1 Sagittal section of the nail unit.

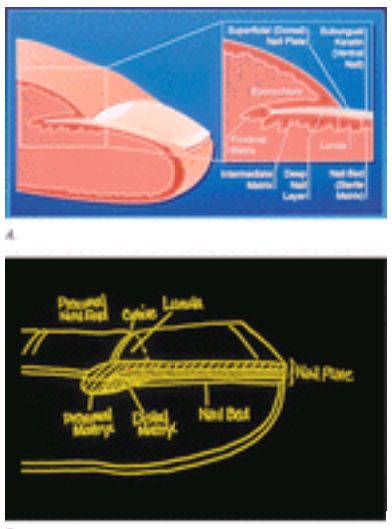

FIGURE 280-2 *A.* Origin of the nail layers. *B.* Origin of the nail plate itself.

The ventral surface of the proximal nail fold adheres closely to the nail for a short distance and forms a gradually desquamating tissue, the cuticle, made of the stratum corneum of both the dorsal and the ventral sides of the proximal nail fold. The cuticle seals and protects the “ungual cul-de-sac.”

The nail plate is bordered by the proximal nail fold, which is continuous with the similarly structured lateral nail fold on each side. The nail bed extends from the lunula to the hyponychium. It presents with parallel, longitudinal rete ridges.

In contrast to the matrix, the nail bed has a firm attachment to the nail plate. Colorless, but translucent, the highly vascular connective tissue, containing glomus organs, transmits a pink color through the nail. Avulsion of the overlying nail plate denudes the nail bed.

Distally, adjacent to the nail bed, the hyponychium, an extension of the volar epidermis under the nail plate, marks the point at which the nail separates from the underlying tissue. The distal nail groove, which is convex anteriorly, separates the hyponychium from the finger tip.

The circulation of the nail apparatus is supplied by two digital arteries that course along the digits and give off branches to the distal and proximal arches. The sensory nerves to the distal phalanx of the three middle fingers are derived from fine, oblique, dorsal branches of the volar collateral nerves. Longitudinal branches of the dorsal collateral nerves supply the terminal phalanx of the fifth digit and also the thumb.

Among its multiple functions, the nail provides counterpressure to the pulp that is essential to the tactile sensation involving the fingers and to the prevention of the hypertrophy of the nail bed. With the loss of the nail plate, the overgrowth of the anterior nail bed forms a distal wall ahead of the advancing, regenerating new nail particularly on the great toe. Histological examination reveals that the nail matrix and nail bed are devoid of a granular layer, in contrast to the upper ventral aspect of the proximal nail fold and the hyponychium.

INSTRUMENTS AND DRAPING

The instruments used in nail surgery are, in general, the same as those used in cutaneous surgery with the addition of nail elevators (dental spatula, Freer septum elevator), single- or double-pronged skin hooks (flexible retractors), double-action nail splitter (bone rongeur), clippers, nail-splitting scissors, English nail splitter, pointed scissors (Gradle scissors), curved iris scissors, small-nosed mosquito hemostats, disposable biopsy punches (2, 3, 3.5, and 4 mm), Penrose drains, Luer-Lok syringe, and 30-gauge needles.

Draping is accomplished with a sterile glove on the involved hand. The tip of the glove is cut off from the finger to be operated on; the open finger residue is then rolled back down the digit. This exsanguinates the digit and provides a tourniquet when it reaches the proximal part of the finger. For toenail surgery, the foot is draped in the usual aseptic manner with sterile towels secured by towel clamps.

ANESTHESIA

Local anesthesia should be administered while the patient is reclining or in a supine position. Lidocaine is widely used because the incidence of allergy to this agent is very low. As the use of epinephrine is still debatable, it is preferable to use 2% lidocaine alone; a tourniquet can provide prolonged hemostasis when a bloodless operative field is required. It has been claimed that using tepid lidocaine minimizes the burning sensation associated with its administration; one part 7.5% bicarbonate with nine parts lidocaine has also been advocated for the same purpose. One should allow 5 to 10 min for the anesthesia to take effect.

Anesthetics are administered via a 30-gauge needle on a Luer-Loc syringe using either a proximal digital block or a distal digital block (wing block). Other techniques, such as median distal anesthesia or transthecal block, have not replaced the classical routes of anesthesia. Although emergencies related to minor surgery occur rarely, the ready availability of resuscitative equipment and expertise are essential.

Proximal Digital Block (Fig. 280-3)

FIGURE 280-3 Proximal digital block.

The proximal digital block procedure is less painful than the distal block but the anesthesia takes 5 to 10 min to become established. The hand is laid down flat, with the fingers spread, in order to inject 1 to 2 mL of anesthetic by a dorsal injection, with a thin needle inserted and directed tangentially to the sides of the bony phalanx at the base of the finger involved and as far as the lateral side of the flexor tendon. Avoid a tourniquet effect, which may inadvertently be produced by injecting more than 5 mL of anesthetic. Verify the absence of blood reflux in the syringe before the injection if using a nondental syringe. When the operation is strictly localized in a lateral region, a block limited to the ipsilateral nerves to the lesion suffices, as in the case of a partial distolateral nail avulsion.

Distal Digital Block (Fig. 280-4)


FIGURE 280-4 Distal digital block.

This procedure is more painful than the proximal block, but immediately effective. However, it is absolutely contraindicated when handling bacterial infection in the region. The latter requires wrist block or general anesthesia.

To perform a distal digital block, the needle is inserted just behind the junction of the proximal nail fold and a lateral nail fold, injecting a few tenths of a milliliter of anesthetic, which whitens the region. The injection is continued by aiming the needle toward the pad. One then returns to the initial area in order to inject the proximal fold transversely, then, at its junction with the lateral fold on the opposite side, one proceeds as described above. The anesthesia is almost immediate and when done correctly, it rarely has to be extended to the distal area of the finger.

Median distal administration is relatively simple and quick (Fig. 280-5). The needle is introduced at a 30-degree angle into the middle of the proximal nail fold and advanced distally into the underlying matrix. Anesthetic is injected slowly as the needle first pierces the nail plate, then the matrix, and, finally, the adjacent nail bed. The nail plate is soft and offers little resistance. Blanching confirms the delivery of anesthetic to the nail matrix and bed. Pain is brief and anesthesia nearly instantaneous. This method is suitable for most procedures performed on the proximal half of the nail unit; it is not suitable for matricectomy or complete nail avulsion.

FIGURE 280-5 Median distal block.

Transthecal Block

The flexor tendon sheath may be used as an avenue for introducing anesthetic to the core of the digit. Through centrifugal anesthetic diffusion all four digital nerves are anesthetized rapidly. This technique involves palmar percutaneous injection of 2 mL of lidocaine into the potential space of the flexor tendon sheath at the level of the palmar flexion crease with a 3-mL syringe and a 25-gauge hypodermic needle.

Wrist Block

There are several instances when it is useful to have anesthesia of more than one digit at the same time. A wrist block may be appropriate in the surgical treatment of numerous warts and the infiltration of more than one finger with triamcinolone in the treatment of nail unit psoriasis. This should be undertaken with the guidance of an experienced clinician.

TOURNIQUETS

For brief intraoperative hemostasis (nail avulsion, punch biopsy of the nail bed, for instance), squeezing the sides of the digits is effective. If a prolonged bloodless field is required, a Penrose drain may be placed around the base of the digit and used as a tourniquet secured with a hemostat. It is preferable not to leave it on for more than 15 to 20 min; the tourniquet application can be interrupted for a few minutes during longer procedures.

To complement anesthesia and facilitate a bloodless field, an “exsanguinating” tourniquet is recommended. [1] A wide Penrose drain is wound tightly in loops that overlap in a distal to proximal fashion, leaving an exposed loose end distally (Fig. 280-6). This “milks” the blood from the digit. The loose end is then grasped and unwound, again working distal to proximal until the nail unit is exposed with the final proximal loop.



FIGURE 280-6 Exsanguinating tourniquet.

DRESSING AND POSTOPERATIVE CARE

At the end of the operation, the digit is either cleansed with sterile 10% hydrogen peroxide solution and sprayed with a colorless disinfectant, or with an antiseptic with hemolytic action. The nail area is then covered with an antiseptic or antibiotic ointment on gauze or pads. Dressing must be done in a way that takes oozing, pain and sensitivity into account. A bulky dressing gives a cushion against local trauma.

Dressings should be done every other day, or daily if there is infection. Several layers of sterile gauze should be kept in place by Micropore (2.5 cm) tape placed first on the dorsal, then on the ventral aspects of the finger or toe, and lastly on the lateral edges in a U-shape (never make a circular dressing in the first week). Finally, an X-span tube dressing or Surgitube will give the patient more freedom to use the hand. During the first 48 h, the arm must be kept in a sling.

Stitches are removed after 7 to 12 days.

When treating the feet, daily chlorhexidine baths precede the care described above.

For all operations involving the toes, the patient should wear an appropriate shoe or sandal, after the dressing has been applied. The patient should be recumbent for 24 to 48 h with the foot elevated to 30 degrees.

POSTOPERATIVE COMPLICATIONS

Bleeding

Bleeding is seen after the tourniquet is removed but can be stopped by compressing the lateral edges of the distal inter-phalangeal joint. In cases of persistent bleeding, 35% aluminium chloride solution or a cellulose application (Gelfoam) should be applied.

Pain

Pain threshold varies from patient to patient. Postoperative pain can be almost nonexistent if, in the absence of infection, the operation is followed by a periungual injection of 0.6 mL 0.5% bupivacaine with 0.4 mL of 4 mg/mL dexamethasone. While the dressing is put in place, the patient must be told what precautions to take. A supply of moderately potent oral analgesics will help the patients to feel in control of their pain, even if they choose not to take the tablets. Sometimes postoperative pain may be severe and it is alleviated by elevating the extremity as much as possible for two days. Pulsating pain beginning after 36 to 48 h may indicate an infection that should be treated according to the results of bacterial culture of the organism. Any bulky dressing, blood-stained after 24 h, should be changed.

Infection

Prophylactic antibiotic treatment is mandatory for patients with valvular heart disease, including a prosthetic valve. Peripheral vascular disease and childhood (when the nail matrix is extremely fragile and behavior less sanitary) are further indications. If there are ragged surfaces to the nail, making thorough preoperative cleaning difficult, antibiotics may prevent wound infection.

Postoperative infection may be caused by preoperative colonization or infection. Preoperative swabs will indicate the best choice of drug after initial coverage with a broad spectrum antibiotic.

Attention to detail is important. Carelessness may result in serious infectious complications in the soft tissue and occasionally bone. Routine or preoperative nail cleansing softens the nail plate and keeps contamination to a minimum.

Misaligned Nail

Misaligned nail may result from a lateral longitudinal nail biopsy especially if the routine 3-mm width is exceeded.

Relapse

Relapse will depend on the nature of the lesion treated. Warts, ingrown nails, and myxoid cysts can be difficult to eradicate.

Residual Dystrophy

Residual dystrophies are not unusual when surgery involves the proximal area of the matrix.

Unpredictable Complications

Implantation epidermoid cysts can occur in operation scars; malalignment of the nail may occur after lateral longitudinal biopsy; reflex sympathetic dystrophy, although exceptional, following nail biopsy, has been reported.

NAIL AVULSION

The removal of the nail plate can be carried out using distal or proximal approaches. In both techniques, inserting the blunt instrument back and forth between the horny layer of the proximal nail fold and the nail plate, loosens the proximal nail fold adherence.

Distal Approach (Fig. 280-7A)

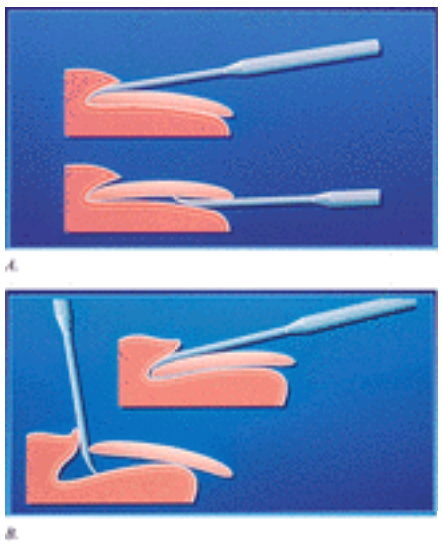

FIGURE 280-7 *A.* Distal nail avulsion. *B.* Proximal nail avulsion.

In the more commonly used distal approach, a Freer septum elevator or a dental spatula is inserted between the nail plate and nail bed. The nail is separated from its nail bed attachment using proximal force applied in anterior–posterior movements so as not to injure the longitudinal ridges of the nail bed. The detachment is completed by firmly pushing the instrument into the posterolateral corners of the nail plate. Then, one of the lateral edges is grasped with a sturdy hemostat, and extracted with an upwards and circular movement to accomplish the removal of the nail plate.

Proximal Approach (Fig. 280-7B)

The proximal approach for nail avulsion is advisable when the subungual distal area adheres strongly to the nail plate and where the hyponychium may be injured by the subungual introduction of the spatula. The proximal nail fold is freed as described above. The spatula is then used to reflect the proximal nail fold, and is delicately inserted under the base of the nail plate where adherence is normally weak. The instrument is advanced distally following the natural cleavage plane, and this operation is repeated on the entire width of the subungual region. After the last attachments are freed, the nail plate is easily pulled out.

Total surgical removal however should be discouraged; the distal nail bed may shrink and become dislocated dorsally. In addition, the loss of counterpressure produced by the removal of the nail plate allows expansion of the distal soft tissue and the distal edge of the regrowing nail then embeds itself. In the management of high-risk patients, nonsurgical removal of the NP should be considered when necessary. This can be affected by the use of 40% urea paste applied directly to the nail after protecting the surrounding skin. Urea acts on the bond between nail keratin and diseased NP, sparing only the normal nail tissue.

Partial Nail Avulsion

The problems that can arise following total nail avulsion may be overcome by partially avulsing the nail. Partial distal avulsion only requires separation of the nail from the distal nail bed. This procedure can be performed under local anesthesia in selected patients, when the fungal infection is of a limited extent. An affected portion of the nail plate may be removed in one session, even when the disease has reached the deeper regions of the subungual tissue beneath the proximal nail fold. Commonly, an English anvil nail splitter or a double-action bone rongeur is used for this procedure.

Partial surgical section of the lateral and/or medial segment of the nail plate may be sufficient for the treatment of distal lateral subungual onychomycosis. Enough normal nail is left to counteract the upward forces exerted on the distal soft tissue when walking and this will prevent the appearance of a distal nail wall.

In proximal subungual onychomycosis, removal of the nonadherent base of the nail plate, cut transversely, leaves the distal portion of the nail in place (Fig. 280-8), which decreases discomfort. Similarly, an acute paronychia that does not respond to appropriate antibiotics within 48 h should be treated surgically by removing the base of the nail plate.

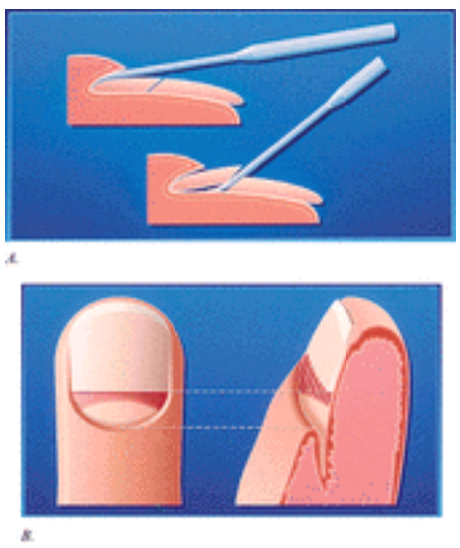

FIGURE 280-8 *A* and *B*. Technique of removal of the base of the nail plate.

Where *Candida* infection or, more rarely, dermatophyte infection result in onycholysis, the detached portion of the nail plate should be thoroughly clipped away. This facilitates the daily application of a topical antifungal drug until nail regrowth is complete. *Candida* lateral nail edge involvement associated with paronychia should be surgically sectioned and the affected nail keratin removed. Recalcitrant *Candida* paronychia with secondary nail plate invasion may be treated by surgical excision of a crescent of thickened nail fold followed by partial or total nail avulsion.

In any type of surgically treated onychomycosis, the avulsed nail segment must always include a margin of normal nail.

SURGICAL APPROACHES TO THE DIFFERENT TISSUES OF THE NAIL APPARATUS

Surgery of the Nail Matrix

When surgery involves the nail matrix, there are four primary approaches, including a reduction in its width or its length for removal of tumors, for instance, by using cold steel procedure or a 2- to 3-mm punch biopsy. In contrast to the three previously discussed procedures, complete matricectomy, that is, ablation of the nail-forming tissue, is rarely performed as the nail is permanently lost.

After reduction of the width, one is left with a narrower nail and after reduction of the length, with a diminution in the thickness of the nail. Reduction of the matrix width is a useful and/or necessary procedure in six major circumstances:

(1) lateral-longitudinal biopsy;
(2) lateral nail splitting;
(3) benign or malignant tumor in the lateral third of the nail apparatus;
(4) longitudinal melanonychia in lateral location;
(5) ingrown nail; and
(6) racquet nail.

Reduction of the matrix length has limited indications: crescent or transverse ellipse biopsy, tumors equal to or greater than 3 mm in width, and thick nails in dystrophic congenital and/or hereditary disorders.

BIOPSY [2] Biopsy of the nail matrix is performed to obtain the histopathology of any lesions or to clarify dubious clinical diagnosis. A 3-mm punch biopsy may be performed through the nail plate into the matrix. Three millimeters is the maximum size that does not produce serious dystrophy except when it is performed in the most proximal portion of the nail matrix. When a punch biopsy is used for longitudinal *melanonychia* of less than 3 mm in width, the circumferential incision is made around the origin of the band, through the NP (Fig. 280-9). This may be distal enough to be reached by pushing back the cuticle, but if it is more proximal, the proximal nail fold (PNF) may have to be reflected using a posterolateral incision. The next step consists of removing the proximal third of the nail plate, but leaving the cylinder of tissue containing the origin of the longitudinal melanonychia still in place. This technique enables the surgeon to inspect the surrounding nail matrix and bed with a magnifying lens to determine whether pigment extends around the punch incision and to facilitate the removal of the biopsied cylinder of tissue with a Gradle scissors.

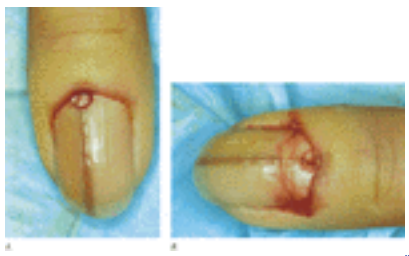

FIGURE 280-9 *A.* Punch biopsy for longitudinal melanonychia of less 3 mm in width. *B.* Removal of the base of the nail plate allowing easy removal of the biopsied cylinder of matrix tissue and pigment left distally.

For lateral longitudinal biopsy (Fig. 280-10), an elliptical incision may be made on either side of the nail plate and proximal nail fold. For the most part, the incisions parallel the lateral edge of the nail plate. Beginning in the lateral nail groove, the incisions should include a 3- to 4-mm nail segment reaching to the bone. This ensures that a full-thickness fragment of the matrix with its lateral horn is obtained. Slightly curved iris scissors are useful for separating the tissue from the bone. Starting at the tip of the digit, one proceeds proximally while maintaining contact with the bony phalanx. Lateral longitudinal biopsy is the advised procedure when longitudinal melanonychia [3] is located in the lateral part of the nail plate.

FIGURE 280-10 Lateral longitudinal biopsy for longitudinal melanonychia located within the lateral third of the nail plate.

For transverse biopsy (Fig. 280-11), two small oblique incisions are made on each side of the PNF; the fold is then reflected in order to expose the matrix area. The proximal third of the nail plate is avulsed. Then, the lesion is removed by an elliptical or a crescent-shaped wedge of tissue with the convex portion of the crescent paralleling the anterior border of the lunula. When longitudinal melanonychia lies within the midportion of the nail plate, the potential for postoperative dystrophy is great and selection of the optimal biopsy method is difficult. It is important to establish preoperatively the matrix origin (proximal or distal) of longitudinal melanonychia because the more proximal the origin, the greater the risk of

nail dystrophy. [3] The origin of pigmentation may be determined by microscopic examination of Fontana-Masson stained clippings from the free edge of the nail.

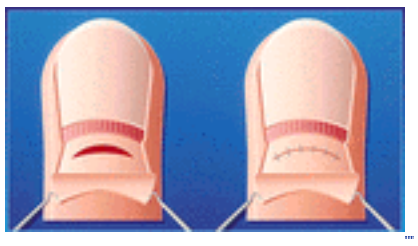

FIGURE 280-11 Transverse biopsy of the nail matrix.

For bands between 3 and 6 mm wide that involve the distal two-thirds of the matrix, a transverse elliptical excision is indicated. Although the potential for postoperative dystrophy is significant, an effort should be made, depending on the clinical circumstances, to completely excise the origin of the band, not only to prevent postoperative recurrence of longitudinal melanonychia, but also to ensure that representative tissue is submitted for study. Because the proximal matrix remains intact, a thinned nail plate will regenerate postoperatively. Tangential matrix biopsy for longitudinal melanonychia is also effective. The scalpel is held parallel to the matrix surface and the entire lesion is removed by cutting horizontally. This leaves a wound area about 1 mm deep.

SURGERY OF SPLIT-NAIL DEFORMITY [4] The common causes of split-nail deformity include trauma, operations, lichen planus, and tumors. Split-nail deformity may occur in either the lateral or the median region. The appropriate surgical technique varies correspondingly. If the split is located within the lateral third of either portion of the nail, especially when it is close to its lateral margin, the best method is the technique recommended for the lateral longitudinal nail biopsy, that is, the removal of the lateral portion of the nail with the defect. If the split is located in the middle region of the nail (Fig. 280-12) and involves its whole length, the PNF, carefully freed from the underlying nail plate, is obliquely incised at both sides and reflected to expose the whole matrix area. The nail plate bordering the split is cautiously cut as a rectangular block about 1 mm wider than the scar that has to be excised. The nail bed and matrix of the defective tissue are dissected from the bone to allow an exact approximation of the remaining bed and matrix, which are sutured with 6–0 monofilament resorbable sutures. To prevent the sutures tearing the tissue, 3–0 sutures are put through the nail plate. When these threads are knotted firmly, the matrix and nail bed are further approximated, relaxing the 6–0 sutures.

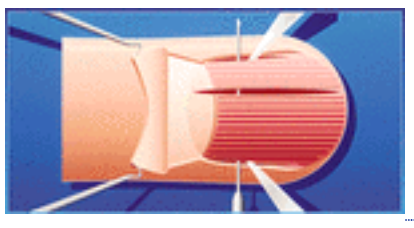

FIGURE 280-12 Treatment of “split nail” in the middle region of the nail plate.

If the scar is too wide to allow primary closure of the defect, relaxing longitudinal incisions along the lateral nail grooves down to the bone usually permit suturing. An alternative approach is the formation of Schernberg's nail bed–matrix flap with an L-shaped incision of the lateral aspect of the finger. The secondary defect below the distal lateral nail fold heals readily by secondary intention.

RACQUET NAIL In this condition, which is caused by an abnormally short and broad terminal bony phalanx, the nail is very short and wide; the lateral nail folds are usually narrow or lacking. Racquet nail usually affects the thumb and is inherited as an autosomal dominant trait. Treatment of racquet nail is aimed at narrowing the soft tissues of the terminal phalanx to about the normal length-to-breadth ratio by using the technique described for lateral longitudinal nail biopsy. This is performed on both sides of the thumb nail. The lateral soft aspects of the distal phalanx are dissected from the bone, and back-stitches are used to create lateral nail folds. The needle is run into the lateral aspect about 2 to 3 mm volar to the plane of the nail bed–bone interface, through the nail bed and plate, and back again through the lateral thumb skin, which, upon knotting, will be elevated, thus forming a lateral nail wall. Sulcus epithelium develops secondarily.

THINNING OF A HYPERPLASTIC NAIL As the thickness of the nail is proportional to the length of the matrix we remove one-third of the distal matrix. This is achieved by two parallel, transverse incisions; one located a third of the way along the distal matrix, and the second at the level of the distal border of the lunula.

NAIL ABLATION AND ISOLATED MATRICECTOMY Nail ablation means the definitive removal of the entire nail organ and matricectomy, the complete extirpation of the nail matrix, resulting in permanent nail loss. The principle of nail ablation is the complete removal of the nail unit with hyponychium, nail bed, matrix, lateral, and proximal nail folds. Except for malignant tumors of the nail apparatus, nail ablation is rarely indicated. It may be necessary in an excessively painful nail treated several times in vain, but this should be an exception. Scalpel excision is strongly advocated whenever the surgical specimen needs a histopathologic examination. If periungual pigmentation is associated with longitudinal melanonychia or if the latter is wider than 6 mm or if the full thickness of the nail is pigmented, a large portion of the matrix would necessarily be involved. Under these circumstances, the underlying disease process in unlikely to be benign. The entire portion of the involved nail apparatus has to be excised en bloc. The nail plate may be left in place as a guiding structure or may be avulsed prior to nail ablation; a sterile staining solution such as methylene blue may be painted into the matrix space and then dried. The matrix surface will then be stained, remaining clearly visible throughout the surgical procedure and helping the surgeon to dissect the matrix horns as well as the lateral and proximal nail grooves, which are often not completely extirpated, giving rise to nail spicules. An incision is carried down to the bone, around the tip of the digit 3 to 5 mm below the hyponychium, along both lateral aspects of the terminal phalanx until the distal dorsal crease of the distal interphalangeal joint, and across the dorsal aspect of the distal phalanx at least 3 mm proximal to the beginning of the matrix. The latter may be made visible by pressing on the free border of the nail plate, which makes a light transverse furrow appear at the base of the proximal nail fold or along the distal joint crease. The nail unit is then dissected from the bone. This is easier using blunt-tipped scissors than a scalpel, especially at the beginning when the nail bed has to be separated from the dorsal tuft of the tip of the terminal phalangeal bone. The nail bed is then removed, with the periosteum, to the base of the phalanx. Particular attention has to be paid to the extensor tendon insertion; this can be severed if a pointed scalpel is used, but this risk is minimized with blunt-tipped curved scissors. The dissection is then directed to the lateral matrix horns; this is easy on fingers and toes but it may require the dissection of

the entire dorsal distal half of the first toe, particularly in patients with pincer nails or ingrown nails. Nail ablation cuts the arteries feeding the nail organ. These arteries should be ligated or electrocoagulated because they are visible, even under regional ischaemia. The defect from nail ablation may be covered with a free graft (split-thickness, full-thickness, reversed dermal graft), which usually takes on the bone in this particular location. A cross-finger flap is a very useful alternative for a free graft; the use of the skin from the intermediate phalanx of a neighboring finger is more convenient for the patient than skin from the thenar area of the palm. If only permanent nail plate removal is necessary, the procedure is less extensive. The proximal third of the nail is avulsed and the proximal nail fold is incised on both sides to allow this fold to be reflected. An incision is made from the nail bed distal and parallel to the lunula border to the lateral aspects of both lateral nail grooves, carried along the lateral nail folds to meet the incisions of the proximal nail fold. Another incision is made along the underside of the proximal nail fold to remove the eponychium and proximal matrix. The entire matrix is then dissected from the bone. The remaining portion of the proximal nail fold may be sutured onto the matrix defect so that only a small defect will be left, which usually is even smaller than the lunula was before operation. The average time away from work is 2 weeks. Where pathologic examination is unnecessary, phenol cautery is, however, the preferred technique for matricectomy. Most patients return to normal ambulation and activity as early as one day after the operation.

Surgery of the Nail Bed

Nail bed surgery is performed for biopsy, removal of tumors and for treating dystrophic nails such as onychogryphosis.

BIOPSY OF THE NAIL BED Biopsy may be useful in any pathologic condition involving the nail bed. Punch biopsy is done with a 3- or 4-mm diameter punch, driven perpendicularly into the nail plate in a circular motion, down to the bone. However, it is not always easy to extract the cylinder cut in this small area. A useful technique consists of perforating the nail with a 6-mm punch, without injuring the underlying tissue. The covering nail is then detached by using the tip of the scalpel to remove the disk of nail and the biopsy is performed easily by using the 4-mm punch to the bone. The tissue can then be released from its tether with fine scissors. It is advisable to replace the 6-mm disk of nail keratin, after cleaning with 10% hydrogen peroxide, to cover the hole. If the nail plate is thick, using rotating grinders will thin it down and facilitate the transungual biopsy. If a larger nail bed fragment is needed, fusiform biopsy with a major longitudinal axis can be done after partial avulsion of the lateral half of the nail or, after total avulsion, if the fragment is central. After excision, the nail bed is undermined to facilitate reapproximation of both sides. The suture needle is used generously on these fragile subungual tissues. The wound is stitched with resorbable thread (Dexon 7–0). It is sometimes useful to make relaxing incisions at the most lateral margins of the nail bed.
SUBUNGUAL HEMATOMA Acute trauma with severe pain is always remembered by the patient. Depending on the site and the intensity of the injury, the hematoma may be visible almost immediately or it will grow out from under the proximal nail fold within a few weeks. When the hematoma is partial (less than 25 percent of the visible portion of the nail), it should be drained with a pointed scalpel or by hot paperclip cautery over the center of the dark spot. This will produce relief from pain. Sometimes the nail sloughs as the new nail regenerates beneath the old one. Small hematomas may be included in the nail but they cannot be degraded to hemosiderin and the Prussian blue test will be negative. Therefore, to demonstrate the nature of the blackish pigment, scrapings are boiled in a small test tube with hemostix, which gives a positive benzidine result. A hematoma involving more than 25 percent of the visible portion of the nail is a sign of significant nail bed injury. An x-ray is mandatory because the phalanx may be fractured. The nail is carefully removed and the hematoma evacuated. Traumatic nail bed laceration or wounds need a surgical approach to avoid delayed complications. Nail bed lacerations can be sutured after thorough cleaning with antiseptics, using 6–0 resorbable monofilament material. The avulsed nail plate should be put back to cover the wound, then kept in place by suturing to the lateral nail folds or the finger tip. Nail bed defects larger than 4 mm can be repaired by using a split-thickness graft taken either from the nail bed of the same digit or from the nail bed of a great toenail. The torn nail bed should be sutured with Dexon 6–0 and large bites of tissue should be taken so that the suture material does not pull through when it is tied. The nail plate is cleaned, shortened, and slightly narrowed, and then replaced with sutures into the lateral nail folds. The stitches are left in for 2 weeks. Chronic hematomas are usually painless and mainly caused by repeated microtrauma from either ill-fitting footwear or sporting activities. A notch is made with a scalpel blade at the distal and proximal border of the pigmented area. Observation over a 3-week period will delineate whether the nail grows independently of the pigmentation or with it. However chronic hematoma may resemble subungual melanoma and pose a distressing problem and nonmigrating hematoma should be ruled out.

Surgery of the Proximal Nail Fold

BIOPSY

- A 2- to 3-mm punch may be used for biopsying a tumor.
- A blister may be completely removed by a shave biopsy using half a razor blade.
- A 3-mm crescent-shaped tissue excision ending in the proximal region of the lateral nail folds may be helpful in the study of collagen diseases.

SURGERY OF A RECALCITRANT CHRONIC PARONYCHIA A foreign body (hair, for instance) under the proximal nail fold is the main cause. A recalcitrant chronic paronychia manifests as a red, painless swelling, except when pressed, with secondary retraction of the paronychial tissue whose cuticle has disappeared and with recurrent episodes of acute paronychial inflammation.
Crescent excision of the PNF A Freer septum elevator is inserted under the proximal nail fold to protect the matrix and extensor tendon. A No. 15 Bard-Parker blade is used to excise, en bloc, a crescent shaped, full-thickness skin segment, 4 mm at its greatest width, which extends from one lateral nail fold to the other. A bevelled incision prevents accidental damage to the proximal nail matrix and the most proximal portion of the PNF, responsible for the normal shine of the nail plate. In patients who experience repeated acute flares associated with a chronic paronychia, additional removal of the base of the nail is useful.
SURGERY OF TUMORS OF THE PROXIMAL NAIL FOLD Different techniques can be used according to the nature of the tumor, its location and the length of its long axis.
Crescentic excision Useful for small distal tumors, the crescent should not exceed 4 mm at its greatest width. Tumors of

the proximal nail fold situated in a median position (Fig. 280-13) and with a longitudinal axis greater than 4 to 5 mm can be excised with a wedge of PNF whose base is located at the free margin and whose apex points proximally. Two relaxing lateral incisions of the PNF then allow suturing of the wedge-shaped defect after the undersurface of the PNF has been released from the nail plate.

FIGURE 280-13 Tumor of the proximal nail fold in median position.

The resulting symmetric narrow defects on both sides heal rapidly by secondary intention. A small tumor on the lateral part of the PNF may be treated with a wedge-shaped excision. Only one lateral relaxing incision is made at the opposite region of the PNF. To obtain better healing of the secondary defect, which is wider than in the procedure using two relaxing incisions, the operation may be supplemented by a relaxing, crescent shaped incision in the PNF. A dorsal flap can be raised from the PNF by using two dorsolateral incisions and a horizontal one, proximal to the cuticle. This gives complete exposure of subcutaneous tumors.
Reconstruction of the proximal nail fold This may be necessary after any injury (accident, burn, avulsion caused by rapidly rotating belts and sanders, etc.). If the irregular tissue is excised, it is sometimes possible to recreate the distal curve of the PNF, which may produce a near perfect restoration. The PNF may also be restored by using two long, narrow, V-shaped transposition flaps from the lateral aspects of the terminal phalanx.

Lateral Nail Fold

A 2- to 4-mm punch can remove a tumor of the lateral nail fold (LNF). Benign tumors may be removed by an elliptical wedge of tissue taken for the LNF and lateral nail wall. Malignant tumors, such as Bowen's disease, are treated by excision of the whole LNF or by Mohs micrographic surgery followed by healing by second intention.

INGROWN NAILS

Ingrown nail is a condition that mainly occurs in the great toe. It is created by impingement of the nail plate into the dermal tissue, distally, or into the distolateral nail groove. Irrespective of the initial cause, the condition finally presents with a nail bed that is too narrow for its nail plate. Logical treatment is therefore aimed at correcting this disparity.

Distal Toenail Embedding

Surgical avulsion, or the loss of the toenail from trauma such as tennis toe, may initiate the pathology. The distal subungual tissues released from the physiologic counterpressure of the nail plate become hypertrophic and the newly formed nail plate abuts this distal wall. A crescent wedge-shaped excision is carried out around the distal phalanx. The wedge should be 4 mm at its greatest width and has to be dissected from the bone. The defect is closed with 5–0 monofilament sutures, which should be removed after 12 to 14 days.

Juvenile (Subcutaneous) Ingrown Nails

This is the most common type of ingrown nail. The nail is usually embedded medially, but both sides are often affected. In an effort to relieve the pain, the patient often tries to cut off the offending corner under the inflamed swollen soft tissue. The remaining portion will give rise to a nail spicule piercing through the epithelium of the lateral nail groove, which produces secondary infection and excessive granulation tissue.

Treatment of the early stage must be conservative but demands a high degree of compliance. The foot is soaked in warm water with povidone-iodine soap, then, under local anesthesia, the nail spicule is removed and a wisp of cotton wool is placed between the nail and the lateral nail groove. It should be moistened repeatedly with a disinfectant.

For definitive cure, surgical excision, or better chemical suppression of the lateral horn of the nail matrix, permanently narrows the nail. The lateral fifth of the NP is freed with a nail elevator from the PNF and the subungual tissues. It is then cut longitudinally with an English nail splitter or nail-splitting scissors and extracted with a sturdy hemostat. The lateral matrix horn is cauterized with a freshly made solution of liquefied phenol (88% solution). Above all, a bloodless field is needed, because blood inactivates phenol. Hemostasis is therefore accomplished with a tourniquet, and the blood is carefully cleaned from the space under the PNF using sterile gauze. The surrounding skin is protected with petroleum jelly. The phenol is rubbed onto the matrix epithelium for 3 min with a Q-tip changed two or three times. Postoperative pain is minimal because phenol has a local anesthetic action and is antiseptic. The matrix epithelium is sloughed off and oozing is usual for 2 to 6 weeks. Daily warm foot baths with povidone iodine soap accelerates healing.

Pincer Nail [5]

Overcurvature of the nails may affect the great toe alone or all the digits. This condition may be so painful that even the bed sheet becomes unbearable.

When the condition is mild, the nail brace technique is aimed at correcting the inward distortion of the nail by maintaining continuous tension on the nail plate. A stainless steel wire brace is fitted to the NP. A series of adjustments adapted to the gradual decrease of curvature is made over a period of 6 months and results in a painless correction of the pincer nail. However, because the underlying bone pathology remains untreated, relapse is usual. Therefore, the definitive cure,

using phenol cautery on the lateral matrix horns is, undoubtedly, the simplest effective treatment modality.

Hypertrophy of the Lateral Nail Fold

Hypertrophic lateral nail folds are usually the result of long-standing ingrown nails. Inflammation may range from the subclinical to the severe. Approximately one-fifth of the nail digging into the lateral nail fold is removed. Then an elliptical wedge of tissue is taken from the lateral nail wall of the toe, down to the bone. Suturing the defect pulls the lateral nail fold away from the offending lateral nail edge. In severe cases, this procedure may be combined with phenol cautery of the lateral horn of the matrix. In contrast to the adult-acquired hypertrophy of the lateral nail fold, congenital lateral hypertrophic lips disappear progressively and spontaneously within 12 months.

Congenital Malalignment of the Big Toenail

Typically, the nail is laterally malaligned, with transverse furrows on a thick brownish or greenish nail. This appearance may correct itself without therapy in 50 percent of cases before the age of 10 years. If the appearance is extreme, surgery diminishes the risk of permanent dystrophy.

REFERENCES

1. Salasche SJ et al: Tips on nail surgery. *Cutis* **35**:428, 1985

2. Rich P: Nail biopsy: Indications and methods. *Dermatol Surg* **27**:229, 2001

3. Haneke E et al: Longitudinal melanonychia. *Dermatol Surg* **27**:580, 2001

4. Desciack EB et al: Split-nail deformities: A surgical approach. *Dermatol Surg* **27**:252, 2001

5. Baran R et al: Pincer nails. Definition and surgical treatment. *Dermatol Surg* **27**:261, 2001

T>